Nelson

TEXTBOOK OF PEDIATRICS

Robert M. Kliegman
Joseph W. St Geme III
NATHAN J. BLUM
ROBERT C. TASKER
KAREN M. WILSON
ABIGAIL M. SCHUH
CARA L. MACK

EDITION
22

ELSEVIER

Volume 2

The Digestive System

PART XVI

Section 1

Clinical Manifestations of Gastrointestinal Disease

Chapter 351

Normal Digestive Tract Phenomena

Asim Maqbool and Chris A. Liacouras

Gastrointestinal function varies with maturity; what is a physiologic event in a newborn or infant might be a pathologic symptom at an older age. A fetus can swallow amniotic fluid as early as 12 weeks of gestation, but nutritive sucking in neonates first develops at about 34 weeks of gestation. The coordinated oral and pharyngeal movements necessary for swallowing solids develop within the first few months of life. Before this time, the tongue thrust is upward and outward to express milk from the nipple, instead of a backward motion, which propels solids toward the esophageal inlet. By 1 month of age, infants appear to show preferences for sweet and salty foods. Infants' interest in solids increases at approximately 4 months of age. The recommendation to begin solids at 6 months of age is based on nutritional and cultural concepts rather than maturation of the swallowing process (see Chapter 61). Infants swallow air during feeding, and burping is encouraged to prevent gaseous distention of the stomach.

A number of normal anatomic variations may be noted in the mouth. A **short lingual frenulum** ("tongue-tie") may be worrisome to parents but only rarely interferes with nursing, bottle feeding, eating, or speech, generally requiring no treatment. **Surface furrowing** of the tongue (a geographic or scrotal tongue) is usually a normal finding. A **bifid uvula** may be isolated or associated with a submucous cleft of the soft palate (Fig. 351.1).

Regurgitation, the result of gastroesophageal reflux, occurs commonly in the first year of life. Effortless regurgitation can dribble out of an infant's mouth but also may be forceful. In an otherwise healthy infant with regurgitation; volumes of emesis are commonly approximately 15-30 mL but occasionally are larger. Most often, the infant remains happy, although possibly hungry, after an episode of regurgitation. Episodes can occur from one to several times per day. Regurgitation gradually resolves in 80% of infants by 6 months of age and in 90% by 12 months. If complications develop or regurgitation persists, gastroesophageal reflux is considered pathologic rather than merely developmental and deserves further evaluation and treatment. Complications of gastroesophageal reflux include failure to thrive, pulmonary disease (apnea or aspiration pneumonitis), and esophagitis with its sequelae (see Chapters 369 and 370).

Infants and young children may be erratic eaters; this may be a worry to parents. A toddler might eat insatiably or refuse to consume food during a meal. Toddlers and young children also tend to eat only a limited variety of foods. Parents should be encouraged to view nutritional intake over several days and not be overly concerned about individual meals. Infancy and adolescence are periods of rapid growth; high nutrient requirements for growth may be associated with voracious appetites. The reduced appetite of toddlers and preschool children is often a worry to parents who are used to the relatively greater dietary intake during infancy. Demonstration of age-appropriate growth on a growth curve is reassuring.

The number, color, and consistency of stools can vary greatly in the same infant and between infants of similar age, without apparent explanation. The earliest stools after birth consist of meconium, a dark, viscous material that is normally passed within the first 48 hours of life. With the onset of feeding, meconium is replaced by green-brown transition stools, often containing curds, and, after 4-5 days, by yellow-brown milk stools. **Stool frequency** is extremely variable in normal infants and can vary from none to seven per day. Breastfed infants can have frequent small, loose stools early (transition stools), and then after 2-3 weeks can have very infrequent soft stools. Some nursing infants might not pass any stool for 1-2 weeks and then have a normal soft bowel movement. The color of stool has little significance except for the presence of blood or absence of bilirubin products (white-gray rather than yellow-brown). The presence of vegetable matter, such as peas or corn, in the stool of an older infant or toddler ingesting solids is normal and suggests poor chewing and not malabsorption. A pattern of intermittent loose stools, known as **toddler's diarrhea,** occurs commonly between 1 and 3 years of age. These otherwise healthy growing children often drink excessive carbohydrate-containing beverages. The stools typically occur during the day and not overnight. The volume of fluid intake is often excessive; limiting sugar and unabsorbable carbohydrate-containing beverages and increasing fat in the diet often lead to resolution of the pattern of loose stools.

A protuberant abdomen is often noted in infants and toddlers, especially after large feedings. This can result from the combination of weak abdominal musculature, relatively large abdominal organs, and lordotic stance. In the first year of life, it is common to palpate the liver 1-2 cm

Fig. 351.1 Classic submucous cleft palate with triad of bifid uvula *(large arrow)*, furrow along the midline of the soft palate *(arrowheads)*, and a notch in the posterior margin of the hard palate *(small arrow)*. The midline furrow is sometimes referred to as the zona pellucida, reflecting the translucent nature of this area in some patients. *(From Hasan A, Gardner A, Devlin M, Russell C. Submucous cleft palate with bifid uvula. J Pediatr. 2014;165:872.)*

below the right costal margin. The normal liver is soft in consistency and percusses to normal size for age. A Riedel lobe is a thin projection of the right lobe of the liver that may be palpated low in the right lateral abdomen. A soft spleen tip might also be palpable as a normal finding. In thin young children, the vertebral column is easily palpable, and an overlying structure may be mistaken for a mass. Pulsation of the aorta can be appreciated. Normal stool can often be palpated in the left lower quadrant in the descending or sigmoid colon.

Blood loss from the gastrointestinal tract is never normal, but swallowed blood may be misinterpreted as gastrointestinal bleeding. Maternal blood may be ingested at the time of birth or later by a nursing infant if there is bleeding near the mother's nipple. Nasal or oropharyngeal bleeding is occasionally mistaken for gastrointestinal bleeding (see Chapter 142). Red dyes in foods or drinks can turn the stool red but do not produce a positive test result for occult blood.

Jaundice is common in neonates, especially among premature infants, and usually results from the inability of an immature liver to conjugate bilirubin, leading to an elevated indirect component (see Chapter 137). Persistent elevation of indirect bilirubin levels in nursing infants may be a result of breast milk jaundice, which is usually a benign entity in full-term infants. An elevated direct bilirubin is not normal and suggests liver disease, although in infants it may be a result of extrahepatic infection (urinary tract infection). The direct bilirubin fraction should account for no more than 15–20% of the total serum bilirubin. Elevations in direct bilirubin levels can follow indirect hyperbilirubinemia as the liver converts excessive indirect to direct bilirubin and the rate-limiting step in bilirubin excretion shifts from the glucuronidation of bilirubin to excretion of direct bilirubin into the bile canaliculus. Indirect hyperbilirubinemia, which occurs commonly in normal newborns, tends to tint the sclerae and skin golden yellow, whereas direct hyperbilirubinemia produces a greenish yellow hue. The degree of jaundice does not always directly correlate with serum bilirubin levels. An elevated total serum bilirubin warrants closer examination, fractionation of bilirubin (direct and indirect), and ongoing surveillance. Atypical elevations of unconjugated bilirubin are associated with risk for kernicterus (see Chapter 140). Elevations in conjugated bilirubin are reviewed in the chapter on cholestasis (see Chapter 404.1).

Visit Elsevier eBooks+ at eBooks.Health.Elsevier.com for Bibliography.

Chapter 352

Major Symptoms and Signs of Digestive Tract Disorders

Asim Maqbool and Chris A. Liacouras

Disorders of organs outside the gastrointestinal (GI) tract can produce symptoms and signs that mimic digestive tract disorders and should be considered in the differential diagnosis (Table 352.1). In children with normal growth and development, treatment may be initiated without a formal evaluation based on a presumptive diagnosis after taking a history and performing a physical examination. Poor weight gain or weight loss is often associated with a significant pathologic process and usually necessitates a more formal evaluation.

Table 352.1 Some Nondigestive Tract Causes of Gastrointestinal Symptoms in Children

ANOREXIA
Systemic disease: inflammatory, neoplastic
Cardiorespiratory compromise
Iatrogenic: drug therapy, unpalatable therapeutic diets
Depression
Anorexia nervosa
VOMITING
Inborn errors of metabolism
Medications: erythromycin, chemotherapy, nonsteroidal antiinflammatory drugs, marijuana
Increased intracranial pressure
Brain tumor
Infection of the urinary tract
Labyrinthitis
Adrenal insufficiency
Pregnancy
Psychogenic
Abdominal migraine
Poisoning/toxins
Renal disease
DIARRHEA
Infection: otitis media, urinary tract infection
Uremia
Medications: antibiotics, cisapride
Tumors: neuroblastoma
Pericarditis
Adrenal insufficiency
CONSTIPATION
Hypothyroidism
Spina bifida
Developmental delay
Dehydration: diabetes insipidus, renal tubular lesions
Medications: narcotics
Lead poisoning
Infant botulism
ABDOMINAL PAIN
Pyelonephritis, hydronephrosis, renal colic
Pneumonia (lower lobe)
Pelvic inflammatory disease
Porphyria
Fabry disease
Angioedema
Endocarditis
Abdominal migraine
Familial Mediterranean fever
Sexual or physical abuse
Systemic lupus erythematosus
School phobia
Sickle cell crisis
Vertebral disk inflammation
Psoas abscess
Pelvic osteomyelitis or myositis
Medications
Anterior (abdominal) cutaneous nerve entrapment syndrome (ACNES)
ABDOMINAL DISTENTION OR MASS
Ascites: nephrotic syndrome, neoplasm, heart failure
Discrete mass: Wilms tumor, hydronephrosis, neuroblastoma, mesenteric cyst, hepatoblastoma, lymphoma
Pregnancy
JAUNDICE
Hemolytic disease
Urinary tract infection
Sepsis
Hypothyroidism
Panhypopituitarism

DYSPHAGIA

Difficulty in swallowing is termed *dysphagia*. Painful swallowing is termed **odynophagia**. **Globus** is the sensation of something stuck in the throat without a clear etiology. Swallowing is a complex process that starts in the mouth with mastication and lubrication of food that is formed into a bolus. The bolus is pushed into the pharynx by the tongue. The pharyngeal phase of swallowing is rapid and involves protective mechanisms to prevent food from entering the airway. The epiglottis is lowered over the larynx while the soft palate is elevated against the nasopharyngeal wall; respiration is temporarily arrested while the upper esophageal sphincter opens to allow the bolus to enter the esophagus. In the esophagus, peristaltic coordinated muscular contractions push the food bolus toward the stomach. The lower esophageal sphincter relaxes shortly after the upper esophageal sphincter, so liquids that rapidly clear the esophagus enter the stomach without resistance.

Dysphagia is classified as oropharyngeal dysphagia and esophageal dysphagia. **Oropharyngeal dysphagia** occurs when the transfer of the food bolus from the mouth to the esophagus is impaired (also termed *transfer dysphagia*). The striated muscles of the mouth, pharynx, and upper esophageal sphincter are affected in oropharyngeal dysphagia. Neurologic and muscular disorders can give rise to oropharyngeal dysphagia (Table 352.2). Chiari malformations, Russell-Silver syndrome, and cri du chat may present with upper esophageal sphincter dysfunction, manifest by dysphagia with solids. The most serious complication of oropharyngeal dysphagia is life-threatening aspiration.

A complex sequence of neuromuscular events is involved in the transfer of foods to the upper esophagus. Abnormalities of the muscles involved in the ingestion process and their innervation, strength, or coordination are associated with transfer dysphagia in infants and children. In such cases, an oropharyngeal problem is usually part of a more generalized neurologic or muscular problem (botulism, diphtheria, neuromuscular disease). Painful oral lesions, such as acute viral stomatitis or trauma, occasionally interfere with ingestion. If the nasal air passage is seriously obstructed, the need for respiration causes severe distress when suckling. Although severe structural, dental, and salivary abnormalities would be expected to create difficulties, ingestion proceeds relatively well in most affected children if they are hungry.

Esophageal dysphagia occurs when there is difficulty in transporting the food bolus down the esophagus. Esophageal dysphagia can result from neuromuscular disorders or mechanical obstruction (Table 352.3). Primary motility disorders causing impaired peristaltic function and dysphagia are rare in children. Eosinophilic esophagitis can present with esophageal dysphagia. Achalasia is an esophageal motility disorder with associated inability of relaxation of the lower esophageal sphincter; it rarely occurs in children. Motility of the distal esophagus is disordered after surgical repair of tracheoesophageal fistula or achalasia. Abnormal motility can accompany collagen vascular disorders. Mechanical obstruction can be intrinsic or extrinsic. Intrinsic structural defects cause a fixed impediment to the passage of food bolus because of a narrowing within the esophagus, as in a stricture, web, or tumor. Extrinsic obstruction is caused by compression from vascular rings, mediastinal lesions, or vertebral abnormalities. Structural defects typically cause more problems in swallowing solids than liquids. In infants, esophageal web, tracheobronchial remnant, or vascular ring can cause dysphagia. An esophageal stricture secondary to esophagitis (chronic gastroesophageal reflux, eosinophilic esophagitis, chronic infections) occasionally has dysphagia as the first manifestation. An esophageal foreign body or a stricture secondary to a caustic ingestion also causes dysphagia. A Schatzki ring, a thin ring of mucosal tissue near the lower esophageal sphincter, is another mechanical cause of recurrent dysphagia, and again is rare in children.

When dysphagia is associated with a delay in passage through the esophagus, the patient may be able to point to the level of the chest where the delay occurs, but esophageal symptoms are usually referred

Table 352.2 Causes of Oropharyngeal Dysphagia

NEUROMUSCULAR DISORDERS
Cerebral palsy
Brain tumors
Cerebrovascular disease/stroke
Chiari malformation
Polio and postpolio syndromes
Multiple sclerosis
Myositis
Dermatomyositis
Myasthenia gravis
Muscular dystrophies
Acquired or inherited dystonia syndrome
Dysautonomia
METABOLIC AND AUTOIMMUNE DISORDERS
Hyperthyroidism
Systemic lupus erythematosus
Sarcoidosis
Amyloidosis
INFECTIOUS DISEASE
Meningitis
Botulism
Diphtheria
Lyme disease
Neurosyphilis
Viral infection: polio, coxsackievirus, herpes, cytomegalovirus
STRUCTURAL LESIONS
Inflammatory: abscess, pharyngitis
Congenital web
Cricopharyngeal bar
Dental problems
Bullous skin lesions
Plummer-Vinson syndrome
Zenker diverticulum
Extrinsic compression: osteophytes, lymph nodes, thyroid swelling, aberrant right subclavian artery (dysphagia lusoria)
OTHER
Corrosive injury
Side effects of medications
After surgery
After radiation therapy

Adapted from Gasiorowska A, Faas R. Current approach to dysphagia. *Gastroenterol Hepatol*. 2009;5(4):269–279.

Table 352.3 Causes of Esophageal Dysphagia

NEUROMUSCULAR
Eosinophilic esophagitis
Achalasia cardia
Diffuse esophageal spasm
Scleroderma
GERD
INTRINSIC LESIONS
Foreign bodies including pills
Esophagitis: GERD, eosinophilic esophagitis, infections
Stricture: corrosive injury, pill induced, peptic
Esophageal webs
Esophageal rings
Esophageal diverticula
Neoplasm
Chagas disease
EXTRINSIC LESIONS
Vascular compression
Mediastinal lesion
Cervical osteochondritis
Vertebral abnormalities

GERD, Gastroesophageal reflux disease.
Adapted from Gasiorowska A, Faas R. Current approach to dysphagia. *Gastroenterol Hepatol*. 2009;5(4):269–279.

to the suprasternal notch. When a patient points to the suprasternal notch, the impaction can be found anywhere in the esophagus.

REGURGITATION

Regurgitation is the effortless movement of stomach contents into the esophagus and mouth. It is not associated with distress, and infants with regurgitation are often hungry immediately after an episode. The lower esophageal sphincter prevents reflux of gastric contents into the esophagus. Regurgitation is a result of gastroesophageal reflux through an incompetent or, in infants, immature lower esophageal sphincter. This is often a developmental process, and regurgitation or "spitting" resolves with maturity. Regurgitation should be differentiated from vomiting, which denotes an active reflex process with an extensive differential diagnosis (Table 352.4).

NAUSEA

Nausea has been described as an unpleasant, subjective sensation of impending/imminent vomiting, often with epigastric sensation that may be painless. Nausea is frequently associated with typical autonomic signs that accompany vomiting. Not all nausea is a prodrome to vomiting. There are multiple potential triggers to nausea, including environmental exposures (toxins, odors), unpleasant visual stimuli, visceral pain, anxiety, stress, and a variety of additional etiologies (Table 352.5).

The central nervous system (CNS) is frequently implicated for nausea. Receptors and neural pathways at the chemoreceptor trigger zone (CTZ) are most often implicated by chemical stimuli with chemotherapy a prime example. Visceral stimuli can include ingestions, gastric hyperacidity, physical stress, psychologic stressors, mechanical distention of the stomach, and impaired GI motility; vagal and sympathetic nerves are involved in this process. Vestibular pathways are most often implicated in nausea related to motion sickness. Increased intracranial pressure can also present with nausea plus or minus vomiting.

Chronic nausea is more common in adolescents and may be coincidental with other functional GI disorders, including functional dyspepsia, delayed gastric emptying/gastroparesis, and constipation. There are gender and ethnic differences with respect to chronic nausea in adolescence, with adolescent White females with anxiety more at risk than other groups; there may be alterations in the brain gut axis coupled with increased visceral hypersensitivity and hyperalgesia at play in the setting (see Chapter 212). Dehydration and autonomic dysfunction may also present with nausea as one facet of GI manifestations.

Nausea is often a clinical diagnosis, and while the differential diagnosis is extensive, negative findings do not equate to the patient not having nausea. Nausea is often distressing, disruptive, and may be disabling with respect to normal function. Table 352.5 reviews common medical conditions associated with nausea, as well as treatment strategies. Hydration is important in many of these conditions. Many of the medications used employ antihistamine, serotonergic, dopaminergic, and potentially even opioid pathways (although these are still controversial). These agents are active at both the CNS and GI level, with significant brain-gut axis interplay. Complementary and

Table 352.4 | Differential Diagnosis of Emesis During Childhood

INFANT	CHILD	ADOLESCENT
COMMON		
Gastroenteritis	Gastroenteritis	Gastroenteritis
Gastroesophageal reflux	Systemic infection	GERD
Overfeeding	Gastritis	Systemic infection
Anatomic obstruction*	Toxic ingestion/poisoning	Toxic ingestion/poisoning/marijuana
Systemic infection†	Pertussis syndrome	Gastritis
Pertussis syndrome	Medication	Sinusitis
Otitis media	Reflux (GERD)	Inflammatory bowel disease
	Sinusitis	Appendicitis
	Otitis media	Migraine
	Anatomic obstruction*	Pregnancy
	Eosinophilic esophagitis	Medications
		Ipecac abuse, bulimia
		Concussion
RARE		
Adrenogenital syndrome	Reye syndrome	Reye syndrome
Inborn errors of metabolism	Hepatitis	Hepatitis
Brain tumor (increased intracranial pressure)	Peptic ulcer	Peptic ulcer
Subdural hemorrhage	Pancreatitis	Pancreatitis
Food poisoning	Brain tumor	Cholecystitis
Rumination	Increased intracranial pressure	Brain tumor
Renal tubular acidosis	Middle ear disease/labyrinthitis	Increased intracranial pressure
Ureteropelvic junction obstruction	Chemotherapy	Concussion
Pseudoobstruction	Achalasia	Middle ear disease/labyrinthitis
	Cyclic vomiting (migraine)	Chemotherapy
	Esophageal stricture	Cyclic vomiting (migraine)
	Duodenal hematoma	Biliary colic
	Inborn error of metabolism	Renal colic
	Pseudoobstruction	Porphyria
	Gastroparesis	Diabetic ketoacidosis
		Adrenal insufficiency
		Pseudoobstruction
		Intestinal tumor
		Gastroparesis
		Achalasia
		Superior mesentery artery syndrome
		Distal intestinal obstruction syndrome

*Includes malrotation, pyloric stenosis, intussusception, Hirschsprung disease, adhesions, and hernias.
†Meningitis, sepsis.
GERD, Gastroesophageal reflux disease.

Table 352.5 Examples of Causes and Management of Nausea

FUNCTIONAL GASTROINTESTINAL DISORDERS	TREATMENT APPROACHES
Gastroesophageal reflux	Diet and lifestyle; acid reduction, refluxate management
Esophagitis (reflux related, eosinophilic, etc.)	Acid reduction, identifying and restricting environmental/dietary triggers
Dyspepsia	Dietary and lifestyle modification; acid reduction; cyproheptadine
Gastroparesis	Smaller, more frequent meals; dietary modification; prokinetic agents (D_2 antagonists such as metoclopramide and domperidone*; low-dose erythromycin or azithromycin)
Constipation	Adequate hydration, diet and lifestyle modification, stool softeners, stimulant laxatives, additional adjunct measures if/as indicated
Visceral hyperalgesia	Tricyclic antidepressants (e.g., amitriptyline), cognitive behavioral therapy, hypnotherapy, biofeedback, physical therapy for desensitization; biofeedback; stress reduction
OTHER GASTROINTESTINAL DISORDERS	
Gastritis (medication/NSAID induced; *Helicobacter pylori*)	Reduce/remove medications involved; treat the underlying cause
Gastrointestinal dysmotility	Adequate hydration; diet/feeding or eating modification; promotility agents
Biliary dysfunction (cholelithiasis, cholecystitis, biliary dyskinesia)	Treat the underlying cause
Fundoplication	Smaller, more frequent meals; cyproheptadine to improve gastric accommodation
CENTRAL NERVOUS SYSTEM	
Increased intracranial pressure	Treat underlying cause
Migraines, headaches	Migraine prophylactic agents, including cyproheptadine. Abortive medications including triptans.
Motion sickness/vestibular dysfunction	Antihistamines (e.g., diphenhydramine, hydroxyzine) anticholinergics (e.g., scopolamine)
Autonomic dysfunction	Adequate hydration, increased salt intake, diet and lifestyle modification
Chemotherapy-induced nausea and vomiting	5-HT_3 receptor antagonists; D_2 antagonists; NK-1 antagonists; butyrophenones; benzodiazepines; dexamethasone; synthetic cannabinoids
Postoperative nausea and vomiting	5-HT_3 receptor antagonists
NON-GI AND NON-CNS ETIOLOGIES OF NAUSEA	
Uremia	Treat the underlying disorder
Endocrine disorders [e.g., hypothyroidism]	Treat the underlying disorder

*D_2 receptor antagonists such as metoclopramide and domperidone have a significant side effect profile, and have a U.S. Food and Drug Administration black box warning, and should be used with caution.
NK-1, Neurokinin 1.

alternative medicine approaches including using ginger, peppermint, aromatherapy, and biofeedback may be helpful. Behavior psychology and social work may be helpful in decreasing disability and enhancing functionality.

VOMITING

Vomiting is a highly coordinated reflex process that may be preceded by increased salivation and begins with involuntary retching. Violent descent of the diaphragm and constriction of the abdominal muscles with relaxation of the gastric cardia actively force gastric contents back up the esophagus. This process is coordinated in the medullary vomiting center, which is influenced directly by afferent innervation and indirectly by the CTZ and higher CNS centers. Many acute or chronic processes can cause vomiting (see Tables 352.1 and 352.4).

Vomiting caused by obstruction of the GI tract is probably mediated by intestinal visceral afferent nerves stimulating the vomiting center (Table 352.6). If obstruction occurs below the second part of the duodenum, vomitus is usually bile stained. Emesis can also become bile stained with repeated vomiting in the absence of obstruction when duodenal contents are refluxed into the stomach. Nonobstructive lesions of the digestive tract can also cause vomiting; this includes diseases of the upper bowel, pancreas, liver, or biliary tree. CNS or metabolic derangements and cyclic vomiting syndrome (see Chapter 390) can lead to severe, persistent emesis. Marijuana use among teens has also led to cannabis hyperemesis syndrome (see Chapter 157.3)

Potential complications of emesis are noted in Table 352.7. Broad management strategies for vomiting in general and specific causes of emesis are noted in Tables 352.8 and 352.9.

DIARRHEA

Diarrhea is best defined as excessive loss of fluid and electrolyte in the stool. Acute diarrhea is defined as sudden onset of excessively loose stools of >10 mL/kg/day in infants and >200 g/24 hr in older children, which lasts <14 days. When the episode lasts longer than 14 days, it is called *chronic* or *persistent diarrhea*.

Normally, a young infant has approximately 5 mL/kg/day of stool output; the volume increases to 200 g/24 hr in an adult. The greatest volume of intestinal water is absorbed in the small bowel; the colon concentrates intestinal contents against a high osmotic gradient. The small intestine of an adult can absorb 10-11 L/day of a combination of ingested and secreted fluid, whereas the colon absorbs approximately 0.5 L. Disorders that interfere with absorption in the small bowel tend to produce voluminous diarrhea, whereas disorders compromising colonic absorption produce lower-volume diarrhea. **Dysentery** (small-volume, frequent bloody stools with mucus, tenesmus, and urgency) is the predominant symptom of colitis.

The basis of all diarrheas is disturbed intestinal solute transport and water absorption. Water movement across intestinal membranes is passive and is determined by both active and passive fluxes of solutes, particularly sodium, chloride, and glucose. The pathogenesis of most episodes of diarrhea can be explained by secretory, osmotic, or motility abnormalities or a combination of these (Table 352.10).

Secretory diarrhea occurs when the intestinal epithelial cell solute transport system is in an active state of secretion. It is often caused by a secretagogue, such as cholera toxin, binding to a receptor on the surface epithelium of the bowel and thereby stimulating intracellular accumulation of cyclic adenosine monophosphate or cyclic guanosine monophosphate. Some intraluminal fatty acids and bile salts cause the colonic mucosa to secrete through this

Table 352.6 Causes of Gastrointestinal Obstruction

ESOPHAGUS

Congenital

Esophageal atresia
Vascular rings
Schatzki ring
Tracheobronchial remnant

Acquired

Esophageal stricture
Foreign body
Achalasia
Chagas disease
Collagen vascular disease

STOMACH

Congenital

Antral webs
Pyloric stenosis

Acquired

Bezoar, foreign body
Pyloric stricture (ulcer)
Chronic granulomatous disease of childhood
Eosinophilic gastroenteritis
Crohn disease
Epidermolysis bullosa

SMALL INTESTINE

Congenital

Duodenal atresia
Annular pancreas
Malrotation/volvulus
Malrotation/Ladd bands
Ileal atresia
Meconium ileus
Meckel diverticulum with volvulus or intussusception
Inguinal hernia
Internal hernia
Intestinal duplication
Pseudoobstruction

Acquired

Postsurgical adhesions
Crohn disease
Intussusception
Distal ileal obstruction syndrome (cystic fibrosis)
Duodenal hematoma
Superior mesenteric artery syndrome

COLON

Congenital

Meconium plug
Hirschsprung disease
Colonic atresia, stenosis
Imperforate anus
Rectal stenosis
Pseudoobstruction
Volvulus
Colonic duplication

Acquired

Ulcerative colitis (toxic megacolon)
Chagas disease
Crohn disease
Fibrosing colonopathy (cystic fibrosis)

Table 352.7 Complications of Vomiting

COMPLICATION	PATHOPHYSIOLOGY	HISTORY, PHYSICAL EXAMINATION, AND LABORATORY STUDIES
Metabolic	Fluid loss in emesis HCl loss in emesis Na, K loss in emesis Acidosis	Dehydration Alkalosis; hypochloremia Hyponatremia; hypokalemia Dehydration
Nutritional	Emesis of calories and nutrients Anorexia for calories and nutrients	Malnutrition; "failure to thrive"
Mallory-Weiss tear	Retching → tear at lesser curve of gastroesophageal junction	Forceful emesis → hematemesis
Esophagitis	Chronic vomiting → esophageal acid exposure	Heartburn; Hemoccult + stool
Aspiration	Aspiration of vomitus, especially in context of obtundation	Pneumonia; neurologic dysfunction
Shock	Severe fluid loss in emesis or in accompanying diarrhea Severe blood loss in hematemesis	Dehydration (accompanying diarrhea can explain acidosis?) Blood volume depletion
Pneumomediastinum, pneumothorax	Increased intrathoracic pressure	Chest x-ray
Petechiae, retinal hemorrhages	Increased intrathoracic pressure	Normal platelet count

From Kliegman RM, Greenbaum LA, Lye PS, eds. *Practical Strategies in Pediatric Diagnosis and Therapy,* 2nd ed. Philadelphia: Elsevier; 2004: p. 318.

Table 352.8 Pharmacologic Therapies for Vomiting Episodes

DISORDER – THERAPEUTIC CLASS	DRUG	DOSAGE	COMMENTS
REFLUX – ANTACIDS			
Histamine-2 receptor antagonist	Famotidine (Pepcid)	<3 months: 0.5 mg/kg/dose PO daily ≥ 3 months: 0.5 mg/kg/dose PO twice daily Children >40 kg: 20 mg twice daily, max: 40 mg/dose	• H2RAs are associated with tachyphylaxis • Ranitidine was withdrawn in 2020 • Cimetidine has antiandrogenic potential, can stimulate prolactin secretion, and may be subject to drug interactions due to enzyme inhibition
	Nizatidine (Axid)	<12 years: 5 mg/kg/dose PO twice daily* ≥12 years: 150 mg PO twice daily, max 300 mg/day	
	Cimetidine	<16 years: 30-40 mg/kg/day PO divided 2-3x daily,* max: 400 mg/dose ≥16 years: 400 mg PO 4 times daily or 800 mg PO twice daily	
Proton pump inhibitors	Omeprazole (Prilosec) Lansoprazole (Prevacid) Esomeprazole (Nexium) Pantoprazole (Protonix)	1-2 mg/kg/day PO in 1-2 divided doses Maximum dose: omeprazole, esomeprazole, pantoprazole: 40 mg/dose; lansoprazole: 30 mg/dose	• Administer 30 minutes before first meal of the day for optimal effect • Long-term side effects include increased risk of infections, bone health abnormalities, hypomagnesemia, vitamin B12 deficiency • Consider weaning in patients on prolonged course (>6 months) to avoid rebound symptoms
GASTROPARESIS – PROKINETICS			
Dopamine antagonist	Metoclopramide (Reglan)	0.1-0.2 mg/kg/dose PO/IV every 6 to 8 hours, max: 10 mg/dose	• Use minimum effective dose and limit duration due to increased risk of extrapyramidal symptoms (EPS) with cumulative exposure • Although some clinicians use diphenhydramine to limit EPS, anticholinergic effects of diphenhydramine may negate prokinetic benefit
Motilin agonist	Erythromycin	5 mg/kg/dose PO 3-4 times daily, titrate up to 10 mg/kg/dose, max: 250 mg/dose	• Prescribe suspension for optimal pharmacokinetic profile in patients with hypomotility • Cycling or drug-holidays may mitigate tachyphylaxis • Subject to drug interactions due to CYP3A4 inhibition • Associated with QTc prolongation, consider baseline EKG and/or periodic monitoring in patients with risk factors (underlying cardiac disorder, concomitant QT prolonging medications, electrolyte derangements) • Routine use of other macrolides (azithromycin, clarithromycin) is not recommended due to limited data to support use, unknown optimal dose/frequency, and concerns for antibiotic resistance

Continued

Table 352.8 Pharmacologic Therapies for Vomiting Episodes—cont'd

DISORDER – THERAPEUTIC CLASS	DRUG	DOSAGE	COMMENTS
Serotonin (5HT-4) agonist	Cisapride	Consult GI specialist	• Withdrawn from the market in most countries due to QTc prolongation risk • Use restricted to regulated/limited-access programs with specialist supervision
	Prucalopride* (Motegrity)	>4 years: 0.04 mg/kg/dose PO once daily, max: 2 mg/dose Dosing range 0.02-0.06 mg/kg/dose to accommodate tablets	• Approved for constipation in adults, but a single-center retrospective study showed improvement in children with refractory upper GI symptoms
Cholinergic agonist	Bethanechol*	0.1-0.2 mg/kg/dose PO 3 to 4 times daily, max: 10 mg/dose	• Administer before feeds/meals • Stimulates antral contractions but does not impact gastric emptying • Caution when using with anticholinergic agents (e.g., glycopyrrolate) due to potential for reduced efficacy/negating effect
CHEMOTHERAPY-INDUCED NAUSEA/VOMITING (CINV), POSTOPERATIVE, GENERAL			
Serotonin 5HT3 antagonist	Ondansetron (Zofran)	0.1-0.15 mg/kg/dose PO/IV q8h, max: 24 mg/day Single dose regimen: 0.3 mg/kg/dose PO/IV, max: 16 mg/dose	• Adverse effects: constipation, headache, QTc prolongation • Dose varies based on chemotherapy emetogenicity
	Granisetron (Kytril)	≥2 years: 0.01 mg/kg/dose PO/IV q12h, max: 2 mg/dose *Single daily dose: 0.02-0.04 mg/kg PO/IV	
Phenothiazine	Prochlorperazine (Compazine)	≥2 years: 0.1 mg/kg/dose PO/IV q6-8h PRN, max: 10 mg/dose	• Due to safety concerns (EPS, sedation, respiratory depression), routine use of phenothiazines is not recommended • Consider concomitant diphenhydramine to decrease risk of dystonic reactions • Promethazine is associated with extravasation; IV/IM administration is generally avoided
	Promethazine (Phenergan)	≥2 years: 0.25 to 0.5 mg/kg/dose PO/rectal q4-6h PRN, max: 25 mg/dose	
	Chlorpromazine (Thorazine)	≥6 months: 0.5 to 1 mg/kg/dose PO/IM/IV q6-8h PRN	
Substance P / neurokinin 1 antagonist	Aprepitant (Emend), for CINV	≥6 months and children <30 kg: 3 mg/kg PO on day 1, then 2 mg/kg once daily on days 2 and 3 Children >30 kg: 125 mg PO daily on day 1, then 80 mg PO daily on days 2 and 3	• Subject to drug interactions due to enzyme inhibition
Steroids	Dexamethasone, for CINV	0.1 mg/kg/dose or 3 mg/m2/dose PO/IV q12h-24h	• Reported regimens vary, dose depends on chemotherapy emetogenicity • May require dose reduction with concomitant aprepitant

Table 352.8 Pharmacologic Therapies for Vomiting Episodes—cont'd

DISORDER – THERAPEUTIC CLASS	DRUG	DOSAGE	COMMENTS
MOTION SICKNESS, VESTIBULAR DISORDERS			
Antihistamine	Diphenhydramine (Benadryl)	0.5-1 mg/kg/dose PO/IV/IM q6-8h, max: 50 mg/dose	• Anticholinergic effects may contribute to decreased motility • Dimenhydrinate is available as 50 mg tablets, prescribe in 12.5 mg increments • Do not cut or manipulate scopolamine transdermal patches • Withdrawal (cholinergic rebound) symptoms reported with long-term use, limit duration or consider weaning with extended use
	Dimenhydrinate (Dramamine)	>2 years: 1 to 1.5 mg/kg/dose PO q6-8h, max: 25 mg/dose	
	Meclizine (Antivert)	>2 to <12 years: 6.25 mg to 12.5 mg PO three times daily PRN >12 years: 25 mg to 50 mg PO 1 to 4 times daily, max: 100 mg/day	
	Scopolamine (Transderm-Scop)	>15 kg: 1 transdermal patch applied behind the ear every 3 days	
MISCELLANEOUS			
Visceral Hypersensitivity, Feeding Intolerance Antihistamine/serotonin antagonist	Cyproheptadine*	0.25 mg/kg/day PO in 1-3 divided doses, usual max: 4 mg/dose	• Consider starting with bedtime dose and titrating up to prevent daytime sedation • Associated with tachyphylaxis • Benefit reported in patients with visceral hypersensitivity • Anticholinergic effects may decrease motility
Pseudo-obstruction Somatostatin analog	Octreotide*	0.5 to 1 mcg/kg subQ once daily, max: 100 mcg/dose	• May cause bradycardia, hypoglycemia
Adrenal Crisis	Hydrocortisone	100 mg/m^2 IV/IM x1, followed by 25 mg/m^2/dose IV/IM q6h, max: 100 mg/day Taper as clinically indicated	• Reported regimens vary, refer to individual protocols

*Limited data available

Table 352.9 Supportive and Nonpharmacologic Therapies for Vomiting Episodes

DISEASE	THERAPY
All	Treat cause • Obstruction: operate • Allergy: change diet (±steroids) • Metabolic error: Rx defect • Acid peptic disease: H_2Ras, PPIs, etc.
COMPLICATIONS	
Dehydration	IV fluids, electrolytes
Hematemesis	Transfuse, correct coagulopathy
Esophagitis	H_2Ras, PPIs
Malnutrition	NG or NJ drip feeding useful for many chronic conditions
Meconium ileus	Gastrografin enema
DIOS	Gastrografin enema; balanced colonic lavage solution (e.g., GoLYTELY)
Intussusception	Barium enema; air reduction enema
Hematemesis	Endoscopic: injection sclerotherapy or banding of esophageal varices; injection therapy, fibrin sealant application, or heater probe electrocautery for selected upper GI tract lesions
Sigmoid volvulus	Colonoscopic decompression
Reflux	Positioning; dietary measures (infants: rice cereal, 1 tbs/oz of formula)
Psychogenic components	Psychotherapy; tricyclic antidepressants; anxiolytics (e.g., diazepam: 0.1 mg/kg PO tid-qid)

DIOS, Distal intestinal obstruction syndrome; GI, gastrointestinal; H_2RA, H_2-receptor antagonist; NG, nasogastric; NJ, nasojejunal; PPIs, proton pump inhibitors; tbs, tablespoon.
From Kliegman RM, Greenbaum LA, Lye PS, eds. *Practical Strategies in Pediatric Diagnosis and Therapy*. 2nd ed. Philadelphia: Elsevier; 2004: p. 319.

Table 352.10 Mechanisms of Diarrhea

PRIMARY MECHANISM	DEFECT	STOOL EXAMINATION	EXAMPLES	COMMENT
Secretory	Decreased absorption, increased secretion, electrolyte transport	Watery, normal osmolality with ion gap <100 mOsm/kg	Cholera, toxigenic *Escherichia coli*; carcinoid, VIP, neuroblastoma, congenital chloride diarrhea, *Clostridium difficile*, cryptosporidiosis (AIDS)	Persists during fasting; bile salt malabsorption can also increase intestinal water secretion; no stool leukocytes
Osmotic	Maldigestion, transport defects ingestion of unabsorbable substances	Watery, acidic, and reducing substances; increased osmolality with ion gap >100 mOsm/kg	Lactase deficiency, glucose-galactose malabsorption, lactulose, laxative abuse	Stops with fasting; increased breath hydrogen with carbohydrate malabsorption; no stool leukocytes
Increased motility	Decreased transit time	Loose to normal-appearing stool, stimulated by gastrocolic reflex	Irritable bowel syndrome, thyrotoxicosis, postvagotomy dumping syndrome	Infection can also contribute to increased motility
Decreased motility	Defect in neuromuscular unit(s) stasis (bacterial overgrowth)	Loose to normal-appearing stool	Pseudoobstruction, blind loop	Possible bacterial overgrowth
Decreased surface area (osmotic, motility)	Decreased functional capacity	Watery	Short bowel syndrome, celiac disease, rotavirus enteritis	Might require elemental diet plus parenteral alimentation
Mucosal invasion	Inflammation, decreased colonic reabsorption, increased motility	Blood and increased WBCs in stool	*Salmonella*, *Shigella* infection; amebiasis; *Yersinia*, *Campylobacter* infection	Dysentery evident in blood, mucus, and WBCs

VIP, Vasoactive intestinal peptide; WBC, white blood cell.
From Kliegman RM, Greenbaum LA, Lye PS. eds. *Practical Strategies in Pediatric Diagnosis and Therapy*. 2nd ed. Philadelphia: Elsevier; 2004: p 274.

mechanism. Diarrhea not associated with an exogenous secretagogue can also have a secretory component (congenital microvillus inclusion disease). Secretory diarrhea is usually of large volume and persists even with fasting. The stool osmolality is predominantly indicated by the electrolytes, and the ion gap is 100 mOsm/kg or less. The ion gap is calculated by subtracting the concentration of electrolytes from total osmolality:

$$\text{Ion gap} = \text{Stool osmolality} - [(\text{Stool Na} + \text{stool K})\,2]$$

Osmotic diarrhea occurs after ingestion of a poorly absorbed solute. The solute may be one that is normally not well absorbed (magnesium, phosphate, lactulose, or sorbitol) or one that is not well absorbed because of a disorder of the small bowel (lactose with lactase deficiency or glucose with rotavirus diarrhea). Malabsorbed carbohydrate is fermented in the colon, and short-chain fatty acids are produced. Although short-chain fatty acids can be absorbed in the colon and used as an energy source, the net effect is increase in the osmotic solute load. This form of diarrhea is usually of lesser volume than a secretory diarrhea and stops with fasting. The osmolality of the stool will not be explained by the electrolyte content, because another osmotic component is present and so the anion gap is >100 mOsm.

Motility disorders can be associated with rapid or delayed transit and are not generally associated with large-volume diarrhea. Slow motility can be associated with bacterial overgrowth leading to diarrhea. The differential diagnosis of common causes of acute and chronic diarrhea is noted in Table 352.11.

CONSTIPATION

Any definition of constipation is relative and depends on stool consistency, stool frequency, and difficulty in passing the stool. A normal child might have a soft stool only every second or third day without difficulty; this is not constipation. A hard stool passed with difficulty every third day should be treated as constipation. Constipation can arise from defects either in filling or emptying the rectum (Table 352.12).

A nursing infant might have very infrequent stools of normal consistency, which is usually a normal pattern. True constipation in the neonatal period is most likely secondary to Hirschsprung disease, intestinal pseudoobstruction, or hypothyroidism.

Defective rectal filling occurs when colonic peristalsis is ineffective (in cases of hypothyroidism or opiate use and when bowel obstruction is caused either by a structural anomaly or by Hirschsprung disease). The resultant colonic stasis leads to excessive drying of stool and a failure to initiate reflexes from the rectum that normally trigger evacuation. Emptying the rectum by spontaneous evacuation depends on a defecation reflex initiated by pressure receptors in the rectal muscle. Therefore stool retention can also result from lesions involving these rectal muscles, the sacral spinal cord afferent and efferent fibers, or the muscles of the abdomen and pelvic floor. Disorders of anal sphincter relaxation can also contribute to fecal retention.

Constipation tends to be self-perpetuating, whatever its cause. Hard, large stools in the rectum become difficult and even painful to evacuate; thus more retention occurs and a vicious circle ensues. Distention of the rectum and colon lessens the sensitivity of the defecation reflex and the effectiveness of peristalsis. Fecal impaction is common and leads to other problems. Eventually, watery content from the proximal colon might percolate around hard retained stool and pass per rectum unperceived by the child. This involuntary **encopresis** may be mistaken for diarrhea. Constipation itself does not have deleterious systemic organic effects, but urinary tract stasis with increased risk of urinary tract infections can accompany severe long-standing cases and constipation can generate anxiety, having a marked emotional impact on the patient and family.

Table 352.11 Differential Diagnosis of Diarrhea

INFANT	CHILD	ADOLESCENT
ACUTE		
Common		
Gastroenteritis (viral > bacterial > protozoal)	Gastroenteritis (viral > bacterial > protozoal)	Gastroenteritis (viral > bacterial > protozoal)
Systemic infection	Food poisoning	Food poisoning
Antibiotic associated	Systemic infection	Antibiotic associated
Overfeeding	Antibiotic associated	
Rare		
Primary disaccharidase deficiency	Toxic ingestion	Hyperthyroidism
Hirschsprung toxic colitis	Hemolytic uremic syndrome	Appendicitis
Adrenogenital syndrome	Intussusception	
Neonatal opiate withdrawal		
CHRONIC		
Common		
Postinfectious secondary lactase deficiency	Postinfectious secondary lactase deficiency	Irritable bowel syndrome
Cow's milk or soy protein intolerance (allergy)	Irritable bowel syndrome	Inflammatory bowel disease
Chronic nonspecific diarrhea of infancy	Celiac disease	Lactose intolerance
Excessive fruit juice (sorbitol) ingestion	Cystic fibrosis	Giardiasis
Celiac disease	Lactose intolerance	Laxative abuse (anorexia nervosa)
Cystic fibrosis	Excessive fruit juice (sorbitol) ingestion	Constipation with encopresis
AIDS enteropathy	Giardiasis	
	Inflammatory bowel disease	
	AIDS enteropathy	
Rare		
Primary immune defects	Primary and acquired immune defects	Secretory tumor
Autoimmune enteropathy	Secretory tumors	Primary bowel tumor
IPEX and IPEX-like syndromes	Pseudoobstruction	Parasitic infections and venereal diseases
Glucose-galactose malabsorption	Sucrase-isomaltase deficiency	Appendiceal abscess
Microvillus inclusion disease (microvillus atrophy)	Eosinophilic gastroenteritis	Addison disease
Congenital transport defects (chloride, sodium)	Secretory tumors	
Primary bile acid malabsorption		
Factitious syndrome by proxy		
Hirschsprung disease		
Shwachman syndrome		
Secretory tumors		
Acrodermatitis enteropathica		
Lymphangiectasia		
Abetalipoproteinemia		
Eosinophilic gastroenteritis		
Short bowel syndrome		

IPEX, Immunodysregulation polyendocrinopathy enteropathy X-linked.
From Kliegman RM, Greenbaum LA, Lye PS, eds. *Practical Strategies in Pediatric Diagnosis and Therapy*, 2nd ed. Philadelphia: Elsevier; 2004: p. 272.

Table 352.12 Causes of Constipation

NONORGANIC (FUNCTIONAL): RETENTIVE

Anatomic
Anal stenosis, atresia with fistula
Imperforate anus
Anteriorly displaced anus
Intestinal stricture (postnecrotizing enterocolitis)
Anal stricture

Abnormal Musculature
Prune-belly syndrome
Gastroschisis
Down syndrome
Muscular dystrophy

Intestinal Nerve or Muscle Abnormalities
Hirschsprung disease
Pseudoobstruction (visceral myopathy or neuropathy)
Intestinal neuronal dysplasia
Spinal cord lesions
Tethered cord
Autonomic neuropathy
Spinal cord trauma
Spina bifida
Chagas disease

Drugs
Anticholinergics
Narcotics
Methylphenidate
Phenytoin
Antidepressants
Chemotherapeutic agents (vincristine)
Pancreatic enzymes (fibrosing colonopathy)
Lead, arsenic, mercury
Vitamin D intoxication
Calcium channel blocking agents

Metabolic Disorders
Hypokalemia
Hypercalcemia
Hypothyroidism
Diabetes mellitus, diabetes insipidus
Porphyria

Intestinal Disorders
Celiac disease
Cow's milk protein intolerance
Cystic fibrosis (meconium ileus equivalent)
Inflammatory bowel disease (stricture)
Tumor
Connective tissue disorders
Systemic lupus erythematosus
Scleroderma

Psychiatric Diagnosis
Anorexia nervosa

ANOREXIA

Anorexia means prolonged lack of appetite. Hunger and satiety centers are located in the hypothalamus; it seems likely that afferent nerves from the GI tract to these brain centers are important determinants of the anorexia that characterizes many diseases of the stomach and intestine. Satiety is stimulated by distention of the stomach or upper small bowel, the signal being transmitted by sensory afferents, which are especially dense in the upper gut. Chemoreceptors in the intestine, influenced by the assimilation of nutrients, also affect afferent flow to the appetite centers. Impulses reach the hypothalamus from higher centers, possibly influenced by pain or the emotional disturbance of an intestinal disease. Other regulatory factors include hormones, ghrelin, leptin, and plasma glucose, which, in turn, reflect intestinal function.

ABDOMINAL PAIN

There is considerable variation among children in their perception and tolerance for abdominal pain. This is one reason the evaluation of chronic abdominal pain is difficult. A child with **functional abdominal pain** (also known as centrally mediated abdominal pain syndrome or brain-gut axis dysfunction) may be as uncomfortable as one with an organic cause. It is very important to distinguish between organic and nonorganic (functional) abdominal pain because the approach for the management is based on this (Table 352.13). Normal growth and physical examination (including a rectal examination) and the absence of anemia or hematochezia are reassuring in a child who is suspected of having functional pain.

A specific cause may be difficult to find, but the nature and location of a pain-provoking lesion can usually be determined from the clinical description. Two types of nerve fibers transmit painful stimuli in the abdomen. In skin and muscle, A fibers mediate sharp localized pain; C fibers from viscera, peritoneum, and muscle transmit poorly localized, dull pain. These afferent fibers have cell bodies in the dorsal root ganglia, and some axons cross the midline and ascend to the medulla, midbrain, and thalamus. Pain is perceived in the cortex of the postcentral gyrus, which can receive impulses arising from both sides of the body. In the gut, the usual stimulus provoking pain is tension or stretching. Inflammatory lesions can lower the pain threshold, but the mechanisms producing pain or inflammation are not clear. Tissue metabolites released near nerve endings probably account for the pain caused by ischemia. Perception of these painful stimuli can be modulated by input from both cerebral and peripheral sources. Psychologic factors are particularly important. Tables 352.14 and 352.15 list features of abdominal pain. Pain that suggests a potentially serious organic etiology is associated with age younger than 5 years; fever; weight loss; bile- or blood-stained emesis; jaundice; hepatosplenomegaly; back or flank pain or pain in a location other than the umbilicus; awakening from sleep in pain; referred pain to shoulder, groin, or back; elevated erythrocyte sedimentation rate, white blood cell count, or CRP; anemia; edema; hematochezia; or a strong family history of inflammatory bowel disease or celiac disease (see Table 352.13).

Table 352.13 Red Flags and Clues to an Organic Cause of Abdominal Pain

Age <5 yr old
Localized pain in nonperiumbilical site
Referred pain
Sudden onset of excruciating pain
Crescendo nature of pain
Sudden worsening of pain
Fever (high fever >39.4°C suggests pneumonia, pyelonephritis, dysentery, cholangitis, more than perforation or abscess)
Jaundice
Distention*
Dysphagia
Dysuria
Emesis (especially bilious)
Anorexia
Weight loss, failure to thrive
Positive family history (metabolic disorders, peptic ulcer disease)†
Change in urine or stool color (blood, acholic) or frequency
Vaginal discharge
Menstrual abnormalities (amenorrhea)
Sexual activity
Delayed sexual development (chronic pain)
Anemia
Elevated erythrocyte sedimentation rate
Elevated stool calprotectin
Specific physical findings (hepatomegaly, splenomegaly, absent bowel sounds, adnexal tenderness, palpable mass, involuntary guarding, focal or diffuse tenderness, positive rectal examination results, perianal disease, joint swelling, rashes)

*Consider 5 Fs: fat, feces, flatus (aerophagia, obstruction), fluid (ascites, hydronephrosis, cysts), and fetus (pregnancy or fetal-like abnormal growth [e.g., tumors]).

†Family history is also positive for chronic pain syndromes (constipation, irritable bowel, dysmenorrhea, and lactase or sucrase deficiency).

Modified from Miranda A. Abdominal pain. In: Kliegman RM, Toth H, Bordini BJ, Basel D, eds. *Nelson Pediatric Symptom-Based Diagnosis.* 2nd ed. Philadelphia: Elsevier; 2023: Table 13.8, p. 229.

Visceral pain tends to be dull and aching and is experienced in the dermatome from which the affected organ receives innervations. So, most often, the pain and tenderness are not felt over the site of the disease process. Painful stimuli originating in the liver, pancreas, biliary tree, stomach, or upper bowel are felt in the epigastrium; pain from the distal small bowel, cecum, appendix, or proximal colon is felt at the umbilicus; and pain from the distal large bowel, urinary tract, or pelvic organs is usually suprapubic. The pain from the cecum, ascending colon, and descending colon sometimes is felt at the site of the lesion because of the short mesocecum and corresponding mesocolon. The pain caused by appendicitis is initially felt in the periumbilical region, and pain from the transverse colon is usually felt in the suprapubic region. The shifting (localization) of pain is a pointer toward diagnosis; for example, periumbilical pain of a few hours localizing to the right lower quadrant suggests appendicitis. Radiation of pain can be helpful in diagnosis; in biliary colic the radiation of pain is toward the inferior angle of the right scapula, pancreatic pain is radiated to the back, and the renal colic pain is radiated to the inguinal region on the same side.

Differentiating abdominal wall pain from visceral pain is important and can prevent unnecessary testing. Nerve entrapment is one of the more common causes in adults. **Costochondritis** can be differentiated from underlying pain by palpating the rib margins, which should reproduce the pain. Treatment with topical anesthetics and NSAIDs if needed usually resolve pain within a few days. **Slipped rib syndrome** can follow overuse or even minor trauma to the ribs on either side. The name originates from a popping/slipping sensation that is often reported. Slipped rib syndrome may be mistaken for hepatobiliary, splenic, pancreatic, esophageal, or gastric etiologies, among others. Rib fractures, costochondritis, perichondritis [Tietze syndrome], and pleuritic pain may also present as an etiology. **Anterior (abdominal) cutaneous nerve entrapment syndrome (ACNES)** may produce acute, recurrent, or chronic unilateral localized abdominal pain. Nerve entrapment is most common at the lateral border of the rectus muscle.

Somatic pain is intense and usually well localized. When the inflamed viscus comes in contact with a somatic organ such as the parietal peritoneum or the abdominal wall, pain is localized to that site. Peritonitis gives rise to generalized abdominal pain with rigidity, involuntary guarding, rebound tenderness, and cutaneous hyperesthesia on physical examination.

Referred pain from extraintestinal locations, from shared central projections with the sensory pathway from the abdominal wall, can give rise to abdominal pain, as in pneumonia when the parietal pleural pain is referred to the abdomen (Fig. 352.1).

GASTROINTESTINAL HEMORRHAGE

Bleeding can occur anywhere along the GI tract, and identification of the site may be challenging (Table 352.16). Bleeding that originates in the esophagus, stomach, or duodenum can cause **hematemesis.** When exposed to gastric or intestinal juices, blood quickly darkens to

Table 352.14 Chronic Abdominal Pain in Children

DISORDER	CHARACTERISTICS	KEY EVALUATIONS
NONORGANIC		
Functional abdominal pain	Nonspecific pain, often periumbilical	Hx and PE; tests as indicated
Irritable bowel syndrome	Intermittent cramps, diarrhea, and constipation	Hx and PE
Nonulcer dyspepsia	Peptic ulcer–like symptoms without abnormalities on evaluation of the upper GI tract	Hx; esophagogastroduodenoscopy
GASTROINTESTINAL TRACT		
Chronic constipation	Hx of stool retention, evidence of constipation on examination	Hx and PE; plain x-ray of abdomen
Lactose intolerance	Symptoms may be associated with lactose ingestion; bloating, gas, cramps, and diarrhea	Trial of lactose-free diet; lactose breath hydrogen test
Parasite infection (especially *Giardia*)	Bloating, gas, cramps, and diarrhea	Stool evaluation for O&P; specific immunoassays for *Giardia*
Excess fructose or sorbitol ingestion	Nonspecific abdominal pain, bloating, gas, and diarrhea	Large intake of apples, fruit juice, or candy or chewing gum sweetened with sorbitol
Crohn disease	See Chapter 382.2	
Peptic ulcer	Burning or gnawing epigastric pain; worse on awakening or before meals; relieved with antacids	Esophagogastroduodenoscopy, upper GI contrast x-rays, or MRI enteroscopy
Esophagitis	Epigastric pain with substernal burning	Esophagogastroduodenoscopy
Meckel diverticulum	Periumbilical or lower abdominal pain; may have blood in stool (usually painless)	Meckel scan or enteroclysis
Recurrent intussusception	Paroxysmal severe cramping abdominal pain; blood may be present in stool with episode	Identify intussusception during episode or lead point in intestine between episodes with contrast studies of GI tract
Internal, inguinal, or abdominal wall hernia	Dull abdomen or abdominal wall pain	PE, CT of abdominal wall
Chronic appendicitis or appendiceal mucocele	Recurrent RLQ pain; often incorrectly diagnosed, may be rare cause of abdominal pain	Barium enema, CT
GALLBLADDER AND PANCREAS		
Cholelithiasis	RUQ pain, might worsen with meals	Ultrasound of gallbladder
Choledochal cyst	RUQ pain, mass ± elevated bilirubin	Ultrasound or CT of RUQ
Recurrent pancreatitis	Persistent boring pain, might radiate to back, vomiting	Serum amylase and lipase ± serum trypsinogen; ultrasound, CT, or MRI-ERCP of pancreas
GENITOURINARY TRACT		
Urinary tract infection	Dull suprapubic pain, flank pain	Urinalysis and urine culture; renal scan
Hydronephrosis	Unilateral abdominal or flank pain	Ultrasound of kidneys
Urolithiasis	Progressive, severe pain; flank to inguinal region to testicle	Urinalysis, ultrasound, IVP, CT
Other genitourinary disorders	Suprapubic or lower abdominal pain; genitourinary symptoms	Ultrasound of kidneys and pelvis; gynecologic evaluation
MISCELLANEOUS CAUSES		
Abdominal migraine	See text; nausea, family Hx migraine	Hx
Abdominal epilepsy	Might have seizure prodrome	EEG (can require >1 study, including sleep-deprived EEG)
Gilbert syndrome	Mild abdominal pain (causal or coincidental?); slightly elevated unconjugated bilirubin	Serum bilirubin
Familial Mediterranean fever	Paroxysmal episodes of fever, severe abdominal pain, and tenderness with other evidence of polyserositis	Hx and PE during an episode, DNA diagnosis
Sickle cell crisis	Anemia	Hematologic evaluation
Lead poisoning	Vague abdominal pain ± constipation	Serum lead level
IgA vasculitis (Henoch-Schönlein purpura)	Recurrent, severe crampy abdominal pain, occult blood in stool, characteristic rash, arthritis	Hx, PE, urinalysis
Angioneurotic edema	Swelling of face or airway, crampy pain	Hx, PE, upper GI contrast x-rays, serum C1 esterase inhibitor
Acute intermittent porphyria	Severe pain precipitated by drugs, fasting, or infections	Spot urine for porphyrins
Anterior cutaneous nerve entrapment syndrome (ACNES)	Exquisite localized (~2 × 2 cm) tenderness that is replicable, most often RLQ	Pain relief within 15 min of abdominal wall injection of local anesthetic; may need surgery

ERCP, Endoscopic retrograde cholangiopancreatography; EEG, electroencephalogram; GI, gastrointestinal; Hx, history; IVP, intravenous pyelography; O&P, ova and parasites; PE, physical exam; RLQ, right lower quadrant; RUQ, right upper quadrant.

Table 352.15 Distinguishing Features of Acute Abdominal Pain in Children

DISEASE	ONSET	LOCATION	REFERRAL	QUALITY	COMMENTS
Pancreatitis	Acute	Epigastric, left upper quadrant	Back	Constant, sharp, boring	Nausea, emesis, tenderness
Intestinal obstruction	Acute or gradual	Periumbilical-lower abdomen	Back	Alternating cramping (colic) and painless periods	Distention, obstipation, emesis, increased bowel sounds
Appendicitis	Acute (1-3 days)	Periumbilical, then localized to lower right quadrant; generalized with peritonitis	Back or pelvis if retrocecal	Sharp, steady	Anorexia, nausea, emesis, local tenderness, fever with peritonitis
Intussusception	Acute	Periumbilical-lower abdomen	None	Cramping, with painless periods	Hematochezia, knees in pulled-up position
Urolithiasis	Acute, sudden	Back (unilateral)	Groin	Sharp, intermittent, cramping	Hematuria
Urinary tract infection	Acute	Back	Bladder	Dull to sharp	Fever, costovertebral angle tenderness, dysuria, urinary frequency
Pelvic inflammatory disease	Acute	Pelvis, lower quadrant	Upper thigh	Aching, peritoneal signs	Vaginal discharge, fever
Small bowel obstruction	Acute to subacute	Periumbilical	None	Cramping diffuse	Emesis and obstipation
Ruptured ectopic pregnancy	Acute sudden	Pelvis, lower quadrant	None	Sharp, intense, localized	Vaginal bleeding, shock

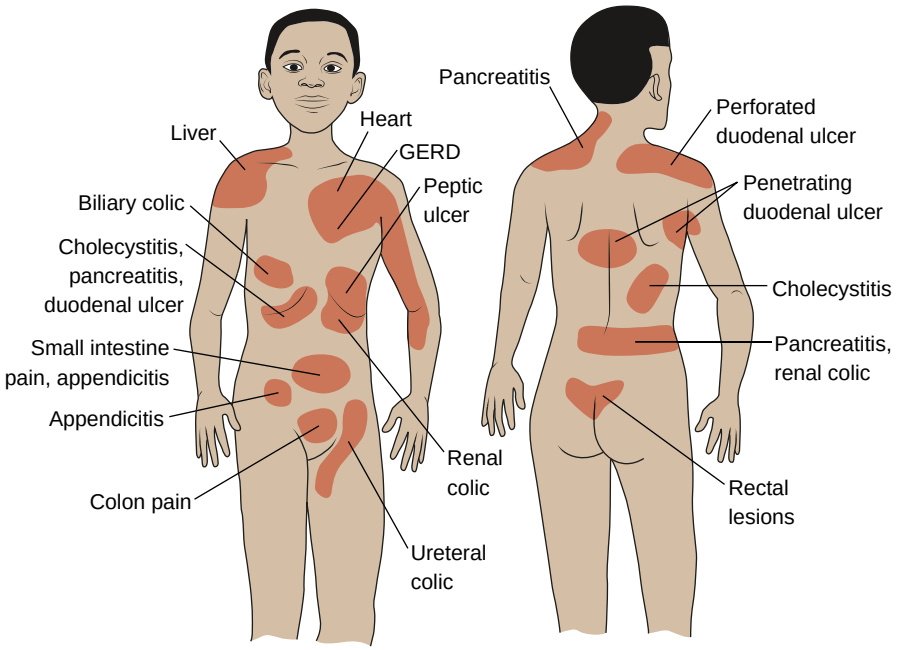

Fig. 352.1 Common sites of referred pain from the abdominal viscera. When a patient gives a history of referred pain from the viscera, the pain's location may not be directly over the impaired organ. Visceral embryologic development is the mechanism of the referred pain pattern. Pain is referred to the site where the organ was located in fetal development.

resemble coffee grounds; massive bleeding is likely to be red. Red or maroon blood in stools, **hematochezia,** signifies either a distal bleeding site or massive hemorrhage above the distal ileum. Moderate to mild bleeding from sites above the distal ileum tends to cause blackened stools of tarry consistency **(melena);** major hemorrhages in the duodenum or above can also cause melena.

Erosive damage to the mucosa of the GI tract is the most common cause of bleeding, although variceal bleeding secondary to portal hypertension occurs often enough to require consideration. Prolapse gastropathy producing subepithelial hemorrhage and Mallory-Weiss lesions secondary to mucosal tears associated with emesis are causes of upper intestinal bleeds. Vascular malformations are a rare cause in children; they are difficult to identify (Figs. 352.2 and 352.3). Upper intestinal bleeding is evaluated with esophagogastroduodenoscopy. Evaluation of the small intestine is facilitated by capsule endoscopy. The capsule-sized imaging device is swallowed in older children or placed endoscopically in younger children. Lower GI bleeding is investigated with a colonoscopy. In brisk intestinal bleeding of unknown location, a tagged red blood cell scan is helpful in locating the site of the bleeding, although CT angiography is usually diagnostic. Occult blood

Table 352.16 Differential Diagnosis of Gastrointestinal Bleeding in Childhood

INFANT	CHILD	ADOLESCENT
COMMON		
Bacterial enteritis	Bacterial enteritis	Bacterial enteritis
Milk protein allergy intolerance	Anal fissure	Inflammatory bowel disease
Intussusception	Colonic polyps	Peptic ulcer/gastritis
Swallowed maternal blood	Intussusception	Prolapse (traumatic) gastropathy secondary to emesis
Anal fissure	Peptic ulcer/gastritis	Mallory-Weiss syndrome
Lymphonodular hyperplasia	Swallowed epistaxis	Colonic polyps
	Prolapse (traumatic) gastropathy secondary to emesis	Anal fissure
	Mallory-Weiss syndrome	
RARE		
Volvulus	Esophageal varices	Hemorrhoids
Necrotizing enterocolitis	Esophagitis	Esophageal varices
Meckel diverticulum	Meckel diverticulum	Esophagitis
Stress ulcer, gastritis	Lymphonodular hyperplasia	Pill ulcer
Coagulation disorder (hemorrhagic disease of newborn)	IgA vasculitis (Henoch-Schönlein purpura)	Telangiectasia-angiodysplasia
Esophagitis	Foreign body	Graft versus host disease
	Hemangioma, arteriovenous malformation	Duplication cyst
	Sexual abuse	Angiodysplasia
	Hemolytic-uremic syndrome	Angiodysplasia with von Willebrand disease
	Inflammatory bowel disease	Blue rubber bleb nevus syndrome
	Coagulopathy	
	Duplication cyst	
	Angiodysplasia	
	Angiodysplasia with von Willebrand disease	
	Blue rubber bleb nevus syndrome	

Fig. 352.2 Intestinal angiodysplasia. A 7-year-old boy had tarry stool for days. Panendoscopy showed multiple cherry red flat spots in the gastric mucosa, compatible with the findings of angiodysplasia in CT angiography. *(From Chuang F, Lin JS, Yeung C, et al. Intestinal angiodysplasia: an uncommon cause of gastrointestinal bleeding in children. Pediatr Neonatol. 2011;52:214–218, Fig. 2.)*

Fig. 352.3 Operative features of blue rubber bleb nevus syndrome. These lesions are similar to cutaneous lesions. *(From Hasosah MY, Abdul-Wahab AA, Bin-Yahab SA, et al. Blue rubber bled nevus syndrome: extensive small bowel vascular lesions responsible for gastrointestinal bleeding. J Pediatr Child Health. 2010;46:63–65. Fig. 3.)*

in stool is usually detected by using commercially available fecal occult blood testing cards, which are based on a chemical reaction between the chemical guaiac and oxidizing action of a substrate (hemoglobin), giving a blue color. The guaiac test is very sensitive, but random testing can miss chronic blood loss, which can lead to iron-deficiency anemia. GI hemorrhage can produce hypotension and tachycardia but rarely causes GI symptoms; brisk duodenal or gastric bleeding can lead to nausea, vomiting, or diarrhea. The breakdown products of intraluminal blood might tip patients into hepatic coma if liver function is already compromised and can lead to elevation of serum bilirubin.

ABDOMINAL DISTENTION AND ABDOMINAL MASSES

Enlargement of the abdomen can result from diminished tone of the wall musculature or from increased content: fluid, gas, or solid. Ascites, the accumulation of fluid in the peritoneal cavity, distends the abdomen both in the flanks and anteriorly when it is large in volume. This fluid shifts with movement of the patient and conducts a percussion wave. Ascitic fluid is usually a transudate with a low protein concentration resulting from reduced plasma colloid osmotic pressure of hypoalbuminemia and/or from raised portal venous pressure. In cases of portal hypertension, the fluid leak probably occurs from lymphatics on the liver surface and from visceral peritoneal capillaries, but ascites does not usually develop until the serum albumin level falls. Sodium excretion in the urine decreases greatly as the ascitic fluid accumulates, and thus additional dietary sodium goes directly to the peritoneal

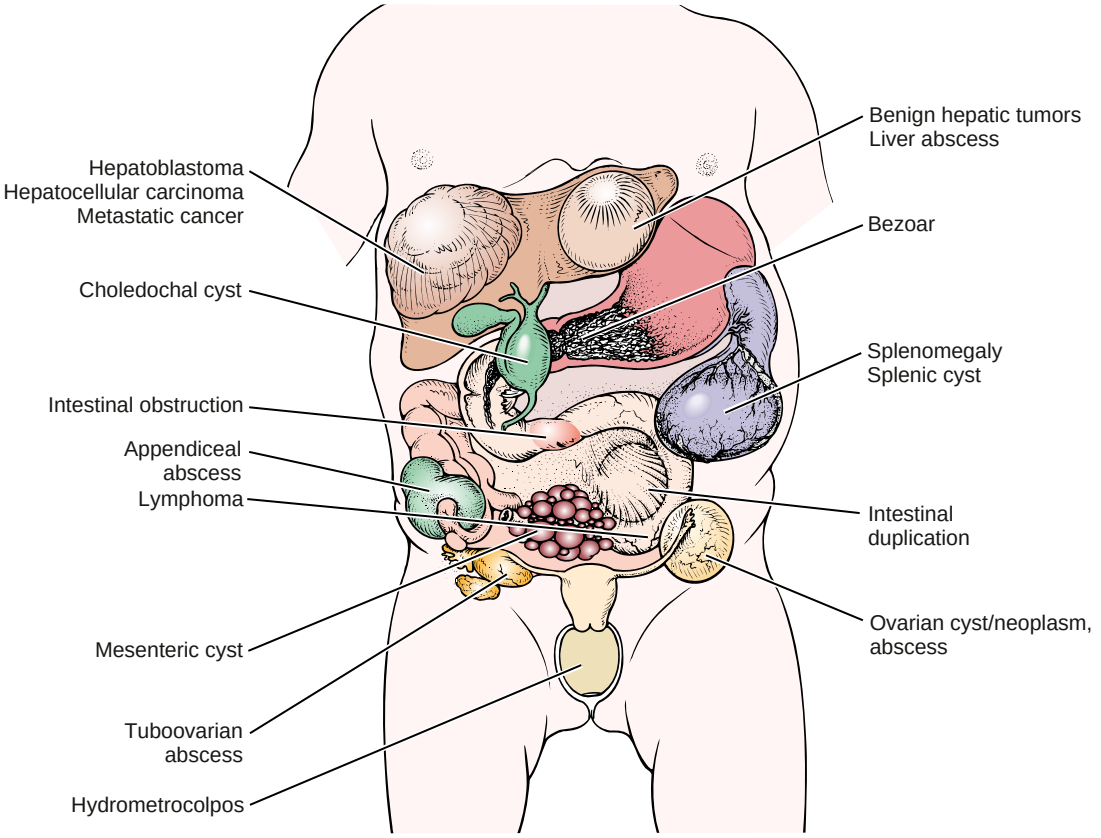

Fig. 352.4 Location of select intrabdominal tumors and masses. *(From Densmore JC, Densmore EM. Abdominal masses. In Kliegman RM, Toth H, Bordini BJ, Basel D, eds. Nelson Pediatric Symptom-Based Diagnosis, 2nd ed. Philadelphia: Elsevier; 2023: Fig. 20.1, p. 354.)*

space, taking with it more water. When ascitic fluid contains a high protein concentration, it is usually an exudate caused by an inflammatory or neoplastic lesion.

When fluid distends the gut, either obstruction or imbalance between absorption and secretion should be suspected. The factors causing fluid accumulation in the bowel lumen often cause gas to accumulate too. The result may be audible gurgling noises. The source of gas is usually swallowed air, but endogenous flora can increase considerably in malabsorptive states and produce excessive gas when substrate reaches the lower intestine. Gas in the peritoneal cavity (pneumoperitoneum) is usually caused by a perforated viscus and can cause abdominal distention depending on the amount of gas leak. A tympanitic percussion note, even over solid organs such as the liver, indicates a large collection of gas in the peritoneum.

An abdominal organ can enlarge diffusely or be affected by a discrete mass (Fig. 352.4). In the digestive tract, such discrete masses can occur in the lumen, wall, omentum, or mesentery. In a constipated child, mobile, nontender fecal masses are often found. Congenital anomalies, cysts, or inflammatory processes can affect the wall of the gut. Gut wall neoplasms are extremely rare in children. The pathologic enlargement of liver, spleen, bladder, and kidneys can give rise to abdominal distention.

ACKNOWLEDGMENT

Thanks to Astrela Moore, PharmD, Clinical Pharmacy Specialist at Children's Hospital of Philadelphia, for reviewing, verifying, and updating the pharmacotherapy table.

Visit Elsevier eBooks+ at eBooks.Health.Elsevier.com for Bibliography.

Section 2

The Oral Cavity

Chapter 353

Development and Developmental Anomalies of the Teeth

Vineet K. Dhar

Newborn infants do not have teeth for about first 6 months after birth (predentate period). At this stage, the upper and lower alveolar ridges in the mouth, also known as gum pads, house the primary (deciduous) and some permanent tooth buds. The primary dentition period starts with eruption of the first primary tooth; all 20 primary teeth erupt by 3 years of age. The permanent teeth start erupting around 6 years of age, and the transition to full permanent dentition is completed by 13 years of age. The transition time between primary and permanent dentition, when a mix of primary and permanent teeth are present, is referred to as mixed dentition.

DEVELOPMENT OF TEETH

Initiation

The primary teeth form in dental crypts that arise from a band of epithelial cells incorporated into each developing jaw. By 12 weeks of fetal life, each of these epithelial bands **(dental laminae)** has five areas of rapid growth on each side of the maxilla and the mandible, seen as rounded, budlike enlargements. Organization of adjacent mesenchyme takes place in each area of epithelial growth, and the two elements together are the beginning of a tooth.

After the formation of these crypts for the 20 primary teeth, another generation of tooth buds forms lingually (toward the tongue); these will develop into the succeeding permanent incisors, canines, and premolars that eventually replace the primary teeth. This process takes place from approximately 3-4 months of gestation for the central incisors to approximately 24-30 months of age for the second premolars. On the other hand, the permanent first, second, and third molars arise from extension of the dental laminae distal to the second primary molars; buds for these teeth develop approximately at birth, 3 years of age, and 7-10 years of age, respectively.

Histodifferentiation–Morphodifferentiation

As the epithelial bud proliferates, the deeper surface invaginates and a mass of mesenchyme becomes partially enclosed. The epithelial cells differentiate into the ameloblasts that lay down an organic matrix that forms enamel; the mesenchyme forms the dentin and dental pulp.

Calcification

After the organic matrix has been laid down, the deposition of the inorganic mineral crystals takes place from several sites of calcification that later coalesce. The characteristics of the inorganic portions of a tooth can be altered by disturbances in formation of the matrix, decreased availability of minerals, or the incorporation of foreign materials. Such disturbances can affect the color, texture, or thickness of the tooth surface. Calcification of primary teeth begins at 3-4 months in utero and concludes postnatally at approximately 12 months, with mineralization of the second primary molars (Table 353.1).

Eruption

At the time of tooth bud formation, each tooth begins a continuous movement toward the oral cavity. Table 353.1 lists the times of eruption of the primary and permanent teeth. Occasionally the permanent teeth may erupt behind the primary teeth ("shark tooth"); this usually causes no problems.

Table 353.1 Calcification, Crown Completion, and Eruption

TOOTH	FIRST EVIDENCE OF CALCIFICATION	CROWN COMPLETED	ERUPTION
PRIMARY DENTITION			
Maxillary			
Central incisor	3-4 mo in utero	4 mo	7.5 mo
Lateral incisor	4.5 mo in utero	5 mo	8 mo
Canine	5.5 mo in utero	9 mo	16-20 mo
First molar	5 mo in utero	6 mo	12-16 mo
Second molar	6 mo in utero	10-12 mo	20-30 mo
Mandibular			
Central incisor	4.5 mo in utero	4 mo	6.5 mo
Lateral incisor	4.5 mo in utero	4½ mo	7 mo
Canine	5 mo in utero	9 mo	16-20 mo
First molar	5 mo in utero	6 mo	12-16 mo
Second molar	6 mo in utero	10-12 mo	20-30 mo
PERMANENT DENTITION			
Maxillary			
Central incisor	3-4 mo	4-5 yr	7-8 yr
Lateral incisor	10 mo	4-5 yr	8-9 yr
Canine	4-5 mo	6-7 yr	11-12 yr
First premolar	1½ -1¾ yr	5-6 yr	10-11 yr
Second premolar	2-2¼ yr	6-7 yr	10-12 yr
First molar	At birth	2½ -3 yr	6-7 yr
Second molar	2½ -3 yr	7-8 yr	12-13 yr
Third molar	7-9 yr	12-16 yr	17-21 yr
Mandibular			
Central incisor	3-4 mo	4-5 yr	6-7 yr
Lateral incisor	3-4 mo	4-5 yr	7-8 yr
Canine	4-5 mo	6-7 yr	9-10 yr
First premolar	1¾-2 yr	5-6 yr	10-12 yr
Second premolar	2¼- 2 ½ yr	6-7 yr	11-12 yr
First molar	At birth	2½ -3 yr	6-7 yr
Second molar	2½-3 yr	7-8 yr	11-13 yr
Third molar	8-10 yr	12-16 yr	17-21 yr

Modified from Logan WHG, Kronfeld R. Development of the human jaws and surrounding structures from birth to age 15 years. *J Am Dent Assoc.* 1993;20:379.

Anomalies Associated with Eruption Pattern

Delayed eruption of the 20 primary teeth can be familial or indicate systemic or nutritional disturbances such as hypopituitarism, hypothyroidism, cleidocranial dysplasia, trisomy 21, and multiple other syndromes. Failure of eruption of single or small groups of teeth can arise from local causes such as malpositioned teeth, supernumerary teeth, cysts, or retained primary teeth. Premature *loss* of primary teeth is commonly caused by premature *eruption* of the permanent teeth. If the entire dentition is advanced for age and gender, precocious puberty or hyperthyroidism should be considered.

Natal teeth are observed in approximately 1 in 2,000 newborn infants, usually in the position of the mandibular central incisors. Natal teeth are present at birth, whereas **neonatal teeth** erupt in the first month of life. Attachment of natal and neonatal teeth is generally limited to the gingival margin, with little root formation or bony support. They may be a supernumerary or a prematurely erupted primary tooth. A radiograph can easily differentiate between the two conditions. Natal teeth are associated with cleft palate, Pierre Robin syndrome, mesoectodermal dysplasia syndrome (Ellis-van Creveld), oculomandibulofacial syndrome (Hallermann-Streiff), pachyonychia

Table 353.2 Syndromes with Natal Teeth

SYNDROME	ASSOCIATED ANOMALIES	INHERITANCE/GENE ABNORMALITY/ PREVALENCE
Ellis-van Creveld (chondroectodermal dysplasia)	Bilateral postaxial polydactyly of hands, chondrodysplasia of long bones resulting in dwarfism, ectodermal dysplasia affecting nails/teeth, congenital heart malformation	Autosomal-recessive *EVC, EVC2* $7/1 \times 10^6$
Hallermann-Streiff	Dyscephaly, hypotrichosis, micro-ophthalmia, cataracts, beaked nose, micrognathia, proportionate short stature	Sporadic Not known >150 cases to date
Pachyonychia congenita (1: Jadassohn-Lewandowsky) (2: Jackson-Lawler)	Dystrophic nails, palmoplantar keratosis, hyperhidrosis, follicular keratosis, oral leukokeratosis, cutaneous cysts	Autosomal-dominant Keratin gene variants: type I: 6a/16, type 2:6b/17 $0.071/1 \times 10^6$ 9:5 male to female
Pallister-Hall (hypothalamic hamartoblastoma)	Hypothalamic hamartoblastoma, craniofacial abnormalities, postaxial polydactyly, cardiac and renal defects	Autosomal-dominant *GLI3* >13 cases to date 8:5 male to female
Wiedemann-Rautenstrauch	Endocrine dysfunction, aged facies, frontal and biparietal bossing, small facial bones, sparse scalp hair, prominent scalp veins, small beaked nose, low-set ears	Autosomal-recessive *POLR3A* >30 cases to date
Natal teeth, patent ductus arteriosus, intestinal pseudoobstruction	Dilatation/hypermobility of small bowel, short or microcolon without obstruction, incomplete rotation of midgut, patent ductus arteriosus	X-linked recessive Not known 2 cases to date, brothers

Modified from Hebert AA. Mucous membrane disorders. In Schachner LA, Hansen RC, eds. *Pediatric Dermatology*. 4th ed. Philadelphia: Elsevier; 2011: Table 9.2, p. 654.

congenita, and other anomalies (Table 353.2). A family history of natal teeth or premature eruption is present in 15–20% of affected children.

Natal or neonatal teeth occasionally result in pain and refusal to feed and can produce maternal discomfort because of abrasion or biting of the nipple during nursing. If the tooth is mobile, there is a danger of detachment, with aspiration of the tooth. Because the tongue lies between the alveolar processes during birth, it can become lacerated **(Riga-Fede disease)**. Decisions regarding extraction of prematurely erupted primary teeth must be made on an individual basis.

Exfoliation failure occurs when a primary tooth is not shed before the eruption of its permanent successor. Most often the primary tooth exfoliates eventually, but in some cases the primary tooth needs to be extracted. This occurs most commonly in the mandibular incisor region.

Anomalies Associated with Tooth Development

Both failures and excesses of tooth initiation are observed. Developmentally missing teeth can result from environmental insult, a genetic defect involving only teeth, or the manifestation of a syndrome.

Anomalies of Number

Anodontia, or absence of teeth, occurs when no tooth buds form (ectodermal dysplasia, or familial missing teeth) or when there is a disturbance of a normal site of initiation (the area of a palatal cleft). The teeth that are most commonly absent are the third molars, the maxillary lateral incisors, and the mandibular second premolars.

If the dental lamina produces more than the normal number of buds, **supernumerary teeth** occur, most often in the area between the maxillary central incisors. Because they tend to disrupt the position and eruption of the adjacent normal teeth, their identification by radiographic examination is important. Supernumerary teeth also occur with cleidocranial dysplasia (see Chapter 356) and in the area of cleft palates.

Anomalies of Size

Twinning, in which two teeth are joined together, is most often observed in the mandibular incisors of the primary dentition. It can result from gemination, fusion, or concrescence. **Gemination** is the result of the division of one tooth germ to form a bifid crown on a single root with a common pulp canal; an extra tooth appears to be present in the dental arch. **Fusion** is the joining of incompletely developed teeth that, due to pressure, trauma, or crowding, continue to develop as one tooth. Fused teeth are sometimes joined along their entire length; in other cases, a single wide crown is supported on two roots. **Concrescence** is the attachment of the roots of closely approximated adjacent teeth by an excessive deposit of cementum. This type of twinning, unlike the others, is found most often in the maxillary molar region.

Disturbances during differentiation can result in alterations in dental morphology, such as **macrodontia** (large teeth) or **microdontia** (small teeth). The maxillary lateral incisors can assume a slender, tapering shape **(peg-shaped laterals).**

Anomalies of Shape

Dens in dente or **dens invaginatus** presents as *tooth within tooth* appearance, which results from invagination of inner enamel epithelium caused by disruption during morphodifferentiation. Dens evaginatus presents as an extra cusp on anterior or posterior teeth, which contains enamel, dentin, and sometimes even pulp tissue. In the anterior teeth the cusp is talon shaped and presents in the cingulum area.

Taurodontism is more common in permanent molars and is characterized by elongated pulp chamber with short-stunted roots due to failure or late invagination of Hertwig epithelial root sheath. It may be associated with several syndromic conditions such as Down syndrome, tricho-dento-osseous syndrome, ectodermal dysplasia (hypohidrotic), and amelogenesis imperfecta (hypomaturation-hypoplastic type).

Dilaceration is an abnormal bend or curve in root possibly due to trauma. It may be subsequent to injury to the primary predecessor tooth.

Fig. 353.1 Amelogenesis imperfecta, hypoplastic type. The enamel defect results in areas of missing or thin enamel, as well as grooves and pits.

Fig. 353.2 Dentinogenesis imperfecta. The bluish, opalescent sheen on several of these teeth results from genetically defective dentin. This condition may be associated with osteogenesis imperfecta. *(From Nazif MM, Martin BS, McKibben DH, et al. Oral disorders. In Zitelli BJ, Davis HW, eds. Atlas of Pediatric Physical Diagnosis. 4th ed. Philadelphia: Mosby; 2002: p. 703.)*

Anomalies of Structure

Amelogenesis imperfecta represents a group of hereditary conditions that manifest in enamel defects of the primary and permanent teeth without evidence of systemic disorders (Fig. 353.1). There are four subtypes: hypoplastic (type I), hypomaturation (type II), hypocalcified (type III), and hypomaturation-hypoplastic-taurodontism (type IV). Of the multiple subtypes, there are 19 genes inherited predominantly as autosomal dominant or recessive traits. The teeth are covered by only a thin layer of abnormally formed enamel through which the yellow underlying dentin is seen. The primary teeth are generally affected more than the permanent teeth. Susceptibility to caries is low, but the enamel is subject to destruction from abrasion. Complete coverage of the crown may be indicated for dentin protection, to reduce tooth sensitivity, and for improved appearance.

Dentinogenesis imperfecta, or hereditary opalescent dentin, is a condition analogous to amelogenesis imperfecta in which the odontoblasts fail to differentiate normally, resulting in poorly calcified dentin (Fig. 353.2). This autosomal dominant disorder can also occur in patients with **osteogenesis imperfecta.** The enamel-dentin junction is altered, causing enamel to break away. The exposed dentin is then susceptible to abrasion, in some cases worn to the gingiva. The teeth are opaque and pearly, and the pulp chambers are generally obliterated by calcification. Both primary and permanent teeth are usually involved. If there is excessive wear of the teeth, selected complete coverage of the teeth may be indicated to prevent further tooth loss and improve appearance.

Localized disturbances of calcification that correlate with periods of illness, malnutrition, premature birth, or birth trauma are common. **Hypocalcification** appears as opaque white patches or horizontal lines on the tooth; **hypoplasia** is more severe and manifests as pitting or areas devoid of enamel. Systemic conditions, such as renal failure and cystic fibrosis, are associated with enamel defects. Local trauma to the primary incisors can also affect calcification of permanent incisors.

Fluorosis (mottled enamel) can result from systemic fluoride consumption >0.05 mg/kg/day during enamel formation. This high fluoride consumption can be caused by residing in an area of high fluoride content of the drinking water (>2.0 ppm), swallowing excessive fluoridated toothpaste, or inappropriate fluoride prescriptions. Excessive fluoride during enamel formation affects ameloblastic function, resulting in inconspicuous white, lacy patches on the enamel to severe brownish discoloration and hypoplasia. The latter changes are usually seen with fluoride concentrations in the drinking water >5.0 ppm.

Anomalies of Color

Discolored teeth can result from incorporation of foreign substances into developing enamel. Neonatal hyperbilirubinemia can produce blue to black discoloration of the primary teeth. Porphyria produces a red-brown discoloration. Tetracyclines are extensively incorporated into bones and teeth and, if administered during the period of formation of enamel, can result in brown-yellow discoloration and hypoplasia of the enamel. Such teeth fluoresce under ultraviolet light. The period at risk extends from approximately 4 months of gestation to 7 years of age. Repeated or prolonged therapy with tetracycline carries the highest risk.

Teething is associated with primary tooth eruption and may manifest with benign symptoms such as gingival hyperemia, irritability, sucking fingers, and drooling; some infants have no symptoms or symptoms not identified by their parents. Low-grade fever is an inconsistent finding. The treatment of symptoms of teething is often unnecessary but could include oral analgesics and iced teething rings. Teething remedies containing benzocaine may cause methemoglobinemia and are not recommended. "Natural" (homeopathic) teething remedies may contain toxic additives and should be avoided. In addition, teething necklaces and bracelets are a risk for foreign body aspiration and choking.

Visit Elsevier eBooks+ at eBooks.Health.Elsevier.com for Bibliography.

Chapter 354

Disorders of the Oral Cavity Associated with Other Conditions

Vineet K. Dhar

Disorders of the teeth and surrounding structures can occur in isolation or in combination with other systemic conditions (Table 354.1). Most commonly, medical conditions that occur during tooth development can affect tooth formation or appearance. Damage to teeth during their development is permanent.

Table 354.1 Dental Problems Associated with Selected Medical Conditions

MEDICAL CONDITION	COMMON ASSOCIATED DENTAL OR ORAL FINDINGS
Cleft lip and palate	Missing teeth, extra (supernumerary) teeth, shifting of arch segments, feeding difficulties, speech problems
Kidney failure	Mottled enamel (permanent teeth), facial dysmorphology
Cystic fibrosis	Stained teeth with extensive medication, mottled enamel
Immunosuppression	Oral candidiasis with potential for systemic candidiasis, cyclosporine-induced gingival hyperplasia
Low birthweight	Palatal groove, narrow arch with prolonged oral intubation; enamel defects of primary teeth
Heart defects with susceptibility to bacterial endocarditis	Bacteremia from dental procedures or trauma
Neutrophil chemotactic deficiency	Aggressive periodontitis (loss of supporting bone around teeth)
Diabetes mellitus type 1 (uncontrolled)	Aggressive periodontitis
Neuromotor dysfunction	Oral trauma from falling; malocclusion (open bite); gingivitis from lack of hygiene
Prolonged illness (generalized) during tooth formation	Enamel hypoplasia of crown portions forming during illness
Seizures	Gingival enlargement if phenytoin is used
Maternal infections	Syphilis: abnormally shaped teeth
Vitamin D–dependent rickets	Enamel hypoplasia

Chapter 355

Malocclusion

Vineet K. Dhar

The oral cavity is essentially a masticatory instrument. The purpose of the anterior teeth is to bite off large portions of food. The posterior teeth reduce foodstuff to a soft, moist bolus. The cheeks and tongue force the food onto the areas of tooth contact. Establishing a proper relationship between the mandibular and maxillary teeth is important for both physiologic and cosmetic reasons.

VARIATIONS IN GROWTH PATTERNS

Growth patterns are classified into three main types of occlusion, determined when the jaws are closed and the teeth are held together (Fig. 355.1). According to the Angle classification of malocclusion, in **class I occlusion** (normal), the cusps of the posterior mandibular teeth interdigitate ahead of and inside of the corresponding cusps of the opposing maxillary teeth. This relationship provides a normal facial profile.

In **class II malocclusion,** *buck teeth*, the cusps of the posterior mandibular teeth are behind and inside the corresponding cusps of the maxillary teeth. This common occlusal disharmony is found in approximately 45% of the population. The facial profile can give the appearance of a *receding chin* (retrognathia) (mandibular deficiency) or protruding front teeth. The resultant increased space between upper and lower anterior teeth encourage finger sucking and tongue-thrust habits. In addition, children with pronounced class II malocclusions are at greater risks of damage to the incisors as a consequence of trauma. Treatment includes orthodontic retraction of the maxilla or stimulation of the mandible.

In **class III malocclusion,** *underbite*, the cusps of the posterior mandibular teeth interdigitate a tooth or more ahead of their opposing maxillary counterparts. The anterior teeth appear in crossbite with the mandibular incisors protruding beyond the maxillary incisors. The facial profile gives the appearance of a *protruding chin* **(prognathia)** with or without an appearance of maxillary deficiency. If necessary,

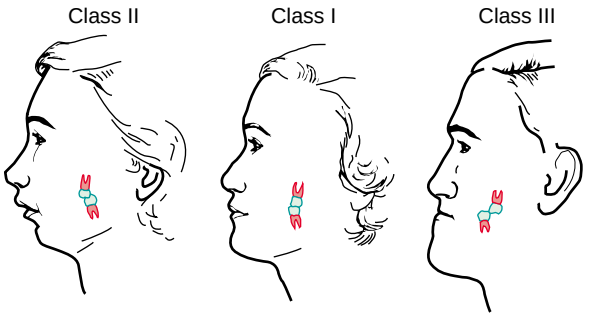

Fig. 355.1 Angle classification of occlusion. The typical correspondence between the facial-jaw profile and molar relationship is shown. *(Data from Borrie FR, Bearn DR, Innes NP, et al. Interventions for the cessation of non-nutritive sucking habits in children. Cochrane Database Syst Rev. 2015;31:CD008694.)*

treatment includes mandibular excess reduction osteotomy or orthodontic maxillary facial protrusion.

The molar relationship in primary dentition/baby teeth also has three main types. The **flush terminal plane** relationship, where the distal surface of mandibular second primary molar is flush with the distal surface of maxillary second primary molar, is most common and can translate into class I occlusion or class II malocclusion in permanent dentition. The **mesial step** relationship, where the distal surface of mandibular second primary molar lies mesial to the distal surface of maxillary second primary molar, is the second most common and often translates into class I occlusion or sometimes into class III malocclusion in permanent dentition. Lastly, the **distal step** relationship, where the distal surface of the mandibular second primary molar lies distal to the distal surface of maxillary second primary molar, almost always translates into class II occlusion in permanent dentition.

CROSSBITE

Normally, the mandibular teeth are in a position just inside the maxillary teeth so that the outside mandibular cusps or incisal edges meet the central portion of the opposing maxillary teeth. A reversal of this relation is referred to as a crossbite. Crossbites can be anterior, involving the incisors; can be posterior, involving the molars; or can involve single or multiple teeth; or can be unilateral or bilateral. Functional posterior crossbites that involve lateral shift of the mandible during closure may result in dental, skeletal adjustments, and even asymmetric condylar positioning; therefore an early diagnosis and correction is recommended.

OPEN AND CLOSED BITES

If the posterior mandibular and maxillary teeth make contact with each other, but the anterior teeth are still apart, the condition is called an *open bite*. Open bites can result from skeletal growth pattern or digit sucking. If digit sucking is terminated before skeletal and dental growth is complete, the open bite might resolve naturally. If mandibular anterior teeth occlude inside the maxillary anterior teeth in an overclosed position, the condition is referred to as a *closed* or *deep bite*.

Treatment of open and closed bites consists of orthodontic correction, generally performed in the preteen or teenage years. Some severe cases require orthognathic surgery to position the jaws optimally in a vertical direction.

DENTAL CROWDING

Overlap of incisors can result when the jaws are too small, or the teeth are too large for adequate alignment of the teeth. Growth of the jaws is mostly in the posterior aspects of the mandible and maxilla; therefore inadequate space for the teeth at 7 or 8 years of age will not resolve with growth of the jaws. Spacing in the primary dentition is normal and favorable for adequate alignment of successor teeth.

DIGIT SUCKING

Various and conflicting etiologic theories and recommendations for correction have been proposed for digit sucking in children. Prolonged digit sucking can cause flaring of the maxillary incisor teeth, an open bite, and a posterior crossbite. The prevalence of digit sucking decreases steadily from the age of 2 years to approximately 10% by the age of 5 years. The earlier the habit is discontinued after the eruption of the permanent maxillary incisors (age 7-8 years), the greater the likelihood that there will be lessening effects on the dentition.

A variety of treatments have been suggested, from behavioral modification to insertion of an appliance with extensions that serves as a reminder when the child attempts to insert the digit. Unfortunately, a systematic review has found only low-quality evidence of the effectiveness of interventions such as orthodontic appliances and psychologic interventions. The greatest likelihood of success occurs in cases in which the child desires to stop. Stopping of the habit will not rectify a malocclusion caused by a prior deviant growth pattern.

Chapter 356

Cleft Lip and Palate

Vineet K. Dhar

Clefts of the lip and palate are distinct entities that are closely related embryologically, functionally, and genetically. It is thought that cleft of the lip appears because of hypoplasia of the mesenchymal layer, resulting in a failure of the medial nasal and maxillary processes to join. Cleft of the palate results from failure of palatal shelves to approximate or fuse.

INCIDENCE AND EPIDEMIOLOGY

The incidence of cleft lip with or without cleft palate is approximately 1 in 1,000 births. The reported incidence of cleft palate alone in the United States is 1 in 1,687 births. Clefts of the lip are more common in males. Possible causes include maternal drug exposure, a syndrome-malformation complex, or genetic factors. Although clefts of lips and palates appear to occur sporadically, the presence of susceptible genes appears important. There are approximately 400 syndromes associated with cleft lip and palates. There are families in which a cleft lip or palate, or both, is inherited in a dominant fashion **(van der Woude syndrome)**, and careful examination of parents is important to distinguish this type from others, because the recurrence risk is 50%. Ethnic factors also affect the incidence of cleft lip and palate; the incidence varies by race, with Asian children most likely to be affected. Cleft lip may be associated with other cranial facial anomalies, whereas cleft palate may be associated with central nervous system anomalies.

CLINICAL MANIFESTATIONS

Cleft lip can vary from a small notch in the vermilion border to a complete separation involving skin, muscle, mucosa, tooth, and bone. Clefts of the lip may be unilateral (more often on the left side) or bilateral and can involve the alveolar ridge (Fig. 356.1).

Isolated cleft palate occurs in the midline and might involve only the uvula or can extend into or through the soft and hard palates to the incisive foramen. When associated with cleft lip, the defect can involve the midline of the soft palate and extend into the hard palate on one or both sides, exposing one or both of the nasal cavities as a unilateral or bilateral cleft palate. The palate can also have a **submucosal cleft** indicated by a bifid uvula, partial separation of muscle with intact mucosa, or a palpable notch at the posterior of the palate (see Fig. 356.1).

TREATMENT

A complete program of habilitation for the child with a cleft lip or palate can require years of special treatment by a team consisting of a pediatrician, plastic surgeon, otolaryngologist, oral and maxillofacial surgeon, pediatric dentist, prosthodontist, orthodontist, speech therapist, geneticist, medical social worker, psychologist, and public health nurse.

The immediate problem in an infant born with a cleft lip or palate is feeding. Although some advocate the construction of a plastic obturator to assist in feedings, most believe that, with the use of soft artificial nipples with large openings, a squeezable bottle, and proper instruction, feeding of infants with clefts can be achieved.

Surgical closure of a cleft lip is usually performed by 3 months of age, when the infant has shown satisfactory weight gain and is free of any oral, respiratory, or systemic infection. Modification of the Millard rotation–advancement technique is the most commonly used technique; a staggered suture line minimizes notching of the lip from retraction of scar tissue. The initial repair may be revised at 4 or 5 years of age. Corrective surgery on the nose may be delayed until adolescence. Nasal surgery can also be performed at the time of the lip repair. Cosmetic results depend on the extent of the original deformity,

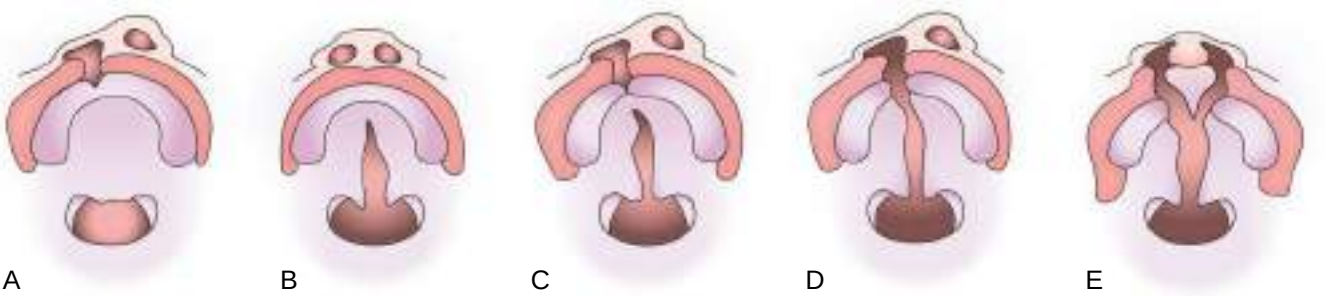

Fig. 356.1 Nonsyndromic orofacial clefts. **A,** Cleft lip and alveolus. **B,** Cleft palate. **C,** Incomplete unilateral cleft lip and palate. **D,** Complete unilateral cleft lip and palate. **E,** Complete bilateral cleft lip and palate. *(From Shaw WC. Orthodontics and Occlusal Management. Oxford, UK: Butterworth-Heinemann; 1993.)*

healing potential of the individual patient, absence of infection, and the skill of the surgeon.

Because clefts of the palate vary considerably in size, shape, and degree of deformity, the timing of surgical correction should be individualized. Criteria such as width of the cleft, adequacy of the existing palatal segments, morphology of the surrounding areas (width of the oropharynx), and neuromuscular function of the soft palate and pharyngeal walls affect the decision. The goals of surgery are the union of the cleft segments, intelligible and pleasant speech, reduction of nasal regurgitation, and avoidance of injury to the growing maxilla.

In an otherwise healthy child, closure of the palate is usually done before 1 year of age to enhance normal speech development. When surgical correction is delayed beyond the third year, a contoured speech bulb can be attached to the posterior of a maxillary denture so that contraction of the pharyngeal and velopharyngeal muscles can bring tissues into contact with the bulb to accomplish occlusion of the nasopharynx and help the child to develop intelligible speech.

A cleft palate usually crosses the alveolar ridge and interferes with the formation of teeth in the maxillary anterior region. Teeth in the cleft area may be displaced, malformed, or missing. Missing teeth or teeth that are nonfunctional are replaced by prosthetic devices.

POSTOPERATIVE MANAGEMENT

During the immediate postoperative period, special nursing care is essential. Gentle aspiration of the nasopharynx minimizes the chances of the common complications of atelectasis or pneumonia. The primary considerations in postoperative care are maintenance of a clean suture line and avoidance of tension on the sutures. The infant is fed with a specially designed bottle, and the arms are restrained with elbow cuffs. A fluid or semifluid diet is maintained for 3 weeks. The patient's hands, toys, and other foreign bodies must be kept away from the surgical site.

SEQUELAE

Recurrent otitis media and subsequent hearing loss are frequent with cleft palate. Displacement of the maxillary arches and malposition of the teeth usually require orthodontic correction. Misarticulations and velopharyngeal dysfunction are often associated with cleft lip and palate and may be present or persist because of physiologic dysfunction, anatomic insufficiency, malocclusion, or inadequate surgical closure of the palate. Such speech is characterized by the emission of air from the nose and by a hypernasal quality with certain sounds, or by compensatory misarticulations (glottal stops). Before and sometimes after palatal surgery, the speech defect is caused by inadequacies in function of the palatal and pharyngeal muscles. The muscles of the soft palate and the lateral and posterior walls of the nasopharynx constitute a valve that separates the nasopharynx from the oropharynx during swallowing and in the production of certain sounds. If the valve does not function adequately, it is difficult to build up enough pressure in the mouth to make such explosive sounds as p, b, d, t, h, y, or the sibilants s, sh, and ch, and such words as "cats," "boats," and "sisters" are not intelligible. After operation or the insertion of a speech appliance, speech therapy is necessary.

VELOPHARYNGEAL DYSFUNCTION

The speech disturbance characteristic of the child with a cleft palate can also be produced by other osseous or neuromuscular abnormalities where there is an inability to form an effective seal between oropharynx and nasopharynx during swallowing or phonation. In a child who has the potential for abnormal speech, adenoidectomy can precipitate overt hypernasality. If the neuromuscular function is adequate, compensation in palatopharyngeal movement might take place and the speech defect might improve, although speech therapy is necessary. In other cases, slow involution of the adenoids can allow gradual compensation in palatal and pharyngeal muscular function. This might explain why a speech defect does not become apparent in some children who have a submucous cleft palate or similar anomaly predisposing to palatopharyngeal incompetence.

Clinical Manifestations

Although clinical signs vary, the symptoms of velopharyngeal dysfunction are similar to those of a cleft palate. There may be hypernasal speech (especially noted in the articulation of pressure consonants such as p, b, d, t, h, v, f, and s); conspicuous constricting movement of the nares during speech; inability to whistle, gargle, blow out a candle, or inflate a balloon; loss of liquid through the nose when drinking with the head down; otitis media; and hearing loss. Oral inspection might reveal a cleft palate or a relatively short palate with a large oropharynx; absent, grossly asymmetric, or minimal muscular activity of the soft palate and pharynx during phonation or gagging; or a submucous cleft.

Velopharyngeal dysfunction may also be demonstrated radiographically. The head should be carefully positioned to obtain a true lateral view; one film is obtained with the patient at rest and another during continuous phonation of the vowel u as in "boom." The soft palate contacts the posterior pharyngeal wall in normal function, whereas in velopharyngeal dysfunction such contact is absent.

In selected cases of velopharyngeal dysfunction, the palate may be retropositioned or pharyngoplasty may be performed using a flap of tissue from the posterior pharyngeal wall. Dental speech appliances have also been used successfully. The type of surgery used is best tailored to the findings on nasoendoscopy.

Visit Elsevier eBooks+ at eBooks.Health.Elsevier.com for Bibliography.

Chapter 357

Syndromes with Oral Manifestations

Vineet K. Dhar

Many syndromes have distinct or accompanying facial, oral, and dental manifestations (see Apert syndrome, Chapter 631.9; Crouzon disease, Chapter 631.9; Down syndrome, Chapter 99.2).

Osteogenesis imperfecta is often accompanied by effects on the teeth, termed **dentinogenesis imperfecta** (see Chapter 353, Fig. 353.2). Depending on the severity of presentation, treatment of the dentition varies from routine preventive and restorative monitoring to covering affected posterior teeth with stainless steel crowns to prevent further tooth loss and improve appearance. Dentinogenesis imperfecta can also occur in isolation without the bony effects.

Another syndrome, **cleidocranial dysplasia,** has orofacial features such as frontal bossing, hypoplastic maxilla, and supernumerary teeth. The primary teeth can be overretained, and the permanent teeth remain unerupted. Supernumerary teeth are common, especially in the premolar area. Extensive dental rehabilitation may be needed to correct severe tooth crowding and unerupted and supernumerary teeth.

Ectodermal dysplasias are a heterogeneous group of conditions in which oral manifestations range from little or no involvement (the dentition is completely normal) to cases in which the teeth can be totally or partially absent or malformed (see Chapter 690). Because alveolar bone does not develop in the absence of teeth, the alveolar processes can be either totally or partially absent, and the resultant overclosure of the mandible causes the lips to protrude. Facial development is otherwise not disturbed. Teeth, when present, can range from normal to small and conical. If aplasia of the buccal and labial salivary glands is present, dryness and irritation of the oral mucosa can occur. People with ectodermal dysplasia might need partial or full dentures, even at a very young age. The vertical height between the jaws is thus restored, improving the position of the lips and facial contours, as well as restoring masticatory function.

Pierre Robin syndrome consists of micrognathia and is usually accompanied by a high arched or cleft palate (Fig. 357.1). The tongue is usually of normal size, but the floor of the mouth is foreshortened. The air passages can become obstructed, particularly on inspiration, usually requiring treatment to prevent suffocation. The infant should be maintained in a prone or partially prone position so that the tongue falls forward to relieve respiratory obstruction. Some patients require tracheostomy. Mandibular distraction procedures in the neonate can improve mandibular size, enhance respiration, and facilitate oral feedings.

Sufficient spontaneous mandibular growth can take place within a few months to relieve the potential airway obstruction. Often the growth of the mandible achieves a normal profile in 4-6 years. Of children with Pierre Robin syndrome, 30–50% have **Stickler syndrome** (types I-VI), an autosomal dominant condition that includes other findings such as prominent joints, arthritis, hypotonia, hypermobile joints, mitral valve prolapse, hearing loss, spine problems (scoliosis, kyphosis, platyspondyly), and ocular problems (high myopia, glaucoma, cataracts, retinal detachment). Symptoms may vary greatly even within a family. Pathogenic variants are noted in the genes that produce collagen (*COL2A1* in most; *COL11A1* in others) in many, but not all, patients with Stickler syndrome. Other syndromes are associated with Pierre Robin syndrome, including 22Q11.2 deletion syndrome (velocardiofacial syndrome).

Mandibulofacial dysostosis (Treacher Collins syndrome or Franceschetti syndrome) is an autosomal dominant syndrome that primarily affects the face. The facial appearance varies but is characterized by downward-sloping palpebral fissures, colobomas of the lower eyelids, sunken cheekbones, blind fistulas opening between the angles of the mouth and the ears, malformed pinnae, atypical hair growth extending toward the cheeks, receding chin, and large mouth. Facial clefts, abnormalities of the ears, and deafness are common. The mandible is usually hypoplastic; the ramus may be deficient, and the coronoid and condylar processes are flat or even aplastic. The palatal vault may be either high or cleft. Dental malocclusions are common. The teeth may be missing, hypoplastic, or displaced or be in an open bite position. Initially, the primary concern is breathing and feeding problems. Surgery to restore normal structure of the face can be performed, which may include repair of cleft palate, zygomatic and orbit reconstruction, reconstruction of the lower eyelid, external ear reconstruction, and orthognathic surgery.

Hemifacial microsomia presentation can be quite variable but is usually characterized by unilateral hypoplasia of the mandible and can be associated with partial paralysis of the facial nerve, underdeveloped ear, and blind fistulas between the angles of the mouth and the ears. Severe facial asymmetry and malocclusion can develop because of the absence or hypoplasia of the mandibular condyle on the affected side. Congenital condylar deformity tends to increase with age. Early craniofacial surgery may be indicated to minimize the deformity. This disorder can be associated with ocular and vertebral anomalies (oculoauriculovertebral spectrum, including Goldenhar syndrome); therefore radiographs of the vertebrae and ribs should be considered to determine the extent of skeletal involvement.

Visit Elsevier eBooks+ at eBooks.Health.Elsevier.com for Bibliography.

Fig. 357.1 Pierre Robin syndrome. *(From Clark DA. Atlas of Neonatology. 7th ed. Philadelphia: Saunders; 2000. p. 144.)*

Chapter 358

Dental Caries

Vineet K. Dhar

ETIOLOGY

The development of dental caries depends on interrelationships among the tooth surface, dietary carbohydrates, and specific oral bacteria. Organic acids produced by bacterial fermentation of dietary carbohydrates reduce the pH of dental plaque adjacent to the tooth to a point where demineralization occurs. The initial demineralization appears as an opaque **white spot lesion** on the enamel, and with progressive loss of tooth mineral, cavitation of the tooth occurs (Fig. 358.1).

The group of microorganisms, *Streptococcus mutans*, is the main bacteria associated with the development of dental caries. These bacteria have the ability to adhere to enamel, produce abundant acid, and survive at low pH. Once the enamel surface cavitates, other oral bacteria (lactobacilli) can colonize the tooth, produce acid, and foster further tooth demineralization. Demineralization from bacterial acid production is determined by the frequency of carbohydrate consumption and by the type of carbohydrate. Sucrose is the most cariogenic sugar because one of its by-products during bacterial metabolism is glucan, a polymer that enables bacteria to adhere more readily to tooth structures. Dietary behaviors, such as consuming sweetened beverages in a nursing bottle or frequently consuming sticky candies, increase the cariogenic potential of foods because of the long retention of sugar in the mouth.

EPIDEMIOLOGY

As per the 2011–2012 National Health and Nutrition Examination Survey (NHANES), approximately 15% of children ranging from 2 to 8 years of age had one or more primary teeth affected by dental caries (Fig. 358.2). In the permanent dentition, over 10% of children age 12-15 years had dental caries and one fourth of children were affected by age 16-19 years (Fig. 358.3).

CLINICAL MANIFESTATIONS

Dental caries of the primary dentition usually begins in the pits and fissures. Small lesions may be difficult to diagnose by visual inspection, but larger lesions are evident as darkened or cavitated lesions on the tooth surfaces (Fig. 358.4). Rampant dental caries in infants and toddlers, referred to as **early childhood caries**, is the result of early colonization of the child with cariogenic bacteria and the frequent ingestion of sugar, either in the bottle or in solid foods. The carious process in this situation is initiated earlier and consequently can affect the maxillary incisors first and then progress to the molars as they erupt.

The prevalence of untreated caries was significantly higher in children between 3 and 9 years of age living at or below 100% of federal poverty level compared with those above the poverty level. Along with

Fig. 358.1 Initial carious lesions (white spot lesions) around the necks of the maxillary central incisors.

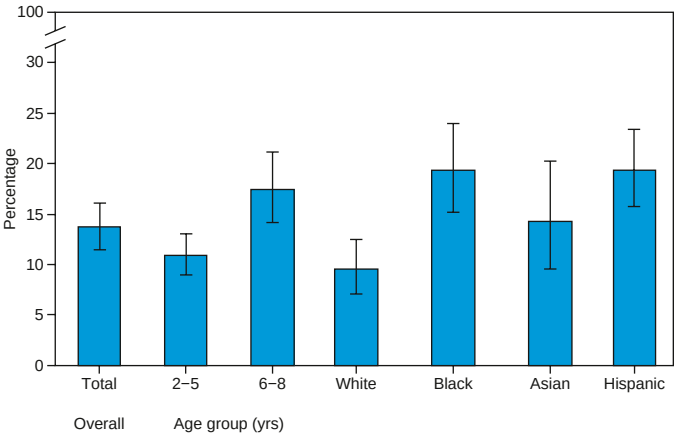

Fig. 358.2 Prevalence* of untreated dental caries† in primary teeth‡ among children age 2-8 yr, by age group, and race/Hispanic origin—National Health and Nutrition Examination Survey, 2011–2014. *With 95% confidence intervals indicated with error bars. †Untreated dental caries is defined as tooth decay (dental cavities) that has not received appropriate treatment. Data were collected by dentists in the mobile examination center as part of the oral health component of the National Health and Nutrition Examination Survey. ‡Primary teeth are the first teeth (baby teeth), that are shed and replaced by permanent teeth. *(From Centers for Disease Control and Prevention: Prevalence of untreated dental caries in primary teeth among children aged 2-8 years, by age group and race/Hispanic origin—National Health and Nutrition Examination Survey, 2011–2014. MMWR. 2017;66[9]:261.)*

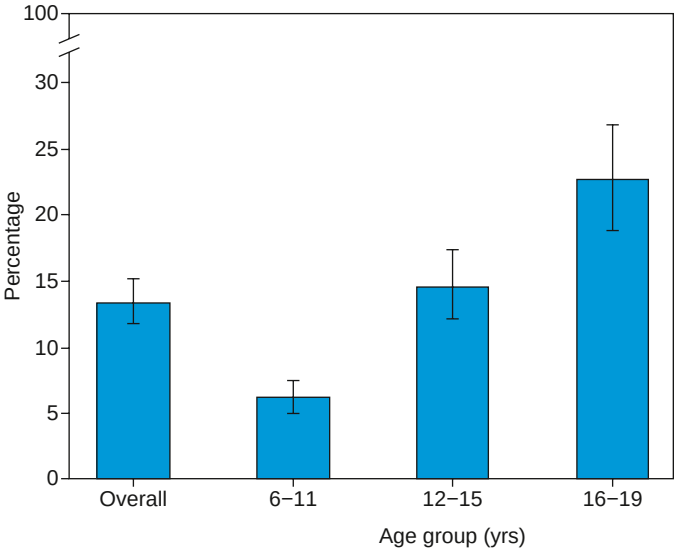

Fig. 358.3 Prevalence* of untreated dental caries† in permanent teeth among children and adolescents age 6-19 yr, by age group—National Health and Nutrition Examination Survey, United States, 2011-2014. *With 95% confidence intervals indicated with error bars. †Untreated dental caries (i.e., dental cavities) are defined as tooth decay that has not received appropriate treatment. Data were collected by dentists in the mobile examination center as part of the oral health component of the National Health and Nutrition Examination Survey. *(From Centers for Disease Control and Prevention: Prevalence of untreated dental caries in permanent teeth among children and adolescents aged 6-19 years, by age group—National Health and Nutrition Examination Survey, United States, 2011–2014. MMWR. 2017;66[1]:36.)*

Fig. 358.4 Rampant caries in a 3-yr-old child. Note darkened and cavitated lesions on the fissure surfaces of mandibular molars.

high frequency of sugar consumption and colonization with cariogenic bacteria, other enabling factors include low socioeconomic status of the family, other family members with carious teeth, recent immigrant status of the child, and the visual presence of dental plaque on the child's teeth. Children who develop caries at a young age are known to be at high risk for developing further caries as they get older. Therefore the appropriate prevention of early childhood caries can result in the elimination of major dental problems in toddlers and less decay in later childhood.

Among adolescents, the prevalence of dental caries was higher in age group 16-19 years (67%) compared with age group 12-15 years (50%). Overall, the caries experience did not significantly differ by race, Hispanic origin, and poverty levels.

COMPLICATIONS

Left untreated, dental caries usually destroy most of the tooth and invade the dental pulp (Fig. 358.5), leading to an inflammation of the pulp **(pulpitis)** and significant pain. Pulpitis can progress to pulp necrosis, with bacterial invasion of the alveolar bone causing a **dental abscess** (Fig. 358.6). Red flags for serious spreading of dental infection are noted in Table 358.1. Infection of a primary tooth can disrupt normal development of the successor permanent tooth. In some cases, this process leads to spread of infection to other facial spaces (Fig. 358.7; Table 358.2).

TREATMENT

The age at which dental caries occurs is important in dental management. Children younger than 3 years of age lack the developmental ability to cooperate with dental treatment and often require sedation or general anesthesia to repair carious teeth. After 4 years of age, children can generally cope with dental restorative care with the use of local anesthesia. Children with neurologic impairment or developmental delay may require general anesthesia for dental procedures at older ages.

Current evidence supports the use of a chronic disease management model to modify risk factors and manage dental caries. The disease management includes at-home strategies and in-office preventive, minimally invasive, and invasive interventions for treating dental caries. Minimally invasive strategies such as interim therapeutic restorations and silver diamine fluoride application can be used to arrest active carious lesions. Conventional dental treatment, using silver amalgam, plastic composite, or stainless steel crowns, can restore most teeth affected with dental caries. If caries involves the dental pulp, a partial removal of the pulp (pulpotomy) or complete removal of the pulp (pulpectomy) may be required. If a tooth requires extraction, a space maintainer may be indicated to prevent migration of teeth, which subsequently leads to malposition of permanent successor teeth.

Clinical management of the pain and infection associated with untreated dental caries varies with the extent of involvement and the medical status of the patient. Dental infection localized to the dentoalveolar unit can be managed by local measures (extraction, pulpectomy).

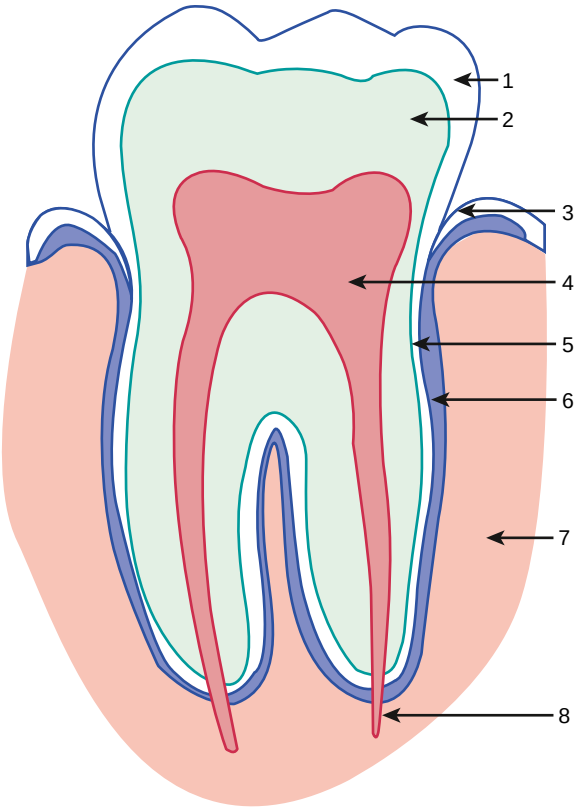

Fig. 358.5 Basic dental anatomy: *1*, enamel; *2*, dentin; *3*, gingival margin; *4*, pulp; *5*, cementum; *6*, periodontal ligament; *7*, alveolar bone; *8*, neurovascular bundle.

Fig. 358.6 Facial swelling from an abscessed primary molar. Resolution of the inflammation can be achieved by a course of antibiotics, followed by either extraction or root canal of the offending tooth.

Table 358.1 Red Flags Suggestive of a Spreading Dental Infection

- Pyrexia
- Tachycardia or tachypnea
- Trismus; may be relative due to pain or absolute due to a collection within the muscle causing muscle spasm in cases of masticator space involvement
- Raised tongue and floor of mouth, drooling
- Periorbital cellulitis
- Difficulty with speaking, swallowing, and breathing
- Hypotension
- Increased white blood cell count
- Lymphadenopathy
- Dehydration

From Robertson DP, Keys W, Rautemaa-Richardson R, et al. Management of severe acute dental infections. *BMJ*. 2015;350:h1300. Box 3, p. 151.

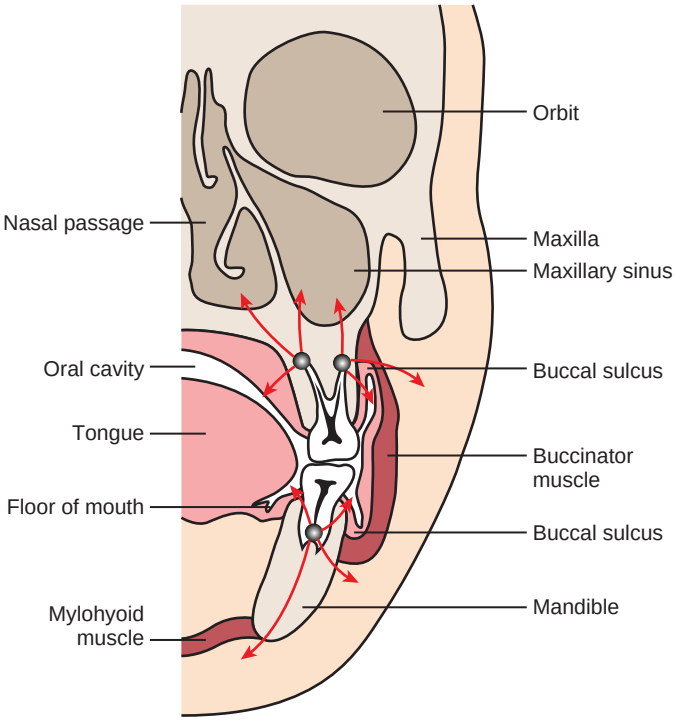

Fig. 358.7 Spread of infection in the maxillofacial region is complicated by the variety of vital structures. Routes of spread are determined by fascial planes and this affects the presentation and management of each subdivision of cervicofacial infection. *(From Robertson DP, Keys W, Rautemaa-Richardson R, et al. Management of severe acute dental infections. BMJ. 2015;350:h1300. Fig. 3, p. 151.)*

Oral antibiotics are indicated for dental infections associated with fever, cellulitis, and facial swelling or if it is difficult to anesthetize the tooth in the presence of inflammation. Penicillin is the antibiotic of choice, except in patients with a history of allergy to this agent. Clindamycin and erythromycin are suitable alternatives. Oral analgesics, such as ibuprofen, are usually adequate for pain control.

Table 358.2 Clinical Presentation of Odontogenic Infections by Location

TYPE OF INFECTION	CLINICAL PRESENTATION
Dentoalveolar	Swelling of the alveolar ridge with periodontal, periapical, and subperiosteal abscess
Submental space	Firm midline swelling beneath the chin; caused by infection from the mandibular incisors
Submandibular space	Swelling of the submandibular triangle of the neck around the angle of the mandible; caused by mandibular molar infections; trismus typical
Sublingual space	Swelling of the floor of the mouth with possible elevation of the tongue and dysphagia
Retropharyngeal space	Stiff neck, sore throat, dysphagia, raspy voice; caused by infections of the molars; infection of retropharyngeal space has a high potential to spread to the mediastinum
Buccal space	Swelling of the cheek; caused by infection of premolar or molar tooth
Masticator space	Swelling on either side of the mandibular ramus; caused by infection of the mandibular third molar; trismus present
Canine space	Swelling of the anterior cheek with loss of the nasolabial fold and possible extension to the infraorbital region

From Ogle OE. Odontogenic infections. *Dent Clin North Am*. 2017;61:235–252. Table 1.

PREVENTION

Dental caries screening, risk assessment, and preventive management in young children need to be part of the scope of medical providers because children younger than 3 years of age often are not under the care of a dentist. Prevention of early childhood caries is critical because, if primary dental care is not initiated or does not succeed, teeth may develop dental caries requiring restorative care. Dental restorative care to treat caries in young children may require the use of sedation or general anesthesia with its associated high costs and possible health risks, and there is high recurrence of carious lesions once they develop.

Because they are seeing infants and toddlers on a periodicity schedule, physicians have an important role in screening children younger than 3 years of age for dental caries; providing preventive instructions; applying preventive measures, such as fluoride varnish; and referring the child to a dentist if problems exist.

Fluoride

The most effective preventive measure against dental caries is communal water supplies with optimal fluoride content. Water fluoridation at the level of 0.7-1.2 mg fluoride per liter (ppm F) was introduced in the United States in the 1940s. Because fluoride from water supplies is now one of several sources of fluoride, the Department of Health and Human Services proposes to not have a fluoride range, but instead to limit the recommendation to the lower limit of 0.7 ppm F. The rationale is to balance the benefits of preventing dental caries with reducing the chance of fluorosis. Children who reside in areas with fluoride-deficient water supplies or who consume primarily bottled water, and are at risk for caries, benefit from dietary fluoride supplements (Table 358.3). If the patient

Table 358.3 Supplemental Fluoride Dosage Schedule

	FLUORIDE IN HOME WATER		
AGE	<0.3 (PPM)	0.3-0.6 (PPM)	>0.6 (PPM)
6 mo-3 yr	0.25*	0	0
3-6 yr	0.50	0.25	0
6-16 yr	1.00	0.50	0

*Milligrams of fluoride per day.

uses a private water supply, it is necessary to get the water tested for fluoride levels before prescribing fluoride supplements. To avoid potential overdoses, no fluoride prescription should be written for more than a total of 1 mg/day of fluoride. However, because of confusion regarding fluoride supplements among practitioners and parents, association of supplements with fluorosis, and lack of parent compliance with the daily administration, supplements may no longer be the first-line approach for preventing caries in preschool-age children.

Topical fluoride on a daily basis can be achieved by using fluoridated toothpaste. Supervised use of less than a *pea-sized* amount of toothpaste (approximately 0.25 g) on the toothbrush in children between 3 and 6 years of age reduces the risk of fluorosis. Children younger than 3 years of age should brush with less than a *smear* or *grain-sized* amount of fluoridated toothpaste. Professional topical fluoride applications performed semiannually reportedly reduce caries by approximately 30%. Fluoride varnish is ideal for professional applications in preschool children because of ease of use, even with non–dental health providers, and its safety because of single-dose dispensers. Products that are available come in containers of 0.25, 0.4, or 0.6 mL of varnish, corresponding to 5.6, 9.0, and 13.6 mg fluoride, respectively. Fluoride varnish should be administered twice a year for preschool children at moderate caries risk and 4 times a year for children at high caries risk.

Oral Hygiene

Daily brushing, especially with fluoridated toothpaste, helps prevent dental caries. Most children younger than 8 years of age do not have the coordination required for adequate tooth brushing. Accordingly, parents should assume responsibility for the child's oral hygiene, with the degree of parental involvement appropriate to the child's changing abilities.

Diet

Frequent consumption of sweetened fruit drinks is not generally recognized by parents for its high cariogenic potential. Consuming sweetened beverages in a nursing bottle or sippy cup should be discouraged and special efforts made to instruct parents that their child should consume sweetened beverages only at meal times and not exceed 6 oz/day.

Dental Sealant

Plastic dental sealants have been shown to be effective in preventing caries on the pit and fissure of the primary and permanent molars. Sealants are most effective when placed soon after teeth erupt and used in children with deep grooves and fissures in the molar teeth. Sealants have been shown to reduce the incidence of caries by 85% over 7 years.

Visit Elsevier eBooks+ at eBooks.Health.Elsevier.com for Bibliography.

Chapter 359

Periodontal Diseases

Vineet K. Dhar

The periodontium includes the gingiva, alveolar bone, cementum, and periodontal ligament (see Fig. 358.5).

GINGIVITIS

Poor oral hygiene results in the accumulation of dental plaque at the tooth-gingival interface that activates an inflammatory response, expressed as localized or generalized reddening and swelling of the gingiva. More than half of American school children experience gingivitis. In severe cases, the gingiva spontaneously bleeds and there is oral malodor. With proper oral hygiene (careful tooth brushing and flossing) complete resolution can be expected. Fluctuations in hormonal levels during the onset of puberty can increase inflammatory responses to plaque. Gingivitis in healthy children is unlikely to progress to periodontitis (inflammation of the periodontal ligament resulting in loss of alveolar bone).

AGGRESSIVE PERIODONTITIS IN CHILDREN (PREPUBERTAL PERIODONTITIS)

Periodontitis in children before puberty is a rare disease that often begins between the time of eruption of the primary teeth and the age of 4 or 5 years. The disease occurs in localized and generalized forms. There is rapid bone loss, often leading to premature loss of primary teeth. It is often associated with systemic problems, including neutropenia, leukocyte adhesion or migration defects, hypophosphatasia, Papillon-Lefèvre syndrome, leukemia, and Langerhans cell histiocytosis. However, in many cases, there is no apparent underlying medical problem. Nonetheless, diagnostic workups are necessary to rule out underlying systemic disease.

Treatment includes aggressive professional teeth cleaning, strategic extraction of affected teeth, and antibiotic therapy. There are few reports of long-term successful treatment to reverse bone loss surrounding primary teeth.

AGGRESSIVE PERIODONTITIS IN ADOLESCENTS

Localized aggressive periodontitis (LAgP) in adolescents is characterized by rapid attachment and alveolar bone loss, on at least two first molars and incisors. Overall prevalence in the United States is <1%, but the prevalence among Black people is reportedly 2.5%. This form of periodontitis is associated with a strain of *Aggregatibacter (Actinobacillus)* bacteria. In addition, the neutrophils of patients with aggressive periodontitis can have chemotactic or phagocytic defects. If left untreated, affected teeth lose their attachment and can exfoliate. Treatment varies with the degree of involvement. Patients whose disease is diagnosed at onset are usually managed by surgical or nonsurgical debridement in conjunction with antibiotic therapy. Prognosis depends on the degree of initial involvement and compliance with therapy.

Generalized aggressive periodontitis (GAgP) occurs more in adolescents and young adults and is characterized by generalized interproximal attachment loss and bone loss, including three teeth that are not first molars and incisors.

CYCLOSPORINE- OR PHENYTOIN-INDUCED GINGIVAL OVERGROWTH

The use of cyclosporine to suppress organ rejection or phenytoin for anticonvulsant therapy, and in some cases calcium channel blockers, is associated with generalized enlargement of the gingiva.

Phenytoin and its metabolites have a direct stimulatory action on gingival fibroblasts, resulting in accelerated synthesis of collagen. Phenytoin induces less gingival hyperplasia in patients who maintain meticulous oral hygiene.

Gingival hyperplasia occurs in 10–30% of patients treated with phenytoin. Severe manifestations can include gross enlargement of the gingiva, sometimes covering the teeth; edema and erythema of the gingiva; secondary infection, resulting in abscess formation; migration of teeth; and inhibition of exfoliation of primary teeth and subsequent impaction of permanent teeth. Treatment should be directed toward prevention and, if possible, discontinuation of cyclosporine or phenytoin. Patients undergoing long-term treatment with these drugs should receive frequent dental examinations and oral hygiene care. Severe forms of gingival overgrowth are treated by gingivectomy, but the lesion recurs if drug use is continued.

ACUTE PERICORONITIS

Acute inflammation of the flap of gingiva that partially covers the crown of an incompletely erupted tooth is common in mandibular permanent molars. Accumulation of debris and bacteria between the gingival flap and tooth precipitates the inflammatory response. A variant of this condition is a gingival abscess caused by entrapment of bacteria because of orthodontic bands or crowns. Trismus and severe pain may be associated with the inflammation. Untreated cases can result in facial space infections and facial cellulitis.

Treatment includes local debridement and irrigation, warm saline rinses, and antibiotic therapy. When the acute phase has subsided, resection of the gingival flap prevents recurrence. Early recognition of the partial impaction of mandibular third molars and their subsequent extraction prevents these areas from developing pericoronitis.

NECROTIZING PERIODONTAL DISEASE (ACUTE NECROTIZING ULCERATIVE GINGIVITIS)

Necrotizing periodontal disease, in the past sometimes referred to as "trench mouth," is a distinct periodontal disease associated with oral spirochetes and fusobacteria. However, it is not clear whether bacteria initiate the disease or are secondary. It rarely develops in healthy children in developed countries, with a prevalence in the United States of <1%, but is seen more often in children and adolescents from developing areas of Africa, Asia, and South America. In certain African countries, where affected children usually have protein malnutrition, the lesion can extend into adjacent tissues, causing necrosis of facial structures (cancrum oris, or noma).

Clinical manifestations of necrotizing periodontal disease include necrosis and ulceration of gingiva between the teeth, an adherent grayish pseudomembrane over the affected gingiva, oral malodor, cervical lymphadenopathy, malaise, and fever. The condition may be mistaken for acute herpetic gingivostomatitis. Dark-field microscopy of debris obtained from necrotizing lesions demonstrates dense spirochete populations.

Treatment of necrotizing periodontal disease is divided into an acute management with local debridement, oxygenating agents (direct application of 10% carbamide peroxide in anhydrous glycerol qid), and analgesics. Dramatic resolution usually occurs within 48 hours. If a patient is febrile, antibiotics (penicillin or metronidazole) may be an important adjunctive therapy. A second phase of treatment may be necessary if the acute phase of the disease has caused irreversible morphologic damage to the periodontium. The disease is not contagious.

Visit Elsevier eBooks+ at eBooks.Health.Elsevier.com for Bibliography.

Chapter 360

Dental Trauma

Vineet K. Dhar

Traumatic oral injuries may be categorized into three groups: injuries to teeth, injuries to soft tissue (contusions, abrasions, lacerations, punctures, avulsions, and burns), and injuries to jaw (mandibular and/or maxillary fractures).

INJURIES TO TEETH

Approximately 10% of children between 18 months and 18 years of age sustain significant tooth trauma. Oral injuries are second most common, covering 18% of all somatic injuries in the age-group 0-6 years. Among oral injuries, injuries to teeth are most common, followed by soft tissue injuries. There appear to be three age periods of greatest predilection: toddlers (1-3 years), usually from falls or child abuse; school-age children (7-10 years), usually from bicycle and playground accidents; and adolescents (16-18 years), often the result of fights, athletic injuries, and automobile accidents. Injuries to teeth are more common among children with protruding front teeth. Children with craniofacial abnormalities or neuromuscular deficits are also at increased risk for dental injury. Injuries to teeth can involve the hard dental tissues, the dental pulp (nerve), and injuries to the periodontal structure (surrounding bone and attachment apparatus) (Fig. 360.1; Table 360.1).

Fractures of teeth may be uncomplicated (confined to the hard dental tissues) or complicated (involving the pulp). Exposure of the pulp results in its bacterial contamination, which can lead to infection and pulp necrosis. Such pulp exposure complicates therapy and can lower the likelihood of a favorable outcome.

The teeth most often affected are the maxillary incisors. Uncomplicated crown fractures are treated by covering exposed dentin and by

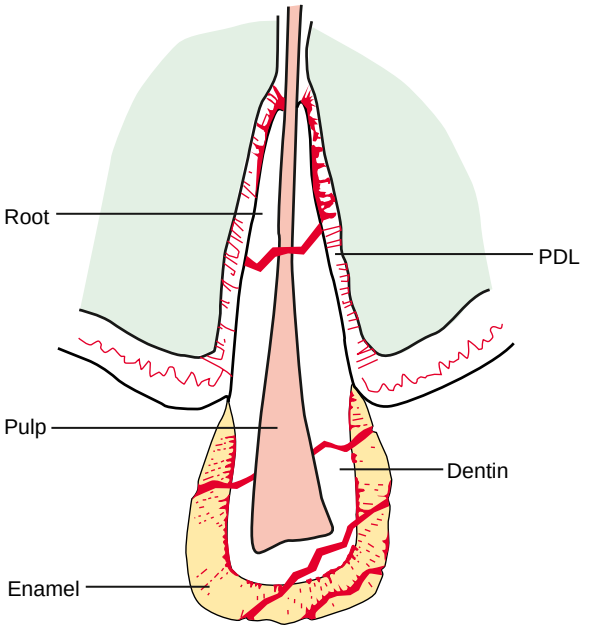

Fig. 360.1 Tooth fractures can involve enamel, dentin, or pulp and can occur in the crown or root of a tooth. PDL, Periodontal ligament. *(From Pinkham JR. Pediatric Dentistry: Infancy Through Adolescence. Philadelphia: Saunders; 1988. p. 172.)*

Phenytoin and its metabolites have a direct stimulatory action on gingival fibroblasts, resulting in accelerated synthesis of collagen. Phenytoin induces less gingival hyperplasia in patients who maintain meticulous oral hygiene.

Gingival hyperplasia occurs in 10–30% of patients treated with phenytoin. Severe manifestations can include gross enlargement of the gingiva, sometimes covering the teeth; edema and erythema of the gingiva; secondary infection, resulting in abscess formation; migration of teeth; and inhibition of exfoliation of primary teeth and subsequent impaction of permanent teeth. Treatment should be directed toward prevention and, if possible, discontinuation of cyclosporine or phenytoin. Patients undergoing long-term treatment with these drugs should receive frequent dental examinations and oral hygiene care. Severe forms of gingival overgrowth are treated by gingivectomy, but the lesion recurs if drug use is continued.

ACUTE PERICORONITIS

Acute inflammation of the flap of gingiva that partially covers the crown of an incompletely erupted tooth is common in mandibular permanent molars. Accumulation of debris and bacteria between the gingival flap and tooth precipitates the inflammatory response. A variant of this condition is a gingival abscess caused by entrapment of bacteria because of orthodontic bands or crowns. Trismus and severe pain may be associated with the inflammation. Untreated cases can result in facial space infections and facial cellulitis.

Treatment includes local debridement and irrigation, warm saline rinses, and antibiotic therapy. When the acute phase has subsided, resection of the gingival flap prevents recurrence. Early recognition of the partial impaction of mandibular third molars and their subsequent extraction prevents these areas from developing pericoronitis.

NECROTIZING PERIODONTAL DISEASE (ACUTE NECROTIZING ULCERATIVE GINGIVITIS)

Necrotizing periodontal disease, in the past sometimes referred to as "trench mouth," is a distinct periodontal disease associated with oral spirochetes and fusobacteria. However, it is not clear whether bacteria initiate the disease or are secondary. It rarely develops in healthy children in developed countries, with a prevalence in the United States of <1%, but is seen more often in children and adolescents from developing areas of Africa, Asia, and South America. In certain African countries, where affected children usually have protein malnutrition, the lesion can extend into adjacent tissues, causing necrosis of facial structures (cancrum oris, or noma).

Clinical manifestations of necrotizing periodontal disease include necrosis and ulceration of gingiva between the teeth, an adherent grayish pseudomembrane over the affected gingiva, oral malodor, cervical lymphadenopathy, malaise, and fever. The condition may be mistaken for acute herpetic gingivostomatitis. Dark-field microscopy of debris obtained from necrotizing lesions demonstrates dense spirochete populations.

Treatment of necrotizing periodontal disease is divided into an acute management with local debridement, oxygenating agents (direct application of 10% carbamide peroxide in anhydrous glycerol qid), and analgesics. Dramatic resolution usually occurs within 48 hours. If a patient is febrile, antibiotics (penicillin or metronidazole) may be an important adjunctive therapy. A second phase of treatment may be necessary if the acute phase of the disease has caused irreversible morphologic damage to the periodontium. The disease is not contagious.

Visit Elsevier eBooks+ at eBooks.Health.Elsevier.com for Bibliography.

Chapter 360

Dental Trauma

Vineet K. Dhar

Traumatic oral injuries may be categorized into three groups: injuries to teeth, injuries to soft tissue (contusions, abrasions, lacerations, punctures, avulsions, and burns), and injuries to jaw (mandibular and/or maxillary fractures).

INJURIES TO TEETH

Approximately 10% of children between 18 months and 18 years of age sustain significant tooth trauma. Oral injuries are second most common, covering 18% of all somatic injuries in the age-group 0-6 years. Among oral injuries, injuries to teeth are most common, followed by soft tissue injuries. There appear to be three age periods of greatest predilection: toddlers (1-3 years), usually from falls or child abuse; school-age children (7-10 years), usually from bicycle and playground accidents; and adolescents (16-18 years), often the result of fights, athletic injuries, and automobile accidents. Injuries to teeth are more common among children with protruding front teeth. Children with craniofacial abnormalities or neuromuscular deficits are also at increased risk for dental injury. Injuries to teeth can involve the hard dental tissues, the dental pulp (nerve), and injuries to the periodontal structure (surrounding bone and attachment apparatus) (Fig. 360.1; Table 360.1).

Fractures of teeth may be uncomplicated (confined to the hard dental tissues) or complicated (involving the pulp). Exposure of the pulp results in its bacterial contamination, which can lead to infection and pulp necrosis. Such pulp exposure complicates therapy and can lower the likelihood of a favorable outcome.

The teeth most often affected are the maxillary incisors. Uncomplicated crown fractures are treated by covering exposed dentin and by

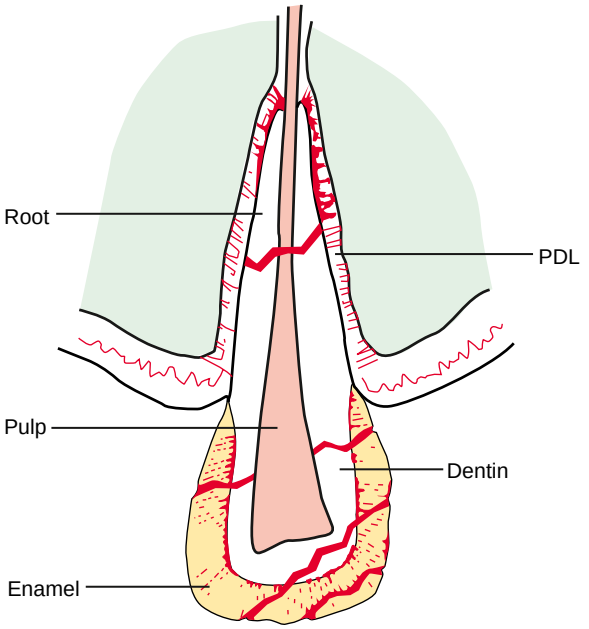

Fig. 360.1 Tooth fractures can involve enamel, dentin, or pulp and can occur in the crown or root of a tooth. PDL, Periodontal ligament. *(From Pinkham JR. Pediatric Dentistry: Infancy Through Adolescence. Philadelphia: Saunders; 1988. p. 172.)*

Table 360.1 Injuries to Crowns of Teeth

TYPE OF TRAUMA	DESCRIPTION	TREATMENT AND REFERRAL
Enamel infraction (crazing)	Incomplete fracture of enamel without loss of tooth structure	Initially might not require therapy but should be assessed periodically by dentist
Enamel fractures	Fracture of only the tooth enamel	Tooth may be smoothed or treated to replace fragment
Enamel and dentin fracture	Fracture of enamel and dentinal layer of the tooth. Tooth may be sensitive to cold or air. Pulp may become necrotic, leading to periapical abscess	Refer as soon as possible. Area should be treated to preserve the integrity of the underlying pulp
Enamel, dentin fracture involving the pulp	Bacterial contamination can lead to pulpal necrosis and periapical abscess. The tooth might have the appearance of bleeding or might display a small red spot	Refer immediately. The dental therapy of choice depends on the extent of injury, the condition of the pulp, the development of the tooth, time elapsed from injury, and any other injuries to the supporting structures. Therapy is directed toward minimizing contamination in an effort to improve the prognosis

From Josell SD, Abrams RG. Managing common dental problems and emergencies. *Pediatr Clin North Am.* 1991;38:1325–1342.

placing an aesthetic restoration. Complicated crown fractures involving the tooth pulp usually require **endodontic therapy** (root canal). Crown-root fractures and root fractures usually require extensive dental therapy. Such injuries in the primary dentition can interfere with normal development of the permanent dentition; therefore significant injuries of the primary incisor teeth are usually managed by extraction.

Traumatic oral injuries should be referred to a dentist as soon as possible. Even when the teeth appear intact, a dentist should promptly evaluate the patient. Baseline data (radiographs, mobility patterns, responses to specific stimuli) enable the dentist to assess the likelihood of future complications.

INJURIES TO PERIODONTAL STRUCTURES

Trauma to teeth with associated injury to periodontal structures that hold the teeth usually manifests as mobile or displaced teeth. Categories of trauma to the periodontium include concussion, subluxation, intrusive luxation, extrusive luxation, and avulsion.

Concussion

Injuries that produce minor damage to the periodontal ligament are termed *concussions*. Teeth sustaining such injuries are not mobile or displaced but react markedly to percussion (gentle hitting of the tooth with an instrument). This type of injury usually requires no therapy and resolves without complication. Primary incisors that sustain concussion can change color, which may indicate pulpal degeneration and should be evaluated by a dentist.

Subluxation

Subluxated teeth exhibit mild to moderate horizontal mobility and/or vertical mobility. Hemorrhage is usually evident around the neck of the tooth at the gingival margin. There is no displacement of the tooth. Many subluxated teeth need to be immobilized by splints to ensure adequate repair of the periodontal ligament. Some of these teeth develop pulp necrosis.

Intrusion

Intruded teeth are pushed up into their socket, sometimes to the point where they are not clinically visible. Intruded primary incisors can give the false appearance of being avulsed (knocked out). To rule out avulsion, a dental radiograph is indicated (Figs. 360.2 and 360.3). Intruded primary teeth are usually monitored for spontaneous repositioning or re-eruption. Depending on the severity, the intruded permanent teeth may be monitored for re-eruption or repositioned surgically or orthodontically. Some of these teeth develop pulp necrosis and infection requiring further management.

Extrusion

Extrusion injury is characterized by displacement of the tooth from its socket. The tooth is usually displaced to the lingual (tongue) side, with fracture of the wall of the alveolar socket. These teeth need immediate treatment; the longer the delay, the more likely the tooth will be fixed in its displaced position. Therapy is directed at reduction (repositioning the tooth) and fixation (splinting). The pulp of such teeth often becomes necrotic and requires endodontic therapy. Extrusive luxation in the primary dentition is usually managed by extraction because complications of reduction and fixation can result in problems with development of permanent teeth.

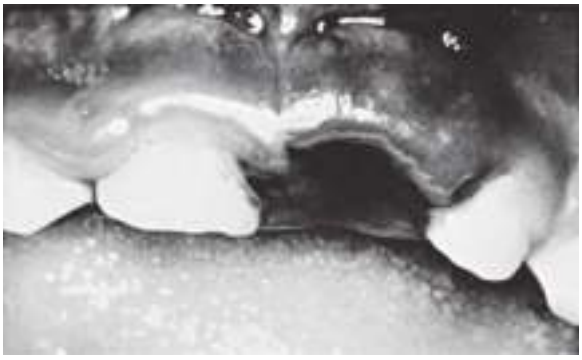

Fig. 360.2 Intruded primary incisor that appears avulsed (knocked out).

Fig. 360.3 Occlusal radiograph documents intrusion of "missing tooth" presented in Figure 360.2.

Avulsion

If avulsed permanent teeth are replanted as soon as possible after injury, there is a good chance that normal reattachment will follow and the tooth will have a good prognosis. However, if the tooth is in a dry environment for longer than 1 hour, the ligament that holds the tooth in place has little chance for survival and failure (root resorption, ankylosis) is common. Parents confronted with this emergency situation can be instructed to do the following:

- Find the tooth.
- Briefly rinse the tooth. (Do not scrub the tooth. Do not touch the root. After plugging the sink drain, hold the tooth by the crown and rinse it under running tap water.)
- Insert the tooth into the socket. (Gently place it back into its normal position. Do not be concerned if the tooth extrudes slightly. If the parent or child is too apprehensive for replantation of the tooth, the tooth should be placed in cold cow's milk or other cold isotonic solution.)
- Go directly to the dentist. (In transit, the child should hold the tooth in its socket with a finger. The parent should place the child in an age-appropriate child seat, buckle a seatbelt around the child, and drive safely.)

After the tooth is replanted, it must be immobilized to facilitate reattachment; endodontic therapy is always required. The initial signs of complications associated with replantation can appear as early as 1 week after trauma or as late as several years later. Close dental follow-up is indicated for at least 1 year.

PREVENTION

To minimize the likelihood of dental injuries:

- Every child or adolescent who engages in contact sports should wear a **mouth guard**, which may be constructed by a dentist or purchased at any athletic goods store.
- Helmets with face guards should be worn by children or adolescents with neuromuscular problems or seizure disorders to protect the head and face during falls.
- Helmets should also be used during biking, skiing, skating, and skateboarding.
- All children or adolescents with protruding incisors should be evaluated by a pediatric dentist or orthodontist.

ADDITIONAL CONSIDERATIONS

Children who experience dental trauma might also have sustained head or neck trauma, and therefore, neurologic assessment is warranted. Tetanus prophylaxis should be considered with any injury that disrupts the integrity of the oral tissues. The possibility of child abuse should always be considered.

Visit Elsevier eBooks+ at eBooks.Health.Elsevier.com for Bibliography.

Chapter 361

Common Lesions of the Oral Soft Tissues

Vineet K. Dhar

OROPHARYNGEAL CANDIDIASIS

Oropharyngeal infection with *Candida albicans* (thrush, moniliasis) (see Chapter 280.1) is common in neonates from contact with the organism in the birth canal or contact with the breast during breastfeeding. The lesions of oropharyngeal candidiasis (OPC) appear as white plaques covering all or part of the oropharyngeal mucosa. These plaques are removable from the underlying surface, which is characteristically inflamed and has pinpoint hemorrhages. The diagnosis is confirmed by direct microscopic examination on potassium hydroxide smears and culture of scrapings from lesions. OPC is usually self-limited in the healthy newborn infant, but topical application of nystatin to the oral cavity of the baby and to the nipples of breastfeeding mothers will hasten recovery.

OPC is also a major problem during myelosuppressive therapy. **Systemic candidiasis**, a major cause of morbidity and mortality during myelosuppressive therapy, develops almost exclusively in patients who have had prior oropharyngeal, esophageal, or intestinal candidiasis. This observation implies that prevention of OPC should reduce the incidence of systemic candidiasis. The use of oral rinses of 0.2% chlorhexidine gluconate solution along with systemic antifungals may be effective in preventing OPC, systemic candidiasis, or candidal esophagitis.

APHTHOUS ULCERS

The aphthous ulcer (canker sore) is a distinct oral lesion (Fig. 361.1), prone to recurrence; Table 361.1 notes the differential diagnosis. Aphthous ulcers are reported to develop in 20% of the population. Their etiology is unclear, but allergic or immunologic reactions, emotional stress, genetics, and injury to the soft tissues in the mouth have been implicated. Aphthous-like lesions may be associated with inflammatory bowel disease, Behçet disease, gluten-sensitive enteropathy, periodic fever-aphthae-pharyngitis-adenitis syndrome, Sweet syndrome, HIV infection (especially if ulcers are large and slow to heal), and cyclic neutropenia (see Table 361.1). Clinically, these ulcers are characterized by well-circumscribed, ulcerative lesions with a white necrotic base surrounded by a red halo. The lesions generally last 10-14 days and heal without scarring. Nonprescription palliative therapies, such as benzocaine and topical lidocaine, are effective, as are topical steroids. Use of soft tissue dental lasers may help manage aphthous ulcers by accelerating wound healing and reducing pain. Tetracycline is beneficial with severe outbreaks, but caution is necessary in pregnant women, because it is classified as U.S. Food and Drug Administration (FDA) pregnancy category D. In younger children (≤8 years), tetracycline can affect developing teeth and cause permanent staining of the teeth.

HERPETIC GINGIVOSTOMATITIS

After an initial incubation period of approximately 1 week, the primary infection with herpes simplex virus manifests as fever and malaise, usually in a child younger than 5 years (see Chapter 299). The oral cavity can show various expressions, including the gingiva becoming erythematous, mucosal hemorrhages, and clusters of small vesicles erupting throughout the mouth. There is often involvement of the mucocutaneous margin and perioral skin (Fig. 361.2). The oral symptoms generally are accompanied by fever, lymphadenopathy, and difficulty eating and drinking. The symptoms usually regress within 2 weeks without scarring. Fluids should be encouraged because the child may become dehydrated. Analgesics and anesthetic rinses can make

Fig. 361.1 Major aphthous in a child. *(From Gürkan A, Özlü SG, Altiaylik-Özer P, et al. Recurrent aphthous stomatitis in childhood and adolescence: a single-center experience. Pediatr Dermatol. 2015;32[4]:476–480. Fig. 1.)*

Table 361.1 Differential Diagnosis of Oral Ulceration

CONDITION	COMMENT
COMMON	
Aphthous ulcers (canker sores)	Painful circumscribed lesions; recurrences
Traumatic ulcers	Accidents, chronic cheek biter, after dental local anesthesia
Hand, foot, and mouth disease	Painful; lesions on tongue, anterior oral cavity, hands, and feet
Herpangina	Painful; lesions confined to soft palate and oropharynx
Herpetic gingivostomatitis	Vesicles on mucocutaneous borders; painful, febrile
Recurrent herpes labialis	Vesicles on lips; painful
Chemical burns	Alkali, acid, aspirin; painful
Heat burns	Hot food, electrical
Medicine effect	NSAIDs, methotrexate, azathioprine, enalapril, losartan, fluoxetine, antiretroviral agents
RIME	Mycoplasma and other agents; predominant oral ulcerations with scattered cutaneous lesions
UNCOMMON	
Neutrophil defects	Agranulocytosis, leukemia, cyclic neutropenia; painful
Systemic lupus erythematosus	Recurrent; may be painless
Behçet syndrome	Resembles aphthous lesions; associated with genital ulcers, uveitis
Necrotizing ulcerative gingivostomatitis	Vincent stomatitis; painful
Syphilis	Chancre or gumma; painless
Oral Crohn disease	Aphthous-like; painful
Histoplasmosis	Lingual
Pemphigus	May be isolated to the oral cavity
Stevens-Johnson syndrome	May be isolated to or appear initially in the oral cavity

NSAIDs, Nonsteroidal antiinflammatory drugs; RIME, reactive infectious mucotaneous eruption.

Fig. 361.2 Herpetic gingivostomatitis. Lip erosions with multiple perioral herpetic lesions involving the mucocutaneous borders. *(From Paller AS, Mancini AJ, eds. Hurwitz Clinical Pediatric Dermatology. 3rd ed. Philadelphia: Saunders; 2006. p. 398.)*

the child more comfortable. Oral valacyclovir, if taken within the first 3 days of symptoms in immunocompetent patients, is beneficial in shortening the duration of symptoms. Caution should be exercised to prevent autoinoculation, especially of the eyes.

RECURRENT HERPES LABIALIS

Approximately 90% of the worldwide population develops antibodies to herpes simplex virus. In periods of quiescence, the virus is thought to remain latent in sensory neurons. Unlike primary herpetic gingivostomatitis, which manifests as multiple painful vesicles on the lips, tongue, palate, gingiva, and mucosa, recurrent herpes is generally limited to the lips. Other than the annoyance of causing pain and being a cosmetic issue, recurrent episodes generally do not involve systemic symptoms. Reactivation of the virus is thought to be the result of exposure to ultraviolet light, tissue trauma, stress, or fevers. There is little advantage of antiviral therapy over palliative therapies in an otherwise healthy patient affected by recurrent herpes.

PARULIS

The parulis (gum boil) is a soft reddish papule located adjacent to the root of a chronically abscessed tooth. It occurs at the end-point of a draining dental sinus tract. Treatment consists of diagnosing which tooth is abscessed and extracting it or performing root canal treatment on the offending tooth.

CHEILITIS

Cheilitis, dryness of the lips followed by scaling and cracking and accompanied by a characteristic burning sensation, is common in children. Cheilitis may be caused by sensitivity to contact substances, lip licking, vitamin deficiency, weakened immune system, or fungal or bacterial infections, and often occurs in association with fever. Treatment may include antifungal or antibacterial agents and frequent application of petroleum jelly.

ANKYLOGLOSSIA

Ankyloglossia, or tongue-tie, is characterized by an abnormally short lingual frenum that can hinder the tongue movement, but rarely interferes with feeding or speech. It is possible that the frenum could spontaneously lengthen as the child gets older. If, in the rare event that the extent of the ankyloglossia is severe, speech may be affected and surgical correction may be indicated.

GEOGRAPHIC TONGUE

Geographic tongue (migratory glossitis) is a benign and asymptomatic lesion that is characterized by one or more smooth bright red patches, often showing a yellow, gray, or white membranous margin on the dorsum of an otherwise normally roughened tongue. The condition has no known cause, and no treatment is indicated (see Chapter 705).

FISSURED TONGUE

The fissured tongue (scrotal tongue) is a malformation manifested clinically by numerous small furrows or grooves on the dorsal surface (see Chapter 705). If the tongue is painful, brushing the tongue or irrigating with water can reduce the bacteria in the fissures.

DEVELOPMENTAL (NORMAL) VARIATIONS

Bohn Nodules

Bohn nodules are small developmental anomalies located along the buccal and lingual aspects of the mandibular and maxillary ridges and in the hard palate of the neonate. These lesions arise from remnants of mucous gland tissue. Treatment is not necessary as the nodules usually disappear within a few weeks.

Dental Lamina Cysts

Dental lamina cysts are small cystic lesions located along the crest of the mandibular and maxillary ridges of the neonate. These lesions arise from epithelial remnants of the dental lamina. Treatment is not necessary; they disappear within a few weeks.

Epstein Pearls

Epstein pearls are small developmental lesions located in the median palatal raphe region due to entrapment of epithelial remnants along the line of fusion of the palatal halves. Treatment is not necessary, as these slough off on their own within a few weeks.

Fordyce Granules

Fordyce granules are common and almost 80% of adults have these yellow-white granules in clusters or plaquelike areas on the oral mucosa, most commonly on the buccal mucosa or lips. They are aberrant sebaceous glands. The glands are present at birth, but they can undergo hypertrophy and first appear as discrete yellowish papules during the preadolescent period in approximately 50% of children. No treatment is necessary.

Visit Elsevier eBooks+ at eBooks.Health.Elsevier.com for Bibliography.

Chapter 362

Diseases of the Salivary Glands and Jaws

Vineet K. Dhar

With the exception of mumps (see Chapter 295), diseases of the salivary glands are rare in children. Bilateral enlargement of the submaxillary glands can occur in HIV/AIDS, cystic fibrosis, Epstein-Barr virus infection, malnutrition, COVID-19, and transiently during acute asthmatic attacks. Chronic vomiting can be accompanied by enlargement of the parotid glands. Benign salivary gland hypertrophy has been associated with endocrinopathies: thyroid disease, diabetes, and Cushing syndrome. Infiltrative disease or tumors are uncommon; red flags include facial nerve palsy, rapid growth, fixed skin, paresthesias, ulceration, or a history of radiation to the head or neck region.

PAROTITIS

Acute parotitis is often caused by blockage, with further inflammation due to bacterial infection. The blockage may be due to a salivary stone or mucus plug. Stones can be removed by physical manipulation, surgery, or lithotripsy. **Recurrent parotitis** is an idiopathic swelling of the parotid gland that can occur in otherwise healthy children. The swelling is usually unilateral, but both glands can be involved simultaneously or alternately. There is little pain; the swelling is limited to the gland and usually lasts 2-3 weeks. Treatment may include local heat, massaging the gland, and antibiotics. **Suppurative parotitis** is usually caused by *Staphylococcus aureus*. It is usually unilateral and may be accompanied by fever. The gland becomes swollen, tender, and painful. Suppurative parotitis responds to antibacterial therapy based on culture obtained from the Stensen duct or by surgical drainage. Viral causes of parotitis include mumps (often in epidemics), Epstein-Barr virus, human herpesvirus 6, enteroviruses, COVID-19, and HIV.

RANULA

A ranula is a cyst associated with a major salivary gland in the sublingual area. It is a large, soft, mucus-containing swelling in the floor of the mouth. It occurs at any age, including infancy. The cyst should be excised, and the severed duct should be exteriorized.

MUCOCELE

Mucocele is a salivary gland lesion caused by a blockage of a salivary gland duct. It is most common on the lower lip and has the appearance of a fluid-filled vesicle, or a fluctuant nodule with the overlying mucosa being normal in color. Treatment is surgical excision, with removal of the involved accessory salivary gland.

CONGENITAL LIP PITS

Congenital lip pits are caused by fistulous tracts that lead to embedded mucous glands in the lower lip. They leak saliva, especially with salivary stimulation. Lip pits can be isolated anomalies, or they can be found in patients with cleft lip or palate. Treatment is surgical excision of the glandular tissue.

ERUPTION CYST

Eruption cyst is a smooth painless swelling over the erupting tooth. If bleeding occurs in the cyst space, it may appear blue or blue-black. In most cases, no treatment is indicated, and the cyst resolves with the full eruption of the tooth.

XEROSTOMIA

Also known as *dry mouth*, xerostomia may be associated with fever, dehydration, anticholinergic drugs, chronic graft-versus-host disease, Mikulicz disease (leukemic infiltrates), Sjögren syndrome, or tumoricidal doses of radiation when the salivary glands are within the field. Long-term xerostomia is a high-risk factor for dental caries.

SALIVARY GLAND TUMORS

See Chapter 549.

HISTIOCYTIC DISORDERS

See Chapter 556.

TUMORS OF THE JAW

Ossifying fibroma is a common benign tumor of the jaw. It is often asymptomatic and is usually discovered on routine radiographic examinations. Treatment is resection due to the possibility of recurrence. **Central giant cell granuloma** is another common lesion thought to be reactive, rather than neoplastic. Although usually asymptomatic, it can be expansile, with or without resorption of the roots of teeth and perforation of the cortical plate. Treatment is complete curettage or surgical excision. **Dentigerous cysts** are common lesions associated with the crown of an impacted or unerupted tooth. Although usually asymptomatic, they can become large and destructive. Treatment is surgical removal.

The malignant primary tumors of the jaw in children include Burkitt lymphoma, osteogenic sarcoma, lymphosarcoma, ameloblastoma, and, more rarely, fibrosarcoma.

Visit Elsevier eBooks+ at eBooks.Health.Elsevier.com for Bibliography.

Chapter 363

Diagnostic Radiology in Dental Assessment

Vineet K. Dhar

Diagnostic dental radiology in children follows the as low as reasonably achievable (ALARA) principle. In children, intraoral radiographs such as bitewings and select periapical radiographs are taken during routine dental visits and repeated every 6 months to 2 years based on the caries risk assessment. Additional radiographs such as panoramic views, cephalometric radiographs, and dental cone beam computed tomography (CBCT) are taken when indicated. In general, the cumulative radiation exposure due to routine dental radiographs is minimal. In addition, precautions such as use of high-speed film, collimated beam, protective aprons and thyroid collars, proper technique, and minimizing number of exposures are all taken to keep radiation exposure minimal.

Intraoral dental radiographs are highly detailed, direct-exposure films that demonstrate sections of the child's teeth and supporting bone structures. The film or image receptor is placed lingual to the teeth, and the x-ray beam is directed through the teeth and supporting structures. The resulting images are used to detect dental caries, loss of alveolar bone (periodontal disease), abscesses at the roots of the teeth, and trauma to the teeth and alveolar bone. These radiographs are also used to demonstrate the developmental status of permanent teeth within the bone.

The **panoramic radiograph** provides a single tomographic image of the upper and lower jaw, including all teeth and supporting structures. The x-ray tube rotates about the patient's head with reciprocal movement of the film or image receptor during the exposure. The panoramic image shows the teeth, mandibular bodies, rami, and condyles; maxillary sinuses; and a majority of the facial buttresses. Such images are used to show abnormalities of tooth number, development and eruption pattern, cystic and neoplastic lesions, bone infections, and fracture, as well as dental caries and periodontal disease (Fig. 363.1).

Cephalometric radiographs are posteroanterior and lateral skull films that are taken using a **cephalostat** (head positioner) and employ techniques that clearly demonstrate the facial skeleton and soft facial tissues. Similar protocols for positioning children are used throughout the world. From these images, cranial and facial points and planes can be determined and compared with standards derived from thousands of images. A child's facial growth can be assessed serially when cephalometric radiographs are taken sequentially. Relationships among the maxilla, mandible, cranial base, and facial skeleton can be determined in a quantitative manner. Additionally, the alignment of the teeth and the relation of the teeth to the supporting bone can be serially measured.

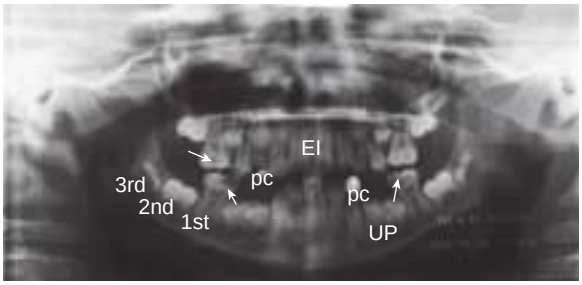

Fig. 363.1 A panoramic radiograph of a 10-yr-old child showing extensive dental caries of the first permanent molars *(arrows)*, as well as normal structures: erupted first permanent molar, unerupted second molar, and unerupted third molar. EI, Erupted incisors, UP, unerupted premolars, pc, erupted primary canines.

Dental CBCT is a variation of traditional CT, used mainly to evaluate oral and maxillofacial regions and teeth. Dental CBCT generally delivers lower radiation exposure than traditional CT, but higher than conventional dental radiography. There are several indications for CBCT, such as evaluation of oral-maxillofacial pathologies, diagnosis of dental trauma, endodontic treatment, visualization of abnormal teeth, orthodontic assessment, or cleft palate assessment, among others.

Visit Elsevier eBooks+ at eBooks.Health.Elsevier.com for Bibliography.

Section 3

The Esophagus

Chapter 364

Embryology, Anatomy, and Function of the Esophagus

Seema Khan and Sravan Kumar Reddy Matta

The esophagus is a hollow muscular tube, separated from the pharynx above and the stomach below by two tonically closed sphincters. Its primary function is to convey ingested material from the mouth to the stomach. Largely lacking digestive glands and enzymes, and exposed only briefly to nutrients, it has no active role in digestion.

EMBRYOLOGY

The esophagus develops from the postpharyngeal foregut and can be distinguished from the stomach in the 4-week-old embryo. At the same time, the trachea begins to bud just anterior to the developing esophagus; the resulting laryngotracheal groove extends and becomes the lung. Disturbance of this stage can result in congenital anomalies such as **tracheoesophageal fistula** (see Chapter 365). The length of the esophagus is 8-10 cm at birth and doubles in the first 2-3 years of life, reaching approximately 25 cm in the adult. The abdominal portion of the esophagus is as large as the stomach in an 8-week-old fetus but gradually shortens to a few millimeters at birth, attaining a final length of approximately 3 cm by a few years of age. This intraabdominal location of both the distal esophagus and the **lower esophageal sphincter** (LES) is an important antireflux mechanism because an increase in intraabdominal pressure is also transmitted to the sphincter, augmenting its defense. Swallowing can be seen in utero as early as 16-20 weeks of gestation, helping to circulate the amniotic fluid; **polyhydramnios** is a hallmark of lack of normal swallowing or of esophageal or upper gastrointestinal tract obstruction. Sucking and swallowing are not fully coordinated before 34 weeks of gestation, a contributing factor for feeding difficulties in premature infants.

ANATOMY

The luminal aspect of the esophagus is covered by thick, protective, nonkeratinized stratified squamous epithelium, which abruptly changes to simple columnar epithelium at the stomach's upper margin at the **gastroesophageal junction (GEJ).** This squamous epithelium is relatively

Chapter 363

Diagnostic Radiology in Dental Assessment

Vineet K. Dhar

Diagnostic dental radiology in children follows the as low as reasonably achievable (ALARA) principle. In children, intraoral radiographs such as bitewings and select periapical radiographs are taken during routine dental visits and repeated every 6 months to 2 years based on the caries risk assessment. Additional radiographs such as panoramic views, cephalometric radiographs, and dental cone beam computed tomography (CBCT) are taken when indicated. In general, the cumulative radiation exposure due to routine dental radiographs is minimal. In addition, precautions such as use of high-speed film, collimated beam, protective aprons and thyroid collars, proper technique, and minimizing number of exposures are all taken to keep radiation exposure minimal.

Intraoral dental radiographs are highly detailed, direct-exposure films that demonstrate sections of the child's teeth and supporting bone structures. The film or image receptor is placed lingual to the teeth, and the x-ray beam is directed through the teeth and supporting structures. The resulting images are used to detect dental caries, loss of alveolar bone (periodontal disease), abscesses at the roots of the teeth, and trauma to the teeth and alveolar bone. These radiographs are also used to demonstrate the developmental status of permanent teeth within the bone.

The **panoramic radiograph** provides a single tomographic image of the upper and lower jaw, including all teeth and supporting structures. The x-ray tube rotates about the patient's head with reciprocal movement of the film or image receptor during the exposure. The panoramic image shows the teeth, mandibular bodies, rami, and condyles; maxillary sinuses; and a majority of the facial buttresses. Such images are used to show abnormalities of tooth number, development and eruption pattern, cystic and neoplastic lesions, bone infections, and fracture, as well as dental caries and periodontal disease (Fig. 363.1).

Cephalometric radiographs are posteroanterior and lateral skull films that are taken using a **cephalostat** (head positioner) and employ techniques that clearly demonstrate the facial skeleton and soft facial tissues. Similar protocols for positioning children are used throughout the world. From these images, cranial and facial points and planes can be determined and compared with standards derived from thousands of images. A child's facial growth can be assessed serially when cephalometric radiographs are taken sequentially. Relationships among the maxilla, mandible, cranial base, and facial skeleton can be determined in a quantitative manner. Additionally, the alignment of the teeth and the relation of the teeth to the supporting bone can be serially measured.

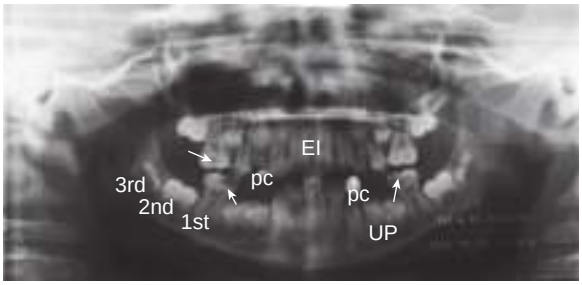

Fig. 363.1 A panoramic radiograph of a 10-yr-old child showing extensive dental caries of the first permanent molars *(arrows)*, as well as normal structures: erupted first permanent molar, unerupted second molar, and unerupted third molar. EI, Erupted incisors, UP, unerupted premolars, pc, erupted primary canines.

Dental CBCT is a variation of traditional CT, used mainly to evaluate oral and maxillofacial regions and teeth. Dental CBCT generally delivers lower radiation exposure than traditional CT, but higher than conventional dental radiography. There are several indications for CBCT, such as evaluation of oral-maxillofacial pathologies, diagnosis of dental trauma, endodontic treatment, visualization of abnormal teeth, orthodontic assessment, or cleft palate assessment, among others.

Visit Elsevier eBooks+ at eBooks.Health.Elsevier.com for Bibliography.

Section 3

The Esophagus

Chapter 364

Embryology, Anatomy, and Function of the Esophagus

Seema Khan and Sravan Kumar Reddy Matta

The esophagus is a hollow muscular tube, separated from the pharynx above and the stomach below by two tonically closed sphincters. Its primary function is to convey ingested material from the mouth to the stomach. Largely lacking digestive glands and enzymes, and exposed only briefly to nutrients, it has no active role in digestion.

EMBRYOLOGY

The esophagus develops from the postpharyngeal foregut and can be distinguished from the stomach in the 4-week-old embryo. At the same time, the trachea begins to bud just anterior to the developing esophagus; the resulting laryngotracheal groove extends and becomes the lung. Disturbance of this stage can result in congenital anomalies such as **tracheoesophageal fistula** (see Chapter 365). The length of the esophagus is 8-10 cm at birth and doubles in the first 2-3 years of life, reaching approximately 25 cm in the adult. The abdominal portion of the esophagus is as large as the stomach in an 8-week-old fetus but gradually shortens to a few millimeters at birth, attaining a final length of approximately 3 cm by a few years of age. This intraabdominal location of both the distal esophagus and the **lower esophageal sphincter** (LES) is an important antireflux mechanism because an increase in intraabdominal pressure is also transmitted to the sphincter, augmenting its defense. Swallowing can be seen in utero as early as 16-20 weeks of gestation, helping to circulate the amniotic fluid; **polyhydramnios** is a hallmark of lack of normal swallowing or of esophageal or upper gastrointestinal tract obstruction. Sucking and swallowing are not fully coordinated before 34 weeks of gestation, a contributing factor for feeding difficulties in premature infants.

ANATOMY

The luminal aspect of the esophagus is covered by thick, protective, nonkeratinized stratified squamous epithelium, which abruptly changes to simple columnar epithelium at the stomach's upper margin at the **gastroesophageal junction (GEJ).** This squamous epithelium is relatively

resistant to damage by gastric secretions, in contrast to the ciliated columnar epithelium of the respiratory tract. However, chronic irritation by gastric contents can result in morphometric changes such as thickening of the basal cell layer and lengthening of papillary ingrowth into the epithelium, and subsequent metaplasia of the cells lining the lower esophagus from squamous to columnar. Deeper layers of the esophageal wall are composed successively of lamina propria, muscularis mucosae, submucosa, and the two layers of muscularis propria (circular surrounded by longitudinal). The two delimiting sphincters of the esophagus, the **upper esophageal sphincter (UES)** at the cricopharyngeus muscle and the **LES** at the **GEJ,** constrict the esophageal lumen at its proximal and distal boundaries. The muscularis propria of the upper third of the esophagus is predominantly striated, and that of the lower two-thirds is smooth muscle. Clinical conditions involving striated muscle (cricopharyngeal dysfunction, cerebral palsy) affect the upper esophagus, whereas those involving smooth muscle (achalasia, reflux esophagitis) affect the lower esophagus. The muscular LES and the mucosal "Z-line" of the GEJ may be discrepant up to several centimeters.

FUNCTION

The esophagus can be divided into three areas: the UES, the esophageal body, and the LES. At rest, the tonic LES pressure is normally approximately 20 mm Hg; values <10 mm Hg are usually considered abnormal, although it seems that competence against retrograde flow of gastric material is maintained if the LES pressure is >5 mm Hg. The LES pressure rises during intragastric pressure amplifications, whether caused by gastric contractions, abdominal wall muscle contractions ("straining"), or external pressure applied to the abdominal wall. It also rises in response to cholinergic stimuli, gastrin, gastric alkalization, and certain drugs (bethanechol, metoclopramide, cisapride). The UES pressure is more variable and often higher than that of the LES; it decreases almost to zero during deep sleep and it increases markedly during stress and straining. The UES and LES relax briefly to allow material to pass through during swallowing, belching, reflux, and vomiting. They can contract in response to subthreshold levels of reflux (esophagoglottal closure reflex).

Swallowing is initiated by elevation of the tongue, propelling the bolus into the pharynx. The larynx elevates and moves anteriorly, pulling open the relaxing UES, while the opposed aryepiglottic folds close. The epiglottis drops back to cover the larynx and direct the bolus over the larynx and into the UES. The soft palate occludes the nasopharynx. The primary peristalsis thus initiated is a contraction originating in the oropharynx that clears the esophagus aborally (Fig. 364.1). Oropharyngeal swallowing related dysfunction may occur at multiple levels (Table 364.1). The LES, tonically contracted as a barrier against gastroesophageal reflux (GER), relaxes as swallowing is initiated, at nearly the same time as the UES relaxation. The LES relaxation persists considerably longer, until the peristaltic wave traverses it and closes it. The normal esophageal peristaltic speed is approximately 3 cm/sec; the wave takes 4 sec or longer to traverse the 12-cm esophagus of a young infant and considerably longer in a larger child. Facial stimulation by a puff of air can induce swallowing and esophageal peristalsis in healthy young infants, a reflex termed the **Santmyer swallow.**

In addition to relaxing to move swallowed material past the GEJ into the stomach, the LES normally relaxes to vent swallowed air or to allow retrograde expulsion of material from the stomach. Perhaps as an extension of these functions, the normal LES also permits physiologic reflux episodes, brief events that occur approximately five times in the first postprandial hour, particularly in the awake state, but are otherwise uncommon. **Transient LES relaxation,** not associated with swallowing, is the major mechanism underlying **pathologic reflux** (see Fig. 364.1).

The close linkage of the anatomy of the upper digestive and respiratory tracts has mandated intricate functional protections of the respiratory tract during retrograde movement of gastric contents as well as during swallowing. The protective functions include the LES tone, the bolstering of the LES by the surrounding diaphragmatic crura, and the *backup protection* of the UES tone. Secondary peristalsis, akin to primary peristalsis but without an oral component, originates in the upper esophagus, triggered mainly by GER, thereby also clearing refluxed gastric contents from the esophagus. Another protective reflex is the *pharyngeal swallow* (initiated above the esophagus, but without lingual participation). There are multiple levels of protection against aspiration, including the rhythmic coordination of swallowing and breathing and a series of protective reflexes with

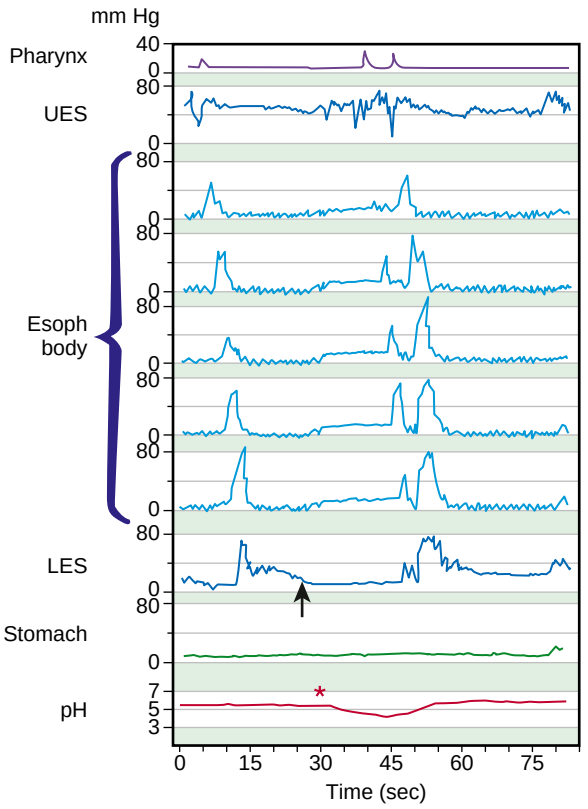

Fig. 364.1 Continuous tracing of esophageal motility showing two swallows, as indicated by the pharyngeal contraction associated with relaxation of the upper esophageal sphincter *(UES)* and followed by peristalsis in the body of the esophagus. The lower esophageal sphincter *(LES)* also displays a transient relaxation *(arrow)* unassociated with a swallow. There is an episode of gastroesophageal reflux *(asterisk)* recorded by a *pH* probe at the time of the transient *LES* relaxation. *(Courtesy John Dent, FRACP, PhD and Geoffrey Davidson, MD.)*

Table 364.1 Mechanical Events of the Oropharyngeal Swallow and Evidence of Dysfunction

MECHANICAL EVENT	EVIDENCE OF DYSFUNCTION
Nasopharyngeal closure	Nasopharyngeal regurgitation Nasal voice
Laryngeal closure	Aspiration during bolus transit
Upper esophageal sphincter opening	Dysphagia Post-swallow residue/aspiration Diverticulum formation
Tongue loading and bolus propulsion	Sluggish misdirected bolus
Pharyngeal clearance	Post-swallow residue in hypopharynx/aspiration

Modified from Pandolfino JE, Kahrilas PJ. Esophageal neuromuscular function and motility disorders. In Feldman M, Friedman LS, Brandt LJ, eds. *Sleisenger and Fordtran's Gastrointestinal and Liver Disease.* 10th ed. Philadelphia: Elsevier; 2016: Table 43.1.

esophagopharyngeal afferents and efferents that close the UES or larynx. These reflexes include the esophago-UES contractile reflex, the pharyngo-UES contractile reflex, the esophagoglottal closure reflex, and two pharyngoglottal adduction reflexes. The last two reflexes have chemoreceptors on the laryngeal surface of the epiglottis and mechanoreceptors on the aryepiglottic folds as their sites of stimulus. It is likely that interactions between the esophagus and the respiratory tract, which cause extraesophageal manifestations of gastroesophageal reflux disease (GERD), will be explained by subtle abnormalities in these protective reflexes.

Visit Elsevier eBooks+ at eBooks.Health.Elsevier.com for Bibliography.

364.1 Common Clinical Manifestations and Diagnostic Aids

Seema Khan and Sravan Kumar Reddy Matta

Manifestations of esophageal disorders include pain, obstruction or difficulty swallowing, abnormal retrograde movement of gastric contents (reflux, regurgitation, or vomiting), or bleeding; esophageal disease can also cause respiratory symptoms. Pain in the chest unrelated to swallowing **(heartburn)** can be a sign of esophagitis, but similar pain might also represent cardiac, pulmonary, or musculoskeletal disease or visceral hyperalgesia. Pain during swallowing **(odynophagia)** localizes the disease more discretely to the pharynx and esophagus and often represents inflammatory mucosal disease. Complete esophageal obstruction can be produced acutely by esophageal foreign bodies, including food impactions; can be congenital, as in esophageal atresia; or can evolve over time as a peptic stricture occludes the esophagus. Difficulty swallowing **(dysphagia)** can be produced by incompletely occlusive esophageal obstruction (by extrinsic compression, intrinsic narrowing, or foreign bodies) but can also result from dysmotility of the esophagus (whether primary/idiopathic or secondary to systemic disease). Inflammatory lesions of the esophagus without obstruction or dysmotility are a third cause of dysphagia; eosinophilic esophagitis (EoE) is also relatively common.

The most common esophageal disorder in children is **GERD** (see Chapter 369)**,** which is from retrograde return of gastric contents into the esophagus. **Esophagitis** can be caused by GERD, by eosinophilic disease, by infection, or by caustic substances. Esophageal **bleeding** can result from severe esophagitis that produces erosions or ulcerations and can manifest as anemia or hemoccult-positive stools. More acute or severe bleeding can be from ruptured **esophageal varices.** The resulting hematemesis must be differentiated from more distal bleeding (gastric ulcer) and from more proximal bleeding (a nosebleed or hemoptysis). Respiratory symptoms of esophageal disease can result from luminal contents incorrectly being directed into the respiratory tract or to reflexive respiratory responses to esophageal stimuli.

DIAGNOSTIC AIDS

The esophagus can be evaluated by radiography, endoscopy, histology, scintigraphy, manometry, pH-metry (linked as indicated with other polysomnography), and multichannel intraluminal impedance. Contrast (usually barium) radiographic study of the esophagus usually incorporates fluoroscopic imaging over time so that motility and anatomy can be assessed. Although most often requested to evaluate for GERD, it is neither sensitive nor specific for this purpose; it can detect complications of GERD (stricture) or conditions mimicking GERD (pyloric stenosis or malrotation with intermittent volvulus), or concurrent hiatal hernia complicating GERD.

Barium fluoroscopy is optimal for evaluating for structural anomalies, such as duplications; strictures; hiatal hernia; congenital esophageal stenosis or external esophageal compression by an aberrant blood vessel; or for causes of dysmotility, such as achalasia. Modifications of the routine barium fluoroscopic study are used in special situations. When an *H-type* tracheoesophageal fistula is suspected, the test is most sensitive if the radiologist, with the patient prone, distends the esophagus with barium via a nasogastric tube. The videofluoroscopic evaluation of swallowing performed with varying consistencies of barium (modified barium swallow, oropharyngeal videoesophagram, or cookie swallow) optimally evaluates children with dysphagia by demonstrating incoordination of the pharyngeal and esophageal phases of swallowing and any associated aspiration.

In some centers, fiberoptic endoscopic evaluation of swallowing uses nasopharyngeal endoscopy to visualize the pharynx and larynx during swallowing of dye-enhanced foods when dysphagia, laryngeal penetration, or aspiration is suspected. This is often combined with sensory testing of the laryngeal adductor reflex in response to a calibrated puff of air through the endoscope to the arytenoids, generating the composite fiberoptic endoscopic evaluation of swallowing sensory testing that examines the mechanisms of any aspiration that is present. Endoscopy allows direct visualization of esophageal mucosa and helps therapeutically in the removal of foreign bodies and treatment of esophageal varices. Endoscopy also allows biopsy samples to be taken, thus improving the diagnosis of **endoscopy-negative GERD**, differentiating GERD from EoE, and identifying viral or fungal causes of esophagitis.

Radionuclide scintigraphy scans are helpful in evaluating the efficiency of peristalsis and demonstrating reflux episodes. They can be specific, although not very sensitive, for aspiration and can quantify gastric emptying, thus hinting at a cause for GERD. The related radionuclide salivagram can demonstrate aspiration of even minute amounts of saliva.

Esophageal manometry evaluates for dysmotility from the pharynx to the stomach; by synchronized quantitative pressure measurements along the esophagus, it detects and characterizes dysfunctions sometimes missed radiographically. Manometry is often challenging in young infants, and sphincters are optimally evaluated with special Dent sleeves, rather than the simple ports available for the esophageal body. High-resolution esophageal manometry (HRM) along with video fluoroscopic swallowing study (VFSS) to evaluate UES relaxation and pharyngeal and peristaltic pressures is now available at a few centers of expertise.

Extended pH monitoring of the distal esophagus is a sensitive test for acidic GER episodes that can quantify duration and degree of acidity, but not volume, of the reflux episodes. It is linked with polysomnography (a pneumogram) when GER is suspected to cause apnea or similar symptoms. Multichannel intraluminal impedance is a method for pH-independent detection of bolus movements in the esophagus; with a pH probe incorporated, it can distinguish between acid and nonacid liquid and gaseous reflux, the proximal extent of reflux, and several aspects of esophageal function, such as direction of bolus flow, duration of bolus presence, and bolus clearance.

The functional luminal imaging probe (FLIP) is another testing modality available in few pediatric motility centers; it is used as a diagnostic tool to guide and measure therapeutic success. FLIP is indicated in patients with EoE to assess esophageal compliance and esophagogastric junction (EGJ) distensibility in patients with achalasia.

Visit Elsevier eBooks+ at eBooks.Health.Elsevier.com for Bibliography.

Chapter 365
Congenital Anomalies

365.1 Esophageal Atresia and Tracheoesophageal Fistula

Seema Khan and Sravan Kumar Reddy Matta

Esophageal atresia (EA) is the most common congenital anomaly of the esophagus, with a prevalence of 1.7 per 10,000 live births. Of these, >90% have an associated tracheoesophageal fistula (TEF). In the most common form of EA, the upper esophagus ends in a blind pouch and the TEF is connected to the distal esophagus (type C). Figure 365.1 shows the types of EA and TEF and their relative frequencies. The exact cause is still unknown; associated features include advanced maternal age, European ethnicity, maternal obesity, low socioeconomic status, and tobacco smoking. This defect has survival rates of >90%, due largely to improved neonatal intensive care, earlier recognition, and appropriate intervention. Infants weighing <1,500 g at birth and those with severe associated cardiac anomalies have the highest risk for mortality. Fifty percent of infants are *nonsyndromic* without other anomalies; the rest have syndromes with associated anomalies, most often associated with the vertebral, anorectal, (cardiac), tracheal, esophageal, renal, radial (limb) (VACTERL) syndrome. Cardiac and vertebral anomalies are seen in 32% and 24%, respectively. VACTERL is a sporadic disorder and is generally associated with normal intelligence. Genetic factors have a role in the pathogenesis of TEF in patients with other non-VACTERL syndromes as suggested by discrete pathogenic variants in syndromic cases: **Feingold syndrome** *(N-MYC),* CHARGE syndrome (*c*oloboma of the eye; *c*entral nervous system anomalies; *h*eart defects; *a*tresia of the choanae; *r*etardation of growth and/or development; *g*enital and/or urinary defects [hypogonadism]; *e*ar anomalies and/or deafness) *(CHD7),* and anophthalmia-esophageal-genital syndrome *(SOX2).*

PRESENTATION

The neonate with EA typically has frothing and bubbling at the mouth and nose after birth as well as episodes of coughing, cyanosis, and respiratory distress. Polyhydramnios is common. Feeding exacerbates these symptoms, causes regurgitation, and can precipitate aspiration. Aspiration of gastric contents via a distal fistula causes more damaging pneumonitis than aspiration of pharyngeal secretions from the blind upper pouch. The infant with an isolated TEF in the absence of EA ("H-type" fistula) might come to medical attention later in life with chronic respiratory problems, including refractory bronchospasm and recurrent aspiration pneumonias.

DIAGNOSIS

In the setting of polyhydramnios, early-onset respiratory distress and the inability to pass a nasogastric or orogastric tube in the newborn suggests EA. Imaging findings of absence of the fetal stomach bubble and maternal polyhydramnios might alert the physician to EA before birth. Plain radiography in the evaluation of respiratory distress might reveal a coiled feeding tube in the esophageal pouch and/or an air-distended stomach, indicating the presence of a coexisting TEF (Fig. 365.2). Conversely, pure EA can manifest as an airless scaphoid abdomen. In isolated TEF (H type), an esophagogram with contrast medium injected under pressure can demonstrate the defect (Fig. 365.3). Alternatively, the orifice may be detected at bronchoscopy or when methylene blue dye injected into the endotracheal tube during endoscopy is observed in the esophagus during forced inspiration. The differential diagnosis of congenital esophageal lesions is noted in Table 365.1.

MANAGEMENT

Initially, maintaining a patent airway, preoperative proximal pouch decompression to prevent aspiration of oral secretions, and use of antibiotics to prevent consequent pneumonia are paramount. Prone positioning minimizes movement of gastric secretions into a distal fistula, and esophageal suctioning minimizes aspiration from a

Fig. 365.1 Gross type classification and esophageal atresia (EA) and trachea-esophageal fistulas (TEF). Left to right: normal anatomy, gross type B (EA with proximal TEF; 2%), gross type C (EA with distal TEF; 86%), gross type D (EA with proximal and distal TEF; 1%), gross type A (pure EA, 7%), and gross type E (TEF without EA; 4%). *(From Harrington AW, Riebold J, Hernandez K, et al. Feeding and growth outcomes in infants with type C esophageal atresia who undergo early primary repair. J Pediatr. 2022;241:77–82, Fig. 1.)*

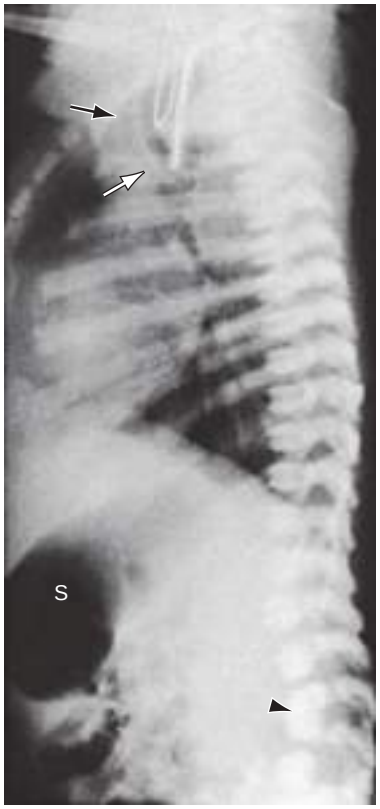

Fig. 365.2 Tracheoesophageal fistula. Lateral radiograph demonstrating a nasogastric tube coiled *(arrows)* in the proximal segment of an atretic esophagus. The distal fistula is suggested by gaseous dilation of the stomach *(S)* and small intestine. The *arrowhead* depicts vertebral fusion, whereas a heart murmur and cardiomegaly suggest the presence of a ventricular septal defect. This patient demonstrated elements of the vertebral, anorectal, tracheal, esophageal, renal, and radial anomalad. *(From Balfe D, Ling D, Siegel M. The esophagus. In Putman CE, Ravin CE, eds. Textbook of Diagnostic Imaging. Philadelphia: WB Saunders; 1988.)*

Fig. 365.3 H-type fistula *(arrow)* demonstrated in an infant after barium swallow on frontal-oblique chest x-ray. The tracheal aspect of the fistula is characteristically superior to the esophageal aspect. Barium is seen to outline the tracheobronchial tree. *(From Wyllie R, Hyams JS, eds. Pediatric Gastrointestinal and Liver Disease. 3rd ed. Philadelphia: Saunders; 2006: p. 299.)*

blind pouch. Endotracheal intubation with mechanical ventilation is to be avoided if possible because it can worsen distention of the stomach. Surgical ligation of the TEF and primary end-to-end anastomosis of the esophagus via right-sided thoracotomy constitute the standard surgical approach. In the premature or otherwise complicated infant, a primary closure may be delayed by temporizing with fistula ligation and gastrostomy tube placement. If the gap between the atretic ends of the esophagus is >3-4 cm (>3 vertebral bodies), primary repair cannot be done; options include using gastric, jejunal, or colonic segments interposed as a neoesophagus. Careful search must be undertaken for the common associated cardiac, renal, and other anomalies. *Thoracoscopic surgical repair is feasible and associated with favorable long-term outcomes.*

OUTCOME

Most children with nonsyndromic EA and TEF grow up to lead normal lives, but complications are often challenging, particularly during the first 5 years of life. Complications of surgery include anastomotic leak, refistulization, and anastomotic stricture formation, necessitating endoscopic dilations. Some recurrent and refractory strictures may need esophageal stent placement or surgical stricture resection. Gastroesophageal reflux disease, resulting from intrinsic abnormalities of esophageal function, often combined with delayed gastric emptying, contributes to management challenges in many cases. Gastroesophageal reflux disease contributes significantly to the respiratory disease **(reactive airway disease)** that often complicates EA and TEF and also worsens the frequent anastomotic strictures after repair of EA.

Many patients have an associated tracheomalacia that improves as the child grows. Hence, it is important to target on prevention of long-term complications using appropriate surveillance techniques such as endoscopy or pH-Impedance.

Visit Elsevier eBooks+ at eBooks.Health.Elsevier.com for Bibliography.

Table 365.1 Clinical Aspects of Esophageal Developmental Anomalies

ANOMALY	AGE AT PRESENTATION	PREDOMINANT SYMPTOMS	DIAGNOSIS	TREATMENT
Isolated atresia	Newborns	Regurgitation of feedings Aspiration	Esophagogram* Plain film: gasless abdomen	Surgery
Atresia + distal TEF	Newborns	Regurgitation of feedings Aspiration	Esophagogram* Plain film: gas-filled abdomen	Surgery
H-type TEF	Infants to adults	Recurrent pneumonia Bronchiectasis	Esophagogram* Bronchoscopy†	Surgery
Esophageal stenosis	Infants to adults	Dysphagia Food impaction	Esophagogram* Endoscopy†	Dilation‡ Surgery§
Duplication cyst	Infants to adults	Dyspnea, stridor, cough (infants) Dysphagia, chest pain (adults)	EUS* MRI/CT†	Surgery
Vascular anomaly	Infants to adults	Dyspnea, stridor, cough (infants) Dysphagia (adults)	Esophagogram* Angiography† MRI/CT/EUS	Dietary modification‡ Surgery§
Esophageal ring	Children to adults	Dysphagia	Esophagogram* Endoscopy†	Dilation‡ Endoscopic incision§
Esophageal web	Children to adults	Dysphagia	Esophagogram* Endoscopy†	Bougienage

*Diagnostic test of choice.
†Confirmatory test.
‡Primary therapeutic approach.
§Secondary therapeutic approach.
TEF, Tracheoesophageal fistula; EUS, endoscopic ultrasound.
From Madanick R, Orlando RC. Anatomy, histology, embryology, and developmental anomalies of the esophagus. In: Feldman M, Friedman LS, Brandt LJ, eds. *Sleisenger and Fordtran's Gastrointestinal and Liver Disease*, 10th ed. Philadelphia: Elsevier; 2016: Table 42.2.

Fig. 365.4 An 18-month-old male with congenital esophageal stenosis. Esophagogram using barium as contrast media shows an anteroposterior (AP) projection (**A**) and an unsuccessful attempt to obtain a lateral projection (**B**) due to poor collaboration of the patient. An asymmetric short narrowing of the distal esophagus is observed as well as proximal dilatation of the esophagus. Gastroesophageal reflux was not identified. *(From Serrao E, Santos, A, Gaivao A. Congenital esophageal stenosis: a rare case of dysphagia. J Radiol Case Rep. 2010;4:8–14. Fig. 2.)*

365.2 Laryngotracheoesophageal Clefts

Seema Khan and Sravan Kumar Reddy Matta

Laryngotracheoesophageal clefts are uncommon anomalies that result when the septum between the esophagus and trachea fails to develop fully, leading to a common channel defect between the pharyngoesophagus and laryngotracheal lumen, thus making the laryngeal closure incompetent during swallowing or reflux. Other developmental anomalies, such as EA and TEF, are seen in 20% of patients with clefts. The severity of presenting symptoms depends on the type of cleft; they are commonly classified as one of four types (I-IV) according to the inferior extent of the cleft. Early in life, the infant presents with stridor, choking, cyanosis, aspiration of feedings, and recurrent chest infections. The diagnosis is difficult and usually requires direct endoscopic visualization of the larynx and esophagus. When contrast radiography is used, material is often seen in the esophagus and trachea. Treatment is surgical repair, which can be complex if the defects are long.

Visit Elsevier eBooks+ at eBooks.Health.Elsevier.com for Bibliography.

Fig. 365.5 An 18-month-old male with congenital esophageal stenosis. Esophagoscopy showed a circumferential, slightly noncentral narrowing at the distal esophagus, 2 cm proximal to the esophagogastric junction. *(From Serrao E, Santos, A, Gaivao A. Congenital esophageal stenosis: a rare case of dysphagia. J Radiol Case Rep. 2010;4:8–14. Fig. 3.)*

365.3 Congenital Esophageal Stenosis

Seema Khan and Sravan Kumar Reddy Matta

Congenital esophageal stenosis (CES) is a rare anomaly of the esophagus with clinical significance. Though the original incidence is not known, it is estimated to affect 1:25,000 to 50,000 live births. The defect results from incomplete separation of respiratory tract from the primitive foregut at the 25th day of fetal life. CES is differentiated by histology into three types: esophageal membrane/web, total bronchial remnants (TBR), and fibromuscular remnants (FMR). Symptoms vary depending on the location and severity of the defect. Higher lesions present with respiratory symptoms and lower lesions present with dysphagia and vomiting. Esophagogram (Fig. 365.4), MRI, CT, and endoscopic ultrasound are used for diagnosis. Endoscopy (Fig. 365.5) is done to evaluate mucosal abnormalities like strictures, foreign bodies, and esophagitis. Treatment option (surgical correction, bougie dilation) is chosen based on the location, severity, and type of stenosis.

Visit Elsevier eBooks+ at eBooks.Health.Elsevier.com for Bibliography.

Chapter 366

Obstructing Disorders of the Esophagus

Seema Khan and Sravan Kumar Reddy Matta

Obstructing lesions classically produce **dysphagia** to *solids* earlier and more noticeably than to liquids and can manifest when the infant liquid diet begins to incorporate solids; this is in contrast to **dysphagia** from **dysmotility,** in which swallowing of *liquids* is affected as early as, or earlier than, solids. In most instances of dysphagia, evaluation begins with fluoroscopy, which may include videofluoroscopic evaluation of swallowing, particularly if aspiration is a primary symptom. Secondary studies are often endoscopic if intrinsic obstruction is suspected or manometric if dysmotility is suspected; other imaging studies may be used in particular cases. Congenital lesions can require surgery, whereas webs and peptic strictures might respond adequately to endoscopic (or bougie) dilation. Peptic strictures, once dilated, should prompt consideration of fundoplication for ongoing prophylaxis.

EXTRINSIC

Esophageal duplication cysts are the most commonly encountered foregut duplications (see Table 365.1). These cysts are lined by intestinal epithelium, have a well-developed smooth muscle wall, and are attached to the normal gastrointestinal tract. Duplication cysts are described as either communicating or noncommunicating with the lumen of the alimentary tract. Most of these affect the distal half of the esophagus on the right side. The most common presentation is respiratory distress caused by compression of the adjacent airways. Dysphagia is a common symptom in older children. Upper gastrointestinal bleeding can occur as a result of acid-secreting gastric mucosa in the duplication wall. **Neuroenteric cysts** might contain glial elements and are associated with **vertebral anomalies.** Diagnosis is made using modalities, such as barium swallow, chest CT, and MRI, or endosonography. Treatment is surgical; laparoscopic approach to excision is also possible.

Enlarged mediastinal or subcarinal **lymph nodes,** caused by infection (tuberculosis, histoplasmosis) or neoplasm (lymphoma), are the most common external masses that compress the esophagus and produce obstructive symptoms. **Vascular anomalies** can also compress the esophagus; *dysphagia lusoria* is a term denoting the dysphagia produced by a developmental vascular anomaly, which is often an aberrant right subclavian artery or right-sided or double aortic arch (see Chapter 481.1).

INTRINSIC

Intrinsic narrowing of the esophageal lumen can be congenital or acquired. The etiology is suggested by the location, the character of the lesion, and the clinical situation. The lower esophagus is the most common location for peptic strictures, which are generally somewhat ragged and several centimeters long. Thin membranous rings, including the **Schatzki ring** at the squamocolumnar junction, can also occlude this area. In the midesophagus, congenital narrowing may be associated with the esophageal atresia–tracheoesophageal fistula complex, in which some of the lesions might incorporate cartilage and might be impossible to dilate safely; alternatively, reflux esophagitis can induce a ragged and extensive narrowing that appears more proximal than the usual peptic stricture, often because of an associated hiatal hernia. Congenital webs or rings can narrow the upper esophagus. The upper esophagus can also be narrowed by an inflammatory stricture occurring after a caustic ingestion or due to epidermolysis bullosa. Cricopharyngeal achalasia can appear radiographically as a cricopharyngeal bar posteriorly in the upper esophagus. **Eosinophilic esophagitis** is one of the most common causes for esophageal obstructive symptoms (see Chapter 370). Although the pathogenesis of obstructive eosinophilic esophagitis is not yet completely explained and seems to vary among individual patients, endoscopy or radiology demonstrates stricture formation in some children with eosinophilic esophagitis, and in others a noncompliant esophagus is evident, with thickened wall layers demonstrable by ultrasonography.

Visit Elsevier eBooks+ at eBooks.Health.Elsevier.com for Bibliography.

Chapter 367

Dysmotility

Seema Khan and Sravan Kumar Reddy Matta

UPPER ESOPHAGEAL AND UPPER ESOPHAGEAL SPHINCTER DYSMOTILITY (STRIATED MUSCLE)

Cricopharyngeal **achalasia** signifies a failure of complete relaxation of the upper esophageal sphincter (UES), whereas cricopharyngeal **incoordination** implies full relaxation of the UES but incoordination of the relaxation with the pharyngeal contraction. These entities are usually detected on videofluoroscopic evaluation of swallowing (sometimes accompanied by visible cricopharyngeal prominence, termed a *bar*), but often the most precise definition of the dysfunction is obtained with manometry. A self-limited form of cricopharyngeal incoordination occurs in infancy and remits spontaneously in the first year of life if nutrition is maintained despite the dysphagia. In children, treatment options for non–self-limited cricopharyngeal achalasia consist of dilation, Botox injection, and transcervical myotomy. It is important to evaluate such children thoroughly, including cranial MRI to detect **Arnold-Chiari malformations,** which can manifest in this way but are best treated by cranial decompression rather than esophageal surgery. Cricopharyngeal spasm may be severe enough to produce posterior pharyngeal (**Zenker**) **diverticulum** above the obstructive sphincter; this entity occurs rarely in children.

Systemic causes of swallowing dysfunction that can affect the oropharynx, UES, and upper esophagus include cerebral palsy, Arnold-Chiari malformations, syringomyelia, bulbar palsy or cranial nerve defects (Möbius syndrome, transient infantile paralysis of the superior laryngeal nerve), transient pharyngeal muscle dysfunction, spinal muscular atrophy, muscular dystrophy, multiple sclerosis, infections (botulism, tetanus, poliomyelitis, diphtheria), inflammatory and autoimmune diseases (dermatomyositis, myasthenia gravis, polyneuritis, scleroderma), and familial dysautonomia. All of these can produce dysphagia. Medications (nitrazepam, benzodiazepines) and tracheostomy can adversely affect the function of the UES and thereby produce dysphagia.

LOWER ESOPHAGEAL AND LOWER ESOPHAGEAL SPHINCTER DYSFUNCTION (SMOOTH MUSCLE)

Causes of dysphagia resulting from more distal primary esophageal dysmotility include achalasia, diffuse esophageal spasm, nutcracker esophagus, and hypertensive lower esophageal sphincter (LES); all but achalasia are rare in children. Secondary causes include Hirschsprung disease, pseudoobstruction syndromes, inflammatory myopathies, scleroderma, and diabetes.

Achalasia is a primary esophageal motor disorder of unknown etiology characterized by loss of LES relaxation and loss of esophageal peristalsis, both contributing to a functional obstruction of the distal esophagus. Degenerative, autoimmune (antibodies to Auerbach

plexus), and infectious (Chagas disease caused by *Trypanosoma cruzi*) factors are possible causes in select cases. In rare cases, achalasia is familial or part of the achalasia, alacrima, and adrenal insufficiency, known as triple A syndrome or **Allgrove syndrome**. *Pseudoachalasia* refers to achalasia caused by various forms of cancer via obstruction of the gastroesophageal junction, infiltration of the submucosa and muscularis of the LES, or as part of the paraneoplastic syndrome with formation of anti-Hu antibodies. Pathologically, in achalasia, inflammation surrounds ganglion cells, which are decreased in number. There is selective loss of postganglionic inhibitory neurons that normally lead to sphincter relaxation, leaving postganglionic cholinergic neurons unopposed. This imbalance produces high basal LES pressures and insufficient LES relaxation. The loss of esophageal peristalsis can be a secondary phenomenon.

Achalasia manifests with regurgitation and dysphagia for solids and liquids and may be accompanied by undernutrition or chronic cough; retained esophageal food can produce esophagitis. *The presentations of chronic regurgitation/vomiting with weight loss, and chronic cough have led to misdiagnoses of anorexia nervosa and asthma, respectively.* The mean age in children is 8.8 years, with a mean duration of symptoms before diagnosis of 23 months; it is uncommon before school age. Chest radiograph shows an air-fluid level in a dilated esophagus. **Barium fluoroscopy** reveals a smooth tapering of the lower esophagus leading to the closed LES, resembling a bird's beak (Fig. 367.1). Loss of primary peristalsis in the distal esophagus with retained food and poor emptying are often present. **Manometry** is the most sensitive diagnostic test and helps differentiate the three types of achalasia; it reveals the defining features of aperistalsis in the distal esophageal body and incomplete or absent LES relaxation, often accompanied by high-pressure LES and low-amplitude esophageal body contractions (Fig. 367.2).

The goals of achalasia therapy are relief of symptoms, improvement of esophageal emptying, and prevention of megaesophagus. The two most effective treatment options are sequential repeated pneumatic dilation and laparoscopic or surgical (Heller) myotomy. Pneumatic dilation is the initial treatment of choice and does not preclude a future myotomy. Surgeons often supplement a myotomy with an antireflux procedure (fundoplication) to prevent the gastroesophageal reflux disease that otherwise often ensues when the sphincter is rendered less competent. Laparoscopic myotomy is a particularly effective procedure in adolescent and young adult males. Peroral endoscopic myotomy (POEM) is a feasible, safe, and effective alternative to the laparoscopic method. Calcium channel blockers (nifedipine) and phosphodiesterase inhibitors offer temporary relief of dysphagia. Endoscopic injection of the LES with **botulinum toxin** counterbalances the selective loss of inhibitory neurotransmitters by inhibiting the release of acetylcholine from nerve terminals and may be an effective initial therapy before a definitive procedure. Botulinum toxin is effective in 50–65% of patients and is expensive; half the patients might require a repeat injection within 1 year. Most eventually require dilation or surgery.

Diffuse esophageal spasm causes chest pain and dysphagia and affects adolescents and adults. It is diagnosed **manometrically** and can be treated with nitrates or calcium-channel-blocking agents.

Gastroesophageal reflux disease (see Chapter 369) constitutes the most common cause of nonspecific abnormalities of esophageal motor function, probably through the effect of the esophageal inflammation on the musculature.

Visit Elsevier eBooks+ at eBooks.Health.Elsevier.com for Bibliography.

Fig. 367.1 Barium esophagogram of a patient with achalasia demonstrating dilated esophagus and narrowing at the lower esophageal sphincter. Note retained secretions layered on top of barium in the esophagus.

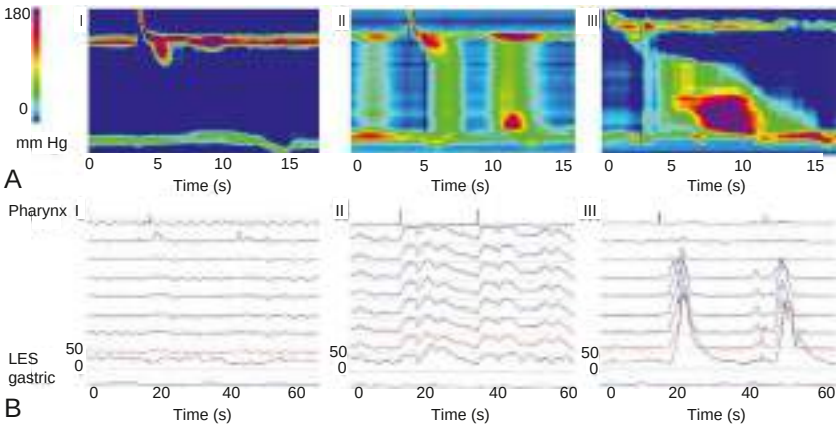

Fig. 367.2 Based on the residual wave type on high-resolution esophageal manometry (HRM), three subtypes of achalasia can be determined. **A,** No distal pressurization is observed in type I (AI), whereas panesophageal pressurizations and spastic contractions are observed in type II (AII) and type III (AIII), respectively. **B,** A similar classification can be made when conventional manometry is used. Note that pressure recordings in type II achalasia are similar in every line tracing, compatible with panesophageal pressurization. LES, Lower esophageal sphincter. *(From Rohof WO, Salvador R, Annese V. Outcomes of treatment for achalasia depend on manometric subtype. Gastroenterology. 2013;144:718–725. Fig. 1.)*

Chapter 368

Hiatal Hernia

Seema Khan and Sravan Kumar Reddy Matta

Herniation of the stomach through the esophageal hiatus can occur as a common sliding hernia (type 1), in which the gastroesophageal junction slides into the thorax, or it can be paraesophageal (type 2), in which a portion of the stomach (usually the fundus) is insinuated next to the esophagus inside the gastroesophageal junction in the hiatus (Figs. 368.1 and 368.2). A combination of sliding and paraesophageal types (type 3) is present in some patients. Sliding hernias are often associated with gastroesophageal reflux disease (see Chapter 369), especially in developmentally delayed children. The relationship to hiatal hernias in adults is unclear. Diagnosis is usually made by an upper gastrointestinal series and upper endoscopy. Medical treatment is not directed at the hernia but at the gastroesophageal reflux, unless failure of medical therapy prompts correction of the hernia at the time of fundoplication.

A paraesophageal hernia can be an isolated congenital anomaly or associated with gastric volvulus, or it may be encountered after fundoplication for gastroesophageal reflux, especially if the edges of a dilated esophageal diaphragmatic hiatus have not been approximated. Fullness after eating and upper abdominal pain are the usual symptoms. Infarction of the herniated stomach is rare.

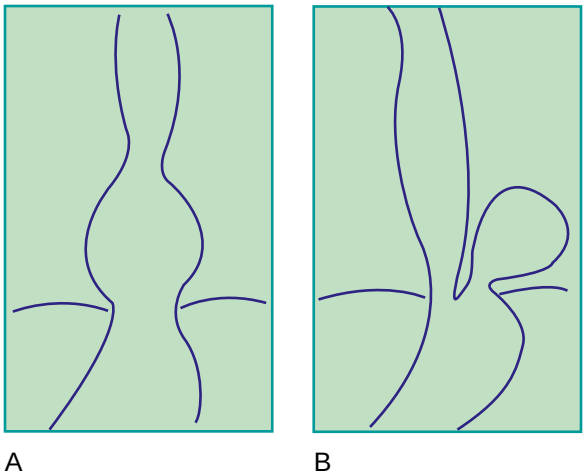

Fig. 368.1 Types of esophageal hiatal hernia. **A,** Sliding hiatal hernia, the most common type. **B,** Paraesophageal hiatal hernia.

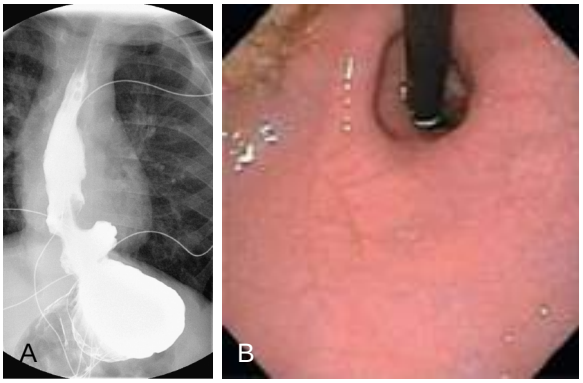

Fig. 368.2 **A,** An upper gastrointestinal series shows a large hiatal hernia that extends above the diaphragm and impedes the exit of contrast from the esophagus into the stomach. Contrast is also noted to reflux to the upper esophagus. **B,** A retroflexed view of the hernia from the stomach during an upper endoscopy.

Chapter 369

Gastroesophageal Reflux Disease

Seema Khan and Sravan Kumar Reddy Matta

Gastroesophageal reflux disease (GERD) is the most common esophageal disorder in children of all ages. Gastroesophageal reflux (GER) signifies the retrograde movement of gastric contents across the lower esophageal sphincter (LES) into the esophagus, which occurs physiologically every day in all infants, older children, and adults. Physiologic GER is exemplified by the effortless regurgitation of normal infants and runs an uncomplicated course. Natural history studies observe that it is uncommon for physiologic GER to have onset before 1 week and to persist beyond 6 months of age, and usually peaks between 3 and 4 months. The phenomenon becomes **pathologic GERD** in infants and children who manifest or report bothersome symptoms because of frequent or persistent GER, producing esophagitis-related symptoms, or extraesophageal presentations, such as respiratory (cough, wheezing, hoarse voice) symptoms, nutritional effects, or growth failure. However, the clinical differentiation between GER and GERD is not straightforward in nonverbal infants who may present with excess crying, fussiness, and intermittent feeding and sleep problems while thriving well, due to non-GERD causes or even to variations of normal infant behavior. Pediatricians may try multiple therapeutic options as they try to diagnose and treat these behaviors. Concerned parents and caregivers may also influence the management through requests for interventions they may have heard about through the internet, or from other parents. As a consequence, we are seeing widespread prescriptions of histamine 2 receptor antagonists (H_2RAs) and proton pump inhibitors (PPIs) to treat neonates and infants with physiologic GER. It is profoundly important for pediatricians and pediatric gastroenterologists to instead address this challenge and curb the trend for over investigation and over treatment through more effective educational campaigns, reassurance of parents, and emphasizing the benign nature of the diagnosis that is best handled with a conservative approach.

PATHOPHYSIOLOGY

Factors determining the esophageal manifestations of reflux include the duration of esophageal exposure (a product of the frequency and duration of reflux episodes), the causticity of the refluxate, and the susceptibility of the esophagus to damage. The LES, defined as a high-pressure zone by manometry, is supported by the crura of the diaphragm at the gastroesophageal junction and, together with valvelike functions of the esophagogastric junction anatomy, form the antireflux barrier. In the context of even the normal intraabdominal pressure augmentations that occur during daily life, the frequency of reflux episodes is increased by insufficient LES tone, by abnormal frequency of LES relaxations, and by hiatal herniation that prevents the LES pressure from being proportionately augmented by the crura during abdominal straining. Normal intraabdominal pressure augmentations may be further exacerbated by straining or respiratory efforts. The duration of reflux episodes is increased by lack of swallowing (e.g., during sleep) and by defective esophageal peristalsis. Vicious cycles ensue because chronic esophagitis produces esophageal peristaltic dysfunction (low-amplitude waves, propagation disturbances), decreased LES tone, and inflammatory esophageal shortening that induces hiatal herniation, all worsening reflux.

Transient LES relaxation (TLESR) is the primary mechanism allowing reflux to occur and is defined as simultaneous relaxation of both LES and the surrounding crura. TLESRs occur independent of swallowing, reduce LES pressure to 0-2 mm Hg (above gastric), and last 10-60 seconds; they appear by 26 weeks of gestation. A vagovagal reflex, composed of afferent mechanoreceptors in the proximal stomach, a brainstem pattern generator, and efferents in the LES, regulates TLESRs. Gastric distention (postprandially, or from abnormal gastric emptying or air swallowing) is the main stimulus for TLESRs. Whether GERD is caused by a higher frequency of TLESRs or by a greater incidence of reflux during TLESRs is debated; each is likely in different persons. Straining during a TLESR makes reflux more likely, as do positions that place the gastroesophageal junction below the air-fluid interface in the stomach. Other factors influencing gastric pressure–volume dynamics, such as increased movement, straining, obesity, large-volume or hyperosmolar meals, gastroparesis, a large sliding hiatal hernia, and increased respiratory effort (coughing, wheezing), can have the same effect.

EPIDEMIOLOGY AND NATURAL HISTORY

Infant reflux becomes evident in the first few months of life, peaks at 4 months, and resolves in up to 88% by 12 months and in nearly all by 24 months. *Happy spitters* are infants who have recurrent regurgitation *without* exhibiting discomfort or refusal to eat and failure to gain weight. Symptoms of GERD in **older children** tend to be chronic, waxing and waning, but completely resolving in no more than half, which resembles adult patterns (Table 369.1). The histologic findings of esophagitis persist in infants who have naturally resolving symptoms of reflux. GERD likely has genetic predispositions: family clustering of GERD symptoms, endoscopic esophagitis, hiatal hernia, Barrett esophagus, and adenocarcinoma have been identified. As a continuously variable and common disorder, complex inheritance involving multiple genes and environmental factors is likely. Genetic linkage is indicated by the strong evidence of GERD in studies with monozygotic twins. A pediatric autosomal dominant form with otolaryngologic and respiratory manifestations has been located to chromosome 13q14, and the locus is termed GERD1.

CLINICAL MANIFESTATIONS

Most of the common clinical manifestations of esophageal disease can signify the presence of GERD and are generally thought to be mediated by the pathogenesis involving acid GER (Table 369.2). Although less noxious for the esophageal mucosa, non–acid-reflux events are recognized to play an important role in extraesophageal disease manifestations. **Infantile reflux** manifests more often with regurgitation (especially postprandially), signs of esophagitis (irritability, arching, choking, gagging, feeding aversion), and resulting failure to thrive; symptoms resolve spontaneously in the majority of infants by 12-24 months. **Older children** can have regurgitation during the preschool years; this complaint diminishes somewhat as children age, and complaints of abdominal and chest pain supervene in later childhood and adolescence. Occasional children present with food refusal or neck contortions (arching, turning of head) that is termed **Sandifer syndrome.** The respiratory presentations are also age dependent: GERD in infants may manifest as obstructive apnea or as stridor or lower airway disease in which reflux complicates primary airway disease such as laryngomalacia or bronchopulmonary dysplasia. Otitis media, sinusitis, lymphoid hyperplasia, hoarseness, vocal cord nodules, and laryngeal edema have all been associated with GERD. Airway manifestations in older children are more commonly related to asthma or to otolaryngologic disease such as laryngitis or sinusitis. Despite the high prevalence of GERD symptoms in asthmatic children, data showing direction of causality are conflicting.

Neurologically challenged children are at an increased risk for GERD. It is not well established if the greater risk is conferred due to inadequate defensive mechanisms and/or inability to express symptoms. A low clinical threshold is important in the early identification and prompt treatment of GERD symptoms in these individuals.

DIAGNOSIS

For most of the typical GERD presentations, particularly in older children, a thorough history and physical examination suffice initially to reach the diagnosis. This initial evaluation aims to identify the pertinent positives in support of GERD and its complications and the negatives that make other diagnoses unlikely. The history may be facilitated and standardized by questionnaires (e.g., the Infant Gastroesophageal Reflux Questionnaire [I-GERQ], and its derivative, the I-GERQ-R), which also permit quantitative scores to be evaluated for their diagnostic discrimination and for evaluative assessment of improvement or worsening of symptoms. The clinician should be alerted to the

Table 369.1 Symptoms According to Age

MANIFESTATIONS	INFANTS	CHILDREN	ADOLESCENTS AND ADULTS
Impaired quality of life	+++	+++	+++
Regurgitation	++++	+	+
Excessive crying/irritability	+++	+	–
Vomiting	++	++	+
Food refusal/feeding disturbances/anorexia	++	+	+
Persisting hiccups	++	+	+
Failure to thrive	++	+	–
Abnormal posturing/Sandifer syndrome	++	+	–
Esophagitis	+	++	+++
Persistent cough/aspiration pneumonia	+	++	+
Wheezing/laryngitis/ear problems	+	++	+
Laryngomalacia/stridor/croup	+	++	–
Sleeping disturbances	+	+	+
Anemia/melena/hematemesis	+	+	+
Apnea/BRUE/desaturation	+	–	–
Bradycardia	+	?	?
Heartburn/pyrosis	?	++	+++
Epigastric pain	?	+	++
Chest pain	?	+	++
Dysphagia	?	+	++
Dental erosions/water brush	?	+	+
Hoarseness/globus pharyngeus	?	+	+
Chronic asthma/sinusitis	–	++	+
Laryngostenosis/vocal nodule problems	–	+	+
Stenosis	–	(+)	+
Barrett/esophageal adenocarcinoma	–	(+)	+

+++, Very common; ++ common; + possible; (+) rare; – absent; ? unknown; BRUE, brief resolved unexplained event; previously called ALTE, or apparent life-threatening event.
From Wyllie R, Hyams JS, Kay M, eds. *Pediatric Gastrointestinal and Liver Disease*. 4th ed. Philadelphia: WB Saunders; 2011: Table 22.3, p. 235.

possibility of other important diagnoses in the presence of any *alarm or warning signs*: bilious emesis, frequent projectile emesis, gastrointestinal bleeding, lethargy, organomegaly, abdominal distention, dysphagia, odynophagia, micro- or macrocephaly, hepatosplenomegaly, anorexia, failure to thrive, diarrhea, fever, bulging fontanelle, and seizures. The important differential diagnoses to consider in the evaluation of an infant or a child with chronic vomiting are milk and other food allergies, eosinophilic esophagitis, pyloric stenosis, intestinal obstruction (especially malrotation with intermittent volvulus), nonesophageal inflammatory diseases, infections, inborn errors of metabolism, hydronephrosis, increased intracranial pressure, rumination, and bulimia. Focused diagnostic testing, depending on the presentation and the differential diagnosis, can then supplement the initial examination.

Most of the esophageal tests are of some use in particular patients with suspected GERD. **Contrast (usually barium) radiographic** study of the esophagus and upper gastrointestinal tract is performed in children with vomiting and dysphagia to evaluate for achalasia, esophageal strictures and stenosis, hiatal hernia, and gastric outlet or intestinal obstruction (Fig. 369.1). It has poor sensitivity and specificity in the diagnosis of GERD as a result of its limited duration and the inability to differentiate physiologic GER from GERD. Furthermore, contrast radiography neither accurately assesses mucosal inflammation nor correlates with severity of GERD.

Extended esophageal pH monitoring of the distal esophagus, no longer considered the sine qua non of a GERD diagnosis, provides a quantitative and sensitive documentation of acidic reflux episodes, the most important type of reflux episodes for pathologic reflux. The distal esophageal pH probe is placed at a level corresponding to 87% of the nares-LES distance, based on regression equations using the patient's height, on fluoroscopic visualization, or on manometric identification of the LES. Normal values of distal esophageal acid exposure (pH <4) are generally established as <5–8% of the total monitored time, but these quantitative normals are insufficient to establish or disprove a diagnosis of pathologic GERD. The most important indications for esophageal pH monitoring are for assessing efficacy of acid suppression during treatment, evaluating apneic episodes in conjunction with a pneumogram and perhaps impedance, and evaluating atypical GERD presentations such as chronic cough, stridor, and asthma. Dual pH probes, adding a proximal esophageal probe to the standard distal one, are used in the diagnosis of extraesophageal GERD, identifying upper esophageal acid exposure times of 1% of the total time as threshold values for abnormality.

Endoscopy allows diagnosis of erosive esophagitis (Fig. 369.2) and complications such as strictures or Barrett esophagus; esophageal biopsies can diagnose histologic reflux esophagitis in the absence of erosions while eliminating allergic and infectious causes. Endoscopy is also used therapeutically to dilate reflux-induced strictures. Radionucleotide scintigraphy using technetium can demonstrate aspiration and delayed gastric emptying when these are suspected.

Table 369.2 Symptoms and Signs That May Be Associated with Gastroesophageal Reflux

SYMPTOMS	SIGNS
Recurrent regurgitation with or without vomiting	Esophagitis
Weight loss or poor weight gain	Esophageal stricture
Irritability in infants	Barrett esophagus
Ruminative behavior	Laryngeal/pharyngeal inflammation
Heartburn or chest pain	Recurrent pneumonia
Hematemesis	Anemia
Dysphagia, odynophagia	Dental erosion
Wheezing	Feeding refusal
Stridor	Dystonic neck posturing (Sandifer syndrome)
Cough	Apnea spells
Hoarseness	Apparent life-threatening events

From Wyllie R, Hyams JS, Kay M, eds. *Pediatric Gastrointestinal and Liver Disease*. 4th ed. Philadelphia: Saunders; 2011: Table 22.1, p. 235.

Fig. 369.1 Barium esophagogram demonstrating free gastroesophageal reflux. Note stricture caused by peptic esophagitis. Longitudinal gastric folds above the diaphragm indicate the unusual presence of an associated hiatal hernia.

The multichannel **intraluminal impedance** is a cumbersome test, but with potential applications both for diagnosing GERD and for understanding esophageal function in terms of bolus flow, volume clearance, and (in conjunction with manometry) motor patterns associated with GERD. Because of the multiple sensors and a distal pH sensor, it is possible to document acidic reflux (pH <4), weakly acidic reflux (pH 4-7), and weakly alkaline reflux (pH >7) with multichannel intraluminal impedance. It is an important tool in those with respiratory symptoms, particularly for the determination of nonacid reflux, but must be cautiously applied in routine clinical evaluation because of limited evidence-based parameters for GERD diagnosis and symptom association.

Esophageal manometry is not useful in demonstrating gastroesophageal reflux but might be of use to evaluate TLESR.

Laryngotracheobronchoscopy evaluates for visible airway signs that are associated with extraesophageal GERD, such as posterior laryngeal inflammation and vocal cord nodules; it can permit diagnosis of silent aspiration (during swallowing or during reflux) by bronchoalveolar lavage with subsequent quantification of lipid-laden macrophages in airway secretions. Detection of pepsin in tracheal fluid is a marker of reflux-associated aspiration of gastric contents. Esophageal manometry permits evaluation for dysmotility, particularly in preparation for antireflux surgery.

Empirical antireflux therapy, using a time-limited trial of high-dose PPI, is a cost-effective strategy for diagnosis in adults; although not formally evaluated in older children, it has also been applied to this age group (Fig. 369.3). Failure to respond to such empirical treatment, or a requirement for the treatment for prolonged periods, mandates formal diagnostic evaluation.

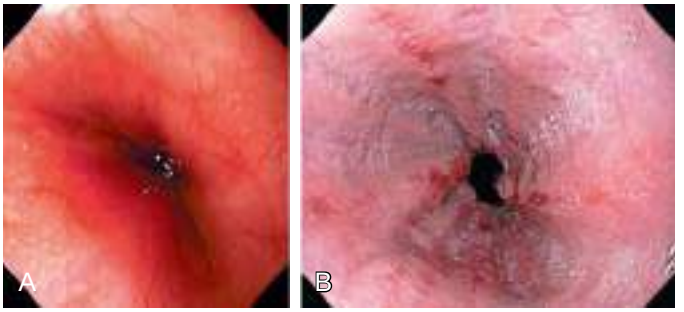

Fig. 369.2 Endoscopic image of a normal esophagus (**A**) and erosive peptic esophagitis (**B**).

MANAGEMENT

The conservative therapy and lifestyle modifications that form the foundation of GERD therapy can be effectively implemented through education and reassurance for parents. Dietary measures for infants include normalization of any abnormal feeding techniques, volumes, and frequencies. Thickening of feeds or use of commercially prethickened formulas increases the percentage of infants with no regurgitation, decreases the frequency of daily regurgitation and emesis, and increases the infant's weight gain. However, caution should be exercised when managing preterm infants because of the possible association between xanthan gum-based thickened feeds and necrotizing enterocolitis. The evidence does not clearly favor one type of thickener over another; the addition of a tablespoon of rice or oat cereal per ounce of formula results in a greater caloric density (30 kcal/oz) and reduced crying time, although it might not modify the number of nonregurgitant reflux episodes. Caution must be exercised while using rice cereal, as studies show increased risk of arsenic exposure in children with excessive rice and rice product consumption. A short trial (2 weeks) of a hypoallergenic diet in infants may be used to exclude milk or soy protein allergy before pharmacotherapy. A combination of modified feeding volumes, hydrolyzed infant formulas, proper positioning, and avoidance of tobacco smoke exposure satisfactorily improve GERD symptoms in 24–59% of infants with GERD. Older children should be counseled to avoid acidic or reflux-inducing foods, particularly if these trigger symptoms (tomatoes, chocolate, mint), and beverages (juices, carbonated and caffeinated drinks, alcohol). Weight reduction for obese patients and elimination of smoke exposure are other crucial measures at all ages.

Positioning measures are particularly important for infants who cannot control their positions independently. Seated position worsens infant reflux and should be avoided in infants with GERD. Esophageal pH monitoring demonstrates more reflux episodes in infants in supine and side positions compared with the prone position, but evidence that the supine position reduces the risk of sudden infant death syndrome (SIDS) has led the American Academy of Pediatrics and the North American Society of Pediatric Gastroenterology and Nutrition to recommend supine positioning during sleep. When the infant is awake and observed, prone position and upright carried position can be used to minimize

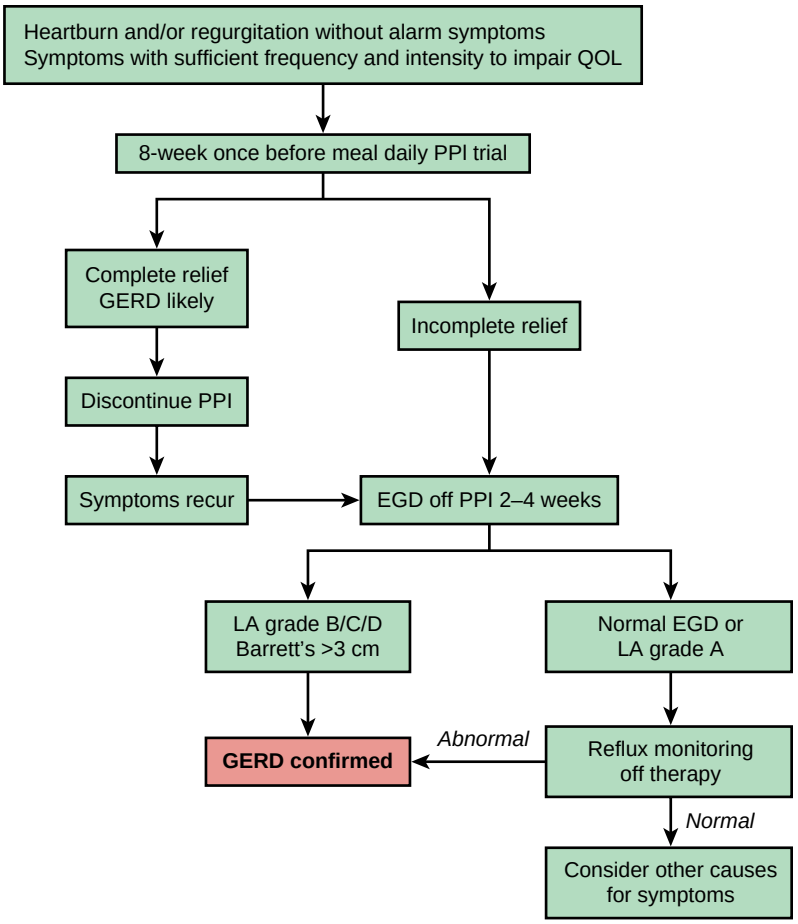

Fig. 369.3 Diagnostic algorithm for GERD. EGD, Esophagogastroduodenoscopy; LA, Los Angeles; PPI, proton pump inhibitor; QOL, quality of life. *(From Katz PO, Dunbar KB, Schnoll-Sussman FH, et al. ACG clinical guideline for the diagnosis and management of gastroesophageal reflux disease. Am J Gastroenterol. 2022;117:27–56. Fig. 1, p. 33.)*

reflux. Lying in the flat supine position and semi-seated positions (e.g., car seats, infant carriers) in the postprandial period are considered provocative positions for GER and therefore should be avoided. The efficacy of positioning for older children is unclear, but some evidence suggests a benefit to left side position and head elevation during sleep. The head should be elevated by elevating the head of the bed, rather than using excess pillows, to avoid abdominal flexion and compression that might worsen reflux, and increases the risk of SIDS (see Chapter 423).

Pharmacotherapy is directed at ameliorating the acidity of the gastric contents or at promoting their aboral movement and should be considered for those symptomatic infants and children who are either highly suspected or proven to have GERD. Antacids are the most commonly used antireflux therapy and are readily available over the counter. They provide rapid but transient relief of symptoms by acid neutralization. The long-term regular use of antacids cannot be recommended because of side effects of diarrhea (magnesium antacids) and constipation (aluminum antacids) and rare reports of more serious side effects of chronic use.

H_2RAs (cimetidine, famotidine, and nizatidine) have been used as antisecretory agents that act by selective inhibition of histamine receptors on gastric parietal cells. It is important to note that ranitidine, one of the most popular H_2RAs was recalled by the FDA in 2020 due to the discovery that it contained concerning amounts of a potential carcinogen called N-nitrosodimethylamine (NDMA). H_2RAs were beneficial in the treatment of mild to moderate reflux esophagitis. They have been recommended because of their excellent overall safety profile, *but they are superseded by PPIs in this role.*

PPIs (omeprazole, lansoprazole, pantoprazole, rabeprazole, and esomeprazole) provide the most potent acid blockade effect by blocking the hydrogen–potassium adenosine triphosphatase channels of the final common pathway in gastric acid secretion. PPIs are superior to H_2RAs in the treatment of severe and erosive esophagitis. Pharmacodynamic studies indicate that children require higher doses of PPIs than adults on a per-weight basis. The use of PPIs to treat infants and children deemed to have GERD on the basis of symptoms is common; however, an important systematic review of the efficacy and safety of PPI therapy in pediatric GERD reveals no clear benefit for PPI over placebo use in *suspected infantile GERD* (crying, arching behavior). Limited pediatric data are available to draw definitive conclusions about potential complications implicated with PPI use, such as respiratory infections, *Clostridium difficile* infection, osteopenic bone fractures (noted in adults), hypomagnesemia, and kidney damage; most randomized controlled studies have not confirmed these side effects.

Prokinetic agents available in the United States include metoclopramide (dopamine-2 and 5-HT_3 antagonist), bethanechol (cholinergic agonist), and erythromycin (motilin receptor agonist). Most of these increase LES pressure, some improve gastric emptying or esophageal clearance, but none affects the frequency of TLESRs. The available controlled trials *have not* demonstrated much efficacy for GERD. The FDA announced a black box warning for metoclopramide, linking its chronic use (longer than 3 months) with tardive dyskinesia, the rarely reversible movement disorder. Baclofen is a centrally acting γ-aminobutyric acid agonist that decreases reflux by decreasing TLESRs in healthy adults and in a small number of neurologically impaired children with GERD. Other agents of interest include peripherally acting γ-aminobutyric acid agonists devoid of central side effects, and metabotropic glutamate receptor 5 antagonists that are reported to reduce TLESRs but are as yet inadequately studied for this indication in children.

Cisapride is a serotonergic-receptor agonist with a prokinetic effect that is only available in the United States through a limited access program because of its cardiac side effects (QT prolongation, dysrhythmias).

Surgery, usually **fundoplication,** is effective therapy for intractable GERD in children, particularly those with refractory esophagitis or strictures and those at risk for significant morbidity from chronic pulmonary disease. It may be combined with a gastrostomy for feeding or venting. The availability of potent acid-suppressing medication mandates more-rigorous analysis of the relative risks (or costs) and benefits of this

relatively irreversible therapy compared with long-term pharmacotherapy. Some of the risks of fundoplication include a wrap that is *too tight* (producing dysphagia or gas-bloat) or *too loose* (and thus incompetent). Surgeons may choose to perform a *tight* (360 degrees, Nissen) or variations of a *loose* (<360 degrees, Thal, Toupet, Boix-Ochoa) wrap, or to add a gastric drainage procedure (pyloroplasty) to improve gastric emptying, based on their experience and the patient's disease. Preoperative accuracy of the diagnosis of GERD and the skill of the surgeon are two of the most important predictors of successful outcome. Long-term studies suggest that fundoplications often become incompetent in children, as in adults, with reflux recurrence rates of up to 14% for Nissen and up to 20% for loose wraps (the rates may be highest with laparoscopic procedures); this fact currently combines with the potency of PPI therapy that is available to shift practice toward long-term pharmacotherapy in many cases. Fundoplication procedures may be performed as open operations, by laparoscopy, or by endoluminal (gastroplication) techniques. Pediatric experience is limited with endoscopic application of radiofrequency therapy (Stretta procedure) to a 2-3 cm area of the LES and cardia to create a high-pressure zone to reduce reflux.

Total esophagogastric dissociation is performed in selective neurologically impaired children with repeated failed fundoplications and with severe life-threatening GERD.

Visit Elsevier eBooks+ at eBooks.Health.Elsevier.com for Bibliography.

369.1 Complications of Gastroesophageal Reflux Disease

Seema Khan and Sravan Kumar Reddy Matta

ESOPHAGEAL: ESOPHAGITIS AND SEQUELAE—STRICTURE, BARRETT ESOPHAGUS, ADENOCARCINOMA

Esophagitis can manifest as irritability, arching, and feeding aversion in infants; chest or epigastric pain in older children; and, rarely, as hematemesis, anemia, or Sandifer syndrome at any age. Erosive esophagitis is found in approximately 12% of children with GERD symptoms and is more common in boys, older children, neurologically challenged children, children with severe chronic respiratory disease, and in those with hiatal hernia. Prolonged and severe esophagitis leads to formation of strictures, generally located in the distal esophagus, producing dysphagia, and requiring repeated esophageal dilations and often fundoplication. Long-standing esophagitis predisposes to metaplastic transformation of the normal esophageal squamous epithelium into intestinal columnar epithelium, termed **Barrett esophagus,** a precursor of esophageal adenocarcinoma. A large multicenter prospective study of 840 consecutive children who underwent elective endoscopies reported a 25.7% prevalence for reflux esophagitis, and a mere 0.12% for Barrett esophagus in children without neurologic disorders or tracheoesophageal anomalies. Both Barrett esophagus and adenocarcinoma occur more in White males and in those with increased duration, frequency, and severity of reflux symptoms. This transformation increases with age to plateau in the fifth decade; adenocarcinoma is rare in childhood. Barrett esophagus, uncommon in children, warrants periodic surveillance biopsies, aggressive pharmacotherapy, and fundoplication for progressive lesions.

NUTRITIONAL

Esophagitis and regurgitation may be severe enough to induce failure to thrive because of caloric deficits. Enteral (nasogastric or nasojejunal, or percutaneous gastric or jejunal) or parenteral feedings are sometimes required to treat such deficits.

EXTRAESOPHAGEAL: RESPIRATORY ("ATYPICAL") PRESENTATIONS

GERD should be included in the differential diagnosis of children with unexplained or refractory otolaryngologic and respiratory complaints. GERD can produce respiratory symptoms by direct contact of the refluxed gastric contents with the respiratory tract (aspiration, laryngeal penetration, or microaspiration) or by reflexive interactions between the esophagus and respiratory tract (inducing laryngeal closure or bronchospasm). Often, GERD and a primary respiratory disorder, such as asthma, interact and a vicious cycle between them worsens both diseases. Many children with these extraesophageal presentations do not have typical GERD symptoms, making the diagnosis difficult. These atypical GERD presentations require a thoughtful approach to the differential diagnosis that considers a multitude of primary otolaryngologic (infections, allergies, postnasal drip, voice overuse) and pulmonary (asthma, cystic fibrosis) disorders. Therapy for the GERD must be more intense (usually incorporating a PPI) and prolonged (usually at least 3-6 months). In these cases a multidisciplinary approach involving otolaryngology, pulmonary for airway disease, and gastroenterology for reflux disease is often warranted for specialized diagnostic testing and for optimizing intensive management.

APNEA AND STRIDOR

These upper airway presentations have been linked with GERD in case reports and epidemiologic studies; temporal relationships between them and reflux episodes have been demonstrated in some but not all patients by esophageal pH–multichannel intraluminal impedance studies, and a beneficial response to therapy for GERD provides further support in a number of case series. An evaluation of 1,400 infants with apnea attributed the apnea to GERD in 50%, but other studies have failed to find an association. Apnea and brief resolved unexplained event (BRUE)-like presentation (previously called an "apparent life-threatening event"; see Chapter 424) caused by reflux is generally obstructive due to laryngospasm that may be conceived as an abnormally intense protective reflex. At the time of such apnea, infants have often been provocatively positioned (supine or flexed seated), have been recently fed, and have shown signs of obstructive apnea, with unproductive respiratory efforts. *The evidence suggests that for the large majority of infants presenting with apnea and BRUE, GERD is not causal.* Stridor triggered by reflux generally occurs in infants anatomically predisposed toward stridor (laryngomalacia, micrognathia). Spasmodic croup, an episodic frightening upper airway obstruction, can be an analogous condition in older children. Esophageal pH probe studies might fail to demonstrate linkage of these manifestations with reflux because of the buffering of gastric contents by infant formula and the episodic nature of the conditions. Pneumograms can fail to identify apnea if they are not designed to identify obstructive apnea by measuring nasal airflow.

Reflux laryngitis and other otolaryngologic manifestations (also known as laryngopharyngeal reflux) can be attributed to GERD. **Hoarseness,** voice fatigue, throat clearing, chronic cough, pharyngitis, sinusitis, otitis media, and a sensation of globus have been cited. Laryngopharyngeal signs of GERD include edema and hyperemia (of the posterior surface), contact ulcers, granulomas, polyps, subglottic stenosis, and interarytenoid edema. The paucity of well-controlled evaluations of the association contributes to the skepticism with which these associations may be considered. Other risk factors irritating the upper respiratory passages can predispose some patients with GERD to present predominantly with these complaints.

Many studies have reported a strong association between asthma and reflux as determined by history, pH–multichannel intraluminal impedance, endoscopy, and esophageal histology. GERD symptoms are present in ~23% (19–80%) of children with asthma; abnormal pH results are noted in ~63%, and esophagitis in ~35% of asthmatic children. However, this association does not clarify the direction of causality in individual cases and thus does not indicate which patients with asthma are likely to benefit from anti-GERD therapy. Children with asthma who are particularly likely to have GERD as a provocative factor are those with symptoms of reflux disease, those with refractory or steroid-dependent asthma, and those with nocturnal worsening of asthma. Endoscopic evaluation that discloses esophageal sequelae of GERD provides an impetus to embark on the aggressive (high dose and many months' duration) therapy of GERD.

Dental erosions constitute the most common oral lesion of GERD, the lesions being distinguished by their location on the lingual surface of the teeth. The severity seems to correlate with the presence of reflux symptoms and the presence of an acidic milieu as the result of reflux in the proximal esophagus and oral cavity. The other common factors that can produce similar dental erosions are juice consumption and bulimia.

Visit Elsevier eBooks+ at eBooks.Health.Elsevier.com for Bibliography.

Chapter 370

Eosinophilic Esophagitis, Pill Esophagitis, and Infective Esophagitis

Seema Khan

EOSINOPHILIC ESOPHAGITIS

Eosinophilic esophagitis (EoE) is a chronic esophageal disorder characterized by esophageal dysfunction and infiltration of the esophageal epithelium by ≥15 eosinophils per high-power field (hpf). The proposed diagnostic criteria are the clinical presentation of esophageal dysfunction in association with esophageal epithelial infiltration of at least 15 eosinophils per hpf or ~60 eosinophils per mm^2; a careful evaluation of non-EoE disorders was warranted. Proton pump inhibitors (PPIs) should be considered as another treatment option rather than a diagnostic criterion to differentiate from gastroesophageal reflux disease (GERD). EoE is a global disease, with incidence and prevalence rates in children of 5 and 29.5 per 100,000. Although infants and toddlers present commonly with vomiting, feeding problems, and poor weight gain, older children and adolescents usually experience solid food dysphagia with occasional food impactions (Figs. 370.1 and 370.2) or strictures and may complain of heartburn and chest or epigastric pain. Many patients are male. The mean age at diagnosis is 7 years (range: 1-17 years), and the duration of symptoms is 3 years. Many patients have other atopic diseases (or a positive family history) and associated food allergies; laboratory abnormalities can include peripheral eosinophilia and elevated immunoglobulin E (IgE) levels. The pathogenesis involves mainly T-helper type 2 (Th2) cytokine-mediated (interleukin [IL]-5 and -13) pathways leading to production of a potent eosinophil chemoattractant, eotaxin-3, by esophageal epithelium.

The eosinophilic esophagitis endoscopic reference score **(EREFS)**, based on commonly observed features of edema (E), rings (R; Fig. 370.3), exudates (E; see Fig. 370.3), furrows (F; Fig. 370.4), and strictures (S), has utility in diagnosis and monitoring response to treatment. Esophageal histology reveals profound eosinophilia, with a currently acceptable cutoff for diagnosis chosen at ≥15-20 eosinophils per hpf. Up to 30% children with EoE have grossly visible normal esophageal mucosa or endoscopy.

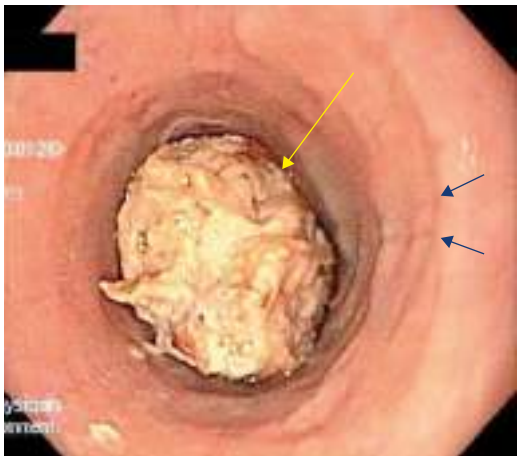

Fig. 370.1 Endoscopic visualization of esophageal food impaction *(yellow arrow)* and mucosal rings *(blue arrows)*.

The role of acid in the pathogenesis and treatment of EoE has been the subject of intense research with studies arguing for and against acid suppression. It is important to highlight that gastric acid, among other functions, activates important digestive enzymes and thereby facilitates digestion of food. Acid suppression is postulated to promote absorption of relatively larger intact proteins with allergenic potential as a consequence of reduced food digestion. Dilated esophageal epithelial intercellular spaces that have been described secondary to proton pump inhibition may increase mucosal permeability of food antigens and further provoke allergic pathways. Retrospective studies have shown that infants treated with histamine receptor antagonists and PPIs are at risk for developing EoE at an earlier age compared to matched control infants. EoE is differentiated from GERD by concurrent atopic diseases, its general lack of erosive esophagitis, its greater eosinophil density, and its normal esophageal pH–multichannel intraluminal impedance results. *A favorable response to PPI therapy should not be considered diagnostic of GERD, as approximately 50% of children with EoE also demonstrate histologic response.* Observations in children and adults with EoE are notable for striking similarities between PPI responders and PPI nonresponders with regard to symptoms, histology, molecular signature, and mechanistic features. This response may be because of an acid suppressive action or downregulation of Th2 allergic cell pathway, an antieosinophil effect of the PPI class that is mediated by inhibition of eotaxin-3 secretion. Evaluation of EoE should include a search for food (aerodigestive) and environmental allergies via skin prick (IgE mediated) and patch (non–IgE mediated) tests to guide decisions regarding dietary elimination and future food challenges.

Initial treatment involves dietary restrictions that take one of three forms: elimination diets guided by circumstantial evidence and food allergy test results, "6-food elimination diet" removing the major food allergens (milk, soy, wheat, egg, peanuts and tree nuts, seafood), and trial of an elemental diet composed exclusively of an amino acid-based formula. Elimination diets are generally successful, with highest histologic response observed in nearly 91% on the elemental diet, in 73% who undergo empiric dietary elimination, and 48% with a targeted elimination diet. The major drawbacks of these dietary therapies lie in their cost, difficult access, and lower quality of life, any or all of which influence adherence and outcome.

Topically acting swallowed corticosteroids (fluticasone without spacer, viscous budesonide suspension) are the only therapy strongly recommended based on moderate quality evidence as first-line therapy, as well as for those who refuse, fail to adhere, or have a poor response to restricted diets. Histologic remission is observed in 68–77% children and adults treated with fluticasone for 3 months. Histologic recurrence after discontinuation of fluticasone is common, and emphasizes the need for maintenance therapy. Ideal approaches carefully balance the risks of adrenocortical insufficiency as well as bone demineralization and fungal infections against the risk of EoE evolving from an inflammatory to fibrostenotic disease, which can produce esophageal stenosis and strictures. Therapies under investigation include esophageal-specific delivery formulation of topical corticosteroids and monoclonal antibodies against IL-13 (RPC4046) and IL-5 (mepolizumab, reslizumab). Dupilumab, a monoclonal antibody that inhibits IL-4 and IL-13 signaling, administered by subcutaneous injection, is approved for patients ≥12 years of age with EoE. Histologic remission and improvement of dysphagia symptoms has occurred during dupilumab therapy with minor side effects (injection site reactions, upper respiratory tract infections, arthralgias, herpes viral infections). Patients require periodic endoscopy and histologic reassessment to accurately monitor response to treatment, particularly given that there can be a significant disconnect between symptoms and histology in the evolution of the disease. Expert clinical guidelines stress the need for long-term studies to develop systematic treatment and best follow-up protocols.

INFECTIVE ESOPHAGITIS

Uncommon, and most often affecting immunocompromised children, infective esophagitis is caused by fungal agents, such as

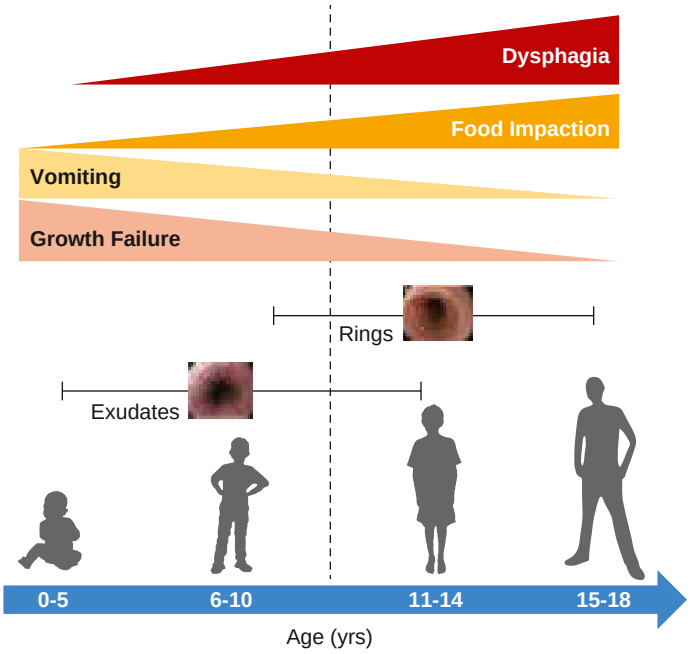

Fig. 370.2 Eosinophilic esophagitis. Graphical representation of symptoms and endoscopic findings by age. *(Modified from Oliva S, Dias JA, Rea F, et al. Characterization of eosinophilic esophagitis from the European pediatric eosinophilic esophagitis registry [pEEr] or ESPGHAN. J Pediatr Gastroenterol Nutr. 2022;75[3]:325–333. Fig. 2.)*

Fig. 370.3 Endoscopic image of eosinophilic esophagitis with characteristic mucosal appearance of furrowing and white specks.

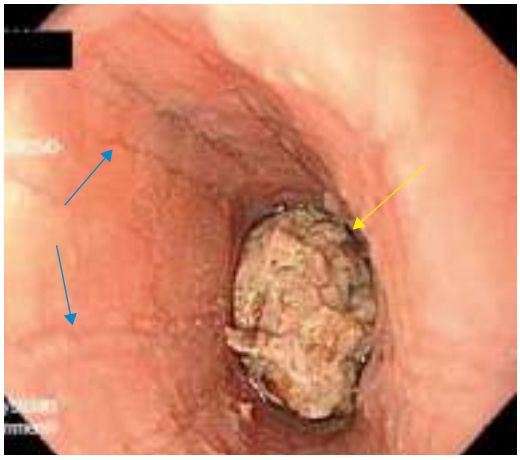

Fig. 370.4 Endoscopy photograph showing mucosal furrowing *(blue arrows)* characteristic of eosinophilic esophagitis in a patient with food impaction *(yellow arrow)*.

Candida albicans and *Torulopsis glabrata;* viral agents, such as herpes simplex (HSV), cytomegalovirus (CMV), HIV, and varicella zoster; and, rarely, bacterial infections, including diphtheria and tuberculosis, or parasites. The typical presenting signs and symptoms are odynophagia, dysphagia, and retrosternal or chest pain; there may also be fever, nausea, and vomiting. *Candida* is the leading cause of infective esophagitis in immunocompetent and immunocompromised children and presents with concurrent oropharyngeal infection in the majority of immunocompromised patients. It may also be an incidental finding in asymptomatic patients, notably in those with EoE receiving topical swallowed corticosteroids. Esophageal viral infections can also manifest in immunocompetent hosts as an acute febrile illness. Infectious esophagitis, like other forms of esophageal inflammation, occasionally progresses to esophageal stricture. Diagnosis of infectious esophagitis is made by endoscopy, usually notable for white plaques in *Candida,* multiple superficial ulcers or *volcano ulcers* in HSV, and single deep ulcer in CMV. Histopathologic examination solidifies the diagnosis with the detection of yeast and pseudohyphae in *Candida;* tissue invasion distinguishes esophagitis from mere colonization. Multinucleated giant cells with intranuclear Cowdry type A (eosinophilic) and type B (ground glass appearance) inclusions in HSV, and both intranuclear and intracytoplasmic inclusions producing an *owl's eye* appearance in CMV are typically described. Adding polymerase chain reaction, tissue-viral culture, and immunocytochemistry enhances the

diagnostic sensitivity and precision. Treatment is with appropriate antimicrobial agents: azole therapy, particularly oral fluconazole for *Candida;* oral acyclovir for HSV; and oral valganciclovir for CMV, or alternatively intravenous ganciclovir in severe CMV disease.

PILL ESOPHAGITIS

This acute injury is produced by contact with a damaging agent. Medications implicated in pill esophagitis include tetracycline, doxycycline, potassium chloride, ferrous sulfate, nonsteroidal antiinflammatory medications, cloxacillin, and alendronate (Table 370.1). Most often the offending tablet is ingested at bedtime with inadequate water. This practice often produces acute discomfort followed by progressive retrosternal pain, odynophagia, and dysphagia. Endoscopy shows a focal lesion often localized to one of the anatomic narrowed regions of the esophagus or to an unsuspected pathologic narrowing (Fig. 370.5). Treatment is supportive; lacking much evidence, sucralfate, antacids, topical anesthetics, and bland or liquid diets are often used. The offending pill may be restarted after complete resolution of symptoms, if deemed necessary, though with clear emphasis on ingestion with an adequate volume of water, usually at least 4 oz.

Visit Elsevier eBooks+ at eBooks.Health.Elsevier.com for Bibliography.

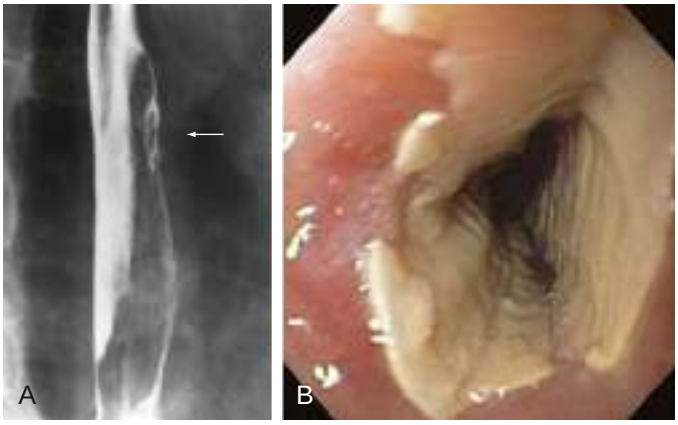

Fig. 370.5 A, Barium esophagogram showing esophageal ulceration secondary to tetracycline, with the *arrow* pointing to an area of ulcerations. B, Endoscopic image of a tetracycline-induced esophageal burn. *(From Katzka DA. Esophageal disorders caused by medications, trauma, and infection. In Feldman M, Friedman LS, Brandt LJ, eds. Sleisenger and Fordtran's Gastrointestinal and Liver Disease. 10th ed. Philadelphia: Elsevier; 2016: Fig. 46.1).*

Table 370.1 Medications Commonly Associated with Esophagitis or Esophageal Injury

ANTIBIOTICS
Clindamycin
Doxycycline
Penicillin
Rifampin
Tetracycline
ANTIVIRAL AGENTS
Nelfinavir
Zalcitabine
Zidovudine
BISPHOSPHONATES
Alendronate
Etidronate
Pamidronate
CHEMOTHERAPEUTIC AGENTS
Bleomycin
Cytarabine
Dactinomycin
Daunorubicin
5-Fluorouracil
Methotrexate
Vincristine
NSAIDs
Aspirin
Ibuprofen
Naproxen
OTHER MEDICATIONS
Ascorbic acid
Ferrous sulfate
Lansoprazole
Multivitamins
Potassium chloride
Quinidine
Theophylline

NSAIDs, Nonsteroidal antiinflammatory drugs.
From Katzka DA. Esophageal disorders caused by medications, trauma, and infection. In Feldman M, Friedman LS, Brandt LJ, eds. *Sleisenger and Fordtran's Gastrointestinal and Liver Disease.* 10th ed. Philadelphia: Elsevier; 2016: Box 46.1.

Chapter 371

Esophageal Perforation

Seema Khan

The majority of esophageal perforations in children are from blunt trauma (automobile injury, gunshot wounds, child abuse) or are iatrogenic. Cardiac massage, the Heimlich maneuver, nasogastric tube placement, traumatic laryngoscopy or endotracheal intubation, excessively vigorous postpartum suctioning of the airway during neonatal resuscitation, difficult upper endoscopy, sclerotherapy of esophageal varices, esophageal compression by a cuffed endotracheal tube, and dilation for therapy of achalasia and strictures have all been implicated. Esophageal rupture has followed forceful vomiting in patients with anorexia and has followed esophageal injury due to caustic ingestion, foreign body ingestion, food impactions, pill esophagitis, or eosinophilic esophagitis. Drinking cold, carbonated beverages rapidly is also known to cause esophageal perforation.

Spontaneous esophageal rupture **(Boerhaave syndrome)** is less common and is associated with sudden increases in intraesophageal pressure brought on by situations such as vomiting, coughing, or straining to stool. Children and adults with eosinophilic esophagitis have also been described with Boerhaave syndrome in the setting of forceful emesis in the aftermath of esophageal food impaction. The prevalence of esophageal perforation in a large retrospective analysis was reported to be 0.05%, the majority of whom were low birthweight (<1,000 g) and ≤28 weeks' gestational age. Importantly, esophageal perforation was not associated with an increased mortality in this pediatric cohort. In older children, as in adults, the tear occurs on the distal left lateral esophageal wall, because the smooth muscle layer here is weakest; in neonates (neonatal Boerhaave syndrome), spontaneous rupture is on the right.

Symptoms of esophageal perforation include pain, neck tenderness, dysphagia, subcutaneous crepitus, fever, and tachycardia; several patients with cervical-level esophageal perforations have displayed cold water polydipsia in an attempt to soothe pain in the throat.

Imaging studies are important for a rapid and accurate diagnosis. Perforations in the proximal thoracic esophagus tend to create signs (pneumothorax, effusions) in the left chest, whereas the signs of distal tears are more often on the right. Plain radiography (posteroanterior and lateral views) and CT of the neck and chest are often used, with the latter as more sensitive and accurate in diagnosis. Signs of perforation include pneumomediastinum, mediastinal widening, subcutaneous emphysema, pneumothorax, hydrothorax, pleural effusion, and lung collapse. If these x-rays are normal, an esophagogram using water-soluble contrast media should be performed, but esophagograms miss >30% of cervical perforations. Therefore, a negative water-soluble contrast esophagogram should be followed by a barium study; the greater density of barium can better demonstrate a small defect, although it has a higher risk of inflammatory mediastinitis. Endoscopy may also be useful but carries a 30% false-negative rate.

Treatment must be individualized. Small tears in contained perforations with minimal mediastinal contamination in hemodynamically stable patients can be treated conservatively with broad-spectrum antibiotics, nothing given orally, gastric drainage, and parenteral nutrition. Endoscopic techniques, considered less invasive and morbid, are now being used more frequently and include clips for defects <2 cm, and placement of stents and suturing for larger defects. Chest exploration and direct surgical repair is infrequently indicated these days. Mortality rates range between 20% and 28%, with poor prognosis correlated with delayed diagnosis and interventions.

Visit Elsevier eBooks+ at eBooks.Health.Elsevier.com for Bibliography.

Chapter 372

Esophageal Varices

Seema Khan

Esophageal varices form in adults and children with portal hypertension with hepatic venous pressure gradient >10 mm Hg and pose a risk for bleeding at >12 mm Hg (see Chapter 415). Spontaneous decompression of this hypertension through portosystemic collateral circulation via the coronary vein, in conjunction with the left gastric veins, gives rise to esophageal varices. Most esophageal varices are *uphill varices;* less commonly, those that arise in the absence of portal hypertension and with superior vena cava obstruction are *downhill varices*. Their treatment is directed at the underlying cause of the superior vena cava abnormality. Hemorrhage from esophageal varices is the major cause of morbidity and mortality from portal hypertension. Presentation is with significant hematemesis and melena; whereas most patients have liver disease, some children with extrahepatic portal venous obstruction (EHPVO) might have been previously asymptomatic. Any child with hematemesis and splenomegaly should be presumed to have esophageal variceal bleeding until proved otherwise. The leading causes of pediatric portal hypertension, biliary atresia, and EHPVO are uniquely distinct from diseases encountered in adults. Hence, children tend to tolerate variceal bleeding better because they have generally well compensated liver disease, with studies reporting mortality risk <1% after initial variceal bleed. The likelihood of esophageal varices in children with EHPVO increases from 1% to 22%, and small (13%) to large (54%) at 1 year and 5 years of age, respectively. Upper endoscopy is the preferred diagnostic test for esophageal varices, as it provides definitive diagnosis and delineation of details that aid in predicting the risk for bleeding, as well as enabling therapy for acute bleeding episodes via either sclerotherapy or band ligation. A report comprising a large series of children with biliary atresia and portal hypertension described endoscopic findings of large varices, red marks, and the presence of gastric varices as predictive of bleeding. Noninvasive methods of evaluating varices include barium contrast studies, ultrasound, computerized tomography, magnetic resonance, and elastography, but they are not recommended for routine diagnostic evaluation because of suboptimal accuracy compared to endoscopy.

Primary prophylaxis with the goal of preventing an initial hemorrhage can decrease the incidence of esophageal bleeding; the various modalities used are nonselective β-blockade (e.g., propranolol or nadolol), sclerotherapy, ligation, and portosystemic shunt surgery. Variceal band ligation is regarded as the preferred endotherapy and can be feasibly performed in children weighing more than 10 kg. Meso-Rex bypass surgery should be offered to children with EHPVO as both primary and secondary prophylaxis in the appropriate context (Fig. 372.1). Due to insufficient evidence, the same cannot be recommended regarding endoscopic therapies and nonselective β blockers for primary prophylaxis in children. In contrast, adults do have a reduced risk of first-time variceal bleeding with endoscopic variceal ligation when compared with untreated controls as well as patients treated with β-blockade; a decrease in mortality is only noted compared with the control group (see Chapter 415). The management of acute variceal bleeding must include attention to hemodynamic stability through blood transfusion, vasoactive drugs (e.g., octreotide), short-term antibiotic use, and endoscopy to perform ligation or sclerotherapy, as needed. Transjugular intrahepatic portosystemic shunt should be considered for variceal bleeding refractory to medical and endoscopic therapy. Secondary prophylaxis to reduce recurrence of bleeding uses nonselective β-blockade and obliteration of varices through serial treatment via ligation or sclerotherapy. The only randomized controlled pediatric study has shown superiority of ligation over sclerotherapy in reducing the risk for rebleeding and complications.

Visit Elsevier eBooks+ at eBooks.Health.Elsevier.com for Bibliography.

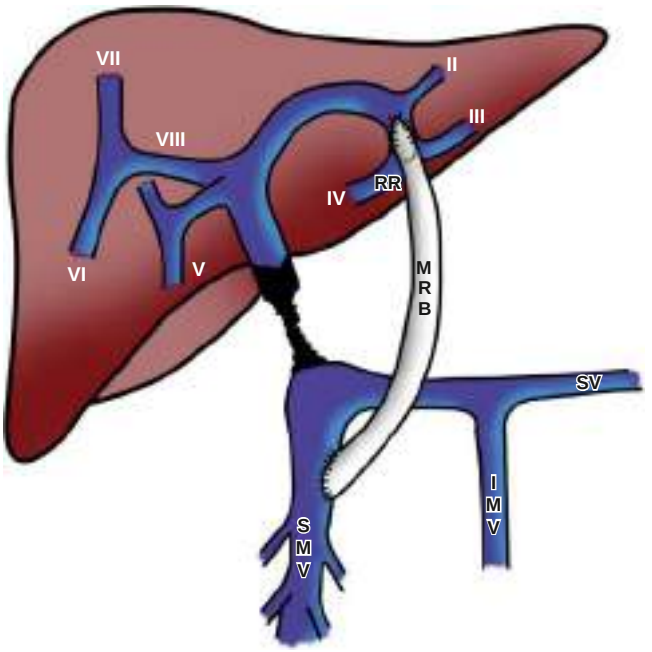

Fig. 372.1 Meso-Rex bypass between the superior mesenteric vein *(SMV)* and the Rex recess *(RR)* of the left portal vein. IMV, Inferior mesenteric vein; MRB, Meso-Rex bypass; SV, splenic vein. *(From Brichard M, Iesari S, Lerut J, et al. Meso-Rex bypass for the management of extrahepatic portal vein obstruction in adults. Hepatobiliary Pancreat Dis Int. 2022;21:25–32. Fig. 3.)*

Imaging studies are important for a rapid and accurate diagnosis. Perforations in the proximal thoracic esophagus tend to create signs (pneumothorax, effusions) in the left chest, whereas the signs of distal tears are more often on the right. Plain radiography (posteroanterior and lateral views) and CT of the neck and chest are often used, with the latter as more sensitive and accurate in diagnosis. Signs of perforation include pneumomediastinum, mediastinal widening, subcutaneous emphysema, pneumothorax, hydrothorax, pleural effusion, and lung collapse. If these x-rays are normal, an esophagogram using water-soluble contrast media should be performed, but esophagograms miss >30% of cervical perforations. Therefore, a negative water-soluble contrast esophagogram should be followed by a barium study; the greater density of barium can better demonstrate a small defect, although it has a higher risk of inflammatory mediastinitis. Endoscopy may also be useful but carries a 30% false-negative rate.

Treatment must be individualized. Small tears in contained perforations with minimal mediastinal contamination in hemodynamically stable patients can be treated conservatively with broad-spectrum antibiotics, nothing given orally, gastric drainage, and parenteral nutrition. Endoscopic techniques, considered less invasive and morbid, are now being used more frequently and include clips for defects <2 cm, and placement of stents and suturing for larger defects. Chest exploration and direct surgical repair is infrequently indicated these days. Mortality rates range between 20% and 28%, with poor prognosis correlated with delayed diagnosis and interventions.

Visit Elsevier eBooks+ at eBooks.Health.Elsevier.com for Bibliography.

Chapter 372

Esophageal Varices

Seema Khan

Esophageal varices form in adults and children with portal hypertension with hepatic venous pressure gradient >10 mm Hg and pose a risk for bleeding at >12 mm Hg (see Chapter 415). Spontaneous decompression of this hypertension through portosystemic collateral circulation via the coronary vein, in conjunction with the left gastric veins, gives rise to esophageal varices. Most esophageal varices are *uphill varices;* less commonly, those that arise in the absence of portal hypertension and with superior vena cava obstruction are *downhill varices*. Their treatment is directed at the underlying cause of the superior vena cava abnormality. Hemorrhage from esophageal varices is the major cause of morbidity and mortality from portal hypertension. Presentation is with significant hematemesis and melena; whereas most patients have liver disease, some children with extrahepatic portal venous obstruction (EHPVO) might have been previously asymptomatic. Any child with hematemesis and splenomegaly should be presumed to have esophageal variceal bleeding until proved otherwise. The leading causes of pediatric portal hypertension, biliary atresia, and EHPVO are uniquely distinct from diseases encountered in adults. Hence, children tend to tolerate variceal bleeding better because they have generally well compensated liver disease, with studies reporting mortality risk <1% after initial variceal bleed. The likelihood of esophageal varices in children with EHPVO increases from 1% to 22%, and small (13%) to large (54%) at 1 year and 5 years of age, respectively. Upper endoscopy is the preferred diagnostic test for esophageal varices, as it provides definitive diagnosis and delineation of details that aid in predicting the risk for bleeding, as well as enabling therapy for acute bleeding episodes via either sclerotherapy or band ligation. A report comprising a large series of children with biliary atresia and portal hypertension described endoscopic findings of large varices, red marks, and the presence of gastric varices as predictive of bleeding. Noninvasive methods of evaluating varices include barium contrast studies, ultrasound, computerized tomography, magnetic resonance, and elastography, but they are not recommended for routine diagnostic evaluation because of suboptimal accuracy compared to endoscopy.

Primary prophylaxis with the goal of preventing an initial hemorrhage can decrease the incidence of esophageal bleeding; the various modalities used are nonselective β-blockade (e.g., propranolol or nadolol), sclerotherapy, ligation, and portosystemic shunt surgery. Variceal band ligation is regarded as the preferred endotherapy and can be feasibly performed in children weighing more than 10 kg. Meso-Rex bypass surgery should be offered to children with EHPVO as both primary and secondary prophylaxis in the appropriate context (Fig. 372.1). Due to insufficient evidence, the same cannot be recommended regarding endoscopic therapies and nonselective β blockers for primary prophylaxis in children. In contrast, adults do have a reduced risk of first-time variceal bleeding with endoscopic variceal ligation when compared with untreated controls as well as patients treated with β-blockade; a decrease in mortality is only noted compared with the control group (see Chapter 415). The management of acute variceal bleeding must include attention to hemodynamic stability through blood transfusion, vasoactive drugs (e.g., octreotide), short-term antibiotic use, and endoscopy to perform ligation or sclerotherapy, as needed. Transjugular intrahepatic portosystemic shunt should be considered for variceal bleeding refractory to medical and endoscopic therapy. Secondary prophylaxis to reduce recurrence of bleeding uses nonselective β-blockade and obliteration of varices through serial treatment via ligation or sclerotherapy. The only randomized controlled pediatric study has shown superiority of ligation over sclerotherapy in reducing the risk for rebleeding and complications.

Visit Elsevier eBooks+ at eBooks.Health.Elsevier.com for Bibliography.

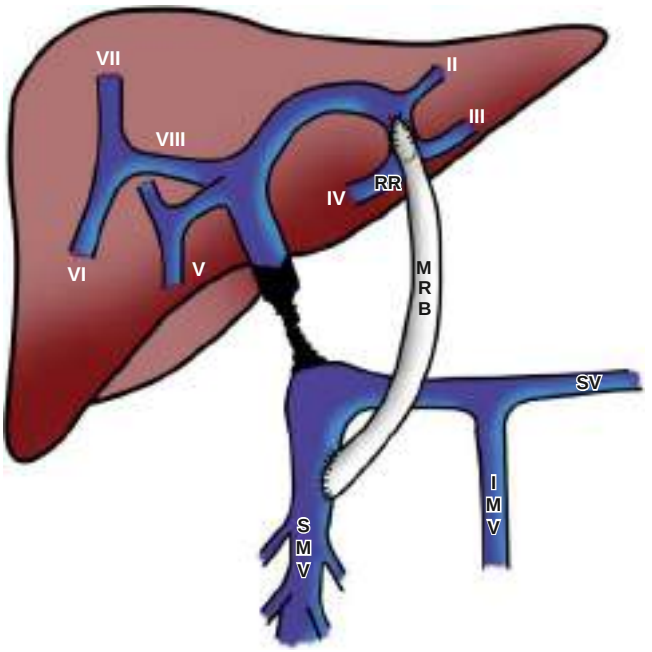

Fig. 372.1 Meso-Rex bypass between the superior mesenteric vein *(SMV)* and the Rex recess *(RR)* of the left portal vein. IMV, Inferior mesenteric vein; MRB, Meso-Rex bypass; SV, splenic vein. *(From Brichard M, Iesari S, Lerut J, et al. Meso-Rex bypass for the management of extrahepatic portal vein obstruction in adults. Hepatobiliary Pancreat Dis Int. 2022;21:25–32. Fig. 3.)*

Chapter 373
Ingestions

373.1 Foreign Bodies in the Esophagus

Seema Khan

The majority (80%) of accidental foreign-body ingestions occur in children, most of whom are 5 years of age or younger. Older children and adolescents with developmental delays and those with psychiatric disorders are also at increased risk. Most ingested foreign bodies are associated with a good outcome as they pass spontaneously through an anatomically normal digestive tract. The presentation of a foreign body lodged in the esophagus constitutes an emergency and is associated with significant morbidity and mortality because of the potential for perforation and sepsis. Although coins are by far the most commonly ingested foreign body, followed by small toy items, it is the ingestion of batteries and multiple magnets that could lead to life-threatening complications. Food impactions are less common in children than in adults and usually occur in children in association with eosinophilic esophagitis (diagnosed in 92% of those presenting with food impactions and dysphagia), repair of esophageal atresia, and Nissen fundoplication. Most esophageal foreign bodies lodge at the level of the cricopharyngeus (upper esophageal sphincter), the aortic arch, or just superior to the diaphragm at the gastroesophageal junction (lower esophageal sphincter).

At least 30% of children with esophageal foreign bodies may be totally asymptomatic, so any history of foreign-body ingestion should be taken seriously and investigated. An initial bout of choking, gagging, and coughing may be followed by excessive salivation, dysphagia, food refusal, emesis, or pain in the neck, throat, or sternal notch regions. Respiratory symptoms such as stridor, wheezing, cyanosis, or dyspnea may be encountered if the esophageal foreign body impinges on the larynx or membranous posterior tracheal wall. Cervical swelling, erythema, or subcutaneous crepitations suggest perforation of the oropharynx or proximal esophagus.

Evaluation of the child with a history of foreign-body ingestion starts with plain anteroposterior radiographs of the neck, chest, and abdomen, along with lateral views of the neck and chest. The flat surface of a coin in the esophagus is seen on the anteroposterior view and the edge on the lateral view (Fig. 373.1). The reverse is true for coins lodged in the trachea; here, the edge is seen anteroposteriorly and the flat side is seen laterally. Disk-shaped button batteries can look like coins and can be differentiated on close examination by the double halo (not obvious in the new slimmer batteries) and step-off (indicating the negative pole) on anteroposterior and lateral views, respectively (Fig. 373.2). The use of button batteries has been increasingly popular, leading to a sharp rise in accidental ingestions, and an increase in morbidity and mortality. The latter is thought to be due to both an increase in diameter and a change to lithium cells. Children younger than 5 years of age with ingestion of batteries ≥20 mm are considered to have the highest risk for catastrophic events such as necrosis, tracheoesophageal fistula, perforation, stricture, vocal cord paralysis, mediastinitis, and aortoenteric fistula (Fig. 373.3). Materials such as plastic, wood, glass, aluminum, and bones may be radiolucent; failure to visualize the object with plain films in a symptomatic patient warrants urgent endoscopy. CT scan with three-dimensional reconstruction may increase the sensitivity of imaging a foreign body. Although barium contrast studies may be helpful in the occasional asymptomatic patient with negative plain films, their use is to be discouraged because of the potential of aspiration, as well as making subsequent visualization and object removal more difficult.

In managing the child with an esophageal foreign body, it is important to assess risk for airway compromise and to obtain a chest CT scan and surgical consultation in cases of suspected airway perforation. Treatment of esophageal foreign bodies usually merits endoscopic visualization of the object and underlying mucosa and removal of the object using an appropriately designed foreign body–retrieving accessory instrument through the endoscope and with an endotracheal tube protecting the airway. Sharp objects in the esophagus, multiple magnets or a single magnet with a metallic object, or foreign bodies associated with respiratory symptoms mandate urgent removal within 12 hours of presentation. Button batteries, in particular, must be emergently removed within 2 hours of presentation regardless of the timing of the patient's last oral intake, because they can induce mucosal injury in as little as 1 hour of contact time and involve all esophageal layers within 4 hours (see Fig. 373.3; Fig. 373.4). In cases of delayed endoscopic intervention, frequent ingestion of honey and sucralfate are recommended as mitigation measures to reduce injury. Asymptomatic blunt objects and coins lodged in the esophagus can be observed for up to 24 hours in anticipation of passage into the stomach. If there are no problems in handling secretions, meat impactions can be observed for up to 24 hours. In patients without prior esophageal surgeries, glucagon (0.05 mg/kg intravenously; maximum pediatric dose, 0.5 mg; adult dose, 1-2 mg) can sometimes be useful in facilitating passage of distal esophageal food boluses by decreasing the lower esophageal sphincter pressure. The use of meat tenderizers or gas-forming agents can lead to perforation and are not recommended. An alternative technique for removing esophageal coins impacted for <24 hours, performed most safely by experienced radiology personnel, consists of passage of a Foley catheter beyond the coin at fluoroscopy, inflating the balloon, and then pulling the catheter and coin back simultaneously with the patient in a prone oblique position. Concerns about the lack of direct mucosal visualization and, when tracheal intubation is not used, the lack of airway protection prompt caution in the use of this technique. Bougienage of esophageal coins toward the stomach in selected uncomplicated pediatric cases has been suggested to be an effective, safe, and economical modality where endoscopy might not be routinely available.

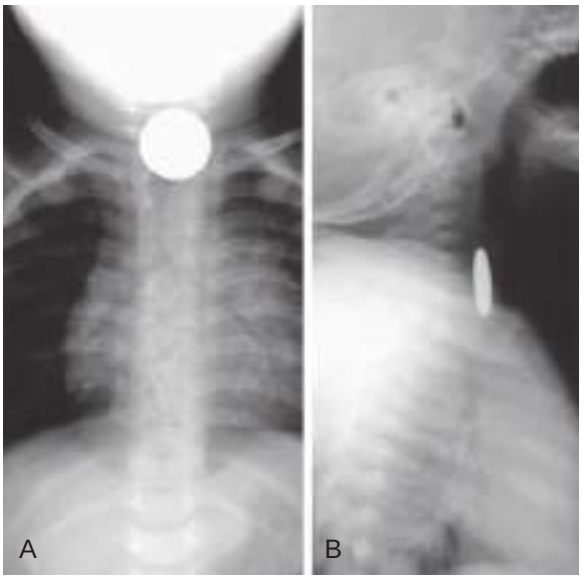

Fig. 373.1 Radiographs of a coin in the esophagus. When foreign bodies lodge in the esophagus, the flat surface of the object is seen in the anteroposterior view (A) and the edge is seen in the lateral view (B). The reverse is true for objects in the trachea. *(Courtesy Beverley Newman, MD.)*

Visit Elsevier eBooks+ at eBooks.Health.Elsevier.com for Bibliography.

373.2 Caustic Ingestions

Seema Khan

Ingestion of caustic substances is a worldwide public health problem accounting for a significant burden on healthcare resources. According

to an inpatient database of U.S. pediatric hospital discharges in 2009, the estimated number of caustic ingestions was 807 (95% confidence interval [CI], 731-882) cases, amounting to $22.9 million in total hospital charges. The medical sequelae of caustic ingestions are esophagitis, necrosis, perforation, and stricture formation (see Chapter 94). Most cases (70%) are accidental ingestions of liquid alkali substances that produce severe, deep liquefaction necrosis; drain decloggers are

Fig. 373.2 Disk battery impacted in esophagus. Note the double rim. *(From Wyllie R, Hyams JS, eds. Pediatric Gastrointestinal and Liver Disease, 3rd ed. Philadelphia: Saunders; 2006.)*

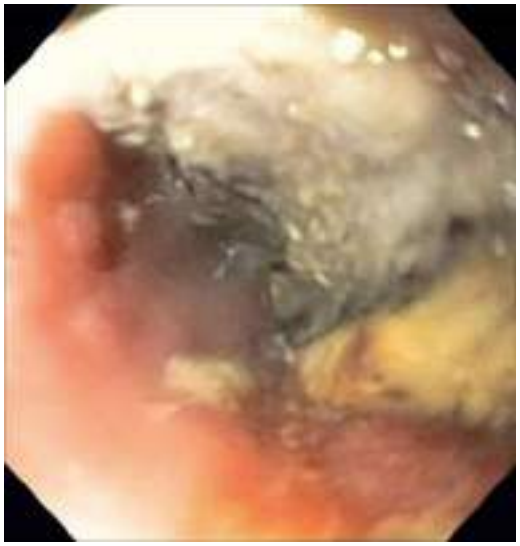

Fig. 373.3 Severe esophageal injury at site of button battery (BB) removal, with necrosis and eschar. *(From Leinwand K, Brumbaugh DE, Kramer RE. Button battery ingestion in children—a paradigm for management of severe pediatric foreign-body ingestions. Gastrointest Endosc Clin North Am. 2016;26:99–118. Fig. 1.)*

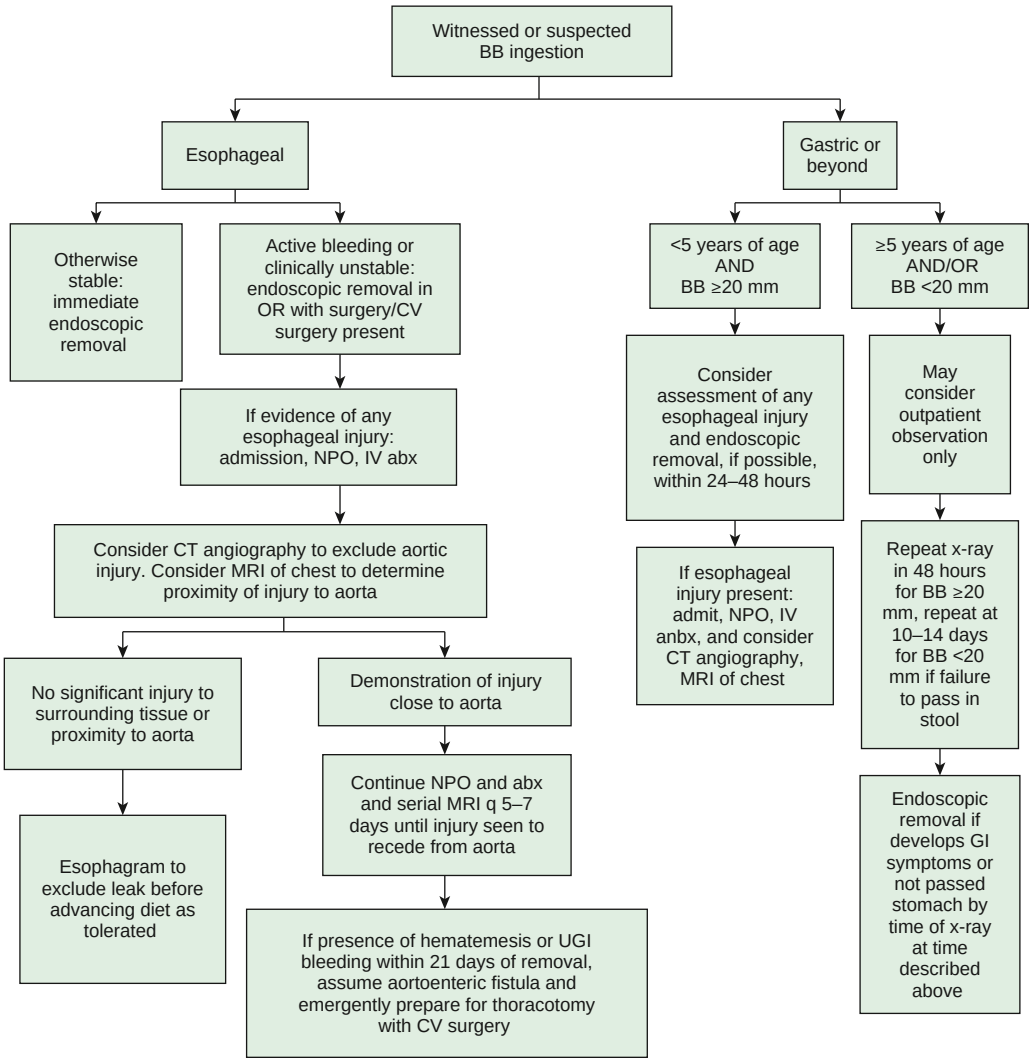

Fig. 373.4 Proposed management algorithm for ingestion of button battery *(BB)* in children. Abx, Antibiotics; CV, cardiovascular; GI, gastrointestinal; IV, intravenous; NPO, nil per os; OR, operating room; q, every; UGI, upper gastrointestinal series. *(From Kramer RE, Lerner DG, Lin T, et al. Management of ingested foreign bodies in children: a clinical report of the NASPGHAN endoscopy committee. J Pediatr Gastroenterol Nutr. 2015;60[4]:562–574. Fig. 1.)*

Table 373.1 Ingestible Caustic Materials Around the House

CATEGORY	MOST DAMAGING AGENTS	OTHER AGENTS
Alkaline drain cleaners, milking machine pipe cleaners	Sodium or potassium hydroxide	Ammonia, sodium hypochlorite, aluminum particles
Acidic drain openers	Hydrochloric acid, sulfuric acid	
Toilet cleaners	Hydrochloric acid, sulfuric acid, phosphoric acid, other acids	Ammonium chloride, sodium hypochlorite
Oven and grill cleaners	Sodium hydroxide, perborate (borax)	
Denture cleaners	Persulfate (sulfur), hypochlorite (bleach)	
Dishwasher detergent		
Liquid	Sodium hydroxide	
Powdered	Sodium hypochlorite	
Packaged	Sodium carbonate	
Bleach	Sodium hypochlorite	Ammonia salt
Swimming pool chemicals	Acids, alkalis, chlorine	
Battery acid (liquid)	Sulfuric acid	
Disk batteries	Electric current	Zinc or other metal salts
Rust remover	Hydrofluoric, phosphoric, oxalic, and other acids	
Household delimers	Phosphoric acid, hydroxyacetic acid, hydrochloric acid	
Barbeque cleaners	Sodium and potassium hydroxide	
Glyphosate surfactant (RoundUp) acid	Glyphosate herbicide	Surfactants
Hair relaxer	Sodium hydroxide	
Weed killer	Dichlorophenoxyacetate, ammonium phosphate, propionic acid	

Source: National Library of Medicine: *Health and Safety Information on Household Products* (website). http://householdproducts.nlm.nih.gov/
From Wyllie R, Hyams JS, Kay M, eds. *Pediatric Gastrointestinal and Liver Disease*, 4th ed. Philadelphia: Saunders; 2011: Table 19.1, p. 198.

most common, and because they are tasteless, more is ingested (Table 373.1). **Acidic agents** (20% of cases) are bitter, so less may be consumed; they produce coagulation necrosis and a somewhat protective thick eschar. They can produce severe gastritis, and volatile acids can result in respiratory symptoms. Children younger than 5 years of age account for half of the cases of caustic ingestions, and boys are far more often involved than girls.

Caustic ingestions produce signs and symptoms such as vomiting, drooling, refusal to drink, oral burns, dysphagia, dyspnea, abdominal pain, hematemesis, and stridor. Twenty percent of patients develop esophageal strictures. Absence of oropharyngeal lesions does not exclude the possibility of significant esophagogastric injury, which can lead to perforation or stricture. The absence of symptoms is usually associated with no or minimal lesions; hematemesis, respiratory distress, or presence of at least three symptoms predicts severe lesions. An upper endoscopy is recommended as the most efficient means of rapid identification of tissue damage and must be undertaken in all symptomatic children within the first 24-48 hours of ingestion. In select situations when endoscopy may not be possible, CT of the chest and abdomen should be considered in the evaluation of transmural and extraesophageal injury, as well as in anticipation of emergent surgical planning.

Dilution by water or milk is recommended as acute treatment, but neutralization, induced emesis, and gastric lavage are contraindicated. Treatment depends on the severity and extent of damage (Table 373.2, Fig. 373.5). Stricture risk is increased by circumferential ulcerations, white plaques, and sloughing of the mucosa and is reported to occur in 70–100% of grade 2b and grade 3 caustic esophagitis. Strictures can require treatment with dilation, and in some severe cases, surgical resection and colon or small bowel interposition are needed. Silicone stents (self-expanding) placed endoscopically after a dilation procedure can be an alternative and conservative approach to the management of strictures. Rare late cases of superimposed esophageal carcinoma are reported. The role of corticosteroids is controversial; they are not recommended in grade 1 burns, but they can reduce the risk of strictures in more-advanced caustic esophagitis. Many centers also use proton pump inhibitors as well as antibiotics in the initial treatment of caustic esophagitis on the premise that reducing superinfection in the necrotic tissue bed will, in turn, lower the risk of stricture formation. Studies examining the role of antibiotics in caustic esophagitis have not reported a clinically significant benefit even in those with grade 2 or greater severity of esophagitis.

There may be an increase of esophageal (not gastric) carcinoma following a caustic ingestion.

Table 373.2 Classification of Caustic Injury

GRADE	VISIBLE APPEARANCE	CLINICAL SIGNIFICANCE
Grade 0	History of ingestion but no visible damage or symptoms	Able to take fluids immediately
Grade 1	Edema, loss of normal vascular pattern, hyperemia, no transmucosal injury	Temporary dysphagia, able to swallow within 0-2 days, no long-term sequelae
Grade 2a	Transmucosal injury with friability, hemorrhage, blistering, exudate, scattered superficial ulceration	Scarring, no circumferential damage (no stenosis), no long-term sequelae
Grade 2b	Grade 2a plus discrete ulceration and/or circumferential ulceration	Small risk of perforation, scarring that may result in later stenosis
Grade 3a	Scattered deep ulceration with necrosis of the tissue	Risk of perforation, high risk of later stenosis
Grade 3b	Extensive necrotic tissue	High risk of perforation and death, high risk of stenosis

From Wyllie R, Hyams JS, Kay M, eds. *Pediatric Gastrointestinal and Liver Disease*, 4th ed. Philadelphia: Saunders; 2011: Table 19.2, p. 199.

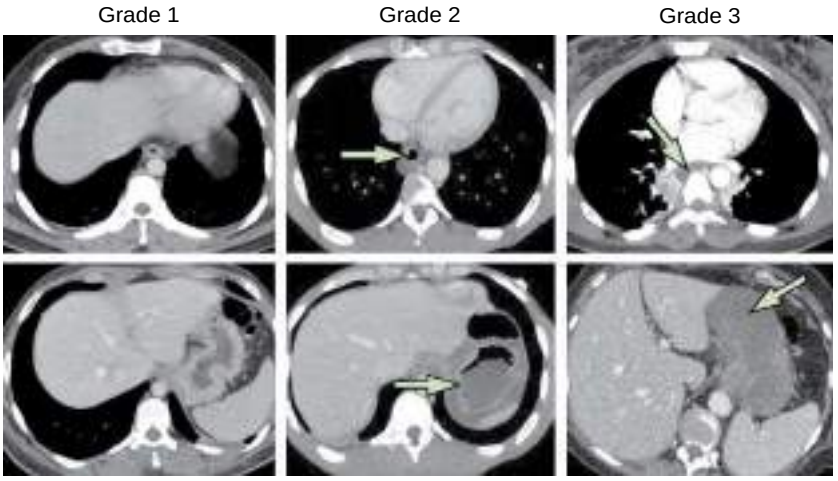

Fig. 373.5 CT grading of corrosive injuries of the esophagus and the stomach. Grade 1, normal appearance; grade 2, wall and soft tissue edema, increased wall enhancement *(arrow)*; grade 3, transmural necrosis with absent wall enhancement *(arrow)*. *(From Chirica M, Bonavina L, Kelly MD, et al. Caustic ingestion. Lancet. 2017;389:2041–2050. Fig. 1.)*

Visit Elsevier eBooks+ at eBooks.Health.Elsevier.com for Bibliography.

Section **4**

Stomach and Intestines

Chapter **374**

Normal Development, Structure, and Function of the Stomach and Intestines

Asim Maqbool and Chris A. Liacouras

DEVELOPMENT

The primitive gut is recognizable by the fourth week of gestation and is composed of the foregut, midgut, and hindgut. The **foregut** gives rise to the upper gastrointestinal tract, which includes the esophagus, stomach, and duodenum to the level of the insertion of the common bile duct. The **midgut** gives rise to the rest of the small bowel and the large bowel to the level of the midtransverse colon. The **hindgut** forms the remainder of the colon and upper anal canal. The rapid growth of the midgut causes it to protrude out of the abdominal cavity through the umbilical ring during fetal development. The midgut subsequently returns to the peritoneal cavity and rotates counterclockwise until the cecum lies in the right lower quadrant. The process is normally complete by the eighth week of gestation.

The liver derives from the hepatic diverticulum that evolves into parenchymal cells, bile ducts, vascular structures, and hematopoietic and Kupffer cells. The extrahepatic bile ducts and gallbladder develop first as solid cords that canalize by the third month of gestation. The dorsal and ventral pancreatic buds grow from the foregut by the fourth week of gestation. The two buds fuse by the sixth week. Exocrine secretory capacity is present by the fifth month.

Cis-regulatory genomic sequences govern gene expression during development. Modules of *cis* sequences are linked and allow a cascade of gene regulation that controls functional development. Extrinsic factors have the capacity to influence gene expression. In the gut, several growth factors, including growth factor-β, insulin-like growth factor, and growth factors found in human colostrum (human growth factor and epidermal growth factor), influence gene expression.

Propulsion of food down the gastrointestinal tract relies on the coordinated action of muscles in the bowel wall. The contractions are regulated by the enteric nervous system under the influence of a variety of peptides and hormones. The enteric nervous system is derived from neural crest cells that migrate in a cranial to caudal fashion. Migration of the neural crest tissue is complete by the 24th week of gestation.

Interruption of the migration results in **Hirschsprung disease**. Newborn bowel motor patterns are different from adults. Normal fasting upper gastrointestinal motility is characterized by a triphasic pattern known as the migrating motor complex. Migrating motor complexes occur less often in neonates, and they have more nonmigrating phasic activity. This leads to ineffective propulsion, particularly in premature infants. Motility in the fed state consists of a series of ring contractions that spread caudad over variable distances.

DIGESTION AND ABSORPTION

The wall of the stomach, small bowel, and colon consists of four layers: mucosa, submucosa, muscularis, and serosa. Eighty-five percent of the gastric mucosa is lined by oxyntic glands containing cells that secrete hydrochloric acid, pepsinogen, and intrinsic factor, and mucous and endocrine cells that secrete peptides having paracrine and endocrine effects. Pepsinogen is a precursor of the proteolytic enzyme pepsin, and intrinsic factor is required for the absorption of vitamin B_{12}. Pyloric glands are located in the antrum and contain gastrin-secreting cells. Acid production and gastrin levels are inversely related to each other except in pathologic secretory states. Acid secretion is low at birth but increases dramatically by 24 hours. Acid and pepsin secretions peak in the first 10 days and decrease from 10 to 30 days after birth. Intrinsic factor secretion rises slowly in the first 2 weeks of life.

The small bowel is approximately 270 cm long at birth in a term neonate and grows to an adult length of 450-550 cm by 4 years of age. The mucosa of the small intestine is composed of villi, which are finger-like projections of the mucosa into the bowel lumen that significantly expand the absorptive surface area. The mucosal surface is further expanded by a brush border containing digestive enzymes and transport mechanisms for monosaccharides, amino acids, dipeptides and tripeptides, and fats. The cells of the villi originate in adjacent crypts and become functional as they migrate from the crypt up the villus. The small bowel mucosa is completely renewed in 4-5 days, providing a mechanism for rapid repair after injury, but in young infants or malnourished children, the process may be delayed. Crypt cells also secrete fluid and electrolytes. The villi are present by 8 weeks of gestation in the duodenum and by 11 weeks in the ileum.

Disaccharidase activities are measurable at 12 weeks, but lactase activity does not reach maximal levels until 36 weeks. Even premature infants usually tolerate lactose-containing formulas because of carbohydrate salvage by colonic bacteria. In children of African and Asian ethnicity, lactase levels may begin to fall at 4 years of age, leading to intolerance to mammalian milk. Mechanisms to digest and absorb protein, including pancreatic enzymes and mucosal mechanisms to transport amino acids, dipeptides, and tripeptides, are in place by the 20th week of gestation.

Carbohydrates, protein, and fat are normally absorbed by the upper half of the small intestine; the distal segments represent a vast reserve of absorptive capacity. Most of the sodium, potassium, chloride, and water are absorbed in the small bowel. Bile salts and vitamin B_{12} are selectively absorbed in the distal ileum, and iron is absorbed in the duodenum and proximal jejunum. Intraluminal digestion depends on the exocrine pancreas. Secretin and cholecystokinin stimulate synthesis and secretion of bicarbonate and digestive enzymes, which are released by the upper intestinal mucosa in response to various intraluminal stimuli, among them components of the diet.

Carbohydrate digestion is normally an efficient process that is completed in the distal duodenum. Starches are broken down to glucose, oligosaccharides, and disaccharides by pancreatic amylase. Residual glucose polymers are broken down at the mucosal level by glucoamylase. Lactose is broken down at the brush border by lactase, forming glucose and galactose; sucrose is broken down by sucrase-isomaltase to fructose and glucose. Galactose and glucose are primarily transported into the cell by a sodium- and energy-dependent process, whereas fructose is transported by facilitated diffusion.

Proteins are hydrolyzed by pancreatic enzymes, including trypsin, chymotrypsin, elastase, and carboxypeptidases, into individual amino acids and oligopeptides. The pancreatic enzymes are secreted as proenzymes, which are activated by release of the mucosal enzyme enterokinase. Oligopeptides are further broken down at the brush border by peptidases into dipeptides, tripeptides, and amino acids. Protein can enter the cell by separate noncompetitive carriers that can transport individual amino acids or dipeptides and tripeptides similar to those in the renal tubule. The human gut is capable of absorbing antigenic intact proteins in the first few weeks of life because of *leaky* junctions between enterocytes. Entry of potential protein antigens through the mucosal barrier might have a role in later food- and microbe-induced symptoms.

Fat absorption occurs in two phases. Dietary triglycerides are broken down into monoglycerides and free fatty acids by pancreatic lipase and colipase. The free fatty acids are subsequently emulsified by bile acids, forming micelles with phospholipids and other fat-soluble substances, and are transported to the cell membrane, where they are absorbed. The fats are reesterified in the enterocyte, forming chylomicrons that are transported through the intestinal lymphatics to the thoracic duct. Medium-chain fats are absorbed more efficiently and can directly enter the cell. They are subsequently transported to the liver via the portal system. Fat absorption can be affected at any stage of the digestion and absorption process. Decreased pancreatic enzymes occur in cystic fibrosis, cholestatic liver disease leads to poor bile salt production and micelle formation, celiac disease affects mucosal surface area, abnormal chylomicron formation occurs in abetalipoproteinemia, and intestinal lymphangiectasia affects transport of the chylomicrons.

Fat absorption is less efficient in the neonate compared with adults. Premature infants can lose up to 20% of their fat calories compared with up to 6% in the adult. Decreased synthesis of bile acids and pancreatic lipase and decreased efficiency of ileal absorption are contributing factors. Fat digestion in the neonate is facilitated by lingual and gastric lipases. Bile salt–stimulated lipase in human milk augments the action of pancreatic lipase. Infants with malabsorption of fat are usually fed with formulas that have a greater percentage of medium-chain triglycerides, which are absorbed independently of bile salts.

The colon is a 75- to 100-cm sacculated tube formed by three strips of longitudinal muscle called *taenia coli* that traverse its length and fold the mucosa into haustra. Haustra and taenia appear by the 12th week of gestation. The most common motor activity in the colon is nonpropulsive rhythmic segmentation that acts to mix the chyme and expose the contents to the colonic mucosa. Mass movement within the colon typically occurs after a meal. The colon extracts additional water and electrolytes from the luminal contents to render the stools partially or completely solid. The colon also acts to scavenge by-products of bacterial degradation of carbohydrates. Stool is stored in the rectum until distention triggers a defecation reflex that, when assisted by voluntary relaxation of the external sphincter, permits evacuation.

THE GASTROINTESTINAL MICROBIOTA

The term "microbiome" refers to organisms and their genomes/functions, whereas "microbiota" refers to the organisms themselves. The difference is very subtle, and sometimes they are used interchangeably.

The gastrointestinal microbiota composition develops early in life; it is influenced by environmental exposures, including specifically exposure to maternal flora (via vaginal delivery vs C-section), birth location (hospital vs at home, suburban vs rural), antibiotic use, and prominently are related to diet and infant feeding practices (breastfed vs formula fed, food supplementation). The richness and diversity of gastrointestinal microbiota developed early, as does gastrointestinal immunotolerance to it. Microbiota concentration and complexity increase from proximal to distal throughout the gastrointestinal tract.

This microflora has implications on human health and disease. There is a symbiotic relationship between the host of the gastrointestinal tract and the commiserate microflora. These microorganisms are involved in the fermentation of undigestible carbohydrates (in particular, fiber), resulting in short-chain fatty acids, the preferred fuel for colonic tissues. Additionally, the microbiota is involved in the metabolism of intraluminal conjugated bile acids, and the synthesis of vitamins (vitamin K), and in the degradation of other compounds. The metabolome specifically refers to the collection of metabolites that organisms produce.

The composition of the intestinal microbiota may render individuals at risk for noncommunicable diseases, including obesity. The intestinal microbiota may have implications for vaccine efficacy. Perturbations in the intestinal microbiota composition may increase risk for gastrointestinal inflammatory conditions and disorders, including inflammatory bowel disease.

Visit Elsevier eBooks+ at eBooks.Health.Elsevier.com for Bibliography.

Chapter 375

Pyloric Stenosis and Other Congenital Anomalies of the Stomach

375.1 Hypertrophic Pyloric Stenosis

Arunjot Singh and Chris A. Liacouras

Hypertrophic pyloric stenosis occurs in 2-5/1,000 infants in the United States. It is common in White people, particularly of northern European ancestry, and less frequent in Black and Asian populations. Males (especially firstborns) are affected approximately 4 times as often as females. There is a familial link with an increased risk in offspring of parent(s) with pyloric stenosis. Pyloric stenosis develops in approximately 20% of the male and 10% of the female descendants of a mother who had pyloric stenosis. Pyloric stenosis has also been associated with other congenital defects, including tracheoesophageal fistula and hypoplasia or agenesis of the inferior labial frenulum.

ETIOLOGY

The etiology of infantile hypertrophic pyloric stenosis is unknown, although many genetic and environmental factors have been implicated. Development of pyloric stenosis is likely postnatal, given that it is unusual in stillbirths. Genetic predisposition, a well-established risk of pyloric stenosis, is more concordant in monozygotic than dizygotic twins. Pyloric stenosis has been associated with eosinophilic gastroenteritis, Apert syndrome, Zellweger syndrome, trisomy 18, Smith-Lemli-Opitz syndrome, and Cornelia de Lange syndrome (Table 375.1). An association has been seen with the use of macrolide antibiotics, particularly erythromycin in neonates, if given within the first 2 weeks of life. There have also been reports of a higher incidence of pyloric stenosis among mostly female infants of mothers treated with macrolide antibiotics during pregnancy and breastfeeding. Other risk factors may include formula feeding and a maternal history of smoking during pregnancy. Abnormal muscle innervation, elevated serum levels of prostaglandins, and infant hypergastrinemia have also been implicated. Multiple genetic susceptibility loci have been identified including *IHPS* genes on chromosomes 12q, 16p13 and 11q14, and Xq23. The etiologic role of nitric oxide synthase gene *(NOS1)* is also apparent with reduced levels of neuronal nitric oxide found via altered expression of the neuronal nitric oxide synthase exon 1c regulatory region.

Table 375.1 Etiology of Gastric Outlet Obstruction

CONGENITAL
Aplasia
Atresia
Diaphragms, webs, valves
Ectopic pancreatic rests
Gastric duplication
Associated with epidermolysis bullosa
IDIOPATHIC HYPERTROPHIC PYLORIC STENOSIS
Infantile-onset pyloric stenosis
Late onset
Associated with medications: erythromycin, prostaglandin E1
ACQUIRED
Peptic ulcer disease
Caustic chemical injury
Bezoars: lacto-, phyto-, tricho-, medications
Associated with Crohn disease
Associated with chronic granulomatous disease
Associated with eosinophilic gastroenteritis
Tumor
Gastric volvulus

CLINICAL MANIFESTATIONS

Nonbilious vomiting is the initial symptom of pyloric stenosis. The vomiting may or may not be projectile initially but is usually progressive, occurring immediately after a feeding. Emesis might follow each feeding, or it may be intermittent. The vomiting usually starts after 3 weeks of age, but symptoms can develop as early as the first week of life and as late as 5 months of age. On rare occasions, late-onset pyloric stenosis may develop between 2 and 8 years of life. Approximately 20% have intermittent emesis from birth that then progresses to the classic picture. After vomiting, the infant is hungry and wants to feed again. As vomiting continues, a progressive loss of fluid, hydrogen ion, and chloride leads to *hypochloremic metabolic alkalosis*. Awareness of pyloric stenosis has led to earlier identification of patients with fewer instances of chronic malnutrition and severe dehydration and at times a subclinical self-resolving hypertrophy.

Hyperbilirubinemia is the most common clinical *association* of pyloric stenosis, also known as *icteropyloric syndrome*. Unconjugated hyperbilirubinemia is more common than the conjugated type and usually resolves with surgical correction of the pyloric stenosis. It may be associated with a decreased level of glucuronyl transferase as seen in approximately 5% of affected infants. Pathogenic gene variants in the bilirubin uridine diphosphate glucuronosyltransferase gene *(UGT1A1)* have also been implicated, supporting the notion that Gilbert syndrome may be linked in pathogenesis. If conjugated hyperbilirubinemia is a part of the presentation, other etiologies need to be investigated including eosinophilic gastroenteritis, hiatal hernia, peptic ulcer, congenital nephrotic syndrome, congenital heart disease, and congenital hypothyroidism.

The diagnosis has clinically been established by palpating a pyloric mass. The mass is firm, movable, approximately 2 cm in length, olive shaped, and best palpated when the patient is lying on the left side. The mass is located above and to the right of the umbilicus in the midepigastrium beneath the liver edge. The olive is easiest palpated after an episode of vomiting. After feeding, there may be a visible gastric peristaltic wave that progresses across the abdomen (Fig. 375.1). *Earlier imaging diagnosis has made the palpable olive a less common physical finding.*

Two imaging studies are used to establish the diagnosis. Ultrasound examination confirms the diagnosis in the majority of cases. Criteria for diagnosis include pyloric thickness 3-4 mm, an overall pyloric

Fig. 375.1 Gastric peristaltic wave in an infant with pyloric stenosis.

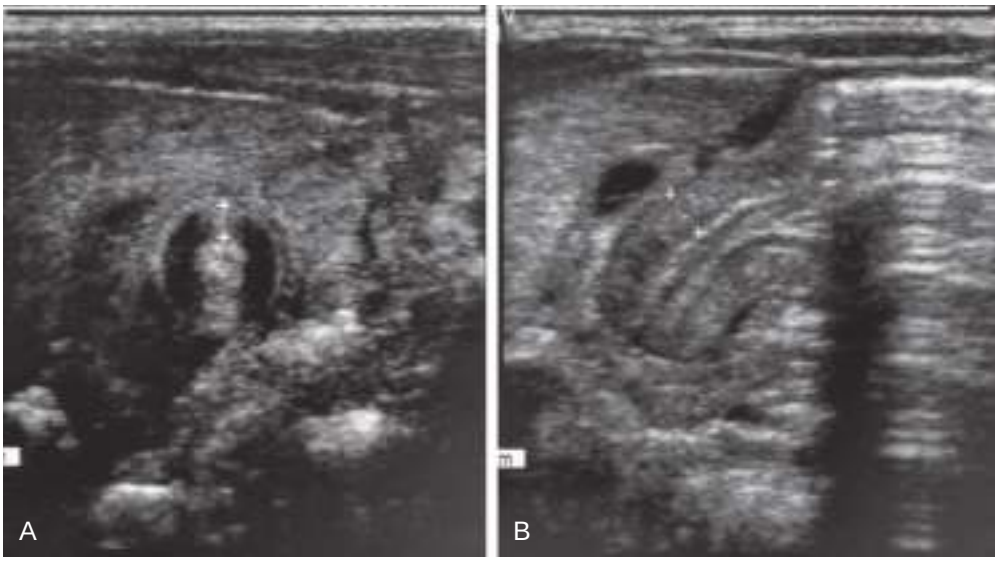

Fig. 375.2 A, Transverse sonogram demonstrating a pyloric muscle wall thickness of >4 mm (distance between *crosses*). B, Horizontal image demonstrating a pyloric channel length >14 mm (wall thickness outlined between *crosses*) in an infant with pyloric stenosis.

Fig. 375.3 Barium in the stomach of an infant with projectile vomiting. The attenuated pyloric canal is typical of congenital hypertrophic pyloric stenosis.

length 15-19 mm, and pyloric diameter of 10-14 mm (Fig. 375.2). Ultrasonography has a sensitivity of approximately 95%. Less commonly, an upper gastrointestinal (GI) contrast study is used. Contrast studies demonstrate an elongated pyloric channel (string sign), a bulge of the pyloric muscle into the antrum (shoulder sign), and parallel streaks of barium seen in the narrowed channel, producing a "double tract sign" (Fig. 375.3).

DIFFERENTIAL DIAGNOSIS

Pyloric stenosis must be differentiated from other causes that present with vomiting, irritability, and dehydration in the infant. Gastroesophageal reflux is one of the most common etiologies of vomiting. In contrast to pyloric stenosis, reflux is typically a self-limiting condition that manifests with frequent effortless regurgitation and vomiting and usually does not cause abnormal chemistries. If symptoms are significant, reflux can be differentiated from pyloric stenosis by radiographic studies. Adrenogenital syndrome can also simulate pyloric stenosis; however, abnormalities including metabolic acidosis and elevated serum potassium and urinary sodium concentrations of adrenal insufficiency aid in differentiation. Inborn errors of metabolism can also cause recurrent emesis and are manifested by alkalosis (urea cycle) or acidosis (organic acidemia) with lethargy, coma, or seizures. Metabolic disorders and adrenogenital syndrome may first be identified on the newborn screening test. Vomiting may also be a presentation of an infection such as urinary tract infection or gastroenteritis, although these are usually accompanied by fever or diarrhea. Rarely, a pyloric membrane or pyloric duplication results in projectile vomiting, visible peristalsis, and, in the case of a duplication, a palpable mass (Table 375.2). Duodenal stenosis proximal to the ampulla of Vater results in the clinical features of pyloric stenosis but can be differentiated by the presence of a pyloric mass on physical examination or ultrasonography.

TREATMENT

The treatment of pyloric stenosis requires surgery in most patients. The preoperative treatment is directed toward **correcting the fluid and electrolyte losses, as well as the acid-base disturbance**. Correction of the alkalosis is essential to prevent postoperative apnea, which may be associated with anesthesia. Most infants can be successfully rehydrated within 24 hours. Vomiting usually stops when the stomach is empty, and only an occasional infant requires nasogastric suction.

Surgical treatment of pyloric stenosis is by open or laparoscopic pyloromyotomy. This procedure is safe and cost-effective. Treatment is curative, with an operative mortality of 0–0.5%. The traditional Ramstedt procedure had been performed through a short transverse skin incision in the right upper quadrant of the abdomen followed by a longitudinal cut of the pyloric mass to the layer of the submucosa. Laparoscopic pyloromyotomy has become the procedure of choice given improved laparoscopic instrumentation and potential of shorter recovery times.

Postoperative vomiting occurs in half the infants and is thought to be secondary to edema of the pylorus at the incision site. In most infants, feedings can be initiated within 12-24 hours after surgery and advanced to maintenance oral feedings within 36-48 hours. Persistent vomiting suggests an incomplete pyloromyotomy, gastritis, gastroesophageal reflux disease, or another cause of the obstruction. Endoscopic balloon dilation has been successful in infants with persistent vomiting secondary to incomplete pyloromyotomy.

Conservative management with nasoduodenal feedings is a rare treatment choice, advisable only in rare patients who are not good surgical candidates. Oral and intravenous atropine sulfate (pyloric muscle relaxant) has also been described when surgical expertise is

Table 375.2 Anomalies of the Stomach

ANOMALY	INCIDENCE	AGE AT PRESENTATION	SYMPTOMS AND SIGNS	TREATMENT
Gastric, antral, or pyloric atresia	3/100,000, when combined with webs	Infancy	Nonbilious emesis	Gastroduodenostomy, gastrojejunostomy
Pyloric or antral membrane (web)	As above	Any age	Failure to thrive, emesis	Incision or excision, pyloroplasty
Microgastria	Rare	Infancy	Emesis, malnutrition	Continuous-drip feedings or jejunal reservoir pouch
Gastric diverticulum	Rare	Any age	Usually asymptomatic	Usually unnecessary
Gastric duplication	Rare; male:female, 1:2	Any age	Abdominal mass, emesis, hematemesis; peritonitis if ruptured	Excision or partial gastrectomy
Gastric teratoma	Rare	Any age	Upper abdominal mass	Resection
Gastric volvulus	Rare	Any age	Emesis, refusal to feed	Reduction of volvulus, anterior gastropexy
Pyloric stenosis (infantile hypertrophic and adult forms)	United States, 3/1,000 (range, 1-8/1,000 in various regions); male:female, 4:1	Infancy	Nonbilious emesis	Pyloromyotomy
Congenital absence of the pylorus	Rare	Childhood, adulthood	Dyspepsia, if symptomatic	Usually unnecessary

Modified from Semrin MG, Russo MA. Anatomy, histology, and developmental anomalies of the stomach and duodenum. In Feldman M, Friedman LS, Brandt LJ, eds. *Sleisenger and Fordtran's Gastrointestinal and Liver Disease*, 10th ed. Philadelphia: Elsevier; 2016; Table 48.1.

not available with 80% success rate described in some studies. Because conservative management takes longer and oral feedings may not be well tolerated, worsening of the nutritional status can occur in these patients and total parenteral nutrition may be required.

Visit Elsevier eBooks+ at eBooks.Health.Elsevier.com for Bibliography.

375.2 Congenital Gastric Outlet Obstruction

Arunjot Singh and Chris A. Liacouras

Gastric outlet obstruction resulting from pyloric atresia and antral webs is uncommon and accounts for <1% of all GI atresias of the alimentary tract (see Tables 375.1 and 375.2). The exact cause of the defect is unknown but is hypothesized to be secondary to incomplete recanalization of the foregut or an intrauterine vascular accident. Pyloric atresia has been associated with **epidermolysis bullosa** and usually presents in early infancy. The gender distribution is equal.

CLINICAL MANIFESTATIONS

Infants with pyloric atresia present with nonbilious vomiting, feeding difficulties, and abdominal distention during the first day of life. Low birthweight is also common. **Polyhydramnios** is a feature seen on prenatal ultrasonography in most cases. The gastric aspirate at birth is large (>20 mL fluid) and should be removed to prevent aspiration. Rupture of the stomach may occur as early as the first 12 hours of life. Infants with an antral web may present with less dramatic symptoms, depending on the degree of obstruction. Older children with antral webs present with nausea, vomiting, abdominal pain, and weight loss.

DIAGNOSIS

The diagnosis of congenital gastric outlet obstruction is suggested by the finding of a large, dilated stomach on abdominal plain radiographs or in utero ultrasonography. Upper GI contrast series is usually diagnostic and demonstrates a pyloric dimple. When contrast studies are performed, care must be taken to avoid possible aspiration. An antral web may appear as a thin septum near the pyloric channel. In older children, endoscopy has been helpful in identifying antral webs.

TREATMENT

The treatment of all causes of gastric outlet obstruction in neonates starts with the correction of dehydration and hypochloremic alkalosis. Persistent vomiting should be relieved with nasogastric decompression. Surgical or endoscopic repair is then required when the patient is medically stable.

375.3 Gastric Duplication

Arunjot Singh and Chris A. Liacouras

Gastric duplications are rare cystic or tubular malformations that usually occur within the wall of the stomach. With an incidence of 1.7 per 100,000, gastric duplications account for 2–9% of all congenital duplications in the alimentary tract. The cystic type is most common and involves the greater curvature of the stomach (see Table 375.2). Most are less than 12 cm in diameter and do not usually communicate with the stomach lumen; however, they do have a common blood supply. Associated anomalies occur in as many as 35% of patients. Several hypotheses for the etiology of gastric duplication have been developed including the splitting notochord theory, diverticulation, canalization defects, and caudal twinning.

CLINICAL MANIFESTATIONS

The most common clinical manifestations are associated with partial or complete gastric outlet obstruction. Presentation can also be complicated by intussusception, volvulus of the small bowel, and bleeding secondary to ulceration of ectopic mucosa. In 33% of patients, the duplication cyst may be palpable. Communicating duplications can cause gastric ulceration and be associated with hematemesis or melena.

DIAGNOSIS
Radiographic studies usually show a paragastric mass displacing the stomach. Ultrasound can show the inner hyperechoic mucosal and outer hypoechoic muscle layers that are typical of gastric duplications. CT and MRI are diagnostic in cases where ultrasound remains unclear, although these should be used judiciously given risk associated with radiation and sedation.

TREATMENT
Surgical treatment for symptomatic gastric duplications with complete resection of the duplication cyst is the gold standard. Avoiding incision into the gastric lumen is preferred whenever possible. Recently laparoscopic resection has shown successful outcomes. For communicating types of duplication, the marsupialization and drainage procedure may also be used.

Visit Elsevier eBooks+ at eBooks.Health.Elsevier.com for Bibliography.

375.4 Gastric Volvulus
Arunjot Singh and Chris A. Liacouras

The stomach is tethered longitudinally by the gastrohepatic, gastrosplenic, and gastrocolic ligaments. In the transverse axis, it is tethered by the gastrophrenic ligament and the retroperitoneal attachment of the duodenum. A volvulus occurs when one of these attachments is absent or elongated, allowing the stomach to rotate around itself. In some children, other associated defects are present, including intestinal malrotation, diaphragmatic defects, hiatal hernia, or adjacent organ abnormalities such as asplenia. Volvulus can occur along the longitudinal axis, producing organo-axial volvulus, or along the transverse axis, producing mesentero-axial volvulus. Combined volvulus occurs if the stomach rotates around both organo-axial and mesentero-axial axes.

CLINICAL MANIFESTATIONS
Gastric volvulus in infancy is usually associated with nonbilious vomiting and abdominal distention. It has also been associated with episodes of dyspnea and apnea in this age group. Acute volvulus can advance rapidly to strangulation and perforation. Chronic gastric volvulus is more common in older children who present with a history of emesis, abdominal pain, distention, early satiety, and failure to thrive.

DIAGNOSIS
The diagnosis is suggested in plain abdominal radiographs by the presence of a dilated stomach. Erect abdominal films demonstrate a double fluid level with a characteristic "beak" near the lower esophageal junction in mesentero-axial volvulus. The stomach tends to lie in a vertical plane. In organo-axial volvulus, a single air-fluid level is seen without the characteristic beak with stomach lying in a horizontal plane. Upper GI series is the more definitive test as it reveals gastric rotation and estimates the degree of obstruction.

TREATMENT
Treatment of acute gastric volvulus requires prompt management given the increased mortality risk. Following immediate stabilization, emergent surgery via laparoscopic gastropexy is the most common surgical approach. Open thoracotomies are also a treatment modality with gastropexy, gastrostomy, and partial/total gastric resection potentially being required. Endoscopic reduction has also been reported in select cases, although gastropexy may ultimately be needed. Chronic gastric volvulus may be treated with conservative measures, including dietary modification, positioning, prokinetics, and antisecretory agents.

Visit Elsevier eBooks+ at eBooks.Health.Elsevier.com for Bibliography.

375.5 Hypertrophic Gastropathy
Arunjot Singh and Chris A. Liacouras

Hypertrophic gastropathy in children is uncommon and usually a transient, benign, and self-limited condition. The mean age at diagnosis is 5 years (range: 2 days to 17 years).

PATHOGENESIS
The condition is often secondary to cytomegalovirus (CMV) infection, but other agents, including herpes simplex virus, *Giardia,* and *Helicobacter pylori* have also been implicated. The pathophysiologic mechanisms underlying the clinical picture are not completely understood but might involve widening of gap junctions between gastric epithelial cells with resultant fluid and protein losses. There is an association with increased expression of transforming growth factor-α in gastric mucosal tissue shown in CMV-induced gastropathy. *H. pylori* infection can cause the elevation of serum glucagon-like peptide-2 levels, a mucosal growth-inducing gut hormone.

CLINICAL MANIFESTATIONS
Clinical manifestations include epigastric abdominal pain, fatigue, vomiting, anorexia, and edema (protein-losing enteropathy). Other symptoms of nausea, diarrhea, and GI bleeding via hematemesis may arise due to gastric erosion or ulceration. In children, disease is typically of acute onset and spontaneously resolves within a few weeks (range: 2-14 weeks).

DIAGNOSIS AND DIFFERENTIAL DIAGNOSIS
Diagnostic imaging such as upper GI series and ultrasound show thickened gastric mucosa, although endoscopy and biopsy is essential for diagnosis. Endoscopy visualizes the enlargement of gastric folds and rugae typically in the fundus or body of the stomach. Histopathology shows characteristic foveolar hyperplasia, reduction in parietal cells, and hyperplasia of smooth muscle, whereas *H. pylori* staining and tissue CMV polymerase chain reaction can identify infectious etiology. The differential diagnosis includes different forms of hyperplastic and nonhyperplastic gastropathy such as Menetrier disease, Zollinger-Ellison syndrome, eosinophilic gastroenteritis, gastric lymphoma, Crohn disease, and inflammatory pseudotumor.

TREATMENT
Therapy is supportive and should include adequate hydration, antisecretory agents (H_2-receptor blockade, proton pump inhibitors), and albumin replacement if hypoalbuminemia is symptomatic. When *H. pylori* are detected, appropriate treatment is recommended. Ganciclovir in CMV-positive gastropathy is indicated only in severe cases. There are no official guidelines as far as the length of treatment. In practice, IV therapy is initiated for the first 24-48 hours. Treatment is continued with oral valganciclovir for a total of 3 weeks. Octreotide therapy has been of benefit in some case reports. Complete recovery is the rule.

Visit Elsevier eBooks+ at eBooks.Health.Elsevier.com for Bibliography.

Chapter 376

Intestinal Atresia, Stenosis, and Malrotation

Christina B. Bales and Chris A. Liacouras

Approximately 1 in 2,000 children is born with intestinal obstruction. Obstruction may be partial or complete, and it may be characterized as simple or strangulating. Luminal contents fail to progress in an aboral direction in simple obstruction, whereas blood flow to the intestine is also impaired in strangulating obstruction. If strangulating obstruction is not promptly relieved, it can lead to bowel infarction and perforation.

Intestinal obstruction can be further classified as either intrinsic or extrinsic based on underlying etiology. Intrinsic causes include inherent abnormalities of intestinal innervation, mucus production, or tubular anatomy. Among these, congenital disruption of the tubular structure is most common and can manifest as obliteration (atresia) or narrowing (stenosis) of the intestinal lumen. More than 90% of intestinal stenosis and atresia occurs in the duodenum, jejunum, and ileum. Rare cases occur in the colon, and these may be associated with more proximal atresias.

Extrinsic causes of congenital intestinal obstruction involve compression of the bowel by vessels (e.g., preduodenal portal vein), organs (e.g., annular pancreas), and cysts (e.g., duplication, mesenteric). Abnormalities in intestinal rotation during fetal development also represent a unique extrinsic cause of congenital intestinal obstruction. Malrotation is associated with inadequate mesenteric attachment of the intestine to the posterior abdominal wall, which leaves the bowel vulnerable to auto obstruction as a result of intestinal twisting or volvulus. Malrotation is commonly accompanied by congenital adhesions that can compress and obstruct the duodenum as they extend from the cecum to the right upper quadrant.

Obstruction is typically associated with bowel distention, which is caused by an accumulation of ingested food, gas, and intestinal secretions proximal to the point of obstruction. As the bowel dilates, absorption of intestinal fluid is decreased and secretion of fluid and electrolytes is increased. This shift results in isotonic intravascular depletion, which is usually associated with hypokalemia. Bowel distention also results in a decrease in blood flow to the obstructed bowel. As blood flow is shifted away from the intestinal mucosa, there is loss of mucosal integrity. Bacteria proliferate in the stagnant bowel, with a predominance of coliforms and anaerobes. This rapid proliferation of bacteria, coupled with the loss of mucosal integrity, allows bacteria to translocate across the bowel wall and potentially lead to endotoxemia, bacteremia, and sepsis.

The clinical presentation of intestinal obstruction varies with the cause, level of obstruction, vascular compromise, and time between the obstructing event and the patient's evaluation. Classic symptoms of obstruction in the neonate include vomiting, abdominal distention, and obstipation. Obstruction high in the intestinal tract results in large-volume, frequent, bilious emesis with little or no abdominal distention. Pain is intermittent and is usually relieved by vomiting. Obstruction in the distal small bowel leads to moderate or marked abdominal distention with emesis that is progressively feculent. Both proximal and distal obstructions are eventually associated with obstipation. However, meconium stools can be passed initially if the obstruction is in the upper part of the intestinal tract or if the obstruction developed late in intrauterine life.

The diagnosis of congenital bowel obstruction relies on a combination of history, physical examination, and radiologic findings. In certain cases, the diagnosis is suggested in the prenatal period. Routine prenatal ultrasound can detect polyhydramnios, which often accompanies high intestinal obstruction. The presence of polyhydramnios should prompt aspiration of the infant's stomach immediately after birth. Aspiration of more than 15-20 mL of fluid, particularly if it is bile stained, is highly indicative of intestinal obstruction.

In the postnatal period, a plain radiograph is the initial diagnostic study and can provide valuable information about potential associated complications. With completely obstructing lesions, plain radiographs reveal bowel distention proximal to the point of obstruction. Upright or cross-table lateral views typically demonstrate a series of air-fluid levels in the distended loops. Caution must be exercised in using plain films to determine the location of intestinal obstruction. Because colonic haustra are not fully developed in the neonate, small and large bowel obstructions may be difficult to distinguish with plain films. In these cases, contrast studies of the bowel or computed tomography images may be indicated. Oral or nasogastric contrast medium may be used to identify obstructing lesions in the proximal bowel, and contrast enemas may be used to diagnose more-distal entities. Indeed, enemas may also play a therapeutic role in relieving distal obstruction caused by meconium ileus or meconium plug syndrome.

Initial treatment of infants and children with bowel obstruction must be directed at fluid resuscitation and stabilizing the patient. Nasogastric decompression usually relieves pain and vomiting. After appropriate cultures, broad-spectrum antibiotics are usually started in ill-appearing neonates with bowel obstruction and those with suspected strangulating infarction. Patients with strangulation must have immediate surgical relief before the bowel infarcts, resulting in gangrene and intestinal perforation. Extensive intestinal necrosis results in short bowel syndrome (see Chapter 385.6). Nonoperative conservative management is usually limited to children with suspected adhesions or inflammatory strictures that might resolve with nasogastric decompression or antiinflammatory medications. If clinical signs of improvement are not evident within 12-24 hours, then operative intervention is usually indicated.

376.1 Duodenal Obstruction

Christina B. Bales and Chris A. Liacouras

Congenital duodenal obstruction occurs in 2.5-10/100,000 live births. In most cases, it is caused by atresia, an intrinsic defect of bowel formation. It can also result from extrinsic compression by abnormal neighboring structures (e.g., annular pancreas, preduodenal portal vein), duplication cysts, or congenital bands associated with malrotation. Although intrinsic and extrinsic causes of duodenal obstruction occur independently, they can also coexist. Thus a high index of suspicion for more than one underlying etiology may be critical to avoiding unnecessary reoperations in these infants.

Duodenal atresia complicates 1/5-10,000 live births and accounts for up to 60% of all intestinal atresias. In contrast to more distal atresias, which likely arise from prenatal vascular accidents, duodenal atresia results from failed recanalization of the intestinal lumen during gestation. Throughout the fourth and fifth week of normal fetal development, the duodenal mucosa exhibits rapid proliferation of epithelial cells. Persistence of these cells, which should degenerate after the seventh week of gestation, leads to occlusion of the lumen (atresia) in approximately two thirds of cases and narrowing (stenosis) in the remaining one third. Duodenal atresia can take several forms, including a thin membrane that occludes the lumen, a short fibrous cord that connects two blind duodenal pouches, or a gap that spans two nonconnecting ends of the duodenum. The membranous form is most common, and it almost invariably occurs near the ampulla of Vater. In rare cases, the membrane is distensible and is referred to as a *windsock web*. This unusual form of duodenal atresia causes obstruction several centimeters distal to the origin of the membrane.

Approximately 50% of infants with duodenal atresia are premature. Concomitant congenital anomalies are common and include congenital heart disease (30%), malrotation (10–30%), annular pancreas (30%), renal anomalies (5–15%), esophageal atresia with or without tracheoesophageal fistula (5–10%), skeletal malformations (5%), and

anorectal anomalies (5%). Of these anomalies, only complex congenital heart disease is associated with increased mortality. Annular pancreas is associated with increased late complications, including gastroesophageal reflux disease, peptic ulcer disease, pancreatitis, gastric outlet and recurrent duodenal obstruction, and gastric cancer. Thus long-term follow-up of these patients into adulthood is warranted. Nearly half of patients with duodenal atresia have chromosome abnormalities; trisomy 21 is identified in up to 40% of patients.

CLINICAL MANIFESTATIONS AND DIAGNOSIS

The hallmark of duodenal obstruction is bilious vomiting without abdominal distention, which is usually noted on the first day of life. Peristaltic waves may be visualized early in the disease process. A history of polyhydramnios is present in up to 80% of pregnancies and is caused by inadequate absorption of amniotic fluid in the distal intestine. This fluid may be bile stained because of intrauterine vomiting. Jaundice is present in one third of the infants.

The diagnosis is suggested by the presence of a *double-bubble* sign on a plain abdominal radiograph (Fig. 376.1). The appearance is caused by a distended and gas-filled stomach and proximal duodenum, which are invariably connected. Contrast studies are occasionally needed to exclude malrotation and volvulus because intestinal infarction can occur within 6-12 hours if the volvulus is not relieved. Contrast studies are generally not necessary and may be associated with aspiration. Prenatal diagnosis of duodenal atresia is readily made by fetal ultrasonography, which reveals a sonographic double-bubble. Prenatal identification of duodenal atresia is associated with decreased morbidity and fewer hospitalization days.

TREATMENT

The initial treatment of infants with duodenal atresia includes nasogastric or orogastric decompression and intravenous fluid replacement. Echocardiography, renal ultrasound, and radiology of the chest and spine should be performed to evaluate for associated anomalies. Definitive correction of the atresia is usually postponed until life-threatening anomalies are evaluated and treated.

The typical surgical repair for duodenal atresia is duodenoduodenostomy. This procedure is also preferred in cases of concomitant or isolated annular pancreas. In these instances, the duodenoduodenostomy is performed without dividing the pancreas. The dilated proximal bowel might have to be tapered to improve peristalsis. Postoperatively, a gastrostomy tube can be placed to drain the stomach and protect the airway. Intravenous nutritional support or a transanastomotic jejunal tube is needed until the infant starts to feed orally. Long-term prognosis is excellent, approaching 90% survival in most series.

Visit Elsevier eBooks+ at eBooks.Health.Elsevier.com for Bibliography.

Fig. 376.1 Abdominal radiograph of a newborn infant held upright. Note the "double-bubble" gas shadow and the absence of gas in the distal bowel in this case of congenital duodenal atresia.

376.2 Jejunal and Ileal Atresia and Obstruction

Christina B. Bales and Chris A. Liacouras

The primary etiologies of congenital small bowel obstruction involve intrinsic abnormalities in anatomic development (jejunoileal stenosis and atresia), mucus secretion (meconium ileus), and bowel wall innervation (long-segment Hirschsprung disease).

Jejunoileal atresias are generally attributed to intrauterine vascular accidents, which result in segmental infarction and resorption of the fetal intestine. Underlying events that potentiate vascular compromise include intestinal volvulus, intussusception, meconium ileus, and strangulating herniation through an abdominal wall defect associated with gastroschisis or omphalocele. Maternal behaviors that promote vasoconstriction, such as cigarette smoking and cocaine use, can also have a role. Only a few cases of familial inheritance have been reported. In these families, multiple intestinal atresias have occurred in an autosomal recessive pattern. Jejunoileal atresias have been linked with multiparity, low birthweight, and prematurity. Unlike atresia in the duodenum, they are not commonly associated with extraintestinal anomalies.

Five types of jejunal and ileal atresias are encountered (Fig. 376.2), with a relatively even distribution among the five types. In type I, a mucosal web occludes the lumen, but continuity is maintained between the proximal and distal bowel. Type II involves a small-diameter solid cord that connects the proximal and distal bowel. Type III is divided into two subtypes. Type IIIa occurs when both ends of the bowel end in blind loops, accompanied by a small mesenteric defect. Type IIIb is similar, but it is associated with an extensive mesenteric defect and a loss of the normal blood supply to the distal bowel. The distal ileum coils around the ileocolic artery, from which it derives its entire blood supply, producing an "apple-peel" appearance. This anomaly is

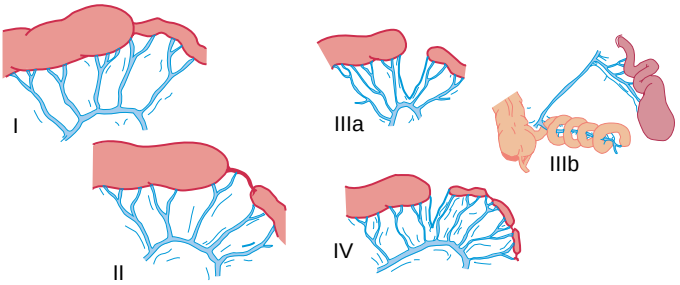

Fig. 376.2 Classification of intestinal atresia. *Type I:* Mucosal obstruction caused by an intraluminal membrane with intact bowel wall and mesentery. *Type II:* Blind ends are separated by a fibrous cord. *Type IIIa:* Blind ends are separated by a V-shaped mesenteric defect. *Type IIIb:* "Apple-peel" appearance. *Type IV:* Multiple atresias. *(From Grosfeld J. Jejunoileal atresia and stenosis. In Welch KJ, Randolph JG, Ravitch MM, eds. Pediatric Surgery, 4th ed. Chicago: Year Book Medical Publishers; 1986.)*

associated with prematurity, an unusually short distal ileum, and significant foreshortening of the bowel. Type IV involves multiple intestinal atresias. In rare cases, Type IV atresia may be associated with pathogenic variants in the *TTC7A* gene, which disrupt normal development of the thymus and intestinal epithelial lining of the intestine. This subset of patients may present with stricturing inflammatory bowel disease, severe combined immune deficiency (SCID), and associated recurrent sepsis. Thus type IV atresia uniquely warrants genetic and immunologic screening.

Meconium ileus occurs primarily in newborn infants with cystic fibrosis, an exocrine gland defect of chloride transport that results in abnormally viscous secretions (see Chapter 454). Approximately 80–90% of infants with meconium ileus have cystic fibrosis, but only 10–15% of infants with cystic fibrosis present with meconium ileus. Pathogenic variants in *GUCY2C* also produce meconium ileus. In simple cases of meconium ileus, the distal 20-30 cm of ileum is collapsed and filled with pellets of pale stool. The proximal bowel is dilated and filled with thick meconium that resembles sticky syrup or glue. Peristalsis fails to propel this viscid material forward, and it becomes impacted in the ileum. In complicated cases, a volvulus of the dilated proximal bowel can occur, resulting in intestinal ischemia, atresia, and/or perforation. Perforation in utero results in **meconium peritonitis**, which can lead to potentially obstructing adhesions and calcifications.

Both intestinal atresia and meconium ileus must be distinguished from long-segment Hirschsprung disease. This condition involves congenital absence of ganglion cells in the myenteric and submucosal plexuses of the bowel wall. In a small subset (5%) of patients, the aganglionic segment includes the terminal ileum in addition to the entire length of the colon. Infants with long-segment Hirschsprung disease present with a dilated small intestine that is ganglionated but has hypertrophied walls, a funnel-shaped transitional hypoganglionic zone, and a collapsed distal aganglionic bowel. Congenital pseudoobstruction syndromes may mimic long-segment Hirschsprung disease and other etiologies of intestinal obstruction (see Chapter 378).

CLINICAL MANIFESTATION AND DIAGNOSIS

Distal intestinal obstruction is less likely than proximal obstruction to be detected in utero. Polyhydramnios is identified in 20–35% of jejunoileal atresias, and it may be the first sign of intestinal obstruction. Abdominal distention is rarely present at birth, but it develops rapidly after initiation of feeds in the first 12-24 hours. Distention is often accompanied by vomiting, which is often bilious. Up to 80% of infants fail to pass meconium in the first 24 hours of life. Jaundice is reported in 20–30% of patients.

In patients with obstruction caused by jejunoileal atresia or long-segment Hirschsprung disease, plain radiographs typically demonstrate multiple air-fluid levels proximal to the obstruction in the upright or lateral decubitus positions (Fig. 376.3). These levels may be absent in patients with meconium ileus because the viscosity of the secretions in the proximal bowel prevents layering. Instead, a typical hazy or ground-glass appearance may be appreciated in the right lower quadrant. This haziness is caused by small bubbles of gas that become trapped in inspissated meconium in the terminal ileal region. If there is meconium peritonitis, patchy calcification may also be noted, particularly in the flanks. Plain films can reveal evidence of pneumoperitoneum due to intestinal perforation. Air may be seen in the subphrenic regions on the upright view and over the liver in the left lateral decubitus position.

Because plain radiographs do not reliably distinguish between small and large bowel in neonates, contrast studies are often required to localize the obstruction. Water-soluble enemas (Gastrografin, Hypaque) are particularly useful in differentiating atresia from meconium ileus and Hirschsprung disease. A small *microcolon* suggests disuse due to in utero obstruction proximal to the ileocecal valve. Abdominal ultrasound may be an important adjunctive study, which can help to distinguish meconium ileus from ileal atresia and identify concomitant intestinal malrotation.

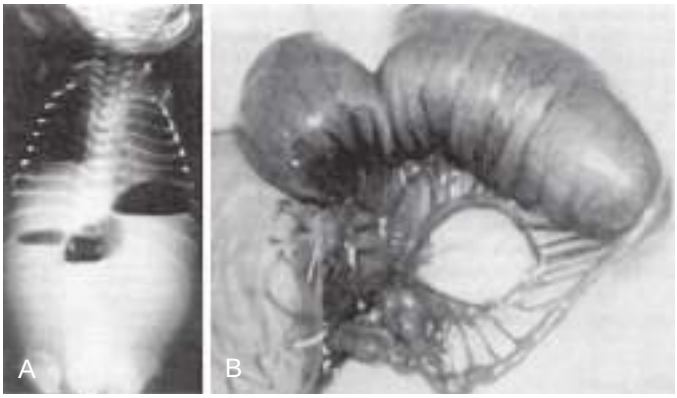

Fig. 376.3 A, Abdominal radiograph in a neonate with bilious vomiting shows a few loops of dilated intestine with air-fluid levels. B, At laparotomy, a type I (mucosal) jejunal atresia was observed. *(From O'Neill JA Jr, Grosfeld JL, Fonkalsrud EW, et al., eds. Principles of Pediatric Surgery, 2nd ed. St. Louis: Mosby; 2003: p 493.)*

TREATMENT

Patients with small bowel obstruction should be stable and in adequate fluid and electrolyte balance before operation or radiographic attempts at disimpaction unless volvulus is suspected. Documented infections should be treated with appropriate antibiotics. Prophylactic antibiotics are usually given before surgery.

Ileal or jejunal atresia requires resection of the atretic portion of the bowel followed by end-to-end anastomosis. In select cases, proximal bowel dilation necessitates initial decompressing ostomy creation and/or bowel tapering before bowel anastomosis. If a simple mucosal diaphragm is present, jejunoplasty or ileoplasty with partial excision of the web is an acceptable alternative to resection. In uncomplicated meconium ileus, Gastrografin enemas diagnose the obstruction and wash out the inspissated material. Gastrografin is hypertonic, and care must be taken to avoid dehydration, shock, and bowel perforation. The enema may have to be repeated after 8-12 hours. Resection after reduction is not needed if there have been no ischemic complications.

Approximately 50% of patients with simple meconium ileus do not adequately respond to water-soluble enemas and need laparotomy. Operative management is indicated when the obstruction cannot be relieved by repeated attempts at nonoperative management and for infants with complicated meconium ileus. The extent of surgical intervention depends on the degree of pathology. In simple meconium ileus, the plug can be relieved by manipulation or direct enteral irrigation with *N*-acetylcysteine following an enterotomy. In complicated cases, bowel resection, peritoneal lavage, abdominal drainage, and stoma formation may be necessary. Total parenteral nutrition is generally required.

Visit Elsevier eBooks+ at eBooks.Health.Elsevier.com for Bibliography.

376.3 Malrotation

Christina B. Bales and Chris A. Liacouras

Disruptions in the normal sequential herniation, rotation, and fixation of the midgut during development give rise to a spectrum of rotational abnormalities. The gut starts as a straight tube from stomach to rectum. Intestinal rotation and attachment begin in the fifth week of gestation when the mid-bowel (distal duodenum to mid-transverse colon) elongates, gradually herniates through the umbilical ring, and then rotates in stages in a counterclockwise direction, using the superior mesenteric artery (SMA) as a rotational axis. As a 270-degree counterclockwise rotation is accomplished, the third portion of the duodenum passes posterior to the SMA and the duodenal-jejunal junction moves to the left upper quadrant and becomes suspended in the ligament of Treitz (LOT), while the cecum settles in the right lower quadrant. The ascending and descending colon subsequently become fixed in the right and

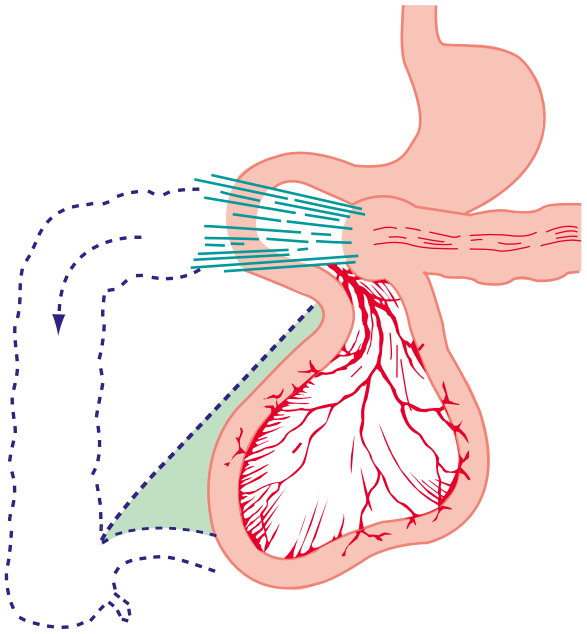

Fig. 376.4 Mechanism of intestinal obstruction with incomplete rotation of the midgut (malrotation). The *dashed lines* show the course the cecum should have taken. Failure to rotate has left obstructing bands across the duodenum and a narrow pedicle for the midgut loop, making it susceptible to volvulus. *(From Nixon HH, O'Donnell B. The Essentials of Pediatric Surgery. Philadelphia: JB Lippincott; 1961.)*

left retroperitoneum, respectively. Fixation of the bowel at the LOT and in the retroperitoneum provides a broad-based support to the mesentery, thus preventing twisting of the mesenteric root and kinking of the vascular supply. Intestinal rotation and attachment are completed by the 12th week of gestation.

Nonrotation occurs when the bowel fails to rotate after it returns to the abdominal cavity. The first and second portions of the duodenum assume their normal position, but the residual small bowel remains on the right side of the abdomen and the colon resides on the left. In contrast, typical malrotation involves failure of the cecum to fully rotate into the right lower quadrant (Fig. 376.4) and form the normal broad-based adherence to the posterior abdominal wall. As a consequence of this incomplete rotation, the mesentery, including the SMA, is tethered by a narrow stalk. This configuration leaves patients with malrotation vulnerable to midgut volvulus, a life-threatening complication that occurs when the small bowel twists around the SMA, leading to vascular compromise and ischemia of the bowel. Bowel obstruction may also be caused by congenital bands of tissue (Ladd bands), which can extend from the cecum to the right upper quadrant, compress, and possibly obstruct the duodenum.

Rotational abnormalities are commonly associated with other congenital anomalies, including intestinal atresia, Hirschsprung disease and other congenital motility disorders, diaphragmatic hernia, gastroschisis, and omphalocele. Malrotation may also be associated with heterotaxy syndrome, which is a complex of congenital anomalies including heart malformations, malrotation, biliary atresia, and asplenia or polysplenia (see Chapter 480.11).

CLINICAL MANIFESTATIONS

Symptomatic malrotation occurs in 1 in 6,000 live births, whereas asymptomatic cases may be as frequent as 1 in 200 live births. Most symptomatic patients present in the first year of life, with approximately 50% presenting in the first week and 75% in the first month of life. Symptomatic infants typically present with bilious emesis due to bowel obstruction caused by volvulus or duodenal compression by Ladd bands or other adhesive bands that constrict the small and large bowel. Infants with volvulus may experience irritability, bloody stools, and rapid clinical deterioration with signs of sepsis. Older children with midgut volvulus may manifest similar features, though symptoms may be more subtle. Sporadic colicky pain and bilious emesis due to intermittent volvulus mandates a high level of suspicion for this entity.

DIAGNOSIS

Upper GI series is considered the gold standard for diagnosis (≥93%) and reveals displacement of duodenojejunal junction (DJJ) from its normal position to the left of the spine, generally posterior and level or superior to the duodenal bulb. DJJ displacement may be appreciated in other conditions, including spleen or left kidney enlargement/tumor, gastric or colonic distention, and enteric feeding tubes. As fixation of the DJJ increases with age (>4 years), the specificity of these findings for malrotation improves. In equivocal cases, a follow-through series or contrast enema may demonstrate malposition of the cecum, though this finding may be absent in up to 20% of patients. Ultrasonography can demonstrate the inversion of the SMA and vein, with the vein located to the left rather than to the right of the artery. In cases of midgut volvulus, the upper GI series may reveal a corkscrew appearance of the small bowel or a *bird's beak* narrowing of the duodenum, consistent with obstruction, and Doppler ultrasound may show a *whirlpool* sign.

TREATMENT

Surgical intervention is recommended for any symptomatic patient with malrotation, regardless of age. Treatment of asymptomatic malrotation appreciated incidentally on imaging is more controversial, particularly in patients with congenital heterotaxy syndrome, who may be at higher risk for surgical complications. In asymptomatic patients careful assessment of imaging, supplemented in some cases by exploratory laparoscopy, guides selection for surgical intervention. Those patients who are older and have a broad-based mesentery may be appropriate for nonsurgical observation with careful parental counseling. If a volvulus is present, surgery is done immediately as an acute emergency. The volvulus is reduced, and a Ladd procedure is typically performed. In the Ladd procedure, the duodenum and upper jejunum are freed of any bands and remain in the right abdominal cavity. The colon is freed of adhesions and placed in the right abdomen with the cecum in the left lower quadrant, usually accompanied by incidental appendectomy. The Ladd procedure may be performed laparoscopically for malrotation without volvulus, but it is generally done as an open procedure if volvulus is present. The purpose of surgical intervention is to minimize the risk of subsequent volvulus rather than to return the bowel to a normal anatomic configuration. Extensive intestinal ischemia from volvulus can result in short bowel syndrome (see Chapter 385.6).

Visit Elsevier eBooks+ at eBooks.Health.Elsevier.com for Bibliography.

Chapter 377

Intestinal Duplications, Meckel Diverticulum, and Other Remnants of the Omphalomesenteric Duct

377.1 Intestinal Duplication

Máire A. Conrad and Chris A. Liacouras

Duplications of the intestinal tract are rare anomalies that consist of well-formed tubular or spherical structures firmly attached to the intestine with a common blood supply. The lining of the duplications resembles that of the gastrointestinal (GI) tract. Duplications are located on the mesenteric border and can communicate with the intestinal lumen. Duplications can be classified into three categories: (1) localized duplications, (2) duplications associated with spinal cord defects and vertebral malformations, and (3) duplications of the colon. Occasionally (10–15% of cases), multiple duplications are found.

Localized duplications can occur in any area of the GI tract but are most common in the ileum and jejunum. They are usually cystic or tubular structures within the wall of the bowel. The cause is unknown, but their development has been attributed to defects in recanalization of the intestinal lumen after the solid stage of embryologic development. Duplication of the intestine occurring in association with **vertebral and spinal cord anomalies** (hemivertebra, anterior spina bifida, band connection between lesion and cervical or thoracic spine) is thought to arise from splitting of the notochord in the developing embryo. **Duplication of the colon** is usually associated with anomalies of the urinary tract and genitals. Duplication of the entire colon, rectum, anus, and terminal ileum rarely occur. The defects are thought to be secondary to caudal twinning, with duplication of the hindgut, genital, and lower urinary tracts.

CLINICAL MANIFESTATIONS

Symptoms depend on the size, location, and type of mucosal lining. Duplications can cause bowel obstruction by compressing the adjacent intestinal lumen, or they can act as the lead point of an intussusception or a site for a volvulus. If they are lined by acid-secreting mucosa, they can cause ulceration, perforation, and hemorrhage of or into the adjacent bowel. Patients can present with abdominal pain, vomiting, palpable mass, or acute GI hemorrhage. Intestinal duplications in the thorax **(neuroenteric cysts)** can manifest as respiratory distress. Duplications of the lower bowel can cause constipation or diarrhea or be associated with recurrent prolapse of the rectum.

The diagnosis is suspected based on the history and physical examination. Radiologic studies such as barium studies, ultrasonography, CT, and MRI are helpful but usually nonspecific, demonstrating cystic structures or mass effects. Radioisotope technetium scanning can localize ectopic gastric mucosa. The treatment of duplications is surgical resection and management of associated defects.

377.2 Meckel Diverticulum and Other Remnants of the Omphalomesenteric Duct

Máire A. Conrad and Chris A. Liacouras

Meckel diverticulum is the most common congenital anomaly of the GI tract and is caused by the incomplete obliteration of the omphalomesenteric duct (also known as the *vitelline duct*) during the seventh week of gestation. The omphalomesenteric duct connects the yolk sac to the gut in a developing embryo and provides nutrition until the placenta is established. Between the fifth and seventh week of gestation, the duct attenuates and separates from the intestine. Just before this involution, the epithelium of the yolk sac develops a lining similar to that of the stomach. Partial or complete failure of involution of the omphalomesenteric duct results in various residual structures. Meckel diverticulum is the most common of these structures, occurring in 2–3% of all infants. A typical Meckel diverticulum is a true diverticulum containing all layers of the small intestinal wall and is a 3- to 6-cm outpouching of the ileum along the antimesenteric border 50-75 cm (approximately 2 feet) from the ileocecal valve (Fig. 377.1). The distance from the ileocecal valve depends on the age of the patient. Meckel diverticulum has been conveniently characterized by the "rule of 2s," which explains the classic presentation of this congenital anomaly. Meckel diverticula are found in approximately 2% of the general population, are usually located 2 feet proximal to the ileocecal valve, are approximately 2 inches in length, can contain two types of ectopic tissue (pancreatic or gastric), generally present before the age of 2 years, and are found twice as often in females. Although intraabdominal in location, a rare presentation of a Meckel diverticulum is entrapment in an inguinal, umbilical, or femoral hernia (known as a *Littre hernia*). Other omphalomesenteric duct remnants occur infrequently, including a persistently patent duct, a solid cord, or a cord with a central cyst or a diverticulum associated with a persistent cord between the diverticulum and the umbilicus.

CLINICAL MANIFESTATIONS

Symptoms of a Meckel diverticulum usually arise in the first or second year of life (average: 2.5 years), but initial symptoms may occur in the first decade. The majority of symptomatic Meckel diverticula are lined by an ectopic mucosa, including an acid-secreting mucosa that causes intermittent painless rectal bleeding by ulceration of the adjacent normal ileal mucosa. This ectopic mucosa is most commonly of gastric origin, but it can also be pancreatic, jejunal, or a combination of these tissues. Unlike in the duodenum, the secreted acid is not neutralized by pancreatic bicarbonate.

The stool is typically described as brick colored or currant jelly colored. Bleeding can cause significant anemia but is usually self-limited because of contraction of the splanchnic vessels, as patients become

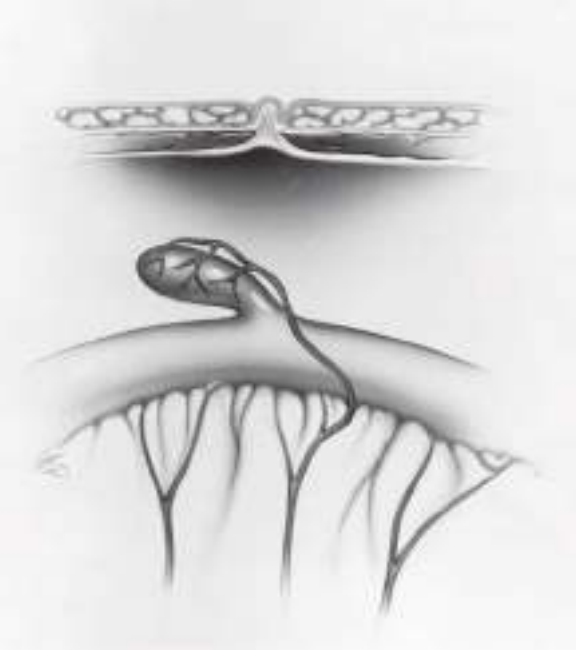

Fig. 377.1 Typical Meckel diverticulum located on the antimesenteric border.

hypovolemic. Bleeding from a Meckel diverticulum can also be less dramatic, with melanotic stools.

Less often, a Meckel diverticulum is associated with partial or complete bowel obstruction. The most common mechanism of obstruction occurs when the diverticulum acts as the lead point of an intussusception. The mean age of onset of obstruction is younger than that for patients presenting with bleeding. Obstruction can also result from intraperitoneal bands connecting residual omphalomesenteric duct remnants to the ileum and umbilicus. These bands cause obstruction by internal herniation or volvulus of the small bowel around the band. A Meckel diverticulum occasionally becomes inflamed **(diverticulitis)** and manifests similarly to acute appendicitis. These children are older, with a mean of 8 years of age. Diverticulitis can lead to perforation and peritonitis.

DIAGNOSIS

The diagnosis of omphalomesenteric duct remnants depends on the clinical presentation. If an infant or child presents with significant painless rectal bleeding, the presence of a Meckel diverticulum should be suspected because Meckel diverticulum accounts for 50% of all lower GI bleeds in children younger than 2 years of age.

Confirmation of a Meckel diverticulum can be difficult. Plain abdominal radiographs are of no value, and routine barium studies rarely fill the diverticulum. The most sensitive study is a Meckel radionuclide scan, which is performed after intravenous infusion of technetium-99m pertechnetate. The mucus-secreting cells of the ectopic gastric mucosa take up pertechnetate, permitting visualization of the Meckel diverticulum (Fig. 377.2). The uptake can be enhanced with various agents, including histamine H_2-blockers such as famotidine or cimetidine, glucagon, and pentagastrin. The sensitivity of the enhanced scan is approximately 85%, with a specificity of approximately 95%. A false-negative scan may be seen in anemic patients; although false-positive results are uncommon, they have been reported with intussusception, appendicitis, duplication cysts, arteriovenous malformations, and tumors. Other methods of detection include radiolabeled tagged red blood cell scan (the patient must be actively bleeding), abdominal ultrasound, superior mesenteric angiography, abdominal CT scan, or exploratory laparoscopy. In patients with omphalomesenteric duct remnants who present with intestinal obstruction or symptoms most similar to appendicitis, the diagnosis is rarely made before surgery.

The treatment of a symptomatic Meckel diverticulum is surgical excision. A diverticulectomy can be performed safely as either a laparoscopic or open procedure. There is significant debate regarding the proper management of an asymptomatic Meckel diverticulum and whether excision versus observation is appropriate. However, the risk of serious complications does seem to exceed the operative risk in children younger than 8 years old.

Visit Elsevier eBooks+ at eBooks.Health.Elsevier.com for Bibliography.

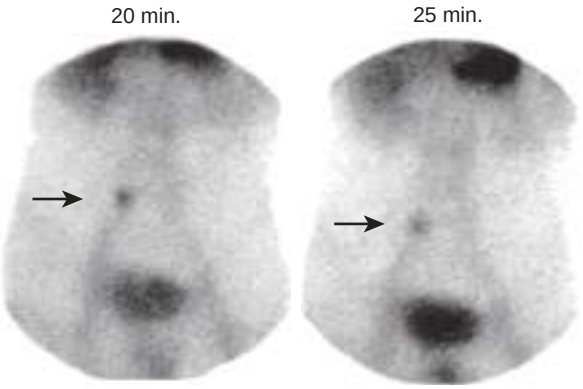

Fig. 377.2 Meckel scan demonstrating accumulation of technetium in the stomach (superior), bladder (inferior) and in the acid-secreting mucosa of a Meckel diverticulum (arrows).

Chapter 378
Motility Disorders and Hirschsprung Disease

378.1 Chronic Intestinal Pseudoobstruction

Jennifer Webster, Kristin N. Fiorino, and Chris A. Liacouras

Chronic intestinal pseudoobstruction (CIPO) comprises a group of primary and secondary disorders characterized as a motility disorder with the dominant defect of impaired peristalsis; symptoms are consistent with intestinal obstruction in the absence of mechanical obstruction (Tables 378.1 and 378.2). It has been suggested that pseudoobstruction in the pediatric population should be referred to as pediatric intestinal pseudoobstruction (PIPO) as it is a distinct entity from adult CIPO (Table 378.3). The natural history of primary pseudoobstruction is that of a progressive disorder, although there are occasional cases of secondary pseudoobstruction caused by conditions that can transiently or permanently alter bowel motility. The most common cause of acute

Table 378.1 Classification of Pediatric Intestinal Pseudoobstruction

PRIMARY PIPO
- Sporadic or familial forms of myopathy and/or neuropathy and/or mesenchymopathy (abnormal ICC development) that relate to disordered development, degeneration, or inflammation. Inflammatory (including autoimmune) conditions include lymphocytic and eosinophilic ganglionitis and/or leiomyositis
- Mitochondrial neuro-gastrointestinal-encephalomyopathy (MNGIE) and other mitochondrial diseases
- Neuropathy associated with multiple endocrine neoplasia type IIB
- Hirschsprung disease, for example, total intestinal aganglionosis*
- MMIHS

SECONDARY PIPO
- Conditions affecting GI smooth muscle:
  - Rheumatologic conditions (dermatomyositis/polymyositis, scleroderma, systematic lupus erythematosus, Ehlers-Danlos syndrome)
  - Other (Duchenne muscular dystrophy, myotonic dystrophy, amyloidosis, ceroidosis or alternatively reported as brown bowel syndrome)
- Pathologies affecting the enteric nervous system (familial dysautonomia, primary dysfunction of the autonomic nervous system, neurofibromatosis, diabetic neuropathy, fetal alcohol syndrome, postviral-related inflammatory neuropathy, e.g., cytomegalovirus, Epstein-Barr virus, varicella zoster virus, JC virus)
- Endocrinologic disorders (hypothyroidism, diabetes, hypoparathyroidism, pheochromocytoma)
- Metabolic conditions (uremia, porphyria, electrolyte imbalances, e.g., potassium, magnesium, calcium)
- Gastroschisis
- Neuropathy post neonatal necrotizing enterocolitis
- Other: celiac disease, eosinophilic gastroenteritis, Crohn disease, radiation injury, Chagas disease, Kawasaki disease, angioedema, drugs (e.g., opiates, anthraquinone laxatives, calcium channel blockers, antidepressants, antineoplastic agents like vinca alkaloids), paraneoplastic CIPO, major trauma/surgery, chromosome abnormalities

Idiopathic (i.e., where forms of primary or secondary PIPO classified earlier do not, as yet, have a defined etiopathogenesis)

*Needs to be excluded in all cases of PIPO
PIPO, Pediatric intestinal pseudoobstruction; ICC, interstitial cells of Cajal; GI, gastrointestinal; MMIHS, megacystis microcolon intestinal hypoperistalsis syndrome.
From Thapar N, Saliakellis E, Benninga M, et al. Paediatric Intestinal Pseudoobstruction: Evidence and Consensus-based Recommendations From an ESPGHAN-Led Expert Group. *J Pediatr Gastroenterol Nutr.* 2018;66(6):991–1019. Table 3.

hypovolemic. Bleeding from a Meckel diverticulum can also be less dramatic, with melanotic stools.

Less often, a Meckel diverticulum is associated with partial or complete bowel obstruction. The most common mechanism of obstruction occurs when the diverticulum acts as the lead point of an intussusception. The mean age of onset of obstruction is younger than that for patients presenting with bleeding. Obstruction can also result from intraperitoneal bands connecting residual omphalomesenteric duct remnants to the ileum and umbilicus. These bands cause obstruction by internal herniation or volvulus of the small bowel around the band. A Meckel diverticulum occasionally becomes inflamed **(diverticulitis)** and manifests similarly to acute appendicitis. These children are older, with a mean of 8 years of age. Diverticulitis can lead to perforation and peritonitis.

DIAGNOSIS

The diagnosis of omphalomesenteric duct remnants depends on the clinical presentation. If an infant or child presents with significant painless rectal bleeding, the presence of a Meckel diverticulum should be suspected because Meckel diverticulum accounts for 50% of all lower GI bleeds in children younger than 2 years of age.

Confirmation of a Meckel diverticulum can be difficult. Plain abdominal radiographs are of no value, and routine barium studies rarely fill the diverticulum. The most sensitive study is a Meckel radionuclide scan, which is performed after intravenous infusion of technetium-99m pertechnetate. The mucus-secreting cells of the ectopic gastric mucosa take up pertechnetate, permitting visualization of the Meckel diverticulum (Fig. 377.2). The uptake can be enhanced with various agents, including histamine H_2-blockers such as famotidine or cimetidine, glucagon, and pentagastrin. The sensitivity of the enhanced scan is approximately 85%, with a specificity of approximately 95%. A false-negative scan may be seen in anemic patients; although false-positive results are uncommon, they have been reported with intussusception, appendicitis, duplication cysts, arteriovenous malformations, and tumors. Other methods of detection include radiolabeled tagged red blood cell scan (the patient must be actively bleeding), abdominal ultrasound, superior mesenteric angiography, abdominal CT scan, or exploratory laparoscopy. In patients with omphalomesenteric duct remnants who present with intestinal obstruction or symptoms most similar to appendicitis, the diagnosis is rarely made before surgery.

The treatment of a symptomatic Meckel diverticulum is surgical excision. A diverticulectomy can be performed safely as either a laparoscopic or open procedure. There is significant debate regarding the proper management of an asymptomatic Meckel diverticulum and whether excision versus observation is appropriate. However, the risk of serious complications does seem to exceed the operative risk in children younger than 8 years old.

Visit Elsevier eBooks+ at eBooks.Health.Elsevier.com for Bibliography.

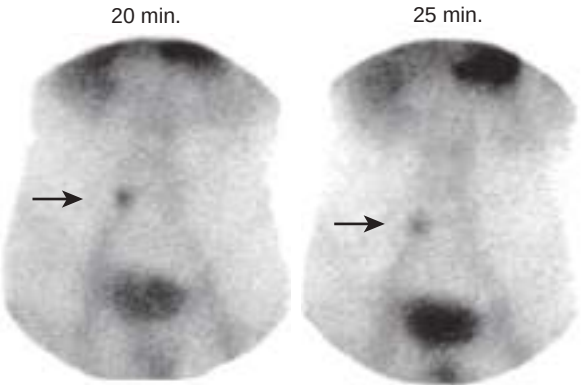

Fig. 377.2 Meckel scan demonstrating accumulation of technetium in the stomach (superior), bladder (inferior) and in the acid-secreting mucosa of a Meckel diverticulum (arrows).

Chapter 378
Motility Disorders and Hirschsprung Disease

378.1 Chronic Intestinal Pseudoobstruction

Jennifer Webster, Kristin N. Fiorino, and Chris A. Liacouras

Chronic intestinal pseudoobstruction (CIPO) comprises a group of primary and secondary disorders characterized as a motility disorder with the dominant defect of impaired peristalsis; symptoms are consistent with intestinal obstruction in the absence of mechanical obstruction (Tables 378.1 and 378.2). It has been suggested that pseudoobstruction in the pediatric population should be referred to as pediatric intestinal pseudoobstruction (PIPO) as it is a distinct entity from adult CIPO (Table 378.3). The natural history of primary pseudoobstruction is that of a progressive disorder, although there are occasional cases of secondary pseudoobstruction caused by conditions that can transiently or permanently alter bowel motility. The most common cause of acute

Table 378.1 Classification of Pediatric Intestinal Pseudoobstruction

PRIMARY PIPO
- Sporadic or familial forms of myopathy and/or neuropathy and/or mesenchymopathy (abnormal ICC development) that relate to disordered development, degeneration, or inflammation. Inflammatory (including autoimmune) conditions include lymphocytic and eosinophilic ganglionitis and/or leiomyositis
- Mitochondrial neuro-gastrointestinal-encephalomyopathy (MNGIE) and other mitochondrial diseases
- Neuropathy associated with multiple endocrine neoplasia type IIB
- Hirschsprung disease, for example, total intestinal aganglionosis*
- MMIHS

SECONDARY PIPO
- Conditions affecting GI smooth muscle:
  - Rheumatologic conditions (dermatomyositis/polymyositis, scleroderma, systematic lupus erythematosus, Ehlers-Danlos syndrome)
  - Other (Duchenne muscular dystrophy, myotonic dystrophy, amyloidosis, ceroidosis or alternatively reported as brown bowel syndrome)
- Pathologies affecting the enteric nervous system (familial dysautonomia, primary dysfunction of the autonomic nervous system, neurofibromatosis, diabetic neuropathy, fetal alcohol syndrome, postviral-related inflammatory neuropathy, e.g., cytomegalovirus, Epstein-Barr virus, varicella zoster virus, JC virus)
- Endocrinologic disorders (hypothyroidism, diabetes, hypoparathyroidism, pheochromocytoma)
- Metabolic conditions (uremia, porphyria, electrolyte imbalances, e.g., potassium, magnesium, calcium)
- Gastroschisis
- Neuropathy post neonatal necrotizing enterocolitis
- Other: celiac disease, eosinophilic gastroenteritis, Crohn disease, radiation injury, Chagas disease, Kawasaki disease, angioedema, drugs (e.g., opiates, anthraquinone laxatives, calcium channel blockers, antidepressants, antineoplastic agents like vinca alkaloids), paraneoplastic CIPO, major trauma/surgery, chromosome abnormalities

Idiopathic (i.e., where forms of primary or secondary PIPO classified earlier do not, as yet, have a defined etiopathogenesis)

*Needs to be excluded in all cases of PIPO
PIPO, Pediatric intestinal pseudoobstruction; ICC, interstitial cells of Cajal; GI, gastrointestinal; MMIHS, megacystis microcolon intestinal hypoperistalsis syndrome.
From Thapar N, Saliakellis E, Benninga M, et al. Paediatric Intestinal Pseudoobstruction: Evidence and Consensus-based Recommendations From an ESPGHAN-Led Expert Group. *J Pediatr Gastroenterol Nutr.* 2018;66(6):991–1019. Table 3.

Table 378.2 Primary Pediatric Intestinal Pseudoobstruction with Identified Genetic Pathogenic Variants

GENE	SYNDROME	INHERITANCE	PHENOTYPE	AGE OF ONSET
Sox 10	Type IV Waardenburg syndrome	Autosomal dominant	Peripheral neuropathy with hypomyelination, sensorineural deafness and pseudoobstruction	Neonatal period
POLG1 (DNA-polymerase gamma)	Congenital myopathy and gastrointestinal pseudoobstruction	Autosomal recessive	Associated with mitochondrial depletion and deletions. Severe hypotonia and generalized muscle weakness, severe abdominal distension and hypoactive bowel	Neonatal period
FLNA (filamin A)	Chronic idiopathic intestinal pseudoobstruction (CIIPX)	X-linked recessive	Abnormal filamin A leads to cytoskeletal abnormalities and potentially disrupts enteric-neuron structure and function. Seizures and progressive abdominal distension and obstruction	Neonatal period
L1CAM (L1 cell adhesion molecule)	Hydrocephalus with stenosis of the aqueduct of Sylvius (HSAS) and congenital idiopathic intestinal pseudoobstruction	Autosomal recessive	Defect in the differentiation of the interstitial cells of Cajal leading to progressive distension and intermittent episodes of obstruction	Neonatal period
ACTG2 (enteric smooth muscle actin–gamma 2)	Familial visceral myopathy; megacystis-microcolon-intestinal hypoperistalsis syndrome	Autosomal dominant, sporadic	Altered ACTG2 protein in the muscularis propria leads to impaired contractility	Neonatal to third decade in life
MYH11 (myosin heavy chain 11)	Megacystis-microcolon-intestinal hypoperistalsis syndrome	Autosomal recessive	Abnormal MYH11 in smooth muscle myosin leads to impaired contractility	Neonatal to third decade in life
MYLK (myosin light chain kinase)	Megacystis-microcolon-intestinal hypoperistalsis syndrome	Autosomal recessive	Abnormal MYLK leads to impaired smooth muscle cell contraction	Neonatal to third decade in life
LMOD1 (leiomodin 1)	Megacystis-microcolon-intestinal hypoperistalsis syndrome	Sporadic	Abnormal LMOD1 leads to impaired intestinal smooth muscle contractility	Neonatal to third decade in life
MYL9 (myosin regulatory light chain 9)	Megacystis-microcolon-intestinal hypoperistalsis syndrome	Autosomal recessive	Abnormal MYL9 leads to impaired intestinal smooth muscle contractility	Neonatal to third decade in life
RET protooncogene (receptor tyrosine kinase)	MEN2B	Autosomal dominant	Gain-in-function mutation associated with intestinal ganglioneuromas leading to increased cell number in the myenteric plexus and dysmotility	Infancy to third decade of life
TYMP (thymidine phosphorylase)	Mitochondrial neurogastrointestinal encephalomyopathy (MNGIE)	Autosomal recessive	Accumulation of thymidine in mitochondrial DNA leads to impaired function. Multisystem mitochondrial disease with progressive gastrointestinal dysmotility	Infancy to third decade of life
RAD21	Mungan syndrome	Autosomal recessive	Pseudoobstruction, megaduodenum, long segment Barrett esophagus and cardiac abnormalities	First to second decade of life
SGOL1	Chronic atrial and intestinal dysrhythmia (CAID)	Autosomal recessive	Accelerated cell cycle progression and enhanced activation of transforming growth factor-β signaling leading to changes in both the enteric nervous system and smooth muscle	First to fourth decade of life
ACTA2	Megacystitis-microcolon-intestinal hypoperistalsis	Autosomal dominant	Smooth muscle dysfunction, congenital mydriasis	Neonatal period

Modified from Gamboa H, Sood M. Pediatric intestinal pseudo-obstruction in the era of genetic sequencing. *Curr Gastroenterol Rep*. 2019;21:1–12. Table 1.

Table 378.3 Common and Distinctive Features of Pediatric Chronic Intestinal Pseudoobstruction

	CHILDREN	ADOLESCENTS AND YOUNG ADULTS
Etiology	Majority of cases appear to be congenital (up to 80%) and primary. Secondary forms rare (<10%)	Secondary forms (mostly to systemic disease) common and account for up to 50% of cases
Disease subtype	Neuropathies more common (~70%) with myopathic forms seen in ~30%	Predominantly neuropathies (majority inflammatory) (~45%) with myopathies accounting for (~30%)
Symptom onset	In utero, from birth or early infancy (65–80% of patients by 12 mo of age)	Median age of onset is 20-40 yr
Clinical features	Recurrent or continuous episodes of intestinal pseudoobstruction with symptoms present from birth/early life Pain infrequently seen (approximately 30%) Urologic involvement common (36–100%) Intestinal malrotation in about 30% of cases High risk of colonic and small bowel volvulus	Chronic abdominal pain and distension with superimposed acute episodes of pseudoobstruction Pain is a cardinal symptom present in at least 80% of patients Urologic involvement rare Intestinal malrotation rarely seen Low risk of colonic and small bowel volvulus
Natural history	Poor outcome predicted by myopathic forms of PIPO; urinary involvement; concurrent intestinal malrotation; and inability to tolerate enteral feeds Risk of mortality in approximately 20% of cases	Low mortality if ability to restore oral feeding and the presence of symptoms <20 yr of age High mortality if systemic sclerosis or paraneoplasia and severe/diffuse esophageal and intestinal dysmotility
Diagnostic approach	Diagnosis relies on clinical picture and radiology together with specialized tests (e.g., intestinal manometry, histopathology) Dilated bowel loops with fluid levels commonly absent (~40%) in patients presenting in the neonatal period Histopathology yield high and used to inform management, for example, use of parenteral nutrition in intestinal myopathies and prokinetics in intestinal neuropathies Apart from specific indications little yield from investigating for secondary PIPO Need to differentiate from feeding problems and fabricated or induced illness.	Diagnosis made on clinical picture and radiology with variable use of intestinal manometry On radiology defined by the presence of dilated loops of bowel with fluid levels Histopathology has a positive yield in the majority of patients but guides treatment only in minority May help support a diagnosis of secondary CIPO with other clinical findings/investigations
Nutritional therapy	Significant number (~80%) require parenteral nutrition to maintain normal growth and development. Specialized feeds (e.g., hydrolyzed protein feeds) and feeding routes (e.g., jejunal) used to promote enteral feed tolerance	Approximately 20–50% need home parenteral nutrition to prevent malnutrition
Pharmacologic therapy	Virtually no evidence base from controlled trials. Use of medication mostly anecdotal, case reports or drawn from adult literature	Few controlled trials, often small studies; few conclusions can be drawn
Surgical therapy	Venting ostomies very commonly used to decompress and reduce pseudoobstructive events; Surgery as a "bridge" to transplantation may be indicated in highly selected cases	Venting or defunctioning ostomies may help some patients. Little role for surgical resection

PIPO, Pediatric intestinal pseudoobstruction.
Modified from Thapar N, Saliakellis E, Benninga M, et al. Paediatric Intestinal Pseudo-obstruction: Evidence and Consensus-based Recommendations From an ESPGHAN-Led Expert Group. *J Pediatr Gastroenterol Nutr.* 2018;66(6):991–1019. Table 2.

pseudoobstruction is Ogilvie syndrome (acute pseudoobstruction of the colon). Pseudoobstruction represents a wide spectrum of pathologic disorders from abnormal myoelectric activity to abnormalities of the nerves (intestinal neuropathy) or musculature (intestinal myopathy) of the gut. The organs involved can include the entire gastrointestinal tract or be limited to certain components, although almost always include the small bowel. The distinctive pathologic abnormalities are considered together because of their clinical similarities. For these reasons, CIPO may be thought of more as a clinical syndrome at times.

Most congenital forms of primary pseudoobstruction occur sporadically, although autosomal dominant *(SOX10, ACTG2, RET)*, autosomal recessive *(RAD2I, SGOL1, TYMP, POLG)*, X-linked *(FLNA, L1CAM)*, and familial patterns of inheritance have been identified (see Table 378.2). Patients with autosomal dominant forms of pseudoobstruction have variable expressions of the disease. Patients with pathogenic variants in *TYMP* and *POLG* genes present with mitochondrial neurogastrointestinal encephalomyopathy (MNGIE) syndrome; mitochondrial encephalomyopathy, lactic acidosis, and stroke-like episodes (MELAS) syndrome is another mitochondrial disorder associated with CIPO. MNGIE is characterized by intestinal dysmotility, abdominal pain and distention, emesis, cachexia, ptosis, leukoencephalopathy, peripheral neuropathy (paresthesia, pain), and myopathy. Sixty percent have symptoms (often subtle) before age 20 years (see Chapter 378.2). Megacystis microcolon intestinal hypoperistalsis (MMIHS) syndrome includes pseudoobstruction plus bladder dysfunction and is due to pathogenic variants in *ACTG2* and other genes (Table 378.2). *Acquired* pseudoobstruction can follow episodes of acute gastroenteritis, presumably resulting in injury to the myenteric plexus.

In *congenital* pseudoobstruction, abnormalities of the muscle or nerves can be demonstrated in most cases. In myopathies, the smooth muscle is involved, in which the outer longitudinal muscle layer is replaced by fibrous material. These manifestations of visceral myopathies may be a primary or secondary phenomenon. The enteric nervous system is usually altered in neuropathies and may involve disorganized ganglia, hypoganglionosis, or hyperganglionosis. Abnormalities in the interstitial cells of Cajal, the intestinal pacemaker, are classified as mesenchymopathies. In others, mitochondrial defects have been identified.

CLINICAL MANIFESTATIONS

More than half the children with congenital pseudoobstruction experience symptoms in the neonatal period (see Table 378.3). Two thirds of the

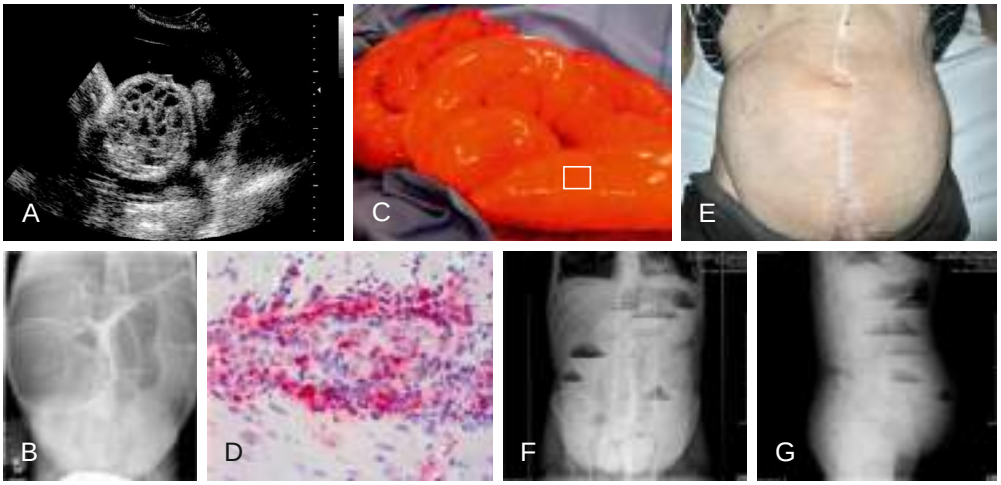

Fig. 378.1 Synoptic view of the chronic intestinal pseudoobstruction (CIPO) spectrum. **A** and **B**, The most severe pediatric cases with antenatal (in utero) evidence of multivisceral dilation, often gut (**B**) and urinary system, commonly associated with an extremely poor prognosis. **C** and **D**, CIPO phenotype with rapid progression to intestinal dilation (± ureter/bladder) and failure, often occurring as a result of an anamnestically reported gastroenteritis. Massive bowel dilation (**C**) and associated histopathology (**D**; corresponds to white squared area in **C**) revealed an intense inflammatory (mainly lymphocytic) neuropathy (hence, myenteric ganglionitis). Alkaline phosphatase anti-alkaline phosphatase immunohistochemical technique using specific anti-CD8 monoclonal antibodies was used to identify a subset of T lymphocytes. **E** and **G**, Examples of another phenotype of the syndrome that may be seen in patients who have more insidious mild and nonspecific symptoms progressing to a classic CIPO over time. **E**, Markedly distended abdomen of a 32-yr-old man who presented with subocclusive episodes after years of unspecific (dyspeptic-like/irritable bowel syndrome–like) symptoms. Note the evident air-fluid levels detectable in upright position in anteroposterior (**F**) and laterolateral (**G**) plain abdominal radiographs. *(**A** from Shen O, Schimmel MS, Eitan R, et al. Prenatal diagnosis of intestinal pseudo-obstruction. Ultrasound Obstet Gynecol. 2007;29:229–231; **B–G** from Di Nardo G, Di Lorenzo C, Lauro A, et al. Chronic intestinal pseudo-obstruction in children and adults: diagnosis and therapeutic options. Neurogastroenterol Motil. 2017;29:e12945.)*

infants presenting in the first few days of life are born prematurely, and approximately 40% have malrotation of the intestine. In 75% of all affected children, symptoms occur in the first year of life, whereas the remainder are usually symptomatic within the next several years. Females present with CIPO more than males during the first year of life, with equal sex distribution in older children. The most common symptoms are abdominal distention (85–95% of patients) and vomiting (55–90%). Constipation, growth failure, and abdominal pain occur in approximately 60% of patients and diarrhea in 25–30%. The symptoms wax and wane in most patients; poor nutrition, psychologic stress, and intercurrent illness tend to exacerbate symptoms. Urinary tract and bladder involvement occurs in 80% of children with myopathic pseudoobstruction and in 20% of those with neuropathic disease. Symptoms can manifest as recurrent urinary tract infection, megacystis, or obstructive symptoms. Megacystis-microcolon-intestinal hypoperistalsis syndrome (MMIHS) is a prenatal or neonatal manifestation of CIPO.

The clinical manifestations depend in large part on the areas of the gastrointestinal tract that are involved, with milder forms more common in older children. Although counterintuitive, older children with CIPO may present with both abdominal distention and diarrhea, related to *small bowel bacterial overgrowth* because of altered motility. Other presentations may include constipation and bilious emesis, as well as failure to thrive, as a consequence of decreased enteral feeding tolerance.

DIAGNOSIS

The diagnosis of pseudoobstruction is based on the presence of compatible symptoms in the absence of mechanical obstruction (Fig. 378.1). If CIPO is considered, diagnosis should start with exclusion of mechanical obstruction, exclusion of alternative diagnoses, and confirmation of impaired motility. Plain abdominal radiographs demonstrate air-fluid levels in the intestine. Contrast studies are integral to rule out mechanical obstruction and often demonstrate slow passage of barium; water-soluble agents should be considered. Gastric emptying scintigraphy can be used to evaluate upper GI dysmotility. Antroduodenal (small intestinal) manometry is integral to

Table 378.4 Findings in Pseudoobstruction

GI SEGMENT	FINDINGS*
Esophageal motility	Abnormalities in approximately half of CIPO, although in some series up to 85% demonstrate abnormalities Decreased LES pressure Failure of LES relaxation Esophageal body: low-amplitude waves, poor propagation, tertiary waves, retrograde peristalsis, occasionally aperistalsis
Gastric emptying	May be delayed
EGG	Tachygastria or bradygastria may be seen
ADM	Postprandial antral hypomotility is seen and correlates with delayed gastric emptying Myopathic subtype: low-amplitude contractions, <10-20 mm Hg Neuropathic subtype: contractions are uncoordinated, disorganized Absence of fed response Fasting MMC is absent, or MMC is abnormally propagated
Colonic	Absence of gastrocolic reflex because there is no increased motility in response to a meal
ARM	Normal rectoanal inhibitory reflex

*Findings can vary according to the segment(s) of the GI tract that are involved.
ADM, Antroduodenal manometry; ARM, anorectal manometry; CIPO, chronic intestinal pseudoobstruction; EGG, electrogastrography; GI, gastrointestinal; LES, lower esophageal sphincter; MMC, migrating motor complex.
From Steffen R: Gastrointestinal motility. In: Wyllie R, Hyams JS, Kay M, eds. *Pediatric Gastrointestinal and Liver Disease*, 3rd ed. Philadelphia: WB Saunders; 2006: p 66.

diagnosis with a normal study conclusively ruling out a diagnosis of CIPO (Table 378.4). Manometric evidence of a normal migrating motor complex and postprandial activity should redirect the diagnostic evaluation. CIPO due to an intestinal myopathy may demonstrate manometry evidence of low-amplitude contractions, whereas CIPO due to enteric neuropathy demonstrates normal amplitude but poorly organized contractions (nonperistaltic or tonic). Anorectal motility is normal and differentiates pseudoobstruction from Hirschsprung disease. Full-thickness intestinal biopsy might show involvement of the muscle layers or abnormalities of the intrinsic intestinal nervous system. *Gene panels or whole exome sequencing helps define the genetic etiology of CIPO.*

The differential diagnosis is broad and includes such etiologies as Hirschsprung disease, MNGIE, mechanical obstruction, psychogenic constipation, neurogenic bladder, and superior mesenteric artery syndrome. Secondary causes of ileus or pseudoobstruction that should be considered include medication side effects, infectious etiologies, metabolic disturbances, immunologic disorders, oncologic processes, vasculitides, neuropathies, and myopathies (see Table 378.1). Examples include use of opiates, hypokalemia, hypothyroidism, hypokalemia, diabetic neuropathy, porphyria, amyloidosis, Chagas disease, scleroderma, hereditary angioedema, mitochondrial disorders, and radiation, and these must be excluded. Other causes of abdominal distention such as small bowel bacterial overgrowth and aerophagia may present similarly and should be considered. *Small bowel bacterial overgrowth is a complication of CIPO.*

TREATMENT

Nutritional support is the mainstay of treatment for pseudoobstruction. Thirty to 50% of patients require partial or complete parenteral nutrition. Some patients can be treated with intermittent enteral supplementation, whereas others can maintain themselves on selective oral diets. Prokinetic drugs are generally used, although studies have not shown definitive evidence of their efficacy. Isolated gastroparesis can follow episodes of viral gastroenteritis and spontaneously resolves, usually in 6-24 months. Erythromycin, a motilin receptor agonist, and cisapride, a serotonin 5-HT_4 receptor agonist, may enhance gastric emptying and proximal small bowel motility and may be useful in this select group of patients. Metoclopramide, a prokinetic and antinausea agent, is effective in gastroparesis, although side effects, such as tardive dyskinesia, limit its use. Domperidone, an antidopaminergic agent, is a prokinetic agent that can be considered. Pain management is difficult and requires a multidisciplinary approach. Intravenous immunoglobulin (IVIG) may be beneficial in immune mediated CIPO.

Symptomatic small bowel bacterial overgrowth is usually treated with rotated nonabsorbable oral antibiotics and/or probiotics. Bacterial overgrowth can be associated with steatorrhea and malabsorption. Octreotide, a long-acting somatostatin analog, has been used in low doses to treat small bowel bacterial overgrowth. Patients with acid peptic symptoms are generally treated with acid suppression. Many patients with CIPO benefit from a gastrostomy for decompression, and some benefit from decompressive enterostomies (Fig. 378.2). Colectomy with ileorectal anastomosis is beneficial if the large bowel is the primary site of the motility abnormality. Bowel transplantation may benefit selected patients with CIPO. The prognosis is better for patients without urinary tract involvement and for those with neuropathic etiologies over myopathic disorders.

Fig. 378.2 Photograph of a child with chronic intestinal pseudoobstruction who improved clinically after ileostomy creation. He receives enteral feeding through his jejunal feeding tube, whereas his gastrostomy tube remains to straight drain. *(From Bitton S, Markowitz JF. Ulcerative colitis in children and adolescents. In: Wyllie R, Hyams JS, Kay M, eds. Pediatric Gastrointestinal and Liver Disease, 5th ed. Philadelphia: Elsevier; 2016: Fig. 44.3.)*

Visit Elsevier eBooks+ at eBooks.Health.Elsevier.com for Bibliography.

378.2 Mitochondrial Neurogastrointestinal Encephalomyopathy

Jennifer Webster, Kristin N. Fiorino, and Chris A. Liacouras

Mitochondrial neurogastrointestinal encephalomyopathy (MNGIE) is a multisystem autosomal recessive disease that initially presents with severe gastrointestinal disturbances; the neurologic manifestations usually occur later in the illness and may initially be subtle or asymptomatic.

MNGIE is caused by a pathogenic variant in the nuclear DNA *TYMP* gene encoding thymidine phosphorylase that results in abnormalities in intergenomic communication with resulting instability of mitochondrial DNA (some patients have pathogenic variants in *POLG1*). There are at least 50 individual variants with a poor genotype-phenotype correlation and varying manifestations within each family. Consanguinity is present in 30% of families.

MNGIE affects both males and females and is usually diagnosed in the second and third decade (average age: 18 years; range: 5 months to 35 years). Onset is usually around age 12 years, but there is often a 5- to 10-year delay in the diagnosis. The disease is progressive with an overall survival of <5% after 50 years of age.

MNGIE *initially* presents with gastrointestinal symptoms. Severe intestinal dysmotility and gastroparesis are associated with early satiety, postprandial emesis, episodic pseudoobstruction, diarrhea, constipation, and abdominal pain and cramping, which leads to significant cachexia. Because of the age of onset, emesis, early satiety, and cachexia

patients are often misdiagnosed with an eating disorder. Radiologic studies may find small bowel diverticulosis or GI dilation.

Most often, neurologic symptoms follow the onset of gastrointestinal manifestations, which include ptosis, progressive external ophthalmoplegia, hearing loss, myopathy, and peripheral neuropathy. The neuropathy is either demyelinating or a mixed axonal demyelinating type and manifests as weakness, decreased or absent deep tendon reflexes, and paresthesias. Leukoencephalopathy is initially asymptomatic and noted on MRI as patchy lesions predominantly in the cortex but also in the basal ganglia and brainstem. Eventually the central nervous system lesions become diffuse and confluent. A small number of patients develop cognitive impairment or dementia.

The diagnosis is suggested by the constellation of gastrointestinal and neurologic symptoms, lactic acidosis, ragged red fibers, and cytochrome C oxidase–deficient fibers seen in most patients on muscle biopsy. Reduced activity of thymidine phosphorylase enzyme and elevated plasma levels of thymidine and deoxyuridine are often diagnostic; genetic testing for the *TYMP* pathogenic variant or other genes *(POLG1)* is recommended.

Treatment is focused on providing sufficient nutritional support and avoidance of infectious complications and of nutritional deficiencies. Hemodialysis, continuous ambulatory peritoneal dialysis, and platelet infusions have been effective in achieving temporary improvement and can be used while waiting for a permanent treatment option or as compassionate care. Domperidone has been used for nausea and emesis, antibiotics for small bowel bacterial overgrowth, amitriptyline or gabapentin for neuropathic pain, and parenteral alimentation for nutritional support. Opiates and any medications that affect intestinal motility or mitochondrial function must be avoided. Stem cell transplantation and liver transplantation have been successful in a small number of patients, although they are limited by posttreatment mortality rates.

Visit Elsevier eBooks+ at eBooks.Health.Elsevier.com for Bibliography.

378.3 Encopresis and Functional Constipation

Jennifer Webster, Kristin N. Fiorino, and Chris A. Liacouras

Constipation is defined as a delay or difficulty in defecation present for >1 month and significant enough to cause distress to the patient. Another approach to the definition is the Rome criteria, outlined in Tables 378.5 and 378.6. Functional constipation, also known as idiopathic constipation or fecal withholding, can usually be differentiated from constipation secondary to organic causes based on a history and physical examination. Unlike anorectal malformations and Hirschsprung disease, functional constipation typically starts *after* the neonatal period. Usually there is an intentional or subconscious withholding of stool. An acute episode usually precedes the chronic course. This acute event could include changes in diet such as transition to formula or addition of pureed/solid foods and can also include a social stressor such as initiation of toilet training, birth of a sibling, starting daycare/school, or abuse. The stool becomes firm, smaller, and difficult to pass, resulting in anal irritation and often an anal fissure. In toddlers, coercive or inappropriately early toilet training is a factor that can initiate a pattern of stool retention. In older children, retentive constipation can develop after entering a situation that makes stooling inconvenient, such as school. Because the passage of bowel movements is painful, voluntary or subconscious withholding of feces to avoid the painful stimulus develops.

CLINICAL MANIFESTATIONS

When children have the urge to defecate, typical behaviors include contracting the gluteal muscles by stiffening the legs while lying down,

Table 378.5 Rome IV Diagnostic Criteria for Defecatory Disorders in Neonates and Toddlers

FGID	AGE RANGE	CRITERIA REQUIREMENTS	CRITERIA ELEMENTS
Functional constipation	All pediatric age groups	Must include 1 month of ≥2 of the criteria elements in infants up to 4 mo of age	• 2 or fewer defecations weekly • History of excessive stool retention • History of hard/painful bowel movements • History of large-diameter stools • Presence of a large fecal mass in the rectum
		In toilet-trained children, the following additional criteria elements may be used	• At least 1 weekly episode of incontinence after being toilet trained • History of large-diameter stools that may clog the toilet

FGID, Functional gastrointestinal disorders.
Modified from Benninga MA, Faure C, Hyman PE, et al. Childhood functional gastrointestinal disorders: neonate/toddler. *Gastroenterology*. 2016;150:1443–1455.

Table 378.6 Rome IV Diagnostic Criteria for Defecatory Disorders in Children and Adolescents

	AGE RANGE	CRITERIA REQUIREMENTS	CRITERIA ELEMENTS
Functional constipation	Developmental age ≥4 yr	Must include ≥2 of the criteria elements for ≥2 months with insufficient criteria to diagnose irritable bowel syndrome	• ≤2 defecations in the toilet per week • ≥1 episode of fecal incontinence per week • History of retentive posturing or excessive volitional stool retention • History of painful or hard bowel movements • Presence of a large fecal mass in the rectum • History of large-diameter stools that can obstruct the toilet
Nonretentive fecal Incontinence	Developmental age ≥4 yr	History of symptoms (criteria elements) for ≥1 month	• Defecation into places inappropriate to the sociocultural context • No evidence of fecal retention • After appropriate evaluation, symptoms cannot be fully explained by another medical condition

Modified from Hyams JS, Di Lorenzo C, Saps M, et al. Childhood functional gastrointestinal disorders: child/adolescent. *Gastroenterology*. 2016;150:1456–1468.

holding onto furniture while standing, or squatting quietly in corners, waiting for the urge to stool to pass. The urge to defecate passes as the rectum accommodates to its contents. A vicious cycle of retention develops, as increasingly larger volumes of stool need to be expelled. Caregivers may misinterpret these withholding behaviors as straining or pain. There is often a history of blood in the stool noted with the passage of a large bowel movement. Findings suggestive of underlying pathology include failure to thrive, weight loss, abdominal pain, significant abdominal distention, vomiting, or persistent anal fissure or fistula.

In functional constipation, encopresis is common. **Encopresis** is defined as voluntary or involuntary passage of feces into inappropriate places at least once a month for 3 consecutive months once a chronological or developmental age of 4 year has been reached. Encopresis is not diagnosed when the behavior is exclusively the result of the direct effects of a substance (e.g., laxatives) or a general medical condition (except through a mechanism involving constipation). Subtypes include retentive encopresis (with constipation and overflow incontinence), representing 65–95% of cases, and nonretentive encopresis (without constipation and overflow incontinence). **Nonretentive fecal incontinence** is defined as no evidence of fecal retention (impaction), ≥1 episodes per week in the previous 1 month, or defecation in places inappropriate to the social context in a child who has been previously toilet trained and without evidence of anatomic, inflammatory, metabolic, endocrine, or neoplastic process that could explain the symptoms. Encopresis can persist from infancy onward (primary) or can appear after successful toilet training (secondary). The updated Rome criteria (IV) differentiate between infants/toddlers and older children who have been toilet trained versus not toilet trained, for practical assessment purposes.

DIAGNOSIS

The physical examination often demonstrates a large volume of stool palpated in the suprapubic area; rectal examination demonstrates a dilated rectal vault filled with guaiac-negative stool. Children with encopresis often present with reports of underwear soiling, and many parents initially presume that diarrhea, rather than constipation, is the cause. In **retentive encopresis**, associated complaints of difficulty with defecation, abdominal or rectal pain, impaired appetite with poor growth, and urinary (day and/or night) incontinence are common. Children often have large bowel movements that obstruct the toilet. There may also be retentive posturing or recurrent urinary tract infections. **Nonretentive encopresis** is more likely to occur as a solitary symptom and have an associated primary underlying psychologic etiology. Children with encopresis can present with poor school performance and attendance that is triggered by the scorn and derision from schoolmates because of the child's offensive odor.

The location of the anus relative to perineal anatomic landmarks by sex also needs to be considered. This is expressed as the **anogenital index**, and it can be calculated when necessary. This is determined by the distance in centimeters from the vagina or scrotum to the anus, divided by the distance from the vagina or scrotum to the coccyx. The normal anogenital index in females is 0.39 ± 0.09, whereas 0.56 ± 0.2 is normal for males.

The presence of a hair tuft over the spine or spinal dimple, or failure to elicit a cremasteric reflex or anal wink suggests spinal pathology. A tethered cord is suggested by decreased or absent lower leg reflexes. **Spinal cord lesions** can occur with overlying skin anomalies. Urinary tract symptoms include recurrent urinary tract infection and enuresis. Children with no evidence of abnormalities on physical examination rarely require radiologic evaluation.

In refractory patients (intractable constipation), specialized testing should be considered to rule out conditions such as hypothyroidism, hypocalcemia, lead toxicity, celiac disease, and disorders of neuromuscular gastrointestinal pathology (Table 378.7). Colonic transit studies using radiopaque markers or scintigraphy techniques may be useful. Selected children can benefit from MRI of the spine to identify an intraspinal process, motility studies to identify underlying myopathic or neuropathic bowel abnormalities, or a contrast enema to identify structural abnormalities. In patients with severe functional constipation, water-soluble contrast enema reveals the presence of a mega rectosigmoid (Fig. 378.3). Anorectal motility studies can demonstrate a pattern of paradoxical contraction of the external anal sphincter during defecation, which can be treated by behavior modification, biofeedback, and pelvic floor physical therapy. Colonic motility can guide therapy in refractory cases, demonstrating segmental problems that might require surgical intervention.

Table 378.7 London Classification of Gastrointestinal Neuromuscular Pathology

1. Neuropathies
   - 1.1 Absent neurons
     - 1.1.1 Aganglionosis*
   - 1.2 Decreased numbers of neurons
     - 1.2.1 Hypoganglionosis
   - 1.3 Increased numbers of neurons
     - 1.3.1 Ganglioneuromatosis†
     - 1.3.2 IND, type B‡
   - 1.4 Degenerative neuropathy§
   - 1.5 Inflammatory neuropathies
     - 1.5.1 Lymphocytic ganglionitis¶
     - 1.5.2 Eosinophilic ganglionitis
   - 1.6 Abnormal content in neurons
     - 1.6.1 Intraneuronal nuclear inclusions
     - 1.6.2 Megamitochondria
   - 1.7 Abnormal neurochemical coding**
   - 1.8 Relative immaturity of neurons
   - 1.9 Abnormal enteric glia
     - 1.9.1 Increased numbers of enteric glia
2. Myopathies
   - 2.1 Muscularis propria malformations††
   - 2.2 Muscle cell degeneration
     - 2.2.1 Degenerative leiomyopathy/‡‡
     - 2.2.2 Inflammatory leiomyopathy
       - 2.2.2.1 Lymphocytic leiomyositis
       - 2.2.2.2 Eosinophilic leiomyositis
   - 2.3 Muscle hyperplasia/hypertrophy
     - 2.3.1 Muscularis mucosae hyperplasia
   - 2.4 Abnormal content in myocytes
     - 2.4.1 Filament protein abnormalities
       - 2.4.1.1 Alpha-actin myopathy§§
       - 2.4.1.2 Desmin myopathy
     - 2.4.2 Inclusion bodies
       - 2.4.2.1 Polyglucosan bodies
       - 2.4.2.2 Amphophilic
       - 2.4.2.3 Megamitochondria¶¶
   - 2.5 Abnormal supportive tissue
     - 2.5.1 Atrophic desmosis***
3. ICC abnormalities (enteric mesenchymopathy)
   - 3.1 Abnormal ICC networks†††

*Can include rare cases of non-Hirschsprung disease severe hypoplastic hypoganglionosis with long interganglionic intervals (zonal aganglionosis).
†Although neurons have not been formally quantified, gross increases of disorganized neurons are evident.
‡Can include retarded neuronal maturation.
§May occur with or without neuronal loss but is best regarded as a separate entity.
¶May occur with neuronal degeneration and/or loss; lymphocytic epithelioganglionitis is a variant.
**Includes neurotransmitter loss (e.g., reduced or absent expression) or loss of a neurochemically defined functional subset of nerves (see text).
††Includes absence, fusion, or additional muscle coats.
‡‡Hollow visceral myopathy may be diagnosed in familial cases with other characteristic phenotypic features; myopathy with autophagic activity and pink blush myopathy with nuclear crowding are rare variants in which degenerative findings are less overt.
§§Smooth muscle alpha-actin deficiency is best described, although deficiencies of other proteins related to the contractile apparatus of myocytes have been reported.
¶¶Mitochondrial neurogastrointestinal encephalomyopathy causes a degenerative appearance predominantly in the longitudinal muscle.
***Absent connective tissue scaffold has been almost exclusively described in the colon.
†††Generally reduced or absent ICC, although abnormal morphology also reported.
ICC, Interstitial cells of Cajal; IND, intestinal neuronal dysplasia.
From Knowles CH, De Giorgio R, Kapur RP, et al. The London classification of gastrointestinal neuromuscular pathology: report on behalf of the Gastro 2009 International Working Group. *Gut.* 2010;59:882–887. Table 1.

Fig. 378.3 Barium enema in a 14-yr-old boy with severe constipation. The enormous dilation of the rectum and distal colon is typical of acquired functional megacolon.

Complications of retentive encopresis include day and night urinary incontinence, urinary retention, urinary tract infection, megacystis, and rarely toxic megacolon.

TREATMENT

Therapy for functional constipation and encopresis includes patient education, behavioral interventions, relief of impaction, and softening of the stool. Caregivers must understand that soiling associated with overflow incontinence is associated with loss of normal sensation and not a willful act. There needs to be a focus on adherence with regular postprandial toilet sitting and adoption of a balanced diet. In addition, caregivers should be instructed not to respond to soiling with retaliatory or punitive measures, because children are likely to become angry, ashamed, and resistant to intervention. From the outset, parents should be actively encouraged to reward the child for adherence to a healthy bowel regimen and to avoid power struggles.

If an impaction is present on the initial physical examination, an enema is usually required to clear the impaction while stool softeners are started as maintenance medications. Typical regimens include the use of polyethylene glycol preparations, lactulose, magnesium, or mineral oil (Tables 378.8 and 378.9). Stimulant laxatives such as senna and bisacodyl can also be helpful.

Compliance can wane, and failure of this standard treatment approach sometimes requires more intensive intervention. In cases where behavioral or psychiatric problems are evident, involvement of a psychologist or behavioral management (e.g., behavior programs and/or biofeedback) is recommended. Maintenance therapy is generally continued until a regular bowel pattern has been established and the association of pain with the passage of stool is abolished.

For children with chronic diarrhea and/or irritable bowel syndrome where stress and anxiety play a major role, stress reduction and learning effective coping strategies can play an important role in responding to the encopresis. Relaxation training, stress inoculation, assertiveness training, and/or general stress management procedures can be helpful, and the participation of behavioral health specialists is valuable.

Neurostimulation (transcutaneous or sacral implantation) and pelvic physiotherapy are novel approaches used in patients with medication refractory constipation. Surgical interventions such as rectal Botox, cecostomy, and colostomy may be considered for severe cases.

Table 378.8 Suggested Medications and Dosages for Disimpaction

MEDICATION	AGE	DOSAGE
RAPID RECTAL DISIMPACTION		
Glycerin suppositories	Infants and toddlers	
Phosphate enema	6 mo-2 yr	66 mL
	≥3 yr	133 mL
SLOW ORAL DISIMPACTION IN OLDER CHILDREN		
Over 2-3 Days		
Polyethylene glycol with electrolytes		25 mL/kg body weight/hr, up to 1,000 mL/hr until clear fluid comes from the anus
Over 5-7 Days		
Polyethylene without electrolytes		1.5 g/kg body weight/day for 3 days
Milk of magnesia		2 mL/kg body weight twice/day for 7 days
Mineral oil		3 mL/kg body weight twice/day for 7 days
Lactulose or sorbitol		2 mL/kg body weight twice/day for 7 days

From Loening-Baucke V. Functional constipation with encopresis. In: Wyllie R, Hyams JS, Kay M, eds. *Pediatric Gastrointestinal and Liver Disease*, 3rd ed. Philadelphia: WB Saunders; 2006: p 183.

Table 378.9 Suggested Medications and Dosages for Maintenance Therapy of Constipation

MEDICATION	AGE	DOSE
TYPICAL DOSES FOR LONG-TERM TREATMENT (YR)		
Milk of magnesia	>1 mo	1-3 mL/kg body weight/day, divided into 1-2 doses
Mineral oil	>12 mo	1-3 mL/kg body weight/day, divided into 1-2 doses
Lactulose or sorbitol	>1 mo	1-3 mL/kg body weight/day, divided into 1-2 doses
Polyethylene glycol 3350 (MiraLAX)	>1 yr	0.7 g/kg body weight/day
FOR SHORT-TERM TREATMENT (MO)		
Senna (Senokot) syrup, tablets	1-5 yr	5 mL (1 tablet) with breakfast, max 15 mL daily
	5-15 yr	2 tablets with breakfast, maximum 3 tablets daily

From Loening-Baucke V. Functional constipation with encopresis. In: Wyllie R, Hyams JS, Kay M, eds. *Pediatric Gastrointestinal and Liver Disease*, 3rd ed. Philadelphia: WB Saunders; 2006: p 185.

Visit Elsevier eBooks+ at eBooks.Health.Elsevier.com for Bibliography.

378.4 Congenital Aganglionic Megacolon (Hirschsprung Disease)

Prasanna K. Kapavarapu, Kristin N. Fiorino, and Chris A. Liacouras

Hirschsprung disease, or congenital aganglionic megacolon, is a developmental disorder (neurocristopathy) of the enteric nervous system, characterized by the absence of ganglion cells in the submucosal and myenteric plexus. It is the most common cause of lower intestinal obstruction in neonates, with an overall incidence of 1 in 5,000 live births. The male:female ratio for Hirschsprung disease is 4:1 for short-segment disease and approximately 2:1 with total colonic aganglionosis. Prematurity is uncommon.

There is an increased familial incidence in long-segment disease. Hirschsprung disease may be associated with other congenital defects, including trisomy 21, Joubert syndrome, Goldberg-Shprintzen syndrome, Smith-Lemli-Opitz syndrome, Shah-Waardenburg syndrome, cartilage-hair hypoplasia, multiple endocrine neoplasm 2 syndrome, neurofibromatosis, neuroblastoma, congenital hypoventilation (Ondine's curse), and urogenital or cardiovascular abnormalities. Hirschsprung disease has been seen in association with microcephaly, intellectual disability, abnormal facies, autism, cleft palate, hydrocephalus, and micrognathia.

PATHOLOGY

Hirschsprung disease is the result of an absence of ganglion cells in the bowel wall, extending proximally from the anus for a variable distance. The absence of neural innervation is a consequence of an arrest of neuroblast migration from the proximal to distal bowel. Without the myenteric and submucosal plexus, there is inadequate relaxation of the bowel wall and bowel wall hypertonicity, which can lead to intestinal obstruction.

Hirschsprung disease is usually sporadic, although dominant and recessive patterns of inheritance have been demonstrated in family groups. Genetic variants have been identified in multiple genes that encode proteins of the RET signaling pathway (*RET, GDNF, NTN, ARTN,* and *PSPN*) and involved in the endothelin (EDN) type B receptor pathway (*EDNRB, EDN3,* and *ECE-1*). **Syndromic forms** of Hirschsprung disease have been associated with the *L1CAM, SOX10, PHOX2B, KIAA1279,* and *ZFHX1B* (formerly *SIP1*) genes.

The aganglionic segment is limited to the rectosigmoid in 80% of patients. Approximately 10–15% of patients have long-segment disease, defined as disease proximal to the sigmoid colon. Total bowel aganglionosis is rare and accounts for approximately 5% of cases. Observed histologically is an absence of Meissner's and Auerbach's plexuses and hypertrophied nerve bundles with high concentrations of acetylcholinesterase between the muscular layers and in the submucosa.

CLINICAL MANIFESTATIONS

Hirschsprung disease is usually diagnosed in the neonatal period secondary to a distended abdomen, failure to pass meconium, and/or bilious emesis or aspirates with feeding intolerance. In 99% of healthy full-term infants, meconium is passed within 48 hours of birth. Hirschsprung disease should be suspected in any full-term infant (the disease is unusual in preterm infants) with delayed passage of stool. Some neonates pass meconium normally but subsequently present with a history of chronic constipation. Failure to thrive with hypoproteinemia from protein-losing enteropathy is a less common presentation because Hirschsprung disease is usually recognized early in the course of the illness but has been known to occur. Breastfed infants might not present as severely as formula-fed infants.

Failure to pass stool leads to dilation of the proximal bowel and abdominal distention. As the bowel dilates, intraluminal pressure increases, resulting in decreased blood flow and deterioration of the mucosal barrier. Stasis allows proliferation of bacteria, which can lead to **enterocolitis** (*Clostridium difficile, Staphylococcus aureus,* anaerobes, coliforms) with associated diarrhea, abdominal tenderness, sepsis, and signs of bowel obstruction. *Red flags* in the neonatal period then include neonatal intestinal obstruction, bowel perforation, delayed passage of meconium, abdominal distention relieved by digital rectal stimulation or enemas, chronic severe constipation, and enterocolitis. Early recognition of Hirschsprung disease before the onset of enterocolitis is essential in reducing morbidity and mortality.

Hirschsprung disease in older patients must be distinguished from other causes of abdominal distention and chronic constipation (see Tables 378.7; Table 378.10 and Figs. 378.4 and 378.5). The history often reveals constipation starting in infancy that has responded poorly to medical management. Failure to thrive is not uncommon. Fecal incontinence, fecal urgency, and stool-withholding behaviors are usually not present. Significant abdominal distention is unusual in non–Hirschsprung-related constipation, as is emesis. The abdomen is tympanitic and distended, with a large fecal mass palpable in the left lower abdomen. Rectal examination demonstrates a normally placed anus that easily allows entry of the finger but feels snug. The rectum is usually empty of feces, and when the finger is removed, there may be an explosive discharge of foul-smelling feces and gas. The stools, when passed, can consist of small pellets, be ribbon-like, or have a fluid consistency, unlike the large stools seen in patients with functional constipation. Intermittent attacks of intestinal obstruction from retained feces may be associated with pain and fever. Urinary retention with enlarged bladder or hydronephrosis can occur secondary to urinary compression.

In neonates, Hirschsprung disease must be differentiated from meconium plug syndrome, meconium ileus, and intestinal atresia. In older patients, the **Currarino triad** must be considered, which includes anorectal malformations (ectopic anus, anal stenosis, imperforate anus), sacral bone anomalies (hypoplasia, poor segmentation), and presacral anomaly (anterior meningoceles, teratoma, cyst). Mimics of Hirschsprung disease include intestinal neuronal dysplasia (IND), hypoganglionosis, absence of argyrophil plexus, and **megacystis**

Table 378.10 Distinguishing Features of Hirschsprung Disease and Functional Constipation

VARIABLE	FUNCTIONAL	HIRSCHSPRUNG DISEASE
HISTORY		
Onset of constipation	After 2 yr of age	At birth
Encopresis	Common	Very rare
Failure to thrive	Uncommon	Possible
Enterocolitis	None	Possible
Forced bowel training	Usual	None
EXAMINATION		
Abdominal distention	Uncommon	Common
Poor weight gain	Rare	Common
Rectum	Filled with stool	Empty
Rectal examination	Stool in rectum	Explosive passage of stool
Malnutrition	None	Possible
INVESTIGATIONS		
Anorectal manometry	Relaxation of internal anal sphincter	Failure of internal anal sphincter relaxation
Rectal biopsy	Normal	No ganglion cells, increased acetylcholinesterase staining
Barium enema	Massive amounts of stool, no transition zone	Transition zone, delayed evacuation (>24 hr)

From Imseis E, Gariepy C. Hirschsprung disease. In: Walker WA, Goulet OJ, Kleinman RE, et al., eds. *Pediatric Gastrointestinal Disease*, 4th ed. Hamilton, ON: BC Decker; 2004: p 1035.

Fig. 378.4 Lateral view of a barium enema in a 3-yr-old with Hirschsprung disease. The aganglionic distal segment is narrow, with distended normal ganglionic bowel above it.

microcolon intestinal hypoperistalsis syndrome (MMIHS). MMIH demonstrates an enlarged bladder and intestinal obstruction with microcolon (Fig. 378.6 and Fig. 378.7); involved genes are noted in Table 378.11.

DIAGNOSIS

Rectal suction biopsy is the "gold standard" for diagnosing Hirschsprung disease (see Fig. 378.5). The biopsy material should contain an adequate amount of submucosa to evaluate for the presence of ganglion cells. To avoid obtaining biopsies in the normal area of hypoganglionosis, which ranges from 3 to 17 mm in length, the suction rectal biopsy should be obtained no closer than 2 cm above the dentate line. The biopsy specimen should be stained for acetylcholinesterase to facilitate interpretation. Patients with aganglionosis demonstrate a large number of hypertrophied nerve bundles that stain positively for acetylcholinesterase with an absence of ganglion cells. Calretinin is a calcium binding protein expressed in ganglion cells in submucosa and myenteric plexus; hence, calretinin staining may provide a diagnosis of Hirschsprung disease when acetylcholinesterase staining may not be sufficient. In Hirschsprung disease, on the hematoxylin and eosin staining there is absence of ganglion cells in the submucosa with abundance of hypertrophic nerves; on acetylcholinesterase staining there is abnormal accumulation of acetylcholinesterase-positive hypertrophied nerve bundles in muscularis mucosa and lamina propria; and on calretinin staining there is paucity of calretinin-immunoreactive nerves in muscularis mucosa and lamina propria.

Anorectal manometry evaluates the internal anal sphincter while a balloon is distended in the rectum. In healthy individuals, rectal distention initiates relaxation of the internal anal sphincter in response to rectal distention (known as the rectoanal inhibitory reflux [RAIR]). In patients with Hirschsprung disease, the internal

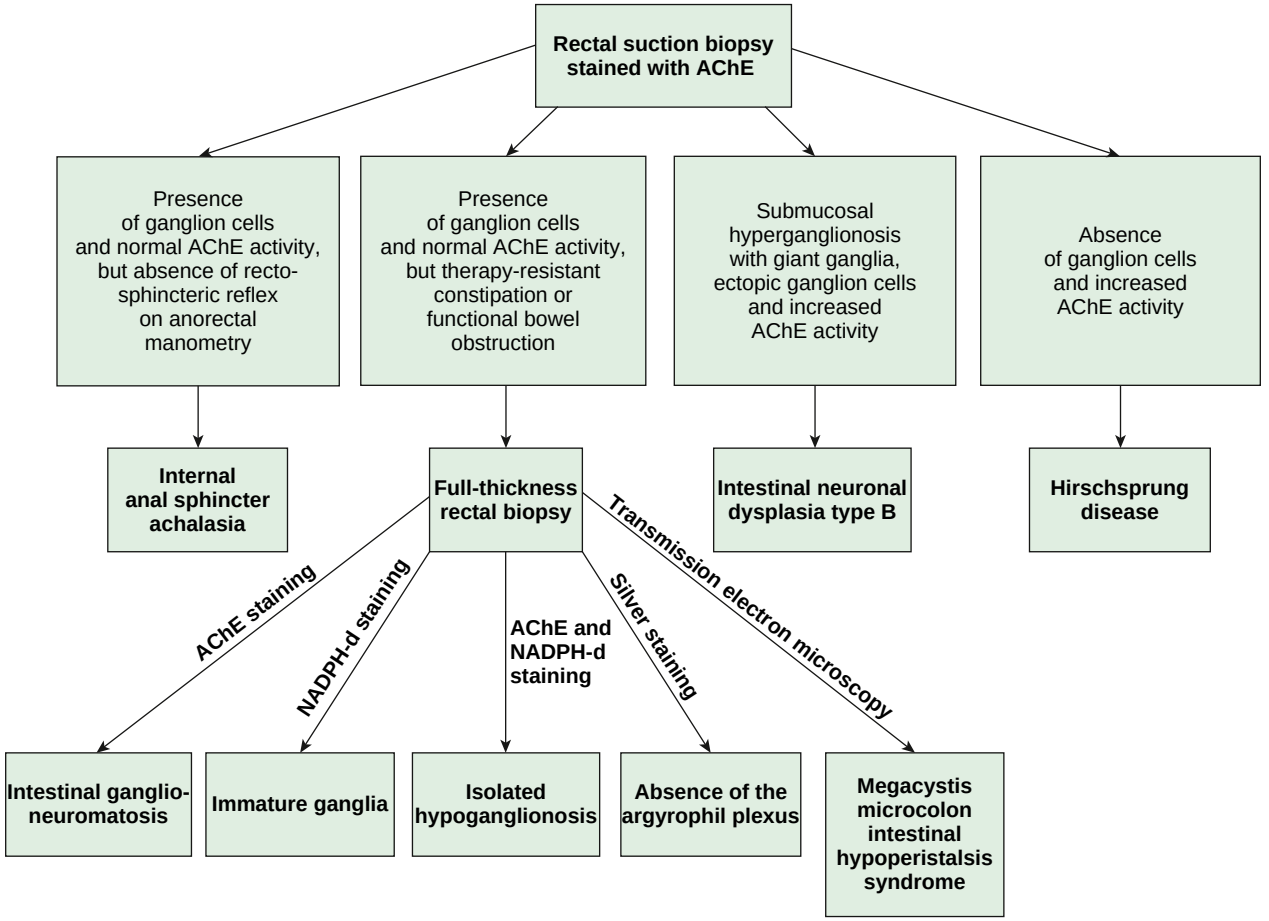

Fig. 378.5 Diagnostic algorithm for investigating chronic constipation and functional bowel obstruction in newborn infants and young children. AChE, Acetylcholinesterase; NADPH-d, nicotinamide adenine dinucleotide phosphate diaphorase. *(From Friedmacher F, Puri P. Classification and diagnostic criteria of variants of Hirschsprung's disease. Pediatr Surg Int. 2013;29:855–872. Fig. 1.)*

Fig. 378.6 Voiding cystourethrogram showing massively enlarged bladder in an MMIHS patient. *(Modified from Puri P, Gosemann JH. Variants of Hirschsprung disease. Semin Pediatr Surg. 2012;21:310–318. Fig. 5A.)*

Fig. 378.7 Megacystis-microcolon-intestinal hypoperistalsis syndrome. Single frontal view of newborn female reveals the microcolon characteristic of this entity. Note the malposition of the cecum, consistent with the malrotation that is common in these patients. Soft tissue density in the pelvis is consistent with a distended urinary bladder. *(From Hernanz-Schulman M. Congenital and neonatal disorders. In Coley BD, ed. Caffey's Pediatric Diagnostic Imaging, 13th ed. Philadelphia: Elsevier; 2019: Fig. 105.16, p. 1019.)*

anal sphincter fails to relax in response to rectal distention, and there is absence of the RAIR. Although the sensitivity and specificity can vary widely, in experienced hands, the test can be quite sensitive. However, the test can be technically difficult to perform in young infants. A normal response in the course of manometric evaluation precludes a diagnosis of Hirschsprung disease; an equivocal or paradoxical response requires a repeat anorectal manometry or rectal suction biopsy. The sensitivity and specificity of anorectal manometry are both >90%.

An unprepared contrast enema is most likely to aid in the diagnosis in children older than 1 month of age because the proximal ganglionic segment might not be significantly dilated in the first few weeks of life. Classic findings are based on the presence of an abrupt narrow transition zone between the normal dilated proximal colon and a smaller-caliber obstructed distal aganglionic segment. In the absence of this finding, it is imperative to compare the diameter of the rectum with that of the sigmoid colon, because a rectal diameter that is the same as or smaller than the sigmoid colon suggests Hirschsprung disease. Radiologic evaluation should be performed without prior preparation (i.e., *unprepped contrast enema study*) to prevent transient dilation of the aganglionic segment. As many as 10% of newborns with Hirschsprung disease have a normal contrast study. This diagnostic test is most valuable in the disease that involves the distal colon, and specifically, the rectosigmoid. A transition zone may not be readily identifiable in total bowel aganglionosis. The 24-hour delayed films are helpful in showing retained contrast (see Fig. 378.4). If significant barium is still present in the colon, it increases the suspicion of Hirschsprung disease even if a transition zone is not identified. Barium enema examination is useful in determining the extent of aganglionosis before surgery and in evaluating other diseases that manifest as lower bowel obstruction in a neonate. The sensitivity (~70%) and specificity (50–80%) of barium enema studies diagnosing Hirschsprung disease is lower than other methodologies. Full-thickness rectal biopsies can be performed at the time of surgery to confirm the diagnosis, level of involvement, and to differentiate other disorders (see Fig. 378.5).

TREATMENT

Once the diagnosis is established, the definitive treatment is operative intervention. Previously, a temporary ostomy was placed, and definitive surgery was delayed until the child was older. Currently, many infants undergo a primary pull-through procedure unless there is associated enterocolitis or other complications, when a decompressing ostomy is usually required.

There are essentially two surgical options. One procedure creates a neorectum, bringing down normally innervated bowel behind the aganglionic rectum. The neorectum created in this procedure has an anterior aganglionic segment with normal sensation and a posterior ganglionic segment with normal propulsion. The **endorectal pull-through procedure** involves stripping the mucosa from the aganglionic rectum and bringing normally innervated colon through the residual muscular cuff, thus bypassing the abnormal bowel from within. Advances in techniques have led to successful laparoscopic single-stage endorectal pull-through procedures, which are the treatment of choice.

In **ultrashort-segment Hirschsprung disease**, also known as **anal achalasia**, the aganglionic segment is limited to the internal sphincter. The clinical symptoms are similar to those of children with functional constipation. Ganglion cells are present on rectal suction biopsy, but the anorectal manometry is abnormal, with failure of relaxation of the internal anal sphincter in response to rectal distention. Current treatment, although controversial, includes anal botulism injection to relax the anal sphincter and anorectal myectomy if indicated.

Long-segment Hirschsprung disease involving the entire colon and, at times, part of the small bowel presents a difficult problem. Anorectal manometry and rectal suction biopsy demonstrate findings of Hirschsprung disease, but radiologic studies are difficult to interpret because a colonic transition zone cannot be identified. The extent of aganglionosis can be determined accurately by biopsy at the time of laparotomy. When the entire colon is aganglionic, often together with a length of terminal ileum, ileal-anal anastomosis is the treatment of choice, preserving part of the aganglionic colon to facilitate water absorption, which helps the stools to become firm.

Table 378.11 Megacystis-Microcolon-Intestinal Hypoperistalsis Syndrome: Genes and Distinguishing Clinical Features

GENE*	% OF ALL MMIHS	MOI	DISTINGUISHING CLINICAL FEATURES	OTHER
ACTG2	44.1%	AD	Classic features of MMIHS (e.g., megacystis, microcolon, intestinal dysmotility)	Greater disease severity reported in probands with a de novo (vs inherited) pathogenic variant Parental somatic and germline mosaicism reported
LMOD1	1 person	AR	Classic features of MMIHS	Large deletions/duplications not reported to date
MYH11	2 persons	AR	Overlapping features of MMIHS and prune-belly sequence (one person) Overlapping features of MMIHS and MSMDS (1 person)	Large del/dups not associated with MMIHS to date
MYL9	1 person	AR	Mydriasis No vascular smooth muscle dysfunction†	Homozygous partial-gene deletion reported
MYLK	2 families	AR	No vascular smooth muscle dysfunction†	Large deletions/duplications not associated with MMIHS to date
Unknown	~55%			

*Genes are listed alphabetically.
†Vascular smooth muscle dysfunction including aortic aneurysms or dissection has not been reported.
AD, Autosomal dominant; AR, autosomal recessive; MMIHS, megacystis-microcolon-intestinal hypoperistalsis syndrome; MOI, mode of inheritance; MSMDS, multisystemic smooth muscle dysfunction syndrome.
Modified from Ambartsumyan L. Megacystis-microcolon-intestinal hypoperistalsis syndrome overview. NIH National Library of Medicine. *GeneRev*. 2019.

The prognosis of surgically treated Hirschsprung disease is generally satisfactory independent of the kind of surgical procedure, about 15–60% experience bowel problems ranging from constipation and/or fecal incontinence and enterocolitis episodes, but these symptoms diminish with age. Children presenting with persistent bowel problems after surgery often need additional diagnostics (contrast enema, three-dimensional [3D] high-definition anorectal manometry, rectal suction biopsy, and colon manometry), advanced bowel regimen (stool softeners, stimulant laxatives, medicated enemas, pelvic floor therapy), and additional surgical procedures (anal dilation, anal myectomy, re-do pull-through corrective surgery, appendicostomy or cecostomy, colostomy, ileostomy). Recent advances in the field of motility include usage of 3D high-definition anorectal manometry to assess the anorectal function of the post-surgical anal sphincter and high-resolution colon manometry to assess and characterize the motility function of the residual colon after Hirschsprung surgery.

Hirschsprung disease–associated **enterocolitis** can occur at any time before or after surgery and is the leading cause of death in these patients. Dysmotility related to partial obstruction, underlying disease, impaired immune function, and the intestinal microbiome may all contribute to this pathophysiologic process. Explosive, foul-smelling and/or bloody diarrhea, abdominal distention, explosive discharge of rectal contents on digital examination, diminished peripheral perfusion, lethargy, and fever are all ominous signs. Management principles include hydration, decompression from above and below (nasogastric Salem Sump, rectal tube, rectal irrigation), and the use of broad-spectrum antibiotics.

Visit Elsevier eBooks+ at eBooks.Health.Elsevier.com for Bibliography.

378.5 Intestinal Neuronal Dysplasia

Prasanna K. Kapavarapu, Kristin N. Fiorino, and Chris A. Liacouras

IND describes different quantitative (hypoganglionosis or hyperganglionosis) and qualitative (immature or heterotropic ganglion cells) abnormalities of the submucosal plexus. The typical histology is that of hyperganglionosis and giant ganglia. **Type A** occurs very rarely and is characterized by congenital aplasia or hypoplasia of the sympathetic innervation. Patients present early in the neonatal period with episodes of intestinal obstruction, diarrhea, and bloody stools. **Type B** accounts for more than 95% of cases. Biopsies for diagnosis of IND type B have to be taken 8 cm proximal to the dentate line with sufficient submucosa and should be cut rectangular to the surface mucosa to avoid false-positive results. Qualitative criteria include hypoganglionosis and hypertrophy of nerve trunks. Quantitative criteria include presence of at least 20% submucosal giant ganglia in 30 serial sections examined, 8 (10 ± 2) nerve cells per ganglion, and children >1 year of age. IND type B mimics Hirschsprung disease, and patients present with chronic constipation (see Table 378.7 and Fig. 378.5). Clinical manifestations include abdominal distention, constipation, and enterocolitis. Various lengths of bowel may be affected from segmental to the entire intestinal tract. IND has been observed in an isolated form and proximal to an aganglionic segment. Other intraintestinal and extraintestinal manifestations are present in patients with IND. It has been reported in all age groups, most commonly in infancy, but is also seen in adults who have had constipation not dating back to childhood.

Associated diseases and conditions include Hirschsprung disease, prematurity, small left colon syndrome, and meconium plug syndrome. Studies have identified a deficiency in substance P in patients with IND. Type A IND may be inherited in a familial, autosomal recessive pattern. Most cases of IND type B are sporadic, with few familial clusters, suggesting autosomal dominant inheritance.

Management includes that for functional constipation, and, if unsuccessful, surgery is indicated including emergency surgeries for acute obstruction.

Visit Elsevier eBooks+ at eBooks.Health.Elsevier.com for Bibliography.

378.6 Superior Mesenteric Artery Syndrome (Wilkie Syndrome, Cast Syndrome, Arteriomesenteric Duodenal Compression Syndrome)

Prasanna K. Kapavarapu, Kristin N. Fiorino, and Chris A. Liacouras

Superior mesenteric artery syndrome results from compression of the third duodenal segment by the superior mesenteric artery against the aorta. Malnutrition or catabolic states may cause mesenteric fat depletion, which collapses the duodenum within a narrowed aortomesenteric angle. Other etiologies include extraabdominal compression (e.g., body cast) and mesenteric tension, as can occur from ileoanal pouch anastomosis. Rapid weight loss and immobilization are risk factors.

Symptoms include intermittent epigastric pain, anorexia, nausea, and vomiting. Risk factors include thin body habitus, prolonged bed rest, abdominal surgery, and exaggerated lumbar lordosis. Onset can be within weeks of a trigger, but some patients have chronic symptoms that evade diagnosis. A classic example is an underweight adolescent who begins vomiting 1-2 weeks after scoliosis surgery or spinal fusion. Recognition may be delayed in the context of an eating disorder. Superior mesenteric artery syndrome can not only simulate anorexia nervosa, but also precipitate and sometimes even complicate anorexia nervosa.

The diagnosis is established radiologically by demonstrating a duodenal cutoff just right of midline along with proximal duodenal dilation, with or without gastric dilation. Although the upper gastrointestinal series remains a mainstay, modalities including abdominal CT or CT/MR angiography, or ultrasound may be more appropriate if there is concern for other etiologies such as malignancy. Upper endoscopy should be considered to rule out intraluminal pathology.

Treatment focuses on obstructive relief, nutritional rehabilitation, and correction of associated fluid and electrolyte abnormalities. Lateral or prone positioning can shift the duodenum away from obstructing structures and allow resumption of oral intake. If repositioning is unsuccessful, patients require nasojejunal enteral nutrition past the obstruction or parenteral nutrition if this is not tolerated. This management is successful in the vast majority of cases, with eventual withdrawal of tube feeding once weight has been regained and enteral feeding tolerance orally has been gradually and fully restored. Patients with refractory courses may require surgery to bypass the obstruction.

Visit Elsevier eBooks+ at eBooks.Health.Elsevier.com for Bibliography.

Chapter 379 Ileus, Adhesions, Intussusception, and Closed-Loop Obstructions

379.1 Ileus

Elizabeth C. Maxwell and Chris A. Liacouras

Ileus is the failure of intestinal peristalsis caused by loss of coordinated gut motility without evidence of mechanical obstruction. In children, it is most often associated with abdominal surgery or infection (gastroenteritis, pneumonia, peritonitis). Ileus also accompanies metabolic abnormalities (e.g., uremia, hypokalemia, hypercalcemia, hypermagnesemia, acidosis) or administration of certain drugs, such as opiates, vincristine, and antimotility agents such as loperamide when given during gastroenteritis.

Ileus manifests with nausea, vomiting, feeding intolerance, abdominal distention with associated pain, and delayed passage of stool and bowel gas. Bowel sounds are minimal or absent, in contrast to early mechanical obstruction, when they are hyperactive. Abdominal radiographs demonstrate multiple air-fluid levels throughout the abdomen. Serial radiographs usually do not show progressive distention as they do in mechanical obstruction. Contrast radiographs, if performed, demonstrate slow movement of barium through a patent lumen. Ileus after abdominal surgery generally resolves within 72 hours.

Treatment involves correcting the underlying abnormality, supportive care of comorbidities, and mitigation of iatrogenic contributions. Electrolyte abnormalities should be identified and corrected, and narcotic agents, when used, should be weaned as tolerated. Nasogastric decompression can relieve recurrent vomiting or abdominal distention associated with pain; resultant fluid losses should be corrected with isotonic crystalloid solution. Prokinetic agents such as erythromycin are not routinely recommended. Selective peripheral opioid antagonists such as methylnaltrexone hold promise in decreasing postoperative ileus, but pediatric data are lacking.

Visit Elsevier eBooks+ at eBooks.Health.Elsevier.com for Bibliography.

379.2 Adhesions

Elizabeth C. Maxwell and Chris A. Liacouras

Adhesions are fibrous tissue bands that result from peritoneal injury. Their formation is a complex process involving inflammation, hypoxia, and the extracellular matrix. They can constrict hollow organs and are a major cause of postoperative small bowel obstruction. Most remain asymptomatic, but problems can arise any time after the second postoperative week to years after abdominal surgery, regardless of surgical extent. In one large meta-analysis, the incidence of bowel obstruction

secondary to adhesive formation (ASBO) was between 1 and 12.6% in children. ASBO is an important cause of pediatric surgical emergency.

The diagnosis is suspected in patients with colicky abdominal pain, constipation, anorexia, emesis, and a history of intraperitoneal surgery. Nausea and vomiting quickly follow onset of pain. Initially, bowel sounds are hyperactive, and the abdomen is flat. Subsequently, bowel sounds disappear, and bowel dilation can cause abdominal distention. Fever and leukocytosis suggest bowel necrosis and peritonitis. Plain radiographs demonstrate obstructive features, and a CT scan or contrast studies may be needed to define the etiology.

Management includes nasogastric decompression, intravenous fluid resuscitation, and broad-spectrum antibiotics in preparation for surgery. The laparoscopic approach is used with increased frequency now compared to open laparotomy. Nonoperative intervention is contraindicated unless a patient is stable with obvious clinical improvement. Gastrografin (diatrizoate meglumine), typically used as an oral contrast agent for radiologic studies, may be a useful nonoperative management tool. A few small pediatric studies have shown promise, including decreased surgical requirement, decreased time to feed after admission, decreased hospital length of stay, and decreased healthcare costs with its use. Long-term complications include formation of new adhesions from surgery to relieve the obstruction, female infertility, failure to thrive, and chronic abdominal and/or pelvic pain.

Visit Elsevier eBooks+ at eBooks.Health.Elsevier.com for Bibliography.

379.3 Intussusception

Elizabeth C. Maxwell and Chris A. Liacouras

Intussusception occurs when a portion of the alimentary tract is telescoped into an adjacent segment. It is the most common cause of intestinal obstruction between 5 months and 3 years of age and the most common abdominal emergency in children younger than 2 years of age. Sixty percent of patients are younger than 1 year of age and 80% of the cases occur before age 24 months; it is rare in neonates. The incidence varies from 1 to 4 per 1,000 live births. The male:female ratio is 3:1. Many small bowel–small bowel and a few small bowel–colonic intussusceptions reduce spontaneously; *if left untreated, ileal-colonic intussusception may lead to intestinal infarction, perforation, peritonitis, and death.*

ETIOLOGY AND EPIDEMIOLOGY

Approximately 90% of cases of intussusception in children are idiopathic. The seasonal incidence has peaks in fall and winter. Correlation with prior or concurrent respiratory adenovirus (type C) infection has been noted, and the condition can complicate otitis media, gastroenteritis, Henoch-Schönlein purpura, COVID-19, or upper respiratory tract infections. A slight increase in intussusception has been noted to occur within 3 weeks of the rotavirus vaccine (especially after the first dose), but this is a very rare side effect.

It is postulated that gastrointestinal infection or the introduction of new food proteins results in swollen Peyer patches in the terminal ileum. Lymphoid nodular hyperplasia is another related risk factor. Prominent mounds of lymph tissue lead to mucosal prolapse of the ileum into the colon, thus causing an intussusception. In 2–8% of patients, **recognizable lead points** for the intussusception are found, such as a Meckel diverticulum, intestinal polyp, neurofibroma, intestinal duplication cysts, inverted appendix stump, leiomyomas, hamartomas, ectopic pancreatic tissue, anastomotic suture line, enterostomy tube, posttransplant lymphoproliferative disease, hemangioma, or malignant conditions such as lymphoma or Kaposi sarcoma. Gastrojejunal and jejunostomy tubes can also serve as lead points for intussusception. Lead points are more common in children older than 2 years of age; the older the child, the higher the risk of a lead point. In adults, lead points are present in 90%. Intussusception can complicate mucosal hemorrhage, as in Henoch-Schönlein purpura, idiopathic thrombocytopenic purpura, or hemophilia. Cystic fibrosis, celiac disease, and Crohn disease are other risk factors. Postoperative intussusception is ileoileal and usually occurs within several days of an abdominal operation. Anterograde intussusception may occur rarely following bariatric surgery with a Roux-en-Y gastric bypass and is noteworthy that there does not seem to be a lead point in these cases. Intussusception occurring during development in utero may be associated with the development of intestinal atresia. Intussusception in premature infants is rare.

Fig. 379.1 Transverse image of an ileocolic intussusception. Note the loops within the loops of bowel.

Ileo-ileal (as compared to ileo-colonic) intussusception may be more common than previously believed, is often idiopathic or associated with Henoch-Schönlein purpura, and usually resolves spontaneously.

PATHOLOGY

Symptomatic intussusceptions are most often ileocolic, less commonly cecocolic, and occasionally ileal. Very rarely, the appendix forms the apex of an intussusception. The upper portion of bowel, the **intussusceptum,** invaginates into the lower, the **intussuscipiens,** pulling its mesentery along with it into the enveloping loop. Constriction of the mesentery obstructs venous return; engorgement of the intussusceptum follows, with edema, and bleeding from the mucosa leads to a bloody stool, sometimes containing mucus. The apex of the intussusception can extend into the transverse, descending, or sigmoid colon, even to and through the anus in neglected cases. This presentation must be distinguished from rectal prolapse. Most intussusceptions do not strangulate the bowel within the first 24 hours but can eventuate in intestinal gangrene and shock.

Fig. 379.2 Intussusception in an infant. The obstruction is evident in the proximal transverse colon. Contrast material between the intussusceptum and the intussuscipiens *(arrows)* is responsible for the coiled-spring appearance.

CLINICAL MANIFESTATIONS

In typical cases, there is sudden onset, in a previously well child, of severe paroxysmal colicky pain that recurs at frequent intervals and is accompanied by straining efforts with legs and knees flexed and loud cries. The child may initially be comfortable and play normally between the paroxysms of pain, but if the intussusception is not reduced, the child becomes progressively weaker and lethargic. At times, the **lethargy** is often disproportionate to the abdominal signs. With progression, a shocklike state, with fever and peritonitis, can develop. The pulse becomes weak and thready, the respirations become shallow and grunting, and the pain may be manifested only by moaning sounds. Vomiting occurs in most cases and is usually more frequent in the early phase. In the later phase, the vomitus becomes bile stained. Stools of normal appearance may be evacuated in the first few hours of symptoms. After this time, fecal excretions are small or more often do not occur, and little or no flatus is passed. Blood is generally passed in the first 12 hours but at times not for 1-2 days and infrequently not at all; 60% of infants pass a stool containing red blood and mucus, the commonly described **currant jelly stool**. Some patients have only irritability and alternating or progressive lethargy. *The classic triad of pain, a palpable sausage-shaped abdominal mass, and bloody or currant jelly stool is seen in <30% of patients with intussusception.* The combination of paroxysmal pain, vomiting, and a palpable abdominal mass has a positive predictive value of >90%; the presence of rectal bleeding increases this to approximately 100%.

Palpation of the abdomen usually reveals a slightly tender sausage-shaped mass, sometimes ill defined, which might increase in size and firmness during a paroxysm of pain and is most often in the right upper abdomen, with its long axis cephalocaudal. If it is felt in the epigastrium, the long axis is transverse. Approximately 30% of patients do not have a palpable mass. The presence of bloody mucus on rectal examination supports the diagnosis of intussusception. Abdominal distention and tenderness develop as intestinal obstruction becomes more acute. On rare occasions, the advancing intestine prolapses through the anus. *This prolapse can be distinguished from prolapse of the rectum by the separation between the protruding intestine and the rectal wall, which does not exist in prolapse of the rectum.*

Ileoileal intussusception in children younger than 2 years can have a less typical clinical picture, and the symptoms and signs are chiefly those of small intestinal obstruction. These often resolve without treatment. **Recurrent intussusception** is noted in 5–8% and is more common after hydrostatic than surgical reduction. Chronic intussusception, in which the symptoms exist in milder form at recurrent intervals, is more likely to occur with or after acute enteritis and can arise in older children as well as in infants.

DIAGNOSIS

When the clinical history and physical findings suggest intussusception, an abdominal ultrasound is typically performed. A plain abdominal radiograph might show a density in the area of the intussusception. Screening ultrasounds for suspected intussusception increases the yield of diagnostic or therapeutic enemas and reduces unnecessary radiation exposure in children with negative ultrasound examinations. The diagnostic findings of intussusception on ultrasound include a tubular mass in longitudinal views and a doughnut or target appearance in transverse images (Fig. 379.1). Ultrasound has a sensitivity of approximately 98–100% and a specificity of approximately 98% in diagnosing intussusception. Air, hydrostatic (saline), and, less often, water-soluble contrast enemas have replaced barium examinations. Contrast enemas demonstrate a filling defect or cupping in the head of the contrast media where its advance is obstructed by the intussusceptum (Fig. 379.2). A central linear column of contrast media may be visible in the compressed lumen of the intussusceptum, and a thin rim of contrast may be seen trapped around the invaginating intestine in the folds of mucosa within the intussuscipiens (coiled-spring sign), especially after evacuation. Retrogression of the intussusceptum under pressure and visualized on x-ray or ultrasound documents successful reduction. Air reduction is associated with fewer complications and lower radiation exposure than traditional contrast hydrostatic techniques.

DIFFERENTIAL DIAGNOSIS

It may be particularly difficult to diagnose intussusception in a child who already has gastroenteritis; a change in the pattern of illness, in the character of pain, or in the nature of vomiting or the onset of rectal bleeding should alert the physician. The bloody stools and abdominal cramps that accompany enterocolitis can usually be differentiated from intussusception because in enterocolitis the pain is less severe and less regular, there is diarrhea, and the infant is recognizably ill between painful episodes. Bleeding from a Meckel diverticulum is usually painless. Joint symptoms, purpura, or hematuria usually but not invariably accompany the intestinal hemorrhage of Henoch-Schönlein purpura. Because intussusception can be a complication of this disorder, ultrasonography may be needed to distinguish the conditions.

It is important in patients with cystic fibrosis to distinguish intussusception from distal intestinal obstruction syndrome. Distal intestinal obstruction syndrome requires antegrade treatment, which would be harmful if there was an intussusception.

TREATMENT

Reduction of an acute intussusception is an emergency procedure and should be performed immediately after diagnosis in preparation for possible surgery. In patients with prolonged intussusception and signs of shock, peritoneal irritation, intestinal perforation, or pneumatosis intestinalis, hydrostatic reduction should not be attempted.

The success rate of radiologic hydrostatic reduction under fluoroscopic or ultrasonic guidance is approximately 80–95% in patients with ileocolic intussusception. Spontaneous reduction of

intussusception occurs in approximately 4–10% of patients. Bowel perforations occur in 0.5–2.5% of attempted barium and hydrostatic (saline) reductions. The perforation rate with air reduction is 0.1–0.2%. Surgical reduction is indicated in the presence of refractory shock, suspected bowel necrosis or perforation, peritonitis, and multiple recurrences (suspected lead point).

An *ileoileal intussusception* is best demonstrated by abdominal ultrasonography. Reduction by instillation of contrast agents, saline, or air might not be possible. Such intussusceptions can develop insidiously after bowel surgery and require reoperation if they do not spontaneously reduce. Ileoileal disease is common with Henoch-Schönlein purpura and other unidentifiable disorders and usually resolves without the need for any specific treatment. If manual operative reduction is impossible or the bowel is not viable, resection of the intussusception is necessary, with end-to-end anastomosis.

PROGNOSIS

Untreated ileal-colonic intussusception in infants is usually fatal; the chances of recovery are directly related to the duration of intussusception before reduction. Most infants recover if the intussusception is reduced in the first 24 hours, but the mortality rate rises rapidly after this time, especially after the second day. Spontaneous reduction during preparation for operation is not uncommon.

The **recurrence rate** after nonsurgical reduction of intussusceptions is approximately 10%, and after surgical reduction it is 2–5%; none has recurred after surgical resection. Most recurrences occur within 72 hours of reduction. Corticosteroids may reduce the frequency of recurrent intussusception but are rarely used for this purpose. Repeated reducible episodes caused by lymphonodular hyperplasia may respond to treatment of identifiable food allergies if present. A single recurrence of intussusception can usually be reduced radiologically. In patients with multiple ileal-colonic recurrences, a lead point should be suspected and laparoscopic surgery considered. It is unlikely that an intussusception caused by a lesion such as lymphosarcoma, polyp, or Meckel diverticulum will be successfully reduced by radiologic intervention. With adequate surgical management, laparoscopic reduction carries a very low mortality.

Visit Elsevier eBooks+ at eBooks.Health.Elsevier.com for Bibliography.

379.4 Closed-Loop Obstructions

Elizabeth C. Maxwell and Chris A. Liacouras

Closed-loop obstructions (i.e., **internal hernia**) result from bowel loops that enter windows created by mesenteric defects or adhesions and become trapped, with the entrapped segment of bowel becoming obstructed at two points. Vascular engorgement of the strangulated bowel results in intestinal ischemia and necrosis unless promptly relieved. Prior abdominal surgery is an important risk factor. Symptoms include abdominal pain, distention, and bilious emesis. Symptoms can be intermittent if the herniated bowel slides in and out of the defect. Peritoneal signs suggest ischemic bowel. Plain radiographs demonstrate signs of small bowel obstruction or free air if the bowel has perforated. CT scan can identify and delineate internal hernias. Supportive management includes intravenous fluids, antibiotics, and nasogastric decompression. Prompt surgical relief of the obstruction is indicated to prevent bowel necrosis.

Visit Elsevier eBooks+ at eBooks.Health.Elsevier.com Bibliography.

Chapter 380 Foreign Bodies and Bezoars

380.1 Foreign Bodies in the Stomach and Intestine

Trusha Patel, Petar Mamula, and Chris A. Liacouras

Foreign body (FB) ingestions are common in children, with most ingestions occurring between 6 months and 3 years of age. Generally, FB ingestions in young children are unintentional and involve small household objects (coins, toys, jewelry, magnets, batteries, etc.). Although children may present with symptoms of abdominal pain or chest pain, stridor, drooling, respiratory distress, fever, dysphagia, or inability to tolerate oral intake after FB ingestions, up to 50% of children may be asymptomatic at the time of presentation. A thorough history and clinical examination is required, including evaluation for respiratory distress, oropharyngeal injury, and signs of perforation such as subcutaneous emphysema or peritoneal signs. When determining the appropriate management of a child after FB ingestion, clinicians must consider patient age and anatomy; object type, location, and size; timing of ingestion; presence or absence of symptoms; nil per os (NPO) status; and logistical factors (availability of necessary staff, social factors that may impact timely follow-up). In addition to history and clinical examination, anteroposterior and lateral radiographs of the neck, chest, and/or abdomen are useful to confirm the presence and determine the location of radiopaque foreign bodies. Object location is particularly important to consider in the context of the most common sites of potential FB impaction, obstruction, or retention, which include multiple locations in the esophagus, pylorus, duodenal sweep, ligament of Treitz, ileocecal valve, rectosigmoid colon, and anus.

Otolaryngologists, gastroenterologists, and general surgeons are all trained in the management of FB ingestions and center-specific availability and expertise should guide consultation with the appropriate specialist. The management of esophageal foreign bodies is reviewed elsewhere (Chapter 373.1). Considerations for management of gastrointestinal foreign bodies in the stomach and intestine are based on object type, along with recommendations regarding timing of potential endoscopic removal as being emergent (<2 hours, regardless of NPO status), urgent (<24 hours, following usual NPO guidelines), or elective (>24 hours from presentation, following usual NPO guidelines). It should be noted, however, that given the great variability in patient and object size, the management of pediatric FB ingestions is case dependent, and clinicians must use their judgment when determining appropriate management.

BUTTON BATTERIES

Button battery ingestion in a child of any age requires emergent evaluation, given the potential for rapid, severe caustic injury and associated complications. For children ≥1 year of age with suspected lithium button battery ingestion in the prior 12 hours or confirmed location in the esophagus, current recommendations are to administer honey 10 mL every 10 minutes (or sucralfate if available) and proceed to the emergency department as soon as possible.

intussusception occurs in approximately 4–10% of patients. Bowel perforations occur in 0.5–2.5% of attempted barium and hydrostatic (saline) reductions. The perforation rate with air reduction is 0.1–0.2%. Surgical reduction is indicated in the presence of refractory shock, suspected bowel necrosis or perforation, peritonitis, and multiple recurrences (suspected lead point).

An *ileoileal intussusception* is best demonstrated by abdominal ultrasonography. Reduction by instillation of contrast agents, saline, or air might not be possible. Such intussusceptions can develop insidiously after bowel surgery and require reoperation if they do not spontaneously reduce. Ileoileal disease is common with Henoch-Schönlein purpura and other unidentifiable disorders and usually resolves without the need for any specific treatment. If manual operative reduction is impossible or the bowel is not viable, resection of the intussusception is necessary, with end-to-end anastomosis.

PROGNOSIS

Untreated ileal-colonic intussusception in infants is usually fatal; the chances of recovery are directly related to the duration of intussusception before reduction. Most infants recover if the intussusception is reduced in the first 24 hours, but the mortality rate rises rapidly after this time, especially after the second day. Spontaneous reduction during preparation for operation is not uncommon.

The **recurrence rate** after nonsurgical reduction of intussusceptions is approximately 10%, and after surgical reduction it is 2–5%; none has recurred after surgical resection. Most recurrences occur within 72 hours of reduction. Corticosteroids may reduce the frequency of recurrent intussusception but are rarely used for this purpose. Repeated reducible episodes caused by lymphonodular hyperplasia may respond to treatment of identifiable food allergies if present. A single recurrence of intussusception can usually be reduced radiologically. In patients with multiple ileal-colonic recurrences, a lead point should be suspected and laparoscopic surgery considered. It is unlikely that an intussusception caused by a lesion such as lymphosarcoma, polyp, or Meckel diverticulum will be successfully reduced by radiologic intervention. With adequate surgical management, laparoscopic reduction carries a very low mortality.

Visit Elsevier eBooks+ at eBooks.Health.Elsevier.com for Bibliography.

379.4 Closed-Loop Obstructions

Elizabeth C. Maxwell and Chris A. Liacouras

Closed-loop obstructions (i.e., **internal hernia**) result from bowel loops that enter windows created by mesenteric defects or adhesions and become trapped, with the entrapped segment of bowel becoming obstructed at two points. Vascular engorgement of the strangulated bowel results in intestinal ischemia and necrosis unless promptly relieved. Prior abdominal surgery is an important risk factor. Symptoms include abdominal pain, distention, and bilious emesis. Symptoms can be intermittent if the herniated bowel slides in and out of the defect. Peritoneal signs suggest ischemic bowel. Plain radiographs demonstrate signs of small bowel obstruction or free air if the bowel has perforated. CT scan can identify and delineate internal hernias. Supportive management includes intravenous fluids, antibiotics, and nasogastric decompression. Prompt surgical relief of the obstruction is indicated to prevent bowel necrosis.

Visit Elsevier eBooks+ at eBooks.Health.Elsevier.com Bibliography.

Chapter 380 Foreign Bodies and Bezoars

380.1 Foreign Bodies in the Stomach and Intestine

Trusha Patel, Petar Mamula, and Chris A. Liacouras

Foreign body (FB) ingestions are common in children, with most ingestions occurring between 6 months and 3 years of age. Generally, FB ingestions in young children are unintentional and involve small household objects (coins, toys, jewelry, magnets, batteries, etc.). Although children may present with symptoms of abdominal pain or chest pain, stridor, drooling, respiratory distress, fever, dysphagia, or inability to tolerate oral intake after FB ingestions, up to 50% of children may be asymptomatic at the time of presentation. A thorough history and clinical examination is required, including evaluation for respiratory distress, oropharyngeal injury, and signs of perforation such as subcutaneous emphysema or peritoneal signs. When determining the appropriate management of a child after FB ingestion, clinicians must consider patient age and anatomy; object type, location, and size; timing of ingestion; presence or absence of symptoms; nil per os (NPO) status; and logistical factors (availability of necessary staff, social factors that may impact timely follow-up). In addition to history and clinical examination, anteroposterior and lateral radiographs of the neck, chest, and/or abdomen are useful to confirm the presence and determine the location of radiopaque foreign bodies. Object location is particularly important to consider in the context of the most common sites of potential FB impaction, obstruction, or retention, which include multiple locations in the esophagus, pylorus, duodenal sweep, ligament of Treitz, ileocecal valve, rectosigmoid colon, and anus.

Otolaryngologists, gastroenterologists, and general surgeons are all trained in the management of FB ingestions and center-specific availability and expertise should guide consultation with the appropriate specialist. The management of esophageal foreign bodies is reviewed elsewhere (Chapter 373.1). Considerations for management of gastrointestinal foreign bodies in the stomach and intestine are based on object type, along with recommendations regarding timing of potential endoscopic removal as being emergent (<2 hours, regardless of NPO status), urgent (<24 hours, following usual NPO guidelines), or elective (>24 hours from presentation, following usual NPO guidelines). It should be noted, however, that given the great variability in patient and object size, the management of pediatric FB ingestions is case dependent, and clinicians must use their judgment when determining appropriate management.

BUTTON BATTERIES

Button battery ingestion in a child of any age requires emergent evaluation, given the potential for rapid, severe caustic injury and associated complications. For children ≥1 year of age with suspected lithium button battery ingestion in the prior 12 hours or confirmed location in the esophagus, current recommendations are to administer honey 10 mL every 10 minutes (or sucralfate if available) and proceed to the emergency department as soon as possible.

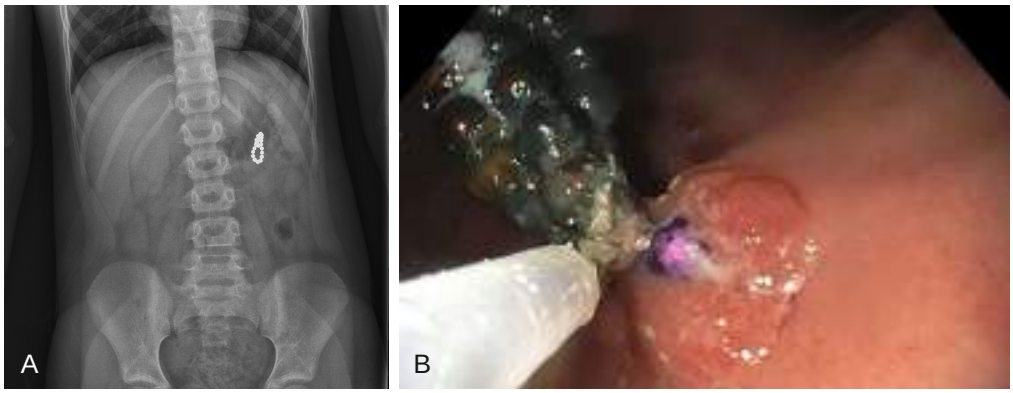

Fig. 380.1 A, Supine abdominal radiograph of 8-yr-old girl with history of ingestion of 23 Buckyball-type magnets over preceding 3-mo period demonstrating loop of magnets. B, Endoscopic image of magnets during retrieval from lesser curvature of the stomach, with additional finding of magnet penetrating the wall of stomach. Subsequent surgical exploration demonstrated fistula between stomach and jejunum, which was repaired.

Immediate two-view radiograph is indicated to determine battery location and negative pole orientation; direct notification of otolaryngology, gastroenterology, and/or general surgery is indicated pending results of this radiograph. Although removal of esophageal button batteries is emergent, management of button batteries in the stomach and more distally depends on the presence of symptoms and whether a single battery or multiple objects have been ingested. If symptoms of anorexia, vomiting, abdominal pain, or fever are present or if there is co-ingestion of a magnet, then urgent endoscopic removal is indicated if the button battery is in the stomach or proximal small intestine. If the patient is asymptomatic after the ingestion of a single button battery ≥15 mm that has passed beyond the esophagus, esophagram should still be considered (particularly in children <6 years of age) to evaluate for esophageal injury. If esophagram is normal, observant management may be appropriate, with repeat abdominal x-ray (AXR) in 2-3 days and consideration of button battery removal if it still has not passed the stomach within 4 days. However, if the esophagram is abnormal or if patient size or other factors make it unlikely that the battery will pass spontaneously, hospital admission for observation, endoscopic evaluation, and potential battery removal is indicated. If the patient is asymptomatic and only a single button battery <15 mm has been ingested and is in the stomach or more distal, observant management is appropriate. AXR should be considered if an ingested button battery has not passed in the stool within 10-14 days.

COINS/BLUNT OBJECTS

Although coins are the most frequently ingested FB, when coin ingestion is reported or identified on imaging, it is important to confirm that the ingested object could not potentially be a button battery (on imaging, it is important to make sure there is no "step-off" sign on lateral view or "double halo" sign on anteroposterior views). Generally, endoscopic removal of coins and other small, blunt objects in the stomach and more distally is only necessary if the patient is symptomatic or if the object is unlikely to pass (child <2 years old and object dimensions of width >2 cm or length >5 cm). Repeat abdominal radiography may be considered in 2-3 weeks if a child under 2 years of age swallowed a quarter or another object that may not pass in a timely fashion.

MAGNETS

In the case of a suspected or confirmed magnet ingestion, two-view radiographs should be obtained to confirm whether a single magnet or multiple magnets have been ingested, as multiple magnet ingestion places the patient at risk for entero-enteric fistula formation between magnets in adjacent loops of bowel, which can lead to perforation, peritonitis, and bowel ischemia/necrosis. If a single magnet has been ingested and is in the stomach or intestine and the patient is asymptomatic, with low risk for ingestion of additional magnets and with good follow-up, allowing spontaneous passage is appropriate. In that case, precautions that should be taken include removing all magnets and metallic objects from the patient's environment (including patient's clothing) and preventing any risk of additional magnet ingestion until the magnet has passed. In the case of multiple magnet ingestion, urgent endoscopic removal is indicated if the magnets are in the stomach to prevent further passage or complications (Fig. 380.1). If multiple magnets are beyond the stomach, consultation with a general surgeon is recommended and magnet removal should be pursued if the patient is symptomatic (either with enteroscopy, laparoscopy or laparotomy, depending on center expertise) (Fig. 380.2). If the patient is asymptomatic, hospital admission for laxative therapy, serial abdominal exams and x-rays (every 4-6 hours) and consideration of later removal if not passing is appropriate.

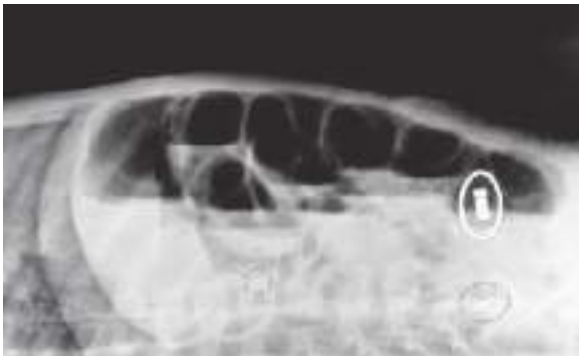

Fig. 380.2 Abdominal radiograph of a 3-yr-old boy, noting three attached magnets that resulted in volvulus (i.e., twisting of the bowel) and multiple bowel perforations. *(Courtesy U.S. Consumer Product Safety Commission. From Centers for Disease Control and Prevention: Gastrointestinal injuries from magnet ingestion in children—United States, 2003–2006. MMWR Morb Mortal Wkly Rep. 2006;55:1296–1300.)*

SHARP OBJECTS

The management of ingested sharp objects depends on size and shape of the object. Radiographic evaluation is key in identifying size, location, and orientation of radiopaque sharp objects, although it will not be beneficial for radiolucent objects. Generally, urgent endoscopic removal is indicated for sharp objects in the stomach or duodenum if the patient is symptomatic, the object is likely to cause perforation if allowed to pass spontaneously, or if the object is unlikely to pass due to large size (>5-6 cm long in teenagers/adults or ≥2-3 cm long in a younger child). If a large, sharp object is beyond the duodenum, consultation with general surgery is recommended, as removal is indicated if the patient is symptomatic. Even if the patient is asymptomatic, serial radiographs are indicated and removal with enteroscopy or surgery may be needed if symptoms develop or if the object does not pass after 3 days. Otherwise, if the patient is asymptomatic and the object is smaller than the aforementioned dimensions, particularly with the sharp end of the object trailing behind a heavier blunt end, allowing spontaneous passage is reasonable. For reported ingestion of sharp, radiolucent objects, urgent endoscopic evaluation and potential removal is indicated if the patient is asymptomatic. If the patient is symptomatic, alternate imaging (CT, ultrasound, MRI, fluoroscopy) may be utilized for assessment and removal may be considered if the object is identified.

SPECIAL CONSIDERATIONS

Other foreign bodies that may require special considerations include those with the potential to cause obstruction or toxicity based on object characteristics. Super-absorbent objects (including expanding children's spongelike toys, tampons) may expand rapidly within the GI tract and cause gastric outlet or bowel obstruction. If not yet expanded and accessible via endoscope, removal should be considered. Lead-containing foreign bodies should be removed promptly if endoscopically accessible, as they have the potential to cause lead toxicity. Consultation with toxicology is recommended and obtaining baseline serum lead level is suggested. If the lead-containing FB is beyond the stomach, bowel irrigation and monitoring of blood lead levels may be appropriate to minimize and monitor toxicity. In the case of ingestion of narcotic packets, endoscopic removal should be avoided to prevent packet rupture and severe toxicity and consultation with Poison Control Center is recommended.

Children occasionally place objects in their rectum. Small blunt objects usually pass spontaneously, but large or sharp objects typically need to be retrieved. Adequate sedation is essential to relax the anal sphincter before attempting endoscopic or speculum removal. If the object is proximal to the rectum, observation for 12-24 hours usually allows the object to descend into the rectum.

IMPORTANT NUMBERS

National Battery Ingestion Hotline: 800-498-8666
Poison Control: 800-222-1222

Visit Elsevier eBooks+ at eBooks.Health.Elsevier.com for Bibliography.

380.2 Bezoars

Trusha Patel, Petar Mamula, and Chris A. Liacouras

A bezoar is an accumulation of exogenous matter in the stomach or intestine. Risk factors for development of a bezoar include anatomic abnormalities (congenital or due to prior gastrointestinal surgery), gastric dysmotility, and medical and psychiatric conditions that lead to consumption of nonfood materials. Bezoars are often incidental findings on imaging or endoscopy in an asymptomatic patient. When they cause symptoms, abdominal pain, nausea, vomiting, decreased appetite, and halitosis are most common. An abdominal plain film can suggest the presence of a bezoar, which can be confirmed on ultrasound, fluoroscopy, or CT examination. On fluoroscopy or CT scan, a bezoar appears as a nonhomogeneous, nonenhancing mass within the lumen of the stomach or intestine. Oral contrast circumscribes the mass.

Fig. 380.3 Large trichobezoar in the shape of the stomach, duodenum, and proximal jejunum after surgical removal. *(Courtesy Dr. Michael L. Nance, Division of Pediatric General, Thoracic and Fetal Surgery, Children's Hospital of Philadelphia.)*

Bezoars are classified on the basis of their composition. **Phytobezoars** are the most common type of bezoar and are composed of undigestible vegetable/fruit matter. Carbonated soda has been demonstrated to help dissolve phytobezoars and should be considered as a first-line option for management. When available, cellulase can also be used for chemical dissolution. Given the risk of gastric ulcer or perforation, the use of papain (meat tenderizer) is not recommended. If endoscopic removal is needed, endotracheal intubation is required and use of an overtube may be considered. In addition to chemical dissolution and endoscopic or removal, prokinetic agents may be used for adjuvant medical therapy as well. **Trichobezoars** are composed of hair and are most frequently a complication of the psychiatric disorder trichotillomania, and the most severe form is known as Rapunzel syndrome (hair bezoar extending beyond the stomach to the small intestine). Large trichobezoars require surgical removal; endoscopic removal is not recommended (Fig. 380.3). **Lactobezoars** are uncommon and are most frequently seen in premature infants and can be attributed to the high casein or calcium content of some premature formulas. These bezoars generally resolve when feedings are withheld for 24-48 hours. **Pharmacobezoars** (composed of ingested medications) and other bezoars composed of various other objects (vinyl gloves, cement, Styrofoam, etc.) may also be seen and management is case-dependent.

Visit Elsevier eBooks+ at eBooks.Health.Elsevier.com for Bibliography.

Chapter 381

Peptic Ulcer Disease in Children

Samra S. Blanchard and Steven J. Czinn

Peptic ulcer disease, the end result of inflammation caused by an imbalance between cytoprotective and cytotoxic factors in the stomach and duodenum, manifests with varying degrees of gastritis or frank ulceration. The pathogenesis of peptic ulcer disease is multifactorial, but the final common pathway for the development of ulcers is the action of acid and pepsin-laden contents of the stomach on the gastric and duodenal mucosa and the inability of mucosal defense mechanisms to allay those effects. Abnormalities in the gastric and duodenal mucosa can be visualized on endoscopy, with or without histologic changes. Deep mucosal lesions that disrupt the muscularis mucosa of the gastric or duodenal wall define **peptic ulcers.** Gastric ulcers are generally located on the lesser curvature of the stomach, and 90% of duodenal ulcers are found in the duodenal bulb. Rates of peptic ulcer disease in childhood appear to be low. Large pediatric centers anecdotally report an incidence of 5-7 children with gastric or duodenal ulcers per 2,500 hospital admissions each year.

Ulcers in children can be classified as **primary** peptic ulcers, which are chronic and more often duodenal, or **secondary,** which are usually more acute in onset and are more often gastric (Table 381.1). Primary ulcers are most often associated with *Helicobacter pylori* infection. Secondary peptic ulcers can result from stress caused by sepsis, shock, or an intracranial lesion (Cushing ulcer), or in response to a severe burn injury (Curling ulcer). Secondary ulcers can also occur as the result of using drugs (nonsteroidal antiinflammatory drugs [NSAIDs], corticosteroids, sodium valproate, iron, potassium supplements, theophylline), hypersecretory states like Zollinger-Ellison syndrome (see Chapter 381.1), G-cell hyperplasia, short bowel syndrome, and hyperparathyroidism. Infections with cytomegalovirus, herpes simplex virus, and tuberculosis and systemic inflammatory diseases like Crohn disease, sarcoidosis, mastocytosis, and eosinophilic gastroenteritis can also cause ulcers.

PATHOGENESIS

Acid Secretion

By 3-4 years of age, gastric acid secretion approximates adult values. Acid initially secreted by the oxyntic cells of the stomach has a pH of approximately 0.8, whereas the pH of the stomach contents is 1-2. Excessive acid secretion is associated with a large parietal cell mass, hypersecretion by antral G cells, and increased vagal tone, resulting in increased or sustained acid secretion in response to meals and increased secretion during the night. The secretagogues that promote gastric acid production include acetylcholine released by the vagus nerve, histamine secreted by enterochromaffin cells, and gastrin released by the G cells of the antrum. Mediators that decrease gastric acid secretion and enhance protective mucin production include prostaglandins.

Table 381.1 Etiologic Classification of Peptic Ulcers

Positive for *Helicobacter pylori* infection
Drug (NSAID)-induced
H. pylori and NSAID-positive
H. pylori and NSAID-negative*
Acid hypersecretory state (Zollinger-Ellison syndrome)
Anastomosis ulcer after subtotal gastric resection
Tumors (cancer, lymphoma, carcinoid syndrome)
Crohn disease of the stomach or duodenum
Eosinophilic gastroduodenitis
Systemic mastocytosis
Radiation damage
Viral infections (cytomegalovirus or herpes simplex infection, particularly in immunocompromised patients)
Colonization of stomach with *Helicobacter heilmannii*
Severe systemic disease
Cameron ulcer (gastric ulcer where a hiatal hernia passes through the diaphragmatic hiatus)
True idiopathic ulcer

*Requires search for other specific causes.
NSAID, Nonsteroidal antiinflammatory drug.
From Vakil N, Megraud F. Eradication therapy for *Helicobacter pylori. Gastroenterology.* 2007;133:985–1001.

Mucosal Defense

A continuous layer of mucous gel that serves as a diffusion barrier to hydrogen ions and other chemicals covers the gastrointestinal (GI) mucosa. Mucus production and secretion are stimulated by prostaglandin E_2. Underlying the mucous coat, the epithelium forms a second-line barrier, the characteristics of which are determined by the biology of the epithelial cells and their tight junctions. Another important function of epithelial cells is to secrete chemokines when threatened by microbial attack. Secretion of bicarbonate into the mucous coat, which is regulated by prostaglandins, is important for neutralization of hydrogen ions. If mucosal injury occurs, active proliferation and migration of mucosal cells occurs rapidly, driven by epithelial growth factor, transforming growth factor-α, insulin-like growth factor, gastrin, and bombesin, and covers the area of epithelial damage.

CLINICAL MANIFESTATIONS

The presenting symptoms of peptic ulcer disease vary with the age of the patient. Hematemesis or melena is reported in up to half of the patients with peptic ulcer disease. School-age children and adolescents more commonly present with epigastric pain and nausea, presentations generally seen in adults. Dyspepsia, epigastric abdominal pain or fullness, is seen in older children. Infants and younger children usually present with feeding difficulty, vomiting, crying episodes, hematemesis, or melena. In the neonatal period, gastric perforation can be the initial presentation.

The classic symptom of peptic ulceration, epigastric pain alleviated by the ingestion of food, is present only in a minority of children. Many pediatric patients present with poorly localized abdominal pain, which may be periumbilical. The vast majority of patients with periumbilical or epigastric pain or discomfort do not have a peptic ulcer, but rather a functional GI disorder, such as irritable bowel syndrome or nonulcer (functional) dyspepsia (see Chapter 389). Patients with peptic ulceration rarely present with acute abdominal pain from perforation or symptoms and signs of pancreatitis from a posterior penetrating ulcer. Occasionally, bright red blood per rectum may be seen if the rate of bleeding is brisk and the intestinal transit time is short. Vomiting can be a sign of gastric outlet obstruction.

The pain is often described as dull or aching, rather than sharp or burning, as in adults. It can last from minutes to hours; patients have frequent exacerbations and remissions lasting from weeks to months. Nocturnal pain waking the child is common in older children. A history of typical ulcer pain with prompt relief after taking antacids is found in <33% of children. Rarely, in patients with acute or chronic blood loss, penetration of the ulcer into the abdominal cavity or adjacent organs produces shock, anemia, peritonitis, or pancreatitis. If inflammation and edema are extensive, acute or chronic gastric outlet obstruction can occur.

DIAGNOSIS

Esophagogastroduodenoscopy is the method of choice to establish the diagnosis of peptic ulcer disease. Endoscopy allows the direct visualization of esophagus, stomach, and duodenum, identifying the specific lesions. Biopsy specimens must be obtained from the esophagus, stomach, and duodenum for histologic assessment as well as to screen for the presence of *H. pylori* infection. Endoscopy also provides the opportunity for hemostatic therapy including clipping, injection, and the use of thermal coagulation.

PRIMARY ULCERS

Helicobacter pylori Gastritis

H. pylori is among the most common bacterial infections in humans. It is a gram-negative, S-shaped rod that produces urease, catalase, and oxidase; these enzymes might play a role in the pathogenesis of peptic ulcer disease. The mechanism of acquisition and transmission of *H. pylori* is unclear, although the most likely mode of transmission is fecal-oral or oral-oral. Viable *H. pylori* organisms can be cultured from the stool or vomitus of infected patients. Risk factors such as low socioeconomic status in childhood or affected family members also influence the prevalence. All children infected with *H. pylori* develop histologic chronic active gastritis but are often asymptomatic. In children, *H. pylori* infection can manifest with abdominal pain or vomiting and, less often, refractory iron-deficiency anemia or poor growth. *H. pylori* can be associated, though rarely, with chronic autoimmune thrombocytopenia. Chronic colonization with *H. pylori* can predispose children to a significantly increased risk of developing a duodenal ulcer, gastric cancer such as adenocarcinoma, or mucosa-associated lymphoid tissue lymphomas. The relative risk of gastric carcinoma is 2.3-8.7 times greater in infected adults compared with uninfected subjects. *H. pylori* is classified by the World Health Organization as a group I carcinogen.

Anemia, idiopathic thrombocytopenic purpura, short stature, and sudden unexplained infant death (SUID) have also been reported as extragastric manifestations of *H. pylori* infection. In one published study, *H. pylori* infection has been correlated with cases of SUID, but there is no evidence to suggest that *H. pylori* plays a role in the pathogenesis of SUID.

The **diagnosis** of *H. pylori* infection is made histologically by demonstrating the organism in the biopsy specimens. The current consensus report does not recommend using antibody-based tests (IgG, IgA) for *H pylori* in serum, whole blood, urine, and saliva in the clinical setting. ^{13}C-urea breath tests and stool antigen tests are reliable noninvasive methods of detecting *H. pylori* infection in patients who do not require endoscopic evaluation. Patients should stop proton pump inhibitor (PPI) therapy 2 weeks before testing as they can cause false-negative results. Nonetheless, for symptomatic children with suspected *H. pylori* infection, an initial upper endoscopy is recommended to evaluate and confirm *H. pylori* disease. The range of endoscopic findings in children with *H. pylori* infection varies from being grossly normal to the presence of nonspecific gastritis with prominent rugal folds, nodularity (Fig. 381.1), or ulcers. Because the antral mucosa appears to be *endoscopically normal* in a significant number of children with primary *H. pylori* gastritis, gastric biopsies should always be obtained from the body and antrum of the stomach regardless of the endoscopic appearance. If *H. pylori* is identified, even in a child with no symptoms, eradication therapy should be offered (Tables 381.2 and 381.3). Successful *H. pylori* eradication is associated with cure of peptic ulcer disease and very low risk of relapse. Therefore monitoring the success of therapy is mandatory in these patients 4-6 weeks after stopping antibiotics and at least 2 weeks after stopping PPI therapy. Eradication must be tested with the ^{13}C-urea breath test or stool antigen test. If there is an eradication failure, the patient should receive *rescue* therapy.

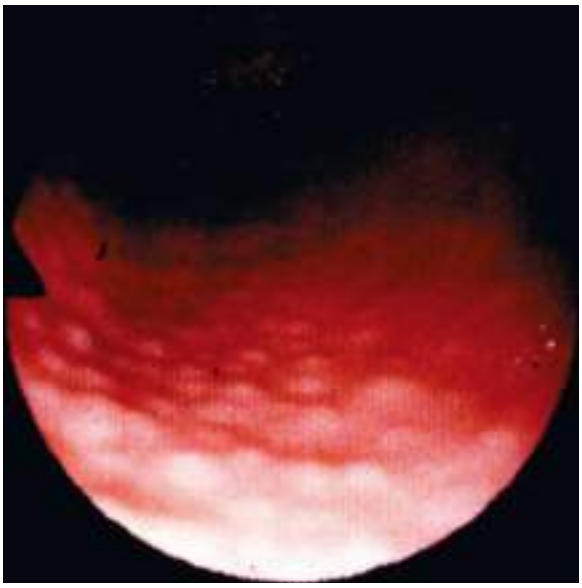

Fig. 381.1 Endoscopic view of lymphoid modular hyperplasia of the gastric antrum. Endoscopic hemostatic therapy is indicated for ulcers with active spurting, active oozing, and nonbleeding but visible vessels. Hemostatic therapy may include bipolar electrocoagulation or heater probe, or injectable soluble alcohol. *(From Campbell DI, Thomas JE. Helicobacter pylori infection in paediatric practice. Arch Dis Child Educ Pract Ed. 2005;90:ep25–ep30.)*

IDIOPATHIC ULCERS

H. pylori–negative peptic ulcers in children who have no history of taking NSAIDs represent 15–20% of pediatric peptic ulcers. The pathogenesis of idiopathic ulcer remains uncertain. These patients do not have nodularity in the gastric antrum or histologic evidence of gastritis. In idiopathic ulcers, acid suppression alone is the preferred effective treatment. Either PPIs or H_2-receptor antagonists may be used. Idiopathic ulcers have a high recurrence rate after discontinuing antisecretory therapy. These children should be followed closely, and if symptoms recur, antisecretory therapy should be restarted. It is also important to consider uncommon but possible conditions like Crohn disease, cytomegalovirus, and Zollinger-Ellison syndrome.

SECONDARY ULCERS

Aspirin and Other Nonsteroidal Antiinflammatory Drugs

NSAIDs produce mucosal injury by direct local irritation and by inhibiting cyclooxygenase (COX) and prostaglandin formation. Prostaglandins enhance mucosal resistance to injury; therefore a decrease in prostaglandin production increases the risk of mucosal injury. The severe erosive gastropathy produced by NSAIDs can ultimately result in bleeding ulcers or gastric perforations. The location of these ulcers is more common in the stomach than in the duodenum, and usually in the antrum. The discovery of two isoforms of COX-1 and COX-2 has led to the development of COX-2-selective NSAIDs, but they can still cause ulcerations in the GI tract.

STRESS ULCERATION

Stress ulceration usually occurs within 24 hours of onset of a critical illness in which physiologic stress is present. In many cases, the patients bleed from gastric erosions, rather than ulcers. Approximately 25% of the critically ill children in a pediatric intensive care unit have macroscopic evidence of gastric bleeding. Preterm and term infants in the neonatal intensive care unit can also develop gastric mucosal lesions and can present with upper GI bleeding or perforated ulcers. Although prophylactic measures to prevent stress ulcers in children are not standardized, drugs that inhibit gastric acid production (PPIs) are often used in the pediatric intensive care unit to reduce the rate of gastric erosions or ulcers. There is a concern that prophylactic PPI therapy increases the risk of ventilator-associated pneumonia and possibly *Clostridium difficile*–associated disease.

TREATMENT

The management of acute hemorrhage includes serial monitoring of pulse, blood pressure, and hematocrit to ensure hemodynamic stability and avoid significant hypovolemia and anemia. Normal saline can be used to resuscitate a patient who has poor intravascular volume status. This can be followed by packed red blood cell transfusions for significant symptomatic anemia. The patient's blood should be typed and cross matched, and a large-bore catheter should be placed for fluid or blood replacement. A nasogastric tube should be placed to determine whether the bleeding has stopped. Significant anemia can occur after fluid resuscitation as a consequence of equilibration or continued blood loss (which can also cause shock). In adults, a conservative threshold for transfusion (<7 g/dL vs 9 g hemoglobin) resulted in improved survival and fewer episodes of rebleeding. Fortunately, most acute peptic ulcer bleeding stops spontaneously.

Table 381.2 Recommended Eradication Therapies for *Helicobacter pylori*–Associated Disease in Children

MEDICATIONS	DOSE		DURATION OF TREATMENT
Proton pump inhibitor	1 mg/kg/dose twice a day		1 mo
ANTIBIOTICS	**WEIGHT**	**DOSE**	**DURATION OF TREATMENT**
Amoxicillin	15-24 kg	500 mg twice a day	14 days
	25-34 kg	750 mg twice a day	
	>35 kg	1,000 mg twice a day	
Clarithromycin	15-24 kg	250 mg twice a day	14 days
	25-34 kg	500 mg in a.m., 250 mg in p.m.	
	>35 kg	500 mg twice a day	
Metronidazole	15-24 kg	250 mg twice a day	14 days
	25-34 kg	500 mg in a.m., 250 mg in p.m.	
	>35 kg	500 mg twice a day	

Depending on previous antibiotic use history, recommended combinations are amoxicillin + clarithromycin + PPI OR amoxicillin + metronidazole + PPI OR clarithromycin + metronidazole + PPI. Adapted from Jones NL, Koletzko S, Goodman K, et al. Joint ESPGHAN/NASPGHAN Guidelines for the Management of Helicobacter pylori in Children and Adolescents. *J Pediatr Gastroenterol Nutr.* 2017;64(6):991–1003.

Table 381.3 Antisecretory Therapy with Pediatric Dosages

MEDICATION	PEDIATRIC DOSE	HOW SUPPLIED
H_2-RECEPTOR ANTAGONISTS		
Ranitidine	4-10 mg/kg/day divided 2 or 3 × a day	Pulled from market
Famotidine	1-2 mg/kg/day divided twice a day	Syrup: 40 mg/5 mL. Tablets: 20, 40 mg
Nizatidine	5-10 mg/kg/day divided twice a day Older than 12 yr: 150 mg twice a day	Pulled from market
PROTON PUMP INHIBITORS		
Omeprazole	1.0-3.3 mg/kg/day weigh <20 kg: 10 mg/day weigh >20 kg: 20 mg/day Approved for use in those older than 1 month	Capsules: 10, 20, 40 mg
Lansoprazole	0.8-4 mg/kg/day weigh <30 kg: 15 mg/day weigh >30 kg: 30 mg/day Approved for use in those older than 1 yr	Capsules: 15, 30 mg Powder packet: 15, 30 mg SoluTab: 15, 30 mg
Rabeprazole	1-11 yr (weigh <15 kg): 5 mg/day 1-11 yr (weigh >15 kg): 10 mg/day >12 yr: 20 mg tablet Approved for use in those older than 1 yr	Delayed release capsule: 5, 10 mg Delayed release tablet: 20 mg
Pantoprazole	1-5 yr: 0.3-1.2 mg/kg/day (limited data) >5 yr of age: weigh >15 kg to <40 kg: 20 mg/day weigh >40 kg: 40 mg/day Approved for use in those older than 1 yr	Tablet: 20, 40 mg Powder pack: 40 mg
Esomeprazole	1 mo - < 1 yr old weigh 3 kg to 5 kg: 2.5 mg weigh >5 kg to 7.5 kg: 5 mg weigh >7.5 kg to 12 kg: 10 mg 1-11 yr old weigh <20 kg: 10 mg weigh >20 kg: 20 mg Approved for use 1 mo and older	Capsules: 20, 40 Delayed-release single-dose packs: 2.5, 5, 10, 20 mg
Dexlansoprazole	12-17 yr: 30-60 mg Approved for use in those older than 12 yr	Capsules: 30, 60
Omeprazole sodium bicarbonate	Safety and efficacy have not been established for those under 18 yr	Capsules: 20, 40 Powder for oral suspension: 20 mg, 40 mg
CYTOPROTECTIVE AGENTS		
Sucralfate	40-80 mg/kg/day	Suspension: 1,000 mg/5 mL Tablet: 1,000 mg

Patients with suspected peptic ulcer hemorrhage should receive high-dose intravenous (IV) PPI therapy, which lowers the risk of rebleeding. Some centers also use octreotide, which lowers splanchnic blood flow and gastric acid production.

Once the patient is hemodynamically stable, endoscopy is indicated to identify the source of bleeding and to treat a potential bleeding site (Fig. 381.2). Methods used to achieve hemostasis include mechanical devices (clipping), injection therapy (diluted epinephrine 1:100,00), and thermal therapy (heater probe). Ulcer therapy has two goals, ulcer healing and elimination of the primary cause. Other important considerations are relief of symptoms and prevention of complications. The **first-line drugs** for the treatment of gastritis and peptic ulcer disease in children are PPIs and H_2-receptor antagonists (see Table 381.3). PPIs are more potent in ulcer healing. Cytoprotective agents can also be used as adjunct therapy if mucosal lesions are present. Antibiotics in combination with a PPI must be used for the treatment of *H. pylori*–associated ulcers (see Table 381.2).

H_2-receptor antagonists (cimetidine, ranitidine, famotidine, nizatidine) competitively inhibit the binding of histamine at the H_2 subtype receptor of the gastric parietal cell. PPIs block the gastric parietal cell H^+/K^+-adenosine triphosphatase pump in a dose-dependent fashion, reducing basal and stimulated gastric acid secretion. Ranitidine and nizatidine were pulled out of the market in April 2020 due to unacceptable levels of N-nitrosodimethylamine (NDMA), a probable human carcinogen. NDMA impurities have been introduced during the manufacturing processes and as the result of product degradation during storage. Currently, seven PPIs are available in the United States: omeprazole, lansoprazole, pantoprazole, esomeprazole, rabeprazole, dexlansoprazole, and omeprazole/sodium bicarbonate. Apart from the last two, they are all approved in children and adolescents. They are well tolerated with only minor adverse effects, such as diarrhea (1–4%), headache (1–3%), and nausea (1%). When one considers therapeutic efficacy, the evidence suggests that all PPIs have comparable efficacy in treatment of peptic ulcer disease using standard doses and are superior to H_2-receptor antagonists. PPIs have their greatest effect when given before a meal. Pantoprazole and esomeprazole are the only PPI available in IV form in United States. IV PPI should be used in acute upper GI bleeding. Studies in adults have demonstrated that twice a day IV PPI is as effective as continuous infusion, and the current recommendation is to start with IV PPI and change to the oral form after evaluating their rebleeding risk at the time of endoscopy.

Treatment of *Helicobacter pylori*–Related Peptic Ulcer Disease

In pediatrics, antibiotics and bismuth salts have been used in combination with PPIs to treat *H. pylori* infection (see Table 381.2). Eradication rates in children range from 68–92% when the dual or triple therapy is used for 14 days. The ulcer healing rate ranges from 91–100%. Triple therapy yields a higher cure rate than dual therapy. The optimal regimen for the eradication of *H. pylori* infection in children has yet to be established, but the use of a PPI in combination with clarithromycin and amoxicillin or metronidazole for 2 weeks is a well-tolerated and recommended triple therapy (see Table 381.2). Although children younger than 5 years of age can become reinfected, the most common reason for treatment failure is poor compliance or antibiotic resistance. *H. pylori* has become more resistant to clarithromycin or metronidazole as a consequence of the extensive use of these antibiotics for other infections. In the case of resistant *H. pylori* infection, *bismuth-based quadruple therapy* or *sequential treatment* with different antibiotics or rescue therapy are acceptable options. The sequential treatment regimen is a 10-day treatment consisting of a PPI and amoxicillin (both twice daily) administered for the first 5 days followed by triple therapy consisting of a PPI, clarithromycin, and metronidazole for the remaining 5 days. Levofloxacin, rifabutin, or furazolidone can be used with amoxicillin and bismuth as a rescue therapy depending on the age of the patient. Fidaxomicin has equivalent efficacy to vancomycin in adults. Knowledge of the community's *H. pylori* resistance pattern to clarithromycin or metronidazole might help choose the initial or rescue therapy. In adults with persistent *H. pylori* infection, a combination of rifabutin with amoxicillin and esomperazole was effective in eradicating *H. pylori*.

Surgical Therapy

Since the discovery of *H. pylori* and the availability of modern medical management, peptic ulcer disease requiring surgical treatment has become extremely rare. The indications for surgery remain uncontrolled bleeding, perforation, and obstruction.

Visit Elsevier eBooks+ at eBooks.Health.Elsevier.com for Bibliography.

381.1 Zollinger-Ellison Syndrome

Samra S. Blanchard and Steven J. Czinn

Zollinger-Ellison syndrome is a rare syndrome characterized by refractory, severe peptic ulcer disease caused by gastric hypersecretion due to the autonomous secretion of gastrin by a neuroendocrine tumor (gastrinoma). Clinical presentations are similar to those of peptic ulcer disease with the addition of diarrhea. The diagnosis is suspected by the presence of recurrent, multiple, or atypically located ulcers. More than 98% of patients have elevated fasting gastrin levels. Zollinger-Ellison syndrome is common in patients with **multiple endocrine neoplasia 1** and rare with **neurofibromatosis** and **tuberous sclerosis**. Prompt and effective management of increased gastric acid secretion is essential in the management. PPIs are the drug of choice due to their long duration of action and potency. H_2-receptor antagonists are also effective, but higher doses are required than those used in peptic ulcer disease.

Visit Elsevier eBooks+ at eBooks.Health.Elsevier.com for Bibliography.

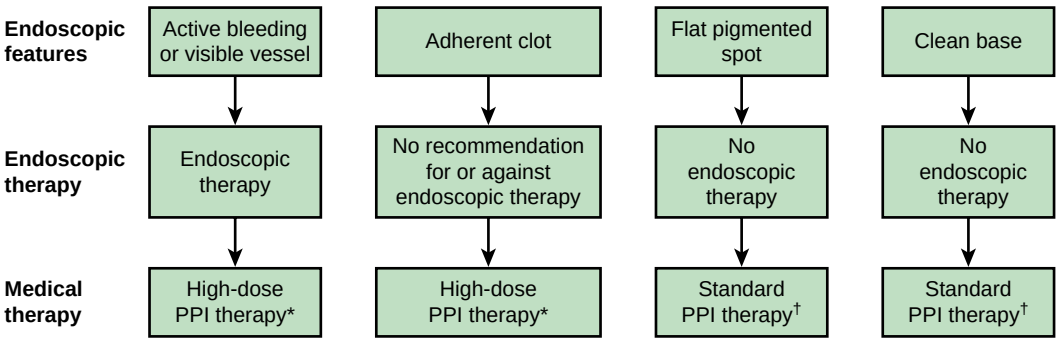

Fig. 381.2 Endoscopic and medical therapy algorithm for ulcer bleeding based on endoscopic features of ulcer. *For continuous regimen, 80-mg bolus followed by 8-mg/min infusion for 3 days is recommended. For intermittent regimens, doses of 40 mg 2 to 4 times daily for 3 days are suggested, given orally if feasible, and an initial bolus of 80 mg may be appropriate. †Standard PPI therapy (e.g., oral PPI once daily) has been recommended by previous guidelines. PPI, Proton pump inhibitor. *(From Laine L, Barkun AN, Saltzman JR, et al. ACG clinical guideline: upper gastrointestinal and ulcer bleeding. Am J Gastrointerol. 2021;116:899–917. Fig. 3.)*

Chapter 382

Inflammatory Bowel Disease

Ronen E. Stein, Sudha A. Anupindi, and Robert N. Baldassano

The term *inflammatory bowel disease* (IBD) is used to represent two distinctive disorders of idiopathic chronic intestinal inflammation: Crohn disease and ulcerative colitis. Their respective etiologies are poorly understood, and both disorders are characterized by unpredictable exacerbations and remissions. The most common time of onset of IBD is during the preadolescent/adolescent era and young adulthood. A bimodal distribution has been shown with an early onset at 10-20 years of age and a second, smaller peak at 50-80 years of age. Approximately 25% of patients present before 20 years of age. IBD may begin as early as the first year of life, and an increased incidence among young children has been observed since the turn of the 20th century. Children with *early-onset* IBD are more likely to have colonic involvement. In developed countries, these disorders are the major causes of chronic intestinal inflammation in children beyond the first few years of life. A third, less-common category, *indeterminate colitis*, represents approximately 10% of pediatric patients.

Genetic and environmental influences are involved in the pathogenesis of IBD. The risk of IBD in family members of an affected person has been reported in the range of 7–30%; a child whose parents both have IBD has a >35% chance of acquiring the disorder. Relatives of a patient with ulcerative colitis have a greater risk of acquiring ulcerative colitis than Crohn disease, whereas relatives of a patient with Crohn disease have a greater risk of acquiring this disorder; the two diseases can occur in the same family. The risk of occurrence of IBD among relatives of patients with Crohn disease is somewhat greater than for patients with ulcerative colitis.

The importance of genetic factors in the development of IBD is noted by a higher chance that both twins will be affected if they are monozygotic rather than dizygotic. The concordance rate in twins is higher in Crohn disease (36%) than in ulcerative colitis (16%). Genetic disorders that have been associated with IBD include Turner syndrome, Hermansky-Pudlak syndrome, glycogen storage disease type Ib, and various immunodeficiency disorders. The first IBD gene, *NOD2,* was identified through association mapping; an IBD5 risk haplotype was also identified. There has been an exponential growth in the set of validated genetic risk factors for IBD (Table 382.1).

A perinuclear antineutrophil cytoplasmic antibody is found in approximately 70% of patients with ulcerative colitis compared with <20% of those with Crohn disease and is believed to represent a marker of genetically controlled immunoregulatory disturbance. Approximately 55% of those with Crohn disease are positive for anti–*Saccharomyces cerevisiae* antibody. Since the importance of these were first described, multiple other serologic and immune markers of Crohn disease and ulcerative colitis have been recognized.

IBD is caused by dysregulated or inappropriate immune response to environmental factors in a genetically susceptible host. An abnormality in intestinal mucosal immunoregulation may be of primary importance in the pathogenesis of IBD, involving activation of cytokines, triggering a cascade of reactions that results in bowel inflammation. These cytokines are recognized as known or potential targets for IBD therapies.

Multiple environmental factors are recognized to be involved in the pathogenesis of IBD, none more critical than the gut microbiota. The increasing incidence of IBD over time is likely in part attributable to alterations in the microbiome. Evidence includes association between IBD and residence in or immigration to industrialized nations, a *Western diet*, increased use of antibiotics at a younger age, high rates of vaccination, and less exposure to microbes at a young age. Although gut microbes likely play an important role in the pathogenesis of IBD, the exact mechanism needs to be elucidated further. Some environmental factors are disease specific; for example, cigarette smoking is a risk factor for Crohn disease but paradoxically protects against ulcerative colitis.

It is usually possible to distinguish between ulcerative colitis and Crohn disease by the clinical presentation and radiologic, endoscopic, and histopathologic findings (Table 382.2). It is not possible to make a definitive diagnosis in approximately 10% of patients with chronic colitis; this disorder is called *indeterminate colitis*. Occasionally, a child initially believed to have ulcerative colitis on the basis of clinical findings is subsequently found to have Crohn colitis. This is particularly true for the youngest patients, because Crohn disease in this patient population can more often manifest as exclusively colonic inflammation, mimicking ulcerative colitis. The medical treatments of Crohn disease and ulcerative colitis overlap.

Extraintestinal manifestations occur slightly more commonly with Crohn disease than with ulcerative colitis (Table 382.3). Poor growth is seen in 15–40% of children with Crohn disease at diagnosis. Decrease in height velocity occurs in nearly 90% of patients with Crohn disease diagnosed in childhood or adolescence. Of the extraintestinal manifestations that occur with IBD, joint, skin, eye, mouth, and hepatobiliary involvement tend to be associated with colitis, whether ulcerative or Crohn. The presence of some manifestations, such as peripheral arthritis, erythema nodosum, and anemia, correlates with activity of the bowel disease. Activity of pyoderma gangrenosum correlates less well with activity of the bowel disease, whereas sclerosing cholangitis, ankylosing spondylitis, and sacroiliitis do not correlate with intestinal disease. Arthritis occurs in three patterns: migratory peripheral arthritis involving primarily large joints, ankylosing spondylitis, and sacroiliitis. The peripheral arthritis of IBD tends to be nondestructive. Ankylosing spondylitis begins in the third decade and occurs most commonly in patients with ulcerative colitis who have the human leukocyte antigen B27 phenotype. Symptoms include low back pain and morning stiffness; back, hips, shoulders, and sacroiliac joints are typically affected. Isolated sacroiliitis is usually asymptomatic but is common when a careful search is performed. Among the skin manifestations, erythema nodosum is most common. Patients with erythema nodosum or pyoderma gangrenosum have a high likelihood of having arthritis as well. Glomerulonephritis, uveitis, and a hypercoagulable state are other rare manifestations that occur in childhood. Cerebral thromboembolic disease has been described in children with IBD.

382.1 Chronic Ulcerative Colitis

Ronen E. Stein, Sudha A. Anupindi, and Robert N. Baldassano

Ulcerative colitis, an idiopathic chronic inflammatory disorder, is localized to the colon and spares the upper gastrointestinal (GI) tract. Disease usually begins in the rectum and extends proximally for a variable distance. When it is localized to the rectum, the disease is ulcerative proctitis, whereas disease involving the entire colon is pancolitis. Approximately 50–80% of pediatric patients have extensive colitis; adults more commonly have distal disease. Ulcerative *proctitis* is less likely to be associated with systemic manifestations, although it may be less responsive to treatment than more diffuse disease. Approximately 30% of children who present with ulcerative proctitis experience proximal spread of the disease. Ulcerative colitis has rarely been noted to present in infancy. Dietary protein intolerance can easily be misdiagnosed as ulcerative colitis in this age-group. Dietary protein intolerance (cow's milk protein) is a transient disorder; symptoms are directly associated with the intake of the offending antigen.

The incidence of ulcerative colitis has increased but not to the extent of the increase in Crohn disease; incidence varies with country of origin. The age-specific incidence rates of pediatric ulcerative colitis in

Table 382.1 Selection of Most Important Genes Associated with Inflammatory Bowel Disease and the Most Commonly Associated Physiologic Functions and Pathways

	GENE NAME	ASSOCIATED DISEASE	GENE FUNCTION AND ASSOCIATED PATHWAYS	PHYSIOLOGIC FUNCTION
NOD2	Nucleotide-binding oligomerization domain- containing protein 2	Crohn disease	Bacterial recognition and response, NFκB activation and autophagy and apoptosis	Innate mucosal defense
IL10	IL-10	Crohn disease	Antiinflammatory cytokine, NFκB inhibition, JAK-STAT regulation	Immune tolerance
IL10RA	IL-10 receptor A	Crohn disease	Antiinflammatory cytokine receptor, NFκB inhibition, JAK-STAT regulation	Immune tolerance
IL10RB	IL-10 receptor B	Crohn disease	Antiinflammatory cytokine receptor, NFκB inhibition, JAK-STAT regulation	Immune tolerance
IL23R	IL-23 receptor	Crohn disease and ulcerative colitis	Immune regulation, proinflammatory pathways—JAK-STAT regulation	IL-23/T helper 17
TKY2	Tyrosine kinase 2	Crohn disease and ulcerative colitis	Inflammatory pathway signaling (IL-10 and -6, etc.) through intracellular activity	IL-23/T helper 17
IRGM	Immunity-related GTPase M	Crohn disease	Autophagy and apoptosis in cells infected with bacteria	Autophagy
ATG16L1	Autophagy-related 16 like 1	Crohn disease	Autophagy and apoptotic pathways	Autophagy
SLC22A4	Solute carrier family 22 member 4	Crohn disease	Cellular antioxidant transporter	Solute transporters
CCL2	C-C motif chemokine ligand 2	Crohn disease	Cytokine involved in chemotaxis for monocytes	Immune cell recruitment
CARD9	Caspase recruitment domain family member 9	Crohn disease and ulcerative colitis	Apoptosis regulation and NFκB pathway activation	Oxidative stress
IL2	IL-2	Ulcerative colitis	Cytokine involved in immune cell activation	T-cell regulation
MUC19	Mucin 19	Crohn disease and ulcerative colitis	Gel-forming mucin protein	Epithelial barrier

IL, Interleukin; JAK-STAT, Janus kinase-signal transducers and activators of transcription; NFκB, nuclear factor κ-light chain enhancer of activated B cells.
From Ashton JJ, Ennis S, Beattie RM. Early-onset paediatric inflammatory bowel disease. *Lancet*. 2017;1:147–158. Table 1.

Table 382.2 Comparison of Crohn Disease and Ulcerative Colitis

FEATURE	CROHN DISEASE	ULCERATIVE COLITIS	FEATURE	CROHN DISEASE	ULCERATIVE COLITIS
Rectal bleeding	Sometimes	Common	Strictures	Common	Rare
Diarrhea, mucus, pus	Variable	Common	Fissures	Common	Rare
Abdominal pain	Common	Variable	Fistulas	Common	Rare
Abdominal mass	Common	Not present	Toxic megacolon	None	Present
Growth failure	Common	Variable	Sclerosing cholangitis	Less common	Present
Perianal disease	Common	Rare	Risk for intestinal cancers	Increased	Greatly increased
Rectal involvement	Occasional	Universal	Discontinuous (skip) lesions	Common	Not present
Pyoderma gangrenosum	Rare	Present	Transmural involvement	Common	Unusual
Erythema nodosum	Common	Less common	Crypt abscesses	Less common	Common
Mouth ulceration	Common	Rare	Granulomas	Common	None
Thrombosis	Less common	Present	Linear ulcerations	Uncommon	Common
Colonic disease	50–75%	100%	Perinuclear antineutrophil cytoplasmic antibody–positive	<20%	70%
Ileal disease	Common	None except backwash ileitis			
Stomach–esophageal disease	More common	Chronic gastritis can be seen			

Table 382.3 Extraintestinal Complications of Inflammatory Bowel Disease

MUSCULOSKELETAL
Peripheral arthritis
Granulomatous monoarthritis
Granulomatous synovitis
Rheumatoid arthritis
Sacroiliitis
Ankylosing spondylitis
Digital clubbing and hypertrophic osteoarthropathy
Periostitis
Osteoporosis, osteomalacia
Rhabdomyolysis
Pelvic osteomyelitis
Chronic recurrent multifocal osteomyelitis (CRMO)
Relapsing polychondritis

SKIN AND MUCOUS MEMBRANES
Oral lesions
Orofacial granulomatosis
Cheilitis
Aphthous stomatitis, glossitis
Granulomatous oral Crohn disease
Inflammatory hyperplasia fissures and cobblestone mucosa
Peristomatitis vegetans

DERMATOLOGIC
Erythema nodosum
Pyoderma gangrenosum
Sweet syndrome
Metastatic Crohn disease
Psoriasis
Epidermolysis bullosa acquisita
Perianal skin tags
Polyarteritis nodosa
Melanoma and nonmelanoma skin cancers

OCULAR
Conjunctivitis
Uveitis, iritis
Episcleritis
Scleritis
Retrobulbar neuritis
Chorioretinitis with retinal detachment
Crohn keratopathy
Posterior segment abnormalities
Retinal vascular disease
Idiopathic orbital inflammation (orbital pseudotumor)

BRONCHOPULMONARY
Chronic bronchitis with bronchiectasis
Chronic bronchitis with neutrophilic infiltrates
Fibrosing alveolitis
Pulmonary vasculitis
Small airway disease and bronchiolitis obliterans
Eosinophilic lung disease
Granulomatous lung disease
Tracheal obstruction

CARDIAC
Pleuropericarditis
Cardiomyopathy
Endocarditis
Myocarditis

MALNUTRITION
Decreased intake of food
- Inflammatory bowel disease
- Dietary restriction

Malabsorption
- Inflammatory bowel disease
- Bowel resection
- Bile salt depletion
- Bacterial overgrowth

Intestinal losses
- Electrolytes
- Minerals
- Nutrients

Increased caloric needs
- Inflammation
- Fever

HEMATOLOGIC/ONCOLOGIC
Anemia: iron deficiency (blood loss)
Vitamin B_{12} (ileal disease or resection, bacterial overgrowth, folate deficiency)
Anemia of chronic inflammation
Anaphylactoid purpura (Crohn disease)
Hyposplenism
Autoimmune hemolytic anemia
Coagulation abnormalities
Increased activation of coagulation factors
Activated fibrinolysis
Anticardiolipin antibody
Increased risk of arterial and venous thrombosis with cerebrovascular stroke, myocardial infarction, peripheral arterial, and venous occlusions and pulmonary embolism
Systemic lymphoma (nonenteric)

RENAL AND GENITOURINARY
Metabolic
- Urinary crystal formation (nephrolithiasis, uric acid, oxalate)

Hypokalemic nephropathy
Inflammation
- Retroperitoneal abscess
- Fibrosis with ureteral obstruction
- Fistula formation

Glomerulitis
Membrane nephritis
Renal amyloidosis, nephrotic syndrome

PANCREATITIS
Secondary to medications (sulfasalazine, 6-mercaptopurine, azathioprine, parenteral nutrition)
Ampullary Crohn disease
Granulomatous pancreatitis
Decreased pancreatic exocrine function
Sclerosing cholangitis with pancreatitis

HEPATOBILIARY
Primary sclerosing cholangitis
Small duct primary sclerosing cholangitis (pericholangitis)
Carcinoma of the bile ducts
Fatty infiltration of the liver
Cholelithiasis
Autoimmune hepatitis

ENDOCRINE AND METABOLIC
Growth failure, delayed sexual maturation
Thyroiditis
Osteoporosis, osteomalacia

NEUROLOGIC
Peripheral neuropathy
Meningitis
Vestibular dysfunction
Idiopathic intracranial hypertension (Pseudotumor cerebri)
Cerebral vasculitis
Migraine

Modified from Kugathasan S. Diarrhea. In Kliegman RM, Greenbaum LA, Lye PS, eds. *Practical Strategies in Pediatric Diagnosis and Therapy*, 2nd ed. Philadelphia: Elsevier; 2004.p. 285.

North America is 2/100,000 population. The prevalence of ulcerative colitis in northern European countries and the United States varies from 100 to 200/100,000 population. Men are slightly more likely to acquire ulcerative colitis than are women; the reverse is true for Crohn disease.

CLINICAL MANIFESTATIONS

Blood, mucus, and pus in the stool as well as diarrhea are the typical presentation of ulcerative colitis. Constipation may be observed in those with proctitis. Symptoms such as tenesmus, urgency, cramping abdominal pain (especially with bowel movements), and nocturnal bowel movements are common. The mode of onset ranges from insidious with gradual progression of symptoms to acute and fulminant (Table 382.4; Figs. 382.1 and 382.2). Fever, severe anemia, hypoalbuminemia, leukocytosis, and more than five bloody stools per day for 5 days define **fulminant colitis**. Chronicity is an important part of the diagnosis; it is difficult to know if a patient has a subacute, transient infectious colitis or ulcerative colitis when a child has had 1-2 weeks of symptoms. Symptoms beyond this duration often prove to be secondary to IBD. Anorexia, weight loss, and growth failure may be present, although these complications are more typical of Crohn disease.

Extraintestinal manifestations that tend to occur more commonly with ulcerative colitis than with Crohn disease include pyoderma gangrenosum, sclerosing cholangitis, chronic active hepatitis, and ankylosing spondylitis. Iron deficiency can result from chronic blood loss as well as decreased intake. Folate deficiency is unusual but may be accentuated in children treated with sulfasalazine, which interferes with folate absorption. Chronic inflammation and the elaboration of a variety of inflammatory cytokines can interfere with erythropoiesis and result in the anemia of chronic disease. Secondary amenorrhea is common during periods of active disease.

Table 382.4 Montreal Classification of Extent and Severity of Ulcerative Colitis

- E1 (proctitis): inflammation limited to the rectum
- E2 (left-sided; distal): inflammation limited to the splenic flexure
- E3 (pancolitis): inflammation extends to the proximal splenic flexure
- S0 (remission): no symptoms
- S1 (mild): four or less stools per day (with or without blood), absence of systemic symptoms, normal inflammatory markers
- S2 (moderate): four stools per day, minimum signs of systemic symptoms
- S3 (severe): six or more bloody stools per day, pulse rate of ≥90 beats/min, temperature ≥37.5°C (99.5°F), hemoglobin concentration <105 g/L, erythrocyte sedimentation rate ≥30 mm/hr

E, Extent; S, severity.
From Ordàs I, Eckmann L, Talamini M, et al. Ulcerative colitis. *Lancet*. 2012;380: 1606–1616. Panel 2.

The clinical course of ulcerative colitis is marked by remission and relapse, often without apparent explanation. After treatment of initial symptoms, approximately 5% of children with ulcerative colitis have a prolonged remission (longer than 3 years). Approximately 25% of children presenting with severe ulcerative colitis require colectomy within 5 years of diagnosis, compared with only 5% of those presenting with mild disease. It is important to consider the possibility of enteric infection with recurrent symptoms, specifically *Clostridium difficile;* these infections can mimic a flare-up or actually provoke a recurrence. The use of nonsteroidal antiinflammatory drugs is considered by some to predispose to exacerbation.

It is generally believed that the risk of colon cancer begins to increase after 8-10 years of disease and can then increase by 0.5–1% per year. The risk is delayed by approximately 10 years in patients with colitis limited to the descending colon. Proctitis alone is associated with virtually no increase in risk over the general population. Because colon cancer is usually preceded by changes of mucosal dysplasia, it is recommended that patients who have had ulcerative colitis for longer than 8-10 years be screened with colonoscopy and biopsies every 1-2 years. Although this is the current standard of practice, it is not clear if morbidity and mortality are changed by this approach. Two competing concerns about this plan of management remain unresolved. The original studies may have overestimated the risk of colon cancer; therefore the need for surveillance has been overemphasized, and screening for dysplasia might not be adequate for preventing colon cancer in ulcerative colitis if some cancers are not preceded by dysplasia.

DIFFERENTIAL DIAGNOSIS

The major conditions to exclude are infectious colitis, allergic colitis, and Crohn colitis. Every child with a new diagnosis of ulcerative colitis should have stool cultured for enteric pathogens, stool evaluation for *C. difficile,* ova and parasites, and perhaps serologic studies for amebae (Table 382.5). Cytomegalovirus infection can mimic ulcerative colitis or be associated with an exacerbation of existing disease, usually in immunocompromised patients. The most difficult distinction is from Crohn disease because the colitis of Crohn disease can initially appear identical to that of ulcerative colitis, particularly in younger children. The gross appearance of the colitis or development of small bowel disease eventually leads to the correct diagnosis; this can occur years after the initial presentation.

At the onset, the colitis of hemolytic uremic syndrome may be identical to that of early ulcerative colitis. Ultimately, signs of microangiopathic hemolysis (the presence of schistocytes on blood smear), thrombocytopenia, and subsequent renal failure should confirm the diagnosis of hemolytic-uremic syndrome. Although IgA vasculitis (Henoch-Schönlein purpura) can manifest as abdominal pain and bloody stools, it is not usually associated with colitis. Behçet disease can be distinguished by its typical features (see Chapter 202). Other considerations are radiation proctitis, viral colitis in immunocompromised patients, and ischemic colitis (Table 382.6). In infancy, dietary protein intolerance can be confused with ulcerative colitis, although the former is a transient problem that resolves on removal of the offending

Fig. 382.1 Mayo endoscopic score for ulcerative colitis. **A,** Score 0 = normal; endoscopic remission. **B,** Score 1 = mild; erythema, decreased vascular pattern, mild friability. **C,** Score 2 = moderate; marked erythema, absent vascular pattern, friability, erosions. **D,** Score 3 = severe; spontaneous bleeding, ulceration. *(Images courtesy Elena Ricart. From Ordàs I, Eckmann L, Talamini M, et al. Ulcerative colitis. Lancet. 2012;380:1606–1616. Fig. 2, p. 1610.)*

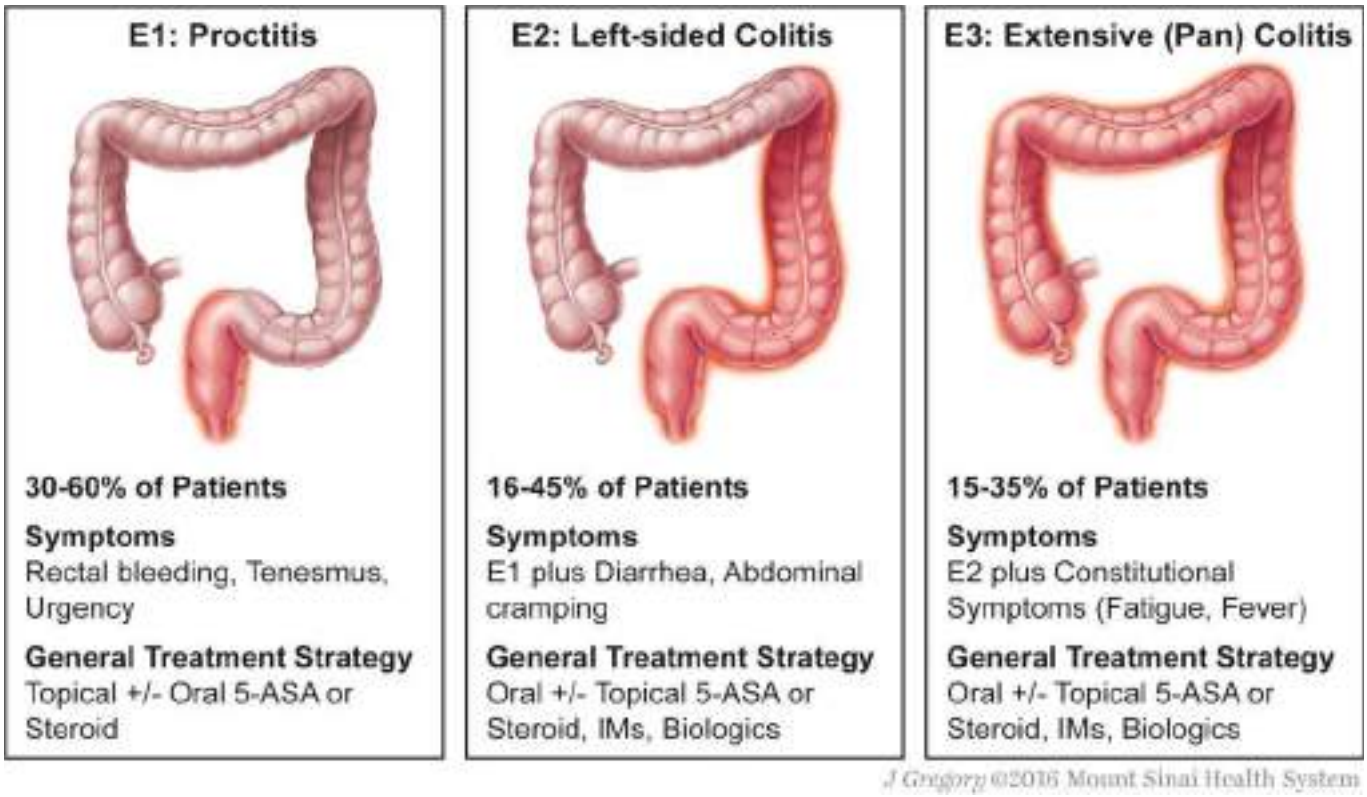

Fig. 382.2 Ulcerative colitis phenotypes by Montreal Classification. Symptoms and treatment strategy can differ based on extent of disease. 5-ASA, 5-Aminosalicylate; IM, immunomodulator. *(Illustration by Jill Gregory. Printed with permission of Mount Sinai Health System.)*

protein, and ulcerative colitis is extremely rare in this age-group. Very early onset monogenic disorders should be considered in infants (see Chapter 382.3 and Table 382.6). Hirschsprung disease can produce an enterocolitis before or within months after surgical correction; this is unlikely to be confused with ulcerative colitis.

DIAGNOSIS

The diagnosis of ulcerative colitis or ulcerative proctitis requires a typical presentation in the absence of an identifiable specific cause (see Tables 382.5 and 382.6) and typical endoscopic and histologic findings (see Tables 382.2 and 382.4). One should be hesitant to make a diagnosis of ulcerative colitis in a child who has experienced symptoms for <2-3 weeks until infection has been excluded. When the diagnosis is suspected in a child with subacute symptoms, the physician should make a firm diagnosis only when there is evidence of chronicity on colonic biopsy. Laboratory studies can demonstrate evidence of anemia (either iron deficiency or the anemia of chronic disease) or hypoalbuminemia. Although the sedimentation rate and C-reactive protein are often elevated, they may be normal even with fulminant colitis. An elevated white blood cell count is usually seen only with more severe colitis. Fecal calprotectin levels are usually elevated and are increasingly recognized to be a more sensitive and specific marker of GI inflammation than typical laboratory parameters. Barium enema is suggestive but not diagnostic of acute (Fig. 382.3) or chronic burned-out disease (Fig. 382.4).

The diagnosis of ulcerative colitis must be confirmed by endoscopic and histologic examination of the colon (see Fig. 382.1). Classically, disease starts in the rectum with a gross appearance characterized by erythema, edema, loss of vascular pattern, granularity, and friability. There may be a *cutoff* demarcating the margin between inflammation and normal colon, or the entire colon may be involved. There may be some variability in the intensity of inflammation even in those areas involved. Flexible sigmoidoscopy can confirm the diagnosis; colonoscopy can evaluate the extent of disease and rule out Crohn colitis. A colonoscopy should not be performed when fulminant colitis is suspected because of the risk of provoking *toxic megacolon* or causing a perforation during the procedure. The degree of colitis can be evaluated by the gross appearance of the mucosa. One does not generally see discrete ulcers, which would be more suggestive of Crohn colitis. The endoscopic findings of ulcerative colitis result from microulcers, which give the appearance of a diffuse abnormality. With very severe chronic colitis, pseudopolyps may be seen. Biopsy of involved bowel demonstrates evidence of acute and chronic mucosal inflammation. Typical histologic findings are cryptitis, crypt abscesses, separation of crypts by inflammatory cells, foci of acute inflammatory cells, edema, mucus depletion, and branching of crypts. The last finding is not seen in infectious colitis. Granulomas, fissures, or full-thickness involvement of the bowel wall (usually on surgical rather than endoscopic biopsy) suggest Crohn disease.

Perianal disease, except for mild local irritation or anal fissures associated with diarrhea, should make the clinician think of Crohn disease. Plain radiographs of the abdomen might demonstrate loss of haustral markings in an air-filled colon or marked dilation with toxic megacolon. With severe colitis, the colon may become dilated; a diameter of >6 cm, determined radiographically, in an adult suggests toxic megacolon. If it is necessary to examine the colon radiologically in a child with severe colitis (to evaluate the extent of involvement or to try to rule out Crohn disease), it is sometimes helpful to perform an upper GI contrast series with small bowel follow-through and then look at delayed films of the colon. Small bowel ultrasonography is another option for evaluation of small intestinal inflammation. CT and MR enterography allow for even higher resolution images of the small intestine. A barium enema is contraindicated in the setting of a potential toxic megacolon.

TREATMENT

Medical

A medical *cure* for ulcerative colitis is not available; treatment is aimed at controlling symptoms and reducing the risk of recurrence, with a secondary goal of minimizing steroid exposure. The intensity of treatment varies with the severity of the symptoms.

The first drug class to be used with mild or mild to moderate colitis is an aminosalicylate. Sulfasalazine is composed of a sulfur moiety linked

Table 382.5 Infectious Agents Mimicking Inflammatory Bowel Disease

AGENT	MANIFESTATIONS	DIAGNOSIS	COMMENTS
BACTERIAL			
Campylobacter jejuni	Acute diarrhea, fever, fecal blood, and leukocytes	Culture	Common in adolescents, may relapse
Yersinia enterocolitica	Acute → chronic diarrhea, right lower quadrant pain, mesenteric adenitis–pseudoappendicitis, fecal blood, and leukocytes Extraintestinal manifestations, mimics Crohn disease	Culture	Common in adolescents as fever of unknown origin, weight loss, abdominal pain
Clostridium difficile	Postantibiotic onset, watery → bloody diarrhea, pseudomembrane on sigmoidoscopy	Cytotoxin assay	May be nosocomial Toxic megacolon possible
Escherichia coli O157:H7	Colitis, fecal blood, abdominal pain	Culture and typing	Hemolytic uremic syndrome
Salmonella	Watery → bloody diarrhea, food-borne, fecal leukocytes, fever, pain, cramps	Culture	Usually acute
Shigella	Watery → bloody diarrhea, fecal leukocytes, fever, pain, cramps	Culture	Dysentery symptoms
Edwardsiella tarda	Bloody diarrhea, cramps	Culture	Ulceration on endoscopy
Aeromonas hydrophila	Cramps, diarrhea, fecal blood	Culture	May be chronic Contaminated drinking water
Plesiomonas shigelloides	Diarrhea, cramps	Culture	Shellfish source
Tuberculosis	Rarely bovine, now *Mycobacterium* tuberculosis Ileocecal area, fistula formation	Culture, purified protein derivative, biopsy	Can mimic Crohn disease
PARASITES			
Entamoeba histolytica	Acute bloody diarrhea and liver abscess, colic	Trophozoite in stool, colonic mucosal flask ulceration, serologic tests	Travel to endemic area
Giardia lamblia	Foul-smelling, watery diarrhea, cramps, flatulence, weight loss; no colonic involvement	"Owl"-like trophozoite and cysts in stool; rarely duodenal intubation	May be chronic
AIDS-ASSOCIATED ENTEROPATHY			
Cryptosporidium	Chronic diarrhea, weight loss	Stool microscopy	Mucosal findings not like inflammatory bowel disease
Isospora belli	As in *Cryptosporidium*		Tropical location
Cytomegalovirus	Colonic ulceration, pain, bloody diarrhea	Culture, biopsy	More common when on immunosuppressive medications

to the active ingredient 5-aminosalicylate (5-ASA). This linkage prevents the absorption of the medication in the upper GI tract, allowing it to reach the colon, where the two components are separated by bacterial cleavage. The dose of sulfasalazine is 30-100 mg/kg/24 hr (divided into two to four doses). Generally, the dose is not more than 2-4 g/24 hr. Hypersensitivity to the sulfa component is the major side effect of sulfasalazine and occurs in 10–20% of patients. Because of poor tolerance, sulfasalazine is used less commonly than other, better tolerated 5-ASA preparations (mesalamine, 50-100 mg/kg/day; balsalazide 2.25-6.75 g/day). Sulfasalazine and the 5-ASA preparations effectively treat active ulcerative colitis and prevent recurrence. It is recommended that the medication be continued even when the disorder is in remission. These medications might also modestly decrease the lifetime risk of colon cancer.

Approximately 5% of patients have an *allergic reaction* to 5-ASA, manifesting as rash, fever, and bloody diarrhea, which can be difficult to distinguish from symptoms of a flare of ulcerative colitis. 5-ASA can also be given in enema or suppository form and is especially useful for proctitis. Hydrocortisone enemas are used to treat proctitis as well, but they are probably not as effective. A combination of oral and rectal 5-ASA as well as monotherapy with rectal preparation has been shown to be more effective than just oral 5-ASA for distal colitis. Extended release budesonide may also induce remission in patients with mild to moderate ulcerative colitis. Rectal preparations of budesonide are also available.

Probiotics are effective in adults for maintenance of remission for ulcerative colitis, although they do not induce remission during an active flare. The most promising role for probiotics has been to prevent *pouchitis*, a common complication following colectomy and ileal-pouch anal anastomosis surgery.

Children with moderate to severe pancolitis or colitis that is unresponsive to 5-ASA therapy should be treated with corticosteroids, most commonly oral prednisone. The usual starting dose of prednisone is 1-2 mg/kg/24 hr (40-60 mg maximum dose). This medication can be given once daily. With severe colitis, the dose can be divided twice daily and can be given intravenously. Steroids are considered an effective medication for acute flares, but they are not appropriate maintenance medications because of loss of effect and side effects, including poor growth, adrenal suppression, cataracts, osteopenia, aseptic necrosis of the head of the femur, glucose intolerance, risk of infection, mood disturbance, and cosmetic effects.

For a hospitalized patient with persistence of symptoms despite intravenous steroid treatment for 3-5 days, escalation of therapy or surgical options should be considered. The validated pediatric ulcerative colitis activity index can be used to help determine current disease severity based on clinical factors and help determine who is more likely to respond to steroids and those who will likely require escalation of therapy (Table 382.7).

With medical management, most children are in remission within 3 months; however, 5–10% continue to have symptoms unresponsive

Table 382.6 Chronic Inflammatory Bowel–Like Intestinal Disorders Including Monogenic Diseases

INFECTION (SEE TABLE 382.5)
AIDS-Associated
Toxin
Immune–Inflammatory
Severe combined immunodeficiency diseases
Agammaglobulinemia
Chronic granulomatous disease
Wiskott-Aldrich syndrome
Common variable immunodeficiency diseases
Acquired immunodeficiency states
Dietary protein enterocolitis
Autoimmune polyendocrine syndrome type 1
Behçet disease
Lymphoid nodular hyperplasia
Eosinophilic gastroenteritis
Omenn syndrome
Graft-versus-host disease
IPEX (immune dysfunction, polyendocrinopathy, enteropathy, X-linked) syndromes
Interleukin-10 signaling defects
Autoimmune enteropathy*
Microscopic colitis
Hyperimmunoglobulin M syndrome
Hyperimmunoglobulin E syndromes
Mevalonate kinase deficiency
Familial Mediterranean fever
Phospholipase $C\gamma_2$ defects
IL10RA pathogenic variant
Familial hemophagocytic lymphohistiocytosis type 5
X-linked lymphoproliferative syndromes types 1, 2 (*XIAP* gene)
Congenital neutropenias
TRIM22 pathogenic variant
Leukocyte adhesion deficiency 1
NLRC4 pathogenic variants
VASCULAR–ISCHEMIC DISORDERS
Systemic vasculitis (systemic lupus erythematosus, dermatomyositis)
Henoch-Schönlein purpura
Hemolytic uremic syndrome
Granulomatosis with angiitis
OTHER
Glycogen storage disease type 1b
Dystrophic epidermolysis bullosa
X-linked ectodermal dysplasia and immunodeficiency
Dyskeratosis congenita
ADAM-17 deficiency
Prestenotic colitis
Diversion colitis
Kindler syndrome
Radiation colitis
Neonatal necrotizing enterocolitis
Typhlitis
Sarcoidosis
Hirschsprung colitis
Intestinal lymphoma
Laxative abuse
Endometriosis
Hermansky-Pudlak syndrome
Trichohepatoenteric syndrome
Phosphatase and tensin homolog (PTEN) hamartoma tumor syndrome

*May be the same as IPEX.

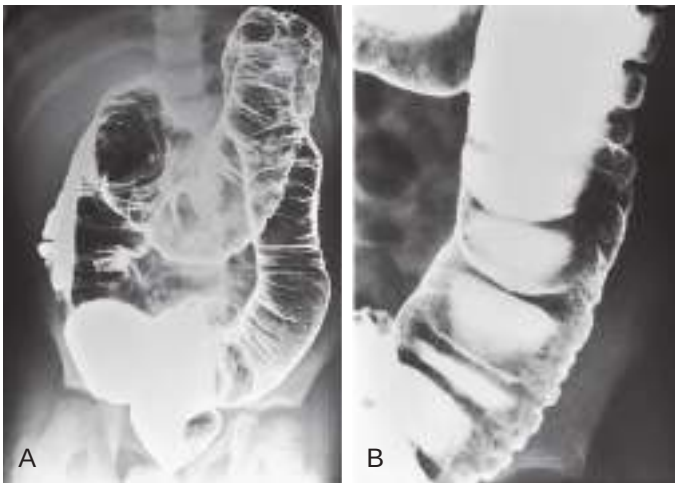

Fig. 382.3 Ulcerative colitis. Double-contrast barium enema in a 5-yr-old child who had had intermittent intestinal and extraintestinal symptoms since the age of 3 yr. **A,** Small ulcerations are distributed uniformly about the colonic circumference and continuously from the rectum to the proximal transverse colon. This pattern of involvement is typical of ulcerative colitis. **B,** In this coned view of the sigmoid in the same patient, small ulcerations are represented by fine spiculation of the colonic contour in tangent and by fine stippling of the colon surface en face. *(From Hoffman AD. The child with diarrhea. In Hilton SW, Edwards DK, eds. Practical Pediatric Radiology, 2nd ed. Philadelphia: WB Saunders; 1994. p. 260.)*

Fig. 382.4 Ulcerative colitis: late changes. This single-contrast barium enema shows the late changes of ulcerative colitis in a 15-yr-old child. The colon is featureless, reduced in caliber, and shortened. Dilation of the terminal ileum (backwash ileitis) is present. *(From Hoffman AD. The child with diarrhea. In Hilton SW, Edwards DK, eds. Practical Pediatric Radiology, 2nd ed. Philadelphia: WB Saunders; 1994. p. 262.)*

to treatment beyond 6 months. Many children with disease requiring frequent corticosteroid therapy are started on immunomodulators such as azathioprine (2.0-2.5 mg/kg/day) or 6-mercaptopurine (1-1.5 mg/kg/day). Uncontrolled data suggest a corticosteroid-sparing effect in many treated patients. This is not an appropriate choice in a patient who is nonresponsive to steroids with acute severe colitis because of longer onset of action. Lymphoproliferative disorders are associated with thiopurine use. Infliximab and adalimumab, which are a fully human monoclonal antibody to tumor necrosis factor (TNF)-α, are effective for induction and maintenance therapy in children and adults with moderate to severe disease. TNF blocking agents are associated with an increased risk of infection (particularly tuberculosis) and malignancies (lymphoma, leukemia). There are a number of other agents that are approved for treatment of refractory ulcerative colitis in adults, but are often used

Table 382.7 Pediatric Ulcerative Colitis Activity Index

ITEM	POINTS
(1) ABDOMINAL PAIN	
No pain	0
Pain can be ignored	5
Pain cannot be ignored	10
(2) RECTAL BLEEDING	
None	0
Small amount only, in <50% of stools	10
Small amount with most stools	20
Large amount (>50% of the stool content)	30
(3) STOOL CONSISTENCY OF MOST STOOLS	
Formed	0
Partially formed	5
Completely unformed	10
(4) NUMBER OF STOOLS PER 24 HR	
0-2	0
3-5	5
6-8	10
>8	15
(5) NOCTURNAL STOOLS (ANY EPISODE CAUSING WAKENING)	
No	0
Yes	10
(6) ACTIVITY LEVEL	
No limitation of activity	0
Occasional limitation of activity	5
Severe restricted activity	10
Sum of Index (0-85)	

off-label in children, including vedolizumab, a humanized monoclonal antibody that inhibits adhesion and migration of leukocytes into the GI tract, and ustekinumab, a monoclonal antibody against interleukins (ILs) 12 and 23. Small molecule agents are another class of medications to be approved for adults with moderate to severe ulcerative colitis in adults, including tofacitinib and upadacitinib; oral Janus kinase inhibitors; and ozanimod, a sphingosine 1-phosphate receptor modulator that leads to peripheral lymphocyte sequestration. A specific combination of three to four broad-spectrum oral antibiotics given over 2-3 weeks may be effective in treating severe pediatric ulcerative colitis refractory to other therapies, but it is being further studied in children.

Surgical

Colectomy is performed for intractable disease, complications of therapy, and fulminant disease that is unresponsive to medical management. No clear benefit of the use of total parenteral nutrition or a continuous enteral elemental diet in the treatment of severe ulcerative colitis has been noted. Nevertheless, parenteral nutrition is used if oral intake is insufficient so that the patient will be nutritionally ready for surgery if medical management fails. With any medical treatment for ulcerative colitis, the clinician should always weigh the risk of the medication or therapy against the fact that colitis can be successfully treated surgically.

Surgical treatment for intractable or fulminant colitis is total colectomy. The optimal approach is to combine colectomy with an endorectal pull-through, where a segment of distal rectum is retained and the mucosa is stripped from this region. The distal ileum is pulled down and sutured at the internal anus with a J pouch created from ileum immediately above the rectal cuff. This procedure allows the child to maintain continence. Commonly, a temporary ileostomy is created to protect the delicate anastomosis between the sleeve of the pouch and the rectum. The ileostomy is usually closed within several months, restoring bowel continuity. At that time, stool frequency is often increased but may be improved with loperamide. The major complication of this operation is *pouchitis,* which is a chronic inflammatory reaction in the pouch, leading to bloody diarrhea, abdominal pain, and, occasionally, low-grade fever. The cause of this complication is unknown, although it is more common when the ileal pouch has been constructed for ulcerative colitis than for other indications (e.g., familial polyposis coli). Pouchitis is seen in 30–40% of patients who had ulcerative colitis. It commonly responds to treatment with oral metronidazole or ciprofloxacin. Probiotics have also been shown to decrease the rate of pouchitis as well as the recurrence of pouchitis following antibiotic therapy.

Support

Psychosocial support is an important part of therapy for this disorder. This may include adequate discussion of the disease manifestations and management between patient and physician, psychologic counseling for the child when necessary, and family support from a social worker or family counselor. Patient support groups have proved helpful for some families. Children with ulcerative colitis should be encouraged to participate fully in age-appropriate activities; however, activity may need to be reduced during periods of disease exacerbation.

PROGNOSIS

The course of ulcerative colitis is marked by remissions and exacerbations. Most children with this disorder respond initially to medical management. Many children with mild manifestations continue to respond well to medical management and may stay in remission on a prophylactic 5-ASA preparation for long periods. An occasional child with mild onset, however, experiences intractable symptoms later. Beyond the first decade of disease, the risk of development of colon cancer begins to increase rapidly. The risk of colon cancer may be diminished with surveillance colonoscopies beginning after 8-10 years of disease. Detection of significant dysplasia on biopsy would prompt colectomy.

Visit Elsevier eBooks+ at eBooks.Health.Elsevier.com for Bibliography.

382.2 Crohn Disease (Regional Enteritis, Regional Ileitis, Granulomatous Colitis)

Ronen E. Stein, Sudha A. Anupindi, and Robert N. Baldassano

Crohn disease, an idiopathic, chronic inflammatory disorder of the bowel, involves any region of the alimentary tract from the mouth to the anus. Although there are many similarities between ulcerative colitis and Crohn disease, there are also major differences in the clinical course and distribution of the disease in the GI tract (see Table 382.2). The inflammatory process tends to be eccentric and segmental, often with skip areas (normal regions of bowel between inflamed areas). Although inflammation in ulcerative colitis is limited to the mucosa (except in toxic megacolon), GI involvement in Crohn disease is often *transmural*.

Compared to adult-onset disease, pediatric Crohn disease is more likely to have extensive anatomic involvement. At initial presentation, more than 50% of patients have disease that involves ileum and colon (ileocolitis), 20% have exclusively colonic disease, and upper GI involvement (esophagus, stomach, duodenum) is seen in up to 30% of children. Isolated small bowel disease is much less common in the pediatric population compared to adults. Isolated colonic disease is common in children younger than 8 years of age and may be indistinguishable from ulcerative colitis. Anatomic location of disease tends to extend over time in children.

Crohn disease tends to have a bimodal age distribution, with the first peak beginning in the teenage years. The incidence of Crohn disease has been increasing. In the United States, the reported incidence of

pediatric Crohn disease is 4.56/100,000 and the pediatric prevalence is 43/100,000 children.

CLINICAL MANIFESTATIONS

Crohn disease can be characterized as inflammatory, stricturing, or penetrating. Patients with small bowel disease are more likely to have an obstructive pattern (most commonly with right lower quadrant pain) characterized by fibrostenosis, and those with colonic disease are more likely to have symptoms resulting from inflammation (diarrhea, bleeding, cramping). Disease phenotypes often change as duration of disease lengthens (inflammatory becomes structuring and/or penetrating) (Figs. 382.5 and 382.6).

Systemic signs and symptoms are more common in Crohn disease than in ulcerative colitis. Fever, malaise, and easy fatigability are common. Growth failure with delayed bone maturation and delayed sexual development can precede other symptoms by 1 or 2 years and is at least twice as likely to occur with Crohn disease as with ulcerative colitis. Children can present with growth failure as the only manifestation of Crohn disease. Decreased height velocity occurs in about 88% of prepubertal patients diagnosed with Crohn disease, and this often precedes GI symptoms. Causes of growth failure include inadequate caloric intake (anorexia, partial obstruction–related pain), suboptimal absorption or excessive loss of nutrients, the effects of chronic inflammation on bone metabolism and appetite, and the use of corticosteroids during treatment. Primary or secondary amenorrhea and pubertal delay are common. In contrast to ulcerative colitis, perianal disease is common (tag, fistula, deep fissure, abscess). Gastric or duodenal involvement may be associated with recurrent vomiting and epigastric pain. **Partial small bowel obstruction**, usually secondary to narrowing of the bowel lumen from *inflammation* or *stricture*, can cause symptoms of cramping abdominal pain (especially with meals), borborygmus, and intermittent abdominal distention (Fig. 382.7). Stricture should be suspected if the child notes relief of symptoms in association with a sudden sensation of gurgling of intestinal contents through a localized region of the abdomen.

Penetrating disease is demonstrated by fistula formation. Enteroenteric or enterocolonic fistulas (between segments of bowel) are often asymptomatic but can contribute to malabsorption if they have high output or result in bacterial overgrowth. Enterovesical fistulas (between bowel and urinary bladder) originate from ileum or sigmoid colon and appear as signs of urinary infection, pneumaturia, or fecaluria. Enterovaginal fistulas originate from the rectum, cause feculent vaginal drainage, and are difficult to manage. Enterocutaneous fistulas (between bowel and abdominal skin) often are caused by prior surgical anastomoses with leakage. Intraabdominal abscess may be associated with fever and pain but might have relatively few symptoms. Hepatic or splenic abscess can occur with or without a local fistula. Anorectal abscesses often originate immediately above the anus at the crypts of Morgagni. The patterns of perianal fistulas are complex because of the different tissue planes. Perianal abscess is usually painful, but perianal fistulas tend to produce fewer symptoms than anticipated. Purulent drainage is commonly associated with perianal fistulas. Psoas abscess secondary to intestinal fistula can present as hip pain, decreased hip extension (psoas sign), and fever.

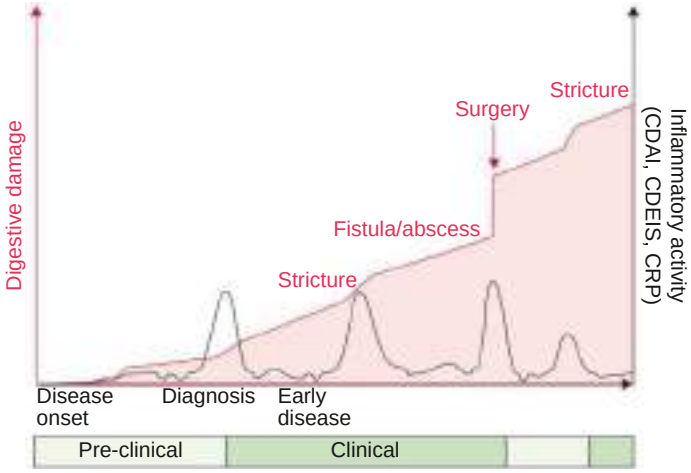

Fig. 382.5 The Lémann Score. Exemplary visualization of the Lémann score, a new technique to score and study intestinal damage in Crohn disease. CDAI, Crohn disease activity index; CDEIS, Crohn disease of endoscopic severity; CRP, C-reactive protein. *(From Baumgart DC, Sandborn WJ. Crohn's disease. Lancet. 2012;380:1590–1602. Fig. 5, p. 1596.)*

Extraintestinal manifestations occur more commonly with Crohn disease than with ulcerative colitis; those that are especially associated with Crohn disease include oral aphthous ulcers, peripheral arthritis, erythema nodosum, digital clubbing, episcleritis, venous thrombosis, pulmonary disease, renal stones (uric acid, oxalate), and gallstones. Any of the extraintestinal disorders described in the section on IBD can occur with Crohn disease (see Table 382.3). The peripheral arthritis is nondeforming. The occurrence of extraintestinal manifestations usually correlates with the presence of colitis. Metastatic Crohn disease is most often cutaneous, presenting with noncaseating granulomas in a location that is not contiguous with an active penetrating lesion; it may resemble erythema nodosum.

Extensive involvement of small bowel, especially in association with surgical resection, can lead to short bowel syndrome, which is rare in children. Complications of terminal ileal dysfunction or resection include bile acid malabsorption with secondary diarrhea and vitamin B_{12} malabsorption, with possible resultant deficiency. Chronic steatorrhea can lead to oxaluria with secondary renal stones. Increasing calcium intake can actually decrease the risk of renal stones secondary to ileal inflammation. The risk of cholelithiasis is also increased secondary to bile acid depletion.

A disorder with this diversity of manifestations can have a major impact on an affected child's lifestyle. Fortunately, the majority of children with Crohn disease are able to continue with their normal activities, having to limit activity only during periods of increased symptoms.

DIFFERENTIAL DIAGNOSIS

The most common diagnoses to be distinguished from Crohn disease are the infectious enteropathies (in the case of Crohn disease: acute terminal ileitis, infectious colitis, enteric parasites, and periappendiceal abscess) (see Tables 382.5 and 382.6; Table 382.8). *Yersinia* can cause many of the radiologic and endoscopic findings in the distal small bowel that are seen in Crohn disease. The symptoms of bacterial dysentery are more likely to be mistaken for ulcerative colitis than for Crohn disease. Celiac disease and *Giardia* infection have been noted to produce a Crohn-like presentation including diarrhea, weight loss, and protein-losing enteropathy. GI tuberculosis is rare but can mimic Crohn disease. Foreign-body perforation of the bowel (toothpick) can mimic a localized region with Crohn disease. Small bowel lymphoma can mimic Crohn disease but tends to be associated with nodular filling defects of the bowel without ulceration or narrowing of the lumen. Bowel lymphoma is much less common in children than is Crohn disease. Recurrent functional abdominal pain can mimic the pain of small bowel Crohn disease. *Lymphoid nodular hyperplasia* of the terminal ileum (a normal finding) may be mistaken for Crohn ileitis. Right lower quadrant pain or mass with fever can be the result of periappendiceal abscess. This entity is occasionally associated with diarrhea as well.

Growth failure may be the only manifestation of Crohn disease; other disorders such as growth hormone deficiency, gluten-sensitive enteropathy (celiac disease), Turner syndrome, or anorexia nervosa must be considered. If arthritis precedes the bowel manifestations, an initial diagnosis of juvenile idiopathic arthritis may be made. Refractory anemia may be the presenting feature and may be mistaken for a primary hematologic disorder. Chronic granulomatous disease of childhood can cause inflammatory changes in the bowel as well as perianal disease. Antral narrowing in this disorder may be mistaken for a stricture secondary to Crohn disease. Other immunodeficiencies or autoinflammatory conditions and monogenetic disorders may

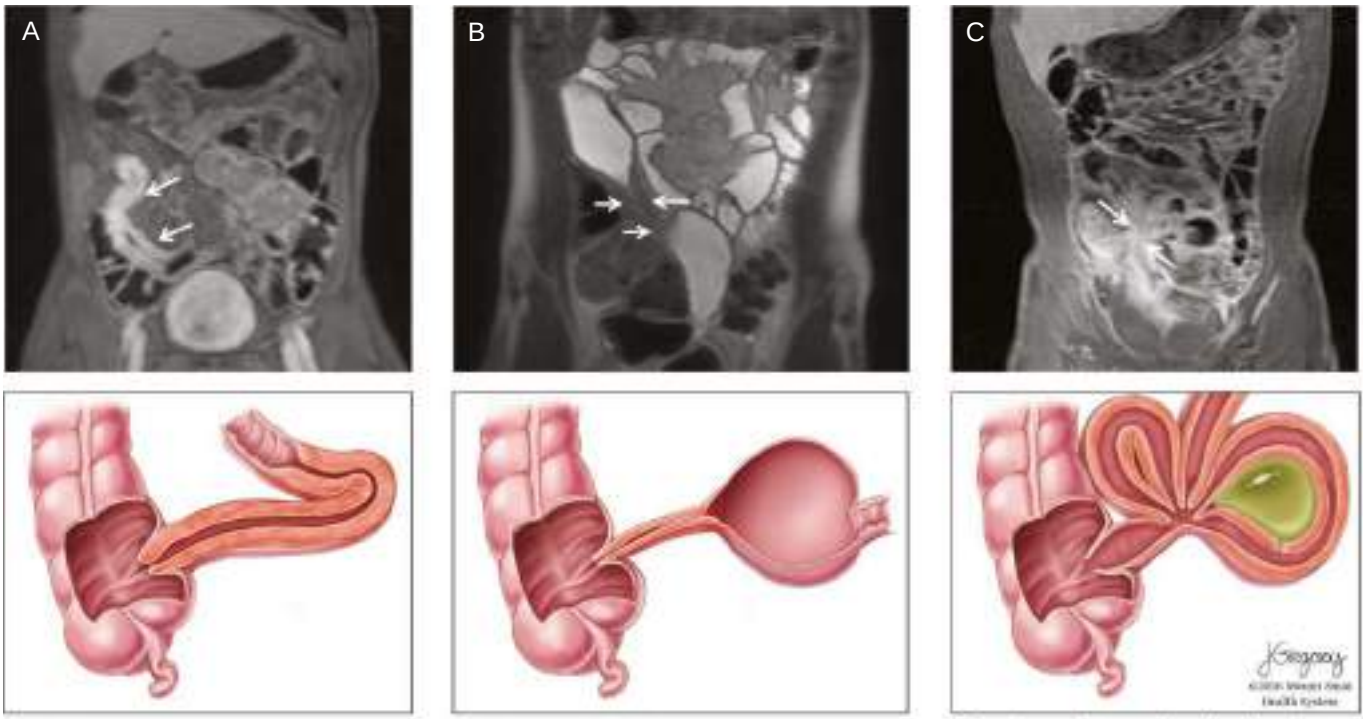

- Diarrhea
- Abdominal pain
- Weight loss
- Low-grade fever
- Fatigue
- Growth retardation
- Malnourishment

- Postprandial pain
- Bloating
- Nausea and vomiting
- Occlusion/subocclusion

- Symptoms depend on the location of fistulae
- Enterourinary fistula: fecaluria, pneumaturia, recurrent UTI
- Rectovaginal fistula: dispareunia, stool discharge through the vagina
- Enteroenteric fistula: asymptomatic, abdominal abscesses

Fig. 382.6 Behavior of Crohn disease (CD) as per Montreal classification represented in MR enterography (MRE) and illustrated with typical symptoms. **A,** T1 weighted MRE imaging with fat saturation after injection of gadolinium chelates shows mural thickening and enhancement in the distal ileum *(arrows)* in a patient with active CD. **B,** T2 weighted MRE imaging shows a narrowed luminal segment with thickened wall and upstream dilation *(arrows),* suggesting the presence of a stricture. **C,** T1 weighted MRE imaging with fat saturation after injection of gadolinium chelates shows multiple converging enhancing loops of small bowel suggestive of enteroenteric fistulas *(arrows).* Lower illustration shows a deep and transmural fissure or ulcer leading to the formation of an abscess. UTI, Urinary tract infection. *(Illustration by Jill Gregory. Printed with permission of Mount Sinai Health System.)*

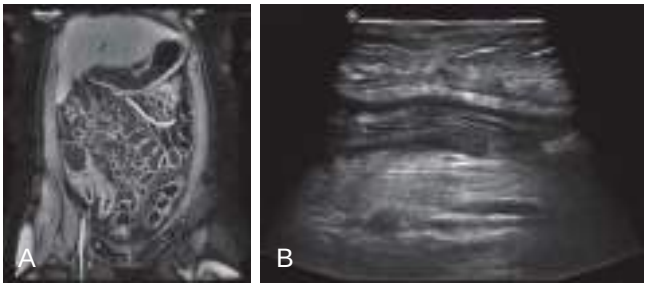

Fig. 382.7 Stenosis in Crohn disease. **A,** MR enterography of Crohn disease restricted to the terminal ileum (Montreal category L1) with inflammatory stenosis. **B,** Ultrasound image of an intestinal stenosis in Crohn disease. *(From Baumgart DC, Sandborn WJ. Crohn's disease. Lancet. 2012;380:1590–1602. Fig. 4.)*

present with GI symptoms suggestive of IBD, particularly in very early or infant/toddler onset of disease (see Table 382.6).

DIAGNOSIS

Crohn disease can manifest as a variety of symptom combinations (see Fig. 382.6). At the onset, symptoms may be subtle (growth failure, abdominal pain alone); this explains why the diagnosis might not be made until 1 or 2 years after the start of symptoms. The diagnosis of Crohn disease depends on finding typical clinical features of the disorder (history, physical examination, laboratory studies, and endoscopic or radiologic findings), ruling out specific entities that mimic Crohn disease, and demonstrating chronicity. The history can include any combination of abdominal pain (especially right lower quadrant), diarrhea, vomiting, anorexia, weight loss, growth retardation, and extraintestinal manifestations. Only 25% initially have the triad of diarrhea, weight loss, and abdominal pain. Most do not have diarrhea, and only 25% have GI bleeding.

Children with Crohn disease often appear chronically ill. They commonly have weight loss and growth failure, and they are often malnourished. The earliest sign of growth failure is decreased height velocity, which can be present in up to 88% of prepubertal patients with Crohn disease and typically precedes symptoms. Children with Crohn disease often appear pale, with decreased energy level and poor appetite; the latter finding sometimes results from an association between meals and abdominal pain or diarrhea. There may be abdominal tenderness that is either diffuse or localized to the right lower quadrant. A tender mass or fullness may be palpable in the right lower quadrant. Perianal disease, when present, may be characteristic. Large anal skin tags (1-3 cm in diameter) or perianal fistulas with purulent drainage suggest Crohn disease. Digital clubbing, findings of arthritis, and skin manifestations may be present.

A complete blood cell count commonly demonstrates anemia, often with a component of iron deficiency, as well as thrombocytosis. Although the erythrocyte sedimentation rate and C-reactive protein are often elevated, they may be unremarkable. The serum albumin level may be low, indicating small bowel inflammation or protein-losing enteropathy. Fecal calprotectin and lactoferrin are more sensitive and specific markers of bowel inflammation as compared to serologic parameters, and these are often elevated. Multiple serologic, immune, and genetic markers can also be abnormal, although the best utilization of these remains to be determined.

The small and large bowel and the upper GI tract should be examined by both endoscopic and radiologic studies in the child with suspected Crohn disease. Esophagogastroduodenoscopy and ileocolonoscopy should be performed to properly assess the upper GI tract, terminal ileum, and entire colon. Findings on colonoscopy can include patchy, nonspecific inflammatory changes (erythema, friability, loss of vascular pattern), aphthous ulcers, linear ulcers, nodularity, and strictures. Findings on biopsy may be only nonspecific chronic inflammatory changes. Noncaseating granulomas, similar to those of sarcoidosis, are the most characteristic histologic findings, although often they are not present. Transmural inflammation is also characteristic but can be identified only in surgical specimens.

Radiologic studies are necessary to assess the entire small bowel and investigate for evidence of structuring or penetrating disease. A variety of findings may be apparent on radiologic studies. Plain films of the abdomen may be normal or might demonstrate findings of partial small bowel obstruction or thumbprinting of the colon wall (Fig. 382.8). An upper GI contrast study with small bowel follow-through might show aphthous ulceration and thickened, nodular folds as well as narrowing or stricturing of the lumen. Linear ulcers can give a cobblestone appearance to the mucosal surface. Bowel loops are often separated as a result of thickening of bowel wall and mesentery (Fig. 382.9). Other manifestations on radiographic studies that suggest more severe Crohn disease are fistulas between bowel (enteroenteric or enterocolonic), sinus tracts, and strictures (see Fig. 382.7).

An upper GI contrast examination with small bowel follow-through has typically been the study of choice for imaging of the small bowel, but CT and MR enterography as well as small bowel ultrasonography are more often performed (Fig. 382.10). MR and ultrasound have the advantage of not exposing the patient to ionizing radiation. CT and MR enterography can also assess for extraluminal findings such as intraabdominal abscess. MR of the pelvis is also useful for delineating the extent of perianal involvement. PET/MRI studies are also helpful in identifying areas of active intestinal and extraintestinal inflammation (Fig. 382.11).

Video capsule endoscopy is another modality that allows for evaluation of the small bowel. This study can uncover mucosal inflammation or ulceration that might not have been detected by traditional imaging. However, video capsule endoscopy is contraindicated in the presence of stricturing disease, as surgical intervention would be required to remove a video capsule that is unable to pass through the bowel because a stricture. If there is concern for stricturing disease, a patency capsule can be swallowed before video capsule endoscopy to assess for passage through the GI tract.

Fig. 382.8 A 19-yr-old patient who presented with bloody stools and later diagnosed with inflammatory bowel disease. Abdominal radiograph at presentation showed classic thumbprinting involving the distal transverse colon, splenic flexure, and descending colon *(arrows)* representing submucosal edema seen in colitis. *(Images from Department of Radiology, Children's Hospital of Philadelphia.)*

Table 382.8 Differential Diagnosis of Presenting Symptoms of Crohn Disease

PRIMARY PRESENTING SYMPTOM	DIAGNOSTIC CONSIDERATIONS
Right lower quadrant abdominal pain, with or without mass	Appendicitis, infection (e.g., *Campylobacter, Yersinia* spp.), lymphoma, intussusception, mesenteric adenitis, Meckel diverticulum, ovarian cyst
Chronic periumbilical or epigastric abdominal pain	Irritable bowel syndrome, constipation, lactose intolerance, peptic disease
Rectal bleeding, no diarrhea	Fissure, polyp, Meckel diverticulum, rectal ulcer syndrome
Bloody diarrhea	Infection, hemolytic-uremic syndrome, Henoch-Schönlein purpura, ischemic bowel, radiation colitis
Watery diarrhea	Irritable bowel syndrome, lactose intolerance, giardiasis, *Cryptosporidium* infection, sorbitol, laxatives
Perirectal disease	Fissure, hemorrhoid (rare), streptococcal infection, condyloma (rare)
Growth delay	Endocrinopathy
Anorexia, weight loss	Anorexia nervosa
Arthritis	Collagen vascular disease, infection
Liver abnormalities	Chronic hepatitis

From Kugathasan S: Diarrhea. In Kliegman RM, Greenbaum LA, Lye PS, eds. *Practical Strategies in Pediatric Diagnosis and Therapy*, 2nd ed. Philadelphia: Elsevier; 2004. p. 287.

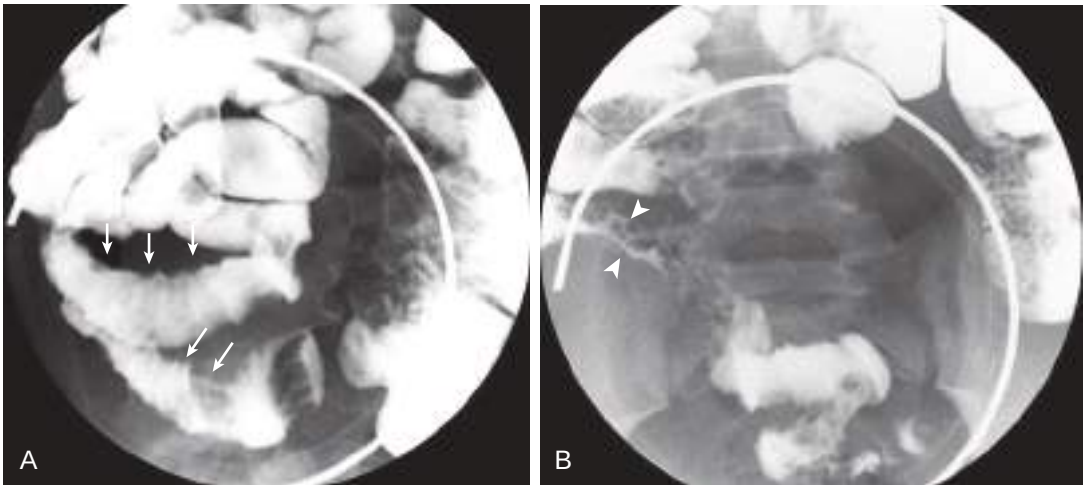

Fig. 382.9 A 12-yr-old child with weight loss and bloody stools diagnosed with Crohn disease. Small bowel follow-through barium examination showed the classic features of Crohn disease. **A,** Mucosal thickening, irregularity *(arrows)*. **B,** Nodularity, "cobblestoning" *(arrowheads)* of the terminal ileum and distal ileal loops. There was also separation of the bowel loops due to fatty proliferation of the mesentery. *(Images from Department of Radiology, Children's Hospital of Philadelphia.)*

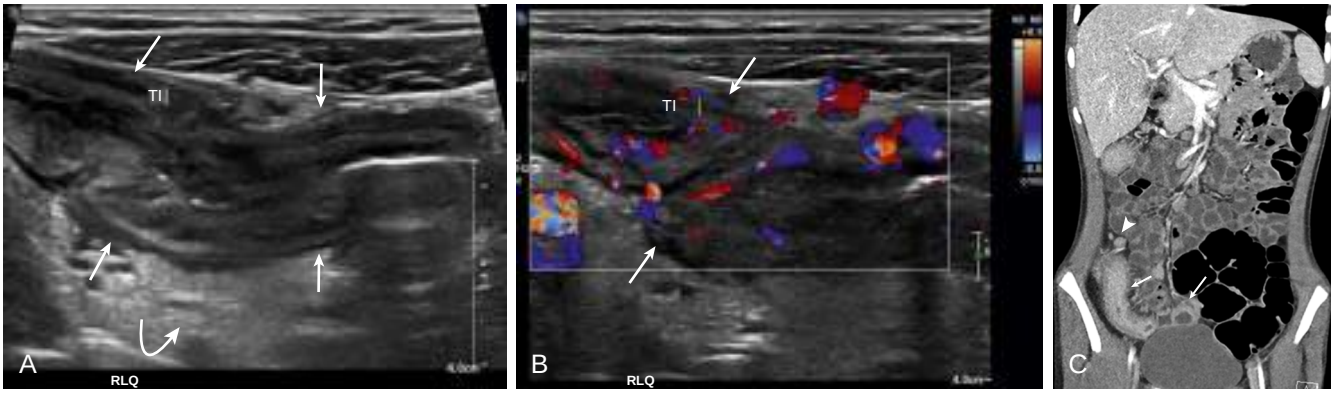

Fig. 382.10 An 11-yr-old child who presented with abdominal pain, weight loss, leukocytosis, and elevated erythrocyte sedimentation rate (ESR)/C-reactive protein (CRP). The patient underwent an initial bowel ultrasound and then CT enterography with assistance from Child Life mitigating use of sedation. Sagittal **(A)** grayscale and color Doppler **(B)** ultrasound images showed markedly thickened abnormal hyperemic terminal ileum *(straight arrows)* and surrounding thickened echogenic mesentery *(curved arrow)* indicative of active inflammation, **C,** Coronal image from a contrast-enhanced CT enterography showed correlating abnormal enhancing and thickened distal and terminal ileum *(arrows)* with enlarged reactive adjacent lymph nodes *(arrowhead)*. *(Images from Department of Radiology, Children's Hospital of Philadelphia.)*

TREATMENT

Crohn disease cannot be *cured* by medical or surgical therapy. The aim of treatment is to relieve symptoms and prevent complications of chronic inflammation (anemia, growth failure), prevent relapse, minimize corticosteroid exposure, and, if possible, effect mucosal healing.

Medical

The specific therapeutic modalities used depend on geographic localization of disease, severity of inflammation, age of the patient, and the presence of complications (abscess). Traditionally, a *step-up* treatment paradigm has been used in the treatment of pediatric Crohn disease, whereby early disease is treated with steroids and less immunosuppressive medications. Escalation of therapy would occur if disease severity increased, the patient was refractory to current medications, or for steroid dependence. A *top-down* approach has also been espoused, particularly in adults after multiple studies demonstrated superior efficacy. With this approach, patients with moderate to severe Crohn disease are treated initially with stronger, disease-modifying agents, with the goal of achieving mucosal healing, or deep remission, early in the disease course. This is thought to increase the likelihood of long-term remission while decreasing corticosteroid exposure. Improvements in remission and growth have been shown using a top-down approach in pediatrics, and this treatment approach is being increasingly used among children.

5-Aminosalicylates

For mild terminal ileal disease or mild Crohn disease of the colon, an initial trial of mesalamine (50-100 mg/kg/day, maximum 3-4 g) may be attempted. Specific pharmaceutical preparations have been formulated to release the active 5-ASA compound throughout the small bowel, in the ileum and colon, or exclusively in the colon. Rectal preparations are used for distal colonic inflammation.

Antibiotics/Probiotics

Antibiotics such as metronidazole (5 mg/kg/dose three times per day, up to 250 mg three times per day) are used for infectious complications and are first-line therapy for perianal disease (although perianal disease usually recurs when antibiotic is discontinued). Additionally, at low doses antibiotics may be effective for treatment of mild to moderate Crohn disease. To date, probiotics have not been shown to be effective in induction or maintenance of remission for pediatric Crohn disease.

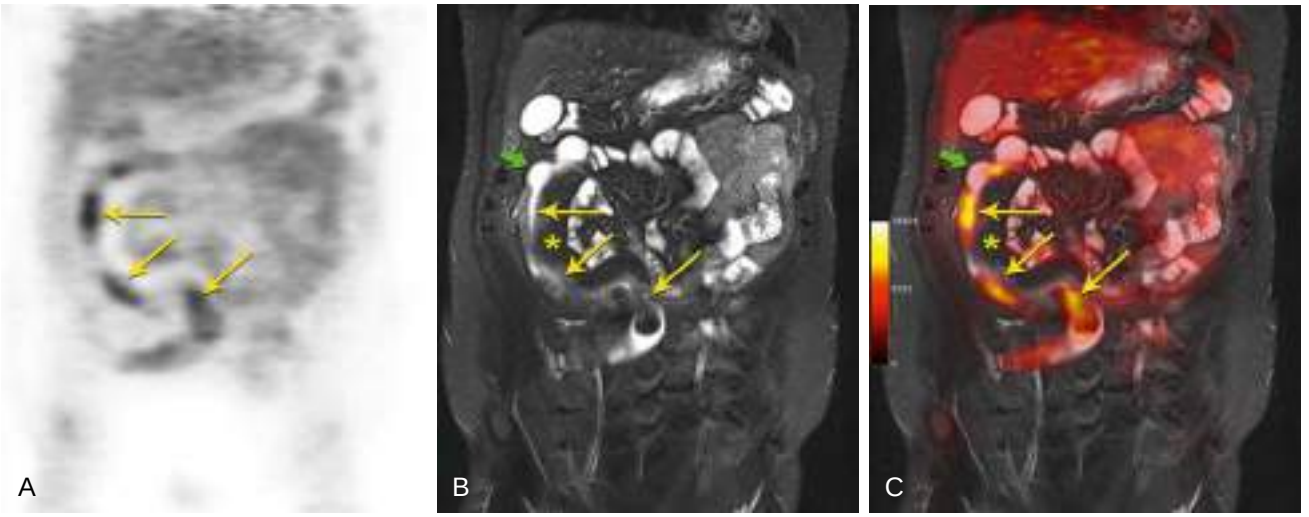

Fig. 382.11 Crohn disease, coexistence of active and chronic changes. Coronal PET (**A**), coronal STIR MRI (**B**), and fused PET/MRI (**C**). Discontinuous areas of active inflammation *(arrows)* demonstrate increased focal FDG uptake, bowel wall thickening, and edema. Note adjacent fibrofatty proliferation *(asterisk)* and pseudosacculations indicative of the chronicity of the process. *(From Furtado FS, Suarez-Weiss KE, Amorim BJ, et al. Gastrointestinal imaging. In Catalano A (ed). Clinical PET/MRI. London: Elsevier, 2023. Fig 14.15.)*

Corticosteroids

Corticosteroids are used for acute exacerbations of pediatric Crohn disease because they effectively suppress acute inflammation, rapidly relieving symptoms (prednisone, 1-2 mg/kg/day, by mouth [PO], maximum 40-60 mg). The goal is to taper dosing as soon as the disease becomes quiescent. Clinicians vary in their tapering schedules, and the disease can flare during this process. There is no role for continuing corticosteroids as maintenance therapy because, in addition to their side effects, tolerance develops, and steroids do not change disease course or promote healing of mucosa. A special controlled ileal-release formulation of budesonide, a corticosteroid with local antiinflammatory activity on the bowel mucosa and high hepatic first-pass metabolism, is also used for mild to moderate ileal or ileocecal disease (adult dose: 9 mg daily). Ileal-release budesonide appears to be more effective than mesalamine in the treatment of active ileocolonic disease but is less effective than prednisone. Although less effective than traditional corticosteroids, budesonide does cause fewer steroid-related side effects.

Immunomodulators

Approximately 70% of patients require escalation of medical therapy within the first year of pediatric Crohn disease diagnosis. Immunomodulators such as azathioprine (2.0-2.5 mg/kg/day) or 6-mercaptopurine (1.0-1.5 mg/kg/day) may be effective in some children who have a poor response to prednisone or who are steroid dependent. Because a beneficial effect of these drugs can be delayed for 3-4 months after starting therapy, they are not helpful acutely. The early use of these agents can decrease cumulative prednisone dosages over the first 1-2 years of therapy. Genetic variations in an enzyme system responsible for metabolism of these agents (thiopurine *S*-methyltransferase) can affect response rates and potential toxicity. Lymphoproliferative disorders have developed from thiopurine use in patients with IBD. Other common toxicities include hepatitis, pancreatitis, increased risk of skin cancer, increased risk of infection, and slightly increased risk of lymphoma.

Methotrexate is another immunomodulator that is effective in the treatment of Crohn disease and has been shown to improve height velocity in the first year of administration. The advantages of this medication include once-weekly dosing by either a subcutaneous or oral route (15 mg/m^2, adult dose 25 mg weekly) and a more rapid onset of action (6-8 weeks) than azathioprine or 6-mercaptopurine. Folic acid is usually administered concomitantly to decrease medication side effects. Administration of ondansetron before methotrexate has been shown to diminish the risk of the most common side effect of nausea. The most common toxicity is hepatitis. The immunomodulators are effective for the treatment of perianal fistulas.

Biologic Therapy

Therapy with antibodies directed against mediators of inflammation is used for patients with Crohn disease. Infliximab, a chimeric monoclonal antibody to TNF-α, is effective for the induction and maintenance of remission and mucosal healing in chronically active moderate to severe Crohn disease, healing of perianal fistulas, steroid sparing, and preventing postoperative recurrence. Pediatric data additionally support improved growth with the administration of this medication. The onset of action of infliximab is quite rapid, and it is initially given as three infusions over a 6-week period (0, 2, and 6 weeks), followed by maintenance dosing beginning every 8 weeks. The durability of response to infliximab is variable, and dose escalation (higher dose and/or decreased interval) is often necessary. Measurement of serum trough infliximab level before an infusion can help guide dosing decisions. Side effects include infusion reactions, increased incidence of infections (especially reactivation of latent tuberculosis), increased risk of lymphoma, and the development of autoantibodies. The development of antibodies to infliximab is associated with an increased incidence of infusion reactions and decreased durability of response. Regularly scheduled dosing of infliximab, as opposed to episodic dosing on an as-needed basis, is associated with decreased levels of antibodies to infliximab. A purified protein derivative test or gamma interferon test for tuberculosis should be done before starting infliximab.

Adalimumab, a subcutaneously administered, fully humanized monoclonal antibody against TNF-α, is effective for the treatment of chronically active moderate to severe Crohn disease in adults and children. After a loading dose, this is typically administered once every 2 weeks, although dose escalation is sometimes required with this medication. Vedolizumab, a humanized monoclonal antibody that inhibits adhesion and migration of leukocytes into the GI tract, is approved for

the treatment of Crohn disease in adults. Like infliximab, vedolizumab is initially given as three infusions over a 6-week period followed by maintenance dosing beginning every 8 weeks. However, the onset of action for vedolizumab is slower compared to infliximab and adalimumab. Therefore concomitant therapies may be needed until response is demonstrated. Dose escalation to every 4 weeks may be necessary in some patients with loss of response, but it is being further studied. Ustekinumab, a monoclonal antibody against both IL-12 and IL-23, is also approved for treatment of chronically active moderate to severe Crohn disease in adults. A loading dose is given intravenously followed by maintenance dosing administered subcutaneously every 8 weeks. Risankizumab, a monoclonal antibody against IL-23A, has demonstrated efficacy for induction and remission maintenance in adults.

Enteral Nutritional Therapy

Exclusive enteral nutritional therapy, whereby all of a patient's calories are delivered via formula, is an effective primary as well as adjunctive treatment. The enteral nutritional approach is as rapid in onset and as effective as the other treatments. Pediatric studies have suggested similar efficacy to prednisone for improvement in clinical symptoms, but enteral nutritional therapy is superior to steroids for actual healing of mucosa. Because affected patients have poor appetite and these formulas are relatively unpalatable, they are often administered via a nasogastric or gastrostomy infusion, usually overnight. The advantages are that it is relatively free of side effects, avoids the problems associated with corticosteroid therapy, and simultaneously addresses the nutritional rehabilitation. Children can participate in normal daytime activities. A major disadvantage of this approach is that patients are not able to eat a regular diet because they are receiving all of their calories from formula. A novel approach where 80–90% of caloric needs are provided by formula, allowing children to have some food intake, has been successful. For children with growth failure, this approach may be ideal.

High-calorie oral supplements, although effective, are often not tolerated because of early satiety or exacerbation of symptoms (abdominal pain, vomiting, or diarrhea). Nonetheless, they should be offered to children whose weight gain is suboptimal even if they are not candidates for exclusive enteral nutritional therapy. The continuous administration of nocturnal nasogastric feedings for chronic malnutrition and growth failure has been effective with a much lower risk of complications than parenteral hyperalimentation.

Surgical

Surgical therapy should be reserved for very specific indications. Recurrence rate after bowel resection is high (>50% by 5 years); the risk of requiring additional surgery increases with each operation. Potential complications of surgery include development of fistula or stricture, anastomotic leak, postoperative partial small bowel obstruction secondary to adhesions, and short bowel syndrome. Surgery is the treatment of choice for localized disease of small bowel or colon that is unresponsive to medical treatment, bowel perforation, fibrosed stricture with symptomatic partial small bowel obstruction, and intractable bleeding. Intraabdominal or liver abscess sometimes is successfully treated by ultrasonographic or CT-guided catheter drainage and concomitant intravenous antibiotic treatment. Open surgical drainage is necessary if this approach is not successful.

Perianal abscess often requires drainage unless it drains spontaneously. In general, perianal fistulas should be managed by a combined medical and surgical approach. Often, the surgeon places a seton through the fistula to keep the tract open and actively draining while medical therapy is administered, to help prevent the formation of a perianal abscess. A severely symptomatic perianal fistula can require fistulotomy, but this procedure should be considered only if the location allows the sphincter to remain undamaged.

The surgical approach for Crohn disease is to remove as limited a length of bowel as possible. There is no evidence that removing bowel up to margins that are free of histologic disease has a better outcome than removing only grossly involved areas. The latter approach reduces the risk of short bowel syndrome. Laparoscopic approach is increasingly being used, with decreased postoperative recovery time. One approach to symptomatic small bowel stricture has been to perform a strictureplasty rather than resection. The surgeon makes a longitudinal incision across the stricture but then closes the incision with sutures in a transverse fashion. This is ideal for short strictures without active disease. The reoperation rate is no higher with this approach than with resection, whereas bowel length is preserved. Postoperative medical therapy with agents, such as mesalamine, metronidazole, azathioprine, and, more recently, infliximab, is often given to decrease the likelihood of postoperative recurrence.

Severe perianal disease can be incapacitating and difficult to treat if unresponsive to medical management. Diversion of fecal stream can allow the area to be less active, but on reconnection of the colon, disease activity usually recurs.

Support

Psychosocial issues for the child with Crohn disease include a sense of being different, concerns about body image, difficulty in not participating fully in age-appropriate activities, and family conflict brought on by the added stress of this disease. Social support is an important component of the management of Crohn disease. Parents are often interested in learning about other children with similar problems, but children may be hesitant to participate. Social support and individual psychologic counseling are important in the adjustment to a difficult problem at an age that by itself often has difficult adjustment issues. Patients who are socially "connected" fare better. Ongoing education about the disease is an important aspect of management because children generally fare better if they understand and anticipate problems. The Crohn and Colitis Foundation has local chapters throughout the United States and supports several regional camps for children with Crohn disease.

PROGNOSIS

Crohn disease is a chronic disorder that is associated with high morbidity but low mortality. Symptoms tend to recur despite treatment and often without apparent explanation. Weight loss and growth failure can usually be improved with treatment and attention to nutritional needs. Up to 15% of patients with early growth retardation secondary to Crohn disease have a permanent decrease in linear growth. Osteopenia is particularly common in those with chronic poor nutrition and frequent exposure to high doses of corticosteroids. Dual-energy x-ray absorptiometry can help identify patients at risk for developing osteopenia. Steroid-sparing agents, weight-bearing exercise, and improved nutrition, including supplementation with vitamin D and calcium, can improve bone mineralization. Some of the extraintestinal manifestations can, in themselves, be major causes of morbidity, including sclerosing cholangitis, chronic active hepatitis, pyoderma gangrenosum, and ankylosing spondylitis.

The region of bowel involved and complications of the inflammatory process tend to increase with time and include bowel strictures, fistulas, perianal disease, and intraabdominal or retroperitoneal abscess. Most patients with Crohn disease eventually require surgery for one of its many complications; the rate of reoperation is high. Surgery is unlikely to be curative and should be avoided except for the specific indications noted previously. An earlier, most aggressive medical treatment approach, with the goal of exacting mucosal healing may improve long-term prognosis, and this is an active area of investigation. The risk of colon cancer in patients with long-standing Crohn colitis approaches that associated with ulcerative colitis, and screening colonoscopy after 8-10 years of colonic disease is indicated.

Despite these complications, most children with Crohn disease lead active, full lives with intermittent flare-up in symptoms.

Visit Elsevier eBooks+ at eBooks.Health.Elsevier.com for Bibliography.

382.3 Very Early Onset Inflammatory Bowel Disease

Ronen E. Stein, Sudha A. Anupindi, and Robert N. Baldassano

IBD may be classified according to age at onset: pediatric onset (<17 years), early onset (<10 years), very early onset (<6 years), infant/toddler onset (0-2 years), and neonatal onset IBD (<28 days). The incidence of pediatric IBD is rising with the greatest rates of increase occurring among young children. Very early onset IBD (VEO-IBD) accounts for up to 15% of pediatric-onset IBD with an estimated prevalence of 14/100,000 children. Approximately 1% of children with IBD are diagnosed before the age of 2 years.

Although IBD is a complex disorder with genetics, the immune system, the microbiome, and environmental factors each contributing to its development, children with VEO-IBD are more likely to have a *monogenic* cause for their disease. Genetic testing has led to the identification of novel genetic pathways linked to the development of VEO-IBD. Many of these pathways contain genes associated with primary immunodeficiencies (see Tables 382.1 and 382.6; Table 382.9). Family history of IBD among first-degree relatives occurs more frequently in children diagnosed at a younger age. Approximately 44% of children diagnosed with ulcerative colitis under the age of 2 years will have a first-degree relative with IBD compared with 19% of older children with IBD.

VEO-IBD has a distinct clinical phenotype characterized by a higher likelihood for extensive colonic involvement and a greater tendency for a more aggressive disease course that is refractory to conventional therapies. However, there is a spectrum of clinical presentations within this population, including patients with milder forms of the disease and a more traditional disease course. Younger patients with IBD can present with any combination of diarrhea, abdominal pain, vomiting, and growth failure. Severe perirectal disease can be present and is often associated with monogenic forms of VEO-IBD, including those caused by IL-10 receptor pathogenic variants. In addition to intestinal symptoms, there may be associated manifestations of the specific monogenetic disorder (Fig. 382.12).

Table 382.9 Known Defects Associated with Very Early Onset Inflammatory Bowel Disease and Its Associated Extraintestinal Manifestations and Laboratory Findings

DEFECTS	GENE DEFECT	EXTRAINTESTINAL IMMUNE, HEMATOLOGIC, OR SOMATIC MANIFESTATIONS	LABORATORY FINDINGS AND FUNCTIONAL EVALUATION
IPEX AND IPEX-LIKE DISORDERS			
IPEX	*FOXP3*	Autoimmune endocrinopathy, cytopenia, hepatitis and kidney disease, eczema, food allergy, eosinophilia	Decrease in Treg cells number and function Decreased Foxp3 expression
CD25 deficiency	*CD25*	Autoimmune endocrinopathy, cytopenia, eczema, gingivitis, alopecia universalis, bullous pemphigoid, CMV, EBV disease	Absent CD25 expression
STAT5b deficiency	*STAT5B*	Autoimmune endocrinopathy, eczema, short stature, interstitial pneumonitis, alopecia universalis, bullous pemphigoid, varicella and herpes zoster infections	Variable immune abnormality Normal to low T, B, and NK cells
STAT1 GOF mutation	*STAT1*	Mucocutaneous candidiasis, short stature, eczema, autoimmune endocrinopathy, sinopulmonary infection, hypertension, aneurysm	Most have normal Treg cell number and Foxp3 expression, abnormal STAT1 phosphorylation studies
STAT3 GOF mutation	*STAT3*	Multisystem autoimmunity, variable short stature, lymphoproliferation	Hypogammaglobulinemia Decreased class switched memory B cells
LRBA deficiency	*LRBA*	Multisystem autoimmunity, cytopenia, arthritis, recurrent sinopulmonary infection, granuloma, hypogammaglobulinemia	Hypogammaglobulinemia Decreased class switched memory B cells
CTLA4 haploinsufficiency	*CTLA4*	Diarrhea, enteropathy, hypogammaglobulinemia, granulomatous lymphocytic interstitial lung disease, multisystem autoimmunity	Hypogammaglobulinemia Decreased class switched memory B cells
DEFECTS IN IL-10 SIGNALING			
Defects in IL-10 and IL-10R	*IL-10RA* *IL-10RB* *IL-10*	Perianal fistula, folliculitis, arthritis, abscess, lymphoma	STAT3 phosphorylation by IL-6 and IL-10 studies*
DEFECTS IN NEUTROPHIL FUNCTION			
CGD	*CYBB* *CYBA* *NCF1* *NCF2* *NCF4*	Perianal fistula, recurrent cold abscess from catalase positive organisms,† gastric outlet obstruction	Decreased neutrophil oxidative burst study Elevated IgG
Glycogen storage disease 1b	*SLC37A4*	Recurrent bacterial infections, hypoglycemic seizures, hepatomegaly	Neutropenia, hypoglycemia, hyperuricemia, hyperlipidemia
Leukocyte adhesion defect	*ITGB2*	Neutrophilia, recurrent bacterial infections, delayed separation of umbilical cord, poor wound healing	Leukocytosis Absent CD18 expression
Congenital neutropenia	*G6PC3*	Cutaneous vascular malformation and cardiac defect	Severe neutropenia

Continued

Table 382.9 Known Defects Associated with Very Early Onset Inflammatory Bowel Disease and Its Associated Extraintestinal Manifestations and Laboratory Findings—cont'd

DEFECTS	GENE DEFECT	EXTRAINTESTINAL IMMUNE, HEMATOLOGIC, OR SOMATIC MANIFESTATIONS	LABORATORY FINDINGS AND FUNCTIONAL EVALUATION
HYPERINFLAMMATORY DISORDERS			
XIAP	*BIRC4*	Perianal fistula, recurrent HLH, EBV, and CMV infections, hypogammaglobinemia	Markedly elevated IL-18 Decreased or absent XIAP protein expression by flow
NLRC4 GOF variant	*NLRC4*	Recurrent macrophage activation, rash	Markedly elevated IL-18
Mevalonate kinase deficiency	*MVK*	Recurrent fever, rash, abdominal pain and emesis	Elevated inflammatory markers Elevated IgD Elevated urine mevalonate
Familial Mediterranean fever	*MEFV*	Recurrent fever, abdominal pain, arthralgia, peritonitis	Elevated inflammatory markers
Familial HLH type 5	*STXBP2*	HLH, hypogammaglobinemia, sensorineural hearing loss	Marked elevated ferritin and sIL-2R Decreased CD107a degranulation
Hermansky-Pudlak syndrome	*HPS1* *HPS4* *HPS6*	Partial albinism, bleeding tendency, recurrent infection and immunodeficiency	Decreased CD107a degranulation
DEFECTS IN EPITHELIAL BARRIER FUNCTION			
TTC7A deficiency	*TTC7A*	Varying degree of intestinal atresia, T-cell immune defect and recurrent infections	Mild to severe T-cell immune deficiency Hypogammaglobinemia
X-linked ectodermal immunodeficiency (NEMO deficiency)	*IKBKG*	Varying degree of ectodermal dysplasia, conical teeth, sparse and brittle hair, recurrent bacterial, viral and mycobacterial infections	Hypogammaglobinemia Decreased class switched memory B cells
ADAM17 deficiency	*ADAM17*	Neonatal inflammatory skin and bowel disease, generalized pustular rash	Normal T-cell and B-cell numbers
Dystrophic epidermolysis bullosa	*COL7A1*	Blistering disorder primarily affect the hands, feet, knees, and elbows	Unremarkable immune findings
Kindler syndrome	*FERMT1*	Acral skin blistering, photosensitivity, progressive poikiloderma, and diffuse cutaneous atrophy	Eosinophilia
ISOLATED OR COMBINED T-CELL AND B-CELL IMMUNE DEFECTS			
X-linked agammaglobulinemia	*BTK*	Recurrent sinopulmonary infection	Absent B cells in peripheral blood Absent plasma cells in tissue Decreased class switched memory B cells
Common variable immune defect (CVID)		Heterogeneous group of defects with sinopulmonary infections, autoimmunity, lymphoproliferation, and variable T-cell immune defect	Hypogammaglobinemia Variable T-cell lymphopenia
X-linked hyper IgM (CD40L)	*CD40L*	Sclerosing cholangitis, Cryptosporidium diarrhea and Pneumocystis infection	Elevated or normal IgM, neutropenia Absent class switched memory B cells
Wiskott-Aldrich syndrome	*WAS*	Eczema, recurrent infection, autoimmunity, vasculitis	Microthrombocytopenia Variable lymphopenia, low IgM Decreased WAS protein
Leaky SCID or Omenn	*RAG1, RAG2* *IL-7Ra* *IL-2RG*	Generalized erythroderma, hepatosplenomegaly, lymphadenopathy	Eosinophilia T-cell lymphopenia Decreased naïve T cells

*STAT3 signaling following IL-6 and IL-10 will only identify IL-10R A and B defects; it will not identify IL-10 deficiency.
†*Staphylococcus aureus, Serratia marcescens, Burkholderia cepacia, Aspergillus,* and *Candida.*
IPEX, Immune dysfunction, polyendocrinopathy, enteropathy, X-linked; Treg, regulatory T cell; CMV, cytomegalovirus; EBV, Epstein-Barr virus; NK, natural killer; GOF, gain of function; IL, interleukin; CGD, chronic granulomatous disease; HLH, hemophagocytic lymphohistiocytosis; SCID, severe combined immune deficiency.
From Chandrakasan S, Venkateswaran S, Kugathasan S. Nonclassic inflammatory bowel disease in young infants – immune dysregulation, polyendocrinopathy, enteropathy, X-linked syndrome, and other disorders. *Pediatr Clin N Am.* 2017;64:139–160. Table 2.

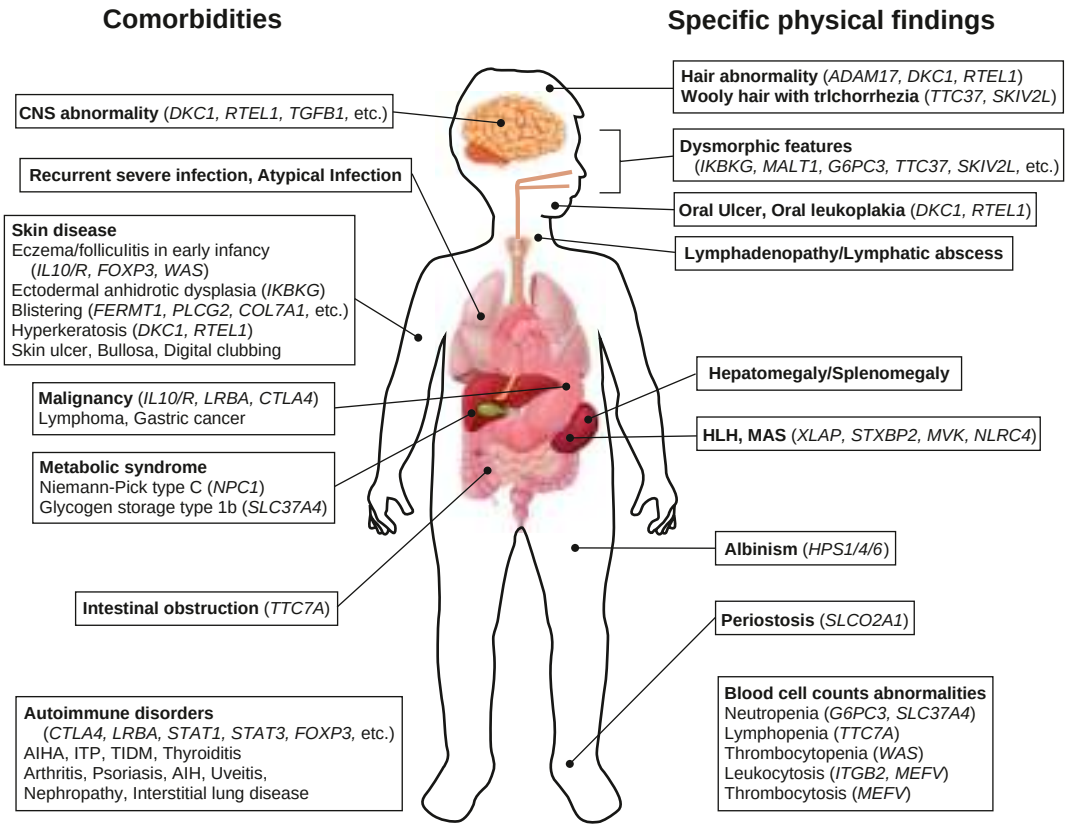

Fig. 382.12 Key indicators of monogenic IBD in clinical practice. Showing physical findings and comorbidities of which physicians should be aware at the initial physical examination and during follow-up. *(Modified from Nambu R, Muise AM. Advanced understanding of monogenic inflammatory bowel disease. Front Pediatr. 2021;8:Article 618918. Fig. 1C.)*

Diagnosis of IBD is ultimately confirmed by upper endoscopy and ileocolonoscopy. Classic histologic findings of IBD can be seen, although atypical findings, such as the presence of extensive epithelial apoptosis, could indicate the presence of monogenic disease. Most children with VEO-IBD will have isolated colonic inflammation on ileocolonoscopy. However, the inflammation can be extensive and involve the entire colon making it challenging to differentiate between Crohn disease and ulcerative colitis; 11–22% of patients with VEO-IBD are diagnosed with *indeterminate colitis* at diagnosis. Additionally, an initial diagnosis of ulcerative colitis occurs in approximately 60% of VEO-IBD patients. However, because children with VEO-IBD are more likely to have disease extension over time, a number of patients felt to have indeterminate colitis or ulcerative colitis at diagnosis may eventually be reclassified as having Crohn disease later in life. As small bowel imaging using CT or MR enterography may not be tolerated in a young child, small bowel ultrasonography is an alternative imaging modality in VEO-IBD.

The differential diagnosis of VEO-IBD is similar to older children and adults including infectious and allergic colitis (see Table 382.5). However, primary immunodeficiencies, such as chronic granulomatous disease, common variable immunodeficiency, severe combined immunodeficiency, Wiskott-Aldrich syndrome and immunodysregulation, polyendocrinopathy, enteropathy, X-linked syndrome, are higher on the differential (see Tables 382.6 and 382.9). Therefore immunologic evaluation is a critical component of diagnosis and management (Table 382.10). History of autoimmunity, atypical infections, recurrent infections, skin disorders, and/or hair abnormalities could indicate an underlying immunodeficiency. Laboratory evaluation could include dihydrorhodamine cytometric testing, quantitative immunoglobulins, vaccine titers, as well as testing of B- and T-cell function. More targeted immunologic testing is guided by clinical history. Genetic testing modalities, such as whole exome sequencing, are helpful in identifying rare monogenic pathways responsible for development of the disease.

A multidisciplinary team approach at a center experienced in VEO-IBD can be helpful in formulating an individualized treatment plan. Younger children are more likely to fail conventional therapies, such as 5-ASA, immunomodulators, and biologics, and require surgical intervention. Surgical decisions must be made with caution in very young children as disease extension from the colon to the small intestine can occur with time. More extensive and severe disease at presentation could explain the higher rates of treatment failure among younger children. However, other children may fail conventional therapies if the inflammation is being driven by a monogenic disease process that is not targeted by conventional therapies. Therefore for children with an underlying primary immunodeficiency or a novel monogenic disease process, the specific disease pathway involved may influence treatment choices. In some cases, bone marrow transplantation may be a necessary treatment for the underlying disease process.

Visit Elsevier eBooks+ at eBooks.Health.Elsevier.com for Bibliography.

Table 382.10 Functional Analysis

FUNCTIONAL SCREENING CONSIDERED	
• Immunoglobulins (IgG, IgM, IgA, IgD, IgE) • Lymphocyte subsets by flow • Antibody to vaccines • TRECs • DHR-123 • Cytokine assay (serum cytokine level during flare)	
TARGETED FUNCTIONAL ANALYSIS *(RECOMMENDED)*	
GENE	FUNCTIONAL ANALYSIS
IL10RA	IL-10-induced STAT3 phosphorylation by flow cytometry or immunoblotting
IL10RB	
NCF1	Neutrophil oxidative burst study, DHR-123 test
NCF2	
CYBA	
CYBB	
*NCF4**	Neutrophil oxidative burst study
CYBC1	
TTC7A	Immunohistochemistry-TTC7A, apoptosis
WAS	WASP expression by flow cytometry
XIAP	XIAP expression by flow cytometry TNF, IL-8, and MCP-1 expression in response to MDP stimulation
SLCO2A1	Immunohistochemistry-SLCO2A1
NPC1	Filipin staining of cultured skin fibroblasts
SLC37A4	G6Pase enzyme activity in Liver tissue (non-frozen)
MVK	Increased urine mevalonic acid when fever
TNFAIP3	A20 expression by immunoblotting RT-PCR using total RNA
CTLA4	CTLA-4 expression within stimulated Treg cells by flow cytometry
LRBA	LRBA expression in response to PHA stimulation by flow cytometry
FOXP3	FOXP3 expression by flow cytometry
STAT1(GOF)	CD25 expression by flow cytometry
STAT3(GOF)	STAT3 reporter luciferase assay under basal or stimulated condition (IL-6/growth hormone) in cell lines SOCS3 expression levels under basal or stimulated condition (IL-21) in EBV-transformed patient cell lines

*The production of ROS in phagocyte is normal and need to examine the bacterial killing activity.

TREC, T-cell receptor excision circles; DHR-123, dihydrorhodamine 123; WASP, Wiskott-Aldrich syndrome protein; IL-8, interleukin-8; MCP-1, monocyte chemoattractant protein; MDP, muramyl dipeptide; RT-PCR, real-time reverse transcription polymerase chain reaction, TNF, tumor necrosis factor; Treg, regulatory T cell; PHA, phytohemagglutinin; SOCS3, suppressor of cytokine signaling 3; EBV, Epstein-Barr virus; ROS, reactive oxygen species.

From Nambu R, Muise AM. Advanced understanding of monogenic inflammatory bowel disease. *Front Pediatr*. 2021;8:Article 618918. Table 1A.

Chapter 383

Eosinophilic Gastroenteritis

Ronen E. Stein and Robert N. Baldassano

Eosinophilic gastroenteritis consists of a group of rare and poorly understood disorders that have in common gastric and small intestine infiltration with eosinophils and peripheral eosinophilia. The esophagus and large intestine may also be involved. Tissue eosinophilic infiltration can be seen in mucosa, muscularis, or serosa. The mucosal form is most common and is diagnosed by identifying large numbers of eosinophils in biopsy specimens of gastric antrum or small bowel. Endoscopy may reveal gastritis or colitis, ulceration, and thickened mucosal folds, as well as nodules. This condition clinically overlaps the dietary protein hypersensitivity disorders of the small bowel and colon. Peripheral eosinophilia may be absent. The differential diagnosis also includes celiac disease, chronic granulomatous disease, connective tissue disorders and vasculitides (eosinophilic granulomatosis with polyangiitis), multiple infections (particularly parasites), hypereosinophilic syndrome, early inflammatory bowel disease, medications (tacrolimus, enalapril, naproxen, interferon, rifampicin, azathioprine), and rarely malignancy. Many patients have allergies to multiple foods, seasonal allergies, atopy, eczema, and asthma. Serum immunoglobulin E is commonly elevated. Laboratory abnormalities may include hypoalbuminemia, iron-deficiency anemia, and elevated liver enzymes. Medications have been associated with eosinophilic gastroenteritis including gold, enalapril, and carbamazepine.

The presentation of eosinophilic gastroenteritis is nonspecific. Clinical symptoms often correlate with which layers of the gastrointestinal tract are affected. Mucosal involvement can produce nausea, vomiting, diarrhea, abdominal pain, gastrointestinal bleeding, protein-losing enteropathy, or malabsorption. Involvement of the muscularis can produce obstruction (especially of the pylorus) or intussusception, whereas serosal activity produces abdominal distention and eosinophilic ascites. Presentation in infants can be similar to pyloric stenosis. Laboratory testing often reveals peripheral eosinophilia, elevated serum immunoglobulin E levels, hypoalbuminemia, and anemia.

The disease usually runs a chronic, debilitating course with sporadic severe exacerbations. Although usually effective for the treatment of isolated eosinophilic esophagitis (see Chapter 370), elemental diets are not always successful for the treatment of eosinophilic gastroenteritis. Orally administered cromolyn sodium and montelukast are sometimes successful. There have been case reports of clinical improvement using ketotifen, an antihistamine and mast cell stabilizer. Many patients require treatment for acute disease exacerbations with systemic corticosteroids, which are often effective. Systemic corticosteroids may also be needed long term. Oral budesonide, a corticosteroid with local antiinflammatory activity on the bowel mucosa and limited systemic absorption due to high hepatic first-pass metabolism, can be attempted for long-term therapy. In adults, biologic agents (e.g., omalizumab) have been used.

Visit Elsevier eBooks+ at eBooks.Health.Elsevier.com Bibliography.

Chapter 384

Celiac Disease

Ankur A. Chugh

ETIOLOGY AND EPIDEMIOLOGY

Celiac disease (CD) is an immune-mediated systemic disorder elicited by gluten in wheat and related prolamins from rye and barley in genetically susceptible individuals, and is characterized by the presence of a variable combination of gluten-dependent clinical manifestations, CD-specific antibodies, human leukocyte antigen (HLA)-DQ2 or DQ8 haplotypes, and enteropathy. CD-specific antibodies comprise autoantibodies against tissue transglutaminase (TG2) including endomysial antibodies (EMAs), and antibodies against forms of deamidated gliadin peptides (DGPs).

CD is a common disorder with 1.4% global prevalence of positive serologies and 0.7% of biopsy-proven disease, with variability across countries. CD affects both children and adults (second to third decade of life). Although CD develops in genetically susceptible individuals, environmental factors might affect the risk of developing CD or the timing of its presentation. Neither breastfeeding during gluten introduction nor any breastfeeding has been shown to reduce the risk of CD. The impact of *early* gluten introduction (age 4 months) on the risk of developing CD is contradictory. *Large* amounts of gluten at a young age (6 months) may convey risk of earlier development of CD autoimmunity (positive serology) and CD, whereas *lower* amounts of gluten in the first 2 years of life may convey lower risk of CD. Infectious agents have been hypothesized to play a causative role, as frequent rotavirus infections were shown to be associated with an increased risk of developing CD. It is plausible that the contact with gliadin at a time when there is an ongoing intestinal inflammation alters intestinal permeability, and the enhanced antigen presentation can increase the risk of developing CD, at least in a subset of persons. The mode of delivery, socioeconomic status, season of birth, and the use of drugs have been associated with the risk of developing CD, but the evidence is contradictory.

GENETICS AND PATHOGENESIS

A genetic predisposition is suggested by the family aggregation and the concordance in monozygotic twins, which approaches 100%. The strongest association is with HLA-DQ2.5 (one or two copies encoded by DQA1*05 [for the alpha] and DQB1*02 genes [for the beta chain]). Such a DQ molecule has been found to be present in more than 90% of CD patients. The highly homologous DQ2.2 molecule confers a much lower risk, whereas the data available on DQ2-negative CD patients indicate that they almost invariably are HLA-DQ8 positive (DQA1*0301/DQB1*0302). A gene dosage effect has been proved in prospective studies, and a molecular hypothesis for such a phenomenon has been proposed, based on the impact of the number and quality of the HLA-DQ2 molecules on gluten peptide presentation to T cells. The HLA locus is the most significant and dominant gene associated with CD; however, other loci known to contribute to CD have been documented. Most have been found to be associated with other autoimmune diseases such as type 1 diabetes. Interestingly, very few polymorphisms associated with CD are in coding regions, as they often are in binding sites for transcription factors, where they then affect gene expression.

CD is a T-cell–mediated chronic inflammatory disorder with an autoimmune component. Altered processing by intraluminal enzymes, changes in intestinal permeability, and activation of innate immunity mechanisms precede the activation of the adaptive immune response. Immunodominant epitopes from gliadin are highly resistant to intraluminal and mucosal digestion; incomplete degradation favors the immunostimulatory and toxic effects of these sequences. Some gliadin peptides activate innate immunity, in particular they induce interleukin (IL)-15. The latter, but also type 1 interferons, may alter the tolerogenic phenotype of dendritic cells, resulting in lamina propria T-cell activation by other peptides presented in the context of HLA-DQ2 or HLA-DQ8 molecules. Gliadin-specific T-cell responses are enhanced by the action of TG2: the enzyme converts particular glutamine residues into glutamic acid, which results in higher affinity of these gliadin peptides for HLA-DQ2 or HLA-DQ8. The pattern of cytokines produced following gliadin activation is dominated by interferon-γ (T-helper type 1 skewed); IL-21 is also upregulated. In downstream T-cell activation a complex remodeling of the mucosa takes place involving increased levels of metalloproteinases and growth factors, which leads to the classical histologic finding of a flat mucosa. A severe impairment of intraepithelial lymphocyte (IEL) homeostasis is present in CD. IL-15 is implicated in the expression of natural killer receptors CD94 and NKG2D, as well as in epithelial expression of stress molecules, thus enhancing cytotoxicity, cell apoptosis, and villous atrophy. The most evident expression of autoimmunity is the presence of serum antibodies to TG2. However, the mechanisms leading to autoimmunity are largely unknown, as well as their pathogenetic significance. *Potential* CD, in which TG2 antibodies can be detected in situ without any histologic abnormality, shows that the production of antibodies does not necessarily lead to intestinal damage. The finding that IgA deposits on extracellular TG2 are not limited to the intestine but can be found in the liver, lymph nodes, and muscles indicates that TG2 is accessible to the gut-derived autoantibodies, turning CD into a systemic disease.

CLINICAL PRESENTATION AND ASSOCIATED DISORDERS

Clinical features of CD vary considerably. Intestinal symptoms are more common in children whose disease is diagnosed *within the first 2 years of life*; failure to thrive, chronic diarrhea, vomiting, abdominal distention, muscle wasting, anorexia, and irritability are present in most cases (Fig. 384.1). Occasionally there is constipation, with cases presenting with intussusception. As the age at presentation of the disease shifts to later in childhood, and with the more extensive use of serologic screening tests, extraintestinal manifestations, without any accompanying digestive symptoms, have increasingly become recognized, affecting

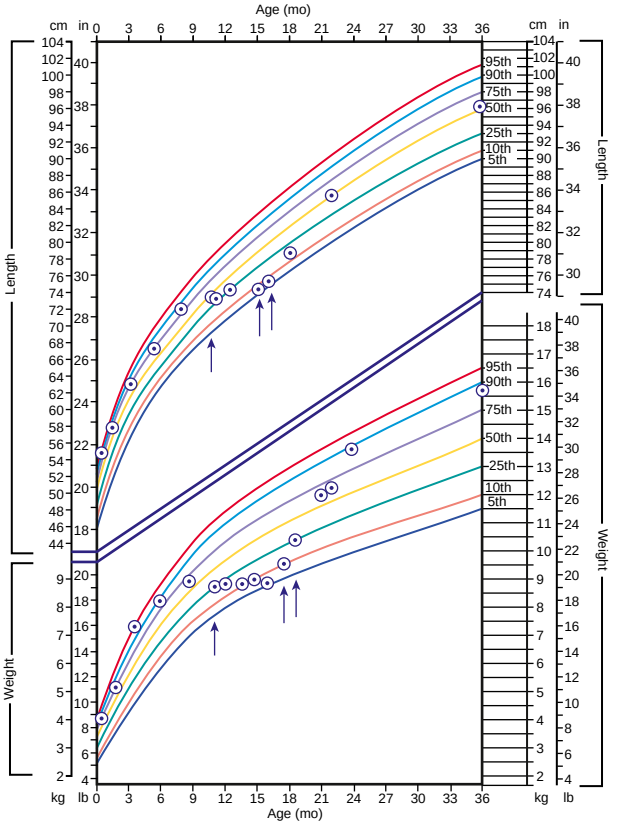

Fig. 384.1 Gluten-sensitive enteropathy. Growth curve demonstrates initial normal growth from 0 to 9 mo, followed by onset of poor appetite with intermittent vomiting and diarrhea after initiation of gluten-containing diet *(single arrow)*. After biopsy confirmed diagnosis and treatment with gluten-free diet *(double arrow)*, growth improves.

almost all organs (Table 384.1). One of the most common extraintestinal manifestation of CD is iron-deficiency anemia, which is usually unresponsive to iron therapy. Osteoporosis may be present; in contrast to adults, it can be reversed by a gluten-free diet in children, with restoration of normal peak bone densitometric values. Other extraintestinal manifestations include short stature, delayed puberty, arthritis and arthralgia, epilepsy with bilateral occipital calcifications, peripheral neuropathies, isolated hypertransaminasemia, dental enamel hypoplasia, and aphthous stomatitis. The mechanisms responsible for the severity and the variety of clinical presentations remain obscure. Nutritional deficiencies or abnormal immune responses have been suggested. Silent CD is recognized, mainly in asymptomatic first-degree relatives of CD patients and in subjects affected by diseases associated with CD (Table 384.2). Small bowel biopsy in silent/subclinical CD reveals severe mucosal damage consistent with CD. Potential CD is defined when patients have positive CD-specific antibodies, but without documented small bowel damage (Table 384.3).

Some diseases, many with an autoimmune pathogenesis, are found with a higher than normal incidence in CD patients. Among these are type 1 diabetes, autoimmune thyroid disease, Addison disease, Sjögren syndrome, rheumatoid arthritis, autoimmune cholangitis, autoimmune hepatitis, primary biliary cholangitis, and juvenile idiopathic arthritis. Such associations have been interpreted as a consequence of the sharing of identical HLA haplotypes, but a direct role of

Table 384.1 Extraintestinal Manifestations of Celiac Disease

MANIFESTATION	PROBABLE CAUSE(S)
CUTANEOUS	
Ecchymoses and petechiae	Vitamin K deficiency; rarely, thrombocytopenia
Edema	Hypoproteinemia
Dermatitis herpetiformis	Epidermal (type 3) tTG autoimmunity
Follicular hyperkeratosis and dermatitis	Vitamin A malabsorption, vitamin B complex malabsorption
ENDOCRINOLOGIC	
Amenorrhea, infertility, impotence, delayed puberty, short stature, type 1 diabetes, thyroiditis, Addison disease, Graves disease	Malnutrition, hypothalamic-pituitary dysfunction, immune dysfunction
Secondary hyperparathyroidism	Calcium and/or vitamin D malabsorption with hypocalcemia
HEMATOLOGIC	
Anemia	Iron, folate, vitamin B_{12}, or pyridoxine deficiency
Hemorrhage	Vitamin K deficiency; rarely, thrombocytopenia due to folate deficiency
Thrombocytosis, Howell-Jolly bodies	Hyposplenism; splenic atrophy; autoantibodies
Pancytopenia	Vitamin B_{12} deficiency; immune medicated
Thrombosis	Venous and arterial, including portal vein
Malignancies	Enteropathy-type T-cell lymphoma, B-cell gut lymphoma, adenocarcinoma of small intestine
HEPATIC	
Elevated liver biochemical test levels	Lymphocytic celiac hepatitis, NAFLD
Autoimmune hepatitis	Associated autoimmune hepatitis
MUSCULAR	
Atrophy	Malnutrition due to malabsorption
Tetany	Calcium, vitamin D, and/or magnesium malabsorption
Weakness	Generalized muscle atrophy, hypokalemia
NEUROLOGIC	
Peripheral neuropathy	Deficiencies of vitamin B_{12} and thiamine; immune-based neurologic dysfunction
Ataxia	Cerebellar and/or posterior column damage
Demyelinating central nervous system lesions	Immune-based neurologic dysfunction
Seizures (difficult to treat)	Unknown; associated occipital calcifications
SKELETAL	
Osteopenia, osteomalacia, and osteoporosis	Malabsorption of calcium and vitamin D, secondary hyperparathyroidism, chronic inflammation
Osteoarthropathy	Unknown
Pathologic fractures	Osteopenia and osteoporosis
OTHER	
Enamel hypoplasia	Vitamin D, calcium malabsorption
Anxiety, schizophrenia	Unknown, uncertain
Pulmonary hemosiderosis	Unknown, uncertain
Aphthous stomatitis	Unknown
Benign inflammatory mass	Granulomatous self-resolving process with treatment

tTG, Tissue transglutaminase; NAFLD, nonalcoholic fatty liver disease.
Modified from Kelly CP. Celiac disease. In: Feldman M, Friedman LS, Brandt LJ, eds. *Sleisenger and Fordtran's Gastrointestinal and Liver Disease*, 10th ed. Philadelphia: Elsevier; 2016: Table 107.1.

Table 384.2 National Institute for Health and Care Excellence Guidelines on the Indications That Should Prompt Testing for Celiac Disease

CELIAC TESTING RECOMMENDED
• Persistent unexplained abdominal or gastrointestinal symptoms
• Faltering growth
• Prolonged fatigue
• Unexpected weight loss
• Severe or persistent mouth ulcers
• Unexplained iron, vitamin B_{12}, or folate deficiency
• Type 1 diabetes
• Autoimmune thyroid disease
• Irritable bowel syndrome
• First degree relatives of people with coeliac disease
• Dermatitis herpetiformis
CELIAC TESTING SHOULD BE CONSIDERED
• Metabolic bone disorders (reduced bone mineral density or osteomalacia)
• Unexplained neurologic symptoms (particularly peripheral neuropathy or ataxia)
• Unexplained subfertility or recurrent miscarriage
• Persistently increased concentrations of liver enzymes with unknown cause
• Dental enamel defects
• Down syndrome
• Turner syndrome
• William syndrome
• Selective IgA deficiency

IgA, Immunoglobulin A.
From Downey L, Houten R, Murch S, Longson D for the Guideline Development Group. Recognition, assessment, and management of coeliac disease: summary of updated NICE guidance. *BMJ*. 2015;351:h4513.

Table 384.3 Clinical Spectrum of Celiac Disease

SYMPTOMATIC
Frank malabsorption symptoms and signs (e.g., chronic diarrhea, failure to thrive, weight loss)
Extraintestinal symptoms and signs (e.g., anemia, fatigue, hypertransaminasemia, neurologic disorders, short stature, dental enamel defects, arthralgia, aphthous stomatitis)
SILENT
No apparent symptoms in spite of histologic evidence of villous atrophy
In most cases identified by serologic screening in at-risk groups (see Table 384.1)
LATENT
Subjects who have a normal intestinal histology, but at some other time have shown a gluten-dependent enteropathy
POTENTIAL
Subjects with positive celiac disease serology but without evidence of altered intestinal histology. Patients may or may not have symptoms and signs of disease and may or may not develop a gluten-dependent enteropathy later

gluten in promoting autoimmunity cannot be excluded. The relation between CD and other autoimmune diseases is poorly defined; once those diseases are established, they are not influenced by a gluten-free diet. Other associated conditions include selective IgA deficiency and Down, Turner, and Williams syndromes (see Table 384.2).

DIAGNOSIS

The diagnosis of CD is based on a combination of symptoms, antibodies, and duodenal histology. The initial approach to symptomatic patients is to test for anti-TG2 IgA antibodies and for total IgA in serum to exclude IgA deficiency. If IgA anti-TG2 antibodies are negative, and serum total IgA is normal for age, CD is unlikely to be the cause of the symptoms. If anti-TG2 antibody testing is positive, the patients should be referred to a pediatric gastroenterologist for further diagnostic workup, which depends on the serum antibody levels.

In patients with selective IgA deficiency, testing is recommended with IgG antibodies to TG2. Patients with positive anti-TG2 antibody levels <10 times the upper limit of normal should undergo upper endoscopy with multiple biopsies. In patients with positive anti-TG2 antibody levels at or >10 times the upper limit of normal, EMA titers should be obtained in a second blood draw (to prevent mislabeling). If the patient has positive antibodies, the diagnosis of CD is essentially confirmed, a lifelong gluten-free diet is started, and the patient is followed for the improvement of symptoms and the decline of antibodies. In the rare case of negative anti-EMA in a child with TG2 antibody titers >10 times the upper limits of normal, the diagnostic workup should be extended, and duodenal biopsies obtained (Fig. 384.2). In asymptomatic persons belonging to high-risk groups with anti-TG2 levels >10 times the upper limit of normal, the decision to utilize the nonbiopsy approach should be a shared decision with the patient/family. When biopsies are indicated, at least four fragments should be obtained from the descending part of the duodenum and at least one from the duodenal bulb. The diagnosis is confirmed by an antibody decline and preferably a clinical response to a gluten-free diet. CD is not the only cause for lymphocytic infiltration or villous atrophy (Table 384.4). HLA testing is helpful for diagnostic uncertainty, patients already on a gluten free diet, and in screening of high-risk individuals. The benefit of obtaining additional DGP antibodies in patients <2 years of age is no longer favored.

TREATMENT

The only treatment for CD is lifelong, strict adherence to a gluten-free diet. This requires a wheat-, barley-, and rye-free diet (Tables 384.5 and 384.6). Despite evidence that oats are safe for most patients with CD, there is concern regarding the possibility of contamination of oats with gluten during harvesting, milling, and shipping. Nevertheless, it seems wise to add oats to the gluten-free diet only when the latter is well established, so that possible adverse reactions can be readily identified. There is a consensus that all CD patients should be treated with a gluten-free diet regardless of the presence of symptoms. However, whereas it is relatively easy to assess the health improvement after treatment of CD in patients with clinical symptoms of the disease, it proves difficult in persons with *asymptomatic* CD. The nutritional risks, particularly osteopenia and increased risk for other autoimmune disorders, along with the increased but rare risk of intestinal lymphoma, are those mainly feared for subjects who have silent CD and continue on a gluten-containing diet. Little is known about the health risks in untreated patients with potential CD. For these patients, adequate gluten intake should be confirmed, the biopsy orientation should be checked, and monitoring should occur at a tertiary medical center, given the potential for serologies to both normalize or progress to villous atrophy.

Some older patients do not respond to a gluten free diet; *refractory or nonresponsive CD* requires a systematic approach to determine the correct diagnosis, compliance, and therapeutic options (Fig. 384.3).

The Codex Alimentarius Guidelines define gluten-free food item for food containing <20 parts per million (ppm; equivalent to 20 mg gluten in 1 kg of product). However, despite analytical methods for gluten detection reaching a satisfactory degree of sensitivity, more information is needed on the daily gluten amount that may be tolerated by CD patients. The data available so far seem to suggest that the threshold should be set to <50 mg/day, although individual variability makes it difficult to set a universal threshold.

It is important that an experienced dietitian with specific expertise in CD counseling educates the family and the child about dietary restriction. Compliance with a gluten-free diet can be difficult, especially in adolescents, and patients should be monitored for signs of depression and referred to psychology or adolescent medicine as appropriate. It is recommended that children with CD be monitored with periodic visits for assessment of symptoms, growth, physical examination, and adherence to the gluten-free diet. Bloodwork, such as complete blood count, hepatic panel, thyroid function, calcium, vitamin D, iron, and ferritin have been suggested at diagnosis, with abnormal values followed until normalized. Periodic measurements of TG2 antibody levels to document reduction in antibody titers are recommended as indirect evidence of adherence to a

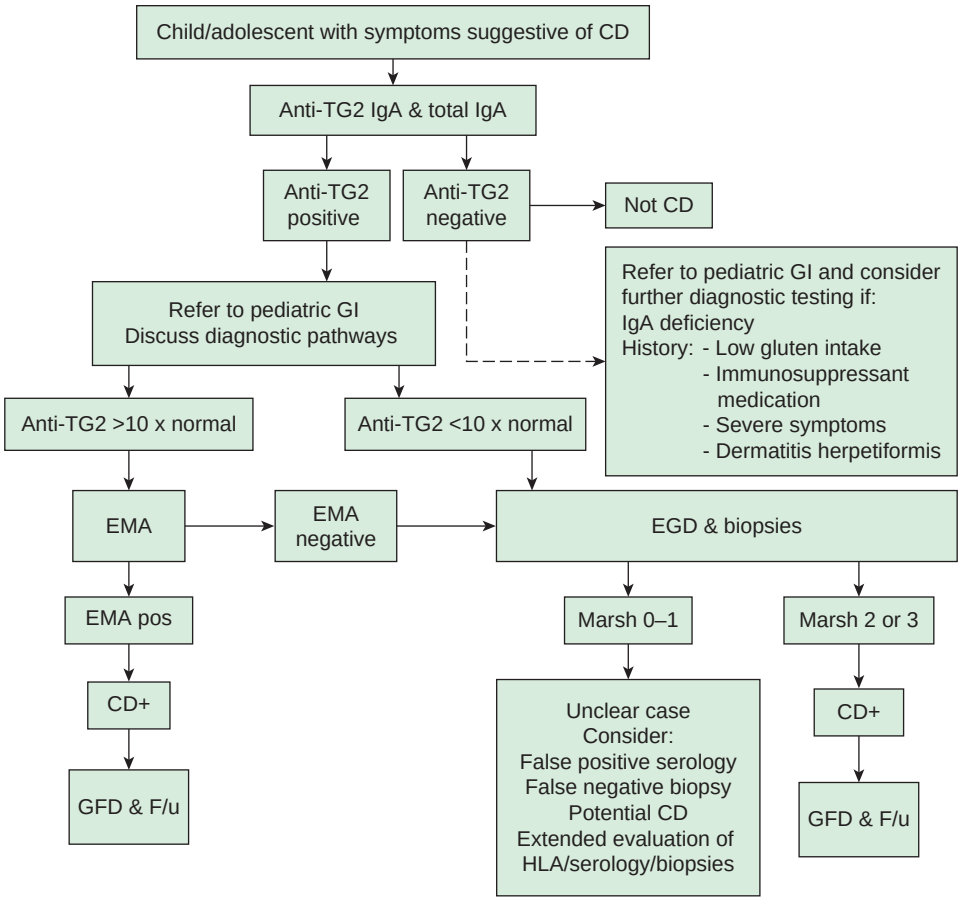

Fig. 384.2 Diagnostic algorithm for celiac disease according to European Society for Paediatric Gastroenterology, Hepatology and Nutrition (ESPGHAN). CD, Celiac disease; EMA, endomysial antibodies; EGD, esophagogastroduodenoscopy; F/u, follow-up; GFD, gluten-free diet; GI, gastrointestinal; HLA, human leukocyte antigen; Ig, immunoglobulin; neg, negative; pos, positive; TG2, transglutaminase. *(Modified from Husby S, Koletzko S, Korponay-Szabò IR, et al. European Society for Pediatric Gastroenterology, Hepatology and Nutrition Guidelines for Diagnosing Coeliac Disease. J Pediatr Gastroenterol Nutr. 2020;70:13841–14157. Fig. 4.)*

Table 384.4 Conditions Other Than Celiac Disease That Can Cause Duodenal Lymphocytosis or Villous Atrophy

DUODENAL LYMPHOCYTOSIS
• Food allergy, non-celiac gluten sensitivity
• Infection (e.g., *Helicobacter pylori* or giardiasis)
• Drugs (e.g., nonsteroidal antiinflammatory drugs)
• Postenteritis syndrome
• Immune deficiency (e.g., selective IgA deficiency, common variable immune deficiency)
• Immune dysregulation (e.g., autoimmune thyroiditis)
• Crohn disease
• Preinfiltrative intestinal T-cell lymphoma
VILLOUS ATROPHY
• Environmental enteropathy (tropical sprue)
• Common variable immune deficiency
• Autoimmune enteropathy
• Drugs (e.g., olmesartan or azathioprine)
• Food allergy
• Giardiasis
• Crohn disease
• Eosinophilic enteritis
• Radiation enteritis
• Intestinal lymphoma
• HIV enteropathy
• Bacterial overgrowth
• Graft-versus-host disease
• Protein energy malnutrition

Modified from Catassi C, Verdu EF, Bai JC, Lionette E. Coeliac disease. *Lancet.* 2022;399:2413–2424.

Table 384.5 Principles of Initial Dietary Therapy for Patients with Celiac Disease

Avoid all foods containing wheat, rye, and barley gluten (pure oats usually safe).
Avoid malt unless clearly labeled as derived from corn.
Use only rice, corn, maize, buckwheat, millet, amaranth, quinoa, sorghum, potato or potato starch, soybean, tapioca, and teff, bean, and nut flours.
Wheat starch and products containing wheat starch should only be used if they contain <20 ppm gluten and are marked "gluten free."
Read all labels and study ingredients of processed foods.
Beware of gluten in medications, supplements, food additives, emulsifiers, or stabilizers.
Limit milk and milk products initially if there is evidence of lactose intolerance.
Avoid all beers, lagers, ales, and stouts (unless labeled gluten free).
Wine, most liqueurs, ciders, and spirits, including whiskey and brandy, are allowed.

ppm, Parts per million.

gluten-free diet, although they are insensitive to slight dietary transgressions and can take up to 2-3 years to normalize. The TG2 antibody levels can be checked every 1-2 years after they normalize, or sooner if symptoms or concerns for compliance arise. Commercial tests are available to monitor for compliance and transgressions via the detection of gluten peptides in the urine and stool, but remain under investigation for validation. If compliance is uncertain or body mass index (BMI) *z* scores are low, bone health should be assessed. Therapeutic treatments, such as those that target IL-15, IL-21, and gluten degradation, remain in clinical trials.

Table 384.6 Some Potential Sources of Hidden Gluten

Beers, ales, other fermented beverages (distilled beverages acceptable)
Bouillon and soups
Candy
Communion wafers
Drink mixes
Gravy and sauces
Herbal tea
Imitation meat and seafood
Nutritional supplements
Play-Doh
Salad dressings and marinades
Self-basting turkeys
Soy sauce

From Kelly CP. Celiac disease. In: Feldman M, Friedman LS, Brandt LJ, eds. *Sleisenger and Fordtran's Gastrointestinal and Liver Disease*, 10th ed. Philadelphia: Elsevier, 2016: Box 107.3.

THE SPECTRUM OF GLUTEN-RELATED DISORDERS

CD is not the only disorder related to gluten ingestion. Symptoms in IgE-mediated wheat allergy are usually immediate (urticaria, angioedema, asthma, exercise-induced anaphylaxis). Diagnosis is based on dietary challenge, in vitro assay for specific IgE, and skin testing.

Nonceliac gluten sensitivity (NCGS) is a poorly understood condition. Diagnosis is suspected in patients who do not have CD or wheat allergy, and yet show GI and non-GI symptoms upon ingestion of gluten- or wheat-containing food. In the general population, the incidence of self-reported gluten avoidance varies from 0.5% to 13%. Similar symptoms are often experienced by patients with irritable bowel syndrome (IBS), and some patients with IBS respond positively to a gluten-free diet or a diet low in fermentable oligosaccharides, disaccharides, monosaccharides, and polyols (FODMAP diet).

Visit Elsevier eBooks+ at eBooks.Health.Elsevier.com for Bibliography.

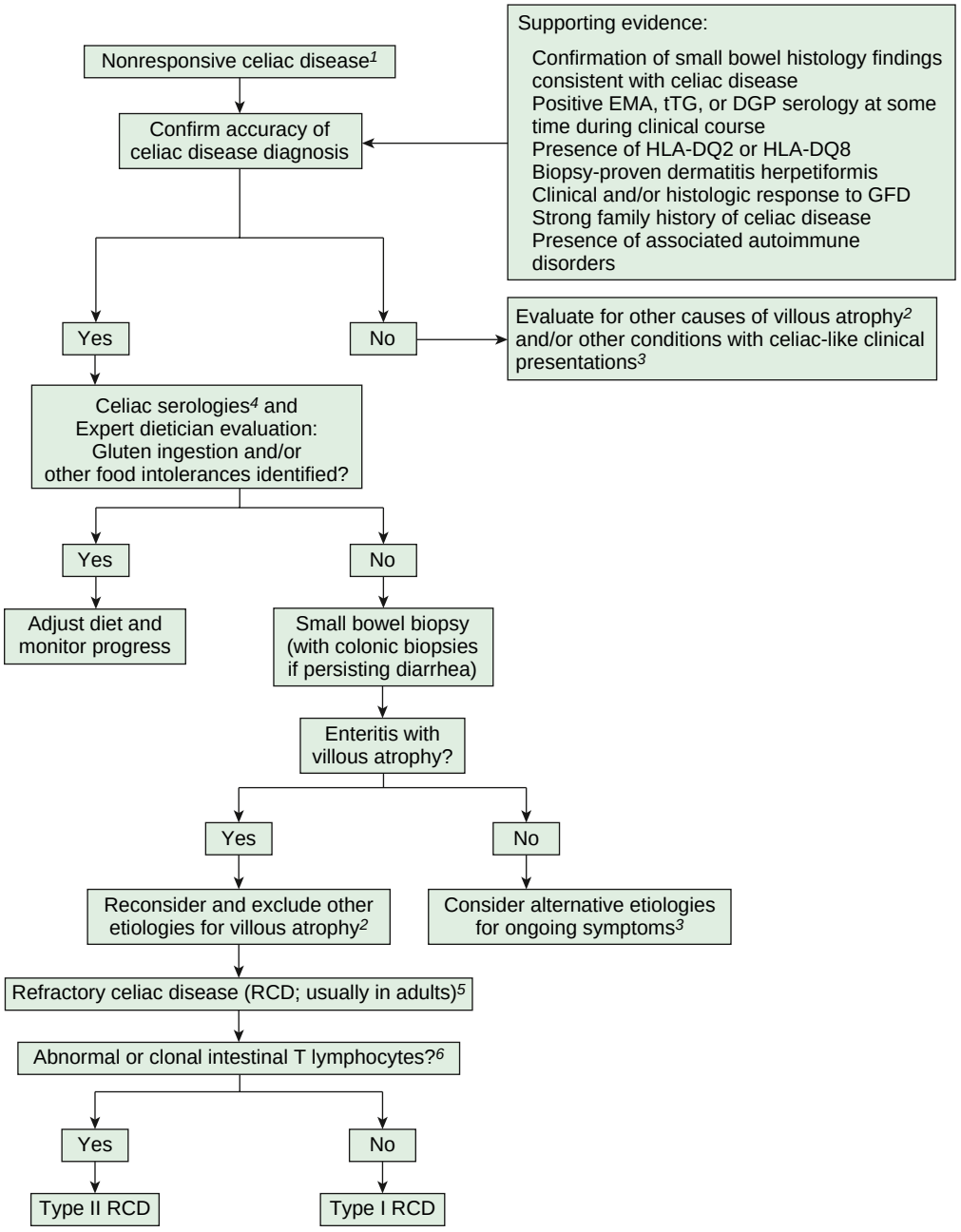

Fig. 384.3 Diagnostic algorithm for the approach to patients with nonresponsive celiac disease. [1]*Nonresponsive celiac disease* may be defined as persistent symptoms and signs despite 6-12 mo of dietary gluten avoidance. Abnormal tissue transglutaminase (tTG) can last even 2-3 yr. [2]Causes of nonceliac small intestinal villous atrophy that may be misdiagnosed as celiac disease include autoimmune enteropathy, tropical sprue, medication induced enteropathy, hypogammaglobulinemia, combined variable immunodeficiency, collagenous sprue, Crohn disease, and peptic duodenitis. [3]Conditions that present clinically in a fashion similar to celiac disease but where villous atrophy is not evident include irritable bowel syndrome (IBS), carbohydrate malabsorption, small intestinal bacterial overgrowth, Crohn's disease, and microscopic colitis. [4]Positive serologic testing for celiac disease despite 12 mo of treatment with a gluten-free diet (GFD) suggest that there may be ongoing gluten ingestion.[5]*Refractory celiac disease (RCD)* is defined as persistent or recurrent malabsorptive symptoms and signs, with small intestinal villous atrophy despite a strict GFD for more than 12 mo and in the absence of other disorders including overt lymphoma. [6]Abnormal intestinal lymphocytes may be identified by immunohistochemistry of intraepithelial lymphocytes or by flow cytometry showing an increased number of CD3-positive cells that lack CD8 or by the identification of clonal T-cell receptor gene rearrangement by molecular analysis. EMA, Endomysial antibody; DGP, deamidated gliadin peptide; HLA, human leukocyte antigen. *(Adapted from Green PHR, Paski S, Ko CW, Rubio-Tapia A. AGA clinical practice update on management of refractory celiac disease: expert review. Gastroenterology 2022;163(5):1461–1469.)*

Chapter 385

Disorders of Malabsorption

Abdul-Aziz K. Elkadri

Malabsorption is defined as a decreased intestinal absorption of one or more dietary elements. The intestinal tract requires several components to properly absorb the required elements from our diet, and the absence or improper **digestion** within the lumen or diminished or dysfunctional mucosal **absorption** is due to the lack of presence or function of these components. Due to the change in composition or volume of luminal contents, many if not all malabsorptive disorders result in diarrhea. Chronic ongoing losses further worsen the malabsorption, resulting in chronic diarrhea (see Chapter 388). Malabsorption can be categorized based on mucosal defects resulting in a more generalized malabsorption with multiple nutrient defects (Table 385.1), or due to the malabsorption of specific components such as carbohydrates, proteins, lipids, vitamins, minerals, and trace elements (Table 385.2).

CLINICAL APPROACH

Because malnutrition leads to the loss of typically absorbed components in stool, the presentation of a patient will differ depending upon the length of time with malabsorption, the extent of losses, and the phase of growth and magnitude of required nutrients. With proper follow-up, the clinical features tend to be growth related, with failure to gain weight and a stagnation of linear growth percentiles. Physical exam findings tend to be subtle, with abdominal distension, diarrhea, and even constipation as presenting features depending on the malabsorbed component. With more extensive losses or delay in presentation, the clinical features become more pronounced. Findings can include muscle wasting, loss of subcutaneous fat, and loose skinfolds (Fig. 385.1). Because toddlers have increased energy requirements, presentation in this age-group can be dramatic and more acute. In older children and adolescents, the presentation may be more subtle, with suboptimal weight gain or weight loss as a more common presentation. Height stunting tends to lag behind weight parameters. In developing areas of the world where access to health resources including enteral and parenteral nutrition (PN) continues to be limited, prolonged malabsorption may lead to death (see Chapter 64). This outcome is uncommon in the developed world, where access to healthcare leads to improved outcomes. Nonetheless, monogenetic causes of malabsorption often produce failure to thrive in any region of the world. Specific findings on examination can guide toward a specific disorder; edema is usually associated with protein-losing enteropathy (PLE), digital clubbing with conditions including cystic fibrosis and celiac disease, perianal excoriation and gaseous abdominal distention with carbohydrate malabsorption, perianal and circumoral rash with acrodermatitis enteropathica, abnormal hair with Menkes syndrome (ATP7A defects), tricho-hepato-enteric syndrome (THE), and the typical facial features diagnostic of the Johanson-Blizzard syndrome.

To compensate for the fecal losses of nutrients and calories, many children present with a history of a good appetite. In exocrine pancreatic insufficiency, fecal losses of up to 40% of ingested protein and energy do not lead to malnutrition, as long as they are compensated by an increased appetite. In conditions associated with villous atrophy or inflammation (Celiac disease, postinfectious enteropathy or Crohn disease), fecal protein and energy losses are usually modest, but associated anorexia and thus reduced food intake results in malnutrition.

The nutritional assessment is an important part of clinical evaluation in children with malabsorptive disorders (see Chapter 60). Long-term calcium and vitamin D malabsorption can lead to reduced bone mineral density and metabolic bone disease (often resistant to oral vitamin D), with increased risk of bone fractures. Vitamin K malabsorption, irrespective of the underlying mechanism (fat malabsorption, mucosal atrophy), can result in coagulopathy. Severe PLE is often associated with malabsorption syndromes (celiac disease, Crohn disease, congenital disorders of glycosylation, intestinal lymphangiectasia [IL]) and causes hypoalbuminemia and edema. Other nutrient deficiencies include iron malabsorption causing microcytic anemia and low reticulocyte count, low serum folate levels in conditions associated with mucosal atrophy, especially in the proximal part of the small intestinal tract, and low serum vitamin A and vitamin E concentrations in fat malabsorption.

Diarrhea is the main clinical expression of malabsorption. Early presentation of diarrhea in early infancy suggests a congenital defect (Table 385.3). In congenital disorders of diarrhea such as microvillus inclusion disease (MVID) and congenital sodium or chloride diarrhea, higher volume fluid losses within the stool lead to watery like diarrhea, often mistaken for urine (see Chapter 388). The onset of symptoms after the introduction of a particular food into a child's diet can provide diagnostic clues, such as with sucrose in sucrase-isomaltase (SI) deficiency. The nature of the diarrhea may be helpful: explosive watery diarrhea suggests carbohydrate malabsorption; loose, bulky stools are associated with celiac disease; and pasty, yellowish, and offensive smelling stools suggest fat malabsorption and an exocrine pancreatic insufficiency. Stool color is usually not helpful, though it may suggest blood loss if red or melena. Green stool with undigested foods can suggest rapid intestinal transit in toddler's diarrhea, which by itself is a self-limiting condition unassociated with failure to thrive.

Following medical history, physical examination, and laboratory testing (see Chapter 385.1), intestinal biopsies may assist in the diagnosis. This is usually done for chronic rather than acute diseases which are typically self-limited. Generalized mucosal villous atrophy (flat mucosa) may be associated with malabsorption of multiple *macronutrients* and *micronutrients* and has a wide range of differential diagnoses (see Chapters 384 and 385.2).

385.1 Evaluation of Children with Suspected Intestinal Malabsorption

Abdul-Aziz K. Elkadri

In a child presenting with chronic or recurrent diarrhea, the initial workup should include nucleic acid amplification tests (NAATs) (viruses, bacteria) and, when not available, by stool cultures and antibody (or antigen testing) tests for parasites. Stool microscopy for ova and parasites can look for parasites such as *Giardia*. Fecal leukocytes and calprotectin and/or lactoferrin may suggest inflammatory disorders. Acidic stool pH and positive reducing substances suggest a component of carbohydrate malabsorption. Stool osmolality helps differentiate between osmotic and secretory diarrhea. Along with a careful diet history focusing on fat intake, quantitative stool fat examination helps determine whether there is fat malabsorption. Elevated fecal α_1-antitrypsin and a low serum albumin (in the absence of hepatic or renal disease) can suggest enteral protein loss. Fecal stool elastase-1 can assess for exocrine pancreatic insufficiency.

A complete blood count, including peripheral smear for microcytic anemia, lymphopenia (lymphangiectasia), neutropenia (Shwachman-Diamond syndrome), and acanthocytosis (abetalipoproteinemia), is useful. If celiac disease is suspected, serum immunoglobulin IgA and anti-tissue transglutaminase IgA (anti-TTG IgA) antibody levels should be determined (see Chapter 384). If inflammation is suspected, CRP and ESR can be drawn. Depending on the initial test results, more specific investigations can be planned.

INVESTIGATIONS FOR CARBOHYDRATE MALABSORPTION

The measurement of acidic stool pH and the amount of reducing substances are simple screening tests for carbohydrate malabsorption. An acidic stool with a pH <5 and >2+ reducing substance suggests carbohydrate malabsorption. Sucrose or starch in the stool is not recognized

Table 385.1 Malabsorption Disorders and Chronic Diarrhea Associated with Generalized Mucosal Defect

ACQUIRED AUTOIMMUNITY
Celiac disease (Gluten sensitive enteropathy)
Cow's milk and other protein intolerance enteropathy
Eosinophilic enteropathy
Crohn disease
Immune Dysregulation
Congenital immunodeficiency disorders
Selective immunoglobulin A deficiency (associated with celiac disease)
Severe combined immunodeficiency
Agammaglobulinemia
X-linked hypogammaglobulinemia
Wiskott-Aldrich syndrome
Common variable immunodeficiency disease
Chronic granulomatous disease
IPEX (immune dysregulation, polyendocrinopathy, enteropathy, X-linked inheritance) and IPEX-like syndromes (tregopathies)
Autoimmune polyendocrine candidiasis ectodermal dystrophy syndrome type 1 (APECED)
CONGENITAL BOWEL MUCOSAL DEFECTS
Microvillus inclusion disease
Tufting enteropathy
Carbohydrate-deficient glycoprotein syndrome
Enterocyte heparan sulfate deficiency
Tricho-hepatic-enteric syndrome
Enteroendocrine Cell Dysfunction
Enteric anendocrinosis *(NEUROG3)*
Proprotein convertase 1/3 deficiency *(PCSK1)*
ACQUIRED IMMUNE DEFICIENCY
HIV infection
Immunosuppressive therapy and post bone marrow transplantation
Mechanical Defects
Short bowel syndrome
Blind loop syndrome
Pseudoobstruction
MISCELLANEOUS
Lymphangiectasia
Immunoproliferative small intestinal disease
Radiation enteritis
Protein-calorie malnutrition

as a reducing sugar until after hydrolysis with hydrochloric acid, which converts them to reducing sugars.

Breath hydrogen test is used to identify the specific carbohydrate that is malabsorbed. After an overnight fast, the suspected sugar (lactose, sucrose, fructose, or glucose) is administered as an oral solution (carbohydrate load up to 2 g/kg, maximum total of 25 g, depending on the specific carbohydrate type). In malabsorption, the sugar is not digested or absorbed in the small bowel; it passes on to the colon and is metabolized by the normal gut microflora. One of the products of this process is hydrogen gas, which is absorbed through the colon mucosa and excreted in the breath. Because human cells are incapable of producing hydrogen, increased hydrogen concentration in the breath samples suggests carbohydrate malabsorption. A rise in breath hydrogen of 20 parts per million (ppm) above the baseline, preferably with associated symptoms, is considered a positive test. The child should not be on antibiotics at the time of the test because antibiotics may suppress the colonic flora, which is essential for fermenting the sugar. Care should be taken in the interpretation of these results as small intestinal bacterial overgrowth can lead to an early elevation of hydrogen.

Small bowel mucosal biopsies can directly measure mucosal disaccharidase (lactase, sucrase, maltase, palatinase) concentrations. In primary enzyme deficiencies the mucosal enzyme levels are low and small bowel

Table 385.2 Classification of Malabsorption Disorders and Chronic Diarrhea Based on the Predominant Nutrient Malabsorbed

CARBOHYDRATE MALABSORPTION
Lactose malabsorption
Congenital lactase deficiency
Hypolactasia (adult type)
Secondary lactase deficiency
Congenital sucrase isomaltase deficiency
Glucose galactose malabsorption
FAT MALABSORPTION
Exocrine pancreatic insufficiency
Cystic fibrosis
Shwachman-Diamond syndrome
Johanson-Blizzard syndrome
Pearson syndrome
Secondary exocrine pancreatic insufficiency
Chronic pancreatitis
Severe protein-calorie malnutrition
Decreased pancreozymin/cholecystokinin secretion
Isolated enzyme deficiency
Enterokinase deficiency
Trypsinogen deficiency
Lipase/colipase deficiency
Disrupted enterohepatic circulation of bile salts
Cholestatic liver disease
Bile acid synthetic defects
Deconjugation of bile acids (bacterial overgrowth)
Bile acid malabsorption (terminal ileal disease or resection)
Intestinal brush border disorders
Allergic enteropathy
Autoimmune enteropathy
Disorders in formation and transport of chylomicrons by enterocytes to the lymphatics
Abetalipoproteinemia
Homozygous hypobetalipoproteinemia
Chylomicron retention disease (Anderson disease)
Disorders of lymph flow
Primary or secondary lymphangiectasia
PROTEIN/AMINO ACID MALABSORPTION
Lysinuric protein intolerance (defect in dibasic amino acid transport)
Hartnup disease (defect in free neutral amino acids)
Blue diaper syndrome (isolated tryptophan malabsorption)
Oasthouse urine disease (defect in methionine absorption)
Lowe syndrome (lysine and arginine malabsorption)
Enterokinase deficiency
Protein-losing enteropathy
Congenital disorders of glycosylation
CD55 deficiency
MINERAL AND VITAMIN MALABSORPTION
Congenital chloride diarrhea
Congenital sodium diarrhea
Acrodermatitis enteropathica (zinc malabsorption)
Menkes disease (copper malabsorption)
Vitamin D–dependent rickets
Folate malabsorption
Secondary to chronic mucosal damage
Vitamin B_{12} malabsorption
Autoimmune pernicious anemia
Decreased gastric acid (H_2 blockers or proton pump inhibitors)
Terminal ileal disease (e.g., Crohn disease) or resection
Inborn errors of vitamin B_{12} transport and metabolism
Primary hypomagnesemia
DRUG INDUCED
Sulfasalazine: folic acid malabsorption
Cholestyramine: calcium and fat malabsorption
Anticonvulsant drugs such as phenytoin (causing vitamin D deficiency and folic acid and calcium malabsorption)
Gastric acid suppression: vitamin B_{12}
Methotrexate: mucosal injury

mucosal morphology is normal. Primary enzymatic deficiencies can also be diagnosed by genetic testing (see Chapters 385.8-385.10 and 388). Partial or total villous atrophy due to autoimmune disorders such as celiac disease or Crohn disease or following acute rotavirus gastroenteritis can result in secondary disaccharidase deficiency and transient lactose intolerance (see Chapters 384 and 385.2 for differential diagnosis of villous atrophy). The disaccharidase levels revert to normal after mucosal healing.

Fig. 385.1 An 18-month-old male with active celiac disease. Note the ill appearance with loose skinfolds, marked proximal muscle wasting, and distended abdomen.

INVESTIGATIONS FOR FAT MALABSORPTION

The presence of fat globules in the stool suggests fat malabsorption. The ability to absorb fat varies with age. While on a typical diet, a premature infant can absorb only 65–75% of dietary fat, a full-term infant absorbs almost 90%, and an older child absorbs more than 95% of fat. Quantitative determination of fat malabsorption requires a 3-day stool collection and dietary fat intake recall for evaluation of fat excretion and determination of the coefficient of fat absorption:

Coefficient of fat absorption % = (fat intake − fecal fat losses/fat intake) × 100

where fat intake and fat losses are in grams. Because fecal fat balance studies are cumbersome, expensive, and unpleasant to perform, simpler tests are often preferred. Among these stool tests, the acid steatocrit test is the most reliable. When bile acid (BA) deficiency is suspected of being the cause of fat malabsorption, the evaluation of BA levels in duodenal fluid aspirate may be useful. Intestinal mucosal abnormalities may not affect only fat absorption, but shorter intestinal transit time may also result in steatorrhea. Steatorrhea from intestinal mucosal disorders such as celiac disease or cow's milk protein enteropathy are usually far less severe in than in exocrine pancreatic insufficiency.

Exocrine pancreatic insufficiency and other fat malabsorption disorders (see Table 385.2) are usually associated with deficiencies of fat-soluble vitamins A, D, E, and K. Serum concentrations of vitamins A, D, and E can be measured. A prolonged prothrombin time is an indirect test to assess vitamin K malabsorption and subsequent deficiency.

INVESTIGATIONS FOR PROTEIN-LOSING ENTEROPATHY

Dietary and endogenous proteins secreted into the bowel are usually completely absorbed; minimal amounts of protein from these sources pass into the colon. The majority of stool nitrogen is derived from gut bacterial proteins. Excessive bowel protein loss usually manifests as

Table 385.3 Disorders Leading to Early-Onset Diarrhea

CATEGORY	DISORDER	GENE(S) INVOLVED	INHERITANCE	FEATURES
Defects in epithelial nutrient and electrolyte transport	Congenital chloride diarrhea	*SLC26A3*	AR	• High chloride in stools • Founder effect from Saudi Arabia (Taif region) and Finland • Premature with IUGR • Absence of meconium • Polyhydramnios and dilated loops of bowel on prenatal imaging, abdominal distension after birth • 24% had renal involvement (chronic kidney disease) • Dental carries • Some overlap with Bartter and Gitelman syndrome
	Congenital sodium diarrhea	*SLC9A3* *GUCY2C*	AR AD	• Increased risk of development of IBD • Polyhydramnios and dilated loops of bowel on prenatal imaging • High sodium in stools • Diarrhea may improve with time
	Glucose-galactose malabsorption	*SLC5A1*	AR	• Treatment requires avoidance of all sugars other than fructose
	Primary bile acid diarrhea	*SLC10A2* *SLC51B*	AR AR	• Associated with cholestasis, increased gamma-glutamyl transferase level, and fat-soluble vitamin deficiency
	Acrodermatitis enteropathica	*SLC39A4*	AR	• Perioral and extremity lesions, alopecia, and diarrhea • Recurrent infection from immune dysfunction

Table 385.3 Disorders Leading to Early-Onset Diarrhea—cont'd

CATEGORY	DISORDER	GENE(S) INVOLVED	INHERITANCE	FEATURES
Defects in epithelial enzymes and metabolism	Congenital lactase deficiency	*LCT*	AR	• Rare form of inherited diarrhea
	Congenital sucrase-isomaltase deficiency	*SI*	AR	• Bloating, diarrhea, and rarely associated with failure to thrive • High prevalence in Greenland and Inuit (5%), with 0.2% prevalence in Europeans • Variable phenotype
	Trehalase deficiency	*TREH*	AR	• Up to 8% of Greenland population • Similar to lactase deficiency
	Enterokinase deficiency	*TMPRSS15*	AR	• Deficiency of activator of pancreatic enzymes
	DGAT1 deficiency	*DGAT1*	AR	• Fat-soluble vitamin deficiency • Avoidance of enteral lipids seems to help
	Sieving protein-losing enteropathy	*PLVAP*	AR	• Protein loss of specific sizes • Syndromic with hydrops, dysmorphic facies, cardiac and renal abnormalities
	Abetalipoproteinemia	*MTTP*	AR	• Enterocytes show lipid-filled vacuoles • Steatorrhea and failure to thrive • Later noted to have fat-soluble vitamin deficiency and bleeding issues
	Hypobetalipoproteinemia	*APOB*	AR	
	Chylomicron retention disease	*SAR1B*	AR	
	Dyskeratosis congenita	*DKC1* *RTEL1*	X AR	• Nail pitting, leukoplakia, and immune defects
	Kabuki syndrome	*KMT2D*	AD	• Multiple congenital anomalies with varying phenotype
Defects in epithelial trafficking and polarity	Microvillus inclusion disease	*MYO5B*	AR	• Microvilli seen on electron microscopy are periodic acid–Schiff positive • May be associated with Fanconi syndrome
		STX3	AR	• Rare form; may be associated with neurologic findings
	Tufting enteropathy	*EPCAM*	AR	• Teardrop-shaped tufts of enterocytes throughout the intestine
	Syndromic sodium-losing diarrhea	*SPINT2*	AR	• Phenotype similar to tufting enteropathy, but with sodium-losing diarrhea
	Trichohepatoenteric syndrome	*TTC37*	AR	• Woolly hair, SCID-like phenotype and hepatic defects
		SKIV2L	AR	
	Familial hemophagocytic lymphohistiocytosis type 5	*STXBP2*	AR	• Recurrence after HSCT, villous blunting
	Multiple intestinal atresia	*TTC7A*	AR	• Variable phenotype with multiple intestinal atresia, SCID-like phenotype, and enterocolitis
Enteroendocrine cell dysfunction	Enteric anendocrinosis	*NEUROG3*	AR	• Severe malabsorptive diarrhea, neonatal-onset diabetes mellitus, and normal intestinal biopsies
	Proprotein convertase 1/3 deficiency	*PCSK1*	AR	• Age-dependent phenotype. Infants have TPN-dependent diarrhea and failure to thrive; later appear to lose intestinal phenotype and develop multiple endocrine abnormalities
	X-linked lissencephaly with abnormal genitalia	*ARX*	X	• Seizures, abnormal genitalia, survival between 6 days and 6 yr
	Mitchell-Riley syndrome	*RFX6*	AR	• Lack of enteroendocrine cells
	Intractable congenital diarrhea in infants	*ICR*	AR	• Secretory diarrhea caused by a noncoding variant with wide-ranging effects on multiple intestinal genes

Continued

Table 385.3 Disorders Leading to Early-Onset Diarrhea—cont'd

CATEGORY	DISORDER	GENE(S) INVOLVED	INHERITANCE	FEATURES
Immune dysregulation–associated enteropathy	Immune dysregulation, polyendocrinopathy, enteropathy X-linked	*FOXP3*	X	• Polyendocrinopathy
	Common variable immune deficiency (CVID) type 1	*ICOS*	AR	• Variable presentation; may have dietary-induced diarrhea
	CVID type 8	*LRBA*	AR	
	ADAM17 deficiency	*ADAM17*	AR	• Fatal in most patients
	EGFR deficiency	*EGFR*	AR	• Described in three patients
	CTLA-4	*CTLA-4*	AD	• Similar to LRBA; may respond to abatacept
	CD55 deficiency	*CD55*	AR	• Protein-losing enteropathy and thrombosis
	X-linked inhibitor of apoptosis	*XIAP*	X	• Responsive to HSCT

AD, Autosomal dominant; AR, autosomal recessive; EGFR, epidermal growth factor receptor; HSCT, hematopoietic stem cell transplantation; IBD, inflammatory bowel disease; IUGR intrauterine growth restriction; SCID, severe combined immunodeficiency; TPN, total parenteral nutrition; X, X-linked.
From Elkadri AA. Congenital diarrheal syndrome. *Clin Perinatol.* 2020;47:87–104. Table 2.

hypoalbuminemia. Because the most common cause of hypoalbuminemia in children is a renal disorder, urinary protein excretion must be determined. Other potential causes of hypoalbuminemia include acute infection, liver disease (reduced production), and inadequate protein intake. Very rarely hypoalbuminemia can result from an extensive skin disorder (burns) causing protein loss via the skin. Measurement of stool α_1-antitrypsin is a useful screening test for PLE. This serum protein has a molecular weight similar to albumin; however, unlike albumin it is resistant to digestion in the gastrointestinal (GI) tract. Excessive α_1-antitrypsin excretion in the stool should prompt further investigations to identify the specific cause of intestinal or stomach (Ménétrier disease) protein loss (Table 385.4).

INVESTIGATIONS FOR EXOCRINE PANCREATIC FUNCTION

Cystic fibrosis (see Chapter 454) is the most common cause of exocrine pancreatic insufficiency in children; therefore a sweat chloride test must be performed before embarking on invasive tests to investigate possible exocrine pancreatic insufficiency (Fig. 385.2). Many cases of cystic fibrosis are detected by neonatal genetic screening programs; occasional rare pathogenic variants are undetected. Other etiologies are noted in Table 385.5.

Fecal elastase-1 estimation is a sensitive test to assess exocrine pancreatic function in chronic cystic fibrosis and pancreatitis. Elastase-1 is a stable endoprotease unaffected by exogenous pancreatic enzymes. One disadvantage of the fecal elastase-1 test is the lack of full differentiation between primary exocrine pancreatic insufficiency and exocrine pancreatic dysfunction secondary to intestinal villous atrophy. The proximal small bowel is the site for pancreozymin/cholecystokinin production; the latter is the hormone that stimulates enzyme secretion from the exocrine pancreas. Mucosal atrophy can lead to diminished pancreozymin/cholecystokinin secretion and subsequently to exocrine pancreatic insufficiency. Fecal elastase-1 can also give a false-positive result during acute episodes of diarrhea.

Serum trypsinogen concentration can also be used as a screening test for exocrine pancreatic insufficiency. In cystic fibrosis, the levels are greatly elevated early in life, and then they gradually fall, so that by 5-7 years of age, most patients with cystic fibrosis with pancreatic insufficiency have subnormal levels. Patients with cystic fibrosis and adequate exocrine pancreatic function tend to have normal or elevated levels. In such patients, observing the trend in serial serum trypsinogen estimation may be useful in monitoring exocrine pancreatic function. In Shwachman-Diamond syndrome, another condition associated with exocrine pancreatic insufficiency, the serum trypsinogen level is low.

Other tests for pancreatic insufficiency (nitroblue tetrazolium–paraaminobenzoic acid test and pancreolauryl test) measure urine or breath concentrations of substances released and absorbed across the mucosal surface following pancreatic digestion. These tests lack specificity and are rarely used in clinical practice.

The gold standard test for exocrine pancreatic function is direct analysis of duodenal aspirate for volume, bicarbonate, trypsin, and lipase upon secretin and pancreozymin/cholecystokinin stimulation. This involves duodenal intubation (see Chapter 396) and is technically difficult.

INVESTIGATIONS FOR INTESTINAL MUCOSAL DISORDERS

Establishing a specific diagnosis for malabsorption often requires histologic examination of small bowel mucosal biopsies. These are obtained during endoscopy, allowing multiple biopsies to be performed. Mucosal involvement can often be patchy, especially in milder forms of celiac disease or Crohn disease. Periodic acid–Schiff (PAS) staining of mucosal biopsies collected in formalin and electron microscopy biopsies collected in fixatives such as glutaraldehyde are necessary in congenital diarrhea to assess cellular ultrastructure and diagnose disorders such as congenital microvillus inclusion disease. Bowel mucosal lesions can also be segmental in cases of intestinal lymphangiectasia. In these situations, radiographic small bowel series, repeated ultrasonographies, lymphoscintigraphy, and/or MRI lymphangiography can identify a region of thickened bowel responsible for protein loss. Intestinal biopsies can also detect infectious agents such as *Giardia lamblia*. During endoscopy, mucosal biopsies can be obtained to measure mucosal disaccharidase activities. Duodenal aspirates can be performed to measure pancreatic enzyme concentration as well as quantitative bacterial cultures.

IMAGING PROCEDURES

Plain radiographs and barium contrast studies might suggest a site and cause of intestinal motility disorders. Although flocculations of barium and dilated bowel with thickened mucosal folds have been attributed to diffuse malabsorptive lesions such as celiac disease, these abnormalities are nonspecific. Diffuse fluid-filled bowel loops during sonography also suggest malabsorption. MRI enterography, though technically difficult in younger children due to the prolonged image acquisition time, provides information about small bowel inflammation and the extent of involvement.

Visit Elsevier eBooks+ at eBooks.Health.Elsevier.com for Bibliography.

Table 385.4 Etiology of Protein-Losing Enteropathy

CATEGORIES		AGENT, DISEASES (*GENE*)
Gastrointestinal infections		CMV, rotavirus, HIV enteropathy *Salmonella, Shigella, Campylobacter, Clostridium difficile, Helicobacter pylori* Whipple disease Small bowel bacterial overgrowth Giardiasis *Strongyloides stercoralis* Tuberculosis
Gastrointestinal inflammatory disorders		Ménétrier disease Eosinophilic gastroenteropathy Food (milk, others)-induced enteropathy Celiac disease Crohn disease Ulcerative colitis Tropical sprue Radiation enteritis GVHD NEC Malrotation/volvulus Lymphoproliferative disorder (posttransplant)
Malignancies		Adenocarcinomas Lymphomas Kaposi sarcoma Neuroblastoma Langerhan cell histiocytosis
Vasculitic disorders		IgA vasculitis (Henoch-Schönlein purpura) Systemic lupus erythematosus
Drugs		NSAID-induced enteropathy
Metabolic/genetic		Congenital disorders of glycosylation (CDG) Variants in *DGAT1* gene Variants in CD55 Congenital enterocyte heparan sulfate deficiency *(ALG6)* *PVLAP* -associated diarrhea Infantile systemic hyalinosis *(ANTRX2)* Familial polyposis *(SMAD4)*
Intestinal lymphangiectasia	Congenital/primary IL Syndromal/genetic/metabolic	Turner, Noonan, Klippel–Trenaunay–Weber Hennekam *(CCBE1, FAT4)* syndromes PLE with skeletal dysplasia *(FGFR3)* Generalized lymphatic dysplasia *(PIEZO1)*
	Secondary	
	Inflammation	Sarcoidosis
	Radiotherapy	Retroperitoneal fibrosis
	Neoplastic disorders	Retroperitoneal malignancies, lymphoma
	Cardiac disorders	Constrictive pericarditis, after Fontan operation, CHF
	Other	Budd-Chiari syndrome, lymphatic-enteric fistula

CHF, Congestive heart failure; CMV, cytomegalovirus; GVHD, graft-versus-host disease; IL, intestinal lymphangiectasia; NEC, necrotizing enterocolitis, NSAID, nonsteroidal antiinflammatory drug; PLE, protein-losing enteropathy.
From Kliegman RM, Toth H, Bordini BJ, Basel D, eds. *Nelson Pediatric Symptom-Based Diagnosis*, 2nd ed. Philadelphia: Elsevier; 2023: Table 12.10, p. 221.

385.2 Other Malabsorptive Syndromes

Abdul-Aziz K. Elkadri

DEFECTS OF ENTEROCYTE DIFFERENTIATION AND POLARIZATION

This group mainly includes two conditions characterized by typical histologic and ultrastructural lesions in the intestinal biopsies, microvillus inclusion disease (MVID) and congenital tufting enteropathy (CTE). Tricho-hepato-enteric syndrome (THE) or syndromic/phenotypic diarrhea is also usually classified in this group.

MICROVILLUS INCLUSION DISEASE (CONGENITAL MICROVILLUS ATROPHY)

MVID is an autosomal recessive disorder that manifests at birth with profuse watery *secretory diarrhea*. A late-onset variant, with onset 2-3 months postnatally, has also been described. It is the most severe cause of congenital diarrhea involving the development of the intestinal mucosa. Light microscopy of the small bowel mucosa demonstrates diffuse thinning of the mucosa, with hypoplastic villous atrophy and no inflammatory infiltrate. If MVID is suspected, electron microscopy should be performed as it shows enterocytes with electron-dense secretory granules as well as vesicles containing microvilli (Fig. 385.3). Using PAS and CD10 staining, light microscopy may show an absent or thin brush border with PAS-positive intracellular inclusions. Polyhydramnios is observed on prenatal sonography, and neonates usually present with very early onset severe watery diarrhea (up to 200-330 mL/kg/day) causing dehydration and failure to thrive. Despite parenteral nutrition, diarrhea continues; fluid management is difficult. Fanconi syndrome has been described in two unrelated patients with MVID, leading to increased renal fluid losses, aminoaciduria, renal tubular acidosis, and resulting phosphaturia with hypophosphatemic rickets. Disease causing variations of the *MYO5B* gene coding for a nonconventional motor

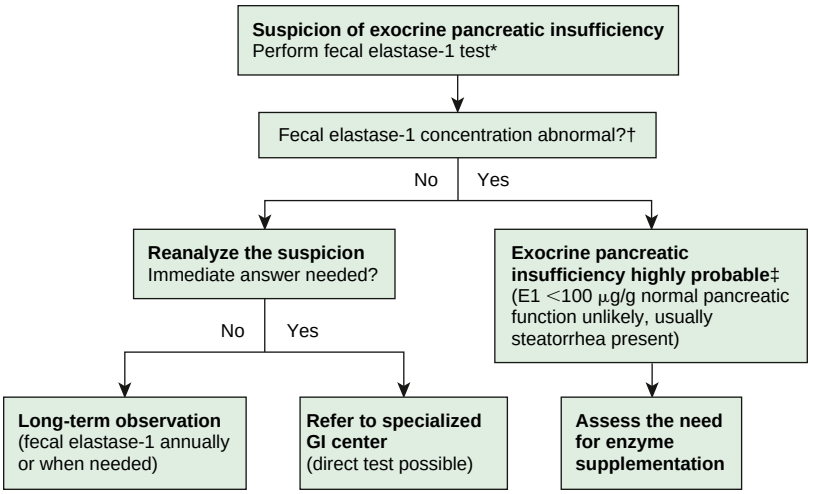

Fig. 385.2 Algorithm for assessment of exocrine pancreatic function. *If not available, use another test. Perform appropriate imaging studies of the pancreas. †In case of borderline values, consider repeating the test with three independent samples. ‡Consider differential diagnosis (especially consider mucosal villous atrophy and dilution effect of watery stool). GI, Gastrointestinal. *(Modified from Walkowiak J, Nousia-Arvanitakis S, Henker J, et al. Indirect pancreatic function tests in children. J Pediatr Gastroenterol Nutr. 2005;40:107–114.)*

Table 385.5 Pancreatic Disorders Leading to Early-Onset Chronic Diarrhea

DISEASE	GENETICS	SYMPTOMS	DIAGNOSIS
Cystic fibrosis	• AR • Pathogenic genetic variants involving CFTR • More than 1,300 pathogenic genetic variants have been described • Most common is pathogenic genetic variant ΔF508	• Meconium ileus in neonate • Megacolon • Chronic diarrhea from pancreatic insufficiency starting from 1 mo of age • Failure to thrive • Conjugated hyperbilirubinemia	• Low stool elastase • High sweat chloride (>60 mEq/L) • Newborn screening • Molecular genetic testing
Shwachman-Diamond syndrome	• AR • *SBDS* gene in over 90%	• Chronic diarrhea from pancreatic insufficiency • Bone marrow failure • Skeletal changes • Pancreatic lipomatosis on diagnostic imaging (ultrasound or computed tomography)	• Clinical features • Molecular genetic testing
Johanson-Blizzard syndrome	• AR • *UBRI* gene	• Chronic diarrhea from pancreatic insufficiency • Dysmorphic features: aplastic alae nasi, extension of the hairline to the forehead with upswept frontal hair, low-set ears, large anterior fontanel, micrognathia, thin lips, microcephaly, aplasia cutis (patchy distribution of hair with areas of alopecia), dental anomalies, poor growth, and anorectal anomalies (mainly imperforate anus)	• Clinical features • Molecular genetic testing
Pearson syndrome	Sporadic: caused by de novo single, large deletions of mtDNA, which can range from 1,000 to 10,000 nucleotides	• Chronic diarrhea from pancreatic insufficiency • Sideroblastic anemia, variable neutropenia, thrombocytopenia, and vacuolization of bone marrow precursors • Lactic acidosis and liver failure	• Clinical features • Molecular genetic testing

AR, Autosomal recessive; CFTR, cystic fibrosis transmembrane conductance regulator; mtDNA, mitochondrial DNA.
From Kliegman RM, Toth H, Bordini BJ, Basel D, eds. *Nelson Pediatric Symptom-Based Diagnosis*, 2nd ed. Philadelphia: Elsevier; 2023: Table 14.12, p. 253.

protein, myosin Vb, results in MVID as is described in a cohort of patients suffering from early-onset MVID.

MYO5B disease causing variants result in mislocalization of apical proteins and disrupted enterocyte polarization, leading to the visualized inclusions in MVID. Another gene, the t-SNARE syntaxin3 *(STX3)*, has been described in patients with a milder form of MVID. Patients with pathologic variants in the STX3 binding protein *STXBP2/Munc18-2*, causing **familial hemophagocytic lymphohistiocytosis type 5**, also demonstrates microvillous atrophy and histologic findings reminiscent of MVID. Loss of STX3 or Munc18-2 inhibits the fusion of vesicles with the apical membrane, resulting in the intracellular retention of apical proteins. *MYO5B* disease causal variants have also been identified in several patients with **progressive familial intrahepatic cholestasis (PFIC)**-like phenotype with normal serum gamma-glutamyl transferase activity and without intestinal disease. Variants in MYO5B have been identified in children of Navajo descent presenting with severe infantile diarrhea.

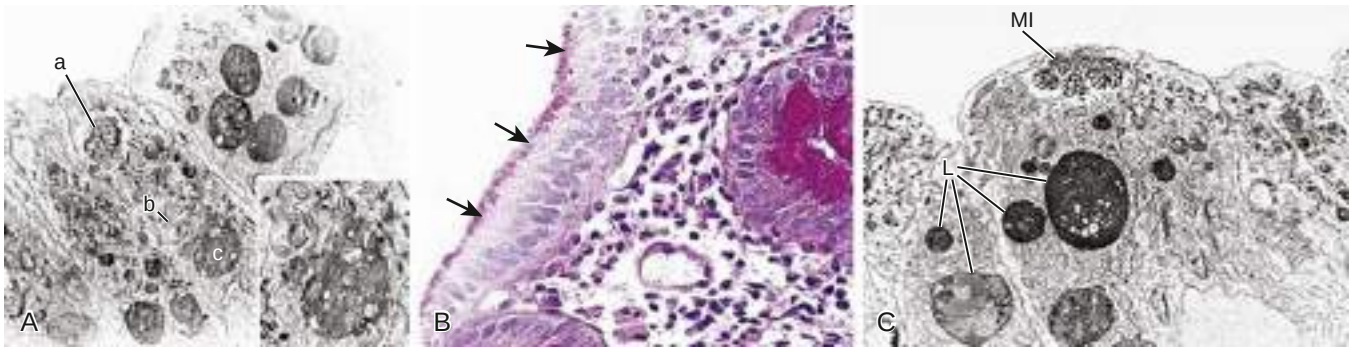

Fig. 385.3 Microvillus inclusion disease. **A,** From top to bottom: microvillus inclusion *(a)*, a granule with few microvilli *(b)*, and a lysosome *(c)* detected in the same enterocyte. *Inset:* Higher magnification of *b* and *c* ×11,000, inset ×21,500. **B,** Microvillus inclusion disease. Periodic acid–Schiff (PAS) staining highlights abundant PAS-positive material *(arrows)* in the apical part of the enterocyte cytoplasm. **C,** Microvillus inclusion disease. The villous enterocytes lack brush border microvilli, whereas their apical cytoplasm contains a microvillus inclusion *(MI)* and numerous lysosomes *(L)* ×5,500. *(A from Morroni M, Cangiotti AM, Guarino A, et al. Unusual ultrastructural features in microvillous inclusion disease: a report of two cases. Virchows Arch. 2006;448:805–810.)*

Management includes parenteral nutrition and, depending upon the severity of the diarrhea, intestinal transplantation (see Chapter 386).

TUFTING ENTEROPATHY (CONGENITAL TUFTING ENTEROPATHY)

CTE (intestinal epithelial dysplasia) manifests in the first few weeks of life with persistent watery diarrhea; it accounts for a small fraction of infants with *intractable diarrhea of infancy*. The distinctive feature on small intestinal mucosal biopsy is focal epithelial tufts (teardrop-shaped groups of closely packed enterocytes with apical rounding of the plasma membrane) involving 80–90% of the epithelial surface. The typical pathology does not appear immediately after birth; other enteropathies may show tufts on the epithelial surface.

CTE is a phenotypic and genetic heterogenous condition. Genetic studies identified causal variants in the epithelial cell adhesion molecule *(EPCAM)* gene in 73% of patients and causal variants in the serine protease inhibitor Kunitz type 2/hepatocyte growth factor activator inhibitor type 2 *SPINT2/HAI2* gene in 21%. A minority of patients do not carry any identifiable variants in either gene. The phenotype associated with pathologic variants of *EPCAM* is usually an isolated congenital diarrhea without associated extra digestive symptoms, except late-onset arthritis or superficial punctuate keratitis. In the **syndromic** form of CTE, diarrhea is associated with one or more of these same anomalies: superficial punctate keratitis (100%), choanal atresia (50%), esophageal or intestinal atresia, anal imperforation, hair dysplasia, skin hyperlaxity, bone abnormalities, hexadactylia, and facial dysmorphism.

No specific treatment exists, and as for MVID, management requires permanent parenteral nutrition with possible intestinal transplantation (see Chapter 386).

TRICHO-HEPATO-ENTERIC SYNDROME (SYNDROMIC DIARRHEA)

THE, also known as *syndromic diarrhea* (SD), is a congenital enteropathy manifesting with early onset of severe diarrhea. Patients are born small for gestational age and present with diarrhea starting in the first 6 months of life. They are noted to have facial dysmorphism with a prominent forehead, broad nose, and hypertelorism. Their hair is noted to have a poor pigmentation, with hair follicles showing **trichorrhexis nodosa,** a distinctly woolly, fragile, and uncombable presentation. Abnormal cutaneous lesions including café-au-lait on the lower limbs have been observed. Liver disease affects about half of the patients, with extensive fibrosis or cirrhosis observed. Cardiac abnormalities and colitis have been reported sporadically, as well as one case involving polyhydramnios, placental abnormalities, and congenital hemochromatosis. The immune phenotype is characterized by defective antibody responses to vaccination, with some patients with hypogammaglobulinemia that improves over time. Antigen-specific skin tests are defective despite positive proliferative responses in vitro. Patients with THE can also present as very early onset inflammatory bowel disease (VEO-IBD; see Chapter 382.3) with involvement of any portion of the GI tract. Small bowel biopsies show nonspecific villous atrophy with or without mononuclear cell infiltration of the lamina propria, and without specific histologic abnormalities involving the epithelium. Causal variants in either tetratricopeptide repeat domain 37 *(TTC37)* gene (60%) or *SKIV2L* (40%) have been identified as a cause of THE syndrome. Enterocytes with *TTC37* variants show reduced expression of brush border–associated NHE-2 and -3, aquaporin-7, the Na^+/I- symporter, and the H^+/K^+-ATPase or mislocalization relative to their normal pattern. Prognosis of this type of intractable diarrhea of infancy is noted to be poor. The long-term follow-up of these children reported that at 15 years about 50% of patients were alive or have been weaned off PN. The main complications are liver disease and infections. Most of the children achieve short final stature, and half are slightly developmentally delayed.

DEFECTS IN ENTEROENDOCRINE CELLS DIFFERENTIATION

This class of congenital diarrhea is characterized by abnormal enteroendocrine cell development, function, or complete absence. The genes causing these disorders encode either transcription factors essential for the development of all or a subset of enteroendocrine cells, or cellular proteins/endopeptidases that are required for the production of active hormones from prohormones. These conditions manifest with *osmotic* diarrhea and may be associated with additional systemic endocrine disorders. The treatment is nutritional support and hormonal replacement if needed. Defects in four genes have been associated with the diseases classified in this group: *NEUROG3, RFX6, ARX,* and *PCSK1*.

ENTERIC ANENDOCRINOSIS

NEUROG3 is a key transcription factor that controls the fate of endocrine cells in both the pancreas and intestine. Variants of the *NEUROG3* gene produce generalized mucosal malabsorption, vomiting, diarrhea, failure to thrive, dehydration, and a hyperchloremic metabolic acidosis. Oral alimentation with anything other than water produces diarrhea. Villus-crypt architecture in small bowel biopsies is normal, but staining for neuroendocrine cells using immunohistochemistry staining for chromogranin A demonstrates a complete absence of this secretory cell lineage with the preservation of goblet cells and Paneth cells.

PROPROTEIN CONVERTASE 1/3 DEFICIENCY

Autosomal recessive proprotein convertase 1/3 (PC1/3) deficiency, caused by variants in the *PCSK1* gene, is characterized by severe congenital malabsorptive diarrhea requiring parenteral nutrition, childhood-onset obesity, and other endocrine abnormalities. All functional hormones produced by endocrine cells, including those in the gut, are processed by a specific Ca^{2+}-dependent serine endoprotease named proprotein convertase 1/3 (also known as neuroendocrine convertase 1). Chronic watery, neonatal-onset diarrhea is described in infants with hyperinsulinism, hypoglycemia, hypogonadism, and hypoadrenalism. A small bowel biopsy reveals a nonspecific

enteropathy. Growth hormone deficiency, adrenal insufficiency, central diabetes insipidus, and hypogonadism are commonly observed.

MITCHELL-RILEY SYNDROME

Mitchell-Riley syndrome is a complex clinical phenotype that includes severe intrauterine growth restriction, neonatal diabetes, multiple GI anomalies including duodenal atresia, intestinal malrotation, gallbladder agenesis, abnormal biliary tract, and an annular pancreas. They also have chronic *osmotic* diarrhea. Several probands previously reported with Mitchell-Riley syndrome were found to carry pathologic variants in *RFX6*. DNA-binding protein RFX6 (regulatory factor X6; encoded by *RFX6*) is a winged helix transcription factor downstream of the neurogenin-3 signal required for islet cell development and enteroendocrine cell function. Immunofluorescence staining in RFX6 knockout mice shows that pancreatic endocrine cells are present, but do not express the islet cell hormones including insulin, glucagon, somatostatin, and ghrelin.

ARISTALESS-RELATED HOMEOBOX GENE VARIANTS

Aristaless-related homeobox (*ARX*) gene encodes a homeodomain containing a transcription factor required for the normal development of mouse and human enteroendocrine cells. ARX expression is detected in a subset of neurogenin-3-positive endocrine progenitors and is also found in a subset of hormone-producing cells. In mice, removal of *Arx* from the developing endoderm results in a decrease of some enteroendocrine cell types, such as gastrin, glucagon/GLP-1, CCK, secretin secreting cells, and an increase of somatostatin-expressing cells. Disease causal variants in the *ARX* gene are associated with a complex X-linked disorder with a clinical phenotype of intellectual disability, seizures, lissencephaly, loss of pancreatic alpha cells, abnormal genitalia, and in approximately half of the patients, congenital malabsorptive diarrhea.

AUTOIMMUNE ENTEROPATHY

The term autoimmune enteropathy describes a subgroup of infants with severe, protracted diarrhea, no response to dietary restriction, the presence of circulating gut autoantibodies and/or associated autoimmune diseases, and the lack of another cause of severe immunodeficiency. Symptoms of autoimmune enteropathy usually occur within the first 6 months of life, presenting with chronic diarrhea, PLE, malabsorption, and failure to thrive. The diagnosis is based on the endoscopic and histologic identification of inflammation of the GI tract, more pronounced in the small bowel. Histologic findings in the small bowel include partial or complete villous atrophy, crypt hyperplasia, and an increase in chronic inflammatory cells in the lamina propria. Marked intraepithelial lymphocytosis reminiscent of celiac disease can be present in a subset of patients. Cryptitis and crypt abscesses can also be seen and may obscure the presence of apoptosis. Immunologic analyses indicate the presence of autoantibodies including *anti–enterocyte antibodies (present in ~85% of patients)*, as well as *anti–autoimmune enteropathy-related 75-kDa antigen*.

Genetic testing in patients with autoimmune enteropathy identified that the majority of patients with autoimmune enteropathy carried disease causal variants in the forkhead box P3 *(FOXP3)* gene on the X chromosome. The term *immune dysregulation*, polyendocrinopathy, enteropathy, X-linked syndrome (IPEX) is used to describe these patients. Patients not found to have a causal variant in FOXP3 had what were termed IPEX-like disorders and were found to have a variable phenotype and presented in females as well. Disease causing variants within other genes include interleukin-2 receptor A (IL2RA), LPS responsive beige-like anchor protein (LRBA), cytotoxic T-lymphocyte associated protein 4 (CTLA-4), and signal transducer and activator of transcription 1 and 3 (STAT1 and STAT3), along with others.

The differential diagnosis of pediatric autoimmune enteropathy includes other immune-mediated disorders, such as food sensitivity enteropathies (e.g., cow's milk protein intolerance and celiac disease), severe Crohn disease, and graft-versus-host disease.

Treatment options are limited and are based on nutritional support, including parenteral nutrition and glucocorticoids followed by immunosuppressive drugs. Hematopoietic stem cell transplantation is indicated in patients with a known molecular defect.

AUTOIMMUNE POLYGLANDULAR SYNDROME TYPE 1

See Chapter 165.

Defects in Lipids Transport and Metabolism

See Chapter 106.3.

After uptake from the lumen, fatty acids and monoacylglycerol are transported to the endoplasmic reticulum (ER). In the ER they are converted to triglycerides in several metabolic steps, the last of which is dependent on acyl CoA:diacylglycerol acyltransferase 1 (DGAT1). Apolipoprotein B (ApoB) and microsomal triglycerides transfer protein (MTTP) act in concert to incorporate triglycerides into chylomicrons. The newly formed chylomicrons bud from the ER in a prechylomicron transport vesicle (PCTV), which subsequently fuses with the Golgi, a process that is dependent on Sar1b. The chylomicron is then transported in a vesicle to the basal membrane, where it exits the cell.

ABETALIPOPROTEINEMIA

Abetalipoproteinemia (Bassen-Kornzweig syndrome) is a rare autosomal recessive disorder of lipoprotein metabolism associated with severe fat malabsorption and steatorrhea from birth (see Chapter 106.3). Children fail to thrive during the first year of life and have stools that are pale, foul smelling, and bulky. The abdomen is distended, and deep tendon reflexes are absent because of peripheral neuropathy secondary to vitamin E deficiency. Intellectual development tends to be delayed. After 10 years of age, intestinal symptoms are less severe, ataxia may develop, with loss of position and vibration sensation, and the onset of intention tremors. These latter symptoms reflect involvement of the posterior columns, cerebellum, and basal ganglia. In adolescence, in the absence of adequate supplement of vitamin E, atypical retinitis pigmentosa develops.

The diagnosis is suggested by the presence of acanthocytes in the peripheral blood smear and extremely low plasma levels of cholesterol (<50 mg/dL); triglycerides are also very low (<20 mg/dL). Chylomicrons and very low density lipoproteins are not detectable, and the low-density lipoprotein (LDL) fraction is virtually absent from the circulation. Marked triglyceride accumulation in villous enterocytes occurs in the duodenal mucosa. Patients with abetalipoproteinemia have pathogenic variants of the *MTTP* gene. MTTP catalyzes the transfer of triglycerides to nascent ApoB particles in the ER.

Specific treatment is not available. Nutritional support and large supplements of the fat-soluble vitamins A, D, E, and K should be given. High doses of vitamin E (100-300 mg/kg/24 hr) appears to arrest neurologic and retinal degeneration, with some children requiring higher doses based on serum levels. Limiting long-chain fat intake can alleviate intestinal symptoms; medium-chain triglycerides (MCTs) can be used to supplement fat intake.

HOMOZYGOUS HYPOBETALIPOPROTEINEMIA

Homozygous hypobetalipoproteinemia (see Chapter 106.3) is a dominantly inherited condition associated with pathogenic variants in the *APOB* gene, encoding ApoB, the apolipoprotein of the nascent chylomicron. The homozygous form is indistinguishable from abetalipoproteinemia. The parents of these patients, as heterozygotes, have reduced plasma LDL and ApoB concentrations, whereas the parents of patients with abetalipoproteinemia have normal levels. On transmission electron microscopy of small bowel biopsies, the size of lipid vacuoles in enterocytes differentiates between abetalipoproteinemia and hypobetalipoproteinemia: many small vacuoles are present in hypobetalipoproteinemia, and larger vacuoles are seen in abetalipoproteinemia.

CHYLOMICRON RETENTION DISEASE (ANDERSON DISEASE)

Chylomicron retention disease (CRD) is a rare autosomal recessive disorder caused by pathogenic variants in the *SAR1B* gene. *SAR1B* variants result in defective trafficking of nascent chylomicrons in PCTVs between the ER and the Golgi apparatus, interfering with the successful

assembly of chylomicrons and their delivery to the lamina propria. The patients with CRD have steatorrhea, chronic diarrhea, and failure to thrive. Acanthocytosis is rare, and neurologic manifestations are less severe than those observed in abetalipoproteinemia. Plasma cholesterol levels are moderately reduced (<75 mg/dL), and fasting triglycerides are normal, but the fat-soluble vitamins, particularly A and E, are very low. Treatment is early aggressive therapy with fat-soluble vitamins and modification of dietary fat intake, as in the treatment of abetalipoproteinemia.

DGAT1 VARIANTS

DGAT1 encodes for DGAT that converts diacylglycerides to triglycerides by adding an acyl CoA moiety. In the small intestine, DGAT1 helps to reassemble the triglycerides, whereas in the liver it produces triglycerides from fatty acids synthesized de novo or taken up from the circulation. The mechanism by which *DGAT1* disease causal variants causes diarrhea is unclear but is likely to involve the buildup of DGAT1 lipid substrates in the enterocytes or in the gut lumen. Pathogenic variants in *DGAT1* gene have been reported in patients presenting with failure to thrive, PLE, hypoalbuminemia, early-onset diarrhea, and oral vitamin D refractory rickets.

WOLMAN DISEASE

Wolman disease is a rare, lethal lipid storage disease that leads to lipid accumulation in multiple organs, including the small intestine and liver. In addition to vomiting, severe diarrhea, and hepatosplenomegaly, patients have steatorrhea as a result of lymphatic obstruction. Insufficient free cholesterol available for steroidogenesis in adrenal glands results in adrenal insufficiency; a characteristic pattern of subcapsular adrenal calcification represents a distinctive marker of disease. Deficiency of lysosomal acid lipase (LAL) is the underlying cause of disease (see Chapter 106.4). LAL is a lysosomal enzyme that hydrolyzes cholesteryl esters and triglycerides within endolysosomes. Loss-of-function variants in the *LIPA* gene are associated with variable phenotypes. Homozygous and compound heterozygous pathogenic variations, resulting in complete LAL deficiency, cause Wolman disease. Variants associated with residual LAL activity cause cholesteryl ester storage disease, an attenuated form of Wolman disease exhibiting a variable phenotype. Common features in infants, children, and adults include elevated serum aminotransferase levels, dyslipidemia, hepatomegaly, liver fibrosis, and cirrhosis. Wolman disease may also present with neonatal cholestasis and severe liver disease as its main feature already in infancy. Hemophagocytic lymphohistiocytosis has been reported in few infants with Wolman disease. The hallmark of the disease is the presence of *adrenal calcification* seen on imaging, and definite diagnosis is done genetically.

Hematopoietic stem cell transplantation has been reported in few patients with variable outcome. A recombinant human enzyme-replacement therapy for LAL deficiency is approved for use in patients suffering from LAL deficiency. This treatment has allowed a small number of infants with Wolman disease to achieve a relatively normal growth rate and to improve survival. In older children and adults, the enzyme has corrected their dyslipidemia and produced significant improvement in markers of hepatic function.

TANGIER DISEASE

See Chapter 106.

Cellular free cholesterol is mobilized, along with phospholipid, through the export pump ABCA1, resulting in the transfer to an extracellular ApoA-I acceptor and the formation of discoidal high-density lipoprotein (HDL) cholesterol. Loss-of-function variants in *ABCA1*genes in patients with Tangier disease cause cholesterol accumulation in the intestine, spleen, tonsils, relapsing neuropathy, orange-brown spots on the colon and ileum, and diarrhea in association with decreased plasma cholesterol levels (ApoA-I and A-II), with virtually no detectable plasma HDL. Heterozygosity of ABCA1 variants leads to low HDL levels (below the 10th percentile). Specific therapy for Tangier disease has not yet been established.

SITOSTEROLEMIA

See Chapter 106.4.

Sitosterol and other sterols are preferentially secreted back into the intestinal lumen through the sterol pump, paired half-transporters ABCG5/G8. Pathogenic variants of the *ABCG5* (sterolin-1) and *ABCG8* (sterolin-2) transporters result in the defective efflux of sterol and leads to the increased absorption of dietary sterols. The disorder is associated with tendon xanthomas, increased atherosclerosis, and hemolytic anemia. Plasma levels of phytosterols (mainly sitosterol) are typically >10 mg/dL.

BILE ACID MALABSORPTION

Bile acids (BAs) are detergent compounds secreted by and excreted from the liver, and are responsible for the solubilization of the dietary lipids, aiding in their digestion and absorption. Approximately 95% of BAs are reabsorbed in the terminal ileum and transported back to the liver, the enterohepatic circulation. The apical Na^+-dependent bile salt transporter (ASBT) or ileal BA transporter (IBAT) is responsible for the active reuptake of BAs in the terminal ileum. Pathogenic variants in the *ASBT/SLC10A2* gene are very rare and are responsible for *primary* BA malabsorption, a disease associated with congenital diarrhea, steatorrhea, and reduced plasma cholesterol levels. Unabsorbed BAs stimulate chloride excretion in the colon, resulting in diarrhea. *Secondary* BA malabsorption can result from ileal disease, such as in Crohn disease, and following ileal resection. The diagnosis of BA malabsorption is typically based on reduced BA retention of radiolabeled ^{75}selenium-homocholic acid taurine (^{75}SeHCAT), increased BA synthesis (serum C4), or increased fecal BA loss (measured by serum FGF-19 levels). In clinical practice, diagnosis is often based on the response to BA sequestrants (e.g., cholestyramine or colesevelam), which are also the treatment of choice for this disorder.

Chronic neonatal-onset diarrhea has also been described in autosomal recessive **cerebrotendinous xanthomatosis**, which is caused by pathogenic variants in CYP27A1 and results in an inborn error of BA synthesis due to 27-hydroxylase deficiency. These children also present with juvenile-onset cataracts and developmental delay. Neonatal cholestasis has also been described as a presenting feature. Tendon xanthomas develop in the second and third decades of life. The diagnosis is important to establish at a younger age, as treatment with oral chenodeoxycholic acid is effective at preventing irreversible neurologic damage.

PROTEIN-LOSING ENTEROPATHY

PLE is a rare entity caused by a variety of intestinal and extraintestinal disorders and characterized by excessive enteric loss of plasma proteins. The clinical presentation of patients with PLE is variable and depends upon the underlying cause, but generally includes edema and hypoproteinemia. Impaired synthesis (malnutrition, liver disease), protein loss through other organs (kidney or skin), or redistribution (septic states) must be excluded before considering PLE. The disorders causing PLE can be divided into those due to protein loss from an inflamed or abnormal mucosal surface or from derangements in intestinal lymphatics, such as in primary or secondary IL (see Table 385.4).

Intestinal lymphangectasia is characterized by diffuse or local dilatation of the enteric lymphatics and is located in the mucosa, submucosa, or subserosa. Lymph rich in proteins, lipids, and lymphocytes leaks into the bowel lumen, resulting in PLE, steatorrhea, and lymphocyte depletion. Hypoalbuminemia, hypogammaglobulinemia, edema, lymphopenia, malabsorption of fat and fat-soluble vitamins, and chylous ascites often occur. IL can also manifest with ascites, peripheral edema, and a low serum albumin. The etiology of *primary* IL is unknown. Several genes, including vascular endothelial growth factor receptor 3 *(VEGFR3)*, prospero-related homeobox-transcriptional factor *(PROX1)*, forkhead transcriptional factor *(FOXC2)*, and SRY (sex determining region Y)-box 18 *(SOX18)*, are involved in the development of the lymphatic system and have been shown to have altered expression in the duodenal mucosa in patients with IL. A pathogenic variant in CD55, a regulator of complement activation, has also been described as a cause for primary PLE. The diagnosis of PLE is suggested

by the typical clinical and laboratory findings in association with an elevated fecal α_1-antitrypsin clearance. Radiologic findings of uniform, symmetric thickening of mucosal folds throughout the small intestine are characteristic but nonspecific. Small bowel mucosal biopsy in patients with IL can show dilated lacteals with distortion of villi and no inflammatory infiltrate. A patchy distribution and deeper mucosal involvement on occasion causes false-negative results on small bowel histology. Video capsule endoscopy may reveal similar lesions (Figs. 385.4 and 385.5). Magnetic resonance lymphangiography may identify lymphatic abnormalities (Fig. 385.6).

Treatment of PLE is generally supportive and consists of a low-fat, high-protein diet. In patients with IL, a low-fat, high-protein diet supplemented with MCTs is recommended. Along with dietary adjustments, appropriate treatment for the underlying etiology is necessary, as well as supportive care to avoid complications of edema. Rarely, PN is required. If only a portion of the intestine is involved, surgical resection may be considered. A few patients with lymphatic malformation and generalized lymphatic anomalies were successfully treated with propranolol. Sirolimus, an mTOR inhibitor, has been used for primary IL and is thought to decrease lymphatic sprouting and proliferation. Everolimus use has been described in a patient with primary IL. Prognosis depends upon the severity and treatment options of the underlying disease.

Visit Elsevier eBooks+ at eBooks.Health.Elsevier.com for Bibliography.

385.3 Intestinal Infections and Infestations Associated with Malabsorption

Abdul-Aziz K. Elkadri

Malabsorption is a rare consequence of primary intestinal infection and infestation in immunocompetent children but is relatively common in previously malnourished or immunocompromised children and is associated with significant mortality. Often malabsorption is associated with diarrhea and triggers a vicious cycle of further weight loss and growth failure. For children living in developing countries, malabsorption is associated with long-term growth failure leading to stunting within a peculiar condition defined as environmental enteropathy, in which diarrhea is not always present. Generally, malabsorption is associated with a duration of an intestinal infection longer than expected. *Prolonged* diarrhea is an acute-onset diarrhea that lasts >7 days, whereas *chronic* diarrhea lasts >14 days, with some using 30 days as a more definitive cutoff.

POSTINFECTIOUS DIARRHEA

Chronic diarrhea can appear following infectious enteritis, regardless of the nature of the pathogen. The pathogenesis of the diarrhea is not always clear and may be related to persistent infection or reinfection, secondary lactase deficiency, food protein allergy, antibiotic-associated diarrhea, or a combination of these. In some cases, postinfectious diarrhea may be the initial manifestation of functional diarrhea, in which case it is not associated with malabsorption.

Treatment of postinfectious diarrhea is supportive and may include a lactose-free diet in the presence of secondary lactase deficiency. Some infants might require a semi-elemental diet. The beneficial effect of specific probiotic products may be indicated in selected conditions.

PROXIMAL INTESTINAL BACTERIAL OVERGROWTH

Bacteria are normally present in large numbers in the colon (10^{11}-10^{13} colony-forming units [CFU]/g of feces) and have a symbiotic relationship with the host, providing nutrients and protecting the host from pathogenic organisms. Within the stomach and small bowel, bacteria are usually present in much smaller numbers. Excessive numbers of bacteria in the stomach or small bowel are noted to be harmful. Bacterial overgrowth can result from clinical conditions that alter the gastric pH or small bowel motility, such as partial bowel obstruction, diverticula, intestinal failure, intestinal duplications, diabetes mellitus, idiopathic intestinal pseudoobstruction syndrome, and scleroderma, as well as proton pump inhibitor use. Prematurity, immunodeficiency, and malnutrition are other factors associated with bacterial overgrowth of the small bowel.

The diagnosis of bacterial overgrowth is often difficult and can be made by culturing small bowel aspirate (>10^5 CFU/mL) or by a lactulose hydrogen breath test. Lactulose is a synthetic disaccharide not digested by mucosal brush border enzymes but is fermented by bacteria producing hydrogen and methane. High baseline breath hydrogen and a quick rise in hydrogen in expired breath samples support the diagnosis of bacterial overgrowth. Some individuals (up to 30%) produce methane as a predominant by-product of carbohydrate digestion. False-positive tests are common and may be due to rapid GI transit time and colonic fermentation.

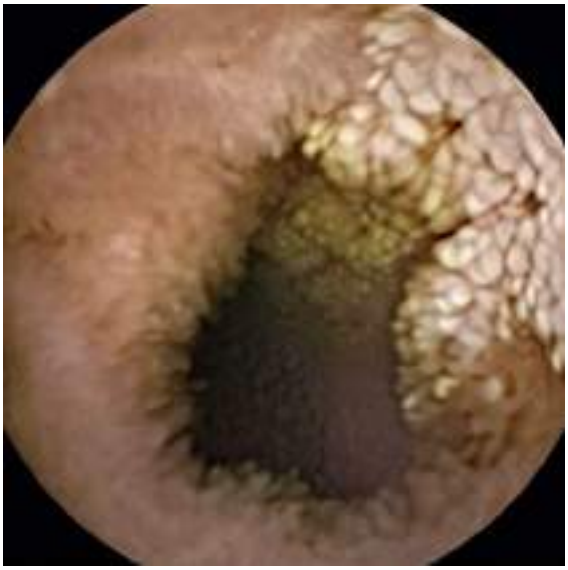

Fig. 385.4 Swollen villi detected by video capsule endoscopy in the proximal ileum. *(From Gortani G, Maschio M, Ventura A. A child with edema, lower limb deformity, and recurrent diarrhea. J Pediatr. 2012;161:1177. Fig. 1.)*

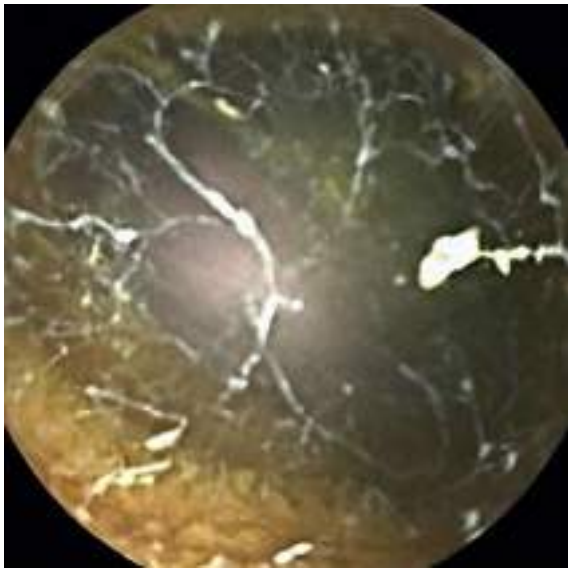

Fig. 385.5 Protein-rich lymphatic fluid aggregates detected by video capsule endoscopy in the intestinal lumen. *(From Gortani G, Maschio M, Ventura A. A child with edema, lower limb deformity, and recurrent diarrhea. J Pediatr. 2012;161:1177. Fig. 2.)*

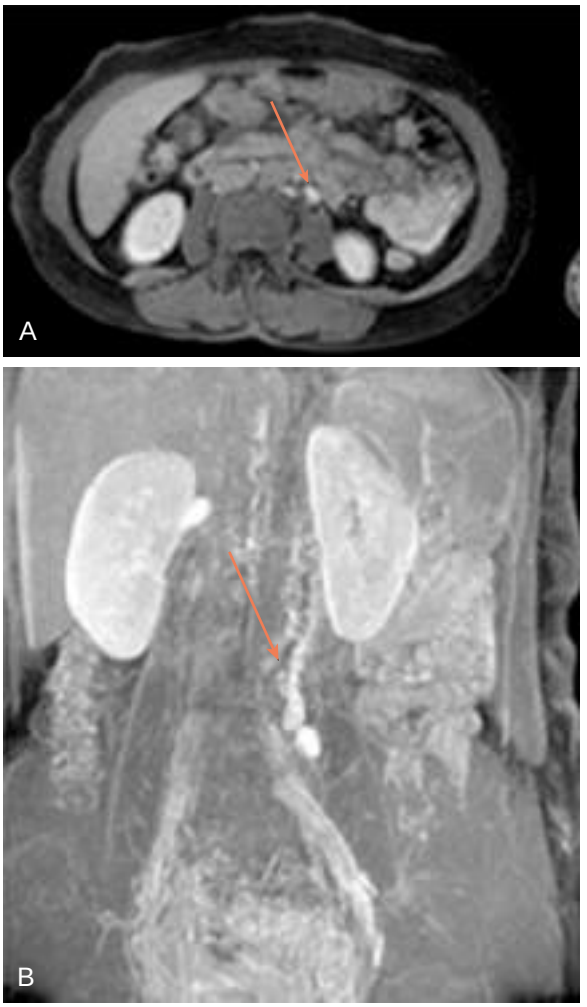

Fig. 385.6 MR lymphangiogram. **A,** Axial T1-weighted fat-saturated MR image showing contrasted-filled dilated retroperitoneal tubular channels *(arrow).* **B,** Thick maximum intensity projection of MR lymphangiogram (T1-weighted) image showing dilated retroperitoneal channels with contrast refluxing into bowel wall *(arrow)* suggestive of associated intestinal lymphangiectasia. *(From Valakada J, Madhusudhan KS, Ranjan G, et al. Abdominal lymphangiomatosis with intestinal lymphangiectasia diagnosed by magnetic resonance lymphangiography: a case study. Curr Prob Diag Radiol. 2018;47:200–202.)*

Bacterial overgrowth leads to inefficient intraluminal processing of dietary fat with steatorrhea due to bacterial deconjugation of bile salts, vitamin B_{12} malabsorption, and microvillus brush border injury with further malabsorption. Bacterial consumption of vitamin B_{12} and enhanced synthesis of folate result in decreased vitamin B_{12} and increased folate serum levels. Overproduction of *D-lactate* (the stereoisomer of L-lactate) can cause stupor, neurologic dysfunction, and shock from D-lactic acidosis. Lactic acidosis should be suspected in children at risk of bacterial overgrowth who show signs of neurologic deterioration and a high anion gap metabolic acidosis not explained by measurable acids such as L-lactate. Measurement of D-lactate is required because standard lactate assay only measures the L-isomer.

The treatment of bacterial overgrowth focuses on the correction of underlying causes such as partial obstruction. Oral metronidazole can provide relief for many months but is not always effective. The cycling of antibiotics, including azithromycin, trimethoprim-sulfamethoxazole, ciprofloxacin, and metronidazole, may be required. Other alternatives are oral nonabsorbable antibiotics such as aminoglycosides, nitazoxanide, or rifaximin. Occasionally, antifungal therapy is required to control fungal overgrowth of the bowel.

ENVIRONMENTAL ENTEROPATHY (TROPICAL SPRUE)

In developing regions of the world, an atypical subclinical form of enteropathy has been described termed environmental enteropathy (tropical sprue). Theorized to be due to chronic fecal-oral exposure, it is thought to be the result of interactions between enteric pathogens, enteropathy, and malnutrition. There is resulting malabsorption, which may be clinically evident or subclinical, at times with or without diarrhea. It is a frequent cause of death in childhood in endemic regions, particularly in South Asian areas, African countries, and other developing regions. Selected pathogens including rotavirus, *Shigella, Cryptosporidium,* and enterotoxigenic *Escherichia coli* cause the majority of intestinal infections leading to moderate to severe diarrhea and often triggers a vicious circle with malnutrition. This tends to progress to wasting and stunting with or without a clear association with diarrhea.

In addition to a high risk of death, environmental enteropathy impairs normal growth and brain development and impacts productivity. There is evidence of oral vaccine failure, pointing to an alteration of the intestinal mucosal immune system. The etiology of this disorder is unclear because it follows outbreaks of acute diarrheal disease and improves with antibiotic therapy. Individuals traveling in endemic regions have developed enteropathy similar to native residents, which improves with return to nonendemic regions. Immigrants with malabsorptive diarrhea were shown to have improved absorption and jejunal biopsies with increasing periods of residence in nonendemic countries. Therefore an infectious etiology within the endemic environment is suspected. Nevertheless, environmental enteropathy includes interrelated mechanisms such as intestinal malabsorption, increased permeability, loss of intestinal mass, inflammation, increased bacterial translocation, and impairment of immune response. The incidence is decreasing worldwide, largely because of an improvement in hygiene and access to nutrients. Clinical symptoms include fever and malaise followed by diarrhea. After about a week the acute features subside, and anorexia, intermittent diarrhea, and chronic malabsorption result in severe malnutrition characterized by glossitis, stomatitis, cheilosis, night blindness, hyperpigmentation, and edema, reflecting the various nutrient deficiencies. Muscle wasting is often marked, and the abdomen is often distended. Megaloblastic anemia results from folate and vitamin B_{12} deficiencies.

Diagnosis is made by small bowel biopsy, which shows villous flattening with crypt hyperplasia and mild intestinal inflammation, with lipid accumulation in the surface epithelium.

Treatment response with nutritional and antimicrobial interventions may be poor, with no clear improvement in weight gain. Nutritional supplementation, including supplementation of folate and vitamin B_{12} as well as glutamine, is recommended. To prevent recurrence, 6 months of therapy with oral folic acid (5-10 mg) and antibiotics are recommended. Relapses occur in 10–20% of patients who continue to reside in an endemic tropical region. This suggests a persistent environmental factor causing recurrence, and that improved overall hygiene is key to treatment and prevention. Improvements in public health infrastructure and educational interventions are the key to prevention rather than medical interventions in individual cases.

WHIPPLE DISEASE

Whipple disease is a rare childhood chronic systemic infectious disorder. It is caused by *Tropheryma whipplei,* which can be cultured from a lymph node in the involved tissue.

The most common symptoms in Whipple disease are diarrhea, abdominal pain, weight loss, and joint pains. Malabsorption, lymphadenopathy, skin hyperpigmentation, and neurologic symptoms are also common. Involvement of other organs, such as eyes, heart, and kidneys, has been reported.

Diagnosis requires a high index of suspicion and is made upon demonstration of PAS-positive macrophage inclusions in the biopsy material, usually a duodenal biopsy. Positive identification using polymerase chain reaction for *T. whipplei* confirms the diagnosis.

Treatment requires antibiotics, such as trimethoprim-sulfamethoxazole, for 1-2 years. A 2-week course of intravenous ceftriaxone or meropenem, followed by trimethoprim-sulfamethoxazole for 1 year, is recommended.

Visit Elsevier eBooks+ at eBooks.Health.Elsevier.com for Bibliography.

385.4 Immunodeficiency Disorders

Abdul-Aziz K. Elkadri

Malabsorption and diarrhea are a common presentation of patients with underlying primary immune deficiencies. It is not surprising that more than half of the primary immunodeficiencies present with GI manifestations because the gut is the largest lymphoid organ in the body and represents an interface between our environment, microbiome, and immune system. Malabsorption can be due to either intestinal inflammation or infection, with chronic diarrhea and failure to thrive one of the main modes of presentation. Multiple defects of humoral and or cellular immunity have been described, including selective IgA deficiency, agammaglobulinemia, common variable immunodeficiency disease (CVID), severe combined immunodeficiency (SCID), hyper-IgM syndrome, Wiskott-Aldrich syndrome, and chronic granulomatous disease. The most common primary immunodeficiency is selective IgA deficiency, with the majority of patients being asymptomatic. Recurrent infections with *Giardia* or nonspecific enteropathy with bacterial overgrowth can occur; celiac disease is noted to be more common in selective IgA deficiency. In CVID and X-linked agammaglobulinemia, lymphoid hyperplasia, villous atrophy, granulomas, and increased intraepithelial lymphocytes have been reported in up to 60% of children these disorders, with relative paucity of plasma cells. Pathology is reminiscent of acute graft-versus-host disease, with the presence of apoptotic bodies in the intestinal epithelia. Malabsorption has also been reported in approximately 10% of patients with CVID or X-linked agammaglobulinemia, often secondary to noroviral infection, giardiasis, *Campylobacter, Salmonella, Cryptosporidium,* enteroviruses, or cytomegalovirus (CMV) infections, and can be hard to eradicate. *Cryptosporidium* is the most common pathogen causing diarrhea and malabsorption in hyper-IgM syndrome patients, though other infections have also been described. SCID-affected children develop severe diarrhea and malabsorption early in life involving viral and opportunistic infections, especially chronic rotavirus infection, CMV, and adenovirus. Malabsorption associated with immunodeficiency is exacerbated by villous atrophy and secondary disaccharidase deficiency. In chronic granulomatous disease, phagocytic function is impaired and granulomas develop throughout the GI tract, mimicking Crohn disease. In addition to failure to thrive, it is important to consider that malabsorption associated with immunodeficiency is often complicated by micronutrient deficiencies, including vitamins A, E, and B_{12}, and calcium, zinc, and iron.

Acquired immunodeficiencies in children are more often secondary to other conditions such as cancer and chemotherapy. Malnutrition, diarrhea, and failure to thrive are common in untreated children with HIV infection. The risk of GI infection is related to the depression of the CD4 count. Opportunistic infections include *Cryptosporidium parvum,* CMV, *Mycobacterium avium-intracellulare, Isospora belli, Enterocytozoon bieneusi, Candida albicans,* astrovirus, calicivirus, adenovirus, and the usual bacterial enteropathogens. In these patients, *Cryptosporidium* can cause a chronic secretory diarrhea.

Chemotherapeutic agents can damage the bowel mucosa, leading to secondary malabsorption of disaccharides such as lactose. After bone marrow transplantation, mucosal damage from conditioning agents and graft-versus-host disease can cause diarrhea and malabsorption. Small bowel biopsies show nonspecific villous atrophy, mixed inflammatory cell infiltrates, and increased apoptosis. Cancer chemotherapy and bone marrow transplantation are associated with pancreatic damage, which may lead to exocrine pancreatic insufficiency.

Visit Elsevier eBooks+ at eBooks.Health.Elsevier.com for Bibliography.

385.5 Immunoproliferative Small Intestinal Disease

Abdul-Aziz K. Elkadri

Lymphoma (see Chapter 545) is the most common small bowel malignancy in the pediatric age-group. Malignant lymphomas of the small intestine are categorized into three subtypes: Burkitt lymphoma, non-Hodgkin lymphomas, and immunoproliferative small intestinal disease (IPSID) (originally termed as Mediterranean lymphoma or α-heavy chain disease but found worldwide). Burkitt lymphoma, the most common form in children, characteristically involves the terminal ileum with extensive abdominal involvement. The relatively uncommon non-Hodgkin lymphomas (usually large B-cell type) can involve various regions of the small intestine. Inflammatory bowel disease and primary immunodeficiencies are risk factors for the development of lymphoproliferative disorders of the intestinal tract. IPSID is a rare extranodal marginal zone B-cell lymphoma occurring primarily in the proximal small intestine. It is a variant of **mucosa-associated lymphoid-tissue (MALT) lymphoma** described in young adults from the developing world and is characterized by lymphoplasmacytic intestinal infiltrates with monotypic α-heavy chain expression.

IPSID occurs most often in the proximal small intestine in older children and young adults in the Mediterranean basin, Middle East, Asia, and Africa. Poverty and frequent episodes of gastroenteritis during infancy are risk factors. The initial clinical presentation is intermittent diarrhea and abdominal pain. Later, chronic diarrhea with malabsorption, PLE, weight loss, digital clubbing, and growth failure ensue. Intestinal obstruction, abdominal masses, and ascites are common in advanced stages.

In contrast to primary nonimmunoproliferative small intestinal lymphomas, in which the pathology in the intestine is usually focal, IPSID involves specific segments of the intestine and leaves the segments between the involved areas free of disease. The pathology in IPSID is diffuse, with a mucosal cellular infiltrate involving large segments of the intestine and sometimes the entire length of the intestine, thus producing malabsorption. Molecular and immunohistochemical studies demonstrated an association with *Campylobacter jejuni* infection. The differential diagnosis includes chronic enteric infections (parasites, tropical sprue), celiac disease, and other lymphomas. Radiologic findings include multiple filling defects, ulcerations, strictures, and enlarged mesenteric lymph nodes on CT scan.

The diagnosis is usually established by endoscopic biopsies and/or laparotomy. Upper endoscopy shows thickening, erythema, and nodularity of the mucosal folds in the duodenum and proximal jejunum. Capsule endoscopy may be helpful in the diagnosis. When the disease progresses, tumors usually appear in the proximal small intestine and rarely in the stomach. The diagnosis requires multiple duodenal and jejunal mucosal biopsies showing dense mucosal infiltrates, consisting of centrocyte-like and plasma cells. Progression to higher grade large cell lymphoplasmacytic and immunoblastic lymphoma is characterized by increased plasmocytic atypia with formation of aggregates and later sheets of dystrophic plasma cells and immunoblasts invading the submucosa and muscularis propria. A serum marker of IgA, a heavy-chain paraprotein, is present in most cases.

Treatment of early-stage IPSID with antibiotics results in complete remission in 30–70% of cases (tetracycline, ampicillin, or metronidazole). Some patients achieve durable remission lasting several years but should be monitored closely for relapse. The majority of untreated IPSID cases progress to lymphoplasmacytic and immunoblastic lymphoma invading the intestinal wall and mesenteric lymph nodes, resulting in metastasis to distant organs, and requiring aggressive treatment with surgery and/or chemotherapy.

Visit Elsevier eBooks+ at eBooks.Health.Elsevier.com for Bibliography.

385.6 Short Bowel Syndrome

Abdul-Aziz K. Elkadri

Short bowel (or short gut) syndrome is defined as a state of reduced functional intestinal mass that is lower than the required amount for the digestion and absorption of nutrients and fluids required for normal growth and survival. It results from congenital malformations or the resection of the small bowel (Table 385.6). Its incidence increases with low birthweight and earlier gestational age and is estimated at 7/1,000 live births in U.S. infants with birthweight <1,500 mg. Depending upon the area of the bowel resected or absent, loss of >50% of the small bowel, with or without a portion of the large intestine, can result in symptoms of generalized malabsorptive disorder or in specific nutrient deficiencies. At birth, the length of small bowel is 200-250 cm; by adulthood, it grows to 300-800 cm. Bowel resection is better tolerated in infants with an improved prognosis relative to adults due to the potential for intestinal growth and adaptation. An infant with as little as 15 cm of bowel with an ileocecal valve, or 20 cm without an ileocecal valve, has the potential to survive and be eventually weaned from PN.

In addition to the length of the bowel, the anatomic location of the resection is also important. The proximal 100-200 cm of jejunum is the main site for carbohydrate, protein, iron, and water-soluble vitamin absorption, whereas fat absorption occurs over a longer length of the small bowel. Depending on the region of the bowel resected, specific nutrient malabsorption can result. Vitamin B_{12} and bile salts are only absorbed in the distal ileum (Fig. 385.7). Jejunal resections are generally tolerated better than ileal resections because the ileum, unlike the jejunum, is better able to adapt to absorb nutrients and fluids. Net sodium and water absorption is relatively higher in the ileum. Ileal resection has a profound effect on fluid and electrolyte absorption due to malabsorption of sodium and water by the remaining ileum. Ileal malabsorption of bile salts stimulates increased colonic secretion of fluid and electrolytes. The presence of a colon in continuity is better tolerated and improves absorption and enteral autonomy.

TREATMENT

After bowel resection, treatment of short bowel syndrome is initially focused on repletion of the massive fluid and electrolyte losses while the bowel initially accommodates to absorb these losses. Proton pump inhibitors are usually added to reduce gastric secretions due to hypersecretion of gastric acids of up to 4 L per day compared to 750 mL in healthy individuals. Nutritional support is often provided via parenteral nutrition. A central venous catheter should be inserted to provide optimized and durable parenteral fluid and nutrition support. The ostomy or stool output should be measured, and fluid and electrolyte losses adequately replaced. Measurement of urinary Na^+ to assess whole body Na^+ stores is useful to prevent Na^+ depletion. Maintaining urinary Na^+ higher than 20 mmol/L ensures that Na^+ intake is adequate. Early introduction of even a small amount of enteral feeding by mouth or tube feeding is essential and enhances bowel adaptation.

Table 385.6 Causes of Short Bowel Syndrome

CONGENITAL
Congenital short bowel syndrome
Intestinal atresia
Gastroschisis
BOWEL RESECTION
Necrotizing enterocolitis
Volvulus with or without malrotation
Long segment Hirschsprung disease
Meconium peritonitis
Crohn disease
Trauma

After the initial few weeks following resection, fluid and electrolyte losses begin to stabilize, and the focus of therapy shifts to bowel rehabilitation with a gradual increase in the volume of enteral feeds. Continuous or bolus small-volume enteral feeding should be promoted with an extensively or partially hydrolyzed protein with MCT-enriched formula if the colon is in continuity. Breast milk is preferable over formula, and its use should be encouraged as it stimulates gut hormones and promotes mucosal growth. Enteral feeding also increases pancreatobiliary flow and reduces parenteral nutrition-induced hepatotoxicity. To maintain interest in oral feeds and minimize oral aversion, infants should be given a small amount of formula or mother's milk by mouth as early as possible. As intestinal adaptation occurs, enteral feeding increases, and parenteral supplementation decreases. The bowel mucosa surface area proliferates, and the bowel lengthens with growth.

Approximately 60% of patients with short bowel syndrome achieve **enteral autonomy** within 5 years of bowel resection, and the majority do so in the first 2-3 years after resection. In addition to bowel length, factors increasing the likelihood of achieving enteral autonomy include the presence of the ileocecal valve, a diagnosis of necrotizing enterocolitis, and care by an intestinal rehabilitation program.

Patients may require repeat surgeries for obstruction or bowel lengthening procedures (longitudinal lengthening, serial transverse enteroplasties or both) to optimize the bowel absorptive capacity. Bowel lengthening procedures are indicated in patients with dilated bowel who are unable to progress toward enteral autonomy or in those with refractory small intestinal bacterial overgrowth.

Vitamin and micronutrient deficiencies are common and increase over time. The management of specific micronutrient and vitamin deficiencies and the treatment of transient problems such as postinfectious mucosal malabsorption are required. GI infections or small bowel bacterial overgrowth can cause setbacks in the progression to full enteral feeding in patients with marginal absorptive function. Marked increase in stool output or evidence of carbohydrate malabsorption (stool pH <5.5 and positive test for reducing substances) is a contraindication for further increases in enteral feeds. Slow advancement of continuous or bolus enteral feeding rates continues until all nutrients are provided enterally.

In patients with large stool output, the addition of soluble fiber and antidiarrheal agents, such as loperamide and anticholinergics, can be beneficial, although these drugs can increase the risk of bacterial

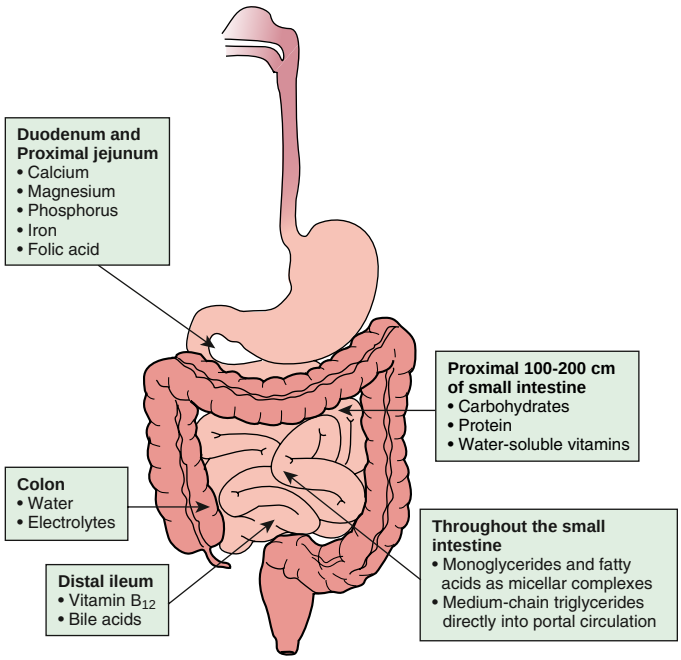

Fig. 385.7 Absorption of nutrients in the small bowel varies with the region.

overgrowth. Cholestyramine can be beneficial for patients with distal ileal resection, but its potential depletion of the BA pool can increase steatorrhea. Bacterial overgrowth is common in infants with a short bowel and can delay progression of enteral feedings. Empirical treatment with metronidazole or other antibiotics (nitazoxanide, rifaximin) is often useful. Diets high in fat and without simple sugars may be helpful in reducing bacterial overgrowth as well as in enhancing adaptation.

COMPLICATIONS

Long-term complications of short bowel syndrome include those of parenteral nutrition: central catheter infection, thrombosis, intestinal failure associated liver disease (IFALD), and gallstones. Appropriate care of the central line to prevent infection and catheter-related thrombosis is extremely important. Sepsis is a leading cause of death and can occur any time after treatment is initiated (months to years later), and is most often bacterial (single organism more common than polymicrobial), although fungal infection may be noted in 20–25% of septic episodes. The use of an ethanol, sodium bicarbonate, or taurolidine lock can reduce the incidence of central catheter infections and prevent infections.

Some patients will continue to require long-term parenteral nutritional support, and lack of central line access is potentially life-threatening. Inappropriate removal or frequent changes of central lines in the neonatal period should be avoided. **IFALD** can lead to cholestasis, cirrhosis, and liver failure and is a common reason for death or need the for transplantation. The incidence and severity of IFALD has significantly reduced over the past decade, probably due to the reduced use of soy-based lipid emulsions and the positive effect of omega-3-based lipid emulsions on cholestasis, as well as the collaboration of specialized intestinal failure teams to prevent recurrent septic episodes. Other complications of terminal ileal resection include vitamin B_{12} deficiency, which might not appear until 1-2 years after parenteral nutrition is withdrawn. Long-term monitoring for deficiencies of vitamin B_{12}, folate, iron, fat-soluble vitamins, and trace minerals, such as zinc and copper, is important. Renal stones can occur as a result of hyperoxaluria secondary to steatorrhea as calcium preferentially binds to the excess fat compared to oxalate, resulting in increased oxalate absorption and excretion in the urine. Venous thrombosis and vitamin deficiency have been associated with hyperhomocysteinemia in short bowel syndrome. Bloody diarrhea secondary to patchy, mild colitis can rarely develop during the progression of enteral feedings. The pathogenesis of this *feeding colitis* is unknown, but it is usually benign and can improve with a hypoallergenic diet or treatment with mesalamine.

In some children with life-threatening complications of parenteral nutrition, especially progressive liver failure and loss of vascular access, small intestine and liver transplantation becomes the preferred therapy (see Chapter 386).

Visit Elsevier eBooks+ at eBooks.Health.Elsevier.com for Bibliography.

385.7 Chronic Malnutrition

Abdul-Aziz K. Elkadri

Malnutrition can be divided into primary malnutrition, which is more common in developing countries and due to the socioeconomic factors leading to inadequate access to an appropriate caloric intake, and secondary malnutrition, which is due to decreased food intake, disease processes that cause abnormal nutrient loss, or an increased expenditure of energy (see Chapter 64). The American Society for Parenteral and Enteral Nutrition (ASPEN) defined pediatric malnutrition in developed countries as an imbalance between nutrient requirements and intake that results in cumulative deficits of energy, protein, or micronutrients that may negatively affect growth, development, and other relevant outcomes. Malnutrition can also be classified into *illness related* (caused by disease/trauma) or *non-illness related* (caused by environmental/behavioral factors). Based upon duration, it can also be further classified into *acute* malnutrition (<3 months; short duration, weight loss without stunting) or *chronic* malnutrition (>3 months; weight loss and stunting) that may differ in their etiology, growth patterns, and outcome. Chronic malnutrition is usually due to decreased food intake, malabsorption syndromes, or increased nutritional needs in children with chronic diseases. Malnutrition is diagnosed in 11–50% of hospitalized children and reports from Europe suggest a prevalence of close to 20% in chronically ill children. Child neglect and improper formula preparation can result in severe malnutrition. A detailed medical history should assess for symptoms that may lead to decreased oral intake, including decreased appetite, vomiting, dysphagia, abdominal pain, diarrhea, and tenesmus, as well as mood and behavioral changes. Obtaining a dietary history to determine caloric intake as well as obtaining anthropometric measurements will help determine nutritional status. Anthropometric measures to assess include reduced weight per age and weight per height, body mass index <5th percentile, and mid upper arm circumference <−1 *z* score. Physical exam findings suggestive of nutrient deficiencies include an atrophic tongue in iron deficiency, decreased subcutaneous fat, and alopecia in zinc deficiency. Laboratory testing can be used to assess vitamin and micronutrient deficiencies, including CBC and iron studies for anemia and serum albumin for protein losing enteropathy. Though screening tools for malnutrition are available in adults to provide a simple and fast way of diagnosing those patients at risk for malnutrition, few such screening tools for the pediatric population have been developed to assess children at risk, and their use in clinical practice is still questionable.

Malnourished children suffer from impaired immunity, chronic enteropathy, poor wound healing, muscle weakness, and diminished psychologic drive. Malnutrition has short-term consequences (increased disability, morbidity, and mortality) and long-term consequences (final adult size, developmental deficiencies, economic productivity). Undernutrition in hospitalized children is associated with increased infectious complications, delayed recovery, increased length of stay and costs, increased readmission rate, and increased mortality.

Nutritional rehabilitation in malnourished children is discussed in Chapter 64.

Chronic malnutrition complicated by diarrheal dehydration is a commonly observed phenomenon. Infectious diarrhea is common in tropical and subtropical countries, in the setting of poor hygiene practices and water quality, in immunocompromised hosts (e.g., HIV, congenital immunodeficiency), and when impairment of the immune response is due to chronic malnutrition itself. In children with chronic disorders, diarrhea may be related to the underlying disease, such as noncompliance with a gluten-free diet in celiac disease, noncompliance with pancreatic enzyme treatment in cystic fibrosis, and cholestatic liver disease with fat malabsorption. Malnutrition per se can lead to exocrine pancreatic insufficiency, which, in turn, aggravates malabsorption and diarrhea.

In infants and children with severe malnutrition, many of the signs normally used to assess the state of hydration or shock are unreliable. Severe malnutrition might be accompanied by sepsis; thus children with septic shock might not have diarrhea, thirst, or sunken eyes but may be hypothermic, hypoglycemic, or febrile. Cardiac reserve is lowered, and heart failure is a common complication.

Despite clinical signs of dehydration, urinary osmolality may be low in the chronically malnourished child. Renal acidifying ability is also limited in patients with malnutrition.

Management of diarrhea in chronically malnourished children is based on three principles: oral rehydration to correct dehydration, prompt resumption of feeds with avoidance of periods of nothing by mouth, and treating the underlying etiology behind the diarrhea.

When treating dehydration in malnutrition, the extracellular space appears to be overexpanded and intra- and extracellular spaces are hypo-osmolar. In this setting, reduced or hypotonic osmolarity oral rehydration solutions are indicated. When oral rehydration is not possible due to etiologies such as feeding aversion, the route of choice is nasogastric, and parenteral rehydration and nutrition should be avoided when possible.

Initial intravenous therapy in profound dehydration is designed to improve the circulation and expand extracellular volume. For patients with edema, the quality of fluid and the rate of administration might

require readjustment from recommended levels to avoid overhydration and pulmonary edema. Blood should be given if the patient is in shock and severely anemic. Potassium salts can be initiated early if urine output is good. Clinical improvement may be more rapid with magnesium therapy.

Children with chronic malnutrition are at risk for refeeding syndrome (see Chapter 63). Therefore initial calorie provision should not exceed the previous daily intake and is usually begun at 50–75% of estimated resting energy expenditure, with rapid increase to caloric goals once there are no severe abnormalities in sodium, potassium, phosphorus, calcium, or magnesium. Correction of malnutrition and catch-up growth are not part of the primary treatment of these children, but a nutrition rehabilitation plan is necessary.

Visit Elsevier eBooks+ at eBooks.Health.Elsevier.com for Bibliography.

385.8 Enzyme Deficiencies

Abdul-Aziz K. Elkadri

CARBOHYDRATE MALABSORPTION

Symptoms of carbohydrate malabsorption include loose watery diarrhea, flatulence, abdominal distention, and pain. Unless consumed in large amounts, children may remain asymptomatic. Disaccharidases are present on the brush border membrane of the small bowel. **Disaccharidase deficiency** can be caused by a genetic defect or secondary to damage to the small bowel epithelium, as occurs with infection or inflammatory disorders.

Nonabsorbed carbohydrates enter the large bowel and are fermented by intestinal bacteria, producing organic acids and gases such as methane and hydrogen. The gases can cause abdominal distension and discomfort, whereas the unabsorbed carbohydrates and the organic acids result in osmotic diarrhea characterized by an acidic pH and the presence of either reducing or nonreducing sugars in the stool. Hydrogen and methane gas can be detected in the breath as a sign of fermentation of unabsorbed carbohydrates **(hydrogen breath test).**

LACTASE DEFICIENCY

Congenital lactase deficiency is rare and is associated with symptoms occurring on exposure to lactose in milk. Fewer than 50 cases have been reported worldwide. In patients with congenital lactase deficiency, five distinct disease causal variants in the coding region of the *LCT* gene were found. In most patients (84%), homozygosity for a nonsense variant, 4170T-A (Y1390X; OMIM 223000), designated Fin (major), was found.

Primary adult-type hypolactasia is caused by a physiologic decline in lactase activity that occurs following weaning in most mammals. The brush border lactase enzyme is expressed at low levels during fetal life; activity increases in late fetal life and peaks from term to 3 years, after which levels gradually decrease with age. This decline in lactase levels varies between ethnic groups. Lactase deficiency occurs in approximately 15% of White adults, 40% of Asian adults, and 85% of Black adults in the United States. Lactase is encoded by a single gene *(LCT)* of approximately 50 kb located on chromosome 2q21. C/T (−13910) polymorphisms of the *MCM6* gene were found to be related to adult-type hypolactasia in most European populations. In three African populations—Tanzanians, Kenyans, and Sudanese—three single-nucleotide polymorphisms, G/C(−14010), T/G(−13915), and C/G(−13907), were identified with lactase persistence and have derived alleles that significantly enhance transcription from the lactase gene promoter in vitro.

Secondary lactose intolerance follows small bowel mucosal damage (celiac disease, acute severe gastroenteritis) and is usually transient, improving with mucosal healing. Lactase deficiency can be diagnosed by the hydrogen breath test (2 g/kg up to 25 g) or by measurement of lactase activity in mucosal tissue retrieved by small bowel biopsy. Diagnostic testing is not mandatory, and often simple dietary changes that reduce or eliminate lactose from the diet relieve symptoms.

Treatment of lactase deficiency consists of a milk-free diet. A lactose-free formula (based on either soy or cow's milk) can be used in infants. In older children, low-lactose milk can be consumed. The addition of lactase to dairy products usually improves the symptoms.

Live-culture yogurt contains bacteria that produce lactase enzymes and is therefore tolerated in most patients with lactase deficiency. Hard cheeses and cottage cheeses have a small amount of lactose and are generally well tolerated.

FRUCTOSE MALABSORPTION

Children consuming a large quantity of juice rich in fructose, corn syrup, or natural fructose in fruit juices can present with diarrhea, abdominal distention, and slow weight gain. Identification by history followed by the restriction of the amount of juice in the diet resolves the symptoms and helps avoid unnecessary investigations. A fructose hydrogen breath test can be helpful in the diagnosis of fructose malabsorption. The reason for fructose malabsorption is a reduced abundance of GLUT-5 transporter on the surface of the intestinal brush border membrane, which occurs in approximately 5% of the population.

SUCRASE-ISOMALTASE DEFICIENCY

Sucrase-isomaltase (SI) deficiency is a rare autosomal recessive disorder with a complete absence of sucrase and reduced maltase digestive activity. The SI complex is composed of 1,927 amino acids encoded by a 3,385 bp messenger RNA. The gene locus on chromosome 3 has 30 exons spanning 106.6 kb. Most SI pathogenic variants result in a lack of enzyme protein synthesis (null variant). Posttranslational processing defects have also been identified.

Approximately 2% of Europeans and Americans are heterozygous for a causal variant. Sucrase deficiency is especially common in indigenous Greenlanders (estimated 5%) in whom it is often accompanied by lactase deficiency. Gene variants of the SI are found to have some implications in irritable bowel syndrome (IBS), as they were found more often in patients with IBS than in controls.

Symptoms of SI deficiency usually begin when the infant is exposed to sucrose or a glucose polymer diet. This can occur with ingestion of non–lactose-based infant formula or on the introduction of pureed food, especially fruits and sweets. Diarrhea, abdominal pain, and poor growth are observed. Occasionally, patients present with symptoms in late childhood or even adult life, but careful history often indicates that symptoms appeared earlier. Diagnosis of SI malabsorption requires acid hydrolysis of stool for reducing substances due to the fact that sucrase is a nonreducing sugar. Alternatively, hydrogen breath testing can be used, as well as direct enzyme assay of small bowel biopsy or genetic testing.

The mainstay of treatment is lifelong dietary restriction of sucrose-containing foods, although symptoms may diminish with age. Enzyme replacement with a purified yeast enzyme sacrosidase is a highly effective adjunct to dietary restriction.

GLUCOSE-GALACTOSE MALABSORPTION

More than 30 different pathogenic variants of the sodium/glucose co-transporter gene *(SGLT1)* have been identified. These variants cause a rare autosomal recessive disorder of intestinal glucose and galactose/Na^+ co-transport system that leads to osmotic diarrhea. Because most dietary sugars are polysaccharides or disaccharides with glucose or galactose moieties, diarrhea follows the ingestion of glucose, breast milk, or conventional lactose-containing formulas. Dehydration and acidosis can be severe, resulting in death.

Stools are noted to be acidic and contain sugar. Patients with the defect have normal absorption of fructose, and their small bowel function and structure are normal in all other aspects. Intermittent or permanent glycosuria after fasting, or after a glucose load, is a common finding due to the transport defect also being present in the kidney. The presence of reducing substances in watery stools and slight glycosuria despite low blood sugar levels is highly suggestive of glucose-galactose malabsorption. Malabsorption of glucose and galactose is easily identified using the breath hydrogen test. It is safe to perform the first test with a dose of

0.5 g/kg of glucose or galactose; if necessary, a second test can be performed using 2 g/kg. Breath hydrogen will rise more than 20 ppm. Biopsy of the small intestine is useful to document a normal villous architecture and normal disaccharidase activities and to rule out other etiologies. The identification of causal variants of *SGLT1* make it possible to perform prenatal screening in families at risk for the disease.

Treatment consists of rigorous restriction of glucose and galactose. Fructose, the only carbohydrate that can be given safely, should be added to a carbohydrate-free formula at a concentration of 6–8%. This formula results in almost immediate cessation of diarrhea. Although the defect is permanent and lifelong, limited amounts of glucose, starches, or sucrose may be tolerated later in life.

EXOCRINE PANCREATIC INSUFFICIENCY

Chapter 397 discusses disorders of exocrine pancreatic insufficiency (see Table 385.5). **Cystic fibrosis** is the most common congenital disorder associated with exocrine pancreatic insufficiency. Although rare, the next most common cause of pancreatic insufficiency in children is **Shwachman-Diamond syndrome**. Other rare disorders with exocrine pancreatic insufficiency include **Johanson-Blizzard syndrome** (severe steatorrhea, aplasia of alae nasi, deafness, hypothyroidism, scalp defects), **Pearson bone marrow syndrome** (sideroblastic anemia, variable degree of neutropenia, thrombocytopenia), and isolated pancreatic enzyme deficiency (lipase, colipase, trypsinogen, amylase). Enterokinase deficiency, a key enzyme produced in the proximal small bowel and responsible for the activation of trypsinogen to trypsin, manifests clinically as exocrine pancreatic insufficiency.

Autoimmune polyendocrinopathy syndrome type 1, a rare autosomal recessive disorder, is caused by pathogenic variants in the autoimmune regulator gene (*AIRE*). Patients develop chronic mucocutaneous candidiasis along with failure of the parathyroid gland, adrenal cortex, pancreatic β cells, gonads, gastric parietal cells, and thyroid gland. Pancreatic insufficiency and steatorrhea are associated with this condition.

ENTEROKINASE (ENTEROPEPTIDASE) DEFICIENCY

Enterokinase (enteropeptidase) is a brush border serine protease enzyme of the small intestine responsible for the cleavage of trypsinogen to trypsin. This in turn results in the cascade activation of a number of other pancreatic enzymes. Deficiency of this enzyme results in severe diarrhea, malabsorption, failure to thrive, and hypoproteinemic edema shortly after birth.

The diagnosis can be established by measuring the enzyme level in intestinal tissue or by genetic testing, as enterokinase deficiency is caused by pathogenic variants in the serine protease-7 gene *(PRSS7)* on chromosome 21q21. Treatment of this rare autosomal recessive disorder consists of replacement with pancreatic enzymes and administration of a protein hydrolyzed formula with added MCT oil in infancy.

TREHALASE DEFICIENCY

The disaccharide trehalose is mainly present in mushrooms and has been approved to add to dried food. It is hydrolyzed by the intestinal trehalase into two molecules of glucose. Trehalase deficiency has been reported in 8% of Greenlanders; only three cases of this deficiency have been reported elsewhere. In untreated celiac disease, the intestinal trehalase activity is reduced as those of other disaccharidases and recovers after introduction of a gluten-free diet.

TRYPSINOGEN DEFICIENCY

Trypsinogen deficiency is a rare syndrome with symptomatology similar to that of enterokinase deficiency. Enterokinase catalyzes the conversion of trypsinogen to trypsin, which, in turn, activates the various pancreatic proenzymes, such as chymotrypsin, procarboxypeptidase, and proelastase, for their active forms. Deficiency of trypsinogen results in severe diarrhea, malabsorption, failure to thrive, and hypoproteinemic edema soon after birth.

The trypsinogen gene is encoded on chromosome 7q35. Treatment is the same as for enterokinase deficiency, with pancreatic enzymes and protein hydrolysate formula with added MCT oil in infancy.

Visit Elsevier eBooks+ at eBooks.Health.Elsevier.com for Bibliography.

385.9 Liver and Biliary Disorders Causing Malabsorption

Abdul-Aziz K. Elkadri

Absorption of lipids and lipid-soluble vitamins depends to a great extent on an adequate bile flow delivering BA to the small intestine, which helps mixed micelle formation of lipid droplets. Most liver and biliary disorders lead to impairment of the bile flow, contributing to malabsorption of long-chain fatty acids and fat-soluble vitamins such as A, D, E, and K. Liver disorders associated with significant malabsorption and failure to thrive are mainly due to these categories:

In **PFIC syndromes and BA synthesis defects**, PFIC type 1 is associated with chronic diarrhea caused by a bile acid transport defect in the gut. It is not uncommon for these children to have symptomatic fat-soluble vitamin deficiencies and suffer from pathologic fractures and peripheral neuropathy.

Children with lipid storage disorders (e.g., **Wolman disease**) also manifest with severe failure to thrive and multiple vitamin deficiencies.

Children with biliary disorders such as biliary atresia after portoenterostomy surgery (Kasai portoenterostomy), cystic fibrosis, neonatal sclerosing cholangitis, Alagille syndrome, and sclerosing cholangitis constitute another major group of disorders with reduced bile flow where malabsorption could be a significant challenge.

Chronic liver disease of any etiology could also lead to lipid malabsorption mechanisms. In addition, severe portal hypertension can lead to portal hypertensive enteropathy, resulting in poor absorption of nutrients.

Decompensated liver disease leads to anorexia and increased energy expenditures, further widening the gap between calorie intake and net absorption and leading to severe malnutrition. Adequate management of nutrition is essential to improve the outcome with or without liver transplantation. This is usually achieved by using MCT-rich milk formula, supplemental vitamins, and continuous or bolus enteral feed where oral intake is poor.

Vitamin D deficiency is commonly observed on biochemical tests, and children can present with pathologic fractures. Simultaneous administration of vitamin D with the water-soluble vitamin E preparation (TPGS 1,000 succinate) enhances absorption of vitamin D as well. In young infants with cholestasis, oral vitamin D_3 is given at a dose of 1,000 IU/kg/24 hr. After 1 month, if the serum 25-hydroxyvitamin D level continues to be low, intramuscular administration of 10,000 units/kg or maximum of 60,000 is recommend. Monitoring of 25-hydroxy vitamin D serum levels every 1-2 months is recommended in children with severe cholestasis.

Vitamin E deficiency in patients with chronic cholestasis is not usually symptomatic but can manifest as a progressive neurologic syndrome, including peripheral neuropathy (manifesting as loss of deep tendon reflexes and ophthalmoplegia), cerebellar ataxia, and posterior column dysfunction. Early in the course, findings are partially reversible with treatment; late features may not be reversible. It may be difficult to identify vitamin E deficiency because the elevated blood lipid levels in cholestatic liver disease can falsely elevate the serum vitamin E level. Therefore it is important to also obtain serum lipid levels to measure the ratio of serum vitamin E to total serum lipids. A normal level for patients younger than 12 years of age is >0.6, and for patients older than 12 years is >0.8. Neurologic sequelae can be prevented with the use of an oral water-soluble vitamin E preparation (TPGS, Liqui-E) at a dose of 25-50 IU/day in neonates and 15-25 IU/kg/day in children.

Vitamin K deficiency can occur because of cholestasis and poor fat absorption. In children with liver disease, it is very important to differentiate between the coagulopathy related to vitamin K malabsorption and one secondary to the synthetic failure of coagulation factors from the liver. A single dose of vitamin K administered intravenously does not correct the prolonged prothrombin time in liver failure but will help correct the deficiency state within a few hours. Easy bruising may be the first sign. In neonatal cholestasis, coagulopathy because of vitamin K deficiency can manifest with intracranial bleeding with devastating consequences, and prothrombin time should be routinely measured to monitor for deficiency in children with cholestasis. All children with cholestasis should receive regular vitamin K supplementation.

Vitamin A deficiency is rare and is associated with night blindness, xerophthalmia, and increased mortality if patients contract measles. Serum vitamin A levels should be monitored, and adequate supplementation considered. Caution should be observed with supplementation, as high levels of vitamin A can cause liver damage.

385.10 Rare Inborn Defects Causing Malabsorption

Abdul-Aziz K. Elkadri

Congenital (primary) malabsorption disorders originate from a multitude of defects, which includes structural or functional defects of enterocytes or disorders involving other cellular lineages of the GI tract such as enteroendocrine or immune cells (see Chapters 385.3 and 388). Integral membrane proteins are another class of primary disorders of malabsorption as they fulfill the function of transporter of nutrients as a receptor or channel across the apical or basolateral membrane of enterocytes. Histologic examination of the mucosa of the small and large bowel is typically normal. Most of these disorders are rare and inherited in an autosomal recessive pattern as they are typically a loss of function of a protein. With increased access to genetic sequencing, patients are being discovered to carry pathologic variants in genes traditionally thought to carry a traditional phenotype. This broader phenotype is thought to be possibly due to modifier genes and variable penetrance and may provide us with a better understanding of the spectrum of these disorders.

DISORDERS OF CARBOHYDRATE ABSORPTION

These are described in Chapter 385.9.

Patients with **Fanconi-Bickel syndrome** present with tubular nephropathy, hypophosphatemic rickets, hepatomegaly, and nephromegaly due to glycogen accumulation in liver and small bowel; failure to thrive; and fasting hypoglycemia and postprandial hyperglycemia. The disorder is caused by homozygous pathogenic variants of GLUT2 *(SLC2A2),* the facilitative monosaccharide transporter at the basolateral membrane of enterocytes, hepatocytes, renal tubules, pancreatic islet cells, and cerebral neurons. Patients exhibit postprandial hyperglycemia secondary to low insulin secretion (impaired glucose-sensing mechanisms in β cells) and fasting hypoglycemia due to altered glucose transport out of the liver. The increased intracellular glucose level inhibits glycogen degradation leading to intracellular glycogen accumulation. Similarly, altered monosaccharide transport out of enterocytes may be responsible for the putative glycogen accumulation and result in the diarrhea and malabsorption observed in some patients. Therapy includes the substitution of electrolyte losses and vitamin D and supplying uncooked cornstarch to prevent hypoglycemia. Patients who present in the neonatal period need frequent small meals and galactose-free milk.

DISORDERS OF AMINO ACID AND PEPTIDE ABSORPTION

Protein digestion and absorption in the intestine is accomplished by a combination of proteases, peptidases, and transporters of peptides and amino acids. Amino acid transporters are essential for the absorption and transport of amino acids from luminal nutrients, through intracellular transfer and finally between cellular compartments. Due to their ontogenic origins, enterocytes and renal tubules share similar amino acid transporters. The highest intestinal transporter activity is found in the jejunum. The transporters causing Hartnup disease, cystinuria, iminoglycinuria, and dicarboxylic aminoaciduria are in the apical membrane, and those causing **lysinuric protein intolerance (LPI)** and blue diaper syndrome are anchored in the basolateral membrane of the intestinal epithelium.

Dibasic amino acids, including cystine, ornithine, lysine, and arginine, are taken up by the Na-independent heterodimeric transporter protein complex made up of SLC3A1 and SLC7A9. Cystinuria, a defect in this transporter, is the most common primary inherited aminoaciduria. This disorder is not associated with any GI or nutritional consequences because of compensation by an alternative transporter. However, hypersecretion of cystine in the urine leads to recurrent cystine stones, which account for up to 6–8% of all urinary tract stones in children. Ample hydration, urine alkalinization, and cystine-binding thiol drugs can increase the solubility of cystine. Cystinuria type A *(SLC3A1)*, or type 1 in the phenotypic classification, is inherited as an autosomal recessive trait, whereas cystinuria type B, classified phenotypically as type II and III, is due to pathogenic variants in SLC7A9. Parents of patients with type B cystinuria have increased cystine levels but do not form stones, which suggests that it is likely inherited in an autosomal dominant manner with incomplete penetrance. Cystinuria type I has been described in association with 2p21 deletion syndrome and hypotonia-cystinuria syndrome.

Lysinuric protein intolerance (LPI) is the second most common disorder of amino acid transport (see Chapter 105.14). It is caused by the y^+LAT-1 (SLC7A7) subunit of the cationic amino acid transporter present at the basolateral membrane of the intestinal and renal epithelium and causes a failure to deliver cytosolic dibasic cationic amino acids into the paracellular space. This defect is not compensated by the SLC3A1/SLC7A9 transporter at the apical membrane. The symptoms of LPI, which appear after weaning, include diarrhea, failure to thrive, hepatosplenomegaly, nephritis, respiratory insufficiency, alveolar proteinosis, pulmonary fibrosis, and osteoporosis. Abnormalities of the bone marrow with anemia and thrombocytopenia have also been described in a subgroup of LPI patients. The disorder is characterized by low plasma concentrations of the dibasic amino acids lysine, arginine, and ornithine, high concentrations of glutamine, alanine, glycine, serine, and proline, and a massive urinary excretion of lysine, as well as orotic acid, ornithine, and arginine to a lesser extent. Hyperammonemia episodes and coma along with emesis usually develop after fasting or with the ingestion of large amounts of protein, specifically alanine, likely due to a deficiency of intramitochondrial ornithine. Some patients show moderate intellectual disability. Cutaneous manifestations can include alopecia, perianal dermatitis, and sparse hair. Some patients learn to avoid protein-containing foods. Immune dysfunction is potentially attributable to nitric oxide overproduction secondary to arginine intracellular trapping and may be the underlying pathophysiologic route explaining many LPI complications such as hemophagocytic lymphohistiocytosis, autoimmune disorders, and an incompletely characterized immune deficiency. Treatment includes dietary protein restriction (<1.5 g/kg/day) and orally administered citrulline (100 mg/kg/day), which is well absorbed from the intestine and carnitine supplementation.

Hartnup disease is characterized by the malabsorption of all neutral amino acids (except proline), including the essential amino acid tryptophan. It is characterized by aminoaciduria, photosensitive pellagra-like rash, headaches, cerebellar ataxia, delayed intellectual development, and diarrhea. The clinical spectrum ranges from asymptomatic to severely affected with progressive neurodegeneration leading to death by adolescence. SLC6A19, which is the major luminal sodium-dependent neutral amino acid transporter of small intestine and renal tubules, has been identified as the defective protein. A similar phenotype is observed in defects in collectrin (CLTRN), and the requirement of angiotensin-converting enzyme 2 may explain the phenotypic heterogeneity of Hartnup disorder. Tryptophan is a precursor of nicotinamide adenine dinucleotide phosphate biosynthesis; therefore the disorder can be treated by nicotinamide in addition to a diet of 4 g protein/kg. The use of lipid-soluble esters of amino acids and tryptophan ethyl ester has also been reported.

Defects in specific, basolateral tryptophan transporter (SLC16A10) are the cause of **blue diaper syndrome** (indicanuria, Drummond syndrome). Intestinal bacteria convert the unabsorbed tryptophan to indican, which is responsible for the bluish discoloration of the urine after its hydrolysis and oxidation. Symptoms can include digestive disturbances such as vomiting, constipation, poor appetite, failure to thrive, hypercalcemia, nephrocalcinosis, fever, irritability, and ocular abnormalities.

The underlying defect of **iminoglycinuria** is the malabsorption of proline, hydroxyproline, and glycine as a consequence of the proton amino acid transporter SLC36A2 defect, with a possible participation

of modifier genes, one of which (SLC6A20) is present in the intestinal epithelium. This disorder is usually benign, but sporadic cases with encephalopathy, intellectual disability, deafness, blindness, kidney stones, hypertension, and gyrate atrophy have been described.

The neuronal glutamate transporter EAAT3 (SLC1A1) is affected in **dicarboxylic aminoaciduria**. This carrier is present in the small intestine, kidney, and brain and transports the anionic acids L-glutamate, L- and D-aspartate, and L-cysteine. There are single-case reports indicating that this disorder could be associated with hyperprolinemia and neurologic symptoms such as POLIP (polyneuropathy, ophthalmoplegia, leukoencephalopathy, intestinal pseudoobstruction) syndrome.

DISORDERS OF FAT TRANSPORT

These are described in Chapters 106.3 and 385.3.

DISORDERS OF VITAMIN ABSORPTION

Transporters and receptors of the intestinal epithelium have been described for water-soluble but not fat-soluble vitamins with the latter absorbed primarily into enterocytes by passive diffusion after the emulsification of fats by bile salts. Transfer proteins (retinol-binding protein [RBP4] and α-tocopherol transfer protein [TTP1]) have been involved in deficiency states of vitamins E (spinocerebellar ataxia) and A (ophthalmologic signs), respectively.

Vitamin B_{12} (cobalamin) is synthesized exclusively by microorganisms and is acquired mostly from meat and milk (see Chapter 503.2). Its absorption starts with the removal of cobalamin from dietary protein by gastric acidity and its binding to haptocorrin. In the duodenum, pancreatic proteases hydrolyze the cobalamin-haptocorrin complex, allowing the binding of cobalamin to intrinsic factor (IF), which originates from parietal cells from the stomach. The receptor of the cobalamin-IF complex (Cbl-IF) is located at the apical membrane of the ileal enterocytes and represents a heterodimer consisting of cubilin (CUBN) and amnionless (AMN). After endocytic uptake into endosomes, the Cbl-IF and its receptor binds to megalin and forms a cobalamin–transcobalamin (TC)-2 complex (after cleavage of IF) for further transcytosis. Vitamin B_{12} exits the lysosome via LMBD1 and ABCD4 and is released to the bloodstream most likely through the basolateral transporter multifunctional multidrug resistance protein 1 (MRP1). Biologically available circulating vitamin B_{12} is bound to TC, a nonglycosylated protein that carries 10–30% of the total vitamin B_{12}. TC-vitamin B_{12} complexes enter the cells via two members of the LDL receptor gene family, CD320 and renal Lrp2/megalin. As a cofactor for methionine synthase, cobalamin converts homocysteine to methionine. Cobalamin deficiency can be caused by inadequate intake of the vitamin (e.g., breastfeeding by mothers on a vegan diet) and primary or secondary achlorhydria including autoimmune gastritis, exocrine pancreatic insufficiency, bacterial overgrowth (see Chapter 385.4), ileal disease (Crohn disease, see Chapter 382.2), ileal (or gastric) resection, infections (fish tapeworm), and Whipple disease (see Chapter 388).

Clinical signs of congenital cobalamin malabsorption, which usually appear from a few months to more than 10 years, are pancytopenia including **megaloblastic anemia**, fatigue, failure to thrive, and neurologic symptoms, including developmental delay. Recurrent infections and bruising may be present. Laboratory evaluation indicates low serum cobalamin, hyperhomocysteinemia, methylmalonic acidemia, and mild proteinuria. The Schilling test is useful to differentiate between a lack of IF and the malabsorption of cobalamin. Several rare autosomal recessive disorders of congenital cobalamin deficiency affect absorption and transport of cobalamin (in addition to seven other inherited defects of cobalamin metabolism). These include pathogenic variants of the gastric IF *(GIF)* gene with absence of IF (but normal acid secretion and lack of autoantibodies against IF or parietal cells), variants of the *AMN* and *CUBN* gene subunits of the Cbl-IF receptor in ileum **(Imerslund-Grasbeck syndrome)**, and variants in the TC 2 cDNA. Two inborn defects were identified recently in the genes encoding LMBD1 and ABCD4 transporters and are responsible for the rare inborn defect in Cbl-IF, which results in the trapping of free vitamin B_{12} in lysosomes. These disorders require long-term parenteral cobalamin treatment: intramuscular injections of cobalamin. High-dose substitution with oral cyanocobalamin (1 mg biweekly) does not seem to be sufficient for all patients with congenital cobalamin deficiency. Intramuscular cobalamine injections of 1000 mcg/day for 7 days, then three times a week for 3 weeks, then once a month for 3 months, followed by a change to 1000 mcg daily oral cobalamine has been successful in some cases.

Folate is an essential vitamin required to synthesize methionine from homocysteine. It is found mainly in green leafy vegetables, legumes, and oranges. After its uptake by enterocytes, folate is converted to 5-methyltetrahydrofolate. Secondary folate deficiency is caused by insufficient folate intake, villous atrophy (e.g., celiac disease, inflammatory bowel disease), treatment with phenytoin and trimethoprim, among others (see Chapter 503.1). Several inherited disorders of folate metabolism and transport have been described.

Three mammalian folate transporter systems have been described in a variety of tissues: (1) the bidirectional reduced folate carrier 1 (RFC1, SLC19A1), (2) the glycosyl-phosphatidylinositol-anchored folate receptors (FOLR1, FOLR2, and FOLR4) responsible for folate-receptor mediated endocytosis, and (3) the human proton-coupled folate transporter (PCFT). Hereditary **folate malabsorption** is characterized by a defect of the PCFT of the brush border, leading to impaired absorption of folate in the upper small intestine as well as impaired transport of folate into the central nervous system. Symptoms of congenital folate malabsorption are diarrhea, failure to thrive, megaloblastic anemia presenting in the first few months of life, glossitis, infections *(Pneumocystis jirovecii)* with episodes of hypogammaglobulinemia, and neurologic abnormalities (seizures, intellectual impairment, and basal ganglia calcifications). Macrocytosis, with or without neutropenia, multilobulated polymorphonuclear cells, increased lactate dehydrogenase and bilirubin, increased saturation of transferrin, and decreased cholesterol can also be found. Low levels of folate are present in serum and cerebrospinal fluid. Plasma homocysteine concentrations as well as urine excretion of formiminoglutamic acid and orotic acid are elevated. Long-standing deficiency of folate (around 3-4 months) is best documented using red cell folate. Therapy involves large doses of oral (up to 150-400 mg/day of folic acid) or systemic (intrathecal) folate. Folinic acid has been used in intramuscular and/or oral form, more readily correcting the systemic and CSF folate levels. 150-400 mg of oral folinic acid daily has been used (starting dose 10-15 mg/kg daily). CSF folate levels should be followed, monitoring for clinical response of the systemic signs of disease. Sulfasalazine and methotrexate are potent inhibitors of PCFT. Therefore folate deficiency may develop during treatment with these drugs. Although the RFC1 is ubiquitously expressed, including the brush border membrane in the small intestine, involvement of RFC1 in intestinal folate uptake has not been confirmed.

The molecular basis of intestinal transport of other water-soluble vitamins such as vitamin C (Na^+-dependent vitamin C transporters 1 and 2), pyridoxine/vitamin B_6, and biotin/vitamin B_5 (Na^+-dependent multivitamin transporter) have been described; congenital defects of these transporter systems have not yet been found in humans. A **thiamine/vitamin B_1–responsive megaloblastic anemia** syndrome, which is associated with early-onset type 1 diabetes mellitus and sensorineural deafness, is caused by pathogenic variants of the thiamine transporter protein gene, THTR-1 (SLC19A2), present in the brush border.

DISORDERS OF ELECTROLYTE AND MINERAL ABSORPTION

Congenital chloride diarrhea (CCD) is a rare but relatively common group of congenital diarrheal disorders. It includes defects in *SLC26A3,* encoding a Na^+-independent Cl^-/HCO_3^- exchanger within the apical membrane of ileal and colonic epithelium, and *GUCY2C*, encoding a guanylate cyclase receptor in the intestine for the bacterial heat-stable enterotoxin. Defects in SLC26A3 have been found to have a prevalence in Finland of 1:20,000. Founder pathogenic variants have been described in Finnish, Polish, and Arab patients: V317del, I675-676ins, and G187X, respectively. The Cl^-/HCO_3^- exchanger absorbs chloride originating from gastric acid and the cystic fibrosis transmembrane conductance regulator and secretes bicarbonate into the lumen, neutralizing the acidity of gastric secretion.

Defects in GUCY2C have been identified, which leads to an autosomal dominant activation defect in guanylate cyclase C. This leads to

elevated levels of cyclic guanosine monophosphate (cGMP) and activation of the CFTR receptor. The mechanism is similar to the response to heat-stable enterotoxins from *Escherichia coli* and results in a chloride-losing diarrhea. Interestingly, a homozygous recessive inactivation defect has been described in a Bedouin cohort resulting in a meconium ileus phenotype due to the inactivation of CFTR.

Prenatally, CCD is characterized by maternal polyhydramnios, dilated fetal bowel loops, and preterm birth. Newborns with CCD present with severe life-threatening *secretory diarrhea* during the first few weeks of life. Volvulus has been reported in few patients with CCD. Laboratory findings are metabolic alkalosis, hypochloremia, hypokalemia, and hyponatremia (with high plasma renin and aldosterone activities). Fecal chloride concentrations are >90 mmol/L and exceed the sum of fecal sodium and potassium. Early diagnosis and aggressive lifelong enteral substitution of KCl in combination with NaCl (chloride doses of 6-8 mmol/kg/day for infants and 3-4 mmol/kg/day for older patients) prevent mortality and long-term complications (such as urinary infections, hyperuricemia with renal calcifications, renal insufficiency, and hypertension) and allow normal growth and development. Orally administered proton pump inhibitors, cholestyramine, and butyrate can reduce the severity of diarrhea. However, febrile diseases are likely to exacerbate symptoms as a consequence of severe dehydration and electrolyte imbalances. (See Chapter 71 for fluid and electrolyte management.) The diarrheal symptoms usually tend to regress with age, but the phenotype is highly variable. In familial cohorts carrying the same variant, individuals have demonstrated an increased incidence of inflammatory bowel disease as well as a phenotype of irritable bowel syndrome and motility issues.

The classic form of **congenital sodium diarrhea** (CSD) manifests with polyhydramnios, massive *secretory diarrhea*, severe metabolic acidosis, alkaline stools (fecal pH >7.5), and hyponatremia because of fecal losses of Na^+ (fecal Na^+ >70 mmol/L). Urinary secretion of sodium is low to normal. CSD is clinically and genetically heterogeneous. A syndromic form of CSD with superficial punctate keratitis, choanal or anal atresia, hypertelorism, and corneal erosions has been related to pathologic variants in *SPINT2,* which encodes a serine-protease inhibitor whose pathophysiologic action on intestinal Na^+ absorption is unclear. This form of CSD is also referred to as **congenital tufting enteropathy** (intestinal epithelial dysplasia) as it often shows clustered enterocytes that form "tufts" with branching crypts on histology (described in Chapter 385.3). Pathogenic variants in *SLC9A3,* the gene encoding the Na^+/H^+ antiporter 3 (NHE3), the major intestinal brush border Na^+/H^+ exchanger, were identified in nine patients with nonsyndromic CSD. IBD developed in two of nine patients with recessive SLC9A3 pathogenic variants, implicating NHE3 in the pathogenesis of IBD in a subset of patients.

The congenital form of **acrodermatitis enteropathica** manifests with severe deficiency of body zinc soon after birth in bottle-fed children or after weaning from breastfeeding (see Chapter 712). Clinical signs of this disorder are anorexia, diarrhea, failure to thrive, humoral and cell-mediated immunodeficiency (poor wound healing, recurrent infections), male hypogonadism, skin lesions (vesiculobullous dermatitis on the extremities and perirectal, perigenital, and perioral regions, and alopecia), and neurologic abnormalities (tremor, apathy, depression, irritability, nystagmus, photophobia, night blindness, and hypogeusia). The genetic defect of acrodermatitis enteropathica is caused by a pathogenic variant in the Zrt-Irt-like protein 4 (ZIP4, SLC39A4), normally expressed on the apical membrane, which enables the uptake of zinc into the cytosol of enterocytes. The zinc-dependent alkaline phosphatase and plasma zinc levels are low. Paneth cells in the crypt of the small intestinal mucosa show inclusion bodies. Acrodermatitis enteropathica requires long-term treatment with elemental zinc at 1-3 mg/kg/day. Maternal zinc deficiency impairs embryonic, fetal, and postnatal development. Chapter 72 described the *acquired* forms of zinc deficiency. Transient neonatal zinc deficiency is an autosomal dominant disorder with similar manifestations as acrodermatitis enteropathica. The disease is caused by pathogenic variants in ZnT2, the transporter responsible for supplying human milk with zinc.

Menkes disease and **occipital horn syndrome** are both caused by pathogenic variants in the gene encoding Cu^{2+} transporting adenosine triphosphatase (ATPase), α-polypeptide (ATP7A), which is also called Menkes or MNK protein. ATP7A is mainly expressed by enterocytes, placental cells, and the central nervous system, and is localized in the *trans*-Golgi network for copper transfer to enzymes in the secretory pathway or to endosomes to facilitate copper efflux. Copper values in liver and brain are low in contrast to an increase in mucosal cells, including enterocytes and fibroblasts. Plasma copper and ceruloplasmin levels decline postnatally. Clinical features of Menkes disease are progressive cerebral degeneration (convulsions), feeding difficulties, failure to thrive, hypothermia, apnea, infections (urinary tract), hypertelorism, hair abnormalities (kinky hair), hypopigmentation, bone changes, and cutis laxa. Patients with the classic form of Menkes disease usually die before the age of 3 years. A therapeutic trial with copper-histidinase should start before the age of 6 weeks. In contrast to Menkes disease, occipital horn syndrome usually manifests during adolescence with borderline intelligence, craniofacial abnormalities, skeletal dysplasia (short clavicles, pectus excavatum, genu valgum), connective tissue abnormalities, chronic diarrhea, orthostatic hypotension, obstructive uropathy, and osteoporosis. It should be differentiated from Ehlers-Danlos syndrome type V.

Active calcium absorption is mediated by the transient receptor potential channel 6 (TRPV6) at the brush border membrane, calbindin, and the Ca-ATPase, or the Na^+-Ca^{2+} exchanger for calcium efflux at the basolateral membrane within the proximal small bowel. A congenital defect of these transporters has not yet been described.

Intestinal absorption of dietary magnesium, which occurs via the transient receptor potential channel TRPM6 at the apical membrane, is impaired in familial **hypomagnesemia with secondary hypocalcemia**, which manifests with neonatal seizures and tetany.

Intestinal iron absorption consists of several complex regulated processes starting with the uptake of heme-containing iron by heme carrier protein 1 (HCP1) and Fe^{2+} (after luminal reduction of oxidized Fe^{3+}) by the divalent metal transporter 1 (DMT1) at the apical membrane, followed by the efflux of Fe^{2+} by ferroportin 1 (also called the iron-regulated transporter) at the basolateral membrane of duodenal enterocytes. Hepatic hormone hepcidin has a key role in iron homeostasis by interacting with ferroportin. When it binds to ferroportin, hepcidin induces phosphorylation of the iron exporter, causing its internalization and degradation. A decrease in the ferroportin protein level on the cell surface inhibits iron export from intracellular pools. Thus hepcidin controls plasma iron levels by reducing iron absorption in the gut, lowering iron release from hepatocytes, and preventing iron recycling by macrophages. Hepcidin deficiency causes iron overload in hereditary hemochromatosis and iron-loading anemias, whereas hepcidin excess causes or contributes to the development of iron-restricted anemia in inflammatory diseases, infections, some cancers, and chronic kidney disease. Pathogenic variants of the ferroportin 1 gene have been found in the autosomal dominant form of **hemochromatosis** type 4. Variants within the hemochromatosis (*HFE*) gene (Cys282 Tyr, His63Asn, Ser65Cys) of classic hemochromatosis reduce the endocytic uptake of diferric transferrin by the transferrin receptor-1 at the basolateral membrane of the intestinal epithelium. Hepcidin is the defective gene of juvenile hemochromatosis (type 2, subtype B). Elevated hepcidin results in hypoferremia and insufficient supply of iron for erythropoiesis, leading to different types of anemia. The underlying causes of hepcidin elevation in iron-restricted anemias are varied. An example of a genetic cause of hepcidin increase is the familial **iron-refractory iron deficiency anemia** (IRIDA), an autosomal recessive disorder caused by a pathogenic variant in matriptase-2 *(TMPRSS6),* a negative regulator of hepcidin expression. This anemia is characterized by very low plasma iron levels, unresponsiveness to oral iron therapy, and partial correction by parenteral iron. Pathologic variants in the DMT1 transporter *(SLC11A2)* are another cause of **IRIDA**. The development of severe microcytic, hypochromic anemia typifies these patients; however, surprisingly, some of them load iron in the liver.

Visit Elsevier eBooks+ at eBooks.Health.Elsevier.com for Bibliography.

Chapter 386

Intestinal Transplantation in Children with Intestinal Failure

Jorge D. Reyes and Danielle R. Wendel

The introduction of tacrolimus and the development of the abdominal multiorgan procurement techniques allowed the tailoring of various types of intestine grafts that can contain other intraabdominal organs, such as the liver, pancreas, and stomach. The understanding that the liver protects the intestine against rejection demonstrates the interaction between recipient and donor immunocytes (host-versus-graft and graft-versus-host), which under the cover of immunosuppression allows varying degrees of graft acceptance and eventual minimization of drug therapy. *Over the past several years the number of patients placed on the list for and those undergoing intestinal transplantation has decreased, which is a result of improvements in the care of patients with intestinal failure (IF) under a multidisciplinary intestinal care team management.* Advances in care include prevention and treatment of intestinal failure–associated liver disease (IFALD), advances in central venous catheter care, improved prevention of life-threatening central line–associated bloodstream infections, and corrective surgery enhancing absorptive surface and motility, which have led to increased survival and decreased morbidity.

INDICATIONS FOR INTESTINAL TRANSPLANT

IF describes a patient who has lost the ability to maintain nutritional support and adequate fluid requirements needed to sustain growth with their own intestine and is permanently dependent on parenteral nutrition (PN). The majority of these patients have short bowel syndrome as a result of a congenital deficiency or acquired condition (see Chapter 385.6). In others, the cause of IF is a functional disorder of motility or absorption (Table 386.1). Rarely do patients receive intestinal transplants for benign neoplasms, hepatic failure secondary to acute diffuse intestinal infarction, and failure of a first intestinal transplant. The complications of IF include loss of venous access, life-threatening infections, and IFALD.

Table 386.1 Causes of Intestinal Failure in Children Requiring Transplantation

SHORT BOWEL
• Volvulus
• Gastroschisis
• Necrotizing enterocolitis
• Intestinal atresia
• Trauma
INTESTINAL DYSMOTILITY
• Intestinal pseudoobstruction
• MMIHS
• Intestinal aganglionosis (Hirschsprung disease)
ENTEROCYTE DYSFUNCTION
• Microvillus inclusion disease
• Tufting enteropathy
• Other congenital enteropathies
TUMORS
• Invasive intraabdominal desmoid tumor
VASCULAR
• Acute diffuse intestinal infarction with hepatic failure

MMIHS, megacystis microcolon intestinal hypoperistalsis syndrome.

Paucity of Venous Access

Administration of PN requires the insertion of a centrally placed venous catheter, there being only six readily accessible sites (bilateral internal jugular, subclavian, iliac veins). The loss of venous access generally occurs in the setting of recurrent catheter sepsis and thrombosis. Children who have lost three of four upper body central veins (right or left subclavian or internal jugular) or have an occlusion of a brachiocephalic vein should be considered for intestinal transplant evaluation due to the risk of losing the ability to provide PN.

Life-Threatening Infections

Life-threatening infections are usually catheter related, although their frequency is decreasing with improvements in central venous catheter care including antimicrobial locks. The absence of significant length of intestine is often associated with abnormal motility of the residual bowel (producing both delayed and/or rapid emptying), with varying degrees of bacterial overgrowth and translocation as a consequence of intestinal inflammation, loss of intestinal barrier function, and/or loss of gut immunity. This situation contributes to IFALD, multisystem organ failure, and metastatic infectious foci in lungs, kidneys, liver, bone, and the brain.

Liver Disease

The development of IFALD is the most serious complication of IF and may be a consequence of the toxic effects of PN on hepatocytes, a disruption of bile flow as a result of lack of enteral intake, alterations in bile acid metabolism, the frequent occurrence of bacterial overgrowth/translocation, and sepsis with endotoxin release into the portal circulation, all often in the setting of a premature liver. Soy-based intravenous lipids may contribute to liver disease; the incidence of liver disease has decreased with the use of fish oil–based products. IFALD varies in frequency depending on the patient's age and the etiology of the IF; it is most common in neonates with extreme short gut. Initially characterized by cholestasis and inflammation, later phases involve steatosis and fibrosis. Cholestasis in IFALD is defined as direct/conjugated bilirubin >2 mg/dL and more than 20% of total bilirubin after other etiologies have been excluded. The histology includes cholestasis, bile ductular reaction, portal inflammation, steatosis, periportal fibrosis, and liver macrophages. Development of IFALD, as evidenced by cholestasis, is one of the greatest predictors of mortality in children with short bowel syndrome.

TRANSPLANTATION OPERATION

Donor Selection

Intestinal grafts are usually procured from hemodynamically stable, ABO-identical brain-dead donors who have minimal clinical or laboratory evidence suggesting intraabdominal ischemia. Size matching varies according to age of the recipients, and present surgical techniques allow for significant reductions of the graft to achieve abdominal closure. Although the exact effect is still unknown, donor-specific antibodies (DSAs) have been linked to rejection and poor long-term outcomes in the recipient leading to increased use of pretransplant cross-matched results to improve organ allocation, especially in sensitized recipients. Exclusion criteria include a history of malignancy and intraabdominal evidence of infection; systemic viral or bacterial infections are not excluded. Donor preparation has been limited to the administration of systemic and enteral antibiotics. Prophylaxis for graft-versus-host disease with graft pretreatment using irradiation or a monoclonal antilymphocyte antibody has varied over time. Grafts have been preserved with the University of Wisconsin solution, as is the case with other types of abdominal organs.

Types of Intestinal Grafts

Intestinal allografts are used in various forms, either alone (as an **isolated intestine graft**) or as a composite graft, which can include the liver, duodenum, and pancreas **(liver-intestine graft)**. When this composite graft includes the stomach, and the recipient operation requires the removal of all of the patient's gastrointestinal tract (as with

intestinal pseudoobstruction) and liver, then this replacement graft is known as a **multivisceral graft**.

The procurement of these various types of grafts focuses on the preservation of the arterial vessels of celiac and/or superior mesenteric arteries, as well as appropriate venous outflow, which would include the superior mesenteric vein or the hepatic veins in the composite grafts. The larger composite grafts inherently retain the celiac and superior mesenteric arteries; this includes multivisceral grafts, liver plus small bowel grafts, and *modified multivisceral grafts* in which the liver is excluded, but the entire gastrointestinal tract is replaced, including the stomach. The isolated intestine graft retains the superior mesenteric artery and vein. This graft can be accomplished with preservation of the vessels going to the pancreas, when that organ has been allocated to another recipient. The graft that is to be used in a particular recipient is dissected out in situ and then removed after cardiac arrest of the donor, with core cooling of the organs, using an infusion of preservation solution (Fig. 386.1).

Various modifications in these grafts have included the preservation of visceral ganglia at the base of the arteries, the inclusion of donor duodenum and pancreas for the liver and intestine graft, the inclusion of colon, the reduction of the liver graft (into left or right side) and variable reduction of the intestine graft, and living donor intestine (4-foot segment of ileum) graft.

The Recipient Operation

Because many children have had multiple previous abdominal operations, intestinal transplantation can be a formidable technical challenge; most children require replacement of the liver because of IFALD and often present with advanced liver failure. Transplantation of an isolated intestinal allograft involves exposure of the lower abdomen, infrarenal aorta, and inferior vena cava. Placement of vascular homografts using donor iliac artery and vein to these vessels allows arterialization and venous drainage of the intestinal graft. In patients who have retained their intestine and then undergo an enterectomy at the time of transplantation, use of the native superior mesenteric vessels is feasible.

Transplantation of a larger composite graft requires the removal and replacement of the native liver in the liver with intestine transplant, and complete abdominal exenteration in the multivisceral transplant. In a similar fashion, the infrarenal aorta is exposed for placement of an arterial conduit graft (donor thoracic aorta) for arterialization of the graft. The venous drainage is achieved to the retained hepatic veins, which are fashioned to a single conduit for anastomosis to the allograft liver.

The intestinal anastomosis to native proximal and distal bowel is performed, leaving an enterostomy of distal allograft ileum; this will be used for routine posttransplantation surveillance endoscopy and biopsy. This ostomy is closed 3-6 months after transplantation (Fig. 386.2).

POSTOPERATIVE MANAGEMENT

Immunosuppression

Successful immunosuppression for intestinal transplantation occurred with the introduction of tacrolimus in addition to corticosteroids. This required high levels of tacrolimus (in the nephrotoxic range), and although initial success rates were high, they were followed by rejection

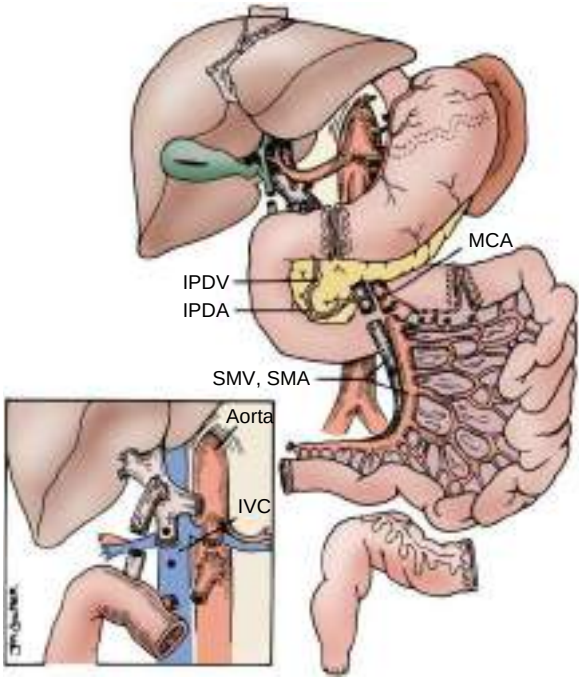

Fig. 386.1 Various abdominal organs can be dissected in situ, providing isolated or composite grafts to fit the individual patient's needs. Separation of intestine and pancreas is feasible, with preservation of the inferior pancreaticoduodenal artery *(IPDA)* and vein *(IPDV)*. The use of vascular grafts from the donor allow connections to the superior mesenteric pedicle (artery *[SMA]* and vein *[SMV]*) to aorta and inferior vena cava *(IVC)* or portal vein *(inset)*. MCA, Major coronary artery. *(From Abu-Elmagd K, Fung J, Bueno J, et al. Logistics and technique for procurement of intestinal, pancreatic and hepatic grafts from the same donor. Ann Surg. 2000;232:680–697.)*

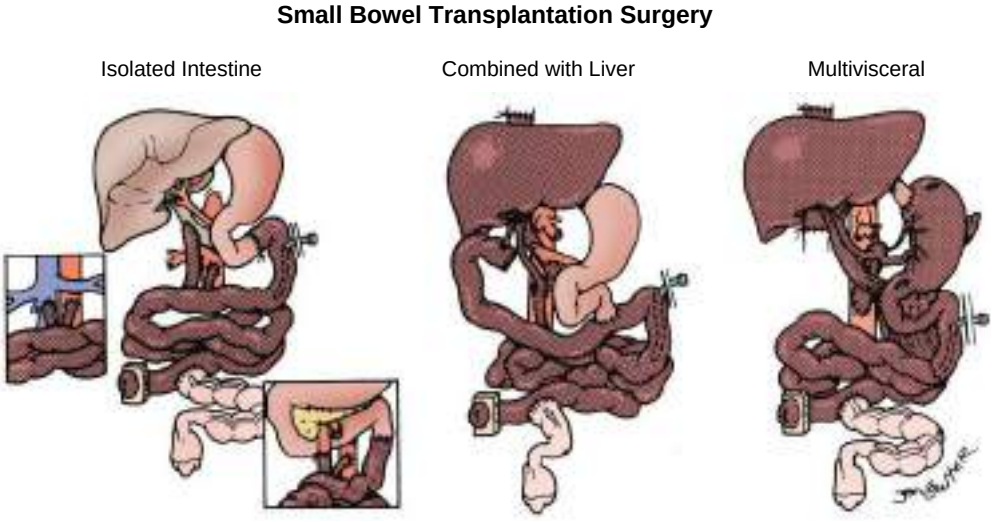

Fig. 386.2 Three basic intestinal transplant procedures (the graft is *shaded*). With the isolated intestine, the venous outflow may be to the recipient portal vein, inferior vena cava *(inset left)*, or superior mesenteric vein *(inset right)*. With the composite grafts, which include the liver, the arterialization is from the aorta with venous drainage out from the liver graft to the recipient inferior vena cava.

rates of >80%, infection, and late drug toxicities, resulting in a gradual loss of grafts and patients. The next generation of protocols incorporated the addition of other agents, such as azathioprine, cyclophosphamide, induction with an interleukin (IL)-2 antibody antagonist, mycophenolate mofetil, and rapamycin. This modification resulted in a decreased incidence in the severity of initial rejection; the inability to decrease immunosuppression later did not allow for stabilization of long-term survival. The introduction of induction therapy has resulted in improved transplant survival as a result of a significant decrease in the incidence of rejection, permitting the gradual decrease of immunosuppressive drug therapy, resulting in a decline in drug toxicity events and infections. The most common induction regimen used is T-cell–depleting agents followed by IL-2 receptor antagonists. A mainstay of maintenance immunosuppression is tacrolimus and prednisone dual therapy, although many centers add mycophenolate mofetil or rapamycin for triple-drug regimens when patients have had episodes of rejection. By 1 year the majority of patients are on tacrolimus monotherapy.

Allograft Assessment

There are no simple laboratory tools that allow assessment of the intestinal allograft. The gold standard for diagnosis of intestinal allograft rejection has been serial endoscopic surveillance and biopsies through the allograft ileostomy. Clinical signs and symptoms of rejection or infection of the allograft can overlap and mimic each other, producing either diarrhea or complete ileus with pseudoobstruction syndromes, abdominal pain, or gastrointestinal bleeding. Any changes in clinical status should warrant thorough evaluation for rejection with endoscopic biopsies and an evaluation for opportunistic infection, malabsorption, and other enteral infections.

The diagnosis of *acute rejection* is based on seeing destruction of crypt epithelial cells from apoptosis, in association with a mixed lymphocytic infiltrate. These histologic findings may or may not correlate with endoscopic evidence of injury, which varies from diffuse erythema and friability to ulcers and, in cases of severe rejection, exfoliation of the intestinal mucosa. *Chronic rejection* of the allograft can be diagnosed only through full-thickness sampling of the intestine, which shows the typical vasculopathy that can result in progressive ischemia of the allograft.

Rejection and Graft-Versus-Host Disease

Acute rejection rates for the intestinal allograft are significantly higher than with any other organ, in the range of 60–70%, and severe rejection requiring the use of antilymphocyte antibody preparations may be as high as 30%. Triple-drug regimens and the use of IL-2 antibody inhibitors have resulted in significant decreases in rejection rates; nonetheless, the amount of immunosuppression was incompatible with improvements in long-term patient and graft survival. Rejection rates of 40% are achievable with the use of antilymphocyte globulin. These protocols induce varying degrees of *prope tolerance (or almost tolerant)*, which can eventually allow for minimization of immunosuppression, thus reducing the risk of drug toxicity and infection. Vascular rejection has been an uncommon occurrence, and chronic rejection has been seen in approximately 10–15% of cases.

Many intestine transplant recipients are immunologically sensitized, increasing the risk of DSA formation. DSA can be pre-formed before transplant or develop de novo afterward. While the negative effects of DSA have been recognized in other types of solid organ transplant for years, the effects in intestinal transplants are less clear. Studies show increased episodes of both acute and chronic rejection as well as graft loss in recipients with positive DSA antibody mediated rejection.

Graft-versus-host disease is infrequent but potentially life-threatening; the mortality rate exceeds 80%, and most recipients die from infectious complications from bone marrow failure. The incidence seen in intestinal transplantation is 5–10% with increased risk associated with liver inclusive grafts. Although no standard treatment is available, early diagnosis, prevention of infection, and initiation of treatment with corticosteroids as soon as possible may improve outcomes.

Infections

Infectious complications are the most significant cause of morbidity and mortality after intestinal transplantation. The most common is infectious enteritis although there are also bacterial, fungal, and polymicrobial infections that occur as a result of a need for venous catheter placement in the immediate posttransplant period or during episodes of intestinal graft dysfunction. Infections as a consequence of immunosuppressive drug management are from cytomegalovirus (CMV; 22% incidence), Epstein-Barr virus (EBV; 21% incidence), and adenovirus enteritis (40% incidence). Despite improvements in monitoring and preventative measures, CMV remains the most common viral infection postintestinal transplantation. CMV may be acquired from blood transfusions, reactivation of endogenous viruses, or the donated allograft. The highest-risk recipients for CMV infection are those who are immunologically naïve and receive an allograft from a donor who is seropositive. The two CMV prevention strategies commonly employed are universal prophylaxis and preemptive therapy. Consensus guidelines recommend prophylaxis treatment for high-risk patients (donor+/recipient–). The preferred drugs for CMV prophylaxis are ganciclovir and oral valganciclovir.

Patients at the highest risk for EBV infection are those who are seronegative at the time of transplantation and those requiring a high-burden immunosuppressive therapy to maintain their graft. EBV disease varies from asymptomatic viremia to **posttransplant lymphoproliferative disorder (PTLD)**. The incidence of EBV-related PTLD is highest in patients receiving intestinal allografts compared to liver, heart, or kidney. Children have a higher incidence of PTLD compared to adults and are most likely to have EBV + PTLD. Early diagnosis and prevention of PTLD is essential, and the mainstay of therapy is to reduce immunosuppression, although some patients have required chemotherapy. The use of anti–B-cell monoclonal antibodies, such as the anti-CD20 antibody rituximab, in PTLD has been successful as noted in anecdotal reports. Successful management of these viral infections is achieved through early detection and preemptive therapy, for both CMV and EBV, before the development of a serious life-threatening infection. This approach has improved outcomes for CMV (see Chapters 223, 301, and 302).

Outcomes

Intestinal transplantation is the standard of care for children with IF who have significant complications of PN and can no longer tolerate such therapy. Graft survival at 1 and 5 years are ~68% and 50%, respectively. One-year graft survival was associated with first-time transplantation and liver-inclusive grafts, whereas poor overall graft survival was associated with retransplantation. Patient survival was associated with elective status of the procedure versus hospitalized status with sepsis continuing to be the most significant factor leading to patient death. Colon inclusion was associated with improved rates of enteral autonomy, which increased in general over the recent decades. Rejection remained the main factor associated with long-term graft loss with decreasing contributions from PTLD and technical complications. Combined adult and pediatric registry data show stable long-term graft survival of approximately 40%, although single centers have reported rates as high as 60–70%. Rehabilitation and quality-of-life studies have shown that more than 80% of survivors reach total independence from PN and have meaningful life activities. Consequently, there has been a shift in efforts to improve long-term outcomes and quality of life.

Visit Elsevier eBooks+ at eBooks.Health.Elsevier.com for Bibliography.

Chapter 387

Acute Gastroenteritis in Children

E. Adrianne Hammershaimb and Karen L. Kotloff

The term *gastroenteritis* denotes inflammation of the gastrointestinal tract, most commonly the result of infections with bacterial, viral, or parasitic pathogens (Tables 387.1-387.3). Many of these infections are food-borne illnesses (Table 387.4). Several clinical syndromes are often described because they have different (albeit overlapping) etiologies, outcomes, and treatments. **Acute gastroenteritis** (AGE) captures the bulk of infectious cases of diarrhea. The most common manifestations are diarrhea and vomiting, which can also be associated with systemic features such as abdominal pain and fever. **Dysentery** refers to a syndrome characterized by frequent small stools containing visible blood, often accompanied by fever, tenesmus, and abdominal pain. This should be distinguished from bloody diarrhea (larger volume bloody stools with less systemic illness) because the etiologies may differ. **Prolonged** (lasting 7-13 days) and **persistent diarrhea** (lasting 14 days or longer) are important because of their impact on growth and nutrition.

BURDEN OF CHILDHOOD DIARRHEA

Although global mortality due to diarrheal diseases has declined substantially (39%) during the past 2 decades, it remains unacceptably high. In 2019 diarrheal disease caused an estimated 500,000, or 10% of all deaths in children under 5 years, making it the third leading cause of under-5 child mortality worldwide. Approximately 88% of those deaths occurred in sub-Saharan Africa and South Asia (71% and 17%, respectively). Over the same period, a smaller decline (10%) was observed in the incidence of diarrheal disease among children younger than 5 years. Almost 1 billion episodes occurred in 2019 worldwide, resulting in an estimated 45.5 million childhood disability-adjusted life years. The decline in diarrheal mortality, despite the lack of significant changes in incidence, is the result of preventive rotavirus vaccination and improved case management of diarrhea, as well as improved nutrition of infants and children. These interventions have included widespread home- and hospital-based oral rehydration solution (ORS) therapy and improved nutritional management of children with diarrhea.

In addition to the risk of mortality, high rates of diarrhea can be associated with long-term adverse outcomes. Diarrheal illnesses, especially episodes among young children that are recurrent, prolonged, or persistent, can be associated with malnutrition, stunting, micronutrient deficiencies, and significant deficits in psychomotor and cognitive development.

PATHOGENS

Rotavirus is the most common cause of AGE among children throughout the world. Several other viruses occur less frequently. Norovirus and sapovirus are the two genera of *caliciviruses* that cause AGE. Norovirus genogroup II, genotype 4 (GII.4) has predominated globally since the mid-1990s. Among the more than 50 serotypes of adenovirus, 40 and 41 are most often associated with diarrhea. Astroviruses are identified less often (see Table 387.1). SARS-CoV-2 is also recognized as a cause of AGE in adults and in children, both as a manifestation of COVID-19 and as a symptom of multisystem inflammatory syndrome in children (MIS-C).

The major bacterial pathogens that cause AGE are nontyphoidal *Salmonella* (NTS), *Shigella, Campylobacter*, and *Yersinia* (see Table 387.2). Five pathotypes of *Escherichia coli* infect humans: Shiga toxin–producing (STEC), also known as enterohemorrhagic (EHEC), enterotoxigenic (ETEC), enteropathogenic (EPEC), enteroaggregative (EAEC), and enteroinvasive (EIEC). Two serogroups of *Vibrio cholerae* (O1 and O139) produce epidemic cholera and cause nearly all sporadic cases. *Clostridioides difficile* (formerly *Clostridium difficile*) disease can be both nosocomial and community acquired in children. Bacterial pathogens that cause food-borne illness due to their ability to produce emetic and/or enterotoxins include *Bacillus cereus*, *Clostridium perfringens*, and *Staphylococcus aureus.* The significance of isolating *Aeromonas* and *Plesiomonas* in a diarrheal stool remains uncertain.

Giardia duodenalis, Cryptosporidium spp., *Cyclospora cayetanensis*, and *Entamoeba histolytica* are the most common parasites that cause diarrhea in the United States (see Table 387.3). At least 13 species of *Cryptosporidium* are associated with human disease, but *C. hominis* and, to a lesser extent, *C. parvum* are most common. The genus *Entamoeba* comprises six species that colonize humans, but only *E. histolytica* is considered a human pathogen. *G. duodenalis* (formerly *G. lamblia* and *G. intestinalis*) is a flagellate protozoan that infects the small intestine and biliary tract. Other protozoa that uncommonly cause AGE are *Cystoisospora belli* (formerly *Isospora belli*) and *Blastocystis hominis.*

EPIDEMIOLOGY IN THE UNITED STATES AND OTHER MIDDLE- AND HIGH-INCOME COUNTRIES

Risk Factors Related to Economic Development

Insufficient access to adequate hygiene, sanitation, and clean drinking water are the main factors leading to the heavy burden of AGE in developing countries. Although the severe consequences have become uncommon, infectious AGE remains ubiquitous in middle- and high-income countries. Economic development poses its own risks for transmission of enteric pathogens. The ability to mass produce and widely distribute food has led to large multistate outbreaks of AGE due to NTS, STEC, and other agents (see Table 387.4). Globalization has cultivated a taste for tropical fruits and vegetables, creating a mechanism for importation of novel pathogens. The increasing frequency of antimicrobial resistance among bacteria that cause AGE has been linked to the use of antibiotics as growth promotors for animals bred for food. Recreational swimming facilities and water treatment systems have provided a vehicle for massive outbreaks of *Cryptosporidium*, a chlorine-resistant organism. Venues serving catered food to large groups of people, such as hotels and cruise ships, are conducive to outbreaks, as are institutions where hygiene is compromised, such as daycare centers, prisons, and nursing homes. Hospitalization and modern medical therapy have created a niche for nosocomial *C. difficile* toxin infection. Childcare and school-based outbreaks are often due to norovirus and *Shigella* spp.

Endemic Diarrhea

In the United States, rotavirus was the most common cause of medically attended AGE among children younger than 5 years until the introduction of rotavirus vaccine for routine immunization of infants in 2006. Before 2006, annual epidemics swept across the country beginning in the southwest in November and reaching the northeast by May, affecting nearly every child by the age of 2 years. Since vaccine introduction, healthcare utilization for AGE has decreased markedly at a considerable cost savings. Norovirus is now the leading cause of AGE among children in the United States seeking healthcare, followed by sapovirus, adenoviruses 40 and 41, and astrovirus (see Table 387.1).

Laboratory-Based Surveillance for Food-Borne Pathogens

The most comprehensive resource for describing the burden of bacterial and protozoal diarrhea in the United States is the Foodborne Diseases Active Surveillance Network (FoodNet) maintained by the Centers for Disease Control and Prevention (CDC) (see Table 387.4). FoodNet performs active laboratory-based surveillance of nine bacterial and protozoal enteric pathogens commonly transmitted by food. Among children 0-19 years of age in 2019, NTS was most common, followed by *Campylobacter*, STEC, and *Shigella*. *Vibrio* and *Yersinia* were the least common. As of January 1, 2018, FoodNet has stopped conducting active surveillance for *Cryptosporidium*;

Table 387.1 Etiologies of Viral Gastroenteritis

ETIOLOGY	INCUBATION PERIOD	SIGNS AND SYMPTOMS	DURATION OF ILLNESS	PRINCIPAL VEHICLE AND TRANSMISSION	RISK FACTORS	COMMERCIALLY AVAILABLE DIAGNOSTIC TEST
Caliciviruses (including noroviruses and sapoviruses)	12-48 hr	Nausea, vomiting, abdominal cramping, diarrhea, fever, myalgia, and some headache	1-3 days	Person-to-person (fecal-oral and aerosolized vomit), and food, water, and fomites contaminated with human feces	Very contagious (chlorine and heat resistant); produces large outbreaks in closed settings such as cruise ships, daycares, schools, and restaurants Shellfish	Multiplex PCR RT-qPCR of stool and vomit is the preferred method for outbreak investigation, available in public health laboratories Immunoassays for norovirus have poor sensitivity Norovirus genotyping (GI and GII) is performed by CDC
Rotavirus (groups A-C), astrovirus, and enteric adenovirus (serotypes 40 and 41)	2-4 days	Often begins with vomiting, followed by watery diarrhea, low-grade fever	3-8 days	Person-to-person (fecal-oral), fomites Aerosol transmission of rotavirus may be possible	Nearly all infants and children worldwide were infected by 2 yr of age before vaccine introduction	Multiplex PCR Immunoassays for rotavirus and enteric adenovirus
SARS-CoV-2	2-14 days	Acute COVID-19: Fever, chills, cough, shortness of breath, difficulty breathing, fatigue, myalgia, headache, anosmia, dysgeusia, sore throat, congestion, runny nose, nausea, vomiting, diarrhea is usually nonbloody but may be blood tinged MIS-C: fever, abdominal pain, vomiting, diarrhea, rash, conjunctivitis, dizziness or light-headedness	Acute COVID-19: May be self-limited, less than 2 wk Prolonged symptoms may last months (e.g., fatigue, anosmia, dysgeusia) MIS-C: unclear; often fatal if untreated	Respiratory aerosols and droplets; airborne precautions recommended	Unvaccinated immune status Local epidemiology and lack of transmission mitigating precautions	RT-PCR (may be included in a multiplex PCR) Antigen immunoassay Serology (may be useful for the diagnosis of MIS-C but not for acute COVID-19)

Note: Commercially available denotes that the diagnostic tests have been cleared by the U.S. Food and Drug Administration
RT, Real-time reverse transcriptase; PCR, polymerase chain reaction; CDC, Centers for Disease Control and Prevention; MIS-C, multisystem inflammatory syndrome in children.
Adapted from Centers for Disease Control and Prevention: Diagnosis and management of foodborne illnesses. *MMWR.* 2004;53(RR-4):1–33.

in 2015, *Cryptosporidium* was the fourth most commonly identified food-borne pathogen in U.S. children less than 19 years of age. Children younger than 5 years have the highest incidence of food-borne diarrheal disease, whereas the elderly have the highest frequency of hospitalization and death. Only 5% of these infections are associated with recognized outbreaks.

Toxin-mediated food-borne gastroenteritis may be infectious or noninfectious. Pathogens that cause toxin-mediated food-borne gastroenteritis include *S. aureus*, *B. cereus*, and *C. perfringens*. Ingestion of food contaminated with the preformed *S. aureus* heat-stable enterotoxin types A to E causes staphylococcal food poisoning. *B. cereus* produces two forms of gastrointestinal illness, one resembling staphylococcal food poisoning and caused by a preformed emetic toxin, and the other caused by a group of three enterotoxins formed in vivo. Ingested *C. perfringens* sporulates in the small intestine, releasing a heat-labile, single-polypeptide enterotoxin. Noninfectious agents may also cause food-borne gastrointestinal symptoms due to a direct toxic effect of the food (mushrooms), contamination (heavy metals), or fish or shellfish toxins (Table 387.5).

Diarrhea Outbreaks

The U.S. Foodborne Disease Outbreak Surveillance System quantifies enteric infections associated with food-borne outbreaks. In 2017, among all age-groups, norovirus was the most common agent (49%), followed by NTS (19%). Less common were *C. perfringens* (6%), *Campylobacter* (4%), STEC (3%), *S. aureus* (2%), and *B. cereus* (2%), followed much less often (each 1%) by *Clostridium botulinum, Shigella, Cryptosporidium, Yersinia, Listeria, Vibrio parahaemolyticus,* and *Shigella*. Outbreaks of enteric pathogens propagated by direct person-to-person contact are most often caused by norovirus and *Shigella* species; other pathogens include NTS, rotavirus, *Giardia*, *Cryptosporidium*, *C. difficile,* and *Campylobacter jejuni.*

Nosocomial Diarrhea

C. difficile is the most common cause of healthcare-associated infection in the United States. Severe disease occurs most often in those with predisposing conditions (e.g., recent antibiotics, gastric acid suppression, immunosuppression, gastrointestinal comorbidities). In contrast to adults, rates of colostomy and in-hospital mortality have not increased in children despite increasing rates of community and

Table 387.2 Etiologies of Bacterial Gastroenteritis

ETIOLOGY	INCUBATION PERIOD	SIGNS AND SYMPTOMS	DURATION OF ILLNESS	PRINCIPAL VEHICLE AND TRANSMISSION	RISK FACTORS	COMMERCIALLY AVAILABLE DIAGNOSTIC TEST
Bacillus cereus (preformed emetic toxin)	1-6 hr	Sudden onset of severe nausea and vomiting; diarrhea may be present	24 hr	Soil and water	Improperly refrigerated cooked or fried rice, meats	Routine stool culture to look for overabundance of pathogen, does not detect toxins Reference laboratory used for outbreaks
B. cereus (enterotoxins formed in vivo)	8-16 hr	Abdominal cramps, watery diarrhea; nausea and vomiting may be present	1-2 days	Soil and water	Meats, stews, gravies, vanilla sauce	Routine stool culture to look for overab undance of pathogen, does not detect toxins Reference laboratory used for outbreaks
Campylobacter jejuni	1-5 days	Diarrhea, (10–20% of episodes are prolonged), cramps, fever, and vomiting; bloody diarrhea, bacteremia, extraintestinal infections, severe disease in immunocompromised	5-7 days (sometimes >10 days) usually self-limiting	Wild and domestic animals and animal products	Raw and undercooked poultry, unpasteurized milk, untreated surface water	Stool culture on selective agar, microaerobic conditions, and incubation at 42°C Antigen detection by EIA Multiplex PCR
Clostridioides difficile toxin	Unknown Can appear weeks after antibiotic cessation	Mild to moderate watery diarrhea that can progress to severe, pseudomembranous colitis with systemic toxicity	Variable	Person-to-person (fecal-oral), mostly within healthcare facilities	Immunosuppression, intestinal disease or surgery, prolonged hospitalization, antibiotics	PCR,† immunoassay Multistep approach using EIA for GDH and toxins A and B ± NAAT
Clostridium perfringens toxin	8-16 hr	Watery diarrhea, nausea, abdominal cramps; fever is rare	1-2 days	Environment, human and animal intestines	Meats, poultry, gravy, dried or precooked foods with poor temperature control	None Reference laboratory used for outbreaks
Escherichia coli O157:H7 and other *Shiga* toxin–producing *E. coli* (STEC)	1-9 days (usually 3-4 days)	Watery diarrhea that becomes bloody in 1-4 days in ~40% of infections; in contrast to dysentery, bloody stools are large volume and fever/toxicity is minimal More common in children <4 yr old	4-7 days	Food and water contaminated with feces from ruminants; infected people and animals (fecal-oral); predominantly high-resource countries	Undercooked beef especially hamburger, unpasteurized milk and juice, raw fruits, and petting zoos, recreational swimming, daycare Antimotility agents and antibiotics increase risk of hemolytic uremic syndrome	Multiplex PCR to detect *E. coli* O157:H7 and non-O157:H7 *Shiga* toxin genes simultaneously with stool culture on sorbitol-MacConkey agar Immunoassay for O157:H7; presumptive *E. coli* O157:H7 isolates and all *Shiga* toxin-positive stool specimens that did not yield a presumptive *E. coli* O157:H7 isolate should be sent to a public health laboratory to identify non-O157:H7 STEC and for serotyping and whole genome sequencing
Enterotoxigenic *E. coli* (ETEC)	1-5 days	Watery diarrhea, abdominal cramps, some vomiting	3-7 days	Water or food contaminated with human feces	Infants and young children in LMIC and travelers	Multiplex PCR,† or reference laboratory
Salmonella, nontyphoidal	1-5 days	Diarrhea, (10–20% prolonged), cramps, fever, and vomiting; bloody diarrhea, bacteremia, extraintestinal infections, severe disease in immunocompromised	5-7 days (sometimes >10 days) usually self-limiting	Domestic poultry, cattle, reptiles, amphibians, birds	Ingestion of raw or undercooked food, improper food handling, travelers, immunosuppression, hemolytic anemia, achlorhydria, contact with infected animal	Multiplex PCR Routine stool culture

Continued

Table 387.2 Etiologies of Bacterial Gastroenteritis—cont'd

ETIOLOGY	INCUBATION PERIOD	SIGNS AND SYMPTOMS	DURATION OF ILLNESS	PRINCIPAL VEHICLE AND TRANSMISSION	RISK FACTORS	COMMERCIALLY AVAILABLE DIAGNOSTIC TEST
Shigella spp.	1-5 days (up to 10 days for *S. dysenteriae* type 1)	Abdominal cramps, fever, diarrhea Begins with watery stools that can be the only manifestation or proceed to dysentery	5-7 days	Infected people or fecally contaminated surfaces (fecal-oral)	Poor hygiene and sanitation, crowding, travelers, daycare, MSM, prisoners	Multiplex PCR Routine stool culture
Staphylococcus aureus (preformed enterotoxin)	1-6 hours	Sudden onset of severe nausea and vomiting Abdominal cramps Diarrhea and fever may be present	1-3 days	Birds, mammals, dairy, and environment	Unrefrigerated or improperly refrigerated meats, potato and egg salads, cream pastries	Routine stool culture to look for overabundance of pathogen, does not detect toxins Reference laboratory used for outbreaks
Vibrio cholerae O1 and O139	1-5 days	Watery diarrhea and vomiting, which can be profuse and lead to severe dehydration and death within hours	3-7 days	Food and water contaminated with human feces	Contaminated water, fish, shellfish, street-vended food from endemic or epidemic settings; blood group O, vitamin A deficiency	Stool culture (requires special TCBS media so laboratory must be notified) Rapid test is useful in epidemics but does not provide susceptibility or subtype so should not be used for routine diagnosis. FDA-approved multiplex PCR
Vibrio parahaemolyticus	2-48 hr	Watery diarrhea, abdominal cramps, nausea, vomiting Bacteremia and wound infections occur uncommonly, especially in high-risk patients, e.g., with liver disease and diabetes	2-5 days	Estuaries and marine environments; currently undergoing pandemic spread	Undercooked or raw seafood, such as fish, shellfish	Culture of stool, wound, or blood depending on suspected source Requires special TCBS media so laboratory must be notified Multiplex PCR
Vibrio vulnificus	1-7 days	Vomiting, diarrhea, abdominal pain Bacteremia and wound infections, particularly in patients with chronic liver disease (presents with septic shock and hemorrhagic bullous skin lesions)	2-8 days	Estuaries and marine environments	Undercooked or raw shellfish, especially oysters, other contaminated seafood, and open wounds exposed to seawater	Culture of stool, wound, or blood depending on suspected source Requires special TCBS media so laboratory must be notified Multiplex PCR
Yersinia enterocolitica and *Y. pseudotuberculosis*	1-5 days	Diarrhea, (10–20% prolonged), cramps, fever, and vomiting; bloody diarrhea, bacteremia, extraintestinal infections, severe disease in immunocompromised; pseudoappendicitis occurs primarily in older children	5-7 days (sometimes >10 days) usually self-limiting	Swine products, occasionally person-to-person and animal-to-humans, water-borne, blood-borne (can multiply during refrigeration)	Undercooked pork, improper food handling, unpasteurized milk, tofu, contaminated water, transfusion from a bacteremic person, cirrhosis, chelation therapy	Stool culture or multiplex PCR Culture requires special media and incubation at 25°C. Not performed in many laboratories unless requested When clinically relevant, can isolate from vomit, blood, throat, lymph nodes, joint fluid, urine, and bile

†FDA-cleared multiplex PCR assays are available but cannot determine antimicrobial susceptibility to guide treatment or speciate the organism for outbreak investigation.
EIA, Enzyme immunoassays; PCR, polymerase chain reaction; GDH, glutamate dehydrogenase; NAAT, nucleic acid amplification test; LMIC, low- and middle-income countries; MSM, men who have sex with men; TCBS, thiosulfate-citrate-bile salts-sucrose agar; FDA, U.S. Food and Drug Administration.
Adapted from Centers for Disease Control and Prevention: Diagnosis and management of foodborne illnesses. *MMWR*. 2004;53(RR-4):1–33.

Table 387.3 Etiologies of Parasitic Gastroenteritis

ETIOLOGY	INCUBATION PERIOD	SIGNS AND SYMPTOMS	DURATION OF ILLNESS	PRINCIPAL VEHICLE AND TRANSMISSION	RISK FACTORS	COMMERCIALLY AVAILABLE DIAGNOSTIC TEST
Cryptosporidium	1-11 days	Diarrhea (usually watery), bloating, flatulence, cramps, malabsorption, weight loss, and fatigue may wax and wane Persons with AIDS or malnutrition have more severe disease	1-2 wk; may be remitting and relapsing over weeks to months	Person-to-person (fecal-oral), contaminated food and water (including municipal and recreational water contaminated with human feces)	Infants 6-18 mo of age living in endemic settings in LMIC, patients with AIDS, childcare settings, drinking unfiltered surface water, MSM, Ig deficiency	Immunoassays, PCR, and multiplex PCR are most sensitive Microscopy (direct fluorescent antibody staining is preferable to modified acid fast)
Cyclospora cayetanensis	1-11 days	Same as *Cryptosporidium*	Same as *Cryptosporidium*	Fresh produce (imported berries, lettuce)	Travelers, consumption of fresh produce imported from the tropics	Fecal microscopy, multiplex PCR May need to examine water or food
Entamoeba histolytica	2-4 wk	Gradual onset of cramps, watery diarrhea and often dysentery with cramps but rarely fever Can wax and wane with weight loss Dissemination to live and other organs can occur	Variable; may be protracted (several weeks to several months)	Fecal-oral transmission Any uncooked food or food contaminated by an ill food handler after cooking; drinking water	Persons living in or traveling to LMIC, institutionalized persons, MSM	Immunoassay or multiplex PCR are preferred Fecal microscopy of fresh stool for cysts and parasites on at least three samples can also be performed Serology for extraintestinal infections
Giardia duodenalis	1-4 wk	Diarrhea, stomach cramps, gas, weight loss; symptoms may wax and wane	2-4 wk	Any uncooked food or food contaminated by an ill food handler after cooking; drinking water	Hikers drinking unfiltered surface water, persons living in or traveling to LMIC, MSM, IgA deficiency	Immunoassay or multiplex PCR preferred Fecal microscopy for ova and parasites can be performed; at least three samples recommended

LMIC, Low- and middle-income countries; PCR, polymerase chain reaction; MSM, men having sex with men.

hospital-acquired *C. difficile* infection, suggesting that *C. difficile* may be less pathogenic in children. Moreover, high rates of asymptomatic carriage among children younger than 2 years create diagnostic uncertainty, so children <1 year should never be routinely tested; testing and treatment in children 1-2 years of age should be reserved for those in whom noninfectious or other infectious causes have been ruled out, and children ≥2 years may be tested if they have prolonged or worsening diarrhea and relevant risk factors or exposures (see Table 387.2).

Zoonotic Transmission

Many diarrheal pathogens are acquired from animal reservoirs (see Tables 387.1-387.3). The ability of NTS to undergo transovarian passage in hens allows infection of intact grade A pasteurized eggs, a source of multiple large outbreaks. Although *Campylobacter* is prevalent in poultry, its lower outbreak potential has been attributed to its lack of transovarian spread in hens and stringent growth requirements, which limit its ability to replicate in foods. On the other hand, *Campylobacter* has an extensive reservoir in domestic and wild animals and remains a major cause of sporadic bacterial foodborne disease in industrialized countries, usually from consumption of contaminated chicken meat, beef, and milk. Its ubiquitous animal reservoir also has resulted in widespread contamination of surface waters, resulting in diarrhea among hikers and campers who drink from streams, ponds, and lakes in wilderness areas. The predilection for STEC to asymptomatically colonize the intestines of ruminant animals explains why unpasteurized dairy products, fruits harvested from fields where cattle graze, and undercooked hamburger are common vehicles. The major animal reservoir for *Yersinia* is pigs, so ingestion of raw or undercooked pork products is an important risk factor. Pets can be the source of NTS (asymptomatic young birds, amphibians, and reptiles), *Campylobacter*, and *Yersinia* (puppies and kittens that are usually ill with diarrhea).

Seasonality

Seasonality provides a clue to implicate specific pathogens, although patterns may differ in tropical and temperate climates. Rotavirus and norovirus peak in cool seasons, while enteric adenovirus infections occur throughout the year, with some increase in summer. *Salmonella*, *Shigella*, and *Campylobacter* favor warm weather, whereas the tendency for *Yersinia* to tolerate cold manifests as a winter seasonality, with higher prevalence in northern countries, and the ability to survive in contaminated blood products during refrigeration.

EPIDEMIOLOGY IN LOW- AND MIDDLE-INCOME COUNTRIES

Large epidemiologic studies conducted during the previous decade have advanced our understanding of the etiology of diarrheal disease among children in low-resource countries. The Global Enteric Multicenter

Table 387.4 Number of Laboratory-Diagnosed Bacterial and Parasitic Infections, Hospitalizations, Deaths, Outbreak-Associated Infections, and Crude Incidence by Pathogen — Foodborne Diseases Active Surveillance Network, 10 U.S. sites,* 2021†

	2021				
		NO. (%)			
PATHOGEN	NUMBER OF INFECTIONS§	HOSPITALIZATIONS¶	DEATHS**	OUTBREAK-ASSOCIATED INFECTIONS††	CRUDE INCIDENCE§§
Total	22,019	5,359 (24)	153 (0.7)	861 (4)	—
Campylobacter	8,974	1,822 (20)	33 (0.4)	51 (0.6)	17.8
Salmonella	7,148	1,974 (28)	52 (0.7)	597 (8)	14.2
STEC	2,542	600 (24)	10 (0.4)	79 (3)	5.0
Shigella	1,699	532 (31)	8 (0.5)	67 (4)	3.4
Yersinia	683	146 (21)	3 (0.4)	2 (0.3)	1.4
Vibrio	461	117 (25)	9 (2)	8 (2)	0.9
Listeria	148	140 (95)	37 (25)	9 (6)	0.3
Cyclospora	364	28 (8)	1 (0.3)	48 (13)	0.7

*Data were obtained from laboratories in Connecticut, Georgia, Maryland, Minnesota, New Mexico, Oregon, Tennessee, and selected counties in California, Colorado, and New York.† 2021 data are preliminary.§ Bacterial infections diagnosed by culture or CIDT. *Cyclospora* infections diagnosed by microcopy or polymerase chain reaction.¶ Admission to an inpatient unit or an observation stay of >24 hours within 7 days before or after specimen collection or determined to be related to the infection if beyond this time frame. Absolute change in percentage of infections resulting in hospitalization during 2021 compared with annual average for 2016–2018: *Campylobacter* (0.3), *Salmonella* (0.3), STEC (1), *Shigella* (8), *Yersinia* (−4), *Vibrio* (−5), *Listeria* (−2), *Cyclospora* (2), and overall (0.6). Unknown hospitalization status (10% of infections during 2021 and 4% during 2016–2018) was classified as not hospitalized.

**Attributed to infection when deaths occurred during hospitalization or within 7 days after specimen collection for nonhospitalized patients. Absolute change in percentage of infections resulting in death during 2021 compared with annual average for 2016–2018: *Campylobacter* (<0.1), *Salmonella* (0.3), STEC (<0.1), *Shigella* (0.4), *Yersinia* (−0.7), *Vibrio* (−0.2), *Listeria* (6), *Cyclospora* (0.1), and overall (0.2). Unknown death status (8% of infections during 2021 and 3% during 2016–2018) was not classified as a death.†† Generally defined as two or more cases of similar illness associated with a common exposure; some sites also stipulate that illnesses be from more than one household. Absolute change in percentage of outbreak-associated infections during 2021 compared with annual average for 2016–2018: *Campylobacter* (0.2), *Salmonella* (1), STEC (−1), *Shigella* (−1), *Yersinia* (0.2), *Vibrio* (−2), *Listeria* (1), *Cyclospora* (−10), and overall (<0.1). Unknown outbreak-association status (0.02% of infections during 2021 and 0% during 2016–2018) was classified as not outbreak-associated.§§ Cases per 100,000 population. Domestic incidences (cases with no or unknown travel) by pathogen during 2021: *Campylobacter* (17.0), *Salmonella* (13.1), STEC (4.6), *Shigella* (3.0), *Yersinia* (1.3), *Vibrio* (0.8), *Listeria* (0.3), and *Cyclospora* (0.6).

CIDT, Culture-independent diagnostic test; STEC, Shiga toxin–producing *E. coli*.

Modified from Collins JP, Shah HJ, Weller DL, et al. Preliminary incidence and trends of infections caused by pathogens transmitted commonly through food – foodborne diseases active surveillance network, 10 U.S. sites, 2016-2021. *MMWR*. 2022;71(4):1260–1263.

Study (GEMS) evaluated children younger than 5 years living in seven low-income countries in sub-Saharan Africa and South Asia and seeking healthcare for moderate to severe diarrhea (Fig. 387.1). Although a broad array of pathogens was identified, most episodes of moderate to severe diarrhea were attributed to four pathogens: rotavirus, *Cryptosporidium*, *Shigella*, and ETEC producing heat-stable toxin (ST) either alone or in combination with heat-labile toxin (LT), herein termed ST-ETEC and LT-ETEC, and, to a lesser extent, adenoviruses 40 and 41. On the other hand, several etiologic agents that are common causes of AGE in high-resource settings are notable for their low frequency in resource-limited settings: NTS, STEC, norovirus, and *C. difficile* toxin. The three agents associated with most deaths among children <5 years are rotavirus (29%), *Cryptosporidium* (12%), and *Shigella* (11%). The Etiology, Risk Factors, and Interactions of Enteric Infections and Malnutrition and the Consequences for Child Health and Development Project (MAL-ED) was a study of less severe, community-based diarrhea. Viral causes predominated (36.4% of the overall incidence), but *Shigella* had the single highest attributable incidence (26.1 attributable episodes per 100 child-years).

Host Risk Factors

Most pathogens show an age predilection. The incidence of rotavirus and NTS are highest in infancy. Endemic shigellosis peaks in 1- to 4-year olds, whereas *Campylobacter* and *Cryptosporidium* show a bimodal distribution with the greatest number of reported cases in infants and young children with a secondary peak in young adults. Pandemic *V. cholerae* and *Shigella. dysenteriae* type 1 produce high attack rates and mortality in all age-groups and often afflict displaced persons in emergency settings. Some agents (e.g., NTS, *Shigella, Campylobacter, Yersinia,* and *Cryptosporidium*) are more frequent and more severe when the host is immunocompromised or malnourished.

Additional risks factors for AGE include immunodeficiency, measles, malnutrition, and lack of exclusive or predominant breastfeeding. Malnutrition increases the risk of diarrhea and associated mortality, and moderate to severe stunting increases the odds of diarrhea-associated mortality. The fraction of such infectious diarrhea deaths that are attributable to nutritional deficiencies varies with the prevalence of deficiencies; the highest attributable fractions are in sub-Saharan Africa, South Asia, and Andean Latin America. The risks are especially high with malnutrition, particularly when associated with micronutrient deficiency. Vitamin A deficiency accounts for 157,000 deaths from diarrhea, measles, and malaria. Zinc deficiency is estimated to cause 116,000 deaths from diarrhea and pneumonia.

PATHOGENESIS OF INFECTIOUS GASTROENTERITIS

Intrinsic properties of the organism help to define the mode of transmission and incubation period (Table 387.6). Enteropathogens that are infectious in small inocula (*Shigella,* STEC, norovirus, rotavirus, *G. duodenalis, Cryptosporidium* spp., *C. difficile, E. histolytica*) are readily transmitted by person-to-person contact via the fecal-oral route. Pathogens with larger infectious doses, such as cholera, NTS, ETEC, and *Campylobacter*, generally require food or water vehicles (see Tables 387.1-387.3). Pathogens that produce preformed toxins (*S. aureus, B. cereus* emetic toxin) have shorter incubation periods (1-6 hours) compared with 8-16 hours for those that must elaborate enterotoxins in situ (e.g., *C. perfringens* and *B. cereus* enterotoxin). Incubation periods of 1-5 days are seen with pathogens that attach to the epithelium and elaborate enterotoxins (e.g., *V. cholerae*, ETEC) or cytotoxins (e.g., *S. dysenteriae* type 1 and STEC) or those that invade and disrupt the intestinal epithelium (*Shigella*, NTS, *Campylobacter*, and *Yersinia*). The requirement for protozoa to progress through a life cycle to trigger pathogenic processes results in a more extended incubation period. Other

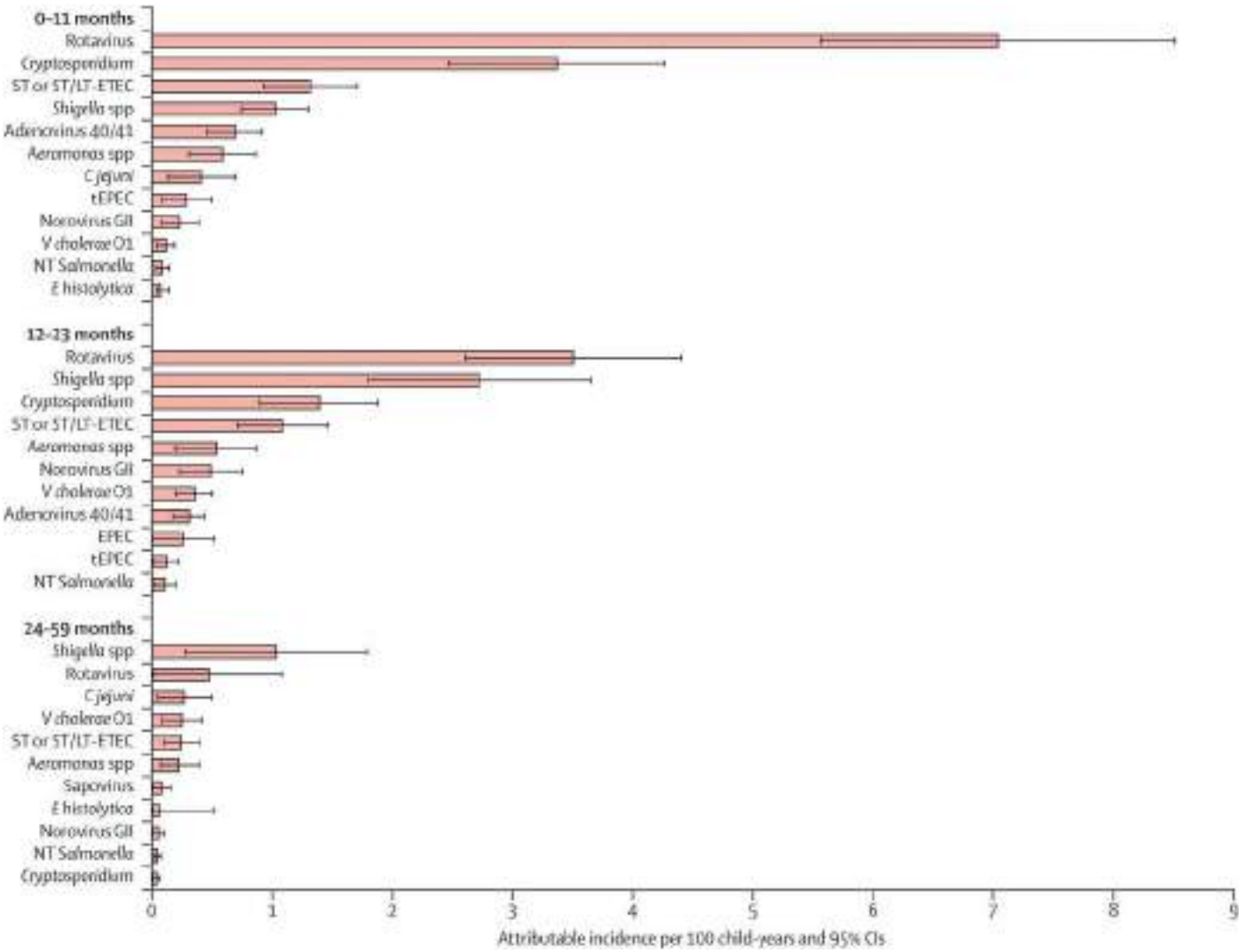

Fig. 387.1 Attributable incidence of pathogen-specific moderate to severe diarrhea per 100 child-years by age stratum, all sites combined. The bars show the incidence rates and the error bars show the 95% confidence intervals. ST/LT-ETEC, heat-stable toxin (ST) / heat labile toxin (LT)-enterotoxigenic *Escherichia coli*; tEPEC, traditional (t) enteropathogenic *Escherichia coli*. *(From Kotloff KL, Nataro JP, Blackwelder WC, et al. Burden and aetiology of diarrhoeal disease in infants and young children in developing countries [the Global Enteric Multicenter Study, GEMS]: a prospective, case-control study. Lancet. 2013;382:209–222. Fig. 4.)*

properties affecting transmissibility are bioavailability as conferred by a copious and/or prolonged fecal shedding, extended infectivity in the environment, and resistance to disinfection (all exhibited by norovirus and *Cryptosporidium*), or a large environmental or animal reservoir (e.g., *Campylobacter*). The ability to circumvent immune surveillance by frequent antigenic changes resulting from recombinational events (e.g., norovirus) or a large serotype diversity (e.g., *Shigella*) maintains a susceptible host population.

Viral AGE causes a cytolytic infection of the small intestinal villus tips resulting in decreased absorption of water, disaccharide malabsorption, inflammation, and cytokine activation. The rotavirus protein NSP4 acts as a viral enterotoxin that causes secretory diarrhea. In addition, rotavirus activates the enteric nervous system, causing decreased gastric emptying and increased intestinal mobility. There is a genetic susceptibility to both rotavirus and norovirus infection that is mediated by histo-blood group antigens on the epithelial cell surface and in mucus secretions (Fig. 387.2).

Pathogens primarily manifesting as secretory diarrhea attach to the surface of the epithelium and stimulate secretion of water and electrolytes by activating adenylate cyclase and raising intracellular cAMP (*V. cholerae* and LT-ETEC) and/or cGMP (ST-ETEC) (Figs. 387.3 and 387.4). The diarrheagenic phenotype of *C. difficile* is attributed to production of toxins A (an enterotoxin) and B (an enterotoxin and cytotoxin). The epidemic hypervirulent NAP1 *C. difficile* also makes binary toxin, which may enhance colonization and augment toxin production.

Shigella, NTS, *Campylobacter*, and *Yersinia* all possess an invasive phenotype and elicit diarrhea by a variety of mechanisms that generally involves elicitation of inflammatory cytokines with or without associated toxin production (Fig. 387.5). The pathogenesis of *Shigella*, the most common cause of bacillary dysentery, has been characterized in greatest detail. Following invasion, *Shigella* induces extensive destruction and inflammation of the intestinal epithelium, producing ulcers and microabscesses that manifest with diarrheal stools containing blood and pus. Production of enterotoxins contributes to secretory diarrhea, which can be seen early in shigellosis or as the sole manifestation. A single serotype of *Shigella*, *S. dysenteriae* type 1, elaborates the Shiga toxin, which increases the severity of illness and is responsible for the development of hemolytic uremic syndrome (HUS).

Cryptosporidia sporozoites released from ingested cysts penetrate intestinal epithelial cells and develop into trophozoites within the intracellular but extracytoplasmic environment. After undergoing asexual multiplication and sexual development, they are released in the colon as infectious oocysts capable of causing autoinfection. Host factors, in particular T-cell function, play a critical role in disease severity. *Cyclospora* cysts are not infectious in freshly passed stools but must sporulate in the environment for 1-2 weeks to become

Table 387.5 Food-Borne Noninfectious Illnesses

ETIOLOGY	INCUBATION PERIOD	SIGNS AND SYMPTOMS	DURATION OF ILLNESS	ASSOCIATED FOODS	LABORATORY TESTING	TREATMENT
Antimony	5 min-8 hr usually <1 hr	Vomiting, metallic taste	Usually self-limited	Metallic container	Identification of metal in beverage or food	Supportive care
Arsenic	Few hours	Vomiting, colic, diarrhea	Several days	Contaminated food	Urine Can cause eosinophilia	Gastric lavage, BAL (dimercaprol)
Cadmium	5 min-8 hr usually <1 hr	Nausea, vomiting, myalgia, increase in salivation, stomach pain	Usually self-limited	Seafood, oysters, clams, lobster, grains, peanuts	Identification of metal in food	Supportive care
Ciguatera fish poisoning (ciguatera toxin)	2-6 hr	GI: abdominal pain, nausea, vomiting, diarrhea	Days to weeks to months	A variety of large reef fish: grouper, red snapper, amberjack, and barracuda (most common)	Radioassay for toxin in fish or a consistent history	Supportive care, IV mannitol Children more vulnerable
	3 hr	Neurologic: paresthesias, reversal of hot or cold, pain, weakness				
	2-5 days	Cardiovascular: bradycardia, hypotension, increase in T-wave abnormalities				
Copper	5 min-8 hr usually <1 hr	Nausea, vomiting, blue or green vomitus	Usually self-limited	Metallic container	Identification of metal in beverage or food	Supportive care
Mercury	1 wk or longer	Numbness, weakness of legs, spastic paralysis, impaired vision, blindness, coma Pregnant women and the developing fetus are especially vulnerable	May be protracted	Fish exposed to organic mercury, grains treated with mercury fungicides	Analysis of blood, hair	Supportive care
Mushroom toxins, short-acting (muscimol, muscarine, psilocybin, *Coprinus atramentaria*, ibotenic acid)	<2 hr	Vomiting, diarrhea, confusion, visual disturbance, salivation, diaphoresis, hallucinations, disulfiram-like reaction, confusion, visual disturbance	Self-limited	Wild mushrooms (cooking might not destroy these toxins)	Typical syndrome and mushroom identified or demonstration of the toxin	Supportive care
Mushroom toxins, long-acting (amanitin)	4-8 hr diarrhea; 24-48 hr liver failure	Diarrhea, abdominal cramps, leading to hepatic and renal failure	Often fatal	Mushrooms	Typical syndrome and mushroom identified and/or demonstration of the toxin	Supportive care, life-threatening, may need life support
Nitrite poisoning	1-2 hr	Nausea, vomiting, cyanosis, headache, dizziness, weakness, loss of consciousness, chocolate-brown blood	Usually self-limited	Cured meats, any contaminated foods, spinach exposed to excessive nitrification	Analysis of the food, blood	Supportive care, methylene blue

Table 387.5 Food-Borne Noninfectious Illnesses—cont'd

ETIOLOGY	INCUBATION PERIOD	SIGNS AND SYMPTOMS	DURATION OF ILLNESS	ASSOCIATED FOODS	LABORATORY TESTING	TREATMENT
Pesticides (organophosphates or carbamates)	Few minutes to few hours	Nausea, vomiting, abdominal cramps, diarrhea, headache, nervousness, blurred vision, twitching, convulsions, salivation, meiosis	Usually self-limited	Any contaminated food	Analysis of the food, blood	Atropine; 2-PAM (pralidoxime) is used when atropine is not able to control symptoms; rarely necessary in carbamate poisoning
Puffer fish (tetrodotoxin)	<30 min	Paresthesias, vomiting, diarrhea, abdominal pain, ascending paralysis, respiratory failure	Death usually in 4-6 hr	Puffer fish	Detection of tetrodotoxin in fish	Life-threatening, may need respiratory support
Scombroid (histamine)	1 min-3 hr	Flushing, rash, burning sensation of skin, mouth and throat, dizziness, urticaria, paresthesias	3-6 hr	Fish: bluefin, tuna, skipjack, mackerel, marlin, escolar, and mahi	Demonstration of histamine in food or clinical diagnosis	Supportive care, antihistamines
Shellfish toxins (diarrheic, neurotoxic, amnesic)	Diarrheic shellfish poisoning: 30 min-2 hr	Nausea, vomiting, diarrhea, and abdominal pain accompanied by chills, headache, and fever	Hours to 2-3 days	A variety of shellfish, primarily mussels, oysters, scallops, and shellfish from the Florida coast and the Gulf of Mexico	Detection of the toxin in shellfish; high-pressure liquid chromatography	Supportive care, generally self-limiting
	Neurotoxic shellfish poisoning: few minutes to hours	Tingling and numbness of lips, tongue, and throat, muscular aches, dizziness, reversal of the sensations of hot and cold, diarrhea, and vomiting				
	Amnesic shellfish poisoning: 24-48 hr	Vomiting, diarrhea, abdominal pain and neurologic problems such as confusion, memory loss, disorientation, seizure, coma				Elderly are especially sensitive to amnesic shellfish poisoning
Shellfish toxins (paralytic shellfish poisoning)	30 min-3 hr	Diarrhea, nausea, vomiting leading to paresthesias of mouth and lips, weakness, dysphasia, dysphonia, respiratory paralysis	Days	Scallops, mussels, clams, cockles	Detection of toxin in food or water where fish are located; high-pressure liquid chromatography	Life-threatening, may need respiratory support
Sodium fluoride	Few minutes to 2 hr	Salty or soapy taste, numbness of mouth, vomiting, diarrhea, dilated pupils, spasms, pallor, shock, collapse	Usually self-limited	Dry foods (e.g., dry milk, flour, baking powder, cake mixes) contaminated with NaF-containing insecticides and rodenticides	Testing of vomitus or gastric washings Analysis of the food	Supportive care
Thallium	Few hours	Nausea, vomiting, diarrhea, painful paresthesias, motor polyneuropathy, hair loss	Several days	Contaminated food	Urine, hair	Supportive care
Tin	5 min-8 hr usually <1 hr	Nausea, vomiting, diarrhea	Usually self-limited	Metallic container	Analysis of the food	Supportive care

Continued

Table 387.5 Food-Borne Noninfectious Illnesses—cont'd

ETIOLOGY	INCUBATION PERIOD	SIGNS AND SYMPTOMS	DURATION OF ILLNESS	ASSOCIATED FOODS	LABORATORY TESTING	TREATMENT
Vomitoxin	Few minutes to 3 hr	Nausea, headache, abdominal pain, vomiting	Usually self-limited	Grains such as wheat, corn, barley	Analysis of the food	Supportive care
Zinc	Few hours	Stomach cramps, nausea, vomiting, diarrhea, myalgias	Usually self-limited	Metallic container	Analysis of the food, blood and feces, saliva or urine	Supportive care

BAL, Bronchoalveolar lavage; GI, gastrointestinal.
From Centers for Disease Control and Prevention: Diagnosis and management of foodborne illnesses, *MMWR*. 53(RR-4):1–33, 2004.

Table 387.6 Comparison of Three General Pathogenic Mechanisms of Enteric Infection

PARAMETER	TYPE OF INFECTION		
Mechanism	Noninflammatory (enterotoxin or adherence/superficial invasion)	Inflammatory, epithelial destruction (invasion, cytotoxin)	Penetrating
Location	Proximal small bowel	Colon	Distal small bowel
Illness	Watery diarrhea	Dysentery	Enteric fever
Stool examination	No fecal leukocytes Mild or no ↑ lactoferrin	Fecal polymorphonuclear leukocytes ↑↑ Lactoferrin	Fecal mononuclear leukocytes
Examples	*Vibrio cholerae* ETEC *Clostridium perfringens* *Bacillus cereus* *Staphylococcus aureus* Also*: *Giardia duodenalis* *Rotavirus* *Noroviruses* *Cryptosporidium* spp. EPEC, EAEC *Cyclospora cayetanensis*	*Shigella* EIEC STEC *Vibrio parahaemolyticus* *Clostridioides difficile* *Campylobacter jejuni* *Entamoeba histolytica*†	NTS *Yersinia enterocolitica* *Campylobacter fetus*

*Although not typically enterotoxic, these pathogens alter bowel physiology via adherence, superficial cell entry, cytokine induction, or toxins that inhibit cell function.
†Although amebic dysentery involves tissue inflammation, the leukocytes are characteristically pyknotic or absent, having been destroyed by the virulent amebae.
EAEC, Enteroaggregative *E. coli;* EIEC, enteroinvasive *E. coli;* EPEC, enteropathogenic *E. coli;* ETEC, enterotoxigenic *E. coli,* STEC, Shiga toxin–producing *E. coli;* NTS: nontyphoidal *Salmonella.*

infectious; they are usually transmitted in contaminated produce and water (see Table 387.3).

CLINICAL MANIFESTATION OF ACUTE GASTROENTERITIS

General Findings

Diarrhea is usually defined as the passage of three or more abnormally loose or liquid stools per day. Frequent passage of formed stools is not diarrhea, nor is the passing of loose, pasty stools by breastfed babies. Clinical clues as to the possible etiology of AGE are noted in Tables 387.1-387.3 and Table 387.7.

In the past, many guidelines divided patients into subgroups for mild (3–5%), moderate (6–9%), and severe (≥10%) dehydration; however, it is difficult to distinguish between mild and moderate dehydration based on clinical signs alone. Therefore current guidelines combine mild and moderate dehydration and simply use none, some, and severe dehydration. Commonly used guidelines include the World Health Organization (WHO) Integrated Management of Childhood Illness scale, the Clinical Dehydration Scale, the Modified Vesikari Score, and the Gorelick scale, but the accuracy and applicability of these scales varies by clinical setting and by the individual assigning the patients' scores. The signs that best predict dehydration are prolonged capillary refill time >2 seconds, abnormal skin turgor, hyperpnea (deep, rapid breathing suggesting acidosis), dry mucous membranes, absent tears, and general appearance (including activity level and thirst). As the number of signs increases, so does the likelihood of dehydration. Tachycardia, altered level of consciousness, and cold extremities with or without hypotension suggest severe dehydration.

Viral Diarrhea

Symptoms of rotavirus AGE usually begin with vomiting followed by frequent passage of watery, nonbloody stools associated with fever in about half the cases (see Table 387.1). The diarrhea lacks fecal leukocytes, but stools from 20% of cases contain mucus. Recovery with complete resolution of symptoms generally occurs within 7 days. Although disaccharide malabsorption is found in 10–20% of episodes, it is rarely clinically significant.

Other viral agents elicit similar symptoms and cannot be distinguished from rotavirus based on clinical findings. In an outbreak setting, the pattern of a brief incubation period (12-48 hours), short duration of illness, and clustering of cases is shared by caliciviruses and preformed bacterial toxin. However, unlike preformed toxins, caliciviruses cause secondary infections, which confirm the contagious nature of the outbreak. Diarrheal illnesses caused by enteric adenovirus infections tend to be more prolonged than rotavirus (7-10 days),

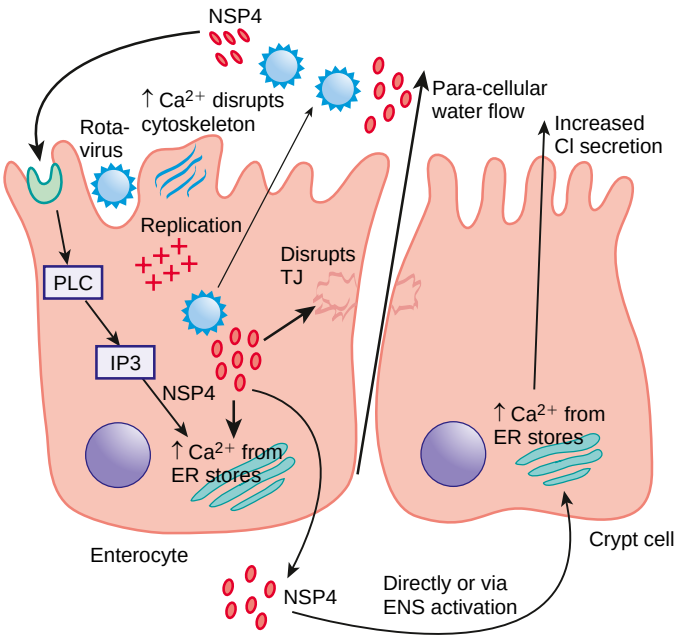

Fig. 387.2 Pathogenesis of rotavirus infection and diarrhea. ENS, Enteric nervous system; ER, endoplasmic reticulum; IP3, inositol trisphosphate; PLC, phospholipase C; TJ, tight junction. *(Adapted from Ramig RF. Pathogenesis of intestinal and systemic rotavirus infection. J Virol. 2004;78:10213–10220.)*

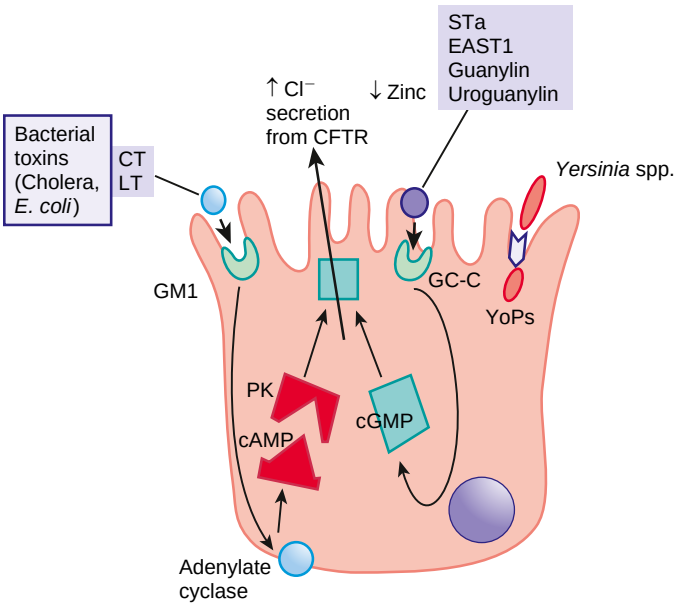

Fig. 387.3 Mechanism of secretory and penetrating diarrhea. cAMP, Cyclic adenosine monophosphate; CFTR, cystic fibrosis transmembrane conductance regulator through which chloride is secreted; cGMP, cyclic guanosine monophosphate; YoPs, *Yersinia* outer proteins that alter host cell functions to promote disease; CT, cholera toxin; EAST1, enteroaggregative *E. coli* ST; GC-C, guanylate cyclase, the transmembrane receptor for STa and other toxins; GM1, a ganglioside containing one sialic acid residue that serves as the receptor for CT and LT; LT, heat labile toxin; PK, protein kinase; STa, heat stable toxin A. *(Modified from Thapar M, Sanderson IR. Diarrhoea in children: an interface between developing and developed countries. Lancet. 2004;363:641–653; and Montes M, DuPont HL. Enteritis, enterocolitis and infectious diarrhea syndromes. In Cohen J, Powderly WG, Opal SM, et al., eds. Infectious Diseases, 2nd ed. London: Mosby; 2004. pp. 31–52.)*

whereas astroviruses cause a shorter course (~5 days), usually without significant vomiting. The incubation period of SARS-CoV-2 varies depending on circulating variant and the host's vaccination status and immunocompetence with symptoms of acute COVID-19 developing 2-14 days after exposure and symptoms of MIS-C developing approximately ~4 weeks after exposure, with or without preceding known symptomatic COVID-19. Acute COVID-19 encompasses a spectrum of disease ranging from mild congestion and headache to acute respiratory failure, hypercoagulability, and multisystem organ failure, but it may be limited to AGE in some patients. Other gastrointestinal manifestations of acute COVID-19 include colitis, mesenteric adenitis, and pseudoappendicitis as a manifestation of mesenteric adenitis. Whereas fever is present in fewer than half of acute COVID-19 cases in children, it is a diagnostic criterion of MIS-C, in which abdominal pain and other gastrointestinal symptoms are a prominent feature, often accompanied by rash, conjunctivitis, and lymphadenopathy, and which may rapidly progress to cardiogenic shock if not identified and treated promptly.

Bacterial Diarrhea

Although there is considerable overlap, high fever >40°C, overt fecal blood, abdominal pain, no vomiting before diarrhea onset, and high stool frequency (>10 per day) are more common with bacterial pathogens (see Table 387.2). Although high fever and overt fecal blood are often absent in bacterial enteritis, when present, there is a high probability of a bacterial etiology. The classical bacterial agents, NTS, *Shigella, Campylobacter,* and *Yersinia,* present with one of five syndromes.

1. Acute diarrhea, the most common presentation, may be accompanied by fever and vomiting. Clinically silent bacteremia associated with uncomplicated NTS AGE can be seen among otherwise healthy children younger than 2 years living in industrialized countries.
2. Bloody diarrhea or frank dysentery is classically caused by *Shigella*. Watery diarrhea typically precedes dysentery and is often the sole clinical manifestation of mild infection. Progression to dysentery indicates colitis and may occur within hours to days. Patients with severe infection may pass more than 20 dysenteric stools in one day. Dysenteric illnesses due to *Campylobacter* have been confused with inflammatory bowel disease.
3. Invasive, nonfocal disease (enteric fever) is a febrile illness associated with bacteremia without localized infection. Diarrhea may be minimal or absent. Although classically the result of *S.* Typhi or Paratyphi A and B, enteric fever can result from systemic spread of the classical bacterial enteropathogens. Whereas enteric fever caused by *S.* Typhi or Paratyphi A and B primarily affect preschool and school-age children in endemic countries, other bacterial enteropathogens most often cause disease in infants (particularly <3 months), the immunocompromised, and children with malnutrition. Additional risk factors include hemolytic anemia and intravascular lesions for NTS, and iron overload, cirrhosis, and chelation therapy for *Yersinia* sepsis. The distinct clones of NTS that have arisen in sub-Saharan Africa described earlier often cause enteric-fever type illnesses in the absence of AGE. *Shigella* sepsis is rare and is seen most often in malnourished and immunocompromised hosts.
4. Localized extraintestinal invasive infections can result from either local invasion or bacteremic spread (see Table 387.7). Examples of local invasion include mesenteric adenitis, appendicitis, and rarely cholecystitis, mesenteric venous thrombosis, pancreatitis, and hepatic or splenic abscess. Bacteremic spread may result in pneumonia, osteomyelitis, meningitis (three conditions seen most commonly with NTS), abscesses, cellulitis, septic arthritis, and endocarditis. *Shigella* can cause noninvasive contiguous infections such as vaginitis and urinary tract infections.
5. Vertical transmission of *Shigella,* NTS, and *Campylobacter* can produce perinatal infection resulting in a spectrum of illness from isolated diarrhea or hematochezia to fulminant neonatal sepsis. One species of *Campylobacter, C. fetus,* is particularly virulent in pregnant women and can result in chorioamnionitis, abortion, and neonatal sepsis and meningitis.

Crampy abdominal pain and nonbloody diarrhea are the first symptoms of STEC infection, sometimes with vomiting. Within several days, diarrhea becomes bloody, and abdominal pain worsens. Bloody diarrhea lasts between 1 and 22 days (median 4 days). In contrast to

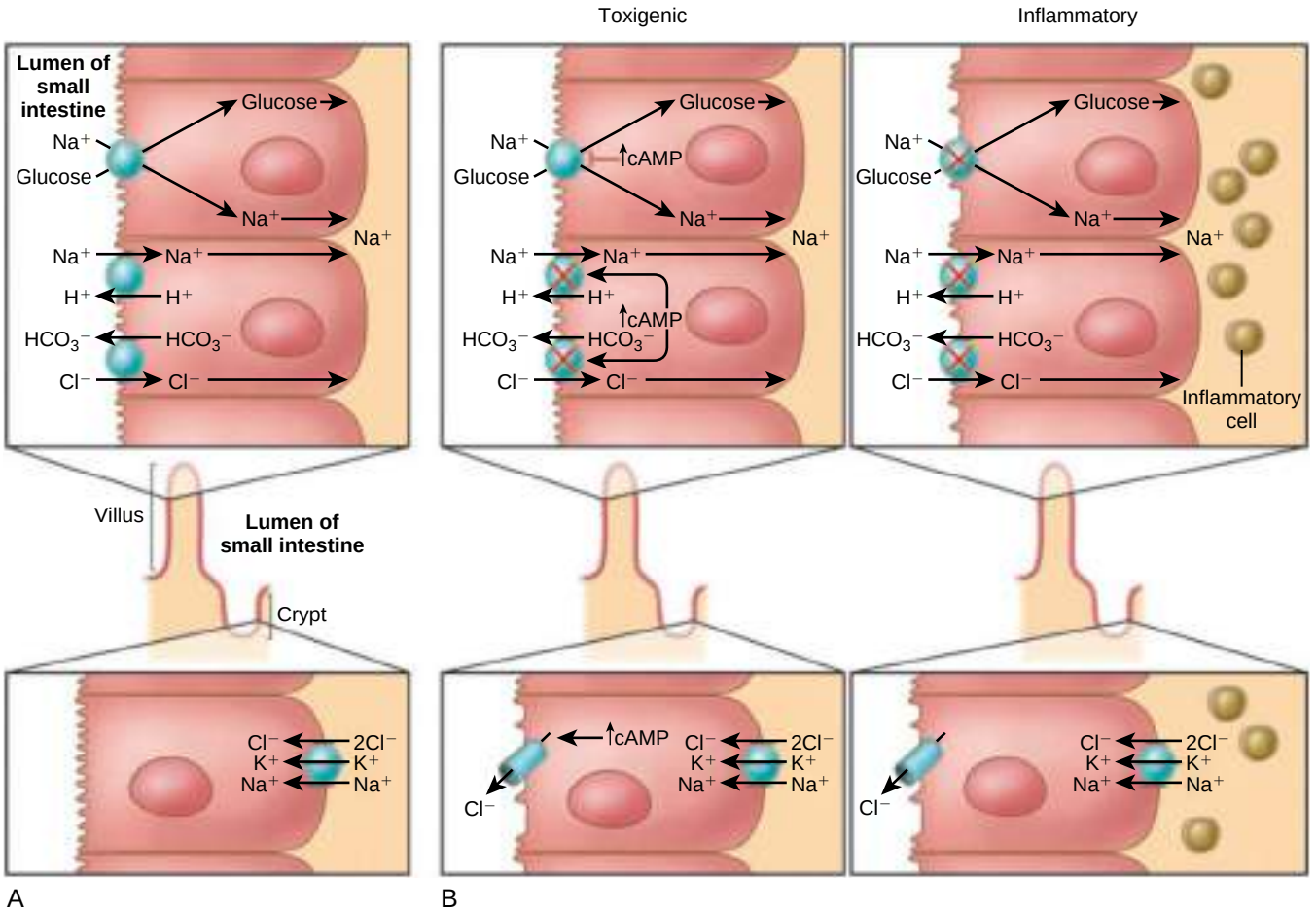

Fig. 387.4 Movement of Na^+ and Cl^- in the small intestine. **A,** Movement in normal subjects. Na^+ is absorbed by two different mechanisms in absorptive cells from villi: glucose-stimulated absorption and electroneutral absorption (which represents the coupling of Na^+/H^+ and Cl^-/HCO_3^- exchanges). **B,** Movement during diarrhea caused by a toxin and inflammation. *(From Petri WA, Miller M, Binder HJ, et al. Enteric infections, diarrhea and their impact on function and development. J Clin Invest. 2008;118:1277–1290.)*

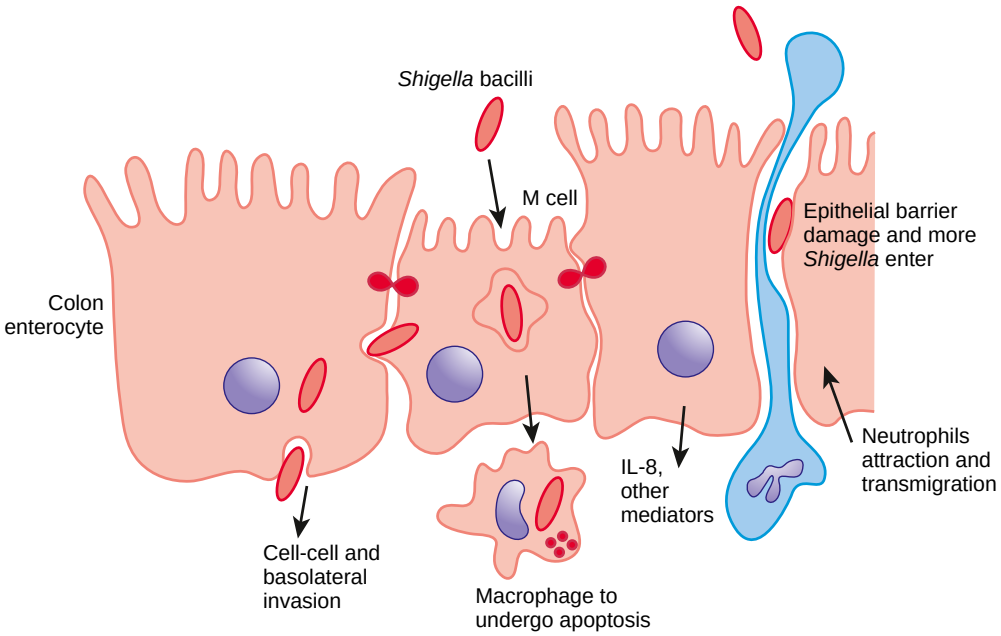

Fig. 387.5 Pathogenesis of *Shigella* infection and diarrhea. IL, Interleukin. *(Adapted from Opal SM, Keusch GT. Host responses to infection. In: Cohen J, Powderly WG, Opal SM, et al., eds. Infectious Diseases, 2nd ed. London: Mosby; 2004. pp. 31–52.)*

dysentery, the stools associated with STEC hemorrhagic colitis are large volume and rarely accompanied by high fever. ETEC causes a secretory watery diarrhea that affects infants and young children in developing countries and is the major causative agents of traveler's diarrhea, accounting for about half of all episodes in some studies. EPEC remains a leading cause of persistent diarrhea associated with malnutrition among infants from developing countries. EIEC, which is genetically, biochemically, and clinically nearly identical to *Shigella,* causes rare food-borne outbreaks in industrialized countries. EAEC has been associated with persistent diarrhea in immunocompromised persons and sporadic diarrhea in infants in countries with varying levels of economic development; however, some other studies have not found an association with disease.

C. difficile toxin is associated with several clinical syndromes. The most common is mild to moderate watery diarrhea, low-grade fever, and mild abdominal pain. Occasionally, the illness will progress to full-blown pseudomembranous colitis characterized by diarrhea, abdominal cramps, and fever. The colonic mucosa contains 2-5 mm raised, yellowish plaques. Fatal cases are associated with toxic megacolon, systemic toxicity, and multisystem organ failure, possibly related to systemic absorption of toxin. The illness associated with *S. aureus* and *B. cereus* emetic toxin is dominated by vomiting, whereas diarrhea is the major manifestation of *C. perfringens* and *B. cereus* enterotoxins.

Protozoal Diarrhea

Illnesses due to intestinal protozoa tend to be more prolonged, sometimes for 2 weeks or more, but are usually self-limited in the otherwise healthy host (see Table 387.3). In general, the duration and severity of *Cryptosporidium* diarrhea is strongly influenced by the immune and nutritional status of the host. A protozoal etiology should be suspected when there is a prolonged diarrheal illness characterized by episodes of sometimes explosive diarrhea with nausea, abdominal cramps, and abdominal bloating. The stools are usually watery but can be greasy and foul smelling due to concomitant malabsorption of fats, which is more likely to occur if the parasite load is high. Occasionally, diarrhea may alternate with constipation.

In addition to diarrhea, *E. histolytica* causes a range of other syndromes. Amebic dysentery is characterized by bloody or mucoid diarrhea, which may be profuse and lead to dehydration or electrolyte imbalances. Amebic granulomas (amebomas) may form in the colon, and extraintestinal disease most commonly manifests as liver abscesses but may also spread to the lungs, pericardium, genitourinary tract, skin, and, hematogenously, to the brain or other sites. Extraintestinal *Entamoeba* disease may occur with or without intestinal disease.

INTESTINAL AND EXTRAINTESTINAL COMPLICATIONS

The major complications of diarrhea from any cause are dehydration and electrolyte or acid-base derangements, which can be life-threatening (see Table 387.7). Avoiding delays in diagnosis and treatment and providing appropriate supportive care using either oral, enteral, or intravenous hydration can prevent or treat most of these conditions. Children who experience frequent episodes of acute diarrhea or prolonged or persistent episodes (seen especially in low-resource settings) are at risk for poor growth and nutrition and complications such as secondary infections and micronutrient deficiencies (iron, zinc, vitamin A). Ensuring continued nutritional support during diarrheal episodes is important because prolonged limitation of the diet may extend diarrheal symptoms. Reestablishing a normal diet generally restores villous anatomy and function with resolution of loose stools.

Viral AGE illnesses are usually self-limited and resolve after several days. Rarely, **intussusception** is triggered by lymphoid hyperplasia associated with viral AGE. Complications of bacterial AGE may be the result of local or systemic spread of the organism; in malnourished children and HIV-infected populations, associated **bacteremia** is well recognized. Toxic megacolon, intestinal perforation, and rectal prolapse can occur, particularly in association with *Shigella* in developing countries and *C. difficile*. The most dreaded complication of pediatric diarrhea in the United States is HUS, the leading cause of acquired renal failure in children, which develops in 5–10% of patients infected with STEC. It is usually diagnosed 2-14 days after the onset of diarrhea. HUS is unlikely to occur once diarrhea has remained resolved for 2 or 3 days with no evidence of hemolysis. Risk factors include age 6 months to 4 years, bloody diarrhea, fever, elevated leukocyte count, and treatment with antibiotics and antimotility agents. Patients may no longer excrete the organism at the time they develop HUS (see Chapter 560.5).

Pseudoappendicitis secondary to mesenteric adenitis is a notable complication of *Yersinia*, sometimes *Campylobacter* and COVID-19. Older children and adolescents are most often affected. It typically presents with fever and abdominal pain with tenderness localized to the right lower quadrant, with or without diarrhea, and can be confused with appendicitis. When available, ultrasound is the preferred method for diagnosing true appendicitis; abdominal CT or MRI may be helpful when ultrasound is not available.

Immune-mediated complications that are thought to result from immunologic cross reactivity between bacterial antigens and host tissues are more often seen in adults than children. These include reactive arthritis following infection with the classical bacterial enteropathogens and Guillain-Barré syndrome following *Campylobacter* infection.

Protozoan illnesses, when persistent, can lead to poor weight gain in the young and in immunocompromised individuals, weight loss, malnutrition, or vitamin deficiencies. Infection with *Entamoeba* can cause severe ulcerating colitis, colonic dilation, and perforation. The parasite may spread systemically, most commonly causing liver abscesses. In high-risk settings, it is critical to exclude *Entamoeba* infection and tuberculosis before initiating corticosteroids for presumed ulcerative colitis.

DIFFERENTIAL DIAGNOSIS

The physician should also consider noninfectious diseases that can present with bright red blood per rectum or hematochezia (Table 387.8). In an infant or young child without systemic symptoms, these may include anal fissures, intermittent intussusception, juvenile polyps, and Meckel diverticulum. Necrotizing enterocolitis can cause lower gastrointestinal bleeding in infants, especially premature neonates. Inflammatory bowel disease should be considered in older children. Examples of noninfectious causes of nonbloody diarrhea include congenital secretory diarrheas, endocrine disorders (hyperthyroidism), neoplasms, food intolerance, and medications (particularly antibiotics). Noninfectious causes of chronic or relapsing diarrhea include cystic fibrosis, celiac disease, milk protein, lactose, fructose, or sucrose intolerance and other food allergies, congenital or acquired disaccharidase deficiency, and functional gastrointestinal disorders. Significant abdominal pain should raise suspicion of other infectious processes in the abdomen such as appendicitis and pelvic inflammatory disease. Prominent vomiting with or without abdominal pain can be a manifestation of pyloric stenosis, intestinal obstruction, pancreatitis, appendicitis, and cholecystitis.

Clinical Evaluation of Diarrhea

In the initial evaluation of all patients with AGE, the physician should focus on the patient's hydration status and electrolyte balance, as well as evidence of sepsis or invasive bacterial infection, which could complicate bacterial AGE (Fig. 387.6). Once the patient is stabilized, the history and physical examination can focus on detecting risk factors and exposures, as well as the clinical features that may suggest specific etiologic agents.

Important elements of the medical history include the duration of diarrhea and a description of stools (frequency, amount, presence of blood or mucus), fever (duration, magnitude, pattern), vomiting (onset, amount, and frequency), and the amount and type of solid and liquid oral intake. Clinical signs of dehydration should be evaluated (Table 387.9): urine output (number of wet diapers per day and time since the last urination), whether eyes appear sunken, whether the child is active, whether the child drinks vigorously, and the date and value of the most recent weight measurement. A documented weight loss can be used to calculate the fluid deficit. The past medical history should identify comorbidities that might increase the risk or severity of AGE.

Table 387.7 Intestinal and Extraintestinal Complications of Enteric Infections

COMPLICATION	ASSOCIATED ENTERIC PATHOGEN(S)
INTESTINAL COMPLICATIONS	
Persistent diarrhea	All causes
Recurrent diarrhea (usually immunocompromised persons)	*Shigella* spp., NTS, *Campylobacter* spp., *Clostridioides difficile*, *Yersinia* spp., *Entamoeba histolytica*, *Cryptosporidium* spp.
Postinfectious irritable bowel syndrome	*Shigella* spp., NTS, *Campylobacter* spp., *C. difficile*
Protein-losing enteropathy	*Shigella* and *Salmonella* spp. rotavirus, CMV, *Giardiasis*, *Strongyloides stercoralis*, tuberculosis, HIV
Toxic megacolon	*Shigella* spp., NTS, *Campylobacter* spp., *C. difficile*, *Yersinia* spp., *E. histolytica*, STEC
Intestinal perforation	*Shigella* spp., NTS, *C. difficile*, *Yersinia* spp., *E. histolytica*, STEC
Rectal prolapse	*Shigella* spp., NTS, *Campylobacter* spp., *C. difficile*, *E. histolytica*, STEC
Pseudomembranous colitis	*Shigella* spp., NTS, *C. difficile*, *Yersinia* spp., STEC
Appendicitis	*Shigella* spp., NTS, *Yersinia* spp., *Schistosoma* spp., *Strongyloides stercoralis*, SARS-CoV-2
Intussusception	*Shigella* spp., NTS, *Campylobacter* spp., *Yersinia* spp., STEC
Chronic carriage	NTS
EXTRAINTESTINAL COMPLICATIONS	
Dehydration, metabolic abnormalities, malnutrition, micronutrient deficiency	All causes
Systemic invasion with bacteremia/parasitemia ± distant foci	*Shigella* spp., NTS, *Campylobacter* spp., *Yersinia* spp., *E. histolytica*
Local invasion Mesenteric adenitis Cholecystitis	 *Campylobacter* spp. (rarely), *Yersinia* spp., COVID-19 NTS, SARS-CoV-2
Local noninvasive spread Vulvovaginitis Urinary tract infection	 *Shigella* spp. *Shigella* spp., *Yersinia* spp.
Seizures, encephalopathy	*Shigella* spp., STEC
Leukemoid reaction, bandemia	*Shigella* spp., *Yersinia* spp.
Pharyngitis, adenopathy, rash	*Yersinia* spp., SARS-CoV-2*
Fetal/placental infection	*Campylobacter* fetus, *Shigella* spp.
POSTINFECTIOUS COMPLICATIONS	
Reactive arthritis	*Shigella* spp., NTS, *Campylobacter* spp., *C. difficile*, *Yersinia* spp.
Guillain-Barré syndrome	*Campylobacter* spp.
Hemolytic uremic syndrome	*Shigella dysenteriae* type 1, STEC
Glomerulonephritis, myocarditis, pericarditis	*Campylobacter* spp., *Yersinia* spp., SARS-CoV-2
Immunoglobulin A (IgA) nephropathy	*Campylobacter* spp.
Erythema nodosum	NTS, *Campylobacter* spp., *Yersinia* spp.
Hemolytic anemia	*Campylobacter* spp., *Yersinia* spp.

**Yersinia* spp. is associated with a scarlatiniform rash, cervical adenopathy, and exudative pharyngitis whereas SARS-CoV-2 is typically associated with a nonexudative pharyngitis and diffuse lymphadenopathy, and the rash of SARS-CoV-2 can be polymorphous.
NTS, Nontyphoidal *Salmonella* spp.; CMV, cytomegalovirus; STEC, Shiga toxin–producing *E. coli*.

Certain physical signs are best assessed before approaching the child directly, so the child remains calm, including general appearance (activity, response to stimulation) and respiratory patterns. Skin turgor is assessed by pinching a small skinfold on the lateral abdominal wall at the level of the umbilicus. If the fold does not promptly return to normal after release, the recoil time is quantified as delayed slightly or ≥2 seconds. Excess subcutaneous tissue and hypernatremia may produce a false-negative test, and malnutrition can prolong the recoil time. To measure capillary refill time, the palmar surface of the child's distal fingertip is pressed until blanching occurs, with the child's arm at heart level. The time elapsed until restoration of normal color after release usually exceeds 2 seconds in the presence of dehydration. Mucous membrane moisture level, presence of tears, and extremity temperature should also be assessed.

Laboratory Diagnosis

Most cases of AGE do not require diagnostic laboratory testing. Stool specimens may be examined for mucus, blood, neutrophils, or fecal lactoferrin, a neutrophil product. The finding of more than five leukocytes per high-power field or a positive lactoferrin assay in an infant not breastfeeding suggests an infection with a classical bacterial enteropathogen; patients infected with STEC and *E. histolytica* usually have negative tests.

Table 387.8 Differential Diagnosis of Acute Dysentery and Inflammatory Enterocolitis

SPECIFIC INFECTIOUS PROCESSES
Bacillary dysentery (*Shigella* spp.; invasive *Escherichia coli*)
Campylobacteriosis (*Campylobacter jejuni*)
Amebic dysentery (*Entamoeba histolytica*)
Bilharzial dysentery (*Schistosoma japonicum, S. mansoni*)
Vibriosis (*Vibrio cholera*)
Salmonellosis (nontyphoidal *Salmonella*)
Enteric fever (*Salmonella Typhi, Salmonella Paratyphi* A, B, and C)
Yersiniosis (*Yersinia enterocolitica*)
PROCTITIS
Gonococcal (*Neisseria gonorrhoeae*)
Herpetic (herpes simplex virus)
Chlamydial (*Chlamydia trachomatis*)
Syphilitic (*Treponema pallidum*)
OTHER SYNDROMES
Necrotizing enterocolitis of the newborn
Enteritis necroticans
Pseudomembranous enterocolitis (*Clostridioides difficile*)
Typhlitis
CHRONIC INFLAMMATORY PROCESSES
Enteropathogenic and enteroaggregative *Escherichia coli*
Gastrointestinal tuberculosis
Gastrointestinal mycosis
Parasitic enteritis
SYNDROMES WITHOUT KNOWN INFECTIOUS CAUSE
Idiopathic ulcerative colitis
Crohn disease
Radiation enteritis
Ischemic colitis
Allergic enteritis

Laboratory diagnosis of viral AGE may be helpful when an outbreak is suspected, cases are linked to a suspected outbreak, or when cohorting of patients is considered to limit the spread of infection. The preferred method of testing norovirus is real-time reverse-transcription quantitative polymerase chain reaction (RT-qPCR), available at most public health and virology laboratories. Commercial multiplex PCR tests are available in the United States for the diagnosis of bacterial, parasitic, and viral enteric pathogens, including rotavirus, enteric adenoviruses, astrovirus, norovirus, and sapovirus (see Table 387.1). Although SARS-CoV-2 has been identified in enteric specimens in research settings, the mainstay of clinical diagnosis remains upper respiratory sampling for either PCR or immunoassay.

Stool cultures for detection of bacterial agents are costly, so requests should be restricted to patients with clinical features predictive of bacterial AGE, have moderate or severe disease, are immunocompromised, in outbreaks with suspected HUS, or have a highly suggestive epidemiologic history. To optimize recovery of pathogens, stool specimens for culture need to be transported and plated quickly; if the latter is not quickly available, specimens might need to be transported in special transport media. If antibiotics will be administered and the child has not produced a stool sample, a rectal swab should be collected promptly so as not to delay initiation of antibiotics. After dipping the cotton tip into the medium that will be used for transport, it is gently inserted into the child's rectum and rotated 360 degrees. A properly collected rectal swab is stained or covered with fecal material. Standard stool culture methods performed in clinical microbiology laboratories recover *Shigella* and *Salmonella* species. If *Campylobacter*, *Yersinia*, or *Vibrio* species are suspected, the laboratory should be notified unless media are routinely used for their detection. All bloody stools should also be inoculated into media specific for detection of *E. coli* 0157:H7 or directly tested for the presence of Shiga-like toxin (or both). Except for *C. difficile*, nosocomial acquisition of a bacterial enteric pathogen is very unlikely. Nucleic acid amplification tests (NAAT) have replaced stool culture in some settings; reflex culture is necessary to identify

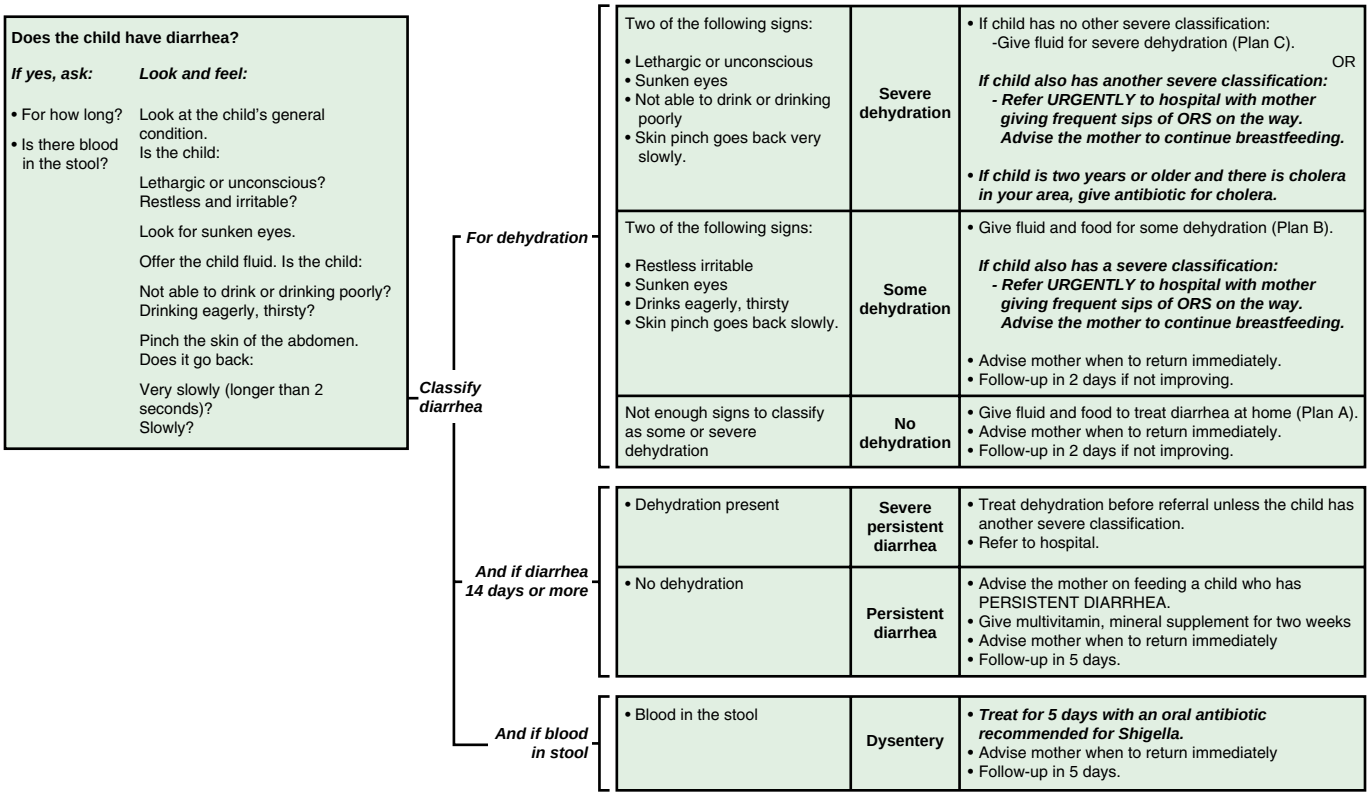

Fig. 387.6 Algorithm showing the Integrated Management of Childhood Illnesses (IMCI) protocol for the recognition and management of diarrhea in developing countries. ORS, Oral rehydration solution.

Table 387.9 Signs and Symptoms Associated with Dehydration

SYMPTOM	MINIMAL OR NO DEHYDRATION	SOME DEHYDRATION	SEVERE DEHYDRATION
Mental status[C,G4,W]	Well; alert	Normal, fatigued or restless, irritable	Apathetic, lethargic, limp, unconscious/comatose
Thirst[W]	Drinks normally; might refuse liquids	Thirsty; eager to drink	Drinks poorly; unable to drink
Heart rate[G10]	Normal	Normal to increased	Tachycardia, with bradycardia in most severe cases
Quality of pulses[G10]	Normal	Normal to decreased	Weak, thready, or impalpable
Breathing [G10]	Normal	Normal; fast	Deep, fast
Eyes[C,G10,W]	Normal	Slightly sunken	Deeply sunken
Tears[C,G4]	Present	Decreased	Absent
Mouth and tongue/mucous membranes[C,G4]	Moist	Dry, "sticky" or "tacky"	Parched
Skinfold[G10,W]	Instant recoil	Recoil in <2 sec (slow)	Recoil in >2 sec (very slow)
Capillary refill[G4]	Normal	Prolonged	Prolonged; minimal
Extremities	Warm	Cool	Cold; mottled; cyanotic
Urine output[G10]	Normal to decreased	Decreased	Minimal

[C]Denotes inclusion in Clinical Dehydration Scale (CDS); CDS scores each category from 0 to 2 with an overall score of 0 = no dehydration (<3%), 1-4 = some dehydration (<6%).
[G4]Denotes inclusion in 4-point and 10-point Gorelick scales: ≥2 Clinical Signs ≥5% ΔBW; ≥3 Clinical Signs ≥10% ΔBW.
[G10]Denotes items included in 10-point Gorelick scale but not in the 4-point Gorelick scale: ≥3 Clinical Signs ≥5% ΔBW; ≥7 Clinical Signs ≥10% ΔBW. Gorelick Scale uses "no or minimal dehydration" and "moderate to severe dehydration."
[W]Denotes inclusion in the World Health Organization (WHO) scale.
BW, Body weight.

antimicrobial sensitivities. Hence, stool microbiologic assays are generally not indicated for patients in whom diarrhea develops more than 3 days after admission unless the patient is immunocompromised or to investigate a hospital outbreak (see Table 387.2).

For children older than 2 years who have recently received antibiotics or have other risk factors, evaluation for *C. difficile* infection may be appropriate. The cytotoxin assay detects toxin B, but testing for toxin A is also available in some laboratories; however, this test is laborious. Several tests are commercially available to detect toxin-producing *C. difficile* in stool, including enzyme immunoassays (EIA) for toxins A and B, cell culture cytotoxicity assay, PCR, and glutamate dehydrogenase (GDH) immunoassay. The sensitivities of cell culture, PCR, and GDH EIA are superior to that of toxin EIA. A multistep diagnostic approach combining toxin testing with NAAT and/or GDH EIA may improve the sensitivity, specificity, and positive predictive value of *C. difficile* testing. Testing for *C. difficile* toxin in children younger than 2 years is discouraged because the organism and its toxins are commonly detected in asymptomatic infants (see Table 387.2).

Evaluation for intestinal protozoa that cause diarrhea is usually indicated in patients who recently traveled to an endemic area, had contact with untreated water, and manifest suggestive symptoms. Previously, the most commonly used method was direct microscopy of stool for cysts and trophozoites. However, this approach is time-consuming and lacks sensitivity, in part because shedding can be intermittent. Analyzing three specimens from separate days is optimal, and fecal concentration techniques provide some benefit. The sensitivity and specificity of microscopy is substantially improved using immunofluorescence antibodies that are commercially available for visualization of *Cryptosporidium* and *Giardia* cysts. In addition, EIAs are available for *Cryptosporidium, Giardia,* and *Entamoeba* that are more sensitive and specific than direct microscopy and provide a useful diagnostic tool. (Not all commercial kits distinguish between pathogenic *E. histolytica* and nonpathogenic *E. dispar.*) Molecular methods (NAATs and multiplex PCR assays) have largely replaced microscopy and EIAs (see Table 387.3)

Several culture-independent rapid multiplex molecular panels for detection of viral, bacterial, and protozoal gastrointestinal pathogens directly from stool samples are approved by the U.S. Food and Drug Administration (FDA), including xTag GPP (14 pathogens), Verigene EP (9 pathogens), and the FilmArray GI Panel (22 pathogens). These methods offer several advantages over conventional diagnostics, including reduced sample volume requirements, broad coverage without the need to select specific tests, enhanced ability to detect co-infections, increased sensitivity, and rapid turnaround. However, the available tests do not provide strain specificity or susceptibility testing, so culture is still necessary to guide outbreak detection and treatment decisions.

Most episodes of diarrheal dehydration are isonatremic and do not warrant serum electrolyte measurements. Electrolyte measurements are most useful in children with severe dehydration, when intravenous fluids are administered, when there is a history of frequent watery stools, yet the skin pinch feels doughy without delayed recoil, which suggests hypernatremia, when the child is unable to drink due to anorexia or emesis, and when inappropriate or inadequate rehydration fluids have been administered at home. A suspicion for HUS prompts a complete blood count with review of the peripheral smear, serum electrolytes, and renal function tests. Patients with shigellosis can demonstrate bandemia or even a leukemoid reaction. Blood culture should be obtained if there is concern for systemic bacterial infection. This includes infants and children with fever and/or blood in the stool who are younger than 3 months, are immunocompromised, or have hemolytic anemia or other risk factors. If diarrhea persists with no cause identified, endoscopic evaluation may be indicated. Biopsy specimens help in diagnosing inflammatory bowel disease or identifying infecting agents that may mimic it. A sweat test is warranted if cystic fibrosis is suspected.

TREATMENT

The broad principles of management of AGE in children include rehydration and maintenance ORS plus replacement of continued losses in diarrheal stools and vomitus after rehydration, continued breastfeeding, and refeeding with an age-appropriate, unrestricted diet as soon as dehydration is corrected. Zinc supplementation is recommended for children in developing countries.

Hydration

Children, especially infants, are more susceptible than adults to dehydration because of the greater basal fluid and electrolyte requirements per kilogram and because they are dependent on others to meet these demands (Table 387.10). Dehydration must be evaluated rapidly and corrected in 4-6 hours according to the degree of dehydration and estimated daily requirements. When there is emesis, small volumes of ORS can be given initially by a dropper, teaspoon, or syringe, beginning with as little as 5 mL at a time. The volume is increased as tolerated. The low-osmolality WHO ORS containing 75 mEq of sodium, 64 mEq of chloride, 20 mEq of potassium, and 75 mmol of glucose/L, with total osmolarity of 245 mOsm/L, is now the global standard of care and more effective than home fluids. Soda beverages, fruit juices, and tea and other home fluids are not suitable for rehydration or maintenance therapy because they have inappropriately high glucose concentration and osmolalities and low sodium concentrations. Tables 387.9 and 387.10 outline a clinical evaluation plan and management strategy for children with moderate to severe diarrhea. Replacement for emesis or stool losses is noted in Table 387.10. Oral rehydration can also be given by a nasogastric tube if needed.

A small minority of children, including those with severe dehydration or unable to tolerate oral fluids, require initial intravenous rehydration, but oral rehydration is the preferred mode of rehydration and replacement of ongoing losses. Signs of severe dehydration that might necessitate intravenous resuscitation include are shown in Table 387.9. Limitations to ORS include shock, decreased level of consciousness, ileus, intussusception, carbohydrate intolerance (rare), severe emesis, and high stool output (>10 mL/kg/hr).

Enteral Feeding and Diet Selection

Continued breastfeeding and refeeding with an age-appropriate, unrestricted diet as soon as dehydration is corrected aids in recovery from the episode. Foods with complex carbohydrates (rice, wheat, potatoes, bread, and cereals), fresh fruits, lean meats, yogurt, and vegetables should be reintroduced while ORS is given to replace ongoing losses from emesis or stools and for maintenance. Fatty foods or foods high in simple sugars (juices, carbonated sodas) should be avoided. The usual energy density of any diet used for the therapy of diarrhea should be around 1 kcal/g, aiming to provide an energy intake of a minimum of 100 kcal/kg/day and a protein intake of 2-3 g/kg/day. In selected circumstances when adequate intake of energy-dense food is problematic, the addition of amylase to the diet through germination techniques can also be helpful.

If the normal diet includes infant formula, it should not be diluted, or changed to a lactose-free preparation unless lactose malabsorption is evident. With the exception of acute lactose intolerance in a small subgroup, most children with diarrhea are able to tolerate milk and lactose-containing diets. Withdrawal of milk and replacement with specialized lactose-free formulations are unnecessary. Although children with persistent diarrhea are not lactose intolerant, administration of a lactose load exceeding 5 g/kg/day may be associated with higher purging rates and treatment failure. Alternative strategies for reducing the lactose load while feeding malnourished children who have prolonged diarrhea include addition of milk to cereals and replacement of milk with fermented milk products such as yogurt.

Rarely, when dietary intolerance precludes the administration of cow's milk–based formulations or whole milk, it may be necessary to administer specialized milk-free diets such as a comminuted or blenderized chicken-based diet or an elemental formulation. Although effective in some settings, the latter are unaffordable in most developing countries. In addition to rice-lentil formulations, the addition of green banana or pectin to the diet has also been shown to be effective in the treatment of persistent diarrhea. Figure 387.7 provides an algorithm for managing children with prolonged diarrhea in developing countries.

Among children in low- and middle-income countries, where the dual burden of diarrhea and malnutrition is greatest and where access to proprietary formulas and specialized ingredients is limited, the use of locally available age-appropriate foods should be promoted for the majority of acute diarrhea cases. Even among those children for whom lactose avoidance may be necessary, nutritionally complete diets comprised of locally available ingredients can be used at least as effectively

Table 387.10 Summary of Treatment Based on Degree of Dehydration

DEGREE OF DEHYDRATION	REHYDRATION THERAPY	REPLACEMENT OF LOSSES
Some dehydration	Infants and children: ORS, 75 mL/kg over 3-4 hr. Continue breastfeeding. After 4 hr, give food every 3-4 hr for children who normally receive solid foods.	*Infants and children:* <2 yr old: 50-100 mL ORS for each diarrheal stool or vomiting episode, up to ~500 mL/day ≥2 yr old: 100-200 mL ORS for each diarrheal stool or vomiting episode, up to ~1 L/day Replace losses as above as long as diarrhea or vomiting continues
Severe dehydration	Malnourished infants may benefit from smaller-volume, frequent boluses of 5-10 mL/kg body weight due to reduced capacity to increase cardiac output with larger volume resuscitation. Infants (<12 mo) and children (12 mo to 5 yr) without malnutrition: Give 20-30 mL/kg boluses of IV isotonic crystalloid solution (e.g., Ringer lactate or normal saline solution) over 30-60 min. Repeat boluses as necessary to restore adequate perfusion. Then give 70 mL/kg over 2.5-5 hr. (Note the slower infusion times are for infants.) If IV hydration is not possible, administer ORS 20 mL/kg/hr × 6 hours via nasogastric tube. Reassess the infant or child frequently and adjust infusion rate if needed. Give ORS as soon as the child can drink. Allow to feed (breast milk or solid food) as described for some dehydration. Adjust electrolytes and administer dextrose based on chemistry values.	*Infants and children:* <10 kg body weight (children <2 yr): 50-100 mL ORS for each diarrheal stool or vomiting episode >10 kg body weight (children ≥2 yr): 100-200 mL ORS for each diarrheal stool or vomiting episode *Adolescents and adults:* Ad libitum Replace losses as above as long as diarrhea or vomiting continue If unable to drink, either administer ORS through a nasogastric tube or give dextrose-containing IV fluids as appropriate based on chemistry values

Note: Low-osmolarity ORS can be given to all age-groups, with any cause of diarrhea. It is safe in the presence of hypernatremia, as well as hyponatremia (except when edema is present). Some commercially available formulations that can be used as ORS include Pedialyte Liters (Abbott Nutrition), CeraLyte (Cera Products), and Enfalac Lytren (Mead Johnson). Popular beverages that should not be used for rehydration include apple juice, Gatorade, and commercial soft drinks.

ORS, Oral rehydration solution; IV, intravenous.

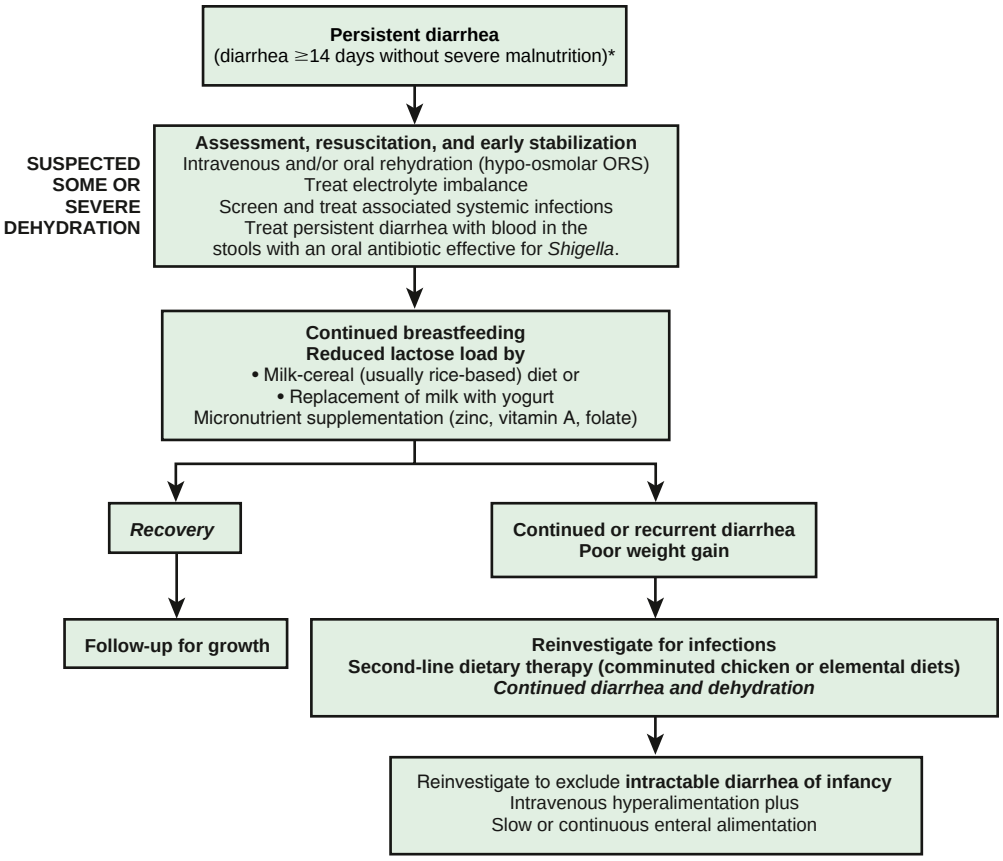

Fig. 387.7 Management algorithm for persistent diarrhea. ORS, Oral rehydration solution.

as commercial preparations or specialized ingredients. These same conclusions may also apply to the dietary management of children with persistent diarrhea, but the evidence remains limited.

Zinc Supplementation

Zinc supplementation in children with diarrhea in developing countries leads to reduced duration and severity of diarrhea and could potentially prevent a large proportion of cases from recurring. Zinc administration for diarrhea management can significantly reduce all-cause mortality by 46% and hospital admission by 23%. In addition to improving diarrhea recovery rates, administration of zinc in community settings leads to increased use of ORS and reduction in the inappropriate use of antimicrobials. All children older than 6 months of age with acute diarrhea in at-risk areas should receive oral zinc (20 mg/day is recommended by most guidelines, but 5 mg/day and 10 mg/day may be better tolerated and equally effective) in some form for 10-14 days during and continued after diarrhea. The role of zinc in well-nourished, zinc replete populations in developed countries is less certain.

Additional Therapies

The use of probiotic nonpathogenic bacteria for prevention and therapy of diarrhea has been successful in some settings, although the evidence does not support a recommendation for their use in all settings. A variety of organisms *(Lactobacillus, Bifidobacterium)* have a good safety record; therapy has not been standardized, and the most effective (and safe) organism has not been identified. *Saccharomyces boulardii* is effective in antibiotic-associated and in *C. difficile* diarrhea, and there is some evidence that it might prevent diarrhea in daycare centers. Two large randomized placebo-controlled trials evaluating the efficacy of two *Lactobacillus*-based probiotic formulations failed to reduce a clinical severity score in Canadian infants and preschool children with AGE. *Lactobacillus rhamnosus* GG or a combination probiotic product containing *L. rhamnosus* R0011 and *L. helveticus* R0052 has shown variable efficacy; reduction is more evident in cases of childhood rotavirus diarrhea.

Ondansetron (oral mucosal absorption preparation) reduces the incidence of emesis, thus permitting more effective oral rehydration, and is well established in emergency management of AGE in high-resource settings, reducing intravenous fluid requirements and hospitalization. Because persistent vomiting can limit oral rehydration therapy, a single sublingual dose of an oral dissolvable tablet of ondansetron (2 mg for children 8-15 kg, 4 mg for children 16-30 kg, and 8 mg for children >31 kg) may be given off-label. However, most children do not require specific antiemetic therapy; careful ORS is usually sufficient. Antimotility agents (loperamide) are contraindicated in children with dysentery and probably have no role in the management of acute watery diarrhea in otherwise healthy children. Similarly, antiemetic agents, such as the phenothiazines, are of little value and are associated with potentially serious side effects (lethargy, dystonia, malignant hyperpyrexia).

Antibiotic Therapy

Judicious antibiotic therapy for suspected or proven bacterial infections can reduce the duration and severity of illness and prevent complications (Table 387.11). Several factors justify limited use. First, most episodes of AGE are self-limited among otherwise healthy children. Second, the increasing prevalence of antibiotic resistance has prompted restricted use of these drugs. Third, antibiotics may worsen outcomes, as some studies have shown that antibiotic therapy with STEC infection increases the risk of HUS and prolongs excretion of NTS without improving clinical outcomes. Therefore antibiotics are used primarily to treat severe infections, prevent complications in high-risk hosts, or to limit the spread of infection. Microbiologic (culture) confirmation of the etiology and susceptibility testing should be sought before treatment if possible.

Treatment of *C. difficile* infection warrants special consideration (see Table 387.11). Removal of the offending antibiotic, if possible, is the first step. Antibiotic therapy directed against *C. difficile* should be instituted if the symptoms are severe or persistent. In children, oral vancomycin and metronidazole for 7-14 days (first-line agents)

displayed equivalent efficacy in a prospective randomized trial; however, metronidazole may be preferred because of lower cost and concerns about inducing vancomycin-resistant enterococci. Twenty percent of patients treated for *C. difficile* diarrhea have a relapse. The first relapse should be treated with another course of antibiotics based on severity of illness. For multiply recurrent disease, tapering and/or pulsed regimen of oral vancomycin over a 4- to 6-week period has been proposed. Rifaximin is an alternative option in children ≥12 years to treat persistent or recurrent *C. difficile* colitis, and fecal microbiota transplant is being explored. Fidaxomicin is an alternate agent approved for patients >6 months of age. The phase 3, multicenter, randomized, single-blind SUNSHINE trial demonstrated equivalent clinical cure rates in pediatric patients receiving either oral vancomycin or fidaxomicin and increased rates of global cure in the fidaxomicin arm, but the study excluded patients with life-threatening and fulminant infection. In patients ≥18 years old, it is now preferred over vancomycin as the first-line therapy for the initial episode (whether severe or nonsevere) and recurrences. Bezlotoxumab, a monoclonal antibody against *C. difficile* toxins A and B, has been shown to reduce the recurrence rate and is recommended in addition to standard antibiotic therapy for adults experiencing a recurrence, but it has not been approved for use in children. Studies are underway to determine the safety, tolerability, pharmacokinetics, and efficacy of bezlotoxumab in children. In the absence of ongoing symptoms, a test of cure is not necessary. The role of probiotics in the prevention of *C. difficile*-associated diarrhea in children has not been established.

Antimicrobial therapy for parasitic infections is shown in Table 387.11. Antivirals such as remdesivir have not been studied for efficacy in the treatment of AGE related to SARS-CoV-2 infection.

PREVENTION

Promotion of Exclusive Breastfeeding and Vitamin A

Exclusive breastfeeding (administration of no other fluids or foods for the first 6 months of life) protects young infants from diarrheal disease through the promotion of passive immunity and through reduction in the intake of potentially contaminated food and water. In developing countries, exclusive breastfeeding for the first 6 months of life is widely

Table 387.11 Antimicrobial Therapy for Infectious Diarrhea

ORGANISM	INDICATION FOR THERAPY	DOSAGE AND DURATION OF TREATMENT
Shigella spp.	In high-income countries, judicious treatment is recommended to curtail growing antibiotic resistance because most shigellosis is self-limited. Treatment should be reserved for severe disease (require hospitalization, have systemic disease or complications), immunocompromised, or to prevent or mitigate outbreaks in certain settings (e.g., childcare or food handling). Also consider treating patients with significant discomfort, intestinal comorbidities, institutional settings, or household exposure to high-risk individuals. WHO recommends empiric antibiotics for all children in developing countries with dysentery assuming that most cases are caused by *Shigella*.	First line: • Ciprofloxacin* 20 mg/kg/day PO bid × 3 days (max. 1.5 g/day); OR • Azithromycin† 12 mg/kg once on first day, then 6 mg/kg once daily on days 2 through 4 (total course: 4 days); OR • Ceftriaxone 50-100 mg/kg/day IV or IM, qd × 3 days for severe illness requiring parenteral therapy. Second line: • Cefixime 8 mg/kg once daily for 3 days if susceptibility is known or likely based on local data; OR • Trimethoprim (TMP)-sulfamethoxazole (SMX): 4 mg/kg/day of TMP and 20 mg/kg/day SMX twice a day for 5 days (if susceptibility known or likely based on local data); OR • Ampicillin 100 mg PO, divided qid, max 2 g/day for 5 days if susceptibility known or likely based on local data (amoxicillin is not effective presumably due to rapid gut absorption)
ETEC	Watery diarrhea in a traveler returning from an endemic area that interferes with planned activities or is persistent (>14 days).	First line: • Azithromycin* 12 mg/kg once on first day, then 6 mg/kg once daily on days 2 and 3 (total course: 3 days) Second line: • Ciprofloxacin† 15 mg/kg/day PO bid × 3 days; OR • Children ≥12 yr: Rifaximin 600 mg/day (not per kilogram), divided tid × 3 days
STEC	Avoid antimicrobials and antimotility drugs.	
Salmonella, nontyphoidal	Antibiotics for uncomplicated gastroenteritis in normal hosts are ineffective, may prolong excretion, and are not recommended. Infection in infants younger than 3 mo and patients with immunocompromise, malignancy, chronic GI disease, severe colitis hemolytic anemia, or HIV infection Most strains are resistant to multiple antibiotics.	See treatment of *Shigella*. Patients without bacteremia can be treated orally for 5-7 days. Patients with bacteremia (proven or until blood culture results are available in a high-risk host) should be treated parenterally until blood cultures clear and then transitioned to PO to complete a total 7- to 10-day course. Focal or disseminated invasive infections (e.g., osteomyelitis, meningitis) and bacteremic patients with HIV/AIDS should be treated parenterally for 4-6 wk. Depending on susceptibilities, ampicillin, TMP-SMX, or fluoroquinolones may be used.
Yersinia spp.	Antibiotics are not usually required for diarrhea, which is usually self-limited and clinical benefits of antibiotics are not established. Neonates and immunocompromised patients and patients with bacteremia and/or focal invasive infections should be treated. Deferoxamine therapy should be withheld for severe infections or associated bacteremia.	For bacteremia or focal invasive infections, use parenteral third-generation cephalosporins. Can also consider TMP-SMX, aminoglycosides, fluoroquinolones, tetracycline or doxycycline, or chloramphenicol. Begin IV then switch to oral when clinically stable, for a total course of 2-6 wk.

Continued

Table 387.11 Antimicrobial Therapy for Infectious Diarrhea—cont'd

ORGANISM	INDICATION FOR THERAPY	DOSAGE AND DURATION OF TREATMENT
Campylobacter spp.	Dysentery, moderate and severe gastroenteritis or at risk for severe disease (e.g., elderly, pregnant, or immunocompromised), and bacteremia or focal invasive infection. Treatment of gastroenteritis appears effective if given within 3 days of onset of illness.	**For gastroenteritis or dysentery:** • Erythromycin PO 40 mg/kg/day divided qid × 5 days • Azithromycin PO 10 mg/kg/day × 3 days **For bacteremia or focal invasive infection:** • Consider parenteral macrolides or carbapenems pending susceptibility results. Fluoroquinolone resistance is >50% in some areas of the world.
Clostridioides difficile	Colitis • Discontinue inciting antibiotics if possible. • Infectious disease consult suggested if disease is persistent or recurrent.	**First occurrence** *Mild-moderate:* • Metronidazole PO (or IV) 7.5 mg/kg/dose tid or qid × 10 days; max 500 mg per dose • If failure to respond in 5-7 days, consider switch to vancomycin PO 40 mg/kg/day divided qid × 10 days; max 125 mg/dose • For metronidazole-intolerant patients, start with vancomycin PO as above • For patients in whom oral therapy cannot reach the colon, add vancomycin PR 500 mg/100 mL normal saline q8h prn until improvement *Severe:* • Vancomycin PO as above *Severe and complicated:* • Vancomycin PO as above PLUS metronidazole IV 30 mg/kg/day divided qid, max 500 mg/dose • If complicated with ileus or toxic colitis and/or significant abdominal distension, give vancomycin PO PLUS metronidazole IV PLUS vancomycin PR as above × 10 days **First recurrence** *Mild-moderate:* • Same regimen as for first occurrence *Severe:* • Vancomycin PO as above **Subsequent recurrences:** • DO NOT use metronidazole due to risk of neurotoxicity with repeated or prolonged use • Vancomycin PO pulsed or prolonged taper (recommend consulting ID or GI for choice of regimen), OR • Vancomycin × 10 days followed by rifaximin 400 mg/dose tid × 14-20 days (N.B. that rifaximin is not approved in the United States for children <12 yr old), OR • Fidaxomicin × 10 days Children 6 mo to 5 yr: 16 mg/kg/dose (max 200 mg/dose) bid Children 6 yr and older: 200 mg/dose bid
Entamoeba histolytica	• Asymptomatic cyst excreters • Mild to moderate intestinal disease • Severe intestinal or extraintestinal disease (including liver abscess)	*Asymptomatic cyst excreters:* • Iodoquinol PO 30-40 mg/kg/day, (max 650 mg/dose) divided tid × 20 days; OR • Paromomycin PO 25-35 mg/kg/day divided tid × 7 days; OR • Diloxanide furoate 20 mg/kg/day (max 500 mg/dose), orally, divided tid × 10 days *Mild to moderate intestinal disease and severe intestinal or extraintestinal disease:* • Metronidazole PO 30-50 mg/kg/day divided tid × 7-10 days; OR • Children ≥3 yr: Tinidazole PO 50 mg/kg, single dose, max 2 g × 3 days, OR 5 days for severe disease FOLLOWED BY EITHER (to prevent relapse) Iodoquinol PO 30-40 mg/kg/day (max. 650 mg/dose) divided tid × 20 days; OR Paromomycin PO 25-35 mg/kg/day divided tid × 7 days
Giardia duodenalis	Persistent symptoms	• Tinidazole PO 50 mg/kg, single dose, max 2 g (for children ≥3 yr) • Nitazoxanide PO Age 1-3 yr: 100 mg bid × 3 days Age 4-11 yr: 200 mg bid × 3 days Age over 11 yr: 500 mg bid × 3 days • Metronidazole PO 15 mg/kg/day (max 250 mg/dose), divided tid × 5–7 days
Cryptosporidium spp.	Treat immunocompromised and HIV-infected hosts, although efficacy is equivocal. Treatment may not be needed in normal hosts.	*Immunocompetent children:* • Nitazoxanide, as for *Giardia* *Solid organ transplants:* • Nitazoxanide, as for *Giardia*, × 14 days or longer *HIV-infected children:* • Combined antiretroviral therapy is the primary treatment • Nitazoxanide, as for *Giardia* • Paromomycin

Table 387.11 Antimicrobial Therapy for Infectious Diarrhea—cont'd

ORGANISM	INDICATION FOR THERAPY	DOSAGE AND DURATION OF TREATMENT
Cyclospora spp.	All symptomatic children	Age >2 mo: 8-10 mg/kg/day TMP and 40-50 mg/kg/day SMX PO divided bid × 7-10 days (HIV-infected children may need longer courses)
Cystoisospora spp.	Immunocompromised patients, symptoms that do not resolve after 5-7 days; treat prophylactically in HIV-infected patients with $CD4^+$ count <200 cells/mm^3	• Age >2 mo: 8-10 mg/kg/day TMP and 40-50 mg/kg/day SMX PO divided bid × 7-10 days; • Adults: 50-75 mg/day pyrimethamine PO, either qd or divided bid PLUS 10-25 mg/day leucovorin PO; OR • Ciprofloxacin 500 mg PO bid × 7 days
Blastocystis hominis	The significance of *B. hominis* as a cause of disease is controversial, so treatment should be reserved for those with suggestive symptoms and no other pathogen that could be the cause.	• Metronidazole PO 35-50 mg/kg/day divided tid × 10 days (max 500-750 mg/dose); OR • Age >2 mo: 8 mg/kg/day TMP and 40 mg/kg/day SMX PO divided BID × 7 days; OR • Nitazoxanide, as for *Giardia*, × 3 days; OR • Age ≥3 yr: 50 mg/kg (max 2 g) tinidazole PO once

*Azithromycin and fluoroquinolones should be avoided in patients taking the antimalarial artemether. These drugs can prolong the QT interval on electrocardiogram and trigger arrhythmias.

WHO, World Health Organization; PO, by mouth; prn, as needed; bid, two times a day; IV, intravenous; IM, intramuscular; qd, every day; ETEC, enterotoxigenic *E. coli*; qid, four times a day; STEC, Shiga toxin–producing *E. coli*; SGI, gastrointestinal; tid, three times a day; ID, infectious diseases; GI, gastrointestinal; N.B., *nota bene*.

regarded as one of the most effective interventions to reduce the risk of premature childhood mortality and has the potential to prevent 12% of all deaths of children younger than 5 years of age. Vitamin A supplementation reduces all-cause childhood mortality by 25% and diarrhea-specific mortality by 30%.

Rotavirus Immunization

Five live-attenuated oral **rotavirus** vaccines are available internationally and WHO prequalified: the three-dose pentavalent G1, G2, G3, G4, P[8] human-bovine vaccine (RotaTeq), the two-dose monovalent human G1P[8] vaccine (Rotarix), the three-dose monovalent human-bovine 116E G6P[11] vaccine (Rotavac), and two formulations of the three-dose pentavalent G1, G2, G3, G4, G9 human-bovine vaccine (Rotasiil and Rotasiil Thermo). The result has been substantial reductions in rotavirus-associated and all-cause hospitalizations for diarrheal disease in both vaccinated infants (direct protection) and unvaccinated individuals (indirect, or herd protection), as well as reductions in office visits for less severe rotavirus diarrhea. Reductions in all-cause diarrhea deaths have been demonstrated in some countries since the introduction of these vaccines.

Programmatic uptake is lagging in low-resource settings where most severe disease and death occurs; however, Gavi, the Vaccine Alliance, has supported introduction of rotavirus vaccine into approximately 45 countries. Even though vaccine efficacy against severe rotavirus AGE is lower (50–64%) in low-resource compared with high- resource countries; the number of severe rotavirus AGE prevented per vaccinated child is higher because of the substantially greater baseline rate of severe rotavirus gastroenteritis in developing countries. Vaccine (live virus)-associated rotavirus infection has been reported in children with severe combined immunodeficiency disease, but the vaccine has been shown to be safe in HIV-infected populations. Because of suboptimal efficacy, alternative vaccine formulations are being explored, including parenteral and neonatal vaccines.

Two licensed, efficacious two-dose oral inactivated cholera vaccines (Dukoral for children 2 years and older and Shanchol for children 1 year or older) are available in many countries but currently have no specific indication in endemic and epidemic settings where they could potentially reduce the burden of severe diarrhea and mortality in young children. For travelers, a single-dose live oral cholera vaccine (Vaxchora) is licensed for adults in the United States.

Improved Water and Sanitary Facilities and Promotion of Personal and Domestic Hygiene

Much of the reduction in diarrhea prevalence in the developed world is the result of improvement in standards of hygiene, sanitation, and water supply. Strikingly, an estimated 88% of all diarrheal deaths worldwide can be attributed to unsafe water, inadequate sanitation, and poor hygiene. Handwashing with soap and safe excreta disposal can reduce the risk of diarrhea by 48% and 36%, respectively, whereas a 17% reduction is estimated as a result of improvements in water quality.

Visit Elsevier eBooks+ at eBooks.Health.Elsevier.com for Bibliography.

387.1 Traveler's Diarrhea

E. Adrianne Hammershaimb and Karen L. Kotloff

Traveler's diarrhea is a common complication of visitors to developing countries and is caused by a variety of pathogens, in part depending on the season and the region visited. It is the most common (28%) travel-associated health problem in children. Traveler's diarrhea can manifest with watery diarrhea or as dysentery. Without treatment, 90% will have resolved within a week and 98% within a month of onset. Some individuals develop more severe or persistent diarrhea and become dehydrated or unwell and may experience complications such as bacteremia and intestinal perforation. Children younger than 2 years are at higher risk for traveler's diarrhea, as well as more severe disease. According to FoodNet, the pathogens identified most commonly in travelers in the United States were ETEC, *C. jejuni, Shigella* spp., and NTS. EAEC and *G. duodenalis* are also important.

TREATMENT

For infants and children, rehydration, as discussed in Chapter 387, is appropriate, followed by a standard diet. Adolescents and adults should increase their intake of electrolyte-rich fluids. Kaolin-pectin, anticholinergic agents, *Lactobacillus,* and bismuth salicylate are not effective therapies. Loperamide, an antimotility and antisecretory agent, reduces the number of stools in older children with watery diarrhea and improves outcomes when used in combination with antibiotics in traveler's diarrhea. However, loperamide should not be used in febrile or toxic patients with dysentery, in those with bloody diarrhea, and in children younger than 6 years.

The effectiveness of antibiotics depends on the pathogen and its susceptibility profile. In forming a treatment plan, the potential side effects should be weighed against the treatment need for a short-lasting and self-limiting disease such as traveler's diarrhea. Antibiotics are not recommended for mild diarrhea that is tolerable, is not distressing, and does not interfere with planned activities but may be considered for moderate diarrhea that is distressing and interferes with planned activities. Antibiotics are recommended for treatment of severe diarrhea that is incapacitating or completely prevents planned activities and

for treatment of dysentery. When empiric therapy is required abroad, azithromycin is suggested for young children, and fluoroquinolones are recommended for older children and adults and as second-line therapy for younger children, depending on local pathogens and susceptibility patterns. Short-duration (3 days) therapy is effective. Rifaximin is approved for use in children 12 years and older but should not be used to treat bloody diarrhea. Rifamycin is an alternative to rifaximin that may be used in patients 18 years and older. Fluoroquinolones, rifaximin, and rifamycin should be avoided in patients of all ages with dysenteric diarrhea. Travelers should be reminded that diarrhea can be a symptom of other severe diseases, such as malaria and MIS-C. Therefore if diarrhea persists or additional symptoms such as fever occur, travelers should seek medical advice. For up-to-date information on local pathogens and resistance patterns, see www.cdc.gov/travel.

If the patient has returned home with diarrhea, a microbiologic evaluation can be obtained before initiating antibiotic therapy. Prolonged diarrhea should prompt further investigation into possible parasitic infections or NTS. Prophylactic antibiotics for travelers are not recommended.

PREVENTION

In the pretravel visit, caregivers should be advised about diarrhea prevention, the signs, symptoms, and management of dehydration, and the use of ORS. ORS and age-appropriate antibiotics should be included in a routine health packet. Travelers should drink bottled or canned beverages or boiled water. They should avoid ice, salads, and fruit they did not peel themselves. Food should be eaten hot, if possible. Raw or poorly cooked seafood is a risk, as is eating in a restaurant rather than a private home. Swimming pools and other recreational water sites can also be contaminated.

Chemoprophylaxis is not routinely recommended for previously healthy children or adults. Nonetheless, travelers should bring azithromycin (younger than 16 years of age) or ciprofloxacin (older than 16 years of age) and begin antimicrobial therapy if diarrhea develops.

Visit Elsevier eBooks+ at eBooks.Health.Elsevier.com for Bibliography.

Chapter 388

Chronic Diarrhea

Anat Guz-Mark and Raanan Shamir

See also Chapters 382.3 and 385.

Chronic diarrhea is defined as stool volume of more than 10 g/kg/day in toddlers/infants and greater than 200 g/day in older children that lasts for 4 weeks or more. **Persistent** diarrhea begins acutely but lasts longer than 14 days. In practice this usually means having loose or watery stools more than 3 times a day, with a deviation from the previous regular stool pattern. *Awakening at night to pass stool, beyond the period of infancy, is often a sign of an organic cause of diarrhea.* The epidemiology has two distinct patterns. In *developing* countries, chronic diarrhea is, in many cases, the result of an intestinal infection that persists longer than expected. This syndrome is often defined as **protracted (persistent) diarrhea**, but there is no clear distinction between protracted (persistent) and chronic diarrhea. In countries with higher socioeconomic conditions, chronic diarrhea is less frequent, and the etiology often varies with age. The outcome of diarrhea depends on the cause and ranges from benign, self-limited conditions, such as toddler's diarrhea, to severe congenital diseases, such as microvillus inclusion disease, which may lead to progressive intestinal failure.

PATHOPHYSIOLOGY

The mechanisms of diarrhea are generally divided into **secretory** and **osmotic**, but often diarrhea is a *combination of both mechanisms*. In addition, *inflammation* and *motility disorders* may contribute to diarrhea. Secretory diarrhea is usually associated with large volume of watery stools and persists when oral feeding is withdrawn. Osmotic diarrhea is dependent on oral feeding, and stool volumes are usually not as massive as in secretory diarrhea (Fig. 388.1). The cessation of diarrhea after a 24-hour fasting trial may define "diet-induced diarrhea," which is mainly osmotic in nature, whereas no or minimal change in stool volume and consistency despite fasting will suggest a secretory mechanism, also defined as "electrolyte-transport-related diarrhea."

Secretory diarrhea is characterized by active electrolyte and water fluxes toward the intestinal lumen, resulting from either the inhibition of neutral NaCl absorption in villous enterocytes or an increase in electrogenic chloride secretion in secretory crypt cells as a result of the opening of the cystic fibrosis transmembrane regulator (CFTR) chloride channel, or both. The result is more secretion from the crypts than absorption in the villi that persists during fasting. The other components of the enterocyte ion secretory machinery are (1) the Na-K 2Cl co-transporter for the electroneutral chloride entrance into the enterocyte; (2) the Na-K pump, which decreases the intracellular Na^+ concentration, determining the driving gradient for further Na^+ influx; and (3) the K^+ selective channel, that enables K^+, once it has entered the cell together with Na^+, to return to the extracellular fluid.

Electrogenic secretion is induced by an increase of intracellular concentration of cyclic adenosine monophosphate, cyclic guanosine monophosphate, or calcium in response to microbial enterotoxins, or to endogenous endocrine or nonendocrine molecules, including inflammatory cytokines. Another mechanism of secretory diarrhea is the inhibition of the electroneutral NaCl-coupled pathway that involves the Na^+/H^+ and the Cl^-/HCO_3^- exchangers. Defects in the genes of the Na^+/H^+ and the Cl^-/HCO_3^- exchangers are responsible for congenital sodium and congenital chloride diarrhea, respectively.

Osmotic diarrhea is caused by nonabsorbed nutrients in the intestinal lumen as a result of one or more of the following mechanisms: (1) intestinal damage (e.g., enteric infection); (2) reduced absorptive surface area (e.g., active celiac disease); (3) defective digestive enzyme or nutrient carrier (e.g., lactase deficiency); (4) decreased intestinal transit time (e.g., functional diarrhea); and (5) nutrient overload, exceeding the digestive capacity (e.g., overfeeding, sorbitol in fruit juice). Whatever the mechanism, the osmotic force generated by nonabsorbed solutes drives water into the intestinal lumen. A very common example of

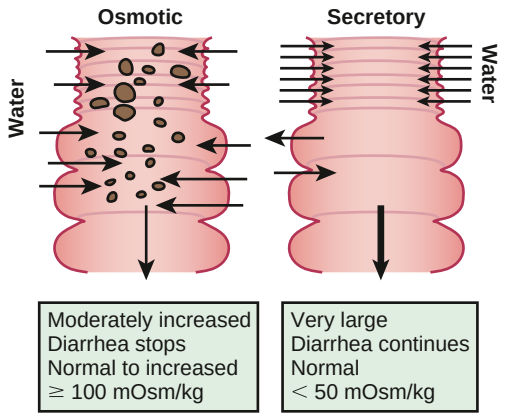

Fig. 388.1 Pathways of osmotic and secretory diarrhea. Osmotic diarrhea is caused by functional or structural damage of intestinal epithelium. Nonabsorbed osmotically active solutes drive water into the lumen. Stool osmolality and ion gap are generally increased. Diarrhea stops or improves dramatically in children when not eating. In secretory diarrhea, ions are actively pumped into the intestine by the action of exogenous and endogenous secretagogues. Usually there is no intestinal damage. Osmolality and ion gap are within normal levels. Large volumes of stools are lost independent of food ingestion.

osmotic diarrhea is lactose intolerance. Lactose, if not absorbed in the small intestine, reaches the colon, where it is fermented to short-chain organic acids, releasing hydrogen that is detected in the lactose breath test, and generating an osmotic overload.

In many children chronic diarrhea may be caused by the combination of multiple mechanisms.

ETIOLOGY

Table 388.1 summarizes the main etiologies of chronic diarrhea in infants and children.

Infectious

Enteric infections are by far the most frequent cause of persistent or chronic diarrhea, both in developing and industrialized countries; however, outcomes are often very different. In the former, comorbid conditions, such as HIV/AIDS, malaria, or tuberculosis, may result in malnutrition that impairs the child's immune response, thereby potentiating the likelihood of prolonging diarrhea or acquiring another enteric infection. Prolonged diarrhea in poor-resource countries may lead to undernutrition, which predisposes the child to additional episodes of diarrhea. Sequential infections with the same or different pathogens may also be responsible for chronic diarrhea. In *developing* countries, enteroadherent *Escherichia coli* and *Giardia lamblia* have been implicated in chronic diarrhea, whereas, in *developed* countries, chronic infectious diarrhea usually runs a more benign course and the etiology is often viral, with rotavirus and norovirus playing major roles (Table 388.2).

Chronic diarrhea in travelers to or expatriates from developing countries may depend on the country of origin. Nonetheless, common pathogens include *Giardia, E. coli, Shigella, Campylobacter, Salmonella,* and enteric viruses. Less common pathogens include amebiasis, *Strongyloides,* and tropical spruce.

Table 388.1 Main Etiologies of Chronic Diarrhea in Children Older and Younger than 2 Years of Age

ETIOLOGY	AGE <2 YR	AGE >2 YR
Infections	+++	+++
Postenteritis syndrome	+++	+++
Immune deficiency	++	Rare
Celiac disease	+++ (after gluten introduction)	+++
Food allergy	+++	+
Inflammatory bowel disease	+ (rare)	+++
Pancreatic insufficiency	++	++
Cholestasis and insufficient bile acids	++	++
Cystic fibrosis	++	+
Lactose intolerance	++ (mostly postinfectious)	+++
Intestinal lymphangiectasia	+	+
Motility disorders	++	Rare
Short bowel syndrome	+++	+
Toddler's and functional diarrhea	++	++
Excessive intake of fruit juices and fluids	++	++
Congenital diarrheal disorders, including structural enterocyte defects and enzymatic or transport malabsorption syndromes	++	Unlikely

Opportunistic microorganisms induce diarrhea exclusively, more severely, or for more prolonged periods, in specific populations, such as immunocompromised children. Specific agents cause chronic diarrhea or exacerbate diarrhea in many chronic diseases. *Clostridium difficile* or cytomegalovirus act as opportunistic agents in patients with malignant diseases as well as in patients with **inflammatory bowel disease (IBD).** *Cryptosporidium* may induce severe and protracted diarrhea in AIDS patients.

Small intestinal bacterial overgrowth (SIBO) results in chronic diarrhea by either a direct interaction between the microorganism and the enterocytes, or the consequence of deconjugation and dihydroxylation of bile salts and hydroxylation of fatty acids due to an increased proliferation of bacteria in the proximal intestine. *Risk factors for SIBO* in children include acid-suppressive therapies, alterations in gastrointestinal (GI) motility and anatomy, as well as poor sanitation conditions.

Postenteritis diarrhea syndrome (see Chapter 387) is a clinicopathologic condition in which small intestinal mucosal damage persists after acute gastroenteritis. Sensitization to food antigens, secondary disaccharidase deficiency, persistent infections, or reinfection with another enteric pathogen may be responsible for causing postenteritis diarrhea syndrome, which is thought to be related to dysregulation of the intestinal microbiota. Functional diarrhea, which may be related to the pathogenesis of irritable bowel syndrome, may be caused by complications of an acute gastroenteritis.

Inflammatory/Immunologic

Celiac disease (see Chapter 384) is a genetically determined immune-mediated intestinal disorder that affects about 1 in 100 individuals, depending on geographic origin. In the genetically susceptible host, gliadin, the major protein of gluten, reacts with the immune system to cause inflammation and villous atrophy. A reduction of intestinal absorptive surface is responsible for the diarrhea in celiac disease, which is reversible upon elimination of gluten from the diet.

Food allergy (mainly cow's milk protein allergy, see Chapter 192) may present during infancy with chronic diarrhea. An abnormal immune response to food proteins can cause a proctitis/colitis or an enteropathy, which may result in inflammatory or malabsorptive diarrhea. **Eosinophilic gastroenteropathy** is characterized by an eosinophilic infiltration of the intestinal wall and is strongly associated with atopy (see Chapter 383). However, although diarrhea in food allergy responds to withdrawal of the responsible food, this does not always occur in eosinophilic gastroenteropathy, in which immune-suppressive therapy may be needed.

IBDs, including Crohn disease, ulcerative colitis, and IBD-undetermined, cause chronic diarrhea that is often associated with abdominal pain, elevated inflammatory markers, and increased concentrations of fecal calprotectin or lactoferrin (see Chapter 382). The age of onset of IBD is broad, with rare cases described in the first few months

Table 388.2 Comparative List of Prevalent Agents and Conditions in Children with Persistent Infectious Diarrhea in Industrialized and Developing Countries

AGENT/DISEASE	
INDUSTRIALIZED COUNTRIES	**DEVELOPING COUNTRIES**
Clostridium difficile	Enteroaggregative *E. coli*
Enteroaggregative *Escherichia coli*	Atypical *E. coli*
Atypical *E. coli*	*Shigella* spp.
	Heat-stable/heat-labile enterotoxin-producing *E. coli*
Astrovirus	Rotavirus*
Norovirus	Cryptosporidium
Sapovirus	*Giardia lamblia*
Rotavirus*	Tropical sprue
Small intestinal bacterial overgrowth (SIBO)	
Postenteritis diarrhea syndrome	

*More frequent in industrialized than in developing countries as agent of chronic diarrhea.

of life, and the peak incidence in childhood occurs in adolescence. The severity of the symptoms is highly variable with a pattern characterized by long periods of well-being followed by exacerbations.

Autoimmune processes may target the intestinal epithelium, alone or in association with extraintestinal symptoms. **Autoimmune enteropathy** is associated with the production of antienterocyte and antigoblet cell antibodies, primarily immunoglobulin A, but also immunoglobulin G, directed against components of the enterocyte brush border or cytoplasm and by a cell-mediated autoimmune response with mucosal T-cell activation. An X-linked immune-dysregulation, polyendocrinopathy, and enteropathy (**IPEX syndrome**) is associated with variable gene mutations and phenotypes of chronic diarrhea (more on autoimmune enteropathy and IPEX syndrome is available in Chapter 382.3).

Immune deficiency can present as chronic diarrhea in children. In these cases (for example, severe combined immunodeficiency or AIDS) the child can be infected by an opportunistic pathogen, can exhibit a persistent diarrhea due to a pathogen usually causing an acute gastroenteritis, or be infected by multiple and recurrent different pathogens causing mucosal damage to the intestines. Other immunoregulatory defects, found in patients with agammaglobulinemia, isolated immunoglobulin A deficiency, and common variable immunodeficiency disorder, may result in mild persistent diarrhea.

Pancreatic Deficiency

Chronic diarrhea may be the manifestation of maldigestion caused by exocrine pancreatic disorders (see Chapters 397 and 399.2). In most patients with **cystic fibrosis**, exocrine pancreatic insufficiency results in steatorrhea and protein malabsorption. In **Shwachman-Diamond syndrome**, exocrine pancreatic hypoplasia may be associated with neutropenia, bone changes, and intestinal protein-losing enteropathy. Specific isolated pancreatic enzyme defects, such as lipase deficiency, result in fat and/or protein malabsorption. Familial pancreatitis, associated with a pathogenic variant in the trypsinogen gene, may be associated with exocrine pancreatic insufficiency and chronic diarrhea. Pathogenic variants in *CFTR, CTRC, PRSS1, PRSS2, SPINK 1,* and *SPINK 5* are associated with hereditary pancreatitis.

Liver and Bile Acids Disorders

Liver disorders and **cholestasis** may lead to a reduction in the bile salts pool resulting in fat malabsorption causing chronic diarrhea in the form of steatorrhea. Bile acid loss may be associated with diseases affecting the terminal ileum, such as Crohn disease, or following ileal resection. In **primary bile acid malabsorption**, neonates and young infants present with chronic diarrhea and fat malabsorption caused by pathogenic variants of the ileal bile transporter gene. In addition to the fat malabsorption, the bile acid loss from the intestinal lumen is a form of secretory diarrhea by itself (called **cholerheic diarrhea or choleretic diarrhea**, which is usually associated with significant diaper dermatitis).

Carbohydrate Malabsorption

Rare genetic pathogenic variants (see Chapters 385.8 and 385.10) can cause carbohydrate malabsorption. More commonly, **lactose intolerance** is *secondary* to lactase deficiency caused by intestinal mucosal damage (usually as part of postenteritis syndrome, which is a self-limited process). Depending on ethnicity, a progressive, age-related, loss of lactase activity may begin around 7 years of age and affects approximately 80% of the non-White population, and acquired hypolactasia may be responsible for chronic diarrhea in older children receiving cow's milk (adult-type lactase deficiency).

Similarly, **fructose malabsorption** is common in Western countries with estimates as high as 40% of the population. These individuals cannot absorb fructose and often develop bloating, abdominal pain, diarrhea, and flatulence. Typically, they do not have liver disease. This is in contrast to **hereditary fructose intolerance**, a rare genetic disorder with incidence estimated to be 1 in 20,000-30,000. This disease is associated with pathogenic variants in the *ASDOB* gene that encodes for the aldolase B enzyme that is found primarily in the liver and is involved in the metabolism of fructose. Individuals with hereditary fructose intolerance may have nausea, abdominal pain/bloating, vomiting, diarrhea, and hypoglycemia. Continued ingestion of fructose results in *hepatomegaly* and eventually cirrhosis.

Protein-Losing Enteropathy

Chronic diarrhea can be the manifestation of obstructed intestinal lymphatic drainage, causing protein-losing enteropathy with steatorrhea, diarrhea, and lymphopenia. Early-onset protein-losing enteropathy and lymphangiectasia, together with complement activation, could be associated with congenital **CD55 deficiency**. Infantile-onset severe protein-losing enteropathy and altered lipid metabolism could be attributed to pathogenic variants in **DGAT1**.

Along with **intestinal lymphangiectasia**, many diseases that cause intestinal mucosal injury can also result in a secondary protein-losing enteropathy, characterized by low serum protein levels and elevated fecal α_1-antitrypsin (see Chapter 385.2).

Motility Disorders

Disorders of intestinal motility include abnormal development and function of the enteric nervous system, such as in **Hirschsprung disease** and **pediatric intestinal pseudoobstruction (PIPO),** previously termed **chronic intestinal pseudoobstruction.** PIPO encompasses both the neurogenic and the myogenic forms, and is sometimes associated with genitourinary manifestations. Other motility disorders may be secondary to extraintestinal disorders, such as in *hyperthyroidism* and *scleroderma*. Motility disorders are associated with either constipation or diarrhea, or both, with the former usually dominating the clinical picture.

Short Bowel Syndrome

Short bowel syndrome is the single most frequent etiology of intestinal failure in children (see Chapter 385.6). Many intestinal abnormalities such as stenosis, segmental atresia, gastroschisis, and malrotation may require surgical resection, but the most frequent primary cause of short bowel is *necrotizing enterocolitis*. Rarely, a child can be born with congenital short bowel. In these conditions, the residual intestine may be insufficient to carry on its digestive-absorptive functions, resulting in severe chronic diarrhea, malnutrition, and failure to thrive, requiring long-term treatment with parenteral nutrition.

Nonspecific Diarrhea, Including Toddler's Diarrhea

The most benign and common etiology of chronic diarrhea is nonspecific diarrhea that encompasses **functional diarrhea** (or **toddler's diarrhea**) in children younger than 4 years of age and **irritable bowel syndrome** in those, usually, 5 years of age and older. Toddler's diarrhea is defined by the daily painless recurrent passage of four or more large unformed stools, for 4 or more weeks, with onset in infancy or preschool years. Nighttime defecation is usually absent. The child appears unperturbed by the diarrhea, there is no evidence of failure to thrive, and the symptoms resolve spontaneously by school age.

Diarrhea may also be the result of an **excessive intake of fluids and nonabsorbable carbohydrates**. If the child's fluid intake was >150 mL/kg/24 hr, *fluid intake should be reduced not to exceed 90 mL/kg/24 hr* to decrease the stool frequency and volume. If the dietary history suggests that the child is ingesting significant amounts of fruit juice, especially apple juice, then *the consumption of juice should be decreased. Sorbitol, which is a nonabsorbable sugar, is found in apple, pear, and prune juices and often causes diarrhea in toddlers.* Moreover, apple and pear juices contain higher amounts of fructose than glucose, a feature postulated to cause diarrhea in toddlers. In older children, irritable bowel syndrome is often associated with abdominal pain and may be related to anxiety, depression, and other psychological disturbances (see Chapter 389). When the cause of the diarrhea remains undetermined and the clinical course is inconsistent with organic disorders, **factitious** disorder by proxy should be considered.

Congenital Diarrheal Disorders

The most severe etiology of chronic diarrhea includes a number of heterogeneous congenital conditions leading to syndromes often referred to as **intractable or protracted diarrhea**. The genetic and molecular basis of many causes of protracted diarrhea has been identified recently, and the classification of **congenital diarrheal disorders (CDDs)** has been proposed (Table 388.3), also referred to as congenital diarrheas and enteropathies (**CODEs**). These terms represent a group of rare but severe enteropathies, with a similar clinical presentation despite different pathogenesis and outcome. The diarrhea can be either secretory,

Table 388.3 Classification of Congenital Diarrheal Disorders Based on Their Molecular Defect and Their Inheritance

DEFECTS OF DIGESTION, ABSORPTION, AND TRANSPORT OF NUTRIENTS AND ELECTROLYTES				
DISEASE	**GENE NAME**	**GENE LOCATION**	**TRANSMISSION AND INCIDENCE**	**MECHANISM**
GENES ENCODING BRUSH-BORDER ENZYMES				
Congenital lactase deficiency (LD)	*LCT*	2q21.3	AR, 1 in 60,000 in Finland; lower in other ethnic groups	Osmotic
Congenital sucrase-isomaltase deficiency (SID)	*SI*	3q26.1	AR, 1 in 5,000; higher incidence in Greenland, Alaska, and Canada	Osmotic
Congenital maltase-glucoamylase deficiency (MGD)	Not defined	—	Few cases described	Osmotic
GENES ENCODING MEMBRANE CARRIERS				
Glucose-galactose malabsorption (GGM)	*SLC5A1*	22q13.1	AR, few hundred cases described	Osmotic
Fructose malabsorption (FM)	Not defined	—	Up to 40%	Osmotic
Fanconi-Bickel syndrome (FBS)	*SLC2A2*	3q26.2	AR, rare, higher frequency in consanguineous	Osmotic
Acrodermatitis enteropathica (ADE)	*SLC39A4*	8q24.3	AR, 1 in 500,000	Osmotic
Congenital chloride diarrhea (CCD)	*SLC26A3*	7q31.1	AR, sporadic; frequent in some ethnicities	Osmotic
Lysinuric protein intolerance (LPI)	*SLC7A7*	14q11.2	AR, about 1 in 60,000 in Finland and Japan; rare in other ethnic groups	Osmotic
Primary bile acid malabsorption (PBAM)	*SLC10A2* *SLC51B*	13q33.1 15q22.31	AR	Secretory
Cystic fibrosis (CF)	*CFTR*	7q31.2	AR, 1 in 2,500	Osmotic
GENES ENCODING PANCREATIC ENZYMES				
Enterokinase deficiency (EKD)	*PRSS7*	21q21	AR	Osmotic
Hereditary pancreatitis (HP)	*PRSS1* *PRSS2* *SPINK1* *CTRC* *CFTR*	7q34 7q34 5q32 1p36.21 7q31.2	AD, cases with compound pathogenic variants in different genes; SPINK1 pathogenic variants may also cause tropical pancreatitis	Osmotic, malabsorption
Congenital absence of pancreatic lipase (APL)	*PNLIP*	10q25.3	AR	Osmotic, malabsorption
GENES ENCODING PROTEINS OF LIPOPROTEIN METABOLISM				
Abetalipoproteinemia (ALP)	*MTP*	4q27	AR, about 100 cases described; higher frequency among Ashkenazi Jews	Osmotic
Hypobetalipoproteinemia (HLP)	*APOB* *ANGPTL3*	2p24.1 1p31.3	Autosomal codominant/AR	Osmotic
Chylomicron retention disease (CRD)	*SAR1B*	5q31.1	AR, about 40 cases described	Osmotic
GENES ENCODING OTHER TYPES OF PROTEINS				
Congenital sodium diarrhea (CSD)	*SPINT2* (only syndromic CSD) *SLC9A3*	19q13.2 5p15.33	AR	Osmotic
Shwachman-Diamond syndrome (SDS)	*SBDS*	7q11	AR	Osmotic
Activating guanylate cyclase-C pathogenic variant	*GUCY2C*	12p12.3	AD	Secretory
GENES ENCODING FOR OTHER ENZYMES				
Defect in triglyceride synthesis	*DGAT1*	8q24.3	AR	Protein-losing enteropathy
DEFECTS OF ENTEROCYTE DIFFERENTIATION AND POLARIZATION				
Microvillus inclusion disease (MVID)	*MYO5B* *STX3*	18q21.1 11q12.1	AR; rare	Secretory
Congenital tufting enteropathy (CTE)	*EPCAM*	2p21	AR; 1 in 50,000-100,000; higher among Arabs	Secretory
Trichohepatoenteric syndrome (THE)	*TTC37* *SKIV2L*	5q15 6p21.33	AR; 1 in 400,000	Secretory
Neonatal-onset chronic diarrhea-9 (DIAR9)	*WNT2B*	1p13.2	AR; few cases described	Osmotic

Continued

Table 388.3 Classification of Congenital Diarrheal Disorders Based on Their Molecular Defect and Their Inheritance—cont'd

DEFECTS OF DIGESTION, ABSORPTION, AND TRANSPORT OF NUTRIENTS AND ELECTROLYTES				
DISEASE	**GENE NAME**	**GENE LOCATION**	**TRANSMISSION AND INCIDENCE**	**MECHANISM**
DEFECTS OF ENTEROENDOCRINE CELL DIFFERENTIATION				
Congenital malabsorptive diarrhea (CMD), Enteric anendocrinosis	*NEUROG3*	10q22.1	AR; few cases described	Osmotic
Proprotein convertase 1/3 deficiency (PCD)	*PCSK1*	5q15	AR	Osmotic
Intractable malabsorptive diarrhea of infancy (DIAR11)	*PERCC1*	16p13.3	AR; few cases described in Jewish Iraqi families	Presumed impaired function of enteroendocrine cells (EECs)
DEFECTS OF MODULATION OF INTESTINAL IMMUNE RESPONSE				
Autoimmune polyglandular syndrome type 1 (APS1)	*AIRE*	21q22.3	AR; AD (1 family)	Inflammatory
Immune dysfunction, polyendocrinopathy, X-linked (IPEX)	*FOXP3*	Xp11.23	X-linked (autosomal cases described), very rare	Inflammatory
IPEX-like syndrome	*CD25* *STAT5b* *STAT3* *STAT1(GOF)* *LRBA* *CTLA4*	Multiple	Not X-linked	Inflammatory
CD55 deficiency	*CD55*	1q32.2	AR, rare	Protein-losing enteropathy

AD, Autosomal dominant; AR, autosomal recessive; GOF, gain of function.

osmotic, or combined, depending on the specific defect. Often severe diarrhea presents at birth or shortly thereafter, but in milder forms diarrhea may go unrecognized for years. *CDDs can be classified in four groups*: defects of digestion, absorption, and transport of nutrients and electrolytes; defects of enterocyte differentiation and polarization; defects of enteroendocrine cell (EEC) differentiation; and defects of modulation of intestinal immune response.

Although CDDs are rare diseases, in most specific disorders the genetic defect and transmission are known. The incidence of genetic disorders associated with CDD can range from 1 in 2,500 for cystic fibrosis, 1 in 5,000 for sucrose-isomaltase deficiency, 1 in 60,000 for congenital lactase deficiency, to 1 in 400,000 for trichohepatoenteric syndrome. For most CDDs, such as IPEX syndrome or autoimmune polyglandular syndrome type 1, the clinical application of exome sequencing is likely to increase identification of more patients with these rare causes of chronic diarrhea. Selected CDDs are more frequent in ethnic groups where consanguineous marriages are common, or in some geographic areas because of founder effects. Congenital lactase deficiency is more common in Finland; lysinuric protein intolerance has a higher incidence either in Finland and in Japan because of founder effect, and a specific pathogenic variant is typically found in each of the two ethnic groups. A defect in the *DGAT1* gene was first identified using whole exome sequencing in an Ashkenazi Jewish family and associated with the early onset of vomiting and nonbloody diarrhea with protein-losing enteropathy. In few families of Jewish Iraqi origin with intractable diarrhea of infancy, a noncoding deletion was recently identified on chromosome 16p13, presumably leading to impairment in EEC function. For specific CDDs see Chapters 385.2 and 385.10.

Most cases of protracted diarrhea syndrome are not easily treated. The natural history of protracted diarrhea is related to the primary intestinal disease or the specific defect in nutrient absorption. Although some specific conditions may improve with nutritional therapy and dietary eliminations (for example, glucose-galactose malabsorption or congenital protein-losing enteropathy), most cases of CDDs result in chronic intestinal failure requiring long-term parenteral nutrition, with poorer prognosis, and are more likely to be candidates for intestinal transplantation (see Chapter 386). Some late-onset CDDs may be relatively mild and are recognized only later in life. Infantile-onset or neonatal IBDs are a distinct group of diseases, also occurring during infancy, characterized by more inflammatory and often bloody component in stools (see Chapter 382.3).

EVALUATION OF PATIENTS

Because of the wide spectrum of etiologies, the medical approach should be based on diagnostic algorithms that begin with assessment for infectious causes, and then consider the age of the child, growth, and clinical and epidemiologic factors. Early onset in the neonatal period is rare and may suggest a congenital or severe condition (see Chapter 382.3); however, infections and food allergy are more frequent in this age group, and together with GI malformations should be high on the differential diagnosis. In later infancy and up to 2 years of age, infections and allergies are the most common causes, while inflammatory diseases are more frequent in older children and adolescents. Celiac disease as well as functional nonspecific diarrhea should always be considered independently of age because of their relatively high frequency at all ages beyond early infancy.

Specific clues in the family and personal history may provide useful indications, suggesting a congenital, allergic, or inflammatory etiology. A history of *polyhydramnios* is consistent with congenital chloride/sodium diarrhea (where a typical sonographic finding of dilated fetal bowel loops is present), microvillus inclusion disease, cystic fibrosis, and other CDDs, as well as a family history of a chronic or intractable diarrhea in a relative presenting in the first month of life, and particularly *consanguinity*. An acute onset of diarrhea that runs a protracted course suggests postenteritis diarrhea, secondary lactase deficiency, SIBO, or the onset of nonspecific functional diarrhea. The association of diarrhea with specific foods may indicate a nutrient basis, such as intolerance to selected nutrients (fructose). Anthropometric evaluation is essential to understand if diarrhea has affected weight gain and growth, providing estimation of the severity of diarrhea. Normal weight and growth strongly support functional diarrhea that may respond to simple dietary management. It should be noted that a child with functional diarrhea may be inappropriately "treated" with a diluted hypocaloric diet in an effort to reduce the diarrhea, resulting in impaired growth.

Initial clinical examination should include the evaluation of general and nutritional status. Dehydration, marasmus, or kwashiorkor require prompt supportive interventions to stabilize the patient. Nutritional

evaluation should start with the evaluation of the weight and height curves, and anthropometric indices to determine the impact of diarrhea on growth. Weight is generally impaired before height, but with time, linear growth also becomes affected, and both parameters may be equally abnormal in the long term. **Assessment of nutritional status** includes a dietary history, physical examination, and biochemical testing including nutritional investigations. *Caloric intake* should be quantitatively determined, energy requirements determined, and the relationship between weight modifications and energy intake should be carefully considered. Assessment of body composition may be performed by measuring mid-arm circumference and triceps skinfold thickness or by bioelectrical impedance analysis, dual-emission x-ray absorptiometry scans, or air plethysmography. Biochemical markers including albumin, prealbumin, retinol binding protein, serum iron, and transferrin may assist in grading malnutrition, as the half-life of serum proteins may distinguish between short- and long-term malnutrition. Evaluation of micronutrient concentrations should always be considered. Zinc, magnesium, vitamin A, and folate deficiency are associated with chronic diarrhea and should be provided if needed.

In infants with chronic diarrhea, feeding history must be carefully obtained, providing clues for allergy or specific food intolerance, such as cow's milk protein allergy or sucrose-isomaltase deficiency. Associated symptoms and selected investigations provide important diagnostic clues. Signs of general inflammation such as fever, mucoid or bloody stools, and abdominal pain may suggest IBD. The presence of eczema or asthma is associated with an allergic disorder, whereas specific extraintestinal manifestations (arthritis, diabetes, thrombocytopenia, etc.) may suggest an autoimmune disease. Specific skin lesions may be suggestive of **acrodermatitis enteropathica,** which might respond to zinc supplementation. Typical facial abnormalities and woolly hair are associated with phenotypic diarrhea **(trichohepatoenteric syndrome)**.

INVESTIGATIONS

Microbiologic investigation should include a thorough list of intestinal bacterial, viral, and protozoan pathogens. Proximal intestinal bacterial overgrowth may be determined using the lactulose hydrogen breath test, but false-positive tests are common (see Chapter 385.8).

Initial investigations of a child with chronic diarrhea beyond the period of infancy should always include an assessment of intestinal inflammation using fecal markers as calprotectin or lactoferrin, and serology for celiac disease (see Chapter 384). The role of intestinal mucosal biopsy is determined by the noninvasive diagnostic evaluation in consultation with a pediatric gastroenterologist.

Noninvasive assessment of digestive-absorptive function and of intestinal inflammation plays a key role in the diagnostic workup (Table 388.4). Abnormalities in the digestive-absorptive function tests suggest small bowel involvement, whereas intestinal inflammation, as demonstrated by increased fecal calprotectin, supports colitis.

Determining the osmotic versus secretory nature of the diarrhea in neonates and infants with protracted diarrhea is especially important. The **stool osmolar gap**, sometimes called stool ion gap, is calculated as 290 mOsm/kg (or measured stool osmolality) minus [2 × (stool Na + stool K)]. If the osmolar gap is above 100 mOsm/kg, fecal osmolality is derived from ingested or nonabsorbed osmotically active solutes or nonmeasured ions. In contrast, a low gap (<50 mOsm/kg) is typically observed in secretory diarrhea. It is also important to measure Cl^- concentration in the stool to rule out **congenital chloride diarrhea**, which is characterized by low osmolar gap combined with high fecal Cl^- loss (>90 mmol/L).

Whereas most etiologies of chronic diarrhea can be exaggerated by feeding and have osmotic or mixed nature to the stool, secretory diarrhea necessitates investigation for congenital defects in enterocytes, defects in the intestinal immune response (IPEX and autoimmune enteropathy), and disorders of bile acid malabsorption. Because of the overlap between secretory and osmotic features of the diarrhea in many diseases, a classification based on the response to bowel rest was also introduced. Severe diarrhea that persists at bowel rest is characteristic of **congenital enteropathies** (**microvillus inclusion disease, tufting enteropathy**). Diarrhea that disappears at bowel rest can imply carbohydrate or fat malabsorptive syndromes, as well as defects in EECs. In most other etiologies the diarrhea can decrease significantly, but not disappear, in response to bowel rest, including some congenital diseases as well as acquired inflammatory and other enteropathies.

Histology is important in establishing mucosal involvement, noting changes in the epithelial cells and villus/crypt ration, presence of mucosal inflammation or in identifying specific intracellular inclusion bodies caused by pathogens, such as cytomegalovirus, or the presence of parasites. Electron microscopy is essential to detect subcellular structural abnormalities such as microvillus inclusion disease, though the latter can be diagnosed with specific staining of the basal membrane on regular biopsies. Immunohistochemistry allows the study of

Table 388.4 Noninvasive Tests for Intestinal Digestive–Absorptive Function and Inflammation

TEST	NORMAL VALUES	IMPLICATION
α_1-Antitripsin concentration	<0.9 mg/g	Increased intestinal permeability/protein loss
Steatocrit	<2.5%-fold (older than 2 yr) increase over age-related values (younger than 2 yr)	Fat malabsorption
Fecal-reducing substances	Absent	Carbohydrate malabsorption
Elastase concentration	>200 μg/g	Pancreatic function
Chymotrypsin concentration	>7.5 units/g >375 units/24 hr	Pancreatic function
Fecal occult blood	Absent	Blood loss in the stools/inflammation
Fecal calprotectin concentration	<100 μg/g (in children upto 4 yr of age) <50 μg/g (older than 4 yr)	Intestinal inflammation
Fecal leukocytes	<5 per microscopic field	Colonic inflammation
Fecal lactoferrin	Absent	Inflammation
Nitric oxide in rectal dialysate	<5 μM of NO_2^-/NO_3^-	Rectal inflammation
Dual sugar (cellobiose/mannitol) absorption test	Urine excretion ratio: 0.010 ± 0.018	Increased intestinal permeability
Xylose oral load	25 mg/dL	Reduced intestinal surface

mucosal immunity as well as of other cell types (smooth muscle cells and enteric neuronal cells).

Imaging may also have a role in the diagnostic approach. Abdominal ultrasound may help in detecting liver and pancreatic abnormalities or an increase in bowel wall thickness that suggests IBD. A preliminary plain abdominal x-ray is useful for detection of abdominal distention, suggestive of intestinal obstruction, or increased retention of colonic feces. Intramural or portal gas may be seen in necrotizing enterocolitis or intussusception. Structural abnormalities such as diverticula, malrotation, stenosis, blind loop, and congenital short bowel, as well as motility disorders, may be investigated through a barium meal and a small bowel follow-through. In older children, capsule endoscopy may be considered to further assess intestinal inflammation or bleeding, and capsule technology can be used to measure pressure, pH, and temperature through the GI tract, assessing motility. Bile malabsorption may be explored by the retention of the bile acid analog ^{75}Se-homocholic acid-taurine (^{75}SeHCAT) in the enterohepatic circulation.

Specific investigations should be carried out for specific diagnostic indications. Prick and patch test may support a diagnosis of food allergy. However, an elimination diet with withdrawal of the suspected harmful food from the diet and subsequent challenge is the most reliable strategy by which to establish a diagnosis.

Once infectious agents have been excluded and nutritional assessment performed, a stepwise approach to the child with chronic diarrhea may be applied. The main causes of chronic diarrhea should be investigated, based on the features of the diarrhea (watery, fatty, mucous, or bloody) and the specific nutrient(s) that is (are) affected. The use of whole exome sequencing or specific molecular analysis may be especially essential in children suspected of having CDD, and early genomic testing is recommended in these circumstances. A step-by-step diagnostic approach is important to minimize the unnecessary use of invasive procedures as well as the cost, while optimizing the yield of the diagnostic evaluation (Table 388.5).

TREATMENT

Chronic diarrhea associated with impaired nutritional status should always be considered a serious disease, and therapy should be started promptly. Treatment includes general supportive measures, nutritional rehabilitation, elimination diet, and medications. The latter include therapies for specific etiologies as well as interventions aimed at counteracting fluid secretion and/or promoting restoration of disrupted intestinal epithelium. Because death may be caused by dehydration or electrolyte abnormalities, replacement of fluid and electrolyte losses is the most important early intervention.

Nutritional rehabilitation is often essential and is based on clinical and biochemical assessment. In moderate to severe malnutrition, caloric intake should be carefully advanced to avoid the development of *refeeding syndrome* and may be progressively increased to 50% or more above the recommended dietary allowances to also allow catch-up growth. In children with steatorrhea, medium-chain triglycerides may be a major source of lipids. A lactose-free diet should be considered in children with chronic diarrhea. In these cases, lactose is generally replaced by maltodextrin or a combination of complex carbohydrates. A sucrose-free formula is indicated in sucrase-isomaltase deficiency. Semi-elemental or elemental diets have the dual purpose of overcoming food intolerance, which may be the primary cause of chronic diarrhea, particularly in infancy and early childhood, and facilitating nutrient absorption. The sequence of elimination should usually begin from less to more restricted diets, that is, cow's milk protein hydrolysate to amino-acid–based formulas, depending on the child's condition. In severely compromised infants, it may be prudent to start with amino-acid–based feeding.

When oral nutrition is not feasible or fails, enteral or parenteral supplementation should be considered. **Enteral nutrition** may be provided via nasogastric or gastrostomy tube and is indicated in a child who is not able to be adequately fed orally. In extreme wasting and in cases of significant intestinal mucosal damage or dysfunction, enteral nutrition may not be tolerated, and **parenteral nutrition** is required.

Micronutrient and vitamin supplementation are part of nutritional rehabilitation, especially in malnourished children in developing countries. Zinc supplementation is important in both prevention and therapy of chronic diarrhea, since it promotes ion absorption, restores epithelial proliferation, and stimulates immune response. Nutritional rehabilitation has a general beneficial effect on the patient's general condition, intestinal function, and immune response.

Functional diarrhea in children may benefit from a diet based on the "4 F" principles (reduce fructose and fluids, increase fat and fiber). The use of probiotics (mostly Lactobacillus GG or *Saccharomyces boulardii*) in infectious and postinfectious diarrhea in children may be tried as adjunctive therapy with reduction in symptom duration, but there is insufficient evidence to recommend their routine use for chronic diarrhea.

Pharmacologic therapy includes, based on the etiology, antiinfectious drugs, immune suppression, and drugs that may inhibit fluid loss and promote cell growth. If a bacterial agent is detected, specific antibiotics should be prescribed. Empiric antibiotic therapy may be used in children with either small bowel bacterial overgrowth or with suspected infectious diarrhea. Table 388.6 summarizes the antimicrobial treatment of infectious persistent diarrhea. Immune suppression

Table 388.5 Stepwise Diagnostic Approach to Children and Infants with Chronic Diarrhea

INITIAL EVALUATION	
Personal and family history: Prenatal sonography; feeding history; family history of protracted diarrhea; consanguinity	**Infectious workup:** Stool cultures; parasites; viruses
Physical examination: Signs of malnutrition; dysmorphism; skeletal abnormalities; organomegaly; dermatitis	**Allergic workup:** Elimination diet trial
↓	
LABORATORY TESTS	
Stool analysis: Stool volume following fasting; stool electrolytes and ion gap; pH and reducing substances; steatocrit; fecal leukocytes and calprotectin; fecal elastase; α_1-antitrypsin	**Blood and serum analysis:** Serum electrolytes; lipid profile; albumin and prealbumin; amylase and lipase; inflammatory markers; ammonia; celiac serology
↓	
IMAGING	
Abdominal ultrasound: Bowel wall thickening; liver and bile disorders	**X-ray, contrast studies, computed tomography, magnetic resonance imaging:** Congenital malformation; signs of motility disorders
↓	
ENDOSCOPIES AND INTESTINAL HISTOLOGY	
Endoscopy and standard jejunal/colonic histology*; morphometry; PAS staining; intestinal immunohistochemistry; electron microscopy	
↓	
GENETIC INVESTIGATION	
Specific molecular analysis	Whole exome sequencing
↓	
OTHER SPECIAL INVESTIGATIONS	
Sweat test; specific carbohydrates breath tests; ^{75}SeHCAT measurement; antienterocyte antibodies; metabolic diseases workup; motility studies; neuroendocrine tumor markers	

*The decision to perform an upper or a lower endoscopy may be supported by noninvasive tests.

PAS, Periodic acid–Schiff; ^{75}SeHCAT, ^{75}Se-homocholic acid-taurine.

Table 388.6 Antimicrobial Treatment for Persistent Diarrhea

	DRUG	INDICATIONS	DOSAGE	DURATION
Antibiotics	Trimethoprim-sulfamethoxazole	*Salmonella* spp., *Shigella* spp.	6-12 mg/kg/day (of trimethoprim) in 2 divided doses daily per os	5-7 days
	Azithromycin	*Shigella* spp., *Campylobacter*	1 day: 12 mg/kg/day once daily per os 2-5 days: 6 mg/kg/day once daily per os * Alternative: 10 mg/kg/day once daily per os, for 3 days	5 days
	Ciprofloxacin	*Shigella* spp.	20-30 mg/kg/day in 2 divided doses, per os or IV	3 days
	Ceftriaxone	*Shigella* spp.	50-100 mg/kg/day once daily per IM or IV	2-5 days
	Metronidazole	*Giardia, Amebiasis, Blastocystis, Clostridium difficile*	15-35 mg/kg/day in 2-3 divided doses per os	7-10 days
	Paromomycin	*Amebiasis*	25-35 mg/kg/day in 3 divided doses per os	7 days
	Vancomycin	*C. difficile*	40 mg/kg/day in 4 divided doses per os	10 days
Antiparasitic	Nitazoxanide	*Amebiasis, Giardiasis, Blastocystis, Cryptosporidiosis*	100 mg every 12 hr for children ages 12-47 mo 200 mg every 12 hr for children ages 4-11 yr 500 mg every 12 hr for children older than 11 yr	3 days
	Albendazole	*Ascaris*, hookworm, and pinworm infection	400 mg	Once

*Depends on local susceptibility profile.
IM, Intramuscular; IV, intravenous; os, by mouth.

should be considered in selected conditions such as autoimmune enteropathy and IBD.

Treatment may be also directed at modifying specific pathophysiologic processes. Secretion of ions may be reduced by antisecretory agents, such as the enkephalinase inhibitor racecadotril. Some benefit from absorbents, such as diosmectite, has been described, with reduction of diarrhea duration in infectious diarrhea. In diarrhea caused by neuroendocrine tumors (NETs), microvillus inclusion disease and enterotoxin-induced severe diarrhea, a trial of somatostatin analog octreotide may be considered. Zinc promotes both enterocyte growth and ion absorption and may be effective when intestinal atrophy and ion secretion are associated.

When therapeutic attempts and other nutritional supportive measures have failed, the only option to treat children with intestinal failure, while maintaining adequate growth and development, may be long-term parenteral nutrition or eventually intestinal transplantation.

Visit Elsevier eBooks+ at eBooks.Health.Elsevier.com for Bibliography.

388.1 Diarrhea from Neuroendocrine Tumors

Shimon Reif and Raanan Shamir

The incidence of NETs originating in the GI tract is increasing globally. Physicians' awareness, endoscopic screening, and increased sensitivity of diagnostic tools may at least in part explain this trend. Most of these tumors involve the gastro-entero-pancreatic tract. Neuroendocrine neoplasm cells possess features of both neural and epithelial cells. The commonly perceived notion of NETs is of slow-growing malignancies with a benign course. Although well-differentiated GI-NETs may exhibit indolent clinical behavior, studies indicate that they are frequently already metastatic at diagnosis, and in which case they are neuroendocrine carcinomas.

The majority of NETs (75–90%) are not associated with elevated hormone levels and do not cause a clinical syndrome such as diarrhea. Functional tumors are tumors that make excess hormone, leading to clinical syndromes. These include insulinoma, gastrinoma, vasoactive intestinal polypeptide (VIP) secreting tumors, glucagonoma, and somatostatinoma. A child with persisted watery secretary diarrhea should be evaluated for a functional NET.

The most common NET in children is **carcinoid,** which is generally a low-grade tumor, especially when it is small (<1 cm). It is equally distributed between the small and large intestine and can commonly be found in the appendix. Most carcinoids are found incidentally and are asymptomatic, especially those that are located in the appendix. Some NET patients (around 10%) will develop secretory diarrhea requiring symptom control to optimize quality of life and clinical outcomes. Such patients are defined as having carcinoid syndrome, characterized by excessive production of one or more peptides, which, when released into the circulation, exert their endocrine effects and can be measured by radioimmunologic methods (in the plasma or as their urinary metabolites). These peptides, therefore, also act as tumor markers. Compared to carcinoid, VIPomas are much less frequent. Because VIP is a more potent vasoactive peptide, it induces more profuse diarrhea, with up to 70% of patients having volumes greater than 3 L/day. Though rare as a cause of watery diarrhea, a NET should be considered in the differential diagnosis when diarrhea is unusually severe or takes a chronic course (resulting in electrolyte and fluid depletion). GI-NETs may be associated with flushing, palpitations, or bronchospasm. Family history may reveal multiple endocrine neoplasia (MEN) 1 or 2 syndromes (Table 388.7).

Baseline tests should include plasma chromogranin A and urinary 5-hydroxyindoloacetic acid (a metabolite of serotonin) and other specific biochemistry being guided by the suspected syndrome (see Table 388.7). Localization of any NET is best achieved using a multimodality approach. *Whole body* CT or MRI with somatostatin receptor PET screening may be required with gallium-68 DOTATOC (synthetic octreotate) PET.

Table 388.7 Diarrhea Caused by Neuroendocrine Tumors

TUMOR AND CELL TYPE	SITE	MARKERS	SIGNS OF HORMONE HYPERSECRETION	THERAPY
Carcinoid	Intestinal argentaffin cells, typically midgut, also foregut and hindgut, ectopic bronchial tree	**Serotonin (5-HT), urine 5-HIAA*** (diagnostic) Also produce substance P, neuropeptide K, somatostatin, VIP chromogranin A	Secretory diarrhea, crampy abdominal pain, flushing, wheezing (and cardiac valve damage if foregut site)	Resection Somatostatin analog, (palliative) Genetic MEN-1
Gastrinoma, Zollinger-Ellison syndrome	Pancreas, small bowel, liver, and spleen	**Gastrin**	Multiple peptic ulcers, secretory diarrhea	H_2-blockers, PPI, tumor resection, (gastrectomy) Genetic MEN-1
Mastocytoma	Cutaneous, intestine, liver, spleen	**Histamine, VIP**	Pruritus, flushing, apnea If VIP, diarrhea	H_1- and H_2-blockers, steroids, resection if solitary
Medullary carcinoma	Thyroid C-cells	**Calcitonin, VIP, prostaglandins**	Secretory diarrhea	Radical thyroidectomy ± lymphadenectomy (genetic MEN-2A/B, familial MTC)
Ganglioneuroma, pheochromocytoma, ganglioneuroblastoma, neuroblastoma	Chromaffin cells; abdominal > other sites; extraadrenal or adrenal	**Metanephrines** and **catecholamines, VIP** VMA, HMA in neuroblastoma	Hypertension, tachycardia, paroxysmal palpitations, sweating, anxiety, watery diarrhea†	Perioperative α-adrenergic (BP) and β-adrenergic blockade with volume support tumor resection Genetic MEN-2 (*RET* gene), VHL, NF-1, SDH
Somatostatinoma	Pancreas	**Somatostatin**	Secretory diarrhea, steatorrhea, cholelithiasis, diabetes	Resection Genetic MEN-1
VIPoma	Pancreas	**VIP, prostaglandins**	Secretory diarrhea, achlorhydria, hypokalemia	Somatostatin analogs, resection Genetic MEN-1

*Bold indicates major markers.
†Diarrhea has been reported only in adult patients with pheochromocytoma.
BP, Blood pressure; H_1, histamine receptor type 1; H_2, histamine receptor type 2; HMA, homovanillic acid; MEN-1, multiple endocrine neoplasia type 1; MTC, medullary thyroid carcinoma; NF-1, neurofibromatosis type 1; PPI, proton pump inhibitor; SDH, succinate dehydrogenase; VHL, von Hippel-Lindau disease; VIP, vasoactive intestinal polypeptide; VMA, vanillylmandelic acid.

Therapeutic interventions to be considered include surgical, pharmacologic, and radioisotope therapy; choice of therapy is based on disease extent and location, tumor grade, pace of disease progression, symptoms, and comorbidities.

Tumor resection is the treatment of choice when the tumor is small and localized. The goals of resection are twofold: (1) management of the endocrine syndrome to control symptoms and (2) tumor control to improve survival. However, resection can precipitate life-threatening adrenergic crises. When arising in the appendix, carcinoid tumors less than 2 cm in size can be managed by simple appendectomy. When greater than 2 cm in size or arising from the base of the appendix, a right hemicolectomy is indicated. Fortunately, in pediatric patients, metastases are rare; when they occur, it is usually in the liver. Tumor histochemistry will confirm the NET type and classification. Pharmacologic treatment may include the use of long-acting somatostatin analogues as first-line therapy. This usually results in a pronounced improvement of symptoms including diarrhea. However, many patients become resistant to somatostatin. Diarrhea caused by pancreatic insufficiency, secondary to somatostatin analog use, is often oily and malodorous and should be treated with pancreatic enzyme replacement. Everolimus is an oral medication and a more specific target of rapamycin (mTOR) inhibitor, and has been reported as add-on treatment to octreotide, primarily in adult patients. The tyrosine kinase inhibitor sunitinib is another option. Data suggest a positive effect of ondansetron, a serotonin-3-receptor antagonist, on diarrhea. Peptide receptor radioisotope therapy also has been reported as a therapeutic modality.

Diarrhea and flushing associated with the carcinoid syndrome can be debilitating. Telotristat ethyl is an inhibitor of tryptophan hydroxylase that acts to reduce serotonin levels and has emerged as a promising agent for control of refractory carcinoid syndrome diarrhea.

The diagnosis of NET in children should prompt a genetic referral to exclude a familial syndrome.

Visit Elsevier eBooks+ at eBooks.Health.Elsevier.com for Bibliography.

Chapter 389

Disorders of Brain-Gut Interaction (Functional Gastrointestinal Disorders)

Asim Maqbool, Chris A. Liacouras, Jefferson N. Brownell, and Paul J. Ufberg

Disorders of brain-gut interaction (DBGI), formerly classified as functional gastrointestinal disorders (FGIDs), comprise a group of conditions that relate to the gastrointestinal (GI) tract and cannot be completely explained by other underlying etiologies such as GI, anatomic, physiologic, or biochemical abnormalities. Conversely, DBGI are defined as a group of disorders classified by GI symptoms related to any combination of motility disturbances, visceral hypersensitivity, altered mucosal and immune function, gut microbiota, and/or central nervous system processing. DBGI are common worldwide in children of all ages and often pose diagnostic challenges, as there is no anatomic or laboratory-based testing that can be used to define them. The symptom-based criteria employed to classify DBGI have been developed and reevaluated through multiple iterations by expert consensus under the auspices of the Rome Foundation and are thus referred to, in their most recent form, as the Rome IV criteria. In this newest iteration, published in May 2016, the term *functional gastrointestinal disorders* has been retired due to its nonspecificity and potential for stigma in favor of the more specific DBGI. The criteria defining DBGI strive not to be entirely based on diagnoses of exclusion, but rather aim to be based on objective, unambiguous, and accurate criteria derived from the presentation as elicited during a medical history and clinical examination. They aim to provide a uniform, reliable, and reproducible framework to minimize unnecessary evaluations that are likely to have low diagnostic yield or relevance. It is important to recognize that DBGI may coexist or interact with other organic GI disorders, such as inflammatory bowel disease, celiac disease, or chronic pancreatitis; at the same time, DBGI themselves exist as related entities on a spectrum with considerable overlap. Ongoing research has implicated a complex interaction between gut microbiota and host immune responses, altered motility, visceral hypersensitivity, genetic factors, and the enteric nervous system in the pathophysiology of DBGI (Fig. 389.1). Furthermore, DBGI may be influenced by psychosocial stressors or a result of an otherwise benign episode of abdominal pain (Fig. 389.2). Early life physical or psychologic stressors may manifest later via DBGI. Maladaptive responses or lack of adequate coping skills may complicate the treatment of DBGI but may also allow for a valuable approach to management using behavioral therapies.

DBGI in children encompass two age-groups: infants/toddlers and children/adolescents. Rumination syndrome, functional constipation, and cyclical vomiting span both age-groups (Fig. 389.3).

DISORDERS OF BRAIN-GUT INTERACTION IN INFANTS AND TODDLERS

Infant regurgitation is the most common DBGI in the first year of life and describes effortless retrograde and involuntary passage of gastric contents from the stomach cephalad and is more commonly referred to as gastroesophageal reflux (Table 389.1). When refluxate reaches the oropharynx and is visible, it is labeled as regurgitation. This phenomenon is normal for healthy infants unless there are complications associated with the process, such as esophageal inflammation, dysphagia, feeding difficulties, inadequate oral intake to meet needs leading to failure to thrive, or the inability to protect the airway with risk for aspiration; in this setting gastroesophageal reflux *disease* is the correct designation (see Chapter 369). Unlike vomiting, regurgitation does not include the forceful expulsion of gastric contents. The peak incidence of infant regurgitation is 4 months of age, followed by a decline in frequency through 12 months of age.

Infant rumination is defined as a habitual regurgitation of gastric contents into the oropharynx to allow for mastication and swallowing (Table 389.2). It is thought to be a form of self-stimulation and may occur in the setting of emotional or sensory deprivation. The regurgitation of gastric contents is effortless, and the refluxate can be chewed and reswallowed instead of expelled from the oropharynx. Infant rumination occurs between 3 and 8 months of age and does not respond to measures used to manage regurgitation. This phenomenon does not occur during socialization/interaction with individuals, does not occur during sleep, and is not associated with distress. Empathy and nurturing lay the foundation for management.

Cyclic vomiting syndrome (CVS) is characterized by repeated episodes of stereotypical vomiting punctuated by periods of normal health in between. It has been reported in infants and children younger than 3 years of age and is most common between ages 2 and 7. The median age of presentation is 4 years (see Chapter 390).

Infant colic (see Chapter 23.1) is a normal developmental process associated with fussiness, irritability, and difficulty consoling the infant (Table 389.3). A trigger is not identifiable; the unexplained episodes of apparent discomfort are often quite stressful to the caregivers and identifying a cause may be their main concern. Infant colic typically occurs between 1 and 4 months of age, with episodes of crying occurring more often in the afternoon or evening. The behavior tends to peak after 4-6 weeks, followed by a gradual decline to resolution about 12 weeks after initial onset. The typical behavior usually leads to consultation with a pediatrician or a pediatric gastroenterologist out of suspicion for abdominal pain despite the absence of any correlating evidence. Associated behaviors, including facial grimace, abdominal distension, increasing gas, skin flushing, and drawing legs up to the abdomen are nondiagnostic but may be worrisome to the caregiver. Patients are often treated for gastroesophageal reflux, gas, or suspected allergy, leading to unnecessary dietary changes and medication use. Treatment includes multiple approaches based on caregiver vulnerabilities. Approaches may include reassuring the caregiver through demonstration that a held, rocked infant may be soothed, prospectively logging crying and other behaviors, and ensuring that caregiver exhaustion is addressed via support system. Probiotics have been investigated as a possible treatment; however, systematic reviews have not demonstrated any beneficial effect. Regardless of the primary approach, providing reassurance, education, and ensuring adequate coping skills and support for caregivers is key. Infant colic ultimately resolves on its own.

Functional diarrhea is often also referred to as *toddler's diarrhea* or *chronic nonspecific diarrhea of toddlerhood* and describes the daily painless passage of three or more large unformed stools for four or more weeks in a well-nourished child. The stools often contain visibly undigested food and mucus, which may be distressing to the caregiver. The onset is typically in infancy or preschool years and excludes steatorrhea and other malabsorptive etiologies (Table 389.4). Nutritional factors such as excessive total calorie intake, as well as excessive dietary intake of the sugar alcohol sorbitol and the carbohydrate fructose, coupled with a low-fat diet, have been implicated in this osmotic process. An evaluation of the diet for other possible etiologies as well as assessment for infections, inflammation, and medication use including antibiotics and laxatives is important. In addition, assessments of growth as well as ruling out fecal impaction and encopresis via digital rectal examination are important. Dietary changes such as reducing fruit juice and processed fructose intake are helpful in resolving symptoms. Care should be taken to not overly restrict the child's diet in an effort to avoid simple sugars. Fiber supplementation may be of some benefit, but evidence is lacking.

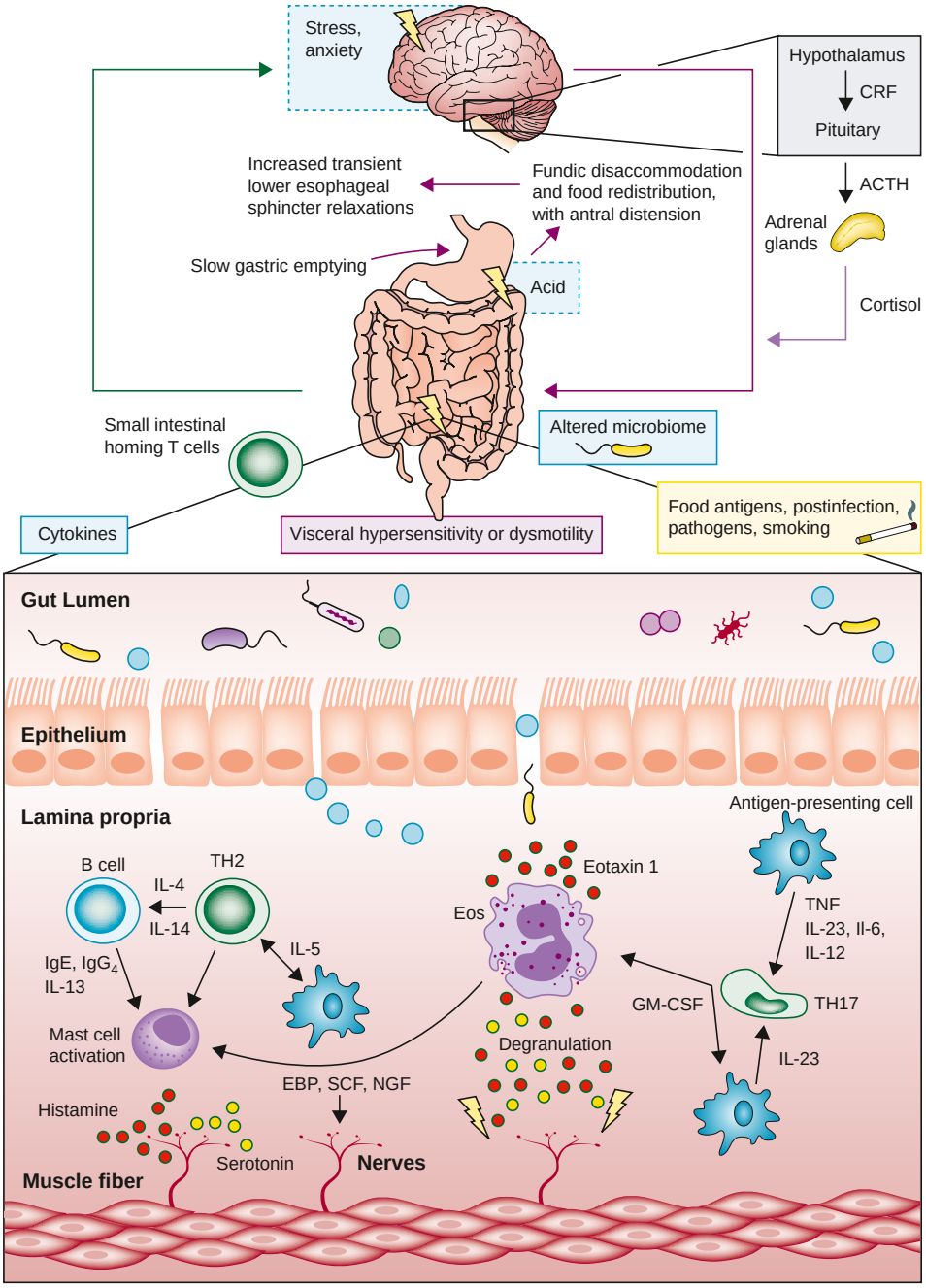

Fig. 389.1 Intestinal immune activation model of functional gastrointestinal disorders. It is hypothesized that, in a genetically primed host, environmental factors induce immune activation. Antigen presentation of luminal antigens, such as pathogens or food peptides, to T cells drives maturation of naive T cells to T-helper (TH) 2 cells. The release of associated cytokines (interleukin [IL]-4, IL-5, and IL-14) promotes the activation and recruitment of eosinophils (Eos), B cells, and mast cells. In addition to the traditional TH2 pathway, secretion of IL-23 from antigen-presenting cells, such as dendritic cells, B cells, and macrophages, promotes TH17 differentiation. The production of granulocyte-macrophage colony-stimulating factor (GM-CSF) from Th17 further drives Eos recruitment. Degranulation of mast cells and eosinophils results in the release of inflammatory mediators, which can damage the intestinal barrier and stimulate and damage enteric nerve fibers, which induces visceral hypersensitivity and motility disturbances resulting in gastrointestinal symptoms. α4β7 gut homing T cells are a marker of intestinal inflammation in both functional dyspepsia and irritable bowel syndrome, and correlate with delayed gastric emptying. Duodenal motor dysfunction might also impair duodenal acid clearance, inducing intestinogastric reflex responses that impair accommodation of the gastric fundus, and increase transient lower esophageal sphincter relaxations leading to gastroesophageal reflux. Signaling cascades, leading to further cytokine release, might result in extraintestinal symptoms, such as anxiety and fatigue. The site and extent of intestinal immune activation can define the phenotype (i.e., proximal intestinal involvement might give rise to functional heartburn, or functional dyspepsia, more distal involvement to irritable bowel syndrome, functional constipation, or functional diarrhea). CRF, Corticotropin-releasing factor; ACTH, adrenocorticotropic hormone; Ig, immunoglobulin; TNF, tumor necrosis factor; EBP, enhancer binding protein; SCF, stem cell factor; NGF, nerve growth factor. *(From Black CJ, Drossman DA, Talley NJ, et al. Functional gastrointestinal disorders: advances in understanding and management. Lancet. 2020;396:16644–16674. Fig. 2.)*

Infant dyschezia describes apparent discomfort before defecation in an infant less than 9 months of age. Infants with dyschezia will strain before defecation for 10-20 minutes with associated screaming, crying, and possible red/purple facial discoloration. Typically, stools are passed several times daily and are not associated with other health problems or anatomic abnormalities. Dyschezia is the result of discoordinated abdominal and pelvic floor musculature contraction, raising the intraabdominal pressure. A good medical history and examination to rule out anatomic or neuromuscular abnormalities are key. Normal growth is to be expected. Reassurance provides the basis of management, and most caregivers will accept the explanation that the infant needs to learn the proper mechanics to stool, relaxing the pelvic floor while bearing down. Laxative, suppository, or digital manipulation is not required and may be counterproductive. Infant dyschezia typically resolves after 3-4 weeks of symptoms.

Functional constipation (see Chapter 378.3) is associated with chronic stool retention, often the result of deliberate withholding as the child voluntarily tries to avoid defecation due to fear or pain. To meet criteria for functional constipation, infants and children must have symptoms for 1 month, including at least two of five criteria listed in Table 389.5. There is often an episode of acute constipation that prompts further avoidance, creating a cycle of pain and withholding. In infancy, the onset is often at the time of diet changes with either the introduction of solid foods or the transition to cow's milk at 12 months of age. In toddlerhood, the initiation of toilet training often correlates with onset of constipation.

In addition to the clinical criteria, symptoms may include hematochezia due to an anal fissure. Though the blood coating the stool is often distressing to caregivers, the blood loss associated with constipation is typically not clinically significant. Physical examination may reveal a palpable abdominal mass, small amounts of fecal matter or a midline fissure on perianal exam, or a hard mass of stool in the rectal vault on digital rectal exam. It should be noted that if the history is typical for functional constipation, a digital rectal examination may not be necessary until treatment failure, if there is diagnostic uncertainty, or an anatomic malformation is suspected. Digital manipulation of the

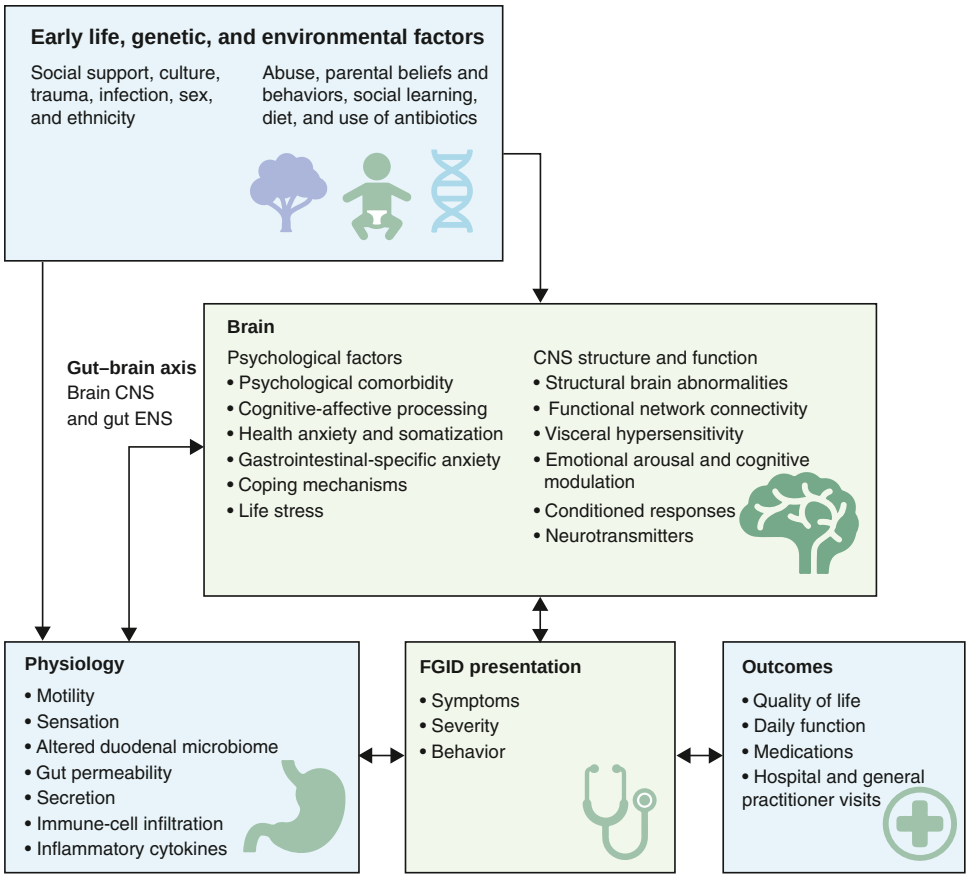

Fig. 389.2 Biopsychosocial model of functional gastrointestinal disorders (FGID). CNS, Central nervous system; ENS, enteric nervous system. *(From Black CJ, Drossman DA, Talley NJ, et al. Functional gastrointestinal disorders: advances in understanding and management. Lancet. 2020;396:16644–1674. Fig. 1, p 1667.)*

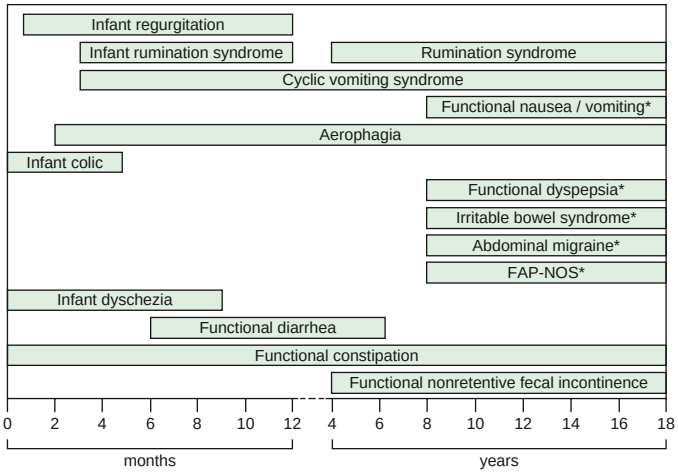

Fig. 389.3 Age distribution of functional gastrointestinal disorders in infants, toddlers, children, and adolescents. *History may not be reliable below this age. FAP-NOS, Functional abdominal pain-not otherwise specified. *(Modified from Benninga MA, Nurko S, Faure C, et al. Childhood functional gastrointestinal disorders: neonate/toddler. Gastroenterology. 2016;150:1443–1455.e2.)*

Table 389.1 Diagnostic Criteria for Infant Regurgitation

Must include both of the following in otherwise healthy infants 3 wk to 12 mo of age:

1. Regurgitation 2 or more times per day for 3 or more weeks
2. No retching, hematemesis, aspiration, apnea, failure to thrive, feeding or swallowing difficulties, or abnormal posturing

From Benninga MA, Nurko S, Faure C, et al. Childhood functional gastrointestinal disorders: neonate/toddler. *Gastroenterology*. 2016;150(6):1443–1455.e2.

Table 389.2 Diagnostic Criteria for Infant Rumination Syndrome

Must include all of the following for at least 2 mo:

1. Repetitive contractions of the abdominal muscles, diaphragm, and tongue
2. Effortless regurgitation of gastric contents, which are either expelled from the mouth or rechewed and reswallowed
3. Three or more of the following:
   a. Onset between 3 and 8 mo
   b. Does not respond to management for gastroesophageal reflux disease and regurgitation
   c. Unaccompanied by signs of distress
   d. Does not occur during sleep and when the infant is interacting with individuals in the environment

From Benninga MA, Nurko S, Faure C, et al. Childhood functional gastrointestinal disorders: neonate/toddler. *Gastroenterology*. 2016;150(6):1443–1455.e2.

anal canal and rectum may further traumatize the child in whom painful defecation has prompted withholding behaviors.

The differential diagnosis for constipation is extensive. In infancy, care must be taken to exclude, via history or physical exam, etiologies including anatomic obstructions, Hirschsprung disease, spinal and neuromuscular abnormalities, and metabolic disorders. A defecation history extending to the first 24 hours of life is particularly important, as 90% of healthy infants and fewer than 10% of infants with Hirschsprung disease will pass their first bowel movement within the first 24 hours of life. Assessment for associated signs and symptoms and growth trends are important, as growth is often affected in the previously mentioned disorders. Red flags are noted in Table 389.6. Management involves naming and explaining the diagnosis, dietary and lifestyle changes, and early use of medications to soften stool with

Table 389.3 Diagnostic Criteria for Infant Colic

For clinical purposes, must include all of the following:

1. An infant who is <5 mo of age when the symptoms start and stop
2. Recurrent and prolonged periods of infant crying, fussing, or irritability reported by caregivers that occur without obvious cause and cannot be prevented or resolved by caregivers
3. No evidence of infant failure to thrive, fever, or illness

"Fussing" refers to intermittent distressed vocalization and has been defined as "behavior that is not quite crying but not awake and content either." Infants often fluctuate between crying and fussing, so that the two symptoms are difficult to distinguish in practice

For clinical research purposes, a diagnosis of infant colic must meet the preceding diagnostic criteria and also include both of the following:

1. Caregiver reports infant has cried or fussed for 3 or more hours per day during 3 or more days in 7 days in a telephone or face-to-face screening interview with a researcher or clinician
2. Total 24-hr crying plus fussing in the selected group of infants is confirmed to be 3 hours or more when measured by at least one prospectively kept, 24-hr behavior diary

From Benninga MA, Nurko S, Faure C, et al. Childhood functional gastrointestinal disorders: neonate/toddler. *Gastroenterology*. 2016;150(6):1443–1455.e2.

Table 389.4 Diagnostic Criteria for Functional Diarrhea

Must include all of the following:

1. Daily painless, recurrent passage of four or more large, unformed stools
2. Symptoms last more than 4 wk
3. Onset between 6 and 60 mo of age
4. No failure to thrive if caloric intake is adequate

From Benninga MA, Nurko S, Faure C, et al. Childhood functional gastrointestinal disorders: neonate/toddler. *Gastroenterology*. 2016;150(6):1443–1455.e2.

Table 389.5 Diagnostic Criteria for Functional Constipation

Must include 1 mo of at least two of the following in infants up to 4 yr of age:

1. Two or fewer defecations per week
2. History of excessive stool retention
3. History of painful or hard bowel movements
4. History of large-diameter stools
5. Presence of a large fecal mass in the rectum

In toilet-trained children, the following additional criteria may be used:

6. At least one episode per week of incontinence after the acquisition of toileting skills
7. History of large-diameter stools that may obstruct the toilet

From Benninga MA, Nurko S, Faure C, et al. Childhood functional gastrointestinal disorders: neonate/toddler. *Gastroenterology*. 2016;150(6):1443–1455.e2.

daily osmotic laxatives preferred over stimulant laxatives. The primary goal is to achieve painless defection to facilitate resolution of the fear and withholding around defecation. Avoidance of toilet training until symptoms resolve and the child shows interest or willingness to proceed are generally advocated. Behavior modification including reassurance and positive incentive reward systems are useful.

DISORDERS OF BRAIN-GUT INTERACTION IN OLDER CHILDREN AND ADOLESCENTS

DBGI in children and adolescents are divided by symptoms into nausea and vomiting disorders, abdominal pain disorders, and defecation disorders. For individual diagnoses, the term *functional* is still used in some cases.

Table 389.6 Potential Alarm Features in Constipation

Passage of meconium >48 hours in a term newborn
Constipation starting in the first month of life
Family history of Hirschsprung disease
Ribbon stools
Blood in the stools in the absence of anal fissures
Failure to thrive
Bilious vomiting
Severe abdominal distension
Abnormal thyroid gland or newborn screen
Abnormal position of the anus
Absent anal or cremasteric reflex
Decreased lower extremity strength/tone/reflex
Sacral dimple
Tuft of hair on lower spine
Gluteal cleft deviation
Anal scars

From Hyams JS, Di Lorenzo C, Saps M, et al. Childhood functional gastrointestinal disorders: child/adolescent. *Gastroenterology*. 2016;150(6):1456–1468.e2. Table 3.

Nausea and Vomiting Disorders

Cyclic vomiting syndrome describes stereotypical, episodic attacks of vomiting with intervening periods of normal health and no vomiting symptoms (see Chapter 390). Per the Rome IV criteria, at least two episodes must occur in a 6-month period and not be attributable to another condition (Table 389.7). CVS can occur from infancy to adulthood, with 46% of patients having symptom onset at or before 3 years of age. In younger patients, extra care must be taken to rule out metabolic and anatomic disorders, as there is a higher likelihood of these disorders at younger ages. Chronic cannabis use in adolescents can be associated with repeated episodes of nausea and vomiting, termed the cannabinoid hyperemesis syndrome (see Chapter 157.3), and should be excluded in this age-group.

Functional nausea and functional vomiting may coexist or may occur independently of one another and describe isolated nausea or isolated vomiting (Table 389.8). Importantly, these conditions occur without coincident abdominal pain. The presentation may be accompanied by autonomic symptoms such as diaphoresis, pallor, tachycardia, and dizziness. The differential diagnosis includes anatomic, inflammatory, infectious, and motility etiologies. Anxiety and other behavioral conditions can be present with these DBGI and should be evaluated for and managed accordingly; children with functional nausea or functional vomiting should undergo psychologic evaluation. In children with psychologic comorbidities, cognitive-behavioral therapy or other psychologic interventions are appropriate. Cyproheptadine and transcutaneous gastric stimulation may be effective in the management of nausea.

Rumination syndrome in children and adolescents is defined similarly to the condition in infants, with the added notation that the effortless regurgitation of stomach contents may be associated with an unpleasant sensation or discomfort such as abdominal pressure or burning (Table 389.9). Repeated regurgitation and remastication or oral repulsion of the regurgitated gastric contents occurs soon after ingesting foodstuffs and does not occur during sleep. It is not preceded by active expulsion of gastric contents/retching and cannot be explained by any other medical condition. The diagnosis does not require prior failure of treatment for gastroesophageal reflux. A triggering event can often be identified before symptoms, which may occur following resolution of an infectious illness or with psychosocial stress. In adolescents, eating disorders may present similarly and must be ruled out. Other GI issues to be considered include anatomic, infectious, inflammatory, and motility disorders. An important distinction between rumination and other GI etiologies of vomiting includes effortless versus forceful regurgitation, and the time course, which is usually immediately following ingestion of foodstuffs. As with most

Table 389.7 Diagnostic Criteria for Cyclic Vomiting Syndrome

Must include all of the following:

1. The occurrence of two or more periods of intense, unremitting nausea and paroxysmal vomiting, lasting hours to days within a 6-mo period
2. Episodes are stereotypical in each patient
3. Episodes are separated by weeks to months with return to baseline health between episodes
4. After appropriate medical evaluation, the symptoms cannot be attributed to another condition

Table 389.8 Diagnostic Criteria* for Functional Nausea and Functional Vomiting

FUNCTIONAL NAUSEA

Must include all of the following fulfilled for the last 2 mo:

1. Bothersome nausea as the predominant symptom, occurring at least twice per week, and generally not related to meals
2. Not consistently associated with vomiting
3. After appropriate evaluation, the nausea cannot be fully explained by another medical condition

FUNCTIONAL VOMITING

Must include all of the following:

1. On average, one or more episodes of vomiting per week
2. Absence of self-induced vomiting or criteria for an eating disorder or rumination
3. After appropriate evaluation, the vomiting cannot be fully explained by another medical condition

*Criteria fulfilled for at least 2 mo before diagnosis.
From Hyams JS, Di Lorenzo C, Saps M, et al. Childhood functional gastrointestinal disorders: child/adolescent. *Gastroenterology*. 2016;150(6):1456–1468.

Table 389.9 Diagnostic Criteria* for Rumination Syndrome in Children

Must include all of the following:

1. Repeated regurgitation and rechewing or expulsion of food that:
   a. Begins soon after ingestion of a meal
   b. Does not occur during sleep
2. Not preceded by retching
3. After appropriate evaluation, the symptoms cannot be fully explained by another medical condition. An eating disorder must be ruled out

*Criteria fulfilled for at least 2 mo before diagnosis.
From Hyams JS, Di Lorenzo C, Saps M, et al. Childhood functional gastrointestinal disorders: child/adolescent. *Gastroenterology*. 2016;150(6):1456–1468.

DBGI, a thorough understanding of the disorder and motivation to overcome it are key to treatment. Because rumination syndrome is essentially a learned habit, therapy focusing on managing the habit has proven effective. Deep breathing exercises to counteract the noxious stimulus are often employed to change the pressure differential and prevent regurgitation of gastric contents.

Aerophagia is often seen in neurocognitively impaired patients. It involves excessive air swallowing occurring throughout the day with progressive abdominal distention and with repetitive passage of gas via belching and/or flatus. Abdominal distension and flatus symptoms may be more severe in those children who cannot belch. Symptoms cannot be attributed to any other causes such as partial obstructions, small bowel bacterial overgrowth, GI dysmotility (pseudoobstruction), or to malabsorptive disorders. In children with age-appropriate cognition and neurologic status, chewing gum and gulping down liquids may be risk factors for aerophagia. Abdominal pain, nausea, and early satiety are possible associated GI symptoms; sleeping difficulty, headaches, and dizziness are also reported. Anxiety is a frequent comorbidity and may contribute to the behavior. Treatment is multidisciplinary and may include behavioral therapy, deep breathing, and potentially medications to relieve anxiety.

Table 389.10 Diagnostic Criteria* for Functional Dyspepsia

Must include one or more of the following bothersome symptoms at least 4 days/mo:

1. Postprandial fullness.
2. Early satiation.
3. Epigastric pain or burning not associated with defecation.
4. After appropriate evaluation, the symptoms cannot be fully explained by another medical condition.

Within functional dyspepsia, the following subtypes are now adopted:

1. Postprandial distress syndrome includes bothersome postprandial fullness or early satiation that prevents finishing a regular meal. Supportive features include upper abdominal bloating, postprandial nausea, or excessive belching.
2. Epigastric pain syndrome, which includes all of the following: bothersome (severe enough to interfere with normal activities) pain or burning localized to the epigastrium. The pain is not generalized or localized to other abdominal or chest regions and is not relieved by defecation or passage of flatus. Supportive criteria can include (1) burning quality of the pain but without a retrosternal component and (2) the pain is commonly induced or relieved by ingestion of a meal but may occur while fasting.

*Criteria fulfilled for at least 2 mo before diagnosis.
From Hyams JS, Di Lorenzo C, Saps M, et al. Childhood functional gastrointestinal disorders: child/adolescent. *Gastroenterology*. 2016;150(6):1456–1468.

Abdominal Pain Disorders

Functional dyspepsia (FD) describes postprandial fullness, early satiety, or epigastric pain or burning that is exclusive of defecation and not fully explainable by another or an underlying medical condition (Table 389.10). Subtypes of FD include *postprandial distress syndrome* (symptoms may preclude finishing a meal or be manifest by bloating, nausea, and excessive belching following a meal) as well as *epigastric pain syndrome* (epigastric pain/burning sufficient to preclude or disrupt normal activities, with pain not generalizable or localizable to other abdominal or chest regions, and not relieved by defecation or passage of flatus). Multiple pathophysiologic mechanisms have been proposed for FD; it is likely that each or multiple etiology contributes. An impaired gastric accommodation, visceral hypersensitivity, food allergy, delayed gastric emptying, and post-viral gastroparesis have all been implicated. The differential diagnosis includes GI etiologies of epigastric pain, including gastritis, esophagitis, and pancreatitis, among others. These etiologies can be guided by family, personal, and medical histories, exam, and by the nature of symptoms including abdominal pain and other alarm features (Tables 389.11 and 389.12). Initial treatment measures include a trial of dietary and lifestyle changes including avoiding spicy foods, caffeine, fatty foods, and nonsteroidal antiinflammatory drugs (NSAIDs). Gastric acid reduction therapy may be initiated. Assessment by a pediatric gastroenterologist and upper endoscopy are often performed. Treatment with cyproheptadine to improve gastric accommodation in patients with early satiety or attempts to treat visceral hypersensitivity in children with FD are reasonable, safe, and supported by available evidence. Low-dose tricyclic antidepressant therapy with amitriptyline may have efficacy in refractory cases. Early satiety may also respond to prokinetic medications such as erythromycin or metoclopramide. Percutaneous electrical stimulation of the stomach is a potential option for patients with FD refractory to standard therapy.

Irritable Bowel Syndrome (IBS) can be classified into the same four subtypes as adult IBS, depending on stool pattern: IBS with constipation (IBS-C), IBS with diarrhea (IBS-D), IBS with constipation and diarrhea, and unspecified IBS. Diagnosis of IBS requires abdominal pain on four or more days per month associated with defecation and/or a change in frequency of stool from baseline and/or a change in form/

Table 389.11 Alarm Symptoms Usually Needing Further Investigations in Children with Chronic Abdominal Pain

- Pain that wakes up the child from sleep
- Persistent right upper or right lower quadrant pain
- Significant vomiting (bilious vomiting, protracted vomiting, cyclical vomiting, or worrisome pattern to the physician)
- Unexplained fever
- Genitourinary tract symptoms
- Dysphagia
- Odynophagia
- Chronic severe diarrhea or nocturnal diarrhea
- Gastrointestinal blood loss
- Involuntary weight loss
- Deceleration of linear growth
- Delayed puberty
- Family history of inflammatory bowel disease, celiac disease, and peptic ulcer disease

Table 389.12 Alarm Signs Usually Needing Further Investigations in Children with Chronic Abdominal Pain

- Localized tenderness in the right *upper* quadrant
- Localized tenderness in the right *lower* quadrant
- Localized fullness or mass
- Hepatomegaly
- Splenomegaly
- Jaundice
- Costovertebral angle tenderness
- Arthritis
- Spinal tenderness
- Perianal disease
- Abnormal or unexplained physical findings
- Hematochezia
- Anemia

appearance of stool (Table 389.13). Symptoms, including the predominant stool pattern, severity of pain, and functional impairment, reflect the degree of disordered brain-gut interaction. Visceral sensitivity may be attenuated or amplified by psychosocial stressors as well as mucosal proinflammatory cytokines related to infections or alterations in the gut microbiota.

As with other DBGI, the GI differential diagnosis includes anatomic, infectious, inflammatory, and motility disorders as well as conditions associated with malabsorption. Differentiation between those GI disorders and IBS is guided by the history, physical, and often biochemical markers of inflammation, particularly fecal calprotectin (see Tables 389.11 and 389.12). Management of symptoms may include dietary modification (under the guidance of a registered dietitian to prevent inadequate intake) to reduce or restrict foods that may provoke symptoms or cause gas (see section on fiber and the FODMAPS [fermentable oligo-di-monosaccharides and polyols] discussion Chapter 60). The use of probiotics has been effective in reducing symptoms in children with IBS, likely through production of short-chain fatty acids; drug therapy for IBS is noted in Table 389.14. In small trials, peppermint was effective in reducing pain in children with IBS. Cognitive-behavioral therapy is important to identify possible psychosocial stressors and to help identify coping mechanisms to maximize daily function and quality of life. Small studies have suggested that transcutaneous neurostimulation may also be efficacious.

Abdominal migraine shares some features with CVS. Stereotypical patterns and symptoms afflict the patient, are typically of acute onset, intense, lasting for at least an hour, either periumbilical or generalized in location, and usually are debilitating (Table 389.15). Episodes may also include associated anorexia, nausea, emesis, headaches, photophobia, and pallor. Episodes are separated by weeks to months, with at least two attacks occurring over a 6-month period. Between bouts, children return to baseline functioning and are symptom free.

Table 389.13 Diagnostic Criteria* for Irritable Bowel Syndrome

Must include all of the following:
1. Abdominal pain at least 4 days/mo associated with one or more of the following:
   a. Related to defecation
   b. A change in frequency of stool
   c. A change in form (appearance) of stool
2. In children with constipation, the pain does not resolve with resolution of the constipation (children in whom the pain resolves have functional constipation, not irritable bowel syndrome)
3. After appropriate evaluation, the symptoms cannot be fully explained by another medical condition

*Criteria fulfilled for at least 2 mo before diagnosis.
From Hyams JS, Di Lorenzo C, Saps M, et al. Childhood functional gastrointestinal disorders: child/adolescent. *Gastroenterology*. 2016;150(6):1456–1468.

Table 389.14 Recommendations for Treatment of Irritable Bowel Syndrome

RECOMMENDATIONS FOR TREATMENT OF IRRITABLE BOWEL SYNDROME (IBS)
- Mild symptoms often respond to dietary changes.
- Antispasmodics can be used as needed for abdominal pain or postprandial symptoms.
- Antidepressants can improve abdominal pain and global symptoms. They may be considered for patients with moderate to severe symptoms.

IBS WITH CONSTIPATION (IBS-C)
- Fiber may relieve constipation in patients with mild symptoms.
- Polyethylene glycol can increase the frequency of bowel movements but may not improve overall symptoms or abdominal pain.
- Lubiprostone or linaclotide can be tried in patients whose symptoms have not responded to polyethylene glycol.

IBS WITH DIARRHEA (IBS-D)
- Taken as needed, loperamide can reduce postprandial urgency and stool frequency, but it does not improve global symptoms.
- Rifaximin and eluxadoline have been modestly more effective than placebo in relieving symptoms.

From Drugs for irritable bowel syndrome. *The Medical Letter*. 2016;58(1504):121–126.

Table 389.15 Diagnostic Criteria* for Abdominal Migraine

Must include all of the following occurring at least twice:
1. Paroxysmal episodes of intense, acute periumbilical, midline, or diffuse abdominal pain lasting 1 hour or more (should be the most severe and distressing symptom)
2. Episodes are separated by weeks to months
3. The pain is incapacitating and interferes with normal activities
4. Stereotypical pattern and symptoms in the individual patient
5. The pain is associated with two or more of the following:
   a. Anorexia
   b. Nausea
   c. Vomiting
   d. Headache
   e. Photophobia
   f. Pallor
6. After appropriate evaluation, the symptoms cannot be fully explained by another medical condition

*Criteria fulfilled for at least 6 mo before diagnosis.
From Hyams JS, Di Lorenzo C, Saps M, et al. Childhood functional gastrointestinal disorders: child/adolescent. *Gastroenterology*. 2016;150(6):1456–1468.

Triggers may vary, but common triggers include sleep hygiene disruption, fatigue, and travel, and are usually alleviated by sleep. The differential diagnosis includes anatomic obstructions or abnormalities predisposing to intermittent obstruction of the GI or urologic tract,

infectious or inflammatory conditions, hepatobiliary and pancreatic disorders, neurologic and metabolic conditions, and psychiatric disorders. Frequently, a family history of migraine headaches or abdominal migraines is present. Preventing exposure to known triggers once identified is important; further treatment depends on the frequency and severity of episodes as well as their impact on quality of life. Acute episodes may be treated similarly to migraine headaches with abortive medications such as triptans. Similar to CVS prophylaxis, cyproheptadine, amitriptyline, and propranolol may be effective. Oral pizotifen (antiserotonin, antihistamine) has been shown in small studies to be an effective prophylactic agent as well. Antimigraine therapies such as triptans may be effective in aborting bouts. A large number of children may have their symptom pattern evolve into migraine headaches as they progress toward adulthood.

Functional abdominal pain not otherwise specified (FAP-NOS) describes pain that occurs at least 4 times per month with either intermittent or continuous abdominal pain not associated with a particular activity or coincident to another physiologic event such as menses or eating and cannot be explained by any other underlying medical condition. These episodes occur in less than a 2-month span. In many ways, it is a DBGI of exclusion, as it does not meet criteria for either IBS, FD, or abdominal migraine. Psychosocial stressors may play a role, and behavioral approaches may be helpful to identify and manage stressors and other exacerbating factors. Pharmacologic data is limited, but small trials have suggested efficacy of amitriptyline and citalopram, though it should be noted that the latter is associated with suicidal ideation in adolescent patients.

DEFECATION DISORDERS

Functional constipation in children and adolescents describes decreased defecation frequency associated with volitional stool retention, similar to the classification in infants and toddlers. Large, hard, painful bowel movements are again a hallmark of the disorder, though patients in this age-group may also demonstrate fecal incontinence related to overflow of liquid stool beyond a large rectal stool ball as well as large-diameter stools that obstruct the toilet (Table 389.16). Onset in children peaks at the time of toilet training; in older children and adolescent, withholding may be triggered by a social stressor such as a major change in the school or home environment. Repeated distension of the rectum with large, hard stool over time may reduce the sensation to defecate and may lead to encopresis, the unintentional passage of liquid stool. Children experiencing encopresis often do not smell the stool that has passed, leading to embarrassment in social situations. Anorexia, abdominal distention, and pain are often coincident, though notably children do not meet criteria for IBS-C.

The diagnosis is based on medical history and physical examination. In addition to the clinical criteria, symptoms may include hematochezia due to an anal fissure. Though the blood coating the stool is often distressing to caregivers, the blood loss associated with constipation is typically not clinically significant. Physical examination may reveal a palpable abdominal mass, small amounts of fecal matter or a midline fissure on perianal exam, or a hard mass of stool in the rectal vault on digital rectal exam. It should be noted that if the history is typical for functional constipation, a digital rectal examination may not be necessary until treatment failure, diagnostic uncertainty, or an anatomic malformation is suspected. Digital manipulation of the anal canal and rectum may further traumatize the child or adolescent in whom painful defecation has prompted withholding behaviors. An abdominal x-ray is not required to make the diagnosis, and the stool burden observed rarely correlates with historical defecation pattern. The diameter of the rectum and any rectal stool on x-ray may be helpful to illustrate the degree of stool accumulation in the rectum.

Table 389.16 Diagnostic Criteria for Functional Constipation in Children with Chronic Abdominal Pain

Must include two or more of the following occurring at least once per week for a minimum of 1 month with insufficient criteria for a diagnosis of irritable bowel syndrome:

1. Two or fewer defecations in the toilet per week in a child of a developmental age of at least 4 years
2. At least one episode of fecal incontinence per week
3. History of retentive posturing or excessive volitional stool retention
4. History of painful or hard bowel movements
5. Presence of a large fecal mass in the rectum
6. History of large-diameter stools that can obstruct the toilet

After appropriate evaluation, the symptoms cannot be fully explained by another medical condition.

From Hyams JS, Di Lorenzo C, Saps M, et al. Childhood functional gastrointestinal disorders: child/adolescent. *Gastroenterology*. 2016;150(6):1456–1468.

The differential diagnosis for constipation in children and adolescents is similar to infants and toddlers, though metabolic and anatomic abnormalities are much less likely to present in older children and adolescents. As in younger children, alarm symptoms should be assessed; in the absence of these symptoms, further testing is not indicated (see Table 389.6). Management includes disimpaction of the rectal stool ball followed by maintenance therapy with osmotic laxatives to soften stools for ease of passage, dietary changes to optimize fiber intake (a general rule is that daily fiber intake in grams can be approximated by adding age in years plus 5 to 10), and behavioral approaches similar to those employed for younger children (see Chapter 378.3).

Nonretentive fecal incontinence (NFI) describes the passage of stool in the absence of fecal retention that occurs in inappropriate settings for a specific society and culture, and that occurs without evidence of another or underlying medical condition in a child 4 years of age or older over at least a 1-month period. These patients otherwise have normal defecatory patterns and function, as well as normal colonic transit time, differentiating and distinguishing them from functional constipation. Another key difference is that children with NFI will have passage of their entire rectal contents as opposed to the smears or small amounts of stool in patients with functional constipation and encopresis. Psychologic comorbidities are frequent in children with NFI. A thorough medical history and physical examination including a comprehensive neurologic and digital rectal exam are required to fully appreciate what factors are involved in this condition. The diagnosis should be based on an otherwise normal defecation frequency, absence of an abdominal or rectal mass, a normal neurologic exam, and a normal transit marker study. Given the significant comorbidity of behavior and emotional axis issues, involvement of behavioral health professionals is essential to the evaluation and management of this condition. Therapy focuses on proactive regular toilet use. Unfortunately, biofeedback therapy, helpful in other disorders of defecation dynamics, has not proven beneficial in children with NFI.

Visit Elsevier eBooks+ at eBooks.Health.Elsevier.com for Bibliography.

Chapter 390

Cyclic Vomiting Syndrome

Asim Maqbool, Prasanna K. Kapavarapu, and Chris A. Liacouras

Cyclic vomiting syndrome (CVS) is an idiopathic disorder manifested as episodic vomiting, usually of sudden onset and high intensity/frequency (4/hr:12-15 episodes per day) of vomiting, with eventual resolution and return to a normal baseline between attacks (Fig. 390.1). Typical bouts last for 24-48 hours and usually respond promptly to hydration. To meet the criteria for CVS, identifiable organic disorders are excluded following an appropriate workup (Fig. 390.2). The guidelines for the frequency of episodes to fulfill the CVS criteria differ between societies. The North American Society of Pediatric Gastroenterology, Hepatology and Nutrition (NASPGHAN) consensus statement in 2008 on CVS requires at least five vomiting episodes in any interval period or a minimum of three episodes in a 6-month period, whereas the 2016 Rome IV criteria on childhood functional gastrointestinal (GI) disorders requires at least two or more episodes in a 6-month period (Table 390.1).

The prevalence of CVS in children is estimated at ~2% in predominantly White populations, although it does occur in those of African or Asian descent, and Hispanic ethnicity. There is a slight female predominance. The median age of onset is 5 years, but it can begin in infancy and adolescence. Typically, there is a delay of 2.5 years in making the diagnosis despite multiple episodes and emergency room visits. The natural history of CVS is that most children outgrow it during preadolescence or adolescence, and of those, many will develop migraines. There are also later pediatric-onset (mean age 13 years) and adult-onset (mean age 32 years) subgroups indicating that in a minority it can begin or persist in adulthood.

One key clinical feature of CVS is its consistent and stereotypical pattern of vomiting within individuals. Typically, symptoms start at the same time, often during early morning hours, last the same duration, and demonstrate identical autonomic symptoms of pallor and listlessness, unrelenting nausea, abdominal pain, and in less than half, headaches and photophobia. About half of cases occur on a cycle as often as monthly; some cycle as infrequently as every 3-4 months. Other patients have unpredictable sporadic vomiting that may be associated with a specific trigger. Potential triggers include infectious illnesses, stress and especially excitement (holidays), sleep deprivation (sleepovers), dietary triggers (chocolate, monosodium glutamate), food allergy, onset of menses, and weather changes. Typically, the vomiting is intense, with greater than four bouts of emesis per hour at the peak, and can include gastric contents or frequent dry heaves. Although most attacks last 2 days, an episode can last anywhere from hours and rarely up to 10 days. CVS attacks are debilitating, often necessitating IV rehydration, and resulting in hospitalization. Seasonal variation apparently occurs in approximately a third of patients, with more attacks in winter and fewer during summer.

Subgroups of CVS include *migraine-related,* with either personal history of migraines or family history of migraines; *Sato variant,* driven by hyperresponsive hypothalamic-pituitary-adrenal axis

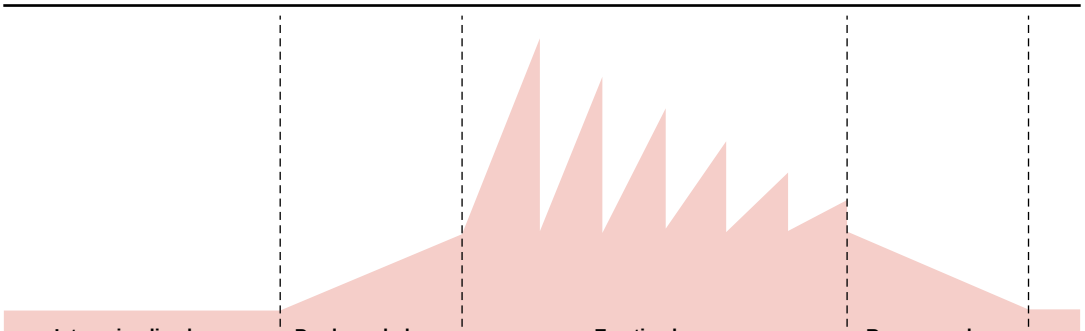

Interepisodic phase	Prodromal phase	Emetic phase	Recovery phase
Lasts weeks to months. The child resumes completely normal or baseline health; 5–12% of children experience mild nausea and emesis (“coalescent” CVS).	Lasts minutes to hours. >90% of patients experience identifiable prodrome with symptoms such as nausea, sweating, abdominal pain or “pressure,” fatigue or weakness, feeling hot and/or cold, having an urge to defecate, and insomnia. The child is still able to take oral and retain oral medication.	Lasts from a few hours to several days. Children experience relentless nausea, vomiting, and retching. The vomiting is typically projectile, forceful, and may contain bile or blood, peaks at 6 times/hour. The nausea persists even after evacuation of gastric contents, often described as the most distressing symptom, only relieved by sleep. Other symptoms include abdominal pain (70–80%), headache, photosensitivity, phonosensitivity, diarrhea, cold sweats, hot flashes, excessive salivation, and vertigo. Patients may be lethargic and withdrawn or agitated, with inability to walk and communicate effectively. Unusual behaviors can be observed such as drinking compulsively, taking long hot shower or bath, drowning in fetal position in a dark and quite room.	Can be very quick or gradual and patients are suddenly able to eat and interact

Fig. 390.1 Temporal pattern of cyclic vomiting syndrome. Schematic representation of the four phases. *(From Raucci U, Borrelli O, Di Nardo G, et al. Cyclic vomiting syndrome in children. Frontiers Neurol. 2020;11:Article 583425. Fig. 1.)*

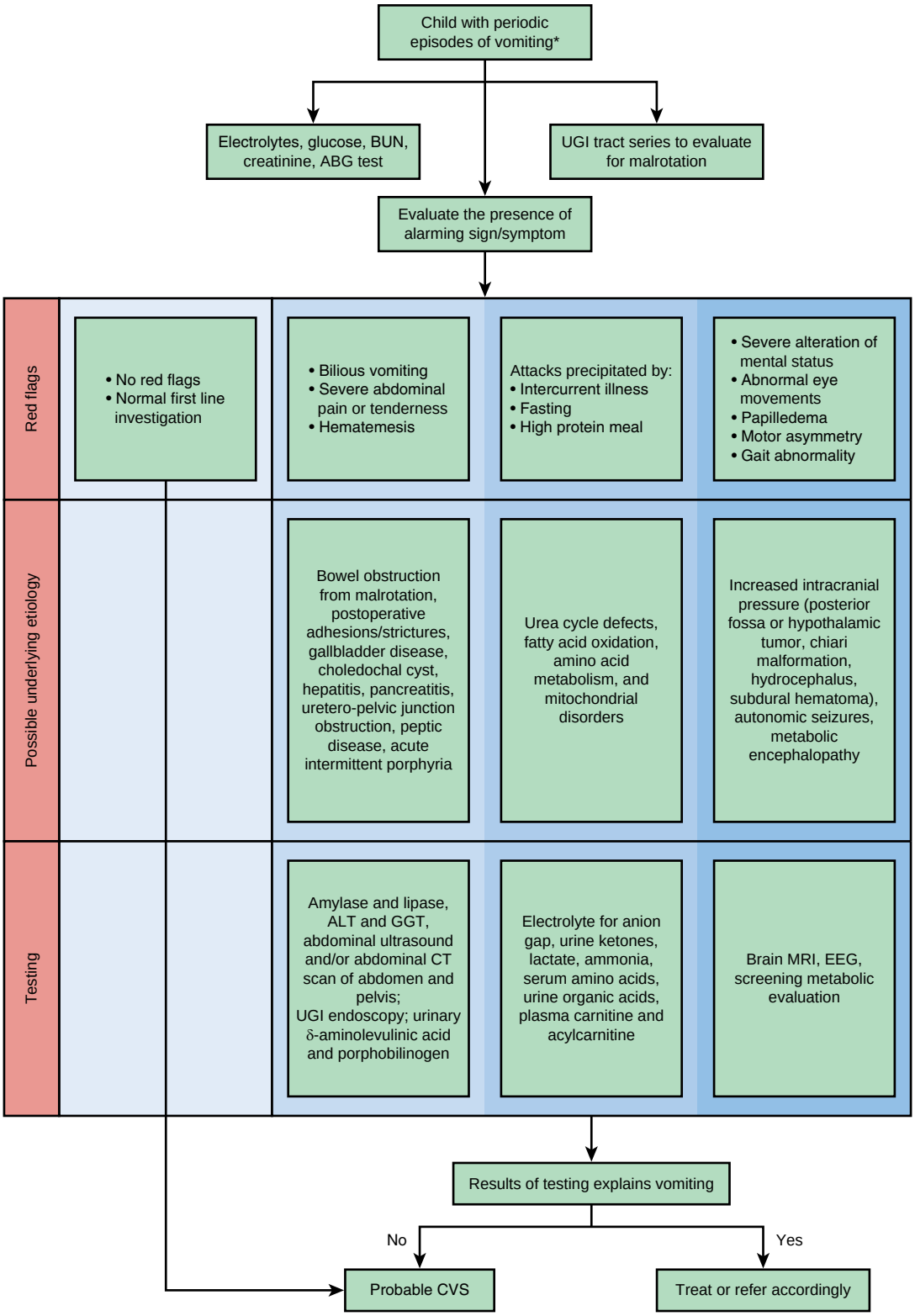

Fig. 390.2 Algorithm for the evaluation of children with cyclic vomiting pattern. *Fulfilling clinical criteria for CVS (see Table 390.1). ABG, Arterial-blood gas; ALT, alanine aminotransferase; CVS, cyclic vomiting syndrome; GGT, γ-glutamyl-transferase; UGI, upper gastrointestinal. *(From Raucci U, Borrelli O, Di Nardo G, et al. Cyclic vomiting syndrome in children. Frontiers Neurol. 2020;11:Article 583425. Fig. 2.)*

(elevated cortisol levels), hypertension, extreme lethargy, and presenting with more severe and prolonged CVS episodes; *catamenial* CVS, occurring in adolescent girls who are hormonally sensitive and presenting with CVS episodes either within a day, prior or post menstrual period; underlying *mitochondrial dysfunction,* associated with single nucleotide polymorphisms and evidence of improvement with mitochondrial supplements like coenzyme Q10; *and the coalescent form*, presenting with daily nausea between episodes of emesis (which becomes less frequent). CVS may also be more common in children with autism.

Table 390.1 North American Society for Pediatric Gastroenterology, Hepatology, and Nutrition, International Classification of Headache Disorders 3, and Rome IV Diagnostic Criteria

NASPGHAN 1. At least five attacks in any interval or a minimum of three attacks during a 6-mo period 2. Episodic attacks of intense nausea and vomiting lasting 1 hour to 10 days, occurring at least 1 wk apart 3. Stereotypical pattern and symptoms in the individual patient 4. Vomiting during attacks at least 4 times per hour for at least 1 hour 5. Return to baseline health between episodes 6. Not attributed to another disorder
ICHD-3 A. At least five attacks of intense nausea and vomiting fulfilling criteria B and C B. Stereotypical in the individual patient and recurring with predictable periodicity C. All of the following: 1. Nausea and vomiting occur ≥4 times per hour 2. Attacks last ≥1 hour and up to 10 days 3. Attacks occur ≥1 wk apart D. Complete freedom from symptoms between attacks E. Not attributable to another disorder
Note: History and physical exam do not show sign of gastrointestinal disease
PEDIATRIC ROME IV 1. Two or more periods of intense unremitting nausea and paroxysmal vomiting, lasting hours to days within a 6-mo period 2. Episodes are stereotypical in each patient 3. Episodes separated by weeks to months with return to baseline health between episodes 4. Symptoms not attributed to another medical condition
ADULT ROME IV Stereotypical episodes of vomiting regarding onset (acute) and duration (<1 wk)
1. ≥3 discrete episodes in the prior year and two episodes in past 6 mo, occurring ≥1 wk apart 2. Absence of vomiting between episodes, but other milder symptoms can be present between cycles
Supportive remarks
1. Personal or family history of migraine headaches
Criteria must be fulfilled for the last 6 mo with symptom onset at least 3 mo before diagnosis.

Note: All respective criteria must be met to meet consensus definitions for both NASPGHAN, ICHD-3, and Rome IV.
NASPGHAN, North American Society for Pediatric Gastroenterology, Hepatology, and Nutrition; ICHD-3, International Classification of Headache Disorders 3.
From Kovacic K, Li BUK. Cyclic vomiting syndrome: a narrative review and guide to management. *Headache*. 2021;61:231–243. Table 1.

Table 390.2 Diagnostic Tests for Ruling Out Conditions in the Differential Diagnosis with Cyclic Vomiting Syndrome

CONDITION	DIAGNOSTIC TESTING
GASTROINTESTINAL DISORDERS	
Peptic ulcer disease	Upper GI endoscopy
Gastroparesis	Scintigraphic gastric emptying study
Hepatitis	Abdominal ultrasound
Pancreatitis	Abdominal ultrasound
Cholecystitis	Abdominal ultrasound
Biliary tract anomalies	Hepatobiliary scintigraphy, endoscopic retrograde cholangiopancreatography, magnetic resonance cholangiopancreatography
Malrotation with volvulus, postoperative adhesions/ strictures	Upper GI series with small bowel follow-through, abdominal CT scans, upper GI endoscopy
Chronic intestinal pseudoobstruction	Plain abdominal x-ray, upper GI series with small bowel follow-through, antroduodenal manometry
EXTRAINTESTINAL DISORDERS	
Central Nervous System	
Mass	Brain MRI, Brain CT
Hydrocephalus	Brain MRI, Brain CT
Subdural hematoma	Brain CT
Autonomic seizures	EEG
Renal Disorders	
Ureteropelvic junction obstruction	Abdominal ultrasound
Nephrolithiasis	Abdominal ultrasound, abdominal CT
Metabolic Disorders	Ammonia, organic acids, lactate, amino gap

From Raucci U, Borrelli O, Di Nardo G, et al. Cyclic vomiting syndrome in children. *Frontiers Neurol*. 2020;11:Article 583425. Table 3.

Multiple comorbid disorders can further comprise quality of life between episodes; these include anxiety, constipation-predominant irritable bowel syndrome, chronic fatigue or limited stamina, sleep disorders, postural orthostatic tachycardia syndrome, daily nausea, and complex regional pain syndrome. There is often a positive family history of migraines in children with CVS; attacks of both conditions share many clinical features. Although the pathophysiology is not fully known, there is suggestive evidence that an overresponsive hypothalamic-pituitary-adrenal axis (including corticotropin-releasing factor), autonomic nervous system dysregulation (sympathetic predominance), mitochondrial dysfunction (16519T and 3010A), and nuclear pathogenic variants *(RYR2)* may play contributory roles.

Patients with chronic vomiting should always be evaluated for potential etiologies other than CVS. The differential diagnosis includes GI anomalies (malrotation, duplication cysts, choledochal cysts, recurrent intussusceptions), CNS disorders (neoplasm, epilepsy, vestibular pathology), nephrolithiasis, cholelithiasis, hydronephrosis, metabolic-endocrine disorders (urea cycle, mitochondrial disorders, fatty acid metabolism, Addison disease, porphyria, hereditary angioedema, familial Mediterranean fever), chronic appendicitis, and inflammatory bowel disease (see Fig. 390.2; Tables 390.2 and 390.3). Laboratory evaluation is based on a careful history and physical examination and may include, if indicated, endoscopy, contrast upper GI radiography, brain MRI, and metabolic studies (lactate, organic acids, ammonia). Bilious emesis usually suggests a small bowel obstruction and is considered a red flag; however, children with CVS may have bile-stained emesis. A tender abdomen is also unusual for CVS and warrants further workup. Acute and chronic appendicitis can mimic CVS. Prior

Table 390.3 Relevant Causes of Vomiting in Metabolic Disorders

ASSOCIATED OR NOT WITH ENCEPHALOPATHY
Organic acidurias
Urea cycle disorders
Fatty acid oxidation disorders
MCT1 defect
Mitochondrial encephalomyopathy, lactic acidosis, and stroke-like episodes (MELAS)
Glutaric aciduria type I
ASSOCIATED WITH ACIDOSIS/KETOACIDOSIS
Organic acidurias
Mitochondrial diseases
ASSOCIATED WITH KETOSIS ONLY
Ketolysis defects
ASSOCIATED WITH SEVERE ABDOMINAL PAIN
Porphyrias (acute intermittent porphyria, coproporphyria)
ASSOCIATED WITH HEPATOPATHY
Organic acidurias
Urea cycle disorders
Galactosemia
Hereditary fructose intolerance
Tyrosinemia type I
Fatty acid oxidation disorders

From Raucci U, Borrelli O, Di Nardo G, et al. Cyclic vomiting syndrome in children. *Frontiers Neurol.* 2020;11:Article 583425, Table 5.

Table 390.4 Abortive and Rescue Pharmacotherapy

ANTI-MIGRAINE
Sumatriptan 20 mg intranasal at episode onset and may repeat once vs 25 mg PO once vs 3-6 mg SC once
SE: Chest and neck burning, coronary vasospasm, headache
Alternatives: *Rizatriptan, zolmitriptan, frovatriptan (longer half-life)*
ANTIEMETIC
Ondansetron 0.2-0.3 mg/kg per dose (≤12 mg) q4-6h IV/PO/rectal/topical
SE: Headache, drowsiness, dry mouth
Alternatives: *Granisetron*
Aprepitant 3-day regimen:
Weight <15 kg: 80 mg at start of episode on day 1, followed by 40 mg on days 2 and 3
Weight 15-20 kg: 80 mg on days 1, 2, and 3
Weight >20 kg: 125 mg on day 1 and 80 mg on days 2 and 3
Fosaprepitant 3-4 mg/kg (max. 150 mg) IV day one (aprepitant days 2-3)
SEDATIVE
Lorazepam 0.05-0.1 mg/kg per dose q6h IV/PO: useful adjunct to ondansetron
SE: Sedation, respiratory depression
Chlorpromazine 0.5-1 mg/kg per dose q6h IV/PO
SE: Drowsiness, hypotension, seizures, dystonic reaction
Diphenhydramine 1.25 mg/kg per dose q6h IV/PO: useful adjunct to chlorpromazine
SE: Hypotension, sedation, dizziness
ANALGESIC
Ketorolac 0.5-1 mg/kg per dose q6h IV/PO
SE: Gastrointestinal bleeding, dyspepsia

IV, Intravenous; PO, orally; SC, subcutaneously; SE, side effects.
Modified from Kovacic K, Li BUK. Cyclic vomiting syndrome: a narrative review and guide to management. *Headache.* 2021;61:231–243. Table 3.

abdominal surgery may increase risk for adhesion-related partial bowel obstructions.

Non-GI causes of frequent vomiting include renal, metabolic, endocrine, and neurologic disorders. Renal abnormalities to consider include acute or chronic ureteropelvic junction (UPJ) obstruction presenting with hydronephrosis (Dietl's crisis) and nephrolithiasis. The clinician must also consider metabolic disorders, especially in the infant or toddler less than 2 years of age. Fasting or high-protein meals that provoke emesis raise a red flag for metabolic disorders, such as disorders of fatty acid oxidation, organic acidemias, or partial ornithine transcarbamylase deficiency. Acute intermittent porphyria can present in the adolescent triggered by alcohol or medications. Endocrine disorders, including diabetic ketoacidosis, Addison disease, and pheochromocytoma, can mimic CVS episodes. Although an atypical presentation, CNS tumors can have episodic vomiting and papilledema; altered mental status and focal neurologic findings are red flags requiring neuroimaging. Pregnancy can present with CVS-like symptoms.

The management of acute CVS episodes includes early and aggressive hydration (especially with dextrose in normal saline), which may shorten episodes in addition to correcting fluid losses. Reducing extraneous sensory stimulation, similar to the management approach for migraines, may also be beneficial (Table 390.4). Regardless of intervention, episodes will eventually spontaneously resolve with return to a normal baseline. Triptans can be used as an *abortive medication* in patients with the *migraine-related* subgroup of CVS, a family history of migraines, at the onset of symptoms. Ondansetron may reduce nausea and emesis. Sedation may reduce severity or stop a CVS episode; drugs include antihistamines such as diphenhydramine and promethazine. Lorazepam or rectal diazepam can also be used. These measures are empiric; a lack of evidence base limits our understanding of efficacy. For rare but severe refractory cases, general anesthetics have been used. A dramatic change in presentation of attacks suggests a red flag such as acute hydronephrosis or small bowel obstruction from volvulus.

Prophylactic management begins with lifestyle measures (maintenance fluid intake, adequate calories, sleep hygiene, and exercise), including avoidance of known triggering foods (allergens, chocolate, aged cheese, monosodium glutamate; Table 390.5). Recommendations for prophylactic regimens include cyproheptadine in patients <5 years of age and amitriptyline in patients ≥5 years; propranolol serves as a secondary agent in both age-groups. When standard care fails, the addition of anticonvulsants such as topiramate has been implemented. For those with *catamenial CVS*, low-dose estrogen oral contraceptives or medroxyprogesterone acetate may prevent episodes. For those with *Sato variant*, CVS treatment with angiotensin-converting enzyme (ACE)-inhibitors or β blockers for acute hypertension may be helpful. Supplements such as coenzyme Q10, l-carnitine, and riboflavin have been reported to be useful adjuncts for those with underlying mitochondrial dysfunction. Treatment of *comorbid disorders*, especially anxiety (cognitive behavioral therapy, antianxiety agents) and postural orthostatic tachycardia syndrome (fluids, salt, fludrocortisone), may be needed for effective management of CVS. Newer drugs that are being explored in the management of CVS include mirtazapine and aprepitant. Mirtazapine is an antidepressant medication and is a potent antagonist of $5HT_2$ and $5HT_3$ receptors, with anti-migraine properties. It is of potential benefit in *migraine-related* CVS, starting at 7.5 mg at bed time, with a maximum dose of 15 mg; common side effects include drowsiness and increased appetite. Aprepitant is a neurokinin-1 receptor (NK_1R) antagonist used in postoperative and chemotherapy-related nausea and vomiting. In CVS, aprepitant is used for both prophylaxis and abortive purposes. In children, aprepitant has been shown to decrease the number of vomiting episodes per hour/frequency of episodes per year/number of hospitalizations per year and increase the interval period in between the episodes. Common reported side effects of aprepitant include headache, hiccups, neutropenia, and fatigue.

Table 390.5 Prophylactic Lifestyle Changes and Pharmacologic Options for Cyclic Vomiting Syndrome

LIFESTYLE MEASURES		
Reassurance and anticipatory guidance	• Episodes are not intentional • The natural history of CVS is that it will resolve with time	
Avoidance of triggers	• Identify dietary triggers ("vomit diary") and avoid precipitating factors • Triggering foods may include chocolate, cheese, monosodium glutamate • Fasting a common trigger • Excitement a potential trigger • Excessive activity/exhaustion • Avoid sleep deprivation and practice good sleep hygiene	
Managing triggers	• Provide supplemental energy as carbohydrates for fasting-induced episodes • Provision of snacks between meals, before sleep, and before exertion	
Migraine headache–type lifestyle interventions	• Aerobic exercise and avoidance of overexertion • Regular mealtime schedule—avoid skipping meals • Avoid/moderate caffeine intake	
PROPHYLACTIC PHARMACOLOGIC APPROACHES		
	AGE <5 YR	**AGE ≥5 YR**

	Antihistamines:
	• Cyproheptadine
	  • 0.25-0.5 mg/kg/day in two daily divided doses or as a single dose qhs
	  • Side effects of increased appetite, weight gain, and sedation
	• Pizotifen
	β blockers: (second choice)
	• Propranolol
	  • 0.25-1 mg/kg/day, most often 10 mg 2-3×/day.
	  • Side effects include lethargy and reduced exercise tolerance
	  • Contraindicated in asthma, diabetes, heart disease, depression
	  • Taper over 1-2 wk to discontinue
		Tricyclic antidepressants:
		• Amitriptyline
		  • Begin at 0.25-0.5 mg/kg qhs and increase weekly by 5-10 mg until achieve 1-1.5 mg/kg
		  • Monitor ECG for prolonged QTc interval at baseline before initiation and 10 days after peak dose achieved
		  • Side effects: constipation, sedation, arrhythmias, behavioral changes
		Alternatives: nortriptyline
		β blockers: (second choice):
		• Propranolol
		Other agents:
		Anticonvulsants:
		• Phenobarbital 2 mg/kg qhs
		• Side effects: sedation, cognitive impairment
		Alternatives:
		• Topiramate, valproic acid, gabapentin, levetiracetam

DIETARY SUPPLEMENTS	• L-Carnitine 50-100 mg/kg/day divided 2-3×/day, maximum dose of 2 g 2×/day • Coenzyme Q10 mg/kg/day divided 2-3×/day, maximum dose 100 mg 3×/day	

Medications listed in table are for off-label use.
CVS, Cyclic vomiting syndrome; qhs, every night at bedtime.
Modified from Li BU, Lefevre F, Chelimsky GG, et al. North American Society for Pediatric Gastroenterology, Hepatology and Nutrition consensus statement on the diagnosis and management of cyclic vomiting syndrome. *J Pediatr Gastroenterol Nutr*. 2008;47(3):379–393.

Cannabinoid hyperemesis syndrome (CHS) involves the endocannabinoid system (ECS), which plays a major role in nausea and vomiting. Cannabinoid receptors (CBRs) consist of cannabinoid receptor 1 (CB1R) and cannabinoid receptor 2 (CB2R); the current hypothesis is that CBR agonists inhibit vomiting and CB1R antagonists initiate or potentiate vomiting. The current theory is that with chronic cannabis use, there is a paradoxical effect with downregulation of CB1R, which in turn potentiates vomiting in CHS. *CHS shares many features with CVS, including patterns of onset, frequency, and duration.* CHS, however, differs from CVS in that it is associated with prolonged cannabis use (>2 years), and relief of episodes occurs following sustained cessation (>6 months) of cannabis use. Another common feature across CHS is the observed association with pathologic bathing behavior, specifically, prolonged hot showers (see Chapter 157.3).

Visit Elsevier eBooks+ at eBooks.Health.Elsevier.com for Bibliography.

Chapter 391

Acute Appendicitis

José H. Salazar and John J. Aiken

Acute appendicitis remains the most common acute surgical condition in children and a major cause of childhood morbidity and healthcare costs, mostly associated with complicated/perforated appendicitis (PA). The peak incidence of acute appendicitis occurs in children in the second decade, and approximately 100,000 children are treated in children's hospitals for appendicitis each year. The broad spectrum of clinical presentation in acute appendicitis has been associated with significant practice variation in evaluation, diagnostic measures, and treatment of abdominal pain and suspected appendicitis. The traditional strategy of the liberal use of computed tomography (CT) to avoid misdiagnosis and early surgery to avoid progression to perforation has lacked validation in large reviews and resulted in high negative appendectomy rates and excessive radiation exposure. Perforation rates have remained ~40% and negative appendectomy rates as high as 10% in the past 2 decades. In current practice, most centers have adopted clinical practice guidelines (CPGs) combining history, physical examination findings, laboratory data, and appendicitis risk scoring systems to standardize care, improve diagnostic accuracy and outcomes, and direct cost-conscious resource use. Appendiceal ultrasound has emerged as a highly sensitive and specific imaging modality for diagnosis and led to a significant decrease in the use of CT and radiation exposure in the initial evaluation of children presenting with abdominal pain and possible suspected appendicitis. Although prompt appendectomy remains the standard treatment in acute appendicitis, advances in imaging techniques, improved antibiotic regimens, increased use of percutaneous drainage procedures by interventional radiologists, and emerging data on high success rates with initial antibiotic treatment alone have led to an increase in the initial nonoperative management of both simple and complicated (abscess, phlegmon) appendicitis. Laparoscopic appendectomy (LA, a minimally invasive technique) has emerged as the preferred surgical approach for both simple and PA, with an open surgical approach reserved as an alternative for selected cases or when attempted LA is technically difficult and/or deemed unsafe.

EPIDEMIOLOGY

The incidence of acute appendicitis increases with age, from a rate of 1-2 per 10,000 children from birth to 4 years of age, to a rate of 19-28 per 10,000 children younger than age 14 years annually. Children have a lifetime risk of 7–9%, and appendicitis is diagnosed in 1–8% of children presenting to the emergency department (ED) for evaluation of abdominal pain. Appendicitis is most common in older children, with peak incidence between the ages of 10 and 18 years; it is rare in children younger than 5 years of age (<5% of cases) and extremely rare (<1% of cases) in children younger than 3 years of age.

Infants with appendicitis are often misdiagnosed with sepsis, and because of the diagnostic delay, they present in advanced stages of the disease. Most infant cases are primary, but some may be associated with Hirschsprung disease, cystic fibrosis, inguinal hernia, prematurity, meconium plug syndrome, or complex multiorgan syndromes.

Mortality is low (<0.01%), but morbidity remains high, mostly in association with PA. Up to 40% of children have PA at presentation, and perforation rates approach 90% in young children (<3 years). Children with simple (nonperforated) appendicitis typically recover easily, with a low complication rate and rapid return to premorbid state and full activities. In contrast, PA is associated with substantial postoperative morbidity, including readmission rates estimated at 12.8%, postoperative intraabdominal abscess rates ~20%, surgical site infection (SSI) rate ~20%, prolonged length of stay (LOS), need for prolonged antibiotic exposure, increased postoperative use of CT, and significant delay in return to wellness and normal activities.

PATHOPHYSIOLOGY

The clinical entity of acute appendiceal inflammation followed by perforation, abscess formation, and peritonitis is most likely a disease of multiple etiologies, the final common pathway of which involves invasion of the appendiceal wall by bacteria. Genetic, environmental, and infectious etiologies (bacterial, viral, fungal, and parasitic) have all been implicated in acute appendicitis. One pathway to acute appendicitis begins with luminal obstruction; inspissated fecal material, lymphoid hyperplasia, ingested foreign body, parasites, and tumors have been described. Obstruction of the appendiceal lumen initiates a progressive cascade involving increasing intraluminal pressure, lymphatic and venous congestion and edema, impaired arterial perfusion, ischemia of the appendiceal wall, bacterial proliferation and invasion of the wall, and necrosis. This sequence correlates with the clinical disease progression from simple appendicitis to gangrenous appendicitis and, thereafter, appendiceal perforation.

Because the appendix has the highest concentration of gut-associated lymphoid tissue (GALT) in the intestine, some have hypothesized that the appendix may have an immune function similar to that of the thymus or bursa of Fabricius. Submucosal lymphoid follicles, which can obstruct the appendiceal lumen, are few at birth but multiply steadily during childhood, reaching a peak in number during the teen years, when acute appendicitis is most common.

Enteric infection likely plays a role in many cases of acute appendicitis in association with mucosal ulceration and invasion of the appendiceal wall by bacteria. Bacteria such as *Yersinia, Salmonella,* and *Shigella* spp. and viruses such as infectious mononucleosis, mumps, coxsackievirus B, and adenovirus are implicated. In addition, case reports demonstrate the occurrence of appendicitis from ingested foreign bodies, in association with carcinoid tumors of the appendix, *Ascaris* infestation, and rarely, after blunt abdominal trauma. Children with cystic fibrosis have an increased incidence of appendicitis; the cause is believed to be the abnormal thickened mucus. Appendicitis in neonates is rare and warrants diagnostic evaluation for cystic fibrosis and Hirschsprung disease.

Appendectomy decreases the risk of ulcerative colitis and increases the risk of recurrent *Clostridium difficile–associated colitis.* Appendicoliths and appendicitis are more common in developed countries with refined, low-fiber diets than in developing countries with a high-fiber diet; no causal relationship has been established between lack of dietary fiber and appendicitis. A family history is associated with a nearly threefold increased appendicitis risk, and genetic factors may account for 30% of appendicitis risk.

Clinical Features

Appendicitis in children has an immensely broad spectrum of clinical presentation; <50% of cases have the classic presentation. The signs and symptoms in acute appendicitis can vary depending on the timing of presentation, patient age, the abdominal/pelvic location of the appendix, and most importantly, individual variability in the evolution of the disease process. Children early in the disease process can appear well and demonstrate mild symptoms, minimal findings on physical examination, and normal laboratory studies, whereas those with perforation and advanced peritonitis can demonstrate severe illness with bowel obstruction, renal failure, and septic shock. Most patients with appendicitis demonstrate an insidious onset of illness characterized by generalized nonspecific malaise or anorexia in the first 12 hours, and a steady, escalating progression in severity of signs and symptoms over 2-3 days with increasing abdominal pain, vomiting, fever, and tachycardia; perforation is common beyond 48 hours of illness. Thus the opportunity for diagnosis before perforation in acute appendicitis in children is most often brief (48-72 hours), and a high percentage of patients are perforated at presentation.

Abdominal pain is consistently the *primary* symptom in acute appendicitis; beginning shortly (hours) after the onset of illness. There are no somatic pain fibers within the appendix; therefore early appendiceal inflammation results in pain that is vague, poorly localized, unrelated to activity or position, often colicky, and periumbilical in location as a result of visceral inflammation from a distended appendix. Progression

of the inflammatory process in the next 24 hours leads to involvement of the adjacent parietal peritoneal surfaces, resulting in somatic pain localized to the right lower quadrant (RLQ)—*thus the classic description of periumbilical mid-abdominal pain migrating to the RLQ. The position of the appendix is a critical factor affecting interpretation of presenting signs and symptoms and accurate diagnosis.* When the appendix is in a retrocecal or pelvic position, a slower progression of illness is typical and clinical presentation is likely to be delayed. Localized pain in the RLQ leads to spasm in the overlying abdominal wall muscles, and now the pain is predictably exacerbated by movement. The child often describes marked discomfort with the bumpy car ride to the hospital, moves cautiously, and has difficulty getting onto the examining room stretcher. Nausea and vomiting occur in more than half of the patients and typically *follow* the onset of abdominal pain by several hours. Anorexia is a classic and consistent finding in acute appendicitis, but occasionally affected patients are hungry. Diarrhea and urinary symptoms are also common, particularly in cases of PA when there is likely inflammation near the rectum and possible abscess in the pelvis. Painful voiding may not be from dysuria, but pressure transmitted to an inflamed peritoneum. As it progresses, appendicitis is often associated with adynamic ileus, leading to the complaint of constipation and possible misdiagnosis.

Because enteric infections can cause appendicitis, diarrhea may be a manifestation and gastroenteritis may be the assumed diagnosis. In contrast to gastroenteritis, the abdominal pain in early appendicitis is *constant* (not cramping or relieved by defecation), the emesis may become bile stained and persistent, and the clinical course worsens steadily rather than demonstrating a waxing and waning pattern often seen in viral gastroenteritis. Fever is common in appendicitis and typically low-grade unless perforation has occurred. Most patients demonstrate at least mild tachycardia, likely secondary to pain and dehydration. The temporal progression of symptoms from vague, mild pain, malaise, and anorexia to severe localized pain, fever, and vomiting typically occurs rapidly (24-48 hours) in the majority of cases. If the diagnosis is delayed beyond 48 hours, perforation is likely (>65%). When several days have elapsed in the progression of appendicitis, patients typically develop signs and symptoms evidencing advanced disease, including worsening and diffuse pain, abdominal distention, and bilious emesis suggestive of developing small bowel obstruction. The retrocecal appendix can demonstrate symptoms suggestive of septic arthritis of the hip or a psoas muscle abscess.

A primary focus in the management of appendicitis is the avoidance of sepsis and the infectious complications leading to increased morbidity, mostly seen with PA.

Bacteria can be cultured from the serosal surface of the appendix before microscopic or gross perforation and bacterial invasion of the mesenteric veins (pylephlebitis) can result (rarely) in thrombosis and possible liver abscess or portal hypertension. A period after perforation of lessened abdominal pain and acute symptoms has been described, presumably with the elimination of pressure within the appendix. If, after perforation, the omentum or adjacent intestine is able to wall off the fecal contamination, the evolution of illness is less predictable and delay in presentation is likely. If perforation leads to diffuse peritonitis, the child generally has escalating diffuse abdominal pain and rapid development of toxicity evidenced by dehydration and signs of sepsis, including hypotension, oliguria, acidosis, and high-grade fever. Young children have a poorly developed omentum and are often unable to control the spread of infection. Perforation and abscess formation with appendicitis can lead to intestinal fistula formation, scrotal cellulitis and abscess through a patent processus vaginalis (indirect inguinal hernia), or small bowel obstruction. The most likely diagnosis in children who present with signs and symptoms of mechanical small bowel obstruction who have not had prior abdominal surgery is complicated appendicitis.

Physical Examination

Although the hallmark of diagnosing acute appendicitis remains a careful and thorough history and physical examination, all clinicians know the arcane nature of acute appendicitis, the consistent or typical clinical features are not present in all patients, and the diagnosis can be a humbling experience even for the most experienced clinicians. A primary focus of the initial assessment is attention to the *temporal evolution* of the illness in relation to specific presenting signs and symptoms. In some patients, the diagnosis can be made on history and physical examination alone; in current practice the selective use of advanced imaging has improved diagnostic accuracy and resulted in significant progress in the lowering of negative appendectomy rates.

Physical examination begins with inspection of the child's demeanor and the appearance of the abdomen. Because appendicitis most often has an insidious onset, children rarely present <12 hours from the onset of illness. Children with early appendicitis (18-36 hours) typically appear mildly ill and move tentatively, hunched forward, and often with a slight limp favoring the right side. Supine, they often lie quietly on their right side with their knees pulled up to relax the abdominal muscles, and when asked to lie flat or sit up, they move cautiously and might use a hand to protect the RLQ. Early in appendicitis, the abdomen is typically flat; abdominal distention suggests more advanced disease characteristic of perforation or developing small bowel obstruction. Auscultation can reveal normal or hyperactive bowel sounds in early appendicitis, which are replaced by hypoactive bowel sounds as the disease progresses to perforation. *The judicious use of morphine analgesia to relieve abdominal pain does not change diagnostic accuracy or interfere with surgical decision-making, and patients should receive adequate pain control.* Localized abdominal tenderness is the single most reliable finding in the diagnosis of acute appendicitis. McBurney described the classic point of localized tenderness in acute appendicitis, which is the junction of the lateral and middle thirds of the line joining the right anterior-superior iliac spine and the umbilicus, but the tenderness can also localize to any of the aberrant locations of the appendix. Localized tenderness is a later and less consistent finding when the appendix is retrocecal in position (>50% of cases). In cases of an appendix localized entirely in the pelvis, tenderness on abdominal examination may be minimal. A gentle touch on the child's arm at the beginning of the examination with the reassurance that the abdominal examination will be similarly gentle can help to establish trust and increase the chance for a reliable and reproducible examination. The examination is best initiated in the left lower abdomen, so that the immediate part of the exam is not uncomfortable, and conducted in a counterclockwise direction, moving gently to the left upper abdomen, right upper abdomen, and, lastly, the right lower abdomen. This should alleviate anxiety, allow relaxation of the abdominal musculature, and enhance trust. The examiner makes several circles of the abdomen with sequentially more pressure. A soft, compressible, nontender abdominal wall is reassuring. In appendicitis, any abdominal wall movement, including coughing (Dunphy sign), may elicit pain. A consistent finding in acute appendicitis is guarding—rigidity of the overlying abdominal wall muscles in the RLQ. This rigidity may be voluntary, to protect the area of tenderness from the examiner's hand, or involuntary, if the inflammation has progressed to peritonitis causing spasm of the overlying muscle.

Abdominal tenderness may be vague or even absent early in the course of appendicitis and is often diffuse after rupture. Rebound tenderness and referred tenderness (Rovsing sign) are also consistent findings in acute appendicitis but are not always present. Rebound tenderness is elicited by deep palpation of the abdomen followed by the sudden release of the examining hand. This is often very painful to the child and has demonstrated poor correlation with peritonitis, so it should be avoided. Gentle finger percussion is a better test for peritoneal irritation. Similarly, digital rectal examination is uncomfortable and unlikely to contribute to the evaluation of appendicitis in most cases in children. Psoas and obturator internus signs are pain with passive stretch of these muscles. The psoas sign is elicited with active right thigh flexion or passive extension of the hip and is typically positive in cases of a retrocecal appendix. The obturator sign is demonstrated by adductor pain after internal rotation of the flexed thigh and typically positive in cases of a pelvic appendix. Physical examination may demonstrate a mass in the RLQ representing an inflammatory

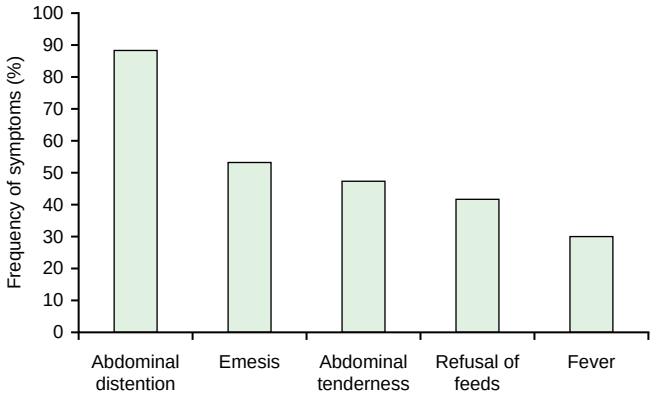

Fig. 391.1 Frequency of presenting symptoms in neonatal appendicitis. *(Data from Raveenthiran V. Neonatal appendicitis (Part 1): a review of 52 cases with abdominal manifestation. J Neonatal Surg. 2015;4:4.)*

Table 391.1 Pediatric Appendicitis Scores

FEATURE	SCORE
Fever >38°C (100.4°F)	1
Anorexia	1
Nausea/vomiting	1
Cough/percussion/hopping tenderness	2
Right lower quadrant tenderness	2
Migration of pain	1
Leukocytosis >10,000 (10^9/L)	1
Polymorphonuclear neutrophilia >7,500 (10^9/L)	1
Total	10

From Acheson J, Banerjee J. Management of suspected appendicitis in children. *Arch Dis Child Educ Pract Ed.* 2010;95:9–13.

mass (phlegmon) around the appendix or a localized intraabdominal abscess (fluid collection).

Appendicitis in infants and toddlers does not follow the characteristic features observed in older children. Perforation is observed in most infants at presentation. The diagnosis is often delayed, and the initial impression is often sepsis (Fig. 391.1)

APPENDICITIS RISK SCORING SYSTEMS

Several risk scoring systems have become commonly used tools to promote standardization of the approach to the child with abdominal pain and suspected appendicitis. The clear aim is to maximize diagnostic accuracy in acute appendicitis and guide imaging evaluation and resource use. They all combine the predictive value of consistent symptoms, physical examination findings, and laboratory data yielding a numerical score. The systems most widely used are the Alvarado score and the Pediatric Appendicitis Score (PAS). The PAS combines elements of history (migration of pain, anorexia, nausea, vomiting) with physical examination findings (RLQ tenderness, rebound tenderness, fever) and laboratory data (white blood cell [WBC] >10,000, polymorphonuclear neutrophils >75%) to assign a risk score in the low, intermediate, or high-risk range for acute appendicitis (Table 391.1). Scores of ≤4 suggest a very low likelihood of appendicitis, whereas scores ≥8 are highly sensitive and specific for appendicitis. Intermediate scores, between 4 and 7 on the PAS, are considered inconclusive and typically trigger advanced imaging studies. Targeted (appendiceal) ultrasound has demonstrated high sensitivity and specificity (~90%) in the diagnosis of acute appendicitis in centers experienced with the technique and has become the initial imaging study of choice for suspected appendicitis. The notable benefits of ultrasound compared to CT scan include that it is well-tolerated, is noninvasive, and lacks ionizing radiation exposure. CT is reserved for cases of nonvisualization of the appendix on ultrasound or when the ultrasound findings are inconclusive.

The use of appendicitis risk scoring systems in conjunction with clinical judgment has demonstrated high sensitivity and specificity for acute appendicitis (80–90%), and their application has reduced practice variability, improved diagnostic accuracy, decreased preoperative radiation exposure, and enabled efficient resource use—all important elements of current quality improvement and safety initiatives. Their greatest value to date appears to be in predicting patients who have a low likelihood of the diagnosis of appendicitis (negative predictive value) and can avoid imaging studies, and particularly ionizing radiation exposure.

LABORATORY FINDINGS

A variety of laboratory tests have been used in the evaluation of children with suspected appendicitis. Individually, none are very sensitive or specific for appendicitis, but collectively they can affect the clinician's level of suspicion and decision-making to proceed with pediatric surgery consultation, discharge, or imaging studies.

A complete blood count with differential and urinalysis are obtained. The leukocyte count in early appendicitis may be normal and typically is only mildly elevated (11,000-16,000/mm^3) with a left shift as the illness progresses in the initial 24-48 hours. Whereas a normal WBC count never completely eliminates appendicitis, a count <8,000/mm^3 in a patient with a history of illness longer than 48 hours should be viewed as highly suspicious for an alternative diagnosis. The leukocyte count may be markedly elevated (>20,000/mm^3) in PA and rarely in nonperforated cases; a markedly elevated WBC count, other than in cases of advanced PA, should raise suspicion of an alternative diagnosis. Urinalysis often demonstrates a few white or red blood cells as a result of the proximity of the inflamed appendix to the ureter or bladder, but it should be free of bacteria. The urine is often concentrated and contains ketones from diminished oral intake and vomiting. Gross hematuria is uncommon, and in association with purpuric skin lesions and arthritis may indicate IgA vasculitis (Henoch-Schönlein purpura).

Electrolytes and liver chemistries are generally normal unless there has been a delay in diagnosis, leading to severe dehydration and/or sepsis. Amylase and liver enzymes are only helpful to exclude alternative diagnoses such as pancreatitis and cholecystitis and are not commonly obtained if appendicitis is the strongly suspected diagnosis. C-reactive protein (CRP) increases in proportion to the degree of appendiceal inflammation. It has not demonstrated high sensitivity or specificity in the diagnosis of appendicitis; some studies have demonstrated an association between disease severity (PA and abscess formation) and elevated CRP levels. In this context, CRP may have a role in identifying patients with complicated appendicitis, which may be managed initially nonoperatively with antibiotics and drainage of fluid collections.

IMAGING STUDIES

After a thorough initial evaluation, including history, physical examination, review of vital signs, and laboratory studies, if the diagnosis is uncertain, radiographic studies can substantially improve diagnostic accuracy.

Plain Radiographs

In the majority of cases, appendiceal ultrasound and CT scan have become the predominant studies in inconclusive cases of acute appendicitis. Plain abdominal radiographs may be helpful in rare select cases of abdominal pain/suspected appendicitis. Plain abdominal x-rays may demonstrate several findings suggestive of acute appendicitis, including sentinel loops of bowel and localized ileus, scoliosis from psoas muscle spasm, a colonic air-fluid level above the right iliac fossa (colon cutoff sign), a RLQ soft tissue mass, or a calcified appendicolith (5–10% of cases); they are normal in 50% of patients, have a low sensitivity, and are not generally recommended (Fig. 391.2). Plain films are most

helpful in evaluating complicated cases in which small bowel obstruction or free air is suspected.

Ultrasound

Ultrasound has emerged as the first-choice tool for children requiring an imaging study in the evaluation of suspected acute appendicitis. Ultrasound has demonstrated sensitivity and specificity approaching 90% in pediatric centers experienced with the technique and has substantial advantages, including low cost, ready availability, rapidity, and avoidance of sedation, contrast agents, and radiation exposure. Ultrasound can be particularly helpful in adolescent females, a group with a high negative appendectomy rate (normal appendix found at surgery), because of its ability to evaluate for ovarian pathology without ionizing radiation. Graded abdominal compression is used to displace the cecum and ascending colon and identify the appendix, which has a typical target appearance (Fig. 391.3). The ultrasound criteria for appendicitis include wall thickness >6 mm, luminal distention, lack of compressibility, a complex mass in the RLQ, or an appendicolith. The visualized appendix usually coincides with the site of localized pain and tenderness. In addition, ultrasound may identify PA on *initial evaluation;* initial management of PA has increasingly moved toward percutaneous drainage procedures, broad-spectrum antibiotics, and nonoperative treatment. An enlarged appendix (>6 mm), hyperemia, noncompressibility of the appendiceal wall, localized tenderness, and associated mesenteric fat stranding or fluid are all consistent with acute appendicitis. Findings that suggest advanced appendicitis on ultrasound include asymmetric wall thickening, abscess formation, associated free intraabdominal/pelvic fluid, surrounding tissue edema, and decreased local tenderness to compression. *The main limitation of ultrasound is an inability to visualize the appendix, which is reported in 25–60% of cases.* It has been postulated that a normal appendix must be visualized to exclude the diagnosis of appendicitis by ultrasound; however, one report concluded that in patients with a nonvisualized appendix on ultrasound imaging, no evidence of secondary inflammatory changes, and an absolute neutrophil count <8,000/mm^3, the likelihood of appendicitis was <3%. Certain conditions predictably decrease the sensitivity and reliability of ultrasound for appendicitis, including obesity, bowel distention, and uncontrolled pain.

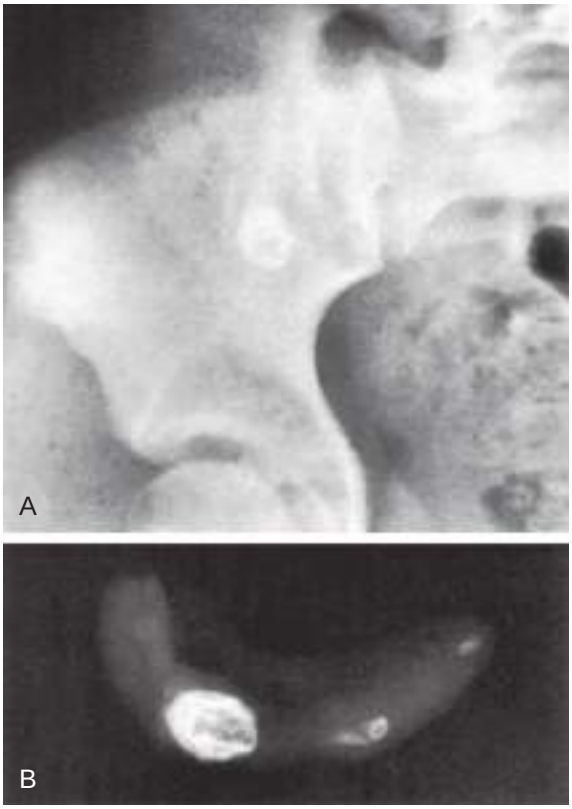

Fig. 391.2 Calcified appendicoliths are seen in a coned-down anteroposterior view of the right lower quadrant (**A**) and in the resected appendix of a 10-yr-old female with acute appendicitis (**B**). *(From Kuhn JP, Sloviso TL, Haller JO. Caffrey's Pediatric Diagnostic Imaging, 10th ed. Philadelphia: Mosby; 2004:1682.)*

Computed Tomography

CT scan has been the gold-standard imaging study for evaluating children with suspected appendicitis and has a sensitivity of 97%, specificity 99%, positive predictive value 98%, and negative predictive value 98% (Figs. 391.4 and 391.5). The advantages of CT imaging include ready availability, rapid acquisition time, and lack of operator dependency. CT carries the significant negative effects of exposure of children to ionizing radiation and increased costs. The exam can be performed using intravenous and enteral (oral or rectal) contrast; however, the administration of enteral contrast has several drawbacks, including delay in diagnostic evaluation, increasing abdominal distention, risk of emesis and aspiration, and increasing radiation exposure without demonstrable improvement in accuracy of diagnosis. The use of oral contrast should be reserved for patients in whom alternative

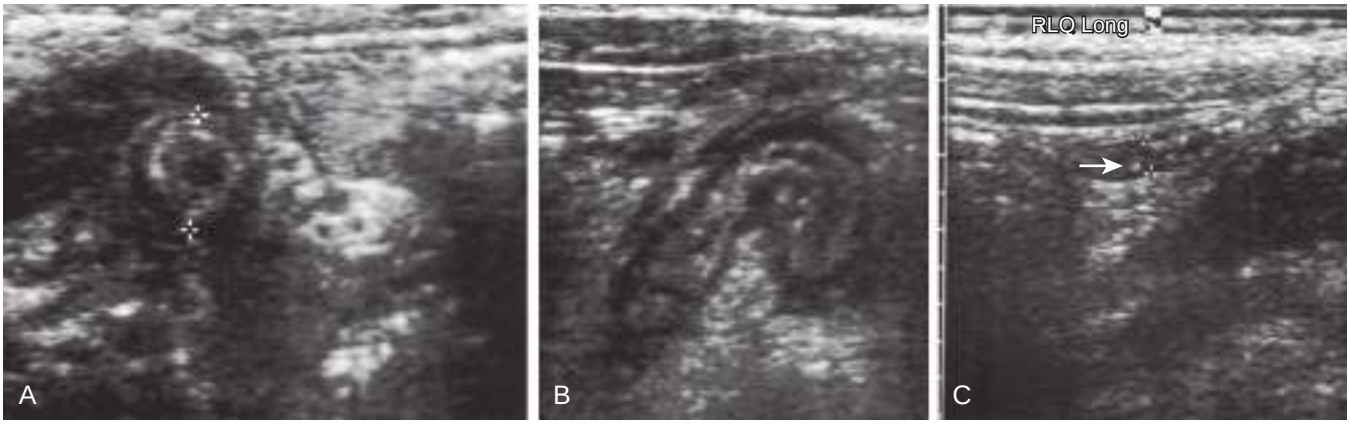

Fig. 391.3 Ultrasound examination of patients with appendicitis. **A,** Transverse ultrasound scan of the appendix demonstrates the characteristic "target sign." In this case, the innermost portion is sonolucent, compatible with fluid or pus. **B,** Longitudinal view of another patient demonstrates the alternating hyperechoic and hypoechoic layers with an outermost hypoechoic layer, suggesting periappendiceal fluid. **C,** Longitudinal ultrasound scan of the right lower quadrant demonstrates a dilated, noncompressible appendix. The bright echo within the appendix represents an appendicolith with acoustic shadowing *(arrow). (From Kuhn JP, Slovis TL, Haller JO. Caffrey's Pediatric Diagnostic Imaging, 10th ed. Philadelphia: Mosby; 2004:1684.)*

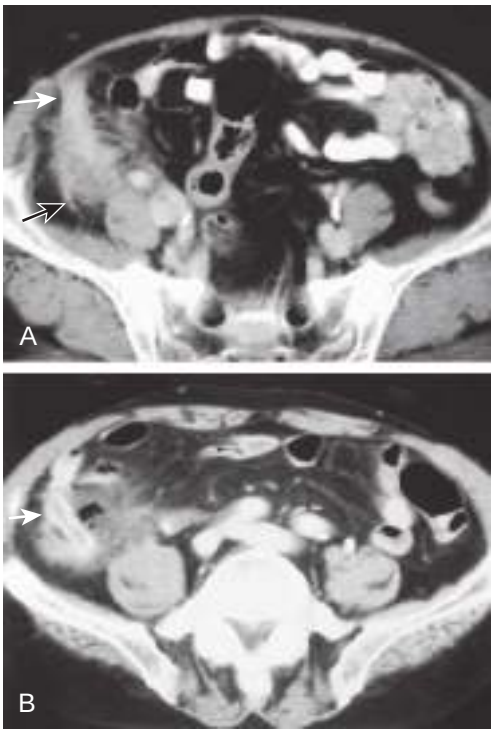

Fig. 391.4 **A,** Phlegmon *(black arrow)* is noted around the enlarged appendix *(white arrow)* in perforated appendicitis. **B,** Extraluminal air is shown adjacent to the wall-enhanced appendix *(arrow)* in perforated appendicitis. *(From Yeung KW, Chang MS, Hsiao CP. Evaluation of perforated and non-perforated appendicitis with CT. Clin Imaging. 2004;28:422–427, Figs. 1 and 3)*

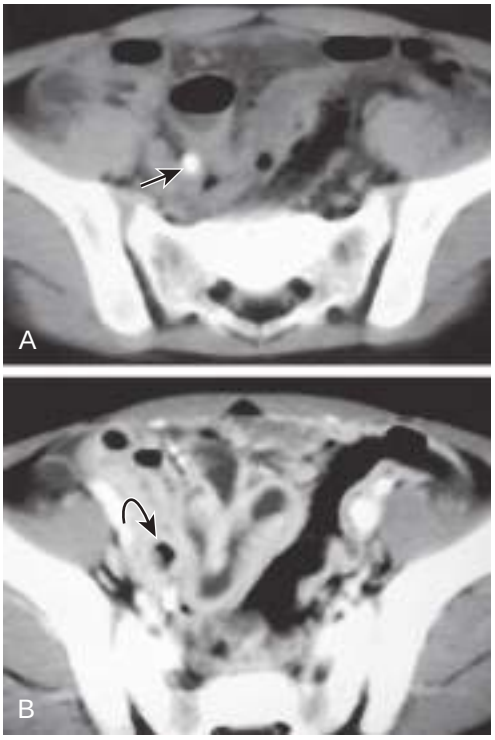

Fig. 391.5 **A,** Precontrast-enhanced CT reveals an appendicolith *(arrow)* in perforated appendicitis. **B,** Postcontrast-enhanced CT (1 cm below the level in **A**) reveals intraluminal air in the appendix *(curved arrow)* associated with ileal wall enhancement in perforated appendicitis. *(From Yeung KW, Chang MS, Hsiao CP. Evaluation of perforated and non-perforated appendicitis with CT. Clin Imaging. 2004;28:422–427, Fig. 5.)*

diagnoses are suspected, particularly Crohn disease. Because the finding of fat stranding in surrounding tissues is a key component of CT evaluation for appendicitis, CT is less reliable in thin children with minimal body fat.

The avoidance of enteral contrast, targeted CT imaging, and the use of pediatric-specific protocols can significantly lower radiation dosages without sacrificing diagnostic accuracy. The use of appendicitis risk scoring systems in conjunction with CPGs and increasing experience with appendiceal ultrasound have led to a decreased use of CT scans (<6.6% in most reports), without negatively affecting time to appendectomy or negative appendectomy rates.

Magnetic Resonance Imaging

MRI is at least equivalent to CT in diagnostic accuracy for appendicitis and does not involve ionizing radiation; however, its use in the evaluation of appendicitis is limited because it is less available, is associated with higher costs, and does not offer equivalent access for drainage of fluid collections. MRI may prove most useful in adolescent females when ultrasound imaging is equivocal. The use of MRI is becoming more common in institutions with high resources, and it has become a good alternative to CT in cases with equivocal ultrasound.

DIAGNOSIS AND TREATMENT

Acute appendicitis is believed to be a time-sensitive condition; thus any delay in diagnosis or treatment may lead to an increased risk of perforation and its attendant morbidity. The misdiagnosis of appendicitis is second only to meningitis as a cause of medical malpractice suits in pediatric emergency care. A careful history and physical examination remain primary in the initial assessment of a child presenting with abdominal symptoms. The classic history in acute appendicitis, although possibly not most common, is a 24-hour history of diffuse mid-abdominal pain that migrates and becomes localized to the RLQ. Patients should have a WBC count with differential analysis, as this is a component of most appendicitis risk scoring systems. A urinalysis is also typically obtained and a pregnancy test in appropriately selected patients. CPGs have become common practice in many centers for evaluation of patients with abdominal pain and suspected appendicitis to reduce practice variability and improve diagnostic accuracy and resource use. CPGs have been shown to have high positive and negative predictive values (~95%) and to decrease both LOS and costs without increasing morbidity or complications. These guidelines combine initial history, physical examination, and laboratory data with predictive risk scoring systems to cohort patients into low, intermediate, and high risk for the diagnosis of acute appendicitis. In general, low-risk patients can be discharged without imaging studies, high-risk patients would have pediatric surgical consultation, and the inconclusive or intermediate-risk group would most predictably benefit from a period of observation or proceeding with advanced imaging studies. If the initial assessment leads to a high level of suspicion for appendicitis, pediatric surgical consultation should be the next step, with the likelihood of an appendectomy without further studies. In patients with a low concern for appendicitis, the child may be discharged with family education regarding the natural history and progression of acute appendicitis and advice to return for repeat evaluation if the child is not improving on liquids and a bland diet in the next 24 hours. The group of patients with an intermediate-risk score would proceed with targeted ultrasound of the appendix if the center has experience with the technique. If the ultrasound study is unable to visualize the appendix, or the appendix is visualized but the findings are inconclusive, the next options would include admission for a period of observation and planned reassessment, CT imaging or MRI, or diagnostic laparoscopy.

The use of observation units, where the child may be observed with intravenous fluids, serial vital signs, and planned reexaminations, is another strategy. At the end of a period of observation, typically 12-24 hours, the clinician decides on discharge based on reassuring clinical status, proceeds to diagnostic laparoscopy and appendectomy, or proceeds with advanced imaging evaluation. The period of observation can occur at home provided the patient is physiologically well; a hospital-based observational unit has the advantage of being able to

provide intravenous fluids. An observation strategy seems most useful in patients who present with a brief history of illness (<12 hours) when advanced imaging studies predictably have lower sensitivity and specificity. If observed patients remain equivocal, advanced imaging should be more reliable further into the disease process.

DIFFERENTIAL DIAGNOSIS

The list of illnesses that can mimic acute appendicitis is extensive because many gastrointestinal, gynecologic, and inflammatory disorders can manifest with similar illness history, signs, and symptoms. Differential diagnosis, even limited to common conditions, includes gastroenteritis, mesenteric adenitis, Meckel diverticulitis, intussusception, inflammatory bowel disease, diabetes mellitus, sickle cell disease, streptococcal pharyngitis, lower lobe pneumonia, cholecystitis, pancreatitis, urinary tract infection (UTI), infectious enteritis, and, in females, ovarian torsion, ectopic pregnancy, ruptured/hemorrhagic ovarian cysts, and pelvic inflammatory disease (including tubo-ovarian abscess). *Epiploic appendagitis,* an inflammation of the fat-filled structures on the antimesenteric surface of the colon, may present with acute lower quadrant abdominal pain after torsion, thrombosis, and ischemic injury to the structure. Viral infections, bacterial infections, and parasitic infections can all closely mimic acute appendicitis. Intestinal tract lymphoma, tumors of the appendix (carcinoid in children), and ovarian tumors are rare but can also masquerade as acute appendicitis. Henoch-Schönlein purpura can initially present as severe abdominal pain. Urinary tract causes of abdominal pain include UTI, nephrolithiasis, and pyelonephritis. In patients with pyelonephritis, the fever and WBC count are likely much higher, symptoms of dysuria will be present, and the tenderness is located more in the flank or costovertebral angle. Rarely, appendicitis may recur in the stump of a previous appendectomy. *Children younger than 3 years of age and adolescent females have historically proven to be at particularly high risk for an incorrect diagnosis.*

Viral illnesses are common in children, often are associated with abdominal pain and vomiting, and thus mimic acute appendicitis. The classic patient with acute appendicitis describes abdominal pain as the preeminent symptom, and in general, symptoms of systemic illness such as headache, chills, and myalgias are infrequent in appendicitis and common when viral illness is the correct diagnosis.

Infection with SARS-CoV-2 (COVID-19) or associated with the development of multisystem inflammatory syndrome in children (MIS-C) has produced a pseudo-appendicitis picture with RLQ pain, mesenteric adenopathy, fat stranding, and phlegmon formation. Additional features of COVID-19 are usually, but not always, present (Fig. 391.6).

The diagnosis of appendicitis in adolescent females is especially challenging, and some series report negative appendectomy rates as high as 30–40%. Ovarian cysts are often acutely painful as a result of rupture, rapid enlargement, or hemorrhage. Rupture of an ovarian follicle associated with ovulation often causes midcycle lateralizing pain (mittelschmerz), but there is no progression of symptoms and systemic illness is absent. Ovarian tumors and torsion can also mimic acute appendicitis, although ovarian torsion is typically characterized by the acute onset of severe pain and is associated with more frequent and forceful nausea and vomiting than is typically seen in early appendicitis. In pelvic inflammatory disease, the pain is typically suprapubic, bilateral, and of longer duration. The need for accurate urgent diagnosis in females is influenced by concern that PA can predispose the patient to future ectopic pregnancy or tubal infertility, although data have not consistently demonstrated increased incidence of infertility after PA. For these reasons, adjunct diagnostic studies (ultrasound, CT, MRI, or diagnostic laparoscopy) should be used more liberally in females to keep negative appendectomy rates low.

Torsion of an undescended testis and epididymitis are common but should be discovered on physical exam. Meckel diverticulitis is an infrequent condition, but the clinical presentation closely mimics appendicitis. The diagnosis is rarely made before surgery. Primary spontaneous peritonitis (PSP) is classically seen in prepubertal females or patients with either nephrotic syndrome or cirrhosis and is frequently mistaken for appendicitis.

Atypical presentations of appendicitis are expected in association with other conditions such as pregnancy, Crohn disease, steroid treatment, and immunosuppressive therapy. Appendicitis in association with Crohn disease often has a protracted presentation with an atypical pattern of recurring but localized abdominal pain. It should be recognized that *missed* appendicitis is the most common cause of small bowel obstruction in children without a history of prior abdominal surgery.

ANTIBIOTICS

Antibiotics should be initiated promptly once the diagnosis of appendicitis is made or highly suspected. Antibiotics substantially lower the incidence of postoperative wound infections (SSIs) and intraabdominal abscesses—the source of the majority of the substantial morbidity and costs in PA. Many believe the time from onset of illness to the initiation of antibiotics has more impact on postoperative complication rates, LOS, and overall costs than time from diagnosis to surgery.

The antibiotic regimen should be directed against the typical bacterial flora found in the appendix, including anaerobic organisms (*Bacteroides, Clostridia,* and *Peptostreptococcus* spp.) and gram-negative aerobic bacteria (*Escherichia coli, Pseudomonas aeruginosa, Enterobacter,* and *Klebsiella* spp.). Many antibiotic combinations have demonstrated equivalent efficacy in controlled trials in terms of wound

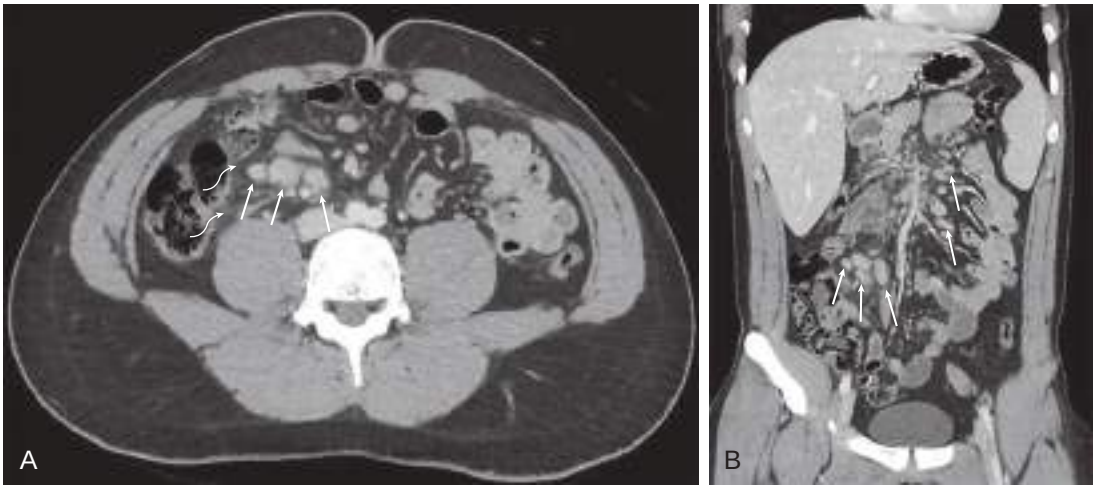

Fig. 391.6 Initial CT scan of a patient with COVID-19 presenting as mesenteric adenopathy. Axial image (**A**) and coronal reformat (**B**) of abdominopelvic CT with intravenous contrast agent in a 17-yr-old male demonstrate enlarged lymph nodes *(straight arrows)* and adjacent fat stranding *(curved arrows). (From Noda S, Ma J, Romberg EK, et al. Severe COVID-19 initially presenting as mesenteric adenopathy. Pediatr Radiol. 2021;51:140–143, Fig. 1.)*

infection rate, resolution of fever, LOS, and incidence of complications. Historically, a triple-antibiotic regimen consisting of ampicillin, gentamicin, and clindamycin was standard. Exhaustive studies of different antibiotic regimens have been performed, mostly aimed at lowering costs and frequency of dosing while maintaining efficacy. Both piperacillin/tazobactam and cefoxitin have demonstrated equivalent effectiveness and may decrease LOS and pharmaceutical costs compared to the triple-antibiotic regimen.

For simple (nonperforated) appendicitis, one preoperative dose of a single broad-spectrum agent (piperacillin/tazobactam) or equivalent is sufficient. In PA, the antibiotic is continued intravenously for 2-3 days postoperatively until the child is afebrile (≥24 hours), tolerating a general diet, and ready for discharge. Some centers prefer to add metronidazole in PA to augment coverage of anaerobes. The decision to discharge patients with PA managed with up-front appendectomy on a course of oral antibiotics (typically 3-5 days) remains controversial. The literature does not support improved outcomes with PA if antibiotics are extended beyond a 4- to 5-day course.

SURGICAL INTERVENTION

Once the diagnosis of appendicitis is confirmed or highly suspected, the standard treatment for acute appendicitis, both simple and complicated, in current practice is most often prompt appendectomy. LA (a minimally invasive technique) is the preferred surgical approach (65–70%) in both simple and PA, with open appendectomy markedly declining in the past decade. The laparoscopic approach has demonstrated slight improvement in clinical outcome measures (wound infection rate, intraabdominal abscess, analgesic requirements, wound cosmesis, and return to full activity); however, costs can be higher. The laparoscopic approach (diagnostic laparoscopy/LA) has particular advantages for obese patients, when alternative diagnoses are suspected, and in adolescent females to evaluate for ovarian pathology and alternative diagnoses while avoiding the ionizing radiation associated with CT imaging. The operation should proceed semi-electively within 12-24 hours of diagnosis. Children with appendicitis are typically at least mildly dehydrated and should receive supportive care before surgery, including fluid resuscitation to correct hypovolemia and electrolyte abnormalities, antipyretics to lower fever, and broad-spectrum antibiotics. These important fundamentals of care ensure safe anesthesia and optimize outcomes. In most cases, preoperative management can be accomplished during the period of diagnostic evaluation and prompt appendectomy can be performed. Pain management begins even before a definitive diagnosis is made, and consultation of a pain service, if available, is appropriate. Emergency surgery (middle of the night) *is rarely* indicated in acute appendicitis and should only be performed in the rare circumstance when physiologic resuscitation requires urgent control of advanced intraabdominal sepsis not amenable to percutaneous drainage by interventional radiology or when this is not available. No correlation has been demonstrated between timing of surgery and perforation rates or postoperative morbidity when the operation proceeds within 24 hours of diagnosis. When comparing emergent appendectomy (within 5 hours of admission) with urgent appendectomy (within 17 hours of admission), no differences in PA, operative time, readmission rate, postoperative complications, LOS, or hospital charges have been noted. In addition, occasionally unexpected pathology (appendiceal tumors, intestinal lymphoma, congenital renal anomalies, Crohn disease) is discovered at operation, and intraoperative consultation with other specialists and/or frozen section evaluation may be required. The laparoscopic approach, in conjunction with standardized, expedited postoperative recovery protocols, and improved (single drug) and shorter-duration antibiotic regimens have led to decreased LOS in both simple and complicated (perforated) appendicitis. The average LOS in most centers is approximately 24 hours for simple appendicitis and 4-5 days for perforated cases that recover without postoperative complications. In simple appendicitis, some centers have initiated same-day discharge.

PERFORATED APPENDICITIS

A major area of focus and challenge in the management of acute appendicitis is the group of patients with delayed presentation (>48 hours) of symptoms. Because acute appendicitis often has an insidious onset of generalized malaise, as many as 40–50% of patients have delayed presentation. This cohort of patients has a high incidence of PA at presentation (40–59%) and a 56% greater LOS stay than those presenting within ≤24 hours of the onset of symptoms. The risk for development of postoperative complications (SSI, intraabdominal abscess, small bowel obstruction) approaches 20–30% for children with PA versus an approximately 3% risk of complications in patients with simple appendicitis.

Management options for children presenting with PA include up-front appendectomy after a brief period of stabilization with intravenous fluids and antibiotics, antibiotics alone, and antibiotics in conjunction with percutaneous drainage of intraabdominal fluid collections/abscesses. The past decade has witnessed a substantial trend toward nonoperative management in children with delayed presentation and suspected PA to avoid the high complication rate in these patients and the potential technical challenges of operative treatment in the setting of marked intraabdominal inflammation/peritonitis. Based on patient status, findings on imaging studies, and availability of experienced interventional radiologists, initial nonoperative management of PA with percutaneous drainage of fluid collections, intravenous fluids, and broad-spectrum antibiotics has demonstrated success in >80% of patients. Antibiotics are initiated and typically continued intravenously for 1-2 days along with pain control. If the child demonstrates clinical recovery by resolution of fever and pain and can tolerate a general diet, the child is converted to oral antibiotics and discharged to complete an outpatient antibiotic course (typically 7-10 days of ciprofloxacin/metronidazole or amoxicillin/clavulanate). A patient who fails to demonstrate clinical recovery proceeds to prompt appendectomy. This nonoperative management, and particularly the transition to oral antibiotics, has contributed to a decreased LOS and costs in the management of PA. Patients who do not have up-front appendectomy will require a decision regarding interval appendectomy (IA) in 4-6 weeks, provided the child does not fail nonoperative management after discharge by recurrence of pain, fever, or vomiting.

NONOPERATIVE MANAGEMENT OF UNCOMPLICATED APPENDICITIS

Multiple studies in adults have demonstrated highly effective treatment of appendicitis with antibiotics alone. In addition, other conditions similar to appendicitis, such as diverticulitis, intraabdominal abscess in Crohn disease, and tubo-ovarian abscess, are primarily treated with antibiotics alone, with surgery reserved for failures of medical management. These outcomes have led many centers to evaluate initial nonoperative management of acute (simple) appendicitis in children, and currently several randomized controlled studies are ongoing. Advantages of the antibiotic-alone/nonoperative approach in acute appendicitis include avoidance of surgical complications and the risk of general anesthesia and an operative procedure that may not be necessary. Selection criteria for nonoperative management are designed to exclude signs and symptoms suggestive of PA and typically include duration of symptoms <48 hours, age >7 years, imaging confirmation of acute non-PA, appendiceal diameter <1.2 cm, *absence* of appendicolith, abscess, or phlegmon, and WBC >5,000 and <18,000 cells/μL. The clinical pathway for children enrolled consists of an initial 1-2 days of intravenous broad-spectrum antibiotics and pain control. If the child demonstrates clinical recovery by resolution of pain and fever and is tolerating a general diet, he or she is discharged to complete 7-10 days of oral antibiotics. If the child does not demonstrate clinical recovery, prompt appendectomy is performed. Early nonoperative trials found that predictors of failure of nonoperative management included pain >48 hours in duration, presence of an appendicolith, inflammatory mass or abscess on imaging, and elevated laboratory values (WBC >18,000, CRP >4 mg/dL). The largest prospective trial (nonrandomized, treatment assigned by parent selection) comparing surgery and medical management of appendicitis in the United States followed patients for 1 year. Out of the children who were initially treated medically, 37% underwent an appendectomy within 1 year. Multiple reports indicate a more rapid return to full activities; however, patients with nonoperative management had more subsequent ED visits, advanced

imaging studies, and hospitalizations compared with those managed operatively at the first visit. Controversies remain in the initial nonoperative management of PA.

RECURRENT APPENDICITIS

Prospective studies of the incidence of early recurrent appendicitis (within 1 year) describe a range between 10% and 30% in patients initially managed nonoperatively. The lifetime risk of recurrent appendicitis in children treated nonoperatively is unknown, but the few data that have been published beyond the 1-year follow-up suggest that the risk for recurrent appendicitis continues to increase past the first year. Currently under review is the need for delayed appendectomy (IA) in patients with complicated appendicitis initially managed nonoperatively. Although the trend in cases of PA at presentation is toward initial nonoperative management, the data remain uncertain, and there are no convincing data to recommend one approach in all patients.

INTERVAL APPENDECTOMY

In patients with PA initially treated nonoperatively, the decision to proceed with IA, typically in 4-6 weeks, is another area of management lacking consensus. Traditionally, most surgeons recommended IA to avoid recurrent appendicitis and to confirm the original diagnosis, citing reports that demonstrated an incidence of unexpected pathology in 30% of IA specimens. This has been questioned, with nonoperative management of simple appendicitis gaining acceptance and many debating the risk of recurrent appendicitis (5–20%), believing it to be lower. The lifetime risk of recurrent appendicitis is unknown. Decision-making for IA must be individualized to balance the risks of recurrent appendicitis with the risks of anesthesia and comorbid conditions such as obesity, congenital heart disease, chronic respiratory conditions, and others.

INCIDENTAL APPENDICOLITHS

The question of the incidental appendicolith is an intriguing one for pediatric practitioners. These are patients who do not have appendicitis but are found to have an appendicolith on imaging studies. An appendicolith is defined as a calcification within the appendiceal lumen. In adults, incidental appendicoliths identified by CT scans vary in incidence from <1% to as high as 10%. They have a characteristic dense and laminated appearance when compared to other lower abdominal calcifications, including phleboliths (venous calcifications) and, in females, ovarian calcifications, most commonly seen in ovarian tumors. They can be appreciated on plain film, ultrasound, and CT scan. When an appendicolith is noted in the evaluation of a child with abdominal pain and suspected appendicitis, the finding of the appendicolith confirms the diagnosis; surgical consultation and prompt appendectomy are indicated. Appendicoliths may be noted in the evaluation of patients who have no signs of appendicitis, such as imaging obtained after trauma or for nonspecific abdominal complaints in patients with a low likelihood of appendicitis. The concern in this setting is that the appendicolith may increase the eventual development of acute appendicitis. In addition, there is the concern that should appendicitis develop in association with an appendicolith, there may be a rapidly escalating course and early perforation. Some physicians believe that a persistent appendicolith may be associated with recurrent RLQ/iliac fossa pain.

Incidental appendicoliths may be transient and in most short-term follow-up studies have a low risk of subsequent acute appendicitis. In addition, the lifetime risk for the development of appendicitis in patients with an incidental appendicolith is approximately 5%, which is not different from the normal population. The risk of subsequent appendicitis may be higher in those presenting with abdominal pain or those younger than 19 years of age. Radiographically detected incidental appendicoliths are usually managed with observation, planned follow-up, and patient education for signs of acute appendicitis. After discussing the risks and benefits with the family and persistence of the appendicolith, an individualized approach is best between the physician and the family relative to elective appendectomy.

Visit Elsevier eBooks+ at eBooks.Health.Elsevier.com for Bibliography.

Chapter 392

Surgical Conditions of the Anus and Rectum

392.1 Anorectal Malformations

Christina M. Shanti

To fully understand the spectrum of anorectal anomalies, it is necessary to consider the importance of the sphincter complex, a mass of muscle fibers surrounding the anorectum (Fig. 392.1). This complex is the combination of the puborectalis, levator ani, external and internal sphincters, and the superficial external sphincter muscles, all meeting at the rectum. Anorectal malformations are defined by the relationship of the rectum to this complex and include varying degrees of stenosis to complete atresia. The incidence is 1/3,000 live births. Significant long-term concerns focus on bowel control and urinary and sexual functions.

EMBRYOLOGY

The hindgut forms early as the part of the primitive gut tube that extends into the tail fold in the second week of gestation. At about day 13, it develops a ventral diverticulum, the allantois, or primitive bladder. The junction of the allantois and hindgut becomes the cloaca, into which the genital, urinary, and intestinal tubes empty. This is covered by a cloacal membrane. The urorectal septum descends to divide this common channel by forming lateral ridges, which grow in and fuse by the middle of the seventh week. Opening of the posterior portion of the membrane (the anal membrane) occurs in the eighth week. Failures in any part of these processes can lead to the clinical spectrum of anogenital anomalies.

Imperforate anus can be divided into low lesions, where the rectum has descended through the sphincter complex, and high lesions, where it has not. Most patients with imperforate anus have a fistula. There is a spectrum of malformation in males and females. In males, low lesions usually manifest with meconium staining somewhere on the perineum along the median raphe (Figs. 392.2A and 392.3). Low lesions in females also manifest as a spectrum from an anus that is only slightly anterior on the perineal body to a fourchette fistula that opens on the moist mucosa of the introitus distal to the hymen (Fig. 392.4A). A high imperforate anus in a male has no apparent cutaneous opening or fistula, but it usually has a fistula to the urinary tract, either the urethra or the bladder (Fig. 392.2B). Although there is occasionally a rectovaginal fistula, in females, high lesions are usually cloacal anomalies in which the rectum, vagina, and urethra all empty into a common channel or cloacal stem of varying length (see Fig. 392.4B).

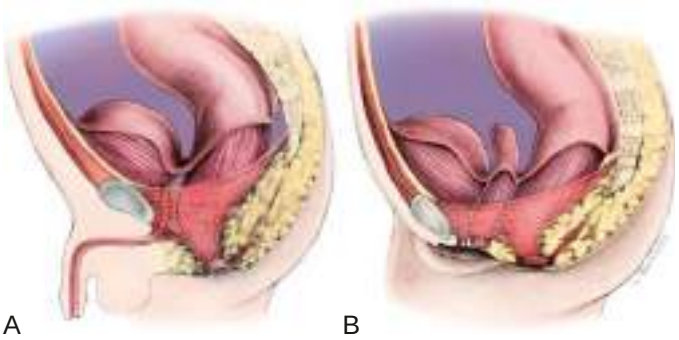

Fig. 392.1 Normal anorectal anatomy in relation to pelvic structures. **A,** Male. **B,** Female. *(From Peña A. Atlas of Surgical Management of Anorectal Malformations. New York: Springer-Verlag; 1989: 3.)*

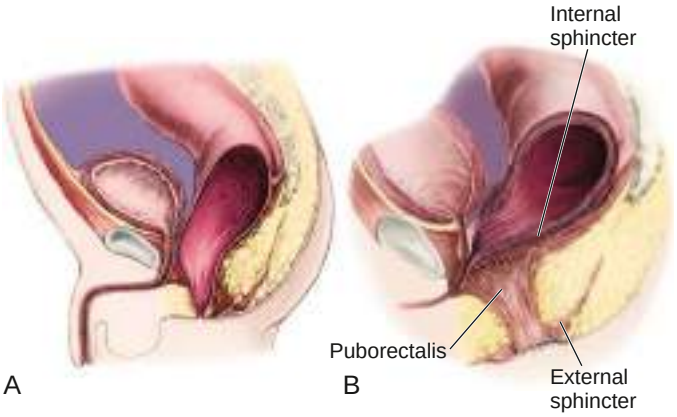

Fig. 392.2 Imperforate anus in males. **A,** Low lesions. **B,** High lesions. *(From Peña A. Atlas of Surgical Management of Anorectal Malformations. New York: Springer-Verlag; 1989:7, 26.)*

Fig. 392.3 This male infant has a rectoperineal fistula with a subepithelial tract filled with either mucus or meconium that extends into the scrotal raphe. *(From Rentea RM, Levitt MA. Anorectal atresia and cloacal malformations. In Holcomb III GW, Murphy JP, St. Peter SD, eds. Holcomb and Ashcraft's Pediatric Surgery, 7th ed. Philadelphia: Elsevier; 2020: Fig. 35.2, p. 578.)*

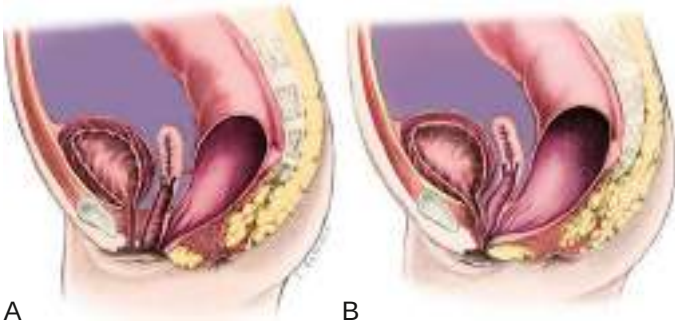

Fig. 392.4 Imperforate anus in females. **A,** Vestibular fistula. **B,** Cloaca. *(From Peña A. Atlas of Surgical Management of Anorectal Malformations. New York: Springer-Verlag; 1989: 50, 60.)*

The interesting category of males with imperforate anus and no fistula occurs mainly in children with trisomy 21. The most common lesions are the rectourethral bulbar fistula in males and the rectovestibular fistula in females; the second most common lesion in both sexes is the perianal fistula (Fig. 392.5).

ASSOCIATED ANOMALIES

Many anomalies are associated with anorectal malformations (Table 392.1). The most common are anomalies of the kidneys and urinary tract in conjunction with abnormalities of the sacrum. This complex is often referred to as *caudal regression syndrome*. Males with a rectovesical fistula and patients with a persistent cloaca have a 90% risk of urologic defects. Other common associated anomalies are cardiac anomalies and esophageal atresia with or without tracheoesophageal fistula. These can cluster in any combination in a patient. When combined, they are often accompanied by abnormalities of the radial aspect of the upper extremity and are termed the *VACTERL* (*v*ertebral, *a*nal, *c*ardiac, *t*racheal, *e*sophageal, *r*enal, *l*imb) *anomalad*.

Anorectal malformations, particularly anal stenosis and rectal atresia, can also present as the Currarino triad, which includes sacral agenesis, a presacral mass, and anorectal stenosis. These patients present with a funnel-appearing anus, have sacral bony defects on plain x-ray, and have a presacral mass (teratoma, meningocele, dermoid cyst, enteric cyst) on exam or imaging. It is an autosomal dominant disorder caused in most patients by a pathogenic variant in the *MNX1* gene.

A good correlation exists between the degree of sacral development and future function. Patients with an absent sacrum usually have permanent fecal and urinary incontinence. Spinal abnormalities and different degrees of dysraphism are often associated with these defects. Tethered cord occurs in approximately 25% of patients with anorectal malformations. Untethering of the cord can lead to improved urinary and rectal continence in some patients, although it seldom reverses established neurologic defects. The diagnosis of spinal defects can be screened for in the first 3 months of life by spinal ultrasound, although MRI is the imaging method of choice if a lesion is suspected. In older patients, MRI is needed.

MANIFESTATIONS AND DIAGNOSIS

Low Lesions

Examination of a newborn includes the inspection of the perineum. The absence of an anal orifice in the correct position leads to further evaluation. Mild forms of imperforate anus are often called *anal stenosis* or *anterior ectopic anus*. These are typically cases of an imperforate anus with a perineal fistula. The normal position of the anus on the perineum is approximately halfway (0.5 ratio) between the coccyx and the scrotum or introitus. Although symptoms, primarily constipation, have been attributed to anterior ectopic anus (ratio: <0.34 in females, <0.46 in males), many patients have no symptoms.

If no anus or fistula is visible, there may be a low lesion or *covered anus*. In these cases, there are well-formed buttocks and often a thickened raphe or *bucket handle*. After 24 hours, meconium bulging may be seen, creating a blue or black appearance. In these cases, an immediate perineal procedure can often be performed, followed by a dilation program.

In a male, the perineal (cutaneous) fistula can track anteriorly along the median raphe across the scrotum and even down the penile shaft (see Fig. 392.3). This is usually a thin track, with a normal rectum often just a few millimeters from the skin. Extraintestinal anomalies are seen in <10% of these patients.

In a female, a low lesion enters the vestibule or fourchette (the moist mucosa outside the hymen but within the introitus). In this case, the rectum has descended through the sphincter complex. Children with a low lesion can usually be treated initially with perineal manipulation and dilation. Visualizing these low fistulas is so important in the evaluation and treatment that one should avoid passing a nasogastric tube for the first 24 hours to allow the abdomen and bowel to distend, pushing meconium down into the distal rectum.

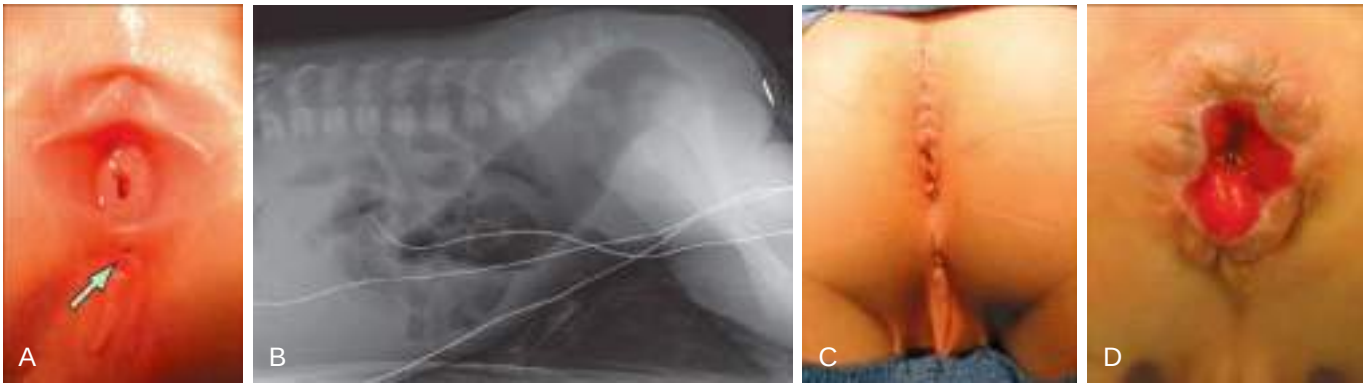

Fig. 392.5 Preoperative and postoperative images of anorectal malformations. **A,** Preoperative rectoperineal fistula. **B,** Radiograph with cross-table lateral film showing neonate in prone position and gas below the coccyx. **C,** Postoperative appearance after a posterior sagittal anorectoplasty. **D,** Postoperative large, patulous, and prolapsed anoplasty. *(From Bischoff A, Bealer J, Pená A. Controversies in anorectal malformations. Lancet Child/Adolesc. 2017;1:323–330.)*

Table 392.1 Associated Malformations
GENITOURINARY Vesicoureteric reflux Renal agenesis Renal dysplasia Ureteral duplication Cryptorchidism Hypospadias Bicornuate uterus Vaginal septa
VERTEBRAL Spinal dysraphism Tethered chord Presacral masses Meningocele Lipoma Dermoid Teratoma
CARDIOVASCULAR Tetralogy of Fallot Ventricular septal defect Transposition of the great vessels Hypoplastic left-heart syndrome
GASTROINTESTINAL Tracheoesophageal fistula Duodenal atresia Malrotation Hirschsprung disease
CENTRAL NERVOUS SYSTEM Spina bifida Tethered cord

High Lesions

In a male with a high imperforate anus, the perineum appears flat. There may be air or meconium passed via the urethra when the fistula is high, entering the bulbar or prostatic urethra, or even the bladder. In *rectobulbar urethral fistulas* (the most common in males), the sphincter mechanism is satisfactory, the sacrum may be underdeveloped, and an anal dimple is present. In *rectoprostatic urethral fistulas,* the sacrum is poorly developed, the scrotum may be bifid, and the anal dimple is near the scrotum. In *rectovesicular fistulas,* the sphincter mechanism is poorly developed, and the sacrum is hypoplastic or absent. In males with trisomy 21, all the features of a high lesion may be present, but there is no fistula, the sacrum and sphincter mechanisms are usually well developed, and the prognosis is good.

In females with high imperforate anus, there may be the appearance of a rectovaginal fistula. A true rectovaginal fistula is rare. Most are either the fourchette fistulas described earlier or are forms of a cloacal anomaly.

Persistent Cloaca

In persistent cloaca, the embryologic stage persists in which the rectum, urethra, and vagina communicate in a common orifice, the cloaca. It is important to realize this anomaly, because the repair often requires repositioning the urethra and vagina as well as the rectum. Children of both sexes with a high lesion require a colostomy before repair.

Rectal Atresia

Rectal atresia is a rare defect occurring in only 1% of anorectal anomalies. It has the same characteristics in both sexes. The unique feature of this defect is that affected patients have a normal anal canal and a normal anus. The defect is often discovered while rectal temperature is being taken. An obstruction is present approximately 2 cm above the skin level. These patients need a protective colostomy. The functional prognosis is excellent because they have a normal sphincteric mechanism (and normal sensation), which resides in the anal canal.

APPROACH TO THE PATIENT

Evaluation includes identifying associated anomalies (see Table 392.1). Careful inspection of the perineum is important to determine the presence or absence of a fistula. If the fistula can be seen, it is a low lesion. The invertogram, or upside-down x-ray, is of little value, but a prone cross-table lateral plain x-ray at 24 hours of life (to allow time for bowel distention from swallowed air) with a radiopaque marker on the perineum can demonstrate a low lesion by showing the rectal gas bubble <1 cm from the perineal skin (see Fig. 392.5). A plain x-ray of the entire sacrum, including both iliac wings, is important to identify sacral anomalies and the adequacy of the sacrum. An abdominal-pelvic ultrasound and voiding cystourethrogram must be performed. The clinician should also pass a nasogastric tube to identify esophageal atresia and should obtain an echocardiogram. In males with a high lesion, the voiding cystourethrogram often identifies the rectourinary fistula. In females with a high lesion, more invasive evaluation, including vaginogram and endoscopy, is often necessary for careful detailing of the cloacal anomaly.

Good clinical evaluation and a urinalysis provide enough data in 80–90% of male patients to determine the need for a colostomy. Voluntary sphincteric muscles surround the most distal part of the bowel in cases of perineal and rectourethral fistulas, and the intraluminal bowel pressure must be sufficiently high to overcome the tone of those muscles before meconium can be seen in the urine or on the perineum. The presence of meconium in the urine and a flat bottom are considered indications for the creation of a colostomy. Clinical findings consistent with the diagnosis of a perineal fistula represent an indication

for an anoplasty without a protective colostomy. Ultrasound is valuable not only for the evaluation of the urinary tract, but it can also be used to investigate spinal anomalies in the newborn and to determine how close to the perineum the rectum has descended.

More than 90% of the time, the diagnosis in females can be established on perineal inspection. The presence of a single perineal orifice is a cloaca. A palpable pelvic mass (hydrocolpos) reinforces this diagnosis. A vestibular fistula is diagnosed by careful separation of the labia, exposing the vestibule. The rectal orifice is located immediately in front of the hymen within the female genitalia and in the vestibule. A perineal fistula is easy to diagnose. The rectal orifice is located somewhere between the female genitalia and the center of the sphincter and is surrounded by skin. Less than 10% of these patients fail to pass meconium through the genitalia or perineum after 24 hours of observation. Those patients can require a prone cross-table lateral film.

OPERATIVE REPAIR

Sometimes a perineal fistula, if it opens in a good position, can be treated by simple dilation. Hegar dilators are employed, starting with a No. 5 or 6 and letting the baby go home when the mother can use a No. 8. Twice-daily dilatations are done at home, increasing the size every few weeks until a No. 14 is achieved. By 1 year of age, the stool is usually well formed and further dilation is not necessary. By the time No. 14 is reached, the examiner can usually insert a little finger. If the anal ring is soft and pliable, dilation can be reduced in frequency or discontinued.

Occasionally, there is no visible fistula, but the rectum can be seen to be filled with meconium bulging on the perineum, or a covered anus is otherwise suspected. If confirmed by plain x-ray or ultrasound of the perineum that the rectum is <1 cm from the skin, the clinician can do a minor perineal procedure to perforate the skin and then proceed with dilation or do a simple perineal anoplasty.

When the fistula orifice is close to the introitus or scrotum, it is often appropriate to move it back surgically. This also requires postoperative dilation to prevent stricture formation. This procedure can be done any time from the newborn period to 1 year. It is preferable to wait until dilatations have been done for several weeks and the child is bigger. The anorectum is a little easier to dissect at this time. The posterior sagittal approach of Peña is used, making an incision around the fistula and then in the midline to the site of the posterior wall of the new location. The dissection is continued in the midline, using a muscle stimulator to be sure there is adequate muscle on both sides. The fistula must be dissected cephalad for several centimeters to allow posterior positioning without tension. If appropriate, some of the distal fistula is resected before the anastomosis to the perineal skin.

In children with a high lesion, a double-barrel colostomy is performed. This effectively separates the fecal stream from the urinary tract. It also allows the performance of an augmented pressure colostogram before repair to identify the exact position of the distal rectum and the fistula. The definitive repair or posterior sagittal anorectoplasty (PSARP) is performed at about 1 year of age. A midline incision is made, often splitting the coccyx and even the sacrum. Using a muscle stimulator, the surgeon stays strictly in the midline and divides the sphincter complex and identifies the rectum. The rectum is then opened in the midline, and the fistula is identified from within the rectum. This allows a division of the fistula without injury to the urinary tract. The rectum is then dissected proximally until enough length is gained to suture it to an appropriate perineal position. The muscles of the sphincter complex are then sutured around (and especially behind) the rectum.

Other operative approaches (such as an anterior approach) are used, but the most popular procedure is by laparoscopy. This operation allows division of the fistula under direct visualization and identification of the sphincter complex by transillumination of perineum. Other imaging techniques in the management of anorectal malformations include 3D endorectal ultrasound, intraoperative MRI, and colonoscopy-assisted PSARPs, which may help perform a technically better operation. None of these other procedures or innovations has demonstrated improved outcomes.

A similar procedure can be done for female high anomalies with variations to deal with separating the vagina and rectum from within the cloacal stem. When the stem is longer than 3 cm, this is an especially difficult and complex procedure.

Usually the colostomy can be closed 6 weeks or more after the PSARP. Two weeks after any anal procedure, twice-daily dilatations are performed by the family. By doing frequent dilatations, each one is not so painful and there is less tissue trauma, inflammation, and scarring.

OUTCOME

The ability to achieve rectal continence depends on both motor and sensory elements. There must be adequate muscle in the sphincter complex and proper positioning of the rectum within the complex. There must also be intact innervation of the complex and of sensory elements, as well as the presence of these sensory elements in the anorectum. Patients with low lesions are more likely to achieve true continence. They are also, however, more prone to constipation, which leads to overflow incontinence. It is very important that all these patients are followed closely and that the constipation and anal dilation are well managed until toilet training is successful. Tables 392.2 and 392.3 outline the results of continence and constipation in relation to the malformation encountered.

Children with high lesions, especially males with rectoprostatic urethral fistulas and females with cloacal anomalies, have a poorer chance of being continent, but they can usually achieve a socially acceptable defecation (without a colostomy) pattern with a bowel management

Table 392.2 Types of Anorectal Malformation by Sex

MALE (PERCENTAGE CHANCE OF BOWEL CONTROL*)
Rectoperineal fistula (100%)
Rectourethral bulbar fistula (85%)
Imperforate anus without fistula (90%)
Rectourethral prostatic fistula (65%)
Rectobladder neck fistula (15%)
FEMALE (PERCENTAGE CHANCE OF BOWEL CONTROL*)
Rectoperineal fistula (100%)
Rectovestibular fistula (95%)
Imperforate anus without fistula (90%)
Rectovaginal fistula (rare anomaly)†
Cloaca (70%)‡

*Provided patients have a normal sacrum, no tethered cord, and they receive a technically correct operation without complications.
†Rectovaginal anomalies are extremely unusual; usually their prognosis is like rectovestibular fistula.
‡Cloaca represents a spectrum; those with a common channel length <3 cm have the best functional prognosis.
From Bischoff A, Bealer J, Peña A. Controversies in anorectal malformations. *Lancet Child/Adolesc.* 2017;1:323–330.

Table 392.3 Constipation and Type of Anogenital Malformation

TYPE	PERCENTAGE
Vestibular fistula	61
Bulbar urethral fistula	64
Rectal atresia/stenosis	50
Imperforate with no fistula	55
Perineal fistula	57
Long cloaca	35
Prostatic fistula	45
Short cloaca	40
Bladder neck fistula	16

Modified from Levitt MA, Peña A. Outcomes from the correction of anorectal malformations. *Curr Opin Pediatr.* 2005;17:394–401.

program. Often, the bowel management program consists of a daily enema to keep the colon empty and the patient clean until the next enema. If this is successful, an *antegrade continence enema* (ACE) procedure, sometimes called the *Malone* or *Malone antegrade continence enema* (MACE) procedure, can improve the patient's quality of life. These procedures provide access to the right colon either by bringing the appendix out the umbilicus in a nonrefluxing fashion or by putting a plastic button in the right lower quadrant to access the cecum. The patient can then sit on the toilet and administer the enema through the ACE, thus flushing out the entire colon. Antegrade regimens can produce successful 24-hour cleanliness rates of up to 95%. Of special interest is the clinical finding that most patients improve their control with growth. Patients who wore diapers or pull-ups to primary school are often in regular underwear by high school. Some groups have taken advantage of this evidence of psychologic influences to initiate behavior modification early with good results.

Visit Elsevier eBooks+ at eBooks.Health.Elsevier.com for Bibliography.

392.2 Anal Fissure

Christina M. Shanti

Anal fissure is a laceration of the anal mucocutaneous junction. It is an acquired lesion of unknown etiology. Although likely secondary to the forceful passage of a hard stool, it is mainly seen in infants younger than 1 year of age when the stool is frequently quite soft. Fissures may be the consequence and not the cause of constipation.

CLINICAL MANIFESTATIONS

A history of constipation is often described, with a recent painful bowel movement corresponding to the fissure formation after passing of hard stool. The patient then voluntarily retains stool to avoid another painful bowel movement, exacerbating the constipation, resulting in harder stools. Complaints of pain on defecation and bright red blood on the surface of the stool are often elicited.

The diagnosis is established by inspection of the perineal area. The infant's hips are held in acute flexion, the buttocks are separated to expand the folds of the perianal skin, and the fissure becomes evident as a minor laceration. Often a small skin appendage is noted peripheral to the lesion. This *skin tag* represents epithelialized granulomatous tissue formed in response to chronic inflammation. Findings on rectal examination can include hard stool in the ampulla and rectal spasm.

TREATMENT

The parents must be counseled as to the origin of the laceration and the mechanism of the cycle of constipation. The goal is to ensure that the patient has soft stools to avoid overstretching the anus. The healing process can take several weeks or even several months. A single episode of impaction with passing of hard stool can exacerbate the problem. Treatment requires that the primary cause of the constipation be identified (see Chapter 378.3). The use of dietary and behavioral modification and a stool softener is indicated. Parents should titrate the dose of the stool softener based on the patient's response to treatment. Stool softening is best done by increasing water intake or using an oral polyethylene glycolate such as MiraLAX or GlycoLax. Surgical intervention, including stretching of the anus, "internal" anal sphincterotomy, or excision of the fissure, is not indicated or supported by scientific evidence.

Chronic anal fissures in older patients are associated with constipation, prior rectal surgery, Crohn disease, and chronic diarrhea. They are managed initially like fissures in infants, with stool softeners with the addition of sitz baths. Topical 0.2% glyceryl trinitrate reduces anal spasm and heals fissures, but it is often associated with headaches. Calcium channel blockers, such as 2% diltiazem ointment and 0.5% nifedipine cream, are more effective and cause fewer headaches than glyceryl trinitrate. Injection of botulinum toxin from 12.5 to 25 units is also effective and probably chemically replicates the action of internal sphincterotomy, which is the most effective treatment in adults, although seldom used in children.

Visit Elsevier eBooks+ at eBooks.Health.Elsevier.com for Bibliography.

392.3 Perianal Abscess and Fistula

Christina M. Shanti

Perianal abscesses usually manifest in *infancy* (~75% ≤1 year) and are of unknown etiology. Fistula appears to be secondary to the abscess rather than the cause. Links to congenitally abnormal crypts of Morgagni have been proposed, suggesting that deeper crypts (3-10 mm rather than the normal 1-2 mm) lead to trapped debris and cryptitis (Fig. 392.6).

Conditions associated with the risk of an anal fistula in *older children* include Crohn disease, tuberculosis, pilonidal disease, hidradenitis, HIV, trauma, foreign bodies, dermal cysts, sacrococcygeal teratoma, actinomycosis, lymphogranuloma venereum, and radiotherapy.

The most common organisms isolated from perianal abscesses are mixed aerobic *(Escherichia coli, Klebsiella pneumoniae, Staphylococcus aureus)* and anaerobic (*Bacteroides* spp., *Clostridium, Veillonella*) flora. A total of 10–15% yield pure growth of *E. coli, S. aureus,* or *Bacteroides fragilis.* There is a strong male predominance in those affected who are younger than 2 years of age, whereas the distribution is more equal in older patients, where the etiology shifts to associated conditions such as inflammatory bowel disease, leukemia, or immunocompromised states.

CLINICAL MANIFESTATIONS

In younger patients, symptoms are usually mild and can consist of low-grade fever, mild rectal pain, and an area of perianal cellulitis (Fig. 392.7). Often these spontaneously drain and resolve without treatment. In older patients with underlying predisposing conditions, the clinical course may be more serious. A compromised immune system can mask fever and allow rapid progression to toxicity and sepsis. Abscesses in these patients may be deeper in the ischiorectal fossa or even supralevator in contrast to those in younger patients, which are usually adjacent to the involved crypt.

Progression to fistula in patients with perianal abscesses occurs in 20–50% of cases and usually manifests with drainage from the perineal skin or multiple recurrences. Similar to abscess formation, fistulas have a strong male predominance. Histologic evaluation of fistula tracts typically reveals an epithelial lining of stratified squamous cells associated with chronic inflammation. It might also reveal an alternative etiology such as the granulomas of Crohn disease or even evidence of tuberculosis.

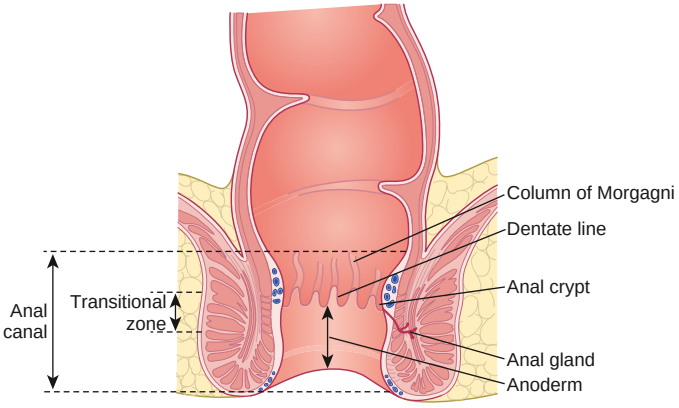

Fig. 392.6 Anatomy of the anal canal. *(Adapted from Brunicardi FC, Anderson DK, Billar TR, et al. Schwartz's Principles of Surgery, 8th ed. New York: McGraw-Hill; 2004.)*

Fig. 392.7 Perianal abscesses are often seen in male infants. The abscess typically presents as a fluctuant, tender mass in the perianal region. Incision and drainage is the initial management of these abscesses if conservative measures have failed. *(From Sullins VF, Jarboe M, Calkins CM. Acquired anorectal disorders. In: Holcomb III GW, Murphy JP, St. Peter SD, eds. Holcomb and Ashcraft's Pediatric Surgery, 7th ed. Philadelphia: Elsevier; 2020: Fig. 37.1, p. 613.)*

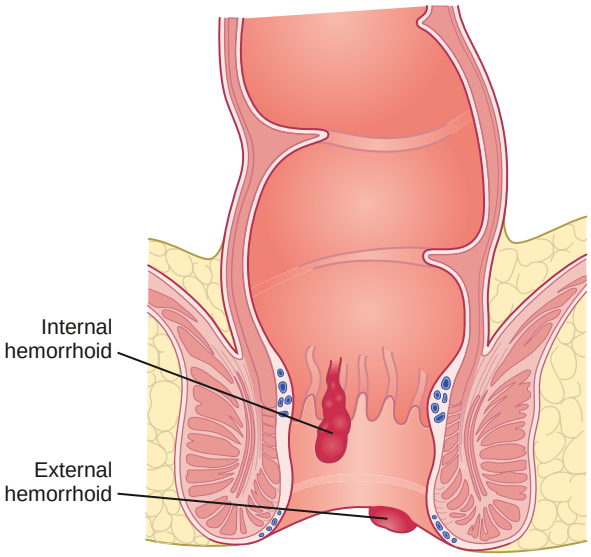

Fig. 392.8 Formation of hemorrhoids.

TREATMENT

Treatment is rarely indicated in infants with no predisposing disease because the condition is often self-limited. Even in cases of fistulization, conservative management (observation) is advocated because the fistula often disappears spontaneously. In one study, 87% of fistulas (in 97/112 infants) closed after a mean of 5 months of observation and conservative management (sitz baths). Antibiotics are not useful in these patients. When dictated by patient discomfort, abscesses may be incised and drained under local anesthesia. Fistulas requiring surgical intervention may be treated by fistulotomy (unroofing or opening), fistulectomy (excision of the tract leaving it open to heal secondarily), or placement of a seton (heavy suture threaded through the fistula, brought out the anus, and tied tightly to itself). In patients with inflammatory bowel disease, topical tacrolimus has been effective.

Older children with predisposing diseases might also do well with minimal intervention. If there is little discomfort and no fever or other sign of systemic illness, local hygiene and antibiotics may be best. The danger of surgical intervention in an immunocompromised patient is the creation of an even larger, nonhealing wound. There certainly are such patients with serious systemic symptoms who require more aggressive intervention along with treatment of the predisposing condition. Broad-spectrum antibiotic coverage must be administered, and wide excision and drainage are mandatory in cases involving sepsis and expanding cellulitis.

Fistulas in older patients are mainly associated with Crohn disease, a history of pull-through surgery for the treatment of Hirschsprung disease, or, in rare cases, tuberculosis. Those fistulas are often resistant to therapy and require treatment of the predisposing condition.

Complications of treatment include recurrence and, rarely, incontinence.

Visit Elsevier eBooks+ at eBooks.Health.Elsevier.com for Bibliography.

392.4 Hemorrhoids

Christina M. Shanti

Hemorrhoidal disease occurs in both children and adolescents, often related to a diet deficient in fiber and poor hydration. In younger children, the presence of hemorrhoids should also raise the suspicion of portal hypertension. A third of patients with hemorrhoids require treatment.

CLINICAL MANIFESTATIONS

Presentation depends on the location of the hemorrhoids. External hemorrhoids occur below the dentate line (Fig. 392.8; see Fig. 392.6) and are associated with extreme pain and itching, often because of acute thrombosis. Internal hemorrhoids are located above the dentate line and manifest primarily with bleeding, prolapse, and occasional incarceration.

TREATMENT

In most cases, conservative management with dietary modification, decreased straining, and avoidance of prolonged time spent sitting on the toilet results in resolution of the condition. Discomfort may be treated with topical analgesics or antiinflammatories such as Anusol (pramoxine) and Anusol-HC (hydrocortisone) and sitz baths. The natural course of thrombosed hemorrhoid involves increasing pain, which peaks at 48-72 hours, with gradual remission as the thrombus organizes and involutes over the next 1-2 weeks. In cases where the patient with external hemorrhoids presents with excruciating pain soon after the onset of symptoms, thrombectomy may be indicated. This is best accomplished with local infiltration of bupivacaine 0.25% with epinephrine 1:200,000, followed by incision of the vein or skin tag and extraction of the clot. This provides immediate relief; recurrence is rare, and further follow-up is unnecessary.

Internal hemorrhoids can become painful when prolapse leads to incarceration and necrosis. Pain usually resolves with reduction of hemorrhoidal tissue. Surgical treatment is reserved for patients failing conservative management. Techniques described in adults include excision, rubber banding, stapling, and excision using the LigaSure device. Complications are rare (<5%) and include recurrence, bleeding, infection, nonhealing wounds, and fistula formation.

Visit Elsevier eBooks+ at eBooks.Health.Elsevier.com for Bibliography.

392.5 Rectal Mucosal Prolapse

Christina M. Shanti

Rectal mucosal prolapse is the exteriorization of the rectal mucosa through the anus. In the unusual occurrence when all the layers of the rectal wall are included, it is called *procidentia* or *rectocele*. Most cases of rectal tissue protruding through the anus are prolapse and not polyps, hemorrhoids, intussusception, or other tissue.

Most cases of prolapse are idiopathic. The onset is often between 1 and 5 years of age. It usually occurs when the child begins standing and then resolves by approximately 3-5 years of age when the sacrum has taken its more adult shape and the anal lumen is oriented posteriorly. Thus the entire weight of the abdominal viscera is not pushing down on the rectum, as it is earlier in development.

Other predisposing factors include intestinal parasites (particularly in endemic areas), malnutrition, diarrhea, ulcerative colitis, pertussis, Ehlers-Danlos syndrome, meningocele (more often associated with procidentia owing to the lack of perineal muscle support), cystic fibrosis, and chronic constipation. Patients treated surgically for imperforate anus can also have varying degrees of rectal mucosal prolapse. This is particularly common in patients with poor sphincteric development. Rectal prolapse is also seen with higher incidence in patients with mental issues and behavior problems. These patients are particularly difficult to manage and are more likely to fail medical treatment.

Fig. 392.9 This 2-year-old child developed persistent rectal prolapse. The prolapse occurred several times daily and was not responsive to medical management. The child underwent submucosal sclerotherapy with 5% morrhuate sodium and the prolapse resolved. *(From Sullins VF, Jarboe M, Calkins CM. Acquired anorectal disorders. In Holcomb III GW, Murphy JP, St. Peter SD, eds. Holcomb and Ashcraft's Pediatric Surgery, 7th ed. Philadelphia: Elsevier; 2020: Fig. 37.8, p. 616.)*

CLINICAL MANIFESTATIONS

Rectal mucosal prolapse usually occurs during defecation, especially during toilet training. Reduction of the prolapse may be spontaneous or accomplished manually by the patient or parent. In severe cases, the prolapsed mucosa becomes congested and edematous, making it more difficult to reduce (Fig. 392.9). Rectal prolapse is usually painless or produces mild discomfort. If the rectum remains prolapsed after defecation, it can be traumatized by friction with undergarments, with resultant bleeding, wetness, and potentially ulceration. The appearance of the prolapse varies from bright red to dark red and resembles a beehive. It can be as long as 10-12 cm. See Chapter 393 for a distinction from a prolapsed polyp.

TREATMENT

Initial evaluation should include tests to rule out any predisposing conditions, especially cystic fibrosis and sacral root lesions. Reduction of protrusion is aided by pressure with warm compresses. An easy method of reduction is to cover the finger with a piece of toilet paper, introduce it into the lumen of the mass, and gently push it into the patient's rectum. The finger is then immediately withdrawn. The toilet paper adheres to the mucous membrane, permitting release of the finger. The paper, when softened, is later expelled.

Conservative treatment consists of careful manual reduction of the prolapse after defecation, attempts to avoid excessive pushing during bowel movements (with the patient's feet off the floor), use of laxatives and stool softeners to prevent constipation, avoidance of inflammatory conditions of the rectum, and treatment of intestinal parasitosis when present. If all this fails, surgical treatment may be indicated. Existing surgical options are associated with some morbidity, and therefore medical treatment should always be attempted first.

Sclerosing injections have been associated with complications such as neurogenic bladder. We have found linear cauterization effective and with few complications other than recurrence. In the operating room, the prolapse is re-created by traction on the mucosa. Linear burns are made through nearly the full thickness of the mucosa using electrocautery. One can usually make eight linear burns on the outside and four on the inside of the prolapsed mucosa. In the immediate postoperative period, prolapse can still occur, but in the next several weeks, the burned areas contract and keep the mucosa within the anal canal. The Delorme mucosal sleeve resection addresses mucosal prolapse via a transanal approach by incising, prolapsing, and amputating the redundant mucosa. The resulting mucosal defect is then approximated with absorbable suture.

For patients with procidentia or full-thickness prolapse or intussusception of the rectosigmoid (usually from myelodysplasia or other sacral root lesions), other, more invasive options exist. Those most commonly in use by pediatric surgeons today include a modification of the Thiersch procedure, which involves placing a subcutaneous suture to narrow the anal opening. Complications include obstruction, fecal impaction, and fistula formation. Laparoscopic rectopexy is effective and can be performed as an outpatient. The Altemeier perineal rectosigmoidectomy is a transanal, full-thickness resection of redundant bowel with a primary anastomosis to the anus.

Visit Elsevier eBooks+ at eBooks.Health.Elsevier.com for Bibliography.

Chapter 393

Tumors of the Digestive Tract

Stacey G. Zahler, Mohammad Nasser Kabbany, and Karen F. Murray

Tumors of the digestive tract in children are also commonly syndromic tumors and tumors with known genetic association (Table 393.1). They usually manifest as painless rectal bleeding, but when large they can cause obstruction or serve as lead points for intussusception. Most intestinal polyps in children can be generally classified into two groups: hamartomatous (as seen in juvenile polyps and Peutz-Jeghers syndrome) or adenomatous (as seen in familial adenomatous polyposis syndrome).

HAMARTOMATOUS TUMORS

Hamartomas are benign tumors composed of tissues that are normally found in an organ but that are not organized normally. Juvenile, retention, or inflammatory polyps are hamartomatous polyps, which represent the most common intestinal tumors of childhood, occurring in 1–2% of children. Patients generally present in the first decade, most often at ages 2-5 years, and rarely at younger than 1 year. Polyps may be found anywhere in the gastrointestinal (GI) tract, most commonly in the rectosigmoid colon, with one third located proximal to splenic flexure; they are often solitary but may be multiple.

Histologically, juvenile polyps are composed of hamartomatous collections of mucus-filled glandular and stromal elements with inflammatory infiltrate, covered with a thin layer of epithelium (Fig. 393.1A). These polyps are often bulky, vascular, and prone to bleed as their growth exceeds their blood supply with resultant mucosal ulceration, or autoamputation with bleeding from a residual central artery.

Patients often present with painless rectal bleeding after defecation. Bleeding is generally scant and intermittent; rarely presenting findings can include iron-deficiency anemia and/or hypoalbuminemia. Extensive bleeding can occur but is generally self-limited, requiring supportive care until the bleeding stops spontaneously after autoamputation. Occasionally endoscopic polypectomy is required for control of bleeding. Abdominal pain or cramps are uncommon unless associated with intussusception. Patients can present with prolapse, with a dark, edematous, pedunculated mass protruding from the rectum. Mucus discharge and pruritus are associated with prolapse.

Patients presenting with rectal bleeding require a thorough workup; differential diagnosis includes anal fissure, other intestinal polyposis syndromes, Meckel's diverticulum, inflammatory bowel disease, intestinal infections, IgA vasculitis (Henoch-Schönlein purpura), angiodysplasia, or coagulopathy.

Diagnosis and therapy are best accomplished via **endoscopy**. Polyps may be visualized via ultrasound or cross-sectional imaging, but this provides no therapeutic advantage. Colonoscopy affords opportunity for biopsy, **polypectomy** by snare cautery, and visualization of synchronous lesions; up to 50% of children have one or more additional polyps, and approximately 20% may have more than five polyps. Retrieved polyps should be sent for histologic evaluation for definitive diagnosis.

Juvenile Polyposis Syndrome

Patients with juvenile polyposis syndrome (JPS) present with multiple juvenile polyps—usually five or more—but typically 50-200 are present within the GI tract. The incidence of JPS is between 1:10,000 and 1:160,000. Polyps are most likely isolated to the colon (98%) but may be distributed throughout the GI tract. There is often a family history (20–50%) with an autosomal dominant pattern of variable penetrance. Alterations in transforming growth factor-β pathways have been identified in some JPS patients and families; pathogenic variants in *SMAD4* or *BMPR1A* are found in 50–60% of patients with JPS. Genetic testing is available for both of these variants. Patients with the *SMAD4* pathogenic variant may have hereditary hemorrhagic telangiectasia and should be evaluated for brain and lung vascular malformations. A clinical diagnosis of JPS is established by the presence of one of the following: a lifetime total of five or more juvenile polyps in the colon, juvenile polyps outside the colon, or any number of juvenile polyps in a patient with a family history of JPS.

Histologically, these polyps are identical to solitary juvenile polyps; however, the risk of malignant transformation is greatly increased (10–50%). Malignancy occurs most commonly in the colorectal region, although gastric, upper GI, and pancreatic tumors have been described. The risk of malignancy is greater in patients with increased polyp burden and a positive family history. These patients should therefore undergo routine esophagogastroduodenoscopy and colonoscopy starting at 12-15 years of age. Age at which surveillance of the upper GI tract should begin varies between guidelines. It is not required during teenage years per current published pediatric guidelines unless symptomatic. Serial polypectomy or polyp biopsy should be undertaken if possible. If dysplasia or malignant degeneration is found, a total colectomy is indicated.

Juvenile polyposis of infancy is characterized by early polyp formation (in patients younger than 2 years of age) and may be associated with protein-losing enteropathy, hypoproteinemia, anemia, failure to thrive, and intussusception. Early **endoscopic or surgical intervention** may be needed.

Peutz-Jeghers Syndrome

Peutz-Jeghers syndrome (PJS) is a rare autosomal dominant disorder (incidence: ~1:120,000 total population) characterized by mucocutaneous pigmentation and extensive GI hamartomatous polyposis. Macular pigmented lesions may be dark brown to dark blue and are found primarily around the lips and oral mucosa, although these lesions may also be found on the hands, feet, or perineum (Fig. 393.2). Lesions can fade by puberty or adulthood, though buccal pigmentation can persist.

Polyps are primarily found in the small intestine (in order of prevalence: jejunum, ileum, duodenum) but may also infiltrate gastric or colonic regions. Histologically, polyps are defined by normal epithelium surrounding bundles of smooth muscle arranged in a branching or frondlike pattern called *arborization* (see Fig 393.1B). They may show "pseudo-invasion," which may be mistaken for malignancy. Symptoms arising from GI polyps in PJS are similar to those of other polyposis syndromes—namely bleeding and abdominal cramping from obstruction or recurrent intussusception. Patients have a 68% risk of intussusception during childhood and may require repeated laparotomies and intestinal resections.

The diagnosis of PJS is made clinically in patients with at least two histologically proven PJS polyps or any number of PJS polyps in patients with a known family history. Diagnosis also can be made in individuals with a family history of PJS with characteristic mucocutaneous hyperpigmentation. Genetic testing can reveal pathogenic variants in *LKB1/STK11* (19p13.3), a serine-threonine kinase that acts as a tumor suppressor gene. Up to 94% of patients with clinical characteristics of PJS have a pathogenic variant at this locus. Only 50% of patients with PJS have an affected family member, suggesting a high rate of de novo mutations

Patients with PJS have increased risk of GI and extraintestinal malignancies. Lifetime cancer risk has been reported to be in the range of 47–93%. Colorectal, breast, and reproductive tumors are most common. Even though risk of GI malignancy in childhood is quite low, GI surveillance for polyps should begin in childhood (by age 8 years of age or when symptoms occur) with upper and lower endoscopy. The small bowel may be evaluated radiographically, with magnetic resonance enterography, endoscopically with balloon or push enteroscopy, or with video capsule endoscopy. Polyps larger than 1.5 cm should be removed, although resection does not lower the cancer risk and is mainly to avoid complications. Patients with PJS should be monitored for signs of precocious puberty given their risk of having sex cord/

Table 393.1 General Features of the Inherited Colorectal Cancer Syndromes

SYNDROME	POLYP DISTRIBUTION	AGE OF ONSET	RISK OF COLON CANCER	GENETIC LESION	CLINICAL MANIFESTATIONS	ASSOCIATED LESIONS
HAMARTOMATOUS POLYPS						
Juvenile polyposis	Large and small intestine, gastric polyps	First decade	~10–50%	*SMAD4, BMPR1A* Autosomal dominant	Possible rectal bleeding, abdominal pain, intussusception	Congenital abnormalities in 20% of the nonfamilial type, clubbing, AV malformations
Peutz-Jeghers syndrome	Small and large intestine	First decade	Increased	*LKB1/STK11* Autosomal dominant	Possible rectal bleeding, abdominal pain, intussusception	Orocutaneous melanin pigment spots
Cowden syndrome	Colon	Second decade	13–18%	*PTEN* gene	Macrocephaly, breast/thyroid/ endometrial cancers, developmental delay	
Bannayan-Riley-Ruvalcaba syndrome	Colon	Second decade	Increased	*PTEN* gene	Macrocephaly, speckled penis, thyroid/breast cancers, hemangiomas, lipomas	
ADENOMATOUS POLYPS						
Familial adenomatous polyposis (FAP)	Large intestine, often >100	16 yr (range: 8-34 yr)	100%	5q (*APC* gene), autosomal dominant	Rectal bleeding, abdominal pain, bowel obstruction	Desmoids, CHRPE, upper GI polyps, osteoma, hepatoblastoma, thyroid cancer
Attenuated familial adenomatous polyposis (AFAP)	Colon (fewer in number)	>18 yr	Increased	*APC* gene	Same as FAP	Fewer associated lesions
MYH-associated polyposis	Colon	>20 yr	High risk	*MYH* autosomal recessive	Same as FAP	May be confused with sporadic FAP or AFAP; few extraintestinal findings
Gardner syndrome	Large and small intestine	16 yr (range: 8-34 yr)	100%	5q (*APC* gene)	Rectal bleeding, abdominal pain, bowel obstruction	Desmoid tumors, multiple osteomas, fibromas, epidermoid cysts
Hereditary nonpolyposis colon cancer (Lynch syndrome)	Large intestine	40 yr	30%	DNA mismatch repair genes *(MMR)* Autosomal dominant	Rectal bleeding, abdominal pain, bowel obstruction	Other tumors (e.g., ovary, ureter, pancreas, stomach)

APC, adenomatous polyposis coli; AV, arteriovenous; CHRPE, congenital hypertrophy of the retinal pigment epithelium; GI, gastrointestinal; PTEN, phosphatase and tensin homolog.

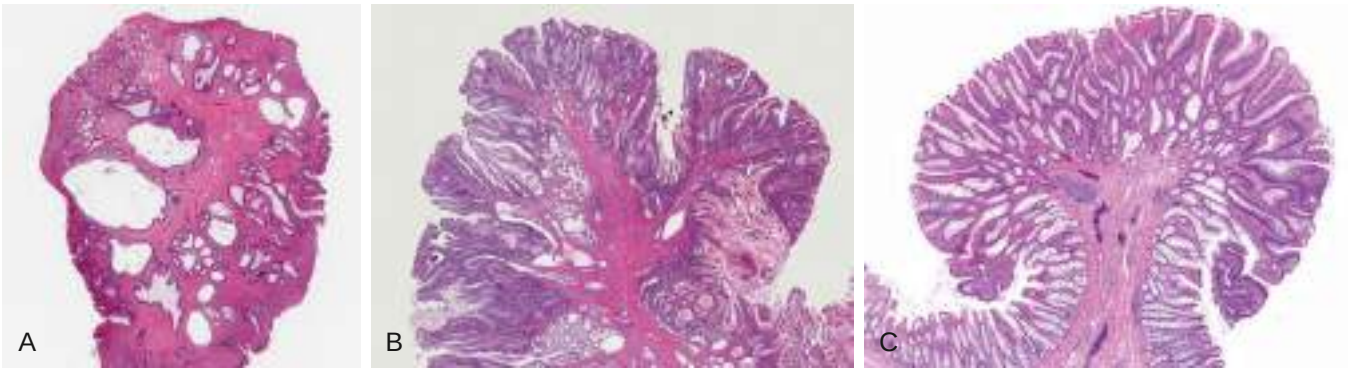

Fig. 393.1 Representative histologic sections of commonly found polyps in pediatric patients. **A**, Juvenile polyp. Cystically dilated and irregular colonic crypts within an inflamed, expanded stroma. **B**, Peutz-Jeghers polyp. Small bowel with large arborizing bundles of smooth muscle and otherwise normal epithelial component. **C**, Adenomatous polyp. Enlarged, hyperchromatic, and stratified nuclei confined to a tubular configuration. *(Images courtesy Dr. Thomas Plesec, Cleveland Clinic.)*

Fig. 393.2 Peutz-Jeghers syndrome. Characteristic bluish brown to black spots were first noted in early childhood on the lips of this boy who later developed hamartomatous gastrointestinal polyps. *(From Paller AS, Mancini AJ, eds. Hurwitz Clinical Pediatric Dermatology, 6th ed. Philadelphia: Elsevier; 2022: Fig. 11.46, p. 312.)*

stromal tumors, particularly large-cell calcifying Sertoli cell tumors. Screening for breast, gynecologic, and testicular cancers should be routine after age 18 years.

Phosphatase and Tensin Homolog Hamartoma Tumor Syndromes

Pathogenic variants in the tumor suppressor gene *PTEN* are associated with several rare autosomal dominant syndromes, including Cowden syndrome, Bannayan-Riley-Ruvalcaba syndrome, and Proteus and Proteus-like syndrome. These patients present with multiple hamartomas in the skin (99%), brain, breast, thyroid, endometrium, and GI tract (60%). Other extraintestinal manifestations include macrocephaly, developmental delay, lipomas, and genital pigmentation. Patients have 9–18% lifetime risk of colorectal cancer. However, this risk is low in childhood. They also have increased risk of thyroid, breast, uterine, renal, and skin malignancies.

ADENOMATOUS TUMORS

Adenomatous Polyposis Coli-Associated Polyposis Syndromes

Familial adenomatous polyposis (FAP) is the most common genetic polyposis syndrome (incidence 1:5,000-1:17,000 persons) and is characterized by numerous adenomatous polyps throughout the colon and extraintestinal manifestations. FAP and related syndromes (attenuated FAP; Gardner and Turcot syndromes) are linked to pathogenic variants in the *APC* gene, a tumor suppressor mapped to 5q21, which is part of the WNT signaling pathway. *APC* regulates degradation of β-catenin, a protein with roles in regulation of the cytoskeleton, tissue architecture organization, cell migration and adherence, and numerous other functions. Intracellular accumulation of β-catenin may be responsible for colonic epithelial cell proliferation and adenoma formation. More than 400 pathogenic variants in the *APC* gene have been described, and up to 30% of patients present with no family history (sporadic variants). There is an association between disease phenotype and the location of the *APC* gene alteration. For example, a more severe colonic phenotype is associated with pathogenic variants between codons 1250 and 1464, specifically variants that include codon 1309.

Polyps generally develop late in the first or second decades of life (mean age of presentation is 16 years). At the time of diagnosis, five or more adenomatous polyps are present in the colon and rectum. By young adulthood, the number of polyps typically increases to hundreds or even thousands. Adenomatous polyps (or adenomas) are precancerous lesions within the surface epithelium of the intestine, displaying various degrees of dysplasia (see Fig. 393.1C). Without intervention, the risk of developing colon cancer is 100% by the fifth decade of life (average age of cancer diagnosis is 40 years). Other GI adenomas can develop, particularly in the stomach and duodenum (50–90%). The risk of periampullary or duodenal carcinoma is significantly elevated (4–12% lifetime risk) and represents, along with desmoid tumors, the most common cause of death after colorectal cancer. Extraintestinal malignancies occur at an increased rate in FAP, including hepatoblastoma in young patients (1.6% before age 5 years) and follicular or papillary thyroid cancer in adolescents.

Extraintestinal manifestations of FAP may be present from birth or develop in early childhood. Lesions include congenital hypertrophy of retinal pigment epithelium, desmoid tumors, epidermoid cysts, osteomas, fibromas, lipomas, and supernumerary, impacted, or missing teeth. Many of these nonmalignant soft tissue tumors appear before intestinal polyps develop. Expression of extraintestinal findings can depend on the location of the *APC* gene alteration.

Other syndromes associated with *APC* pathogenic variants include *Gardner syndrome,* classically characterized by multiple colorectal polyps, desmoid tumors, and soft tissue tumors, including fibromas, osteomas (typically mandibular), epidermoid cysts, and lipomas. Once thought to be a distinct clinical entity, Gardner syndrome shares many characteristics with FAP. Up to 20% of FAP patients present with the classic extraintestinal manifestations once associated with Gardner syndrome. Some (but not all) cases of *Turcot syndrome* are also related to *APC.* These patients present with colorectal polyposis and primary brain tumors (medulloblastoma). Attenuated FAP is characterized by a significantly increased risk of colorectal cancer but fewer polyps than classic FAP (average: 30 polyps). The average age of cancer diagnosis in this form of FAP is 50-55 years. Upper GI tumors and extraintestinal manifestations may be present but are less common.

The clinical presentation of FAP is variable. Polyps are generally sessile, of variable size, and initially asymptomatic. If symptoms develop, they can include rectal bleeding (possibly with secondary anemia), cramping, and diarrhea. The presence of symptoms at presentation does not correlate with malignant changes. Diagnosis should be suspected from family history, and ensuing colonoscopy is confirmatory. Histologic examination of biopsied polyps reveals adenomatous architecture (as opposed to inflammatory or hamartomatous polyps found in other polyposis syndromes) with varying degrees of dysplasia. Genetic testing for *APC* variants is clinically available, and index patients should be tested. If a pathogenic variant is identified, affected family members should be screened and appropriate genetic counseling should be provided. If the index patient does not demonstrate a defined variant, family members may undergo genetic testing, which might identify novel *APC* alterations. Children with identified *APC* mutations must undergo careful surveillance, with colonoscopy every 1-2 years starting early in the second decade of life or earlier if symptomatic. Once polyps are identified, colonoscopy should be performed annually. Patients should also have upper endoscopy in the third decade of life to monitor for gastric and especially duodenal lesions, earlier if symptomatic or if there is family history of aggressive duodenal adenoma burden or cancer.

Treatment of FAP requires **prophylactic proctocolectomy** to prevent inevitable colon cancer. Prophylactic colectomy should be planned in the late teens or early twenties, earlier if significant polyposis burden or malignancy is suspected. Ileoanal pull-through procedures restore bowel continuity, with acceptable functional outcomes. Surgical approaches include ileal pouch anal anastomosis (with J-pouch) versus ileorectal anastomosis; the type of surgery depends on rectal and colonic polyp burden and surgeon preference. It is very important to note that ongoing surveillance of the ileal pouch or rectal cuff is warranted after surgery. **Nonsteroidal antiinflammatory agents**, such as sulindac, and cyclooxygenase-2 inhibitors, such as celecoxib, might inhibit polyp progression. No guidelines have been established, however, and their efficacy in preventing malignant transformation of existing polyps is unknown.

Carcinoma

Primary carcinomas of the esophagus, stomach, or colon are extremely rare in children. Development of adenocarcinoma in adolescence or

early adulthood may be associated with a genetic predisposition or syndrome such as FAP, hereditary nonpolyposis colon carcinoma, PJS, radiation exposure, or inflammatory bowel disorders such as Crohn disease or ulcerative colitis.

Colorectal carcinoma (CRC), though rare (reported incidence of 1 case per 1,000,000 persons younger than 19 years of age), is the most common primary GI carcinoma in children. Patients with long-standing ulcerative colitis are at increased risk. Many cases are spontaneous (i.e., not associated with a genetic predisposition or syndrome); associated genetic syndromes occur in 3–5% of all CRC cases (see Table 393.1). Histologically, tumors tend to be poorly differentiated and pathologically aggressive. Patients may be asymptomatic, or they present with nonspecific signs and symptoms such as abdominal pain, constipation, and vomiting. Delay in diagnosis is common. Adolescents and young adults present with advanced-stage disease more often than in older patients; microscopic or gross metastases are often present at the time of diagnosis. **Surgical resection** is the primary treatment modality, although with delayed presentation and advanced-stage disease, complete resection may not be possible. Complete resection is necessary for cure, however. **Chemotherapy** is standard treatment for patients with more advanced, surgically unresectable disease, though its efficacy is variable. Targeted immunotherapy agents such as monoclonal antibodies against epidermal growth factor receptor or vascular endothelial growth factor receptor are gaining traction as useful systemic therapies. **Radiation therapy** has a limited role in patients with metastatic disease.

OTHER GASTROINTESTINAL TUMORS

Lymphoma

Lymphoma is the most common GI malignancy in the pediatric population. Approximately 30% of children with non-Hodgkin lymphoma present with abdominal tumors. Immunocompromised patients have an increased incidence of lymphoma. Predisposing conditions include HIV/AIDS, agammaglobulinemia, long-standing celiac disease, and bone marrow or solid-organ transplantation. Examples of non-Hodgkin lymphoma subtypes that commonly occur in the GI tract are Burkitt lymphoma and posttransplant lymphoproliferative disorder (PTLD). Lymphoma can occur anywhere in the GI tract, but it most commonly occurs in the distal small bowel and ileocecal region; for instance, Burkitt lymphoma is classically located at the terminal ileum. Presenting symptoms include crampy abdominal pain, vomiting, obstruction, bleeding, or palpable mass. Lymphoma should be considered in patients older than 3 years of age who present with intussusception. Treatment consists of a combination of **surgical resection** and **chemotherapy**, and the intensity of chemotherapy regimens depends on the extent of the tumor burden.

Nodular Lymphoid Hyperplasia

Lymphoid follicles in the lamina propria and submucosa of the gut normally aggregate in Peyer patches, most prominently in the distal ileum. These follicles can become hyperplastic, forming nodules that protrude into the lumen of the bowel during times of developmental lymphoid proliferation such as early childhood and adolescence. Some suggested etiologies are infectious (classically *Giardia*), allergic, or immunologic. Nodular lymphoid hyperplasia has been described in infants with enterocolitis secondary to dietary protein sensitivity. This phenomenon has also been described in patients with inflammatory bowel disease and Castleman disease. Patients may be asymptomatic or, especially in cases of immunodeficiency, may present with abdominal pain, rectal bleeding, diarrhea, or intussusception. Nodular lymphoid hyperplasia usually resolves spontaneously. The use of antiinflammatory medications or elimination diets is unlikely to change the clinical course, although in cases with severe pain or bleeding, **corticosteroids** may be effective.

Gastroenteric Neuroendocrine Tumors

Gastroenteric neuroendocrine tumors (NETs) arise from neuroendocrine cells found in the intestines (and in the pancreas; however, pancreatic NETs will not be discussed here). These tumors can be low, intermediate, or high-grade tumors, depending on the Ki-67 proliferative index on histopathology (i.e., how rapidly the cells proliferate). The World Health Organization (WHO) classification separates NETs from "neuroendocrine carcinomas." NETs can be functional or nonfunctional; some NETs overproduce and secrete hormones such as gastrin, serotonin, or ectopic hormones such as adrenocorticotropic hormone (ACTH). Several heritable tumor syndromes are associated with gastroenteric NETs, including multiple endocrine neoplasia type 1 (MEN1), von Hippel-Lindau (VHL) disease, tuberous sclerosis (TSC), or neurofibromatosis type 1 (NF1). Two of the most common NETs of the GI tract in children and adolescents are carcinoid tumors and gastrinomas.

Carcinoid Tumor

Carcinoid tumors are neuroendocrine tumors of enterochromaffin cells, which can occur throughout the GI tract, but in children they are typically found in the appendix. This is often an incidental diagnosis at the time of appendectomy. **Complete surgical resection** of small tumors (<1 cm) with clear surgical margins is curative. Appendiceal tumors >1.5 cm are at increased risk for nodal metastasis and thus mandate further bowel resection, typically a right hemicolectomy.

Carcinoid tumors outside the appendix (small intestine, rectum, stomach) are more likely to metastasize. Serum tumor markers may be helpful in monitoring for development of metastatic disease—chromogranin A is the most sensitive tumor marker for intestinal NETs. Carcinoid tumors of the midgut can metastasize to the liver and give rise to a constellation of symptoms called **carcinoid syndrome**. Serotonin, 5-hydroxytryptophan, or histamine may be secreted by the tumor, and elevated serum levels cause cramps, diarrhea, vasomotor disturbances (flushing), bronchoconstriction, and right heart failure. The diagnosis is confirmed by elevated urinary 5-hydroxyindoleacetic acid (5-HIAA). Symptomatic relief of carcinoid syndrome may be achieved with administration of **somatostatin analogs** (i.e., octreotide). Treatment of metastatic NETs is again **surgical resection**, and the extent of resection may be curative or palliative, depending on the goals of care and risk of surgical morbidity. Because NETs tend to be slow-growing, some patients may be closely monitored for periods without surgical intervention. **Chemotherapy** has been used, including medications such as temozolomide, 5-fluorouracil, and cisplatin. Clinical trials studying various targeted systemic therapies are ongoing. A mammalian target of rapamycin (mTOR) inhibitor, called **everolimus**, is FDA-approved for the treatment of nonfunctional NETs based on the results of several clinical trials.

Gastrinoma

A malignant NET that arises in the duodenum or the pancreas is called *gastrinoma,* and these tumors secrete gastrin, which causes gastric acid hypersecretion and Zollinger-Ellison syndrome. Clinical symptoms of gastrinoma include diarrhea (because of large amounts of acid secretion into the duodenum), abdominal pain, peptic ulcer disease, and bleeding. Strictures and perforation may develop with more severe disease. Unfortunately, about 75–80% of patients with gastrinoma present with metastases to the liver or lymph nodes at diagnosis, and approximately 12% can have bone metastases at diagnosis as well. Treatment of gastrinoma includes **proton pump inhibitors** and **surgical resection**.

Leiomyoma

Leiomyomas are rare benign tumors that can arise anywhere in the GI tract, although most often in the stomach, jejunum, or distal ileum. Age of presentation is variable, from the newborn period through adolescence. Patients may be asymptomatic or can present with an abdominal mass, obstruction, intussusception, volvulus, or pain and bleeding from central necrosis of the tumor. **Surgical resection** is the treatment of choice. Pathologically, these tumors may be difficult to distinguish from malignant leiomyosarcomas. Smooth muscle tumors occur with increased incidence in children with HIV or those requiring immunosuppression after transplantation.

Gastrointestinal Stromal Cell Tumors

Gastrointestinal stromal cell tumors (GISTs) are intestinal mesenchymal tumors that probably arise from interstitial cells of Cajal or their

precursors. Historically, these may have been diagnosed as tumors of smooth muscle or neural cell origin. The WHO recognized GIST in 1990 as a distinct neoplasm. Typically, GISTs arise in adults, after the third decade of life. Cases have also been reported in the pediatric population, generally in adolescents with a female predominance. A minority of pediatric cases were reported with Carney's triad (gastric gastrointestinal stromal tumor, pulmonary chondroma, and extraadrenal paraganglioma) or a history of neurofibromatosis. In children, tumors are most commonly found in the stomach, though they can occur anywhere in the GI tract or even the mesentery or omentum. Many patients (~45%) present with metastatic disease primarily to the lymph nodes, although metastases to the peritoneum or liver occur as well. Patients may be asymptomatic for years to decades or can present with an abdominal mass, lower GI bleeding, or obstruction. Treatment consists of **surgical resection** of local disease. Recurrence rates are high, and early postoperative surveillance is recommended. GISTs occurring in adults are typically associated with pathogenic variants in the *KIT* oncogene. This alteration is less commonly found in pediatric GISTs (~15%). Adjuvant systemic therapy for *KIT*+ lesions can be given, and typically **tyrosine kinase inhibitors (such as imatinib, sunitinib, or dasatinib)** are used. These medications are conveniently available as oral therapy. Patients with persistent, recurrent, or metastatic disease may benefit from treatment.

Vascular Tumors

Vascular malformations and hemangiomas are rare in children. The usual presentation is painless rectal bleeding, which may be chronic or acute, with massive or even fatal hemorrhage. There are usually no associated symptoms, although intussusception has been described. Half of patients have associated cutaneous hemangiomas or telangiectasia. These lesions may be associated with blue rubber bleb nevus syndrome, hereditary hemorrhagic telangiectasia, and other syndromes. About half of these lesions are in the colon and can be identified on colonoscopy. During acute bleeding episodes, bleeding can be localized via nuclear medicine bleeding scans, mesenteric angiography, or endoscopy. Colonic bleeding may be controlled by endoscopic means. Surgical intervention is required occasionally for isolated lesions.

Visit Elsevier eBooks+ at eBooks.Health.Elsevier.com for Bibliography.

Chapter 394

Inguinal Hernias

José H. Salazar and John J. Aiken

Inguinal hernias are one of the most common conditions seen in pediatric practice, with an overall incidence of 0.8–4.5% in term infants and children and increasing to nearly 30% in premature and low birthweight (<1 kg) infants. Most inguinal hernias in infants and children are **congenital indirect** hernias (99%) because of a patent processus vaginalis (PV), an evagination of peritoneum in the inguinal area important in testicular descent. There is rarely any defect or deficiency in the abdominal wall musculature in congenital indirect inguinal hernia. Inguinal hernias are more common in males compared with females (8:1 ratio), but females have a higher incidence of bilateral inguinal hernias (~25%) compared with males (~12%). Two other types of inguinal hernia are seen rarely in children: **direct** (acquired) hernia (0.5–1.0%) and **femoral** hernia (<0.5%). Femoral hernias are substantially more common in females (2:1 ratio). Approximately 50% of inguinal hernias manifest clinically in the first year of life, most in the first 6 months. The incidence of incarceration in untreated hernias varies between 6% and 18% across ages. The risk of incarceration is greatest in infancy, with some reports of incarceration rates of 30–40% in the first year of life, mandating prompt identification and operative repair to minimize morbidity and complications related to incarceration and strangulation. Laparoscopic hernia (LH) repair has increasingly emerged in many pediatric centers as an effective alternative to traditional open hernia (OH) repair.

EMBRYOLOGY AND PATHOGENESIS

Indirect inguinal hernias in infants and children are congenital and result from an arrest of embryologic development—failure of obliteration of the PV rather than a weakness in the abdominal wall musculature. The pertinent developmental anatomy of indirect inguinal hernia relates to development of the gonads and descent of the testes through the inguinal canal and into the scrotum late in gestation. The testes descend from the urogenital ridge in the retroperitoneum to the area of the internal ring by about 28 weeks of gestation. The final descent of the testes into the scrotum occurs late in gestation, between weeks 28 and 36, guided by the PV and the gubernaculum. The PV, an outpouching of peritoneum in the inguinal region, is present in the developing fetus at 12 weeks of gestation. The PV develops lateral to the deep inferior epigastric vessels and descends anteriorly along the spermatic cord within the cremasteric fascia through the internal inguinal ring. The testis accompanies the PV as it exits the abdomen and descends into the scrotum. The gubernaculum testis forms from the mesonephros (developing kidney), attaches to the lower pole of the testis, and directs the testis through the internal ring, inguinal canal, and into the scrotum. The testis passes through the inguinal canal in a few days but takes about 4 weeks to migrate from the external ring to its final position in the scrotum. The cordlike structures of the gubernaculum occasionally pass to ectopic locations (perineum or femoral region), resulting in ectopic testes.

In the last few weeks of gestation or shortly after birth, the layers of the PV normally fuse together and obliterate the patency from the peritoneal cavity through the inguinal canal to the testis. The PV also obliterates distally just above the testes, and the portion of the PV that envelops the testis becomes the tunica vaginalis. In females, the PV obliterates earlier, at approximately 7 months of gestation, and may explain why females demonstrate a much lower incidence of inguinal hernia. Proper closure of the PV effectively *seals off* the opening from the abdominal cavity into the inguinal region, containing the abdominal viscera within the abdominal cavity. Failure of the PV to close permits fluid or abdominal viscera to escape the abdominal cavity into the extraabdominal inguinal canal and accounts for a variety of inguinal-scrotal abnormalities commonly seen in infancy and childhood. Involution of the left-sided PV precedes that of the right, which is consistent with the increased incidence of indirect inguinal hernias on the right side (60%).

The ovaries descend into the pelvis from the urogenital ridge but do not exit from the abdominal cavity. The cranial portion of the gubernaculum in females differentiates into the ovarian ligament, and the inferior aspect of the gubernaculum becomes the round ligament, which passes through the internal ring and terminates in the labia majora. The PV in females is also known as the *canal of Nuck*.

Androgenic hormones produced by the fetal testis, adequate end-organ receptors, and mechanical factors such as increased intraabdominal pressure combine to regulate complete descent of the testis. The testes and spermatic cord structures (spermatic vessels and vas deferens) are located in the retroperitoneum but are affected by increases in intraabdominal pressure as a consequence of their intimate attachment to the descending PV. The genitofemoral nerve also has an important role: it innervates the cremaster muscle, which develops within the gubernaculum, and experimental division or injury to both nerves in the fetus prevents testicular descent. Failure of regression of smooth muscle (present to provide the force for testicular descent) has also been postulated to play a role in the development of indirect inguinal hernias. Several studies have investigated genes involved in the control of testicular descent for their role in closure of

precursors. Historically, these may have been diagnosed as tumors of smooth muscle or neural cell origin. The WHO recognized GIST in 1990 as a distinct neoplasm. Typically, GISTs arise in adults, after the third decade of life. Cases have also been reported in the pediatric population, generally in adolescents with a female predominance. A minority of pediatric cases were reported with Carney's triad (gastric gastrointestinal stromal tumor, pulmonary chondroma, and extraadrenal paraganglioma) or a history of neurofibromatosis. In children, tumors are most commonly found in the stomach, though they can occur anywhere in the GI tract or even the mesentery or omentum. Many patients (~45%) present with metastatic disease primarily to the lymph nodes, although metastases to the peritoneum or liver occur as well. Patients may be asymptomatic for years to decades or can present with an abdominal mass, lower GI bleeding, or obstruction. Treatment consists of **surgical resection** of local disease. Recurrence rates are high, and early postoperative surveillance is recommended. GISTs occurring in adults are typically associated with pathogenic variants in the *KIT* oncogene. This alteration is less commonly found in pediatric GISTs (~15%). Adjuvant systemic therapy for *KIT*+ lesions can be given, and typically **tyrosine kinase inhibitors (such as imatinib, sunitinib, or dasatinib)** are used. These medications are conveniently available as oral therapy. Patients with persistent, recurrent, or metastatic disease may benefit from treatment.

Vascular Tumors

Vascular malformations and hemangiomas are rare in children. The usual presentation is painless rectal bleeding, which may be chronic or acute, with massive or even fatal hemorrhage. There are usually no associated symptoms, although intussusception has been described. Half of patients have associated cutaneous hemangiomas or telangiectasia. These lesions may be associated with blue rubber bleb nevus syndrome, hereditary hemorrhagic telangiectasia, and other syndromes. About half of these lesions are in the colon and can be identified on colonoscopy. During acute bleeding episodes, bleeding can be localized via nuclear medicine bleeding scans, mesenteric angiography, or endoscopy. Colonic bleeding may be controlled by endoscopic means. Surgical intervention is required occasionally for isolated lesions.

Visit Elsevier eBooks+ at eBooks.Health.Elsevier.com for Bibliography.

Chapter 394

Inguinal Hernias

José H. Salazar and John J. Aiken

Inguinal hernias are one of the most common conditions seen in pediatric practice, with an overall incidence of 0.8–4.5% in term infants and children and increasing to nearly 30% in premature and low birthweight (<1 kg) infants. Most inguinal hernias in infants and children are **congenital indirect** hernias (99%) because of a patent processus vaginalis (PV), an evagination of peritoneum in the inguinal area important in testicular descent. There is rarely any defect or deficiency in the abdominal wall musculature in congenital indirect inguinal hernia. Inguinal hernias are more common in males compared with females (8:1 ratio), but females have a higher incidence of bilateral inguinal hernias (~25%) compared with males (~12%). Two other types of inguinal hernia are seen rarely in children: **direct** (acquired) hernia (0.5–1.0%) and **femoral** hernia (<0.5%). Femoral hernias are substantially more common in females (2:1 ratio). Approximately 50% of inguinal hernias manifest clinically in the first year of life, most in the first 6 months. The incidence of incarceration in untreated hernias varies between 6% and 18% across ages. The risk of incarceration is greatest in infancy, with some reports of incarceration rates of 30–40% in the first year of life, mandating prompt identification and operative repair to minimize morbidity and complications related to incarceration and strangulation. Laparoscopic hernia (LH) repair has increasingly emerged in many pediatric centers as an effective alternative to traditional open hernia (OH) repair.

EMBRYOLOGY AND PATHOGENESIS

Indirect inguinal hernias in infants and children are congenital and result from an arrest of embryologic development—failure of obliteration of the PV rather than a weakness in the abdominal wall musculature. The pertinent developmental anatomy of indirect inguinal hernia relates to development of the gonads and descent of the testes through the inguinal canal and into the scrotum late in gestation. The testes descend from the urogenital ridge in the retroperitoneum to the area of the internal ring by about 28 weeks of gestation. The final descent of the testes into the scrotum occurs late in gestation, between weeks 28 and 36, guided by the PV and the gubernaculum. The PV, an outpouching of peritoneum in the inguinal region, is present in the developing fetus at 12 weeks of gestation. The PV develops lateral to the deep inferior epigastric vessels and descends anteriorly along the spermatic cord within the cremasteric fascia through the internal inguinal ring. The testis accompanies the PV as it exits the abdomen and descends into the scrotum. The gubernaculum testis forms from the mesonephros (developing kidney), attaches to the lower pole of the testis, and directs the testis through the internal ring, inguinal canal, and into the scrotum. The testis passes through the inguinal canal in a few days but takes about 4 weeks to migrate from the external ring to its final position in the scrotum. The cordlike structures of the gubernaculum occasionally pass to ectopic locations (perineum or femoral region), resulting in ectopic testes.

In the last few weeks of gestation or shortly after birth, the layers of the PV normally fuse together and obliterate the patency from the peritoneal cavity through the inguinal canal to the testis. The PV also obliterates distally just above the testes, and the portion of the PV that envelops the testis becomes the tunica vaginalis. In females, the PV obliterates earlier, at approximately 7 months of gestation, and may explain why females demonstrate a much lower incidence of inguinal hernia. Proper closure of the PV effectively *seals off* the opening from the abdominal cavity into the inguinal region, containing the abdominal viscera within the abdominal cavity. Failure of the PV to close permits fluid or abdominal viscera to escape the abdominal cavity into the extraabdominal inguinal canal and accounts for a variety of inguinal-scrotal abnormalities commonly seen in infancy and childhood. Involution of the left-sided PV precedes that of the right, which is consistent with the increased incidence of indirect inguinal hernias on the right side (60%).

The ovaries descend into the pelvis from the urogenital ridge but do not exit from the abdominal cavity. The cranial portion of the gubernaculum in females differentiates into the ovarian ligament, and the inferior aspect of the gubernaculum becomes the round ligament, which passes through the internal ring and terminates in the labia majora. The PV in females is also known as the *canal of Nuck*.

Androgenic hormones produced by the fetal testis, adequate end-organ receptors, and mechanical factors such as increased intraabdominal pressure combine to regulate complete descent of the testis. The testes and spermatic cord structures (spermatic vessels and vas deferens) are located in the retroperitoneum but are affected by increases in intraabdominal pressure as a consequence of their intimate attachment to the descending PV. The genitofemoral nerve also has an important role: it innervates the cremaster muscle, which develops within the gubernaculum, and experimental division or injury to both nerves in the fetus prevents testicular descent. Failure of regression of smooth muscle (present to provide the force for testicular descent) has also been postulated to play a role in the development of indirect inguinal hernias. Several studies have investigated genes involved in the control of testicular descent for their role in closure of

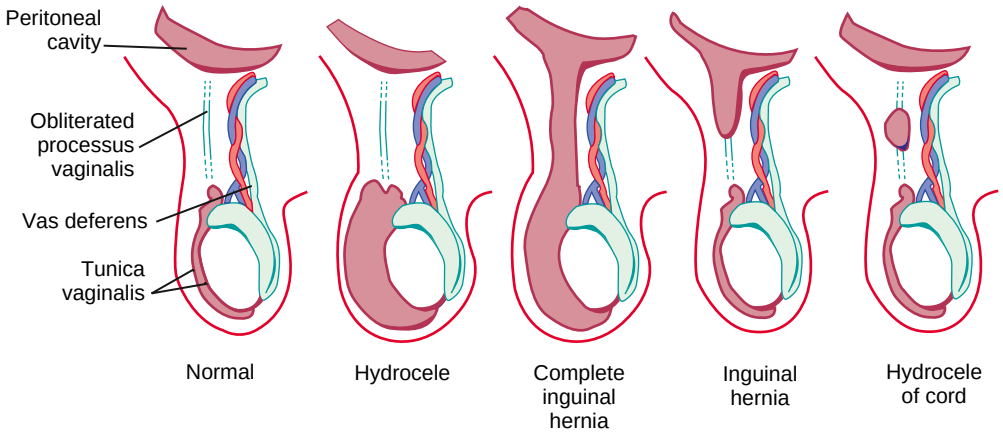

Fig. 394.1 Hernia and hydroceles. *(Modified from Scherer LR III, Grosfeld JL. Inguinal and umbilical anomalies. Pediatr Clin North Am. 1993;40:1121–1131.)*

the patent PV—for example, hepatocyte growth factor and calcitonin gene–related peptide. Unlike in adult hernias, there does not appear to be any deficiency in collagen synthesis associated with inguinal hernia in children (Fig. 394.1).

A **direct inguinal hernia** results from a weakness in the abdominal wall musculature in the inguinal region, specifically the transverse abdominis muscle, which forms the floor of the inguinal canal. A direct inguinal hernia originates **medial** to the deep inferior epigastric vessels and is external to the cremasteric fascia; the hernia sac protrudes directly through the posterior wall of the inguinal canal and does not protrude through the external ring. A **femoral hernia** originates medial to the femoral vein and descends inferior to the inguinal ligament along the femoral canal.

Incidence

The incidence of congenital indirect inguinal hernia in full-term newborn infants is estimated at 3.5–5.0%. The incidence of hernia in preterm and low birthweight infants is considerably higher, ranging from 9% to 11%, and approaches 30% in very low birthweight infants (<1,000 g) and preterm infants (<28 weeks of gestation). Inguinal hernia is much more common in males than in females, with a male-to-female ratio of approximately 8:1. Approximately 60% of inguinal hernias occur on the right side, 30% are on the left side, and 10% are bilateral. The incidence of bilateral hernias is higher in females (20–40%) and young children (<2 years). An increased incidence of congenital inguinal hernia has been documented in twins and in family members of patients with inguinal hernia. There is a history of another inguinal hernia in the family in 11.5% of patients. The sisters of affected females are at the highest risk, with a relative risk of 17.8. In general, the risk of brothers of a sibling is approximately 4-5, as is the risk of a sister of an affected brother. Both a multifactorial threshold model and autosomal dominance with incomplete penetrance and sex influence have been suggested as an explanation for this pattern of inheritance.

Inguinal hernia, scrotal hydrocele (communicating and noncommunicating), and hydrocele of the spermatic cord are conditions resulting from varying degrees of failure of closure of the PV. Closure of the PV is often incomplete at birth and continues postnatally; the rate of patency is inversely proportional to the age of the child. It has been estimated that the patency rate of the PV is as high as 80% at birth and decreases to ~40% during the first year of life and that ~20% of males have a persistent patency of the PV at 2 years of age. Patency of the PV after birth is an opening from the abdominal cavity into the inguinal region, and therefore a potential hernia, but not all patients will develop a clinical hernia. An inguinal hernia occurs clinically when intraabdominal contents escape the abdominal cavity and enter the inguinal region through the PV patency. Depending on the extent of patency of the PV, the hernia may be confined to the inguinal region or pass down into the scrotum. Complete failure of obliteration of the PV, mostly seen in infants, predisposes to a complete inguinal hernia characterized by a protrusion of abdominal contents into the inguinal canal and extending into the scrotum. Obliteration of the PV distally (around the testis) with patency proximally results in the classic indirect inguinal hernia with a bulge in the inguinal canal.

Table 394.1 Predisposing Factors for Hernias

Prematurity
Urogenital
• Cryptorchidism
• Exstrophy of the bladder or cloaca
• Ambiguous genitalia
• Hypospadias/epispadias
Increased peritoneal fluid
• Ascites
• Ventriculoperitoneal shunt
• Peritoneal dialysis catheter
Increased intraabdominal pressure
• Repair of abdominal wall defects
• Severe ascites (chylous)
• Meconium peritonitis
Chronic respiratory disease
• Cystic fibrosis
Connective tissue disorders
• Ehlers-Danlos syndrome
• Hunter-Hurler syndrome
• Marfan syndrome
• Mucopolysaccharidosis

A **hydrocele** occurs when only fluid enters the patent PV; the swelling may exist only in the scrotum (scrotal hydrocele), only along the spermatic cord in the inguinal region (hydrocele of the spermatic cord), or extend from the scrotum through the inguinal canal and even into the abdomen (abdominal-scrotal hydrocele). A hydrocele is termed a **communicating hydrocele** if it demonstrates fluctuation in size, often increasing in size after activity and, at other times, being smaller when the fluid decompresses into the peritoneal cavity often after lying recumbent. Occasionally, hydroceles develop in older children after trauma, inflammation, torsion of the appendix testes, or in association with tumors affecting the testis.

Although reasons for failure of closure of the PV are unknown, it is more common in cases of testicular nondescent (cryptorchidism) and prematurity. In addition, persistent patency of the PV is twice as common on the right side, presumably related to later descent of the right testis and interference with obliteration of the PV from the developing inferior vena cava and external iliac vein. Table 394.1 lists the risk factors identified as contributing to failure of closure of the PV and to the development of clinical inguinal hernia. The incidence of inguinal hernia in patients with cystic fibrosis is approximately 15%, believed to be related to an altered embryogenesis of the Wolffian duct structures, which

leads to an absent vas deferens and infertility in males with this condition. There is also an increased incidence of inguinal hernia in patients with **testicular feminization syndrome** and other disorders of sexual development. The rate of recurrence after repair of an inguinal hernia in patients with a connective tissue disorder approaches 50%, and often the diagnosis of connective tissue disorders in children results from investigation after development of a recurrent inguinal hernia.

Clinical Presentation and Diagnosis

An inguinal hernia typically appears as an intermittent, asymptomatic bulge or mass in the inguinal region or scrotum, most often noted on routine physical examination or by a parent; after bathing or urination are classic presentations. In females, the mass typically occurs in the upper portion of the labia majora. The bulge or mass is most visible at times of irritability or increased intraabdominal pressure (crying, straining, coughing). Most inguinal hernias present clinically in young children, approximately 50% in the first year, and most are asymptomatic or minimally symptomatic. The classic history from the parents is of intermittent groin, labial, or scrotal swelling that spontaneously reduces but that is gradually enlarging or is more persistent and is becoming more difficult to reduce. *Rarely an incarcerated hernia may present in an infant with emesis, dehydration, and abdominal distention suggestive of gastroenteritis or a bowel obstruction*. The **hallmark sign** of an inguinal hernia on physical examination is a smooth, firm mass that emerges through the external inguinal ring lateral to the pubic tubercle and enlarges with increased intraabdominal pressure. When the child relaxes, the hernia typically reduces spontaneously or can be reduced by gentle pressure, first posteriorly to free it from the external ring and then upward toward the peritoneal cavity. In males, the hernia sac contains intestines; female infants often have an ovary and fallopian tube in the hernia sac.

The diagnosis of inguinal hernia is clinical and generally is made by history and physical examination. Methods used to demonstrate the hernia on examination vary depending on the age of the child. A quiet infant can be made to strain the abdominal muscles by stretching the infant out supine on the bed with legs extended and arms held straight above the head. Most infants struggle to get free, thus increasing the intraabdominal pressure and pushing out the hernia. Older children can be asked to perform the Valsalva maneuver by blowing up a balloon or coughing. The older child should be examined while standing, and examination after voiding also can be helpful. With increased intraabdominal pressure, the protruding mass is obvious on inspection of the inguinal region or can be palpated by an examining finger invaginating the scrotum to palpate at the external ring. Another subtle and less definitive test is the *silk glove sign,* which describes the feeling of the layers of the hernia sac as they slide over the spermatic cord structures with rolling of the spermatic cord beneath the index finger at the pubic tubercle. In the absence of a bulge, the finding of increased thickness of the inguinal canal structures on palpation also suggests the diagnosis of an inguinal hernia. It is important on examination to note the position of the testes because retractile testes are common in infants and young males and can mimic an inguinal hernia with a bulge in the region of the external ring. Because in the female patient approximately 20–25% of inguinal hernias are **sliding** hernias (the contents of the hernia sac are adherent within the sac and therefore not reducible), a fallopian tube or ovary can be palpated in the inguinal canal as a firm, slightly mobile, nontender mass in the labia or inguinal canal. A **femoral** hernia appears as a protrusion on the medial aspect of the thigh, below the inguinal region, and does not enter the scrotum or labia.

Because most hernias in young children reduce spontaneously, the physical examination in the office can be equivocal. Infants and children with a strong history suggestive of inguinal hernia and an equivocal clinical examination may be offered ultrasound or referral to a pediatric surgeon. Diagnostic laparoscopy has been increasingly used to evaluate for suspected inguinal hernia; particularly in infants where the risk of incarceration and potential injury to the intestines or testis is high. In an older child with low risk of incarceration, the parents can be reassured and educated relative to the low risk of incarceration and morbidity. If an inguinal hernia is present, it will predictably become increasingly observed. A plan for a period of observation is thoughtful and safe, and the parents can be asked to take a digital image at home if the bulge is noted.

EVALUATION OF ACUTE INGUINAL-SCROTAL SWELLING

Commonly in pediatric practice, an inguinal-scrotal mass appears suddenly in an infant or child and is associated with pain and discomfort. The differential diagnosis includes incarcerated inguinal hernia, acute hydrocele, torsion of an undescended testis, infection (epididymitis/orchitis), and suppurative inguinal lymphadenitis. Differentiating between the incarcerated inguinal hernia and the acute hydrocele is probably the most difficult. The infant or child with an incarcerated inguinal hernia is likely to have associated findings suggesting intestinal obstruction, such as colicky abdominal pain, abdominal distention, vomiting, and cessation of stool, and may appear ill. Plain radiographs, if obtained, typically demonstrate distended intestines with multiple air-fluid levels. The infant with an acute hydrocele may have discomfort but is consolable and tolerates feedings without signs or symptoms suggesting intestinal obstruction.

On examination of the child with the acute scrotal hydrocele, the clinician may note that the mass is somewhat mobile. In addition, the inguinal region is flat and the mass confined to the scrotum. With the incarcerated hernia, there is a lack of mobility of the groin mass and marked swelling or a mass extending from the scrotal mass through the inguinal area and up to and including the internal ring. An experienced clinician can selectively use a bimanual examination to help differentiate groin abnormalities. The examiner palpates the internal ring per rectum, with the other hand placing gentle pressure on the inguinal region over the internal ring. In cases of an indirect inguinal hernia, intraabdominal viscera can be palpated extending through the internal ring.

Another method used in diagnostic evaluation is **transillumination** to ascertain if the mass contains only fluid (hydrocele) versus intestine (hernia); however, it must be noted that transillumination can be misleading because the thin wall of the infant's intestine can approximate that of the hydrocele wall, and both may transilluminate. This is also the reason aspiration to assess the contents of a groin mass is discouraged. **Ultrasonography** can help distinguish between a hernia, a hydrocele, and lymphadenopathy and is a simple and well-tolerated test. An expeditious diagnosis is important to avoid the potential complications of an incarcerated hernia, which can develop rapidly. Diagnostic laparoscopy is an effective and reliable tool in this setting by pediatric surgeons but requires general anesthesia.

The occurrence of suppurative adenopathy in the inguinal region can be confused with an incarcerated inguinal hernia. Examination of the watershed area of the inguinal lymph nodes might reveal a superficial infected or crusted skin lesion. In addition, the swelling associated with inguinal lymphadenopathy is typically located more inferior and lateral than the mass of an inguinal hernia, and there may be other associated enlarged nodes in the area. Torsion of an undescended testis can manifest as a painful erythematous mass in the groin. The absence of a gonad in the scrotum in the ipsilateral side should clinch this diagnosis. Infectious etiologies typically demonstrate swelling and tenderness of the testis, but often there is associated urinary symptoms and the swelling is confined to the scrotum and does not extend into the inguinal canal.

Incarcerated Hernia

Incarceration is a common consequence of untreated inguinal hernia in infants and presents as a *nonreducible* mass in the inguinal canal, scrotum, or labia. Contained structures can include the small bowel, appendix, omentum, colon, bladder, or, rarely, Meckel diverticulum. In females, the ovary, fallopian tube, or both are commonly incarcerated. Rarely, the uterus in infants can also be pulled into the hernia sac. A **strangulated hernia** is one that is tightly constricted in its passage through the inguinal canal, and as a result, the hernia contents have become ischemic or gangrenous. The incidence of incarceration of an inguinal hernia is between 6% and 18% throughout childhood

years, and two thirds of incarcerated hernias occur in the first year of life. The greatest risk is in infants younger than 6 months of age, with reported incidences of incarceration between 25% and 30%. Reports vary, but many believe a history of prematurity imparts an increased risk of incarceration in the first year of life.

Although incarceration may be tolerated in adults for years, most nonreducible inguinal hernias in children, unless treated, rapidly progress to *strangulation* with potential infarction of the hernia contents or intestinal obstruction. Initially, pressure on the herniated viscera leads to impaired lymphatic and venous drainage. This leads to swelling of the herniated viscera, which further increases the compression in the inguinal canal, ultimately resulting in total occlusion of the arterial supply to the trapped viscera. Progressive ischemic changes take place, culminating in gangrene and/or perforation of the herniated viscera. The testis is at risk of ischemia because of compression of the testicular blood vessels by the strangulated hernia. In females, herniation/incarceration of the ovary places it at risk of torsion with resultant ischemia.

The symptoms of an incarcerated hernia are irritability, feeding intolerance, and abdominal distention in the infant; pain presents in the older child. Within a few hours, the infant becomes inconsolable; lack of flatus or stool signals complete intestinal obstruction. A somewhat tense, nonfluctuant mass is present in the inguinal region and can extend down into the scrotum or labia. The mass is well defined, firm, and does not reduce. With the onset of ischemic changes, the pain intensifies, and the vomiting becomes bilious or feculent. Blood may be noted in the stools. The mass is typically markedly tender, and there is often edema and erythema of the overlying skin. The testes may be normal, demonstrate a reactive hydrocele, or may be swollen and hard on the affected side because of venous congestion resulting from compression of the spermatic veins and lymphatic channels at the inguinal ring by the tightly strangulated hernia mass. Abdominal radiographs demonstrate features of partial or complete intestinal obstruction, and gas within the incarcerated bowel segments may be seen below the inguinal ligament or within the scrotum.

Ambiguous Genitalia

Infants with disorders of sexual development commonly present with inguinal hernias, often containing a gonad, and require special consideration. In female infants with inguinal hernias, particularly if the presentation is bilateral inguinal masses, **testicular feminization syndrome** should be suspected (>50% of patients with testicular feminization have an inguinal hernia; see Chapter 628). Conversely, the true incidence of testicular feminization in all female infants with inguinal hernias is difficult to determine but is approximately 1%. In phenotypic females, if the diagnosis of testicular feminization is suspected preoperatively, the child should be screened with a buccal smear for Barr bodies and appropriate genetic evaluation before proceeding with the hernia repair. The diagnosis of testicular feminization is occasionally made at the time of operation by identifying an abnormal gonad (testis) within the hernia sac or absence of the uterus on laparoscopy or rectal exam. In the normal female infant, the uterus is easily palpated as a distinct midline structure beneath the symphysis pubis on rectal examination. Preoperative diagnosis of testicular feminization syndrome or other disorders of sexual development such as mixed gonadal dysgenesis and selected pseudohermaphrodites enables the family to receive genetic counseling, and gonadectomy can be accomplished at the time of the hernia repair if indicated.

Indications for Surgery

The presence of an inguinal hernia in the pediatric age-group constitutes the indication for operative repair. An inguinal hernia does not resolve spontaneously, and prompt repair eliminates the risk of incarceration and the associated potential complications, particularly in the first 6-12 months of life. The timing of operative repair depends on several factors, including age, general condition of the patient, and comorbid conditions. In full-term, healthy infants (younger than 1 year) with an inguinal hernia, repair should proceed promptly (within 2-3 weeks) after diagnosis because as many as 70% of incarcerated inguinal hernias requiring emergency operation occur in infants younger than 11 months. In addition, the incidence of complications associated with elective hernia repair (intestinal injury, testicular atrophy, recurrent hernia, wound infection) are low (~1%) but rise to as high as 18–20% when repair is performed emergently at the time of incarceration. The incidence of testicular atrophy after incarceration in infants younger than 3 months of age has been reported as high as 30%. Therefore an approach emphasizing prompt elective repair in infants is warranted; anesthetic risks must be considered when determining timing of elective surgery for inguinal hernia repair. The risk factors for apnea after general anesthesia include prematurity, multiple congenital anomalies, history of apnea and bradycardia, chronic lung disease, postconceptual age <60 weeks at the time of surgery, and anemia. Unfortunately, although this group of patients would be ideal for inguinal hernia repair under regional (spinal/caudal) anesthesia, inguinal hernia repair in this group is often remarkably technically challenging even for experienced pediatric surgeons, and success is elusive under regional techniques. The outcome advantage of a regional technique is lost if additional intravenous sedation is required. Institutional policies vary, but in general, full-term infants <50 weeks postconceptual age and preterm infants <55 weeks postconceptual age should be observed after repair for a minimum of 12 hours postoperatively and potentially overnight after general anesthesia for the development of apnea and bradycardia.

In children older than 1 year, the risk of incarceration is less, and the repair can be scheduled with less urgency. For the routine reducible hernia, the operation should be carried out electively shortly after diagnosis. Elective inguinal hernia repair in healthy children can be safely performed in an outpatient setting, with an expectation for full recovery within 48 hours. A regional caudal block or local inguinal nerve block using local anesthetic is useful to diminish perioperative pain and optimize recovery. Prophylactic antibiotics are not routinely used except for associated conditions, such as congenital heart disease or the presence of a ventriculoperitoneal shunt. *The operation should be performed at a facility with the ability to admit the patient to an inpatient unit as needed should concerns or complications arise.*

There is controversy as to the optimal timing of inguinal herniorrhaphy in preterm and low birthweight infants. In the past 2 decades, most pediatric surgeons have planned hernia repair shortly before discharge from the neonatal intensive care unit. This group has a high rate of incarceration but also a high risk of anesthesia-related postoperative complications with elective surgery, such as apnea, bradycardia, inability to extubate, hemodynamic instability (5–10%), and even cardiopulmonary arrest. In addition, this group has an increased rate of postoperative surgical-related complications such as wound infection (5–10%) and recurrent hernia (10%). At present, studies to develop evidence-based data for timing of inguinal hernia repair in premature infants are ongoing, but there is a lack of consensus, and patients should be individualized, with important consultation with both neonatology and pediatric anesthesia. The operation for inguinal hernia repair is most often performed under general anesthesia, but it can be performed under spinal/caudal anesthesia in selected high-risk infants in whom avoidance of intubation is preferable (e.g., because of chronic lung disease or bronchopulmonary dysplasia). In this setting, open repair (OH) is preferable to the laparoscopic approach, as it can be performed under local/regional techniques.

An incarcerated, irreducible hernia without evidence of strangulation in a clinically stable patient should initially be managed nonoperatively, unless there is evidence of bowel obstruction, peritonitis, or hemodynamic instability, because 70–95% of incarcerated inguinal hernias are successfully reduced. Manual reduction is performed using a surgical technique called *taxis,* first with traction caudad and posteriorly to free the mass from the external inguinal ring, and then upward to reduce the contents back into the peritoneal cavity. Reduction attempts usually require sedation (intravenous) and analgesics, and thus appropriate experience with monitoring and airway management are critical concerns. In addition, if reduction of the incarcerated hernia is successful, the infant may rapidly become somnolent and apneic, requiring important supportive measures by skilled personnel. Other techniques advocated to assist in the nonoperative reduction of an incarcerated inguinal hernia include elevation of the lower torso

and legs. Ice packs should be avoided in infants because of the risk of hypothermia but may be used for brief periods in the older child. If reduction is successful but difficult, the patient should be observed for several hours to ensure that feedings are tolerated and there is no concern that necrotic intestine was reduced; fortunately, this is an uncommon occurrence. Given the risk of early recurrent incarceration after a successful reduction, it is recommended that herniorrhaphy be performed after a brief period (1-4 days), by which time there is less edema, handling of the sac is easier, and the risk of complications is reduced.

If the inguinal hernia is unable to be reduced, or there is concern for an incomplete reduction, then operative reduction should be performed emergently. In addition, for any patient who presents with a prolonged history of incarceration of an inguinal hernia, signs of peritoneal irritation, or small bowel obstruction, surgery and operative reduction and repair of the hernia should be urgently performed. Initial management includes nasogastric intubation, intravenous fluids, and administration of broad-spectrum antibiotics. When fluid and electrolyte imbalance has been corrected and the child's condition is satisfactory, exploration is undertaken. In current practice, the laparoscopic approach may have advantages, as the abdominal cavity insufflation expands the internal ring, potentially aiding reduction of the incarcerated viscera and enabling visualization of the viscera for possible ischemic injury and/or perforation. The risk of postoperative complications such as testicular atrophy, bowel ischemia, wound infections, and recurrence of hernia is increased after emergency inguinal hernia repair: 4.5–33% compared with 1% in elective hernia repairs in healthy, full-term infants.

A common presentation in female patients is an irreducible ovary in the inguinal hernia in an otherwise asymptomatic patient. The inguinal mass is soft and nontender to gentle exam, and there is no swelling or edema; thus there are no findings suggesting strangulation. This represents a *sliding* hernia, with the fallopian tube and ovary fused to the wall of the hernia sac preventing reduction to the abdominal cavity. Overzealous attempts to reduce the hernia are unwarranted and potentially harmful to the tube and ovary. The risk that incarceration, most often resulting from torsion of the ovary in this setting, will lead to strangulation is not known. Most pediatric surgeons recommend elective repair of the hernia within 24-48 hours.

The appearance of necrotic ovaries and testes at the time of operation does not consistently provide evidence of irreversible damage or predict future functionality. Multiple studies report that even when ovaries appear persistently ischemic after relief of incarceration and detorsion, most ovaries, if preserved, will recover and demonstrate evidence of follicular development. Similarly, ischemic-appearing testes after relief of incarceration survive in as much as 50% of cases. Testicular atrophy occurs in 2.5–15% of incarcerated hernias. Given the potential for retained functionality, the current recommendation is to avoid testicular resection unless frank necrosis is present.

Open Inguinal Hernia Repair

The operation is performed through a small (2-3 cm) inguinal skin crease incision. The procedure involves opening of the inguinal canal; reduction of the contents of the hernia sac if present, careful separation of the hernia sac from the cremasteric muscle fibers, spermatic cord vessels, and vas deferens to avoid injury to these structures in the inguinal canal, division of the hernia sac, and high ligation of the hernia sac at the internal ring, thus preventing protrusion of abdominal contents into the inguinal canal. A communicating hydrocele is approached with the same technique, separation of the spermatic cord structures from the hernia sac, high ligation of the proximal portion of the hernia sac, and opening of the distal sac to relieve the hydrocele. In older children with a noncommunicating hydrocele, the approach may be through a scrotal incision with avoidance of manipulation of the spermatic cord vessels and vas deferens. Open inguinal hernia repair has a low rate of recurrence, vas deferens injury, and testicular atrophy (~1–2%).

In females, surgical repair is technically simpler because the hernia sac and round ligament can be ligated without concern for injury to the ovary and its blood supply, which generally remain within the abdomen. The hernia sac and round ligament are divided from their distal attachment in the labia majora, proximal dissection away from the cremasteric muscle fibers to the internal ring, and high ligation at the internal ring. In female infants, opening of the sac to visualize the ovary and fallopian tube may help avoid injury to these structures during suture ligation of the sac and also rule out testicular feminization syndrome. If the ovary and fallopian tube are within the sac and not reducible, the sac is suture ligated distal to these structures, and the internal ring is closed after reducing the sac and its contents to the abdominal cavity.

Laparoscopic Inguinal Hernia Repair

Laparoscopic repair (LH) is used by most pediatric surgeons. There are several techniques described, both transperitoneal and preperitoneal, depending on surgeon preference. The laparoscopic technique is fundamentally a high ligation of the indirect inguinal hernia sac (PV) at the internal ring to prevent protrusion of abdominal viscera into the inguinal canal. The laparoscopic technique affords confirmation of the diagnosis and inspection of the contralateral side for the presence of a hernia or a patent PV (potential hernia). Reported advantages of laparoscopic repair (LH) compared with open repair (OH) include better cosmesis, shorter length of stay (LOS), faster recovery, and greater ability to visualize and repair a contralateral hernia.

In LH, the inguinal canal is not explored, and the spermatic cord structures are not manipulated, which may portend reduced risk to the testicular blood supply or vas deferens, particularly in younger patients. Disadvantages of LH in infants and younger children are the increased risk associated with general anesthesia, the potential hemodynamic effects of abdominal insufflation (e.g., acidosis, compromised venous return), and technical challenges of the LH technique. Operative times have been similar for the OH and LH approaches; however, there is wide variability with the LH technique based on the experience of the surgeon and surgical team. Laparoscopic procedures in infants should always be performed expeditiously and with low insufflation pressure to avoid the risk of cardiorespiratory compromise and development of acidosis. Postoperative pain in both techniques is managed with oral acetaminophen for 24-48 hours; older children may require a brief period of postoperative NSAIDs or narcotics. In a prospective, randomized study, the laparoscopic approach was associated with decreased pain, parental perception of faster recovery, and parental perception of better wound cosmesis. At present, outcomes, recurrence rates, recovery metrics, complications, and family satisfaction appear similar for both approaches (OH and LH), and evidence is lacking to recommend one approach over the other.

Contralateral Inguinal Exploration

Most children (85%) present with a unilateral inguinal hernia. Controversy exists regarding when to proceed with contralateral groin exploration. The only purpose of contralateral exploration is to avoid the occurrence of a hernia on that side at a later date. The advantages of contralateral exploration include avoidance of parental anxiety and possibly a second anesthesia, the cost of additional surgery, and the risk of contralateral incarceration. The disadvantages of exploration include potential injury to the spermatic cord vessels, vas deferens, and testis and increased operative and anesthesia time.

Laparoscopy enables assessment of the contralateral side without risk of injury to the spermatic cord structures or testis. When performing OH repair, the laparoscope can be introduced through an umbilical incision or by passing a 30-degree or 70-degree oblique scope through the OH sac before ligation of the hernia sac on the involved side. If patency of the contralateral side is demonstrated, the surgeon can proceed with bilateral hernia repair, and if the contralateral side is properly obliterated, exploration and potential complications are avoided. When performing LH, visualization of the contralateral side is easily performed. The downside of this approach includes the risks associated with laparoscopy and that laparoscopy cannot differentiate between a patent PV and a true hernia (Figs. 394.2 and 394.3). In experienced hands, ultrasound has been proven to be a good alternative to surgical approaches to explore the contralateral groin. Infants and children

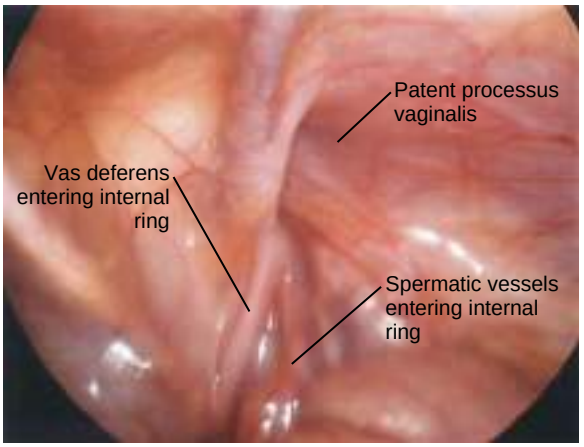

Fig. 394.2 Laparoscopic image of patent processus vaginalis on right side.

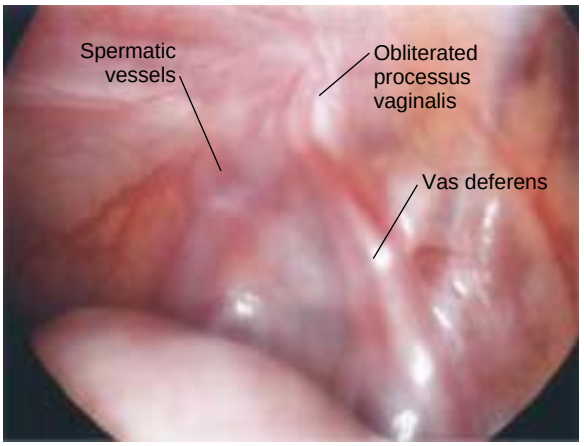

Fig. 394.3 Diagnostic laparoscopic image of obliterated processus vaginalis on left side.

with risk factors for development of an inguinal hernia or with medical conditions that increase the risk of general anesthesia should be approached with a low threshold for routine contralateral exploration.

DIRECT INGUINAL HERNIA

Direct inguinal hernias are rare in children, approximately 0.5–1%. Direct hernias appear as groin masses that extend toward the femoral vessels with exertion or straining. The etiology is from a muscular defect or weakness in the floor of the inguinal canal *medial* to the epigastric vessels. Thus direct inguinal hernias in children are generally considered an acquired problem. In one third of cases, the patient has a history of a prior indirect hernia repair on the side of the direct hernia, which suggests a possible missed direct hernia at the initial surgery or injury to the floor muscles of the inguinal canal at the time of the first herniorrhaphy. Patients with **connective tissue disorders** such as Ehlers-Danlos syndrome or Marfan syndrome and mucopolysaccharidosis such as Hunter-Hurler syndrome are at increased risk for the development of direct inguinal hernias either independently or after indirect inguinal hernia repair.

Operative repair of a direct inguinal hernia involves strengthening of the floor of the inguinal canal, and many standard techniques have been described, similar to repair techniques used in adults. The repair can be performed through a single limited incision, and therefore LH does not offer a significant advantage. Recurrence after repair, in contrast to that in adults, is extraordinarily rare. Because typically the area of muscular weakness is small and pediatric tissues have greater elasticity, primary repair is usually possible. Prosthetic material (mesh) for direct hernia repair or other approaches, such as preperitoneal repair, are rarely required in the pediatric age-group. The older child with a direct inguinal hernia and a connective tissue disorder may be the exception, and a laparoscopic approach and prosthetic material in such a case can be useful for repair.

FEMORAL HERNIA

Femoral hernias are rare in children (<1% of groin hernias in children). They are more common in females than in males (2:1 ratio). They are extremely rare in infancy and occur typically in older children, believed to most often be an acquired defect. Femoral hernias represent a protrusion through the femoral canal. The bulge of a femoral hernia is located below the inguinal ligament and typically projects on the medial aspect of the proximal thigh. Femoral hernias are more often missed clinically than direct hernias on physical examination or at the time of indirect hernia repair. Repair of a femoral hernia involves closure of the defect at the femoral canal, generally suturing the inguinal ligament to the pectineal ligament/fascia.

COMPLICATIONS

Complications after elective inguinal hernia repair are uncommon (~1.5%) but significantly higher in association with incarceration (~10%). The major risk of elective inguinal hernia repair in infants and children relates to the need for general anesthesia, and spinal/caudal anesthesia should be considered based on the experience of the surgeon and anesthesia team. Surgical complications can be related to technical factors (recurrence, iatrogenic cryptorchidism or *trapped testicle,* inadvertent injury to the vas deferens or spermatic vessels) or to the underlying process, such as bowel ischemia, gonadal infarction, and testicular atrophy after incarceration. Because LH repair generally does not involve inguinal exploration or manipulation of the testicular vessels or vas deferens, the risk of injury is potentially lower, but supportive data are unavailable at present.

Wound Infection

Wound infection occurs in <1% of elective inguinal hernia repairs in infants and children, but the incidence increases to 5–7% in association with incarceration and emergent repair. The patient typically develops fever and irritability 3-5 days after the surgery, and the wound demonstrates warmth, erythema, and fluctuance. Management consists of opening and draining the wound, a short course of antibiotics, and a daily wound dressing. The most common organisms are gram-positive (*Staphylococcus* and *Streptococcus* spp.), and consideration should be given to coverage of methicillin-resistant *Staphylococcus aureus.* The wound generally heals in 1-2 weeks with low morbidity and a good cosmetic result.

Recurrent Hernia

The recurrence rate of inguinal hernias after elective inguinal hernia repairs is generally reported as 0.5–1.0%, with rates as high as 2% for premature infants. The rate of recurrence after emergency repair of an incarcerated hernia is much higher, reported as 3–6% in most large series. The true incidence of recurrence is most certainly even higher, given the problem of accurate long-term follow-up. In the group of patients who develop recurrent inguinal hernia, the recurrence occurs in 50% within 1 year of the initial repair and in 75% by 2 years. Recurrence of an indirect hernia may be the result of a technical problem in the original procedure, such as failure to identify the sac properly, failure to perform high ligation of the sac at the level of the internal ring, or a tear in the sac that leaves a strip of peritoneum along the cord structures. Recurrence as a direct hernia can result from injury to the inguinal floor (transversalis fascia) during the original procedure or, more likely, failure to identify a direct hernia during the original exploration. Patients with *connective tissue disorders* (collagen deficiency) or

conditions that cause *increased intraabdominal pressure* (ventriculoperitoneal shunts, ascites, chronic lung disease, peritoneal dialysis) are at increased risk for recurrence.

Iatrogenic Cryptorchidism (Trapped Testicle)

Iatrogenic cryptorchidism describes malposition of the testis after inguinal hernia repair. This complication is usually related to disruption of the testicular attachment in the scrotum at the time of hernia repair or failure to recognize an undescended testis during the original procedure, allowing the testes to retract, typically to the region of the external ring. At the completion of inguinal hernia repair, the testis should be placed in a dependent intrascrotal position. If the testis will not remain in this position, proper fixation in the scrotum should be performed at the time of the hernia repair.

Incarceration

Incarceration of an inguinal hernia can result in injury to the intestines, the fallopian tube and ovary, or the ipsilateral testis. The incidence of incarceration of a congenital indirect inguinal hernia is reported as 6–18% throughout childhood and as high as 30% for infants younger than 6 months of age. Intestinal injury requiring bowel resection is uncommon, occurring in only 1–2% of incarcerated hernias. In cases of incarceration in which the hernia is reduced nonoperatively, the likelihood of intestinal injury is low; however, these patients should be observed closely for 6-12 hours after reduction of the hernia for signs and symptoms of intestinal obstruction, such as fever, vomiting, abdominal distention, or bloody stools. Laparoscopy affords the opportunity to inspect the reduced viscera for injury or necrosis in select cases.

The reported incidence of testicular infarction and subsequent testicular atrophy with incarceration is 4–12%, with higher rates among the irreducible cases requiring emergency operative reduction and repair. The testicular insult can be caused by compression of the gonadal vessels by the incarcerated hernia mass or as a result of damage incurred during operative repair. Young infants are at highest risk, with testicular infarction rates reported as high as 30% in infants younger than 2-3 months of age. These problems underscore the need for prompt reduction of incarcerated hernias and early repair once the diagnosis is known to avoid repeat episodes of incarceration.

Injury to the Vas Deferens and Male Fertility

Similar to the gonadal vessels, the vas deferens can be injured as a consequence of compression from an incarcerated hernia or during operative repair. This injury is almost certainly underreported because it is unlikely to be recognized until adulthood and, even then, possibly only if the injury is bilateral. Although the vulnerability of the vas deferens has been documented in many studies, no good data exist as to the actual incidence of this complication. One review reported an incidence of injury to the vas deferens of 1.6% based on pathology demonstrating segments of the vas deferens in the hernia sac specimen; this may be overstated, because others have shown that small glandular inclusions found in the hernia sac can represent müllerian duct remnants and are of no clinical importance. The relationship between male fertility and previous inguinal hernia repair is also unknown. There appears to be an association between infertile males with testicular atrophy and abnormal sperm count and a previous hernia repair. A relationship has also been reported between infertile males with spermatic autoagglutinating antibodies and previous inguinal hernia repair. The proposed etiology is that operative injury to the vas deferens during inguinal hernia repair might result in obstruction of the vas with diversion of spermatozoa to the testicular lymphatics, and this breach of the blood-testis barrier produces an antigenic challenge, resulting in formation of spermatic autoagglutinating antibodies.

Visit Elsevier eBooks+ at eBooks.Health.Elsevier.com for Bibliography.

Section 5

Exocrine Pancreas

Chapter 395

Embryology, Anatomy, and Physiology of the Pancreas

Steven L. Werlin and Michael Wilschanski

INTRODUCTION

The human pancreas develops from the ventral and dorsal domains of the primitive duodenal endoderm beginning at about the fifth week of gestation (Fig. 395.1). The larger dorsal anlage, which develops into the tail, body, and part of the head of the pancreas, grows directly from the duodenum. The smaller ventral anlage develops as one or two buds from the primitive liver and eventually forms the major portion of the head of the pancreas. At about the 17th week of gestation, the dorsal and ventral anlagen fuse as the buds develop and the gut rotates. The ventral duct forms the proximal portion of the major pancreatic duct of Wirsung, which opens into the ampulla of Vater. The dorsal duct forms the distal portion of the duct of Wirsung and the accessory duct of Santorini, which empties independently in approximately 5% of people. Variations in fusion might account for pancreatic developmental anomalies. Pancreatic agenesis has been associated with a base pair deletion in the insulin promoter factor 1-*HOX* gene, *PDX1 (PAGEN1)*, *PTF1A (PAGEN 2)*, and *GATA 6 haploinsufficiency* genes. Other genes involved in pancreatic organogenesis include the *IHH*, *SHH* or sonic hedgehog gene, *SMAD2*, and *TGF-1β* genes.

The pancreas lies transversely in the upper abdomen between the duodenum and the spleen in the retroperitoneum (Fig. 395.2). The head, which rests on the vena cava and renal vein, is adherent to the C loop of the duodenum and surrounds the distal common bile duct. The tail of the pancreas reaches to the left splenic hilum and passes above the left kidney. The lesser sac separates the tail of the pancreas from the stomach.

By the 13th week of gestation, exocrine and endocrine cells can be identified. Primitive acini containing immature zymogen granules are found by the 16th week. Mature zymogen granules containing amylase, trypsinogen, chymotrypsinogen, and lipase are present at the 20th week. Centroacinar and duct cells, which are responsible for water, electrolyte, and bicarbonate secretion, are also found by the 20th week. The final three-dimensional structure of the pancreas consists of a complex series of branching ducts surrounded by grapelike clusters of epithelial cells. Cells containing glucagon are present at the 8th week. Islets of Langerhans appear between the 12th and 16th weeks.

Visit Elsevier eBooks+ at eBooks.Health.Elsevier.com for Bibliography.

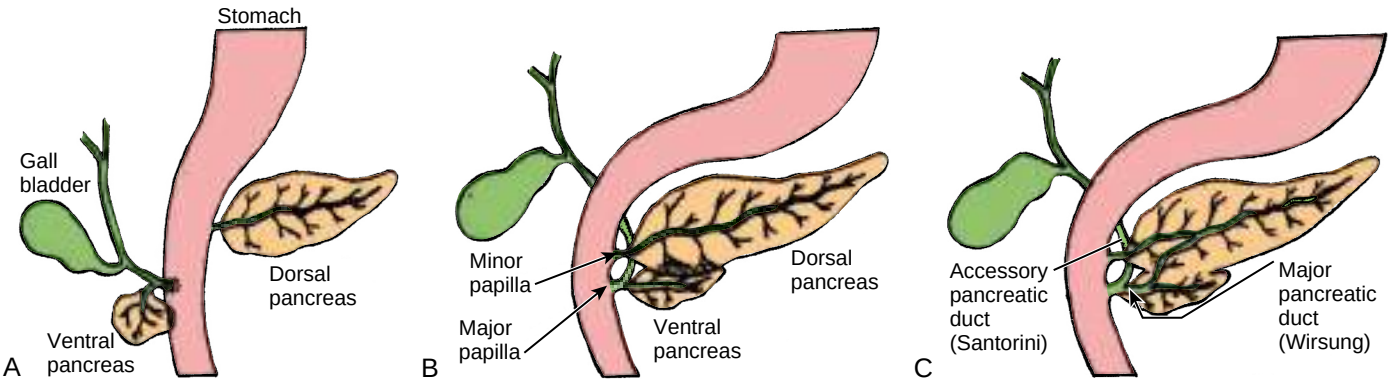

Fig. 395.1 Development of the exocrine pancreas. **A,** Gestational age 6 wk. **B,** Gestational age 7-8 wk. The ventral pancreas has rotated but has not yet fused with the dorsal pancreas. **C,** The ventral and dorsal pancreatic ductal systems have fused. *(From Werlin SL. The exocrine pancreas. In: Kelly VC, ed. Practice of Pediatrics, vol 3. Hagerstown, MD: Harper and Row, 1980: Fig. 16.1.)*

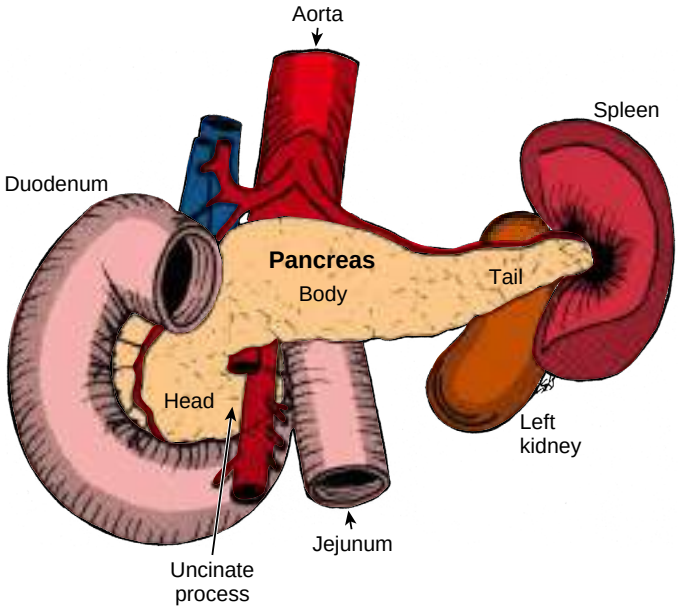

Fig. 395.2 Anterior view of the pancreas and relationship to neighboring structures. *(From Werlin SL. The exocrine pancreas. In: Kelly VC, ed. Practice of Pediatrics, vol 3. Hagerstown, MD: Harper and Row, 1980: Fig. 16.2.)*

395.1 Pancreatic Anatomic Abnormalities

Steven L. Werlin and Michael Wilschanski

Complete or partial **pancreatic agenesis** is a rare condition. Complete agenesis is associated with severe neonatal diabetes and usually death at an early age (see Chapter 629). Partial or dorsal pancreatic agenesis is often asymptomatic but may be associated with diabetes, congenital heart disease, polysplenia, and recurrent pancreatitis. Pancreatic agenesis is also associated with malabsorption.

An **annular pancreas** results from incomplete rotation of the left (ventral) pancreatic anlage, which may be a result of recessive pathogenic variants in the *IHH* or *SHH* genes. Patients usually present in infancy with symptoms of complete or partial bowel obstruction or in the fourth or fifth decade. There is often a history of maternal polyhydramnios. Other congenital anomalies, such as Down syndrome, tracheoesophageal fistula, intestinal atresia, imperforate anus, malrotation and cardiorenal abnormalities, and pancreatitis, may be associated with annular pancreas. Some children present with chronic vomiting, pancreatitis, or biliary colic. The treatment of choice is duodenojejunostomy. Division of the pancreatic ring is not attempted because a duodenal diaphragm or duodenal stenosis often accompanies annular pancreas.

Ectopic pancreatic rests in the stomach or small intestine occur in approximately 3% of the population. Most cases (70%) are found in the upper intestinal tract. Recognized on barium contrast studies by their typical umbilicated appearance, they are rarely of clinical importance. On endoscopy, they are irregular, yellow nodules 2-4 mm in diameter. A pancreatic rest may rarely be the lead point of an intussusception, produce hemorrhage, or cause bowel obstruction.

Pancreas divisum, which occurs in 5–15% of the population, is the most common pancreatic developmental anomaly. Because of the failure of the dorsal and ventral pancreatic anlagen to fuse, the tail, body, and part of the head of the pancreas drain through the small accessory duct of Santorini rather than the main duct of Wirsung. Some researchers believe that this anomaly may be associated with recurrent pancreatitis when there is relative obstruction of the outflow of the ventral pancreas. Diagnosis is made by endoscopic retrograde cholangiopancreatography or by magnetic resonance cholangiopancreatography. Pancreatitis in patients with pancreas divisum may be associated with pathogenic *CFTR* variants. Sphincterotomy is not recommended unless other anomalies are present or the patient has classic pancreatobiliary-type pain, recurrent pancreatitis, or chronic pancreatitis, and no other etiology is found.

Choledochal cysts are dilations of the biliary tract and usually cause biliary tract symptoms, such as jaundice, pain, and fever. On occasion, the presentation may be pancreatitis. The diagnosis is usually made with ultrasonography, CT or biliary scanning, or magnetic resonance cholangiopancreatography. Similarly, a choledochocele—an intraduodenal choledochal cyst—may manifest with pancreatitis. The diagnosis can be difficult and require magnetic resonance cholangiopancreatography, endoscopic retrograde cholangiopancreatography, or endoscopic ultrasound.

A number of rare conditions, such as Ivemark (pathogenic variant in *GDF* gene) and Johanson-Blizzard (pathogenic variant in *UBR1* gene) syndromes, include pancreatic dysgenesis or dysfunction among their features. Many of these syndromes include renal and hepatic dysgenesis along with the pancreatic anomalies.

Visit Elsevier eBooks+ at eBooks.Health.Elsevier.com for Bibliography.

395.2 Pancreatic Physiology

Steven L. Werlin and Michael Wilschanski

The acinus is the functional unit of the exocrine pancreas. Acinar cells are arrayed in a semicircle around a lumen. Ducts that drain the acini are lined by centroacinar and ductular cells. This arrangement allows the secretions of the various cell types to mix.

The acinar cell synthesizes, stores, and secretes more than 20 enzymes, which are stored in zymogen granules, some in inactive forms. The relative concentration of the various enzymes in pancreatic juice is affected and perhaps controlled by the diet, probably by regulating the synthesis of specific messenger RNA. The main enzymes involved in digestion include *amylase*, which splits starch into maltose, isomaltose, and maltotriose; dextrins; and *trypsin* and *chymotrypsin*, endopeptidases secreted by the pancreas as inactive proenzymes. Trypsinogen is activated in the gut lumen by enterokinase, a brush-border enzyme. Trypsin can then activate trypsinogen, chymotrypsinogen, and procarboxypeptidase into their respective active forms. Pancreatic lipase requires *colipase*, a coenzyme also found in pancreatic fluid, for activity. Lipase liberates fatty acids from the 1 and 3 positions of triglycerides, leaving a monoglyceride.

The stimuli for exocrine pancreatic secretion are neural and hormonal. Acetylcholine mediates the cephalic phase; cholecystokinin (CCK) mediates the intestinal phase. CCK is released from the duodenal mucosa by luminal amino acids and fatty acids. Feedback regulation of pancreatic secretion is mediated by pancreatic proteases in the duodenum. Secretion of CCK is inhibited by the digestion of a trypsin-sensitive, CCK-releasing peptide released in the lumen of the small intestine or by a monitor peptide released in pancreatic fluid.

Centroacinar and duct cells secrete water and bicarbonate. Bicarbonate secretion is under feedback control and is regulated by duodenal intraluminal pH. The stimulus for bicarbonate production is secretin in concert with CCK. Secretin cells are abundant in the duodenum.

Although normal pancreatic function is required for digestion, maldigestion occurs only after considerable reduction in pancreatic function; lipase and colipase secretion must be decreased by 90–98% before fat maldigestion occurs.

Although amylase and lipase are present in the pancreas early in gestation, secretion of both amylase and lipase is low in infants. Adult levels of these enzymes are not reached in the duodenum until late in the first year of life. Digestion of the starch found in many infant formulas depends in part on the low levels of salivary amylase that reach the duodenum. This explains the diarrhea that may be seen in infants who are fed formulas high in glucose polymers or starch. Neonatal secretion of trypsinogen and chymotrypsinogen is at approximately 70% of the level found in the 1-year-old infant. The low levels of amylase and lipase in duodenal contents of infants may be partially compensated by salivary amylase and lingual lipase. This explains the relative starch and fat intolerance of premature infants.

Visit Elsevier eBooks+ at eBooks.Health.Elsevier.com for Bibliography.

Chapter 396
Pancreatic Function Tests

Michael Wilschanski and Steven L. Werlin

Pancreatic function can be measured by direct and indirect methods. An indirect test, the measurement of *fecal elastase*, which is the standard screening test for pancreatic insufficiency, has a sensitivity and specificity >90%. When compared with a 72-hour fecal fat content in both pancreatic insufficient and sufficient patients, an elastase value of 100 μg/g stool has a 99% predictive value in ruling out pancreatic insufficiency based on an abnormal fecal fat finding. Falsely abnormal results can occur in many enteropathies and when the stool is very loose.

DIRECT TESTS

Classically, a triple-lumen tube was used to isolate the pancreatic secretions in the duodenum. Measurement of bicarbonate concentration and enzyme activity (*trypsin*, *chymotrypsin*, *lipase*, and *amylase*) is performed on the aspirated secretions. This test is cumbersome and infrequently used in children. Endoscopic collection of pancreatic secretions after stimulation with secretin and/or cholecystokinin is the commonly used direct test.

A 72-hour stool collection for quantitative analysis of fat content is the gold standard for the diagnosis of *malabsorption*. The collection can be performed at home, and the parent is asked to keep a careful dietary record, from which fat intake is calculated. A preweighed, sealable plastic container is used, which the parent keeps in the freezer. Freezing helps to preserve the specimen and reduce odor. Infants are dressed in disposable diapers with the plastic side facing the skin so that the complete sample can be transferred to the container. Normal fat absorption is >93% of intake. The presence of fat malabsorption does not differentiate between pancreatic dysfunction and enteropathies, such as celiac disease. Qualitative examination of the stool for microscopic fat globules can give false-positive and false-negative results.

Visit Elsevier eBooks+ at eBooks.Health.Elsevier.com for Bibliography.

Chapter 397
Disorders of the Exocrine Pancreas

Steven L. Werlin and Michael Wilschanski

DISORDERS ASSOCIATED WITH PANCREATIC INSUFFICIENCY

Other than cystic fibrosis (CF), conditions that cause pancreatic insufficiency are very rare in children. They include Shwachman-Diamond syndrome (SDS), Johanson-Blizzard syndrome, Ivemark syndrome, Pearson syndrome, isolated enzyme deficiencies (see Chapter 385.8), enterokinase deficiency, chronic pancreatitis, protein-calorie malnutrition (see Chapters 64 and 385.7), and IMNEPD (infantile onset multisystem neurologic, endocrine, and pancreatic disease).

CYSTIC FIBROSIS

See Chapter 454.

By the end of the first year of life, 85–90% of children with CF have pancreatic insufficiency, which, if untreated, will lead to malnutrition. Treatment of the associated pancreatic insufficiency leads to improvement in absorption, better growth, and more normal stools. Pancreatic function can be monitored in children with CF with serial measurements of fecal elastase. Between 10–15% of children present with a *neonatal* intestinal obstruction called **meconium ileus**; in later life, a common intestinal complication is **distal intestinal obstruction syndrome,** which is unique to CF.

Ten percent of CF patients develop severe liver disease. Between 10–15% of CF patients are pancreatic sufficient, and their presentation tends to be later in life, including recurrent pancreatitis, male infertility, and chronic bronchiectasis. CF is part of the newborn screen in every state in the United States and in most countries in the Western world. Pathogenic gene variant specific therapy has caused great improvements in pulmonary function and weight gain, which is probably a direct effect on the gastrointestinal tract. The first drug to be released, Ivacaftor, reduced the number of episodes of pancreatitis in CF patients who were prone to recurrent pancreatitis; in younger patients, fecal elastase was significantly increased.

SHWACHMAN-DIAMOND SYNDROME

See Chapter 171.

SDS is an autosomal recessive syndrome (1/20,000 births) caused by a pathogenic variant of the Shwachman-Bodian-Diamond syndrome *(SBDS)* gene on chromosome 7, which causes ribosomal dysfunction in 90–95% of patients. Signs and symptoms of SDS include pancreatic insufficiency, neutrophil chemotaxis defects, metaphyseal dysostosis, failure to thrive, short stature, and neutropenia, which may be cyclic. Some patients with SDS have liver or kidney involvement, dental disease, or learning difficulty. SDS is a common cause of congenital neutropenia.

Patients typically present in infancy with poor growth and steatorrhea. More varied phenotypes have been described, including absence of pancreatic lipomatosis on imaging, normal fecal elastase levels, and normal skeletal survey. These children can be readily differentiated from those with CF by their normal sweat chloride levels, lack of pathogenic variants in the CF gene, characteristic metaphyseal lesions, and fatty pancreas characterized by a hypodense appearance on CT and MRI scans (Fig. 397.1).

Despite adequate pancreatic replacement therapy and correction of malabsorption, poor growth commonly continues. Pancreatic insufficiency is often transient, and steatorrhea frequently spontaneously improves with age. Recurrent pyogenic infections (otitis media, pneumonia, osteomyelitis, dermatitis, sepsis) are frequent and are a common cause of death. Thrombocytopenia is found in 70% of patients and anemia in 50%. Development of aplastic anemia or a *myelodysplastic syndrome* can occur, with transformation to *acute myeloid leukemia* in 24%. The pancreatic acini are replaced by fat with little fibrosis. Islet cells and ducts are normal. Bone marrow transplant is the treatment of choice in patients who develop acute myeloid leukemia.

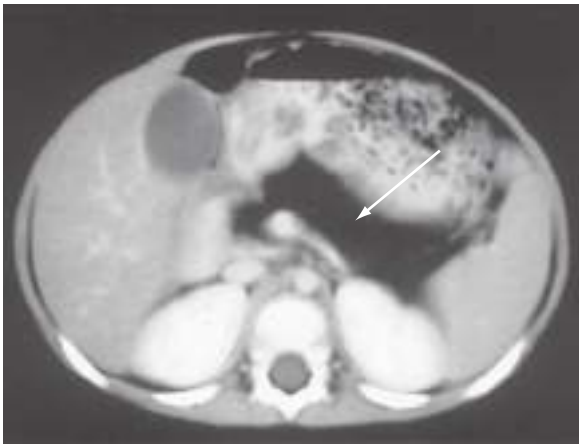

Fig. 397.1 CT appearance of the pancreas in a patient with Shwachman-Diamond syndrome. Note that the pancreas *(arrow)* retains a typical size and shape, but it is highly fatty and therefore appears as a very low-density structure. *(Courtesy Prof. Peter Durie, Hospital for Sick Children, Toronto, Ontario.)*

PEARSON SYNDROME

Pearson (marrow-pancreas) syndrome is caused by a contiguous mitochondrial gene depletion involving several mitochondrial genes affecting oxidative phosphorylation, which manifests in infants with severe macrocytic anemia and variable thrombocytopenia. The bone marrow demonstrates vacuoles in erythroid and myeloid precursors as well as ringed sideroblasts. In addition to its role in severe bone marrow failure, pancreatic insufficiency contributes to growth failure. Mitochondrial DNA mutations are transmitted through maternal inheritance to both sexes or are sporadic.

JOHANSON-BLIZZARD SYNDROME

The features of Johanson-Blizzard syndrome include exocrine pancreatic deficiency, aplasia or hypoplasia of the alae nasi, congenital deafness, hypothyroidism, developmental delay, short stature, ectodermal scalp defects, absence of permanent teeth, urogenital malformations, and imperforate anus. This syndrome is caused by a pathogenic variant in the *UBR1* gene found on chromosome 15.

ISOLATED ENZYME DEFICIENCIES

Isolated deficiencies of trypsinogen, enterokinase, lipase, and colipase have been reported. Although enterokinase is a brush-border enzyme, deficiency causes pancreatic insufficiency because enterokinase is required to activate trypsinogen to trypsin in the duodenum. Deficiencies of trypsinogen or enterokinase manifest with failure to thrive, hypoproteinemia, and edema. Isolated amylase deficiency is typically developmental and resolves by age 2-3 years.

OTHER SYNDROMES ASSOCIATED WITH PANCREATIC INSUFFICIENCY

Pancreatic agenesis, congenital pancreatic hypoplasia, and congenital rubella are rare causes of pancreatic insufficiency. Pancreatic insufficiency has also been reported in celiac disease and inflammatory bowel disease. It may occur in duodenal atresia and stenosis and may also be seen in infants with familial or nonfamilial hyperinsulinemic hypoglycemia after a 95–100% pancreatectomy to control hypoglycemia. Pathogenic variants in at least six genes have been described. Pancreatic insufficiency, which may be found in children with celiac disease and undernutrition, recovers with nutritional rehabilitation.

Infantile onset multisystem neurology endocrine and pancreatic disease (IMNEPD) is a rare disease caused by pathogenic variants in the *PTRH2* gene. Neurologic features dominate the phenotype (microcephaly, intellectual disability, cerebellar atrophy, deafness, and neuropathy), but pancreatic insufficiency is seen in most patients.

Visit Elsevier eBooks+ at eBooks.Health.Elsevier.com for Bibliography.

Chapter 398

Treatment of Pancreatic Insufficiency

Michael Wilschanski and Steven L. Werlin

The most important treatment of pancreatic insufficiency (PI) is pancreatic enzyme replacement therapy (PERT). In modern enzyme capsules, the enzymes are enterically coated to protect the enzymes from degradation by gastric acid and from autodigestion in the small intestine. It is common for patients to change from one product to another using a 1:1 lipase ratio and then titrating for maximum efficacy (Table 398.1).

The North American CF Foundation has published dosing guidelines based on age and fat ingestion (Table 398.2). Because these products contain excess protease compared with lipase, the dosage is estimated from the lipase requirement. The final dosage of PERT for children is often established by trial and error. An adequate dose is one that is followed by resumption of normal growth and the return of stools to normal fat content, which, when desired, can be verified by a 72-hour fecal fat collection and normalization of stool consistency and color. Because there is no elastase in enzyme preparations, fecal elastase cannot be used to monitor appropriateness of PERT dosage. Enzyme replacement should be divided and given at the beginning of and during the meal. Enzymes should not be chewed, crushed, or dissolved in food, which would allow gastric acid to penetrate the enteric coating and destroy the enzymes. Enzymes must also be given with snacks that contain fat. Increasing enzyme supplements beyond the recommended dose does not improve absorption, might retard growth, and can cause fibrosing colonopathy (see later).

Table 398.1 FDA-Approved Pancreatic Enzyme Replacement Products for Exocrine Pancreatic Insufficiency*

DRUG	AVAILABLE STRENGTHS
IMMEDIATE-RELEASE	
Viokace (Allergan)‡,§,‖	10,440 or 20,880 units of lipase¶
DELAYED-RELEASE	
Creon (AbbVie)	3,000, 6,000, 12,000, 24,000, or 36,000 USP units of lipase¶,**
Pancreaze (Janssen)	2,600, 4,200, 10,500, 16,800, or 21,000 units of lipase¶,**
Pertzye (Digestive Care)	4,000, 8,000, 16,000, or 24,000 units of lipase¶,**
Zenpep (Allergan)	3,000, 5,000, 10,000, 15,000, 20,000, 25,000, or 40,000 units of lipase¶,**

*Pancrelipase products are not interchangeable. All of these products contain a combination of porcine-derived lipases, proteases, and amylases.
‡Viokace is only approved for use in adults.
§Should be used in combination with a proton pump inhibitor to maximize absorption in the duodenum.
‖FDA-approved only for treatment of adults with EPI because of chronic pancreatitis or pancreatectomy.
¶Should not be crushed or chewed.
**Capsules can be opened and contents sprinkled on soft acidic food (pH ≤ 4.5) such as applesauce.
From The Medical Letter. Pancreatic enzyme replacement products. Med Lett. 2017;59(1531):170.

Table 398.2 Pancreatic Enzyme Replacement Therapy: North American CF Foundation Consensus Statement

Infants (up to 12 mo)	2,000-4,000 U lipase/120 mL breast milk or formula
12 mo to 4 yr	1,000 U lipase/kg/meal initially, then titrate per response
Children >4 yr and adults	500 U lipase/kg/meal initially, up to maximum of 2,500 U lipase/kg/meal or 10,000 U lipase/kg/day or 4,000 U lipase/g fat ingested per day

PLUS: one half the standard meal dose to be given with snacks.

A major concern has been the ingestion of enzymes by infants. The importance of correct enzyme ingestion in infants and children is obvious, but there may be difficulty in feeding the infant microspheres, however small they may be. Enterically coated microspheres can be mixed with applesauce for oral use or crushed for use in tube feeding. Patients treated with this approach do achieve growth and weight gain. Pancreatic enzymes specifically prepared for infants and young children with smaller granules have been developed.

Treatment of exocrine PI by oral enzyme replacement usually corrects protein malabsorption, but steatorrhea is difficult to correct completely. Factors contributing to fat malabsorption include inadequate dosage, incorrect timing of doses in relation to food consumption or gastric emptying, lipase inactivation by gastric acid, and the observation that *chymotrypsin* in the enzyme preparation digests and thus inactivates *lipase*.

When adequate fat absorption is not achieved, gastric acid neutralization with an H_2-receptor antagonist or, more commonly, a proton pump inhibitor, decreases enzyme inactivation by gastric acid and thus improves delivery of lipase into the intestine. Enteric coating also protects lipase from acid inactivation.

Untoward effects secondary to PERT include allergic reactions and kidney stones. Fibrosing colonopathy, consisting of colonic fibrosis and strictures, can occur 7-12 months after severe overdose of PERT. This iatrogenic complication is now very uncommon.

Fat-soluble vitamin supplements are required by PI patients because of the ongoing mild to moderate fat malabsorption that occurs despite PERT.

Knowledge of novel mechanisms affecting absorption, such as intestinal microbiota, may, in the future, be therapeutic targets in the treatment of exocrine pancreatic insufficiency.

Visit Elsevier eBooks+ at eBooks.Health.Elsevier.com for Bibliography.

Chapter 399
Pancreatitis

399.1 Acute Pancreatitis

Steven L. Werlin and Michael Wilschanski

Acute pancreatitis (AP) is the most common pancreatic disorder in children; 50 or more cases are usually seen in major pediatric centers per year. In children, blunt abdominal injuries, multisystem disease such as the hemolytic uremic syndrome and inflammatory bowel disease, biliary stones or microlithiasis (sludging), and drug toxicity are the most common etiologies. Although many drugs and toxins can induce AP in susceptible persons, in children, valproic acid, L-asparaginase, 6-mercaptopurine, and azathioprine are the most common causes of drug-induced pancreatitis. Alcohol should be considered in adolescents. Other cases follow organ transplantation or are caused by infections, metabolic disorders, or mutations in susceptibility genes. Only 10–20% of cases are idiopathic (Table 399.1).

After an initial insult, such as ductal disruption or obstruction, there is premature activation of trypsinogen to trypsin within the acinar cell. Trypsin then activates other pancreatic proenzymes, leading to autodigestion, further enzyme activation, and release of active proteases. Lysosomal hydrolases co-localize with pancreatic proenzymes within the acinar cell. Pancreastasis (similar in concept to cholestasis) with continued synthesis of enzymes occurs. Lecithin is activated by phospholipase A_2 into the toxic lysolecithin. Prophospholipase is unstable and can be activated by minute quantities of trypsin. After the insult, cytokines and other proinflammatory mediators are released.

The healthy pancreas is protected from autodigestion by pancreatic proteases that are synthesized as inactive proenzymes; digestive enzymes that are segregated into secretory granules at pH 6.2 by low calcium concentration, which minimizes trypsin activity; the presence of protease inhibitors both in the cytoplasm and zymogen granules; and enzymes that are secreted directly into the ducts.

Histopathologically, interstitial edema appears early. Later, as the episode of pancreatitis progresses, localized and confluent necrosis, blood vessel disruption leading to hemorrhage, and an inflammatory response in the peritoneum can develop.

The diagnosis of pancreatitis in children is made when two of three of the following are present: abdominal pain; serum amylase and/or lipase activity at least 3 times greater than the upper limit of normal; and imaging findings characteristic of, or compatible with, AP.

CLINICAL MANIFESTATIONS

The severity of AP in children has been defined by a consensus committee.

Mild Acute Pancreatitis: AP that is not associated with organ failure, local or systemic complications, and usually resolves within the first week after presentation. This is the most common form of pediatric AP.

The patient with mild AP has moderate to severe abdominal pain, persistent vomiting, and possibly fever. The pain is epigastric or in either upper quadrant and steady, often resulting in the child's assuming an antalgic position with hips and knees flexed, sitting upright, or lying on the side. The child is uncomfortable, irritable, and appears acutely ill. The abdomen may be distended and tender, and a mass may be palpable. The pain can increase in intensity for 24-48 hours, during which time vomiting may increase and the patient can require hospitalization for fluid and electrolyte therapy and analgesia. There is no other organ failure, and imaging does not demonstrate peri- or pancreatic necrosis. The prognosis for complete recovery in the acute uncomplicated case after 4-7 days is excellent.

Moderately Severe Acute Pancreatitis: AP with either transient organ failure/dysfunction (lasting <48 hours) or development of local or systemic complications, such as exacerbation of previously diagnosed comorbid disease (such as lung or kidney disease). Imaging may reveal sterile (peri-) pancreatic necrosis. The prognosis for these patients is also excellent, but recovery may be prolonged.

Severe Acute Pancreatitis: AP with development of other organ dysfunction (lung, cardiac, renal) that persists longer than 48 hours. Persistent organ failure may be single or multiple. Severe AP is uncommon in children. In this life-threatening condition, the patient is acutely ill with severe nausea, vomiting, and abdominal pain. Shock, high fever, jaundice, ascites, hypocalcemia, and pleural effusions can occur. A bluish discoloration may be seen around the umbilicus (Cullen sign) or in the flanks (Grey Turner sign). The pancreas is necrotic and can be transformed into an inflammatory hemorrhagic mass. The mortality rate, which is approximately 20%, is related to the systemic inflammatory response syndrome with multiple organ dysfunction, shock, renal failure, acute respiratory distress syndrome, disseminated intravascular coagulation, gastrointestinal bleeding, and systemic or intraabdominal infection. The percentage of necrosis seen on CT and failure of pancreatic tissue to enhance on CT (suggesting necrosis) predicts the severity of the disease.

DIAGNOSIS

AP is usually diagnosed by measurement of serum lipase and amylase activities. Serum lipase is considered the test of choice for AP because it is more specific than amylase for acute inflammatory pancreatic disease and should be determined when pancreatitis is suspected. The serum lipase rises by 4-8 hours, peaks at 24-48 hours, and remains elevated 8-14 days longer than serum amylase. Serum lipase greater than 7 times the upper limit of normal obtained within 24 hours of presentation may predict a severe course. Serum lipase can be elevated in nonpancreatic diseases. The serum amylase level is typically elevated for up to 4 days. A variety of other conditions can also cause hyperamylasemia without pancreatitis (Table 399.2). Elevation of salivary amylase can mislead the clinician to diagnose pancreatitis in a child with abdominal pain. The laboratory can separate amylase isoenzymes into pancreatic and salivary fractions. Initially serum amylase levels are normal in 10–15% of patients.

Other laboratory abnormalities that may be present in AP include hemoconcentration, coagulopathy, leukocytosis, hyperglycemia, glucosuria, hypocalcemia, elevated γ-glutamyl transpeptidase, and hyperbilirubinemia.

X-ray of the chest and abdomen might demonstrate nonspecific findings such as atelectasis, basilar infiltrates, elevation of the hemidiaphragm, left- (rarely right-) sided pleural effusions, pericardial effusion, and pulmonary edema. Abdominal x-rays might demonstrate a sentinel loop, dilation of the transverse colon (cutoff sign), ileus, pancreatic calcification (if recurrent), blurring of the left psoas margin, a pseudocyst, diffuse abdominal haziness (ascites), and peripancreatic extraluminal gas bubbles.

CT has a major role in the diagnosis and follow-up of children with pancreatitis. Findings can include pancreatic enlargement; a hypoechoic, sonolucent edematous pancreas; pancreatic masses; fluid collections; and abscesses (Fig. 399.1). Normal imaging studies at the time of diagnosis are not uncommon. In adults, CT findings are the basis of a widely accepted prognostic system (Table 399.3). Ultrasonography is more sensitive than CT for the diagnosis of biliary stones. Magnetic resonance cholangiopancreatography (MRCP) and endoscopic retrograde cholangiopancreatography (ERCP) are essential in the investigation of recurrent pancreatitis, nonresolving pancreatitis, and disease associated with gallbladder pathology. Endoscopic ultrasonography also helps visualize the pancreaticobiliary system. Complications of AP are noted in Table 399.4.

Table 399.1 Etiology of Acute and Recurrent Pancreatitis in Children

DRUGS AND TOXINS
Acetaminophen overdose
Alcohol
Anabolic androgenic steroids
L-Asparaginase
Azathioprine
Cannabis
Carbamazepine
Cimetidine
Cisplatin
Corticosteroids
Cytosine arabinoside
Dapsone
Didanosine
Enalapril
Erythromycin
Estrogen
Furosemide
Glucagon-like peptide-1 agents
Interferon-α
Isoniazid
Lamivudine
Lisinopril
6-Mercaptopurine
Methyldopa
Mesalamine
Metronidazole
Organophosphate poisoning
Pentamidine
Procainamide
Retrovirals: DDC (dideoxycytidine), DDI (dideoxyinosine), tenofovir
Rifampin
Sulfonamides: mesalamine, 5-aminosalicytates, sulfasalazine, trimethoprim-sulfamethoxazole
Sulindac
Tetracycline
Thiazides
Valproic acid
Venom (spider, scorpion, Gila monster lizard)
Vincristine
Volatile hydrocarbons

GENETIC
Cationic trypsinogen gene *(PRSS1)*
Carboxypeptidase A1 (*CPA1*)
Chymotrypsin C gene *(CTRC)*
Cystic fibrosis gene *(CFTR)*
Trypsin inhibitor gene *(SPINK1)*

INFECTIOUS
Ascariasis
COVID-19
Coxsackie B virus
Echovirus
Enterovirus
Epstein-Barr virus
Hepatitides A, B
Herpes viruses
Influenzae A, B
Leptospirosis
Malaria
Measles
Mumps
Mycoplasma
Rabies
Rubella
Reye syndrome: varicella, influenza B
Septic shock
Thyroid fever

OBSTRUCTIVE
Ampullary disease
Ascariasis
Biliary tract malformations
Choledochal cyst
Choledochocele
Cholelithiasis, microlithiasis, and choledocholithiasis (stones or sludge)
Duplication cyst
Endoscopic retrograde cholangiopancreatography (ERCP) complication
Pancreas divisum
Pancreatic ductal abnormalities
Postoperative
Sphincter of Oddi dysfunction
Tumor

SYSTEMIC DISEASE
Autoimmune pancreatitis (IgG4-related systemic disease)
Brain tumor
Collagen vascular diseases
Congenital partial lipodystrophy
Crohn disease
Diabetes mellitus (ketoacidosis)
Head trauma
Henoch-Schönlein purpura
Hemochromatosis
Hemolytic uremic syndrome
Hyperlipidemia: types I, IV, V
Hyperparathyroidism/hypercalcemia
Kawasaki disease
Malnutrition
Organic acidemia
Peptic ulcer
Periarteritis nodosa
Renal failure
Scorpion venom
Systemic lupus erythematosus
Transplantation: bone marrow, heart, liver, kidney, pancreas
Vasculitis

TRAUMATIC
Blunt injury
Burns
Child abuse
Hypothermia
Surgical trauma
Total-body cast

TREATMENT

The aims of medical management are to relieve pain (often needing opioids) and restore metabolic homeostasis. Analgesia should be given in adequate doses. Fluid, electrolyte, and mineral balance should be restored and maintained. Intravenous fluids (lactated Ringer's solution) is often required to correct hypovolemia because of poor fluid intake and the fluid losses secondary to capillary leak from the systemic inflammatory response syndrome. Excessive fluids should be avoided; fluid therapy should be titrated to improve vital signs and renal function. Nasogastric suction is useful in patients who are vomiting. Early refeeding decreases the complication rate and length of stay. In patients with pancreatitis who are not vomiting, oral nutrition should not be stopped. Recovery is usually complete within 4-5 days.

Prophylactic antibiotics are not recommended in inflammatory pancreatitis or with sterile necrosis, but broad-spectrum antibiotics are used to treat *infected* areas of pancreatic necrosis. Elevated serum procalcitonin levels suggest infection. Gastric acid secretion is suppressed with proton pump inhibitors. Enteral alimentation by mouth, nasogastric tube, or nasojejunal tube (in severe cases or for those intolerant of oral or nasogastric feedings) within 2-3 days of onset reduces the length of hospitalization, complication rate, and survival in patients with severe AP. In children, surgical therapy of nontraumatic AP is rarely required but may include drainage of necrotic material or abscesses. Endotherapy for common bile duct stones, ductal strictures, and for drainage of fluid collections is the standard of care when indicated.

Table 399.2 Differential Diagnosis of Hyperamylasemia

PANCREATIC PATHOLOGY
Acute or chronic pancreatitis
Complications of pancreatitis (pseudocyst, ascites, abscess)
Factitious pancreatitis
SALIVARY GLAND PATHOLOGY
Parotitis (mumps, *Staphylococcus aureus*, cytomegalovirus, HIV, Epstein-Barr virus)
Sialadenitis (calculus, radiation)
Eating disorders (anorexia nervosa, bulimia)
INTRAABDOMINAL PATHOLOGY
Biliary tract disease (cholelithiasis)
Peptic ulcer perforation
Peritonitis
Intestinal obstruction
Appendicitis
SYSTEMIC DISEASES
Metabolic acidosis (diabetes mellitus, shock)
Renal insufficiency, transplantation
Burns
Pregnancy
Drugs (morphine)
Head injury
Cardiopulmonary bypass

PROGNOSIS

Children with mild AP do well and recover within 4-5 days. When pancreatitis is associated with trauma or systemic disease, the prognosis is typically related to the associated medical conditions.

Visit Elsevier eBooks+ at eBooks.Health.Elsevier.com for Bibliography.

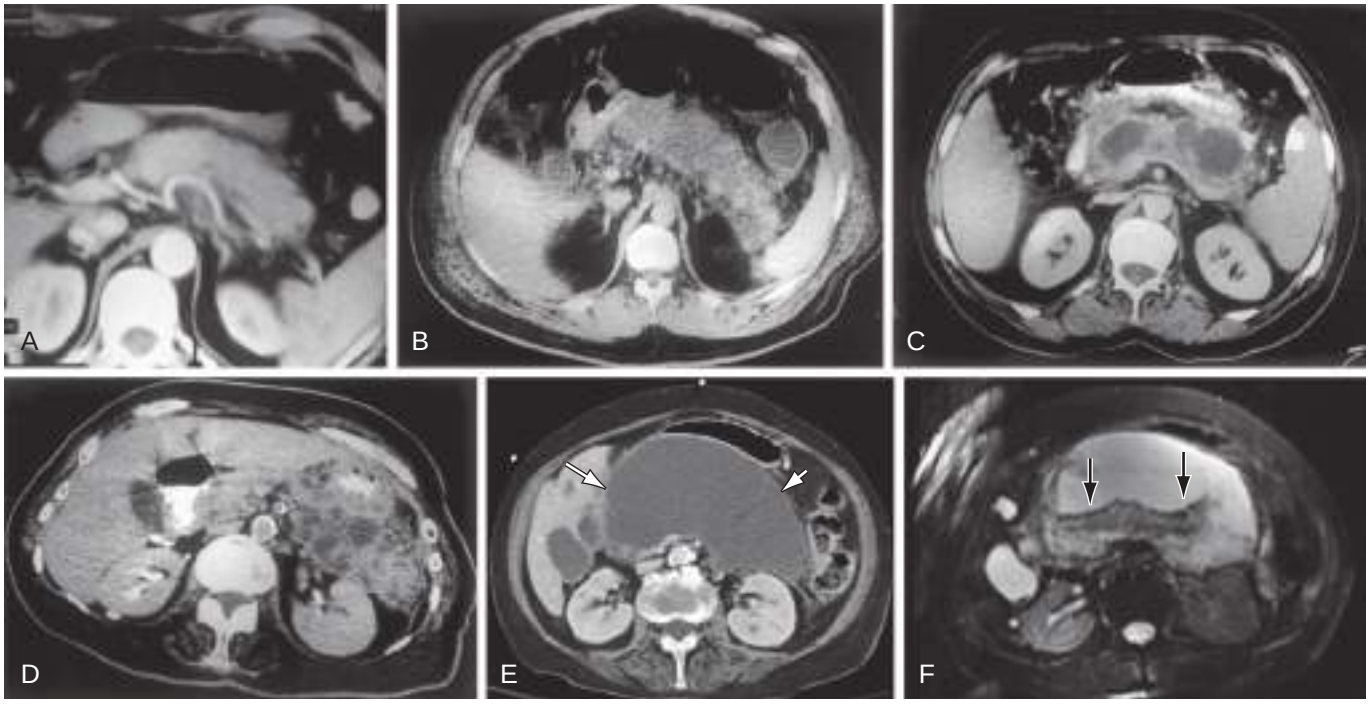

Fig. 399.1 CT and MRI appearance of pancreatitis. **A,** Mild acute pancreatitis. Arterial phase spiral CT. Diffuse enlargement of pancreas without fluid accumulation. **B,** Severe acute pancreatitis. Lack of enhancement of the pancreatic parenchyma because of the necrosis of the entire pancreatic gland. **C,** Pancreatic pseudocyst. A round fluid collection with thin capsule is seen within the lesser sac. **D,** Acute severe pancreatitis and peripancreatic abscess formation. Peripancreatic abscess formation is observed within the peripancreatic and the left anterior pararenal space. **E,** Pancreatic necrosis. A well-defined fluid attenuation collection in the pancreatic bed *(white arrows)* seen on contrast-enhanced CT imaging. **F,** The same collection is more complex appearing on the corresponding T2-weighted MR image. The internal debris and necrotic tissue are better appreciated because of the superior soft tissue contrast of MRI *(black arrows)*. *(**A-D** from Elmas N. The role of diagnostic radiology in pancreatitis. Eur J Radiol. 2001;38[2]:120–132. Figs. 1, 3b, 4a, and 5; E and F from Soakar A, Rabinowitz CB, Sahani DV. Cross-sectional imaging in acute pancreatitis. Radiol Clin North Am. 2007;45[3]:447–460. Fig. 14.)*

Table 399.3 Revised Definitions of Morphologic Features of Acute Pancreatitis

INTERSTITIAL EDEMATOUS PANCREATITIS Acute inflammation of the pancreatic parenchyma and peripancreatic tissues but without recognizable tissue necrosis
CECT criteria • Pancreatic parenchyma enhancement by intravenous contrast agent • No peripancreatic necrosis
NECROTIZING PANCREATITIS Inflammation associated with pancreatic parenchymal necrosis and/or peripancreatic necrosis
CECT criteria • Lack of pancreatic parenchymal enhancement by intravenous contrast agent • Presence of findings of peripancreatic necrosis
ACUTE PANCREATITIS FLUID COLLECTION Peripancreatic fluid associated with interstitial edematous pancreatitis with no associated peripancreatic necrosis. Applies only to areas of peripancreatic fluid seen within the first 4 wk after onset of interstitial edematous pancreatitis and without the features of a pseudocyst.
CECT criteria • Occurs in the setting of interstitial edematous pancreatitis • Homogeneous collection with fluid density • Confined by normal peripancreatic fascial planes • No definable wall encapsulating the collection • Adjacent to pancreas (no intrapancreatic extension)
PANCREATIC PSEUDOCYST An encapsulated collection of fluid with a well-defined inflammation wall, usually outside the pancreas, with little or no necrosis. Usually occurs more than 4 wk after onset of interstitial edematous pancreatitis.
CECT criteria • Well circumscribed; usually round or oval • Homogeneous fluid density • No nonliquid component • Well-defined wall that is wholly encapsulated • Maturation usually needs >4 wk after onset of acute pancreatitis; occurs after interstitial edematous pancreatitis
ACUTE NECROTIC COLLECTION A collection containing variable amounts of both fluid and necrosis associated with necrotizing pancreatitis; the necrosis can include the pancreatic parenchyma and/or the peripancreatic tissue.
CECT criteria • Occurs only in the setting of acute necrotizing pancreatitis • Heterogeneous and nonliquid density of varying degrees in different locations (some seem homogeneous early in their course) • No definable wall encapsulating the collection • Intrapancreatic and/or extrapancreatic
WALLED-OFF NECROSIS A mature, encapsulated collection of pancreatic and/or peripancreatic necrosis that has developed a well-defined inflammatory wall. Usually occurs >4 wk after onset of necrotizing pancreatitis.
CECT criteria • Heterogeneous with liquid and nonliquid density, with varying locations (some can seem homogeneous) • Well-defined wall that is wholly encapsulated • Intrapancreatic and/or extrapancreatic • Maturation usually needs 4 wk after onset of acute necrotizing pancreatitis

CECT, Contrast-enhanced CT.
From PA Banks, TL Bollen, C Dervenis, et al. The Acute Pancreatitis Classification Working Group Classification of acute pancreatitis—2012: revision of the Atlanta classification and definitions by international consensus. *Gut.* 2013;62:102–111.

Table 399.4 Complications of Acute Pancreatitis

LOCAL Pseudocyst Sterile necrosis Infected necrosis Abscess GI bleeding • Pancreatitis-related • Splenic artery or splenic artery pseudoaneurysm rupture • Splenic vein rupture • Portal vein rupture • Splenic vein thrombosis leading to gastroesophageal variceal bleeding • Pseudocyst or abscess hemorrhage • Postnecrosectomy bleeding Nonpancreatitis-related • Mallory-Weiss tear • Alcoholic gastropathy • Stress-related mucosal gastropathy Splenic complications • Infarction • Rupture • Hematoma • Splenic vein thrombosis Fistulization to or obstruction of the small intestine or colon Hydronephrosis
SYSTEMIC Respiratory failure Renal failure Shock Hyperglycemia Hypocalcemia Disseminated intravascular coagulation Fat necrosis (subcutaneous nodules) Retinopathy
PSYCHOSIS

From Tenner S, Steinberg WM. Acute pancreatitis. In: Feldman M, Friedman LS, Brandt LJ, eds. *Sleisenger and Fordtran's Gastrointestinal and Liver Disease,* 10th ed. Philadelphia: Elsevier; 2016: Box 58.7, p. 991.

399.2 Acute Recurrent and Chronic Pancreatitis

Steven L. Werlin and Michael Wilschanski

Acute recurrent pancreatitis (ARP) is defined as ≥2 distinct episodes of AP with intervening return of enzymes to baseline. Chronic pancreatitis (CP) is defined as the presence of typical abdominal pain plus characteristic imaging findings including pancreatic calcifications, inflammation and fibrosis, or exocrine insufficiency plus imaging findings, or endocrine insufficiency plus imaging findings. Most children with CP describe a history of ARP and tend to be older at the time of diagnosis compared with children with ARP, suggesting that ARP and CP are a disease continuum. CP without prior AP or ARP may occur.

ARP and CP in children are often caused by pathogenic gene variants or congenital anomalies of the pancreatic or biliary ductal system (Tables 399.5 and 399.6). Variants in *PRSS1* (cationic trypsinogen), *SPINK1* (pancreatic trypsin inhibitor), in the cystic fibrosis gene *(CFTR)*, *CPA1*, and chymotrypsin C *(CTRC)* may all lead to CP (Fig. 399.2).

Cationic trypsinogen has a trypsin-sensitive cleavage site. Loss of this cleavage site in the abnormal protein permits uncontrolled activation of trypsinogen to trypsin, which leads to autodigestion of the pancreas. Pathogenic variants in *PRSS1* act in an autosomal dominant fashion with incomplete penetrance and variable expressivity. Symptoms often begin in the first decade but are usually mild at the onset.

Although spontaneous recovery from each attack occurs in 4-7 days, episodes become progressively more severe. Hereditary pancreatitis may be diagnosed by the presence of the disease in successive generations of a family. An evaluation during symptom-free intervals may be unrewarding until calcifications, pseudocysts, or pancreatic exocrine and endocrine insufficiency develop (Fig. 399.3; see Fig. 399.2). CP is a risk factor for the development of pancreatic cancer. Multiple variants of *PRSS1* associated with hereditary pancreatitis have been described.

Trypsin inhibitor acts as a fail-safe mechanism to prevent uncontrolled autoactivation of trypsin. Pathogenic variants in *SPINK1* have been associated with ARP or CP. In *SPINK1* variants, this fail-safe mechanism is lost; this gene may be a modifier gene and not the direct etiologic factor.

Pathogenic variants of *CFTR* that are associated with pancreatic sufficiency, or which do not typically produce pulmonary disease, can cause CP, possibly because of ductal obstruction. Patients with genotypes associated with mild phenotypic effects have a greater risk of developing pancreatitis than those with genotypes associated with moderate to severe phenotypes.

Pathogenic variants in the chymotrypsin C gene, which cause a loss of function, may also cause recurrent pancreatitis. Indications for genetic testing include recurrent episodes of AP, CP, a family history of pancreatitis, or unexplained pancreatitis in children. Pathogenic variants in carboxypeptidase A1 *(CPA1)* have been associated with early onset (<10 years) of CP.

Other conditions associated with chronic, relapsing pancreatitis are hyperlipidemia (types I, IV, and V), hyperparathyroidism, and ascariasis. Previously, most cases of recurrent pancreatitis in childhood were considered idiopathic; with the discovery of gene families associated with recurrent pancreatitis, this has changed. Congenital anomalies of the ductal systems, such as pancreas divisum, are also more common than previously recognized.

Table 399.5 Factors Contributing to the Etiology of Chronic Pancreatitis

	NO. (%)*
Chronic pancreatitis patients with history of ≥1 episode acute pancreatitis	73 (96)
Risk factors for pancreatitis	
Genetic	*51 (67)*
PRSS1	33 (43)
SPINK1	14 (19)
CFTR	11 (14)
CTRC	2 (3)
CPA1	~1%
Autoimmune	*3 (4)*
Obstructive	*25 (33)*
Pancreas divisum	15 (20)
Sphincter of Oddi dysfunction	1 (1)
Gallstones	3 (4)
Pancreatic duct malunion	2 (3)
Pancreatic duct obstruction	1 (1)
Other	*5 (7)*
Toxic/metabolic	8 (11)
Alcohol (determined by doctor)	1 (1)
Passive smoking (exposure)	3 (4)
Hyperlipidemia	1 (1)
Medication	1 (1)
Metabolic disease	1 (1)
None cited	8 (11)

PRSS1, serine protease 1; SPINK1, pancreatic trypsin inhibitor; CFTR, cystic fibrosis transmembrane conductance regulator; CTRC, chymotrypsin C; CPA1, carboxypeptidase A1.
*The total exceeds 100% because some children have more than one factor.
Modified from Schwarzenberg SJ, Bellin M, Husain SZ, et al. Pediatric chronic pancreatitis is associated with genetic risk factors and substantial disease burden. *J Pediatr*. 2015;166:890–896. Table II.

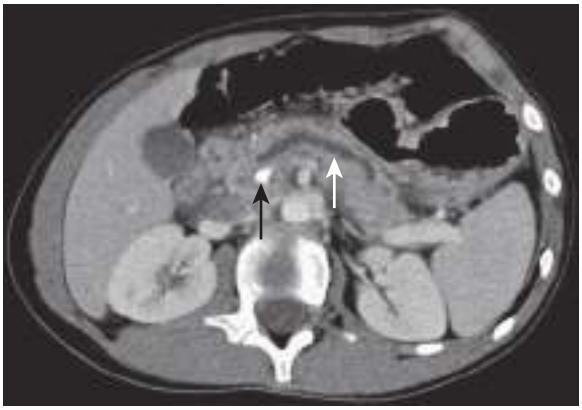

Fig. 399.2 Chronic pancreatitis. Computed tomogram showing calcification in the head of the pancreas *(black arrow)* and dilated pancreatic duct *(arrow)* in a 12-yr-old patient. *(Courtesy Dr. Janet Reid. From Wyllie R, Hyams JS, eds. Pediatric Gastrointestinal and Liver Disease, 3rd ed. Philadelphia: WB Saunders, 2006.)*

Table 399.6 Classification of Chronic Pancreatitis

CHRONIC CALCIFYING PANCREATITIS	CHRONIC OBSTRUCTIVE PANCREATITIS	STEROID-RESPONSIVE PANCREATITIS
Alcohol	Stricture	Autoimmune Pancreatitis
Smoking	Blunt trauma	Type 1
Genetic	Endoscopic stenting	Type 2 (IDCP)
Idiopathic	Acute pancreatitis	
Juvenile-onset	Anastomotic stricture	
Tropical	Tumor	
	Adenocarcinoma	
	IPMN	
	Serous cystadenoma Islet cell tumor	

IDCP, Idiopathic duct-centric pancreatitis; IPMN, intraductal papillary mucinous neoplasm.
From Majumder S, Chari ST. Chronic pancreatitis. *Lancet*. 2016;387:1957–1966. Fig 1.

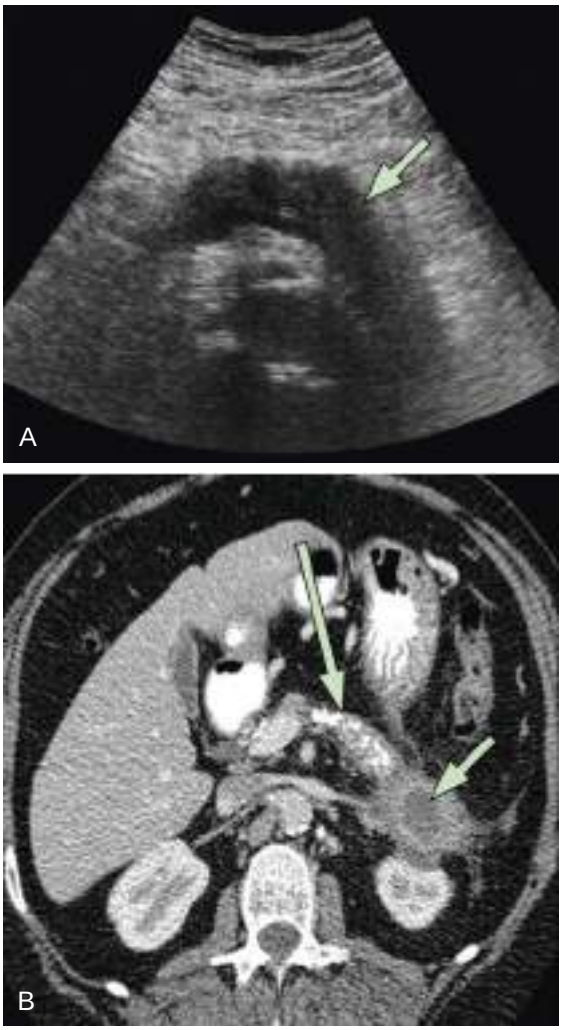

Fig. 399.3 Examples of ultrasound and multidetector images in patients with chronic pancreatitis. **A,** Transabdominal ultrasound scan showing a uniformly swollen, hypoechoic pancreas *(arrow)* typical of autoimmune pancreatitis. **B,** Multidetector CT showing pancreatic calculi in an atrophic pancreas *(long arrow)* and a pseudocyst at the tail of the pancreas *(short arrow)*. *(From Braganza JM, Lee SH, McCloy RF, McMahon MJ. Chronic pancreatitis. Lancet. 2011;377:1184–1197. Fig. 5.)*

Autoimmune pancreatitis (AIP) typically manifests with jaundice, abdominal pain, and weight loss. The pancreas is typically enlarged and is hypodense on CT. The pathogenesis is unknown. **Type 1** is a systemic disease and is associated with high serum immunoglobulin G4 (IgG4). In addition to pancreatitis in type 1 disease, the patient may have retroperitoneal fibrosis, orbital inflammation, aortitis, sclerosing cholangitis, cutaneous vasculitis, pulmonary fibrosis, and sialadenitis. These extrapancreatic features may also be present in the absence of pancreatitis (Table 399.7). Tissue biopsy shows fibrosis, plasmacytosis, and positive staining for IgG4; serum IgG4 levels are not always elevated.

Type 2 is limited to diffuse or focal involvement of just the pancreas. IgG4 levels are normal. *Both types respond to steroids*. Children with AIP typically have type 2.

Table 399.7 Chronic Disorders Recognized to Be Part of IgG4-Related Disease

Autoimmune pancreatitis (lymphoplasmacytic sclerosing pancreatitis)
Eosinophilic angiocentric fibrosis (affecting the orbits and upper respiratory tract)
Fibrosing mediastinitis
Hypertrophic pachymeningitis
Idiopathic hypocomplementemic tubulointerstitial nephritis with extensive tubulointerstitial deposits
Inflammatory pseudotumor (affecting the orbits, lungs, kidneys, and other organs)
Küttner tumor (affecting the submandibular glands)
Mikulicz disease (affecting the salivary and lacrimal glands)
Multifocal fibrosclerosis (commonly affecting the orbits, thyroid gland, retroperitoneum, mediastinum, and other tissues and organs)
Periaortitis and periarteritis
Inflammatory aortic aneurysm
Retroperitoneal fibrosis (Ormond disease)
Riedel thyroiditis
Sclerosing mesenteritis
Conditions once regarded as individual disorders now recognized to be part of IgG4-related disease

From Kamisawa T, Zen Y, Pillai S, Stone JH. IgG4-related disease. *Lancet.* 2015;385:1460–1471. Panel 1.

Juvenile tropical pancreatitis is the most common form of CP in developing equatorial countries. The highest prevalence is in the Indian state of Kerala. Tropical pancreatitis occurs during late childhood or early adulthood, manifesting with abdominal pain and irreversible pancreatic insufficiency followed by diabetes mellitus within 10 years. The pancreatic ducts are obstructed with inspissated secretions, which later calcify. This condition is associated with pathogenic variants in *SPINK* in 50% of cases.

A thorough diagnostic evaluation of every child with more than one episode of pancreatitis is indicated. Serum lipid, calcium, and phosphorus levels are determined. Stools are evaluated for ascaris, and a sweat test is performed. Plain abdominal films are evaluated for the presence of pancreatic calcifications. Abdominal ultrasound or CT scanning is performed to detect the presence of a pseudocyst. The biliary tract is evaluated for the presence of stones. After genetic counseling, evaluation of *PRSS1*, *SPINK1*, *CFTR*, *CPA1*, and *CRTC* genotypes can be measured. Electrophysiologic tests such as nasal potential difference testing may be recommended when the diagnosis of cystic fibrosis (CF) is uncertain.

MRCP and ERCP are techniques that can be used to define the anatomy of the gland and are mandatory if surgery is considered. MRCP is the test of choice when endotherapy is not being considered and should be performed as part of the evaluation of any child with idiopathic, nonresolving, or recurrent pancreatitis and in patients with a pseudocyst before drainage. In these cases, a previously undiagnosed anatomic defect that may be amenable to endoscopic or surgical therapy may be detected. Endoscopic treatments include sphincterotomy, stone extraction, drainage of pseudocysts, and insertion of pancreatic or biliary endoprosthetic stents. These treatments allow the successful nonsurgical management of conditions previously requiring surgical intervention.

Visit Elsevier eBooks+ at eBooks.Health.Elsevier.com for Bibliography.

Chapter 400

Pancreatic Fluid Collections

Michael Wilschanski and Steven L. Werlin

Pancreatic pseudocyst formation is an uncommon sequela to acute or chronic pancreatitis. A pancreatic pseudocyst is a circumscribed collection of fluid rich in pancreatic enzymes, blood, and necrotic tissue, typically located in the lesser sac of the abdomen. Pancreatic pseudocysts are usually complications of pancreatitis, although in children they frequently occur after abdominal trauma. They can enlarge or extend in almost any direction, thus producing a wide variety of symptoms (Fig. 400.1; see also Fig. 399.1C).

A pancreatic pseudocyst is suggested when an episode of pancreatitis fails to resolve or when a mass develops after an episode of pancreatitis. Clinical features usually include pain, nausea, and vomiting, but many patients are asymptomatic. The most common signs are a palpable mass in 50% of patients and jaundice in 10%. Other findings include ascites and pleural effusions (usually left-sided).

Pancreatic pseudocysts can be detected by transabdominal ultrasonography, CT scan, magnetic resonance cholangiopancreatography (MRCP), endoscopic retrograde cholangiopancreatography (ERCP), and endoscopic ultrasound (EUS). Because of its ease, availability, and reliability, ultrasonography is the first choice. Sequential ultrasonography studies have demonstrated that most small pseudocysts (<6 cm) resolve spontaneously. It is recommended that the patient with acute pancreatitis undergo an ultrasonographic evaluation 4 weeks after resolution of the acute episode for an evaluation of possible pseudocyst formation.

TREATMENT OF FLUID COLLECTIONS AND NECROSIS

Percutaneous and endoscopic drainage of pseudocysts have replaced open surgical drainage, except for complicated or recurrent pseudocysts. Whereas a pseudocyst must be allowed to mature for 4-6 weeks before surgical drainage is attempted, percutaneous or endoscopic drainage can be attempted earlier. In some cases, endoscopic creation of a cyst-gastrostomy is performed. When a surgical treatment is planned, an MRCP or ERCP is performed to define anatomic abnormalities and aid the surgeon in planning the approach. EUS is helpful when an endoscopic approach is chosen.

Necrotizing pancreatitis includes both pancreatic gland necrosis and peripancreatic fat necrosis. In the initial phases, the necrotic collection is a mix of semisolid and solid tissue. Over a period of 4 weeks or longer, the collection becomes more liquid and becomes encapsulated by a visible wall. At this point, the process is termed *walled-off pancreatic necrosis*. Sterile necrosis does not require therapy except in the rare case of a collection that obstructs a nearby viscus (e.g., duodenal, bile duct, or gastric obstruction).

The development of *infected* necrosis is the main indication for broad-spectrum antibiotic therapy. The development of fever, leukocytosis, an elevated procalcitonin level, and increasing abdominal pain suggests infection of the necrotic tissue. A CT scan may reveal evidence of air bubbles in the necrotic cavity.

Visit Elsevier eBooks+ at eBooks.Health.Elsevier.com for Bibliography.

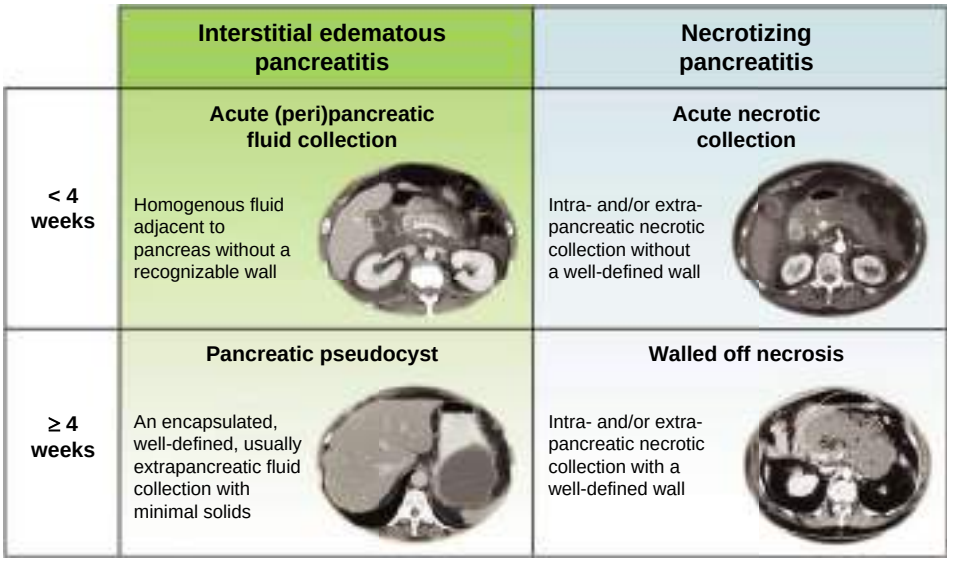

Fig. 400.1 Classification of acute pancreatitis and associated fluid collections. Based on international consensus according to the Acute Pancreatitis Classification Working Group (revised Atlanta criteria). *(From Trikudanathan, G, Wolbrink DRJ, van Santvoort HC, et al. Current concepts in severe acute and necrotizing pancreatitis: an evidence-based approach. Gastroenterol. 2019;156:1994–2007e3. Fig. 1.)*

Chapter 401

Pancreatic Tumors

Meghen B. Browning, Steven L. Werlin, and Michael Wilschanski

Pancreatic tumors can be of either endocrine or nonendocrine origin. Tumors of endocrine origin include gastrinomas and insulinomas, which are more typically seen in nonpancreatic sites. These occur in the autosomal dominantly inherited multiple endocrine neoplasia type 1 (MEN-1) and are often benign. Hypoglycemia accompanied by higher-than-expected insulin levels or refractory gastric ulcers (Zollinger-Ellison syndrome) indicate the possibility of a functional endocrine pancreatic tumor (see Chapter 381.1). The treatment of choice is surgical removal. If the primary tumor cannot be found, or if it has metastasized, cure might not be possible. Treatment with a high dose of a proton pump inhibitor to inhibit gastric acid secretion is then indicated. Insulinomas and persistent hyperinsulinemic hypoglycemia of infancy produce symptomatic hypoglycemia caused by pathogenic variants in a variety of genes, most commonly *GUUD1* and *KATP*. Massive subtotal or total pancreatectomy is the treatment of choice when medical treatment fails. These children might then develop pancreatic insufficiency and diabetes as a complication of surgery.

Nonfunctioning pancreatic endocrine tumors make up most of the remainder of the pancreatic endocrine tumors (PETs). Diagnosis is either incidental, because they tend to be asymptomatic, or made after the tumors are large enough to have mass effects. The nonfunctioning PETs, as well as the even-more-rare functioning PETs, are less likely to be histologically benign. Pancreatic tumors secreting a variety of hormones, including glucagon, somatostatin, parathyroid hormone, adrenocorticotropic hormone, and pancreatic polypeptide, have been described (Table 401.1). The treatment is surgical resection when possible.

The watery diarrhea–hypokalemia–acidosis syndrome is usually produced by the secretion of vasoactive intestinal peptide by a non–α-cell tumor (VIPoma). Vasoactive intestinal peptide levels are often, but not always, increased in the serum. Again, treatment is surgical removal of the tumor. When this is not possible, symptoms may be controlled by the use of octreotide acetate (cyclic somatostatin [Sandostatin]), a synthetic analog of somatostatin.

Pancreatoblastomas, pancreatic adenocarcinomas, and sarcomas of the pancreas are also rarely encountered. Pancreatoblastoma, a malignant embryonal tumor that secretes α-fetoprotein and can contain both endocrine and exocrine elements, is the most common pancreatic neoplasm in young children (<10 years of age). Genetic associations include familial adenomatous polyposis and Beckwith-Wiedemann syndromes. Presurgical chemotherapy should be considered for lesions not primarily resectable. Resection can be curative. The effectiveness of adjuvant chemotherapy is less clear. Sarcomas are very rarely primarily pancreatic but may include Ewing family tumors (Ewing sarcoma and primitive neuroectodermal tumor), rhabdomyosarcoma, or undifferentiated soft tissue sarcomas. They are treated with multimodality therapy, including chemotherapy and either resection or radiation. The pancreas can be a site of metastases for any of these entities. Histologically benign tumors, such as teratomas and vascular anomalies, may also rarely involve the pancreas.

Carcinoma of the exocrine pancreas, or ductal adenocarcinoma, is a major problem in adults, accounting for 2% of diagnoses and 5% of deaths from cancer. However, it is exceptionally rare in childhood. Pathogenic variants in the *PRSS1* and *MEN-1* genes lead to an increased incidence of pancreatic cancer in adult life but do not appear to account for pediatric cases. Acinar cell carcinoma is very rarely seen in children. The solid pseudopapillary tumor of the pancreas, also called *Frantz tumor*, is the most common pancreatic tumor in adolescents. It is a more indolent pancreatic carcinoma usually found in adolescent/young adult females. Typical presenting symptoms are abdominal pain, mass, or jaundice. The treatment of choice is total surgical removal. Prognosis is very good.

Pancreatic lesions in von Hippel-Lindau disease are usually benign and cystic. Cystadenomas, familial adenocarcinomas, and islet cell tumors are less common. Metastases have been reported, but effective adjuvant therapy has not been established.

Prognosis is good for completely resected endocrine tumors but very poor for sarcomas and carcinomas, except for rare subtypes. Children who survive partial or complete pancreatectomy may have decreased pancreatic exocrine and endocrine reserve.

Inflammatory myofibroblastic tumors (resembling IgG4-related lesions) may cause obstruction and be identified during evaluation for pain or jaundice. Pancreatic tumors and other entities, including intrapancreatic accessory spleens, may be found incidentally during imaging. Pancreatic imaging and biopsy when indicated confirm the diagnosis.

Visit Elsevier eBooks+ at eBooks.Health.Elsevier.com for Bibliography.

Table 401.1 Syndromes Associated with Pancreatic Neuroendocrine Tumors (pNETs)*

SYNDROME	INCIDENCE/10^6/YR	MALIGNANCY (%)	HORMONE
Insulinoma	1-2	<10	Insulin
Gastrinoma (ZES)	0.5-1.5	60–90	Gastrin
VIPoma (Verner-Morrison syndrome, WDHA, pancreatic cholera)	0.05-0.2	>60	VIP
Glucagonoma	0.01-0.1	50–80	Glucagon
Somatostatinoma	Rare	>70	Somatostatin
GRFoma	Unknown	>30	GH-RF
ACTHoma	Uncommon	>95%	ACTH
pNET secreting PTH-rP	Rare	84%	PTH-rP
Pancreatic carcinoid tumor	Rare (<1% of all carcinoids)	77%	Serotonin, tachykinins
pNET secreting renin	Rare	Unknown	Renin
pNET secreting erythropoietin	Rare	Unknown	Erythropoietin
pNET secreting luteinizing hormone	Rare	Unknown	Luteinizing hormone
pNET secreting cholecystokinin (CCKoma)	Rare	Unknown	CCK

*These syndromes may also be caused by a GI-NET (carcinoid).
GH-RF, Growth hormone–releasing factor; PP, pancreatic polypeptide; PTH-rP, parathyroid hormone–related protein; VIP, vasoactive intestinal polypeptide; WDHA, watery diarrhea, hypokalemia, achlorhydria; ZES, Zollinger-Ellison syndrome; ACTH, adrenocorticotropic hormone.
From Jensen RT, Norton JA, Oberg K. Neuroendocrine tumors. In: Feldman M, Friedman LS, Brandt LJ, eds. *Sleisenger and Fordtran's Gastrointestinal and Liver Disease*, 10th ed. Philadelphia: Elsevier; 2016: Table 33.1.

Section 6

The Liver and Biliary System

Chapter 402

Morphogenesis of the Liver and Biliary System

Stacey S. Huppert and William F. Balistreri

During the early embryonic process of gastrulation, the three embryonic germ layers (endoderm, mesoderm, and ectoderm) are formed. The definitive endoderm is an epithelial sheet that occupies the ventral surface of the early embryo by approximately the second week of human gestation. The digestive and respiratory organs, as well as the thymus and thyroid, are all derived from the definitive endoderm.

Hepatogenesis can be divided into three distinct processes. First, through unknown mechanisms, the ventral foregut endoderm intrinsically acquires *competence* to receive signals arising from the cardiac mesoderm and the septum transversum mesenchyme (Fig. 402.1A). The thickened epithelium of the ventral foregut endoderm is visible morphologically just before the onset of hepatic-specific gene expression. "Pioneer" transcription factors, including the Forkhead Box A (FOXA) and GATA protein families, have the unique ability to engage closed and silent chromatin locally, converting it to an open and permissive chromatin state marking genes as competent. However, hepatic-specific genes will be expressed only if they are induced by additional transcription factors. There are no known hepatic-specific molecular markers associated with the morphologic initial ventral foregut endoderm thickening.

Signals originating from the mesoderm lead to *specification* of cells that have the potential to form the liver and activate hepatic-specific genes (see Fig. 402.1B). Fibroblast growth factor (FGF) from the cardiac mesoderm and bone morphogenetic protein (BMP) from septum transversum mesenchyme cells coordinately specify the hepatic—and suppress the pancreas—transcriptional programs in the cells of the ventral foregut endoderm.

The newly specified hepatic cells initially compose a columnar epithelium that transitions to a single-layer of pseudostratified epithelium attached to a laminin-containing basement membrane. The basement membrane is then broken down, and the hepatic cells delaminate from the ventral foregut endoderm and migrate in a rostral ventral direction into the septum transversum in the third to fourth week of human gestation to initiate liver *morphogenesis* (see Fig. 402.1C). After foregut closure, the hepatic cells proliferate and continue to migrate into the surrounding mesenchyme, interacting to form a bud that becomes vascularized. The rostral hepatic bud gives rise to the liver, including the intrahepatic bile ducts, and the caudal hepatic bud develops into the gallbladder and the extrahepatic common bile duct. The gallbladder anlage is visible around the seventh week of human gestation. Careful orchestration of signals between epithelial, mesenchymal, and endothelial cells are required to guide hepatogenesis (Table 402.1).

HEPATIC ARCHITECTURE

Within the ventral mesentery, proliferation of migrating cells forms anastomosing hepatic cords, with the network of primitive liver progenitors (i.e., hepatoblasts), sinusoids, and septal mesenchyme establishing the basic architectural pattern of the liver lobule (Fig. 402.2). The hepatic lobules are identifiable in the sixth week of human gestation. The bile canalicular structures, including microvilli and junctional complexes, are specialized intralobular network channels; these appear very early in gestation, and large canaliculi bounded by several hepatocytes are seen by the sixth to seventh week of human gestation.

The *caudal* part (pars cystica) of the hepatic diverticulum becomes the gallbladder, cystic duct, and common bile duct. The distal portions of the right and left hepatic ducts develop from the extrahepatic ducts, whereas the proximal portions develop from the first intrahepatic ductal plates. The extrahepatic bile ducts and the developing intrahepatic biliary tree maintain luminal continuity and patency from the beginning of organogenesis (see Fig. 402.2C).

Fetal hepatic blood flow is derived from the hepatic artery and from the portal and umbilical veins, which form the portal sinus. The portal venous inflow is directed mainly to the right lobe of the liver and umbilical flow primarily to the left. The ductus venosus shunts blood from the portal and umbilical veins to the hepatic vein, bypassing the

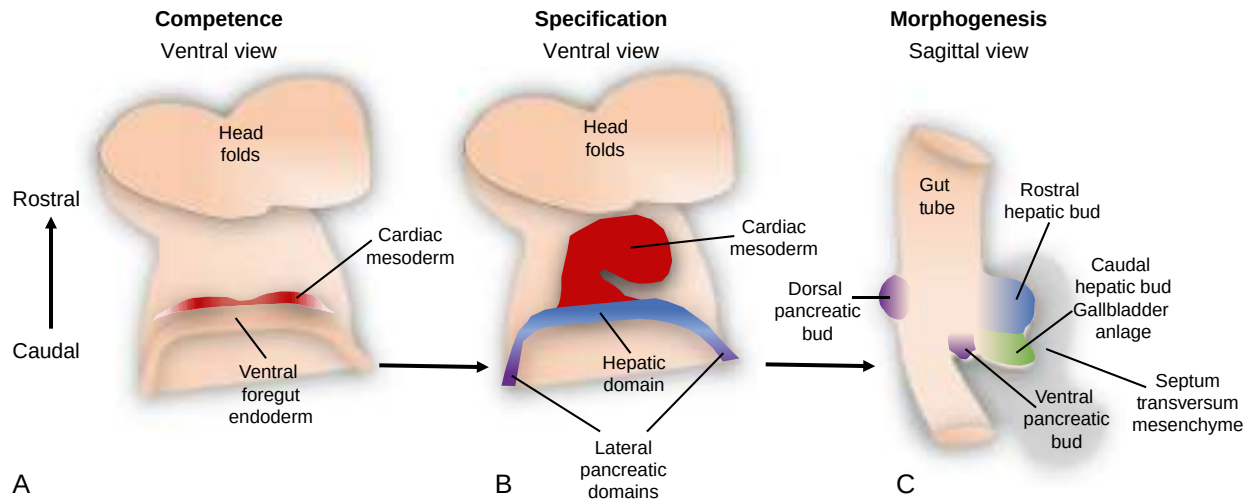

Fig. 402.1 Processes involved in early liver development. **A,** The ventral foregut endoderm acquires *competence* to receive signals arising from the cardiac mesoderm and septum transversum mesenchyme. **B,** Specific cells of the ventral foregut endoderm undergo *specification* and activation of liver-specific genes under the influence of mesodermal signals. **C,** Liver *morphogenesis* is initiated as the newly specified cells migrate into the septum transversum under the influence of signaling molecules and extracellular matrix released by septum transversum mesenchymal cells and of primitive endothelial cells.

Table 402.1	Selected Growth Factors, Receptors, Protein Kinases, and Transcription Factors Required for Normal Liver Development in Animal Models

INDUCTION OF HEPATIC FATE THROUGH CARDIAC MESODERM
- Fibroblast growth factors (FGFs) 1, 2, 8
- FGF receptors 1, 4

INDUCTION OF HEPATIC FATE THROUGH SEPTUM TRANSVERSUM
- Bone morphogenetic proteins 2, 4, 7

STIMULATION OF HEPATOBLAST GROWTH AND PROLIFERATION
- Hepatocyte growth factor (HGF)
- HGF receptor c-met
- "Pioneer" transcription factors Foxa1, Foxa2, FoxA3, and Gata4, Gata6
- Transcription factors Xbp1, Foxm1b, Hlx, Hex, Prox1, Tbx3
- Wnt signaling pathway, β-catenin

SPECIFICATION OF HEPATOCYTE LINEAGE
- HGF
- Transcription factors
- Hepatocyte nuclear factors (HNFs) 1α, 4α, 6, Cebpa

SPECIFICATION OF CHOLANGIOCYTE LINEAGE
- Jagged 1 (Notch ligand) and Notch receptors 1, 2
- Transforming growth factor-β and its downstream effectors Smad 2, Smad 3
  - Hippo/Yap
- HNF6, HNF1β, Cebpb, Sox9, Sox4

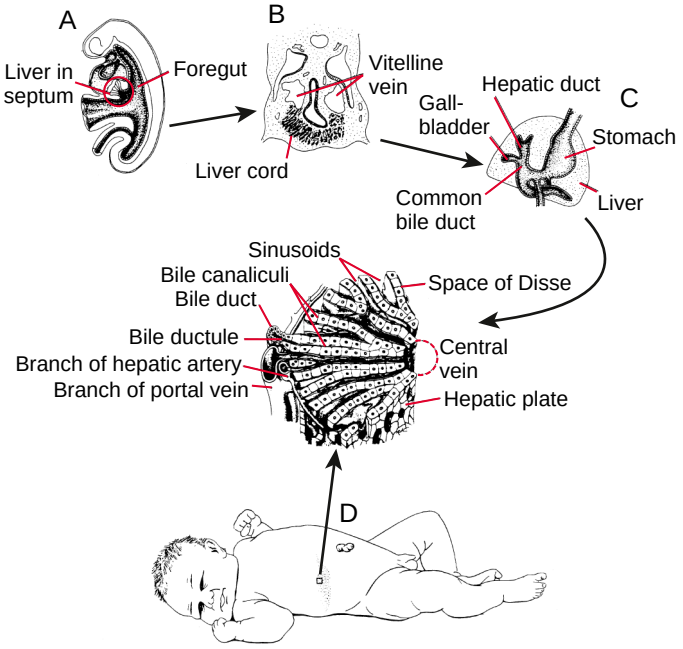

Fig. 402.2 Hepatic morphogenesis. **A,** Ventral outgrowth of hepatic diverticulum from foregut endoderm in the 3.5-wk embryo. **B,** Between the two vitelline veins, the enlarging hepatic diverticulum buds off epithelial (liver) cords that become the liver parenchyma, around which the endothelium of capillaries (sinusoids) align (4-wk embryo). **C,** Hemisection of embryo at 7.5 wk. **D,** Three-dimensional representation of the hepatic lobule as present in the newborn. *(From Andres JM, Mathis RK, Walker WA. Liver disease in infants. Part I: developmental hepatology and mechanisms of liver dysfunction. J Pediatr. 1977;90:686–697.)*

sinusoidal network. After birth, the ductus venosus becomes obliterated when oral feedings are initiated. The fetal oxygen saturation is lower in portal than in umbilical venous blood; accordingly, the right hepatic lobe has lower oxygenation and greater hematopoietic activity than the left hepatic lobe.

The transport and metabolic activities of the liver are facilitated by the structural arrangement of liver cell cords, which are formed by rows of hepatocytes, separated by sinusoids that converge toward the tributaries of the hepatic vein (the central vein) located in the center of the lobule (see Fig. 402.2D). This establishes the pathways and patterns of flow for substances to and from the liver. In addition to arterial input from the systemic circulation, the liver also receives venous input from the gastrointestinal tract via the portal system. The products of the hepatobiliary system are released by two different paths: through the hepatic vein and through the biliary system back into the intestine. Plasma proteins and other plasma components are secreted by the liver. Absorbed and circulating nutrients arrive through the portal vein or the hepatic artery and pass through the sinusoids and past the hepatocytes to the systemic circulation at the central vein. Biliary components are transported via the series of enlarging channels from the bile canaliculi through the bile ductule to the common bile duct. The intrahepatic bile duct system relies on its intricate three-dimensional structure to access all of the hepatocytes and effectively clear bile out of the liver.

Hepatocytes and cholangiocytes (i.e., bile duct epithelial cells) originate from the bipotential hepatoblast progenitor. Single-cell RNA sequencing data suggest that hepatoblasts enter the hepatocyte transcriptional program after hepatic specification from ventral foregut endodermal progenitors and transcriptionally move in unison toward the hepatocyte fate. The synchronicity suggests that the hepatocyte lineage specification is the default cell identity. Cholangiocyte differentiation is more nonsynchronous. Individual hepatoblasts upregulate the cholangiocyte transcriptional program coincident with repression of the hepatocyte transcriptional program. Cholangiocyte identity is initiated specifically in portal vein regions around the seventh to tenth week of human gestation, reinforcing that hepatoblasts are not pre-fated to the cholangiocyte transcriptional program but rather their location and signals arising from a niche influence their ultimate fate. Potential cholangiocytes form a temporary structure, termed the *intrahepatic ductal plate*, encircling the portal veins (Fig. 402.3A). Primitive ductal structures are asymmetrically composed of lumen-forming cells. The portal vein adjacent cells express early cholangiocyte markers, and parenchymal adjacent cells still express hepatoblast and hepatocyte markers. Remodeling of the ductal plate or tubulogenesis begins around the 11th to 15th week of human gestation starting at the larger hilar portal vein regions and moving toward the peripheral region of liver following the portal vein system. Newly committed cholangiocytes are incorporated into a *homogeneous intrahepatic bile duct network* encircling the portal vein (see Fig. 402.3B). The final rearrangement of the *hierarchical intrahepatic bile duct network* is thought to be associated with hepatocyte excretion of bilirubin into bile (see Fig. 402.3C). The intrahepatic bile duct architecture remains incomplete in the human liver periphery during the first years of life. If the unincorporated ductal plate or primitive ductal cells do not receive, or are unresponsive to, the proper signals, they may contribute to ductal plate malformation. This histopathologic lesion has been observed in liver biopsies of a variety of liver conditions, including congenital hepatic fibrosis, Caroli disease, biliary atresia, and autosomal dominant polycystic liver disease.

METABOLIC FUNCTIONS OF THE LIVER

The liver reaches a peak relative size of approximately 10% of the fetal weight at the ninth week of human gestation. Early in development, the liver is a primary site of hematopoiesis. In the seventh week of human gestation, hematopoietic cells outnumber functioning hepatocytes in the hepatic anlage. These early hepatocytes are smaller than at maturity (~20 μm vs 30-35 μm) and contain less glycogen. Near term, the hepatocyte mass expands to dominate the organ, as cell size and glycogen content increase. Hematopoiesis is virtually absent by the second postnatal month in full-term infants. As the density of hepatocytes increases with gestational age, the relative volume of the sinusoidal network decreases. The liver constitutes 5% of body weight at birth but only 2% in an adult.

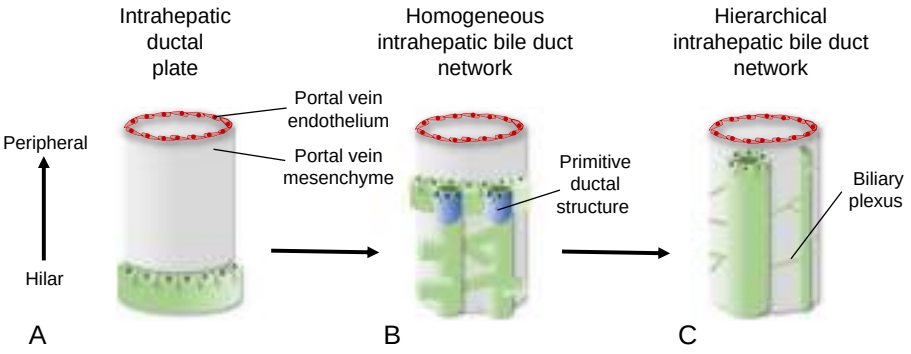

Fig. 402.3 Process of intrahepatic bile duct formation. **A,** Cholangiocytes are specified in the region adjacent to the portal vein system forming transient ductal plate. **B,** Ductal plates are quickly remodeled into luminal or primitive ductal structures surrounded by asymmetric gene expressing cells. These luminal structures form a dense homogeneous network that is communicating with the extrahepatic bile duct. **C,** Upon hepatocyte bile production, secretion, and canalicular membrane lengthening, the homogenous network begins to reorganize into a hierarchical network.

Several metabolic processes are immature in a healthy newborn infant, owing in part to the fetal patterns of activity of various enzymatic processes. Many fetal hepatic functions are carried out by the maternal liver, which provides nutrients and serves as a route of elimination of metabolic end products and toxins. Fetal liver metabolism is devoted primarily to the production of proteins required for growth. Toward term, primary functions become production and storage of essential nutrients, excretion of bile, and establishment of processes of elimination. Extrauterine adaptation requires de novo enzyme synthesis. Modulation of these processes depends on substrate and hormonal input via the placenta and on dietary and hormonal input in the postnatal period.

Carbohydrate Metabolism

The liver regulates serum glucose levels closely via several processes, including storage of excess carbohydrate as glycogen, a polymer of glucose readily hydrolyzed to glucose during fasting. To maintain serum glucose levels, hepatocytes produce free glucose by either glycogenolysis or gluconeogenesis. Immediately after birth, an infant is dependent on hepatic glycogenolysis. Gluconeogenic activity is present at a low level in the fetal liver and increases rapidly after birth. Fetal glycogen synthesis begins at about the ninth week of gestation, with glycogen stores most rapidly accumulated near term, when the liver contains 2-3 times the amount of glycogen of adult liver. Most of this stored glycogen is used in the immediate postnatal period. Re-accumulation is initiated at about the second week of postnatal life, and glycogen stores reach adult levels at approximately the third week in healthy full-term infants. In preterm infants, serum glucose levels fluctuate in part because efficient regulation of the synthesis, storage, and degradation of glycogen develops only near the end of full-term gestation. Dietary carbohydrates such as galactose are converted to glucose, but there is a substantial dependence on gluconeogenesis for glucose in early life, especially if glycogen stores are limited.

Protein Metabolism

During the rapid fetal growth phase, specific decarboxylases that are rate limiting in the biosynthesis of physiologically important polyamines have higher activities than in the mature liver. The rate of synthesis of albumin and secretory proteins in the developing liver parallels the quantitative changes in the endoplasmic reticulum. Synthesis of albumin appears at the seventh to eighth week in the human fetus and increases in inverse proportion to that of α-fetoprotein, which is the dominant fetal protein. By the third to fourth month of gestation, the fetal liver is able to produce fibrinogen, transferrin, and low-density lipoproteins. From this period on, fetal plasma contains each of the major protein classes at concentrations considerably below those achieved at maturity.

The postnatal patterns of protein synthesis vary with the class of protein. Lipoproteins of each class rise abruptly in the first week after birth to reach levels that vary little until puberty. Serum albumin concentrations are low in a neonate (~2.5 g/dL), reaching adult levels (~3.5 g/dL) after several months. Levels of ceruloplasmin and complement factors increase slowly to adult values in the first year. In contrast, transferrin levels at birth are similar to those of an adult, decline for 3-5 months, and rise thereafter to achieve their final concentrations. Low levels of activity of specific proteins have implications for the nutrition of an infant. A low level of cystathionine γ-lyase (cystathionase) activity impairs the *trans*-sulfuration pathway by which dietary methionine is converted to cysteine. Consequently, the latter must be supplied in the diet. Similar dietary requirements might exist for other sulfur-containing amino acids, such as taurine.

Lipid Metabolism

Fatty acid oxidation provides a major source of energy in early life, complementing glycogenolysis and gluconeogenesis. Newborn infants are relatively intolerant of prolonged fasting, owing in part to a restricted capacity for hepatic ketogenesis. Rapid maturation of the ability of the liver to oxidize fatty acid occurs in the first few days after birth. Milk provides the major source of calories in newborns; this high-fat, low-carbohydrate diet mandates active gluconeogenesis to maintain blood glucose levels. When the glucose supply is limited, ketone body production from endogenous fatty acids can provide energy for hepatic gluconeogenesis and an alternative fuel for brain metabolism. When carbohydrates are in excess, the liver produces triglycerides. Metabolic processes involving lipids and lipoproteins are predominantly hepatic; liver immaturity or disease affects lipid concentrations and lipoproteins.

Biotransformation

Newborn infants have a decreased capacity to metabolize and detoxify certain drugs, owing to underdevelopment of the hepatic microsomal component that is the site of the specific oxidative, reductive, hydrolytic, and conjugation reactions required for these biotransformations. The major components of the monooxygenase system, such as cytochrome P450, cytochrome-*c* reductase, and the reduced form of nicotinamide-adenine dinucleotide phosphate, are present in low concentrations in fetal microsomal preparations. In full-term infants, hepatic uridine diphosphate glucuronosyltransferase and enzymes involved in the oxidation of polycyclic aromatic hydrocarbons are expressed at very low levels.

Age-related differences in pharmacokinetics vary from compound to compound. The half-life of acetaminophen in a newborn is similar to that of an adult, whereas theophylline has a half-life of approximately 100 hours in a premature infant, as compared with 5-6 hours in an adult. These differences in metabolism, as well as factors such as binding to plasma proteins and renal clearance, determine appropriate drug dosage to maximize effectiveness and to avoid toxicity. Dramatic historical examples of the susceptibility of newborn infants to drug toxicity are the responses to chloramphenicol (the *gray baby* syndrome) or to benzoyl alcohol and its metabolic products, which involve ineffective glucuronide and glycine conjugation, respectively. The low concentrations of antioxidants (vitamin E, superoxide dismutase, glutathione peroxidase) in the fetal and early newborn liver lead to increased susceptibility to deleterious effects of oxygen toxicity and oxidant injury through lipid peroxidation.

Conjugation reactions, which convert drugs or metabolites into water-soluble forms that can be eliminated in bile, are also catalyzed by hepatic microsomal enzymes. Newborn infants have decreased activity of hepatic uridine diphosphate glucuronosyltransferase, which converts unconjugated bilirubin to the readily excreted glucuronide conjugate and is the rate-limiting enzyme in the excretion of bilirubin. There is rapid postnatal development of transferase activity irrespective of gestational age, which suggests that birth-related, rather than age-related, factors are of primary importance in the postnatal development of activity of this enzyme. Microsomal activity can be stimulated by administration of phenobarbital, rifampin, or other inducers of cytochrome P450. Alternatively, drugs such as cimetidine can inhibit microsomal P450 activity.

Table 402.2 Causes of Impaired Bile Acid Metabolism and Enterohepatic Circulation

DEFECTIVE BILE ACID SYNTHESIS OR TRANSPORT
• Inborn errors of bile acid synthesis
• Progressive familial intrahepatic cholestasis
• Intrahepatic cholestasis (neonatal hepatitis)
• Acquired defects in bile acid synthesis secondary to severe liver disease
ABNORMALITIES OF BILE ACID DELIVERY TO THE BOWEL
• Celiac disease (sluggish gallbladder contraction)
• Extrahepatic bile duct obstruction (e.g., biliary atresia, gallstones)
ALTERED ENTEROHEPATIC CIRCULATION OF BILE ACIDS
• External bile fistula
• Cystic fibrosis
• Small bowel bacterial overgrowth syndrome (with bile acid precipitation, increased jejunal absorption, and "short-circuiting")
• Drug-induced entrapment of bile acids in intestinal lumen (e.g., cholestyramine)
BILE ACID MALABSORPTION
• Primary bile acid malabsorption (absent or inefficient ileal active transport)
• Secondary bile acid malabsorption
• Ileal disease or resection
DEFECTIVE UPTAKE OR ALTERED INTRACELLULAR METABOLISM
• Parenchymal disease
• Regurgitation from cells
• Portosystemic shunting
• Cholestasis

Hepatic Excretory Function

Hepatic excretory function and bile flow are closely related to hepatic *bile acid* excretion and enterohepatic recirculation. Bile secretion is first noted at the 12th week of human gestation. Bile acids, the major products of cholesterol degradation, are incorporated into mixed micelles with cholesterol and phospholipid. These micelles act as efficient vehicles for solubilization and intestinal absorption of lipophilic compounds, such as dietary fats and fat-soluble vitamins. Secretion of bile acids by the liver cells is the major determinant of bile flow in the mature animal. Accordingly, maturity of bile acid metabolic processes affects overall hepatic excretory function, including biliary excretion of endogenous and exogenous compounds.

In humans, the two primary bile acids, cholic acid and chenodeoxycholic acid, are synthesized in the liver. Before excretion, they are conjugated with glycine or taurine. In response to a meal, contraction of the gallbladder delivers bile acids (micelles) to the intestine to assist in fat digestion and absorption. After mediating fat digestion, the bile acids themselves are reabsorbed from the terminal ileum through specific active transport processes. They return to the liver via portal blood, are taken up by liver cells, and are re-excreted in bile. In an adult, this enterohepatic circulation involves 90–95% of the circulating bile acid pool. Bile acids that escape ileal reabsorption reach the colon, where the bacterial flora, through dihydroxylation and deconjugation, produce the secondary bile acids, deoxycholic and lithocholic acid. In an adult, the composition of bile reflects the excretion of the primary and also the secondary bile acids, which are reabsorbed from the distal intestinal tract.

Intraluminal concentrations of bile acids are low in newborn infants and increase rapidly after birth. The expansion of the bile acid pool is important because bile acids are required to stimulate bile flow and absorb lipids, a major component of the diet of a newborn. Nuclear receptors, such as farnesoid X receptor (FXR), control intrahepatic bile acid homeostasis through several mechanisms, including regulation of expression of the genes encoding two key proteins, cholesterol 7α-hydroxylase (CYP7A1) and bile salt export pump (BSEP). These proteins are important for bile acid synthesis and canalicular secretion, respectively. Neonatal expression of these nuclear receptors varies depending on the studied animal model.

Because of inefficient ileal reabsorption of bile acids and the low rate of hepatic clearance of bile acids from portal blood, serum concentrations of bile acids are commonly elevated in healthy newborns, often to levels that would suggest liver disease in older persons. Transient phases of *physiologic cholestasis* and *physiologic steatorrhea* can often be observed in low birthweight infants and in full-term infants after perinatal stress, such as hypoxia or infection, but are otherwise uncommon in healthy full-term newborns.

Many of the processes related to immaturity of the newborn in liver morphogenesis and function, as discussed earlier, are implicated in the increased susceptibility of infants to liver disease associated with parenteral nutrition. The reduced bile acid pool size, hepatic glutathione depletion, and deficient sulfation contribute to production of toxic lithocholic acid and thus to cholestasis, whereas deficiencies of essential amino acids, including taurine and cysteine, and excessive lipid infusion can lead to hepatic steatosis in these infants. Beyond the neonatal period, disturbances in bile acid metabolism may be responsible for diverse effects on hepatobiliary and intestinal function (Table 402.2).

Visit Elsevier eBooks+ at eBooks.Health.Elsevier.com for Bibliography.

Chapter 403

Manifestations of Liver Disease

James E. Squires and William F. Balistreri

PATHOLOGIC MANIFESTATIONS

Congenital and acquired alterations in hepatic structure and function (acute or chronic) can be manifest by varying patterns of reaction of the liver to cell injury. Hepatocyte injury can be caused by infection (viral, bacterial, parasitic), drugs or toxins, hypoxia, immunologic and structural disorders, or inborn errors of metabolism. The injury results in inflammatory cell infiltration and cell death (necrosis), which may be followed by a healing process of scar formation (fibrosis) and, potentially, nodule formation (regeneration). Cirrhosis is the result of any progressive fibrotic liver disease.

Cholestasis is an alternative or concomitant response to injury caused by extrahepatic or intrahepatic obstruction to bile flow. Substances that are normally excreted in bile, such as bile acids, conjugated bilirubin, cholesterol, and trace elements, accumulate in serum. Bile pigment accumulation in liver parenchyma can be seen in liver biopsy specimens. In *extrahepatic* obstruction, bile pigment may be visible in the intralobular bile ducts or throughout the parenchyma as bile lakes or infarcts. In *intrahepatic* cholestasis, an injury to hepatocytes or an alteration in hepatic physiology leads to a reduction in the rate of secretion of solute and water. Etiologies include alterations in enzymatic or canalicular transporter activity, permeability of the bile canalicular apparatus, organelles responsible for bile secretion, or ultrastructure of the cytoskeleton of the hepatocyte. The result may be clinically indistinguishable from obstructive cholestasis.

Cirrhosis, defined histologically by the presence of bands of fibrous tissue that link central and portal areas and form parenchymal nodules, is an end stage of any prolonged acute or chronic liver disease. Cirrhosis can be *macronodular,* with nodules of various sizes (up to 5 cm) separated by broad septa, or *micronodular,* with nodules of uniform size (<1 cm) separated by fine septa; mixed forms occur. The progressive scarring results in altered hepatic blood flow, with further impairment of liver cell function. Increased intrahepatic resistance to portal blood flow leads to portal hypertension.

The liver can be secondarily involved in neoplastic (metastatic) and nonneoplastic (storage diseases, fat infiltration) processes, as well as several systemic conditions and infectious processes. The liver can be affected by chronic passive congestion (congestive heart failure) or acute hypoxia, with hepatocellular damage.

CLINICAL MANIFESTATIONS

Hepatomegaly

Enlargement of the liver can be caused by several mechanisms (Table 403.1). Normal liver size estimations are based on age-related clinical indices, such as the degree of extension of the liver edge below the costal margin, the span of dullness to percussion, or the length of the vertical axis of the liver, as estimated from imaging techniques. In children, the normal liver edge can be felt up to 2 cm below the right costal margin. In a newborn infant, extension of the liver edge more than 3.5 cm below the costal margin in the right midclavicular line suggests hepatic enlargement. Measurement of liver span is carried out by percussing the upper margin of dullness and by palpating the lower edge in the right midclavicular line. This may be more reliable than an extension of the liver edge alone. The two measurements may correlate poorly.

The liver span increases linearly with body weight and age in both sexes, ranging from approximately 4.5-5.0 cm at 1 week of age to approximately 7-8 cm in males and 6.0-6.5 cm in females by 12 years of age. The lower edge of the right lobe of the liver extends downward (Riedel lobe) and can normally be palpated as a broad mass in some people. An enlarged left lobe of the liver is palpable in the epigastrium of some patients with cirrhosis. Downward displacement of the liver by the diaphragm (hyperinflation) or thoracic organs can create an erroneous impression of hepatomegaly.

Examination of the liver should note the consistency, contour, tenderness, and presence of any masses or bruits, as well as assessment of spleen size, along with documentation of the presence of ascites and any stigmata of chronic liver disease.

Ultrasound is useful in assessment of liver size and consistency, along with gallbladder size. Gallbladder length normally varies from 1.5 to 5.5 cm (average: 3 cm) in infants to 4 to 8 cm in adolescents; width ranges from 0.5 to 2.5 cm for all ages. Gallbladder distention may be seen in infants with sepsis. The gallbladder is often absent or abnormal in infants with biliary atresia.

Jaundice (Icterus)

Yellow discoloration of the sclera, skin, and mucous membranes is a sign of hyperbilirubinemia (see Chapter 137). Clinically apparent jaundice in children and adults occurs when the serum concentration of bilirubin reaches 2-3 mg/dL (34-51 μmol/L); the neonate might not appear jaundiced until the bilirubin level is >5 mg/dL (>85 μmol/L). Jaundice may be the earliest and only sign of hepatic dysfunction. Liver disease must be suspected in the infant who appears only mildly jaundiced but has dark urine or acholic (light-colored) stools. Immediate evaluation to establish the cause is required.

Measurement of the total serum bilirubin concentration allows quantitation of jaundice. Bilirubin occurs in plasma in four forms: *unconjugated* bilirubin tightly bound to albumin; *free* or *unbound bilirubin* (the form responsible for kernicterus, because it can cross cell membranes); *conjugated bilirubin* (the only fraction to appear in urine); and *δ fraction* (bilirubin covalently bound to albumin), which appears in serum when hepatic excretion of conjugated bilirubin is impaired in patients with hepatobiliary disease. The δ fraction permits conjugated bilirubin to persist in the circulation and delays resolution of jaundice. Although the terms *direct* and *indirect* bilirubin are used equivalently with *conjugated* and *unconjugated* bilirubin, this is not quantitatively correct, because the direct fraction includes both conjugated bilirubin and δ bilirubin.

Investigation of jaundice in an infant or older child must include determination of the accumulation of both unconjugated and conjugated bilirubin. Unconjugated hyperbilirubinemia might indicate increased production, hemolysis, reduced hepatic removal, or altered metabolism of bilirubin (Table 403.2). Conjugated hyperbilirubinemia reflects decreased excretion by damaged hepatic parenchymal cells or disease of the biliary tract, which may be a result of obstruction, sepsis, toxins, inflammation, and genetic or metabolic disease (Table 403.3).

Pruritus

Intense generalized itching can occur in patients with chronic liver disease, often in association with cholestasis (conjugated hyperbilirubinemia). Symptoms can be generalized or localized (commonly to palms and soles), are usually worse at night, are exacerbated with stress and heat, and are relieved by cool temperatures. Pruritus is unrelated to the degree of hyperbilirubinemia; deeply jaundiced patients can be asymptomatic.

The pathogenesis of pruritus remains unknown; however, multiple suspected pruritogens have been reported, including bile acids, histamine, serotonin, progesterone metabolites, endogenous opioids, the potent neuronal activator lysophosphatidic acid (LPA), and the LPA-forming enzyme, autotaxin (ATX). Ultimately, a multifactorial process is suspected, as evidenced by the symptomatic relief of pruritus after administration of various therapeutic agents, including bile acid–binding agents (cholestyramine), choleretic agents (ursodeoxycholic acid), opiate antagonists (naltrexone), antihistamines, serotonin reuptake inhibitors (sertraline), antibiotics, and ileal bile acid transporter (IBAT) inhibitors. Plasmapheresis, molecular adsorbent recirculating system therapy, and surgical diversion of bile (partial and total biliary

Table 403.1 Causes of Hepatomegaly in Infants and Children

INFECTION AND INFLAMMATION	**STORAGE/METABOLIC DISEASE**
Viral hepatitis (hepatitis A, B, C, D, E; EBV; adenovirus, adeno-associated virus, echovirus, TORCH)	α_1-Antitrypsin deficiency
Autoimmune hepatitis	Wilson disease
Sepsis	Infants of diabetic mothers
Perinatal infections	Glycogen storage disease
Allograft rejection	Galactosemia
Graft-versus-host disease	Tyrosinemia
Systemic lupus erythematosus	Cystic fibrosis
Juvenile idiopathic arthritis	Gaucher disease
Primary sclerosing cholangitis	Niemann-Pick disease
Systemic granulomatous disorders with hepatic involvement	Gangliosidoses
Sarcoid	Hereditary fructose intolerance
Tuberculosis	Mitochondrial hepatic disorders including DNA depletion syndrome
Hepatic abscess (bacterial and parasitic)	Mucopolysaccharidoses
Parasitic infection	Amyloidosis
Visceral larva migrans	Hepatic porphyrias
Schistosomiasis	**EXPANSION OF EXTRACELLULAR MATRIX**
Leishmaniasis	Cirrhosis
Malaria	Fibrocystic disease (congenital hepatic fibrosis)
Liver flukes	**STEATOSIS**
Kupffer cell hyperplasia	Malnutrition
Macrophage activation syndrome	Nonalcoholic steatohepatitis (obesity)
Gestational alloimmune liver disease	Cystic fibrosis
BILIARY OBSTRUCTION	Parenteral nutrition
Biliary atresia	Diabetes mellitus
Choledochal cysts	Hereditary fructose intolerance
Stricture of common bile duct	Galactosemia
Primary sclerosing cholangitis	Wolman disease
INFILTRATION	Cholesterol ester storage disease
Extramedullary hematopoiesis	Mitochondrial hepatopathies
Erythroblastosis fetalis	β-Oxidation defects
Thalassemias	Medication toxicity (tetracycline, valproic acid)
Metastatic tumors	**HEPATIC MALIGNANCY/TUMOR**
Neuroblastoma	Primary or metastatic
Wilms tumor	**VASCULAR CONGESTION**
Leukemia	Congestive heart failure
Lymphoma	Budd-Chiari syndrome
Hemophagocytic lymphohistiocytosis (HLH)	Venoocclusive disease (VOD): radiation, high-dose chemotherapy, stem cell transplant, bush tea, pyrrolizidine alkaloids, familial VOD with immunodeficiency
Langerhans cell histiocytosis	**CYSTIC DISEASE**
	Fibrocystic disease
	Autosomal dominant polycystic kidney disease
	Congenital hepatic fibrosis
	Caroli syndrome
	Isolated polycystic liver disease

EBV, Epstein-Barr virus; TORCH, toxoplasmosis, other infections, rubella, cytomegalovirus, herpes simplex virus.
From Telega GW. Hepatomegaly. In Kliegman RM, Toth H, Bordini BJ, Basel D, eds. Nelson Pediatric Symptom-Based Diagnosis, 2nd ed. Philadelphia: Elsevier; 2023: Table 17.1, p. 307.

diversion) have been used in attempts to provide relief for medically refractory pruritus.

Spider Angiomas

Vascular spiders *(telangiectasias)*, characterized by central pulsating arterioles from which small, wiry venules radiate, may be seen in patients with chronic liver disease. These are usually most prominent in the superior vena cava distribution area (on the face and chest). Their size varies between 1 and 10 mm, and they exhibit central clearing with pressure. They presumably reflect altered estrogen metabolism in the presence of hepatic dysfunction.

Palmar Erythema

Blotchy erythema, most noticeable over the thenar and hypothenar eminences and on the tips of the fingers, is also noted in patients with chronic liver disease. Abnormal serum estradiol levels and regional alterations in peripheral circulation have been identified as possible causes.

Xanthomas

The marked elevation of serum cholesterol levels (to >500 mg/dL) associated with some forms of chronic cholestasis, especially Alagille syndrome, can cause the deposition of lipid in the dermis and subcutaneous tissue. Brown nodules can develop, first over the extensor surfaces of the extremities; rarely, xanthelasma of the eyelids develops.

Portal Hypertension

Portal hypertension occurs when there is increased portal resistance and/or increased portal flow. The portal system drains the splanchnic area (abdominal portion of the gastrointestinal tract, pancreas, and spleen) into the hepatic sinusoids. Normal portal pressure is between 1 and 5 mm Hg. Portal hypertension is defined as a portal pressure greater than or equal to 6 mm Hg. Clinically significant portal hypertension exists when pressure exceeds a threshold of 10-12 mm Hg. Portal hypertension is the main complication of cirrhosis and is directly responsible for two of the most common and potentially lethal complications: ascites and variceal hemorrhage.

Table 403.2 Differential Diagnosis of Unconjugated Hyperbilirubinemia

Physiologic Jaundice	Sepsis
Breastfeeding/Breast Milk Jaundice	Hemangioma
Polycythemia	Congenital erythropoietic porphyria
Diabetic mother	HUS
Fetal transfusion (maternal, twin)	Familial TTP *(ADAM TS 13)*
Intrauterine hypoxemia	Hemolysis from Wilson disease
Delayed cord clamping	**Infection**
Congenital adrenal hyperplasia	**Intestinal Obstruction**
Neonatal thyrotoxicosis	Pyloric stenosis
Hemolysis	Intestinal atresia
Isoimmune	Hirschsprung disease
Rh incompatibility	Cystic fibrosis
ABO incompatibility	**Enclosed Hematoma (Cephalohematoma, Ecchymoses)**
Other (M, S, Kidd, Kell, Duffy)	**Congestive Heart Failure**
Autoimmune	**Hypoxia**
Cold antibody	**Acidosis**
Warm antibody	**Hypothyroidism or Hypopituitarism**
Erythrocyte membrane defects	**Drugs/Toxins**
Hereditary spherocytosis	Maternal oxytocin
Hereditary elliptocytosis	Vitamin K
Infantile pyknocytosis	Antibiotics
Erythrocyte enzyme defects	Phenol disinfectants
Glucose-6-phosphate dehydrogenase	Herbs
Pyruvate kinase	**Familial Disorders of Bilirubin Metabolism**
Hexokinase	Gilbert syndrome
Other	Crigler-Najjar syndrome types I and II
Hemoglobinopathy	Lucey-Driscoll syndrome
Thalassemia	
Sickle cell anemia	

TTP, Thrombotic thrombocytopenic purpura; HUS, hemolytic uremic syndrome.
Modified from Telega GW. Jaundice. In: Kliegman RM, Toth H, Bordini BJ, Basel D, eds. Nelson Pediatric Symptom-Based Diagnosis, 2nd ed. Philadelphia: Elsevier; 2023: Table 18.2, p. 326.

Ascites

Ascites is a consequence of increased hydrostatic and osmotic pressures within the hepatic and mesenteric capillaries resulting in transfer of fluid from the blood vessels to the lymphatics that overcomes the drainage capacity of the lymphatic system. Ascites can also be associated with nephrotic syndrome and other urinary tract abnormalities, metabolic diseases (such as lysosomal storage diseases), congenital or acquired heart disease, and hydrops fetalis. Factors favoring the intraabdominal accumulation of fluid include decreased plasma colloid (albumin) osmotic pressure, increased capillary hydrostatic pressure, increased ascitic colloid osmotic fluid pressure, and decreased ascitic fluid hydrostatic pressure. Abnormal renal sodium retention plays a central role.

Gastrointestinal Bleeding

Chronic liver disease may manifest as gastrointestinal hemorrhage. Bleeding may result from portal hypertensive gastropathy, gastric antral vascular ectasia, or varix rupture. Variceal hemorrhage is classically from an esophageal origin but may be caused by gastric, duodenal, peristomal, or rectal varices. Variceal hemorrhage results from increased pressure within the varix, which leads to changes in the diameter of the varix and increased wall tension. When the variceal wall strength is exceeded, physical rupture of the varix results. Given the high blood flow and pressure in the portosystemic collateral system, coupled with the lack of a natural mechanism to tamponade variceal bleeding, the rate of hemorrhage can be striking.

Encephalopathy

Hepatic encephalopathy can be manifest as any neurologic dysfunction, but it is most likely to present in subtle forms such as deterioration of school performance, sleep disturbances, depression, or emotional outbursts. It can be recurrent and precipitated by intercurrent illness, drugs, bleeding, or electrolyte and acid-base disturbances. The appearance of hepatic encephalopathy depends on the presence of portosystemic shunting, alterations in the blood-brain barrier, and the interactions of toxic metabolites with the central nervous system. Postulated causes include altered ammonia metabolism, synergistic neurotoxins, decreased cerebral oxygen metabolism and blood flow, or false neurotransmitters with plasma amino acid imbalance.

Endocrine Abnormalities

Endocrine abnormalities are more common in older adolescents and adults with hepatic disease than in children. They reflect alterations in hepatic synthetic, storage, and metabolic functions, including those concerned with hormonal metabolism in the liver. Proteins that bind hormones in plasma are synthesized in the liver, and steroid hormones are conjugated in the liver and excreted in the urine; failure of such functions can have clinical consequences. Endocrine abnormalities can also result from malnutrition or specific deficiencies.

Renal Dysfunction

Systemic disease or toxins can affect the liver and kidneys simultaneously, or parenchymal liver disease can produce secondary impairment of renal function. In hepatobiliary disorders, there may be renal alterations in sodium and water economy, impaired renal concentrating ability, and alterations in potassium metabolism. Ascites in patients with cirrhosis may be related to inappropriate retention of sodium by the kidneys and expansion of plasma volume, or it may be related to sodium retention mediated by diminished effective plasma volume.

Hepatorenal syndrome (HRS) is defined as functional renal failure in patients with end-stage liver disease. The pathophysiology of

Table 403.3 Mechanistic Classification of the Etiologies of Cholestasis

EXTRAHEPATIC DUCTS
Biliary atresia
Choledochal cyst
Spontaneous bile duct perforation
Choledocholithiasis, biliary sludge
Duct compression (may also be intrahepatic; e.g., hepatoblastoma, neuroblastoma, rhabdomyosarcoma, neonatal leukemia, systemic juvenile xanthogranuloma, Langerhans cell histiocytosis)
Bile duct stenosis, stricture
INTRAHEPATIC DUCT OBSTRUCTION/FORMATION
Alagille syndrome
"Nonsyndromic paucity of interlobular bile ducts" (e.g., Williams syndrome)
Cystic fibrosis
Ductal plate malformations: congenital hepatic fibrosis; ARPKD; Caroli disease; Ivemark, Jeune, Joubert, Bardet-Biedl syndromes
Sclerosing cholangitis
CANALICULAR MEMBRANE TRANSPORTERS
PFIC type 1, BRIC, Nielsen syndrome (familial Greenland cholestasis)
PFIC type 2 (bile salt export pump deficiency)
PFIC type 3 (MDR3 deficiency)
Tight junction protein 2 deficiency
Farnesoid X receptor variants
MYO5B deficiency
Neonatal Dubin-Johnson syndrome
Villin functional defect
Overload of excretory mechanism capacity: ABO blood group incompatibility with hemolysis
HEPATOCYTE TIGHT JUNCTIONS
Neonatal ichthyosis–sclerosing cholangitis syndrome–claudin-1 protein
Familial hypercholanemia caused by TJP2 (zonulin-2) deficiency
BILE ACID SYNTHESIS
First-degree: BASD
3-Oxo-Δ4-steroid 5β-reductase deficiency
3β-Hydroxy-Δ5-C27-steroid dehydrogenase/isomerase deficiency
Oxysterol 7α-hydroxylase deficiency
Familial hypercholanemia due to BAAT deficiency
Second-degree: organelle dysfunction
Smith-Lemli-Opitz syndrome (cholesterol formation)
Peroxisomal disorders: Zellweger, infantile Refsum, neonatal ALD
INFECTIOUS
Bacterial: sepsis (endotoxemia, e.g., UTI, gastroenteritis)
Listeria
Syphilis
TB
VIRAL
Herpes viruses: CMV, HSV, HHV-6, varicella
Parvovirus B19
Hepatitis A, B, C
Enterovirus: coxsackieviruses, echoviruses, "numbered" enteroviruses
Adenovirus
Adeno-associated virus
Rubella
HIV
Paramyxovirus
PROTOZOAL
Toxoplasmosis
TOXIC
Parenteral nutrition–associated liver disease
Fetal alcohol syndrome
Drugs: maternal amphetamines, anticonvulsants; infant antifungals
ENDOCRINE
Panhypopituitarism
Hypothyroidism, cortisol deficiency
McCune-Albright syndrome
Donohue syndrome (leprechaunism)
METABOLIC
α_1-Antitrypsin deficiency
Galactosemia
Fructosemia (hereditary fructose intolerance)
Glycogen storage disease type IV (Andersen disease)
Congenital disorders of glycosylation
Tyrosinemia type I
Niemann-Pick disease type C
Gaucher disease
Cerebrotendinous xanthomatosis
Farber disease
Wolman disease
β-Oxidation defects: short- and long-chain acyl-CoA dehydrogenase deficiencies
Mucopolysaccharidosis VI (Maroteaux-Lamy syndrome)
Mucolipidosis II (I-cell disease)
Urea cycle defects
Citrin deficiency (formerly type II citrullinemia)
Mitochondrial respiratory chain disorders
Growth retardation, amino aciduria, cholestasis, iron overload, lactic acidosis, and early death (GRACILE)
Wilson disease (>5 yr)
IMMUNE MEDIATED
Gestational alloimmune liver disease
Neonatal or acquired lupus erythematosus
Autoimmune hemolytic anemia with giant cell hepatitis
Hemophagocytic lymphohistiocytosis
Autoimmune hepatitis
OTHER
Hypoxic/ischemic/vascular
Shock/hypoperfusion/hypoxia
Budd-Chiari syndrome
Cardiac insufficiency (congenital heart disease, arrhythmia)
Multiple hemangiomata
Sinusoidal obstruction syndrome
ARC syndrome (arthrogryposis–renal tubular dysfunction–cholestasis; defective vacuolar protein sorting)
Chromosomal: trisomy 17, 18, 21
Congenital disorders of glycosylation
Hardikar syndrome
Lymphedema cholestasis syndrome (Aagenaes syndrome)
Kabuki syndrome
North American Indian childhood cirrhosis (*UTP4* variant)
Pseudo-TORCH (PTORCH-1) syndrome (*OCLN* variant)
"Idiopathic neonatal hepatitis"
COACH syndrome (coloboma, oligophrenia, ataxia, cerebellar vermis hypoplasia, hepatic fibrosis)

ALD, Adrenoleukodystrophy; ARC, arthrogryposis-renal-cholestasis; ARPKD, autosomal recessive polycystic kidney disease; BAAT, bile acid coenzyme A: amino acid N-acyltransferase; BASD, bile acid synthetic defects; BRIC, benign recurrent intrahepatic cholestasis; CMV, cytomegalovirus; HHV-6, human herpesvirus type 6; HIV, human immunodeficiency virus; HSV, herpes simplex virus; PFIC, progressive familial intrahepatic cholestasis; TORCH, toxoplasmosis, other (syphilis, varicella-zoster, parvovirus B19), rubella, cytomegalovirus, and herpes infections; UTI, urinary tract infection.

Modified from Telega GW. Jaundice. In: Kliegman RM, Toth H, Bordini BJ, Basel D, eds. *Nelson Pediatric Symptom-Based Diagnosis,* 2nd ed. Philadelphia: Elsevier; 2023: Table 18.3, p. 327.

hepatorenal syndrome is related to splanchnic vasodilation, mesenteric angiogenesis, and decreased effective blood volume with resulting decreased renal perfusion. The hallmark is intense renal vasoconstriction (mediated by hemodynamic, humoral, or neurogenic mechanisms) with coexistent systemic vasodilation. The diagnosis is supported by the findings of oliguria (<1 mL/kg/day), a characteristic pattern of urine electrolyte abnormalities (urine sodium <10 mEq/L, fractional excretion of sodium of <1%, urine:plasma creatinine ratio <10, and normal urinary sediment), absence of hypovolemia, and exclusion of other kidney pathology. Both acute (HRS-AKI) and chronic (HRS-CKD) forms have been described. The best treatment of HRS is timely liver transplantation, with complete renal recovery expected.

Pulmonary Involvement

Hepatopulmonary syndrome (HPS) is characterized by the typical triad of hypoxemia, intrapulmonary vascular dilations, and liver disease. There is intrapulmonic right-to-left shunting of blood resulting from enlarged pulmonary vessels that prevents adequate exposure to oxygen-rich alveoli of red blood cells traveling through the center of the vessel. Shunting of vasodilatory mediators from the mesentery away from the liver is thought to contribute. HPS should be suspected and investigated in the child with chronic liver disease with a history of shortness of breath or exercise intolerance and clinical examination findings of cyanosis (particularly of the lips and fingers), digital clubbing, and oxygen saturations <96%, particularly in the upright position. Treatment is timely liver transplantation; resolution of pulmonary involvement usually follows.

Portopulmonary hypertension is a condition characterized by an increase in the resistance to pulmonary arterial blood flow in the setting of portal hypertension. It is defined by a pulmonary arterial pressure >25 mm Hg at rest and above 30 mm Hg with exercise, elevated pulmonary vascular resistance with pulmonary arterial occlusion pressure, or a left ventricular end diastolic pressure of <15 mm Hg. Although the pathophysiology is unclear, deficiency in endothelial prostacyclin synthase and increased circulating endothelin-1 have been implicated as a cause for the vasculopathy. Autopsy studies have demonstrated the coexistence of portal hypertension, microscopic pulmonary artery thromboembolism, endothelial and smooth muscle proliferation, and platelet aggregates contributing to portopulmonary hypertension development. Symptoms suggesting a diagnosis include exertional dyspnea, fatigue, syncope, palpitations, and chest pain. Pulmonary artery–directed therapy is the cornerstone of management, along with consideration of liver transplant.

Recurrent Cholangitis

Ascending infection of the biliary system is often seen in pediatric cholestatic disorders, most commonly because of gram-negative enteric organisms such as *Escherichia coli, Klebsiella, Pseudomonas,* and *Enterococcus.* Liver transplantation is the definitive treatment for recurrent cholangitis, especially when medical therapy is not effective.

Miscellaneous Manifestations of Liver Dysfunction

Nonspecific signs of acute and chronic liver disease include anorexia, which often affects patients with anicteric hepatitis and with cirrhosis associated with chronic cholestasis; abdominal pain or distention resulting from ascites, spontaneous peritonitis, or visceromegaly; malnutrition and growth failure; and bleeding, which may be a result of altered synthesis of coagulation factors (biliary obstruction with vitamin K deficiency or excessive hepatic damage) or to portal hypertension with hypersplenism. In the presence of hypersplenism, there can be decreased synthesis of specific clotting factors, production of qualitatively abnormal proteins, or alterations in platelet number and function. Altered drug metabolism can prolong the biologic half-life of commonly administered medications.

Visit Elsevier eBooks+ at eBooks.Health.Elsevier.com for Bibliography.

403.1 Evaluation of Patients with Possible Liver Dysfunction

James E. Squires and William F. Balistreri

Adequate evaluation of an infant, child, or adolescent with suspected liver disease begins with an appropriate and accurate history, a carefully performed physical examination, and skillful interpretation of signs and symptoms. Further evaluation is aided by judicious selection of diagnostic tests, followed using imaging modalities and/or a liver biopsy (Fig. 403.1). Most of the so-called liver "function" tests *do not* measure any specific hepatic function: a rise in serum aminotransferase levels reflects liver cell *injury,* an increase in immunoglobulin levels reflects an immunologic response to injury, or an elevation in serum bilirubin levels can reflect any of several disturbances of bilirubin metabolism (see Tables 403.2 and 403.3). Any single biochemical assay provides limited information, which must be placed in the context of the entire clinical picture. The most cost-efficient approach is to become familiar with the rationale, implications, and limitations of a selected group of tests so that specific questions can be answered. Young infants with cholestatic jaundice should be evaluated promptly to identify patients needing specific medical treatment or surgical intervention.

For a patient with suspected liver disease, evaluation addresses the following issues in sequence: Is liver disease present? If so, what is its nature? What is its severity? Is specific treatment available? How can we monitor the response to treatment? What is the prognosis? Importantly, more recent rapid genotype testing and gene chip technologies have transformed the field of diagnostics. These advances, paired with a greater understanding of the genetic basis for many pediatric liver diseases, are enabling more accurate and timely diagnoses while simultaneously eliminating the need for more invasive, costly, and time-intensive testing.

BIOCHEMICAL TESTS

Laboratory tests commonly used to screen for or to confirm a suspicion of liver disease include measurements of serum aminotransferase (Table 403.4), bilirubin (total and fractionated), alkaline phosphatase (AP), and gamma glutamyl-transpeptidase (GGT) levels, as well as determinations of prothrombin time (PT) or international normalized ratio (INR) and serum albumin level. These tests are complementary, provide an estimation of synthetic and excretory functions, and might suggest the nature of the disturbance (inflammation or cholestasis).

The severity of the liver disease may be reflected in clinical signs or biochemical alterations. Clinical signs include encephalopathy, variceal hemorrhage, worsening jaundice, apparent shrinkage of liver mass owing to massive necrosis, or onset of ascites. Biochemical alterations reflective of severity include hypoglycemia, acidosis, hyperammonemia, electrolyte imbalance, continued hyperbilirubinemia, marked hypoalbuminemia, or a prolonged PT or INR that is *unresponsive* to parenteral administration of vitamin K.

Acute liver cell injury (parenchymal disease) caused by viral hepatitis, drug- or toxin-induced liver disease, shock, hypoxemia, or metabolic disease is best suggested by a marked increase in serum aminotransferase levels. Cholestasis (obstructive disease) involves regurgitation of bile components into serum; the serum levels of total and conjugated bilirubin and serum bile acids are elevated. Elevations in serum AP, 5′ nucleotidase, and GGT levels are also sensitive indicators of obstruction or inflammation of the biliary tract. Fractionation of the total serum bilirubin level into conjugated and unconjugated bilirubin fractions helps to distinguish between elevations caused by processes such as hemolysis and those caused by hepatic dysfunction. A predominant elevation in the conjugated bilirubin level provides a relatively sensitive index of hepatocellular disease or hepatic excretory dysfunction.

Alanine aminotransferase (ALT, serum glutamate pyruvate transaminase) is *liver* specific, whereas aspartate aminotransferase (AST, serum glutamic-oxaloacetic transaminase) is derived from other

differences in density of liver parenchyma, the average liver attenuation coefficient being reduced with fatty infiltration.

MRI is a useful alternative that limits radiation exposure. Magnetic resonance cholangiography can be of value in differentiating biliary tract lesions. MRI with Eovist (gadoxetate disodium) can assist in the detection and characterization of known or suspected focal liver lesions. In differentiating obstructive from nonobstructive cholestasis, CT scanning or MRI identifies the precise level of obstruction more often than ultrasound. Either CT scanning or ultrasound may be used to guide percutaneously placed fine needles for biopsies, aspiration of specific lesions, or cholangiography.

Elastography is a novel noninvasive method to assess for liver *stiffness,* a measure of the development of hepatic fibrosis in patients with liver disease. Both ultrasound and MR methods have been developed. These noninvasive techniques allow for monitoring fibrosis progression and development of cirrhosis, characterization of hepatic tumors, improved diagnostic capabilities in certain disease processes such as biliary atresia, and prognostic stratification of diseases such as nonalcoholic fatty liver disease and NASH.

Radionuclide scanning relies on selective uptake of a radiopharmaceutical agent. Commonly used agents include technetium-99m–labeled sulfur colloid, which undergoes phagocytosis by Kupffer cells; ^{99m}Tc-iminodiacetic acid agents, which are taken up by hepatocytes and excreted into bile in a fashion similar to bilirubin; and gallium-67, which is concentrated in inflammatory and neoplastic cells. The anatomic resolution possible with hepatic scintiscans is generally less than that obtained with CT scanning, MRI, or ultrasound.

The ^{99m}Tc-sulfur colloid scan can detect focal lesions (tumors, cysts, abscesses) >2-3 cm in diameter. This modality can help to evaluate patients with possible cirrhosis and with patchy hepatic uptake and a shift of colloid uptake from liver to bone marrow.

Cholangiography, direct visualization of the intrahepatic and extrahepatic biliary tree after injection of opaque material, may be required in some patients to evaluate the cause, location, or extent of biliary obstruction. Percutaneous transhepatic cholangiography with a fine needle is the technique of choice in infants and young children. The likelihood of opacifying the biliary tract is excellent in patients in whom CT scanning, MRI, or ultrasound demonstrates dilated ducts. Percutaneous transhepatic cholangiography has been used to outline the biliary ductal system.

Endoscopic retrograde cholangiopancreatography is an alternative method of examining the bile ducts in older children. The papilla of Vater is cannulated under direct vision through a fiberoptic endoscope, and contrast material is injected into the biliary and pancreatic ducts to outline the anatomy. The advantage of endoscopic retrograde cholangiopancreatography is that it allows therapeutic interventions of the extrahepatic biliary tree (stone extraction, stent placement).

Selective angiography of the celiac, superior mesenteric, or hepatic artery can be used to visualize the hepatic or portal circulation. Both arterial and venous circulatory systems of the liver can be examined. Angiography is often required to define the blood supply of tumors before surgery and is useful in the study of patients with known or presumed portal hypertension. The patency of the portal system, the extent of collateral circulation, and the caliber of vessels under consideration for a shunting procedure can be evaluated. MRI can provide similar information.

DIAGNOSTIC APPROACH TO INFANTS WITH JAUNDICE

Well-appearing infants can have cholestatic jaundice. Biliary atresia and neonatal hepatitis are the most common causes of cholestasis in early infancy. Biliary atresia portends a poor prognosis unless it is identified early. The best outcome for this disorder is with early surgical reconstruction (45-60 days of age). History, physical examination, and the detection of a conjugated hyperbilirubinemia via examination of total and direct bilirubin are the first steps in evaluating the jaundiced infant (see Fig. 403.1). Consultation with a pediatric gastroenterologist should be sought early in the course of the evaluation.

Visit Elsevier eBooks+ at eBooks.Health.Elsevier.com for Bibliography.

Chapter 404

Cholestasis

Simon Lam and William F. Balistreri

404.1 Neonatal Cholestasis

Simon Lam and William F. Balistreri

Neonatal cholestasis is defined as conjugated hyperbilirubinemia occurring within the neonatal period. Cholestasis implies impediment to normal bile flow. In contrast to unconjugated hyperbilirubinemia, cholestasis (conjugated bilirubin elevation of any degree) in the neonate is *always pathologic,* and prompt differentiation of the cause is imperative.

Neonatal cholestasis occurs in approximately 1 in 2,500 live births. Although the clinical features for the diverse causes of neonatal cholestasis can be similar, the differential diagnosis remains broad, including infections, endocrine disorders, genetic/metabolic conditions, and various forms of mechanical obstruction. One approach is to evaluate the pathologies of the biliary system with an anatomic perspective, from the large extrahepatic bile ducts, to the smaller intrahepatic bile ducts, to the bile canaliculus, to the membrane transporters on the hepatocyte, and finally to the level of the hepatocyte (Fig. 404.1).

DISORDERS OF THE EXTRAHEPATIC BILE DUCTS

Biliary Atresia

Biliary atresia is an important cause of neonatal cholestasis and the leading indication for pediatric liver transplantations worldwide. The prevalence of biliary atresia varies from 1 in 3,000 in French Polynesia to 1 in 12,000-22,000 in North America and Europe. In most cases, infants with biliary atresia appear well but are jaundiced with a history of acholic stools (i.e., stools devoid of pigment appearing white or pale colored) (Fig. 404.2). **Biliary atresia splenic malformation (BASM)** syndrome affects 15% of patients with biliary atresia and is associated with other congenital abnormalities, including situs inversus (heterotaxia syndrome), congenital heart disease, intestinal malformation, primary ciliary dyskinesia, Kabuki syndrome, caudal regression syndrome, and polysplenia. The pathogenesis of biliary atresia is unknown. For nonsyndromic biliary atresia, it appears that bile duct destruction may be initiated in utero but is primarily a progressive postnatal event. Evidence for this includes elevated levels of conjugated/direct bilirubin in the first 1-3 days after birth. Leading hypotheses include (1) a complex interplay between genetic predisposition/susceptibility, (2) prenatal or postnatal biliary injury from viruses, toxins, or vascular insults, (3) increased susceptibility to ongoing biliary injury caused by a descending glycocalyx on the apical surface of the cholangiocytes or abnormal intracellular glutathione production, and (4) aberrant immune responses. Biliary atresia has been discordant among identical twins. The final common pathway is an *obliterative cholangiopathy,* leading to the destruction of the biliary tree, most commonly at the porta hepatis. Bile is therefore unable to flow through the atretic region of the *extrahepatic* bile ducts, causing increased pressure and reflux of biliary contents back into the *intrahepatic* biliary system resulting in hepatic injury, inflammation, and fibrosis (Fig. 404.3). Because bile is not excreted into the small bowel, fat/fat-soluble vitamin digestion is impaired, and stools are acholic. If left untreated, end-stage liver disease usually occurs by 2 years of life.

Typical abdominal ultrasound findings include nonvisualization of the gallbladder, a small-contracted gallbladder, and nonvisualization of the common bile duct. The triangular cord sign has also been reported as a specific ultrasound finding for biliary atresia, but may lack sensitivity. Notably, dilation of intrahepatic ducts is not a feature consistent with biliary atresia. Characteristic features on liver biopsy include bile duct proliferation, bile duct plugs, and portal stromal edema. Although abdominal ultrasonography and liver biopsies are helpful in the diagnostic workup for biliary atresia, an intraoperative cholangiogram remains the gold standard for diagnosis. After catheterization of the

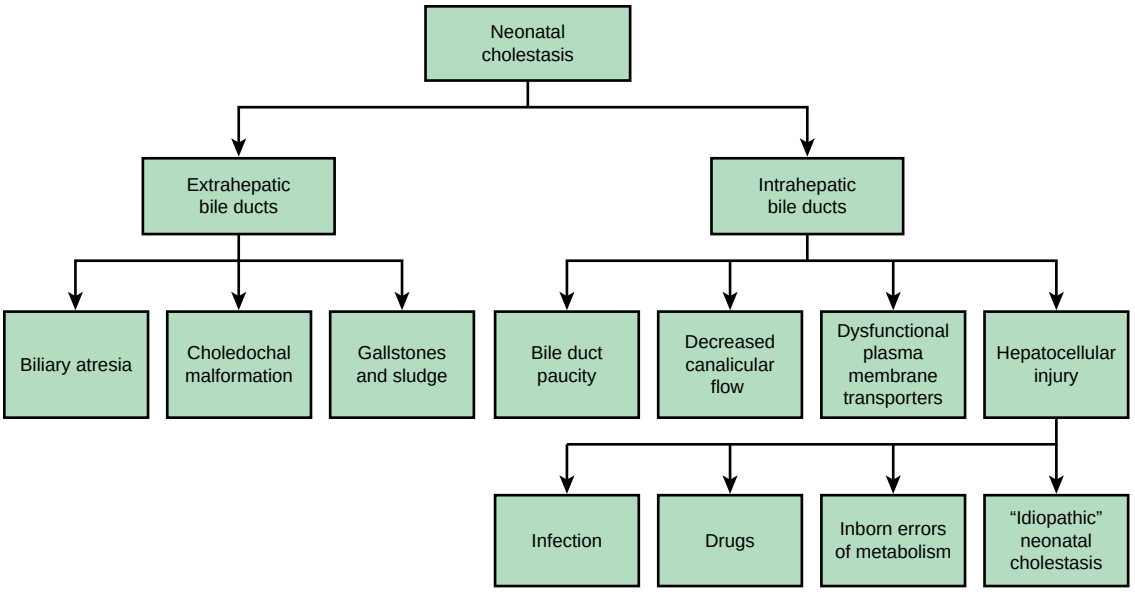

Fig. 404.1 Conceptual approach to neonatal cholestasis. There are areas of overlap: patients with biliary atresia will have some degree of intrahepatic/hepatocellular injury. Additional patients with "idiopathic" neonatal hepatitis may be determined in the future to be related to an enzyme or membrane transporter defect.

Fig. 404.2 Acholic stools from a 1-mo-old patient with biliary atresia. *(Courtesy Dr. S. Lam.)*

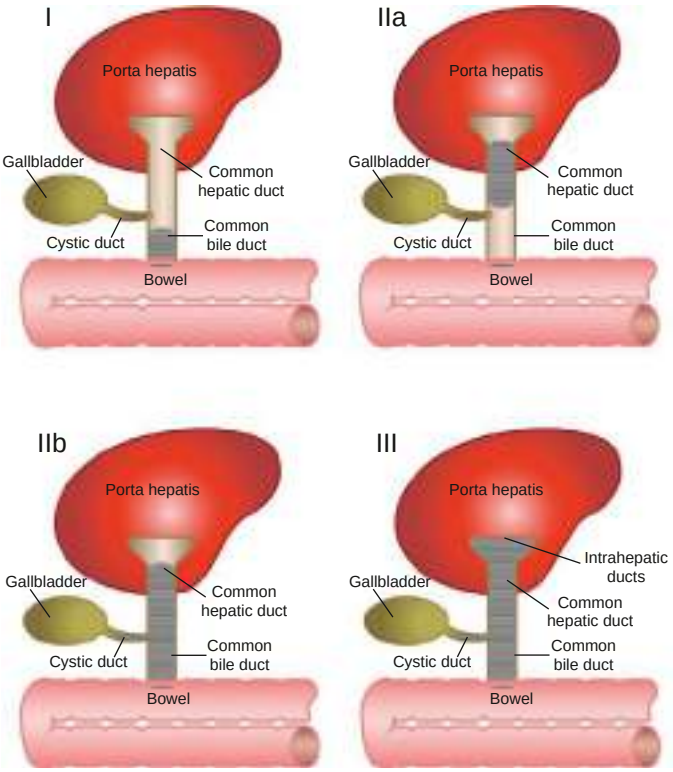

Fig. 404.3 Biliary atresia classified according to the area of involvement *(gray colored)*. Type I: Atresia of the distal bile duct with patent proximal extrahepatic bile duct. Type IIa: Atresia of the common hepatic duct. Type IIb: Atresia of the common hepatic duct, cystic duct, and common bile duct. Type III: Nonpatency of the entire extrahepatic biliary system and intrahepatic bile ducts at the hilum. *(Modified from A-Kader HH, Feerick J, Rodriguez-Davalos M. After two centuries biliary atresia remains the darkest chapter in pediatric hepatology. Ann Pediatr Child Health. 2015;3:1044, Fig. 2.)*

gallbladder, a diagnosis of biliary atresia is made if contrast does not fill the intrahepatic biliary tree or drain into the small bowel. After the diagnosis is confirmed, the Kasai hepatoportoenterostomy (KPE) is typically performed. The atretic biliary remnant is removed and a Roux-en-Y jejunostomy is anastomosed to the biliary hilum to reestablish bile flow; this remains the accepted surgical intervention for patients with biliary atresia (Fig. 404.4). A prompt diagnosis of biliary atresia is key because the timing of surgical correction is strongly linked to the prognosis. Historically, KPE performed before 60 days

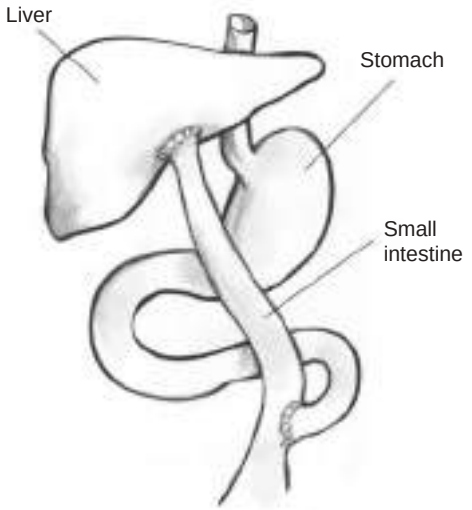

Fig. 404.4 Hepatoportoenterostomy (Kasai procedure). The atretic biliary remnant is removed and a Roux-en-Y jejunostomy is anastomosed to the biliary hilum to reestablish bile flow. *(Courtesy National Institute of Diabetes and Digestive and Kidney Diseases, National Institutes of Health. https://www.niddk.nih.gov/news/media-library/18094.)*

of life was used as the benchmark surgical intervention. However, the earlier that the KPE is established, the better the outcome. A national study across all Canadian centers showed that when the KPE was performed at ≤30 days of age, survival with the native liver at 4 years of age was higher than when the surgery was performed between 31 and 90 days. Given the strong impact of early intervention with KPE, biliary atresia screening programs have been implemented in select countries. Clearly any infant with jaundice persisting beyond the first few weeks of life should have serum total and conjugated bilirubin levels assessed. In Taiwan, the national rate of KPE before 60 days of age increased from 60% to 74% after the implementation of a biliary atresia stool card screening program. Similarly, the proportion of patients with total bilirubin <2 mg/dL 3 months post-KPE, an important prognostic marker for survival with native liver, significantly increased from 37% to 60% after the implementation of the program. A two-stage screening protocol assessing conjugated bilirubin levels in the state of Texas also led to a significant decrease in the age at which patients with biliary atresia underwent the KPE. The first stage was performed before 60 hours of life; the second stage was performed at 2 weeks of age if an elevated conjugated bilirubin was detected in the first stage. Stage two conjugated bilirubin levels that were increasing or were greater than 1 mg/dL were considered positive and underwent further testing. A novel serum biomarker, matrix metalloproteinase 7 (MMP7), has been identified as a possible sensitive and specific marker for biliary atresia.

Choledochal Malformations

Choledochal malformations, formerly known as *choledochal cysts,* are rare congenital dilations of the biliary tree (Fig. 404.5). With a 4:1 female predominance, these malformations have also been reported to be more common in the Asian population, with an incidence of approximately 1 in 13,000 compared with 1 in 100,000-150,000 in Western populations. The underlying pathogenesis is unknown; however, the presence of an anomalous pancreaticobiliary ductal union present in approximately 90% of patients may contribute to the development of choledochal malformations. Leading hypotheses suggest that an anomalous pancreaticobiliary union leads to reflux of pancreatic contents into the common bile duct, causing chronic inflammation and biliary damage leading to cystic changes.

Approximately 80% of choledochal malformations are detected in infancy and early childhood. Although these lesions are often first discovered by ultrasonography, magnetic resonance cholangiopancreatography (MRCP) and, less commonly, an endoscopic retrograde cholangiopancreatography, may be needed to further characterize the malformation according to the Todani classification (see Fig. 405.5).

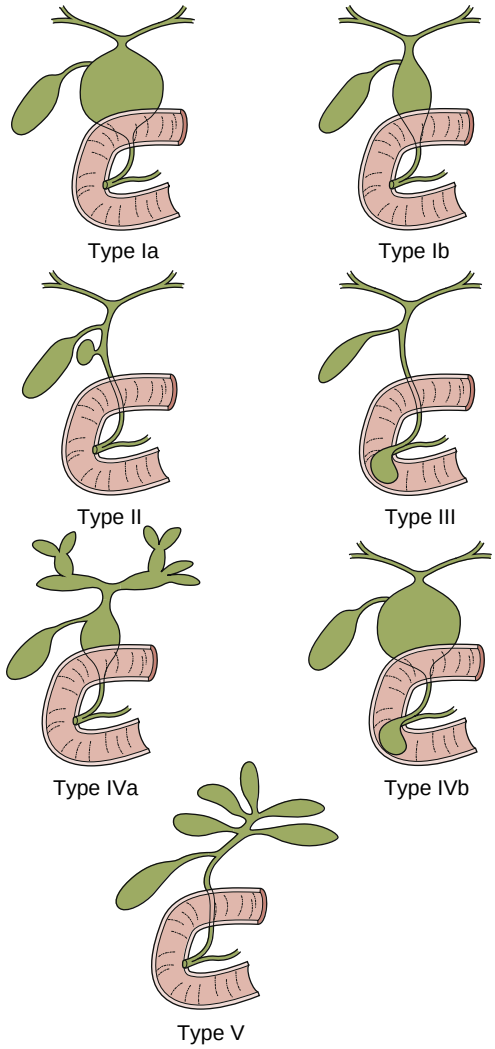

Fig. 404.5 These diagrams depict the five classifications for choledochal cyst according to Todani. *(From Todani T, Watanabe Y, Narusue M, et al. Congenital bile duct cysts: classification, operative procedures, and review of thirty-seven cases including cancer arising from choledochal cyst. Am J Surg. 1977;134:263–269.)*

In the neonatal period, choledochal malformations present with cholestasis and clay-colored stools; duodenal obstruction has also been reported. If untreated, long-term complications include cholangitis, pancreatitis, portal hypertension, and liver dysfunction. Importantly, biliary malignancies have also been associated with choledochal malformations, particularly with type I and IV malformations. Therefore although the approach differs based on subtype, surgical excision is the treatment of choice. The exceptions are type III cysts (choledochocele), which may be managed by endoscopic sphincterotomy. In those with extensive intrahepatic involvement (type IVa and V) not amenable to surgical resection, orthotropic liver transplantation may be required if symptomatic chronic liver disease develops.

Choledocholithiasis and Biliary Sludge

Choledocholithiasis in the neonatal age-group is rare. The incidence of biliary sludge or inspissated bile causing cholestasis has been reported to affect 1 in 175,000 births. Both choledocholithiasis and biliary sludge are often detected by abdominal ultrasound. In patients with choledocholithiasis, a stone is typically visualized, whereas biliary sludge is suspected when low-level echoes are seen without evidence of choledocholithiasis on abdominal ultrasound. Factors altering bile acid composition, such as hemolytic disease, or bile flow, such as fasting or use of parenteral nutrition, contribute to the formation of sludge and stones. Ceftriaxone, a third-generation cephalosporin, has been identified as a risk factor in neonates;

Table 404.1 Classic Criteria Based on Five Body Systems for a Diagnosis of Alagille Syndrome

SYSTEM/PROBLEM	DESCRIPTION
Liver/cholestasis	Usually presenting as jaundice with conjugated hyperbilirubinemia in the neonatal period, often with pale stools
Dysmorphic facies	Broad forehead; deep-set eyes, sometimes with upslanting palpebral fissures; prominent ears; straight nose with bulbous tip; and pointed chin giving the face a somewhat triangular appearance
Congenital heart disease	Most frequently peripheral pulmonary artery stenosis, but also pulmonary atresia, atrial septal defect, ventricular septal defect, and tetralogy of Fallot
Axial skeleton/vertebral anomalies	"Butterfly" vertebrae may be seen on an anteroposterior radiograph and occasionally hemivertebrae, fusion of adjacent vertebrae, and spina bifida occulta
Eye/posterior embryotoxon	Anterior chamber defects, most commonly posterior embryotoxon, which is prominence of the Schwalbe ring at the junction of the iris and cornea

From Turnpenny PD, Ellard S. Alagille syndrome: pathogenesis, diagnosis and management. *Eur J Hum Genet.* 2012;20(3):251–257, Table 1.

biliary sludge has been reported to occur in 30–46% of children after a mean of 9 days. It is thought that high drug concentrations in the biliary system may precipitate with calcium salts, causing sludge or gallstones.

Both choledocholithiasis and biliary sludge in the infant is usually managed conservatively because cholestasis usually resolves with spontaneous passage of the stone or sludge. Ursodeoxycholic acid has also been used to treat gallstones and sludge. However, its ability to significantly alter the natural history has not been demonstrated. Endoscopic or surgical interventions are rarely required, but may be reserved for those with severe disease.

INTRAHEPATIC DISORDERS

Alagille Syndrome

Alagille syndrome (ALGS) is a multisystem autosomal dominant disorder with hepatic, ophthalmologic (i.e., posterior embryotoxon), cardiac (i.e., peripheral pulmonary stenosis), skeletal (i.e., butterfly vertebrae), renal, and vascular involvement (i.e., moyamoya or aneurysms) (Table 404.1). Characteristic triangular facies, a prominent forehead, deep-set eyes, bulbous nose tip, and pointed chin may be noted. ALGS is caused by pathogenic variants in the *JAG1* gene in 98% of patients and the *NOTCH2* gene in the remaining 2%. Other genes associated with paucity of bile ducts, but not typical ALGS, include *KDM6A* and *HNF1β*. The estimated prevalence of ALGS is approximately 1 in 30,000 live births. A clinical diagnosis can also be made in the presence of cholestatic liver disease and associated eye (Fig. 404.6), heart, skeletal (Fig. 404.7), and facial features.

The majority of patients with ALGS are diagnosed within the first year of life, with many presenting with cholestasis and elevated liver enzymes. Cholestasis is thought to be a result of the paucity of intrahepatic bile ducts, a characteristic hepatic manifestation of AGLS, defined as an intrahepatic bile duct–to–hepatic artery ratio in the portal areas of <0.5; this is present in 75–100% of patients. However, bile duct paucity may not be present in the newborn period, and the liver biopsy may show inflammation and bile ductular proliferation. In addition, nonvisualization of the extrahepatic biliary tree because of intrahepatic disease may lead to a misdiagnosis of biliary atresia in some cases. Therefore expert review of histologic and

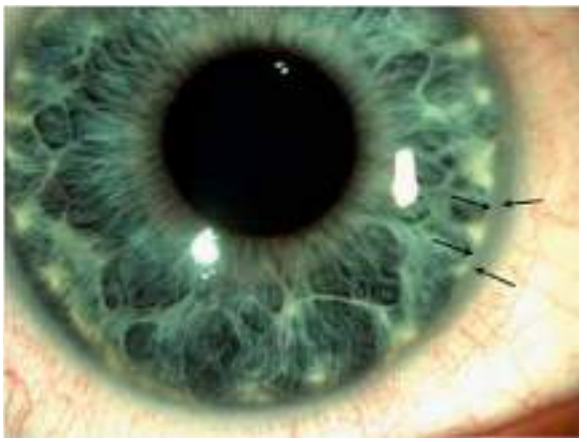

Fig. 404.6 Posterior embryotoxon. *(From Turnpenny PD, Ellard S. Alagille syndrome: pathogenesis, diagnosis and management. Eur J Hum Genet. 2012;20:251–257, Fig. 1.)*

Fig. 404.7 Butterfly vertebrae seen in the thoracic and upper lumbar regions. The child had undergone cardiac surgery, hence the presence of visible wires. *(From Turnpenny PD, Ellard S. Alagille syndrome: pathogenesis, diagnosis and management. Eur J Hum Genet. 2012;20:251–257, Fig. 2.)*

radiographic studies is essential to making the correct diagnosis. The spectrum of bile duct paucity is noted in Figure 404.8.

In general, cholestasis in patients with ALGS typically worsens until 5-6 years of age and then stabilizes or improves in some children. Pruritus, a prominent and debilitating complication of this condition, can be noted within the first 6 months of life. Choleretics, rifampin, sertraline, and naltrexone have been traditionally used in attempts to reduce pruritus in patients with ALGS. Clinical approval of apical sodium-dependent bile acid transporter inhibitors (also known as *ileal bile acid cotransporters*) (such as maralixibat and odevixibat) offers an option for debilitating pruritus and reducing serum bile acid levels.

End-stage liver disease develops in approximately 18% of children, but cardiac and vascular complications are the leading causes of mortality. Therefore a multisystem approach is critical to ensure adequate care for a patient with ALGS.

CYSTIC FIBROSIS–ASSOCIATED LIVER DISEASE

Cystic fibrosis (CF) is caused by a pathogenic variant in the *CFTR* gene. The incidence of CF varies based on ethnicity, from 1 in 2,500 in Northern Europe to 1 in 350,000 in the Japanese population. In Europe and North America, newborn screening for CF is widely available. Sweat chloride measurements and genetic testing are required to confirm

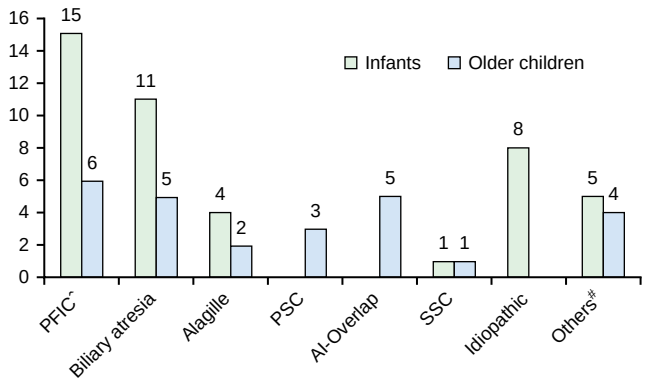

Fig. 404.8 Etiologic spectrum of ductal paucity. ^PFIC type 2 and type 3 were present in 14 and 1 infants and 3 and 3 older children, respectively. SSC was secondary to Langerhans cell histiocytosis in 2 children. #Other etiologies included in infants: cystic fibrosis (n = 1), giant cell hepatitis (n = 1), cytomegalovirus infection (n = 1), Caroli syndrome (n = 1), and Niemann-Pick type C (n = 1), whereas in older children: oxcarbazepine-induced vanishing bile duct syndrome (n = 1), congenital portosystemic shunt (n = 1), myeloproliferative disorder (n = 1), and hereditary fructose intolerance (n = 1). AI-Overlap, Autoimmune-overlap; PFIC, progressive familial intrahepatic cholestasis; PSC, primary sclerosing cholangitis; SSC, secondary sclerosing cholangitis. *(From Meena BL, Khanna R, Bihari C, et al. Bile duct paucity in childhood – spectrum, profile, and outcome. Eur J Pediatr. 2018;177:1261–1289.)*

the diagnosis. Cholestasis can be the first presenting symptom of CF-associated liver disease and has been reported to be present in approximately 6% of infants with CF. Infants with meconium ileus have been identified to be at increased risk for developing cholestasis in the neonatal period.

The cystic fibrosis transmembrane conductance regulator (CFTR), expressed on the apical surface of the biliary epithelial cells, functions to regulate chloride and bicarbonate secretion into the biliary canaliculus to provide adequate hydration for bile flow. When CFTR is nonfunctional or dysfunctional, the secretions become thick, leading to biliary obstruction. Postmortem examination of infants with CF revealed excessive mucus within the biliary tree.

Cholestasis in most infants with CF resolves by 9-10 months of age without significant sequelae. However, reports of clinically significant CF-associated liver disease causing liver failure and death have been reported in early childhood.

DISORDERS OF PLASMA MEMBRANE TRANSPORTERS

Progressive Familial Intrahepatic Cholestasis

Progressive familial intrahepatic cholestasis (PFIC) is the term used to denote a group of autosomal recessive disorders affecting bile acid transport (Table 404.2). Notably, all PFIC disorders typically present with low or normal GGT cholestasis except for PFIC3, which is associated with high GGT concentrations. Genetic testing is available to aid in the diagnosis of these disorders. **PFIC1** is caused by a pathogenic variant in *ATP8B1* encoding for a P-type ATPase (FIC1) highly expressed on the apical membrane of epithelial cells. Although its exact role is unknown, it likely functions as an aminophospholipid flippase to maintain homeostasis within the phospholipid bilayer by translocating phospholipids from the outer leaflet into the inner leaflet of the plasma membrane. Loss of ATP8B1 may result in an imbalance in the distribution of phospholipids, leading to instability of the canalicular membrane and decreased function of the transmembrane proteins, including the bile acid transporter (i.e., ABCB11). ATP8B1 is expressed on other epithelial cells, including the pancreas and small intestines. Therefore extrahepatic manifestations of *ATP8B1 (FIC1) deficiency* include diarrhea, pancreatic exocrine insufficiency, and sensorineural hearing loss. The liver histology was first described in Amish descendants with the surname Byler. Characteristic findings of "bland cholestasis" include preserved liver architecture with canalicular cholestasis and mild ductular proliferation. Inflammation is typically not a prominent feature with the absence of giant cells. On electron microscopy, the bile has a granular appearance and has been referred to as *Byler bile.* Progression to end-stage liver disease may occur. Significant diarrhea and hepatic steatosis have been reported in children after liver transplantation.

PFIC2 is caused by a pathogenic variant in *ABCB11* encoding the bile salt export pump (BSEP) located on the canalicular membrane of the hepatocyte. BSEP actively transports bile acids out of the hepatocyte into the canaliculus against a large concentration gradient. Pathogenic variants in *ABCB11 (BSEP deficiency)* lead to the inability to transport bile acids, resulting in cholestasis. In contrast to PFIC1, liver histology shows features of neonatal hepatitis with disruption of the liver architecture and giant cell transformation. Immunohistochemistry (IHC) may reveal the absence of the BSEP protein; however, the presence of staining does not exclude a dysfunctional protein. Medical therapies are generally supportive; there are currently no proven approaches to halt progression toward cirrhosis. Hepatocellular carcinoma is a recognized complication of this condition, with 10 patients diagnosed before 5 years of age in one report. Most children will eventually require liver transplantation. Notably, recurrence of BSEP deficiency has been reported in the liver allograft, likely the result of recipient antibody production against the BSEP protein in the transplanted liver.

PFIC3 is caused by a pathogenic variant in *ABCB4* encoding the class III multidrug resistance P-glycoprotein (MDR3) located on the canalicular membrane of the hepatocyte. MDR3 functions as an aminophospholipid floppase, transporting phosphatidylcholine (PC) from the inner leaflet to the outer leaflet (canalicular lumen) of the plasma membrane. With an abundance of PC in the canalicular lumen, mixed micelles containing PC, cholesterol, and excreted bile acids can be formed, thus protecting the biliary tree against the detergent properties of the bile acids. In the absence of available PC, biliary injury results from exposure to inadequately solubilized bile acids. Unlike other forms of PFIC, *MDR3 deficiency* is associated with elevated serum γ-glutamyl transferase (GGT) concentrations. Liver biopsies may show portal inflammation, fibrosis, and prominent ductal proliferation. Medical and surgical therapies are limited; however, ursodeoxycholic acid (UDCA), a hydrophilic bile acid, may have a role. In a single-center study, 77% of children with a clinical diagnosis of PFIC3 showed normalization or improvement in liver enzymes during treatment with UDCA. Furthermore, patients who responded to UDCA also showed resolution of hepatosplenomegaly and pruritus. Liver histology in four children also showed decreased fibrosis after 2 years of UDCA administration. However, response to UDCA has been linked to the type of pathogenic variant, with no response in children with a truncated protein from premature stop codons.

PFIC4 is caused by a pathogenic variant in *TJP2* encoding the tight junction protein 2, a cytosolic component for several classes of cell-cell junctions; TJP2 plays an important role in the localization of paracellular structures. When dysfunctional, the tight junctions between hepatocytes are impaired, predisposing to reflux of bile into the paracellular spaces and resulting in hepatocellular injury. Hepatocellular carcinoma has been reported. Extrahepatic manifestations include neurologic and respiratory involvement, thought to be related to the widespread distribution of the TJP2 protein. Histologic characteristics include nonspecific features with intracellular cholestasis and scant giant cells. There are no proven effective medical therapies, and liver transplantation has only been reported in a small number of patients.

PFIC5 is caused by a pathogenic variant in *NR1H4* encoding for the farnesoid X receptor (FXR), a master regulator of bile acid homeostasis. All patients described had severe liver dysfunction and coagulopathy not responsive to vitamin K beginning within the first several months of life. Progression to liver failure has been reported within the first 2 years of life with worsening coagulopathy, hypoglycemia, and hyperammonemia. Liver biopsy features include ductular reaction, diffuse giant cell transformation, intralobular cholestasis with variable degrees of inflammation, and fibrosis. None of the reported patients showed BSEP expression. Outcomes are universally poor, necessitating liver transplantation. Survival after liver transplantation has been reported to be satisfactory, but graft steatosis has been noted.

Table 404.2 Progressive Intrahepatic Familial Cholestasis Genetics and Transporter Defects and Associated γ-Glutamyl Transferase Levels

	LOCUS	GENE	DEFECT	GGT
PFIC-1 BRIC-1	18q21-22	*ATP8B1/FIC1*	ATP-dependent amino-phospholipid transport	Normal
PFIC-2 BRIC-2	2q24	*ABCB11/BSEP*	ATP-dependent bile acid transport	Normal
PFIC-3	7q21	*ABCB4/MDR3*	ATP-dependent translocation of phosphatidylcholine	High
PFIC-4		*TJP2*	Tight junction protein	Normal
PFIC-5		*NR1H4/FXR*	Nuclear bile acid receptor	Normal
PFIC-6		*MYO5B*	Myosin5b	Normal

BRIC, Benign recurrent intrahepatic cholestasis; GGT, γ-glutamyl transferase; PFIC, progressive familial intrahepatic cholestasis.
From Loomes KM, Emerick KM. Pediatric cholestatic liver disease. In: Wyllie R, Hyams JS, Kay M, eds. *Pediatric Gastrointestinal and Liver Disease*, 6th ed. Philadelphia: Elsevier; 2021: Table 70.2, p. 771.

PFIC6 is caused by a pathogenic variant in *MYO5B* encoding for myosin 5B. *MYO5B deficiency* has also been linked to **microvillus inclusion disease**, in which some patients develop low GGT cholestasis. It is recognized that a form of low GGT cholestasis, resembling other PFIC disorders, can develop in the absence of intestinal disease in patients with MYO5B defects. Histologic features show giant cell hepatitis, fibrosis, and hepatocellular cholestasis. IHC reveals abnormal organization of both BSEP and MDR3 in the canaliculi and a granular and patchy pattern in the subcanalicular area. The prognosis for patients with PFIC6 appears to be better than with other forms of PFIC, with the median age of 5 years without progressive liver failure in the first case series reported. Cholestatic liver disease has developed in some patients who had undergone isolated intestinal transplant because of intestinal failure. This has prompted some to advocate for the consideration of a combined liver-intestine transplant in this patient population.

Endocrinopathies

Congenital hypothyroidism has long been associated with neonatal cholestasis. In a single-center study, 35% of patients with congenital hypothyroidism presented with cholestasis. Liver biopsies in these infants revealed intracellular bile pigment accumulation and variable giant cell formation. The pathogenesis remains unknown, but it is postulated that hormones, including thyroid hormone, regulate bile production and flow. Although screening for congenital hypothyroidism using thyroid-stimulating hormone (TSH) is common in many countries, central hypothyroidism resulting from pan-hypopituitarism (i.e., septo-optic dysplasia) may be missed because of a falsely low TSH. Prompt recognition and treatment are vital, as delayed treatment in congenital hypothyroidism may have severe neurodevelopmental consequences and lead to death in those with adrenal insufficiency. Fortunately, cholestasis usually resolves after appropriate hormone supplementation, and progression of liver disease is not expected.

HEPATOCYTE INJURY

Infections, drugs, metabolic disorders, and genetic conditions should also be considered as causes of cholestasis in an infant.

Infections

Bacterial, fungal, and viral infections may manifest as neonatal cholestasis. In a single-center study, urinary tract infections were found in 7.5% of asymptomatic, afebrile infants less than 8 weeks of age presenting with jaundice. Infections may result in hepatic injury through direct invasion from hepatotrophic microorganisms (i.e., cytomegalovirus [CMV]), or secondarily by exposure to endotoxins released from microbe membranes. In animal models, endotoxin has been shown to decrease bile flow. In sepsis, perfusion to the liver may also be impaired.

Congenital infections are unique to neonates and require particular attention. The so-called "TORCHeS" infections (*Toxoplasma gondii*, rubella, CMV, herpes simplex virus, and syphilis) are recognized causes of neonatal cholestasis. Although some affected infants are born with stigmata of a congenital infection, such as thrombocytopenic purpura in congenital rubella syndrome, others may present with neonatal cholestasis alone. Therefore is it important to assess for congenital infections in the cholestatic infant, as treatment and additional screening may be necessary upon diagnosis (i.e., hearing tests in congenital CMV infection).

Infusions, Drugs, and Medications

Although a multitude of drugs and medications can cause cholestasis, parenteral nutrition–associated liver disease (PNALD) is a common iatrogenic cause of cholestasis, particularly in the neonatal intensive care unit. Typically observed in infants requiring parenteral nutrition for more than 2 weeks, other risk factors for the development of PNALD include prematurity, low birthweight, nil per os (NPO), long duration of parenteral nutrition, imbalanced amino acid composition, bacteremia, and abdominal surgeries. The lipid emulsion used also has a significant impact on the development of PNALD. Specifically, soybean lipid emulsions contain ω-6 fatty acids and plant-based cholesterol products called phytosterols. ω-6 Fatty acids are thought to be proinflammatory, whereas phytosterols can impair bile flow caused by inefficient metabolism in the liver. In contrast, fish oil emulsions are rich in ω-3 fatty acids, which are antiinflammatory and do not contain phytosterols, thus protecting the liver against PNALD. The availability of SMOF—a soy, medium-chain triglyceride (MCT), olive oil, and fish oil emulsion—also offers the benefits of an ω-3 rich emulsion but also contains adequate essential fatty acids. Clinical trials have shown that SMOF was hepatoprotective in preterm infants, resulting in a lower incidence of PNALD with a lower peak bilirubin level and was associated with decreased hospital length of stay. UDCA may also provide some benefit to patients with PNALD; it was well tolerated without reported adverse events. Therefore the benefits of reducing liver enzymes must be weighed against the unknown efficacy of UDCA. Fortunately, as parenteral nutrition is weaned and enteral feeds are increased, PNALD resolves in most patients without long-term sequelae.

Alpha$_1$-Antitrypsin Deficiency

α_1-Antitrypsin (A1AT) deficiency is the most common form of inherited neonatal cholestasis, occurring in approximately 1 in 2,000-3,500 live births in North America. This autosomal recessive disorder is diagnosed by a low serum A1AT level, protein electrophoresis to identify pathologic phenotypes—most commonly ZZ—and molecular testing. Pathogenic variants in the *SERPINA1* gene may result in abnormal folding of the A1AT protein within the rough endoplasmic reticulum. The misfolded A1AT protein is unable to be secreted out of the hepatocyte, and intracellular accumulation leads to autophagy, mitochondrial injury, and progression to hepatocellular injury. It should be noted that A1AT is also an acute-phase reactant and may be falsely elevated during systemic inflammation; therefore a normal A1AT level in this clinical context may not exclude a diagnosis of A1AT deficiency.

A large Swedish study prospectively screened 200,000 newborns to identify those with A1AT deficiency; neonatal cholestasis occurred in ~11% of infants with the ZZ phenotype. A multicenter study of 350 patients with A1AT deficiency with a mean follow-up time of 2.5 years reported a slightly increased risk of developing portal hypertension in those with a history of neonatal cholestasis compared with those without, although there was no difference in the risk of liver transplantation or death.

Inborn Errors of Metabolism

Galactosemia is a rare inborn error of galactose metabolism cause by a deficiency in the galactose-1-phosphate uridyltransferase (GALT), galactokinase (GALK), or UDP-galactose-4′-epimerase (GALE) enzyme. As such, galactose cannot be metabolized to glucose, leading to hypoglycemia and accumulation of toxic intermediate metabolites causing vomiting; feed intolerance; and hepatic, neurologic, ocular, and renal injury. An association between galactosemia and *Escherichia coli* sepsis has also been reported. Although rare, neonatal cholestasis may be the presenting symptom of an infant with galactosemia. Early diagnosis with enzyme and genetic testing and treatment with a strict galactose-free diet are essential to preserving neurologic function. Fortunately, many countries have adopted galactosemia as part of their newborn metabolic screen, which has aided in the early diagnosis and improved outcomes of these patients.

Type I tyrosinemia is an autosomal recessive disorder caused by a defect in the fumarylacetoacetate hydrolase (FAH) enzyme required for tyrosine metabolism. Accumulation of metabolites upstream of the FAH enzyme, including fumarylacetoacetate, succinylacetate, and succinylacetone, may precipitate hepatic and renal injury. Infants with tyrosinemia can be present with cholestasis, but usually also have evidence of hepatic dysfunction, including severe coagulopathy out of keeping with the degree of hepatocellular injury. High urine succinylacetone levels are highly suggestive of tyrosinemia type I. Treatment with nitisinone, a potent inhibitor of tyrosine degradation, and dietary therapy are the mainstays of therapy to prevent acute and chronic complications of tyrosinemia type I.

Hereditary fructose intolerance (HFI) is an autosomal recessive disorder caused by the deficiency of aldolase B enzyme. In the absence of aldolase B activity, large amounts of fructose-1-phosphate accumulate in the liver, leading to depletion of inorganic phosphate and adenosine triphosphate (ATP). As a result of depleted inorganic phosphate, new ATP cannot be generated, leading to hepatocyte necrosis and liver dysfunction. Although breast milk is fructose free, common infant formulas may contain fructose in various forms. Furthermore, sucrose, a disaccharide made up of glucose and fructose monosaccharides, is a common component of oral medications for infants. Therefore a careful review of unexpected fructose exposure should be undertaken in infants with liver dysfunction in which HFI is suspected. A diagnosis is confirmed by measuring enzyme activity or through molecular testing. Symptoms resolve with the institution of a strict fructose-free diet, and patients are expected to develop normally.

Lysosomal and peroxisomal disorders, including Niemann-Pick type A and C and Zellweger syndrome, respectively, are another group of conditions that may present with neonatal cholestasis. Typically, these conditions are multisystemic resulting in neurologic, cardiac, and hematologic manifestations depending on the disorder. Liver biopsies may show accumulation of storage materials within organelles on electron microscopy. The diagnosis is usually confirmed by genetic testing.

Mitochondrial hepatopathies result from deletion or depletion of mitochondrial genes including *POLG1, DGUOK,* and *MPV17* (Table 404.3). These conditions typically present with neonatal cholestasis and may evolve into neonatal acute liver failure characterized by lactic acidosis, coagulopathy, hypoglycemia, and hyperammonemia. An elevated lactate-to-pyruvate ratio >25 mol/mol is suggestive of a mitochondrial disorder. Liver biopsy may reveal microsteatosis and abnormal mitochondrial staining or abnormal architecture on electron microscopy. There is often multisystem involvement, including neurologic, cardiac, and musculoskeletal manifestations of mitochondrial dysfunction. Prognosis is poor with limited proven therapies.

Table 404.3 Phenotypic Classification of Primary Mitochondrial Hepatopathies

RC (electron transport) defects (OXPHOS)
- Neonatal liver failure
  - Complex I deficiency
  - Complex IV deficiency (*SCO1* variants)
  - Complex III deficiency (*BCS1L* variants)
  - Coenzyme Q deficiency
  - Multiple complex deficiencies (transfer and elongation factor variants)
  - mtDNA depletion syndrome (*DUGOK, MPV17, POLG, SUCLG1, C10orf2/Twinkle* variants)
- Later-onset liver dysfunction or failure
  - Alpers-Huttenlocher disease (*POLG* variants)
  - Pearson marrow pancreas syndrome (mtDNA deletion)
  - Mitochondrial neurogastrointestinal encephalopathy (*TYMP* variants)
  - NNH (*MPV17* variants)

Fatty acid oxidation defects
- Long-chain 3 hydroxyacyl-coenzyme A dehydrogenase
- Carnitine palmitoyltransferase I and II deficiencies
- Carnitine-acylcarnitinetranslocase deficiency

Urea cycle enzyme deficiencies

Electron transfer flavoprotein and electron transfer flavoprotein dehydrogenase deficiencies

Phosphoenol pyruvate carboxykinase (mitochondrial) deficiency; nonketotic hyperglycemia

Citrin deficiency; neonatal intrahepatic cholestasis caused by citrin deficiency (*SLC25A13* variants)

NN, Navajo neurohepatopathy; OXPHOS, oxidative phosphorylation; RC, respiratory chain.

From Lee WS, Sokol RJ. Mitochondrial hepatopathies: advances in genetics, therapeutic approaches, and outcomes. *J Pediatr*. 2013;163(4):942–948, Table 1.

Bile Acid Synthesis Defects

Bile acid synthesis defects are a rare cause of neonatal cholestasis. Liver injury is postulated to result from the accumulation of hepatotoxic intermediate metabolites and absence of the normal trophic and choleretic effects of primary bile acids. Inborn errors of bile acid biosynthesis typically present with a form of low GGT cholestasis and low serum bile acid levels. Clinical presentation may vary from neonatal cholestasis to neonatal acute liver failure. Characteristic urine bile acid profiles may indicate specific enzyme defects. Supplementation with cholic acid may be helpful; however, patients who do not respond to bile acid replacement therapy may require liver transplantation.

Gestational Alloimmune Liver Disease

Gestational alloimmune liver disease (GALD) is a rapidly progressive disease characterized by iron deposition in the liver, heart, salivary glands, and endocrine organs without increased iron stores in the reticuloendothelial system. Infants present with liver dysfunction within the first few days of life. Familial cases and repeated miscarriages are commonly reported. The postulated pathophysiology involves maternal sensitization to fetal liver antigens. As a result, maternal antibodies against the fetal liver are transported across the placenta causing fetal liver injury in utero. Liver injury results in decreased hepatic hepcidin expression and thus dysregulated iron update into the developing fetus. Laboratory findings include hypoglycemia, hyperbilirubinemia, hypoalbuminemia, elevated ferritin, and coagulopathy. The diagnosis is usually confirmed by salivary biopsy or MRI demonstrating extrahepatic siderosis in the pancreas, myocardium, or thyroid follicles. Liver biopsies almost universally show cirrhosis, and positive staining for C5b-9 membrane attack complex has also been reported. The differential diagnosis is noted in Table 404.4. Treatment with exchange transfusion and intravenous immunoglobulin (IVIG) has been shown to

Table 404.4 Typical Laboratory Findings in Neonatal Liver Failure

	GALD	HLH	MITOCHONDRIAL	VIRAL	ISCHEMIC
Transaminase levels (IU/L)	Normal/mild increase (<100)	Moderate/significant increase (>1,000)	Moderate increase (100-500)	Significant increase (>1,000)	Significant increase (>1,000-6,000)
INR	Significant increase	Moderate/significant increase	Moderate/significant increase	Moderate/significant increase	Moderate/significant increase
Ferritin level (ng/mL)	800-7,000	Significant increase (>20,000)	Variable	Significant increase (>20,000)	Variable depending on underlying cause of ischemia
Triglyceride levels	Normal	Increased	Normal	Normal	Normal
Hypoglycemia	Yes	Often	Yes	Often	Variable
Lactic acidosis	Normal	Normal	Increased	Normal	Often
α-Fetoprotein level (for age)	Increased	Normal	Normal/increased	Normal	Normal
Cholestasis	Progressive after birth	Moderate/significant	Moderate	None/mild at presentation	Mild/moderate

HLH, Hemophagocytic lymphohistiocytosis.
From Larson-Nath C, Vitola BE. Neonatal acute liver failure. *Clin Perinatol*. 2020;47:25–39: Table 2; with data from Sundaram et al. *J Pediatr*. 2011;159:813–818; Taylor et al. *Liver Transpl*. 2016;22(5):677–685; Bitar et al. *J Pediatr Gastroenterol Nutr*. 2017;64(1):70–75; Fellman et al. *Semin Fetal Neonatal Med*. 2011;16(4):222–228.

improve outcomes and reduce the need for liver transplantation. Given the high rate of recurrence of GALD in future pregnancies of affected mothers, maternal treatment with weekly IVIG beginning at 18 weeks gestational age should be considered and has been shown to decrease GALD in the developing fetus.

OTHER SYNDROMES ASSOCIATED WITH NEONATAL CHOLESTASIS

Neonatal Ichthyosis and Sclerosing Cholangitis

Neonatal ichthyosis and sclerosing cholangitis (NISCH) syndrome is a rare autosomal recessive condition caused by pathogenic variants in claudin-1 *(CLDN1)*, a membrane protein needed for the formation of tight junctions between cells. Infants may present with dry scaly skin, alopecia, and jaundice within the first few weeks of life. Defects in CLDN1 (similar to TJP2 deficiency) increase paracellular leakage and regurgitation of the toxic components of bile, leading to bile duct injury and cholestasis. Liver histology is variable, with most infants having evidence of hepatocellular cholestasis and bile duct plugs. Ductular proliferation, portal fibrosis, ductopenia, and characteristic findings of sclerosing cholangitis on cholangiogram have been described later in adolescence. Severity of liver disease is also variable ranging from transient neonatal cholestasis to progressive cirrhosis requiring liver transplantation.

Lymphedema-Cholestasis Syndrome (Aagenaes Syndrome)

Lymphedema-cholestasis syndrome is a rare cholestatic disorder manifest by cholestasis with pale stools by 1 week of life. On liver biopsy, multinucleated giant cell hepatitis was described in affected patients. The clinical course is variable, but jaundice reportedly resolves by 1-5 years of age. Intermittent episodes of cholestasis may recur but typically resolve in a period of months. Lower extremity lymphedema develops during the prepuberty period in all patients and can be disfiguring. Pathogenesis remains unknown, but a locus has been mapped to chromosome 15q and is thought to play a role in the abnormal development of lymphatic structures. The natural history of liver disease has been reported to be favorable, with cirrhosis developing in a small minority of patients.

Arthrogryposis, Renal Dysfunction, and Cholestasis

Arthrogryposis, renal dysfunction, and cholestasis (ARC) syndrome is a rare and autosomal recessive disorder caused by *VPS33B* or *VIPAR* pathogenic variants. Prominent clinical features include arthrogryposis, renal tubular acidosis, and a low GGT cholestasis. Additional features include agenesis of the corpus callosum, deafness, hypothyroidism, ichthyosis, recurrent infections, and congenital cardiac defects. With abnormal platelet count and function having also been described, life-threatening bleeding has been reported both spontaneously and after liver biopsy in affected patients. *VPS33B* or *VIPAR* plays a role in intracellular vesicular trafficking pathways, cell polarity, and membrane protein localization. As such, abnormal localization of canalicular membrane proteins, including BSEP and MDR3, have been reported in liver biopsies of patients with ARC syndrome and may contribute to the pathogenesis of cholestasis. Although the prognosis has been reported to be poor, successful liver transplantation for severe intractable pruritus and poor quality of life has been reported.

IDIOPATHIC NEONATAL HEPATITIS

Idiopathic neonatal hepatitis was a term used to describe infants with neonatal cholestasis for which a specific cause could not be determined. However, with the advent of molecular testing, the number of patients with "idiopathic neonatal hepatitis" is decreasing owing to the expanding knowledge of the molecular causes of cholestasis.

Management

Management of patients with neonatal cholestasis requires the clinician to identify the cause of cholestasis while ruling out conditions that require prompt intervention. Delayed diagnosis of sepsis, pan-hypopituitarism, or inborn errors of metabolism may have fatal consequences. Similarly, failure to promptly treat galactosemia or congenital hypothyroidism can have devastating neurologic sequelae. In patients with biliary atresia, the most common indication for pediatric liver transplant worldwide, early surgical intervention with KPE has been shown to improve survival with the native liver. Table 404.5 provides a framework for the initial investigation of a patient with neonatal cholestasis.

Table 404.5 Etiologies and Suggested Investigations for Patients with Neonatal Cholestasis

ETIOLOGY	RECOMMENDED INVESTIGATIONS
General investigations for all infants with cholestasis	CBC and differential, ALT, AST, total and conjugated bilirubin, GGT and ALP, INR, albumin, blood glucose Abdominal ultrasound with Doppler Review newborn metabolic screen Urinalysis
DISORDERS OF EXTRAHEPATIC BILE DUCTS	
Biliary atresia	MMP7, liver biopsy, intraoperative cholangiogram, examination of the biliary remnant
Choledochal malformation and choledocholithiasis/microlithiasis	Abdominal US, MRCP
INTRAHEPATIC DISORDERS	
Alagille syndrome	Ophthalmologic examination, chest x-ray, echocardiogram, liver biopsy, and genetic testing for *JAG1* and *NOTCH2*
Cystic fibrosis	Sweat chloride, *CFTR* testing
Membrane transporter defects	
• PFIC1	*ATP8B1* genetic testing
• PFIC2	*ABCB11* genetic testing
• PFIC3	*MDR3* genetic testing
• PFIC4	*TJP2* genetic testing
• PFIC5	*NR1H4* (*FXR*) genetic testing
• PFIC6	*MYO5B* genetic testing
• ARC syndrome	*VPS33B* and *VIPAR* genetic testing
• NISCH syndrome	*CLDN1* genetic testing
Endocrinopathies	
• Hypothyroidism	TSH, free T_4
• Hypopituitarism	TSH, free T_4, cortisol and electrolytes, MRI brain
Hepatocyte injury	
• Infection	Complete blood count and differential, blood and urine cultures, urinalysis, "ToRCHeS" screen
• Total parental nutrition	History
Inborn errors of metabolism	
• Galactosemia	Galactose-1-phosphate uridyltransferase enzyme activity, genetic testing for *GALT*, *GALK*, or *GALE*
• Tyrosinemia	Urine succinylacetone, *FAH* genetic testing
• Hereditary fructose intolerance	Aldolase B (*ALDOB*) enzyme activity and genetic testing
Bile acid synthesis defect	Serum bile acids, urine bile acid profile, genetic testing
α_1-Antitrypsin deficiency	Blood α_1-antitrypsin concentrations, electrophoretic phenotyping, *SERPINA1* genetic testing
Lysosomal disorders	
• Neimann Pick A and C	Genetic testing for *SMPD1* for Neimann Pick A and *NPC1* or *NPC2* genes for Neimann Pick C
• Cholesterol esterase storage disease/Wolman	Liposomal acid lipase enzyme testing and *LIPA* genetic testing
• Mucopolysaccharidoses	Urine screen for glycosaminoglycans. Genetic testing for specific pathogenic variants associated with mucopolysaccharidoses
Peroxisomal biogenesis disorders	
• Zellweger syndrome • Infantile Refsum	Very long-chain fatty acid concentrations, genetic testing for PEX genes
Mitochondrial hepatopathy	Ammonia, lactate, pyruvate, creatinine kinase, echocardiogram, genetic testing for mitochondrial genes
Gestational alloimmune liver disease	MRI, buccal biopsy, serum ferritin, total iron-binding capacity ammonia

CBC, Complete blood count; ALT, alanine aminotransferase; AST, aspartate aminotransferase; GGT, gamma-glutamyl transferase; ALP, alkaline phosphatase; INR, international normalized ratio; MMP7, matrix metalloproteinase 7; US, ultrasound; MRCP, magnetic resonance cholangiopancreatography; JAG1, jagged-1; NOTCH2, notch receptor 2; CFTR, cystic fibrosis transmembrane conductance regulator; ATP8B1, ATPase phospholipid transporting 8B1; ABCB11, ATP-binding cassette subfamily B member 11; MDR3, class III multidrug resistance P-glycoproteins; TJP2, tight junction protein 2; NR1H4, nuclear receptor subfamily 1 group H member 4; MYO5B, myosin VB; VPS33B, vacuolar protein sorting-associated protein 33B; VIPAR, VPS33B interacting protein, apical-basolateral polarity regulator, Spe-39 homolog; CLDN1, claudin 1; TSH, thyroid-stimulating hormone; GALT, galactose-1-phosphate uridylyl transferase; GALK, galactokinase; GALE, UDP-galactose-4′-epimerase; FAH: fumarylacetoacetate hydrolase; SERPINA1, serpin family A member 1; SMPD1, sphingomyelin phosphodiesterase 1; NPC1, NPC intracellular cholesterol transporter 1; NPC2, NPC intracellular cholesterol transporter 2; LIPA, lysosomal acid lipase.

Table 404.6 Recommended Nutritional Support for Children with Cholestasis

ENERGY/NUTRIENT	REQUIREMENT
Energy	~130% of requirement for age
Fat	30–50% of total calories Start with MCT/LCT = 30%/70% of total fat calories
Protein	~130–150% of requirement for age
Carbohydrate	40–60% of total calories
Vitamin A	<10 kg: 5,000 IU/day >10 kg: 10,000 IU/day
Vitamin D	Cholecalciferol: 2,000-5,000 IU/day
Vitamin E	D-alpha-tocopheryl polyethylene glycol 1000 succinate: 15-25 IU/kg/day
Vitamin K	2-5 mg/day
Calcium	Meet DRI

Adapted from Mouzaki M, Bronsky J, Gupte G, et al. Nutrition support of children with chronic liver diseases: a joint position paper of the North American Society for Pediatric Gastroenterology, Hepatology, and Nutrition and the European Society for Pediatric Gastroenterology, Hepatology, and Nutrition. *J Pediatr Gastroenterol Nutr*. 2019;69(4):498–511.

In infants with chronic cholestasis, growth failure and malnutrition are major concerns. Bile is an essential component of lipid digestion; therefore cholestasis leads to fat maldigestion and fat-soluble vitamin deficiencies (i.e., vitamin A, D, E, and K). Caloric support by an MCT-containing formula may be helpful, as MCT can be absorbed in a bile acid–independent manner. Supplementation with aqueous vitamin A, D, E, and K formations should be considered to avoid the complications of fat-soluble vitamin deficiencies. Table 404.6 has been adapted to provide initial guidance toward nutritional support in children with neonatal cholestasis. Regular monitoring of anthropometrics and fat-soluble vitamin levels is needed to ensure patients are provided with adequate nutrition for growth and development.

404.2 Cholestasis in the Older Child

Simon Lam and William F. Balistreri

Cholestasis with onset after the neonatal period is most often caused by acute viral hepatitis or exposure to hepatotoxic drugs. However, many of the conditions causing neonatal cholestasis can also cause chronic cholestasis in older patients (see Table 403.3). Consequently, older children and adolescents with conjugated hyperbilirubinemia should be evaluated for acute and chronic viral hepatitis, α_1-antitrypsin deficiency, Wilson disease, liver disease associated with inflammatory bowel disease, sclerosing cholangitis, autoimmune hepatitis, drug-induced liver injury, and the syndromes of intrahepatic cholestasis. Other causes include obstruction related to cholelithiasis, abdominal tumors, enlarged lymph nodes, or hepatic inflammation resulting from drug ingestion. Management of cholestasis in the older child is similar to that proposed for neonatal cholestasis.

Visit Elsevier eBooks+ at eBooks.Health.Elsevier.com for Bibliography.

Chapter 405

Metabolic Diseases of the Liver

Julie Bonn and William F. Balistreri

INTRODUCTION

Metabolic liver diseases in children, although individually rare, altogether represent a significant cause of morbidity and mortality. This is because the liver has a central role in synthetic, degradative, and regulatory pathways involving carbohydrate, protein, lipid, trace element, and vitamin metabolism. Therefore inborn errors of metabolism will result in metabolic abnormalities, specific enzyme deficiencies or defects, and disorders of protein transport that can have primary or secondary effects on the liver (Table 405.1). Liver disease can arise when absence of an enzyme produces a block in a metabolic pathway, when unmetabolized substrate accumulates proximal to a block, when deficiency of an essential substance produced distal to an aberrant chemical reaction develops, or when synthesis of an abnormal metabolite occurs. The spectrum of pathologic changes includes **hepatocyte injury**, with subsequent failure of other metabolic functions, often resulting in cirrhosis and/or liver cancer; abnormal **storage** of lipid, glycogen, or other products manifested as hepatomegaly, often with complications specific to deranged metabolism (hypoglycemia with glycogen storage disease); and absence of structural change despite profound **metabolic effects**, as seen in patients with urea cycle defects. Clinical manifestations of metabolic diseases of the liver mimic infections, intoxications, and hematologic and immunologic diseases (Table 405.2).

Many metabolic diseases are detected in expanded newborn metabolic screening programs (see Chapter 104). Clues are provided by family history of a similar illness or by the observation that the onset of symptoms is closely associated with a change in dietary habits; in patients with hereditary fructose intolerance, symptoms follow ingestion of fructose (sucrose). Clinical and laboratory evidence often guides the evaluation. Liver biopsy offers morphologic study and permits enzyme assays, as well as quantitative and qualitative assays of various other constituents (e.g., hepatic copper content in Wilson disease). Genetic/molecular diagnostic approaches are also available. Such studies require cooperation of experienced laboratories and careful attention to collection and handling of specimens. Treatment depends on the specific type of defect, and although relatively uncommon, altogether metabolic diseases of the liver account for up to 10% of the indications for liver transplantation in children, a number that may be underestimated given the acute nature of some of these conditions, precluding complete diagnostic investigation before transplantation.

405.1 Inherited Deficient Conjugation of Bilirubin (Familial Nonhemolytic Unconjugated Hyperbilirubinemia)

Julie Bonn and William F. Balistreri

Bilirubin is the metabolic end product of heme. Before excretion into bile, it is first glucuronidated and made water-soluble by the enzyme bilirubin-uridine diphosphoglucuronate glucuronosyltransferase (UDPGT). UDPGT activity is deficient or altered in three genetically and functionally distinct disorders (Crigler-Najjar [CN] syndromes type I and II and Gilbert syndrome), producing congenital nonobstructive, nonhemolytic, **unconjugated** hyperbilirubinemia. UGT1A1

Table 404.6 Recommended Nutritional Support for Children with Cholestasis

ENERGY/NUTRIENT	REQUIREMENT
Energy	~130% of requirement for age
Fat	30–50% of total calories Start with MCT/LCT = 30%/70% of total fat calories
Protein	~130–150% of requirement for age
Carbohydrate	40–60% of total calories
Vitamin A	<10 kg: 5,000 IU/day >10 kg: 10,000 IU/day
Vitamin D	Cholecalciferol: 2,000-5,000 IU/day
Vitamin E	D-alpha-tocopheryl polyethylene glycol 1000 succinate: 15-25 IU/kg/day
Vitamin K	2-5 mg/day
Calcium	Meet DRI

Adapted from Mouzaki M, Bronsky J, Gupte G, et al. Nutrition support of children with chronic liver diseases: a joint position paper of the North American Society for Pediatric Gastroenterology, Hepatology, and Nutrition and the European Society for Pediatric Gastroenterology, Hepatology, and Nutrition. *J Pediatr Gastroenterol Nutr*. 2019;69(4):498–511.

In infants with chronic cholestasis, growth failure and malnutrition are major concerns. Bile is an essential component of lipid digestion; therefore cholestasis leads to fat maldigestion and fat-soluble vitamin deficiencies (i.e., vitamin A, D, E, and K). Caloric support by an MCT-containing formula may be helpful, as MCT can be absorbed in a bile acid–independent manner. Supplementation with aqueous vitamin A, D, E, and K formations should be considered to avoid the complications of fat-soluble vitamin deficiencies. Table 404.6 has been adapted to provide initial guidance toward nutritional support in children with neonatal cholestasis. Regular monitoring of anthropometrics and fat-soluble vitamin levels is needed to ensure patients are provided with adequate nutrition for growth and development.

404.2 Cholestasis in the Older Child

Simon Lam and William F. Balistreri

Cholestasis with onset after the neonatal period is most often caused by acute viral hepatitis or exposure to hepatotoxic drugs. However, many of the conditions causing neonatal cholestasis can also cause chronic cholestasis in older patients (see Table 403.3). Consequently, older children and adolescents with conjugated hyperbilirubinemia should be evaluated for acute and chronic viral hepatitis, α_1-antitrypsin deficiency, Wilson disease, liver disease associated with inflammatory bowel disease, sclerosing cholangitis, autoimmune hepatitis, drug-induced liver injury, and the syndromes of intrahepatic cholestasis. Other causes include obstruction related to cholelithiasis, abdominal tumors, enlarged lymph nodes, or hepatic inflammation resulting from drug ingestion. Management of cholestasis in the older child is similar to that proposed for neonatal cholestasis.

Visit Elsevier eBooks+ at eBooks.Health.Elsevier.com for Bibliography.

Chapter 405

Metabolic Diseases of the Liver

Julie Bonn and William F. Balistreri

INTRODUCTION

Metabolic liver diseases in children, although individually rare, altogether represent a significant cause of morbidity and mortality. This is because the liver has a central role in synthetic, degradative, and regulatory pathways involving carbohydrate, protein, lipid, trace element, and vitamin metabolism. Therefore inborn errors of metabolism will result in metabolic abnormalities, specific enzyme deficiencies or defects, and disorders of protein transport that can have primary or secondary effects on the liver (Table 405.1). Liver disease can arise when absence of an enzyme produces a block in a metabolic pathway, when unmetabolized substrate accumulates proximal to a block, when deficiency of an essential substance produced distal to an aberrant chemical reaction develops, or when synthesis of an abnormal metabolite occurs. The spectrum of pathologic changes includes **hepatocyte injury**, with subsequent failure of other metabolic functions, often resulting in cirrhosis and/or liver cancer; abnormal **storage** of lipid, glycogen, or other products manifested as hepatomegaly, often with complications specific to deranged metabolism (hypoglycemia with glycogen storage disease); and absence of structural change despite profound **metabolic effects**, as seen in patients with urea cycle defects. Clinical manifestations of metabolic diseases of the liver mimic infections, intoxications, and hematologic and immunologic diseases (Table 405.2).

Many metabolic diseases are detected in expanded newborn metabolic screening programs (see Chapter 104). Clues are provided by family history of a similar illness or by the observation that the onset of symptoms is closely associated with a change in dietary habits; in patients with hereditary fructose intolerance, symptoms follow ingestion of fructose (sucrose). Clinical and laboratory evidence often guides the evaluation. Liver biopsy offers morphologic study and permits enzyme assays, as well as quantitative and qualitative assays of various other constituents (e.g., hepatic copper content in Wilson disease). Genetic/molecular diagnostic approaches are also available. Such studies require cooperation of experienced laboratories and careful attention to collection and handling of specimens. Treatment depends on the specific type of defect, and although relatively uncommon, altogether metabolic diseases of the liver account for up to 10% of the indications for liver transplantation in children, a number that may be underestimated given the acute nature of some of these conditions, precluding complete diagnostic investigation before transplantation.

405.1 Inherited Deficient Conjugation of Bilirubin (Familial Nonhemolytic Unconjugated Hyperbilirubinemia)

Julie Bonn and William F. Balistreri

Bilirubin is the metabolic end product of heme. Before excretion into bile, it is first glucuronidated and made water-soluble by the enzyme bilirubin-uridine diphosphoglucuronate glucuronosyltransferase (UDPGT). UDPGT activity is deficient or altered in three genetically and functionally distinct disorders (Crigler-Najjar [CN] syndromes type I and II and Gilbert syndrome), producing congenital nonobstructive, nonhemolytic, **unconjugated** hyperbilirubinemia. UGT1A1

Table 405.1 Inborn Errors of Metabolism that Affect the Liver

COMMON DISORDERS OF CARBOHYDRATE METABOLISM
Disorders of galactose metabolism
• Galactosemia (galactose-1-phosphate uridyltransferase deficiency)
Disorders of fructose metabolism
• Hereditary fructose intolerance (aldolase deficiency)
• Fructose-1,6 diphosphatase deficiency
Glycogen storage diseases
• Type I
• Von Gierke Ia (glucose-6-phosphatase deficiency)
• Type Ib (glucose-6-phosphatase transport defect)
• Type III Cori/Forbes (glycogen debrancher deficiency)
• Type IV Andersen (glycogen branching enzyme deficiency)
• Type VI Hers (liver phosphorylase deficiency)
Congenital disorders of glycosylation (multiple subtypes)
DISORDERS OF AMINO ACID AND PROTEIN METABOLISM
Disorders of tyrosine metabolism
• Hereditary tyrosinemia type I (fumarylacetoacetate hydrolase deficiency)
• Tyrosinemia, type II (tyrosine aminotransferase deficiency)
Inherited urea cycle enzyme defects
• CPS deficiency (carbamoyl phosphate synthetase I deficiency)
• OTC deficiency (ornithine transcarbamoylase deficiency)
• Citrullinemia type I (argininosuccinate synthetase deficiency)
• Argininosuccinic aciduria (argininosuccinate deficiency)
• Argininemia (arginase deficiency)
• N-AGS deficiency (*N*-acetylglutamate synthetase deficiency)
Maple serum urine disease (multiple possible defects*)
DISORDERS OF LIPID METABOLISM
Wolman disease (lysosomal acid lipase deficiency)
Cholesteryl ester storage disease (lysosomal acid lipase deficiency)
Homozygous familial hypercholesterolemia (low-density lipoprotein receptor deficiency)
Gaucher disease type I (β-glucocerebrosidase deficiency)
Niemann-Pick type C (NPC 1 and 2 variants)
DISORDERS OF BILE ACID METABOLISM
Defects in bile acid synthesis (several specific enzyme deficiencies)
Zellweger syndrome—cerebrohepatorenal (multiple pathogenic variants in peroxisome biogenesis genes)
DISORDERS OF METAL METABOLISM
Wilson disease (ATP7B pathogenic variants)
Hepatic copper overload
Indian childhood cirrhosis
Neonatal hemochromatosis
DISORDERS OF BILIRUBIN METABOLISM
Crigler-Najjar (bilirubin-uridine diphosphoglucuronate glucuronosyltransferase pathogenic variants)
• Type I
• Type II
Gilbert disease (bilirubin-uridine diphosphoglucuronate glucuronosyltransferase polymorphism)
Dubin-Johnson syndrome (multiple drug-resistant protein 2 pathogenic variants)
Rotor syndrome
MISCELLANEOUS
α_1-Antitrypsin deficiency
Citrullinemia type II (citrin deficiency)
Cystic fibrosis (cystic fibrosis transmembrane conductance regulator pathogenic variants)
Erythropoietic protoporphyria (ferrochelatase deficiency)
Polycystic kidney disease
Mitochondrial hepatopathies (see Table 404.4 and Chapter 409)

*Maple syrup urine disease can be caused by mutations in branched-chain α-keto dehydrogenase, keto acid decarboxylase, lipoamide dehydrogenase, or dihydrolipoamide dehydrogenase.

is the primary UDPGT isoform needed for bilirubin glucuronidation. Complete absence of UGT1A1 activity causes CN type I, while CN type II is caused by decreased UGT1A1 activity to ~10% of normal.

Table 405.2 Clinical Manifestations that Suggest the Possibility of Metabolic Disease

Recurrent vomiting, failure to thrive, short stature
Dysmorphic features
Jaundice, hepatomegaly (± splenomegaly), fulminant hepatic failure, edema/anasarca
Hypoglycemia, organic acidemia, lactic acidemia, hyperammonemia, bleeding (coagulopathy)
Developmental delay, hypotonia, progressive neuromuscular deterioration, seizures, myopathy, neuropathy
Cardiac dysfunction/failure
Unusual odors
Rickets
Cataracts
Multiorgan involvement
Family history

Gilbert syndrome, the most common hereditary hyperbilirubinemia syndrome, occurs in 5–10% of the White population. Common polymorphisms resulting in a TA insertion in the promoter region of *UGT1A1* lead to decreased binding of the TATA binding protein and decrease normal gene activity by ~30%. Snapback primer genotyping can distinguish all *UGT1A1* promoter genotypes and can provide a definitive diagnosis. Unlike the CN syndromes, Gilbert syndrome usually occurs after puberty, is not associated with chronic liver disease, and no treatment is required. Disease manifestations include fluctuating mild elevations in total serum bilirubin concentration from 1 to 6 mg/dL with no evidence of liver injury or hemolysis. Fasting or dehydration may result in visible jaundice. Because UGT1A1 catalyzes water-soluble glucuronidation and detoxification of multiple substrates other than bilirubin (i.e., drugs, hormones, environmental toxins, and aromatic hydrocarbons), pathogenic variants in the *UGT1A1* gene are implicated in cancer risk and predispose to drug toxicity and episodic jaundice specifically in cancer chemotherapy.

CRIGLER-NAJJAR SYNDROME TYPE I (GLUCURONYL TRANSFERASE DEFICIENCY)

CN type I is a rare, autosomal recessive disease caused by homozygous or compound heterozygous pathogenic variants in the *UGT1A1* gene that result in a premature stop codon or frameshift pathogenic variant and complete absence of UGT1A1 activity. At least 59 pathogenic variants have been identified to date. Parents of affected children have partial defects in conjugation, as determined by hepatic-specific enzyme assay or by measurement of glucuronide formation, but have normal serum unconjugated bilirubin levels.

Clinical Manifestations

Severe unconjugated hyperbilirubinemia develops in homozygous affected infants in the first 3 days of life. Without treatment, serum unconjugated bilirubin concentrations reach 25-35 mg/dL in the first month, which can cause **kernicterus**. Stools are pale yellow. Persistent unconjugated hyperbilirubinemia at levels >20 mg/dL without hemolysis after the first week of life should suggest the syndrome.

Diagnosis

The diagnosis of CN type I is based on the early age of onset and the extreme level of bilirubin elevation in the absence of hemolysis. In affected infants, bile contains no bilirubin glucuronide and bilirubin concentration in bile is <10 mg/dL compared with normal concentrations of 50-100 mg/dL. The diagnosis is established by measuring hepatic glucuronyl transferase activity in a liver specimen obtained by percutaneous liver biopsy; open liver biopsy should be avoided because surgery and anesthesia can precipitate kernicterus. DNA diagnosis is also available and may be preferable. Identification of the heterozygous state in parents also strongly suggests the diagnosis. The differential diagnosis of unconjugated hyperbilirubinemia is discussed in Chapter 137.

Treatment

The serum unconjugated bilirubin concentration should be maintained at <20 mg/dL for the first few weeks of life, and even lower in low birthweight infants. This usually requires repeated exchange transfusions and phototherapy in the immediate neonatal period. Oral calcium phosphate supplementation renders phototherapy more effective, as it forms complexes with bilirubin in the gut. Phenobarbital therapy, through CYP450 enzyme induction, should be considered to determine responsiveness and differentiation between CN types I and II. In patients with type I, there is no response to phenobarbital treatment.

The risk of kernicterus persists into adult life, although the serum bilirubin levels required to produce brain injury beyond the neonatal period are considerably higher (usually >35 mg/dL). Therefore phototherapy is generally continued through the early years of life. In older infants and children, phototherapy is used mainly during sleep so as not to interfere with normal activities. Despite the administration of increasing intensities of light for longer periods, the serum bilirubin response to phototherapy decreases with age. Additional adjuvant therapy using agents that bind photobilirubin products such as cholestyramine or agar can also be used to interfere with the enterohepatic recirculation of bilirubin.

Prompt treatment of intercurrent infections, febrile episodes, and other types of illness might help prevent the later development of kernicterus, which can occur at bilirubin levels of 45-55 mg/dL. All reported patients with CN type I have eventually experienced severe kernicterus by young adulthood.

Orthotopic liver transplantation cures the disease and has been successful in a small number of patients. Isolated hepatocyte transplantation has been reported as bridge therapy to liver transplantation, with most, but not all, patients eventually requiring orthotopic transplantation. Other therapeutic modalities have included plasmapheresis and limitation of bilirubin production. The latter option, inhibiting bilirubin generation, is possible via inhibition of heme oxygenase using metalloporphyrin therapy. Finally, gene therapy using adeno-associated viral vectors has shown promise in a murine model and is in clinical trials in humans.

CRIGLER-NAJJAR SYNDROME TYPE II (PARTIAL GLUCURONYL TRANSFERASE DEFICIENCY)

CN type II is an autosomal recessive disease caused by homozygous missense pathogenic variants in *UGT1A1* resulting in reduced (partial) enzymatic activity. More than 45 pathogenic variants have been identified to date. Type II disease can be distinguished from type I by the marked decline in serum bilirubin level that occurs in type II disease after treatment with phenobarbital secondary to an inducible phenobarbital response element on the *UGT1A1* promoter.

Clinical Manifestations

When this disorder appears in the neonatal period, unconjugated hyperbilirubinemia usually occurs in the first 3 days of life; serum bilirubin concentrations can be in a range compatible with physiologic jaundice or can be at pathologic levels. The concentrations characteristically remain elevated into and after the third week of life, persisting in a range of 1.5-22 mg/dL; concentrations in the lower part of this range can create uncertainty about whether chronic hyperbilirubinemia is present. Development of kernicterus is unusual. Stool color is normal, and the infants are without clinical signs or symptoms of disease. There is no evidence of hemolysis. Liver enzymes, albumin, and prothrombin time/international normalized ratio (PT/INR) are typically normal.

Diagnosis

The concentration of bilirubin in the bile is nearly normal in patients with CN type II. Jaundiced infants and young children with type II respond readily to 5 mg/kg/day of oral phenobarbital, with a decrease in serum bilirubin concentration to 2-3 mg/dL in 7-10 days.

Treatment

Long-term reduction in serum bilirubin levels can be achieved with continued administration of phenobarbital at 5 mg/kg/day. Therapy must be lifelong. The cosmetic and psychosocial benefit should be weighed against the risks of an effective dose of the drug because there is a small long-term risk of kernicterus even in the absence of hemolytic disease. Orlistat, an irreversible inhibitor of intestinal lipase, increases fecal fat excretion and may decrease plasma unconjugated bilirubin concentrations (~10%) in patients with CN types I and II.

INHERITED CONJUGATED HYPERBILIRUBINEMIA

Conjugated hyperbilirubinemia can be caused by rare autosomal recessive conditions characterized by asymptomatic mild jaundice. In these conditions, the transfer of bilirubin and other organic anions from the hepatocyte into bile is defective. Chronic mild conjugated hyperbilirubinemia is usually detected during adolescence or early adulthood but can occur as early as 2 years of age. The results of other routine liver tests are normal. Jaundice can be exacerbated by infection, pregnancy, oral contraceptives, alcohol consumption, and surgery. There is usually no morbidity, and life expectancy is normal.

DUBIN-JOHNSON SYNDROME

Dubin-Johnson syndrome is an autosomal recessive inherited defect in hepatocyte secretion of bilirubin glucuronide. The defect in hepatic excretory function is not limited to conjugated bilirubin excretion but also involves several organic anions normally excreted from the liver cell into bile. Disease results from absent function of MRP2, encoded by the gene *ABCC2*, an adenosine triphosphate–dependent canalicular transporter. More than 10 different pathogenic variants, including compound heterozygous pathogenic variants in the *CMOAT* gene, have been identified and either affect localization of MRP2 with resultant increased degradation or impair MRP2 transporter activity in the canalicular membrane. Bile acid excretion and serum bile acid levels are normal. Total urinary coproporphyrin excretion is normal in quantity, but coproporphyrin I excretion increases to approximately 80% with a concomitant decrease in coproporphyrin III excretion. Normally, coproporphyrin III is >75% of the total. Cholangiography fails to visualize the biliary tract, and x-ray of the gallbladder is also abnormal. Liver histology demonstrates normal architecture, but hepatocytes contain black pigment similar to melanin. Liver function is normal, and the prognosis is excellent. The most commonly reported symptoms are abdominal pain and fatigue, jaundice, dark urine, and slight enlargement of the liver. Jaundice fluctuates in intensity and is aggravated by intercurrent disease. Rarely, Dubin-Johnson can present in the neonatal period with severe conjugated hyperbilirubinemia with serum bilirubin >20 mg/dL and hepatosplenomegaly. No treatment is indicated for disease that presents outside of the neonatal period.

Rotor Syndrome

Rotor syndrome is an autosomal recessive disease resulting from biallelic inactivating pathogenic variants in *SLCO1B1* and *SLCO1B3* that result in functional deficiencies of both OATP1B1 and OATP1B protein. Importantly, these pathogenic variants may confer significant drug toxicity risk. These patients present similarly to Dubin-Johnson syndrome, with asymptomatic mild and fluctuating conjugated hyperbilirubinemia, with total serum bilirubin levels between 2 and 5 mg/dL. Unlike Dubin-Johnson syndrome, total urinary coproporphyrin excretion is elevated with a relative increase in the amount of the coproporphyrin I isomer. If liver biopsy is performed, there is no abnormal pigmentation, in contrast to Dubin-Johnson. The gallbladder is normal by roentgenography. Rotor syndrome is benign, and no treatment is indicated.

Visit Elsevier eBooks+ at eBooks.Health.Elsevier.com for Bibliography.

405.2 Wilson Disease

Julie Bonn and William F. Balistreri

Wilson disease (hepatolenticular degeneration) is an autosomal recessive disorder that can be associated with liver disease, degenerative changes in the brain, psychiatric symptoms, and Kayser-Fleischer (K-F) rings in the cornea (Fig. 405.1 and Table 405.3). The incidence is approximately 1/30,000 births worldwide. Specific treatment is available; however, this disease is progressive and potentially fatal if untreated. Prompt diagnostic evaluation for Wilson disease in all patients over age 5 presenting with any form of liver disease facilitates expeditious initiation of treatment of the disease, appropriate genetic counseling, and screening of first-degree relatives and also allows appropriate treatment of non-Wilsonian liver disease once copper toxicosis is ruled out.

PATHOGENESIS

The variant gene for Wilson disease is found on chromosome 13 (13q14.3) and encodes *ATP7B*, a copper transporting P-type adenosine triphosphatase (ATPase), which is mainly expressed in hepatocytes and is critical for biliary copper excretion and for copper incorporation into ceruloplasmin. Absence or malfunction of ATP7B results in decreased biliary copper excretion and diffuse accumulation of copper in the cytosol of hepatocytes. With time, liver cells become overloaded and copper is redistributed to other tissues, including the brain and kidneys, causing toxicity, primarily as a potent inhibitor of enzymatic processes. Ionic copper inhibits pyruvate oxidase in the brain and ATPase in membranes, leading to decreased adenosine triphosphate-phosphocreatine and potassium content of tissue.

More than 500 pathogenic variants have been identified, of which >380 have a confirmed role in disease pathogenesis; genetic testing should be able to identify a pathologic variant. Most patients are compound heterozygotes. Pathogenic variants that abolish gene function are associated with an onset of disease symptoms as early as 3 years of age, when Wilson disease might not typically be considered in the differential diagnosis. Milder variants can be associated with neurologic symptoms or liver disease as late as 80 years of age. The most commonly occurring disease-causing *ATP7B* pathogenic variants result in a protein that binds copper but is unable to effectively traffic to the apical surface of hepatocytes to perform its copper-exporting function.

CLINICAL MANIFESTATIONS

Forms of Wilsonian hepatic disease include asymptomatic hepatomegaly (with or without splenomegaly), subacute or chronic hepatitis, and acute hepatic failure (with or without hemolytic anemia). Cryptogenic cirrhosis, portal hypertension, ascites, edema, variceal bleeding,

Fig. 405.1 Kayser-Fleischer ring. Brown discoloration at the outer margin of the cornea caused by deposition of copper in Descemet's membrane. Here it is clearly seen against the light green iris. Slit-lamp examination is required for secure detection. *(From Ala A, Walker AP, Ashkan K, et al. Wilson's disease. Lancet. 2007;369:397–408.)*

Table 405.3 The Most Common Clinical Manifestations of WD and Their Frequency of Disease Diagnosis

WD PRESENTATION AND FREQUENCY	SYMPTOMS
Hepatic (40–60%)	Asymptomatic elevation of liver enzymes (aminotransferases) Acute hepatitis (e.g., jaundice, abdominal pain) Acute liver failure (coagulopathy, jaundice, encephalopathy) Liver cirrhosis symptoms (compensated or decompensated) (fatigue, spider naevi, portal hypertension, splenomegaly, bleeding)
Neurologic (40–50%)	Involuntary movements (tremor, dystonia, ataxia, ballism, chorea, parkinsonian syndrome) Speech disturbances: dysarthria (extrapyramidal, dystonic, cerebellar, mixed, unclassified) Dysphagia Autonomic dysfunction (e.g., salivation, electrocardiographic abnormalities, orthostatic hypotension) Gait and balance disturbances
Psychiatric (10–25%)	Personality disorders (e.g., abnormal, antisocial behavior, irritability, disinhibition) Mood disorders (bipolar disorders, depression, suicidal attempts) Psychosis and other psychiatric alterations (rarely: e.g., psychosis, anorexia, sleep disturbances) Cognitive impairment
Ophthalmologic (K-F ring: 90–100% in neurologic patients, 40–50% in hepatic and 20–30% in presymptomatic); SC (1,2–25%)	Kayser–Fleischer ring (K-F ring); sunflower cataract (SC)
Other (lack of systematic multicenter data, mostly case reports, series reports, or single-center studies)	Renal (tubular dysfunction, nephrolithiasis and nephrocalcinosis, aminocyduria, hypercalciuria, hyperphosphaturia) Bone (osteoporosis, chondrocalcinosis, osteoarthritis, joints pain) Heart (cardiac arrhythmia, cardiomyopathy, myopathy) Skin (hyperpigmentation of lower legs, azure lunulae ("sky-blue moon") of the nails, anetoderma, xerosis, acanthosis nigricans, subcutaneous lipomas, dermatomyositis) Hematopoietic system (thrombocytopenia, hemolytic anemia, leukopenia) Gynecologic abnormalities (menstrual irregularity, delayed puberty, gynecomastia) Endocrinologic abnormalities (glucose intolerance, parathyroid insufficiency, disorders of growth)

From Litwin T, Dusek P, Szafranski T, et al. Psychiatric manifestations in Wilson's disease: possibilities and difficulties for treatment. *Therap Adv Psychopharmacol.* 2018;8(7):199–221, Table 1.

or other effects of hepatic dysfunction (delayed puberty, amenorrhea, coagulation defects) can be manifestations of Wilson disease.

Disease presentations are variable, with a tendency to familial patterns. Liver disease is the most common disease manifestation in children and can precede neurologic symptoms by as long as 10 years. Females are 3 times more likely than males to present with acute hepatic failure. When Wilson disease presents after age 20, *neurologic symptoms* are the most common manifestation.

Neurologic disorders can develop insidiously or precipitously, with intention tremor, dysarthria, rigid dystonia, parkinsonism, choreiform movements, lack of motor coordination, deterioration in school performance, psychosis, or behavioral changes. K-F rings are absent in young patients with hepatic Wilson disease up to 50% of the time but are present in 95% of patients with neurologic symptoms. **Psychiatric manifestations** include depression, personality changes, anxiety, obsessive-compulsive behavior, or psychosis.

Coombs-negative **hemolytic anemia** may be an initial manifestation, possibly related to the release of large amounts of copper from damaged hepatocytes; this form of Wilson disease is usually fatal without liver transplantation. During hemolytic episodes, urinary copper excretion and serum free copper levels are markedly elevated. Manifestations of renal Fanconi syndrome and progressive renal failure with alterations in tubular transport of amino acids, glucose, and uric acid may be present. Unusual manifestations include arthritis, pancreatitis, nephrolithiasis, infertility or recurrent miscarriages, cardiomyopathy, and hypoparathyroidism.

PATHOLOGY

All grades of hepatic injury occur in patients with Wilson disease, with steatosis, hepatocellular ballooning and degeneration, glycogen granules, minimal inflammation, and enlarged Kupffer cells being most common. The earliest histologic feature of Wilson disease is mild steatosis, which may mimic nonalcoholic fatty liver disease or nonalcoholic steatohepatitis. Additionally, the lesion may be indistinguishable from that of autoimmune hepatitis. With progressive parenchymal damage, fibrosis and cirrhosis develop. Ultrastructural changes primarily involve the mitochondria and include increased density of the matrix material, inclusions of lipid and granular material, and increased intracristal space with dilation of the tips of the cristae.

DIAGNOSIS

Wilson disease should be considered in children and teenagers with unexplained acute or chronic liver disease, neurologic symptoms of unknown cause, acute hemolysis, psychiatric illnesses, behavioral changes, Fanconi syndrome, or unexplained bone (osteoporosis, fractures) or muscle disease (myopathy, arthralgia). The clinical suspicion is confirmed by study of indices of copper metabolism.

Most patients with Wilson disease have decreased serum ceruloplasmin levels (<20 mg/dL). The failure of copper to be incorporated into ceruloplasmin leads to a plasma protein with a shorter half-life and therefore a reduced steady-state concentration of ceruloplasmin in the circulation. *Serum ceruloplasmin levels should be interpreted with caution.* Acute inflammatory states and elevated estrogen levels (pregnancy, hormone therapy, or use of oral contraception) can falsely increase ceruloplasmin levels. Additionally, serum ceruloplasmin may be low in autoimmune hepatitis, celiac disease, familial aceruloplasminemia, or carriers of ATP7B pathogenic variants (mild variants of Menkes disease: occipital horn syndrome) who do not show copper overload disease. The serum free copper level may be elevated in early Wilson disease (>1.6 μmol/L), and urinary copper excretion (normally <40 μg/day) is increased to >100 μg/day and often up to 1,000 μg or more per day. Typical urinary copper excretion in patients with untreated Wilson disease is >1.6 μmol/24 hr in adults and >0.64 μmol/24 hr in children. In equivocal cases, the response of urinary copper output to chelation may be of diagnostic help. Before a 24-hour urine collection patients are given two 500-mg oral doses of D-penicillamine 12 hours apart; affected patients excrete >1,600 μg/24 hr.

Demonstration of K-F rings, which might not be present in younger children, requires a slit-lamp examination by an ophthalmologist. After adequate treatment, K-F rings resolve. Liver biopsy can determine the extent and severity of liver disease and for measuring the hepatic copper content (normally <10 μg/g dry weight) but is only required if clinical signs and noninvasive tests do not allow a final diagnosis or if another liver disorder is suspected. Hepatic copper accumulation is the hallmark of Wilson disease, and measurement of hepatic parenchymal copper concentration is the method of choice for diagnosis. Hepatic copper content >250 μg/g dry weight (>4 μmol/g dry weight) is the best biochemical evidence for Wilson disease, but lowering the threshold to 1.2 μmol/g dry weight improves sensitivity without significantly affecting specificity. Intermediate levels of hepatic copper may be present in asymptomatic carriers. In later stages of Wilson disease, hepatic copper content can be unreliable because cirrhosis leads to variable hepatic copper distribution and sampling error.

First-degree relatives of patients with Wilson disease should be screened for presymptomatic disease. This screening should include determination of the serum ceruloplasmin level and 24-hr urinary copper excretion. If these results are abnormal or equivocal, liver biopsy should be carried out to determine morphology and hepatic copper content. Genetic screening by either linkage analysis or direct DNA gene analysis is possible, especially if the mutation for the proband case is known or the patient is from an area where a specific gene variant is prevalent, such as in Central and Eastern Europe, where the *H1069Q* variant is present in 50–80% of patients.

TREATMENT

Once the diagnosis of Wilson disease is made, lifelong treatment should be initiated and is focused on limiting copper uptake and promoting copper excretion through dietary and pharmacologic measures. The normal diet contains 2-5 mg of copper per day. For patients with Wilson disease, the dietary intake of copper should be restricted to <1 mg/day. High copper content foods such as liver, shellfish, nuts, and chocolate should be avoided. If the copper content of the drinking water exceeds 0.1 mg/L, it may be necessary to demineralize the water.

The initial treatment in symptomatic patients is the administration of copper-chelating agents, which leads to rapid excretion of excess deposited copper. Chelation therapy is managed with oral administration of triethylene tetramine dihydrochloride (Trien, TETA, trientine) at a dose of 750-1500 mg/day in two or three divided doses, with 750 or 1000 mg used for maintenance therapy, for adults and 20 mg/kg/day rounded to the nearest 250 mg, given in two or three divided doses for children. D-penicillamine (β,β-dimethylcysteine) can be used as an alternative at a maximum of 1000-1500 mg/day in two to four divided doses before meals for adults and 20 mg/kg/day, rounded to the nearest 250 mg and given in two or three divided doses for pediatric patients. In response to chelation, urinary copper excretion increases, with marked improvement in hepatic and neurologic function and the disappearance of K-F rings.

Approximately 10–50% of patients initially treated with penicillamine for *neurologic* symptoms have a worsening of their condition. Toxic effects of penicillamine occur in 10–20% and consist of hypersensitivity reactions (i.e., Goodpasture syndrome, systemic lupus erythematosus, and polymyositis), interaction with collagen and elastin, deficiency of other elements such as zinc, and aplastic anemia and nephrosis. Because penicillamine is an antimetabolite of vitamin B_6, additional amounts of this vitamin are necessary. For these reasons, trientine is the preferred alternative and is considered first-line therapy for some patients. Trientine has few known side effects. Ammonium tetrathiomolybdate is another alternative chelating agent under investigation for patients with neurologic disease; initial results suggest that significantly fewer patients

experience neurologic deterioration with this drug compared to penicillamine. The initial dose is 120 mg/day (20 mg between meals 3 times daily and 20 mg with meals 3 times daily). Side effects include anemia, leukopenia, thrombocytopenia, and mild elevations of alanine aminotransferase (ALT) and aspartate aminotransferase (AST). Because of its extensive decoppering effect, ammonium tetrathiomolybdate also has antiangiogenic effects.

Zinc has also been used as adjuvant therapy, maintenance therapy, or primary therapy in presymptomatic patients, owing to its unique ability to impair the gastrointestinal absorption of copper. Zinc acetate can be given to adults at a dose of 50 mg of elemental zinc 3 times a day, and 25 mg 3 times a day in children over age 5 years. Side effects are predominantly limited to gastric irritation but also include reduced leukocyte chemotaxis and elevations in serum lipase and/or amylase. Guidelines recommend that all symptomatic patients with Wilson disease receive a chelating agent (penicillamine or trientine). Patients should be counseled not to suddenly stop these medications, because sudden discontinuation of therapy can precipitate fulminant Wilson disease. Zinc may have a role as a first-line therapy in patients with neurologic disease, but exclusive monotherapy with zinc in symptomatic liver disease is controversial and not recommended. Antioxidants (vitamin E and curcumin) and pharmacologic chaperones (4-phenylbutyrate and curcumin) may have a role as adjunctive treatment, but more research is needed.

PROGNOSIS

Untreated patients with Wilson disease can die of hepatic, neurologic, renal, or hematologic complications. Medical therapy is rarely effective in those presenting with acute liver failure. The prognosis for patients receiving prompt and continuous penicillamine is variable and depends on the time of initiation of and the individual response to chelation. Liver transplantation should be considered for patients with acute liver failure or decompensated cirrhosis caused by Wilson disease. Liver transplantation for progressive neurologic disease remains controversial. Liver transplantation is curative, with a 5-year survival rate of 85–90%. In asymptomatic siblings of affected patients, early institution of chelation or zinc therapy can prevent disease manifestations.

Visit Elsevier eBooks+ at eBooks.Health.Elsevier.com for Bibliography.

405.3 Indian Childhood Cirrhosis

Julie Bonn and William F. Balistreri

Indian childhood cirrhosis (ICC) is a chronic liver disease of infants and young children unique to the Indian subcontinent, but variants of this syndrome have been described in other populations and have been named accordingly (Tyrolean or North American childhood cirrhosis). ICC-like disease has also been reported in the Middle East, West Africa, and Central America. Affected children present with jaundice, pruritus, lethargy, and hepatosplenomegaly with rapid progression to cirrhosis. Untreated severe ICC has a mortality of 40–50% within 4 weeks. Histologically, ICC is characterized by hepatocyte necrosis, Mallory bodies, intralobular fibrosis, inflammation, and excess hepatic copper deposition. Treatment is supportive, especially in the late stages of disease. Copper chelation with D-penicillamine has been beneficial in open-label preicteric cases of ICC; however, it is unclear whether these cases were simply less severely affected and would have spontaneously improved without treatment.

The etiology of ICC has remained elusive. It was once believed that excess copper ingestion in the setting of a genetic susceptibility to copper toxicosis was the most likely cause. Epidemiologic data demonstrate that the copper toxicity theory is unlikely. The increased hepatic copper content, usually >700 μg/g dry weight, seen in ICC is only seen in the late stages of disease and is accompanied by even higher levels of zinc, a non-hepatotoxic metal. Furthermore, the copper-contaminated utensils used to feed babies and implicated in excess copper ingestion are found in only 10–15% of all cases. The current hypothesis implicates the postnatal use of local hepatotoxic therapeutic remedies, although the exact causative agent is unknown. North American ICC is caused by pathogenic variants in the *UTP4* gene; it is seen in the Ojibway-Cree nation of Quebec.

Over the past few decades, as the awareness of the disease has increased, the incidence of ICC has decreased to the point of being virtually eliminated in some areas of India. However, established and atypical cases are probably being missed because of lack of histologic confirmation and lack of awareness of the protean manifestations and natural history of this disease.

Visit Elsevier eBooks+ at eBooks.Health.Elsevier.com for Bibliography.

405.4 Neonatal Hemochromatosis

Julie Bonn and William F. Balistreri

See Chapter 404.

Neonatal hemochromatosis (NH) is a rare form of fulminant liver disease that manifests in the first few days of life. NH is associated with siderosis of extrahepatic tissues, similar to hereditary hemochromatosis, but is unrelated to the familial forms of hereditary hemochromatosis that occur in adulthood. **Gestational alloimmune liver disease (GALD)** has been identified as the cause of nearly all cases of NH, but they are not synonymous. GALD has a high rate of recurrence in families, with over 90% probability that subsequent infants will be affected. During gestation, the maternal immune system becomes sensitized to an unknown fetal hepatocyte cell surface antigen. Maternal immunoglobulin G (IgG) to this fetal antigen then crosses the placenta and induces hepatic injury via immune system activation. The defining feature of GALD is complement-mediated hepatocyte injury, the evidence for which comes from detection of the C5b-9 complex by immunohistochemistry on liver tissue of affected infants. Additional evidence of a gestational insult is given by the fact that affected infants may be born prematurely or with intrauterine growth restriction. Severely affected infants may also have renal hypoplasia and dysgenesis.

Excess non-transferrin-bound iron in GALD results from fetal liver injury that causes reduced synthesis of key iron regulatory and transport proteins. The pattern of extrahepatic siderosis appears to be determined by the normal capacity of various tissues to import non-transferrin-bound iron and not export cellular iron. It is thought that fetal liver injury is the primary event leading to the development of the NH phenotype, providing further evidence that this is not a primary iron overload disease.

GALD can be a rapidly fatal, progressive illness characterized by hepatomegaly, hypoglycemia, hypoprothrombinemia, hypoalbuminemia, hyperferritinemia, and hyperbilirubinemia (see Table 404.4). The coagulopathy is refractory to therapy with vitamin K. Liver biopsy demonstrates severe liver injury with acute and chronic inflammation, fibrosis, and cirrhosis; in some cases there are no surviving hepatocytes. The diagnosis is established in the neonate with severe liver injury and evidence of extrahepatic siderosis either by MRI indicating increased iron deposition in organs such as the pancreas or heart or by increased iron staining in oral submucosal gland biopsy. The differential diagnosis includes other causes of neonatal hepatic failure such as citrin deficiency, herpes simplex virus (HSV) hepatitis, and familial hemophagocytic lymphohistiocytosis (see Table 404.4).

The survival rate (50–80%) depends on the severity of the initial presentation and response to therapy. Intravenous immunoglobulin (IVIG) combined with double volume exchange transfusion has been shown to remove the injury-causing maternal IgG and

improve outcomes in infants with GALD. Liver transplantation should also be an early consideration. Recurrences of GALD in subsequent pregnancies may be modified with IVIG administered to the mother once weekly from the 18th week of gestation until delivery. The largest experience reports 48 women with previous infants with GALD who successfully delivered 52 babies after IVIG treatment. The majority of infants had biochemical evidence of liver disease with elevated serum α-fetoprotein and ferritin. All infants survived with medical therapy or no therapy.

Visit Elsevier eBooks+ at eBooks.Health.Elsevier.com for Bibliography.

405.5 Miscellaneous Metabolic Diseases of the Liver

Julie Bonn and William F. Balistreri

α_1-ANTITRYPSIN DEFICIENCY

α_1-Antitrypsin deficiency is an autosomal recessive disorder caused by a pathogenic variant in the *SERPINA1* gene. α_1-Antitrypsin, a protease inhibitor (Pi) synthesized by the liver, protects lung alveolar tissues from destruction by neutrophil elastase (see Chapter 442). α_1-Antitrypsin is present in more than 20 different codominant alleles, only a few of which are associated with defective Pis. The most common allele of the Pi system is M, and the normal phenotype is PiMM. The Z allele predisposes to clinical deficiency; patients with liver disease are usually PiZZ homozygotes and have serum α_1-antitrypsin levels <2 mg/mL (~10–20% of normal). The incidence of the PiZZ genotype in the White population is estimated at 1 in 2,000-4,000 live births. A small percentage of patients homozygous for deficiency of the major serum Pi α_1-antitrypsin develop neonatal cholestasis or later-onset childhood cirrhosis. Compound heterozygotes PiZ, PiSZ, and PiZI are not a cause of liver disease alone but can act as modifier genes, increasing the risk of progression in other liver diseases such as nonalcoholic fatty liver disease and hepatitis C. The null phenotype only causes lung disease and results from either stop codons in the coding exon of the *SERPINA1* gene or complete deletion of *SERPINA1* coding exons leading to the absence of α_1-antitrypsin protein.

Newly formed α_1-antitrypsin polypeptide normally enters the endoplasmic reticulum, where it undergoes enzymatic modification and folding before transport to the plasma membrane, where it is excreted as a 55-kDa glycoprotein. In affected patients with PiZZ, the rate at which the α_1-antitrypsin polypeptide folds is decreased, and this delay allows the formation of polymers that are retained in the endoplasmic reticulum. How the polymers cause liver damage is not completely elucidated, but research indicates that accumulation of abnormally folded protein leads to activation of stress and proinflammatory pathways in the endoplasmic reticulum and hepatocyte programmed cell death. In liver biopsies from patients, polymerized α_1-antitrypsin peptides can be seen by electron microscopy and histochemically as periodic acid–Schiff-positive diastase-resistant globules, primarily in periportal hepatocytes, but also in Kupffer cells and biliary epithelial cells. The pattern of neonatal liver injury can be highly variable, and liver biopsies might demonstrate hepatocellular necrosis, inflammatory cell infiltration, bile duct proliferation, periportal fibrosis, or cirrhosis.

The course of liver disease is highly variable in patients with α_1-antitrypsin deficiency. Prospective studies in Sweden have shown that only 10% of patients develop clinically significant liver disease by their fourth decade, indicating that other genetic traits or environmental factors likely influence the development of liver disease. Infants with liver disease are indistinguishable from other infants with "idiopathic" neonatal hepatitis, of whom they constitute approximately 5–10%. Jaundice, acholic stools, and hepatomegaly are present in the first week of life, but the jaundice usually clears by 2-4 months of age. Complete resolution, persistent liver disease, or the development of cirrhosis can follow. Older children can present with asymptomatic hepatomegaly or manifestations of chronic liver disease or cirrhosis with evidence of portal hypertension. Patients with cirrhosis due to α_1-antitrypsin deficiency are at high risk for developing hepatocellular carcinoma. Emphysema is not typically observed in children, but an increased risk for developing asthma is reported. Cigarette smoking promotes development of lung disease, so parents should be counseled on smoking cessation and exposure reduction as part of their anticipatory guidance, and older children and adolescents should be advised not to smoke or use electronic cigarettes and given cessation counseling if they do (see Chapter 157.2).

Treatment is supportive, although research is ongoing to develop therapies for α_1-antitrypsin deficiency–associated liver disease that stimulate intracellular degradation of the abnormally folded Z protein polymers. Liver transplantation is indicated for hepatocellular carcinoma or end-stage liver disease with portal hypertension, with survival rates of ~90%.

CITRIN DEFICIENCY

Neonatal intrahepatic cholestasis caused by citrin deficiency (NICCD) presents in the first few months of life with manifestations that initially may be indistinguishable from other causes of neonatal cholestasis, especially biliary atresia. Patients may have jaundice, hepatomegaly, liver dysfunction with coagulopathy, fatty liver infiltration, and hyperammonemia with or without hypoglycemia. Presymptomatic patients may be identified from the newborn metabolic screen with hypergalactosemia, hypermethionemia, and hyperphenylalaninemia, but not all patients are identified by newborn screening.

Pathogenic variants in the *SLC25A13* gene cause NICCD with an autosomal recessive pattern of inheritance. SLC25A13 encodes citrin, a mitochondrial carrier protein (calcium binding aspartate-glutamate carrier) involved in the urea cycle, gluconeogenesis, and glycolysis. Pathogenic variants are more common in those of East Asian descent. Affected infants have hypergalactosemia, elevated bile acids, vitamin K–dependent coagulopathy, and elevated levels of citrulline and methionine. Treatment is supportive in the form of providing fat-soluble vitamin supplementation and dietary feeding with a low-galactose/-lactose formula enriched with medium-chain triglycerides. More severely affected patients can develop liver failure requiring liver transplantation in the first year of life.

Visit Elsevier eBooks+ at eBooks.Health.Elsevier.com for Bibliography.

Chapter 406

Viral Hepatitis

Michael E. Rogers and William F. Balistreri

Viral hepatitis continues to be a major health problem in both developing and developed countries, but there has been significant progress in efforts to recognize and to treat infected subjects. This disorder is caused by at least five known pathogenic hepatotropic viruses: hepatitides A (HAV), B (HBV), C (HCV), D (HDV), and E (HEV) viruses (Table 406.1). Many other viruses (and diseases) can cause hepatitis, usually as a component of a multisystem disease. These include herpes simplex viruses (1, 2, 6a, 6b), cytomegalovirus, Epstein-Barr virus, varicella-zoster virus, HIV, rubella, measles, adenoviruses, adeno-associated virus, enteroviruses, parvovirus B19, arboviruses, and perhaps SARS-CoV-2 (Table 406.2).

The hepatotropic viruses are a heterogeneous group of infectious agents that cause similar acute clinical illness. In most pediatric patients, the acute phase causes no or mild clinical disease. Morbidity is related to rare cases of **acute liver failure (ALF)** in susceptible patients or to the development of a chronic disease state and attendant complications that several of these viruses (HBV, HCV, HDV) may cause.

ISSUES COMMON TO ALL FORMS OF VIRAL HEPATITIS

Differential Diagnosis

Although often asymptomatic or nonspecific, the clinical features that may raise the suspicion of viral hepatitis is clinical icterus, with yellow skin and/or mucous membranes. The liver is usually enlarged and tender to palpation and percussion. Splenomegaly and lymphadenopathy may be present. Clinical signs of bleeding, altered sensorium, or hyperreflexia should be carefully sought, because they mark the onset of encephalopathy and ALF.

The differential diagnosis varies with the age of presentation. In the newborn period, infection is a common cause of conjugated hyperbilirubinemia; the infectious cause is either a bacterial agent (e.g., *Escherichia coli*, *Listeria*, syphilis) or a nonhepatotropic virus (e.g., enteroviruses, cytomegalovirus, and herpes simplex virus, which may also cause a nonicteric severe hepatitis). Metabolic diseases (α_1-antitrypsin deficiency, cystic fibrosis, tyrosinemia), anatomic causes (biliary atresia, choledochal cysts), and inherited forms of intrahepatic cholestasis should always be excluded.

In later childhood, extrahepatic obstruction (gallstones, primary sclerosing cholangitis, pancreatic pathology), inflammatory conditions (autoimmune hepatitis, juvenile inflammatory arthritis, Kawasaki disease), immune dysregulation (hemophagocytic lymphohistiocytosis), infiltrative disorders (malignancies), toxins and medications, metabolic disorders (Wilson disease, cystic fibrosis), and infection (Epstein-Barr virus, varicella, malaria, leptospirosis, syphilis) should be ruled out.

Table 406.1 Features of the Hepatotropic Viruses

VIROLOGY	HAV RNA	HBV DNA	HCV RNA	HDV RNA	HEV RNA
Incubation (days)	15-19	60-180	14-160	21-42	21-63
Transmission					
Parenteral	Rare	Yes	Yes	Yes	No
Fecal-oral	Yes	No	No	No	Yes
Sexual	No	Yes	Rare	Yes	No
Perinatal	No	Yes	Uncommon (5–15%)	Yes	No
Chronic infection	No	Yes	Yes	Yes	No
Fulminant disease	Rare	Yes	Rare	Yes	Yes

HAV, Hepatitis A virus; HBV, hepatitis B virus; HCV, hepatitis C virus; HDV, hepatitis D virus; HEV, hepatitis E virus.

Pathogenesis

The acute response of the liver to hepatotropic viruses involves a direct cytopathic and/or an immune-mediated injury. The entire liver is involved. Necrosis is usually most marked in the centrilobular areas. An acute mixed inflammatory infiltrate predominates in the portal areas but also affects the lobules. The lobular architecture remains intact, although balloon degeneration and necrosis of single cells or groups of parenchymal cells commonly occur. Fatty change is rare. Bile duct proliferation, but not bile duct damage, is common. Diffuse Kupffer cell hyperplasia is noticeable in the sinusoids. Neonates often respond to hepatic injury by forming *giant cells*. In fulminant hepatitis, parenchymal collapse occurs on the described background. With recovery, the liver morphology returns to normal within 3 months of the acute infection. If chronic hepatitis develops, the inflammatory infiltrate settles in the periportal areas and often leads to progressive scarring.

Common Biochemical Profiles in the Acute Infectious Phase

Acute liver injury caused by these viruses manifests in three main liver biochemical profiles. These serve as an important guide to diagnosis, supportive care, and monitoring in the acute phase of the infection for all viruses. As a reflection of *cytopathic injury* to the hepatocytes, there is a rise in serum levels of alanine aminotransferase (ALT) and aspartate aminotransferase (AST). The magnitude of enzyme elevation does not correlate with the extent of hepatocellular necrosis and has little prognostic value. There is usually slow improvement over several weeks, but AST and ALT levels *lag* the serum bilirubin level, which tends to normalize first. Rapidly falling aminotransferase levels can predict a poor outcome, particularly if their decline occurs in conjunction with a rising bilirubin level and a prolonged international normalized ratio (INR) or prothrombin time (PT); this combination of findings usually indicates that massive hepatic injury has occurred.

Cholestasis, defined by elevated serum conjugated bilirubin levels, results from abnormal bile flow at the canalicular and cellular level because of hepatocyte damage and inflammatory mediators. Elevation of serum alkaline phosphatase, 5-nucleotidase, and γ-glutamyl transpeptidase levels marks cholestasis. Absence of cholestatic markers does not rule out progression to chronicity in HCV or HBV infections.

Altered synthetic function is the most important marker of liver injury. Synthetic dysfunction is reflected by abnormal protein synthesis (prolonged PT, high INR, low serum albumin levels), metabolic disturbances (hypoglycemia, lactic acidosis, hyperammonemia), poor clearance of medications dependent on liver function, and altered sensorium with increased deep tendon reflexes (hepatic encephalopathy). Monitoring of synthetic function should be the main focus in clinical follow-up to define the severity of the disease. In the acute phase, the degree of liver synthetic dysfunction guides treatment and helps to establish intervention criteria. *Abnormal liver synthetic function is a marker of liver failure and is an indication for prompt referral to a transplant center.* Serial assessment is necessary because liver dysfunction does not progress linearly.

HEPATITIS A

Hepatitis A virus is responsible for most forms of acute and benign hepatitis. Although fulminant hepatic failure caused by HAV can occur, it is rare (<1% of cases in the United States) and occurs more often in adults than in children and in hyperendemic communities.

Etiology

HAV is an RNA virus, a member of the picornavirus family. It is heat stable and has a limited host range—namely, the human and other primates.

Table 406.2 Causes and Differential Diagnosis of Hepatitis in Children

INFECTIOUS
Hepatotropic viruses
HAV
HBV
HCV
HEV
HDV
HFV
HGV
TT virus
Non–hepatitis A-E viruses
SYSTEMIC INFECTION THAT MAY INCLUDE HEPATITIS
Adenovirus
Arbovirus
Coxsackievirus
Cytomegalovirus
Dengue virus
Enterovirus
Epstein-Barr virus
Herpes simplex viruses (1, 2, 6)
Human immunodeficiency virus
Lassa fever
Paramyxovirus (measles)
Parvovirus
Rubella
Varicella-zoster
Yellow fever
Unknown
NONVIRAL LIVER INFECTIONS
Abscess
Amebiasis
Bacterial sepsis
Brucellosis
Fitz-Hugh-Curtis syndrome
Histoplasmosis
Leptospirosis
Syphilis
Tuberculosis
Other
AUTOIMMUNE/INFLAMMATORY
Chronic autoimmune hepatitis
Other (e.g., systemic lupus erythematosus, juvenile idiopathic arthritis)
Celiac disease
Hemophagocytic lymphohistiocytosis
METABOLIC
α_1-Antitrypsin deficiency
Glycogen storage disease
Tyrosinemia
Wilson disease
Other
TOXIC
Iatrogenic/drug induced (e.g., acetaminophen)
Environmental (e.g., pesticides)
Mushroom poisoning
Hepatotoxic herbal agents (pyrrolizidine alkaloids, other toxins)
ANATOMIC
Choledochal cyst
Biliary atresia
Other
HEMODYNAMIC
Shock
Congestive heart failure
Budd-Chiari syndrome
Venoocclusive disease
Other
NONALCOHOLIC FATTY LIVER DISEASE
Idiopathic
Sclerosing cholangitis
Reye syndrome
Other

Modified from Wyllie R, Hyams JS, Kay M, eds. *Pediatric Gastrointestinal and Liver Disease*, 6th ed. Philadelphia: Elsevier; 2021: Box 75.1, p. 820.

Epidemiology

HAV infection occurs throughout the world but is most prevalent in developing countries. In the United States, 30–40% of the adult population has evidence of previous HAV infection. In 2018, more than 12,000 cases of HAV were reported in the United States to the Centers for Disease Control and Prevention (CDC). The overall incidence rate was 3.8 cases per 100,000 population, an increase from recent years (specifically in patients over the age of 20 years). However, as a result of aggressive implementation of childhood vaccination programs, the prevalence of symptomatic HAV cases worldwide has declined significantly. Nonetheless, outbreaks in developing countries and in daycare centers (where the spread of HAV from young, nonicteric, infected children can occur easily) as well as multiple foodborne and waterborne outbreaks have justified the implementation of intensified universal vaccination programs.

HAV is highly contagious. Transmission is almost always by person-to-person contact through the fecal-oral route. Perinatal transmission occurs rarely. HAV infection during pregnancy or at the time of delivery does not appear to result in increased complications of pregnancy or clinical disease in the newborn. In the United States, increased risk of infection is found in contacts with infected persons, childcare centers, and household contacts. Infection is also associated with contact with contaminated food or water and after travel to endemic areas. Common-source foodborne and waterborne outbreaks continue to occur, including several caused by contaminated shellfish, frozen berries, and raw vegetables; no known source is found in about half of the cases.

The mean incubation period for HAV is approximately 3 weeks. Fecal excretion of the virus starts late in the incubation period, reaches its peak just before the onset of symptoms, and resolves by 2 weeks after the onset of jaundice in older subjects. The duration of fecal viral excretion is prolonged in infants. The patient is therefore contagious before clinical symptoms are apparent and remains so until viral shedding ceases.

Clinical Manifestations

HAV is responsible for acute hepatitis only. Often, this is an *anicteric* illness, with clinical symptoms indistinguishable from other forms of viral gastroenteritis, particularly in young children.

The illness is more likely to be symptomatic in older adolescents or adults, in patients with underlying liver disorders, and in those who are immunocompromised. It is characteristically an acute febrile illness with an abrupt onset of anorexia, nausea, malaise, vomiting, and jaundice. The typical duration of illness is 7-14 days (Fig. 406.1).

Other organ systems can be affected during acute HAV infection. Regional lymph nodes and the spleen may be enlarged. The bone marrow may be moderately hypoplastic, and aplastic anemia has been reported. Tissue in the small intestine might show changes in villous structure, and ulceration of the gastrointestinal tract can occur, especially in fatal cases. Acute pancreatitis and myocarditis have been reported, though rarely, and nephritis, arthritis, leukocytoclastic vasculitis, and cryoglobulinemia can result from circulating immune complexes.

Diagnosis

Acute HAV infection is diagnosed by detecting antibodies to HAV, specifically, anti-HAV (immunoglobulin [Ig] M) by radioimmunoassay or, rarely, by identifying viral particles in stool. An HAV viral polymerase chain reaction (PCR) assay is commercially available (Table 406.3). Anti-HAV is detectable when the symptoms are clinically apparent, and it remains positive for 4-6 months after the acute infection. A neutralizing anti-HAV (IgG) is usually detected within 8 weeks of symptom onset and is measured as part of a total anti-HAV in the serum. Anti-HAV (IgG) confers long-term protection. Rises in serum levels of ALT, AST, bilirubin, alkaline phosphatase, 5′-nucleotidase, and γ-glutamyl transpeptidase are almost universally found and do not help to differentiate the cause of hepatitis.

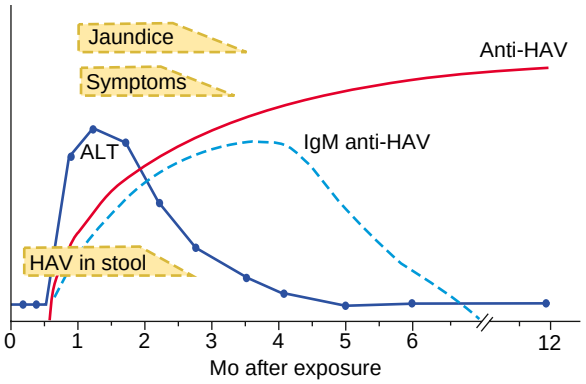

Fig. 406.1 The serologic course of acute hepatitis A. ALT, Alanine aminotransferase; HAV, hepatitis A virus; IgM, immunoglobulin class M. *(From Goldman L, Ausiello D, eds. Cecil Textbook of Medicine, 22nd ed. Philadelphia: WB Saunders; 2004:913.)*

Complications

Although most patients achieve full recovery, distinct complications can occur. *ALF* from HAV infection is an infrequent complication. Those at risk for this complication are elderly adults, but also immunocompromised patients or those with underlying liver disorders. The height of HAV viremia may be linked to the severity of hepatitis. In the United States, HAV represents <0.5% of pediatric-age ALF; HAV is responsible for up to 3% mortality in the adult population with ALF. In endemic areas of the world, HAV constitutes up to 40% of all cases of pediatric ALF. HAV can also progress to a *prolonged cholestatic syndrome* that waxes and wanes over several months. Pruritus and fat malabsorption are problematic and require symptomatic support with antipruritic medications and fat-soluble vitamin supplementation. This syndrome occurs in the absence of any liver synthetic dysfunction and resolves without sequelae.

Treatment

There is no specific treatment for hepatitis A. Supportive treatment consists of intravenous hydration as needed and antipruritic agents and fat-soluble vitamins for the prolonged cholestatic form of disease. There is no benefit to the use of corticosteroid treatment during acute illness. Serial monitoring for signs of ALF is prudent and, if ALF is diagnosed, a prompt referral to a transplantation center can be lifesaving.

Prevention

Patients infected with HAV are contagious for 2 weeks before and approximately 7 days after the onset of jaundice and should be excluded from school, childcare, or work during this period. Careful handwashing is necessary, particularly after changing diapers and before preparing or serving food. In hospital settings, contact and standard precautions are recommended for 1 week after onset of symptoms.

Immunoglobulin

Indications for intramuscular administration of Ig include preexposure and postexposure prophylaxis (Table 406.4). Ig is recommended for *preexposure* prophylaxis for susceptible travelers to countries where HAV is endemic, and it provides effective protection for up to 2 months. *HAV vaccine* given any time before travel is preferred for *preexposure* prophylaxis in healthy persons, but *Ig* ensures an appropriate prophylaxis in children *younger than 6 months* old, patients allergic to a vaccine component, or those who elect not to receive the vaccine. If travel is planned in <2 weeks, older patients, immunocompromised

Table 406.3 Diagnostic Blood Tests: Serology and Viral Polymerase Chain Reaction

HAV	HBV	HCV	HDV	HEV
ACUTE/ACTIVE INFECTION				
Anti-HAV IgM (+)	Anti-HBc IgM (+)	Anti-HCV (+)	Anti-HDV IgM (+)	Anti-HEV IgM (+)
Blood PCR positive*	HBsAg (+) Anti-HBs (–) HBV DNA (+) (PCR)	HCV RNA (+) (PCR)	Blood PCR positive HBsAg (+) Anti-HBs (–)	Blood PCR positive*
PAST INFECTION (RECOVERED)				
Anti-HAV IgG (+)	Anti-HBs (+) Anti-HBc IgG (+)†	Anti-HCV (+) Blood PCR (–)	Anti-HDV IgG (+) Blood PCR (–)	Anti-HEV IgG (+) Blood PCR (–)
CHRONIC INFECTION				
N/A	Anti-HBc IgG (+) HBsAg (+) Anti-HBs (–) PCR (+) or (–)	Anti-HCV (+) Blood PCR (+)	Anti-HDV IgG (+) Blood PCR (–) HBsAg (+) Anti-HBs (–)	N/A
VACCINE RESPONSE				
Anti-HAV IgG (+)	Anti-HBs (+) Anti-HBc (–)	N/A	N/A	N/A

*Research tool.
†Still poses a risk for reactivation.
HAV, Hepatitis A virus; HBs, hepatitis B surface; HBsAg, hepatitis B surface antigen; Ig, immunoglobulin; PCR, polymerase chain reaction.

Table 406.4 Indications and Updated Dosage Recommendations for GamaSTAN S/D Human Immune Globulin for Preexposure and Postexposure Prophylaxis Against Hepatitis A Infection

INDICATION	UPDATED DOSAGE RECOMMENDATION
Preexposure prophylaxis	
Up to 1 mo of travel	0.1 mL/kg
Up to 2 mo of travel	0.2 mL/kg
2 mo of travel or longer	0.2 mL/kg (repeat every 2 mo)
Postexposure prophylaxis	0.1 mL/kg

From Nelson NP. Updated dosing instruction for immune globulin (human) GamaSTAN S/D for hepatitis A virus prophylaxis. *MMWR*. 2017;66(36):959–960.

hosts, and those with chronic liver disease or other medical conditions should receive *both* Ig and the HAV vaccine.

Ig prophylaxis in *postexposure* situations should be used as soon as possible (it is not effective if administered more than 2 weeks after exposure). It is exclusively used alone for children younger than 12 months old or in whom vaccine is contraindicated (e.g., serious allergy to the vaccine). Ig in combination with HAV vaccine may be used in patients older than 40 years of age, with HAV vaccine preferred in healthy persons 12 months to 40 years old. An alternative approach is to immunize previously unvaccinated patients who are 12 months old or older with the age-appropriate vaccine dosage as soon as possible. Ig is not routinely recommended for sporadic nonhousehold exposure (e.g., protection of hospital personnel or schoolmates). The vaccine has several advantages over Ig, including long-term protection, availability, and ease of administration, with cost similar to, or less than, that of Ig.

Vaccine

The availability of at least three inactivated, highly immunogenic, and safe HAV vaccines has had a major impact on the prevention of HAV infection. These vaccines are approved for children older than 12 months. They are administered intramuscularly in a two-dose schedule, with the second dose given 6-12 months after the first dose. Seroconversion rates in children exceed 90% after an initial dose and approach 100% after the second dose; protective antibody titer persists for longer than 10 years in most patients. The immune response in immunocompromised persons, older patients, and those with chronic illnesses may be suboptimal; in those patients, combining the vaccine with Ig for preexposure and postexposure prophylaxis is indicated. HAV vaccine may be administered simultaneously with other vaccines. A combination HAV and HBV vaccine is approved in adults older than age 18. For healthy persons at least 12 months old, vaccine is preferable to Ig for preexposure and postexposure prophylaxis (see Table 406.3).

In the United States and some other countries, universal vaccination is recommended for all children older than 12 months. Nevertheless, studies show <50% of U.S. adolescents have received even a single dose of the vaccine and <30% have received the complete vaccine series. The vaccine is effective in curbing outbreaks of HAV because of rapid seroconversion and the long incubation period of the disease.

Prognosis

The prognosis for the patient with HAV is excellent, with no long-term sequelae. The only feared complication is ALF. Nevertheless, HAV infection remains a major cause of morbidity; it has a high socioeconomic impact during epidemics and in endemic areas.

HEPATITIS B

Etiology

HBV, a member of the Hepadnaviridae family, has a circular, partially double-stranded DNA genome composed of approximately 3,200 nucleotides. Four constitutive genes have been identified: the S (surface), C (core), X, and P (polymer) genes. The surface of the virus includes particles, designated as the hepatitis B surface antigen (HBsAg), which consist of 22-nm-diameter spherical particles and 22-nm-wide tubular particles with a variable length of up to 200 nm. The inner portion of the virion contains the hepatitis B core antigen (HBcAg), the nucleocapsid that encodes the viral DNA, and a nonstructural antigen called the hepatitis B e antigen (HBeAg), a nonparticulate soluble antigen derived from HBcAg by proteolytic self-cleavage. HBeAg serves as a marker of active viral replication and usually correlates with the HBV DNA levels. Replication of HBV occurs predominantly in the liver but also occurs in the lymphocytes, spleen, kidney, and pancreas.

Epidemiology

HBV has been detected worldwide, with an estimated 250 million persons chronically infected. The areas of highest prevalence of HBV infection are sub-Saharan Africa, China, parts of the Middle East, the Amazon basin, and the Pacific Islands. In the United States, the indigenous population in Alaska had the highest prevalence rate before the implementation of their universal vaccination programs. An estimated 1.25 million persons in the United States are chronic HBV carriers, with approximately 300,000 new cases of HBV occurring each year, the highest incidence being among adults 20-39 years of age. One in four chronic HBV carriers will develop serious sequelae in their lifetime. The number of new cases in children reported each year is thought to be low but is difficult to estimate because many infections in children are asymptomatic. In the United States, since the first vaccine for HBV was introduced, the overall incidence of HBV infection has been reduced by more than half. Since the implementation of universal vaccination programs in Taiwan and the United States, substantial progress has been made toward eliminating HBV infection in children in these countries. In fact, in Alaska, where HBV neared epidemic proportions, universal newborn vaccination with mass screening and immunization of susceptible Alaska indigenous peoples virtually eliminated symptomatic HBV and secondary hepatocellular carcinoma (HCC).

HBV is present in high concentrations in blood, serum, and serous exudates and in moderate concentrations in saliva, vaginal fluid, and semen. Efficient transmission occurs through blood exposure and sexual contact. Risk factors for HBV infection in children and adolescents include acquisition by intravenous drugs or blood products, contaminated needles used for acupuncture or tattoos, sexual contact, institutional care, and intimate contact with carriers. No risk factors are identified in approximately 40% of cases. HBV is not thought to be transmitted via indirect exposure, such as sharing toys. After infection, the incubation period ranges from 45 to 160 days, with a mean of approximately 120 days. In children, the most important risk factor for acquisition of HBV remains perinatal exposure to an HBsAg-positive mother. The risk of transmission is greatest if the mother is HBeAg-positive; up to 90% of these infants become chronically infected if untreated. Additional risk factors include high maternal HBV viral load (HBeAg/HBV DNA titers) and delivery of a prior infant who developed HBV despite appropriate prophylaxis. In most perinatal cases, serologic markers of infection and antigenemia appear 1-3 months after birth, suggesting that transmission occurred at the time of delivery. Virus contained in amniotic fluid or in maternal feces or blood may be the source. Immunoprophylaxis with hepatitis B immunoglobulin (HBIG) and the HBV immunization, given within 12 hours of delivery, is highly effective in preventing infection and protects >95% of neonates born to HBsAg-positive mothers. Of the ~22,000 infants born each year to HBsAg-positive mothers in the United States, >98% receive immunoprophylaxis and are thus protected. Infants who fail to receive the complete vaccination series (e.g., homeless children, international adoptees, and children born outside the United States) have the highest incidence of developing chronic HBV. These and all infants born to HBsAg-positive mothers should have follow-up HBsAg and anti-HBs testing to determine appropriate follow-up. The mothers (HBeAg positive) of these infants who develop chronic HBV infection should receive antiviral therapy during the third trimester for subsequent pregnancies.

HBsAg is inconsistently recovered in human milk of infected mothers. Breastfeeding of nonimmunized infants by infected mothers does not seem to confer a greater risk of hepatitis than does formula feeding.

The risk of developing **chronic HBV infection**, defined as being positive for HBsAg for longer than 6 months, is inversely related to the age of acquisition. In the United States, although <10% of infections occur in children, these infections account for 20–30% of all chronic cases. This risk of chronic infection is 90% in children younger than 1 year; the risk is 30% for those 1-5 years of age and 2% for adults. Chronic HBV infection is associated with the development of chronic liver disease and HCC. The carcinoma risk is independent of the presence of cirrhosis and was the most prevalent cancer-related death in young adults in Asia, where HBV was endemic.

HBV has 10 genotypes (A-J). A is pandemic, B and C are prevalent in Asia, D is seen in Southern Europe, E in Africa, F in the United States, G in the United States and France, H in Central America, I in Southeast Asia, and J in Japan. Genetic variants have become resistant to some antiviral agents.

Pathogenesis

The acute response of the liver to HBV is similar to that of other viruses. Persistence of histologic changes in patients with hepatitis B indicates development of chronic liver disease. HBV, unlike the other hepatotropic viruses, is a predominantly noncytopathogenic virus that causes injury mostly by immune-mediated processes. The severity of hepatocyte injury reflects the degree of the immune response, with the most complete immune response associated with the greatest likelihood of viral clearance but also the most severe injury to hepatocytes. The first step in the process of acute hepatitis is infection of hepatocytes by HBV, resulting in expression of viral antigens on the cell surface. The most important of these viral antigens may be the nucleocapsid antigens—HBcAg and HBeAg. These antigens, in combination with class I major histocompatibility proteins, make the cell a target for cytotoxic T-cell lysis.

The mechanism for development of chronic hepatitis B is less well understood. To permit hepatocytes to continue to be infected, the core protein or major histocompatibility class I protein might not be recognized, the cytotoxic lymphocytes might not be activated, or some other, yet unknown mechanism might interfere with destruction of hepatocytes. This tolerance phenomenon predominates in the perinatally acquired cases, resulting in a high incidence of persistent HBV infection in children with no or little inflammation in the liver, normal liver enzymes, and markedly elevated HBV viral load. Although end-stage liver disease rarely develops in those patients, the inherent HCC risk is high, possibly related, in part, to uncontrolled viral replication cycles.

ALF has been seen in infants of chronic carrier mothers who have anti-HBe or are infected with a precore-variant strain. This fact led to the postulate that HBeAg exposure in utero in infants of chronic carriers likely induces tolerance to the virus once infection occurs postnatally. In the absence of this tolerance, the liver is massively attacked by T cells and the patient presents with ALF.

Immune-mediated mechanisms are also involved in the extrahepatic conditions that can be associated with HBV infections. Circulating immune complexes containing HBsAg can result in polyarteritis nodosa, membranous or membranoproliferative glomerulonephritis, polymyalgia rheumatica, leukocytoclastic vasculitis, and Guillain-Barré syndrome.

Clinical Manifestations

Many acute cases of HBV infection in children are asymptomatic, as evidenced by the high carriage rate of serum markers in persons who have no history of acute hepatitis (Table 406.5). The usual acute symptomatic episode is similar to that of HAV and HCV infections but may be more severe and is more likely to include involvement of the skin and joints (Fig. 406.2).

The first biochemical evidence of HBV infection is elevation of serum ALT levels, which begin to rise just before development of fatigue, anorexia, and malaise, at approximately 6-7 weeks after exposure. The illness is preceded, in a few children, by a serum sickness–like prodrome marked by arthralgia or skin lesions, including urticarial, purpuric, macular, or maculopapular rashes. Papular acrodermatitis, Gianotti-Crosti syndrome, can also occur. Other extrahepatic conditions associated with HBV infections in children include polyarteritis nodosa, glomerulonephritis, and aplastic anemia. Jaundice is present in approximately 25% of acutely infected patients and usually begins approximately 8 weeks after exposure and lasts approximately 4 weeks. In the usual course of resolving HBV infection, symptoms persist for 6-8 weeks. The percentage of children in whom clinical evidence of hepatitis develops is higher for HBV than for HAV, and the rate of ALF is also greater. Most patients do recover, but the chronic carrier state complicates up to 10% of cases acquired in adulthood. The rate of development of chronic infection depends largely on the mode and age of acquisition and occurs in up to 90% of perinatally infected cases. Cirrhosis and HCC are only seen with chronic infection. Chronic HBV infection has three identified phases: immune tolerant, immune active, and inactive. Most children fall in the immune-tolerant phase, against

Table 406.5 Typical Interpretation of Test Results for Hepatitis B Virus Infection

HBsAg	TOTAL ANTI-HBc	IgM ANTI-HBc	ANTI-HBs	HBV DNA	INTERPRETATION
–	–	–	–	–	Never infected
+	–	–	–	+ or –	Early acute infection; transient (up to 18 days) after vaccination
+	+	+	–	+	Acute infection
–	+	+	+ or –	+ or –	Acute resolving infection
–	+	–	+	–	Recovered from past infection and immune
+	+	–	–	+	Chronic infection
–	+	–	–	+ or –	False-positive (i.e., susceptible), past infection, "low-level" chronic infection, or passive transfer of anti-HBc to infant born to HBsAg-positive mother
–	–	–	+	–	Immune if anti-HBs concentration is ≥10 mIU/mL after vaccine series completion; passive transfer after hepatitis B immune globulin administration

–, Negative; +, positive; anti-HBc, antibody to hepatitis B core antigen; anti-HBs, antibody to hepatitis B surface antigen; HBsAg, hepatitis B surface antigen; HBV DNA, hepatitis B virus deoxyribonucleic acid; IgM, immunoglobulin class M.

From Schillie S, Vellozzi C, Reingold A, et al. Prevention of hepatitis B virus infection in the United States: recommendations of the Advisory Committee on Immunization Practices. *MMWR*. 2018;67(1):1–29, Table 1.

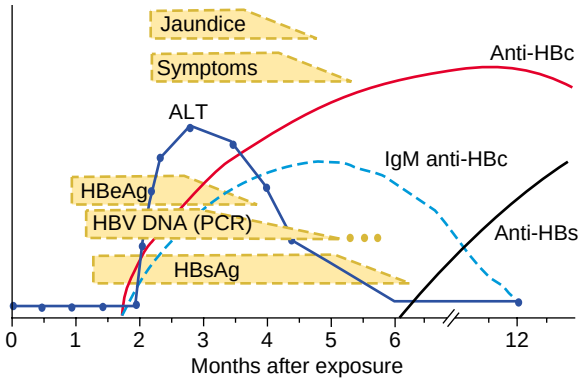

Fig. 406.2 The serologic course of acute hepatitis B. ALT, Alanine aminotransferase; HBc, hepatitis B core; HBeAg, hepatitis B e antigen; HBsAg, hepatitis B surface antigen; HBV DNA, hepatitis B virus deoxyribonucleic acid; IgM, immunoglobulin class M; PCR, polymerase chain reaction. *(From Goldman L, Ausiello D, eds. Cecil Textbook of Medicine, 22nd ed. Philadelphia: WB Saunders; 2004:914.)*

which no effective therapy has been developed. Most treatments target the immune active phase of the disease, characterized by active inflammation, elevated ALT/AST levels, and progressive fibrosis. Spontaneous HBeAg seroconversion, defined as the development of anti-HBe and loss of HBeAg, occurs in the immune-tolerant phase, albeit at low rates of 4–5% per year. It is more common in childhood-acquired HBV rather than in perinatally transmitted infections. Seroconversion can occur over many years, during which time significant damage to the liver may take place. There are no large studies that accurately assess the lifetime risks and morbidities of children with chronic HBV infection, making decisions regarding the rationale, efficacy, and timing of still less-than-ideal treatments difficult. Reactivation of chronic infection has been reported in immunosuppressed children treated with chemotherapy, biologic immunomodulators such as infliximab, or T-cell–depleting agents, leading to an increased risk of ALF or to rapidly progressing fibrotic liver disease (Table 406.6).

Table 406.6 Causes of Hepatitis Flares in Patients with Chronic Hepatitis B

CAUSE OF FLARE	COMMENT
Spontaneous	Factors that precipitate viral replication are unclear
Immunosuppressive therapy	Flares are often observed during withdrawal of the agent; preemptive antiviral therapy is required
Antiviral therapy for HBV	
Interferon Nucleoside analog	Flares are often observed during the second to third month of therapy in 30% of patients; may herald virologic response
During treatment	Flares are no more common than with placebo
Drug-resistant HBV	Severe consequences can occur in patients with advanced liver disease
On withdrawal	Flares are caused by the rapid reemergence of wild-type HBV; severe consequences can occur in patients with advanced liver disease
HIV treatment	Flares can occur as a result of the direct toxicity of HAART or with immune reconstitution; HBV increases the risk of antiretroviral drug hepatotoxicity
Genotypic variation	
Precore and core promoter variants	Fluctuations in serum alanine aminotransferase levels are common with precore variants
Superinfection with other hepatitis viruses	May be associated with suppression of HBV replication

HAART, Highly active antiretroviral therapy; HBV, hepatitis B virus.
From Wells JT, Perillo R. Hepatitis B. In Feldman M, Friedman LS, Brandt LJ, eds. *Sleisenger and Fordtran's Gastrointestinal and Liver Disease*, 10th ed. Philadelphia: Elsevier; 2016: Table 79.1.

Diagnosis

The serologic profile of HBV infection is more complex than for HAV infection and differs depending on whether the disease is acute or chronic (Fig. 406.3, see Table 406.5). Several antigens and antibodies are used to confirm the diagnosis of acute HBV infection (see Table 406.3). Routine screening for HBV infection requires assay of multiple serologic markers (HBsAg, anti-HBc, anti-HBs). HBsAg is an early serologic marker of infection and is found in almost all infected persons; its rise closely coincides with the onset of symptoms. *Persistence of HBsAg beyond 6 months defines the chronic infection state*. During recovery from acute infection, because HBsAg levels fall before symptoms wane, IgM antibody to HBcAg (anti-HBc IgM) might be the only marker of acute infection. Anti-HBc IgM rises early after the infection and remains positive for many months before being replaced by anti-HBc IgG, which then persists for years. Anti-HBs marks serologic recovery and protection. Only anti-HBs is present in persons immunized with hepatitis B vaccine, whereas both anti-HBs and anti-HBc are detected in persons with resolved infection. HBeAg is present in active acute or chronic infection and is a marker of infectivity. The development of anti-HBe, termed *seroconversion*, marks improvement and is a goal of therapy in chronically infected patients. HBV DNA can be detected in the serum of acutely infected patients and chronic carriers. High DNA titers are seen in patients with HBeAg, and they typically fall once anti-HBe develops.

Complications

ALF with coagulopathy, encephalopathy, and cerebral edema occurs more commonly with HBV than the other hepatotropic viruses. The risk of ALF is further increased when there is coinfection or superinfection with HDV or in an immunosuppressed host. Mortality

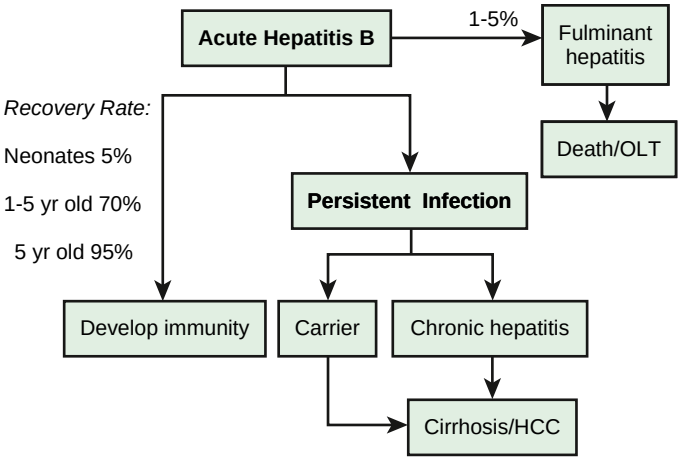

Fig. 406.3 Natural history of hepatitis B virus infection. HCC, Hepatocellular carcinoma; OLT, orthotopic liver transplant.

from ALF is >30%, and liver transplantation is the only effective intervention. Supportive care aimed at sustaining patients and early referral to a liver transplantation center can be lifesaving. As mentioned, HBV infection can also result in chronic hepatitis, which can lead to cirrhosis, end-stage liver disease complications, and HCC. Membranous glomerulonephritis with deposition of complement and HBeAg in glomerular capillaries is a rare complication of HBV infection.

Treatment

Treatment of *acute* HBV infection is largely supportive. Close monitoring for liver failure and extrahepatic morbidities is key. Treatment of *chronic* HBV infection is in evolution; no drug currently achieves consistent, complete eradication of the virus. The natural history of chronic HBV infection in children is complex, and there is a lack of reliable long-term outcome data on which to base treatment recommendations. Treatment of chronic HBV infection in children should be individualized and done under the care of a pediatric hepatologist experienced in treating the disease.

The goal of treatment is to reduce viral replication, defined by having undetectable HBV DNA in the serum and development of anti-HBe, termed *seroconversion*. The development of anti-HBe transforms the disease into an inactive form, thereby decreasing infectivity, active liver injury and inflammation, fibrosis progression, and the risk of HCC. Treatment is only indicated for patients in the immune-active form of the disease, as evidenced by elevated ALT and/or AST, who have fibrosis on liver biopsy, putting the child at higher risk for cirrhosis during childhood.

Treatment Strategies

Interferon-α2b **(IFN-α2b)** has immunomodulatory and antiviral effects. It has been used in children, with long-term viral response rates similar to the 25% rate reported in adults. IFN use is limited by its subcutaneous administration, treatment duration of 24 weeks, and side effects (flulike symptoms, marrow suppression, depression, retinal changes, autoimmune disorders). IFN is further contraindicated in decompensated cirrhosis. One advantage of IFN, compared with other treatments, is that viral resistance does not develop with its use.

Lamivudine is an oral synthetic nucleoside analog that inhibits the viral enzyme reverse transcriptase. In children older than 2 years of age, its use for 52 weeks resulted in HBeAg clearance in 34% of patients with an ALT >2 times normal; 88% remained in remission at 1 year. It has a good safety profile. Lamivudine must be used for ≥6 months after viral clearance, and the emergence of a variant viral strain (YMDD) poses a barrier to its long-term use. Combination therapy in children using IFN and lamivudine did not seem to improve the rates of response in most series.

Adefovir (a purine analog that inhibits viral replication) is approved for use in children older than 12 years of age, in whom a prospective 1-year study showed 23% seroconversion. No viral resistance was noted in that study but has been reported in adults.

Entecavir (a nucleoside analog that inhibits replication) is currently approved for use in children older than 2 years of age. Prospective data have shown a 21% seroconversion rate in adults with minimal resistance developing. Patients in whom resistance to lamivudine developed have an increased risk of developing resistance to entecavir.

Tenofovir (a nucleotide analog that inhibits viral replication) is also approved for use in children older than 12 years of age. Prospective data have shown a 21% seroconversion rate with a very low rate of developing resistance. Patients with lamivudine-resistant variants do not appear to have an increased rate of resistance. Concern exists over long-term use and bone mineral density.

Peginterferon-α_2 has the same mechanism of action as IFN but is given once weekly. This formulation has not been approved in the United States but is recommended for the treatment of chronic HBV in other countries. Patients most likely to respond to currently available drugs have low serum HBV DNA titers, are HBeAg-positive, have active hepatic inflammation (ALT greater than twice the upper limit of normal for at least 6 months), and have recently acquired disease.

Immune-tolerant patients—those with normal ALT and AST and who are HBeAg-positive with elevated viral load—are currently not considered for treatment, although the emergence of new treatment paradigms is promising for this large, yet hard-to-treat, subgroup of patients.

Prevention

The most effective prevention strategies have resulted from the screening of pregnant mothers and the use of HBIG and hepatitis B vaccine in infants (Tables 406.7 to 406.10). In HBsAg-positive and HBeAg-positive mothers, a 10% risk of chronic HBV infection exists compared with 1% in HBeAg-negative mothers. This knowledge offers screening strategies that may affect both mother and infant by using antiviral medications during the third trimester. Guidelines suggest that mothers with an HBV DNA viral load >200,000 IU/mL receive an antiviral such as telbivudine, lamivudine, or tenofovir during the third trimester, especially if they had a previous child who developed chronic HBV after receiving HBIG and the hepatitis B vaccine. This practice has proven safe, with normal growth and development in infants of treated mothers.

Table 406.7 Strategy to Eliminate Hepatitis B Virus Transmission in the United States*

- Screening of all pregnant women for HBsAg
  - HBV DNA testing for HBsAg-positive pregnant women, with suggestion of maternal antiviral therapy to reduce perinatal transmission when HBV DNA is >200,000 IU/mL
  - Prophylaxis (HepB vaccine and hepatitis B immunoglobulin) for infants born to HBsAg-positive† women
- Universal vaccination of all infants beginning at birth‡,§ as a safeguard for infants born to HBV-infected mothers not identified prenatally
- Routine vaccination of previously unvaccinated children age <19 yr
- Vaccination of adults at risk for HBV infection, including those requesting protection from HBV without acknowledgment of a specific risk factor

*Sources: Mast EE, Margolis HS, Fiore AE, et al. A comprehensive immunization strategy to eliminate transmission of hepatitis B virus infection in the United States: recommendations of the Advisory Committee on Immunization Practices (ACIP). Part 1: immunization of infants, children, and adolescents, *MMWR Recomm Rep*. 2005;54(No. RR-16):1–31; Mast EE, Weinbaum CM, Fiore AE, et al. A comprehensive immunization strategy to eliminate transmission of hepatitis B virus infection in the United States: recommendations of the Advisory Committee on Immunization Practices (ACIP). Part II: immunization of adults, *MMWR Recomm Rep*. 2006;55(No. RR-16):1–33.

†Refer to Table 406.8 for prophylaxis recommendations for infants born to women with unknown HBsAg status.

‡Within 24 hr of birth for medically stable infants weighing ≥2,000 g.

§Refer to Table 406.8 for birth dose recommendations for infants weighing <2,000 g.

HBsAg, Hepatitis B surface antigen; HBV, hepatitis B virus.

From Schillie S, Vellozzi C, Reingold A, et al. Prevention of hepatitis B virus infection in the United States: recommendations of the Advisory Committee on Immunization Practices. *MMWR*. 2018;67(1):1–29, Box 2.

Household, sexual, and needle-sharing contacts of patients with chronic HBV infection should be identified and vaccinated if they are susceptible to HBV infection. Patients should be advised about the perinatal and intimate contact risk of transmission of HBV. HBV is not spread by breastfeeding, kissing, hugging, or sharing water or utensils. Children with HBV should not be excluded from school, play, childcare, or work, unless they are prone to biting. A support group might help children to cope better with their disease. Families should not feel obligated to disclose the diagnosis, as this information may lead to prejudice or mistreatment of the patient or the patient's family. All patients positive for HBsAg should be reported to the state or local health department.

HBIG is indicated only for specific *postexposure* circumstances and provides only temporary protection (3-6 months). It plays a pivotal role in preventing *perinatal* transmission when administered within 12 hours of birth.

Universal Vaccination

Two single-antigen vaccines (Recombivax HB and Engerix-B) are approved for children and are the only preparations approved for infant dosing under 6 weeks of life. Heplisav-B is approved only for people 18 years of age and older. Combination vaccines can be used for subsequent immunization dosing and enable integration of the HBV vaccine into the regular immunization schedule. The safety profile of the HBV vaccine is excellent. The most reported side effects are pain at the

Table 406.8 Hepatitis B Vaccine Schedules for Infants by Infant Birthweight and Maternal Hepatitis B Surface Antigen Status

BIRTHWEIGHT	MATERNAL HBsAg STATUS	SINGLE-ANTIGEN VACCINE		SINGLE-ANTIGEN + COMBINATION VACCINE†	
		DOSE	AGE	DOSE	AGE
≥2,000 g	Positive	1	Birth (≤12 hr)	1	Birth (≤12 hr)
		HBIG‡	Birth (≤12 hr)	HBIG	Birth (≤12 hr)
		2	1-2 mo	2	2 mo
		3	6 mo§	3	4 mo
				4	6 mo§
	Unknown*	1	Birth (≤12 hr)	1	Birth (≤12 hr)
		2	1-2 mo	2	2 mo
		3	6 mo§	3	4 mo
				4	6 mo§
	Negative	1	Birth (≤24 hr)	1	Birth (≤24 hr)
		2	1-2 mo	2	2 mo
		3	6-18 mo§	3	4 mo
				4	6 mo§
<2,000 g	Positive	1	Birth (≤12 hr)	1	Birth (≤12 hr)
		HBIG	Birth (≤12 hr)	HBIG	Birth (≤12 hr)
		2	1 mo	2	2 mo
		3	2-3 mo	3	4 mo
		4	6 mo§	4	6 mo§
	Unknown	1	Birth (≤12 hr)	1	Birth (≤12 hr)
		HBIG	Birth (≤12 hr)	HBIG	Birth (≤12 hr)
		2	1 mo	2	2 mo
		3	2-3 mo	3	4 mo
		4	6 mo§	4	6 mo§
	Negative	1	Hospital discharge or age 1 mo	1	Hospital discharge or age 1 mo
		2	2 mo	2	2 mo
		3	6-18 mo§	3	4 mo
				4	6 mo§

*Mothers should have blood drawn and tested for HBsAg as soon as possible after admission for delivery; if the mother is found to be HBsAg positive, the infant should receive HBIG as soon as possible but no later than age 7 days.
†Pediarix should not be administered before age 6 wk.
‡HBIG should be administered at a separate anatomic site from the vaccine.
§The final dose in the vaccine series should not be administered before age 24 wk (164 days).
HBIG, Hepatitis B immune globulin; HBsAg, hepatitis B surface antigen.
From Schillie S, Vellozzi C, Reingold A, et al. Prevention of hepatitis B virus infection in the United States: recommendations of the Advisory Committee on Immunization Practices. *MMWR*. 2018;67(1):1–29, Table 3.

Table 406.9 Recommended Doses of Hepatitis B Vaccine by Group and Vaccine Type

	SINGLE-ANTIGEN VACCINE				COMBINATION VACCINE			
	RECOMBIVAX		ENGERIX		PEDIARIX*		TWINRIX†	
Age-Group (yr)	Dose (μg)	Vol (mL)	Dose (μg)	Vol (mL)	Dose (μg)	Vol (mL)	Dose (μg)	Vol (mL)
Birth-10	5	0.5	10	0.5	10*	0.5	N/A	N/A
11-15	10‡	1	N/A	N/A	N/A	N/A	N/A	N/A
11-19	5	0.5	10	0.5	N/A	N/A	N/A	N/A
≥20	10	1	20	1	N/A	N/A	20†	1
HEMODIALYSIS PATIENTS AND OTHER IMMUNE-COMPROMISED PERSONS								
<20	5	0.5	10	0.5	N/A	N/A	N/A	N/A
≥20	40	1	40	2	N/A	N/A	N/A	N/A

*Pediarix is approved for use in persons age 6 wk through 6 yr (before the seventh birthday).
†Twinrix is approved for use in persons age ≥18 yr.
‡Adult formulation administered on a two-dose schedule.
N/A, Not applicable.
From Schillie S, Vellozzi C, Reingold A, et al. Prevention of hepatitis B virus infection in the United States: recommendations of the Advisory Committee on Immunization Practices. *MMWR*. 2018;67(1):1–29, Table 2.

Table 406.10 Hepatitis B Vaccine Schedules for Children, Adolescents, and Adults

AGE GROUP	SCHEDULE* (INTERVAL REPRESENTS TIME IN MONTHS FROM FIRST DOSE)
Children (1-10 yr)	0, 1, and 6 mo 0, 1, 2, and 12 mo
Adolescents (11-19 yr)	0, 1, and 6 mo 0, 12, and 24 mo 0 and 4-6 mo† 0, 1, 2, and 12 mo 0, 7 days, 21-30 days, 12 mo‡
Adults (≥20 yr)	0, 1, and 6 mo 0, 1, 2, and 12 mo 0, 1, 2, and 6 mo§ 0, 7 days, 21-30 days, 12 mo‡

*Refer to package inserts for further information. For all ages, when the hepatitis B vaccine schedule is interrupted, the vaccine series does not need to be restarted. If the series is interrupted after the first dose, the second dose should be administered as soon as possible, and the second and third doses should be separated by an interval of at least 8 wk. If only the third dose has been delayed, it should be administered as soon as possible. The final dose of the vaccine must be administered at least 8 wk after the second dose and should follow the first dose by at least 16 wk; the minimum interval between the first and second doses is 4 wk. Inadequate doses of hepatitis B vaccine or doses received after a shorter-than-recommended dosing interval should be readministered, using the correct dosage or schedule. Vaccine doses administered ≤4 days before the minimum interval or age are considered valid. Because of the unique accelerated schedule for Twinrix, the 4-day guideline does not apply to the first three doses of this vaccine when administered on a 0-day, 7-day, 21 to 30-day, and 12-mo schedule (new recommendation).

†A two-dose schedule of Recombivax adult formulation (10 μg) is licensed for adolescents age 11-15 yr. When scheduled to receive the second dose, adolescents age >15 yr should be switched to a three-dose series, with doses two and three consisting of the pediatric formulation administered on an appropriate schedule.

‡Twinrix is approved for use in persons age ≥18 yr and is available on an accelerated schedule with doses administered at 0, 7, 21-30 days, and 12 mo.

§A four-dose schedule of Engerix administered in two-1 mL doses (40 μg) on a 0-, 1-, 2-, and 6-mo schedule is recommended for adult hemodialysis patients.

From Schillie S, Vellozzi C, Reingold A, et al. Prevention of hepatitis B virus infection in the United States: recommendations of the Advisory Committee on Immunization Practices. *MMWR*. 2018;67(1):1–29, Table 4.

injection site (up to 29% of cases) and fever (up to 6% of cases). Seropositivity is 90–95% with all vaccines, achieved after the second dose in most patients. The third dose serves as a booster and may have an effect on maintaining long-term immunity. For immunocompromised individuals, annual anti-HBs testing should be considered, with a fourth booster dose given when anti-HBs concentrations are <10 mIU/mL. Similar consideration may be given to children with cystic fibrosis, liver disease, or celiac disease if there is an ongoing risk for HBV exposure. In infants whose birthweight is <2,000 g born to HBsAg-positive mothers (or if their HBsAg status remains unknown), a fourth dose is recommended at 6 months of age (the birth dose does not count as part of the three-dose series) and these infants should be checked for anti-HBs and HBsAg after completing these shots. In this group of infants, if the anti-HBs level is <10 mIU/mL, they should repeat the three-dose series. Despite declines in the anti-HBs titer in time, most healthy vaccinated persons remain protected against HBV infection.

HBV vaccination recommendations are as noted in Tables 406.8 to 406.10.

Postvaccination testing for HBsAg and anti-HBs should be done at 9-18 months. If the result is positive for anti-HBs, the child is immune to HBV. If the result is positive for HBsAg only, the parent should be counseled and the child evaluated by a pediatric hepatologist. If the result is negative for both HBsAg and anti-HBs, a second complete hepatitis B vaccine series should be administered, followed by testing for anti-HBs to determine if subsequent doses are needed.

Administration of four doses of vaccine is permissible when combination vaccines are used after the birth dose; this does not affect vaccine response.

Postexposure Prophylaxis

Recommendations for postexposure prophylaxis for prevention of hepatitis B infection depend on the conditions under which the person is exposed to HBV (see Table 406.10). Vaccination should never be postponed if written records of the exposed person's immunization history are not available, but every effort should still be made to obtain those records.

Special Populations

Patients with cirrhosis may not respond as well to the HBV vaccine, and repeat anti-HBs titers should be performed. Adult studies suggest a higher dosage or shorter interval between dosages may increase immunization effectiveness. Patients with inflammatory bowel disease frequently have not been immunized or did not develop complete immunity to HBV, as demonstrated by inadequate anti-HBs levels. These patients may be at risk for fulminant HBV (reactivation) when immunosuppression is started as part of their treatment regimen, specifically with biologic agents such as infliximab.

Prognosis

In general, the outcome after acute HBV infection is favorable, despite a risk of ALF. The risk of developing chronic infection brings the risks of liver cirrhosis and HCC to the forefront. Perinatal transmission leading to chronicity is responsible for the high incidence of HCC in young adults in endemic areas. Importantly, HBV infection and its complications are effectively controlled and prevented with vaccination, and multiple clinical trials are ongoing in an effort to improve and guide treatment regimens.

HEPATITIS C

Etiology

HCV is a single-stranded RNA virus, classified as a separate genus within the Flaviviridae family, with marked genetic heterogeneity. It has at least six major genotypes and numerous subtypes and quasi-species, which permit the virus to escape host immune surveillance. Genotype variation might partially explain the differences in clinical course and response to treatment. Genotype 1 (a and b) is the most common genotype in the United States. The advent of direct-acting antiviral (DAA) therapy has brought a new and highly successful approach to the treatment and cure of hepatitis C.

Epidemiology

DAA therapy has made a major impact on decreasing the prevalence of HCV in the United States. However, HCV continues to be a major cause of chronic liver disease in adults and is associated with >10,000 deaths per year. Approximately 2.5 million people in the United States and 70 million people worldwide are estimated to be currently infected with HCV. The reported global estimated viremic prevalence in children with HCV (age 0-17 years) is hypothesized to be around 3.25 million children as of 2018. Appropriate identification and screening for infected individuals should be implemented.

Risk factors for HCV transmission in the United States included blood transfusion before 1992; with current blood donor screening practices, the risk of HCV transmission is approximately 0.001% per unit transfused. Illegal drug use with exposure to blood or blood products from HCV-infected persons accounts for the majority of adult cases in the United States. Sexual transmission, especially through multiple sexual partners, is the second most common cause of infection. Other risk factors include occupational exposure, but approximately 10% of new infections have no known transmission source. In children, perinatal transmission is the *most* prevalent mode of transmission (see Table 406.1). HCV infection rates in the United States in women of childbearing age and those who are pregnant have increased in parallel with the rising opioid epidemic. Based on the most recent census data, an estimated 29,000 women with HCV infection give birth each year in the United States, with the majority of their infants being infected with HCV. HIV coinfection and high viremia titers (HCV RNA-positive) in the mother can increase the transmission rate to 20%. The incubation period is 7-9 weeks (range: 2-24 weeks).

In 2020, the United States Preventive Services Task Force (USPSTF) and the CDC issued updated recommendations that encourage clinicians to screen all adults age 18-79 years for HCV infection. The USPSTF recommendations specifically suggest HCV screening for all pregnant women. This is important because the rate of HCV infection in pregnant women has continued to increase, with an associated increase in the number of infants exposed to HCV. The mode of delivery (vaginal vs cesarean section) does not typically affect risk of transmission. HCV RNA may be detected in breast milk and colostrum; however, breastfeeding does not appear to increase the rate of HCV transmission (with the exception of HIV coinfected mothers).

Pathogenesis

The pattern of acute hepatic injury is indistinguishable from that of other hepatotropic viruses. In chronic cases, lymphoid aggregates or follicles in portal tracts are found, either alone or as part of a general inflammatory infiltrate of the portal areas. HCV appears to cause injury primarily by cytopathic mechanisms, but immune-mediated injury can also occur. The cytopathic component appears to be mild because the acute illness is typically the least severe of all hepatotropic virus infections.

Clinical Manifestations

Acute HCV infection tends to be mild and insidious in onset (Fig. 406.4; see also Table 406.1). ALF rarely occurs. HCV is the most likely of all these viruses to cause chronic infection (Fig. 406.5). Of affected adults, <15% clear the virus; the rest develop chronic hepatitis. In pediatric studies, 20–40% of children achieved spontaneous sustained clearance of the virus within the first 5 years of life.

Chronic HCV infection is also clinically silent until a complication develops. Serum aminotransferase levels fluctuate and are sometimes normal, but histologic inflammation is universal. Progression of liver fibrosis is slow over several years, unless comorbid factors are present, which can accelerate fibrosis progression. Approximately 25% of infected patients ultimately progress to cirrhosis, liver failure, and, occasionally, primary HCC within 20-30 years of the acute infection. Although progression is rare within the pediatric age range, cirrhosis and HCC from HCV have been reported in children. The long-term morbidities constitute the rationale for diagnosis and treatment in children with HCV.

Chronic HCV infection can be associated with small vessel vasculitis and is a common cause of essential mixed cryoglobulinemia. Other extrahepatic manifestations predominantly seen in adults include cutaneous vasculitis, porphyria cutanea tarda, lichen planus, peripheral neuropathy, cerebritis, polyarthritis, membranoproliferative glomerulonephritis, and nephrotic syndrome. Antibodies to smooth muscle, antinuclear antibodies, and low thyroid hormone levels may also be present.

Diagnosis

In children older than 18 months of age, diagnostic criteria are the same as those established for adults. Clinically available assays for detection of HCV infection are based on detection of antibodies to HCV antigens (anti-HCV) or detection of viral RNA (see Table 406.3); neither can predict the severity of liver disease.

The most widely used serologic test is the third-generation enzyme immunoassay to detect anti-HCV. The predictive value of this assay is greatest in high-risk populations, but the false-positive rate can be as high as 50–60% in low-risk populations. False-negative results also occur because antibodies remain negative for as long as 1-3 months after clinical onset of illness. Anti-HCV is not a protective antibody and does not confer immunity; it is usually present simultaneously with the virus. The next step is to verify viral infection by detecting HCV RNA. This is accomplished via PCR testing. The diagnosis of chronic HCV infection is made based on the presence of detectable HCV RNA for more than 6 months. The *quantitative* PCR also aids in monitoring response to therapy.

For infants under 18 months of age, the diagnosis may be confounded by the passive transfer of maternal antibodies, which can last for 1 year or more postnatally. Thus anti-HCV testing is of limited value during the first year of life. Diagnosis in this age-group can be reliably established by HCV RNA positivity on two or more occasions after 2 months of age. Criteria for spontaneous clearance requires two negative HCV RNA tests spread at least 6 months apart, followed by negative anti-HCV testing after 18 months of age.

Screening for HCV should include all patients with the following risk factors: history of illegal drug use (even if only once), receiving clotting factors made before 1987 (when inactivation procedures were introduced) or blood products before 1992, hemodialysis, idiopathic liver disease, and children born to HCV-infected women (qualitative PCR in infancy and anti-HCV after 12-18 months of age). In children, it is also important to consider whether the mother has any of the risk factors noted earlier that would increase her possibility of developing HCV.

Determining HCV genotype is also important, particularly when therapy is considered, as certain DAA therapies may only target specific genotypes. Newer pangenotypic DAA agents, however, will hopefully lead to the practice of genotyping becoming moot in the near future (as discussed later).

Aminotransferase levels typically fluctuate during HCV infection and do not correlate with the degree of liver fibrosis. A liver biopsy was

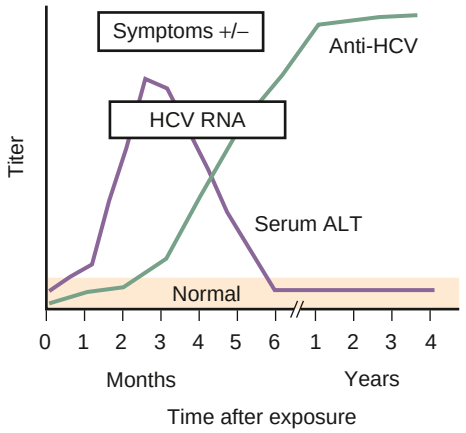

Fig. 406.4 Typical course of acute hepatitis C virus infection followed by recovery. Symptoms may or may not be present during acute infection. Anti-HCV, Antibody to HCV; ALT, alanine aminotransferase. *(Modified from the Centers for Disease Control and Prevention, www.cdc.gov/hepatitis/Resources/Professionals/Training/Serology/training.htm#one.)*

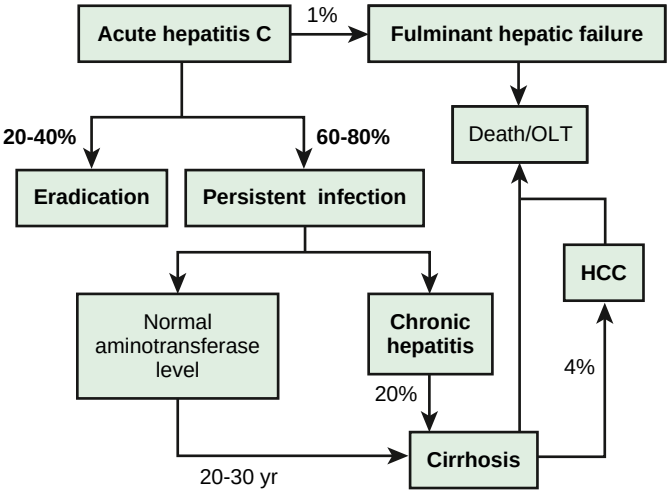

Fig. 406.5 Natural history of hepatitis C virus infection. HCC, Hepatocellular carcinoma; OLT, orthotopic liver transplant. *(From Hochman JA, Balistreri WF. Chronic viral hepatitis: always be current! Pediatr Rev. 2003;24[12]:399–410.)*

previously the only means to assess the presence and extent of hepatic fibrosis, outside of overt signs of chronic liver disease. Newer noninvasive modalities using ultrasound or magnetic resonance elastography, however, are now used to estimate the degree of fibrosis and decrease the need for biopsy. This technology, coupled with newer drug regimens, has eliminated the need for liver biopsy in many cases of HCV infection. A liver biopsy is now primarily indicated to rule out other causes of overt liver disease.

Complications

The risk of ALF caused by HCV is low, but the risk of chronic hepatitis is the highest of all the hepatitis viruses. In adults, risk factors for progression to hepatic fibrosis include older age, obesity, being male, and even moderate alcohol ingestion (two 1-oz. drinks per day). Progression to cirrhosis or HCC is a major cause of morbidity and one of the most common indications for liver transplantation in adults in the United States.

Treatment

The arrival of DAA therapies has led to a paradigm shift in the treatment and eradication of HCV in all populations. These DAAs are now available and have been shown to be as safe and effective in children (>3 years) and adolescents as in the adult populations. Pegylated-interferon (PEG-IFN) and ribavirin (RBV), the initial recommended combination for treatment of HCV in children and adolescents, are no longer recommended.

The goal of treatment is to achieve a sustained viral response (SVR), defined as the absence of viremia at a variable period after stopping the medications. SVR is associated with improved histology and decreased risk of morbidities. DAA therapies can achieve SVR after 8-12 weeks of treatment, as compared with the RBV and PEG-IFN combination, which required 48 weeks of treatment, close monitoring, and significant side effect profiles including pancytopenia. Furthermore, regimens of PEG-IFN have sustained efficacy of 50% in achieving SVR, whereas DAA regimens have been shown to be consistently more effective (SVR >95%) in children.

DAAs target three HCV proteins involved in the life cycle of this virus: (1) the nonstructural protein 3/4A (NS3/4A) protease inhibitors (PIs), which work by inhibiting HCV polyprotein processing; (2) NS5A inhibitors, which inhibit viral replication and assembly; and (3) NS5B polymerase inhibitors, which block HCV RNA replication. By combining two or more of these classes of drugs with different mechanisms attacking HCV, DAAs are able to achieve high SVR rates.

Several phase 2 clinical trials have been completed, revealing the safety and efficacy of DAA therapy in children as young as 3 years of age. For example, the first pediatric trial showed the safety and efficacy of the combination of ledipasvir (90 mg) and sofosbuvir (400 mg) for treatment of HCV genotype 1 over a 12-week period in children ages 12-17 years. This combination is Food and Drug Administration (FDA) approved for children as young as 3 years of age.

It is important to note that one of the main obstacles is determining an age when a young child is capable of daily compliance with the medications for the recommended 8- to 12-week period. The arrival of DAA therapies in the form of granules is a promising strategy for younger children who cannot swallow whole tablets. These granules can be sprinkled on a spoonful of nonacidic soft food (e.g., pudding or peanut butter). SVR has been achieved in 97% of patients as young as 3 years in phase 2 clinical trials using this formulation of delivery.

Treatment recommendations involve obtaining HCV PCR at baseline (before initiation of DAA therapy), at 12 weeks, and at 24 weeks post initiation of therapy. As long as there was no evidence of long-term damage (e.g., fibrosis, cirrhosis), then patients can have a repeat HCV PCR assessment at 1 year after completion of therapy to affirm SVR.

Newer Treatments

Pangenotypic agents, capable of being >92% effective at achieving SVR for all genotypes, have now been FDA approved for children ≥3 years. These include the agents sofosbuvir-velpatasvir, given at once-daily weight-based dosing for 12 weeks, and the combination of glecaprevir-pibrentasvir at three weight-based doses per day for 8 weeks. Thus the need to obtain expensive genotype testing may be unnecessary. With the rapid development of new medications and regimens, frequent review of up-to-date resources, such as www.hcvguidelines.org, will be vital to provide optimal care (Table 406.11).

Prevention

No vaccine is yet available to prevent HCV, although ongoing research suggests this will be possible in the future. Currently available Ig preparations are not beneficial, likely because preparations produced in the United States do not contain high titers of antibodies to HCV, because blood and plasma donors are screened for anti-HCV and excluded from the donor pool. Broad neutralizing antibodies to HCV were found to be protective and might pave the road for vaccine development.

Once HCV infection is identified, patients should be screened yearly with a liver ultrasound and serum α-fetoprotein for HCC and for any clinical evidence of liver disease. Vaccinating the affected patient against HAV and HBV will prevent superinfection with these viruses and the increased risk of developing severe liver failure. Beginning education to families on DAA therapies and initiating treatment at 3 years of age (or as soon as the child is developmentally ready to complete therapy) are also crucial to prevent the development of fibrosis. However, children with evidence of liver fibrosis should continue to be closely monitored even after eradication of their underlying HCV. Fortunately, adult studies are emerging that reveal mild reversal of fibrosis by DAA treatment. However, for patients with evidence of high-grade fibrosis or cirrhosis, they are still at high risk of developing HCC even after achieving SVR. More histologic data are needed to further support the hypothesis of improved liver scarring post DAA treatment. Children with evidence of fibrosis must be closely followed, given the continued risk of complications such as HCC and portal hypertension.

Prognosis

DAA therapies have revolutionized treatment for HCV and allow for resolution of the underlying hepatitis in young children and adolescents before development of irreversible chronic liver disease (fibrosis, cirrhosis, HCC). The World Health Organization (WHO) in 2016 set the ambitious goal of eliminating HCV by 2030, and these new DAA therapeutic agents have provided an important step toward achieving this goal.

HEPATITIS D

Etiology

HDV, the smallest known animal virus, is considered defective because it cannot produce infection without concurrent HBV infection. The 36-nm-diameter virus is incapable of making its own coat protein; its outer coat is composed of excess HBsAg from HBV. The inner core of the virus is single-stranded circular RNA that expresses the HDV antigen.

Epidemiology

HDV can cause an infection at the same time as the initial HBV infection (coinfection), or HDV can infect a person who is already infected with HBV (superinfection). Transmission usually occurs by intrafamilial or intimate contact in areas of high prevalence, which are primarily developing countries (see Table 406.1). In areas of low prevalence, such as the United States, the parenteral route is far more common. HDV infections are uncommon in children in the United States but must be considered when ALF occurs. The incubation period for HDV superinfection is approximately 2-8 weeks; with coinfection, the incubation period is similar to that of HBV infection.

Pathogenesis

Liver pathology in HDV-associated hepatitis has no distinguishing features except that damage is usually severe. In contrast to HBV, HDV causes injury directly by cytopathic mechanisms. The most severe cases of HBV infection appear to result from coinfection of HBV and HDV.

Table 406.11 Completed Studies with Direct-Acting Antiviral Combinations in Children with Chronic Hepatitis C Virus Infection

THERAPY (DURATION)	HCV GENOTYPE	PARTICIPANT AGE IN YEARS (N)	YEAR	SVR12 (%)
Ledipasvir 90 mg + sofosbuvir 400 mg (12 wk)	1	12-17 (100)	2016	98
Sofosbuvir 400 mg + ribavirin (variable)	2 or 3	12-17 (52)	2017	98
Sofosbuvir 400 mg + ribavirin (variable)	1 or 3	5-18 (35)	2017	97
Ledipasvir 45 mg + sofosbuvir 200 mg (12 wk)	1,4-6	12-17 (144)	2018	99
Ledipasvir 45 mg + sofosbuvir 200 mg (12 wk)	1	6-11 (90)	2018	98
Ledipasvir 90 mg + sofosbuvir 400 mg (12 wk)	4	12-18 (40)	2018	100
Ledipasvir + sofosbuvir ± ribavirin (variable)		7-18 (22)	2018	91
Ledipasvir 22.5 mg + sofosbuvir 100 mg (12 wk)	4	0.5 (1)	2018	100
Ledipasvir 45 mg + sofosbuvir 200 mg (12 wk)	4	6-12 (20)	2018	95
Ledipasvir + sofosbuvir (variable)	1 or 4	6-18 (9)	2019	100
Ledipasvir 90 mg + sofosbuvir 400 mg (12 wk)	4	11-17.5 (51)	2019	100
Ledipasvir 90 mg + sofosbuvir 400 mg (8 wk)	1	12-17 (14)	2019	100
Ledipasvir 90 mg + sofosbuvir 400 mg (12 wk)	4	13, 16 (2)	2019	100
Ledipasvir 180 mg + sofosbuvir 400 mg (12 wk)	not performed	12-18 (46)	2020	98
Ledipasvir 45 mg + sofosbuvir 200 mg (8 or 12 wk)	4	3-6 (22)	2020	100
Ledipasvir 90 mg + sofosbuvir 400 mg (12 wk)	4	9-12 (100)	2020	100
Sofosbuvir 400 mg + ribavirin (variable)	1 or 4	3-11 (54)	2020	98
Ledipasvir + sofosbuvir (variable)	1 or 4	3 to <6 (34)	2020	97
Glecaprevir 300 mg + pibrentasvir 120 mg (8-16 wk)	1-4	12-17 (47)	2020	100
Elbasvir + grazoprevir (12 wk)	1 or 4	3-17 (57)	2020	100
Sofosbuvir + velpatasvir (12 wk)	1-4, 6	3-17 (216)	2020	92
Ledipasvir 45 mg + sofosbuvir 200 mg (8 wk)	4	4-10 (30)	2020	100
Sofosbuvir + velpatasvir (12 wk)	1-6	3-17 (160)	2021	92
Glecaprevir + pibrentasvir (8 wk)	1-6	3-12 (81)	2021	96

Clinical Manifestations

The symptoms of hepatitis D are similar to, but usually more severe than, those of the other hepatotropic viruses. The clinical outcome for HDV infection depends on the mechanism of infection. In *coinfection,* acute hepatitis, which is much more severe than for HBV alone, is common, but the risk of developing chronic hepatitis is low. In *superinfection,* acute illness is rare and chronic hepatitis is common. The risk of ALF is highest with superinfection. Hepatitis D should be considered in any child who experiences ALF.

Diagnosis

HDV has not been isolated, and no circulating antigen has been identified. The diagnosis is made by detecting IgM antibody to HDV; the antibodies to HDV develop approximately 2-4 weeks after coinfection and approximately 10 weeks after a superinfection. A test for anti-HDV antibody is commercially available. PCR assays for viral RNA are available as research tools (see Table 406.2).

Treatment

The treatment is based on supportive measures once an infection is identified. There are no specific HDV-targeted treatments to date. The treatment is mostly based on controlling and treating HBV infection, without which HDV cannot induce hepatitis. Small research studies suggest that IFN is the preferred treatment regimen, but ongoing studies still seek the ideal management strategy, and the regimen should be personalized for each patient.

Prevention

There is no vaccine for hepatitis D. Because HDV replication cannot occur without hepatitis B coinfection, immunization against HBV also prevents HDV infection. Hepatitis B vaccines and HBIG are used for the same indications as for hepatitis B alone.

HEPATITIS E

Etiology

HEV has been cloned using molecular techniques. This RNA virus has a nonenveloped sphere shape with spikes and is similar in structure to the caliciviruses.

Epidemiology

Hepatitis E is the epidemic form of viral hepatitis. Transmission is fecal-oral (often waterborne) and is associated with shedding of 27- to 34-nm particles in the stool (see Table 406.1). The highest prevalence of HEV infection has been reported in the Indian subcontinent, the Middle East, Southeast Asia, and Mexico, especially in areas with poor sanitation. The prevalence, however, appears to be increasing in the United States and other developed countries and has been postulated to be the most common cause of acute hepatitis and jaundice in the world. The mean incubation period is approximately 40 days (range: 15-60 days).

Pathogenesis

HEV appears to act as a cytopathic virus. The pathologic findings are similar to those of the other hepatitis viruses.

Clinical Manifestations

The clinical illness associated with HEV infection is similar to that of HAV but is often more severe. As with HAV, chronic illness does not occur—the sole exception noted to date is chronic hepatitis E occurring in immunosuppressed patients (e.g., post-transplant). In addition to often causing a more severe episode than HAV, HEV tends to affect older patients, with a peak age between 15 and 34 years. HEV is a major pathogen in pregnant women, in whom it causes ALF with a high fatality incidence. HEV could also lead to decompensation of preexisting chronic liver disease.

Diagnosis

Recombinant DNA technology has resulted in the development of antibodies to HEV particles, and IgM and IgG assays are available to distinguish between acute and resolved infections (see Table 406.3). IgM antibody to viral antigen becomes positive after approximately 1 week of illness. Viral RNA can be detected in stool and serum by PCR.

Prevention

A recombinant hepatitis E vaccine is highly effective in adults. No evidence suggests that Ig is effective in preventing HEV infections. Ig pooled from patients in endemic areas might prove to be effective.

Acute Hepatitis of Unknown Etiology

In 2021 and 2022 multiple medical centers in over 35 countries reported cases of acute and often severe hepatitis. Clinical manifestations included jaundice, emesis, diarrhea, and hepatomegaly; fever was not always present. Liver enzyme (ALT, AST) and bilirubin levels were elevated in most; ~77% had hepatic failure requiring liver transplantation. Adenovirus (type 41) was detected by PCR in blood but not consistently in liver biopsy specimens (by immune histopathology, electron microscopy, or PCR). Adeno-associated virus 2 has been recovered in both plasma and liver tissue from most patients. A collaborative registry from 25 centers reported a median age of onset of 41 months (range <1-16 years) with ~27% requiring intensive care unit (ICU)–level care. In that cohort, only 22% had evidence of adenovirus infection. The WHO working case definition is noted in Table 406.12. Treatment is supportive, as indicated for other etiologies of acute hepatitis and hepatic failure. The use of corticosteroids is controversial (especially with adenoviremia); some centers have used cidofovir, an inhibitor of viral (adenovirus) DNA polymerases.

Until further clarification of the etiology, the initial evaluation must include the traditional viral, immune, and toxic etiologies of hepatitis and acute hepatic failure (see Table 406.2)

APPROACH TO ACUTE OR CHRONIC HEPATITIS

Identifying deterioration of the patient with acute hepatitis and the development of ALF is a major contribution of the primary care provider (Fig. 406.6). If ALF is identified, the clinician should immediately refer the patient to a transplantation center; this can be lifesaving.

Table 406.12 WHO Working Case Definitions of Severe Acute Hepatitis of Unknown Etiology

- **Confirmed case:** Not available at present
- **Probable case:** A person presenting with an acute hepatitis (nonhepatitis A-E[1]) with serum transaminase >500 IU/L (AST or ALT), who is 16 yr and younger, since October 1, 2021
- **Epidemiologically linked:** A person presenting with an acute hepatitis (nonhepatitis A-E[1]) of any age who is a close contact of a probable case, since October 1, 2021

[1]If hepatitis A-E serology results are pending but other criteria are met, these can be reported and will be classified as "pending classification." Cases with other explanations for their clinical presentation are discarded. Delta testing is not required, as it is only undertaken in persons who are HBsAg positive to establish presence of coinfection.

From World Health Organization: Disease Outbreak News. Acute hepatitis of unknown aetiology in children – Multi-country. Geneva: World Health Organization, July 12, 2022. Available at https://www.who.int/emergencies/disease-outbreak-news/item/2022-DON400.

Once chronic infection is identified, close follow-up and referral to a pediatric hepatologist is recommended to enroll the patient in appropriate treatment trials. Treatment of chronic HBV in children should preferably be delivered within, or using data from, pediatric controlled trials, as indications, timing, regimen, and outcomes remain to be defined and cannot be extrapolated from adult data. New DAA therapies have changed the approach to treatment of HCV in children as young as 3 years of age. All patients with chronic viral hepatitis should avoid as much as possible further insult to the liver; HAV and HBV vaccines are recommended. Patients must avoid alcohol consumption and obesity, and they should exercise care when taking new medications, including nonprescription drugs and herbal medications.

International adoption and ease of travel continue to change the epidemiology of hepatitis viruses. In the United States, chronic HBV and HCV have a high prevalence among international adoptee patients; vigilance is required to establish early diagnosis in order to offer appropriate treatment and prophylactic measures to limit viral spread.

Chronic hepatitis can be a stigmatizing disease for children and their families. The pediatrician should offer, with proactive advocacy, appropriate support for them and needed education for their social circle. Scientific data and information about support groups are available for families on the websites for the American Liver Foundation (www.liverfoundation.org) and the North American Society for Pediatric Gastroenterology, Hepatology and Nutrition (www.naspghan.org) and through pediatric gastroenterology centers.

Visit Elsevier eBooks+ at eBooks.Health.Elsevier.com for Bibliography.

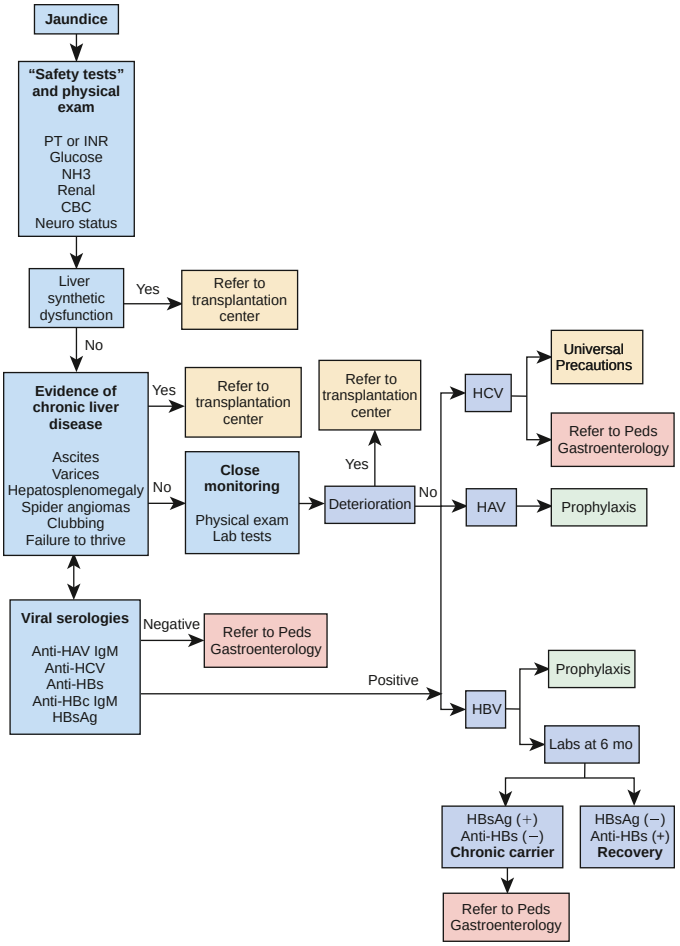

Fig. 406.6 Algorithm showing the clinical approach to viral hepatitis. CBC, Complete blood count with differential; HAV, hepatitis A virus; HBc, hepatitis B core; HBsAg, hepatitis B surface antigen; HBV, hepatitis B virus; HCV, hepatitis C virus; IgM, immunoglobulin M; INR, international normalization ratio; NH_3, ammonia; PT, prothrombin time.

Chapter 407

Liver Abscess

Hilary E. Miller-Handley and Joshua K. Schaffzin

Liver abscesses typically have one of two infectious etiologies: pyogenic, meaning involving bacteria, or parasitic, such as with amebiasis, ascariasis, or toxocariasis. Liver abscesses are typically difficult to detect because of their nonspecific presentation, and diagnosis requires a high index of suspicion. Radiographic diagnosis is often contributory, but further confirmation is often indicated to differentiate infectious abscess from hydatid cyst and noninfectious causes, such as malignancy (primary hepatic or metastasis). The differential diagnosis also includes traumatic injury (including procedural, such as a misplaced vascular catheter).

Pyogenic liver abscesses (PLA) are uncommon in children but have been reported in all ages. Bacteria can invade the liver through one of four sources: hematogenously through the hepatic artery (e.g., in the presence of bacteremia), through the biliary tract, through the portal vein (portal sepsis), and directly by contiguous infection. In neonates, a portal vein source can include the umbilical vein (e.g., in the presence of omphalitis or injury caused by an umbilical venous catheter). PLA of unknown source are classified as cryptogenic. Children with hepatobiliary malignancy, liver transplantation, primary immune deficiency disorders (i.e., chronic granulomatous disease [CGD] and hyper-IgE syndrome), and gastrointestinal pathology are at increased risk for a liver abscess. Diabetes mellitus is a risk factor associated with PLA in adults; however, it is not as clearly linked in children. PLA are also uncommon in adults, although the annual incidence is higher in Southeast Asia (estimated 17.6/100,000 population) than in the United States or Europe (estimated 2-5/100,000 population). They tend to occur more frequently in males and with older age.

Clinical signs and symptoms of PLA are nonspecific and can include fever, chills, malaise, fatigue, nausea, abdominal pain (with or without right upper quadrant tenderness), and hepatomegaly; jaundice is uncommon. The most common abnormal laboratory findings are elevated inflammatory markers and hypoalbuminemia. Hepatic function testing can be abnormally elevated, and leukocytosis is common. Radiologic confirmation is often obtained by ultrasound or CT (Fig. 407.1). Chest x-rays may show elevation of the right hemidiaphragm with a right pleural effusion. Solitary lesions of the right hepatic lobe are most common, although solitary abscesses can appear in any hepatic lobe or as multiple disseminated lesions (such as with disseminated candidiasis, bartonellosis, or, rarely, brucellosis).

Cultures of pyogenic liver abscesses are often polymicrobial. In children, *Staphylococcus aureus, Streptococcus* spp., enteric gram-negative organisms *(Escherichia coli, Klebsiella pneumoniae),* and anaerobic organisms are most common. In immunocompromised children, particularly those with CGD, *Serratia* spp. and *Aspergillus* spp. are also commonly identified. Among adults, *E. coli* and *K. pneumoniae* are the most common organisms, and aerobic gram-positive and anaerobic organisms are less common. Blood cultures are positive in about 25–35% of individuals with a PLA and may be helpful to determine a therapy plan.

Because of the wide range of causative organisms (i.e., aerobic gram-negative, *S. aureus*, and anaerobic organisms) empiric antimicrobial treatment needs to be broad. Potential empiric antimicrobial choices include piperacillin-tazobactam, ampicillin-sulbactam, or metronidazole with a third-generation cephalosporin. Depending on local prevalence and degree of suspicion, vancomycin may be added to cover methicillin-resistant *S. aureus*. Therapy should be modified based on culture susceptibilities. Treatment duration is not standardized and should be based on fever resolution, clinical and inflammatory marker improvement, and serial ultrasound monitoring. Many sources recommend completing 4-6 weeks of therapy, with the first 2 weeks administered parentally. Depending on the size and extent of the lesion(s), percutaneous or surgical drainage may be added to obtain samples for cultures and to shorten illness duration. Percutaneous options include single-pass needle or catheter aspiration, or insertion of a continuously draining catheter. In adults, unless there is evidence of rupture or spread, percutaneous drainage should be attempted first for large lesions (≥5-7 cm in diameter). Numerous case series of PLA in premature infants described complete resolution with antibiotic therapy alone, and some advocate for this as an initial approach in smaller lesions. Resolution can be monitored by trending inflammatory markers and/or serial imaging.

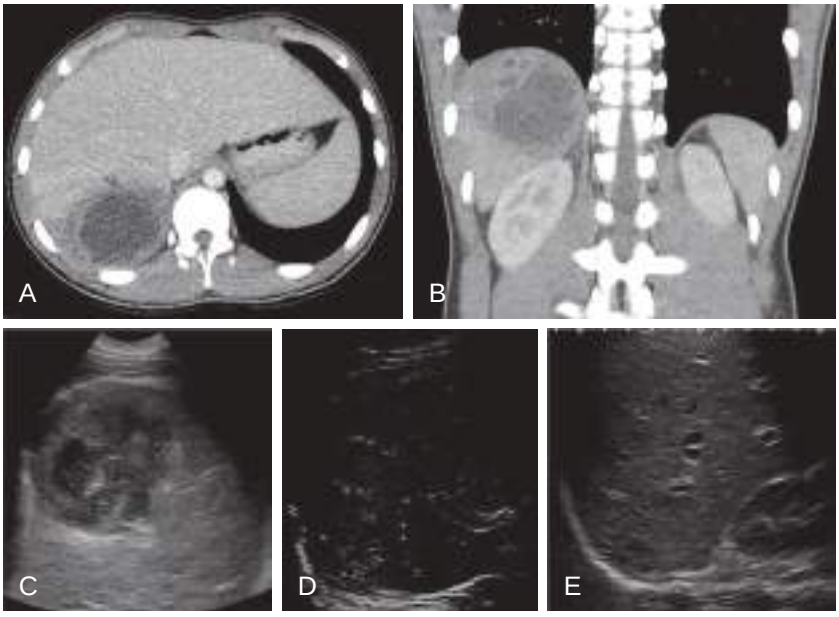

Fig. 407.1 CT (**A** and **B**) and ultrasound (**C**) images of a cryptogenic liver abscess in a 16-yr-old male without known risk factors. The lesion was drained percutaneously, and cultures grew multiple anaerobic organisms (*Fusobacterium nucleatum* and *Parvimonas micra*). He was successfully treated with 2 wk of parenteral followed by 4 wk of oral therapy and was followed with serial ultrasounds 5 days (**D**) and 34 days (**E**) after drainage. *(Courtesy Dr. Alexander Towbin, Cincinnati Children's Hospital, Cincinnati, Ohio.)*

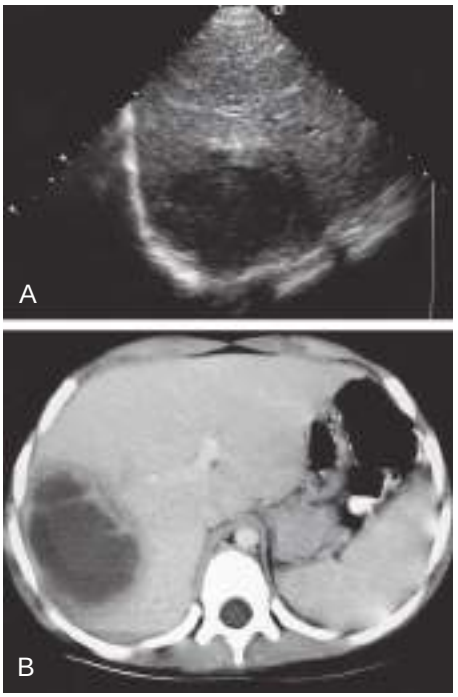

Fig. 407.2 Amebic abscess. **A,** Sonogram demonstrates a hypoechogenic mass in the right lobe of the liver with a more hypoechoic surrounding rim. **B,** CT scan demonstrates a low-attenuation mass in the right lobe of the liver with a prominent halo. *(From Kuhn JP, Slovis TL, Haller JO. Caffrey's Pediatric Diagnostic Imaging, 10th ed. Philadelphia: Mosby, 2004: p. 1473.)*

Amebic liver abscess (ALA) is the most common extraintestinal manifestation of *Entamoeba histolytica* infection. Although more common in endemic areas, cases can be diagnosed in the United States among travelers to, and immigrants from, endemic areas. Presentation can be delayed by months to years. ALA is more common among adults aged 18-55 years, and males predominate. Amoebic trophozoites invade colonic mucosa and reach the liver through the portal circulation. Patients may not have an associated colitis. Fever, right upper quadrant pain, anorexia, and weight loss are often present. Laboratory evaluation typically reveals a leukocytosis without eosinophilia and increased alkaline phosphatase. Ultrasonography or CT demonstrates the abscess (Fig. 407.2).

Diagnosis of ALA is often confirmed by serum ELISA. Serology is considered reliable in nonendemic areas but can be prone to false negatives early in the infection and cannot distinguish active infection from previous exposure. Testing for *E. histolytica* presence in stool is specific but not very sensitive, and patients with ALA may not have detectable organisms in their stool. Most sensitive and specific among stool assays is polymerase chain reaction (PCR), followed by stool antigen detection. Least reliable is microscopy because *E. histolytica* cannot easily be distinguished microscopically from its clinically benign relatives *Entamoeba dispar* and *Entamoeba moshkovskii*.

Before effective treatment, ALA-associated mortality was high; it has since decreased significantly. Treatment involves 7-10 days of a nitroimidazole (most commonly metronidazole) to kill trophozoites, followed by 7 days of a luminal agent (such as paromomycin) to kill colonic cysts. Patients with large abscesses (≥5-7 cm in diameter) may benefit from percutaneous aspiration in addition to medical therapy.

Visit Elsevier eBooks+ at eBooks.Health.Elsevier.com for Bibliography.

Chapter 408

Liver Disease Associated with Systemic Disorders

Batul Kaj-Carbaidwala and William F. Balistreri

Liver involvement in systemic illnesses can be the result of the primary pathologic process, secondary to inflammatory or immune responses, or as a complication of therapy.

INFLAMMATORY BOWEL DISEASE

Hepatobiliary involvement in patients with inflammatory bowel disease (IBD, see Chapter 382) is relatively common; up to 30% of patients will have elevated liver enzymes, and 5% may develop chronic hepatobiliary diseases. Autoimmune diseases (primary sclerosing cholangitis [PSC], autoimmune hepatitis [AIH], PSC-AIH overlap syndrome, and immunoglobulin G4 [IgG4] sclerosing cholangitis) are commonly associated with IBD. Drug-induced liver injury has been associated with both induction and maintenance therapies (thiopurines, methotrexate, 5-ASA, biologics). IBD-related malnutrition can lead to hepatic steatosis and cholelithiasis. Poor intestinal health increases the risk of developing hepatic abscesses secondary to bacterial translocation and systemic infection. Hypercoagulability in IBD can predispose to infarction, Budd-Chiari, and portal venous thrombosis). Figure 408.1 shows a diagnostic approach in IBD patients with abnormal liver tests.

Primary sclerosing cholangitis (PSC) is the most common hepatobiliary disease associated with IBD, occurring in 2–8% of adult patients with ulcerative colitis and less often in Crohn disease. Up to 90% of patients with PSC have ulcerative colitis. In children with IBD, PSC typically occurs in the second decade of life, at a median age of 14 years. PSC is characterized by progressive inflammation and fibrosis of intra- and extrahepatic bile ducts, with eventual progression to cirrhosis and end-stage liver disease. Small- and large-duct disease differs in phenotype, with small-duct PSC reported to confer lower mortality and incidence of cholangiocarcinoma and longer transplant-free survival. Concomitant PSC-IBD is a distinct entity with multifactorial pathogenesis, including genetic predisposition, altered intestinal microbiome, and immune-mediated processes. Distinguishing features of PSC-IBD include pancolitis, rectal sparing and backwash ileitis in patients with UC-PSC and extensive colitis in Crohn-PSC. The clinical course is milder but with subclinical persistent intestinal inflammation. Presentation of PSC is typically asymptomatic with elevated liver enzymes (particularly serum alkaline phosphatase and gamma glutamyl transferase) and bilirubin. Ten percent to 15% of adults present with symptoms of anorexia, weight loss, pruritus, fatigue, right upper quadrant pain, and jaundice; intermittent acute cholangitis can also occur. Diagnosis is made with cholangiography demonstrating characteristic multifocal stricturing and dilation of the intra- and extrahepatic bile ducts (referred to as *beading*). Liver biopsy reveals periductal fibrosis and inflammation, fibroobliterative cholangitis, and portal fibrosis. Biopsy is not necessary for diagnosis but can be helpful when imaging findings are not clear (e.g., in small-duct disease) or when overlap syndrome is suspected. There are no approved pharmacologic therapies for PSC. Ursodeoxycholic acid (UDCA), corticosteroids, immunomodulators, and oral antibiotics (such as vancomycin) have been studied, without clear improvement in survival or long-term outcomes. UDCA is widely used in children with PSC; it may improve pruritus and lab parameters; however, it has not been shown to alter the clinical course. Endoscopic intervention (stents, dilatation) for dominant strictures is reserved for patients with symptoms or complications of biliary obstruction. Liver

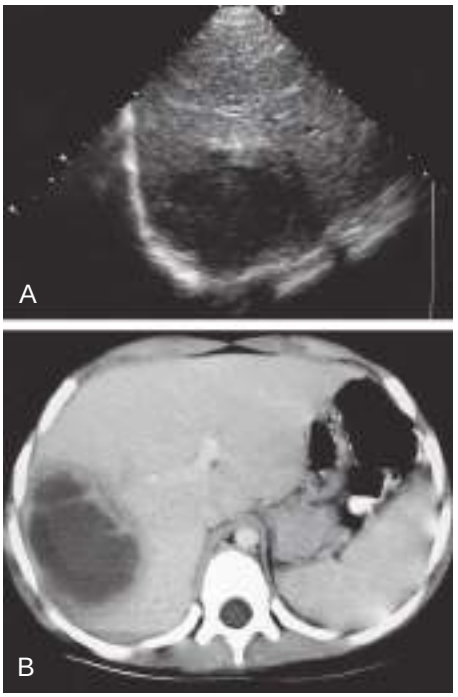

Fig. 407.2 Amebic abscess. **A,** Sonogram demonstrates a hypoechogenic mass in the right lobe of the liver with a more hypoechoic surrounding rim. **B,** CT scan demonstrates a low-attenuation mass in the right lobe of the liver with a prominent halo. *(From Kuhn JP, Slovis TL, Haller JO. Caffrey's Pediatric Diagnostic Imaging, 10th ed. Philadelphia: Mosby, 2004: p. 1473.)*

Amebic liver abscess (ALA) is the most common extraintestinal manifestation of *Entamoeba histolytica* infection. Although more common in endemic areas, cases can be diagnosed in the United States among travelers to, and immigrants from, endemic areas. Presentation can be delayed by months to years. ALA is more common among adults aged 18-55 years, and males predominate. Amoebic trophozoites invade colonic mucosa and reach the liver through the portal circulation. Patients may not have an associated colitis. Fever, right upper quadrant pain, anorexia, and weight loss are often present. Laboratory evaluation typically reveals a leukocytosis without eosinophilia and increased alkaline phosphatase. Ultrasonography or CT demonstrates the abscess (Fig. 407.2).

Diagnosis of ALA is often confirmed by serum ELISA. Serology is considered reliable in nonendemic areas but can be prone to false negatives early in the infection and cannot distinguish active infection from previous exposure. Testing for *E. histolytica* presence in stool is specific but not very sensitive, and patients with ALA may not have detectable organisms in their stool. Most sensitive and specific among stool assays is polymerase chain reaction (PCR), followed by stool antigen detection. Least reliable is microscopy because *E. histolytica* cannot easily be distinguished microscopically from its clinically benign relatives *Entamoeba dispar* and *Entamoeba moshkovskii*.

Before effective treatment, ALA-associated mortality was high; it has since decreased significantly. Treatment involves 7-10 days of a nitroimidazole (most commonly metronidazole) to kill trophozoites, followed by 7 days of a luminal agent (such as paromomycin) to kill colonic cysts. Patients with large abscesses (≥5-7 cm in diameter) may benefit from percutaneous aspiration in addition to medical therapy.

Visit Elsevier eBooks+ at eBooks.Health.Elsevier.com for Bibliography.

Chapter 408

Liver Disease Associated with Systemic Disorders

Batul Kaj-Carbaidwala and William F. Balistreri

Liver involvement in systemic illnesses can be the result of the primary pathologic process, secondary to inflammatory or immune responses, or as a complication of therapy.

INFLAMMATORY BOWEL DISEASE

Hepatobiliary involvement in patients with inflammatory bowel disease (IBD, see Chapter 382) is relatively common; up to 30% of patients will have elevated liver enzymes, and 5% may develop chronic hepatobiliary diseases. Autoimmune diseases (primary sclerosing cholangitis [PSC], autoimmune hepatitis [AIH], PSC-AIH overlap syndrome, and immunoglobulin G4 [IgG4] sclerosing cholangitis) are commonly associated with IBD. Drug-induced liver injury has been associated with both induction and maintenance therapies (thiopurines, methotrexate, 5-ASA, biologics). IBD-related malnutrition can lead to hepatic steatosis and cholelithiasis. Poor intestinal health increases the risk of developing hepatic abscesses secondary to bacterial translocation and systemic infection. Hypercoagulability in IBD can predispose to infarction, Budd-Chiari, and portal venous thrombosis). Figure 408.1 shows a diagnostic approach in IBD patients with abnormal liver tests.

Primary sclerosing cholangitis (PSC) is the most common hepatobiliary disease associated with IBD, occurring in 2–8% of adult patients with ulcerative colitis and less often in Crohn disease. Up to 90% of patients with PSC have ulcerative colitis. In children with IBD, PSC typically occurs in the second decade of life, at a median age of 14 years. PSC is characterized by progressive inflammation and fibrosis of intra- and extrahepatic bile ducts, with eventual progression to cirrhosis and end-stage liver disease. Small- and large-duct disease differs in phenotype, with small-duct PSC reported to confer lower mortality and incidence of cholangiocarcinoma and longer transplant-free survival. Concomitant PSC-IBD is a distinct entity with multifactorial pathogenesis, including genetic predisposition, altered intestinal microbiome, and immune-mediated processes. Distinguishing features of PSC-IBD include pancolitis, rectal sparing and backwash ileitis in patients with UC-PSC and extensive colitis in Crohn-PSC. The clinical course is milder but with subclinical persistent intestinal inflammation. Presentation of PSC is typically asymptomatic with elevated liver enzymes (particularly serum alkaline phosphatase and gamma glutamyl transferase) and bilirubin. Ten percent to 15% of adults present with symptoms of anorexia, weight loss, pruritus, fatigue, right upper quadrant pain, and jaundice; intermittent acute cholangitis can also occur. Diagnosis is made with cholangiography demonstrating characteristic multifocal stricturing and dilation of the intra- and extrahepatic bile ducts (referred to as *beading*). Liver biopsy reveals periductal fibrosis and inflammation, fibroobliterative cholangitis, and portal fibrosis. Biopsy is not necessary for diagnosis but can be helpful when imaging findings are not clear (e.g., in small-duct disease) or when overlap syndrome is suspected. There are no approved pharmacologic therapies for PSC. Ursodeoxycholic acid (UDCA), corticosteroids, immunomodulators, and oral antibiotics (such as vancomycin) have been studied, without clear improvement in survival or long-term outcomes. UDCA is widely used in children with PSC; it may improve pruritus and lab parameters; however, it has not been shown to alter the clinical course. Endoscopic intervention (stents, dilatation) for dominant strictures is reserved for patients with symptoms or complications of biliary obstruction. Liver

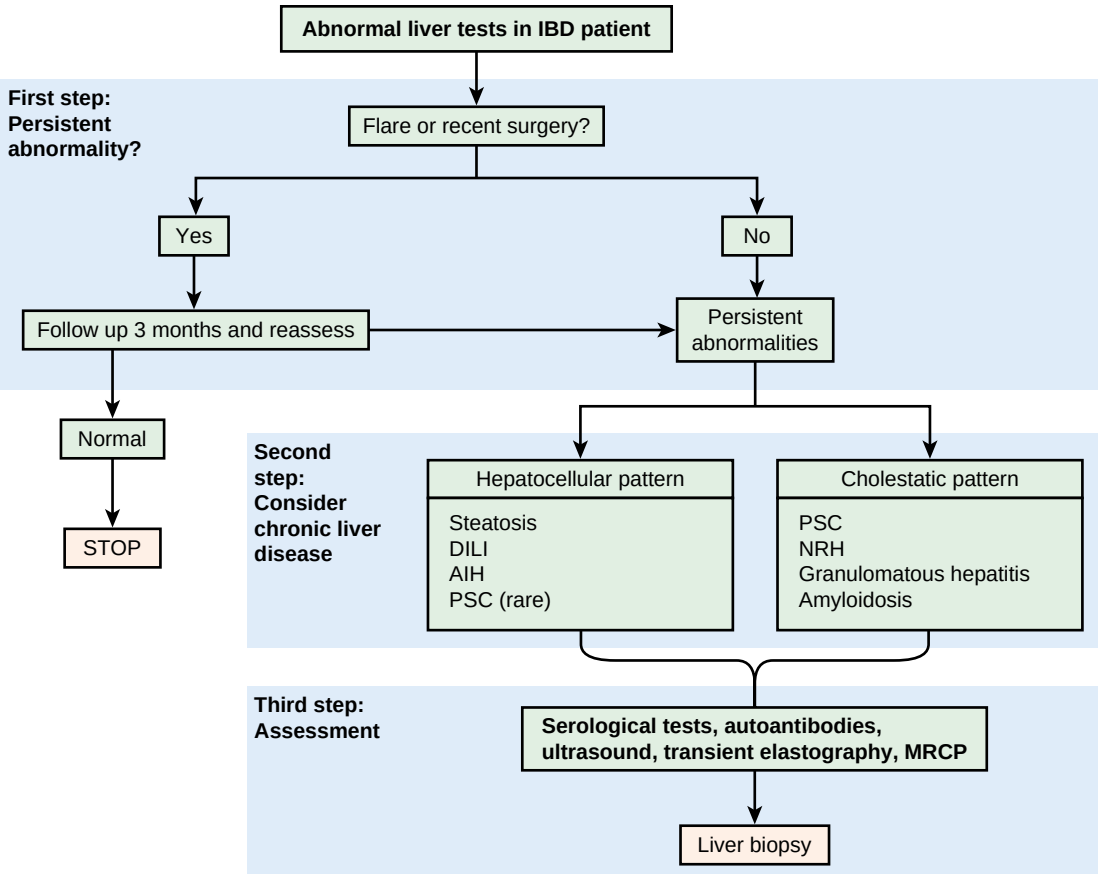

Fig. 408.1 Algorithm showing diagnostic approach to elevated liver enzymes in patients with IBD. AIH, Autoimmune hepatitis; DILI, drug induced liver injury; MRCP, magnetic resonance cholangiopancreatography; NRH, nodular regenerative hyperplasia; PSC, primary sclerosing cholangitis. *(From Restellini S, Chazouillères O, Frossard JL. Hepatic manifestations of inflammatory bowel diseases. Liver Int. 2017;37[4]:475–489. Fig 3)*

transplantation remains the only definitive treatment for PSC, with high 5-year survival rates but a relapse rate of ~20% in the allograft. Other management considerations include enteral supplementation to mitigate malnutrition related to chronic liver disease and antibiotic treatment of ascending cholangitis.

PSC is strongly associated with hepatobiliary malignancies (cholangiocarcinoma, hepatocellular carcinoma, gallbladder carcinoma) with a reported incidence varying between 9% and 14% in adults. Concomitant PSC-IBD also confers increased risk of colorectal carcinoma. There are no universal surveillance guidelines for children with PSC-IBD given the rarity of malignancy. In adults, ultrasound or MRCP with or without serum CA 19-9 assessment every 6-12 months are generally recommended.

PSC-autoimmune hepatitis overlap is a less common, unique phenotype with clinical and serologic features of AIH, as well as pruritus, cholestasis, histologic bile duct abnormalities, and/or abnormal cholangiography. Prevalence is estimated to be ~2% of children with IBD. Immunosuppressive medication (corticosteroids, azathioprine) is the mainstay of therapy for PSC-AIH overlap syndrome; however, long-term outcomes are not as favorable as in AIH alone. Long-term survival in children with overlap syndrome appears to be similar to those with PSC, with an overall median (50%) survival with native liver of 12.7 years.

CRITICAL ILLNESS

Mechanisms of liver injury in patients with sepsis/critical illness include hypoxic hepatitis because of ischemia and shock, cholestasis related to altered bile flow, drug-induced hepatocellular damage, and distinct pathologies, such as secondary sclerosing cholangitis. The management of critical illness–associated liver injury involves prompt recognition, early initiation of antimicrobials, and otherwise supportive care.

Bacterial sepsis should be excluded in any critically ill patient who develops cholestasis in the absence of markedly elevated serum aminotransferase or alkaline phosphatase (ALP) levels, even when other signs of infection are not evident. Gram-negative bacteremia is most common in these patients, in particular *Escherichia coli, Klebsiella pneumoniae,* and *Pseudomonas aeruginosa.* Lipopolysaccharides, bacterial endotoxins, and proinflammatory cytokines are thought to produce cholestatic liver injury either by impairing bile formation in hepatocytes or altering bile flow via disruption of canalicular transporters. Liver biopsy shows intrahepatic cholestasis with little or no hepatocyte necrosis. Kupffer cell hyperplasia and an increase in inflammatory cells are also common.

Secondary sclerosing cholangitis is a distinct entity in critical illness characterized by inflammation, fibrosis, and destruction of the bile ducts that can quickly progress to cirrhosis. It is thought to occur because of the vulnerability of biliary epithelium to hypoxia, leading to apoptosis or necrosis. Major risk factors include severe systemic hypotension, trauma, acute respiratory distress syndrome, and systemic inflammatory response syndrome.

CELIAC DISEASE

Celiac disease (see Chapter 384) is an autoimmune condition triggered by ingestion of gluten. Liver involvement in patients with celiac disease presents either as mild to moderate hepatitis with or without prolonged prothrombin time, or secondary to associated autoimmune disorders. In the former, histology demonstrates mild periportal and lobular inflammation. **Celiac hepatitis** refers to liver injury in patients with confirmed celiac disease in whom serum biochemistries and histology normalizes after establishment of a gluten-free diet. The exact mechanism remains unclear; it has been proposed that increased intestinal permeability may allow toxins, cytokines, and antigens to reach the liver and produce liver injury through release of proinflammatory

Table 408.1 Host- and Parenteral Nutrition–Related Factors in Development of Intestinal Failure–Associated Liver Disease

FACTORS IN THE DEVELOPMENT OF INTESTINAL FAILURE–ASSOCIATED LIVER DISEASE		
HOST	**TOTAL PARENTERAL NUTRITION**	
• Incompletely expressed enzyme activity • Inadequate bile salt uptake and excretion • Liver injury from endotoxins, inflammatory cytokines • Impaired biliary excretion • Prolonged parenteral nutrition (PN) exposure • SBBO, dilated bowel, mucosal atrophy → increased bacterial translocation → recurrent sepsis / direct endotoxin mediated liver injury • Impaired enterohepatic circulation • Decreased cholecystokinin release → biliary stasis • Extensive small bowel resection → more severe hepatic fibrosis	EXCESS MACRONUTRIENTS	• Glucose → Hyperinsulinism → Steatosis • Lipid minimization strategies may require additional dextrose calories
	AMINO ACID DEFICIENCY	• Decreased taurine conjugation of bile acids • Choline deficiency worsens steatosis
	LIPIDS	• Hepatotoxic phytosterols in soy-based lipids • Omega-6 LCPUFA is proinflammatory • Antioxidant imbalance
	MINERALS / TRACE ELEMENTS	• Mg, Cu, Al accumulate in cholestasis causing hepatocellular injury

SBBO, small bowel bacterial overgrowth; LCPUFA, long-chain polyunsaturated fatty acids; Mg, manganese; Cu, copper; Al, aluminum.

mediators. **Autoimmune liver diseases** (AIH, primary sclerosing cholangitis) have been associated with celiac disease; these are best treated with combination of gluten-free diet and immunosuppressive medications. Children with persistent, unexplained elevation of serum aminotransferase levels should be evaluated for celiac disease, given up to 9% reported incidence of celiac disease in this setting.

CARDIAC DISEASE

Cardio-hepatic interactions are complex and bidirectional; congestive heart failure (see Chapter 491), congenital cyanotic heart disease (see Chapters 475-480) and acute ischemic shock can all lead to liver injury. There exist distinct cardiac disorders associated with cirrhosis and end-stage liver disease. Various mechanisms are thought to contribute to liver injury in cardiac disease: (1) elevated central venous pressure transmitted to hepatic veins and ultimately hepatocytes results in centrilobular hepatocellular atrophy (congestive hepatopathy); and (2) decreased cardiac output leads to decreased hepatic arterial blood flow, causing centrilobular hepatocellular necrosis due to ischemia. Congenital cyanotic heart disease (hypoplastic left heart syndrome and coarctation of the aorta) are occasionally associated with hepatic necrosis or acute liver failure. Patients with hepatic manifestations of cardiac disease may present with lactic acidosis, elevated aminotransferase levels, cholestasis, prolonged prothrombin time, hyperammonemia, and hypoglycemia because of impaired hepatocellular metabolism. Jaundice, tender hepatomegaly, and, in some cases, ascites and splenomegaly can also occur.

Acute cardiogenic liver injury (shock liver or ischemic hepatitis) occurs after circulatory disturbances and can cause a dramatic rise in serum aminotransferase levels to >1,000 units/mL. These rapidly return to normal when perfusion and cardiac function improve, with delayed-onset hyperbilirubinemia that can persist for days to weeks.

Fontan-associated liver disease (FALD) is a distinct clinical entity that occurs in patients who have undergone surgical palliation for single ventricle heart disease. Chronically elevated systemic venous pressure after the Fontan procedure causes venous congestion and impaired hepatic blood flow. Patients almost invariably develop progressive hepatic fibrosis, which can lead to cirrhosis, portal hypertension, and hepatocellular carcinoma (HCC). Annual risk of HCC in FALD-cirrhosis is reported as 1.5–5%; cases have been reported of HCC occurring in early adolescence.

The aim of therapy in all causes of cardiac-associated liver disease is to improve cardiac output, reduce systemic venous pressures, and correct hypoxemia. Even mild liver disease may increase mortality after cardiac surgery, with poorer outcomes in patients with progressive liver disease. Combined heart-liver transplant should be considered in Fontan patients with evidence of cirrhosis, especially if decompensated.

INTESTINAL FAILURE ASSOCIATED LIVER DISEASE

Intestinal failure–associated liver disease (IFALD; previously referred to as parenteral nutrition–associated liver disease) in children is characterized by progressive cholestasis, biliary cirrhosis, and steatohepatitis (see Chapters 385.6 and 386). Advanced IFALD is one of the most important factors contributing to mortality of children on long-term parenteral nutrition (PN) and is a major indication for intestinal and multivisceral transplantation. Host- and PN-related factors contribute to its development (Table 408.1). The pathogenesis of IFALD is multifactorial; sepsis, bacterial translocation, excess caloric intake, high amounts of protein, fat, or carbohydrate, nutrient deficiencies, and toxicities related to components such as manganese, aluminum, and copper can all contribute to hepatic injury. The type (soy-based), volume, and frequency of lipid administered are important risk factors. Prolonged enteral fasting compromises mucosal integrity and increases bacterial mucosal translocation. Fasting also decreases release of cholecystokinin, which leads to biliary stasis, cholestasis, and formation of biliary sludge and gallstones, which can exacerbate hepatic dysfunction. Sepsis, especially gram-negative bacteremia, can also exacerbate liver damage. Clinical manifestations range from mildly elevated serum aminotransferase levels to severe cholestatic liver injury, cirrhosis with portal hypertension and, rarely, hepatocellular carcinoma. Histologic findings include macrovesicular steatosis, canalicular cholestasis, and periportal inflammation.

In addition to cholestasis, biliary complications of intravenous (IV) nutrition include cholelithiasis and the development of biliary sludge, associated with thick, inspissated gallbladder contents. Hepatic steatosis or elevated serum aminotransferase levels can also occur in the absence of cholestasis, particularly in older children. This is generally mild and resolves after total PN (TPN) is discontinued. Serum bilirubin and bile acid levels remain within the normal range. Other causes of liver disease should also be considered, especially if evidence of hepatic dysfunction persists despite weaning from TPN and initiating enteral feeds. If serum ALP or aminotransferase levels remain elevated, liver biopsy may be necessary for accurate diagnosis.

Strategies in the management of IFALD aim to prevent or reverse the disease (Table 408.2). General goals include early initiation of enteral nutrition, minimization of fasting, and advancement of enteral feeds as tolerated. Improved TPN solutions that meet the specific needs of neonates can prevent deficiencies and toxicities. Introducing alternate sources of IV lipid, including fish oil and olive oil to provide more omega-3 fatty acids (and less of the harmful omega-6 fatty acids), have been beneficial. Ursodeoxycholic acid is widely used and may be beneficial in improving bile flow.

CYSTIC FIBROSIS

Cystic fibrosis (CF; see Chapter 454) is an autosomal recessive genetic disorder characterized by impaired chloride transport

Table 408.2 Evidence-Based IFALD Prevention and Treatment Strategies for Children on TPN

PREVENTION	EXAMPLES
Advancing enteral nutrition	Prokinetic and anti-diarrheal agents to improve enteral tolerance
	Medical induction of intestinal adaptation, i.e., glucagon-like peptide 2 (GLP-2) agonist
	Surgical lengthening procedures; serial transverse enteroplasty (STEP), Bianchi
Modifying lipid emulsions	**Lipid dose reduction
	*Use of combined lipid emulsion (soybean oil, medium chain triglyceride, olive oil, and fish oil)
Cycling TPN	Non-continuous TPN, with time off in a 24-hr period
Microbiome therapies	Addition of various pre- or probiotics
Prevention of central line infections	Antibiotic treatment to prevent bacterial translocation and small bowel bacterial overgrowth
	Use of ethanol locks
Prevention of cholestasis	***Oral choleretic agent: urso-deoxycholic acid
	**Trophic (small volume) feedings
TREATMENT	
Modifying lipid emulsions	Use of combined lipid emulsion (soybean oil, medium chain triglyceride, olive oil, and fish oil)
	**Use of fish oil emulsion
Organ transplantation	Consider isolated intestinal or liver-intestinal transplantation

*Possibly effective
**Probably effective
***Proven effective
Adapted from Lee WS, Chew KS, Ng RT, et al. Intestinal failure-associated liver disease (IFALD): insights into pathogenesis and advances in management. *Hepatol Int.* 2020;14(3):305–316.

across the apical membranes of epithelial cells in numerous organs. Up to 40% of patients with CF develop some form of hepatobiliary disease, usually in the first 2 decades of life. Hepatobiliary complications account for approximately 2.5% of overall mortality in patients with CF, with development of portal hypertension being a key prognostic factor.

Manifestations range from liver enzyme elevations to cirrhosis with portal hypertension. This can be related to recurrent infections, drug hepatotoxicity, steatosis (because of diabetes, chronic diarrhea, pancreatic insufficiency, malnutrition), cardiopulmonary disease–associated hepatic congestion, biliary disease (neonatal cholestasis, sclerosing cholangitis, micro-gallbladder, gallbladder dysfunction or pigmentary cholelithiasis) and the distinct clinical entity of cystic fibrosis-related liver disease (CLFD); the latter includes two main, sometimes concomitant, entities: primary focal biliary fibrosis and porto-sinusoidal vascular disease. The precise pathogenesis of CFLD remains incompletely understood but is likely multifactorial (Fig. 408.2). Genetic factors associated with increased risk of CFLD include the presence of two abnormal *CFTR* alleles without residual function or presence of *SERPINA1* Z allele. Clinical risk factors include older age, pancreatic insufficiency, male sex, and a history of meconium ileus.

Focal biliary fibrosis is the pathognomonic liver lesion in patients with CF, characterized by periductal inflammation, bile duct proliferation, and increased fibrosis within focal portal tracts. Most patients are asymptomatic. Liver stiffness measurements may aid in differentiating focal fibrosis from steatosis. Gradual progression to multi-lobular cirrhosis can occur and result in portal hypertension and end-stage liver disease in 1–8% of patients.

Porto-sinusoidal vascular disease occurs more frequently in adults than in children and presents as noncirrhotic portal hypertension. Features that may suggest this diagnosis include evidence of portal hypertension without hepatic parenchymal changes, marked splenomegaly, and development of porto-systemic shunts. A macronodular liver, likely related to regenerative nodular hyperplasia, is a common finding. Liver stiffness measures, however, are typically lower than with cirrhotic portal hypertension, which can aid in differentiation. Typical histologic features include obliterative portal venopathy, nodular regenerative hyperplasia, arterialization, periportal vessels, aberrant portal vessels, irregular portal tracts with centrilobular vein distribution, and sinusoidal dilatation.

Management of CFLD is primarily supportive and targeted at symptoms, including through optimization of nutrition and management of portal hypertensive complications. Treatment with oral UDCA (10-15 mg/kg/day) is widespread, but the survival benefit and effect on

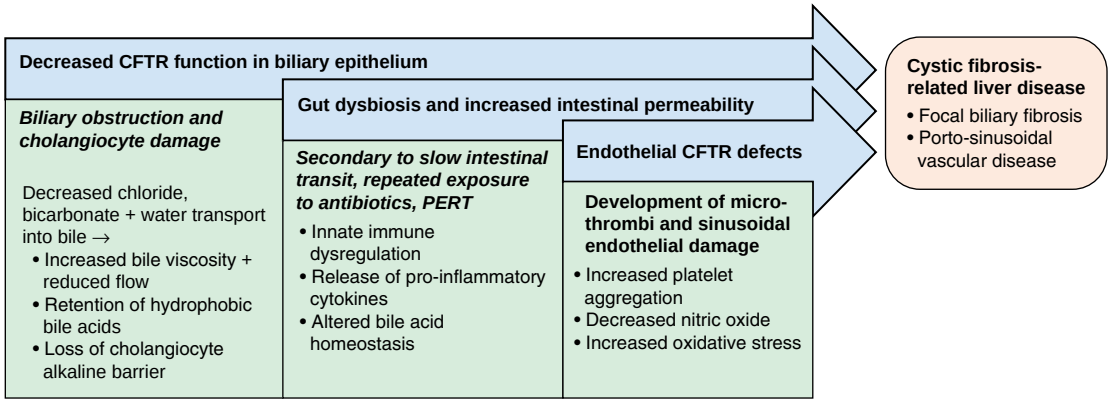

Fig. 408.2 Proposed mechanisms in the development of cystic fibrosis-related liver disease. PERT, Pancreatic enzyme replacement therapy. *(Data from Dana J, Debray D, Beaufrère A, et al. Cystic fibrosis-related liver disease: clinical presentations, diagnostic and monitoring approaches in the era of CFTR modulator therapies. J Hepatol. 2021;S0168-8278:02115–2.)*

clinical course remains controversial. Surgical porto-systemic shunts (distal splenorenal, portocaval) are useful in patients with refractory portal hypertensive complications. Liver transplantation may be offered in severe cases of parenchymal disease with acceptable long-term outcomes with combined liver-lung transplantation being offered at some centers. *CFTR* modulator therapies have shifted the paradigm of pulmonary and nutritional management in CF; however, their role in preventing or reversing CFLD remains unclear. All currently approved modulators may cause elevated liver enzymes; however, small studies have yielded promising results in improving CFLD.

BONE MARROW TRANSPLANTATION

Liver disease after hematopoietic stem cell transplantation (SCT, see Chapters 177-181) occurs in up to 90% of patients in the first 100 days. Etiologies are listed in Table 408.3. Graft-versus-host disease (GVHD), drug toxicity, and sepsis are the most common causes of liver dysfunction after allogeneic SCT. Diagnosis is often challenging because of the coexistence of multiple risk factors. Clinical course, symptoms and signs, liver biochemistries, and viral serology are helpful in making the correct diagnosis. Percutaneous liver biopsy may be necessary; histology can show extensive bile duct injury in GVHD, viral inclusions in cytomegalovirus disease, or the characteristic endothelial lesion in sinusoidal obstruction syndrome (SOS). Prompt and accurate diagnosis is key because treatment for GVHD with corticosteroids may worsen infectious hepatitis, and delayed treatment in SOS can lead to poorer outcomes. Management of liver disease post-HSCT is mainly supportive. Oral UDCA can decrease the incidence of severe liver disease in patients undergoing SCT and has been shown to reduce the incidence of SOS and transplant-related mortality in adults.

Graft-versus-host disease (see Chapter 179) results from donor immunocompetent cells triggering an inflammatory response in recipient organs. Acute GVHD comprises a triad of hepatitis, dermatitis, and enteritis, and usually occurs within 100 days of hematopoietic SCT (HSCT; typically at time of engraftment, 14-21 days after HSCT). Serum aminotransferase and bilirubin levels are markedly elevated. Chronic GVHD occurs later, with liver involvement (slowly progressive cholestasis) in up to 80%. Histologic features of GVHD include loss of intralobular bile ducts, endothelial injury of hepatic and portal venules, and hepatocellular necrosis. Treatment of GVHD varies depending on organ system involved (e.g., skin, intestine) and acute vs chronic presentation. Therapy comprises systemic corticosteroids, optimization of maintenance immunosuppression, and newer agents like ruxolitinib (JAK inhibitor), and it is recommended that management occur in collaboration with the hematopoietic stem cell transplant team. Oral UDCA has also been shown to be beneficial, particularly in chronic GVHD.

Sinusoidal obstruction syndrome (SOS; hepatic venoocclusive disease) usually develops in the first 21 days after SCT. The incidence ranges from 5–39% in pediatric patients, with reported mortality rates ranging from 0–47%. Risk factors for SOS are listed in Table 408.4. Pathogenesis is thought to be related to sinusoidal endothelial cell activation and hepatocyte damage from accumulation of toxic metabolites because of conditioning regimens. Patients typically present with jaundice, painful hepatomegaly, rapid weight gain, and ascites. Severe SOS has high morbidity and mortality, with multisystem organ failure. Diagnostic criteria for SOS include presence of hepatomegaly, right upper quadrant pain, ascites, weight gain >5% from baseline, and bilirubin >2 mg/dL before day 21 post HSCT. Exclusion of other causes of liver disease is also necessary. Liver biopsy is generally not needed for diagnosis, and indeed can be contraindicated because of the bleeding risk. However, the classic histologic features of sinusoidal dilatation, erythrocyte extravasation in space of Disse, collagen deposition in sinusoids and small hepatic veins and centrilobular necrosis, are diagnostic.

Treatment of SOS is with defibrotide, a mixture of oligonucleotides that has antithrombotic and thrombolytic properties. There is a survival benefit of defibrotide in both children and adults. Few significant adverse events are noted; bleeding and infection are the most common adverse effects seen in patients with severe SOS.

Table 408.3 Etiologies of Liver Disease After Hematopoietic Stem Cell Transplantation (HSCT)

Sepsis (viral, bacterial, fungal)
Toxicity (chemotherapy, PN, radiation)
Sinusoidal obstruction syndrome
Acute and chronic GVHD
Hemosiderosis / iron overload
Cholecystitis
Extrahepatic biliary obstruction

PN, Parenteral nutrition; GVHD, graft-versus-host disease.

Table 408.4 Risk Factors for the Development of Sinusoidal Obstruction Syndrome (SOS) After Hematopoietic Stem Cell Transplantation (HSCT)

PATIENT-RELATED FACTORS	HSCT-RELATED FACTORS
Younger age	Allogenic transplant
Hematologic malignancy	Bone marrow–derived stem cells
Disease relapse state	Fever during conditioning therapy
Preexisting liver disease	Second transplant
Previous liver radiation therapy	Myeloablative conditioning
Chronic viral hepatitis	Drug hepatotoxicity
Iron overload	

HEMOGLOBINOPATHIES

Hepatic dysfunction in patients with sickle cell anemia (see Chapter 511.1) or thalassemia (see Chapter 511.10) result from acute or chronic viral hepatitis, chronic iron overload, venous thrombosis, biliary obstruction (cholestasis, cholelithiasis), or acute hepatic crisis (sequestration, ischemic necrosis). Cholelithiasis and chronic iron overload (because of frequent blood transfusions) are common and treatable. Oral chelation therapy (commonly with deferasirox) in iron overload has been demonstrated to reverse or stabilize hepatic fibrosis in patients with thalassemia. Surgical and endoscopic management of gallstones may be necessary, especially in patients with choledocholithiasis.

Sickle Cell Disease

The pathogenesis of hepatobiliary manifestations in sickle cell disease (SCD) is shown in Figure 408.3. **Hepatic sickle cell crisis** or "sickle hepatopathy" occurs in ~10% of patients, when sickled cells obstruct small vessels and sinusoids. This leads to ischemia, inflammation, endothelial dysfunction, and, when flow is restored, reperfusion injury, manifest as intense RUQ pain and tenderness, fever, leukocytosis, and jaundice. Bilirubin levels may be markedly elevated; serum ALP levels may be only moderately elevated. Prompt diagnosis is key to allow early institution of therapy, although this can be challenging because of overlapping symptoms and signs with other hepatobiliary disorders detailed above. In general, hepatic sickle cell crisis is self-limited and symptoms resolve within 1-3 weeks. However, along the spectrum of sickle crises is the distinct entity of **sickle cell intrahepatic cholestasis** (SCIC), thought to be caused by the trapping of sickle cells in sinusoids causing localized hypoxia, hepatocyte ballooning and intra-canalicular cholestasis. This too manifests as hepatomegaly, abdominal pain, hyperbilirubinemia, and coagulopathy but can progress to acute liver failure, multiorgan dysfunction and death. Management of hepatic crises involves exclusion of biliary complications, supportive care, and exchange transfusion if there is evidence of liver synthetic dysfunction or (prolonged prothrombin time) or clinical concern for SCIC. Liver transplantation in SCD (in setting of cirrhosis, end-stage liver disease, and severe SCIC) remains controversial. Although there are some positive experiences reported in adults (with acceptable 5-year survival rates), there remain limited data in children and many clinical challenges. Preoperative optimization in tertiary centers involving

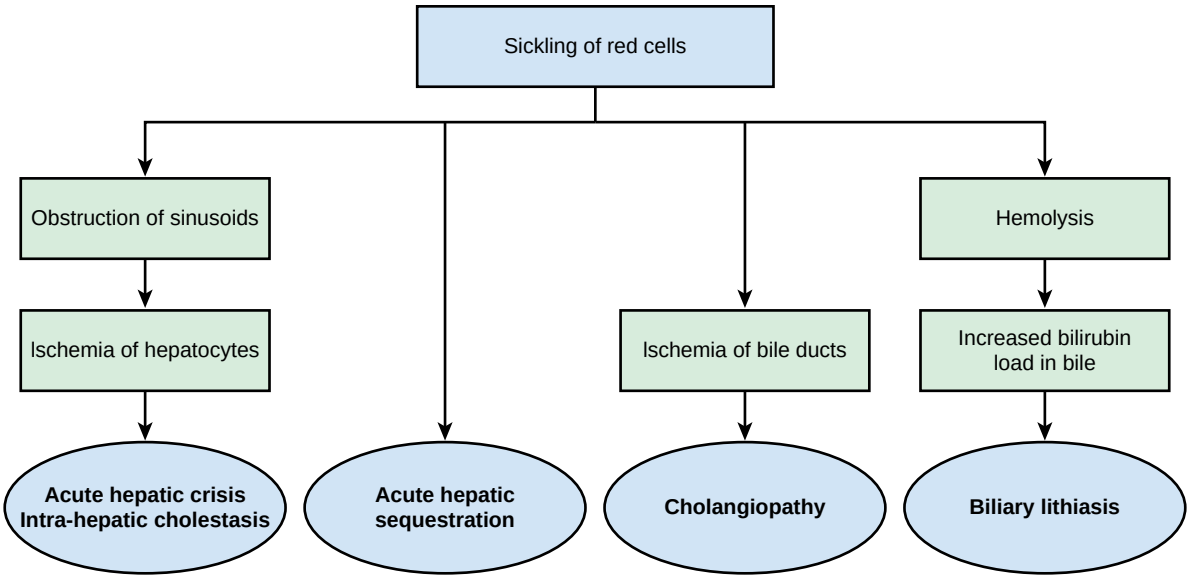

Fig. 408.3 Pathogenesis of liver disease in sickle cell disease. *(From Lacaille F, Allali S, de Montalembert M. The liver in sickle cell disease. J Pediatr Gastroenterol Nutr. 2021;72:5–10. Fig 1.)*

transplant hepatology and hematology teams is paramount, with attention to transfusion parameters, potential drug toxicity, nephroprotective measures, and intraoperative management to prevent acute crises. Of course, hepatic crises may recur in the allograft, with potential for allograft dysfunction and loss.

HISTIOCYTIC DISORDERS

Langerhans cell histiocytosis (LCH, see Chapter 556.1) is a rare disorder characterized by proliferation and accumulation of Langerhans cells (dendritic antigen-presenting histiocytes). It can affect single or multiple organs, with common sites being bone, skin, pituitary gland, spleen, lungs, and lymph nodes. In the liver, histiocytosis can cause hepatocellular dysfunction and/or a mass lesion. Liver involvement in LCH should be suspected in patients with hepatomegaly, ascites, and/or biochemical evidence of liver injury (elevated liver enzymes, bilirubin, or prothrombin time). Liver biopsy demonstrates Langerhans cell infiltrates (identified with positive immunohistochemical staining for CD1a and S100 antigen). Hepatic LCH carries a high mortality rate (30–50%, compared to <10% in patients without liver involvement). Three-year survival with liver involvement is >96% compared to 52% with liver involvement. In children, LCH is an important cause of secondary sclerosing cholangitis, which can lead to chronic liver disease and need for liver transplantation.

Treatment approaches in LCH vary by clinical severity; those with single-organ involvement and mild disease may be observed or offered immunomodulator monotherapy (oral 6 mercaptopurine, methotrexate, and others). Those with hepatic or multiorgan involvement may need to undergo systemic chemotherapy.

Hemophagocytic lymphohistiocytosis (HLH) (see Chapter 556.2) is a multiorgan, severe, and potentially fatal inflammatory process from excessive activation of lymphocytes and macrophages. Hepatobiliary manifestations include elevated aminotransferases (50–100%), cholestasis (50%), and hepatomegaly (90%). Acute liver failure may also occur. Liver biopsy shows portal inflammatory infiltrates, hemophagocytosis, and Kupffer cell hyperplasia but is not routinely obtained because of coagulopathy. The mainstay of treatment of HLH involves etoposide-based chemotherapy and bone marrow transplantation.

Visit Elsevier eBooks+ at eBooks.Health.Elsevier.com for Bibliography.

408.1 Nonalcoholic Fatty Liver Disease

Sarah H. Orkin and William F. Balistreri

The term *nonalcoholic fatty liver disease* (NAFLD) spans a wide spectrum of histologic liver disease, from nonalcoholic fatty liver (NAFL; steatosis without inflammation) to nonalcoholic steatohepatitis (NASH; steatosis with lobular inflammation); the latter may then progress to fibrosis and end-stage liver disease (ESLD) requiring liver transplantation (Figs. 408.4 and 408.5). In fact, NASH currently is the fastest rising indication for liver transplantation in young adults. The burden of pediatric NAFLD is large; it is the most common cause of chronic liver disease in children and currently affects 1 in 10 youth in the general population, and 1 in 3 youth with obesity. Obesity has contributed to an increased prevalence of NAFLD in children; the severity of obesity is associated with more severe liver disease.

Known risk factors for pediatric NAFLD include male sex, Hispanic ethnicity, genetic predisposition (see Fig. 408.4), obesity, insulin resistance, obstructive sleep apnea, celiac disease, and psychotropic drug use (see Fig. 408.4). There is a lower prevalence of NAFLD in Black children. Autopsy data suggest that 10% of all children, and 38% of children with obesity age 2-19 years old have histologically confirmed NAFLD. Up to 25% of affected children may already have advanced fibrosis at the time of first liver biopsy. There are currently no available clinical, biochemical, or radiographic variables to help predict which children will have severe histologic disease on liver biopsy or who will be at risk of rapid progression. Recommendations in adults are to screen at-risk patients (see Fig. 408.4) with liver function tests as well as additional testing to exclude other diagnoses (chronic hepatitis). If there is evidence of liver disease, hepatic ultrasonography and noninvasive assessment of liver stiffness are indicated (see Fig. 408.5D,E).

Most patients with NAFLD are asymptomatic. The North American Society for Pediatric Gastroenterology, Hepatology and Nutrition Clinical Practice Guideline recommend assessing the serum alanine aminotransferase (ALT) level as a screening tool for children starting between 9-11 years of age who are either obese (body mass index [BMI] ≥95th%) or overweight (BMI ≥ 85th% and <95th% with additional metabolic risk factors). In the United States, sex-specific cutoffs for serum ALT values have been determined to be 22 mg/dL in females and 26 mg/dL in males, and values persistently greater than

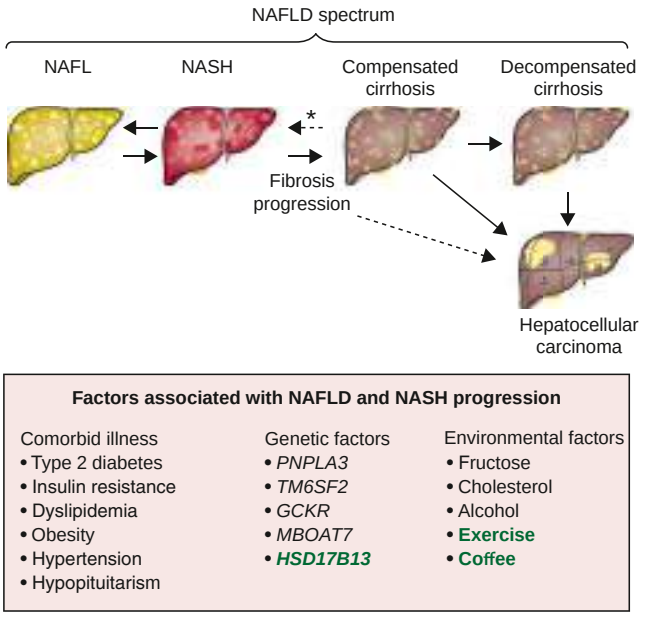

Fig. 408.4 Spectrum of NAFLD. Factors in black type have an established association with NAFLD and NASH progression (broadly classified into comorbid illness, genetic factors, and environmental factors). **Green type indicates a protective factor**. NAFL, Nonalcoholic fatty liver; NAFLD, nonalcoholic fatty liver disease; NASH, nonalcoholic steatohepatitis. *Fibrosis regression. *(From Powell EE, Wong VWS, Rinella M. Non-alcoholic fatty liver disease. Lancet. 2021; 397:2212–2222. Fig. 2.)*

two times the sex-specific upper limit of normal, in the absence of any other identified etiology for liver disease is generally regarded as presumed NAFLD. Most children presenting with obesity and elevated liver enzymes and presumed or confirmed NAFLD will have a negative workup for any alternative etiology for liver disease. Although imaging modalities such as ultrasonography or magnetic resonance imaging with proton-density fat fraction and magnetic resonance elastography (MRI-PDFF /MRE) can be used to evaluate the degree of steatosis and fibrosis by using liver stiffness on MRE as a surrogate for fibrosis, the gold standard for diagnosis of NAFLD is liver biopsy examination.

Histologically, NAFLD is diagnosed when steatosis involves >5% of hepatocytes (see Fig. 408.5). Other pertinent histologic characteristics include the presence and severity of lobular inflammation, cellular ballooning, and fibrosis (graded 0-4). The NASH Clinical Research Network has developed a validated tool for histologic assessment. Unlike adults, NASH in children manifest two distinct histologic types: **Type 1 NASH** resembles adult histologic findings with steatosis and balloon degeneration of hepatocytes and/or periportal fibrosis while **Type 2 NASH** includes steatosis and portal inflammation.

During evaluation other causes of steatosis should be kept in mind. **Lysosomal acid lipase deficiency (LAL-D)**, an autosomal recessive disorder due to pathogenic variants in *LIPA* gene, may result in hepatic steatosis. However, in contrast to NAFLD, patients with LAL-D usually demonstrate microvesicular or mixed micro- and macrovesicular steatosis, and not macrovesicular changes alone.

Children diagnosed with NAFLD should be screened for celiac disease plus comorbid conditions, including diabetes, hypertension,

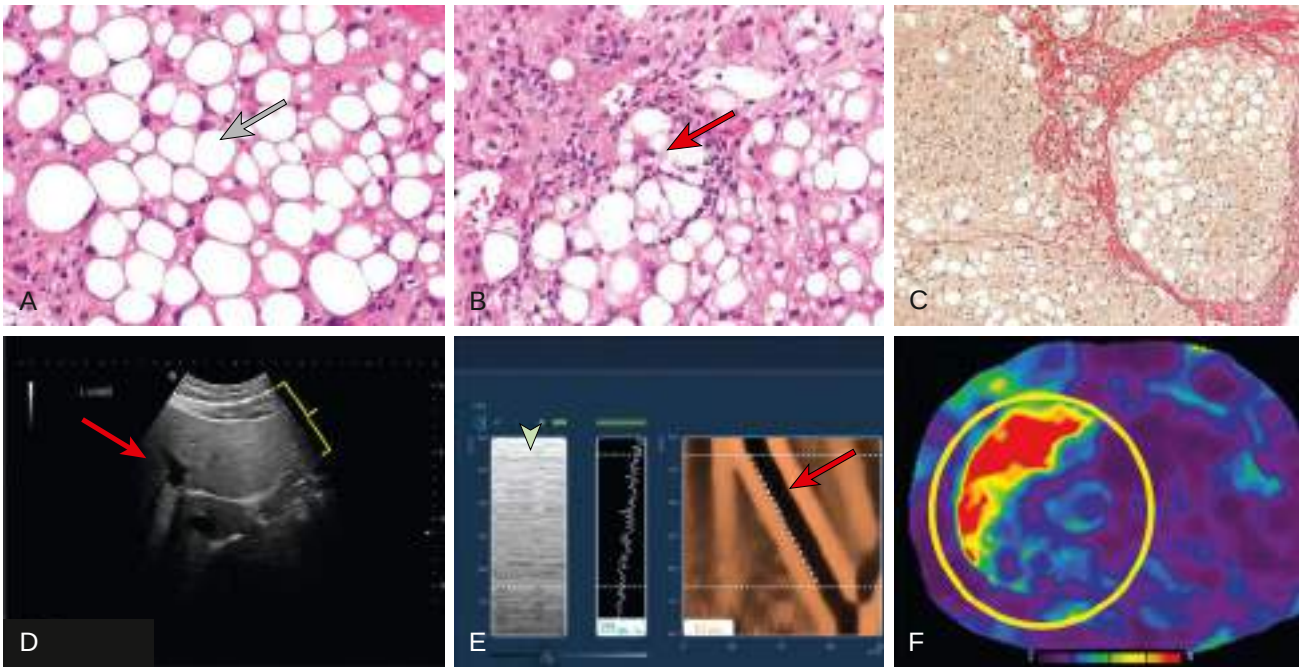

Fig. 408.5 Histologic and radiologic assessment of nonalcoholic fatty liver disease. **A,** Nonalcoholic fatty liver is characterized by macrovesicular steatosis with no or little necroinflammation. Large round nonstaining areas represent lipid droplets in hepatocytes *(arrow;* hematoxylin and eosin stain; magnification ×40). **B,** Apart from fat accumulation, nonalcoholic steatohepatitis (NASH) is characterized by the presence of lobular inflammation and hepatocyte ballooning. At the center of the image is a ballooned hepatocyte surrounded by inflammatory cells (*arrow*; hematoxylin and eosin stain; magnification ×40). **C,** As disease progresses, accumulating liver fibrosis will eventually result in cirrhosis. On the right of this image is a cirrhotic nodule surrounded by thick fibrous tissue. In some cases, steatosis and necroinflammation might reduce or disappear as the disease progresses to cirrhosis, a condition referred to as burned-out NASH (Sirius red; magnification ×10). **D,** Ultrasonography, the most common method to diagnose fatty liver, characterized by bright liver echotexture *(bracket)* and blurring of deeper structures *(arrow).* **E,** Vibration-controlled transient elastography, a point-of-care measurement of liver stiffness for the estimation of fibrosis that can also estimate hepatic steatosis using the controlled attenuation parameter. The machine is equipped with an M-mode ultrasound for the localization of liver parenchyma *(arrowhead).* The elastogram *(arrow)* represents the measurement of liver stiffness. A steeper slope indicates that the shear-wave velocity is higher, and the liver is stiffer. **F,** Magnetic resonance elastography of a patient with NASH cirrhosis, currently one of the most accurate noninvasive tests of liver fibrosis, with the color scheme reflecting stiffness in different parts of the liver. Red shows areas with greater stiffness *(circle). (From Powell EE, Wong VWS, Rinella M. Non-alcoholic fatty liver disease. Lancet. 2021;397:2212–2222. Fig. 1.)*

Table 408.5 Potential Use of Off-Label Therapy for Nonalcoholic Steatohepatitis in Adults

	EFFECTS ON THE LIVER	QUALITY OF EVIDENCE	OTHER BENEFITS	KEY ADVERSE EVENTS	CONTRAINDICATIONS AND CAUTIONS
Pioglitazone	Improves hepatic steatosis and necroinflammation and can improve fibrosis	Several small* to moderate† phase 2 randomized controlled trials	Improves insulin sensitivity and diabetic control	Weight gain, fluid retention, bone loss, and might increase bladder cancer	Contraindicated in patients with New York Heart Association (NYHA) class III or IV heart failure; maximum dose 15 mg if used in combination with gemfibrozil or other strong CYP2C8 inhibitors
Vitamin E	Improves hepatic steatosis and necroinflammation; might prevent liver decompensation and mortality in patients with advanced liver fibrosis	Several small* to moderate† randomized controlled trials; data on clinical outcomes based on a retrospective cohort study with propensity score matching	Neutral metabolic effects	A meta-analysis suggests a small increase in overall mortality at high doses; might increase risk of bleeding, prostate cancer, heart failure, and hemorrhagic stroke	Caution in patients with high cardiovascular risk and those at high risk of bleeding
GLP-1 agonists‡	Improves hepatic steatosis and necroinflammation	Several small* to moderate† randomized controlled trials	Improves diabetic control, reduces major adverse cardiovascular events and weight	Nausea, vomiting, dyspepsia, diarrhea, and constipation	Discontinue GLP-1 agonists immediately in case of acute pancreatitis; might cause acute kidney injury rarely; semaglutide might increase diabetic retinopathy complications
SGLT2 inhibitors§	Improves hepatic steatosis, necroinflammation, and liver enzymes	Several small* randomized controlled trials with noninvasive tests; two small* uncontrolled paired liver biopsy studies	Improves diabetic control; modest weight reduction; might have renoprotective benefits; canagliflozin and empagliflozin reduce major adverse cardiovascular events	Genitourinary infection, acute kidney injury, and euglycemic diabetic ketoacidosis; might increase the risk of fractures and limb amputations	Contraindicated if estimated glomerular filtration rate is less than 45 mL/min per 1.73 m^2

*Small was defined as less than 50 participants in the active group.
†Moderate was defined as 50–100 participants in the active group.
‡For example, liraglutide and semaglutide.
§For example, canagliflozin, dapagliflozin, and empagliflozin.
From Powell EE, Wong VWS, Rinella M. Non-alcoholic fatty liver disease. *Lancet*. 2021;397:2212–2222.

dyslipidemia, and obstructive sleep apnea, and should be followed clinically at least annually. Counseling against use of alcohol should be provided, as well as minimization of other potentially hepatotoxic drugs, when medically feasible. Prior vaccination against hepatitis A and B should be verified.

There are no approved medical therapies for treatment of pediatric NAFLD. Thus the current management requires lifestyle modification, specifically diet and physical activity changes targeted at weight reduction. A key dietary change includes removal or reduction of sugar sweetened beverages because fructose can be taken up in an insulin-independent fashion and is a prime contributor to hepatic inflammation and steatosis.

Many studies have investigated therapeutic options for treatment of pediatric NAFLD. Vitamin E has been shown to improve balloon degeneration in a subset of children with NASH. Other potential therapeutic options being investigated include thiazolidinediones (pioglitazone), glucagon-like peptide 1 receptor agonists (GLP-1 agonists), and sodium-glucose cotransporter-2 inhibitors (SGLT2 inhibitors) as well as bariatric surgery for obesity (Table 408.5). Furthermore, emerging data on the role of the gut microbiome in the pathogenesis of NAFLD has positioned the gut flora as a suggested therapeutic target.

Visit Elsevier eBooks+ at eBooks.Health.Elsevier.com for Bibliography.

Chapter 409

Mitochondrial Hepatopathies

Sindhu Pandurangi and William F. Balistreri

A wide variety of mitochondrial disorders are associated with liver disease. Hepatocytes contain a high density of mitochondria because the liver, with its biosynthetic and detoxifying functions, is highly dependent on adenosine triphosphate. Defects in mitochondrial function can lead to impaired oxidative phosphorylation, increased generation of reactive oxygen species, impairment of other metabolic pathways, and activation of mechanisms of cellular death.

Mitochondrial disorders can be divided into primary, in which the mitochondrial defect is the primary cause of the disorder, and secondary, in which mitochondrial function is affected by exogenous injury or a genetic variant that affects nonmitochondrial proteins (see Chapter 107.4). Primary mitochondrial disorders can be caused by pathogenic variants affecting mitochondrial DNA (mtDNA) or by nuclear genes that encode mitochondrial proteins or cofactors (Table 409.1; see also Chapter 404). Specific patterns may be noted (Table 409.2). Secondary mitochondrial disorders include diseases with an uncertain etiology, such as Reye syndrome; disorders caused by endogenous or exogenous toxins, drugs, or metals; and other conditions in which mitochondrial oxidative injury may be involved in the pathogenesis of liver injury.

EPIDEMIOLOGY

Mitochondrial respiratory chain disorders of all types affect 1 in 20,000 children younger than 16 years of age; liver involvement has been reported in 10–20% of patients with respiratory chain defect. Primary mitochondrial disorders, including mtDNA depletion syndromes (MDSs), occur in 1 in 5,000 live births and are a known cause of acute liver failure in children <2 years of age.

More than 200 pathogenic variants, deletions, insertions, and rearrangements that involve mtDNA and nuclear DNA and encodes mitochondrial proteins are identified. Mitochondrial genetics are unique because mitochondria can replicate, transcribe, and translate their mitochondrial-derived DNA independently. A typical hepatocyte contains approximately 1,000 copies of mtDNA. Oxidative phosphorylation (the process of adenosine triphosphate production) occurs in the

Table 409.2 Hepatic Phenotypes of Mitochondrial Cytopathies

- Infantile liver failure
- Neonatal cholestasis
- Pearson syndrome
- Alpers disease
- Chronic liver disease
- Drug-induced mitochondrial toxicity

From Wyllie R, Hyams JS, Kay M, eds. *Pediatric Gastrointestinal and Liver Disease*, 5th ed. Philadelphia: Elsevier, 2016: Box 71.2, p. 876.

Table 409.1 Genotypic Classification of Primary Mitochondrial Hepatopathies and Organ Involvement

GENE	RESPIRATORY CHAIN COMPLEX	HEPATIC HISTOLOGY	OTHER ORGANS INVOLVED	CLINICAL FEATURES
Deletion	Multiple (Pearson)	Steatosis, fibrosis	Kidney, heart, CNS, muscle	Sideroblastic anemia, variable thrombocytopenia and neutropenia, persistent diarrhea
MPV17	I, III, IV	Steatosis	CNS, muscle, gastrointestinal tract	Adult-onset multisystemic involvement: myopathy, ophthalmoplegia, severe constipation, parkinsonism
DGUOK	I, III, IV	Steatosis, fibrosis	Kidneys, CNS, muscle	Nystagmus, hypotonia, renal Fanconi syndrome, acidosis
MPV17	I, III, IV	Steatosis, fibrosis	CNS, PNS	Hypotonia
SUCLG1	I, III, IV	Steatosis	Kidneys, CNS, muscle	Myopathy, sensorineural hearing loss, respiratory failure
POLG1	I, III, IV	Steatosis, fibrosis	CNS, muscle	Liver failure preceded by neurologic symptoms, intractable seizures, ataxia, psychomotor regression
C10orf2/Twinkle	I, III, IV	Steatosis	CNS, muscle	Infantile-onset spinocerebellar ataxia, loss of skills
BCS1L	III (GRACILE)		CNS ±, muscle ±, kidneys	Fanconi-type renal tubulopathy
SCO1	IV	Steatosis, fibrosis	Muscle	
TRMU	I, III, IV	Steatosis, fibrosis		Infantile liver failure with subsequent recovery
EFG1	I, III, IV	Steatosis	CNS	Severe, rapidly progressive encephalopathy
EFTu	I, III, IV	Unknown	CNS	Severe lactic acidosis, rapidly fatal encephalopathy

CNS, Central nervous system; *GRACILE*, growth restriction, aminoaciduria, cholestasis, iron overload, lactic acidosis, and early death; *PNS*, peripheral nervous system.
From Lee WS, Sokol RJ. Mitochondrial hepatopathies: advances in genetics, therapeutic approaches, and outcomes. *J Pediatr*. 2013;163:942–948. Table 2.

respiratory chain located in the inner mitochondrial membrane and is divided into five multienzyme complexes: reduced nicotinamide adenine dinucleotide coenzyme Q reductase (complex I), succinate–coenzyme Q reductase (complex II), reduced coenzyme Q–cytochrome-*c* reductase (complex III), cytochrome-*c* oxidase (complex IV), and adenosine triphosphate synthase (complex V). The respiratory chain peptide components are encoded by both nuclear and mtDNA genes; thus pathogenic variants in either genome can result in disorders of oxidative phosphorylation. Thirteen essential polypeptides are synthesized from the small 16.5-kilobase circular double-stranded mtDNA. mtDNA also encodes the 24 transfer RNAs required for intramitochondrial protein synthesis, whereas nuclear genes encode more than 70 respiratory chain subunits and an array of enzymes and cofactors required to maintain mtDNA, including DNA polymerase-γ (POLG), thymidine kinase 2, and deoxyguanosine kinase.

The expression of mitochondrial disorders is complex, and epidemiologic studies are hampered by technical difficulties in collecting and processing the tissue specimens needed to make accurate diagnoses, the variability in clinical presentation, and the fact that most disorders display maternal inheritance with variable penetrance (see Chapter 97). mtDNA undergoes pathogenic variant generation 10 times more often than nuclear DNA because of a lack of introns, protective histones, and an effective repair system in mitochondria. Mitochondrial genetics also displays a threshold effect in that the type and severity of pathogenic variants required for clinical expression varies among people and organ systems; this is explained by the concept of heteroplasmy, in which cells and tissues harbor both normal and pathologic variant mtDNA in various amounts because of random partitioning during cell division. Pathogenic variants, deletions, or duplications in either mitochondrial or nuclear genes can cause disease, and variants in nuclear genes that control mtDNA replication, transcription, and translation may lead to **MDS** or to a translational disorder.

CLINICAL MANIFESTATIONS

Defects in oxidative phosphorylation can affect any tissue to a variable degree, with the most energy-dependent organs being the most vulnerable. *One should consider the diagnosis of a mitochondrial disorder in a patient of any age who presents with progressive, multisystem involvement that cannot be explained by a specific diagnosis.* Certain mitochondrial disorders have characteristic gastrointestinal presentations, including vomiting, diarrhea, constipation, failure to thrive, and abdominal pain. Pearson marrow-pancreas syndrome manifests with sideroblastic anemia and exocrine pancreatic insufficiency, whereas mitochondrial neurogastrointestinal encephalomyopathy manifests with chronic intestinal pseudoobstruction and cachexia. Hepatic presentations range from chronic cholestasis, hepatomegaly, cirrhosis, and steatosis to fulminant hepatic failure and death. Patients with certain mitochondrial diseases may have normal or minimally elevated lactate levels even in the setting of a metabolic crisis. The lactate-to-pyruvate molar ratio (L:P) has been proposed as a screening test for mitochondrial disorders because it reflects the equilibrium between the product and substrate of the reaction catalyzed by lactase dehydrogenase. An L:P ≥ 25 has been considered to be highly suggestive of respiratory chain dysfunction; however, an elevated lactate or an elevated L:P can also represent secondary mitochondrial dysfunction occurring as a result of severe liver disease.

PRIMARY MITOCHONDRIAL HEPATOPATHIES

Neonatal Liver Failure

A common presentation of respiratory chain defects is severe liver failure manifested as jaundice, hypoglycemia, coagulopathy, renal dysfunction, and hyperammonemia, with onset within the first few weeks to months of life. **Cytochrome-*c* oxidase** (complex IV) is the most common deficiency in these infants, although complexes I and III and MDSs are also implicated (see Tables 409.1 and Chapter 404). The key biochemical features include a markedly elevated plasma lactate concentration, an elevated molar ratio of plasma lactate to pyruvate (L:P) (>25), and a raised ratio of β-hydroxybutyrate to acetoacetate (>4.0). Symptoms are nonspecific and include lethargy and vomiting. Most patients additionally have neurologic involvement that manifests as a weak suck, recurrent apnea, or myoclonic epilepsy. Liver biopsy shows predominantly microvesicular steatosis, cholestasis, bile duct proliferation, glycogen depletion, and iron overload. With standard therapy, the prognosis is poor, and most patients die from liver failure or infection in the first few months of life.

Alpers Syndrome (Alpers-Huttenlocher Syndrome or Alpers Hepatopathic Poliodystrophy)

Diagnostic criteria include refractory mixed-type seizures with a focal component; psychomotor regression that is episodic and triggered by intercurrent infections; and hepatopathy with or without acute liver failure. Alpers syndrome manifests from infancy up to 8 years of age with seizures, hypotonia, feeding difficulties, psychomotor regression, and ataxia. Patients develop hepatomegaly and jaundice and have a slower progression to liver failure than those with cytochrome-*c* oxidase deficiency. Elevated blood or cerebrospinal fluid lactate and pyruvate levels are supportive of the diagnosis, in addition to characteristic electroencephalographic findings (high-amplitude slow activity with polyspikes), asymmetric abnormal visual evoked responses, and low-density areas or atrophy in the occipital or temporal lobes on computed tomography scanning of the brain. In some patients, complex I deficiency has been found in liver or muscle mitochondria. The disease is inherited in an autosomal recessive fashion; pathogenic variants in the catalytic subunit of the nuclear gene mtDNA *POLG* have been identified in multiple families with Alpers syndrome, leading to the advent of molecular diagnosis for Alpers syndrome. Patients with *POLG* pathogenic variants are susceptible to *valproate-induced* liver dysfunction.

Mitochondrial DNA Depletion Syndrome

MDS is characterized by a tissue-specific reduction in mtDNA copy number, leading to deficiencies in complexes I, III, and IV. MDS manifests with phenotypic heterogeneity; multisystem and localized disease forms include myopathic, hepatocerebral, and liver-restricted presentations. Infants with the hepatocerebral form present in the neonatal period. The first symptoms are metabolic; these rapidly progress to hepatic failure with hypoglycemia and vomiting. This stage is followed by neurologic involvement affecting the central and peripheral systems. Laboratory studies are characterized by lactic acidosis, hypoglycemia, and markedly elevated α-fetoprotein in plasma. In some patients, iron overload has been found with elevated transferrin saturation, high ferritin levels, and iron accumulation in hepatocytes and Kupffer cells. Death usually occurs by 1 year of age. Spontaneous recovery has been reported in a patient with liver-restricted disease. Inheritance is autosomal recessive and pathogenic variants in the nuclear deoxyguanosine kinase gene *(DGUOK)* have been identified in many patients with hepatocerebral MDS. Thymidine kinase 2 has been implicated in the myopathic form; no known genetic defect has been identified in liver-restricted MDS. Multiple other nuclear genes including *POLG, MPV17,* Twinkle helicase gene, and *SUCLG1* have been implicated in hepatocerebral MDS. Greater than 100 affected individuals with *MPV17* MDS have been identified, most with early-onset hepatic and neurologic manifestations, although rare late-onset neuromyopathic phenotypes have also been identified.

Liver biopsies of patients with MDS show microvesicular steatosis, cholestasis, focal cytoplasmic biliary necrosis, and cytosiderosis in hepatocytes and sinusoidal cells. Ultrastructural changes are characteristic, with oncocytic transformation of mitochondria, which is characterized by mitochondria with sparse cristae, granular matrix, and dense or vesicular inclusions. If the native DNA-encoded complex II is normal and the activities of the other complexes are decreased, one should investigate mtDNA copy numbers for an MDS. Diagnosis is established by the demonstration of a low ratio of mtDNA (<10%) to nuclear DNA in affected tissues and/or genetic testing. Importantly, the sequence of the mitochondrial genome is normal.

Navajo Neurohepatopathy

Navajo neurohepatopathy (NNH) is an autosomal recessive sensorimotor neuropathy with progressive liver disease found only in Navajo

people of the southwestern United States. The incidence is 1 in 1,600 live births. Diagnostic criteria include sensory neuropathy, motor neuropathy, corneal anesthesia, and liver disease. Metabolic or infectious complications include failure to thrive, short stature, delayed puberty, or systemic infection. Affected individuals have evidence of central nervous system demyelination on radiographic imaging and peripheral nerves biopsies. An *MPV17* gene variant is implicated in the pathogenesis of NNH. Interestingly, this is the same gene implicated in MDS (see earlier), demonstrating that NNH may be a specific type of MDS found only in Navajos. NNH is divided into three phenotypic variations based on age of presentation and clinical findings.

Classic NNH appears in infancy with severe progressive neurologic deterioration manifesting clinically as weakness, hypotonia, loss of sensation with accompanying acral mutilation, corneal ulcerations, and poor growth. Liver disease, present in the majority of patients, is secondary and variable; it includes asymptomatic elevations of liver function tests, Reye syndrome–like episodes, and hepatocellular carcinoma or cirrhosis. γ-Glutamyl transpeptidase levels tend to be higher than in other forms of NNH. Liver biopsy might show chronic portal tract inflammation and cirrhosis but shows less cholestasis, hepatocyte ballooning, and giant cell transformation than in other forms of NNH.

Infantile NNH manifests between the ages of 1 and 6 months with jaundice and failure to thrive and progresses to liver failure and death by 2 years of age. Patients have hepatomegaly with moderate elevations in aspartate aminotransferase, alanine aminotransferase, and γ-glutamyl transpeptidase. Liver biopsy demonstrates pseudoacinar formation, multinucleate giant cells, portal and lobular inflammation, canalicular cholestasis, and microvesicular steatosis. Progressive neurologic symptoms are not usually noticed at presentation but develop later.

Childhood NNH manifests from age 1-5 years with the acute onset of fulminant hepatic failure leading to death within months. Most patients also have evidence of neuropathy at presentation. Liver biopsies are similar to those in infantile NNH, except for significant hepatocyte ballooning and necrosis, bile duct proliferation, and cirrhosis, which are also seen.

There is no effective treatment for any of the forms of NNH, and neurologic symptoms often preclude liver transplantation. The identical *MPV17* pathogenic variant is seen in patients with both the infantile and classic forms of NNH, highlighting the clinical heterogeneity of NNH.

Pearson Syndrome

Pearson marrow-pancreas syndrome has a neonatal-onset with severe macrocytic anemia, variable neutropenia and thrombocytopenia, and ringed sideroblasts in the bone marrow. Diarrhea and fat malabsorption develop in early childhood secondary to extensive pancreatic fibrosis, acinar atrophy, and partial villous atrophy of the small intestine. The liver involvement includes hepatomegaly, steatosis, and cirrhosis. Liver failure and death have been reported before the age of 4 years. Other features of the syndrome include renal tubular disease, photosensitivity, diabetes mellitus, hydrops fetalis, and the late development of visual impairment, tremor, ataxia, proximal muscle weakness, external ophthalmoplegia, and a pigmentary retinopathy. Methylglutaconic aciduria is a useful diagnostic marker. Large deletions of mtDNA are reported in most patients, resulting in deficiency of complexes I and III. mtDNA deletions can be detected in patients' cultured fibroblasts as well as in peripheral blood lymphocytes.

Villous Atrophy Syndrome

Children with this disease present with severe anorexia, vomiting, chronic diarrhea, and villous atrophy in the first year of life. Hepatic involvement includes mild elevation of aminotransferase levels, hepatomegaly, and steatosis. Lactic acidosis is worsened with high-dextrose intravenous infusions or enteral nutrition. Diarrhea improves by 5 years of age in association with the normalization of intestinal biopsies. Subsequently, patients develop retinitis pigmentosa, cerebellar ataxia, sensorineural deafness, and proximal muscle weakness, with eventual death late in the first decade of life. The disease is attributed to a mtDNA rearrangement defect. A complex III deficiency was found in the muscle of affected patients.

GRACILE Syndrome

The acronym GRACILE summarizes the most important clinical features, namely fetal growth restriction (birthweight about −4 SD), aminoaciduria (caused by Fanconi-type tubulopathy), cholestasis (with steatosis and cirrhosis), iron overload, severe lactic acidosis, and early death. The syndrome is associated with pathogenic variants of the complex III assembly factor BCS1L. The liver histology shows microvesicular steatosis and cholestasis with abundant iron accumulation in hepatocytes and Kupffer cells. The liver iron content decreases slightly with age, concomitantly with increasing fibrosis and cirrhosis. Abnormal aminotransferase levels and coagulation are noted, but the cause of death seems to be related more to energy depletion than to liver failure. About half of these patients die within the first 2 weeks of life.

Pathogenic Variants in Nuclear Translation and Elongation Factor Genes

Pathogenic variants in nuclear translation factor genes *(TRMU)* of the respiratory chain enzyme complexes have been identified as the etiology of acute liver failure manifesting at ages 1 day to 6 months. The respiratory chain deficit was similar to that seen in MDS, where the activity of the native DNA-encoded complex II was normal whereas complexes I, III, and IV were decreased. The elongation factor EFG1 (gene *GFM1*) variant was associated with fetal growth restriction, lactic acidosis, and liver dysfunction that progresses into liver failure and death. The variant in the elongation factor EFTu manifests as severe lactic acidosis and lethal encephalopathy with mild hepatic involvement.

Secondary Mitochondrial Hepatopathies

Secondary mitochondrial hepatopathies are caused by exposure to a hepatotoxic metal, drug, toxin, or endogenous metabolite. In the past, the most common secondary mitochondrial hepatopathy was *Reye syndrome*, the prevalence of which peaked in the 1970s and had a mortality rate of >40%. Although mortality has not changed, the prevalence has decreased from >500 cases in 1980 to fewer than four cases annually since 1994. The decline in the reported incidence of Reye syndrome may be partially related to more accurate modern diagnosis of infectious, genetic, metabolic, or toxic disease, thus reducing the percentage of idiopathic or true cases of Reye syndrome. Reye syndrome is precipitated in a genetically susceptible person by the interaction of a viral infection (influenza, varicella) and salicylate and/or antiemetic use. Clinically it is characterized by a preceding viral illness that appears to be resolving and the acute onset of vomiting and encephalopathy (Table 409.3). Neurologic symptoms can rapidly progress to seizures, coma, and death. Liver dysfunction is invariably present when vomiting develops, with coagulopathy and elevated serum levels of aspartate aminotransferase, alanine aminotransferase, and ammonia. Importantly, patients remain anicteric and serum bilirubin levels are normal. Liver biopsies show microvesicular steatosis without evidence of liver inflammation or necrosis. Death is usually secondary to increased intracranial pressure and cerebral herniation. Patients who survive

Table 409.3 Clinical Staging of Reye Syndrome and Reye-Like Diseases

Symptoms at the time of admission:

I. Usually quiet, **lethargic,** and sleepy, vomiting, laboratory evidence of liver dysfunction
II. Deep lethargy, **confusion,** delirium, combativeness, hyperventilation, hyperreflexia
III. Obtunded, **light coma** ± seizures, **decorticate** rigidity, intact pupillary light reaction
IV. Seizures, deepening coma, **decerebrate rigidity,** loss of oculocephalic reflexes, fixed pupils
V. Coma, loss of deep tendon reflexes, respiratory arrest, fixed dilated pupils, **flaccidity/decerebration** (intermittent); isoelectric electroencephalogram

Table 409.4 Diseases That Present a Clinical or Pathologic Picture Resembling Reye Syndrome

- Metabolic disease
  - Organic aciduria
  - Disorders of oxidative phosphorylation
  - Urea cycle defects (carbamoyl phosphate synthetase, ornithine transcarbamylase)
  - Defects in fatty acid oxidation metabolism
  - Acyl–coenzyme A dehydrogenase deficiencies
  - Systemic carnitine deficiency
  - Hepatic carnitine palmitoyltransferase deficiency
  - 3-OH, 3-methylglutaryl-coenzyme A lyase deficiency
  - Fructosemia
  - Infantile liver failure syndrome 1. Caused by leucyl-tRNA synthetase (LARS) gene variants
- Central nervous system infections or intoxications (meningitis), encephalitis, toxic encephalopathy
- Hemorrhagic shock with encephalopathy
- Drug or toxin ingestion (salicylate, valproate)

have full recovery of liver function but should be carefully screened for fatty-acid oxidation and fatty-acid transport defects (Table 409.4).

Acquired abnormalities of mitochondrial function can be caused by several drugs and toxins, including valproic acid, cyanide, amiodarone, chloramphenicol, iron, the emetic toxin of *Bacillus cereus*, and nucleoside analogs. Valproic acid is a branched fatty acid that can be metabolized into the mitochondrial toxin 4-envalproic acid. Children with underlying respiratory chain defects appear more sensitive to the toxic effects of this drug, and valproic acid is reported to precipitate liver failure in patients with **Alpers syndrome** and **cytochrome-*c* oxidase deficiency.** Nucleoside analogs directly inhibit mitochondrial respiratory chain complexes. The reverse transcriptase inhibitors zidovudine, didanosine, stavudine, and zalcitabine—used to treat patients infected with HIV—inhibit DNA POLG of mitochondria and can block elongation of mtDNA, leading to mtDNA depletion. Other conditions that can lead to mitochondrial oxidative stress include cholestasis, nonalcoholic steatohepatitis, α_1-antitrypsin deficiency, and Wilson disease.

DIAGNOSTIC EVALUATION

Screening tests include common biochemical tests (comprehensive metabolic profile, INR, α-fetoprotein, CPK, phosphorus, complete blood cell count, ammonia, lactate, pyruvate, serum ketone bodies: both quantitative 3-hydroxybutyrate and quantitative acetoacetate, total free fatty acids, serum acylcarnitine profile; serum-free and total carnitines, urine organic acids, and serum amino acids) (Table 409.5). These results will guide subsequent confirmatory testing to establish a molecular diagnosis. Genotyping, including single gene or panel screening for common mitochondrial disease, is used in clinical practice. Whole exome or genome sequencing is also helpful and is replacing single gene or gene panel testing. However, the identification of multiple gene variants of uncertain significance will require detailed clinical and biochemical confirmation for interpretation. Tissue (liver biopsy, skin fibroblast, and muscle biopsy) may be needed to make a specific biochemical diagnosis.

TREATMENT OF MITOCHONDRIAL HEPATOPATHIES

There is no effective therapy for most patients with mitochondrial hepatopathies; neurologic involvement often precludes orthotopic liver transplantation. Patients with mitochondrial disorders remain at risk for transplant-related worsening of their underlying metabolic disease, especially patients with *POLG*-related disease. Children who receive liver transplants for *DGUOK* MDS have decreased rates of survival post-transplant than those who are transplanted for other diseases. Liver transplantation for *MPV17*- related mtDNA depletion syndrome is associated with poor post-transplant outcomes because of multiorgan failure and sepsis. Several therapeutic drug combinations—including antioxidants, vitamins, cofactors, and electron acceptors—have been proposed, but no randomized controlled trials have been completed to evaluate them.

Treatment strategies are supportive and include the infusion of sodium bicarbonate for acute metabolic acidosis, transfusions for anemia and thrombocytopenia, and exogenous pancreatic enzymes for pancreatic insufficiency. It is important to discontinue or avoid medications that may exacerbate hepatopathy, including sodium valproate, tetracycline, and macrolide antibiotics, azathioprine, chloramphenicol, quinolones, and linezolid. Ringer lactate should be avoided because patients with liver dysfunction may not be able to metabolize lactate. Propofol should be avoided during anesthesia because of potential interference with mitochondrial function. In patients with lactic acidosis, lactate levels should be monitored during procedures. It is important to maintain anabolism using a balanced intake of fat and carbohydrates while avoiding unbalanced intakes (e.g., glucose only at a high intravenous rate) or fasting for >12 hours.

Table 409.5 Tiered Investigations in Suspected Mitochondrial Liver Disease

TIER 1
Pre-/postprandial plasma lactate, glucose, FFA, and 3-OH
Plasma carnitine, acylcarnitines
Plasma amino acids, creatine kinase, thymidine
Urinary organic acids, amino acids, tubular resorption phosphate, albumin/creatinine ratio CSF lactate/protein (if feasible)
Electrocardiography and echocardiography
Electroencephalography and visual-evoked potentials
Pathogenic variants in *POLG, DGUOK, MPV17*, and *TRMU*
TIER 2
Tissue analysis
Liver biopsy: (if feasible). Tissue for light microscopy, electron microscopy, and Oil Red O stain
Frozen tissue for respiratory chain enzyme activity analysis and mtDNA copy number
Muscle biopsy: Tissue for light microscopy, electron microscopy, Oil Red O stain, and histochemistry for respiratory chain complexes
Frozen tissue for respiratory chain enzyme activity analysis and mtDNA copy number
Skin biopsy: Set up for fibroblast culture
TIER 3
Cranial MRI/MRS
TIER 4
Extended molecular screening. This will be guided by the clinical phenotype, results of the tissue analysis, and local facilities.
Currently suggested genes should include *SUCLG1, BCS1L, SOC1, TFSM, TWINKLE, ACAD9, EARS2, GFM1, RRM2B, TK2*, and *SUCLA2.*

FFA, Free fatty acid; CSF, cerebrospinal fluid; MRS, magnetic resonance spectroscopy. From Wyllie R, Hyams JS, Kay M, eds. *Pediatric Gastrointestinal and Liver Disease*, 5th ed. Philadelphia: Elsevier, 2016: Box 71-3, p. 876.

Visit Elsevier eBooks+ at eBooks.Health.Elsevier.com for Bibliography.

Chapter 410

Autoimmune Hepatitis

Amy G. Feldman and Frederick J. Suchy

Autoimmune hepatitis (AIH) is an immune-mediated liver disease manifested by elevated serum aminotransaminase concentrations, liver-associated serum autoantibodies, and/or hypergammaglobulinemia. The serologic autoantibody profile defines two main types of autoimmune hepatitis: **AIH type 1**, with positivity for antinuclear antibodies (ANA) and/or anti–smooth muscle antibody (SMA) and **AIH type 2**, with positivity for anti–liver kidney microsomal type 1 antibody (anti-LKM-1). The targets of the inflammatory process can include hepatocytes and, to a lesser extent, bile duct epithelium. Autoimmune hepatitis typically refers to a primarily hepatocyte-specific process, whereas **autoimmune cholangiopathy** and **sclerosing cholangitis** predominately involve intrahepatic and extrahepatic bile duct injury. **Overlap** of the process involving both hepatocyte and bile duct–directed injury may be more common in children. Chronicity is determined either by duration of liver disease (typically >3-6 months), by evidence of chronic hepatic decompensation (hypoalbuminemia, thrombocytopenia) or physical stigmata of chronic liver disease (clubbing, spider telangiectasia, splenomegaly, ascites). The severity is variable; the affected child might have only biochemical evidence of liver dysfunction, might have stigmata of chronic liver disease, or can present in hepatic failure. De novo hepatitis can be seen in a subset of liver transplant recipients whose initial disease was not autoimmune.

ETIOLOGY

Autoimmune hepatitis arises in a genetically predisposed host after an unknown trigger leads to a T cell–mediated immune response targeting liver autoantigens. A dense portal mononuclear cell infiltrate invades the surrounding parenchyma and comprises T and B lymphocytes, macrophages, and plasma cells. The immunopathogenic mechanisms underlying autoimmune hepatitis are unsettled. Triggering factors can include molecular mimicry, infections, drugs, and the environment (toxins) in a genetically susceptible host. Several human leukocyte antigen class II molecules—particularly DR3, DR4, and DR7 isoforms—confer susceptibility to autoimmune hepatitis. Self-antigenic peptides are processed by populations of antigen-presenting cells and presented to CD4 and CD8 effector T cells. $CD4^+$ T lymphocytes recognizing a self-antigenic liver peptide orchestrate liver injury. Cell-mediated injury by cytokines released by $CD8^+$ cytotoxic T cells and/or antibody-mediated cytotoxicity can be operative. There is also evidence that regulatory T cells from patients with autoimmune hepatitis are impaired in their ability to control the proliferation of CD4 and CD8 effector cells. Cytochrome P450 2D6 is the main autoantigen in type 2 autoimmune hepatitis.

Antibody-coated hepatocytes may be lysed by complement or Fc-bearing natural killer lymphocytes. Heterozygous pathogenic variants in the autoimmune regulator gene *(AIRE),* which encodes a transcription factor controlling the negative selection of autoreactive thymocytes, can be found in some children with autoimmune hepatitis types 1 and 2. *AIRE* variants also cause **autoimmune polyendocrinopathy-candidiasis-ectodermal dystrophy** (also called *autoimmune polyendocrinopathy syndrome*), in which autoimmune hepatitis occurs in approximately 20% of patients.

PATHOLOGY

The histologic features common to untreated cases include inflammatory infiltrates, consisting of lymphocytes and plasma cells that expand portal areas and often penetrate the lobule (interface hepatitis); moderate to severe piecemeal necrosis of hepatocytes extending outward from the limiting plate; variable necrosis, fibrosis, and zones of parenchymal collapse spanning neighboring portal triads or between a portal triad and central vein (bridging necrosis); and variable degrees of bile duct epithelial injury. Distortion of hepatic architecture can be severe; cirrhosis may be present in over a third of children at the time of diagnosis. Histologic features in acute liver failure may be obscured by massive necrosis and multilobular collapse. Other histologic features may suggest an alternative diagnosis; characteristic periodic acid–Schiff-positive, diastase-resistant granules are seen in α_1-antitrypsin deficiency, and macrovesicular and microvesicular steatosis is found in nonalcoholic steatohepatitis and often in Wilson disease. Bile duct injury can suggest an autoimmune cholangiopathy or an overlap syndrome. Ultrastructural analysis might suggest distinct types of storage disorders.

CLINICAL MANIFESTATIONS

The clinical features and course of autoimmune hepatitis are extremely variable. Signs and symptoms at the time of presentation comprise a wide spectrum of disease including a substantial number of asymptomatic patients and some who have an acute, even fulminant, onset. In 25–30% of patients with autoimmune hepatitis, particularly children, the illness mimics acute viral hepatitis. *In most, the onset is insidious*. Patients can be asymptomatic or have fatigue, malaise, behavioral changes, anorexia, and amenorrhea, sometimes for many months before jaundice or stigmata of chronic liver disease are recognized. **Extrahepatic manifestations** can include arthritis, vasculitis, nephritis, thyroiditis, Coombs-positive anemia, and rash (vitiligo, Sweet syndrome, pyoderma gangrenosum, erythema nodosum). Some patients' initial clinical features reflect cirrhosis (ascites, hypersplenism, bleeding esophageal varices, or hepatic encephalopathy). There may be mild to moderate jaundice in severe cases. Spider telangiectasias and palmar erythema may be present. The liver may be tender and slightly enlarged but might not be felt in patients with cirrhosis. The spleen is commonly enlarged. Edema and ascites may be present in advanced cases.

LABORATORY FINDINGS

The findings are related to the severity of presentation. In many asymptomatic cases, serum aminotransferase ranges between 100 and 300 IU/L, whereas levels in excess of 1,000 IU/L can be seen in young symptomatic patients. Serum bilirubin concentrations may be normal in mild cases but are commonly 2-10 mg/dL in more severe cases. Serum alkaline phosphatase and γ-glutamyl transpeptidase activities are normal to slightly increased but may be more significantly elevated in autoimmune cholangiopathy or in the setting of overlap with sclerosing cholangitis. Serum γ-globulin levels can show marked polyclonal elevations. Hypoalbuminemia is common. The prothrombin time or international normalized ratio (INR) is prolonged, most often as a result of vitamin K deficiency but also as a reflection of impaired hepatocellular function. A normochromic normocytic anemia, leukopenia, and thrombocytopenia are present and become more severe with the development of portal hypertension and hypersplenism.

Most patients with autoimmune hepatitis have hypergammaglobulinemia. Serum immunoglobulin G levels usually exceed 16 g/L. Characteristic patterns of serum autoantibodies define distinct subgroups of autoimmune hepatitis (Table 410.1). The most common pattern (type 1) is associated with the formation of non–organ-specific antibodies, such as antiactin (smooth muscle) and ANA. Approximately 50% of these patients are 10-20 years of age. High titers of a liver-kidney microsomal antibody are detected in another form (type 2) that usually affects children 2-14 years of age. A subgroup of primarily young females might demonstrate autoantibodies against a soluble liver antigen but not against nuclear or microsomal proteins. Antineutrophil cytoplasmic antibodies may

Table 410.1 Classification of Autoimmune Hepatitis

VARIABLE	TYPE 1 AUTOIMMUNE HEPATITIS	TYPE 2 AUTOIMMUNE HEPATITIS
Characteristic autoantibodies	Antinuclear antibody*	Antibody against liver-kidney microsome type 1*
	Smooth-muscle antibody*	
	Antiactin antibody	Antibody against liver cytosol type 1*
	Autoantibodies against soluble liver antigen and liver-pancreas antigen‡	Antibody against liver-kidney microsome type 3
	Atypical perinuclear antineutrophil cytoplasmic antibody	
Geographic variation	Worldwide	Worldwide; rare in North America
Age at presentation	Any age	Predominantly early childhood
Sex of patients	Female in ~75% of cases	Female in ~95% of cases
Association with other autoimmune diseases	Common	Common§
Clinical severity	Broad range, variable	Generally severe
Histopathologic features at presentation	Broad range, mild disease to cirrhosis	Generally advanced
Treatment failure	Infrequent	Frequent
Relapse after drug withdrawal	Variable	Common
Need for long-term maintenance	Variable	~100%

*The conventional method of detection is immunofluorescence.
‡This antibody is detected by enzyme-linked immunosorbent assay.
§Autoimmune polyendocrinopathy-candidiasis-ectodermal dystrophy is seen only in patients with type 2 disease.
Modified from Krawitt EL. Autoimmune hepatitis. *N Engl J Med.* 2006;354:54–66.

be seen more commonly in autoimmune cholangiopathy. Autoantibodies are rare in healthy children, so that titers as low as 1:40 may be significant, although nonspecific elevation in autoantibodies can be observed in a variety of liver diseases. Up to 20% of patients with apparent autoimmune hepatitis might not have autoantibodies at presentation but have histologic features and clinical course consistent with the disorder. Other, less common autoantibodies include rheumatoid factor, antiparietal cell antibodies, atypical p-ANCA, antithyroid antibodies, and anti–liver cytosol type 1 antibody (anti-LC-1).

DIAGNOSIS

The diagnosis of autoimmune hepatitis is based on clinical, biochemical, immunologic, and histologic features and the exclusion of other known causes of liver disease. Diagnostic criteria with scoring systems have been developed for adults and modified slightly for children, although these scoring systems were developed as research rather than diagnostic tools and lack validation by prospective studies and lack accuracy in the setting of concurrent sclerosing cholangitis, nonalcoholic fatty liver disease, or fulminant liver failure. Autoimmune hepatitis should be considered in all children presenting with elevated liver function tests and/or signs of chronic liver disease, including children who are asymptomatic, in liver failure, or who have autoantibody-negative hepatitis. Important positive features include primary elevation in transaminases and not alkaline phosphatase (or GGT), elevated γ-globulin levels, the presence of autoantibodies (most commonly antinuclear, smooth muscle, or liver-kidney microsome), and characteristic histologic findings (Fig. 410.1). Other causes of acute hepatitis and chronic liver disease must be excluded including infection (Epstein-Barr virus [EBV], hepatitis A [Hep A], B, C, D), drug or toxin exposure, α_1-antitrypsin deficiency (see Chapter 405) and Wilson disease (see Chapter 405.2) (Table 410.2). To exclude these processes viral

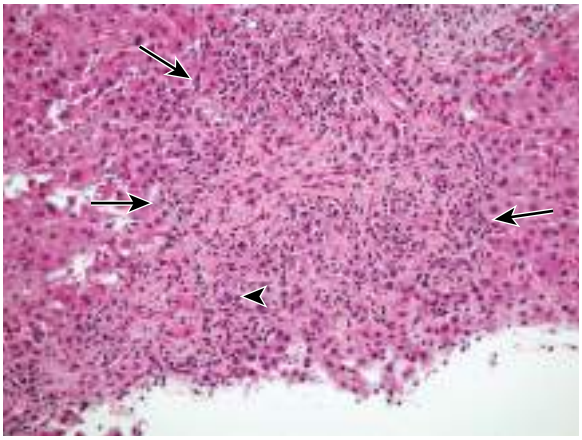

Fig. 410.1 Autoimmune hepatitis. Liver biopsy showing fibrous expansion of the portal tracts with moderate portal lymphocytic infiltrates rich in plasma cells *(arrowhead)*. There is extensive interface hepatitis *(arrows)*. Original magnification ×20. *(Courtesy Dr Margret Magid, Mount Sinai School of Medicine.)*

titers (Hep A IgM, Hep B surface Ag, Hep C Ab), α_1-antitrypsin level/phenotype and serum ceruloplasmin should be obtained. Magnetic resonance (MR) cholangiography may be very useful for screening for evidence of sclerosing cholangitis. An **overlap syndrome** with features of primary sclerosing cholangitis and autoimmune hepatitis is being increasingly recognized with wider application of MR cholangiography. Ultimately, liver biopsy is necessary to confirm compatible histologic features as well as to look for features of small duct primary sclerosing cholangitis.

Table 410.2 Disorders Producing Chronic Hepatitis

- Chronic viral hepatitis
  - Hepatitis B
  - Hepatitis C
  - Hepatitis D
- Autoimmune hepatitis
  - Anti–actin antibody-positive
  - Anti-nuclear antibody
  - Anti–liver-kidney microsomal antibody-positive
  - Anti–soluble liver antigen antibody-positive
  - Others (includes antibodies to liver-specific lipoproteins or asialoglycoprotein)
  - Overlap syndrome with sclerosing cholangitis and autoantibodies
  - Systemic lupus erythematosus
  - Celiac disease
- Drug-induced hepatitis
- Metabolic disorders associated with chronic liver disease
  - Wilson disease
  - Nonalcoholic steatohepatitis
  - α_1-Antitrypsin deficiency
  - Tyrosinemia
  - Niemann-Pick disease type 2
  - Glycogen storage disease type IV
  - Cystic fibrosis
  - Galactosemia
  - Bile acid biosynthetic abnormalities

TREATMENT

Prednisone, with or without azathioprine, improves the clinical, biochemical, and histologic features in most patients with autoimmune hepatitis and prolongs survival in most patients with severe disease. The goal is to suppress or eliminate hepatic inflammation with minimal side effects. Prednisone at an initial dose of 1-2 mg/kg/24 hr is continued until aminotransferase values return to normal. Budesonide (9 mg/daily) can be used instead of prednisone for children who do not have cirrhosis or severe acute autoimmune hepatitis. In some centers, azathioprine (1.5-2.0 mg/kg/24 hr, up to 100 mg/24 hr) is started at the same time as glucocorticoids, whereas other centers prefer to wait ~2 weeks before starting azathioprine to confirm steroid responsiveness and allow improvement in liver function. Measurement of thiopurine methyltransferase activity should be performed at some point in the beginning of therapy as patients with low activity (10% prevalence) or absent activity (prevalence 0.3%) are at risk for developing severe drug-induced myelotoxicity from accumulation of the unmetabolized drug. Once liver function tests normalize and biochemical remission is achieved the prednisone or budesonide dose should then be lowered (in 5-mg decrements for prednisone and 3-mg decrements for budesonide) over several months. Liver function tests should be monitored every 1-2 weeks while tapering steroids to ensure the child stays in biochemical remission. Once tapered off steroids, liver function tests should be monitored every 3-4 months to ensure the child stays in biochemical remission. Cyclosporine, tacrolimus, and mycophenolate mofetil can be trialed as *second-line agents* for cases refractory to standard therapy. Use of these agents should be reserved for practitioners with extensive experience in their administration because the agents have a more restricted therapeutic to toxic ratio.

If the child has sustained normal serum levels of aminotransferases, negative autoantibodies and normal IgG levels for at least 2 years after steroids have been withdrawn, a follow-up liver biopsy can be performed and if there is no evidence of ongoing inflammation, then gradual withdrawal of azathioprine can be attempted. However, there is a high rate of relapse after discontinuation of therapy and many children with autoimmune hepatitis require lifelong azathioprine.

Patients with primary sclerosing cholangitis/autoimmune hepatitis overlap syndrome respond similarly to immunosuppressive therapy. Prednisone, azathioprine and ursodeoxycholic acid (UDCA) (10 mg/kg/dose BID) are recommended for children with overlap syndrome.

PROGNOSIS

The initial response to therapy in autoimmune hepatitis is generally prompt, with a >75% rate of remission. Transaminases and bilirubin fall to near-normal levels, often in the first 1-3 months. When present, abnormalities in serum albumin and prothrombin time respond over a longer period (3-9 months). In patients meeting the criteria for tapering and then withdrawal of treatment (25–40% of children), 50% are weaned from all medication. However, long-term biochemical remission has been possible in only 20% of children with type 1 autoimmune hepatitis and rarely in children with type 2 autoimmune hepatitis. Relapse usually responds to retreatment. Many children will not meet the criteria for an attempt at discontinuation of immunosuppression and should be maintained on the smallest dose of prednisone or azathioprine that minimizes biochemical activity of the disease. A careful balance of the risks of continued immunosuppression and ongoing hepatitis must be continually evaluated. This requires frequent screening for complications of medical therapy (monitoring of linear growth velocity, ophthalmologic examination, bone density measurement, blood pressure monitoring). Intermittent flares of hepatitis can occur and can necessitate recycling of prednisone therapy.

Some children have a relatively steroid-resistant form of hepatitis. More extensive evaluations of the etiology of their hepatitis should be undertaken, directed particularly at reassessing for the presence of either sclerosing cholangitis or Wilson disease. Nonadherence to medical therapy is one of the most common causes of "resistance" to medical therapy. Progression to cirrhosis can occur in autoimmune hepatitis despite a good response to drug therapy and prolongation of life. Corticosteroid therapy in fulminant autoimmune disease may be useful, although it should be administered with caution, given the predisposition of these patients to systemic bacterial and fungal infections.

Liver transplantation has been successful in patients with end-stage or fulminant liver disease associated with autoimmune hepatitis (see Chapter 416). Disease recurs after transplantation in approximately 30% of patients and is associated with increased concentrations of serum autoantibodies and interface hepatitis on liver biopsy. Patients generally respond well to an increase in immunosuppression, particularly to the addition of azathioprine.

Visit Elsevier eBooks+ at eBooks.Health.Elsevier.com for Bibliography.

Chapter 411

Drug- and Toxin-Induced Liver Injury

Frederick J. Suchy and Amy G. Feldman

The liver is the main site of drug metabolism and is particularly susceptible to structural and functional injury after the ingestion, parenteral administration, or inhalation of chemical agents, drugs, plant derivatives (home remedies), herbal or nutritional supplements, or environmental toxins. The possibility of drug use or toxin exposure at home or in the parents' workplace should be explored for every child with liver dysfunction. Host factors related to hepatotoxicity include age, genetic predisposition, nutritional status, concomitant medications, and underlying diseases. The clinical spectrum of illness can vary from asymptomatic biochemical abnormalities of liver function to fulminant failure (Table 411.1). Liver injury may be the only clinical feature of an adverse drug reaction or may be accompanied by systemic manifestations and damage to other organs. In hospitalized patients, clinical and laboratory findings may be confused with the underlying illness. After acetaminophen, antimicrobials, supplements, and central nervous system agents are the most commonly implicated drug classes causing liver injury in children.

There is growing concern about environmental hepatotoxins that are insidious in their effects. Many environmental toxins—including the plasticizers, biphenyl A, and the phthalates—are ligands for nuclear receptors that transcriptionally activate the promoters of many genes involved in xenobiotic and lipid metabolism and may contribute to obesity and **nonalcoholic fatty liver disease**. Some herbal, weight loss, and body building supplements have been associated with hepatic injury or even liver failure (Table 411.2) related to their intrinsic toxicity or because of contamination with fungal toxins, pesticides, or heavy metals.

Hepatic metabolism of drugs and toxins is mediated by a sequence of enzymatic reactions that in large part transform hydrophobic, less-soluble molecules into more nontoxic, hydrophilic compounds that can be readily excreted in urine or bile (see Chapter 94). Relative liver size, liver blood flow, and extent of protein binding also influence drug metabolism. Phase 1 of the process involves enzymatic activation of the substrate to reactive intermediates containing a carboxyl, phenol, epoxide, or hydroxyl group. Mixed-function monooxygenase, cytochrome-*c* reductase, various hydrolases, and the cytochrome P450 (CYP) system are involved in this process. Nonspecific induction of these enzymatic pathways, which can occur during intercurrent viral infection, with starvation, and with the administration of certain drugs such as anticonvulsants, can alter drug metabolism and increase the potential for hepatotoxicity. A single agent can be metabolized by more than one biochemical reaction. The reactive intermediates that are potentially damaging to the cell are enzymatically conjugated in phase 2 reactions with glucuronic acid, sulfate, acetate, glycine, or glutathione. Some drugs may be directly metabolized by these conjugating reactions without first undergoing phase 1 activation. Phase 3 is the energy-dependent excretion of drug metabolites and their conjugates by an array of membrane transporters in the liver and kidney such as the multidrug resistant protein 1.

Pathways for **biotransformation** are expressed early in the fetus and infant, but many phase 1 and phase 2 enzymes are immature, particularly in the first year of life. CYP3A4 is the primary hepatic CYP expressed postnatally and metabolizes more than 75 commonly used therapeutic drugs and several environmental pollutants and procarcinogens. Hepatic CYP3A4 activity is poorly expressed in the fetus but increases after birth to reach 30% of adult values by 1 month and 50% of adult values between 6 and 12 months of age. CYP3A4 can be induced by a number of drugs, including phenytoin, phenobarbital, and rifampin. Enhanced production of toxic metabolites can overwhelm the capacity of phase 2 reactions. Conversely, numerous inhibitors of CYP3A4 from several different drug classes, such as erythromycin and cimetidine, can lead to toxic accumulations of CYP3A4 substrates. By contrast, although CYP2D6 is also developmentally regulated (maturation by 10 years of age), its activity depends more on genetic polymorphisms than on sensitivity to inducers and inhibitors because more than 70 allelic variants of CYP2D6 significantly influence the metabolism of many drugs. Uridine diphosphate glucuronosyltransferase 1A6, a phase 2 enzyme that glucuronidates acetaminophen, is also absent in the human fetus, increases slightly in the neonate, but does not reach adult levels until sometime after 10 years of age. Mechanisms for the uptake and excretion of organic ions can also be deficient early in life. Impaired drug metabolism via phase 1 and phase 2 reactions present in the first few months of life is followed by a period of enhanced metabolism of many drugs in children through 10 years of age compared with adults.

Genetic polymorphisms in genes encoding enzymes and transporters mediating phases 1, 2, and 3 reactions can also be associated with impaired drug metabolism and an increased risk of hepatotoxicity. Some cases of **idiosyncratic hepatotoxicity** can occur as a result of aberrations (polymorphisms) in phase 1 drug metabolism, producing intermediates of unusual hepatotoxic potential combined with developmental, acquired, or relative inefficiency of phase 2 conjugating reactions. Genome-wide association studies have identified HLA associations in certain cases of **drug- and toxin-induced liver injury (DILI)**. Children may be less susceptible than adults to hepatotoxic reactions; liver injury after the use of the anesthetic halothane is rare in children, and acetaminophen toxicity is less common in infants than in adolescents, whereas most cases of fatal hepatotoxicity associated with sodium valproate use have been reported in children. Excessive or prolonged therapeutic administration of acetaminophen combined with reductions in caloric or protein intake can produce hepatotoxicity in children. In this setting, acetaminophen metabolism may be impaired by reduced synthesis of sulfated and glucuronated metabolites and reduced stores of glutathione. Immaturity of hepatic drug metabolic pathways can prevent degradation of a toxic agent; under other circumstances, the same immaturity might limit the formation of toxic metabolites. Severe sodium valproate hepatotoxicity is often associated with an underlying inherited mitochondrial disorder **(Alpers syndrome).**

Chemical hepatotoxicity can be predictable or idiosyncratic. Predictable hepatotoxicity implies a high incidence of hepatic injury in exposed persons depending on dose. It is understandable that only a few drugs in clinical use fall into this category. These agents might damage the hepatocyte directly through alteration of membrane lipids (peroxidation) or through denaturation of proteins; such agents include carbon tetrachloride and trichloroethylene. Indirect injury can occur through interference with metabolic pathways essential for cell integrity or through distortion of cellular constituents by covalent binding of a reactive metabolite; examples include the liver injury produced by acetaminophen or by antimetabolites such as methotrexate or 6-mercaptopurine.

Idiosyncratic hepatotoxicity is unpredictable and accounts for the majority of adverse reactions. Higher doses of drugs metabolized in the liver pose a greater risk for hepatotoxicity. Idiosyncratic drug reactions in certain patients can reflect aberrant pathways for drug metabolism, possibly related to genetic polymorphisms, with production of toxic intermediates (isoniazid and sodium valproate can cause liver damage through this mechanism). Duration of drug use before liver injury varies (weeks to ≥1 year) and the response to reexposure may be delayed.

An idiosyncratic reaction can also be immunologically mediated as a result of prior sensitization **(hypersensitivity)**; extrahepatic manifestations of hypersensitivity can include fever, rash, arthralgia, and eosinophilia. Duration of exposure before reaction is generally 1-4 weeks, with prompt recurrence of injury on reexposure. Studies indicate that arene oxides, generated through oxidative (CYP) metabolism of aromatic anticonvulsants (phenytoin, phenobarbital, carbamazepine),

Table 411.1 Most Common or Well-Described Drug-Induced Liver Injury Agents and the Patterns of Their Liver Injury

	LATENCY*	TYPICAL PATTERN OF INJURY/IDENTIFYING FEATURES
ANTIBIOTICS		
Amoxicillin/clavulanate	Short to moderate	Cholestatic injury but can be hepatocellular; drug-induced liver injury onset is frequently detected after drug cessation
Isoniazid	Moderate to long	Acute hepatocellular injury similar to acute viral hepatitis
Trimethoprim/sulfamethoxazole	Short to moderate	Cholestatic injury but can be hepatocellular; often with immunoallergic features (e.g., fever, rash, and eosinophilia)
Fluoroquinolones	Short	Variable—hepatocellular, cholestatic, or mixed in relatively similar proportions
Macrolides	Short	Hepatocellular but can be cholestatic
Nitrofurantoin		Hepatocellular
Acute form (rare)	Short	Typically hepatocellular; often resembles idiopathic autoimmune hepatitis
Chronic form	Moderate to long (months-years)	Hepatocellular
Minocycline	Moderate to long	Hepatocellular and often resembles autoimmune hepatitis
ANTIEPILEPTICS		
Phenytoin	Short to moderate	Hepatocellular, mixed, or cholestatic often with immune-allergic features (e.g., fever, rash, and eosinophilia) (anticonvulsant hypersensitivity syndrome)
Carbamazepine	Moderate	Hepatocellular, mixed, or cholestatic often with immune-allergic features (anticonvulsant hypersensitivity syndrome)
Lamotrigine	Moderate	Hepatocellular often with immune-allergic features (anticonvulsant hypersensitivity syndrome)
Valproate		
Hyperammonemia	Moderate to long	Elevated blood ammonia and encephalopathy
Hepatocellular	Moderate to long	Hepatocellular
Reye-like syndrome	Moderate	Hepatocellular, acidosis; microvesicular steatosis on biopsy
ANALGESICS		
Nonsteroidal antiinflammatory agents	Moderate to long	Hepatocellular injury
Diclofenac		Hepatocellular injury with autoimmune features
IMMUNE MODULATORS		
Interferon-beta	Moderate to long	Hepatocellular
Interferon-alpha	Moderate	Hepatocellular, autoimmune hepatitis–like
Anti-TNF agents	Moderate to long	Hepatocellular. Can have autoimmune hepatitis features
Azathioprine	Moderate to long	Cholestatic or hepatocellular but can present with portal hypertension (veno-occlusive disease and nodular regenerative hyperplasia)
IMMUNE-CHECKPOINT INHIBITORS		
Ipilimumab (CTLA-4 inhibitor) Nivolumab, pembrolizumab, and cemiplimab (PD-1 inhibitors) Atezolizumab, avelumab, and durvalumab (PDL-1 inhibitors)	Under 12 wk	Initially mixed pattern but evolves primarily into hepatocellular pattern, without significant autoantibodies
MISCELLANEOUS		
Methotrexate (oral)	Long	Fatty liver, fibrosis
Allopurinol	Short to moderate	Hepatocellular or mixed. Often with immune-allergic features. Granulomas often present on biopsy
Amiodarone (oral)	Moderate to long	Hepatocellular, mixed, or cholestatic. Macrovesicular steatosis and steatohepatitis on biopsy
Androgen-containing steroids	Moderate to long	Cholestatic. Can present with peliosis hepatis, nodular regenerative hyperplasia, or hepatocellular carcinoma
Inhaled anesthetics	Short	Hepatocellular. May have immune-allergic features ± fever
Sulfasalazine	Short to moderate	Mixed, hepatocellular, or cholestatic. Often with immunoallergic features
Proton pump inhibitors	Short	Hepatocellular; very rare

*Short = 3-30 days; moderate = 30-90 days; long >90 days.
CTLA-4, Cytotoxic T-lymphocyte antigen-4; PD-1, programmed cell death receptor-1; PDL-1, programmed cell death receptor-ligand 1; TNF, tumor necrosis factor.
From Chalasani NP, Maddur H, Russo MW, et al. ACG clinical guideline: diagnosis and management of idiosyncratic drug-induced liver injury. *Am J Gastroenterol.* 2021;116(5):878–898. Table 6.

Table 411.2 Hepatotoxic Herbal Remedies, Dietary Supplements, and Weight Loss Products

REMEDY	POPULAR USES	SOURCE	HEPATOTOXIC COMPONENT	TYPE OF LIVER INJURY
Ayurvedic herbal medicine	Multiple	Multiple	Uncertain (may contain heavy metal contaminants)	Hepatitis
Barakol	Anxiolytic	*Cassia siamea*	Uncertain	Reversible hepatitis or cholestasis
Black cohosh	Menopausal symptoms	*Cimicifuga racemosa*	Uncertain	Hepatitis (causality uncertain)
"Bush tea"	Fever	*Senecio, Heliotropium, Crotalaria* spp.	Pyrrolizidine alkaloids	SOS
Cascara	Laxative	*Cascara sagrada*	Anthracene glycoside	Cholestatic hepatitis
Chaparral leaf (greasewood, creosote bush)	"Liver tonic," burn salve, weight loss	*Larrea tridentata*	Nordihydroguaiaretic acid	Acute and chronic hepatitis, FHF
Chaso/onshido	Weight loss	—	*N*-nitro-fenfluramine	Acute hepatitis, FHF
Chinese medicines (traditional)				
Jin bu huan	Sleep aid, analgesic	*Lycopodium serratum*	Levo-tetrahydropalmatine	Acute or chronic hepatitis or cholestasis, steatosis
Ma huang	Weight loss	*Ephedra* spp.	Ephedrine	Severe hepatitis, FHF
Shou-wu-pian	Antiaging, neuroprotection, laxative	*Polygonum multiflorum* Thunb. (fleeceflower root)	Anthraquinone	Acute hepatitis or cholestasis
Syo-saiko-to	Multiple	*Scutellaria* root	Diterpenoids	Hepatocellular necrosis, cholestasis, steatosis, granulomas
Comfrey	Herbal tea	*Symphytum* spp.	Pyrrolizidine alkaloid	Acute SOS, cirrhosis
Germander	Weight loss, fever	*Teucrium chamaedrys, T. capitatum, T. polium*	Diterpenoids, epoxides	Acute and chronic hepatitis, FHF, autoimmune injury
Greater celandine	Gallstones, IBS	*Chelidonium majus*	Isoquinoline alkaloids	Cholestatic hepatitis, fibrosis
Green tea leaf extract	Multiple	*Camellia sinensis*	Catechins	Hepatitis (causality questioned)
Herbalife	Nutritional supplement, weight loss	—	Various; ephedra	Severe hepatitis, FHF
Hydroxycut	Weight loss	*Camellia sinensis*, among other constituents	Uncertain	Acute hepatitis, FHF
Impila	Multiple	*Callilepis laureola*	Potassium atractylate	Hepatic necrosis
Kava	Anxiolytic	*Piper methysticum*	Kava lactone, pipermethystine	Acute hepatitis, cholestasis, FHF
Kombucha	Weight loss	Lichen alkaloid	Usnic acid	Acute hepatitis
Limbrel (Flavocoxid)	Osteoarthritis	Plant bioflavonoids	Baicalin, epicatechin	Acute mixed hepatocellular-cholestatic injury
Lipokinetix	Weight loss	Lichen alkaloid	Usnic acid	Acute hepatitis, jaundice, FHF
Mistletoe	Asthma, infertility	*Viscus album*	Uncertain	Hepatitis (in combination with skullcap)
Oil of cloves	Dental pain	Various foods, oils	Eugenol	Zonal necrosis
Pennyroyal (squawmint oil)	Abortifacient	*Hedeoma pulegioides, Mentha pulegium*	Pulegone, monoterpenes	Severe hepatocellular necrosis
Prostata	Prostatism	Multiple	Uncertain	Chronic cholestasis
Sassafras	Herbal tea	*Sassafras albidum*	Safrole	HCC (in animals)
Senna	Laxative	*Cassia angustifolia*	Sennoside alkaloids; anthrone	Acute hepatitis
Skullcap	Anxiolytic	*Scutellaria*	Diterpenoids	Hepatitis
Valerian	Sedative	*Valeriana officinalis*	Uncertain	Elevated liver enzymes

FHF, Fulminant hepatic failure; HCC, hepatocellular carcinoma; SOS, sinusoidal obstruction syndrome.
From Lewis JH. Liver disease caused by anesthetics, chemicals, toxins, and herbal preparations. In: Feldman M, Friedman LS, Brandt LJ, eds. *Sleisenger and Fordtran's Gastrointestinal and Liver Disease*, 10th ed. Philadelphia: Elsevier; 2016: Table 89.6.

can initiate the pathogenesis of some hypersensitivity reactions. Arene oxides, formed in vivo, can bind to cellular macromolecules, thus perturbing cell function and possibly initiating immunologic mechanisms of liver injury.

The pathogenesis of hepatoxicity is most likely multifactorial, particularly the role played by the host immune system. Activation of liver nonparenchymal Kupffer cells and infiltration by neutrophils perpetuate toxic injury by many drugs by release of reactive oxygen and nitrogen species as well as cytokines. Stellate cells can also be activated, potentially leading to hepatic fibrosis and cirrhosis.

The pathologic spectrum of drug-induced liver disease is extremely wide, is rarely specific, and can mimic other liver diseases (Table 411.3; see also Table 411.1). Predictable hepatotoxins, such as acetaminophen, produce centrilobular necrosis of hepatocytes. **Steatosis** is an important feature of tetracycline (microvesicular) and ethanol (macrovesicular) toxicities. A cholestatic hepatitis can be observed, with injury caused by erythromycin estolate and chlorpromazine. **Cholestasis** without inflammation may be a toxic effect of estrogens and anabolic steroids. Use of oral contraceptives and androgens has also been associated with benign and malignant liver tumors. Some idiosyncratic drug reactions can produce mixed patterns of injury, with diffuse cholestasis and cell necrosis. Chronic hepatitis has been associated with the use of methyldopa and nitrofurantoin.

Clinical manifestations can be mild and nonspecific, such as fever and malaise. Fever, rash, and arthralgia may be prominent in cases of hypersensitivity. In ill hospitalized patients, the signs and symptoms of hepatic drug toxicity may be difficult to separate from the underlying illness. The differential diagnosis should include acute and chronic viral hepatitis, biliary tract disease, septicemia, ischemic and hypoxic liver injury, malignant infiltration, and inherited metabolic liver disease.

The laboratory features of drug- or toxin-related liver disease are extremely variable. Hepatocyte damage can lead to elevations of serum aminotransferase activities and serum bilirubin levels and to impaired synthetic function as evidenced by decreased serum coagulation factors and albumin. Hyperammonemia can occur with liver failure or with selective inhibition of the urea cycle (sodium valproate). Toxicologic screening of blood and urine specimens can aid in detecting drug or toxin exposure. Percutaneous liver biopsy may be necessary to distinguish drug injury from complications of an underlying disorder or from intercurrent infection. Vanishing bile duct syndrome can be seen in a small portion of patients with idiosyncratic DILI.

Slight elevation of serum aminotransferase activities (generally <2-3 times normal) can occur during therapy with drugs, particularly anticonvulsants, capable of inducing microsomal pathways for drug metabolism. Liver biopsy reveals proliferation of smooth endoplasmic reticulum but no significant liver injury. Liver test abnormalities often resolve with continued drug therapy.

Table 411.3 Patterns of Hepatic Drug Injury

DISEASE	DRUG
Centrilobular necrosis	Acetaminophen Carbon tetrachloride Cocaine Ecstasy Iron Halothane
Microvesicular steatosis	Valproic acid Tetracycline Toluene Methotrexate
Acute hepatitis	Isoniazid Anti–tumor necrosis factor agents Valproic acid
General hypersensitivity	Sulfonamides Phenytoin Minocycline
Fibrosis	Methotrexate
Cholestasis	Chlorpromazine Aniline Erythromycin Paraquat Estrogens Sertraline
Sinusoidal obstruction syndrome (venoocclusive disease)	Irradiation plus busulfan Arsenic Cyclophosphamide
Portal and hepatic vein thrombosis	Estrogens Androgens
Biliary sludge	Ceftriaxone
Hepatic adenoma or hepatocellular carcinoma	Oral contraceptives Anabolic steroids

TREATMENT

Treatment of drug- or toxin-related liver injury is mainly supportive. Contact with the offending agent should be avoided. Corticosteroids might have a role in immune-mediated disease. Treatment with *n*-acetylcysteine, by stimulating glutathione synthesis, is effective in preventing or attenuating hepatotoxicity when administered within 16 hours after an acute overdose of acetaminophen and appears to improve survival in patients with severe liver injury even up to 36 hours after ingestion. Intravenous L-carnitine may be of value in treating valproic acid–induced hepatotoxicity. Orthotopic liver transplantation may be required for treatment of drug- or toxin-induced hepatic failure.

PROGNOSIS

The prognosis of DILI depends on its type and severity. Injury is usually completely reversible when the hepatotoxic factor is withdrawn. The mortality of submassive hepatic necrosis with fulminant liver failure can, however, exceed 50%. Hyperbilirubinemia, coagulopathy, and elevated serum creatinine are associated with an increased risk of death or need for liver transplantation. With continued use of certain drugs, such as methotrexate, effects of hepatoxicity can proceed insidiously to cirrhosis, even with normal or near normal liver tests. Neoplasia can follow long-term androgen therapy. Rechallenge with a drug suspected of having caused previous liver injury is rarely justified and can result in fatal hepatic necrosis.

PREVENTION

The prevention of drug-induced liver injury remains a challenge. Monitoring of liver biochemical tests may be useful in some cases, but it can prove difficult to sustain for agents used for many years. Children who take medications with potential for hepatotoxicity, such as some anticonvulsants and antineoplastic drugs, require frequent monitoring for evidence of liver injury. Such testing may be particularly important in patients with preexisting liver disease. For drugs with hepatotoxic potential, even if episodes are infrequent in children, such as with the use of isoniazid, patients should be advised to immediately stop the medication with onset of nausea, vomiting, abdominal pain, and fatigue until liver damage is excluded. Obvious symptoms of liver disease, such as jaundice and dark urine, can lag behind severe hepatocellular injury. Monitoring for toxic metabolites and genotyping can be effective in preventing severe toxicity with the use of azathioprine. Advances in pharmacogenomics, such as the use of gene chips to detect variants in some of the CYP enzymes, hold promise of a personalized approach to prevent hepatotoxicity.

Visit Elsevier eBooks+ at eBooks.Health.Elsevier.com for Bibliography.

Chapter 412

Acute Hepatic Failure

Frederick J. Suchy and Amy G. Feldman

Acute liver failure is a clinical syndrome associated with significant morbidity and mortality resulting from massive necrosis of hepatocytes or from severe functional impairment of hepatocytes. The synthetic, excretory, and detoxifying functions of the liver are all severely impaired. In adults, hepatic **encephalopathy** has been an essential diagnostic feature. However, in pediatrics, this narrow definition may be problematic because early hepatic encephalopathy can be difficult to detect in infants and children, and some children in acute liver failure may not develop encephalopathy (Table 412.1). The accepted definition in children includes biochemical evidence of acute liver injury (usually <8 weeks duration); no evidence of chronic liver disease; and hepatic-based coagulopathy defined as a prothrombin time (PT) >15 seconds or international normalized ratio (INR) >1.5 not corrected by vitamin K in the *presence* of clinical hepatic encephalopathy, or a PT >20 seconds or INR >2 *regardless* of the presence of clinical hepatic encephalopathy.

Liver failure in the perinatal period can be associated with prenatal liver injury and even cirrhosis. Examples include **gestational alloimmune liver disease** (GALD), tyrosinemia, familial **hemophagocytic lymphohistiocytosis** (HLH), and some cases of congenital viral (herpes simplex virus [HSV]) infection. Liver disease may be noticed at birth or after several days of apparent well-being. Fulminant **Wilson disease** and fulminant **autoimmune hepatitis** also occurs in older children who were previously asymptomatic but, by definition, have preexisting liver disease (Table 412.2). Other forms of acute-on-chronic liver failure can occur when a patient with an underlying liver disease such as biliary atresia develops hepatic decompensation after viral or **drug-induced hepatic injury**. In some cases of liver failure, particularly in the idiopathic form of acute hepatic failure, the onset of encephalopathy occurs later, from 8 to 28 weeks after the onset of jaundice.

ETIOLOGY

Infection

Acute hepatic failure can be a complication of **viral hepatitis** (A, B, D, and, rarely, E), Epstein-Barr virus (EBV), HSV, adenovirus, adeno-associated virus, enterovirus, influenza A, cytomegalovirus, parvovirus B19, human herpesvirus (HHV)-6, varicella zoster infection, parechovirus, coronavirus-2 (SARS-CoV-2) and other respiratory illnesses (see Table 412.2; see also Chapter 406). An unusually high rate of fulminant hepatic failure occurs in young people who have combined infections with the hepatitis B virus (HBV) and hepatitis D. Pathogenic gene variants in the precore and/or promoter region of HBV DNA are associated with fulminant and severe hepatitis. HBV is also responsible for some cases of fulminant liver failure in the absence of serologic markers of HBV infection but with HBV DNA found in the liver. Hepatitis E virus is an uncommon cause of fulminant hepatic failure in the United States but can occur in pregnant women, in whom mortality rates rise dramatically to up to 25%. Patients with chronic hepatitis C are at risk if they have superinfection with hepatitis A virus.

Autoimmune Hepatitis

Acute hepatic failure is caused by **autoimmune hepatitis** in approximately 5–28% of cases (see Chapter 410). Patients have a positive autoimmune marker (e.g., antinuclear antibody, anti–smooth muscle antibody, liver-kidney microsomal antibody, or soluble liver antigen) and possibly an elevated serum immunoglobulin G level. If a biopsy can be performed, liver histology often demonstrates interface hepatitis and a plasma cell infiltrate.

Metabolic Diseases

Metabolic disorders account for 28–36% of cases of pediatric acute liver failure and include galactosemia, tyrosinemia, hereditary fructose intolerance, Niemann-Pick type C, mitochondrial hepatopathies (in particular, mitochondrial DNA depletion disorders), urea cycle defects, defects in β-oxidation of fatty acids, and disorders of bile acid synthesis in infants and young children and **Wilson disease** and acute fatty liver of pregnancy in older children (see Table 412.2; see also Chapters 405.1 and 405.5). Family history of consanguinity, recurrent pregnancy loss, stillbirths, or death of children before the age of 1 and/or patient history of diarrhea, vomiting, failure to thrive, or developmental delay should alert one to the possibility of metabolic disease. Patients with Wilson disease who present in acute

Table 412.1 Hepatic Encephalopathy in Pediatric Acute Liver Failure

STAGE		CLINICAL	REFLEXES	NEUROLOGIC SIGNS	EEG CHANGES
0		None	Normal	None	Normal
I	Infant/child	Inconsolable, crying, inattention to task, parents describe child as "not acting like self"	Normal or hyperreflexia	Difficult or impossible to assess	Normal or diffuse slowing to theta rhythm, triphasic waves
	Adolescent/young adult	Confused, mood changes, altered sleep habits, forgetful	Normal	Tremor, apraxia, impaired handwriting	
II	Infant/child	Inconsolable, crying, inattention to task, parents describe child as "not acting like self"	Normal or hyperreflexia	Difficult or impossible to assess	Abnormal, generalized slowing, triphasic waves
	Adolescent/young adult	Drowsy, inappropriate behavior, decreased inhibitions	Hyperreflexia	Dysarthria, ataxia	
III	Infant/child	Somnolence, stupor, combativeness	Hyperreflexia	Difficult or impossible to assess	Abnormal, generalized slowing, triphasic waves
	Adolescent/young adult	Stuporous, obeys simple commands	Hyperreflexia, (+) Babinski	Rigidity	
IV	Infant/child	Comatose, arouses with painful stimuli (IVa) or no response (IVb)	Absent	Decerebrate or decorticate	Abnormal, very slow, delta activity
	Adolescent/young adult	Comatose, arouses with painful stimuli (IVa) or no response	Absent	Decerebrate or decorticate	

EEG, Electroencephalography.
Modified from Squires RH Jr. Acute liver failure in children. *Semin Liver Dis*. 2008;28(2):157–166. Table 1.

Table 412.2 Etiologies of Acute Liver Failure

DRUG-INDUCED LIVER INJURY
Acetaminophen
Antibiotics: amoxicillin-clavulanate, ciprofloxacin, nitrofurantoin, minocycline, dapsone, doxycycline, trimethoprim-sulfamethoxazole, efavirenz, didanosine, abacavir, ketoconazole
Antiepileptics: valproic acid, phenytoin, carbamazepine
Antituberculosis drugs: isoniazid, rifampin-isoniazid, pyrazinamide
Antihypertensives: methyldopa, hydralazine, labetalol, nicotinic acid (slow release)
NSAIDs: diclofenac, ibuprofen, indomethacin, naproxen
Herbs and supplements: ma huang, kava kava, Herbalife, green tea extract, ginseng, black cohosh, anabolic steroids
Anesthetics: halothane
Miscellaneous: propylthiouracil, amitriptyline, statins, amiodarone, methotrexate
VIRAL HEPATITIS
Hepatitis A, B (±D), C, and E
Adenovirus, adeno-associated virus, CMV, EBV, herpes virus, parvovirus, varicella zoster virus
PREGNANCY-RELATED LIVER DISEASE
Acute fatty liver of pregnancy
HELLP syndrome
Preeclampsia-associated liver disease
Acute hepatic rupture
ISCHEMIC HEPATITIS
Systemic hypotension
Budd-Chiari syndrome
Hepatic artery thrombosis
Congestive hepatopathy
REVERSIBLE ETIOLOGIES
Autoimmune hepatitis
Leptospirosis, hepatic amoebiasis, malaria, rickettsial disease
GENETIC
Wilson disease
Galactosemia
Urea cycle defects
Hereditary fructose intolerance
Hemochromatosis
Mitochondrial disorders
α_1-Antitrypsin deficiency
Tyrosinemia
Pathogenic variants in *NBAS, DLD, CPT1A, FAH, LARS1, MPV17, NPC1, POLG, SUCLG1, TWINK, DGUOK, RINT1, SCYL1, ITCH*
MISCELLANEOUS
Malignancy
Mushroom poisoning
Heat injury
Reye syndrome
Hemophagocytic lymphohistiocytosis
Gestational alloimmune liver disease
Idiopathic

NSAID, Nonsteroidal antiinflammatory drug; CMV, cytomegalovirus; EBV, Epstein-Barr virus; HELLP, hemolysis, elevated liver enzymes, low platelet count.
Modified from Montrief T, Koyfman A, Long B. Acute liver failure: a review for emergency physicians. *Am J Emerg Med.* 2019;37:329–337. Table 3.

liver failure often have high bilirubin levels, low alkaline phosphatase levels, low uric acid levels, aspartate aminotransferase levels that are higher than alanine aminotransferase levels, and a Coombs-negative hemolytic anemia.

Neoplasm

Acute liver failure can occur with malignancies, including leukemia, lymphoma, and **familial HLH**. Acute liver failure is a common feature of HLH caused by several gene defects, infections by mostly viruses of the herpes group, and a variety of other conditions, including organ transplantation and malignancies. Impaired function of natural killer cells and cytotoxic T-lymphocyte cells with uncontrolled hemophagocytosis and cytokine overproduction is characteristic for genetic and acquired forms of HLH. Patients with HLH present with a combination of fever, splenomegaly, cytopenias, high triglyceride levels, very high ferritin levels, low natural killer cell activity, and high soluble CD25 levels; they may also have hemophagocytosis on bone marrow or liver biopsy (see Chapter 556).

Gestational Alloimmune Liver Disease

GALD is the most common cause of acute liver failure in the neonate (see Chapter 405.4). In this alloimmune process, maternal immunoglobulin (Ig) G antibodies bind to fetal liver antigens and activate the terminal complement cascade, resulting in hepatocyte injury and death. Infants with GALD present at birth or within the first few days of life with low/normal aminotransferases that are out of proportion to their degree of liver failure. They may have significant hypoglycemia, jaundice, coagulopathy, and hypoalbuminemia. Alpha fetoprotein levels are typically high, as are serum ferritin levels. Extrahepatic iron deposition can be observed on MRI or buccal biopsy.

Drug-Induced Liver Injury

Various hepatotoxic drugs and chemicals can also cause drug-induced liver injury and acute hepatic failure (see Table 412.2; see also Chapter 411). Predictable liver injury can occur after exposure to carbon tetrachloride or *Amanita phalloides* mushrooms or after acetaminophen overdose. Acetaminophen is the most common identifiable etiology of acute hepatic failure in children and adolescents in the United States and England. In addition to the acute intentional ingestion of a massive dose, a therapeutic misadventure leading to severe liver injury can also occur in ill children given doses of acetaminophen exceeding weight-based recommendations for many days. Such patients can have reduced stores of glutathione after a prolonged illness and a period of poor nutrition. Idiosyncratic damage can follow the use of drugs such as halothane, isoniazid, ecstasy, or sodium valproate. Herbal and weight loss supplements are additional causes of hepatic failure (see Chapter 411). The website Liver Tox (https://www.ncbi.nlm.nih.gov/books/NBK547852/) is available to provide up-to-date information about liver injury attributable to medications, herbals, and dietary supplements.

Vascular

Ischemia and hypoxia resulting from hepatic vascular occlusion, severe heart failure, cyanotic congenital heart disease, or circulatory shock can produce liver failure. Venoocclusive disease (VOD) is a clinical process characterized by weight gain, painful hepatomegaly, ascites, and hyperbilirubinemia resulting from hepatic sinusoidal obstruction, most commonly after hematopoietic stem cell transplant. Liver failure is uncommon with VOD but can occur.

Idiopathic Acute Liver Failure

Idiopathic acute liver failure accounts for 40–50% of acute hepatic failure cases in children. The disease occurs sporadically and usually without the risk factors for common causes of viral hepatitis. It is likely that the etiology of these cases is heterogeneous, including unidentified or variant viruses, excessive immune activation, and undiagnosed genetic or metabolic disorders. There is increasing recognition of some children presenting with indeterminate acute hepatitis or acute liver failure who have evidence of immune activation, including markedly elevated soluble interleukin 2 receptor (sIL-2R) levels but never fulfilling diagnostic criteria for HLH.

Other

There is a growing category of autosomal recessive disorders including pathogenic variants in the neuroblastoma amplified sequence gene *NBAS*, *LARS*, *SCYL1*, and *RINT1* that can result in recurrent episodes of pediatric acute liver failure, sometimes associated with concurrent fevers (see Table 412.2). Patients with *NBAS* variants may also have short stature, skeletal abnormalities, intellectual disability, ophthalmic and facial abnormalities, cardiac abnormalities, and low serum

immunoglobulins. Patients with *SCYL1* variants may have low gamma-glutamyl transpeptidase (GGT), cholestasis, and a variable neurologic phenotype. Patients with *RINT1* variants may have persistently abnormal liver function tests (LFTs) between acute liver failure episodes. Most patients recovered with restoration of normal liver function after control of fever and maintenance of energy balance with the infusion of intravenous glucose.

PATHOLOGY

Liver biopsy usually reveals patchy or confluent massive necrosis of hepatocytes. Multilobular or bridging necrosis can be associated with collapse of the reticulin framework of the liver. There may be little or no regeneration of hepatocytes. A zonal pattern of necrosis may be observed with certain insults. Centrilobular damage is associated with acetaminophen hepatotoxicity or with circulatory shock. Evidence of severe hepatocyte dysfunction rather than cell necrosis is occasionally the predominant histologic finding (microvesicular fatty infiltrate of hepatocytes is observed in Reye syndrome, β-oxidation defects, and tetracycline toxicity).

PATHOGENESIS

It is unknown why only approximately 1–2% of patients with viral hepatitis experience liver failure. Massive destruction of hepatocytes might represent both a direct cytotoxic effect of the virus and an immune response to the viral antigens. Of patients with HBV-induced liver failure, 30–50% become negative for serum hepatitis B surface antigen within a few days of presentation and often have no detectable HBV antigen or HBV DNA in serum. These findings suggest a hyperimmune response to the virus that underlies the massive liver necrosis. Formation of hepatotoxic metabolites that bind covalently to macromolecular cell constituents is involved in the liver injury produced by drugs such as acetaminophen and isoniazid; acute hepatic failure can follow depletion of intracellular substrates involved in detoxification, particularly glutathione. Whatever the initial cause of hepatocyte injury, various factors can contribute to the pathogenesis of liver failure, including impaired hepatocyte regeneration, altered parenchymal perfusion, endotoxemia, and decreased hepatic reticuloendothelial function.

CLINICAL MANIFESTATIONS

Acute hepatic failure can be the presenting feature of liver disease, or it can complicate previously known liver disease **(acute-on-chronic liver failure)**. Progressive jaundice, fetor hepaticus, fever, anorexia, vomiting, and abdominal pain are common. A rapid decrease in liver size without clinical improvement is an ominous sign. A hemorrhagic diathesis and ascites can develop. In addition, acute liver failure is a multisystem disorder (Fig. 412.1).

Patients should be closely observed for hepatic encephalopathy, which is initially characterized by minor disturbances of consciousness or motor function. Irritability, poor feeding, and a change in sleep rhythm may be the only findings in infants; asterixis may be demonstrable in older children. Patients are often somnolent, confused, or combative on arousal and can eventually become responsive only to painful stimuli. Patients can rapidly progress to deeper stages of coma in which extensor responses and decerebrate and decorticate posturing appear. Respirations are usually increased early, but respiratory failure can occur in stage IV coma (see Table 412.1). The pathogenesis of hepatic encephalopathy is likely related to increased serum levels of ammonia, false neurotransmitters, amines, increased γ-aminobutyric acid receptor activity, or increased circulating levels of endogenous benzodiazepine-like compounds. Decreased hepatic clearance of these substances can produce marked central nervous system dysfunction. The mechanisms responsible for cerebral edema and intracranial hypertension in acute liver failure suggest both cytotoxic and vasogenic injury (Fig. 412.2). There is increasing evidence for an inflammatory response (synthesis and release of inflammatory factors from activated microglia and endothelial cells), which acts in synergy with hyperammonemia to cause severe astrocyte swelling/brain edema.

LABORATORY FINDINGS

Serum direct and indirect bilirubin levels and serum aminotransferase activities may be markedly elevated. Serum aminotransferase activities do not correlate well with the severity of the illness and can decrease as a patient deteriorates. The blood ammonia concentration is usually increased, but hepatic coma can occur in patients with a normal blood ammonia level. PT and the INR are prolonged and do not improve after parenteral administration of vitamin K. Hypoglycemia can occur,

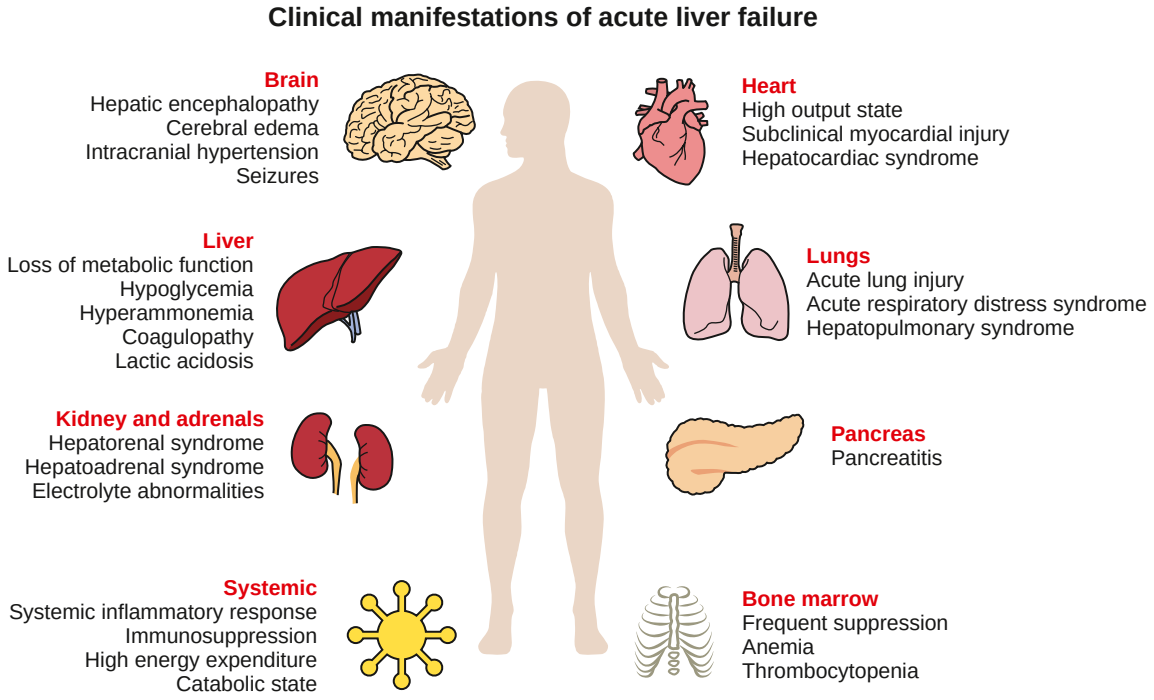

Fig. 412.1 Clinical manifestations of acute liver. *(From Montrief T, Koyfman A, Long B. Acute liver failure: a review for emergency physicians. Am J Emerg Med. 2019;37:329–337. Fig.1.)*

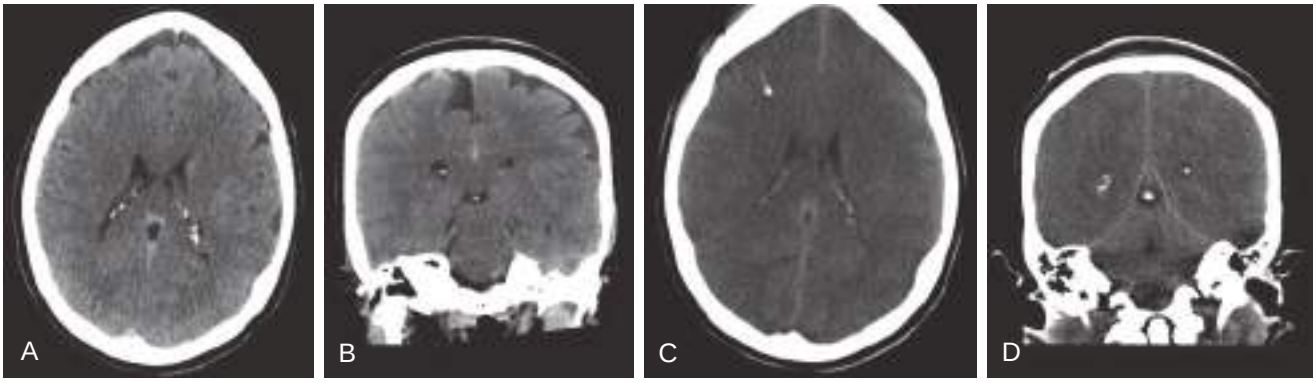

Fig. 412.2 CT of the head in a patient with acute liver failure (ALF) who developed cerebral edema. **A,** Axial scan before the development of cerebral edema. **B,** Coronal scan before the development of cerebral edema. **C,** Axial scan after the development of cerebral edema. **D,** Coronal scan after development of cerebral edema. All in a dying patient with brainstem herniation because of acetaminophen-induced ALF. **C** and **D** show the loss of gray–white demarcation and effacement of sulci. *(From Stravitz RT, Lee WM. Acute liver failure. Lancet. 2019;394:869–880. Fig. 3.)*

Table 412.3 Investigations in Acute Liver Failure

SERUM CHEMISTRIES Basic metabolic panel: sodium, potassium, bicarbonate, calcium, magnesium, phosphate, glucose, blood urea nitrogen, creatinine Amylase, lipase Serum lactate	**VIRAL HEPATITIS SEROLOGIES** Anti-HAV IgM Hep B surface Ag, anti-hep B core Ab IgM Hep D Ab, hep D RNA Anti-HCV, ±hepatitis C RNA PCR ±Anti-HEV IgM Anti-VZV IgM Anti-HSV IgM
HEPATIC PANEL AST, ALT, albumin, total bilirubin, alkaline phosphatase	**AUTOIMMUNE MARKERS** Antinuclear antibody Anti–smooth muscle antibody Serum IgG levels
ARTERIAL BLOOD Blood gas Serum ammonia	**URINE** Pregnancy test Urinalysis and urine culture Toxicology
TOXICOLOGIC Blood alcohol level Acetaminophen level Urine toxicology screen Serum salicylate level	**MISCELLANEOUS** Serum ceruloplasmin Blood cultures Electrocardiogram Exome sequencing Mitochondrial DNA Specific gene panels
HEMATOLOGIC Complete blood count Blood type and screen Coagulation studies: PT/INR, fibrinogen, PTT, TEG, D-dimer	**IMAGING** CT brain scan without contrast Abdominal US Chest x-ray Echocardiogram Transcranial Doppler

PT, Prothrombin time; INR, international normalized ratio; PTT, partial thromboplastin time; TEG, thromboelastography.
Modified from Montrief T, Koyfman A, Long B. Acute liver failure: a review for emergency physicians. *Am J Emerg Med.* 2019;37:329–337. Table 4.

Table 412.4 Potential Disease-Directed Therapies in Pediatric Acute Liver Failure

	THERAPY
Acetominophen toxicity	*N*-acetylcysteine
Drug-induced liver injury	Cessation of offending agent; consider steroids
Neonatal acute liver failure secondary to gestational alloimmune disease	Exchange transfusion and immunoglobulin
Autoimmune liver disease	Steroids
Vascular etiologies (e.g., Budd-Chiari syndrome and sinusoidal obstruction syndrome)	Anticoagulation and hepatic decompression (usually with a transhepatic portosystemic shunt)
Wilson disease	Copper chelation
Herpes simplex virus	Acyclovir
Adenovirus	Cidofovir
Hepatitis A	No specific treatment
Hepatitis B	Lamivudine, entecavir, tenofovir
Hepatitis E	Ribavirin, α-interferon
Galactosemia	Lactose-free diet
Hereditary fructose intolerance	Fructose-free, sucrose-free, and sorbitol-free diet
Tyrosinemia	2-(2-nitro-4-trifluoromethylbenzoyl)-1,3- cyclohexanedione in addition to a diet restricted in tyrosine and phenylalanine
Urea cycle defects	Protein restriction, ammonia scavengers; renal replacement therapy might be required

Modified from Deep A, Alexander EC, Bulut Y, et al. Advances in medical management of acute liver failure in children: promoting native liver survival. *Lancet Child Adolesc.* 2022;6:725–737.

particularly in infants. Hypokalemia, hyponatremia, metabolic acidosis, or respiratory alkalosis can also develop. Laboratory studies are important to monitor the course of liver failure, to detect complications, and to better define the etiology (Table 412.3).

TREATMENT

Specific therapies for identifiable causes of acute liver failure include *N*-acetylcysteine (acetaminophen), acyclovir (HSV), penicillin (*Amanita* mushrooms), nucleos(t)ide analogs such as entecavir (HBV), and prednisone (autoimmune hepatitis) (Table 412.4). Immunosuppression with corticosteroids should also be considered in children with the indeterminate form of fulminant hepatic failure with immune activation to avoid progression to liver transplantation or death. However, controlled trials have shown a worse outcome in patients treated with corticosteroids in patients without an immune basis for liver injury. Treatment of GALD involves intravenous immunoglobulin (IVIG)

(1 g/kg) followed by a combination of double-volume exchange transfusion to remove existing reactive antibody and a second dose of IVIG (1 g/kg) to block antibody-induced complement activation.

Management of other types of acute hepatic failure is supportive. No therapy is known to reverse hepatocyte injury or to promote hepatic regeneration (Fig. 412.3). Continuous kidney replacement therapy and extracorporeal liver support have been used as potential bridging therapies pending native liver recovery or liver transplantation.

An infant or child with acute hepatic failure should be cared for in an institution able to perform a liver transplantation if necessary and managed in an intensive care unit (ICU) with continuous monitoring of vital functions. Endotracheal intubation may be required to prevent aspiration, to reduce cerebral edema by hyperventilation, and to facilitate pulmonary toilet. Mechanical ventilation and supplemental oxygen are often necessary in advanced coma. Sedatives should be avoided unless needed in the intubated patient because these agents can aggravate or precipitate encephalopathy. Opiates may be better tolerated than benzodiazepines. Prophylactic use of proton pump inhibitors should be considered because of the high risk of gastrointestinal bleeding.

Hypovolemia should be avoided and treated with cautious infusions of *isotonic* fluids and blood products. Renal dysfunction can result from dehydration, acute kidney injury, or functional renal failure **(hepatorenal syndrome)**. Electrolyte and glucose solutions should be administered intravenously to maintain urine output, to correct or prevent hypoglycemia, and to maintain normal serum potassium concentrations. In a cardiovascularly stable patient, fluids should be kept around 90% of maintenance. Hyponatremia is common and should be avoided; it is usually dilutional and not a result of sodium depletion. Parenteral supplementation with calcium, phosphorus, and magnesium may be required. Hypophosphatemia, probably a reflection of liver regeneration, and early phosphorus administration are associated with a better prognosis in acute liver failure, whereas hyperphosphatemia predicts a failure of spontaneous recovery. Coagulopathy should be treated with parenteral administration of vitamin K. Fresh-frozen plasma, cryoprecipitate, platelets, activated factor VII, or prothrombin complex concentrates can be used to treat clinically significant bleeding or can be given if an invasive procedure such as placement of a central line or an intracranial monitor needs to be performed. Plasmapheresis can permit temporary correction of the bleeding diathesis without resulting in volume overload. Continuous hemofiltration is useful for managing fluid overload, acute renal failure, and hyperammonemia.

Patients should be monitored closely for infection, including sepsis, pneumonia, peritonitis, and urinary tract infections. At least 50% of patients experience serious infection. Gram-positive organisms *(Staphylococcus aureus, Staphylococcus epidermidis)* are the most common pathogens, but gram-negative and fungal infections are also observed.

Gastrointestinal hemorrhage, infection, constipation, sedatives, electrolyte imbalance, and hypovolemia can precipitate encephalopathy and should be identified and corrected. Protein intake should be restricted to 1 g/kg, depending on the degree of encephalopathy. If encephalopathy or hyperammonemia develops, lactulose or rifaximin can be administered. *N*-acetylcysteine is not effective in improving the outcome of patients with acute liver failure not associated with acetaminophen.

Cerebral edema is an extremely serious complication of hepatic encephalopathy that responds poorly to measures such as corticosteroid

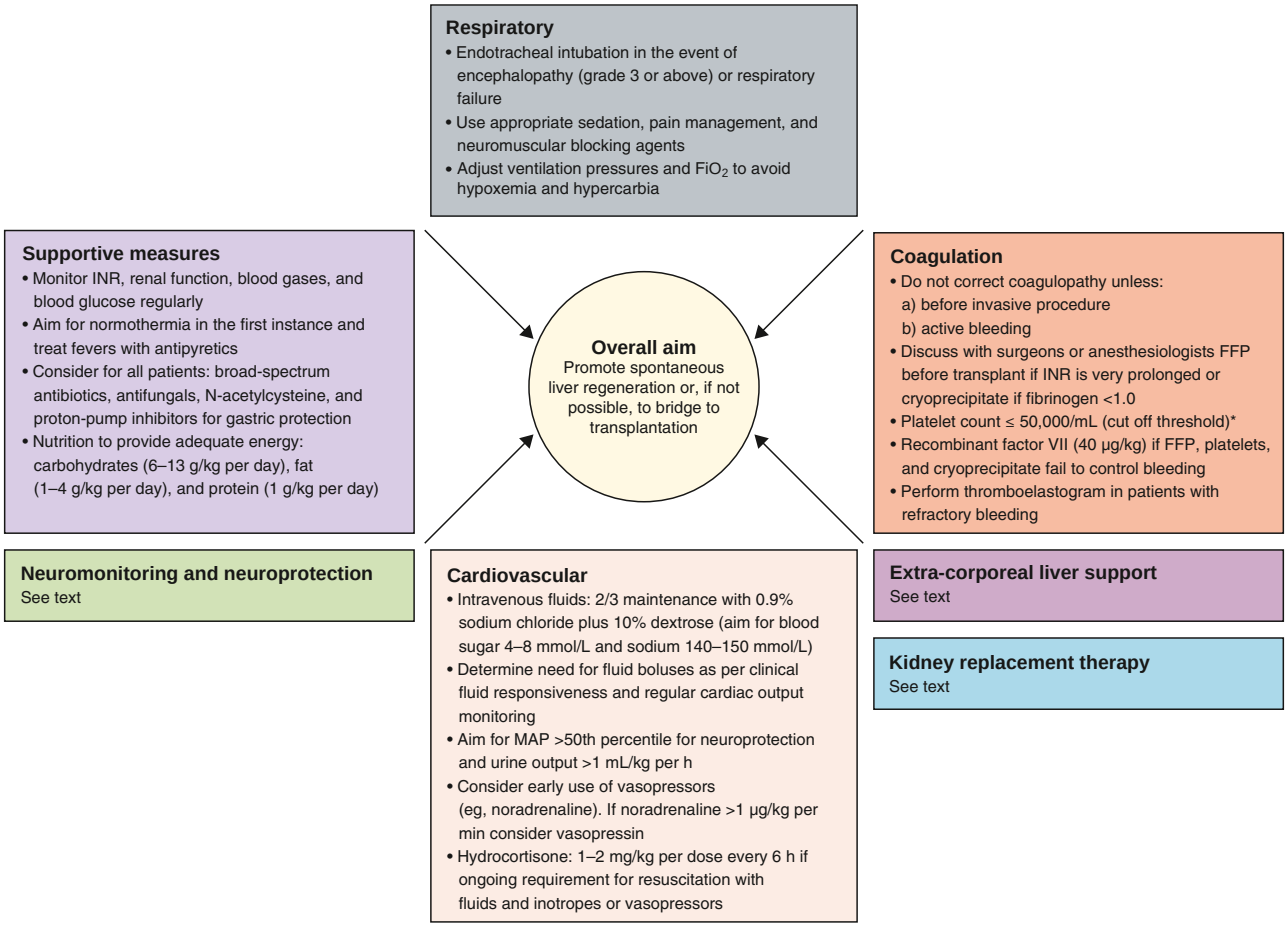

Fig. 412.3 Nontransplant management for pediatric acute liver failure. FFP, Fresh-frozen plasma; FiO_2, fractional concentration of oxygen in inspired air; INR, international normalized ratio; MAP, mean arterial pressures. *Platelet counts of ≤50,000 is controversial. *(Modified from Deep A, Alexander EC, Bulut Y, et al. Non-transplant management for paediatric acute liver failure. Advances in medical management of acute liver failure in children: promoting native liver survival. Lancet Child Adolesc. 2022;6:725–737. Fig. 2.)*

administration and osmotic diuresis. Monitoring intracranial pressure can be useful in preventing severe cerebral edema, maintaining cerebral perfusion pressure, and establishing the suitability of a patient for liver transplantation.

Temporary liver support continues to be evaluated as a bridge for the patient with liver failure to liver transplantation or regeneration. Nonbiologic systems, essentially a form of liver dialysis with an albumin-containing dialysate, and biologic liver support devices that involve perfusion of the patient's blood through a cartridge containing liver cell lines or porcine hepatocytes can remove some toxins, improve serum biochemical abnormalities, and, in some cases, improve neurologic function, but there has been little evidence of improved survival, and few children have been treated.

Orthotopic liver transplantation can be lifesaving in patients who reach advanced stages (III, IV) of hepatic coma. Various predictive tests suggest a poor prognosis and need for liver transplantation (Table 412.5). Reduced-size allografts and living donor transplantation have been important advances in the treatment of infants with hepatic failure. Partial auxiliary orthotopic or heterotopic liver transplantation is successful in a small number of children, and, in some cases, it has allowed regeneration of the native liver and eventual withdrawal of immunosuppression. Orthotopic liver transplantation should not be done in patients with liver failure and neuromuscular dysfunction secondary to a mitochondrial disorder because progressive neurologic deterioration is likely to continue after transplantation.

PROGNOSIS

Children with acute hepatic failure fare better than adults. Improved survival can be attributed to careful intensive care and if necessary, liver transplantation. In the largest prospective study from the Pediatric Acute Liver Failure Study Group, 709 children were assessed at 21 days: 50.3% of patients survived with supportive care alone, 36.2% survived after liver transplantation, and 13.4% died. Prognosis varies considerably with the cause of liver failure and stage of hepatic encephalopathy. Survival rates with supportive care may be as high as 90% in acetaminophen overdose and with fulminant hepatitis A. By contrast, spontaneous recovery can be expected in only approximately 40% of patients with liver failure caused by the idiopathic (indeterminate) form of acute liver failure or an acute onset of Wilson disease. Prognosis is also poor for spontaneous recovery in patients with mitochondrial deficits, hemophagocytic syndromes, herpes simplex disease, and idiosyncratic drug reactions. In patients who progress to stage IV coma (see Table 412.1), the prognosis is extremely poor. Brain stem herniation is the most common cause of death. Major complications such as sepsis, severe hemorrhage, or renal failure increase the mortality. The prognosis is particularly poor in patients with liver necrosis and multiorgan failure. Age <1 year, stage IV encephalopathy, an INR >4, PT >90 seconds, low factor V levels, and the need for dialysis before transplantation are associated with increased mortality. Pre-transplantation serum bilirubin concentration or the height of hepatic enzymes is *not* predictive of posttransplantation survival. A plasma ammonia concentration >200 μmol/L is associated with a fivefold increased risk of death. Children with acute hepatic failure are more likely to die while on the waiting list compared with children with other liver transplant–requiring diagnoses. Because of the severity of their illness, the 6-month post–liver transplantation survival of approximately 75% for acute liver failure is significantly lower than the 90% achieved in children with chronic liver disease. Patients who recover from fulminant hepatic failure with only supportive care do not usually develop cirrhosis or chronic liver disease. Aplastic anemia occurs in approximately 10% of children with the idiopathic form of fulminant hepatic failure and is often fatal without bone marrow transplantation. Long-term survivors demonstrate average IQ and visual spatial ability but greater than expected impairments in motor skills, attention, executive function, and health-related quality of life.

Visit Elsevier eBooks+ at eBooks.Health.Elsevier.com for Bibliography.

Table 412.5 Tests and Indices for Predicting Mortality and Need for Liver Transplantation in Patients with Acute Liver Failure

	CAUSE OF ACUTE LIVER FAILURE	THRESHOLD FOR POOR PROGNOSIS OR NEED FOR LIVER TRANSPLANTATION
King's College Criteria	Acetominophen	Arterial pH <7.30 or all of the following: prothrombin time >100 s (international normalized ratio >6.5), creatinine >3.4 mg/dL, and grade 3 or 4 encephalopathy
King's College Criteria	Non-acetominophen	Prothrombin time >100 s (international normalized ratio >6.5) or any three of the following: non-A, non-B viral hepatitis, or drug or halothane cause; jaundice to encephalopathy >7 days; age between 10 and 40 years; prothrombin time >50 s; bilirubin >17.4 mg/dL
Factor V (Clichy criteria)	Viral	Age <30 years with clotting factor V <20% or any age with clotting factor V <30% and grade 3 or 4 encephalopathy
Liver biopsy	Mixed causes	Hepatocyte necrosis >70%
Arterial phosphate	Acetominophen	>1.2 mmol/L
Serum lactate	Acetominophen	>3.5 mmol/L
APACHE II score	Acetominophen	Score >15
MELD score	Acetominophen	Score >33
BiLE score	Mixed causes	Score >6.9
Volumetric CT	Non-acetominophen	Liver volume <1000 cm^3
ALFSG Prognostic Index*	Mixed causes	Continuous

*The ALFSG Prognostic Index, in contrast to the other indices listed, is designed to predict transplant-free survival rather than death or need for liver transplantation.
MELD, Model for end-stage liver disease; BiLE, bilirubin, lactate, and etiology score; ALFSG, Acute Liver Failure Study Group.
From Stravitz RT, Lee WM. Acute liver failure. *Lancet*. 2019;394:869–880. Table 2.

Chapter 413

Cystic Diseases of the Biliary Tract and Liver

Frederick J. Suchy and Amy G. Feldman

Cystic lesions of liver may be initially recognized during infancy and childhood. Hepatic fibrosis can also occur as part of an associated developmental defect (Table 413.1). Cystic *renal* disease is usually associated and often determines the clinical presentation and prognosis. Virtually all proteins encoded by genes mutated in combined cystic diseases of the liver and kidney are at least partially localized to primary cilia in renal tubular cells and cholangiocytes.

A solitary, congenital **liver cyst** (nonparasitic) can occur in childhood and has been identified in some cases on prenatal ultrasound. Abdominal distention and pain may be present, and a poorly defined right-upper-quadrant mass may be palpable. These benign lesions are best left undisturbed unless they compress adjacent structures or a complication occurs, such as hemorrhage into the cyst. Operative management is generally reserved for symptomatic patients and enlarging cysts.

Table 413.1 Syndromes Associated with Congenital Hepatic Fibrosis

DISORDER	ASSOCIATED FEATURES
Autosomal recessive polycystic kidney disease	Ductal plate malformation, Caroli syndrome
Autosomal dominant polycystic kidney disease	Ductal plate malformation, Caroli syndrome
Autosomal dominant polycystic liver disease	Rarely, congestive heart failure
Jeune syndrome	Asphyxiating thoracic dystrophy, with cystic renal tubular dysplasia, Caroli syndrome
Joubert syndrome	Central nervous system defects, cardiac malformations
COACH syndrome	Cerebellar vermis hypoplasia, oligophrenia, congenital ataxia, ocular coloboma, hepatic fibrosis
Meckel-Gruber syndrome	Cystic renal dysplasia, abnormal bile duct development with fibrosis, posterior encephalocele, polydactyly
Carbohydrate-deficient glycoprotein syndrome type 1b	Phosphomannose isomerase 1 deficiency chronic diarrhea, protein-losing enteropathy
Ivemark syndrome type 2	Autosomal-recessive renal-hepatic-pancreatic dysplasia
Nephronophthisis type 3	Tapetoretinal degeneration
Bardet-Biedl syndrome	Retinal degeneration, obesity, limb deformities, hypogonadism
Oral-facial-digital syndrome type 1	Oral clefts, hamartomas or cysts of the tongue, digital anomalies pancreatic cysts
Miscellaneous syndromes	Intestinal lymphangiectasia, enterocolitis, cystic short rib (Beemer-Langer) syndrome, osteochondrodysplasia

Adapted from Suchy FJ, Sokol RJ, Balistreri WF, eds. *Liver Disease in Children*, 3rd ed. New York: Cambridge University Press; 2014: p. 713.

CHOLEDOCHAL MALFORMATIONS

Choledochal malformations (previously known as **choledochal cysts**) are congenital dilatations of the common bile duct that can cause progressive biliary obstruction and biliary cirrhosis. Cylindrical (fusiform) and spherical (saccular) dilatations of the extrahepatic ducts are the most common types (see Table 413.1). Choledochal malformations are classified according to the Todani method (see Fig. 404.5). **Type 1** choledochal malformations, the most common variant, involve a saccular or fusiform dilation of the common bile duct. **Type II** malformations are congenital diverticula protruding from the common bile duct. **Type III** malformations, or choledochoceles, involve a herniation of the intraduodenal segment of the common bile duct into the duodenum. **Type IVa** malformations, or **Caroli disease**, involve multiple intrahepatic and extrahepatic cysts. **Type IVb** malformations involve only the extrahepatic duct. Solitary liver cysts **(type V)** are very rare.

The pathogenesis of choledochal malformations remains uncertain. Some reports suggest that junction of the common bile duct and the pancreatic duct before their entry into the sphincter of Oddi might allow reflux of pancreatic enzymes into the common bile duct, causing inflammation, localized weakness, and dilation of the duct. It has also been proposed that a distal congenital stenotic segment of the biliary tree leads to increased intraluminal pressure and proximal biliary dilation.

Approximately 75% of cases appear during childhood. The infant typically presents with cholestatic jaundice; severe liver dysfunction including ascites and coagulopathy can rapidly evolve if biliary obstruction is not relieved. An abdominal mass is rarely palpable. In an older child, the classic triad of abdominal pain, jaundice, and mass occurs in <33% of patients.

Features of acute cholangitis (fever, right-upper-quadrant tenderness, jaundice, and leukocytosis) may be present. The diagnosis is made by ultrasonography; choledochal malformations have been identified prenatally using this technique. Magnetic resonance cholangiography is useful in the preoperative assessment of choledochal malformations anatomy.

Because of bile stasis and inflammation, choledochal malformations have the potential to develop into cholangiocarcinoma; therefore the treatment of choice is primary excision of the abnormal biliary segment and a Roux-en-Y choledochojejunostomy. The postoperative course can be complicated by recurrent cholangitis or stricture at the anastomotic site. Long-term follow-up is necessary to ensure that no malignancy develops.

Autosomal Recessive Polycystic Kidney Disease

Autosomal recessive polycystic kidney disease (ARPKD) manifests predominantly in childhood (see Chapter 563.2). Bilateral enlargement of the kidneys is caused by a generalized dilation of the collecting tubules. The disorder is invariably associated with **congenital hepatic fibrosis** and various degrees of biliary ductal ectasia, discussed in detail later. Approximately 40% of patients have nonobstructive intrahepatic ductal dilatation **(Caroli disease)**.

The polycystic kidney and hepatic disease 1 *(PKHD1)* gene, altered in ARPKD, encodes a protein that is called fibrocystin, which is localized to cilia on the apical domain of renal collecting cells and cholangiocytes. The primary defect in ARPKD may be ciliary dysfunction related to the abnormality in this protein. Fibrocystin appears to have a role in the regulation of cellular adhesion, repulsion, and proliferation and/or the regulation and maintenance of renal collecting tubules and bile ducts, but its exact role in normal and cystic epithelia remains unknown.

Kidney and liver disease are independent and variable in severity; they are not readily explainable by the type of *PKHD1* pathogenic variants. Approximately 750 *PKHD1* pathogenic variants have been identified, of which approximately half are missense changes. Phenotypic variability among affected siblings suggests the importance of modifier genes as well as possibly environmental influences.

In ARPKD, the cysts arise as ectatic expansions of the collecting tubules and bile ducts, which remain in continuity with their structures of origin. ARPKD normally presents in early life, often shortly after birth, and is generally more severe than autosomal dominant polycystic kidney disease (ADPKD). Fetal ultrasound may visualize large echogenic kidneys, also described as bright, with low or absent amniotic fluid (oligohydramnios). However, in many instances, the features of ARPKD are not visualized on sonography until the third trimester or after birth.

Patients with ARPKD can die in the perinatal period from renal failure or lung dysgenesis. The kidneys in these patients are usually markedly enlarged and dysfunctional. Respiratory failure can result from compression of the chest by grossly enlarged kidneys, from fluid retention, or from concomitant pulmonary hypoplasia. The clinical pathologic findings within a family tend to breed true, although there has been some variability in the severity of the disease and the time for presentation within the same family. In patients surviving infancy because of a milder renal phenotype, liver disease may be a prominent part of the disorder. The liver disease in ARPKD is related to congenital malformation of the liver with varying degrees of periportal fibrosis, bile ductular hyperplasia, ectasia, and dysgenesis. Initial symptoms are liver related in approximately 26% of patients. This can manifest clinically as variable cystic dilation of the intrahepatic biliary tree with congenital hepatic fibrosis. Congenital hepatic fibrosis and Caroli disease likely result from an abnormality in remodeling of the embryonic ductal plate of the liver. **Ductal plate malformation** refers to the persistence of excess embryonic bile duct structures in the portal tracts. The synthetic function of the liver remained largely intact even in patients with advanced portal hypertension. ARPKD patients with recurrent cholangitis or complications of portal hypertension may require combined liver-kidney transplant.

Cystic Dilation of the Intrahepatic Bile Ducts (Caroli Disease/Caroli Syndrome)

In Caroli disease, there is isolated ectasia or nonobstructing segmental dilatation of the larger intrahepatic ducts. Caroli syndrome is the more common variant, in which malformations of small bile ducts are associated with congenital hepatic fibrosis. Congenital saccular dilation can affect several segments of the intrahepatic bile ducts; the dilated ducts are lined by cuboidal epithelium and are in continuity with the main duct system, which is usually normal. Choledochal malformations have also been associated with Caroli disease. Bile duct dilation leads to stagnation of bile and formation of biliary sludge and intraductal lithiasis. There is a marked predisposition to ascending cholangitis, which may be exacerbated by calculus formation within the abnormal bile ducts.

Affected patients usually experience symptoms of acute cholangitis as children or young adults. Fever, abdominal pain, mild jaundice, and pruritus occur, and a slightly enlarged, tender liver is palpable. Elevated alkaline phosphatase activity, direct-reacting bilirubin levels, and leukocytosis may be observed during episodes of acute infection. In patients with Caroli disease, clinical features may be the result of a combination of recurring episodes of cholangitis, reflecting the intrahepatic ductal abnormalities and portal hypertensive bleeding resulting from hepatic fibrosis. Ultrasonography shows the dilated intrahepatic ducts, but definitive diagnosis and extent of disease must be determined by percutaneous transhepatic, endoscopic, or magnetic resonance cholangiography.

Cholangitis and sepsis should be treated with appropriate antibiotics. Calculi can require surgery. Partial hepatectomy may be curative in rare cases in which cystic disease is confined to a single lobe. The prognosis is otherwise guarded, largely because of difficulties in controlling cholangitis and biliary lithiasis and because of a significant risk for developing cholangiocarcinoma.

Congenital Hepatic Fibrosis

Congenital hepatic fibrosis is usually associated with ARPKD and is characterized pathologically by diffuse periportal and perilobular fibrosis in broad bands that contain distorted bile duct–like structures and that often compress or incorporate central or sublobular veins (see Table 413.1). Irregularly shaped islands of liver parenchyma contain normal-appearing hepatocytes. Caroli disease and choledochal malformations may be associated. Most patients have renal disease, mostly ARPKD and rarely nephronophthisis. Congenital hepatic fibrosis also occurs as part of the **COACH syndrome** (cerebellar vermis hypoplasia, oligophrenia, congenital ataxia, coloboma, and hepatic fibrosis). Congenital hepatic fibrosis has been described in children with a congenital disorder of glycosylation caused by mutations in the gene encoding phosphomannose isomerase (see Chapter 107.7).

Several different forms of congenital hepatic fibrosis have been defined clinically: portal hypertensive (most common) cholangitic, mixed, and latent. The disorder usually has its onset in childhood, with hepatosplenomegaly or with bleeding secondary to portal hypertension. In a recent study, splenomegaly, as a marker for portal hypertension, developed early in life and was present in 60% of children younger than 5 years of age.

Cholangitis can occur in these patients because they have abnormal biliary tracts even without Caroli disease. Hepatocellular function is usually well preserved. Serum aminotransferase activities and bilirubin levels are usually normal in the absence of cholangitis and choledocholithiasis; serum alkaline phosphatase activity may be slightly elevated. The serum albumin level and prothrombin time are normal. Liver biopsy is rarely required for diagnosis, particularly in patients with obvious renal disease.

Treatment of this disorder should focus on control of bleeding from esophageal varices and aggressive antibiotic treatment of cholangitis. Infrequent mild bleeding episodes may be managed by endoscopic sclerotherapy or band ligation of the varices. After more severe hemorrhage, portacaval anastomosis can relieve portal hypertension. The prognosis may be greatly improved by a shunting procedure, but survival in some patients may be limited by renal failure.

AUTOSOMAL DOMINANT POLYCYSTIC KIDNEY DISEASE

ADPKD (see Chapter 563.3), the most commonly inherited cystic kidney disease, affects 1 in 1,000 live births. It is characterized by progressive renal cyst development and cyst enlargement and an array of extrarenal manifestations. There is a high degree of intrafamilial and interfamilial variability in the clinical expression of the disease. The prevalence of hepatic cysts in children with ADPKD is <5%, with no reports of severe cases. However, hepatic cysts increase in number and size with age with prevalence in patients ages 15-24 years on MRI close to 60%.

ADPKD is caused by pathogenic variants in one of two genes, *PKD1* or *PKD2*, which account for 85–90% and 10–15% of cases, respectively. The proteins encoded by these genes, polycystin-1 and polycystin-2, are expressed in renal tubule cells and in cholangiocytes. Polycystin-1 functions as a mechanosensor in cilia, detecting the movement of fluid through tubules and transmitting the signal through polycystin-2, which acts as a calcium channel.

Dilated noncommunicating cysts are most commonly observed. Other hepatic lesions are rarely associated with ADPKD, including the **ductal plate malformation, congenital hepatic fibrosis**, and **biliary microhamartomas** (the von Meyenburg complexes). Approximately 50% of patients with renal failure have demonstrable hepatic cysts that are derived from the biliary tract but not in continuity with it. The hepatic cysts increase with age. In one study, the prevalence of hepatic cysts was 58% in patients 15-24 years old. Hepatic cystogenesis appears to be influenced by estrogens. Although the frequency of cysts is similar in males and females, the development of large hepatic cysts is mainly a complication in females. Hepatic cysts are often asymptomatic but can cause pain and are occasionally complicated by hemorrhage, infection, jaundice from bile duct compression, portal hypertension with variceal bleeding, or hepatic venous outflow obstruction from mechanical compression of hepatic veins, resulting in tender hepatomegaly and exudative ascites. Cholangiocarcinoma can occur. Subarachnoid hemorrhage can result from the associated cerebral arterial aneurysms.

Selected patients with severe symptomatic polycystic liver disease and favorable anatomy benefit from liver resection or fenestration. Combined liver-kidney transplantation may be required. There is considerable evidence for a role of cyclic adenosine monophosphate in epithelial proliferation and fluid secretion in experimental renal and hepatic cystic disease. Several clinical trials in adults have shown that somatostatin analogs can blunt hepatic cyst expansion by blocking secretin-induced cyclic adenosine monophosphate generation and fluid secretion by cholangiocytes. Surgical or pharmacologic therapies for hepatic cysts are not likely to be required in childhood.

AUTOSOMAL DOMINANT POLYCYSTIC LIVER DISEASE

Autosomal dominant polycystic *liver* disease is a distinct clinical and genetic identity in which multiple cysts develop and are unassociated with cystic kidney disease. Liver cysts arise from but are not in continuity with the biliary tract. Females are more commonly affected than males, and the cysts often enlarge during pregnancy. Cysts are rarely identified in children. Cyst complications are related to effects of local compression, infection, hemorrhage, or rupture. The genes associated with autosomal dominant polycystic liver disease are *PRKCSH* and *SEC63*, which encode hepatocystin and Sec63, respectively. Hepatocystin is a protein kinase C substrate adK-H, which is involved in the proper folding and maturation of glycoproteins. It has been localized to the endoplasmic reticulum. *SEC63* encodes the protein SEC63P, which is a component of the protein translocation machinery in the endoplasmic reticulum.

Visit Elsevier eBooks+ at eBooks.Health.Elsevier.com for Bibliography.

Chapter 414

Diseases of the Gallbladder

Frederick J. Suchy and Amy G. Feldman

The incidence of gallbladder disease, particularly cholelithiasis and biliary dyskinesia, has been increasing in children and has been associated with a rise in the number of cholecystectomies.

ANOMALIES

The gallbladder is congenitally absent in approximately 0.1% of the population. Hypoplasia or absence of the gallbladder can be associated with extrahepatic biliary atresia or cystic fibrosis. Duplication of the gallbladder occurs rarely. Gallbladder ectopia may occur with a transverse, intrahepatic, left-sided, or retroplaced location. Multiseptate gallbladder, characterized by the presence of multiple septa dividing the gallbladder lumen, is another rare congenital anomaly of the gallbladder.

ACUTE HYDROPS

Table 414.1 lists the conditions associated with hydrops of the gallbladder.

Acute noncalculous, noninflammatory distention of the gallbladder can occur in infants and children. It is defined by the absence of calculi, bacterial infection, or congenital anomalies of the biliary system. The disorder may complicate acute infections and Kawasaki disease, but the cause is often not identified. Hydrops of the gallbladder may also develop in patients receiving long-term parenteral nutrition, presumably because of gallbladder stasis during the period of enteral fasting. Hydrops is distinguished from acalculous cholecystitis by the absence of a significant inflammatory process and is a generally benign prognosis.

Table 414.1 Conditions Associated with Hydrops of the Gallbladder

Cholelithiasis
Cholecystitis
Kawasaki disease
Streptococcal pharyngitis
Staphylococcal infection
Leptospirosis
Ascariasis
Threadworm
Sickle cell crisis
Typhoid fever
Thalassemia
Total parenteral nutrition
Prolonged fasting
Viral hepatitis
Sepsis
IgA vasculitis (Henoch-Schönlein purpura)
Mesenteric adenitis
Necrotizing enterocolitis

Affected patients usually have right upper quadrant pain with a palpable mass. Fever, vomiting, and jaundice may be present and are usually associated with a systemic illness such as streptococcal infection. Ultrasonography shows a markedly distended echo-free gallbladder, without dilation of the biliary tree. Acute hydrops is usually treated conservatively with a focus on supportive care and managing the intercurrent illness; cholecystostomy and drainage are rarely needed. Spontaneous resolution and return of normal gallbladder function usually occur over a period of several weeks. If a laparotomy is required, a large edematous gallbladder is found to contain white, yellow, or green bile. Obstruction of the cystic duct by mesenteric adenopathy is occasionally observed. Cholecystectomy is required if the gallbladder is gangrenous. Pathologic examination of the gallbladder wall shows edema and mild inflammation. Cultures of bile are usually sterile.

CHOLECYSTITIS AND CHOLELITHIASIS

Acute acalculous cholecystitis is uncommon in children and is usually caused by infection. Pathogens include streptococci (groups A and B), gram-negative organisms—particularly *Salmonella* and *Leptospira interrogans*—and a number of viral infections (hepatitis A, Epstein-Barr [EB] virus, and cytomegalovirus). Parasitic infestation with *Ascaris* or *Giardia lamblia* may be found. Acalculous cholecystitis may be associated with abdominal trauma or burn injury or with a severe systemic illness such as leukemia, end-stage liver disease, and systemic vasculitis.

Clinical features include right upper quadrant or epigastric pain, nausea, vomiting, fever, and jaundice. Right upper quadrant guarding and tenderness are present. Ultrasonography discloses an enlarged, thick-walled gallbladder without calculi. Serum alkaline phosphatase activity and direct-reacting bilirubin levels are elevated. Leukocytosis is usual.

Patients may recover with treatment of systemic and biliary infection. Because the gallbladder can become gangrenous, daily ultrasonography is useful in monitoring gallbladder distention and wall thickness. Cholecystectomy is required in patients who fail to improve with conservative management. Cholecystostomy drainage is an alternative approach in a critically ill patient.

Cholelithiasis is relatively rare in otherwise healthy children, occurring more commonly in patients with various predisposing disorders (Table 414.2). Gallstones are rarely detected by ultrasonography in the fetus but generally remain asymptomatic and resolve spontaneously during the first year of life. In an ultrasonographic survey of

Selected patients with severe symptomatic polycystic liver disease and favorable anatomy benefit from liver resection or fenestration. Combined liver-kidney transplantation may be required. There is considerable evidence for a role of cyclic adenosine monophosphate in epithelial proliferation and fluid secretion in experimental renal and hepatic cystic disease. Several clinical trials in adults have shown that somatostatin analogs can blunt hepatic cyst expansion by blocking secretin-induced cyclic adenosine monophosphate generation and fluid secretion by cholangiocytes. Surgical or pharmacologic therapies for hepatic cysts are not likely to be required in childhood.

AUTOSOMAL DOMINANT POLYCYSTIC LIVER DISEASE

Autosomal dominant polycystic *liver* disease is a distinct clinical and genetic identity in which multiple cysts develop and are unassociated with cystic kidney disease. Liver cysts arise from but are not in continuity with the biliary tract. Females are more commonly affected than males, and the cysts often enlarge during pregnancy. Cysts are rarely identified in children. Cyst complications are related to effects of local compression, infection, hemorrhage, or rupture. The genes associated with autosomal dominant polycystic liver disease are *PRKCSH* and *SEC63*, which encode hepatocystin and Sec63, respectively. Hepatocystin is a protein kinase C substrate adK-H, which is involved in the proper folding and maturation of glycoproteins. It has been localized to the endoplasmic reticulum. *SEC63* encodes the protein SEC63P, which is a component of the protein translocation machinery in the endoplasmic reticulum.

Visit Elsevier eBooks+ at eBooks.Health.Elsevier.com for Bibliography.

Chapter 414

Diseases of the Gallbladder

Frederick J. Suchy and Amy G. Feldman

The incidence of gallbladder disease, particularly cholelithiasis and biliary dyskinesia, has been increasing in children and has been associated with a rise in the number of cholecystectomies.

ANOMALIES

The gallbladder is congenitally absent in approximately 0.1% of the population. Hypoplasia or absence of the gallbladder can be associated with extrahepatic biliary atresia or cystic fibrosis. Duplication of the gallbladder occurs rarely. Gallbladder ectopia may occur with a transverse, intrahepatic, left-sided, or retroplaced location. Multiseptate gallbladder, characterized by the presence of multiple septa dividing the gallbladder lumen, is another rare congenital anomaly of the gallbladder.

ACUTE HYDROPS

Table 414.1 lists the conditions associated with hydrops of the gallbladder.

Acute noncalculous, noninflammatory distention of the gallbladder can occur in infants and children. It is defined by the absence of calculi, bacterial infection, or congenital anomalies of the biliary system. The disorder may complicate acute infections and Kawasaki disease, but the cause is often not identified. Hydrops of the gallbladder may also develop in patients receiving long-term parenteral nutrition, presumably because of gallbladder stasis during the period of enteral fasting. Hydrops is distinguished from acalculous cholecystitis by the absence of a significant inflammatory process and is a generally benign prognosis.

Table 414.1 Conditions Associated with Hydrops of the Gallbladder

Cholelithiasis
Cholecystitis
Kawasaki disease
Streptococcal pharyngitis
Staphylococcal infection
Leptospirosis
Ascariasis
Threadworm
Sickle cell crisis
Typhoid fever
Thalassemia
Total parenteral nutrition
Prolonged fasting
Viral hepatitis
Sepsis
IgA vasculitis (Henoch-Schönlein purpura)
Mesenteric adenitis
Necrotizing enterocolitis

Affected patients usually have right upper quadrant pain with a palpable mass. Fever, vomiting, and jaundice may be present and are usually associated with a systemic illness such as streptococcal infection. Ultrasonography shows a markedly distended echo-free gallbladder, without dilation of the biliary tree. Acute hydrops is usually treated conservatively with a focus on supportive care and managing the intercurrent illness; cholecystostomy and drainage are rarely needed. Spontaneous resolution and return of normal gallbladder function usually occur over a period of several weeks. If a laparotomy is required, a large edematous gallbladder is found to contain white, yellow, or green bile. Obstruction of the cystic duct by mesenteric adenopathy is occasionally observed. Cholecystectomy is required if the gallbladder is gangrenous. Pathologic examination of the gallbladder wall shows edema and mild inflammation. Cultures of bile are usually sterile.

CHOLECYSTITIS AND CHOLELITHIASIS

Acute acalculous cholecystitis is uncommon in children and is usually caused by infection. Pathogens include streptococci (groups A and B), gram-negative organisms—particularly *Salmonella* and *Leptospira interrogans*—and a number of viral infections (hepatitis A, Epstein-Barr [EB] virus, and cytomegalovirus). Parasitic infestation with *Ascaris* or *Giardia lamblia* may be found. Acalculous cholecystitis may be associated with abdominal trauma or burn injury or with a severe systemic illness such as leukemia, end-stage liver disease, and systemic vasculitis.

Clinical features include right upper quadrant or epigastric pain, nausea, vomiting, fever, and jaundice. Right upper quadrant guarding and tenderness are present. Ultrasonography discloses an enlarged, thick-walled gallbladder without calculi. Serum alkaline phosphatase activity and direct-reacting bilirubin levels are elevated. Leukocytosis is usual.

Patients may recover with treatment of systemic and biliary infection. Because the gallbladder can become gangrenous, daily ultrasonography is useful in monitoring gallbladder distention and wall thickness. Cholecystectomy is required in patients who fail to improve with conservative management. Cholecystostomy drainage is an alternative approach in a critically ill patient.

Cholelithiasis is relatively rare in otherwise healthy children, occurring more commonly in patients with various predisposing disorders (Table 414.2). Gallstones are rarely detected by ultrasonography in the fetus but generally remain asymptomatic and resolve spontaneously during the first year of life. In an ultrasonographic survey of

Table 414.2 Conditions Associated with Cholelithiasis

Chronic hemolytic disease (sickle cell anemia, spherocytosis, thalassemia, others)
Ileal resection or disease
Cystic fibrosis
Cirrhosis
Cholestasis
Crohn disease
Obesity
Insulin resistance
Prolonged parenteral nutrition
Prematurity with complicated medical or surgical course
Prolonged fasting or rapid weight reduction
Treatment of childhood cancer
Abdominal surgery
Pregnancy
Sepsis
Genetic *(ABCB4, ABCG5/G8)* progressive familial intrahepatic cholestasis
Gilbert disease
Cephalosporins

1570 children (ages 6-19 years) the overall prevalence of gallstone disease was 0.13% (0.27% in female subjects). Older reports consistently found that >70% of gallstones were the pigment type, 15–20% were cholesterol stones, and the remainder were composed of a mixture of cholesterol, organic matrix, and calcium bilirubinate. Black pigment gallstones, composed mostly of calcium bilirubinate and glycoprotein matrix, are a frequent complication of chronic hemolytic anemias. However, because of obesity, cholesterol gallstones now predominate in children, while the number of patients with hemolytic anemia-associated gallstones have remained stable.

Brown pigment stones form mostly in infants as a result of biliary tract infection. Unconjugated bilirubin is the predominant component, formed by the high β-glucuronidase activity of infected bile. Cholesterol gallstones are composed purely of cholesterol or contain >50% cholesterol along with a mucin glycoprotein matrix and calcium bilirubinate. Calcium carbonate stones have also been described in children.

Patients with hemolytic disease (including sickle cell anemia, the thalassemias, and red blood cell enzymopathies) and Wilson disease are at increased risk for black pigment cholelithiasis. In sickle cell disease, pigment gallstones can develop before age 4 years and have been reported in 17–33% of patients 2-18 years of age. Genetic variation in the promoter of uridine diphosphate-glucuronosyltransferase 1A1 (the [TA]7/[TA]7 and [TA]7/[TA]8 genotypes) underlies Gilbert syndrome, a relatively common, chronic form of unconjugated hyperbilirubinemia, and is a risk factor for pigment gallstone formation in sickle cell disease.

Cirrhosis and chronic cholestasis also increase the risk for pigment gallstones. Sick premature infants may also have gallstones; their treatment is often complicated by such factors as bowel resection, necrotizing enterocolitis, prolonged parenteral nutrition without enteral feeding, cholestasis, frequent blood transfusions, and use of diuretics. Cholelithiasis in premature infants is often asymptomatic and may resolve spontaneously. Brown pigment stones are found in infants with obstructive jaundice and infected intra- and extrahepatic bile ducts. These stones are usually radiolucent, owing to a lower content of calcium phosphate and carbonate and a higher amount of cholesterol than in black pigment stones. MDR3 deficiency caused by *ABCB4* pathologic gene variant is a cholestatic syndrome related to impaired biliary phospholipid excretion. It is associated with symptomatic and recurring cholelithiasis. Patients may show intrahepatic lithiasis, sludge, or microlithiasis along the biliary tree.

Obesity has assumed an increasingly important role as a risk factor for cholesterol cholelithiasis in children, particularly in adolescent females. Cholesterol gallstones are also found in children with disturbances of the enterohepatic circulation of bile acids, including patients with ileal disease and bile acid malabsorption, such as those with ileal resection, ileal Crohn disease, and cystic fibrosis. Pigment stones can also occur in these patients.

Cholesterol gallstone formation results from an excess of cholesterol in relation to the cholesterol-carrying capacity of micelles in bile. Supersaturation of bile with cholesterol, leading to crystal and stone formation, could result from decreased bile acid or from an increased cholesterol concentration in bile. Other initiating factors that may be important in stone formation include gallbladder stasis or the presence in bile of abnormal mucoproteins or bile pigments that may serve as a nidus for cholesterol crystallization.

Prolonged use of high-dose ceftriaxone, a third-generation cephalosporin, has been associated with the formation of calcium-ceftriaxone salt precipitates *(biliary pseudolithiasis)* in the gallbladder. Biliary sludge or cholelithiasis can be detected in >40% of children who are treated with ceftriaxone for at least 10 days. In rare cases, children become jaundiced and develop abdominal pain; precipitates usually resolve spontaneously within several months after discontinuation of the drug.

Acute or chronic cholecystitis is often associated with gallstones. The acute form may be precipitated by impaction of a stone in the cystic duct. Proliferation of bacteria within the obstructed gallbladder lumen can contribute to the process and lead to biliary sepsis. Chronic calculous cholecystitis is more common. It can develop insidiously or follow several attacks of acute cholecystitis. The gallbladder epithelium commonly becomes ulcerated and scarred.

More than 50% of patients with gallstones have symptoms, and 18% present with a complication as the first indication of cholelithiasis, such as pancreatitis, choledocholithiasis or acute calculous cholecystitis. The most important clinical feature of cholelithiasis is recurrent abdominal pain, which is often colicky and localized to the right upper quadrant. An older child may have intolerance for fatty foods. Acute cholecystitis is characterized by fever, pain in the right upper quadrant, and often a palpable mass. Jaundice occurs more commonly in children than adults. Pain may radiate to an area just below the right scapula. A plain x-ray of the abdomen may reveal opaque calculi, but radiolucent (cholesterol) stones are not visualized. Accordingly, ultrasonography is the method of choice for gallstone detection. Hepatobiliary scintigraphy is a valuable adjunct in that failure to visualize the gallbladder provides evidence of cholecystitis. Laboratory evaluation may reveal elevated aminotransferase levels, leukocytosis, and mild hyperbilirubinemia. Marked elevations of the direct bilirubin, alkaline phosphatase, or gamma-glutamyl transpeptidase (GGT) levels should prompt evaluation for choledocholithiasis.

Patients with cholecystitis and persistent fever or concern for obstruction should be hospitalized and started on antibiotics. Cholecystectomy is curative. Laparoscopic cholecystectomy is routinely performed in symptomatic infants and children with cholelithiasis. Common bile duct stones are unusual in children, occurring in 2–6% of cases with cholelithiasis, often in association with obstructive jaundice and pancreatitis. Rarely a common bile duct stone may appear after a successful cholecystectomy. Operative cholangiography should be done at the time of surgery, however, to detect unsuspected common duct calculi. Endoscopic retrograde cholangiography with extraction of common duct stones is an option before laparoscopic cholecystectomy in older children and adolescents.

Asymptomatic patients with cholelithiasis pose a more difficult management problem. Studies in adults indicate a lag time of more than a decade between initial formation of a gallstone and development of symptoms. Spontaneous resolution of cholelithiasis has been reported in infants and children. However, if surgery is deferred for any patient, parents should be counseled about signs and symptoms consistent with cholecystitis or obstruction of the common bile duct by a gallstone. In patients with chronic hemolysis or ileal disease, cholecystectomy can be carried out at the same time as another surgical procedure. Because laparoscopic surgery can safely be performed in children with sickle cell disease, elective cholecystectomy is being

done more frequently at the time of gallstone diagnosis before symptoms or complications develop. In cases associated with liver disease, severe obesity, or cystic fibrosis, the surgical risk of cholecystectomy may be substantial so that the risks and benefits of the operation need to be carefully considered.

BILIARY DYSKINESIA

Biliary dyskinesia is a motility disorder of the biliary tract that may cause biliary colic in children, often in association with nausea and fatty food intolerance, but symptoms may overlap with functional abdominal pain. There are no gallstones on imaging. Sphincter of Oddi dysfunction may be a variant that can present with chronic abdominal pain and recurrent pancreatitis. The diagnosis is based on a cholecystokinin–di-isopropyl iminodiacetic acid scan or an ultrasound done with a fatty meal demonstrating a gallbladder ejection fraction of <35%. Reproduction of pain on cholecystokinin administration may also be seen, as well as the absence of gallbladder filling on an otherwise normal ultrasound examination. Although laparoscopic cholecystectomy is performed for many patients with this disorder, short-term and long-term symptomatic improvement is highly variable.

Visit Elsevier eBooks+ at eBooks.Health.Elsevier.com for Bibliography.

Chapter 415

Portal Hypertension and Varices

Amy G. Feldman and Frederick J. Suchy

Portal hypertension, defined as an elevation of portal pressure >10-12 mm Hg or a hepatic venous pressure gradient >4 mm Hg, is a major cause of morbidity and mortality in children with liver disease. Portal hypertension occurs when there is increased portal resistance or increased blood flow through the portal system. When portal hypertension occurs, children can develop varices, splenomegaly, ascites, and gastrointestinal bleeding.

ETIOLOGY

Portal hypertension can result from obstruction to portal blood flow anywhere along the course of the portal venous system (prehepatic, intrahepatic, or posthepatic). Table 415.1 outlines the various disorders associated with portal hypertension.

Portal vein thrombosis is the most common cause of extrahepatic portal hypertension. The obstruction can occur at any level of the portal vein. In neonates, portal vein thrombosis can occur from umbilical infection (omphalitis) with or without a history of catheterization of the umbilical vein, dehydration, and/or sepsis. Rare developmental anomalies producing extrahepatic portal hypertension include agenesis, atresia, stenosis, or a web of the portal vein. In older children, portal vein thrombosis can occur with intraabdominal infection (appendicitis, peritonitis, pancreatitis), inflammatory bowel disease, celiac disease, primary sclerosing cholangitis, or biliary infection. Portal vein thrombosis is also associated with hypercoagulable states, such as deficiencies of factor V Leiden, protein C, or protein S. The portal vein can be replaced by a fibrous remnant or contain an organized thrombus. At least half of reported cases have no defined cause. Uncommonly, presinusoidal hypertension can be caused by increased flow through the portal system as a result of a congenital or acquired arteriovenous fistula.

Table 415.1 Causes of Portal Hypertension

EXTRAHEPATIC PORTAL HYPERTENSION
Portal vein agenesis, atresia, stenosis
Portal vein thrombosis or cavernous transformation
Splenic vein thrombosis
Increased portal flow
Arteriovenous fistula
INTRAHEPATIC PORTAL HYPERTENSION
Hepatocellular disease
Acute and chronic viral hepatitis
Cirrhosis
Congenital hepatic fibrosis
Wilson disease
α_1-Antitrypsin deficiency
Glycogen storage disease type IV
Hepatotoxicity
Methotrexate
Parenteral nutrition
Biliary tract disease
Biliary atresia
Cystic fibrosis
Choledochal cyst
Sclerosing cholangitis
Intrahepatic bile duct paucity
Idiopathic portal hypertension
Postsinusoidal obstruction
Budd-Chiari syndrome
Venoocclusive disease

Fig. 415.1 Coronal CT image of the abdomen in a patient with cirrhosis. The liver is shrunken *(green cross)*, shows nodularity *(white arrowhead)*, and is surrounded by ascites *(green arrowheads)*. The spleen is enlarged *(star)*. Gastro-esophageal varices are seen *(white arrow)*. There is a splenorenal shunt between a tributary of the splenic vein *(green arrow)* and the left renal vein *(red arrow)*. The left renal vein is seen entering the inferior vena cava *(green curved arrow)*. *(From Ginés P, Krag A, Abraldes JG, et al. Liver cirrhosis. Lancet. 2021;398:1359–1374. Fig. 1.)*

The intrahepatic causes of portal hypertension are numerous. The most common cause of portal hypertension in children is **cirrhosis** (Fig. 415.1). The numerous causes of cirrhosis include recognized disorders such as biliary atresia, autoimmune hepatitis, chronic viral

hepatitis, and metabolic liver disease such as α_1-antitrypsin deficiency, Wilson disease, glycogen storage disease type IV, hereditary fructose intolerance, and cystic fibrosis.

Portal infiltration with malignant cells or granulomas can also contribute. An idiopathic form of portal hypertension characterized by splenomegaly, hypersplenism, and portal hypertension without occlusion of portal or splenic veins and with no obvious disease in the liver has been described. In some patients, noncirrhotic portal fibrosis has been observed.

Postsinusoidal causes of portal hypertension are also observed in childhood. **Budd-Chiari syndrome** occurs with obstruction to hepatic veins anywhere between the efferent hepatic veins and the entry of the inferior vena cava into the right atrium. In most cases, no specific cause can be found, but thrombosis can occur from inherited and acquired hypercoagulable states (antithrombin III deficiency, protein C or S deficiency, factor V Leiden or prothrombin gene variants, paroxysmal nocturnal hemoglobinemia, antiphospholipid syndrome, pregnancy, oral contraceptives) and can complicate hepatic or metastatic neoplasms, collagen vascular disease, infection, and trauma. Additional causes of the Budd-Chiari syndrome include Behçet syndrome, inflammatory bowel disease, celiac disease, sarcoidosis, pancreatitis, aspergillosis, dacarbazine therapy, autoinflammatory-recurrent fever syndromes, and inferior vena cava webs.

Sinusoidal obstruction syndrome (venoocclusive disease) is the most common cause of hepatic vein obstruction in children. In this disorder, occlusion of the centrilobular venules or sublobular hepatic veins occurs. The disorder most frequently occurs in bone marrow transplant recipients after total body irradiation with or without cytotoxic drug therapy, but it can also be seen in patients on azathioprine, mercaptopurine, thioguanine, and those taking herbal remedies that contain pyrrolizidine alkaloids.

PATHOPHYSIOLOGY

The primary hemodynamic abnormality in portal hypertension is increased resistance to portal blood flow. This is the case whether the resistance to portal flow has an intrahepatic cause such as cirrhosis or is because of portal vein obstruction. Portosystemic shunting should decompress the portal system and thus significantly lower portal pressures. However, despite the development of significant collaterals deviating portal blood into systemic veins, portal hypertension is maintained by an overall increase in portal venous flow and thus maintenance of portal hypertension. A hyperdynamic circulation is achieved by tachycardia, an increase in cardiac output, decreased systemic vascular resistance, and increased splanchnic dilation. Overall, the increase in portal flow likely contributes to an increase in variceal transmural pressure. The increase in portal blood flow is related to the contribution of hepatic and collateral flow; the actual portal blood flow reaching the liver is reduced. It is also likely that hepatocellular dysfunction and portosystemic shunting lead to the generation of various humoral factors that cause vasodilation and an increase in plasma volume.

Many complications of portal hypertension can be accounted for by the development of a remarkable collateral circulation. Collateral vessels can form prominently in areas in which absorptive epithelium joins stratified epithelium, particularly in the esophagus or anorectal region. The superficial submucosal collaterals, especially those in the esophagus and stomach, and, to a lesser extent, those in the duodenum, colon, or rectum, are prone to rupture and bleeding under increased pressure. In portal hypertension, the vascularity of the stomach is also abnormal and demonstrates prominent submucosal arteriovenous communications between the muscularis mucosa and dilated precapillaries and veins. The resulting lesion, a vascular ectasia, has been called *congestive gastropathy* and contributes to a significant risk of bleeding from the stomach.

CLINICAL MANIFESTATIONS

Bleeding is the most common presentation of portal hypertension in children. In large series of children with portal hypertension, two thirds presented with hematemesis or melena, most commonly from rupture of an esophageal varix (see Fig. 415.1). Less commonly, patients bleed from portal gastropathy, gastric antral ectasia, or stomal, intestinal, or anorectal varices. The risk of a first bleed in children with cirrhosis is 22% but rises to 38% in children with known varices over a 5-year period. In children with biliary atresia, 15–25% have bleeding on long-term follow-up. The age of first bleed is dependent on the underlying etiology of portal hypertension. Hemorrhage, particularly in children with portal vein obstruction, can be precipitated by a minor febrile, intercurrent illness. The mechanism is often unclear; aspirin or other nonsteroidal antiinflammatory drugs may be a contributing factor by damaging the integrity of a congested gastric mucosa or interfering with platelet function. Coughing during a respiratory illness can also increase intravariceal pressure.

Splenomegaly is the second most common finding in children with portal hypertension and may be initially recognized on routine physical examination (see Fig. 415.1). Because more than half of patients with portal vein obstruction do not experience bleeding until after 6 years of age, underlying liver disease should be considered in any child with splenomegaly, especially if there is concurrent cytopenia. Most children with splenomegaly are asymptomatic.

Ascites is the presenting sign of portal hypertension in 7–21% of children. Ascites can develop at any time with cirrhosis or if there is new onset portal vein obstruction. Children with portal hypertension can also suffer from growth impairment, minimal hepatic encephalopathy, and impaired quality of life. Some develop **portal hypertensive biliopathy**, where portal vein obstruction occurs as a result of external compression of the bile ducts by cavernous transformation of the portal vein.

Children with portal hypertension may also develop pulmonary complications, including **hepatopulmonary syndrome** (HPS) and **portopulmonary hypertension** (PP-HTN). HPS is defined as an arterial oxygenation defect induced by intrapulmonary microvascular dilation, resulting from release of a number of endogenous vasoactive molecules, including endothelin-1 and nitric oxide into the venous circulation. HPS develops in ≥10% of patients with portal hypertension. Patients with HPS may present with dyspnea, cyanosis, clubbing, and spider nevi. PP-HTN is defined by a pulmonary arterial pressure greater than 25 mm Hg at rest or a left-ventricular end-diastolic pressure of less than 15 mm Hg. Patients with PP-HTN most commonly present with exertional dyspnea. Histologically, these patients have pulmonary arteriopathy with laminar intimal fibrosis.

DIAGNOSIS

In patients with established chronic liver disease or in those in whom portal vein obstruction is suspected, an experienced ultrasonographer should be able to demonstrate the patency of the portal vein, and Doppler flow ultrasonography can demonstrate the direction of flow within the portal system. The pattern of flow correlates with the severity of cirrhosis and encephalopathy. Reversal of portal vein blood flow (hepatofugal flow) is more likely to be associated with variceal bleeding. Ultrasonography is also effective in detecting the presence of esophageal varices. Another important feature of extrahepatic portal vein obstruction is cavernous transformation of the portal vein, in which an extensive complex of small collateral vessels forms in the paracholedochal and epicholedochal venous system to bypass the obstruction. Other imaging techniques also contribute to further definition of the portal vein anatomy but are required less often; contrast-enhanced CT and magnetic resonance angiography provide information similar to ultrasonography. Selective arteriography of the celiac axis, superior mesenteric artery, and splenic vein may be useful in precise mapping of the extrahepatic vascular anatomy. This is not required to establish a diagnosis but can prove valuable in planning surgical decompression of portal hypertension. The platelet count, spleen length measured by ultrasonography, and serum albumin are the best noninvasive predictors of portal hypertension in children.

In a patient with hypoxia (HPS), intrapulmonary microvascular dilation is demonstrated with contrast-enhanced bubble echocardiography that shows delayed appearance in the left heart of microbubbles from a saline bolus injected into a peripheral vein.

Endoscopy is the most reliable method for detecting esophageal varices and for identifying the source of gastrointestinal bleeding. Although bleeding from esophageal or gastric varices is most common in children with portal hypertension, up to one third of patients, particularly those with cirrhosis, have bleeding from some other source, such as portal hypertensive gastropathy or gastric or duodenal ulcerations. There is a strong correlation between variceal size as assessed endoscopically and the probability of hemorrhage. Red spots apparent over varices at the time of endoscopy are a strong predictor of imminent hemorrhage.

TREATMENT

The therapy of portal hypertension can be divided into emergency treatment of potentially life-threatening hemorrhage and prophylaxis directed at prevention of initial or subsequent bleeding.

Treatment of patients with acute variceal hemorrhage must focus on stabilization of the patient. Fluid resuscitation should be administered, initially in the form of crystalloid infusion, followed by the replacement of red blood cells. Care should be taken to avoid over transfusing children with portal hypertension-induced bleeding because this can result in overfilling the intravascular space and increasing portal pressure. A reasonable goal hemoglobin level after variceal bleed is between 7 and 9 g/dL. Correction of coagulopathy by administration of vitamin K and/or infusion of platelets or fresh-frozen plasma may be required. A nasogastric tube should be placed to document the presence of blood within the stomach and to monitor for ongoing bleeding. An H_2-receptor blocker or proton pump inhibitor should be given intravenously to reduce the risk of bleeding from gastric erosions. Intravenous antibiotics should be considered because there is high risk of infectious complications during variceal bleeding.

Pharmacologic therapy to decrease portal pressure should be initiated in patients with continued bleeding. Vasopressin or one of its analogs is commonly used and is thought to act by increasing splanchnic vascular tone and thus decreasing portal blood flow. Vasopressin is administered initially with a bolus of 0.33 units/kg over 20 min, followed by a continued infusion of the same dose on an hourly basis or a continuous infusion of 0.2 units/1.73 m^2/min. The drug has a half-life of approximately 30 minutes. Its use may be limited by the side effects of vasoconstriction, which can impair cardiac function and perfusion to the heart, bowel, and kidneys and can also, as a result, exacerbate fluid retention. More commonly, the somatostatin analog, octreotide, is used because it decreases splanchnic blood flow with few side effects. Octreotide is initially administered with a bolus of 1 μg/kg followed by a continuous intravenous infusion of 1.0-5.0 μg/kg/hr. A total of 15% of children with a portal hypertensive bleed will have persistent hemorrhage despite initiation of some form of splanchnic vasoconstriction.

After an episode of variceal hemorrhage or in patients in whom bleeding cannot be controlled with pharmacologic therapy, endoscopy with variceal band ligation or variceal sclerotherapy should be performed. Endoscopic band ligation is preferred because it has been shown in adults to be more effective and has fewer side effects. For smaller children in whom the banding device cannot be used, sclerosants can be injected either intra- or paravariceal until bleeding has stopped. Sclerotherapy treatments may be associated with bleeding, bacteremia, esophageal ulceration, and stricture formation. After band ligation or sclerosis, repeat endoscopy should be performed until varices are obliterated.

In patients who continue to bleed despite pharmacologic and endoscopic methods to control hemorrhage, a Sengstaken-Blakemore tube may be emergently placed to stop hemorrhage by mechanically compressing esophageal and gastric varices. The device is rarely used now, but it may be the only option to control life-threatening hemorrhage until a more definite procedure can be performed. It carries a significant rate of complications and a high rate of bleeding when the device is removed, and it poses a particularly high risk for pulmonary aspiration. The tube is not well tolerated in children without significant sedation and intubation.

Various surgical procedures have been devised to divert portal blood flow and to decrease portal pressure. A portacaval shunt diverts nearly all of the portal blood flow into the subhepatic inferior right vena cava. Although portal pressure is significantly reduced, because of the significant diversion of blood from the liver, patients with parenchymal liver disease have a marked risk for hepatic encephalopathy. Even mild hepatic encephalopathy can impair cognitive function, including school performance. More selective shunting procedures, such as mesocaval or distal splenorenal shunt (see Fig. 415.1), can effectively decompress the portal system while allowing a greater amount of portal blood flow to the liver. The small size of the vessels makes these operations technically challenging in infants and small children, and there is a significant risk of failure as a result of shunt thrombosis. A shunt may be a good option for a child with relatively well-preserved liver function, as sometimes occurs in patients with biliary atresia, congenital hepatic fibrosis, or cystic fibrosis. For children with an extrahepatic portal vein thrombosis, a Meso-Rex shunt (superior mesenteric vein to left portal vein bypass) may successfully restore physiologic portal blood flow and inflow of hepatotrophic factors. In one large single-center experience, 84% of children with idiopathic extrahepatic portal vein thrombosis were successfully treated with a Meso-Rex shunt. Growth and cognitive function improve after this procedure.

A transjugular intrahepatic portosystemic shunt (TIPS), in which a stent is placed by an interventional radiologist between the right hepatic vein and the right or left branch of the portal vein, can aid in the management of portal hypertension in children, especially in those needing temporary relief before liver transplantation. The transjugular intrahepatic portosystemic shunt procedure can precipitate hepatic encephalopathy and is prone to thrombosis.

Orthotopic liver transplantation represents a much better therapy for portal hypertension resulting from intrahepatic disease and cirrhosis. A prior portosystemic shunting operation does not preclude a successful liver transplantation but makes the operation technically more difficult.

Long-term treatment with nonspecific β blockers, such as propranolol, has been used extensively in adults with portal hypertension. These agents might act by lowering cardiac output and inducing splanchnic vasoconstriction. Evidence in adult patients shows that β blockers can reduce the incidence of variceal hemorrhage and improve long-term survival. A therapeutic effect is thought to result when the pulse rate is reduced by ≥25%. There is limited published experience with the use of this therapy in children.

PROGNOSIS

Portal hypertension secondary to intrahepatic disease has a poor prognosis. Portal hypertension is usually progressive in these patients and is often associated with deteriorating liver function. Efforts should be directed toward prompt treatment of acute bleeding and prevention of recurrent hemorrhage with available methods. Patients with progressive liver disease and significant esophageal varices ultimately require orthotopic liver transplantation. Liver transplantation is the only effective therapy for HPS and should also be considered for patients with portal hypertension secondary to hepatic vein obstruction or resulting from severe venoocclusive disease.

Visit Elsevier eBooks+ at eBooks.Health.Elsevier.com for Bibliography.

Chapter 416

Liver Transplantation

Jorge D. Reyes and Evelyn K. Hsu

Survival rates for pediatric liver transplantation are >90% in the United States, in large part thanks to refinements made in the critical care management of children with liver failure and advances in perioperative care and immunosuppression management. Protocols for immune suppression withdrawal in the setting of allograft tolerance have introduced the possibility of transplantation for children without the need for long-term immunosuppression. In the United States, a national allocation system matches donor organs with waitlist candidates (the Organ Procurement and Transplantation Network and the United Network for Organ Sharing [UNOS]); this organization has been given the responsibility of allocating scarce organs to the neediest patients and has undergone continuous revisions with this goal in mind—the most significant in 2002, with the adoption of the Pediatric End-Stage Liver Disease (PELD) and Medical End-Stage Liver Disease (MELD; for adolescents) illness severity scoring system.

INDICATIONS

The diseases for which liver transplantation is indicated can be categorized into the following groups:

- *Obstructive biliary tract disease:* biliary atresia, sclerosing cholangitis, and traumatic or postsurgical injury
- *Metabolic disorders with liver parenchymal disease:* α_1-antitrypsin deficiency, tyrosinemia type I, glycogen storage disease type IV, Wilson disease, gestational alloimmune liver disease (GALD, previously known as *neonatal hemochromatosis*), and cystic fibrosis
- *Metabolic disorders without liver parenchymal disease:* Crigler-Najjar type I, familial hypercholesterolemia, primary oxalosis (with kidney), organic acidemia, and urea cycle defects
- *Acute hepatitis:* fulminant hepatic failure, viral, toxin, or drug-induced
- *Chronic hepatitis with cirrhosis:* hepatitis B or C, autoimmune
- *Intrahepatic cholestasis:* idiopathic neonatal hepatitis, Alagille syndrome, progressive familial intrahepatic cholestasis, and bile acid synthetic disorders
- *Primary liver tumors:* benign tumors (hamartomas, hemangioendothelioma), unresectable hepatoblastoma, and hepatocellular carcinoma
- *Miscellaneous:* cryptogenic cirrhosis, congenital hepatic fibrosis, Caroli disease, polycystic kidney and liver disease, and cirrhosis induced by total parenteral nutrition
- *Emerging indications:* graft-versus-host disease (a complication of bone marrow transplantation), hemophilia, and portosystemic shunts

Biliary atresia is the most common indication for liver transplantation in children, accounting for about half of all pediatric liver transplants performed in the United States, followed by metabolic liver disease and inborn errors of metabolism, autoimmune and familial cholestatic disorders, and acute hepatic necrosis. Biliary atresia may present in two clinical patterns: an acquired form for which there may be nonrandom clustering of potential etiologies (80% of cases) and a syndromic/embryonic form that includes other anomalies, such as polysplenia preduodenal portal vein, intestinal malrotation, situs anomalies, and absence of the retrohepatic vena cava. Hepatoportoenterostomy benefits survival if performed within the first 60 days of life; however, some patients with successful drainage later develop cirrhosis with portal hypertension (variceal bleeding and ascites). Children with biliary atresia (or any other obstructive biliary disorder) who do not achieve successful drainage will experience continued decline and end-stage liver disease, usually requiring liver transplantation within the first year of life.

Inborn errors of metabolism result from a single enzyme deficiency that results in alteration of synthesis, breakdown, transport, or function of carbohydrate, fat, or protein. These disorders can be grouped into those diseases that cause liver parenchymal disease and eventual cirrhosis with end-stage liver disease, as well as liver cancer (i.e., α_1-antitrypsin deficiency, Wilson disease, cystic fibrosis, progressive familial intrahepatic cholestasis), and those inborn errors that manifest principally by their hepatic enzyme deficiency with no hepatocellular injury; complications occur in "satellite" systems such as the brain (hyperammonemic conditions), the kidney (hyperoxaluria type 1), or heart (familial hypercholesterolemia). Some metabolic disorders place patients at risk for decompensation throughout their entire lives, and others manifest principally after adolescence. Liver transplantation is a form of enzyme replacement; the value and risk: benefit of doing so in the absence of cirrhosis has prompted the pursuit of gene therapy and hepatocyte transplantation as possible alternatives, but the therapeutic benefit of these modalities of treatment is as yet equivocal.

Although a proportion of children with **acute hepatic failure** will survive without transplant, it accounts for approximately 10% of pediatric liver transplantation and requires the most intense concentration of multimodal management/support yet devised. This diagnosis lacks clear etiology in the majority of cases, and posttransplantation survival varies but is worse than the general population, likely because of multifactorial issues related to comorbidities and listing/transplantation graft option availability.

Primary hepatic malignancies in children are rare (<2% of all pediatric malignancies) and account for about 7% of pediatric transplants. Hepatoblastoma accounts for the majority of cases (75% of primary liver tumors in childhood) and usually presents in an advanced stage; adjuvant chemotherapy and total hepatectomy with transplantation provide cure and long-term survival for the majority of these children. Survival of >85% has been reported by the International Society of Pediatric Oncology and several American centers.

The impact of chronic liver disease and its impact on growth, development, and quality of life of children can be devastating. Liver transplantation is a valid therapy and cure. The allocation of deceased donor livers in the United States follows guidelines based on the severity of liver disease as reflected in the PELD/MELD scoring system implemented in 2002, which is calculated from the measurable values of bilirubin, albumin, or creatinine (depending on age) and international normalization ratio. The PELD scoring system was initially modeled from a cohort of 884 children on the pediatric liver transplant wait list and is intended to predict death, decompensation, or transplantation within 3 months. Since 2002, the number of liver transplants performed in children in the United States has remained relatively stable, whereas the number of liver transplants performed in adults has steadily increased by approximately 10% per year. A change (2020) to the allocation algorithm that prioritized local adults over critically ill children nationally has in the short term led to increased rates of transplantation in adolescent patients. This and other issues highlight the importance of advocacy on behalf of children in this growing field.

Contraindications to liver transplantation include uncontrolled infection of extrahepatic origin, extrahepatic malignancies, and severely disabling and uncorrectable disease in other organ systems, principally the brain, heart, and lungs. Although combined liver and heart or lung transplantation has been performed in adults and children, such cases require special consideration and centers dedicated to the complexities of posttransplantation management.

TECHNICAL INNOVATIONS

There are no limitations on age or weight for liver transplantation. To enhance the availability of liver grafts to children and optimize the timing of transplantation, techniques allowing the use of reduced-size or segmental grafts (a right or left lobe of liver, or the left lateral segment of the left lobe) were developed; this allows a liver from a larger donor to be implanted into a child, overcoming the barrier of size mismatch. In the same era, techniques were developed for the use of segments from living donors (usually the left lateral segment for small pediatric recipients), and then split-liver grafts from deceased donors where the

left lateral segment is transplanted into a child and the remaining segments of right lobe and medial segment of left lobe are transplanted into an adult, allowing increased utilization of deceased donor grafts without affecting adult waitlist mortality. Reduction of a liver graft is performed ex vivo (i.e., outside of the body); split-liver procurement surgery can be performed either ex vivo or in situ (in the hemodynamically stable brain-dead donor). Donors suitable for aforementioned graft variants should ideally be young (younger than 45 years of age), healthy, and nonobese; however, variations are guided by the severity of illness and urgency for transplantation of the recipient. Not all centers have the degree of surgical expertise required to perform these more complex surgeries; thus options may be limited for children at centers that accept only size-matched organs. This has implications for their waitlist survival.

The implantation of a liver (either whole organ or segment) involves removal of the native liver and encompasses four anastomoses: the suprahepatic vena cava, the portal vein, the hepatic artery, and the bile duct. Modifications of the procedure generally involve retaining (or not) of the retrohepatic vena cava, the performance (or not) of a temporary portocaval shunt to decompress the splanchnic venous system during the anhepatic phase, and the use of vascular homografts of donor iliac vein or artery to replace the native inflow (guided by the presence of recipient anomalies or thrombosis of native vessels). The donor bile duct may be connected to a loop of recipient intestine (Roux-en-Y limb) or the native bile duct. UNOS reported outcomes analyzing graft types, and outcomes have shown improved graft survival in children younger than 3 years of age for live donor grafts when compared with deceased donor whole, split, and reduced grafts. After the first year, however, patient and allograft survivals were similar, independent of graft type.

IMMUNOSUPPRESSION

The long-term goal of effective clinical immunosuppression after solid-organ transplantation is to inhibit antigen-induced T-lymphocyte activation and cytokine production and to interrupt alloimmune–major histocompatibility complex recognition. To prevent weakening the host response to infection, this goal should be achieved while preserving host immunocompetence. A major emphasis is on the prevention of acute and chronic rejection and preserving the ability to reverse refractory acute rejection. These efforts have been successful; the challenge for the future of pediatric liver transplantation is achieving long-term survival and improved quality of life. This inherently involves strategies to minimize the long-term toxicity of immunosuppressive drug therapy, which can include renal failure, cardiovascular complications, and infections. Strategies of drug minimization, steroid-free therapy, and complete withdrawal of drugs have been accomplished in select patients and under careful medical supervision.

Immediately peri- or posttransplantation induction immunosuppressive therapy can involve antilymphocyte antibody induction with depleting antibodies (monoclonal or polyclonal), such as antithymocyte globulin antibody or the use of a chimeric mouse–human antibody that blocks the interleukin-2 receptor of the T cell, thus preventing activation and replication of antigen-selected T cells. Corticosteroids act through the suppression of antibody production and cytokine synthesis (interleukin-2, and interferon-γ), decreasing proliferation of T cells (helper, suppressor, and cytotoxic), B cells, and neutrophils. Maintenance immunosuppression is achieved by using calcineurin phosphatase inhibitor (cyclosporine or tacrolimus); these drugs interfere with the production and release of interleukin-2, a critical factor in the cytotoxic T-cell response. Calcineurin phosphatase inhibitors are most effectively directed toward inhibiting T-cell–mediated acute cellular rejection. Tacrolimus is the mainstay of most immunosuppressive regimens, and its ability to progress or initiate maintenance immunosuppression in the absence of corticosteroids is of particular benefit in children. Adjuvant immunosuppression, such as azathioprine or mycophenolate mofetil, which inhibits the synthesis of purine nucleosides and subsequently the proliferation of T and B lymphocytes as well as antibody formation, may be added to enhance the antirejection profile, allow for decrease in the calcineurin dosage, or manage chronic rejection. Rapamycin, a macrolide that binds its molecular target of mammalian target of rapamycin receptor, decreases interleukin-2 production and, in turn, T- and B-cell activation and proliferation.

COMPLICATIONS

Posttransplantation complications can be related to the pretransplantation condition of the recipient and the donor match and type, immunologic responses to the graft and the need for enhanced immunosuppressive drug therapy, and toxicity effects of these drugs or infections from over-immunosuppression. Post-transplant complications can occur at varying specific frequencies over a fairly well-defined time course (early, late, remote).

The most anticipated early complications involve those inherent to the transplantation operation: primary nonfunction of the graft, hepatic artery thrombosis, portal/hepatic venous strictures or occlusions, and biliary strictures. Primary nonfunction of the graft is rare in pediatric recipients given the selection criteria of potential donors. Hepatic artery thrombosis is the most frequent and early vascular complication; it occurs in 5–10% of recipients and can have devastating consequences on the graft (acute necrosis and gangrene, biliary leaks/stricture/bilomas) and may require urgent retransplantation. Portal vein or hepatic vein strictures/occlusions are rare and generally occur later posttransplantation. Biliary strictures are the most frequent surgical complication (10–30%) after liver transplantation and should be included in the differential diagnosis of any posttransplantation liver allograft dysfunction. Management of these complications varies and may include interventional radiologic procedures, reoperation, or retransplantation. Advancements in interventional radiology technique have allowed for a less invasive and equally efficacious approach to resolving these complications.

Rejection usually occurs after the first 2 weeks after transplantation, with the highest incidence (30–60%) within the first 90 days. Diagnosis of rejection is suspected based on abnormal liver function studies; rarely are there systemic signs such as fever, abdominal pain, new-onset ascites, or hydrothorax. Diagnosing rejection requires biopsy confirmation; treatment algorithms include high doses of corticosteroids and antilymphocyte antibodies. Chronic rejection is less frequent (5–10%) and is characterized by progressive damage and loss of bile ductules with consequent cholestasis; treatment involves long-term enhancement of maintenance immunosuppression with corticosteroids and other agents.

The need to treat rejection can place the patient at a higher risk of drug toxicity or infection. The most common transplantation-related infections are cytomegalovirus and Epstein-Barr virus infections, for which there are well-developed algorithms of prophylaxis and screening. Epstein-Barr virus–induced **posttransplant lymphoproliferative disease** (PTLD) represents a unique complication of over-immunosuppression and infection occurring in approximately 10% of patients. It is managed primarily by withdrawal of immunosuppression and antiviral therapy; some patients require chemotherapy.

OUTCOMES

UNOS data reveal a 1-year patient and graft survival for biliary atresia of 95% and 87%, respectively. Examination of 461 5-year survivors of pediatric liver transplantation in a North American registry found a first graft survival of 88%, with 12% requiring a second graft and 2% requiring a third transplant. The same investigators published a study of 167 10-year survivors and found that only 30% of the group had an "ideal outcome" of normal liver-associated enzymes, no retransplant, and no evidence of PTLD, chronic rejection, hypertension, or renal disease. Longer-term survival is inherently dependent on adequacy of long-term immunosuppression management, adherence to care protocols, and prevention of infection/toxicities/chronic rejection.

Visit Elsevier eBooks+ at eBooks.Health.Elsevier.com for Bibliography.

Section 7

Peritoneum

Chapter 417

Peritoneal Malformations

Jamie F. Merves and Chris A. Liacouras

Numerous anomalies can occur during peritoneal development. Many are rarely of clinical importance, but peritoneal bands and cysts can result in manifestations such as abdominal pain and obstruction. Additionally, peritoneal encapsulation can occur because of an accessory peritoneal sac. Absence or duplication of the omentum occurs rarely.

Congenital peritoneal bands represent anatomically unabsorbed portions of omentum and mesentery and most commonly occur in the regions of the duodenum, duodenojejunal flexure, ileocecal junction, and ascending colon. Although usually benign, they may be responsible for symptoms ranging from nonspecific chronic abdominal pain to intestinal obstruction, malrotation, volvulus, and internal herniation with potential for resulting associated necrosis. Evaluation includes abdominal radiography, fluoroscopy, and, less commonly, CT and angiography. Even when discovered incidentally, surgical management generally remains the standard of care to prevent complications.

Omental cysts arise from obstructed or ectopic lymphatic channels within the omentum. They may be congenital or can result from trauma. They are usually asymptomatic, but abdominal pain or partial small bowel obstruction can result from compression or torsion of the small bowel from traction on the omentum. **Mesenteric cysts** are also rare and may coexist with omental cysts. They most commonly arise from the small bowel mesentery but can also occur in the large bowel mesentery or retroperitoneum. They too arise from lymphatic anomalies, and the cysts can be single or multiple and are often large. Presentation varies but most frequently involves abdominal pain, distention, and appreciation of an abdominal mass and/or suspected ascites on examination. Gastrointestinal symptoms may also include nausea, emesis, constipation, or loose stools. Mesenteric cysts are mostly benign lesions but may act as lead points for torsion and intussusception and can develop hemorrhage, infection, and, rarely, malignant transformation. Cysts are usually well defined and identified on imaging via ultrasound or CT scan. Treatment is typically simple excision, which can be performed laparoscopically in most cases, with excellent results and generally good prognosis.

Visit Elsevier eBooks+ at eBooks.Health.Elsevier.com for Bibliography.

Chapter 418

Ascites

Jessica W. Wen and Chris A. Liacouras

Ascites is the pathologic accumulation of fluid within the peritoneal cavity. Multiple causes of ascites have been described in different age-groups (Tables 418.1-418.3). In children, hepatic and renal disease are the most common causes, but ascites can also be caused by cardiac disease, trauma, infection, or neoplasia.

Table 418.1 Causes of Fetal Ascites

Gastrointestinal disorders
Meconium peritonitis
Intestinal malrotation
Small intestinal or colonic atresia
Intussusception
Volvulus
Hepatobiliary disorders
Gestational alloimmune liver disease
Cystic fibrosis
Biliary atresia
Portal venous malformations
Infection
Parvovirus
Syphilis
Cytomegalovirus
Toxoplasmosis
Acute maternal hepatitis
Genitourinary disorders
Hydronephrosis
Polycystic kidney disease
Urinary obstruction
Ovarian cyst
Persistent cloaca
Chylous ascites
Lymphangiectasia
Lymphatic malformations
Cardiac disorders
Arrhythmia
Heart failure
Chromosomal abnormalities
Trisomy
Turner syndrome
Neoplasm
Neuroblastoma
Leukemia
Hematologic
Hemolytic anemias
Metabolic disease
Niemann-Pick type C
Congenital disorders of glycosylation
Lysosomal storage diseases
Other
Maternal/fetal injury
Congenital lupus erythematosus
Idiopathic

Modified from Giefer MJ, Murray KF, Colletti RB. Pathophysiology, diagnosis, and management of pediatric ascites. *J Pediatr Gastroenterol Nutr.* 2011;52(5):503–513. Table 1.

The clinical hallmark of ascites is abdominal distention. Early satiety and dyspnea can occur with a moderate amount of ascites. Considerable intraperitoneal fluid can accumulate before ascites is detectable by the classic physical signs: bulging flanks, dullness to percussion, shifting dullness, a fluid wave, and the *puddle sign* (percussion of a supine person's abdomen over the umbilicus becomes dull as the patient is moved to a prone position and ascitic fluid puddles in dependent regions). Umbilical herniation can be associated with tense ascites. Ultrasound examination is useful for detecting small amounts of ascites.

Abdominal paracentesis can provide symptomatic relief and may be diagnostic of the cause of the ascites. Determining the serum-ascites albumin gradient can help determine the cause of ascites. A gradient greater than 1.1 g/dL (high-gradient ascites) is consistent with ascites caused by portal hypertension, whereas a gradient <1.1 g/dL (low-gradient ascites) indicates ascites of non-portal-hypertensive etiology.

The course, prognosis, and treatment of ascites depend entirely on the cause. For most patients, treatment consists of dietary sodium restriction and diuretic therapy with spironolactone, with the addition of furosemide in more severe cases. Supplemental albumin can also aid in ascitic fluid mobilization. Refractory cases may require large volume paracentesis or transjugular intrahepatic portosystemic shunting. Patients with any type of ascites are at increased risk for spontaneous bacterial peritonitis.

Section 7

Peritoneum

Chapter 417

Peritoneal Malformations

Jamie F. Merves and Chris A. Liacouras

Numerous anomalies can occur during peritoneal development. Many are rarely of clinical importance, but peritoneal bands and cysts can result in manifestations such as abdominal pain and obstruction. Additionally, peritoneal encapsulation can occur because of an accessory peritoneal sac. Absence or duplication of the omentum occurs rarely.

Congenital peritoneal bands represent anatomically unabsorbed portions of omentum and mesentery and most commonly occur in the regions of the duodenum, duodenojejunal flexure, ileocecal junction, and ascending colon. Although usually benign, they may be responsible for symptoms ranging from nonspecific chronic abdominal pain to intestinal obstruction, malrotation, volvulus, and internal herniation with potential for resulting associated necrosis. Evaluation includes abdominal radiography, fluoroscopy, and, less commonly, CT and angiography. Even when discovered incidentally, surgical management generally remains the standard of care to prevent complications.

Omental cysts arise from obstructed or ectopic lymphatic channels within the omentum. They may be congenital or can result from trauma. They are usually asymptomatic, but abdominal pain or partial small bowel obstruction can result from compression or torsion of the small bowel from traction on the omentum. **Mesenteric cysts** are also rare and may coexist with omental cysts. They most commonly arise from the small bowel mesentery but can also occur in the large bowel mesentery or retroperitoneum. They too arise from lymphatic anomalies, and the cysts can be single or multiple and are often large. Presentation varies but most frequently involves abdominal pain, distention, and appreciation of an abdominal mass and/or suspected ascites on examination. Gastrointestinal symptoms may also include nausea, emesis, constipation, or loose stools. Mesenteric cysts are mostly benign lesions but may act as lead points for torsion and intussusception and can develop hemorrhage, infection, and, rarely, malignant transformation. Cysts are usually well defined and identified on imaging via ultrasound or CT scan. Treatment is typically simple excision, which can be performed laparoscopically in most cases, with excellent results and generally good prognosis.

Visit Elsevier eBooks+ at eBooks.Health.Elsevier.com for Bibliography.

Chapter 418

Ascites

Jessica W. Wen and Chris A. Liacouras

Ascites is the pathologic accumulation of fluid within the peritoneal cavity. Multiple causes of ascites have been described in different age-groups (Tables 418.1-418.3). In children, hepatic and renal disease are the most common causes, but ascites can also be caused by cardiac disease, trauma, infection, or neoplasia.

Table 418.1 Causes of Fetal Ascites

Gastrointestinal disorders
Meconium peritonitis
Intestinal malrotation
Small intestinal or colonic atresia
Intussusception
Volvulus
Hepatobiliary disorders
Gestational alloimmune liver disease
Cystic fibrosis
Biliary atresia
Portal venous malformations
Infection
Parvovirus
Syphilis
Cytomegalovirus
Toxoplasmosis
Acute maternal hepatitis
Genitourinary disorders
Hydronephrosis
Polycystic kidney disease
Urinary obstruction
Ovarian cyst
Persistent cloaca
Chylous ascites
Lymphangiectasia
Lymphatic malformations
Cardiac disorders
Arrhythmia
Heart failure
Chromosomal abnormalities
Trisomy
Turner syndrome
Neoplasm
Neuroblastoma
Leukemia
Hematologic
Hemolytic anemias
Metabolic disease
Niemann-Pick type C
Congenital disorders of glycosylation
Lysosomal storage diseases
Other
Maternal/fetal injury
Congenital lupus erythematosus
Idiopathic

Modified from Giefer MJ, Murray KF, Colletti RB. Pathophysiology, diagnosis, and management of pediatric ascites. *J Pediatr Gastroenterol Nutr.* 2011;52(5):503–513. Table 1.

The clinical hallmark of ascites is abdominal distention. Early satiety and dyspnea can occur with a moderate amount of ascites. Considerable intraperitoneal fluid can accumulate before ascites is detectable by the classic physical signs: bulging flanks, dullness to percussion, shifting dullness, a fluid wave, and the *puddle sign* (percussion of a supine person's abdomen over the umbilicus becomes dull as the patient is moved to a prone position and ascitic fluid puddles in dependent regions). Umbilical herniation can be associated with tense ascites. Ultrasound examination is useful for detecting small amounts of ascites.

Abdominal paracentesis can provide symptomatic relief and may be diagnostic of the cause of the ascites. Determining the serum-ascites albumin gradient can help determine the cause of ascites. A gradient greater than 1.1 g/dL (high-gradient ascites) is consistent with ascites caused by portal hypertension, whereas a gradient <1.1 g/dL (low-gradient ascites) indicates ascites of non-portal-hypertensive etiology.

The course, prognosis, and treatment of ascites depend entirely on the cause. For most patients, treatment consists of dietary sodium restriction and diuretic therapy with spironolactone, with the addition of furosemide in more severe cases. Supplemental albumin can also aid in ascitic fluid mobilization. Refractory cases may require large volume paracentesis or transjugular intrahepatic portosystemic shunting. Patients with any type of ascites are at increased risk for spontaneous bacterial peritonitis.

Table 418.2 Causes of Neonatal Ascites

Hepatobiliary disorders
Cirrhosis
α_1-Antitrypsin deficiency
Congenital hepatic fibrosis
Viral hepatitis
Budd-Chiari syndrome
Gestational alloimmune liver disease
Biliary atresia
Bile duct perforation
Portal venous malformation
Ruptured mesenchymal hamartoma
Gastrointestinal disorders
Intestinal malrotation
Intestinal perforation
Acute appendicitis
Intestinal atresia
Pancreatitis
Chylous ascites
Intestinal lymphangiectasia
Lymphatic duct obstruction
Lymphatic duct trauma
Parenteral nutrition extravasation
Metabolic disease (see Table 418.1)
Genitourinary disorders
Obstructive uropathy
Posterior urethral valves
Ureterocele
Lower ureteral stenosis
Ureteral atresia
Imperforate hymen
Bladder rupture
Bladder injury from umbilical artery catheterization
Nephrotic syndrome
Ruptured corpus luteum cyst
Cardiac
Arrhythmia
Heart failure
Other
Cutis marmorata telangiectatica congenita
Intravenous vitamin E
Pseudo-ascites
Small bowel duplication
Abdominal trauma
Idiopathic

From Giefer MJ, Murray KF, Colletti RB. Pathophysiology, diagnosis, and management of pediatric ascites. *J Pediatr Gastroenterol Nutr.* 2011;52(5):503–513. Table 2.

418.1 Chylous Ascites

Jessica W. Wen and Chris A. Liacouras

Chylous ascites refers to peritoneal fluid that contains lymphatic drainage with a characteristic milky appearance that is rich in triglycerides. Chylous ascites can result from congenital anomaly, injury, or obstruction of the intraabdominal portion of the thoracic duct. Although uncommon, it can occur at any age. In the pediatric population, the most common cause is lymphatic malformation (lymphangiectasia). Other causes include surgical injury to the lymphatics, trauma, cirrhosis, peritoneal bands, generalized lymphangiomatosis, chronic inflammatory processes of the bowel, and mycobacterial infection. Malignancy is a common cause in the adult population but uncommon in pediatrics. Congenital anomalies of the lymphatic system can be associated with Turner, Noonan, yellow nail, and Klippel-Trenaunay-Weber syndromes. Other etiologies include nephrotic syndrome, familial visceral myopathy, sarcoidosis, intestinal malrotation and volvulus, pancreatitis, constrictive pericarditis, and Behçet disease. Postsurgical chylous ascites has been associated with a variety of abdominal surgical procedures, including Nissen fundoplication, appendectomy, liver and kidney transplant, and others. It can occur early, within a week post operation, or weeks to months later due to adhesions and extrinsic compression of lymphatic vessels.

The most common presentation is painless abdominal distention, and it may be accompanied by poor weight gain and loose stools. Peripheral edema is common. Massive chylous ascites can result in scrotal edema, inguinal and umbilical herniation, and respiratory difficulties.

Diagnosis of chylous ascites depends on the demonstration of milky ascitic fluid obtained via paracentesis after a fat-containing feeding. Ascites fluid analysis reveals high protein content, elevated triglycerides, and lymphocytosis. If the patient has had nothing by mouth, the fluid may appear serous. Hypoalbuminemia, hypogammaglobulinemia, and lymphopenia are common in these patients. MR lymphangiography will identify lymphatic malformations.

Table 418.3 Causes of Ascites in Infants and Children

Hepatobiliary disorders	**Neoplasm**
Cirrhosis	Lymphoma
Congenital hepatic fibrosis	Wilms tumor
Acute hepatitis	Clear cell renal sarcoma
Budd-Chiari syndrome	Glioma
Bile duct perforation	Germ cell tumor
Liver transplantation	Ovarian tumor
Gastrointestinal disorders	Mesothelioma
Acute appendicitis	Neuroblastoma
Intestinal atresia	**Metabolic disease**
Pancreatitis	**Genitourinary disorders**
Pyloric duplication	Nephrotic syndrome
Serositis	Peritoneal dialysis
Crohn disease	**Cardiac**
Eosinophilic enteropathy	Heart failure
IgA vasculitis (Henoch-Schönlein purpura)	**Pseudo-ascites**
Chylous ascites	Celiac disease
Intestinal lymphangiectasia	Cystic mesothelioma
Lymphatic duct obstruction	Omental cyst
Lymphatic duct trauma	Ovarian cyst
Parenteral nutrition extravasation	**Other**
Infectious	Systemic lupus erythematosus
Tuberculosis	Ventriculoperitoneal shunt
Abscess	Vitamin A toxicity
Schistosomiasis	Chronic granulomatous disease
	Nonaccidental trauma
	Protein losing enteropathy
	Idiopathic

Modified from Giefer MJ, Murray KF, Colletti RB. Pathophysiology, diagnosis, and management of pediatric ascites. *J Pediatr Gastroenterol Nutr.* 2011;52(5):503–513. Table 3.

Treatment includes a high-protein, low-fat diet supplemented with medium-chain triglycerides that are absorbed directly into the portal circulation and decrease lymph production. Parenteral alimentation may be necessary if nutrition remains impaired on oral feedings; this may also significantly decrease lymph flow and facilitate sealing at the point of lymph leakage. Octreotide, a somatostatin analog, has been used subcutaneously in chylous ascites. The mechanism is not clearly understood; however, it decreases intestinal blood flow, leading to decreased portal pressure, and it also inhibits lymphatic secretion through somatostatin receptors in the intestinal wall. Paracentesis should be repeated only if abdominal distention causes respiratory distress. Lymphangiography with adjunctive embolization may be very successful in treating chylous ascites with identified site of leakage or a malformation. Laparotomy may be indicated if conservative management has been unsuccessful for potential surgical ligation of lymphatics.

Visit Elsevier eBooks+ at eBooks.Health.Elsevier.com for Bibliography.

Chapter 419
Peritonitis

Jessica W. Wen and Chris A. Liacouras

Inflammation of the peritoneal lining of the abdominal cavity can result from infectious, autoimmune, neoplastic, and chemical processes. Infectious peritonitis is usually defined as primary (spontaneous) or secondary. In primary peritonitis, the source of infection originates outside the abdomen and seeds the peritoneal cavity via hematogenous, lymphatic, or transmural spread. Secondary peritonitis arises from the abdominal cavity itself through extension from or rupture of an intraabdominal viscus or an abscess within an organ. Tertiary peritonitis refers to recurrent diffuse or localized disease and is associated with poorer outcomes than secondary peritonitis.

Clinically, patients have abdominal pain, abdominal tenderness, and rigidity on exam. Peritonitis can result from rupture of a hollow viscus, such as the appendix or a Meckel diverticulum; disruption of the peritoneum from trauma or peritoneal dialysis catheter; chemical peritonitis from other bodily fluid, including bile and urine; and infection. Meconium peritonitis is described in Chapter 135. Peritonitis is considered a surgical emergency and requires exploration and lavage of the abdomen, except in spontaneous bacterial peritonitis.

419.1 Acute Primary Peritonitis

Jessica W. Wen and Chris A. Liacouras

ETIOLOGY AND EPIDEMIOLOGY

Primary peritonitis usually refers to bacterial infection of the peritoneal cavity without a demonstrable intraabdominal source. Most cases occur in children with ascites resulting from cirrhosis or nephrotic syndrome. Infection can result from translocation of gut bacteria as well as immune dysfunction. Rarely, primary peritonitis occurs in previously healthy children. Pneumococci (most common), group A streptococci, enterococci, staphylococci, and gram-negative enteric bacteria, especially *Escherichia coli* and *Klebsiella pneumoniae*, are most commonly found. *Mycobacterium tuberculosis*, *Neisseria meningitidis*, and *Mycobacterium bovis* are rare causes. A small percentage are polymicrobial or culture negative.

CLINICAL MANIFESTATIONS

Onset may be insidious or rapid and is characterized by fever, abdominal pain, and a toxic appearance. Vomiting and diarrhea may be present. Hypotension and tachycardia are common, along with shallow, rapid respirations because of discomfort associated with breathing. Abdominal palpation might demonstrate rebound tenderness and rigidity. Bowel sounds are hypoactive or absent. However, signs and symptoms may be subtle at times, and increased vigilance is needed in cirrhotic patients who have ascites and present with unexplained leukocytosis, azotemia, or metabolic acidosis.

DIAGNOSIS AND TREATMENT

Peripheral leukocytosis with a marked predominance of polymorphonuclear cells is common, although the white blood cell (WBC) count can be affected by preexisting hypersplenism in patients with cirrhosis. Patients with nephrotic syndrome generally have proteinuria, and low serum albumin in these patients is associated with an increased risk of peritonitis. X-ray examination of the abdomen reveals dilation of the large and small intestines, with increased separation of loops secondary to bowel wall thickening. Distinguishing primary peritonitis from appendicitis may be difficult in patients without a history of nephrotic syndrome or cirrhosis; accordingly, the diagnosis of primary peritonitis is made by CT scan, laparoscopy, or laparotomy. In a child with known renal or hepatic disease and ascites, the presence of peritoneal signs should prompt diagnostic paracentesis. Infected fluid usually reveals a WBC count of ≥250 cells/mm^3, with >50% polymorphonuclear cells.

Primary peritonitis is usually *monomicrobial*. The presence of mixed bacterial flora on ascitic fluid examination or free air on abdominal roentgenogram in children with presumed peritonitis mandates further evaluation to localize a perforation as a likely *intraabdominal* source of the infection. Inoculation of ascitic fluid obtained at paracentesis directly into blood culture bottles increases the yield of positive cultures. Parenteral antibiotic therapy with broad-spectrum coverage, such as cefotaxime, should be started promptly, with subsequent changes dependent on sensitivity testing (vancomycin for resistant pneumococci). Patients with risk factor for multidrug resistant organisms such as nosocomial infection, recent exposure to antibiotics, or with sepsis or septic shock should receive broad-spectrum coverage with piperacillin/tazobactam with consideration for addition of vancomycin if prior infection or positive surveillance swab for methicillin-resistant *Staphylococcus aureus*. Therapy should be continued for 5-10 days.

Culture-negative neutrocytic ascites is a variant of primary peritonitis with an ascitic fluid WBC count of >500 cells/mm^3, a negative culture, no intraabdominal source of infection, and no prior treatment with antibiotics. It should be treated in a similar way to primary peritonitis.

Visit Elsevier eBooks+ at eBooks.Health.Elsevier.com for Bibliography.

419.2 Acute Secondary Peritonitis

Jessica W. Wen and Chris A. Liacouras

Acute secondary peritonitis most often results from entry of enteric bacteria into the peritoneal cavity through a necrotic defect in the wall of the intestines or other viscus as a result of obstruction or infarction or after rupture of an intraabdominal visceral abscess. It most commonly follows perforation of the appendix. Other causes include incarcerated hernias, rupture of a Meckel diverticulum, midgut volvulus, intussusception, hemolytic uremic syndrome, peptic ulceration, inflammatory bowel disease, necrotizing cholecystitis, necrotizing enterocolitis, typhlitis, and traumatic perforation.

Peritonitis in the neonatal period most often occurs as a complication of necrotizing enterocolitis but may be associated with meconium ileus or spontaneous (or indomethacin-induced) rupture of the stomach or intestines. In postpubertal females, bacteria from the genital tract *(Neisseria gonorrhoeae, Chlamydia trachomatis)* can gain access to the peritoneal cavity via the fallopian tubes, causing secondary peritonitis. The presence of a foreign body, such as a ventriculoperitoneal catheter or peritoneal dialysis catheter, can predispose to peritonitis, with skin microorganisms, such as *Staphylococcus epidermidis, S. aureus,* and *Candida albicans*, contaminating the shunt. Secondary peritonitis results from direct toxic effects of bacteria as well as local and systemic release of inflammatory mediators in response to organisms and their products (lipopolysaccharide endotoxin). The development of sepsis depends on various host and disease factors, as well as the promptness of antimicrobial and surgical intervention.

CLINICAL MANIFESTATIONS

Similar to primary peritonitis, characteristic symptoms include fever, diffuse abdominal pain, nausea, and vomiting. Physical findings of peritoneal inflammation include rebound tenderness, abdominal wall rigidity, a paucity of body motion (lying still), and decreased or absent bowel sounds from paralytic ileus. Massive exudation of fluid into the peritoneal cavity, along with the systemic release of vasodilative substances, can lead to the rapid development of shock. A toxic appearance, irritability, and restlessness are common. Basilar atelectasis, as well as intrapulmonary shunting, can develop, with progression to acute respiratory distress syndrome.

Laboratory studies reveal a peripheral WBC count >12,000 cells/mm^3, with a marked predominance of polymorphonuclear forms. X-rays of the abdomen can reveal free air in the peritoneal cavity, evidence of ileus or obstruction, peritoneal fluid, and obliteration of the psoas shadow. Other peritoneal fluid findings suggestive of secondary peritonitis include elevated total protein (>1 g/dL), and low glucose (<50 mg/dL).

TREATMENT

Aggressive fluid resuscitation and support of cardiovascular function should begin immediately. Stabilization of the patient before surgical intervention is mandatory. Antibiotic therapy must provide coverage for organisms that predominate at the site of presumed origin of the infection. Initial empiric antibiotics for spontaneous bacterial peritonitis has included cefotaxime or ceftriaxone. In contrast to primary peritonitis, secondary peritonitis is typically *polymicrobial*. For perforation of the lower gastrointestinal tract, a regimen of ampicillin, gentamicin, and clindamycin or metronidazole will adequately address infection by *E. coli*, *Klebsiella*, and *Bacteroides* spp. and enterococci. Alternative therapy could include piperacillin/tazobactam or a carbapenem. Surgery to repair a perforated viscus should proceed after the patient is stabilized and antibiotic therapy is initiated. Intraoperative peritoneal fluid cultures will indicate whether a change in the antibiotic regimen is warranted. Empirical treatment for peritoneal dialysis catheter–related peritonitis may include intraperitoneal vancomycin or a first-generation cephalosporin (such as cefazolin) for gram-positive organism coverage, and third- or fourth-generation cephalosporin (such as cefepime or ceftazidime), aminoglycoside, carbapenem or aztreonam (for patients allergic to cephalosporins) for gram-negative organism coverage. Serious infection from peritoneal dialysis catheters can generally be prevented with good catheter hygiene and prompt removal and replacement with signs of progressive infection.

Visit Elsevier eBooks+ at eBooks.Health.Elsevier.com for Bibliography.

419.3 Acute Secondary Localized Peritonitis (Peritoneal Abscess)

Jessica W. Wen and Chris A. Liacouras

ETIOLOGY

Intraabdominal abscesses occur less commonly in children and infants than in adults, but they can develop in visceral intraabdominal organs (hepatic, splenic, renal, pancreatic, tubo-ovarian abscesses) or in the interintestinal, periappendiceal, subdiaphragmatic, subhepatic, pelvic, or retroperitoneal spaces. Most commonly, periappendiceal and pelvic abscesses arise from a perforation of the appendix. Transmural inflammation with fistula formation can result in intraabdominal abscess formation in children with inflammatory bowel disease.

CLINICAL MANIFESTATIONS

Prolonged fever, anorexia, vomiting, and lassitude suggest the development of an intraabdominal abscess. The peripheral WBC count is elevated, as is the erythrocyte sedimentation rate. With an appendiceal abscess, there is localized tenderness and a palpable mass in the right lower quadrant. A pelvic abscess is suggested by abdominal distention, rectal tenesmus with or without the passage of small-volume mucous stools, and bladder irritability. Rectal examination might reveal a tender mass anteriorly. Subphrenic gas collection, basal atelectasis, elevated hemidiaphragm, and pleural effusion may be present with a subdiaphragmatic abscess. Psoas abscess can develop from extension of infection from a retroperitoneal appendicitis, Crohn disease, or perirenal or intrarenal abscess. Abdominal findings may be minimal, and presentation can include a limp, hip pain, and fever. Ultrasound examination, CT scanning, and MRI may be used to localize intraabdominal abscesses; MRI gives the best resolution of disease involvement.

TREATMENT

An abscess should be drained, and appropriate antibiotic therapy provided. Drainage can be performed under radiologic control (ultrasonogram or CT guidance) and an indwelling drainage catheter left in place, or surgically depending on location of abscess. Initial broad-spectrum antibiotic coverage such as a combination of ampicillin, gentamicin, and clindamycin or ciprofloxacin and metronidazole should be started and can be modified, depending on the results of sensitivity testing. The treatment of appendiceal rupture complicated by abscess formation may be problematic because intestinal phlegmon formation can make surgical resection more difficult. Intensive antibiotic therapy for 4-6 weeks followed by an interval appendectomy is often the treatment course followed.

Visit Elsevier eBooks+ at eBooks.Health.Elsevier.com for Bibliography.

Chapter 420
Epigastric Hernia

John J. Aiken

Epigastric hernias in children are ventral hernias in the midline of the abdominal wall between the xiphoid process of the sternum and the umbilicus. Epigastric hernias are more likely to be congenital than acquired. The defect typically contains only preperitoneal fat without a peritoneal sac or abdominal viscera. Because most epigastric hernias are small and asymptomatic, the true incidence is unknown, but the reported incidence in childhood varies from <1% to as high as 5%. The etiology of epigastric hernia is unknown. The two main hypotheses are the vascular lacunae hypothesis and the tendinous fiber decussation hypothesis; the former proposes that the protrusion is through small spaces created where the vascular lacunae penetrate the linea alba, and the latter proposes that epigastric hernia occurs exclusively at sites where affected patients do not have triple lines of decussation. In addition, undiagnosed collagen disorders, increased intraabdominal pressure, and, in older patients, previous midline incision may play a role in the development of epigastric hernia. Epigastric hernias may be single or multiple and are 2-3 times more common in males than females. Through the small midline defect there is often herniation of preperitoneal fat into the superficial abdominal wall, although as the defect becomes progressively larger, the rare possibility exists of herniation of intraabdominal contents. Epigastric (incisional) hernias can occur in a previous incision site or be associated with ventricular-peritoneal shunts.

CLINICAL PRESENTATION

Epigastric hernias typically appear in young children as a visible or palpable mass in the midline, between the umbilicus and the xiphoid process of the sternum, noted by the parents or primary care practitioner. The mass is almost always small (<1 cm), asymptomatic, and typically reported as always present, but most apparent at times of irritability or straining. Occasionally the mass is intermittent, and the child relates pain localized to the site. Physical examination demonstrates a firm mass, directly in the midline, anywhere between the umbilicus and the xiphoid process. The mass may be intermittent if the fat reduces with relaxation of the abdominal muscles. Epigastric hernias typically contain only preperitoneal fat, and most are not reducible because of the small size of the fascial defect. Rarely, a fascial defect is noted without a palpable mass. Herniation of intestines or abdominal viscera in an epigastric hernia would be exceptionally rare if the defect enlarges over time. The mass may be tender to examination, but strangulation of the hernia contents is uncommon. Physical examination is almost always diagnostic, and imaging studies are generally unnecessary. If the diagnosis is unclear, imaging may be useful. Ultrasound typically shows a small mass that is isoechoic to the adjacent subcutaneous fat and possibly connection through a small fascial defect with the preperitoneal fat. MRI imaging might be helpful in diagnosis but is not routinely used.

The natural history of epigastric hernia is for gradual enlargement over time as intermittently more preperitoneal fat is extruded through the defect at times of straining or increased intraabdominal pressure. Left untreated, the defect can enlarge and allow herniation of intraabdominal viscera within a peritoneal sac, mostly seen in adults. Epigastric hernias do not resolve spontaneously, and therefore operative repair is the recommended treatment. The site should be carefully marked preoperatively because the mass and defect can be difficult to localize in a relaxed abdominal wall after induction of anesthesia. A limited transverse incision is made over the mass, and dissection is performed to delineate the edges of the fascial defect. If herniated fat is present, it is dissected free of the subcutaneous tissues and can be reduced or ligated and excised. The defect is closed using absorbable suture. The skin is closed with an absorbable subcuticular suture. Postoperative complications are rare, and the recurrence rate is low.

420.1 Incisional Hernia

John J. Aiken

Hernia formation in the site of a previous laparotomy is uncommon in childhood. Incisional hernias can also occur at the incision sites for the laparoscopic ports used in minimally invasive surgery. Factors associated with an increased risk of incisional hernia include increased intraabdominal pressure, wound infection, and midline incision. The laparoscopic port sites pose a technical challenge to visualize the fascia in a small incision. Transverse abdominal incisions are favored because of their increased strength and blood supply, which reduces the likelihood of wound infection and incisional hernia. Although most incisional hernias require repair, operation should be deferred until the child is in optimal medical condition. Some incisional hernias resolve, especially those occurring in infants. Some recommend elastic bandaging to discourage enlargement of the hernia and to promote spontaneous healing. Initial management should be conservative, with repair deferred until around 1 year of age. Incarceration is very uncommon in incisional hernias but is an indication for prompt repair. Newborns with abdominal wall defects represent the largest group of children with incisional hernias.

Visit Elsevier eBooks+ at eBooks.Health.Elsevier.com for Bibliography.

The Respiratory System

PART XVII

Section 1

Development and Function

Chapter 421

Diagnostic Approach to Respiratory Disease

Daniel J. Lesser, Julie Ryu, Kelan G. Tantisira, and Gabriel G. Haddad

HISTORY

The history of the illness begins with a narrative provided by the parent/caretaker with input from the patient when possible. It should include questions about respiratory symptoms (dyspnea, cough, pain, wheezing, snoring, apnea, cyanosis, exercise intolerance), as well as their chronicity, timing during day or night, and associations with environmental exposures and activities including exercise or food intake. The respiratory system interacts with a number of other systems, and questions related to cardiac, gastrointestinal, central nervous, hematologic, and immune systems may be relevant. Questions related to gastrointestinal reflux, congenital abnormalities (airway anomalies, ciliary dyskinesia), or immune status may be important in a patient with repeated pneumonia. The family history is essential and should include inquiries about siblings and other close relatives with similar symptoms or any chronic disease with respiratory components.

PHYSICAL EXAMINATION

Respiratory dysfunction usually produces detectable alterations in the pattern of breathing. Values for normal respiratory rates are presented in Table 79.1 and depend on many factors—most importantly, age. Repeated respiratory rate measurements are necessary because respiratory rates, especially in the young, are exquisitely sensitive to extraneous stimuli. Sleeping respiratory rates are more reproducible in infants than those obtained during feeding or activity. These rates vary among infants but average 40-50 breaths/min in the first few weeks of life and usually <60 breaths/min in the first few days of life.

Respiratory control abnormalities can cause the child to breathe at a low rate or periodically. Mechanical abnormalities produce compensatory changes that are generally directed at altering minute ventilation to maintain alveolar ventilation. Decreases in lung compliance require increases in muscular force and breathing rate, leading to variable increases in chest wall retractions and nasal flaring. The respiratory excursions of children with restrictive disease are shallow. An expiratory grunt is common as the child attempts to raise the **functional residual capacity (FRC)** by closing the glottis at the end of expiration. The FRC is the amount of air left in the lungs after tidal expiration. Children with obstructive disease might take slower, deeper breaths. When the obstruction is **extrathoracic** (from the nose to the mid-trachea), inspiration is more prolonged than expiration, and an inspiratory stridor (a predominant inspiratory monophonic noise) can usually be heard (Fig. 421.1). When the obstruction is **intrathoracic**, expiration is more prolonged than inspiration, and the patient often has to make use of accessory expiratory muscles. Intrathoracic obstruction results in air trapping and therefore a larger residual volume along with a possible increase in FRC (Fig. 421.2).

Lung percussion has limited value in small infants because it cannot discriminate between noises originating from tissues that are close to each other. In adolescents and adults, percussion is usually dull in restrictive lung disease (pleural effusion, pneumonia, atelectasis), but it is tympanitic in obstructive disease (asthma, pneumothorax).

Auscultation confirms the presence of inspiratory or expiratory prolongation and provides information about the symmetry and quality of air movement. In addition, it often detects abnormal or adventitious sounds such as **stridor**; **crackles** or **rales**, high-pitched, interrupted sounds found during inspiration and, more rarely, during early expiration, which denote opening of previously closed air spaces; or **wheezes**, musical, continuous sounds usually caused by the development of turbulent flow in narrow airways (Table 421.1). **Digital clubbing** is a sign of chronic hypoxia and chronic lung disease (Fig. 421.3) but may be a result of nonpulmonary etiologies (Table 421.2).

BLOOD GAS ANALYSIS

The main function of the respiratory system is to remove carbon dioxide from and add oxygen to the systemic venous blood brought to the lung. The composition of the inspired gas, ventilation, perfusion, diffusion, and tissue metabolism has a significant influence on the arterial blood gases.

The total pressure of the atmosphere at sea level is 760 torr. With increasing altitude, the atmospheric pressure decreases. The total atmospheric pressure is equal to the sum of partial pressures exerted by each of its component gases. Alveolar air is 100% humidified, so in alveolar gas calculations, the inspired gas is also presumed to be 100% humidified. At a temperature of 37°C (98.6°F) and 100% humidity, water vapor exerts a pressure of 47 torr, regardless of altitude. In a natural setting, the atmosphere consists of 20.93% oxygen. **Partial pressure of oxygen in inspired gas (P_{IO_2})** at sea level is therefore (760 − 47) × 20.93% = 149 torr. When breathing 40% oxygen at sea level, P_{IO_2} is (760 − 47) × 40% = 285 torr. At higher altitudes, breathing different concentrations of oxygen, P_{IO_2} is less than at sea level, depending on the prevalent atmospheric pressures. In Denver (altitude of 5,000 feet and barometric pressure of 632 torr), P_{IO_2} in room air is (632 − 47) × 20.93% = 122 torr, and in 40% oxygen, it is (632 − 47) × 40% = 234 torr.

Minute volume is a product of V_T and respiratory rate. Part of the V_T occupies the conducting airways (anatomic dead space), which does not contribute to gas exchange in the alveoli. **Alveolar ventilation** is the volume of atmospheric air entering the alveoli and is calculated as (V_T − dead space) × respiratory rate. Alveolar ventilation is inversely proportional to arterial P_{CO_2} (P_{aCO_2}). When alveolar ventilation is halved, P_{aCO_2} is doubled. Conversely, doubling of alveolar ventilation decreases P_{aCO_2} by 50%. **Alveolar P_{O_2} (P_{aO_2})** is calculated by the **alveolar air equation** as follows, where R is the respiratory quotient. For practical purposes, P_{ACO_2} is substituted by **arterial P_{CO_2}** (P_{aCO_2}), and R is assumed to be 0.8. According to the alveolar air equation, for a given P_{IO_2}, a rise in P_{aCO_2} of 10 torr results in a decrease in P_{AO_2} by 10 ÷ 0.8, or 10 × 1.25, or 12.5 torr. Thus proportionately inverse changes in P_{AO_2} occur to the extent of 1.25 times the changes in P_{ACO_2} (or P_{aCO_2}).

After the alveolar gas composition is determined by the inspired gas conditions and the process of ventilation, gas exchange occurs by the process of diffusion and equilibration of alveolar gas with pulmonary capillary blood. Diffusion depends on the alveolar capillary barrier and the amount of available time for equilibration. In health, the

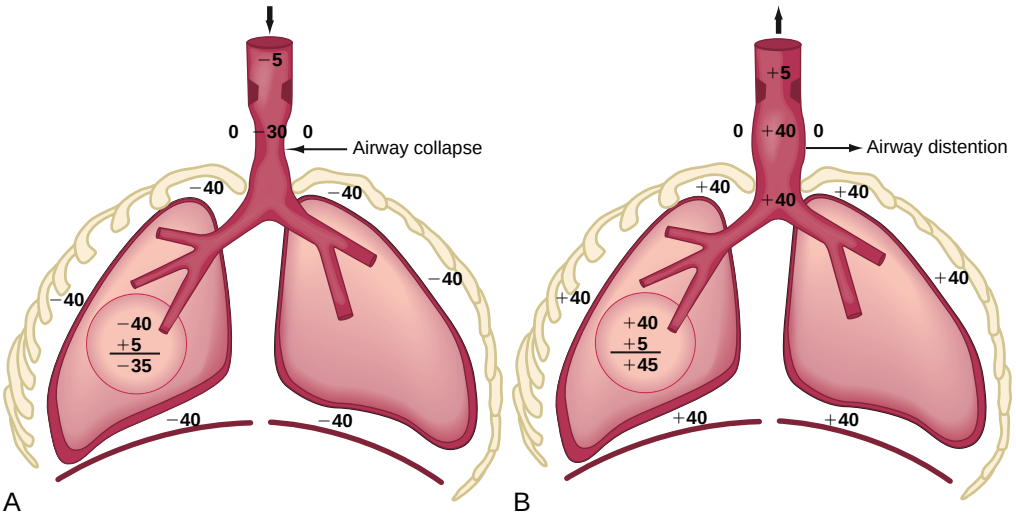

Fig. 421.1 A, In extrathoracic airway obstruction, the increased negative pressure during inspiration is transmitted up to the site of obstruction. This results in collapse of the extrathoracic airway below the site of obstruction, making the obstruction worse during inspiration. Note that the pressures are compared with the atmospheric pressure, which is traditionally represented as 0 cm. Terminal airway pressure is calculated as intrapleural pressure plus lung recoil pressure. Lung recoil pressure is arbitrarily chosen as 5 cm for the sake of simplicity. B, During expiration, the positive pressure below the site of obstruction results in distention of the extrathoracic airway and amelioration of symptoms. *(Courtesy Dr. Ashok Sarnaik.)*

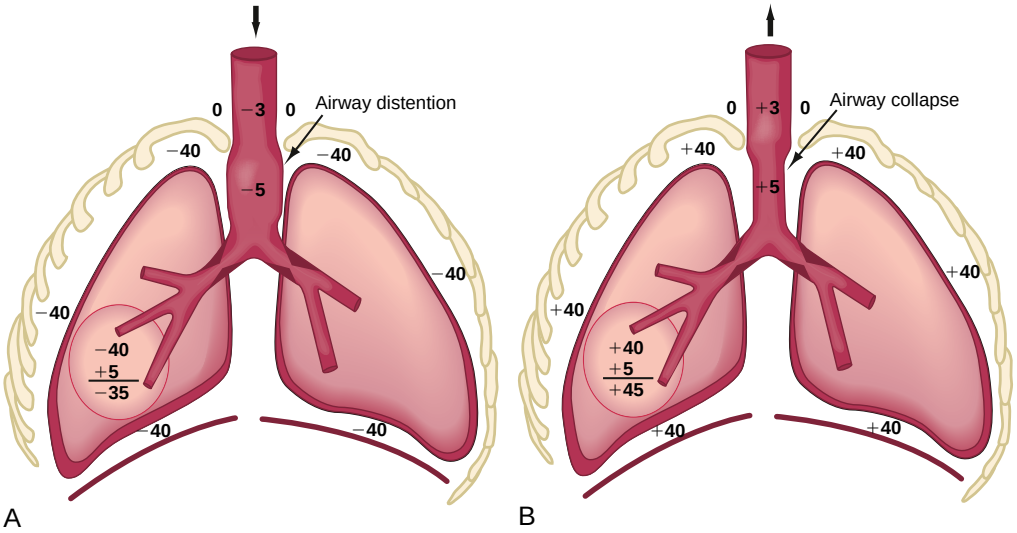

Fig. 421.2 A and B, In intrapulmonary airway obstruction, an even wider segment of intrathoracic airway is subjected to pressure changes compared with those observed in intrathoracic-extrapulmonary airway obstruction. Such lesions are associated with marked increase in airway obstruction during expiration. *(Courtesy Dr. Ashok Sarnaik.)*

Table 421.1 Respiratory Sounds

BASIC SOUNDS	MECHANISMS	ORIGIN	ACOUSTICS	RELEVANCE
Lung	Turbulent flow, vortices, other	Central (expiration), lobar to segmental airways (inspiration)	Low-pass filtered noise (<100 to >1,000 Hz)	Regional ventilation, airway caliber
Tracheal	Turbulent flow, flow impinging on airway walls	Pharynx, larynx, trachea, large airways	Noise with resonances (<100 to >3,000 Hz)	Upper airway configuration
ADVENTITIOUS SOUNDS				
Wheezes	Airway wall flutter, vortex shedding, other	Central and lower airways	Sinusoidal (<100 to >1,000 Hz, duration typically >80 msec)	Airway obstruction, flow limitation
Rhonchi	Rupture of fluid films, airway wall vibration	Larger airways	Series of rapidly dampened sinusoids (typically <300 Hz and duration <100 msec)	Secretions, abnormal airway collapsibility
Crackles	Airway wall stress-relaxation	Central and lower airways	Rapidly dampened wave deflections (duration typically <20 msec)	Distal airway and alveolar closure, secretions

Modified from Pasterkamp H, Kraman SS, Wodicka GR. Respiratory sounds. Advances beyond the stethoscope. *Am J Respir Crit Care Med.* 1997;156(3):974–987.

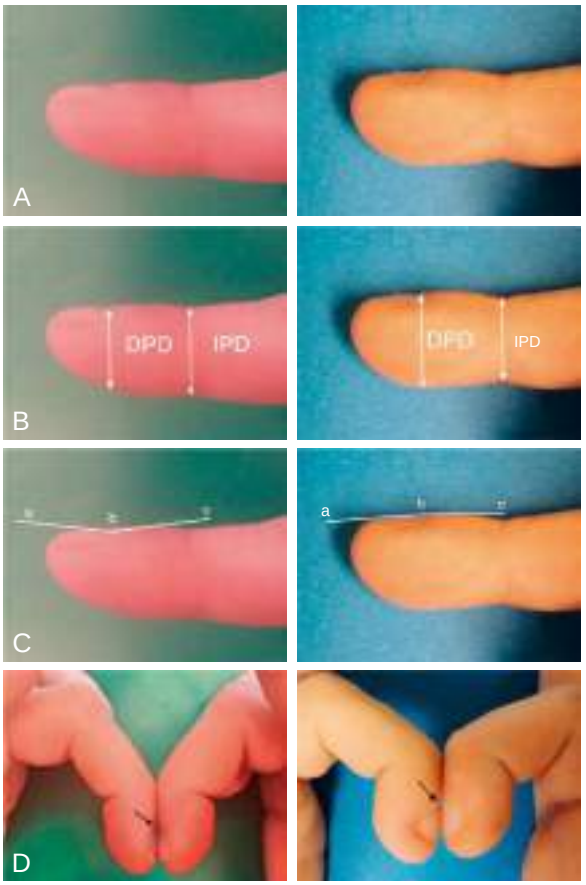

Fig. 421.3 **A,** Normal and clubbed finger viewed in profile. **B,** The normal finger demonstrates a distal phalangeal finger depth *(DPD)/* interphalangeal finger depth *(IPD)* ratio <1. The clubbed finger demonstrates a DPD/IPD ratio >1. **C,** The normal finger on the left demonstrates a normal profile *(abc)* with an angle less than 180 degrees. The clubbed finger demonstrates a profile angle >180 degrees. **D,** Schamroth sign is demonstrated in the clubbed finger with the loss of the diamond-shaped window in between finger beds *(arrow)* that is demonstrated in the normal finger. *(From Wilmott RW, Deterding RR, Li A, et al, eds. Kendig's Disorders of the Respiratory Tract in Children, 9th ed. Philadelphia: Elsevier; 2019: Fig. 1.14, p. 20.)*

Table 421.2 Nonpulmonary Diseases Associated with Clubbing

CARDIAC
Cyanotic congenital heart disease
Bacterial endocarditis
Chronic heart failure
HEMATOLOGIC
Thalassemia
Congenital methemoglobinemia (rare)
GASTROINTESTINAL
Crohn disease
Ulcerative colitis
Celiac disease
Chronic dysentery, sprue
Polyposis coli
Severe gastrointestinal hemorrhage
Small bowel lymphoma
Liver cirrhosis (including α1-antitrypsin deficiency)
Chronic active hepatitis
OTHER
Thyroid deficiency (thyroid acropachy)
Thyrotoxicosis
Chronic pyelonephritis (rare)
Toxic (e.g., arsenic, mercury, beryllium)
Lymphomatoid granulomatosis
Fabry disease
Raynaud disease, scleroderma
Hodgkin disease
Familial
UNILATERAL CLUBBING
Vascular disorders (e.g., subclavian arterial aneurysm, brachial arteriovenous fistula)
Subluxation of shoulder
Median nerve injury
Local trauma

From Pasterkamp H. The history and physical examination. In: Wilmott RW, Boat TF, Bush A, et al., eds. *Kendig and Chernick's Disorders of the Respiratory Tract in Children*, 8th ed. Philadelphia: Elsevier; 2012.

equilibration of alveolar gas and pulmonary capillary blood is complete for both oxygen and carbon dioxide. In diseases in which the alveolar capillary barrier is abnormally increased (alveolar interstitial diseases) and/or when the time available for equilibration is decreased (increased blood flow velocity), diffusion is incomplete. Because of its greater solubility in liquid medium, carbon dioxide is 20 times more diffusible than oxygen. Therefore diseases with diffusion defects are characterized by marked **alveolar-arterial oxygen (A-aO_2)** gradients and hypoxemia. Significant elevation of CO_2 does not occur as a result of a diffusion defect unless there is coexistent hypoventilation.

Venous blood brought to the lungs is "arterialized" after diffusion is complete. After complete arterialization, the pulmonary capillary blood should have the same P_{O_2} and P_{CO_2} as in the alveoli. The arterial blood gas composition is different from that in the alveoli, even in normal conditions, because there is a certain amount of dead space ventilation and venous admixture in a normal lung. Dead space ventilation results in a higher Pa_{CO_2} than PA_{CO_2}, whereas venous admixture or right-to-left shunting results in a lower Pa_{O_2} compared with the alveolar gas composition (Fig. 421.4). Pa_{O_2} is a reflection of the amount of oxygen dissolved in blood, which is a relatively minor component of total blood oxygen content. For every 100 torr P_{O_2}, there is 0.3 mL of dissolved O_2 in 100 mL of blood. The total blood oxygen content is composed of the dissolved oxygen and the oxygen bound to hemoglobin (Hb). Each gram of Hb carries 1.34 mL of O_2 when 100% saturated with oxygen. Thus 15 g of Hb carry 20.1 mL of oxygen. **Arterial oxygen content (Ca_{O_2})**, expressed as mL O_2/dL blood, can be calculated as $(Pa_{O_2} \times 0.003) + (Hb \times 1.34 \times S_{O_2})$, where Hb is grams of Hb per deciliter of blood and S_{O_2} is the percentage of oxyhemoglobin saturation. The relationship of P_{O_2} and the amount of oxygen carried by the Hb is the basis of the O_2-Hb dissociation curve (Fig. 421.5). The P_{O_2} at which Hb is 50% saturated is referred to as P_{50}. At a normal pH, Hb is 94% saturated at P_{O_2} of 70, and little further gain in saturation is accomplished at a higher P_{O_2}. At P_{O_2} <50, there is a steep decline in saturation and therefore the oxygen content.

Oxygen delivery to tissues is a product of oxygen content and cardiac output. When Hb is near 100% saturated, blood contains approximately 20 mL of oxygen per 100 mL or 200 mL/L. In a healthy adult, cardiac output is approximately 5 L/min, oxygen delivery 1,000 mL/min, and oxygen consumption 250 mL/min. Mixed venous blood returning to the heart has a P_{O_2} of 40 torr and is 75% saturated with oxygen. Blood oxygen content, cardiac output, and oxygen consumption are important determinants of mixed venous oxygen saturation. Given a steady-state blood oxygen content and oxygen consumption, the mixed venous saturation is an important indicator of cardiac output. A declining mixed venous saturation in such a state indicates decreasing cardiac output.

Clinical observations and interpretation of blood gas values are critical in localizing the site of the lesion and estimating its severity (Table 421.3). In airway obstruction above the carina (subglottic stenosis, vascular ring), blood gases reflect overall alveolar hypoventilation. This is manifested by an elevated PA_{CO_2} and a proportionate decrease in Pa_{O_2} as determined by the alveolar air equation. A rise in Pa_{CO_2} of 20 torr decreases Pa_{O_2} by 20 × 1.25 or 25 torr. In the absence of

significant parenchymal disease and intrapulmonary shunting, such lesions respond very well to supplemental oxygen in reversing hypoxemia. Similar blood gas values, demonstrating alveolar hypoventilation and response to supplemental oxygen, are observed in patients with a depressed respiratory center and ineffective neuromuscular function, resulting in respiratory insufficiency. Such patients can be easily distinguished from those with airway obstruction by their poor respiratory effort.

In intrapulmonary airway obstruction (asthma, bronchiolitis), blood gases reflect ventilation-perfusion imbalance and venous admixture. In these diseases, the obstruction is not uniform throughout the lungs, resulting in areas that are hyperventilated and others that are hypoventilated. Pulmonary capillary blood coming from hyperventilated areas has a higher P_{O_2} and lower P_{CO_2}, whereas that coming from hypoventilated regions has a lower P_{O_2} and higher P_{CO_2}. A lower blood P_{CO_2} can compensate for the higher P_{CO_2} because the Hb-CO_2 dissociation curve is relatively linear. In mild disease, the hyperventilated areas predominate, resulting in hypocarbia. An elevated P_{aO_2} in hyperventilated areas cannot compensate for the decreased P_{aO_2} in hypoventilated areas because of the shape of the O_2-Hb dissociation curve. This results in venous admixture, arterial desaturation, and decreased P_{aO_2} (see Fig. 421.4). With increasing disease severity, more areas become hypoventilated, resulting in normalization of P_{aCO_2} with a further decrease in P_{aO_2}. A normal or slightly elevated P_{aCO_2} in asthma should be viewed with concern as a potential indicator of impending respiratory failure. In severe intrapulmonary airway obstruction, hypoventilated areas predominate, leading to hypercarbia, respiratory acidosis, and hypoxemia. The degree to which supplemental oxygenation raises P_{aO_2} depends on the severity of the illness and the degree of venous admixture.

In alveolar and interstitial diseases, blood gas values reflect both intrapulmonary right-to-left shunting and a diffusion barrier. Hypoxemia is a hallmark of such conditions occurring early in the disease process. P_{aCO_2} is either normal or decreased. An increase in P_{aCO_2} is observed only later in the course, as muscle fatigue and exhaustion result in hypoventilation. Response to supplemental oxygen is relatively poor with shunting and diffusion disorders compared with other lesions.

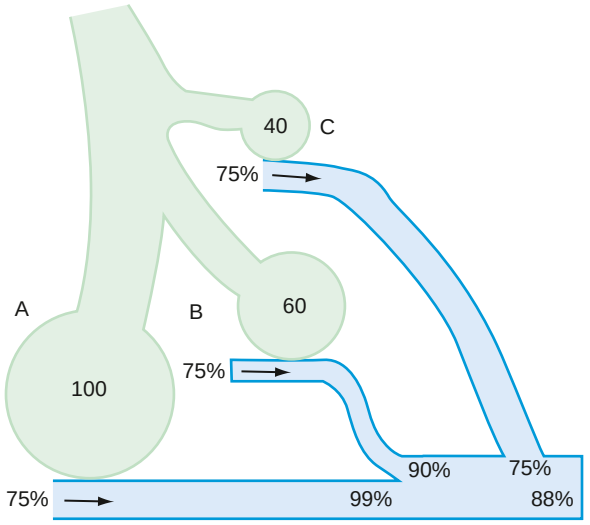

Fig. 421.4 Diagram demonstrating the effects of decreased ventilation-perfusion ratios on arterial oxygenation in the lungs. Three alveolar-capillary units are illustrated. Unit *A* has normal ventilation and an alveolar P_{O_2} of 100 mm Hg (shown by the number in the middle of the space). The blood that circulates through this unit raises its oxygen saturation from 75% (the saturation of mixed venous blood) to 99%. Unit *B* has a lower ventilation-perfusion ratio and a lower alveolar P_{O_2} of 60 mm Hg. The blood that circulates through this unit reaches a saturation of only 90%. Finally, unit *C* is not ventilated at all. Its alveolar P_{O_2} is equivalent to that of the venous blood, which travels through the unit unaltered. The oxygen saturation of the arterial blood reflects the weighted contributions of these three units. If it is assumed that each unit has the same blood flow, the arterial blood would have a saturation of only 88%. Ventilation-perfusion mismatch is the most common mechanism of arterial hypoxemia in lung disease. Supplemental oxygen increases the arterial P_{O_2} by raising the alveolar P_{O_2} in lung units that, like *B*, have a ventilation-perfusion ratio >0.

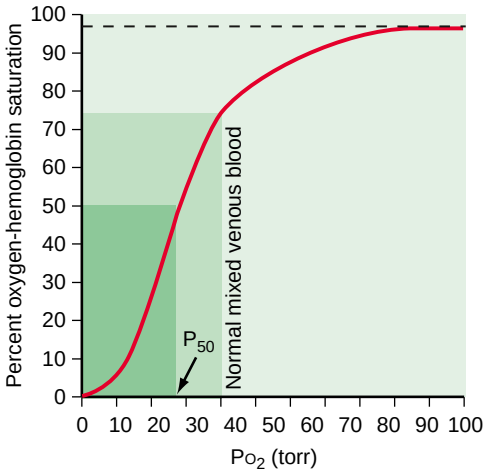

Fig. 421.5 Oxygen-hemoglobin dissociation curve. P_{50} of adult blood is around 27 torr. Under basal conditions, mixed venous blood has a P_{O_2} of 40 torr and oxygen-hemoglobin saturation of 75%. In arterial blood, these values are 100 torr and 97.5%, respectively. Note that there is a steep decline in oxygen-hemoglobin saturation at P_{aO_2} <50 torr, but relatively little increase in saturation is gained at P_{O_2} >70 torr. *(Courtesy Dr. Ashok Sarnaik.)*

Table 421.3 Interpretation of Arterial Blood Gas Values

LESION	EFFECT	TYPICAL ABG
Central (above the carina) airway obstruction *or* Depressed respiratory center *or* Ineffective neuromuscular function	Uniform alveolar hypoventilation	Early increase in P_{CO_2}. Proportionate decrease in P_{O_2} depending on alveolar air equation Response to supplemental oxygen: excellent
Intrapulmonary airway obstruction	Venous admixture mismatch	*Mild*: ↓ P_{CO_2}, ↓ P_{O_2} *Moderate*: "normal" P_{CO_2}, ↓↓ P_{O_2} *Severe*: ↑↑ P_{CO_2}, ↓↓↓ P_{O_2} Response to supplemental oxygen: good
Alveolar-interstitial pathology	Diffusion defect R → L shunt	Early decrease in P_{O_2} depending on severity Normal or low P_{CO_2}, ↑ P_{CO_2} if fatigue develops Response to supplemental oxygen: fair to poor

ABG, Arterial blood gas.
Courtesy Dr. Ashok Sarnaik.

Most clinical entities present with mixed lesions. A child with a vascular ring might also have an area of atelectasis; the arterial blood gas reflects both processes. The blood gas values reflect the more dominant lesion.

An arterial blood gas analysis is probably the single most useful rapid test of pulmonary function. Although this analysis does not specify the cause of the condition or the specific nature of the disease process, it can give an overall assessment of the functional state of the respiratory system and clues about the pathogenesis of the disease. Because the detection of cyanosis is influenced by skin color, perfusion, and blood Hb concentration, the clinical detection by inspection is an unreliable sign of hypoxemia. Arterial hypertension, tachycardia, and diaphoresis are late, and not exclusive, signs of hypoventilation.

Blood gas exchange is evaluated most accurately by the direct measurement of arterial pressure of oxygen (Po_2), pressure of carbon dioxide (Pco_2), and pH. The blood specimen is best collected anaerobically in a heparinized syringe containing only enough heparin solution to displace the air from the syringe. The syringe should be sealed, placed in ice, and analyzed immediately. Although these measurements have no substitute in many conditions, they require arterial puncture and have been replaced to a great extent by less invasive monitoring, such as capillary samples and/or oxygen saturation.

The age and clinical condition of the patient need to be taken into account when interpreting blood gas tensions. With the exception of neonates, values of arterial Po_2 <85 mm Hg are usually abnormal for a child breathing room air at sea level. Calculation of the alveolar-arterial oxygen gradient is useful in the analysis of arterial oxygenation, particularly when the patient is not breathing room air or in the presence of hypercarbia. Values of arterial Pco_2 >45 mm Hg usually indicate hypoventilation or a severe ventilation-perfusion mismatch, unless they reflect respiratory compensation for metabolic alkalosis (see Chapter 73).

In general practice **pulse oximetry** is used to monitor a patient's peripheral arterial saturation (SpO_2). This noninvasive method uses spectrophotometry to assess oxygenated and deoxygenated hemoglobin ratios to determine the SpO_2. Values are most accurate with arterial saturations above 90%; with saturations <90%, the accuracy is reduced. *Pulse oximetry often produces falsely high SpO_2 values in Black and dark-skinned patients, creating a risk for missed (occult) hypoxia, which may lead to underuse of oxygen therapy for Black patients.*

TRANSILLUMINATION OF THE CHEST

In infants up to at least 6 months of age, a pneumothorax (see Chapter 132) can often be diagnosed by transilluminating the chest wall using a fiberoptic light probe. Free air in the pleural space often results in an unusually large halo of light in the skin surrounding the probe. Comparison with the contralateral chest is often helpful in interpreting findings. This test is unreliable in older patients and in those with subcutaneous emphysema or atelectasis.

RADIOGRAPHIC TECHNIQUES

Chest X-Rays

A posteroanterior and a lateral view (upright and in full inspiration) should be obtained, except in situations in which the child is medically unstable (Fig. 421.6). Portable images, although useful in the latter situation, can give a somewhat distorted image. Expiratory images can be misinterpreted, although a comparison of expiratory and inspiratory images may be useful in evaluating a child with a suspected foreign body (localized failure of the lung to empty reflects bronchial obstruction: see Chapter 435). Although images taken in a recumbent position are difficult to interpret when there is fluid within the pleural space or a cavity, if pleural fluid is suspected (see Chapter 451), decubitus images are indicated.

Upper Airway Film

A lateral view of the neck can yield invaluable information about upper airway obstruction (see Chapter 433) and particularly about the condition of the retropharyngeal, supraglottic, and subglottic spaces (which should also be viewed in an anteroposterior projection) (Fig. 421.7).

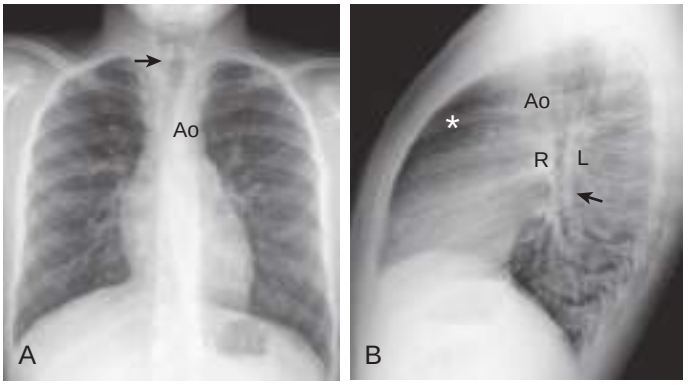

Fig. 421.6 Normal appearance of the trachea and lungs on chest radiography. **A,** On the frontal view, there is normal shouldering of the subglottic trachea *(arrow)*. The trachea courses inferiorly with a fairly uniform diameter to the level of the carina apart from a mild, smooth indentation at the level of the aortic arch *(Ao)*. The lungs are symmetrically inflated, with normal arborization of the vasculature. The hemidiaphragms are domed, not flattened. The normal heart size is less than 50% of the transverse dimension of the chest. **B,** On the lateral view, the trachea is of uniform diameter to the level of the aortic arch, with the exception of a mild, smooth impression from the aortic arch anteriorly (Ao). The hemidiaphragms are domed. The heart occupies less than 50% of the anteroposterior dimension of the chest and should not fill the retrosternal clear space *(asterisk)*. The bronchus intermedius *(arrow)* courses posterior to the right pulmonary artery *(R)*, and the arch of the left pulmonary artery *(L)* projects posterior to the carina. *(From Walters MM, Robertson RL, eds. Pediatric Radiology: The Requisites, 4th ed. Philadelphia: Elsevier; 2017: Fig. 2.11.)*

Knowing the phase of respiration during which the film was taken is often essential for accurate interpretation. Magnified airway images are often helpful in delineating the upper airways. Patients with suggested obstruction should not be unattended in the radiology department.

Sinus and Nasal Images

The general utility of radiologic examination of the sinuses is uncertain because a large number of images have positive findings (low sensitivity and specificity). Imaging studies are not necessary to confirm the diagnosis of sinusitis in children younger than age 6 years. CT scans are indicated if surgery is required, in cases of complications caused by sinus infection, in immunodeficient patients, in those with cystic fibrosis, and for recurrent infections unresponsive to medical management.

Chest Ultrasound

Chest ultrasound, which has no radiation and is more available in low-resource settings, has been shown to have more sensitivity and similar specificity in diagnosing community-acquired pneumonia compared to chest x-ray. Chest ultrasound can also detect pleural effusions and differentiate atelectasis from pneumonia.

Chest Computed Tomography

Chest CT often provides images of higher quality and sensitivity compared with radiography. Chest CT identifies early abnormalities such as air trapping, mucus plugging, or bronchiectasis in young children with cystic fibrosis before pathologic changes are detectable by either plain chest radiographs or pulmonary function testing. However, several caveats must be noted. Conventional chest CT involves higher radiation doses than plain images (see Chapter 758). The time required to perform chest CT examinations and the complications of respiratory and body motion mandate the use of sedation for this procedure in many infants and young children. However, improvements in imaging protocols and techniques have drastically reduced required radiation doses and imaging time. Chest CT is particularly useful in evaluating pulmonary nodules, pleural lesions, solid or cystic parenchymal lesions, pulmonary embolism, bronchiectasis, interstitial lung disease, and air trapping. The use of intravenous contrast material during CT

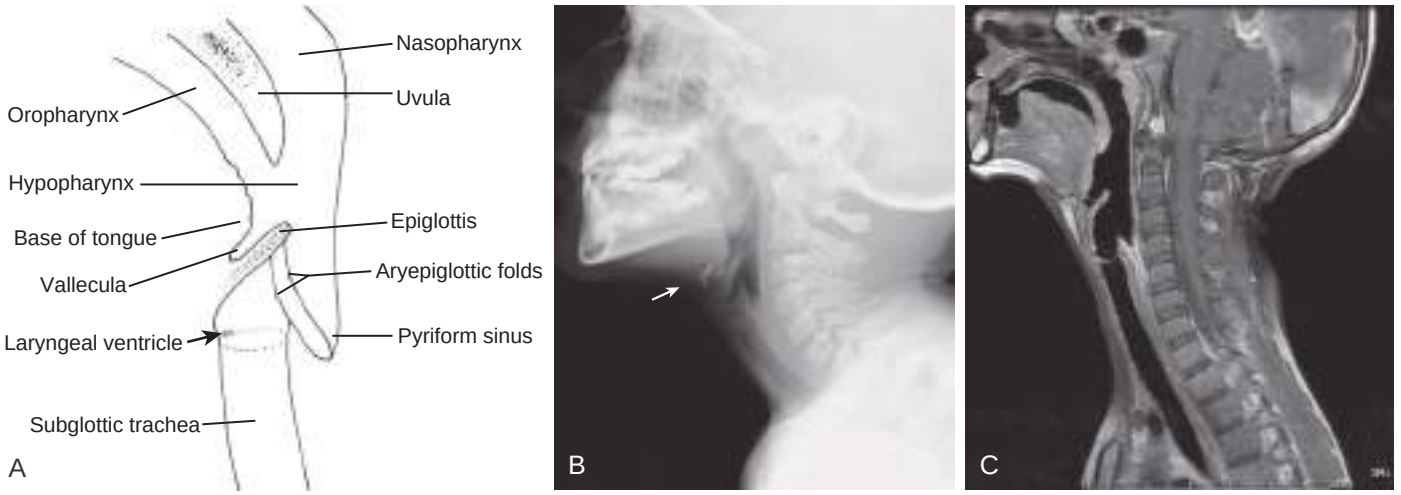

Fig. 421.7 A, Diagram depicting the normal anatomy of the upper airway. B, Corresponding lateral radiograph of the neck soft tissues. C, Sagittal T1-weighted magnetic resonance image. The hyoid bone "points to" the epiglottis on the radiograph *(arrow)*. *(From Walters MM, Robertson RL, eds. Pediatric Radiology: The Requisites, 4th ed. Philadelphia: Elsevier; 2017: Fig. 2.5.)*

imaging enhances vascular structures, distinguishing vessels from other soft tissue densities.

Magnetic Resonance Imaging

Although CT is often considered the gold standard for chest imaging, advances in MRI techniques have broadened the indications for pediatric chest MRI. Pediatric chest MRI has shown utility in imaging several disease processes. In cases of pneumonia, chest MRI can be used to demonstrate pulmonary consolidation in addition to complications such as abscess, necrosis, and effusions with or without loculation. Congenital malformations can also be visualized using chest MRI. Bronchogenic cysts, congenital pulmonary airway malformation, sequestration, and pulmonary aplasia or agenesis can be well characterized using MR techniques. Furthermore, MRI can be applied to imaging congenital large airway disorders such as airway malacia and external airway compression caused by vascular rings and slings. Last, dynamic techniques using cine MR imaging provide four-dimensional imaging as airway structure changes throughout the breathing cycle. Cine MRI assesses both lower airway caliber in children with trachea or bronchomalacia and upper airway anatomy to diagnose a site of obstruction in children with obstructive sleep apnea. Aside from imaging time, MR may in some cases be inferior to CT for imaging of bronchiectasis without airway wall thickening, focal air trapping, signs of interstitial lung disease, and small pulmonary nodules. MR protocols currently vary across centers, and collaboration with radiologists experienced in specialized chest imaging will result in high-quality imaging with minimization of ionizing radiation while weighing the need for sedation.

Fluoroscopy

Fluoroscopy can be used to assess diaphragm function in cases of suspected paralysis and to differentiate from eventration. Occasionally, the modality is used to evaluate airway dynamics with the benefit of visualization during awake and spontaneous breathing. The use of ionizing radiation with this modality should be taken into consideration, especially if repeated studies in the same patient are undertaken. Procedures such as needle aspiration or biopsy of a peripheral lesion may be accomplished with the aid of fluoroscopy, CT, or ultrasonography.

Barium Swallow

A barium swallow study, performed with fluoroscopy and spot images, is indicated in the evaluation of patients with recurrent pneumonia, persistent cough of undetermined cause, stridor, or persistent wheezing. The technique can be modified by using barium of different textures and thicknesses, ranging from thin liquid to solids, to evaluate swallowing mechanics and test for laryngeal penetration or pulmonary aspiration. Imaging of the esophageal phase is important and can be used to detect the presence of esophageal dysfunction, vascular rings (see Chapter 434), and tracheoesophageal fistulas (see Chapter 365). A contrast esophagram has been used in evaluating newborns with suggested esophageal atresia, but this procedure entails a high risk of pulmonary aspiration and is not usually recommended for this indication. Barium swallows have lower utility in evaluating gastroesophageal reflux (see Chapter 369).

Pulmonary Arteriography and Aortograms

Pulmonary arteriography has been used to allow detailed evaluation of the pulmonary vasculature. This imaging technique has also been helpful in assessing pulmonary blood flow and in diagnosing congenital anomalies, such as lobar agenesis, unilateral hyperlucent lung, vascular rings, and arteriovenous malformations. Thoracic aortograms demonstrate the aortic arch, its major vessels, and the systemic (bronchial) pulmonary circulation. They are useful in evaluating vascular rings and suspected pulmonary sequestration.

Ventilation-Perfusion Relation and Radionuclide Lung Scans

Gravitational force pulls the lung away from the nondependent part of the parietal pleura. Consequently, alveoli and airways in the nondependent parts (the upper lobes in upright position) of the lung are subjected to greater negative intrapleural pressure during tidal respiration and are kept relatively more inflated compared with the dependent alveoli and airways (the lower lobes in upright position). The nondependent alveoli are less compliant because they are already more inflated. Ventilation therefore occurs preferentially in the dependent portions of the lung that are more amenable to expansion during tidal inspiration. Although perfusion is also greater in the dependent portions of the lung because of greater pulmonary arterial hydrostatic pressure from gravity, the increase in perfusion is greater than the increase in ventilation in the dependent portions of the lung. Thus the ratios favor ventilation in the nondependent portions and perfusion in the dependent portions. Because the airways in the dependent portion of the lung are narrower, they close earlier during expiration. The lung volume at which the dependent airways start to close is referred to as the **closing capacity**. In normal children, the FRC is greater than the closing capacity. During tidal respiration, airways remain patent both in the dependent and the nondependent portions of the lung. In newborns, the closing capacity is greater than the FRC, resulting in perfusion of poorly ventilated alveoli during tidal respiration. Therefore normal neonates have a lower Pa_{O_2} compared with older children.

The relationship is adversely affected in a variety of pathophysiologic states. Air movement in areas that are poorly perfused is referred to as **dead space ventilation**. Examples of dead space ventilation include

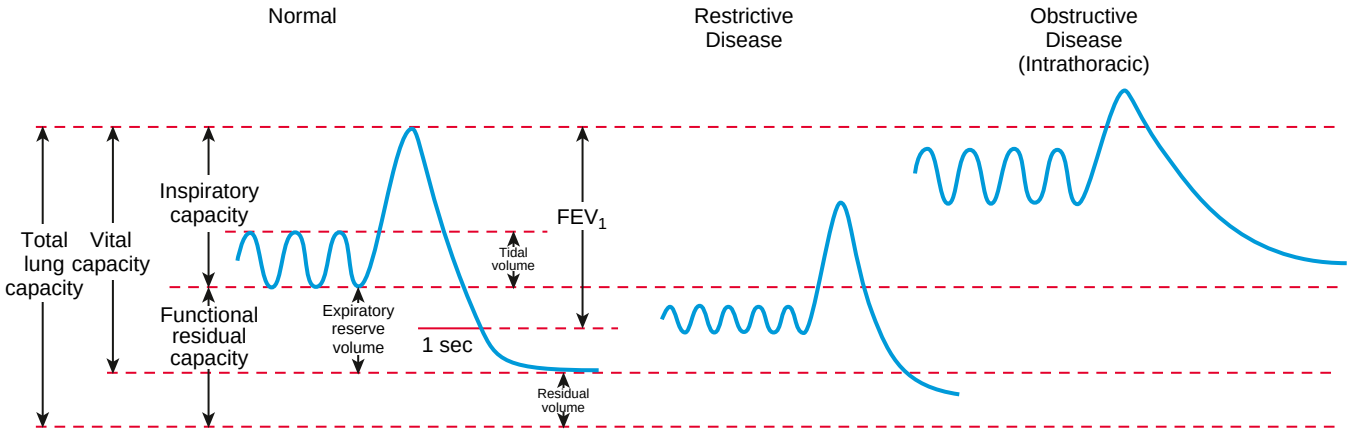

Fig. 421.8 Spirogram showing lung volumes and capacities. Forced expiratory volume 1 *(FEV_1)* is the maximum volume exhaled in 1 second after maximum inspiration. Restrictive diseases are usually associated with decreased lung volumes and capacities. Intrathoracic airway obstruction is associated with air trapping and abnormally high functional residual capacity and residual volume. FEV_1 and vital capacity are decreased in both restrictive and obstructive diseases. The ratio of FEV_1 to vital capacity is normal in restrictive disease but decreased in obstructive disease.

pulmonary thromboembolism and hypovolemia. Perfusion of poorly ventilated alveoli is referred to as **intrapulmonary right-to-left shunting** or **venous admixture**. Examples include pneumonia, asthma, and hyaline membrane disease. In intrapulmonary airway obstruction, the closing capacity is abnormally increased and can exceed the FRC. In such situations, perfusion of poorly ventilated alveoli during tidal respiration results in venous admixture.

The usual scan uses intravenous injection of material (macroaggregated human serum albumin labeled with ^{99m}Tc) that will be trapped in the pulmonary capillary bed. The distribution of radioactivity, proportional to pulmonary capillary blood flow, is useful in evaluating pulmonary embolism, as well as congenital cardiovascular and pulmonary defects. Acute changes in the distribution of pulmonary perfusion can reflect alterations of pulmonary ventilation.

The distribution of pulmonary ventilation can also be determined by scanning after the patient inhales a radioactive gas such as xenon-133. After the intravenous injection of xenon-133 dissolved in saline, pulmonary perfusion and ventilation can be evaluated by continuous recording of the rate of appearance and disappearance of the xenon over the lung. Appearance of xenon early after injection is a measure of perfusion, and the rate of washout during breathing is a measure of ventilation in the pediatric population. The most important indication for this test is the demonstration of defects in the pulmonary arterial distribution that can occur with congenital malformations or pulmonary embolism. **Spiral reconstruction CT** with contrast medium enhancement is helpful in evaluating pulmonary thrombi and emboli. Abnormalities in regional ventilation are also easily demonstrable in congenital lobar emphysema, cystic fibrosis, and asthma.

PULMONARY FUNCTION TESTING

Traditionally, lung volumes are measured with a spirogram (Fig. 421.8). **Tidal volume (V_T)** is the amount of air moved in and out of the lungs during each breath; at rest, V_T is normally 6-7 mL/kg body weight. **Inspiratory capacity** is the amount of air inspired by maximum inspiratory effort after tidal expiration. **Expiratory reserve volume** is the amount of air exhaled by maximum expiratory effort after tidal expiration. The volume of gas remaining in the lungs after maximum expiration is **residual volume**. **Vital capacity (VC)** is defined as the amount of air moved in and out of the lungs through maximum inspiration and expiration. VC, inspiratory capacity, and expiratory reserve volume are decreased in lung pathology but are also effort dependent. **Total lung capacity (TLC)** is the volume of gas occupying the lungs after maximum inhalation.

The **flow-volume relationship** offers a valuable means at the bedside or in an office setting to detect abnormal pulmonary mechanics and response to therapy with relatively inexpensive and easy-to-use devices. After maximum inhalation, the patient forcefully exhales

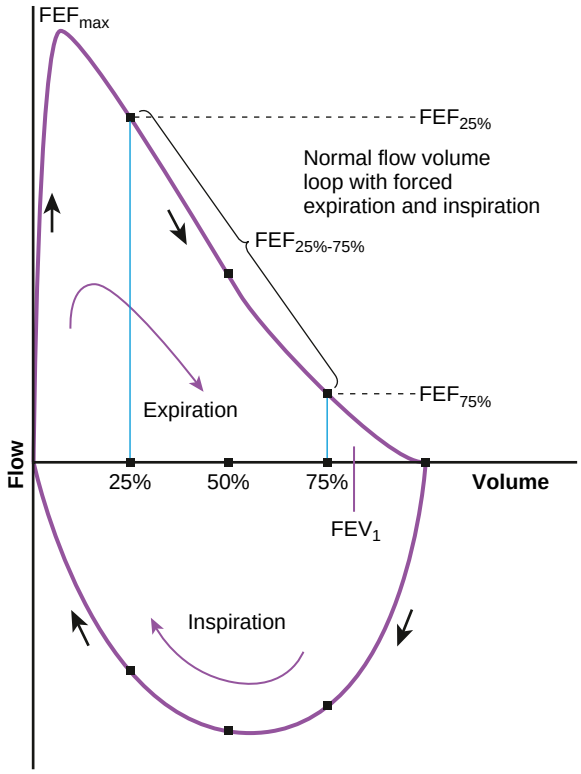

Fig. 421.9 Flow-volume loop in a normal person performed after maximal inspiration followed by forced complete expiration and forced complete inhalation. Maximum forced expiratory flow *(FEF_{max})* represents maximum flow during expiration. This is attained soon after initiation of the expiration. Fall in expiratory flow is gradual until it reaches zero after exhalation is complete. $FEF_{25–75\%}$ represents mean flow from 25% ($FEF_{25\%}$) to 75% ($FEF_{75\%}$) of exhaled forced expiratory volume *(FEV)*, also termed *forced vital capacity* (FVC). FEV_1 is the amount of volume after 1 second of forced exhalation. Normally FEV_1 is around 80% of FVC. *(Courtesy Dr. Ashok Sarnaik.)*

through a mouthpiece into the device until residual volume is reached, followed by maximum inhalation (Fig. 421.9). Flow is plotted against volume. **Maximum forced expiratory flow (FEF_{max})** is generated in the early part of exhalation, and it is a commonly used indicator of airway obstruction in asthma and other obstructive lesions. Provided maximum pressure is generated consistently during exhalation, a decrease in flow is a reflection of increased airway resistance

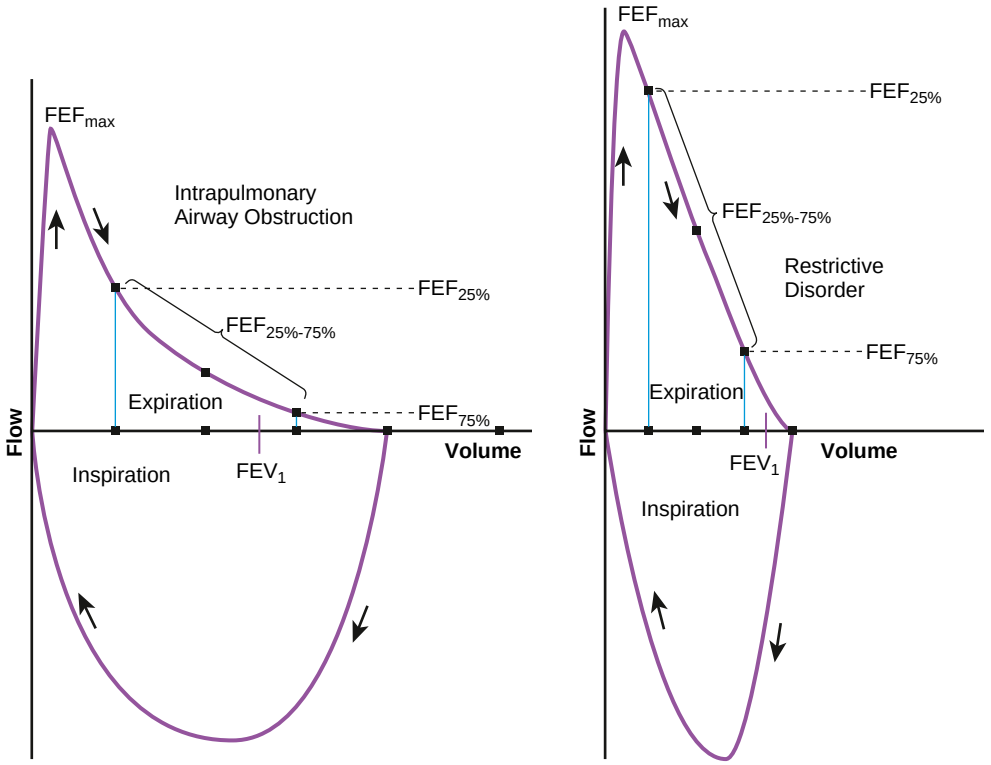

Fig. 421.10 Flow-volume loops in intrapulmonary airway obstruction and restrictive disorders. Note that in intrapulmonary airway obstruction, there is a decrease in maximum forced expiratory flow *(FEF_{max})*, $FEF_{25–75\%}$, and forced expiratory volume 1/forced vital capacity *($FEV_1/FVC\%$)*. The middle part of the expiratory loop appears concave. In restrictive disorders, the flow-volume loop assumes a more vertically oblong shape with reduction in FVC but not the FEV_1/FVC%. Expiratory and inspiratory flow rates are relatively unaffected. *(Courtesy Dr. Ashok Sarnaik.)*

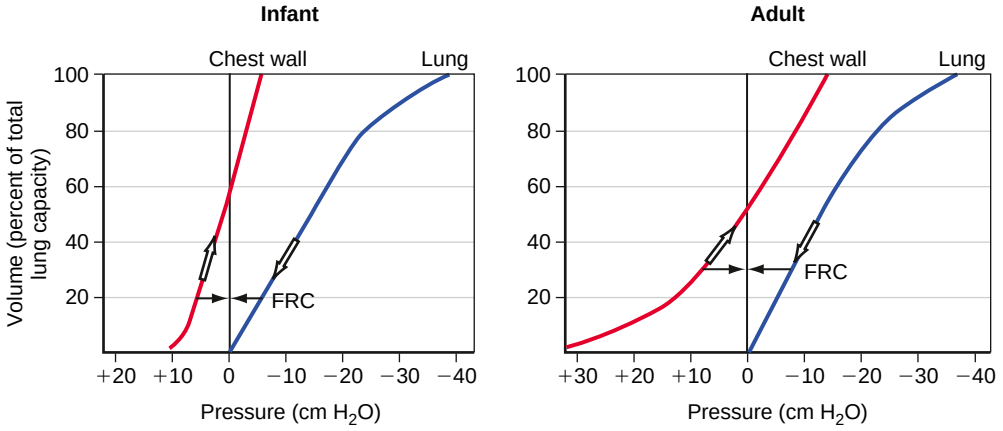

Fig. 421.11 Schematic of interaction between chest wall and lung recoil in infants compared with adults. The elastic recoil of a relatively more compliant chest wall is balanced by the lung recoil at a lower-volume functional residual capacity *(FRC)* in infants compared with adults. *(Courtesy Dr. Ashok Sarnaik.)*

(R_{AW}). The total volume exhaled during this maneuver is **forced vital capacity (FVC)**. **Volume exhaled in 1 second** is referred to as **forced expiratory volume 1 (FEV_1)**. FEV_1/FVC is expressed as a percentage of FVC. $FEF_{25–75\%}$ is the mean flow between 25% and 75% of FVC, and is considered relatively effort independent. Individual values and shapes of flow-volume curves show characteristic changes in obstructive and restrictive respiratory disorders (Fig. 421.10). In intrapulmonary airway obstruction such as asthma or cystic fibrosis, there is a reduction of FEF_{max}, $FEF_{25–75\%}$, FVC, and FEV_1/FVC. Also, there is a characteristic concavity in the middle part of the expiratory curve. In restrictive lung disease such as interstitial pneumonia (see Chapter 448.5) and kyphoscoliosis (see Chapter 467.5), FVC is decreased with relative preservation of airflow and FEV_1/FVC. The flow-volume curve assumes a vertically oblong shape compared with normal. Changes in shape of the flow-volume loop and individual values depend on the type of disease and the extent of severity. Serial determinations provide valuable information regarding disease evolution and response to therapy.

FRC has important pathophysiologic implications. Chest wall compliance is a major determinant of FRC. Because the chest wall and the lungs recoil in opposite directions at rest, FRC is reached at the point where the outward elastic recoil of the thoracic cage counterbalances the inward lung recoil. This balance is attained at a lower lung volume in a young infant's ribs because they are oriented much more horizontally and the diaphragm is flatter and less domed. Consequently, the infant is unable to duplicate the efficiency of upward and outward movement of obliquely oriented ribs or the downward displacement of a domed diaphragm in an adult to expand the thoracic capacity. This creates an extremely high thoracic compliance compared with older children and adults (Fig. 421.11). The measured FRC in infants is higher than expected because infant respiratory muscles maintain the thoracic cage in an inspiratory position at all times. In addition, young infants experience some amount of air trapping during expiration.

Alveolar gas composition changes during inspiration and expiration. **Alveolar P_{O_2} (PA_{O_2})** increases and **alveolar P_{CO_2} (PA_{CO_2})** decreases during inspiration as fresh atmospheric gas enters the lungs. During exhalation, PA_{O_2} decreases and PA_{CO_2} increases as pulmonary capillary blood continues to remove oxygen from and add CO_2 into the alveoli (Fig. 421.12). FRC acts as a buffer, minimizing the changes in PA_{O_2} and PA_{CO_2} during inspiration and expiration. FRC represents the

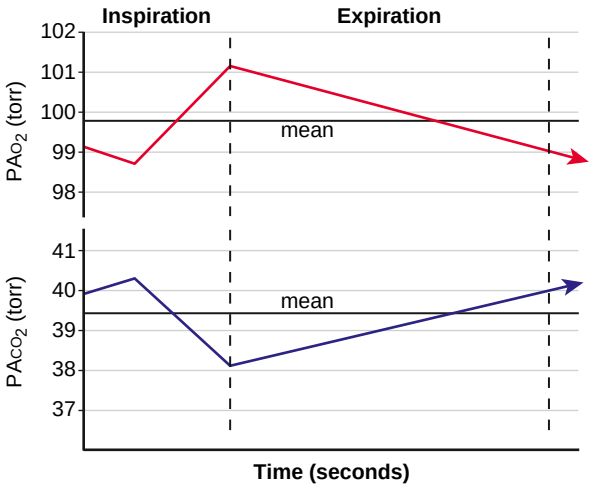

Fig. 421.12 Alveolar P_{O_2} rises and P_{CO_2} falls during inspiration as fresh atmospheric gas is brought into the lungs. During expiration, the opposite changes occur as pulmonary capillary blood continues to remove O_2 and add CO_2 from the alveoli without atmospheric enrichment. Note that during the early part of inspiration, alveolar P_{O_2} continues to fall and P_{CO_2} continues to rise because of inspiration of the dead space that is occupied by the previously exhaled gas. *(Courtesy Dr. Ashok Sarnaik; modified from Comroe JH. Physiology of Respiration, 2nd ed. Chicago: Year Book Medical Publishers; 1974:12.)*

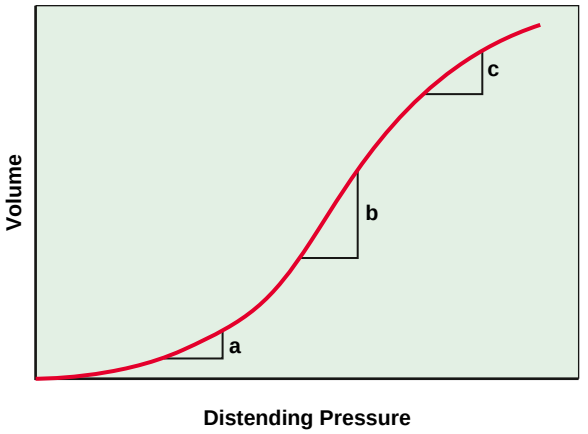

Fig. 421.13 Lung compliance is significantly influenced by the functional residual capacity (FRC). The same change in pressure is associated with less change in volume when FRC is abnormally decreased *(a)* or abnormally increased *(c)* compared with the normal state *(b)*. *(Courtesy Dr. Ashok Sarnaik.)*

environment available for pulmonary capillary blood for gas exchange at all times.

A decrease in FRC is often encountered in alveolar interstitial diseases and thoracic deformities. The major pathophysiologic consequence of decreased FRC is **hypoxemia**. Reduced FRC results in a sharp decline in PA_{O_2} during exhalation because a limited volume is available for gas exchange. P_{O_2} of pulmonary capillary blood therefore falls excessively during exhalation, leading to a decline in **arterial P_{O_2} (PA_{O_2})**. Any increase in PA_{O_2} (and therefore Pa_{O_2}) during inspiration cannot compensate for the decreased Pa_{O_2} during expiration. The explanation for this lies in the shape of the O_2-Hb dissociation curve, which is sigmoid shaped (see Fig. 421.5). Because most of the oxygen in blood is combined with Hb, it is the percentage of **oxyhemoglobin (S_{O_2})** that gets averaged rather than the P_{O_2}. Although an increase in arterial P_{O_2} cannot increase O_2-Hb saturation >100%, there is a steep desaturation of Hb below a P_{O_2} of 50 torr; thus decreased S_{O_2} during exhalation as a result of low FRC leads to overall arterial desaturation and hypoxemia. The adverse pathophysiologic consequences of decreased FRC are ameliorated by applying **positive end-expiratory pressure (PEEP)** and increasing the inspiratory time during mechanical ventilation.

The lung pressure-volume relationship is markedly influenced by FRC (Fig. 421.13). Pulmonary compliance is decreased at abnormally low or high FRC.

FRC is abnormally increased in intrathoracic airway obstruction, which results in incomplete exhalation, and is abnormally decreased in alveolar-interstitial diseases. At excessively low or high FRC, tidal respiration requires higher inflation pressures compared to normal FRC. Abnormalities of FRC result in increased work of breathing with spontaneous respiration and increased barotrauma in mechanical ventilation.

The measurement of respiratory function in infants and young children can be difficult because of the lack of cooperation. Attempts have been made to overcome this limitation by creating standard tests that do not require the patient's active participation. Respiratory function tests still provide only a partial insight into the mechanisms of respiratory disease at early ages.

Whether restrictive or obstructive, most forms of respiratory disease cause alterations in lung volume and its subdivisions. Restrictive diseases typically decrease **TLC**. TLC includes residual volume, which is not accessible to direct determinations. It must therefore be measured indirectly by gas dilution methods or, preferably, by **plethysmography**. Restrictive disease also decreases **VC**. Obstructive diseases produce gas trapping and thus increase residual volume and FRC, particularly when these measurements are considered with respect to TLC.

Lung Clearance Index (LCI) is a test that uses multiple-breath washouts to demonstrate airway physiology. The test involves the gradual replacement of a tracer gas such as nitrogen, which is normally in the lungs or within biologically inert gas, with 100% oxygen. This gradual washout of the tracer gas requires no complex respiratory maneuvers but has some technical challenges. The variability of LCI in healthy children and adolescents is low, and LCI has been shown to discriminate against healthy individuals and patients with chronic conditions such as cystic fibrosis or asthma. LCI reports gas mixing efficiency, which is an index of lung function, with the diseased lung taking a longer time to wash out the tracer gas than a healthy lung. LCI has been shown to be able to detect lung disease before FEV_1 and therefore may be a tool for early detection of lung pathology.

Airway obstruction is most commonly evaluated from determinations of gas flow in the course of a forced expiratory maneuver. The **peak expiratory flow** is reduced in advanced obstructive disease. The wide availability of simple devices that perform this measurement at the bedside makes it useful for assessing children who have airway obstruction. Evaluation of peak flows requires a voluntary effort, and peak flows may not be altered when the obstruction is moderate or mild. Other gas flow measurements require that the child inhale to TLC and then exhale as far and as fast as possible for several seconds. Cooperation and good muscle strength are therefore necessary for the measurements to be reproducible. FEV_1 correlates well with the severity of obstructive diseases. The **maximal midexpiratory flow rate**, the average flow during the middle 50% of the forced VC, is a more reliable indicator of mild airway obstruction. Its sensitivity to changes in residual volume and VC, however, limits its use in children with more severe disease. The construction of flow-volume relationships during the forced VC maneuvers overcomes some of these limitations by expressing the expiratory flows as a function of lung volume.

A **spirometer** is used to measure VC and its subdivisions and expiratory (or inspiratory) flow rates (see Fig. 421.8). A simple manometer can measure the maximal inspiratory and expiratory force a subject generates, normally at least 30 cm H_2O. This is useful in evaluating the neuromuscular component of ventilation. Expected normal values for VC, FRC, TLC, and residual volume are obtained from prediction equations based on body height.

Flow rates measured by spirometry usually include the FEV_1 and the **maximal midexpiratory flow rate**. More information results from a maximal expiratory flow-volume curve, in which expiratory flow rate

is plotted against expired lung volume (expressed in terms of either VC or TLC). Flow rates at lung volumes less than approximately 75% VC are relatively independent of effort. Expiratory flow rates at low lung volumes (<50% VC) are influenced much more by small airways than flow rates at high lung volumes (FEV_1). The flow rate at 25% VC is a useful index of small airway function. Low flow rates at high lung volumes associated with normal flow at low lung volumes suggest upper airway obstruction.

Airway resistance (R_{AW}) is measured in a plethysmograph, or alternatively, the reciprocal of R_{AW}, **airway conductance**, may be used. Because R_{AW} measurements vary with the lung volume at which they are taken, it is convenient to use **specific airway resistance**, SR_{AW} ($SR_{AW} = R_{AW}$/lung volume), which is nearly constant in subjects older than age 6 years (normally <7 sec/cm H_2O).

Impulse oscillometry (IOS) is a tool that can be used in minimally cooperative patients such as young children. This technology uses properties of sound waves at different frequencies during normal tidal breathing to estimate resistance in airflow. This tool can differentiate small from large airway obstruction and measures bronchodilatory response. Although the tool is fairly easy to use, normative values are few, which limits the use across patients, but it may be a good tool to track airway resistance across time in conditions such as asthma.

The **diffusing capacity for carbon monoxide** is related to oxygen diffusion and is measured by rebreathing from a container with a known initial concentration of carbon monoxide or by using a single-breath technique. Decreases in diffusing capacity for carbon monoxide reflect decreases in effective alveolar capillary surface area or decreases in diffusibility of the gas across the alveolar-capillary membrane. Primary diffusion abnormalities are unusual in children; therefore this test is most commonly employed in children with rheumatologic or autoimmune diseases and in children exposed to toxic drugs to the lungs (e.g., oncology patients) or chest wall radiation. Regional gas exchange can be conveniently estimated with the perfusion-ventilation xenon scan. Determining arterial blood gas levels also discloses the effectiveness of alveolar gas exchange.

Pulmonary function testing, although rarely resulting in a diagnosis, is helpful in defining the type of process (obstruction, restriction) and the degree of functional impairment, in following the course and treatment of disease, and in estimating the prognosis. It is also useful in preoperative evaluation and in confirming functional impairment in patients with subjective complaints but a normal physical examination. In most patients with obstructive disease, a repeat test after administering a bronchodilator is warranted.

Most tests require some cooperation and understanding by the patient. Interpretation is greatly facilitated if the test conditions and the patient's behavior during the test are known. Infants and young children who cannot or will not cooperate with test procedures can be studied in a limited number of ways, which often require sedation. Flow rates and pressures during tidal breathing, with or without transient interruption of the flow, may be useful to assess some aspects of R_{AW} or obstruction and to measure compliance of the lungs and thorax. Expiratory flow rates can be studied in sedated infants with passive compression of the chest and abdomen using a rapidly inflatable jacket. Gas dilution or plethysmographic methods can also be used in sedated infants to measure FRC and R_{AW}.

The measurement of **fractional exhaled nitric oxide** (FENO) is used as a surrogate measure for eosinophilic inflammation of the lower airways. It can be used as a part of a diagnostic evaluation for asthma, a tool for predicting or assessing an individual's response to antiinflammatory therapy, and in monitoring adherence to treatment. A number of commercially available devices are available for measurement of FENO. Some degree of cooperation is required, but FENO has been measured in preschool-age children. Normal cutoff values vary by age and device. FENO has been used to distinguish asthma (particularly allergic asthma) from other wheezing phenotypes. FENO achieves moderate diagnostic performance for the detection of asthma in children, with sensitivity, specificity, and diagnostic odds ratios of 0.79, 0.81, and 16.52, respectively. Children managed using FENO may have fewer asthma exacerbations. A decrease of FENO by 20% is considered indicative of a positive response to antiinflammatory therapy. Some studies using FENO have contradictory results, and it is likely that FENO may be more useful in some asthma phenotypes than in others.

The measurement of **nasal nitric oxide** (nNO) is accomplished by collecting exhaled gas from a nostril during glottic closure and correlates to nasal mucosal inflammation. There is great interest in the use of nNO to diagnose **primary ciliary dyskinesia** (PCD, see Chapter 425), because of challenges diagnosing PCD with currently available techniques. A cutoff value of less than or equal to 77 nL/min showed excellent sensitivity and specificity using a standardized technique at multiple centers. Equipment for measurement of nNO is not yet FDA-approved in the United States.

MICROBIOLOGY: EXAMINATION OF LUNG SECRETIONS

The specific diagnosis of infection in the lower respiratory tract depends on the proper handling of an adequate specimen obtained in an appropriate fashion. Nasopharyngeal or throat cultures are often used but might not correlate with cultures obtained by more direct techniques from the lower airways. Sputum specimens are preferred and are often obtained from patients who do not expectorate by deep throat swab immediately after coughing or by saline nebulization. Specimens can also be obtained directly from the tracheobronchial tree by nasotracheal aspiration (usually heavily contaminated), by transtracheal aspiration through the cricothyroid membrane (useful in adults and adolescents but hazardous in children), and in infants and children by a sterile catheter inserted into the trachea either during direct laryngoscopy or through a freshly inserted endotracheal tube. A specimen can also be obtained at bronchoscopy.

A specimen obtained by direct expectoration is usually assumed to be of tracheobronchial origin, but often, especially in children, it is not from this source. The presence of alveolar macrophages (large mononuclear cells) is the hallmark of tracheobronchial secretions. Nasopharyngeal and tracheobronchial secretions can contain ciliated epithelial cells, which are more commonly found in sputum. Nasopharyngeal and oral secretions often contain large numbers of squamous epithelial cells. Sputum can contain both ciliated and squamous epithelial cells.

During sleep, mucociliary transport continually brings tracheobronchial secretions to the pharynx, where they are swallowed. An early-morning fasting gastric aspirate often contains material from the tracheobronchial tract that is suitable for culture for acid-fast bacilli.

The absence of polymorphonuclear leukocytes in a Wright-stained smear of sputum or **bronchoalveolar lavage** (BAL) fluid containing adequate numbers of macrophages may be significant evidence against a bacterial infectious process in the lower respiratory tract, assuming that the patient has normal neutrophil counts and function. Eosinophils suggest allergic disease. Iron stains can reveal hemosiderin granules within macrophages, suggesting pulmonary hemosiderosis. Specimens should also be examined by Gram stain. Bacteria within or near macrophages and neutrophils can be significant. Viral pneumonia may be accompanied by intranuclear or cytoplasmic inclusion bodies visible on Wright-stained smears, and fungal forms may be identifiable on Gram or silver stains.

With advances in the area of genomics and the speed with which it is possible to identify microbes, microbiologic analysis has been expanded. Specific bacteria in the lungs of children with cystic fibrosis (see Chapter 454) are linked to morbidity and mortality. There is a correlation between patient age and morbidity and mortality (as expected), but important microbes also are correlated either negatively or positively with early or late pathogenic processes. *Haemophilus influenzae* (see Chapter 240) is negatively correlated, and *Pseudomonas aeruginosa* and *Stenotrophomonas maltophilia* (see Chapter 251.3) have a strong positive correlation with patient age in cystic fibrosis. The microbiota diversity is much broader in those who are healthier individuals or those who are younger patients with cystic fibrosis than the older and sicker population.

In addition, the microbiomes in the respiratory tract of smokers and nonsmokers differ substantially. In all patients, most of the bacteria found in the lungs are also present in the oral cavity, but some bacteria,

such as *Haemophilus* and enterobacteria, are much more represented in the lungs than in the mouth. Principal differences in microbiome composition between smokers and nonsmokers are found in the mouth. For example, *Neisseria* levels are much lower in smokers as compared with nonsmokers. Overall, the microbiome diversity in smokers was also reduced compared with nonsmokers.

THE MICROBIOME

Whereas some studies have looked at the microbiome in the lungs and others in the gut, there is evidence to believe that there is a gut-lung axis regarding the microbiome. For example, the airway epithelium regulates local immunity (IgA antibodies, defensins) and can stimulate a Th2 airway response. Other cytokines are also involved such as transforming growth factor beta (TGFB). Bacteriophages are also important in the airways because these may protect the airways from certain bacteria. Importantly, the gut microbiome, influenced by many factors such as diet, environment, mode of childbirth, socioeconomic status, and antibiotic use, affects in a major way the development of immunity in the growing infant and child. Similarly, the lungs are not sterile, and bacteria exist in the lungs of children. It is possible therefore that the microbiome in one site affects the response to the microbiome in another through either immunity or predisposition to inflammation.

The Amish and Hutterite populations are genetically identical, but they have very different asthma prevalence, with the Hutterite having 4-6 times more asthma than the Amish population. One study showed that the Amish household had ~7 times more dust endotoxin. Extracts from the Amish dust inhibited airway hyper-responsiveness, but this did not happen from the Hutterite samples. Although this does not separate between the lung and gut, it suggests that the hygiene hypothesis is important and that microbes and immunity are tied together in the genesis of asthma, especially in children, and in the formative stages of immunity and allergic diseases.

Ciliary Structure and Function

Cilia are cellular organelles that project from respiratory epithelial surfaces into the lumen. They are microscopic hairlike structures, are motile, and beat in a coordinated fashion from distal to proximal airways to clear mucus, fluid, and inhaled particles. They generally beat at a fast pace, on the order of 10-20 Hz.

Their structure is typical, consisting of nine peripheral doublet microtubules arranged in a circular fashion, with two single microtubules centrally located. As such, this structure is called an *axoneme*. Each microtubule has an inner and an outer dynein arm, with radial spokes connecting each peripheral pair with the central microtubules.

Each epithelial cell lining the respiratory tract has around 200 such cilia. The cilia on the surface beat synchronously not only over the surface of one such cell but across many cells. How cells communicate to induce the rhythmic beating function of cilia across a sheet of cells is not well understood.

Hundreds of proteins make up each cilium in the respiratory tract, and many pathogenic variants have been described. Such variants render these cilia dysfunctional, leading to a respiratory disease, PCD. Often the structure is also abnormal, but cilia can be dysfunctional without an apparent EM abnormal structure (Fig. 421.14).

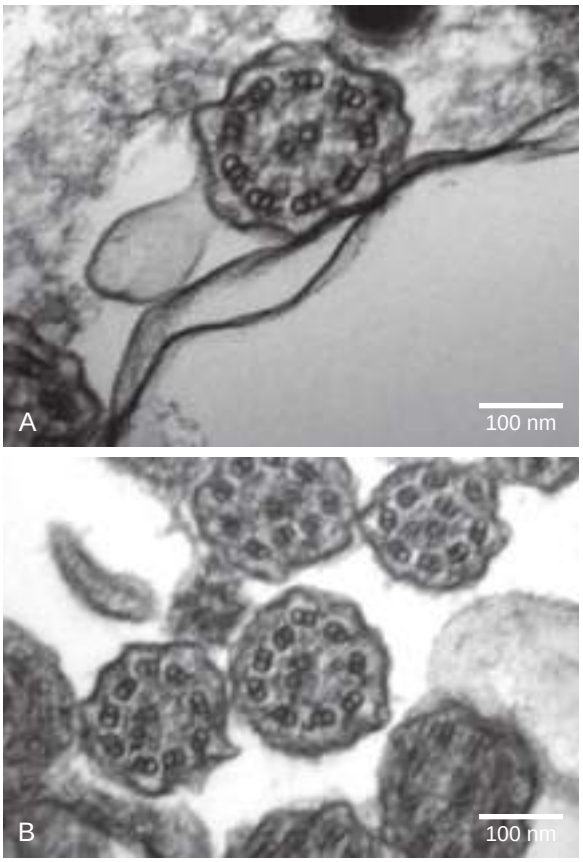

Fig. 421.14 **A,** Cross-section of a normal EM cilium structure. Note the typical axoneme structure, consisting of the nine peripheral doublet microtubules arranged in a circular fashion, with two single microtubules centrally located. Each microtubule has an inner and an outer dynein arm. **B,** Abnormal axoneme, as there are a number of doublets missing the dynein arms, which are clear in **A,** with normal cilium. Note also the disorganized location of the nine peripheral microtubules in some of the cilia. *(Courtesy Dr. Denise Malicki, UCSD/Rady Children's Hospital.)*

Cardiopulmonary Exercise Testing

Exercise testing (see Chapter 472.5) is a direct approach for measuring respiratory gas exchange and assessing causes of exercise limitations. Measurements of heart and respiratory rate, minute ventilation, oxygen consumption, carbon dioxide production, and arterial blood gases during incremental exercise loads often provide invaluable information about the physiologic source of the symptom. Exercise is a strong provocateur of bronchospasm in susceptible patients, so exercise testing can be useful in the diagnosis of asthma as the cause of difficulty breathing with exertion. Several diseases or physiologic states distinct from asthma may mimic symptoms of exercise-induced bronchoconstriction. In addition to cardiac disease and decreased fitness, exercise-induced laryngeal obstruction (EILO) leads to significant limitations. In selected cases, performance of laryngoscopy during cardiopulmonary exercise testing lends essential diagnostic information. Application of cardiopulmonary testing for assessment of aerobic fitness and disease limitations provides invaluable diagnostic information to aid clinicians investigating exercise intolerance.

Sleep Studies

See Chapter 31.

AIRWAY VISUALIZATION AND LUNG SPECIMEN–BASED DIAGNOSTIC TESTS

Laryngoscopy

The evaluation of stridor, problems with vocalization, and other upper airway abnormalities usually requires direct inspection. Although indirect (mirror) laryngoscopy may be reasonable in older children and adults, it is rarely feasible in infants and small children. Direct laryngoscopy may be performed with either a rigid or a flexible instrument. The safe use of the rigid scope for examining the upper airway requires topical anesthesia and either sedation or general anesthesia, whereas the flexible laryngoscope can often be used in the office setting with or without sedation. Further advantages to the flexible scope include the ability to assess the airway without the distortion that may be introduced by the use of the rigid scope and the ability to assess airway dynamics more accurately. Because there is a relatively high incidence of concomitant lesions in the upper and lower airways, it is often prudent to examine the airways above and below the glottis, even when the primary indication is in the upper airway (stridor).

Bronchoscopy and Bronchoalveolar Lavage

Bronchoscopy is the inspection of the airways. Flexible bronchoscopy is commonly used in pediatrics to visualize the airways. There are several sizes of scopes that enable visualization of the proximal and distal airways. Many fiberoptic bronchoscopes also have a channel that allows for the collection of fluids, or in larger scopes allows for the insertion of tools such as forceps, baskets, or brushes. The smallest scope is a 2.2-mm-outer-diameter bronchoscope that does not have a channel; therefore only visualization of the airways is possible. The smallest bronchoscope with a channel is a 2.8-mm-outer-diameter scope, which has a 1.2-mm working channel. This scope is commonly used in pediatrics and is predominately used to visualize the airways and to collect a lavage sample. In larger "adult" scopes (4.9-5.5 mm outer diameter and 2.0 mm working channel), small instruments such as forceps can be inserted. Therapeutic bronchoscopes require an even larger channel (2.8 mm working channel, which requires a larger outer diameter of 6.0-6.3 mm), so they are not used often in the pediatric population. A smaller scope (4.1 mm outer diameter) with a larger working channel (2.0 mm) has become available and may make interventional pediatric bronchoscopy more common in the future. For urgent or emergent therapeutic interventions, such as foreign body aspiration or large volume hemoptysis, surgical rigid bronchoscopy remains the preferred approach, as it provides the largest working channel and permits simultaneous ventilation during the procedure.

Visualization of the airway has improved through advances in optics and insertable tools. **Narrow-band imaging** and **autofluorescence** imaging bronchoscopes are two types of bronchoscopes that can aid in the detection of airway lesions. These scopes appear no different than the conventional bronchoscope but use different bandwidths of lights to highlight mucosal and submucosal vasculature. These bronchoscopes allow the operator to see airway mucosal lesions that would be difficult to see or not be seen under normal white light. The autofluorescence imaging bronchoscope uses the fluorophores, such as tryptophan, collagen, elastin, and porphyrins, within the airway tissue to emit fluorescence when irradiated with a light source. Changes in concentrations of the fluorophores in bronchial mucosa would appear as an irregular lesion when viewed with an autofluorescence imaging bronchoscope. The narrow-band imaging bronchoscope also uses light absorption characteristics of Hb to enhance images of blood vessels. This bronchoscope uses blue wavelengths in the range of 390-445 nm to visualize the mucosal layer capillaries and green wavelengths at 530 and 550 nm to detect deeper submucosal thick blood vessels. Both types of bronchoscopes allow the operator to detect findings that would not be seen under normal white light. These scopes are being used more often in adults, where lesions are biopsied to detect premalignant and malignant lesions, although use has been described to better delineate characteristics of a subglottic cyst in a 3-month-old infant. These scopes are noninvasive and would be well tolerated in children, but are currently only available in larger "adult" sizes.

The most common diagnostic tool used in conjunction with fiberoptic bronchoscopy is **bronchoalveolar lavage (BAL)**. BAL is a method used to obtain a representative specimen of fluid and secretions from the lower respiratory tract, which is useful for the cytologic and microbiologic diagnosis of lung diseases, especially in those who are unable to expectorate sputum. BAL is performed after the general inspection of the airways and before tissue sampling with a brush or biopsy forceps. It is accomplished by gently wedging the scope into a lobar, segmental, or subsegmental bronchus and sequentially instilling and withdrawing sterile nonbacteriostatic saline in a volume sufficient to ensure that some of the aspirated fluid contains material that originated from the alveolar space. Nonbronchoscopic BAL can be performed in intubated patients by instilling and withdrawing saline through a catheter passed though the artificial airway and blindly wedged into a distal airway, although nonbronchoscopic BAL is less accurate and therefore has less reliable results. In either case, the presence of alveolar macrophages documents that an alveolar sample has been obtained. Because the methods used to perform BAL involve passage of the equipment through the upper airway, there is a risk of contamination of the specimen by upper airway secretions. Careful cytologic examination and quantitative microbiologic cultures are important for correct interpretation of the data. BAL can often obviate the need for more invasive procedures such as open lung biopsy, especially in immunocompromised patients.

Indications for diagnostic bronchoscopy and BAL include recurrent or persistent pneumonia or atelectasis, unexplained or localized and persistent wheeze, the suspected presence of a foreign body, hemoptysis, suspected congenital anomalies, mass lesions, interstitial disease, and pneumonia in the immunocompromised host. Indications for therapeutic bronchoscopy and BAL include bronchial obstruction by mass lesions, foreign bodies or mucus plugs, and general bronchial toilet and bronchopulmonary lavage. The patient undergoing bronchoscopy ventilates around the flexible scope, whereas with the rigid scope, ventilation is accomplished through the scope. Rigid bronchoscopy is preferentially indicated for extracting foreign bodies and removing tissue masses. It is also indicated in patients with massive hemoptysis. In other cases, the flexible scope has multiple advantages: it can be passed through endotracheal or tracheostomy tubes, can be introduced into bronchi that come off the airway at acute angles, and can be safely and effectively inserted with topical anesthesia and conscious sedation.

Transbronchial and endobronchial biopsies. Transbronchial biopsies are performed by passing forceps (1.2 mm pediatric or 2.0 mm adult) through the distal visualized airways to sample small airways and alveolar tissues. Transbronchial biopsy (TBB) in children is standard practice to monitor the lung allograft after transplantation, either as a surveillance or clinically indicated procedure. For the nontransplant patient, transbronchial biopsies can be used to facilitate the diagnosis of diffuse lung disease (such as interstitial pneumonitis, bronchiolitis obliterans, lymphoma, eosinophilic pneumonia, sarcoidosis, or hypersensitivity pneumonia) or large focal processes (such as infections or unresolving pneumonia). Transbronchial biopsies do produce smaller samples than video-assisted thoracoscopic surgery (VATS) or open lung biopsies, but with a lower attendant risk; the risk of pneumothorax has been estimated to be 2–8%. Endobronchial biopsies can be performed in children, but there are relatively few clinical situations where they are broadly applied.

The **endobronchial ultrasound (EBUS)**, is a scope that allows ultrasound images to be captured from the tip of the scope and also contains a working channel to collect a needle biopsy. This technology is particularly useful in the evaluation of mediastinal lymph nodes. This scope may be useful in the diagnosis of other conditions such as sarcoidosis, tuberculosis, and the staging of lung cancers. EBUS has been investigated in older pediatric patients as an alternative to CT-guided transthoracic fine needle aspiration for the evaluation of mediastinal lymph nodes and can be safely performed in children age 9+ years. A meta-analysis of 153 pediatric patients revealed a pooled sampling adequacy and combined diagnostic yield of EBUS of 98% (95% confidence interval [CI], 92–100%) and 61% (95% CI, 43–77%), respectively, and was generally safely tolerated.

Bronchial thermoplasty (BT) is a technology that can be used to treat patients with severe asthma. This technique uses the working channel of a fiberoptic bronchoscope to deliver targeted thermal energy to the airways to ablate the airway smooth muscle (ASM). The ablation of ASM may reduce the ability to bronchoconstrict. It may also affect the ASM's role in immunomodulation, ultimately altering the pathophysiology of asthma. BT requires a minimum of a 2.0-mm working channel, which limits this technology to bronchoscopes of at least an outer diameter of 4.1 mm. BT is performed over three bronchoscopy sessions to ablate different sections of the lung: right lower lobe, left lower lobe, and bilateral upper lobes. The right middle lobe is usually not ablated because of the potential risk of stenosis. The treatments are divided into three separate procedures to allow for shorter procedure times (30-60 minutes per session) and decrease the risk of widespread irritation. Patients are also given oral steroids for 3 days before the procedure to decrease airway inflammation associated with the ablation procedure. Although BT is gaining momentum in the treatment of severe asthma in the adult population, the long-term ramifications of ASM ablation in a child are still unknown. In adult studies that investigated BT as a therapeutic tool for asthma, small studies

demonstrated an improvement in clinical symptoms, and in a smaller cohort of patients (12 patients), no significant structural abnormalities were seen on chest radiographs 5 years after the procedure.

Complications: Regardless of the instrument used, the procedure performed, or the resulting indications, the most common complications are related to sedation. The relatively more common complications related to the bronchoscopy itself include transient hypoxemia, laryngospasm, bronchospasm, and cardiac arrhythmias. Iatrogenic infection, bleeding, pneumothorax, and pneumomediastinum are rare but reported complications of bronchoscopy or BAL, with increased complications when concomitant biopsies are taken. Bronchoscopy in the setting of possible pulmonary abscess or hemoptysis must be undertaken with advance preparations for definitive airway control, mindful of the possibility that pus or blood might flood the airway. Subglottic edema is a more common complication of rigid bronchoscopy than of flexible procedures, in which the scopes are smaller and less likely to traumatize the mucosa. Post-bronchoscopy croup is treated with oxygen, mist, vasoconstrictor aerosols, and corticosteroids as necessary.

Thoracoscopy

The pleural cavity can be examined through a thoracoscope, which is similar to a rigid bronchoscope. The thoracoscope is inserted through an intercostal space and the lung is partially deflated, allowing the operator to view the surface of the lung, the pleural surface of the mediastinum and the diaphragm, and the parietal pleura. Multiple thoracoscopic instruments can be inserted, allowing endoscopic biopsy of the lung or pleura, resection of blebs, abrasion of the pleura, and ligation of vascular rings.

Thoracentesis

For diagnostic or therapeutic purposes, fluid can be removed from the pleural space by needle. In general, as much fluid as possible should be withdrawn, and an upright chest roentgenogram should be obtained after the procedure. Complications of thoracentesis include infection, pneumothorax, and bleeding. Thoracentesis on the right may be complicated by puncture or laceration of the capsule of the liver and, on the left, by puncture or laceration of the capsule of the spleen. Specimens obtained should always be cultured, examined microscopically for evidence of bacterial infection, and evaluated for total protein and total differential cell counts. Lactic acid dehydrogenase, glucose, cholesterol, triglyceride (chylous), and amylase determinations may also be useful. If malignancy is suspected, cytologic examination is imperative.

Transudates result from mechanical factors influencing the rate of formation or reabsorption of pleural fluid and generally require no further diagnostic evaluation. Exudates result from inflammation or other disease of the pleural surface and underlying lung, so they require a more complete diagnostic evaluation. In general, transudates have a total protein of <3 g/dL or a ratio of pleural protein to serum protein <0.5, a total leukocyte count of less than 2,000/mm^3 with a predominance of mononuclear cells, and low lactate dehydrogenase levels. Exudates have high protein levels and a predominance of polymorphonuclear cells (although malignant or tuberculous effusions can have a higher percentage of mononuclear cells). Complicated exudates often require continuous chest tube drainage and have a pH <7.2. Tuberculous effusions can have low glucose and high cholesterol content.

Lung Biopsy

Lung biopsy may be the only way to establish a diagnosis, especially in protracted, noninfectious disease. In infants and small children, thoracoscopic or open surgical biopsies are the procedures of choice, and in expert hands there is low morbidity. Biopsy through the 3.5-mm-diameter pediatric bronchoscopes limits the sample size and diagnostic abilities. In addition to ensuring that an adequate specimen is obtained, the surgeon can inspect the lung surface and choose the site of biopsy. In older children, transbronchial biopsies can be performed using flexible forceps through a bronchoscope, an endotracheal tube, a rigid bronchoscope, or an endotracheal tube, usually with fluoroscopic guidance. This technique is most appropriately used when the disease is diffuse, as in the case of *Pneumocystis* pneumonia, or after rejection of a transplanted lung. The diagnostic limitations related to the small size of the biopsy specimens can be mitigated by the ability to obtain several samples. The risk of pneumothorax related to bronchoscopy is increased when transbronchial biopsies are part of the procedure; however, the ability to obtain biopsy specimens in a procedure performed with topical anesthesia and conscious sedation is advantageous.

Genetic Testing

Genetic testing enables precise diagnosis of an expanding array of respiratory diseases. In addition to diagnosis, genetic testing can contribute to discussions of disease severity and prognosis, aids counseling surrounding family planning, and serves as a cornerstone for development and application of novel therapeutics. Applications range from identification of known diseases in a child with nonspecific symptoms to early identification in an otherwise asymptomatic individual. Whole genome sequencing can be applied to rapidly diagnose children presenting with rare diseases or new phenotypes of known disorders.

Acute respiratory distress in the neonatal period rarely occurs secondary to several known genetic disorders. Genetic testing can be considered for *full-term* infants with unexplained severe respiratory disease or premature infants with lung disease *out of proportion* to what would be expected for gestational age. Genetic pulmonary disorders causing neonatal respiratory distress include surfactant dysfunction from pathogenic variants in *ABCA3, SFTPB,* or *SFTPC* genes; brain-lung-thyroid syndrome due to variants in *NKX2-1;* pulmonary alveolar proteinosis associated with abnormalities in the granulocyte macrophage colony-stimulating factor (GM-CSF) receptor; and primary disorders of lung development, such as alveolar capillary dysplasia, caused by pathogenic variants in *FOXF1*.

Although disorders associated with obstructive lung disease, abnormal mucus clearance, and bronchiectasis may present at any age, newborn screening for cystic fibrosis can often facilitate genetic diagnosis in infancy with subsequent early interventions to prevent or slow the onset of lung disease. Although cystic fibrosis is a monogenic disorder, pathogenic variants in many different genes cause PCD. Presently, the spectrum of genetic variants leading to PCD has not yet been fully identified, and the disease should still be suspected even if a genetic panel is negative. As clinical genetic panels and understanding of variants of unknown significance expand, it is expected that diagnosis of PCD will streamline.

Several systemic diseases associated with diffuse lung disease can be diagnosed genetically, including Birt-Hogg-Dube, Ehlers-Danlos, Marfan, hereditary hemorrhagic telangiectasia, and Hermansky-Pudlak syndrome. Children presenting with unexplained alveolar hypoventilation suspected of congenital central hypoventilation syndrome should undergo *PHOX2B* pathogenic variant specific testing, the gold standard for diagnosis. The previous disorders are only a partial list of the many known childhood diseases associated with a genetic and respiratory component. When there is high suspicion for a genetic condition but gene panels or single-gene analysis are normal, practitioners can pursue whole exome/genome sequencing. Whole exome/genome sequencing can also be applied as first-line genetic testing in critically ill patients in need of rapid diagnosis. Genetic counseling is paramount when pursuing genetic testing, especially in the pediatric population. The spectrum of diseases able to be diagnosed using genetic testing will continue to grow and is expected to not only encompass the rare disorders discussed earlier but also the more common respiratory disorders seen in childhood.

ACKNOWLEDGMENT

The editors are grateful to Dr. Ashok Sarnaik, much of whose work on the "Blood Gas Analysis" and "Pulmonary Function Testing" sections from previous editions of this chapter is retained here.

Visit Elsevier eBooks+ at eBooks.Health.Elsevier.com for Bibliography.

Chapter 422

Chronic or Recurrent Respiratory Symptoms

Anne G. Griffiths

Respiratory tract symptoms, including cough, dyspnea, wheeze, and stridor, may persist for long periods in a number of children; other children have persistent or recurring lung infiltrates with or without symptoms. Determining the cause of these chronic findings can be difficult because symptoms can be caused by a close succession of unrelated acute respiratory tract infections or by a single pathophysiologic process. Specific and easily performed diagnostic tests do not exist for many acute and chronic respiratory conditions. Pressure from the affected child's family for a quick remedy because of concern over symptoms related to breathing may complicate diagnostic and therapeutic efforts.

A systematic approach to the diagnosis and treatment of these children consists of assessing whether the symptoms are the manifestation of a minor problem or a life-threatening process; determining the likely underlying pathogenic mechanism; selecting the simplest effective therapy for the underlying process, which often is only symptomatic therapy; and then carefully evaluating its effect. Failure of this approach to identify the process responsible or to effect improvement signals the need for more extensive and perhaps invasive diagnostic efforts, including bronchoscopy.

JUDGING THE SERIOUSNESS OF CHRONIC RESPIRATORY COMPLAINTS

Clinical manifestations suggesting that respiratory tract illness may be life-threatening or associated with the potential for chronic disability are listed in Table 422.1. If none of these findings is detected, the chronic respiratory process is less likely to be serious. Active, well-nourished, and appropriately growing infants who present with intermittent noisy breathing but no other physical or laboratory abnormalities require only symptomatic treatment and parental reassurance. Benign-appearing but persistent symptoms are occasionally the harbinger of a serious lower respiratory tract problem. By contrast, occasionally children (e.g., with infection-related asthma) have recurrent life-threatening episodes but few or no symptoms in the intervals. Repeated examinations over an extended period, both when the child appears healthy and when the child is symptomatic, may be helpful in sorting out the severity and chronicity of lung disease.

RECURRENT OR PERSISTENT COUGH

Cough is a reflex response of the lower respiratory tract to stimulation of irritant or cough receptors in the airways' mucosa. The most common cause of recurrent or persistent cough in children is airway reactivity (asthma). Because cough receptors also reside in the pharynx, paranasal sinuses, stomach, and external auditory canal, the source of a persistent cough may need to be sought beyond the lungs. Specific lower respiratory stimuli include excessive secretions, aspirated foreign material, inhaled dust particles or noxious gases, cold or dry air, and an inflammatory response to infectious agents or allergic processes. Table 422.2 lists some of the conditions responsible for chronic cough. Table 422.3 presents characteristics of cough that can aid in distinguishing a cough's origin. Additional useful information can include a history of atopic conditions (asthma, eczema, urticaria, allergic rhinitis), a seasonal or environmental variation in frequency or intensity of cough, and a strong family history of atopic conditions, all suggesting an allergic cause; symptoms of malabsorption or a family history indicating cystic fibrosis; symptoms related to feeding, suggesting aspiration or gastroesophageal reflux; a choking episode, suggesting foreign body aspiration; headache or facial edema associated with sinusitis; and a smoking or vaping history in older children and adolescents or the presence of a smoker in the home (Table 422.4).

The physical examination can provide further information pertaining to the cause of chronic cough. Posterior pharyngeal drainage combined with a nighttime cough suggests chronic upper airway disease such as sinusitis. An overinflated chest suggests chronic airway obstruction, as in asthma or cystic fibrosis. An expiratory wheeze, with or without diminished intensity of breath sounds, strongly suggests asthma or asthmatic bronchitis, but may also be consistent with a diagnosis of cystic fibrosis, bronchomalacia, vascular ring, aspiration of foreign material, or pulmonary hemosiderosis. Careful auscultation during forced expiration may reveal expiratory wheezes that are otherwise undetectable and that are the only indication of underlying reactive airways. Coarse crackles suggest bronchiectasis, including cystic fibrosis, but can also occur with an acute or subacute exacerbation of asthma. Clubbing of the digits is often seen in most patients with bronchiectasis but in only a few other respiratory conditions with chronic cough (see Table 422.2). Tracheal deviation suggests foreign body aspiration, pleural effusion, a mediastinal mass or an enlarged lymph node.

Allowing sufficient examination time to detect a spontaneous cough is important. If a spontaneous cough does not occur, asking the child to take a maximal breath and forcefully exhale repeatedly usually induces a cough reflex. Most children can cough on request by 4-5 years of age. Children who cough as often as several times a minute with regularity are likely to have a habit (tic) cough (see Chapter 37). If the cough is loose, every effort should be made to obtain sputum; many older children can comply. It is sometimes possible to pick up sputum with a throat swab quickly inserted into the lower pharynx while the child coughs with the tongue protruding. Clear mucoid sputum is most often associated with an allergic reaction or asthmatic bronchitis. Cloudy (purulent) sputum suggests a respiratory tract infection but can also reflect increased cellularity (eosinophilia) from an asthmatic process. Very purulent sputum is characteristic of bronchiectasis (see Chapter 452). Malodorous expectorations suggest anaerobic infection of the lungs. In cystic fibrosis (see Chapter 454), the sputum, even when purulent, is rarely foul smelling.

Laboratory tests can help in the evaluation of a chronic cough. Sputum quality assessment includes a low number of squamous epithelial cells, found only in the upper airway, and a higher number of leukocytes. However, laboratories use different values, and in the case of cystic fibrosis, pathogens found are associated with lower respiratory infection even in the absence of satisfactory quality by various criteria. Sputum eosinophilia suggests asthma, asthmatic bronchitis, or hypersensitivity reactions of the lung (see Chapter 448), but a polymorphonuclear cell response suggests infection; if sputum is unavailable, the presence of eosinophilia in nasal secretions also suggests atopic disease. If most of the cells in sputum are macrophages, postinfectious hypersensitivity of cough receptors should be suspected. Sputum macrophages can be stained for hemosiderin content, which is diagnostic of pulmonary hemosiderosis (see Chapter 457), or for lipid content, which in large amounts suggests, but is not specific for, repeated aspiration. Rarely, children may expectorate partial casts of the airway, which can be characterized by investigating causes of plastic bronchitis. However, in young children, bronchoalveolar lavage may be needed for optimal ascertainment of alveolar macrophages. Children whose coughs persists for more than 6 weeks should be tested for cystic fibrosis regardless of their race or ethnicity (see Chapter 454). Sputum culture is helpful in evaluation of cystic fibrosis, but less so for other conditions because throat flora can contaminate the sample.

Hematologic assessment can reveal a microcytic anemia that is the result of pulmonary hemosiderosis (see Chapter 457) or hemoptysis, or eosinophilia that accompanies asthma and other hypersensitivity reactions of the lung. Infiltrates on the chest radiograph suggest cystic fibrosis, bronchiectasis, foreign body, hypersensitivity pneumonitis, tuberculosis, or other infection. When asthma-equivalent cough is suggested, a trial of bronchodilator therapy may be diagnostic. If the cough does not respond to initial therapeutic efforts, more specific diagnostic procedures may be warranted, including an immunologic or allergic evaluation, chest and paranasal sinus imaging, esophagograms,

Table 422.1 Indicators of Serious Chronic Lower Respiratory Tract Disease in Children

Persistent fever
Ongoing limitation of activity
Failure to grow
Failure to gain weight appropriately
Clubbing of the digits
Persistent tachypnea and labored ventilation
Shortness of breath and exercise intolerance
Chronic purulent sputum
Persistent hyperinflation
Substantial and sustained hypoxemia
Refractory infiltrates on chest x-ray
Persistent pulmonary function abnormalities
Hemoptysis
Family history of heritable lung disease
Cyanosis and hypercarbia
Unusual (opportunistic) or recurrent nonpulmonary infections

Table 422.2 Differential Diagnosis of Recurrent and Persistent Cough in Children

RECURRENT COUGH
Asthma
Drainage from upper airways
Aspiration
Frequently recurring respiratory tract infections in immunocompetent or immunodeficient patients
Symptomatic Chiari malformation
Idiopathic pulmonary hemosiderosis
Hypersensitivity (allergic) pneumonitis

PERSISTENT COUGH
Hypersensitivity of cough receptors after infection
Reactive airway disease (asthma)
Chronic sinusitis
Chronic rhinitis (allergic or nonallergic)
Bronchitis or tracheitis caused by infection or smoke exposure
Bronchiectasis, including cystic fibrosis, primary ciliary dyskinesia, immunodeficiency
Tic cough
Foreign body aspiration
Recurrent aspiration owing to pharyngeal incompetence, tracheolaryngoesophageal cleft, or tracheoesophageal fistula
Gastroesophageal reflux, with or without aspiration
Pertussis
Extrinsic compression of the tracheobronchial tract (vascular ring, neoplasm, lymph node, lung cyst)
Tracheomalacia, bronchomalacia
Endobronchial or endotracheal tumors
Endobronchial tuberculosis
Hypersensitivity pneumonitis
Fungal infections
Inhaled irritants, including tobacco smoke
Irritation of external auditory canal
Angiotensin-converting enzyme inhibitors

Table 422.3 Characteristics of Cough and Other Clinical Features and Possible Causes

SYMPTOMS AND SIGNS	POSSIBLE UNDERLYING ETIOLOGY*
Auscultatory findings (wheeze, crepitations/crackles, differential breath sounds)	Asthma, bronchitis, pneumonia, congenital lung disease, foreign body aspiration, airway abnormality
Cough characteristics (e.g., cough with choking, cough quality, cough starting from birth)	Congenital airway or lung abnormalities
Cardiac abnormalities (including murmurs)	Any cardiac illness
Chest pain	Asthma, functional, pleuritis
Chest wall deformity	Any chronic lung disease, neuromuscular disorders
Daily moist or productive cough	Chronic bronchitis, suppurative lung disease
Digital clubbing	Suppurative lung disease, arteriovenous shunt
Dyspnea (exertional or at rest)	Compromised lung function of any chronic lung or cardiac disease
Failure to thrive	Compromised lung function, immunodeficiency, cystic fibrosis
Feeding difficulties (including choking and vomiting)	Compromised lung function, aspiration, anatomic disorders
Hemoptysis	Bronchitis, foreign body aspiration, suctioning trauma, pulmonary hemorrhage
Immune deficiency	Atypical and typical recurrent respiratory or nonrespiratory infections
Medications or drugs	Angiotensin-converting enzyme inhibitors, puffers, illicit drug use
Neurodevelopmental abnormality	Aspiration
Recurrent pneumonia	Immunodeficiency, congenital lung problem, airway abnormality
Symptoms of upper respiratory tract infection	Can coexist or be a trigger for an underlying problem

*This is not an exhaustive list; only the more common respiratory diseases are mentioned.
Modified from Chang AB, Landau LI, Van Asperen PP, et al. Cough in children: definitions and clinical evaluation. Thoracic Society of Australia and New Zealand. *Med J Aust*. 2006;184(8):398–403, Table 2.

tests for gastroesophageal reflux (see Chapter 369), and special microbiologic studies including rapid viral testing. Evaluation of ciliary morphology, nasal endoscopy, laryngoscopy, and bronchoscopy may also be indicated.

Tic cough or somatic cough disorder (psychogenic cough or habit cough) must be considered in any child with a cough that has lasted for weeks or months, that has been refractory to treatment, and that disappears with sleep or with distraction. Typically, the cough is abrupt and loud and has a harsh, honking, or barking quality. A disassociation between the intensity of the cough and the child's affect is typically striking. This cough may be absent if the physician listens outside the examination room, but it will reliably appear immediately on direct attention to the child and the symptom. It typically begins with an upper respiratory infection but then lingers. The child misses many days of school because the cough disrupts the classroom. This disorder accounts for many unnecessary medical procedures and courses of medication. It is treatable with assurance that a pathologic lung condition is absent and that the child should resume full activity, including school. This assurance, together with speech therapy techniques that allow the child to reduce musculoskeletal tension in the neck and chest and that increase the child's awareness of the initial sensations that trigger cough, has been highly successful. Self-hypnosis is another successful therapy, often effective with one session. The designation "tic cough" or "somatic cough disorder" is preferable to "habit cough" or "psychogenic cough" because it carries no stigma and because most of

Table 422.4 Clinical Clues About Cough

CHARACTERISTIC	THINK OF
Staccato, paroxysmal	Pertussis, cystic fibrosis, foreign body, *Chlamydia* spp., *Mycoplasma* spp.
Followed by "whoop"	Pertussis
All day, never during sleep	Tic cough
Barking, brassy	Croup, tic cough, tracheomalacia, tracheitis, epiglottitis
Hoarseness	Laryngeal involvement (croup, recurrent laryngeal nerve involvement), papillomatosis
Abrupt onset	Foreign body, pulmonary embolism
During or following exercise	Reactive airway disease
Accompanies eating, drinking	Aspiration, gastroesophageal reflux, tracheoesophageal fistula
Throat clearing	Postnasal drip, vocal tic
Productive (sputum)	Infection, cystic fibrosis, bronchiectasis
Night cough	Sinusitis, reactive airway disease, gastroesophageal reflux
Seasonal	Allergic rhinitis, reactive airway disease
Immunosuppressed patient	Bacterial pneumonia, *Pneumocystis jiroveci, Mycobacterium tuberculosis, Mycobacterium avium-intracellulare,* cytomegalovirus, fungi
Dyspnea	Hypoxia, hypercarbia
Animal exposure	*Chlamydia psittaci* (birds), *Yersinia pestis* (rodents), *Francisella tularensis* (rabbits), Q fever (sheep, cattle), hantavirus (rodents), histoplasmosis (pigeons)
Geographic	Histoplasmosis (Mississippi, Missouri, Ohio River Valley), coccidioidomycosis (Southwest), blastomycosis (North and Midwest)
Workdays with clearing on days off	Occupational exposure

From Kliegman RM, Greenbaum LA, Lyle PS. *Practical Strategies in Pediatric Diagnosis and Therapy,* 2nd ed. Philadelphia: WB Saunders; 2004:19.

these children do not have significant emotional problems. When the cough disappears, it does not reemerge as another symptom. Nonetheless, other symptoms such as irritable bowel syndrome may be present in the patient or family.

FREQUENTLY RECURRING OR PERSISTENT STRIDOR

Stridor, a harsh, medium-pitched, inspiratory sound associated with obstruction of the laryngeal area or the extrathoracic trachea, is often accompanied by a croupy cough and hoarse voice. Stridor is most commonly observed in children with croup (see Chapter 433); foreign bodies and trauma can also cause acute stridor. A few children, however, acquire recurrent stridor or have persistent stridor from the first days or weeks of life (Table 422.5). Most congenital anomalies of large airways that produce stridor become symptomatic soon after birth. Increase of stridor when a child is supine suggests **airway malacia**, such as laryngomalacia or tracheomalacia. It is important to note that when evaluating for a specific anatomic cause of abnormal breath sounds, it is not uncommon to identify additional congenital anomalies of the airway. An accompanying history of hoarseness or aphonia suggests involvement of the vocal cords. Associated dysphagia may also suggest a vascular ring. In a child with intermittent stridor (with wheezing) that accompanies physical activity and is not responsive to asthma therapies, **paradoxical vocal cord dysfunction** may be considered. Paradoxical vocal cord dysfunction may be highly supported by history and confirmed by laryngoscopy during an exercise challenge test if symptoms are successfully elicited. Speech therapy and behavior modification may be therapeutic.

Table 422.5 Causes of Recurrent or Persistent Stridor in Children

RECURRENT
Allergic (spasmodic) croup
Respiratory infections in a child with otherwise asymptomatic anatomic narrowing of the large airways
Laryngomalacia
PERSISTENT
Laryngeal obstruction
Laryngomalacia
Papillomas, hemangiomas, other tumors
Cysts and laryngoceles
Laryngeal webs
Bilateral abductor paralysis of the cords
Foreign body
Tracheobronchial disease
Tracheomalacia
Subglottic tracheal webs
Endobronchial, endotracheal tumors
Subglottic tracheal stenosis, congenital or acquired
Extrinsic masses
Mediastinal masses
Vascular ring
Lobar emphysema
Bronchogenic cysts
Thyroid enlargement
Esophageal foreign body
Tracheoesophageal fistula
OTHER
Gastroesophageal reflux
Macroglossia, Pierre Robin syndrome
Cri-du-chat syndrome
Paradoxical vocal cord dysfunction
Hypocalcemia
Vocal cord paralysis
Chiari crisis
Severe neonatal episodic laryngospasm caused by *SCN4A* pathogenic variant

Physical examination for recurrent or persistent stridor is usually unrewarding, although changes in its severity and intensity resulting from changes of body position should be assessed. Anteroposterior and lateral radiographs, contrast esophagography, fluoroscopy, computed tomography (CT), and magnetic resonance imaging (MRI) are potentially useful diagnostic tools. In most cases, direct observation by laryngoscopy is necessary for definitive diagnosis. Undistorted views of the larynx are best obtained with fiberoptic laryngoscopy.

RECURRENT OR PERSISTENT WHEEZE

See also Chapter 439.

Parents often complain that their child wheezes, when, in fact, they are reporting respiratory sounds that are audible without a stethoscope, produce palpable resonance throughout the chest, and occur most prominently in inspiration. Some of these children have stridor, although many have audible sounds when the supraglottic airway is incompletely cleared of feedings or secretions.

True wheezing is a relatively common and particularly troublesome manifestation of obstructive *lower* respiratory tract disease in children. The site of obstruction may be anywhere from the intrathoracic trachea to the small bronchi or large bronchioles, but the sound is generated by turbulence in larger airways that collapse with forced expiration (see Chapter 421). Children younger than 2-3 years are especially prone to wheezing, because bronchospasm, mucosal edema, and accumulation of excessive secretions have a relatively greater obstructive effect on their smaller airways. In addition, the compliant airways in young children collapse more readily with active expiration. Isolated episodes of acute wheezing, such as can occur with bronchiolitis, are not uncommon, but wheezing that recurs or persists for more than 4 weeks suggests other diagnoses. Most recurrent or persistent wheezing in children is the result of airway reactivity. Nonspecific environmental factors such as cigarette smoke may be important contributors.

Frequently recurring or persistent wheezing starting at or soon after birth suggests a variety of other diagnoses, including congenital structural abnormalities involving the lower respiratory tract or tracheobronchomalacia (see Chapter 434). Wheezing that attends cystic fibrosis is most common in the first year of life. Sudden onset of severe wheezing in a previously healthy child should suggest foreign body aspiration.

Either wheezing or coughing when associated with tachypnea and hypoxemia may be suggestive of **interstitial lung disease** (see Chapter 448.5). However, many patients with interstitial lung disease demonstrate no symptoms other than rapid breathing on initial physical examination. Although chest roentgenograms may be normal in interstitial lung disease, diffuse abnormalities on chest x-ray may support further evaluation in patients suspected to have interstitial lung disease with characteristic findings described on high-resolution CT scan and lung biopsy.

Repeated examination may be required to verify a history of wheezing in a child with episodic symptoms and should be directed toward assessing air movement, ventilatory adequacy, and evidence of chronic lung disease, such as fixed overinflation of the chest, growth failure, and digital clubbing. Patients should be assessed for oropharyngeal dysphagia in cases of suspected recurrent aspiration. Clubbing suggests chronic lung infection and is rarely prominent in uncomplicated asthma. Tracheal deviation from foreign body aspiration should be sought. It is essential to rule out wheezing secondary to congestive heart failure. Allergic rhinitis, urticaria, eczema, or evidence of ichthyosis vulgaris suggests asthma or asthmatic bronchitis. The nose should be examined for polyps, which can exist with allergic conditions or cystic fibrosis.

Sputum eosinophilia and elevated serum immunoglobulin E levels suggest allergic reactions. A forced expiratory volume in 1 second increase of 15% in response to bronchodilators confirms reactive airways. Specific microbiologic studies, special imaging studies of the airways and cardiovascular structures, diagnostic studies for cystic fibrosis, and bronchoscopy should be considered if the response is unsatisfactory.

RECURRENT AND PERSISTENT LUNG INFILTRATES

Radiographic lung infiltrates resulting from acute pneumonia usually resolve within 1-3 weeks, but a substantial number of children, particularly infants, fail to completely clear infiltrates within a 4-week period. These children may be febrile or afebrile and may display a wide range of respiratory symptoms and signs. Persistent or recurring infiltrates present a diagnostic challenge (Table 422.6).

Table 422.6 Diseases Associated with Recurrent, Persistent, or Migrating Lung Infiltrates Beyond the Neonatal Period

Aspiration
Pharyngeal incompetence (e.g., cleft palate)
Laryngotracheoesophageal cleft
Tracheoesophageal fistula
Gastroesophageal reflux
Lipid aspiration
Neurologic dysphagia
Developmental dysphagia
Congenital anomalies
Lung cysts (congenital pulmonary airway malformation)
Bronchopulmonary sequestration
Congenital lobar emphysema
Bronchogenic cysts
Bronchial stenosis or aberrant bronchus
Vascular ring
Congenital heart disease with large left-to-right shunt
Pulmonary lymphangiectasia
Genetic conditions
Cystic fibrosis
Primary ciliary dyskinesia
Sickle cell disease (acute chest syndrome)
Immunodeficiency, phagocytic deficiency
Humoral, cellular, combined immunodeficiency states
Chronic granulomatous disease and related phagocytic defects
Hyper–immunoglobulin E syndromes
Complement deficiency states
Immunologic and autoimmune diseases
Asthma
Allergic bronchopulmonary aspergillosis
Hypersensitivity pneumonitis
Pulmonary hemosiderosis
Collagen-vascular diseases
Granulomatosis with polyangiitis
Infection, congenital
Cytomegalovirus
Rubella
Syphilis
Infection, acquired
Cytomegalovirus
Tuberculosis
HIV
Other viruses
Chlamydia
Mycoplasma, Ureaplasma
Pertussis
Fungal organisms
Pneumocystis jiroveci
Visceral larva migrans
Inadequately treated bacterial infection
Interstitial pneumonitis and fibrosis
Usual interstitial pneumonitis
Lymphocytic interstitial pneumonia (AIDS)
Nonspecific interstitial pneumonia (NSIP)
Genetic disorders of surfactant synthesis, secretion
Desquamative interstitial pneumonia
Cryptogenic organizing pneumonia
Acute interstitial pneumonia (Hamman-Rich syndrome)
Alveolar proteinosis
Drug-induced, radiation-induced inflammation and fibrosis
Neoplasms and neoplastic-like conditions
Primary or metastatic pulmonary tumors
Leukemia
Histiocytosis
Eosinophilic pneumonias
Other etiologies
Bronchiectasis (congenital, postinfectious)
Sarcoidosis

Symptoms associated with chronic lung infiltrates in the first several weeks of life (but not related to neonatal respiratory distress syndrome) suggest infection acquired in utero or during descent through the birth canal. Early appearance of chronic infiltrates can also be associated with cystic fibrosis or congenital anomalies that result in aspiration or airway obstruction. A history of recurrent infiltrates such as in **middle lobe syndrome** (see Chapter 444), wheezing, and cough may reflect asthma, even in the first year of life.

A controversial association has been posed regarding recurrent lung infiltrates in pulmonary hemosiderosis related to cow's milk hypersensitivity or unknown causes appearing in the first year of life. Children with a history of bronchopulmonary dysplasia often have episodes of respiratory distress attended by wheezing and new lung infiltrates. **Recurrent pneumonia** in a child with frequent otitis media, nasopharyngitis, adenitis, or dermatologic manifestations suggests an immunodeficiency state, complement deficiency, or phagocytic defect (see Chapters 164, 167, and 172). Primary ciliary dyskinesia is also of consideration in patients with frequent otitis media and suppurative sinopulmonary disease, with or without accompanying heterotaxy or history of neonatal respiratory distress (see Chapter 455). Pulmonary sequestration may be suspected in patients with recurrent findings on radiograph that occur in the same location, both during illness and when well (see Chapter 444). Traction bronchiectasis may also be suggested on radiography with persistent findings in a given region of the film after a history of respiratory infection. Particular attention must be directed to the possibility that the infiltrates represent lymphocytic interstitial pneumonitis or opportunistic infection associated with HIV infection or immunocompromise (see Chapter 322). A history of paroxysmal coughing in an infant suggests pertussis syndrome or cystic fibrosis. Persistent infiltrates in a toddler, especially with loss of volume, may suggest foreign body aspiration.

Overinflation and infiltrates suggest cystic fibrosis or chronic asthma. A silent chest with infiltrates should arouse suspicion of alveolar proteinosis (see Chapter 456), *Pneumocystis jiroveci* infection (see Chapter 290), genetic disorders of surfactant synthesis and secretion causing interstitial pneumonitis, or tumors. Growth should be carefully assessed to determine whether the lung process has had systemic effects, indicating substantial severity and chronicity, as in cystic fibrosis or alveolar proteinosis. Cataracts, retinopathy, or microcephaly suggest in utero infection. Chronic rhinorrhea can be associated with atopic disease, cow's milk intolerance, cystic fibrosis, primary ciliary dyskinesia, or congenital syphilis. The absence of tonsils and cervical lymph nodes suggests an immunodeficiency state.

Diagnostic studies should be performed selectively, based on information obtained from history and physical examination and on a thorough understanding of the conditions listed in Table 422.6. Cytologic evaluation of sputum, if available, may be helpful. Chest CT often provides more precise anatomic detail concerning the infiltrate or further characterizes a region of anatomic abnormality. Bronchoscopy is indicated for detecting foreign bodies, congenital or acquired anomalies of the tracheobronchial tract, and obstruction by endobronchial or extrinsic masses (see Chapters 434-438). Bronchoscopy provides access to secretions that can be studied cytologically and microbiologically. Alveolar lavage fluid is diagnostic for alveolar proteinosis and persistent pulmonary hemosiderosis and can suggest aspiration syndromes. Ciliary biopsy may be obtained from the inferior epithelial surface of nasal turbinates or from the lower airway during bronchoscopy. If all appropriate studies have been completed and the condition remains undiagnosed, lung biopsy might yield a definitive diagnosis, such as in interstitial lung disease or fungal disease.

Optimal medical or surgical treatment of chronic lung infiltrates often depends on a specific diagnosis, but chronic conditions may be self-limiting (severe and prolonged viral infections in infants); in these cases, symptomatic therapy can maintain adequate lung function until spontaneous improvement occurs. Helpful measures include airway clearance therapy for excessive secretions, antibiotics for bacterial infections, supplementary oxygen for hypoxemia, and maintenance of adequate nutrition. Because the lung of a young child has remarkable recuperative potential, normal lung function may ultimately be achieved with treatment despite the severity of pulmonary insult occurring in infancy or early childhood.

Visit Elsevier eBooks+ at eBooks.Health.Elsevier.com for Bibliography.

422.1 Extrapulmonary Diseases with Pulmonary Manifestations

John Palla and Susanna A. McColley

Respiratory symptoms commonly originate from extrapulmonary processes. The respiratory system adapts to metabolic demands and is exquisitely responsive to cortical input; therefore **tachypnea** is common in the presence of metabolic stress such as fever, and dyspnea may be related to anxiety. **Cough** most commonly arises from upper or lower respiratory tract disorders, but it can originate from the central nervous system, as with cough tic or somatic cough, and it can be a prominent symptom in children with gastroesophageal reflux disease. **Chest pain** does not commonly arise from pulmonary processes in otherwise healthy (no history of asthma) children but more often has a neuromuscular, musculoskeletal, or inflammatory etiology. **Cyanosis** can be caused by cardiac and/or hematologic disorders. **Dyspnea** and **exercise intolerance** can have a number of extrapulmonary causes. These extrapulmonary disorders may be suspected on the basis of the history and physical examination, or they may be considered in children in whom diagnostic studies have atypical findings or who show poor response to usual therapy. Table 422.7 lists more common extrapulmonary causes of such symptoms.

EVALUATION

In the evaluation of a child or adolescent with respiratory symptoms, it is important to obtain a detailed medical history, family history, and review of systems to evaluate the possibility of extrapulmonary origin. A comprehensive physical examination is also essential to identify signs of extrapulmonary disease.

Disorders of other organ systems, and many systemic diseases, can have significant respiratory system involvement. Although it is most common to encounter these complications in patients with known diagnoses, respiratory system disease is sometimes the sole or most prominent symptom at the time of presentation. Acute aspiration during feeding can be the presentation of neuromuscular disease in an infant who initially appears to have normal muscle tone and development. Pulmonary complications can be life-threatening, particularly in immunocompromised patients. The onset of respiratory findings may be insidious; for example, pulmonary vascular involvement in patients with systemic vasculitis may appear as an abnormality in diffusing capacity of the lung for carbon monoxide before the onset of symptoms. Table 422.8 lists disorders that commonly have respiratory complications.

Visit Elsevier eBooks+ at eBooks.Health.Elsevier.com for Bibliography.

Table 422.7 Respiratory Signs and Symptoms Originating from Outside the Respiratory Tract

SIGN OR SYMPTOM	NONRESPIRATORY CAUSE(S)	PATHOPHYSIOLOGY	CLUES TO DIAGNOSIS
Chest pain	Musculoskeletal	Inflammation (overuse, postviral, idiopathic), injury	Reproducible pain with palpation
Chest pain	Cardiac disease	Inflammation (pericarditis), ischemia (anomalous coronary artery, vascular disease)	Precordial pain, friction rub on examination; exertional pain, radiation to arm or neck
Chest pain	Gastroesophageal reflux disease	Esophageal inflammation and/or spasm	Heartburn, abdominal pain
Cyanosis	Congenital heart disease	Right-to-left shunt	Neonatal onset, lack of response to oxygen
	Methemoglobinemia	Increased levels of methemoglobin interfere with delivery of oxygen to tissues	Drug or toxin exposure, lack of response to oxygen
Dyspnea	Toxin exposure, drug side effect, or overdose	Variable, but often metabolic acidosis	Drug or toxin exposure confirmed by history or toxicology screen, normal oxygen saturation measured by pulse oximetry
	Anxiety, panic disorder	Increased respiratory drive and increased perception of respiratory efforts	Occurs during stressful situation, other symptoms of anxiety and/or depression
Exercise intolerance	Anemia	Inadequate oxygen delivery to tissues	Pallor, tachycardia, history of bleeding, prolonged or heavy menstrual periods, history of inadequate diet
Exercise intolerance	Deconditioning	Self-explanatory	History of inactivity, obesity
Hemoptysis	Nasal bleeding	Posterior flow of bleeding leads to suspicion of pulmonary origin	History and physical findings suggest nasal source; normal chest examination and chest radiography
	Upper gastrointestinal tract bleeding	Hematemesis mimics hemoptysis	History and physical examination suggest gastrointestinal source; normal chest examination and chest radiography
Wheezing, cough, dyspnea	Congenital or acquired cardiac disease	Pulmonary overcirculation (atrioseptal defect, ventriculoseptal defect, patent ductus arteriosus), left ventricular dysfunction	Murmur Refractory to bronchodilators Radiographic changes (prominent pulmonary vasculature, pulmonary edema)
Wheezing, cough	Gastroesophageal reflux disease	Laryngeal and bronchial response to stomach contents	Emesis, pain, heartburn
		Vagally mediated bronchoconstriction	Refractory to bronchodilators

Table 422.8 Disorders with Frequent Respiratory Tract Complications

UNDERLYING DISORDER(S)	RESPIRATORY COMPLICATIONS	DIAGNOSTIC TESTS
Autoimmune disorders	Pulmonary vascular disease, restrictive lung disease, pleural effusion (especially systemic lupus erythematosus), upper and lower airway disease (granulomatosis with polyangiitis)	Spirometry, lung volume determination, oximetry, diffusing capacity of the lung for carbon monoxide, chest radiography, upper airway endoscopy, and/or CT
Central nervous system disease (static or progressive)	Aspiration of oral or gastric contents, impaired airway clearance	Chest radiography, videofluoroscopic swallowing study, esophageal pH probe, fiberoptic bronchoscopy
Immunodeficiency	Infection, bronchiectasis, impaired mucociliary clearance	Chest radiography, fiberoptic bronchoscopy, chest CT
Liver disease	Pleural effusion, hepatopulmonary syndrome	Chest radiography, assessment of platypnea-orthodeoxia
Malignancy and its therapies	Infiltration, metastasis, malignant or infectious effusion, parenchymal infection, graft versus host disease (bone marrow transplant), fibrosis	Chest radiography, chest CT, fiberoptic bronchoscopy, lung biopsy
Neuromuscular disease	Hypoventilation, atelectasis, pneumonia, restrictive lung disease, impaired airway clearance	Spirometry, lung volume determination, respiratory muscle force measurements
Obesity	Restrictive lung disease, obstructive sleep apnea syndrome, asthma	Spirometry, lung volume determination, nocturnal polysomnography

Chapter 423

Sudden Infant Death Syndrome

Fern R. Hauck, Rebecca F. Carlin, Rachel Y. Moon, and Carl E. Hunt

Sudden infant death syndrome (SIDS) is defined as the sudden, unexpected death of an infant that remains unexplained after a thorough postmortem examination, which includes a complete autopsy, investigation of the scene of death, review of the medical history, and appropriate laboratory testing. An autopsy is essential to identify possible natural explanations for sudden unexpected death such as congenital anomalies or infection and to diagnose nonaccidental trauma. The autopsy typically cannot distinguish between SIDS and intentional suffocation, but the scene investigation and medical history may be of help if inconsistencies are evident. **Sudden unexpected infant death (SUID)** is a term that generally encompasses all SUIDs that occur during sleep, including SIDS (ICD-10 R95), accidental suffocation and strangulation in bed (ICD-10 W75), and ill-defined deaths, also known as *undetermined* (ICD-10 R99).

EPIDEMIOLOGY

SIDS, accidental suffocation and strangulation in bed, and ill-defined deaths are among the most common causes of overall infant mortality. SIDS is one of the leading causes of postneonatal (28 days to 1 year of age) mortality. The annual rate of SIDS in the United States was stable at 1.3-1.4 per 1,000 live births (approximately 7,000 infants per year) before 1992, when it was recommended that infants sleep nonprone as a way to reduce the risk for SIDS. Since then, particularly after initiation of the national Back to Sleep (now called *Safe to Sleep*) campaign in 1994, the rate of SIDS progressively declined and then leveled off in 2001 at 0.55 per 1,000 live births (2,234 infants). There has been a slower rate of decline since that time; in 2020 the rate was 0.38 per 1,000 live births (~1,200 infants). The initial decline in the number of SIDS deaths in the United States and other countries has been largely attributed to increasing use of the supine position for sleep. In 1992, 82% of sampled infants in the United States were placed prone for sleep. Although several other countries have decreased prone sleeping prevalence to ≤2%, in the United States in 2016, only 78% of infants were usually being placed supine for sleep. Among Black infants, these rates were even lower, at 62%.

There is increasing evidence that infant deaths previously classified as SIDS are now being classified by medical examiners and coroners as the result of other causes, notably **accidental suffocation and strangulation in bed** (ICD 10 W75) and **ill-defined deaths** (ICD 10 R99). Between 1994 and 2018, there was a sevenfold increase in the rate of accidental suffocation and strangulation in bed, from 0.03 to 0.22 deaths per 1,000 live births. There was also a 57% increase in the rate of ill-defined deaths between 1995 and 2018, from 0.21 to 0.33 deaths per 1,000 live births. These sudden and unexpected infant deaths are primarily associated with unsafe sleeping environments, including side and prone positioning, sharing a sleep surface with others, and soft bedding in the sleep environment. Based on these trends and the commonality of many of the sleep environment risk factors that are associated with both SIDS and other sleep-related SUID, risk-reduction measures that will be described later are applicable to all sleep-related SUID.

PATHOLOGY

There are no autopsy findings *pathognomonic* for SIDS, and no findings are required for the diagnosis, but some findings are commonly seen on postmortem examination (Table 423.1). Petechial hemorrhages are found in 68–95% of infants who died of SIDS and are more extensive than in explained causes of infant mortality. Pulmonary edema is often present and may be substantial. The reasons for these findings are unknown.

SIDS infants have several identifiable changes in the lungs and other organs (see Table 423.1). Nearly 65% of these infants have structural evidence of preexisting, chronic, low-grade asphyxia, and other studies have identified biochemical markers of asphyxia. Infants who died of SIDS have higher levels of vascular endothelial growth factor (VEGF) in the cerebrospinal fluid (CSF). These increases may be related to VEGF polymorphisms (see "Genetic Risk Factors" and Table 423.3) or might indicate recent hypoxemic events because VEGF is upregulated by hypoxia.

Numerous studies have shown brain abnormalities that may cause or contribute to an impaired autonomic response to an exogenous stressor, including in the hippocampus and brainstem, the latter being the major area responsible for respiratory and autonomic regulation (see Table 423.1). The primary affected sites of chemoreception and respiratory drive include peripheral chemoreceptors (e.g., carotid body) and multiple central chemoreceptors, including the retrotrapezoid nucleus, serotonergic raphe nuclei, locus coeruleus, orexinergic neurons, solitary tract nucleus, and the dorsal motor nucleus of the vagus.

The ventral medulla has been a particular focus for studies in infants who died of SIDS (see Table 423.1). It is an integrative area for vital autonomic functions, including breathing, arousal, and chemosensory function. Some SIDS infants have hypoplasia of the arcuate nucleus and up to 60% have histopathologic evidence of less extensive bilateral or unilateral hypoplasia. Consistent with the apparent overlap between putative mechanisms for SIDS and for unexpected late fetal deaths, approximately 30% of sudden intrauterine unexplained deaths also have hypoplasia of the arcuate nucleus. Imaging mass spectroscopy of postmortem medullary tissue has identified abnormal expression of multiple peptides, especially in the raphe, hypoglossal, and pyramidal nuclei that include components for developmental neuronal/glial/axonal growth, cell metabolism, cytoarchitecture, and apoptosis. These findings suggest that SIDS infants have abnormal neurologic development

Table 423.1 Common Postmortem and Research Pathologic Abnormalities Observed in Sudden Infant Death Syndrome Infants

COMMON OBSERVATIONS
Petechial hemorrhages, lungs, and pleura
Pulmonary edema
RESEARCH FINDINGS
Evidence of preexisting chronic low-grade asphyxia
Increased cerebrospinal levels of vascular endothelial growth factor (VEGF)
• Secondary to preexisting asphyxia
• VEGF polymorphisms
NEUROPATHOLOGY RESEARCH FINDINGS
Abnormalities leading to impaired autonomic responses
Peripheral and central chemoreceptor abnormalities
Ventral medullary abnormalities
• Hypoplastic arcuate nucleus
• Abnormalities in serotonin (5-HT) neurons
• Decreases in 5-HT_{1A} and 5-HT_{2A} receptor immunoreactivity
• Extensive serotonergic brainstem abnormalities

contributing to pathogenesis, with the impairments suggesting delayed neurologic maturation.

Neurotransmitter studies of the arcuate nucleus have also identified several receptor abnormalities relevant to state-dependent autonomic control overall and to ventilatory and arousal responsiveness in particular. These deficits include significant decreases in binding to kainate, muscarinic cholinergic, and serotonin (5-HT) receptors. Studies of the ventral medulla have identified morphologic and biochemical deficits in 5-HT neurons and decreased γ-aminobutyric acid receptor A receptor binding in the medullary serotonergic system. Immunohistochemical analyses reveal an increased number of 5-HT neurons and an increase in the fraction of 5-HT neurons showing an immature morphology, suggesting a failure or delay in the maturation of these neurons (see Table 423.1). High neuronal levels of interleukin (IL)-1β are present in the arcuate and dorsal vagal nuclei in infants with SIDS compared with controls, perhaps contributing to molecular interactions affecting cardiorespiratory and arousal responses.

The neuropathologic data provide compelling evidence for altered 5-HT homeostasis creating an underlying vulnerability contributing to SIDS. 5-HT is an important neurotransmitter, and the 5-HT neurons in the medulla project extensively to neurons in the brainstem and spinal cord that influence respiratory drive, arousal, cardiovascular control, circadian regulation and non–rapid eye movement (NREM) sleep, thermoregulation, and upper airway reflexes. Decreases in 5-HT_{1A} and 5-HT_{2A} receptor immunoreactivity have been observed in the dorsal nucleus of the vagus, solitary nucleus, and ventrolateral medulla. There are extensive serotoninergic brainstem abnormalities in infants with SIDS, including increased 5-HT neuronal count, a lower density of 5-HT_{1A} receptor-binding sites in regions of the medulla involved in homeostatic function, and a lower ratio of 5-HT transporter (5-HTT) binding density to 5-HT neuronal count in the medulla (see Table 423.1). Male infants with SIDS have lower receptor-binding density than do female infants with SIDS. Overall, these 5-HT–related studies suggest that the synthesis and availability of 5-HT are decreased within 5-HT pathways, and medullary tissue levels of 5-HT and its primary biosynthetic enzyme (tryptophan hydroxylase) are lower in infants with SIDS compared with age-matched controls. Although a subset of infants with SIDS has serotonergic abnormalities in serotonin neurons in the medullary reticular formation, the neuropathologic abnormalities in SIDS involve more than just a serotonergic deficiency in specific medullary nuclei and appear to involve failure of the network of neurochemical transmitters in various subcortical locations. For example, there is a complex relationship between serotonergic neurotransmission in the medulla and acetylcholine and nicotinic receptors.

ENVIRONMENTAL RISK FACTORS

Major risk factors for SIDS and SUID are outlined in Table 423.2 and include both nonmodifiable and modifiable risk factors.

The persistent ethnic disparities seen in SIDS and SUID rates likely reflect broader societal inequities. Low socioeconomic status (SES), unemployment, housing instability, and other factors that create barriers to optimal health outcomes are highly correlated with race/ethnicity in the United States and are also associated with both higher risk of SIDS and increased prevalence of known risk factors for these deaths (see the next section). Although these factors are consistently associated with higher risk, SIDS affects infants from all social strata. In the United States, Black, American Indian, and Alaska Native infants are 2-3 times more likely than White infants to die of SIDS, whereas Asian, Pacific Islander, and Hispanic infants have the lowest incidence. Greater efforts are needed to address this persistent disparity and to ensure that SIDS risk-reduction education reaches all parents and other care providers, including other family members and personnel at daycare centers.

Table 423.2 Risk Factors Associated with Sudden Infant Death Syndrome

MATERNAL AND ANTENATAL RISK FACTORS
Elevated second-trimester serum α-fetoprotein
Smoking
Alcohol use
Drug use (cocaine, heroin)
Nutritional deficiency
Inadequate prenatal care
Low socioeconomic status
Younger age
Lower education
Single marital status
Shorter interpregnancy interval
Intrauterine hypoxia
Fetal growth restriction
INFANT RISK FACTORS
Age (peak 1-4 mo)
Male gender
Ethnicity (Black, American Indian, Alaska Native)
Growth failure
No breastfeeding
No pacifier (dummy)
Preterm birth
Prone and side sleep position
Recent febrile illness (mild infections)
Inadequate immunizations
Smoking exposure (prenatal and postnatal)
Unsafe sleep environment, including soft sleeping surface, soft bedding
Bed sharing with parent(s) or other children
Sleeping in a room separate from parent(s)
Thermal stress, overheating
Colder season, no central heating

Nonmodifiable Environmental Risk Factors

Infants are at greatest risk of SIDS at 1-4 months of age, with most deaths having occurred by 6 months. This characteristic age has decreased in some countries as the SIDS incidence has declined, with deaths occurring at earlier ages and with a flattening of the peak age incidence. Similarly, the commonly observed winter seasonal predominance of SIDS has declined or disappeared in some countries as prone prevalence has decreased, supporting prior findings of an interaction between sleep position and factors more common in colder months (overheating as a consequence of elevated interior temperatures or bundling with blankets and heavy clothing, or infection). Male infants are 30–50% more likely to be affected by SIDS than are female infants.

Modifiable Environmental Risk Factors

Pregnancy-Related Factors

An increased SIDS risk is associated with numerous obstetric factors, suggesting that the in utero environment of future SIDS infants is suboptimal. SIDS infants are more commonly of higher birth order, independent of maternal age, and of gestations after shorter interpregnancy intervals. Parents of SIDS infants generally receive less prenatal care and initiate care later in pregnancy, and this likely reflects difficulties in accessing care. In addition, low birthweight, preterm birth, and slower intrauterine and postnatal growth rates are risk factors.

Cigarette Smoking

There is a major association between **intrauterine exposure to cigarette smoking** and risk for SIDS. The incidence of SIDS was 2-3 times greater among infants of mothers who smoked in

studies conducted before SIDS risk-reduction campaigns and 4 times higher in studies after implementation of SIDS risk-reduction campaigns. The risk of death is progressively greater as daily cigarette use increases. The effects of smoking by the infant's father and other household members are more difficult to interpret because they are highly correlated with maternal smoking. There appears to be a small independent effect of paternal smoking, but data on other household members have been inconsistent. The effect of prenatal smoking on SIDS risk is not believed to be caused by lower birthweight, which is often found among infants of smoking mothers, but more likely because of alterations in autonomic function, cardiovascular reflexes, or arousal making the infants more vulnerable to a sleep-related death.

It is difficult to assess the independent effect of infant exposure to **environmental tobacco smoke** because parental smoking behaviors during and after pregnancy are also highly correlated. However, a twofold increased risk of SIDS is found for infants exposed only to postnatal maternal environmental tobacco smoke. There is a dose-response for the number of household smokers, number of people smoking in the same room as the infant, and the number of cigarettes smoked. These data suggest that keeping the infant free of environmental tobacco smoke can further reduce an infant's risk of SIDS.

Drug and Alcohol Use

Most studies link maternal **prenatal drug use**, especially opiates, with an increased risk of SIDS, ranging from a 2- to 15-fold increased risk. Studies looking at the association between maternal **alcohol use** prenatally or postnatally and SIDS have conflicting results. In one study, periconceptional alcohol use and binge drinking in the first trimester were associated with a sixfold and an eightfold increased risk of SIDS, respectively. Similarly, a study from Western Australia found that a report of maternal alcohol use during pregnancy was associated with an almost sevenfold increased risk of SIDS. A Danish cohort study found that mothers admitted to the hospital for an alcohol- or drug-related disorder at any time before or after the birth of their infants had a 3-times higher risk of their infant dying from SIDS, and a Dutch study reported that maternal alcohol consumption in the 24 hours before the infant died carried an eightfold increased risk of SIDS. Siblings of infants with fetal alcohol syndrome have a 10-fold increased risk of SIDS compared with controls. Although there are conflicting reports of illicit drug use and SIDS overall, prenatal drug use, especially opiates, is associated with an increased risk of SIDS, ranging from 2- to 15-fold. Data on cannabis use and SIDS are extremely limited, with only one study from New Zealand reporting results for postpartum maternal use. This study found that nighttime cannabis use was associated with a twofold increased risk of SIDS, whereas daytime use was not associated with increased risk.

Infant Sleep Environment

Sleeping prone has consistently been shown to increase the risk of SIDS. As rates of prone positioning have decreased in the general population, the odds ratios for SIDS in infants still sleeping prone have increased. *The highest risk of SIDS occurs in infants who are usually placed nonprone but are placed prone for last sleep ("unaccustomed prone") or found prone ("secondary prone").* The "unaccustomed prone" position may be more likely to occur in daycare or other settings outside the home and highlights the need for all infant caretakers to be educated about appropriate sleep positioning.

Side-Sleeping: A Significant Risk Factor. The initial SIDS risk-reduction campaign recommendations considered side-sleeping to be nearly equivalent to the supine position in reducing the risk of SIDS. Subsequent studies documented that side-sleeping infants were twice as likely to die of SIDS as infants sleeping supine. This increased risk may be related to the relative instability of the position. Infants who are placed on their side and roll to prone are at exceptional risk, with one study finding they are almost 9 times more likely to die of SIDS than those placed supine. Although the majority of SIDS occurrences are still associated with infants being found prone, a higher proportion of SIDS is now attributed to being placed on the side for sleeping than for being placed prone. The current recommendations call for supine position for sleeping for all infants except those few with specific medical conditions for which recommending a different position may be justified, such as those with anatomic or functional upper airway compromise when supine.

Many parents and healthcare providers were initially concerned that supine sleeping would be associated with an increase in adverse consequences, such as difficulty sleeping, vomiting, or aspiration. However, evidence suggests that the risk of regurgitation and choking is highest for prone-sleeping infants. Some newborn nursery staff still tend to favor side positioning, which models inappropriate infant care practice to parents. Infants sleeping on their backs do not have more episodes of cyanosis or apnea, and reports of apparent life-threatening events actually decreased in Scandinavia after increased use of the supine position. These results provide reassurance for parents and healthcare providers and should contribute to universal acceptance of supine as the safest and optimal sleep position for infants.

Soft Sleep Surfaces and Soft or Loose Bedding. Infants should sleep on firm, flat, noninclined surfaces without soft or loose bedding. Soft sleep surfaces and soft or loose bedding, including comforters, pillows of any kind, bumper pads, stuffed animals, mattress toppers, pillow-top mattresses, sheepskins, polystyrene bean pillows, and old or soft mattresses, are associated with increased risk of SIDS. Infant sleep positioners, including pillows and wedges, which are often marketed to hold infants on their side or at an angle to help with reflux, are also not recommended. Based on available research, swaddling infants, or wrapping them in a blanket, is not recommended as a strategy to reduce SIDS. Infants who roll to the prone position while swaddled are at particularly high risk of SIDS. Wearable blankets are an acceptable alternative. Weighted blankets, weighted sleepers, weighted swaddles, or other weighted objects should not be placed on or near the sleeping infant.

Overheating. Overheating, based on indicators such as higher room temperature, a history of fever, sweating, and excessive clothing or bedding, has been associated with increased risk of SIDS. Some studies have identified an interaction between overheating and prone sleeping, with overheating increasing the risk of SIDS only when infants are sleeping prone. Higher external environmental temperatures have not been associated with increased SIDS incidence in the United States.

Bed Sharing. Several studies have implicated bed sharing as a risk factor for SIDS. Bed sharing is particularly hazardous when other children are in the same bed; when the parent is sleeping with an infant on a couch, sofa, or other soft or confining sleeping surface; when the mother is a smoker; and when the bed sharer has used alcohol or arousal-altering drugs or medications. Infants younger than 4 months of age are at increased risk even when mothers are nonsmokers. A meta-analysis of 19 studies found that low-risk infants (i.e., those who were breastfed and never exposed to cigarette smoke in utero or after birth) still had a fivefold increased risk of SIDS until the age of 3 months if bed sharing. Risk is also increased with longer duration of bed sharing during the night, whereas returning the infant to the infant's own crib has not been associated with increased risk. It is recommended that infants who are brought into the parents' bed for feeding or comforting be returned to their crib or bassinet when the parent is ready to sleep. Room sharing *without* bed sharing is associated with lower SIDS rates and is therefore recommended.

Commercial Devices Marketed to Reduce the Risk of SIDS. A large number of commercial devices have been marketed that claim to reduce the risk of SIDS or other sleep-related infant deaths, including in-bed sleepers, but there is no evidence that any of these devices reduce the risk of these deaths. A 2021 Consumer Product Safety Commission

ruling states that any infant sleep product must meet existing federal safety standards for cribs, bassinets, play yards, and bedside sleepers.

Infant Feeding Care Practices and Exposures

Breastfeeding Is Associated with a Lower Risk of Sudden Infant Death Syndrome. A meta-analysis found that breastfeeding was associated with a 45% reduction in SIDS after adjusting for confounding variables and that this protective effect increased for exclusive breastfeeding compared with partial breastfeeding. A subsequent meta-analysis found that breastfeeding for under 2 months was not associated with a reduced risk of SIDS, but any breastfeeding for 2 months or more and exclusive breastfeeding for 2-6 months was associated with an approximate halving of risk. Nursing pillows are a risk factor for infant suffocation and should be avoided.

Pacifier use is associated with a lower risk of SIDS in the majority of studies. Although it is not known if this is a direct effect of the pacifier itself or from associated infant or parental behaviors, use of the pacifier is protective even if it is dislodged during sleep. Concerns have been expressed about recommending pacifiers as a means of reducing the risk of SIDS for fear of adverse consequences, particularly interference with breastfeeding. However, well-designed clinical trials have found no association between pacifiers and breastfeeding duration.

Upper respiratory tract infections have generally not been found to be an independent risk factor for SIDS, but these and other minor infections may still have a role in the causal pathway of SIDS when other risk factors are present. Risk for SIDS has been found to be increased after illness among prone sleepers, those who were heavily wrapped, and those whose heads were covered during sleep.

No adverse association between **immunizations** and SIDS has been found. Indeed, SIDS infants are less likely to be immunized than control infants, and in immunized infants who die of SIDS, no temporal relationship between vaccine administration and death has been identified. In a meta-analysis of case-control studies that adjusted for potentially confounding factors, the risk of SIDS for infants immunized with diphtheria, tetanus, and pertussis was half that for nonimmunized infants.

GENETIC RISK FACTORS

There are some genetic differences identified in infants who died of SIDS compared with healthy infants and to infants dying from other causes (see Table 423.3). Pathogenic gene variants occurring at higher incidence in SIDS infants compared with controls include multiple cardiac ion channelopathy genes that are proarrhythmic, autonomic nervous system development genes, proinflammatory genes related to infection and immunity, and several serotonin (5-HT) genes. In ~15% of patients with SIDS, postmortem gene sequencing reveals a specific monogenic pathogenic variant (see Table 423.4; Fig. 423.1). Some of these genes are more plausible than others in predisposing *infants* to sudden unexpected death.

Multiple studies have established the importance of a pathway to SIDS that involves cardiac sodium or potassium channel dysfunction resulting in either **long QT syndrome (LQTS)** or other proarrhythmic conditions (see Table 423.4 and Fig. 423.1). LQTS is a known cause of sudden death in children and adults as the result of a prolonged cardiac action potential causing either increased depolarization or decreased repolarization current. The first evidence supporting a causal role for LQTS in SIDS was a large Italian study in which a corrected QT interval >440 msec on an electrocardiogram (ECG) performed on days 3-4 of life was associated with an odds ratio of 41 for SIDS. Several case reports have subsequently provided proof of the concept that cardiac channelopathy polymorphisms are associated with SIDS. LQTS is associated with polymorphisms related mainly to gain-of-function variants primarily in the sodium channel gene *(SCN5A)* that encodes critical channel pore-forming α subunits or essential channel-interacting proteins. LQTS also is associated with mainly loss-of-function variants in potassium channel genes. **Short QT syndrome (SQTS)** is another cause of life-threatening arrhythmia or sudden death, often during rest or sleep. Gain-of-function variants in genes including *KCNH2* and *KCNQ1* have been causally linked to SQTS, and some of these deaths have occurred in infants, suggesting that SQTS may also be causally linked to SIDS (see Table 423.4).

Table 423.3 Genetic Risk Factors for Sudden Infant Death Syndrome (SIDS): Observed Polymorphisms

Multiple cardiac ion channelopathy genes
Autonomic developmental genes
Proinflammatory genes affecting infection and immunity
- Increased proinflammatory function
- Decreased antiinflammatory function

Genes affecting both serotonergic and adrenergic neurons

Table 423.4 Identified and Possible Monogenic Associations with SIDS

ARRHYTHMIAS/CHANNELOPATHIES
LQTS* *(SCN5A, ANK2, CALM2)*
SQTS *(KCNH2, KCNQ1)*
Brugada syndrome* *(SCN5A, TRPM4, SCN3B, GPD1L, SCN10A)*
Catecholaminergic polymorphic ventricular tachycardia* *(RYR2)*
EPILEPSY SYNDROMES
Genes associated with sudden unexpected death in epilepsy *(SCN1A, DEPDC5)*
Nondystrophic myotonia *(SCN4A)*
Dravet syndrome *(SCN1A)*
METABOLIC DISORDERS
Pyruvate dehydrogenase deficiency
Medium-chain acyl-dehydrogenase deficiency
Systemic primary carnitine deficiency
Carnitine palmitoyltransferase deficiency
Glutaric acidemia type II
Maple syrup urine disease
Congenital disorders of glycosylation
Glycogen storage disease
CARDIAC/CARDIOMYOPATHIES*
Hypertrophic cardiomyopathy
Dilated cardiomyopathy
Arrhythmogenic right ventricular cardiomyopathy *(RYR2)*
Catecholaminergic ventricular tachycardia *(RYR2, CASQ2, CALM2)*
Left ventricular noncompaction
Marfan syndrome
Mitral valve prolapse
Ehlers-Danlos syndrome

*For many phenotypic disorders, most, but not all, genes have been identified
LQTS, Long QT syndrome; SQTS, short QT syndrome.

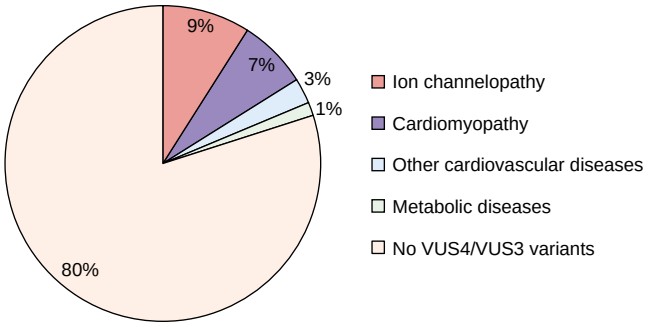

Fig. 423.1 Percentage of SIDS infants with likely causative variants in genes associated with cardiomyopathies, ion channelopathies, other cardiovascular diseases, and metabolic diseases. VUS, variant of unknown significance. *(From Neubauer J, Lecca MR, Russo G, et al. Postmortem whole-exome analysis in a large sudden infant death syndrome cohort with a focus on cardiovascular and metabolic genetic diseases. Eur J Hum Genetics. 2017;25:404–409, Fig. 1.)*

Other cardiac ion–related channelopathy pathogenic gene variants that are also proarrhythmic include Brugada syndrome *(BrS1, BrS2)* and catecholaminergic polymorphic ventricular tachycardia *(CPVT1)* (see Table 423.4). Collectively, these pathogenic variants in cardiac ion channels provide a lethal proarrhythmic substrate in some infants and may account for 5–10% or more of SIDS cases. In one study, using targeted massively parallel sequencing, 15.7–18.6% of Dutch SIDS cases were considered to be explained genetically by cardiac arrhythmias.

Impaired central respiratory regulation is an important biologic abnormality in SIDS, and genetic polymorphisms have been identified in SIDS infants that affect both serotonergic and adrenergic neurons. Monoamine oxidase A (MAOA) metabolizes both of these neurotransmitters, and a recent study has observed a high association between SIDS and low-expressing MAOA alleles in males, perhaps contributing to the higher incidence of SIDS in males. Many genes are involved in the control of 5-HT synthesis, storage, membrane uptake, and metabolism. Polymorphisms in the promoter region of the 5-HTT protein gene occur with greater frequency in SIDS than in control infants. The long "L" allele increases effectiveness of the promoter and reduces extracellular 5-HT concentrations at nerve endings compared with the short "S" allele. The L/L genotype has been associated with increased 5-HT transporters in some studies of neuroimaging and postmortem binding, but more recent studies have not found any relationship between SIDS and the long (L) allele or the LL genotype.

An association has also been observed between SIDS and a 5-HTT intron 2 polymorphism, which differentially regulates *5-HTT* expression. There were positive associations between SIDS and the intron 2 genotype distributions in Black infants who died of SIDS compared with Black controls. The human *FEV* gene is specifically expressed in central 5-HT neurons in the brain, with a predicted role in specification and maintenance of the serotoninergic neuronal phenotype. An insertion pathogenic variant has been identified in intron 2 of the *FEV* gene, and the distribution of this variant differs significantly in SIDS compared with control infants.

Molecular genetic studies in infants who died of SIDS have also identified pathogenic genetic variants pertinent to early embryologic development of the autonomic nervous system. Protein-changing pathogenic variants related to the *PHOX2a, RET, ECE1, TLX3,* and *EN1* genes have been identified, particularly in Black infants who died of SIDS. Eight polymorphisms in the *PHOX2B* gene occurred significantly more frequently in SIDS compared with control infants. Abnormalities in both the structure and expression of the *PHOX2B* gene, which is involved in neuronal maturation, have also been reported in significantly more SIDS infants than in controls. One study has reported an association between SIDS and a distinct tyrosine hydroxylase gene *(THO1)* allele, which regulates gene expression and catecholamine production.

Multiple studies have observed altered expression of genes involved in the inflammatory process and immune system regulation. Differences in SIDS infants compared with controls have been reported for two complement *C4* genes. Some SIDS infants have loss-of-function polymorphisms in the gene promoter region for IL-10, another antiinflammatory cytokine. IL-10 polymorphisms associated with decreased IL-10 levels could contribute to SIDS by delaying initiation of protective antibody production or reducing capacity to inhibit inflammatory cytokine production. However, other studies have not found differences in IL-10 genes in SIDS infants compared with age-matched controls.

An association has been reported between single-nucleotide polymorphisms in the proinflammatory gene encoding IL-8 and SIDS infants found prone compared with SIDS infants found in other sleep positions. IL-1 is another proinflammatory gene, and a higher prevalence of the IL-1 receptor antagonist, which would predispose to higher risk for infection, has been reported in infants who died of SIDS. Significant associations with SIDS are also reported for polymorphisms in VEGF, IL-6, and tumor necrosis factor-α (TNF-α). These three cytokines are proinflammatory, and these gain-of-function polymorphisms would result in increased inflammatory response to infectious or inflammatory stimuli and hence contribute to an adverse imbalance between proinflammatory and antiinflammatory cytokines. As apparent proof of principle, elevated levels of IL-6 and VEGF have been reported from CSF in SIDS infants. There were no group differences in the IL6-174G/C polymorphism in a Norwegian SIDS study, but the aggregate evidence nevertheless suggested an activated immune system in SIDS and implicated genes involved in the immune system. Almost all SIDS infants in one study had positive histories for prone sleeping and fever before death and positive HLA-DR expression in laryngeal mucosa, and high HLA-DR expression was associated with high levels of IL-6 in CSF.

GENE-ENVIRONMENT INTERACTIONS

Interactions between genetic and environmental risk factors determine the actual risk for SIDS in individual infants (see Fig. 423.2; Table 423.5). Equally important, there is a dynamic interaction between genetic or intrinsic vulnerability and the *sleep environment* (see Fig. 423.3). There appears to be an interaction between prone sleep position and impaired ventilatory and arousal responsiveness. Facedown or nearly facedown sleeping does occasionally occur in prone-sleeping infants, but normal healthy infants arouse before such episodes become life-threatening. However, infants with insufficient arousal responsiveness to hypoxia may be at risk for sudden death from resulting episodes of airway obstruction and asphyxia. There may also be links between modifiable risk factors (such as soft bedding, prone sleep position, and thermal stress) and genetic risk factors, such as ventilatory and arousal abnormalities and temperature or metabolic regulation deficits. Cardiorespiratory control deficits could be related to

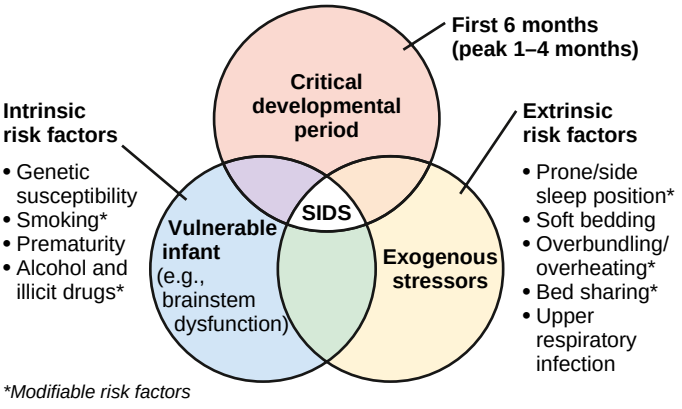

Fig. 423.2 Schematic of the triple-risk model for sudden infant death syndrome (SIDS) showing the critical interactions between intrinsic risk factors (including genetic risk factors) resulting in a vulnerable infant, a critical developmental period or age, and exogenous stressors or extrinsic risk factors. *(Modified from Filiano JJ, Kinney HC. A perspective on the neuropathologic findings in victims of the sudden infant death syndrome: the triple risk model. Biol Neonate. 1994;65:194–197.)*

Table 423.5 Interactions Between Genetic and Environmental Risk Factors that Determine the Actual Risk for SIDS in Individual Infants

GENETIC RISK FACTOR	ENVIRONMENTAL RISK FACTOR
Intrinsic vulnerability Impaired ventilatory and arousal responses	Sleep environment Nonsupine sleep position Soft bedding
Cardiac ion channelopathy	Sleep-related hypoxemia or hypercarbia leading to acidosis
Diminished immune responses to infections	Respiratory or other benign infections
Diminished brainstem autonomic control	Cigarette smoke exposure

5-HTT polymorphisms, for example, or to polymorphisms in genes pertinent to autonomic nervous system development. Affected infants could be at increased risk for sleep-related hypoxemia and hence more susceptible to adverse effects associated with unsafe sleep position or sleep environment. Infants at increased risk for sleep-related hypoxemia could also be at greater risk for fatal arrhythmias in the presence of a cardiac ion channelopathy polymorphism.

In >50% of SIDS victims, recent febrile illnesses, often related to upper respiratory infection, have been documented (see Table 423.2). Benign infections might increase the risk for SIDS if interacting with genetically determined proinflammatory or impaired immune responses. Deficient inflammatory responsiveness can also occur as a result of mast cell degranulation, which has been reported in SIDS infants. This is consistent with an anaphylactic reaction to a bacterial toxin, and some family members of SIDS infants also have mast cell activation and degranulation, suggesting that increased susceptibility to an anaphylactic reaction is another genetic factor influencing fatal outcomes to otherwise minor infections. Interactions between upper respiratory infections or other minor illnesses and factors such as prone sleeping might also play a role in the pathogenesis of SIDS.

The increased risk of SIDS associated with fetal and postnatal exposure to cigarette smoke may be related at least in part to genetic or epigenetic factors, including those affecting brainstem autonomic control. Infant studies document decreased ventilatory and arousal responsiveness to hypoxia after fetal nicotine exposure, and impaired autoresuscitation after apnea has been associated with postnatal nicotine exposure. Decreased brainstem immunoreactivity to selected protein kinase C and neuronal nitric oxide synthase isoforms occurs in rats exposed to cigarette smoke prenatally, another potential cause of impaired hypoxic responsiveness. Tobacco smoke exposure also increases susceptibility to viral and bacterial infections and increases bacterial binding after passive coating of mucosal surfaces with smoke components, implicating interactions between smoking, cardiorespiratory control, and immune status. Flavin-monooxygenase 3 *(FMO3)* is one of the enzymes that metabolizes nicotine, and a polymorphism has been identified that occurs more frequently in SIDS infants compared with controls and more frequently in infants whose mothers reported heavy smoking. This polymorphism would result in increased nicotine levels and hence is a potential genetic risk factor for SIDS in infants exposed to cigarette smoke.

In infants with a cardiac ion channelopathy, risk for a fatal arrhythmia during sleep may be significantly enhanced by predisposing perturbations that increase electrical instability. These perturbations could include REM sleep with bursts of vagal and sympathetic activation, minor respiratory infections, or any other cause of sleep-related hypoxemia or hypercarbia, especially if resulting in acidosis. The prone sleeping position is associated with increased sympathetic activity.

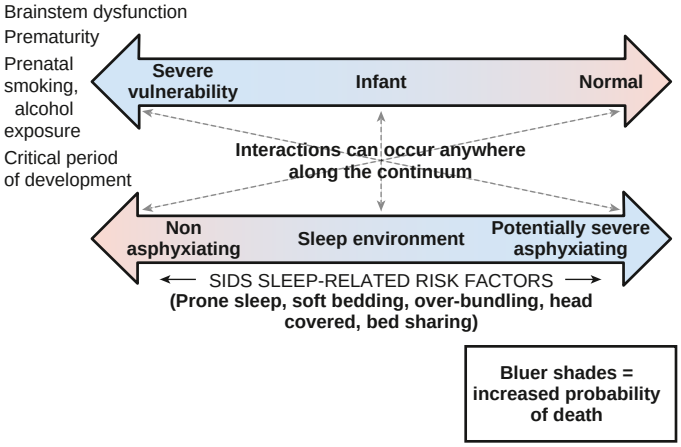

Fig. 423.3 Dynamic interactions between intrinsic vulnerability to sudden infant death syndrome (SIDS) and degree of risk in the sleep environment, ranging from nonasphyxiating (completely safe) to potentially severe asphyxiating (highly unsafe). Intrinsic vulnerability could be related to genetic risk factors, fetal or early infant exposures, or other factors. *(Modified from Hunt CE, Darnall RA, McEntire BL, Hyma BA. Assigning cause for sudden unexpected infant death. Forensic Sci Med Pathol. 2015;11:283–288.)*

INFANT GROUPS AT INCREASED RISK FOR SUDDEN INFANT DEATH SYNDROME

Subsequent Siblings of an Infant Who Died of Sudden Infant Death Syndrome

The next-born siblings of first-born infants dying of any noninfectious natural cause are at significantly increased risk for infant death from the same cause, including SIDS. The relative risk is 9.1 for the same cause of recurrent death versus 1.6 for a different cause of death. The relative risk for recurrent SIDS (range: 5.4-5.8) is similar to the relative risk for non-SIDS causes of recurrent death (range: 4.6-12.5). The risk for recurrent infant mortality from the same cause as in the index sibling thus appears to be increased to a similar degree in subsequent siblings for both explained causes and for SIDS. This increased risk for recurrent SIDS in families is consistent with genetic risk factors interacting with environmental risk factors (see Table 423.5 and Figs. 423.2 and 423.3). *Recurrent SIDS in a family should also alert the clinician to consider other causes of sudden and unexpected death, such as metabolic diseases, cardiac channelopathies, or nonaccidental causes.*

Preterm Birth

Despite reductions of more than 50% in SIDS and SUID among infants born preterm since initiation of the Back to Sleep (Safe to Sleep) campaign in the United States in 1994, the risk of death remains significantly higher for these infants than for those born full term. The risk increases as gestational age decreases. Compared with infants born at 37-42 weeks, the odds ratio for SIDS is greatest for infants born at 24-28 weeks of gestation (2.57, 95% confidence interval 2.08, 3.17). Even at 33-36 weeks gestational age at birth, the risk of SIDS remains significantly increased compared with infants born at term. The peak chronological age for SIDS is later in infants born preterm, with chronological age at death inversely proportional to gestational age at birth.

Although infants born preterm are at increased risk for apnea, apnea of prematurity per se *does not* seem to be related to the increased SIDS risk. Premature infants' increased risk is instead likely related in part to immaturity of brainstem responses; physiologic studies have found impaired cortical arousals, lower baroreflex sensitivity, and impaired autonomic control. Sociodemographic and environmental risk are also important. Infants born preterm have more sociodemographic risk factors overall than infants born at term. In addition, infants born preterm are more likely to be placed prone at home; this may be in part because these infants are often placed prone while mechanically ventilated in the neonatal intensive care unit (NICU), and safe sleep practices are often not well-modeled during the remainder of the NICU admission. The association between prone position and SIDS in preterm and low birthweight infants is equal to or greater than this association in infants born full term.

Physiologic Studies

Physiologic studies have been performed in healthy infants in early infancy, a few of whom later died of SIDS. Physiologic studies have also been performed on infant groups who were believed to be at increased risk for SIDS, especially those with brief resolved unexplained events (**BRUEs**; see Chapter 424) and subsequent siblings of infants who died of SIDS. In the aggregate, these studies have indicated brainstem abnormalities in the neuroregulation of cardiorespiratory control or other autonomic functions and are consistent with the autopsy findings and genetic studies in infants who died of SIDS. In addition to physiologic abnormalities in chemoreceptor sensitivity, other observed physiologic abnormalities have been found in respiratory pattern, control of heart and respiratory rate or variability, and arousal responsiveness to asphyxial situations. A deficit in arousal responsiveness may be a necessary prerequisite for death to occur but may be insufficient to cause death in the absence of other genetic or environmental risk factors.

Autoresuscitation (gasping) is a critical component of the arousal response to asphyxia, and a failure of autoresuscitation in infants may be the final and most devastating physiologic failure. In one study, most normal full-term infants younger than 9 postnatal weeks of age aroused in response to mild hypoxia, whereas only 10–15% of infants older than 9 weeks of age aroused. These data suggest that ability to arouse to mild to moderate hypoxic stimuli may be at a nadir at the age range of greatest risk for SIDS.

The ability to shorten the QT interval as heart rate increases appears to be impaired in some infants who died of SIDS, suggesting that such infants may be predisposed to ventricular arrhythmia. Although this is consistent with the observations of cardiac ion channel gene polymorphisms in some infants who subsequently die of SIDS, there are no antemortem QT interval data for these infants that confirm the importance of this finding. Infants who were studied physiologically and then died of SIDS a few weeks later had higher heart rates and lower heart rate variability in all sleep-wake states and diminished heart rate variability during wakefulness. These infants also had longer QT intervals than control infants during both REM and NREM sleep, especially in the late hours of the night when SIDS most likely occurs. However, the QT interval exceeded 440 msec in only one of these infants who subsequently died.

It has been postulated that the decreased heart rate variability and increased heart rate observed in infants who later died of SIDS may in part be related to decreased vagal tone, perhaps from vagal neuropathy or brainstem damage in areas responsible for parasympathetic cardiac control. The power spectrum analysis of heart rate variability is one way to assess sympathetic and parasympathetic cardiac control. In a comparison of heart rate power spectra before and after obstructive apneas in clinically asymptomatic infants, infants later dying of SIDS did not have the decreases in low-frequency to high-frequency power ratios observed in infants who survived. Some infants may thus have different autonomic responsiveness to obstructive apnea, perhaps indicating impaired autonomic nervous system control associated with higher vulnerability to external or endogenous stresses, and hence reduced electrical stability of the heart; this may create a vulnerability for SIDS.

Home cardiorespiratory monitors with memory capability have recorded the terminal events in some infants who died of SIDS. However, these recordings did not include pulse oximetry and could not identify obstructed breaths because of reliance on transthoracic impedance for breath detection. In most instances, there was sudden and rapid progression of severe bradycardia that was either unassociated with central apnea or appeared to occur too soon to be explained by the central apnea. These observations are consistent with an abnormality in autonomic control of heart rate variability or with obstructed breaths resulting in bradycardia or hypoxemia and associated with impaired autoresuscitation or arousal.

CLINICAL STRATEGIES

Home Monitoring

SIDS cannot be *prevented* in individual infants because it is not possible to identify prospectively infants who will go on to have SIDS, and no effective intervention has been established even if infants at risk could be prospectively identified. Studies of cardiorespiratory pattern or other autonomic abnormalities do not have sufficient sensitivity and specificity to be clinically useful as screening tests. Although there are a growing number of consumer products marketed to monitor infants during sleep, there is no evidence that home electronic surveillance using existing technology reduces the risk of SIDS. Although a prolonged QT interval in an infant may be treated if diagnosed, neither the role of routine postnatal electrocardiographic screening, the cost-effectiveness of diagnosis and treatment, nor the safety of treatment in infants has been established. Parental electrocardiographic screening is not helpful, in part because spontaneous pathogenic variants are common.

Reducing the Risk of SIDS and SUID

Reducing risk behaviors and increasing protective behaviors among infant caregivers to achieve further reductions and eventual elimination of SIDS and SUID is a critical goal. Plateaus in placing infants supine for sleep and persistent high rates of soft bedding use and surface sharing in the United States are cause for concern and require renewed educational efforts. Recent studies indicate soft or loose bedding is present in the sleep environment of greater than 50% of infants in the United States. A 2015 Centers for Disease Control and Prevention (CDC) survey of parents in 14 states and New York City found that 52.7% of White non-Hispanic, 76.5% of Black non-Hispanic, 66.7% of Hispanic, 76.8% of Asian or Pacific Islander, and 83.9% of American Indian or Alaska Native parents reported surface sharing with their infants. The American Academy of Pediatrics (AAP) guidelines for reducing infant deaths in the sleep environment were updated in 2022 and are aimed at reducing the risk of all sudden and unexpected sleep-related infant deaths. The guidelines are appropriate for most infants, but physicians and other healthcare providers might, on occasion, need to consider alternative approaches. The major components of the AAP guidelines are:

- Full-term and premature infants should be placed for sleep in the supine position. There are no adverse health outcomes from supine sleeping. Side-sleeping is not recommended.
- Infants should be put to sleep on a noninclined, firm mattress. Waterbeds, sofas, soft mattresses, or other soft surfaces should not be used. In addition, car seats, strollers, swings, and other sitting devices should not be used for sleeping. Sleeping in such sitting devices can increase the risk of gastroesophageal reflux and upper airway obstruction from head or neck flexion. Sleeping on an inclined surface can also increase the risk of head or neck flexion and makes it easier for infants to roll into an unsafe side or prone position.
- Feeding of human milk is recommended. Unless it is contraindicated or the parent is unable to do so, it is recommended that infants be fed with human milk (i.e., not offered any formula or other nonhuman milk-based supplements) exclusively for ~6 months, with continuation of human milk feeding for 1 year or longer as mutually desired by parent and infant.
- It is recommended that infants sleep in the same room as their parents but in their own crib or bassinet that conforms to the safety standards of the Consumer Product Safety Commission. Placing the crib or bassinet near the parents' bed facilitates feeding and contact. If parents bring the infant into the adult bed for feeding or comforting, the infant should be returned to a separate sleep surface when the parents are ready for sleep. Couches and armchairs are associated with an extremely high increased risk of SIDS, accidental suffocation, and entrapment and should never be used for infant sleep.
- There should be no soft materials and loose bedding in the infant's sleep environment (over, under, or near the infant). These include pillows, including nursing pillows, comforters, quilts, sheepskins, bumper pads, positioners, and stuffed toys. Sleep clothing, such as a wearable blanket, can be used in place of blankets. Weighted blankets, weighted sleepers, weighted swaddles, or other weighted objects should not be placed on or near the sleeping infant.
- Offering a pacifier at bedtime and naptime is recommended. The pacifier should be used when placing the infant down for sleep and need not be reinserted once it falls out. For breastfed infants, delay introduction of the pacifier until breastfeeding is firmly established. This is defined as having sufficient milk supply, con-

sistent, comfortable, and effective latch for milk transfer, and appropriate infant weight gain as defined by established normative growth curves. The time required to establish breastfeeding is variable.

- Parents should not smoke during pregnancy or after birth, and infants should not be exposed to secondhand smoke.
- Parents should avoid alcohol, marijuana, opioids, and illicit drug use during pregnancy and after birth.
- Avoid overheating and overbundling. The infant should be lightly clothed for sleep and the thermostat set at a comfortable temperature. The use of hats or other infant head coverings indoors is not recommended.
- Pregnant persons should obtain regular prenatal care, following guidelines for prenatal visits.
- Infants should be immunized in accordance with recommendations of the AAP and the CDC. There is no evidence that immunizations increase the risk of SIDS. Indeed, recent evidence suggests that immunizations may have a protective effect against SIDS.
- Avoid the use of commercial devices that are inconsistent with safe sleep recommendations. Devices advertised to maintain sleep position, "protect" a bed-sharing infant, or reduce the risk of rebreathing are not recommended because there is no evidence to support their safety or efficacy.
- Home cardiorespiratory and/or O_2 saturation monitoring may be of value for selected infants who have extreme instability, but there is no evidence that monitoring decreases the incidence of SIDS, and it is therefore not recommended for this purpose.
- Infants should have some time in the prone position (tummy time) while awake and observed. Alternating the placement of the infant's head and orientation in the crib can also minimize the risk of head flattening from supine sleeping (positional plagiocephaly).
- Swaddling cannot be recommended as a strategy to reduce SIDS, as there is insufficient evidence. If infants are placed in a swaddle, it should be using a light blanket that is snug around the shoulders but looser around the hips to avoid hip dysplasia. Swaddled infants should always be placed supine, and once infants can roll to the prone or side position, all swaddling should be discontinued.
- Healthcare professionals, staff in newborn nurseries and NICUs, and childcare providers should adopt the SIDS reduction recommendations beginning at birth, or as soon as clinically able, to model safe sleep for caregivers.
- Media and manufacturers should follow safe sleep guidelines in their messaging, advertising, and social media.
- The national Safe to Sleep campaign should be continued with additional emphasis placed on strategies to increase breastfeeding while decreasing bed sharing and tobacco smoke exposure. The campaign should continue to have a special focus on the groups with higher rates of SIDS, including educational strategies tailored to individual racial-ethnic groups. Secondary care providers need to be targeted to receive these educational messages, including daycare providers, grandparents, foster parents, and babysitters. Efforts should also be made to introduce sleep recommendations before pregnancy and ideally in early education settings and school curricula to educate older siblings and teenage and adult babysitters and establish these practices as normative behavior. Research and surveillance should be continued on the risk factors, causes, and pathophysiologic mechanisms of SIDS and other sleep-related SUID, with the ultimate goal of preventing these deaths entirely. Federal and private funding agencies need to remain committed to this research.

Visit Elsevier eBooks+ at eBooks.Health.Elsevier.com for Bibliography.

423.1 Sudden Unexpected Postnatal Collapse/Sudden Unexpected Early Neonatal Death

Sarah Vepraskas

Sudden unexplained postnatal collapse (SUPC) is a rare but potentially fatal event that occurs when a spontaneously breathing, previously healthy newborn suddenly becomes limp, pale, or cyanotic, bradycardic, unresponsive, apneic, and/or has cardiac and/or respiratory failure and requires cardiopulmonary resuscitation. SUPC results in death in about half of the infants and significant impairment in many survivors.

There is not a consensual definition for SUPC in the medical literature, although there is increasing awareness of SUPC as a clinical entity, with over 400 cases described. The most common definition of SUPC used is by the British Association of Perinatal Medicine and includes any term or near-term (defined as >35 weeks' gestation) infant who meets the following criteria: (1) is well at birth (normal 5-minute Apgar and deemed well enough for routine care),(2) collapses unexpectedly in a state of cardiorespiratory extremis such that resuscitation with intermittent positive-pressure ventilation is required, (3) collapses within the first 7 days of life, and (4) either dies, goes on to require intensive care, or develops encephalopathy. A majority of reported events occur within 2 hours after birth, often at the time of the first breastfeeding attempt. Other potential medical conditions that place infants at higher risk, such as prematurity (<35 weeks' gestation), perinatal asphyxia, sepsis, or congenital malformations, should be excluded before a diagnosis of SUPC is made.

Population-based studies estimate the incidence of SUPC to be 2.6-38 cases per 100,000 live births. The incidence varies widely because of the lack of both a definition consensus and standardized reporting system as well as differing inclusion and exclusion criteria. Furthermore, a consensus for coding SUPC has not been established, which likely also contributes to it being underreported.

The published estimations of SUPC are lower than what occur in the hospital and reflect only the critical events. When a defined time for the SUPC event is described, approximately one third of reported events occur during the first 2 hours, another one third between 2 and 24 hours, and another one third between 1 and 7 days after birth.

PATHOGENESIS

In most SUPC cases an underlying condition is never identified, although the literature suggests there is a variety of etiologies. Many of the events may be related to suffocation or entrapment, but it seems to have a complex pathophysiology that is poorly understood. One hypothesis is that the transition from fetal to extrauterine life could make the newborn more vulnerable during the first hour of life. During birth there is an initial surge of adenosine and prostaglandins, followed by a postnatal surge of catecholamines. A healthy newborn baby is aroused and awake after birth and starts continuous breathing movements. Shortly after birth, there is a rapid decrease in the inhibitory neuromodulator adenosine as the partial pressure of oxygen in the arterial blood rapidly increases and contributes to the increased activity in the newborn infant compared with the fetus. After the hormone surges, there is a period of diminished responsiveness to external stimuli and increased vagal tone; it is possible that autonomic instability could make infants vulnerable during this transitioning period.

It is also possible that impaired cardiorespiratory control resulting from hypoxic ischemic injury occurring days *before* birth could contribute to fatal cases of SUPC. Mild gliosis in brainstem areas involved in cardiorespiratory control was found at autopsy of seven infants with

SUPC. However, there are insufficient data to support an association between in utero hypoxic events and SUPC. Monogenic etiologies have not been explored to the same degree reported for SIDS in infants ≥2 months (see Table 423.4).

RISK FACTORS

Many reported SUPC cases occur while the infant is in the prone position, during skin-to-skin contact (SSC) with their mothers. SSC is traditionally defined as beginning at birth and lasting continually until the end of the first breastfeeding.

Additional risk factors for SUPC include the first breastfeeding attempt, cosleeping, a mother in the episiotomy position, a primiparous mother, and parents left alone with baby during the first hour after birth.

SSC and rooming-in have become common practice for healthy newborns and align with the Baby-Friendly Hospital Initiative (BFHI), a global program launched by the World Health Organization (WHO) and the United Nations Children's Fund (UNICEF) to encourage and recognize hospitals and birthing centers that promote the optimal level of care for infant feeding and mother/baby bonding. The BFHI recognizes and awards birthing facilities that successfully implement the "Ten Steps to Successful Breastfeeding," with step 4 being to initiate breastfeeding within 1 hour of birth and step 7 recommending the practice of rooming-in. The AAP clinical report on safe sleep and SSC in the newborn period both reviews the evidence supporting SSC and rooming-in during the newborn period and addresses the safety concerns and provides suggestions to improve safety after delivery. The literature supporting SSC also emphasizes the importance that mother and baby should not be left unattended during this early period.

DIAGNOSIS AND DIFFERENTIAL DIAGNOSIS

The diagnosis of SUPC should be made only after other pathologic causes are excluded. One study consisting of 45 cases of unexpected collapse in newborns found that one third of infants had an underlying pathologic or clinical condition, such as sepsis, ductal-dependent congenital heart disease, congenital diaphragmatic hernia, intracranial hemorrhage, or a metabolic disorder. Additional etiologies to consider include airway obstruction, pneumonia, respiratory distress syndrome, hypoglycemia, vascular thrombosis or embolism, and pulmonary hypertension of the newborn. The differential diagnosis of SUPC is broad, and many conditions overlap with the differential diagnoses for BRUE (see Chapter 424), SUID, and SIDS.

For those infants who survive the event, testing to screen for an underlying pathology should be performed and tailored to the specific details of each case. A thorough history and physical exam should be performed before initiating the diagnostic workup to assist one in focusing the evaluation. Laboratory tests to consider include electrolytes; metabolic evaluation including glucose, ammonia, and lactate; an infectious evaluation including blood cultures, urinalysis, and urine cultures; and CSF analysis with CSF culture. Chest radiography, neuroimaging, echocardiogram, electrocardiogram, and comprehensive metabolic screening (included as part of the newborn screen in most states) could also be useful diagnostic tools. Postmortem examination in the case of death from presumed SUPC should be performed because underlying etiology of the event may be discovered during autopsy. In the event that no identifiable etiology is discovered, next-generation gene testing for at-risk pathogenic variants should be performed (see Table 423.4).

OUTCOME

Approximately half of SUPC cases are thought to result in death, and there is remaining disability in most reported cases. A review of 17 and 45 SUPC cases in Germany and the United Kingdom showed a mortality rate of 42% and 27%, respectively. In the German study, almost two thirds of the surviving cases had neurologic deficits, and in the United Kingdom study, one third of infants either died or had residual neurologic deficits. Rates of death and neurologic abnormalities reported in the two aforementioned studies are comparable with other available case reports.

TREATMENT

Although there is no definitive treatment for infants who have suffered from SUPC, therapeutic hypothermia (TH) has been studied as a plausible therapy because 75% of newborns with no known cause for collapse develop a typical postasphyxia encephalopathy, evoking hypoxic-ischemic encephalopathy (HIE) (see Chapter 122.4). Given the low incidence, diversity of etiologies, uncertain pathophysiology, and underreporting, it would be difficult to perform an outcomes trial using TH for infants with SUPC. Case reports on outcomes using TH for SUPC infants report variable short-term outcomes; long-term data are lacking. In a sample of 22 infants who suffered SUPC and were treated in Portuguese hypothermia centers, a significant proportion had poor outcomes. In contrast, another case report of four patients with HIE and TH treatment after SUPC described three children as developmentally normal at 24-month follow-up and one child as having mild cerebral palsy.

PREVENTION

The known risk factors for SUPC can be used to aid in preventive efforts. Specifically, safety during SSC and rooming-in should be emphasized. Initiatives developed to standardize the procedure for immediate postnatal SSC have not proven to reduce the risk of SUPC. Frequent assessments of newborns should be performed, including observation of breathing, activity, color, tone, and position, to ensure they are in a position to avoid obstructive breathing or events leading to SUPC. It has also been suggested that continuous monitoring by trained staff members be done during SSC. However, that may be obtrusive to mother-infant bonding. Some have suggested continuous pulse oximetry during this period, but there is no evidence to support this practice, and this overmonitoring could lead to unnecessary parental concern. Because many cases of SUPC occur within the first few hours of life, the delivery unit should be staffed to permit frequent newborn assessments while preserving the developing mother-child bond.

Many of the same safety concerns that occur during SSC immediately after birth continue to be a concern during rooming-in if the mother is not given guidance on the safe rooming-in practices. Cosleeping should not be permitted on the postpartum unit. Mothers and families need to be informed of the risks of cosleeping. Staffing ratios should be determined to meet the needs of both mother and infant to allow for frequent assessments, rapid response time to call lights, and time for maternal education.

Visit Elsevier eBooks+ at eBooks.Health.Elsevier.com for Bibliography.

Chapter 424

Brief Resolved Unexplained Events and Other Acute Events in Infants

Amy M. DeLaroche and Joel S. Tieder

Infants may experience acute, self-resolving changes in their breathing, tone, mental status, and skin color. Usually these events are normal manifestations of developmental immaturity. Nonetheless, caregivers may worry that the acute event could have been life-threatening or is a sign of an undiagnosed medical problem and seek medical attention. In most cases, after a comprehensive history and physical examination, a clinician will determine the event to have been a benign or normal process, such as gastroesophageal reflux (GER) or periodic breathing of the newborn. At times, however, the event defies a simple explanation and drives uncertainty about risk from a serious underlying cause or a future event. This situation poses a diagnostic and management challenge for both the family and the clinician.

Historically, these events were feared as precursors to sudden infant death syndrome (SIDS) and were referred to as *near-miss SIDS, aborted crib deaths,* or *apparent life-threatening events (ALTEs)*. These terms have been replaced because we now know that these events are not associated with SIDS and are rarely life-threatening. These terms were additionally problematic because they relied on the subjective interpretation of the caregiver, included a nonspecific constellation of symptoms, and did not distinguish well-appearing patients from those with symptoms.

Most of these acute events in infants are best described as brief resolved unexplained events (BRUEs). A BRUE is a diagnosis of exclusion and should be used only when the event is transient and remains unexplained after an appropriate medical evaluation.

DEFINITION

A BRUE (pronounced *brew*) is an event that occurs in an infant younger than 1 year that is described by the observer as a *sudden, brief,* and *resolved* episode that involved at least one of the following:

- Cyanosis or pallor
- Absent, decreased, or irregular breathing
- Marked change in tone, either hypertonia or hypotonia
- Altered level of responsiveness

The diagnosis of BRUE applies only to infants who were asymptomatic before the event and during the initial medical evaluation and when no explanation for the event is found through appropriate history and physical examination (Fig. 424.1).

Infants who experience a BRUE are categorized as either lower or higher risk for a subsequent event or a serious underlying disorder based on patient factors, characterization of the event, additional historical factors, and the physical examination.

A lower-risk infant is defined as:

- Age >60 days
- Gestational age ≥32 weeks and postconceptional age ≥45 weeks
- Occurrence of only 1 BRUE (no prior BRUE ever and not occurring in a cluster)
- Duration of event <1 minute
- No cardiopulmonary resuscitation (CPR) by trained medical provider required
- No concerning historical features
- No concerning physical examination finding

EPIDEMIOLOGY

The exact incidence of BRUEs is unknown, but BRUEs may account for up to 0.02% of pediatric emergency department visits. In a multicenter study of hospitals, 87% of patients met higher-risk criteria and 63% were hospitalized. Since the American Academy of Pediatrics published the Clinical Practice Guideline and introduced the term *BRUE,* hospitalizations have been decreasing, especially for lower-risk infants.

BRUEs are not precursors to SIDS. The incidence of mortality after a BRUE from an underlying cause is extremely low, as only 1 patient in a cohort of 2,036 patients died during a readmission after being evaluated for a BRUE. Overall, the risk of death among patients with a BRUE is estimated to approximate the baseline risk of death among infants in the first year of life.

For patients presenting with a BRUE, numerous risks must still be considered. First is the risk of an underlying diagnosis that could lead to serious morbidity or mortality if not diagnosed in a timely fashion. This is estimated to be 4% for patients presenting to the emergency department with a BRUE and includes a wide variety of illnesses, such as cardiac arrhythmias, infections, and brain injury. In one study of infants with a serious underlying diagnosis identified after evaluation for a BRUE, seizures were the most commonly identified diagnosis followed by airway abnormalities, abusive head trauma, bacterial or viral infections, and intussusception. Less common etiologies were arrhythmias, central apnea, and ingestions. These diagnoses may become evident in the emergency department, the inpatient service, outpatient follow-up, or on readmission to the hospital.

In contrast, it is more common for a benign explanation to be identified, with choking, reflux, breath-holding spells, acrocyanosis, colic, viral infections, dysphagia, and overfeeding noted in over half of patients diagnosed with a less serious explanation for the event (Table 424.1). Second is the risk of a recurrent event, which occurred in 2.7% of patients during their emergency department visit for a BRUE and in 18.2% of patients hospitalized for a BRUE. These events can be stressful for caregivers, particularly when the cause is unknown. Third is the risk that the caregivers become unnecessarily concerned about their healthy child. Clinicians should be aware of the challenges caregivers face when perceiving a threat of losing their child, there is medical uncertainty, or when their child is hospitalized. Recurrent events that occur during a period of observation can lead to better characterization and explanation of the event and, in some cases, may reassure caregivers. Fourth are the risks associated with medical care, such as nosocomial infections and inaccurate testing.

INITIAL HISTORY

An appropriate history and physical examination are key to evaluating an infant who has experienced an acute event (Table 424.2). Attention should be given to characterizing the event and interpreting the subjective experience of the caregiver to provide an objective description. The following questions can guide this process:

What was the infant doing before, during, and after the event? An event occurring during or after feeding will likely have a different explanation than one occurring during sleep or after crying. The sequence of events can also be diagnostic. A **breath-holding spell** begins with crying, followed by a period of apnea, perioral cyanosis, change of consciousness, and return to baseline.

Did the infant change color? It is often normal for infants to have blue discoloration **(perioral cyanosis or acrocyanosis)** around the lips or hands because of circulatory immaturity. Turning red or purple is also common when infants cry or become upset. The clinician's goal is to distinguish less concerning color change from **central cyanosis**, which is blue discoloration of the face, trunk, gums, or tongue that can indicate hypoxemia.

Did the infant experience central or obstructive apnea, or just choking or gagging? It is normal for infants to exhibit respiratory pauses of up to 20 seconds while awake and asleep. These can reflect **periodic breathing of the newborn** or normal REM sleep. Much more concerning are periods of no air movement that last longer than 20 seconds. **Obstructive apnea** results in paradoxical movement of the diaphragm and upper airway. In infants, this is most commonly caused by upper

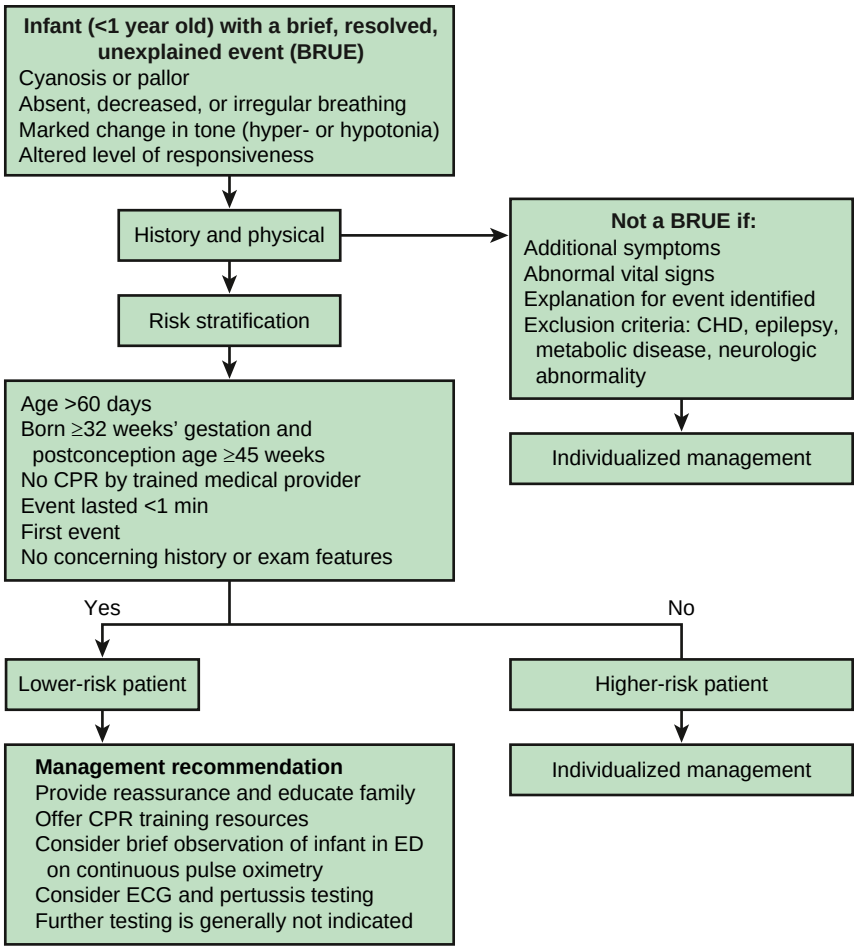

Fig. 424.1 Algorithm for diagnosis, risk stratification, and management of a brief resolved unexplained event (BRUE). CHD, Congenital heart disease; ECG, electrocardiogram; ED, emergency department. *From The Harriet Lane House Staff at The Charlotte R. Bloomberg Children's Center of The Johns Hopkins Hospital. The Harriet Lane Handbook. 23rd ed. Philadelphia: Elsevier, 2024. Fig 25.11; with data from Tieder JS, Bonkowsky JL, Etzel RA, et al. Brief Resolved Unexplained Events (Formerly Apparent Life-Threatening Events) and Evaluation of Lower-Risk Infants [published correction appears in Pediatrics. 2016 Aug;138(2):]. Pediatrics. 2016;137(5):e20160590.*

and lower respiratory tract infections (e.g., bronchiolitis) and may precede the recognition of symptoms typically seen in viral respiratory infections. Infants also commonly gag or choke briefly during or shortly after feeds or with GER or vomiting. The resulting reflexive pause in respiration to protect the airway is sometimes referred to as **laryngospasm**. **Central apnea** is always concerning and occurs when the brainstem does not properly control the respiratory muscles. This may be seen in brain trauma from **nonaccidental trauma** and in rare disorders such as **congenital central hypoventilation syndrome**.

Was there a concerning change in muscle tone? Seizures in infants are concerning and difficult to diagnose, and they rarely present as typical seizure activity. They can present as staring spells, periods of episodic increased or decreased tone, or **infantile spasms**. It is normal for infants to have rapid jerking movements because of neurologic immaturity and infant reflexes (e.g., Moro, startle, and fencing reflex), and sometimes these can appear similar to seizures. One of the most serious and time-sensitive causes of seizures or central apnea is undiagnosed brain trauma from nonaccidental trauma, which may result in no other symptoms or physical examination findings upon presentation.

Was there an altered level of responsiveness? Episodic changes in consciousness and mental status can be difficult to assess in infants because of neurologic immaturity and variability in sleep-wake cycles. However, abrupt changes where the infant appears to lose consciousness after episodes of apnea or color change can be concerning for hypoxemia, hypoglycemia, or seizures.

Did the event self-resolve, or was an intervention required? Infants with choking from GER, vomit, or feeding difficulties generally improve spontaneously or with help clearing the airway. A serious underlying cause is more likely if CPR was indicated and then provided, though this may be difficult to assess if no medically trained individuals witnessed the event.

Additional History

A careful, detailed history can lead to an explanation; the key elements are summarized in Tables 424.1 and 424.2. A clinician should inquire about other symptoms (e.g., fever, upper respiratory infection [URI] symptoms, spitting up). A history of breathing problems, prenatal or perinatal concerns, prematurity, and growth and developmental problems is important. Premature infants, particularly those still under 43 weeks corrected gestational age, are at higher risk for underlying causes, such as apnea of prematurity. A careful feeding history can detect oropharyngeal dysphagia or GER-related problems (i.e., laryngospasm).

A targeted family history can reveal risk for sudden death, cardiac arrhythmias, and metabolic, genetic, and neurologic disease. A social history, particularly by someone trained to detect nonaccidental trauma, can reveal recent trauma, prior child welfare involvement, substance abuse, poisoning or misuse of medications, and environmental exposures (e.g., secondhand tobacco smoke and mold). It is important to understand who observed the event, who normally takes care of the infant, and if there are any discrepancies in the explanation of the event.

Consider infectious exposures. Infants exposed to underimmunized family members are at risk for pertussis. Respiratory syncytial virus (RSV) and other respiratory viruses, as well as pertussis, can present with apnea before the onset of URI symptoms.

Physical Examination

A careful physical examination may reveal a causative or underlying diagnosis. Abnormal growth and head circumference may reflect feeding, developmental, and neurologic problems. Abnormal vital signs and pulse oximetry can suggest infectious, cardiac, and neurologic abnormalities. A careful skin and mouth examination can reveal subtle signs. For example, child abuse should be suspected in infants with bruises, petechiae, or a torn frenulum. Signs of airway abnormalities,

Table 424.1 Symptom-Based Approach to BRUEs: Other Conditions that Might Be Confused with a BRUE

DIAGNOSTIC CATEGORIES	EXPLANATORY CAUSES TO CONSIDER	SUGGESTIVE HISTORICAL FINDINGS	SUGGESTIVE PHYSICAL EXAMINATION FINDINGS	TESTING TO CONSIDER
Gastrointestinal	GER Intussusception Volvulus Oropharyngeal dysphagia	Coughing, vomiting, choking, gasping temporally related to feeds or regurgitation of gastric contents Feeding difficulties Recent preceding feed Irritability after feeds Milk in mouth/nose Bilious emesis Pulling legs to chest Bloody/mucousy stool Lethargy after event	Gastric contents in the nose and mouth Choking, gagging, or oxygen desaturation temporally related to feeding or regurgitation of gastric contents	Upper GI to assess for anatomic anomalies Clinical swallow evaluation Abdominal ultrasound pH probe
Infectious	Upper and lower respiratory tract infection (RSV, pertussis, pneumonia) Bacteremia Meningitis Urinary tract infection	Preceding URI symptoms Multiple events on the day of presentation Sick exposures Foul-smelling urine	Fever/hypothermia Lethargy Ill appearance Coryza Cough Wheeze Tachypnea	NP swab for RSV, pertussis Chest radiograph CBC and blood culture Cerebrospinal fluid analysis and culture Urinalysis and culture
Neurologic	Seizures Breath-holding spells Congenital central hypoventilation syndrome Neuromuscular disorders Congenital malformations of the brain and brainstem Malignancy Intracranial hemorrhage	Multiple events Loss of consciousness Change in tone Abnormal muscular movements Eye deviation Preceding triggers	Papilledema Abnormal muscular movements Hypertonicity or flaccidity Abnormal reflexes Microcephaly or macrocephaly Dysmorphic features Signs of trauma or poisoning (see "Child maltreatment" below)	EEG Neuroimaging
Respiratory/ ENT	Apnea of prematurity Apnea of infancy Periodic breathing Airway anomaly Aspiration Foreign body Obstructive sleep apnea	Prematurity Foreign body Aspiration Noisy breathing	Wheezing Stridor Crackles Rhonchi Tachypnea	Chest radiograph Neck radiograph Laryngoscopy Bronchoscopy Esophagoscopy Polysomnography
Child maltreatment	Nonaccidental head trauma Smothering Poisoning Factitious syndrome imposed on another (formerly Munchausen syndrome by proxy)	Multiple events Unexplained vomiting or irritability Recurrent BRUEs Historical discrepancies Family history of unexplained death, SIDS, or BRUEs Single witness of event Delay in seeking care	Bruising (especially in a nonmobile child) Ear trauma, hemotympanum Acute abdomen Painful extremities Oral bleeding/trauma Frenulum tears Unexplained irritability Retinal hemorrhages Depressed mental status	Skeletal survey CT/MRI of the head Dilated funduscopic examination if head imaging concerning for trauma Toxicology screen Social work evaluation
Cardiac	Dysrhythmia (prolonged QT syndrome, Wolff-Parkinson-White syndrome) Cardiomyopathy Congenital heart disease Myocarditis	Feeding difficulties Growth difficulties Diaphoresis Prematurity	Abnormal heart rate/rhythm Murmur Decreased femoral pulses	Four-extremity blood pressure Preductal and postductal oxygen saturation measurements ECG Echocardiogram Serum electrolytes, calcium, magnesium
Metabolic/ genetic	Hypoglycemia Inborn errors of metabolism Electrolyte abnormalities Genetic syndromes including those with craniofacial malformations	Severe initial event Multiple events Event associated with period of stress or fasting Developmental delay Associated anomalies Growth difficulties Severe/frequent illnesses Family history of BRUE, consanguinity, seizure disorder, or SIDS	Dysmorphic features Microcephaly Hepatomegaly	Serum electrolytes; glucose, calcium, and magnesium levels Lactate Ammonia Pyruvate Urine organic and serum amino acids Newborn screen

BRUE, Brief resolved unexplained event; ECG, electrocardiogram; EEG, electroencephalogram; ENT, ear, nose, and throat; GER, gastroesophageal reflux; GI, gastrointestinal; NP, nasopharyngeal; RSV, respiratory syncytial virus; SIDS, sudden infant death syndrome; URI, upper respiratory infection.

From Kliegman RK, Lye PS, Bordini BJ, et al., eds. *Nelson Pediatric Symptom-Based Diagnosis.* Philadelphia: Elsevier; 2018: Table 5.3.

Table 424.2 Important Historical Features of a BRUE

PREEVENT	
Condition of child	Awake vs asleep
Location of child	Prone vs supine, flat or upright, in crib/car seat, with pillows, blankets
Activity	Feeding, crying, sleeping
EVENT	
Respiratory effort	None, shallow, gasping, increased Duration of respiratory pauses
Color	Pallor, red, cyanotic Peripheral, whole body, circumoral, lighting of room
Tone/movement	Rigid, tonic-clonic, decreased, floppy Focal vs diffuse Ability to suppress movements
Level of consciousness	Alert, interactive, sleepy, nonresponsive
Duration	Time until normal breathing, normal tone, normal behavior Detailed history of caregiver actions during event to aid in defining time course
Associated symptoms	Vomiting, sputum production, blood in mouth/nose, eye rolling
POSTEVENT	
Condition	Back to baseline, sleepy, postictal, crying If altered after event, duration of time until back to baseline
INTERVENTIONS	
What was performed	Gentle stimulation, blowing in face, mouth-to-mouth, cardiopulmonary resuscitation
Who performed intervention	Medical professional vs caregiver
Response to intervention	Resolution of event vs self-resolving
Duration of intervention	How long was intervention performed
MEDICAL HISTORY	
History of present illness	Preceding illnesses, fever, rash, irritability, sick contacts
Medical history	Prematurity, prenatal exposures, gestational age, birth trauma Noisy breathing since birth Any medical problems, prior medical conditions, prior hospitalizations Developmental delay Medications
Feeding history	Gagging, coughing with feeds, poor weight gain
Family history	Neurologic problems Cardiac arrhythmias Sudden death, childhood deaths, BRUEs Neonatal problems Consanguinity
Social history	Home situation Caregivers Smoke exposure Medications in the home

BRUE, Brief resolved unexplained event.
From Kliegman RK, Lye PS, Bordini BJ, et al., eds. *Nelson Pediatric Symptom-Based Diagnosis.* Philadelphia: Elsevier; 2018: Table 5.4.

such as inspiratory or expiratory stridor or stertor, can lead to a diagnosis of respiratory infections, vascular rings, hemangioma, laryngomalacia, tracheomalacia, or facial dysmorphism.

Testing

In the past, it was common for clinicians to routinely test infants presenting with such events using complete blood counts (CBCs), appropriate cultures, and GER testing. However, it is known that these tests are unlikely to reveal a cause and even more likely to lead to a false-positive result. False positives can, in turn, contribute to missed diagnoses, additional unnecessary testing, patient harm, greater parental concern, and increased costs.

In lower-risk infants, routine laboratory testing and diagnostic imaging (CBC, bacterial cultures, blood gas and glucose, metabolic panels, urinalysis, GER testing, chest radiograph, neuroimaging, electroencephalogram [EEG], sleep study) is *not* recommended. *The few situations where testing may be considered in the lower-risk population include:*

- *Pertussis* testing in underimmunized or exposed individuals.
- ECG may reveal a prolonged QtC syndrome if there is a concerning family history, but routine testing is not indicated.
- Rapid viral testing can help diagnose subclinical viral causes, but these tests can be positive from recent past infections that may not be the cause of the concerning event.
- A brief period of continuous pulse oximetry and serial observations to detect hypoxemia and apnea.

In higher-risk infants, routine screening tests may not be needed. Testing should be done because of concerns from the history and physical or to further characterize repeat BRUEs.

- Continuous pulse oximetry or cardiorespiratory monitoring under a period of observation may help characterize repeat events.
- A swallow evaluation by a trained feeding expert might reveal oropharyngeal dysphagia in premature or young infants.
- Head imaging with CT or MRI is indicated when there is suspicion of nonaccidental trauma because of bruising in nonambulatory infants, concerning bruising patterns, history of unexplained death in a sibling, or inconsistent history of the event.
- Neurology consult or EEG or head imaging may lead to a diagnosis of epilepsy if there is a concern for seizure. However, it is reasonable to perform this consultation and testing as an outpatient in well-appearing infants.
- Otolaryngology consultation to detect anatomic disorders of the airway (e.g., laryngomalacia, tracheomalacia, and tracheoesophageal fistula).
- Pulmonary/sleep medicine consultation to detect disordered breathing (e.g., central apnea and obstructive sleep apnea).

Management

Although the value of hospital admission is debatable, lower-risk infants are much less likely to benefit from admission compared to higher-risk infants. Nationally, there is a trend away from routine admission for all BRUE patients, particularly those meeting lower-risk BRUE criteria. For all BRUEs, it is uncommon for a hospital admission to lead to a diagnosis of a serious underlying disorder. Sometimes, however, a longer period of observation than is practical in a clinic or emergency department can help characterize repeat events, should they recur, and reduce the uncertainty of a recurrent event for caregivers. Additional benefits of hospitalization include serial assessments of feeding, breathing, sleep, and social patterns. *The decision for hospital admission should incorporate the needs and preferences of the family and patient and the ability to follow up closely with a primary care physician.* In weighing the risks and benefits of this decision, it is important to recognize that hospitalization can unnecessarily increase stress for the family and patient through false alarms and iatrogenic complications. CPR education should be considered for all families. Home apnea monitoring should not be done. Close outpatient follow-up with a primary care physician is important, as almost half of serious underlying diagnoses are not identified during the first visit for a BRUE.

Visit Elsevier eBooks+ at eBooks.Health.Elsevier.com for Bibliography.

Section 2

Disorders of the Respiratory Tract

Chapter 425

Congenital Disorders of the Nose

Joseph Haddad Jr.

NORMAL NEWBORN NOSE

In contrast to children and adults, who *preferentially* breathe through their nose unless nasal obstruction interferes, most newborn infants are *obligate* nasal breathers. Significant nasal obstruction presenting at birth, such as choanal atresia, may be a life-threatening situation for the infant unless an alternative to the nasal airway is established. Acquired nasal congestion with obstruction is common in the first year of life and can affect the quality of breathing during sleep; it may be associated with a narrow nasal airway, viral or bacterial infection, enlarged adenoids, or maternal estrogenic stimuli similar to rhinitis of pregnancy. The internal nasal airway doubles in size in the first 6 months of life, leading to resolution of symptoms in many infants. Supportive care with a bulb syringe and saline nose drops, topical nasal decongestants, and antibiotics, when indicated, improve symptoms in affected infants.

PHYSIOLOGY

The nose is responsible for the initial warming and humidification of inspired air and olfaction. In the anterior nasal cavity, turbulent airflow and coarse hairs enhance the deposition of large particulate matter; the remaining nasal airways filter out particles as small as 6 μm in diameter. In the turbinate region, the airflow becomes laminar and the airstream is narrowed and directed superiorly, enhancing particle deposition, warming, and humidification. Nasal passages contribute as much as 50% of the total resistance of normal breathing. Nasal flaring, a sign of respiratory distress, reduces the resistance to inspiratory airflow through the nose and can improve ventilation (see Chapter 421).

Although the nasal mucosa is more vascular (especially in the turbinate region) than in the lower airways, the surface epithelium is similar, with ciliated cells, goblet cells, submucosal glands, and a covering blanket of mucus. The nasal secretions contain lysozyme and secretory immunoglobulin A (IgA), both of which have antimicrobial activity, and IgG, IgE, albumin, histamine, bacteria, lactoferrin, and cellular debris, as well as mucous glycoproteins, which provide viscoelastic properties. Aided by the ciliated cells, mucus flows toward the nasopharynx, where the airstream widens, the epithelium becomes squamous, and secretions are wiped away by swallowing. Replacement of the mucous layers occurs about every 10-20 minutes. Estimates of daily mucus production vary from 0.1 to 0.3 mg/kg/24 hr, with most of the mucus being produced by the submucosal glands.

CONGENITAL DISORDERS

Congenital *structural nasal malformations* are uncommon compared with acquired abnormalities. The nasal bones can be congenitally absent so that the bridge of the nose fails to develop, resulting in *nasal hypoplasia.* Congenital absence of the nose *(arrhinia),* complete or partial duplication, or a single centrally placed nostril can occur in isolation but is usually part of a malformation syndrome. Rarely, *supernumerary teeth* are found in the nose, or teeth grow into it from the maxilla.

Nasal bones can be sufficiently malformed to produce severe narrowing of the nasal passages. Often, such narrowing is associated with a high and narrow hard palate. Children with these defects can have significant obstruction to airflow during infections of the upper airways and are more susceptible to the development of chronic or recurrent hypoventilation (see Chapter 31). Rarely, the alae nasi are sufficiently thin and poorly supported, resulting in inspiratory obstruction, or there may be congenital nasolacrimal duct obstruction with cystic extension into the nasopharynx, causing respiratory distress.

CHOANAL ATRESIA

This is the most common congenital anomaly of the nose and has a frequency of approximately 1 in 7,000 live births. It consists of a unilateral or bilateral bony (90%) or membranous (10%) septum between the nose and the pharynx; most cases are a combination of bony and membranous atresia. The pathogenesis is unknown, but theories include persistence of the buccopharyngeal membranes or failure of the oronasal membrane to rupture. The unilateral defect is more common, and the female:male ratio is approximately 2:1. Approximately 50–70% of affected infants have other congenital anomalies (CHARGE syndrome [see later], Treacher-Collins, Kallmann syndrome, VATER [vertebral defects, imperforate anus, tracheoesophageal fistula, and renal defects] association, Pfeiffer syndrome), with the anomalies occurring more often in bilateral cases.

CHARGE syndrome (*c*oloboma, *h*eart disease, *a*tresia or stenosis of the choanae, *r*etarded growth and development or central nervous system [CNS] anomalies or both, *g*enital anomalies or hypogonadism or both, and *e*ar [external, middle, inner ear] anomalies or deafness or both) is one of the more common anomalies associated with choanal atresia—approximately 10–20% of patients with choanal atresia have it. The CNS involvement (~90%) includes reduced function of cranial nerves I, V, VII, VIII, IX, and X, as well as vision and hearing deficits. Most (~90%) patients with CHARGE syndrome have autosomal dominant de novo pathogenic variants in the *CHD7* gene, which is involved in chromatin organization. Immunologic deficiencies may be noted that overlap with the 22q11.2 deletion syndrome.

Clinical Manifestations

Newborn infants have a variable ability to breathe through their mouths, so nasal obstruction does not produce the same symptoms in every infant. When the obstruction is unilateral, the infant may be asymptomatic for a prolonged period, often until the first respiratory infection, when unilateral nasal discharge or persistent nasal obstruction can suggest the diagnosis. Infants with bilateral choanal atresia who have difficulty with mouth breathing make vigorous attempts to inspire, often suck in their lips, and develop cyanosis. Distressed children then cry (which relieves the cyanosis) and become calmer, with normal skin color, only to repeat the cycle after closing their mouths. Those who can breathe through their mouths at once have trouble when sucking and swallowing, becoming cyanotic when they attempt to feed.

Diagnosis

The diagnosis is established by the inability to pass a firm catheter through each nostril 3-4 cm into the nasopharynx. The atretic plate may be seen directly with fiberoptic rhinoscopy. The anatomy is best evaluated by using high-resolution CT (Fig. 425.1).

Treatment

Initial treatment consists of prompt placement of an oral airway, maintaining the mouth in an open position, or intubation. A standard oral airway (such as that used in anesthesia) can be used, or a feeding nipple can be fashioned with large holes at the tip to facilitate air passage. Once an oral airway is established, the infant can be fed by gavage until breathing and eating without the assisted airway is possible. In

bilateral cases, intubation or, less often, tracheotomy may be indicated. If the child is free of other serious medical problems, operative intervention is considered in the neonate; transnasal repair is the treatment of choice, with the introduction of small magnifying endoscopes and smaller surgical instruments and drills. Stents are usually left in place for weeks after the repair to prevent closure or stenosis, although a large meta-analysis demonstrated that there is no benefit to stenting. Another option is a transpalatal repair, and this is done when a transnasal endoscope cannot be placed through the nose because of thick bony atresia or stenosis. Tracheotomy should be considered in cases of bilateral atresia in which the child has other potentially life-threatening problems and in whom early surgical repair of the choanal atresia may not be appropriate or feasible. Operative correction of unilateral obstruction may be deferred for several years. In both unilateral and bilateral cases, restenosis necessitating dilation or reoperation, or both, is common. Mitomycin C has been used to help prevent the development of granulation tissue and stenosis, although its efficacy is questionable.

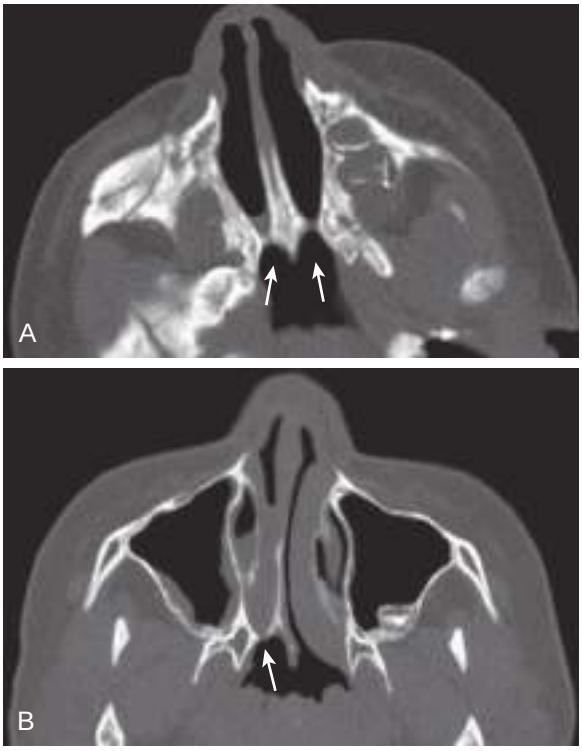

Fig. 425.1 Choanal atresia. **A,** Axial CT image in a 1-day-old neonate with severe respiratory distress shows bilateral bony choanal atresia with retained fluid in the right nasal cavity, medial bowing of the lateral nasal wall, and a thickened vomer *(arrows)*. **B,** Axial CT image in a 12-yr-old child with chronic nasal obstruction and purulent rhinorrhea shows unilateral *(right)* bony atresia with fluid in the nasal cavity *(arrow)*. *(From Coley BD, ed. Caffey's Pediatric Diagnostic Imaging, 12th ed. Philadelphia: Saunders; 2013: Fig. 8.13.)*

CONGENITAL DEFECTS OF THE NASAL SEPTUM

Perforation of the septum is most commonly acquired after birth secondary to infection, such as syphilis or tuberculosis, or trauma; rarely, it is developmental. Continuous positive airway pressure cannulas are a cause of iatrogenic perforation. Trauma from delivery is the most common cause of septal deviation noted at birth. When recognized early, it can be corrected with immediate realignment using blunt probes, cotton applicators, and topical anesthesia. Formal surgical correction, when required, is usually postponed to avoid disturbance of midface growth.

Mild septal deviations are common and usually asymptomatic; abnormal formation of the septum is uncommon unless other malformations are present, such as cleft lip or palate.

Congenital isolated absence of a membranous nasal septum has also been reported.

PYRIFORM APERTURE STENOSIS

Infants with this bony abnormality of the anterior nasal aperture present at birth or shortly thereafter with severe nasal obstruction leading to noisy breathing and respiratory distress that worsen with feeding and improve with crying. It can occur in isolation or in association with other malformations including holoprosencephaly, hypopituitarism, and cardiac and urogenital malformations. Diagnosis is made by CT of the nose (Fig. 425.2) with a pyriform aperture width less than ~11 mm. Medical management (nasal decongestants, humidification, nasopharyngeal airway insertion, management of reflux) is typically attempted for about 2 weeks; if the child still cannot feed or breathe without difficulty, then surgical repair by means of an anterior, sublabial approach may be needed. A drill is used to enlarge the stenotic anterior bone apertures.

CONGENITAL MIDLINE NASAL MASSES

Dermoids, gliomas, and *encephaloceles* (in descending order of frequency) occur intranasally or extranasally and can have intracranial connections or extend intracranially with communication to the subarachnoid space. The theory for the embryologic development of congenital midline nasal masses is faulty retraction of the dural diverticulum. Dermoids and epidermoids are the most common

Fig. 425.2 Congenital nasal pyriform aperture stenosis in a 1½-mo-old infant with episodes of respiratory distress during breastfeeding. **A,** Axial CT image shows a triangular hard palate and solitary central maxillary mega-incisor *(arrow)*. **B,** An axial CT image shows narrowing of the anterior and inferior nasal passages *(arrows)*. **C,** Normal infant maxilla for comparison. *(From Coley BD, ed. Caffey's Pediatric Diagnostic Imaging, 12th ed. Philadelphia: Saunders; 2013: Fig. 8.14.)*

Fig. 425.3 Nasal dermoid manifesting as a midline sinus *opening. (From Elluru RG. Congenital and acquired malformations of the nose and nasopharynx. In: Lesperance MM, ed. Cummings Pediatric Otolaryngology, 2nd ed. Philadelphia: Elsevier; 2022: Fig. 5.5, p. 67.)*

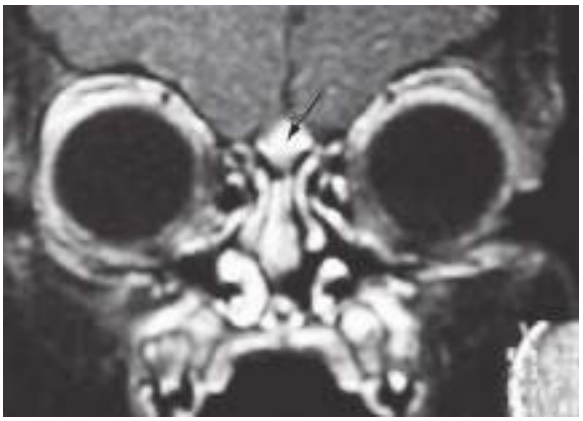

Fig. 425.4 Coronal CT scan of nasal dermoid with intracranial extension *(arrow). (From Manning SC, Bloom DC, Perkins JA, et al. Diagnostic and surgical challenges in the pediatric skull base. Otolaryngol Clin North Am. 2005;38:773–794, Fig. 2.)*

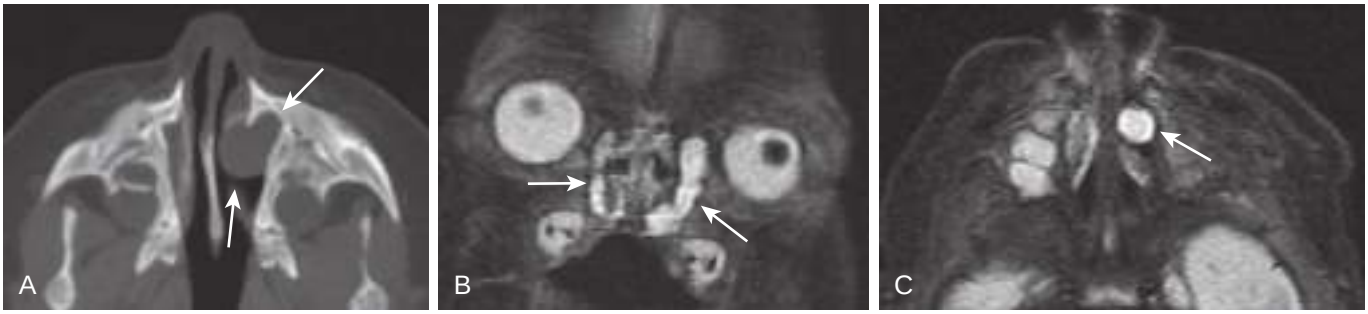

Fig. 425.5 Congenital nasolacrimal duct mucoceles in a 1-day-old neonate. **A,** Axial CT image shows a left nasal round soft tissue mass with enlargement of the ipsilateral nasolacrimal duct and canal *(arrows).* **B** and **C,** Coronal and axial fast spin echo inversion recovery MR images show bilateral cystic enlargement of the nasolacrimal sacs and ducts *(arrows). (From Coley BD, ed. Caffey's Pediatric Diagnostic Imaging, 12th ed. Philadelphia: Saunders; 2013: Fig. 8.15, p. 78.)*

type of congenital midline nasal mass and have been reported to represent up to 61% of lesions. Nasal dermoids are firm, noncompressible, and painless and often have a dimple or pit on the nasal dorsum (sometimes with hair being present) (Fig. 425.3). They can predispose to intracranial infections if an intracranial fistula or sinus is present, although recurrent infection of the dermoid itself is more common; given the risk for serious infection, surgical excision is always indicated for nasal dermoids. Gliomas or heterotopic brain tissue are firm, whereas encephaloceles are soft and enlarge with crying or the Valsalva maneuver. Diagnosis is based on physical examination findings and results from imaging studies. CT provides the best bony detail, but magnetic resonance imaging (MRI) is also helpful because of its superior ability to define intracranial extension (Fig. 425.4). Surgical excision of these masses is generally required, with the extent and surgical approach based on the type and size of the mass.

Encephaloceles may be *sincipital* (nasofrontal, nasoethmoidal, naso-orbital) or *basal* (transethmoidal, sphenoethmoidal, transsphenoidal, spheno-orbital); presentations include a glabellar or nasal mass, nasal obstruction, hypertelorism, and orbital/visual changes.

Other nasal masses include *hemangiomas, congenital nasolacrimal duct obstruction* (which can occur as an intranasal mass) (Fig. 425.5), nasal polyps, and tumors such as rhabdomyosarcoma (see Chapter 549). Nasal polyps are rarely present at birth, but the other masses often present at birth or in early infancy (see Chapter 427).

Poor development of the paranasal sinuses and a narrow nasal airway are associated with recurrent or chronic upper airway infection in Down syndrome (see Chapter 57).

DIAGNOSIS AND TREATMENT

In children with congenital nasal disorders, supportive care of the airway is given until the diagnosis is established. Diagnosis is made through a combination of flexible scoping and imaging studies, primarily CT scan. In the case of surgically correctable congenital problems such as choanal atresia, surgery is performed after the child is deemed healthy and free of life-threatening problems such as congenital heart disease.

Visit Elsevier eBooks+ at eBooks.Health.Elsevier.com for Bibliography.

Chapter 426

Acquired Disorders of the Nose

Joseph Haddad Jr. and Sonam N. Dodhia

Tumors, septal perforations, and other acquired abnormalities of the nose and paranasal sinuses can manifest with epistaxis. Midface trauma with a nasal or facial fracture may also be accompanied by epistaxis. Trauma to the nose can cause a *septal hematoma;* if treatment is delayed, this can lead to necrosis of septal cartilage and a resultant *saddle nose deformity.* Other abnormalities that can cause a change in the shape of the nose and paranasal bones, with obstruction but few other symptoms, include *fibroosseous lesions* (ossifying fibroma, fibrous dysplasia, cementifying fibroma) and *mucoceles of the paranasal sinuses.* These conditions may be suspected on physical examination and confirmed by CT scan and biopsy. Although these are considered benign lesions, they can all greatly change the anatomy of surrounding bony structures and often require surgical intervention for management.

426.1 Nasal Foreign Bodies

Joseph Haddad Jr. and Sonam N. Dodhia

ETIOLOGY

Foreign bodies (food, beads, crayons, small toys, erasers, paper wads, buttons, batteries, beans, stones, pieces of sponge or capsule sponge toys, and other small objects) are often placed in the nose by young or developmentally delayed children and constitute ≤1% of pediatric emergency department visits. Nasal foreign bodies can go unrecognized for long periods because they initially produce few symptoms and are difficult to visualize. First symptoms include unilateral obstruction, sneezing, relatively mild discomfort, and, rarely, pain. Presenting clinical symptoms include history of insertion of foreign bodies (86%), mucopurulent nasal discharge (24%), foul nasal odor (9%), epistaxis (6%), nasal obstruction (3%), and mouth breathing (2%). Irrigation results in mucosal swelling because some foreign bodies are hygroscopic and increase in size as water is absorbed; signs of local obstruction and discomfort can increase with time. The patient might also present with a generalized body odor known as *bromhidrosis.*

DIAGNOSIS

Unilateral nasal discharge and obstruction should suggest the presence of a foreign body, which can often be seen on examination with a nasal speculum or wide otoscope placed in the nose. Purulent secretions may have to be cleared so that the foreign object can be visualized; a headlight, suction, and topical decongestants are often needed. The object is usually situated anteriorly, but unskilled attempts at removal can force the object deeper into the nose. A long-standing foreign body can become embedded in granulation tissue or mucosa and appear as a nasal mass. A lateral skull radiograph assists in diagnosis if the foreign body is metallic or radiopaque or if foreign body is suspected but physical exam with sinus endoscopy or anterior rhinoscopy is negative.

TREATMENT

An initial examination of the nose is made to determine if a foreign body is present and whether it needs to be removed emergently. Planning is then made for office or operating room extrication of the foreign body. Prompt removal minimizes the danger of aspiration and local tissue necrosis, and this can usually be performed with the aid of topical anesthesia, with forceps or nasal suction. Common noninvasive techniques include simple nose blowing and the "mother's kiss" technique. The "mother's kiss" approach has been successful in acute situations where a person occludes the unaffected nostril and then, with a complete seal over the child's mouth, attempts to dislodge the foreign body by blowing into the mouth. A similar approach uses an Ambu bag over the mouth with the unaffected nostril occluded. Other noninvasive options include blowing air into a drinking straw in a child's mouth and applying high-flow oxygen (10-15 L/min) to the unaffected nostril. Alternatively, a Katz catheter (made specifically for the removal of foreign bodies from the nose and ear) can be inserted above and distal to the object, inflated, and drawn back with gentle traction. If there is marked swelling, bleeding, or tissue overgrowth, general anesthesia may be needed to remove the object. Infection usually clears promptly after the removal of the object, and generally no further therapy is necessary. Magnets can be used to extract metal foreign bodies, 2% lidocaine can be used to kill live insects before removal, and irrigation should be avoided with vegetable matter or sponges because of the risk of foreign body swelling. Age (>5) and disk-shaped foreign body are predictors for operating room removal of foreign body.

COMPLICATIONS

Serious complications include posterior dislodgement and aspiration, trauma caused by the object itself or removal attempts, infection, and choanal stenosis. Infection is common and gives rise to a purulent, malodorous, or bloody discharge. Local tissue damage from long-standing foreign body or alkaline injury from a disk battery can lead to local tissue loss and cartilage destruction. A synechia or scar band can then form, causing nasal obstruction. Loss of septal mucosa and cartilage can cause a septal perforation or saddle nose. Disk batteries are especially dangerous when placed in the nose; they leach base, which causes pain and local tissue destruction in a matter of hours. Magnets also carry a risk of septal perforation and necrosis.

Tetanus is a rare complication of long-standing nasal foreign bodies in nonimmunized children (see Chapter 257). Toxic shock syndrome is also rare and most commonly occurs from nasal surgical packing (see Chapter 227.2); oral antibiotics should be administered when nasal surgical packing is placed.

PREVENTION

Tempting objects, such as round, shiny beads, should be used only under adult supervision. Disk batteries should be stored away from the reach of small children.

Visit Elsevier eBooks+ at eBooks.Health.Elsevier.com for Bibliography.

426.2 Epistaxis

Joseph Haddad Jr. and Sonam N. Dodhia

Although rare in infancy, nosebleeds are common in children between the ages of 3 and 8, then decline in incidence after puberty. They are also more common during winter months. Diagnosis and treatment depend on the location and cause of the bleeding.

ANATOMY

The most common site of bleeding is the Kiesselbach plexus, an area in the anterior septum where vessels from both the internal carotid (anterior and posterior ethmoid arteries) and external carotid (sphenopalatine and terminal branches of the internal maxillary arteries) converge. The thin mucosa in this area and the anterior location make it prone to exposure to dry air and trauma.

ETIOLOGY

Epistaxis can be classified as primary (idiopathic; majority of cases) or secondary based on cause, and this has implications for diagnosis and management. Common causes of secondary nosebleeds from the anterior septum include digital trauma, foreign bodies, dry air, and inflammation, including upper respiratory tract

infections, sinusitis, and allergic rhinitis (Table 426.1). There is often a family history of childhood epistaxis. Nasal steroid sprays are commonly used in children, and their chronic use may be associated with nasal mucosal bleeding. Young infants with significant gastroesophageal reflux into the nose rarely present with epistaxis secondary to mucosal inflammation. Susceptibility is increased during respiratory infections and in the winter when dry air irritates the nasal mucosa, resulting in formation of fissures and crusting. Severe bleeding may be encountered with congenital vascular abnormalities, such as *hereditary hemorrhagic telangiectasia (HHT)* (see Chapter 481.3), varicosities, hemangiomas, and in children with thrombocytopenia, deficiency of clotting factors, particularly von Willebrand disease (see Chapter 526), hypertension, renal failure, or venous congestion. Screening for HHT is recommended for patients with obvious nasal/oral telangiectasias and those with a personal or familial history of recurrent nosebleeds. Recurrent epistaxis despite cauterization is associated with mild coagulation disorders. The family history may be positive for abnormal bleeding (epistaxis or other sites); specific testing for von Willebrand disease is indicated because the prothrombin time or partial thromboplastin time may be normal despite having a bleeding disorder. Nasal polyps or other intranasal growths may be associated with epistaxis. Recurrent, and often severe, unilateral nosebleeds may be the initial presenting symptom in **juvenile nasal angiofibroma**, which occurs in adolescent males.

CLINICAL MANIFESTATIONS

Epistaxis usually occurs without warning, with blood flowing slowly but freely from one nostril or occasionally from both. In children with nasal lesions, bleeding might follow physical exercise. When bleeding occurs at night, the blood may be swallowed and become apparent only when the child vomits or passes blood in the stools. Posterior epistaxis can manifest as anterior nasal bleeding, or, if bleeding is copious, the patient might vomit blood as the initial symptom.

Table 426.1 Possible Causes of Epistaxis

Epistaxis digitorum (nose picking)
Rhinitis (allergic or viral)
Chronic sinusitis
Foreign bodies
Intranasal neoplasm or polyps
Irritants (e.g., cigarette smoke)
Septal deviation
Septal perforation
Trauma, including child abuse
Vascular malformation or telangiectasia (hereditary hemorrhage telangiectasia)
Hemophilia
von Willebrand disease
Platelet dysfunction
Thrombocytopenia
Hypertension
Leukemia
Liver disease (e.g., cirrhosis)
Medications (e.g., aspirin, anticoagulants, nonsteroidal antiinflammatory drugs, topical corticosteroids)
Cocaine use

From Kucik CJ, Clenney T. Management of epistaxis. *Am Fam Physician*. 2005;71(2):305–311.

TREATMENT

Most nosebleeds stop spontaneously in a few minutes. The nares (lower third of the nose) should be compressed for 5 minutes, and the child kept as quiet as possible, in an upright position with the head tilted forward to avoid blood trickling back into the throat. Cold compresses applied to the nose can also help. If these measures do not stop the bleeding, local application of a solution of oxymetazoline (Afrin) or phenylephrine (Neo-Synephrine) (0.25–1%) may be useful. If bleeding persists, an anterior nasal pack may need to be inserted; if bleeding originates in the posterior nasal cavity, combined anterior and posterior packing is necessary. After bleeding is under control, and if a bleeding site is identified, its obliteration by cautery with silver nitrate may prevent further difficulties. Because the septal cartilage derives its nutrition from the overlying mucoperichondrium, only one side of the septum should be cauterized at a time to reduce the chance of a septal perforation. During the winter, or in a dry environment, a room humidifier, saline drops, and petrolatum (Vaseline) applied to the septum can help to prevent epistaxis. Ointments prevent infection, increase moisture, decrease bleeding, and are commonly used in clinical practice. Patients with severe epistaxis despite conservative medical measures should be considered for surgical ligation techniques or embolization. In patients with severe or repeated epistaxis, blood transfusions may be necessary. Otolaryngologic evaluation is indicated for these children and for those with bilateral bleeding or with hemorrhage that does not arise from the Kiesselbach plexus. For those with recurrent epistaxis, there may be short-term benefits to using bipolar electrocautery over silver nitrate chemical cautery, although treatments were equivocal after 2 years. Secondary epistaxis should be managed by identification of the cause, application of appropriate nasal therapy, and correct systemic medical management. Hematologic evaluation (for coagulopathy and anemia), along with nasal endoscopy and diagnostic imaging, may be needed to make a definitive diagnosis in cases of severe recurrent epistaxis. Replacement of deficient clotting factors may be required for patients who have an underlying hematologic disorder (see Chapter 525). Profuse unilateral epistaxis associated with a nasal mass in an adolescent boy near puberty might signal a **juvenile nasopharyngeal angiofibroma**. This unusual tumor has also been reported in a 2-year-old and in 30- to 40-year-olds, but the incidence peaks in adolescent and preadolescent boys. CT with contrast medium enhancement and magnetic resonance imaging (MRI) are part of the initial evaluation; arteriography, embolization, and extensive surgery may be needed.

Surgical intervention may also be needed for bleeding from the internal maxillary artery or other vessels that can cause bleeding in the posterior nasal cavity.

PREVENTION

The discouragement of nose picking and attention to proper humidification of the bedroom during dry winter months help to prevent many nosebleeds. Prompt attention to nasal infections and allergies is beneficial to nasal hygiene. Prompt cessation of nasal steroid sprays prevents ongoing bleeding.

Visit Elsevier eBooks+ at eBooks.Health.Elsevier.com for Bibliography.

Chapter 427

Nasal Polyps

Joseph Haddad Jr.

Nasal polyps are benign pedunculated tumors formed from edematous, usually chronically inflamed nasal mucosa. They commonly arise from the ethmoidal sinus and occur in the middle meatus. Occasionally they appear within the maxillary antrum and can extend to the nasopharynx (antrochoanal polyp).

It is estimated that between 1% and 4% of the population will develop nasal polyps at some point; the incidence of nasal polyps increases with age. Antrochoanal polyps represent only 4–6% of all nasal polyps in the general population but account for approximately one third of polyps in the pediatric population. Large or multiple polyps can completely obstruct the nasal passage. The polyps originating from the ethmoidal sinus are usually smaller and multiple as compared with the large and usually single antrochoanal polyp.

Cystic fibrosis (CF; see Chapter 454) is the most common childhood cause of nasal polyposis, and up to 50% of CF patients experience obstructing nasal polyposis, which is rare in non-CF children. Therefore CF should be suspected in any child younger than 12 years old with nasal polyps, even in the absence of typical respiratory and digestive symptoms. Nasal polyposis is also associated with chronic sinusitis (see Chapter 429) and allergic rhinitis. Large population studies have noted a significant familial risk in having chronic rhinosinusitis with polyposis. In the *Samter triad,* nasal polyps are associated with aspirin sensitivity and asthma; this condition is rare in children.

CLINICAL MANIFESTATIONS

Obstruction of nasal passages is prominent, with associated hyponasal speech and mouth breathing. Profuse unilateral mucoid or mucopurulent rhinorrhea may also be present. An examination of the nasal passages shows glistening, gray, grapelike masses squeezed between the nasal turbinates and the septum.

DIAGNOSIS AND DIFFERENTIAL DIAGNOSIS

Examination of the external nose and rhinoscopy should be performed. Ethmoidal polyps can be readily distinguished from the well-vascularized turbinate tissue, which is pink or red; antrochoanal polyps may have a fleshier appearance (Fig. 427.1). Antrochoanal polyps may prolapse into the nasopharynx; flexible nasopharyngoscopy can assist in making this diagnosis. Prolonged presence of ethmoidal polyps in a child can widen the bridge of the nose and erode adjacent osseous structures. Tumors of the nose cause more local destruction and distortion of the anatomy. CT scan of the midface is key to diagnosis and planning for surgical treatment (Fig. 427.2).

TREATMENT

Local or systemic decongestants are not usually effective in shrinking the polyps, although they may provide symptomatic relief from the associated mucosal edema. Intranasal steroid sprays, and sometimes systemic steroids, can provide some shrinkage of nasal polyps with symptomatic relief and have proved useful in children with CF and adults with nasal polyps. Topical nasal steroid therapy, fluticasone, mometasone, and budesonide appear to result in nasal symptom improvement but were found to have no effect on those with CF. Dupilumab inhibits interleukin (IL)-4 and IL-13, proinflammatory cytokines involved in polyp formation, and is approved in patients ≥18 years of age for the treatment of chronic rhinosinusitis with nasal polyps.

Polyps should be removed surgically if complete obstruction, uncontrolled rhinorrhea, or deformity of the nose appears. If the underlying pathogenic mechanism cannot be eliminated (such as CF), the polyps may soon return. Functional endoscopic sinus surgery provides more complete polyp removal and treatment of other associated nasal disease; in some cases, this has reduced the need for frequent surgeries. Nasal steroid sprays should also be started preventively, once postsurgical healing occurs.

Antrochoanal polyps do not respond to medical measures and must be removed surgically, typically via endoscopic sinus surgery, or, alternatively, with a mini-Caldwell procedure. Because these types of polyps are not associated with any underlying disease process, the recurrence rate is much less than for other types of polyps.

Visit Elsevier eBooks+ at eBooks.Health.Elsevier.com for Bibliography.

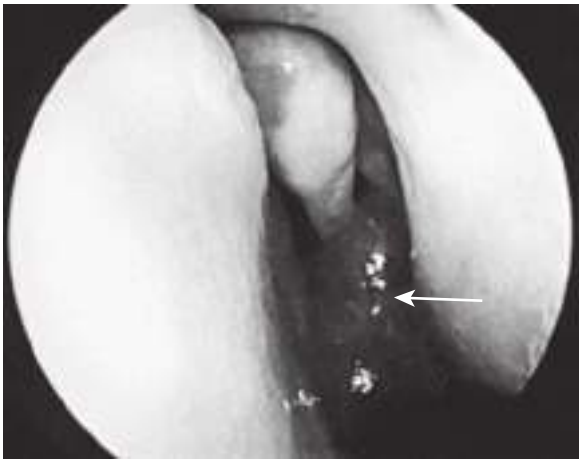

Fig. 427.1 Antrochoanal polyp viewed endoscopically *(arrow). (From Basak S, Karaman CZ, Akdilli A, et al. Surgical approaches to antrochoanal polyps in children. Int J Pediatr Otorhinolaryngol. 1998;46:197–205.)*

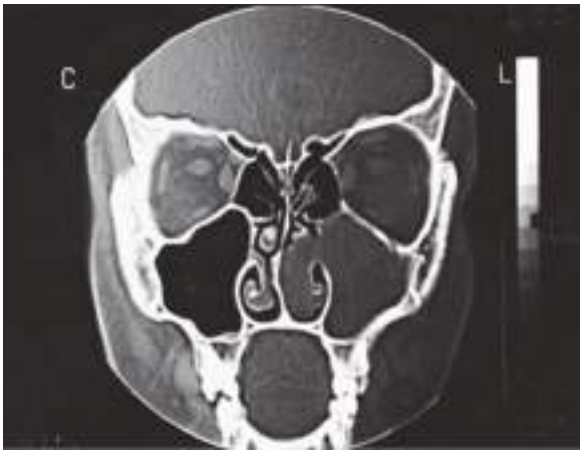

Fig. 427.2 A typical CT image of an isolated antrochoanal polyp on the left side. *(From Basak S, Karaman CZ, Akdilli A, et al. Surgical approaches to antrochoanal polyps in children. Int J Pediatr Otorhinolaryngol. 1998;46:197–205.)*

Chapter 428

The Common Cold

Katherine M. Richardson and Jennifer E. Schuster

The common cold is an acute viral infection of the upper respiratory tract in which the symptoms of rhinorrhea and nasal obstruction are prominent. Systemic symptoms and signs such as headache, myalgia, and fever are absent or mild. The common cold is frequently referred to as *infectious rhinitis* but may also include self-limited involvement of the sinus mucosa and is more correctly termed *rhinosinusitis.*

ETIOLOGY

The most common pathogens associated with the common cold are the more than 200 types of human rhinoviruses (see Chapter 310), but the syndrome can be caused by many different virus families (Table 428.1). Human rhinoviruses (HRVs) are associated with more than 50% of colds in adults and children. In young children, other viral etiologies of the common cold include respiratory syncytial virus (RSV; see Chapter 307), human metapneumovirus (MPV; see Chapter 308), parainfluenza viruses (PIVs; see Chapter 306), seasonal coronaviruses (see Chapter 311), and adenoviruses (see Chapter 309). Common cold symptoms may also be caused by influenza viruses and nonpolio enteroviruses. Many viruses that cause rhinitis are also associated with other symptoms and signs such as cough, wheezing, and fever.

EPIDEMIOLOGY

Colds occur year-round, but the incidence is greatest from the early fall until the late spring, reflecting the seasonal prevalence of the viral pathogens associated with cold symptoms. In the Northern Hemisphere, the highest incidence of HRV infection occurs in the early fall (August-October) and in the late spring (April-May); however, HRVs are typically detected year-round. Historically, the seasonal incidence for PIV usually peaks in the summer, fall, and late spring and is highest between December and April for RSV, influenza viruses, MPV, and coronaviruses. Adenoviruses are detected at a low prevalence throughout the cold season, and enteroviruses may also be detected during summer months or throughout the year.

Young children have an average of six to eight colds per year, but 10–15% of children have at least 12 infections per year. The incidence of illness decreases with increasing age, with two to three illnesses per year by adulthood. The incidence of infection is primarily a function of exposure to the virus. Children in out-of-home daycare centers during the first year of life have 50% more colds than children cared for only at home. The difference in the incidence of illness between these groups of children decreases as the length of time spent in daycare increases, and in fact many children in daycare have asymptomatic viral infections. However, the incidence of illness remains higher in the daycare group through at least the first 3 years of life. When they begin primary school, children who attended daycare have less frequent colds than those who did not. Mannose-binding lectin deficiency with impaired innate immunity may be associated with an increased incidence of colds in children.

PATHOGENESIS

Viruses that cause the common cold are spread by three mechanisms: direct hand contact (self-inoculation of one's own nasal mucosa or conjunctivae after touching a contaminated person or object), inhalation of small-particle aerosols that are airborne from coughing, or deposition of large-particle aerosols that are expelled during a sneeze and land on nasal or conjunctival mucosa. Although the different common cold pathogens could be spread by any of these mechanisms, some routes of transmission appear to be more efficient than others for particular viruses. Studies of HRV and RSV indicate that direct contact is an efficient mechanism of transmission of these viruses, although transmission by large-particle aerosols can also occur. By contrast, influenza viruses and coronaviruses appear to be most efficiently spread by small-particle aerosols.

The respiratory viruses have evolved different mechanisms to avoid host defenses. Infections with HRV and adenoviruses result in the development of serotype-specific protective immunity. Repeated infections with these pathogens occur because there are a large number of distinct serotypes of each virus. Influenza viruses change the antigens presented on the surface of the virus because of genetic drift and thus behave as though there were multiple viral serotypes. The interaction of coronaviruses (see Chapter 311) with host immunity is not well defined, but it appears that multiple distinct strains of coronaviruses are capable of inducing at least short-term protective immunity, with possibility for some cross protection between different coronaviruses. There are four types of PIV, two antigenic subgroups of RSV, and four genotypes of MPV. In addition to antigenic diversity, many of these viruses are able to reinfect the upper airway because mucosal immunoglobulin A (IgA) induced by previous infection is short lived, and the brief incubation period of these viruses allows the establishment of infection before immune memory is able to respond. Although reinfection is not completely prevented by the adaptive host response to these viruses, the severity of illness is moderated by preexisting immunity.

Table 428.1 Pathogens* Associated with the Common Cold

ASSOCIATION	PATHOGEN	RELATIVE FREQUENCY**	OTHER COMMON SYMPTOMS AND SIGNS
Agents primarily associated with the common cold	Rhinoviruses	Frequent	Wheezing/bronchiolitis
	Coronaviruses, including SARS-CoV-2 variants	Frequent	
Agents primarily associated with other clinical syndromes that also cause common cold symptoms	Respiratory syncytial virus	Occasional	Bronchiolitis in children <2 yr of age
	Human metapneumovirus	Occasional	Pneumonia and bronchiolitis
	Bocavirus	Occasional	Uncertain role
	Influenza viruses	Uncommon	Influenza-like illness, pneumonia, croup
	Parainfluenza viruses	Uncommon	Croup, bronchiolitis
	Adenoviruses	Uncommon	Pharyngoconjunctival fever (palpebral conjunctivitis, watery eye discharge, pharyngeal erythema)
	Enteroviruses Coxsackievirus A Other nonpolio enteroviruses	Uncommon	Herpangina (fever and ulcerated papules on posterior oropharynx) Aseptic meningitis

*It is not unusual to have one or more respiratory pathogens.
**Relative frequency of colds caused by the agent.

Viral infection of the nasal epithelium can be associated with destruction of the epithelial lining, as with influenza viruses and adenoviruses, or there can be no apparent histologic damage, as with HRV, coronaviruses, and RSV. Regardless of the histopathologic findings, infection of the nasal epithelium is associated with an acute inflammatory response characterized by release of a variety of inflammatory cytokines, such as interleukin-8, that attract polymorphonuclear cells into the nasal submucosa and epithelium and infiltration of the mucosa by inflammatory cells. This acute inflammatory response appears to be partially or largely responsible for many of the symptoms associated with the common cold, rather than direct damage to the respiratory tract by the virus. Viral shedding of most respiratory viruses peaks 3-5 days after inoculation, often coinciding with symptom onset; low levels of viral shedding may persist for up to 3 weeks in the otherwise recovering healthy host. Inflammation can obstruct the sinus ostia or eustachian tube, predisposing to bacterial sinusitis or otitis media, respectively.

CLINICAL MANIFESTATIONS

Symptoms of the common cold vary by age and virus. In infants, fever and nasal discharge may predominate. Fever is uncommon in older children and adults. The onset of common cold symptoms typically occurs 1-3 days after viral infection. The first symptom noted is often sore or scratchy throat, followed closely by nasal obstruction and rhinorrhea. The sore throat usually resolves quickly, and, by the second and third day of illness, nasal symptoms predominate. Cough is associated with two thirds of colds in children and usually begins after the onset of nasal symptoms. Cough may persist for an additional 1-2 weeks after resolution of other symptoms. Influenza viruses, RSV, MPV, and adenoviruses are more likely than HRV or coronaviruses to be associated with fever and other constitutional symptoms, and HRV is more commonly associated with wheezing, particularly in older children. Other symptoms of a cold may include headache, hoarseness, irritability, difficulty sleeping, or decreased appetite. Vomiting and diarrhea are uncommon. The usual cold persists for approximately 1 week, although 10% last for 2 weeks.

The physical findings of the common cold are limited to the upper respiratory tract. Increased nasal secretion is usually obvious; a change in the color or consistency of the secretions is common during the course of the illness and does not indicate sinusitis or bacterial superinfection, but may indicate accumulation of polymorphonuclear cells. Examination of the nasal cavity might reveal swollen, erythematous nasal turbinates, although this finding is nonspecific and of limited diagnostic value. Abnormal middle ear pressure is common during a cold. Anterior cervical lymphadenopathy or conjunctival injection may also be noted on exam.

DIAGNOSIS

The most important task of the physician caring for a patient with a cold is to exclude other conditions that are potentially more serious or treatable. The differential diagnosis of the common cold includes noninfectious disorders and other upper respiratory tract infections (Table 428.2).

Table 428.2 Conditions that Can Mimic the Common Cold

CONDITION	DIFFERENTIATING FEATURES
Allergic rhinitis	Prominent itching and sneezing, nasal eosinophils; Hansel stain can aid diagnosis
Vasomotor rhinitis	May be triggered by irritants, weather changes, spicy foods, etc.
Rhinitis medicamentosa	History of nasal decongestant use
Foreign body	Unilateral, foul-smelling secretions
	Bloody nasal secretions
Sinusitis	Presence of fever, headache or facial pain, or periorbital edema or persistence of rhinorrhea or cough for longer than 10-14 days
Streptococcosis	Mucopurulent nasal discharge that excoriates the nares, no cough
Pertussis	Onset of persistent or severe paroxysmal cough
Congenital syphilis	Persistent rhinorrhea with onset in the first 3 mo of life

LABORATORY FINDINGS

Routine laboratory studies are not helpful for the diagnosis and management of the common cold. A nasal smear for eosinophils (Hansel stain) may be useful if allergic rhinitis is suspected (see Chapter 184). A predominance of polymorphonuclear cells in the nasal secretions is characteristic of uncomplicated colds and *does not* indicate bacterial superinfection. Self-limited radiographic abnormalities of the paranasal sinuses are common during an uncomplicated cold; imaging is not indicated for most children with simple rhinitis.

The viral pathogens associated with the common cold can be detected by polymerase chain reaction (PCR), culture, antigen detection, or serologic methods. These studies are generally not indicated in patients with colds, because a specific etiologic diagnosis is useful only when treatment with an antiviral agent is contemplated, such as for influenza viruses. Bacterial cultures, PCR, or antigen detection are useful only when group A streptococcus (see Chapter 229) or *Bordetella pertussis* (see Chapter 243) is suspected. The isolation of bacterial pathogens from nasopharyngeal specimens is not an indication of bacterial nasal infection and is not a specific predictor of the etiologic agent in sinusitis.

TREATMENT

The management of the common cold consists primarily of supportive care and anticipatory guidance.

Antiviral Treatment

Specific antiviral therapy is not available for HRV infections. The neuraminidase inhibitors oseltamivir, zanamivir, and peramivir, as well as polymerase acidic endonuclease inhibitor baloxavir marboxil, have a modest effect on the duration of symptoms associated with influenza viral infections in children. The difficulty of distinguishing influenza from other common cold pathogens and the necessity that therapy be started early in the illness (within 48 hours of onset of symptoms) to be beneficial are practical limitations to the use of these agents for mild upper respiratory tract infections. Antibacterial therapy is of no benefit in the treatment of the common cold and should be avoided to minimize possible adverse effects and the development of antibiotic resistance.

Supportive Care and Symptomatic Treatment

Supportive interventions are frequently recommended by providers. Maintaining adequate oral hydration may help to prevent dehydration and to thin secretions and soothe respiratory mucosa. The common home remedy of ingesting warm fluids may soothe mucosa, increase nasal mucus flow, or loosen respiratory secretions. Topical nasal saline may temporarily remove secretions, and saline nasal irrigation may reduce symptoms. Cool, humidified air has not been well studied but may loosen nasal secretions; however, cool-mist humidifiers and vaporizers must be cleaned after each use. The World Health Organization suggests that neither steam nor cool-mist therapy be used in treatment of a cold.

The use of oral nonprescription therapies (often containing antihistamines, antitussives, and decongestants) for cold symptoms in children is controversial. Although some of these medications are effective in adults, no study demonstrates a significant effect

in children, and there may be serious side effects. Young children cannot participate in the assessment of symptom severity, so studies of these treatments in children have generally been based on observations by parents or other observers, a method that is likely to be insensitive for detection of treatment effects. Because of the lack of direct evidence for effectiveness and the potential for unwanted side effects, it is recommended that nonprescription cough and cold products not be used for infants and children younger than 4 years of age. A decision whether to use these medications in older children must consider the likelihood of clinical benefit compared with the potential adverse effects of these drugs. The prominent or most bothersome symptoms of colds vary in the course of the illness. If symptomatic treatments are used, it is reasonable to target therapy to specific bothersome symptoms, and care should be taken to ensure that caregivers understand the intended effect and can determine the proper dosage of the medications. It is also important to instruct caregivers to read labels carefully in case multiple medications are present in one formula to avoid overdose.

Zinc, given as oral lozenges to previously healthy patients, reduces the duration but not the severity of symptoms of a common cold if begun within 24 hours of symptoms. The function of the HRV 3C protease, an essential enzyme for HRV replication, is inhibited by zinc, but there has been no evidence of an antiviral effect of zinc in vivo. The effect of zinc on symptoms has been inconsistent, with some studies reporting dramatic treatment effects (in adults), whereas other studies find no benefit. Side effects are common and include decreased taste, bad taste, and nausea.

Fever

Fever is not usually associated with an uncomplicated common cold, and antipyretic treatment is generally not indicated**.** Nonsteroidal anti-inflammatory drugs (NSAIDs) may decrease discomfort from cold-related headache or myalgias.

Nasal Obstruction

Either topical or oral adrenergic agents may be used as nasal decongestants in older children and adults. Effective topical adrenergic agents such as xylometazoline, oxymetazoline, or phenylephrine are available as either intranasal drops or nasal sprays. Reduced-strength formulations of these medications are available for use in younger children, although they are not recommended for use in children younger than 6 years old. Systemic absorption of the imidazolines (oxymetazoline, xylometazoline) has very rarely been associated with bradycardia, hypotension, and coma. Prolonged use of the topical adrenergic agents should be avoided to prevent the development of **rhinitis medicamentosa**, an apparent rebound effect that causes the sensation of nasal obstruction when the drug is discontinued. The oral adrenergic agents are less effective than the topical preparations and are occasionally associated with systemic effects such as central nervous system stimulation, hypertension, and palpitations. Pseudoephedrine may be more effective than phenylephrine as an oral agent to treat nasal congestion—its benefit seems to be greatest in the first day of treatment; after this it does not show much benefit over placebo. Aromatic vapors (such as menthol) for external rub may improve the perception of nasal patency but do not affect spirometry.

Saline nose drops (wash, irrigation) can improve nasal symptoms and may be used in all age-groups.

Rhinorrhea

The first-generation antihistamines may reduce rhinorrhea by 25–30%. The effect of the antihistamines on rhinorrhea appears to be related to the anticholinergic rather than the antihistaminic properties of these drugs, and therefore the second-generation or nonsedating antihistamines have no effect on common cold symptoms. The major adverse effects associated with the use of the antihistamines are sedation or paradoxical hyperactivity. Overdose may be associated with respiratory depression or hallucinations. Rhinorrhea may also be treated with ipratropium bromide, a topical anticholinergic agent. This drug produces an effect comparable to the antihistamines but is not associated with sedation. The most common side effects of ipratropium are nasal irritation and bleeding.

Sore Throat

The sore throat associated with colds is generally not severe, but treatment with mild analgesics is occasionally indicated, particularly if there is associated myalgia or headache. The use of acetaminophen during HRV infection is associated with suppression of neutralizing antibody responses, but this observation has no apparent clinical significance. Aspirin *should not* be given to children with respiratory infections because of the risk of Reye syndrome in children with influenza (see Chapter 305). NSAIDs are somewhat effective in relieving discomfort caused by a cold, but there is no clear evidence of an effect on respiratory symptoms.

Cough

Cough suppression is generally not necessary in patients with colds. Cough in some patients appears to be from upper respiratory tract irritation associated with postnasal drip. Cough in these patients is most prominent during the time of greatest nasal symptoms, and treatment with a first-generation antihistamine may be helpful. Cough lozenges or hard candy may be temporarily effective and are unlikely to be harmful in children for whom they do not pose risk of aspiration (older than age 6 years). **Honey** has a modest effect on relieving nocturnal cough and is unlikely to be harmful in children older than 1 year of age. Honey should be avoided in children younger than 1 year of age because of the risk for botulism (see Chapter 237).

In some patients, cough may be a result of **virus-induced reactive airways disease**. These patients can have cough that persists for days to weeks after the acute illness and might benefit from bronchodilator or other therapy. Dextromethorphan hydrobromide has no effect on cough from colds and has potential enhanced toxicity. Expectorants such as guaifenesin are not effective antitussive agents.

Ineffective Treatments

Vitamin C, guaifenesin, and inhalation of warm, humidified air are no more effective than placebo for the treatment of cold symptoms.

Echinacea is a popular herbal treatment for the common cold. Although echinacea extracts have biologic effects, echinacea is not effective as a common cold treatment. The lack of standardization of commercial products containing echinacea also presents a formidable obstacle to the rational evaluation or use of this therapy.

There is no evidence that the common cold or persistent acute purulent rhinitis of less than 10 days in duration benefits from antibiotics. In fact, there is evidence that antibiotics cause significant adverse effects when given for acute purulent rhinitis.

COMPLICATIONS

The most common complication of a cold is **acute otitis media** (AOM; see Chapter 680), which may be indicated by new-onset fever and earache after the first few days of cold symptoms. AOM is reported in 5–30% of children who have a cold, with the higher incidence occurring in young infants and in children cared for in a group daycare setting. Symptomatic treatment of the common cold symptoms has no effect on the subsequent development of AOM, which can be viral or bacterial.

Sinusitis is another complication of the common cold (see Chapter 429). Self-limited sinus inflammation is a part of the pathophysiology of the common cold, but 0.5–2% of viral upper respiratory tract infections in adults and 5–9% in children are complicated by acute bacterial sinusitis. The differentiation of common cold symptoms from bacterial sinusitis may be difficult. The diagnosis of bacterial sinusitis should be considered if rhinorrhea or daytime cough persists without improvement for at least 10-14 days; if acute symptoms worsen over time; or if acute signs of more severe sinus involvement

such as fever, facial pain, or facial swelling develop. There is no evidence that symptomatic treatment of the common cold alters the frequency of development of bacterial sinusitis. Bacterial pneumonia is an uncommon complication of the common cold; however, both RSV and HRV have been implicated in pneumonia, especially in developing and emerging countries.

Exacerbation of **asthma** is a potentially serious complication of colds. The majority of asthma exacerbations in children are associated with common cold viruses. There is no evidence that treatment of common cold symptoms prevents this complication; however, studies are underway in patients with underlying asthma to determine effectiveness of preventive or acute treatment at the onset of upper respiratory tract infection symptoms.

PREVENTION

Chemoprophylaxis or immunoprophylaxis is generally not available for the common cold. Immunization or chemoprophylaxis against influenza can prevent colds caused by this pathogen, but influenza is responsible for only a small proportion of all colds. Palivizumab is recommended to prevent severe RSV lower respiratory infection in high-risk infants but does not prevent upper respiratory infections from this virus. Vitamin C, garlic, or echinacea do not prevent the common cold. Zinc sulfate taken for a minimum of 5 months may reduce the rate of cold development. However, because of duration of use and adverse effects of bad taste and nausea, this is not a recommended prevention modality in children.

Hand-to-hand transmission of HRV followed by self-inoculation may be prevented by frequent handwashing and avoiding touching one's mouth, nose, and eyes. Some studies report the use of alcohol-based hand sanitizers and virucidal hand treatments were associated with decreased transmission. In the experimental setting, virucidal disinfectants or virucidal-impregnated tissues also reduce transmission of cold viruses; under natural conditions none of these interventions prevents common colds.

Visit Elsevier eBooks+ at eBooks.Health.Elsevier.com for Bibliography.

Chapter 429

Sinusitis

Diane E. Pappas and Sarah R. Boggs

Sinusitis is a common illness of childhood and adolescence. There are two common etiologies of acute sinusitis—viral and bacterial—with significant acute and chronic morbidity as well as the potential for serious complications. Fungal sinusitis is rare in immunocompetent patients but can also occur. The common cold produces a viral, self-limited *rhinosinusitis* (see Chapter 428). Approximately 6–7% of viral upper respiratory tract infections in children and adolescents are complicated by acute symptomatic bacterial sinusitis. Some children with underlying predisposing conditions (cystic fibrosis, primary ciliary dyskinesia, immunoglobulin deficiencies) have chronic sinus disease that may or may not be infectious.

Typically, the ethmoidal and maxillary sinuses are present at birth, but only the ethmoidal sinuses are pneumatized. The maxillary sinuses are not pneumatized until 4 years of age. The sphenoidal sinuses are present by 5 years of age, whereas the frontal sinuses begin development at age 7-8 years and are not completely developed until adolescence. The ostia draining the sinuses are narrow (1-3 mm) and drain into the ostiomeatal complex in the middle meatus. The paranasal sinuses are normally sterile and maintained by the mucociliary clearance system.

The bacterial pathogens causing **acute bacterial sinusitis** in children and adolescents include *Streptococcus pneumoniae* (~30%; see Chapter 228), nontypeable *Haemophilus influenzae* (~50%; see Chapter 240), and *Moraxella catarrhalis* (~10%; see Chapter 242). Approximately 50% of *H. influenzae* and 100% of *M. catarrhalis* are β-lactamase positive. As a result of routine use of pneumococcal conjugate vaccine (PCV) 13 in children, nontypeable *H. influenzae* is the most common cause of acute bacterial sinusitis in children; *S. pneumoniae* resistance has also decreased. Similarly, as a result of routine use of the *H. influenzae* type b vaccination in children, almost all *H. influenzae* infections are nontypeable *H. influenzae*. Approximately 25% of *S. pneumoniae* may be penicillin resistant. *Staphylococcus aureus,* other streptococci, and anaerobes are uncommon causes of *acute* bacterial sinusitis in children. Although *S. aureus* (see Chapter 227.1) is an uncommon pathogen for acute sinusitis in children, the increasing prevalence of methicillin-resistant *S. aureus* is a significant concern. *H. influenzae*, α- and β-hemolytic streptococci, *M. catarrhalis, S. pneumoniae,* and coagulase-negative staphylococci are commonly recovered from children with *chronic* sinus disease. *Fusobacterium necrophorum* and *Streptococcus anginosus* are emerging pathogens causing sinusitis with high potential for intracranial extension.

EPIDEMIOLOGY

Acute bacterial sinusitis can occur at any age, though it is more common in older children and adolescents as the sinus cavities become pneumatized. Predisposing conditions may include viral upper respiratory tract infections (associated with out-of-home daycare or a school-age sibling), allergic rhinitis, and tobacco smoke exposure. Children with immune deficiencies, particularly of antibody production (immunoglobulin [Ig]G, IgG subclasses, IgA; see Chapter 166), cystic fibrosis (see Chapter 454), ciliary dysfunction (see Chapter 455), abnormalities of phagocyte function, gastroesophageal reflux, anatomic defects (cleft palate), nasal polyps, cocaine abuse, and nasal foreign bodies (including nasogastric tubes), can develop chronic or recurrent sinus disease. Immunosuppression for bone marrow transplantation or malignancy with profound neutropenia and lymphopenia predisposes to severe fungal *(Aspergillus, Mucor)* sinusitis, often with intracranial extension. Patients with nasotracheal intubation or nasogastric tubes may have obstruction of the sinus ostia and develop sinusitis with the multiple-drug-resistant organisms of the intensive care unit.

Acute sinusitis is defined by a duration of <30 days, subacute by a duration of 1-3 months, and chronic by a duration of longer than 3 months.

PATHOGENESIS

Acute bacterial sinusitis typically follows a viral upper respiratory tract infection (including COVID-19 infection). Initially, the viral infection produces a viral rhinosinusitis; magnetic resonance imaging (MRI) evaluation of the paranasal sinuses demonstrates abnormalities (mucosal thickening, edema, inflammation) of the paranasal sinuses in 68% of healthy children in the normal course of the common cold. Nose blowing has been demonstrated to generate sufficient force to propel nasal secretions into the sinus cavities. Bacteria from the nasopharynx that enter the sinuses are normally cleared readily, but during viral rhinosinusitis, inflammation and edema can block sinus drainage and impair mucociliary clearance of bacteria. The growth conditions are favorable, and high titers of bacteria are produced.

CLINICAL MANIFESTATIONS

Children and adolescents with sinusitis can present with nonspecific complaints, including nasal congestion, purulent nasal discharge

Table 429.1 Symptoms of Acute Bacterial Sinusitis

MAJOR SYMPTOMS	MINOR SYMPTOMS
Purulent anterior nasal discharge	Headache
Purulent or discolored posterior nasal discharge	Ear pain, pressure, or fullness
Nasal congestion or obstruction	Halitosis
Facial congestion or fullness	Dental pain
Facial pain or pressure alone or exacerbated by bending forward	Cough
Hyposmia or anosmia	Fever (for subacute or chronic sinusitis)
Fever (for acute sinusitis only)	Fatigue

Modified from Chow AW, Benninger MS, Brook I, et al. IDSA clinical practice guideline for acute bacterial rhinosinusitis in children and adults. *CID*. 2012;54:e72–e112, Table 2.

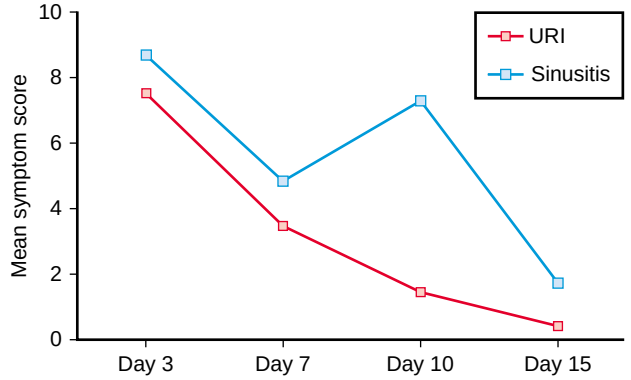

Fig. 429.1 Sinusitis vs URI biphasic symptoms. Mean symptom score by day of illness. *(Modified from DeMuri GP, Eickhoff JC, Gern JC, Wald ER. Clinical and virological characteristics of acute sinusitis in children. Clin Infect Dis. 2019;69:1764–1770, Fig. 1.)*

(unilateral or bilateral), fever, and cough. Less common symptoms include bad breath (halitosis), a decreased sense of smell (hyposmia), and periorbital edema (Table 429.1). Complaints of headache and facial pain are rare in children. Additional symptoms include maxillary tooth discomfort and facial pain or pressure exacerbated by bending forward. Physical examination might reveal erythema and swelling of the nasal mucosa with purulent nasal discharge. Sinus tenderness may be detectable in adolescents and adults.

DIAGNOSIS

The clinical diagnosis of *acute* bacterial sinusitis is based on history, which unfortunately overlaps significantly with that of the common cold. In order to differentiate between the two, current pediatric guidelines define acute bacterial sinusitis as either (1) persistent symptoms of upper respiratory tract infection (rhinitis, common cold), including nasal discharge and/or daytime cough for longer than 10 days without improvement, (2) sudden worsening or new symptoms, known as two-phase illness, or "double sickening," including nasal discharge, daytime cough, or fever after initial improvement (Fig. 429.1), or (3) severe onset with temperature of at least 39°C (102°F) and purulent nasal discharge for 3-4 consecutive days. Bacteria are recovered from maxillary sinus aspirates in 70% of children with such persistent or severe symptoms. Children with *chronic* sinusitis have a history of persistent respiratory symptoms, including cough, nasal discharge, or nasal congestion, lasting longer than 90 days.

Sinus aspirate culture is the only accurate method of diagnosis but is not practical for routine use for immunocompetent patients. It may be a necessary procedure for immunosuppressed patients with suspected fungal sinusitis. In adults, *rigid nasal endoscopy* is a less invasive method for obtaining culture material from the sinus but detects a great excess of positive cultures compared with aspirates. Findings on radiographic studies (sinus plain films, computed tomography [CT] scans), including opacification, mucosal thickening, or presence of an air-fluid level, are not diagnostic and are not recommended in otherwise healthy children. Such findings can confirm the presence of sinus inflammation but cannot be used to differentiate among viral, bacterial, or allergic causes of inflammation.

Given the nonspecific clinical picture, differential diagnostic considerations include viral upper respiratory tract infection (including COVID-19), allergic rhinitis, nonallergic rhinitis, and nasal foreign body. Viral upper respiratory tract infections are characterized by clear and usually nonpurulent nasal discharge, cough, and initial fever; symptoms do not usually persist beyond 10-14 days, although a few children (10%) have persistent symptoms even at 14 days. In a study using nasal sampling, new viruses were present in 29% of sinusitis episodes in children, suggesting sequential upper respiratory infections (URIs) as the cause of persistent symptoms in many cases. Allergic rhinitis can be seasonal; evaluation of nasal secretions should reveal significant eosinophilia.

TREATMENT

It is unclear whether antimicrobial treatment of clinically diagnosed acute bacterial sinusitis offers any substantial benefit. Two randomly controlled trials in children with acute bacterial sinusitis showed improvement after antibiotic therapy, whereas a third found that antimicrobial therapy did not affect resolution of symptoms, duration of symptoms, or days missed from school. A similar study in adults demonstrated improved symptoms at day 7 but not day 10 of treatment. Approximately 50% of children with acute bacterial sinusitis recover without antimicrobial treatment. Centers for Disease Control and Prevention (CDC) guidelines offer that either (1) antibiotic treatment is initiated at the time of diagnosis or (2) the clinician/family may choose continued observation for an additional 3 days, with the caveat that antibiotic therapy will be initiated if symptoms worsen or do not improve. Continued observation is generally not recommended for children with persistent symptoms treated with antibiotics in the preceding 30 days or those with underlying conditions.

Due to the high prevalence of antibiotic-resistant *S. pneumoniae* in some communities, amoxicillin-clavulanate is recommended by some authorities as the preferred initial therapy for acute bacterial sinusitis; high-dose amoxicillin alone may also be considered. In a large cohort of pediatric and adolescent patients from a nationwide healthcare utilization database, both antibiotics were equally effective (equivalent treatment failure rates), but those who received amoxicillin-clavulanate had a higher rate of adverse events. Alternative treatments for the penicillin-allergic patient include cefpodoxime, cefdinir, or levofloxacin. *Azithromycin and trimethoprim-sulfamethoxazole are no longer indicated because of a high prevalence of antibiotic resistance.* Ceftriaxone (50 mg/kg, IV or IM) may be given to children who are vomiting or who are at risk for poor compliance; it should be followed by a course of oral antibiotics. For those with worsening symptoms or failure to improve after 3 days of antibiotic therapy, antibiotic therapy may be changed or the child may be referred to an otolaryngologist for further evaluation (maxillary sinus aspiration for culture and susceptibility testing may be necessary) (Table 429.3). The appropriate duration of therapy for sinusitis has yet to be determined; individualization of therapy is a reasonable approach, with treatment recommended in children for a minimum of 10 days or 7 days after resolution of symptoms. Frontal sinusitis can rapidly progress to serious intracranial complications and may necessitate initiation of parenteral ampicillin-sulbactam, ceftriaxone, or levofloxacin until substantial clinical improvement is achieved (Figs. 429.2 and 429.3). Treatment is then completed with oral antibiotic therapy.

The use of decongestants, antihistamines, mucolytics, and intranasal corticosteroids has not been adequately studied in children and is not recommended for the treatment of acute uncomplicated bacterial sinusitis. Likewise, saline nasal washes or nasal sprays can help liquefy secretions and act as a mild vasoconstrictor, but the effects have not been systematically evaluated in children.

Table 429.2 Antimicrobial Regimens for Acute Bacterial Rhinosinusitis in Children

INDICATION	TREATMENT
Initial empirical therapy for mild to moderate disease*	Amoxicillin-clavulanate (45 mg amoxicillin/kg/day PO divided bid, max 4 g amoxicillin/day) × 10 days*
Initial therapy for acute worsening ("double sickening") of symptoms OR severe disease†	Amoxicillin-clavulanate (90 mg amoxicillin/kg/day PO divided bid, max 4 g amoxicillin/day) × 10 days
β-Lactam allergy	
Type I hypersensitivity	Levofloxacin (10-20 mg/kg/day PO divided every 12-24 hr, max 500 mg/day) × 10 days
Non–type I hypersensitivity	Cefpodoxime‡ (10 mg/kg/day PO divided bid) × 10 days
Severe infection requiring hospitalization	Ampicillin/sulbactam (200-400 mg ampicillin/kg/day IV divided every 6 hr, max 8g ampicillin/day) Ceftriaxone (50 mg/kg/day IV divided every 12 hr, max 4 g/day) Levofloxacin (10-20 mg/kg/day IV divided every 12-24 hr, max 500 mg/day)

*Amoxicillin 90 mg/kg/day, divided bid, max 4g/day, can also be considered.
†Acute worsening ("double sickening") OR severe disease: worsening nasal discharge, daytime cough, or fever starting after a period of initial improvement OR severe onset with temperature of at least 39°C (102°F) and purulent nasal discharge for 3-4 consecutive days.
‡Cefdinir (14 mg/kg/day in one or two divided doses, max 600 mg/day) is an alternative that is more palatable in liquid form than cefpodoxime but has less coverage of bacterial sinusitis pathogens.

Table 429.3 Indications for Referral to a Specialist

- Severe infection (high persistent fever with temperature >39°C [>102°F], orbital edema, severe headache, visual disturbance, altered mental status, meningeal signs)
- Recalcitrant infection with failure to respond to extended courses of antimicrobial therapy
- Immunocompromised host
- Multiple medical problems that might compromise response to treatment (e.g., hepatic or renal impairment, hypersensitivity to antimicrobial agents, organ transplant)
- Unusual or resistant pathogens
- Fungal sinusitis or granulomatous disease
- Nosocomial infection
- Anatomic defects causing obstruction and requiring surgical intervention
- Multiple recurrent episodes of acute bacterial rhinosinusitis (three to four episodes per year) suggesting chronic sinusitis
- Chronic rhinosinusitis (with or without polyps or asthma) with recurrent acute bacterial rhinosinusitis exacerbations
- Evaluation of immunotherapy for allergic rhinitis

From Chow AW, Benninger MS, Brook I, et al. IDSA clinical practice guideline for acute bacterial rhinosinusitis in children and adults. *CID*. 2021;54:e72–e112, Table 14.

COMPLICATIONS

Because of the close proximity of the paranasal sinuses to the brain and eyes, serious orbital and/or **intracranial complications** can result from acute bacterial sinusitis and progress rapidly. Organisms causing orbital and/or intracranial complications of bacterial sinusitis in children include members of the *Streptococcus anginosus* group, *S. aureus, S. pneumoniae,* methicillin-resistant *S. aureus* (MRSA), and methicillin-sensitive *S. aureus* (MSSA); ~30% of infections were polymicrobial.

Orbital complications, including periorbital cellulitis and more often orbital cellulitis (see Chapter 674), are most often secondary to acute bacterial ethmoiditis. *Periorbital* cellulitis produces erythema and swelling of the tissues surrounding the globe, whereas *orbital* cellulitis involves the intraorbital structures and produces proptosis, chemosis, decreased visual acuity, double vision and impaired extraocular movements, and eye pain (Fig. 429.4). In addition to IV antibiotics, orbital cellulitis may require surgical drainage of the ethmoid sinuses or orbit.

Intracranial complications can include epidural abscess, meningitis, cavernous sinus thrombosis, subdural empyema, and brain abscess (see Chapter 644). Children with altered mental status, nuchal rigidity, severe headache, focal neurologic findings, or signs of increased intracranial pressure (headache, vomiting) require immediate CT scan with contrast of the brain, orbits, and sinuses to evaluate for the presence of intracranial complications of acute bacterial sinusitis. Diagnosis of intracranial complications may be challenging, as many patients present with nonspecific symptoms present for the preceding 7-10 days (most commonly headache, fever, congestion, nausea, and vomiting); typically, patients will have been seen by a healthcare provider one or more times before diagnosis. About 50% of patients will present with an abnormal neurologic exam, although only ~30% of patients will present with neurologic symptoms (altered mental status, seizures).

Treatment with broad-spectrum IV antibiotics (usually cefotaxime or ceftriaxone combined with vancomycin and metronidazole) should be initiated immediately, pending culture and susceptibility results. Abscesses can require surgical drainage; endoscopic sinus surgery (ESS) without powered instruments and proper personal protective equipment (PPE) are recommended to minimize risks of aerosolization. Other complications include osteomyelitis of the frontal bone **(Pott puffy tumor)**, which is characterized by edema and swelling of the forehead (see Fig. 429.2), and **mucoceles**, which are chronic inflammatory lesions commonly located in the frontal sinuses that can expand, causing displacement of the eye with resultant diplopia. Surgical drainage is usually required.

PREVENTION

Prevention is best accomplished by frequent handwashing and avoiding persons with colds. This was confirmed most recently in New Zealand: when strict nonpharmaceutical infection control measures were implemented during the COVID-19 pandemic, infections caused by common cold viruses (influenza, respiratory syncytial virus [RSV], human metapneumovirus, enterovirus, adenovirus, parainfluenza virus, and rhinovirus) were greatly reduced. Once restrictions were eased, only rhinovirus infections quickly increased, whereas the prevalence of other respiratory viral infections remained reduced. This may be because of the fact that most rhinovirus infections are transmitted in the home where public restrictions are not in place. Commercially available alcohol-based hand sanitizers have been shown in vitro to be effective against COVID-19 and the common cold viruses.

Because acute bacterial sinusitis can be a complication of influenza infection, prevention of influenza infection by yearly influenza vaccine will prevent some cases of complicating sinusitis. Chemoprophylaxis against influenza with oseltamivir or zanamivir may be useful for prevention of influenza-associated sinusitis.

Visit Elsevier eBooks+ at eBooks.Health.Elsevier.com for Bibliography.

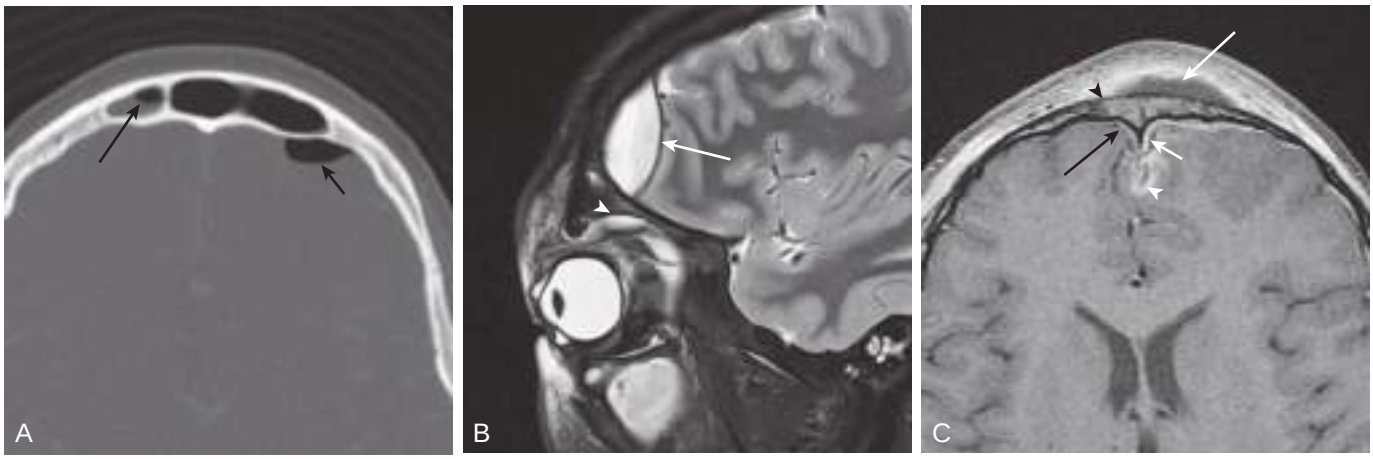

Fig. 429.2 Acute complicated sinusitis. **A,** Frontal sinusitis and epidural abscess. Axial computed tomography image shows a frontal sinus air-fluid level *(long arrow)*. There is also an intracranial air-fluid level associated with an epidural abscess *(short arrow)*. **B,** Frontal sinusitis, epidural abscess, and orbital abscess. Sagittal fat-suppressed (FS) T2-weighted magnetic resonance (MR) image demonstrates a biconvex epidural abscess *(arrow)* containing a sediment level. There is also a small superior extraconal subperiosteal abscess *(arrowhead)*. Periorbital STS is present, and there are secretions within the maxillary antrum. **C,** Pott puffy tumor, frontal osteomyelitis, and subdural empyema. Axial gadolinium-enhanced FS T1-weighted MR image shows frontal scalp swelling ventral to an elliptical low signal intensity, peripherally enhancing, frontal subperiosteal abscess *(long white arrow)*. There is enhancement of the subjacent frontal bone, consistent with osteomyelitis *(black arrowhead)*. There is also dural enhancement *(black arrow)* and a small left frontal interhemispheric subdural empyema *(short white arrow)* with subtle enhancement of the adjacent frontal leptomeninges and cortex caused by meningitis and cerebritis *(white arrowhead)*. *(From Walters MM, Robertson RL, eds. Pediatric Radiology: The Requisites, 4th ed. Philadelphia: Elsevier; 2017: Fig. 10.40.)*

Fig. 429.3 Axial plane contrast-enhanced CT scan of an 11-yr-old obtunded female with a subfrontal lobe abscess secondary to frontal sinusitis. The CT scan demonstrates an eliptiform ring-enhancing fluid-filled cavity adjacent to the frontal lobe with contralateral shift of the midline. *(From Parikh SR, Brown SM. Image-guided frontal sinus surgery in children. Operative Tech Otolaryngol Head Neck Surg. 2004;15:37–41.)*

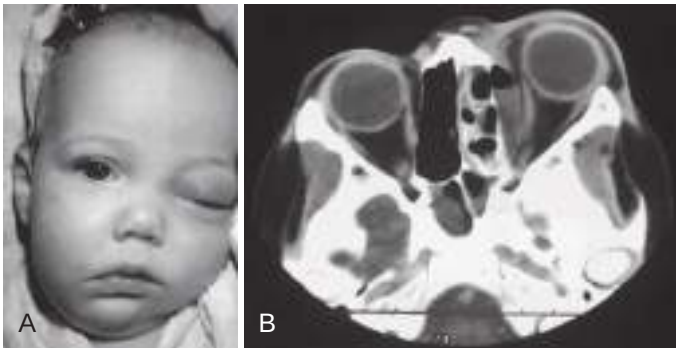

Fig. 429.4 Orbital complications of acute sinusitis. **A,** An 11-mo-old infant with a swollen left eye and limited ocular movement. **B,** Axial CT shows opacification of sinuses and an inflammatory mass with an air-fluid level displacing the medial rectus laterally. *(From Cooper ML, Slovis T. The sinuses. In Slovis T, ed. Caffey's Pediatric Diagnostic Imaging, 11th ed. Philadelphia: Mosby; 2008: Fig. 43-7, p. 573.)*

Chapter 430

Acute Pharyngitis

Joseph Gigante

Pharyngitis refers to inflammation of the pharynx, including erythema, edema, exudates, or an enanthem (ulcers, vesicles). Pharyngeal inflammation can be related to environmental exposures, such as tobacco smoke, air pollutants, and allergens; from contact with caustic substances, hot food, and liquids; and from infectious agents. The pharynx and mouth can be involved in various inflammatory conditions such as periodic fever, aphthous stomatitis, pharyngitis, adenitis (PFAPA) syndrome, Kawasaki disease, multisystem inflammatory syndrome in children (MIS-C), inflammatory bowel disease (IBD), Stevens-Johnson syndrome, and systemic lupus erythematous (SLE). Noninfectious etiologies are typically evident from history and physical exam, but it can be more challenging to distinguish from among the numerous infectious causes of acute pharyngitis.

Acute infections of the upper respiratory tract account for a substantial number of visits to pediatricians, and many feature sore throat as a symptom or evidence of pharyngitis on physical examination. The usual clinical task is to distinguish important, potentially serious, and treatable causes of acute pharyngitis from those that are self-limited and require no specific treatment or follow-up. Specifically, identifying patients who have **group A streptococcus** (GAS; *Streptococcus pyogenes*; see Chapter 229) pharyngitis and treating them with antibiotics forms the core of the management paradigm.

INFECTIOUS ETIOLOGIES

Viruses

In North America and most industrialized countries, GAS is the most important bacterial cause of acute pharyngitis, but viruses predominate as acute infectious causes of pharyngitis. Viral upper respiratory tract infections are typically spread by contact with oral or respiratory secretions and occur most commonly in fall, winter, and spring—that is, the respiratory season. Important viruses that cause pharyngitis include influenza, parainfluenza, adenoviruses, coronaviruses, enteroviruses, rhinoviruses, respiratory syncytial virus (RSV), cytomegalovirus, Epstein-Barr virus (EBV), herpes simplex virus (HSV), and human metapneumovirus (HMPV) (Table 430.1). Most viral pharyngitis, except mononucleosis, is mild. Common nonspecific symptoms such as rhinorrhea and cough develop gradually before they become prominent. However, specific findings are sometimes helpful in identifying the infectious viral agent (Table 430.2). Sore throat is also seen in COVID-19 infection and MIS-C; it is rare to be the only symptom and is part of the multisystem involvement in both disorders.

Table 430.1 Infectious Agents that Cause Pharyngitis

VIRUSES	BACTERIA
Adenovirus	*Streptococcus pyogenes* (group A streptococcus)
Coronavirus including COVID-19	*Arcanobacterium haemolyticum*
Cytomegalovirus	*Fusobacterium necrophorum*
Epstein-Barr virus	*Corynebacterium diphtheriae*
Enteroviruses	*Neisseria gonorrhoeae*
Herpes simplex virus (1 and 2)	Group C streptococci
Human immunodeficiency virus	Group G streptococci
Human metapneumovirus	*Francisella tularensis*
Influenza viruses (A and B)	*Yersinia pestis*
Measles virus	*Chlamydophila pneumoniae*
Parainfluenza viruses	*Chlamydia trachomatis*
Respiratory syncytial virus	*Mycoplasma pneumoniae*
Rhinoviruses	Mixed anaerobes (Vincent angina)

Gingivostomatitis and ulcerating vesicles throughout the anterior pharynx and on the lips and perioral skin are seen in primary oral HSV infection. High fever and difficulty taking oral fluids are common. This infection can last for 14 days.

Discrete **papulovesicular** lesions or **ulcerations** in the posterior oropharynx, severe throat pain, and fever are characteristic of **herpangina**, caused by various enteroviruses. In **hand-foot-mouth disease**, there are vesicles or ulcers throughout the oropharynx, on the palms and soles, and sometimes on the trunk and extremities. Coxsackie A16 is the most common agent, but enterovirus 71 and Coxsackie A6 can also cause this syndrome. Enteroviral infections are most common in the summer.

Various adenoviruses cause pharyngitis. When there is concurrent **conjunctivitis**, the syndrome is called *pharyngoconjunctival fever*. The pharyngitis tends to resolve within 7 days, but conjunctivitis may persist for up to 14 days. Pharyngoconjunctival fever can be epidemic or sporadic; outbreaks have been associated with exposure in swimming pools.

Intense, diffuse pharyngeal erythema and Koplik spots, the pathognomonic enanthem, occur in advance of the characteristic rash of measles. Splenomegaly, lymphadenopathy, or hepatomegaly may be the clue to EBV infectious mononucleosis in an adolescent with exudative tonsillitis. Primary infection with HIV can manifest as **acute retroviral syndrome**, with nonexudative pharyngitis, fever, arthralgia, myalgia, adenopathy, and often a maculopapular rash.

Bacteria Other than Group A Streptococcus

In addition to GAS, bacteria that cause pharyngitis include group C and group G streptococcus, *Arcanobacterium haemolyticum, Francisella tularensis, Neisseria gonorrhoeae, Mycoplasma pneumoniae, Chlamydophila (formerly Chlamydia) pneumoniae, Chlamydia trachomatis, Fusobacterium necrophorum,* and *Corynebacterium diphtheriae. Haemophilus influenzae* and *Streptococcus pneumoniae* may be cultured from the throats of children with pharyngitis, but their role in causing pharyngitis has not been established.

Group C and group G streptococcus and *A. haemolyticum* pharyngitis have been diagnosed most commonly in adolescents and adults.

Table 430.2 Epidemiologic and Clinical Features Suggestive of Group A Streptococcal and Viral Pharyngitis

FEATURE, BY SUSPECTED ETIOLOGIC AGENT

Group A Streptococcal
- Sudden onset of sore throat
- Age 5-15 yr
- Fever
- Headache
- Nausea, vomiting, abdominal pain
- Tonsillopharyngeal inflammation
- Patchy tonsillopharyngeal exudates
- Palatal petechiae
- Anterior cervical adenitis (tender nodes)
- Winter and early spring presentation
- History of exposure to strep pharyngitis
- Scarlatiniform rash
- No cough or coryza

Viral
- Conjunctivitis
- Coryza
- Cough
- Diarrhea
- Hoarseness
- Discrete ulcerative stomatitis
- Viral exanthema
- As part of the spectrum of COVID-19 and MIS-C

From Shulman ST, Bisno AL, Clegg HW, et al. Clinical practice guideline for the diagnosis and management of group A streptococcal pharyngitis: 2012 update by the Infectious Diseases Society of America. *Clin Infect Dis.* 2012;55(10):e86–e102, Table 4.

They resemble group A β-hemolytic streptococcus (GABHS) pharyngitis. A scarlet fever–like rash may be present with *A. haemolyticum* infections.

F. necrophorum is an important etiology of pharyngitis in older adolescents and adults (15-30 years old). Prevalence in studies has varied from 10% to 48% of patients with non-GABHS pharyngitis, but large surveillance studies have not been performed. *F. necrophorum* was detected by polymerase chain reaction (PCR) in 20.5% of patients with pharyngitis in a study based in a university health clinic and in 9.4% of an asymptomatic convenience sample; some patients had more than one bacterial species detected by PCR. Pharyngitis patients with *F. necrophorum* had signs and symptoms similar to GAS pharyngitis: ~30% had fever, ~30% had tonsillar exudates, ~65% had anterior cervical adenopathy, and most did not have cough. This organism is difficult to culture from the throat, and diagnostic testing with PCR is not generally available. *F. necrophorum* pharyngitis is associated with the development of **Lemierre syndrome** (see Chapter 432): internal jugular vein septic thrombophlebitis. Approximately 80% of cases of Lemierre syndrome are caused by this bacterium. Patients present initially with fever, sore throat, exudative pharyngitis, and/or peritonsillar abscess. The symptoms may persist, neck pain and swelling develop, and the patient appears toxic. Septic shock may ensue, along with metastatic complications from septic emboli that can involve the lungs, bones and joints, central nervous system, abdominal organs, and soft tissues. The case fatality rate is 4–9%.

Gonococcal pharyngeal infections are usually asymptomatic but can cause acute ulcerative or exudative pharyngitis with fever and cervical lymphadenitis. Young children with proven gonococcal disease should be evaluated for sexual abuse.

Diphtheria is extremely rare in most developed countries because of extensive immunization with diphtheria toxoid. However, it remains endemic in many areas of the world, including the former Soviet bloc countries, Africa, Asia, the Middle East, and Latin America. It can be considered in patients with recent travel to or from these areas and in unimmunized patients. Key physical findings are bull neck (extreme neck swelling) and a gray pharyngeal pseudomembrane that can cause respiratory obstruction.

Ingestion of water, milk, or undercooked meat contaminated by *F. tularensis* can lead to oropharyngeal tularemia. Severe throat pain, tonsillitis, cervical adenitis, oral ulcerations, and a pseudomembrane (as in diphtheria) may be present. *M. pneumoniae* and *C. pneumonia*e cause pharyngitis, but other upper and lower respiratory infections are more important and more readily recognized. Development of a severe or persistent cough subsequent to pharyngitis may be the clue to infection with one of these organisms.

Group A Streptococcus

Streptococcal pharyngitis is relatively uncommon before 2-3 years of age, is quite common among children 5-15 years old, and declines in frequency in late adolescence and adulthood. Illness occurs throughout the year but is most prevalent in winter and spring. It is readily spread among siblings and schoolmates. GAS causes 15–30% of pharyngitis in school-age children.

Colonization of the pharynx by GAS can result in either asymptomatic carriage or acute infection. After an incubation period of 2-5 days, pharyngeal infection with GAS classically presents as rapid onset of significant sore throat and fever (see Table 430.2). The pharynx is red, and the tonsils are enlarged and often covered with a white, grayish, or yellow exudate that may be blood-tinged. There may be petechiae or doughnut lesions on the soft palate and posterior pharynx, and the uvula may be red and swollen. The surface of the tongue can resemble a strawberry when the papillae are inflamed and prominent (strawberry tongue). Initially, the tongue is often coated white, and with the swollen papillae, it is called a *white strawberry tongue*. When the white coating is gone after a few days, the tongue is often quite red and is called a *red strawberry tongue*. Enlarged and tender anterior cervical lymph nodes are frequently present. Headache, abdominal pain, and vomiting are frequently associated with the infection, but in the absence of clinical pharyngitis, gastrointestinal signs and symptoms should not be attributed to GAS. Ear pain is a frequent complaint, but the tympanic membranes are usually normal. Diarrhea, cough, coryza, ulcerations, croup/laryngitis/hoarseness, and conjunctivitis *are not* associated with GAS pharyngitis and increase the likelihood of a viral etiology (see Table 430.2).

Patients infected with GAS that produce streptococcal pyrogenic exotoxin A, B, or C may demonstrate the fine, red, papular (sandpaper) rash of **scarlet fever**. It begins on the face and then becomes generalized. The cheeks are red, and the area around the mouth is less intensely red (more pale), giving the appearance of circumoral pallor. The rash blanches with pressure, and it may be more intense in skin creases, especially in the antecubital fossae, axillae, and inguinal creases (Pastia lines or sign). Pastia lines are sometimes petechial or slightly hemorrhagic. Capillary fragility can cause petechiae distal to a tourniquet or constriction from clothing, a positive tourniquet test or Rumpel-Leeds phenomenon. Erythema fades in a few days, and when the rash resolves, it typically peels like a mild sunburn. Sometimes there is sheetlike desquamation around the free margins of the fingernails. Streptococcal pyrogenic exotoxin A, encoded by the gene *spe A,* is the exotoxin most commonly associated with scarlet fever.

The M protein is an important GAS virulence factor that facilitates resistance to phagocytosis. The M protein is encoded by the *emm* gene and determines the M type (or *emm* type). Molecular methods have identified more than 240 *emm* genes (*emm* types, M types). The M protein is immunogenic and protects against reinfection with the homologous M type; an individual can experience multiple episodes of GAS pharyngitis in a lifetime because natural immunity is M type–specific and does not prevent infection with a new M type. Numerous GAS M types can circulate in a community simultaneously, and they enter and leave communities unpredictably and for unknown reasons.

DIAGNOSIS

The clinical presentations of streptococcal and viral pharyngitis often overlap. In particular, the pharyngitis of mononucleosis can be difficult to distinguish from GAS pharyngitis. Physicians relying solely on clinical judgment often overestimate the likelihood of a streptococcal etiology. Various clinical scoring systems have been described to assist in identifying patients who are likely to have GAS pharyngitis. Criteria developed for adults by Centor and modified for children by McIsaac give one point for each of the following criteria: history of temperature >38°C (100.4°F), absence of cough, tender anterior cervical adenopathy, tonsillar swelling or exudates, and age 3-14 years. It subtracts a point for age ≥45 years. At best, a McIsaac score ≥4 is associated with a positive laboratory test for GAS in less than 70% of children with pharyngitis (Table 430.3), so it, too, overestimates the likelihood of GAS. *Consequently, laboratory testing is essential for an accurate diagnosis*. Clinical findings and/or scoring systems can best be used to assist the clinician in identifying patients in need of testing. Evaluating patients indiscriminately can lead to overdiagnosis and overtreatment. Streptococcal antibody tests are not useful in assessing patients with acute pharyngitis.

Throat culture, rapid antigen-detection tests (RADTs), or PCR tests are the diagnostic tests for GAS most available in routine clinical care. Throat culture plated on blood agar remains the gold standard for diagnosing streptococcal pharyngitis. There are both false-negative cultures as a consequence of sampling errors or prior antibiotic treatment and false-positive cultures as a consequence of misidentification of other bacteria as GAS. Streptococcal RADTs detect the group A carbohydrate of GAS. They are used by the vast majority of office-based pediatricians. All RADTs have very high specificity, generally ≥95%, so when a RADT is positive, it is assumed to be accurate and throat culture is unnecessary. Because RADTs are generally much less sensitive than culture, confirming a negative rapid test with a throat culture is recommended. RADTs and throat culture exhibit spectrum bias: they are more sensitive when the pretest probability of GAS is high (signs and symptoms are typical of GAS infection, higher McIsaac scores) and less sensitive when the pretest probability is low. Avoidance of testing when patients have signs and symptoms more suggestive of a viral infection is recommended by expert guidelines.

Table 430.3 Positive Predictive Value of McIsaac Score in Children in Clinical Studies*

SCORE	McISAAC, 2004 (n = 454) (%)	EDMONSON, 2005 (n = 1184) (%)	TANZ, 2009 (n = 1848) (%)	FINE, 2012 (n = 64,789) (%)
0	–	–	7	17
1	–	0.5	19	23
2	20.5	8.9	20	34
3	27.5	42.4	29	50
≥4	67.8	48.2	49	68
GAS prevalence	34	38	30	37

*One point is given for each of the following criteria: history of temperature >38°C (100.4°F), absence of cough, tender anterior cervical adenopathy, tonsillar swelling or exudates, and age 3-14 yr.

Note that the Centor score lacks only the age criterion. Positive predictive value refers to the proportion of patients with documented GAS by rapid antigen-detection test and/or throat culture.

Many laboratories have replaced throat culture with one of the highly sensitive and specific **GAS molecular tests**. A variety of methods are available to amplify the DNA of a specific GAS gene from a throat swab in less than 1 hour. In studies both sensitivity and specificity are reported to be ≥98% when compared with standard throat culture. PCR usually matches the molecular test when used to adjudicate discrepancies between the culture and molecular test results. Some of these nucleic acid amplification tests are approved by the FDA for use in physician office laboratories and can be used as the initial test for GAS or as a confirmatory test when the RADT is negative. Unlike throat culture and RADTs, molecular tests may not exhibit spectrum bias—that is, although test sensitivity is extremely high, it is independent of the pretest probability that GAS is the cause of illness (using signs and symptoms, McIsaac score), thus increasing the potential to identify a chronic GAS carrier who actually has an intercurrent illness not caused by GAS (discussed later). However, the ability of these stand-alone tests to deliver a definitive result in less than 1 hour makes them attractive (there is one test that takes 15 minutes)—the potential to swab symptomatic children, have them wait or send them home, and electronically prescribe an antibiotic when the test is positive can speed initiation of therapy and subsequent return to school and activities. Concerns about molecular tests include the following: (1) they are so sensitive they may cause unnecessary treatment of more patients who are carriers than would ordinarily occur with RADT and/or culture; (2) unless rigorous technique is followed, they may be prone to contamination with exogenous GAS DNA from other swabs, a particular concern in physician offices when performed by staff who are not trained laboratory technologists; and (3) they are much more expensive than throat culture.

Testing for bacteria other than GAS is performed infrequently and should be reserved for patients with persistent symptoms and symptoms suggestive of a specific non-GAS bacterial pharyngitis—for example, when there is concern for gonococcal infection or sexual abuse. Special culture media and a prolonged incubation are required to detect *A. haemolyticum*. A complete blood cell count showing many atypical lymphocytes and a positive mononucleosis slide agglutination test can help confirm a clinical suspicion of EBV infectious mononucleosis. Viral cultures are often unavailable and are generally too expensive and slow to be clinically useful. PCR is more rapid, and multiplex PCR (respiratory viral panel) testing for respiratory pathogens can identify a variety of viral and bacterial agents within a few hours. This may be useful in determining the isolation needs of hospitalized patients, assisting in patient prognosis, and epidemiology, but in the absence of specific treatment for most viral infections, such testing is usually not necessary or useful. In fact, interpreting such tests can be difficult unless the patient has signs or symptoms characteristic of a specific pathogen.

TREATMENT

Specific therapy is unavailable for most viral pharyngitis. However, nonspecific, symptomatic therapy can be an important part of the overall treatment plan. An oral antipyretic/analgesic agent (acetaminophen or ibuprofen) can relieve fever and sore throat pain. Anesthetic sprays and lozenges (often containing benzocaine, phenol, or menthol) can provide local relief in children who are developmentally appropriate to use them. Systemic corticosteroids are sometimes used in children who have evidence of upper airway compromise caused by mononucleosis. Although corticosteroids are used commonly in adults with pharyngitis, large-scale studies capable of providing safety and efficacy data are lacking in children. *Corticosteroids cannot be recommended for treatment of most cases of pediatric pharyngitis.*

Antibiotic therapy of bacterial pharyngitis depends on the organism identified. On the basis of in vitro susceptibility data, oral penicillin is often suggested for patients with group C streptococcal isolates, and oral erythromycin is recommended for patients with *A. haemolyticum,* but the clinical benefit of such treatment is uncertain.

Most untreated episodes of GAS pharyngitis resolve uneventfully within a few days, but early antibiotic therapy hastens clinical recovery by 12-24 hours and also reduces suppurative complications of GAS pharyngitis such as peritonsillar abscess and cervical adenitis. *The primary benefit and intent of antibiotic treatment is the prevention of acute rheumatic fever (ARF)*; it is highly effective when started within 10 days of onset of illness. Antibiotic therapy does not prevent acute poststreptococcal glomerulonephritis (APSGN). Antibiotic treatment should not be delayed for children with symptomatic pharyngitis and a positive test for GAS. Presumptive antibiotic treatment can be started when there is a clinical diagnosis of scarlet fever, a symptomatic child has a household contact with documented streptococcal pharyngitis, or there is a history of ARF in the patient or a family member, but a diagnostic test should be performed to confirm the presence of GAS, and antibiotics should be discontinued if GAS is not identified.

A variety of antimicrobial agents are effective for GAS pharyngitis (Table 430.4). Group A streptococci are universally susceptible to penicillin and all other β-lactam antibiotics. Penicillin is inexpensive, has a narrow spectrum of activity, and has few adverse effects. Amoxicillin is often preferred for children because of its taste, availability as chewable tablets and liquid, and the convenience of once-daily dosing. The duration of oral penicillin and amoxicillin therapy is 10 days. A single intramuscular dose of benzathine penicillin or a benzathine–procaine penicillin G combination is effective and ensures compliance. Follow-up testing for GAS is unnecessary after completion of therapy and is not recommended unless symptoms recur.

Patients allergic to the penicillins can be treated with a 10-day course of a narrow-spectrum, first-generation cephalosporin (cephalexin or cefadroxil) if the previous reaction to penicillin was not an immediate, type I hypersensitivity reaction. Frequently, penicillin-allergic patients are treated for 10 days with erythromycin, clarithromycin, or clindamycin, or for 5 days with azithromycin.

The increased use of macrolides and related antibiotics for a variety of infections, especially the azalide azithromycin, is associated with increased rates of resistance to these drugs among GAS in many

Table 430.4 Recommended Treatment for Acute Streptococcal Pharyngitis

MOST PATIENTS				
	WEIGHT <27 KG	**WEIGHT ≥27 KG**	**ROUTE**	**DURATION**
Amoxicillin	50 mg/kg once daily (maximum 1,000 mg)		Oral	10 days
Penicillin V	250 mg bid	500 mg bid	Oral	10 days
Benzathine penicillin G	600,000 units	1.2 million units	IM	Once
Benzathine penicillin G + procaine penicillin G	900,000 units + 300,000 units	900,000 units + 300,000 units	IM	Once
PENICILLIN-ALLERGIC PATIENTS				
	ORAL DOSE	**FREQUENCY**	**DURATION**	
Cephalosporins*	Varies with agent chosen		10 days	
Erythromycins				
Ethylsuccinate	40 mg/kg/day up to 1,000 mg/day	bid	10 days	
Estolate	20-40 mg/kg/day up to 1,000 mg/day	bid	10 days	
Clarithromycin	15 mg/kg/day up to 500 mg/day	bid	10 days	
Azithromycin†	12 mg/kg day 1; 6 mg/kg days 2-5	qd	5 days	
Clindamycin	20 mg/kg/day up to 1.8 g/day	tid	10 days	

*First-generation cephalosporins are preferred; dosage and frequency vary among agents. Do not use in patients with a history of immediate (anaphylactic) hypersensitivity to penicillin or other β-lactam antibiotics.
†Maximum dose is 500 mg the first day and 250 mg subsequent days.

countries. Approximately 5% of GAS in the United States and more than 10% in Canada are macrolide-resistant (macrolide resistance includes azalide resistance), but there is considerable local variation in both countries. Rates are much higher in many European and Asian countries. Some macrolide-resistant GAS isolates are also resistant to clindamycin. Although not a major hindrance for treatment of pharyngitis, clindamycin resistance may be important in management of invasive GAS infections. The use of macrolides and related antibiotics should be restricted to patients who cannot safely receive a β-lactam drug for GAS pharyngitis. Tetracyclines, fluoroquinolones, or sulfonamides should *not* be used to treat GAS pharyngitis.

CHRONIC GROUP A STREPTOCOCCUS CARRIERS

Streptococcal carriers are patients who continue to harbor GAS in the pharynx despite appropriate antibiotic therapy or when they are well. They have little or no evidence of an inflammatory response to the organism. The pathogenesis of chronic carriage is not known; it is assuredly not related to penicillin resistance or nonadherence to therapy, and there is little direct evidence to support the concept of co-pathogenicity (presence of β-lactamase–producing organisms in the pharynx). Carriage generally poses little risk to patients and their contacts, but it can confound testing in subsequent episodes of sore throat. A child who is chronically colonized with GAS (streptococcal carrier) can have a positive test for GAS if it is obtained when the child is evaluated for pharyngitis that is actually caused by a viral infection. Patients with repeated test-positive pharyngitis create anxiety among their families and physicians. It is usually unnecessary to attempt to eliminate chronic carriage. Instead, evaluation and treatment of clinical pharyngitis should be undertaken without regard for chronic carriage, using clinical criteria to determine the need for testing, treating test-positive patients in routine fashion, and avoiding antibiotics in patients who have negative tests. This approach often requires considerable effort to reassure the patient and family that chronic carriage is not a significant health risk. Expert opinion suggests that eradication might be attempted in select circumstances: a community outbreak of ARF or APSGN; personal or family history of ARF; an outbreak of GAS pharyngitis in a closed or semiclosed community, nursing home, or healthcare facility; repeated episodes of symptomatic GAS pharyngitis in a family with ping pong spread among family members despite adequate therapy; when tonsillectomy is being considered because of chronic carriage or recurrent streptococcal pharyngitis; and extreme, unmanageable anxiety related to GAS carriage ("streptophobia") among family members. Clindamycin given by mouth for 10 days is effective therapy (20 mg/kg/day divided in three doses; adult dose 150-450 mg tid). Amoxicillin-clavulanate (40 mg amoxicillin/kg/day up to 2,000 mg amoxicillin/day divided tid for 10 days) and 4 days of oral rifampin (20 mg/kg/day up to 600 mg divided in two doses) plus either intramuscular benzathine penicillin given once or oral penicillin given for 10 days have also been used (rifampin is started on the first day of penicillin therapy).

RECURRENT PHARYNGITIS

True recurrent GAS pharyngitis can occur for several reasons: reinfection with the same M type if type-specific antibody has not developed, poor compliance with oral antibiotic therapy, macrolide resistance if a macrolide was used for treatment, and infection with a new M type. Unfortunately, determining the GAS M type in an acute infection is not available to the clinician. Treatment with intramuscular benzathine penicillin eliminates nonadherence to therapy. Apparent recurrences can represent pharyngitis of another cause in the presence of streptococcal carriage. Chronic GAS carriage is particularly likely if the illnesses are mild and otherwise atypical for GAS pharyngitis.

Tonsillectomy may lower the incidence of pharyngitis for 1-2 years among children with frequent episodes of documented pharyngitis (≥7 episodes in the previous year or ≥5 in each of the preceding 2 years, or ≥3 in each of the previous 3 years). However, the frequency of pharyngitis (GAS and non-GAS) generally declines over time without tonsillectomy. By 2 years posttonsillectomy, the incidence of pharyngitis in severely affected children is similar among those who have tonsillectomy and those who do not. Few children are so severely affected, and the limited clinical benefit of tonsillectomy for most must be balanced against the risks of anesthesia and surgery. *Undocumented history of recurrent pharyngitis is an inadequate basis for recommending tonsillectomy.*

Recurrent GAS pharyngitis is rarely, if ever, a sign of an immune disorder. However, recurrent pharyngitis can be part of a recurrent fever or autoinflammatory syndrome such as PFAPA syndrome. Prolonged

pharyngitis (>1 week) can occur in infectious mononucleosis and Lemierre syndrome, but it also suggests the possibility of another disorder such as neutropenia, a recurrent fever syndrome, or an autoimmune disease such as SLE or IBD. In such instances, pharyngitis would be one of a number of clinical findings that together should suggest the underlying diagnosis.

COMPLICATIONS AND PROGNOSIS

Viral respiratory tract infections can predispose to bacterial middle ear infections and bacterial sinusitis. The complications of GAS pharyngitis include local suppurative complications, such as parapharyngeal abscess, and subsequent nonsuppurative illnesses, such as ARF, APSGN, poststreptococcal reactive arthritis, and possibly pediatric autoimmune neuropsychiatric disorders associated with streptococci (PANDAS, sometimes referred to as *CANS* [childhood acute neuropsychiatric symptoms] or *PANS* [pediatric acute-onset neuropsychiatric syndrome], recognizing that many infections other than GAS may predispose to these syndromes).

PREVENTION

Vaccines intended to prevent infection with various viruses (e.g., RSV) and GAS are being developed. A recombinant multivalent GAS M-type vaccine uses the terminal portions of various M proteins to take advantage of their immunogenicity. Other GAS vaccines are based on more conserved epitopes in order to avoid the necessity of matching the vaccine with the M types prevalent in a community or target population. None of the investigational GAS vaccines are near licensing for use. A recent comprehensive study of the immune response to childhood GAS pharyngeal acquisition raises questions about how to best design effective vaccines. This is complicated by the variety of clinical scenarios and clinical syndromes associated with GAS and the need to determine the intended clinical benefit(s) of vaccination. Antimicrobial prophylaxis with daily oral penicillin prevents recurrent GAS infections but is recommended only to prevent recurrences of ARF.

Visit Elsevier eBooks+ at eBooks.Health.Elsevier.com for Bibliography.

Chapter 431

Tonsils and Adenoids

Karen B. Zur

The *Waldeyer ring* (the lymphoid tissue surrounding the opening of the oral and nasal cavities into the pharynx) comprises the palatine tonsils, the pharyngeal tonsil or adenoid, lymphoid tissue surrounding the eustachian tube orifice in the lateral walls of the nasopharynx, the lingual tonsil at the base of the tongue, and scattered lymphoid tissue throughout the remainder of the pharynx, particularly behind the posterior pharyngeal pillars and along the posterior pharyngeal wall. The *palatine tonsil* consists of lymphoid tissue located between the palatoglossal fold (anterior tonsillar pillar) and the palatopharyngeal fold (posterior tonsillar pillar). This lymphoid tissue is separated from the surrounding pharyngeal musculature by a thick fibrous capsule. The *adenoid* is a single aggregation of lymphoid tissue that occupies the space between the nasal septum and the posterior pharyngeal wall. A thin fibrous capsule separates it from the underlying structures; the adenoid does not contain the complex crypts that are found in the palatine tonsils, but rather more simple crypts. Lymphoid tissue at the base of the tongue forms the *lingual tonsil* that also contains simple tonsillar crypts.

NORMAL FUNCTION

Located at the opening of the pharynx to the external environment, the tonsils and adenoid are well situated to provide primary defense against foreign matter. The immunologic role of the tonsils and adenoids is to induce secretory immunity and to regulate the production of the secretory immunoglobulins. Deep crevices within tonsillar tissue form tonsillar crypts that are lined with squamous epithelium and host a concentration of lymphocytes at their bases. The lymphoid tissue of the Waldeyer ring is most immunologically active between 4 and 10 years of age, with a decrease after puberty. Adenotonsillar hypertrophy is greatest between ages 3 and 6 years; in most children tonsils begin to involute after age 8 years. No major immunologic deficiency has been demonstrated after removal of either or both of the tonsils and adenoid.

PATHOLOGY

Acute Infection

Most episodes of acute pharyngotonsillitis are caused by viruses (see Chapter 430). Group A β-hemolytic streptococcus (GABHS) is the most common cause of bacterial infection in the pharynx (see Chapter 229).

Chronic Infection

The tonsils and adenoids can be chronically infected by multiple microbes, which can include a high incidence of β-lactamase–producing organisms. Both aerobic species, such as streptococci and *Haemophilus influenzae,* and anaerobic species, such as *Peptostreptococcus, Prevotella,* and *Fusobacterium,* contribute. The tonsillar crypts can accumulate desquamated epithelial cells, lymphocytes, bacteria, and other debris, causing cryptic tonsillitis. With time, these cryptic plugs can calcify into tonsillar concretions or tonsilloliths. Biofilms appear to play a role in chronic inflammation of the tonsils.

Upper Airway Obstruction

Enlargement of the tonsils and/or adenoids is a major cause of upper airway obstruction in children. Airway obstruction in children is typically manifested in sleep-disordered breathing, including obstructive sleep apnea, obstructive sleep hypopnea, and upper airway resistance syndrome (see Chapter 31). Sleep-disordered breathing secondary to adenotonsillar hypertrophy is a cause of growth failure. Solid dysphagia can also be seen in this group of patients, with symptoms such as prolonged chewing, pocketing of solids in the mouth, choking or gagging when swallowing solids, and weight loss.

Tonsillar Neoplasm

Rapid enlargement of one tonsil is highly suggestive of a tonsillar malignancy, typically lymphoma, in children.

CLINICAL MANIFESTATIONS

Acute Infection

Symptoms of GABHS infection include odynophagia, dry throat, malaise, fever and chills, dysphagia, referred otalgia, headache, muscular aches, and enlarged cervical nodes. Signs include dry tongue, erythematous enlarged tonsils, tonsillar or pharyngeal exudate, palatine petechiae, and enlargement and tenderness of the jugulodigastric lymph nodes (Fig. 431.1; see Chapter 229).

Chronic Infection

Children with chronic or cryptic tonsillitis often present with halitosis, chronic sore throats, foreign-body sensation, or a history of expelling foul-tasting and foul-smelling cheesy lumps. Examination reveals tonsils of a range of sizes, often containing copious debris within the crypts. The offending organism is not usually GABHS.

Airway Obstruction

The diagnosis of airway obstruction (see Chapter 31) can frequently be made by history and physical examination. Daytime symptoms of airway obstruction secondary to adenotonsillar hypertrophy include chronic mouth breathing, nasal obstruction, hyponasal speech, hyposmia,

Fig. 431.1 Pharyngotonsillitis. This common condition has a number of causative pathogens and a wide spectrum of severity. **A,** The diffuse tonsillar and pharyngeal erythema seen here is a nonspecific finding that can be produced by a variety of pathogens. **B,** This intense erythema, seen in association with acute tonsillar enlargement and palatal petechiae, is highly suggestive of group A β-streptococcal infection, though other pathogens can produce these findings. **C,** This picture of exudative tonsillitis is most commonly seen with either group A streptococcal or Epstein-Barr virus infection. *(B courtesy Michael Sherlock, MD, Lutherville, MD. From Yellon RF, McBride TP, Davis HW. Otolaryngology. In Zitelli BJ, Davis HW, eds. Atlas of Pediatric Physical Diagnosis, 4th ed. Philadelphia: Mosby; 2002:852.)*

decreased appetite, poor school performance, hyperactivity, and, rarely, symptoms of right-sided heart failure. Nighttime symptoms consist of loud snoring, choking, gasping, frank apnea, restless sleep, abnormal sleep positions, sleep walking, night terrors, diaphoresis, enuresis, and sleep talking. Large tonsils are typically seen on examination, although the absolute size might not indicate the degree of obstruction. The size of the adenoid tissue can be demonstrated on a lateral neck radiograph or with flexible endoscopy. Other signs that can contribute to airway obstruction include the presence of a craniofacial syndrome or hypotonia.

These daytime and nocturnal comorbidities should be explored in patients with enlarged tonsils and/or adenoids. Sleep studies (polysomnograms, PSG) are not routinely recommended unless significant co-morbidities exist.

Tonsillar Neoplasm

The rapid unilateral enlargement of a tonsil, especially if accompanied by systemic signs of night sweats, fever, weight loss, and lymphadenopathy, is highly suggestive of a tonsillar malignancy. The diagnosis of a tonsillar malignancy should also be entertained if the tonsil appears grossly abnormal. Among 54,901 patients undergoing tonsillectomy, 54 malignancies were identified (0.087% prevalence); all but 6 malignancies had been suspected based on suspicious anatomic features preoperatively.

TREATMENT

Medical Management

The treatment of acute pharyngotonsillitis is discussed in Chapter 430 and antibiotic treatment of GABHS in Chapters 229 and 430. Because copathogens such as staphylococci or anaerobes can produce β-lactamase that can inactivate penicillin, the use of cephalosporins or clindamycin may be more efficacious in the treatment of *chronic* throat infections. A tonsillolith or debris may be expressed manually with either a cotton-tipped applicator, gargling after meals, or the use of a water jet.

Tonsillectomy

The American Academy of Otolaryngology (AAO)–Head and Neck Surgery *Taskforce on Clinical Practice Guidelines: Tonsillectomy in Children* most recently issued evidence-based guidelines in 2019 (Table 431.1, Fig. 431.2).

Tonsillectomy alone is most often performed for recurrent or chronic pharyngotonsillitis, and in young children is often accompanied by an adenoidectomy (see next section). Tonsillectomy has been shown to be effective in reducing the number of infections and the symptoms of chronic tonsillitis such as halitosis, persistent or recurrent sore throats, and recurrent cervical adenitis in severely affected patients. In resistant cases of cryptic tonsillitis, tonsillectomy may be curative. The 2019 guidelines recommend watchful waiting for recurrent throat infections if there have been <7 episodes in the past year, <5 episodes/yr in the past 2 years, or <3 episodes/yr in the past 3 years (see Table 431.1 and Fig. 431.2).

Table 431.1 Paradise Criteria for Tonsillectomy

CRITERION	DEFINITION
Minimum frequency of sore throat episodes	At least seven episodes in the previous year **OR** at least five episodes in each of the previous 2 years **OR** at least three episodes in each of the previous 3 years
Clinical features	Sore throat *plus* at least one of the following features qualifies as a counting episode: • Temperature of greater than 38.3°C (101°F) ***OR*** • Cervical adenopathy (tender lymph nodes or lymph node size >2 cm) ***OR*** • Tonsillar exudate ***OR*** • Culture positive for group A β-hemolytic streptococcus
Treatment	Antibiotics had been administered in the conventional dosage for proven or suspected streptococcal episodes
Documentation	Each episode of throat infection and its qualifying features substantiated by contemporaneous notation in a medical record ***OR*** If the episodes are *not fully documented* in the patient record, subsequent observation by a physician of two episodes of throat infection with patterns of frequency and clinical features consistent with the initial history*

*Allows for tonsillectomy recommendation in patients who meet all but the documentation criterion. A 12-mo observation period is usually recommended before consideration of tonsillectomy because of the tendency to improve with time.
Adapted from Mitchell RB, Archer SM, Ishman SL, et al. Clinical practice guideline: tonsillectomy in children (update). *Otolaryngol Head Neck Surg.* 2019;160(1S):S1–S42, Table 5.

Rarely in children, tonsillectomy is indicated for biopsy of a unilaterally enlarged tonsil to exclude a neoplasm or to treat recurrent hemorrhage from superficial tonsillar blood vessels.

Tonsillectomy has not been shown to offer clinical benefit over conservative treatment in children with mild infectious symptoms 2 years after surgery unless other factors or comorbidities exist. However, the 2019 Clinical Practice Guidelines did recommend assessing for additional modifying factors that may favor the need for a tonsillectomy,

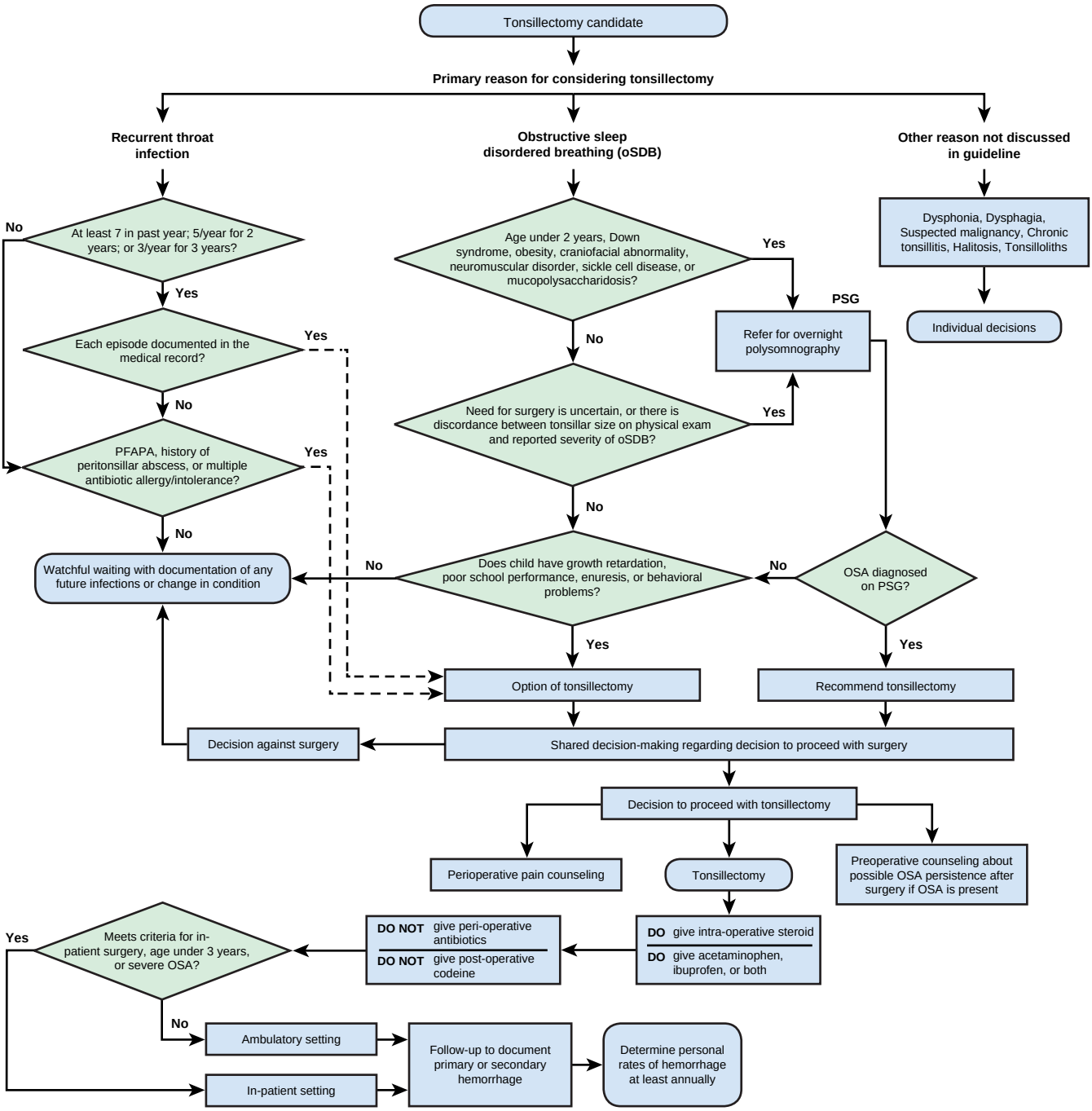

Fig. 431.2 Tonsillectomy in children: clinical practice algorithm. OSA, Obstructive sleep apnea; PFAPA, periodic fever, aphthous stomatitis, pharyngitis, and adenitis; PSG, polysomnography. *(Modified from Mitchell RB, Archer SM, Ishman SL, et al. Clinical practice guideline: tonsillectomy in children, update. Otolaryngol Head Neck Surg. 2019;160:S1–S42, Fig. 2.)*

including intolerance or allergies to antibiotics, PFAPA (periodic fever, aphthous stomatitis, pharyngitis, adenitis), or a history of more than one peritonsillar abscess (PTA).

Adenoidectomy

Adenoidectomy alone may be indicated for the treatment of chronic nasal infection (chronic adenoiditis), chronic sinus infections that have failed medical management, and recurrent bouts of acute otitis media, including those in children with tympanostomy tubes who suffer from recurrent otorrhea. Adenoidectomy may be helpful in children with chronic or recurrent otitis media with effusion. Adenoidectomy alone may be curative in the management of patients with nasal obstruction, chronic mouth breathing, and loud snoring suggesting sleep-disordered breathing. Adenoidectomy may also be indicated for children in whom upper airway obstruction is suspected of causing craniofacial or occlusive developmental abnormalities.

Tonsillectomy and Adenoidectomy

The criteria for a tonsillectomy and adenoidectomy (T&A) for recurrent infections are the same as those for tonsillectomy alone. The other major indication for performing both procedures together is upper airway obstruction secondary to adenotonsillar hypertrophy that results in sleep-disordered breathing, failure to thrive, craniofacial or occlusive developmental abnormalities, speech abnormalities, or, rarely, cor pulmonale. A high proportion of children with failure to thrive in the context of adenotonsillar hypertrophy resulting in sleep-disordered

Table 431.2 Role of PSG in Assessing High-Risk Populations Before Tonsillectomy for oSDB

ROLE OF PSG	RATIONALE
Avoid unnecessary or ineffective surgery in children with primarily nonobstructive events	Identify primarily nonobstructive events or central apnea that may not have been suspected before the study and may not benefit from surgery
Confirm the presence of obstructive events that would benefit from surgery	The increased morbidity of surgery in high-risk children requires diagnostic certainty before proceeding
Define the severity of oSDB to assist in preoperative planning	Children with severe OSA may require preoperative cardiac assessment, pulmonary consultation, anesthesia evaluation, or postoperative inpatient monitoring in an intensive care setting
Provide a baseline PSG for comparison after surgery	Persistent OSA despite surgery is more common in high-risk patients than in otherwise healthy children
Document the baseline severity of oSDB	High-risk patients are more prone to complications of surgery or anesthesia

OSA, Obstructive sleep apnea; oSDB, obstructive sleep-disordered breathing; PSG, polysomnography.
From Mitchell RB, Archer SM, Ishman SL, et al. Clinical practice guideline: tonsillectomy in children (update). *Otolaryngol Head Neck Surg.* 2019;160(IS):S1–S42, Table 6.

breathing experience significant growth acceleration after a T&A. Most children do not require a sleep study before surgery; however, in a high-risk population, polysomnography may help in the decision for or against surgery (Table 431.2). High risk factors include age under 2 years, Down syndrome, obesity, craniofacial abnormality, neuromuscular disorder, sickle cell disease, and mucopolysaccharidosis.

COMPLICATIONS

Poststreptococcal Glomerulonephritis and Acute Rheumatic Fever

The two major complications of untreated GABHS infection are poststreptococcal glomerulonephritis and acute rheumatic fever (see Chapters 559.4 and 229).

Peritonsillar Infection

Peritonsillar infection can occur as either cellulitis or a frank abscess in the region superior and lateral to the tonsillar capsule (see Chapter 432). These infections usually occur in children with a history of recurrent tonsillar infection and are polymicrobial, including both aerobes and anaerobes. Unilateral throat pain, referred otalgia, drooling, and trismus are presenting symptoms. The affected tonsil is displaced down and medially with swelling of the anterior tonsillar pillar and palate. The diagnosis of an abscess can be confirmed by CT or by needle aspiration, the contents of which should be sent for culture.

Retropharyngeal Space Infection

Infections in the retropharyngeal space develop in the lymph nodes that drain the oropharynx, nose, and nasopharynx (see Chapter 432).

Parapharyngeal Space Infection

Tonsillar infection can extend into the parapharyngeal space, causing symptoms of fever, neck pain and stiffness, and signs of swelling of the lateral pharyngeal wall and neck on the affected side. The diagnosis is confirmed by contrast medium–enhanced CT, and treatment includes intravenous antibiotics and external incision and drainage if an abscess is demonstrated on CT (see Chapter 432). Septic thrombophlebitis of the jugular vein, **Lemierre syndrome**, manifests with fever, toxicity, neck pain and stiffness, and respiratory distress caused by multiple septic pulmonary emboli and is a complication of a parapharyngeal space or odontogenic infection from *Fusobacterium necrophorum*. Concurrent Epstein-Barr virus mononucleosis (see Chapter 301) can be a predisposing event before the sudden onset of fever, chills, and respiratory distress in an adolescent patient. Treatment includes high-dose intravenous antibiotics (ampicillin-sulbactam, clindamycin, penicillin, or ciprofloxacin) and anticoagulation.

Table 431.3 Risks of Tonsillectomy or Adenoidectomy or Both

Cost
Risk of anesthetic events
- Malignant hyperthermia
- Cardiac arrhythmia
- Vocal cord trauma
- Aspiration with resulting bronchopulmonary obstruction or infection
- Postoperative nausea and vomiting (PONV)

Risk of miscellaneous surgical or postoperative complications
- Pain
- Dysphagia
- Hemorrhage
- Airway obstruction from edema of tongue, palate, or nasopharynx, or retropharyngeal hematoma
- Prolonged muscular paralysis
- Dehydration
- Palatopharyngeal insufficiency
- Facial edema
- Trauma: dental, larynx, vessels, pharyngeal wall, soft palate
- Laryngospasm
- Mediastinitis
- Cardiac arrest

Modified from Bluestone CD, ed. *Pediatric Otolaryngology*, 4th ed. Philadelphia: WB Saunders; 2003:1213.

Recurrent or Chronic Pharyngotonsillitis

See Chapter 430.

CHRONIC AIRWAY OBSTRUCTION

Although rare, children with chronic airway obstruction from enlarged tonsils and adenoids can present with cor pulmonale.

The effects of chronic airway obstruction and mouth breathing on facial growth remain a subject of controversy. Studies of chronic mouth breathing, both in humans and animals, have shown changes in facial development, including prolongation of the total anterior facial height and a tendency toward a retrognathic mandible, the so-called *adenoid facies*. Adenotonsillectomy can reverse some of these abnormalities. Other studies have disputed these findings.

Tonsillectomy and Adenoidectomy

The risks and potential benefits of surgery must be considered (Table 431.3). The mortality is low (~0.007%); most often associated with other complex medical conditions. Dehydration caused by odynophagia (painful swallowing) is not uncommon in the first postoperative week. The child is encouraged to drink liquids; however, early resumption of a solid diet is also recommended to help with the pain and return of oral function.

Postoperative pain needs to be managed, and opioid-free tonsillectomies are now recommended. Clinicians are encouraged to counsel the caregivers about the importance of hydration and managing postoperative pain with nonsteroidal antiinflammatory drugs (NSAIDs) and acetaminophen and to reinforce this information on the day of surgery. The child is encouraged to hydrate, chew, and rest. Codeine is associated with excessive sedation and fatalities and *is not* recommended.

Bleeding can occur in the immediate postoperative period or be delayed after separation of the eschar. The risk of bleeding is variable among institutions, ranging in the literature from 0.1 to 7.5% and averaging around 4.2% in the first 10 days after surgery. Although recurrent bleeding is unlikely, a bleeding diathesis should be ruled out if it occurs.

The updated Clinical Guidelines for Tonsillectomy include a recommendation for a single intravenous dose of intraoperative dexamethasone (0.5 mg/kg), which decreases postoperative nausea and vomiting and reduces swelling. There is no evidence that use of dexamethasone in postoperative tonsillectomy patients results in an increased risk of postoperative bleeding, and it could be used as a supplement to the pain management regimen.

Routine use of antibiotics in the postoperative period is ineffective, and thus the AAO Clinical Practice Guidelines advise against its use.

Swelling of the tongue and uvula can lead to acute airway obstruction and globus sensation in the first few hours after surgery. Children with underlying hypotonia (trisomy 21) or craniofacial anomalies are at greater risk for suffering this complication.

Rare complications include anesthesia-related issues (malignant hyperthermia, arrhythmias, intubation trauma, aspiration), velopharyngeal insufficiency, nasopharyngeal or oropharyngeal stenosis, torticollis, and, very rarely, death from uncontrolled bleeds.

Visit Elsevier eBooks+ at eBooks.Health.Elsevier.com for Bibliography.

Chapter 432

Retropharyngeal Abscess, Lateral Pharyngeal (Parapharyngeal) Abscess, and Peritonsillar Cellulitis/Abscess

Diane E. Pappas and Sarah R. Boggs

The *retropharyngeal* and the *lateral pharyngeal lymph nodes* that drain the mucosal surfaces of the upper airway and digestive tracts are located in the neck within the *retropharyngeal space* (located between the pharynx and the cervical vertebrae and extending down into the superior mediastinum) and the *lateral pharyngeal space* (bounded by the pharynx medially, the carotid sheath posteriorly, and the muscles of the styloid process laterally). The lymph nodes in these deep neck spaces communicate with each other, allowing bacteria from either cellulitis or node abscess to spread to other nodes. Infection of the nodes usually occurs as a result of extension from a localized infection of the oropharynx. A **retropharyngeal abscess** can also result from penetrating trauma to the oropharynx, dental infection, and vertebral osteomyelitis. Once infected, the nodes may progress through three stages: *cellulitis, phlegmon,* and *abscess.* Infection in the retropharyngeal and lateral pharyngeal spaces can result in airway compromise or posterior mediastinitis, making timely diagnosis important.

RETROPHARYNGEAL AND LATERAL PHARYNGEAL ABSCESS

Retropharyngeal abscess occurs most commonly in children younger than 3-4 years of age; as the retropharyngeal nodes involute after 5 years of age, infection in older children and adults is much less common. In the United States, abscess formation occurs most commonly in winter and early spring. Males are affected more often than females, and approximately two thirds of patients have a history of recent ear, nose, or throat infection.

Clinical manifestations of retropharyngeal abscess are nonspecific and include fever, irritability, decreased oral intake, and drooling. Neck stiffness, torticollis, and refusal to move the neck may also be present. The verbal child might complain of sore throat and neck pain. Other signs can include muffled voice, stridor, respiratory distress, or even obstructive sleep apnea. Physical examination can reveal bulging of the posterior pharyngeal wall, although this is present in <50% of infants with retropharyngeal abscess. Cervical lymphadenopathy may also be present. Lateral pharyngeal abscess commonly presents as fever, dysphagia, and a prominent bulge of the lateral pharyngeal wall, sometimes with medial displacement of the tonsil. The differential diagnosis includes acute epiglottitis and foreign body aspiration. In the young child with limited neck mobility, meningitis must also be considered. Other possibilities include lymphoma, hematoma, and vertebral osteomyelitis.

Incision and drainage and culture of an abscessed node provides the definitive diagnosis, but CT can be useful in identifying the presence of a retropharyngeal, lateral pharyngeal, or parapharyngeal abscess (Figs. 432.1 and 432.2). Deep neck infections can be accurately identified and localized with CT scans, but CT accurately identifies abscess formation in only 63% of patients. Soft tissue neck films taken during inspiration with the neck extended might show increased width or an air-fluid level in the retropharyngeal space. CT with contrast medium enhancement can reveal central lucency, ring enhancement, or scalloping of the walls of a lymph node. Scalloping of the lymph node wall is thought to be a late finding and predicts abscess formation.

Retropharyngeal and lateral pharyngeal infections are most often polymicrobial; the usual pathogens include group A streptococcus (see Chapter 229), oropharyngeal anaerobic bacteria (see Chapter 259), and *Staphylococcus aureus* (see Chapter 227.1). In children younger than age 2 years, there has been an increase in the incidence of retropharyngeal abscess, particularly with *S. aureus,* including methicillin-resistant strains. Other pathogens can include *Haemophilus influenzae, Klebsiella,* and *Mycobacterium avium-intracellulare.* When a retropharyngeal abscess is associated with cervical osteomyelitis, it may be secondary to retropharyngeal extension to the vertebral body (often polymicrobial) or a primary osteomyelitis with extension to the retropharyngeal space. In endemic areas and among patients at risk for tuberculosis, Pott disease should be considered (Fig. 432.3).

Treatment options include intravenous antibiotics with or without surgical drainage. Empiric antibiotic coverage should be guided by local susceptibility patterns for *S. aureus.* Initial therapy should include either ampicillin-sulbactam (50 mg ampicillin/kg every 6 hours, max 2000 mg ampicillin/dose) or clindamycin (15 mg/kg every 8 hours, max 600 mg/dose). For patients who are ill-appearing at presentation or who do not improve after 24-48 hours of antibiotic therapy, consideration should be given to the addition of either vancomycin or linezolid for coverage of methicillin-resistant *S. aureus* (MRSA). When narrowing antibiotic selection based on culture results, it is important to remember that these infections are typically polymicrobial and some pathogens, particularly oral anaerobes, may not be easily cultured.

Studies show that >50% of children with retropharyngeal or lateral pharyngeal abscess as identified by CT can be successfully treated without surgical drainage; the older the child, the more likely it is that antimicrobial treatment alone will be successful. Drainage is necessary in the patient with respiratory distress or failure to improve with intravenous antibiotic treatment. The typical treatment course is intravenous antibiotic therapy for several days until the patient has begun to improve, followed by a course of oral antibiotics for an additional 14 days. Amoxicillin-clavulanate (90 mg amoxicillin/kg/day, divided every 12 hours, max 2000 mg amoxicillin/dose) or clindamycin (13 mg/kg every 8 hours, max 450 mg/dose) are recommended oral regimens. Complications of retropharyngeal or lateral pharyngeal abscess include significant upper airway obstruction, rupture leading to

Bleeding can occur in the immediate postoperative period or be delayed after separation of the eschar. The risk of bleeding is variable among institutions, ranging in the literature from 0.1 to 7.5% and averaging around 4.2% in the first 10 days after surgery. Although recurrent bleeding is unlikely, a bleeding diathesis should be ruled out if it occurs.

The updated Clinical Guidelines for Tonsillectomy include a recommendation for a single intravenous dose of intraoperative dexamethasone (0.5 mg/kg), which decreases postoperative nausea and vomiting and reduces swelling. There is no evidence that use of dexamethasone in postoperative tonsillectomy patients results in an increased risk of postoperative bleeding, and it could be used as a supplement to the pain management regimen.

Routine use of antibiotics in the postoperative period is ineffective, and thus the AAO Clinical Practice Guidelines advise against its use.

Swelling of the tongue and uvula can lead to acute airway obstruction and globus sensation in the first few hours after surgery. Children with underlying hypotonia (trisomy 21) or craniofacial anomalies are at greater risk for suffering this complication.

Rare complications include anesthesia-related issues (malignant hyperthermia, arrhythmias, intubation trauma, aspiration), velopharyngeal insufficiency, nasopharyngeal or oropharyngeal stenosis, torticollis, and, very rarely, death from uncontrolled bleeds.

Visit Elsevier eBooks+ at eBooks.Health.Elsevier.com for Bibliography.

Chapter 432

Retropharyngeal Abscess, Lateral Pharyngeal (Parapharyngeal) Abscess, and Peritonsillar Cellulitis/Abscess

Diane E. Pappas and Sarah R. Boggs

The *retropharyngeal* and the *lateral pharyngeal lymph nodes* that drain the mucosal surfaces of the upper airway and digestive tracts are located in the neck within the *retropharyngeal space* (located between the pharynx and the cervical vertebrae and extending down into the superior mediastinum) and the *lateral pharyngeal space* (bounded by the pharynx medially, the carotid sheath posteriorly, and the muscles of the styloid process laterally). The lymph nodes in these deep neck spaces communicate with each other, allowing bacteria from either cellulitis or node abscess to spread to other nodes. Infection of the nodes usually occurs as a result of extension from a localized infection of the oropharynx. A **retropharyngeal abscess** can also result from penetrating trauma to the oropharynx, dental infection, and vertebral osteomyelitis. Once infected, the nodes may progress through three stages: *cellulitis, phlegmon,* and *abscess.* Infection in the retropharyngeal and lateral pharyngeal spaces can result in airway compromise or posterior mediastinitis, making timely diagnosis important.

RETROPHARYNGEAL AND LATERAL PHARYNGEAL ABSCESS

Retropharyngeal abscess occurs most commonly in children younger than 3-4 years of age; as the retropharyngeal nodes involute after 5 years of age, infection in older children and adults is much less common. In the United States, abscess formation occurs most commonly in winter and early spring. Males are affected more often than females, and approximately two thirds of patients have a history of recent ear, nose, or throat infection.

Clinical manifestations of retropharyngeal abscess are nonspecific and include fever, irritability, decreased oral intake, and drooling. Neck stiffness, torticollis, and refusal to move the neck may also be present. The verbal child might complain of sore throat and neck pain. Other signs can include muffled voice, stridor, respiratory distress, or even obstructive sleep apnea. Physical examination can reveal bulging of the posterior pharyngeal wall, although this is present in <50% of infants with retropharyngeal abscess. Cervical lymphadenopathy may also be present. Lateral pharyngeal abscess commonly presents as fever, dysphagia, and a prominent bulge of the lateral pharyngeal wall, sometimes with medial displacement of the tonsil. The differential diagnosis includes acute epiglottitis and foreign body aspiration. In the young child with limited neck mobility, meningitis must also be considered. Other possibilities include lymphoma, hematoma, and vertebral osteomyelitis.

Incision and drainage and culture of an abscessed node provides the definitive diagnosis, but CT can be useful in identifying the presence of a retropharyngeal, lateral pharyngeal, or parapharyngeal abscess (Figs. 432.1 and 432.2). Deep neck infections can be accurately identified and localized with CT scans, but CT accurately identifies abscess formation in only 63% of patients. Soft tissue neck films taken during inspiration with the neck extended might show increased width or an air-fluid level in the retropharyngeal space. CT with contrast medium enhancement can reveal central lucency, ring enhancement, or scalloping of the walls of a lymph node. Scalloping of the lymph node wall is thought to be a late finding and predicts abscess formation.

Retropharyngeal and lateral pharyngeal infections are most often polymicrobial; the usual pathogens include group A streptococcus (see Chapter 229), oropharyngeal anaerobic bacteria (see Chapter 259), and *Staphylococcus aureus* (see Chapter 227.1). In children younger than age 2 years, there has been an increase in the incidence of retropharyngeal abscess, particularly with *S. aureus,* including methicillin-resistant strains. Other pathogens can include *Haemophilus influenzae, Klebsiella,* and *Mycobacterium avium-intracellulare.* When a retropharyngeal abscess is associated with cervical osteomyelitis, it may be secondary to retropharyngeal extension to the vertebral body (often polymicrobial) or a primary osteomyelitis with extension to the retropharyngeal space. In endemic areas and among patients at risk for tuberculosis, Pott disease should be considered (Fig. 432.3).

Treatment options include intravenous antibiotics with or without surgical drainage. Empiric antibiotic coverage should be guided by local susceptibility patterns for *S. aureus.* Initial therapy should include either ampicillin-sulbactam (50 mg ampicillin/kg every 6 hours, max 2000 mg ampicillin/dose) or clindamycin (15 mg/kg every 8 hours, max 600 mg/dose). For patients who are ill-appearing at presentation or who do not improve after 24-48 hours of antibiotic therapy, consideration should be given to the addition of either vancomycin or linezolid for coverage of methicillin-resistant *S. aureus* (MRSA). When narrowing antibiotic selection based on culture results, it is important to remember that these infections are typically polymicrobial and some pathogens, particularly oral anaerobes, may not be easily cultured.

Studies show that >50% of children with retropharyngeal or lateral pharyngeal abscess as identified by CT can be successfully treated without surgical drainage; the older the child, the more likely it is that antimicrobial treatment alone will be successful. Drainage is necessary in the patient with respiratory distress or failure to improve with intravenous antibiotic treatment. The typical treatment course is intravenous antibiotic therapy for several days until the patient has begun to improve, followed by a course of oral antibiotics for an additional 14 days. Amoxicillin-clavulanate (90 mg amoxicillin/kg/day, divided every 12 hours, max 2000 mg amoxicillin/dose) or clindamycin (13 mg/kg every 8 hours, max 450 mg/dose) are recommended oral regimens. Complications of retropharyngeal or lateral pharyngeal abscess include significant upper airway obstruction, rupture leading to

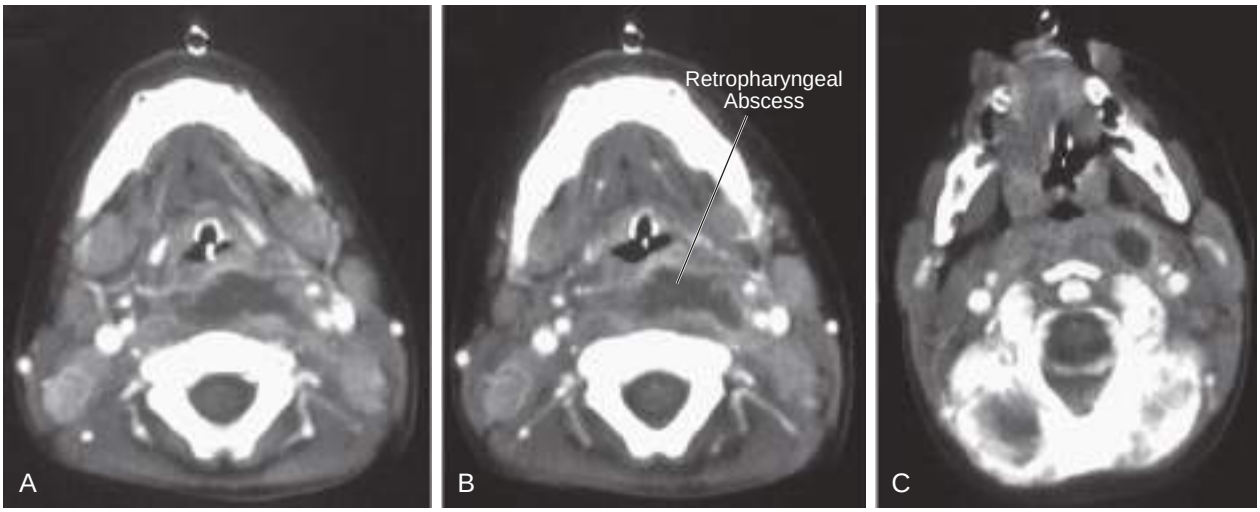

Fig. 432.1 CT of retropharyngeal abscess. **A,** CT image at level of epiglottis. **B,** Sequential CT slice exhibiting ring-enhancing lesion. **C,** Further sequential CT slice demonstrating inferior extent of lesion. *(From Philpott CM, Selvadurai D, Banerjee AR. Paediatric retropharyngeal abscess. J Laryngol Otol. 2004;118:925.)*

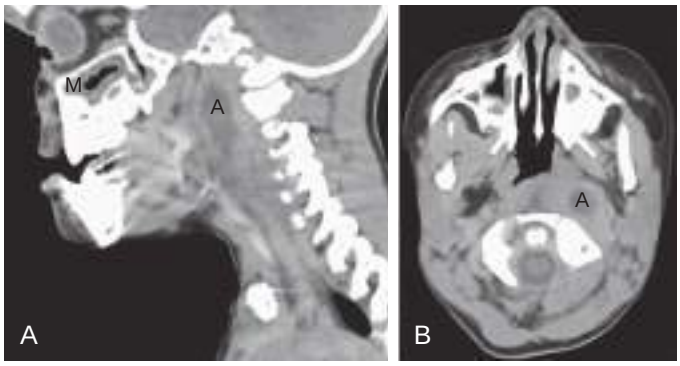

Fig. 432.2 CT of parapharyngeal abscess in a 3-yr-old child. **A,** Sagittal section demonstrating parapharyngeal abscess *(A)* and mucosal swelling *(M)* in the maxillary sinus. **B,** Coronal section of parapharyngeal abscess *(A)*.

Fig. 432.3 Pott disease. Cervical spine radiography, lateral view, showed prevertebral soft tissue anterior to the C1-C7 level *(white arrow)*, focal destruction of the C3 vertebra *(black arrow)*, and straightening of the cervical spine. *(Modified from Hsu HE, Chen CY. Tuberculous retropharyngeal abscess with Pott disease and tuberculous abscess of the chest wall – a case report. Medicine. 2019;98:e16280, Fig. 1A.)*

aspiration pneumonia, and extension to the mediastinum with resultant mediastinitis. Thrombophlebitis of the internal jugular vein and erosion of the carotid artery sheath can also occur.

An uncommon but characteristic infection of the parapharyngeal space is **Lemierre disease**, in which infection from the oropharynx extends to cause septic thrombophlebitis of the internal jugular vein and embolic abscesses in the lungs (Fig. 432.4). The causative pathogen is *Fusobacterium necrophorum*, an anaerobic bacterial constituent of the oropharyngeal flora. The typical presentation is that of a previously healthy adolescent or young adult with a history of recent pharyngitis who becomes acutely ill with fever and septic pulmonary emboli producing hypoxia, tachypnea, and respiratory distress. Other upper respiratory infections (parotitis, otitis media, mastoiditis, sinusitis, and dental infections) are much less likely to precipitate Lemierre disease. There is a known association with recent Epstein-Barr infection.

Chest x-ray or CT demonstrates multiple cavitary nodules, often bilateral and often accompanied by pleural effusion. Blood culture may be positive. Treatment involves prolonged intravenous antibiotic therapy with either piperacillin-tazobactam, imipenem or meropenem, or ceftriaxone *plus* metronidazole; vancomycin should be added in areas with a high prevalence of MRSA. Surgical drainage of extrapulmonary metastatic abscesses may occasionally be necessary (see Chapters 430 and 431).

PERITONSILLAR CELLULITIS AND/OR ABSCESS

Peritonsillar cellulitis and/or abscess, which is relatively common compared to the deep neck infections, is caused by bacterial invasion through the capsule of the tonsil, leading to cellulitis and/or abscess formation in the surrounding tissues. The typical patient with a peritonsillar abscess is an adolescent with a recent history of acute pharyngotonsillitis. Clinical manifestations include sore throat, fever, trismus, muffled or garbled voice, and dysphagia. Physical examination reveals an asymmetric tonsillar bulge with displacement of the uvula. An asymmetric tonsillar bulge is diagnostic, but it may be poorly visualized because of trismus. CT is helpful for revealing the abscess, but small studies in adults and children have demonstrated that ultrasound may be used to differentiate

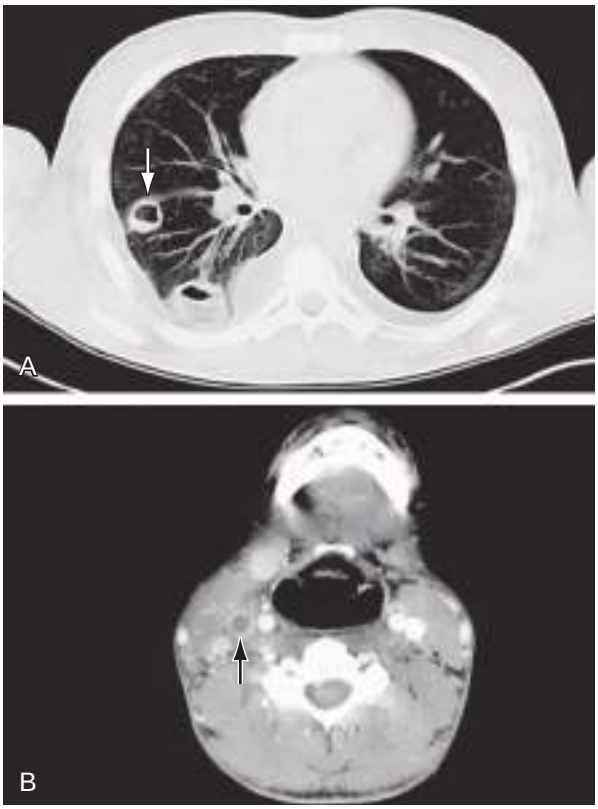

Fig. 432.4 CT of Lemierre disease. **A,** CT demonstrating the nodular appearance of pulmonary infiltrates *(arrow)*. **B,** CT of the neck demonstrating thrombosis of the right internal jugular vein *(arrow)*. *(From Plymyer MR, Zoccola DC, Tallarita G. An 18 year old man presenting with sepsis following a recent pharyngeal infection. Arch Pathol Lab Med. 2004;128:813. Copyright 2004. College of American Pathologists.)*

peritonsillar abscess from peritonsillar cellulitis and avoids radiation exposure, as well as the need for sedation that CT often necessitates in children. Group A streptococci and mixed oropharyngeal anaerobes are the most common pathogens, with more than four bacterial isolates per abscess typically recovered by needle aspiration.

A study in Britain evaluating the impact of outpatient management recommendations (increased outpatient or short-stay management, drainage under local anesthetic, prompt discharge) found that admissions were reduced by over 50% and aspiration under local anesthetic increased with no change in readmission or mortality rates. Similarly, a U.S. study found that initial outpatient management is associated with greater use of antibiotics alone and less frequent use of incision and drainage; the recurrence rate was the same regardless of inpatient or outpatient management. These studies suggest that initial outpatient management of peritonsillar abscess in pediatric patients should be considered, especially for older patients who have mild to moderate symptoms; inpatient therapy is indicated for younger patients and those presenting with more severe illness, including trismus and odynophagia. Either amoxicillin-clavulanate or clindamycin would be an acceptable oral regimen.

Inpatient therapy is indicated for younger patients and for those presenting with more severe illness, including significant trismus and odynophagia. If outpatient management with antibiotics alone is unsuccessful or if inpatient management is indicated initially, treatment consists of surgical drainage or needle aspiration along with intravenous antibiotic therapy. As with retropharyngeal abscesses, empiric antibiotic therapy should include either ampicillin-sulbactam or clindamycin, with the addition of vancomycin in patients who are not improving or in areas with high rates of MRSA.

Surgical drainage may be accomplished through needle aspiration, incision and drainage, or tonsillectomy. Needle aspiration can involve aspiration of the superior, middle, and inferior aspects of the tonsil to locate the abscess. Intraoral ultrasound can be used to diagnose and guide needle aspiration of a peritonsillar abscess. General anesthesia may be required for the uncooperative patient. Approximately 95% of peritonsillar abscesses resolve after needle aspiration and antibiotic therapy. A small percentage of these patients require a repeat needle aspiration. The 5% with infections that fail to resolve after needle aspiration require incision and drainage. Tonsillectomy should be considered if there is failure to improve within 24 hours of antibiotic therapy and needle aspiration, history of recurrent peritonsillar abscess or recurrent tonsillitis, or complications from peritonsillar abscess. The feared, albeit rare, complication is rupture of the abscess, with resultant aspiration pneumonitis. There is a 10% recurrence risk for peritonsillar abscess.

Visit Elsevier eBooks+ at eBooks.Health.Elsevier.com for Bibliography.

Chapter 433

Acute Inflammatory Upper Airway Obstruction (Croup, Epiglottitis, Laryngitis, and Bacterial Tracheitis)

Kristine Knuti Rodrigues and Genie E. Roosevelt

Airway resistance is inversely proportional to the fourth power of the radius (see Chapter 421). Because the lumen of an infant's or child's airway is narrow, minor reductions in cross-sectional area resulting from mucosal edema or other inflammatory processes cause an exponential increase in airway resistance and a significant increase in the work of breathing. The larynx is composed of four major cartilages (epiglottic, arytenoid, thyroid, and cricoid cartilages, ordered from superior to inferior) and the soft tissues that surround them. The cricoid cartilage encircles the airway just below the vocal cords and defines the narrowest portion of the upper airway in children younger than 10 years of age.

Inflammation involving the vocal cords and structures inferior to the cords is called **laryngitis**, **laryngotracheitis**, or **laryngotracheobronchitis**, and inflammation of the structures superior to the cords (i.e., arytenoids, aryepiglottic folds ["false cords"], epiglottis) is called **supraglottitis**. The term **croup** refers to a heterogeneous group of mainly acute and infectious processes that are characterized by a bark-like or metallic/brassy cough and may be associated with hoarseness, inspiratory stridor, and respiratory distress. **Stridor** is a harsh, high-pitched respiratory sound that is usually inspiratory but can be biphasic and is produced by turbulent airflow; it is not a diagnosis, but a sign of upper airway obstruction (see Chapter 421). Croup typically affects the larynx, trachea, and bronchi. When the involvement of the larynx is sufficient to produce symptoms, these symptoms dominate the clinical picture more so than the tracheal and bronchial signs. A distinction has been made between spasmodic or recurrent croup and laryngotracheobronchitis. Some clinicians believe that spasmodic croup might have an allergic component and improves rapidly without treatment, whereas laryngotracheobronchitis is always associated with a viral infection of the respiratory tract. Others believe that the signs and symptoms are similar enough to consider them within the spectrum of a single disease because studies have documented viral etiologies in both acute and recurrent croup.

433.1 Infectious Upper Airway Obstruction

Kristine Knuti Rodrigues and Genie E. Roosevelt

With the exceptions of diphtheria (see Chapter 233), bacterial tracheitis, and epiglottitis, most other acute infections of the upper airway are caused by viruses. The parainfluenza viruses (types 1, 2, and 3; see Chapter 306) account for approximately 75% of cases; other viruses associated with croup include influenza A and B, adenovirus, respiratory syncytial virus, COVID-19, and measles. Influenza A is associated with severe laryngotracheobronchitis. *Mycoplasma pneumoniae* has rarely been isolated from children with croup and causes mild disease (see Chapter 269). Most patients with croup are between the ages of 3 months and 5 years, with the peak in the second year of life. The incidence of croup is higher in males. It occurs most commonly in the late fall and winter but can occur throughout the year. Approximately 15% of patients have a strong family history of croup. Recurrences are frequent from 3 to 6 years of age and decrease with growth of the airway. Recurrent croup is defined as two or more crouplike episodes. Patients with recurrent croup have a higher incidence of asthma, allergies, and gastroesophageal reflux; less than 9% of patients with recurrent croup demonstrate clinically significant findings on bronchoscopy (e.g., subglottic stenosis, reflux changes, bronchomalacia/tracheomalacia).

In the past, *Haemophilus influenzae* type b was the most commonly identified etiology of **acute epiglottitis**. Since the widespread use of the *H. influenzae* type b vaccine, invasive disease caused by *H. influenzae* type b in pediatric patients has been reduced by 99% (see Chapter 240). Therefore other agents, such as *Streptococcus pyogenes, Streptococcus pneumoniae,* nontypable *H. influenzae,* and *Staphylococcus aureus,* represent a larger portion of pediatric cases of epiglottitis in vaccinated children. In the prevaccine era, the typical patient with epiglottitis caused by *H. influenzae* type b was 2-4 years of age, although cases were seen in the first year of life and in patients as old as 7 years of age. Currently, the most common presentation of epiglottitis is an adult with a sore throat, although cases still do occur in underimmunized children or with other less common bacteria; vaccine failures have rarely been reported.

CLINICAL MANIFESTATIONS

Croup (Laryngotracheobronchitis)

Viruses typically cause croup, the most common form of acute upper respiratory obstruction. The term *laryngotracheobronchitis* refers to viral infection of the glottic and subglottic regions. Some clinicians use the term *laryngotracheitis* for the most common and most typical form of croup and reserve the term *laryngotracheobronchitis* for the more severe form that is considered an extension of laryngotracheitis associated with bacterial superinfection that occurs 5-7 days into the clinical course.

Most patients have an upper respiratory tract infection with some combination of rhinorrhea, pharyngitis, mild cough, and low-grade fever for 1-3 days before the signs and symptoms of upper airway obstruction become apparent. The child then develops the characteristic barking cough, hoarseness, and inspiratory stridor. The low-grade fever can persist, although temperatures may occasionally reach 39–40°C (102.2–104°F); some children are afebrile. Symptoms are characteristically worse at night and often recur with decreasing intensity for several days and resolve completely within a week. Agitation and crying greatly aggravate the symptoms and signs. The child may prefer to sit up in bed or be held upright. Other family members might have mild respiratory illnesses with laryngitis. Most young patients with croup progress only as far as stridor and slight dyspnea before they start to recover.

Physical examination can reveal a hoarse voice, coryza, normal to moderately inflamed pharynx, and a slightly increased respiratory rate. Patients vary substantially in their degrees of respiratory distress. Rarely, the upper airway obstruction progresses and is accompanied by an increasing respiratory rate; nasal flaring; suprasternal, infrasternal, and intercostal retractions; and continuous stridor. Croup is a disease of the upper airway, and alveolar gas exchange is usually normal.

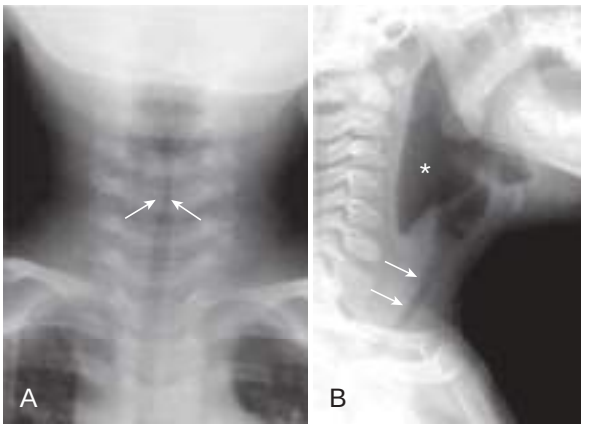

Fig. 433.1 Croup. **A,** Frontal soft tissue neck radiograph demonstrates a "steeple" appearance of the subglottic trachea *(arrows).* **B,** Lateral soft tissue neck radiograph in another patient shows a dilated hypopharynx *(asterisk),* along with haziness and narrowing of the subglottic region *(arrows). (From Laya BF, Lee EY. Upper airway disease. In Coley BD, ed. Caffey's Pediatric Diagnostic Imaging, 13th ed. Philadelphia: Elsevier; 2019: Fig. 51.8, p. 481.)*

Hypoxia and low oxygen saturation are seen only when complete airway obstruction is imminent. *The child who is hypoxic, cyanotic, pale, or obtunded needs immediate airway management.* Occasionally, the pattern of severe laryngotracheobronchitis is difficult to differentiate from epiglottitis, despite the usually more acute onset and rapid course of the latter.

Croup is a clinical diagnosis and does not require a radiograph of the neck. Radiographs of the neck can show the typical subglottic narrowing, or steeple sign, of croup on the posteroanterior view (Fig. 433.1). However, the steeple sign may be absent in patients with croup, may be present in patients without croup as a normal variant, and may rarely be present in patients with epiglottitis. The radiographs do not correlate well with disease severity. Radiographs should be considered only after airway stabilization in children who have an atypical presentation or clinical course. Radiographs may be helpful in distinguishing between severe laryngotracheobronchitis and epiglottitis, but airway management should always take priority.

Acute Epiglottitis (Supraglottitis)

This now rare, but still dramatic and potentially lethal, condition is characterized by an acute rapidly progressive and potentially fulminating course of high fever, sore throat, dyspnea, and rapidly progressing respiratory obstruction. The degree of respiratory distress at presentation is variable. The initial lack of respiratory distress can deceive the unwary clinician; respiratory distress can also be the first manifestation. Often, the otherwise healthy child suddenly develops a sore throat and fever. Within a matter of hours, the patient appears toxic, swallowing is difficult, and breathing is labored. Drooling is usually present, and the neck is hyperextended in an attempt to maintain the airway. The child may assume the tripod position, sitting upright and leaning forward with the chin up and mouth open while bracing on the arms. A brief period of air hunger with restlessness may be followed by rapidly increasing cyanosis and coma. Stridor is a late finding and suggests near-complete airway obstruction. Complete obstruction of the airway and death can ensue unless adequate treatment is provided. *The barking cough typical of croup is rare.* Usually, no other family members are ill with acute respiratory symptoms.

The diagnosis requires visualization under controlled circumstances of a large, cherry red, swollen epiglottis by laryngoscopy. Occasionally, the other supraglottic structures, especially the aryepiglottic folds, are more involved than the epiglottis itself. In a patient in whom the

diagnosis is certain or probable based on clinical grounds, laryngoscopy should be performed expeditiously in a controlled environment such as an operating room or intensive care unit. Anxiety-provoking interventions such as phlebotomy, intravenous line placement, placing the child supine, or direct inspection of the oral cavity should be avoided until the airway is secure. If epiglottitis is thought to be possible but not certain in a patient with acute upper airway obstruction, the patient may first undergo lateral radiographs of the upper airway. Classic radiographs of a child who has epiglottitis show the thumb sign (Fig. 433.2). Proper positioning of the patient for the lateral neck radiograph is crucial to avoid some of the pitfalls associated with interpretation of the film. Adequate hyperextension of the head and neck is necessary. In addition, the epiglottis can appear to be round if the lateral neck is taken at an oblique angle. If the concern for epiglottitis still exists after the radiographs, direct visualization should be performed. A physician skilled in airway management and use of intubation equipment should accompany patients with suspected epiglottitis at all times. An older cooperative child might voluntarily open the mouth wide enough for a direct view of the inflamed epiglottis.

Establishing an airway by endotracheal or nasotracheal intubation or, less often, by tracheostomy is indicated in patients with epiglottitis, regardless of the degree of apparent respiratory distress, because as many as 6% of children with epiglottitis without an artificial airway die compared with <1% of those with an artificial airway. No clinical features have been recognized that predict mortality. Pulmonary edema can be associated with acute airway obstruction. The duration of intubation depends on the clinical course of the patient and the duration of epiglottic swelling, as determined by frequent examination using direct laryngoscopy or flexible fiberoptic laryngoscopy. In general, children with acute epiglottitis are intubated for 2-3 days, because the response to antibiotics is usually rapid. Most patients have concomitant bacteremia; occasionally, other infections are present, such as pneumonia, cervical adenopathy, or otitis media. Meningitis, arthritis, and other invasive infections with *H. influenzae* type b are rarely found in conjunction with epiglottitis (but bacteremia is present).

Fig. 433.2 Epiglottitis in a 5-yr-old male with respiratory distress and drooling. A lateral soft tissue neck radiograph shows a markedly thickened epiglottis *(white arrow)*, which is referred to as the "thumb" sign. The aryepiglottic folds *(black arrow)* also are thickened. *(From Laya BF, Lee EY. Upper airway disease. In Coley BD, ed. Caffey's Pediatric Diagnostic Imaging, 13th ed. Philadelphia: Elsevier; 2019: Fig. 51.2, p. 477.)*

Acute Infectious Laryngitis

Laryngitis is a common illness. Viruses cause most cases; diphtheria is an exception but is extremely rare in highly developed, industrialized countries (see Chapter 233). The onset is usually characterized by an upper respiratory tract infection during which sore throat, cough, and hoarseness appear. The illness is generally mild; respiratory distress is unusual except in the young infant. Hoarseness and loss of voice may be out of proportion to systemic signs and symptoms. The physical examination is usually not remarkable except for evidence of pharyngeal inflammation. Inflammatory edema of the vocal cords and subglottic tissue may be demonstrated laryngoscopically. The principal site of obstruction is usually the subglottic area.

Spasmodic Croup

Spasmodic croup occurs most often in children 1-3 years of age and is clinically similar to acute laryngotracheobronchitis, except that the history of a viral prodrome and fever in the patient and family are often absent. The cause is viral in some cases, but allergic and other factors may also contribute.

Occurring most commonly in the evening or nighttime, spasmodic croup begins with a sudden onset that may be preceded by mild to moderate coryza and hoarseness. The child awakens with a characteristic barking, metallic/brassy cough, noisy inspiration, and respiratory distress and appears anxious and frightened. The patient is usually afebrile. The severity of the symptoms generally diminishes within several hours, and the following day, the patient often appears well except for slight hoarseness and cough. Similar, but usually less severe, attacks without extreme respiratory distress can occur for another night or two. Such episodes often recur several times. Spasmodic croup might represent more of an allergic reaction to viral antigens than direct infection, although the pathogenesis is unknown.

DIFFERENTIAL DIAGNOSIS

These four syndromes must be differentiated from one another and from a variety of other entities that can present as upper airway obstruction. **Bacterial tracheitis** is the most important differential diagnostic consideration and has a high risk of airway obstruction. Diphtheritic croup is extremely rare in North America and Europe, although a major epidemic of diphtheria occurred in countries of the former Soviet Union beginning in 1990 from the lack of routine immunization. Early symptoms of **diphtheria** include malaise, sore throat, anorexia, and low-grade fever. Within 2-3 days, pharyngeal examination reveals the typical gray-white membrane, which can vary in size from covering a small patch on the tonsils to covering most of the soft palate. The membrane is adherent to the tissue, and forcible attempts to remove it cause bleeding. The course is usually insidious, but respiratory obstruction can occur suddenly. **Measles** croup almost always coincides with the full manifestations of systemic disease, and the course may be fulminant (see Chapter 293).

Sudden onset of respiratory obstruction can be caused by aspiration of a **foreign body** (see Chapter 435). The child is usually 6 months to 3 years of age. Choking and coughing occur suddenly, usually without prodromal signs of infection, although children with a viral infection can also aspirate a foreign body. A **retropharyngeal** or **peritonsillar abscess** can mimic respiratory obstruction (see Chapter 432). CT scans of the upper airway are helpful in evaluating for possible retropharyngeal abscess. A peritonsillar abscess is a clinical diagnosis. Other possible causes of upper airway obstruction include extrinsic compression of the airway (laryngeal web, vascular ring) and intraluminal obstruction from masses (laryngeal papilloma, subglottic hemangioma); these tend to have chronic or recurrent symptoms.

Upper airway obstruction is occasionally associated with **angioedema** of the subglottic areas as part of anaphylaxis and generalized allergic reactions, edema after endotracheal intubation for either general anesthesia or respiratory failure, hypocalcemic tetany, infectious mononucleosis, trauma, and tumors or malformations of the larynx. A

crouplike cough may be an early sign of asthma. Vocal cord dysfunction can also occur. Epiglottitis, with the characteristic manifestations of drooling or dysphagia and stridor, can also result from the accidental ingestion of very hot liquid.

COMPLICATIONS

Complications occur in approximately 15% of patients with viral croup. The most common is extension of the infectious process to involve other regions of the respiratory tract, such as the middle ear, the terminal bronchioles, or the pulmonary parenchyma. Bacterial tracheitis may be a complication of viral croup rather than a distinct disease. If associated with toxin-producing *S. aureus* or *S. pyogenes,* toxic shock syndrome can develop. **Bacterial tracheitis** may have a biphasic illness, with the second phase after a crouplike illness associated with high fever, toxicity, and airway obstruction. Alternatively, the onset of tracheitis occurs without a second phase and appears as a continuation of the initial crouplike illness, but with higher fever and worsening respiratory distress rather than the usual recovery after 2-3 days of viral croup. Pneumonia, cervical lymphadenitis, otitis media, or, rarely, meningitis or septic arthritis can occur during the course of epiglottitis. Pneumomediastinum and pneumothorax are the most common complications of tracheotomy.

TREATMENT

The mainstay of treatment for children with **croup** is airway management and treatment of hypoxemia. Treatment of the respiratory distress should take priority over any testing. Most children with either acute spasmodic croup or infectious croup can be managed safely at home. Despite the observation that cold night air is beneficial, a Cochrane review has found no evidence supporting the use of cool mist in the emergency department for the treatment of croup.

Nebulized racemic epinephrine is the established treatment for moderate and severe croup. The mechanism of action is believed to be constriction of the precapillary arterioles through the β-adrenergic receptors, causing fluid resorption from the interstitial space and a decrease in the laryngeal mucosal edema. Traditionally, racemic epinephrine, a 1:1 mixture of the D- and L-isomers of epinephrine, has been administered. A dose of 0.25-0.5 mL of 2.25% racemic epinephrine in 3 mL of normal saline can be used as often as every 20 minutes. Racemic epinephrine was initially chosen over the more active and more readily available L-epinephrine to minimize anticipated cardiovascular side effects such as tachycardia and hypertension. Current evidence does not favor racemic epinephrine over L-epinephrine (5 mL of 1:1,000 solution) in terms of efficacy or safety.

The indications for the administration of nebulized epinephrine include moderate to severe stridor at rest, the possible need for intubation, respiratory distress, and/or hypoxemia. The duration of activity of racemic epinephrine is <2 hours. Consequently, observation is mandated. The symptoms of croup might reappear, but racemic epinephrine does not cause rebound worsening of the obstruction. Patients can be safely discharged home after a 2- to 3-hour period of observation provided they have no stridor at rest; have received steroids; and have normal air entry, normal pulse oximetry, and normal level of consciousness. Nebulized epinephrine should still be used cautiously in patients with tachycardia, heart conditions such as tetralogy of Fallot, and ventricular outlet obstruction because of possible side effects.

The effectiveness of oral corticosteroids in viral croup is well established. Corticosteroids decrease the edema in the laryngeal mucosa through their antiinflammatory action. Oral steroids are beneficial, even in mild croup, as measured by improved symptoms at 2 hours, reduced return visits, reduced hospitalization, shorter duration of hospitalization, and reduced need for subsequent interventions such as epinephrine administration. Most studies that demonstrated the efficacy of oral dexamethasone used a single dose of 0.6 mg/kg to a maximum dose of 16 mg; a dose as low as 0.15 mg/kg may be just as effective. More randomized controlled trials are needed to further evaluate the effectiveness of lower dose dexamethasone compared to 0.6 mg/kg. Prednisolone at a dose of 1 mg/kg has also been found to be noninferior to standard and low-dose dosing of dexamethasone. Intramuscular dexamethasone and nebulized budesonide have an equivalent clinical effect; oral dosing of dexamethasone is as effective as intramuscular administration. The only adverse effect in the treatment of croup with corticosteroids is the development of *Candida albicans* laryngotracheitis in a patient who received dexamethasone 1 mg/kg/24 hr for 8 days. Corticosteroids should not be administered to children with varicella or tuberculosis (unless the patient is receiving appropriate antituberculosis therapy) because they worsen the clinical course.

Antibiotics are not indicated in croup. Nonprescription cough and cold medications should not be used in children younger than 6 years of age. A helium-oxygen mixture (heliox) may be considered in the treatment of children with severe croup for whom intubation is being considered, although the evidence is inconclusive. Children with croup should be hospitalized for any of the following: progressive stridor, severe stridor at rest, respiratory distress, hypoxemia, cyanosis, depressed mental status, poor oral intake, persistent moderate croup symptoms (stridor and/or retractions at rest without agitation) after 4 hours after one dose of nebulized epinephrine and systemic glucocorticoids requiring more than one dose of nebulized epinephrine, or the need for reliable observation.

Epiglottitis is a medical emergency and warrants immediate treatment with an artificial airway placed under controlled conditions, either in an operating room or intensive care unit. All patients should receive oxygen en route unless the mask causes excessive agitation. Racemic epinephrine and corticosteroids are ineffective. Cultures of blood, epiglottic surface, and, in selected cases, cerebrospinal fluid should be collected after the airway is stabilized. Ceftriaxone (dose 100 mg/kg/24 hr in one or two divided doses) plus vancomycin (dose 15 mg/kg/24 hr every 8 hours) should be given parenterally, pending culture and susceptibility reports, because 10–40% of *H. influenzae* type b cases are resistant to ampicillin. After insertion of the artificial airway, the patient should improve immediately, and respiratory distress and cyanosis should disappear. Epiglottitis resolves after a few days of antibiotics, and the patient may be extubated; antibiotics should be continued for at least 10 days. Chemoprophylaxis is not routinely recommended for household, childcare, or nursery contacts of patients with invasive *H. influenzae* type b infections, but careful observation is mandatory, with prompt medical evaluation when exposed children develop a febrile illness. **Indications for rifampin prophylaxis** (20 mg/kg orally once a day for 4 days; maximum dose: 600 mg) for all household members include if a child within the home is younger than 4 years of age and incompletely immunized, is younger than 12 months of age and has not completed the primary vaccination series, or is immunocompromised.

Acute laryngeal swelling on an **allergic basis** responds to epinephrine (1 mg/mL concentration, previously referred to as 1:1,000 dilution, in dosage of 0.01 mL/kg to a maximum of 0.5 mL/dose) administered intramuscularly or racemic epinephrine (dose of 0.5 mL of 2.25% racemic epinephrine in 3 mL of normal saline) (see Chapter 190). Corticosteroids may be considered, although there is little evidence of benefit (1-2 mg/kg/24 hr of prednisone for 1-2 days). However, patients who require hospitalization or have a history of asthma may benefit from corticosteroids. After recovery, the patient and parents should be discharged with a preloaded syringe of epinephrine to be used in emergencies. Reactive mucosal swelling, severe stridor, and respiratory distress unresponsive to mist therapy may follow endotracheal intubation for general anesthesia in children. Racemic epinephrine and corticosteroids are helpful.

Endotracheal/Nasotracheal Intubation and Tracheotomy

With the introduction of routine intubation or, less often, tracheotomy for epiglottitis, the mortality rate for epiglottis has decreased to almost zero. These procedures should always be performed in an operating room or intensive care unit if time permits; prior intubation and general anesthesia greatly facilitate performing a tracheotomy without complications. The use of an endotracheal or nasotracheal tube that is 0.5-1.0 mm smaller than estimated by age or height is recommended to facilitate intubation and reduce long-term sequelae. The choice of procedure should be based on the local expertise and experience with the procedure and postoperative care.

Intubation or, less often, tracheotomy is required for most patients with bacterial tracheitis and all young patients with epiglottitis. It is rarely required for patients with laryngotracheobronchitis, spasmodic croup, or laryngitis. Severe forms of laryngotracheobronchitis that require intubation in a high proportion of patients have been reported during severe measles and influenza A virus epidemics. Assessing the need for these procedures requires experience and judgment because they should not be delayed until cyanosis and extreme restlessness have developed (see Chapter 86). An endotracheal or nasotracheal tube that is 0.5-1.0 mm smaller than estimated by age or height is recommended.

The endotracheal tube or tracheostomy must remain in place until edema and spasm have subsided and the patient is able to handle secretions satisfactorily. It should be removed as soon as possible, usually within a few days. Adequate resolution of epiglottic inflammation that has been accurately confirmed by fiberoptic laryngoscopy, permitting much more rapid extubation, often occurs within 24 hours. Racemic epinephrine and dexamethasone (0.5 mg/kg/dose 6-12 hr before extubation with a maximum dose of 16 mg) may be useful in the treatment of upper airway edema seen postintubation.

PROGNOSIS

In general, the length of hospitalization and the mortality rate for cases of acute infectious upper airway obstruction increase as the infection extends to involve a greater portion of the respiratory tract, except in epiglottitis, in which the localized infection itself can prove to be fatal. Most deaths from croup are caused by a laryngeal obstruction or by the complications of tracheotomy. Rarely, fatal out-of-hospital arrests caused by viral laryngotracheobronchitis have been reported, particularly in infants and in patients whose course has been complicated by bacterial tracheitis. Untreated epiglottitis has a mortality rate of 6% in some series, but if the diagnosis is made and appropriate treatment is initiated before the patient is moribund, the prognosis is excellent. The outcome of acute laryngotracheobronchitis, laryngitis, and spasmodic croup is also excellent.

Visit Elsevier eBooks+ at eBooks.Health.Elsevier.com for Bibliography.

433.2 Bacterial Tracheitis

Kristine Knuti Rodrigues and Genie E. Roosevelt

Bacterial tracheitis is an acute bacterial infection of the upper airway that is potentially life-threatening. *S. aureus* (see Chapter 227.1) is the most commonly isolated pathogen, with isolated reports of methicillin-resistant *S. aureus*, *S. pneumoniae, S. pyogenes, Moraxella catarrhalis,* and nontypable *H. influenzae*; anaerobic organisms have also been implicated. The mean age is between 5 and 7 years. There is a slight male predominance. Bacterial tracheitis often follows a viral respiratory infection (especially laryngotracheitis or influenza virus infection), so it may be considered a bacterial complication of a viral disease, rather than a primary bacterial illness. This life-threatening entity is more common than epiglottitis in vaccinated populations.

CLINICAL MANIFESTATIONS

Typically, the child has a metallic/brassy cough, apparently as part of a viral laryngotracheobronchitis. High fever and toxicity with respiratory distress can occur immediately or after a few days of apparent improvement. The patient can lie flat, does not drool, and does not have the dysphagia associated with epiglottitis. The usual treatment for croup (racemic epinephrine) is ineffective. Intubation or tracheostomy may be necessary, but only 50–60% of patients require intubation for management, with younger patients more likely to need intubation. The major pathologic feature appears to be mucosal swelling at the level of the cricoid cartilage, complicated by copious, thick, purulent secretions, sometimes causing pseudomembranes. Suctioning these secretions, although occasionally affording temporary relief, usually does not sufficiently obviate the need for an artificial airway.

DIAGNOSIS

The diagnosis is based on evidence of bacterial upper airway disease, which includes high fever, purulent airway secretions, and an absence of the classic findings of epiglottitis. X-rays are not needed but can show the classic findings (Fig. 433.3); purulent material is noted below the cords during endotracheal intubation (Fig. 433.4).

Fig. 433.3 Bacterial tracheitis in a 9-yr-old female with a high fever, cough, and stridor. **A,** Frontal soft tissue neck radiograph shows subglottic tracheal narrowing *(arrows).* **B,** Lateral soft tissue neck radiograph shows irregular linear membranous debris within the trachea *(arrows). (From Laya BF, Lee EY. Upper airway disease. In Coley BD, ed. Caffey's Pediatric Diagnostic Imaging, 13th ed. Philadelphia: Elsevier; 2019: Fig. 51.9, p. 481.)*

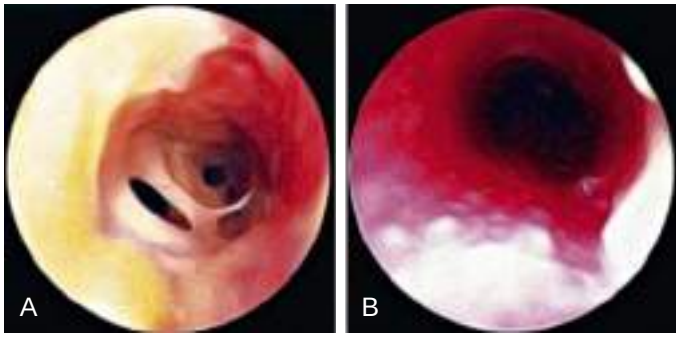

Fig. 433.4 Thick tracheal membranes seen on rigid bronchoscopy. The supraglottis was normal. **A,** Thick adherent membranous secretions. **B,** The distal tracheobronchial tree is unremarkable. In contrast to croup, tenacious secretions are seen throughout the trachea, and in contrast to bronchitis, the bronchi are not affected. *(From Salamone FN, Bobbitt DB, Myer CM, et al. Bacterial tracheitis reexamined: is there a less severe manifestation? Otolaryngol Head Neck Surg. 2004;131:871–876.Copyright 2004 American Academy of Otolaryngology–Head and Neck Surgery Foundation, Inc.)*

TREATMENT

Appropriate antimicrobial therapy, which usually includes antistaphylococcal agents, should be instituted in any patient whose course suggests bacterial tracheitis. Empiric therapy recommendations for bacterial tracheitis include vancomycin or clindamycin and a third- or fourth-generation cephalosporin (e.g., ceftriaxone or cefepime). When bacterial tracheitis is diagnosed by direct laryngoscopy or is highly suspected on clinical grounds, an artificial airway should be strongly considered. Supplemental oxygen is usually necessary.

COMPLICATIONS

Chest radiographs often show patchy infiltrates and may show focal densities. Subglottic narrowing and a rough and ragged tracheal air column can often be demonstrated radiographically. If airway management is not optimal, cardiorespiratory arrest can occur. Toxic shock syndrome has been associated with staphylococcal and group A streptococcal tracheitis (see Chapter 227.2).

PROGNOSIS

The prognosis for most patients is excellent. Patients usually become afebrile within 2-3 days of the institution of appropriate antimicrobial therapy, but prolonged hospitalization may be necessary. In recent years, there appears to be a trend toward a less morbid condition. With a decrease in mucosal edema and purulent secretions, extubation can be accomplished safely, and the patient should be observed carefully while antibiotics and oxygen therapy are continued.

Visit Elsevier eBooks+ at eBooks.Health.Elsevier.com for Bibliography.

Chapter 434

Congenital Anomalies of the Larynx, Trachea, and Bronchi

Michael Gorelik and James W. Schroeder Jr.

The larynx functions as a breathing passage, a valve to protect the lungs during swallowing, and the primary organ of communication. Symptoms related to congenital anomalies of the larynx include airway obstruction, noisy breathing, difficulty feeding, and abnormalities of phonation (see Chapter 421). Obstructive congenital lesions of the upper airway create turbulent airflow according to the laws of fluid dynamics. Turbulent airflow across a narrowed segment of the respiratory tract produces distinctive sounds that are diagnostically useful. The location of the obstruction produces characteristic changes in the sound of inspiration and/or expiration. Intrathoracic lesions typically cause expiratory wheezing and/or stridor, often masquerading as asthma or other pulmonary processes. The expiratory wheezing contrasts to the inspiratory stridor caused by the extrathoracic lesions of congenital laryngeal anomalies, specifically laryngomalacia and bilateral vocal cord paralysis. Stertor describes the low-pitched inspiratory snoring sound typically produced by soft tissue from nasal or nasopharyngeal obstruction.

The timing of noisy breathing in relation to the sleep–wake cycle is important. Obstruction of the pharyngeal airway (by enlarged tonsils, adenoids, pharyngeal soft tissue, tongue, or syndromes with midface hypoplasia) typically produces worse obstruction during sleep than during waking. Obstruction that is worse when awake is typically laryngeal, tracheal, or bronchial and is exacerbated by exertion. The location of the obstruction dictates the respiratory phase, tone, and nature of the sound, and these qualities direct the differential diagnosis.

With airway obstruction, the degree of the obstructing lesion and the resulting work of breathing determine the necessity for diagnostic procedures and surgical intervention. Obstructive symptoms vary from mild to severe stertor or stridor with episodes of apnea, cyanosis, suprasternal (tracheal tugging) and subcostal retractions, dyspnea, and tachypnea. Significant congenital anomalies of the trachea and bronchi can create serious respiratory difficulties from the first minute of life and may sometimes be diagnosed in the prenatal period. If a severe obstruction is suspected prenatally, an airway birth plan should be developed by a high-risk maternal–fetal medicine expert, a neonatologist, and a pediatric airway surgeon. *Congenital high airway obstruction syndrome,* or *CHAOS,* can lead to immediate postnatal distress (see Chapters 117 and 118). Chronic obstruction can cause failure to thrive and chronic hypoxemia and may have long-term effects on growth and development.

Visit Elsevier eBooks+ at eBooks.Health.Elsevier.com for Bibliography.

434.1 Laryngomalacia

Michael Gorelik and James W. Schroeder Jr.

Laryngomalacia accounts for 45–75% of congenital laryngeal anomalies in children with stridor. Stridor is inspiratory and can vary from high- to low-pitched. It can be present at rest and exacerbated by any exertion: crying, agitation, or feeding. The stridor is caused, in part, by decreased laryngeal tone leading to supraglottic collapse during inspiration, which creates a narrow airway and turbulent airflow. Symptoms usually appear within the first 2 weeks and increase in severity for up to 6 months, although gradual improvement can begin at any time. Many infants who do not require surgical intervention often have spontaneous resolution of stridor around 7-9 months of age, and the majority will have complete resolution of stridor by 18 months of age. Gastroesophageal reflux disease, laryngopharyngeal reflux disease, and neurologic disease with associated muscle hypotonia can influence the severity of the disease and thereby the clinical course.

DIAGNOSIS

The diagnosis is made primarily based on clinical symptoms and is confirmed by outpatient, awake flexible laryngoscopy (Fig. 434.1). When the work of breathing is moderate to severe, airway films and chest radiographs are indicated. Laryngomalacia can contribute to feeding difficulties and dysphagia in some children because of decreased laryngeal sensation and poor suck-swallow-breath coordination. When the inspiratory stridor sounds wet or is associated with a cough or when there is a history of repeat upper respiratory illness or pneumonia, dysphagia should be considered. When dysphagia is suspected, a contrast swallow study and/or a fiberoptic endoscopic evaluation of swallowing (FEES) may be considered. Because 15–60% of infants with laryngomalacia have synchronous airway anomalies, complete bronchoscopy is undertaken for patients with moderate to severe obstruction.

TREATMENT

Expectant observation is suitable for most infants because most symptoms resolve spontaneously as the child and airway grow. Laryngopharyngeal reflux is managed with antireflux medications, such as histamine H_2-receptor antagonists or proton pump inhibitors (PPIs).

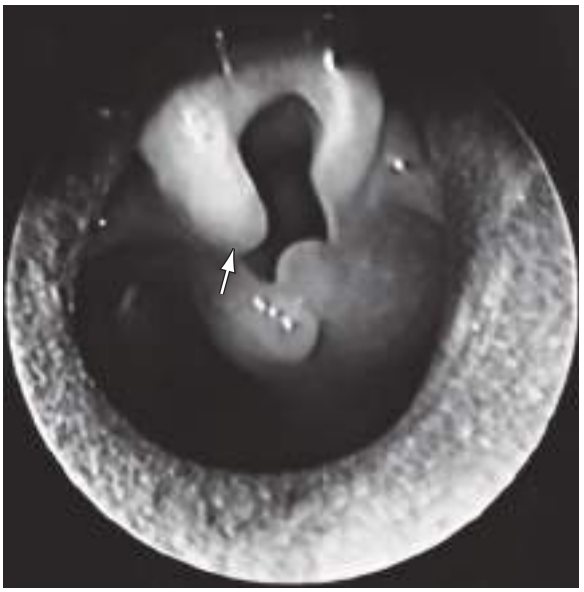

Fig. 434.1 Endoscopic example of laryngomalacia. On inspiration, the epiglottic folds collapse into the airway. The lateral tips of the epiglottis are also collapsing inward *(arrow)*. *(From Slovis T, ed. Caffey's Pediatric Diagnostic Imaging, 11th ed. Philadelphia: Mosby; 2008.)*

The risk-to-benefit ratio should be assessed in each patient because these medications, particularly PPIs, have been associated with iron-deficiency anemia and increased incidence of pneumonia, gastroenteritis, and *Clostridium difficile* infections, among others. In 15–20% of patients with laryngomalacia, symptoms are severe enough to cause progressive respiratory distress, cyanosis, failure to thrive, or cor pulmonale. In these patients, surgical intervention via supraglottoplasty is considered. Supraglottoplasty is 90% successful in relieving upper airway obstruction caused by laryngomalacia. Some comorbidities, such as cardiac disease, neurologic disease, pulmonary disorders, or craniofacial anomalies, may be poor prognostic indicators that would suggest earlier intervention.

Visit Elsevier eBooks+ at eBooks.Health.Elsevier.com for Bibliography.

434.2 Congenital Subglottic Stenosis

Michael Gorelik and James W. Schroeder Jr.

Congenital subglottic stenosis is the second most common cause of stridor. The subglottis is the narrowest part of the upper airway in a child and is located in the space extending from the undersurface of the true vocal folds to the inferior margin of the cricoid cartilage. Subglottic stenosis is a narrowing of the subglottic larynx and in a term newborn is defined as a cricoid diameter of less than 3.5 mm resulting from malformation of the cricoid cartilage. Subglottic stenosis manifests in the infant with respiratory distress and biphasic or primarily inspiratory stridor. It may be congenital or acquired. Symptoms may present spontaneously with a higher degree of stenosis but manifest after a respiratory tract infection because of edema and thickened secretions of a narrow and already compromised airway leading to recurrent or persistent crouplike symptoms.

Biphasic or primarily inspiratory stridor is the typical presenting symptom for congenital subglottic stenosis. In a child with recurrent bronchiolitis or croup, a diagnosis of congenital subglottic stenosis should be considered. The stenosis can be caused by an abnormally shaped elliptical cricoid cartilage; by a first tracheal ring that becomes trapped underneath the cricoid cartilage; or by soft tissue thickening caused by ductal cysts, submucosal gland hyperplasia, or fibrosis. Acquired subglottic stenosis refers to stenosis caused by extrinsic factors, most commonly resulting from prolonged intubation, and is discussed in further detail in Chapter 436.

DIAGNOSIS

The diagnosis made by airway radiographs is confirmed by direct laryngoscopy and bronchoscopy. During diagnostic laryngoscopy, the subglottic larynx is visualized directly and sized objectively using endotracheal tubes (Fig. 434.2). The percentage of stenosis is determined by comparing the size of the patients' larynx to a standard of laryngeal dimensions based on age. Stenosis >50% is usually symptomatic and often requires treatment. As with all cases of upper airway obstruction, tracheostomy is avoided when possible. Subglottic stenosis is typically measured using the Myer-Cotton system, with grade I through grade IV subglottic stenosis indicating the severity of narrowing. Other factors to consider aside from the degree of narrowing are whether the stenotic segment is soft or firm, which can determine the appropriate type of surgical intervention. Dilation and endoscopic laser surgery can be attempted in grade I and II, although they may not be effective because most congenital stenoses are cartilaginous. Anterior cricoid split, anterior-posterior cricoid split, tracheostomy, or laryngotracheal reconstruction with cartilage graft augmentation are surgical options typically reserved for grade III and IV subglottic stenosis. The differential diagnosis includes other anatomic anomalies, as well as a subglottic hemangiomas or respiratory papillomatosis.

Visit Elsevier eBooks+ at eBooks.Health.Elsevier.com for Bibliography.

434.3 Vocal Cord Paralysis

Michael Gorelik and James W. Schroeder Jr.

Vocal cord paralysis is the third most common congenital laryngeal anomaly that produces stridor in infants and children. Congenital central nervous system lesions such as Chiari malformation, myelomeningocele, and hydrocephalus or birth trauma may be associated with bilateral paralysis. Additionally, congenital anomalies of the heart or great vessels can be associated with vocal cord paralysis. Bilateral vocal cord paralysis produces airway obstruction at the level of the glottis and is manifested by respiratory distress and high-pitched inspiratory stridor, aphonatory or dysphonic sound, or inspiratory weak cry. More than 50% of cases of vocal cord paralysis in children are bilateral.

Unilateral vocal cord paralysis is most often iatrogenic, as a result of surgical treatment for aerodigestive (tracheoesophageal fistula) and cardiovascular (patent ductus arteriosus repair) anomalies and thyroid or parathyroid surgery, although it may also be idiopathic. Unilateral paralysis can lead to aspiration, coughing, and choking. Often the cry is weak and breathy, whereas stridor and other symptoms of airway obstruction are less common. Vocal cord paralysis in older children may be the result of a Chiari malformation or tumors compressing the vagus or recurrent laryngeal nerve. Vocal cord paralysis/palsies have also been reported in patients with Guillain-Barré syndrome (GBS) and its Miller Fisher variant either as an isolated finding or associated with other features of GBS. Other neurologic disorders producing vocal cord paralysis include stroke, multiple sclerosis, and other polyneuropathies. The prognosis for spontaneous recovery is better for unilateral, acquired, and right-sided paralysis.

DIAGNOSIS

The diagnosis of vocal cord paralysis is made by awake flexible laryngoscopy. The examination will demonstrate an inability or weakness to abduct the involved vocal cord. A thorough investigation for the underlying primary cause is indicated. Because of the association with other congenital lesions, evaluation includes neurology and cardiology consultations, imaging of the course of the recurrent laryngeal nerve, and diagnostic endoscopy of the larynx, trachea, and bronchi. During endoscopy, it is critical to palpate the cricoarytenoid joint to rule out joint fixation, which can be

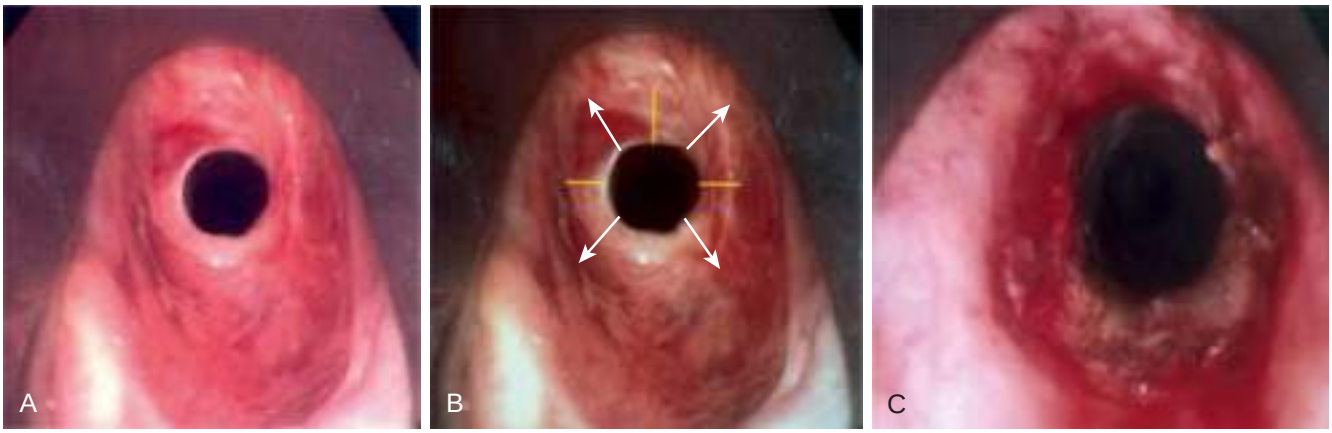

Fig. 434.2 Endoscopic repair of subglottic stenosis with radial cuts at 12, 3, and 9 o'clock positions using a laryngeal sickle knife or laser. **A,** Preoperative view. **B,** Diagram of planned incisions. **C,** After cuts and balloon dilation. *(From Lawlor CM, Rahbar R, Choi SS. Glottic and subglottic stenosis and related voice disorders. In: Lesperance MM, ed. Cummings Pediatric Otolaryngology, 2nd ed. Philadelphia: Elsevier; 2022: Fig. 28.8, p. 409.)*

mistaken for bilateral vocal fold paralysis. Intraoperative laryngeal electromyography (EMG) is the most specific and sensitive test to determine the presence of vocal cord paralysis.

TREATMENT

Treatment is based on the severity of the symptoms. Idiopathic vocal cord paralysis in infants usually resolves spontaneously within 6-12 months. If it is not resolved by 2-3 years of age, function typically does not recover. Patients with unilateral vocal cord paralysis often do not require intervention secondary to spontaneous recovery or compensation for the contralateral vocal cord. If there is persistent dysphonia or aspiration, surgical options include vocal fold injection, surgical medialization, or reinnervation using the ansa cervicalis, which has been successful in regaining unilateral vocal cord function. Postoperative voice therapy is helpful to achieve optimum results.

Bilateral paralysis may require temporary tracheotomy in 50% of patients. Airway augmentation procedures in bilateral vocal cord paralysis typically focus on widening the posterior glottis, such as an endoscopically placed or open posterior glottis cartilage graft, arytenoidectomy, or arytenoid lateralization, sometimes in conjunction with cordotomy. These procedures are generally successful in reducing the obstruction; however, they may result in dysphagia and aspiration.

Visit Elsevier eBooks+ at eBooks.Health.Elsevier.com for Bibliography.

434.4 Congenital Laryngeal Webs and Atresia

Michael Gorelik and James W. Schroeder Jr.

Congenital laryngeal webs account for about 5% of congenital laryngeal anomalies. They are typically located in the anterior glottis with subglottic extension and associated subglottic stenosis. During early embryogenesis, laryngeal webs form if the laryngotracheal lumen fails to fully recannulate. The clinical presentation ranges from asymptomatic, to dysphonia, to severe airway compromise secondary to the degree of obstruction caused by the web. Laryngeal webs are categorized from type I to type IV, which is the most severe.

Fig. 434.3 Anterior glottic web, endoscopic view. *(Courtesy Dr. Jeff Rastatter, Division of Pediatric Otolaryngology, Lurie Children's Hospital, Chicago, IL.)*

Laryngeal atresia occurs as a complete glottic web due to failure of laryngeal and tracheal recanalization and may be associated with tracheal agenesis and tracheoesophageal fistula. Laryngeal atresia may be detected in the prenatal period, and preparations should be made for establishment of definitive airway, either before or at birth. Other times, congenital laryngeal atresia is a cause of respiratory distress in the newborn and is diagnosed only upon initial direct laryngoscopy.

Diagnosis is made by direct laryngoscopy (Fig. 434.3). Thick webs may be suspected in lateral radiographs of the airway. Chromosomal and congenital cardiovascular anomalies, as well as chromosome 22q11 deletion, are common in patients with laryngeal webs. Treatment may require only incision or dilation for thin webs. Thick webs can require laryngofissure and temporary stenting. Webs with associated subglottic stenosis are likely to require cartilage augmentation of the cricoid cartilage (laryngotracheal reconstruction). Voice outcomes are variable after surgical management.

Visit Elsevier eBooks+ at eBooks.Health.Elsevier.com for Bibliography.

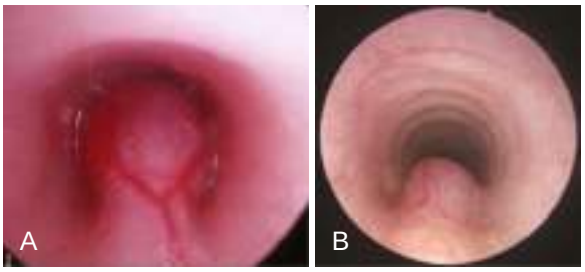

Fig. 434.4 A and B, Case of tracheal hemangioma prepropranolol and postpropranolol therapy (pictures 2 weeks apart). *(From Bush A, Abel R, Chitty L, et al. Congenital lung disease. In: Wilmott RW, Deterding RR, Li A, et al., eds. Kendig's Disorders of the Respiratory Tract in Children, 9th ed. Philadelphia: Elsevier; 2019: Fig. 18.18, p. 308.)*

434.5 Congenital Subglottic Hemangioma

Michael Gorelik and James W. Schroeder Jr.

See also Chapter 438.3.

Subglottic infantile hemangiomas are benign vascular malformations and a rare cause of early infancy respiratory distress. They present more commonly in females than in males, with symptoms of a barky cough and inspiratory or biphasic stridor in the absence of dysphonia. Symptoms typically present within the first 1-6 months of life. The most common presenting symptom is biphasic stridor, somewhat more prominent during inspiration. This is exacerbated by crying and acute viral illnesses. A barking cough, hoarseness, and symptoms of recurrent or persistent croup are typical and can mask the diagnosis. Roughly 50% of those with a subglottic hemangioma will have a cutaneous hemangioma, but only 1% of children who have cutaneous hemangiomas will have a subglottic hemangioma (see Chapter 691). However, a facial hemangioma in the beard distribution (preauricular area, lips, chin, and neck) is associated with a much higher incidence of subglottic hemangiomas and, when present, should prompt further investigation. Chest and neck radiographs can show the characteristic asymmetric narrowing of the subglottic larynx. CT and MRI can also assist with the diagnosis. Airway vascular lesions may also be associated with **PHACES syndrome**, characterized by posterior fossa malformations, hemangioma, arterial lesions of the head and neck, cardiac anomalies, eye anomalies, and sternal cleft (see Chapter 691). More than 50% of children with PHACES syndrome have an airway vascular lesion. Treatment options range from conservative monitoring, medical management, steroid injection, laser treatment, and open surgical resection to tracheotomy and airway reconstruction. Propranolol has become a mainstay in initial therapy of subglottic hemangioma; however, it is estimated that up to 50% of patients with subglottic hemangioma may not have a long-term response to propranolol, indicating a need for close airway monitoring in these patients (Fig. 434.4). Treatment is further discussed in Chapter 438.3.

Visit Elsevier eBooks+ at eBooks.Health.Elsevier.com for Bibliography.

434.6 Laryngoceles and Saccular Cysts

Michael Gorelik and James W. Schroeder Jr.

Saccular cysts and laryngoceles are uncommon etiologies of pediatric airway obstruction. A laryngocele is an abnormal air-filled dilation of the laryngeal saccule that arises vertically between the false vocal cord, the base of the epiglottis, and the inner surface of the thyroid cartilage. As there is open communication with the laryngeal lumen when it intermittently fills with air, this can lead to hoarseness and dyspnea. Laryngoceles may be confined to the larynx or extend into the neck and are described as internal, external, or both. A saccular cyst (congenital cyst of the larynx) is distinguished from the laryngocele in that its lumen is isolated from the interior of the larynx and it contains mucus, not air. Saccular cysts can be located in the anterior and lateral portions of the glottis and supraglottis. In infants and children, laryngoceles cause hoarseness and dyspnea that may increase with crying. Saccular cysts may cause respiratory distress and stridor at birth and may require early airway intervention. Infection of saccular cysts can lead to rapid expansion and acute airway compromise. Intubation can be challenging because the supraglottic and laryngeal anatomy may be distorted. In addition, complete airway obstruction may occur on induction with neuromuscular blockade because of decreased laryngeal tone. A saccular cyst may be visible on radiography, but the diagnosis is made by laryngoscopy (Fig. 434.5). Needle aspiration of the cyst confirms the diagnosis but rarely provides a cure. Surgical excision is the therapy of choice for management of saccular cysts and laryngoceles. Approaches include endoscopic CO_2 laser excision, endoscopic extended ventriculotomy (marsupialization or unroofing), or, traditionally, external excision.

Fig. 434.5 Endoscopic photograph of a saccular cyst. *(From Ahmad SM, Soliman AMS. Congenital anomalies of the larynx. Otolaryngol Clin North Am. 2007;40:177–191, Fig. 3.)*

Visit Elsevier eBooks+ at eBooks.Health.Elsevier.com for Bibliography.

434.7 Posterior Laryngeal Cleft and Laryngotracheoesophageal Cleft

Michael Gorelik and James W. Schroeder Jr.

The posterior laryngeal cleft is the result of a deficiency in the midline of the posterior larynx caused by a failure of fusion of the posterior cricoid lamina. This results in an abnormal communication between the posterior larynx and esophagus leading to aspiration. Posterior laryngeal clefts are categorized into four types depending how far inferiorly the cleft extends. A **type I cleft** extends to, but not beyond, the vocal cords. A **type II cleft** extends beyond the vocal cords to, but not through, the cricoid cartilage. A **type III cleft** extends through the cricoid cartilage into the cervical trachea. A

type IV cleft extends into the thoracic trachea. Laryngeal clefts can occur in families and are likely to be associated with tracheal agenesis, tracheoesophageal fistula, and multiple congenital anomalies, including Opitz-Frias syndrome, Townes-Brock syndrome, chromosome 1q43 deletion, trisomy 21, and Pallister-Hall syndrome.

Type I clefts may cause mild symptoms, but at least 60% of these will cause no symptoms and will not require surgical repair. Type I and, more commonly, type II clefts can present with feeding problems, recurrent aspiration, pneumonias, or respiratory complaints. Infants with type III and IV clefts will present more commonly in the newborn period with significant aspiration and respiratory distress.

Diagnostic workup includes an esophagogram, which is undertaken to evaluate the presence of aspiration or laryngeal penetration of ingested contrast material. A FEES exam may be undertaken by an otolaryngologist with the assistance of a speech-language and pathology team to observe patterns of liquid spillage during swallow and may identify a cleft. However, the gold standard of diagnosis remains operative laryngoscopy and bronchoscopy with palpation of the posterior larynx. This assists in determining the length of the cleft and guides treatment options.

Treatment is based on the cleft type and the symptoms; in general, a type I cleft may be managed endoscopically, whereas higher grades may require an open procedure. Stabilization of the airway is the first priority. Gastroesophageal reflux must be controlled, and a careful assessment for other congenital anomalies is undertaken before repair. Several endoscopic and open cervical and transthoracic surgical repairs have been described.

Visit Elsevier eBooks+ at eBooks.Health.Elsevier.com for Bibliography.

434.8 Vascular and Cardiac Anomalies

Michael Gorelik and James W. Schroeder Jr.

Aberrant cardiopulmonary vascular anatomy may directly affect the trachea and bronchi, resulting in respiratory and feeding problems (Fig. 434.6). The aberrant innominate artery is the most common cause of secondary tracheomalacia (see Chapter 481). It may be asymptomatic and discovered incidentally, or it may cause severe symptoms. Expiratory wheezing and cough occur and, rarely, reflex apnea or "dying spells." Surgical intervention is rarely necessary. Infants are most commonly treated expectantly because the problem is often self-limited.

The term *vascular ring* is used to describe vascular anomalies that result from abnormal development of the aortic arch complex. Vascular rings are categorized as complete or incomplete. Double aortic arch is the most common type of complete vascular ring, followed by right aortic arch with aberrant left subclavian artery and left ligamentum arteriosum. These account for more than 95% of complete rings. The double aortic arch encircles and compresses both the trachea and esophagus. With few exceptions, these patients are symptomatic by 3 months of age. Respiratory symptoms predominate, but dysphagia may be present. The diagnosis is established by barium esophagogram that shows a posterior indentation of the esophagus by the vascular ring (see Fig. 434.6). CT or MRI with angiography provides the cardiothoracic surgeon the information needed. Surgical treatment for symptomatic patients entails division of the vascular ring.

Other vascular anomalies include the pulmonary artery sling, which also requires surgical correction. The most common open (incomplete) vascular ring is the left aortic arch with aberrant right subclavian artery. It is usually asymptomatic, although dysphagia lusoria has been described. This is characterized as dysphagia caused by an aberrant subclavian artery coursing behind the esophagus, leading to esophageal compression and difficulty with bolus transit.

Congenital cardiac defects are likely to compress the left main bronchus or lower trachea. Any condition that produces significant pulmonary hypertension increases the size of the pulmonary arteries, which in turn causes compression of the left main bronchus. Surgical correction of the underlying pathology to relieve pulmonary hypertension relieves the airway compression.

Visit Elsevier eBooks+ at eBooks.Health.Elsevier.com for Bibliography.

434.9 Tracheal Stenoses, Webs, and Atresia

Michael Gorelik and James W. Schroeder Jr.

Long-segment congenital tracheal stenosis with *complete* tracheal rings typically presents within the first year of life, usually after a crisis has been precipitated by an acute respiratory illness. The diagnosis may be suggested by plain radiographs. CT with contrast delineates associated intrathoracic anomalies such as the pulmonary artery sling (in ~30%) or other cardiac anomalies (in about 25%), which can occur in one third of patients to one fourth of patients, respectively. Bronchoscopy is the best method to define the degree and extent of the stenosis and the associated abnormal bronchial branching pattern. Care must be taken to avoid traumatic passage of a telescope or bronchoscope through a stenotic or edematous segment, as even minor mucosal trauma may precipitate complete airway obstruction. Treatment of clinically significant stenosis involves tracheal resection of short-segment stenosis, slide tracheoplasty for long-segment stenosis, or tracheal rings. Total autologous tracheal replacement is another option. Congenital soft tissue stenosis and thin webs are rare. Dilation may be all that is required.

Visit Elsevier eBooks+ at eBooks.Health.Elsevier.com for Bibliography.

434.10 Foregut Cysts

Michael Gorelik and James W. Schroeder Jr.

The embryologic foregut gives rise to the pharynx, lower respiratory tract, esophagus, stomach, duodenum, and hepatobiliary tract. Foregut duplication cysts arise if heterotopic rests of foregut-derived epithelium persist anywhere along this tract. Foregut duplications account for approximately one third of all duplications. The bronchogenic cyst, intramural esophageal cyst (esophageal duplication), and enteric cyst can all produce symptoms of respiratory obstruction and dysphagia. The diagnosis is suspected when chest radiographs or CT scan delineates the mass and, in the case of enteric cyst, the associated vertebral anomaly. The treatment of all foregut cysts is surgical excision.

Visit Elsevier eBooks+ at eBooks.Health.Elsevier.com for Bibliography.

434.11 Tracheomalacia and Bronchomalacia

See Chapter 437.

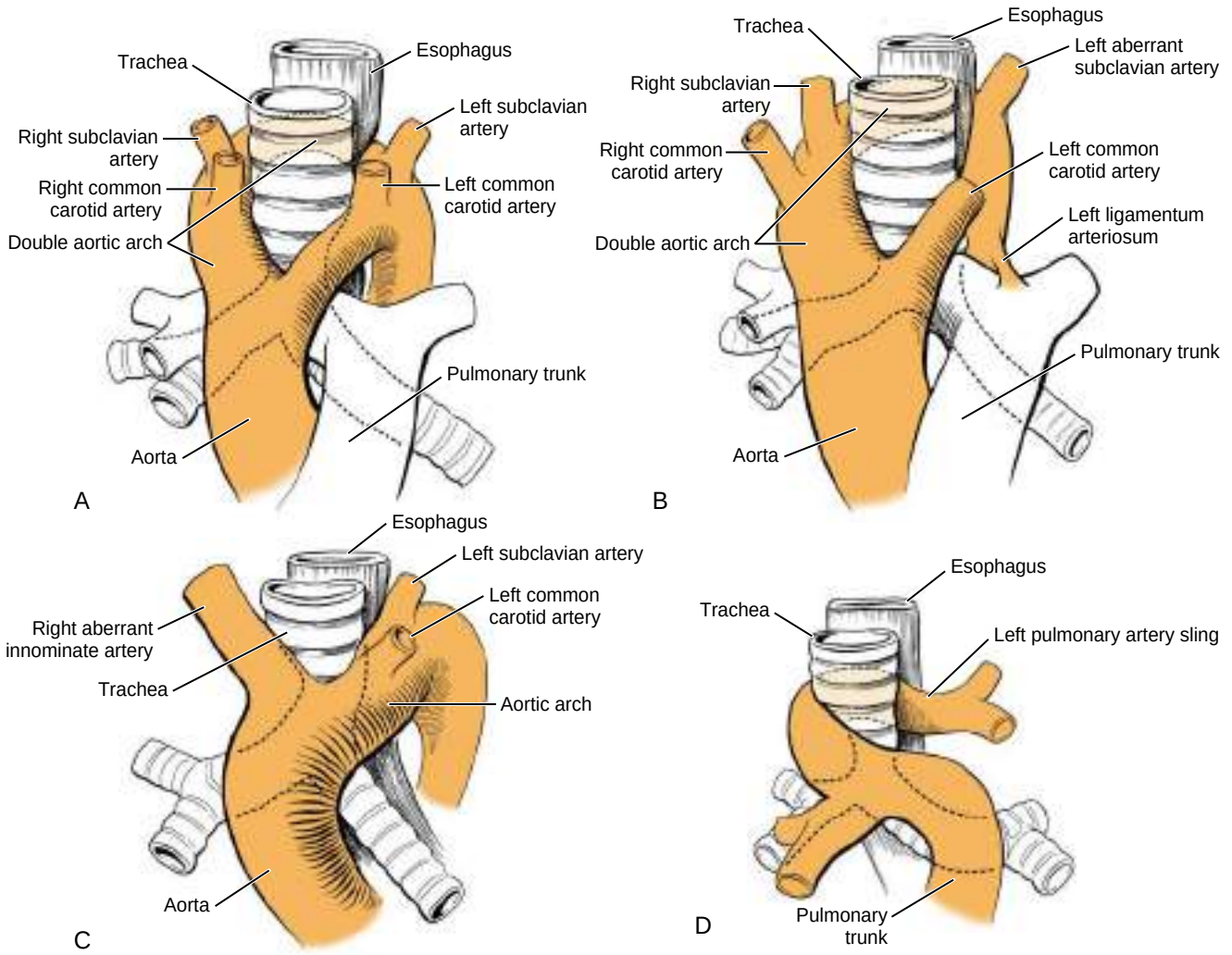

Fig. 434.6 Vascular rings. **A,** Double aortic arch. **B,** Right aortic arch with aberrant left subclavian artery and left ligamentum arteriosum. **C,** Aberrant innominate artery. **D,** Left pulmonary artery sling. *(From Green GF, Ohye RG. Diagnosis and management of tracheal anomalies and tracheal stenosis. In: Lesperance MM, ed. Cummings Pediatric Otolaryngology, 2nd ed. Philadelphia: Elsevier; 2022: Fig. 30.6, p. 445.)*

Chapter 435

Foreign Bodies in the Airway

Michael Gorelik and James W. Schroeder Jr.

Choking is a leading cause of morbidity and mortality among children, especially those younger than 4 years of age. From 2001 to 2009, an average of 12,435 children ages 0-14 years in the United States were treated in emergency departments for choking on food without fatality. The majority of children found to have foreign body aspiration are older infants and toddlers (Fig. 435.1), with males being 1.7 times more likely than females to aspirate a foreign body. Roughly 80% of airway foreign body aspirations occur in children younger than 3 years old, with a peak in incidence between ages 1 and 2. Food items ranging from nuts, seeds, popcorn, and food particles to hardware and pieces of toys account for 59.5–81% of all cases. Nonfood and inorganic objects such as coins, paper clips, pen caps, or small toys are more commonly aspirated by older children. Globular, compressible, or round objects such as hot dogs, grapes, nuts, balloons, marshmallows, meats, and candies are particularly hazardous because of their ability to completely occlude the airway.

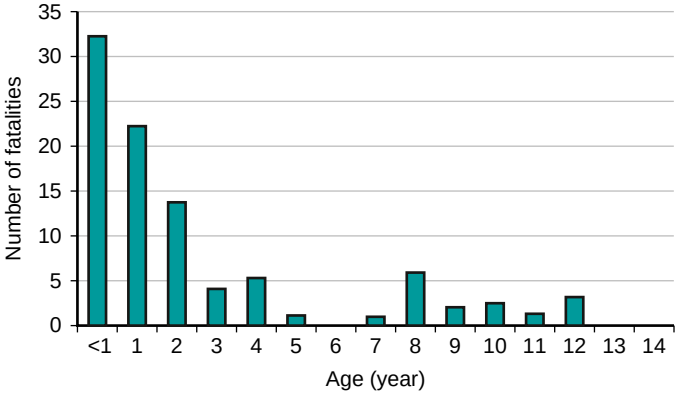

Fig. 435.1 Number of fatalities versus victim age, all fatality types. *(From Milkovich SM, Altkorn R, Chen X, et al. Development of the small parts cylinder: lessons learned. Laryngoscope. 2008;118[11]:2082–2086.)*

Younger children are at a higher risk for foreign body aspiration largely secondary to their developmental vulnerabilities and immature swallow function. Infants and toddlers often use their mouths to explore their surroundings, and children are more likely to be distracted, playing, or ambulatory while eating. Infants have the ability to suck and swallow and are equipped with basic involuntary reflexes (gag, cough, and glottis closure) that help to protect against aspiration during swallowing. Dentition develops at approximately 6 months of age with the eruption of the incisors, whereas molars do not erupt until approximately 1.5 years of age. Mature mastication takes longer to develop.

Despite these various protective mechanisms, a child's airway is more vulnerable to obstruction than an adult's airway. Young children are more likely to experience significant obstruction by small foreign bodies because of the smaller diameter of the pediatric airway. Mucus and secretions may form a seal around the foreign body, making it more difficult to dislodge by forced exhalation. In addition, the force of air generated by an infant's or young child's cough is less effective in dislodging an airway obstruction. For these reasons, it is recommended that children younger than 5 years of age avoid foods like hard candy or chewing gum and that raw fruits and vegetables be cut into small pieces. Additionally, children with developmental delays or neurologic and muscular disorders are at higher risk for foreign body aspiration.

CLINICAL MANIFESTATIONS

Foreign bodies of the airway have variable presentations and complications, depending on the characteristics, duration, and location of the foreign body. The clinical manifestations range from an asymptomatic state to severe respiratory distress. A high index of suspicion is often required, as delayed presentation is common, with more than 50% of cases presenting after 24 hours of the suspected aspiration event. The most serious complication of foreign body aspiration is complete obstruction of the airway, which may be recognized in the conscious child as sudden respiratory distress followed by an inability to speak or cough.

There are typically three stages of symptoms that result from aspiration of an object into the airway:

1. **Initial event:** Paroxysms of coughing, choking, gagging, and possible airway obstruction occur immediately after aspiration of the foreign body. This may be accompanied by tachypnea and stridor. The child is sometimes able to expel the foreign body during this stage.
2. **Asymptomatic interval:** The foreign body becomes lodged, reflexes fatigue, and the immediate irritating symptoms subside. The lack of symptoms can be particularly misleading to the provider when a child presents in this stage and accounts for a large percentage of delayed diagnoses and overlooked foreign bodies. Some patients with delayed presentation may eventually develop dyspnea, wheezing, or chronic cough.
3. **Complications:** Obstruction, erosion, or infection develops, which again directs attention to the presence of a foreign body. In this third stage, complications include fever, cough, hemoptysis, pneumonia, and atelectasis. Acute or chronic complications have been reported in almost 15% of cases of foreign bodies of the airway.

DIAGNOSIS

The clinical history is the most important factor in determining the need for operative bronchoscopy. A positive history must never be ignored, but a negative history can be misleading. Because nuts and seeds are the most common bronchial foreign bodies, the physician should specifically question the child's parents about these items, though it is important to keep in mind that aspiration events can be unwitnessed. Choking or coughing episodes accompanied by new-onset wheezing and asymmetric breath sounds are highly suggestive of a foreign body in the airway, and bronchoscopy should be carried out promptly. A comprehensive physical exam is also essential, including examination of the nose, oral cavity, pharynx, neck, and lungs. Several reliable physical exam findings for airway foreign bodies include cough, decreased lung sounds, and wheezing. In addition to history and physical examination, radiology studies have an important role in diagnosing foreign bodies in the airway. Plain films are typically recommended first, although many foreign bodies are radiolucent (80–96%), and therefore providers often must rely on secondary findings (such as air trapping, asymmetric hyperinflation, obstructive emphysema, atelectasis, mediastinal shift, and consolidation) to indicate suspicion of a foreign body. Expiratory or lateral decubitus films can assist in revealing these suggestive secondary findings. The indication for computed tomography of the chest is currently being explored because of its high sensitivity and specificity, its ability to detect radiolucent objects, and its potential to eliminate the need for anesthesia and a procedure. However, with the known risks of radiation and the time-sensitive need for intervention, advanced imaging is rarely obtained. However, even in the absence of radiologic evidence on plain films, when the history and physical examination are suggestive of aspiration, bronchoscopy should be pursued.

TREATMENT

The treatment of choice for airway foreign bodies is prompt endoscopic removal with rigid instruments by a specialist (otolaryngologist or pulmonologist). Bronchoscopy is deferred only until providers have obtained preoperative studies and the patient has been prepared by adequate hydration and emptying of the stomach, though this can depend on the acuity of the clinical scenario. Airway foreign bodies are usually removed the same day the diagnosis is first considered. As with any treatment modality, providers must give careful consideration to the risks and benefits of the bronchoscopy procedure when the diagnosis is unclear. Potential complications of rigid bronchoscopy include bronchospasm, desaturation, bleeding, and airway edema; need for intubation; repeat procedures; and the inherent risks of anesthesia. Many surgeons maintain a lower threshold for intervention with the appropriate clinical history given the high risk of complications for a missed foreign body. Beyond the understanding of diagnosis and management of airway foreign bodies, there is a strong need and push for awareness, education, and prevention among caregivers, healthcare providers, and manufacturers of food and toys.

435.1 Laryngeal Foreign Bodies

Michael Gorelik and James W. Schroeder Jr.

Although laryngeal foreign bodies are less common (2–12% of cases) than bronchial or tracheal foreign bodies, they are particularly dangerous because of the risk of complete laryngeal obstruction, which can lead to asphyxiation unless it is promptly relieved with the Heimlich maneuver (see Chapter 79 and Figs. 79.6 and 79.7). As with airway foreign bodies in other locations, the presenting symptoms of laryngeal foreign bodies are determined by the size, shape, nature, and degree of obstruction. Objects that conform to the larynx can lead to complete obstruction, whereas with smaller objects the presentation can range from dysphonia, aphonia, stridor, cough, dyspnea, cyanosis, hemoptysis, and crouplike symptoms.

Clinical history is critical to establish an early diagnosis, and prompt intervention is critical.

435.2 Tracheal Foreign Bodies

Michael Gorelik and James W. Schroeder Jr.

Tracheal foreign bodies account for 3–12% of airway foreign body cases. Children who have tracheal foreign bodies can present with dysphonia, dysphagia, dry cough, or biphasic stridor. Posteroanterior and lateral soft tissue neck radiographs (airway films) are abnormal in 92% of children, whereas chest radiographs are abnormal in only 58% of these cases.

435.3 Bronchial Foreign Bodies

Michael Gorelik and James W. Schroeder Jr.

The majority of airway foreign bodies lodge in a bronchus (80–90% of cases) with a propensity to the right side. Occasionally, fragments of a foreign body may produce bilateral involvement or shifting infiltrates if they move from lobe to lobe. Some children with bronchial foreign bodies present asymptomatically, whereas others have asymmetric breath sounds, cough, and wheezing. Posteroanterior and lateral chest radiographs (including the abdomen) are standard in the diagnostic evaluation of infants and children suspected of having aspirated a foreign object. An expiratory posteroanterior chest film is most helpful. During expiration, the bronchial foreign body obstructs the exit of air from the obstructed lung, producing obstructive emphysema and air trapping. The persistent inflation of the obstructed lung causes a shift of the mediastinum toward the opposite side (Fig. 435.2). Air trapping is an immediate complication, whereas atelectasis is a late finding. Lateral decubitus chest films or fluoroscopy can provide the same information as expiratory films but are often unnecessary. Low-dose CT is considered by some a standard imaging study if previous conventional imaging is nondiagnostic. Clinical history and physical examination, not radiographs, ultimately determine the indication for bronchoscopy.

Visit Elsevier eBooks+ at eBooks.Health.Elsevier.com for Bibliography.

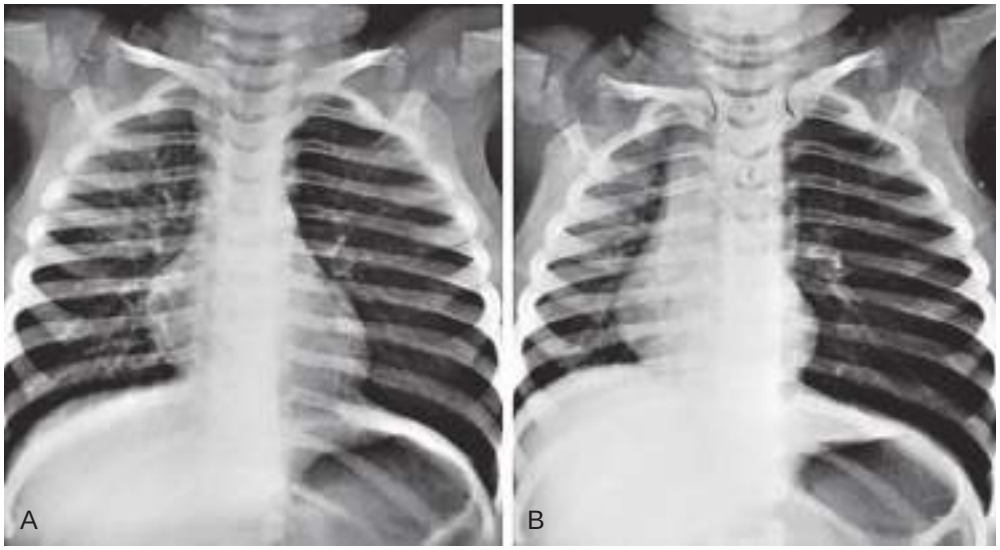

Fig. 435.2 A, Normal inspiratory chest radiograph in a toddler with a peanut fragment in the left main bronchus. B, Expiratory radiograph of the same child showing the classic obstructive emphysema (air trapping) on the involved (left) side. Air leaves the normal right side, allowing the lung to deflate. The medium shifts toward the unobstructed side.

Chapter 436

Laryngotracheal Stenosis and Subglottic Stenosis

Taher S. Valika and James W. Schroeder Jr.

Laryngotracheal stenosis is the second most common cause of stridor in neonates and is the most common cause of airway obstruction requiring tracheostomy in infants. The glottis (vocal cords) and the upper trachea are compromised in most cases of laryngeal stenosis, particularly those that develop after endotracheal intubation. Subglottic stenosis is a narrowing of the subglottic larynx, which is the space extending from the undersurface of the true vocal cords to the inferior margin of the cricoid cartilage. **Subglottic stenosis** is considered congenital when there is no other apparent cause such as a history of laryngeal trauma or intubation. Approximately 90% of cases manifest in the first year of life. Management relies on optimizing the airway, while ensuring the patient continues to grow. Knowledge of preventive measures is imperative to all healthcare members.

436.1 Congenital Subglottic Stenosis

See Chapter 434.2.

436.2 Acquired Laryngotracheal Stenosis

Taher S. Valika and James W. Schroeder Jr.

Ninety percent of acquired stenoses are a result of endotracheal intubation. The narrowest portion of the pediatric larynx is the subglottic region because of the narrow cricoid cartilage. When the pressure of the endotracheal tube against the cricoid mucosa is greater than the capillary pressure, ischemia occurs, followed by necrosis and ulceration. Secondary infection and perichondritis develop with exposure of cartilage (Fig. 436.1). Granulation tissue forms around the ulcerations. These changes and edema throughout the larynx usually resolve spontaneously after extubation. Chronic edema and fibrous stenosis develop in only a small percentage of cases.

A number of factors predispose to the development of laryngeal stenosis. Laryngopharyngeal reflux of acid and pepsin from the stomach is known to exacerbate endotracheal tube trauma. More damage is caused in areas left unprotected, owing to loss of mucosa. Congenital subglottic stenosis narrows the larynx, which makes the patient more likely to develop acquired subglottic stenosis because significant injury is more likely to occur with use of an endotracheal tube of age-appropriate size. *Other risk factors for the development of acquired subglottic stenosis include sepsis, malnutrition, chronic inflammatory disorders, and immunosuppression.* An oversized endotracheal tube is the most common factor contributing to laryngeal injury. A tube that allows a small air leak at the end of the inspiratory cycle minimizes potential trauma. Other extrinsic factors—traumatic intubation, multiple reintubations, movement of the endotracheal tube, and duration of intubation—can contribute to varying degrees in individual patients.

CLINICAL MANIFESTATIONS

Symptoms of acquired and congenital stenosis are similar. Spasmodic croup, the sudden onset of severe croup in the early morning hours, is usually caused by laryngopharyngeal reflux with transient laryngospasm and subsequent laryngeal edema. These frightening episodes resolve rapidly, often before the family and child reach the emergency department. Other presentations can also involve neonates who fail extubation, despite multiple attempts, and children with permanent dyspnea, stridor, or dysphonia.

Fig. 436.1 Bronchoscopy in a 2-mo-old infant showing mucosal erosion and cartilage exposure in the subglottic region. The child was intubated with an age-appropriate tube but with an excess of air in the cuff. *(Courtesy Dr. Taher S. Valika, Division of Pediatric Otolaryngology, Ann & Robert H. Lurie Children's Hospital of Chicago.)*

DIAGNOSIS

The diagnosis can be made by posteroanterior and lateral airway radiographs. The gold standard to confirm the diagnosis is via direct laryngoscopy and bronchoscopy in the operating room. High-resolution CT imaging and ultrasonography are of limited value. This is similar to the workup associated with congenital subglottic stenosis.

TREATMENT

The severity, location, and type (cartilaginous or soft tissue) of the stenosis determine the treatment. Mild cases can be managed without operative intervention because the airway will improve as the child grows. Moderate soft tissue stenosis is treated by endoscopy using gentle dilations or CO_2 laser. Severe laryngotracheal stenosis is likely to require laryngotracheal reconstructive (expansion) surgery or resection of the narrowed portion of the laryngeal and tracheal airway (cricotracheal resection). Every effort is made to avoid tracheotomy using endoscopic techniques or open surgical procedures.

Fundamental knowledge of the airway can help reduce the incidence of stenoses. The use of age-appropriate tubes and cuffless tubes, treatment of gastroesophageal reflux, and reducing the duration of mechanical ventilation have led to an overall decrease in laryngotracheal stenoses in the past decade.

Visit Elsevier eBooks+ at eBooks.Health.Elsevier.com for Bibliography.

Chapter 437

Bronchomalacia and Tracheomalacia

Jonathan D. Finder

Tracheomalacia and bronchomalacia refer to *chondromalacia* of a central airway, leading to insufficient cartilage to maintain airway patency throughout the respiratory cycle. These are common causes of persistent wheezing in infancy. Tracheomalacia and bronchomalacia can be either primary or secondary (Table 437.1). Primary tracheomalacia and bronchomalacia are often seen in premature infants, although most affected patients are born at term. Secondary tracheomalacia and bronchomalacia refer to the situation in which the central airway is compressed by an adjacent structure (e.g., vascular ring; see Fig. 434.6) or is deficient in cartilage because of tracheoesophageal fistula (see Chapter 365). Bronchomalacia is common after lung transplantation, assumed to be secondary to the loss of bronchial artery supply leading to ischemia of the bronchial cartilage. This form of bronchomalacia may take months to

Table 437.1 Classification of Tracheomalacia

PRIMARY TRACHEOMALACIA
Congenital absence of tracheal-supporting cartilages
SECONDARY TRACHEOMALACIA
Esophageal atresia, tracheoesophageal fistula
Vascular rings (double aortic arch)
Tracheal compression from an aberrant innominate artery
Tracheal compression from mediastinal masses
Abnormally soft tracheal cartilages associated with connective tissue disorders
Prolonged mechanical ventilation, chronic lung disease

From McNamara VM, Crabbe DC. Tracheomalacia. *Paediatr Respir Rev.* 2004;5:147–154.

436.2 Acquired Laryngotracheal Stenosis

Taher S. Valika and James W. Schroeder Jr.

Ninety percent of acquired stenoses are a result of endotracheal intubation. The narrowest portion of the pediatric larynx is the subglottic region because of the narrow cricoid cartilage. When the pressure of the endotracheal tube against the cricoid mucosa is greater than the capillary pressure, ischemia occurs, followed by necrosis and ulceration. Secondary infection and perichondritis develop with exposure of cartilage (Fig. 436.1). Granulation tissue forms around the ulcerations. These changes and edema throughout the larynx usually resolve spontaneously after extubation. Chronic edema and fibrous stenosis develop in only a small percentage of cases.

A number of factors predispose to the development of laryngeal stenosis. Laryngopharyngeal reflux of acid and pepsin from the stomach is known to exacerbate endotracheal tube trauma. More damage is caused in areas left unprotected, owing to loss of mucosa. Congenital subglottic stenosis narrows the larynx, which makes the patient more likely to develop acquired subglottic stenosis because significant injury is more likely to occur with use of an endotracheal tube of age-appropriate size. *Other risk factors for the development of acquired subglottic stenosis include sepsis, malnutrition, chronic inflammatory disorders, and immunosuppression.* An oversized endotracheal tube is the most common factor contributing to laryngeal injury. A tube that allows a small air leak at the end of the inspiratory cycle minimizes potential trauma. Other extrinsic factors—traumatic intubation, multiple reintubations, movement of the endotracheal tube, and duration of intubation—can contribute to varying degrees in individual patients.

CLINICAL MANIFESTATIONS

Symptoms of acquired and congenital stenosis are similar. Spasmodic croup, the sudden onset of severe croup in the early morning hours, is usually caused by laryngopharyngeal reflux with transient laryngospasm and subsequent laryngeal edema. These frightening episodes resolve rapidly, often before the family and child reach the emergency department. Other presentations can also involve neonates who fail extubation, despite multiple attempts, and children with permanent dyspnea, stridor, or dysphonia.

Fig. 436.1 Bronchoscopy in a 2-mo-old infant showing mucosal erosion and cartilage exposure in the subglottic region. The child was intubated with an age-appropriate tube but with an excess of air in the cuff. *(Courtesy Dr. Taher S. Valika, Division of Pediatric Otolaryngology, Ann & Robert H. Lurie Children's Hospital of Chicago.)*

DIAGNOSIS

The diagnosis can be made by posteroanterior and lateral airway radiographs. The gold standard to confirm the diagnosis is via direct laryngoscopy and bronchoscopy in the operating room. High-resolution CT imaging and ultrasonography are of limited value. This is similar to the workup associated with congenital subglottic stenosis.

TREATMENT

The severity, location, and type (cartilaginous or soft tissue) of the stenosis determine the treatment. Mild cases can be managed without operative intervention because the airway will improve as the child grows. Moderate soft tissue stenosis is treated by endoscopy using gentle dilations or CO_2 laser. Severe laryngotracheal stenosis is likely to require laryngotracheal reconstructive (expansion) surgery or resection of the narrowed portion of the laryngeal and tracheal airway (cricotracheal resection). Every effort is made to avoid tracheotomy using endoscopic techniques or open surgical procedures.

Fundamental knowledge of the airway can help reduce the incidence of stenoses. The use of age-appropriate tubes and cuffless tubes, treatment of gastroesophageal reflux, and reducing the duration of mechanical ventilation have led to an overall decrease in laryngotracheal stenoses in the past decade.

Visit Elsevier eBooks+ at eBooks.Health.Elsevier.com for Bibliography.

Chapter 437

Bronchomalacia and Tracheomalacia

Jonathan D. Finder

Tracheomalacia and bronchomalacia refer to *chondromalacia* of a central airway, leading to insufficient cartilage to maintain airway patency throughout the respiratory cycle. These are common causes of persistent wheezing in infancy. Tracheomalacia and bronchomalacia can be either primary or secondary (Table 437.1). Primary tracheomalacia and bronchomalacia are often seen in premature infants, although most affected patients are born at term. Secondary tracheomalacia and bronchomalacia refer to the situation in which the central airway is compressed by an adjacent structure (e.g., vascular ring; see Fig. 434.6) or is deficient in cartilage because of tracheoesophageal fistula (see Chapter 365). Bronchomalacia is common after lung transplantation, assumed to be secondary to the loss of bronchial artery supply leading to ischemia of the bronchial cartilage. This form of bronchomalacia may take months to

Table 437.1 Classification of Tracheomalacia

PRIMARY TRACHEOMALACIA
Congenital absence of tracheal-supporting cartilages
SECONDARY TRACHEOMALACIA
Esophageal atresia, tracheoesophageal fistula
Vascular rings (double aortic arch)
Tracheal compression from an aberrant innominate artery
Tracheal compression from mediastinal masses
Abnormally soft tracheal cartilages associated with connective tissue disorders
Prolonged mechanical ventilation, chronic lung disease

From McNamara VM, Crabbe DC. Tracheomalacia. *Paediatr Respir Rev.* 2004;5:147–154.

present after transplantation. Laryngomalacia can accompany primary bronchomalacia or tracheomalacia. Involvement of the entire central airway (laryngotracheobronchomalacia) is also seen.

CLINICAL MANIFESTATIONS

Primary tracheomalacia and bronchomalacia are principally disorders of infants, with a male:female ratio of 2:1. The dominant finding—low-pitched, monophonic wheezing heard predominantly during expiration—is most prominent over the central airways. Parents often describe persistent respiratory congestion even in the absence of a viral respiratory infection. When the lesion involves only one main bronchus (more commonly the left), the wheezing is louder on that side and there may be unilateral palpable fremitus. In cases of tracheomalacia, the wheeze is loudest over the trachea. Hyperinflation and/or subcostal retractions do not occur unless the patient has concurrent dysphagia with chronic aspiration, viral bronchiolitis, asthma, or other causes of peripheral airway obstruction. In the absence of asthma, patients with tracheomalacia and bronchomalacia are not helped by administration of a bronchodilator. Acquired tracheomalacia and bronchomalacia are seen in association with vascular compression (vascular rings, slings, and innominate artery compression) or in association with the loss of bronchial artery supply in lung transplantation. Persistent tracheomalacia is the rule after correction of tracheoesophageal fistula. Other causes of acquired tracheomalacia and bronchomalacia (especially left-sided) include cardiomegaly. The importance of the physical exam cannot be understated; one study found that pediatric pulmonologists made a correct assessment of malacia based on symptoms, history, and lung function before bronchoscopy in ~70% of cases. The cough in tracheomalacia and bronchomalacia can lead to collapse of the airway, which can lead to difficulty in airway clearance. The cough in tracheomalacia and bronchomalacia often has a barking, croupy quality. This can be managed in older patients with handheld positive expiratory pressure devices. Persistent cough in older children with tracheomalacia can cause irritation of the airway mucosa from the physical trauma and induce some degree of habitual cough.

DIAGNOSIS

Definitive diagnoses of tracheomalacia and bronchomalacia are established by flexible or rigid bronchoscopy (Fig. 437.1). The lesion is difficult to detect on plain radiographs. Although fluoroscopy can demonstrate dynamic collapse and avoid the need for invasive diagnostic techniques, it is poorly sensitive. Pulmonary function testing can show a pattern of decreased peak flow and flattening of the flow-volume loop. Other important diagnostic modalities include MRI and CT scanning. Dynamic airway assessment using three-dimensional CT reconstruction at end-inspiration and end-expiration can be diagnostic and avoid the need for invasive evaluation. MRI with angiography is especially useful when there is a possibility of vascular ring and should be performed when a right aortic arch is seen on plain film radiography.

TREATMENT

Postural drainage can help with clearance of secretions. β-Adrenergic agents *should be avoided* in the absence of asthma because they can exacerbate loss of airway patency due to decreased airway tone. Nebulized ipratropium bromide may be useful. Endobronchial stents have been used in severely affected patients but have a high incidence of complications, ranging from airway obstruction caused by granulation tissue to erosion into adjacent vascular structures. Continuous positive airway pressure via tracheostomy may be indicated for severe cases. A surgical approach (aortopexy and bronchopexy) is rarely required and only for patients who have life-threatening apnea, cyanosis, and bradycardia (cyanotic spells) from airway obstruction and/or who demonstrated vascular compression. Reports of creation and use of three-dimensional (3D) printed, bioresorbable external tracheobronchial stents in pediatric patients with life-threatening tracheobronchomalacia have shown great promise.

PROGNOSIS

Primary bronchomalacia and tracheomalacia have excellent prognoses because airflow improves as the child and the airways grow. Patients with primary airway malacia usually take longer to recover from common respiratory infections. Wheezing at rest usually resolves by age 3 years. Prolonged bacterial bronchitis has been reported as a complication of bronchomalacia. The prognosis in secondary and acquired forms varies with cause. Patients with concurrent asthma need considerable supportive treatment and careful monitoring of respiratory status.

Visit Elsevier eBooks+ at eBooks.Health.Elsevier.com for Bibliography.

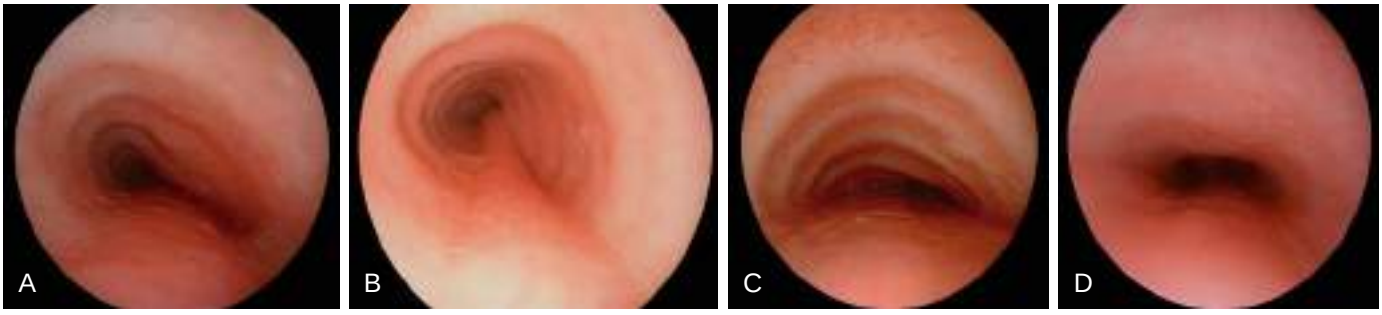

Fig. 437.1 Four examples of tracheomalacia appearances. **A,** Comma-shaped trachea caused by innominate artery compression requiring aortopexy. **B,** Bunched-up trachealis muscle and compressed trachea caused by a double aortic arch. **C,** Flattened trachea and increased trachealis diameter with a tracheoesophageal fistula in the posterior wall. **D,** Ovoid-shaped trachea from external compression by the innominate artery. *(From Deacon JWF, Widger J, Soma MA. Paediatric tracheomalacia—a review of clinical features and comparison of diagnostic imaging techniques. Int J Pediatr Otorhinolaryngol. 2017;98:75–81.)*

Chapter 438

Neoplasms of the Larynx, Trachea, and Bronchi

Saied Ghadersohi, Lauren D. Holinger, and James W. Schroeder Jr.

438.1 Vocal Nodules

Saied Ghadersohi and James W. Schroeder Jr.

Vocal nodules, which are not true neoplasms, are the most common cause of chronic hoarseness in children. Chronic vocal abuse or misuse (i.e., frequent yelling and screaming) produces localized vascular congestion, edema, hyalinization, and epithelial thickening in the bilateral vocal cords. This grossly appears as nodules that disrupt the normal vibration of the cords during phonation. Vocal abuse is the main factor, and the voice is worse in the evenings. The differential diagnosis can include unilateral lesions such as vocal cord cysts and polyps; however, these usually have an acute inciting event and are rarer in children.

Diagnosis is typically via laryngoscopy and stroboscopy to assess the characteristics of the bilateral nodules. Occasionally biopsy is needed in atypical-behaving/-appearing lesions. Treatment is primarily nonsurgical, with voice therapy used in children >4 years of age who can participate in therapy and clinical monitoring with behavioral therapy in younger children or those with developmental delay. In addition, laryngopharyngeal reflux commonly exacerbates vocal abuse–induced irritation of the cord; therefore antireflux therapy can also be implemented (see Chapter 369). Surgical excision of vocal cord nodules in children is controversial and is rarely indicated but may be necessary if the child is unable to communicate adequately, becomes aphonic, or requires tension and straining to make an utterance.

438.2 Recurrent Respiratory Papillomatosis

Saied Ghadersohi and James W. Schroeder Jr.

Papillomas are the most common respiratory tract neoplasms in children, occurring in 4.3 in 100,000. They are simply warts—benign tumors—caused by the human papillomavirus (HPV), most commonly types 6 and 11 (see Chapter 313). Seventy-five percent of recurrent respiratory papilloma (RRP) cases occur in children younger than age 5 years, but the diagnosis may be made at any age. In general, neonatal-onset disease is a poor prognostic factor with higher mortality and need for tracheostomy. Sixty-seven percent of children with RRP are born to mothers who had condylomas during pregnancy or parturition. The mode of HPV transmission is still not clear but is thought to be through exposure to HPV when traversing the birth canal of an infected mother. Other identified risk factors include first born, >10 hours of labor, and a young mother. However, HPV exposure is fairly common and RRP remains rare; additionally, in mothers with vaginal condylomata, only 1 in 231-400 vaginal births go on to develop respiratory papillomatosis. Therefore other risk factors contribute to transmission, and cesarean-section delivery for prevention cannot be recommended. However, preventive measures can include the prospective widespread use of the quadrivalent HPV vaccine to help eliminate maternal and paternal HPV reservoirs and possibly decrease cases of RRP caused by HPV-6 and -11.

CLINICAL MANIFESTATIONS

The clinical course involves remissions and exacerbations of recurrent papilloma, most commonly on the larynx (usually the vocal cords), causing progressively worsening hoarseness, sleep-disordered breathing, exertional dyspnea, stridor, and, if left untreated, eventually severe airway obstruction (Fig. 438.1). Although it is a benign disease, lesions can spread throughout the aerodigestive tract in 31% of patients, most commonly the oral cavity, trachea, and bronchi. Rarely these lesions can undergo malignant conversion (1.6%); however, some patients may have spontaneous remission. Patients may be initially diagnosed with asthma, croup, vocal nodules, or allergies.

Fig. 438.1 Laryngoscopic view of respiratory papillomas causing near-complete obstruction at glottic level. *(From Derkay CS, Wiatrak B. Recurrent respiratory papillomatosis: a review. Laryngoscope. 2008;118:1236–1245.)*

DIAGNOSIS AND TREATMENT

Diagnosis of RRP is via laryngoscopy and bronchoscopy. Biopsy should be obtained at the initial surgical intervention and regular intervals to rule out malignancy and to subtype the HPV, as it can affect prognosis. Treatment of RRP is endoscopic surgical removal with three goals. First, debulking/complete removal of the lesions; second, preservation of normal structures; and finally, prevention of scar formation in the affected areas. Most surgeons in North America prefer the microdebrider, although microsurgery, CO_2, and KTP laser techniques have been described. Despite these techniques, some form of adjunct therapy may be needed in up to 20% of cases. The most widely accepted indications for adjunct therapy are a need for more than four surgical procedures per year, rapid regrowth of papillomata with airway compromise, or distal multisite spread of disease. Adjunct therapies can be inhaled or administered intralesionally or systemically and include antiviral modalities (interferon, ribavirin, acyclovir, cidofovir), antiangiogenic agents such as bevacizumab (Avastin), photodynamic therapy, dietary supplement (indole-3-carbinol), nonsteroidal antiinflammatory drugs (COX-2 inhibitors, Celebrex), retinoids, and mumps vaccination.

Visit Elsevier eBooks+ at eBooks.Health.Elsevier.com for Bibliography.

438.3 Congenital Subglottic Hemangioma

Saied Ghadersohi and James W. Schroeder Jr.

See also Chapter 434.5.

Typically, congenital subglottic hemangiomas are symptomatic within the first 2 months of life, with almost all occurring before 6 months of age. Much like the cutaneous infantile hemangiomas, these lesions have two phases: a **proliferative phase** with rapid growth in the first 6 months of life and then they stabilize by 1 year and a slow **involution phase** typically by age 3. Patients present with usually inspiratory but sometimes biphasic stridor. The infant can have a barking cough and temporarily respond to steroids, similar to persistent croup. Fifty percent of congenital subglottic hemangiomas are associated

with facial lesions, but the converse is not true. Radiographs classically delineate an asymmetric subglottic narrowing. The diagnosis is made by direct laryngoscopy.

DIAGNOSIS AND TREATMENT

The diagnosis of subglottic hemangioma is based on history and laryngoscopic exam. MRI imaging with contrast can also be obtained to confirm the diagnosis of a vascular lesion. If the lesion does not respond to medical therapy, then biopsy (with GLUT1 staining; positive suggests hemangioma) may be indicated to rule out other vascular tumors. Subglottic hemangiomas are treated similarly to cutaneous hemangiomas (see Chapter 691). Propranolol is the first-line treatment of cutaneous and subglottic infantile hemangiomas. Typically, treatment is with 1-3 mg/kg/day of propranolol for 4-12 months (see Chapter 691). Prescreening patients with cardiology workup (i.e., electrocardiogram) is advised. Side effects include hypotension, bradycardia, bronchospasm, and hypoglycemia, which can be avoided by giving the medication with a feed.

There remains a role for systemic steroids, racemic epinephrine, and helium/oxygen treatment in the acute management of the airway and in lesions that are slow or nonresponsive to propranolol treatment (i.e., large hemangiomas with critical airway narrowing).

Surgical management is offered in severe cases or those not responsive to medical therapy. Interventions can range from intralesional steroid injection to avoid systemic steroid side effects, CO_2, or KTP laser endoscopic excision or open surgical excision, and ultimately as a last resort tracheostomy can establish a safe airway, allowing time for the lesion to involute per its natural course.

Visit Elsevier eBooks+ at eBooks.Health.Elsevier.com for Bibliography.

438.4 Vascular Malformations

Saied Ghadersohi and James W. Schroeder Jr.

Based on the International Society for the Study of Vascular Anomalies classification system, these lesions can be classified into vascular malformations and vascular tumors. The most common vascular tumors are infantile/subglottic hemangiomas. Vascular malformations are not true neoplastic lesions. They have a normal rate of endothelial turnover and various channel abnormalities. They are subcategorized based on high or low flow and by their predominant type (capillary, venous, arterial, lymphatic, or a combination thereof). Overall, vascular malformations are uncommon, and they rarely occur in the larynx and airway. When they do occur, they are often an extension from elsewhere in the head and neck. It should be noted that these lesions can expand with a viral upper respiratory infection or hemorrhage into the lesion. They can be diagnosed with direct visualization during laryngoscopy or bronchoscopy or seen on CT/MRI imaging. Treatment usually entails a tailored multidisciplinary team approach with early surgery, laser resection, or sclerotherapy.

Visit Elsevier eBooks+ at eBooks.Health.Elsevier.com for Bibliography.

438.5 Other Laryngeal Neoplasms

James W. Schroeder Jr. and Lauren D. Holinger

Neurofibromatosis (see Chapter 636.1) rarely involves the larynx. When children are affected, limited local resection is undertaken to maintain an airway and optimize the voice. Complete surgical extirpation is virtually impossible without debilitating resection of vital laryngeal structures. Most surgeons select the option of less aggressive symptomatic surgery because of the poorly circumscribed and infiltrative nature of these fibromas. **Rhabdomyosarcoma** (see Chapter 549) and other malignant tumors of the larynx are rare. Symptoms of hoarseness and progressive airway obstruction prompt initial evaluation by flexible laryngoscopy in the office.

438.6 Tracheal Neoplasms

Saied Ghadersohi, James W. Schroeder Jr., and Lauren D. Holinger

Tracheal tumors are extremely rare and include malignant and benign neoplasms; they may initially be misdiagnosed as asthma. The two most common benign tumors are inflammatory pseudotumor and hamartoma. The **inflammatory pseudotumor** is probably a reaction to a previous bronchial infection or traumatic insult. Growth is slow, and the tumor may be locally invasive. Hamartomas are tumors of primary tissue elements that are abnormal in proportion and arrangement.

Tracheal neoplasms manifest with stridor, wheezing, cough, or pneumonia and are rarely diagnosed until 75% of the lumen has been obstructed (Fig. 438.2). Chest radiographs or airway films can identify the obstruction. Pulmonary function studies demonstrate an abnormal flow-volume loop. A mild response to bronchodilator therapy may be misleading. Treatment is based on the histopathology.

Visit Elsevier eBooks+ at eBooks.Health.Elsevier.com for Bibliography.

438.7 Bronchial Tumors

Saied Ghadersohi and James W. Schroeder Jr.

Bronchial tumors are rare. In one series, carcinoid tumors were the most common, followed by mucoepidermoid and inflammatory pseudotumors. These patients can present with persistent pneumonia despite adequate treatment. The diagnosis is confirmed at bronchoscopy and biopsy; treatment depends on the histopathology.

Visit Elsevier eBooks+ at eBooks.Health.Elsevier.com for Bibliography.

Fig. 438.2 CT scan of the trachea with a circumscribed intraluminal tracheal mass *(arrow)* in the tracheal wall. *(From Venizelos I, Papathomas T, Anagnostou E, et al. Pediatric inflammatory myofibroblastic tumor of the trachea: a case report and review of the literature. Pediatr Pulmonol. 2008;43:831–835.)*

Chapter 439
Wheezing, Bronchiolitis, and Bronchitis

439.1 Wheezing in Infants: Bronchiolitis

Samantha A. House and Shawn L. Ralston

Wheezing, the production of a musical continuous sound that originates in narrowed airways, is heard on expiration as a result of airway obstruction. Infants are more likely to wheeze than are older children as a result of differing lung mechanics. Obstruction of airflow is affected by both airway size and compliance of the infant lung. Resistance to airflow through a tube is inversely related to the radius of the tube to the fourth power. In children younger than 5 years, small-caliber peripheral airways can contribute up to 50% of the total airway resistance. Marginal additional narrowing, such as that caused by inflammation related to viral infection, is then more likely to result in wheezing.

Infant chest wall compliance is also quite high; thus the inward pressure produced in normal expiration subjects the intrathoracic airways to collapse. Differences in tracheal cartilage and airway smooth muscle tone increase the collapsibility of the infant airways in comparison with older children. These mechanisms combine to make the infant more susceptible to airway obstruction, increased resistance, and subsequent wheezing. The mechanical portion of the infant propensity to wheeze resolves with normal growth and muscular development.

Although wheezing in infants most frequently results from inflammation due to acute viral infections, there are many potential causes of wheezing (Table 439.1).

Acute Bronchiolitis

Acute bronchiolitis is a diagnostic term used to describe the clinical picture produced by multiple different viral lower respiratory tract infections in infants and very young children. The respiratory findings observed in bronchiolitis include tachypnea, wheezing, crackles, and rhonchi, which result from inflammation of the small airways (Fig. 439.1). Despite its commonality, a universal set of diagnostic criteria for bronchiolitis does not exist, with significant disagreement about the upper age limit for appropriate use of the diagnosis. Some clinicians restrict the term to children younger than 1 year, and others extend it to the age of 2 years or beyond.

The pathophysiology of acute bronchiolitis is characterized by bronchiolar obstruction with edema, mucus, and cellular debris (see Fig. 439.1). Resistance in the small air passages is increased during both inspiration and exhalation, but because the radius of an airway is smaller during expiration, the resultant respiratory obstruction leads to expiratory wheezing, air trapping, and lung hyperinflation. If obstruction becomes complete, trapped distal air will be resorbed and the child will develop atelectasis. Hypoxemia may result from ventilation-perfusion mismatch. Hypercapnia may develop with severe obstructive disease.

Respiratory syncytial virus (RSV) is responsible for more than 50% of cases of bronchiolitis. Other causal agents include human metapneumovirus, rhinovirus, parainfluenza, influenza, coronavirus, bocavirus, and adenovirus, among others. Viral *co-infection* can occur; the impact of co-infection on severity and clinical manifestations of bronchiolitis remains unclear. Respiratory viruses can be identified in more than one third of asymptomatic patients younger than the age of 1 year, calling into question the specificity of nucleic acid amplification tests for active infection with some viruses. Although bacterial pneumonia is sometimes confused clinically with bronchiolitis, viral bronchiolitis is only rarely followed by bacterial superinfection.

Over 100,000 young children are typically hospitalized annually in the United States with the diagnosis of bronchiolitis, making it the most common diagnosis resulting in hospitalization for children younger than 1 year of age in the United States over the past several decades. Hospitalization rates have been relatively stable in pre–COVID-19 pandemic years despite introduction and routine use of RSV immunoprophylaxis in selected high-risk populations. Nonetheless, variants of COVID-19 have been associated with a bronchiolitis-like syndrome. In addition, a robust RSV surge was observed in the late-pandemic period. Co-infection with COVID-19 has been observed,

Table 439.1 Differential Diagnosis and Etiologies of Wheezing in Infancy

INFECTION
Viral
Respiratory syncytial virus
Human metapneumovirus
Parainfluenza
Adenovirus
Influenza
Rhinovirus
Bocavirus
Coronavirus, including COVID-19 variants
Enterovirus
Other
Chlamydia trachomatis
Tuberculosis
Histoplasmosis
Papillomatosis
ASTHMA
ANATOMIC ABNORMALITIES
Central Airway Abnormalities
Malacia of the larynx, trachea, and/or bronchi
Laryngeal or tracheal web
Tracheoesophageal fistula (specifically H-type fistula)
Laryngeal cleft (resulting in aspiration)
Extrinsic Airway Anomalies Resulting in Airway Compression
Vascular ring or sling
Mediastinal lymphadenopathy from infection or tumor
Mediastinal mass or tumor
Esophageal foreign body
Intrinsic Airway Anomalies
Airway hemangioma or other tumor
Congenital pulmonary airway malformation (cystic adenomatoid malformation)
Bronchial or lung cyst
Congenital lobar emphysema
Aberrant tracheal bronchus
Sequestration
Congenital heart disease with left-to-right shunt (increased pulmonary edema)
Foreign body
Immunodeficiency States
Immunoglobulin A deficiency
B-cell deficiencies
AIDS
Bronchiectasis
MUCOCILIARY CLEARANCE DISORDERS
Cystic fibrosis
Primary ciliary dyskinesia
Bronchiectasis
ASPIRATION SYNDROMES
Gastroesophageal reflux disease
Pharyngeal/swallow dysfunction
OTHER
Bronchopulmonary dysplasia
Eosinophilic granulomatosis with polyangiitis
Interstitial lung disease, including bronchiolitis obliterans
Heart failure
Anaphylaxis
Inhalation injury—burns

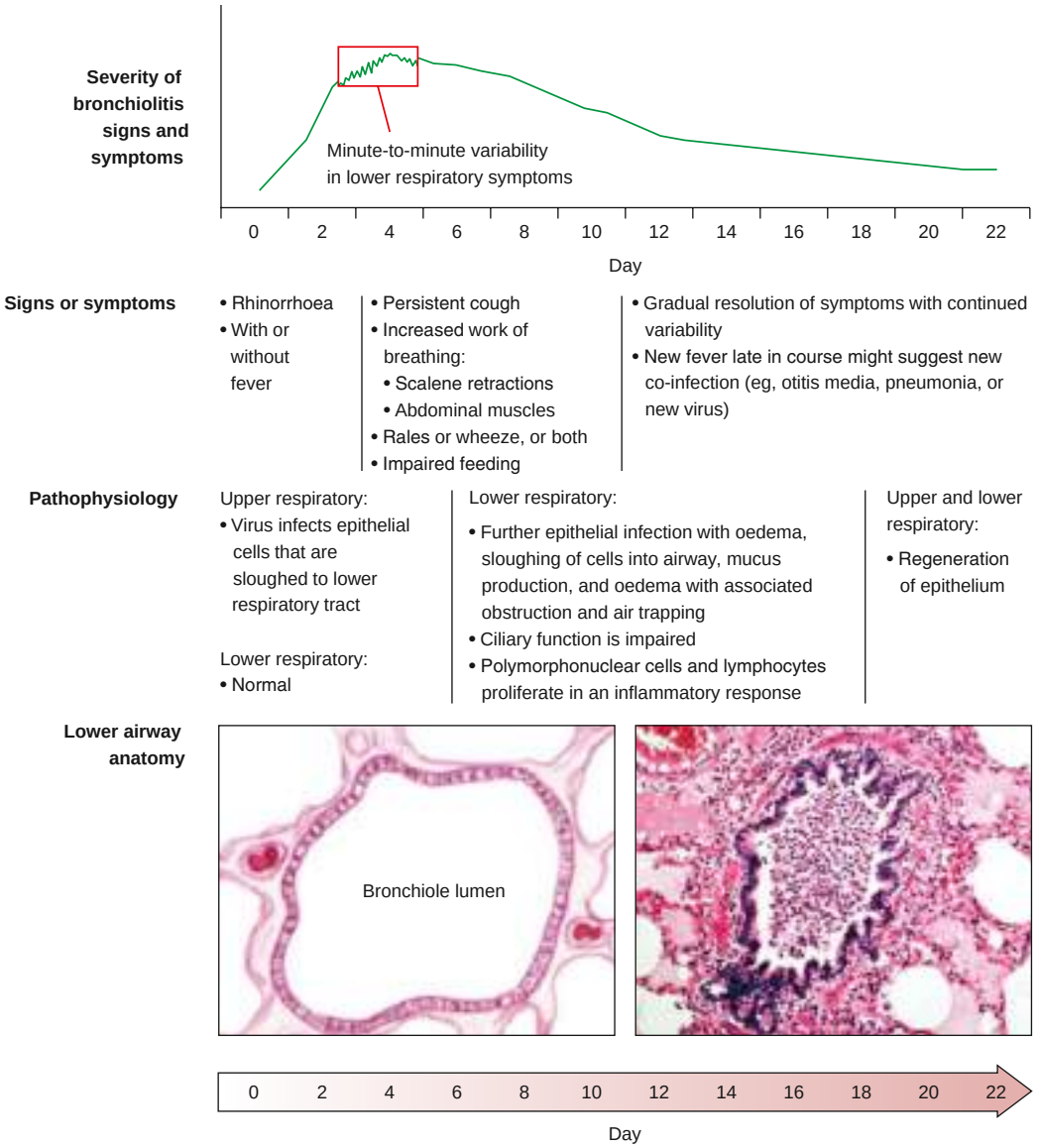

Fig. 439.1 Typical clinical course and pathophysiology of viral bronchiolitis. *(From Florin TA, Plint PC, Zorc JJ. Viral bronchiolitis. Lancet. 2017;389:211–224, Fig. 1.)*

but its implications on disease presentation and severity are not well characterized.

Bronchiolitis is more common in males, those exposed to secondhand tobacco smoke, those who have not been breastfed, and those living in crowded conditions. The risk is also higher for infants with mothers who smoked during pregnancy. Older family members, including older siblings, are a common source of infection; they might experience only minor upper respiratory symptoms (colds) given that bronchiolar edema may be less clinically apparent as airway size increases.

Asthma (see Chapter 185) is another important cause of wheezing, and the possibility of this diagnosis complicates the treatment of young children with bronchiolitis, although diagnosing asthma in the very young can be difficult. In prospective, longitudinal population cohort studies of infants, up to half of the cohort experienced a wheezing illness before school age, although when followed into adulthood only about 5–8% of patients prove to have asthma. In the largest U.S. cohort, three patterns of infant wheezing were proposed: transient early wheezing, comprising about 20% of the cohort, characterized by lower lung function at birth that improves with growth, resulting in resolution of wheezing by age 3; persistent wheezing, comprising about 14% of the cohort, characterized by declining lung function and wheezing before and after age 3; and late-onset wheezing, comprising 15% of the cohort, characterized by relatively stable lung function and wheezing that does not begin until after age 3. The remaining 50% of the population did not suffer a wheezing illness. Following the cohort into adulthood revealed continued declines in the rates of persistent symptoms. Similar patterns are also seen in birth cohort studies in other countries.

Multiple studies attempting to predict which infants suffering from early wheezing illnesses will go on to have asthma in later life have failed to achieve discriminant validity. Interestingly, in both U.S. and UK prospective cohorts, wheezing with an onset *after* the first 18-36 months of life is one of the strongest predictors of eventual asthma in both cohorts. Other proposed risk factors for persistent wheezing include parental history of asthma and allergies, maternal smoking, persistent rhinitis (apart from acute upper respiratory tract infections), allergen sensitization, eczema, and peripheral eosinophilia, although no single factor is strongly discriminative. There is no evidence that early administration of systemic or inhaled corticosteroids to high-risk populations can prevent the development of asthma.

Table 439.2 Pertinent Medical History in the Wheezing Infant

Did the onset of symptoms begin at birth or thereafter?
Is the infant a noisy breather, and when is it most prominent?
Is the noisy breathing present on inspiration, expiration, or both?
Is there a history of cough apart from wheezing?
Was there an earlier lower respiratory tract infection?
Is there a history of recurrent upper or lower respiratory tract infections?
Have there been any emergency department visits, hospitalizations, or intensive care unit admissions for respiratory distress?
Is there a history of eczema?
Does the infant cough after crying or cough at night?
How is the infant growing and developing?
Is there associated failure to thrive?
Is there a history of electrolyte abnormalities?
Are there signs of intestinal malabsorption, including frequent, greasy, or oily stools?
Is there a maternal history of genital herpes simplex virus infection?
What was the gestational age at delivery?
Was the patient intubated as a neonate?
Does the infant bottle-feed in the bed or the crib, especially in a propped position?
Are there any feeding difficulties, including choking, gagging, arching, or vomiting with feeds?
Is there any new food exposure?
Is there a toddler in the home or lapse in supervision in which foreign body aspiration could have occurred?
Is there a change in caregivers or a chance of nonaccidental trauma?

Clinical Manifestations

The initial history of a wheezing infant should explore the onset, duration, and associated factors (Table 439.2), as well as *birth history* (weeks of gestation, neonatal complications including history of intubation or oxygen requirement, maternal complications) and prenatal smoke exposure. Past medical history, including any comorbid conditions, should be assessed. *Family history* of cystic fibrosis, immunodeficiencies, asthma in a first-degree relative, or any other recurrent respiratory conditions in children should be obtained. *Social history* should include any tobacco or other smoke exposure, daycare exposure, number of siblings, pets, and concerns regarding the home environment (e.g., dust mites, construction dust, heating and cooling techniques, mold, cockroaches). The patient's growth chart should be reviewed for signs of failure to thrive.

Acute bronchiolitis is usually preceded by exposure (daycare, preschool, siblings) to contacts with a minor respiratory illness within the previous week (see Fig. 439.1). The infant first develops signs of upper respiratory tract infection with sneezing and clear rhinorrhea. This may be accompanied by diminished appetite and fever. Gradually, respiratory distress ensues, with paroxysmal cough, dyspnea, and irritability. The infant is often tachypneic, which can interfere with feeding. Though rare, apnea may occur in very young infants and may precede lower respiratory signs early in the disease. Infants at a postconceptual age of <44 weeks are at highest risk for *apneic* events, with premature birth providing an additional risk factor.

On physical examination, evaluation of the patient's vital signs with special attention to the respiratory rate and oxygen saturation is an important initial step. The exam is often dominated by wheezing and crackles. Expiratory time may be prolonged. Work of breathing may be markedly increased, with nasal flaring and retractions. *Complete obstruction to airflow can eliminate the turbulence that causes wheezing; thus the lack of audible wheezing is not reassuring if the infant shows other signs of respiratory distress.* Poorly audible breath sounds suggest severe disease with nearly complete bronchiolar obstruction.

Diagnostic Evaluation

Evaluation of wheezing in infancy and early childhood depends on suspected etiology. The diagnosis of **acute bronchiolitis** is clinical and should be considered in an infant presenting with a first episode of wheezing after a period of upper respiratory symptoms. Chest radiography is not routinely indicated in children with suspected bronchiolitis. Areas of atelectasis associated with bronchiolitis are often observed on chest radiographs and may be difficult to distinguish from bacterial pneumonia; as a result, obtaining chest radiography in a patient whose clinical course and exam are consistent with bronchiolitis may lead to unnecessary antibiotic use. Laboratory testing is also not routinely indicated; the white blood cell and differential counts are usually normal and are not predictive of bacterial superinfection. Viral testing (polymerase chain reaction or rapid immunofluorescence) is not routinely recommended in the diagnosis of bronchiolitis but may be helpful if such testing prevents more invasive evaluations or treatments. Concurrent serious bacterial infection (sepsis, pneumonia, meningitis) is unlikely, although confirmation of viral bronchiolitis may obviate the need for a sepsis evaluation in the young febrile infant. Otitis media may complicate bronchiolitis.

For young children with wheezing in whom the presentation does not clinically fit with the diagnosis of bronchiolitis, including those without other signs of viral infection, with very severe presentation, or with a complicated clinical course, further workup should be considered and should be dictated by individual clinical context. Children with recurrent or refractory episodes of wheezing in infancy, particularly if associated with failure to thrive, may require evaluation for chronic disorders such as cystic fibrosis or immunodeficiency.

Treatment

The treatment of children with viral bronchiolitis is supportive management. Those who are experiencing hypoxia, respiratory distress (inability to feed, extreme tachypnea, or significantly increased work of breathing), or apnea should be hospitalized. Risk factors for severe disease include younger age, preterm birth, or underlying comorbidity. Hypoxemic children should receive supplemental oxygen. There is a developing consensus surrounding target oxygen saturations; national guidelines in the United States propose a threshold of 90%. Oxygen can be administered via a number of delivery devices, and some children with severe disease may require positive pressure ventilation. High-flow nasal oxygen cannula (HFNC) use has become common, though studies to date have failed to demonstrate a consistent benefit on clinical outcomes. Despite an apparent stabilization with HFNC, such therapy has not consistently shortened the length of hospital stay or duration of oxygen therapy. Continuous pulse oximetry monitoring can be discontinued once patients are no longer requiring supplemental oxygen and are clinically improving.

Some children may also require support with supplemental hydration. Fluid can be administered intravenously or enterally via nasogastric tube, with some preference given to the latter because of an association between better outcomes with continued provision of enteral nutrition. If intravenous fluids are administered, care should be taken to use isotonic fluids because of the risk of hyponatremia. Frequent suctioning of nasal and oral secretions often provides relief of distress and improves work of breathing and ability to feed, although this should be limited to the nares or oropharynx because deep tracheal suctioning does not provide additional benefit and may cause harm. Chest physiotherapy has been extensively evaluated and provides *no benefit* to children with bronchiolitis.

Pharmacologic agents have largely proven *ineffective* in the management of bronchiolitis. Multiple systematic reviews and meta-analyses have failed to demonstrate any impact on clinical outcomes with use of albuterol or corticosteroids in bronchiolitis; neither are currently recommended for management. Response to bronchodilators is unlikely and unpredictable in children younger than 1 year. The use of inhaled or oral steroids in very young children with wheezing has not been shown to affect the disease trajectory or prevent the progression of childhood wheezing or development of asthma. There is debate over the use of

inhaled hypertonic saline in children with bronchiolitis, although most studies and meta-analyses fail to demonstrate any major benefit. Racemic epinephrine has not been found to improve the length of stay or clinical outcomes among inpatients with bronchiolitis, although there is some evidence to suggest that it may reduce the risk of hospitalization when used in the outpatient setting. Ribavirin, the only currently available antiviral medication targeting RSV, is also *not* currently recommended because of minimal impact on disease outcomes and because it is costly, difficult to administer, and associated with important toxicities.

PROGNOSIS

Infants with acute bronchiolitis are generally considered to be at highest risk for further respiratory compromise in the first 72 hours after onset of cough and dyspnea. The case fatality rate is <1% in developed countries, with death attributable to respiratory arrest and/or failure or severe dehydration and electrolyte disturbances. *A majority of deaths caused by bronchiolitis occur in children with complex medical conditions or comorbidities such as bronchopulmonary dysplasia, congenital heart disease, or immunodeficiency.* The median duration of symptoms in ambulatory patients is approximately 14 days; 10% may be symptomatic for 3 weeks. Severe lower respiratory tract infection at an early age has been identified as a possible risk factor for the development of asthma, although most children with early childhood wheezing will not go on to suffer from asthma. It is unclear whether viral infections causing bronchiolitis incite an immune response that manifests as asthma later in life or whether those infants have an inherent predilection for asthma that is first manifested as viral bronchiolitis.

PREVENTION (See also Chapter 307)

Meticulous hand hygiene is the best measure to prevent transmission of the viruses responsible for bronchiolitis. Nirsevimab, a one dose long-acting monoclonal antibody, is approved for prevention of RSV infection in newborns and infants. Nirsevimab is indicated for infants < 8 months of age born during or entering their first RSV season (in the continental US this may be October to March, although there may be regional differences), including those previously recommended to receive palivizumab (which is not given). Nirsevimab dose in the first RSV season is 50 mg if < 5 kg and 100 mg in infants ≥ 5 kg. In addition, older infants (8-19 months) who are at increased risk of severe RSV infection entering their second RSV season should also receive nirsevimab. These older infants include those with:

- Chronic lung disease of prematurity that requires chronic steroid or diuretic therapy or supplemental oxygen
- Severe immunocompromising conditions
- Cystic fibrosis with severe lung disease or poor weight gain
- American Indian and Alaska Native

The single dose of nirsevimab in the second RSV season is 200 mg given as two 100 mg injections in different sites. Nirsevimab may be co-administered with other routine childhood immunizations. Because of the availability of nirsevimab, immunization of high-risk populations with palivizumab is no longer recommended even if they received palivizumab in the previous RSV season.

In addition to immunization after birth, there is an FDA-approved maternal vaccine to prevent neonatal and infant RSV infections. The one dose vaccine (bivalent RSV prefusion F protein) is approved for use in women between 32-36 weeks' gestation. Nirsevimab is the only recommended approach to RSV prevention by the ACIP (CDC) and the AAP.

Visit Elsevier eBooks+ at eBooks.Health.Elsevier.com for Bibliography.

439.2 Bronchitis

Samantha A. House and Shawn L. Ralston

Nonspecific bronchial inflammation is termed *bronchitis* and can occur in multiple childhood conditions. Acute bronchitis is a clinical syndrome, usually viral in origin, with cough as a prominent feature. *Acute tracheobronchitis* is a term used when the trachea is prominently involved, such as with pertussis, parainfluenza, or diphtheria.

ACUTE BRONCHITIS

Acute bronchitis often follows a viral upper respiratory tract infection. It is more common in the winter when respiratory viral syndromes predominate. The tracheobronchial epithelium is invaded by the infectious agent, leading to activation of inflammatory cells and release of cytokines. Constitutional symptoms, including fever and malaise, follow. The tracheobronchial epithelium can become damaged or hypersensitized, leading to a protracted cough lasting 1-3 weeks.

The child first presents with nonspecific upper respiratory infectious symptoms, such as rhinitis. Three to four days later, a frequent, hacking cough develops, which may or may not be productive. After several days, the sputum can become purulent, indicating leukocyte migration but not necessarily bacterial infection. Many children swallow their sputum, which can produce emesis. Chest pain may be a prominent complaint in older children and is exacerbated by coughing. The mucus gradually thins, usually within 5-10 days, and then the cough gradually abates. The entire episode usually lasts about 2 weeks and seldom longer than 3 weeks.

Findings on physical examination vary with the age of the patient and stage of the disease. Early findings include no or low-grade fever and upper respiratory signs such as nasopharyngitis, conjunctivitis, and rhinitis. Auscultation of the chest may be unremarkable at this early phase. As the syndrome progresses and cough worsens, breath sounds become coarse, with coarse and fine crackles and scattered wheezing possible. Chest radiographs may be normal or may demonstrate increased bronchial markings.

The principal objective of the clinician is to exclude bacterial illnesses requiring antibiotic treatment, such as pneumonia, pertussis, or bacterial tracheitis. Obtaining sputum can be difficult in young children, and isolation of bacteria may not always indicate infection; thus sputum cultures are not generally recommended outside of specific diseases such as cystic fibrosis. Absence of vital sign abnormalities (tachycardia, tachypnea, fever) and a normal physical examination of the chest reduce the likelihood of pneumonia.

Differential Diagnosis

Persistent or recurrent symptoms should lead the clinician to consider entities other than acute bronchitis. Many entities manifest with cough as a prominent symptom (Table 439.3).

Table 439.3 Disorders with Cough as a Prominent Finding

CATEGORY	DIAGNOSES
Inflammatory	Asthma
Chronic pulmonary processes	Bronchopulmonary dysplasia Postinfectious bronchiectasis Cystic fibrosis Tracheomalacia or bronchomalacia Primary ciliary dyskinesia Other chronic lung diseases
Other chronic disease or congenital disorders	Laryngeal cleft Swallowing disorders Gastroesophageal reflux Airway compression (such as a vascular ring or hemangioma) Congenital heart disease
Infectious or immune disorders	Immunodeficiency Eosinophilic lung disease Tuberculosis Allergy Sinusitis Tonsillitis or adenoiditis *Chlamydia, Ureaplasma* (infants) *Bordetella pertussis* *Mycoplasma pneumoniae*
Acquired	Foreign body aspiration, tracheal or esophageal

Treatment

There is no specific therapy for acute bronchitis. The disease is typically a response to a viral infection and is self-limited. Antibiotics, although often prescribed, do not hasten improvement. Frequent shifts in position can facilitate pulmonary drainage in infants. Older children are sometimes more comfortable with humidity, but this does not shorten the disease course. Cough suppressants are contraindicated in the youngest children, and although they may relieve symptoms, they can also increase the risk of superinfection and therefore should be used judiciously. Antihistamines and expectorants are not indicated. Nonprescription cough and cold medicines should not be used in children younger than 4 years of age, and their use is cautioned in children age 4-11 years.

CHRONIC BRONCHITIS

Chronic bronchitis is well recognized in adults, formally defined as 3 months or longer of productive cough each year for 2 or more years. The disease can develop insidiously, with episodes of acute obstruction alternating with quiescent periods. Some predisposing conditions can lead to progression of airflow obstruction or chronic obstructive pulmonary disease, with smoking as the major factor (up to 80% of patients have a smoking history). Other conditions include air pollution, occupational exposures, and repeated infections.

The applicability of this definition to children is unclear. The existence of chronic bronchitis as a distinct entity in children is controversial. Like adults, children with chronic inflammatory diseases or those with toxic exposures can develop damaged pulmonary epithelium. Thus chronic or recurring cough in children should lead the clinician to search for underlying pulmonary or systemic disorders (see Table 439.3). One proposed entity that shares characteristics with asthma and other forms of suppurative lung disease is persistent or protracted bacterial bronchitis. Protracted bacterial bronchitis is defined as three or more of the following criteria: (1) continuous wet or productive cough >4 weeks, (2) no signs or symptoms to suggest other causes, and (3) cough resolves with appropriate course of oral antibiotics.

CIGARETTE SMOKING AND AIR POLLUTION

Exposure to environmental irritants, such as tobacco smoke and air pollution, can incite or aggravate cough. There is a well-established association between tobacco exposure and pulmonary disease, including bronchitis and wheezing. This can occur through cigarette smoking or by exposure to secondhand smoke. Marijuana smoke, electronic cigarettes, and other inhalants are irritants sometimes overlooked when eliciting a history.

A number of pollutants compromise lung development and likely precipitate lung disease, including particulate matter, ozone, acid vapor, and nitrogen dioxide. Proximity to motor vehicle traffic is an important source of these pollutants. Because these substances coexist in the atmosphere, the relative contribution of any one to pulmonary symptoms is difficult to discern.

Visit Elsevier eBooks+ at eBooks.Health.Elsevier.com for Bibliography.

Chapter 440

Plastic Bronchitis

Brett J. Bordini

Plastic bronchitis is a rare condition characterized by recurrent episodes of airway obstruction secondary to the formation of large proteinaceous branching casts that take on the shape of and obstruct the tracheobronchial tree. It is not a single disease entity, but rather represents a state of altered respiratory epithelial function and is most frequently encountered in the setting of underlying pulmonary or cardiac disease, although plastic bronchitis may also arise in lymphatic disorders, pulmonary infections, and the acute chest syndrome of sickle cell disease (Table 440.1). In comparison with the smaller bronchial and bronchiolar casts seen with mucus plugging, the lesions of plastic bronchitis are more extensive, with casts that can outline large segments of the airway to the level of the terminal bronchioles (Fig. 440.1). These casts may be spontaneously expectorated or may require bronchoscopic removal for relief of potentially fatal airway obstruction. Cast composition varies, although it typically consists of either a fibrin-predominant or mucin-predominant laminated matrix with or without inflammatory cell infiltration. Plastic bronchitis may be classified according to an associated disease, the cast histology, or a combination.

Table 440.1 Conditions Associated with Plastic Bronchitis

PROVEN CONDITIONS
Congenital heart disease with Fontan physiology
Pulmonary lymphatic anomalies
Influenza A pulmonary infection
Adenovirus infection
Mycoplasma pneumoniae infection
POSSIBLE CONDITIONS
Toxic inhalation
Sickle cell acute chest syndrome
Hypersecretory and near-fatal asthma (eosinophilic casts)
Noonan syndrome
UNLIKELY AND UNPROVEN CONDITIONS
Bacterial pneumonia
Bronchiectasis
Cystic fibrosis
Chronic obstructive pulmonary disease
Nephrotic syndrome

Modified from Rubin BK. Plastic bronchitis. *Clin Chest Med.* 2016;37:405–408, Box 1.

Fig. 440.1 Tracheobronchial casts after bronchoscopic extraction. Casts show branched architecture corresponding to the bronchial tree. *(From Corrin B, Nicholson AG. Pathology of the Lungs, 3rd ed. London: Churchill Livingstone; 2011: Fig. 3.20.)*

EPIDEMIOLOGY

Plastic bronchitis is rare, with an estimated prevalence of 6.8 cases per 100,000 pediatric patients. Prevalence varies according to the underlying associated disease with rates as high as 14% in patients who have undergone staged palliation of complex congenital heart disease and much lower rates in patients with asthma and atopic disease. A slight male predominance exists for cast formation in the setting of structural heart disease, whereas cast formation in the setting of asthma and atopic disease demonstrates a female predominance. Children with single-ventricle Fontan physiology are at high risk for developing plastic bronchitis.

PATHOGENESIS

The mechanism of cast formation is unclear, although it is believed to vary based on the underlying disease association and cast type. One

classification system differentiates type 1 inflammatory casts, composed primarily of fibrin with neutrophilic or, more often, eosinophilic infiltration, and type 2 acellular casts, composed primarily of mucin with little to no cellular infiltration. Type 1 casts tend to be associated with inflammatory and infectious disorders of the lung, whereas type 2 casts tend to be associated with surgically palliated structural heart disease, particularly single-ventricle lesions. However, these distinctions are not absolute; patients with structural heart disease can have fibrin-predominant casts, and patients with asthma or atopic disease can have mucin-predominant casts, with both mucin casts and fibrin casts demonstrating various degrees of cellular infiltration.

Cast formation in the setting of structural heart disease may result from alterations in pulmonary blood flow or lymphatic drainage, particularly after staged surgical palliation. Under these circumstances, increased central venous pressure is believed to compromise the integrity of the bronchial mucosa, impeding lymphatic flow and resulting in the development of collateral lymphatic vessels and potentially of lymphoalveolar fistulae that may exude proteinaceous material into the airway lumen.

CLINICAL MANIFESTATIONS

Patients with plastic bronchitis may present with cough, dyspnea, wheeze, or pleuritic chest pain. Depending on the degree of airway obstruction, patients may be hypoxemic or in severe respiratory distress. The expectoration of large, branched casts that are often tan in color and rubbery in consistency is pathognomonic for plastic bronchitis. Lung examination may reveal diminished breath sounds or wheezing in the affected area. Rarely, auscultation may reveal a sound similar to a flag flapping in the wind *(bruit de drapeau)*, believed to be related to the free end of a cast striking the bronchial wall during inspiration or expiration. Further examination may provide clues to underlying comorbidities.

DIAGNOSIS

The expectoration or endoscopic discovery of large tracheobronchial casts is pathognomonic for plastic bronchitis. History should be directed at assessing for conditions known to have an associated risk of tracheobronchial cast formation, such as uncorrected or surgically palliated complex congenital heart disease (Fontan physiology); a history of atopic disease or asthma; lymphatic disorders such as Noonan syndrome, Turner syndrome, lymphangiectasia, and yellow nail syndrome; sickle cell disease; and infectious exposures, particularly to tuberculosis, adenovirus, influenza, or atypical mycobacteria. Other predisposing conditions include cystic fibrosis, allergic bronchopulmonary aspergillosis, bronchiectasis, toxic inhalants, and granulomatous lung diseases.

Physical examination may provide indications of an underlying diagnosis. Digital clubbing of the fingers or toes may suggest long-standing hypoxemia associated with cardiac or pulmonary disease. Cardiac examination may provide information suggesting the presence of unrecognized structural heart disease.

Chest radiography may demonstrate collapse of the involved areas of the lung or areas of bronchiectasis distal to sites of long-standing obstruction.

There should be a high index of suspicion for plastic bronchitis in patients with known comorbidities who present with sudden respiratory decompensation. In the absence of cast expectoration, direct visualization of casts via bronchoscopy is required for diagnosis and is potentially therapeutic in relieving airway obstruction. Cast histology should be defined to allow for specific therapies directed at alleviating residual obstruction or preventing recurrence. In particular, the predominant component of the cast's laminated matrix—either fibrin or mucin—should be defined, and signs of inflammation or infiltration, such as the presence of neutrophils, eosinophils, or Charcot-Leyden crystals, should be documented.

TREATMENT

Treatment is directed at correcting the underlying condition associated with the development of plastic bronchitis, at relieving acute airway obstruction secondary to the presence of casts, and at preventing the development of further casts. Rigid or flexible bronchoscopy is typically required for cast removal, and if the predominant content of the cast is known, therapy with either fibrinolytics such as tissue plasminogen activator or mucolytics such as *N*-acetylcysteine or deoxyribonuclease may be considered as an adjunct to direct removal. Aerosolized heparin or mucolytics have also been used for treatment or prevention of recurrence, with varying success.

In the setting of inflammatory airway disease, additional preventive measures include inhaled or systemic corticosteroids, low-dose azithromycin, and leukotriene inhibitors to minimize airway inflammation. Bronchodilators have not been shown to prevent cast formation or aid in their removal, though may be used in the setting of concomitant bronchospasm.

In patients with surgically palliated complex congenital heart disease, measures aimed at decreasing central venous pressure, such as sildenafil or Fontan conduit fenestration, have had varied success. Lymphangiography may be undertaken to identify aberrant lymphatic vessels contributing to plastic bronchitis in the setting of congenital heart disease or lymphangitic disorders. MRI-guided selective lymphatic embolization of these channels has led to resolution of plastic bronchitis while preserving central lymphatic flow. Thoracic duct ligation has been helpful in patients in whom selective embolization has failed. Mammalian target of rapamycin (mTOR) inhibitors such as sirolimus have been used to treat lymphatic malformations, with varying success. Octreotide and low-fat diets have demonstrated modest success in adult patients. Cardiac transplantation typically results in resolution of plastic bronchitis in the setting of repaired complex congenital heart disease.

COMPLICATIONS AND PROGNOSIS

Prognosis is related primarily to the underlying condition associated with the development of plastic bronchitis. Patients whose plastic bronchitis is related to surgically palliated complex congenital heart disease are at high risk for plastic bronchitis–related mortality. Mortality can be high if casts obstruct significant portions of the airway, regardless of underlying etiology. Mortality estimates vary from 6% to 50% in the setting of asthma or atopic disease and from 14% to 50% in the setting of complex congenital heart disease, with central airway obstruction leading to death in the majority of patients.

Visit Elsevier eBooks+ at eBooks.Health.Elsevier.com for Bibliography.

Chapter 441

Emphysema and Overinflation

Steven R. Boas and Vicki K. Masson

Pulmonary emphysema consists of distention of air spaces with irreversible disruption of the alveolar septa. It can involve part or all of a lung. **Overinflation** is distention with or without alveolar rupture and is often reversible. **Compensatory overinflation** can be acute or chronic and occurs in normally functioning pulmonary tissue when, for any reason, a sizable portion of the lung is removed or becomes partially or completely airless, which can occur with pneumonia, atelectasis, empyema, and pneumothorax. **Obstructive overinflation** results from partial obstruction of a bronchus or bronchiole, when it becomes more difficult for air to leave the alveoli than to enter. Air gradually accumulates distal to the obstruction, the so-called *bypass, ball-valve,* or *check-valve* type of obstruction.

LOCALIZED OBSTRUCTIVE OVERINFLATION

When a ball-valve type of obstruction partially occludes the main stem bronchus, the entire lung becomes overinflated; individual lobes are affected when the obstruction is in lobar bronchi. Segments or subsegments are affected when their individual bronchi are blocked. When most or all of a lobe is involved, the percussion note is hyperresonant over the area and the breath sounds are decreased in intensity. The distended lung can extend across the mediastinum into the opposite hemithorax. Under fluoroscopic scrutiny during exhalation, the overinflated area does not decrease and the heart and the mediastinum shift to the opposite side because the unobstructed lung empties normally.

Unilateral Hyperlucent Lung

The differential diagnosis for this resultant **unilateral hyperlucent lung** is quite broad and can involve the lung parenchyma, airways, pulmonary vasculature, chest wall (see Chapter 467), and mediastinum. Localized obstructions that can be responsible for overinflation include airway foreign bodies and the inflammatory reaction to them (see Chapter 435), abnormally thick mucus (cystic fibrosis, see Chapter 454), endobronchial tuberculosis or tuberculosis of the tracheobronchial lymph nodes (see Chapter 261), and endobronchial or mediastinal tumors.

Patients with unilateral hyperlucent lung can present with clinical manifestations of pneumonia, but in some patients the condition is discovered only when a chest radiograph is obtained for an unrelated reason. A few patients have hemoptysis. Physical findings can include hyperresonance and a small lung with the mediastinum shifted toward the more abnormal lung.

Swyer-James or Macleod Syndrome

The condition is thought to result from an insult to the lower respiratory tract after, most commonly, adenovirus (see Chapter 309) or respiratory syncytial virus (see Chapter 307), *Mycoplasma pneumoniae* (see Chapter 269), or measles (see Chapter 293). The infection can cause pulmonary vascular hypoplasia with resultant hypoperfusion, leading to unilateral hyperlucent lung (underdevelopment). Clinically, children with this condition often have chronic cough, recurrent pneumonia, hemoptysis, and wheezing, although some are asymptomatic. Some patients show a classic mediastinal shift away from the lesion with exhalation. CT scanning or bronchography can often demonstrate bronchiectasis. Thoracoscopic evaluation may be useful. The triad of unilateral hyperlucent lung, diffusely decreased ventilation, and matching decreased perfusion of the affected lung supports the diagnosis. In some patients, previous chest radiographs have been normal or have shown only an acute pneumonia, suggesting that a hyperlucent lung is an acquired lesion. For those with recurrent infection or severe lung destruction, treatment may include immunization with influenza and pneumococcal vaccines, as well as surgical resection. However, without treatment, some individuals may become less symptomatic with time.

Congenital Lobar Emphysema (Congenital Large Hyperlucent Lobe)

Congenital lobar emphysema (CLE) can result in severe respiratory distress in early infancy and can be caused by localized obstruction. Familial occurrence has been reported. In 50% of cases, a cause of CLE can be identified (Table 441.1). Congenital deficiency of the bronchial cartilage, external compression by aberrant vessels, bronchial stenosis, redundant bronchial mucosal flaps, and kinking of the bronchus caused by herniation into the mediastinum have been described as leading to bronchial obstruction and subsequent CLE and commonly affect the left upper lobe. Extrapulmonary lesions are noted in Table 441.2.

Clinical manifestations usually become apparent in the neonatal period but are delayed for as long as 5-6 years in 5% of patients. Many cases are diagnosed by antenatal ultrasonography. Infants with prenatally diagnosed cases are not always symptomatic at birth. In some patients, CLE remains undiagnosed until school age or beyond. Clinical signs range from mild tachypnea and wheeze to severe dyspnea with cyanosis. CLE can affect one or more lobes; it affects the upper and middle lobes, and the left upper lobe is the most common site. The affected lobe is essentially nonfunctional because of the overdistention, and atelectasis of the ipsilateral normal lung can ensue. With further distention, the mediastinum is shifted to the contralateral side, with impaired function seen as well

Table 441.1 Etiology of Congenital Lobar Emphysema

1. Idiopathic (50%)
2. Bronchial cartilage absence, hypoplasia, or dysplasia (25%)
3. Parenchymal diseases
   - Polyalveolar lobe
   - Pulmonary alveolar glycogenosis
4. Internal bronchial obstruction
   - Bronchial stenosis
   - Bronchomalacia
   - Meconium aspiration
   - Hypertrophic mucosa membranes
   - Mold mucous plaques
   - Foreign body aspiration
   - Bronchial polyp
5. External bronchial obstruction
   - Pulmonary artery sling anomaly
   - Pulmonary rotation anomaly
   - Bronchogenic cyst
   - Lymphadenopathy
   - Mediastinal mass
   - Duplication of esophagus

From Demir OF, Hangul M, Kose M. Congenital lobar emphysema: diagnosis and treatment options. *J Chronic Obstr Pulm Dis.* 2019;14:921–928, Table 1. Originally published by and used with permission from Dove Medical Press Ltd.

Table 441.2 Concomitant Malformations Accompanying Congenital Lobar Emphysema

Cardiac malformations 14–20%	Patent ductus arteriosus Atrial septal defect Ventricular septal defect Tetralogy of Fallot Pulmonary stenosis Pulmonary valve atresia Aortic coarctation Pulmonary hypertension Left aortic arch Right descending aorta Left ligamentum arteriosum Double superior vena cava
Renal anomalies	Aplastic kidney Horseshoe kidney
Musculoskeletal anomalies	Pectus excavatum Hiatal hernia Diaphragmatic hernia
Gastrointestinal tract	Omphalocele Pyloric stenosis
Others	Cleft palate Chondroectodermal dysplasia Chondrodystrophy Cystinosis Bronchial atresia Tracheal bronchus
Syndromes	Williams-Beuren syndrome Miller-Dieker syndrome Niemann-Pick disease Fanconi aplastic anemia

From Demir OF, Hangul M, Kose M. Congenital lobar emphysema: diagnosis and treatment options. *J Chronic Obstr Pulm Dis.* 2019;14:921–928, Table 2. Originally published by and used with permission from Dove Medical Press Ltd.

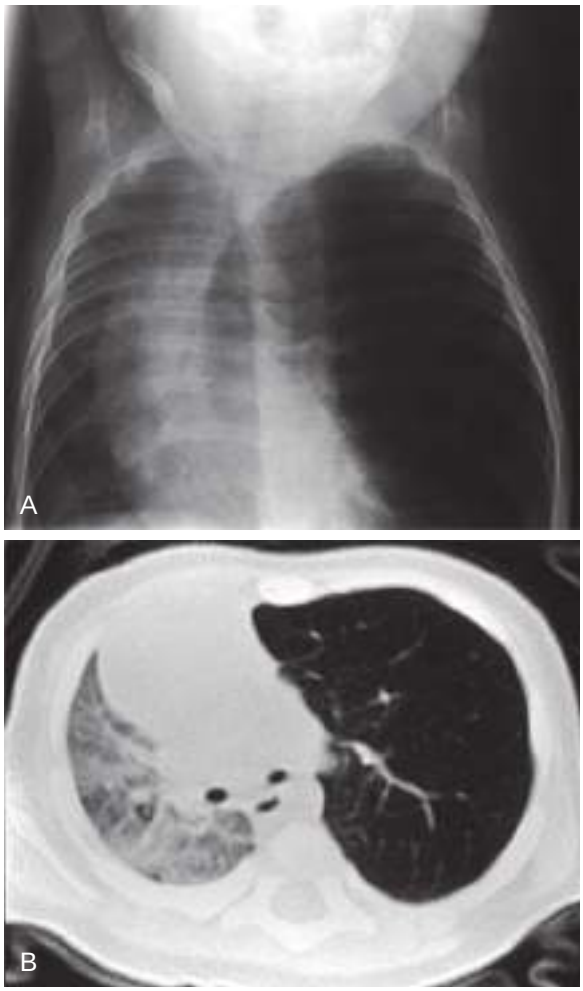

Fig. 441.1 Chest x-ray (A) and CT scan (B) of a congenital large hyperlucent lobe (congenital lobar emphysema). *(From Bush A, Abel R, Chitty L, et al. Congenital lung disease. In: Wilmott RW, Deterding RR, Li A, et al., eds. Kendig's Disorders of the Respiratory Tract in Children, 9th ed. Philadelphia: Elsevier; 2019: Fig. 18.32.)*

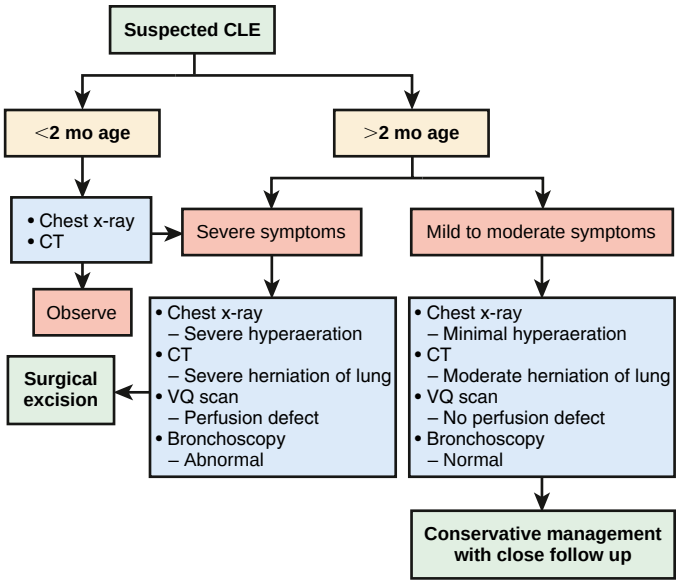

Fig. 441.2 Algorithm for evaluation and treatment of congenital lobar emphysema (CLE). *(Adapted from Karnak I, Senocak ME, Ciftci AO, et al. Congenital lobar emphysema: diagnostic and therapeutic considerations. J Pediatr Surg. 1999;34:1347–1351, Fig. 4.)*

(Fig. 441.1). A radiolucent lobe and a mediastinal shift are often revealed by radiographic examination. A CT scan can demonstrate the aberrant anatomy of the lesion, and MRI or MR angiography can demonstrate any vascular lesions that might be causing extraluminal compression. Nuclear imaging studies are useful to demonstrate perfusion defects in the affected lobe. Figure 441.2 outlines the evaluation of an infant presenting with suspected CLE. The differential diagnosis includes pneumonia with or without an effusion, pneumothorax, and cystic adenomatoid malformation.

Treatment by immediate surgery and excision of the lobe may be lifesaving when cyanosis and severe respiratory distress are present, but some patients respond to medical treatment. Selective intubation of the unaffected lung may be of value. Some children with apparent CLE have reversible overinflation, without the classic alveolar septal rupture implied in the term *emphysema.* Bronchoscopy can reveal an endobronchial lesion.

Pulmonary Vascular Abnormalities

Unilateral hyperlucency may result from **unilateral pulmonary agenesis** (see Chapter 444) that typically presents in the neonatal period. Volume loss of the affected lung results in a mediastinal shift with hyperinflation of the contralateral lung. An **anomalous origin of the left pulmonary artery** (see Chapter 481), also known as a *pulmonary artery sling,* can impinge the right main stem bronchus with resultant right-sided hyperinflation or atelectasis producing hyperlucency on either the ipsilateral or contralateral side. **Pulmonary venolobar syndrome** (see Chapter 475), also known as **scimitar syndrome**, can also result in a hyperlucent contralateral lung dependent on the extent of hypoplasia of the right lung.

GENERALIZED OBSTRUCTIVE OVERINFLATION

Acute generalized overinflation of the lung results from widespread involvement of the bronchioles and is usually reversible. It occurs more commonly in infants than in children and may be secondary to a number of clinical conditions, including asthma, cystic fibrosis, acute bronchiolitis, interstitial pneumonitis, atypical forms of acute laryngotracheobronchitis, aspiration of zinc stearate powder, chronic passive congestion secondary to a congenital cardiac lesion, and miliary tuberculosis.

Pathology

In chronic overinflation, many of the alveoli are ruptured and communicate with one another, producing distended saccules. Air can also enter the interstitial tissue (i.e., interstitial emphysema), resulting in pneumothorax and pneumomediastinum (see Chapters 461 and 462).

Clinical Manifestations

Generalized obstructive overinflation is characterized by dyspnea, with difficulty in exhaling. The lungs become increasingly overdistended, and the chest remains expanded during exhalation. An increased respiratory rate and decreased respiratory excursion result from the overdistention of the alveoli and their inability to be emptied normally through the narrowed bronchioles. Air hunger is responsible for forced respiratory movements. Overaction of the accessory muscles of respiration results in retractions at the suprasternal notch, the supraclavicular spaces, the lower margin of the thorax, and the intercostal spaces. Unlike the flattened chest during inspiration and exhalation in cases of laryngeal obstruction, minimal reduction in the size of the overdistended chest during exhalation is observed. The percussion note is hyperresonant. On auscultation, the inspiratory phase is usually less prominent than the expiratory phase, which is prolonged and roughened. Fine or medium crackles may be heard. Cyanosis is more common in the severe cases.

Fig. 441.3 Increased transradiancy in the right lower zone. A large emphysematous bulla occupies the lower half of the right lung, and the apical changes are in keeping with previous tuberculosis. *(From Padley SPG, Hansell DM. Imaging techniques. In: Albert RK, Spiro SG, Jett JR, eds. Clinical Respiratory Medicine, 3rd ed. Philadelphia: Mosby; 2008: Fig. 1.48.)*

Diagnosis

Radiographic and fluoroscopic examinations of the chest assist in establishing the diagnosis. Both leaves of the diaphragm are low and flattened, the ribs are farther apart than usual, and the lung fields are less dense. The movement of the diaphragm during exhalation is decreased, and the excursion of the low, flattened diaphragm in severe cases is barely discernible. The anteroposterior diameter of the chest is increased, and the sternum may be bowed outward.

Bullous Emphysema

Bullous emphysematous blebs or cysts (pneumatoceles) result from overdistention and rupture of alveoli during birth or shortly thereafter, or they may be sequelae of pneumonia and other infections. They have been observed in tuberculosis lesions during specific antibacterial therapy and in end-stage cystic fibrosis lung disease. Bullous emphysema can also result from inhalational marijuana use. These emphysematous areas presumably result from rupture of distended alveoli, forming a single or multiloculated cavity. The cysts can become large and might contain some fluid; an air-fluid level may be demonstrated on the radiograph (Fig. 441.3). The cysts should be differentiated from pulmonary abscesses. In most cases, treatment is not required, as the cysts disappear spontaneously within a few months, although they can persist for a year or more. Aspiration or surgery is not indicated except in cases of severe respiratory and cardiac compromise.

Subcutaneous Emphysema

Subcutaneous emphysema results from any process that allows free air to enter into the subcutaneous tissue (Fig. 441.4). The most common causes include pneumothorax or pneumomediastinum (see Chapters 461 and 462). In addition, it can be a complication of fracture of the orbit, which permits free air to escape from the nasal sinuses. In the neck and thorax, subcutaneous emphysema can follow tracheotomy, deep ulceration in the pharyngeal region, esophageal wounds, or any perforating lesion of the larynx or trachea. It is occasionally a complication of thoracentesis, asthma, or abdominal surgery. Rarely, air is formed in the subcutaneous tissues by gas-producing bacteria.

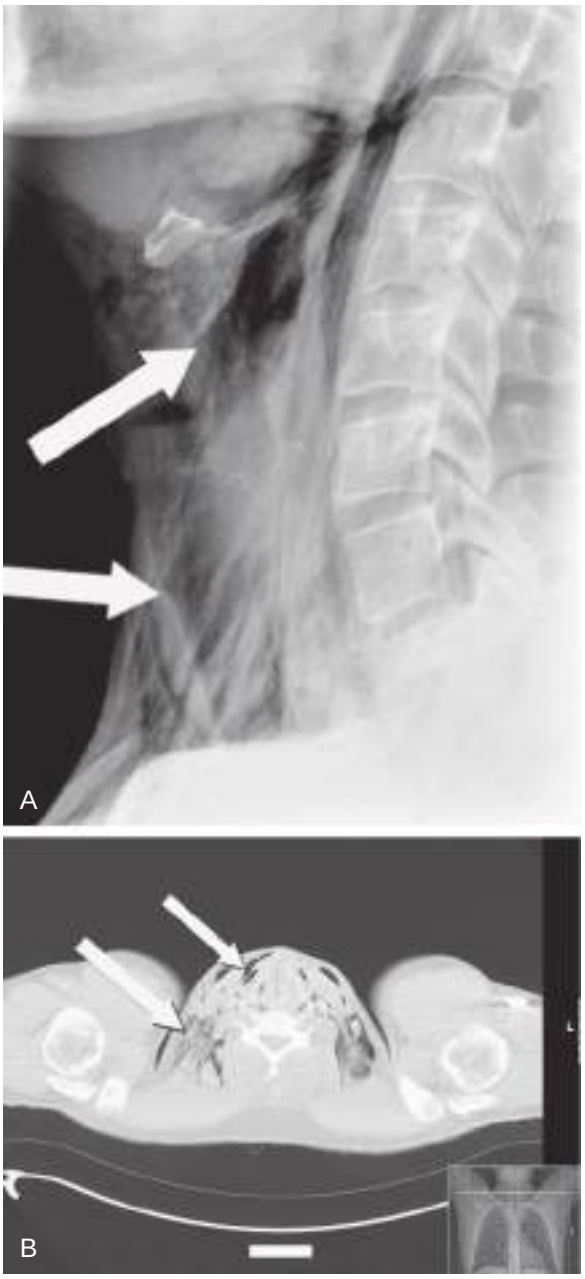

Fig. 441.4 **A,** Lateral x-ray of neck showing subcutaneous emphysema. **B,** Axial section CT neck/thorax showing subcutaneous emphysema and pneumomediastinum. *(From Zakaria R, Khwaja H. Subcutaneous emphysema in a case of infective sinusitis: a case report. J Med Case Rep. 2010;4:235, Figs. 1 and 2.)*

Tenderness over the site of emphysema and a crepitant quality on palpation of the skin are classic manifestations. Subcutaneous emphysema is usually a self-limited process and requires no specific treatment. Minimization of activities that can increase airway pressure (cough, performance of high-pressure pulmonary function testing maneuvers) is recommended. Resolution occurs by resorption of subcutaneous air after elimination of its source. Rarely, dangerous compression of the trachea by air in the surrounding soft tissue requires surgical intervention.

Visit Elsevier eBooks+ at eBooks.Health.Elsevier.com for Bibliography.

Chapter 442

α_1-Antitrypsin Deficiency and Emphysema

Vicki K. Masson and Steven R. Boas

Homozygous deficiency of α_1-antitrypsin (α_1-AT) rarely produces lung disease in children, but it is an important cause of early-onset severe panacinar pulmonary emphysema in adults in the third and fourth decades of life and a significant cause of liver disease in children (see Chapter 405.5). It is associated with panniculitis and antineutrophil cytoplasmic antibody (cANCA)–associated vasculitis in adults with the PI MZ phenotype.

PATHOGENESIS

The type and concentration of α_1-AT are inherited as a series of codominant alleles on chromosomal segment 14q31-32.3. (See Chapter 405.5 for a discussion of genotypes and liver disease.) The autosomal recessive deficiency affects 1 in 1,600-5,000 people, but it remains underdiagnosed. Worldwide there are an estimated 116,000,000 carriers and 1,100,000 subjects with severe α_1-AT deficiency. The normal α_1-AT PiM protein is secreted by the liver into the circulation at a rate of approximately 34 mg/kg/day; it is also produced by lung epithelial cells and monocytes. Pathogenic variant proteins are not produced (null) or are misfolded (PiZ and others); they can polymerize in the endoplasmic reticulum or be degraded, with subsequent low serum levels. Early adult-onset emphysema associated with α_1-AT deficiency occurs most commonly with PiZZ (pathogenic variant in *SERPINA1* gene), although Pi (null) (null) and, to a lesser extent, other pathogenic Pi types such as SZ have been associated with emphysema.

α_1-AT and other serum antiproteases help to inactivate proteolytic enzymes released from dead bacteria or leukocytes in the lung. Deficiency of these antiproteases leads to an accumulation of proteolytic enzymes in the lung, resulting in destruction of pulmonary tissue with subsequent development of emphysema. Polymerized pathogenic proteins in the lungs may also be proinflammatory, and there is evidence of increased oxidative stress. The concentration of proteases (elastase) in an individual's leukocytes may also be an important factor in determining the severity of clinical pulmonary disease with a given level of α_1-AT.

CLINICAL MANIFESTATIONS

Most patients who have the PiZZ defect have little or no detectable pulmonary disease during childhood. A few have early onset of chronic pulmonary symptoms, including dyspnea, wheezing, and cough, and panacinar emphysema has been documented by lung biopsy; it is probable that these findings occur secondarily to infection, which caused inflammation with consequent early disease. Smoking increases the risk of emphysema in patients with mutant Pi types. A newborn screen to identify children with the PiZZ phenotype provides useful guidance in support of smoking cessation for close contacts and reduces adolescent smoking rates.

Physical examination in *childhood* is usually normal. Affected children rarely have growth failure, an increased anteroposterior diameter of the chest with a hyperresonant percussion note, crackles to indicate active infection, or clubbing. Severe emphysema can depress the diaphragm, making the liver and spleen more easily palpable.

LABORATORY FINDINGS

Serum immunoassay measures low levels of α_1-AT; normal serum levels are ~80-220 mg/dL. Serum electrophoresis reveals the phenotype, and genotype is determined by polymerase chain reaction; whole gene sequencing is possible. In the rare patient with lung disease in adolescence, chest radiograph reveals overinflation with depressed diaphragms. Chest CT can show more hyperexpansion in the lower lung zones, with occasional bronchiectasis; CT densitometry can be a sensitive method to follow changes in lung disease. Lung function testing is usually normal in children, but it can show airflow obstruction and increased lung volumes, particularly in adolescents who smoke.

TREATMENT

Therapy for α_1-AT deficiency is intravenous replacement **(augmentation)** with enzyme derived from pooled human plasma. A level of 80 mg/dL is protective for emphysema. This target level for augmentation therapy is usually achieved with initial doses of 60 mg/kg IV weekly and results in the appearance of the transfused antiprotease in pulmonary lavage fluid. The Food and Drug Administration has approved the use of purified blood-derived human enzyme for ZZ and null-null patients. Replacement therapy is indicated for those with moderately severe obstructive lung disease (forced expiratory volume in 1 second is 30–65% of predicted) or those with mild lung disease experiencing a rapid decline in lung function. Augmentation therapy is not indicated for persons with the PiMZ type who have pulmonary disease, because their disease is not from enzyme deficiency. Recombinant sources of α_1-AT are under development, but current products are rapidly cleared from the circulation when given intravenously; they may be useful for inhalation therapy. Inhalation of the plasma-derived product is under evaluation. Lung transplantation has been performed for end-stage disease. Multiple strategies for gene therapy are under development.

SUPPORTIVE THERAPY

Standard supportive therapy for chronic lung disease includes aggressive treatment of pulmonary infection, routine use of pneumococcal and influenza vaccines, bronchodilators, and advice about the serious risks of smoking and smoke exposure. Such treatment is also indicated for asymptomatic family members found to have PiZZ or null-null phenotypes but not those with the PiMZ type. The clinical significance of the PiSZ type is unclear, but nonspecific treatment is reasonable. All persons with low levels of serum antiprotease should be warned that the development of emphysema is partially mediated by environmental factors and that cigarette smoking is particularly deleterious. Although early identification of affected persons could help to prevent development of obstructive lung disease, population screening programs are being considered but are currently suspended.

Visit Elsevier eBooks+ at eBooks.Health.Elsevier.com for Bibliography.

Chapter 443
Other Distal Airway Diseases

443.1 Bronchiolitis Obliterans

Catherine Kier and Steven R. Boas

Bronchiolitis obliterans (BO) is a histopathologic diagnosis characterized by chronic obstructive lung disease of the bronchioles and smaller airways resulting from an insult to the lower respiratory tract leading to inflammation and fibrosis of the small airways. In the nontransplant patient, BO most commonly occurs in the pediatric population after respiratory infections, particularly adenovirus (see Chapter 309), but also *Mycoplasma pneumoniae* (see Chapter 269), measles (see Chapter 293), *Legionella pneumophila* (see Chapter 254), influenza (see Chapter 305), and pertussis (see Chapter 243); other causes include inflammatory diseases (juvenile idiopathic arthritis, systemic lupus erythematosus [see Chapter 199], scleroderma [see Chapter 201], Stevens-Johnson syndrome [see Chapter 193]) and inhalation of toxic fumes or particulate exposure (NO_2, incinerator fly ash, NH_3, diacetyl flavorings from microwave popcorn, papaverine, fiberglass) (Table 443.1). Postinfectious BO (PIBO) may be more common in the Southern Hemisphere. BO is also commonly seen in post lung or bone marrow transplant recipients.

Bronchiolitis obliterans syndrome (BOS) is a clinical diagnosis related to graft deterioration after transplantation, defined as a progressive decline in lung function based on forced expiratory volume in 1 second (FEV_1). The airway obstruction is generally irreversible. BOS is considered once other causes of airway obstruction are excluded. It is recognized as a long-term complication of both lung and bone marrow transplantation, with more than one third of survivors of lung transplantation developing this disorder. Risk factors for the development of BOS include the presence of cytomegalovirus (CMV) pneumonitis, *Aspergillus* colonization, primary graft dysfunction, gastroesophageal reflux, and community-acquired respiratory viruses, as well as prolonged transplantation ischemic time.

PATHOGENESIS

After the initial insult, inflammation affecting terminal bronchioles, respiratory bronchioles, and alveolar ducts can result in the obliteration of the airway lumen (Fig. 443.1). Epithelial damage resulting in abnormal repair is characteristic of BO. Complete or partial obstruction of the airway lumen can result in air trapping or atelectasis. Parenchymal involvement is not seen. **Bronchiolitis obliterans organizing pneumonia (BOOP)**, or what is now termed **cryptogenic organizing pneumonia (COP)**, is a histopathologic diagnosis. Although it is similar to many of the histologic features of BO, COP is also characterized by extension of the inflammatory process from distal alveolar ducts into alveoli with proliferation of fibroblasts (parenchymal involvement).

CLINICAL MANIFESTATIONS AND DIAGNOSIS

Cough, fever, cyanosis, dyspnea, chest pain, and respiratory distress followed by initial or no improvement with antibiotics may be the early signs of BO. In this phase, BO is easily confused with pneumonia, bronchitis, or bronchiolitis. Progression of the disease can ensue, with increasing dyspnea, chronic cough, sputum production, and wheezing. Physical examination findings are usually nonspecific and can include wheezing, hypoxemia, and crackles. Chest radiographs may be relatively normal compared with the extent of physical findings but can demonstrate hyperlucency and patchy infiltrates. Occasionally, Swyer-James syndrome (unilateral hyperlucent lung; see Chapter 441) develops. Pulmonary function tests demonstrate variable findings but typically show signs of airway obstruction with a variable degree of bronchodilator response, although more commonly irreversible. Exercise testing shows reduced exercise capacity and impaired oxygen consumption. Ventilation-perfusion scans reveal a typical moth-eaten appearance of multiple matched defects in ventilation and perfusion. High-resolution chest CT often demonstrates patchy areas or a mosaic pattern of hyperlucency, air trapping, and bronchiectasis (Fig. 443.2). Table 443.2 provides an overview of CT findings of BO and related disorders. Physical and radiologic signs can wax and wane over weeks or months. Open lung biopsy or transbronchial biopsy remains the best means of establishing the diagnosis of BO or COP.

TREATMENT

Treatment is a combination of optimal supportive care and anti-inflammatory therapy to impair lymphocyte proliferation. For PIBO, it is recommended that bronchoscopy with bronchoalveolar lavage be performed to rule out persistent viral, bacterial, or fungal pathogens before initiation of systemic antiinflammatory treatment. Corticosteroids should be given early, pulse steroid therapy with methylprednisolone is preferred, and a prolonged course of oral steroids should be avoided to minimize severe side effects and complications or mortality from infections. Immunomodulatory agents, such as sirolimus, tacrolimus, aerosolized cyclosporine, hydroxychloroquine, and macrolide antibiotics, have been used in post–lung transplantation recipients with BO with variable success. Supportive measures with oxygen, antibiotics for secondary infections, and bronchodilators are adjunct therapies. The role of gastroesophageal reflux and its association with BO has been raised, with treatment suggested whenever the diagnosis is made. Azithromycin may be effective in patients with BOS. A combination of fluticasone, azithromycin, montelukast, and pulse steroid may halt pulmonary progression of BOS. Potential future treatment options include using mesenchymal stem/stromal cells (MSCs) for immunomodulatory and possibly profibrotic effects and extracorporeal photopheresis (ECP) and total lymphoid irradiation (TLI) for BOS, but additional trials and studies are needed. Patients with asymptomatic or nonprogressive COP can be observed.

PROGNOSIS

Some patients with BO experience rapid deterioration in their condition and die within weeks of the initial symptoms; most nontransplant patients survive with chronic disability. BO tends to be severe once progression ensues. In contrast to BO, a better prognosis exists for patients with COP, with complete recovery seen in many patients, although outcome depends on the underlying systemic disease. COP can relapse, especially if treatment duration is <1 year; COP is amenable to repeat courses of oral corticosteroids. Unlike the more common idiopathic COP, progressive COP characterized by acute respiratory distress syndrome is rare but is aggressive in its clinical course, leading to death.

Visit Elsevier eBooks+ at eBooks.Health.Elsevier.com for Bibliography.

443.2 Follicular Bronchitis

Catherine Kier and Steven R. Boas

Follicular bronchitis and pediatric lymphocytic interstitial pneumonia are lymphoproliferative lung disorders characterized by the presence of lymphoid follicles alongside the airways (bronchi or bronchioles) and

Table 443.1 Etiology of Bronchiolitis Obliterans

POSTINFECTION
Adenovirus types 3, 7, and 21
Influenza
Parainfluenza
Measles
Respiratory syncytial virus
Varicella
Mycoplasma pneumoniae
POSTTRANSPLANTATION
Chronic rejection of lung or heart/lung transplantation
Graft versus host disease associated with bone marrow transplantation
CONNECTIVE TISSUE DISEASE/INFLAMMATORY
Juvenile idiopathic arthritis
Sjögren syndrome
Scleroderma
Systemic lupus erythematosus
Castleman disease
Inflammatory bowel disease
TOXIC FUME INHALATION
NO_2
NH_3
Diacetyl flavorings (microwave popcorn)
Sulfur mustards
Fly ash (incinerator)
Fiberglass
CHRONIC HYPERSENSITIVITY PNEUMONITIS
Avian antigens
Mold
ASPIRATION
Stomach contents: gastroesophageal reflux
Foreign bodies
DRUGS
Penicillamine
Cocaine
STEVENS-JOHNSON SYNDROME
Idiopathic
Drug induced
Infection related

From Moonnumakal SP, Fan LL. Bronchiolitis obliterans in children. *Curr Opin Pediatr.* 2008;20:272–278.

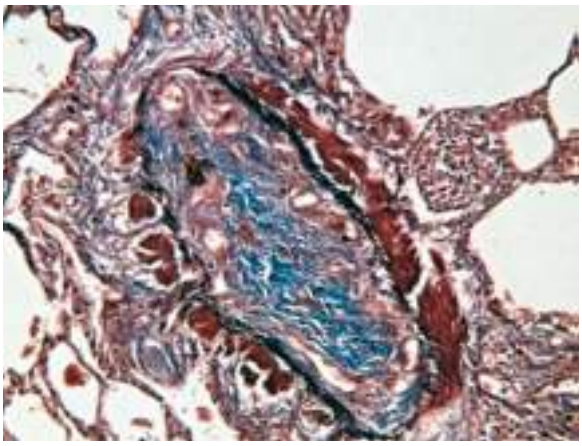

Fig. 443.1 Complete obliteration of airway lumen with fibromyxoid tissue in lung transplant recipient with bronchiolitis obliterans. *(From Kurland G, Michelson P. Bronchiolitis obliterans in children. Pediatr Pulmonol. 2005;39:193–208.)*

Fig. 443.2 High-resolution CT scan of the chest of a child with bronchiolitis obliterans demonstrating mosaic perfusion and vascular attenuation. Air-trapping is demonstrated by lack of increase in attention or decrease in lung volume in dependent lung. *(Image courtesy Alan Brody, MD, Cincinnati Children's Hospital Medical Center, Cincinnati, Ohio.)*

infiltration of the walls of bronchi and bronchioles. The disease presents early and is associated with immune dysregulation. Autoantibodies have been found in some children, and in a few patients, disease-causing pathogenic variants have been found in *COPA*. Most children present with symptoms in the first 2 years of life, but with a lag time of diagnosis to about 4 years. Cough, moderate respiratory distress, fever, and fine crackles are common clinical findings. Fine crackles generally persist over time, and recurrence of symptoms is common. Chest radiographs may be relatively benign initially (air trapping, peribronchial thickening) but evolve into the typical interstitial pattern. Chest CT can show hilar lymphadenopathy, pulmonary nodules, ground-glass opacity, focal consolidation, and bronchiectasis but can also appear normal (see Table 443.2). Definitive diagnosis is made by open lung biopsy (Fig. 443.3). Treatment is limited—systemic steroids, intravenous pulse or oral, showed high response rates. Prognosis is related to early diagnosis and treatment, which are critical to improve the outcome. Some patients have significant progression of pulmonary disease, and others develop only mild obstructive airway disease.

Visit Elsevier eBooks+ at eBooks.Health.Elsevier.com for Bibliography.

443.3 Pulmonary Alveolar Microlithiasis

Catherine Kier and Steven R. Boas

Pulmonary alveolar microlithiasis (PAM) is a rare disease characterized by the formation of lamellar concretions of calcium phosphate, or "microliths," within the alveoli, creating a classic pattern on the radiograph (Fig. 443.4).

EPIDEMIOLOGY AND ETIOLOGY

Although the mean age at the time of diagnosis is in the mid-30s, the onset of the disease can occur in childhood and in newborns. PAM is inherited in an autosomal recessive disorder and is caused by a pathogenic variant in the type II sodium phosphate cotransporter NPT2b *(SCL34A2)*. To date, there are 27 identified pathogenic variants. This gene is expressed in high levels in the lungs,

Table 443.2 High-Resolution CT Patterns in a Child with Interstitial Lung Disease

	STUDIES (N)	GROUND-GLASS OPACITY	THICK SEPTA	NODULES	MOSAIC PATTERN	HONEYCOMBING
Bronchiolitis obliterans	4	—	—	—	X	—
Nonspecific interstitial pneumonitis	6	X	—	—	—	X
Desquamative interstitial pneumonitis	4	X	—	—	—	X
Follicular bronchitis or neuroendocrine cell hyperplasia of infancy	4	X	—	—	X	—
Lymphocytic interstitial pneumonitis	4	—	—	X	—	—
Lymphangiomatosis	2	—	X	—	—	—
Lymphangiectasia	2	—	X	—	—	—
Pulmonary alveolar proteinosis	2	X	X	—	—	—

From Long FR. Interstitial lung disease. In: Slovis T, ed. *Caffey's Pediatric Diagnostic Imaging,* 11th ed. Philadelphia: Mosby; 2008: Table 74.1; original data from Lynch DA, Hay T, Newell JD Jr, et al. Pediatric diffuse lung disease: diagnosis and classification using high-resolution CT. *AJR Am J Roentgenol.* 1999;173:713–718; and Copley SJ, Coren M, Nicholson AG, et al. Diagnostic accuracy of thin-section CT and chest radiography of pediatric interstitial lung disease. *AJR Am J Roentgenol.* 2000;174:549–554.

Fig 443.3 Follicular bronchiolitis in a 3-year-old child with mosaic attenuation and cylindrical bronchiectasis. CT findings suggested bronchiolitis obliterans, but a biopsy documented the presence of follicular bronchiolitis. *(From Long FR, Druhan SM, Kuhn JP. Diseases of the bronchi and pulmonary aeration. In Slovis T, ed. Caffey's Pediatric Diagnostic Imaging, 11th ed. Philadelphia: Mosby; 2008: Fig. 73.71.)*

predominantly on the surface of alveolar type II cells. Although the precise role of this protein is unknown, it is speculated that it helps to remove phosphate generated from surfactant metabolism in the alveolar space, as well as functioning as a phosphate regulator in other organs.

In some families, progression of disease is rapid. An equal male and female incidence is noted. Although PAM is found throughout the world, there is a high incidence in Turkey and a lesser incidence in Italy and Japan.

CLINICAL MANIFESTATIONS

In early stages of the disease, patients are usually asymptomatic. When symptomatic, patients with PAM usually complain of dyspnea on exertion, nonproductive cough, and fever. Physical examination of the lungs can reveal fine inspiratory crackles and diminished breath sounds. Clubbing occurs, although this is usually a more advanced sign. Discordance between the clinical and radiographic manifestations is common. Many children are often asymptomatic on initial presentation and present with symptoms during adulthood. Complications of pneumothorax, pleural adhesions and calcifications, pleural fibrosis, apical bullae, and extrapulmonary sites of microliths have been reported (kidneys, prostate, gallbladder, sympathetic chain, and testes). Progression to respiratory failure may occur.

DIAGNOSIS

Chest radiography typically reveals bilateral infiltrates with a fine micronodular appearance or sandstorm appearance with greater density in the lower and middle lung fields (see Fig. 443.4). CT of the chest shows diffuse micronodular calcified densities, with thickening of the microliths along the septa and around distal bronchioles, especially in the inferior and posterior regions (see Table 443.2). Diffuse uptake of technetium-99 methylene diphosphonate by nuclear scan has been reported. Bronchoalveolar lavage (BAL) may be helpful. Open lung and transbronchial lung biopsy reveal 0.1- to 0.3-mm laminated calcific concretions within the alveoli. Although the alveoli are often normal initially, progression to pulmonary fibrosis with advancing disease usually ensues. Sputum expectoration might reveal small microliths, although this finding is not diagnostic for PAM and is not typically seen in children. Detection of calcium deposits in BAL fluid on bronchoscopy supports the diagnosis. Pulmonary function testing reveals restrictive lung disease with impaired diffusing capacity as the disease progresses, whereas exercise testing demonstrates arterial oxygen desaturation.

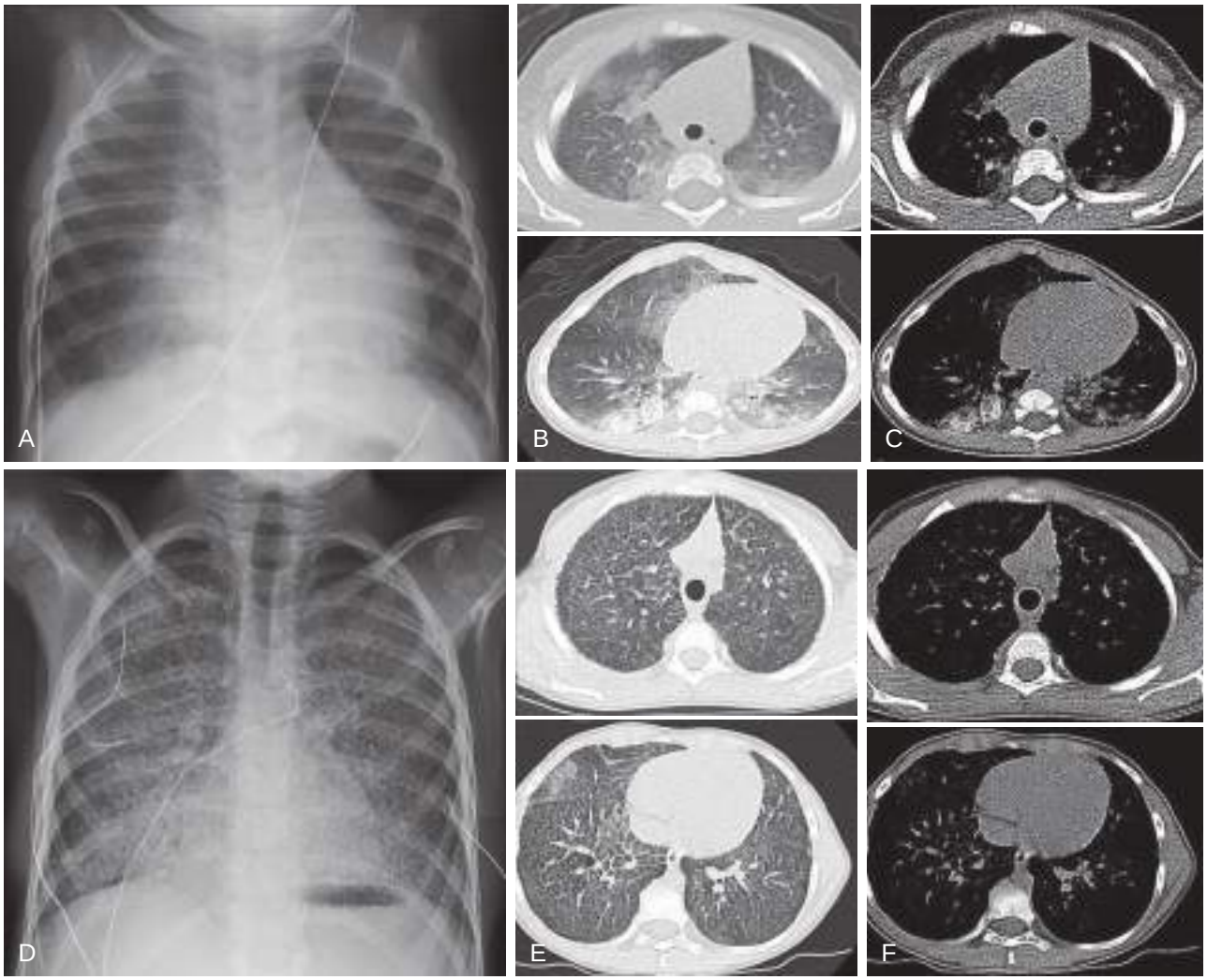

Fig. 443.4 Pulmonary alveolar microlithiasis. Chest radiograph and high-resolution CT performed at the age of 1 year and 8 years. **A,** Chest radiograph shows bilateral alveolo-interstitial opacities with middle lobe consolidation. Chest CT imaging shows diffuse but patchy ground-glass opacities, alveolar consolidations in the middle and lower lobes, and calcifications in the lower lobes, at parenchymal (**B**) and mediastinal (**C**) windows. **D,** Chest radiograph shows diffuse, even predominant in the lower and middle lobes, dense reticulonodular opacities. Chest CT imaging shows patchy ground-glass opacities, homogenous miliary consolidations with micronodular calcifications and subpleural and interlobular reticulations, parenchymal retractions, and architectural distortion suggestive of fibrosis onset mostly in the upper lobes, at parenchymal (**E**) and mediastinal (**F**) windows. *(From Sigur E, Roditis L, Labouret G, et al. Pulmonary alveolar microlithiasis in children less than 5 years of age. J Pediatr. 2020;217:158–164.e1, Fig. 1.)*

The diagnosis can usually be established radiographically. However, lung tissue biopsy, BAL, and detection of a pathogenic variant in the *SCL34A2* gene can also be used to help confirm the diagnosis. The differential diagnosis includes sarcoidosis, miliary tuberculosis, hemosiderosis, healed disseminated histoplasmosis, pulmonary calcinosis, and metastatic pulmonary calcifications.

TREATMENT

No specific treatment is effective, although some clinicians have used glucocorticosteroids, etidronate disodium, and bronchopulmonary lavage with limited success. Lung transplantation has been performed for this condition without recurrence in the transplanted lung.

PROGNOSIS

Progressive cardiopulmonary disease can ensue, leading to cor pulmonale, superimposed infections, and subsequent death in mid-adulthood. Because of the familial nature of this disease, counseling and chest radiographs of family members are indicated.

Visit Elsevier eBooks+ at eBooks.Health.Elsevier.com for Bibliography.

Chapter 444
Congenital Disorders of the Lung

444.1 Pulmonary Agenesis and Aplasia

Joshua A. Blatter and Jonathan D. Finder

Pulmonary agenesis differs from hypoplasia in that agenesis entails the complete absence of a lung. Agenesis differs from aplasia by the absence of a bronchial stump or carina that is seen in aplasia. Bilateral pulmonary agenesis is incompatible with life, manifesting as severe respiratory distress and failure. Pulmonary agenesis is thought to be an autosomal recessive trait, with an estimated incidence of 1 in 10,000-15,000 births.

CLINICAL MANIFESTATIONS AND PROGNOSIS

Unilateral agenesis or hypoplasia can have few symptoms and nonspecific findings, resulting in only 33% of the cases being diagnosed while the patient is living. Symptoms tend to be associated with central airway complications of compression, stenosis, and/or tracheobronchomalacia. In patients in whom the right lung is absent, the aorta can compress the trachea and lead to symptoms of central airway compression. Right lung agenesis has a higher morbidity and mortality than left lung agenesis. Pulmonary agenesis is often seen in association with other congenital anomalies such as the **VACTERL sequence** (*v*ertebral anomalies, *a*nal atresia, *c*ongenital heart disease, *t*racheoesophageal fistula, *r*enal anomalies, and *l*imb anomalies), ipsilateral facial and skeletal malformations, and central nervous system and cardiac malformations. Compensatory growth of the remaining lung allows improved gas exchange, but the mediastinal shift can lead to scoliosis and airway compression. Scoliosis can result from unequal thoracic growth.

DIAGNOSIS AND TREATMENT

Chest radiographic findings of unilateral lung or lobar collapse with a shift of mediastinal structures toward the affected side can prompt referral for suspected foreign body aspiration, mucus plug occlusion, or other bronchial mass lesions. The diagnosis requires a high index of suspicion to avoid the unnecessary risks of bronchoscopy, including potential perforation of the rudimentary bronchus. CT of the chest is diagnostic, although the diagnosis may be suggested by chronic changes in the contralateral aspect of the chest wall and lung expansion on chest radiographs. Because pulmonary agenesis can be associated with a wide variety of congenital lesions, whole body MRI can be useful to determine whether other systems (e.g., cardiac, gastrointestinal) are affected. Conservative treatment is usually recommended, although surgery has offered benefit in selected cases. Referral for management of scoliosis may be necessary.

Visit Elsevier eBooks+ at eBooks.Health.Elsevier.com for Bibliography.

444.2 Pulmonary Hypoplasia

Joshua A. Blatter and Jonathan D. Finder

Pulmonary hypoplasia involves a decrease in both the number of alveoli and the number of airway generations. The hypoplasia may be bilateral in the setting of bilateral lung constraint, as in oligohydramnios or thoracic dystrophy. Pulmonary hypoplasia is usually secondary to other intrauterine disorders that produce an impairment of normal lung development (see Chapter 124). Conditions such as deformities of the thoracic spine and rib cage (thoracic dystrophy), pleural effusions with fetal hydrops, congenital pulmonary airway malformation, and congenital diaphragmatic hernia physically constrain the developing lung. Any condition that produces oligohydramnios (fetal renal insufficiency or prolonged premature rupture of membranes) can also lead to diminished lung growth. In these conditions, airway and arterial branching are inhibited, thereby limiting the capillary surface area. Large unilateral lesions, such as congenital diaphragmatic hernia or pulmonary airway malformation, can displace the mediastinum and thereby produce a contralateral hypoplasia, although usually not as severe as that seen on the ipsilateral side. **Fetal akinesia deformation syndrome** is also associated with pulmonary hypoplasia, in part because of decreased fetal breathing movements.

CLINICAL MANIFESTATIONS

Pulmonary hypoplasia is usually recognized in the newborn period, owing to either the respiratory insufficiency or the presentation of persistent pulmonary hypertension (see Chapter 130). Later presentation (tachypnea) with stress or respiratory viral infection can be seen in infants with mild pulmonary hypoplasia.

DIAGNOSIS AND TREATMENT

A variety of imaging techniques, including MRI and ultrasound, with estimation of oligohydramnios, can be helpful to identify hypoplasia but not to predict pulmonary function. Mechanical ventilation and oxygen may be required to support gas exchange. Specific therapy to control associated pulmonary hypertension, such as inhaled nitric oxide, may be useful. In cases of severe hypoplasia, the limited capacity of the lung for gas exchange may be inadequate to sustain life. Extracorporeal membrane oxygenation can provide gas exchange for a critical period of time and permit survival. Rib-expanding devices (vertically expansible prosthetic titanium ribs and magnetic expansion control rods) can improve the survival of patients with thoracic dystrophies (see Chapter 741).

Visit Elsevier eBooks+ at eBooks.Health.Elsevier.com for Bibliography.

444.3 Congenital Pulmonary Airway Malformation (Congenital Cystic Adenomatoid Malformation)

Joshua A. Blatter and Jonathan D. Finder

Congenital pulmonary airway malformation **(CPAM)**, formerly known as *cystic adenomatoid malformation,* consists of hamartomatous or dysplastic lung tissue mixed with more normal lung, usually confined to one lobe. This congenital pulmonary disorder occurs in approximately 1-4 in 100,000 births. Prenatal ultrasonographic findings are classified as **macrocystic** (single or multiple cysts >5 mm) or **microcystic** (echogenic cysts <5 mm). Five histologic and location patterns have been described (Fig. 444.1). **Type 0** (acinar dysplasia) is least common (<2%) and consists of microcystic disease throughout the lungs. The prognosis is poorest for this type, and infants die at birth. **Type 1** (60–70%) is macrocystic and consists of a single or several large (>2 cm in diameter) cysts lined with ciliated pseudostratified epithelium; the lesion is localized involving only a part of one lobe. One third of cases have mucus-secreting cells. Presentation is in utero or in the newborn period. Cartilage is rarely seen in the wall of the cyst. This type has a good prognosis for survival. **Type 2** (15–20%) is microcystic and consists of multiple small cysts with histology similar to that of the type 1 lesion. Type 2 is associated with other serious congenital anomalies (renal, cardiac, diaphragmatic hernia, esophageal atresia, skeletal) and carries a poor prognosis. **Type 3** (5–10%) is seen mostly in males; the lesion is a mixture of microcysts and solid tissue with bronchiole-like structures lined with cuboidal ciliated epithelium and separated by areas of nonciliated cuboidal epithelium. The prognosis for this type, like type 0, is poor. **Type 4** (~10%) is commonly macrocystic and lacks mucus cells. It is associated with malignancy (type 1

pleuropulmonary blastoma) and can present either in childhood or in asymptomatic adults.

ETIOLOGY

The lesion probably results from an embryologic injury before the 35th day of gestation, with maldevelopment of terminal bronchiolar structures. Histologic examination reveals little normal lung and many glandular elements. Cysts are common; cartilage is rare. The presence of cartilage might indicate a somewhat later embryologic insult, perhaps extending into the 10th to 24th week. Although growth factor interactions and signaling mechanisms have been implicated in altered lung-branching morphogenesis, the exact roles in the maldevelopment seen here remain obscure.

DIAGNOSIS

Cystic airway malformations can be diagnosed in utero by ultrasonography (Fig. 444.2). To better define and differentiate the lesion from other congenital lung malformations, fetal MRI is indicated (Fig. 444.3). Fetal cystic lung abnormalities can include CPAM (40%), pulmonary sequestration (14%) (see Chapter 444.4), or both (26%); the median age at diagnosis is usually 21 weeks of gestation. In one series, only 7% had severe signs of fetal distress, including hydrops, pleural effusion, polyhydramnios, ascites, or severe facial edema; 96% of the fetuses were born alive, two of whom died in the neonatal period. CPAM volume ratio (CVR)—CPAM volume divided by head circumference—can be used to predict the risk of fetal hydrops. A CVR >1.6 is a high-risk factor for developing hydrops. Lesions causing fetal hydrops have a poor prognosis. Large lesions, by compressing adjacent lung, can produce pulmonary hypoplasia in nonaffected lobes (see Chapter 444.2). Even lesions that appear large in early gestation can regress considerably or decrease in relative size and be associated with good pulmonary function in childhood. MRI allows accurate diagnosis and sizing of the lesion and is indicated even in asymptomatic neonates.

CLINICAL MANIFESTATIONS

Patients can present in the newborn period or early infancy with respiratory distress, recurrent respiratory infection, and pneumothorax. The lesion may be confused with a diaphragmatic hernia (see Chapter 131). Neonatal presentations include respiratory distress, cyanosis, tachypnea, or a pneumothorax; hydrops is the most severe presentation. Patients with smaller lesions are usually asymptomatic until mid-childhood, when episodes of recurrent or persistent pulmonary infection or chest pain occur. Breath sounds may be diminished, with mediastinal shift away from the lesion on physical examination. Chest radiographs reveal a cystic mass, sometimes with mediastinal shift (Fig. 444.4). Occasionally, an air-fluid level suggests a lung abscess (see Chapter 453).

TREATMENT

Antenatal intervention in severely affected infants is controversial but can include excision of the affected lobe for microcystic lesions, aspiration of macrocystic lesions, and, rarely, open fetal surgery. Maternal therapy with intravenous betamethasone may inhibit CPAM growth and reverse hydrops. If hydrops persists, a thoracoamniotic shunt may

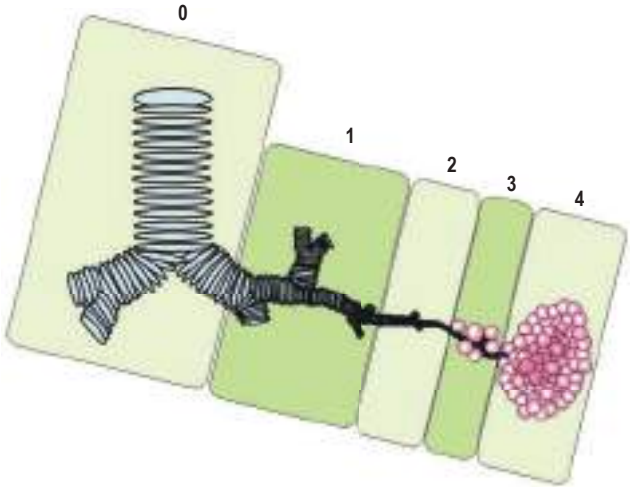

Fig. 444.1 Types of congenital pulmonary airway malformations. Type 0, tracheobronchial; type 1, bronchial; type 2, bronchiolar; type 3, alveolar duct; type 4, distal acinar. *(Adapted from Stocker JT. Cystic lung disease in infants and children. Fetal Pediatr Pathol. 2009;28:155–184.)*

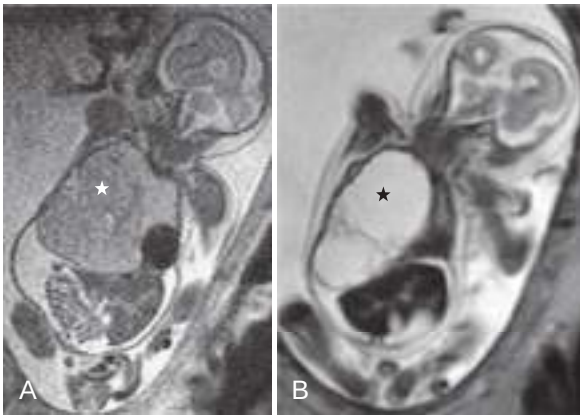

Fig. 444.3 These two fetal MRIs depict a practical prenatal classification for congenital pulmonary airway malformations. **A,** Microcystic lesion presenting as a solid hyperintense mass *(star)*. **B,** Macrocystic lesion containing a large cyst >5.0 mm in diameter *(star)*. *(From Laje P, Flake AW. Congenital bronchopulmonary malformations. In: Holcomb III GW, Murphy JP, St. Peter SD, eds. Holcomb and Ashcraft's Pediatric Surgery, 7th ed. Philadelphia: Elsevier; 2020: Fig. 22.3, p. 350.)*

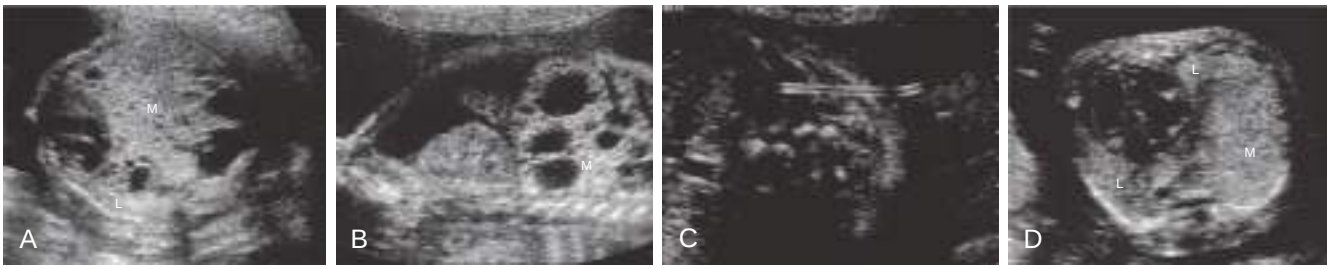

Fig. 444.2 Congenital pulmonary airway malformation (CPAM). **A,** Massive right CPAM mass *(M)* with pronounced mediastinal shift is seen. Note the small size of the compressed left lung *(L)*. **B,** Hydrops fetalis was present; ascites can be seen. **C,** A shunt was placed in the largest cavity. **D,** Resolution of the hydrops was seen within 1 week. Cross section through the thorax shows expansion of the ipsilateral and contralateral lungs, repositioning of the heart, and reduction of the mass. *(From Obican SG, Odibo A. Invasive fetal therapy. In: Lockwood CJ, Copel JA, Dugoff L, et al., eds. Creasy & Resnik's Maternal-Fetal Medicine, 9th ed. Philadelphia: Elsevier; 2023: Fig 34-11, p. 633.)*

be indicated. In the postnatal period, surgery is indicated for symptomatic patients. Although surgery may be delayed for asymptomatic infants because postnatal resolution has been reported, true resolution appears to be quite rare in that abnormalities usually remain detectable on CT or MRI. Sarcomatous and carcinomatous degeneration have been described in patients with CPAM, so surgical resection by 1 year of age is typically recommended to limit malignant potential. If surgery is not performed, the child should have imaging at least yearly to track progression of the lesion. The mortality rate is <10%. Another indication for surgery is to rule out **pleuropulmonary blastoma (PPB)**, a malignancy that can appear radiographically similar to type 1 CPAM or appear concurrently in a type 4 CPAM (mixed lesion). PPB is associated with germline or somatic pathogenic variants in *DICER1*. PPB usually has a systemic feeding vessel and is not connected to the bronchial tree. However, it is often difficult to distinguish a PPB from a CPAM without surgery. In addition to the risk of malignancy, "asymptomatic" patients may have chronic inflammation with subtle systemic manifestations, which parents report resolves after the lesion is resected.

Visit Elsevier eBooks+ at eBooks.Health.Elsevier.com for Bibliography.

444.4 Pulmonary Sequestration

Joshua A. Blatter and Jonathan D. Finder

Pulmonary sequestration is a congenital anomaly of lung development that can be intrapulmonary or extrapulmonary, according to the location within the visceral pleura. The majority of sequestrations are intrapulmonary.

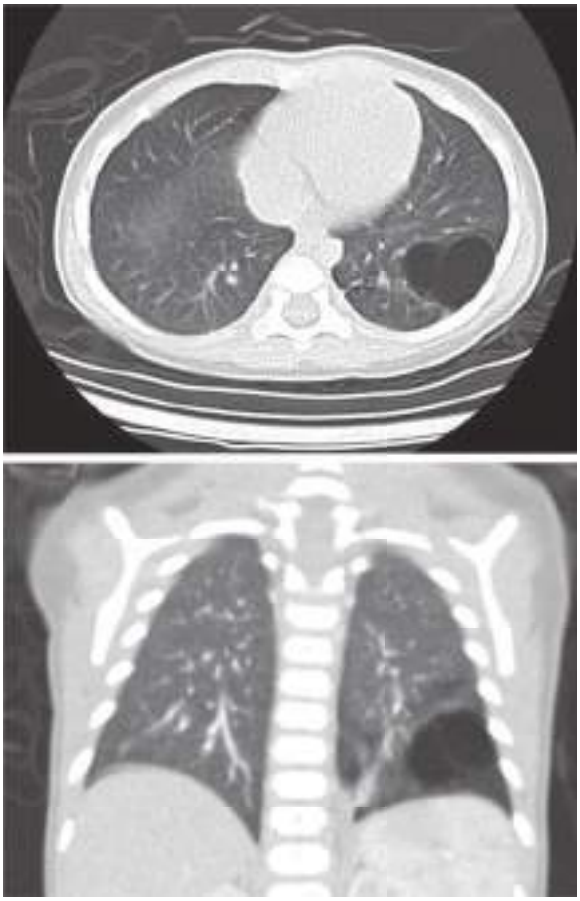

Fig. 444.4 CT scans of CPAM in the left lower lobe of the lung. *(From Wong KKY, Flake AW, Tibboel D, et al. Congenital pulmonary airway malformation: advances and controversies. Lancet Child Adolesc. 2018;2:290–296, Fig. 1.)*

PATHOPHYSIOLOGY

The lung tissue in a sequestration does not connect to a bronchus and receives its arterial supply from the systemic arteries (commonly off the aorta) and returns its venous blood to the right side of the heart through the inferior vena cava **(extralobar)** or pulmonary veins **(intralobar)**. The sequestration functions as a space-occupying lesion within the chest; it does not participate in gas exchange and does not lead to a left-to-right shunt or alveolar dead space. Communication with the airway can occur as the result of rupture of infected material into an adjacent airway. Collateral ventilation within intrapulmonary lesions via pores of Kohn can occur. Pulmonary sequestrations can arise through the same pathoembryologic mechanism as a remnant of a diverticular outgrowth of the esophagus. Some propose that intrapulmonary sequestration is an acquired lesion primarily caused by infection and inflammation; inflammation leads to cystic changes and hypertrophy of a feeding systemic artery. This is consistent with the rarity of this lesion in an autopsy series of newborns. Gastric or pancreatic tissue may be found within the sequestration. Cysts also may be present. Other associated congenital anomalies, including CPAM (see Chapter 444.3), diaphragmatic hernia (see Chapter 131), and esophageal cysts, are not uncommon. Some believe that intrapulmonary sequestration is often a manifestation of CPAM and have questioned the existence of intrapulmonary sequestration as a separate entity.

CLINICAL MANIFESTATIONS AND DIAGNOSIS

Recurrent pneumonia in the same lung location is suggestive of a sequestration. Physical findings in patients with sequestration include an area of dullness to percussion and decreased breath sounds over the lesion. During infection, crackles may also be present. A continuous or purely systolic murmur may be heard over the back. If findings on routine chest radiographs are consistent with the diagnosis, further delineation is indicated before surgical intervention (Fig. 444.5). CT with contrast can demonstrate both the extent of the lesion and its vascular supply. MR angiography is also useful. Ultrasonography can help to rule out a diaphragmatic hernia and demonstrate the systemic artery. Surgical removal is recommended. Identifying the blood supply before surgery avoids inadvertently severing its systemic artery. Coil embolization (transumbilical in neonates; arterial in older patients) has been successful in treating patients with sequestration.

Intrapulmonary sequestration is generally found in a lower lobe and does not have its own pleura. Patients usually present with infection. In older patients, hemoptysis is common. A chest radiograph during a period when there is no active infection reveals a mass lesion; an air-fluid level may be present. During infection, the margins of the lesion may be blurred. There is no difference in the incidence of this lesion in each lung.

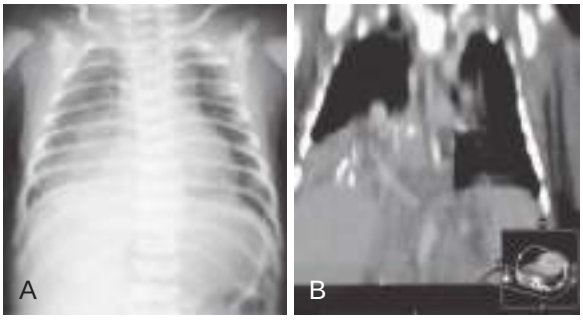

Fig. 444.5 **A,** Plain chest x-ray showing changes in the region of the right lower/middle lobe of the lung. **B,** CT showing parenchymal changes in the right lower lobe of the lung in keeping with a sequestration. *(From Corbett HJ, Humphrey GME. Pulmonary sequestration. Paediatr Respir Rev. 2004;5:59–68.)*

Extrapulmonary sequestration is much more common in boys and almost always involves the left lung. This lesion is enveloped by a pleural covering and is associated with diaphragmatic hernia and other abnormalities such as colonic duplication, vertebral abnormalities, and pulmonary hypoplasia. Many of these patients are asymptomatic when the mass is discovered by routine chest radiography. Other patients present with respiratory symptoms or heart failure. Subdiaphragmatic extrapulmonary sequestration can manifest as an abdominal mass on prenatal ultrasonography. The advent of prenatal ultrasonography has also enabled evidence that fetal pulmonary sequestrations can spontaneously regress.

TREATMENT

Treatment of intrapulmonary sequestration is surgical removal of the lesion, a procedure that usually requires excision of the entire involved lobe. Segmental resection occasionally suffices. Surgical resection of the involved area is often recommended for extrapulmonary sequestration as well, but observation can be considered for asymptomatic patients with small lesions. Coil embolization of the feeding artery has also been successful.

Visit Elsevier eBooks+ at eBooks.Health.Elsevier.com for Bibliography.

444.5 Bronchogenic Cysts

Joshua A. Blatter and Jonathan D. Finder

ETIOLOGY AND PATHOLOGY

Bronchogenic cysts arise from abnormal budding of the tracheal diverticulum of the foregut before the 16th week of gestation and are originally lined with ciliated epithelium. They are more commonly found on the right and near a midline structure (trachea, esophagus, carina), but peripheral lower lobe and perihilar intrapulmonary cysts are not infrequent. Diagnosis may be precipitated by enlargement of the cyst, which causes symptoms by pressure on an adjacent airway. When the diagnosis is delayed until an infection occurs, the ciliated epithelium may be lost, and accurate pathologic diagnosis is then impossible. Cysts are rarely demonstrable at birth. Later, some cysts become symptomatic by becoming infected or by enlarging and compromising the function of an adjacent airway.

CLINICAL MANIFESTATIONS AND TREATMENT

Fever, chest pain, and productive cough are the most common presenting symptoms. Dysphagia may be present; some bronchogenic cysts are asymptomatic. A chest radiograph reveals the cyst, which can contain an air-fluid level (Fig. 444.6). CT scan or MRI is obtained in most cases to better demonstrate the anatomy and extent of the lesion before surgical resection. Treatment of symptomatic cysts is surgical excision after appropriate antibiotic management. Asymptomatic cysts are generally excised in view of the high rate of infection.

Visit Elsevier eBooks+ at eBooks.Health.Elsevier.com for Bibliography.

444.6 Congenital Pulmonary Lymphangiectasia

Joshua A. Blatter and Jonathan D. Finder

Congenital pulmonary lymphangiectasia is characterized by greatly dilated lymphatic ducts throughout the lung. It can occur in three pathologic circumstances: **pulmonary venous obstruction** that produces an elevated transvascular pressure and engorges the pulmonary lymphatics and **generalized lymphangiectasia**, as a generalized disease of several organ systems, including lymphedema, lungs, and the intestines either associated with other syndromes (Noonan, Hennekam, yellow nail, trisomy 21) or nonsyndromic. Gorham-Stout disease (vanishing bone disease) presents with pulmonary and abdominal chylous effusions, destructive bone cysts, and multiple lymphangiomas; **primary lymphangiectasia** limited to the lung is the third type, which is a manifestation of an abnormality in lymphatic development.

Fig. 444.6 Chest x-ray showing an ovoid, well-defined soft tissue density causing splaying of the carina because of a bronchogenic cyst. *(From Williams HJ, Johnson KJ. Imaging of congenital cystic lung lesions. Paediatr Respir Rev. 2002;3:120–127.)*

CLINICAL MANIFESTATIONS AND TREATMENT

Children with pulmonary venous obstruction or severe pulmonary lymphangiectasia present with dyspnea and cyanosis in the newborn period. Hydrops fetalis may be diagnosed antenatally. Chest radiographs reveal diffuse, dense, reticular densities with prominence of Kerley B lines. Pleural effusions are common; thoracentesis will reveal **chylothorax** in this setting. If the lung is not completely involved, the spared areas appear hyperlucent. Respiration is compromised because of impaired diffusion and decreased pulmonary compliance. The diagnosis can be suggested by CT scan and/or cardiac catheterization; definitive diagnosis requires lymphangiography, lymphoscintigraphy, or lung biopsy (either thoracoscopic or open) (Fig. 444.7).

Treatment is supportive and includes administration of oxygen, mechanical ventilation, nutritional support (including gastrostomy placement and use of feedings containing medium-chain triglycerides), and careful fluid management with diuretics. Octreotide, the somatostatin analog, can reduce chylous effusion in some patients. Primary pulmonary lymphangiectasia in the neonate can produce severe pulmonary dysfunction that can require long-term mechanical ventilation; long-term survival and resolution of respiratory insufficiency are possible even in severe cases, especially if the chylous effusions can be managed. Occasionally, the pulmonary venous obstruction is secondary to left-sided cardiac lesions; relief of the latter can produce improvement in pulmonary dysfunction. Sildenafil may reduce pulmonary venous resistance and decrease lymphatic congestion. Sirolimus, which suppresses lymphangiogenesis, may also be beneficial. Lymphangiographic-directed lymphatic injection with ethiodized oil may be another therapeutic option. Generalized lymphangiectasia produces milder pulmonary dysfunction, and survival to mid-childhood and beyond is not unusual.

Visit Elsevier eBooks+ at eBooks.Health.Elsevier.com for Bibliography.

444.7 Lung Hernia

Joshua A. Blatter and Jonathan D. Finder

A lung hernia is a protrusion of the lung beyond its normal thoracic boundaries. Approximately 20% are congenital, with the remainder being noted after chest trauma or thoracic surgery or in patients with pulmonary diseases such as cystic fibrosis (see Chapter 454) or asthma (see Chapter 185), which cause frequent cough and generate high intrathoracic pressure. A congenital weakness of the suprapleural membrane (Sibson fascia) or musculature of the neck can play a role in the appearance of a lung hernia. More than half of congenital lung hernias and almost all acquired hernias are cervical. Congenital cervical hernias usually occur anteriorly through a gap between the scalenus anterior and sternocleidomastoid muscles. Cervical herniation is usually prevented by the trapezius muscle (posteriorly, at the thoracic inlet) and by the three scalene muscles (laterally).

CLINICAL MANIFESTATIONS AND TREATMENT

The presenting sign of a cervical hernia (Sibson hernia) is usually a neck mass noticed while straining or coughing. Some lesions are asymptomatic and detected only when a chest film is taken for another reason. Findings on physical examination are normal except during Valsalva maneuver, when a soft bulge may be noticed in the neck. In most cases, no treatment is necessary, although these hernias can cause problems during attempts to place a central venous catheter through the jugular or subclavian veins. They can resolve spontaneously.

Paravertebral or parasternal hernias are usually associated with rib anomalies. Intercostal hernias usually occur parasternally, where the external intercostal muscle is absent. Posteriorly, despite the seemingly inadequate internal intercostal muscle, the paraspinal muscles usually prevent herniation. Straining, coughing, or playing a musical instrument can have a role in causing intercostal hernias, but in most cases, there is probably a preexisting defect in the thoracic wall.

Surgical treatment for lung hernia is occasionally justified for cosmetic reasons. In patients with severe chronic pulmonary disease and chronic cough and for whom cough suppression is contraindicated, permanent correction might not be achieved.

Visit Elsevier eBooks+ at eBooks.Health.Elsevier.com for Bibliography.

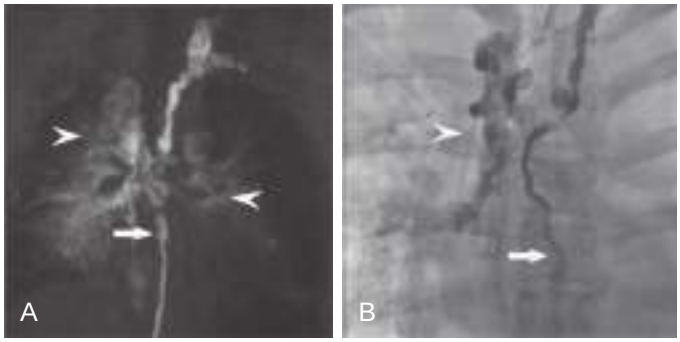

Fig. 444.7 **A,** Dynamic contrast MR lymphangiogram (DCMRL) in a patient with pulmonary lymphangiectasia demonstrating dilated thoracic duct (TD) *(arrow)* and abnormal pulmonary lymphatic perfusion in the lung hilum *(arrowheads).* **B,** Corresponding fluoroscopy image of the TD of the same patient after injection of contrast material through the microcatheter positioned in the proximal part of the TD, which confirms the dilation of the TD *(arrow)* and retrograde flow of the contrast in the mediastinal lymphatic ducts *(arrowhead). (From Itkin M, McCormack FX. Nonmalignant adult thoracic lymphatic disorders. Clin Chest Med. 2016;37:409–420, Fig. 7.)*

444.8 Other Congenital Malformations of the Lung

Joshua A. Blatter and Jonathan D. Finder

CONGENITAL LOBAR EMPHYSEMA AND PULMONARY CYSTS

See Chapter 441.

PULMONARY ARTERIOVENOUS MALFORMATION

See Chapters 481 and 493.

BRONCHOBILIARY FISTULA

A bronchobiliary fistula consists of a fistulous connection between the right middle lobe bronchus and the left hepatic ductal system (Fig. 444.8). Although diagnosis can be delayed until adulthood, this rare anomaly typically manifests with life-threatening bronchopulmonary infections in early infancy. Females are more commonly affected. Definitive diagnosis requires endoscopy or exploratory surgery. Treatment includes surgical excision of the entire intrathoracic portion of the fistula. If the hepatic portion of the fistula does not communicate with the biliary system or duodenum, the involved segment might also have to be resected. Bronchobiliary communications also occur as acquired lesions resulting from hepatic disease complicated by infection.

Visit Elsevier eBooks+ at eBooks.Health.Elsevier.com for Bibliography.

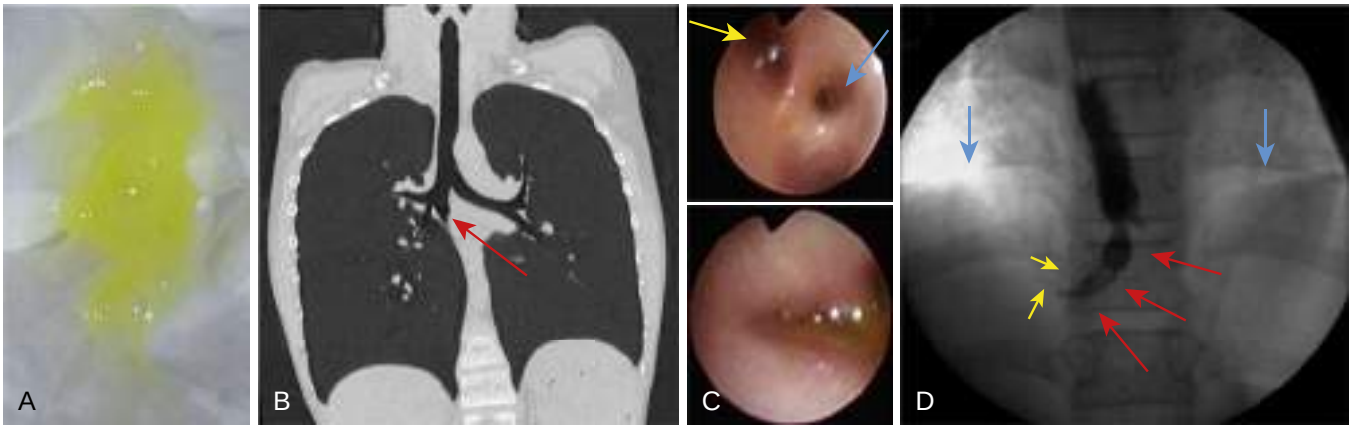

Fig. 444.8 Bronchobiliary fistula. **A,** Unusually bright yellow, serous sputum was observed. The sputum differed in appearance from the yellow sputum containing leukocytes associated with infections. **B,** CT scan revealed an abnormal bronchial bifurcation originating in the right main bronchus and extending downward *(arrow).* **C (Top),** Bronchoscopic images of the right second carina revealed an anomalous orifice *(yellow arrow)* in the medial side of the right intermediate bronchus *(blue arrow).* **(Bottom),** Close-up photo of the abnormal orifice with yellow, serous secretion. **D,** Fistulography with a balloon catheter revealed contrast material slowly proceeding through the intraabdominal region *(red arrows)* to the intrahepatic region *(yellow arrows)* below the diaphragm *(blue arrow). (From Shimizu A, Otani Y, Ishitate M. Congenital bronchobiliary fistula with bright yellow serous sputum. J Pediatr. 2020;243:235–236, Fig. 1.)*

Chapter 445

Pulmonary Edema

Brandon T. Woods

Pulmonary edema is an abnormal fluid collection in the interstitium and air spaces of the lung resulting in oxygen desaturation, decreased lung compliance, and respiratory distress. The condition is common in the acutely ill child.

PATHOPHYSIOLOGY

Although pulmonary edema is traditionally separated into two categories according to cause (*cardiogenic* and *noncardiogenic*), the end result of both processes is a net fluid accumulation within the interstitial and alveolar spaces. Noncardiogenic pulmonary edema in its most severe state is also known as *acute respiratory distress syndrome* (see Chapters 86 and 421).

The *hydrostatic pressure* and colloid *osmotic (oncotic) pressure* on either side of a pulmonary vascular wall, along with vascular permeability, are the forces and physical factors that determine fluid movement through the vessel wall. Baseline conditions lead to a net filtration of fluid from the intravascular space into the interstitium. This extra interstitial fluid is usually rapidly reabsorbed by pulmonary lymphatics. Conditions that lead to altered vascular permeability, increased pulmonary vascular pressure, and decreased intravascular oncotic pressure increase the net flow of fluid out of the vessel (Table 445.1). Once the capacity of the lymphatics for fluid removal is exceeded, water accumulates in the lung.

To understand the sequence of lung water accumulation, it is helpful to consider its distribution among four distinct compartments, as follows:

- *Vascular compartment:* This compartment consists of all blood vessels that participate in fluid exchange with the interstitium. The vascular compartment is separated from the interstitium by capillary endothelial cells. Several endogenous inflammatory mediators, as well as exogenous toxins, are implicated in the pathogenesis of pulmonary capillary endothelial damage, leading to the leakiness seen in several systemic processes.
- *Interstitial compartment:* The importance of this space lies in its interposition between the alveolar and vascular compartments. As fluid leaves the vascular compartment, it collects in the interstitium before overflowing into the air spaces of the alveolar compartment.
- *Alveolar compartment:* This compartment is lined with type 1 and type 2 epithelial cells. These epithelial cells have a role in active fluid transport from the alveolar space, and they act as a barrier to exclude fluid from the alveolar space. The potential fluid volume of the alveolar compartment is many times greater than that of the interstitial space, perhaps providing another reason that alveolar edema clears more slowly than interstitial edema.
- *Pulmonary lymphatic compartment:* There is an extensive network of pulmonary lymphatics. Excess fluid present in the alveolar and interstitial compartments is drained via the lymphatic system. When the capacity for drainage of the lymphatics is surpassed, fluid accumulation occurs.

ETIOLOGY

The specific clinical findings vary according to the underlying mechanism (see Table 445.1).

Transudation of fluid as a result of increased pulmonary vascular pressure *(capillary hydrostatic pressure)* occurs in several cardiac processes. A significant left-to-right shunting lesion, such as a septal defect, leads to a pressure and volume load on the pulmonary vasculature. The resultant pulmonary edema is one of the hallmarks of congestive heart failure. Left ventricular failure, mitral valve disease, and pulmonary venous obstructive lesions cause increased backpressure in the pulmonary vasculature. This results in an increase in pulmonary capillary pressure.

Table 445.1 Etiology of Pulmonary Edema

INCREASED PULMONARY CAPILLARY PRESSURE
Cardiogenic, such as left ventricular failure
Noncardiogenic, as in pulmonary venoocclusive disease, pulmonary venous fibrosis, mediastinal tumors
INCREASED CAPILLARY PERMEABILITY
Bacterial and viral pneumonia
Acute respiratory distress syndrome
Immune reconstitution inflammatory syndrome (IRIS)
Cytokine release syndrome (CRS): CAR-T therapy
Inhaled toxic agents
Circulating toxins
Vasoactive substances such as histamine, leukotrienes, and thromboxanes
Diffuse capillary leak syndrome, as in sepsis, SIRS
Immunologic reactions, such as transfusion reactions
Smoke inhalation
Aspiration pneumonia/pneumonitis
Drowning and near drowning
Radiation pneumonia
Uremia
LYMPHATIC INSUFFICIENCY
Congenital and acquired
DECREASED ONCOTIC PRESSURE
Hypoalbuminemia, as in renal and hepatic diseases, protein-losing states, and malnutrition
INCREASED NEGATIVE INTERSTITIAL PRESSURE
Upper airway obstructive lesions, such as croup and epiglottitis
Reexpansion pulmonary edema
MIXED OR UNKNOWN CAUSES
Neurogenic pulmonary edema
High-altitude pulmonary edema
Eclampsia
Pancreatitis
Pulmonary embolism
Heroin (narcotic) pulmonary edema

SIRS, systemic inflammatory response syndrome.
Modified from Robin E, Carroll C, Zelis R. Pulmonary edema. *N Engl J Med.* 1973;288:239, 292; and Desphande J, Wetzel R, Rogers M. In: Rogers M, ed. *Textbook of Pediatric Intensive Care*, 3rd ed. Baltimore: Williams & Wilkins; 1996:432–442.

Increased capillary permeability is usually secondary to endothelial damage. Such damage can occur secondary to direct injury to the alveolar epithelium or indirectly through systemic processes that deliver circulating inflammatory mediators or toxins to the lung. Inflammatory mediators (tumor necrosis factor, leukotrienes, thromboxanes) and vasoactive agents (nitric oxide, histamine) formed during pulmonary and systemic processes potentiate the altered capillary permeability that occurs in many disease processes, with sepsis being a common cause.

Fluid homeostasis in the lung largely depends on drainage via the lymphatics. Experimentally, pulmonary edema occurs with obstruction of the lymphatic system. Increased lymph flow and dilation of lymphatic vessels occur in chronic edematous states.

A decrease in intravascular oncotic pressure leads to pulmonary edema by altering the forces promoting fluid reentry into the vascular space. This occurs in dilutional disorders, such as fluid overload with hypotonic solutions, and in protein-losing states, such as nephrotic syndrome and malnutrition.

The **excessive negative interstitial pressure** seen in upper airway diseases, such as croup and laryngospasm, may promote pulmonary edema. Aside from the physical forces present in these diseases, other mechanisms may also be involved. Theories implicate an increase in CO_2 tension, decreased O_2 tension, and extreme increases in cardiac afterload, leading to transient cardiac insufficiency.

The mechanism causing **neurogenic pulmonary edema** is not clear. A massive sympathetic discharge secondary to a cerebral injury may produce increased pulmonary and systemic vasoconstriction, resulting in a shift of blood to the pulmonary vasculature, an increase in capillary pressure, and edema formation. Inflammatory mechanisms may also play a role by increasing capillary permeability.

The mechanism responsible for **high-altitude pulmonary edema** is unclear, but it may also be related to sympathetic outflow, increased pulmonary vascular pressures, and hypoxia-induced increases in capillary permeability (see Chapter 87).

Active ion transport followed by passive osmotic water movement is important in clearing the alveolar space of fluid. There are some experimental data that β-agonists and growth factors increase alveolar fluid removal. Interindividual genetic differences in the rates of these transport processes may be important in determining which individuals are susceptible to altitude-related pulmonary edema. Although the existence of these mechanisms suggests that therapeutic interventions may be developed to promote resolution of pulmonary edema, no such therapies currently exist.

CLINICAL MANIFESTATIONS

The clinical features depend on the mechanism of edema formation. In general, interstitial edema and alveolar edema prevent the inflation of alveoli, leading to atelectasis and decreased surfactant production. This results in diminished pulmonary compliance and tidal volume. The patient must increase respiratory effort and/or the respiratory rate so as to maintain minute ventilation. The earliest clinical signs of pulmonary edema include increased work of breathing, tachypnea, and dyspnea. As fluid accumulates in the alveolar space, auscultation reveals fine crackles and wheezing, especially in dependent lung fields. In cardiogenic pulmonary edema, a gallop may be present as well as peripheral edema and jugular venous distention.

Chest radiographs can provide useful ancillary data, although findings of initial radiographs may be normal. Early radiographic signs that represent accumulation of interstitial edema include peribronchial and perivascular cuffing. Diffuse streakiness reflects interlobular edema and distended pulmonary lymphatics. Diffuse, patchy densities, the so-called *butterfly pattern,* represent bilateral interstitial or alveolar infiltrates and are a late sign. Cardiomegaly is often seen with cardiogenic causes of pulmonary edema. Heart size is usually normal in noncardiogenic pulmonary edema (Table 445.2). Chest tomography demonstrates edema accumulation in the dependent areas of the lung. As a result, changing the patient's position can alter regional differences in lung compliance, functional residual capacity, and alveolar ventilation.

Measurement of brain natriuretic peptide, often elevated in heart disease, can help to differentiate cardiac from pulmonary causes of pulmonary edema. A brain natriuretic peptide level >500 pg/mL suggests heart disease; a level <100 pg/mL suggests lung disease.

TREATMENT

The treatment of a patient with noncardiogenic pulmonary edema is largely supportive, with the primary goal being to ensure adequate

Table 445.2 Distinguishing Cardiogenic and Noncardiogenic Pulmonary Edema

	HISTORY	EXAMINATION	LABORATORY TESTS	IMAGING

CARDIOGENIC	• Heart disease
	• Renal disease
	• Uncontrolled HTN
	• Edema
	• Orthopnea
	• Recent administration of IV fluids or blood products
		• Heart failure examination findings:
		  • Distended neck veins
		  • S3 heart sound
		  • Dependent edema
		  • Elevated blood pressure
		  • Cool extremities
			• ↑ BNP >1200 pg/mL
			• ↑ Creatinine (in setting of volume overload)
			• ↑ Troponin
				• CXR:
				  • CMG pleural effusions
				  • Kerley B lines*
				  • Bedside USG: homogenous B lines and sliding pleura in at least two lung regions
				• TEE:
				  • ↓ LVEF
				  • Diastolic filling defect
				  • Severe mitral or aortic valvular disease
				  • Pericardial effusion with tamponade
				  • VSD

NONCARDIOGENIC	• Sepsis
	• Aspiration event
	• Trauma (long bone fractures)
	• Burn injury
	• Pancreatitis
	• Multiple transfusions
		• Signs of active infection
		• Extensive burn injury
		• Evidence of trauma (absence of heart failure examination findings)
			• ↑ WBC
			• BNP <200 pg/mL
				• CXR:
				  • Diffuse central and peripheral infiltrates
				  • Normal heart size
				  • No or minimal pleural effusions
				• Bedside USG: Presence of nonhomogeneous B lines, limited pleural sliding, and other patterns such as subpleural consolidations in at least two to three lung regions
				• TEE:
				  • Normal LV and valvular function
				  • No evidence of volume overload

*Thin 1–2 cm hyperechoic lines indicating thickened interlobular septae in the lung apices or bases.
BNR, brain natriuretic peptide.
Modified from Pannu SR, Christman JW, Crouser ED: Pulmonary edema. In Vincent JL, Moore FA, Bellomo R, Marini JJ (eds). *Textbook of Critical Care,* 8th ed. Philadelphia: Elsevier, 2024. Table 11.1.

ventilation and oxygenation. Additional therapy is directed toward the underlying cause. Patients should receive supplemental oxygen to increase alveolar oxygen tension and pulmonary vasodilation. Patients with pulmonary edema of cardiogenic causes should be managed with diuretics, inotropic agents, and systemic vasodilators to reduce left ventricular afterload. Diuretics are also valuable in the treatment of pulmonary edema associated with total body fluid overload (sepsis, renal insufficiency). Morphine is often helpful as a vasodilator and a mild sedative.

Positive airway pressure improves gas exchange in patients with pulmonary edema. In tracheally intubated patients, positive end-expiratory pressure can be used to optimize pulmonary mechanics. Noninvasive forms of ventilation, such as mask or nasal prong continuous positive airway pressure, are also effective. The mechanism by which positive airway pressure improves pulmonary edema is not entirely clear but is not associated with decreasing lung water. Rather, continuous positive airway pressure prevents complete closure of alveoli at the low lung volumes present at the end of expiration. It may also recruit already collapsed alveolar units. This leads to increased functional residual capacity and improved pulmonary compliance, improved surfactant function, and decreased pulmonary vascular resistance. The net effect is to decrease the work of breathing, improve oxygenation, and decrease cardiac afterload.

When mechanical ventilation becomes necessary, especially in noncardiogenic pulmonary edema, care must be taken to minimize the risk of development of complications from volutrauma or barotrauma, including pneumothorax, pneumomediastinum, and primary alveolar damage (see Chapter 86.1). Lung protective strategies include setting low tidal volumes, relatively high positive end-expiratory pressure, and allowing for permissive hypercapnia.

High-altitude pulmonary edema should be managed with altitude descent and supplemental oxygen. Portable continuous positive airway pressure or a portable hyperbaric chamber is also helpful. Nifedipine (10 mg initially and then 20-30 mg by slow release every 12-24 hours) in adults is also helpful. If there is a history of high-altitude pulmonary edema, nifedipine and β-adrenergic agonists (inhaled) may prevent recurrence (see Chapter 87).

Visit Elsevier eBooks+ at eBooks.Health.Elsevier.com for Bibliography.

Chapter 446

Acute Aspiration

Anastassios C. Koumbourlis

ASPIRATION SYNDROMES

Aspiration of material that is foreign to the lower airway produces a varied clinical spectrum ranging from an asymptomatic condition to acute life-threatening events. Except for cases of self-harm, episodes of acute aspiration are almost always unintentional. Whether the aspiration will lead to the development of symptoms and how severe these will be depends on the amount and nature of the aspirated material.

This chapter focuses on aspiration of **biologic liquids** (e.g., gastric contents) and chemical substances such as hydrocarbons or oils. Other chapters discuss the mechanical obstruction of large- or intermediate-size airways from solid foreign bodies (see Chapter 435), drowning (see Chapter 88), and chronic or recurrent (micro)aspiration (see Chapter 447).

GASTRIC CONTENTS

Aspiration of gastric contents may occur in the context of vomiting in persons who are not able to protect their airways. This can be the result of either a chronic neurologic impairment or temporary suppression of the normal protective reflexes. Such circumstances include drowning, seizures, trauma (especially head injury), and cardiopulmonary resuscitation. The most common nonacute condition that may predispose to aspiration is anesthesia that suppresses the protective airway reflexes (e.g., cough, glottic closure) not only during the procedure but even for hours afterward. Fortunately, because of the strict guidelines of fasting before receiving anesthesia, the actual incidence of aspiration during anesthesia is extremely low (<0.4%). It should be noted that in-office sedation/anesthesia for dental procedures also has the potential to cause suppression of the protective airway reflexes. Other conditions that may lead to vomiting and aspiration are alcohol intoxication and use of illicit drugs such as opiates, both of which can cause severe suppression of the level of consciousness.

The consequences of aspiration of gastric contents vary, depending primarily on the pH and volume of the aspirate and on the amount of particulate material it contains. Increased clinical severity is noted with aspirated volumes greater than 0.8 mL/kg and/or pH <2.5, but significant injury may also occur by fluids with alkaline pH such as bile or even with human breast milk.

Acute aspiration may cause **chemical pneumonitis** that may progress to **acute respiratory distress syndrome (ARDS)** consisting of hypoxemia, hemorrhagic pneumonitis, atelectasis, intravascular fluid shifts, and pulmonary edema. These processes occur rapidly (within minutes to 1-2 hours). There is also a marked increase in lung parenchymal neutrophil infiltrations, mucosal sloughing, and alveolar consolidation that often correlates with increasing infiltrates on chest radiographs. These changes tend to occur later (24-72 hours) and are more prolonged after aspiration of particulate material. Aspiration of gastric contents does not cause infection per se, but it predisposes to infection because of impairment of the airway epithelial defenses. If the patient demonstrates clinical worsening, especially with fever and leukocytosis, secondary bacterial pneumonia should be suspected.

HYDROCARBON ASPIRATION

Hydrocarbons are organic compounds that consist entirely of hydrogen and carbon. They are found in abundance in nature in fossil fuels (crude oil, coal, natural gas) and in plants (and some animals). Hydrocarbons are used in numerous common household or industrial products, thus increasing the possibility of accidental (and/or intentional) exposure. The major types of hydrocarbons and their common uses can be found in Table 446.1.

There are thousands of unintentional exposures to hydrocarbons each year, with the vast majority occurring in children under the age of 5, who drink out of curiosity from poorly secured and unlabeled containers. During adolescence, many exposures are intentional for recreational purposes (e.g., glue sniffing). Among adults a common accidental exposure occurs while attempting to siphon gasoline or among performers such as "fire eaters." Aspiration of hydrocarbons can occur while drinking the substance or often in the context of vomiting that follows an ingestion. Hydrocarbons have a noxious, unpleasant taste, and they are highly irritating to mucous membranes, thus preventing ingestion and aspiration of large volumes. One exception is the **mineral seal oil** that has a sweet taste that can lead to the ingestion of fairly large amounts.

The toxicity of the hydrocarbons depends on the specific properties of the compound and the amount that was aspirated. The major properties are:

- **Viscosity:** that is the resistance to flow through an orifice. Low viscosity allows *deeper penetration* into the tracheobronchial tree, and it is the property that primarily determines the aspiration potential for hydrocarbons.
- **Surface tension:** that refers to the cohesiveness of molecules along a liquid surface. Low surface tension allows compounds to *spread over a larger area.*

ventilation and oxygenation. Additional therapy is directed toward the underlying cause. Patients should receive supplemental oxygen to increase alveolar oxygen tension and pulmonary vasodilation. Patients with pulmonary edema of cardiogenic causes should be managed with diuretics, inotropic agents, and systemic vasodilators to reduce left ventricular afterload. Diuretics are also valuable in the treatment of pulmonary edema associated with total body fluid overload (sepsis, renal insufficiency). Morphine is often helpful as a vasodilator and a mild sedative.

Positive airway pressure improves gas exchange in patients with pulmonary edema. In tracheally intubated patients, positive end-expiratory pressure can be used to optimize pulmonary mechanics. Noninvasive forms of ventilation, such as mask or nasal prong continuous positive airway pressure, are also effective. The mechanism by which positive airway pressure improves pulmonary edema is not entirely clear but is not associated with decreasing lung water. Rather, continuous positive airway pressure prevents complete closure of alveoli at the low lung volumes present at the end of expiration. It may also recruit already collapsed alveolar units. This leads to increased functional residual capacity and improved pulmonary compliance, improved surfactant function, and decreased pulmonary vascular resistance. The net effect is to decrease the work of breathing, improve oxygenation, and decrease cardiac afterload.

When mechanical ventilation becomes necessary, especially in noncardiogenic pulmonary edema, care must be taken to minimize the risk of development of complications from volutrauma or barotrauma, including pneumothorax, pneumomediastinum, and primary alveolar damage (see Chapter 86.1). Lung protective strategies include setting low tidal volumes, relatively high positive end-expiratory pressure, and allowing for permissive hypercapnia.

High-altitude pulmonary edema should be managed with altitude descent and supplemental oxygen. Portable continuous positive airway pressure or a portable hyperbaric chamber is also helpful. Nifedipine (10 mg initially and then 20-30 mg by slow release every 12-24 hours) in adults is also helpful. If there is a history of high-altitude pulmonary edema, nifedipine and β-adrenergic agonists (inhaled) may prevent recurrence (see Chapter 87).

Visit Elsevier eBooks+ at eBooks.Health.Elsevier.com for Bibliography.

Chapter 446

Acute Aspiration

Anastassios C. Koumbourlis

ASPIRATION SYNDROMES

Aspiration of material that is foreign to the lower airway produces a varied clinical spectrum ranging from an asymptomatic condition to acute life-threatening events. Except for cases of self-harm, episodes of acute aspiration are almost always unintentional. Whether the aspiration will lead to the development of symptoms and how severe these will be depends on the amount and nature of the aspirated material.

This chapter focuses on aspiration of **biologic liquids** (e.g., gastric contents) and chemical substances such as hydrocarbons or oils. Other chapters discuss the mechanical obstruction of large- or intermediate-size airways from solid foreign bodies (see Chapter 435), drowning (see Chapter 88), and chronic or recurrent (micro)aspiration (see Chapter 447).

GASTRIC CONTENTS

Aspiration of gastric contents may occur in the context of vomiting in persons who are not able to protect their airways. This can be the result of either a chronic neurologic impairment or temporary suppression of the normal protective reflexes. Such circumstances include drowning, seizures, trauma (especially head injury), and cardiopulmonary resuscitation. The most common nonacute condition that may predispose to aspiration is anesthesia that suppresses the protective airway reflexes (e.g., cough, glottic closure) not only during the procedure but even for hours afterward. Fortunately, because of the strict guidelines of fasting before receiving anesthesia, the actual incidence of aspiration during anesthesia is extremely low (<0.4%). It should be noted that in-office sedation/anesthesia for dental procedures also has the potential to cause suppression of the protective airway reflexes. Other conditions that may lead to vomiting and aspiration are alcohol intoxication and use of illicit drugs such as opiates, both of which can cause severe suppression of the level of consciousness.

The consequences of aspiration of gastric contents vary, depending primarily on the pH and volume of the aspirate and on the amount of particulate material it contains. Increased clinical severity is noted with aspirated volumes greater than 0.8 mL/kg and/or pH <2.5, but significant injury may also occur by fluids with alkaline pH such as bile or even with human breast milk.

Acute aspiration may cause **chemical pneumonitis** that may progress to **acute respiratory distress syndrome (ARDS)** consisting of hypoxemia, hemorrhagic pneumonitis, atelectasis, intravascular fluid shifts, and pulmonary edema. These processes occur rapidly (within minutes to 1-2 hours). There is also a marked increase in lung parenchymal neutrophil infiltrations, mucosal sloughing, and alveolar consolidation that often correlates with increasing infiltrates on chest radiographs. These changes tend to occur later (24-72 hours) and are more prolonged after aspiration of particulate material. Aspiration of gastric contents does not cause infection per se, but it predisposes to infection because of impairment of the airway epithelial defenses. If the patient demonstrates clinical worsening, especially with fever and leukocytosis, secondary bacterial pneumonia should be suspected.

HYDROCARBON ASPIRATION

Hydrocarbons are organic compounds that consist entirely of hydrogen and carbon. They are found in abundance in nature in fossil fuels (crude oil, coal, natural gas) and in plants (and some animals). Hydrocarbons are used in numerous common household or industrial products, thus increasing the possibility of accidental (and/or intentional) exposure. The major types of hydrocarbons and their common uses can be found in Table 446.1.

There are thousands of unintentional exposures to hydrocarbons each year, with the vast majority occurring in children under the age of 5, who drink out of curiosity from poorly secured and unlabeled containers. During adolescence, many exposures are intentional for recreational purposes (e.g., glue sniffing). Among adults a common accidental exposure occurs while attempting to siphon gasoline or among performers such as "fire eaters." Aspiration of hydrocarbons can occur while drinking the substance or often in the context of vomiting that follows an ingestion. Hydrocarbons have a noxious, unpleasant taste, and they are highly irritating to mucous membranes, thus preventing ingestion and aspiration of large volumes. One exception is the **mineral seal oil** that has a sweet taste that can lead to the ingestion of fairly large amounts.

The toxicity of the hydrocarbons depends on the specific properties of the compound and the amount that was aspirated. The major properties are:

- **Viscosity:** that is the resistance to flow through an orifice. Low viscosity allows *deeper penetration* into the tracheobronchial tree, and it is the property that primarily determines the aspiration potential for hydrocarbons.
- **Surface tension:** that refers to the cohesiveness of molecules along a liquid surface. Low surface tension allows compounds to *spread over a larger area.*

Table 446.1 Classes and Uses of Common Hydrocarbons (HC)

CLASS AND CHEMICAL COMPOSITION	SOURCES AND EXAMPLES	USES
Aliphatic HC: Straight-chain compounds	**Source**: crude oil **Examples:** propane, kerosene, mineral seal oil	Furniture polishes, lamp oil, and lighter fluid
Aromatic HC: Cyclic compounds containing a benzene ring	**Source**: fossil fuels **Examples**: benzene, toluene, xylene	Solvents, glues, nail polishes, paints, and paint removers
Halogenated HC: compounds in which at least one hydrogen atom is replaced by a halogen (chlorine, bromine, fluorine)	**Source**: synthetic **Examples:** chloroform, bromopropane, carbon tetrachloride, methylene chloride, tetrachloroethylene	Solvents for dry cleaning, solvents for degreasing of metals, adhesives, refrigeration (Freon); insecticides
Terpene HC: cyclic hydrocarbons that consist of 5-carbon building blocks (isoprene)	**Source**: mostly plants **Examples**: turpentine, pine oil	Paint thinners (turpentine) and cleaning products (pine oil)

Fig. 446.1 Chest radiographs of a 17-mo-old toddler with hydrocarbon ingestion. **A,** Three hours after ingestion, the lungs are clear. **B,** At 24 hours, there are bibasilar coalescing nodular opacities. **C,** Three days later there is much clearing. *(From Slovis T, ed. Caffey's Pediatric Diagnostic Imaging, 11th ed. Philadelphia: Mosby; 2008:1287.)*

- **Volatility:** that is the *ability to vaporize*. High volatility increases the risk of pulmonary absorption and central nervous system (CNS) depression.

Hydrocarbons with lower surface tensions (gasoline, turpentine, naphthalene) have more potential for aspiration toxicity than heavier mineral or fuel oils. Ingestion of >30 mL of hydrocarbon, the approximate volume of an adult swallow, is associated with an increased risk of severe pneumonitis.

Most patients with hydrocarbon aspiration tend to remain asymptomatic. When symptomatic, patients have cough, choking, gagging, and vomiting. These usually appear within the first 30 minutes after the aspiration, but they may appear as late as 24 hours. Radiographic findings may present within hours and consist of interstitial or alveolar infiltrates in the perihilar regions and/or in the lower lobes (Fig. 446.1). Additional symptoms develop gradually and may include fever and increased work of breathing. Breath sounds may be decreased (or even absent) with wheezing and/or crackles (especially in the lower lobes). Symptomatic patients (especially those with radiographic abnormalities) require hospitalization for prolonged observation and treatment. Most patients require only supportive therapy (e.g., supplemental oxygen and hydration), and they get discharged within 2-3 days. A small number of patients (~5%) may develop ARDS with severe hypoxemia. Because hydrocarbons evaporate, they displace the alveolar gas, thus exacerbating the hypoxemia that is caused by the development of pulmonary edema and atelectasis that characterize ARDS. Necrotizing pneumonia with pneumatoceles, lipoid pneumonia, and hemorrhagic pulmonary edema are typical manifestations of severe cases, and they are often complicated by bacterial superinfection and sepsis, pleural effusions, and air leaks. Fatalities may occur, but most patients are expected to recover. Pneumatoceles can resolve over the course of months.

ASPIRATION OF OTHER SUBSTANCES

Any substance that is not supposed to be found in the airways can cause clinically significant disease. Other substances that can cause significant lung injury when aspirated or inhaled include baby powder (talc), chlorine, shellac, beryllium, and mercury vapors. Repeated exposure to low concentrations of these agents can lead to chronic lung disease, such as interstitial pneumonitis and granuloma formation. Corticosteroids may help reduce fibrosis development and improve pulmonary function, although the evidence for this benefit is limited.

One substance that deserves special mentioning is cinnamon, which achieved "notoriety" during the past decade because of the popularity among teenagers and young adults of the so-called "cinnamon-challenge" in which a person attempts to swallow dry cinnamon. Cinnamon is a caustic substance that causes the person to cough violently while it elicits a severe gag that is apparently the "amusing" part of the challenge for the spectators. Despite the gag, the possibility of aspiration is relatively high. Cinnamon causes significant airway inflammation and a potential hypersensitivity reaction that in rare cases may lead to respiratory distress and failure.

PRINCIPLES OF MANAGEMENT

Suctioning of the aspirated material can be effective only if it is performed during or immediately after the aspiration occurs (e.g., vomiting occurring in a patient who is seizing). Once aspiration occurs, the aspirated fluid will be drawn (or pushed) quickly into the distal airways with every spontaneous or positive pressure breath. Thus gastric emptying is generally contraindicated because the vomiting increases the possibility of aspiration. An exception to this rule is the ingestion of a large volume (>30 mL) of certain hydrocarbons with inherent systemic toxicity, especially if the patient exhibits signs of altered mental status. Such compounds include **c**amphor, **h**alogenated carbons, **a**romatic hydrocarbons, and those containing metals and **p**esticides (mnemonic: CHAMP). *Gastric emptying should be performed after a cuffed endotracheal tube has been inserted for protection from aspiration.* However, because intubating a patient with a full stomach is a high-risk procedure by itself, it should be performed by a specialist with experience in rapid sequence intubation to prevent vomiting and further aspiration.

Bronchoscopy should be considered if there is suspicion of aspiration of significant particulate material that could be potentially removed (see Chapter 435).

Patients in whom large-volume or toxic aspiration is suspected should be observed for several hours (e.g., 6-8 hours) for signs of respiratory distress and/or hypoxemia. A chest radiograph is warranted. A "negative" chest radiograph taken shortly after the event does not rule out the presence, nor does it predict the severity of aspiration, because the radiographic findings usually lag behind the clinical symptoms (see Fig. 447.1).

If the chest radiograph findings and oxygen saturation are normal and the patient remains asymptomatic after several hours of observation, no other treatment is necessary. The caregivers should be instructed to bring the child back to the hospital if respiratory symptoms or fever develop.

Supplemental oxygen is indicated to treat hypoxemia and/or to decrease the work of breathing. High-flow nasal cannula or noninvasive ventilation such as continuous positive airway pressure or bilevel positive airway pressure should be instituted for patients who develop increased work of breathing, progressive hypoxemia, and/or progressive hypercapnia. If these measures fail to control the symptoms, endotracheal intubation and mechanical ventilation are indicated. In rare cases of refractory respiratory failure, extracorporeal membrane oxygenation may become necessary. Exogenous surfactant has been used with success in some reported cases.

There is no specific pharmacologic therapy for aspiration. Bronchodilators may be tried to prevent and/or reverse the bronchospasm triggered by the aspirate (especially if the patient has a history of airway hyperreactivity/asthma). Use of inhaled and especially of systemic corticosteroids may be reasonable considering that severe aspiration triggers a massive inflammatory response, but their actual benefit is rather inconclusive. Animal studies suggest that to be effective corticosteroids should be given nearly simultaneously with the aspiration event. Prophylactic *antibiotics are not generally indicated* because aspiration causes a "chemical" and not an infectious pneumonitis. However, the possibility of a secondary infection is high because of organisms (usually anaerobes) from the oropharynx that enter the lower airways with the aspirate and/or organisms that may already colonize the lower airways (e.g., in patients with artificial airways and/or underlying conditions such as bronchiectasis). Thus the decision to start antibiotics prophylactically should be based on the patient's respiratory status, immune status, and colonization status (if known). Empiric antibiotic therapy is usually targeted against anaerobic organisms. In hospitalized or chronically ill patients (especially those with an artificial airway), coverage of *Pseudomonas, Staphylococcus aureus,* and enteric gram-negative organisms should also be considered. If empiric antibiotics are given, they can be discontinued if the condition improves rapidly and the cultures are negative.

PREVENTION

The best prevention of unintentional aspiration is to keep toxic substances out of reach from young children in containers that are clearly labeled and with safety caps. Prevention of aspiration should always be the goal when airway manipulation is necessary for intubation or other invasive procedures. Feeding with enteral tubes passed beyond the pylorus, elevating the head of the bed 30-45 degrees in mechanically ventilated patients, and oral decontamination reduce the incidence of aspiration complications in the intensive care unit. Acid neutralization is not routinely recommended, but it may be considered if the airway epithelium is damaged and thus unable to neutralize the acid. Minimizing use of sedation, monitoring for gastric residuals, and gastric acid suppression may all help prevent aspiration. *Any patient with altered consciousness, especially one who is receiving nasogastric or gastrostomy tube feedings, is at high risk for aspiration.*

PROGNOSIS

Most patients without any underlying conditions usually recover in 2-3 weeks with minimal or no chronic residual clinical symptoms, abnormal radiographic, or lung function changes. Prolonged lung damage may occur, including scarring, bronchiolitis obliterans, and bronchiectasis. The mortality is relatively low (approximately 5%) and occurs primarily among patients with severe acute or chronic comorbidities. In adults the mortality is much higher (exceeding 20%), but it is difficult to separate the contribution of the aspiration from the effect of the underlying conditions.

Visit Elsevier eBooks+ at eBooks.Health.Elsevier.com for Bibliography.

Chapter 447

Chronic Recurrent Aspiration

Anastassios C. Koumbourlis

The air that enters the lungs with every breath travels through the same narrow spaces that solid foods and liquids use to enter the esophagus. That aspiration does not occur routinely is the result of several mechanisms that protect the lower airways. The swallowing mechanism is a complex process that starts early in fetal life but fully matures months after birth; its goal is to receive, process, and transfer the food bolus from the mouth to the esophagus while preventing food particles and/or fluids from entering the trachea. When fully developed, the swallow consists of four phases. The first two (oral preparatory and oral) are voluntary and involve the preparation of the food bolus and its transfer to the back of the throat, whereas the last two (pharyngeal and esophageal) are involuntary. Under normal circumstances, by the time the food bolus reaches the pharynx, the respiration transiently stops, the vocal cords close at the midline, the arytenoid cartilages come close to each other, and the epiglottis flexes toward the posterior wall covering the larynx. This allows the food bolus to slide around the epiglottis into the pyriform sinuses and then into the esophagus where peristalsis and gravity help it move to the stomach. If these four phases are not synchronized (e.g., drinking too fast), aspiration may occur. Oropharyngeal incoordination is reportedly the most common underlying problem (with prevalence as high as 48%) associated with recurrent pneumonia in hospitalized children. A wide variety of conditions may impair one or more of the phases of the normal swallow (Table 447.1). Various maxillofacial and oropharyngeal anatomic abnormalities such as micrognathia, macroglossia, and cleft palate affect primarily the first two phases of swallowing, whereas neurologic conditions (affecting the central or the peripheral nervous system and the motor neuron junction) and primary muscle conditions affect the last two. In addition to the mechanisms for airway protection that are part of the normal swallow, there are several reflexes that can prevent aspiration. These include:

1. **The pharyngeal reflex**: Commonly referred to as the "gag" reflex, it can be elicited by touching the posterior pharyngeal wall, the soft palate, the tonsils, and/or the larynx. The gag reflex causes bilateral acute contraction of the pharyngeal muscles and elevation of the soft palate that prevent the bolus from advancing to the glottis. Damage to the glossopharyngeal and/or vagal nerves affects the reflex unilaterally or bilaterally.
2. **The laryngeal spasm**: When the glottis and/or subglottis get irritated, they produce acute contraction of the laryngeal muscles that close the vocal cords. This mechanism is very important when liquid and/or particles reach the larynx from below (gastroesophageal reflux [GER] or regurgitation) without involving the normal swallowing mechanism. Despite its protective role, laryngospasm may have negative consequences, especially in infants, who have normally low breathing reserves and can develop hypoxemia and hypercapnia within seconds. In addition, if during laryngospasm the infant attempts to exhale, the

Table 447.1 Conditions Associated with Chronic Aspiration

DIRECT	IMPAIRED SWALLOWING MECHANISM	PREDISPOSING FACTORS
Anatomic causes • Tracheoesophageal fistula • Bronchoesophageal fistula • Laryngotracheal cleft	Anatomic causes • Cleft lip/cleft palate* • Micrognathia • Macroglossia • Scarring (e.g., burns) • Trauma • Facial rigidity (scleroderma, dermatomyositis)	Anatomic causes • Choanal stenosis • Laryngomalacia • Esophageal stricture • Esophageal foreign body • External compression of the esophagus (e.g., vascular ring, mass)
Functional causes • Vocal cord paralysis in abduction • Central nervous system disorders suppressing the airway-protective reflexes (severe encephalopathy, coma)	Functional causes • Muscle weakness (neuromuscular disorders) • Bulbar dysfunction (motor neuron disorders) • Nonspecific hypotonia (e.g., trisomy 21)	Functional causes • Gastroesophageal reflux • Esophageal achalasia • Immature swallowing (e.g., prematurity) • Severe tachypnea

*Preoperative and postoperative.

Hering-Breuer reflex may cause apnea (this may be a cause of the GER-related apnea often seen among premature infants).

3. **The cough reflex**: The presence of material in the glottis and subglottis will normally elicit a cough to expel the "foreign substance." Thus coughing while eating or drinking is an indication of impaired swallowing and of possible aspiration. However, the absence of cough while eating or drinking does not rule out aspiration because several groups of patients (e.g., premature infants or patients with neuromuscular disorders) may not be able to cough, resulting into the so-called "silent aspiration."

When anatomic abnormalities connect the respiratory and gastrointestinal tracts, the airway protective mechanisms are completely bypassed, and chronic aspiration ensues. Such abnormalities can be found at the level of the larynx (e.g., laryngotracheoesophageal cleft) or at the proximal tracheobronchial tree (e.g., tracheoesophageal and/or bronchoesophageal fistula).

CLINICAL PRESENTATION

Repeated aspiration of even small quantities of gastric, nasal, or oral contents can lead to chronic airway inflammation presenting as recurrent bronchitis, bronchiolitis, and/or pneumonitis. The symptoms vary, but they usually include chronic unexplained cough (especially during or after feeding), gagging, and wheezing. Noisy ("gurgly") breathing caused by accumulation of secretions in the hypopharynx is both a predisposing and a predictive factor of aspiration. Infants (especially those born prematurely) may present with apneic episodes associated with laryngospasm. This can happen while drinking, as a result of oropharyngeal incoordination, or in between feedings due to episodes of GER that reaches the laryngeal area eliciting the laryngeal spasm. Fever is not usually a symptom of aspiration, but it may develop at any point because the chronic airway inflammation caused by the aspiration predisposes to secondary infections.

Pathologic Sequelae

Chronic aspiration can lead to irreversible lung damage in the form of bronchiectasis, granulomatous inflammation, fibrosis, and bronchiolitis obliterans. Recurrent episodes of lipoid pneumonia have been reported after use of oil-based home/folk remedies popular in several parts of the world that are given orally or nasally to children with impaired swallow.

Predisposing Factors

Many of the anatomic and functional abnormalities listed in Table 447.1 predispose the affected patients to aspiration, although technically they do not cause aspiration by themselves. These include but are not limited to the following:

- **Gastroesophageal reflux** (see Chapter 369): GER is a physiologic mechanism that is present from birth and throughout life. When severe, it predisposes to aspiration by bringing gastric contents near the larynx. However, aspiration will not occur unless the protective airway reflexes are defective. In general, GER is less frequently associated with recurrent pneumonia than is dysphagia. Gastroesophageal reflux disease (GERD; see Chapter 369) can cause pharyngeal and laryngeal edema and vocal cord nodules that may interfere with the swallowing mechanism and lead to aspiration. GERD has been associated with chronic microaspiration and bronchiolitis obliterans in lung transplant recipients.
- **Anatomic and functional abnormalities** such as cleft lip/palate, micrognathia, macroglossia, and laryngomalacia can interfere with the mechanism of bolus formation.
- **Nonspecific hypotonia**, seen in conditions such as trisomy 21 and in otherwise healthy infants (especially those born prematurely), may cause oropharyngeal discoordination and lead to recurrent microaspiration.
- **Increased work of breathing**, due to conditions that cause significant nasal obstruction and/or significant tachypnea place otherwise healthy infants at risk for aspiration because they may attempt to breathe and drink at the same time. Thus when a child with an acute respiratory illness who is being fed enterally deteriorates unexpectedly, the possibility of aspiration should be considered.

DIAGNOSIS

A history of unexplained recurrent/persistent respiratory symptoms such as cough and wheezing should always raise suspicions of chronic aspiration. It is then important to determine whether the aspiration occurs from above because of swallowing impairment or from below because of GER. The circumstances around and the timing of the symptoms may offer clues about the exact mechanism. Observation of a feeding is an essential part of the examination when a diagnosis of recurrent aspiration is being considered. Particular attention should be given to nasopharyngeal reflux and difficulty with sucking or swallowing. Symptoms such as choking, cough, stridor, or wheezing occurring during feedings are much more likely the result of impaired swallow. Coughing during or immediately after swallowing points toward anatomic abnormalities (e.g., laryngeal cleft or tracheoesophageal fistula). Symptoms occurring in between feedings, especially in a child with frequent spitting up, vomiting, arching, or complaining of epigastric discomfort, are more likely to be associated with GER.

Voice changes such hoarseness or muffled cry suggest GERD, whereas noisy (wet) breathing suggests pooling of secretions in the hypopharynx. The oral cavity should be inspected for gross abnormalities and

Table 447.2 Diagnostic Modalities for the Detection of Chronic Aspiration

DIAGNOSTIC MODALITY	ADVANTAGES	DISADVANTAGES
Chest radiograph	• Easy to obtain and inexpensive • Low radiation exposure	• Findings are not pathognomonic • Does not distinguish between aspiration from above or from below
Computed tomography of the chest	• Provides details that may be missed in plain chest x-ray (CXR)	• Findings are not pathognomonic • Does not distinguish between aspiration from above or from below • More expensive • Considerably higher radiation exposure
Esophagogram	• Provides information on the anatomy and function of the esophagus (e.g., stricture, hiatal hernia, foreign body, achalasia, decreased motility) • Detects gastroesophageal reflux (GER) • Detects tracheoesophageal fistula and external compression (vascular ring)	• Considerable radiation exposure • Short viewing time • May miss a small H-type tracheoesophageal fistula if the patient is in the supine position
Videofluoroscopic swallowing study (VFSS)	• Gold standard for the detection of aspiration even in patients without obvious respiratory symptoms	• Considerable radiation exposure • Requires the presence of a trained speech pathologist • May lead to aspiration of barium that cannot be cleared by the lung
Milk scintiscan	• More "physiologic" • Provides significantly longer viewing time • High specificity • No radiation exposure	• Low sensitivity • Does not provide any anatomic details
Salivagram	• High sensitivity (similar to VFSS) • No radiation exposure	• Infants may spit out the radionucleotide before it is mixed with the saliva and swallowed • Does not provide information about GER
Fiberoptic endoscopic evaluation of swallowing (FEES)	• Provides direct observation of the swallowing mechanism • Can be performed at the bedside or in the office	• Moderately invasive • Young patients may "fight" the insertion of the laryngoscope in their nose
"Dye" studies	• Simple, easy to perform even at home	• Requires the presence of an artificial airway • Possible toxicity from repeated use
Quantification of lipid-laden macrophages in the bronchoalveolar lavage (BAL) fluid	• High sensitivity	• Requires the performance of a bronchoscopy and BAL • Low specificity • Does not distinguish whether the lipids are the result of aspiration or release from cell damage/death

stimulated to assess the gag reflex. Drooling or excessive accumulation of secretions in the mouth suggests dysphagia. Sudden development of crackles or wheezes, especially in the dependent lung segments after feeding, is highly suggestive of aspiration.

The laboratory diagnosis of recurrent microaspiration is challenging because of the lack of pathognomonic tests. Several diagnostic modalities are currently used for the diagnosis of aspiration (Table 447.2) that can be grouped in the following:

- **Radiographs and computed tomography of the chest**: Aspiration may produce the "typical" segmental or lobar infiltrates in the dependent areas of the lung. However, their presence is not pathognomonic, and their absence does not rule out the diagnosis. Thus any abnormal radiographic finding (e.g., diffuse infiltrates, lobar infiltrates, bronchial wall thickening, and bronchiectasis) that cannot be explained by any other process should raise the possibility of chronic aspiration, especially if the patient has any of the aforementioned predisposing factors (Fig. 447.1).
- **Contrast studies**: Various tests, such as esophagogram, modified barium swallow (MBS), and videofluoroscopic swallowing study (VFSS), are currently considered the "gold standard" for the diagnosis of chronic aspiration. The patient swallows the contrast material (usually barium) under direct fluoroscopic visualization, which provides information on the swallow itself, on the presence of penetration and/or aspiration, and on the anatomy and function of the esophagus.
- **Nuclear scans**: These tests (milk scintigram and salivagram) are based on the oral administration of radionucleotides. Their detection in the lungs is proof of aspiration. A major benefit is that they do not expose the patient to radiation. However, the milk scan has very low sensitivity; the salivagram has much better sensitivity but it does not provide any information on the anatomy or function of the esophagus.
- **Endoscopic studies**: The fiberoptic endoscopic evaluation of swallowing (FEES) allows direct observation of the swallow and documents the aspiration in real time without radiation exposure. However, the child's reaction to placement of the endoscope may alter the assessment of function, depending on the level of comfort and cooperation.

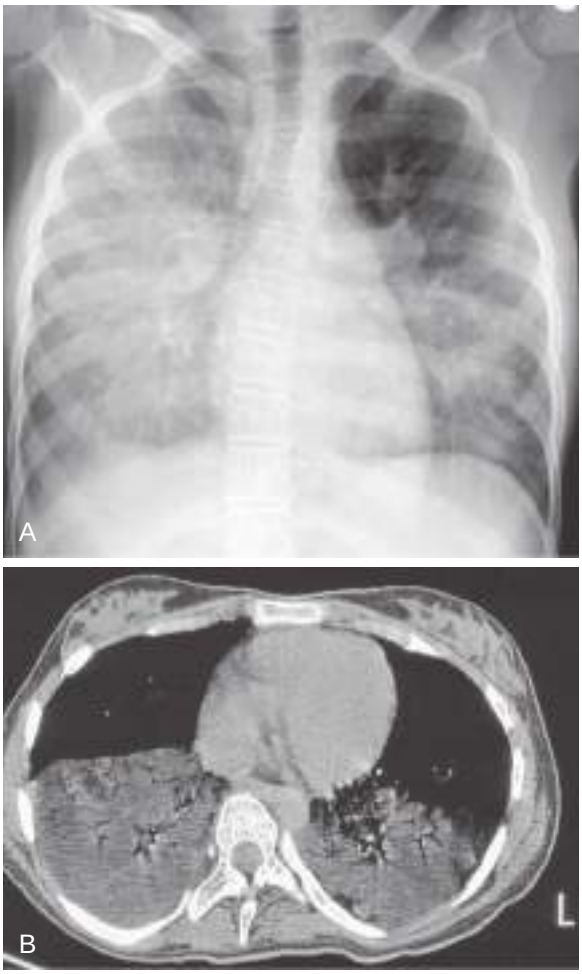

Fig. 447.1 A, Chest radiograph of a developmentally delayed 15-yr-old with chronic aspiration of oral formula. Note posterior (dependent areas) distribution with sparing of heart borders. B, Chest CT scan of same patient. Note lung consolidation in dependent regions is of similar density to subcutaneous fat.

- **Dye studies**: These can be useful tests for patients with artificial airways. A small amount of food coloring (such as methylene blue) is placed in the patient's mouth or into the stomach. If it appears in the tracheobronchial secretions in a few minutes, it confirms aspiration.
- **Analysis of bronchoalveolar lavage (BAL) fluid**: The quantification of lipid-laden alveolar macrophages is a sensitive test for aspiration in children. Its major limitation is that it cannot distinguish between exogenous and endogenous origin of the lipids. The BAF fluid can be also examined for various food substances, including lactose, glucose, food fibers, and milk antigens, as well as pepsin. The specificity and sensitivity of these tests have not been well studied.

MANAGEMENT

There is no specific treatment for aspiration. The focus of its management is the prevention or at least the minimization of the resulting morbidity. The recommended interventions depend largely on the severity of the aspiration and on the nature and prognosis of the underlying condition.

Mild morbidity (e.g., oropharyngeal incoordination due to prematurity):

- **Modifications of the food intake** based on the results of the MBS (e.g., thickening of the liquids, pureed food).
- **Modification of the feeding techniques** (e.g., positioning of the infant in a semierect position, use of special nipples, limiting the amount of food).

These approaches can be used in dysphagia caused by immaturity of the swallowing mechanism (such as that observed in prematurely born and even in term infants) and in impaired swallowing caused by factors that can improve spontaneously (e.g., GER, laryngomalacia) or be corrected surgically (e.g., cleft lip/palate).

Moderate morbidity (e.g., difficulty sucking and swallowing because of chronic lung disease, neuromuscular disorders; presence of tracheostomy):

- **Nasogastric tube feedings**: they can be used temporarily during periods of transient dysphagia. They are minimally invasive but they have several drawbacks such as easy dislodgement and exacerbation of GER (because the lower esophageal sphincter remains open). They can also cause aspiration if placed incorrectly by inexperienced caregivers.
- **Gastrostomy**: should be strongly considered for patients who are not expected to develop or recover the ability to eat by mouth within a relatively short period.
- **Postpyloric feedings**: providing the nutrition into the duodenum or the jejunum is safer because it minimizes (but does not eliminate) GER. Postpyloric feedings can be given either by nasoduodenal or nasojejunal tube or by gastrojejunal (G-J) tube (the latter can be easily threaded through the existing gastrostomy). G-J tubes are recommended for patients with neuromuscular disorders who tend to have significant problems with gastric and intestinal motility.

Severe morbidity:

- **Surgical repair**: Abnormalities such as tracheoesophageal fistula and laryngeal cleft require surgical repair as soon as the infant is stable enough to undergo the operation.
- **Nissen fundoplication** should be reserved for patients whose recurrent aspiration is primarily the result of GER not responding to medical treatment and conservative management. Fundoplication minimizes, but does not eliminate, GER. If tight, it can cause severe retching in patients without muscle weakness.

Management of Oropharyngeal Secretions

The management of nasopharyngeal and oropharyngeal secretions poses a big problem in patients with impaired swallow because the secretions tend to pool in the hypopharynx from where they can easily be aspirated. Saliva can cause inflammation in the tracheobronchial mucosa and introduces organisms from the oropharynx into the lower airways, where they can become pathogenic. The currently available treatments and interventions include the following:

- **Anticholinergic agents**: Medications such as glycopyrrolate and scopolamine are widely used but are of limited effectiveness. When they are given via the gastrostomy tube, they may cause significant dryness in the lower airway, promoting mucus plugging. Nebulization of the intravenous preparation of glycopyrrolate can be effective, but this is not an officially approved use, and the preparation cannot be bought in retail pharmacies.
- **Botox (botulinum toxin type A) injection**: Botox injections in the salivary glands provide a transient decrease in the amount of secretions. To be effective, they need to be repeated every few months under anesthesia.
- **Salivary gland ligation**: This is currently the more definitive intervention for the management of oropharyngeal secretions. Once done, it is irreversible, and therefore it is reserved for very severe cases that are refractory to any other intervention.
- **Tracheostomy**: The role of tracheostomy in the management of chronic aspiration and/or in the management of excessive oropharyngeal secretions is rather controversial. Tracheostomy per se does not prevent aspiration (unless a cuffed tube is used). It actually impairs the swallowing mechanism, and because it is a "foreign body" inside the trachea, it tends to stimulate the production

of more secretions than usual. In addition, it bypasses the natural defenses of the upper airways while it exposes the lower airways directly to the environment, thus increasing the possibility of infection. Its major advantage is that it provides easy access for the suctioning of the lower airways. Most importantly, it provides a secure airway from which positive pressure can be applied, avoiding the risks of emergency endotracheal intubations. It should be considered for patients at high risk for recurrent severe respiratory failure.

Visit Elsevier eBooks+ at eBooks.Health.Elsevier.com for Bibliography.

Chapter 448
Immune and Inflammatory Lung Disease

448.1 Hypersensitivity Pneumonia

Michelle L. Hernandez and Stephanie D. Davis

Hypersensitivity pneumonia (HP), aptly called *extrinsic allergic alveolitis* because the inciting agent is almost uniformly inhaled from the environment, is a complex immunologic-mediated syndrome of the pulmonary alveoli and interstitium. There are numerous specific disease names based on the origin of the inhaled offending antigen to describe HP. Prompt recognition of the signs and symptoms allows for complete reversal of the disease without long-term adverse consequences if the source of the exposure is recognized and abated. Failure to recognize the disease early may lead to chronic irreversible lung changes with persistent symptoms in the patient.

ETIOLOGY

The most common sources of offending agents that cause HP include agricultural aerosols, inhaled protein antigens from animals, antigens from microorganisms of bacteria, fungi, or protozoan origin, and chemicals of low and high molecular weight (Table 448.1). Many of these inciting agents are associated with *occupational diseases,* which occur in locations where children do not regularly work. However, these same diseases can occur in children because of exposures to many similar antigen sources in nonoccupational environments, or in occupational environments with teenage workers. In addition to HP, the same antigens (i.e., antigens from animal proteins and contaminated metal working fluids or other inhaled antigens) may lead to allergic asthma or chronic bronchitis.

More than 300 antigens have been associated with HP. In children, the primary sources have been the result of exposure to **pet birds** (or feathers in bedding and pillows) such as parakeets, canaries, cockatiels, or cockatoos. Aerosol spread of bird droppings can also occur through the vent of a clothes dryer or through heating vents from a garage where the birds were housed. Humidifiers and hot tubs are notorious for contamination with **thermophilic organisms** (bacteria and mold) as well as *Mycobacterium avium* complex. Buildings with inadequate ventilation and insufficient air turnover present an increased risk of mold exposure from prior flooding or damp condensation. Despite exposures to the same antigen sources, members of the same family may exhibit different presentations of allergic disease. For instance, some family members may have symptoms of asthma or rhinitis, whereas another may have HP.

PATHOGENESIS

The pathogenesis of HP is complex and appears to have a genetic component. Recurrent exposures to environmental agents associated with HP (see Table 448.1) trigger an inflammatory response promoting the development of immune complexes. These immune complexes activate the complement pathway, ultimately resulting in the accumulation of neutrophils in the airway that release enzymes such as neutrophil elastase that damage surrounding lung tissue. Activated macrophages in the lung promote recruitment of lymphocytes into the tissues. Pathology shows alveolitis with a mixed cellular infiltration composed of lymphocytes, macrophage, plasma cells, and neutrophils. Continued exposure to the offending antigen results in the formation of loose, noncaseating granulomas located near the respiratory or terminal bronchioles. Some patients with chronic exposure develop progressive pulmonary fibrosis similar to patients with interstitial pulmonary fibrosis (IPF). Although the mechanisms are not entirely clear, this is thought to occur secondary to recruitment and activation of fibroblasts and uncontrolled production of extracellular matrix cytokines, including transforming growth factor beta (TGF-ß). It is critical when a biopsy is being performed (transbronchial or surgical) that the pathologist knows that HP is being considered because there are other **interstitial lung diseases** that produce similar granulomas with subtle location differences depending on their disease origin. Genetic predisposition also appears to be important, primarily in genes involved with antigen processing and presentation (such as major histocompatibility complex [MHC] I and II), lung homeostasis and wound repair, and telomere-related gene mutations.

Clinical Manifestations and Classification

The prevalence of HP is higher among older individuals but can affect children and young adults. It is estimated that HP accounts for 50% of all childhood idiopathic lung diseases (ILDs). HP had been traditionally classified as acute, subacute, or chronic. However, because of the great variability and overlap in the presentation and course of HP, the American Thoracic Society, Japanese Respiratory Society, and Asociación Latinoamericana de Tórax (ATS/JRS/ALAT) guidelines recategorized HP into two phenotypes based on the predominant presence or absence of fibrosis on imaging or histopathologic examination: (1) **nonfibrotic phenotype** and (2) **fibrotic phenotype**.

Regardless of fibrotic or nonfibrotic phenotype, common symptoms include cough and dyspnea after exposure. The time to symptom presentation after exposure can vary from hours to years and may be recurrent in nature. Acute symptoms can be confused with bacterial or viral disease leading to treatment with antibiotics. For example, as early as 4-8 hours after exposure, patients can present with the abrupt onset of cough, chest tightness, dyspnea, fever, chills, body aches, and fatigue (Table 448.2). Rarely, findings of wheezing are present on the initial examination. Rather, tachypnea with fine crackles may be heard by auscultation in the lung bases and presence of mid-inspiratory squeaks. The duration of symptoms has not been definitively associated with the fibrotic or nonfibrotic phenotype.

The long-term prognosis of HP is quite variable, with some patients developing progressive shortness of breath, cough (productive), weight loss, malaise, loss of appetite, hypoxia, and clubbing of the fingers. Those who have been diagnosed with nonfibrotic HP and are able to avoid exposure to the responsible agent may achieve stabilization or full recovery. In contrast, fibrotic HP is associated with reduced survival secondary to respiratory failure, especially among those with a usual interstitial pneumonia (UIP)–like pattern.

Diagnosis

A diagnosis of HP is certain when the known exposure with the associated immune response to the offending antigen is identified, the medical history and physical examination findings are abnormal on examination, and the pattern of the high-resolution computed tomography (HRCT) of the chest and bronchoalveolar lavage (BAL) findings

Table 448.1 Antigen Sources Associated with Specific Causes of Hypersensitivity Pneumonitis

HYPERSENSITIVITY PNEUMONITIS	ANTIGEN SOURCE
Bagassosis (mold on pressed sugar cane)	*Thermoactinomyces sacchari* *Thermoactinomyces vulgaris*
Bat lung (bat droppings)	Bat serum protein
Bible printer's lung	Moldy typesetting water
Bird fancier's lung (parakeets, budgerigars, pigeons, parrots, cockatiels, geese)	Droppings, feathers, serum proteins
Byssinosis ("brown lung") (unclear if a true cause of hypersensitivity pneumonitis; asthma is common)	Cotton mill dust (carding and spinning areas of cotton, flax, and soft hemp)
Canary fancier's lung	Serum proteins
Cheese washer's lung (moldy cheese)	*Penicillium casei* *Aspergillus clavatus*
Chemical hypersensitivity pneumonitis	Diphenylmethane diisocyanate (MDI) Toluene diisocyanate (TDI)
Coffee worker's lung	Coffee bean dust
Composter's lung	*T. vulgaris* *Aspergillus* species
Contaminated basement (sewage) pneumonitis	*Cephalosporium*
Coptic lung (mummy handler's lung)	Cloth wrappings of mummies
Detergent worker's lung (washing powder lung)	*Bacillus subtilis* enzymes
Dry rot lung	*Merulius lacrymans*
Duck fever	Feathers, serum proteins
Epoxy resin lung	Phthalic anhydride (heated epoxy resin)
Esparto dust (mold in plaster dust)	*Aspergillus fumigatus* Thermophilic actinomycetes
Feather duvet lung (feather bed, pillow, duvet)	Avian proteins on feathers
Fish meal worker's lung	Fish meal
Furrier's lung (sewing furs; animal fur dust)	Animal pelts
Grain measurer's lung	Cereal grain *(Sporobolomyces)* Grain dust (mixture of dust, silica, fungi, insects, and mites)
Hot tub lung (mists; mold on ceiling and around tub)	*Cladosporium* spp. *Mycobacterium avium* complex
Humidifier fever	*Thermoactinomyces (T. vulgaris, T. sacchari, T. candidus)* *Klebsiella oxytoca* *Naegleria gruberi* *Acanthamoeba polyphaga* *Acanthamoeba castellani*
Laboratory worker's lung (rats, gerbils)	Urine, serum, pelts, proteins
Lifeguard lung	Aerosolized endotoxin from pool-water sprays and fountains
Lycoperdonosis (*Lycoperdon* puffballs)	Puffball spores
Machine operator's lung	*Pseudomonas fluorescens* Aerosolized metal working fluid
Malt worker's disease (moldy barley)	*Aspergillus fumigatus, Aspergillus clavatus*
Maple bark disease (moldy maple bark)	*Cryptostroma corticale*
Miller's lung (dust-contaminated grain)	*Sitophilus granarius* (i.e., wheat weevil)
Moldy hay, grain, silage (farmer's lung)	Thermophilic actinomycetes Fungi (e.g., *Aspergillus umbrosus*)
Mollusk shell hypersensitivity pneumonitis	Sea snail shell
Mushroom worker's lung	Mushroom spores Thermophilic actinomycetes
Paprika slicer's lung (moldy paprika pods)	*Mucor stolonifer*
Pauli reagent alveolitis	Sodium diazobenzene sulfate
Pearl oyster shell pneumonitis	Oyster shells
Pituitary snuff taker's disease	Dried, powdered cattle or pig pituitary proteins
Potato riddler's lung (moldy hay around potatoes)	Thermophilic actinomycetes *T. vulgaris* *Faenia rectivirgula* *Aspergillus spp.*
Poultry worker's lung (feather plucker's disease)	Serum proteins (chicken products)
Pyrethrum (pesticide)	Pyrethrum
Sauna taker's lung	*Aureobasidium* spp., other sources
Sequoiosis (moldy wood dust)	*Graphium* *Pullularia* *Trichoderma spp.* *Aureobasidium pullulans*
Suberosis (moldy cork dust)	*Thermoactinomyces viridis* *Penicillium glabrum* *Aspergillus conidia*
Summer-type pneumonitis	*Trichosporon cutaneum*
Tea grower's lung	Tea plants
Thatched-roof lung (huts in New Guinea)	*Saccharomonospora viridis* (dead grasses and leaves)
Tobacco grower's lung	*Aspergillus* spp. *Scopulariopsis brevicaulis*
Turkey handling disease	Serum proteins (turkey products)
Unventilated shower	*Epicoccum nigrum*
Upholstery fabric (nylon filament, cotton/polyester, and latex adhesive)	Aflatoxin-producing fungus, *Fusarium* spp.
Velvet worker's lung	Unknown (? nylon velvet fiber, tannic acid, potato starch)
Vineyard sprayer's lung	Copper sulfate (Bordeaux mixture)
Wine maker's lung (mold on grapes)	*Botrytis cinerea*
Wood dust pneumonitis (oak, cedar, and mahogany dust, pine and spruce pulp)	*Alternaria* spp. *Bacillus subtilis*
Wood pulp worker's disease (oak and maple trees)	*Penicillium* spp.
Wood trimmer's disease (contaminated wood trimmings)	*Rhizopus* spp., *Mucor* spp.

Table 448.2 Clinical History Leading to a Diagnosis of Hypersensitivity Pneumonitis

Recurrent pneumonia
Pneumonia after repeat exposures (week, season, situation)
Cough, fever, and chest symptoms after making a job change or home change
Cough, fever, wheezing after return to school or only at school
Pet exposure (especially birds that shed dust such as pigeons, canaries, cockatiels, cockatoos)
Bird contaminant exposure (e.g., pigeon infestation)
Farm exposure to birds and hay
History of water damage
Use of hot tub, sauna, swimming pool
Other family members or workers with similar recurrent symptoms
Improvement after temporary environment change (e.g., vacation)

are consistent with HP (Table 448.3). These findings must prompt the clinician to identify the exposure in order to secure the diagnosis and eliminate the offending antigen. Without therapy, the progressive inflammatory response leads to air trapping, honeycombing, emphysema, and mild fibrosis in the chronic state. Diagnostic components are reviewed next.

LABORATORY

Most of the abnormal laboratory findings in HP are not specific and represent evidence of activated inflammatory markers or lung injury. For example, nonspecific elevation of immune globulins or the erythrocyte sedimentation rate and C-reactive protein may be found. Circulating immune complexes may be detected. Lactate dehydrogenase may be elevated in the presence of lung inflammation and normalizes with response to therapy.

Serum IgG precipitins to the offending agent are frequently positive and have a poor positive predictive value for disease. For example, among asymptomatic pigeon breeders, precipitating antibodies are nearly universal. False negatives can also be seen as a result of fluctuating serum antibody levels over time and a lack of standardized commercial antigens and reagents available for laboratory testing. It is critical that laboratories familiar with the performance of these tests be used. Those laboratories often recognize the value of processing antigens for precipitation from the environmental source directly as the test substrate with patient serum. Skin testing for immunoglobulin E (IgE)-mediated disease is not warranted unless there is evidence of mixed lung pathology such as asthma and interstitial lung opacities.

Radiology

Chest radiograph almost always precedes the use of HRCT of the chest in children because of the need for sedation and concerns regarding the risk of being exposed to an increased radiation dose from HRCT. The plain radiograph may demonstrate a ground-glass appearance, interstitial prominence, with a predominant location in the upper and middle lung fields. It is common for a chest radiograph to be considered normal by a radiologist early in the disease. Late in the disease, interstitial fibrosis may become prominent in the presence of increasing dyspnea, hypoxemia on room air, and even clubbing of the fingers. Mediastinum widening from lymphadenopathy is not usually present; when present, the lymph nodes are prominent along the airway near the carina, suggesting that the antigen source is inhaled, and this represents the response of the immune system.

HRCT of the chest is important in distinguishing nonfibrotic from fibrotic HP and may reduce the need for a lung biopsy. HRCT of the chest in **nonfibrotic HP** demonstrates (1) at least one abnormality revealing evidence of parenchymal infiltration (such as ground-glass opacities or mosaic attenuation) and (2) at least one abnormality revealing evidence of small airway disease (such as ill-defined, centrilobular nodules or air trapping), both distributed in a diffuse pattern. **Fibrotic HP** is characterized by (1) a lung fibrosis (irregular linear opacities/coarse reticulation; traction bronchiectasis and honeycombing) located in a random or mid-lung zone and (2) at least one abnormality that is consistent with small airway disease.

Table 448.3 Criteria Used in the Diagnosis of Hypersensitivity Pneumonitis

1. Identified exposure to offending antigen(s) by:
- Medical history of exposure to suspected antigen in the patient's living environment
- Investigations of the environment confirm the presence of an inciting antigen
- Identification of specific immune responses (immunoglobulin G serum precipitin antibodies against the identified antigen) are suggestive of the potential etiology but are insufficient in isolation to confirm a diagnosis
- Abnormal response to an inhalation challenge testing to the offending antigen via reexposure to the environment or inhalation challenge to the suspected antigen

2. Clinical, radiographic, or physiologic findings compatible with hypersensitivity pneumonitis:
- Respiratory and often constitutional signs and symptoms
  - Cough
  - Breathlessness
  - Crackles on auscultation of the chest
  - Weight loss
  - Episodic fever
  - Wheezing
  - Fatigue

NOTE: These findings are especially suggestive of hypersensitivity pneumonitis when they appear or worsen several hours after antigen exposure.

- High-resolution chest CT findings typical of HP:
  - Nonfibrotic HP pattern:
    - At least one HRCT abnormality indicative of parenchymal infiltration (such as ground-glass opacities or mosaic attenuation) in a diffuse distribution
    - At least one HRCT abnormality indicative of small airway disease (such as ill-defined, centrilobular nodules or air trapping) in a diffuse distribution
  - Fibrotic HP pattern:
    - Lung fibrosis (irregular linear opacities/coarse reticulation with lung distortion; traction bronchiectasis and honeycombing) in a random or mid-lung zone predominant location
    - At least one abnormality that is indicative of small airway disease

3. Bronchoalveolar lavage with lymphocytosis (>20%, often >50%):
- Usually with low CD4:CD8 ratio (i.e., CD8 is higher than normal)

4. Histopathology showing compatible changes with nonfibrotic or fibrotic hypersensitivity pneumonitis and the absence of features in any biopsy site to suggest an alternative diagnosis
- Nonfibrotic HP (purely inflammatory):
  - Cellular interstitial pneumonia
  - Chronic cellular bronchiolitis with a lymphocytic peribronchial infiltration
  - Poorly formed nonnecrotizing granulomas located near respiratory or terminal bronchioles
- Fibrotic HP (mixed inflammatory plus fibrotic or purely fibrotic):
  - Chronic fibrosing interstitial pneumonia
  - Airway-centered fibrosis
  - Poorly formed nonnecrotizing granulomas

Data from Raghu G, Remy-Jardin M, Ryerson CJ, et al. Diagnosis of hypersensitivity pneumonitis in adults. An official ATS/JRS/ALAT clinical practice guideline [published correction appears in *Am J Respir Crit Care Med.* 2021 Jan 1;203(1):150–151] [published correction appears in *Am J Respir Crit Care Med.* 2022 Aug 15;206(4):518]. *Am J Respir Crit Care Med.* 2020;202(3):e36–e69.

Bronchoalveolar Lavage

BAL is one of the most sensitive tests in supporting the diagnosis of HP. Lymphocytosis frequently exceeding 50% of the recovered cells is seen in the BAL fluid and should alert the clinician to the possibility of HP. Sarcoid, IPF, cryptogenic organizing pneumonia, berylliosis, granite workers lung disease, amiodarone pneumonia, lymphoma, and Langerhans cell histiocytosis may demonstrate lymphocytosis on BAL. All BAL specimens should have *flow cytometry* measurements of T-cell markers (CD3, CD4, and CD8 at a minimum). The predominant phenotype of the lymphocytosis is $CD3^+/CD8^+/CD56^+/CD57^+/CD10^-$. In the normal circulation, lymphocytes with CD4 markers predominate at a ratio of approximately 2:1 compared with CD8 lymphocytes. *In HP, this ratio becomes approximately equal to or less than 1 (CD4:CD8 ≤1) with either an increase in CD8 lymphocytes or a decline in CD4 lymphocytes.* Although this ratio helps the clinician in making a diagnosis of HP, this BAL finding is not 100% diagnostic for HP. Cryptogenic organizing pneumonia, a rare disease in children, also may present with BAL, where the CD4:CD8 is ≤1, and may be confused initially with HP. This is in sharp contrast to other lymphocytic granulomatous diseases, like sarcoidosis, where the CD4:CD8 is ≥2.

Lung Biopsy

Lung biopsy is necessary to confirm a diagnosis of HP when critical elements are not present, including antigen exposure, a medical history classic for HP, characteristic physical exam findings, chest HRCT findings, and $CD8^+$ lymphocytes in the BAL. Open lung biopsy is often the route of choice in young children because of the difficulty in safely obtaining satisfactory amounts of tissue by transbronchial biopsy. Lack of positive serum precipitins to an offending antigen and lack of an exposure history are common reasons for obtaining lung biopsies. It is crucial to inform the pathologist about the suspicion of HP so that the findings can be interpreted appropriately.

Histopathologic examination of **nonfibrotic HP (purely inflammatory)** demonstrates three primary features: (1) cellular interstitial pneumonia, (2) chronic cellular bronchiolitis with a lymphocytic peribronchial infiltration, and (3) nonnecrotizing granulomas near respiratory or terminal bronchioles. **Fibrotic HP (mixed inflammatory plus fibrotic or purely fibrotic)** is histologically characterized by (1) chronic fibrosing interstitial pneumonia, (2) airway-centered fibrosis, and (3) poorly formed nonnecrotizing granulomas. Furthermore, there is an absence of features in any biopsy site to suggest an alternative diagnosis.

Of note, poorly formed noncaseating granulomas and multinucleated giant cells are seen in HP. This is in sharp contrast to the well-formed granulomas seen in sarcoidosis.

Antigen Challenge by Inhalation

Inhalation challenge can support the diagnosis of HP by demonstrating a causal relationship between environmental exposure and symptoms. Inhalation challenge can be performed by two methods: (1) reexposure to the environment where the suspected antigen is present and (2) a direct inhalation challenge at the hospital to material collected from the suspected source of the antigen. As the second method has resulted in severe exacerbation of disease in some individuals, performing this challenge is discouraged.

Two abnormal response patterns may be seen. Most commonly, where there is **HP without asthma**, symptoms occur 8-12 hours after direct challenge in the hospital or after reexposure to the source of the antigen. The challenges replicate some or all of the symptoms observed in the acute syndrome with fever, dyspnea, fatigue, and crackles on lung auscultation. Blood drawn before challenge and then repeated during these symptoms often demonstrates an increased neutrophil count compared to baseline. Pulmonary function tests demonstrate a fall in forced vital capacity (FVC) and often a concurrent fall in the forced expiratory volume at 1 second (FEV_1), with a stable or increasing ratio of FEV_1:FVC reflecting a restrictive defect. Hypoxemia may accompany this decline in pulmonary function along with a fall in the diffusion capacity of carbon monoxide (DLCO). To see the complete effect, exercise during this period may show a considerable fall in oxygenation despite normal arterial blood gas oxygen tension and normal pulse oximetry at rest. This finding denotes the onset of worsening restrictive lung disease.

Where there is **HP with concomitant allergic asthma**, these patients may experience a biphasic response to the inhalation challenge. These patients may develop an early reduction in FEV_1, followed by a second drop in FEV_1 and FVC 4-6 hours later. The patient may also have accompanying fever and leukocytosis.

TREATMENT

The control of environmental exposure to the offending antigen is key to curing HP and remains the ideal method of treatment and prevention of recurrence. The clinical and pathologic manifestations of nonfibrotic (purely inflammatory) HP are reversible with removal of the offending antigen. Counseling parents and children about the risk of exposure to birds and feathered bedding or other environmental antigens, biologic aerosols, or agricultural dusts that are known to induce HP is important. Certainly, the source of the antigen and type of antigen appear to affect the response to treatment and long-term prognosis. Older individuals who contract farmer's lung are likely to recover with minimal permanent residual effect, whereas individuals with bird fancier's lungs from antigens produced by pigeons have a worse prognosis, especially if fibrosis is detected on lung biopsy. The pediatrician should advise—in the strongest terms—removal of the antigen source from the affected child's environment. This may be an extraordinary challenge given various children's living circumstances and lack of independent control of the environment in which they live.

In addition, pediatricians should be familiar with recommendations about the maintenance of heating, ventilation, and air conditioning systems, in addition to humidifiers and vaporizers. Daily drainage, cleansing of residue, and routine cleaning with hydrogen peroxide or bleach help rid humidifiers and vaporizers of harmful pathogens such as thermophiles that cause HP.

Removal of the antigen alone is sufficient to normalize lung function in most patients, but symptoms and pulmonary functions return to normal faster with the use of glucocorticoids. Among those with nonfibrotic HP, glucocorticoids at a dose of 0.5 mg/kg/day of prednisone or equivalent (up to a maximum dose of 30 mg prednisone daily) will reduce the immune inflammatory response in the lungs. Comparative trials in adults demonstrate that the use of 4 weeks of therapy is as effective as 12 weeks of therapy. Because of the rapid reversal of symptoms, successful abatement of the environment is sometimes compromised when the family sees improvement before the antigen source removal.

As with nonfibrotic HP, removal of the offending antigen is also recommended for fibrotic HP. However, there is a paucity of clinical trial data outlining the best immunomodulatory strategies for fibrotic HP. Among those patients with fibrotic HP with inflammatory features present, a trial of glucocorticoids may be pursued at a dose of 0.5 mg/kg per day (up to 30 mg per day) for 4-8 weeks, followed by tapering for 3 months. For patients who have not responded to both antigen removal and corticosteroid treatment, azathioprine and mycophenolate mofetil have been used, but their efficacy has not been tested in clinical trials. Case reports have also reported the use of rituximab for HP treatment because of its ability to reduce immune cell complexes. Results have reported mixed clinical efficacy. Antifibrotic drugs that are used for IPF such as nintedanib or pirfenidone are being tested in clinical trials.

Visit Elsevier eBooks+ at eBooks.Health.Elsevier.com for Bibliography.

448.2 Occupational and Environmental Lung Disease

Michelle L. Hernandez and Stephanie D. Davis

Although occupational and environmental lung diseases include **occupational asthma**, **irritant-induced asthma**, HP, hard metal inhalation lung disease, berylliosis, and air pollution, this chapter focuses on occupational asthma and irritant-induced asthma. Berylliosis has a propensity to form granulomas (see Chapter 448.3). Although some diseases will be seen with regularity, the important role that a workplace, school, daycare, neighbors' housing, multiple family housing, and indoor and outdoor environments may have in the causation of signs and symptoms in the patient is often not considered by the clinician.

Occupational asthma *differs* from work-exacerbated asthma. Individuals with occupational asthma develop asthma after exposure to immunologic or nonimmunologic stimuli found in the workplace, whereas those with work-exacerbated asthma already have asthma that worsens in the workplace because of a myriad of exposures.

The vast array of exposures that may cause disease of the lungs is daunting, such as the inhalation of baking flour or household cleaning fluids causing asthma, microwave popcorn that uses diacetyl flavoring resulting in bronchiolitis obliterans, and exposure to thermophilic organisms or mold resulting in HP. The acute eosinophilic pneumonias associated with the new onset of smoking and chemical inhalation of 1,1,1-trichloroethane (Scotchgard) require a high index of suspicion and unique lines of questioning. The same antigen encountered in a work, school, home, or outdoor environment may result in different disease presentations among patients because of host factors, dose exposure, and genetic susceptibility. One of the most prominent examples is an investigation of workers who inhaled metal working fluid. Despite similar exposures, some developed HP, others developed asthma, and some displayed no symptoms at all. Immunologic evaluation in some exposures has shown similar immune responses in different individuals, but a wide range of disease provocation. When high molecular weight proteins cause asthma, symptoms of rhinoconjunctivitis frequently precede the onset of pulmonary symptoms. The medical history in occupational and environmental lung diseases has used an expanded construct with a simple acronym, **WHACOS** (Table 448.4).

CLASSIFICATION AND PATHOGENESIS

Occupational and environmental lung diseases include numerous syndromes of human lung disease such as **occupational asthma**, **irritant-induced asthma**, reactive upper airway disease syndrome, HP (see Chapter 448.1), air pollution–induced disease, hard metal inhalation lung disease, berylliosis, occupation-induced lung cancer (e.g., mesothelioma from asbestosis), and chronic obstructive pulmonary disease. Most of these diseases are not problematic for children, but adolescents may be at risk to develop lung disease through exposure through part-or full-time work or by single exposures, as seen in some types of irritant-induced asthma.

Table 448.4 A Construct (WHACOS) that Has Been Used in Medical Interviewing of Patients, Coworkers, and Family Members when Environmental or Occupational Lung Disease Is Being Considered

W	***W**hat* do you do?
H	***H**ow* do you do what you do?
A	Are symptoms ***A**cute* or are they *Chronic?*
C	Do any ***C**oworkers,* family, classmates, or friends have the same symptoms?
O	Do you have any hobbies, travel, or animal/pet exposures ***O**utside* of school or work?
S	Are you ***S**atisfied* with work or school?

Occupational and Environmental Asthma

It is important to remember that in patients with occupational- or environmental-induced disease, the onset of symptoms has a lag time between exposure and symptoms. In **occupational asthma**, there may be an immediate response within 30 minutes to 2 hours of exposure, demonstrated as a decline in pulmonary function, specifically the FEV_1. Usually, lung function returns to normal spontaneously unless persistent exposure occurs. Some patients demonstrate no immediate reduction in lung function, but rather experience a delayed response of 4-6 hours after the exposure. Treating physicians can take advantage of this physiology by using spirometry before and after work or school or using peak flow measurements hourly during exposure and after leaving the exposure. Because workers and school children have prolonged periods of exposure followed by a number of days without exposure, the use of pulmonary function plus nonspecific bronchial responsiveness (e.g., methacholine) testing is helpful. For example, pulmonary function tests before starting work or school on a Monday of a typical week may be normal. By Friday of this typical work or school week, the baseline pulmonary function indices may have fallen, and nonspecific bronchial responsiveness may have become more sensitive to a lower concentration of histamine, methacholine, or mannitol. By Monday, the tests may have returned to normal or near normal with no change other than reduced exposure.

High molecular weight causes of occupational and environmental asthma can be characterized as allergens, which are normally proteins and enzymes, inhaled from multiple sources (Table 448.5). These include various animals, shellfish, fish, enzymes (e.g., *Bacillus subtilis* in laundry detergent), and flour or cereals. Occupational and environmental asthma is also caused by a number of low molecular weight agents, including reactive chemicals, transition metals, and wood dusts (Table 448.6). These **low molecular weight agents** are sufficient to induce an immune response, but often *not by an IgE-mediated mechanism.* These low molecular weight chemicals appear to act as haptens that bind directly to human proteins, causing an immune response in the human host.

The pathogenesis of asthma in patients exposed to **high molecular weight** antigens follows the experience of nonoccupational asthma in patients where atopy, sex, genetics, concentration of antigen, duration of exposure, and other individual factors all contribute to the development of disease. Most individuals require a concentration and duration of exposure sufficient to cause IgE antibody sensitization to the offending allergen with development of bronchial hyperresponsiveness and airway inflammatory disease upon reexposure. If the allergen exposure is sufficient, these proteins can drive the immune response to a T-lymphocyte type 2 phenotype (Th2), even in patients without prior atopic disposition. This occurred in the case of latex allergy, where many nonatopic individuals and patients exposed to allergen in their personal healthcare environment developed occupational allergy to multiple proteins from natural rubber latex. Atopic individuals are at the highest risk of developing latex allergy. A longitudinal study demonstrated that powdered latex gloves with high allergen content were the reason for the epidemic of latex allergy and occupational asthma. Unfortunately, despite primary removal of the offending sensitizing agent, symptoms caused by asthma and bronchial hyperresponsiveness continue in roughly 70% of individuals.

Diagnosis of Occupational Asthma

Occupational asthma should be assessed with a full history, physical examination and objective confirmation of an asthma diagnosis using spirometry, and nonspecific bronchial responsiveness. The negative predictive value of methacholine challenge while the patient is still in the workplace is high (98%): a negative methacholine challenge makes the diagnosis of occupational asthma very unlikely in a patient who is continuously exposed to the suspected causative agent. In addition to comparing measures of nonspecific bronchial responsiveness while on and off work, induced sputum and fractional exhaled nitric oxide (FeNO) can increase the diagnostic sensitivity to 94% through identifying the presence of eosinophilic inflammation. Specific IgE testing

Table 448.5 High Molecular Weight Antigens Known to Induce Occupational or Environmental Asthma

OCCUPATION OR ENVIRONMENT	SOURCE
ANIMAL-DERIVED ANTIGENS	
Agricultural worker	Cow dander
Bakery	Lactalbumin
Butcher	Cow bone dust, pig, goat dander
Cook	Raw beef
Dairy industry	Lactoserum, lactalbumin
Egg producer	Egg protein
Farmer	Deer dander, mink urine
Frog catcher	Frog
Hairdresser	Sericin
Ivory worker	Ivory dust
Laboratory technician	Bovine serum albumin, laboratory animal, monkey dander
Nacre buttons	Nacre dust
Pharmacist	Endocrine glands
Pork producer	Pig gut (vapor from soaking water)
Poultry worker	Chicken
Tanner	Casein (cow's milk)
Various	Bat guano
Veterinarian	Goat dander
Zookeeper	Birds
CRUSTACEANS, SEAFOOD, FISH	
Canning factory	Octopus
Diet product	Shark cartilage
Fish food factory	Gammarus shrimp
Fish processor	Clam, shrimp, crab, prawn, salmon, trout, lobster, turbot, various fishes
Fisherman	Red soft coral, cuttlefish
Jewelry polisher	Cuttlefish bone
Laboratory grinder	Marine sponge
Oyster farm	Hoya (oyster farm prawn or sea-squirt)
Restaurant seafood handler	Scallop and shrimp
Scallop plant processor	King scallop and queen scallop
Technician	Shrimp meal *(Artemia salina)*
ARTHROPODS	
Agronomist	Bruchus lentis
Bottling	Ground bug
Chicken breeder	Herring worm *(Anisakis simplex)*
Engineer at electric power plant	Caddis flies *(Phryganeidae)*
Entomologist	Lesser mealworm (*Alphitobius diaperinus* Panzer), moth, butterfly
Farmer	Grain pests (*Eurygaster* and *Pyrale*)
Fish bait handler	Insect larvae *(Galleria mellonella)*, mealworm larvae *(Tenebrio molitor)*, green bottle fly larvae *(Lucila caesar)*, daphnia, fish-feed Echinodorus larva *(Echinodorus plasmosus)*, Chiromids midge *(Chironomus thummi thummi)*
Fish processing	Herring worm *(Anisakis simplex)*
Flight crew	Screw worm fly *(Cochliomyia hominivorax)*
Honey processors	Honeybee
Laboratory worker	Cricket, fruit fly, grasshopper *(Locusta migratoria)*, locust
Mechanic in a rye plant	Confused flour beetle *(Tribolium confusum)*
Museum curator	Beetles (Coleoptera)
Seed house	Mexican bean weevil *(Zabrotes subfasciatus)*
Sericulture	Silkworm, larva of silkworm
Sewage plant worker	Sewer fly *(Psychoda alternata)*
Technician	Arthropods *(Chrysoperla carnea, Leptinotarsa decemlineata, Ostrinia nubilalis,* and *Ephestia kuehniella)*, sheep blowfly *(Lucilia cuprina)*
Wool worker	*Dermestidae* spp.
ACARIANS	
Apple grower	Fruit tree red spider mite *(Panonychus ulmi)*
Citrus farmer	Citrus red mite *(Panonychus citri)*
Farmer	Barn mite, two-spotted spider mite *(Tetranychus urticae)*, grain mite
Flour handler	Mites and parasites
Grain-store worker	Grain mite
Horticulturist	*Amblyseius cucumeris*
Poultry worker	Fowl mite
Vine grower	McDaniel spider mite *(Tetranychus mcdanieli)*
MOLDS	
Agriculture	*Plasmopara viticola*
Baker	*Alternaria, Aspergillus* (unspecified)
Beet sugar worker	*Aspergillus* (unspecified)
Coal miner	*Rhizopus nigricans*
Coffee maker	*Chrysonilia sitophila*
Laborer	*Sooty molds (Ascomycetes,* deuteromycetes)
Logging worker	*Chrysonilia sitophila*
Plywood factory worker	*Neurospora*
Sausage processing	*Penicillium nalgiovense*
Sawmill worker	*Trichoderma koningii*
Stucco worker	*Mucor* spp. (contaminating esparto fibers)
Technician	*Dictyostelium* discoideum (mold), *Aspergillus niger*
MUSHROOMS	
Agriculture	*Agaricus bisporus* (white mushroom)
Baker	Baker's yeast *(Saccharomyces cerevisiae), Boletus edulis*
Greenhouse worker	Sweet pea *(Lathyrus odoratus)*
Hotel manager	*Boletus edulis*
Mushroom producer	*Pleurotus cornucopiae*

Table 448.5 High Molecular Weight Antigens Known to Induce Occupational or Environmental Asthma—cont'd

OCCUPATION OR ENVIRONMENT	SOURCE
Mushroom soup processor	Mushroom unspecified
Office worker	Boletus edulis
Seller	*Pleurotus ostreatus* (spores of white spongy rot)
ALGAE	
Pharmacist	Chlorella
Thalassotherapist	Algae (species unspecified)
FLOURS	
Animal fodder	Marigold flour *(Tagetes erecta)*
Baker	Wheat, rye, soya, and buckwheat flour; Konjac flour; white pea flour *(Lathyrus sativus)*
Food processing	White Lupin flour *(Lupinus albus)*
POLLENS	
Florist	Cyclamen, rose
Gardener	Canary island date palm *(Phoenix canariensis)*, bell of Ireland *(Moluccella laevis)*, bell pepper, chrysanthemum, eggplant *(Solanum melongena)*, *Brassica oleracea* (cauliflower and broccoli)
Laboratory worker	Sunflower (*Helianthus* spp.), thale cress *(Arabidopsis thaliana)*
Olive farmers	White mustard *(Sinapis alba)*
Processing worker	*Helianthus annuus*
PLANTS	
Brewery chemist	Hops
Brush-makers	Tampico fiber in agave leaves
Butcher	Aromatic herb
Chemist	Linseed oilcake, *Voacanga africana* seed dust
Cosmetics	Dusts from seeds of sacha inchi *(Plukenetia volubilis)*, chamomile (unspecified)
Decorator	Cacoon seed (Entage gigas)
Floral worker	Decorative flower, safflower *(Carthamus tinctorius)* and yarrow *(Achillea millefolium)*, spathe flower, statice *(Limonium tataricum)*, baby's breath *(Gypsophila paniculata)*, ivy *(Hedera helix)*, flower (various), sea lavender *(Limonium sinuatum)*
Food industry	Aniseed, fenugreek, peach, garlic dust, asparagus, coffee bean, sesame seed, grain dust, carrot *(Daucus carota L.)*, green bean *(Phaseolus multiflorus)*, lima bean *(Phaseolus lunatus)*, onion, potato, Swiss chard *(Beta vulgaris L.)*, courgette, carob bean, spinach powder, cauliflower, cabbage, chicory, fennel seed, onion seeds (*Allium cepa*, red onion), rice, saffron *(Crocus sativus)*, spices, grain dust
Gardener	Copperleaf *(Acalypha wilkesiana)*, grass juice, weeping fig *(Ficus benjamina)*, umbrella tree (*Schefflera* spp.), amaryllis (*Hippeastrum* spp.), Madagascar jasmine sap *(Stephanotis floribunda)*, vetch *(Vicia sativa)*
Hairdresser	Henna (unspecified)
Herbal tea processor	Herbal tea, sarsaparilla root, sanyak *(Dioscorea batatas)*, Korean ginseng *(Panax ginseng)*, tea plant dust *(Camellia sinensis)*, chamomile (unspecified)
Herbalist	Licorice roots (*Glycyrrhiza* spp.), wonji *(Polygala tenuifolia)*, herb material
Horticulture	Freesia (Freesia hybrida), paprika *(Capsicum annuum)*, Brazil ginseng *(Pfaffia paniculata)*
Laborer	Citrus food handling (*dl*-limonene, *l*-citronellol, and dichlorophen)
Oil industry	Castor bean, olive oil cake
Pharmaceutical	Rose hip, passion flower *(Passiflora alata)*, cascara sagrada *(Rhamnus purshiana)*
Powder	Lycopodium powder
Sewer	Kapok
Sheller	Almond shell dust
Stucco handler	Esparto (*Stipa tenacissima* and *Lygeum spartum)*
Tobacco manufacturer	Tobacco leaf
PLANT-DERIVED NATURAL PRODUCTS	
Baker	Gluten, soybean lecithin
Candy maker	Pectin
Glove manufacturer	Latex
Health professional	Latex
Rose extraction	Rose oil
BIOLOGIC ENZYMES	
Baker	Fungal amylase, fungal amyloglucosidase and hemicellulase
Cheese producer	Various enzymes in rennet production (proteases, pepsine, chymosins)
Detergent industry	Esterase, *Bacillus subtilis*
Factory worker	*Bacillus subtilis*
Fruit processor	Pectinase and glucanase
Hospital personnel	Empynase (pronase B)
Laboratory worker	Xylanase, phytase from *Aspergillus niger*
Pharmaceutical	Bromelin, flaviastase, lactase, pancreatin, papain, pepsin, serratia peptidase, and lysozyme chloride; egg lysozyme, trypsin
Plastic	Trypsin
VEGETABLE GUMS	
Carpet manufacturing	Guar
Dental hygienist	*Gutta-percha*
Gum importer	Tragacanth
Hairdresser	Karaya
Printer	Acacia

Table 448.6 Low Molecular Weight Chemicals Known to Induce Occupational or Environmental Asthma

CHEMICALS	OCCUPATION OR ENVIRONMENT SOURCE
Diisocyanates	
• Diphenylmethane • Hexamethylene • Naphthalene • Toluene	• Polyurethane • Roofing materials • Insulations • Paint
Anhydrides	Manufacturers or users
• Trimellitic • Phthalic	• Paint • Plastics • Epoxy resins
Dyes	Personal or business use of dyes
• Anthraquinone • Carmine • Henna • Persulfate	• Hair dye • Fur dye • Fabric dye
Glue or resin	Plastic
• Methacrylate • Acrylates • Epoxy	• Manufacturers • Healthcare professionals • Orthopedic specialists
Metals	Metal work
• Chromic acid • Potassium dichromate • Nickel sulfate • Vanadium • Platinum salts	• Plating • Welding
Drugs	Exposure to drugs in environment
• β-Lactams • Opioids • Other	• Pharmaceutical workers • Farmers • Healthcare workers
Chemicals	Exposure in the healthcare field
• Formaldehyde • Glutaraldehyde • Ethylene oxide	• Laboratory work • Healthcare professionals
Wood dust	Workers/hobbyists
• Western red cedar (plicatic acid) • Exotic woods • Maple • Oak	• Sawmill • Carpentry • Woodworking

(via percutaneous skin testing or serum IgE) to the causative agent is often impractical given the lack of commercial extracts to the over 300 known causative agents for occupational asthma (see Table 448.5).

Treatment of Occupational Asthma

The management of occupational asthma is centered on exposure reduction and optimized pharmacotherapy with inhaled corticosteroids (ICS) following the National Asthma Education and Prevention Program (NAEPP) and the Global Initiative for Asthma (GINA) guidelines (reviewed in Chapter 185). Ideally, patients would be completely removed from the exposure for the best outcomes. However, in cases where this is not feasible, respiratory protection devices and work accommodations to reduce the exposure should be pursued under the guidance of an occupational hygienist. Because of a lack of commercially available extracts for the causative agent, allergen-specific immunotherapy has limited applicability for the treatment of occupational asthma for patients who cannot avoid the exposure. For these reasons, omalizumab therapy has been successfully used in small case series to attenuate the IgE response, resulting in reduced exacerbations and systemic and/or inhaled corticosteroid requirements.

Irritant-Induced Asthma and Reactive Airways Disease Syndrome

Irritant-induced asthma is also a form of work-related asthma and has both **acute and subacute** phenotypes. As opposed to occupational asthma, irritant-induced asthma results from **nonimmunologic** provocation of bronchial hyperresponsiveness with airflow obstruction.

The most well-characterized presentation of **acute irritant-induced asthma** is **reactive airways dysfunction syndrome (RADS)**, where patients present with acute respiratory symptoms within minutes or hours after a single inhalation of an *elevated concentration* of irritant aerosol, gas, or smoke. Many of these exposures are accidental in nature. The clinical manifestations and pathophysiology of RADS have been studied through experimental design or epidemiology studies involving exposure to chlorine gas, acetic acid, dimethylaminoethanol, chlorofluorocarbons, epichlorohydrin, and diisocyanates. Patients with RADS typically can pinpoint the exact time of onset of symptoms and the exact number of hours post exposure. The symptoms are so severe that nearly 80% of subjects in one study presented to an emergency department for care. The lower airway symptoms of cough, dyspnea, chest tightness, and wheezing are prominent features in RADS, with cough being most prevalent. Because of the toxic nature of the inhaled chemical, it is predictable that an upper airway syndrome of throat and nose burning will often accompany the lower airway symptoms. This part of the complex has been referred to as **respiratory upper airway dysfunction syndrome**.

Predisposing factors for the development of RADS are not well characterized. Cigarette smoking may increase the risk of developing RADS when exposure through inhalation of irritant chemicals occurs. In addition to host factors, the type of chemical appears to be important. Higher concentrations of chemicals, the type of chemical (vapor or wet aerosols), and bleaching agents are the most offending agents to cause RADS. Dry particle aerosols are less likely to cause RADS. Analysis of the World Trade Center firefighters indicates that the presence of bronchial hyperresponsiveness before this catastrophe did not increase the risk for an individual to develop RADS.

The pathogenesis of RADS follows a typical pattern, driven by the initial injury to the airway epithelium. Initial histology demonstrates rapid mucosal denudation accompanied by a submucosal fibrinous, hemorrhagic exudate. Subepithelial edema subsequently occurs with epithelial layer regeneration, basal and parabasal cells increase, and eventually areas of fibrosis form. The desquamation, fibrosis, basement membrane thickening, and basal cell regeneration are more characteristic of RADS than occupational asthma. This may explain the limited response to bronchodilator therapy in this syndrome compared to asthma.

In contrast to the acute onset of symptoms after exposure seen with RADS, individuals with **subacute irritant-induced asthma** present with a more insidious onset of symptoms. Because of the recurrent nature of the low concentration of the chemical exposure, patients may initially not be able to identify the underlying trigger. **Subacute irritant-induced asthma** has been described through epidemiologic studies and characterized by (1) the insidious onset of symptoms occurring after *multiple high exposures to irritants* (such as what occurred among some rescue workers at the World Trade Center) or (2) single or multiple exposures to irritant chemicals in *low concentrations*. Similar to allergic rhinitis, patients may describe nasal congestion, rhinorrhea, sneezing, postnasal drip, ocular irritation, and conjunctival injection. Pulmonary symptoms include those typically seen with asthma exacerbations.

Table 448.7 Criteria for Reactive Airways Disease (Dysfunction) Syndrome

- Documented absence of preceding respiratory symptoms
- Onset after single specific high-level exposure incident
- Exposure to very high concentration of gas, smoke, fumes, or vapors with *irritant* properties
- Onset of symptoms within 24 hours after exposure with persistence for ≥3 months
- Symptoms similar to asthma with cough, wheeze, and dyspnea
- Presence of airflow obstruction on pulmonary function ± nonspecific bronchial (methacholine) hyper-responsiveness
- Other pulmonary disease excluded

Data from Varney VA, Evans J, Bansal. Successful treatment of reactive airways dysfunction syndrome by high-dose vitamin D. *J Asthma Allergy*. 2011;4:87–91.

Diagnosis of Irritant-Induced Asthma

Initial evaluation of the patient with acute (RADS) or subacute irritant-induced asthma usually includes the medical history, physical examination, and pulse oximetry. Because of the acute nature of RADS, a chest radiograph is obtained in order to rule out other acute causes of dyspnea, including pneumonia or pulmonary edema. In patients with both acute and subacute irritant-induced asthma, the chest radiograph is frequently normal or may reveal hyperinflation. Ideally, if the patient is not in significant distress, complete pulmonary function testing with spirometry, assessment of bronchodilator reversibility, and nonspecific bronchial provocation with methacholine are helpful in the initial evaluation.

Table 448.7 lists the criteria for a diagnosis of **RADS**. Asthma-like symptoms and airway hyperresponsiveness occur and often persist for prolonged periods. Unlike typical asthma, *RADS is often not reversible after administration of a bronchodilator*. This is probably a consequence of the direct injury to the epithelium and subsequent submucosal fibrosis.

Treatment of RADS and Irritant-Induced Asthma

Treatment of acute (RADS) and subacute irritant-induced asthma focuses on prevention of exposure. Because the exposure in RADS is often associated with a single known exposure, this task is readily accomplished. The low, persistent exposures associated with subacute irritant-induced asthma are more challenging to identify and remove.

Implementing treatment guidelines for asthma is recommended when intervention is required beyond antigen removal. Managing an acute presentation of RADS is exactly the same as managing an acute asthma exacerbation. Short-acting β-agonist treatment may not be effective; a trial of inhaled ipratropium may add benefit in the short term. For moderate to severe symptoms and FEV_1 values that are less than 70% of predicted, administration of systemic glucocorticoids (2 mg/kg prednisone equivalent, up to 60 mg daily) can be beneficial based on some clinical case studies and animal studies. Unlike the typical 5-day courses of systemic glucocorticoids for asthma exacerbations, many patients remain symptomatic beyond 5 days as a result of the extent of the airway epithelial injury. Steroid treatment may be prolonged up to 10-15 days after the onset of symptoms; a slow taper of corticosteroids may be implemented after the 10-15 days. High-dose ICS therapy with or without long-acting β-agonists may be added while the systemic steroids are being tapered. The initial high-dose ICS regimens are based on the NAEPP and the GINA guidelines. For patients whose initial symptoms are not as severe and/or spirometry demonstrates milder airway obstruction (FEV_1 greater than or equal to 70% of predicted), high-dose ICS therapy alone can be started without requiring systemic corticosteroid treatment. Once patients' asthma symptoms are improved, ICS doses can be tapered by increments of 25–50% over a period of up to 6 months in some case series based on patient symptoms. However, prolonged ICS treatment beyond 6 months has also been noted.

Visit Elsevier eBooks+ at eBooks.Health.Elsevier.com for Bibliography.

448.3 Granulomatous Lung Disease

Timothy J. Vece, Eveline Y. Wu, and Stephanie D. Davis

GRANULOMATOSIS WITH POLYANGIITIS

Granulomatosis with polyangiitis (GPA), formerly *Wegener granulomatosis,* is a disease that involves both the lower and upper respiratory tracts with granulomatous inflammation of small- to medium-sized vessels (see Chapter 210). Pulmonary disease is frequently associated with glomerulonephritis. The simultaneous presence of pulmonary and renal disease should immediately raise the suspicion for GPA, microscopic polyangiitis, or anti–glomerular basement membrane (anti-GBM) disease (see Chapter 448.5).

Epidemiology

The prevalence of GPA during childhood is rare, but epidemiologic data suggest an increase in cases in the last 2 decades. The median age at diagnosis is 10-14 years, and there is a female predominance of 3-4:1. Improved clinical recognition, disease classification, and tests, such as antineutrophil cytoplasmic antibodies (ANCAs), have helped in the diagnosis of this rare disorder.

Etiology and Pathogenesis

In GPA, the development of both upper and lower airway disease with granulomas implies that exposure to antigens in the airways of an endogenous or exogenous source is involved with aberrant innate and adaptive immune responses. Neutrophils are a key effector cell. There is also a predominantly T-lymphocyte type 1 response with overexpression of interferon-γ (IFN-γ) and tumor necrosis factor (TNF). In vitro studies demonstrate a skewed T-lymphocyte type 17 response by blood $CD4^+$ T cells in GPA, suggesting there is an immune regulatory defect that leads to excessive production of T-lymphocyte type 1 and type 17 cytokines (interleukin [IL]-17, TNF, and IFN-γ). Such an inflammatory response may be sufficient to induce and sustain granuloma formation.

ANCAs are autoantibodies reactive against proteins in the cytoplasmic granules of neutrophils and monocytes and are found in 90% of patients with GPA. The most common ANCAs in GPA have a cytoplasmic fluorescence pattern (c-ANCA) and usually indicate antibodies against proteinase-3 (PR3-ANCA). Perinuclear fluorescence (p-ANCA) usually indicate antibodies directed toward myeloperoxidase (MPO-ANCA), which are less common in GPA. Approximately 5–10% of children develop the clinical phenotype of GPA in the absence of detectable ANCA.

Clinical Manifestations

Children with GPA present with respiratory complaints accompanied by fever, loss of energy, and vague joint symptoms. Some may present with severe nasal disease manifested as ulceration, septal perforation, pain, sinusitis, and/or epistaxis. The septal perforation may lead to deformation of the nasal bridge from erosion of the underlying cartilage, but this is more common in adults. Sinusitis may be present, and pulmonary disease occurs in the majority of patients. Symptoms range from cough, hemoptysis (seen in less than 50% of pediatric patients), dyspnea, and chest discomfort to asymptomatic infiltrates on chest radiography. Occasionally, patients with GPA will present with hemoptysis or recurrent fleeting infiltrates from *pulmonary hemorrhage*. The pathology is confusing because granulomatous disease may be difficult to demonstrate, and *pulmonary capillaritis,* the other main component seen on histology, can be seen in other disorders, including anti-GBM disease, microscopic polyangiitis, idiopathic pulmonary capillaritis, and IgA vasculitis (Henoch-Schönlein purpura). Distinguishing GPA from other pulmonary-renal syndromes is easiest when there are classical symptoms of upper airway disease (nasal/sinus), lower airway disease with necrosis and granulomas on lung biopsy along with vasculitis, and renal disease consistent with glomerulonephritis.

As many as 20% of patients with GPA will present with subglottic or endobronchial stenosis from scarring and inflammatory changes.

Although it may be the presenting symptom, it often occurs in conjunction with other disease manifestations. Dyspnea and voice changes are common complaints from patients.

Skin, ocular (uveitis), and joint symptoms are common in GPA and have been found to accompany the lung and renal disease up to 50% of the time. Biopsy of the skin may show nonspecific leukocytoclastic vasculitis, venulitis, or capillaritis.

Laboratory and Pathology

PR3-ANCA are found in 70–90% of children with GPA, and in the correct clinical situation are sufficient for the diagnosis of ANCA-associated vasculitis, although it may be difficult to differentiate GPA from MPA. In unusual or uncertain cases, tissue diagnosis is required. In lung tissue, the usual pathology demonstrates multiple parenchymal nodules that may be located in either the bronchial, vascular, or interstitial tissues (Fig. 448.1). The granulomatous inflammation is often found in areas of necrosis and/or vasculitis.

Renal biopsy rarely demonstrates granulomas or vasculitis. Rather, kidney tissues may show focal, segmental, or necrotizing glomerulonephritis without deposits of immune complexes. Kidney biopsy is preferred when a histopathologic diagnosis is required, as kidney biopsy has a lower morbidity and mortality than lung biopsy. When the tissues fail to demonstrate classical findings, a variety of diseases (e.g., tuberculosis, sarcoid, microscopic polyangiitis, malignancy, and other autoimmune disorders) must be considered in the evaluation.

Radiology

Chest imaging findings are quite variable in GPA. Chest radiography may reveal multiple infiltrates, nodules, cavitary lesions, or ILD. Fleeting infiltrates may be seen when recurrent hemorrhage is a clinical manifestation. HRCT of the chest often demonstrates more extensive lung disease and the cavitation associated with the necrotizing nature of the disease (Fig. 448.2).

Treatment

Rapidly progressive, debilitating disease may occur if there is a failure to diagnose GPA. One early series of patients reported that death occurred in 90% of patients within 2 years of diagnosis. Glucocorticoid therapy alone resulted in relapses and inadequate control of disease in many subjects.

Therapy is divided into *induction* and *maintenance* phases. Systemic corticosteroids, while ineffective as monotherapy, are a mainstay of therapy in conjunction with other immune-suppressive agents. Prednisone can be given orally. Alternatively, intravenous methylprednisolone may be used at a dosage of 10-30 mg/kg (max 1 g) administered weekly or for 3 consecutive days monthly. Combination therapy traditionally includes cyclophosphamide given either orally at 2 mg/kg/day or intravenous dosing at 15 mg/kg monthly. Rituximab, an anti-CD20 antibody, is as effective as cyclophosphamide in inducing remission of GPA. Rituximab dosing is either 350 mg/m^2 given weekly for the first 4 weeks or 750 mg/m^2 given on initiation of therapy and 2 weeks after initiation. A second dose of 500 mg/m^2 is often given 6 months after the first course of rituximab. Induction therapy should be continued for 3-6 months.

Continued therapy is required past the initial induction phase to maintain remission. Because of the toxicity of cyclophosphamide, other immune-suppressive agents are preferred. Methotrexate and azathioprine have been shown to be noninferior to cyclophosphamide in maintaining remission, whereas mycophenolate mofetil has higher relapse rates than azathioprine. Rituximab is also used for maintenance remission and is associated with lower risk of major relapse compared with azathioprine, particularly for patients with GPA and PR3-ANCA. Systemic steroid dosages should be progressively weaned at the beginning of the maintenance phase of therapy to a dosage of 5-10 mg/day. Maintenance therapy should be continued for an additional 1.5-2 years.

Adjuvant therapy with plasma exchange may be considered when life-threatening GPA disease presents. This is advocated on the premise that ANCAs are inducing disease and will be removed from the circulation with this intervention; its use has been favorably evaluated in GPA-induced renal disease. Adjuvant plasma exchange has been studied mainly in patients with severe renal vasculitis, but there are also reports of success in severe pulmonary hemorrhage. The results

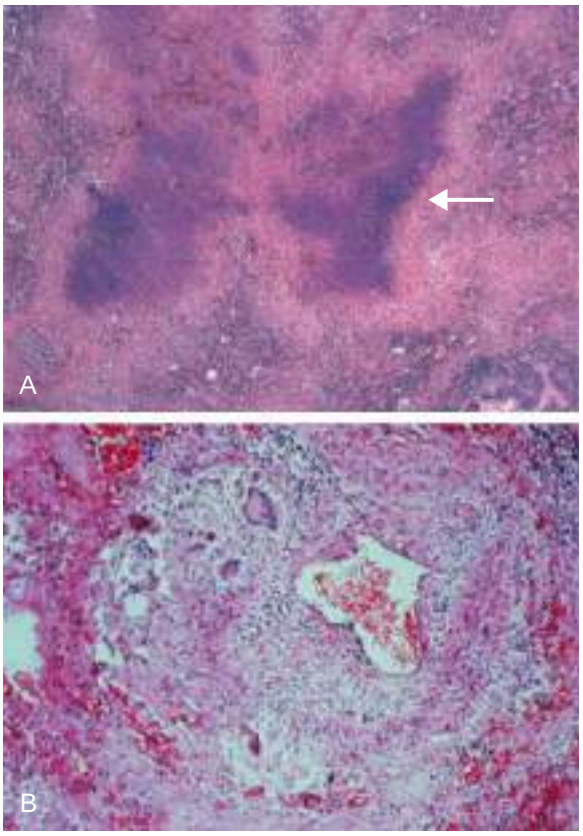

Fig. 448.1 **A,** Low-power view of granulomatous inflammation and geographic necrosis *(arrow)* in a lung biopsy from a patient with GPA. **B,** Granulomatous vasculitis involving a small pulmonary artery in the lung of a patient with GPA. The vessel wall is markedly thickened with an inflammatory infiltrate that includes multinucleated giant cells. *(From Sneller MC, Fontana JR, Shelhamer JH. Immunologic nonasthmatic diseases of the lung. In Adkinson NF Jr, Bochner BS, Burks AW, et al., eds. Middleton's Allergy Principles and Practice, 8th ed. Philadelphia: Elsevier; 2014: Fig. 62.1B and C.)*

Fig. 448.2 Chest CT scan of a patient with granulomatosis with polyangiitis shows typical nodular lung infiltrate with cavitation. *(From Sneller MC, Fontana JR, Shelhamer JH. Immunologic nonasthmatic diseases of the lung. In Adkinson NF Jr, Bochner BS, Burks AW, et al., eds. Middleton's Allergy Principles and Practice, 8th ed. Philadelphia: Elsevier; 2014: Fig. 62.1A.)*

of a meta-analysis of patients with renal vasculitis in nine trials suggest that adjuvant plasma exchange may be associated with improved renal outcome. Other adjuvant therapy includes high-dose intravenous immunoglobulin (IVIG) in recalcitrant disease, which acts to cross-link IgG and likely decrease circulating ANCA antibodies.

Recurrent disease remains a major problem, with relapse rates of up to 50% reported in most studies. ANCA levels do not always correlate with disease activity or severity. Patients with isolated disease of the sinuses and nose may not require such toxic therapy. Therapy with topical corticosteroid and antibiotics for infection appear to be warranted. If unsuccessful, steroids with methotrexate appear to be an effective therapy.

The development of subglottic stenosis requires specific treatment. Use of cyclophosphamide with oral corticosteroid may only partially treat the airway disease or not treat the airway disease at all. Local injection of a prolonged-acting corticosteroid may reduce the inflammation and prevent further scarring. If this complication is found at presentation, simultaneous airway intervention with induction of corticosteroid and cyclophosphamide is warranted and encouraged.

SARCOIDOSIS

Sarcoidosis is an idiopathic multisystem inflammatory disease with a characteristic histology of *noncaseating granulomas* (see Chapter 209). It has been postulated that sarcoidosis represents an exaggerated immune response to a yet-to-be-identified agent from the environment that is likely inhaled in a susceptible host. Sarcoidosis remains a diagnosis of exclusion from other diseases, with granuloma formation noted on histology, such as chronic granulomatous disease (CGD), granulomatous lymphocytic interstitial lung disease (GLILD) associated with common variable immune deficiency (CVID), HP associated with some drugs and inhalation agents, GPA, typical and atypical *Mycobacterium, Pneumocystis jiroveci,* and malignancy.

Epidemiology and Pathogenesis

The Black population is disproportionately affected by sarcoidosis; however, it can present in any group. Because an asymptomatic sarcoid-like distribution of noncaseating granulomas may be found at autopsy, the contribution of the granulomas to the disease is not clear. In countries that perform chest radiograph screening, up to 50% of people diagnosed with sarcoidosis are asymptomatic. The mortality and severity of sarcoidosis are poorer among Black patients; this is likely multifactorial, with racism and healthcare inequities playing a significant role. Sarcoidosis is more endemic in the Southeastern and South Central United States. There have been clusters of disease in families, and genetic testing suggests that the MHC linkage on the short arm of chromosome 6 is most likely to be observed.

Unrecognized infection or inhalation of an immune response–inducing antigen continues to be at the forefront of consideration as a cause of the disease. Clusters of sarcoidosis in small populations, variable prevalence by geography and race, the transfer of disease by organ transplant, and the reproducible noncaseating granuloma formation only noted in patients with sarcoidosis in the skin when homogenized lymph node tissue from patients with sarcoid is injected intradermally (Kveim-Siltzbach test) have supported this hypothesis.

Clinical Manifestations

Sarcoidosis is rarely found in young children. Skin rash, uveitis, and arthritis are seen most often in younger children without pulmonary symptoms. In older children, the presentation is similar to adults, with multisystem disease being the most common. In Northern Europe, erythema nodosum with the ocular involvement of iridocyclitis is seen most frequently. Despite the lack of symptoms, chest radiography may be abnormal in approximately 90% of children. The pulmonary disease can be less progressive compared with adults, and patients can recover spontaneously without corticosteroids. Rarely, pulmonary disease may progress to fibrosis. Ocular disease is more likely to be progressive and warrant intervention, as the inflammatory response may lead to blindness from complications of iritis.

Patients may present with malaise, fever, and weight loss. Those with lung disease are more likely to be asymptomatic as the presentation. When symptomatic, patients demonstrate shortness of breath, cough, and dyspnea. Younger children are more likely to manifest the disease as iridocyclitis, skin rash, and arthritis. Black children appear to have more frequent lymph node involvement, nonspecific elevations of gamma globulin, erythema nodosum, and hypercalcemia.

Physical exam may reveal only an elevated respiratory rate without crackles or rales by auscultation. Pleural involvement has been seen but is uncommon. When present, a lymphocytic predominant exudate may be observed in the pleural fluid. Unusual but reported findings include cases of pneumothorax, hemothorax, and chylothorax. One specific syndrome, **Lofgren syndrome**, with hilar lymphadenopathy, erythema nodosum, and migratory polyarthralgias, is almost exclusively seen in females. This syndrome has a strong association with HLA-DQB1*0201 and polymorphisms in the C-C chemokine receptor 2 (CCR2); these genetic markers are a predictor of a good outcome.

Although almost 90% of patients with sarcoidosis demonstrate parenchymal or mediastinal disease on chest radiography, there are many who have minimal to no symptoms. Approximately 40% of adults with stage 1 disease have endobronchial involvement found at bronchoscopy. The higher the staging level of the disease, the more likely patients are to have airway involvement.

Diagnostic Laboratory Testing

The most common but nonspecific findings are hypergammaglobulinemia, elevated acute-phase reactants, hypercalciuria, hypercalcemia, elevated alkaline phosphatase when liver disease is present, and, occasionally, anemia of chronic disease. Serum angiotensin-converting enzyme may be elevated in 75% of patients with untreated sarcoidosis. False-positive tests occur from other diseases, so it is not considered a diagnostic test but may be used for monitoring disease activity.

Pulmonary function tests can be performed accurately in most children older than the age of 4 years. There are no specific diagnostic findings of spirometry, lung volumes, or diffusion capacity in sarcoidosis. Restrictive lung disease has been reported, but obstruction may be present because of an airway granuloma or lymph node compression. A decline in diffusion capacity when alveolitis is present in hypersensitivity pneumonitis could help diagnostically when attempting to differentiate sarcoidosis from HP before biopsy.

BAL is of great help when differentiating other diseases from sarcoidosis. BAL in sarcoidosis shows a marked predominance of $CD4^+$ T cells. *A lymphocyte percentage >16% on BAL, a CD4:CD8 ratio >4:1, and noncaseating granulomas on bronchial biopsy in the presence of abnormal angiotensin-converting enzyme levels are nearly completely diagnostic for sarcoidosis.* In addition, T cells are activated on BAL in sarcoidosis. BAL in HP shows a significant change in the balance of $CD4^+$ to $CD8^+$ T cells, with the two cell types being nearly equal compared with the normal mild predominance of $CD4^+$ T cells in the circulation. A ratio of CD4:CD8 of <1 predicts 100% of patients with BAL lymphocytosis to *not* have sarcoidosis. Neutrophil counts >2% and/or eosinophil counts >1% exclude the diagnosis of sarcoidosis.

The analysis of D-dimers in BAL fluid from subjects with sarcoidosis demonstrates an elevation in 80% of patients compared with no detectable D-dimers in unaffected controls.

Histopathology

The characteristic feature of sarcoidosis is the noncaseating granuloma formation in the lung (Fig. 448.3). These granulomas are found in the bronchial walls, alveolar septa, and vascular walls of pulmonary arteries and veins. The formation of noncaseating granulomas is likely preceded by alveolitis involving the interstitium more than the alveolar spaces. There is an accumulation of inflammatory cells, including monocytes, macrophages, and lymphocytes, that accompanies the granulomas. Multinucleated giant cells are frequently found among the epithelioid cells within the granuloma follicle. These may show cytoplasmic inclusions (e.g., asteroid bodies and Schaumann bodies) and some birefringent crystalline particles made of calcium oxalate and other calcium salts. These are most often identified in the upper lobes of the lungs, which may lead to confusion with diseases such as HP, eosinophilic granuloma, collagen vascular disease, pneumoconiosis, and infectious disease such as tuberculosis or histoplasmosis.

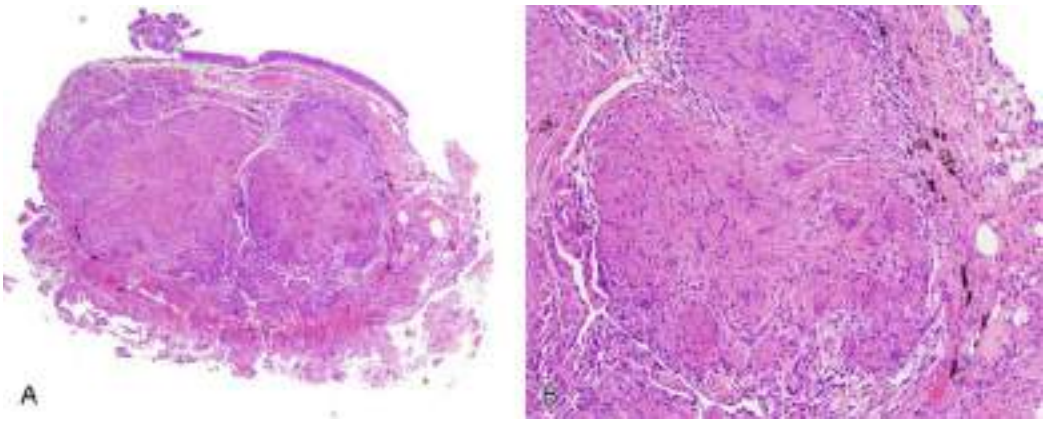

Fig. 448.3 Transbronchial biopsy specimen showing a sarcoid granuloma. **A,** The granulomas are located below the bronchiolar epithelial layer that appears at the top of the frame. **B,** A higher-power view of the same biopsy specimen. The epithelioid granuloma is tightly packed and contains multiple multinucleated giant cells. There is no caseous necrosis. Special stains for acid-fast bacilli and fungi were negative. *(From Sneller MC, Fontana JR, Shelhamer JH. Immunologic nonasthmatic diseases of the lung. In Adkinson NF Jr, Bochner BS, Burks AW, et al., eds. Middleton's Allergy Principles and Practice, 8th ed. Philadelphia: Elsevier; 2014: Fig. 62.6.)*

Radiology

Pulmonary imaging in sarcoidosis has included plain chest radiography, HRCT of the chest, positron emission tomography using fluorine-18-fluorodeoxyglucose, or radiotracer using gallium-67. The staging of sarcoidosis is performed using plain radiography and is outlined as follows:

- Stage I—Bilateral hilar lymphadenopathy accompanied by right paratracheal lymphadenopathy.
- Stage II—Bilateral hilar lymphadenopathy accompanied by reticular opacities. If symptomatic, patients have cough and dyspnea. Occasional fever and fatigue accompany the respiratory symptoms.
- Stage III—Reticular opacities are found predominantly in the upper lobes with regression of hilar lymphadenopathy.
- Stage IV—Reticular opacities start to coalesce and lead to volume loss in the lung fields and traction bronchiectasis from conglomeration of the inflamed tissues. Extensive calcium deposits may be seen at this stage.

HRCT of the chest may be helpful in further staging of the disease and in revealing abnormalities not appreciated on chest radiography. Findings in patients with sarcoidosis by HRCT of the chest include hilar lymphadenopathy, paratracheal nodules, middle to upper lung parenchymal ground-glass appearance, bronchial wall thickening, bronchiectasis, cystic changes, and fibrosis. The ground-glass appearance suggests that alveolitis, as seen in hypersensitivity pneumonitis, may be present. Biopsy has usually shown granuloma formation as the predominant histologic finding.

Treatment

Because pulmonary sarcoidosis spontaneously resolves without therapy in almost 75% of patients, clear guidelines for treatment focused on minimizing therapeutic side effects is imperative. Glucocorticosteroids (GCSs) have long been the mainstay of therapy in sarcoidosis and are often used because of extrapulmonary disease. When pulmonary disease is progressive, GCS therapy is aimed at the prevention of fibrosis, honeycombing, and irreversible lung disease. Assuring that disseminated infections, heart failure, thromboembolism, or pulmonary hypertension are not present is important. In addition to HRCT of the chest, performance of pulmonary function tests, electrocardiogram, and echocardiogram should be considered before starting GCS therapy.

GCS therapy is often not started in the asymptomatic patient with stage I or II disease. This scrutiny of the benefit of therapy was highlighted when a prospective evaluation of GCS therapy for pulmonary disease found that nearly 50% of patients receiving GCSs had active or relapsing disease 2 years later. In contrast, 90% of patients who did not receive GCSs had spontaneous remission of disease, with the other 10% needing intervention 2 years later. Absolute indications include progressive stage III disease with symptoms of shortness of breath, cough, or other chest symptoms such as pain. Progressive restriction shown on pulmonary function testing is an indication for therapy. Specific pulmonary function changes where lung capacity declines a total of 10% or greater, FVC declines 15% or more, or diffusion capacity degradation is noted to be ≥20% are all indications for GCS intervention.

Initially, patients are treated with oral prednisone depending on the severity of symptoms. Stability is usually achieved within 6-8 weeks, after which slow, progressive tapering of GCS may occur every 4-8 weeks. Many favor the use of alternate-day steroids to reduce the side effects of GCSs, but little data exist to show efficacy.

For patients who do not tolerate GCSs or develop progressive disease, alternative immunosuppressive agents may add benefit to the regimen. Progressive disease also is a reminder for the clinician to reassess the diagnosis of sarcoidosis and review the possibility that beryllium or an infection may be the underlying reason for the progressive disease.

BERYLLIOSIS

Chronic berylliosis disease (CBD), a rare disease, is caused almost exclusively by environmental, and specifically occupational, exposure to beryllium. Examples of these high-risk industries include beryllium and beryllium alloy production, nuclear weapon development, the dental industry, and aircraft/automotive manufacturing. CBD is similar in appearance and pathogenesis to sarcoidosis; however, patients have had a previous exposure to beryllium. Although uncommon in pediatrics, CBD is important to consider in adolescents who work in high-risk industries.

Diagnosis

The most important step in the diagnosis of CBD is establishing a beryllium exposure by performing a thorough history. Special attention should be given to the patient's work history, and in younger children, the work history of the parents, as there are reports of secondary exposure to beryllium causing CBD in at-risk patients. Symptom history is nonspecific, with the most common being dry cough, shortness of breath particularly on exertion, and weight loss. Workplace screening for beryllium sensitization is now implemented in high-risk professions. Given this, the majority of patients are often asymptomatic at the time of diagnosis. The physical exam is also nonspecific in CBD, with most patients having a normal examination; however, crackles and digital clubbing may develop as the disease progresses.

Laboratory testing is a critical step in establishing a diagnosis. Beryllium sensitization is established by performing a beryllium lymphocyte proliferation test (BeLPT). This test is performed by isolating mononuclear cells from patients (either through blood or bronchoalveolar lavage fluid [BALF]) and culturing these cells in different concentrations of beryllium salts. Results are reported as a ratio of stimulated lymphocytes in the beryllium culture versus a control. A BeLPT is considered positive if two or more of the six stimulation indices exceed normal. A diagnosis of beryllium sensitization is confirmed by two positive blood BeLPT tests or one positive BALF BeLPT test. BeLPT screening is performed for employees in high-risk occupations.

Radiography is often obtained but may be nonspecific. Chest x-rays are often not sensitive enough to diagnose CBD. Computed tomography (CT) of the chest reveals a pattern similar to sarcoidosis, with nodules following a bronchovascular distribution. Hilar lymphadenopathy is less common in CBD compared to sarcoidosis. In later stages of the disease, evidence of fibrosis may be seen on the CT scan of the chest.

Pulmonary function testing (PFT) is also commonly performed in the evaluation of CBD. As a result of increased screening with BeLPT, most patients with CBD are now diagnosed before PFT abnormalities become apparent. If PFT abnormalities are noted, these changes are variable, demonstrating an obstructive, restrictive, or mixed pattern. Diffusion capacity for carbon monoxide is often low, especially in advanced disease. Finally, exercise stress testing is also abnormal in advanced CBD.

Bronchoscopy and BAL are important in the evaluation of CBD. BALF often reveals lymphocyte counts above 20%. Furthermore, BeLPT can be performed on BALF, which can confirm beryllium sensitivity. In conjunction with a positive BeLPT and a history of beryllium exposure, lung biopsy is needed to establish a definitive diagnosis of CBD. Biopsy can be obtained either through transbronchial biopsies or surgical lung biopsy. Unlike most pediatric ILDs, transbronchial biopsies are acceptable because of the bronchovascular distribution of CBD. Biopsies reveal noncaseating granulomas with a core of epithelial histiocytes surrounded by a rim of $CD4^+$ lymphocytes. Although lung biopsy is essential for diagnosis, a presumptive diagnosis of CBD can be made with a combination of a history of symptoms consistent with CBD, beryllium exposure, beryllium sensitization, PFT abnormalities, radiography changes, and BALF abnormalities.

Treatment

Treatment is not well studied in CBD. Most physicians do not treat asymptomatic patients with normal lung function indices. If lung function declines, first-line therapy is often systemic corticosteroids. Although some patients can stop corticosteroids over time, many will continue to progress without systemic treatment. In patients with persistent disease despite corticosteroids or in those patients who require ongoing treatment and would benefit from steroid-sparing therapy, other medications have been used such as azathioprine, methotrexate, mycophenolate, infliximab, or cyclophosphamide.

GRANULOMATOUS LUNG DISEASE IN PRIMARY IMMUNE DEFICIENCY

Primary immune deficiency (PID) often presents with recurrent or persistent pulmonary symptoms. Patients may experience recurrent infections, pneumonia, bronchiectasis, and ILD with or without fibrosis. Immune dysregulation occurs in many of the PIDs and may manifest with development of granulomatous lung disease and an autoimmune response. Most effort is focused on identifying the infectious pathogens in the PID that may be leading to the pulmonary symptoms; however, immune dysregulation may be the primary problem. This requires counterintuitive therapies with suppression of the immune system concurrently with immune deficiency therapy such as IVIG. The two most prominent PIDs associated with granulomatous lung disease are **chronic granulomatous disease** (see Chapter 170) and **common variable immune deficiency** (see Chapter 166.2).

The classic organism causing granuloma formation in the lung is *Mycobacterium tuberculosis*. Nontuberculous mycobacterial infections also can cause granulomas in the presence of a specific PID. These infections have been seen in patients with defective IL-12, IL-23, and IFN-γ signaling or when there are autoantibodies to IFN-γ. Defective regulation of nuclear factor-kappa B (nuclear factor-kappa B essential modifier defects) have also been reported in patients with nontuberculous mycobacteria. The clinician must be certain that this low-virulence organism is not causing disease before therapy for immune dysregulation is considered. Another PID associated with granulomatous disease involves defects in the INF-γ pathway. These disorders are grouped under the name **Mendelian susceptibility to mycobacterial disease**.

Pathogenesis

In CGD, there are defects in the phagocytic nicotinamide adenine dinucleotide phosphate oxidase system. These defects lead to impairment in the respiratory burst capacity to generate reactive oxygen species (see Chapter 170).

Patients with CVID have abnormalities in B lymphocytes and hypogammaglobulinemia. Pulmonary manifestations of CVID include organizing pneumonia, ILD, mucosa-associated lymphoid tissue lymphoma, and noncaseating granulomas in **granulomatous and lymphocytic interstitial lung disease (GLILD)** (see Chapter 166.2). Elevated levels of TNF from polymorphisms have been implicated as a possible mechanism. GLILD is becoming recognized more frequently in CVID and other immune disorders. It is defined by the presence of a granulomatous and a lymphocytic proliferative pattern in the lung. Granulomas may be found in other organs, including the bone marrow, spleen, gastrointestinal tract, skin, and liver in GLILD.

The etiology of GLILD is unknown. In a case cohort study, a majority of subjects with pathology diagnostic of GLILD were found to have human herpesvirus-8 infection of the lung. These findings in this subgroup of patients with GLILD may point to a mechanism underlying the development of pulmonary granulomas.

GLILD is sometimes misdiagnosed as sarcoidosis initially because both involve pulmonary granuloma, often accompanied by hilar and/or mediastinal lymphadenopathy. Sarcoidosis has several features that distinguish it from GLILD, such as normal or elevated serum immunoglobulin levels and frequent spontaneous remissions.

Clinical Manifestations of Granulomatous Lung Disease in Primary Immune Deficiency

Chronic respiratory disease as a result of recurrent infections is common in CGD. This is accompanied by clubbing in some patients and additional organ manifestations in the skin, liver, and genitourinary and gastrointestinal tracts. Granulomas are especially problematic in the gastrointestinal and genitourinary tracts. The inhalation of fungal spores and hyphae has led to acute pneumonia in CGD with rapid progression to respiratory failure, with hypoxemia, dyspnea, and fever. This entity, characterized as *mulch pneumonia,* appears to be best treated with antifungal medications and corticosteroids. Patients with GLILD present with progressive exercise intolerance and hypoxemia.

Radiography

Hilar and/or mediastinal lymphadenopathy occur with granulomatous lung involvement. These may manifest as parenchymal nodules and/or ground-glass abnormalities and can be seen commonly in CVID and CGD. Differentiating infectious causes of pulmonary infiltration in PID is often difficult on chest radiography; HRCT of the chest is often mandatory in the initial evaluation of the patients with CVID as a result of nonspecific findings on chest radiograph.

Laboratory and Pulmonary Function Testing

A definitive diagnosis of GLILD is made by lung biopsy with granulomatous disease. Transbronchial biopsy in children is often insufficient, and lung biopsy by video-assisted thoracoscopy or open biopsy is preferred. Unless the patient's underlying immune deficiency is unknown, other laboratory testing (except testing for infectious organisms) does not contribute significantly to the diagnosis of GLILD. When the child is old enough, complete PFT with spirometry, lung volumes, and diffusion capacity should be obtained at baseline and then followed serially to assess therapeutic response or progression of disease.

Therapy

The presence of GLILD in CVID can be associated with significant morbidity and possibly death. Without therapy, progressive pulmonary fibrosis and respiratory failure may occur in GLILD. The parenchymal disease may not always be controlled or relieved by glucocorticoid treatment. Other treatments include TNF antagonists, cyclosporine, or a combination therapy with rituximab and azathioprine. Response to therapy is monitored clinically and by interval HRCT of the chest and PFT, including spirometry, lung volumes, and diffusing capacity.

Visit Elsevier eBooks+ at eBooks.Health.Elsevier.com for Bibliography.

448.4 Eosinophilic Lung Disease

Timothy J. Vece and Stephanie D. Davis

The eosinophilic lung diseases are a group of heterogeneous pulmonary disorders with a predominant diffuse infiltration of eosinophils in the alveolar spaces or interstitial pulmonary spaces. Collectively, the disorders are often referred to as *pulmonary infiltrates with eosinophilia* and include acute eosinophilic pneumonia, chronic eosinophilic pneumonia, simple eosinophilic pneumonia (also known as *Loeffler eosinophilic pneumonia*), and eosinophilic granulomatosis with polyangiitis (previously Churg-Strauss). The lung architecture is well preserved throughout the inflammatory response, often with complete reversal of the inflammation without long-term sequelae in the majority of cases. The peripheral white blood cell count often (but not always) reveals elevated eosinophils, and BALF shows an elevation in eosinophils. Prompt recognition of these diseases allows for lifesaving interventions in idiopathic **acute eosinophilic pneumonia (AEP) syndrome** or resolution of persistent symptoms in patients with chronic disease.

ETIOLOGY

Eosinophilic lung diseases are often classified under two subheadings: idiopathic disease and known causation (Tables 448.8-448.10). They are frequently further subdivided into acute and chronic or infectious and noninfectious. The division of acute or chronic is arbitrary based on the length of symptoms present but is relevant to the clinician in determining the etiology of the symptoms (Table 448.11). Loeffler eosinophilic pneumonia, induced by *Ascaris lumbricoides, Strongyloides,* and other ascarids, produces transient symptoms that self-resolve and is classified as neither acute nor chronic.

PATHOLOGY AND PATHOGENESIS

Eosinophilic lung disease, regardless of the stage of disease or etiology, shows mixed cellular infiltration of the alveoli and interstitial spaces with a predominance of eosinophils when open lung biopsy is performed. This may be accompanied by a fibrinous exudate with intact lung architecture. Other findings include eosinophilic microabscesses, a nonnecrotizing nongranulomatous vasculitis, and occasional multinucleated giant cells, again without granuloma formation. BAL is the diagnostic procedure of choice, especially with the acute types of eosinophilic pneumonia, where peripheral eosinophilia is often absent; the differential cell count on the BAL is ≥20% eosinophils and is often more than 40%. This highly sensitive and specific test has allowed clinicians to forego lung biopsy.

Eosinophils are filled with numerous toxic granules. Evidence of eosinophil degranulation may be found by electron microscopy, biopsy, urine excretion, and BALF. Most commonly, eosinophil-derived neurotoxin, leukotriene E_4, and other granule proteins, such as major basic protein, Charcot Leyden crystals, or proinflammatory cytokines, are identified and support the evidence that eosinophils are not only present but contributing to the disease process.

CLINICAL MANIFESTATIONS

Specific eosinophilic lung diseases present with a variable clinical picture; however, there are some common findings across many of the eosinophilic diseases. Dyspnea is the most common and prevalent symptom in patients with acute or chronic eosinophilic pneumonia and is accompanied by cough in the majority of patients (90%). Rhinitis and sinusitis symptoms are of lower prevalence with wide variability in children with eosinophilic pulmonary disease. **Acute eosinophilic pneumonia** often presents with respiratory failure and the requirement for mechanical ventilation at high levels of positive end expiratory pressure and high concentrations of oxygen, whereas chronic eosinophilic pneumonia has a more indolent presentation (see Table 448.11). Although malignancy (e.g., eosinophilic leukemia) and organizing pneumonia may present with a need for mechanical ventilation, this is uncommon. A history of asthma is common in the chronic eosinophilic pneumonias and in **allergic bronchopulmonary aspergillosis (ABPA)**; it often precedes the diagnosis of these two conditions.

Table 448.8 Key Elements in the Medical History, Laboratory Findings, and Physical Exam to Raise Clinical Suspicion for Diagnostic Testing to Confirm Eosinophilic Lung Disease

MEDICAL HISTORY AND EXAMINATION
- Drug exposure (especially antibiotics, NSAIDs, antiepileptics, antileukotriene modifiers in EGPA)
- Environmental inhalation exposures to dust or inhaled chemicals
- New onset of smoking cigarettes
- Travel or immigration status from areas endemic with various parasites or coccidioidomycosis
- Asthma (may be severe or poorly controlled with ABPA, CSS, or is relatively new in onset with IAEP)
- ABPA concurrent in 7–15% of patients with cystic fibrosis
- Extrapulmonary symptoms suggestive of vasculitis, neuropathy, heart failure, or neoplasm
- Rash (creeping eruption in visceral larval migrans disease or ulceration in EGPA)

DIAGNOSTIC IMAGING AND TESTING
- Radiography helpful in AEP, CEP, and ABPA
  - Radiography not diagnostic in EGPA or drug-induced eosinophilic disease of the lung
- Simple chest radiography findings
  - Nonlobar infiltrate
  - Classic description as mirror image of pulmonary edema with peripheral infiltrates
  - Bilateral pleural effusion in AEP
  - Central bronchiectasis in ABPA
- High-resolution computed tomography of the chest
  - Middle and upper lobe nonlobar infiltrates with areas of ground-glass appearance
  - Mucus plugging in ABPA
  - Central bronchiectasis in ABPA (confused with cystic fibrosis)
- Blood eosinophil count
  - Elevated in many eosinophilic lung diseases
  - Magnitude of eosinophil blood count does not distinguish different pulmonary diseases
  - Not elevated in AEP
  - May occasionally not be elevated in CEP or after use of corticosteroids
- Total serum IgE elevated in ABPA but not always in patients with cystic fibrosis with ABPA
- Serology for helminthic infections or parasites may be diagnostic but are usually not available acutely
- P-ANCA (MPO ANCA) is positive in 40–70% of EGPA (CSS)
- BAL eosinophil percentage
  - ≥25% eosinophils diagnostic in AEP
  - ≥40% eosinophils diagnostic in CEP or tropical pulmonary eosinophilia
  - Eosinophil percentages below these criteria may require lung biopsy
  - <25% eosinophils seen in connective tissue disease, sarcoid, drug-induced disease, histiocytosis X of pulmonary Langerhans cells, and interstitial pulmonary fibrosis

ABPA, Allergic bronchopulmonary aspergillosis; AEP, acute eosinophilic pneumonia; BAL, bronchoalveolar lavage; CEP, chronic eosinophilic pneumonia; CSS, Churg-Strauss syndrome; EGPA, eosinophilic granulomatosis with polyangiitis; IAEP, idiopathic acute eosinophilic pneumonia; MPO ANCA, myeloperoxidase antineutrophil cytoplasmic antibody; NSAID, nonsteroidal antiinflammatory drug; P-ANCA, perinuclear antineutrophil cytoplasmic antibody.

Other symptoms of fever, myalgia, fatigue, weight loss, poor appetite, and night sweats may accompany the acute or chronic eosinophilic pneumonias. When abnormalities of the liver are detected, or if arthralgia, skin changes, pericardial effusion, or peripheral neuropathy accompany the disease presentation, a diagnosis of **eosinophilic granulomatosis with polyangiitis (EGPA)** (formerly known as *Churg-Strauss syndrome*) or **hypereosinophilic syndrome (HES)** should be aggressively investigated.

Chest Imaging

The chest radiograph is one of the most helpful tests for evaluating the child with dyspnea. The characteristic feature of fluffy alveolar

Table 448.9 Classification of the Eosinophilic Pneumonias in Clinical Practice

Eosinophilic Pneumonias of Unknown Cause
Solitary idiopathic eosinophilic pneumonias
Idiopathic chronic eosinophilic pneumonia
Idiopathic acute eosinophilic pneumonia
Eosinophilic pneumonia in systemic syndromes
Eosinophilic granulomatosis with polyangiitis
Idiopathic hypereosinophilic syndromes (lymphocytic or myeloproliferative variant)
Eosinophilic Pneumonias of Known Cause
Allergic bronchopulmonary aspergillosis and related syndromes (including bronchocentric granulomatosis)
Eosinophilic pneumonias of parasitic origin
Eosinophilic pneumonias of other infectious causes
Drug-induced eosinophilic pneumonias
Eosinophilic Airways Diseases
Idiopathic hypereosinophilic constrictive bronchitis
Other Pulmonary Syndromes with Possible (Usually Mild) Eosinophilia
Organizing pneumonia, asthma, idiopathic pulmonary fibrosis, Langerhans cell histiocytosis, malignancies, and so forth

From Cottin V. Eosinophilic lung diseases. *Clin Chest Med.* 2016;37:535–556, Box 1, p. 536.

Table 448.10 Drugs Commonly Causing Eosinophilic Pneumonia

Antiinflammatory drugs and related drugs: acetylsalicylic acid, diclofenac, ibuprofen, naproxen, phenylbutazone, piroxicam, sulindac, and tolfenamic acid
Antibiotics: ethambutol, fenbufen, minocycline, nitrofurantoin, penicillins, pyrimethamine, sulfamides, sulfonamides, and trimethoprim-sulfamethoxazole
Other drugs: captopril, carbamazepine, and GM-CSF
A more extensive list of drugs reported to cause eosinophilic pneumonia may be found at www.pneumotox.com.

From Cottin V, Cordier JF. Eosinophilic lung diseases. *Immunol Allergy Clin North Am.* 2012;32(4):557–586, Box 6, p. 575.

Table 448.11 Diagnostic Criteria for Idiopathic Chronic Eosinophilic Pneumonia and for Idiopathic Acute Eosinophilic Pneumonia

IDIOPATHIC CHRONIC EOSINOPHILIC PNEUMONIA
1. Diffuse pulmonary alveolar consolidation with air bronchogram and/or ground-glass opacities at chest imaging, especially with peripheral predominance.
2. Eosinophilia at bronchoalveolar lavage differential cell count ≥40% (or peripheral blood eosinophils ≥1,000/mm^3).
3. Respiratory symptoms present for at least 2-4 wk.
4. Absence of other known causes of eosinophilic lung disease (especially exposure to drug susceptible to induce pulmonary eosinophilia).
IDIOPATHIC ACUTE EOSINOPHILIC PNEUMONIA
1. Acute onset with febrile respiratory manifestations (≤1 mo, and especially ≤7 days duration before medical examination).
2. Bilateral diffuse infiltrates on imaging.
3. Pa_{O_2} on room air ≤60 mm Hg (8 kPa), or Pa_{O_2}/F_{IO_2} ≤300 mm Hg (40 kPa), or oxygen saturation on room air <90%.
4. Lung eosinophilia, with ≥25% eosinophils at BAL differential cell count (or eosinophilic pneumonia at lung biopsy when done).
5. Absence of determined cause of acute eosinophilic pneumonia (including infection or exposure to drugs known to induce pulmonary eosinophilia). Recent onset of tobacco smoking or exposure to inhaled dusts may be present.

BAL, Bronchoalveolar lavage.
From Cottin V. Eosinophilic lung diseases. *Clin Chest Med.* 2016;37:535–556, Box 2, p. 538.

infiltrates in the peripheral lung field is classic (Fig. 448.4). The images may be easily recognizable by astute clinicians who have identified the etiology of the disease without elevated blood eosinophil counts or BAL.

HRCT of the chest is the best advanced imaging modality for eosinophilic lung disease. Spontaneous migration of lung opacities is commonly seen in the chronic pneumonias. Most often HRCT of the chest shows simultaneous evidence of bilateral alveolar infiltrates with both confluent consolidations and ground-glass appearance. The most prominent areas of abnormality are visualized in the upper lobes and subpleural regions. Specific diseases have unique findings, such as *proximal bronchiectasis* in **ABPA** and pleural effusion in acute eosinophilic pneumonia. HRCT of the chest is most sensitive in identifying the correct etiology of the disease when chest radiographic findings are nonspecific.

LOEFFLER SYNDROME

The **transient pulmonary infiltrates with eosinophilia syndrome** that is most often seen in children (formerly known as Loeffler syndrome) is characterized by migrating pulmonary infiltrates with peripheral blood eosinophilia. This syndrome is caused by helminthic infections. *A. lumbricoides* or roundworm is the most common parasite causing this disease in the United States. When a fertilized egg is ingested from contaminated food from areas with poor sanitation, it becomes a larval worm that can penetrate the duodenum of the small intestine and migrate in the circulation to the liver, heart, and lungs. In the pulmonary venous circulation, the larvae can break through the interstitial space to the alveoli. The juvenile larva may subsequently migrate to the trachea, where they are expectorated and swallowed. Other nematodes cannot mature in the intestinal tract, so their disease is limited to a single passage into the lungs.

Visceral larva migrans from multiple nematodes may cause eosinophilic lung disease. The most common etiologies are the dog roundworm, *Toxocara canis,* but *Toxocara cati, Strongyloides stercoralis, Baylisascaris procyonis,* and *Lagochilascaris minor* can all produce visceral larva migrans. Outside the United States, the common lung fluke, *Paragonimus westermani,* may cause a similar pulmonary disease in older children and adolescents. Western Africa, Central and South America, and East Asia are regions where paragonimiasis may be found, especially in those who eat raw crabs or crawfish. Many other parasites may have a transient pulmonary syndrome, but their manifestations are most commonly in other organs.

The pulmonary syndrome is classic with cough, dyspnea, migratory peripheral pulmonary infiltrates, and blood eosinophilia that is self-limited. Young children most often have a history of pica and eating dirt that is contaminated with the eggs. Because the larva can migrate to other organs and multiply in the intestinal and biliary tract, symptoms of abdominal pain, vomiting, rarely obstruction, cholecystitis, and pancreatitis may be found. Diagnosis is frequently made by examination of the stool, where the eggs may be detected microscopically. Treatment is aimed at the intestinal disease and not the pulmonary disease per se. It is possible that anthelminthic treatment of other organ disease during the pulmonary phase will increase the inflammatory response in the lung, leading to the need for treatment with corticosteroids.

ACUTE EOSINOPHILIC PNEUMONIA

A unique and dramatic presentation of the eosinophilic pneumonias is **AEP** (see Table 448.11). AEP mimics infectious pneumonia or acute respiratory distress syndrome with its rapid onset and marked hypoxemia. This disease most frequently occurs in the teenage and young adult populations. Essentially all patients present within 7 days of symptom onset with dyspnea, fever, and cough, and more than 50% have chest pain. Myalgia and abdominal pain also frequently accompany this disease. Rarely, patients have presented up to 4-5 weeks after the onset of symptoms. Physical exam demonstrates tachypnea, tachycardia, and crackles in the lung fields. Many patients rapidly deteriorate and require mechanical ventilation.

There is an *absence* of circulating eosinophilia, which contrasts with the dramatic number of eosinophils seen in the BAL representing at

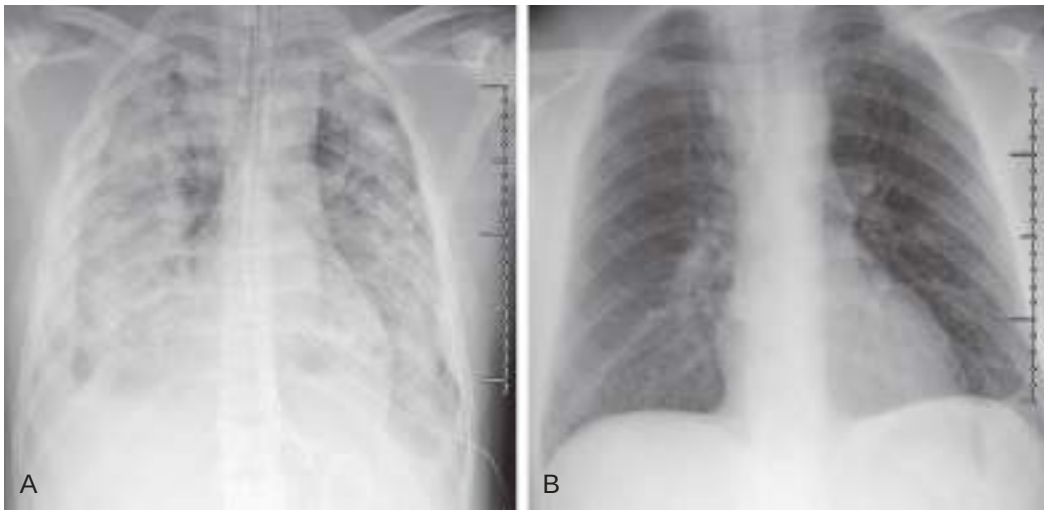

Fig. 448.4 **A,** Acute eosinophilic pneumonia demonstrating the mirror image pulmonary edema with a right pleural effusion on admission. **B,** Complete clearing upon discharge from the hospital after corticosteroid usage.

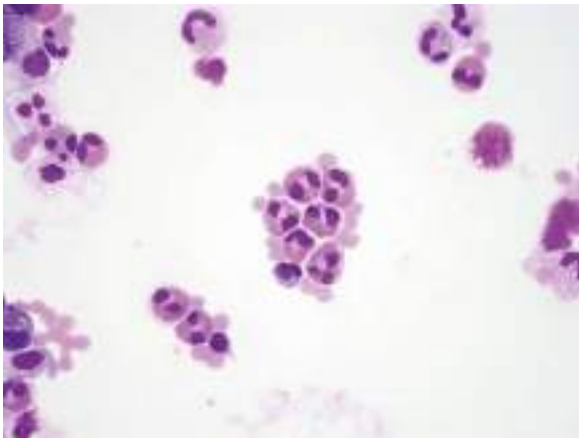

Fig. 448.5 Light microscopy of eosinophils in bronchoalveolar lavage fluid.

least 20% of the inflammatory cells (often 40–55%) (Fig. 448.5). This feature helps distinguish it from the chronic pulmonary disease of eosinophilic origin.

Although this disease has been labeled as idiopathic, there have been identifiable exposures (e.g., 1,1,1-trichloroethane or Scotchgard). Numerous reports link the onset of smoking tobacco, change in smoking frequency, reinitiation of smoking in young male adolescents or adults, and even massive secondary smoke exposure as critical associations with the onset of AEP. World Trade Center dust is associated with development of AEP. A single smoke challenge study is associated with recurrence. Some medications are also linked to the onset of AEP. The most complete and current resource for medications linked to pulmonary disease is "The Drug-Induced Respiratory Disease Website" (http://www.pneumotox.com). When AEP is identified in a patient, the pediatrician should educate the patient and family about the link to smoking exposure and the risk of AEP upon reexposure.

In addition to smoke exposure, AEP has been reported after smoking cocaine; typically, within hours to days after use. Whether this is a unique eosinophilic response to cocaine that represents one manifestation of *crack lung* or is a separate disease is unknown. Crack lung refers to diffuse alveolitis with pulmonary hemorrhage from an unknown mechanism that occurs within 48 hours of cocaine smoke inhalation.

Lung function has not been measured frequently in the disease because the patients have proceeded rapidly to the intensive care unit (ICU) for mechanical ventilation. When measured, a restrictive pattern of lung disease and reduced diffusion capacity are the usual findings. Arterial blood gases will also show a significant increase in the alveolar-arterial gradient.

The criteria for diagnosis include the acute onset of disease, bilateral pulmonary infiltrates, reduced oxygen saturation or Pa_{O_2} ≤60 mm Hg, BAL of ≥25% eosinophils, and absence of a determined cause of eosinophilia (see Table 448.11). The recent onset of tobacco exposure, dust, or chemical inhalation are supporting factors in confirming a diagnosis.

Treatment has uniformly been the use of a corticosteroid (e.g., methylprednisolone 1-2 mg/kg/day) either intravenously or orally. A minimum or maximum treatment time has not been determined. Rare fatalities have been reported. Complete recovery has been seen in days, with resolution of pleural effusions within 4 weeks of treatment. Most important, relapse and persistent symptoms are rare, which sharply contrasts with the idiopathic chronic eosinophilic pneumonias. Follow-up testing of pulmonary function is usually normal, which supports the contention that lung parenchyma heals without evidence of compromise or fibrosis.

CHRONIC EOSINOPHILIC PNEUMONIA

Chronic eosinophilic pneumonia is another idiopathic pulmonary condition without a known exposure to toxin, dust, or chemical inhalation. Eosinophils infiltrate the lung parenchyma resulting in dyspnea, cough, fever, and weight loss. It is primarily a problem for adults, with a female predominance (2:1 female:male) and usually in patients who are nonsmokers. Chest examination reveals tachypnea, crackles, and wheezing; a diagnosis of asthma is a common finding. The classic finding on chest x-ray of the *radiographic negative of pulmonary edema* is found in these patients: central clear lung fields but fluffy, patchy peripheral infiltrates; however, this is not seen in all cases.

When compared to AEP, the onset of disease is indolent and subtle, but the accompanying fever and weight loss may lead the clinician toward a concern for an underlying malignancy before the chest radiograph and laboratory investigation. *Peripheral* blood eosinophilia is commonly as high as 5,000/mm^3 or greater, accompanied by BAL eosinophilia >40% on the differential count (see Table 448.11). The peripheral eosinophilia sharply contrasts with the lack of eosinophils seen in the blood in AEP. HRCT scan of the chest contrasts with the AEP, with pleural effusion as a rare finding, as well as rare cavitation.

In contrast to AEP, PFT shows a mixed obstructive and restrictive pattern, especially given that asthma often occurs concurrently with this disease.

Inflammatory markers associated with migration and activation of eosinophils are predictably found in BAL and the urine. These include the T-lymphocyte type 2 cytokines of IL-4, IL-5, IL-6, IL-10, IL-13, and IL-18. However, T-lymphocyte type 1 cytokines of IL-2 and IL-12 are also present with many of the potent eosinophilic chemoattractants such as CCL5 (RANTES [regulated upon activation, normal T-cell expressed and secreted]) and CCL11 (eotaxin-1).

Toxic granule proteins of major basic protein, eosinophil-derived neurotoxin, and eosinophil cationic protein are frequently present. Unfortunately, these important molecules help confirm the eosinophilic nature of the disease, but their presence adds no additional sensitivity or specificity over the presence of eosinophils on BAL.

Treatment is similar to most eosinophilic lung syndromes, where corticosteroids (oral) are the mainstay of treatment. The minimum dose of steroid needed to induce remission is not known, but most clinicians recommend prednisone (or equivalent) at 0.5 mg/kg/day for 2 weeks. The dose is reduced to half (0.025 mg/kg/day) for an additional 2 weeks if symptoms have abated. The remaining dose of steroid may need to be weaned over 6 months. Alternatively, IV methylprednisolone is used, starting with 10-30 mg/kg/dose (maximum 1 g) given either 3 consecutive days per month or 1 day per week. Symptoms and pulmonary infiltrates rapidly disappear after initiation of this treatment but frequently recur with tapering of the steroid. Asthma that occurs concurrently in patients with chronic eosinophilic pneumonia represents a phenotype of the disease that appears to have lower relapse risk, yet up to 50% of all identified patients with chronic eosinophilic pneumonia relapse during or after corticosteroid taper.

Many believe that this disease is a precursor to the development of EGPA (formerly Churg-Strauss syndrome). The utility of ICS in chronic eosinophilic pneumonia is unknown but is warranted for the persistent asthma phenotype of the disease. A subset of patients develops permanent lower airway obstruction without reversibility, which requires patients with this disease to have close follow-up and monitoring of pulmonary function tests.

EOSINOPHILIC GRANULOMATOSIS WITH POLYANGIITIS (CHURG-STRAUSS SYNDROME)

EGPA syndrome is a systemic disease involving multiple organs but most prominently the lung. Patients present with difficult-to-control asthma, allergic rhinitis, and peripheral eosinophilia (>10% or >1,500 cells/μL) in the blood. Evidence of vasculitis must be present in at least two organs. The polyangiitis appears later in the disease process, with asthma being the precursor symptom in more than 90% of the cases reported. EGPA affects multiple organs, including the skin, heart, gastrointestinal tract, kidneys, and central nervous system (Table 448.12). Rhinitis and upper airway disease are present in 75% of the patients but are not specific. Symptoms of fever, weight loss, fatigue, arthralgia, and myalgia may be seen in approximately two thirds of patients. Cardiac and renal involvement is insidious in onset, and screening should occur for these manifestations. The multiple organ involvement results in the morbidity and mortality of this disease. The typical progression of the disease is in three phases: rhinitis and asthma first, tissue eosinophilia second, and, finally, systemic vasculitis of small and medium vessels.

The pathogenesis of EGPA is still unknown but several factors are suspected to contribute to the development of the disease. The possible link between leukotriene-receptor antagonists (zafirlukast, montelukast, or pranlukast) is controversial but still considered possible. It is suspected that use of this class of adjunctive medications in severe asthma allows for the reduction in the use of corticosteroids leading to the full-blown (unmasking) manifestation of EGPA. Many refrain from use of leukotriene-receptor antagonists when EGPA syndrome has been diagnosed.

Clinical and laboratory findings pinpoint the diagnosis with high specificity (99.7%) and sensitivity (85%) when at least four of six criteria developed by the American College of Rheumatology are met (asthma, eosinophilia >10%, mononeuropathy or polyneuropathy, nonfixed pulmonary infiltrates, paranasal sinus abnormalities, and biopsy findings of extravascular eosinophil infiltrates). In contrast to GPA, the rhinitis is not destructive, and nasal septal perforation does not occur in EGPA.

Radiography of the chest or HRCT of the chest demonstrates migratory, peripheral predominant opacities, ground-glass appearance, nodules, bronchiectasis, and bronchial wall thickening. Pleural effusion should raise suspicion for the presence of heart failure from cardiomyopathy.

Laboratory findings include striking eosinophilia, with values generally between 5,000 and 20,000/mm^3 at the time of diagnosis. These counts often parallel vasculitis activity. The BAL shows striking eosinophilia with differential counts often >60%. Biopsies of other organ systems reflect the activity of eosinophils and are not specific for the EGPA diagnosis.

ANCAs may be present in EGPA syndrome. The perinuclear-ANCA targeting myeloperoxidase is specifically found in EGPA in approximately 40% of the patients; the absence of myeloperoxidase-ANCA does not exclude the diagnosis. Those patients with eosinophilic pneumonia, fever, and cardiac involvement are less likely to have myeloperoxidase-ANCA detected. Those with peripheral neuropathy, renal glomerular disease, and skin purpura usually have detectable myeloperoxidase-ANCAs (see Table 448.12).

Pulmonary function tests show an obstructive pattern caused by the asthma component. The pulmonary obstruction is responsive to oral corticosteroid use, but often mild obstruction persists.

Treatment of EGPA with systemic oral corticosteroids remains the mainstay of therapy at a starting dose of 0.5 to 1 mg/kg/day. This therapy is often required for up to 12 months or longer, with a steady taper in dosage over that time. EGPA resistant to corticosteroids has responded to cyclophosphamide, IFN-α, cyclosporine, IVIG, and plasmapheresis. The use of anti–IL-5 (mepolizumab) has been encouraging and may be used as a steroid-sparing agent in the future.

Table 448.12 Eosinophilic Granulomatosis with Polyangiitis

	VASCULITIC PHENOTYPE	EOSINOPHILIC TISSULAR DISEASE PHENOTYPE
Respective frequency	~40%	~60%
ANCA	Present (mostly perinuclear-ANCA with anti-MPO specificity)	Absent
Predominant manifestations	Glomerular renal disease Peripheral neuropathy Purpura Biopsy-proven vasculitis	Cardiac involvement (eosinophilic myocarditis) Eosinophilic pneumonia Fever

ANCA, Antineutrophil cytoplasmic antibody; MPO, myeloperoxidase.
Data from Sablé-Fourtassou R, Cohen P, Mahr A, et al. Antineutrophil cytoplasmic antibodies and the Churg-Strauss syndrome. *Ann Intern Med.* 2005;143:632–638; and Sinico RA, Di Toma L, Maggiore U, et al. Prevalence and clinical significance of antineutrophil cytoplasmic antibodies in Churg-Strauss syndrome. *Arthritis Rheum.* 2005;52:2926–2935.
From Cottin V, Cordier JF. Eosinophilic lung diseases. *Immunol Allergy Clin North Am.* 2012;32(4):557–586, Table 2, p. 569.

ALLERGIC BRONCHOPULMONARY ASPERGILLOSIS

ABPA is a complex hypersensitivity reaction that occurs in the lungs and bronchi in response to exposure and colonization of *Aspergillus* species (usually *Aspergillus fumigatus*; see Chapter 283). This disease occurs in patients with preexisting asthma and up to 15% of patients with cystic fibrosis (see Chapter 454). The quantity of *Aspergillus* exposure does not correlate with the severity of disease.

The clinical pattern of disease (Table 448.13) is remarkably similar with a presentation of difficult-to-treat asthma. The patient suffers from periods of acute obstructive lung disease with bronchial mucous plugs, elevated total IgE antibody, elevated specific IgE and IgG anti-*Aspergillus* antibodies, skin prick test reactions to *Aspergillus* species, precipitating antibodies to *Aspergillus* species, and proximal bronchiectasis. Other clinical manifestations include dyspnea, cough, shortness of breath, and peripheral eosinophilia, along with pulmonary eosinophilia seen on BAL with infiltration of the parenchyma. The use of systemic corticosteroids may lower the total IgE antibody levels such that a diagnosis may be in question when the initial tests are conducted.

ABPA should be considered in patients with cystic fibrosis when clinical deterioration occurs without evidence of an identifiable cause. Symptoms heralding such deterioration include increasing cough, wheezing, loss of exercise tolerance, worsening exercise-induced asthma, reduction of pulmonary function, or increased sputum production without another discernible reason. Clinical findings of elevated total IgE antibody, anti-*Aspergillus* IgE antibodies, precipitating antibodies to *A. fumigatus,* and/or new abnormalities on chest radiography that fail to clear with antibiotics should alert the clinician to the possibility of ABPA.

Table 448.13 Criteria for the Diagnosis of Allergic Bronchopulmonary Aspergillosis

ALLERGIC BRONCHOPULMONARY ASPERGILLOSIS–CENTRAL BRONCHIECTASIS
• Medical history of asthma*
• Immediate skin prick test reaction to *Aspergillus* antigens*
• Precipitating (IgG) serum antibodies to *Aspergillus fumigatus**
• Total IgE concentration >500 IU/mL (>1,000 ng/mL)*
• Central bronchiectasis on chest CT*
• Peripheral blood eosinophilia >500/mm^3
• Lung infiltrates on chest x-ray or chest HRCT
• Elevated specific serum IgE and IgG to *A. fumigatus*
ALLERGIC BRONCHOPULMONARY ASPERGILLOSIS SEROPOSITIVE†
• Medical history of asthma†
• Immediate skin prick test reaction to *A. fumigatus* antigens†
• Precipitating (IgG) serum antibodies to *A. fumigatus*†
• Total IgE concentration >417 IU/mL (>1,000 ng/mL)†

*The criteria required for a diagnosis of ABPA with central bronchiectasis.
†The first four criteria are required for a diagnosis of seropositive ABPA.
ABPA, Allergic bronchopulmonary aspergillosis; CSD, corticosteroid dependent; HRCT, high-resolution computed tomography.

When evaluating a child with asthma symptoms, the clinician must distinguish asthma from ABPA. If the diagnosis is suspected, skin prick test for evidence of IgE-specific antibody directed against *A. fumigatus* is essential. Intradermal skin testing, when the skin prick test is negative, although not routinely performed because of poor specificity, may be conducted. The absence of a positive skin prick test and intradermal test to *A. fumigatus* excludes the diagnosis of ABPA. The prevalence of ABPA in patients with an existing diagnosis of asthma and an abnormal immediate skin prick test response to *A. fumigatus* has been evaluated. Between 2% and 32% of patients with asthma with concurrent skin prick test–positive reactions to *Aspergillus* have evidence of ABPA.

Patients with cystic fibrosis who are less than 6 years of age rarely develop ABPA. When the total IgE antibody in patients with cystic fibrosis exceeds 500 IU/mL (1,200 ng/mL), a strong clinical suspicion of ABPA is necessary.

ABPA pathology has characteristic findings of mucoid bronchi impaction, eosinophilic pneumonia, and granulomas. Histologic features characteristic of asthma are also present. Septated hyphae are often found in the mucus-impacted bronchial tree. However, the fungi are not invasive in this unique disease. *Aspergillus* may be cultured from sputum in more than 60% of patients. Interestingly, hyphae may not be detected on microscopy.

Staging of the disease (Table 448.14) represents distinct phases; however, progression does not necessary occur in sequence from stage 1 to stage 5. Staging of ABPA is important for treatment considerations. In many hypersensitivity diseases where IgE antibody contributes to the pathogenesis (e.g., asthma), total IgE is often used to screen for an atopic state but is not a test that helps the clinician with serial measures. In sharp contrast, the measurement of IgE during acute exacerbations, remission, and recurrent ABPA disease is helpful in identifying the activity of disease and may herald the recurrence. During stage 1 disease, the level of IgE antibody is often very high. During stage 2 remission, a fall in the levels may be as much as 35% or more. Recurrence of activity may result in a marked rise of total IgE with a doubling of the baseline level seen during remission. During the use of glucocorticoid therapy, monthly or bimonthly levels of IgE are followed serially to assist the clinician in tapering therapy. Because exacerbations of ABPA are not accompanied by changes in symptoms in approximately 25% of the recurrences, serial IgE accompanied by chest radiography is helpful to the clinician to guide therapy.

Radiography

Plain chest x-ray shows evidence of infiltrates, especially in the upper lobes and the classic findings of bronchiectasis (Fig. 448.6). HRCT of the chest demonstrates central bronchiectasis (Fig. 448.7) and mucus impaction of the airways (finger-in-glove appearance). HRCT may add value for the patient with a positive skin prick test and normal chest radiograph to detect characteristic abnormalities of ABPA.

Treatment

The mainstay of therapy for ABPA has been systemic glucocorticoids with adjunct therapy including antifungal medications and anti-IgE therapy with omalizumab. Exacerbations in stages 1 and 3

Table 448.14 Staging of Allergic Bronchopulmonary Aspergillosis

Stage 1	Acute	Upper and middle lobe infiltration	High IgE
Stage 2	Remission	No infiltrate off steroids >6 mo	Normal to high IgE
Stage 3	Exacerbation	Upper and middle lobe infiltration	High IgE
Stage 4	CSD asthma	Minimal infiltrate	Normal to high IgE
Stage 5	End stage	Fibrosis and/or bullae	Normal

CSD, Corticosteroid dependent.

may be treated for 14 days with 0.5-1 mg/kg of glucocorticoids followed by every-other-day usage and tapering over 3 months or as long as 6 months. Stage 2 remission phase and stage 5 where fibrosis has occurred do not require glucocorticoid therapy. Stage 4 denotes a state where glucocorticoid weaning has not been successful and continued long-term therapy is required.

Antifungal therapy with a 16-week course of itraconazole improves the response rate during exacerbations, allowing the reduction of glucocorticoid dosage by 50% and resulting in a reduction of total serum IgE of 25% or more. The proposed mechanisms of action have been to either reduce the antigen load driving the immune response or possibly raising the corticosteroid serum levels by slowing the metabolism of the steroid. This latter mechanism would be true for prednisone, which is methylated in the liver, but not for methylprednisolone, which does not require methylation.

The adult dosage recommendation for itraconazole is 200 mg 3 times per day for 3 days followed by 200 mg twice daily for the remainder of the 16 weeks. Children should receive 5 mg/kg/day in a single dose. If the proper calculated dose exceeds 200 mg, then the total dose should be divided equally and given twice daily. Serum levels of itraconazole are necessary to ensure proper drug absorption when in capsule form. The liquid form is more readily absorbed and has achieved substantially higher levels. The use of proton pump inhibitors and histamine 2 antagonists may reduce absorption of itraconazole. Voriconazole has been used as a substitute antifungal medication. Proper dosing has been established for invasive *Aspergillus* disease but not for ABPA. Hepatotoxicity may occur with these drugs so liver function must be monitored.

Omalizumab, an anti-IgE humanized monoclonal antibody, has been used in a case series of patients with cystic fibrosis and ABPA and in a small cohort of adults without cystic fibrosis but with ABPA. Both case series demonstrated significant reductions in asthma exacerbations, ABPA exacerbations, and glucocorticoid usage. The dose prescribed has been 300-375 mg every 2 weeks by subcutaneous injection.

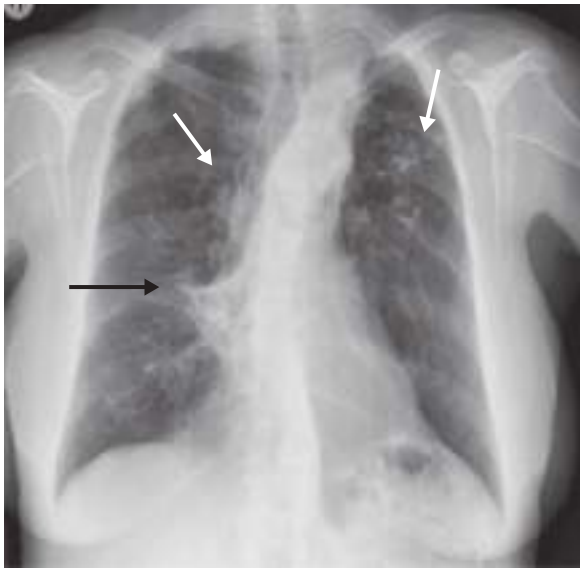

Fig. 448.6 Transitory opacities *(white arrows)* and lobar collapse *(black arrow)* in patient with allergic bronchopulmonary aspergillosis. *(From Douglass JA, Sandrini A, Holgate ST, O'Hehir RE. Allergic bronchopulmonary aspergillosis and hypersensitivity pneumonitis. In Adkinson NF Jr, Bochner BS, Burks AW, et al., eds. Middleton's Allergy Principles and Practice, 8th ed. Philadelphia: Elsevier; 2014: Fig. 61.2.)*

HYPEREOSINOPHILIC SYNDROME

See Chapter 169.

HES is a descriptive name of a group of disorders that are characterized by the persistent overproduction of eosinophils accompanied by eosinophil infiltration in multiple organs with end-organ damage from mediator release. The term *HES* should only be used when there is eosinophilia with end-organ damage from the eosinophils and not from another cause. The discovery of underlying genetic, biochemical, or neoplastic reasons for HES has led to the classification of primary, secondary, and idiopathic HES (Table 448.15). Specific

Table 448.15 Hypereosinophilic Syndrome Variants

Myeloproliferative	Nonclonal Clonal–F1P1L1/PDGFRA-positive chronic eosinophilic leukemia
Lymphocytic	Nonclonal T cells Clonal T-cell expansion with T-cell activation
Overlap	Organ restricted
Familial	Family history of eosinophilia without known cause
Associated	Eosinophilia in chronic disease like inflammatory bowel disease or EGPA (Churg-Strauss syndrome)
Undefined	Asymptomatic Cyclic angioedema with eosinophilia (Gleich syndrome) Symptomatic without myeloproliferation or lymphocytic form

EGPA, Eosinophilic granulomatosis with polyangiitis; PDGFRA, platelet-derived growth factor receptor-α.

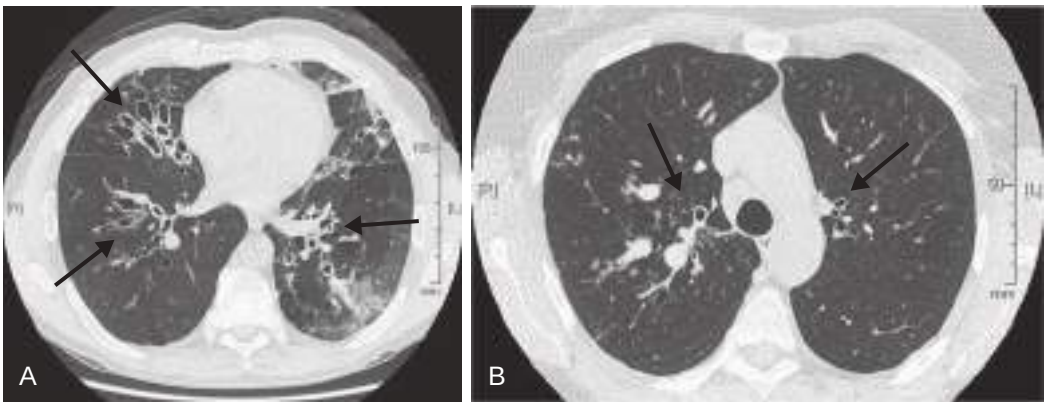

Fig. 448.7 **A,** Central bronchiectasis in patient with ABPA *(arrows).* **B,** Central bronchiectasis in the upper lobes *(arrows). (From Douglass JA, Sandrini A, Holgate ST, O'Hehir RE. Allergic bronchopulmonary aspergillosis and hypersensitivity pneumonitis. In Adkinson NF Jr, Bochner BS, Burks AW, et al., eds. Middleton's Allergy Principles and Practice, 8th ed. Philadelphia: Elsevier; 2014: Fig. 61.3.)*

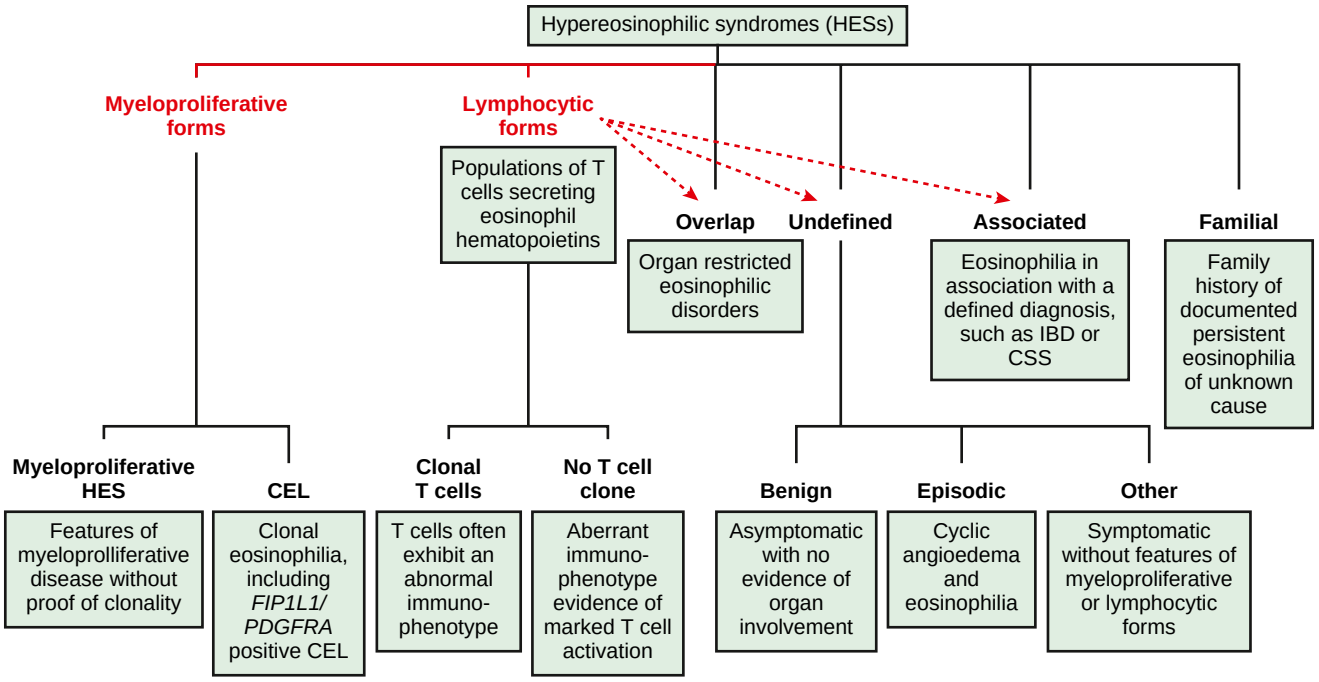

Fig. 448.8 A revised classification of hypereosinophilic syndrome (HES). Changes from the previous classification are indicated in *red type*. *Dashed arrows* identify HES forms in some patients who have T-cell–driven disease. Classification of myeloproliferative forms has been simplified, and patients with HES and eosinophil hematopoietin-producing T cells in the absence of a T-cell clone are included in the lymphocytic forms of HES. CSS, Churg-Strauss syndrome; IBD, inflammatory bowel disease. *(From Simon H, Rothenberg ME, Bochner BS, et al. Refining the definition of hypereosinophilic syndrome. J Allergy Clin Immunol. 2010;126:45–49, Fig. 1.)*

syndromes such as EGPA have eosinophilia, but the contribution of eosinophils to the organ damage is incompletely understood.

Some variants of HES have pathogenic variants in tyrosine kinase receptor platelet-derived growth factor receptor-α (*PDGFRA*); males are almost exclusively affected. *PDGFRA* can also form a fusion gene with *FIP1L1* in some patients with HES. Patients with *PDGFRA-PIP1L1* are more likely to be responsive to imatinib, a tyrosine kinase inhibitor. Otherwise, HES appears to be distributed equally among females and males.

Hypereosinophilia is defined as an absolute eosinophil number in the blood that exceeds 1.5×10^9 eosinophils on two separate occasions separated by at least 1 month and/or a tissue diagnosis of hypereosinophilia. Tissues are abnormal when more than 20% of nucleated cells in the bone marrow are of eosinophil origin, a pathologist determines the presence of eosinophilia, or the presence of extensive eosinophilic granule proteins are determined on biopsy to be deposited in large quantities. These disorders can be subclassified into primary (neoplastic), secondary (reactive), and idiopathic (Fig. 448.8).

Clinical manifestations of HES include organ involvement of the heart (5%), gastrointestinal tract (14%), skin (37%), and respiratory system (25–63%). HES is complicated by thrombosis and/or neurologic disease in many patients, although the exact prevalence of this problem is incompletely categorized. Peripheral neuropathy, encephalopathy, transverse sinus thrombosis, or cerebral emboli are the most common neurologic complications. The exact mechanism of the manifestations is unclear, especially in major artery thrombosis such as the femoral artery.

The most frequent pulmonary symptoms include cough and dyspnea. Many patients have obstructive lung disease with clinical wheezing. Evidence of pulmonary fibrosis and pulmonary emboli are seen with regularity. Because biopsy shows eosinophilic infiltrates similar to other pulmonary eosinophilic diseases of the lung, it is the constellation of other organ involvement or thromboembolic phenomena that leads the clinician to a high index of suspicion for HES.

Laboratory evaluation should include evaluation of liver enzymes, kidney function tests, creatine kinase, and troponin. The extent of cardiac involvement should be evaluated by electrocardiogram and echocardiogram. Some unique biomarkers may be tested when evaluating the myeloproliferative and T-lymphocyte HES diagnoses. Vitamin B_{12} and serum tryptase may be elevated, especially the latter, when the myeloproliferative disease is accompanied by mastocytosis. These two biomarkers are most frequently elevated when the *FIP1L1-PDGFRA* fusion pathogenic variant is present.

Because of the extensive pulmonary disease that is seen in HES, pulmonary function tests (spirometry, lung volumes) should be performed at diagnosis. Dead space ventilation may be significantly elevated in patients with pulmonary emboli. Pulse oximetry may be helpful in the evaluation as well.

Chest radiography and CT of the chest are helpful in the evaluation. Spiral chest CT should also be performed when pulmonary emboli are being considered. In one series of patients, nearly half of the patients with HES had evidence of pulmonary abnormalities, including ground-glass–appearing infiltrates, pulmonary emboli, mediastinal lymphadenopathy, and/or pleural effusion.

Treatment of HES depends on the type of variant (myeloproliferative, lymphocytic forms, undefined, associated with systemic diseases such as EGPA, or familial). Rarely, some patients present with marked eosinophilia, where the total count exceeds 100,000 cells/μL, and vascular insufficiency symptoms. Prednisone is indicated to acutely reduce the eosinophil count after diagnostic tests are performed and when safe. If the patient is unstable, the glucocorticoid should be administered to prevent progression of symptoms. Other acute therapies aimed at reduction of eosinophil counts include vincristine, imatinib mesylate, or even leukapheresis. Imatinib is especially used in patients found to have the *FIP1L1-PDGFRA* fusion variant.

When eosinophil counts are not as dramatically elevated, therapy begins with glucocorticoids at 1 mg/kg for patients who do not have the *FIP1L1-PDGFRA* variant. Patients with this variant are resistant

to glucocorticoids, and initial treatment should begin with imatinib, a tyrosine kinase inhibitor. In cases where genetic testing for *FIP1L1-PDGFRA* is not readily available, surrogate markers for the presence of this variant are vitamin B_{12} levels >2,000 pg/mL or serum tryptase >11.5 ng/mL. These findings denote the presence of resistant disease that should initially be treated with imatinib. The goal of therapy is to reduce and maintain eosinophil counts below 1.5×10^9 at the lowest dose of prednisone possible to reduce or avoid corticosteroid-related side effects. If corticosteroid doses cannot be lowered below 10 mg/day, then imatinib can be added as combination therapy in order to spare the dose of steroid. Caution must be used in the presence of cardiac disease, as introduction of imatinib has precipitated left ventricular failure.

Additional or alternative adjunct therapies that have shown promise include hydroxyurea, IFN-α, anti–IL-5 monoclonal antibody therapy, and a monoclonal antibody directed against CD52. Failure of these modalities may signal a need for hematopoietic stem cell transplantation. This therapy has been successful in some patients.

Visit Elsevier eBooks+ at eBooks.Health.Elsevier.com for Bibliography.

448.5 Interstitial Lung Disease

Timothy J. Vece and Stephanie D. Davis

Interstitial lung disease in children (chILD) is caused by a large group of rare, heterogeneous, familial, or sporadic diseases that involve the pulmonary parenchyma and cause significant impairment of gas exchange (Tables 448.16-448.18). Although there are some shared diseases, childhood ILD is often different from ILD in adults, especially notable for the absence of IPF in children. Furthermore, certain ILDs only occur in children (e.g., neuroendocrine cell hyperplasia of infancy, pulmonary interstitial glycogenosis). Despite wide variations in cause, these disorders are classified together because of the similar clinical, physiologic, radiographic, and pathologic processes involving disruption of the alveolar interstitium and/or airways. Prevalence estimates vary widely with a range of 0.13-16.2 cases/100,000 children. This large range in prevalence is likely a result of the lack of standardization of the diseases that are included in the definition of ILD in children. The pathophysiology is more complex than that of adult disease because pulmonary injury occurs during the process of lung growth and differentiation. In ILD, the initial injury causes damage to the alveolar epithelium and capillary endothelium. Genetic causes of ILD are becoming increasingly important, especially the disorders of surfactant metabolism (DSM) and immune dysregulatory disorders.

CLASSIFICATION AND PATHOLOGY

Through the work of the children's ILD research network in the United States and the children's ILD-European Union group, consensus on a classification scheme has been reached. The classification is broken down based on histologic pattern and by age, with 2 years of age serving as a cutoff. The classification scheme was first applied to biopsies from children less than 2 years of age and was later extended to children greater than 2 years of age (see Tables 448.16 and 448.17). Growth disorders such as alveolar simplification, unique diseases of infancy such as neuroendocrine cell hyperplasia of infancy **(NEHI)**, and disorders of surfactant metabolism **(DSM)** are common in children less than 2 years of age. In contrast, disorders of the immunocompromised host, such as ILD related to immune deficiency, and disorders of systemic diseases such as the collagen vascular disorders, are much more common in older children.

Neuroendocrine Cell Hyperplasia of Infancy

See Chapter 448.6.

Table 448.16 The Pediatric Interstitial Lung Diseases in Children Under 2 Years of Age

AGE-RELATED INTERSTITIAL LUNG DISEASES IN INFANCY AND EARLY CHILDHOOD
Diffuse developmental disorders
Acinar dysplasia
Congenital alveolar dysplasia
Alveolar capillary dysplasia with misalignment of pulmonary veins (some caused by *FOXF1* pathogenic variants)
Growth abnormalities reflecting deficient alveolarization
Pulmonary hypoplasia
Chronic neonatal lung disease
Chromosomal disorders
Congenital heart disease
Neuroendocrine cell hyperplasia of infancy
Pulmonary interstitial glycogenosis (infantile cellular interstitial pneumonia)
Surfactant dysfunction disorders (pulmonary alveolar proteinosis)
Surfactant protein B variant
Surfactant protein C variant
ABCA3 variant
Granulocyte-macrophage colony-stimulating factor receptor *(CSF2RA)* variant
NKX2.1 (transcription factor for SP-B, SPC, ABCA3)
INTERSTITIAL LUNG DISEASE DISORDERS WITH KNOWN CAUSES
Infectious/postinfectious processes
Adenovirus viruses
Influenza viruses
Chlamydia pneumoniae
Mycoplasma pneumoniae
Environmental agents
Hypersensitivity pneumonitis
Toxic inhalation
Aspiration syndromes
PULMONARY DISEASES ASSOCIATED WITH PRIMARY AND SECONDARY IMMUNE DEFICIENCY
Opportunistic infections
Granulomatous lymphocytic interstitial lung disease associated with common variable immunodeficiency syndrome
Lymphoid intestinal pneumonia (HIV infection)
Therapeutic interventions: chemotherapy, radiation, transplantation, and rejection
IDIOPATHIC INTERSTITIAL LUNG DISEASES
Desquamative interstitial pneumonitis
Lymphocytic interstitial pneumonitis and related disorders
Nonspecific interstitial pneumonitis (cellular/fibrotic)
Eosinophilic pneumonia
Bronchiolitis obliterans syndrome
Pulmonary hemosiderosis and acute idiopathic pulmonary hemorrhage of infancy
Pulmonary vascular disorders
Pulmonary lymphatic disorders
Pulmonary microlithiasis
SYSTEMIC DISORDERS WITH PULMONARY MANIFESTATIONS
Anti-GBM disease
Granulomatosis with polyangiitis
Microscopic polyangiitis
Idiopathic pulmonary capillaritis
Gaucher disease and other storage diseases
Malignant infiltrates
Hemophagocytic lymphohistiocytosis
Langerhans cell histiocytosis
Sarcoidosis
Systemic sclerosis
Polymyositis/dermatomyositis
Systemic lupus erythematosus
Rheumatoid arthritis
Lymphangioleiomyomatosis
Pulmonary hemangiomatosis
Neurocutaneous syndromes
Hermansky-Pudlak syndrome

Modified from Deutsch GH, Young LR, Deterding RR, et al. Diffuse lung disease in young children: application of a novel classification scheme. *Am J Respir Crit Care Med.* 2007;176:1120–1128.

Table 448.17 The Pediatric Interstitial Lung Diseases in Children over 2 Years of Age

DISORDERS OF THE IMMUNOCOMPETENT HOST
Disorders of Infancy
Growth abnormalities
NEHI
Disorders of surfactant metabolism
Systemic Disease
Immune-mediated disorders
• Connective tissue disease related lung disease
• Pulmonary hemorrhage syndromes
Storage diseases
Sarcoidosis
DISORDERS OF THE IMMUNOCOMPROMISED HOST
Opportunistic infections
Related to treatment
• Chemotherapy
• Radiation
Drug hypersensitivity
Related to transplantation
• Rejection
• GVHD
• PTLD
Lymphoid Infiltrates

GVHD, Graft-versus-host disease; NEHI, neuroendocrine cell hyperplasia of infancy; PTLD, posttransplant lymphoproliferative disease.
Modified from Fan LL, Dishop MK, Galambos C, et al. Diffuse lung disease in biopsied children 2 to 18 years of age. Application of the chILD Classification Scheme. *Ann Am Thorac Soc.* 2015;12(10):1498–1505.

Disorders of Surfactant Metabolism

One of the more important groups of disorders in childhood ILD is the **DSM** (Table 448.19). These disorders likely account for previously unknown cases of neonatal respiratory distress in full-term infants. Surfactant protein B deficiency, caused by pathogenic variants in the surfactant protein B gene, leads to severe neonatal respiratory distress. Chest CT imaging often reveals a pattern of diffuse ground-glass opacities with septal thickening. Histopathology reveals alveolar proteinosis with interstitial widening, and electron microscopy shows disorganized lamellar bodies. Most children die within the first 2 months of life without a lung transplant. Surfactant protein C deficiency can cause disease in older infants, children, or adults. Chest CT imaging reveals diffuse ground-glass opacities with septal thickening early in the disease or significant fibrosis and honeycombing with cyst formation in more advanced disease. Histopathologic findings vary with age, with alveolar proteinosis and interstitial widening seen in young children, and fibrosis seen in older children and adults. Electron microscopy reveals normal lamellar bodies. *ABCA3* variants cause variable lung disease in children, with some having severe disease similar to surfactant protein B deficiency, whereas others have less severe disease similar to surfactant protein C. Chest CT imaging most often reveals diffuse ground-glass opacities with septal thickening early in the disease (Fig. 448.9). Histopathology depends on the age of the child; however, electron microscopy shows characteristic changes in the lamellar bodies with an eccentric electron dense body without the characteristic concentric circles, the so-called *fried egg appearance*. **DSM** caused by pathogenic variants in the gene *NKX2.1* has also been described. *NKX2.1* encodes for thyroid transcription factor 1 (TTF-1), which is a major regulator of surfactant protein transcription. Pathogenic variants in *NKX2.1* cause variable disease in the lungs, brain, and thyroid **(brain-lung-thyroid syndrome)** (see Table 448.19). Lung disease is variable and can present similar to surfactant protein B deficiency, similar to surfactant protein C deficiency, or as recurrent pulmonary infections. Finally, variants in the α and β subunits of the granulocyte-macrophage colony-stimulating factor (GM-CSF) receptor leads to alterations in surfactant catabolism. Alveolar macrophages are critical for surfactant recycling and are unable to perform this function effectively in patients with these variants. The inability to recycle surfactant leads to subsequent accumulation of proteinaceous material and pulmonary alveolar proteinosis.

Interstitial Lung Disease Due to Systemic Disease

ILD due to systemic disease is more common in older children with diffuse lung disease. The most common lung disease seen on biopsy is nonspecific interstitial pneumonia; however, other patterns are seen depending on the underlying disorder. For example, lymphocytic interstitial pneumonia may be seen in Sjögren syndrome or cryptogenic organizing pneumonia in dermatomyositis. Findings on chest CT scans depend on the underlying ILD, with nonspecific interstitial pneumonia revealing areas of ground-glass opacities and septal thickening in the early cellular phase of the disease (Fig. 448.10) and progressing to diffuse fibrosis with traction bronchiectasis and peripheral cysts in the later fibrotic stage of the disease. The exact mechanism for disease is unknown but likely is caused by autoantibodies to respiratory tissue.

Pulmonary vasculitis, either caused by granulomatosis with polyangiitis, microscopic polyangiitis, idiopathic pulmonary capillaritis, or anti-GBM syndrome (formerly Goodpasture disease), is another common manifestation of systemic diseases. The disease is likely the result of autoantibody stimulation of lymphocytes with resultant inflammation of pulmonary endothelium causing interstitial changes and pulmonary hemorrhage. Histopathology reveals diffuse alveolar hemorrhage, interstitial widening, and with the exception of anti-GBM disease, neutrophilic inflammation of the pulmonary vasculature.

Genetic causes of immune dysregulation may also be responsible for ILD in children. Pathogenic variants in both *STAT3b* and *LRBA* have been shown to cause lymphocytic interstitial pneumonia and lymphoproliferative disease. Pathogenic variants in coatomer-associated protein-alpha *(COPA)*, a protein involved in endoplasmic reticulum to Golgi transport, cause familial pulmonary hemorrhage and/or ILD.

Persistent pulmonary symptoms can occur after respiratory infections caused by adenoviruses, influenza viruses, *Chlamydia pneumoniae,* and *Mycoplasma pneumoniae*. The resultant pulmonary disease is called **bronchiolitis obliterans** and is characterized by obstructive lung disease and obliteration or constriction of the bronchioles on lung biopsy. There is a characteristic appearance on HRCT of the chest with mosaicism, vascular attenuation, and central bronchiectasis, which if present, can obviate the need for lung biopsy (Fig. 448.11). Aspiration is a frequent cause of chronic lung disease in childhood and can mimic ILD. Children with developmental delay or neuromuscular weakness are at an increased risk for aspiration of food, saliva, or foreign matter secondary to swallowing dysfunction and/or gastroesophageal reflux (GER). An undiagnosed tracheoesophageal fistula can also result in pulmonary complications related to aspiration of gastric contents leading to interstitial pneumonia.

Children experiencing an exaggerated immunologic response to organic dust, molds, or bird antigens may demonstrate hypersensitivity pneumonitis. Children with malignancies may have ILD related to the primary malignancy, an opportunistic infection, or related to chemotherapy or radiation treatment.

CLINICAL MANIFESTATIONS

A detailed history is needed to assess the severity of symptoms and the possibility of an underlying systemic disease in a patient with suspected ILD. One should also ask about any family history of lung disease. Identification of precipitating factors, such as exposure to

Table 448.18 Pathogenic Variants Associated with Children's Interstitial and Diffuse Lung Disease

DISORDER (GENE)	INHERITANCE	CLINICAL PRESENTATION	TREATMENT APPROACH
ABCA3 deficiency *(ABCA3)*	Autosomal recessive	Loss of functional protein causes severe respiratory failure in newborn babies or gradual development of respiratory symptoms in older children and adults	Reported responses to immune suppression with hydroxychloroquine; azithromycin; lung transplantation considered
COPA syndrome *(COPA)*	Autosomal dominant	Autoimmune interstitial lung, joint, and kidney disease arising in the first 2 decades of life	Janus kinase inhibitors; lung transplantation considered
Pulmonary alveolar proteinosis (colony stimulating factor 2 receptor α *[CSF2RA]*)	X-linked	Primary PAP; dyspnea and cough in early childhood	Whole lung lavage
Pulmonary alveolar proteinosis (colony-stimulating factor 2 receptor β *[CSF2RB]*)	Autosomal recessive	Primary PAP; dyspnea and cough in early childhood	Whole lung lavage
Filamin A syndrome *(FLNA)*	X-linked recessive	Dyspnea in infancy	Symptomatic; lung transplantation considered
Alveolar capillary dysplasia with misalignment of the pulmonary veins *(FOXF1)*	Autosomal dominant (usually with paternal imprinting)	Acute respiratory distress within first few hr of birth; without transplant few survive to 1 yr	Lung transplantation considered
Immunodeficiency 21: profound deficiency with pulmonary alveolar proteinosis *(GATA2)*	PAP form is autosomal dominant	Profound B-cell loss with normal T-cell numbers leads to opportunistic infection and PAP	Hematopoietic stem cell transplantation
Interstitial lung and liver disease (*MARS*[methionyl-tRNA synthetase])	Autosomal recessive	Failure to thrive, hypotonia, intermittent lactic acidosis, severe cirrhosis, respiratory failure (PAP), and interstitial lung disease in infancy or early childhood	Symptomatic; whole lung lavage considered
Brain-lung-thyroid syndrome *(NKX2-1)*	Autosomal dominant	Infant respiratory distress and recurrent pulmonary infection with associated hypothyroidism and neurologic impairment	Symptomatic; lung transplantation considered
Lung disease, immunodeficiency, and chromosome breakage syndrome *(NSMCE3)*	Autosomal recessive	Failure to thrive in infancy with immunodeficiency and viral-induced fatal lung disease	Hematopoietic stem cell transplantation
Infantile-onset pulmonary alveolar proteinosis *(OAS1)*	Autosomal dominant	Onset of dyspnea and respiratory distress often associated with a viral infection; hypogammaglobulinemia and splenomegaly	Hematopoietic stem cell transplantation
Surfactant protein B deficiency *(SFTPB)*	Autosomal recessive	Acute neonatal fatal respiratory distress; some reports of dyspnea in older children	Symptomatic; lung transplantation considered
Surfactant protein C mutation *(SFTPC)*	Autosomal dominant	Acute neonatal respiratory distress, but also presents in older children and adults	Consider corticosteroids and hydroxychloroquine; lung transplantation considered in severe or progressive cases
Lysinuric protein intolerance *(SLC7A7)*	Autosomal recessive	Short stature, hepatosplenomegaly; recurrent infection; early childhood respiratory failure in some (PAP); pulmonary fibrosis in a third in later life	Poor response to GMCSF; low-protein diet and citrulline supplementation
Acinar dysplasia *(TBX4)*	Autosomal dominant	Acute fatal neonatal respiratory insufficiency; patellar aplasia or hypoplasia syndrome; pulmonary arterial hypertension	Lung transplantation considered
STING associated vasculopathy with onset in infancy *(TMEM173)*	Autosomal dominant	Infant-onset systemic inflammation with skin lesions, vasculopathy, and pulmonary fibrosis	Janus kinase inhibitors

PAP, Pulmonary alveolar proteinosis; GMCSF, granulocyte-macrophage colony-stimulating factor.
From Cunningham S, Jaffe A, Young LR. Children's interstitial and diffuse lung disease. *Lancet Child Adolesc.* 2019;3:568–577.

Table 448.19 Clinical Features, Age, and Onset of Surfactant Protein Dysfunction Syndromes (SPDS)

SPDS	CLINICAL FEATURES	AGE AND ONSET
SFTPB	*Neonatal* • Respiratory distress	Neonate, acute
ABCA3	*Neonatal* • Respiratory distress *Infancy* • Cough • Tachypnoea, hypoxemia • Failure to thrive *Childhood* • Wheeze, crackles • Exercise intolerance • Dyspnea • Retractions, crackles, digital clubbing • Low body weight	Neonate, acute Infancy and childhood, subacute Late childhood and adulthood, chronic
SFTPC	*Neonatal* • Respiratory distress *Childhood* • Cough • Tachypnea, hypoxemia	Neonate, acute (infrequent) Infancy and childhood, subacute Late childhood and adulthood, chronic
NKX2.1	*Respiratory* • Neonatal respiratory distress • Recurrent infections • Chronic interstitial lung disease *Neurologic* • Chorea • Ataxia • Developmental delay • Hypotonia • Hypothyroidism	Any age Acute or chronic
GMCSFR	*Infancy* Respiratory distress Cough	*Infancy* Chronic
Anti-GMCSF antibodies	Respiratory Cough Exercise intolerance Hypoxemia	*Teenage years* Chronic

ABCA3, ATP binding cassette number A3.
From Gupta A, Zheng SL. Genetic disorders of surfactant protein dysfunction: when to consider and how to investigate. *Arch Dis Child.* 2017;102:84–90, Table 2, p. 86.

molds or birds and a severe lower respiratory infection, is important in establishing the diagnosis and instituting potential avoidance measures. Patients may develop hypoxia and hypercarbia. Tachypnea, crackles on auscultation, retractions, and digital clubbing may be noted on physical examination in children with ILD. However, chest physical examination findings can be normal. Failure to thrive, likely because of increased work of breathing leading to high caloric needs, is also common in ILD. Wheeze and fever are less common but have been noted in childhood ILD, especially in bronchiolitis obliterans. Cyanosis accompanied by a prominent P_2 heart sound is indicative of severe disease with the development of secondary pulmonary hypertension. Anemia or hemoptysis suggests a pulmonary vascular disease or pulmonary hemosiderosis. Rashes or joint complaints are consistent with an underlying connective tissue disease.

Fig. 448.9 Chest CT from a 2-year-old with a disorder of surfactant metabolism from pathogenic variants in *ABCA3*. Note the ground-glass opacities *(white arrow)*, septal thickening *(circle)*, and early cyst formation *(black arrow)*. *(Courtesy R. Paul Guillerman, MD.)*

Fig. 448.10 Chest CT from an 11-yr-old patient with systemic sclerosis and cellular nonspecific interstitial pneumonia. Note the areas of ground-glass opacities in the periphery *(arrows)*. *(Courtesy R. Paul Guillerman, MD.)*

DIAGNOSIS

Radiography

Chest radiographic abnormalities can be classified as interstitial, reticular, nodular, reticulonodular, or honeycombed. The chest radiographic appearance may also be normal despite significant clinical impairment and may correlate poorly with the extent of disease. HRCT of the chest better defines the extent and distribution of disease and can provide specific information for selection of a biopsy site. Chest CT imaging may reveal air trapping, ground-glass patterns, mosaic patterns of attenuation, hyperinflation, bronchiectasis, cysts, and/or nodular opacities. Serial HRCT scans have been beneficial in monitoring disease progression and severity.

Pulmonary Function Tests

Pulmonary function tests are important in defining the degree of respiratory dysfunction and in following the response to treatment. In ILD, pulmonary function abnormalities demonstrate a restrictive ventilatory deficit with decreased lung volumes and reduced

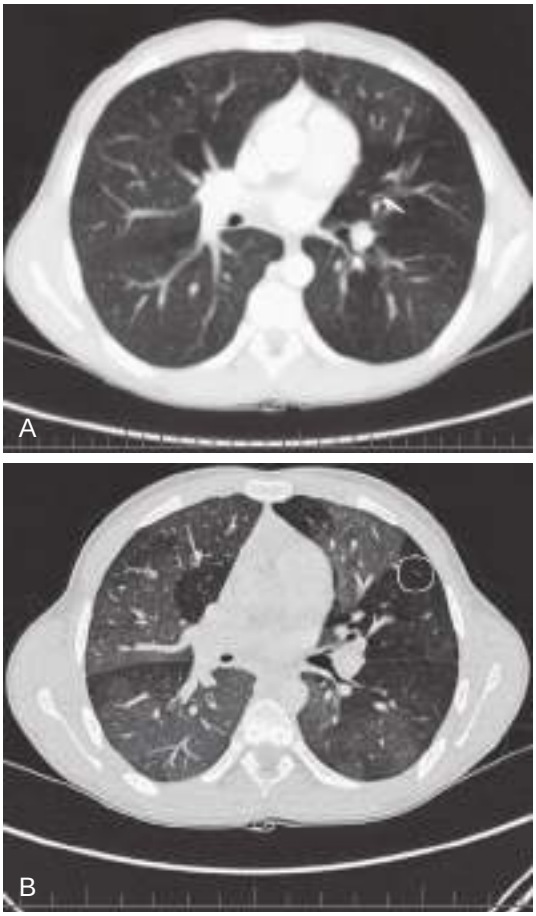

Fig. 448.11 Chest CT from an 11-yr-old patient with bronchiolitis obliterans after Stevens-Johnson syndrome. **A,** Volumetric scan at full inspiration shows central bronchiectasis *(arrow)* and mosaic attenuation. **B,** High-resolution image taken in exhalation better highlights the mosaic attenuation and vascular attenuation *(circle)*.

lung compliance. However, obstructive impairment may be seen in some forms of ILD such as bronchiolitis obliterans. The functional residual capacity is often reduced but is usually less affected than vital capacity and total lung capacity (TLC). The residual volume (RV) is usually maintained; therefore ratios of functional residual capacity:total lung capacity and RV:TLC are increased. Diffusion capacity of the lung is often reduced. Exercise testing may detect pulmonary dysfunction, even in the early stage of ILD, with a decline in oxygen saturation.

Bronchoalveolar Lavage

BAL may provide helpful information regarding secondary infection, bleeding, and aspiration and allows cytology and molecular analyses. Evaluation of cell counts, differential, and lymphocyte markers may be helpful in determining the presence of hypersensitivity pneumonitis or sarcoid. Although BAL does not usually determine the exact diagnosis, it can be diagnostic for disorders such as pulmonary alveolar proteinosis.

Lung Biopsy

Lung biopsy for histopathology by conventional thoracotomy or video-assisted thoracoscopy *is sometimes the final step and is often necessary for a diagnosis*. Biopsy yields a diagnosis in greater than 80% of patients. Because of the low diagnostic yield, transbronchial biopsies are not recommended for the evaluation of ILD in children. Evaluation for possible systemic disease may also be necessary.

Molecular Diagnosis

For those genetic-based disorders, gene panels or whole exome sequencing may yield a rapid diagnosis (see Table 448.18).

TREATMENT

Supportive care of patients with ILD is essential and includes supplemental oxygen for hypoxia and adequate nutrition for growth failure. Antimicrobial treatment may be necessary for secondary infections. Some children may receive symptomatic relief from the use of bronchodilators. Antiinflammatory treatment with corticosteroids remains the initial treatment of choice for many forms of childhood ILD. Controlled trials in children are lacking, however, and the clinical responses reported in case studies are variable. The usual dose of prednisone is 1-2 mg/kg/24 hr or 10-30 mg/kg of IV methylprednisolone given either weekly or for 3 consecutive days per month. Treatment length varies but is often initially given for 3-6 months with tapering of dosage dictated by clinical response. Alternative but not adequately evaluated agents include hydroxychloroquine, azathioprine, cyclophosphamide, cyclosporine, methotrexate, and IVIG. Investigational approaches involve specific agents directed against the action of cytokines, growth factors, or oxidants. In severe, progressive, or end-stage ILD, lung transplantation is an option, and outcomes are similar to other end-stage lung diseases in children. Appropriate treatment for underlying systemic disease or aspiration syndrome is indicated. Preventive measures include avoidance of all inhalation irritants, such as tobacco smoke and, when appropriate, molds and bird antigens. Supervised pulmonary rehabilitation programs may be helpful.

For those disorders with fibrotic ILD, antifibrotic therapy may be another option. The greatest experience with antifibrotic therapy has been in adults with IPF. Other indications for antifibrotic therapy include fibrosing ILD, autoimmune ILD, hypersensitivity pneumonitis, and nonspecific ILD. Nintedanib and pirfenidone have been approved for patients ≥18 years; both have demonstrated efficacy in slowing the decline in pulmonary function.

Genetic Counseling

A high incidence of ILD in some families suggests a genetic predisposition to either development of the disease or severity of the disorder. Genetic counseling may be beneficial if a positive familial history is obtained.

PROGNOSIS

The overall mortality of ILD is variable and depends on the specific diagnosis. Some children recover spontaneously without treatment, but other children steadily progress to death. Pulmonary hypertension and severe fibrosis are considered poor prognostic indicators.

ANTI–GLOMERULAR BASEMENT MEMBRANE DISEASE (ANTI-GBM DISEASE)

Anti-GBM disease, formerly known as Goodpasture disease, is the prototypical immunologic-mediated ILD (see Chapter 560.4). Because of the concurrent presentation of renal (glomerulonephritis) and pulmonary (alveolar hemorrhage) disease, the differential diagnosis focuses on distinguishing anti-GBM disease from vasculitis, infection, and other syndromes such as GPA, microscopic polyangiitis, Henoch-Schönlein purpura, and idiopathic pulmonary hemorrhage syndromes.

Pathophysiology

Immunology Factors

The development of anti-GBM antibodies against antigens that are present on the basement membranes of the glomerulus and alveolar directly correlates with the development of pulmonary and renal

disease. Removal of such antibodies by plasmapheresis results in improvement of the disease process in some patients but not in all.

Genetic Factors

Genetics appears to contribute strongly to the development of this disease, with the presence of MHC class II alleles DR15, DR4, DRB1*1501, DRB1*04, and DRB1*03 predisposing to disease. The disease is triggered by environmental factors in those with a genetic predisposition. There may be other genetic factors as well, and our understanding of the genetics involved in anti-GBM disease is evolving.

Environmental Factors

Exposure to cigarette smoke appears to be a strong factor in the development anti-GBM disease. Whether smoking alters the ultrastructure of the basement membrane or exogenous particles or noxious substances in smoke alter the type IV collagen is unknown. Smokers are more likely to develop pulmonary hemorrhage than nonsmokers who have anti-GBM disease. Other injuries to the alveoli from infection, hydrocarbon inhalation, or cocaine inhalation have been reported as associated events before the development of anti-GBM disease.

Clinical Manifestations

The majority of patients present with many days or weeks of cough, dyspnea, and fatigue, and up to 60% present with hemoptysis. Young children tend to swallow small amounts of blood from hemoptysis and may present with vomiting blood. Occasionally, the hemoptysis is large and resultant anemia is a consequence of large quantities of blood loss. Younger patients tend to present with both the pulmonary and renal syndrome concurrently. Adults are less likely to develop pulmonary disease.

Laboratory

Serologic detection of anti-GBM antibodies is positive in more than 90% of patients with anti-GBM disease. A complete blood count may show anemia that is normocytic and normochromic, as seen in chronic inflammatory disease. Urinalysis may reveal hematuria and proteinuria, and blood tests demonstrate renal compromise with elevated blood urea nitrogen and creatinine. Studies for ANCAs should also be performed and are positive in approximately 25–30% of patients concurrently with anti-GBM antibodies. The ANCA that is often positive is anti–myeloperoxidase ANCA.

Chest Radiography

Chest radiography in anti-GBM disease will often show widely scattered patches of pulmonary infiltrates. If these infiltrates are in the periphery of the lung, they may be difficult to distinguish from the eosinophilic lung diseases. Interstitial patterns of thickening may be found as well. HRCT of the chest reveals a diffuse ground-glass pattern or opacities.

Pulmonary Function Testing

Spirometry may be suggestive of a restrictive defect with reduction in FVC and FEV_1. DLCO is a valuable test when pulmonary hemorrhage is a strong consideration. The intent of this test is to measure the ability of the lung to transfer inhaled gas to the red blood cell in the pulmonary capillary bed. This test takes advantage of hemoglobin's high affinity to bind carbon monoxide. Current data suggest that DLCO directly correlates with the volume of blood in the pulmonary capillary bed. In pulmonary hemorrhage syndromes, blood in the alveoli plus the blood in the capillary bed increase the DLCO significantly and should alert the clinician to the possibility of pulmonary hemorrhage.

Bronchoscopy and Bronchoalveolar Lavage

Defining pulmonary hemorrhage can often be best assessed through bronchoscopy with BAL. The visual presence of blood during bronchoscopy will be obvious. Infections must be ruled out in many cases. The cytology from the BAL may reveal hemosiderin-laden macrophages through Prussian blue staining. These macrophages would have engulfed and broken down the red blood cells, leaving iron in these cells.

Tissue Histopathology

The most common tissue obtained for diagnosis is a kidney biopsy. Kidney biopsies most commonly reveal crescentic glomerulonephritis with positive anti-GBM. Staining for IgG and complement is found by immunofluorescence along the basement membrane in a linear pattern. This antibody deposition pattern led to the investigation of endogenous antigens in the basement membrane. Although less likely to be performed in anti-GBM disease, lung biopsy in patients with active disease reveals capillaritis from neutrophils, hemosiderin-laden macrophages, type II pneumocyte hyperplasia, and interstitial thickening at the level of the alveolus.

Treatment

More than half of patients with anti-GBM disease who forego treatment die within 2 years from either respiratory failure, renal failure, or both. After a diagnosis is made, therapy with corticosteroids coupled with oral cyclophosphamide is initiated. The addition of daily plasmapheresis may accelerate improvement. Alternative therapies are rituximab or mycophenolate. Anti-GBM antibodies are monitored during treatment. Survival is affected by the need for ongoing dialysis. Kidney transplant is an option for those with significant renal impairment. Patients who do not require persistent dialysis have a survival rate at 1 year of 80% or more.

Visit Elsevier eBooks+ at eBooks.Health.Elsevier.com for Bibliography.

448.6 Neuroendocrine Cell Hyperplasia of Infancy

W. Adam Gower

NEHI is an idiopathic form of diffuse lung disease that typically presents during the first year of life with persistent tachypnea, retractions, hypoxemia, crackles, and failure to thrive. Initial descriptions of NEHI used the term *persistent tachypnea of infancy*; some authors now use this to refer to both NEHI and pulmonary interstitial glycogenosis. Characteristic findings are seen on chest imaging studies and lung histopathology. Pulmonary function studies typically demonstrate an obstructive pattern with air trapping. *There are no effective specific therapies for NEHI, and the usual approach is supportive care.* The natural course is typically one of gradual improvement of symptoms, although exacerbations may occur throughout childhood, and potentially into adulthood. The long-term consequences of this disorder are not well-delineated.

EPIDEMIOLOGY

The prevalence of NEHI is not known, but it is generally considered to be a rare lung disease. Some studies have noted a slight male predominance. Otherwise, no other clear maternal or patient-level risk factors have been identified. Cases of NEHI have been reported in the literature from North and South America, Europe, Asia, and Australia.

PATHOPHYSIOLOGY

The primary clue to the pathophysiology of NEHI is increased numbers of neuroendocrine cells (NECs) in the airways of affected children. NECs are normally found in the airways, where they exist as both as individual cells and innervated clusters known as *neuroendocrine bodies* (NEBs), and secrete factors such as gastrin releasing peptide (GRP) and serotonin (5-HT). They are thought to be involved in local oxygen sensing and may transmit signals to other cells. Increases in NECs are seen in several respiratory disorders

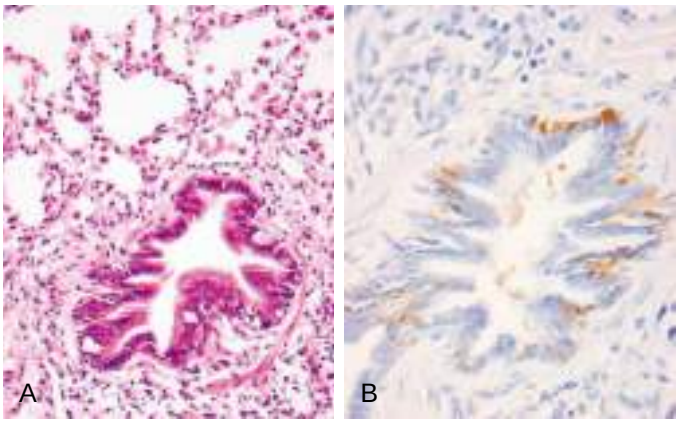

Fig. 448.12 Neuroendocrine cell hyperplasia of infancy. **A,** A small airway showing only minimal chronic inflammation on routine staining. **B,** Staining for bombesin shows increased numbers of neuroendocrine cells within the surface epithelium. *(From Corrin B, Nicholson AG. Pathology of the Lungs, 3rd ed. Philadelphia: Churchill Livingstone; 2011: Fig. 2.19.)*

of childhood, usually with other additional findings, where they are thought to be reactive to other primary pathology. It is unclear whether their presence in increased numbers in NEHI causes the clinical picture or is the result of abnormal pulmonary physiology secondary to some other primary factor. Increased numbers of NECs seem to be associated with increased small airway obstruction in those with NEHI.

Although most cases appear to be sporadic, familial NEHI has been described, suggesting a possible inherited mechanism and/or shared environmental factors between affected siblings. The association of NEHI with heterozygosity for a variant in the gene *Nkx2.1* has been described in one kindred. Variants in this gene are also known to cause a wide spectrum of disorders, including more severe forms of diffuse lung disease (see Chapter 448.5).

CLINICAL PRESENTATION

The symptoms of NEHI characteristically appear during infancy, although the diagnosis may be delayed until after the first year of life. The typical presentation includes persistent tachypnea, hypoxemia, retractions, and poor weight gain in an otherwise healthy infant. The exam reveals crackles or clear lung sounds, and cough, wheezing, and digital clubbing are not typical.

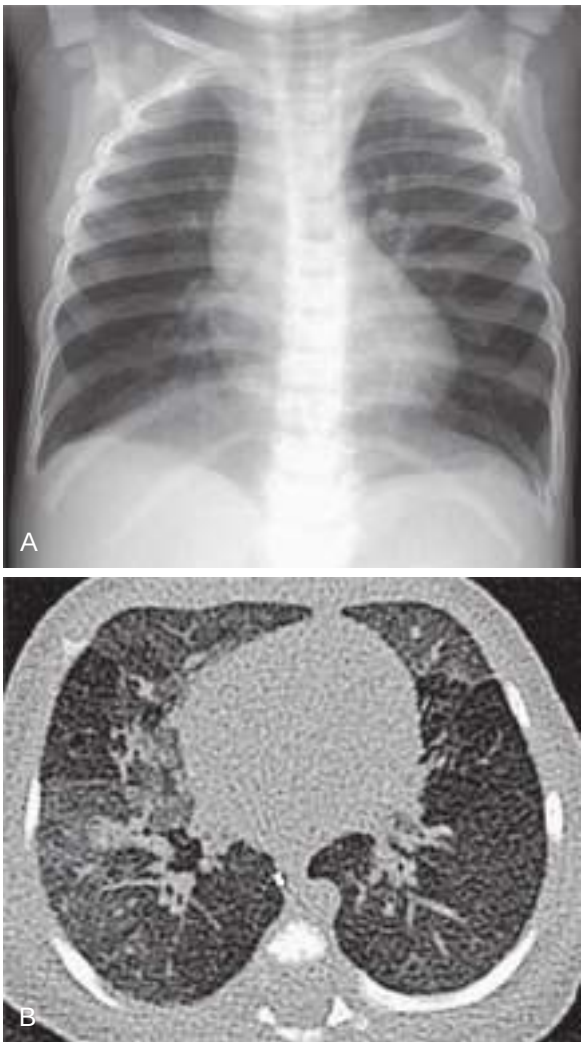

Fig. 448.13 **A,** Neuroendocrine cell hyperplasia of infancy in a 15-mo-old. Chest radiograph demonstrates pulmonary hyperinflation and parahilar opacities resembling reactive airways disease or bronchiolitis. **B,** Neuroendocrine cell hyperplasia of infancy. Axial expiratory CT image shows characteristic geographic ground-glass opacities involving the paramediastinal right middle lobe and lingula and the right lower lobe. *(From Zucker EJ, Lee EY. Diffuse lung disease. In Coley BD, ed. Caffey's Pediatric Diagnostic Imaging, 13th ed. Philadelphia: Elsevier; 2019: Figs. 56.7 and 56.8, p. 541.)*

DIAGNOSIS

The diagnosis of NEHI requires that other more common causes of the presenting symptoms be ruled out. Strong consideration should be given to consultation with a pediatric pulmonologist when possible. Although children with NEHI may have comorbid GER and/or swallowing dysfunction, this is thought to be secondary to tachypnea and increased work of breathing rather than the cause of respiratory symptoms. Plain chest films may show hyperinflation. When biopsy material from the lung is stained with immunohistochemical reagents highlighting bombesin, increased numbers of positive-staining cells are noted in the airways. In general, biopsies from children with NEHI are remarkably void of fibrosis, inflammation, or signs of injury (Fig. 448.12).

Although the pattern of NEC hyperplasia seen in histopathology has classically been the gold standard for diagnosis of NEHI, HRCT of the chest has a high specificity, such that biopsy may be avoided in most cases. The classic pattern seen on chest CT is ground-glass opacities in the lingula, right middle lobe, and perihilar regions, with air trapping on expiratory images. The lungs otherwise appear normal (Fig. 448.13). If a patient with clinically diagnosed NEHI has a more severe clinical course than expected, biopsy may be helpful to rule out other pathology.

The diagnosis of NEHI is supported by an obstructive pattern that does not reverse with bronchodilators, on either infant pulmonary function testing (iPFT) or standard spirometry. Static lung volumes may show air trapping with increased RV relative to the TLC. BAL findings are notable for lack of inflammatory markers, as compared to other pulmonary diseases of infancy.

Genetic testing may be useful to rule out disorders of surfactant metabolism and other causes of infant diffuse lung disease. Targeted testing for variants in *Nkx2.1* can be considered, but as this association has been found in only one kindred thus far, the diagnostic value of such testing is limited.

NATURAL COURSE AND TREATMENT

Because the symptoms of NEHI typically improve and eventually largely resolve over the first few years of life, the standard approach to treatment of NEHI is supportive. The time frame for clinical improvement in NEHI is variable. Symptoms with rest may improve, whereas those on exertion or with sleep persist. Affected children may require supplemental oxygen to maintain normal saturations, sometimes only with sleep or illnesses, but often at all times. Clinicians should have a low threshold to evaluate for sleep-related breathing disorders, and these should be treated accordingly. Inhaled or systemic corticosteroids are generally not thought to be helpful in treating the primary manifestations of NEHI.

Because they may expend more energy to breathe, children with NEHI may have difficulty gaining weight and often require supplemental nutrition. This may be delivered by gastrostomy tube. Management of GER and/or dysfunctional swallowing, when present, may be helpful. Mild abnormalities of the immune system may be seen in some patients with NEHI and, when present, may be addressed with specific therapy such as prophylactic antibiotics and/or immunoglobulin replacement.

When clinical symptoms improve, the need for supplemental oxygen and/or nutritional support typically decreases, and patients may be weaned as tolerated. Children with NEHI whose symptoms have improved may experience exacerbations later in childhood. These episodes may be associated with increased air trapping.

Although the symptoms of NEHI typically resolve during childhood, limited data suggest that some may persist into the adult years. This may manifest as exercise intolerance or an asthma-like picture. Obstruction with air trapping may be seen on PFT, and persistent abnormalities may be identified on chest imaging. No cases of respiratory failure, need for lung transplantation, or death caused by NEHI have been reported.

Visit Elsevier eBooks+ at eBooks.Health.Elsevier.com for Bibliography.

448.7 Fibrotic Lung Disease

Deborah R. Liptzin, Jason P. Weinman, and Robin R. Deterding

Pulmonary fibrosis is scarring in the lung parenchyma (as opposed to bronchiectasis, which is scarring of the airways). Idiopathic pulmonary fibrosis is a common form of fibrotic lung disease in adults. This presents with usual interstitial pneumonia (a pathologic finding with patchy interstitial fibrosis, fibroblastic foci, and honeycomb change) (see Chapter 448.5). Additional adult fibrotic lung diseases include sarcoidosis, silicosis, coal worker's pneumoconiosis, and hypersensitivity pneumonitis (e.g., farmer's lung). In children, fibrotic lung disease is rare, and *idiopathic* pulmonary fibrosis has not been described. The differential diagnosis of *fibrotic* lung disease includes surfactant dysfunction pathogenic variants (see Chapter 444); immunocompromised patients with opportunistic infections, radiation-induced fibrosis, or status-post hematopoietic stem cell transplantation; patients with systemic disease processes that can lead to pulmonary fibrosis (systemic vasculitis, collagen vascular disease, juvenile idiopathic arthritis, storage diseases, Langerhans cell histiocytosis, sarcoidosis, systemic lupus erythematosus, systemic sclerosis, and nonspecific interstitial pneumonia); and pleuropulmonary fibroelastosis. Airway fibrosis can be seen in bronchiolitis obliterans (see Chapter 443.1) and aspiration (see Chapter 446) (Tables 448.20-448.22).

CLINICAL PRESENTATION

Pulmonary fibrosis classically presents with nonspecific respiratory symptoms such as cough, crackles, wheezes, prolonged expiratory phase, exercise intolerance, and hypoxemia, especially at nighttime.

Table 448.20 Diseases Associated with Pulmonary Fibrosis

- Idiopathic pulmonary fibrosis/nonspecific interstitial pneumonia
- Familial pulmonary fibrosis/familial interstitial pneumonia
- Hypersensitivity pneumonitis (many agents)
- Cryptogenic organizing pneumonia
- Adverse reaction to therapy (drugs, radiation)
- Pleuroparenchymal fibroelastosis
- Hermansky-Pudlak syndrome
- Sarcoidosis
- Eosinophilic pneumonia (primary or parasitic)
- Langerhans cell histiocytosis
- Dyskeratosis congenita
- Tuberous sclerosis
- Neurofibromatosis
- Erdheim-Chester disease
- Gaucher disease
- Niemann-Pick disease
- Familial hypocalciuric hypercalcemia
- Lysinuric protein intolerance
- IgG4-mediated immune disorder
- Myelodysplastic syndrome
- Progressive systemic sclerosis
- Other connective tissue diseases (SLE, dermatomyositis)
- Granulomatosis with polyangiitis
- Eosinophilic granulomatosis with polyangiitis

Symptom onset can be insidious or rapid. In children, oxygen desaturation with activity may be the earliest sign of fibrotic lung disease, and cough, crackles, and wheezes may be later findings. Children with surfactant dysfunction pathogenic variants can present with respiratory failure in the neonatal period.

EVALUATION

Pulmonary function tests typically show restriction and reduced diffusion capacity. Air trapping can also be seen. Patients may desaturate with exercise challenges such as 6-minute walks, and this may be the first indication of disease in children.

There are a variety of findings on CT scan that suggest pulmonary fibrosis, and these findings can evolve over time. In surfactant dysfunction variants, ground-glass opacities are prominent early on with subsequent evolution to more typical findings of fibrosis such as reticular abnormalities, honeycombing, architectural distortion, and/or traction bronchiectasis. Typical findings in pediatric nonspecific interstitial pneumonia include subpleural sparing, ground-glass opacities, cystic change, reticular abnormalities, and bronchiectasis (Fig. 448.14). Novel measures of quantifying fibrosis have been described in the literature, and CT findings consistent with fibrosis are being used as criteria for study enrollment. Of note, CT findings and pulmonary function tests can be discrepant with stable pulmonary function tests over time, whereas the CT scan can evolve over the same period.

In certain disease processes such as surfactant deficiency (positive genetic testing) or genetic disorders of surfactant metabolism, biopsy is not necessary for diagnosis of fibrosis. Cryobiopsy is becoming popular in the adult pulmonary landscape but is in its infancy in the pediatric pulmonary field. In the absence of a definitive diagnosis, a thoracoscopic wedge biopsy is necessary for diagnosis and to guide treatment. Transbronchial biopsies in pediatrics are of limited utility because the small instruments typically obtain inadequate tissue specimens; transbronchial biopsies in pediatrics are limited to monitoring post–lung transplantation and for diagnosis of sarcoidosis. Pathologic findings in pulmonary fibrosis are variable, depending on the duration and etiology of disease (see Table 448.21), but typically include a component of interstitial inflammation, interstitial expansion by dense collagen, and lobular

Table 448.21 Pediatric Fibrotic Lung Diseases

DISEASES	CT FINDINGS	PATHOLOGY FINDINGS	ADDITIONAL EVALUATION	TREATMENT
Surfactant dysfunction	**Early:** Diffuse ground-glass opacities, septal thickening (crazy paving) **Chronic:** Decreased ground-glass opacities with reticulation and cystic lucencies	Variable: fibrosis, honeycomb cysts at end stage, NSIP, CPI, few globules of pulmonary alveolar proteinosis, foamy macrophages and cholesterol clefts (endogenous lipoid pneumonia)	Genetic testing	Supportive care (nutrition, respiratory support, vaccinations), antifibrotic therapy *plus* hydroxychloroquine, azithromycin, high-dose intravenous steroids; genetic counseling
Aspiration	**Acute:** Consolidation and centrilobular (tree in bud) nodules with a dependent distribution **Chronic:** bronchiectasis, architectural distortion	Airway-centered lesions/ bronchiolitis, food particles with or without granulomas, foamy macrophages (endogenous lipoid pneumonia), organizing pneumonia	Video fluoroscopic or fiberoptic endoscopic swallow evaluation	Stop aspiration through thickening feeds, gastric feeds, cleft repair
Radiation fibrosis	Architectural distortion, volume loss, traction bronchiectasis; often with geometric distribution related to radiation field	Pleural, septal, and paraseptal fibrosis; reactive atypia of alveolar epithelium and endothelium		Steroids may help
Bronchopulmonary dysplasia	Hyperlucent regions, cystic lucencies, architectural distortion (linear and subpleural triangular opacities)	Alveolar simplification and enlargement; patchy hyperinflation; interstitial fibrosis, with or without interlobular septal fibrosis	Consider evaluation for pulmonary hypertension and/or aspiration	Consider inhaled corticosteroids, inhaled steroids, diuretics
Nonspecific interstitial pneumonia (NSIP)	Basilar predominant findings of ground-glass opacities (often with subpleural sparing), reticulation, architectural distortion, and traction bronchiectasis	Interstitial lymphocytic inflammation and fibrosis with homogenous distribution		Consider steroids
Hypersensitivity pneumonitis (chronic)	Patchy and often parahilar reticulation, ground-glass opacities, centrilobular nodules; honeycombing (rare)	Airway-centered small noncaseating granulomas, multinucleated giant cells, lymphocytic bronchiolitis and peribronchiolitis, airway fibrosis, organizing pneumonia	Lymphocytosis in bronchoalveolar lavage, precipitins to specific antigen	Remove trigger, intravenous steroids
Autoimmune connective tissue disorders (collagen vascular disease)	See NSIP; honeycombing (rare)	NSIP; lymphoid hyperplasia; fibrosis and cystic change; pleuritis and pleural fibrosis (variable); chronic vasculopathy (variable); airway fibrosis (variable)	Serologic studies	Disease-specific immune modulation
Drug reactions	Peripheral predominant consolidation or ground glass opacities; reverse halo sign; see NSIP; honeycombing (rare)	Variable: organizing pneumonia, NSIP, UIP, DAD, pulmonary hemorrhage, eosinophilic pneumonia		Drug avoidance
Infection	**Acute:** Consolidation and centrilobular (tree in bud) nodules; appearance and distribution vary with type of infection **Chronic:** May progress to IPF/UIP with honeycombing	**Acute:** Neutrophilic alveolitis (bacterial) or lymphocytic bronchiolitis (viral) **Chronic:** Variable airway fibrosis (constrictive/obliterative bronchiolitis) and interstitial fibrosis		Antimicrobials
Immunodeficiency	Bronchiectasis, consolidation, centrilobular nodules	Follicular bronchiolitis or diffuse lymphoid hyperplasia; NSIP; LIP; GLILD	Immunologic and genetic testing	Treat underlying immunodeficiency
Usual interstitial pneumonia (UIP)	Honeycombing, reticulation, traction bronchiectasis, ground-glass opacities (less prominent than NSIP)	Fibroblast foci; interstitial, septal, and pleural fibrosis with heterogenous distribution; minimal to absent inflammation	Genetic testing	

Table 448.22 Genes Associated with Familial* or Idiopathic Pulmonary Fibrosis

GENE	GENE FUNCTION
IL1RN	Inhibitor of proinflammatory effect of IL-1α and IL-1β
IL8	Proinflammatory cytokine
FAM13A	Signal transduction
TLR3	Pathogen recognition and activation of innate immunity
TERT	Enzyme in telomerase complex maintaining telomere length
HLA-DRB1	Major histocompatibility complex—immune system
DSP	Tightly links adjacent cells
OBFC1	Stimulates the activity of DNA polymerase-α-primase
MUC5B	Influence on rheological properties of airway mucus, mucociliary transport, and airway defense
MUC2	Mucin production
TOLLIP	Regulator of innate immune responses mediated by toll-like receptor and the transforming growth factor β signaling pathway
ATP11A	Phospholipid translocation
MDGA2	Cell-cell interaction
MAPT	Promotes microtubule assembly and stability
SPPL2C	Protein cleavage
DPP9	Cell-cell adhesion
TGFB1	Set of peptides that controls proliferation, differentiation, and other functions in many cell types
SFTPC†	Component of surfactant fluid
SFTPA2†	To modulate innate and adaptive immunity
ABCA3†	Transport of lipids across plasma membrane
TERC†	Template in telomerase complex
DKC1†	Stabilization of the template in telomerase complex
TINF2†	Telomere maintenance
RTELI†	DNA helicase
PARN†	mRNA stability

*Also called familial interstitial pneumonia.
†Rarer variant.
Adapted from Kaur A, Mathai SK, Schwartz DA. Genetics in idiopathic pulmonary fibrosis pathogenesis, prognosis, and treatment. *Frontiers Med.* 2017;4:154, Tables 1 and 2.

remodeling (parenchymal architectural distortion and honeycomb cysts). Interlobular septal fibrosis, pleural fibrosis, and chronic pulmonary arteriopathy are common associated findings. Dense globules of pulmonary alveolar proteinosis material in infancy may indicate a genetic disorder of surfactant metabolism. Reactive lymphoid follicles suggest an immunologic process, such as autoimmune disease or immunodeficiency. Organizing pneumonia (polypoid aggregates of fibroblasts, *Masson bodies*) is a common feature in hypersensitivity pneumonitis and autoimmune diseases. The usual interstitial pneumonia pattern signaled by fibroblast foci arising within a background of dense interstitial fibrosis is almost never seen in children. Connective tissue stains, such as Masson trichrome, elastic Verhoff von Giesen, and Movat pentachrome, aid in determining the severity and distribution of collagen deposition.

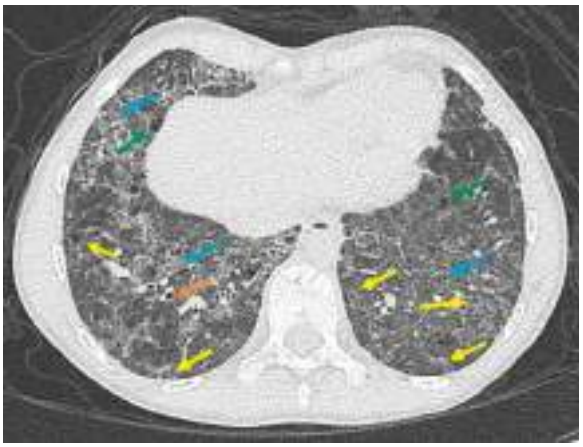

Fig. 448.14 Chest CT demonstrates typical CT findings in a pediatric patient with nonspecific interstitial pneumonia, including basilar-predominant ground-glass opacities *(blue arrows)*, reticulation *(yellow arrows)*, mild cystic change *(green arrows)*, and bronchiectasis *(orange arrow)*.

TREATMENT

Treatment varies based on disease process (see Tables 448.20-448.22). Because of the nature of rare disease, treatment regimens are largely based on expert opinion, as controlled clinical trials are challenging to perform. *Antifibrotic agents approved in adults with fibrotic lung disease include pirfenidone and nintedanib, and weight-based dosing of nintedanib has been shown to have an acceptable safety profile in children.*

Monitoring may include evaluation of pulmonary function (spirometry, lung volumes, and diffusion capacity); functional evaluation of exercise (6-minute walk); and screening for comorbidities such as pulmonary hypertension, aspiration, poor weight gain, and sleep-associated breathing disorders. Respiratory support varies depending on each patient's needs, from no support to oxygen via nasal cannula and with ventilation (noninvasive or invasive); treatments may occur only with exercise and/or sleep or may be all the time. Comorbidities such as pulmonary hypertension or aspiration should be treated appropriately. Genetic counseling and recurrence risk should be provided with genetic forms of fibrotic lung disease. Patients should be counseled about preventing further lung damage from infection (up-to-date on vaccines, including pneumococcus, influenza, SARS-CoV-2, and respiratory syncytial virus) or particulate matter (air pollution, wildfires, wood-burning stoves, and environmental exposure to tobacco or marijuana).

Visit Elsevier eBooks+ at eBooks.Health.Elsevier.com for Bibliography.

Chapter 449

Community-Acquired Pneumonia

Matthew S. Kelly and Thomas J. Sandora

Pneumonia, defined as inflammation of the lung parenchyma, is the leading infectious cause of death globally among children younger than 5 years, accounting for an estimated 880,000 deaths in 2015 (Fig. 449.1). Pneumonia mortality is closely linked to poverty; more than 99% of child pneumonia deaths are in low- and middle-income countries, with the highest pneumonia mortality rate occurring in Africa and South Asia.

In the United States, mortality from pneumonia in children declined by 97% between 1939 and 1996. This decline can largely be attributed to the development of antibiotics and vaccines and the expansion of medical insurance coverage for children. Effective vaccines against measles (see Chapter 293) and pertussis (see Chapter 243) contributed to the decline in child pneumonia mortality during the 20th century. *Haemophilus influenzae* type b (see Chapter 240) was also an important cause of bacterial pneumonia in young children but became uncommon after licensure of a conjugate vaccine in 1987. The introduction of pneumococcal conjugate vaccines (PCVs) (see Chapter 228) has been an important contributor to the further reductions in pneumonia mortality achieved over the past 2 decades. Epidemics (influenza, severe acute respiratory system coronavirus, Middle East respiratory syndrome, respiratory syncytial virus [RSV]) and pandemics (COVID-19) contribute to the incidence, morbidity, and mortality in pediatric patients with pneumonia. In addition, unexpected global increases in group A streptococcus (GAS) infections have contributed to both morbidity and mortality in children with pneumonia.

ETIOLOGY

Although most cases of pneumonia are caused by microorganisms, noninfectious causes include aspiration (of food or gastric acid, foreign bodies, hydrocarbons, and lipoid substances), hypersensitivity reactions, and drug- or radiation-induced pneumonitis (see Chapter 448). The cause of pneumonia in an individual patient is often difficult to determine because direct sampling of lung tissue is invasive and rarely performed. Bacterial cultures of sputum or upper respiratory tract samples typically do not accurately reflect the cause of lower respiratory tract infection in children. *Streptococcus pneumoniae* (pneumococcus) is the most common bacterial pathogen in children 3 weeks to 5 years of age, whereas *Mycoplasma pneumoniae* and *Chlamydophila pneumoniae* are the most frequent bacterial pathogens in children 5 years and older. In addition to pneumococcus, other bacterial causes of pneumonia in previously healthy children in the United States include GAS (*Streptococcus pyogenes*; see Chapter 229) and *Staphylococcus aureus* (see Chapter 227.1) (Tables 449.1-449.3). *S. pneumoniae* or *S. aureus* pneumonia often complicates an illness caused by influenza viruses.

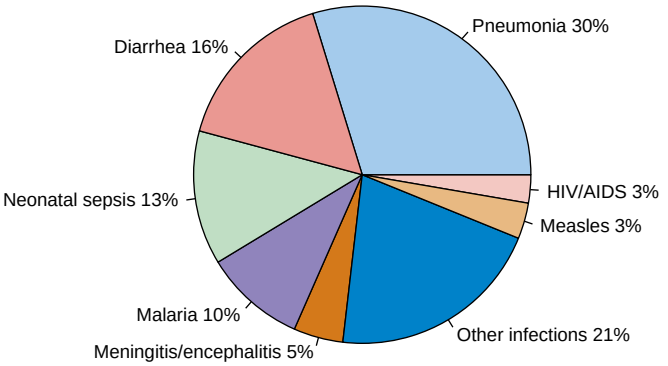

Fig. 449.1 Pneumonia is the leading infectious killer of children worldwide, as shown by this illustration of global distribution of cause-specific infectious mortality among children younger than age 5 yr in 2017. Pneumonia causes nearly one third of all under-5 deaths from infection. *(From World Health Organization Global Health Observatory Data Repository, 2017 estimates.)*

S. pneumoniae, H. influenzae, GAS, and *S. aureus* are the major causes of hospitalization and death from bacterial pneumonia among children in developing countries, although in children with HIV infection, *Mycobacterium tuberculosis* (see Chapter 261), nontuberculous mycobacteria (see Chapter 263), *Salmonella* (see Chapter 244), *Escherichia coli* (see Chapter 246), *Pneumocystis jirovecii* (see Chapter 290), and cytomegalovirus (see Chapter 302) should also be considered. The incidence of pneumonia caused by *H. influenzae* or *S. pneumoniae* has been significantly reduced in areas where routine immunization has been implemented.

Viral pathogens are the most common causes of lower respiratory tract infections in infants and children older than 1 month but younger than 5 years of age (see Table 449.2). Viruses can be detected in 40–80% of children with pneumonia using molecular diagnostic methods (e.g., polymerase chain reaction [PCR]), with more than one respiratory virus identified in up to 20% of cases. Of the respiratory viruses, RSV (see Chapter 307) and rhinoviruses (see Chapter 310) are the most commonly identified pathogens, especially in children younger than 2 years of age. However, the role of rhinoviruses in severe lower respiratory tract infection remains unclear, as these viruses are frequently detected with co-infecting pathogens and among asymptomatic children. Other common viruses causing pneumonia include influenza viruses (see Chapter 305), human metapneumovirus (see Chapter 308), parainfluenza viruses (see Chapter 306), adenoviruses (see Chapter 309), enteroviruses (see Chapter 297), and coronaviruses (see Chapter 311), including severe acute respiratory syndrome coronavirus 2 (SARS-CoV-2), the cause of coronavirus disease 2019 (COVID-19; see Chapter 449.1).

Lower respiratory tract viral infections are much more common in the fall and winter in both the Northern and Southern Hemispheres in relation to the seasonal epidemics of respiratory viruses that occur each year. The typical pattern of these epidemics usually begins in the fall, when parainfluenza virus infections appear and most often manifest as croup. Later in winter, RSV, human metapneumovirus, and influenza viruses cause widespread infection, including upper respiratory tract infections, bronchiolitis, and pneumonia. RSV is particularly severe among infants and young children, whereas influenza viruses cause disease and excess hospitalization in all age groups. Knowledge of the prevailing viruses circulating in the community may lead to a presumptive initial diagnosis for children with acute respiratory illnesses.

Immunization status is relevant because children fully immunized against *H. influenzae* type b and *S. pneumoniae* are less likely to have pneumonia caused by these pathogens. Children who are immunocompromised or who have certain medical comorbidities may be at risk for specific pathogens, such as *Pseudomonas* spp. in patients with cystic fibrosis (see Chapter 454).

PATHOGENESIS

The lower respiratory tract possesses a number of defense mechanisms against infection, including mucociliary clearance, macrophages and secretory immunoglobulin A, and clearing of the airways by coughing. Previously, it was believed that the lower respiratory tract was—in the absence of infection—kept sterile by these mechanisms, supported primarily by culture-based studies. However, recent use of culture-independent techniques, including high-throughput sequencing methods, suggests that the lower respiratory tract contains diverse microbial communities. These data have challenged the traditional model of pneumonia pathogenesis that maintained that pneumonia was the result of invasion of the sterile lower respiratory tract by a single pathogen. More recent conceptual models postulate that pneumonia results from disruption of a complex lower respiratory ecosystem that is the

Table 449.1 Causes of Infectious Pneumonia

BACTERIAL	
Common	
Streptococcus pneumoniae	Consolidation, empyema
Group B streptococcus	Neonates
Group A streptococcus	Empyema
Staphylococcus aureus	Pneumatoceles, empyema; infants; nosocomial pneumonia
*Mycoplasma pneumoniae**	Adolescents; summer to fall epidemics
*Chlamydophila pneumonie**	Adolescents
Chlamydia trachomatis	Infants
Mixed anaerobes	Aspiration pneumonia
Gram-negative enterics	Nosocomial pneumonia
Uncommon	
Haemophilus influenzae type b	Unimmunized
Moraxella catarrhalis	
Neisseria meningitidis	
Francisella tularensis	Animal, tick, fly contact; bioterrorism
Nocardia species	Immunocompromised patients
*Chlamydophila psittaci**	Bird contact (especially parakeets)
Yersinia pestis (plague)	Rat contact; bioterrorism
Legionella species*	Exposure to contaminated water; nosocomial
*Coxiella burnetii** (Q fever)	Animal (goat, sheep, cattle) exposure
VIRAL	
Common	
Respiratory syncytial virus	Bronchiolitis
Parainfluenza types 1-4	Croup
Influenza A, B	High fever; winter months
Adenovirus	Can be severe; often occurs between January and April
Human metapneumovirus	Similar to respiratory syncytial virus
Severe acute respiratory syndrome coronavirus 2 (SARS-CoV-2):COVID-19	Global pandemic
Uncommon	
Rhinovirus	Rhinorrhea
Enterovirus D68, others	Neonates
VIRAL	
Uncommon	
Herpes simplex	Neonates, immunocompromised persons
Cytomegalovirus	Infants; immunocompromised persons (particularly HIV-infected infants)
Measles	Rash, coryza, conjunctivitis
Varicella	Unimmunized; immunocompromised persons
Hantavirus	Southwestern United States, rodents
Coronaviruses (SARS-CoV-1, Middle East respiratory syndrome [MERS])	Asia, Arabian Peninsula
FUNGAL	
Histoplasma capsulatum	Ohio/Mississippi River valley; bird, bat contact
Blastomyces dermatitidis	Ohio/Mississippi River valley, upper Midwest states
Coccidioides immitis	Southwestern United States, Great Lakes states
Cryptococcus neoformans and *C. gattii*	Bird contact; immunocompromised; Northwestern United States (*C. gattii*)
Aspergillus species	Immunocompromised persons; nodular lung infection
Mucormycosis	Immunocompromised persons
Pneumocystis jirovecii	Immunocompromised persons (particularly HIV-infected infants); steroids
RICKETTSIAL	
Rickettsia rickettsiae	Tick bite
MYCOBACTERIAL	
Mycobacterium tuberculosis	Travel to endemic region; exposure to high-risk persons
Mycobacterium avium complex	Immunocompromised (particularly HIV-infected) persons
Other nontuberculous mycobacteria	Immunocompromised persons; cystic fibrosis
PARASITIC	
Various parasites (e.g., *Ascaris*, *Strongyloides* species)	Eosinophilic pneumonia

*Atypical pneumonia syndrome; may have extrapulmonary manifestations, low-grade fever, patchy diffuse infiltrates, and poor response to β-lactam antibiotics.
Adapted from Kliegman RM, Greenbaum LA, Lye PS, eds. *Practical Strategies in Pediatric Diagnosis and Therapy*, 2nd ed. Philadelphia: Elsevier; 2004: p. 29.

Table 449.2 Pneumonia Etiologies Grouped by Age of the Patient

AGE GROUP	FREQUENT PATHOGENS (IN ORDER OF FREQUENCY)
Neonates (<3 wk)	Group B streptococcus, *Escherichia coli*, other gram-negative bacilli, *Streptococcus pneumoniae*, *Haemophilus influenzae* (type b,* nontypeable)
3 wk-3 mo	Respiratory syncytial virus, other respiratory viruses (rhinoviruses, parainfluenza viruses, influenza viruses, human metapneumovirus, adenovirus), enterovirus D68, *S. pneumoniae*, *H. influenzae* (type b,* nontypeable); if patient is afebrile, consider *Chlamydia trachomatis*
4 mo-4 yr	Respiratory syncytial virus, other respiratory viruses (rhinoviruses, parainfluenza viruses, influenza viruses, human metapneumovirus, adenovirus), enterovirus D68, *S. pneumoniae*, *H. influenzae* (type b,* nontypeable), *Mycoplasma pneumoniae*, group A streptococcus
≥5 yr	*M. pneumoniae*, *S. pneumoniae*, *Chlamydophila pneumoniae*, *H. influenzae* (type b,* nontypeable), influenza viruses, adenovirus, COVID-19, other respiratory viruses, *Legionella pneumophila*

**H. influenzae* type b is uncommon with routine immunization.
Adapted from Kliegman RM, Marcdante KJ, Jenson HJ, et al., eds. *Nelson Essentials of Pediatrics*, 5th ed. Philadelphia: Elsevier; 2006: p. 507.

site of dynamic interactions between potential pneumonia pathogens, resident microbial communities, and host immune defenses.

Viral pneumonia usually results from spread of infection along the airways, accompanied by direct injury of the respiratory epithelium, which results in airway obstruction from swelling, abnormal secretions, and cellular debris. The small caliber of airways in young infants makes such patients particularly susceptible to severe infection. Atelectasis, interstitial edema, and hypoxemia from ventilation-perfusion

Table 449.3 Pneumonia: Etiology Suggested by Exposure History

EXPOSURE HISTORY	INFECTIOUS AGENT
Exposure to concurrent illness in school dormitory or household setting	*Neisseria meningitidis, Mycoplasma pneumoniae*
Exposure to persons with known or suspected COVID-19	SARS-CoV-2
ENVIRONMENTAL EXPOSURES	
Exposure to contaminated aerosols (e.g., air coolers, hospital water supply)	Legionnaires' disease
Exposure to goat hair, raw wool, animal hides	Anthrax
Ingestion of unpasteurized milk	Brucellosis
Exposure to bat droppings (caving) or dust from soil enriched with bird droppings	Histoplasmosis
Exposure to water contaminated with animal urine	Leptospirosis
Exposure to rodent droppings, urine, saliva	Hantavirus
Potential bioterrorism exposure	Anthrax, plague, tularemia
ZOONOTIC EXPOSURES	
Employment as abattoir work or veterinarian	Brucellosis
Exposure to cattle, goats, pigs	Anthrax, brucellosis
Exposure to ground squirrels, chipmunks, rabbits, prairie dogs, rats in Africa or southwestern United States	Plague
Hunting or exposure to rabbits, foxes, squirrels	Tularemia
Bites from flies or ticks	Tularemia
Exposure to birds (parrots, budgerigars, cockatoos, pigeons, turkeys)	Psittacosis
Exposure to infected dogs and cats	*Pasteurella multocida*, Q fever *(Coxiella burnetii)*
Exposure to infected goats, cattle, sheep, domestic animals, and their secretions (milk, amniotic fluid, placenta, feces)	Q fever *(C. burnetii)*
TRAVEL EXPOSURES	
Residence in or travel to San Joaquin Valley, southern California, southwestern Texas, southern Arizona, New Mexico	Coccidioidomycosis
Residence in or travel to Mississippi or Ohio river valleys, Great Lakes States, Caribbean, Central America, or Africa	Histoplasmosis, blastomycosis
Residence in or travel to southern China	Avian influenza
Residence in or travel to Arabian Peninsula	MERS-CoV
Residence in or travel to Southeast Asia	Paragonimiasis, melioidosis
Residence in or travel to West Indies, Australia, or Guam	Melioidosis

MERS-CoV, Middle East respiratory syndrome coronavirus; COVID-19, coronavirus disease 2019; SARS-CoV-2, severe acute respiratory syndrome coronavirus 2.
From Ellison RT III, Donowitz GR. Acute pneumonia. In: Bennett JE, Blaser MJ, Dolin R, et al., eds. *Mandell, Douglas, and Bennett's Principles and Practice of Infectious Diseases*, 8th ed. Philadelphia: Saunders; 2015: Table 69.3, p. 828.

mismatch often accompany airway obstruction. Viral infection of the respiratory tract can also predispose to secondary bacterial infection by disturbing normal host defense mechanisms, altering secretions, and disrupting the microbial communities that reside in the respiratory tract.

Bacterial pneumonia most often occurs when respiratory tract organisms colonize the upper respiratory tract and subsequently gain access to the lungs, but pneumonia may also result from direct seeding of lung tissue in the setting of bacteremia. When bacterial infection is established in the lung parenchyma, the pathologic process varies according to the invading organism. *M. pneumoniae* (see Chapter 269) attaches to the respiratory epithelium, inhibits ciliary action, and leads to cellular destruction and an inflammatory response in the submucosa. When the infection progresses, sloughed cellular debris, inflammatory cells, and mucus cause airway obstruction, with spread of infection occurring along the bronchial tree, as is seen in viral pneumonia. *S. pneumoniae* produces local edema that aids in the proliferation of organisms and their spread into adjacent portions of the lung, often resulting in the characteristic lobar consolidation. Lower respiratory tract infection caused by GAS typically results in more diffuse lung involvement with interstitial pneumonia. The pathology includes necrosis of tracheobronchial mucosa; formation of large amounts of exudate, edema, and local hemorrhage, with extension into the interalveolar septa; and involvement of lymphatic vessels with frequent pleural involvement. *S. aureus* pneumonia manifests as confluent bronchopneumonia, which is often bilateral and characterized by the presence of extensive areas of hemorrhagic necrosis and irregular areas of cavitation of the lung parenchyma, resulting in pneumatoceles, empyema, and, at times, bronchopulmonary fistulas.

Recurrent pneumonia is defined *as two or more* episodes in a single year *or three or more* episodes ever, with radiographic clearing between occurrences. An underlying disorder should be considered if a child experiences recurrent pneumonia (Table 449.4).

CLINICAL MANIFESTATIONS

Pneumonia is frequently preceded by several days of symptoms of an upper respiratory tract infection, typically rhinitis and cough. In viral pneumonia, fever is usually present but temperatures are generally lower than in bacterial pneumonia. Tachypnea is the most consistent clinical manifestation of pneumonia. Increased work of breathing manifested by intercostal, subcostal, and suprasternal retractions; nasal flaring; and use of accessory muscles is also common. Severe infection may be accompanied by cyanosis and lethargy, especially in infants. Auscultation of the chest may reveal crackles and wheezing, but it is often difficult to localize the source of these adventitious sounds in young children with hyperresonant chests. It is often not possible to distinguish viral pneumonia clinically from disease caused by *Mycoplasma* and other bacterial pathogens.

Bacterial pneumonia in adults and older children typically begins suddenly with high fever, cough, and chest pain. Other symptoms that may be seen include drowsiness with intermittent periods of restlessness; rapid respirations; anxiety; and, occasionally, delirium. In many children, splinting on the affected side to minimize pleuritic pain and improve ventilation is noted; such children may lie on one side with the knees drawn up to the chest. Lower lobe pneumonia may cause abdominal pain (but no tenderness), or the pain may be referred to the ipsilateral shoulder.

Physical findings depend on the stage of pneumonia. Early in the course of illness, diminished breath sounds, scattered crackles, and rhonchi are commonly heard over the affected lung field. With the development of increasing consolidation or complications of pneumonia such as pleural effusion or empyema, dullness on percussion is noted and breath sounds may be diminished. A lag in respiratory excursion often occurs on the affected side. Abdominal distention may be prominent because of gastric dilation from swallowed air or ileus. The liver may seem enlarged because of downward displacement of the diaphragm secondary to hyperinflation of the lungs or superimposed congestive heart failure.

Table 449.4 Differential Diagnosis of Recurrent Pneumonia

HEREDITARY DISORDERS
Cystic fibrosis
Sickle cell disease
DISORDERS OF IMMUNITY
HIV/AIDS
Bruton agammaglobulinemia
Selective immunoglobulin G subclass deficiencies
Common variable immunodeficiency syndrome
Severe combined immunodeficiency syndrome
Chronic granulomatous disease
Hyperimmunoglobulin E syndromes
Leukocyte adhesion defect
DISORDERS OF CILIA
Primary ciliary dyskinesia
Kartagener syndrome
ANATOMIC DISORDERS
Pulmonary sequestration
Lobar emphysema
Congenital pulmonary airway malformation
Gastroesophageal reflux
Foreign body
Tracheoesophageal fistula (H type)
Bronchiectasis
Aspiration (oropharyngeal incoordination)
Aberrant bronchus

Adapted from Kliegman RM, Marcdante KJ, Jenson HJ, et al., eds. *Nelson Essentials of Pediatrics*, 5th ed. Philadelphia: Elsevier; 2006: p. 507.

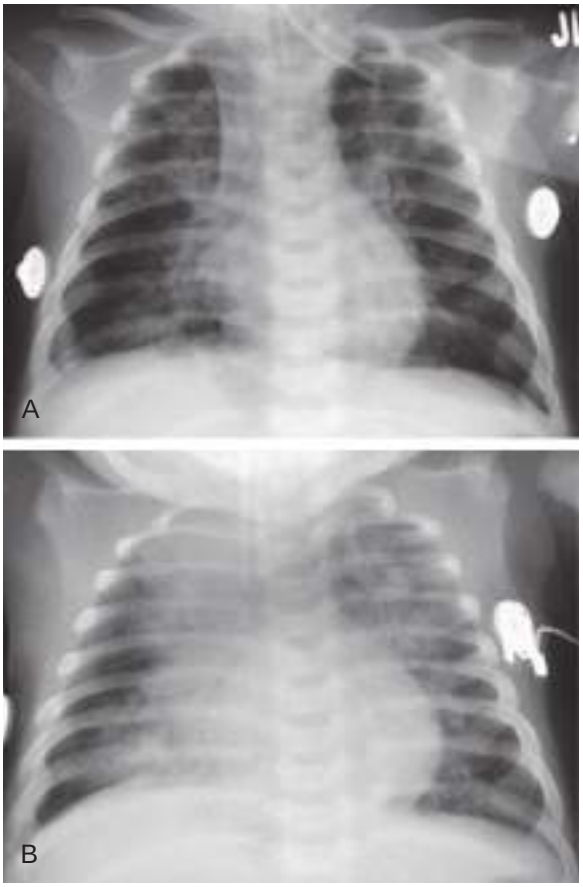

Fig. 449.2 A, Radiographic findings characteristic of respiratory syncytial virus pneumonia in a 6-mo-old infant with rapid respirations and fever. Anteroposterior radiograph of the chest shows hyperexpansion of the lungs with bilateral fine air space disease and streaks of density, indicating the presence of both pneumonia and atelectasis. An endotracheal tube is in place. B, One day later, the anteroposterior radiograph of the chest shows increased bilateral pneumonia.

Symptoms described in adults with pneumococcal pneumonia may be noted in older children but are rarely observed in infants and young children, in whom the clinical pattern is considerably more variable. In infants, there may be a prodrome of upper respiratory tract infection and poor feeding, leading to the abrupt onset of fever, restlessness, apprehension, and respiratory distress. These infants typically appear ill, with respiratory distress manifested as grunting; nasal flaring; retractions of the supraclavicular, intercostal, and subcostal areas; tachypnea; tachycardia; air hunger; and often cyanosis. Auscultation may be misleading, particularly in young infants, with meager findings disproportionate to the degree of tachypnea. Some infants with bacterial pneumonia may have associated gastrointestinal disturbances characterized by vomiting, anorexia, diarrhea, and abdominal distention secondary to a paralytic ileus. Rapid progression of symptoms is characteristic in the most severe cases of bacterial pneumonia. Cyanosis often predicts multilobular involvement. Risk factors for severe pneumonia include temperature >38.5°C, tachypnea, retractions, nasal flaring, grunting, capillary refill >2 seconds, cyanosis, tachycardia, and poor feeding.

DIAGNOSIS

In 2011, the Pediatric Infectious Diseases Society (PIDS) and the Infectious Diseases Society of America (IDSA) published clinical practice guidelines for community-acquired pneumonia in children older than 3 months of age. These evidence-based guidelines provide recommendations for diagnostic testing and treatment of previously healthy children with pneumonia in both outpatient and inpatient settings. With the advent of advanced technologies and changing epidemiologic pathogens, these guidelines have required modifications.

An infiltrate on chest radiograph (posteroanterior and lateral views) supports the diagnosis of pneumonia; images may also identify a complication such as a pleural effusion or empyema. Viral pneumonia is usually characterized by hyperinflation with bilateral interstitial infiltrates and peribronchial cuffing (Fig. 449.2). Confluent lobar consolidation is typically seen with pneumococcal pneumonia (Fig. 449.3). The radiographic appearance alone does not accurately identify

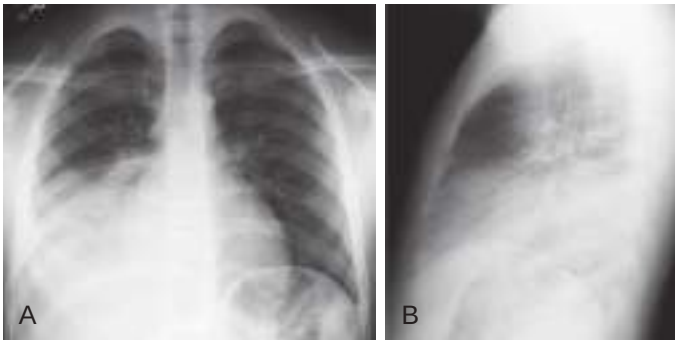

Fig. 449.3 Radiographic findings characteristic of pneumococcal pneumonia in a 14-yr-old male with cough and fever. Posteroanterior (A) and lateral (B) chest radiographs reveal consolidation in the right lower lobe, strongly suggesting bacterial pneumonia.

pneumonia etiology, and other clinical features of the illness must be considered. Repeat chest radiographs are not required for proof of cure for patients with uncomplicated pneumonia. Moreover, current PIDS-IDSA guidelines do not recommend that a chest radiograph be performed for children with suspected pneumonia (tachypnea, cough, fever, localized crackles, or decreased breath sounds) who are well enough to be managed as outpatients because imaging in this context only rarely changes management.

Point-of-care use of portable or handheld ultrasonography is highly sensitive and specific in diagnosing pneumonia in children by

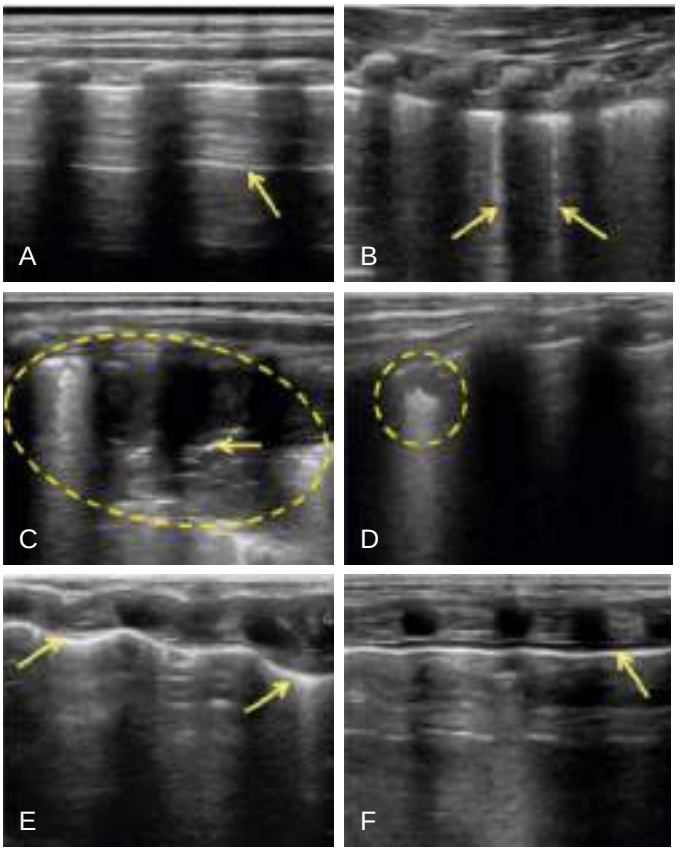

Fig. 449.4 Lung ultrasound patterns. **A,** Negative lung ultrasound pattern with A-line *(arrow)* and no other findings. Positive lung ultrasound patterns with **(B)** B-lines *(arrows)*; **(C)** large consolidation (>1 cm) with tissue-like echo-texture *(circle)* and ultrasonographic bronchograms *(arrow)*; **(D)** small consolidation (<1 cm; *circle*); **(E)** pleural line abnormality with thickening and irregularity *(arrows)*; and **(F)** pleural effusion *(arrow). (From Varshney T, Mok E, Shapiro AJ, et al. Point-of-care lung ultrasound in young children with respiratory tract infections and wheeze. Emerg Med J. 2016;33:603–610, Fig. 1.)*

determining lung consolidations and air bronchograms or effusions (Fig. 449.4). However, the reliability of this imaging modality for pneumonia diagnosis is highly user-dependent, which has limited its widespread use.

The peripheral white blood cell (WBC) count can be useful in differentiating viral from bacterial pneumonia. In viral pneumonia, the WBC count can be normal or elevated but is usually not higher than 20,000/mm^3, with a lymphocyte predominance. Bacterial pneumonia is often associated with an elevated WBC count, in the range of 15,000-40,000/mm^3, and a predominance of polymorphonuclear leukocytes. A large pleural effusion, lobar consolidation, and a high fever at the onset of the illness are also suggestive of a bacterial etiology. Atypical pneumonia caused by *C. pneumoniae* or *M. pneumoniae* is difficult to distinguish from pneumococcal pneumonia on the basis of radiographic and laboratory findings; although pneumococcal pneumonia is associated with a higher WBC count, erythrocyte sedimentation rate, procalcitonin, and C-reactive protein level, there is considerable overlap.

The definitive diagnosis of a viral infection rests on the detection of the viral genome or antigen in respiratory tract secretions. Reliable PCR assays are widely available for the rapid detection of many respiratory viruses, including RSV, parainfluenza, influenza, human metapneumovirus, adenovirus, enterovirus, rhinovirus, and SARS-CoV-2. Serologic techniques can also be used to diagnose a recent respiratory viral infection but generally require testing of acute and convalescent serum samples for a rise in antibodies to a specific virus. This diagnostic technique is laborious, slow, and not generally clinically useful because the infection usually has resolved by the time it is confirmed serologically. Serologic testing may be valuable as an epidemiologic tool to define the incidence and prevalence of various respiratory viral pathogens.

Table 449.5 Factors Suggesting Need for Hospitalization of Children with Pneumonia

Age <6 mo
Immunocompromised state
Toxic appearance
Moderate to severe respiratory distress (retractions, nasal flaring, grunting)
Cyanosis/hypoxemia (oxygen saturation <90% breathing room air, sea level)
Shock (tachycardia, hypotension, prolonged capillary refill time)
Complicated pneumonia*
Sickle cell anemia with acute chest syndrome
Vomiting or inability to tolerate oral fluids or medications
Severe dehydration
No response to appropriate oral antibiotic therapy
Social factors (e.g., inability of caregivers to administer medications at home or follow up appropriately)
High-risk pathogen

*Pleural effusion, empyema, abscess, bronchopleural fistula, necrotizing pneumonia, acute respiratory distress syndrome, extrapulmonary infection (meningitis, arthritis, pericarditis, osteomyelitis, endocarditis), hemolytic uremic syndrome, or sepsis.
Adapted from Baltimore RS. Pneumonia. In: Jenson HB, Baltimore RS, eds. *Pediatric Infectious Diseases: Principles and Practice.* Philadelphia: WB Saunders; 2002: p. 801.

The definitive diagnosis of a typical bacterial infection requires isolation of an organism from the blood, pleural fluid, or lung. Culture of sputum is of little value in the diagnosis of pneumonia in young children, and percutaneous lung aspiration is invasive and not routinely performed. Blood culture is positive in only 10% of children with pneumococcal pneumonia (bacteremia is more common in GAS and *H. influenzae* pneumonias) and is not recommended for nontoxic-appearing children treated as outpatients. Blood cultures are recommended for children who fail to improve or have clinical deterioration, have complicated pneumonia (Table 449.5), or require hospitalization. Pertussis infection can be diagnosed by PCR or culture of a nasopharyngeal specimen; although culture is considered the gold standard for pertussis diagnosis, it is less sensitive than the available PCR assays. Acute infection caused by *M. pneumoniae* can be diagnosed on the basis of a PCR test result from a respiratory specimen or seroconversion in an immunoglobulin G assay. Cold agglutinins at titers >1:64 are also found in the blood of roughly half of patients with *M. pneumoniae* infections; however, cold agglutinins are nonspecific because other pathogens such as influenza viruses may also cause increases. Serologic evidence, such as antistreptolysin O and anti-DNase B titers, may also be useful in the diagnosis of GAS pneumonia.

Noninvasive diagnostic tests *may* help differentiate children with bacterial versus viral causes of pneumonia. Various biomarkers, including C-reactive protein, procalcitonin, and ESR, have been evaluated for their ability to differentiate these pneumonia etiologies. For many of these biomarkers, values differ in children with bacterial compared with viral causes of pneumonia (except adenovirus and influenza), but the reliability of these tests is not sufficiently high to justify routine clinical use. Cell-free next-generation sequencing of plasma or blood has been helpful in identifying pathogens in patients suspected of having bacterial pneumonia; identified pathogens include *S. pneumoniae, S. aureus,* and *Fusobacterium nucleatum* (blood cultures were negative in most of these patients). In addition, culture and PCR analysis of pleural fluid may also yield an organism.

TREATMENT

Treatment of suspected bacterial pneumonia is based on the presumptive cause and the age and clinical appearance of the child. For mildly ill children who do not require hospitalization, amoxicillin is recommended. With the emergence of penicillin-resistant pneumococci, high doses of amoxicillin (90 mg/kg/day orally divided twice daily) should be prescribed unless local data indicate a low prevalence of resistance.

Therapeutic alternatives include cefuroxime and amoxicillin/clavulanate. For school-age children and adolescents or when infection with *M. pneumoniae* or *C. pneumoniae* is suspected, a macrolide antibiotic is an appropriate choice for outpatient management. Azithromycin is generally preferred, but clarithromycin or doxycycline (for children 8 years or older) are alternatives. For adolescents, a respiratory fluoroquinolone (levofloxacin, moxifloxacin) may also be considered as an alternative if there are contraindications to other agents.

The empiric treatment of suspected bacterial pneumonia in a hospitalized child requires an approach based on local epidemiology, the immunization status of the child, and the clinical manifestations at the time of presentation. In areas without substantial high-level penicillin resistance among *S. pneumoniae,* children who are fully immunized against *H. influenzae* type b and *S. pneumoniae* and are not severely ill should receive ampicillin or penicillin G. For children who do not meet these criteria, ceftriaxone or cefotaxime may be used. If infection with *M. pneumoniae* or *C. pneumoniae* is suspected, a macrolide antibiotic should be included in the treatment regimen. If clinical features suggest staphylococcal pneumonia (pneumatoceles, empyema), initial antimicrobial therapy should also include vancomycin or clindamycin. For children with respiratory failure in the setting of influenza–methicillin-resistant *S. aureus* (MRSA) co-infection, data from a multicenter study support combination therapy with vancomycin and a second antibiotic with MRSA activity (e.g., clindamycin).

If viral pneumonia is suspected, it is reasonable to withhold antibiotic therapy, especially for preschool-age patients who are mildly ill, have clinical evidence suggesting viral infection, and are in no respiratory distress. However, up to 30% of patients with known viral infection, particularly influenza viruses, may have coexisting bacterial pathogens. Therefore if the decision is made to withhold antibiotic therapy on the basis of presumptive diagnosis of a viral infection, deterioration in clinical status should signal the possibility of superimposed bacterial infection, and antibiotic therapy should be initiated.

Table 449.5 notes the indications for admission to a hospital. Hospitalized children should receive supportive care and may require intravenous fluids; respiratory support, including supplemental oxygen, continuous positive airway pressure (CPAP), or mechanical ventilation; or vasoactive medications for hypotension or sepsis physiology.

The optimal duration of antibiotic treatment for pneumonia has not been well-established in controlled studies. However, antibiotics should generally be continued until the patient has been afebrile for 72 hours. Several studies suggest that shorter courses (5-7 days) may also be effective, particularly for children managed on an outpatient basis. Available data do not support prolonged courses of treatment for uncomplicated pneumonia. Some studies suggest that a reduction of previously elevated serum procalcitonin levels to an absolute level (0.1-0.25 μg/L) may help determine when to stop treatment.

Despite substantial gains over the past 15 years, less than two thirds of children with symptoms of pneumonia are taken to an appropriate caregiver in low- and middle-income countries, and fewer than half receive antibiotics. The World Health Organization and other international groups have developed systems to train mothers and local healthcare providers in the recognition and appropriate antibiotic treatment of pneumonia. In addition to antibiotics, oral zinc (10 mg/day for <12 months, 20 mg/day for ≥12 months given for 7 days) may reduce mortality among children in low- and middle-income countries with clinically defined severe pneumonia. Bubble CPAP improves mortality from pneumonia with hypoxemia compared with standard oxygen therapy in settings without access to ventilator-derived CPAP or mechanical ventilation.

PROGNOSIS

Typically, patients with uncomplicated community-acquired bacterial pneumonia show response to therapy, with improvement in clinical symptoms (fever, cough, tachypnea, chest pain), within 48-72 hours of initiation of antibiotics. Radiographic evidence of improvement lags substantially behind clinical improvement. A number of possibilities must be considered when a patient does not improve with appropriate antibiotic therapy: (1) complications, such as pleural effusion or empyema (see Table 449.5); (2) bacterial resistance; (3) nonbacterial etiologies such as viruses or fungi and aspiration of foreign bodies or food; (4) bronchial obstruction from endobronchial lesions, foreign body, or mucous plugs; (5) preexisting diseases such as immunodeficiencies, ciliary dyskinesia, cystic fibrosis, pulmonary sequestration, or congenital pulmonary airway malformation; and (6) other noninfectious causes (including bronchiolitis obliterans, hypersensitivity pneumonitis, eosinophilic pneumonia, and granulomatosis with polyangiitis, formerly called *Wegener granulomatosis*). A chest radiograph is the first step in determining the reason for a lack of response to initial treatment. Bronchoalveolar lavage may be indicated in children with respiratory failure. High-resolution CT scans may better identify complications or an anatomic reason for a poor response to therapy.

Mortality from community-acquired pneumonia in developed countries is rare, and most children with pneumonia do not experience long-term pulmonary sequelae. Some data suggest that up to 45% of children have symptoms of asthma 5 years after hospitalization for pneumonia; this finding may reflect either undiagnosed asthma at the time of presentation or a propensity for development of asthma after pneumonia.

COMPLICATIONS

Complications of pneumonia (see Table 449.5) are usually the result of direct spread of bacterial infection within the thoracic cavity (pleural effusion, empyema, and pericarditis) or bacteremia and hematologic spread (Figs. 449.5-449.7). Meningitis, endocarditis, suppurative arthritis, and osteomyelitis are rare complications of hematologic spread of pneumococcal or *H. influenzae* type b infection.

S. aureus, S. pneumoniae, and *S. pyogenes* (GAS) are the most common causes of parapneumonic effusions and empyema. Nonetheless many effusions that complicate bacterial pneumonia are sterile. Analysis of pleural fluid parameters, including pH, glucose, protein, and lactate dehydrogenase, can differentiate transudative from exudative effusions (Table 449.6). However, current PIDS-IDSA guidelines do not recommend that these tests be performed because this distinction rarely changes management. Pleural fluid should be sent for Gram stain and bacterial culture, as this may identify the bacterial cause of pneumonia. Molecular methods, including bacterial species–specific PCR

Fig. 449.5 Chest radiograph of large right-sided pleural effusion complicating community-acquired pneumonia. *(From de Benedictis FM, Kerem E, Chang AB, et al. Complicated pneumonia in children. Lancet. 2010;396:786–798, Fig. 1, p. 789.)*

assays, detect pathogens and can often determine the bacterial etiology of the effusion if the culture is negative, particularly if the pleural fluid sample was obtained after initiation of antibiotics. A pleural fluid WBC count with differential may be helpful if there is suspicion for pulmonary tuberculosis or a noninfectious etiology for the pleural effusion, such as malignancy.

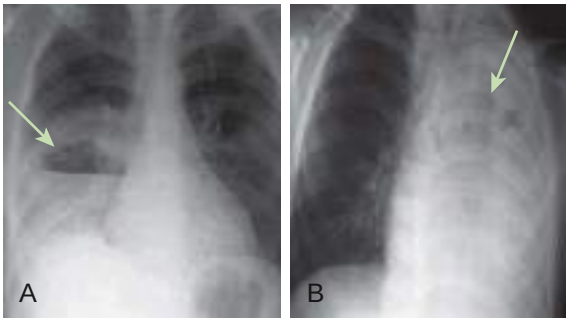

Fig. 449.6 Chest radiographs of lung abscess and necrotizing pneumonia. **A,** Lung abscess. A single thick walled, irregular cavity containing an air-fluid level can be seen *(arrow).* **B,** Necrotizing pneumonia. A completely opacified left hemithorax with multiple necrotic areas can be seen *(arrow). (From de Benedictis FM, Kerem E, Chang AB, et al. Complicated pneumonia in children. Lancet. 2010;396:786–798, Fig. 2, p. 789.)*

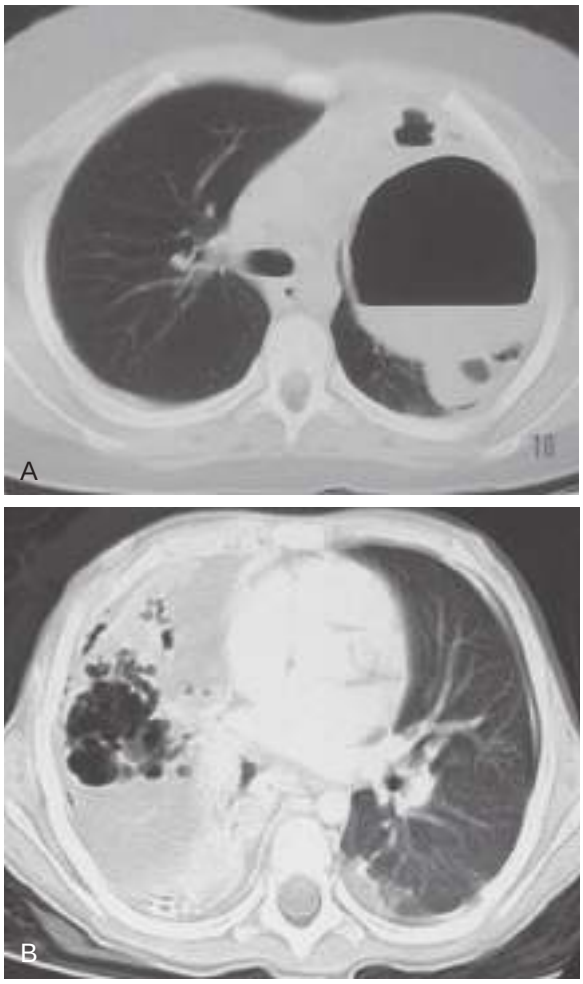

Fig. 449.7 Chest CT in complicated community-acquired pneumonia. **A,** Lung abscess. A large cavity containing an air-fluid level can be seen. **B,** Necrotizing pneumonia with cavitation. *(From de Benedictis FM, Kerem E, Chang AB, et al. Complicated pneumonia in children. Lancet. 2010;396:786–798, Fig. 4, p. 790.)*

Small (<1 cm on lateral decubitus radiograph), free-flowing parapneumonic effusions often do not require drainage but respond to appropriate antibiotic therapy. Larger effusions should typically be drained, particularly if the effusion is purulent or associated with respiratory distress. Chest ultrasound, or alternatively CT, may be helpful in determining whether loculations are present. The mainstays of therapy include antibiotic therapy and drainage by tube thoracostomy with the instillation of fibrinolytic agents (tissue plasminogen activator). Video-assisted thoracoscopy is a less often employed alternative that enables debridement or lysis of adhesions and drainage of loculated areas of pus. Early diagnosis and intervention, particularly with fibrinolysis or, less often, video-assisted thoracoscopy, may obviate the need for thoracotomy and open debridement.

PREVENTION

The introduction of PCVs resulted in a substantial reduction in the incidence of pneumonia hospitalizations among children. The annual rate of all-cause pneumonia hospitalization among children younger than 2 years of age in the United States was 12.5 per 1,000 children during the period from 1997 to 1999. In 2000, seven-valent pneumococcal conjugate vaccine (PCV7) was licensed and recommended. In 2006, the pneumonia hospitalization rate in this age-group was 8.1 per 1,000 children, a 35% decrease from the prevaccine rate. In 2010, 13-valent pneumococcal conjugate vaccine (PCV13) was licensed in the United States; data indicate that introduction of this vaccine resulted in a 16–27% further reduction in pneumonia hospitalizations among children relative to the post-PCV7 era.

Influenza vaccine may also prevent pneumonia hospitalizations among children and should be administered to all children >6 months of age. For infants <6 months of age, household contacts and other primary caregivers should receive the influenza vaccine. Maintaining high rates of vaccination for *H. influenzae* type b, pertussis, and measles remains important for the prevention of pneumonia from these causes. Several RSV vaccines are currently under development; introduction of an effective vaccine against RSV would be anticipated to substantially reduce pneumonia incidence among children, particularly young infants. Several vaccines that are highly effective in preventing COVID-19 have received Emergency Use Authorization by the U.S. Food and Drug Administration for use in children 6 months of age or older (see Chapter 449.1); such vaccines are often updated to cover emergence of new variants.

Visit Elsevier eBooks+ at eBooks.Health.Elsevier.com for Bibliography.

449.1 COVID-19

Matthew S. Kelly and Thomas J. Sandora

See also Chapter 311.

Severe acute respiratory syndrome coronavirus 2 (SARS-CoV-2), the etiologic agent of coronavirus disease 2019 (COVID-19), has created a global pandemic. As of July 2023, SARS-CoV-2 caused more than 767 million cases and 6.9 million deaths worldwide. SARS-CoV-2 is spread primarily through person-to-person respiratory transmission; viral particles in respiratory secretions that are released when an infected individual coughs, sneezes, or talks can infect another person when inhaled or through contact with mucous membranes. Direct person-to-person contact and fomites are believed to play minor roles in SARS-CoV-2 transmission. The incubation period for the virus can be up to 14 days after exposure, with most cases occurring within 4-5 days. Public health measures such as face masks, physical distancing, stay-at-home orders, and restrictions on public gatherings are highly effective in interrupting SARS-CoV-2 transmission (see Chapter 214). Several vaccines have been developed that are effective in preventing SARS-CoV-2 infection and severe COVID-19. SARS-CoV-2 has undergone substantial genetic evolution since it was first identified; several viral variants have emerged that are associated with different clinical symptoms along with increased transmissibility and reduced vaccine effectiveness.

Table 449.6 Features Differentiating Exudative from Transudative Pleural Effusion

FEATURE	TRANSUDATE	EXUDATE
Appearance	Serous	Cloudy
Leukocyte count	<10,000/mm^3	>50,000/mm^3
pH	>7.2	<7.2
Protein	<3.0 g/dL	>3.0 g/dL
Ratio of pleural fluid protein to serum	<0.5	>0.5
LDH	<200 IU/L	>200 IU/L
Ratio of pleural fluid LDH to serum	<0.6	>0.6
Glucose	≥60 mg/dL	<60 mg/dL

LDH, Lactate dehydrogenase.
From Septimus EJ. Pleural effusion and empyema. In: Bennett JE, Blaser MJ, Dolin R, et al. eds. *Mandell, Douglas, and Bennett's Principles and Practice of Infectious Diseases*, 8th ed. Philadelphia: Saunders; 2015: Table 70-1, p. 851.

Some data suggest that children and adolescents may be less susceptible to SARS-CoV-2 infection than adults. In a meta-analysis that included data from 18 contact-tracing studies, children and adolescents less than 20 years of age had a 44% lower odds of being an infected contact compared to adults 20 years of age or older. However, widespread transmission of SARS-CoV-2 has occurred among children in schools and other congregate childcare settings, typically when face masks and other mitigation measures have not been in place.

CLINICAL MANIFESTATIONS

In children, COVID-19 is generally a mild illness, characterized most frequently by low-grade fever (30–50%) and cough (30–50%). Other commonly reported symptoms include nasal congestion or rhinorrhea, myalgias, and pharyngitis. Older children and adolescents often report headache, loss of smell (anosmia), or loss of taste (dysgeusia). Gastrointestinal symptoms such as abdominal pain, diarrhea, and vomiting occur less frequently but may be the presenting complaints in some children. Skin findings occur infrequently with SARS-CoV-2 infection, although maculopapular rash, urticarial lesions, and reddish-purple nodules on the toes (sometimes referred to as "COVID toes") have been described. Tachypnea and signs of increased work of breathing should raise suspicion for pneumonia, the most common serious clinical manifestation of COVID-19. Severe neurologic symptoms such as seizures and encephalopathy have been reported among children hospitalized for severe COVID-19. *There are no signs or symptoms that can reliably distinguish COVID-19 from other illnesses caused by respiratory viruses or bacteria.* Up to 20–30% of children and adolescents with COVID-19 have asymptomatic infections; these individuals can still effectively transmit the virus to others.

Children and adolescents with SARS-CoV-2 infection are at a lower risk of severe COVID-19 than adults. Despite accounting for 10–20% of SARS-CoV-2 infections in the United States as of August 2021, children and adolescents represented less than 3% of hospitalizations and less than 0.5% of deaths from COVID-19. Children with underlying medical conditions are at higher risk of developing severe COVID-19. Data on risks associated with specific conditions in children are currently lacking, but the Centers for Disease Control and Prevention suggests that children with obesity, medical complexity, neurodevelopmental disorders, congenital heart disease, asthma or chronic lung disease, diabetes, or sickle cell disease may be at higher risk of progression to severe illness (Table 449.7). Children are also at higher risk of **multisystem inflammatory syndrome in children** (MIS-C; see Chapter 207), a postinfectious inflammatory condition that typically occurs in the 4-6 weeks after SARS-CoV-2 infection.

DIAGNOSIS

The IDSA recommends that children who have symptoms compatible with COVID-19, or asymptomatic individuals with known or suspected exposure to an individual diagnosed with COVID-19, be tested for SARS-CoV-2 using a nucleic acid amplification test (NAAT). In symptomatic individuals with a low clinical suspicion of COVID-19, a single NAAT test is considered sufficient, and testing should not be repeated if the result is negative. If the clinical suspicion for COVID-19 is considered intermediate or high but the initial test is negative, a repeat test should be performed 24-48 hours after initial testing. When available, standard laboratory-based NAATs or rapid reverse transcriptase (RT)-PCR tests are recommended over rapid isothermal NAATs because of higher sensitivity (98% for both standard laboratory-based NAATs and rapid RT-PCR vs 81% for rapid isothermal NAATs), despite comparable specificity. Rapid antigen tests are widely available and have high specificity but low to modest sensitivity compared with NAAT. Antigen test sensitivity is highly dependent on viral load, and therefore is influenced by the presence of symptoms and the timing of the test. For these reasons, IDSA does not recommend antigen tests as the preferred testing strategy, but rather maintains that antigen testing can identify some individuals infected with SARS-CoV-2 when molecular testing is not available.

A variety of specimen types can be tested for the presence of SARS-CoV-2, including nasopharyngeal (NP) swab, NP wash/aspirate, nasal wash/aspirate, oropharyngeal (OP) swab, nasal mid-turbinate (MT) swab, anterior nares (AN) swab, or saliva. Assay performance is highly dependent on collection procedure. IDSA recommends collecting an NP swab, MT swab, AN swab, saliva, or a combined AN/OP swab rather than an OP swab alone for symptomatic individuals suspected of having COVID-19. For hospitalized patients with suspected pneumonia and clinical suspicion for COVID-19, IDSA suggests a strategy of initially obtaining an upper respiratory specimen (e.g., NP swab) rather than a lower respiratory sample. However, if the initial specimen is negative and suspicion for disease remains high, a lower respiratory specimen (e.g., sputum, bronchoalveolar lavage fluid, or tracheal aspirate) should be collected rather than repeating the test from an upper respiratory sample.

Common laboratory abnormalities among children hospitalized for severe COVID-19 include lymphopenia, elevated aminotransaminases, and elevated markers of inflammation (e.g., C-reactive protein). Although imaging findings are neither sensitive nor specific for COVID-19, the most common abnormalities on chest radiography in children are perihilar bronchial wall thickening and/or air space consolidation. CT scans may show ground-glass opacities (mainly in the lower lobes) and/or air space consolidation. Chest radiography should be used as the first imaging modality to assess for pneumonia in symptomatic children, whereas CT should be reserved for assessing

Table 449.7 Framework for Assessing the Risk of Progression to Severe COVID-19 Based on Patient Conditions and COVID-19 Vaccination Status

CONDITIONS	RISK LEVEL BY VACCINATION STATUS[a]		
	UNVACCINATED	PRIMARY SERIES	UP TO DATE
STRONG OR CONSISTENT ASSOCIATION WITH PROGRESSION TO SEVERE COVID-19			
• Moderately or severely immunocompromised	High	High	High
• Obesity (BMI ≥95th percentile for age), especially severe obesity (BMI ≥120% of 95th percentile for age)[b] • Medical complexity with dependence on respiratory technology[c] • Severe neurologic, genetic, metabolic, or other disability that results in impaired airway clearance or limitations in self-care or activities of daily living • Severe asthma or other severe chronic lung disease requiring ≥2 inhaled or ≥1 systemic medications daily • Severe congenital or acquired cardiac disease • Multiple moderate to severe chronic diseases	High	Intermediate	Intermediate
MODERATE OR INCONSISTENT ASSOCIATION WITH PROGRESSION TO SEVERE COVID-19			
• Age <1 yr • Prematurity in children age ≤2 yr • Sickle cell disease • Diabetes mellitus (poorly controlled) • Nonsevere cardiac, neurologic, or metabolic disease[d]	Intermediate	Intermediate	Intermediate
WEAK OR UNKNOWN ASSOCIATION WITH PROGRESSION TO SEVERE COVID-19			
• Mild asthma • Overweight • Diabetes mellitus (well controlled)	Low	Low	Low

[a]**Unvaccinated** = individuals who are not eligible for COVID-19 vaccination or are <2 wk from the final dose of the primary series. **Vaccinated with primary series** = individuals who completed the primary series of two or three doses (the current CDC term is *fully vaccinated*) and are >2 wk after the final dose of the primary series but have not received a booster if they are eligible for a booster. **Vaccinated and up to date** = individuals who received the recommended primary series and booster doses.
[b]The degree of risk conferred by obesity in younger children is less clear than it is in older adolescents.
[c]This includes patients with a tracheostomy and those who require NIV.
[d]The data for this group are particularly limited.
BMI, Body mass index; CDC, Centers for Disease Control and Prevention; NIV, noninvasive ventilation; the Panel, the COVID-19 Treatment Guidelines Panel
From NIH COVID-19 Treatment Guidelines (Table 3b). https://www.covid19treatmentguidelines.nih.gov/tables/assessing-risk/

for complications, particularly in children with coexisting medical conditions.

TREATMENT

For ambulatory patients with mild to moderate COVID-19 at high risk for progression to severe disease (e.g., obesity or overweight, immunosuppression, medical-related technologic dependence, or a chronic medical condition such as kidney disease, diabetes, cardiovascular disease, sickle cell disease, or neurodevelopmental disorders), current treatment options include nirmatrelvir/ritonavir (≥12 years of age) or a 3-day course of remdesivir. Nirmatrelvir is an inhibitor of the main protease of SARS-CoV-2; coadministration with ritonavir results in higher concentrations and a longer half-life. Remdesivir is an antiviral agent that works by interfering with viral RNA transcription (see Table 449.8). As of July 2023, no monoclonal antibodies have been authorized for COVID-19 treatment or prophylaxis because of reduced susceptibility of circulating Omicron subvariants to these products.

For hospitalized children with severe illness (SpO_2 ≤94% on room air, including patients on supplemental oxygen) or critical illness (mechanical ventilation or extracorporeal membrane oxygenation [ECMO]), dexamethasone treatment is recommended (Table 449.8). Inflammatory injury from the host immune response is thought to play a role in patients with severe or critical illness.

The IDSA recommends remdesivir for hospitalized patients with SpO_2 ≤94% on room air, including patients on supplemental oxygen, but suggests against routine administration to patients on mechanical ventilation and/or ECMO. A panel of pediatric infectious diseases physicians and pharmacists recommended that remdesivir could be considered on a case-by-case basis for children with severe or critical COVID-19. Children receiving remdesivir should have daily measurements of creatinine and transaminases.

Tocilizumab is a monoclonal anti–interleukin (IL)-6-receptor blocking antibody. The IDSA suggests tocilizumab in addition to standard of care for hospitalized adults with progressive severe or critical COVID-19 who have elevated markers of systemic

inflammation. Baricitinib is a selective Janus kinase 1 and 2 inhibitor that has been studied as a substitute for dexamethasone in patients who cannot receive corticosteroids because of a contraindication (see Table 449.8).

PREVENTION

Vaccination is the most effective intervention to prevent COVID-19 infection and is highly protective against severe illness, hospitalization, and death. COVID-19 vaccination is available for use in children ≥6 months of age. Vaccine modifications are necessary when new variants emerge.

Because the emergence of viral variants with the potential to escape vaccine-induced immunity remains a threat, nonpharmaceutical interventions to mitigate transmission of SARS-CoV-2 still play an important role in the public health response. Face mask use, eye protection, and physical distancing have all been demonstrated to reduce the risk of infection. A cross-sectional study conducted in the United States found an increase in reported mask-wearing was associated with an increased odds of transmission control. A modeling study by the Centers for Disease Control and Prevention demonstrated that high vaccination coverage and compliance with nonpharmaceutical interventions are essential to control COVID-19.

Visit Elsevier eBooks+ at eBooks.Health.Elsevier.com for Bibliography.

Table 449.8 Therapeutic Management of Hospitalized Children with COVID-19

DISEASE SEVERITY	PANEL'S RECOMMENDATIONS
Hospitalized for COVID-19	For children age ≥12 yr admitted for COVID-19, use prophylactic anticoagulation unless contraindicated.
Does Not Require Supplemental Oxygen	For children admitted for COVID-19 who are at the highest risk of progression to severe COVID-19,[a] consider using remdesivir[b] for children age 12-17 yr. There is insufficient evidence for using remdesivir in children age 28 days to <12 yr. For children admitted for reasons other than COVID-19 who have mild to moderate COVID-19 and are at the highest risk of progression, see footnote *a*.
Requires Conventional Oxygen	Use one of the following options: • Remdesivir[b] • Dexamethasone plus remdesivir[b] for children with increasing oxygen needs, particularly adolescents
Requires Oxygen Through High-Flow Device or NIV[d]	Use one of the following options: • Dexamethasone • Dexamethasone plus remdesivir[b] For children who do not have rapid (e.g., within 24 hr) improvement in oxygenation after initiation of dexamethasone, baricitinib[e] or tocilizumab can be considered for children aged 12-17 yr (BIII) and for children age 2-11 yr, respectively.
Requires MV or ECMO[f]	Dexamethasone[f] For children who do not have rapid (e.g., within 24 hr) improvement in oxygenation after initiation of dexamethasone, baricitinib[e] or tocilizumab may be considered for children age 12-17 yr and for children age 2-11 yr, respectively.

[a] For example, for children who are severely immunocompromised regardless of COVID-19 vaccination status and those who are unvaccinated and have additional risk factors for progression.
[b] The clinical benefit of remdesivir is greatest if it is initiated within 10 days of symptom onset. Remdesivir should be given for 5 days or until hospital discharge, whichever comes first.
[c] Conventional oxygen refers to oxygen supplementation that is not high-flow oxygen, NIV, MV, or ECMO.
[d] Patients who are receiving NIV or MV at baseline and require a substantial increase in baseline support should be treated per the recommendations for patients requiring new NIV or MV.
[e] Tofacitinib is an alternative if baricitinib is not available.
[f] For children who started receiving remdesivir before admission to the ICU, remdesivir should be continued to complete the treatment course.
ECMO, Extracorporeal membrane oxygenation; ICU, intensive care unit; MV, mechanical ventilation; NIV, noninvasive ventilation.
From NIH COVID-19 Treatment Guidelines (Table 3c). https://www.covid19treatmentguidelines.nih.gov/management/clinical-management-of-children/hospitalized-children-therapeutic-management/

Chapter 450

E-Cigarette or Vaping Product Use–Associated Lung Injury (EVALI)

Lynn A. D'Andrea and Louella B. Amos

Beginning in 2019, there was a nationwide outbreak of patients who presented with acute lung injury believed to be related to vaping, designated as *E-cigarette or vaping product use–associated lung injury* (EVALI).

EPIDEMIOLOGY

As of January 2020, there were >2,500 hospitalized EVALI patients reported by all 50 states (approximately two thirds of patients were male). The median patient age was 21 years (range 13-85 years). The Centers for Disease Control and Prevention (CDC) stopped collecting data on EVALI cases in early 2020 because of the COVID-19 pandemic; although the number of cases may have decreased, EVALI must be considered in patients with features associated with the condition (Fig. 450.1).

Among hospitalized patients with information on substances used, ~90% reported using any tetrahydrocannabinol (THC)-containing product and ~70% reported using any nicotine-containing product; 40–60% reported both THC and nicotine use. The THC products were often flavored, prefilled THC cartridges obtained from black market sources.

PATHOPHYSIOLOGY

Carrier solvents or humectants such as propylene glycol and glycerin, as well as nicotine vapor itself, can cause airway inflammation

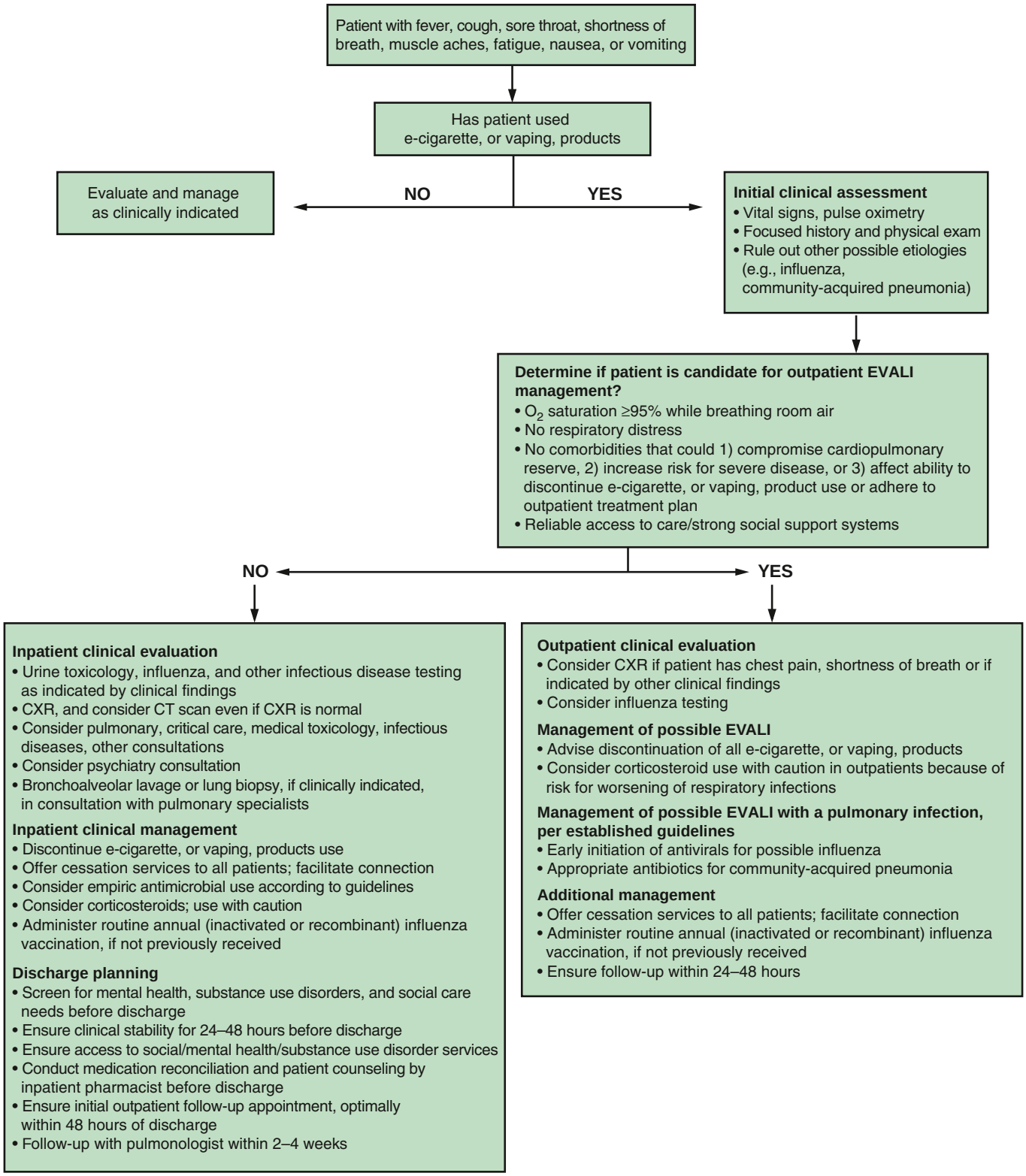

Fig. 450.1 Updated algorithm for management of patients with suspected e-cigarette, or vaping, product use–associated lung injury (EVALI), December 2019. CT, Computed tomography; CXR, chest x-ray.* Influenza vaccination recommendations: https://www.cdc.gov/mmwr/volumes/68/rr/rr6803a1.htm?s_cid=rr6803a1_w. *(From Evans ME, Twentyman E, Click ES, et al. Update: interim guidance for health care professionals evaluating and caring for patients with suspected E-cigarette, or vaping, product use-associated lung injury and for reducing the risk of rehospitalization and death following hospital discharge – United States, December 2019. MMWR. 2020;68:1189-1194, Fig. p. 1191.)*

that can induce airway remodeling and disrupt alveolar macrophage function. Flavoring additives generate by-products that directly injure airway epithelium. Vitamin E acetate that was used as a diluent in the THC-containing products disrupts alveolar macrophage function and surfactant homeostasis. EVALI is best considered an airway-centered chemical pneumonitis rather than an exogenous lipoid pneumonia. Thermal injury can also be a factor in acute lung injury.

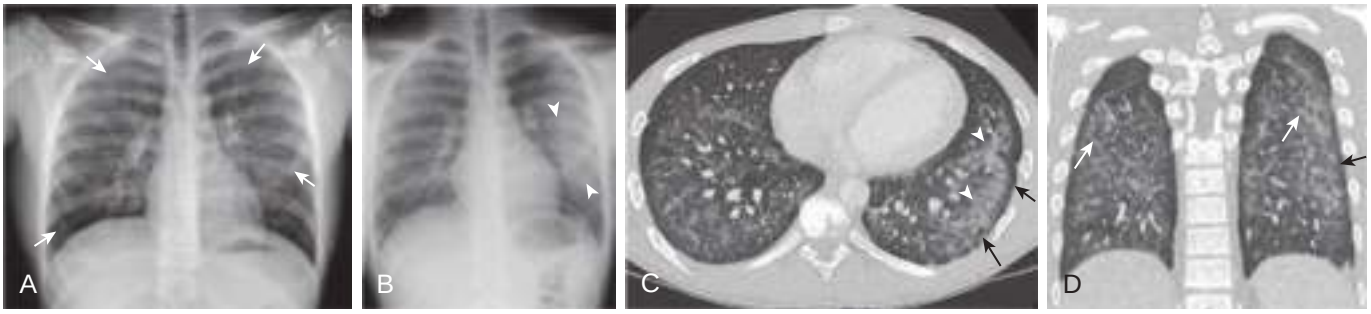

Fig. 450.2 E-cigarette, or vaping, product use–associated lung injury in a 16-yr-old male who presented with chest pain, shortness of breath, and cough for 1 month. **A,** Posteroanterior (PA) radiograph of the chest demonstrates faint nodular opacities in both lungs *(arrows)* with diffusely increased interstitial markings. **B,** PA radiograph of the chest obtained 2 days later demonstrates progression of the nodular opacities into confluent opacities in the left mid-lung *(arrowheads)*. Axial **(C)** and coronal **(D)** chest CT images in lung windows (slice thickness 0.63 mm, kVp 100, mAs 61-106) obtained 4 days after the initial chest radiograph demonstrate centrilobular ground-glass nodules in both lungs and confluent ground-glass opacities in the left lower lobe *(arrowheads)* with subpleural sparing *(black arrows)* and interstitial septal thickening *(white arrows)*. *(From Thakrar PD, Boyd KP, Swanson CP, et al. E-cigarette, or vaping, product use-associated lung injury in adolescents: a review of imaging features. Pediatr Radiol. 2020;50:338–344, Fig. 1, p. 340.)*

CLINICAL MANIFESTATIONS

Acutely, patients often present with a combination of respiratory distress, gastrointestinal (GI), and constitutional symptoms. Respiratory symptoms include shortness of breath, cough, hemoptysis, and chest or pleuritic pain. On physical examination, patients have tachypnea with hypoxemia and tachycardia. GI symptoms include nausea, vomiting, diarrhea, and abdominal pain.

Subacute constitutional and GI symptoms can occur day to weeks before the acute presentation. Constitutional symptoms include weight loss, fatigue, fever, myalgias, and chills.

DIAGNOSIS

There is no specific test for lung injury associated with EVALI; rather, evaluation should primarily focus on excluding infectious causes. It is important to evaluate for other possible causes (rheumatologic, neoplastic, cardiac) as appropriate (see Fig. 450.1).

Imaging

Chest radiographic evaluation is key in the diagnosis of EVALI, although findings are generally nonspecific (Fig. 450.2). Chest CT imaging is most consistent with acute lung injury from toxic inhalation, with centrilobular ground-glass opacities with subpleural sparing. The most common radiologic findings reported on chest x-ray are bilateral infiltrates, and ground-glass opacities predominantly at the bases. The most common radiologic findings reported on chest CT are bilateral infiltrates, bilateral ground-glass opacities, and subpleural sparing, followed by small pleural effusions and centrilobular nodularity. Pneumothorax and pneumomediastinum are less common.

Laboratory

Laboratory evaluation is suggestive of inflammation with neutrophilic leukocytosis, elevated C-reactive protein (CRP), and erythrocyte sedimentation rate (ESR). Elevated transaminases (AST/ALT) and lactate dehydrogenase (LDH) have been reported in some patients. Urine drug screening is useful to confirm the presence of THC or nicotine.

Other Testing

Pulmonary Function Testing

The acute effects of EVALI on lung function are variable. In a case series of adolescents hospitalized with EVALI, predischarge testing demonstrated that >50% had an abnormality on spirometry, with a restrictive pattern occurring twice as often as obstruction; ~60% of patients had a decreased diffusion capacity, and ~50% had an abnormal 6-minute walk test. Patients continued to have abnormal testing at follow-up, including abnormal spirometry (both obstructive and restrictive patterns), decreased diffusion capacity, and rarely, 6-minute walk test. One follow-up study also identified abnormal 6-minute walk tests as a marker of lung injury and submaximal exercise capacity. However, another follow-up study showed ~85% of previously hospitalized pediatric patients had normal spirometry.

Bronchoscopy

Bronchoscopy with bronchoalveolar lavage is used to evaluate for possible infectious processes. Gross pathologic abnormalities can include mucosal hypervascularity, diffuse mucosal erythema, punctate mucosal hemorrhage, and frank airway bleeding consistent with a pulmonary hemorrhage. Cytopathologic findings commonly include lipid-laden macrophages on oil-red-O staining and elevated neutrophil counts more than 10% of total cell differential. Hemosiderin-laden macrophages are absent. Bacterial cultures are negative.

Caution is required when performing bronchoscopy with lavage, as it may worsen the patient's respiratory status. Many patients develop significant airway reactivity (bronchospasm) that requires intraprocedure management.

TREATMENT

Treatment focuses on supportive care. Supplemental oxygen may be required to maintain oxygen saturations in an appropriate range. Bronchodilators should be considered if there is an element of bronchospasm. Some patients have been treated with systemic corticosteroids with good improvement of their symptoms, but this should be considered on a case-by-case basis (see Fig. 450.1). Antibiotics should *only* be used for secondary infection.

Less often, patients have required more invasive respiratory support, including high-flow nasal cannula, mechanical ventilation, and rarely, extracorporeal membrane oxygenation (ECMO). There are rare case reports of patients requiring lung transplantation.

Follow-up should include recommendations regarding vaping cessation; some patients will require assistance with nicotine replacement therapy (see Chapter 157.2). Many adolescents require support from a mental health provider (see Fig. 450.1).

Advocacy and Prevention

In December 2019, the federal government passed legislation raising the age for purchasing tobacco products, including e-cigarettes, from 18 to 21 years. The FDA set the deadline for e-cigarette manufacturers to submit their marketing applications or risk having their products taken off the market. As of September 2021, the FDA ordered over 90% of e-cigarette products off the market; however, many products appealing to youth, including disposable flavored e-cigarettes, remain available, and the black market continues to thrive.

The initial EVALI outbreak primarily affected young adults, was driven by the use of THC-containing products from black market sources, and was strongly linked to vitamin E acetate. However, 15–20% of reported EVALI cases describe the exclusive use of nicotine-containing products. It is recommended that the term *EVALI* refer to all e-cigarette-related lung injuries, including other chronic respiratory symptoms of vaping (e.g., chronic wheeze, recurrent bronchitis, asthma exacerbations, emphysema).

Visit Elsevier eBooks+ at eBooks.Health.Elsevier.com for Bibliography.

Chapter 451

Pleurisy, Pleural Effusions, and Empyema

Aarthi P. Vemana and Suraiya K. Haider

Pleurisy is the inflammation of the pleura; it may be accompanied by an effusion. The most common cause of pleural effusion in children is bacterial pneumonia (see Chapter 449); other common causes include heart failure (see Chapter 491), rheumatologic and immune causes, and metastatic or intrathoracic malignancy. A variety of other diseases account for the remaining cases, including tuberculosis (see Chapter 261), lupus erythematosus (see Chapter 199), aspiration pneumonitis (see Chapter 446), uremia, pancreatitis, subdiaphragmatic abscess, and rheumatoid arthritis.

Inflammatory processes in the pleura are usually divided into three types: dry pleurisy, serofibrinous or serosanguineous, and purulent pleurisy or empyema.

451.1 Dry Pleurisy

Aarthi P. Vemana and Suraiya K. Haider

Dry pleurisy, formerly called *plastic pleurisy,* may be associated with acute bacterial or viral pulmonary infections or may develop during the course of an acute upper respiratory tract illness. The condition is also associated with tuberculosis and autoimmune and systemic inflammatory diseases such as systemic lupus erythematosus.

PATHOLOGY AND PATHOGENESIS

The process is usually limited to the visceral pleura, with small amounts of yellow serous fluid and adhesions between the pleural surfaces. In tuberculosis, pleurisy can be caused by a severe delayed-type hypersensitivity reaction to *Mycobacterium tuberculosis*; the adhesions develop rapidly, and the pleura are often thickened. Occasionally, fibrin deposition and adhesions are severe enough to produce a fibrothorax that markedly inhibits the excursions of the lung.

CLINICAL MANIFESTATIONS

The primary disease often overshadows signs and symptoms of pleurisy. Pain, the principal symptom, is exaggerated by deep breathing, coughing, and straining. Occasionally, pleural pain is described as a dull ache, which is less likely to vary with breathing. The pain is often localized over the chest wall and is referred to the shoulder or the back. Pain with breathing is responsible for grunting and guarding of respirations, and the child often lies on the affected side in an attempt to decrease respiratory excursions. Early in the illness, a leathery, rough, inspiratory, and expiratory friction rub may be audible, but it usually disappears rapidly. If the layer of exudate is thick, increased dullness to percussion and decreased breath sounds may be heard. Pleurisy may be asymptomatic. Chronic pleurisy is occasionally encountered with conditions such as atelectasis, pulmonary abscess, connective tissue diseases, and tuberculosis.

LABORATORY FINDINGS

Dry pleurisy may be detected on radiographs as a diffuse haziness at the pleural surface or a dense, sharply demarcated shadow (Figs. 451.1 and 451.2). The latter finding may be indistinguishable from small amounts of pleural exudate. Chest radiographic findings may be normal, but ultrasonography or CT findings will be positive.

DIFFERENTIAL DIAGNOSIS

Pleurisy pain must be distinguished from other diseases, such as epidemic pleurodynia, trauma to the rib cage (rib fracture), lesions of the dorsal root ganglia, tumors of the spinal cord, herpes zoster, gallbladder disease, and trichinosis. Even if evidence of pleural fluid is not found on physical or radiographic examination, a CT- or ultrasound-guided pleural tap in suspected cases often results in the recovery of a small amount of exudate, which, when cultured, may reveal the underlying bacterial cause in patients with an acute pneumonia. Patients with pleurisy and pneumonia should always be screened for tuberculosis.

TREATMENT

Therapy should be aimed at the underlying disease. When pneumonia is present, neither immobilization of the chest with adhesive plaster nor therapy with drugs capable of suppressing the cough reflex is indicated. If pneumonia is not present or is under good therapeutic control, strapping of the chest to restrict expansion may afford relief from pain. Analgesia with nonsteroidal antiinflammatory agents may be helpful.

Visit Elsevier eBooks+ at eBooks.Health.Elsevier.com for Bibliography.

451.2 Serofibrinous or Serosanguineous Pleurisy with Pleural Effusion

Aarthi P. Vemana and Suraiya K. Haider

Serofibrinous pleurisy is defined by a fibrinous exudate on the pleural surface and an exudative effusion of serous fluid into the pleural cavity. In general, it is associated with infections of the lung or with inflammatory conditions of the abdomen or mediastinum; occasionally, it is found with connective tissue diseases such as lupus erythematosus, periarteritis, and rheumatoid arthritis, and it may be seen with primary or metastatic neoplasms of the lung, pleura, or mediastinum. Tumors are commonly associated with a hemorrhagic fluid. Infectious etiologies include *Streptococcus pneumonia, Staphylococcus aureus* including methicillin-resistant *S. aureus* (MRSA), group A streptococcus, and viral infections, including COVID-19 (although pleural disease is seen in approximately 10%).

PATHOGENESIS

Pleural fluid originates from the capillaries of the parietal pleura and is absorbed from the pleural space via pleural stomas and the lymphatics of the parietal pleura. The rate of fluid formation is dictated by the Starling law, by which fluid movement is determined by the balance of hydrostatic and osmotic pressures in the pleural space and pulmonary capillary bed and the permeability of the pleural membrane. Normally, approximately 10 mL of fluid is present in the pleural space, but if formation exceeds clearance, fluid accumulates. Pleural inflammation increases the permeability of the plural surface, with increased proteinaceous fluid formation; there may also be some obstruction to lymphatic absorption.

CLINICAL MANIFESTATIONS

Because serofibrinous pleurisy is often preceded by the dry type, early signs and symptoms may be those of dry pleurisy. As fluid accumulates, pleuritic pain may disappear. The patient may become asymptomatic if the effusion remains small, or there may be only signs and symptoms of the underlying disease. Large fluid collections can produce cough, dyspnea, retractions, tachypnea, orthopnea, or cyanosis. In children with bacterial pneumonia, pleural effusion should be suspected when symptoms do not improve after 48 hours of appropriate therapy.

Physical findings depend on the amount of effusion. Dullness to flatness may be found on percussion. Breath sounds are decreased or absent, and there is a diminution in tactile fremitus, a shift of the mediastinum away from the affected side, and, occasionally, fullness of the intercostal spaces. If the fluid is not loculated, these signs may shift with changes in position. If extensive pneumonia is present, crackles and

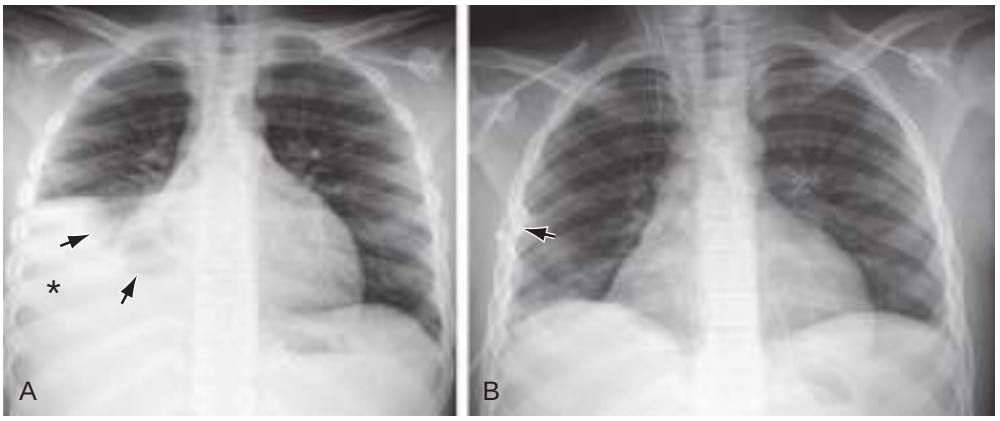

Fig. 451.1 A, Right pleural effusion *(asterisk)* caused by lupus erythematosus in a 12-yr-old child. Note compressed middle and lower lobes of the right lung *(arrows)*. B, The effusion was evacuated, and the right lung was completely reexpanded after insertion of the pigtail chest tube *(arrow)*.

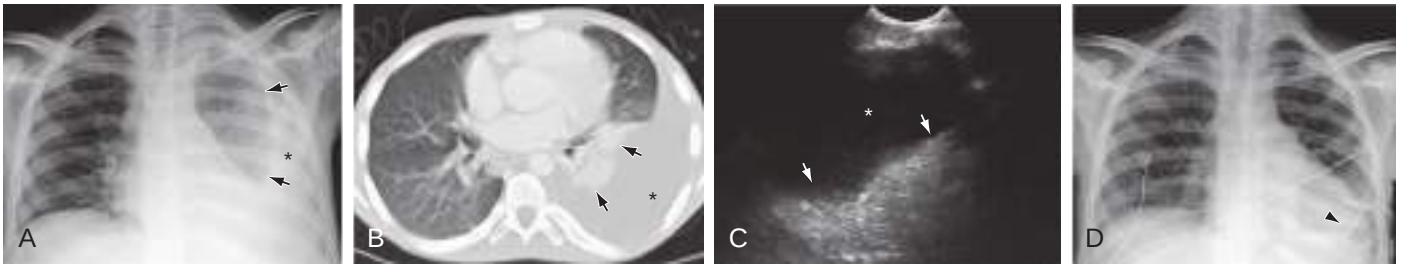

Fig. 451.2 Left pleural effusion in a teenager with AIDS and *Mycobacterium avium-intracellulare* infection. The pleural effusion *(asterisk)* is clearly seen on the chest radiograph (A), CT scan (B), and ultrasonogram (C) of the left chest. *Arrows* point to the compressed and atelectatic left lung. D, A pigtail chest tube *(arrowhead)* was inserted, resulting in reexpansion of the left lung.

rhonchi may also be audible. Friction rubs are usually detected only during the early or late plastic stage. In infants, physical signs are less definite, and bronchial breathing may be heard instead of decreased breath sounds.

LABORATORY FINDINGS

Radiographic examination shows a homogeneous density obscuring the normal markings of the underlying lung, obliterating the costophrenic or cardiophrenic angles. Radiographs should be performed with the patient both supine and upright to demonstrate a shift of the effusion with a change in position; the decubitus position may be helpful. Especially with large effusions, ultrasonography can identify the presence of septations, the lack of free movement of the fluid with gravity, and guide placement of a chest tube or site of thoracentesis loculated. Examination of the fluid is essential to differentiate **exudates** from **transudates** and to determine the type of exudate (see Table 449.6). Depending on the clinical scenario, pleural fluid is sent for culture for bacterial, fungal, and mycobacterial cultures; microbial analysis (quantitative polymerase chain reaction [qPCR], rapid antigen testing, and immunochromatography); Gram staining; and chemical evaluation of content, including protein, lactic dehydrogenase and glucose, amylase, specific gravity, total cell count and differential, cytologic examination for malignancy, and pH. Complete blood count and serum chemistry analysis should be obtained; hypoalbuminemia is often present. **Exudates** usually have at least one of the following features: protein level >3.0 g/dL, with pleural fluid:serum protein ratio >0.5; pleural fluid lactic dehydrogenase values >200 IU/L; or fluid:serum lactic dehydrogenase ratio >0.6. Although systemic acidosis reduces the usefulness of pleural fluid pH measurements, pH <7.20 suggests an exudate. Glucose is usually <60 mg/dL in malignancy, rheumatoid disease, and tuberculosis; the finding of many small lymphocytes and a pH <7.20 suggest tuberculosis. The fluid of serofibrinous pleurisy is clear or slightly cloudy and contains relatively few leukocytes and, occasionally, some erythrocytes. Gram staining may occasionally show bacteria; however, acid-fast staining rarely demonstrates tubercle bacilli. Cytologic examination may reveal malignant cells, if present.

DIAGNOSIS AND DIFFERENTIAL DIAGNOSIS

Unless the patient has a classic-appearing lobar pneumonia and the effusion is small, thoracentesis should be performed when pleural fluid is present or is suggested. Thoracentesis can differentiate serofibrinous pleurisy, empyema, hydrothorax, hemothorax, and chylothorax. Exudates are usually associated with an infectious process. In hydrothorax, the fluid has a specific gravity <1.015, and evaluation reveals only a few mesothelial cells rather than leukocytes. Chylothorax and hemothorax usually have fluid with a distinctive appearance, but differentiating serofibrinous from purulent pleurisy is impossible without microscopic examination of the fluid. Serofibrinous fluid may rapidly become purulent.

COMPLICATIONS

Unless the fluid becomes purulent, it usually disappears relatively rapidly, particularly with appropriate treatment of bacterial pneumonia. It persists somewhat longer if a result of tuberculosis or a connective tissue disease and may recur or remain for a long time if caused by a neoplasm. When the effusion is absorbed, adhesions often develop between the two layers of the pleura, but usually little or no functional impairment results. Pleural thickening may develop and is occasionally mistaken for small quantities of fluid or for persistent pulmonary infiltrates. Pleural thickening may persist for months, but the process usually disappears, leaving no residua.

TREATMENT

Treatment of the underlying pneumonia with antibiotics should be continued. If the effusion is less than 10 mm in size on a chest x-ray, there is no need for drainage. Drainage of large effusions can shorten the course of treatment and provide symptomatic relief. When a diagnostic thoracentesis is performed, as much fluid as possible should be removed for therapeutic purposes. Rapid removal of ≥1 L of pleural fluid may be associated with the development of **reexpansion pulmonary edema**. If sufficient fluid reaccumulates to cause tachypnea, chest tube drainage should be performed. In older children, tube thoracostomy is considered necessary if the pleural fluid pH is <7.20

or the pleural fluid glucose level is <50 mg/dL. If the fluid is thick, loculated, or clearly purulent, chest tube drainage with fibrinolytic therapy or, less often, video-assisted thoracoscopic surgery (VATS) is indicated. Patients with pleural effusions may need analgesia, particularly after thoracentesis or insertion of a chest tube. Those with acute pneumonia may need supplemental oxygen in addition to specific antibiotic treatment. Monitoring with serial chest x-ray should be considered in children who have had complications or needed fibrinolytic treatment.

Visit Elsevier eBooks+ at eBooks.Health.Elsevier.com for Bibliography.

451.3 Empyema

Aarthi P. Vemana and Suraiya K. Haider

Empyema is an accumulation of pus in the pleural space. It is most often associated with pneumonia (see Chapter 449) caused by gram-positive organisms such as *S. pneumoniae* (see Chapter 228), group A streptococcus, and *S. aureus* (see Chapter 227.1). The relative incidence of *Haemophilus influenzae* (see Chapter 240) empyema has decreased since the introduction of the *H. influenzae* type b vaccination. Gram-negative organisms, tuberculosis, fungi, viruses, and malignancy are less common causes. The disease can also be produced by rupture of a lung abscess into the pleural space, contamination introduced from trauma or thoracic surgery, or, rarely, mediastinitis or the extension of intraabdominal abscesses.

EPIDEMIOLOGY

Empyema is most frequently encountered in infants and preschool children. Although rates of bacterial pneumonia have decreased, the incidence of parapneumonic effusions has increased. This may be related to a shift toward more virulent organisms after the introduction of the 13-valent pneumococcal conjugate vaccine, with a trend toward serotypes not covered by the vaccine. Empyema occurs in 5–10% of children with bacterial pneumonia and in up to 86% of children with necrotizing pneumonia.

PATHOLOGY

Empyema has three stages: exudative, fibrinopurulent, and organizational. During the exudative stage, fibrinous exudate forms on the pleural surfaces. In the fibrinopurulent stage, fibrinous septa form, causing loculation of the fluid and thickening of the parietal pleura. If the pus is not drained, it may dissect through the pleura into lung parenchyma, producing bronchopleural fistulas and pyopneumothorax, or into the abdominal cavity. Rarely, the pus dissects through the chest wall (i.e., empyema necessitatis). During the organizational stage, there is fibroblast proliferation; pockets of loculated pus may develop into thick-walled abscess cavities, or the lung may collapse and become surrounded by a thick, inelastic envelope (peel).

CLINICAL MANIFESTATIONS

The initial signs and symptoms are primarily those of bacterial pneumonia. Children treated with antibiotic agents may have an interval of a few days between the clinical pneumonia phase and the evidence of empyema. Most patients are febrile, develop increased work of breathing or respiratory distress, and often appear more ill. Physical findings are identical to those described for serofibrinous pleurisy, and the two conditions are differentiated only by thoracentesis, which should always be performed when empyema is suspected.

LABORATORY FINDINGS

Radiographically, all pleural effusions appear similar, but the absence of a shift of the fluid with a change of position indicates a loculated empyema (Figs. 451.3-451.5 and see Fig. 449.5). Ultrasonography, CT, and, less frequently, magnetic resonance imaging can all be used to further define the size of the effusion, identify septations, and assess loculations. The maximal amount of fluid obtainable should be withdrawn by thoracentesis and studied (see Chapter 451.2). The effusion is an empyema if bacteria are present on Gram staining, the pH is <7.20, and there are >100,000 neutrophils/μL (see Chapter 449). Cultures of the fluid must always be performed to help identify the causal organism. Using standard culture methods, the organism can be identified in up to 60% of cases. The yield improves significantly with concomitant use of nucleic acid amplification techniques. Blood cultures may be positive and have a higher yield than cultures of the pleural fluid. Laboratory analysis shows leukocytosis and elevated erythrocyte sedimentation rate and elevated C-reactive protein.

COMPLICATIONS

With staphylococcal infections, bronchopleural fistulas and pyopneumothorax commonly develop. Other local complications include purulent pericarditis, pulmonary abscesses, peritonitis from extension through the diaphragm, and osteomyelitis of the ribs. Septic complications such as meningitis, arthritis, and osteomyelitis may also occur. Septicemia is often encountered in *H. influenzae* and pneumococcal infections. The effusion may organize into a thick "peel," which may restrict lung expansion and may be associated with persistent fever and temporary scoliosis.

TREATMENT

The aim of empyema treatment is to sterilize pleural fluid and restore normal lung function. Treatment includes systemic antibiotics, thoracentesis, chest tube drainage, and use of a fibrinolytic agent; VATS and open decortication are used if there is poor resolution with the preceding therapies (see Chapter 461).

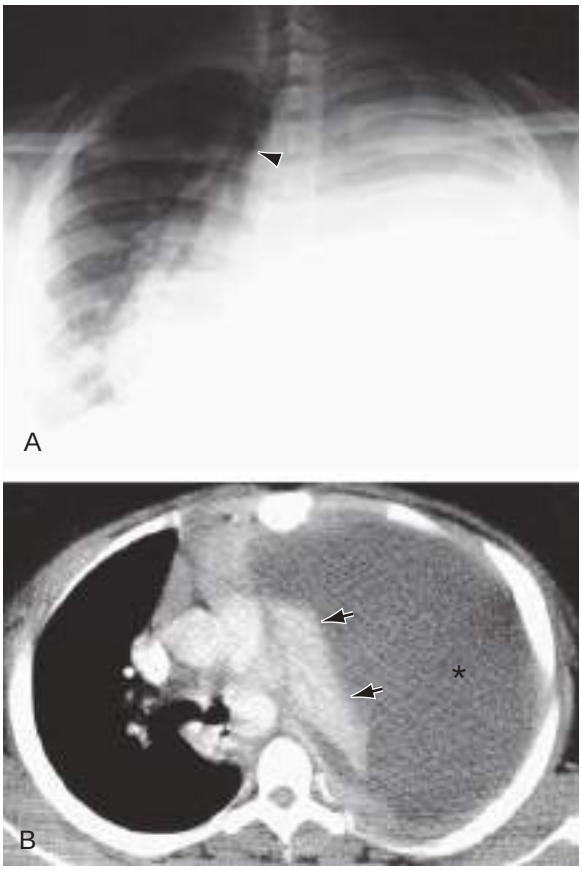

Fig. 451.3 Empyema and pneumonia in a teenager. **A,** Chest radiograph shows opacification of the left thorax. Note shift of mediastinum and trachea *(arrowhead)* to the right. **B,** Thoracic CT scan shows massive left pleural effusion *(asterisk)*. Note the compression and atelectasis of the left lung *(arrows)* and shift of the mediastinum to the right.

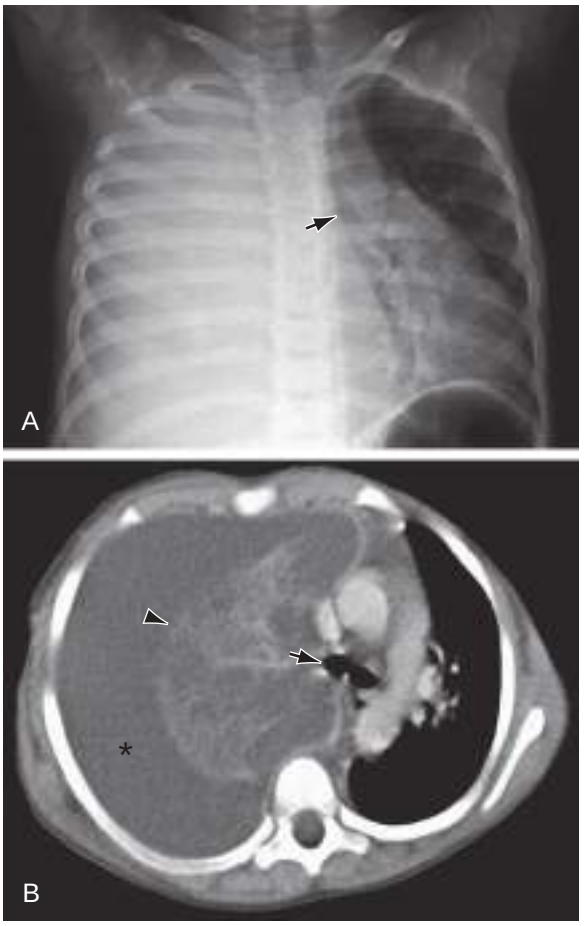

Fig. 451.4 Pneumonia and parapneumonic effusion in a 4-yr-old child. **A,** Chest radiograph shows complete opacification of the right thorax as a result of a large pleural effusion. Note the shift of the mediastinum and trachea *(arrow)* to the left. **B,** Thoracic CT scan shows a large right pleural effusion *(asterisk)* surrounding and compressing the consolidated right lung *(arrowhead)*. Note the shift of the mediastinum and tracheal carina *(arrow)* to the left.

If empyema is diagnosed early, antibiotic treatment plus thoracentesis achieves a complete cure. The selection of antibiotic should be based on the in vitro sensitivities of the responsible organism. See Chapters 227, 228, and 240 for treatment of infections by *Staphylococcus, S. pneumoniae*, and *H. influenzae*, respectively. Treatment with systemic antibiotics is usually needed for 2-4 weeks, with the duration being guided by individual clinical response to treatment. Instillation of antibiotics into the pleural cavity does not improve results.

After empyema has been confirmed, interventions include closed chest tube drainage with fibrinolytics, decortication with VATS (video-assisted thoracoscopic surgery), and, less often, open thoracotomy. Multiple aspirations of the pleural cavity should not be attempted. Closed-chest tube drainage is controlled by an underwater seal or continuous suction; sometimes more than one tube is required to drain loculated areas. Closed drainage is usually continued for 5-7 days. Chest tubes that are no longer draining are removed.

Instillation of fibrinolytic agents into the pleural cavity via the chest tube often promotes drainage, decreases the length of time a chest tube is in place, decreases fever, lessens the need for surgical intervention, and shortens hospitalization. The optimal fibrinolytic drug and dosages have not been determined. Streptokinase 15,000 units/kg in 50 mL of 0.9% saline, urokinase 40,000 units in 40 mL saline, and tissue plasminogen activator (tPA) 4 mg in 20-40 mL of saline have been used in the pediatric population. Although the combination of fibrinolytic therapy with dornase alfa (DNAse) improves outcomes in adults with empyema, it has not been shown to consistently improve outcomes in pediatric patients with empyema. There is a risk of anaphylaxis with streptokinase, and all three drugs can be associated with hemorrhage and other complications.

If pneumatoceles form, no attempt should be made to treat them surgically or by aspiration, unless they reach sufficient size to cause respiratory compromise or become secondarily infected. Pneumatoceles usually resolve spontaneously with time. Extensive fibrinous changes may take place over the surface of the lungs owing to empyema, but they eventually resolve. The long-term clinical prognosis for adequately treated empyema is excellent, and follow-up pulmonary function studies suggest that residual restrictive disease is uncommon, with or without surgical intervention.

Visit Elsevier eBooks+ at eBooks.Health.Elsevier.com for Bibliography.

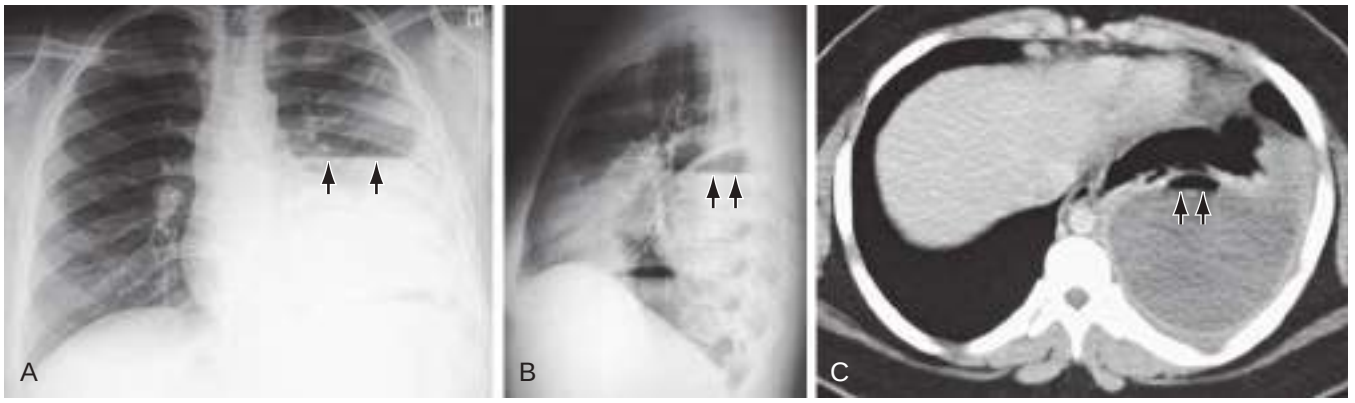

Fig. 451.5 Loculated hydropneumothorax. Frontal (**A**) and lateral (**B**) chest radiographs show loculated hydropneumothorax that complicated pneumonia in a 14-yr-old child. *Arrows* point to the horizontal air-fluid level at the interface between the intrapleural effusion and air. **C,** Thoracic CT scan helps to localize the loculated hydropneumothorax, with its air-fluid level *(arrows)*.

Chapter 452

Bronchiectasis

Oren J. Lakser

Bronchiectasis is characterized by irreversible abnormal dilation and anatomic distortion of the bronchial tree and represents the common end stage of many nonspecific and unrelated antecedent events. Its incidence has been decreasing overall in industrialized countries, but it persists as a problem in lower- and middle-income countries and among some ethnic groups in industrialized nations (particularly in aboriginal children). Females are afflicted more frequently than males.

PATHOPHYSIOLOGY AND PATHOGENESIS

In industrialized nations, cystic fibrosis (see Chapter 454) is the most common cause of clinically significant bronchiectasis. Other conditions associated with bronchiectasis include primary ciliary dyskinesia (see Chapter 455), postinfectious conditions, especially pertussis, measles, and tuberculosis, immune deficiency syndromes (especially humoral immunity), foreign body aspiration, and aspiration of gastric contents (Table 452.1). Bronchiectasis has also been associated with severe asthma in children. It can also be congenital, as in **Williams-Campbell syndrome**, in which there is an absence of annular bronchial cartilage, and **Marnier-Kuhn syndrome** (congenital tracheobronchomegaly), in which there is a connective tissue disorder. Other disease entities associated with bronchiectasis are **yellow nail syndrome** (pleural effusion, lymphedema, discolored nails) and **right middle lobe syndrome**. Right middle lobe syndrome is mostly associated with other generalized causes of bronchiectasis, including asthma, cystic fibrosis, primary ciliary dyskinesia, severe pneumonia, aspiration pneumonia, foreign bodies, and immune-deficient states.

Three basic mechanisms are involved in the pathogenesis of bronchiectasis. **Obstruction** can occur because of tumor, foreign body, impacted mucus because of poor mucociliary clearance, external compression, bronchial webs, and atresia. **Infections** caused by *Bordetella pertussis,* measles, rubella, togavirus, respiratory syncytial virus, adenovirus, and *Mycobacterium tuberculosis* induce chronic inflammation, progressive bronchial wall damage, and dilation. More recently, nontypeable *Haemophilus influenzae* seems to be a common cause of infection in adults and children with bronchiectasis. *Streptococcus pneumoniae* and *Moraxella catarrhalis* are more common in children with bronchiectasis than in adult patients. **Chronic inflammation** similarly contributes to the mechanism by which obstruction leads to bronchiectasis. Both inadequate and exaggerated/dysregulated immune responses may play a role in the development of bronchiectasis. Activation of toll-like receptors results in the activation of nuclear factor κB and the release of proinflammatory cytokines interleukin (IL)-1β, IL-8, and tumor necrosis factor-α. IL-8 is a chemoattractant for neutrophils, which are the main inflammatory cell involved in the pathogenesis of bronchiectasis. Once activated, neutrophils produce neutrophil elastase and matrix metalloproteinase (MMP)-8 and MMP-9. IL-6, IL-8, and tumor necrosis factor-α are elevated in the airways of patients with bronchiectasis. Eosinophils are also elevated in the airways of indigenous children with bronchiectasis, which promotes neutrophil recruitment, goblet cell hyperplasia, and airway destruction. There is an increase in proinflammatory cytotoxic T lymphocytes in the peripheral blood of children with bronchiectasis. The mechanism by which bronchiectasis occurs in congenital forms is likely related to abnormal cartilage formation. The common thread in the pathogenesis of bronchiectasis consists of difficulty clearing secretions and recurrent infections with a "vicious cycle" of infection and inflammation resulting in airway injury and remodeling. This cycle results in a spectrum of pediatric suppurative lung disorders: protracted bacterial bronchitis (PBB), chronic suppurative lung disease (CSLD), and bronchiectasis. CSLD patients suffer from symptoms of bronchiectasis without its radiographic features. In early stages, bronchiectasis consists primarily of bronchiolar wall thickening and destruction of elastin resulting in bronchial dilatation. In later stages, the bronchial walls develop cartilage destruction with associated pulmonary artery/arteriole vascular remodeling, resulting in pulmonary hypertension.

Bronchiectasis can manifest in any combination of three pathologic forms, best defined by high-resolution CT (HRCT) scan (Fig. 452.1). In **cylindrical** bronchiectasis, the bronchial outlines are regular, but there is diffuse dilation of the bronchial unit. The bronchial lumen ends abruptly because of mucous plugging. In **varicose** bronchiectasis, the degree of dilation is greater, and local constrictions cause an irregularity of outline resembling that of varicose veins. There may also be small sacculations. In **saccular** (cystic) bronchiectasis, bronchial dilation progresses and results in ballooning of bronchi that end in fluid- or mucus-filled sacs. This is the most severe form of bronchiectasis. The following definitions have been proposed: **prebronchiectasis** (chronic or recurrent endobronchial infection with nonspecific HRCT changes; may be reversible), **HRCT bronchiectasis** (clinical symptoms with HRCT evidence of bronchial dilation; may persist, progress, or improve and resolve), and **established bronchiectasis** (like the previous but with no resolution within 2 years). Early diagnosis and aggressive therapy are important to prevent the development of established bronchiectasis.

CLINICAL MANIFESTATIONS

The most common complaints in patients with bronchiectasis are chronic wet cough and/or production of copious purulent sputum. Younger children may swallow the sputum. In particular, wet or productive cough failing to respond to 4 weeks of oral antibiotics is predictive of the presence of chest CT–defined bronchiectasis. Hemoptysis is seen with some frequency. Fever can occur with infectious exacerbations. Anorexia and poor weight gain may occur as time passes. Physical examination typically reveals crackles localized to the affected area, but wheezing and digital clubbing may also occur. In severe cases, dyspnea and hypoxemia can occur. Pulmonary function studies may demonstrate an obstructive, restrictive, or mixed pattern. Typically, impaired diffusion capacity is a late finding.

Table 452.1 Conditions That Predispose to Bronchiectasis in Children

PROXIMAL AIRWAY NARROWING
Airway wall compression (i.e., vascular ring, adenopathy impinging on airways)
Airway intraluminal obstruction (e.g., inhaled foreign body, granulation tissue)`
Airway stenosis and malacia (tracheal, bronchial)
AIRWAY INJURY
Bronchiolitis obliterans (e.g., postviral, after lung transplantation)
Recurrent pneumonitis or pneumonia (e.g., pneumococcal pneumonia, aspiration pneumonia, tuberculosis, *B. pertussis*)
ALTERED PULMONARY HOST DEFENSES
Cystic fibrosis
Primary ciliary dyskinesia
Impaired cough (e.g., neuromuscular weakness conditions)
ALTERED IMMUNE STATES
Primary abnormalities (e.g., agammaglobulinemia, hypogammaglobulinemia, common variable immune deficiency, hyper IgE, hyper IgM, neutrophil dysfunction, gain-of-function *STAT1* variants)
Secondary abnormalities (e.g., HIV infection, immunosuppressive agents)
OTHER
Systemic pseudohypoaldosteronism
Epithelial sodium channel variants *(SCNN1A, SCNN1B)*
Allergic bronchopulmonary aspergillosis
Plastic bronchitis
Right middle lobe syndrome

From Redding GJ. Bronchiectasis in children. *Pediatr Clin North Am.* 2009;56:157–171, Box 1.

DIAGNOSIS

Conditions that can be associated with bronchiectasis should be ruled out by appropriate investigations (e.g., sweat test, immunologic workup). Chest radiographs of patients with bronchiectasis tend to be nonspecific. Typical findings can include increase in size and loss of definition of bronchovascular markings, crowding of bronchi, and loss of lung volume. In more severe forms, cystic spaces, occasionally with air-fluid levels and honeycombing, may occur. Compensatory overinflation of the unaffected lung may be seen. Thin-section HRCT scanning and multidetector CT scanning are the gold standards because they have excellent sensitivity and specificity. CT provides further information on disease location, presence of mediastinal lesions, and the extent of segmental involvement. The main features of bronchiectasis in CT scans include (1) increased bronchoarterial ratio and *signet-ring* appearance; (2) bronchial wall thickening; (3) mucous plugging; (4) lack of bronchial tapering to the lung periphery—"tramlines"; (5) bronchial structures in the lung periphery; and (6) air trapping (mosaic perfusion), most obvious on expiration. The lower lobes (left > right) are more commonly affected. Early in the course, tree-in-bud appearance can also be seen. These CT findings are used to define the bronchiectasis as *cylindrical* ("tram lines," "signet ring appearance"), *varicose* (bronchi with "beaded contour"), *cystic* (cysts in "strings and clusters"), or mixed forms (Fig. 452.2).

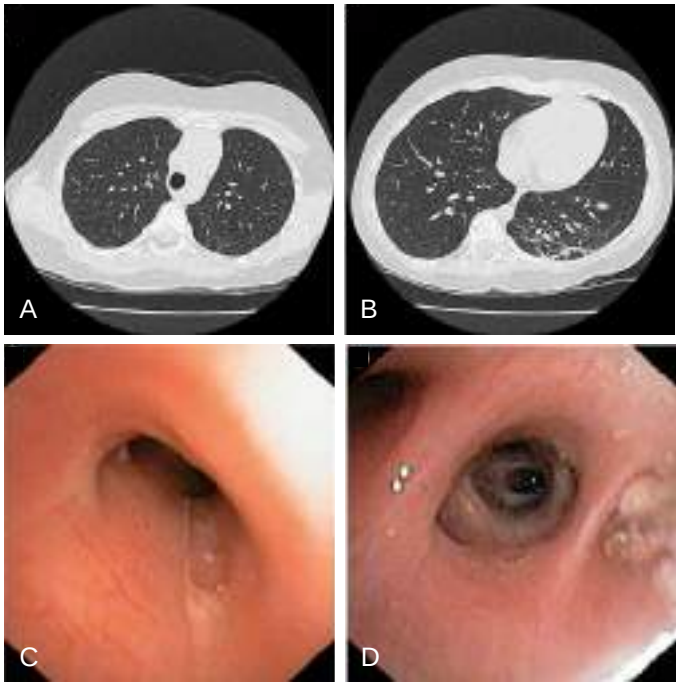

Fig. 452.1 High-resolution chest CT scans (**A** and **B**) and bronchoscopy images (**C** and **D**) in a child with bronchiectasis. (**C** and **D**) Bronchoscopy findings. Images from a chest high-resolution computed tomography (cHRCT) scan (**A** and **B**) in a 10-yr-old girl who presented with a chronic wet cough. The child was treated with a 2-wk course of IV antibiotics (after failing oral antibiotic treatment). The scan was reported as having no evidence of bronchiectasis by pediatric radiologists. At bronchoscopy thick mucus was seen in the trachea (**C**) and the right lower lobe (**D**). The case highlights the need to consider the diagnosis of bronchiectasis on the basis of history, examination findings, and using the pediatric cutoff (bronchoarterial ratio >0.8) for defining bronchiectasis on the cHRCT scan. *(From Goyal V, Grimwood K, Marchant J, et al. Pediatric bronchiectasis: no longer an orphan disease. Pediatr Pulmonol. 2016;51:450–469.)*

TREATMENT

The initial therapy for patients with bronchiectasis is medical and aims at decreasing airway obstruction and controlling infection. Airway clearance techniques (e.g., gravity-assisted drainage, active cycle of breathing, positive expiratory pressure [PEP], acapella, high-frequency chest wall oscillation), antibiotics, and bronchodilators are essential. Two to four weeks of parenteral antibiotics (in hospital or at home) is often necessary to manage more severe acute exacerbations adequately. Exacerbations can be defined as the presence of one major criteria (wet cough enduring longer than 72 hours, increased cough frequency over 72 hours) *plus* one laboratory criteria (C-reactive protein >3 mg/L, serum IL-6 >2 ng/L, serum amyloid A >5 mg/L, elevated neutrophil percentage), two major criteria, or one major criterion *plus* two minor criteria (change in sputum color, breathlessness, chest pain, crackles/crepitations, wheeze). The presence of dyspnea (increased work of breathing) and/or hypoxemia should be considered a severe exacerbation, irrespective of duration.

Antibiotic choice is dictated by the identification and sensitivity of organisms found on deep throat, sputum (induced or spontaneous), or bronchoalveolar lavage fluid cultures. The most common organisms found in children with bronchiectasis include *H. influenzae* non–type b, *S. pneumoniae*, *M. catarrhalis*, *Mycoplasma pneumoniae*, *Pseudomonas aeruginosa*, and *Staphylococcus aureus*. Viruses (most commonly human rhinovirus) are often found in children with bronchiectasis suffering from an exacerbation. A 14-day course of amoxicillin/clavulanic acid (22.5 mg/kg/dose twice daily) has been particularly successful at treating most pulmonary exacerbations. Azithromycin (5 mg/kg/day) is a reasonable alternative in those with penicillin allergy. For those experiencing frequent exacerbations of more than three per year, long-term prophylactic macrolide antibiotics (which also have immunomodulatory and antiinflammatory properties) or nebulized antibiotics (e.g., tobramycin, colistin, aztreonam, ciprofloxacin) may be beneficial (reduced exacerbations and hospitalizations, improved lung function) but may also increase antibiotic

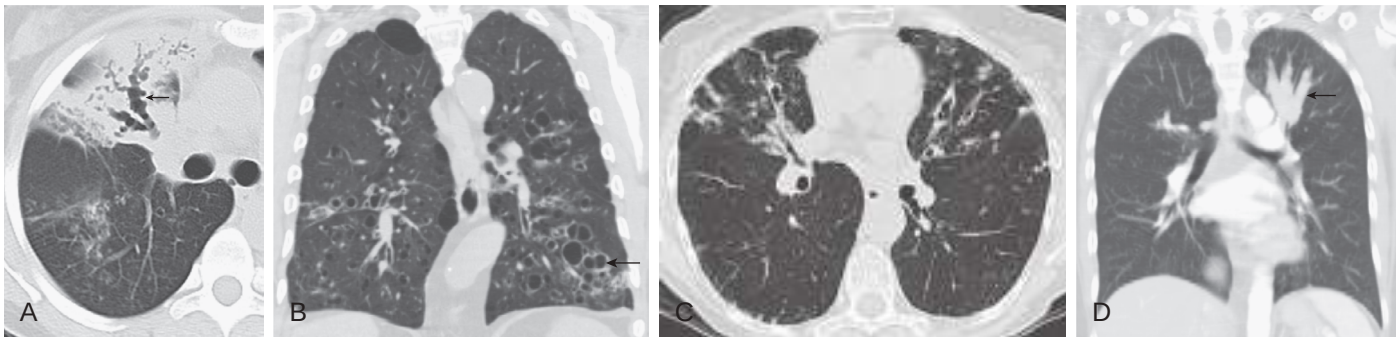

Fig. 452.2 Bronchiectasis. **A,** Axial CT image demonstrates a beaded appearance of dilated bronchi *(arrow)* in the right upper lobe, consistent with varicoid bronchiectasis. **B,** Coronal reformation CT image shows multiple foci of cystic bronchiectasis, with a few air-fluid levels *(arrow)*. Also note paraseptal emphysema, most marked at the right apex. **C,** Bronchiectatic form of chronic atypical mycobacterial infection. Axial CT scan shows extensive bronchiectasis, bronchial wall thickening, and centrilobular nodules, most severe in the middle lobe and lingula. **D,** Allergic bronchopulmonary aspergillosis. Coronal reformation CT image demonstrates impacted bronchi in the left upper lobe *(arrow)* producing a "gloved finger" appearance. *(From Boiselle PM. Airway. In: Haaga JR, Boll DT, eds. CT and MRI of the Whole Body, 6th ed. Philadelphia: Elsevier; 2017: Figs 40-30, 32-34.)*

resistance. Airway hydration (inhaled hypertonic saline or mannitol) also improves quality of life in adults with bronchiectasis, but there are few studies in children. Any underlying disorder (immunodeficiency, aspiration) that may be contributing must be addressed. When localized bronchiectasis becomes more severe or resistant to medical management, segmental or lobar resection may be warranted and may improve growth and reduce the need for intravenous antibiotics. Lung transplantation can also be performed in patients with bronchiectasis. There is no strong evidence to support the routine use of inhaled corticosteroids, although some studies demonstrate improved quality of life and reduced exacerbations in patients with bronchiectasis treated with inhaled corticosteroids. Preventive strategies, including immunization against typical respiratory pathogens (influenza, pneumococci), are generally recommended.

Development of novel treatments is ongoing and centered around targeting three components of the vicious cycle of bronchiectasis: bacterial infection (vitamin D supplementation, exogenous granulocyte-macrophage stimulating factor, phosphodiesterase 4 inhibitors, statins), neutrophilic inflammation (e.g., neutrophil elastase inhibitors, cathepsin C inhibitors, CXCR2 receptor antagonists), and mucociliary clearance (epithelial sodium channel inhibitors).

PROGNOSIS

Children with bronchiectasis often suffer from recurrent pulmonary illnesses, resulting in missed school days, stunted growth, osteopenia, and osteoporosis. The prognosis for patients with bronchiectasis has improved considerably in the past few decades. In some children and adolescents, their bronchiectasis is reversible and/or preventable. Factors important for reversibility and/or prevention of bronchiectasis include early identification and treatment of inhaled foreign bodies, preventing early and severe pneumonia, preventing recurrent protracted bacterial bronchitis, treating primary immunodeficiency disorders causing bronchiectasis, promoting breastfeeding and immunization, and avoiding tobacco smoke and other pollutants.

Thus earlier recognition or prevention of predisposing conditions, specialist multidisciplinary management, more powerful and broad-spectrum antibiotics, and improved surgical outcomes will further improve the prognosis for children with bronchiectasis.

Visit Elsevier eBooks+ at eBooks.Health.Elsevier.com for Bibliography.

Chapter 453

Pulmonary Abscess

Oren J. Lakser

Lung infection that destroys the lung parenchyma, resulting in cavitations and central necrosis, can result in localized areas composed of thick-walled purulent material called *lung abscesses. Primary* lung abscesses occur in previously healthy patients with no underlying medical disorders and are usually solitary. *Secondary* lung abscesses occur in patients with underlying or predisposing conditions and may be multiple. Lung abscesses are much less common in children (estimated at 0.7 per 100,000 admissions per year) and result in less morbidity than in adults.

PATHOLOGY AND PATHOGENESIS

Multiple conditions predispose children to the development of pulmonary abscesses, including aspiration, pneumonia, cystic fibrosis (see Chapter 454), gastroesophageal reflux (see Chapter 369), tracheoesophageal fistula (see Chapter 365.1), immunodeficiencies, postoperative complications of tonsillectomy and adenoidectomy, seizures, a variety of neurologic diseases, and other conditions associated with impaired mucociliary defense. Lung abscesses have been associated with e-cigarette or vaping product use–associated lung injury (EVALI; see Chapter 450). In children, aspiration of infected materials or a foreign body is the predominant source of the organisms causing abscesses. Initially, pneumonitis impairs drainage of fluid or the aspirated material. Inflammatory vascular obstruction occurs, leading to tissue necrosis, liquefaction, and abscess formation. Abscess can also occur as a result of pneumonia and hematogenous seeding from another site.

If the aspiration event occurred while the child was recumbent, the right and left upper lobes and apical segment of the right lower lobes are the dependent areas most likely to be affected. In a child who was upright, the posterior segments of the upper lobes were dependent and therefore are most likely to be affected. Primary abscesses are found most often on the right side, whereas secondary lung abscesses, particularly in immunocompromised patients, have a predilection for the left side.

Both anaerobic and aerobic organisms can cause lung abscesses. Common anaerobic bacteria that can cause a pulmonary abscess include *Bacteroides* spp., *Fusobacterium* spp., and *Peptostreptococcus* spp. Abscesses can be caused by aerobic organisms such as *Streptococcus angiosus*, group A streptococcus, *Staphylococcus aureus, Escherichia coli, Klebsiella pneumoniae, Pseudomonas aeruginosa,* and very rarely, *Mycoplasma pneumoniae.* Aerobic and anaerobic cultures should be part of the workup for all patients with lung abscess. Occasionally, concomitant viral-bacterial infection can be detected. Fungi can also cause lung abscesses, particularly in immunocompromised patients.

CLINICAL MANIFESTATIONS

The most common symptoms of pulmonary abscess in the pediatric population are fever, cough, and emesis. Other common symptoms include tachypnea, dyspnea, chest pain, sputum production, weight loss, and hemoptysis. Physical examination typically reveals tachypnea, dyspnea, retractions with accessory muscle use, decreased breath sounds, and dullness to percussion in the affected area. Crackles and, occasionally, a prolonged expiratory phase may be heard on lung examination.

DIAGNOSIS

Diagnosis is most commonly made on the basis of chest radiography. Classically, the chest radiograph shows a parenchymal inflammation with a cavity containing an air-fluid level (Fig. 453.1). A chest CT scan can provide better anatomic definition of an abscess, including location and size (Fig. 453.2). Ultrasound can also help provide rapid diagnosis and procedural guidance.

An abscess is usually a thick-walled lesion with a low-density center progressing to an air-fluid level. Abscesses should be distinguished from **pneumatoceles**, which often complicate severe bacterial pneumonias and are characterized by thin- and smooth-walled, localized air collections with or without air-fluid level (Fig. 453.3). Pneumatoceles often resolve spontaneously with the treatment of the specific cause of the pneumonia. The differential diagnosis of a cavitary lung lesion is noted in Table 453.1.

The determination of the etiologic bacteria in a lung abscess can be helpful in guiding antibiotic choice. Although Gram stain of sputum can provide an early clue as to the class of bacteria involved, sputum cultures typically yield mixed bacteria and therefore are not always reliable. Attempts to avoid contamination from oral flora include direct lung puncture, percutaneous (aided by CT guidance) or transtracheal aspiration, and bronchoalveolar lavage specimens obtained bronchoscopically. Bronchoscopic aspiration should be avoided, as it can be complicated by massive intrabronchial aspiration, and great care should therefore be taken during the procedure. To avoid invasive procedures in previously normal hosts, empiric therapy can be initiated in the absence of culturable material.

TREATMENT

Conservative management is recommended for pulmonary abscess. Most experts advocate a 2- to 3-week course of parenteral antibiotics

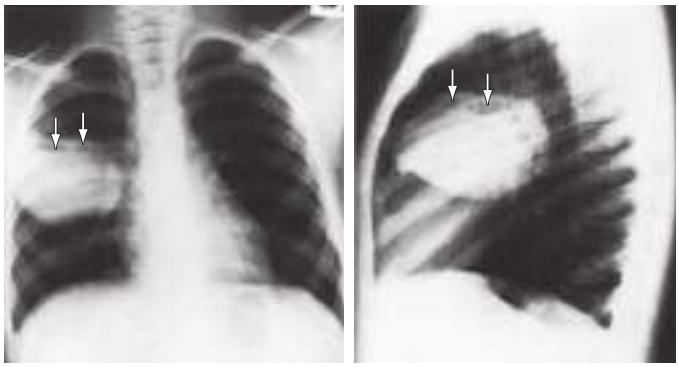

Fig. 453.1 Multiloculated lung abscess *(arrows). (From Brook I. Lung abscess and pulmonary infections due to anaerobic bacteria. In Chernick V, Boat TF, Wilmott RW, et al., eds. Kendig's Disorders of the Respiratory Tract in Children, 7th ed. Philadelphia: WB Saunders; 2006:482.)*

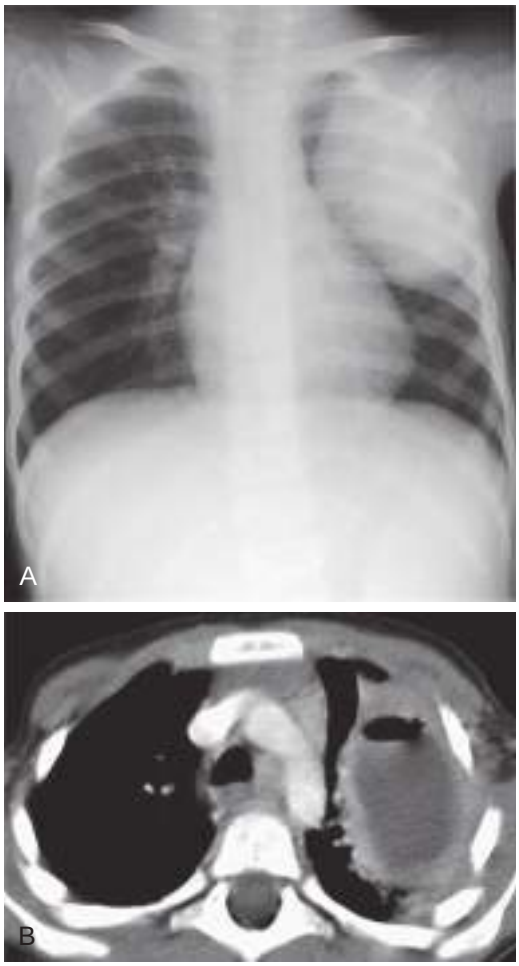

Fig. 453.2 Pulmonary abscess in a 2-yr-old male with persistent cough. **A,** Chest radiograph shows large oval mass in the left upper lobe. **B,** CT scan demonstrates an abscess with a thick enhancing wall that contains both air and fluid. *(From Slovis T, ed. Caffey's Pediatric Diagnostic Imaging, 11th ed. Philadelphia: Mosby; 2008, Fig. 78-3, p. 1297.)*

for uncomplicated cases, followed by a course of oral antibiotics to complete a total of 3-4 weeks. Antibiotic choice should be guided by results of Gram stain and culture but initially should include agents with aerobic and anaerobic coverage. Treatment regimens should include a penicillinase-resistant agent active against *S. aureus* and anaerobic coverage, typically with clindamycin or ampicillin-sulbactam. If gram-negative

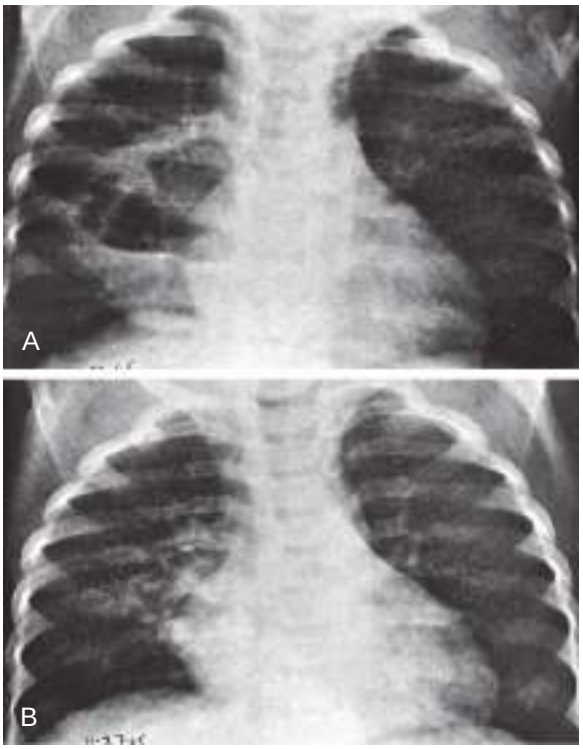

Fig. 453.3 Appearance over a period of 5 days of a large, multiloculated pneumatocele in a segment of alveolar consolidation. **A,** There is a large cavity with two air-fluid levels in a segment of alveolar pneumonia in the right upper lobe. **B,** Five days later, the cavity and most of the pneumonic consolidation have disappeared. *(From Silverman FN, Kuhn JP. Essentials of Caffey's Pediatric X-ray Diagnosis. Chicago: Year Book; 1990:303.)*

bacteria are suspected or isolated, piperacillin-tazobactam or a carbapenem should be added. With improvement, oral antibiotics (clindamycin or amoxicillin-clavulanate) can be used to finish the 4 weeks of total therapy. Early CT-guided percutaneous aspiration or drainage has been advocated by some; it may hasten the recovery and shorten the course of parenteral antibiotic therapy. Nonetheless, antibiotic therapy is successful in ~85% of patients with uncomplicated lung abscesses.

For severely ill patients, patients with larger abscess, or those whose status fails to improve after 7-10 days of appropriate antimicrobial therapy, surgical intervention should be considered. Minimally invasive percutaneous aspiration techniques, often with CT guidance, are the initial and, often, only intervention required. Thoracoscopic drainage has also been successfully used with minimal complications. In rare, complicated cases, thoracotomy (e.g., video-assisted thoracoscopic surgery [VATS] with or without bronchoscopic occlusion) with surgical drainage or lobectomy and/or decortication may be necessary. Abscess drainage is reportedly required in ~20% of cases of pulmonary abscess in children.

PROGNOSIS

Overall, the prognosis for children with primary pulmonary abscesses is excellent. The presence of aerobic organisms may be a negative prognostic indicator, particularly in those with secondary lung abscesses. Most children become asymptomatic within 7-10 days, although the fever can persist for as long as 3 weeks. Radiologic abnormalities usually resolve in 1-3 months but can persist for years (e.g., B-line artifacts on lung ultrasound). Long-term sequalae can also include air trapping/hyperinflation on lung function testing. With treatment, mortality is typically less than 5%.

Visit Elsevier eBooks+ at eBooks.Health.Elsevier.com for Bibliography.

Table 453.1 Differential Diagnosis of a Cavitary Lesion on Chest Radiograph

INFECTIOUS CAUSES
Bacteria
Oral anaerobes
Less commonly: *Staphylococcus aureus, Klebsiella pneumoniae, Pseudomonas aeruginosa,* enteric gram-negative rods, *Pasteurella multocida, Burkholderia cepacia, Burkholderia pseudomallei, Haemophilus influenzae* types b and c, *Legionella,* group A streptococcus, *Streptococcus pneumoniae, Streptococcus anginosus, Nocardia, Rhodococcus equi, Actinomyces, Clostridium, Capnocytophaga*
Septic Pulmonary Embolism
Originating in septic phlebitis, including Lemierre syndrome and vegetations from tricuspid endocarditis
Mycobacteria
Tuberculosis and nontuberculous pathogens
Fungi
Endemic mycoses (*Histoplasma, Coccidioides,* blastomycosis), *Cryptococcus, Aspergillus,* Zygomycetes
Parasites
Paragonimus westermani, Entamoeba histolytica, Echinococcus
NONINFECTIOUS CAUSES
Neoplasm
Primary lung cancer, metastatic carcinoma (particularly squamous cell)
Pulmonary infarction caused by bland embolus
Vasculitis
Wegener granulomatosis, rheumatoid lung nodule
Airway Disease
Bullae, blebs, or cystic bronchiectasis
Developmental cause
Pulmonary sequestration
Other
Sarcoidosis, achalasia, or transdiaphragmatic bowel herniation giving appearance of cavity with air-fluid level

Modified from Lorber B. Bacterial lung abscess. In: Bennett JE, Dolin R, Blaser M, eds. *Principles and Practice of Infectious Diseases*, 8th ed. Philadelphia: Elsevier; 2014:855–859.

Table 454.1 Complications of Cystic Fibrosis

RESPIRATORY
Bronchiectasis, bronchitis, bronchiolitis, pneumonia
Atelectasis
Hemoptysis
Pneumothorax
Nasal polyps
Sinusitis
Reactive airway disease
Mucoid impaction of the bronchi
Allergic bronchopulmonary aspergillosis
Cor pulmonale
Respiratory failure
GASTROINTESTINAL
Meconium ileus, meconium plug (neonate)
Meconium peritonitis (neonate)
Distal intestinal obstruction syndrome (non-neonatal obstruction)
Rectal prolapse
Intussusception
Volvulus
Fibrosing colonopathy (strictures)
Appendicitis
Intestinal atresia
Pancreatitis (recurrent)
Biliary cirrhosis (portal hypertension: esophageal varices, hypersplenism)
Neonatal obstructive jaundice
Hepatic steatosis
Gastroesophageal reflux
Cholelithiasis
Inguinal hernia
Growth failure (malabsorption)
Vitamin deficiency states (vitamins A, K, E, D)
Insulin deficiency, symptomatic hyperglycemia, diabetes
Malignancy (rare)
OTHER
Infertility (female)
Congenital absence of vas deferens, azoospermia
Delayed puberty
Edema: hypoproteinemia
Dehydration: heat exhaustion
Hyperchloremic metabolic alkalosis: dehydration
Hypertrophic osteoarthropathy: arthritis
Urinary calculi
Clubbing
Amyloidosis
Diabetes mellitus
Aquagenic palmoplantar keratoderma (skin wrinkling)

Adapted from Silverman FN, Kuhn JP. *Essentials of Caffey's Pediatric X-ray Diagnosis.* Chicago: Year Book; 1990:649.

Chapter 454

Cystic Fibrosis

Marie E. Egan, Michael S. Schechter, and Judith A. Voynow

Cystic fibrosis (CF) is an inherited multisystem disorder of children and adults; it is the most common life-limiting recessive genetic trait among Whites. Dysfunction of the cystic fibrosis transmembrane conductance regulator (CFTR) protein, the primary defect, leads to a wide and variable array of presenting manifestations and complications.

CF is responsible for most cases of exocrine pancreatic insufficiency in early life and is the major cause of severe chronic lung disease in children. It is also responsible for many cases of hyponatremic salt depletion, nasal polyposis, pansinusitis, rectal prolapse, pancreatitis, cholelithiasis, and nonautoimmune insulin-dependent hyperglycemia. Because CF may manifest as failure to thrive and hepatic dysfunction, including cirrhosis, this disorder enters into the differential diagnosis of many pediatric conditions (Table 454.1).

GENETICS

CF occurs most frequently in White populations of Northern Europe, North America, and Australia/New Zealand. The prevalence in these populations varies but approximates 1 in 3,500 live births (compared with 1 in 9,200 individuals of Hispanic descent and 1 in 15,000 African Americans). Although less frequent in African, Hispanic, Middle Eastern, South Asian, and Eastern Asian populations, the disorder does exist in these populations as well (Fig. 454.1).

CF is inherited as an autosomal recessive trait. The *CF* gene codes for the CFTR protein, which is 1,480 amino acids. CFTR is expressed largely in epithelial cells of airways, the gastrointestinal tract (including the pancreas and biliary system), the sweat glands, and the genitourinary system, but is expressed in other cell types at lower levels. CFTR is a member of

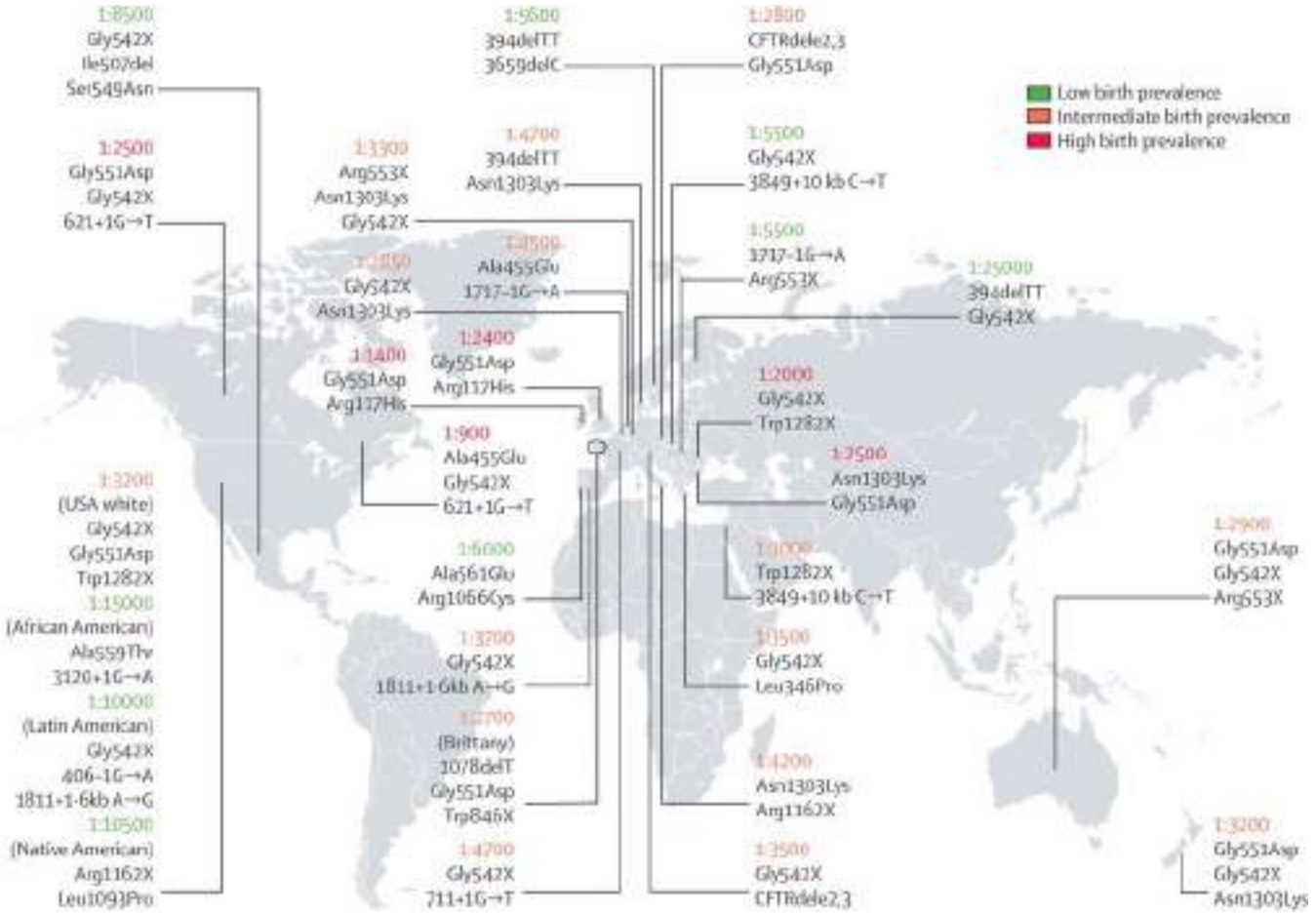

Fig. 454.1 Approximate cystic fibrosis birth prevalence and common pathogenic variants for selected countries. Birth prevalence is reported as the number of live births per case of cystic fibrosis. Common/important pathogenic variants in each region are listed below the prevalence figures. The birth prevalence can vary greatly among ethnic groups in a country. *(From O'Sullivan BP, Freedman SD. Cystic fibrosis. Lancet. 2009;373:1891–1902.)*

the adenosine triphosphate (ATP)–binding cassette superfamily of proteins. It functions as an anion channel and is essential for proper chloride and bicarbonate transport across epithelia. More than 1,900 *CFTR* polymorphisms have been described, many of which are not clearly of clinical significance. Those that are associated with clinical manifestations may be grouped into six main classes based on how they affect protein structure and function (Fig. 454.2). Class I-III pathogenic variants are generally considered to be *severe* pathogenic variants in that they lead to a complete or nearly complete absence of CFTR function, whereas class IV-VI pathogenic variants are associated with some residual functional protein. The most prevalent pathogenic variant of *CFTR* is the deletion of a single phenylalanine residue at amino acid 508 (F508del). This pathogenic variant is responsible for the high incidence of CF in northern European populations and is considerably less frequent in other populations, such as those of southern Europe and Israel. Nearly 50% of individuals with CF in the United States Cystic Fibrosis Foundation (CFF) Patient Registry are homozygous for F508del, and approximately 87% carry at least one F508del gene. The remaining patients have an extensive array of pathogenic variants, none of which has a prevalence of more than several percentage points, except in certain populations; for example, the W1282X pathogenic variant occurs in 60% of Ashkenazi Jews with CF. Through the use of probes for 40 of the most common pathogenic variants, the genotype of 80–90% of Americans with CF can be ascertained. Genotyping using a discrete panel of pathogenic variant probes is quick and less costly than more comprehensive sequencing and is the approach typically used in state newborn screening (NBS) programs. In remaining patients, sequencing the entire *CFTR* gene and looking for deletions and duplications are necessary to establish the genotype.

The relationship between CFTR genotype and clinical phenotype is highly complex. The CFTR pathogenic variant class is strongly associated with pancreatic dysfunction and will usually predict this manifestation in any given patient. Respiratory complications and lung function decline are also correlated with pathogenic variant class severity but with greater variation because of the influence of non-CFTR modifier gene polymorphisms and environmental influences on the manifestations of lung disease in any one individual. Studies have identified specific non-CFTR modifier genes of importance; genome-wide association studies identified a polymorphism on chromosome 11 in the intergenic region between EHF (an epithelial transcription factor) and APIP (an inhibitor of apoptosis) that is associated with lung disease severity and may influence the expression of *EHF* and *APIP*, as well as other genes in the region, including *PDHX, CD44,* and *ELF5*. A region on chromosome 20 may also be found to relate to lung disease severity. This region encompasses several genes *(MC3R, CASS4, AURKA)* that may play a role in lung host defense involving neutrophil function, apoptosis, and phagocytosis. Genome-wide association studies analysis also identified genetic regions that predispose to risk for liver disease, CF-related diabetes, and meconium ileus.

The high frequency of *CFTR* pathogenic variants has been ascribed to resistance to the morbidity and mortality associated with infectious dysenteries through the ages. Cultured CF intestinal epithelial cells homozygous for the F508del pathogenic variant are unresponsive to the secretory effects of cholera toxin. CFTR heterozygous mice experience less mortality when treated with cholera toxin than their unaffected wild-type littermates.

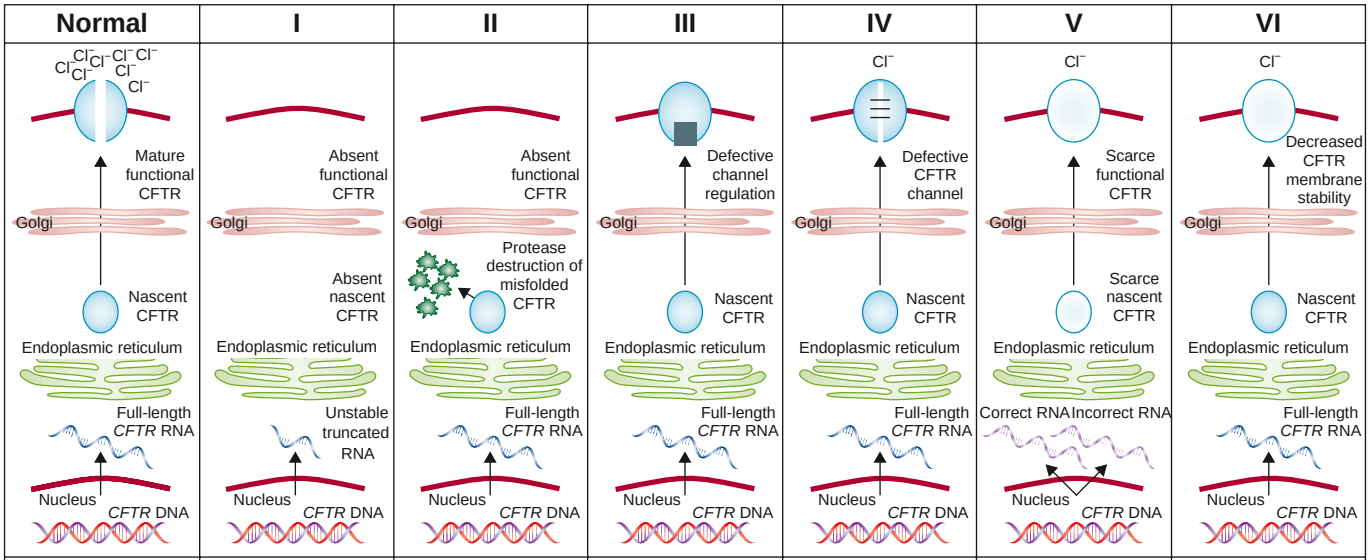

	Normal	I	II	III	IV	V	VI
CFTR defect		No functional CFTR protein	CFTR trafficking defect	Defective channel regulation	Decreased channel conductance	Reduced synthesis of CFTR	Decreased CFTR stability
Type of mutations		Nonsense; frameshift; canonical splice	Missense; aminoacid deletion	Missense; aminoacid change	Missense; aminoacid change	Splicing defect; missense	Missense; aminoacid change
Specific mutation examples		Gly542X Trp1282X Arg553X 621+1G→T	Phe508del Asn1303Lys Ile507del Arg560Thr	Gly551Asp Gly178Arg Gly551Ser Ser549Asn	Arg117His Arg347Pro Arg117Cys Arg334Trp	3849+10kbC→T 2789+5G→A 3120+1G→A 5T	4326delTC Gln1412X 4279insA

Fig. 454.2 Classes of cystic fibrosis transmembrane conductance regulator *(CFTR)* pathogenic variants. Pathogenic variants in the *CFTR* gene can be divided into six classes. Class I pathogenic variants result in no protein production. Class II pathogenic variants (including the most prevalent, Phe508del) cause retention of a misfolded protein at the endoplasmic reticulum and subsequent degradation in the proteasome. Class III pathogenic variants affect channel regulation, impairing channel opening (e.g., Gly551Asp). Class IV pathogenic variants show reduced conduction—that is, decreased flow of ions (e.g., Arg117His). Class V pathogenic variants cause substantial reduction in mRNA or protein, or both. Class VI pathogenic variants cause substantial plasma membrane instability and include Phe508del when rescued by most correctors (rPhe508del). *(From Boyle MP, De Boeck K. A new era in the treatment of cystic fibrosis: correction of the underlying CFTR defect. Lancet Respir Med. 2013;1:158–163.)*

PATHOGENESIS

A number of long-standing observations of CF are of fundamental pathophysiologic importance; they include failure to clear mucous secretions, a paucity of water in mucous secretions, an elevated salt content of sweat and other serous secretions, and chronic infection limited to the respiratory tract. In addition, there is a greater negative potential difference across the respiratory epithelia of patients with CF than across the respiratory epithelia of control subjects. Aberrant electrical properties are also demonstrated for CF sweat gland duct and rectal epithelia. The membranes of CF epithelial cells are unable to secrete chloride or bicarbonate in response to cyclic adenosine monophosphate–mediated signals, and at least in the respiratory epithelial cells, excessive amounts of sodium are absorbed through these membranes. These defects can be traced to a dysfunction of CFTR. CFTR function is highly regulated and energy dependent; it requires both cyclic adenosine monophosphate–stimulated protein kinase A phosphorylation of the regulatory domain and ATP binding and hydrolysis at the nucleotide binding domains. CFTR also interacts with other ion channels, signal transduction proteins, and the cytoskeleton (Fig. 454.3 and see Fig. 454.2).

Many hypotheses have been postulated to explain how CFTR dysfunction results in the clinical phenotype (Fig. 454.4). It is likely that no one hypothesis explains the full spectrum of disease. One model is that airway hydration homeostasis requires both CFTR and $P2Y_2$-regulated calcium-activated chloride secretion. When extracellular ATP is depleted, such as after viral infections, calcium-activated chloride secretion is not activated, and the failure of CFTR chloride secretion results in dehydrated airway secretions, increased concentration of mucin solids, and more viscoelastic mucus that is not cleared by normal mucociliary transport. Another mechanism that is supported by both primary human airway studies and investigations in the CF pig is that variant CFTR causes failure of HCO_3^- secretion and a more acidic airway surface liquid, which increases mucous viscoelasticity, resulting in poor mucociliary clearance. Mucous secretions are tethered to submucosal gland ducts and are retained and obstruct airways, starting with those of the smallest caliber, the bronchioles. Airflow obstruction at the level of small airways is the earliest observable physiologic abnormality of the respiratory system. CFTR dysfunction in airway smooth muscle has been implicated in tracheal and airway abnormalities in humans and in animal models of the disease (pig and mice). These data suggest that CFTR expression in this nonepithelial tissue contributes to airway constriction.

It is plausible that similar pathophysiologic events take place in the pancreatic and biliary ducts (and in the vas deferens), leading to desiccation of proteinaceous secretions and obstruction. Because the function of sweat gland duct cells is to absorb rather than secrete chloride, salt is not retrieved from the isotonic primary sweat as it is transported to the skin surface; chloride and sodium levels are consequently elevated.

Chronic infection in CF is limited to the airways. One explanation for infection is a sequence of events starting with failure to clear inhaled bacteria promptly and then proceeding to persistent infection and an inflammatory response in airway walls. Another explanation for early infection is the failure of innate immune proteins to kill bacteria in an abnormally acidic airway milieu. In addition, it has been proposed that abnormal CFTR creates a proinflammatory state or amplifies the inflammatory response to initial infections (viral or bacterial). Some investigators have identified primary differences in CF-affected immune cells (including macrophage, neutrophils, lymphocytes, and

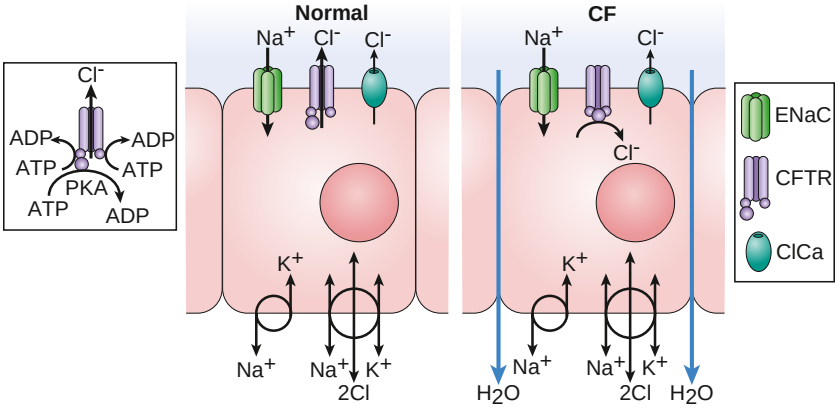

Fig. 454.3 Schematic diagram depicting cystic fibrosis *(CF)* epithelial channel defects, characterized by impaired chloride secretion, massive sodium absorption, and movement of water through the epithelium, leading to a dehydrated airway surface. ADP, Adenosine diphosphate; ATP, adenosine triphosphate; CFTR, cystic fibrosis transmembrane conductance regulator; ClCa, alternative chloride channel; ENaC, epithelium sodium channel; PKA, protein kinase A. *(From Michelson P, Faro A, Ferkol T. Pulmonary disease in cystic fibrosis. In Wilmott RW, Deterding RR, Li A et al., eds. Kendig's Disorders of the Respiratory Tract in Children, 9th ed. Philadelphia: Elsevier; 2019: Fig. 51.1, p. 778.)*

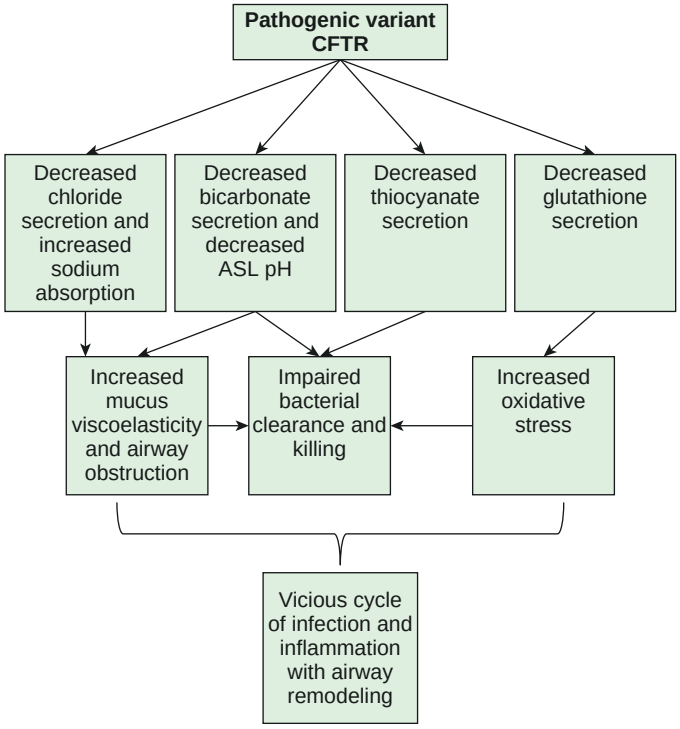

Fig. 454.4 Schema of variant cystic fibrosis transmembrane conductance regulator *(CFTR)* mechanisms of chronic airway disease. CFTR conducts several anions, including chloride, bicarbonate, thiocyanate, and glutathione. The loss of CFTR function affects critical airway epithelial functions: (1) It increases the risk for dehydration of airway surface liquid *(ASL)* with loss of chloride efflux and associated increased sodium channel activity. (2) The loss of secreted bicarbonate and/or acidic pH of the ASL increases mucous viscoelasticity resulting in failure of mucociliary transport. (3) Acidic pH in the ASL impairs normal innate immune clearance of bacteria. (4) Loss of thiocyanate impairs lactoperoxidase bacterial killing. (5) Loss of glutathione secretion depletes the antioxidant capacity of the airway resulting in increased inflammation, increased mucous secretion, and increased mucous viscoelasticity. These factors lead to a vicious cycle of infection and inflammation that is progressive.

dendritic cells) and have suggested that these alterations contribute to this proinflammatory state and to a dysregulated immune response. It appears that inflammatory events occur first in small airways, perhaps because it is more difficult to clear altered secretions and microorganisms from these regions. The agents of airway injury include neutrophil products, such as oxidative radicals and proteases, and immune reaction products. These inflammatory products further aggravate airway obstruction by increasing mucin secretion and altering mucin structure to promote both intramolecular and intermolecular interactions. Excessive inflammatory cell polymers in CF sputum, including DNA, filamentous actin, and glycosaminoglycans, further contribute to abnormal mucous viscoelastic properties and airway obstruction. Chronic bronchiolitis and bronchitis are the initial lung manifestations (see Chapter 439), but after months to years, structural changes in airway walls produce bronchiolectasis and **bronchiectasis**. With advanced lung disease, infection may extend to peribronchial lung parenchyma.

A central feature of lung disease in patients with CF is the high prevalence of airway infection with *Staphylococcus aureus* (see Chapter 227.1), *Pseudomonas aeruginosa* (see Chapter 251.1), and *Burkholderia cepacia* complex (see Chapter 251.2), organisms that rarely infect the lungs of other individuals. It has been postulated that the CF airway epithelial cells or surface liquids may provide a favorable environment for harboring these organisms. CF airway epithelium may be compromised in its innate defenses against these organisms, through either acquired or genetic alterations. Antimicrobial activity is diminished in CF secretions; this diminution may be related to hyperacidic surface liquids or other effects on innate immunity. Another puzzle is the propensity for *P. aeruginosa* to undergo mucoid transformation in the CF airways. The complex polysaccharide produced by these organisms generates a biofilm that provides a hypoxic environment and thereby protects *Pseudomonas* against antimicrobial agents.

Altered lipid homeostasis has been implicated as a predisposing factor for respiratory tract infection and inflammation. Concentrations of lipoxins—molecules that suppress neutrophilic inflammation—are suppressed in CF airways. There is an imbalance of lipids with increased arachidonic acid and decreased docosahexaenoic acid, which promotes inflammation. There is also an imbalance of ceramide in the CF airway that is proinflammatory. Supporting the idea that altered lipid uptake affects infection and inflammation is the observation that the 10–15% of individuals with CF who retain substantial exocrine pancreatic function have delayed acquisition of *P. aeruginosa* and slower deterioration of lung function. However, it appears that nutritional factors are contributory only because preservation of pancreatic function does not preclude development of typical lung disease.

The variation in progression of lung disease seen in patients with CF is also influenced by social and physical environment factors, whose impact matches that of the CFTR genotype. Exposure to environmental tobacco smoke and outdoor air pollutants and early acquisition of respiratory virus infections, as well as pathogenic organisms like *P. aeruginosa* and methicillin-resistant *S. aureus* (MRSA), have been implicated as causes of worsening disease. Sex/gender disparities also seem to exist, with females having a poorer prognosis. Although studies have suggested that estrogen may influence disease exacerbations, the gap seems to be narrowing.

Although most CF care is delivered at specialty centers and is broadly influenced by current clinical guidelines, there is enough variability in treatment approaches to cause large variation in respiratory and

nutritional outcomes across the care networks in both North America and Europe. Social determinants of health are associated with significant disparities in outcome; socioeconomic status has been shown to be a strong predictor of mortality, as well as both nutritional status and lung function on both sides of the Atlantic. The specific mechanism of effect is unclear, but evidence suggests a role for socioeconomic status–related differences in health behaviors and disease self-management practices, stress and mental health issues, and environmental tobacco smoke exposure. Differential access to specialty care and medications are also known to affect clinical outcomes.

PATHOLOGY

The earliest pathologic lesion in the lung is that of bronchiolitis (mucous plugging and an inflammatory response in the walls of the small airways); with time, mucous accumulation and inflammation extend to the larger airways *(bronchitis)* (see Chapter 439.2). Goblet cell hyperplasia and submucosal gland hypertrophy become prominent pathologic findings, which is most likely a response to chronic airway infection. Organisms appear to be confined to the endobronchial space; invasive bacterial infection is not characteristic. With long-standing disease, evidence of airway destruction such as **bronchiolar obliteration**, **bronchiolectasis**, and **bronchiectasis** (see Chapter 452) becomes prominent. Imaging modalities demonstrate both increased airway wall thickness and luminal cross-sectional area relatively early in lung disease evaluation. Bronchiectatic cysts and emphysematous bullae or subpleural blebs are frequent with advanced lung disease, with the upper lobes being most commonly involved. These enlarged air spaces may rupture and cause pneumothorax. Interstitial disease is not a prominent feature, although areas of fibrosis appear eventually. Bronchial arteries are enlarged and tortuous, contributing to a propensity for hemoptysis in bronchiectatic airways. Small pulmonary arteries eventually display medial hypertrophy, which would be expected in secondary pulmonary hypertension.

The **paranasal sinuses** are uniformly filled with secretions containing inflammatory products, and the epithelial lining displays hyperplastic and hypertrophied secretory elements (see Chapter 429). Polypoid lesions within the sinuses and erosion of bone have been reported. The nasal mucosa may form large or multiple **polyps**, usually from a base surrounding the ostia of the maxillary and ethmoidal sinuses.

The **pancreas** is usually small, occasionally cystic, and often difficult to find at postmortem examination. The extent of involvement varies at birth. In infants, the acini and ducts are often distended and filled with eosinophilic material. In 85–90% of patients, the lesion progresses to complete or almost complete disruption of acini and replacement with fibrous tissue and fat. Infrequently, foci of calcification may be seen on radiographs of the abdomen. The islets of Langerhans contain normal-appearing β cells, although they may begin to show architectural disruption by fibrous tissue in the second decade of life.

The **intestinal tract** shows only minimal changes. Esophageal and duodenal glands are often distended with mucous secretions. Concretions may form in the appendiceal lumen or cecum. Crypts of the appendix and rectum may be dilated and filled with secretions.

Focal biliary cirrhosis secondary to blockage of intrahepatic bile ducts is uncommon in early life, although it is responsible for occasional cases of prolonged neonatal jaundice. This lesion becomes much more prevalent and extensive with age and is found in 70% of patients at postmortem examination. This process can proceed to symptomatic multilobular biliary cirrhosis that has a distinctive pattern of large, irregular parenchymal nodules and interspersed bands of fibrous tissue. Approximately 30–70% of patients have fatty infiltration of the liver, in some cases despite adequate nutrition. At autopsy, hepatic congestion secondary to cor pulmonale can be observed. The gallbladder may be hypoplastic and filled with mucoid material and often contains stones. The epithelial lining often displays extensive mucous metaplasia. Atresia of the cystic duct and stenosis of the distal common bile duct have been observed.

Glands of the uterine cervix are distended with mucus, copious amounts of which collect in the cervical canal. In >95% of males, the body and tail of the epididymis, the vas deferens, and the seminal vesicles are obliterated or atretic, resulting in male infertility.

CLINICAL MANIFESTATIONS

Since the universal adoption of CF NBS, along with the evolution of aggressive and proactive treatment approaches, the clinical face of CF is quite different from what it was in earlier decades. Diagnosis is typically accomplished before 1 month of age, before any obvious clinical symptoms or signs, and treatment is targeted at immediately correcting nutritional deficiencies and delaying the respiratory complications of the disease. The interaction of pathogenic variant heterogeneity and environmental factors leads to highly variable involvement of the lungs, pancreas, and other organs. A summary of the time course of potential development of clinical manifestations is shown in Figure 454.5.

Respiratory Tract

Infants diagnosed by CF NBS are generally asymptomatic from a respiratory standpoint. Nonetheless, the majority are infected with *S. aureus*, *Haemophilus influenza*, or even *P. aeruginosa* within the first month of life, and chest CT scans show characteristic heterogeneous air trapping in ~65% of infants by their first birthday, and bronchiectasis is found in more than

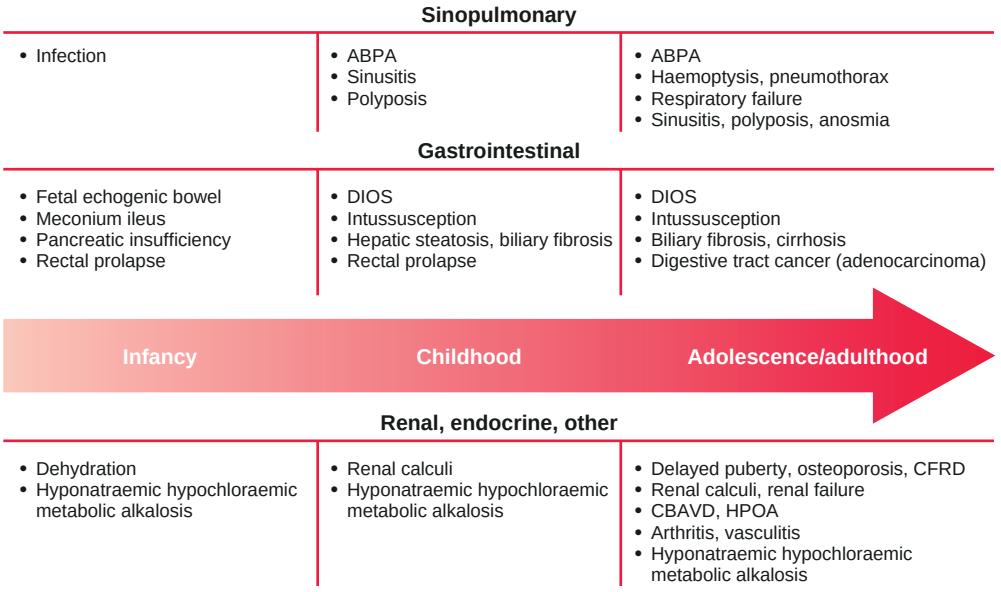

Fig. 454.5 Approximate age of onset of clinical manifestations of cystic fibrosis. ABPA, Allergic bronchopulmonary aspergillosis; CBAVD, congenital bilateral absence of the vas deferens; *CFRD,* cystic fibrosis–related diabetes mellitus; DIOS, distal intestinal obstruction syndrome; HPOA, hypertrophic pulmonary osteoarthritis. *(From O'Sullivan BP, Freedman SD. Cystic fibrosis. Lancet. 2009;373:1891–1902.)*

10% of 1-year-olds and ~60% of 5-year-olds. The earliest symptom is usually a cough that may begin with a viral respiratory tract infection but then persists unless treated with antibiotics. With treatment, the generally realized goal is for patients to remain asymptomatic throughout childhood, except for the periodic development of cough, chest congestion, sputum production, and/or wheezing that define a *pulmonary exacerbation*.

The rate of progression of lung disease is the chief determinant of morbidity and mortality. As lung disease slowly progresses, chronic cough, sputum production, exercise intolerance, shortness of breath, and inability to maintain weight are noted. Common pulmonary complications include atelectasis, hemoptysis, and pneumothorax; these usually appear in late adolescence or beyond. Cor pulmonale, respiratory failure, and death eventually supervene unless lung transplantation is accomplished; this has become increasingly uncommon in childhood. Infection with certain strains of *B. cepacia* and other multidrug-resistant organisms such as non-tuberculous mycobacteria may be associated with particularly rapid pulmonary deterioration.

Children with CF are unlikely to exhibit any abnormal findings on physical exam except during pulmonary exacerbations. Eventual physical findings include increased anteroposterior diameter of the chest, generalized hyperresonance, scattered or localized coarse crackles, and digital clubbing. Expiratory wheezes may be heard, a manifestation of airway inflammation and edema that may or may not be associated with bronchodilator responsiveness. Cyanosis is a late sign. Even though the paranasal sinuses are virtually always opacified radiographically, acute sinusitis is infrequent. Nasal obstruction, rhinorrhea, and anosmia are common, caused by inflamed, swollen mucous membranes or, in some cases, nasal polyposis. Nasal polyps are most troublesome between 5 and 20 years of age and often require repeated surgeries to control.

Intestinal Tract

In 15–20% of newborn infants with CF, the ileum is completely obstructed by meconium **(meconium ileus)**. The frequency is greater among siblings born subsequent to a child with meconium ileus, and concordance is particularly striking in monozygotic twins, reflecting a genetic contribution from one or more unknown modifying genes. Abdominal distention, emesis, and failure to pass meconium appear in the first 24-48 hours of life (see Chapter 135) and often require surgical intervention. Abdominal radiographs (Fig. 454.6) show dilated loops of bowel with air-fluid levels and, frequently, a collection of granular, "ground-glass" material in the lower central abdomen. Rarely, **meconium peritonitis** results from intrauterine rupture of the bowel wall and can be detected radiographically as the presence of peritoneal or scrotal calcifications. These infants may need bowel resection, leading to significant nutritional challenges caused by short bowel syndrome superimposed upon pancreatic insufficiency.

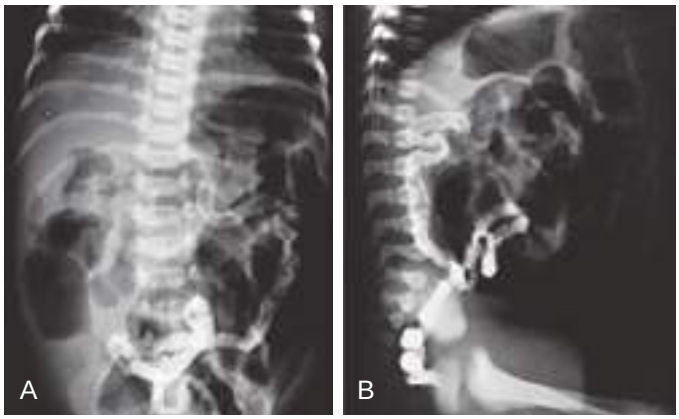

Fig. 454.6 A and B, Contrast enema study in a newborn infant with abdominal distention and failure to pass meconium. Notice the small diameter of the sigmoid and ascending colon and dilated, air-filled loops of small intestine. Several air-fluid levels in the small bowel are visible on the upright lateral view.

Constipation and ileal obstruction with fecal material **(distal intestinal obstruction syndrome [DIOS])** occur in older children, causing cramping abdominal pain, abdominal distention, and obstruction that can be treated with medical approaches to bowel evacuation—typically oral hyperosmotic polyethylene glycol preparations, and occasionally, in more severe cases, hyperosmotic contrast enemas.

More than 85% of children with CF have *exocrine* pancreatic insufficiency, causing protein and fat malabsorption. Symptoms, if untreated, include frequent, bulky, greasy stools and failure to gain weight even when food intake appears to be large. Weight gain can be challenging, but attainment of normal growth and development is an expectation of treatment. A protuberant abdomen, decreased muscle mass, poor growth, and delayed maturation are classic and rarely seen physical signs. Excessive flatus may be a problem even in well-nourished children. Supplementation with fat-soluble vitamin preparations has made deficiencies of vitamins A, E, and K unusual, but vitamin D deficiency continues to be prevalent, and although rickets is rare, osteoporosis is common, especially in older patients and those with more severe lung disease. Class IV-VI pathogenic variants are associated with pancreatic *sufficiency,* but patients with these pathogenic variants are prone to recurrent pancreatitis when they reach adolescence.

Historically a relatively common event, **rectal prolapse** occurs much less frequently as the result of earlier diagnosis and initiation of pancreatic enzyme replacement therapy.

Biliary Tract

Infants may occasionally present with **neonatal jaundice** suggestive of biliary obstruction. Evidence of later liver dysfunction is most often detected in the first 15 years of life and can be found in up to 30% of individuals. **Biliary cirrhosis** develops in about 5–7% of patients. Manifestations can include icterus, ascites, hematemesis from esophageal varices, and evidence of hypersplenism. Biliary colic secondary to cholelithiasis may occur in the second decade or later. Liver disease occurs independent of genotype but is associated with meconium ileus and pancreatic insufficiency.

Cystic Fibrosis–Related Diabetes and Pancreatitis

Endocrine pancreatic insufficiency tends to develop in the second decade and beyond and is more common in patients with a family history of type 2 diabetes mellitus. It most commonly begins with postprandial hyperglycemia and may or may not be accompanied by weight loss or flattening weight gain. Fasting hyperglycemia and elevated hemoglobin A_{1c} are later manifestations. Ketoacidosis usually does not occur because insulin deficiency is relative and not absolute, but eye, kidney, and other vascular complications have been noted in patients living ≥10 years after the onset of hyperglycemia. Recurrent acute pancreatitis occurs occasionally in adolescents and adults who have residual function CFTR pathogenic variants with exocrine pancreatic sufficiency.

Genitourinary Tract

Virtually all males are **azoospermic** because of failure of development of wolffian duct structures, but sexual function is generally unimpaired. The female fertility rate is diminished, especially in women who have poor nutrition or advanced lung disease. Pregnancy is generally tolerated well by women with good pulmonary function but may accelerate pulmonary progression in those with advanced lung disease and may lead to glucose intolerance that persists after the pregnancy is over. Urinary incontinence associated with cough occurs in 18–47% of female children and adolescents.

Sweat Glands

Excessive loss of salt in the sweat predisposes young children to salt depletion episodes, especially during episodes of gastroenteritis and during warm weather. These children may present with **hypochloremic alkalosis**. Hyponatremia is a risk particularly in warm climates. Frequently, parents notice salt *frosting* of the skin or a salty taste when they kiss the child. A few genotypes are associated with relatively normal sweat chloride values.

DIAGNOSIS AND ASSESSMENT

CF is diagnosed when an individual has both a clinical presentation of the disease (such as elevated immunoreactive trypsinogen in the newborn period or signs and symptoms discussed earlier in older patients) and evidence of CFTR dysfunction (physiologic assays and/or the presence of disease-causing CFTR genetic variants) (Table 454.2). This simple formulation is complicated by the existence of CFTR genetic variants that are associated with little or no compromise of CFTR function and are therefore of no or varying clinical consequence, leading to a number of patients who fall into "gray" areas.

DIAGNOSIS OF CF VIA NEWBORN SCREENING

All CF NBS algorithms begin in the first days of life with the measurement of serum immunoreactive trypsinogen (IRT), a pancreatic proenzyme that is elevated in almost all infants with CF. Because IRT levels can fluctuate day by day and season by season, most states set a cutoff level based on an average of IRT levels (e.g., ≥95% percentile). Depending on the state, three different CF NBS algorithms are used:

1. IRT/DNA: This is the most commonly used algorithm. A CFTR gene pathogenic variant screening panel (whose composition varies by state) is applied to the original blood spot. Because not all pathogenic variants are included in the screening panel, the finding of just one CFTR pathogenic variant represents a positive screen. Some states (California, New York) perform gene sequencing from the dried blood spot in response to finding one CFTR gene pathogenic variant.
2. IRT/IRT: The IRT is repeated 2-4 weeks later. In infants without CF, the second IRT is usually normal, whereas in infants with CF, it is persistently elevated, representing a positive screen. This approach has been shown to have lower sensitivity than IRT/DNA.
3. IRT/IRT/DNA: Lower cutoffs are used for IRT than in the states with IRT/IRT algorithms, and in infants with persistently elevated IRT, pathogenic variant screening is performed, and the finding of at least one pathogenic variant represents a positive screen.

A positive CF NBS test only identifies infants with a high likelihood of having CF, but it is not diagnostic for CF. Any infant with a positive CF NBS test should have a sweat chloride test (SCT) performed to confirm the diagnosis of CF. In states using the IRT-IRT algorithm, about 20% of those who have a positive CF NBS are subsequently diagnosed with CF by SCT. In states using the IRT-DNA algorithm, only about 10% of infants who are found to have just one CF-causing pathogenic variant from the screening panel are found to have CF (depending on the pathogenic variant screening panel and ethnic background of the child). Even in cases where two CF-causing pathogenic variants have been identified, sweat testing is indicated to rule out laboratory error or misidentification of newborn blood spots.

Table 454.2 Diagnostic Criteria for Cystic Fibrosis (CF)

Presence of typical clinical features (respiratory, gastrointestinal, or genitourinary)
or
A history of CF in a sibling
or
A positive newborn screening test
plus
Laboratory evidence for CFTR (CF transmembrane regulator) dysfunction:
Two elevated sweat chloride concentrations obtained on separate days
or
Identification of two CF pathogenic variants
or
An abnormal nasal potential difference measurement

DIAGNOSIS OF CYSTIC FIBROSIS OUTSIDE OF NEWBORN SCREENING

Although most cases of CF are diagnosed through NBS, there is still a need to consider the diagnosis in the occasional older patient. This is because NBS is not performed everywhere, and even for individuals who were screened, there is the possibility of a false negative. Most older patients whose diagnosis was missed early in life will have unusual class IV, V, or VI pathogenic variants and therefore *normal* pancreatic function. A CF diagnosis in individuals outside of NBS relies on (1) clinical evidence, such as a chronic productive cough resulting from either bronchitis or chronic sinusitis, nasal polyps, allergic bronchopulmonary aspergillosis or unexplained bronchiectasis, congenital bilateral absence of the vas deferens (CBAVD) (in males) or recurrent pancreatitis, and (2) evidence of CFTR dysfunction (such as CFTR molecular genetic analysis, SCT, or other CFTR physiologic tests).

Sweat Testing

The sweat test, which involves using pilocarpine iontophoresis to collect sweat and performing chemical analysis of its chloride content, is the standard approach to the diagnosis of CF. The procedure requires meticulous attention to detail, and its accuracy can only be assumed when performed at CF Foundation–accredited care centers. An electric current is used to carry pilocarpine into the skin of the forearm and locally stimulate the sweat glands because the measurement is validated under conditions of maximal sweat production. Sweat testing is accurate at any postnatal age, but adequate sweat rates are harder to attain in infants less than 36 weeks gestational age and/or less than 2 kg in weight. Positive results should be confirmed; for a negative result, the test should be repeated if suspicion of the diagnosis remains.

More than 60 mmol/L of chloride in sweat is diagnostic of CF when one or more criteria are present. In individuals with a positive NBS, a sweat chloride level less than 30 mmol/L indicates that CF is unlikely. Borderline (or intermediate) values of 30-59 mmol/L have been reported in patients of all ages who have CF with atypical involvement and require further testing. Table 454.3 lists the conditions associated with false-negative and false-positive sweat test results.

Table 454.3 Conditions Associated with False-Positive and False-Negative Sweat Test Results

WITH FALSE-POSITIVE RESULTS
Eczema (atopic dermatitis)
Ectodermal dysplasia
Malnutrition/failure to thrive/deprivation
Anorexia nervosa
Congenital adrenal hyperplasia
Adrenal insufficiency
Glucose-6-phosphatase deficiency
Mauriac syndrome
Fucosidosis
Familial hypoparathyroidism
Hypothyroidism
Nephrogenic diabetes insipidus
Pseudohypoaldosteronism
Klinefelter syndrome
Familial cholestasis syndrome
Autonomic dysfunction
Prostaglandin E infusions
Munchausen syndrome by proxy
WITH FALSE-NEGATIVE RESULTS
Dilution
Malnutrition
Edema
Insufficient sweat quantity
Hyponatremia
Cystic fibrosis transmembrane conductance regulator pathogenic variants with preserved sweat duct function

DNA Testing

Several commercial laboratories provide screening panels that test for the most common CFTR pathogenic variants. The American College of Medical Genetics recommends at least 23; other panels screen for >100 pathogenic variants. The sensitivity of these panels depends on the race/ethnicity of the population tested, but is always well under 100%, so it is important to view them as screening, but not definitive, diagnostic tests. Whole CFTR gene sequencing with additional attention to deletions and duplications is available but is expensive and only helpful in very select situations.

Other Physiologic Measures of CFTR Function

The finding of increased potential differences across nasal epithelium **(nasal potential difference)**, that is the increased voltage response to topical amiloride application, followed by the absence of a voltage response to a β-adrenergic agonist, has been used to confirm the diagnosis of CF in patients with equivocal or frankly normal sweat chloride values. Intestinal current measurements may also provide additional helpful information, particularly in children who are unable to cooperate with nasal potential difference testing. These procedures are primarily used in research applications and have never undergone extensive validation as a clinical tool.

OTHER LABORATORY TESTING OF IMPORTANCE IN DIAGNOSIS AND MANAGEMENT

Pancreatic Function

The diagnosis of pancreatic insufficiency can be made by the quantification of *elastase-1 activity* in a fresh stool sample by an enzyme-linked immunosorbent assay specific for human elastase. The quantification of fat malabsorption with a 72-hour stool collection is rarely performed in the clinical setting. CF-related diabetes affects approximately 20% of adolescents and 40–50% of adults, and clinical guidelines recommend yearly oral glucose tolerance testing (OGTT) after age 10. OGTT may sometimes be clinically indicated at an earlier age. Spot testing of blood and urine glucose levels and glycosylated hemoglobin levels are not sufficiently sensitive.

Radiology

Hyperinflation of lungs occurs early and is often accompanied by nonspecific peribronchial thickening (Fig. 454.7). Bronchial thickening and plugging and ring shadows suggesting bronchiectasis usually appear first in the upper lobes. Nodular densities, patchy atelectasis, and confluent infiltrate follow. Hilar lymph nodes may be prominent. With advanced disease, impressive hyperinflation with markedly depressed diaphragms, anterior bowing of the sternum, and a narrow cardiac shadow are noted.

Fig. 454.7 Serial radiographs in a child show the changing appearance of cystic fibrosis over 6 yr. **A,** At 9 yr, frontal radiograph shows minimal peribronchial thickening and hyperaerated lungs indistinguishable from asthma. **B,** Nineteen mo later, the radiographic picture has worsened considerably. Extensive peribronchial thickening is now noted. Mucoid impaction of the bronchus is seen in the left upper lobe, and hilar shadows have become abnormally prominent. **C,** Ten mo later, further deterioration is obvious. Widespread typical changes of cystic fibrosis (CF) are noted throughout both lungs. **D,** Follow-up studies show considerable improvement, which suggested that some of the changes evident on (C) were from superimposed infection. **E,** One yr later, note the progressive changes of CF—most severe in the upper lobes bilaterally. *(From Long FR, Druhan SM, Kuhn JP. Diseases of the bronchi and pulmonary aeration. In Slovis T, ed. Caffey's Pediatric Diagnostic Imaging, 11th ed. Philadelphia: Mosby; 2008: Fig. 73-54.)*

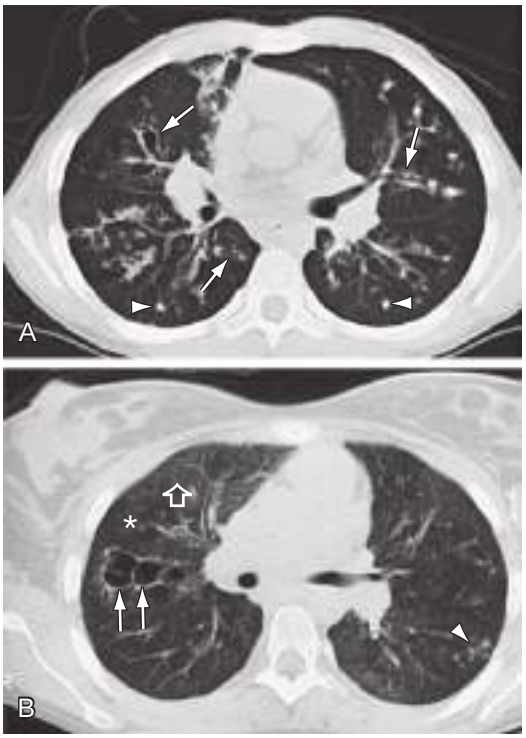

Fig. 454.8 CT scans of the chest in cystic fibrosis. **A,** A 12-yr-old male with moderate lung disease. Airway and parenchymal changes are present throughout both lungs. Multiple areas of bronchiectasis *(arrows)* and mucous plugging *(arrowheads)* can be seen. **B,** A 19-yr-old female has mostly normal lung with one area of saccular bronchiectasis in the right upper lobe *(arrows)* and a focal area of peripheral mucous plugging in the left lower lobe *(arrowhead).* Lung density is heterogeneous with areas of normal lung *(open arrow)* and areas of low attenuation reflecting segmental and subsegmental air trapping *(asterisk).*

Cyst formation, extensive bronchiectasis, dilated pulmonary artery segments, and segmental or lobar atelectasis is often apparent with advanced disease. Most CF centers obtain chest radiographs (posteroanterior [PA] and lateral) at least annually. CT of the chest can detect heterogeneous hyperinflation and localized thickening of bronchial airway walls, mucous plugging, focal hyperinflation, and bronchiectasis (Fig. 454.8). CT abnormalities are commonly seen as early as the first year of life and even in asymptomatic children with normal lung function.

Radiographs of paranasal sinuses reveal panopacification and, often, failure of frontal sinus development. CT provides better resolution of sinus changes if this information is required clinically.

Fetal ultrasonography may show pancreatic changes indicative of CF and suggest ileal obstruction with meconium early in the second trimester, but this finding is not predictive of meconium ileus at birth.

Pulmonary Function

Infant pulmonary function testing is done routinely for clinical evaluation at a few CF centers, but given its complexity and the need for sedation, for the most part it is reserved for research protocols. Lung clearance index (LCI), measured by multiple breath washout, can be done in infants and young children and is a sensitive measure of ventilation inhomogeneity caused by small airways disease. Currently it is primarily used for research, but given its ease and applicability, it may be adopted as a standard monitoring tool in the future as CF care centers become more accustomed to its use.

Standard pulmonary function studies are usually obtained starting at about 4 years of age and are routinely done by age 6. **Forced expiratory volume in 1 second** (FEV_1) is the measurement that has been shown to correlate most closely with mortality and shows a gradual decline averaging 2–3% per year throughout childhood. Although a small number of children may already show evidence of airway obstruction

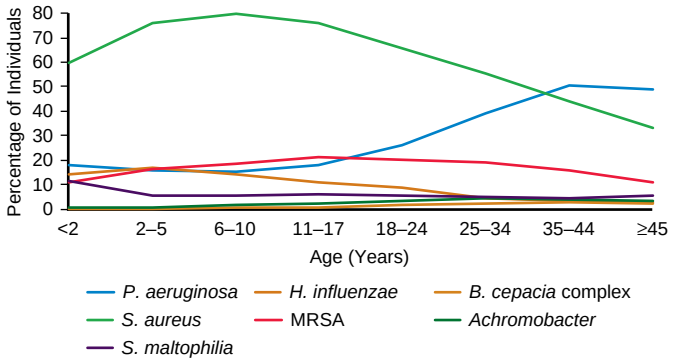

Fig. 454.9 Prevalence of respiratory microorganisms by age cohort, 2021. *(From the Cystic Fibrosis Patient Registry 2021. Annual Data Report. p. 30. © 2022 Cystic Fibrosis Foundation. Bethesda, Maryland.* https://www.cff.org/sites/default/files/2021-11/Patient-Registry-Annual-Data-Report.pdf*)*

by age 6, trends over the past several decades, as reported by the CFF patient registry, show a steady improvement in average FEV_1 of the CF population. The proportion of people with CF age 18 years who are in the normal/mild lung disease category (FEV_1 ≥70% predicted) has increased from 33.8% in 1989 to 78.3% in 2019. The proportion in the severe lung disease category (FEV_1 <40% predicted) has decreased from 24.0% in 1988 to 2.6% in 2019. Residual volume and functional residual capacity are increased early in the course of lung disease and are the cause of decreasing forced vital capacity (FVC) measurement. Restrictive changes, characterized by declining total lung capacity and vital capacity, correlate with extensive lung injury and fibrosis and are a late finding. Testing at each clinic visit is recommended to evaluate the course of the pulmonary involvement and allow for early intervention when clinically significant decrements are documented—an acute drop in FEV_1 is probably the most sensitive indicator of a pulmonary exacerbation that should be treated with systemic antibiotics.

Microbiologic Studies

H. influenza and *S. aureus* are the most common organisms recovered in young children (Fig. 454.9). *Pseudomonas* may be acquired early and is an organism of key significance. *P. aeruginosa* appears to have a special propensity for the CF airway and over time characteristically develops a biofilm associated with a mucoid appearance in the microbiology lab and which correlates with more rapid progression of lung disease. Once *P. aeruginosa* develops a mucoid phenotype, it is extremely difficult to eradicate from the airway. A wide range of other organisms are frequently recovered, particularly in advanced lung disease; they include a variety of gram-negative rods, including the *B. cepacia* complex, which may be associated with a fulminant downhill course **(cepacia syndrome)**; *Stenotrophomonas maltophilia* and *Achromobacter xylosoxidans;* assorted fungi, especially *Aspergillus fumigatus,* which is most important because of the relatively common development of **allergic bronchopulmonary aspergillosis**; and nontuberculous mycobacterial species, especially *Mycobacterium avium* complex and *Mycobacterium abscessus*. Airway cultures are obtained regularly, most typically using oropharyngeal swabs in young children, and then sputum (which may be induced) in older children capable of expectoration. Oropharyngeal swabs typically give a good indication of the lower airway flora, but fiberoptic bronchoscopy may be used to gather lower respiratory tract secretions of infants and young children who do not expectorate if there is a concern for false-negative cultures, especially regarding the presence of *P. aeruginosa*.

The CF airway microbiome consists of a large number of additional organisms, especially anaerobes that are identified through antigen detection but not culture methods. The significance of this finding and its therapeutic implications remain somewhat unclear, but it has long been appreciated that response to antibiotic treatment of pulmonary exacerbations is not always predictable based on culture and sensitivity of airway cultures.

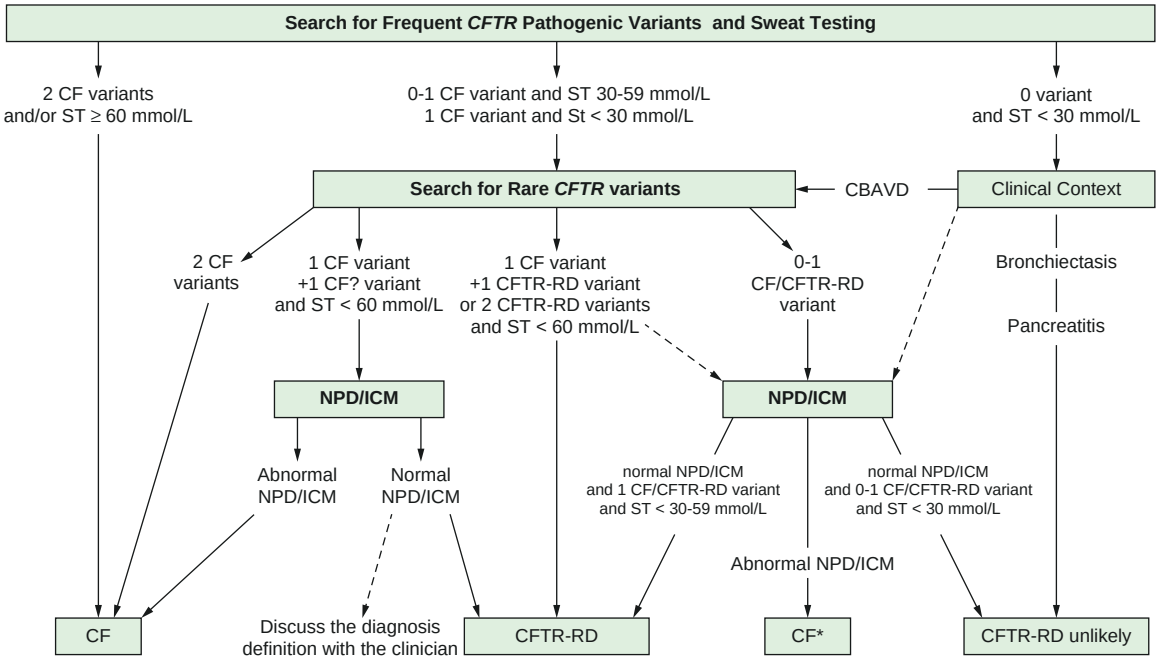

Fig. 454.10 2015 European Cystic Fibrosis Society recommended algorithm for diagnosis of CFTR-RD. Global diagnostic algorithm for CF and CFTR-RD. A global flowchart of genetic and functional diagnostic testing in CF and CFTR-RD is presented. CBAVD, Congenital bilateral absence of the vas deferens; CF, cystic fibrosis; CF? pathogenic variant, pathogenic variant of unproven or uncertain clinical significance; CF*, diagnosis of CF or consider this diagnosis; CFTR, cystic fibrosis transmembrane conductance regulator; CFTR-RD, CFTR-related disorders; ICM, intestinal current measurement; NPD, nasal potential difference; ST, sweat test (repeated; false positive should be excluded/sought in a specialized center). *(From Bombieri C, Claustres M, De Boeck K, et al. Recommendations for the classification of diseases as CFTR-related disorders. J Cyst Fibros. 2011;10[Suppl 2]:S86–102, Fig 1.)*

MANIFESTATIONS OF REDUCED CFTR FUNCTION THAT DO NOT MEET CRITERIA FOR CF

CFTR-Related Metabolic Syndrome

There is a subset of infants with a positive newborn screen for CF who have inconclusive diagnostic testing. The term for this condition, used in the United States, is *CFTR-related metabolic syndrome* (CRMS); in Europe, the analogous term is *CF screen positive, inconclusive diagnosis* (CFS-PID). Data from the CF Foundation National Patient Registry show that approximately one infant is diagnosed with CRMS for every five cases of CF. An infant is determined to have CRMS if they are asymptomatic with a positive CF NBS test and either (1) sweat test <30 mmol/L and two *CFTR* pathogenic variants, at least one of which has unclear phenotypic consequences, or (2) sweat test 30-59 mmol/L and zero or one CF-causing CFTR pathogenic variant.

CRMS should be *distinguished* from CFTR-related disorder (CFTR-RD), described later, in that CRMS is a diagnosis that arises only from CF NBS in otherwise asymptomatic individuals.

Data on long-term outcomes of infants with CRMS are limited because universal CF NBS is relatively new and CRMS has only recently been recognized. The majority of CRMS infants appear to have normal growth and do not develop any pulmonary manifestations of CF, although it is not unusual for them to grow *P. aeruginosa* from their airways in the absence of any other clinical manifestations. However, a small percentage (~5–10%) will develop signs and symptoms of CF, including measures of CFTR dysfunction such as a clinically elevated sweat chloride or abnormalities in other CFTR functional assays. This is a diagnosis that it is important for the general pediatrician to be aware of, because these children are often lost to follow-up by CF care centers.

CFTR-Related Disorder

The diagnosis of CFTR-RD has been defined as a monosymptomatic clinical entity associated with CFTR dysfunction that does not fulfill the diagnostic criteria for CF. Common manifestations include CBAVD, recurrent pancreatitis, chronic sinusitis, nasal polyposis, or bronchiectasis. This is more typically diagnosed in adults but sometimes might appear in late adolescence. An approach to the evaluation of patients with CFTR-RD is seen in Figure 454.10.

TREATMENT

General Approach to Care

Initial efforts after diagnosis should be intensive and should include baseline assessment, initiation of treatment to prevent pulmonary involvement in young infants or reverse it in those diagnosed later, nutritional maintenance or remediation, and education of the patient and parents. Follow-up evaluations are scheduled every 1-3 months, depending on the age at diagnosis, because many aspects of the condition require careful monitoring. An interval history and physical examination should be obtained at each visit. A sputum sample or, if that is not available, a lower pharyngeal swab taken during or after a forced cough is obtained for culture and antibiotic susceptibility studies. Because irreversible loss of pulmonary function from low-grade infection can occur gradually and without acute symptoms, emphasis is placed on a thorough pulmonary history and physical exam and routine pulmonary function testing. Table 454.4 lists symptoms and signs that suggest the need for more intensive antibiotic and physical therapy (PT). Protection against exposure to MRSA, *P. aeruginosa, B. cepacian,* and other resistant gram-negative organisms is essential, including contact isolation procedures and careful attention to cleaning of inhalation therapy equipment. A nurse, physical therapist, respiratory therapist, social worker, and dietitian, as members of the multidisciplinary care team, should evaluate children regularly and contribute to the development of a comprehensive daily care plan. Considerable education and programs to empower families and older children to take responsibility for care are likely to result in the best adherence to daily care programs. Screening patients and caregivers for anxiety and depression annually is expected to identify issues that can interfere with adherence to daily care. Standardization of practice, on the part of both caregivers and families, as well as close monitoring and early intervention for new or increasing symptoms, appears to result in the best long-term outcomes.

Because secretions of CF patients are not adequately hydrated, attention in early childhood to oral hydration, especially during warm weather or with acute gastroenteritis, may minimize complications associated with impaired mucous clearance. Intravenous therapy for dehydration should be initiated early.

Table 454.4 Symptoms and Signs Associated with Exacerbation of Pulmonary Infection in Patients with Cystic Fibrosis

SYMPTOMS
Increased frequency and duration of cough
Increased sputum production
Change in appearance of sputum
Increased shortness of breath
Decreased exercise tolerance
Decreased appetite
Feeling of increased congestion in the chest
SIGNS
Increased respiratory rate
Use of accessory muscles for breathing
Intercostal retractions
Change in results of auscultatory examination of chest
Decline in measures of pulmonary function consistent with the presence of obstructive airway disease
Fever and leukocytosis
Weight loss
New infiltrate on chest radiograph

From Ramsey B. Management of pulmonary disease in patients with cystic fibrosis. *N Engl J Med.* 1996;335:179.

The goal of therapy is to maintain a stable condition for prolonged periods. This can be accomplished for most patients by interval evaluation and adjustments of the home treatment program. Some children have episodic acute or low-grade chronic lung infection that progresses. For these patients, intensive inhalation and airway clearance and intravenous antibiotics are indicated. Improvement is most reliably accomplished in a hospital setting; selected patients have demonstrated successful outcomes while completing these treatments at home. Intravenous antibiotics may be required infrequently or as often as every 2-3 months. The goal of treatment is to return patients to their previous pulmonary and functional status.

The basic daily care program varies according to the age of the child, the degree of pulmonary involvement, other system involvement, and the time available for therapy. The major components of this care are pulmonary and nutritional therapies. Because therapy is medication intensive, iatrogenic problems frequently arise. Monitoring for complications is also an important part of management.

Cystic Fibrosis Transmembrane Conductance Regulator Modulator Therapies

CFTR modulator therapies are small molecules taken orally that correct the processing and function of the variant CFTR protein in multiple organs and reduce or correct manifestations of disease. They have been developed to target specific classes of pathogenic variants (see Fig. 454.2). Ivacaftor is a small-molecule potentiator of the CFTR pathogenic variant G551D (present in ~5% of patients). Ivacaftor activates the CFTR-G551D variant protein, a class III CFTR pathogenic variant that results in protein localized to the plasma membrane but loss of chloride channel function (Table 454.5; Fig. 454.11). Ivacaftor therapy results in improvement in FEV_1 by an average of 10.6%, decreases the frequency of pulmonary exacerbations by

Table 454.5 Cystic Fibrosis Transmembrane Regulator Modulators for Cystic Fibrosis

DRUG	FDA-APPROVED INDICATION	FORMULATIONS	USUAL DOSAGE
Ivacaftor	4 mo with a responsive pathogenic variant*	25, 50, 75 mg granule packets† 150 mg tablets	<6 yr: weight-based dosing‡; ≥6 yr: 150 mg q12h
Lumacaftor/ivacaftor	≥2 yr, F508del-homozygous	100/125, 200/125 mg tabs; 100/125, 150/188 mg granule packets†	6-11 yr: 200/250 mg q12h ≥12 yr: 400/250 mg q12h§
Tezacaftor/ivacaftor	≥6 yr, F508del-homozygous or F508del-heterozygous with another responsive pathogenic variant‖	Tablets: tezacaftor once per day and ivacaftor twice per day q12h	6-11 yr, <30 kg; AM: 50 mg tezacaftor + 75 mg ivacaftor PM: 75 mg ivacaftor 6-11 yr, ≥30 kg and 12 yr: AM: 100 mg tezacaftor + 150 mg tab ivacaftor PM: 150 mg tab ivacaftor
Elexacaftor/tezacaftor/ivacaftor	≥6 yr, one copy of F508del	Tablets: 2 triple-combination tablets (orange) in AM and one ivacaftor tablet (blue) in PM	6-11 yr, <30 kg; AM: elexacaftor 50 mg/tezacaftor 25 mg/ivacaftor 37.5 mg (2 combination tablets) PM: ivacaftor 75 mg 6-11 yr, ≥30 kg and 12 yr: AM: elexacaftor 100 mg/tezacaftor 50 mg/ivacaftor 75 mg (2 combination tablets) PM: ivacaftor 150 mg
	2 yr - <6 yr, one copy of F508del	ELX 80 or 100 mg TEZ 40 or 50 mg IVA 60 or 75 mg	<14 kg: AM: ELX 80 / TEZ 40 AM and PM: IVA 60 ≥14 kg: AM: ELX 100 / TEZ 50 AM and PM: IVA 75

*Approved pathogenic variants: G551D, S549N, G1244E, G178R, S1251N, G551S, G1349D, S1255P, R117H, E56K, K1060T, P67L, E193K, A1067T, R74W, L206W, G1069R, D110E, R347H, D579G, R1070Q, D1270N, D110H, R352Q, S945L, R1070W, R117C, A455E, S977F, F1074L, F1052V, D115H; 3849 þ 10 kb C>T, 2789 þ5G>A, 3273-26A>G, 711þ3A>G, E831X.
†The granules should be mixed with 5 mL of room-temperature or cold soft food or liquid and consumed within 1 hr.
‡In patients 4 mo to 6 yr old, the recommended dosage is 25 mg every 12 hr for weight 5 kg to <7 kg, 50 mg every 12 hr for those weighing <14 kg, and 75 mg every 12 hr for those weighing ≥14 kg.
§In patients 2-5 yr old, the recommended dosage is 100/125 mg every 12 hr for those weighing <14 kg and 150/188 mg every 12 hr for those weighing ≥14 kg.
‖F508del heterozygotes with the following pathogenic variants: E56K, K1060T, P67L, E193K, A1067T, R74W, L206W, D110E, D110H, R347H, D579G, R1070Q, D1270N, R352Q, S945L, R1070W, R117C, A455E, S977F, F1074L, F1052V, D1152H, 3849þ10kb C>T, 2789 þ5G>A, 3273-26A>G, 711þ3A>G.
Modified from The Medical Letter on Drugs and Therapeutics: Tezacaftor/Ivacaftor (Symdeko) for cystic fibrosis. *Med Lett.* 2018;60(1558):174–176, Table 3.

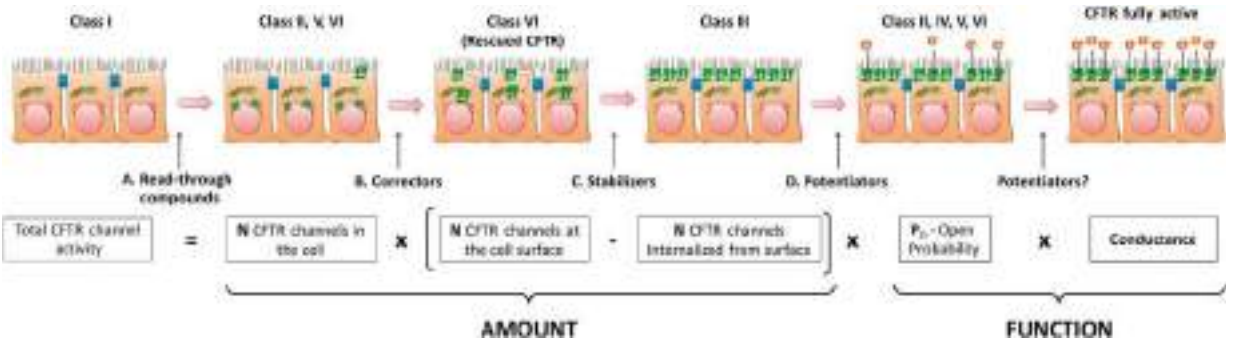

Fig. 454.11 Cystic fibrosis transmembrane conductance regulator *(CFTR)* pharmacologic modulators have different modes of action. **A,** Read-through compounds, which include aminoglycoside antibiotics (e.g., gentamicin, tobramycin), act by suppressing premature termination codons (PTCs), thus permitting translation to continue to the normal termination of the transcript and thus increasing the total amount of complete CFTR being produced in the cell. **B,** Correctors (e.g., VX-809, also known as lumacaftor; VX-661) potentially promote folding of variant CFTR protein, allowing it to escape ER degradation and reach the cell surface, thus increasing the number of channels present at the plasma membrane. **C,** Stabilizers include compounds (e.g., hepatocyte growth factor) that enhance CFTR retention/anchoring at the cell surface, thus also contributing to increase the number of channels present at the cell surface. **D,** Potentiators (e.g., VX-770, also known as ivacaftor) activate CFTR, that is, increase the open probability *(P_o)* of the channel by regulating its gating and possibly also the conductance. *(From Bell SC, De Boeck K, Amaral MD. New pharmacological approaches for cystic fibrosis: promises, progress, pitfalls. Pharmacol Therapeu. 2015;145:19–34, Fig. 4.)*

55%, decreases sweat chloride by an average of 48 mEq/L, and increases weight gain by an average of 2.7 kg. Ivacaftor is approved for patients older than 2 years of age with class III and class IV pathogenic variants.

The combination of ivacaftor with lumacaftor, a corrector that stabilizes misfolded F508del and enables trafficking of the variant molecule to the apical cell membrane where it is potentiated by ivacaftor, is available for patients older than 6 years of age who are homozygous for the F508del pathogenic variant (see Fig. 454.11). This medication is associated with smaller increments in pulmonary and nutritional outcomes but is an important proof-of-concept treatment.

Tezacaftor and ivacaftor is another combination indicated for patients ≥6 years with one or two Phe508del alleles. This combination improves predicted FEV_1 and overall well-being (see Table 454.5). VX-445 combined with tezacaftor-ivacaftor adds another CFTR correction agent; the triple combination improves predicted FEV_1 and reduces sweat chloride levels.

Elexacaftor/tezacaftor/ivacaftor, a triple combination therapy for patients ≥6 years with at least one copy of Phe508del alleles was approved in 2019 (see Table 454.5). This therapy is a highly effective modulator, and 90% of patients with CF are eligible to use this treatment. In a phase 3 randomized, double-blind trial for patients homozygous for Phe508del comparing elexacaftor/tezacaftor/ivacaftor to tezacaftor/ivacaftor alone, patients on triple therapy had a significant increase in FEV_1 percent predicted of 10% and a dramatic decrease in sweat chloride levels by 45 mM compared with double therapy at 4 weeks. In a phase 3 randomized, double-blind, placebo-controlled clinical trial for patients with one copy of Phe508del, triple therapy was associated with a decrease in sweat chloride by 41.8 mmol/L and a marked increase in FEV_1 percent predicted of 14% at 24 weeks. The success of these highly effective CFTR modulator therapies, ivacaftor for class III pathogenic variants and elexacaftor/tezacaftor/ivacaftor for Phe508del, has been life-changing. Ivacaftor and the triple combination therapy are being evaluated for therapeutic efficacy in younger children and infants with CF.

However, at least 10% of patients with CF have pathogenic variants that are not responsive to these highly effective modulator therapies. Patients with class I pathogenic variants caused by premature termination codons and failure to translate CFTR protein will require new approaches to therapy to acquire normal CFTR protein and function. Gene therapy, gene editing, and antisense oligonucleotide therapeutic approaches are currently being developed.

Pulmonary Therapy

The object of pulmonary therapy is to clear secretions from airways and to control infection. When a child is not doing well, every potentially useful aspect of therapy should be reconsidered.

Inhalation Therapy

Human recombinant Dnase (2.5 mg) enzymatically dissolves extracellular DNA released by neutrophils, a major contributor to the characteristically sticky and viscous CF airway secretions. Recombinant human Dnase is usually given as a single daily aerosol dose; it improves pulmonary function, decreases the number of pulmonary exacerbations, and promotes a sense of well-being. Benefit for those with mild, moderate, and severe lung disease has been documented. Improvement is sustained for 12 months or longer with continuous therapy.

Nebulized hypertonic saline, acting as a hyperosmolar agent, is believed to draw water into the airway and rehydrate mucus and the periciliary fluid layer, resulting in improved mucociliary clearance. Seven percent hypertonic saline nebulized 2-4 times daily increases mucous clearance and reduces pulmonary exacerbation, with only a slight short-term improvement in pulmonary function.

Airway Clearance Therapy

Airway clearance treatment begins in infancy with chest percussion (with or without postural drainage) and derives its rationale from the idea that cough clears mucus from large airways, but chest vibrations are required to shear secretions from the airway wall and move secretions from small airways, where expiratory flow rates are low. **Chest PT** can be particularly useful for patients with CF because they accumulate secretions in small airways first, even before the onset of symptoms. Cessation of chest PT in children with mild to moderate airflow limitation results in deterioration of lung function within 3 weeks, and prompt improvement of function occurs when therapy is resumed, but it is less clear which available modality is best. Airway clearance therapy is recommended 2-4 times a day, depending on the severity of lung dysfunction, and usually increased during acute exacerbations. Cough, huffing, or forced expirations are encouraged intermittently throughout the session. Vest-type mechanical percussors *(high-frequency chest wall oscillation)* are commonly used past infancy because of their convenience, as are a variety of oscillatory positive expiratory pressure devices (such as Acapella and Aerobika) and other controlled breathing techniques (e.g., *autogenic drainage*). Routine aerobic exercise appears to slow the rate of decline of pulmonary function, and benefit has also been documented with weight training. No one airway clearance technique can be shown to be superior to any other, so all modes should be considered in the development of an airway clearance prescription. Adherence to daily therapy is important but rarely achieved; therefore airway clearance technique plans are individualized for each patient.

Antibiotic Therapy

Antibiotics are the mainstay of therapy designed to control progression of lung infection. The goal is to reduce the intensity of endobronchial infection and to delay progressive lung damage. The usual guidelines

Table 454.6 Antimicrobial Agents for Cystic Fibrosis Lung Infection

ROUTE	ORGANISMS	AGENTS	DOSAGE (mg/kg/24 hr)	NO. DOSES/24 hr
Oral	*Staphylococcus aureus*	Dicloxacillin	25-50	4
		Linezolid	20	2
		Cephalexin	50	4
		Clindamycin	10-30	3-4
		Amoxicillin-clavulanate	25-45	2-3
	Haemophilus influenzae	Amoxicillin	50-100	2-3
	Pseudomonas aeruginosa	Ciprofloxacin	20-30	2-3
	Burkholderia cepacia	Trimethoprim-sulfamethoxazole	8-10*	2-4
	Empirical	Azithromycin	10, day 1; 5, days 2-5	1
		Erythromycin	30-50	3-4
Intravenous	*S. aureus*	Nafcillin	100-200	4-6
		Vancomycin	40	3-4
	P. aeruginosa	Tobramycin	8-12	1
		Amikacin	15-30	2-3
		Ticarcillin	400	4
		Piperacillin	300-400	4
		Ticarcillin-clavulanate	400†	4
		Piperacillin-tazobactam	240-400‡	3
		Meropenem	60-120	3
		Imipenem-cilastatin	45-100	3-4
		Ceftazidime	150	3
		Aztreonam	150-200	4
	B. cepacia	Chloramphenicol	50-100	4
		Meropenem	60-120	3
Aerosol		Tobramycin (inhaled)	300§	2
		Aztreonam (inhaled)	75	3

*Quantity of trimethoprim.
†Quantity of ticarcillin.
‡Quantity of piperacillin.
§In mg per dose.

for acute chest infections, such as fever, tachypnea, or chest pain, are often absent. Consequently, all aspects of the patient's history and examination, including anorexia, weight loss, and diminished activity, must be used to guide the frequency and duration of therapy. Antibiotic treatment varies from intermittent short courses of one antibiotic to nearly continuous treatment with one or more antibiotics. Dosages for some antibiotics are often 2-3 times the amount recommended for minor infections because patients with CF have proportionately more lean body mass and higher clearance rates for many antibiotics than other individuals. In addition, it is difficult to achieve effective drug levels of many antimicrobials in respiratory tract secretions.

Oral Antibiotic Therapy

Indications for oral antibiotic therapy in a patient with CF include the presence of respiratory tract symptoms, physical signs, or changes in pulmonary function testing or chest x-ray. Treatment is guided by identification of pathogenic organisms in respiratory tract cultures and in vitro sensitivity testing. Common organisms, including *S. aureus (MRSA or methicillin-susceptible S. aureus [MSSA]),* nontypeable *H. influenzae, P. aeruginosa, B. cepacian,* and other gram-negative rods, are encountered with increasing frequency. The usual course of therapy is 2 weeks, and maximal doses are recommended. Table 454.6 lists useful oral antibiotics. The quinolones are the only broadly effective oral antibiotics for *Pseudomonas* infection, but resistance against these agents may emerge. Macrolides may reduce the virulence properties of *P. aeruginosa,* such as biofilm production, and contribute antiinflammatory effects. Long-term therapy with azithromycin 3 times a week improves lung function in patients with chronic *P. aeruginosa* infection.

Aerosolized Antibiotic Therapy

Aerosolized antibiotics are often used as part of daily therapy when the airways are infected with *P. aeruginosa*. Aerosolized tobramycin inhalation solution or powder, or aztreonam inhalation solution used as a suppressive therapy (on 1 month, off 1 month), may reduce symptoms, improve pulmonary function, and decrease the occurrence of pulmonary exacerbations. Although these therapies are sometimes used in acute pulmonary exacerbations, the evidence to support this application is limited.

Another important indication for aerosolized antibiotic therapy is to eradicate *P. aeruginosa* in the airways after initial detection. Early infection may be cleared for months to several years in this way, although eventual reinfection is common. Other antibiotics have been used via

inhalation, including liposomal amikacin and levofloxacin for *P. aeruginosa,* and there was no inferiority of efficacy compared with inhaled tobramycin.

Intravenous Antibiotic Therapy

For the patient who has not responded to oral antibiotics and intensive home measures with return of signs, symptoms, and FEV_1 to baseline, intravenous antibiotic therapy is indicated. This therapy is usually initiated in the hospital but is sometimes completed on an ambulatory basis if the likelihood of complete adherence to the therapeutic regimen is good. The ideal duration of treatment is unknown; although many patients show improvement within 7 days, many CF physicians believe that it is usually advisable to extend the period of treatment to at least 14 days. Permanent intravenous access can be provided for long-term or frequent courses of therapy in the hospital or at home. Thrombophilia screening should be considered before the use of totally implantable intravenous devices or for recurring problems with venous catheters.

Table 454.6 lists commonly used intravenous antibiotics. In general, treatment of *Pseudomonas* infection is thought to require two-drug therapy. A third agent may be given for optimal coverage of *S. aureus* or other organisms. Aminoglycosides are usually effective when given every 24 hours to minimize toxicity and optimize convenience. Some CF physicians use peak and trough levels to guide dosing, but most clinical pharmacists recommend measuring levels at other times, commonly 2 and 12 hours, to use pharmacokinetic calculations to guide dosing. Changes in therapy should be guided by lack of improvement more than by culture results; sensitivities do not always predict response to therapy, and this may be because of the presence of other organisms that are not detected by culture methods. If patients do not show improvement, complications such as right heart failure; asthma; or infection with viruses, *A. fumigatus* (especially allergic bronchopulmonary aspergillosis, ABPA) (see Chapter 283), nontuberculous mycobacteria (see Chapter 263), or other unusual organisms should be considered. *B. cepacia* complex and *Acinetobacter* are gram-negative rods that may be particularly refractory to antimicrobial therapy. Infection control in both the outpatient and inpatient medical setting is critically important to prevent nosocomial spread of resistant bacterial organisms between patients.

Bronchodilator Therapy

Reversible airway obstruction occurs in many children with CF, sometimes in conjunction with frank asthma or allergic bronchopulmonary aspergillosis. Reversible obstruction is conventionally defined as improvement of ≥12% in FEV_1 or FVC after inhalation of a bronchodilator. In many patients with CF, these may improve by only 5–10% (physiologic response), but subjects may report subjective benefit.

Antiinflammatory Agents

Corticosteroids are useful for the treatment of allergic bronchopulmonary aspergillosis and severe asthma occasionally encountered in children with CF. Prolonged systemic corticosteroid treatment of CF lung disease reduces the decline in lung function modestly but causes predictably prohibitive side effects. Inhaled corticosteroids have theoretical appeal, but there are contradictory and weak data regarding efficacy unless the patient has clinically diagnosable asthma. Ibuprofen, given chronically in high doses adjusted to achieve a peak serum concentration of 50-100 μg/mL, is associated with a slowing of disease progression, particularly in younger patients with mild lung disease. However, there are concerns regarding side effects of nonsteroidal antiinflammatory drugs, so this therapy has not gained broad acceptance. Macrolide antibiotics have an antiinflammatory effect, and 3 days/week of azithromycin has been shown to reduce the likelihood of the development of pulmonary exacerbations, especially in patients with chronic *Pseudomonas* airway infection, so this is a commonly used therapy.

Other Therapies

Attempts to clear recalcitrant atelectasis and airway plugging with bronchopulmonary lavage and direct instillation of various medications are sometimes used in exceptional cases; there is no evidence for sustained benefit from repeated procedures. Expectorants such as iodides and guaifenesin do not effectively assist with the removal of secretions from the respiratory tract. Inspiratory muscle training can enhance maximum oxygen consumption during exercise along with FEV_1.

TREATMENT OF PULMONARY COMPLICATIONS

Atelectasis

Lobar atelectasis occurs relatively infrequently; it may be asymptomatic and noted only at the time of a routine chest radiograph. Aggressive intravenous therapy with antibiotics and increased chest PT directed at the affected lobe may be effective. If there is no improvement in 5-7 days, bronchoscopic examination of the airways may be indicated. If the atelectasis does not resolve, continued intensive home therapy is indicated because atelectasis may resolve during a period of weeks or months.

Hemoptysis

Endobronchial bleeding usually reflects airway wall erosion into hypertrophied bronchial vessels secondary to infection. Although more common in patients with advanced disease, it is sometimes seen in adolescents with relatively mild lung disease. Blood streaking of sputum is particularly common. Small-volume hemoptysis (<20 mL) is usually viewed as a need for intensified antimicrobial therapy and chest PT. **Massive hemoptysis**, defined as total blood loss of ≥250 mL in a 24-hr period, is rare in the first decade and occurs in <1% of adolescents, but it requires close monitoring and the capability to replace blood losses rapidly. Bronchoscopy rarely reveals the site of bleeding. Bronchial artery embolization can be useful to control persistent, significant hemoptysis.

Pneumothorax

Pneumothorax (see Chapter 461) is encountered uncommonly in children and teenagers with CF, although it may lead to significant compromise in lung function and occasionally may be life-threatening. The episode may be asymptomatic but is often attended by chest and shoulder pain, shortness of breath, or hemoptysis. A small air collection that does not grow can be observed closely. Chest tube placement with or without pleurodesis is often the initial therapy. Intravenous antibiotics are also begun on admission. Video-assisted thoracoscopic surgery (VATS) with plication of blebs, apical pleural stripping, and basal pleural abrasion should be considered if the air leak persists. Surgical intervention is usually well tolerated even in cases of advanced lung disease. The thoracotomy tube is removed as soon as possible. Previous pneumothorax with or without pleurodesis is not a contraindication to subsequent lung transplantation.

Allergic Bronchopulmonary Aspergillosis

Allergic bronchopulmonary aspergillosis occurs in 5–10% of patients with CF and may manifest as wheezing, increased cough, shortness of breath, and marked hyperinflation or, most commonly, a decrease in FEV_1 that does not respond to antibiotic therapy (see Chapter 283). In some patients, a chest radiograph shows new focal infiltrates. A highly elevated total serum immunoglobulin E (IgE) level (>1,000) is usually the initial indication of the diagnosis. The presence of rust-colored sputum, the recovery of *Aspergillus* organisms from the sputum, a positive skin test for *A. fumigatus,* the demonstration of specific IgE and IgG antibodies against *A. fumigatus,* or the presence of eosinophils in a fresh sputum sample supports the diagnosis. Treatment is directed at controlling the inflammatory reaction with oral corticosteroids. Oral antifungals are usually reserved for patients who relapse after initial steroid treatment. For refractory cases, omalizumab, humanized monoclonal anti-IgE, has been effective.

Nontuberculous Mycobacteria Infection

See Chapter 263.

Injured airways with poor clearance may be colonized by *M. avium*-complex but also *M. abscessus, Mycobacterium chelonae,* and *Mycobacterium kansasii.* Distinguishing endobronchial colonization (frequent) from invasive infection (infrequent) is challenging. Persistent fevers and new infiltrates or cystic lesions coupled with the finding of acid-fast organisms on sputum smear suggest infection. Infection with these organisms, or at least its recognition, has become increasingly

common. Treatment is prolonged and requires multiple antimicrobial agents. Symptoms may improve, but the nontuberculous mycobacteria are not usually cleared from the lungs.

Sleep-Disordered Breathing

Particularly with advanced pulmonary disease and during chest exacerbations, individuals with CF may experience more sleep arousals, less time in rapid eye movement sleep, nocturnal hypoxemia, hypercapnia, and associated neurobehavioral impairment. Nocturnal hypoxemia may hasten the onset of pulmonary hypertension and right-sided heart failure. Efficacy of specific interventions for this complication of CF has not been systematically assessed. Prompt treatment of airway symptoms and nocturnal oxygen supplementation or bilevel positive airway pressure support should be considered in selected cases, especially in patients with advanced lung disease.

Acute Respiratory Failure

Acute respiratory failure (see Chapter 86) rarely occurs in patients with mild to moderate lung disease and is usually the result of a severe viral or other infectious illness. Because patients with this complication can regain their previous status, intensive therapy is indicated. In addition to aerosol, postural drainage, and intravenous antibiotic treatment, oxygen is required to raise the arterial Pa_{O_2}. An increasing P_{CO_2} may require ventilatory assistance. Endotracheal or bronchoscopic suction may be necessary to clear airway inspissated secretions and can be repeated daily. Right-sided heart failure should be treated vigorously. High-dose steroids have been anecdotally reported to be of benefit in this setting. Recovery is often slow. Intensive intravenous antibiotic therapy and postural drainage should be continued for 1-2 weeks after the patient has regained baseline status.

Chronic Respiratory Failure

Patients with CF acquire chronic respiratory failure after prolonged deterioration of lung function. Although this complication can occur at any age, it is seen most frequently in adult patients. Because a long-standing Pa_{O_2} <50 mm Hg promotes the development of right-sided heart failure, patients usually benefit from low-flow oxygen to raise arterial P_{O_2} to ≥55 mm Hg. Increasing hypercapnia may prevent the use of optimal fraction of inspired oxygen. Most patients improve somewhat with intensive antibiotic and pulmonary therapy measures and can be discharged from the hospital. Low-flow oxygen therapy is needed at home, especially with sleep. Noninvasive ventilatory support can improve gas exchange and has been documented to enhance quality of life. Ventilatory support may be particularly useful for patients awaiting lung transplantation. These patients usually display pulmonary hypertension and cor pulmonale, and this complication should be treated. Caution should be exercised to avoid ventilation-suppressing metabolic alkalosis that results from CF-related chloride depletion and, in many cases, from diuretic-induced bicarbonate retention. Chronic pain (headache, chest pain, abdominal pain, and limb pain) is frequent at the end of life and responds to judicious use of analgesics, including opioids. Dyspnea has been ameliorated with nebulized fentanyl.

Pulmonary Hypertension and Cor Pulmonale

Individuals with long-standing, advanced pulmonary disease, especially those with severe hypoxemia (Pa_{O_2} <50 mm Hg), often acquire pulmonary hypertension and chronic right-sided heart failure. Evidence for concomitant left ventricular dysfunction is often found. The arterial P_{O_2} should be maintained at >50 mm Hg, if possible, and hypercarbia corrected with noninvasive ventilation or intubation if necessary. Intensive pulmonary therapy, including intravenous antibiotics, is most important. Adjunctive therapy with salt restriction, diuretics, and pulmonary vasodilators may be indicated. The prognosis for heart failure is poor, but a number of patients survive for ≥5 years after the appearance of heart failure. Heart-lung transplantation may be an option.

Lung Transplantation

Lung transplantation is an option for end-stage lung disease (see Chapter 492). Criteria for referral continue to be a subject of investigation and ideally include estimates of longevity with and without transplant based on lung function and exercise tolerance data. Survival and quality of life after lung transplantation are better in patients with CF than other chronic lung diseases, probably because of the relatively younger age of recipients with CF, but the current estimated 5-year survival is about 50%, somewhat reduced compared with that of other solid organ transplants. Because of bronchiolitis obliterans (see Chapter 443.1) and other transplant-related complications, transplanted lungs cannot be expected to function for the lifetime of a recipient, and repeat transplantation is increasingly common. The demand for donor lungs exceeds the supply, and waiting lists and duration of waits continue to be a problem. Importantly, since the initiation of treatment with elexacaftor/tezacaftor/ivacaftor, some patients with chronic lung disease have significantly improved so that they no longer require listing for lung transplantation.

Nutritional Therapy

Up to 90% of patients with CF have loss of exocrine pancreatic function leading to inadequate digestion and absorption of fats and proteins. They require dietary adjustment and augmentation, pancreatic enzyme replacement, and supplementary vitamins. In general, children with CF need to exceed the usual required daily caloric intake to grow. Daily supplements of the fat-soluble vitamins are required.

Diet

Historically, at the time of diagnosis, many infants presented with nutritional deficits; this situation has changed because of newborn screening, but even at 2-4 weeks, it is not uncommon to see that weight gain has begun to fall off the standard curve.

Most children with CF have a higher-than-normal caloric need because of malabsorption despite the use of pancreatic enzyme supplementation. Encouragement to eat high-calorie foods is important and often begins with more concentrated, high-calorie formulas in the first year. Even so, most mothers can breastfeed successfully. It is vitally important to promote adequate weight gain in the early years, both because of a clear relationship to later lung function and because early deficiencies make later catch-up growth more difficult. Not infrequently, feeding problems can negatively affect parent–child interactions at meal time, and behavioral interventions can improve caloric intake. The liberal use of appetite stimulants, especially cyproheptadine, in early childhood makes the struggle a bit easier. Poorly controlled lung disease increases metabolism and decreases appetite and needs to be considered when efforts to improve weight gain are unsuccessful.

Maintenance of good weight gain and body mass index in the first year of life leads to better long-term preservation of lung function, but there is a strong correlation between body mass index and FEV_1 that persists through all ages in people with CF. Better nutrition also leads to improved quality of life and psychologic well-being and provides better reserves when weight loss occurs in association with intermittent acute pulmonary exacerbations.

Malabsorption is an important contributor to nutritional deficiencies, and it is important to ensure that pancreatic enzyme dosing is adequate and consistently being taken correctly with all meals and feedings. Appetite stimulants when cyproheptadine is not successful may include megestrol, oxandrolone, dronabinol, antidepressants such as mirtazapine, and even growth hormone. CF-related diabetes needs to be ruled out.

When all these therapies fail, weight stabilization or gain can be achieved with nocturnal feeding via nasogastric tube or gastrostomy tube. These are most commonly resorted to in infants and adolescents, the two age-groups that have the most difficulty with weight gain because of high-normal demands.

Pancreatic Enzyme Replacement

Pancreatic exocrine replacement therapy given with ingested food reduces, but does not fully correct, stool fat and nitrogen losses. Current products are enteric-coated, pH-sensitive enzyme microspheres that come in capsules and are given to children before they can swallow by opening the capsule and mixing the beads in small amounts of acidic foods such as applesauce. Strengths ranging from 3 to 40,000 IU of lipase/capsule are available. Administration of excessive doses has been linked to fibrosing colonopathy and **colonic strictures**, so

recommendations are for enzyme dosing to stay below 2,500 lipase units/kg/meal in most circumstances. Snacks should also be covered. Some enzyme replacement therapies provide bicarbonate in addition to the enzymes, which may be helpful for a subset of patients to correct acid pH in the duodenum, which is caused by a lack of exocrine pancreatic secretions; neutralization of duodenal pH permits optimal activation of enteric-coated pancreatic exocrine replacement therapy granules. Some individuals prefer proton pump inhibitor therapy to achieve the same effect.

Vitamin and Mineral Supplements

Because pancreatic insufficiency results in malabsorption of fat-soluble vitamins (A, D, E, K), vitamin supplementation is recommended. Several vitamin preparations containing all four vitamins for patients with CF are available. They should be taken daily. Despite this supplementation, vitamin D deficiency is common and should be treated with doses of cholecalciferol (vitamin D3) rather than ergocalciferol (vitamin D2). The CF Foundation recommends that all individuals with CF, from birth to 12 months of age, be treated with an initial dose of 400-500 IU vitamin D3 per day, from 12 months to 10 years of age, an initial dose of 800 to 1000 IU of vitamin D3 per day, and from 10 years of age and older, an initial dose of 800 to 2000 IU of vitamin D3 per day. Higher doses are recommended for those who are vitamin D deficient. Salt supplementation is also needed during infancy and is started at the time of diagnosis. There may be additional vitamin and micronutrient needs if a child with CF required an intestinal resection as a newborn as a result of meconium ileus.

TREATMENT OF INTESTINAL COMPLICATIONS

Meconium Ileus

When meconium ileus (see Chapter 135) is suspected, contrast enemas with reflux of contrast material into the ileum not only confirm the diagnosis but may also result in the passage of meconium and clearing of the obstruction. Children in whom this procedure fails require operative intervention. Children who have had meconium ileus are at greater risk for nutritional deficiency and are more likely to develop problems with DIOS when older. Infants with meconium ileus should be assumed to have CF unless proven otherwise.

Distal Intestinal Obstruction Syndrome and Other Causes of Abdominal Symptoms

Despite appropriate pancreatic enzyme replacement, a number of patients accumulate fecal material in the terminal portion of the ileum and in the cecum, which may result in partial or complete obstruction. For intermittent symptoms, pancreatic enzyme replacement should be continued or even increased, and stool hydrators such as polyethylene glycol should be given. If this fails or symptoms are more severe, large-volume bowel lavage with a balanced salt solution containing polyethylene glycol may be taken by mouth or by nasogastric tube. When there is complete obstruction, a contrast enema, accompanied by large amounts of intravenous fluids, can be therapeutic.

Rectal Prolapse

See Chapter 392.5.

Although uncommon, rectal prolapse occurs most often in infants with CF and less frequently in older children with the disease. It was much more frequently seen in the past among undiagnosed young children with steatorrhea, malnutrition, and repetitive cough. The prolapsed rectum can usually be replaced manually by continuous gentle pressure with the patient in the knee-chest position. To prevent an immediate recurrence, the buttocks can be temporally taped closed. Adequate pancreatic enzymes, stool softener, and control of pulmonary infection result in improvement. On very rare occasions, a patient may continue to have rectal prolapse and may require referral to a pediatric surgeon.

Hepatobiliary Disease

A wide range of hepatobiliary complications are observed in CF, including asymptomatic elevations in liver function tests, biliary cirrhosis, and portal hypertension. Often liver function abnormalities (elevations in aspartate aminotransferase [AST], alanine aminotransferase [ALT], gamma-glutamyl transferase [GGT]) associated with biliary cirrhosis are treated with ursodeoxycholic acid, leading to a reduction in these values. However, the evidence to support ursodeoxycholic acid's effectiveness in preventing the progression of CF-related liver disease has not been clearly documented. Portal hypertension with esophageal varices, hypersplenism, or ascites occurs in ≤8% of children with CF (see Chapter 415).

Obstructive jaundice in newborns with CF needs no specific therapy once the etiology has been established. End-stage liver disease is an indication for liver transplantation in children with CF (see Chapter 416).

Pancreatitis

Recurrent pancreatitis is seen primarily in patients with pancreatic sufficiency, and it can lead to the development of pancreatic insufficiency. Patients can be treated with pancreatic enzyme therapy and a low-fat diet (in well-nourished patients) to rest the pancreas. Further treatment of this disorder is discussed in Chapter 399.

Cystic Fibrosis–Related Hyperglycemia and Diabetes

Onset of hyperglycemia occurs most frequently *after* the first decade. Approximately 20% of young adults are treated for hyperglycemia, although the incidence of CF-related diabetes may be up to 50% in adults with CF. Ketoacidosis is rarely encountered. The pathogenesis includes both impaired insulin secretion and insulin resistance. Routine screening consisting of an annual 2-hour OGTT is recommended in children older than 10 years of age, although some cases may begin earlier. Although glucose intolerance with blood sugars that remain less than 200 are not treated unless nutrition is compromised or lung function seems affected, recent data suggest the prediabetic state is associated with clinical decline, so close monitoring is warranted. The development of significant hyperglycemia favors acquisition of *P. aeruginosa* and *B. cepacia* in the airways and may adversely affect pulmonary function. Thus careful control of blood glucose level is an important goal. When treatment is indicated, insulin should be instituted, as it is the only therapy shown to improve the nutritional and metabolic outcomes in CFRD. In addition to insulin therapy, patients are often encouraged to exercise, which has been shown to reduce postprandial glycemic excursions. Medical nutritional therapy for CFRD differs from that recommended in type 1 diabetes and type 2 diabetes, as patients are encouraged to continue the nutritional therapy needed to manage CF, that is a higher-caloric diet that is high in fat and salt and not carbohydrate restricted. Strict carbohydrate counting with adjustments in insulin dosing is essential for good glycemic control. Patients with CFRD are at risk for microvascular complications, including retinopathy, nephropathy, and neuropathy, providing an additional rationale for good control of blood glucose levels. These long-term vascular complications of diabetes are more commonly observed in adults with CFRD, as they occur more commonly after a decade of the disease.

Bone and Joint Complications

Hypertrophic osteoarthropathy causes elevation of the periosteum over the distal portions of long bones and bone pain, overlying edema, and joint effusions. Acetaminophen or ibuprofen may provide relief. Control of lung infection usually reduces symptoms. Intermittent arthropathy unrelated to other rheumatologic disorders occurs occasionally, has no recognized pathogenesis, and usually responds to nonsteroidal antiinflammatory agents. Back pain or rib fractures from vigorous coughing may require pain management to permit adequate airway clearance. These and other fractures may stem from diminished bone mineralization, the result of reduced vitamin D absorption, corticosteroid therapy, diminished weight-bearing exercises, and perhaps other factors. There may be a bone phenotype in CF that is unrelated to therapies or nutritional status and may be related to CFTR dysfunction.

OTHER COMPLICATIONS

Nasal Polyps

Nasal polyps (see Chapter 427) occur in 15–20% of patients with CF and are most prevalent in the second decade of life. Local corticosteroids and nasal decongestants occasionally provide some relief. When the polyps completely obstruct the nasal airway, rhinorrhea becomes constant, or widening of the nasal bridge is noticed, surgical removal of the polyps is

indicated; polyps may recur promptly or after a symptom-free interval of months to years. Polyps inexplicably stop developing in many adults.

Rhinosinusitis

Opacification of paranasal sinuses is universal in CF and is not an indication for intervention. Acute or chronic sinus-related symptoms are treated initially with antimicrobials, with or without maxillary sinus aspiration for culture. Functional endoscopic sinus surgery has anecdotally provided benefit.

Salt Depletion

Salt losses from sweat in patients with CF can be high, especially in warm arid climates. Children should have free access to salt, especially when thirsty in hot weather. Salt supplements are often prescribed to newborns and to children who live in hot weather climates. Hypochloremic alkalosis should be suspected in any patient who feels unwell in hot weather or who has had symptoms of gastroenteritis, and prompt fluid and electrolyte therapy should be instituted as needed.

Anxiety and Depression

The stress and emotional impact of caring for CF is significant. Studies have found high rates of depression and anxiety in both patients and their parent caregivers, 2-3 times that of the general population. Positive screening for depression in particular is associated with decreased lung function, lower body mass index, worse adherence, worse health-related quality of life, more frequent hospitalizations, and increased mortality. Annual screening for anxiety and depression, with psychologic and/or pharmacologic interventions and follow-up, is therefore indicated.

Surgery

Patients with good or excellent pulmonary status can tolerate general anesthesia without any intensive pulmonary measures before the procedure but should be adherent to their usual prescribed airway clearance therapy. Those with moderate or severe pulmonary infection usually do better with a 1- to 2-week course of intensive antibiotic treatment and increased airway clearance before surgery. If this approach is impossible, prompt intravenous antibiotic therapy is indicated once it is recognized that major surgery is required. General anesthesia may provide an opportunity to perform bronchoscopy to evaluate the airway and obtain good cultures, and this should be considered in any child with CF who will undergo surgery for any indication.

After major surgery, cough should be encouraged, and airway clearance treatments should be reinstituted as soon as possible, usually within 24 hours.

PROGNOSIS

CF remains a life-limiting disorder, although survival has dramatically improved (Figs. 454.12 and 454.13). With exceptions, most children remain relatively healthy into adolescence or adulthood. The slow progression of lung disease eventually does reach disabling proportions. Life table data indicate a median cumulative survival of more than 40 years, and the expectation is younger children with the disease have a life expectancy far in excess of this estimate. Outcomes are variable and related to CFTR pathogenic variant class, modifier genes, biologic and chemical exposures, disease management, and socioeconomic status. With the advent of highly effective CFTR modulator therapies, the landscape is expected to change even more dramatically. Not only will quality of life and longevity further improve, but investigations have begun into how the burden of care may be lessened by a decrease in the current dependence on onerous daily airway clearance therapies and the need for recurrent hospitalizations for pulmonary exacerbations.

Children with CF should not be restricted in their activities. A high percentage eventually attend and graduate from college. Most adults with CF find satisfactory employment, and an increasing number marry. Transitioning care from pediatric to adult care centers by 21 years of age is an important objective and requires a thoughtful, supportive approach involving both the pediatric and internal medicine specialists.

With increasing life span for patients with CF, a new set of psychosocial considerations has emerged, including the impact of anxiety and depression, dependence-independence issues, self-care, peer relationships, sexuality, reproduction, substance abuse, educational and vocational planning, medical care costs and other financial burdens, and anxiety concerning health and prognosis. Many of these issues are best addressed in an anticipatory fashion, before the onset of psychosocial dysfunction. With appropriate medical and psychosocial support, children and adolescents with CF generally cope well. Achievement of an independent and productive adulthood is a realistic goal for many.

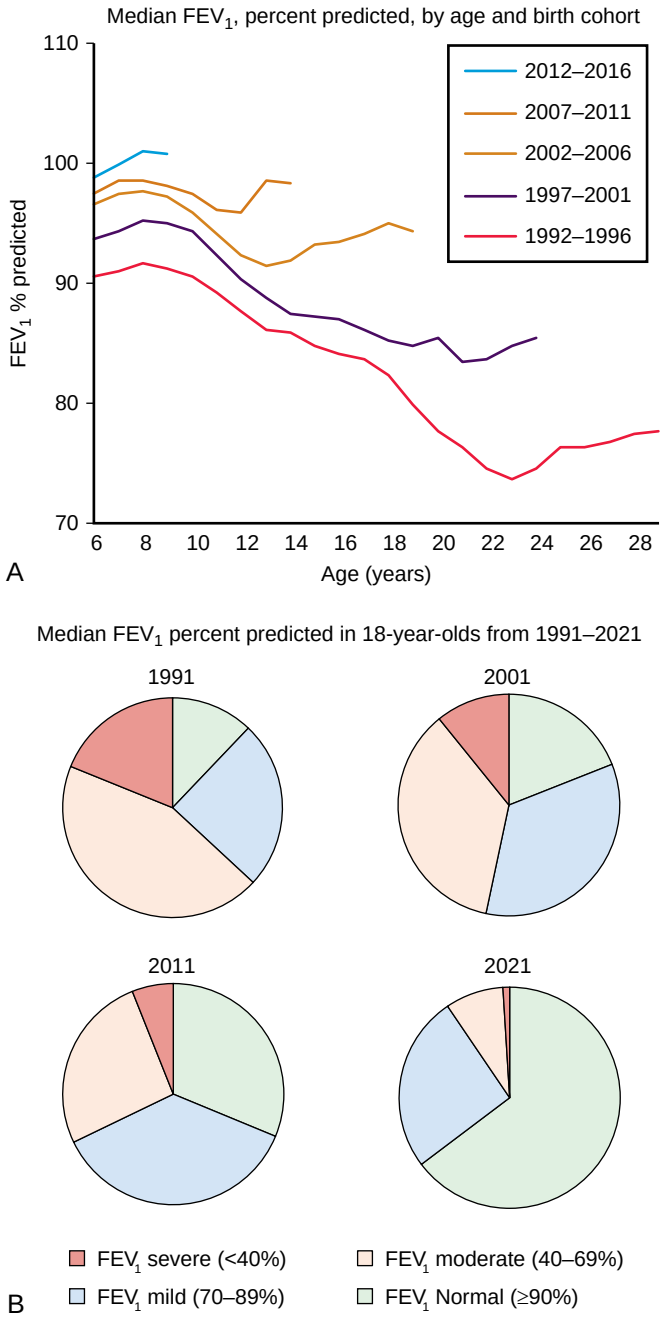

Fig. 454.12 Median FEV_1, percent predicted, by age and birth cohort (A), and in 18-yr-olds from 1991 to 2021 (B). *(From the Cystic Fibrosis Patient Registry 2021. Annual Data Report. pp. 42–43. © 2022 Cystic Fibrosis Foundation. Bethesda, Maryland.* https://www.cff.org/sites/default/files/2021-11/Patient-Registry-Annual-Data-Report.pdf*)*

Visit Elsevier eBooks+ at eBooks.Health.Elsevier.com for Bibliography.

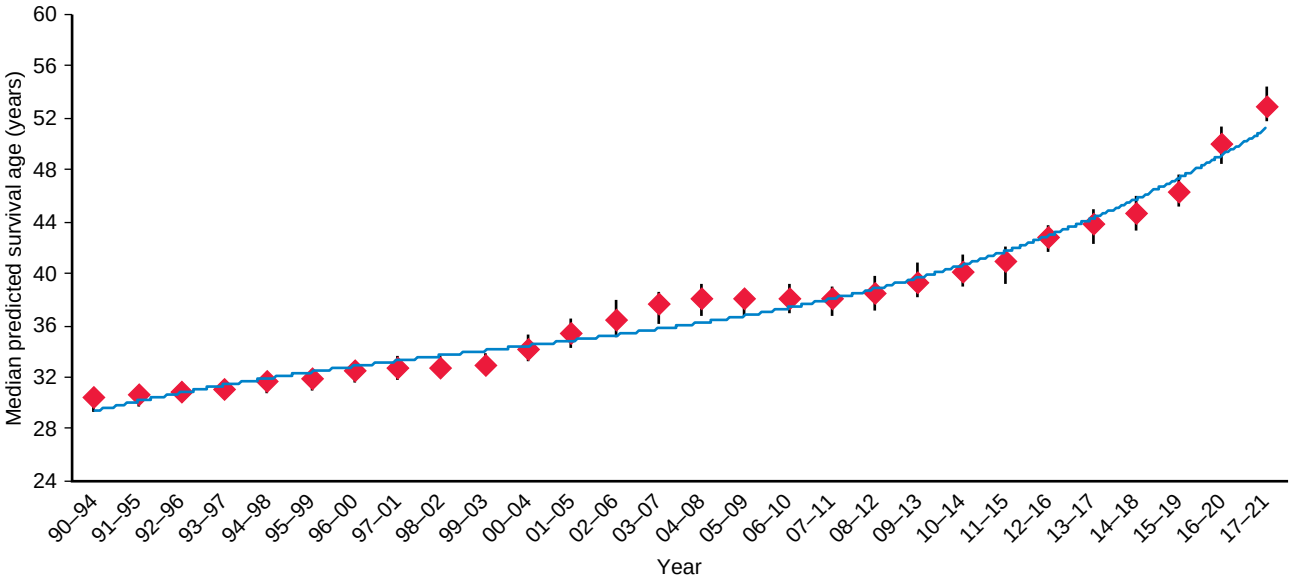

Fig. 454.13 Median predicted survival age, 1990–2021 in 5-yr increments. Created using the currently recommended method for calculating median predicted survival. For more information about the methodology, please see the Technical Supplement available at cff.org. *(From the Cystic Fibrosis Patient Registry 2021. Annual Data Report. p. 70. © 2022 Cystic Fibrosis Foundation. Bethesda, Maryland.* https://www.cff.org/sites/default/files/2021-11/Patient-Registry-Annual-Data-Report.pdf*)*

Chapter 455

Primary Ciliary Dyskinesia (Immotile Cilia Syndrome, Kartagener Syndrome)

Thomas W. Ferkol Jr.

See also Chapter 101.3.

Primary ciliary dyskinesia (PCD) is an inherited disorder characterized by ciliary dysfunction leading to chronic sinopulmonary disease, persistent middle ear effusions, laterality defects, and infertility. The reported prevalence in the general population varies, ranging between 1 in 2,200 and 40,000 live births, but in children with repeated respiratory infections, it has been estimated to be as high as 5%.

NORMAL CILIARY ULTRASTRUCTURE AND FUNCTION

Three types of cilia exist in humans: motile cilia, primary (sensory) cilia, and nodal cilia. The respiratory epithelium in the nasopharynx, middle ear, paranasal sinuses, and larger airways are lined by a ciliated, pseudostratified columnar epithelium that is essential for mucociliary clearance. A mature ciliated epithelial cell has approximately 200 uniform **motile cilia**, hairlike organelles that move fluids, mucus, and inhaled particulates vectorially from conducting airways (Fig. 455.1). Motile cilia are anatomically and functionally oriented in the same direction, moving with intracellular and intercellular synchrony. Anchored by a basal body to the apical cytoplasm and extending from the apical cell surface into the airway lumen, each cilium is a complex, specialized structure, composed of hundreds of proteins. A cilium contains a central fibrillar structure, or axoneme, that consists of helical protofilaments made of alpha- and beta-tubulin monomers. A circular array of peripheral microtubular doublets are arranged around a central pair, leading to the characteristic "9+2" arrangement seen on cross-sectional views on transmission electron microscopy (see Fig. 455.1). Distinct inner and outer dynein arms are attached to the A microtubule. Each dynein arm is a multimer, containing multiple adenosine triphosphatases, called *dyneins,* that serve as motors of the cilium and promote microtubule sliding, which is converted into bending. The inner dynein arm influences the bend shape of the cilium, whereas the outer dynein arm controls beat force and frequency. The inner dynein arm and radial spokes are also parts of the dynein regulatory complex, a key regulator of motor activity. Nexin links connecting adjacent outer microtubular doublets limit the degree of sliding between microtubules. All these structures lead to synchronized ciliary beating, resulting in a ciliary stroke and coordinated beating at a frequency constant throughout the airway, ranging between 8 and 14 hertz, but this can be negatively affected by several factors, such as anesthetics and dehydration. Alternatively, beat frequency may be accelerated by exposure to irritants or bioactive molecules, including β-adrenergic agents, acetylcholine, and serotonin. Cilia beat frequency can be increased through the activity of nitric oxide synthases that are localized in the apical cytoplasm. The coordinated wavelike pattern of ciliary motion has

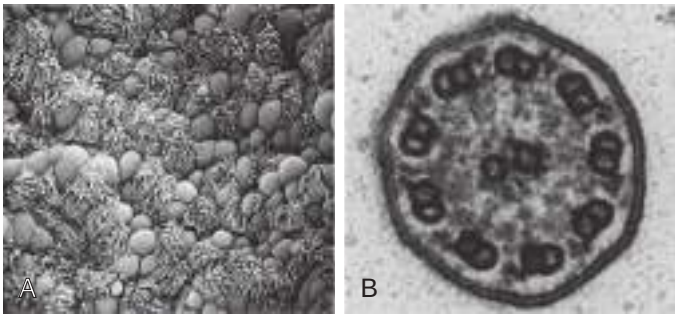

Fig. 455.1 Electron photomicrographs showing an airway epithelium grown in primary culture showing ciliated and nonciliated cells (**A**) and a normal motor cilium (**B**).

important functions in fluid and cell movement, and any disturbance in the precise, orchestrated movement of the cilia can lead to disease.

Primary (sensory) cilia are solitary, immotile organelles present during interphase on most cell types. These cilia lack a central microtubule doublet and dynein arms, thus creating a "9+0" arrangement (Fig. 455.2). Once considered nonfunctional vestigial remnants, primary cilia are important signaling organelles that sense the extracellular environment. They are mechanoreceptors, chemosensors, and osmosensors and, in specialized cases, detect changes in light, temperature, and gravity. Primary cilia defects (ciliopathies) are linked to wide-ranging pediatric conditions, such as various polycystic kidney diseases, nephronophthisis, Bardet-Biedl syndrome, Meckel-Gruber syndrome, Joubert syndrome, Alström syndrome, Ellis-van Creveld syndrome, and Jeune thoracic dystrophy (see Chapter 101.3).

The third type of cilia exists only during a brief period of embryonic development. **Nodal cilia** have a "9+0" microtubule arrangement similar to that of primary cilia, but they exhibit a whirling, rotational movement (see Fig. 455.2), resulting in leftward flow of extracellular fluid that establishes body sidedness. Nodal cilia defects result in body orientation abnormalities, such as **situs inversus totalis**, **situs ambiguus**, and **heterotaxy** associated with congenital heart disease, asplenia, and polysplenia (see Chapter 480.11).

GENETICS OF PRIMARY CILIARY DYSKINESIA

PCD is a genetically heterogeneous disorder, usually inherited by an autosomal recessive pattern, but autosomal dominant and X-linked inheritance are known. Pathogenic variants in any of the hundreds of proteins that are involved in ciliary assembly, structure, or function could theoretically cause disease. Indeed, 50 different genes have been linked to PCD (Fig. 455.3), including those that encode proteins integral to the outer dynein arm, dynein regulatory complex, radial spoke, and central apparatus proteins. Pathogenic variants in genes coding several cytoplasmic proteins not part of the cilia axoneme have also been identified, leading to defective protein transport and cilia assembly. Over 70% of all people with PCD tested have pathogenic variants in one of these genes. In addition, motile ciliopathies *distinct* from classical PCD have been described. Children with biallelic variants in *CCNO* and *MCIDAS,* two proteins required for centriole production, have oligocilia and clinical features similar to PCD.

Insights into the genetic bases of motile ciliopathies have also yielded greater understanding of genotype-phenotype relationships in PCD. For instance, cross-sectional and longitudinal studies showed that children with the inner dynein arm–microtubular disorganization defect, primarily the result of biallelic pathogenic variants in *CCDC39* or *CCDC40,* had more severe lung disease. In contrast, people with pathogenic variants in *RSPH1* appear to have milder respiratory phenotypes.

CLINICAL MANIFESTATIONS OF PRIMARY CILIARY DYSKINESIA

PCD has several characteristic clinical features (Table 455.1). **Neonatal respiratory distress** (NRD) is a common feature, and most affected term newborns develop increased work of breathing, tachypnea, and upper and middle lobe atelectasis on chest radiographs. The association of respiratory distress in *term neonates* with PCD has been underappreciated. Often diagnosed with transient tachypnea of the newborn or pneumonia, PCD infants frequently require supplemental oxygen flow for days to weeks.

Chronic, year-round productive (wet) cough that begins before 6 months of age is another characteristic feature of PCD. Bacterial cultures of sputum or lavage fluid frequently yield nontypeable *Haemophilus influenzae* (see Chapter 240), *Staphylococcus aureus* (see Chapter 227.1), *Streptococcus pneumoniae* (see Chapter 228), and *Pseudomonas aeruginosa* (see Chapter 251.1). Persistent airway infection and inflammation lead to **bronchiectasis**, even in preschool children (see Chapter 452). Children with PCD also have a higher prevalence of pectus excavatum and scoliosis.

Roughly 80% of patients with PCD have **chronic rhinosinusitis**, manifested by daily nasal congestion and copious, watery nasal

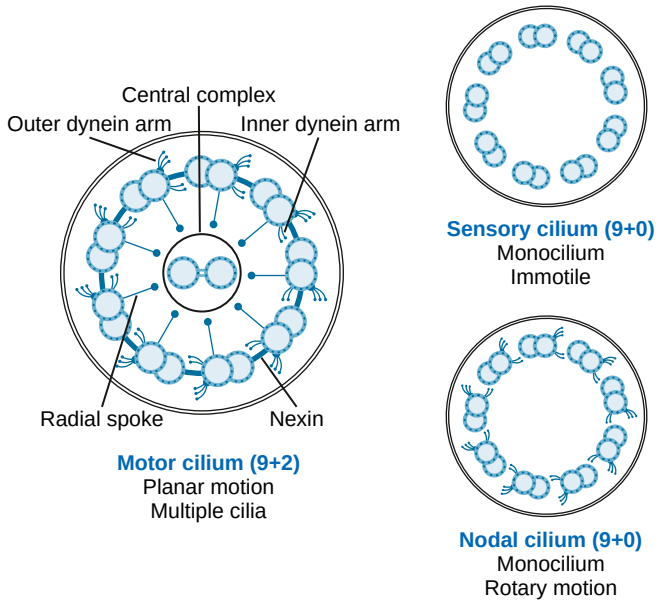

Fig. 455.2 Schemata showing the three general classes of normal cilia: motile cilia (motile "9+2"), nodal cilia (motile "9+0"), and primary cilia (nonmotile "9+0"), which demonstrate the complex structure and arrangement of the ciliary axoneme.

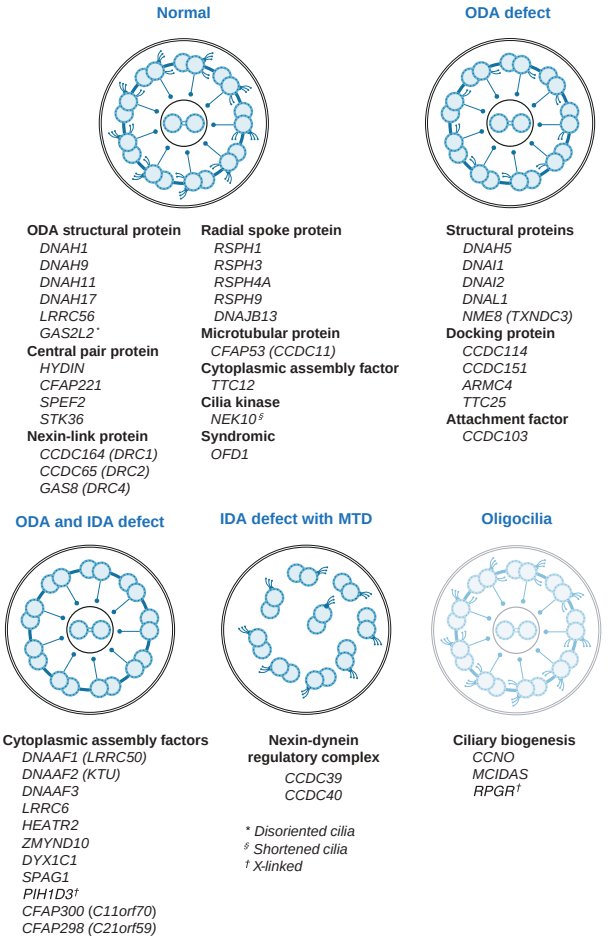

Fig. 455.3 Classification of genes associated with primary ciliary dyskinesia based on ultrastructural findings. IDA, Inner dynein arm; MTD, microtubular disorganization; ODA, outer dynein arm.

Table 455.1 Clinical Features of Primary Ciliary Dyskinesia

LOWER RESPIRATORY
Unexplained respiratory distress in term neonate
Daily productive (wet) cough since early infancy
Chronic bronchitis
Bronchiectasis
UPPER RESPIRATORY
Chronic otitis media and persistent middle ear effusions
Conductive hearing loss
Sensorineural hearing loss
Daily nonseasonal rhinosinusitis since early infancy
Chronic rhinosinusitis
Nasal polyposis
CARDIAC
Situs inversus totalis
Heterotaxy
Congenital cardiac defects
GENITOURINARY
Male subfertility
Female subfertility
MUSCULOSKELETAL
Pectus excavatum
Scoliosis
CENTRAL NERVOUS SYSTEM
Retinitis pigmentosa
Hydrocephalus (rare)

Table 455.2 Consensus-Based Primary Ciliary Dyskinesia (PCD) Diagnostic Criteria by Age

NEWBORNS (0-1 MO OF AGE)
Situs inversus totalis and unexplained neonatal respiratory distress (NRD) at term birth, plus at least one of the following: • Diagnostic ciliary ultrastructure on electron micrographs • Two pathogenic variants in PCD-associated gene
CHILDREN (1 MO TO 5 YR)
Two or more major PCD clinical criteria (NRD,* daily wet cough, persistent nasal congestion, laterality defect), plus at least one of the following (nasal nitric oxide not included in this age-group because it is not yet sufficiently tested): • Diagnostic ciliary ultrastructure on electron micrographs • Two pathogenic variants in one PCD-associated gene • Persistent and diagnostic ciliary waveform abnormalities on high-speed videomicroscopy on multiple occasions
CHILDREN (5-18 YR OF AGE) AND ADULTS
Two or more PCD clinical criteria (NRD,* daily productive cough or bronchiectasis, persistent nasal congestion, laterality defect), plus at least one of the following: • Nasal nitric oxide during plateau <77 nL/min on two occasions, >2 mo apart (with CF excluded) • Diagnostic ciliary ultrastructure on electron micrographs • Two pathogenic variants in one PCD-associated gene • Persistent and diagnostic ciliary waveform abnormalities on high-speed videomicroscopy on multiple occasions

*In term neonates.

discharge that begins early in infancy and persists into childhood. Inadequate innate mucous clearance leads to chronic sinusitis (see Chapter 429) and nasal polyposis. Middle ear disease occurs in many children with PCD, with varying degrees of **chronic otitis media with effusion**. Both conductive and sensorineural hearing loss occur at increased frequency in people with PCD, though the former is more common. Middle ear findings may be most helpful in distinguishing PCD from cystic fibrosis (CF) (see Chapter 454) or other causes of chronic lung disease.

Left-right laterality defects (e.g., *situs inversus totalis*) are found in ~50% of all children with PCD. Without functional nodal cilia in the embryonic period, thoracoabdominal orientation is random. Approximately 25% of children who have situs inversus totalis have PCD. Thus situs inversus totalis alone does not establish the diagnosis. Other laterality defects, such as **heterotaxy**, are also associated with PCD and may coexist with congenital cardiac defects, asplenia, or polysplenia. PCD should be strongly considered in term infants who have unexplained NRD and situs anomalies.

Most males with PCD have dysmotile spermatozoa because flagellar and ciliary ultrastructure is similar. Male infertility or subfertility is typical but not always found in this disease. Subfertility has also been reported in affected women, possibly related to ciliary dysfunction in the fallopian tubes.

A few case reports have associated neonatal hydrocephalus with PCD. The ependyma of the brain ventricles are lined by ciliated epithelium and are important for cerebrospinal fluid flow through the ventricles and aqueduct of Sylvius. The finding of enlarged brain ventricles on sonograms, when linked with situs inversus totalis, has been proposed as a prenatal diagnostic marker for PCD.

Several conditions have overlapping features of motile and primary ciliopathies. X-linked retinitis pigmentosa has been associated with recurrent respiratory infections in families with *RPGR* gene pathogenic variants. Intraflagellar transport proteins are essential for photoreceptor assembly and, when mutated, lead to apoptosis of the retinal pigment epithelium (see Chapter 670).

DIAGNOSIS OF PRIMARY CILIARY DYSKINESIA

The diagnosis of PCD has been challenging. A high index of suspicion is necessary, but pediatricians should only perform testing in children who have clinical manifestations consistent with the disease. PCD has four criteria-defined features that should be used to screen at-risk children: unexplained NRD in full-term infants, left-right laterality defects, persistent rhinitis that begins before 6 months of age, and daily wet or productive cough that also starts before 6 months of age (Table 455.2). Even though chronic otitis media is common in PCD, many unaffected infants and toddlers also have chronic middle ear involvement, which makes this feature less useful in distinguishing children with PCD from others.

Imaging studies show extensive involvement of the paranasal sinuses. Chest radiographs frequently demonstrate bilateral lung overinflation, peribronchial infiltrates, and lobar atelectasis. Computed x-ray tomography of the chest often reveals bronchiectasis, often involving the anatomic right middle lobe or lingula, even in young children. Situs inversus totalis in a child who has chronic respiratory tract symptoms is highly suggestive of PCD, but this configuration occurs in only 50% of people with the condition. Pulmonary function tests may be normal early but demonstrate obstructive airway disease as the disease progresses. Typical findings include decreased forced expiratory volume in 1 second (FEV_1), reduced expiratory flow rates, and increased residual volume. Bronchodilator responsiveness is variable. Longitudinal analyses of children with PCD show wide variation in intrathoracic airway obstruction.

No single test will diagnose every person with PCD. Historically, transmission electron microscopy has been the gold standard to assess structural defects within the cilium. These ultrastructural defects are found in cilia throughout the upper and lower airways and oviduct and in sperm flagella. Curettage from the nasal epithelium or endobronchial brushing can provide an adequate specimen for review. Identification of a specific, previously established defect in the ciliary structure with concurrent phenotypic features is sufficient to make the diagnosis. There are several characteristic ciliary abnormalities: outer dynein arm defects, combined inner and outer dynein arm defects, and inner

dynein arm defects with microtubular disorganization (see Fig. 455.3). Inner dynein arm defects alone are largely artifactual. It is important to note that ultrastructural examination of cilia as a diagnostic test for PCD has limitations. First, the absence of axonemal defects does not exclude PCD; nearly 30% of affected individuals have normal ciliary ultrastructure. Other children with symptoms consistent with PCD have been found to have ciliary aplasia or few motile cilia on the epithelial surface (see Fig. 455.3)

Careful interpretation of the ultrastructural findings is necessary because ciliary defects can be acquired. Nonspecific changes (e.g., compound cilia or blebs) may be seen in relation to exposure to environmental pollutants or infection. Frequently, the diagnosis of PCD can be delayed or missed because of inadequate tissue collection or sample processing or misinterpretation of ciliary defects. Some investigators have advocated culturing of airway epithelial cells and allowing the secondary changes to resolve. Alternatively, immunofluorescent staining for axonemal protein markers may overcome some limitations of transmission electron microscopy.

Another useful approach has exploited the observation that nasal nitric oxide concentrations are reduced in subjects with PCD. Because nasal nitric oxide measurements are relatively easy to perform and noninvasive, this method is a valuable screen for PCD. When compared to other diagnostic tools, nasal nitric oxide can be sensitive and specific for PCD in cooperative older children and adults. Unfortunately, few studies in children under 5 years have been reported, and the accuracy of nasal nitric oxide measurements in infants has not been established. It is important to note that children who have pathogenic variants in some PCD-associated genes can have nondiagnostic nasal nitric oxide concentrations. Conversely, people with CF (see Chapter 454) or primary immunodeficiencies (see Chapter 165), conditions that have clinical features that overlap with PCD, can have reduced nasal nitric oxide levels. Thus reduced nasal nitric oxide concentrations alone are never sufficient to make the diagnosis of PCD.

Qualitative tests to assess ciliary function have been used to screen for PCD. Ciliary beat frequency measurements using standard light microscopy have been used as a screen, but this approach can be misleading and should never be used as a diagnostic tool. High-resolution, high-speed digital imaging of ciliary motion in multiple planes permits comprehensive analysis of cilia beating, which has shown that certain beat patterns are associated with specific ultrastructural defects. This technique is available only at specialized centers, primarily in Europe, and requires sophisticated software and expertise.

PCD is highly heterogenic owing to the large number of proteins involved in cilia assembly, structure, and function. Advances in gene sequencing techniques have led to the identification of a growing number of disease-associated genes. Genetic testing has become increasingly available and is considered a first-line test for PCD, incorporated into published diagnostic algorithms. Nevertheless, current, commercially available testing for pathogenic variants in at least 30 genes will only identify approximately 70% of affected children (see Fig. 455.3).

TREATMENT

No therapies have been shown to correct ciliary dysfunction in PCD. Many of the treatments applied to children with the condition are similar to those used in other chronic suppurative lung diseases characterized by impaired airway clearance and bronchiectasis, such as CF (see Chapter 454), but few have been adequately studied to demonstrate efficacy in PCD.

Strategies to enhance mucociliary clearance are central to PCD therapy, and routine airway clearance techniques using postural drainage, percussion vests, positive expiratory pressure devices, or other techniques should be instituted daily. Because ciliary function is impaired, cough becomes a critical mechanism for mucous clearance and should not be suppressed. Exercise can enhance airway clearance in people with PCD and should be encouraged. Inhaled hypertonic saline and mucolytic agents are often used in CF care, but only small case series or single-site clinical trials showed any improvement in people with PCD after treatment. Thrice-weekly azithromycin as an antiinflammatory agent is reported to reduce the frequency of pulmonary exacerbations but has no effect on lung function or quality-of-life measures.

When children with PCD develop increasing respiratory symptoms consistent with infection, antimicrobial therapy should be instituted based on respiratory culture results and bacterial sensitivities. Maintenance therapy with inhaled or oral antibiotics can be used cautiously in patients with PCD who have bronchiectasis or frequent respiratory exacerbations. Immunizations against pertussis, influenza, and pneumococci are cornerstones of care. Additional preventive measures include avoidance of cigarette or marijuana smoke, electronic cigarette aerosols, and other airway irritants.

Rarely, surgical resection of bronchiectatic lung has been performed on people with PCD, typically in cases of localized disease with severe hemoptysis or intractable infections. It is unclear whether surgical interventions provide reduction in symptoms or survival benefit.

Progression to end-stage lung disease and respiratory failure has been reported in people with PCD. Adults have undergone successful heart-lung, double-lung, or living-donor lobar lung transplantation. Situs inversus totalis complicates the procedure because of anatomic considerations. Otherwise, survival is similar to that for other transplant recipients.

Treatment of chronic otitis media and middle ear effusions in people with PCD is controversial. Myringotomy tubes are frequently placed in affected children, and some studies reported enhanced hearing in children with chronic conductive hearing loss after the procedure. However, others did not find improvement in hearing acuity. Intractable mucoid otorrhea, tympanosclerosis, and permanent membrane perforation are known complications of myringotomy tubes in people with PCD, leading some to recommend against surgical management. Although hearing tends to improve with time, children and adolescents with PCD should be routinely screened and hearing aids used when necessary.

Chronic rhinitis and sinusitis are frequent clinical manifestations of PCD. No treatments have been shown to be effective, although patients are often treated with nasal washes, paranasal sinus lavage, and systemic antibiotics when they are symptomatic. As with any overuse of antimicrobial agents, the development of resistant organisms is a concern. When nasal symptoms are severe or refractory to medical management, endoscopic sinus surgery can be used to promote drainage or local delivery of medications, but the benefit may be short lived.

PROGNOSIS

Although signs and symptoms related to upper respiratory involvement predominate early in PCD, clinical manifestations of lower respiratory tract disease tend to increase with age and become the leading cause of morbidity and mortality in patients with PCD. It is believed that progression and extent of lung disease can be slowed with early diagnosis and therapy. Routine surveillance studies recommended the following for the care of children with PCD: (1) regular spirometry to monitor pulmonary function, (2) chest imaging, and (3) sputum or oropharyngeal cultures to assess respiratory flora.

Children with PCD usually have a slower decline in pulmonary function than those with CF, and its prognosis and long-term survival are better. Many can have a normal or near-normal life span, whereas others experience progressive bronchiectasis and respiratory deterioration at a younger age.

Visit Elsevier eBooks+ at eBooks.Health.Elsevier.com for Bibliography.

Chapter 456
Diffuse Lung Diseases in Childhood

See also Chapter 448.

456.1 Inherited Disorders of Surfactant Metabolism

Jennifer A. Wambach, Lawrence M. Nogee, Aaron Hamvas, and F. Sessions Cole III

Pulmonary surfactant is a mixture of phospholipids and proteins synthesized, packaged, and secreted by alveolar type II pneumocytes (AEC2s) that line the distal air spaces. This mixture forms a monolayer at the air-liquid interface that lowers surface tension at end expiration of the respiratory cycle, preventing atelectasis and ventilation-perfusion mismatch. Four surfactant-associated proteins have been characterized: surfactant proteins A and D (SP-A, SP-D) participate in host defense in the lung, whereas surfactant proteins B and C (SP-B, SP-C) contribute to the surface tension–lowering activity of pulmonary surfactant. The adenosine triphosphate–binding cassette protein member A3, ABCA3, is a transporter located on the limiting membrane of lamellar bodies, the intracellular storage organelle for surfactant within AEC2s, and has an essential role in surfactant phospholipid metabolism. The proper expression of the surfactant proteins and ABCA3 is dependent on a number of transcription factors, particularly thyroid transcription factor 1 (TTF-1). Two genes for SP-A *(SFTPA1, SFTPA2)* and one gene for SP-D *(SFTPD)* are located on human chromosome 10, whereas single genes encode SP-B *(SFTPB)*, SP-C *(SFTPC)*, TTF-1 *(NKX2-1)*, and ABCA3 *(ABCA3)*, which are located on human chromosomes 2, 8, 14, and 16, respectively. Inherited disorders of SP-B, SP-C, ABCA3, and TTF-1 have been recognized in humans and are collectively termed **surfactant dysfunction disorders** (Table 456.1). Variants in *SFTPD* have not been associated with disease, and pathogenic variants in the genes encoding SP-A have only been found in adults with idiopathic pulmonary fibrosis or lung cancer.

PATHOLOGY

These disorders share a unique constellation of features, including AEC2 hyperplasia, alveolar macrophage accumulation, interstitial thickening and inflammation, and alveolar proteinosis. A number of different descriptive terms have historically been applied to these disorders, including ones borrowed from adult forms of interstitial lung disease (**desquamative interstitial pneumonia**, nonspecific interstitial pneumonia) and a disorder unique to infancy **(chronic pneumonitis of infancy)**. These diagnoses in infants and children are strongly indicative of surfactant dysfunction disorders but do not distinguish which gene is responsible. Because the prognosis and inheritance patterns differ depending on the gene involved, genetic testing should be offered when one of these conditions is reported in the lung biopsy or autopsy of an infant or child. Other disorders, including genetic causes of **pulmonary alveolar proteinosis** (see Chapter 456.2), and disorders of immune dysregulation can be associated with similar pathologies.

DEFICIENCY OF SURFACTANT PROTEIN B (SURFACTANT METABOLISM DYSFUNCTION, PULMONARY, 1; SMDP1; OMIM #265120)

Clinical Manifestations

Infants with an inherited deficiency of SP-B present in the *immediate* neonatal period with respiratory failure. This autosomal recessive disorder is clinically and radiographically similar to the respiratory distress syndrome (RDS) of premature infants (see Chapter 126) but typically affects full-term infants. The initial degree of respiratory distress is variable, but the disease is progressive and is refractory to

Table 456.1 Comparison of Surfactant Dysfunction Disorders

	SP-B DEFICIENCY	SP-C DISEASE	ABCA3 DEFICIENCY	TTF-1 DISORDERS
Gene name	*SFTPB*	*SFTPC*	*ABCA3*	*NKX2-1*
Age of onset	Birth	Birth to adulthood	Birth to childhood; rarely adult	Birth to childhood
Inheritance	Recessive	Dominant/sporadic	Recessive	Sporadic/dominant
Mechanism	Loss of function	Gain in toxic function or dominant negative	Loss of function	Loss of function Gain in function
Natural history	Lethal	Variable	Generally lethal, may be chronic	Variable
DIAGNOSIS				
Biochemical (tracheal aspirate)	Absence of SP-B and presence of incompletely processed proSP-C	None	None	None
Genetic (DNA)	Sequence *SFTPB*	Sequence *SFTPC*	Sequence *ABCA3*; copy number variant detection	Sequence *NKX2-1*; copy number variant detection
Ultrastructural (lung biopsy–electron microscopy)	Disorganized lamellar bodies	Not specific; may have dense aggregates	Small dense lamellar bodies with eccentrically placed dense cores	Variable
Treatment	Lung transplantation or compassionate care	Supportive care, lung transplantation if progressing	Lung transplantation or compassionate care for infants with biallelic null variants; lung transplantation for other variants if progressing	Supportive care; treat coexisting conditions (hypothyroidism)

SP, Surfactant protein.

mechanical ventilation, surfactant replacement therapy, and glucocorticoid administration. Almost all affected infants have died without lung transplantation, but prolonged survival is possible in cases of partial deficiency of SP-B. Humans heterozygous for loss-of-function variants in *SFTPB* are clinically healthy as adults but may be at increased risk for obstructive lung disease if they also have a history of smoking.

Genetics

Multiple loss-of-function variants in *SFTPB* have been identified. The most common is a net two base-pair insertion in codon 133 (originally termed *121ins2,* currently termed *c.397delCinsGAA, p.Pro133Glufs*95*) that results in a frameshift, an unstable SP-B messenger RNA (mRNA) transcript, and absence of SP-B protein production. This pathogenic variant has accounted for 60–70% of the alleles found to date in infants identified with SP-B deficiency and is present in approximately 0.07% of European-descent individuals in large-scale sequencing projects. Most other pathogenic variants have been family-specific. A large deletion encompassing two exons of *SFTPB* has also been reported.

Diagnosis

A rapid, definitive diagnosis can be established with sequence analysis of *SFTPB,* which is available through clinical laboratories (Genetic Testing Registry, https://www.ncbi.nlm.nih.gov/gtr). Sequencing of *SFTPB* is usually performed as part of a multigene panel using next-generation sequencing (NGS) methods that includes genes for other surfactant dysfunction disorders and can be designed to detect deletions or duplications of one or more exons (copy number variants). For families in which *SFTPB* variants were previously identified, antenatal diagnosis can be established by preimplantation genetic diagnosis (PGD) or molecular assays of DNA from chorionic villous biopsy or amniocytes, which permit advanced planning of a therapeutic regimen. Other laboratory tests remain investigational, including analysis of tracheal aspirate (effluent) for the presence or absence of SP-B protein and for incompletely processed precursor proSP-C peptides that have been identified in SP-B–deficient human infants. Immunostaining of lung biopsy tissue for the surfactant proteins can also support the diagnosis, although immunohistochemical assays for SP-B and SP-C are also generally available only on a research basis. Staining for SP-B is usually absent, but robust extracellular staining for proSP-C because of incompletely processed proSP-C peptides is observed and is diagnostic for SP-B deficiency. Such studies require a lung biopsy in a critically ill infant but may be performed on lung blocks acquired at the time of autopsy, allowing for retrospective diagnosis. With electron microscopy, a lack of tubular myelin, disorganized lamellar bodies, and an accumulation of abnormal-appearing multivesicular bodies suggest abnormal lipid packaging and secretion.

SURFACTANT PROTEIN C–ASSOCIATED INTERSTITIAL LUNG DISEASE (SURFACTANT METABOLISM DYSFUNCTION, PULMONARY, 2; SMDP2; OMIM #610913)

SP-C is a very low molecular weight, extremely hydrophobic protein that, along with SP-B, enhances the surface tension–lowering properties of surfactant phospholipids. The mature SP-C protein (35 amino acids) is derived from proteolytic processing of a larger precursor protein (proSP-C).

Clinical Manifestations

The clinical presentation of patients with *SFTPC* pathogenic variants is quite variable. Some patients present at birth with symptoms, signs, and radiographic findings typical of RDS. Others present later in life, *ranging from early infancy until well into adulthood,* with gradual onset of respiratory insufficiency, hypoxemia, failure to thrive, and chest radiograph findings of **interstitial lung disease**, or as **pulmonary fibrosis** in the fifth or sixth decade of life. The age and severity of disease vary even within families with the same *SFTPC* variant. The natural history is also quite variable, with some patients improving either spontaneously or as the result of therapy or prolonged mechanical ventilation, some with persistent respiratory insufficiency, and some progressing to the point of requiring lung transplantation. This variability in presentation, severity, and course of the disease does not appear to correlate with the specific *SFTPC* variant and also hinders accurate assessment of prognosis.

Genetics

Multiple pathogenic variants in *SFTPC* have been identified in association with acute and chronic lung disease in patients ranging in age from newborn to adult. A pathogenic variant on only *one SFTPC* allele is sufficient to cause disease. Approximately half of these variants arise spontaneously, resulting in sporadic disease, but the remainder are inherited as a *dominant trait*. *SFTPC* pathogenic variants have been identified in diverse racial and ethnic groups. A threonine substitution for isoleucine in codon 73 (termed *p.I73T* or *p.Ile73Thr*) has accounted for 25–35% of the cases identified to date but is rare (not identified in gnomAD in ~140,000 individuals). Pathogenic variants in *SFTPC* are thought to cause disease because of a toxic gain in function resulting from the production of misfolded or abnormal proSP-C that accumulates within the AEC2 and causes cellular injury or alters the normal intracellular routing of proSP-C. Lung tissue from individuals with pathogenic variants in *SFTPC* demonstrates accumulation of pro-SPC. Many pathogenic *SFTPC* variants are located in the carboxy-terminal domain of pro-SP-C, which has a similar homology to other members of the *BRICHOS* family of membrane proteins, the abnormal aggregation of which have been implicated in the pathophysiology of familial dementia and some cancers. Pathogenic variants within the BRICHOS domain (amino acid residues 90-197) of *SFTPC* result in aggregation of misfolded protein in the endoplasmic reticulum, activation of the unfolded protein response, inflammation, and subsequent fibrosis. Non-BRICHOS domain pathogenic variants result in mistrafficking of pro-SPC to the plasma membrane and endosomes rather than the lamellar bodies, a late block in macroautophagy, inflammation, and subsequent fibrosis. The different underlying pathogenic mechanisms of *SFTPC* variants do not appear to correlate with the clinical presentation and may necessitate different therapeutic approaches.

Diagnosis

Sequencing of *SFTPC,* the only definitive diagnostic test, is available usually as part of an NGS multiple-gene panel in clinical laboratories. Because most *SFTPC* pathogenic variants are missense variants, distinguishing true disease-causing variants from rare yet benign sequence variants may be difficult. Immunostaining of lung tissue may demonstrate proSP-C aggregates but is available only on a research basis.

DISEASE CAUSED BY PATHOGENIC VARIANTS IN *ABCA3* (SURFACTANT METABOLISM DYSFUNCTION, PULMONARY, 3; SMDP3; OMIM #610921)

Clinical Manifestations

Lung disease caused by pathogenic variants in *ABCA3* generally presents as either a severe, lethal form that manifests in the *immediate newborn period,* clinically similar to SP-B deficiency, or a chronic form that appears most typically in the first year of life with **interstitial lung disease** similar to SP-C–associated interstitial lung disease. Infants who are homozygous or compound heterozygous for null variants, that is, the variant is predicted to result in the absence of protein expression (i.e., nonsense or frameshift variants), typically present with lethal neonatal respiratory failure, whereas infants with missense, in-frame insertion/deletions or splicing variants have more variable age of onset and outcomes. Heterozygosity for an *ABCA3* variant may contribute to the risk for RDS in late preterm and term infants, who, in contrast to ABCA3-deficient infants with variants on both alleles, may eventually completely recover from their initial lung disease.

Genetics

Recessive variants in *ABCA3* were first described among infants who presented with lethal RDS in the newborn period, but now have been identified in older infants and children with **interstitial lung disease**. There is considerable allelic heterogeneity: more than 400 variants

scattered throughout the gene have been identified, most of which are family-specific. The presence of null variants on both alleles that are predicted to preclude any ABCA3 production has been associated with early-onset disease and a uniformly fatal prognosis without lung transplant. A missense variant that results in a valine substitution for glutamine in codon 292 (p.Glu292Val or p.E292V) in association with a second *ABCA3* variant has been found in children with severe neonatal respiratory failure and in older children with interstitial lung disease and is present in approximately 0.7% of European-descent individuals. *ABCA3* variants have been identified in diverse racial and ethnic groups. The precise frequency of disease is unknown; large-scale sequencing projects indicate that the overall carrier rate for *ABCA3* variants may be as high as 1 in 50 to 1 in 70 individuals. However, many *ABCA3* variants are private, have not been previously identified in affected individuals, and functional data are only available for a limited number of disease-associated variants, thereby limiting these estimates. Two mechanistic classes of *ABCA3* variants have been identified: those that disrupt intracellular trafficking of ABCA3 to the lamellar bodies with retention of the variant protein in the endoplasmic reticulum and those that traffic normally but impair adenosine triphosphate (ATP)–mediated phospholipid transport into the lamellar bodies. ABCA3 deficiency may contribute to a substantial proportion of *unexplained fatal lung disease* in term infants and of *interstitial lung disease* in older children.

Diagnosis

Sequence analysis of *ABCA3* is available in clinical laboratories, usually as part of an NGS multiple-gene panel, and is the most definitive approach for diagnosis. Considerable variation in *ABCA3* necessitates careful interpretation regarding the functionality of an individual variant and its contribution to the clinical presentation. Additionally, *sequence analysis is not 100% sensitive,* as functionally significant variants may exist in untranslated regions that are not generally analyzed. As large deletions spanning one or more exons have been identified, it is important that the gene panel be able to detect such variants. In situations when the sequence analysis results are inconclusive, lung biopsy with electron microscopy to examine lamellar body morphology may be a useful adjunct to the diagnostic approach. Small lamellar bodies that contain electron-dense inclusions may be observed in association with *ABCA3* pathogenic variants. These findings support the hypothesis that ABCA3 function is necessary for lamellar body biogenesis. There are no biochemical markers to establish the diagnosis.

DISEASE CAUSED BY PATHOGENIC VARIANTS IN *NKX2-1* (THYROID TRANSCRIPTION FACTOR 1, CHOREOATHETOSIS, HYPOTHYROIDISM, AND NEONATAL RESPIRATORY DISTRESS, OMIM #600635)

Clinical Manifestations

A large deletion of the region of chromosome 14 (14q13.3) encompassing the *NKX2-1* locus was first recognized in an infant with *hypothyroidism* and *neonatal RDS*. Multiple large deletions involving the *NKX2-1* locus and contiguous genes as well as missense, frameshift, nonsense, and small insertion or deletion variants scattered throughout the gene have been reported in individuals with hypothyroidism, lung disease, and neurologic symptoms, including benign familial chorea. Manifestation of dysfunction in all three organ systems has been referred to as **brain-thyroid-lung syndrome**, but disease may manifest in only one or two organ systems. The lung disease can range from severe and eventually *lethal neonatal respiratory distress* to *chronic lung disease in childhood and adulthood*. Recurrent pulmonary infections have been reported, likely caused by reduced expression of the pulmonary collectins, SP-A and SP-D, but could also result from decreased expression of other *NKX2-1* transcriptionally regulated proteins. No clear genotype-phenotype correlations have emerged, but children harboring complete gene deletions have generally had more severe and earlier-onset disease. This observation could also be related to the deletion of other adjacent genes. Although limited data are available, the pulmonary phenotype may depend on the expression of which *NKX2-1* target genes are most affected. Children with decreased SP-B or ABCA3 expression may present with acute neonatal respiratory failure, whereas those with decreased SP-C or pulmonary collectin expression are more likely to have chronic lung disease.

Genetics

The *NKX2-1* gene is small, spanning less than 3,000 bases, with only three exons. TTF-1 is expressed not only in the lung but also in the thyroid gland and in the central nervous system. In the lung it is important for the expression of a wide variety of proteins, including the surfactant proteins, ABCA3, club cell secretory protein, and many others. Two transcripts that differ depending on whether the transcriptional start site is in the first or second exon have been recognized, although the shorter transcript is the predominant transcript in the lung. Most *NKX2-1* pathogenic variants are thought to result in a loss of function, with the mechanism of disease thus being haploinsufficiency, but discordant effects on different target genes have been reported. Loss-of-function variants in *NKX2-1* are rare in large sequencing projects, but the prevalence of disease is unknown. Pathogenic variants in diverse ethnic groups have been recognized. Most reported variants and deletions have occurred de novo, resulting in sporadic disease, but familial disease transmitted in a dominant manner has been recognized.

Diagnosis

Sequence analysis of the *NKX2-1* gene is available through clinical laboratories, usually as part of an NGS multiple-gene panel, and is the preferred method for diagnosis. Because large deletions comprise a significant fraction of reported variant alleles, specific methods to assess for deletions should also be performed, such as a chromosomal microarray or gene-targeted deletion/duplication analysis. A pathogenic variant on one allele is sufficient to cause disease. Although isolated pulmonary disease has been recognized, the majority of reported affected individuals have manifestations in two or more other organ systems. Thus the presence of **hypothyroidism** or neurologic abnormality in a proband or a family history of chorea should prompt consideration of the diagnosis. The most specific neurologic finding is **chorea**, but hypotonia, developmental delay, ataxia, and dysarthria have been reported. In very young, nonambulatory infants the neurologic symptoms may not be evident, or muscle weakness or hypotonia may be attributed to the severity of lung disease or a result of the hypothyroidism. Affected individuals may not be overtly hypothyroid but have compensated hypothyroidism with borderline low thyroxine (T_4) and high thyroid-stimulating hormone levels. The lung pathology associated with *NKX2-1* pathogenic variants may be typical of that of other surfactant dysfunction disorders, but because *NKX2-1* is important for lung development, growth abnormalities and arrested pulmonary development also may be seen. Immunostaining studies of surfactant protein expression have yielded variable results, with decreased expression of one or more surfactant-related proteins observed in some patients. No characteristic electron microscopy findings have been identified.

TREATMENT OF SURFACTANT DYSFUNCTION DISORDERS

Virtually all patients with SP-B deficiency die within the first year of life. Conventional neonatal intensive care interventions can maintain extrapulmonary organ function for a limited time (weeks to several months). Replacement therapy with commercially available surfactants is ineffective. Lung transplantation has been successful, but the pretransplantation, transplantation, and posttransplantation medical and surgical care is highly specialized and available only at pediatric pulmonary transplantation centers. Prompt recognition is critical if patients are to be considered for lung transplantation. Palliative care consultation is helpful.

No specific treatment is available for patients with lung disease caused by pathogenic variants in *SFTPC* or *ABCA3*. Therapeutic approaches used for interstitial lung diseases, such as the use of corticosteroids, quinolones, and macrolide antibiotics, have been reported but not systematically evaluated (Fig. 456.1). Infants with severe and progressive respiratory failure attributable to ABCA3 deficiency may be candidates

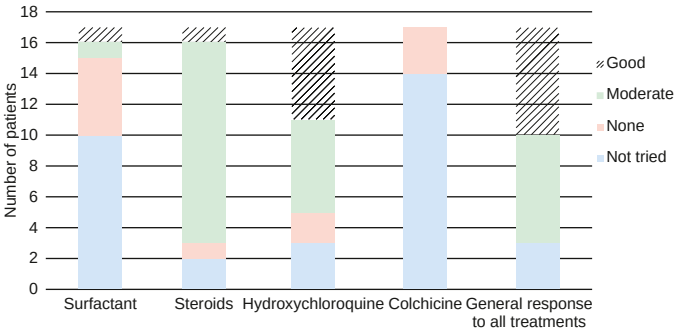

Fig. 456.1 Response to therapies for 17 patients with *SFTPC* variants. *(Data from Kröner C, Reu S, Teusch V, et al. Genotype alone does not predict the clinical course of SFTPC deficiency in paediatric patients. Eur Respir J. 2015;46:197–206.)*

for lung transplantation. The variable natural history of patients with *SFTPC* variants and older children with ABCA3 deficiency makes predictions of prognosis difficult. Lung transplantation is reserved for patients with progressive and refractory respiratory failure who would otherwise qualify for transplantation irrespective of their diagnosis.

Treatment for patients with *NKX2-1* variants is largely supportive. Hypothyroidism, if present, should be treated with thyroid hormone replacement. Corticosteroids and other agents used for other types of surfactant dysfunction have not been formally evaluated. Some individuals have progressive lung disease and have undergone lung transplantation. The variable progression of disease and presence of extrapulmonary disease may make evaluation and selection of subjects for transplantation particularly difficult.

Parents of children with surfactant dysfunction disorders should be offered genetic counseling to inform recurrence risk for future pregnancies, to present antenatal diagnostic options and offer delivery at a center with neonatal intensive care, and to facilitate discussions regarding whether testing should be offered to other family members who may not be symptomatic.

Visit Elsevier eBooks+ at eBooks.Health.Elsevier.com for Bibliography.

456.2 Pulmonary Alveolar Proteinosis

Jennifer A. Wambach, Lawrence M. Nogee, F. Sessions Cole III, and Aaron Hamvas

Pulmonary alveolar proteinosis (PAP) is a rare syndrome characterized by the intraalveolar and terminal airway accumulation of surfactant leading to progressive hypoxemic respiratory failure. PAP can result from abnormalities in surfactant production or surfactant clearance. Histopathologic examination shows distal air spaces are filled with a granular, eosinophilic material that stains positively with periodic acid–Schiff reagent and is diastase resistant. This material contains large amounts of surfactant proteins and lipids, and the primary mechanism for its accumulation is impaired catabolism by alveolar macrophages. PAP is classified as either *primary* due to disruption of granulocyte-macrophage colony-stimulating factor (GM-CSF) signaling or *secondary* due to several different diseases that reduce alveolar macrophage number or function (Table 456.2). A fulminant, usually lethal, form of PAP manifesting shortly after birth has been termed **congenital alveolar proteinosis**, but because this condition is caused by disrupted surfactant metabolism or surfactant dysfunction within alveolar type II cells, the disease is included under inherited disorders of surfactant metabolism (see Chapter 456.1).

ETIOLOGY AND PATHOPHYSIOLOGY

Primary Alveolar Proteinosis

Disordered signaling of GM-CSF leading to impaired alveolar macrophage maturation is the major underlying cause of primary PAP in children and adults. Most cases of primary PAP in older children and adults are mediated by *neutralizing autoantibodies* directed against GM-CSF, which can be detected in serum and bronchoalveolar lavage (BAL) fluid. These autoantibodies block binding of GM-CSF to its receptor, thereby inhibiting alveolar macrophage maturation and function and surfactant clearance. Variants in the genes encoding both the α and β subunits of the GM-CSF receptor *(CSF2RA, CSFR2B)* in children with PAP account for a genetic basis for some cases of primary PAP in childhood.

Secondary Alveolar Proteinosis

Alveolar proteinosis has also been reported in children, including young infants, with **lysinuric protein intolerance**, a rare autosomal recessive disorder caused by pathogenic variants in the cationic amino acid transporter SLC7A7 (see Chapter 105.14). These children generally present with vomiting, hyperammonemia, and failure to thrive, although their pulmonary disease may prove fatal. A case of *recurrence* of the disease after lung transplantation supports a primary role for alveolar macrophage dysfunction in the pathogenesis of PAP associated with lysinuric protein intolerance. PAP is also a prominent feature in patients with biallelic variants in the gene encoding methionyl tRNA synthetase *(MARS)*, who have a multiorgan phenotype that also includes liver disease as a prominent feature and is prevalent among individuals on Reunion Island. The mechanism for PAP in patients with *MARS* variants is unknown. Heterozygous variants in the gene encoding the transcription factor GATA2 have also been associated with a phenotype that includes PAP, as well as immune deficiencies, myelodysplasia, and lymphatic abnormalities. The mechanism for PAP in patients with such variants likely is related to the role of GATA2 in alveolar macrophage development. Heterozygous gain-in-function variants in the *OAS1* gene have been identified in infants and children with a phenotype that includes PAP, hypogammaglobulinemia, and immune dysfunction. *OASl* gene products are important in the innate immune response to viral infection, and gene activation leads to inhibition of protein synthesis and apoptosis, with apoptosis of alveolar macrophages likely resulting in PAP. PAP may also be associated with some subtypes of Niemann-Pick disease (see Chapter 106.4).

Secondary alveolar proteinosis also may occur in association with *infection,* particularly in immunocompromised individuals. However, because the same pathologic process occurs in severely immunodeficient mice raised in a pathogen-free environment, it is not clear whether this phenotype results from a secondary infection or the underlying immunodeficiency. Environmental exposures to dust, silica, and chemicals and chemotherapeutic agents; hematologic disorders (myelodysplastic syndrome); and nonhematologic malignancies have also been associated with the development of secondary alveolar proteinosis.

CLINICAL MANIFESTATIONS

Infants and children with PAP present with dyspnea, fatigue, cough, weight loss, chest pain, or hemoptysis. In the later stages, cyanosis and digital clubbing may be seen. Pulmonary function changes include decreased diffusing capacity of carbon monoxide, lung volumes with a restrictive abnormality, and arterial blood gas values indicating marked hypoxemia and/or chronic respiratory acidosis. Alveolar proteinosis in infants and children is rare, and males are affected three times as often as females.

DIAGNOSIS

Histopathologic examination of lung biopsy specimens currently remains the gold standard for diagnosis of PAP in children, although this is likely to change as molecular tests become available. Immunohistochemical staining reveals abundant quantities of alveolar and intracellular surfactant proteins A, B, and D. Latex agglutination tests for the presence of anti–GM-CSF antibodies in BAL fluid or blood are highly sensitive and specific for the autoimmune forms of alveolar proteinosis. Elevations of GM-CSF in peripheral blood suggest a GM-CSF receptor defect, and molecular analysis of these genes should be pursued. The examination of sputum or BAL fluid for surfactant components has been used for diagnosis in adults, but these methods have not been validated in children. Examination of peripheral blood and/or bone marrow for clonogenic stimulation of monocyte-macrophage

Table 456.2 Comparison of Pulmonary Alveolar Proteinosis Syndromes

	AUTO-IMMUNE	GM-CSF RECEPTOR DEFICIENCY	LYSINURIC PROTEIN INTOLERANCE	*MARS* DEFICIENCY	*GATA2* DEFICIENCY	*OAS1*-ASSOCIATED POLYMORPHIC AUTOINFLAMMATORY IMMUNO-DEFICIENCY
Gene(s)		*CSFR2A, CSFR2B*	*SLC7A7*	*MARS*	*GATA2*	*OAS1*
Age of onset	Adult > child	Childhood to adult	Childhood	Childhood to adult	Childhood to adult	Infancy
Inheritance	NA	Recessive	Recessive	Recessive	Sporadic/dominant	Sporadic/dominant
Mechanism	Neutralizing antibodies to GM-CSF	Loss of function	Loss of function	Loss of function	Loss of function; haploinsufficiency	Gain in function
Other manifestations			Emesis; failure to thrive	Liver disease; hypothyroidism	Immune deficiency; myelodysplasia	Systemic inflammation, including fever, dermatitis, diarrhea, leukocytosis, splenomegaly
DIAGNOSIS						
Biochemical	Detection of serum GM-CSF autoantibody	Elevated serum GM-CSF levels	Increased cationic amino acids in urine, especially lysine	None	None	Hypogammaglobulinemia
Genetic (*DNA*)	NA	Sequence CSFR2A, CSFR2B	Sequence *SLC7A7*	Sequence *MARS*	Sequence *GATA2*	Sequence *OAS1*
Treatment	Whole lung lavage; inhaled GM-CSF	Whole lung lavage; hematopoietic stem cell transplantation	Whole lung lavage, dietary protein restriction, administration of citrulline and nitrogen scavenging drugs	Whole lung lavage	Whole lung lavage; hematopoietic stem cell transplantation	Whole lung lavage, intravenous immunoglobulin (IVIG), hematopoietic stem cell transplantation

GM-CSF, Granulocyte-macrophage colony-stimulating factor.

precursors, GM-CSF receptor and ligand expression, and GM-CSF binding and signaling studies are available through research protocols.

TREATMENT

The natural history of primary PAP is highly variable, making prognostic and therapeutic decisions difficult. Total lung lavage has been associated with prolonged remission of PAP in adults and remains a therapeutic option for patients with childhood PAP (Fig. 456.2). Younger infants with PAP may be more likely to have genetic mechanisms underlying their disease, and the role of repeated BAL in children has not been well studied, nor is it likely to be effective. It may provide a temporizing measure in some circumstances and may benefit patients with autoimmune or secondary PAP. Subcutaneous or inhaled administration of recombinant GM-CSF may improve pulmonary function in some adults with later-onset PAP. The role of exogenous GM-CSF treatment in children has not been well studied, although successful treatment with inhaled recombinant GM-CSF (molgramostim) has been reported in adults with autoimmune-mediated PAP. Because children with GM-CSF receptor defects generally have high serum levels of GM-CSF, exogenous GM-CSF seems unlikely to be effective in most such cases. Depending on the nature of the variant(s) responsible for the deficiency, some responsiveness of the receptor may be retained such that a response to exogenous GM-CSF is possible. Because the primary defect for PAP resides in the alveolar macrophage, which is a bone marrow–derived cell, lung transplantation would not be expected to correct primary PAP.

Visit Elsevier eBooks+ at eBooks.Health.Elsevier.com for Bibliography.

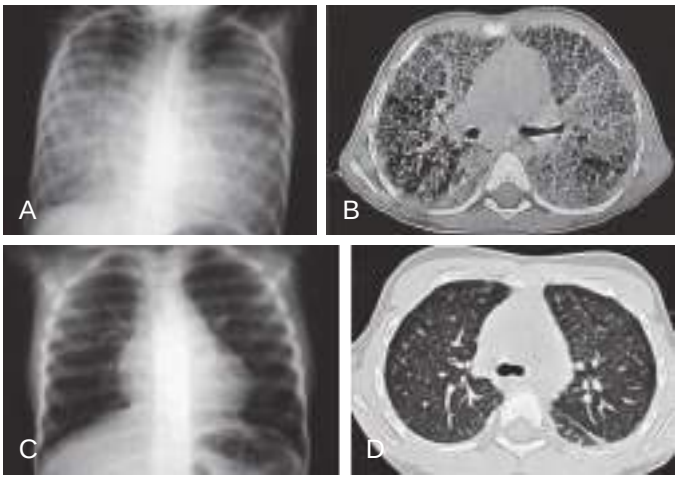

Fig. 456.2 **A** and **B**, Severe pulmonary alveolar proteinosis in a 5-year-old child before therapeutic lung lavage. **A**, Chest radiograph shows diffuse alveolar and interstitial infiltrates. **B**, CT scan demonstrates major air space opacities and crazy-paving pattern. **C** and **D**, Same patient after 12 therapeutic lung lavages. **C**, Chest radiograph demonstrates improvement of alveolointerstitial infiltrates. **D**, CT scan shows regression of the air space opacities with a residual micronodular pattern. *(From De Blic J. Pulmonary alveolar proteinosis in children. Paediatr Respir Rev. 2004;5:316–322.)*

Chapter 457

Pulmonary Hemosiderosis

Mary A. Nevin

Pulmonary hemorrhage may be characterized as focal or diffuse based on the location(s) of bleeding (see Chapter 458.2). The diagnosis of pulmonary hemosiderosis refers to the subset of patients with **diffuse alveolar hemorrhage (DAH)**. Bleeding in DAH occurs as a result of injury to the microvasculature of the lung and may be slow and insidious because of the low-pressure pulmonary circulation. Pulmonary hemosiderosis has classically been characterized by the triad of iron-deficiency anemia, hemoptysis, and radiographic evidence of alveolar infiltration. However, many of those affected, particularly young patients, are likely to present atypically, and a high index of suspicion for this condition must be maintained. Pulmonary hemosiderosis can exist in isolation, but more commonly occurs in association with an underlying condition. Defining a precise etiology for hemorrhage may be elusive. A diagnosis of **idiopathic pulmonary hemosiderosis (IPH)** is made when DAH occurs in isolation and an exhaustive evaluation for an underlying pathologic etiology is found to be unrevealing or nondiagnostic.

ETIOLOGY

The pathogenesis of pulmonary hemosiderosis is diverse, but DAH may be classified based on histopathologic examination. Three histopathologic patterns have been described: pulmonary capillaritis, bland pulmonary hemorrhage, and diffuse alveolar damage. Of these, pulmonary capillaritis is most frequently encountered and appears to carry a negative prognosis in those affected with DAH.

The histopathologic finding of **pulmonary capillaritis** is characterized by neutrophilic inflammation of the alveolar interstitium, endothelial edema, and fibrinoid necrosis. DAH with pulmonary capillaritis is frequently associated with an underlying systemic vasculitic process or collagen vascular disease.

Disorders associated with pulmonary capillaritis include systemic lupus erythematosus (SLE; see Chapter 199), drug-induced capillaritis, anti–glomerular basement membrane (GBM) antibody syndrome (Goodpasture syndrome), IgA vasculitis (Henoch-Schönlein purpura) (see Chapter 210), and antineutrophil cytoplasmic antibody (ANCA)–associated vasculitis, including granulomatosis with polyangiitis (formerly Wegener granulomatosis), microscopic polyangiitis (MPA; see Chapter 210), and eosinophilic granulomatosis with polyangiitis (Churg-Strauss syndrome). Additional etiologies of pulmonary capillaritis include primary antiphospholipid antibody syndrome, rheumatoid arthritis, hypocomplementemic urticarial vasculitis, and acute lung transplant rejection. DAH in individuals with ANCA-associated vasculitis (granulomatosis with polyangiitis and microscopic polyangiitis) is frequently associated with pathologic evidence of pulmonary capillaritis. In patients with Goodpasture syndrome, antiphospholipid syndrome, and SLE, DAH has been reported with pathologic evidence of capillaritis, but bland hemorrhage has also been described. Isolated pulmonary capillaritis may also be seen in the absence of ANCA positivity.

Drugs, including propylthiouracil, aspirin, hydralazine, and tumor necrosis factor alpha (TNF-α) antagonists, have been implicated as an etiology for pulmonary capillaritis and DAH. Finally, alveolar hemorrhage with capillaritis has been increasingly described as a complication of hematopoietic cell transplantation

Pulmonary hemosiderosis with the histopathologic finding of **bland hemorrhage** is found when there is an absence of alveolar capillary inflammation or endothelial and cellular disruption. Both anti-GBM disease and SLE may be associated with bland hemorrhage, although the finding of capillaritis is more typical. Other causes of bland hemorrhage include cardiac or cardiopulmonary derangements (pulmonary hypertension, mitral stenosis, mitral regurgitation, arteriovenous malformation), disseminated intravascular coagulation (DIC), coagulopathies, and anticoagulant therapy. Bland hemorrhage is also described in IPH.

Diffuse alveolar damage (DAD) is characterized by diffuse alveolar and interstitial edema with hyaline membrane formation. It is the pathognomonic finding in acute respiratory distress syndrome (ARDS) and is seen with a variety of infections, including opportunistic pathogens in immunocompromised individuals. Drug toxicity (sirolimus, nitrofurantoin, amphetamines, vaping), radiation therapy, and pulmonary embolus and infarction are other described etiologies for DAD with pulmonary hemorrhage. Table 457.1 provides a summary and classification of the diagnoses that may manifest with recurrent or chronic pulmonary hemorrhage.

EPIDEMIOLOGY

Disorders that present as DAH are highly variable in their severity and in their associated symptomatology and identifiable

Table 457.1 Diffuse Alveolar Hemorrhage Syndromes

DISORDERS WITH PULMONARY CAPILLARITIS
Granulomatosis with polyangiitis (Wegener granulomatosis)
Microscopic polyangiitis
Systemic lupus erythematosus (SLE)
Systemic sclerosis
Polymyositis
Anti-GBM antibody syndrome (Goodpasture)
Antiphospholipid antibody syndrome
IgA vasculitis (Henoch-Schönlein purpura)
Hypocomplementemic urticarial vasculitis
Rheumatoid arthritis
Immunoglobulin A nephropathy
Behçet syndrome
Cryoglobulinemia
Endocarditis
Drug-induced capillaritis (retinoic acid, propylthiouracil, etanercept, infliximab, hydralazine)
Idiopathic pulmonary-renal syndrome
Acute lung transplant rejection
Eosinophilic granulomatosis with polyangiitis (Churg-Strauss syndrome)
Hematopoietic cell transplantation
DISORDERS WITH BLAND HEMORRHAGE
Anti-GBM antibody syndrome (Goodpasture)
Systemic lupus erythematosus (SLE)
Idiopathic pulmonary hemosiderosis
Heiner syndrome
Acute idiopathic pulmonary hemorrhage of infancy
Thrombocytopenia syndromes (ITP, TTP)
Hemolytic uremic syndrome
Mitral stenosis
Celiac disease (Lane-Hamilton syndrome)
Nonaccidental trauma
Drugs (anticoagulation, toxins)
DISORDERS WITH DIFFUSE ALVEOLAR DAMAGE
Systemic lupus erythematosus (SLE)
Polymyositis
Immunodeficiency and opportunistic infection
Pulmonary infarction
Radiation therapy
Acute respiratory distress syndrome (ARDS)
Pulmonary hypertension
Pulmonary edema
Drugs (amphetamines, propylthiouracil, penicillamine, vaping)

Modified from Susarla SC, Fan LL. Diffuse alveolar hemorrhage syndromes in children. *Curr Opin Pediatr.* 2007;19:314–320.

abnormalities in laboratory testing; the diagnosis may be significantly delayed, making frequency estimates unreliable. Similarly, the prevalence of IPH is largely unknown. Of children and young adults diagnosed with IPH in the past, it has been postulated that the etiology of the hemorrhage might have been discovered if they had been studied with the newer and more advanced diagnostics available today; specific serologic testing has vastly improved our ability to appreciate immune-mediated disease. Estimates of prevalence obtained from Swedish and Japanese retrospective case analyses vary from 0.24 to 1.23 cases per million. Children and adolescents have traditionally accounted for 30% of cases. The ratio of affected males:females is 1:1 in the childhood diagnosis group, and males are only slightly more affected in the group diagnosed as young adults. In pediatric and adolescents undergoing allogeneic hematopoietic cell transplantation, pulmonary hemorrhage has been described in 2% of the population.

PATHOLOGY

DAH has been associated with diffuse inflammation, cytokine activation, and autoimmune responses. Elevations of both ferritin and interleukin (IL)-6 have been described as key factors in the exaggerated inflammatory response seen in pulmonary hemorrhage. In pulmonary capillaritis, key histologic features include (1) fibrin thrombi, which occlude capillaries, (2) fibrin clots adherent to interalveolar septae, (3) fibrinoid necrosis of capillary walls, and (4) interstitial erythrocytes and hemosiderin. Illustrative but nonspecific pathologic findings, such as vascular smooth muscle hypertrophy (pulmonary hypertension) or thrombosis (vascular thrombosis with infarction), may be found in those disorders that cause DAH without pulmonary capillaritis. The finding of blood in the airways or alveoli is representative of a recent hemorrhage. With repeated episodes of pulmonary hemorrhage, lung tissue appears brown secondary to this presence of hemosiderin. The presence of persistent blood in three bronchoalveolar lavage (BAL) specimens from the same lobe is highly suggestive of the diagnosis. **Hemosiderin-laden macrophages *(HLMs)*** are seen with recovering, recurrent, or chronic pulmonary hemorrhage and are identifiable both in BSL fluid and in pathologic specimens of lung tissue. Approximately 48 hours is necessary for the alveolar macrophages to convert iron from erythrocytes into hemosiderin. In a murine model, HLMs appear 3 days after a single episode of pulmonary hemorrhage and peak at 7-10 days. HLMs may be detectable for weeks to months after a hemorrhagic event. Other nonspecific pathologic findings include thickening of alveolar septa, goblet cell hyperplasia, and hypertrophy of type II pneumocytes. Fibrosis may be seen with chronic disease.

PATHOPHYSIOLOGY

Diffuse Alveolar Hemorrhage Associated with Pulmonary Capillaritis

Granulomatosis with polyangiitis is a recognized etiology for DAH in children (see Chapter 448.3). This disease is classically characterized by necrotizing granuloma formation (with or without cavitation) of the upper and lower respiratory tract and by a necrotizing glomerulonephritis and small vessel vasculitis. In children, presentations attributable to the upper airway, including subglottic stenosis, may suggest the diagnosis. The presence of ANCAs may be helpful in diagnosis and management, but the clinician must be aware that other ANCA-positive vasculitides, such as MPA and **eosinophilic granulomatosis with polyangiitis**, may share this nonspecific laboratory finding. In small vessel vasculitides, ANCAs cause an inflammatory reaction that results in injury to the microvasculature. Antiproteinase-3 antibodies (cANCAs) are classically associated with granulomatosis with polyangiitis, whereas antimyeloperoxidase antibodies (pANCAs) are typically found in patients with MPA.

Patients with **MPA** (previously the microscopic variant of polyarteritis nodosa) demonstrate a systemic necrotizing vasculitis with a predilection for small vessels (venules, arterioles, capillaries) but without necrotizing granuloma formation. This diagnosis is precluded by the finding of immune complex deposition in order to differentiate MPA from other diseases (Henoch-Schönlein purpura, cryoglobulinemic vasculitis) that are associated with immune complex–mediated small vessel vasculitis.

Anti-GBM antibody syndrome (Goodpasture disease) is an immune complex–mediated disease in which anti-GBM antibody binds to the basement membrane of both the alveolus and the glomerulus. GBM antibodies attach to type IV collagen contained in the vascular endothelium. At the alveolar level, immunoglobulin (Ig) G, IgM, and complement are deposited at alveolar septa. Electron microscopy shows disruption of basement membranes and vascular integrity, which allows blood to escape into alveolar spaces.

Although alveolar hemorrhage is a relatively uncommon complication in SLE, its occurrence is often severe and potentially life-threatening; mortality rates exceed 50% in some cohorts, and early recognition is crucial to allow timely implementation of immunomodulatory therapies.

In **IgA vasculitis (Henoch-Schönlein purpura),** pulmonary hemorrhage is a rare but recognized complication. Pathologic findings have included transmural neutrophilic infiltration of small vessels, alveolar septal inflammation, and intraalveolar hemorrhage. Vasculitis is the proposed mechanism for hemorrhage.

Pulmonary renal syndromes are defined as those where pulmonary and renal disease manifestations are predominant. These include the aforementioned granulomatosis with polyangiitis, anti-GBM antibody syndrome, SLE, and MPA. As Henoch-Schönlein purpura may also have renal involvement, it has been suggested for inclusion as a pulmonary renal syndrome.

Pulmonary Hemorrhage in Infancy

An infant's neonatal course may be complicated by pulmonary hemorrhage. The most common diagnoses in infants with DAH are congenital heart disease (including pulmonary hypertension) and prematurity. Additional diagnostic considerations in an infant with pulmonary hemorrhage include congenital or acquired lung disease (congenital diaphragmatic hernia, sepsis), congenital or acquired coagulopathies (extracorporeal membrane oxygenation [ECMO], liver failure), and infection. Pulmonary hemorrhage in infants may be unrecognized if the volume of blood is insufficient to reach the proximal airways. Even with more significant blood loss, the tussive force of an infant may be insufficient to produce hemoptysis. Because the radiographic findings in pulmonary hemorrhage may be appreciated instead as a worsening picture of respiratory distress syndrome, edema, or infection, a high index of suspicion is required.

Acute Idiopathic Pulmonary Hemorrhage of Infancy

In 1994 and 1997, case reports suggested clusters of infantile pulmonary hemorrhage in association with environmental exposure to *Stachybotrys chartarum*. A review by the Centers for Disease Control and Prevention did not support an association between exposure to the mold and infantile pulmonary hemorrhage. Acute idiopathic pulmonary hemorrhage of infancy (AIPHI) has been defined as pulmonary hemorrhage in a previously healthy infant who is less than 1 year of age and born at a gestational age of greater than 32 weeks. Three criteria must simultaneously be met; these include (1) the sudden onset of bleeding or "frank" evidence of blood in the airway; (2) severe presentation leading to respiratory distress or failure and resulting in hospitalization in intensive care with intubation and mechanical ventilation; and (3) diffuse bilateral pulmonary infiltrates found on chest radiographs or computerized tomographic imaging. AIPHI is believed to be a rare diagnosis, and an exhaustive search for an identifiable etiology of pulmonary hemorrhage is advocated.

Pulmonary hemosiderosis in association with non-IgE–mediated cow's milk hypersensitivity is characterized by variable and

reversible (with elimination of cow's milk protein) symptoms of milk intolerance in infants and young children. Symptoms can include grossly bloody or occult heme-positive stools, vomiting, failure to thrive, gastroesophageal reflux, upper airway congestion, and iron-deficiency anemia. Association with pulmonary hemorrhage has remained controversial, but multiple case series have provided support for the anecdotal association.

A number of case reports and case series have suggested an association between **celiac disease** (see Chapter 384) and DAH. In these reports, a resolution of intestinal and pulmonary symptoms along with resolution of radiographic disease has been seen after the adoption of a gluten-free diet. Consideration of testing for celiac disease in those patients with pulmonary hemorrhage and suggestive gastrointestinal symptomatology may be warranted.

DAH has been described in association with numerous other conditions. These are typically noninflammatory in nature and may be diversely attributable to cardiac, vascular, lymphatic, or hematologic etiologies. DAH has also rarely been attributed to nonaccidental trauma.

The diagnosis of IPH is a diagnosis of exclusion and is only made when there is evidence of chronic or recurrent DAH and when exhaustive evaluations for primary or secondary etiologies have negative results. Renal and systemic involvement should be absent, and a biopsy specimen should not reveal any evidence of granulomatous disease, vasculitis, infection, infarction, immune complex deposition, or malignancy. Some patients initially diagnosed with IPH will later be found to have Goodpasture syndrome, SLE, or MPA; therefore some cases of IPH may represent unrecognized immune-mediated disorders.

CLINICAL MANIFESTATIONS

The clinical presentation of pulmonary hemosiderosis is highly variable. In most symptomatic cases, DAH is heralded by symptoms of hemoptysis and dyspnea with associated hypoxemia and the finding of alveolar infiltration on chest radiograph. The diagnosis may be problematic, as young children often lack the ability to effectively expectorate and may not present with hemoptysis. Because the presence of blood in the lung is a trigger for airway irritation and inflammation, the patient may present after an episode of hemorrhage with wheezing, cough, dyspnea, and ventilatory derangements, reflecting bronchospasm, edema, mucus plugging, and inflammation; this presentation may result in an incorrect diagnosis of asthma or bronchiolitis. A lack of pulmonary symptoms does not preclude the diagnosis of DAH, and children may present only with chronic fatigue or pallor. In particular, young infants and children with DAH may come to attention with entirely nonspecific and nonpulmonary symptomatology such as failure to thrive or jaundice.

Primary or reported symptoms may reflect an underlying and associated disease process or comorbid condition. Presentations can vary widely from a relative lack of symptoms to shock or sudden death. Bleeding may occasionally be recognized from the presence of alveolar infiltrates on a chest radiograph alone. It should be noted, however, that the absence of an infiltrate does not rule out an ongoing hemorrhagic process.

On physical examination, the patient may be pale with tachycardia and tachypnea. During an acute exacerbation, children are frequently febrile. Examination of the chest may reveal retractions and differential or decreased aeration, with crackles or wheezes. The patient may present in shock with respiratory failure from massive hemoptysis.

LABORATORY FINDINGS AND DIAGNOSIS

Bronchoscopic evaluation is an important tool in the diagnosis of pulmonary hemosiderosis. The yield is highest if performed within the first 48-72 hours after an acute hemorrhage. Cultures should be sent for bacterial, viral, fungal, and mycobacterial pathogens. In addition, the evaluation of BAL fluid with silver stain for pneumocystis is advocated. When the pulmonologist recovers persistent or worsening blood with repeated BAL of the same lung segment, the diagnosis of DAH is supported. The presence of greater than 20% HLMs in BAL fluid is considered diagnostic. In the absence of bronchoscopy, sputum or pulmonary secretions should be analyzed for significant evidence of blood or HLMs and may provide supportive evidence in a patient who is able to adequately expectorate secretions from the lower airway. Gastric secretions may also reveal HLMs.

Pulmonary hemorrhage is classically associated with a microcytic, hypochromic anemia. Reduced serum iron levels, a decreased or normal total iron-binding capacity, and normal to increased ferritin levels may be found with chronic disease. The reticulocyte count is frequently elevated. Patients with pulmonary capillaritis have lower hematocrits and higher erythrocyte sedimentation rates. The anemia of IPH can mimic a hemolytic anemia. Elevations of plasma bilirubin are caused by absorption and breakdown of hemoglobin in the alveoli. Any or all of these hematologic manifestations may be absent in the presence of recent hemorrhage.

White blood cell count and differential should be evaluated for evidence of infection and eosinophilia. A peripheral smear and direct Coombs test may suggest a vasculitic process. A stool specimen positive for occult blood may suggest associated gastrointestinal disease but can also reflect swallowed blood. Renal and liver functions should be reviewed. A urinalysis should be obtained to assess for evidence of a pulmonary-renal syndrome. A coagulation profile, quantitative immunoglobulins (including IgE), and complement studies are recommended. Testing for von Willebrand disease is also indicated.

Testing for ANCA (cANCA, pANCA), antinuclear antibody, anti–double-stranded DNA, rheumatoid factor, antiphospholipid antibody (APL), myeloperoxidase, lupus anticoagulant, anticardiolipin antibody, and anti-GBM antibody evaluates for a number of immune-mediated and vasculitic processes that may be associated with pulmonary capillaritis.

Chest x-rays may reveal evidence of acute or chronic disease. Hyperaeration is frequently seen, especially during an acute hemorrhage. Infiltrates are typically symmetric and may spare the apices of the lung. Atelectasis may be appreciated. With chronic disease, fibrosis, lymphadenopathy, and nodularity may be seen. High-resolution CT imaging may reveal diffuse ground-glass opacification and alveolar opacification. With large bleeds, a fluid collection may be appreciated.

The presence of a cardiac murmur, cardiomegaly on x-ray, or a clinical suspicion of congenital or acquired heart disease suggests the need for a complete cardiac evaluation, including electrocardiogram and echocardiogram.

Pulmonary function tests generally reveal obstructive lung disease in the acute period. With more chronic disease, fibrosis and restrictive disease tend to predominate. Oxygen saturation levels may be decreased. Lung volumes may reveal air trapping acutely and decreases in total lung capacity chronically. The diffusing capacity of carbon monoxide may be low or normal in the chronic phase but is likely to be elevated in the setting of an acute hemorrhage, because carbon monoxide binds to the hemoglobin in extravasated red blood cells.

Lung biopsy is warranted when DAH occurs without discernible etiology, extrapulmonary disease, serologic evidence of vasculitis, or circulating GBM antibodies. When surgically obtained, pulmonary tissue should be evaluated for evidence of immune complex deposition, inflammatory change in the pulmonary vascular bed, and granulomatous disease. Transbronchial biopsy is not generally recommended, as the lung involvement in DAH is frequently nonhomogeneous and "patchy" in character.

Many have supported a diagnosis of IPH without lung biopsy if the patient has a typical presentation with diffuse infiltration on

radiography, anemia, HLMs in BAL, sputum or gastric aspirate, absence of systemic disease, and negative serology for immune-mediated disease. However, a number of patients meeting these criteria have been proven to have pulmonary capillaritis on review of pathologic lung tissue specimens. Therefore a lung biopsy may be recommended in an effort to guide therapy or determine prognosis in an individual with DAH of unknown etiology.

TREATMENT

Supportive therapy, including volume resuscitation, ventilatory support, supplemental oxygen, and transfusion of blood products, may be warranted in the patient presenting acutely with pulmonary hemorrhage. In the presence of ARDS, high oxygen concentrations and high positive end-expiratory pressure (PEEP) may be required. Surgical or medical therapy should be directed at any treatable underlying condition. High-dose systemic corticosteroids are frequently used as first-line treatment and are expected to be of particular benefit in the setting of immune-mediated disease. Steroids inhibit the acute inflammatory response (neutrophil influx, cytokine storm) associated with hemorrhage and may decrease progression toward fibrotic disease. High-dose steroids may contribute to morbidity and mortality in patients who have an infectious etiology for their hemorrhage and in those who are immunocompromised. A thorough evaluation for immunocompetence and pan-cultures for infectious organisms are therefore strongly advocated.

Medication dosing may vary with regard to primary diagnosis, age, comorbidities, and other factors. Clinical-pharmacologic correlation is advocated. Low- to moderate-dose treatment regimens may be provided in the form of methylprednisolone 2-4 mg/kg/day divided every 6-12 hours or in the form of prednisone 0.5-1 mg/kg daily and decreased to every other day after resolution of acute symptoms. High-dose corticosteroid therapy generally uses 10-30 mg/kg/day of IV methylprednisolone for 3-5 days and is followed by a tapering dose over 4-6 weeks. Successful treatment is also associated with the use of pulse steroid therapy; methylprednisolone may be given at a dose of 10-30 mg/kg (maximum 1 g) infused over 1 hour for 3-5 consecutive days and repeated weekly or monthly. Early treatment with corticosteroids appears to decrease episodes of hemorrhage, but high doses of steroids carry the risk of renal disease, immunosuppression, and potentially fatal infections.

A variety of steroid-sparing and alternative immunosuppressive agents, including cyclophosphamide, Cytoxan, azathioprine, hydroxychloroquine, methotrexate, 6-mercaptopurine, and IVIG, have all been used successfully as adjunctive therapy in patients with severe, chronic, unremitting, or recurrent hemorrhage.

Plasmapheresis is a recognized adjunctive therapy for DAH with pulmonary capillaritis in ANCA-associated vasculitis, SLE, and anti-GBM antibody disease. Pheresis is generally performed daily or every other day for 14 days. In each plasma exchange, the total volume of plasma is replaced with fresh-frozen plasma (FFP) or albumin. In recent analyses, the long-term efficacy of plasmapheresis as compared with corticosteroid therapy has been questioned. At this time, treatment guidelines suggest the use of plasmapheresis in patients with ANCA-associated vasculitis who are critically ill with hypoxemic respiratory failure.

Rituximab has evolved as an additional adjunctive therapeutic option. It is a monoclonal antibody that targets CD-20 and has been found to be an effective option for individuals with connective tissue and autoimmune disorders.

Any coagulopathic disorders should be corrected in an effort to achieve hemostasis. Cryoprecipitates, FFP, and platelets may be transfused depending on the identified deficiency. Vitamin K may also be supplemented.

Prothrombotic factors, including antifibrinolytics such as tranexamic acid (TXA), thrombin, and factor VIIa, have been used in the treatment of DAH. TXA acts by preventing the conversion of plasminogen into plasmin and hinders fibrinolysis. Inhalational TXA has been associated with favorable treatment outcomes in children with DAH. TXA has been described as being less efficacious in those with hematologic malignancies and those individuals with massive or recurrent bleeding. Further study is indicated to define associated risk and populations expected to benefit most consistently from this therapy.

Recombinant factor VIIa (FVIIa) may be used in an effort to achieve hemostasis in those with massive hemorrhage. A therapeutic response to low doses of FVIIa has been reported with direct intrapulmonary instillation, but the use of this agent is still anecdotal outside of hemophilia. Factor VIIa appears to decrease the requirement for transfusions and to be an effective adjunctive therapy for critically ill children with massive hemorrhage. The efficacy of FVIIa in neonates and infants less than 1 year of age is yet to be established.

In the most critically ill children, additional life-sustaining interventions may be required; ECMO combined with immunosuppression was reported to be successful in allowing recovery from a severe hemorrhage with hypoxemic respiratory failure in the setting of pANCA-positive MPA. In neonatal and infantile pulmonary hemorrhage, clinical improvement in blood gas and ventilatory requirements have been described with intrapulmonary administration of exogenous surfactant.

The potential adverse effects of these pharmacologic and therapeutic interventions should be recognized, and treated patients must be closely monitored for drug-related complications. Cushing syndrome, systemic hypertension, diabetes, and immunodeficiency are well-recognized complications of chronic steroid therapy. Thrombocytopenia in association with low-dose cyclophosphamide has also been reported. Chronically immunosuppressed patients are at risk for opportunistic infection; *Legionella* pneumonia infection has been described in a survivor of IPH.

In chronic disease, progression to debilitating pulmonary fibrosis has been described. Lung transplantation has been performed in patients with IPH refractory to immunosuppressive therapy. In one reported case study, IPH recurred in the transplanted lung.

PROGNOSIS

The outcome of patients suffering from DAH is multideterminant; underlying disease process, recurrence patterns, severity of hemorrhage, and delays in presentation are recognized prognostic factors. Some conditions respond well to immunosuppressive therapies, and remissions of disease are well documented. Other syndromes, especially those associated with pulmonary capillaritis, carry a poorer prognosis. In IPH, mortality is generally attributable to massive hemorrhage or, alternatively, to progressive fibrosis, respiratory insufficiency, and right-sided heart failure.

The long-term prognosis in patients with IPH varies among studies. Initial case study reviews suggested an average survival after symptom onset of only 2.5 years. Subsequent reviews have demonstrated vastly improved 5-year (86%) and 8-year (93%) survival in association with the use of immunosuppressive therapies. In IPH, the presence of hypoxia at clinical presentation and a positive antinuclear antibody have been demonstrated to be risk factors for recurrence.

Visit Elsevier eBooks+ at eBooks.Health.Elsevier.com for Bibliography.

Chapter 458

Pulmonary Embolism, Infarction, and Hemorrhage

458.1 Pulmonary Embolus and Infarction

Mary A. Nevin

Venous thromboembolism (VTE) is a term that describes both deep venous thrombosis (DVT) and pulmonary embolism (PE). PE is defined as obstruction of a pulmonary artery, typically as a result of thrombus formation. Although VTE remains relatively rare in occurrence, these events have become recognized as increasingly prevalent clinical problems and are associated with significant morbidity and mortality in the pediatric population. An increased incidence of VTE has been described in infants, children, and adolescents; this has been attributed to multiple factors, including increased survival from previously fatal critical and chronic illnesses, the increased use of central venous catheters, and improved diagnostic tools. Pulmonary emboli are more likely to be silent or to present atypically in infants and children as compared to adults, and a delay in diagnosis is commonly encountered. A diagnosis of PE may only be discovered on postmortem examination. In a retrospective study of PE found at the time of autopsy, the investigators discovered antemortem consideration of the diagnosis in only 15% of cases. Although children are more likely than their adult counterparts to have one or more predisposing factors favoring VTE (Table 458.1), a PE is often the first presenting symptom, and a high index of suspicion is needed to allow timely and accurate recognition as well as optimal management of PE in children.

ETIOLOGY

In the adult population, PE and VTE may be idiopathic in ~30% of patients. Children with DVT and PE are much more likely to have one or more identifiable conditions or circumstances placing them at risk. At least one identifiable risk factor for PE and VTE has been found in ≥80% of affected children. Most children have multiple and coexisting risk factors. In the pediatric population, the most common risk factors for VTE include the presence of an indwelling central venous catheter, congenital heart disease or vascular anomalies, trauma, immobility, recent surgery, malignancy, congenital and acquired thrombophilia, obesity and pregnancy, or hormonal drug therapies, including oral contraceptives. Individuals with nephrotic syndrome, inflammatory bowel disease, systemic lupus erythematosus, and sickle cell disease are also recognized as being at increased risk for thromboembolic disease. Both SARS-CoV-2/COVID-19 infection and the COVID-19–associated multisystem inflammatory syndrome in children (MIS-C) have been associated with a hypercoagulable state and increased risk for VTE, particularly in children and young adults who are critically ill with respiratory complications.

Although an embolus can also consist of air, septic material, amniotic fluid, or neoplastic tissue, emboli most commonly originate from thrombus formation. The most common risk factor for VTE in children is the presence of a central venous catheter (CVC); these indwelling lines are used for long-term administration of chemotherapy, antibiotics, and parental nutrition. The presence of a catheter in a vessel lumen, as well as instilled medications, can induce endothelial damage and favor thrombus formation. The use of a CVC is associated with ~90% of recognized VTE in neonates and ~30–60% of VTE in children. Septic emboli are rare in children but have been seen in osteomyelitis, endocarditis, Lemierre syndrome, and individuals with cellulitis.

Children with malignancy are recognized as being at high risk for VTE. Thromboembolic disease has been described in 7–16% of those with soft tissue sarcoma and in 5.2% of individuals with acute lymphocytic leukemia (ALL). A child with malignancy may have numerous risk factors that relate to both the primary disease process and therapeutic interventions. Infection related to chronic immunosuppression, indwelling catheters, and the hypercoagulable state of malignancy itself are additional factors that favor VTE. Chemotherapeutic agents such as L-asparaginase have been implicated as conferring risk for VTE. In addition, steroids may contribute to the risk of VTE by increasing factor VIII. In a retrospective cohort of patients with VTE, pediatric malignancy was the chronic medical condition most strongly associated with recurrent VTE.

In the neonatal period, VTE is frequently associated with the presence of an indwelling CVC. Comorbid medical conditions often confer additional risk for thromboembolic disease in the neonate; the most common associated diagnoses are congenital heart disease and sepsis. Another known contributor is the relative immaturity of newborn infant coagulation; plasma concentrations of vitamin K–dependent coagulation factors (II, VII, IX, X); factors XII, XI, and pre-kallikrein and high molecular weight kininogen are physiologically lower in neonates and children (see Chapter 524). Infants with congenitally acquired homozygous deficiencies of antithrombin, protein C, and protein S may also present with thromboembolic disease in the neonatal period. Testing for these acquired thrombophilias is frequently problematic in this age-group, as physiologic levels of protein S and antithrombin are not seen until 6 months of age, and mature levels of protein C may not occur until a child reaches adolescence. Furthermore, coagulant proteins may be artificially low in the setting of acute VTE (see Chapter 527).

Pulmonary air embolism is a defined entity in the newborn or young infant and is attributed to the conventional ventilation of critically ill (and generally premature) infants with severe pulmonary disease. Usually, the pulmonary air embolism is preceded by an air-leak syndrome. Infants may become symptomatic and critically compromised by as little as 0.4 mL/kg of intravascular air; these physiologic derangements are thought to be secondary to the effects of nitrogen.

Thrombophilia may be inherited or acquired and may manifest in neonates and in older infants, children, and adolescents. **Inherited thrombophilias** include deficiencies of antithrombin, protein C, and protein S, as well as pathogenic variants of factor V Leiden (FVL) and prothrombin G20210 pathogenic variant (see Chapter 527). The most frequent inherited thrombophilia is the FVL pathogenic variant. It is more common in people of European descent and relatively uncommon in those of African and Asian heritage. Acquired thrombophilic conditions include the presence of lupus anticoagulant (may be present without the diagnosis of systemic lupus erythematosus), anticardiolipin antibody, and anti–β_2-glycoprotein 1 antibody. Methylenetetrahydrofolate reductase (MTHFR) pathogenic variants associated with high levels of plasma homocysteine have also been hypothesized to be a risk factor for VTE, but the prognostic significance is unclear, and an isolated MTHFR pathogenic variant is not an absolute indication for VTE prophylaxis. Diagnostic testing for thrombophilic disorders is unlikely to be beneficial in the acute management of VTE but may be indicated to determine risk of recurrent VTE in both the index case and their relatives. Avoidance of prothrombotic risk factors such as oral contraceptive agents may also be recommended in those individuals with an inherited thrombophilia.

Sickle cell disease is associated with an increased risk for PE and pulmonary infarction. The primary risk factor for VTE in sickle cell disease is the presence of an indwelling CVC. Other risk factors for thrombosis include infection, splenectomy, and immobility.

The incidence of VTE in female adolescents 12-18 years of age is ~3 per 10,000. In patients with known exposure to estrogen-containing long-acting reversible contraception (LARC), more than 96% also had one or more comorbidities. Over 50% of those with VTE had four or more comorbidities. The most common comorbid conditions were obesity and tobacco use. Although estrogen is a known procoagulant, VTE in female adolescents does not appear attributable *solely* to estrogen-containing LARC, and additional risk factors should be sought in affected individuals.

EPIDEMIOLOGY

A wide range of incidence of PE has been described in both hospitalized (8.6-57 per 100,000) children and in the general population (0.14-0.9 per 100,000). There is a suggestion that the incidence of PE has increased over time. The etiology for these increases in pediatric thromboembolism is

Table 458.1 Risk Factors for Pulmonary Embolism

ENVIRONMENTAL
Long-haul air travel (>4 hr)
Obesity
Cigarette smoking
Hypertension
Immobility
WOMEN'S HEALTH
Oral contraceptives, including progesterone-only and, especially, third-generation pills
Pregnancy or puerperium
Hormone replacement therapy
Septic abortion
MEDICAL ILLNESS
Personal or family history of prior pulmonary embolism or deep venous thrombosis
Cancer
L-Asparaginase therapy
Heart failure
Chronic obstructive pulmonary disease
Diabetes mellitus
Inflammatory bowel disease
Antipsychotic drug use
Long-term indwelling central venous catheter
Permanent pacemaker
Internal cardiac defibrillator
Stroke with limb paresis
Spinal cord injury
Nursing home confinement or current or repeated hospital admission
SURGICAL
Trauma, including fractures
Orthopedic surgery
General surgery
Neurosurgery, especially craniotomy for brain tumor
Vascular anomalies
May-Turner syndrome
THROMBOPHILIA
Factor V Leiden mutation
Prothrombin gene (20210G A) pathogenic variant
Hyperhomocysteinemia (including pathogenic variant in methylenetetrahydrofolate reductase)
Antiphospholipid antibody syndrome
Deficiency of antithrombin III, protein C, or protein S
High concentrations of factor VIII or XI
Increased lipoprotein (a)
Heparin-induced thrombocytopenia
Paroxysmal nocturnal hemoglobinuria
Nephrotic syndrome
NONTHROMBOTIC
Air
Foreign particles (e.g., hair, talc, as a consequence of intravenous drug misuse)
Amniotic fluid
Bone fragments, bone marrow
Fat
Tumors (Wilms tumor)

Modified from Goldhaber SZ. Pulmonary embolism. *Lancet.* 2004;363:1295–1305.

regarded as multifactorial, with increased survival from chronic and critical illnesses, increased frequency of indwelling CVCs, increased clinical suspicion, and more precise imaging and diagnostic techniques being cited as contributing factors. The 2-year mortality rate from PE in two studies was ~8.5%, with the highest mortality rates occurring in infants. In other analyses, inpatient VTE has been estimated to increase the risk of mortality by two to six times. Massive PE has historically been associated with death in up to 30% of cases. Currently, the mortality from PE in children approximates the rates of mortality from VTE. In survivors of VTE, chronic complications, increased healthcare use, and increased healthcare costs are recognized.

The incidence of pediatric VTE is recognized as having a bimodal distribution, with peaks occurring in infants less than 1 year of age and in adolescence. Males are statistically more likely to have VTE, except for the 13- to 18-year-old age-group, where females are affected more frequently.

Pediatric deaths from isolated pulmonary emboli are rare. The source of the emboli may be lower or upper extremity veins as well as the pelvis and right heart. In adults, the most common location for DVT is the lower leg. However, one pediatric VTE/PE registry found ~65% of DVTs occurring in the upper extremity.

PATHOPHYSIOLOGY

Favorable conditions for thrombus formation include injury to the vessel endothelium, hemostasis, and hypercoagulability. In the case of PE, a thrombus is dislodged from a vein, travels through the right atrium, and lodges within the pulmonary arteries. VTE is most common in segmental pulmonary arteries (52%), with central arteries being obstructed less frequently (6%). In children, emboli that obstruct <50% of the pulmonary circulation are generally clinically silent unless there is significant coexistent cardiopulmonary disease. When greater than 50% of the pulmonary circulation is obstructed, right ventricular afterload is increased, with resultant right ventricular dilation and increases in right ventricular and pulmonary arterial pressures. In severe cases, a reduction of cardiac output and hypotension may result from concomitant decreases in left ventricular filling. In rare instances of death from massive pulmonary embolus, marked increases in pulmonary vascular resistance and heart failure are usually present.

Arterial hypoxemia results from unequal ventilation and perfusion; the occlusion of the involved vessel prevents perfusion of distal alveolar units, thereby creating an increase in dead space and hypoxia with an elevated alveolar-arterial oxygen tension difference (see Chapter 421). The vascular supply to lung tissue is abundant, and pulmonary infarction is unusual with PE but may result from distal arterial occlusion and alveolar hemorrhage.

CLINICAL MANIFESTATIONS

The presentation of VTE is highly variable and more likely to present atypically or silently in the pediatric age-group. A high index of suspicion is therefore necessary. The symptoms reported most in association with PE include chest pain, hypoxia (cyanosis), dyspnea, tachycardia, tachypnea, and syncope. A tenderness, swelling, or palpable cord may be palpated at the location of a DVT. Hemoptysis may also be a presenting symptom. Pleuritic chest pain is the most common presenting symptom in adolescents (84%). Massive PE may manifest as cardiopulmonary (hypotension) failure. Confirmatory testing should follow a clinical suspicion for PE.

In older adolescents and adults, clinical prediction rules have been published and are based on risk factors, clinical signs, and symptoms (Table 458.2). The Pulmonary Embolism Rule Out Criteria (PERC) and Wells criteria are clinical prediction rules that are commonly used in adults but lack reliability in the pediatric population. The Wells score has a sensitivity of 72–86% and a specificity of 60% when applied to children. The PERC tool has a higher sensitivity but a specificity of only 24% in children. When the PERC tool is applied in the pediatric setting, a high false-positive rate is seen, with over 75% of patients without PE having a positive PERC result. In a population at high risk from exposure to ionizing radiation, more discerning tools have been sought for this age-group.

In children and adolescents less than 22 years of age, the risk of PE is low (1.3%) in children who were not receiving estrogen therapy or in those who did not present with tachycardia or hypoxia (SpO_2 <95%); the prediction model reported a sensitivity of 89% and a specificity of 56%. Another clinical prediction model for the diagnosis of PE in adolescents and young adults identified five risk factors, including immobilization, hypercoagulability, exposure to estrogen-containing drugs, indwelling CVC, and a prior history of PE and/or DVT; the probability of PE as demonstrated by computed tomography pulmonary angiography (CTPA) with the presence of any three or more risk factors was 89%, and the probability of PE was extremely low (0.5%) when none of these risk factors were identified. These data and prediction tools may allow risk stratification and optimal use of diagnostic testing, including CTPA, but require prospective analysis and clinical validation.

Table 458.2 Scores to Assess the Clinical Probability of Venous Thromboembolism

WELLS SCORE FOR DEEP VEIN THROMBOSIS	POINTS
Active cancer	+1
Paralysis, paresis, or recent plaster cast on lower extremities	+1
Recent immobilization >3 days or major surgery within past 4 wk	+1
Localized tenderness of deep venous system	+1
Swelling of entire leg	+1
Calf swelling >3 cm compared with asymptomatic side	+1
Unilateral pitting edema	+1
Collateral superficial veins	+1
Previously documented deep vein thrombosis	+1
Alternative diagnosis at least as likely as deep vein thrombosis	−2
Clinical pretest probability	
Unlikely	Total score ≤2 (prevalence 4%)
Likely	Total score >2 (prevalence 27%)
WELLS SCORE FOR PULMONARY EMBOLISM	
Original	
Alternative diagnosis less likely than pulmonary embolism	+3
Clinical signs and symptoms of deep vein thrombosis	+3
Heart rate >100 beats per min	+1.5
Previous deep vein thrombosis or pulmonary embolism	+1.5
Immobilization or surgery within the past 4 wk	+1.5
Active cancer	+1
Hemoptysis	+1
Clinical Pretest Probability	
Low	Total score ≤1 (prevalence 4%)
Intermediate	Total score 2-6 (prevalence 21%)
High	Total score >6 (prevalence 67%)
Unlikely	Total score ≤4 (prevalence 8%)
Likely	Total score >4 (prevalence 41%)
Simplified	
Alternative diagnosis less likely than pulmonary embolism	+1
Clinical signs and symptoms of deep vein thrombosis	+1
Heart rate >100 beats per min	+1
Previous deep vein thrombosis or pulmonary embolism	+1
Immobilization or surgery within the past 4 wk	+1
Active cancer	+1
Hemoptysis	+1
Clinical Pretest Probability	
Unlikely	Total score ≤1 (prevalence 11%)
Likely	Total score >1 (prevalence 36%)
REVISED GENEVA SCORE FOR PULMONARY EMBOLISM	
Original	
Heart rate ≥95 beats per min	+5
Heart rate 75-94 beats per min	+3
Pain on lower-limb deep venous palpation and unilateral edema	+4
Unilateral lower-limb pain	+3

Table 458.2 Scores to Assess the Clinical Probability of Venous Thromboembolism—cont'd

REVISED GENEVA SCORE FOR PULMONARY EMBOLISM	
Previous deep vein thrombosis or pulmonary embolism	+3
Active cancer	+2
Hemoptysis	+2
Surgery or fracture within the past 4 wk	+2
Age >65 yr	+1
Clinical Pretest Probability	
Low	Total score <4 (prevalence 9%)
Intermediate	Total score 4-10 (prevalence 28%)
High	Total score >10 (prevalence 72%)
Simplified	
Heart rate ≥95 beats per min	+2
Heart rate 75-94 beats per min	+1
Pain on lower-limb deep venous palpation and unilateral edema	+1
Unilateral lower-limb pain	+1
Previous deep vein thrombosis or pulmonary embolism	+1
Active cancer	+1
Hemoptysis	+1
Surgery or fracture within the past 4 wk	+1
Age >65 yr	+1
Clinical Pretest Probability	
Unlikely	Total score ≤2 (prevalence 13%)
Likely	Total score >2 (prevalence 42%)
YEARS CRITERIA FOR PULMONARY EMBOLISM	
Clinical signs of deep vein thrombosis	+1
Hemoptysis	+1
Pulmonary embolism is the most likely diagnosis	+1
Clinical Pretest Probability	
Low	Total score 0 (prevalence 3%)
High	Total score ≥1 (prevalence 23%)
PULMONARY EMBOLISM RULE-OUT CRITERIA	
Age <50 yr	—
Heart rate <100 beats per min	—
Pulse oximetry reading on room air >94%	—
No unilateral leg swelling	—
No hemoptysis	—
No recent trauma or surgery	—
No history of venous thromboembolism	—
No oral hormone use	—

Pulmonary embolism can be considered excluded in patients with all Pulmonary Embolism Rule-Out Criteria and a low clinical pretest probability, assessed by gestalt, or in clinical settings with a low (<5%) prevalence of pulmonary embolism. If any criterion applies, pulmonary embolism cannot be ruled out in these patients. Prevalence estimates correspond to emergency department settings. Vital signs should be age adjusted.

Modified from Khan F, Tritschler T, Kahn SR, Rodger MA. Venous thromboembolism. *Lancet*. 2021;398:64–77.

LABORATORY FINDINGS AND DIAGNOSIS

Blood gas analysis is expected to reveal hypoxemia with an abnormal A-a gradient. Lower-than-normal Pa_{CO_2} levels may also be seen secondary to hyperventilation, a finding that may persist even when oxygenation is optimized. Abnormalities of oxygenation and ventilation are likely to be less significant in the pediatric population, in the setting of less underlying cardiopulmonary disease and greater reserve. The results of an electrocardiogram and chest radiograph are expected to be nonspecific. ECG findings may include ST-T segment changes, tachycardia, right axis deviation, and right bundle branch block. Chest radiographs are frequently abnormal (88%); the most common finding is cardiomegaly (27%) and pleural

effusion (23%). These studies lack sensitivity and specificity in the diagnosis of PE.

A review of results of a complete blood count and coagulation profile is warranted. Prothrombotic diseases should be highly suspected based on medical or family history; additional laboratory evaluations include fibrinogen assays, protein C, protein S, and antithrombin III studies and analysis for FVL pathogenic variant, along with evaluation for lupus anticoagulant and anticardiolipin antibodies.

Echocardiograms may be used to assess ventricular size and function. An echocardiogram is indicated if there is any suspicion of intracardiac thrombi or endocarditis.

Noninvasive venous ultrasound testing with Doppler flow can be used to confirm DVT in the lower extremities; in pediatrics, the utility of ultrasonography is limited, as it may not detect thrombi in the upper extremities or pelvis (Fig. 458.1A).

In children, D-dimer levels demonstrate reasonable sensitivity but poor specificity for venous thrombosis because D-dimer levels are also increased in infectious, inflammatory, and neoplastic disorders, all of which are also risk factors for PE. Other studies have suggested that D-dimer may be a sensitive tool for PE in adolescents when a level of >750 mg/mL is seen; these data have not been found to be applicable to younger children or neonates.

In the evaluation of a suspected PE, a ventilation–perfusion **($\dot{V}$–$\dot{Q}$)** radionuclide scan is a safe diagnostic study associated with exposure to low levels of ionizing radiation. With a definitive or high-probability scan, the likelihood of PE is 85%. With low-probability results, there is still a 20% chance of PE. In addition, children may have difficulty cooperating with the ventilation portion of the $\dot{V}$–$\dot{Q}$ scan.

Although conventional pulmonary angiography had been considered the gold standard for detection of PE, the invasive nature of this study, the high exposure to radiation, and the risk of complications have limited its use. *Computed tomography/multidetector CT with pulmonary angiography has become the diagnostic study of choice for PE* (see Fig. 458.1B). The criteria for PE include two or more consecutive images revealing a complete or partial filling defect of a pulmonary artery. CT studies detect emboli in lobar and segmental vessels with acceptable sensitivities. Poorer sensitivities may be encountered in the evaluation of the subsegmental pulmonary vasculature. Dual-energy scanning provides additional functional and anatomic information without additional radiation exposure. In most institutions, dose reduction techniques can be employed to limit a child's radiation exposure.

Magnetic resonance angiography (MRA) is also considered a viable diagnostic option for patients with VTE. High-resolution 3D contrast-enhanced MRA and time-resolved MRA are sensitive and specific for PE. The lack of ionizing radiation is attractive, but longer imaging times and the need for general anesthesia in most children may limit its use.

TREATMENT

In the acute management of VTE, careful monitoring and support of cardiopulmonary stresses are crucial. Once the affected individual has been stabilized, the primary approach to treatment of VTE is with anticoagulation. Appropriate and timely treatment with anticoagulation may prevent thrombus extension and recurrence. It is also indicated to prevent embolization.

Evaluations for prothrombotic disease must precede anticoagulation. Acute-phase anticoagulation therapy may be provided with unfractionated heparin (UFH) or low molecular weight heparin (LMWH). UFH binds reversibly to antithrombin III and potentiates its ability to inhibit thrombin and coagulation factor Xa. LMWH has become the drug of choice for both short-term and longer-term anticoagulation in children; enoxaparin is the LMWH most used in the pediatric population. It acts similarly to inhibit factor Xa but can be administered subcutaneously, and the need for serum monitoring is decreased. The risk of heparin-induced thrombocytopenia is also decreased with LMWH as compared to UFH. UFH may still be chosen in patients who have an elevated risk of bleeding, as UFH has a shorter half-life than LMWH. UFH is also used preferentially in patients with compromised renal function.

In monitoring of drug levels, laboratories must be aware of the drug chosen in order to use the appropriate assay. For UFH, the therapeutic range is 0.3-0.7 anti-Xa activity units/mL. In LMWH, the therapeutic range is 0.50-1.0 units/mL. When the anti-Xa assay is not available, the activated partial thromboplastin time may be used, with a goal of 60-85 seconds, or approximately 1.5-2 times the upper limit of age-appropriate normal values. The recommended duration of heparinization during acute treatment is 5-10 days; this length of therapy has been extrapolated from adult data. Long-term therapy with heparin should be avoided whenever possible. Side effects include heparin-induced thrombocytopenia, bleeding, and osteoporosis.

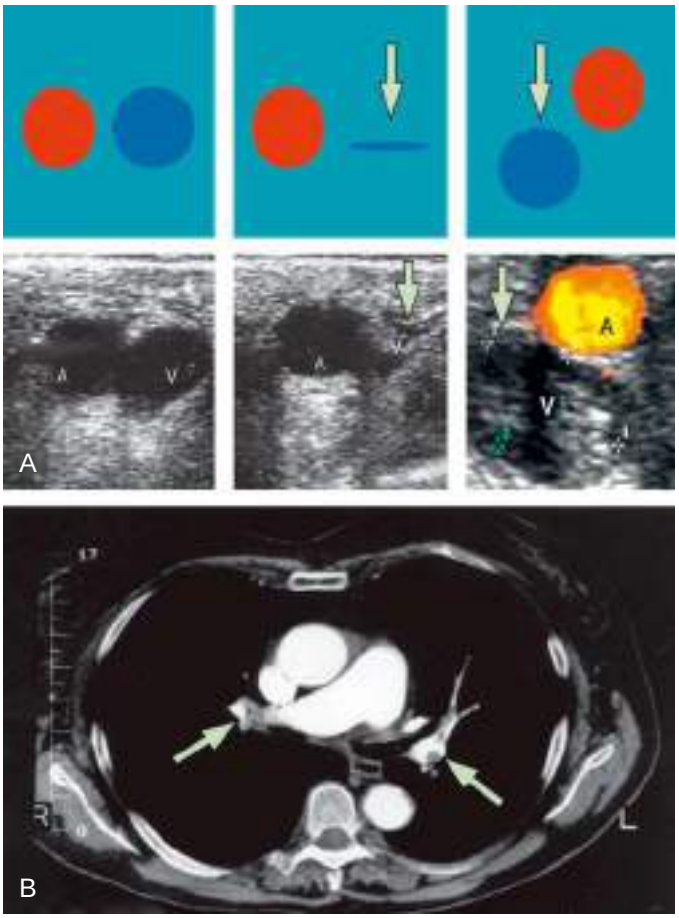

Fig. 458.1 A, Compression ultrasound. *Top images,* from left to right, representation of vein and artery without and with *(arrow)* gentle compression with the echocardiographic probe. *Bottom images,* corresponding echocardiographic findings. The third image from the left shows a thrombus in the vein (vein not compressible by the probe). B, CT angiography showing several emboli *(arrows)* in the main right pulmonary artery and in left lobar and segmental arteries. A, Artery; V, vein. *(From Goldhaber SZ, Bounameaux H. Pulmonary embolism and deep vein thrombosis. Lancet. 2012;379:1835–1844, Fig. 2, p. 1838.)*

THERAPEUTIC OPTIONS

Extension of anticoagulation therapy occurs in the subacute phase and may use LMWH, LMWH analogues, or warfarin. Warfarin is a vitamin K antagonist that may be used in children and adolescents; use is generally initiated after establishing effective anticoagulation with heparin because severe congenital deficiencies of protein C may be associated with warfarin skin necrosis. When the international normalized ratio (INR) is measured between 1.0 and 1.3, the starting dose for warfarin in children is recommended as 0.2 mg/kg administered orally once daily. Titration of dosing may be needed to achieve a therapeutic INR of 2 to 3. Dosing requirements may vary, and clinical pharmacologic correlation is required. The INR is generally monitored 5 days after initiating therapy or a similar period after dose changes and weekly thereafter until stable. The INR should be obtained with any evidence of abnormal bleeding and should be discontinued at least 5 days before invasive procedures. The use of an anticoagulation team and/or established treatment algorithms is recommended in order to optimize patient safety.

With the first occurrence of VTE, anticoagulation is recommended for 3-6 months in the setting of an identifiable, reversible, and resolved risk factor (e.g., postoperative state). Longer treatment is indicated in patients with idiopathic VTE (6-12 months) and in those with chronic clinical risk factors (12 months to lifelong). In the setting of a congenital thrombophilic condition, the duration of therapy is often indefinite. Inhibitors of factor Xa (e.g., enoxaparin) may become an alternative therapy for both acute PE and long-term treatment (Table 458.3).

In adults with DVT or PE, subsequent therapy with apixaban, dabigatran, edoxaban, or rivaroxaban (direct oral anticoagulants [DOACs]) is recommended over vitamin K antagonists. Some pediatric centers have adapted this therapy, particularly for adolescent patients. The recommended duration of such therapy for uncomplicated patients is 3 months.

Thrombolytic agents such as recombinant tissue plasminogen activator by peripheral vein may be used in combination with anticoagulants in the early stages of treatment; their use is most likely to be considered in children with hemodynamically significant PE (hypotension, echocardiogram evidence of right ventricular dysfunction) or other severe potential clinical sequelae of VTE. Combined therapy may reduce the incidences of progressive thromboembolism, PE, and postthrombotic syndrome. The mortality rate appears to be unaffected by additional therapies; nonetheless, the additional theoretical risk of hemorrhage limits the use of combination therapy in all but the most compromised patients. The use of thrombolytic agents in patients with active bleeding, recent cerebrovascular accidents, or trauma is contraindicated.

Catheter-assisted thrombus removal (thrombectomy) should be limited to those with large emboli that result in persistent hemodynamic compromise refractory to standard therapy. Catheter-assisted thrombus removal (less often, surgical embolectomy) is indicated in patients with hypotension who are a high bleeding risk or have failed systemic thrombolysis or are in life-threatening shock before systemic thrombolysis can be effective (within hours of thrombolysis). Surgical embolectomy is indicated with embolic Wilms tumor.

In adults with acute proximal DVT of the leg, inferior vena cava filters are used *only* if there is a contraindication to anticoagulation therapy.

PROGNOSIS

Mortality in pediatric patients with PE is likely to be attributable to an underlying disease process rather than to the embolus itself. Short-term complications include major hemorrhage (either because of the thrombosis or secondary to anticoagulation). Chronic complications include recurrence and pulmonary hypertension with the risk of cor pulmonale. Conditions associated with a poorer prognosis include malignancy, infection, and cardiac disease. The mortality rate in children from PE is 2.2%. An exhaustive evaluation for underlying pathology is advocated in an effort to prevent recurrence and progressive disease. Postthrombotic syndrome is a recognized complication of pediatric thrombotic disease. Venous valvular damage can be initiated by the presence of DVT and may result in persistent venous hypertension with ambulation and valvular reflux. Symptoms include edema, pain, increases in pigmentation, and ulcerations. Affected pediatric patients may suffer lifelong disability.

Visit Elsevier eBooks+ at eBooks.Health.Elsevier.com for Bibliography.

Table 458.3 Anticoagulant Therapies for Deep Vein Thrombosis and Pulmonary Embolism

	ROUTE	RENAL CLEARANCE (%)	HALF-LIFE	INITIAL TREATMENT DOSING	MAINTENANCE TREATMENT DOSING	EXTENDED TREATMENT DOSING
Unfractionated heparin (UFH)	Intravenous	~30	~1.5 hr	Maintain aPTT 1.5 times upper limit of normal		
Low molecular weight heparin (LMWH)	Subcutaneous	~80	3-4 hr	Weight-based dosing	Weight-based dosing*	
Fondaparinux	Subcutaneous	100	17-21 hr	Weight-based dosing	Weight-based dosing	
Vitamin K antagonists	Oral	Negligible	Acenocoumarol 8-11 hr; warfarin 36 hr; phenprocoumon 160 hr	Target at INR at 2.0-3.0 and give parallel heparin treatment for at least 5 days	Maintain INR at 2.0-3.0	Maintain INR at 2.0-3.0
Dabigatran	Oral	~80†	14-17 hr	Requires at least 5 days heparin lead-in	150 mg twice a day	150 mg twice a day
Rivaroxaban	Oral	~33‡	7-11 hr	15 mg twice a day for 3 wk	20 mg once a day	20 mg once a day
Apixaban	Oral	~25‡	8-12 hr	10 mg twice a day for 1 wk	5 mg twice a day	2.5 mg twice a day
Edoxaban	Oral	~35‡	6-11 hr	Requires at least 5 days heparin lead-in	60 mg once a day§	60 mg once a day§
Aspirin	Oral	~10	15 min			80-100 mg once a day

*Treatment with low molecular weight heparin is recommended for patients with active cancer and pregnant women.
†Dabigatran is contraindicated in patients with a creatinine clearance below 30 mL/min.
‡Apixaban, edoxaban, and rivaroxaban are contraindicated in patients with a creatinine clearance below 15 mL/min.
§The recommended edoxaban dose is 30 mg once a day for patients with a creatinine clearance of 30-50 mL/min, a body weight less than or equal to 60 kg, or for those on certain strong P-glycoprotein inhibitors.
Medication dosing may vary with regard to primary diagnosis, age, comorbidities, and other factors. Clinical-pharmacologic correlation is advocated.
aPTT, Activated partial thromboplastin time; INR, international normalized ratio.
From Di Nisio M, van Es N, Büller HR. Deep vein thrombosis and pulmonary embolism. *Lancet*. 2016;388:3060–3069, Table 2.

458.2 Pulmonary Hemorrhage and Hemoptysis

Mary A. Nevin

Hemoptysis may be defined as the expectoration of blood from the lower respiratory tract. Infants and small children lack the tussive force to expectorate blood, and if blood from the lower airway is expectorated, it is frequently swallowed. Pulmonary hemorrhage in children and adolescents is uncommon but represents a serious and potentially fatal occurrence in children.

ETIOLOGY

Table 458.4 and Table 457.1 in Chapter 457 present conditions that can manifest as pulmonary hemorrhage or hemoptysis in children. The most common etiologies for pulmonary hemorrhage in the neonate and infant are congenital heart disease, premature lung disease, and coagulopathy (congenital or acquired with liver failure or anticoagulant medications). Infection and foreign body aspiration are the most common etiologies for hemoptysis in children. The chronic presence of a foreign body can lead to localized airway inflammation and hemorrhage. Secondary infection may also be present if the foreign body has been in the airway for days to weeks. Bleeding is more likely to occur in association with a chronically retained foreign body of vegetable origin.

Hemorrhage may be related to chronic airway inflammation and infection with bronchiectasis in the setting of cystic fibrosis (CF). Non-CF bronchiectasis may also be seen in children with chronic aspiration disorders, immunodeficiency syndromes, primary ciliary dyskinesia with or without Kartagener syndrome, HIV, and other infections. Hemoptysis attributable to inflammation and erosion of bronchial and bronchiolar airways may therefore occur in these clinical settings as well. Pulmonary hemorrhage caused by infection is also seen in patients with cavitary disease in association with tuberculosis. Hemoptysis may also occasionally reflect the intense inflammation of an acute pulmonary infection such as bronchitis or bronchopneumonia.

Bleeding is frequently encountered in patients with tracheostomies and is often attributable to suction trauma or friable granulation tissue. In these situations, bleeding tends to be limited and responsive to modifications of the care regimen. Rarely, bleeding from a tracheostomy may be brisk and bright red. In this case, otolaryngology should evaluate for the presence of a tracheo-innominate artery fistula.

Cardiopulmonary disease is associated with hemoptysis in children and adolescents. Associated conditions include mitral stenosis, pulmonary edema in the setting of congestive heart failure, high-altitude pulmonary edema (HAPE), pulmonary venous obstructive disease, and pulmonary hypertension. Although early corrective surgical intervention has been associated with improved hemodynamics, collateral circulations may contribute to bleeding.

Traumatic injury to the airway and pulmonary contusion may result from motor vehicle crashes or other direct-force injuries. Children who have been victims of nonaccidental trauma or deliberate suffocation can also be found to have blood in the mouth or airway (see Chapter 17). Factitious hemoptysis may rarely be encountered in the setting of self-inflicted trauma to the oral mucosa by biting or in the setting of factitious disorder by proxy (formerly Munchausen by proxy; see Chapter 17.2).

Rare causes for hemoptysis include tumors and vascular anomalies such as arteriovenous malformations (AVMs) (Fig. 458.2). Congenital vascular malformations in the lung may be seen in the setting of **hereditary hemorrhagic telangiectasia (HHT)**. Symptoms and signs of pulmonary AVM include dyspnea, hemoptysis, poor exercise tolerance, digital clubbing, and cyanosis. A high index of suspicion is needed, as more than half of children with pulmonary AVM may be asymptomatic. AVMs in individuals with HHT may be associated with severe complications, including massive hemoptysis, hemothorax, and stroke. In individuals with HHT, pulmonary AVMs are prevalent (60%) and can occur at any age. Any tumors or lesions must be cautiously investigated when encountered with a flexible fiberoptic bronchoscope, as bleeding may be massive and difficult to control.

Bronchial **Dieulafoy disease** has been recognized as a rare etiology for pulmonary hemorrhage. The classic bronchoscopic appearance is a small, submucosal bronchial lesion with a white cap. Massive hemorrhage may ensue. If nonsurgical bronchial artery embolization is not able to achieve hemostasis, surgical resection of the affected lung segment or lobe may be considered.

Table 458.4 Etiology of Pulmonary Hemorrhage (Hemoptysis)

FOCAL HEMORRHAGE
Bronchitis and bronchiectasis (especially cystic fibrosis related)
Infection (acute or chronic), pneumonia, abscess
Tuberculosis
Trauma
Pulmonary arteriovenous malformation (with or without hereditary hemorrhagic telangiectasia)
Foreign body (chronic)
Neoplasm, including hemangioma and metastatic disease
Pulmonary embolus with or without infarction
Bronchogenic cysts
DIFFUSE HEMORRHAGE
Idiopathic of infancy
Congenital heart disease (including pulmonary hypertension, venoocclusive disease, and congestive heart failure)
Prematurity
Cow's milk hyperreactivity (Heiner syndrome)
Goodpasture syndrome
Collagen vascular diseases (systemic lupus erythematosus, rheumatoid arthritis)
IgA vasculitis (Henoch-Schönlein purpura) and other vasculitic disorders
Granulomatous disease (granulomatosis with polyangiitis)
Celiac disease
Coagulopathy (congenital or acquired)
Malignancy
Immunodeficiency
Exogenous toxins, especially inhaled
Hyperammonemia
Pulmonary hypertension
Pulmonary alveolar proteinosis
Idiopathic pulmonary hemosiderosis
Tuberous sclerosis
Lymphangiomyomatosis or lymphangioleiomyomatosis
Physical injury or abuse
Catamenial
Vaping

See also Table 457.1.

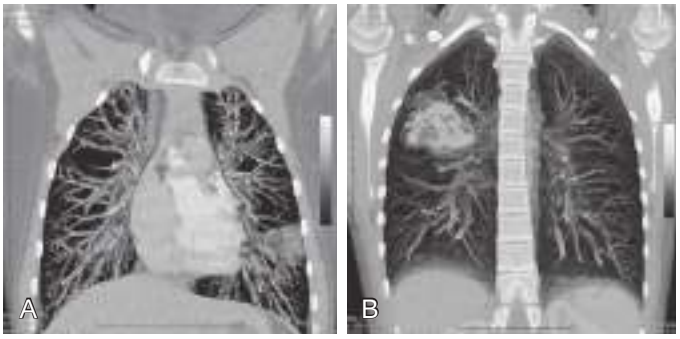

Fig. 458.2 A, Volume-rendering reconstruction of the contrast-enhanced spiral CT showing a large arteriovenous fistula in the left upper lobe (lingula). B, Volume-rendering reconstruction of the contrast-enhanced spiral CT showing an arteriovenous fistula in the right upper lobe. *(From Grzela K, Krenke K, Kulus M. Pulmonary arteriovenous malformations: clinical and radiological presentation. J Pediatr. 2011;158:856, Figs. 1 and 2.)*

Syndromes associated with vasculitic, autoimmune, and idiopathic disorders may be associated with diffuse alveolar hemorrhage (see Chapter 457).

EPIDEMIOLOGY

The frequency with which pulmonary hemorrhage occurs in the pediatric population is difficult to define. The difficulties in timely diagnosis are primarily related to the variability in disease presentation. As such, the incidence of pulmonary hemorrhage may be significantly underestimated. Chronic bronchiectasis as seen in CF (see Chapter 454) or ciliary dyskinesia (see Chapter 455) can cause hemoptysis, but usually occurs in children older than 10 years of age.

PATHOPHYSIOLOGY

The vascular supply of the lung has two components. The pulmonary artery provides blood to the bronchi to the level of the terminal bronchioles and to the alveolar capillary bed. The pulmonary circulation is characterized by low pressure and high volume. Conversely, the bronchial circulation originates from the aorta or intercostal arteries. The pressure in the bronchial artery circulation is systemic. This circulation provides blood the conducting airways. Hemoptysis may occur from either the pulmonary or bronchial circulation. Bleeding from the pulmonary circulation is expected to be insidious; slow bleeding in the lower airways typically manifests with anemia, fatigue, and dyspnea, and hemoptysis may be absent. Syndromes associated with diffuse alveolar hemorrhage are discussed in Chapter 457. Bleeding from the bronchial circulation may be massive and associated with rapid exsanguination. Blood that comes from the lung is frequently difficult to differentiate from blood that originates at the nasopharynx, mouth, or gastrointestinal (GI) tract. The blood that originates from the airway is classically bright red or rust colored. Alveolar blood may have a frothy appearance. Blood originating from the GI tract is typically brownish in color. The pH of pulmonary blood is alkaline, whereas blood from the GI tract is expected to be acidic.

In patients with CF, chronic endobronchial infection, inflammation, mucus plugging, and thickening of the airway surface layer predispose to growth and dilation of the bronchial arteries. Blood in the airway is highly irritative and initiates an influx of neutrophils and inflammatory mediators that serve to exacerbate the already vibrant inflammatory response. As such, pulmonary hemorrhage may be recurrent in late-stage CF. Massive and life-threatening hemorrhage may occur. With repeated or chronic hemorrhage, pulmonary fibrosis can become a prominent pathologic finding.

CLINICAL MANIFESTATIONS

The presenting symptoms and signs of pulmonary hemorrhage are highly variable in the pediatric population. Older children and young adults experiencing focal hemorrhage may be able to localize the bleeding by a sensation of "warmth" or "bubbling" in the chest. This can occasionally aid the clinician in locating the area involved. Rapid and large-volume blood loss manifests as hypoxemic and hypercarbic respiratory failure and hypovolemic shock. Chronic, insidious blood loss may manifest as anemia, fatigue, dyspnea, or poor exercise tolerance. Severely anemic individuals may present with syncope. Radiographic infiltrates may be seen in a focal or diffuse distribution on chest radiograph. The presence of a cavitary lesion or radiopaque foreign body suggests tubercular or fungal infection and foreign body aspiration, respectively.

LABORATORY FINDINGS AND DIAGNOSIS

A patient with suspected hemorrhage should have a laboratory evaluation with complete blood count and coagulation studies. The complete blood count result may demonstrate a microcytic, hypochromic anemia but may be normal in acute blood loss. The diagnosis of pulmonary hemorrhage is best confirmed by bronchoscopy with direct visualization of bleeding and/or a bronchoalveolar lavage specimen that confirms the presence of **hemosiderin-laden macrophages** on Prussian blue staining. Within 48-72 hours of an episode of bleeding, alveolar macrophages convert the iron from erythrocytes into hemosiderin. It may take weeks to clear these hemosiderin-laden macrophages completely from the alveolar spaces, thereby allowing differentiation between acute and chronic hemorrhage.

Fig. 458.3 Radiographic appearance of acute idiopathic pulmonary hemorrhage in infancy. *(From Brown CM, Redd SC, Damon SA, Centers for Disease Control and Prevention. Acute idiopathic pulmonary hemorrhage among infants: recommendations from the Working Group for Investigation and Surveillance. MMWR Recomm Rep. 2004;53:1–12.)*

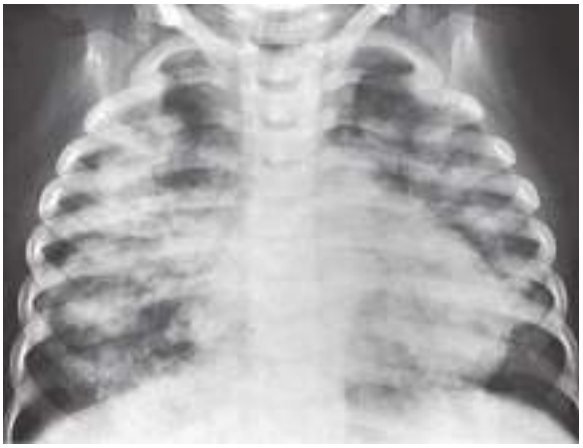

Fig. 458.4 Diffuse pulmonary hemorrhage that was thought to be the result of idiopathic pulmonary hemosiderosis in a 3-yr-old child. Frontal radiograph reveals bilateral air space consolidation that is patchy. Tracheal washing contained large numbers of macrophages filled with hemosiderin. Ten days later, most of the consolidative changes in the lungs had cleared. The patient's anemia was successfully treated with blood transfusion. *(Courtesy Bertram Girdany, MD, Pittsburgh, PA; from Slovis T, ed. Caffey's Pediatric Diagnostic Imaging, 11th ed. Philadelphia: Mosby; 2008.)*

Chest radiographs may demonstrate fluffy bilateral densities, as seen in acute idiopathic pulmonary hemorrhage of infancy (Fig. 458.3) or the patchy consolidation seen in idiopathic pulmonary hemosiderosis (Fig. 458.4). Alveolar infiltrates seen on chest radiograph may be regarded as a representation of recent bleeding, but their absence does not rule out the occurrence of pulmonary hemorrhage. Infiltrates, when present, are often symmetric and diffuse and may be preferentially located in the perihilar regions and lower lobes. The costophrenic angles and lung apices are frequently spared. CT may be indicated to assess for underlying disease processes.

Lung biopsy is rarely necessary unless bleeding is chronic or an etiology cannot be determined with other methods. Pulmonary function testing, including a determination of gas exchange, is important to assess the severity of the ventilatory defect. In older children, spirometry may demonstrate evidence of predominantly obstructive disease in the acute

period. Restrictive disease secondary to fibrosis is typically seen with more chronic disease. Diffusion capacity of carbon monoxide measurements are typically elevated in the setting of pulmonary hemorrhage because of the strong affinity of the intraalveolar hemoglobin for carbon monoxide.

TREATMENT

In mild to moderate hemoptysis (>5 mL blood), potential irritants to the lung (hypertonic saline, DNase, chest physiotherapy, and inhaled antibiotics) are typically held. In patients with CF, vitamin K may be given empirically, given a predilection toward vitamin K deficiency with comorbid pancreatic insufficiency.

In the setting of massive hemorrhage (>240 mL), emergent circulatory and ventilatory support is provided and a requirement for volume resuscitation and transfusion of blood products should be anticipated. If respiratory failure ensues, mechanical ventilatory support with high positive end-expiratory pressure (PEEP) may tamponade a bleeding vessel and improve oxygenation. If bleeding is unilateral, selective ventilation of the unaffected lung may be recommended. Rigid bronchoscopy may be used for localization of bleeding and for removal of debris, but active bleeding may be exacerbated by airway manipulation. In patients with CF who are unstable with massive hemorrhage, proceeding directly to bronchial artery embolization (BAE) has been advocated. Improved outcomes of BAE have been seen when the bleeding vessel is identified by multidetector CT imaging. Cessation of bleeding is achieved in approximately 80% of patients, but bleeding may be recurrent, and more than one BAE may be required. Rare complications include inadvertent embolization of spinal and mesenteric arteries, leading to paralysis and ischemic bowel, respectively. If embolization fails, total or partial lobectomy may be required.

Antifibrinolytic therapy with tranexamic acid (TXA) has been used to control bleeding in patients with hemophilia and in patients with CF, as well as in other conditions (bronchiectasis, tuberculosis, allergic bronchopulmonary aspergillosis). This medication may be administered by inhaled, oral, or parenteral routes. Inhaled TXA may be as effective as intravenous dosing; the inhaled route has fewer systemic effects. The use of this medication is currently off label.

Depending on institutional capabilities, extracorporeal membrane oxygenation (ECMO) and emergent listing for lung transplantation may also be considered for patients with end-stage disease.

Visit Elsevier eBooks+ at eBooks.Health.Elsevier.com for Bibliography.

Chapter 459

Atelectasis

Ranna A. Rozenfeld

Atelectasis is the incomplete expansion or complete collapse of air-bearing tissue, resulting from obstruction of air intake into the alveolar sacs. Segmental, lobar, or whole lung collapse is associated with the absorption of air contained in the alveoli, which are no longer ventilated.

PATHOPHYSIOLOGY

The causes of atelectasis can be divided into five groups (Table 459.1). Respiratory syncytial virus (see Chapter 307) and other viral infections, including influenza viruses in young children, can cause multiple areas of atelectasis. Mucous plugs are a common predisposing factor to atelectasis. Massive collapse of one or both lungs is most often a postoperative complication but occasionally results from other causes, such as trauma, asthma, pneumonia, tension pneumothorax (see Chapter 461), aspiration of foreign material (see Chapters 435 and 446), paralysis, or after extubation. Massive atelectasis is usually produced by a combination of factors, including immobilization or decreased use of the diaphragm and the respiratory muscles, obstruction of the bronchial tree, and abolition of the cough reflex.

Table 459.1 Anatomic Causes of Atelectasis

CAUSE	CLINICAL EXAMPLES
External compression on the pulmonary parenchyma	Pleural effusion, pneumothorax, intrathoracic tumors, diaphragmatic hernia
Endobronchial obstruction completely obstructing the ingress of air	Enlarged lymph node, tumor, cardiac enlargement, foreign body, mucoid plug, broncholithiasis
Intraluminal obstruction of a bronchus	Foreign body, asthma, granulomatous tissue, tumor, secretions including mucous plugs, bronchiectasis, pulmonary abscess, chronic bronchitis, acute laryngotracheobronchitis, plastic bronchitis
Intrabronchiolar obstruction	Bronchiolitis, interstitial pneumonitis, asthma
Respiratory compromise or paralysis	Neuromuscular abnormalities, osseous deformities, overly restrictive casts and surgical dressings, defective movement of the diaphragm, or restriction of respiratory effort

CLINICAL MANIFESTATIONS

Symptoms vary with the cause and extent of the atelectasis. A small area is likely to be asymptomatic. When a large area of previously normal lung becomes atelectatic, especially when it does so suddenly, dyspnea accompanied by rapid shallow respiration, tachycardia, cough, and often cyanosis occurs. If the obstruction is removed, the symptoms disappear rapidly. Although it was once believed that atelectasis alone can cause fever, studies have shown no association between atelectasis and fever. Physical findings include limitation of chest excursion, decreased breath sound intensity, and coarse crackles. Breath sounds are decreased or absent over extensive atelectatic areas.

Massive atelectasis usually presents with dyspnea, cyanosis, and tachycardia. An affected child is extremely anxious and, if old enough, complains of chest pain. The chest appears flat on the affected side, where decreased respiratory excursion, dullness to percussion, and feeble or absent breath sounds are also noted. Postoperative atelectasis usually manifests within 24 hours of operation but may not occur for several days.

Acute lobar collapse is a frequent occurrence in patients receiving intensive care. If undetected, it can lead to impaired gas exchange, secondary infection, and subsequent pulmonary fibrosis. Initially, hypoxemia may result from ventilation-perfusion mismatch. In contrast to atelectasis in adult patients, in whom the lower lobes and, in particular, the left lower lobe is most often involved, 90% of cases in children involve the upper lobes and 63% involve the right upper lobe. There is also a high incidence of upper lobe atelectasis and, especially, right upper lobe collapse in patients with atelectasis being treated in neonatal intensive care units. This high incidence may be a result of the movement of the endotracheal tube into the right mainstem bronchus, where it obstructs or causes inflammation of the bronchus to the right upper lobe.

DIAGNOSIS

The diagnosis of atelectasis can usually be established by chest radiograph. Typical findings include volume loss and displacement of fissures. Atypical presentations include atelectasis manifesting as a masslike opacity and atelectasis in an unusual location. Lobar atelectasis may be associated with pneumothorax. Several studies have shown

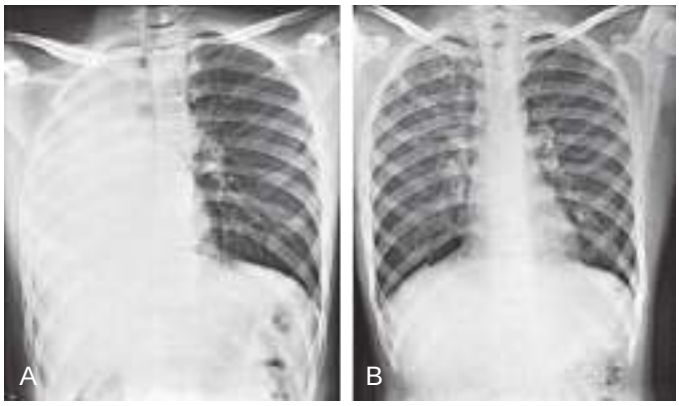

Fig. 459.1 A, Massive atelectasis of the right lung. The patient has asthma. The heart and other mediastinal structures shift to the right during the atelectatic phase. B, Comparison study after reaeration subsequent to bronchoscopic removal of a mucous plug from the right mainstem bronchus.

lung ultrasound to be a viable alternative to chest radiograph when diagnosing atelectasis, especially in patients with neuromuscular disease, to avoid radiation exposure.

In children with asthma, chest radiography demonstrates an abnormality rate of 44%, compared with a thorax high-resolution CT scan abnormality rate of 75%. Children with asthma and atelectasis have an increased incidence of right middle lobe syndrome, acute asthma exacerbations, pneumonia, and upper airway infections.

In foreign-body aspiration, atelectasis is one of the most common radiographic findings. The site of atelectasis usually indicates the site of the foreign body (see Chapter 426.1). Atelectasis is more common when diagnosis of foreign-body aspiration is delayed for greater than 2 weeks. Bronchoscopic examination reveals a collapsed main bronchus when the obstruction is at the tracheobronchial junction and may also disclose the nature of the obstruction.

Massive atelectasis is typically diagnosed on chest radiograph. Typical findings include elevation of the diaphragm, narrowing of the intercostal spaces, and displacement of the mediastinal structures and heart toward the affected side (Fig. 459.1).

TREATMENT

Treatment depends on the cause of the collapse (Table 459.2). If effusion or pneumothorax is responsible, the external compression must first be removed. Often vigorous efforts at cough, deep breathing, and percussion will facilitate expansion. Aspiration with sterile tracheal catheters may facilitate removal of mucous plugs. Continuous positive airway pressure may improve atelectasis.

Bronchoscopic examination is immediately indicated if atelectasis is the result of a foreign body or any other bronchial obstruction that can be relieved. For bilateral atelectasis, bronchoscopic aspiration should also be performed immediately. It is also indicated when an isolated area of atelectasis persists for several weeks. If no anatomic basis for atelectasis is found and no material can be obtained by suctioning, the introduction of a small amount of saline followed by suctioning allows recovery of bronchial secretions for culture and, possibly, for cytologic examination. Frequent changes in the child's position, deep breathing, and chest physiotherapy may be beneficial. Intrapulmonary percussive ventilation is a chest physiotherapy technique that is safe and effective. Oxygen therapy is indicated when there is dyspnea or desaturation. Intermittent positive pressure breathing and incentive spirometry are recommended when atelectasis does not improve after chest physiotherapy.

In some conditions, such as asthma, bronchodilator and corticosteroid treatment may accelerate atelectasis clearance. Recombinant human deoxyribonuclease, which is approved only for the treatment of cystic fibrosis, has been used off-label for patients without cystic fibrosis who have persistent atelectasis. This product reduces the viscosity of purulent bronchial debris. In patients with acute severe asthma, diffuse airway plugging with thick viscous secretions frequently occurs, with the resulting atelectasis often refractory to conventional therapy. Recombinant human deoxyribonuclease is used in the nebulized form for nonintubated patients with acute asthma and intratracheally for atelectasis in intubated asthmatics, with resolution of atelectasis unresponsive to conventional asthma therapies. Recombinant human deoxyribonuclease is also used in ventilated infants and children with atelectasis not caused by asthma.

Table 459.2 Treatment for Atelectasis

CAUSE OF ATELECTASIS	TREATMENT
Pleural effusion or pneumothorax	Relieve compression
Mucous plug	Tracheal or bronchoscopic aspiration Continuous positive airway pressure
Foreign body	Bronchoscopic examination
Asthma	Bronchodilator and corticosteroid treatment Recombinant human deoxyribonuclease (off-label use) Hypertonic saline with or without bronchodilator
Neuromuscular diseases	Intermittent positive pressure breathing Mechanical insufflator-exsufflator Noninvasive bilevel positive pressure ventilation
Cystic fibrosis	Airway clearance therapies Hypertonic saline with or without bronchodilator Recombinant human deoxyribonuclease

Hypertonic saline solution increases mucociliary clearance in patients with asthma, bronchiectasis, and cystic fibrosis and infants with acute bronchiolitis. It is delivered via nebulization either via face mask or endotracheal tube. It can be delivered alone or in combination with a bronchodilator. This therapy is being used in the outpatient and inpatient setting and in both the neonatal intensive care unit and the pediatric intensive care unit to help facilitate airway clearance, though studies of its use in bronchiolitis have had mixed results (see Chapter 439.1). Lobar atelectasis in cystic fibrosis is discussed in Chapter 454.

Atelectasis can occur in patients with neuromuscular diseases. These patients tend to have an ineffective cough and difficulty expelling respiratory tract secretions, which lead to pneumonia and atelectasis. Several devices and treatments are available to assist these patients, including intermittent positive-pressure breathing, a mechanical insufflator-exsufflator, and noninvasive bilevel positive-pressure ventilation via nasal mask or full-face mask. Patients with neuromuscular disease who have undergone surgery are at substantial risk for postoperative atelectasis and subsequent pneumonia. Migrating atelectasis in the newborn infant, a rare and unique presentation, may be secondary to neuromuscular disease.

There is an association between the development of lobar collapse and the requirement for mechanical ventilation. Although lobar collapse is rarely a cause of long-term morbidity, its occurrence may necessitate the prolongation of mechanical ventilation or reintubation. In ventilated patients, positive-end expiratory pressure or continuous positive airway pressure is generally indicated.

Airway clearance therapies used for adults are often recommended and/or used in pediatric populations. However, given the differences in respiratory physiology and anatomy between children and adults, practices applicable to one may or may not apply to the other. Atelectasis caused by cystic fibrosis is the only pediatric entity that clearly benefits from airway clearance therapy, although atelectasis caused by neuromuscular disease, cerebral palsy, or mechanical ventilation probably benefits from such therapy. Thus far, no specific airway clearance therapy has been demonstrated to be superior.

Visit Elsevier eBooks+ at eBooks.Health.Elsevier.com for Bibliography.

Chapter 460

Pulmonary Tumors

John Palla and Susanna A. McColley

See also Chapter 438.

Primary tumors of the lung are rare in children and adolescents (Table 460.1). An accurate estimate of frequency is currently not possible because the literature is composed of case reports and case series. A high incidence of "inflammatory pseudotumors" further clouds the statistics. Bronchial adenomas (including bronchial carcinoid, adenoid cystic carcinoma, and mucoepidermoid carcinomas) are the most common primary malignant tumors; bronchial carcinoid tumors represent ~80%. Pediatric carcinoid tumors are predominantly low-grade malignancies, but children with these tumors should be evaluated and monitored by a pediatric oncologist. Carcinoid syndrome from a bronchial carcinoid tumor is rare in children. Metastatic lesions are the most common forms of pulmonary malignancy in children; primary processes include Wilms tumor, osteogenic sarcoma, germ cell tumors, and hepatoblastoma (see Part XX, Cancer and Benign Tumors). Adenocarcinoma and undifferentiated histology are the most common pathologic findings in primary lung cancer; pulmonary blastoma is rarer and frequently occurs in the setting of a primary cystic lesion or is associated with a congenital pulmonary airway malformation (see Chapter 444.3). Lymphoma is the most common cause of mediastinal mass in children; other mediastinal tumors include thymoma, thyroid cancer, and teratoma. Neuroblastoma may present as a posterior mediastinal mass.

Table 460.1 Pulmonary Tumors in Children

MALIGNANT
Bronchial adenomas (40–60%)
Carcinoid
Mucoepidermoid carcinoma
Adenoid cystic carcinoma
Pleuropulmonary blastoma (15%)
Bronchogenic carcinoma (10–15%)
Adenocarcinoma
Small-cell carcinoma
Bronchoalveolar carcinoma
Squamous-cell carcinoma
Undifferentiated carcinoma
Fetal-lung adenocarcinoma
Pulmonary mesothelioma
Sarcomas (20–25%)
Rhabdomyosarcoma
Synovial sarcoma
Hemangiopericytoma (solitary fibrous tumor)
Leiomyosarcoma
Angiosarcoma
Bronchopulmonary fibrosarcoma
BENIGN
Hamartomas
Hemangiomas
Lymphangioma
Leiomyomas
Myofibroblastic tumors
Inflammatory myofibroblastic tumor
Myofibromatosis
Congenital peribronchial myofibroblastic tumor
Neurogenic tumors
Mature teratoma

From Goldberg JM, Pappo AS, Bishop M. Rare tumors of childhood. In Orkin SH, Fisher DE, Ginsburg D, et al., eds. *Nathan and Oski's Hematology and Oncology of Infancy and Childhood*, 8th ed. Philadelphia: Elsevier; 2015: Table 65.4, p. 2130.

CLINICAL MANIFESTATIONS AND EVALUATION

There is often a delay in the diagnosis of pediatric pulmonary tumors given their rarity and nonspecific presenting symptoms. Pulmonary tumors may manifest as fever, hemoptysis, wheezing, cough, pleural effusion, chest pain, dyspnea, recurrent or persistent pneumonia, and/or atelectasis. Localized wheezing, and wheezing unresponsive to bronchodilators, can occur with bronchial tumors. Tumors may be suspected from plain chest radiographs; however, CT or MRI imaging of the chest is necessary for precise anatomic definition (Table 460.2; Figs. 460.1 and 460.2). Depending on the

Table 460.2 Imaging Characteristics of Primary Malignant Lung Tumors

NEOPLASM	IMAGING CHARACTERISTICS
Inflammatory myofibroblastic tumor (IMT)	Solitary (95%) or multiple (5%) Usually sharply circumscribed, lobulated mass Typically located in the peripheral portion of the lungs Soft tissue mass with either homogeneous or heterogeneous attenuation may have both solid and cystic and calcific components
Carcinoid or salivary gland tumor	Centrally located lesion: intraluminal soft tissue mass with distal atelectasis or obstructive pneumonitis Peripherally located lesion: oval or lobulated intraluminal or exophytic mass and occasionally calcify
Bronchogenic carcinoma	Central mass lesion with bronchial obstruction or, less commonly, small peripheral lesion
Pleuropulmonary blastoma	Cystic or mixed cystic and solid lesion adjacent to pleura; can be very large, with mediastinal displacement
Epithelioid hemangioendothelioma	Multiple well- or ill-defined nodular opacities up to 3 cm in diameter; very rare in childhood

From Chu WCW, Epelman M, Lee EY. Neoplasia. In Coley BD, ed. *Caffey's Pediatric Diagnostic Imaging*, 13th ed. Philadelphia: Elsevier; 2019: Table 55.3, p. 531.

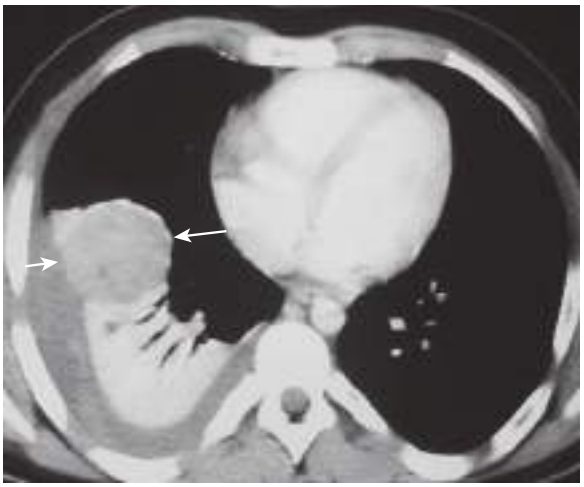

Fig. 460.1 Inflammatory myofibroblastic tumor. An afebrile 13-yr-old male who presented with increasing dyspnea and right-sided pleuritic chest pain. Axial contrast-enhanced CT of the chest shows a rounded heterogeneously enhancing lesion *(arrows)* located adjacent to an area of atelectatic lung. Pleural fluid at the same level demonstrates increased attenuation consistent with a hemothorax. *(Modified from Chu WCW, Epelman M, Lee EY. Neoplasia. In Coley BD, ed. Caffey's Pediatric Diagnostic Imaging, 13th ed. Philadelphia: Elsevier; 2019: Fig. 55.8A, p. 531.)*

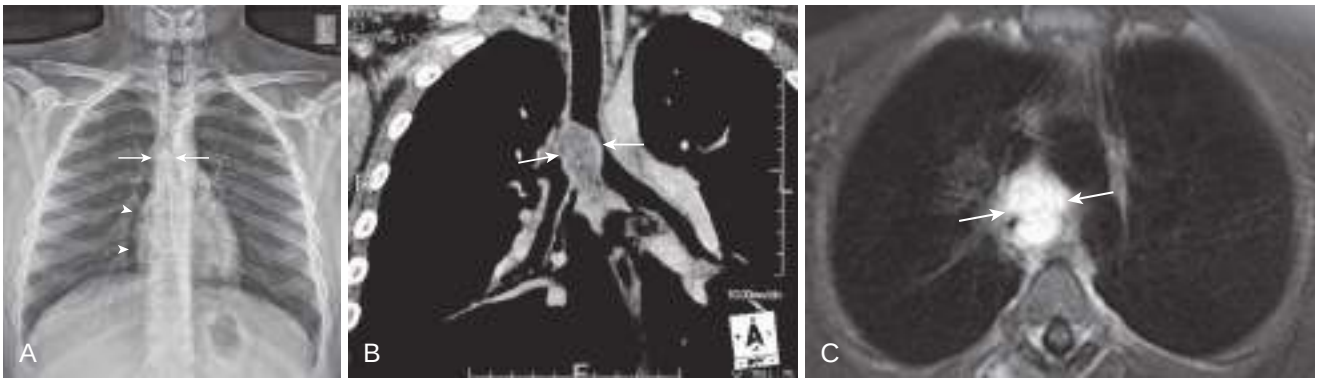

Fig. 460.2 Adenoid cystic carcinoma. A 14-yr-old male with a progressively worsening chronic cough and respiratory difficulty for 1 yr who presented with hoarseness and crepitus over the neck. **A,** Chest radiograph shows pneumomediastinum *(arrowheads)* and an apparent soft tissue density projecting over the carina *(arrows)*. **B,** Coronal contrast-enhanced CT image shows a lobulated soft tissue mass *(arrows)* centered near the carina, which results in the narrowing of the adjacent airway. **C,** Axial contrast-enhanced T1-weighted MRI demonstrates avid enhancement of the mass *(arrows)*. *(From Chu WCW, Epelman M, Lee EY. Neoplasia. In Coley BD, ed. Caffey's Pediatric Diagnostic Imaging, 13th ed. Philadelphia: Elsevier; 2019. Fig. 55.11: p. 532.)*

tumor size and location, pulmonary function tests may be normal or may show an obstructive, restrictive, or mixed pattern; there is no responsiveness to bronchodilators. Bronchial tumors are occasionally diagnosed during fiberoptic bronchoscopy performed for persistent or recurrent pulmonary infiltrates or hemoptysis (see Chapter 438).

Patients with symptoms or with radiographic or other laboratory findings suggesting pulmonary malignancy should be evaluated carefully for a tumor at another site before surgical excision is carried out. Isolated primary lesions and isolated metastatic lesions discovered long after the primary tumor has been removed are best treated by excision. The prognosis varies and depends on the type of tumor involved; outcomes for inflammatory pseudotumors and primary pulmonary carcinoid tumors treated with resection are good.

Visit Elsevier eBooks+ at eBooks.Health.Elsevier.com for Bibliography.

Chapter **461**

Pneumothorax

Suraiya K. Haider and Aarthi P. Vemana

Pneumothorax is the accumulation of extrapulmonary air within the chest, most commonly from leakage of air from within the lung. Air leaks can occur spontaneously and be classified as primary or secondary, or occur due to trauma or an iatrogenic cause (Table 461.1). Pneumothorax in the neonatal period is also discussed in Chapter 132.

ETIOLOGY AND EPIDEMIOLOGY

A **primary spontaneous pneumothorax** occurs without trauma or obvious underlying lung disease. Spontaneous pneumothorax with or without exertion occurs occasionally in teenagers and young adults, most frequently in males who are tall and thin and thought to have subpleural blebs. Smoking cigarettes, marijuana, crack cocaine, e-cigarette vaping, and ecstasy/MDMA (methylenedioxymethamphetamine) have been associated with developing a pneumothorax.

A pneumothorax arising as a complication of an underlying lung disorder but without trauma is a **secondary spontaneous pneumothorax.** Familial cases of spontaneous pneumothorax occur and have been associated with pathogenic variants in the folliculin gene *(FCLN)*. Over 150 unique *FCLN* variants have been associated with the **Birt-Hogg-Dube syndrome** (skin fibrofolliculomas, multiple basal lung cysts, renal malignancies) or in patients with familial or recurrent spontaneous pneumothoraces. Individuals with other inherited disorders, such as α_1-antitrypsin (see Chapter 442) and homocystinuria, are also predisposed to pneumothorax. Patients with collagen synthesis defects such as vascular Ehlers-Danlos syndrome (see Chapter 700) and Marfan syndrome (see Chapter 743) are at increased risk for the development of pneumothorax.

Pneumothorax can occur in pneumonia, usually with empyema; it can also be secondary to a pulmonary abscess, gangrene, infarct, rupture of a cyst or an emphysematous bleb (in asthma), or foreign bodies in the lung. In infants with staphylococcal pneumonia, the incidence of pneumothorax is relatively high. It can be found in children hospitalized with asthma exacerbations and usually resolves without treatment. Pneumothorax is a serious complication of cystic fibrosis (see Chapter 454). Pneumothorax also occurs in patients with lymphoma or other malignancies and in graft-versus-host disease with bronchiolitis obliterans. Catamenial pneumothorax, an unusual condition that is related to menses, is associated with diaphragmatic defects and pleural blebs.

External chest or abdominal blunt or penetrating trauma can tear a bronchus or abdominal viscus, with leakage of air into the pleural space. Iatrogenic pneumothorax can complicate transthoracic needle aspiration, tracheotomy, subclavian line placement, thoracentesis, or transbronchial biopsy. It may occur during mechanical or noninvasive ventilation, high-flow nasal cannula therapy, acupuncture, and other diagnostic or therapeutic procedures.

Pneumothorax can be associated with a serous effusion (hydropneumothorax), a purulent effusion (pyopneumothorax), or blood (hemopneumothorax). Bilateral pneumothorax is rare after the neonatal period but has been reported after lung transplantation and with *Mycoplasma pneumoniae* infection and tuberculosis.

Table 461.1 Causes of Pneumothorax in Children

SPONTANEOUS
Primary Idiopathic (no underlying lung disease)
Spontaneous rupture of subpleural blebs
Drug use (smoking cigarettes, marijuana, crack cocaine, use of e-cigarettes)
Valsalva maneuver
Secondary (underlying lung disease)
Congenital lung disease
• Congenital pulmonary airway malformation
• Bronchogenic cysts
• Pulmonary hypoplasia
• Birt-Hogg-Dube syndrome
Conditions associated with increased intrathoracic pressure
• Asthma
• Bronchiolitis
• Cystic fibrosis
• Airway foreign body
Infection
• Tuberculosis
• *Pneumocystis jirovecii*
• Echinococcosis
• Pneumatocele
• Lung abscess
• Bronchopleural fistula
• COVID-19 infection
Lung disease
• Langerhans cell histiocytosis
• Tuberous sclerosis
• Marfan syndrome
• Vascular Ehlers-Danlos syndrome
• Pulmonary fibrosis
• Sarcoidosis
• Rheumatoid arthritis, scleroderma, ankylosing spondylitis
• Metastatic neoplasm—usually osteosarcoma (rare)
• Pulmonary blastoma
• Catamenial
TRAUMATIC
Noniatrogenic
Penetrating trauma
Blunt trauma
Iatrogenic
Thoracotomy
Thoracoscopy, thoracentesis
Tracheostomy
Tube or needle puncture
Mechanical ventilation
High-flow therapy (moved from noniatrogenic)

Adapted from Noppen M. Spontaneous pneumothorax: epidemiology, pathophysiology and cause. *Eur Respir Rev.* 2010;19(117):217–219, 2010. Tables 1 & 2, p. 218.

PATHOGENESIS

The tendency of the lung to collapse, or elastic recoil, is balanced in the normal resting state by the inherent tendency of the chest wall to expand outward, creating negative pressure in the intrapleural space. When air enters the pleural space, the lung collapses. Hypoxemia occurs because of alveolar hypoventilation, ventilation-perfusion mismatch, and intrapulmonary shunt. In simple pneumothorax, intrapleural pressure is atmospheric, and the lung collapses up to 30%. In **tension pneumothorax**, a continuing leak causes increasing positive pressure in the pleural space, with further compression of the lung, shift of mediastinal structures toward the contralateral side, and decreases in venous return and cardiac output causing hemodynamic instability.

CLINICAL MANIFESTATIONS

The onset of pneumothorax is usually abrupt, and the severity of symptoms depends on the extent of the lung collapse and the amount of preexisting lung disease. Pneumothorax may cause dyspnea, chest pain, and cyanosis. When it occurs in infancy, symptoms and physical signs may be difficult to recognize. Moderate pneumothorax may cause little displacement of the intrathoracic organs and few or no symptoms. The severity of pain usually does not directly reflect the extent of the collapse.

Usually, there is respiratory distress, with retractions; markedly decreased breath sounds; and a tympanitic percussion note over the involved hemithorax. The larynx, trachea, and heart may be shifted toward the unaffected side. When fluid is present, there is usually a sharply limited area of tympany above a level of flatness to percussion. The presence of bronchial breath sounds or, when fluid is present in the pleural cavity, of gurgling sounds synchronous with respirations suggests an open fistula connecting with air-containing tissues.

DIAGNOSIS AND DIFFERENTIAL DIAGNOSIS

The diagnosis of pneumothorax is usually established by radiographic examination (Figs. 461.1-461.6). The amount of air outside the lung varies with time. A radiograph that is taken early shows less lung collapse than one that was taken later if the leak continues. Expiratory views accentuate the contrast between lung markings and the clear area of the pneumothorax (see Fig. 461.1). Variations exist in the measurement techniques defining the size of a pneumothorax. A large pneumothorax is measured by The American College of Chest Physicians as ≥3 cm from the lung apex to the thoracic cupola, and by the British Thoracic Society as ≥2 cm from the lung margin to the chest wall at the level of the hilum (Table 461.2).

It may be difficult to determine whether a pneumothorax is under tension. Tension pneumothorax is present when there is a shift of mediastinal structures away from the side of the air leak. A shift may be absent in situations in which the other hemithorax resists the shift, such as in the case of bilateral pneumothorax. On occasion, the diagnosis of tension pneumothorax is made only based on evidence of circulatory compromise or on hearing a "hiss" of rapid exit of air under tension with the insertion of the thoracostomy tube. When the lungs are both stiff, such as in cystic fibrosis or respiratory distress syndrome, the unaffected lung may not collapse easily, and shift may not occur (see Fig. 461.3).

Pneumothorax must be differentiated from localized or generalized emphysema, an extensive emphysematous bleb, large pulmonary cavities or other cystic formations, diaphragmatic hernia, compensatory overexpansion with contralateral atelectasis, and gaseous distention of the stomach. In most cases, chest radiography or CT differentiates among these possibilities. In addition, CT may identify underlying pathology such as blebs (Fig. 461.7). Further evaluation to determine if a diaphragmatic hernia is present should include a barium swallow with a small amount of barium to demonstrate that it is not free air but is a portion of the gastrointestinal tract that is in the thoracic cavity (see Chapter 131). Ultrasound can also be used to establish the diagnosis.

TREATMENT

Therapy varies with the extent of the collapse and the nature and severity of the underlying disease. A small or even moderate-sized pneumothorax in an otherwise normal child may resolve without specific treatment, usually within 1 week. A small pneumothorax-complicating asthma may also resolve spontaneously. Administering 100% oxygen may hasten resolution, but patients with chronic hypoxemia should be monitored closely during the administration of supplemental oxygen. Pleural pain deserves analgesic treatment.

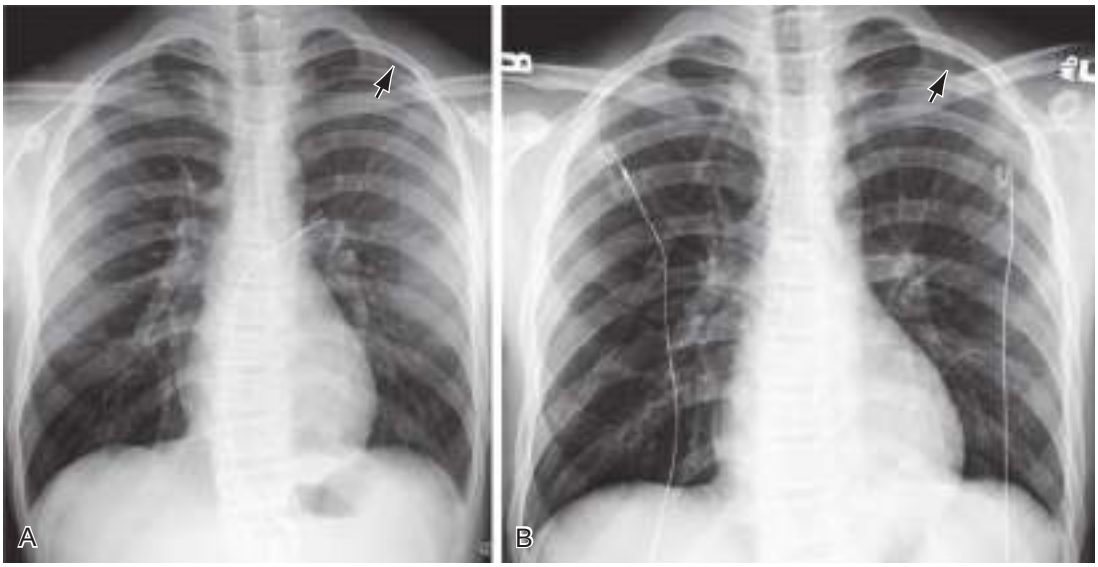

Fig. 461.1 Utility of an expiratory film in detection of a small pneumothorax. **A,** Teenager with stab wound and subtle radiolucency in the left apical region *(arrow)* on inspiratory chest radiograph. The margin of the visceral pleura is very faintly visible. **B,** On an expiratory film, the pneumothorax *(arrow)* is more obvious as the right lung has deflated and become more opaque, providing better contrast with the air in the pleural space.

Fig. 461.2 Right pneumothorax, with lung collapse of a compliant lung. Shift of the mediastinum to the left *(arrow)* indicates that this is a tension pneumothorax.

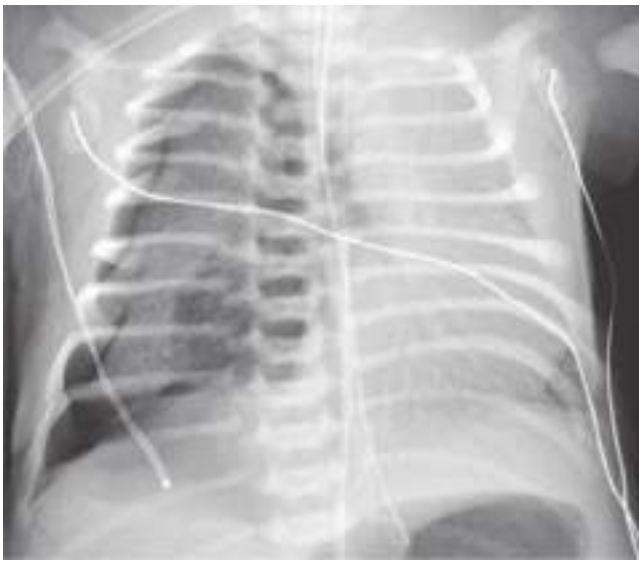

Fig. 461.3 Right pneumothorax, with only limited collapse of a poorly compliant lung.

Needle aspiration into the second intercostal space in the midclavicular line may be required on an emergency basis for tension pneumothorax and is as effective as tube thoracostomy in the emergency room management of primary spontaneous pneumothorax. If the pneumothorax is recurrent, secondary, or under tension, or there is more than a small collapse, catheter drainage or other invasive measures may be necessary. Pneumothorax in patients with cystic fibrosis or Marfan syndrome frequently recurs, and definitive treatment may be justified with the first episode. Similarly, if pneumothorax-complicating malignancy does not improve rapidly with observation, chemical pleurodesis or surgical thoracotomy is often necessary. In cases with severe air leaks or bronchopleural fistula, occlusion with an endobronchial balloon has been successful.

Closed thoracotomy (simple insertion of a chest tube) and drainage of the trapped air through a catheter, the external opening of which is kept in a dependent position under water, is adequate to reexpand the lung in most patients; pigtail catheters are frequently used. Consideration can be given to a sclerosing procedure to induce the formation of

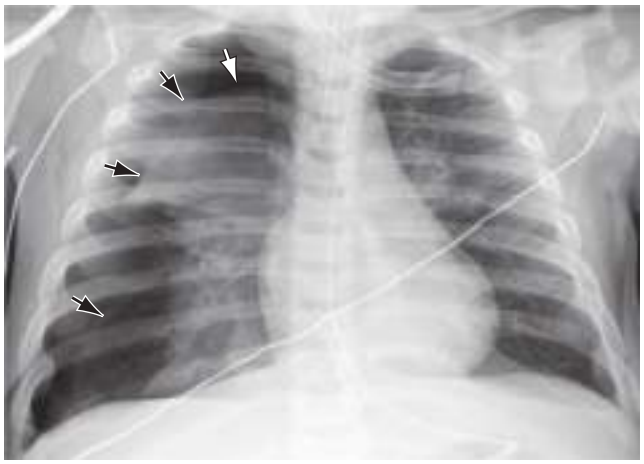

Fig. 461.4 Pneumothorax, with collapse of right lung *(arrows)*, caused by barotrauma in a 7-mo-old child who was intubated for respiratory failure.

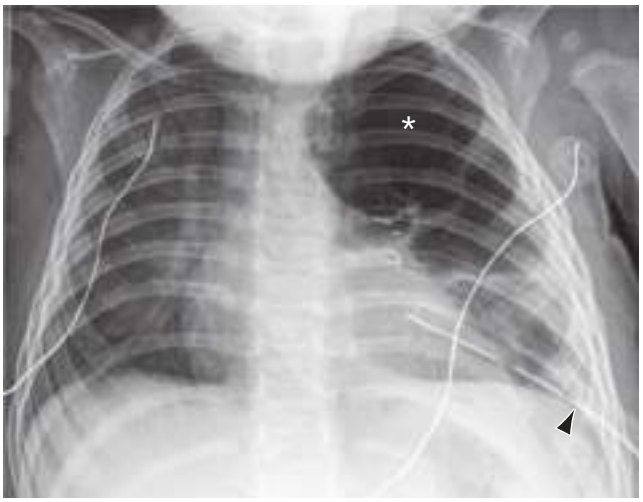

Fig. 461.6 Bronchopleural fistula following surgical resection of the left upper lobe as a result of congenital lobar emphysema. Chest radiograph shows localized pneumothorax *(asterisk)* that persisted despite prior insertion of a large-bore chest tube *(arrowhead)*.

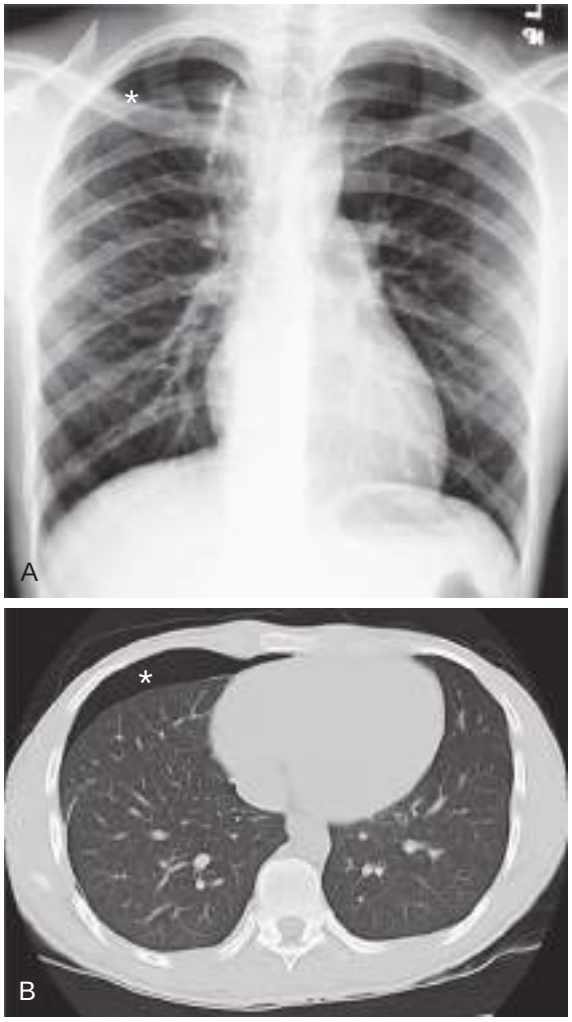

Fig. 461.5 Teenager in whom a spontaneous right pneumothorax developed because of a bleb. Patient had a persistent air leak despite recent surgical resection of the causative apical bleb. Chest radiograph (**A**) and CT scan (**B**) clearly show the persistent pneumothorax *(asterisk)*.

strong adhesions between the lung and chest wall with the introduction of doxycycline or iodopovidone into the pleural space (chemical pleurodesis).

Open thoracotomy through a limited incision, with plication of blebs, closure of the fistula, stripping of the pleura (usually in the apical lung, where the surgeon has direct vision), and basilar pleural abrasion is also an effective treatment for *recurrent* pneumothorax. Stripping and abrading the pleura leaves raw, inflamed surfaces that heal with sealing adhesions. Video-assisted thoracoscopic surgery (VATS) is a preferred therapy for blebectomy, pleural stripping, pleural brushing, and instillation of sclerosing agents, with less morbidity than occurs with traditional open thoracotomy. In cases with a persistent air leak following thoracic surgery, an autologous blood patch pleurodesis may also be considered.

There is a risk of recurrence after surgical treatment in the pediatric population, although this is often not related to surgical failure but rather associated with the formation of new or undetected bullae. Clear benefit for treatment of asymptomatic blebs/bullae in the contralateral lung has not been established in the pediatric population.

Pleural adhesions help prevent recurrent pneumothorax, but they also make subsequent thoracic surgery difficult. When lung transplantation may be a future consideration (e.g., in cystic fibrosis), steps should be taken to avoid, if at all possible, chemical or mechanical pleurodesis. It should also be kept in mind that the longer a chest tube is in place, the greater the chance of pulmonary deterioration, particularly in a patient with cystic fibrosis in whom strong coughing, deep breathing, and postural drainage are important. These are all difficult to accomplish with a chest tube in place.

Visit Elsevier eBooks+ at eBooks.Health.Elsevier.com for Bibliography.

Table 461.2 Summary of the Main Features of the BTS, Belgian, and ACCP Guidelines for Spontaneous Pneumothorax Management

	BTS	BELGIAN	ACCP
Definition of large pneumothorax	>2 cm between lung margin and chest wall (at level of the hilum)	≥20% using light index and/or complete dehiscence from lateral chest wall	≥3 cm apex-to-cupola distance
First line small PSP management	Observation if asymptomatic; aspiration if symptomatic	Observation if asymptomatic; aspiration if symptomatic	Observation for 3-6 hr and outpatient follow-up Aspirate or ICC if pneumothorax enlarges Presence of symptoms >24 hr does not alter treatment
First line large PSP management	Observation if asymptomatic; aspiration if symptomatic	Aspiration	Insertion of ICC
First line small SSP management	Admission and insertion of ICC; aspiration can be considered as an alternative	Admission and observation; aspiration if symptomatic	Admission and observation; insertion of ICC if symptomatic
First line large SSP management	Admission and insertion of ICC	Admission and insertion of ICC	Admission and insertion of ICC

BTS, British Thoracic Society; ACCP, American College of Chest Physicians; PSP, primary spontaneous pneumothorax; SSP, secondary spontaneous pneumothorax; ICC, intercostal chest catheter.
From Lieu N, Ngo P, Chennapragada SM, et al. Update in management of paediatric primary spontaneous pneumothorax. *Paediat Respir Rev.* 2022;41:73–79. Table 1.

Fig. 461.7 High-resolution CT thorax showing multiple basal cysts. *(From Hopkins TG, Maher ER, Reid E, et al. Recurrent pneumothorax. Lancet. 2011;377:1624. Fig. 1.)*

Chapter 462

Pneumomediastinum

Aarthi P. Vemana and Suraiya K. Haider

Air or gas in the mediastinum is called *pneumomediastinum* and is typically caused by alveolar rupture, which can be due to either a spontaneous or traumatic cause. A spontaneous pneumomediastinum can either be primary without an underlying etiology or can occur secondary to an underlying cause. *Primary* pneumomediastinum can be due to increases in intrathoracic pressure as is seen with a Valsalva maneuver, vomiting, Boerhaave syndrome (esophageal perforation), weightlifting, inhalation of recreational drugs, use of e-cigarettes, recreational use of MDMA, and choking events. Causes of *secondary* pneumomediastinum include lower respiratory tract infections including COVID-19, asthma exacerbations, mechanical ventilation, anorexia nervosa, normal menses, and diabetes mellitus with ketoacidosis. Traumatic causes of pneumomediastinum include both iatrogenic (dental extractions, adenotonsillectomy, high flow nasal cannula therapy, esophageal perforation, inhalation of helium gas, and flexible bronchoscopy) and noniatrogenic (inhaled foreign body and penetrating chest trauma).

PATHOGENESIS

According to the **Macklin effect**, after an intrapulmonary alveolar rupture, air dissects along the pressure gradient through the perivascular sheaths and other soft tissue planes toward the hilum and enters the mediastinum.

CLINICAL MANIFESTATIONS

Dyspnea and transient stabbing chest pain that may radiate to the neck are the principal features of pneumomediastinum. Other symptoms may be present and may include globus pharyngeus, abdominal pain, cough, chest tightness, facial swelling, choking, tachypnea, fever, stridor, and sore throat. Pneumomediastinum is difficult to detect by physical examination alone. Subcutaneous emphysema is present in the majority of patients. When present, **Hamman sign** (a mediastinal "crunch") is nearly pathognomonic for pneumomediastinum. Cardiac dullness to percussion may be decreased, but if the chest is chronically overinflated, it is unlikely that the clinician can be sure of this finding.

LABORATORY FINDINGS

Chest radiography reveals mediastinal air, with a more distinct cardiac border than normal (Figs. 462.1 and 462.2). A "spinnaker sail sign" or "angel wing sign" occurs when air deviates the thymus upward and outward, which is seen more often in pediatric patients. On the lateral projection, the posterior mediastinal structures are clearly defined, there may be a lucent ring ("ring sign") around the right pulmonary artery, and retrosternal air can usually be seen. Vertical streaks of air in the mediastinum and subcutaneous air are often observed (see Fig. 462.1). If a pneumomediastinum is clinically suspected but is not visualized on a chest x-ray, a chest CT can be performed to confirm the diagnosis and identify tracheal injury, if present.

TREATMENT

Treatment is directed primarily at the underlying obstructive pulmonary disease or other precipitating condition. Children who have had pneumomediastinum should be screened for asthma. Analgesics are occasionally needed for chest pain. Children can be observed in the emergency room and discharged if stable. They should be cautioned to avoid heavy lifting and the Valsalva maneuver. Hospital admission with supplemental oxygen administration is more common for patients with secondary pneumomediastinum. In severe cases, consideration should be given to

the use of more invasive interventions, including tracheotomy, surgical repair, and skin incisions over the neck and anterior chest wall. The use of prophylactic antibiotics to prevent deep neck space infections and mediastinitis has not been shown to provide additional benefit.

COMPLICATIONS

Pneumomediastinum is rarely a major problem in older children because the mediastinum can be depressurized by escape of air into the neck or abdomen. In the newborn, however, the rate at which air can leave the mediastinum is limited, and pneumomediastinum can lead to dangerous cardiovascular compromise or pneumothorax (see Chapters 132 and 461).

Visit Elsevier eBooks+ at eBooks.Health.Elsevier.com for Bibliography.

Fig. 462.1 Large pneumomediastinum surrounding the heart and dissecting into the neck. *(From Clark DA. Atlas of Neonatology, 7th ed. Philadelphia: WB Saunders; 2000.)*

Fig. 462.2 Sail sign—thymic elevation. *(From Clark DA. Atlas of Neonatology, 7th ed. Philadelphia: WB Saunders; 2000: p. 94.)*

Chapter 463

Hydrothorax

Aarthi P. Vemana and Suraiya K. Haider

Hydrothorax is a transudative pleural effusion; typically, it is caused by abnormal pressure gradients in the lung. Hydrothorax is most often associated with cardiac, renal, or hepatic disease. It can also be a manifestation of severe nutritional edema and hypoalbuminemia. Rarely, it results from superior vena cava obstruction by neoplasms, enlarged lymph nodes, pulmonary embolism, or adhesions. It may occur from a ventriculoperitoneal (VP) shunt, central venous catheter, peritoneal dialysis, or after corrective spinal fusion for treatment of adolescent idiopathic scoliosis.

CLINICAL MANIFESTATIONS

Hydrothorax is usually bilateral, but in cardiac or hepatic disease it can be limited to the right side or greater on the right than on the left side. The physical signs are the same as those described for serofibrinous pleurisy (see Chapter 451.2), but in hydrothorax there is more rapid shifting of the level of dullness with changes of position. Depending on the etiology, it can be associated with an accumulation of fluid in other parts of the body.

LABORATORY FINDINGS

The fluid is **transudative**, noninflammatory, has few cells, and has a lower specific gravity (<1.015) than that of a serofibrinous exudate (see Chapters 449 and 451). The ratio of pleural fluid to serum total protein is <0.5, the ratio of pleural fluid to serum lactic dehydrogenase is <0.6, and the pleural fluid lactic dehydrogenase value is less than 66% of the upper limit of the normal serum lactic dehydrogenase range. In a patient with a VP shunt, B-transferrin assays and radionuclide tracer shunt series may be helpful for diagnosis. Peritoneal scintigraphy may be considered to evaluate for a peritoneal-pleural leak. In hepatic hydrothorax, the pleural fluid resembles spontaneous bacterial peritonitis, with positive bacterial cultures and polymorphonuclear leukocyte counts >250 cell/mm^3.

TREATMENT

Therapy is directed at the underlying disorder. If a transudative fluid is clinically suspected, aspiration may not be needed unless pressure symptoms are noted or there are atypical symptoms, such as fever, pleuritic pain, or asymmetric effusions. Aspirated fluid may be diagnostic using PCR for bacteria and cytology and flow cytometry for malignancies.

Visit Elsevier eBooks+ at eBooks.Health.Elsevier.com Bibliography.

Chapter 464

Hemothorax

Suraiya K. Haider and Aarthi P. Vemana

Hemothorax, an accumulation of blood in the pleural cavity, is rare in children. Bleeding into the chest cavity most commonly occurs after chest trauma, either blunt or penetrating. It can be the result of iatrogenic trauma, including surgical procedures and venous line insertion. Hemothorax can also result from erosion of a blood vessel in association with inflammatory processes, such as tuberculosis

and empyema. It may complicate a variety of congenital anomalies, including sequestration, patent ductus arteriosus, and pulmonary arteriovenous malformation (see Fig. 458.2 in Chapter 458), or occur in association with vascular Ehlers-Danlos syndrome. It is also an occasional manifestation of intrathoracic neoplasms, costal exostoses, blood dyscrasias, bleeding diatheses, thrombolytic therapy, thoracic endometriosis, or rarely COVID-19 infections. Rupture of an aneurysm is unlikely during childhood. Hemothorax may occur spontaneously but is rare in children. A pleural hemorrhage associated with a pneumothorax is a *hemopneumothorax;* it is usually the result of a ruptured bulla with lung volume loss causing a torn pleural adhesion.

CLINICAL MANIFESTATIONS

In addition to the symptoms and signs of pleural effusion (see Chapter 451.2), hemothorax is associated with hemodynamic compromise related to the amount and rapidity of bleeding, with ventilatory collapse. Spontaneous hemothorax presents with sudden onset of chest or back pain or dyspnea and can progress rapidly to hemorrhagic shock.

DIAGNOSIS

The diagnosis of a hemothorax is initially suspected from radiographs, ultrasounds, or CT scans but can be made definitively with thoracentesis (Fig. 464.1). In every case, an effort must be made to determine and treat the cause.

TREATMENT

Therapy includes supplemental oxygen, fluid resuscitation (including possible blood transfusion), and tube thoracostomy. Video-assisted thorascopic surgery (VATS) can be considered in most patients with stable vital signs to visualize the source of bleeding, remove blood clots, resect bullae or blebs, and to perform pleurodesis. An open thoracotomy may be indicated if there is uncontrolled bleeding or in a hemodynamically compromised patient. Inadequate removal of blood in extensive hemothorax leading to a retained hemothorax can increase the risk for development of pneumonia, empyema, or substantial restrictive disease secondary to organization of fibrin. Fibrinolytic therapy or a decortication may then be necessary. Embolization is the treatment of choice for an arteriovenous malformation.

Visit Elsevier eBooks+ at eBooks.Health.Elsevier.com for Bibliography.

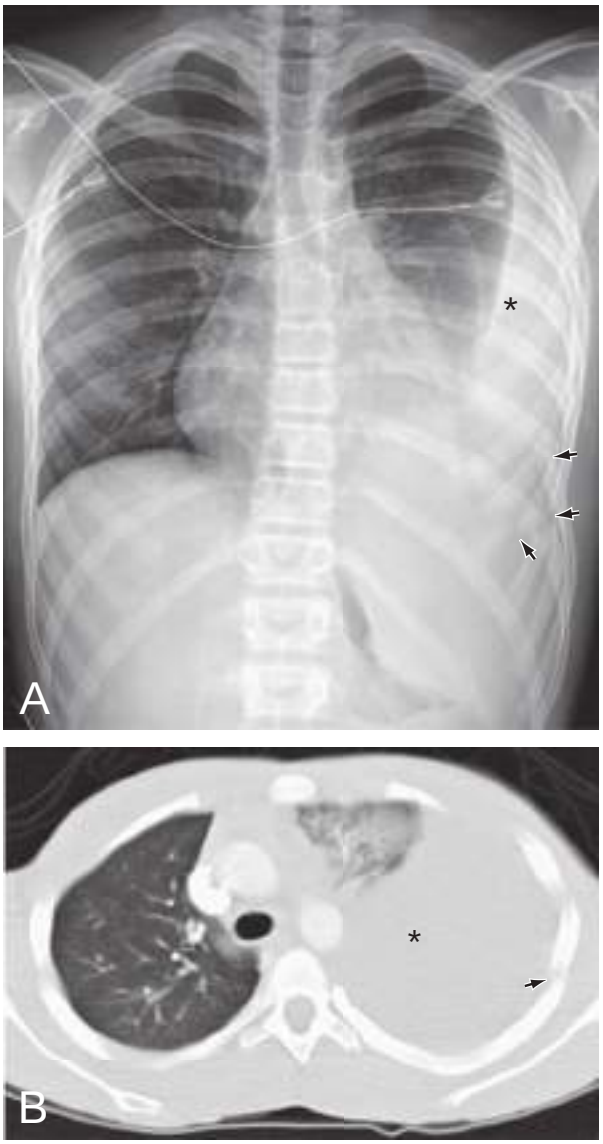

Fig. 464.1 Chest radiograph (A) and CT scan (B) of hemothorax *(asterisk)* and associated rib fractures *(arrows)* in a teenager involved in a motor vehicle accident.

Chapter 465

Chylothorax

Suraiya K. Haider and Aarthi P. Vemana

Chylothorax is a pleural collection of fluid formed by the escape of chyle from the thoracic duct or lymphatics into the thoracic cavity. Chylothorax in children occurs most frequently because of thoracic duct injury as a complication of cardiothoracic surgery (post Fontan surgery) (Fig. 465.1). Other cases are associated with chest injury (Fig. 465.2), extracorporeal membrane oxygenation, or primary or metastatic intrathoracic malignancy, particularly lymphoma. In newborns, rapidly increased venous pressure during delivery may lead to thoracic duct rupture. Chylothorax has also been associated with Down syndrome, Noonan syndrome, Turner syndrome, and congenital myotonic dystrophy. Genetic pathogenic variants involving the VEGFC/VEGFR3, PI3K/AKT/mTOR, and RAS/MAPK pathways can impact lymphangiogenesis leading to lymphatic malformations. Refractory chylothorax in the fetus has been associated with a missense variant in integrin $\alpha_9\beta_1$ gene. Persistent or recurrent chylothorax has been described in association with pathogenic variants in the *PIEZO1* gene. Less common causes include lymphangiomatosis (Fig. 465.3), restrictive pulmonary diseases, thrombosis of the duct, superior vena cava, or subclavian vein; tuberculosis or histoplasmosis, Gorham-Stout disease, and congenital anomalies of the lymphatic system (Fig. 465.4). Chylothorax can occur in trauma and child abuse (see Chapter 16). It is important to establish the etiology because treatment varies with the cause. In some patients, no specific cause is identified.

CLINICAL MANIFESTATIONS

The signs and symptoms of chylothorax are the same as those from pleural effusion of similar size, including cough, chest discomfort, and dyspnea. Chyle is not irritating, so pleuritic pain is uncommon. Onset is often gradual. However, after trauma to the thoracic duct, chyle may accumulate in the posterior mediastinum for days and then rupture into the pleural space with sudden onset of dyspnea, hypotension, and hypoxemia. Approximately 50% of newborns with chylothorax present with respiratory distress in the first day of life. Chylothorax is rarely bilateral and usually occurs on the right side.

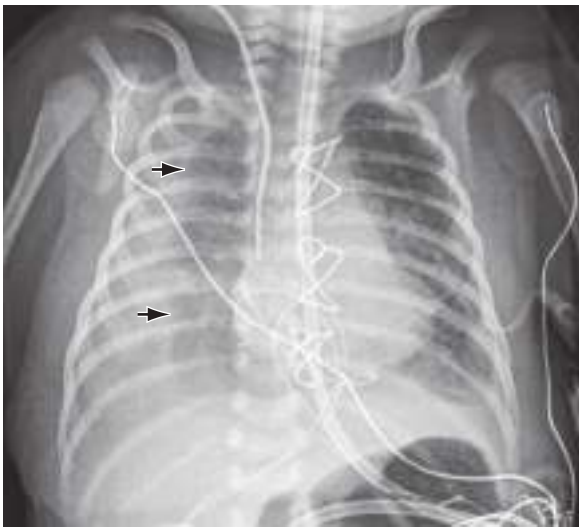

Fig. 465.1 Chylothorax *(arrows)* following cardiac surgery in a 2-wk-old infant.

Fig. 465.2 Left chylothorax *(arrows)* following spinal fusion with Harrington rods. It is postulated that the thoracic duct was injured during spine surgery. The pigtail chest tube *(arrowhead)* needed to be retracted to better drain the effusion.

LABORATORY FINDINGS AND IMAGING

Chest radiographs can help to delineate the location of an effusion; CT scans show normal pleural thickness and may demonstrate a mediastinal mass such as a lymphoma, as the etiology of the chylothorax. Thoracentesis demonstrates a chylous effusion, a milky fluid containing triglycerides, protein, lymphocytes, and other constituents of chyle; fluid may be yellow or bloody. In newborn infants or those who are not ingesting food, the fluid may be clear. A pseudochylous milky fluid may be present in chronic serous effusion, in which fatty material arises from degenerative changes in the fluid and not from lymph. In chylothorax, the fluid triglyceride level is >110 mg/dL, the pleural fluid:serum triglyceride ratio is >1.0, and pleural fluid:serum cholesterol ratio is <1.0; lipoprotein analysis reveals chylomicrons. Fluid immunoglobulin levels are elevated. The cells are primarily (>80%) lymphocytes and often exceed 1,000 cells per mm^3. After diagnosing chylothorax, a lymphangiogram can localize the site of the leak, and lymphoscintigraphy may

Fig. 465.3 Large right chylous effusion opacifying much of the right thorax in a teenager with pulmonary lymphangiomatosis and hemangiomatosis. Note the associated interstitial lung disease.

demonstrate abnormalities of the lymphatic trunks and peripheral lymphatics. MR lymphangiography also allows for visualization of the peripheral and segments of the central lymphatics. Dynamic contrast-enhanced magnetic resonance lymphangiography can provide real-time evaluation of the central lymphatic flow with good spatial resolution to guide management options.

TREATMENT

Treatment involves symptomatic support and decreasing or stopping chyle accumulation. Management is divided into two categories: nonsurgical and surgical. Nutritional management strategies include a combination of nil-per-os (NPO) and total parenteral nutrition, or enteral feeds using either a low-fat or medium-chain triglyceride diet or defatted human milk (also known as skimmed human milk). Thoracentesis is repeated as needed to relieve pressure symptoms; tube thoracostomy is often performed. Somatostatin and octreotide have been used to manage chylothorax. Various octreotide dosages have been described, including 1–4 μg/kg/hr intravenously and 10 μg/kg/day subcutaneously. Retrospective analyses have shown beneficial effects with the use of steroids, in particular, hydrocortisone, methylprednisolone, and dexamethasone combined with somatostatin or octreotide. Use of propranolol or sirolimus in severe or refractory cases may be effective. Further studies are required to confirm the optimal dosage for steroids, propranolol, and sirolimus. Other therapeutic approaches include pressure control ventilation with positive end-expiratory pressure and inhalation of nitric oxide. If medical management is unsuccessful, surgical options should be considered and can include a pleuroperitoneal shunt, thoracic duct ligation, and pleurodesis with the use of a sclerosing agents such as fibrin glue or povidone-iodine. Treatment is similar for traumatic chylothorax. Chemical pleurodesis or irradiation is used in malignant chylothorax. OK432 (picibanil) has been used to treat fetal and newborn chylothorax. Etilefrine, a sympathomimetic agent with both α- and β-adrenergic activity, has been successfully used in a few patients. Constriction of the thoracic duct by this drug may reduce pleural chyle accumulation. Percutaneous thoracic duct embolization or treatment of other lymphatic vessels is a successful interventional radiology strategy. Surgery should be considered earlier in neonates with massive chylothorax and chyle output of >50 mL/kg/day despite maximum medical therapy for 3 days.

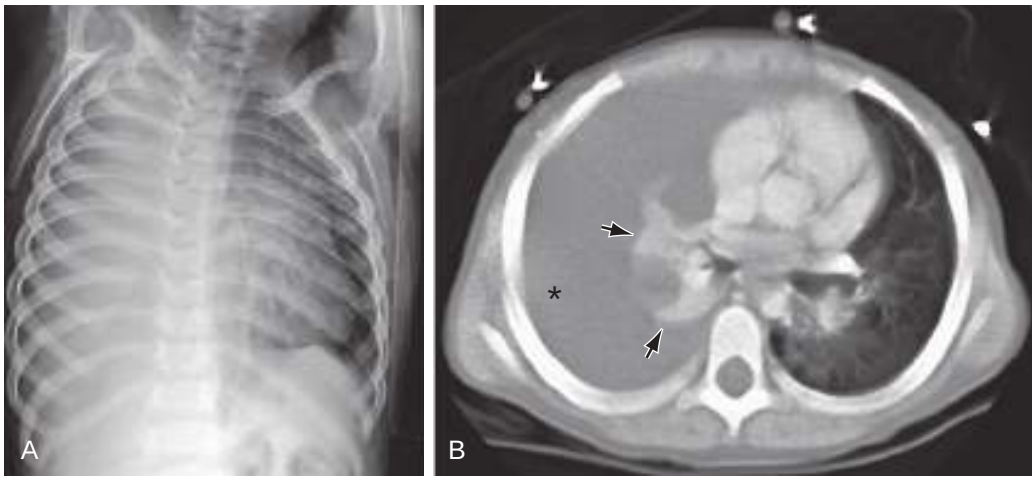

Fig. 465.4 Spontaneous chylothorax in a 4 yr old with a duplication of chromosome 6. **A,** Chest radiograph shows opacification of the right thorax. **B,** CT scan shows the chylous pleural effusion *(asterisk)* compressing the atelectatic right lung *(arrows)*.

COMPLICATIONS

If repeated thoracenteses are required due to the rapid reaccumulation of chyle, malnutrition may occur with significant loss of calories, protein, and electrolytes. Immunodeficiencies, including hypogammaglobulinemia and abnormal cell-mediated immune responses, have been associated with repeated and chronic thoracenteses for chylothorax. The loss of T lymphocytes is associated with increased risk of infection in neonates; otherwise, infection is uncommon, but patients should not receive live virus vaccines. Lack of resolution of chylothorax can lead to malnutrition, infection, and death.

Visit Elsevier eBooks+ at eBooks.Health.Elsevier.com for Bibliography.

Chapter 466

Bronchopulmonary Dysplasia

Sharon A. McGrath-Morrow and J. Michael Collaco

Bronchopulmonary dysplasia (BPD) is a chronic lung disease of infancy and childhood that occurs primarily in preterm infants born at less than 32 weeks' gestation. BPD is characterized by alveolar hypoplasia, often with concomitant small airway dysfunction and impaired pulmonary vascular growth. Contributing factors to the development of BPD may include early gestational age, low birthweight, lung barotrauma, exposure to hyperoxia, lung inflammation, and pre- and postnatal infections, as well as potential modifier genes and epigenetic factors. The currently accepted definition for diagnosis includes an oxygen requirement for 28 days postnatally, and the disorder is graded as mild, moderate, or severe based on supplemental oxygen and ventilation requirements at specific time points (Table 466.1). For initial inpatient presentation and management, see Chapter 127.

CLINICAL MANIFESTATIONS

Physical findings of the pulmonary exam vary with the severity of the disease and with respiratory illnesses. Although some patients may appear to be comfortably breathing when well, they can experience significant deterioration when ill or with periods of stress due to decreased pulmonary reserve secondary to alveolar hypoplasia and small airway disease. Children with BPD may exhibit tachypnea, head bobbing, and retractions when ill or at baseline depending on the severity of the disease. Although breath sounds may be clear, many patients have baseline wheeze or coarse crackles. A persistent, fixed wheeze or stridor suggests subglottic stenosis (see Chapter 436) or large airway malacia. Fine crackles may be present in patients prone to fluid overload. Chest radiographs may demonstrate air trapping, focal atelectasis, interstitial changes, and/or peribronchial thickening.

The most severely affected patients may require respiratory support to achieve adequate gas exchange. Supplemental oxygen may be required to maintain acceptable oxygen saturations and often is needed to minimize the work of breathing. Chronic respiratory insufficiency may be evidenced as elevation of serum bicarbonate, elevated carbon dioxide on blood gas analysis, hypoxemia, or polycythemia; the most severe cases may require tracheostomy and ventilation to achieve long-term respiratory stability. Patients must be monitored for the development of pulmonary hypertension, especially if they require supplemental oxygen and have chronic respiratory insufficiency.

Aspiration from dysphagia and/or gastroesophageal reflux (GERD) (see Chapter 369) can compromise pulmonary status. The risk of aspiration may increase during periods of illness due to worsening tachypnea and air trapping. Other comorbidities resulting from premature birth that complicate the management of BPD include fixed and functional upper airway obstruction, CNS injuries leading to abnormal control of breathing, abnormal airway tone, increased aspiration risk, gastrointestinal dysmotility, systemic hypertension, and poor growth. Of note, infants with significant lung disease can exhibit growth failure from the elevated energy expenditure essential to maintaining the increased metabolic demands of respiration and/or ongoing hypoxia.

A *pulmonary exacerbation* in a child with BPD is typically triggered during viral respiratory infections. Other frequent risk factors for pulmonary exacerbations may include weather changes, exposure to cigarette smoke, exposure to emissions from vaping devices, attending daycare, and aspiration. During an exacerbation, the infant may exhibit increased work of breathing, crackles, and wheezing, with tachypnea and retractions becoming more prominent. Underlying pulmonary hypertension may worsen with pulmonary exacerbations as well.

Table 466.1 Definition of Bronchopulmonary Dysplasia: Diagnostic Criteria

GESTATIONAL AGE	<32 WEEKS	≥32 WEEKS
Time point of assessment	36 weeks' PMA or discharge to home, whichever comes first	>28 days but <56 days' postnatal age or discharge to home, whichever comes first
TREATMENT WITH >21% OXYGEN FOR AT LEAST 28 DAYS PLUS		
Mild BPD	Breathing room air by 36 weeks' PMA or discharge, whichever comes first	Breathing room air by 56 days' postnatal age or discharge, whichever comes first
Moderate BPD	Need for <30% oxygen at 36 weeks' PMA or discharge, whichever comes first	Need for <30% oxygen at 56 days' postnatal age or discharge, whichever comes first
Severe BPD	Need for ≥30% oxygen and/or positive pressure (PPV or NCPAP) at 36 weeks' PMA or discharge, whichever comes first	Need for ≥30% oxygen and/or positive pressure (PPV or NCPAP) at 56 days' postnatal age or discharge, whichever comes first

BPD, Bronchopulmonary dysplasia; NCPAP, nasal continuous positive airway pressure; PMA, postmenstrual age; PPV, positive pressure ventilation.
Adapted from Jobe AH, Bancalari E. Bronchopulmonary dysplasia. *Am J Respir Crit Care Med.* 2001;163:1723.

TREATMENT

Treatment is directed toward decreasing the work of breathing and normalizing gas exchange to allow for optimal growth and neurodevelopment. After initial hospital discharge, infants and children with BPD are at high risk for rehospitalization. Up to 50% of infants with BPD are readmitted for acute respiratory illnesses within the first 2 years of life. These children also may require multiple daily medications, supplemental oxygen, and/or chronic ventilation.

Adherence to prescribed daily medication regimens may decrease the risk of acute care use and chronic respiratory symptoms; however, there are no standard guidelines for the management of BPD concerning post-NICU care. Although commonly used, there are limited data regarding the efficacy of diuretics in the outpatient setting.

With regard to respiratory support, targeted oxygen saturations should be ≥92% outside of the NICU to ensure adequate growth and neurocognitive development. Pulse-oximetry and polysomnography may be helpful for titration purposes. Before initial hospital discharge, infants and children who require chronic ventilatory support have been shown to benefit from standardized protocols to determine medical readiness, assess familial proficiency in respiratory care, and establish adequate support in an outpatient setting. After discharge, these patients will require close follow-up from pulmonologists and otolaryngologists to manage ventilator titration and weaning and tracheostomy care and decannulation, respectively. As infants and children with tracheostomies are at high risk for adverse events, including death, an awake and alert trained caregiver is recommended at all times.

Pulmonary function testing in children with a history of BPD has consistently demonstrated obstructive small airway disease. Small airway disease in this population may be partially responsive to bronchodilators but may also have a fixed obstructive component. Inhaled corticosteroids and β-agonists may be effective in treating symptoms, such as wheezing or chronic cough.

Adequate caloric intake is important to ensure catch-up lung growth. Some children may require fortified breast milk or formula to achieve adequate growth. Patients at risk for aspiration and those with inadequate oral intake may require tube feeding to meet nutritional goals. Placement of a gastrostomy tube should be considered before discharging home. Aspiration secondary to dysphagia and/or gastroesophageal reflux should be considered in patients with recurrent respiratory symptoms or pneumonia without obvious infectious etiologies. Because of their tenuous respiratory status, some infants and children with BPD may not be able to tolerate even minimal amounts of aspiration from gastroesophageal reflux. There are limited data regarding risks and benefits of antireflux medications in infants with BPD, such as histamine-2 blockers, proton pump inhibitors, and motility agents. Medications that reduce gastric acidity may increase the risk of pneumonia in some children. Consideration for either Nissen fundoplication or gastrojejunostomy tubes may be required in cases of failure of antireflux medical therapy.

Up to 15–25% of infants with severe BPD will be diagnosed with pulmonary hypertension, which may be secondary to decreased pulmonary vascular growth and/or a reactive vascular bed. Other risk factors for developing pulmonary hypertension may include extreme prematurity and decreased intrauterine growth; recurrent aspiration, hypoxia, and hypercarbia may worsen severity. Pulmonary hypertension in infants is associated with increased morbidity and mortality compared to infants without pulmonary hypertension. Although definitive diagnosis of pulmonary hypertension requires cardiac catheterization, in practice transthoracic echocardiography provides a low-risk screening tool. Screening should also attempt to identify potential structural causes of pulmonary hypertension, such as pulmonary vein stenosis. Serum biomarkers, such as brain natriuretic protein, may be useful in tracking response to therapy. Abrupt worsening of pulmonary hypertension *(pulmonary hypertensive crises)* can occur in the context of illnesses and with anesthesia. Crises can occur even in stable children with a history of pulmonary hypertension who become acutely ill. Although pulmonary hypertension that is associated with BPD can improve with adequate lung growth, therapies such as sildenafil and other antipulmonary hypertensive agents have been used in management.

Prevention of respiratory viral illness is vitally important; frequent handwashing by caregivers (especially before they handle the baby) and avoidance of contact with children and adults with current respiratory symptoms are essential. Respiratory syncytial virus (see Chapter 307) immunoprophylaxis should be considered based on the severity of lung disease and the patient's gestational age and current age. Another environmental factor that can worsen respiratory symptoms is exposure to secondhand tobacco smoke (see Chapter 759.1).

PROGNOSIS

The prognosis for infants with BPD is generally good, although the presence of BPD may result in a longer initial hospitalization compared with preterm infants without BPD. Most infants are weaned off of oxygen during the first year of life, and those requiring home mechanical ventilation are often weaned from this support during toddlerhood. Many children exhibit an asthma-like phenotype during early childhood, characterized by episodes of wheezing or coughing triggered by upper respiratory tract infections, exertion, allergens, etc. For some of these children, symptoms improve by school age; others may continue to have asthma-like exacerbations with viral illnesses and exercise throughout childhood that may persist into adulthood. Even asymptomatic patients with a history of BPD can continue to demonstrate small airway flow limitations by spirometry. Lastly, obstructive sleep apnea may also be more common in infants, children, and young adults with a history of BPD.

Visit Elsevier eBooks+ at eBooks.Health.Elsevier.com for Bibliography.

Chapter 467

Skeletal Diseases Influencing Pulmonary Function

Steven R. Boas and Catherine Kier

Pulmonary function is influenced by the structure of the chest wall (see Chapter 421). Chest wall abnormalities can lead to restrictive or obstructive pulmonary disease, impaired respiratory muscle strength, and decreased ventilatory performance in response to physical stress. The congenital chest wall deformities include *pectus excavatum, pectus carinatum, sternal clefts, Poland syndrome*, and skeletal and *cartilage dysplasias*. Vertebral anomalies such as kyphoscoliosis can alter pulmonary function in children and adolescents.

467.1 Pectus Excavatum (Funnel Chest)

Steven R. Boas and Catherine Kier

ETIOLOGY

Pectus excavatum—midline narrowing of the thoracic cavity—is usually an isolated skeletal abnormality. The cause is unknown. Pectus excavatum can occur in isolation, or it may be associated with a connective tissue disorder—Marfan (see Chapter 743) or Ehlers-Danlos syndrome (see Chapter 700). It may be acquired secondarily to chronic lung disease, neuromuscular disease, or trauma.

EPIDEMIOLOGY

Pectus excavatum occurs in 1 in 400 births with a 9:1 male preponderance and accounts for >90% of congenital chest wall anomalies. There is a positive family history in ~30% of cases.

CLINICAL MANIFESTATIONS

The deformity is present at or shortly after birth in one third of cases but is usually not associated with any symptoms at that time. In time, fatigue, chest pain, palpitations, recurrent respiratory infections, wheezing, stridor, and cough may be present. Decreased exercise tolerance is one of the most common symptoms. Because of the cosmetic nature of this deformity, children may experience significant psychologic stress. Physical examination may reveal sternal depression, protracted shoulders, kyphoscoliosis, dorsal lordosis, inferior rib flares, rib cage rigidity, forward head tilt, scapular winging, and loss of vertebral contours (Fig. 467.1). Patients may exhibit paroxysmal sternal motion and a shift of point of maximal impulse to the left. Innocent systolic murmurs may be heard.

LABORATORY FINDINGS

Lateral chest radiograms demonstrate sternal depression. The Haller index on chest CT (maximal internal transverse diameter of the chest divided by the minimal anteroposterior diameter at the same level) in comparison with age- and gender-appropriate normative values have been used historically to help determine the extent of the anatomic abnormality. However, the correlation of the Haller index with the physiologic compromise or associated systems appears suboptimal. The use of 3D chest optical imaging or "surface scan" is gaining popularity in the evaluation. An electrocardiogram may show a right-axis deviation or Wolff-Parkinson-White syndrome (see Chapter 485); an echocardiogram may demonstrate mitral valve prolapse (see Chapter 477.3) and ventricular compression. Results of static pulmonary function tests may be normal but commonly show an obstructive defect in the lower airways and, less commonly, a restrictive defect as the result of abnormal chest wall mechanics. Exercise testing may demonstrate either normal tolerance or limitations from underlying cardiopulmonary dysfunction that are associated with the severity of the defect. Pulmonary limitations, such as ventilatory limitations and associated flow volume loop abnormalities, are commonly seen in younger children and adolescents, whereas additional cardiac limitations secondary to stroke volume impairments are more commonly seen in older adolescents and young adults.

TREATMENT

Treatment is based on the severity of the deformity and the extent of physiologic compromise as defined by physical examination and physiologic assessment of cardiopulmonary function (lung function and exercise tolerance assessment). Therapeutic options include careful observation, the use of physical therapy to address musculoskeletal compromise, corrective surgery, cosmetic surgery, and noninvasive thorascopic techniques. For patients with significant physiologic compromise, surgical correction may improve the cosmetic deformity and may help minimize progression or even improve the cardiopulmonary compromise. The two main surgical interventions are the Ravitch and Nuss procedures. The Nuss procedure is a minimally invasive thoracoscopic repair that has been associated with good cosmetic and functional outcomes.

The extent of the anatomic defect, including the degree of asymmetry, may help determine the appropriate surgical approach. Although surgical repair may result in improved exercise tolerance for some individuals, usually observed at submaximal exercise intensities, many patients do not show improvement in either respiratory or cardiac function. Normalization of lung perfusion scans and maximal voluntary ventilation have also been observed after surgery. Use of a magnetic brace with gradual remodeling (Magnetic Mini Mover procedure) of the pectus deformity is under clinical investigation, with some promising results seen for prepubertal children. Surgically placed silicone implants for cosmetic appearance have also been used with high patient satisfaction. For selected patients, the use of a more noninvasive approach (i.e., cup suction) has been gaining popularity. Regardless of the treatment approach, addressing secondary musculoskeletal findings is commonly employed before and after any intervention.

Visit Elsevier eBooks+ at eBooks.Health.Elsevier.com for Bibliography.

467.2 Pectus Carinatum and Sternal Clefts

Steven R. Boas and Catherine Kier

PECTUS CARINATUM

Pectus carinatum is a sternal deformity accounting for 5–15% of congenital chest wall anomalies. Anterior displacements of the mid and lower sternum and adjacent costal cartilages are the most common types. They are most commonly associated with protrusion of the upper sternum; depression of the lower sternum occurs in only 15% of patients. Asymmetry of the sternum is common, and localized depression of the lower anterolateral chest is also often observed. Males are affected four times more often than females. There is a high familial occurrence and a common association of mild to moderate scoliosis. Mitral valve disease and coarctation of the aorta are associated with this anomaly. Three types of anatomic deformity occur (upper, lower, and lateral pectus carinatum), with corresponding physiologic changes and treatment algorithms.

CLINICAL MANIFESTATIONS

In early childhood, symptoms appear minimal. School-age children and adolescents commonly complain of dyspnea with mild exertion, decreased endurance with exercise, and exercise-induced wheezing. The incidence of increased respiratory infections and use of asthma

Fig. 467.1 Pectus excavatum in a 15-yr-old male. Note the presence of protracted shoulders, inferior rib flares, and sternal depression.

medication is higher than in nonaffected individuals. On physical examination, a marked increase in the anteroposterior chest diameter is seen, with a resultant reduction in chest excursion and expansion (Fig. 467.2). Spirometry has demonstrated both restrictive and obstructive patterns, although the majority of individuals have normal values. Increases in residual volume are often present and result in tachypnea and diaphragmatic respirations. Exercise testing shows variable results. Chest radiographs show an increased anteroposterior diameter of the chest wall, emphysematous-appearing lungs, and a narrow cardiac shadow. The pectus severity score (width of chest divided by distance between sternum and spine; analogous to the Haller index) is reduced.

TREATMENT

For symptomatic patients with pectus carinatum, minimally invasive surgical correction procedures may result in an improvement of the clinical symptoms. Many surgeons prefer to use **bracing techniques** as a first-line treatment, especially for younger patients. Although surgery is performed for some individuals who are symptomatic, it is often performed for cosmetic and psychologic reasons.

STERNAL CLEFTS

Sternal clefts are rare congenital malformations that result from the failure of the fusion of the sternum during the eighth week of gestation. No familial predisposition has been described. Sternal clefts occur in less than 1% of all chest wall deformities. Sternal clefts are classified as partial or complete. Partial sternal clefts are more common and may involve the superior sternum in association with other lesions, such as vascular dysplasias and supraumbilical raphe, or the inferior sternal clefts, which are often associated with other midline defects (pentalogy of Cantrell). Complete sternal clefts with complete failure of sternal fusion are rare. These disorders may also occur in isolation. The paradoxic movement of thoracic organs with respiration may alter pulmonary mechanics. Rarely, respiratory infections and even significant compromise result. Surgery is required early in life before fixation and immobility occur.

Visit Elsevier eBooks+ at eBooks.Health.Elsevier.com for Bibliography.

467.3 Asphyxiating Thoracic Dystrophy (Thoracic-Pelvic-Phalangeal Dystrophy)

Steven R. Boas and Catherine Kier

A multisystem autosomal recessive disorder, asphyxiating thoracic dystrophy results in a constricted and narrow rib cage. Also known as *Jeune syndrome*, the disorder is associated with characteristic skeletal abnormalities as well as variable involvement of other systems, including renal, hepatic, neurologic, pancreatic, and retinal abnormalities (see Chapter 741).

Fig. 467.2 Pectus carinatum in a 13-yr-old male. Note the central sternal prominence.

CLINICAL MANIFESTATIONS

Most patients with this disorder die shortly after birth from respiratory failure, although less-aggressive forms have been reported in older children. For those who survive the neonatal period, progressive respiratory failure often ensues, owing to impaired lung growth, recurrent pneumonia, and atelectasis originating from the rigid chest wall.

DIAGNOSIS

Physical examination reveals a narrowed thorax that, at birth, is much smaller than the head circumference. The ribs are horizontal, and the child has short extremities. Chest radiographs demonstrate a bell-shaped chest cage with short, horizontal, flaring ribs, and high clavicles.

TREATMENT

No specific treatment exists, although thoracoplasty to enlarge the chest wall and long-term mechanical ventilation have been tried. Rib-expanding (vertical expandable prosthetic titanium rib [VEPTR]) procedures have resulted in improved survival (Fig. 467.3).

PROGNOSIS

For some children with asphyxiating thoracic dystrophy, improvement in the bony abnormalities occurs with age. However, children younger than age 1 year often succumb to respiratory infection and failure. Progressive renal disease often occurs in older children. Use of vaccines for influenza and other respiratory pathogens is warranted, as is the aggressive use of antibiotics for respiratory infections.

Visit Elsevier eBooks+ at eBooks.Health.Elsevier.com for Bibliography.

467.4 Achondroplasia

Steven R. Boas and Catherine Kier

Achondroplasia is the most common condition characterized by disproportionate short stature (see Chapter 737). This condition is inherited as an autosomal dominant disorder that results in disordered growth. Much has been learned about this disorder, including its genetic origins (95% of cases are caused by pathogenic variants in the gene coding for fibroblast growth factor receptor type 3) and how to minimize its serious complications.

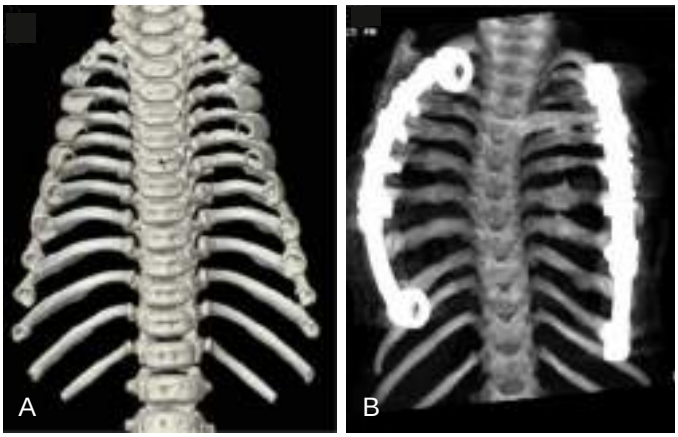

Fig. 467.3 A, Seven-mo-old with Jeune syndrome preoperatively. B, 18 mo after VEPTR insertion. *(From Mayer OH. Chest wall hypoplasia—principles and treatment. Pediatr Respir Rev. 2015;16:30–34, Fig. 3.)*

CLINICAL MANIFESTATIONS

Restrictive pulmonary disease, affecting <5% of children with achondroplasia who are younger than 3 years, is more likely at high elevation. Recurrent infections, cor pulmonale, and dyspnea are commonly associated. There is an increased risk of obstructive sleep apnea or hypopneas. Hypoxemia during sleep is a common feature. Risk of airway malacia is greater than the general population. Onset of restrictive lung disease can begin at a very young age. On examination, the breathing pattern is rapid and shallow, with associated abdominal breathing. The anteroposterior diameter of the thorax is reduced. Special growth curves for chest circumference of patients with achondroplasia from birth to 7 years are available. Three distinct phenotypes exist: phenotypic group 1 patients possess relative adenotonsillar hypertrophy, group 2 patients have muscular upper airway obstruction and progressive hydrocephalus, and group 3 patients have upper airway obstruction without hydrocephalus. Kyphoscoliosis may develop during infancy.

DIAGNOSIS

Pulmonary function tests reveal a reduced vital capacity that is more pronounced in males. The lungs are small but functionally normal. Sleep studies are recommended because of the high prevalence of sleep-disordered breathing. Chest radiographs demonstrate the decreased anteroposterior diameter along with anterior cupping of the ribs. The degree of foramen magnum involvement correlates with the extent of respiratory dysfunction.

TREATMENT

Treatment of sleep apnea, if present, is supportive (see Chapter 31). Physiotherapy and bracing may minimize the complications of both kyphosis and severe lordosis. Aggressive treatment of respiratory infections and scoliosis is warranted.

PROGNOSIS

The life span is normal for most children with this condition, except for the phenotypic groups with hydrocephalus or with severe cervical or lumbar spinal compression.

Visit Elsevier eBooks+ at eBooks.Health.Elsevier.com for Bibliography.

467.5 Kyphoscoliosis: Adolescent Idiopathic Scoliosis and Congenital Scoliosis

Steven R. Boas and Catherine Kier

Adolescent idiopathic scoliosis (AIS) is characterized by lateral bending of the spine (see Chapter 720). It commonly affects children during their teen years and during periods of rapid growth. The cause is unknown. Congenital scoliosis is uncommon, affecting females more than males, and is apparent in the first year of life (see Chapter 720.2).

CLINICAL MANIFESTATIONS

The pulmonary manifestations of scoliosis may include chest wall restriction, leading to a reduction in total lung capacity, abnormal gas exchange, airway obstruction, and hypoinflation with associated atelectasis. The angle of scoliosis deformity has been correlated with the degree of lung impairment only for patients with thoracic curves. Vital capacity, forced expiratory volume in 1 sec (FEV_1), work capacity, oxygen consumption, diffusion capacity, chest wall compliance, and partial pressure of arterial oxygen decrease as the severity of thoracic curve increases. These findings can be seen in even mild to moderate AIS (Cobb angle <30 degrees) but generally do not occur in other, nonthoracic curves. Respiratory compromise is often more severe in children younger than 5 years of age with large scoliotic curves. Reduction in peripheral muscle function is associated with AIS through either intrinsic mechanisms or deconditioning. Severe impairment can lead to cor pulmonale or respiratory failure and can occur before 20 years old. Children with severe scoliosis (Cobb's angle >70 degrees), especially males, may have abnormalities of breathing during sleep, and the resultant periods of hypoxemia may contribute to the eventual development of pulmonary hypertension.

DIAGNOSIS

Physical examination and an upright, posteroanterior radiograph with subsequent measurement of the angle of curvature (Cobb technique) remain the gold standard for the assessment of scoliosis. Curves >10 degrees define the presence of scoliosis. Lung volume, respiratory muscle strength, and exercise capacity determination are essential in assessing the degree of respiratory compromise associated with scoliosis.

TREATMENT

Depending on the extent of the curve and the degree of skeletal maturation, treatment options include reassurance, observation, physical therapy, bracing, and surgery (spinal fusion). Influenza vaccine should be administered, given the extent of pulmonary compromise that may coexist. Because vital capacity is a strong predictor for the development of respiratory failure in untreated AIS, surgical goals are to diminish the scoliotic curve, maintain the correction, and prevent deterioration in pulmonary function. Abnormalities of vital capacity and total lung capacity, exercise intolerance, and the rate of change of these variables over time should be taken into consideration for the timing of surgical correction. Preoperative assessment of lung function (i.e., lung volumes, oxygen consumption, muscle strength, ventilation/perfusion) may assist in predicting postsurgical pulmonary difficulties. Many patients undergoing surgical correction may be managed postoperatively without mechanical ventilation. Even patients with mild scoliosis may have pulmonary compromise immediately after spinal fusion, secondary to pain, and a body cast that may restrict breathing and interfere with coughing. Children with a preoperative FEV_1 <40% predicted are at risk for requiring prolonged postoperative mechanical ventilation. Rib-expanding procedures have been successful in severe cases of congenital scoliosis. Choice of surgical approach may also impact lung function postoperatively.

Visit Elsevier eBooks+ at eBooks.Health.Elsevier.com for Bibliography.

467.6 Congenital Rib Anomalies

Steven R. Boas and Catherine Kier

Isolated defects of the highest and lowest ribs have minimal clinical pulmonary consequences. Missing midthoracic ribs are associated with the absence of the pectoralis muscle (Poland syndrome), and lung function can become compromised. Associated kyphoscoliosis and hemivertebrae may accompany this defect. If the rib defect is small,

no significant sequelae ensue. When the second to fifth ribs are absent anteriorly, lung herniation and significant abnormal respiration ensue. The lung is soft and nontender and may be easily reducible on examination. Complicating sequelae include severe lung restriction (secondary to scoliosis), cor pulmonale, and congestive heart failure. Symptoms are often minimal but can cause dyspnea. Respiratory distress is rare in infancy.

DIAGNOSIS

Chest radiographs demonstrate the deformation and absence of ribs with secondary scoliosis. Most rib abnormalities are discovered as incidental findings on a chest film.

TREATMENT

If symptoms are severe enough to cause clinical compromise or significant lung herniation, then homologous rib grafting can be performed. Rib-expanding procedures are also of great value. A modified Nuss procedure has been used to correct associated chest wall anomalies with rib abnormalities. Adolescent girls with congenital rib anomalies may require cosmetic breast surgery.

Visit Elsevier eBooks+ at eBooks.Health.Elsevier.com for Bibliography.

Chapter 468
Chronic Respiratory Insufficiency

468.1 Chronic Respiratory Failure and Long-Term Mechanical Ventilation

Denise M. Goodman and Steven O. Lestrud

Care has improved for the growing population of children with chronic respiratory failure requiring invasive (ventilation through a tracheostomy) and noninvasive (mask ventilation) ventilation, including those with predisposing conditions such as acute respiratory failure, prematurity, and neuromuscular disease. Although it is difficult to determine the prevalence of chronic ventilation, estimates range from approximately 4-6/100,000 children, or 3,000-4,000 children nationally who receive home ventilation. There may be roughly three times more children receiving mask ventilation than invasive mechanical ventilation. The conditions leading to the need for home ventilation are diverse. About 65% of children have a primary neurologic indication, including neuromuscular weakness or abnormal ventilatory control, and ~30% have chronic lung disease (Table 468.1).

Patients with primarily pulmonary indications have a greater likelihood of ultimately being weaned from the need for ventilation than do those with neuromuscular or central nervous system disease. Mortality for patients requiring chronic ventilation is ~12–34%, depending on underlying disease. The lower mortality range is for children with neonatal lung disease, with the higher value for children with complex congenital heart disease. Approximately 12–40% of children are eventually weaned from ventilation and decannulated, reflecting the underlying cause for which ventilation is required. This can usually be accomplished within the first 5 years of life. Nonetheless, the care of these children can be challenging. One study reported that up to 40% of chronically ventilated children are readmitted within the first year of discharge, usually within the first 3 months. Children requiring long-term mechanical ventilation (LMV) benefit from comprehensive care coordination incorporating generalists, specialists, home nursing, therapies, and a durable medical equipment (DME) resource.

Table 468.1 Indications for Long-Term Mechanical Ventilation

PULMONARY/ALVEOLAR
Bronchopulmonary dysplasia (BPD)
Severe acquired lung disease, such as after pediatric acute respiratory distress syndrome (PARDS)
Pulmonary fibrosis syndromes
AIRWAY
Severe tracheomalacia
Severe bronchomalacia
Obstructive sleep apnea (OSA)
Storage diseases
CHEST
Kyphoscoliosis
Skeletal dysplasias
Obesity
NEUROMUSCULAR
Spinal muscular atrophy
Spinal cord injury
Diaphragmatic dysfunction
Mitochondrial diseases
CENTRAL NERVOUS SYSTEM (CNS)
Congenital central hypoventilation syndrome (CCHS)
Rapid-onset obesity with hypothalamic dysregulation, hypoventilation, and autonomic dysfunction (ROHHAD)
Severe ischemic brain injury
Myelomeningocele with Arnold-Chiari type II malformation
Acquired hypoventilation syndromes

MODALITIES FOR RESPIRATORY SUPPORT

The goals of home mechanical ventilation are to maintain adequate oxygenation and ventilation, minimizing metabolic demands of chronic respiratory failure to ensure adequate somatic growth and optimal developmental gains.

Invasive Positive Pressure Ventilation

The term *invasive* designates ventilation through a tracheostomy. Some devices are suitable for both noninvasive positive pressure ventilation (NPPV) and invasive ventilation, whereas other devices are suitable for only one approach. The ideal home ventilator is lightweight, portable, and quiet. All home ventilators differ from hospital-based ventilators in that air movement is affected either by a piston or turbine that is electrically controlled. This contrasts with hospital ventilators, which are often gas-driven. A home ventilator should be able to provide continuous flow and have a wide range of settings (particularly for pressure, volume, pressure support, and rate) that allows ventilatory support from infancy to adulthood. Battery power for the ventilator, both internal and external, should be sufficient to permit unrestricted portability in the home and community. The equipment must also be impervious to electromagnetic interference and must be relatively easy to understand and troubleshoot.

Although families and care teams may at first resist placement, a **tracheostomy** has several advantages. It provides a secure and stable airway, a standardized interface for attaching the ventilator circuit to the patient, and the ability to easily remove airway secretions and deliver inhaled medications. Pediatric tracheostomy tubes typically have a single lumen and may have an inflatable cuff. Tracheostomy tubes with and without cuff inflation should be sized to control the

air leak around the tube and promote adequate gas exchange, yet allow enough space around the tube to facilitate vocalization and prevent tracheal irritation and erosion from the tube. The child's caregivers need to learn stoma care, elective and emergent tracheostomy changes, proper securing of the tube, suctioning of secretions, and recognition of emergencies such as tube obstruction or decannulation.

Optimal Ventilator Support

Factors such as underlying neuromuscular disease; medications such as sedatives, analgesics, steroids, and muscle relaxants; and prolonged immobility, as well as use of mechanical ventilation, may decondition the respiratory muscles and the diaphragm, resulting in muscle weakness. Consequently, it is important to avoid 24 hour a day patient synchrony with ventilation and titrate the amount of ventilator support to prevent fatigue yet facilitate spontaneous breathing. While assessing ventilator needs, frequent evaluation of gas exchange is needed and can usually be done noninvasively. Ventilator settings should be stable for a given period, dictated by the severity of pulmonary disease, before discharge home.

OTHER MANAGEMENT CONSIDERATIONS

Airway Clearance

One of the most important considerations is maintenance of airway patency. Adequate removal of secretions may minimize intercurrent pulmonary infections. In turn, infections may cause a transient increase in secretions, requiring an escalation of clearance strategies. If the child has an adequate cough, then periodic suctioning may be all that is needed. Some children, however, need additional help mobilizing and clearing secretions. This becomes particularly important in children with neuromuscular disease, for whom regularly scheduled clearance therapies are an imperative. **Vest therapy** (high-frequency chest wall oscillation) uses an inflatable vest that encircles the chest. Air inflates and deflates the vest with phasic pulses against the chest wall, loosening secretions. This device still requires a preserved and strong enough cough to expel secretions. The **cough assist** device provides more active airway clearance, delivering a forceful positive pressure adjunct during inspiration and active negative pressure during expiration. Thus the cough is more effective because of the rapid pressure changes. The cough assist can be used with an artificial airway or mask. Controls will set the inspiratory and expiratory pressures and periods.

Inhalation Medications

Clearance of secretions may be promoted with delivery of hypertonic (3% saline) nebulizations. These are often timed to cough-assist sessions to maximize the clearance benefits of both. Children requiring ventilation also commonly need bronchodilators.

Mucolytics and Anticholinergics

Some patients may need additional interventions as a result of excess secretions. Anticholinergic drugs, principally glycopyrrolate, are often effective, but must be dosed carefully to avoid thickening secretions excessively, which can lead to inspissated secretions and life-threatening plugging of the airway. Oral secretions are sometimes amenable to localized injection of botulinum toxin or select surgical ligation of salivary ducts. It is also wise to ensure that the patient is adequately hydrated, as dehydration may produce thick tenacious secretions. At times a mucolytic may be used. Hypertonic saline is the most common mucolytic, but a number of other agents have been tried, such as dornase alfa and *N*-acetylcysteine.

Monitoring

A patient who is ventilated in the home must be electronically and/or physically monitored at all times. Infants and young children, children who are cognitively impaired, and children who are completely tracheostomy dependent for airway patency because of suprastomal obstruction must be under direct observation of the caregivers at all times. Caregivers should also closely monitor children whose pulmonary status is fragile or fluctuant. Continuous monitoring of O_2 saturation and heart rate is recommended during sleep and either continuous or intermittent monitoring during the daytime, depending on patient stability. Patients with congenital central hypoventilation syndrome (CCHS) or pulmonary hypertension are particularly vulnerable to episodes of hypoxemia and/or hypercarbia, and those with pulmonary hypertension are particularly susceptible to rapid drops in O_2 saturation.

Supplemental Oxygen

Supplemental oxygen may be delivered from a tank or concentrator. Whether on room air or oxygen at baseline, even mild intercurrent infections may lead to an increase in oxygen requirement. In these situations, the child should be evaluated in person rather than over the phone to ensure that a more serious illness is not developing.

Physical, Occupational, and Speech Therapy

The technology needed to support physical well-being should not overshadow the inherent needs common to all children—to play, grow, develop, and interact. Ongoing physical therapy, occupational therapy, and speech therapy can help a child reach full potential, and many achieve complete catch-up development. Early intervention programs and access to play groups are important factors to attaining cognitive and social milestones. When typical development is not attainable, therapies can improve mobilization and muscle strength. Core trunk and abdominal strength is particularly important for pulmonary rehabilitation and essential for successful weaning off ventilation. Other important skills include oromotor skills for feeding and communication. Evaluation of swallow is a key component of therapy for children with chronic respiratory failure. Sign language is frequently used for communication because of delayed speech or hearing loss. Audiology specialists should be involved in the assessment of hearing because there is a higher incidence of hearing loss in patients undergoing long-term ventilation.

PREPARING FOR DISCHARGE

A number of threads need to come together for a safe and effective discharge, including medical stability, family education, financial support (insurance or a state waiver program), availability of a DME company, and, when appropriate, home private-duty nursing. A poor outcome may occur with any of the many medical or process factors or family factors, including not only education but also home readiness and psychosocial supports. A standardized discharge process can ensure that all details are addressed, minimizing length of stay and improving safety. An awake and attentive trained caregiver should be in the home of a child with invasive ventilation at all times; this expectation may differ for those receiving NPPV depending on clinical circumstance. For those receiving invasive ventilation, the caregiver may be a nurse, but nursing resources are often scarce, so many programs require two trained family caregivers. The training given to the family includes tracheostomy stoma care, suctioning, equipment expertise, administration of medications, and facility with other devices, such as gastrostomy tubes. In addition, the family is instructed in emergency preparedness, including what to do for acute changes in clinical status, desaturation, or airway obstruction or decannulation. Cardiopulmonary resuscitation training is essential. Parents also need to be able to travel portably with the child and equipment. A standardized emergency bag containing critical tracheostomy and ventilator supplies should accompany the child at all times. Other preparations center around home readiness, including accessibility (number of stairs, if any), members of the household, assuring no smoking in the home, and notification of utility companies such as the electric or heating company to ensure the home is serviced quickly in the event of power interruption. The family must also have a functioning telephone to ensure adequate accessibility and communication between the family and care team. For those going home with invasive mechanical ventilation, both a primary and backup ventilator may be needed, as well as batteries, a self-inflating bag and mask, suctioning equipment, supplemental oxygen, and appropriate monitoring, including a pulse oximeter. The use of high-fidelity

simulation as a means to rehearse skills is increasing. Family training often culminates in an autonomous 24-hour stay *in the hospital* during which time one caregiver must continuously remain awake, and all cares, including ventilator checks, suctioning, tracheostomy tube changes, medications, and the like, are provided by the family.

CARE BY THE GENERAL PEDIATRICIAN

See Chapter 468.4.

Nutrition

Ventilated patients may have nutritional needs that are equal to, greater than, or lesser than those of comparably aged well children. Growth should be tracked at each well child and subspecialty visit. Excessive growth is as harmful as inadequate growth, and excess calories may lead to increased carbon dioxide (CO_2) production. Anthropometry or measured energy expenditure may be needed to assure a more precise prescription of nutritional support. Many children with tracheostomies have oral aversion and/or dyscoordination of swallowing, with resultant risk for aspiration. In these children a gastrostomy tube may ensure adequate nutrition in the interim, while ongoing speech therapy promotes oral feeding.

Infections

Tracheitis (see Chapter 433.2), bronchiolitis (see Chapter 439), and pneumonia (see Chapter 449) are common in patients with chronic respiratory failure. Infections may be caused by community-acquired viruses (adenovirus, influenza, respiratory syncytial virus, parainfluenza, rhinovirus) or community- or hospital-acquired bacteria. Common pathogens are gram-negative, highly antimicrobial-resistant pathogens that may cause further deterioration in pulmonary function. Bacterial infection is most likely in the presence of fever, deteriorating lung function (hypoxia, hypercarbia, tachypnea, and retractions), leukocytosis, and mucopurulent sputum. The presence of leukocytes and organisms on Gram stain of tracheal aspirate, along with the visualization of new infiltrates on radiographs, may be consistent with bacterial infection.

Infection must be distinguished from tracheal *colonization* of bacteria, which is asymptomatic and associated with normal amounts of clear tracheal secretions. Colonization may also be distinguished from infection in that colonization usually has few, if any, white blood cells on Gram stain of tracheal secretions. If infection is suspected, it must be treated with antibiotics, based on the culture and sensitivities of organisms recovered from the tracheal aspirate. At times an inhaled antibiotic such as tobramycin might avert progression of infection. Antibiotics should be used judiciously to prevent further colonization with drug-resistant organisms. However, some patients who have recurrent infections may benefit from prophylaxis with inhaled antibiotics. Clinical decisions will be based on the child's appearance, any increased need for ventilation or supplemental oxygen, and consultation with the subspecialist. A final caveat is that if a respiratory viral panel is desired, this must be obtained from nasal secretions similar to a well child; tracheal aspirate does not provide an appropriate specimen.

CARE BY THE SUBSPECIALTY TEAM

Weaning Off of the Ventilator

Typically, the ventilator settings are reduced, minimizing ventilator parameters to achieve physiologic respiratory rates and 6-8 mL/kg tidal volumes. Subsequent maneuvers will evaluate the patient free breathing, initially with simple observed transition times of 5-10 minutes, extending time off as clinically indicated. This can be done in the outpatient setting during visits with the pulmonologist or other subspecialist responsible for ventilator management. Additional factors that reflect tolerance of increased work of breathing, including weight gain, energy levels, general behavior, and sleep patterns, are also monitored carefully. When the child has completely weaned off ventilator support while awake and is only on the ventilator approximately 6 hours nightly during sleep, a polysomnogram study performed off the ventilator may be considered before complete liberation from the mechanical ventilation device. Successful liberation from mechanical ventilation, if it occurs, often takes place between the ages of 2 and 5 years. One thought is that with ambulation and development of core strength, respiratory reserve improves, facilitating weaning. Even so, residual lung disease is common. Children with a history of bronchopulmonary dysplasia (BPD) and previous ventilator dependence often have significant airway obstruction on pulmonary function testing.

PSYCHOSOCIAL CONSIDERATIONS

Caring for a child on long-term ventilatory support in the home is a complex, physically demanding, emotionally taxing, and expensive process for the family. It changes the family routines, priorities, and overall lifestyle and may adversely affect relationships both within the family and with extended family and friends. Practical considerations include loss of spontaneity in family outings, sleep disturbance, extra expenses, having strangers in the house providing care, and adhering to medical regimens and follow-up visits. Intangible stresses are also prominent, including disruption in the usual parent–child caregiving roles and stresses between parent partners and with other children. The loss of normality, sense of isolation, and concerns regarding what is best for the child are additional sources of distress. All of these stresses are exacerbated by challenges in securing reliable home private-duty nurse resources; this issue may delay hospital discharge and complicate postdischarge care, at times even leading to readmission because of lack of adequate support. For children with a life-limiting condition, there is the additional need to periodically revisit the child's current medical state, sense of well-being, and trajectory of illness, as critical decisions will eventually arise regarding end-of-life care. The general pediatrician can often be a familiar and comfortable safe place to explore these issues, as parents may be conflicted in wanting to be a "good" parent while feeling guilty about their own needs and vulnerabilities. Finally, families may find transportation to frequent outpatient visits difficult; telemedicine may offer an alternative for select situations.

ADULT TRANSITION

There are a growing number of children surviving into adulthood who require chronic ventilation. There are little empiric data regarding this transition, including identifying patients for whom transition is appropriate, implementing a standardized transition process, partnering with adult pulmonologists, or replicating in an adult environment the care coordination provided by the pediatric care team. The pulmonary team ideally initiates ongoing discussions regarding self-care responsibilities and transitioning of medical care to adult providers with the adolescent and his or her parents when the patient reaches the early teens. Discussion about self-care should take into consideration realistic expectations about the adolescent's physical and cognitive capabilities. The actual transition of care occurs for most young adults at age 18-21 years and includes referral to an internist and an adult pulmonologist. Transition of medical care also includes transition from pediatric to adult support services for funding sources and nursing care. Ideally, an outpatient visit that includes current and future adult medical providers together is completed to facilitate communication and formally transition care.

Visit Elsevier eBooks+ at eBooks.Health.Elsevier.com for Bibliography.

468.2 Congenital Central Hypoventilation Syndrome

Amy Zhou, Susan M. Slattery, Casey M. Rand, and Debra E. Weese-Mayer

CCHS is a clinically complex *neurocristopathy* that includes a variable severity of respiratory and autonomic dysregulation, as well as Hirschsprung disease and neural crest tumors in a subset of patients. In the **classic** CCHS presentation, symptoms of alveolar hypoventilation manifest in the newborn period and during sleep only—with

Table 468.2 Clinical Manifestations of CCHS

ORGAN SYSTEM	CLINICAL MANIFESTATIONS
Ophthalmologic	Decreased/absent pupillary light response Anisocoria Strabismus Lack of convergent gaze Marcus Gunn jaw winking
Respiratory	Alveolar hypoventilation Absent perception of dyspnea
Cardiovascular	Bradycardia Prolonged sinus pauses (>3 seconds) Transient asystole Decreased heart rate variability Low normal daytime blood pressure Orthostatic hypotension Nondipping blood pressure circadian pattern Decreased BP response to exercise Syncope
Gastrointestinal	Hirschsprung disease (20%) Constipation Esophageal dysmotility
Endocrine	Hyperinsulinism Hypoglycemia Hyperglycemia
Neurologic	Decreased anxiety Decreased pain perception Seizures Neurocognitive deficits
Skin	Sporadic profuse sweating
Tumors	Neuroblastoma Ganglioneuroma Ganglioneuroblastoma
Others	Decreased baseline body temperature Poor heat tolerance

CCHS, Congenital central hypoventilation syndrome; BP, blood pressure; GI, gastrointestinal.

From Bishara J, Keens TG, Perez IA. The genetics of congenital central hypoventilation syndrome: clinical implications. *App Clin Genetics*. 2018;11:135–144, Table 1. Originally published by and used with permission from Dove Medical Press Ltd.

diminished tidal volume and a typically monotonous respiratory rate leading to cyanosis and hypercarbia. In more **severe** cases of CCHS, the hypoventilation manifests during wakefulness and sleep. In the **later-onset** cases of CCHS **(LO-CCHS)**, onset of overt symptoms is delayed until 1 month of age or older (often into childhood and adulthood). Hypoventilation is typically during sleep only and usually milder in LO-CCHS. CCHS and LO-CCHS are further characterized by partial to complete failure of peripheral and central chemoreceptors to properly respond to hypercarbia and hypoxemia during wakefulness and sleep, coupled with physiologic and/or anatomic autonomic nervous system (ANS) dysregulation (ANSD). Physiologic dysregulation may include all organ systems affected by the ANS, specifically the respiratory, cardiac, sudomotor, vasomotor, ophthalmologic, neurologic, and enteric systems (Table 468.2). The anatomic or structural ANSD includes Hirschsprung disease and tumors of neural crest origin (neuroblastoma, ganglioneuroma, or ganglioneuroblastoma).

GENETICS

The *PHOX2B* gene is the disease-defining gene for CCHS. *PHOX2B* encodes a highly conserved homeodomain transcription factor, is essential to the embryologic development of the ANS from the neural crest, and is expressed in key regions and systems that explain much of the CCHS phenotype. Individuals with CCHS are *heterozygous* for either a **polyalanine repeat expansion pathogenic variant (PARPV)** in exon 3 of the *PHOX2B* gene (normal number of alanines is 20 with normal genotype 20/20), such that individuals with CCHS have 24-33 alanines on the affected allele (genotype range is 20/24-20/33), or a **nonpolyalanine repeat expansion pathogenic variant (NPARPV)** resulting from a missense, nonsense, frameshift, stop codon, in-frame indels (in-frame insertions, deletions, or duplications), full exon/gene deletions, or splice-site pathologic genetic variant. Approximately 90–92% of cases of CCHS have PARPVs and the remaining 8–10% of cases have NPARPVs (Table 468.3).

Stepwise clinical *PHOX2B* testing for probands with the CCHS phenotype is advised. **Step 1**: *PHOX2B* screening test (fragment analysis), then if negative; **Step 2**: *PHOX2B* sequencing test, then if negative; **Step 3**: *PHOX2B* multiplex ligation-dependent probe amplification (MLPA) test to minimize the risk of false-negative findings, minimize the expense and need for more than one blood sample, and expedite confirmation of the diagnosis.

Genetic counseling is essential for family planning and for delivery room preparation in anticipation of a CCHS birth and ensuring adequate ventilation for the mother during pregnancy. *PHOX2B* testing is also advised for both parents of a child with CCHS to anticipate the risk of recurrence in subsequent pregnancies (if mosaic) and to determine if a parent has yet-undiagnosed LO-CCHS. Fragment analysis *PHOX2B* testing (also known as the *screening test*) will best identify low-level somatic mosaicism. Prenatal testing for a *PHOX2B* variant is clinically available (www.genetests.org) for families with a known *PHOX2B* gene variant.

Ventilator Dependence and Control of Breathing

Patients with CCHS have deficient CO_2 sensitivity during wakefulness *and* sleep such that they do not respond with a normal increase in ventilation in either state, nor do they arouse in response to hypercarbia and/or hypoxemia during sleep. During wakefulness, a subset of patients may respond sufficiently to avoid significant hypercarbia, but most individuals with CCHS have hypoventilation that is severe enough that hypercarbia is apparent in the resting *awake* state. Children with CCHS also have altered sensitivity to hypoxia while awake and asleep. A key feature of CCHS is the *lack* of respiratory distress or sense of asphyxia with physiologic compromise (hypercarbia and/or hypoxemia). This lack of responsiveness to hypercarbia and/or hypoxemia, which can result in respiratory failure, does not consistently improve with advancing age. A subset of older children with CCHS may show an increase in ventilation (specifically an increase in respiratory rate rather than an increase in tidal volume) when they are exercised at various work rates. This response is possibly secondary to neural reflexes from rhythmic limb movements, although an increase in minute ventilation is often insufficient to avoid physiologic compromise.

The greater the number of extra alanines, the more likely the need for continuous ventilatory support, at least among the most common *PHOX2B* PARPV genotypes (20/25, 20/26, 20/27). Although *PHOX2B* genotype seems to anticipate the severity of hypoventilation, it does not correlate with exogenous ventilatory challenge responses. Infants and young children as a group have reasonable ventilatory response slopes while awake, but this advantage seems to vanish by school age.

Hirschsprung Disease (see Chapter 378.4)

Overall, 20% of children with CCHS also have Hirschsprung disease (HSCR), known as *Haddad syndrome,* and any infant or child with CCHS who presents with constipation should undergo rectal biopsy to screen for the absence of ganglion cells. The frequency of Hirschsprung disease seems to increase with the longer polyalanine repeat tracts (genotypes 20/27-20/33) and in those with NPARPVs. Even in cases without frank HSCR disease, individuals with CCHS may display symptoms of gastrointestinal abnormalities such as severe constipation and abnormal esophageal motility, suggesting ganglion cell dysfunction.

Table 468.3 Congenital Central Hypoventilation Syndrome–Related Symptoms by PARPV vs NPARPV and PARPV Genotype

		GENOTYPE				
		PARPV GENOTYPE			NPARPVS	
FEATURE		20/24[1], 20/25	20/26	20/27	NPARPV IN GENERAL	38BP DELETION
Respiratory (hypoventilation)		Asleep only	Awake with exertion and eating and asleep	Awake and asleep	Awake and asleep	Awake and asleep
Cardiac arrhythmia: Abrupt sinus pauses ≥3 seconds warranting cardiac pacemaker		Variable: None with childhood onset; a subset will have prolonged sinus pauses in adulthood	19%	>80%	None with childhood onset to date	
Hirschsprung disease		<0.1%	20–30%	30%	80–90%	95–100% severe long segment disease (i.e., entire colon and some small intestine)
Severe constipation			~50+%	~50+%		
Esophageal dysmotility/dysphagia			First year of life	First year of life		
Neural crest tumors	Neuroblastoma	0%	0%	See footnote 2	50%	
	Ganglioneuroblastoma	0%	0%	0%	<5%	
	Ganglioneuroma	0%	0%	0%	<5%	
ANSD: Pupillary response to light		Normal response	Midsize pupils with attenuated response to light	Small pupils at rest; nearly absent response to light	Large pupils at rest; negligible response to light	

ANSD, Autonomic nervous system dysregulation; NPARPV, nonpolyalanine repeat expansion pathogenic variant (i.e., missense, nonsense, frameshift, stop codon, splice site); PARPV, polyalanine repeat expansion pathogenic variant.

1. Genotype 20/24 would be considered a susceptibility allele (needs another factor to manifest) or a low- or variable-penetrance allele with features that can be triggered by pharmacologic agents (a pharmaco-genetic phenomenon) or a gene × environment interaction (without main effects).

2. Generally 0%; however, an infant with the 20/33 genotype had metastatic neuroblastoma (12).

From Weese-Mayer DE, Rand CM, Khaytin I, et al. Congenital central hypoventilation syndrome. Updated 2021 Jan 28. In: Adam MP, Ardinger HH, Pagon RA, et al., eds. GeneReviews [Internet]. Seattle (WA): University of Washington, Seattle; 1993-2021. Available from https://www.ncbi.nlm.nih.gov/books/NBK1427/. Table 2, pp. 7–8.

Tumors of Neural Crest Origin (see Chapter 547)

Tumors of neural crest origin are more frequent in patients with NPARPVs (50%) than in those with PARPVs (1%). These extracranial tumors are more often neuroblastomas in individuals with NPARPVs, but ganglioneuromas and ganglioneuroblastomas occur in a small subset of patients.

Cardiac Asystoles

Transient, abrupt, and prolonged sinus pauses have been identified in patients with CCHS, necessitating implantation of cardiac pacemakers when the pauses are ≥3 seconds. Among patients with the most common *PHOX2B* genotypes, 19% of those with the 20/26 genotype and 83% of those with the 20/27 genotype have cardiac pauses of 3 seconds or longer. The risk for sinus pauses among children with NPARPVs is unknown at present.

Heart rate variability is characteristically decreased in CCHS, likely because of reduced cardiac baroreflex sensitivity and blunted sympathetic response. One report demonstrated a genotype-phenotype relationship for heart rate variability during exogenous ventilatory response testing, prompting assessment of risk for sinus pauses. Introduction of 72-hour Holter recordings every 12 months, at a minimum, has allowed for early identification of these abrupt sinus pauses, permitting timely cardiac pacemaker implantation.

Autonomic Nervous System Dysregulation

A higher number of polyalanine repeats on the affected allele among patients with a PARPV is associated with an increased number of physiologic symptoms of ANSD. In addition, there is a spectrum of physiologic ANSD symptoms, including decreased heart rate variability, esophageal/gastric/colonic dysmotility, decreased pupillary response to light, reduced basal body temperature, altered distribution and amount of diaphoresis, altered vasomotor tone, and altered pain and anxiety perception.

Characteristic Facial Morphology

Characteristic facial features have been described for children with CCHS. Using facial photogrammetry, five features were used to correctly predict 86% of CCHS cases and 82% of controls in a matched case control study. A typical CCHS face is characterized by an upper and midface that is short relative to its width, resulting in a characteristic broad, flat, boxlike appearance (Fig. 468.1). The lateral one third of the upper lip vermillion border is overturned so it is flesh-colored instead of pink. Results also suggest that male CCHS patients are more strongly affected than females.

Neuropathology

Brain imaging studies and functional MRI (fMRI) responses have identified structural anomalies in CCHS cases that may contribute to the observed respiratory and autonomic phenotypes. These findings may be primarily the result of *PHOX2B* variant–induced failure of neurogenesis in the human embryo, but a significant contribution from postnatal hypoxic, hypercarbic, or perfusion damage cannot be excluded. The neuroanatomic defects in CCHS are likely the result of focal *PHOX2B* (mis)expression coupled with sequelae of recurrent hypoxemia/hypercarbia in the subset of suboptimally managed patients. The following regions pertinent to respiratory control in the pons and medulla of the brainstem show *PHOX2B* expression: locus coeruleus, dorsal respiratory group, nucleus ambiguus, and parafacial respiratory group, among other areas. Physiologic evidence suggests that the respiratory failure in these children is mostly based on defects in central mechanisms, but peripheral mechanisms (mainly carotid bodies) may also be important.

CLINICAL MANIFESTATIONS

Patients with CCHS usually present with symptoms in the first few hours after birth. Most children are the products of uneventful pregnancies and are term infants with appropriate weight for gestational age. Variable Apgar scores have been reported. The affected infants do not show signs of respiratory distress, but their shallow respirations and respiratory pauses (apnea) usually evolve to respiratory failure with apparent cyanosis in the first days of life. In neonates with CCHS, $Paco_2$ accumulates during sleep to very high levels, sometimes >90 mm Hg, and may decline to normal levels after the infants awaken. This problem becomes most apparent when multiple attempts at extubation fail in an intubated neonate who appears well with ventilatory support but develops respiratory failure without respiratory distress after removal of the support. However, more *severely* affected infants with CCHS hypoventilate awake and asleep; thus the previously described difference in $Paco_2$ between states may not be apparent. Often, the respiratory rate is higher in rapid eye movement (REM) sleep than in non-REM sleep in individuals with CCHS, and in general, respiratory rates are higher in infants and children with CCHS than similarly aged peers with intact control of breathing.

Fig. 468.1 Characteristic CCHS facies. Photographs of representative CCHS. These two children with CCHS both have the representative facies. The female with CCHS (**A**) has a *PHOX2B* genotype of 20/25, and the male with CCHS (**B**) has a 20/27 genotype. Note the decreases in sloping of the forehead, upper face height, upper facial inclination, nasolabial angle, upper and lower lip heights, and the inferior inflection of the lateral vermillion border of the upper lip. *(Modified from Todd ES, Weinberg SM, Berry-Kravis EM, et al. Facial phenotype in children and young adults with PHOX2B-determined congenital central hypoventilation syndrome: quantitative pattern of dysmorphology. Pediatr Res. 2006;59:39–45, Fig. 2A and 2C.)*

LO-CCHS should be suspected in infants, children, and adults who have unexplained centrally mediated hypoventilation and/or seizures or cyanosis, especially subsequent to the use of anesthetic agents and/or sedation, acute respiratory illness or recurrent severe respiratory illness with difficulty weaning from ventilator support (and failed extubations), and potentially obstructive sleep apnea (OSA) unresponsive to traditional intervention. These individuals may have other evidence of chronic hypoventilation, including pulmonary hypertension, polycythemia, elevated bicarbonate concentration, difficulty concentrating, and mild unexplained neurocognitive impairment. A heightened level of suspicion has led to increasing numbers of older children and adults diagnosed with LO-CCHS receiving proper treatment. This later presentation reflects the variable penetrance of a subset of *PHOX2B* variants and the potential role of an exogenous cofactor in unmasking the hypoventilation phenotype.

In addition to treatment for the alveolar hypoventilation, children with CCHS require comprehensive physiologic evaluation during sleep and wakefulness, including age-appropriate activities of daily living such as eating, as their hypoxemia and hypercarbia from insufficient artificial ventilation may go unnoticed. It is necessary to provide coordinated care to optimally manage associated multisystem abnormalities such as Hirschsprung disease, tumors of neural crest origin, and symptoms of physiologic ANSD, including cardiac asystole, among other findings (details provided in American Thoracic Society [ATS] 2010 Statement on CCHS) (Table 468.4).

DIFFERENTIAL DIAGNOSIS

Testing should be performed to rule out primary neuromuscular, lung, and cardiac disease as well as an identifiable brainstem lesion that could account for the symptoms characteristic of CCHS (Table 468.5). The availability of clinical *PHOX2B* genetic testing allows for early and definitive diagnosis of CCHS (see Table 468.3). Because individual subfeatures of CCHS mimic many treatable and/or genetic diseases, the following disorders should also be considered: altered airway or intrathoracic anatomy (diagnosis made with bronchoscopy and chest CT), diaphragm dysfunction (diagnosis made with diaphragm fluoroscopy), a structural hindbrain or brainstem abnormality (diagnosis made with MRI of the brain and brainstem), Möbius syndrome (diagnosis made with MRI of the brain and brainstem and neurologic examination), and specific metabolic diseases, such as Leigh syndrome, pyruvate dehydrogenase deficiency, and discrete carnitine deficiency. However, profound hypercarbia without respiratory distress during sleep will quickly lead the clinician to consider the diagnosis of CCHS or LO-CCHS.

MANAGEMENT

Supported Ventilation: Diaphragm Pacing

Depending on the severity of the hypoventilation, the individual with CCHS can have various options for artificial ventilation: positive pressure ventilation (noninvasive via mask or invasive via tracheostomy) or negative pressure ventilation (pneumosuit, chest cuirass, or diaphragm pacing). Chronic mechanical ventilation is addressed in Chapters 468.1 and 468.4. Diaphragm pacing offers another mode of supported ventilation, involving bilateral thoracoscopic implantation of electrodes beneath the phrenic nerves, with connecting wires to subcutaneously implanted receivers. The external transmitter, which is much smaller and lighter in weight than a ventilator, sends a signal to flat, donut-shaped antennae that are placed on the skin over the subcutaneously implanted receivers. A signal travels from the external transmitter to the phrenic nerve to stimulate contraction of the diaphragm. A tracheostomy is typically required, because the pacers induce a negative pressure on inspiration as a result of the contraction of the diaphragm being unopposed by pharyngeal dilatation, resulting

Table 468.4 Recommended Evaluations in Patients with CCHS

	EVALUATION	FREQUENCY	*PHOX2B* GENOTYPE
Pulmonary	Comprehensive physiologic testing during sleep and wakefulness, including continuous pulse oximetry, cardiorespiratory monitoring, capnography, and polysomnography	<3 yr of age: every 6 mo ≥3 yr: annually	All *PHOX2B* PARM and NPARM
Cardiovascular	Ambulatory cardiac monitoring (≥72 hr), blood pressure, and echocardiogram	Annually	All *PHOX2B* PARM and NPARM
Gastrointestinal	Barium enema or anorectal manometry; confirmation by rectal biopsy	At initial diagnosis and subsequently if symptoms appear	20/26-20/33 PARM and NPARM
Neurodevelopmental	Comprehensive neurocognitive tests	<3 yr of age: every 6 mo ≥3 yr: annually	All *PHOX2B* PARM and NPARM
Oncologic	Chest radiograph, abdominal ultrasound, and urine catecholamines (homovanillic acid and vanillylmandelic acid)	0-6 yr of age: every 3 mo 6-10 yr of age: every 6 mo >10 yr of age: per oncologist recommendation	20/28-20/33 PARM and NPARM
Ophthalmologic	Comprehensive ocular testing by an ophthalmologist	Annually	All *PHOX2B* PARM and NPARM

NPARM, Nonpolyalanine repeat expansion mutation; PARM, polyalanine repeat expansion mutation; PHOX2B, paired-like homeobox 2B.
Data from the 2010 American Thoracic Society Statement on CCHS *Am J Respir Crit Care Med.* 2010;181:626–644.
From Kasi AS, Li H, Harford KL, et al. Congenital central hypoventilation syndrome: optimizing care with a multidisciplinary approach. *J Multidisp Healthcare.* 2022;15:455–469, Table 1. Originally published by and used with permission from Dove Medical Press Ltd.

Table 468.5 Differential Diagnoses of Congenital Central Hypoventilation Syndrome

METABOLIC
Mitochondrial defects (e.g., Leigh disease)
Pyruvate dehydrogenase deficiency
Hypothyroidism
NEUROLOGIC
Structural central nervous system abnormalities (e.g., Arnold Chiari malformation, Möbius syndrome)
Vascular injury (e.g., central nervous system [CNS] hemorrhage, infarct)
Trauma
Tumor
PULMONARY
Primary lung disease
Respiratory muscle weakness (e.g., diaphragm paralysis, congenital myopathy, myasthenia gravis)
GENETIC
Prader-Willi syndrome
Familial dysautonomia and other neuropathies
OTHER
Sedative drugs
Rapid-onset obesity, hypothalamic dysregulation hypoventilation, autonomic dysregulation (ROHHAD)

Modified from Healy F, Marcus CL. Congenital central hypoventilation syndrome in children. *Pediatr Respir Rev.* 2011;12:253–263, Table 1.

in airway obstruction with paced breaths. Individuals with CCHS who are ventilator-dependent for 24 hours a day are ideal candidates for diaphragm pacing to provide increased ambulatory freedom (without the ventilator tether) while they are awake; however, they still require mechanical ventilator support while they are asleep. This balance between awake pacing and asleep mechanical ventilation allows for a rest from phrenic nerve stimulation at night. In addition, a growing but still limited number of children and adults who require artificial ventilatory support only during sleep are now using diaphragm pacing. This is likely because of the introduction of thoracoscopic diaphragm pacer implantation and shortened postoperative recovery time. However, in the absence of a tracheostomy, diaphragm pacing during sleep may cause airway obstruction at varied levels of the airway, depending on the specific patient. The potential for these obstructions needs to be carefully considered before diaphragm pacer implantation, and certainly before tracheal decannulation.

Monitoring in the Home

Home monitoring for individuals with CCHS and LO-CCHS is *distinctly different* from and more conservative than that for other children requiring long-term ventilation, because CCHS individuals lack innate ventilatory and arousal responses to hypoxemia and hypercarbia. In the event of physiologic compromise, other non-CCHS children will show clinical signs of respiratory distress. By contrast, for children and adults with CCHS and LO-CCHS, the only means of determining adequate ventilation and oxygenation is with objective measures from a pulse oximeter, end-tidal CO_2 monitor, and close supervision of these values by a highly trained registered nurse (RN) in the home and at school. While awake, patients with CCHS themselves are unable to sense or adequately respond to a respiratory challenge that may occur with ensuing respiratory illness, increased exertion, or even the simple activity of eating. At a minimum, it is essential that individuals with CCHS have continuous monitoring with pulse oximetry and end-tidal CO_2 with RN supervision during all sleep time, but ideally 24 hours a day. These recommendations apply to all CCHS and LO-CCHS patients regardless of the nature of their artificial ventilatory support, but especially those with diaphragm pacers, as only the most recent transmitter has mechanical dysfunction alarms intrinsic to the diaphragm pacer device.

Noninvasive Ventilatory Support Equipment

Supplemental oxygen with positive pressure support can be administered by nasal cannula, pillows, nasal mask, or full-face mask via an actual ventilator, but this is suitable only for highly cooperative children with milder hypoventilation during sleep only. Long-term use of mask ventilation in infants and young children may result in

midface dysplasia or pressure wounds. Mask ventilation does not offer the stable airway provided by a tracheostomy with mechanical ventilation, especially in the rapidly developing infant and young child.

Positive Pressure Ventilators

Ideally, a ventilator intended for home use is lightweight and small, quiet so it does not interfere with activities of daily living or sleep, is able to entrain room air, preferably has continuous flow, and has a wide range of settings (particularly for pressure support, pressure, volume, and rate) that allows ventilatory support from infancy to adulthood. Battery power for the ventilator, both internal and external, should be sufficient to permit unrestricted portability in the home and community. The equipment must also be impervious to electromagnetic interference and must be relatively easy to understand and troubleshoot. Children who are chronically ventilated via positive pressure ventilation will require surgical placement of a tracheostomy tube. The tracheostomy tube provides stable access to the airway, a standardized interface for attaching the ventilator circuit to the patient, and the ability to easily remove airway secretions or deliver inhaled medications. Pediatric tracheostomy tubes typically have a single lumen and may have an inflatable tight-to-the-shaft cuff. Tracheostomy tubes with and without cuff inflation should be sized to control the air leak around the tube and promote adequate gas exchange yet allow enough space around the tube to facilitate vocalization and prevent tracheal irritation and erosion from the tube.

Optimizing Neurocognitive Performance

Impaired oxygen delivery to the brain, whether acute or chronic, can have detrimental effects on neurocognitive development. The ATS statement on CCHS recommends positive pressure ventilation via tracheostomy in the first several years of life to ensure optimal oxygenation and ventilation. The method of choice for respiratory support in later years will depend on a variety of factors, including severity of disease, patient age, level of patient and family cooperation, and availability and quality of home healthcare, among other factors. The level of oxygen stability obtained with each modality varies. Thus the method of respiratory assistance, especially in infancy and early childhood, is likely to play a factor in neurocognitive outcome.

Past literature has indicated reduced neurocognitive performance in school-age children with CCHS, with mean full scale intellectual quotient (IQ) values one standard deviation below the normal IQ of 100. Even in preschool years, children with CCHS and the 20/26 and 20/27 *PHOX2B* genotypes demonstrate reduced neurocognitive performance compared to children with the 20/25 genotype. In these cases, *PHOX2B* genotype is clearly associated with both mental and motor outcomes. An association is also found between IQ and CCHS-related features such as severe cyanotic breath holding spells, sinus pauses, seizures, and severity of hypoventilation. One study reported a negative correlation between neurocognitive performance scores and length of polyalanine expansion, suggesting that both the specific gene variant and ventilatory method may influence neurocognitive outcome. Findings from a neurocognition study in preschool-age children suggest the potential for excellent neurocognitive outcome in some patients with CCHS. Neurodevelopmental monitoring would be most beneficial beginning in early infancy and followed closely with advancing age.

Efforts are underway to evaluate and characterize the CCHS phenotype longitudinally through the International CCHS Registry (https://clinicaltrials.gov/show/NCT03088020) (Northwestern University). Delineating markers of disease progression and understanding the clinical manifestations of CCHS with advancing age will provide more accurate guidelines to healthcare providers, allowing physicians, families, and patients to better anticipate healthcare needs of affected individuals and for use as biomarkers for future pharmacologic intervention studies.

Visit Elsevier eBooks+ at eBooks.Health.Elsevier.com for Bibliography.

468.3 Rapid-Onset Obesity with Hypothalamic Dysfunction, Hypoventilation, and Autonomic Dysregulation

Sarah F. Barclay, Ilya Khaytin, Amy Zhou, Casey M. Rand, and Debra E. Weese-Mayer

Rapid-onset obesity with hypothalamic dysfunction, hypoventilation, and autonomic dysregulation (ROHHAD) is a rare, poorly understood disorder with childhood onset, the first sign of which is sudden, rapid, and extreme weight gain in a previously healthy child. The acronym describes the presenting symptoms and the typical order in which they will manifest or unfold, as the condition evolves over months to years. Despite its rarity, *ROHHAD must be considered whenever rapid-onset obesity is observed in a child, because in the absence of appropriate treatment, a high mortality rate is associated with the severe central hypoventilation that will invariably develop.*

The diagnosis is initially considered after the observation of rapid-onset obesity (15-20 lb gain) after age 1.5 years, accompanied by at least one additional sign of hypothalamic dysfunction (HD). *Central hypoventilation may not be present at the time of rapid weight gain but will develop over time, and artificial ventilatory support will be required at least during sleep, if not 24 hours a day.* Signs of autonomic nervous system dysregulation typically occur after the weight gain, HD, and hypoventilation have been identified. Additionally, approximately 40% of ROHHAD patients will have or develop a tumor of neural crest origin, typically ganglioneuroma or ganglioneuroblastoma (a small number of neuroblastomas have been identified).

ROHHAD is distinct from LO-CCHS (see Chapter 468.2). ROHHAD is primarily distinguished from LO-CCHS by the presence of obesity and other signs of HD and by the absence of a CCHS-related pathogenic *PHOX2B* variant.

CLINICAL MANIFESTATIONS

Children with ROHHAD initially appear healthy, with an unremarkable medical history. The *initial* symptoms present between ages 18 months and 7 years. Typically, the first symptom observed is **rapid-onset obesity**, with weight gain of 15-30 lb in 6-12 months. The growth charts from a representative child followed longitudinally illustrate the characteristic accelerated increase in weight and body mass index (BMI) (Fig. 468.2). This is considered one sign of HD in these patients.

The second common sign of HD, seen in most ROHHAD patients, is **disordered water balance**, including hypernatremia and hyponatremia and both adipsia and polydipsia. **Growth hormone (GH) deficiency** is also observed in most patients. In some, this manifests clinically as slowed growth rate and short stature, whereas in others a failed GH stimulation test is the only manifestation. **Hyperprolactinemia** is observed near universally in patients with ROHHAD. Other symptoms of HD, occurring in >25–50% of ROHHAD patients, include **poor thermoregulation**, **central hypothyroidism**, **central adrenal insufficiency**, and **delayed or precocious puberty**. The number of hypothalamic abnormalities that will be observed and the sequential order in which they will appear are variable, and some symptoms may not manifest for months to 1-2 years after the initial diagnosis. However, all ROHHAD patients will present with at least one of these signs of HD beyond the rapid-onset weight gain.

Sleep-disordered breathing (SDB) is one of the key symptoms of ROHHAD, often manifesting as one of the most severe features of the phenotype, with the greatest potential for severe morbidity and death. More than half of ROHHAD patients have initial **obstructive sleep apnea (OSA)**; although SDB is known to be associated with obesity and OSA is often seen in obese individuals, over time, when the ROHHAD phenotype unfolds, SDB will evolve beyond what could potentially be explained as obesity related. All ROHHAD patients will eventually develop **central alveolar hypoventilation**, requiring artificial ventilation as life support, even when the upper airway obstruction is relieved as an intervention for OSA. About half of ROHHAD patients will require artificial ventilation only during sleep, whereas half will require

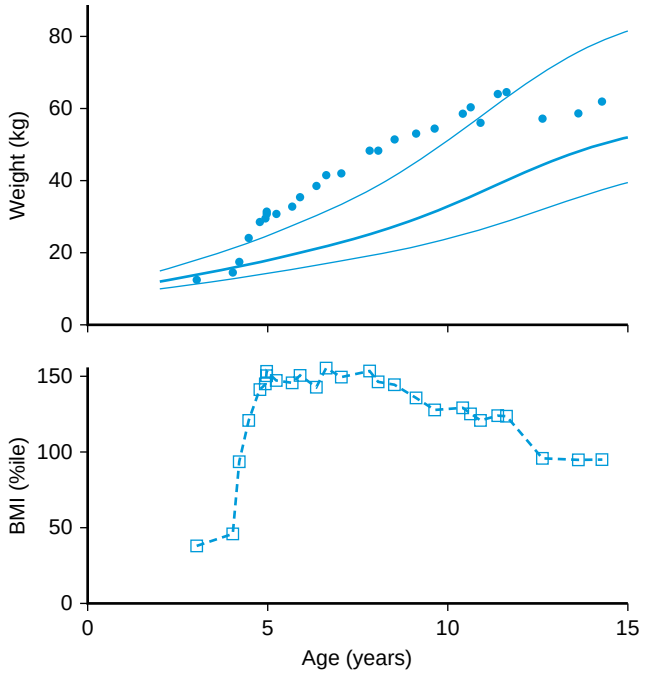

Fig. 468.2 Growth curves of weight and body mass index *(BMI)* from an individual child with ROHHAD. Weight and BMI percentiles for a child with ROHHAD from the time of diagnosis until age 14.3 yr, demonstrating the rapid onset of obesity. Weight and BMI percentiles were calculated using published CDC growth charts and methods. *Solid lines* in weight graph represent 3rd, 50th, and 97th percentiles. *Dots* and *open squares* are individual measurements for the child.

continuous artificial ventilation (during sleep and wakefulness). Up to 50% of children with ROHHAD will have a cardiorespiratory arrest before their hypoventilation is identified and treated. Unfortunately, many ROHHAD patients die from cardiorespiratory arrest because of unrecognized or inadequately managed hypoventilation. Thus if a ROHHAD diagnosis is suspected, it is crucial that a comprehensive respiratory physiology evaluation be performed, including overnight polysomnography and awake physiologic recording in activities of daily living and followed serially long after the hypoventilation is identified and intervention provided.

All ROHHAD patients have symptoms of **autonomic nervous system (ANS) dysregulation (ANSD)**; the specific symptoms and the order and timing of their appearance will vary among patients. The most common manifestations of ANSD in ROHHAD are ophthalmologic, including **pupillary dysfunction**, **strabismus**, and **alacrima**. Many ROHHAD patients will have **gastrointestinal dysmotility**, presenting as either chronic constipation or, less commonly, chronic diarrhea. Other signs of ANSD include **altered sweating**, **decreased body temperature**, **decreased sensitivity to pain**, and **cold hands and feet** indicating altered vasomotor tone. **Bradycardia** is observed in some ROHHAD patients, typically related to **extreme hypothermia**.

Neural crest tumors are observed in ~40% of ROHHAD patients, most frequently ganglioneuromas and ganglioneuroblastomas of the chest or abdomen; rarely a neuroblastoma has been reported. These tumors can occur at any age, so proactive imaging evaluation throughout childhood and adolescence to identify the tumors is essential.

Patients do not always have behavioral or psychologic disorders if artificial ventilation is optimized. For those who do, however, the disorders can be quite severe, including anxiety, depression, rage, lethargy, irritability, aggressiveness, psychosis, and obsessive-compulsive disorder. Developmental disorders described include neurocognitive delay, developmental regression, attention-deficit/hyperactivity disorder, and pervasive developmental disorder. These disorders are most likely accentuated by poorly managed hypoventilation because the majority of ROHHAD patients have no behavioral issues and a normal IQ.

Seizures have been reported in some ROHHAD patients, likely caused by episodes of hypoxemia, when hypoventilation either has not yet been diagnosed or has been inadequately managed.

DIAGNOSIS

The diagnostic criteria for ROHHAD include rapid-onset obesity after 1.5 years of age; central hypoventilation beginning after age 1.5 years; ≥1 of the following signs of HD: disordered water balance, hyperprolactinemia, failed GH stimulation test, central hypothyroidism, corticotropin deficiency, and altered onset of puberty; and features of autonomic dysregulation. Additionally, it must be *confirmed* that no CCHS-related *PHOX2B* pathogenic variant is present to rule out a diagnosis of CCHS or LO-CCHS.

Because no single diagnostic test is currently available for ROHHAD, the diagnosis must be based on observation of the clinical presentation and therefore requires expert consultation in multiple pediatric subspecialties, including respiratory physiology, endocrinology, autonomic medicine, cardiology, oncology, nutrition, critical care, sleep, and psychiatry, with orchestration by the child's pediatrician. When a child with rapid-onset obesity is seen by a general pediatrician or family physician, the steep trajectory of weight gain should signal prompt consideration of a ROHHAD diagnosis, with immediate referral to a center with expertise in this unique constellation of symptoms. Early recognition is critical for a positive outcome in children with ROHHAD. *If alveolar hypoventilation is not identified and aggressively managed, cardiorespiratory arrest can occur and has proved fatal in many cases.*

A **characteristic set of facial features** has been described for CCHS, which, using facial photogrammetry, is able to identify 86% of genetically confirmed CCHS cases (see Chapter 468.2). Although such formal evaluation of ROHHAD facies has not been completed, a preliminary report indicates that ROHHAD patients have similar facial mapping characteristics to CCHS patients, especially the characteristic **"lip trait,"** in which the lateral one third of the upper vermillion border is flesh-colored instead of pink (Fig. 468.3). This is distinct from the general lip changes observed with increasing BMI in a study of adolescent females, which include fuller-looking lips and downturned corners of the mouth.

Initial evaluations should include overnight polysomnography to identify OSA or central hypoventilation, awake comprehensive physiologic recording in age-appropriate activities of daily living, cardiac evaluation to assess for cor pulmonale and rhythm disturbance, endocrine function evaluation, screening for neural crest tumors (chest radiograph, abdominopelvic ultrasound, or meta-iodobenzylguanidine [MIBG] scan), and a behavioral and psychological evaluation, especially if any behavioral, psychologic, or developmental disorders are seen or suspected. Brain imaging should be performed to rule out intracranial lesions that may account for the observed hypothalamic-pituitary abnormalities (using the hypothalamic-pituitary protocol). If the criteria are met and a ROHHAD diagnosis is made, successful management requires ongoing teamwork among the various subspecialists, with a pediatrician team leader to orchestrate all testing, the family, and the child to provide optimized integrated care for the child.

MANAGEMENT

There is currently no cure for ROHHAD. Rather, treatment consists of early identification, meticulous monitoring, and anticipatory along with symptomatic management of the various phenotypic features as they develop ("unfold"). Comprehensive initial evaluations should determine the nature and severity of hypoventilation, HD, and ANSD, and appropriate interventions should be implemented in a time-sensitive manner. Obesity in ROHHAD is very difficult to control, but in consultation with a nutritionist and endocrinologist, the trajectory of advancing weight gain can be diminished with moderate exercise and calorie restriction, leading to improved BMI with advancing age. Specific signs of HD and ANSD should be evaluated by a pediatric endocrinologist and expert in pediatric autonomic medicine, respectively, and treated as necessary longitudinally as the phenotype

Fig. 468.3 Characteristic CCHS "lip trait" shown in a child with ROHHAD. Shown here is the mouth of a child with ROHHAD at age 4 (A) and 11 (B) years. The lateral one third of the upper vermillion border is flesh-colored instead of pink. This is not a characteristic feature of obese faces in general (the upper lip is neural crest in origin).

"unfolds" and "refolds." Such treatments or management strategies may include hormone replacement; regimented fluid intake; ophthalmologic assessment and treatment; longitudinal monitoring of peripheral, core, and ambient temperature; and management of constipation with stool softeners. Disordered water balance to prevent dehydration should be addressed, as well as regulation of heart rate, because bradycardia is seen in some patients (usually with decreased core temperature), though cardiac pacemakers are rarely indicated.

Neural crest tumors should be assessed and resected by a pediatric surgeon together with a pediatric oncologist, because the sheer size of these benign tumors creates serious compromise to surrounding tissues. If no tumor is identified initially, screening should continue every 6 months until adulthood, because a malignant neuroblastoma has been identified in an adolescent ROHHAD patient.

Most critical is the management of hypoventilation. Initial intervention for OSA will likely involve surgical relief of the upper airway obstruction. This will usually unveil central hypoventilation, and initiation of supported ventilation will be required. If no central hypoventilation is identified, the patient should continue to be vigilantly monitored by a respiratory physiologist because all ROHHAD patients will eventually develop central hypoventilation requiring artificial ventilation during sleep at a minimum. Individuals with ROHHAD have attenuated to absent physiologic responsiveness to hypoxemia/hypercarbia, and they lack behavioral awareness of hypoxemia/hypercarbia. Optimal oxygenation and ventilation can then be maintained using a mechanical ventilator with mask initially then, if necessary, by tracheostomy to secure the airway and optimize ventilation. This should be accompanied by highly trained home nursing and continuous monitoring with oximetry and capnography during sleep, with spot checks during wakefulness. The goal should be to maintain hemoglobin saturation values of ≥95% and end-tidal CO_2 values of 35-45 mm Hg, with vigilant evaluation for awake hypoventilation necessitating artificial ventilation up to 24 hours a day as necessary.

Given that the ROHHAD phenotype evolves with advancing age, ongoing care requires regularly scheduled evaluation of all the systems involved to identify and treat further symptoms as they appear. Comprehensive evaluation should ideally occur at a Center of Excellence for ROHHAD and should include respiratory physiology assessment both asleep and awake (in varied levels of age-appropriate exertion, concentrational tasks, quiet play, and eating), screening of chest and abdomen for neural crest tumors in the adrenals or along the sympathetic chain, evaluation of the hypothalamic-pituitary axis with hormonal replacement as necessary, age-appropriate noninvasive evaluation of ANS dysregulation, comprehensive cardiac evaluation for sequelae of recurrent hypoxemia and/or bradycardia, and neurocognitive testing. These evaluations should initially occur at 2- to 3-month intervals, but this schedule may be altered with advancing age, depending on each patient's clinical condition.

With proper and meticulous management, the ROHHAD phenotype has been observed to "refold," with the possibility of achieving weight control, eventually recovering spontaneous awake breathing, and improvement of other autonomic measures. Without proper management, oxygen deprivation can lead to irreversible deterioration in patients. However, with prompt diagnosis and aggressive management, including careful attention to the child's airway, breathing, and circulation, complications can be minimized and the prognosis can be quite favorable, although long-term outcome remains the focus of an international registry (https://clinicaltrials.gov/show/NCT03135730).

Paraneoplastic/Autoimmune Hypothesis

Paraneoplastic syndromes are rare disorders caused by a neoplasm triggering an altered immune response that aberrantly attacks and destroys neurons, leading to the nervous system symptoms. An autoimmune or paraneoplastic basis for ROHHAD has been suggested based on neural crest tumors occurring in 40% of ROHHAD patients and reports of encephalitis seen on autopsy. The evidence so far is conflicting, with some reports supporting the autoimmune hypothesis, whereas others do not. Further, the onset of ROHHAD symptoms often precedes identification of a neural crest tumor in ROHHAD patients, and in many cases, neural crest tumors have not been discovered with MRI or even an autopsy. Of note, with excision of the identified neural crest tumor there has not been consistent "recovery" from ROHHAD. Rather, the ROHHAD phenotype continues to "unfold."

DIFFERENTIAL DIAGNOSIS

Congenital central hypoventilation syndrome is a rare pediatric disorder of the ANS and respiratory control. CCHS is caused by pathogenic variants in the *PHOX2B* gene, which plays an important role in the differentiation and development of the ANS from neural crest progenitor cells (see Chapter 468.2). The hallmark feature of CCHS is life-threatening hypoventilation while sleeping (and, in some cases, also while awake). CCHS patients require artificial ventilatory life support, typically by tracheostomy and mechanical ventilator. Unlike ROHHAD, however, CCHS usually presents in the newborn period, although later-onset CCHS has been diagnosed after 1 month of age, in later childhood, in adolescence, and even in adulthood. CCHS also presents with other symptoms of ANS dysregulation, including altered heart rate regulation, vasomotor tone, and temperature regulation, ophthalmologic manifestations, and reduced gastrointestinal motility. However, CCHS patients *are not* obese and only rarely have isolated measures of HD. When hypoventilation is observed, a simple blood test can confirm a CCHS diagnosis by looking for pathogenic *PHOX2B* variants.

Prader-Willi syndrome (PWS) shares childhood obesity as one of the most prominent features with ROHHAD. PWS is caused by chromosomal abnormalities at chromosome 15q11-q13, specifically by a lack of the paternal contribution at this region (from genomic deletion, uniparental disomy, or imprinting error), whereas methylation differences, loss of heterozygosity, and pathogenic variants in this region

have been ruled out in a ROHHAD cohort. Infants with PWS present with neonatal hypotonia and failure to thrive (malnutrition). Later, children with PWS develop extreme hyperphagia and obesity. Other major symptoms of PWS include intellectual impairment, maladaptive behaviors, short stature caused by GH insufficiency, hypogonadism, and SDB. In addition, many PWS patients show signs of ANS dysregulation, including altered temperature perception and regulation, strabismus, and high pain threshold.

ROHHAD should also be distinguished from other **obesity-related genetic disorders**. Smith-Magenis syndrome, Carpenter syndrome, and 16p11.2 deletion syndrome present with obesity. However, all of them are additionally marked by early developmental delay, unlike ROHHAD, which has normal neurodevelopment in the absence of cardiorespiratory arrest. Therefore testing for genetic causes of obesity should be undertaken in obese children whose phenotype does not appear to match that of ROHHAD.

Visit Elsevier eBooks+ at eBooks.Health.Elsevier.com for Bibliography.

468.4 Long-Term Ventilation and Technology Support: Indications, Principles, Decision-Making, Pragmatics, and Home Provision

Robert J. Graham

INDICATIONS, GOALS, AND DECISION-MAKING

The decision to implement LMV has many challenges from a diversity of underlying pathophysiology, uncertain disease trajectories, the development of new condition-specific therapies, personal experiences, and values held by providers, patients, parents, and the broader community, variability in resources, and lack of standards. Although optimizing gas exchange (i.e., oxygenation and CO_2 removal), mitigating the impact of intercurrent respiratory infections, and supporting neuromuscular-skeletal limitations, growth, and development remain among the primary objectives, LMV represents a tool for the comprehensive care of children with complex needs.

LMV has a role within the broad spectrum of palliative care. It is used proactively to attenuate cumulative morbidities (respiratory and cardiac) associated with progressive neuromuscular conditions, such as Duchenne muscular dystrophy. LMV is also used reactively when acute illness (e.g., acute respiratory distress syndrome or an acute flaccid myelitis) does not resolve. In infants with premature lung disease or complex airway anomalies, LMV may be implemented as a temporary measure, as these conditions may improve with maturity or surgical interventions. LMV can also represent a bridge to lung transplant for those with intrinsic pulmonary or pulmonary vascular disease. More commonly, LMV has become a destination therapy to optimize symptom management and prolong life in complex conditions. Etiologies of the chronic respiratory failure include but are not limited to congenital anomalies (e.g., complex cardiac conditions, central nervous system disorders, interruptions in aerodigestive morphogenesis, and skeletal dysplasias), acquired central neurologic injuries from perinatal, infectious, traumatic, and hypoxic-ischemic events, metabolic disorders, or progressive neuromuscular conditions. Progress in other areas of medicine, such as gene-targeted therapy in spinal muscular atrophy and myotubular myopathy, may alter the LMV decision-making landscape as families foresee the prospect of improvement.

NONINVASIVE AND TRANSTRACHEAL SUPPORTS

The essential modalities for LMV include negative pressure, noninvasive positive pressure ventilation (NIPPV with either continuous or biphasic support provided through an occlusive mask interface), or transtracheal positive pressure. Considerations for a given child or young adult should include but are not limited to anatomic factors, physiologic goals, long-term care goals, comfort, tolerability/compliance, and safety (mobility/portability, monitoring, device availability and backup, training capacity).

Negative pressure devices, such as the cuirass ventilator, do not require any interface with the face or trachea and are more *natural* from a mechanical perspective. The need for oxygen supplementation is not addressed directly through such a device. *NIPPV* can address dynamic upper airway obstruction and can augment respiratory mechanics and gas exchange. This modality may, however, have limitations if upper airway obstruction is severe or fixed or the need for oxygen supplementation is high. Masks, prongs, and pillows of varying sizes are available for nasal, oral, combination, and full interface, including those for infants. A mouthpiece interface has also been demonstrated to be effective and feasible. The choice of continuous positive airway pressure (CPAP) versus biphasic positive airway pressure (BiPAP) is dependent on the underlying pathophysiology. Conceptually, CPAP can overcome a dynamic upper airway obstruction and allow for spontaneous ventilation, while BiPAP is more versatile in compensating for upper airway obstruction and supporting lung recruitment and gas exchange. CPAP is limited to management of mild OSA. In addition, BiPAP may allow for home escalation for the management of intercurrent illness with oversight of the medical team. Although NIPPV can be maintained 24 hours a day, efficacy of ventilation, difficult airway considerations (i.e., whether the child can anatomically be intubated), developmental needs, implications for midface hypoplasia, and secretion clearance are among factors that affect the decision to pursue tracheostomy placement and invasive LMV.

Transtracheal LMV provides the most secure and effective respiratory support. Fixed and dynamic upper airway obstruction is bypassed with tracheostomy tube placement. Secretions are more readily cleared from the lower airway. Positive pressure and oxygen delivery via a tracheostomy tube more consistently address primary impairments in gas exchange (within limits) as well as mechanical disadvantages from neuromuscular insufficiency and restrictive disease. When possible, placement of a tracheostomy tube in a child should be coordinated at an institution with pediatric expertise, including in long-term tracheostomy care, because the short-term morbidities and, potentially, mortality are not insignificant.

Individuals using NIPPV are at risk for pressure ulcerations on the face and on the scalp. Proper fit of the interface must be assured because a tighter fit is not necessarily commensurate with better support. Alternating masks on a regular basis may alleviate pressure on a given site. Additional nonadhesive dressings can also be used to facilitate the mask seal and minimize skin breakdown. For those with a tracheostomy tube in place, care of tracheostomy ties and regular assessment of the stoma are required. Moisture-wicking dressings can attenuate risk of maceration, but their use should be balanced against the value of exposure to air for drying. Stomal assessment should include evaluation for granulation, fissures, and traction created by additional torque from ventilator tubing, which should be maintained midline and without weight displacement on the tracheostomy tube itself. Any areas of integument interruption are potential niduses for infection and of great concern for immunocompromised hosts.

AUGMENTED SECRETION CLEARANCE

See Chapter 468.1.

AERODIGESTIVE AND COMMUNICATION CONSIDERATIONS

Assessment of swallowing and speaking capacity should be part of an assessment for LMV and may help guide the modality. Implementation of noninvasive or transtracheal supports will not further impair either of these functions. Rather, the underlying condition is the primary determinant. This consideration is most notable in children or young adults with neurologic injury or neuromuscular conditions. Decision-making around placement of a transabdominal gastric or gastrojejunal enteral feeding tube, if not already in place, should coincide with decisions around LMV. Nasogastric tubes, it should be appreciated, may impair the NIPPV mask seal and cause laryngeal irritation in the long term. Antireflux surgery (i.e., fundoplication) should also be discussed

at this time as providers consider ongoing implications of esophageal reflux, aerophagia, and challenges maintaining jejunostomy tubes.

Use of NIPPV must be approached cautiously in those with impaired swallowing, as positive pressure will increase the risk of macroaspiration and microaspiration. Individuals using NIPPV can eat and drink while on support with risk versus benefit determination and assessment of impact on quality of life. Aerophagia on NIPPV is also problematic, regardless of bulbar function and swallowing capacity; abdominal distention is uncomfortable, contributes to satiety and vomiting risk, and further impairs respiratory mechanics with decreased functional residual capacity and increased inspiratory workload. If a gastrostomy is present, active evacuation of swallowed air and use of passive *venting* tubes can be helpful.

Children with swallowing capacity can continue to eat and drink by mouth with a tracheostomy tube in place on LMV. The presence of a cuffed tracheostomy tube does not prevent aspiration if swallowing is impaired. Speaking may be facilitated by LMV, as settings can be increased or a speaking valve used to increased airflow across the vocal cords. Regardless, multidisciplinary care with a speech-language pathologist, feeding specialist, and augmented communication services can be helpful for many children and their families using LMV. Conditioned aversions to oral stimulation can be challenging for infants, but developmental gains should not be impeded by LMV.

GAS EXCHANGE AND VENTILATOR STRATEGIES

Pressure- or volume-regulated modes, spontaneous or controlled settings, and mixed modes are all feasible for NIPPV and transtracheal supports with new devices. The appropriate support should coincide with oxygenation and ventilation goals on a case-by-case basis. Consideration, however, should be given to the site of care and contingencies for presentation to acute cure during intercurrent illness or emergency. Providers should assess limitations in oxygen supplementation outside of the hospital; measured or estimated delivered fractional inspired oxygen (FIO_2) will inform families and providers of capacity when adding oxygen in liters/minute flow to the ventilator circuit; dilution can have a dramatic effect, and achieving FIO_2 >0.60 may be difficult when oxygen is added to a home ventilator circuit. Safety allowances should also account for the duration of portable oxygen provision, which is based upon liter flow and tank/reservoir volume.

Monitoring of CO_2 in the homecare setting is not usual, although portable end-tidal CO_2 devices are available. Conditions such as CCHS warrant vigilance, and parameters for implementation, or titration, of mechanical ventilation should be discussed with families. Recognition that significant and indolent hypercapnia can precede hypoxia is necessary, and long-term effects on cerebral and pulmonary vasculature should be considered. In the absence of direct CO_2 monitoring, periodic measurement of serum bicarbonate may be helpful to assess for renal compensation for altered CO_2 clearance; however, interpretation may be altered in the presence of diuretic therapy, metabolic disease, or ketogenic diets.

CARDIOPULMONARY INTERACTIONS

Closely linked to the gas-exchange goals are considerations for cardiopulmonary interactions. Although there are subtle implications for systemic venous return of any form of positive pressure ventilation, LMV can be used to decrease transmural myocardial load and to optimize right ventricular afterload through lung recruitment and pulmonary vascular reactivity. The prolonged survival of young males with Duchenne muscular dystrophy is in part the result of consistent respiratory support to optimize lung health and to attenuate myocardial dysfunction. Primary or secondary pulmonary hypertension, whether overt or indolent, requires consideration of oxygenation and ventilation goals. Echocardiograms are not required for all children or young adults with LMV, but this modality may be helpful to guide management in cohorts with congenital heart lesions, cardiomyopathies, severe obstructive pulmonary disease, significant central dysregulation, and on a case-by-case basis.

When considering gas-exchange goals and cardiopulmonary interactions, providers must also consider daytime and nocturnal differences. Neuromuscular-derived hypoventilation is more prominent at night, as is upper airway obstructive disease; the latter is more important for those using noninvasive LMV. Daytime support provision must account for increased oxygen consumption and demand based on variable activity and stressors, including environmental temperature. Providers and families must factor in mobility, behavioral tolerance, and quality of life.

CHEST WALL/THORACIC CONFIGURATION

Positive pressure through LMV in early childhood for children with neuromuscular conditions and/or restrictive lung disease is also used to improve thoracic compliance and configuration. Lung inflation can be used to attenuate the impact of thoracic asphyxiation as well as progressive parasol chest deformation in diaphragm-dependent conditions, such spinal muscular atrophy. This use has implications for atelectasis and secretion inspissation, associated pulmonary vasoconstriction, and cumulative restrictive or asymmetric pulmonary mechanics.

NUTRITION AND WEIGHT GAIN

See Chapter 468.1.

DEVELOPMENTAL CONSIDERATIONS

Decisions regarding the LMV modality, noninvasive or transtracheal, requires consideration of development as well. Beyond safety factors, tolerance of interventions, availability of appropriate-sized interfaces, and portability, there remains substantial subjectivity with respect to perspective on the implication for social interactions (i.e., devices covering the face versus a device in the neck). Although there are no published series, long-term or near-continuous NIV also has implications for midface hypoplasia and potentially compounds upper airway obstructive symptoms, as is evident by images of *BiPAP faces*. Swallowing and speech capacity primarily reflect the child's underlying condition and conditioned aversions rather than the LMV itself.

PROJECTED INTERVENTIONS AND NEEDS

The trajectory and management of the underlying disease, as well as symptom management, are the primary drivers in determining the need and duration of LMV. Stakeholders should also consider future interventions, specifically surgical procedures. LMV, noninvasive or transtracheal, can be used to optimize perioperative standing and facilitate recovery and provision of opiate-based analgesia that could alter respiratory drive. The maintenance of a tracheostomy tube in anticipation of sequential surgeries (e.g., spinal instrumentation, craniofacial and airway reconstruction, or serial cardiac interventions) may be required for practical reasons but also minimizes the need for repeated intubation.

PREPARING FOR THE LIVED EXPERIENCE OF LMV AND OTHER TECHNOLOGY SUPPORTS

Emotional challenges are associated with the integration of technology supports into "routine" care and assuming an altered role as a parent and care provider. Addressing practical needs, however, can help attenuate some of the anxiety and allow families to focus on, or revisit, the global goals of care, quality of life, and the role of technology. The family will need to consider each of the following implications.

Financial (e.g., insurance, subsidies, alternative funding, and parental employment): Independent of personal resources, the majority of families with children requiring technology assistance report some degree of financial burden. These costs arise from the direct outlay for equipment and medications, lost work time or need to discontinue/change vocations, home adaptations, and other indirect costs. Accessing a financial counselor or case manager may help identify and navigate through local, state/regional, and government/federal resources. Additional considerations should also be paid to personal trusts, wills, and estate planning, as all of these have implications for long-term benefits and financial supports for the individual with special healthcare needs.

Equipment and supplies: Ideally, the equipment intended for use at home will be tested before discharge to home. Testing ensures proper function and any tolerance. Electrical compatibility with the home

service should be confirmed. Delivery of backup devices (e.g., tracheostomy tubes, including a smaller size for contingency planning; batteries for ventilators; and portable oxygen tanks as a supplement to electric oxygen concentrators) and emergency supplies (e.g., self-inflating respiratory bags, epinephrine for those who have allergy histories, or prophylactic antiepileptic medication for those prone to breakthrough seizures) should be confirmed. Medication supplies and refills should be sufficient to allow for the scheduling of follow-up visits. Providers responsible for recertification or reordering should be identified.

Training: Standards for training and demonstration of competency vary among institutions and across providers. Families and their medical teams should come to an agreement on minimum safety preparation and the number of responsible parties available to assist in the home. Hospital-based training around ventilator use and troubleshooting, central-line care, tracheostomy tube exchanges and suctioning, wound care, and other interventions could include basic life support classes and one-on-one sessions with nurses, respiratory therapists, or other staff, with hands-on or mannequin simulation. Assumption of full care by families while in the hospital can be informative for all stakeholders and reassuring to families; supported replication of the demands of homecare before discharge is ideal.

Augmented staff: Home nursing, hospice, personal care assistants, extended family, and friends represent additional resources for the child and their family. Allowances vary based on the child's age, independence, medical condition, technology dependence, goals of care, and other factors. These individuals may require additional training, but augmenting numbers of proficient homecare providers is crucial for safety and consistency of care. When considering homecare provision, families should consider the type of personnel and how additional supports would allow the child to attend school, the parent to work or maintain the household, continue care when the parent is sick or incapacitated, or assist with other children. The challenges of establishing, training, and maintaining a home staff require time and tolerance, recognizing that the child's safety is the priority.

Monitoring: Conceptually, monitoring is used to detect early physiologic changes, determine adequacy of LMV, and minimize cumulative morbidities or risk of mortality. Continuous direct observation is not practical, or often desirable, in the community setting. Recommendations for monitoring children and young adults on LMV vary based on underlying vulnerability, care setting, activity (e.g., home, long-term care facility, school, or in transport via car), and adjuvant supports (e.g., home nursing or personal care assistant). Pulse oximetry can be used intermittently or on a continuous basis, with oxygen and heart rate parameters determined on a case-by-case basis. Typically, capnography is not available except in cases of central hypoventilation syndromes but can complement oximetry. Internal ventilator alarm settings for both NIPPV and transtracheal ventilators are used to monitor high- and low-pressure parameters and minute ventilation. Stakeholders must acknowledge, however, that internal alarms may be insufficient in the setting of a large mask or peritracheal leak or in the event of a device malfunction.

The child's individual risks and the environmental circumstances drive the balance of extrinsic monitoring (e.g., pulse oximetry and heart rate) and intrinsic device alarms. There are also pragmatic considerations of signal-to-noise when determining monitoring parameters; recurrent false alarms will desensitize providers and may disturb a child's sleep; conversely, wide alarm parameters circumvent early warning systems with significant consequences. Alarm fatigue, as experienced by hospital-based providers, should be discussed, as it can be of great consequence where the resources are not as robust. Simple audio and video monitors (i.e., video cameras) can be used to augment surveillance and may help families in their activities of daily living.

Adaptations to the homecare setting: Modifications to the home may be required to ease care and optimize safety. Ramps for wheelchair access will permit ingress and egress. Lift systems can minimize physical burden and injury risk to providers. Doorways can be expanded to permit access to multiple rooms. Alternative bath and toileting accommodations may be needed. Electrical system upgrades with grounding and increased amperage are often required for equipment demand and safety.

Transportation: Discharge planning for a child or young adult with technology dependence should include transportation to school, community programs, routine family activities, and scheduled or urgent medical services. Proximity (rural or urban), the child's mobility, weather, and the need for monitoring en route are other considerations. Adaptive car seats or car beds can be purchased. Personal vehicles may need expensive modifications, including lifts and power inverters. Allowances may also be required for one person to drive while another (i.e., nurse, parent, or care assistant) tends to the child. If traveling long distances, perhaps on vacation, advanced planning might include identification of hospitals along the route and reciprocal equipment companies to assist with unexpected supply needs.

Air transportation: If a family anticipates travel by plane, contingencies should be made for oxygen support at altitude, recognizing that most commercial airlines pressurize their cabins to the equivalent of 7,000-8,000 feet. Portable oxygen sources may have less liter flow capacity than stationary or home devices; there is also a need to differentiate continuous versus on-demand flow options. Space and limited supplies inflight should be considerations. Power wheelchairs are prone to damage when placed in cargo holds, and ground crews likely require explicit instructions. Providers may need to write letters for airport security and airlines for excess baggage, electronic equipment, medication, and fluid allowance. Families can also consider sending additional supplies to the final destination in advance.

Environmental stressors: Extreme temperatures, heat or cold, variability in humidity, and other environmental variables can greatly affect the well-being of a child with underlying cardiorespiratory insufficiency or other special healthcare needs. Home adaptations to permit climate control for the child's room may be required. Families may consider prewarming, or cooling, vehicles for routine excursions, and limitations on day-to-day activities are warranted at times. Augmented hydration needs should be reviewed with medical providers, along with routine sunscreen and preventive measures.

Preparation for transition to the homecare setting may include a period of quiescence, depending on the circumstances and family preferences. Establishing a period of stability, when there has been no need to alter supports, may minimize unplanned readmissions.

Community Resources

The transition from the acute care or rehabilitation facility to homecare setting is often much anticipated and welcomed. This step can also be frightening and overwhelming, whether it represents the first time home or a return after an acute illness or planned surgery. Hospital-based providers can partner with families to alleviate some anxiety and to avoid potential pitfalls through proactive engagement. Hand-off to outpatient and community stakeholders can include the following:

The community medical practice: Updates on problem lists, projected follow-up, medication and equipment needs, routine health maintenance and preventive measures (e.g., immunizations), special considerations for nutrition, identification of specialty providers and follow-up schedules, and case-specific risks.

First responders: Confirmation that the family has the capacity to call emergency services, outreach to police and ambulance services to outline baseline needs, special condition-specific interventions or precautions, identification of equipment that may need to be taken with the child in the event of an emergency, determination of emergency destination (i.e., local hospital or referral center), and clarification of resuscitation status and life-sustaining therapies.

Therapy programs: Physical, occupational, speech-language/feeding, and other therapists benefit from hospital-based assessments and outlines of expectations, restrictions, and uncertainties.

Educational programs/schools/day habilitation: Integration into community services requires evaluation of developmental needs and potential adaptive settings, equipment, services, staffing, and transportation for all ages.

Power and water: Alerting local housing, social, power, and water authorities to medical necessities can facilitate prioritization of service

restoration during natural disasters or other interruptions and identify programs to defray incurred costs with increased technology-driven electrical usage (e.g., home ventilators, oxygen concentrators, and climate control).

Families may find additional resources through faith-based institutions, nonprofit and advocacy groups (e.g., Kiwanis, Shriners, Boy Scouts), and condition-specific entities, such as the Muscular Dystrophy Association. Outreach to other families with similar circumstances can also be helpful with the caveat that their recommendations reflect their own goals and lived experience with special healthcare needs.

Subacute Care

Local resources for medical services should be identified in advance. This begins with the primary care and first responders but extends to local and regional hospitals. It is important to determine the range of services available and to identify specific providers who would familiarize themselves with a given case. The child with technology dependence will experience intercurrent illnesses or unexpected accidents that require evaluation, but may not always necessitate transport to tertiary care or referral centers. Individual care plans can be developed in conjunction with the family and local providers and may include thresholds for transfer.

Families should also consider bringing home equipment and supplies when presenting to urgent and acute care settings. Devices such as pediatric NIPPV masks and cough-assist machines or compounded medications may not be available at every facility. Short-term evaluations may become protracted, and lack of routine care provision may compound the immediate issues.

Emergency and Acute Care

Providers and families should acknowledge that children with special healthcare needs (CSHCN) and LMV are at risk for repeated hospitalization. Progression of underlying illnesses (e.g., heart failure), planned surgical interventions (e.g., spinal instrumentation, bronchoscopy surveillance, tendon releases), or superimposed acute illnesses (e.g., pneumonia, gastroenteritis, appendicitis, recurrent seizures) may necessitate readmission. Those children who are technology dependent have a higher likelihood of requiring critical care services because of the nature of their needs and their vulnerability. Preventable equipment-related issues may be obviated through the planning described previously. Once hospitalized, CSHCN are at greater risk of medical error and incur more interventions when compared with otherwise healthy children. Parents should be encouraged to develop a medical passport and reference list of providers to facilitate communication and consistency of care. Referencing established care guidelines and, again, developing individualized care plans may be helpful.

Quality of Life

CSHCN of increasing complexity and technology dependence are thriving in the homecare setting as a result of advances in medical care, shared decision-making, community services, and most notably, extensive, vigilant, and proactive care efforts by their families. Adaptations allow for participation in all aspects of family, school, and community activities. Although individual trajectory and subsequent needs may be difficult to predict, all stakeholders should acknowledge the impact of chronic care on the family unit and health-related quality of life. The evolution of a medical home for this cohort of children will require provisions for family mental health, sibling supports, respite, and other measures to optimize outcomes.

TRANSITIONING FROM ACUTE CARE TO REHABILITATION OR COMMUNITY SETTING

Disposition of children and young adults with LMV will vary based on their relative stability, local support services, and goals of care. A proactive, flexible, comprehensive care model is required to assure safe and effective provision. The impacts of care needs on the child and family are inextricably linked.

ROUTINE HEALTH MAINTENANCE

Airway Evaluation

There is no standard for regular airway assessment for children with LMV, specifically those with transtracheal support, but annual evaluation should represent the minimum. Office-based transtracheal tube endoscopy can facilitate assessment of tube upsizing for linear growth, presence of granulation tissue, airway inflammation, and general mucosal integrity. Formal diagnostic laryngoscopy and bronchoscopy under general anesthesia are required to assess for suprastomal and laryngeal-level pathology along with the rare acquired trachea-esophageal fistulae. Independent of routine evaluation, recurrent or unexpected tracheal bleeding may warrant evaluation for a trachea-vascular fistula via CT angiogram and bronchoscopy.

Bacterial Colonization

Chronic respiratory failure lends itself to airway bacterial colonization because of alterations in secretion clearance, aerodigestive interactions, the presence of artificial airways with the development of biofilms, and other factors. Hydrophilic and gram-negative bacteria (e.g., *Pseudomonas, Serratia,* and *Stenotrophomonas*) are common. There is no standard of care for determining pathogenicity versus colonization. Use of systemic or inhaled antibacterial agents to decrease colonization load, frequency of tracheostomy tube exchanges to reduce biofilm accumulation, utility of viral screening, and threshold for treatment of an acute lower airway process or tracheitis is provider and case dependent. Providers should appreciate that recurrent empiric antibacterial treatment may select for resistant bacterial strains and has implications for enteric bacterial colonization.

Dental Care

Routine daily and office-based dental care should follow standard recommendations for all children. Extrapolation from the acute care setting and general population would suggest that oropharyngeal care and minimization of bacterial overgrowth would affect the risk of superimposed respiratory illness in LMV and long-term cardiovascular outcomes, respectively. Special consideration with respect to aspiration risk, developmental tolerance, and prophylaxis and procedural sedation for intervention may require engagement of specialty providers.

Immunizations

No immunizations are specifically indicated for individuals receiving LMV. Routine provision is recommended, including seasonal vaccinations for viral pathogens. Expansion of exposure precautions, as experienced during the COVID-19 pandemic, also remain essential.

Radiography, Laboratory, Polysomnography, and Pulmonary Function Testing

There are no recommendations for routine chest radiography, standard or cross-sectional, in the context of LMV. The cumulative radiation exposure would need to be considered. Gas exchange adequacy can often be assessed noninvasively. Venous, capillary, or arterial puncture for determining resting and long-term oxygenation and ventilation status may be of limited utility and validity, as intercurrent illness, technique with tourniquet, and associated agitation will alter results. Condition-specific (e.g., muscular dystrophy) recommendations for polysomnography, spirometry, or pulmonary function testing have been established and may be extrapolated with some validity. Regular assessment may also be helpful when gauging disease trajectory, LMV titration, safety parameters, and weaning potential.

LONG-TERM MECHANICAL VENTILATION WEANING AND TRACHEAL DECANNULATION

Reassessment of the role of LMV should be part of routine and family-centered care. Determination should include but is not limited to the factors described earlier with open discussion of goals of care, developmental appropriateness, physiologic and anatomic consideration, growth implications, new treatments, and contingencies. As there are currently no definitive conditioning regimens or LMV

weaning strategies, providers can determine the value of time off versus decreased level of supports as well as pragmatic considerations for the child and family. Continuity of care, however, holds implicit value. Monitoring provision may need to be increased during weaning.

If tracheal decannulation is required, a formal diagnostic laryngoscopy and bronchoscopy should be considered to rule out granulation (suprastomal and infrastomal) and dynamic airway collapse that may prohibit immediate tracheostomy tube removal. If positive pressure or oxygen supplementation will still be required after decannulation, determination of the child's tolerance of noninvasive ventilation or other interventions (e.g., cough assist) should be determined in advance. Desensitization may be required.

Ultimately, LMV has an increasing role in the support of children and young adults with chronic respiratory failure. Decision-making about any technology supports can be challenging from an emotional, practical, and ethical perspective. As families and other stakeholders explore options, the goal at these consequential junctures should be to align expectations, hopes, and potential lived experiences. Everyone should acknowledge the uncertainties and the potential to withhold, withdraw, and regularly reassess, even in the community setting. As this population of CSHCN and technology dependence ages, transition from pediatric to adult services should also be anticipated.

Visit Elsevier eBooks+ at eBooks.Health.Elsevier.com for Bibliography.

The Cardiovascular System

PART XVIII

Section 1

Developmental Biology of the Cardiovascular System

Chapter 469

Cardiac Development

Daniel Bernstein and William R. Goodyer

INTRODUCTION

Cardiac defects have traditionally been grouped by common morphologic patterns: for example, **abnormalities of the outflow tracts** (conotruncal lesions such as tetralogy of Fallot and truncus arteriosus) and **abnormalities of atrioventricular septation** (primum atrial septal defect, atrioventricular septal defect). These morphologic categories may be revised or eventually supplanted by new categories as our understanding of the genetic and molecular basis of congenital heart disease progresses.

469.1 Early Cardiac Morphogenesis

Daniel Bernstein and William R. Goodyer

In the early presomite embryo, the first identifiable cardiac progenitor cell clusters migrate from the primitive streak and are arranged in the anterior lateral plate mesoderm on both sides of the embryo's central axis in a horseshoe pattern, also known as the *cardiac crescent*. These cell clusters are marked by their expression of the basic helix-loop-helix (bHLH) transcription factor mesoderm posterior 1 (MESP1) and subsequently form paired cardiac tubes by 18 days of gestation. This *cardiac progenitor zone* is shaped by a balanced gradient of positive and negative signals arising from the tissues surrounding the cardiac mesodermal cells, with signals from the surrounding ventral/lateral tissues promoting cardiogenesis through signaling molecules such as bone morphogenetic protein (BMP), sonic hedgehog (SHH), and fibroblast growth factor 8 (FGF8) and signals from dorsal/medial structures such as members of the canonical Wnt/β-catenin pathway inhibiting cardiogenesis. Cardiogenic signals activate the genetic expression of cardiac-specific transcription factors (e.g., *TBX, GATA, NKX2.5*) to activate developmental cardiac gene expression The paired tubes fuse in the midline on the ventral surface of the embryo to form the primitive *heart tube* by 22 days. This straight heart tube is composed of an outer myocardial layer, an inner endocardium, and a middle layer of extracellular matrix (ECM) known as the *cardiac jelly*. There are two distinct cell lineages: the **first heart field** (regulated mainly by *NKX2.5*) provides precursor cells for the left ventricle and parts of the atria; the **second heart field** (regulated mainly by *ISL1*) provides precursors for the right ventricle, outflow tracts, and caudal aspects of the atria. Premyocardial cells, including epicardial cells and cells derived from the neural crest, continue their migration into the region of the heart tube. Regulation of this early phase of cardiac morphogenesis is controlled in part by the interaction of specific signaling molecules or ligands, usually expressed by one cell type, with specific receptors, usually expressed by another cell type. Positional information is conveyed to the developing cardiac mesoderm by factors such as *retinoids* (isoforms of vitamin A), which bind to specific nuclear receptors and regulate gene transcription. Migration of epithelial cells into the developing heart tube is directed by ECM proteins (e.g., fibronectin) that interact with cell surface receptors (the *integrins*). The clinical importance of these signaling pathways is revealed by the spectrum of **cardiac teratogenic effects** caused by the retinoid-like drug isotretinoin.

As early as 20-22 days, before cardiac looping, the embryonic heart begins to contract and exhibit phases of the cardiac cycle that are surprisingly similar to those in the mature heart. Morphologists initially identified segments of the heart tube that were believed to correspond to structures in the mature heart (Fig. 469.1). The *sinus venosus* (systemic venous system and part of right atrium), *primitive atrium* (right and left atria), *primitive ventricle* (left ventricle), and *bulbus cordis* that can be broken down into three sections (the proximal one third, right ventricle; mid-third, conus cordis to outflow tracts; and distal third, truncus arteriosus to aorta and pulmonary artery). However, this model is oversimplified. Only the **trabecular** (most heavily muscularized) portions of the left ventricular myocardium are present in the early cardiac tube; the cells that will become the inlet portion of the left ventricle migrate into the cardiac tube at a later stage (after looping is initiated). Even later to appear are the primordial cells that give rise to the great arteries (truncus arteriosus), including cells derived from the neural crest, which are not present until after cardiac looping is complete. Chamber-specific transcription factors participate in the differentiation of atria from ventricles and in the right and left ventricles. The bHLH transcription factor gene *(HAND2)* is expressed in the developing right ventricle. Disruption of this gene or of other transcriptional factors such as *MEF2c* in mice leads to hypoplasia of the right ventricle. Other genetic markers of the second heart field (early right ventricle) cells include *IRX4, TBX20, ISL1, TNNT2, MLC2v,* and *TBX1*. The transcription factor *HAND1* is expressed in the developing left ventricle and conotruncus and is also critical to their development. Other genetic markers of the first heart field (early left ventricle) cells include *TBX5, NKX2.5, TNNT2, MLC2v,* and *HCN4*.

One mechanism of how regulation of developmentally coordinated groups of genes is achieved is through the expression of small, noncoding RNAs known as **microRNAs**, each of which regulates the expression of multiple target genes. Another is through modifications in **chromatin**, the DNA scaffolding that acts as a controller of gene expression. Chromatin remodeling mediated by genes or enzymes such as *BRG1, CHD7,* histone demethylases, and methyltransferases is associated with cardiac developmental defects, including septal defects, dilated cardiomyopathy, and double-outlet right ventricle.

469.2 Cardiac Looping

Daniel Bernstein and William R. Goodyer

At approximately 22-24 days, the heart tube begins to bend ventrally and toward the right (see Fig. 469.1). The heart is the first organ to escape from the bilateral symmetry of the early embryo. An asymmetric signaling program that also affects the position of the lungs, liver, spleen, and gastrointestinal tract determines the direction of cardiac looping. During gastrulation, before organ formation begins, asymmetric expression of *SHH* and nodal (a member of the transforming growth factor beta [TGF-β] family) are directed in the lateral

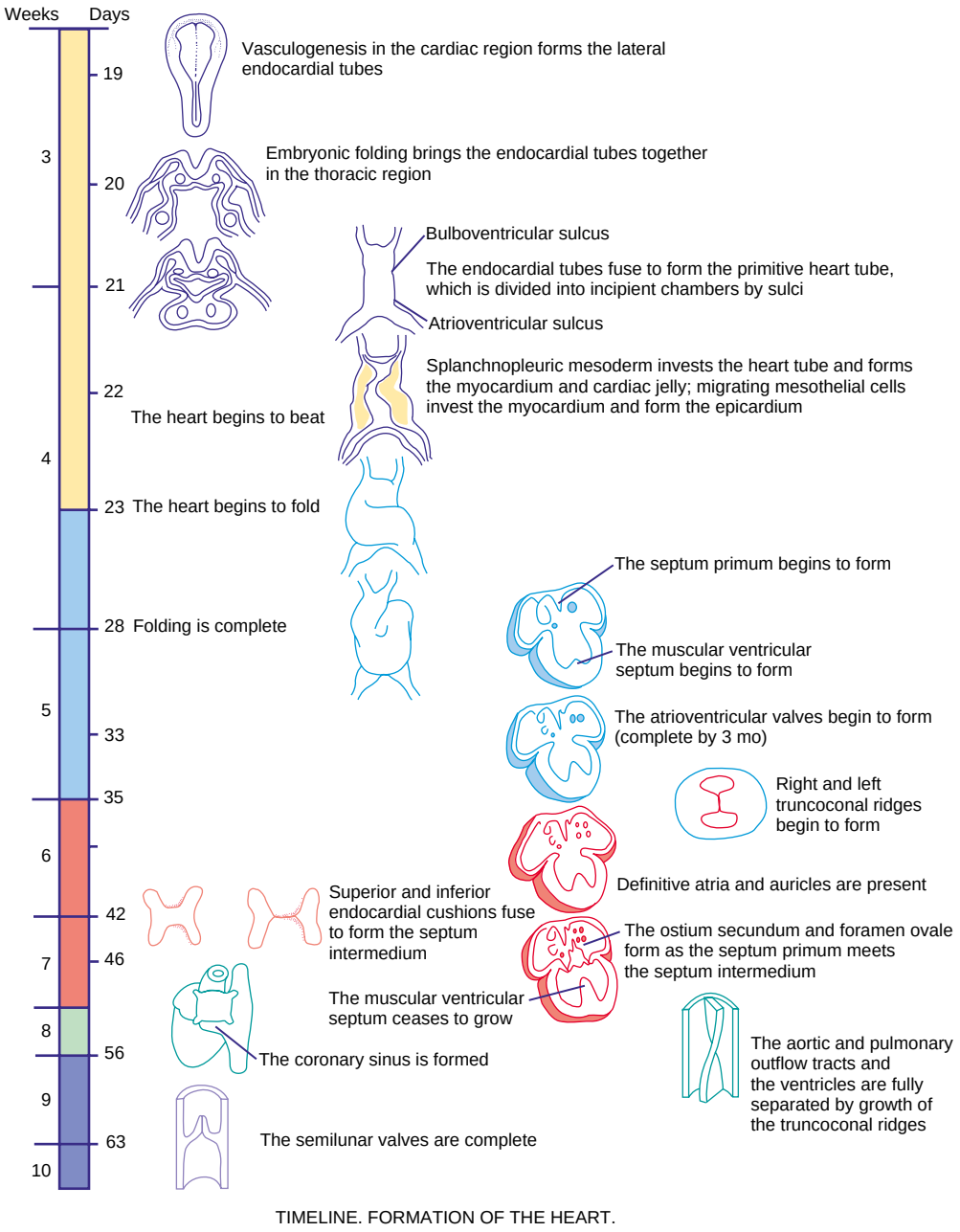

Fig. 469.1 Timeline of cardiac morphogenesis. *(From Larsen WJ. Essentials of Human Embryology. New York: Churchill Livingstone; 1998.)*

mesoderm. These directionality signals set up a concentration gradient between the right and left sides of the embryo in the expression of critical signaling molecules. This asymmetric signaling is then amplified and propagated through the transcription factor gene (*PITX2*), which is expressed on the left side of the early heart tube, *LEFTY1* and *left-right Dynein* (*LRD*). Interestingly, mice in which *LRD* has been inactivated display random left-right (L-R) orientation of the heart and abdominal viscera, with 50% of their hearts looping to the right and 50% looping to the left. Other potential mechanisms of cardiac looping include differential growth rates for myocytes on the convex versus the concave surface of the curve, differential rates of programmed cell death (apoptosis), and mechanical forces generated within myocardial cells at the inner and outer edges of the bending heart tube through their actin cytoskeleton.

Looping brings the future left ventricle leftward and in continuity with the sinus venosus (future left and right atria), whereas the future right ventricle is shifted rightward and in continuity with the truncus arteriosus (future aorta and pulmonary artery). This pattern of development explains the relatively common occurrence of the cardiac anomalies **double-outlet right ventricle** and **double-inlet left ventricle** and the extreme rarity of double-outlet left ventricle and double-inlet right ventricle (see Chapter 479.5). When cardiac looping is abnormal **(situs inversus, heterotaxia)**, the incidence of serious cardiac malformations is high, and there are usually associated abnormalities in the L-R patterning of the lungs and abdominal viscera, including absence of the spleen **(asplenia)** or multiple small spleens **(polysplenia)**.

469.3 Cardiac Septation

Daniel Bernstein and William R. Goodyer

When looping is complete, the external appearance of the heart is like that of a mature heart; internally, the structure resembles a single continuous tube, although it now has several bulges resulting in the appearance of primitive chambers. The common atrium (comprising both right and left atria) is connected to the primitive ventricle (future

left ventricle) via the atrioventricular canal. The primitive ventricle is connected to the *bulbus cordis* (future right ventricle) via the *bulboventricular foramen*. The distal portion of the bulbus cordis is connected to the *truncus arteriosus* via an outlet segment (the *conus*).

The heart tube now consists of several layers of myocardium and a single layer of endocardium separated by cardiac jelly (acellular ECM secreted by the myocardium). Septation of the heart begins at approximately day 26 with the ingrowth of large tissue masses, the *endocardial cushions,* at both the atrioventricular and conotruncal junctions (see Fig. 469.1). These cushions consist of protrusions of ECM (cardiac jelly), which, in addition to their role in development, also serve a physiologic function as primitive heart valves. Endocardial cells dedifferentiate and migrate into the cardiac jelly in the region of the endocardial cushions, eventually becoming mesenchymal cells (endothelial-mesenchymal transformation) that will form part of the atrioventricular valves. The endocardium, secondary heart field, and neural crest all contribute to the formation of the valve leaflets. Besides direct contribution to valve tissue, these progenitor cells also interact with each other and with other cells in the heart to orchestrate cardiac valve development.

Complete septation of the atrioventricular canal occurs with fusion of the endocardial cushions. Most of the atrioventricular valve tissue is derived from the ventricular myocardium in a process involving undermining of the ventricular walls. Because this process occurs asymmetrically, the tricuspid valve annulus sits closer to the apex of the heart than the mitral valve annulus. Physical separation of these two valves produces the atrioventricular septum, the absence of which is the primary common defect in patients with **atrioventricular canal defects** (see Chapter 475.5). If the process of undermining is incomplete, the right atrioventricular valve may not separate normally from the ventricular myocardium, a possible cause of **Ebstein anomaly** (see Chapter 479.7).

Septation of the atria begins at around 30 days with growth of the septum primum downward toward the endocardial cushions (see Fig. 469.1). The orifice that remains is the ostium primum. The endocardial cushions then fuse and, together with the completed septum primum, divide the atrioventricular canal into right and left segments. A second opening appears in the posterior portion of the septum primum, the ostium secundum, and it allows a portion of the fetal venous return to the right atrium to pass across to the left atrium. Finally, the septum secundum grows downward, just to the right of the septum primum. Together with a flap of the septum primum, the ridge of the ostium secundum forms the *foramen ovale,* through which fetal blood passes from the inferior vena cava to the left atrium (see Chapter 470).

Septation of the ventricles begins at about embryonic day 25 with protrusions of endocardium in both the inlet (primitive ventricle) and outlet (bulbus cordis) segments of the heart. The inlet protrusions fuse into the bulboventricular septum and extend posteriorly toward the inferior endocardial cushion, where they give rise to the inlet and trabecular portions of the interventricular septum. **Ventricular septal defects** can occur in any portion of the developing interventricular septum (see Chapter 475.6). The outlet or conotruncal septum develops from ridges of cardiac jelly, similar to the atrioventricular cushions. These ridges fuse to form a spiral septum that brings the future pulmonary artery into communication with the anterior and rightward right ventricle and the future aorta into communication with the posterior and leftward left ventricle. Differences in cell growth of the outlet septum lead to lengthening of the segment of smooth muscle beneath the pulmonary valve (conus), a process that separates the tricuspid and pulmonary valves. In contrast, disappearance of the segment beneath the aortic valve leads to fibrous continuity of the mitral and aortic valves. Within the lumen of distal outflow tract, local tissue swellings *(truncal cushions)* arise and are later populated by mesenchymal cells originating from the neural crest, participating in the formation of the semilunar (pulmonary and aortic) valves. Defects in these processes are responsible for **conotruncal** and **aortic arch defects** (truncus arteriosus, tetralogy of Fallot, pulmonary atresia, double-outlet right ventricle, interrupted aortic arch), a group of cardiac anomalies often associated with deletions of the **DiGeorge** critical region of **chromosome 22q11** (see Chapters 472 and 473). The transcription factor gene *(TBX1)* has been implicated as a candidate gene, which may be responsible for DiGeorge syndrome. Several genes have been implicated in valve formation, including *PTPN11,* which encodes the tyrosine phosphatase SHP-2, and when present in a mutated form, is one of the genes responsible for **Noonan syndrome**, associated with pulmonary valve stenosis, and *NOTCH1,* a regulator of cell differentiation associated with aortic valve disease.

469.4 Aortic Arch Development

Daniel Bernstein and William R. Goodyer

The aortic arch, head and neck vessels, proximal pulmonary arteries, and ductus arteriosus develop from the aortic sac, arterial arches, and dorsal aortae. When the straight heart tube develops, the distal outflow portion bifurcates into the right and left first aortic arches, which join the paired dorsal aortae (Fig. 469.2). The dorsal aortae will fuse to form the descending aorta. The proximal aorta from the aortic valve to the left carotid artery arises from the aortic sac. The first and second arches largely regress by about 22 days, with the first aortic arch giving rise to the maxillary artery and the second to the stapedial and hyoid arteries. The third arches participate in the formation of the innominate artery and the common and internal carotid arteries. The right fourth arch gives rise to the innominate and right subclavian arteries, and the left fourth arch participates in formation of the segment of the aortic arch between the left carotid artery and the ductus arteriosus. The fifth arch does not persist as a major structure in the mature circulation. The sixth arches join the more distal pulmonary arteries, with the right sixth arch giving rise to a portion of the proximal right pulmonary artery and the left sixth arch to the proximal left pulmonary artery and to the ductus arteriosus. The aortic arch between the ductus arteriosus and left subclavian artery is derived from the left-sided dorsal aorta, whereas the aortic arch distal to the left subclavian artery is derived from the fused right and left dorsal aortae. Abnormalities in development of the paired aortic arches are responsible for **right aortic arch**, **double aortic arch**, and **vascular rings** (see Chapter 481.1).

469.5 Cardiac Differentiation

Daniel Bernstein and William R. Goodyer

The process by which the totipotential cells of the early embryo become committed to specific cell lineages is termed *differentiation*. Precardiac mesodermal cells differentiate into mature cardiac muscle cells with an appropriate complement of cardiac-specific contractile elements, regulatory proteins, receptors, and ion channels. Expression of the contractile protein myosin occurs at an early stage of cardiac development, even before fusion of the bilateral heart primordia. Differentiation in these early mesodermal cells is regulated by signals from the anterior endoderm, a process known as *induction*. Several putative early signaling molecules include fibroblast growth factor, activin, and insulin. Signaling molecules interact with receptors on the cell surface; these receptors activate second messengers, which in turn activate specific nuclear transcription factor genes (*GATA-4, MEF2, NKX, bHLH,* and retinoic acid receptor family) that induce the expression of specific gene products to regulate cardiac differentiation. Some of the primary disorders of cardiac muscle, the **cardiomyopathies**, may be related to defects in some of these signaling molecules (see Chapter 488).

Developmental processes are chamber specific. Early in development, ventricular myocytes express both ventricular and atrial isoforms of several proteins, such as atrial natriuretic peptide (ANP) and myosin light chain (MLC). Mature ventricular myocytes do not express ANP and express only a ventricular-specific MLC 2v isoform, whereas mature atrial myocytes express ANP and an atrial-specific MLC 2a isoform. Heart failure (see Chapter 491), volume overload (see Chapters 475 and 477), and pressure overload hypertrophy (see Chapter 476)

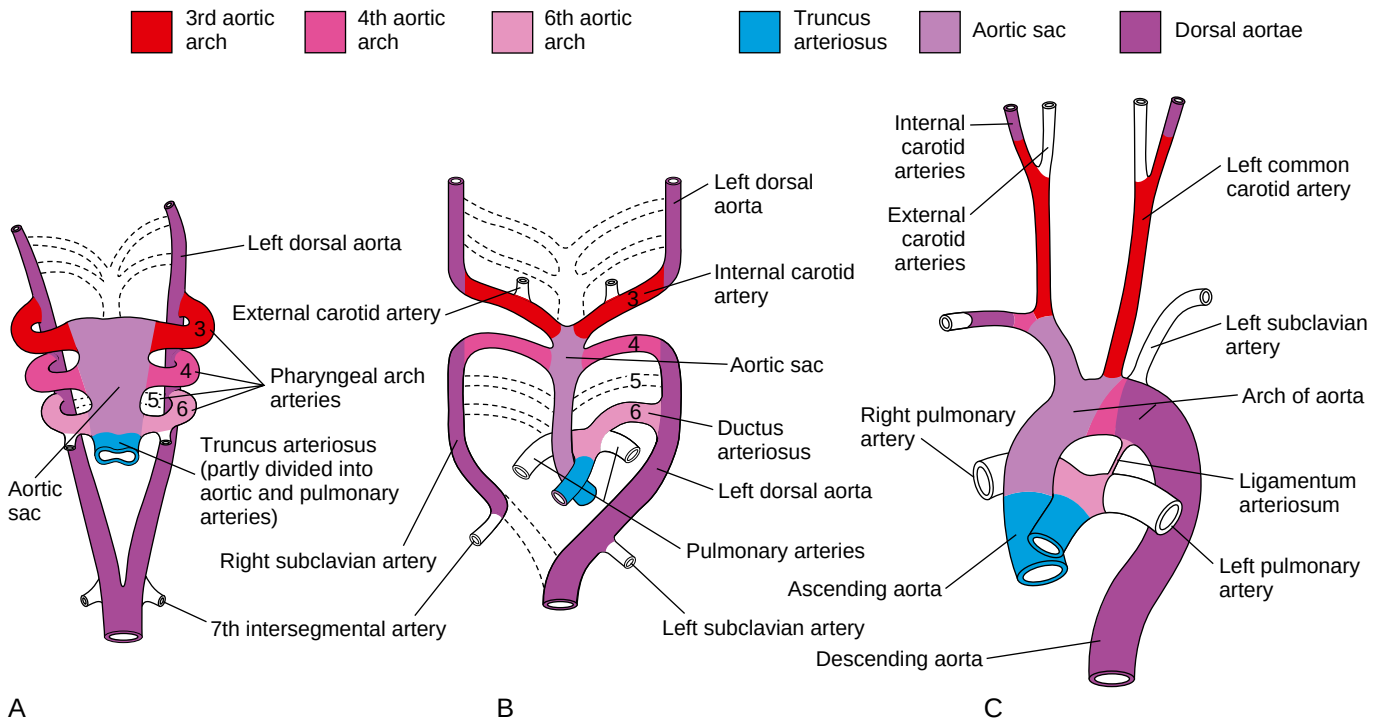

Fig. 469.2 Schematic drawings illustrating the changes that result during transformation of the truncus arteriosus, aortic sac, aortic arches, and dorsal aortae into the adult arterial pattern. The vessels that are *not* shaded or colored are not derived from these structures. **A,** Aortic arches at 6 weeks; by this stage, the first two pairs of aortic arches have largely disappeared. **B,** Aortic arches at 7 weeks; the parts of the dorsal aortae and aortic arches that normally disappear are indicated by *broken lines*. **C,** Arterial vessels of 6-mo-old infant. *(From Moore KL, Persaud TVN, Torchia M. The Developing Human. Philadelphia: Elsevier; 2007.)*

are associated with a recapitulation of fetal cell phenotypes in which mature myocytes re-express fetal proteins. Because different isoforms have different contractile behavior (fast vs slow activation, high vs low adenosine triphosphatase activity), expression of different isoforms may have important functional consequences.

469.6 Developmental Changes in Cardiac Function

Daniel Bernstein and William R. Goodyer

During development, the composition of the myocardium undergoes profound changes that result in an increase in the number and size of myocytes. During prenatal life, this process involves myocyte division **(hyperplasia)**, whereas after the first few postnatal weeks, subsequent cardiac growth occurs mostly by an increase in myocyte size **(hypertrophy)**. The myocytes themselves change shape from round to cylindrical, the proportion of myofibrils (which contain the contractile apparatus) increases, and the myofibrils become more regular in their orientation.

The *plasma membrane* (known as the *sarcolemma* in myocytes) is the location of the ion channels and transmembrane receptors that regulate the exchange of chemical information from the cell surface to the cell interior. Ion fluxes through these channels control the processes of depolarization and repolarization. Developmental changes have been described for the sodium-potassium pump, the sodium-hydrogen exchanger, and voltage-dependent calcium channels. As the myocyte matures, extensions of the sarcolemma develop toward the interior of the cell (the T-tubule system), which dramatically increases its surface area and enhances rapid activation of the myocyte. Regulation of the membrane's α- and β-adrenergic receptors with development enhances the ability of the sympathetic nervous system to control cardiac function as the heart matures.

The *sarcoplasmic reticulum* (SR), a series of tubules surrounding the myofibrils, is the principal mediator of the intracellular calcium concentration. Calcium release to the myofibrils for initiation of contraction is mediated by the ryanodine receptor (RYR), and calcium reuptake for initiation of relaxation is mediated by the sarcoplasmic reticulum calcium ATPase (SERCA). This SR calcium transport system is less well developed in immature hearts, which thus depend more on transport of calcium from outside the cell for contraction. In a mature heart, the majority of the calcium required for contraction comes from within the cardiomyocyte via the SR. This developmental phenomenon may explain the sensitivity of the infant heart to sarcolemmal calcium channel blockers such as verapamil, which can result in a marked depression in contractility (see Chapter 484).

The major contractile proteins (myosin, actin, tropomyosin, and troponin) are organized into the functional unit of cardiac contraction, the *sarcomere*. Each has several isoforms that are expressed differentially by location (atrium vs ventricle) and by developmental stage (embryo, fetus, newborn, adult).

Changes in myocardial structure and myocyte biochemistry result in easily quantifiable differences in cardiac function with development. Fetal cardiac function is less responsive to changes in preload (filling volume). Thus the most effective means of increasing cardiac output in the fetus is through increasing the heart rate. After birth and with further maturation, preload and afterload play an increasing role in regulating cardiac function. The rate of cardiac relaxation is also developmentally regulated. The decreased ability of the immature SR calcium pump (SERCA) to remove calcium from the contractile apparatus is manifested as a decreased ability of the fetal heart to enhance relaxation in response to sympathetic stimulation.

Visit Elsevier eBooks+ at eBooks.Health.Elsevier.com for Bibliography.

Chapter 470

The Fetal to Neonatal Circulatory Transition

Daniel Bernstein

470.1 The Fetal Circulation

Daniel Bernstein

The transition from the fetal to the postnatal circulation represents one of the most dramatic circulatory adaptations at any time of life. In the fetal circulation, the right and left ventricles exist in a parallel circuit, as opposed to the series circuit of the newborn or adult (Fig. 470.1A). In the fetus, the placenta provides for gas and metabolite exchange. Because the lungs do not provide gas exchange, blood is diverted away from the pulmonary circulation, which is vasoconstricted. Three cardiovascular structures unique to the fetus are important for maintaining this parallel circulation: the *ductus venosus, foramen ovale,* and *ductus arteriosus.*

The placenta is not as efficient an oxygen-exchange organ as the lungs, so that umbilical venous partial pressure of oxygen (Po_2), the highest O_2 level provided to the fetus, is only 30-35 mm Hg. Approximately 50% of the umbilical venous blood enters the hepatic circulation, whereas the rest bypasses the liver and joins the inferior vena cava (IVC) via the ductus venosus, where it partially mixes with poorly oxygenated IVC blood derived from the lower part of the fetal body. This combined lower body plus umbilical venous blood flow (Po_2 of 26-28 mm Hg) enters the right atrium and is preferentially directed by a flap of tissue at the right atrium–IVC junction, the eustachian valve, across the foramen ovale to the left atrium (see Fig. 470.1B). This is the major source of left ventricular (LV) blood flow in the fetus, because pulmonary venous return from the vasoconstricted lungs is minimal. LV blood is then ejected into the ascending aorta, where it supplies predominantly the fetal upper body and brain.

Fetal superior vena cava (SVC) blood, which is considerably less oxygenated (Po_2 of 12-14 mm Hg) than IVC blood, enters the right atrium and preferentially flows across the tricuspid valve, rather than the foramen ovale, into the right ventricle. From the right ventricle, this blood is ejected into the pulmonary artery. Because the pulmonary arterial circulation is vasoconstricted, only approximately 5% of right ventricular (RV) outflow enters the lungs. The major portion of this blood bypasses the lungs and flows right to left through the ductus arteriosus into the descending aorta to perfuse the lower part of the fetal body, including providing flow to the placenta via the two umbilical arteries. Thus the upper part of the fetal body (including the coronary and cerebral arteries and those to the upper extremities) is perfused exclusively from the left ventricle with blood that has a slightly higher Po_2 than the blood perfusing the lower part of the fetal body, which is derived mostly from the right ventricle. Only a small volume of blood from the ascending aorta (10% of fetal cardiac output) flows all the way around the aortic arch (aortic isthmus) to the descending aorta.

The **total fetal cardiac output**—the combined output of both the left and right ventricles—is approximately 450 mL/kg/min. Approximately 65% of descending aortic blood flow returns to the placenta; the remaining 35% perfuses the fetal organs and tissues. In the human fetus, RV output is approximately 1.3 times LV flow. Thus during fetal life the right ventricle is not only pumping against the higher systemic blood pressure but also performing slightly greater volume work than the left ventricle. This results in the RV wall being as thick (hypertrophied) as the LV wall during fetal and immediate neonatal life, explaining the unique features of the neonatal electrocardiogram (showing what would be read as *right ventricular hypertrophy* in an adult).

Blood flow is believed to be an important determinant of growth of fetal cardiac chambers, valves, and blood vessels. Thus in the presence of a narrowing (stenosis) of an upstream structure such as the mitral valve, flow downstream into the left ventricle is limited and LV growth may be compromised, which may be one of the mechanisms of **hypoplastic left heart syndrome** (HLHS; see Chapter 480.10). Similarly, stenosis of a downstream structure such as the aortic valve can also disrupt flow into the LV and contribute to HLHS. Fetal cardiac interventional treatments, currently experimental, are aimed at opening stenotic aortic valves in mid-gestation fetuses and allowing more normal LV growth. However, the outcome of these procedures does not enhance LV growth in all patients, suggesting that in the majority of cases of HLHS there is a different mechanism, suspected to be a defect in the LV cardiomyocytes themselves (i.e., a cell-autonomous defect).

470.2 The Transitional Circulation

Daniel Bernstein

At birth, mechanical expansion of the lungs and an increase in arterial Po_2 result in a rapid decrease in pulmonary vascular resistance (PVR). Concomitantly, removal of the low-resistance placental circulation leads to an increase in systemic vascular resistance (SVR). The output from the right ventricle now flows entirely into the pulmonary circulation, and because PVR becomes lower than SVR, the shunt through the ductus arteriosus reverses and becomes left to right. Over several days the high arterial Po_2 constricts and eventually closes the ductus arteriosus, which eventually becomes the ligamentum arteriosum. The increased volume of pulmonary blood flow returning to the left atrium from the lungs increases left atrial volume and pressure sufficiently to close the flap of the foramen ovale functionally, although the foramen may remain patent on probing with a catheter for several years. A patent foramen ovale can be a source of embolic stroke in later life.

Removal of the placenta from the circulation also results in closure of the ductus venosus. The left ventricle is now coupled to the high-resistance systemic circulation, and its wall thickness and mass begin to increase. In contrast, the right ventricle is now coupled to the low-resistance pulmonary circulation, and its wall thickness and mass decrease. The left ventricle, which in the fetus pumped blood only to the upper part of the body and brain, must now deliver the entire systemic cardiac output (approximately 350 mL/kg/min), an almost 200% increase in output. This marked increase in LV performance is achieved through a combination of hormonal and metabolic signals, including an increase in the level of circulating catecholamines and in the density of myocardial β-adrenergic receptors, through which catecholamines have their effect.

When superimposed on these dramatic physiologic changes, congenital structural cardiac defects often impede this smooth transition and greatly increase the burden on the newborn myocardium. Importantly, because the ductus arteriosus and foramen ovale do not close completely at birth, they can provide a lifesaving pathway for blood to bypass a congenital defect (the patent ductus arteriosus in tetralogy of Fallot, pulmonary atresia, coarctation of aorta or HLHS; the foramen ovale in transposition of the great vessels). Alternatively, persistent fetal pathways can present an additional stress to the circulation (patent ductus arteriosus in the premature infant). Therapeutic agents can be used to either maintain these fetal pathways open (e.g., *prostaglandin E_1*) or hasten their closure (e.g., *indomethacin*). This pharmacology explains why indomethacin and similar drugs are contraindicated or used with extreme caution during the third trimester.

470.3 The Neonatal Circulation

Daniel Bernstein

At birth, the fetal circulation must immediately adapt to extrauterine life as gas exchange is transferred from the placenta to the lungs (see

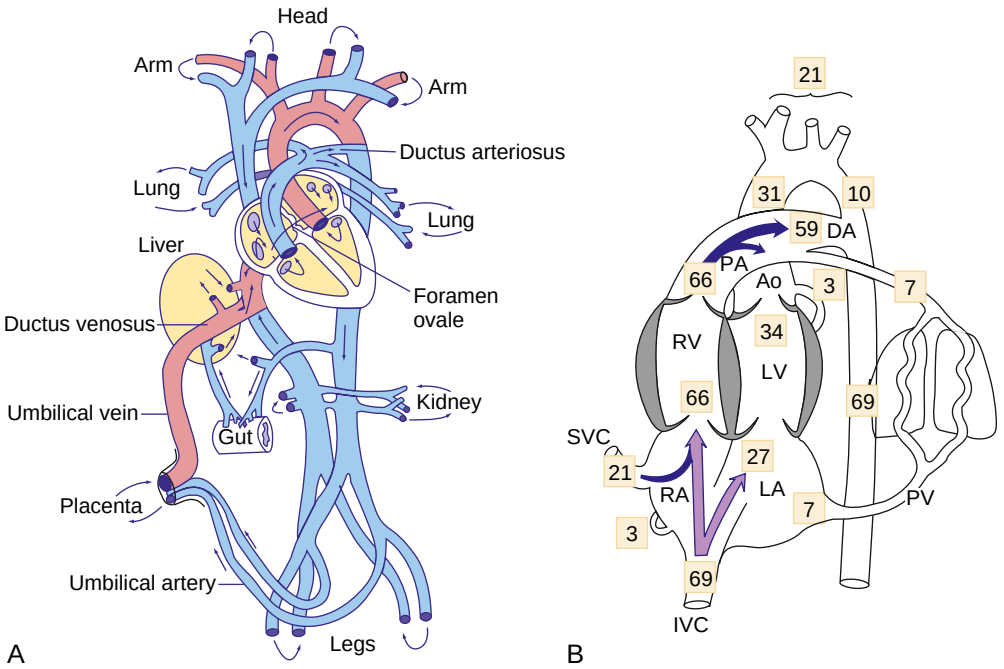

Fig. 470.1 **A,** The human circulation before birth (partly after Dawes). *Red* indicates more highly oxygenated blood, and *arrows* indicate the direction of flow. More highly oxygenated blood from the placenta passes through the foramen ovale from the right to the left atrium, thus bypassing the lungs. **B,** Percentages of combined ventricular output that return to the fetal heart, that are ejected by each ventricle, and that flow through the main vascular channels. Figures are those obtained from studies of late-gestation fetal lambs. Ao, Aorta; DA, ductus arteriosus; IVC, inferior vena cava; LA, left atrium; LV, left ventricle; PA, pulmonary artery; PV, pulmonary veins; RA, right atrium; RV, right ventricle; SVC, superior vena cava. *(From Rudolph AM. Congenital Diseases of the Heart. Chicago: Year Book; 1974.)*

Chapter 124). Some of these changes are virtually instantaneous with the first breath, whereas others develop over hours or weeks. With the onset of breathing and lung ventilation, pulmonary vascular resistance is greatly decreased because of both active (i.e., Po_2-metabolic-related) and passive (i.e., mechanical stretch-related) pulmonary vasodilation. In a normal neonate, closure of the ductus arteriosus and the fall in PVR decreases pulmonary arterial and RV pressures. The largest decline in PVR from the high fetal levels to the lower "adult" levels in the human infant usually occurs within 2-3 days, but may be prolonged for ≥7 days after birth. However, over the next several weeks of life, PVR continues to decrease further, now secondary to physical remodeling of the pulmonary vasculature, including thinning of vascular smooth muscle and recruitment of new vessels. This decrease in PVR significantly influences the timing of the clinical appearance of many congenital heart lesions dependent on the relative levels of SVR and PVR. For example, the left-to-right shunt through a large ventricular septal defect (VSD) may be minimal in the first week after birth, when PVR is still high. As PVR decreases in the next 1-2 weeks, the volume of the left-to-right shunt through the VSD increases and eventually leads to the signs and symptoms of heart failure.

There are several significant differences between the neonatal circulation and that of older infants: (1) right-to-left or left-to-right shunting may persist across the patent foramen ovale; (2) in the presence of cardiopulmonary disease, continued patency of the ductus arteriosus may allow left-to-right, right-to-left, or bidirectional shunting; (3) the neonatal pulmonary vasculature constricts more vigorously in response to hypoxemia, hypercapnia, and acidosis; (4) the wall thickness and muscle mass of the neonatal left and right ventricles are almost equal; and (5) newborn infants at rest have a relatively high oxygen consumption, associated with a relatively high cardiac output. The newborn cardiac output, indexed to body weight (200 mL/kg/min), falls in the first 2 months of life to approximately 150 mL/kg/min and then more gradually to the normal adult cardiac output of 75 mL/kg/min. Although fetal hemoglobin is beneficial to delivery of oxygen in the low-Po_2 fetal circulation, the high percentage of fetal hemoglobin present in the newborn may actually interfere with delivery of oxygen to tissues in the high-systemic Po_2 neonatal circulation, and therefore adult hemoglobin production begins immediately (see Chapter 124).

The foramen ovale is usually functionally closed by the third month of life, although it is possible to pass a catheter through the overlapping flaps in a large percentage of children and in 15–25% of adults. Functional closure of the ductus arteriosus is usually complete by 10-15 hours of postnatal age in a normal neonate, although the ductus may remain patent much longer in the presence of congenital heart disease, especially when associated with cyanosis. In premature newborn infants, a systolic murmur with late accentuation or a continuous murmur may be audible beneath the left clavicle, and in the context of respiratory distress syndrome, the presence of a patent ductus arteriosus should be suspected (see Chapter 126.1).

The normal ductus arteriosus differs morphologically from the adjoining aorta and pulmonary artery in that the ductus has a significant amount of circularly arranged smooth muscle in its medial layer. During fetal life, patency of the ductus arteriosus appears to be maintained by the combined relaxant effects of low oxygen tension and endogenously produced prostaglandins, specifically prostaglandin E_2. In a full-term neonate, oxygen is the most important factor controlling ductal closure. When the Po_2 of the blood passing through the ductus reaches about 50 mm Hg, the ductal wall begins to constrict. The effects of oxygen on ductal smooth muscle may be direct or mediated by its effects on prostaglandin synthesis. Gestational age also appears to play an important role; the ductus of a premature infant is less responsive to oxygen, even though its musculature is well developed.

470.4 Persistent Pulmonary Hypertension of the Neonate (Persistence of Fetal Circulatory Pathways)

See Chapter 130.

Visit Elsevier eBooks+ at eBooks.Health.Elsevier.com for Bibliography.

Section 2

Evaluation of the Cardiovascular System and the Child with a Heart Murmur

Chapter 471

History and Physical Examination in Cardiac Evaluation

Daniel Bernstein

One of the most common reasons for cardiac evaluation in young children is the heart murmur; **innocent or functional murmurs (Still murmurs)** may be heard in up to 30% of patients at some time during childhood. Functional murmurs are usually accentuated by fever and first noticed during a visit for an intercurrent illness. Thus the general pediatrician must be able to distinguish those murmurs that are functional from those that are potentially pathologic and refer patients with pathologic-sounding murmurs or murmurs of uncertain nature for evaluation by a pediatric cardiologist.

Patients may require further laboratory evaluation (e.g., electrocardiogram and echocardiogram), or the family may be reassured that no significant problem exists. Although the ready availability of echocardiography may entice the clinician to skip a good history and physical exam, an initial evaluation by a skilled cardiologist is preferred for several reasons: (1) a cardiac examination allows the cardiologist to guide the echocardiographic evaluation toward confirming or eliminating specific diagnoses, thereby increasing its accuracy; (2) because most childhood murmurs are innocent, evaluation by a pediatric cardiologist can eliminate unnecessary and expensive laboratory tests; and (3) the cardiologist's knowledge and experience are important in reassuring the patient's family and preventing unnecessary, and all too common, restrictions on healthy physical activity. An experienced pediatric cardiologist can differentiate an innocent murmur from serious congenital heart disease by history and physical examination alone with high sensitivity and specificity.

HISTORY

The evaluation begins with a comprehensive cardiac history because a diagnosis of a functional murmur can only be made in the absence of any concerning symptoms, signs, or family history. A comprehensive cardiac history starts with details of the perinatal period, including the presence of cyanosis, respiratory distress, or prematurity. **Maternal complications** such as gestational diabetes, teratogenic medications, infections, systemic lupus erythematosus, or substance misuse can be associated with cardiac problems. If cardiac symptoms began during infancy, the timing of the initial symptoms should be noted to provide important clues about the specific cardiac condition.

Many of the symptoms of **heart failure** in infants and children are age specific. In infants, feeding difficulties are common. Inquiry should be made about the frequency of feeding and either the volume of each feeding or the time spent on each breast. An infant with heart failure often takes less volume per feeding and becomes dyspneic or diaphoretic while nursing. After falling asleep exhausted, the baby, inadequately fed, will awaken for the next feeding after a brief time. This cycle continues around the clock and must be carefully differentiated from colic or other feeding disorders. Additional symptoms and signs include those of respiratory distress: rapid breathing, nasal flaring, cyanosis, and chest retractions. In older children, heart failure may be manifested as exercise intolerance, difficulty keeping up with peers during sports or the need for a nap after coming home from school, poor growth, or chronic abdominal complaints. Eliciting a history of fatigue in an older child requires questions about age-specific activities, including stair climbing, walking, bicycle riding, physical education class, and competitive sports; information should be obtained regarding more severe manifestations such as orthopnea and nocturnal dyspnea.

Parents often overlook their baby's **cyanosis** at rest; it may be mistaken for a normal individual variation in color. Cyanosis during crying or exercise, however, is more often noted as abnormal by observant parents. Many infants and toddlers turn "blue around the lips" when crying vigorously or during breath-holding spells; this condition must be carefully differentiated from **cyanotic heart disease** by inquiring about inciting factors, the length of episodes, and whether the tongue and mucous membranes also appear cyanotic. Newborns often have cyanosis of their extremities **(acrocyanosis)** when undressed and cold; this response to cold must be carefully differentiated from true cyanosis, where the mucous membranes are also blue.

Chest pain is an unusual manifestation of cardiac disease in pediatric patients, although it is a frequent cause for referral to a pediatric cardiologist, especially in adolescents. Nonetheless, a careful history, physical examination, and, if indicated, laboratory or imaging tests will assist in identifying the cause of chest pain (Table 471.1). For patients with some forms of repaired congenital heart disease (CHD), for example, those with surgery on the aortic root or those with a history of Kawasaki disease (see Chapter 493.1), chest pain should be evaluated carefully for a coronary etiology.

Cardiac disease may be a manifestation of a known congenital malformation syndrome with typical physical findings (Table 471.2) or a manifestation of a generalized disorder affecting the heart and other organ systems (Table 471.3). **Extracardiac malformations** may be noted in 20–45% of infants with CHD. Between 5% and 10% of patients have a known chromosomal abnormality. Specific gene or whole exome sequencing can enhance the diagnostic approach to CHD (Fig. 471.1).

A careful family history may also reveal early (at age <50 years) coronary artery disease or stroke (suggestive of familial hypercholesterolemia or thrombophilia), sudden death (suggestive of cardiomyopathy or familial arrhythmic disorder), generalized muscle disease (suggestive of one of the muscular dystrophies, dermatomyositis, or familial or metabolic cardiomyopathy), or first-degree relatives with CHD.

GENERAL PHYSICAL EXAMINATION

In the evaluation of a child with a heart murmur, a general physical examination is always performed, with specific attention directed toward the presence of cyanosis, abnormalities in growth, chest wall abnormalities, and any evidence of respiratory distress. Although the murmur may be the most prominent part of the overall examination, any murmur must be placed in context of other physical findings. Associated findings such as quality of the pulses, presence of a ventricular heave or thrill, or splitting of the second heart sound provide important clues to a specific cardiac diagnosis.

Accurate measurement of height and weight and plotting on a standard growth chart are important because both cardiac failure and chronic cyanosis can result in failure to thrive. Growth failure is manifested predominantly by poor weight gain; if length and especially head circumference is also affected, additional congenital malformations or metabolic disorders should be suspected.

Mild cyanosis may be too subtle for early detection, and clubbing of the fingers and toes is not usually manifested until late in the first year of life, even in the presence of severe arterial oxygen desaturation. Cyanosis is best observed over the nail beds, lips, tongue, and mucous membranes. Delayed recognition of cyanosis in infants with darker skin color

Table 471.1 Differential Diagnosis of Chest Pain in Pediatric Patients

MUSCULOSKELETAL (COMMON)
Trauma (accidental, abuse)
Exercise, overuse injury (strain, bursitis)
Costochondritis
Tietze syndrome
Herpes zoster (cutaneous or without rash)
Pleurodynia
Fibrositis
Slipping rib
Rib fracture
Precordial catch
Sickle cell anemia vasoocclusive crisis
Osteomyelitis (rare)
Primary or metastatic tumor (rare)
Fibromyalgia
Nerve entrapment, radiculopathy
PULMONARY (COMMON)
Pneumonia
Pleurisy
Pleurodynia
Asthma
Chronic cough
Pneumothorax
Infarction (sickle cell anemia)
Foreign body
Embolism (rare)
Pulmonary hypertension (rare)
Tumor (rare)
Bronchiectasis
GASTROINTESTINAL (LESS COMMON)
Esophagitis (gastroesophageal reflux, infectious, pill)
Esophageal foreign body
Esophageal spasm
Cholecystitis
Subdiaphragmatic abscess
Perihepatitis (Fitz-Hugh-Curtis syndrome)
Peptic ulcer disease
Pancreatitis
Splenic rupture
CARDIAC (LESS COMMON)
Pericarditis
Postpericardiotomy syndrome
Endocarditis
Myocarditis
Cardiomyopathy
Mitral valve prolapse
Aortic or subaortic stenosis
Arrhythmias (supraventricular, ventricular, tachycardias)
Marfan syndrome (dissecting aortic aneurysm)
Kawasaki disease
Cocaine, sympathomimetic ingestion
Ischemia (familial hypercholesterolemia, anomalous coronary artery, post-repair of congenital heart disease involving reimplantation of the coronary arteries [e.g., d-transposition of the great arteries])
Takotsubo cardiomyopathy (primary or secondary)
IDIOPATHIC (COMMON)
Anxiety, hyperventilation
Panic disorder
OTHER (LESS COMMON)
Spinal cord or nerve root compression
Breast-related pathologic condition (mastalgia)
Castleman disease (lymph node neoplasm)

can lead to delayed treatment and poorer outcomes. Careful observation of the color of the tongue, mucous membranes, and nail beds, where cyanosis is most noticeable, is critical in recognizing cyanosis in these patients. Confirmation with pulse oximetry is easily performed.

Differential cyanosis, manifested as blue lower extremities and pink upper extremities (usually the right arm), is seen with right-to-left shunting across a ductus arteriosus in the presence of coarctation or an interrupted aortic arch. Circumoral cyanosis or blueness around the forehead may be the result of prominent venous plexuses in these areas, rather than decreased arterial oxygen saturation. The extremities of infants often turn blue when the infant is unwrapped and cold (acrocyanosis), and this condition can be distinguished from central cyanosis by examination of the tongue and mucous membranes.

Heart failure in infants and children usually results in some degree of hepatomegaly and occasionally splenomegaly. The sites of **peripheral edema** are age dependent. In infants, edema is usually seen around the eyes and over the flanks, especially on initially waking. Older children and teenagers manifest both periorbital edema and pedal edema. An initial complaint in these older patients may be that their clothes are now too tight.

The **heart rate** of newborn infants is rapid and subject to wide fluctuations (Table 471.4). The average rate ranges from 120 to 140 beats/min and may increase to 170+ beats/min during crying and activity or drop to 70-90 beats/min during sleep. As the child grows older, the average pulse rate decreases and may be as low as 40 beats/min at rest in very athletic adolescents. Persistent **tachycardia** (>200 beats/min in neonates, 150 beats/min in infants, or 120 beats/min in older children), bradycardia, or an irregular heartbeat other than sinus arrhythmia requires investigation to exclude pathologic arrhythmias (see Chapter 484). **Sinus arrhythmia** can usually be distinguished by the rhythmic nature of the heart rate variations, occurring in concert with the respiratory cycle, with a P wave before every QRS complex, and a normal p-wave axis.

Careful evaluation of the character of the **pulses** is an important early step in the physical diagnosis of CHD. A wide pulse pressure with bounding pulses may suggest an aortic runoff lesion such as patent ductus arteriosus (PDA), aortic insufficiency, an arteriovenous communication, or increased cardiac output secondary to anemia, anxiety, or conditions associated with increased catecholamine or thyroid hormone secretion. The presence of diminished pulses in all extremities is associated with pericardial tamponade, left ventricular outflow obstruction, or cardiomyopathy. The radial and femoral pulses should always be palpated simultaneously. Normally, the femoral pulse should be appreciated immediately before the radial pulse. In infants with coarctation of the aorta, the femoral pulses may be decreased. However, in older children with coarctation of the aorta, blood flow to the descending aorta may channel through collateral vessels and results in the femoral pulse being palpable but delayed until after the radial pulse **(radial-femoral delay)**.

Blood pressure (BP) should be measured in either leg and in the right arm to be certain that coarctation of the aorta is not overlooked. Palpation of the femoral or dorsalis pedis pulse, or both, is not reliable alone to exclude coarctation because collaterals may have developed. Most commonly, BP is measured using an automated oscillatory device, but it is often necessary for the physician to manually recheck BP by auscultation. In older children, a cuff that covers approximately two thirds of the upper part of the arm or leg should be used for BP measurement. A cuff that is too small results in falsely high readings, whereas a cuff that is too large records slightly decreased BP. Pediatric clinical facilities should be equipped with 3-, 5-, 7-, 12-, and 18-cm cuffs to accommodate the large spectrum of pediatric patient sizes. When auscultating blood pressure directly, the first Korotkoff sounds indicate systolic pressure. As cuff pressure is slowly decreased, the sounds usually become muffled before they disappear. Diastolic pressure may be recorded when the sounds become muffled (preferred) or when they disappear altogether; the former is usually slightly higher and the latter slightly lower than true diastolic pressure. For lower-extremity BP determination, the stethoscope is placed over the popliteal artery. Typically, the BP recorded in the legs with the cuff technique is approximately 10 mm Hg higher than that in the arms. In infants, BP can be determined by auscultation or palpation.

BP varies with the age of the child and is closely correlated to height and weight. Significant increases occur during adolescence, and many temporary variations take place before the more stable levels of adult life are attained. Exercise, excitement, coughing, crying, and struggling may raise the systolic BP of infants and children as much as 40-50 mm Hg greater than their usual levels. Variability in BP in children of

Table 471.2 Congenital Malformation Syndromes Associated with Congenital Heart Disease

SYNDROME	FEATURES
CHROMOSOMAL DISORDERS	
Trisomy 21 (Down syndrome)	Endocardial cushion defect, VSD, ASD
Trisomy 21p (cat-eye syndrome)	Miscellaneous, total anomalous pulmonary venous return
Trisomy 18	VSD, ASD, PDA, TOF, coarctation of aorta, bicuspid aortic or pulmonary valve
Trisomy 13	VSD, ASD, PDA, coarctation of aorta, bicuspid aortic or pulmonary valve
Trisomy 9	Miscellaneous, VSD
XXXXY	PDA, ASD
Penta X	PDA, VSD
Triploidy	VSD, ASD, PDA
XO (Turner syndrome)	Bicuspid aortic valve, coarctation of aorta
Fragile X	Mitral valve prolapse, aortic root dilatation
Duplication 3q2	Miscellaneous
Deletion 4p	VSD, PDA, aortic stenosis
Deletion 9p	Miscellaneous
Deletion 5p (cri du chat syndrome)	VSD, PDA, ASD, TOF
Deletion 10q	VSD, TOF, conotruncal lesions*
Deletion 13q	VSD
Deletion 18q	VSD
Deletion 1p36	ASD, VSD, PDA, TOF, cardiomyopathy
Deletion/duplication 1q21.1	ASD, VSD, PS
Deletion 17q11 (William syndrome)	Supravalvar AS, branch PS
Deletion 11q 24-25 (Jacobsen syndrome)	VSD, left sided lesions
SYNDROME COMPLEXES	
CHARGE association (*c*oloboma, *h*eart, *a*tresia choanae, *r*etardation, *g*enital, and *e*ar anomalies)	VSD, ASD, PDA, TOF, endocardial cushion defect
DiGeorge sequence, CATCH 22 (*c*ardiac defects, *a*bnormal facies, *t*hymic aplasia, *c*left palate, *h*ypocalcemia, and deletion 22q11)	Aortic arch anomalies, conotruncal anomalies
Alagille syndrome (arteriohepatic dysplasia)	Peripheral pulmonic stenosis, PS, TOF
VATER association (*v*ertebral, *a*nal, *t*racheo*e*sophageal, *r*adial, and *r*enal anomalies)	VSD, TOF, ASD, PDA
FAVS (*f*acio*a*uriculo*v*ertebral *s*pectrum)	TOF, VSD
CHILD (*c*ongenital *h*emidysplasia with *i*chthyosiform erythroderma, *l*imb *d*efects)	Miscellaneous
Mulibrey nanism (muscle, liver, brain, eye)	Pericardial thickening, constrictive pericarditis
Asplenia syndrome	Complex cyanotic heart lesions with decreased pulmonary blood flow, transposition of great arteries, anomalous pulmonary venous return, dextrocardia, single ventricle, single atrioventricular valve
Polysplenia syndrome	Acyanotic lesions with increased pulmonary blood flow, azygos continuation of inferior vena cava, partial anomalous pulmonary venous return, dextrocardia, single ventricle, common atrioventricular valve
PHACE syndrome (*p*osterior brain fossa anomalies, facial *h*emangiomas, *a*rterial anomalies, *c*ardiac anomalies and aortic *c*oarctation, *e*ye anomalies)	VSD, PDA, coarctation of aorta, arterial aneurysms
TERATOGENIC AGENTS	
Congenital rubella	PDA, peripheral pulmonic stenosis
Fetal hydantoin syndrome	VSD, ASD, coarctation of aorta, PDA
Fetal alcohol syndrome	ASD, VSD

Continued

Table 471.2 Congenital Malformation Syndromes Associated with Congenital Heart Disease—cont'd

SYNDROME	FEATURES
Fetal valproate effects	Coarctation of aorta, hypoplastic left side of heart, aortic stenosis, pulmonary atresia, VSD
Maternal phenylketonuria	VSD, ASD, PDA, coarctation of aorta
Retinoic acid embryopathy	Conotruncal anomalies
OTHERS	
Apert syndrome	VSD
Autosomal dominant polycystic kidney disease	Mitral valve prolapse
Carpenter syndrome	PDA
Conradi syndrome	VSD, PDA
Crouzon disease	PDA, coarctation of aorta
Cutis laxa	Pulmonary hypertension, pulmonic stenosis
De Lange syndrome	VSD
Ellis–van Creveld syndrome	Single atrium, VSD
Holt-Oram syndrome	ASD, VSD, first-degree heart block
Infant of diabetic mother	Hypertrophic cardiomyopathy, VSD, conotruncal anomalies
Kartagener syndrome	Dextrocardia
Meckel-Gruber syndrome	ASD, VSD
Noonan syndrome	Pulmonic stenosis, ASD, cardiomyopathy
Pallister-Hall syndrome	Endocardial cushion defect
Primary ciliary dyskinesia	Heterotaxia disorders
Rubinstein-Taybi syndrome	VSD
Scimitar syndrome	Hypoplasia of right lung, anomalous pulmonary venous return to inferior vena cava
Smith-Lemli-Opitz syndrome	VSD, PDA
TAR syndrome (thrombocytopenia and absent radius)	ASD, TOF
Treacher Collins syndrome	VSD, ASD, PDA

*Conotruncal includes TOF, pulmonary atresia, truncus arteriosus, and transposition of great arteries.
ASD, Atrial septal defect; AV, aortic valve; PDA, patent ductus arteriosus; PS, pulmonary stenosis; TOF, tetralogy of Fallot; VSD, ventricular septal defect.

approximately the same age and body build should be expected, and at least three serial measurements on different dates should be obtained when confirming the diagnosis of hypertension (Figs. 471.2 and 471.3).

Although of little use in infants, in cooperative older children, inspection of the **jugular venous pulse** wave provides information about central venous and right atrial pressure. The neck veins should be inspected with the patient sitting at a 90-degree angle. The external jugular vein should not be visible above the clavicles unless central venous pressure is elevated. Increased venous pressure transmitted to the internal jugular vein may appear as venous pulsations without visible distention; such pulsation is not seen in normal children reclining at an angle of 45 degrees. Because the great veins are in direct communication with the right atrium, changes in pressure and the volume of this chamber are also transmitted to the veins. The one exception occurs in superior vena cava obstruction, in which venous pulsatility is lost.

CARDIAC EXAMINATION

The heart should be examined in a systematic manner, starting with inspection and palpation. Any abnormalities on inspection and/or palpation strongly suggest a pathologic rather than a functional etiology of any heart murmur. A **precordial bulge** to the left of the sternum with or without increased precordial activity suggests cardiac enlargement, especially in younger children where the chest wall is still relatively flexible; such bulges can often best be appreciated by having the child lay supine with the examiner looking up from the child's feet. A **substernal heave** indicates the presence of right ventricular hypertrophy or enlargement, whereas an **apical heave** is noted with left ventricular hypertrophy or enlargement. An overall **hyperdynamic precordium** suggests a volume load such as that found with a large left-to-right shunt, although it may be normal in a thin patient. An overly silent precordium with a barely detectable apical impulse suggests a large pericardial effusion or severe cardiomyopathy but may be normal in an obese patient.

The relationship of the **apical impulse** to the midclavicular line is also helpful in the estimation of cardiac size: the apical impulse shifts laterally and inferiorly with enlargement of the left ventricle. Right-sided apical impulses signify dextrocardia, tension pneumothorax, or left-sided thoracic space-occupying lesions (e.g., diaphragmatic hernia).

Thrills are the palpable equivalent of murmurs and correlate with the area of maximal auscultatory intensity of the murmur. It is important to palpate the suprasternal notch and neck for aortic bruits, which may indicate the presence of aortic stenosis. Right lower sternal border and apical systolic thrills are characteristic of ventricular septal defect (VSD) and mitral insufficiency, respectively. Diastolic thrills are occasionally palpable in the presence of atrioventricular valve stenosis. The timing and localization of thrills should be carefully noted. Although the presence of a thrill is usually linked to a murmur of grade IV or greater, after a patient has had cardiac surgery, the presence of scar within the chest may eliminate the ability to feel a thrill even with a very loud murmur.

Table 471.3 Cardiac Manifestations of Systemic Diseases

SYSTEMIC DISEASE	CARDIAC COMPLICATIONS
INFLAMMATORY DISORDERS	
Sepsis	Hypotension, myocardial dysfunction, pericardial effusion, pulmonary hypertension
COVID-19	Myocarditis, multisystem inflammatory syndrome in children (MIS-C)
Juvenile idiopathic arthritis	Pericarditis, rarely myocarditis
Systemic lupus erythematosus	Pericarditis, Libman-Sacks endocarditis, coronary arteritis, coronary atherosclerosis (with steroids), congenital heart block
Scleroderma	Pulmonary hypertension, myocardial fibrosis, cardiomyopathy
Dermatomyositis	Cardiomyopathy, arrhythmias, heart block
Kawasaki disease	Coronary artery aneurysm and thrombosis, myocardial infarction, myocarditis, valvular insufficiency
Sarcoidosis	Granuloma, fibrosis, amyloidosis, biventricular hypertrophy, arrhythmias
Lyme disease	Arrhythmias, myocarditis
Löffler hypereosinophilic syndrome	Endomyocardial disease
INBORN ERRORS OF METABOLISM	
Refsum disease	Arrhythmia, sudden death
Hunter or Hurler syndrome	Valvular insufficiency, heart failure, hypertension
Fabry disease	Mitral insufficiency, coronary artery disease with myocardial infarction
Glycogen storage disease IIa (Pompe disease)	Short P-R interval, cardiomegaly, heart failure, arrhythmias
Carnitine deficiency	Heart failure, cardiomyopathy
Gaucher disease	Pericarditis
Homocystinuria	Coronary thrombosis
Alkaptonuria	Atherosclerosis, valvular disease
Morquio-Ullrich syndrome	Aortic incompetence
Scheie syndrome	Aortic incompetence
CONNECTIVE TISSUE DISORDERS	
Arterial calcification of infancy	Calcinosis of coronary arteries, aorta, heart failure, hypertension
Marfan syndrome	Aortic and mitral insufficiency, dissecting aortic aneurysm, mitral valve prolapse
Congenital contractural arachnodactyly	Mitral insufficiency or prolapse
Ehlers-Danlos syndrome	Mitral valve prolapse, dilatated aortic root
Osteogenesis imperfecta	Aortic incompetence
Pseudoxanthoma elasticum	Peripheral arterial disease
NEUROMUSCULAR DISORDERS	
Friedreich ataxia	Cardiomyopathy
Duchenne dystrophy	Cardiomyopathy, heart failure
Tuberous sclerosis	Cardiac rhabdomyoma
Familial deafness	Occasionally arrhythmia, sudden death
Neurofibromatosis	Pulmonic stenosis, pheochromocytoma, coarctation of aorta
Riley-Day syndrome	Episodic hypertension, postural hypotension
Von Hippel-Lindau disease	Hemangiomas, pheochromocytomas
ENDOCRINE-METABOLIC DISORDERS	
Graves disease	Tachycardia, arrhythmias, heart failure
Hypothyroidism	Bradycardia, pericardial effusion, cardiomyopathy, low-voltage electrocardiogram
Pheochromocytoma	Hypertension, myocardial ischemia, myocardial fibrosis, cardiomyopathy
Carcinoid	Right-sided endocardial fibrosis

Continued

Table 471.3 Cardiac Manifestations of Systemic Diseases—cont'd

SYSTEMIC DISEASE	CARDIAC COMPLICATIONS
HEMATOLOGIC DISORDERS	
Sickle cell anemia	High-output heart failure, cardiomyopathy, pulmonary hypertension
Thalassemia major	High-output heart failure, hemochromatosis
Hemochromatosis (first or second degree)	Cardiomyopathy
OTHERS	
Appetite suppressants (fenfluramine and dexfenfluramine)	Cardiac valvulopathy, pulmonary hypertension
Cockayne syndrome	Atherosclerosis
Jervell and Lange-Nielsen syndrome	Prolonged Q-T interval, sudden death
Kearns-Sayre syndrome	Heart block
LEOPARD syndrome (lentiginosis)	Pulmonic stenosis, prolonged Q-T interval
Progeria	Accelerated atherosclerosis
Osler-Weber-Rendu disease	Arteriovenous fistula (lung, liver, mucous membrane)
Romano-Ward syndrome	Prolonged Q-T interval, sudden death
Weill-Marchesani syndrome	Patent ductus arteriosus
Werner syndrome	Vascular sclerosis, cardiomyopathy

LEOPARD, Multiple *l*entigines, *e*lectrocardiographic conduction abnormalities, *o*cular hypertelorism, *p*ulmonary stenosis, *a*bnormal genitals, *r*etardation of growth, sensorineural *d*eafness.

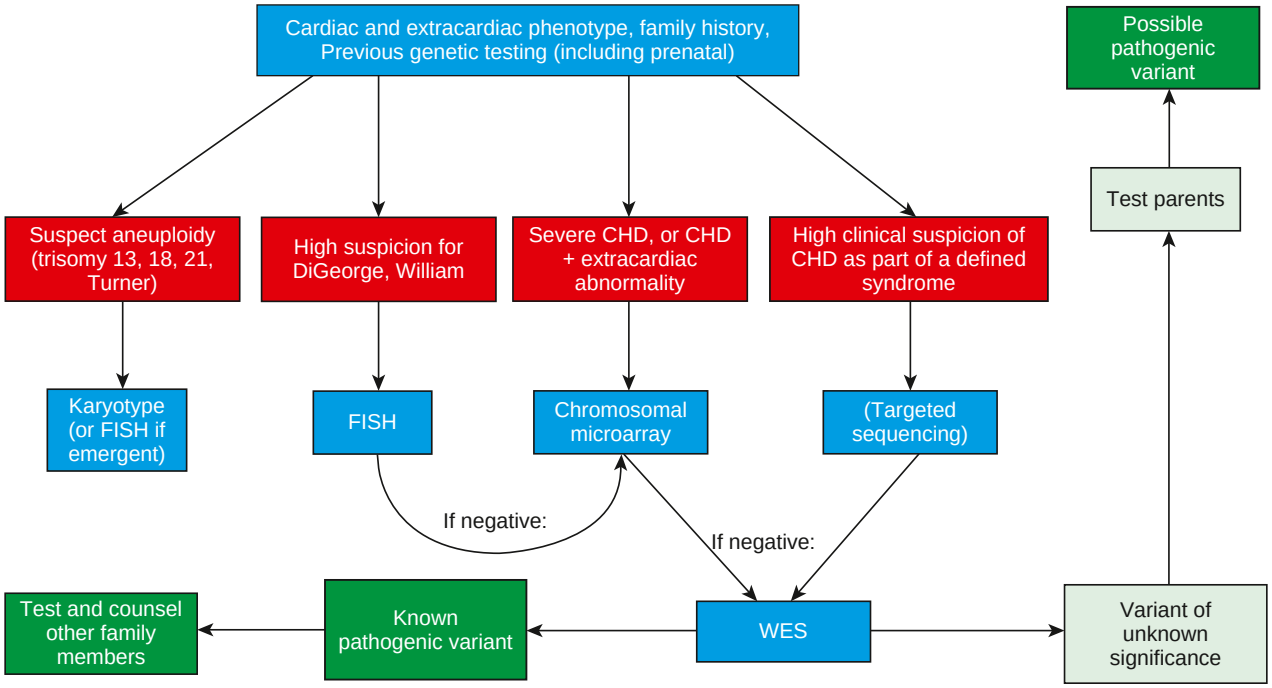

Fig. 471.1 Genetics screening algorithm for congenital heart disease (CHD) patients. FISH, Fluorescence in situ hybridization; WES, whole exome sequencing. *(From Simmons MA, Brueckner M. The genetics of congenital heart disease . . . understanding and improving long-term outcomes in congenital heart disease: a review for the general cardiologist and primary care physician. Curr Opin Pediatr. 2017;29:520–528, Fig 2.)*

Auscultation is an art that improves with practice. The diaphragm of the stethoscope is placed firmly on the chest for high-pitched sounds; a lightly placed bell is optimal for low-pitched sounds. The physician should initially move the stethoscope across the chest, concentrating on the characteristics of the heart sounds; their variation with respiration; and the presence of clicks, rubs, or gallops. Repeat the process, concentrating on murmurs, their maximum location, and their radiation. In some CHDs, such as atrial septal defect (ASD), the murmur is nonspecific and sounds identical to many functional murmurs; it is the abnormality of the second heart sound that points to a pathologic condition. The patient should ideally be supine, lying quietly, and breathing normally. The **first heart sound** (S_1) is best heard at the apex, whereas the **second heart sound** (S_2) should be evaluated at the upper left and right sternal borders. S_1 is caused by closure of the atrioventricular valves (mitral and tricuspid) and can be either single or split. S_2 is caused by closure of the semilunar valves (aortic and pulmonary) (Fig. 471.4). During inspiration, the decrease in intrathoracic pressure results in increased filling of the right side of the heart, which leads to

Table 471.4 Pulse Rates at Rest

AGE	LOWER LIMITS OF NORMAL (beats/min)		AVERAGE (beats/min)		UPPER LIMITS OF NORMAL (beats/min)	
Newborn	70		125		190	
1-11 mo	80		120		160	
2 yr	80		110		130	
4 yr	80		100		120	
6 yr	75		100		115	
8 yr	70		90		110	
10 yr	70		90		110	
	FEMALES	MALES	FEMALES	MALES	FEMALES	MALES
12 yr	70	65	90	85	110	105
14 yr	65	60	85	80	105	100
16 yr	60	55	80	75	100	95
18 yr	55	50	75	70	95	90

an increased right ventricular ejection time and thus delayed closure of the pulmonary valve; inspiration decreases pulmonary venous return, decreasing filling of the left ventricle and moving closure of the aortic valve earlier. Consequently, **splitting of the second heart sound** widens during inspiration and narrows during expiration.

S_2 can appear to be single during expiration, because we can only hear two sounds if they are separated by 20-30 msec. The presence of a normally split S_2 is strong evidence against the diagnosis of ASD, defects associated with pulmonary arterial hypertension, severe pulmonary valve stenosis, aortic and pulmonary atresia, and truncus arteriosus. Wide S_2 splitting is noted in ASD, pulmonary stenosis (where the pulmonary second sound is soft), Ebstein anomaly, total anomalous pulmonary venous return, and right bundle branch block. An accentuated pulmonic component of S_2 with narrow splitting is a sign of pulmonary hypertension. A single S_2 occurs in pulmonary or aortic atresia or severe stenosis, truncus arteriosus, and, often, transposition of the great arteries.

A **third heart sound** (S_3) is best heard with the bell at the apex in mid-diastole, during passive ventricular filling. An S_3 can be pathologic but may be normal in children, often accentuated in patients with fever and tachycardia. A **fourth heart sound** (S_4), occurring in conjunction with atrial systole and the final stages of ventricular filling, may be heard just before the S_1 in late diastole. An S_4 is always pathologic and an indication of decreased ventricular compliance, as occurs in patients with ventricular dysfunction (e.g., in dilated cardiomyopathy). An S_3 may merge with an S_4, a finding known as a **summation gallop**.

Ejection clicks, which are heard in early systole, are usually caused by a mildly to moderately stenotic aortic or pulmonary valve or to a dilated ascending aorta or pulmonary artery. They are heard so close to S_1 that they may be mistaken for a split S_1. However, ejection clicks are heard at the upper left or right sternal borders, whereas a split S_1 is heard at the lower left sternal border or apex. **Aortic** ejection clicks are best heard at the left middle to right upper sternal border and are constant in intensity. They occur in conditions where the aortic valve (mild to moderate aortic stenosis) is stenotic or the aorta is dilated (e.g., tetralogy of Fallot, truncus arteriosus). **Pulmonary** ejection clicks are associated with mild to moderate pulmonary stenosis and are best heard at the left middle to upper sternal border and vary with respiration, often disappearing with inspiration. A good place to hear ejection clicks is right over the sternum, since bone conducts high-frequency sound much better than the muscle of the intercostal spaces. A midsystolic click heard at the apex, often preceding a late systolic murmur, suggests mitral valve prolapse.

Murmurs should be described according to their intensity, pitch, timing (systolic or diastolic), variation in intensity, time to peak intensity, location of maximal intensity, and radiation to other areas. Auscultation for murmurs should be carried out starting at the upper right sternal border then moving slowly across the upper precordium, down the left and right sternal borders, and out to the apex and to the left axilla. Auscultation should also always be performed in the right axilla and over both sides of the back, as many CHD murmurs radiate to these locations. Systolic murmurs are classified as ejection, holosystolic or pansystolic, or late systolic according to the timing of the murmur in relation to S_1 and S_2. The intensity of systolic murmurs is graded from I to VI: **I**, barely audible; **II**, medium intensity; **III**, loud but no thrill; **IV**, loud with a thrill; **V**, very loud but still requiring positioning of the stethoscope at least partly on the chest; and **VI**, so loud that the murmur can be heard with the stethoscope off the chest. In patients who have undergone prior heart surgery, a murmur of grade IV or greater may be heard in the absence of a thrill because of scar tissue, which does not transmit vibrations well, within the chest.

Systolic ejection murmurs start a short time after a well-heard S_1, increase in intensity, peak, and then decrease in intensity; they usually end before S_2. In patients with severe pulmonary stenosis, however, the murmur may extend beyond the first component of S_2, thus obscuring it. **Pansystolic or holosystolic murmurs** begin simultaneously with S_1 and continue throughout systole, on occasion becoming gradually decrescendo. It is important to remember that after closure of the atrioventricular valves (S_1), a brief period occurs during which ventricular pressure increases but the semilunar valves remain closed (isovolumic contraction; see Fig. 471.4). Thus holosystolic murmurs (heard during both isovolumic contraction and the ejection phases of systole) cannot be caused by flow across the semilunar valves because these valves are closed during isovolumic contraction! Holosystolic murmurs must therefore be related to blood exiting the contracting ventricle via either an abnormal opening (VSD) or atrioventricular (mitral or tricuspid) valve insufficiency. Systolic ejection murmurs usually imply increased flow or stenosis across one of the ventricular outflow tracts (aortic or pulmonic). In infants with rapid heart rates, it is often difficult to distinguish between ejection and pansystolic murmurs. If a clear and distinct S_1 can be appreciated, the murmur is most likely ejection in nature.

A **continuous murmur** is a murmur that continues from systole into diastole and indicates continuous flow, such as in the presence of a PDA or other aortopulmonary communication. This murmur should be differentiated from a **to-and-fro murmur**, where the systolic component of the murmur ends at or before S_2 and the diastolic murmur begins after S_2 with semilunar valve closure (aortic stenosis and insufficiency; pulmonary stenosis and insufficiency). A **late systolic murmur** begins well beyond S_1 and continues until the end of systole and is usually heard after a midsystolic click in patients with mitral valve prolapse and insufficiency.

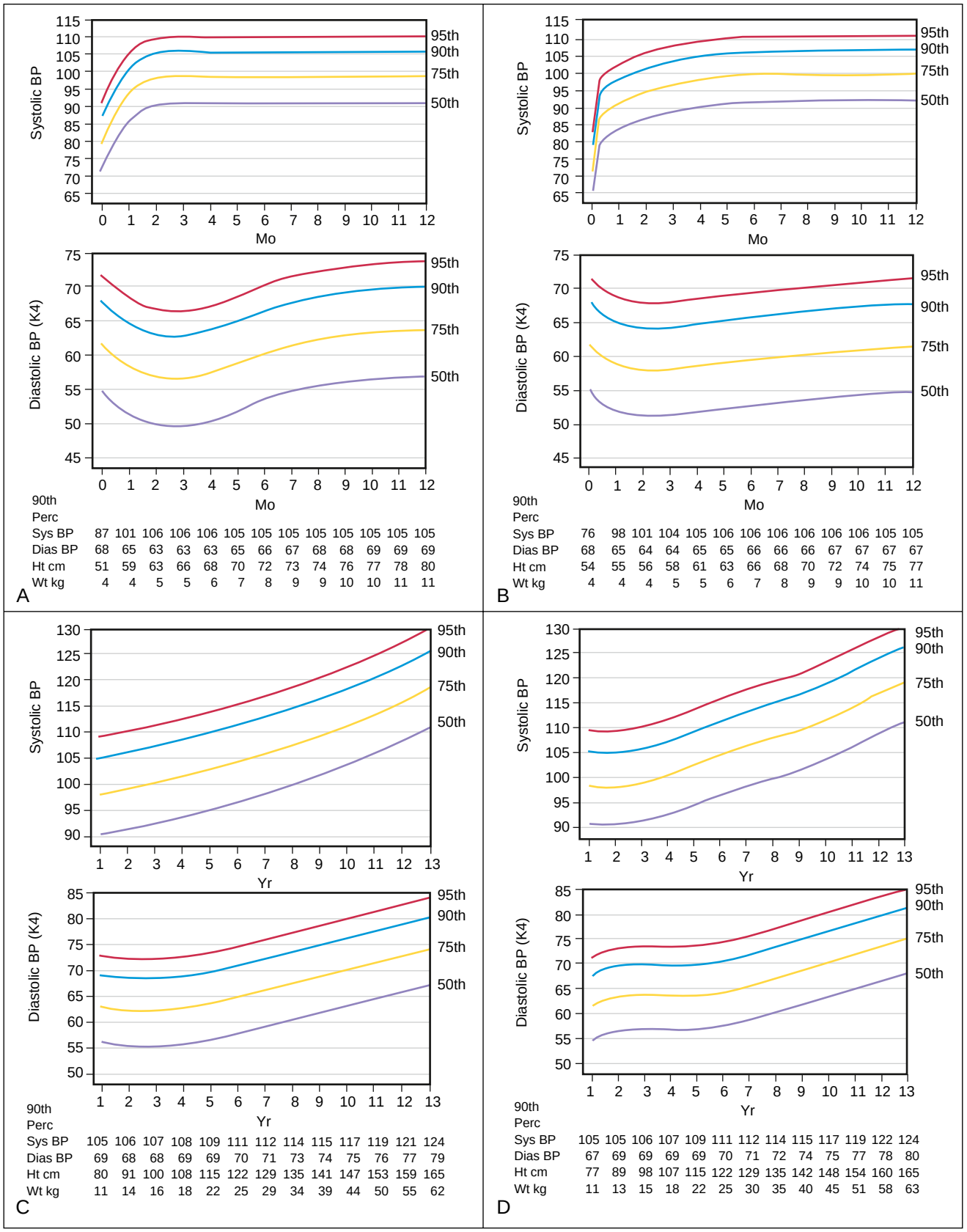

Fig. 471.2 Age-specific percentiles of blood pressure (BP) measurements: birth to 13 yr. **A,** Males from birth to 12 mo of age. **B,** Females from birth to 12 mo of age. **C,** Males 1-13 yr of age. **D,** Females 1-13 yr of age. Korotkoff phase IV (K4) used for diastolic BP. Dias, Diastolic; Ht, height; Perc, percentile; Sys, systolic; Wt, weight. *(From Report of the Second Task Force on Blood Pressure Control in Children—1987. National Heart, Lung, and Blood Institute, Bethesda, MD. Pediatrics. 1987;79:1–25. Copyright 1987 by the American Academy of Pediatrics.)*

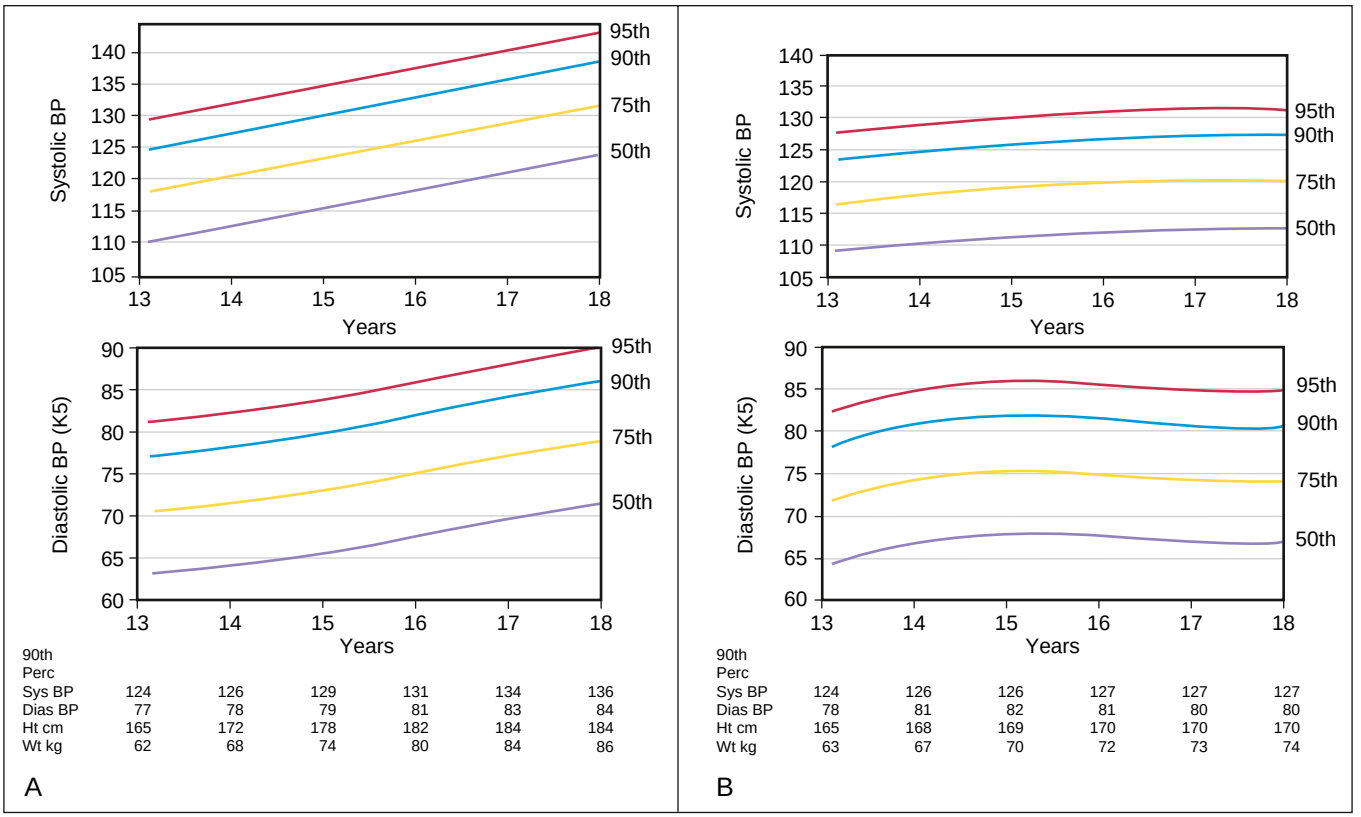

90th Perc	13	14	15	16	17	18
Sys BP	124	126	129	131	134	136
Dias BP	77	78	79	81	83	84
Ht cm	165	172	178	182	184	184
Wt kg	62	68	74	80	84	86

90th Perc	13	14	15	16	17	18
Sys BP	124	126	126	127	127	127
Dias BP	78	81	82	81	80	80
Ht cm	165	168	169	170	170	170
Wt kg	63	67	70	72	73	74

Fig. 471.3 Age-specific percentiles of blood pressure (BP) measurements: age 13-18 yr. **A**, Males 13-18 yr of age. **B**, Females 13-18 yr of age. Korotkoff phase V (K5) used for diastolic BP. Dias, Diastolic; Ht, height; Perc, percentile; Sys, systolic; Wt, weight. *(From Report of the Second Task Force on Blood Pressure Control in Children—1987, National Heart, Lung, and Blood Institute, Bethesda, MD. Pediatrics. 1987;79:1–25. Copyright 1987 by the American Academy of Pediatrics.)*

Several types of **diastolic murmurs** (graded I-IV) can be identified. A **decrescendo diastolic murmur** is a blowing murmur usually along the left sternal border that begins with S_2 and diminishes toward mid-diastole. When louder and high-pitched, this murmur is usually associated with aortic valve insufficiency or pulmonary insufficiency related to pulmonary hypertension. When softer and low-pitched, this murmur is usually associated with pulmonary valve insufficiency in the absence of pulmonary hypertension. A to-and-fro murmur is typically noted after surgical repair of the pulmonary outflow tract in patients with tetralogy of Fallot. A **rumbling mid-diastolic murmur** at the left mid and lower sternal border may be caused by increased blood flow across the tricuspid valve, such as occurs with ASD or, much less often, because of actual stenosis of this valve. When this murmur is heard at the apex, it is caused by increased flow across the mitral valve, such as occurs with large left-to-right shunts at the ventricular level (VSDs), at the great vessel level (PDA, aortopulmonary shunts), or with increased flow because of mitral insufficiency. When an apical diastolic rumbling murmur is longer and is accentuated at the end of diastole (presystolic), it usually indicates anatomic mitral valve stenosis.

The absence of a precordial murmur does not rule out significant congenital or acquired heart disease. Congenital heart defects, some of which are ductal dependent, may not demonstrate a murmur if the ductus arteriosus closes. These lesions include pulmonary or tricuspid valve atresia and transposition of the great arteries. Murmurs may seem insignificant in patients with ASDs, anomalous pulmonary venous return, some forms of atrioventricular septal defects, coarctation of the aorta, or anomalous origin of a coronary artery. Careful attention to other components of the physical examination (growth failure, cyanosis, peripheral pulses, precordial impulse, heart sounds) increases the index of suspicion of congenital heart defects in these patients. In contrast, loud murmurs may be present in the absence of structural heart disease, for example, in patients with a large noncardiac arteriovenous malformation, mitral regurgitation caused by left ventricular dilation associated with myocarditis or cardiomyopathy, and severe anemia.

Many murmurs are not associated with significant hemodynamic abnormalities. These murmurs are referred to as *functional, normal, insignificant,* or *innocent*. During routine random auscultation, >30% of children may have an innocent murmur at some time in their lives; this percentage increases when auscultation is done under nonbasal circumstances (high cardiac output because of fever, infection, or anxiety). The most common **innocent murmur** is a medium-loud, medium-pitched, vibratory or "musical," relatively short *systolic ejection murmur,* which is heard best along the left sternal border and has no significant radiation to the apex, base, or back. It is heard most frequently in children between 3 and 7 years of age. The intensity of the murmur often changes with respiration and position and may be attenuated or even disappear in the sitting or prone position. Innocent *pulmonic* murmurs are also common in children and adolescents and originate from normal turbulence during ejection into the pulmonary artery. These are higher pitched, brief, early systolic murmurs of grades I-II in intensity and are best heard in the second left parasternal space with the patient in the supine position. Features suggestive of heart disease include murmurs that are holosystolic, grade III or higher, harsh, located at the left upper sternal border, and associated with an early or midsystolic click or an abnormal S_2.

A **venous hum** is another example of a common innocent murmur heard during childhood. Venous hums are produced by turbulence of blood in the jugular venous system; they have no pathologic significance and may be heard in the neck or anterior portion of the upper part of the chest. Appreciated as a soft humming sound heard in both systole and diastole, it can be exaggerated or made to disappear by

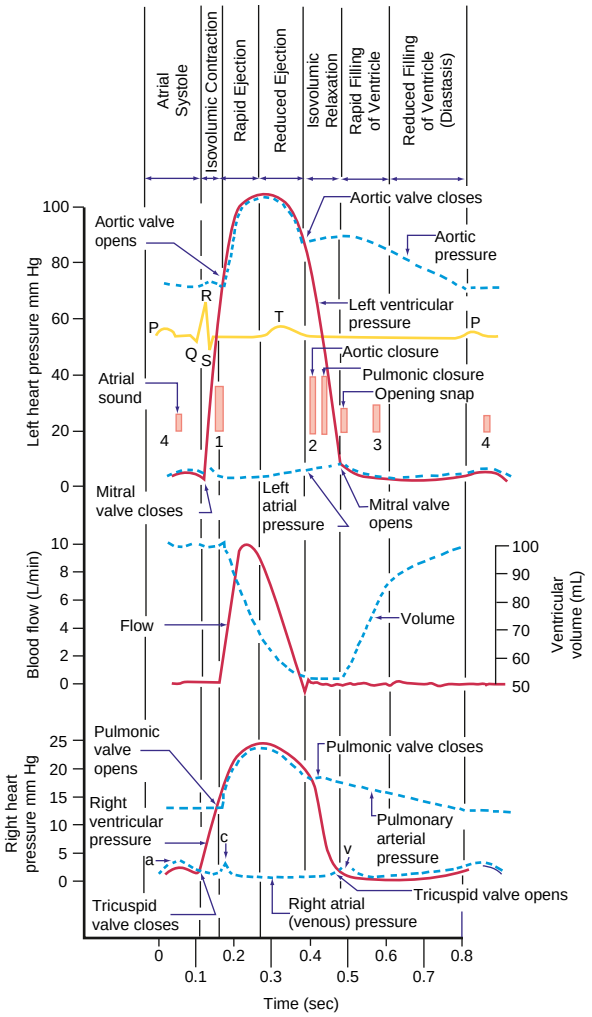

Fig. 471.4 Idealized diagram of the temporal events of a cardiac cycle (the Wiggers diagram).

varying the position of the head, or it can be decreased by lightly compressing the jugular venous system in the neck. These simple maneuvers are sufficient to differentiate a venous hum from the murmurs produced by organic cardiovascular disease, particularly a PDA.

The lack of significance of an innocent murmur should be discussed with the child's parents. It is important to offer complete reassurance because lingering doubts about the importance of a cardiac murmur may have profound effects on child-rearing practices, most often in the form of overprotectiveness. An underlying fear that a cardiac abnormality is present may negatively affect a child's self-image and development. The physician should explain that an innocent murmur is simply a "noise" and does not indicate the presence of a cardiac defect. When asked, "Will it go away?" the best response is to state that because the murmur has no clinical significance, it does not matter whether it "goes away." Parents should be warned that the intensity of the murmur might increase during febrile illnesses, a time when, typically, another physician may examine the child (e.g., in the emergency department). With growth, however, innocent murmurs are less well heard and often disappear completely. If there is a suspicion of structural heart disease, additional studies are indicated to rule out a congenital heart defect. However, "routine" electrocardiographic, chest radiographic, and echocardiographic examinations should be avoided in well children with a clearly innocent murmur.

Visit Elsevier eBooks+ at eBooks.Health.Elsevier.com for Bibliography.

Chapter 472

Laboratory Cardiac Evaluation

Daniel Bernstein

472.1 Radiologic Cardiac Assessment

Daniel Bernstein

Despite the widespread easy access to advanced imaging techniques, such as echocardiography, computed tomography (CT) scan, and magnetic resonance imaging (MRI), the chest x-ray film remains a highly valuable diagnostic tool and is often the first imaging study performed in a child suspected of having a cardiac defect. It can provide important information about cardiac size and shape, pulmonary blood flow (vascularity), pulmonary edema, and associated lung and thoracic anomalies that may be associated with congenital syndromes (e.g., skeletal dysplasias, extra or deficient number of ribs, abnormal vertebrae, diaphragmatic hernia, previous cardiac surgery). Combined with a careful physical examination, the chest radiograph can help the clinician to establish a diagnosis of congenital heart disease (CHD), as opposed to pulmonary disease, and to narrow the differential diagnosis to specific categories of CHD (e.g., left-to-right shunt lesions vs obstructive lesions).

The most frequently used measurement of cardiac size is the maximal width of the cardiac shadow in a posteroanterior (PA) chest film taken mid-inspiration. A vertical line is drawn down the middle of the sternal shadow, and perpendicular lines are drawn from the sternal line to the extreme right and left borders of the heart; the sum of the lengths of these lines is the **maximal cardiac width**. The **maximal chest width** is obtained by drawing a horizontal line between the right and left inner borders of the rib cage at the level of the top of the right diaphragm. When the maximal cardiac width is more than half the maximal chest width (cardiothoracic ratio >50%), the heart is usually enlarged. Cardiac size should be evaluated only when the film is taken during inspiration with the patient in an upright position, which can be difficult to achieve in younger patients. A diagnosis of "cardiac enlargement" on expiratory or prone films is a common cause of unnecessary referrals and laboratory studies.

The **cardiothoracic ratio** is a less useful index of cardiac enlargement in infants than in older children because the horizontal position of the heart may increase the ratio to about 60% in the absence of true enlargement. Furthermore, the thymus may overlap not only the base of the heart but also virtually the entire mediastinum, thus obscuring the true cardiac silhouette.

A *lateral* chest radiograph may be helpful in infants and in older children with pectus excavatum or other conditions that result in a narrow anteroposterior (AP) chest dimension. The heart may appear small in the lateral view and suggest that the apparent enlargement in the PA projection was caused by either the thymus (anterior mediastinum only) or flattening of the cardiac chambers as a result of a structural chest abnormality.

In the PA view, the left border of the cardiac shadow consists of three convex shadows produced, from above downward, by the aortic knob, the main and left pulmonary arteries, and the left ventricle (Fig. 472.1). In cases of moderate to marked left atrial enlargement, the atrium may be visualized between the pulmonary artery and the left ventricle. The right ventricular outflow tract (RVOT) does not contribute to the shadows formed by the left border of the heart. The aortic knob is not as easily seen in infants and children as in adults. The side of the aortic arch (left or right) can often be inferred as being opposite the side of the midline from which the air-filled trachea is visualized. This observation is important because a right-sided aortic arch is often present in

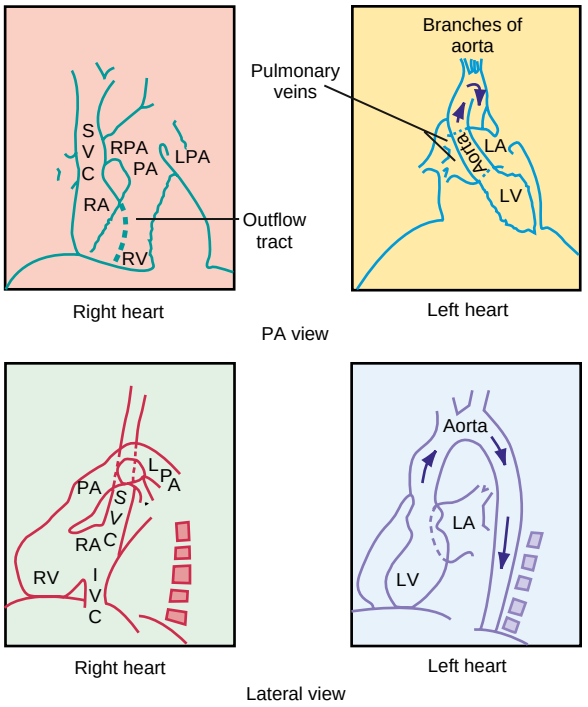

Fig. 472.1 Idealized diagrams showing normal position of the cardiac chambers and great blood vessels. IVC, Inferior vena cava; LA, left atrium; LPA, left pulmonary artery; LV, left ventricle; PA, pulmonary artery; RA, right atrium; RPA, right pulmonary artery; RV, right ventricle; SVC, superior vena cava. *(Adapted and redrawn from Dotter CT, Steinberg I. Angiocardiographic interpretation. Radiology. 1949;153:513.)*

cyanotic CHD, particularly in tetralogy of Fallot. Three structures contribute to the right border of the cardiac silhouette. In the view from above, they are the superior vena cava, the ascending aorta, and the right atrium.

Enlargement of cardiac chambers (i.e., increased chamber volume) or major arteries and veins results in prominence of the areas in which these structures are normally outlined on the chest radiograph. In contrast, the electrocardiogram is a more sensitive and accurate index of **ventricular hypertrophy**, which is a thickening of the ventricular wall and may or may not be associated with dilation of the affected cardiac chamber.

The chest radiograph is also an important tool for assessing the degree of pulmonary vascularity. **Pulmonary overcirculation** is usually associated with left-to-right shunt lesions, whereas **pulmonary undercirculation** is associated with obstruction of the RVOT in cyanotic lesions. The esophagus is closely related to the great vessels, and a barium esophagogram can help delineate these structures in the initial evaluation of suspected vascular rings, although this has largely been supplanted by CT.

Echocardiographic examination best defines the morphologic features of intracardiac chambers, cardiac valves, and intracardiac shunts. CT is used as an adjunct to echocardiogram to evaluate extracardiac vascular morphology. MRI is used most often to provide a more quantitative assessment of inflammation as well as ventricular volumes, cardiac function, and shunt and regurgitant fractions than is possible with echocardiogram.

472.2 Electrocardiography

Daniel Bernstein

DEVELOPMENTAL CHANGES

The marked changes that occur in cardiac physiology and chamber dominance during the perinatal transition (see Chapter 470) are reflected in the evolution of the electrocardiogram (ECG) during the neonatal period. Because vascular resistance in the pulmonary and systemic circulations is nearly equal in a term fetus, the intrauterine work of the heart results in an equal mass of both the right and left ventricles. After birth, systemic vascular resistance (SVR) rises when the placental circulation is eliminated, and pulmonary vascular resistance (PVR) falls when the lungs expand. These changes are reflected in the ECG over the first few weeks of life as the right ventricular (RV) wall begins to thin.

The ECG demonstrates these anatomic and hemodynamic features principally by changes in QRS and T-wave morphologic features. Typically, pediatric ECGs include several additional leads rarely used in adults, such as V_3R and V_4R, which are mirror images of leads V_3 and V_4 and are important in the evaluation of **right ventricular hypertrophy** (RVH). On occasion, lead V_1 is inappropriately positioned too far leftward to reflect RV forces accurately. This problem is present particularly in premature infants, in whom the electrocardiographic electrode gel may produce contact among all the precordial leads. An additional lead used in children is V_7, located more laterally than V_6 and useful for assessing left-sided forces.

During the first postnatal days of life, right axis deviation, large R waves, and upright T waves in the right precordial leads (V_3R or V_4R and V_1) are the norm (Fig. 472.2). As PVR decreases in the first few days after birth, the right precordial T waves become negative. In the great majority of cases, this change occurs within the first 48 hours of postnatal life. Upright T waves that persist in leads V_3R, V_4R, or V_1 beyond 1 week of life are an abnormal finding indicating RVH or RV strain, even in the absence of QRS voltage criteria. The T wave in V_1 should never be positive before 6 years of age; however, it may remain negative into adolescence or early adulthood. This finding represents one of the most important yet subtle differences between pediatric and adult ECGs and is a common source of error when adult cardiologists interpret pediatric ECGs.

In a newborn the mean **QRS frontal-plane axis** normally lies in the range of +110 to +180 degrees, reflecting the codominance of the fetal right and left ventricles. The right-sided chest leads reveal a larger positive **(R)** than negative **(S)** wave and may do so for months because the right ventricle remains relatively thick throughout early infancy. Left-sided leads (V_5 and V_6) also reflect right-sided dominance in the early neonatal period, when the R:S ratio in these leads may be <1. A dominant R wave in V_5 and V_6, reflecting left ventricular (LV) forces, quickly becomes evident within the first few days of life (Fig. 472.3). As the child matures, the QRS axis gradually shifts leftward and the RV forces slowly regress. Leads V_1, V_3R, and V_4R display a prominent R wave until 6 months to 8 years of age. Most children have an R:S ratio >1 in lead V_4R until age 4 years. The T waves are inverted in leads V_4R, V_1, V_2, and V_3 during infancy and may remain so into the middle of the second decade of life and beyond. The processes of RV thinning and LV growth are best reflected in the QRS-T pattern over the right precordial leads. The diagnosis of RVH or left ventricular hypertrophy (LVH) in a pediatric patient can be made only with an understanding of the normal developmental physiology of these chambers at various ages until adulthood is reached. As the left ventricle becomes dominant, the ECG evolves to the characteristic pattern of older children (Fig. 472.4) and adults (Fig. 472.5).

Ventricular hypertrophy usually results in increased voltage in the R and S waves in the chest leads. The height of these deflections is governed by the proximity of the specific electrode to the surface of the heart; by the sequence of electrical activation through the ventricles, which can result in variable degrees of cancellation of right vs left forces; and by hypertrophy of the myocardium.

The diagnosis of **pathologic RVH** is difficult in the first week of postnatal life because physiologic RVH is a normal finding. Serial tracings are often necessary to determine whether marked right axis deviation and potentially abnormal right precordial forces or T waves, or both, will persist beyond the neonatal period (Fig. 472.6). In contrast, an adult ECG pattern (see Fig. 472.5) seen in a neonate suggests LVH. The exception is a premature infant, who may display a more "mature" ECG than a full-term infant (Fig. 472.7) as a result of lower PVR secondary

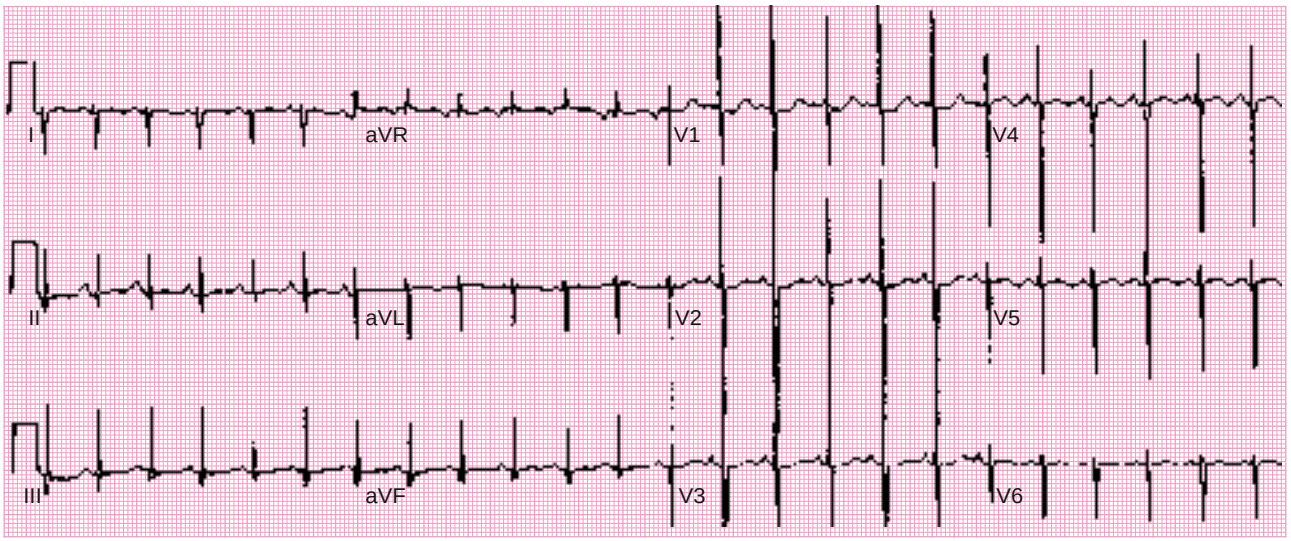

Fig. 472.2 Normal ECG from a 5-day-old, term-gestation infant. The frontal plane QRS axis is 150 degrees. There is prominent voltage in the precordial leads and a suggestion of right ventricular preponderance but not right ventricular hypertrophy. The QRS duration is 60 ms. *(From Gering LE, Knilans TK, Surawicz B, et al. Normal electrocardiograms in the fetus, infants, and children. In: Surawicz B, Knilans TK. Chou's Electrocardiography in Clinical Practice, 6th ed. Philadelphia: Saunders; 2008: Fig. 28.2, p. 651).*

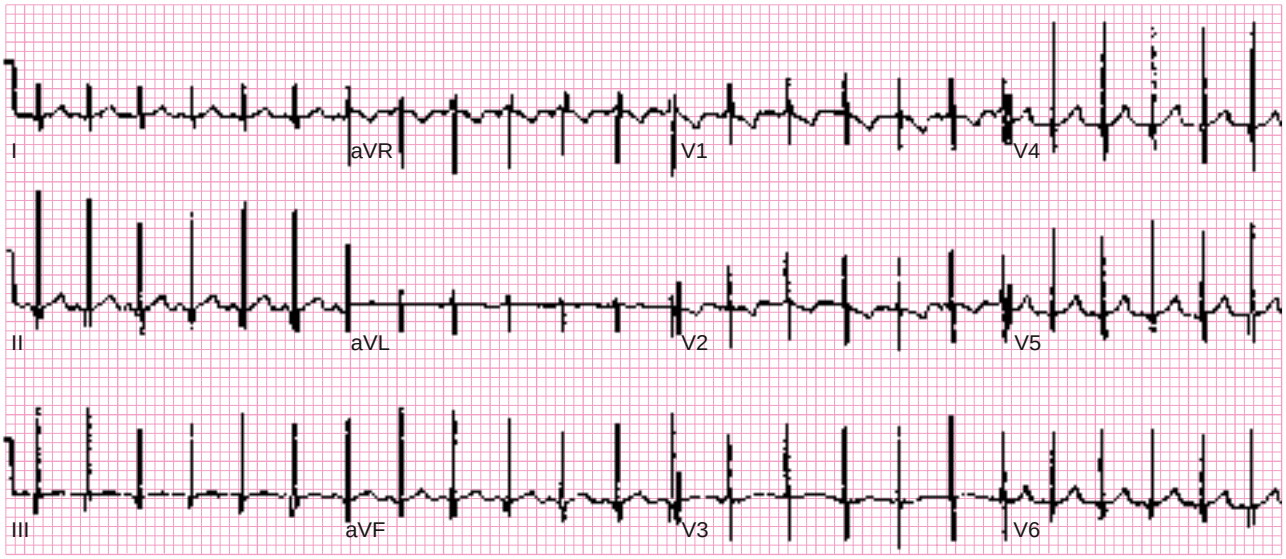

Fig. 472.3 Normal ECG from a healthy 8-mo-old infant. The frontal plane QRS axis is 60 degrees. There is less evidence of right ventricular preponderance than in the newborn tracing, with a smaller R wave in lead V_1 and smaller S wave in lead V_6. *(From Gering LE, Knilans TK, Surawicz B, et al. Normal electrocardiograms in the fetus, infants, and children. In: Surawicz B, Knilans TK. Chou's Electrocardiography in Clinical Practice, 6th ed. Philadelphia: Saunders; 2008: Fig. 28.3, p. 652).*

to underdevelopment of the medial muscular layer of the pulmonary arterioles. Some premature infants display a pattern of generalized low voltage across the precordium.

The ECG should always be evaluated systematically to avoid overlooking a minor but important abnormality. One approach is to begin with an assessment of rate and rhythm, followed by a calculation of the mean frontal-plane QRS axis, measurements of segment intervals, assessment of voltages, and lastly assessment of ST and T-wave abnormalities.

RATE AND RHYTHM

A brief rhythm strip should be examined to assess whether a P wave always precedes each QRS complex. Using the full 12-lead ECG, the P-wave axis should then be estimated as an indication of whether the rhythm is originating from the **sinus node**. If the atria are situated normally in the chest, the P-wave axis should be oriented downward and to the left (i.e., should be upright in leads I and aVF and inverted in lead aVR). With atrial inversion **(situs inversus)**, the P wave may be inverted in lead I. Inverted P waves in leads II and aVF are seen in low atrial, nodal, or junctional rhythms. The absence of P waves indicates a rhythm originating more distally in the conduction system. In this case, the morphologic features of the QRS complexes are important in differentiating a **junctional** (usually a narrow QRS complex) from a **ventricular** (usually a wide QRS complex) rhythm.

P WAVES

Tall (>2.5 mm), narrow, and spiked P waves are indicative of **right atrial enlargement** and are seen in pulmonary stenosis, Ebstein anomaly of the tricuspid valve, tricuspid atresia, and sometimes cor pulmonale. These abnormal waves are most obvious in leads II, V_3R,

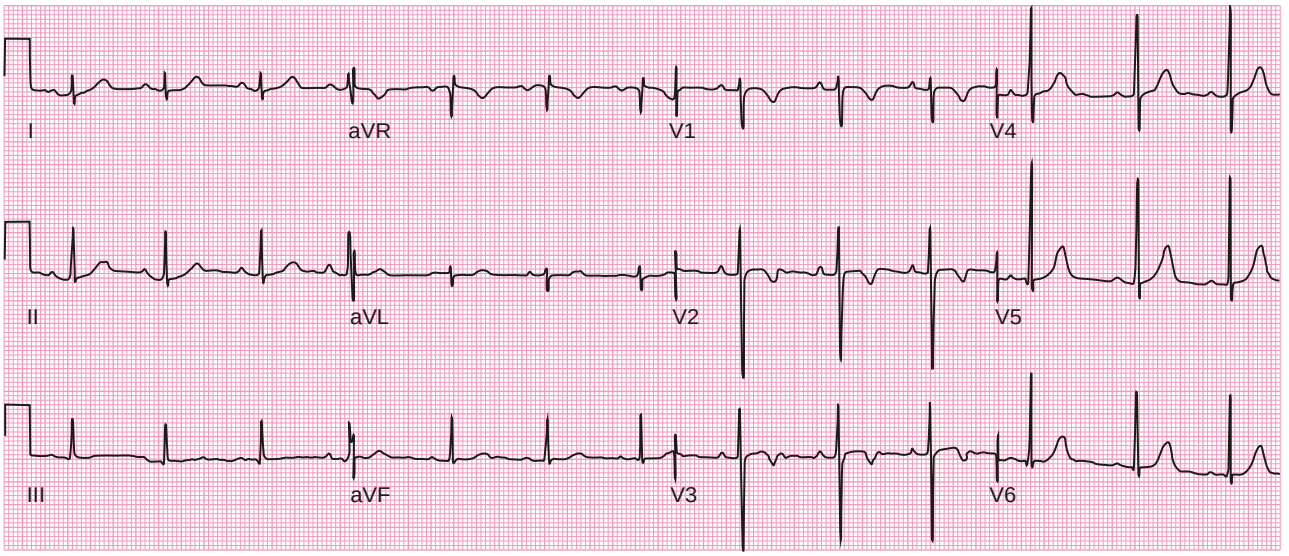

Fig. 472.4 Normal ECG from a healthy 3-yr-old child. The frontal plane QRS axis is 60 degrees. The R/S ratio in lead V_1 is less than 1, and there is no appreciable S wave in lead V_6. The R wave in lead V_6 is more prominent than that of the infant, suggesting more left ventricular preponderance but not left ventricular hypertrophy. *(From Gering LE, Knilans TK, Surawicz B, et al. Normal electrocardiograms in the fetus, infants, and children. In: Surawicz B, Knilans TK. Chou's Electrocardiography in Clinical Practice, 6th ed. Philadelphia: Saunders; 2008: Fig. 28.4, p. 652).*

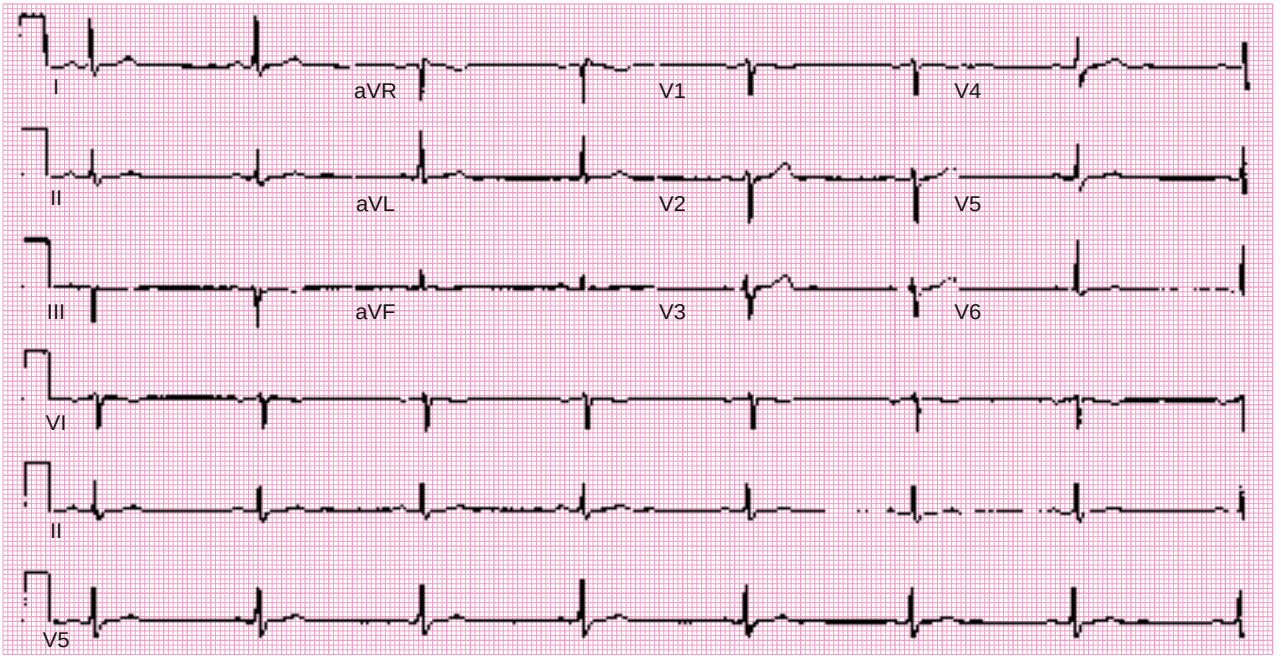

Fig. 472.5 Electrocardiogram of a normal 17-yr-old, a member of the school's track team. At this age the ECG should be similar to that in a normal adult: the dominant wave in V_1 should be the S wave and there is a normal R-wave progression, growing taller across the precordium from right to left. The heart rate is slow at 43 bpm (sinus bradycardia), which can be typical of a performance athlete. Note that all precordial lead T waves are positive, except for V_1. This R-wave progression pattern in a young infant, where there should be right ventricular dominance, would indicate the presence of left ventricular hypertrophy.

and V_1 (Fig. 472.8A). Similar waves are sometimes seen in thyrotoxicosis. **Broad P waves**, commonly **bifid** and sometimes **biphasic**, are indicative of **left atrial enlargement** (Fig. 472.8B). They are seen in some patients with large left-to-right shunts (ventricular septal defect [VSD], patent ductus arteriosus) and with severe mitral stenosis or mitral regurgitation. Left atrial enlargement, however, is one of the most common false-positive readings generated by computerized ECG machines. Flat P waves may be encountered in patients with hyperkalemia.

QRS COMPLEX

Right Ventricular Hypertrophy

For the most accurate assessment of ventricular hypertrophy, pediatric ECGs should include the right precordial leads V_3R and V_4R. The diagnosis of RVH depends on demonstration of the following changes (see Fig. 472.6): (1) a qR pattern in the RV surface leads; (2) a positive T wave in leads V_3R-V_4R and V_1-V_3 between ages 6 days and 6 years; (3) a monophasic R wave in V_3R, V_4R, or V_1; (4) an rsR′ pattern in the right precordial leads with the second R wave

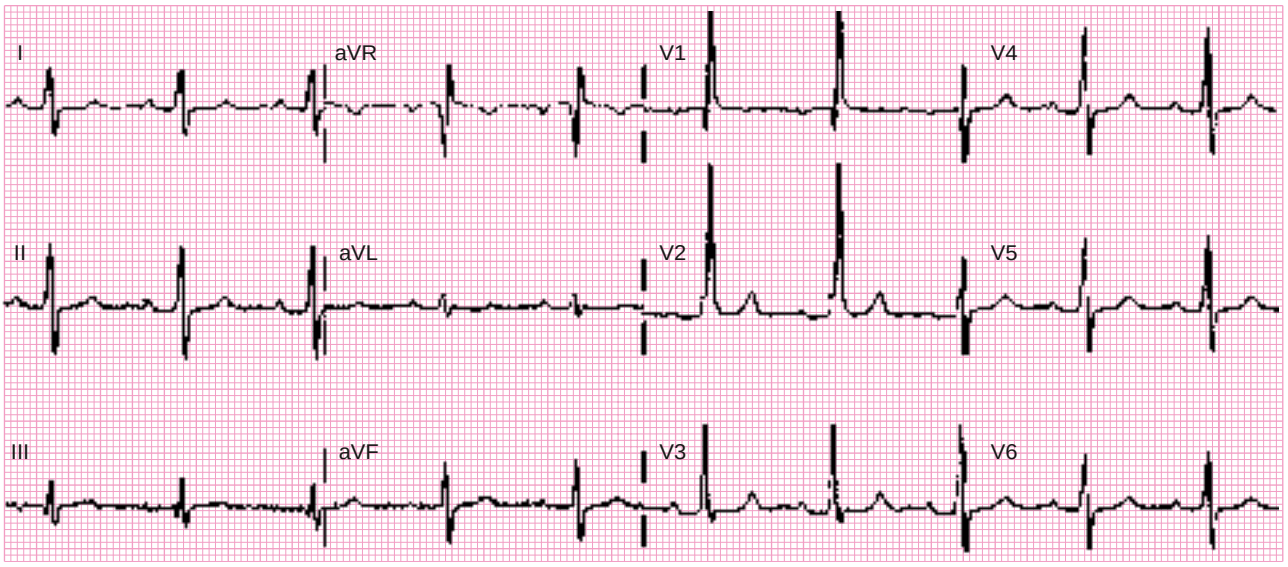

Fig. 472.6 Electrocardiogram of an infant with right ventricular hypertrophy (tetralogy of Fallot). Note the tall R waves in the right precordial leads (V_1-V_2) and deep S waves in V_6. The R-wave progression (taller in the right precordial leads vs the left) is counter to the normal pattern.

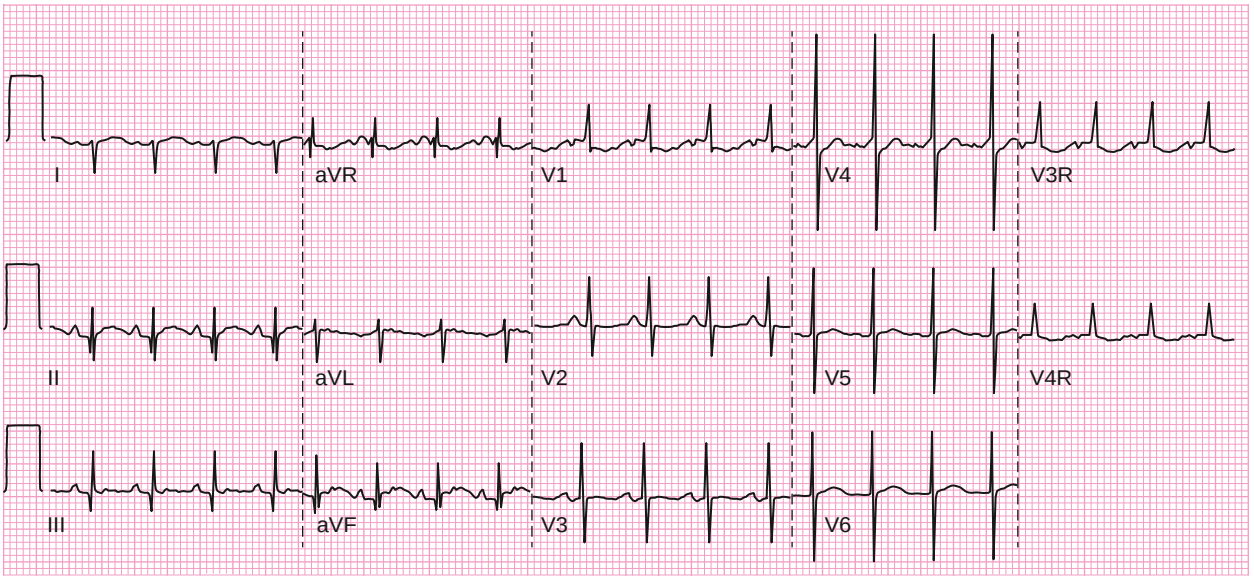

Fig. 472.7 Normal ECG from an 8-day-old, 28-wk-gestation premature infant. The frontal plane QRS axis is 150 degrees, there is a monophasic R wave in lead V_1, and the R/S ratio is less than 1 in lead V_6. This illustrates relative right ventricular preponderance without right ventricular hypertrophy. The QRS duration is less than 40 ms. *(From Gering LE, Knilans TK, Surawicz B, Tavel ME. Normal electrocardiograms in the fetus, infants, and children. In: Surawicz B, Knilans TK. Chou's Electrocardiography in Clinical Practice, 6th ed. Philadelphia: Saunders; 2008: Fig. 28.1, p. 650).*

taller than the first; (5) age-corrected increased voltage of the R wave in leads V_3R-V_4R or the S wave in leads V_6-V_7, or both; (6) marked right axis deviation (>120 degrees in patients beyond the newborn period); and (7) complete reversal of the normal adult precordial RS pattern. At least two of these changes should be present to support a diagnosis of RVH.

Abnormal ventricular loading can be characterized as either pressure overload (as a result of RVOT obstruction, as in pulmonic stenosis) or volume overload (as a result of a left-to-right shunt as in atrial septal defect [ASD], semilunar valve regurgitation, or dilated cardiomyopathy). These two types of abnormal loads result in distinct electrocardiographic patterns. The **pressure overload pattern** is characterized by tall, pure R waves in the right precordial leads. In older children, the T waves in these leads are initially upright and later become inverted. In infants and children <6 years, the T waves in V_3R-V_4R and V_1 are abnormally upright. The **volume overload pattern** (typically seen in patients with ASD) is characterized by an rsR′ pattern (Fig. 472.9) and a slightly increased QRS duration (which is known as a *minor right ventricular conduction delay* rather than a true bundle branch block). Patients with mild to moderate pulmonary stenosis may also exhibit an rsR′ pattern in the right precordial leads.

Left Ventricular Hypertrophy

The following features indicate the presence of LVH (Fig. 472.10): (1) increased voltage (for age) of the S wave in V_3R and V_1 or the R wave in V_6-V_7, or both. In older children and adults, the criteria for LVH **(Sokolow index)** is a combination of S wave in V_1 or V_2 plus R wave in V_5 or V_6 ≥35 mm and (2) a deep Q wave in the left precordial leads. Remember that an infant with an ECG that would be considered "normal" for an older child may in fact have LVH; therefore reference to

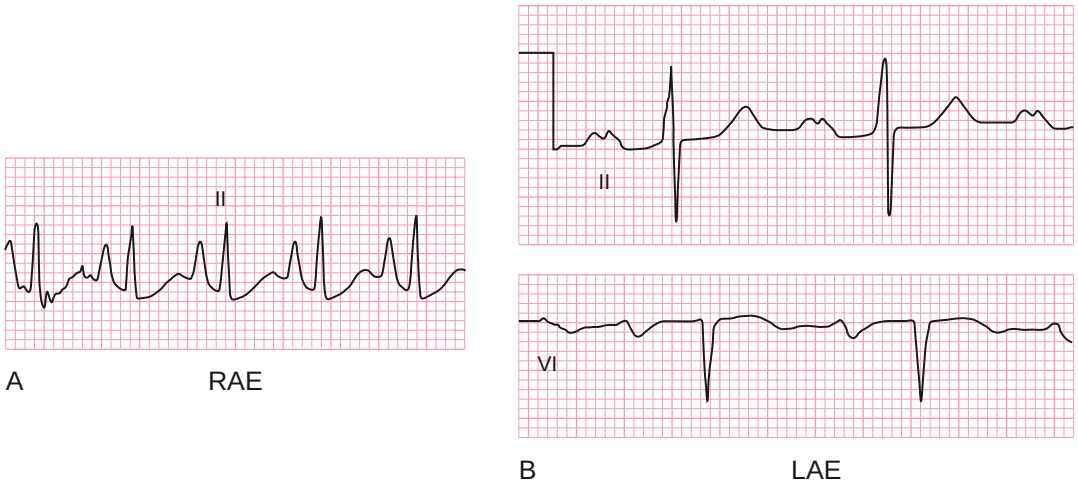

Fig. 472.8 Atrial enlargement. **A,** Peaked narrow P waves in lead II characteristic of right atrial enlargement (RAE). **B,** Wide, bifid, M-shaped P waves in lead II and biphasic p waves in lead V_1 typical of left atrial enlargement (LAE).

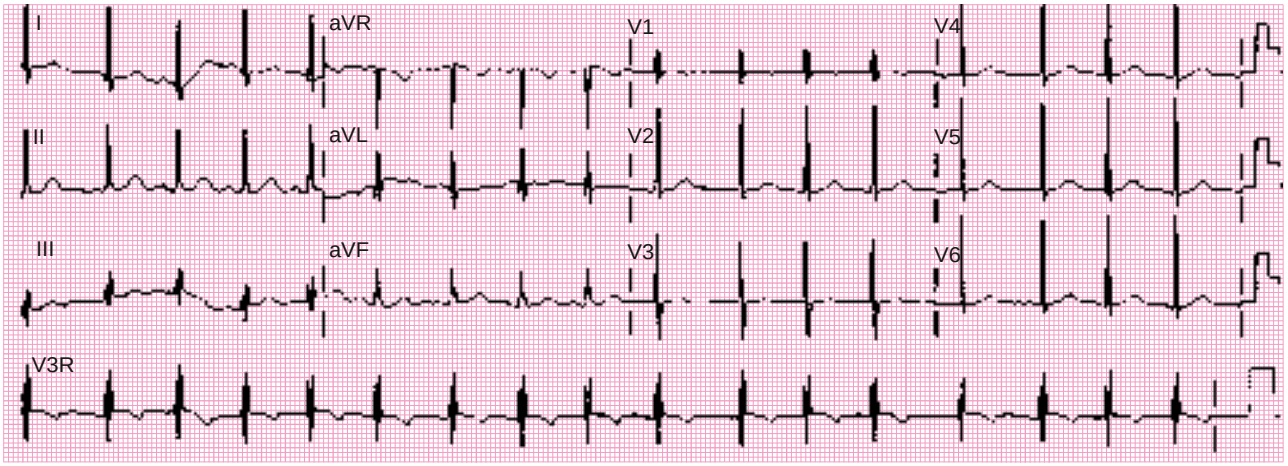

Fig. 472.9 Electrocardiogram showing a minor right ventricular conduction delay characterized by an RsR′ pattern in V_1. Note that the QRS duration is not prolonged (60 msec) as it would be if this were a right bundle branch block (RBBB).

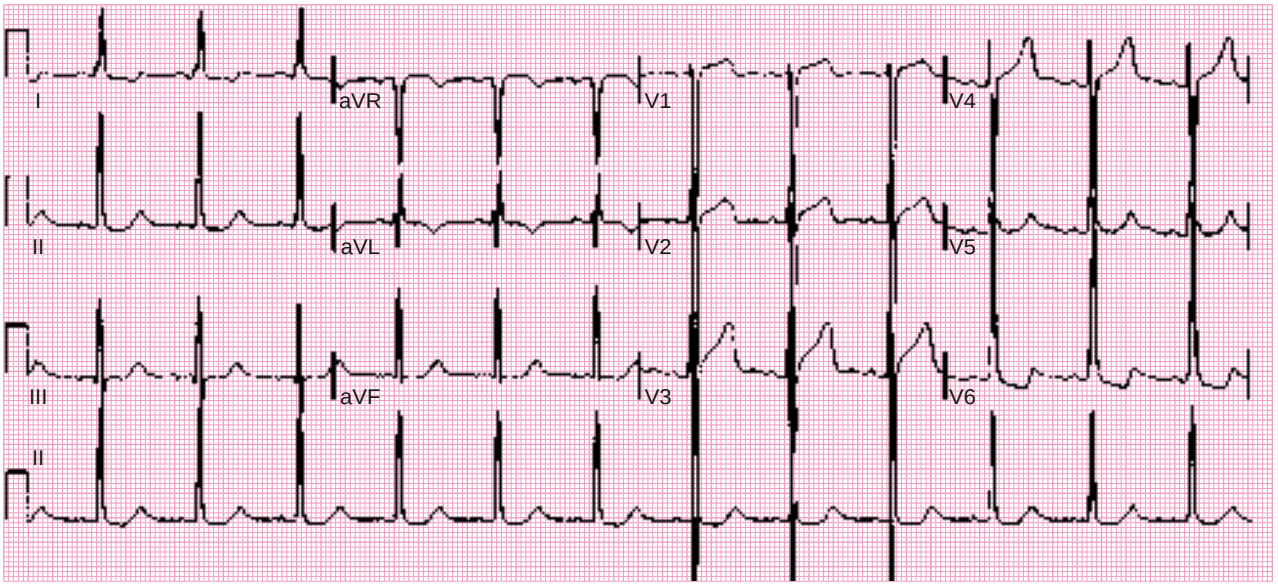

Fig. 472.10 Electrocardiogram showing left ventricular hypertrophy (LVH) in a 12-yr-old child with aortic stenosis. Note the deep S waves in V_1-V_3 and tall R in V_5-V_6. In addition, T-wave inversion is present in lead V_6, a sign of left ventricular strain.

standard voltages for age is always important. Further evidence for LVH includes depression of the ST segments and inversion of the T waves in the left precordial leads (V_5, V_6, and V_7), known as a **left ventricular strain** pattern—these findings suggest the presence of more severe hypertrophy.

Bundle Branch Block

A complete **right bundle branch block** (RBBB; prolonged QRS complex, which is usually upright with an rSR′ in lead V_1; wide S wave in lead V_6) may be congenital or may be acquired after surgery for CHD, especially when a right ventriculotomy has been performed, as in repair of the tetralogy of Fallot. **Left bundle branch block** (LBBB; prolonged QRS complex, which is usually upright with an rSR′ in lead V_6; wide S wave in lead V_1) is less common in children; this pattern is often seen in adults with cardiomyopathy, but much less in children with cardiomyopathy. LBBB may be seen after surgery on the aortic or mitral valve caused by surgical injury to one of the left-sided conduction bundles. Alternatively, a bundle branch block pattern may be indicative of a bypass tract associated with one of the preexcitation syndromes (see Chapter 484).

P-R AND Q-T INTERVALS

The duration of the P-R interval shortens with increasing heart rate; assessment of this interval should be based on age- and rate-corrected nomograms. A long P-R interval is diagnostic of a **first-degree heart block**, the cause of which may be congenital, postoperative (after open heart surgery), inflammatory (myocarditis, pericarditis, Lyme disease, rheumatic fever), or pharmacologic (digitalis, calcium channel blockers).

The duration of the Q-T interval varies with the cardiac rate; a corrected Q-T interval (Q-Tc) can be calculated by dividing the measured Q-T interval by the square root of the preceding R-R interval. A normal Q-Tc should be <0.45. It is often lengthened with hypokalemia and hypocalcemia; in the former, a U wave may be noted at the end of the T wave (Fig. 472.11). A significant number of medications can also lengthen the Q-T interval, so a careful history of medication exposure is important in evaluating a patient with a borderline or long QT interval. A congenitally prolonged Q-T interval may also be seen in children with one of the long QT syndromes (Fig. 472.12). These patients are at high risk for ventricular arrhythmias, including a dangerous form of ventricular tachycardia known as **torsades de pointes**, and sudden death (see Chapter 484.5).

ST SEGMENT AND T-WAVE ABNORMALITIES

Coronary ischemia, leading to typical ST and T-wave abnormalities seen in adults, is rare in children. A slight elevation of the ST segment is often seen in normal teenagers, especially males, and is attributed to **early repolarization** of the heart (Fig. 472.13). It can sometimes be difficult to distinguish between ischemic ST segment changes and benign early repolarization; however, the following characteristics suggest early repolarization: (1) ST elevation limited to the lateral leads (V_5-V_6), (2) a characteristic notch at the J point (junction between the end of the QRS and the beginning of the ST segment), and (3) a concave rather than convex ST segment. Lack of any concerning symptoms is also critical. Early repolarization often resolves with exercise-induced tachycardia. In pericarditis, irritation of the epicardium may cause elevation of the ST segment, followed by abnormal T-wave inversion as healing progresses.

Depression of the ST segment may also occur in coronary ischemia or in any condition that produces myocardial injury, including severe anemia, carbon monoxide poisoning, glycogen storage disease of the heart, myocardial tumors, and mucopolysaccharidoses. An aberrant origin of the left coronary artery from the pulmonary artery may lead to changes indistinguishable from those of acute myocardial infarction in adults. ECG findings of ischemia may be seen in patients with Kawasaki disease who have developed coronary artery aneurysms (see Chapters 208 and 493.1). Similar changes may occur in patients with other rare abnormalities of the coronary arteries and in those with cardiomyopathy, even in the presence of normal coronary arteries. These patterns are often misread in young infants because of the unfamiliarity of pediatricians with this "infarct" pattern, and thus a high index of suspicion must be maintained in infants with dilated cardiomyopathy or with symptoms compatible with coronary ischemia (e.g., inconsolable crying).

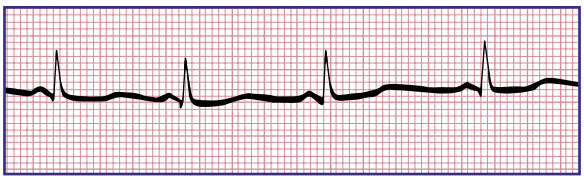

Fig. 472.12 Prolonged Q-T interval in a patient with long QT syndrome.

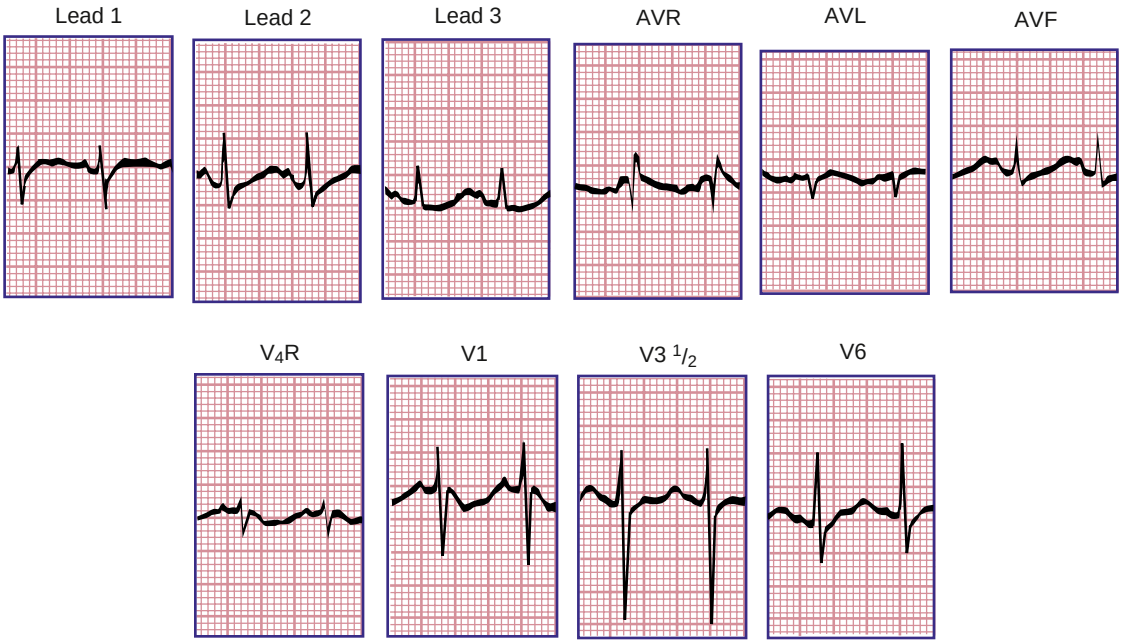

Fig. 472.11 Electrocardiogram in hypokalemia. Serum potassium, 2.7 mEq/L; serum calcium, 4.8 mEq/L at the time of the tracing. Note the widened TU wave and depression of the ST segment in V_4R, V_1, and V_6.

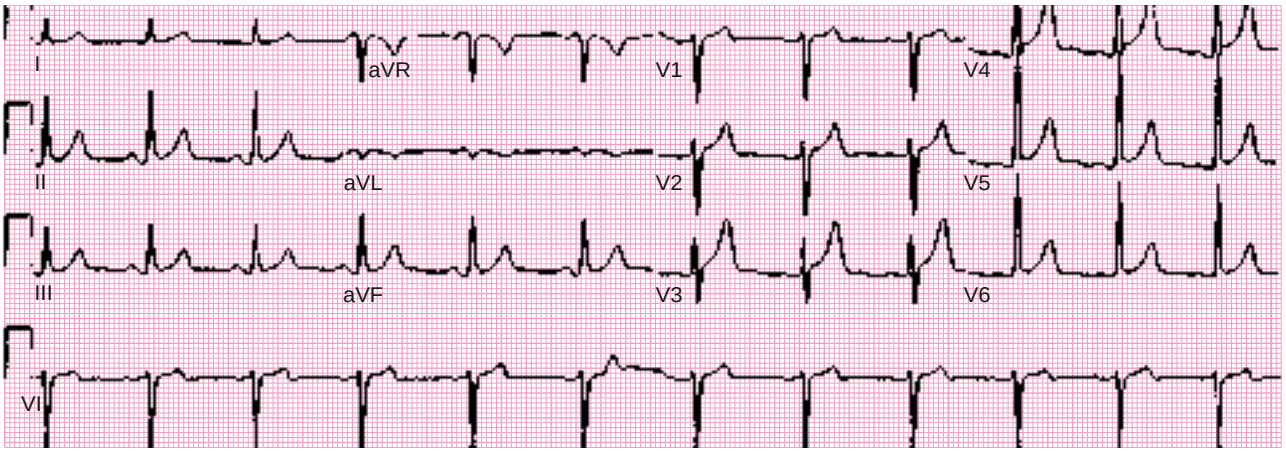

Fig. 472.13 Early repolarization seen in the mid-precordial to lateral leads (V_2-V_5) in a teenage boy. These minor ST segment elevations, with typical concave slope and combined with a high J point, suggest this is a benign variant and not true ischemia.

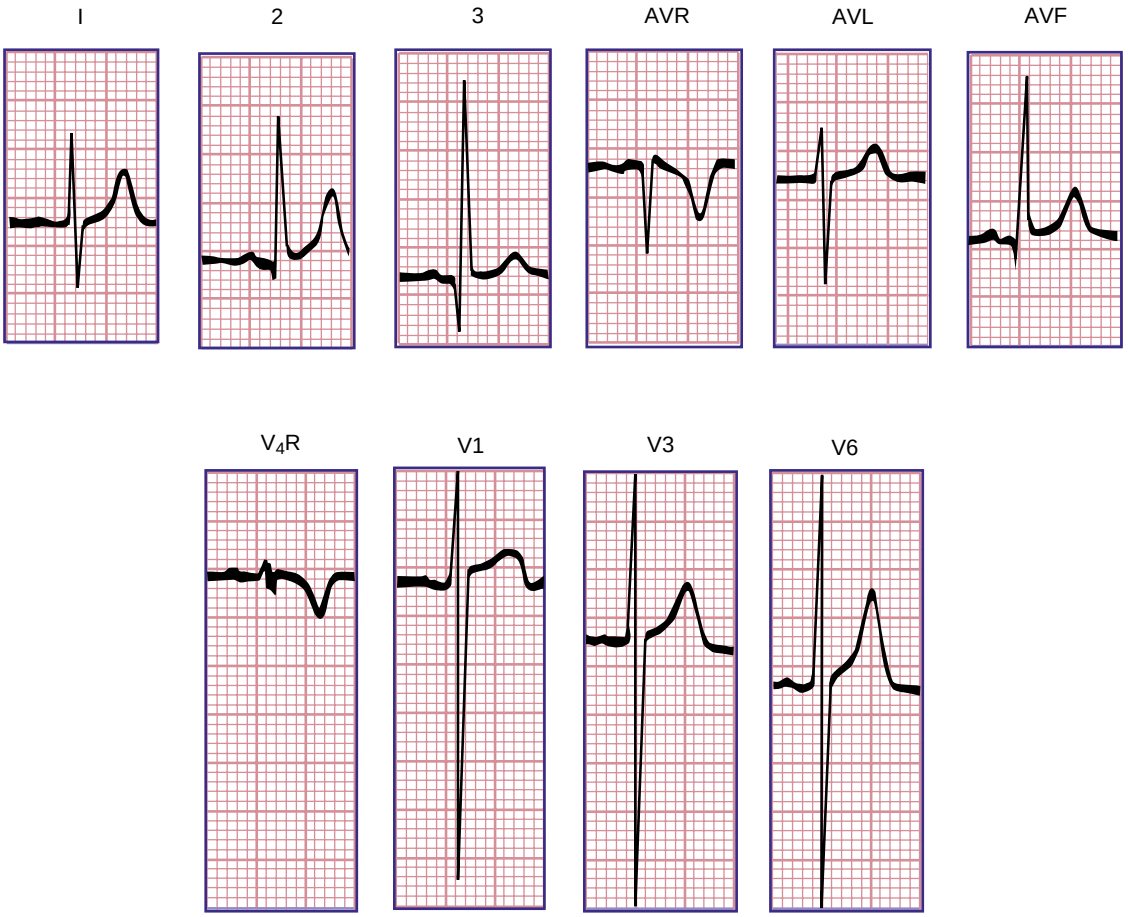

Fig. 472.14 Electrocardiogram in hyperkalemia. Serum potassium, 6.5 mEq/L. Note the tall, tent-shaped T waves, especially in leads 1, 2, and V_6.

T-wave inversion may occur in myocarditis and pericarditis, or it may be a sign of either RVH or LVH and ventricular strain. Hypothyroidism may produce flat or inverted T waves in association with generalized low voltage. In hyperkalemia, the T waves are usually of high voltage and are tent shaped (Fig. 472.14), although tall T waves can be an early sign of myocardial infarction.

Visit Elsevier eBooks+ at eBooks.Health.Elsevier.com for Bibliography.

472.3 Hematologic Data in Cardiovascular Evaluation

Daniel Bernstein

In acyanotic infants with large left-to-right shunts, the onset of heart failure often coincides with the nadir of the normal physiologic anemia of infancy. Increasing the hematocrit in these patients to >40% may decrease shunt volume and result in an improvement in symptoms; however, this form of treatment is generally reserved for infants who are not otherwise surgical candidates (extremely premature infants or others in whom surgery is delayed for other reasons). In these select infants, regular evaluation of the hematocrit and booster transfusions when appropriate may be helpful in improving growth.

Polycythemia is frequently noted in chronically *cyanotic* patients with right-to-left shunts. Patients with severe polycythemia, rarely seen in this age of early surgical repair, are in a delicate balance between the risks of intravascular thrombosis and a bleeding diathesis. The preparation of cyanotic, polycythemic patients for elective noncardiac surgery, such as dental extraction, includes evaluation and treatment of abnormal coagulation.

Because of the high viscosity of polycythemic blood (hematocrit >65%), patients with unrepaired cyanotic CHD are at risk for the development of **vascular thromboses**, especially of cerebral veins. Dehydration increases the risk of thrombosis, and thus adequate fluid intake must be maintained during hot weather or intercurrent gastrointestinal illnesses. Diuretics should be used with caution in these patients and may need to be decreased if fluid intake is a concern. Polycythemic infants with concomitant **iron deficiency** are at even greater risk for cerebrovascular accidents, thought to be the result of the decreased deformability of microcytic red blood cells. Iron therapy may reduce this risk, but surgical repair of the cardiac anomaly is the best therapy.

Severely cyanotic patients who are inoperable should have periodic determinations of hemoglobin and hematocrit. Increasing polycythemia is often associated with headache, fatigue, dyspnea, or a combination of these conditions. Partial exchange transfusion may be required to treat symptomatic (most often headache or chest pain) individuals whose hematocrit has risen to the 65–70% level. This procedure is not without risk, especially in patients with an extreme elevation in pulmonary vascular resistance. Because these patients do not tolerate wide fluctuations in circulating blood volume, blood should be replaced with fresh-frozen plasma or albumin.

472.4 Echocardiography

Daniel Bernstein

Transthoracic echocardiography (TTE) has replaced cardiac catheterization for the *diagnosis* of most forms of CHD. The echocardiographic examination can be used to evaluate cardiac structures in congenital heart lesions using two-dimensional (2D) and three-dimensional (3D) imaging, estimate intracardiac pressures and gradients across stenotic valves and vessels using **echo-Doppler** and color flow Doppler, quantitate cardiac contractile function (both systolic and diastolic), determine the direction of flow across a defect, examine the integrity of the coronary arteries, and detect the presence of vegetations from endocarditis, pericardial fluid, cardiac tumors, and chamber thrombi.

Echocardiography may also be used to assist in the performance of interventional procedures, including pericardiocentesis, balloon atrial septostomy (see Chapter 480.2), ASD or VSD closure, transcatheter valve implantation, and endocardial biopsy. **Transesophageal echocardiography** (TEE) is used routinely to monitor ventricular function in patients during surgical procedures and can provide an immediate assessment of the results of surgical repair of congenital heart lesions. A complete TTE examination usually entails a combination of M-mode and 2D and 3D imaging, as well as pulsed, continuous, and color Doppler flow studies. Doppler tissue imaging provides a more quantitative assessment of ventricular systolic and diastolic function.

M-MODE ECHOCARDIOGRAPHY

M-mode echocardiography displays a one-dimensional slice of cardiac structure varying over time (Fig. 472.15). It is used mostly for the measurement of cardiac dimensions (wall thickness and chamber size) and cardiac function (fractional shortening, wall thickening). M-mode echocardiography is also useful for assessing the motion of intracardiac structures: the opening and closing of valves and movement of free walls and septa (Fig. 472.16). The most frequently used index of cardiac function in children is **percent fractional shortening** (%FS), which contrasts to adults, where **ejection fraction** is the most common functional measurement. %FS is calculated as (LVED − LVES)/LVED, where LVED is left ventricular dimension at end diastole and LVES is left ventricular dimension at end systole. Normal fractional shortening is approximately 28–42%. Other M-mode indices of cardiac function include the mean velocity of fiber shortening (mean V_{CF}), systolic time intervals (LVPEP = LV preejection period, LVET = LV ejection time), and isovolemic contraction time. M-mode assessments of cardiac function are more susceptible to errors because of differences in wall motion between different segments of the heart (more frequently seen in adults with ischemic heart disease, but which can be seen in

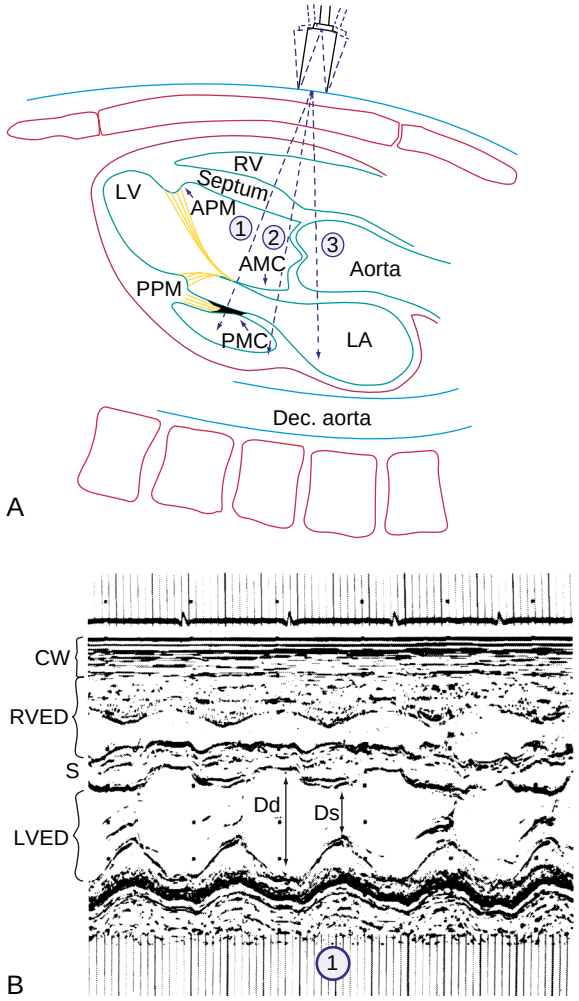

Fig. 472.15 M-mode echocardiogram. A, Diagram of a sagittal section of a heart showing the structures traversed by the echo beam as it is moved superiorly to positions (1), (2), and (3). B, Echocardiogram from transducer position (1); this view is the best one for measuring cardiac dimensions and fractional shortening. Fractional shortening is calculated as (LVED − LVES)/LVED. AMC, Anterior mitral cusp; APM, anterior papillary muscle; Dec. aorta, descending aorta; LA, left atrium; LV, left ventricle; PMC, posterior mitral cusp; PPM, posterior papillary muscle; RV, right ventricle. CW, Chest wall; Ds, LV dimension in systole; LVED, LV dimension at end diastole (Dd); RVED, RV dimension at end diastole.

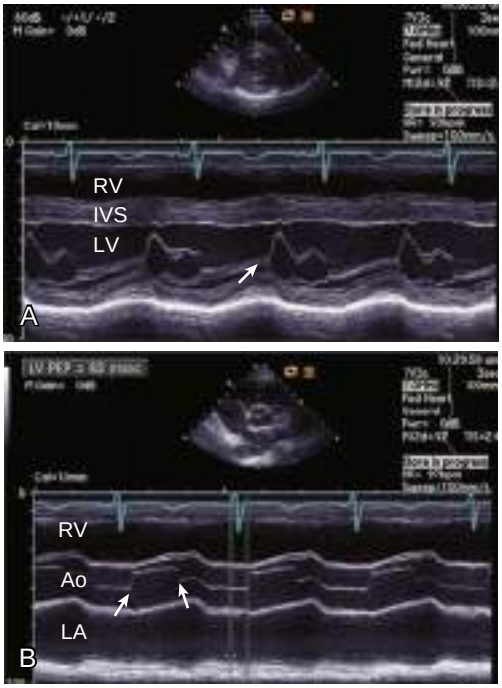

Fig. 472.16 M-mode echocardiograms. The small figure at the top of each panel shows the 2D parasternal short-axis echocardiogram image from which the M-modes are derived. The cursor can be seen midway through the image, indicating the one-dimensional line through which the M-mode is being sampled. **A,** M-mode echocardiogram of a normal mitral valve. *Arrow* shows the opening of the anterior leaflet in early diastole (see ECG tracing earlier for reference). **B,** M-mode echocardiogram of a normal aortic valve. The opening and closing of the aortic leaflets in systole are outlined by the two *arrows*. Ao, Aorta; IVS, interventricular septum; LV, left ventricle; RV, right ventricle.

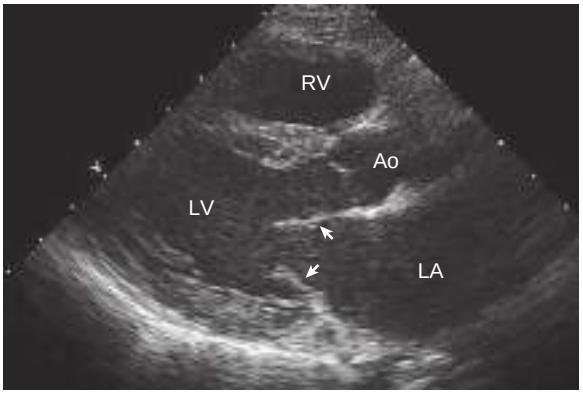

Fig. 472.17 Normal parasternal long-axis echocardiographic window. The transducer is angulated slightly posteriorly, imaging the left-sided cardiac structures. If the transducer were to be angulated more anteriorly, the right ventricular structures would be imaged. The mitral valve leaflets can be seen in the partially open position in early diastole *(arrows)*. The closed aortic valve leaflets can be seen just below the label Ao (aorta). LA, Left atrium; LV, left ventricle; RV, right ventricle.

children with congenital and acquired heart disease, especially after surgical repair).

TWO-DIMENSIONAL ECHOCARDIOGRAPHY

Two-dimensional echocardiography provides a real-time image of cardiac structures. The contracting heart is imaged using several standard views, including parasternal long axis (Fig. 472.17), parasternal short axis (Fig. 472.18), apical four-chamber (Fig. 472.19), subcostal (Fig. 472.20), and suprasternal (Fig. 472.21), each of which emphasizes specific structures. Two-dimensional echocardiography

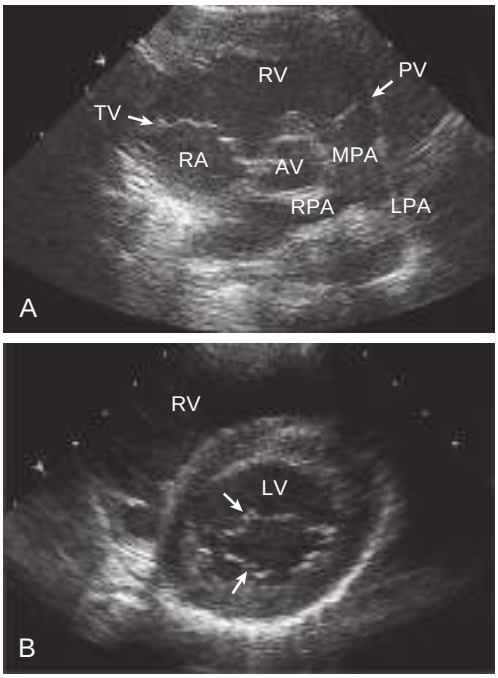

Fig. 472.18 Normal parasternal short-axis echocardiographic windows. **A,** With the transducer angled superiorly and rightward, the aortic valve (AV) is imaged, surrounded by both inflow and outflow portions of the right ventricle (RV). **B,** With the transducer angled inferiorly and leftward, the left ventricular chamber is imaged along with a cross-sectional view of the mitral valve *(arrows)*. LPA, Left pulmonary artery; MPA, main pulmonary artery; PV, pulmonary valve; RA, right atrium; RPA, right pulmonary artery; TV, tricuspid valve. LV, left ventricle; RV, right ventricle.

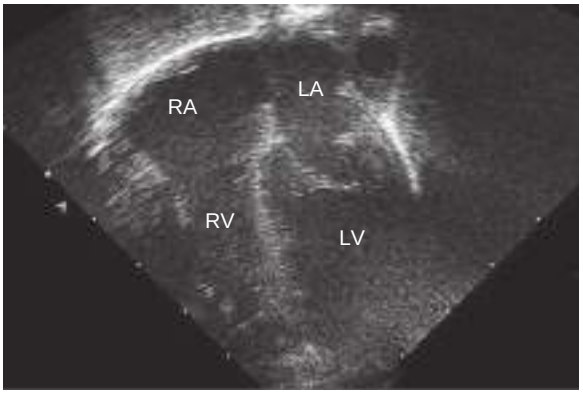

Fig. 472.19 Normal apical four-chamber echocardiographic window showing all four cardiac chambers and both atrioventricular valves opened in diastole. LA, Left atrium; LV, left ventricle; RA, right atrium; RV, right ventricle.

has replaced cardiac angiography for the preoperative diagnosis and follow-up of the vast majority of congenital heart lesions. However, when information from the cardiac examination or other studies is not consistent with the echocardiogram, or in very complex defects, cardiac catheterization remains an important tool to confirm the anatomic diagnosis and evaluate the degree of physiologic derangement. MRI is an extremely valuable adjunct to provide a better quantification of ventricular size and function. Cardiac CT is another modality that is valuable to assess cardiac and adjacent vascular structures.

DOPPLER ECHOCARDIOGRAPHY

Doppler echocardiography displays blood flow based on the change in frequency imparted to sound waves by the movement of

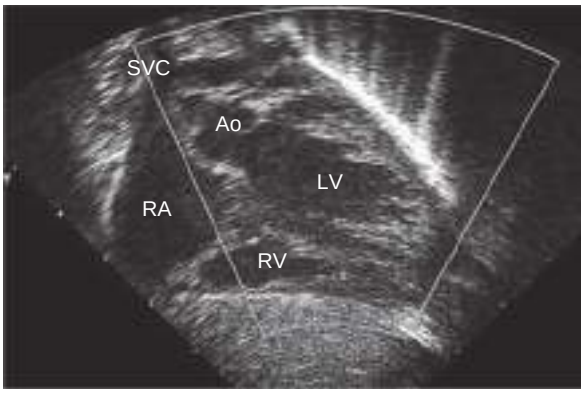

Fig. 472.20 Normal subcostal echocardiographic window showing the left ventricular outflow tract. The right-sided structures are not fully imaged in this view. Ao, Ascending aorta; LV, left ventricle; RA, right atrium; RV, right ventricle; SVC, superior vena cava.

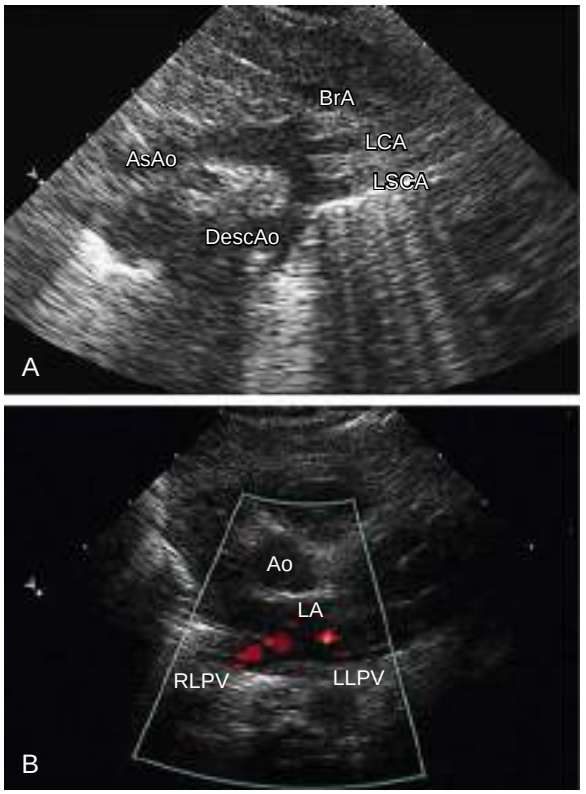

Fig. 472.21 **A,** Normal suprasternal echocardiographic window showing the aortic arch and its major branches. **B,** Normal high parasternal window showing color Doppler imaging of normal pulmonary venous return to the left atrium (LA) of both right (RLPV) and left (LLPV) lower pulmonary veins. AsAo, Ascending aorta; BrA, brachiocephalic artery; DescAo, descending aorta; LCA, left carotid artery; LSCA, left subclavian artery.

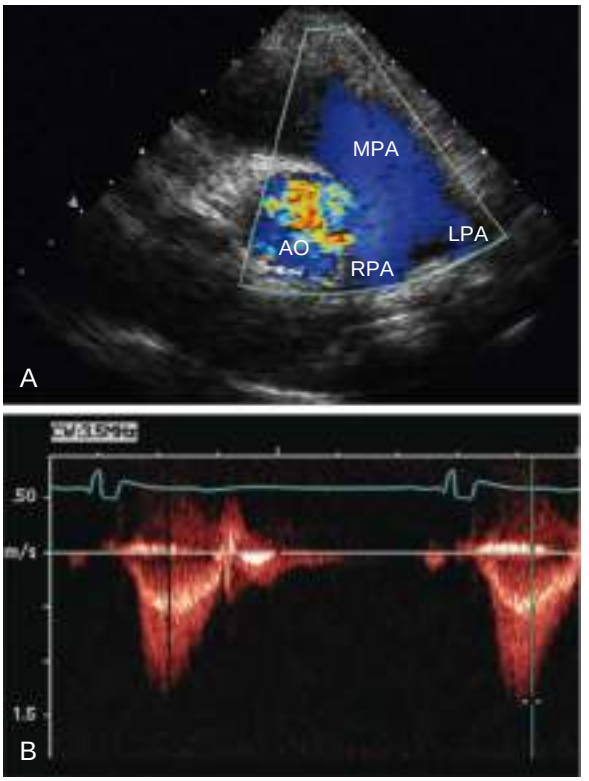

Fig. 472.22 Color and pulsed Doppler evaluation of pulmonary arterial flow. **A,** Color Doppler evaluation of a parasternal short-axis view showing normal flow through the pulmonary valve to the main and branch pulmonary arteries. The color of the Doppler flow is *blue,* indicating that the flow is moving away from the transducer (which is located at the top of the figure, at the apex of the *triangular* ultrasound window). Note that the color assigned to the Doppler signal does not indicate the oxygen saturation of the blood. **B,** Pulsed-wave Doppler flow pattern through the pulmonary valve showing a low velocity of flow (<1.5 m/sec), indicating the absence of a pressure gradient across the valve. The envelope of the flow signal is below the line, indicating that the flow is moving away from the transducer. AO, Aorta; LPA, left pulmonary artery; MPA, main pulmonary artery; RPA, right pulmonary artery.

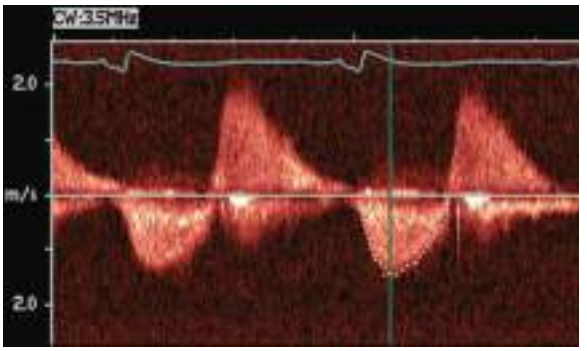

Fig. 472.23 Doppler evaluation of a patient who had previously undergone repair of tetralogy of Fallot and who has mild pulmonary stenosis and moderate pulmonary regurgitation. The tracing shows the to-and-fro flow across the pulmonary valve, with the signal below the line representing forward flow in systole (see ECG tracing for reference) and the signal above the line representing regurgitation during diastole.

erythrocytes. The speed and direction of blood flow in the line of the echo beam change the transducer's reference frequency. This frequency change can be translated into volumetric flow (L/min) data for estimating systemic or pulmonary blood flow and into pressure (mm Hg) data for estimating gradients across valves or across septal defects or vascular communications such as shunts. Color Doppler permits highly accurate assessment of the presence and direction of intracardiac shunts and allows identification of small or multiple left-to-right or right-to-left shunts (Fig. 472.22). The severity of valvular insufficiency can be evaluated qualitatively with both pulsed and color Doppler (Fig. 472.23). Alterations in venous Doppler flow patterns can be used to detect abnormalities of systemic and pulmonary veins, and alterations of atrioventricular valve Doppler flow patterns can be used to assess ventricular

diastolic functional abnormalities, particularly the **E/A ratio**, the ratio of peak velocity flow in diastole (i.e., the ratio of the early diastole E wave to the peak velocity flow in late diastole caused by atrial contraction).

M-mode, 2D, and Doppler echocardiographic methods of assessing LV systolic and diastolic function (e.g., end-systolic wall stress, dobutamine stress echocardiography, Doppler tissue imaging) have proved useful in the serial assessment of patients at risk for the development of both systolic and diastolic ventricular dysfunction and ventricular dyssynchrony (where the coordination of left and right ventricular contraction is abnormal). Such patients include those with cardiomyopathies, those receiving anthracycline drugs for cancer chemotherapy, those at risk for iron overload, and those being monitored for rejection or coronary artery disease after heart transplantation.

THREE-DIMENSIONAL ECHOCARDIOGRAPHY

Real-time 3D echocardiographic reconstruction is most valuable for the detailed assessment of cardiac morphology (Fig. 472.24). Details of valve structure, the size and location of septal defects, abnormalities of the ventricular myocardium, and details of the great vessels, which may not be as readily apparent using 2D imaging, can often be appreciated on 3D echocardiography. Reconstruction of the view that the surgeon will encounter in the operating room makes this technique a valuable adjunct for preoperative imaging.

TRANSESOPHAGEAL ECHOCARDIOGRAPHY

TEE is a sensitive imaging technique that produces a clearer view of smaller lesions such as vegetations in endocarditis, especially in larger patients. It is useful in visualizing posteriorly located structures such as the atria, aortic root, and atrioventricular valves. TEE is useful as an intraoperative technique for monitoring cardiac function during both cardiac and noncardiac surgery and for screening for residual cardiac defects after the patient is initially weaned from cardiopulmonary bypass but before being disconnected from the bypass circuit. This technique has been especially helpful in evaluating the degree of residual regurgitation or stenosis after valve repairs and in searching for small muscular VSDs that may have been missed during the closure of larger defects. It is always preferable to make the diagnosis of **excessive valve regurgitation** while the patient is still in the operating room, so that the repair can be revised or the valve replaced, rather than after surgery, when the patient is already in the postoperative care unit. However, hemodynamic measurements made while the chest is open and the patient is still under anesthesia may be different from those made under more normal conditions, as when the patient is ready to be discharged from the hospital.

Fig. 472.24 Three-dimensional echocardiogram showing a short-axis view of the left ventricle. AV, Aortic valve; MV, mitral valve. *(Courtesy Dr. Norman Silverman, Stanford University, Stanford, CA.)*

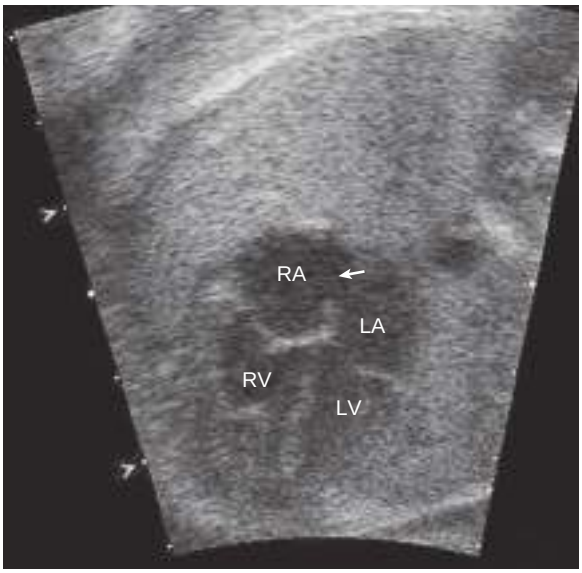

Fig. 472.25 Normal four-chamber view echocardiogram on a fetus at 20 wk of gestation. The foramen ovale *(arrow)* can be seen between the right and left atria. LA, Left atrium; LV, left ventricle; RA, right atrium; RV, right ventricle.

FETAL ECHOCARDIOGRAPHY

Fetal echocardiography can be used to evaluate cardiac structures and function or disturbances in cardiac rhythm (Fig. 472.25). Obstetricians may detect a possible heart defect when screening during routine obstetric ultrasonography (e.g., cardiac four-chamber view) or may refer the patient because of unexplained hydrops fetalis, a family history of CHD, or a maternal condition associated with fetal cardiac pathology, such as gestational diabetes, drug use, or infection. Fetal echocardiography can diagnose most significant congenital heart lesions as early as 17-19 weeks of gestation; accuracy at this early stage is limited, however, and families should understand that these studies cannot totally eliminate the possibility of CHD. Serial fetal echocardiograms have also demonstrated the importance of flow disturbance in the pathogenesis of CHD; such studies can show the intrauterine progression of a moderate lesion, such as aortic stenosis, into a more severe lesion, such as **hypoplastic left heart syndrome** (HLHS). M-mode echocardiography can diagnose rhythm disturbances in the fetus and can determine the success of antiarrhythmic therapy administered to the mother. A screening fetal echocardiogram is recommended for women with a previous child or first-degree relative with CHD, for those who are at higher risk of having a child with cardiac disease (e.g., insulin-dependent diabetes, women exposed to teratogenic drugs during early pregnancy), and in any fetus in whom a chromosomal abnormality is suspected or confirmed.

Early detection provides the opportunity to counsel and educate the parents about the severity of the cardiac lesion and potential therapeutic or palliative care options. Referral to a high-risk perinatal service is then performed for further ultrasound screening for associated anomalies of other organs and potential amniocentesis or sequencing of cell-free DNA in maternal blood for karyotyping. For fetuses with ductal dependent lesions, delivery can be planned at a tertiary care center, enhancing safety by avoiding the requirement for postnatal transport of an unstable infant. For fetuses with complex CHD at high risk for complications immediately at birth (e.g., HLHS with intact atrial septum), delivery can be arranged with an operating room and surgeon standing by. In utero treatment of CHD is an experimental procedure, with the most common procedure being aortic balloon valvuloplasty for HLHS.

Visit Elsevier eBooks+ at eBooks.Health.Elsevier.com for Bibliography.

472.5 Exercise Testing

Daniel Bernstein

The normal cardiorespiratory system adapts to the extensive demands of exercise with a several-fold increase in oxygen consumption and cardiac output. Because of the large reserve capacity for exercise, significant abnormalities in cardiovascular performance may be present without symptoms at rest or during ordinary activities. When patients are evaluated in a resting state, significant abnormalities in cardiac function may not be appreciated, or if detected, their implications for quality of life may not be recognized. Permission for children with cardiovascular disease to participate in various forms of physical activity is frequently based on totally subjective criteria. As the importance of aerobic exercise is increasingly recognized, even for children with complex congenital heart lesions, exercise testing can provide a quantitative evaluation of the child's ability to participate safely in both competitive and noncompetitive sports. Exercise testing can also play an important role in evaluating symptoms and quantitating the severity of cardiac abnormalities. In children with coronary artery abnormalities (e.g., Kawasaki disease or COVID-19 with coronary aneurysms), exercise testing can detect ischemia that might otherwise be overlooked.

In older children, exercise studies are generally performed on a graded treadmill apparatus with timed intervals of increasing grade and speed. In younger children, exercise studies are often performed on a bicycle ergometer. Many laboratories have the capacity to measure both cardiac and pulmonary function noninvasively during exercise. This allows measurement of both resting and maximal oxygen consumption (Vo_{2max}) and the point at which anaerobic threshold is reached, which are important indicators of cardiovascular fitness.

As a child grows, the capacity for muscle work is enhanced with increased body size and skeletal muscle mass. All indices of cardiopulmonary function do not increase in a uniform manner. A major response to exercise is an increase in cardiac output, principally achieved through an increase in heart rate, but stroke volume (SV), systemic venous return, and pulse pressure are also increased. SVR is greatly decreased as the blood vessels in working muscle dilate in response to increasing metabolic demands. As the child becomes older and larger, the response of the heart rate to exercise remains prominent, but cardiac output increases because of growing cardiac volume capacity and thus SV. Responses to dynamic exercise are not dependent solely on age. For any given body surface area, boys have a larger SV than size-matched girls. This increase is also mediated by posture. Augmentation of SV with upright, dynamic exercise is facilitated by the pumping action of working muscles, which overcomes the static effect of gravity and increases systemic venous return.

Dynamic exercise testing defines not only endurance and exercise capacity but also the effect of such exercise on myocardial blood flow and cardiac rhythm. Significant ST segment depression or elevation reflects abnormalities in myocardial perfusion, such as might occur during exercise in children with extremely hypertrophied left ventricles. The **exercise ECG** is considered abnormal if the ST segment depression is >2 mm and extends for at least 0.06 seconds after the J point (onset of the ST segment) in conjunction with a horizontal-, upward-, or downward-sloping ST segment. A decrease in blood pressure before maximal exercise is reached is regarded as a risk indicator in patients with hypertrophic cardiomyopathy. Provocation of rhythm disturbances during an exercise study is an important method of evaluating select patients with known or suspected rhythm disorders. The effect of pharmacologic management can also be tested in this manner.

Visit Elsevier eBooks+ at eBooks.Health.Elsevier.com for Bibliography.

472.6 Cardiac Imaging Studies

Daniel Bernstein

Magnetic resonance imaging (MRI) and **magnetic resonance angiography (MRA)** are extremely helpful in the diagnosis and management of patients with CHD and inflammatory lesions (Table 472.1). These techniques produce tomographic images of the heart in any projection (Fig. 472.26 and Fig. 472.27), with excellent contrast resolution of fat, myocardium, and lung, as well as moving blood from blood vessel walls. MRI is useful in evaluating areas that are less well visualized by echocardiography, such as distal branch pulmonary artery anatomy and anomalies in systemic and pulmonary venous return.

MRA allows the acquisition of images in several tomographic planes. Within each plane, images are obtained at different phases of the cardiac cycle. Thus when displayed in a dynamic "cine" format, changes in wall thickening, chamber volume, and valve function can be displayed and analyzed. Blood flow velocity and blood flow volume can be calculated. MRA is an excellent technique for following patients serially after repair of complex CHD, such as tetralogy of Fallot. In these patients, MRA can be used to assess RV volume and mass and to quantify the amount of regurgitation through either the pulmonary or tricuspid valve. Other MRI techniques, such as myocardial delayed enhancement and tissue T1 weighting, can be used to quantify areas of myocardial scar in patients with cardiomyopathy or in patients after CHD repair, especially tetralogy of Fallot. **Magnetic resonance spectroscopy**, predominantly a research tool at present, provides a means of demonstrating relative concentrations of high-energy metabolites (adenosine triphosphate, adenosine diphosphate, inorganic phosphate, and phosphocreatine) within regions of the working myocardium.

Computer processing of MRA images allows the noninvasive visualization of the cardiovascular system from inside of the heart or vessels, a technique known as *fly-through imaging.* These images allow the cardiologist to image the interiors of various cardiovascular structures (Fig. 472.28). These techniques are especially helpful in imaging complex peripheral arterial stenoses.

CT scanning can be used to perform rapid, respiration-gated cardiac imaging in children with resolutions down to 0.5 mm. Three-dimensional reconstruction of CT images is especially useful in evaluating branch pulmonary arteries, anomalies in systemic and pulmonary venous return, and great vessel anomalies such as coarctation of the aorta (Fig. 472.29).

Radionuclide angiography may be used to detect and quantify shunts and to analyze the distribution of blood flow to each lung. This technique is particularly useful in quantifying the volume of blood flow distribution between the two lungs in patients with abnormalities of the pulmonary vascular tree or to quantify the success of balloon angioplasty and intravascular stenting procedures. Gated blood pool scanning can be used to calculate hemodynamic measurements, quantify valvular regurgitation, and detect regional wall motion abnormalities. Thallium imaging can be performed to evaluate cardiac muscle perfusion. These methods can be used at the bedside of seriously ill children and can be performed serially, with minimal discomfort and low radiation exposure.

Visit Elsevier eBooks+ at eBooks.Health.Elsevier.com for Bibliography.

472.7 Diagnostic and Interventional Cardiac Catheterization

Daniel Bernstein

The catheterization laboratory, once the site for initial diagnosis of CHD, has become the center of high-technology interventional procedures, allowing for the nonsurgical repair or palliation of heart defects that once required open heart surgery. Some centers have developed

Table 472.1 Cardiac MRI Assessment of Myocardial Inflammation

CAUSE	SPECIFIC CAUSE OF MECHANISM	KEY MRI FINDING
Infection	Infectious agents can induce cardiac injury by directly infecting cardiomyocytes or through cellular or humoral immune activation Viral: Enteroviruses, coronaviruses, adenoviruses, parvovirus B19, Herpesviridae 6, CMV, EBV, HIV, influenza; SARS-CoV-2 can infect cardiomyocytes by binding to the ACE2 receptor, although immune dysregulation is likely a more prominent mechanism of myocardial injury Bacterial: *Borrelia burgdorferi* (Lyme disease), *Treponema pallidum,* group A streptococcus (likely postinfectious) Protozoal: *Trypanosoma cruzi* (Chagas disease), *Toxoplasma gondii* Parasitic: *Echinococcus granulosus, Trichinella spiralis*	**Viral myocarditis:** Linear subepicardial or midwall LGE, commonly involving the basal inferolateral wall, basal anterior septum, mid-inferolateral wall, and basal to mid-inferior wall, with corresponding T2 hyperintensity or high T2 **Chagas disease:** LGE present in up to 70% of patients, most commonly at the left ventricular apex, apical inferior and lateral wall, and basal to mid-inferolateral wall; LGE is usually midwall or subepicardial and, less commonly, subendocardial or transmural with apical aneurysms **Bacterial and parasitic myocarditis:** Limited data on MRI findings with no specific pattern **COVID-19:** Findings may be similar to non-COVID viral myocarditis, although some studies have indicated a higher prevalence of diffuse myocardial edema, with global elevation of T1 and T2 mapping values
Postvaccination	mRNA COVID-19 vaccines: Proposed mechanisms include immune activation and dysregulation and molecular mimicry between viral spike protein and an unknown cardiac protein	**mRNA COVID-19 vaccination:** There are currently limited MRI data, mostly from case series to date; MRI findings appear to be typical for viral myocarditis, although the severity and extent of MRI abnormalities reported have been relatively mild; axillary lymphadenopathy ipsilateral to the vaccination site may be present and may be a useful clue, particularly if a history of recent vaccine administration is not provided
Systemic disease	Several systemic diseases are associated with myocardial inflammation: Vasculitides: EGPA, Kawasaki disease Connective tissue disorders: Systemic sclerosis, SLE, rheumatoid arthritis, dermatomyositis Granulomatous disease: Sarcoidosis	**EGPA:** MRI findings include patchy midwall and subepicardial LGE with corresponding T2 hyperintensity and subendocardial apical LGE with or without apical thrombus; concomitant pulmonary opacities might be present **SLE:** Patchy or linear midwall and subepicardial LGE in one third of patients; elevated T1 and T2 value decrease after antiinflammatory treatment; higher prevalence of pericardial and pleural effusion and thickening than in other causes of myocarditis **Sarcoidosis**: Patchy and nodular LGE with associated high T2, most common at the basal septum and basal inferolateral segment; associated findings include mediastinal and hilar lymphadenopathy and pulmonary opacities
Drug related	Hypersensitivity reactions: Penicillin, cephalosporins, benzodiazepines, tricyclic antidepressants Toxic reactions: Anthracyclines, amphetamines, cyclophosphamide Immune activation or dysregulation: ICI-related myocarditis	**ICI-related myocarditis**: Diffusely elevated T1 and T2 values in 78% and 43% of patients, respectively; in one study, only 48% of patients met both T1 and T2 modified Lake Louise criteria; LGE present in 48% of patients, most commonly subepicardial or midmyocardial, and predominating in the basal and mid-inferior and inferolateral segments
Other	Hypereosinophilic syndrome, cocaine, postradiation injury, thyrotoxicosis, giant cell myocarditis	**Hypereosinophilic syndrome:** Similar MRI findings to EGPA, with higher prevalence of subendocardial LGE **Giant cell myocarditis:** MRI appearance is similar to cardiac sarcoidosis, although LGE tends to be more extensive and right ventricular involvement more common

ACE2, Angiotensin-converting enzyme 2; CMV, cytomegalovirus; EBV, Epstein-Barr virus; EGPA, eosinophilic granulomatosis with polyangiitis; ICI, immune checkpoint inhibitor; LGE, late gadolinium enhancement; SLE, systemic lupus erythematosus.
From Sanchez Tijmes F, Thavendiranathan P, Udell JA, et al. Cardiac MRI assessment of nonischemic myocardial inflammation: state of the art review and update on myocarditis associated with COVID-19 vaccination. *Radiol Cardiothorac Imaging.* 2021;3(6):e210252, Table 1.

hybrid catheterization laboratories, combining standard fluoroscopic imaging with an operating suite, allowing combined approaches to treat complex congenital heart lesions.

DIAGNOSTIC CARDIAC CATHETERIZATION

Diagnostic catheterization is still performed (1) to assist in the initial diagnosis of some complex congenital heart lesions (e.g., tetralogy of Fallot with pulmonary atresia and major aortopulmonary collateral arteries, pulmonary atresia with intact ventricular septum and coronary sinusoids, HLHS with mitral stenosis); (2) in cases in which other imaging studies are equivocal; (3) in patients for whom hemodynamic assessment is critical (to determine the size of a left-to-right shunt in borderline cases or to determine the presence or absence of pulmonary vascular disease in an older patient with a left-to-right shunt); (4) between stages of repair of complex CHD (e.g., hypoplastic left or right heart syndromes); (5) for long-term surveillance of patients with complex CHD (e.g., after Fontan palliation for single ventricles); (6) for myocardial biopsy in the diagnosis of cardiomyopathy or in screening for cardiac rejection after cardiac transplantation; and (7) for electrophysiologic study in the evaluation of cardiac arrhythmias (see Chapter 484).

Cardiac catheterization should be performed with the patient in as close to a basal state as possible. Conscious sedation or low-level anesthesia is routine. If a deeper level of general anesthesia is required, careful choice of an anesthetic agent is warranted to avoid depression of cardiovascular function and subsequent distortion of the calculations of cardiac output, PVR and SVR, and shunt ratios.

Cardiac catheterization in critically ill infants with CHD should be performed in a center where a pediatric cardiovascular surgical team is available in the event that an operation is required immediately afterward. The complication rate of cardiac catheterization is greatest in critically ill infants; they must be studied in a thermally neutral

environment and monitored closely for hypothermia, hypoglycemia, acidosis, or excessive blood loss.

Catheterization may be limited to the right-sided cardiac structures, the left-sided structures, or both the right and left sides of the heart. The catheter is passed into the heart under fluoroscopic guidance through a percutaneous entry point in a femoral or jugular vein. In infants and in a number of older children, the left side of the heart can be accessed by passing the catheter across a patent foramen ovale to the left atrium and left ventricle. If the foramen is closed, the left side of the heart can be catheterized by passing the catheter retrograde via a percutaneous entry site in the femoral artery or, if necessary, via a transatrial septal puncture. The catheter can also be manipulated through abnormal intracardiac defects (ASD, VSD). Blood samples are obtained for measuring oxygen saturation in each cardiac chamber or blood vessel, allowing the calculation of shunt volumes. Pressures are measured for gradients across septal defects or valves and for calculating valve areas. Radiopaque contrast is injected to delineate cardiac and vascular structures. A catheter with a thermosensor tip (Swan-Ganz catheter) can be used to measure cardiac output by thermodilution. Specialized catheters can be used to measure more sophisticated indices of cardiac function; those with pressure-transducer tips can measure the first derivative of LV pressure (dP/dt). Conductance catheters can be used to generate pressure-volume loops, from which indices of both contractility (end-systolic elastance) and relaxation can be

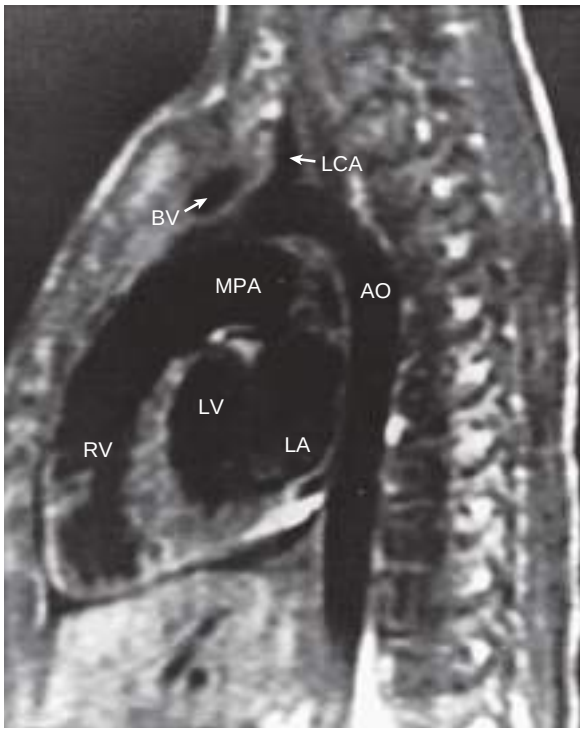

Fig. 472.26 Normal sagittal MRI. AO, Aorta; BV, brachiocephalic vein; LA, left atrium; LCA, left coronary artery; LV, left ventricle; MPA, main pulmonary artery; RV, right ventricle. *(From Bisset GS III. Cardiac and great vessel anatomy. In: El-Khoury GY, Bergman RA, Montgomery WJ, eds. Sectional Anatomy by MRI/CT. New York: Churchill Livingstone; 1990.)*

Fig. 472.28 Fly-through CT imaging in a patient with an aberrant right subclavian artery. Compression of the trachea by the aberrant artery can be visualized.

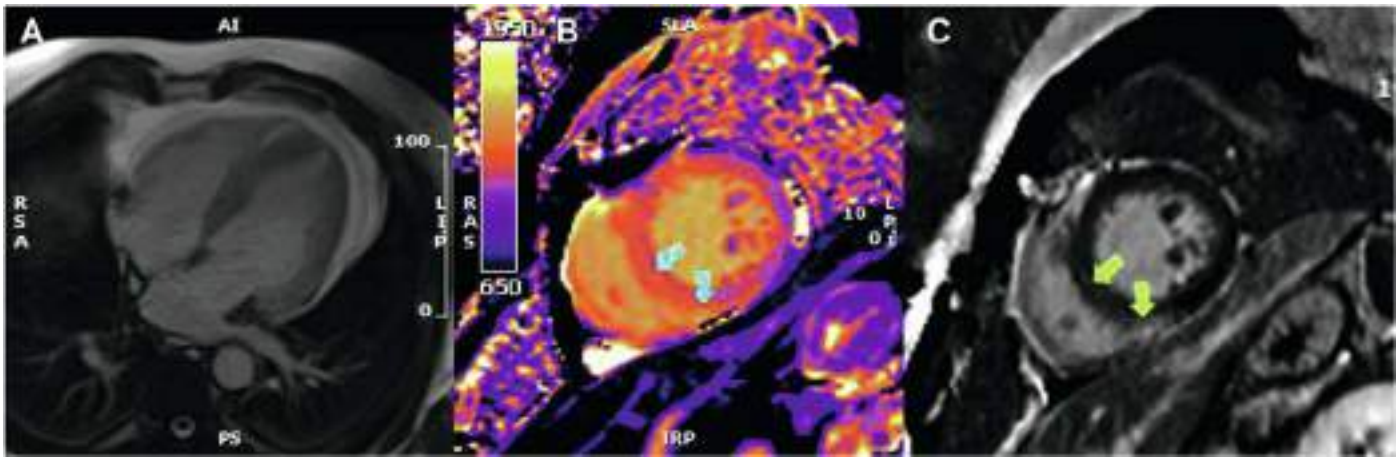

Fig 472.27 Cardiac magnetic resonance imaging (CMRI) findings in a patient with mRNA vaccine-associated myocarditis. Patient presented to hospital 2 days after the second COVID-19 mRNA vaccine with chest pain. Troponin T was elevated at 105 ng/L (normal < 15 ng/L). **A,** CMRI demonstrated normal left ventricular function. **B,** T1 mapping suggested myocardial edema in the inferoseptum and inferior segments (arrows) with corresponding nonischemic scar on late gadolinium enhancement imaging (**C,** *arrows*). *(From Crosier R, Kafil TS, Paterson DI. Imaging for Cardiovascular Complications of COVID-19: Cardiac Manifestations in Context. Can J Cardiol. 2023;39:779–792. Fig. 7.)*

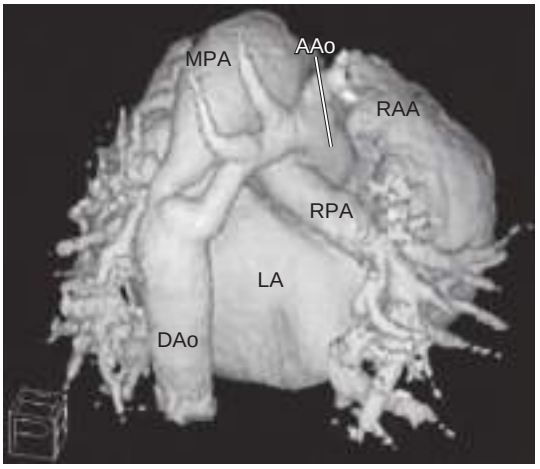

Fig. 472.29 Three-dimensional reconstruction of CT images from a neonate with severe coarctation of the aorta. The patent ductus arteriosus can be seen toward the left leading from the main pulmonary artery to the descending aorta. The tortuous and narrow coarctated segment is just to the right of the ductus. The transverse aorta is hypoplastic as well. AAo, Ascending aorta; DAo, descending aorta; LA, left atrium; MPA, main pulmonary artery; RAA, right atrial appendage; RPA, right pulmonary artery. *(Courtesy Dr. Paul Pitlick, Stanford University, Stanford, CA.)*

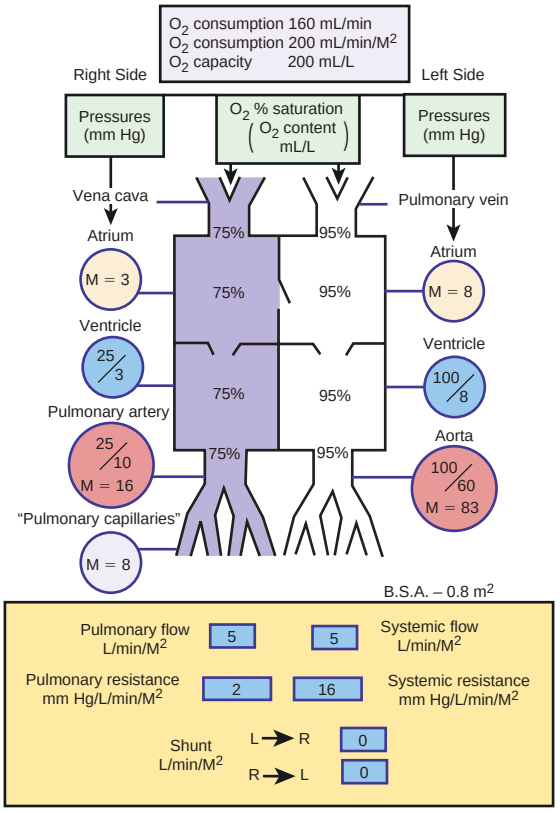

Fig. 472.30 Diagram of normal circulatory dynamics with pressure readings, oxygen content, and percent saturation. B.S.A., body surface area. *(Modified from Nadas AS, Fyler DC. Pediatric Cardiology, 3rd ed. Philadelphia: Saunders; 1972.)*

derived, although these are almost exclusively used in research studies. Complete hemodynamics can be calculated, including cardiac output, intracardiac left-to-right and right-to-left shunts, and SVR and PVR. Figure 472.30 depicts normal circulatory dynamics.

THERMODILUTION MEASUREMENT OF CARDIAC OUTPUT

The thermodilution method for measuring cardiac output is performed with a flow-directed, thermistor-tipped Swan-Ganz catheter. A known change in the heat content of the blood is induced at one point in the circulation (usually the right atrium or inferior vena cava) by injecting room-temperature saline, and the resultant change in temperature is detected at a point downstream (usually the pulmonary artery). This method is used to measure cardiac output in the catheterization laboratory in patients without shunts. Monitoring cardiac output by the thermodilution method can occasionally be useful in managing critically ill infants and children in an intensive care setting after cardiac surgery or in the presence of shock. In this case, a triple-lumen catheter is used for both cardiac output determination and measurement of pulmonary artery and pulmonary capillary wedge pressures.

ANGIOCARDIOGRAPHY

The major blood vessels and individual cardiac chambers may be visualized by selective injection of contrast material into specific chambers or great vessels. **Fluoroscopy** is used to visualize the catheter as it passes through the various heart chambers. After the cardiac catheter is properly placed in the chamber to be studied, contrast medium is injected with a power injector and cineangiograms are exposed. Modern catheterization labs use digital imaging technology, allowing for a significant reduction in radiation exposure. **Biplane cineangiocardiography** allows detailed evaluation of specific cardiac chambers and blood vessels in two planes simultaneously with the injection of a single bolus of contrast material. Various angled views (e.g., left anterior oblique, cranial angulation) are used to display specific anatomic features optimally in individual lesions.

Rapid injection of contrast medium under pressure into the circulation is not without risk, and each injection should be carefully planned. Contrast agents consist of hypertonic solutions, with some containing organic iodides, which can cause complications, including nausea, a generalized burning sensation, central nervous system symptoms, renal insufficiency, and allergic reactions. For patients with known renal insufficiency who require angiography, there are protocols to protect the kidneys involving prehydration and medications. Hypertonicity of the contrast medium may result in transient myocardial depression and a drop in blood pressure, followed soon afterward by tachycardia, an increase in cardiac output, and a shift of interstitial fluid into the circulation. This shift can transiently increase the symptoms of heart failure in critically ill patients.

INTERVENTIONAL CARDIAC CATHETERIZATION

Catheter treatment is the standard of practice for most cases of isolated pulmonary or aortic valve stenosis and for recoarctation of the aorta. A special catheter with a sausage-shaped balloon at the distal end is passed through the obstructed valve. Rapid filling of the balloon with a mixture of contrast material and saline solution results in tearing of the stenotic valve tissue, usually at the site of inappropriately fused raphe. Valvular pulmonary stenosis can be treated successfully by **balloon angioplasty**; in most patients, angioplasty has replaced surgical repair as the initial procedure of choice. The clinical results of this procedure are similar to those obtained by open heart surgery, but without the need for sternotomy or prolonged hospitalization. **Balloon valvuloplasty** for aortic stenosis has also yielded excellent results, although, as with surgery, aortic stenosis often recurs as the child grows, and multiple procedures may thus be required. One complication of both valvuloplasty and surgery is the creation of **valvular insufficiency**. This complication has more serious implications when it occurs on the aortic vs the pulmonary side of the circulation because regurgitation is less well tolerated at systemic arterial pressures.

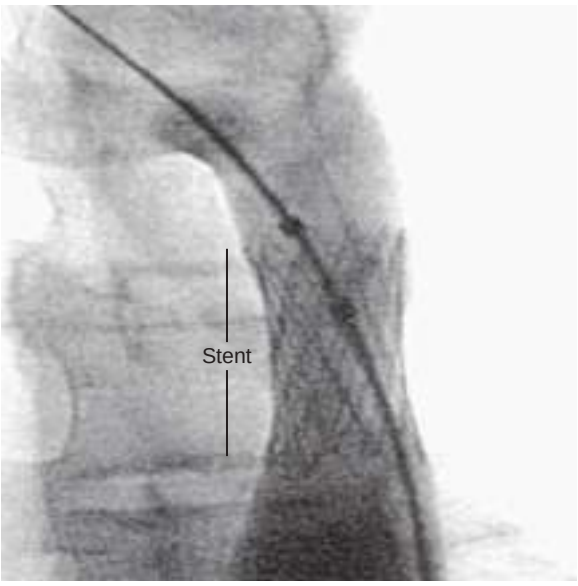

Fig. 472.31 Descending aortic angiogram showing intravascular stent placed in the descending aorta for treatment of recurrent coarctation of the aorta.

Fig. 472.32 Illustration of implantation of a Melody stent-valve delivered to the pulmonary position by a catheter inserted into the right femoral vein. *(Copyright Medtronic 2017, used with permission.)*

Balloon angioplasty is the procedure of choice for patients with restenosis of **coarctation of the aorta** after earlier surgery. It remains controversial whether angioplasty is the best procedure for native (unoperated) coarctation of the aorta in the infant because of greater recurrence risk and reports of late aneurysm formation, and most centers still refer primary coarctation in infants and young children for surgical repair. However, in older patients with previously undiagnosed coarctation, especially those with decreased LV function, primary angioplasty with stent placement may be considered. Other applications of the balloon angioplasty technique include amelioration of mitral stenosis, dilation of surgical conduits (e.g., RV-PA conduits), relief of branch pulmonary artery (PA) narrowing, dilation of systemic or pulmonary venous obstructions, and the pioneering balloon atrial septostomy **(Rashkind procedure)** for transposition of the great arteries (see Chapter 480.2).

Interventional catheterization techniques are being adapted for use in the fetus with lesions such as aortic stenosis to prevent their progression to more complex lesions such as HLHS. In these procedures, after administration of appropriate anesthesia, a needle is passed through the maternal abdominal wall, the uterine wall, and the fetal chest wall and directly into the fetal left ventricle (see Fig. 480.13). A coronary angioplasty balloon catheter is passed through the needle and across the stenotic aortic valve, which is then dilated. With the restoration of normal LV blood flow, it is hoped that normal LV growth potential is restored. Midterm results with this technique in a growing number of patients continue to show mixed results, with good ventricular growth leading to a two-ventricle circulation in approximately 25% of highly preselected patients.

In patients with branch pulmonary artery stenoses, **intravascular stents** are delivered over a balloon catheter and expanded within the vessel lumen (Fig. 472.31). Once placed, the stents can often be dilated to successively greater sizes as the patient grows, although their use in younger infants and children is limited by the extent they can be further expanded.

Closure of a small patent ductus arteriosus (PDA) is routinely achieved with catheter-delivered **coils** (see Fig. 475.11), whereas a larger PDA can be closed with a variety of sandwich-type devices. Closure of anomalous vascular connections (coronary fistulas, venovenous collaterals in cyanotic heart lesions) can also be achieved using coils. Secundum ASDs are now routinely closed with a double disk occluder (e.g., **Amplatzer**) device (see Fig. 475.3). Versions of these devices are currently in clinical trials for closure of surgically difficult-to-reach muscular VSDs and for the more common perimembranous VSD. Catheter-delivered devices may also be used as an adjunct to complex surgical repairs (e.g., dilation or stenting of branch pulmonary artery or pulmonary vein stenosis). High-risk patients undergoing the Fontan operation (see Fig. 479.9) often have a small fenestration created between the right and left sides of the circulation to serve as a "pop-off valve" for high right-sided pressure in the early surgical period. Patients with these "fenestrated Fontans" are usually candidates for subsequent closure of the fenestration with a catheter-delivered device.

One of the greatest advances in interventional catheterization over the past decade has been **transcatheter valve implantation**. Typically, a porcine valve is sewn into an expandable stent (commercially available), which is then collapsed around a balloon catheter. The device is positioned across a stenotic or insufficient pulmonary or aortic valve and the balloon inflated, expanding both the stent and the tissue valve. The balloon catheter is then removed, leaving the new valve in place, well anchored by the stent to the walls of the main pulmonary artery or aorta. At this time, the most common application in children is replacement of the **pulmonary valve** (Melody or Harmony Valve) in patients who have had prior surgery for tetralogy of Fallot (usually because of residual pulmonary insufficiency) (Fig. 472.32). In older adults, the most common application is replacement of a stenotic aortic valve (transcatheter aortic valve replacement or TAVR). Stent valves have even been placed in the tricuspid position in children with tricuspid insufficiency. For older patients with mitral and tricuspid valve insufficiency, a clip device (Mitraclip) can be delivered by catheter to create a double-orifice valve, reducing the amount of insufficiency.

Visit Elsevier eBooks+ at eBooks.Health.Elsevier.com for Bibliography.

Section 3

Congenital Heart Disease

Chapter 473

Epidemiology and Genetic Basis of Congenital Heart Disease

Daniel Bernstein

Congenital heart disease (CHD) occurs in approximately 0.6–1.3% of live births. The incidence is higher in stillborns (3–4%), spontaneous abortuses (10–25%), and premature infants (approximately 2%, excluding patent ductus arteriosus [PDA]). This overall incidence does not include mitral valve prolapse, PDA of preterm infants, and bicuspid aortic valve (present in 1–2% of adults). Congenital cardiac defects have a wide spectrum of severity in infants: approximately 2-3 in 1,000 newborn infants will be symptomatic with heart disease in the first year of life. The diagnosis is established by 1 week of age in 40–50% of patients with CHD and by 1 month of age in 50–60%. Approximately 13% of infants with CHD have associated extracardiac malformations. With advances in both corrective and palliative surgery, 90% of children with CHD survive to adulthood, and in the United States, there are more adults living with CHD than there are children with CHD. Despite these advances, CHD remains the leading cause of death in children with congenital malformations. When patients with repaired or palliated CHD reach older adulthood, the risk of morbidity and mortality begins to increase (see Chapter 483.1). Table 473.1 summarizes the relative frequency of the most common congenital cardiac lesions.

Most congenital defects are well tolerated in the fetus because of the parallel nature of the fetal circulation. Even the most severe cardiac defects, such as **hypoplastic left heart syndrome (HLHS)**, can usually be well compensated for by the fetal circulation. In HLHS the entire fetal cardiac output is ejected by the right ventricle via the ductus arteriosus into both the descending and ascending aortae (the latter filling in a retrograde fashion), so that fetal organ blood flow is minimally perturbed. Because the placenta provides for gas exchange and the normal fetal circulation has mixing between more highly and more poorly oxygenated blood at the foramen ovale and ductus arteriosus, fetal organ oxygen delivery is also not dramatically affected. It is only after birth, when the fetal pathways begin to close and the umbilical cord is cut, that the full hemodynamic impact of an anatomic abnormality becomes apparent. One notable exception is the case of severe regurgitant lesions, most frequently of the tricuspid valve. In these lesions, such as **Ebstein anomaly** of the tricuspid valve or severe right ventricular outflow obstruction (see Chapter 479.7), the parallel fetal circulation cannot compensate for the severe volume or pressure load imposed on the right side of the heart. In utero heart failure, often with fetal pleural and pericardial effusions, and generalized ascites **(nonimmune hydrops fetalis)** may occur.

Although the most significant transitions in the circulation occur in the immediate perinatal period, the circulation continues to undergo changes after birth, and these later changes may also have a hemodynamic impact on cardiac lesions and their apparent incidence. When pulmonary vascular resistance (PVR) falls in the first several weeks of life, left-to-right shunting through intracardiac defects increases and symptoms and signs become more apparent. Thus in patients with a **ventricular septal defect (VSD)**, heart failure is often first noticed between 1 and 3 months of age (see Chapter 475.6) and not in the immediate newborn period. The severity of various defects can also change dramatically with growth; some VSDs may become smaller and even close as the child ages. Alternatively, stenosis of the aortic or pulmonary valve, which may be only moderate in the newborn period, may become worse if valve orifice growth does not keep pace with patient growth (see Chapter 476.5). The physician should always be alert for associated noncardiac congenital malformations, which can adversely affect the patient's prognosis (Tables 473.2 and 473.3). Developmental delay of various degrees is also a concern in many patients with CHD and may have its origins in alterations in fetal blood flow patterns caused by the heart defect, postnatal hypoxemia, and the effects of cardiopulmonary bypass during open heart surgery.

ETIOLOGY

The cause of most congenital heart defects is still unknown. Many cases of CHD are multifactorial and may result from a combination of **genetic** predisposition and an as-yet-to-be-determined **environmental** stimulus. Overall, variants in approximately 400 genes have been identified as potentially causative of CHD. Despite these advances, half of cases still lack a known genetic cause. A small percentage of congenital heart lesions are related to known chromosomal abnormalities, in particular, trisomies 21, 13, and 18 and Turner syndrome; heart disease is found in >90% of patients with trisomy 18, 50% of patients with trisomy 21, and 40% of those with Turner syndrome (see Table 473.3). Ethnic factors may have a role in CHD; certain types of VSDs (supracristal) are more common in Asian children. There are also male:female differences for many common forms of CHD. The risk of CHD increases if a first-degree relative (parent or sibling) is affected, again emphasizing the role of genetics, even if the individual genes have not yet been identified.

A growing list of congenital heart lesions has been associated with specific chromosomal abnormalities, and several have even been linked to specific gene defects (see Table 473.3 and Table 473.4). **Fluorescence**

Table 473.1 Relative Frequency of Major Congenital Heart Lesions*

LESION	% OF ALL LESIONS
Ventricular septal defect	35–30
Atrial septal defect (secundum)	6–8
Patent ductus arteriosus	6–8
Coarctation of aorta	5–7
Tetralogy of Fallot	5–7
Pulmonary valve stenosis	5–7
Aortic valve stenosis	4–7
D-Transposition of great arteries	3–5
Hypoplastic left ventricle	1–3
Hypoplastic right ventricle	1–3
Truncus arteriosus	1–2
Total anomalous pulmonary venous return	1–2
Tricuspid atresia	1–2
Single ventricle	1–2
Double-outlet right ventricle	1–2
Others	5–10

*Excluding patent ductus arteriosus in preterm neonates, bicuspid aortic valve, physiologic peripheral pulmonic stenosis, and mitral valve prolapse.

Table 473.2 Genes and Loci Associated with Congenital Heart Disease

SYNDROME	GENE(S)	LOCI	CARDIAC DISEASE	CONGENITAL HD (%)	OTHER CLINICAL FINDINGS
Alagille	*JAG 1* *NOTCH2*	20p12.2 1p12-p11	PPS, TOF, PA	>90	Bile duct paucity, posterior embryotoxon, butterfly vertebrae, renal defects
CFC	*BRAF* *KRAS* *MAP2K1* *MAP2K2*	7q34 12p12.1 15q22.31 19p13.3	PVS, ASD, HCM	75	Curly hair, sparse eyebrows, feeding problems, developmental delay, intellectual disability
Cantu	*ABCC9*	12p12.1	PDA, BAV, HCM, CoA, PE, AS	75	Hypertrichosis at birth, macrocephaly, narrow thorax, coarse facies, macroglossia, broad hands, advanced bone age
Char	*TFAP2B*	6p12.3	PDA, VSD	58	Wide-set eyes, down-slanting palpebral fissures, thick lips, hand anomalies
CHARGE	*CHD7*	8q12	TOF, PDA, DORV, AVSD, VSD	75–85	Coloboma, choanal atresia, genital hypoplasia, ear anomalies, hearing loss, developmental delay, poor growth, intellectual disability
Costello	*HRAS*	11p15.5	PVS, ASD, VSD, HCM, arrhythmias	44–52	Short stature, feeding problems, broad facies, bitemporal narrowing, redundant skin, intellectual disability
22q11.2DS	*TBX1*	22q11.2 deletion	Conotruncal defects, VSD, IAA, ASD, VR	74–85	Cleft palate, bifid uvula, velopharyngeal insufficiency, microcephaly, hypocalcemia, immune deficit, psychiatric disorder, learning disability
Ellis-van Creveld	*EVC* *EVC2*	4p16.2 4p16.2	Common atrium	60	Skeletal dysplasia, short limbs, polydactyly, short ribs, dysplastic nails, respiratory insufficiency
Holt-Oram	*TBX5*	12q24.1	VSD, ASD, AVSD, conduction defects	50	Absent, hypoplastic, or triphalangeal thumbs; phocomelia; defects of radius; limb defects more prominent on left
Kabuki	*KMT2D* *KDM6A*	12q13 Xp11.3	CoA, BAV, VSD, TOF, TGA, HLHS	50	Growth deficiency, wide palpebral fissures, large protuberant ears, fetal finger pads, intellectual disability, clinodactyly
Noonan	*PTPN11* *SOS1* *RAF1* *KRAS* *NRAS* *RIT1* *SHOC2* *SOS2* *BRAF*	12q24.13 2p22.1 3p25.2 12p12.1 1p13.2 1q22 10q25.2 14q21.3 7q34	Dysplastic PVS, ASD, TOF, AVSD, HCM, VSD, PDA	75	Short stature, hypertelorism, down-slanting palpebral fissures, ptosis, low posterior hairline, pectus deformity, bleeding disorder, chylothorax, cryptorchidism
VACTERL association	Unknown		VSD, ASD, HLHS, PDA, TGA, TOF, TA	53–80	Vertebral anomalies, anal atresia, tracheoesophageal fistula, renal anomalies, radial dysplasia, thumb hypoplasia, single umbilical artery
Williams-Beuren	7q11.23 deletion *(ELN)*	7q11.23	SVAS, PAS, VSD, ASD	80	Unusual facies, thick lips, strabismus, stellate iris pattern, intellectual disability
Carpenter	*RAB23*	6p11.2	VSD, ASD, PDA, PS, TOF, TGA	50	Craniosynostosis, brachydactyly, syndactyly, polydactyly, obesity

Table 473.2 Genes and Loci Associated with Congenital Heart Disease—cont'd

SYNDROME	GENE(S)	LOCI	CARDIAC DISEASE	CONGENITAL HD (%)	OTHER CLINICAL FINDINGS
Coffin-Siris	*ARID1B* *SMARCB1* *ARID1A* *SMARCB1* *SMARCA4* *SMARCE1*	6q25 22q11 1p36.1 22q11.23 19p13.2 17q21.2	ASD, AVSD, VSD, MR, PDA, PS, DEX, AS	20–44	Developmental delay, coarse facies, hypoplastic distal phalanges, short stature, intellectual disability
Cornelia de Lange	*NIPBL* *SMC1L1* *SMC3*	5p13 Xp11.22 10q25	PVS, VSD, ASD, PDA	33	Microbrachycephaly, synophrys, arching eyebrows, growth retardation, intellectual disability, micromelia
Goldenhar	Unknown		VSD, PDA, TOF, CoA, conotruncal defects	32	Hemifacial microsomia, epibulbar dermoids, microtia, hemivertebrae
Mowat-Wilson	*ZEB2*	2q22.3	VSD, CoA, ASD, PDA, PAS	54	Short stature, microcephaly, Hirschsprung disease, intellectual disability, seizures
Rubinstein-Taybi	*CBP* *EP300*	16p13.3 22q13.2	PDA, VSD, ASD, HLHS, BAV	33	Microcephaly, growth retardation, down-slanting palpebral fissures, low-set malformed ears, prominent or beaked nose, intellectual disability, broad thumbs and toes
Smith-Lemli-Opitz	*DHCR7*	11q12-13	AVSD, HLHS, ASD, PDA, VSD	50	Microcephaly, ptosis, genital anomalies, renal anomalies, broad nasal tip with anteverted nostrils, intellectual disability, syndactyly
Adams-Oliver	*ARHGAP31* *DOCK6* *RBPJ* *EOGT* *NOTCH1* *DLL4*	3q13 19p13.2 4p15.2 3p14.1 9q34.3 15q15.1	ASD, VSD, CoA, HLHS, DORV	20	Aplasia cutis congenita, terminal transverse defects of hands, fingers, toes, feet
Baller-Gerold	*RECQL4*	8q24.3	VSD, TOF, subaortic disease	25	Craniosynostosis, micrognathia, small mouth, radial aplasia/hypoplasia, imperforate anus, renal anomalies
Beckwith-Wiedemann	*CDKNIC*	11p15.4	VSD, HLHS, PS	6.5	Macrosomia, macroglossia, omphalocele, risk of malignancy
Coffin-Lowry	*RSK2*	Xp22.2	LVNC, MVP, AVA	5–14	Growth deficiency, coarse facies, everted lower lip, hypodontia, intellectual disability
Duane-radial ray (Okihiro)	*SALL4*	20q13.2	ASD, PVS, VSD	<10	Unilateral or bilateral Duane anomaly, hypoplasia of thumbs, hypoplastic radius and ulna, renal malformations, ear anomalies
Fragile X	*FMR1*	Xq27.3	MVP, aortic dilation	<10	Macrocephaly, intellectual disability, hand flapping, speech abnormality, autism spectrum disorder, macroorchidism, seizures, prominent forehead, large ears
Nance-Horan	*NHS*	Xp22.13	TOF, VSD, PDA	<10	Congenital cataracts, strabismus, peg-shaped supernumerary teeth, other dental anomalies, prominent ears, brachymetacarpalia

Continued

Table 473.2 Genes and Loci Associated with Congenital Heart Disease—cont'd

SYNDROME	GENE(S)	LOCI	CARDIAC DISEASE	CONGENITAL HD (%)	OTHER CLINICAL FINDINGS
Peter's Plus	*B3GALTL*	13q12.3	ASD, VSD, PVS, BPV, subvalvular AS	<30	Short limb growth deficiency, intellectual disability, autism spectrum disorder, prominent forehead, cupid's bow upper lip, cleft lip ± cleft palate, Peter's anomaly, cataracts, hydronephrosis
Roberts	*ESC02*	8p21.1	ASD, AS	<20	Growth deficiency of prenatal onset, cleft lip ± cleft palate, hypertelorism, sparse hair, hypomelia with variable limb reduction defects, cryptorchidism
Robinow	*RDR2 (AR)* *WNT5A (AD)*	9q22	RVOTO	29 AD 13 AR	Macrocephaly, frontal bossing, prominent eyes, small upturned nose, short forearms, hemivertebrae, hypoplastic phalanges of hands and toes, hypoplastic genitalia
Saethre-Chotzen	*TWIST*	7p21p22	VSD	<10	Craniosynostosis, brachycephaly, high flat forehead, hypertelorism, ptosis, partial cutaneous syndactyly, broad great toes, strabismus
Short rib polydactyly type I	*DYNC2H1*	11q22.3	TGA, DORV, DOLV, AVSD, HRH	<25	Short stature, postaxial polydactyly of hands or feet, short horizontal ribs, small iliac bones, polycystic kidneys, early death from respiratory insufficiency
Simpson-Golabi-Behmel	*GPC3*	Xq26.2	TGA, VSD, PVS, CoA, AS, PDA, BAV, CM	26	Macrosomia, coarse face, macroglossia, hepatosplenomegaly, nephromegaly, variable cognitive disability
Sotos	*NSD1*	5q35.3	ASD, PDA, VSD	21	Excessive size, large hands and feet, prominent forehead, hypotonia, variable intellectual disability, scoliosis, advanced bone age
Townes-Brocks	*SALL1*	16p12.1	ASD, TOF, VSD, TA, PA, PDA	14–25	Auricular anomalies, preauricular tags, hearing loss, thumb hypoplasia/polydactyly, imperforate anus, renal agenesis, multicystic kidney, microphthalmia

22q11.2DS, 22q11.2 deletion syndrome; AD, autosomal dominant; AR, autosomal recessive; AS, aortic stenosis; ASD, atrial septal defect; AVA, aortic valve anomaly; AVSD, atrioventricular septal defect; BAV, bicuspid aortic valve; BPV, bicuspid pulmonary valve; CFC, cardiofaciocutaneous; CHARGE, coloboma, heart defects, choanal atresia, retarded growth and development, genital anomalies, and ear anomalies; CM, cardiomyopathy; CoA, coarctation of the aorta; DEX, dextrocardia; DOLV, double-outlet left ventricle; DORV, double-outlet right ventricle; HCM, hypertrophic cardiomyopathy; HD, heart disease; HLHS, hypoplastic left heart; HRH, hypoplastic right heart; IAA, interruption of aortic arch; LVNC, left ventricular noncompaction; MR, mitral regurgitation; MVP, mitral valve prolapse; PA, pulmonary atresia; PAS, pulmonary artery stenosis; PDA, patent ductus arteriosus; PE, pericardial effusion; PPS, peripheral pulmonary stenosis; PS, pulmonary stenosis; PVS, pulmonary stenosis; RVOTO, right ventricular outflow tract obstruction; SVAS, supravalvular aortic stenosis; TA, truncus arteriosus; TGA, transposition of great arteries; TOF, tetralogy of Fallot; VACTERL, association of vertebral defects, anal atresia, cardiac defects, tracheoesophageal fistula, renal and limb anomalies; VR, vascular ring; VSD, ventricular septal defect.

From Pierpont ME, Brueckner M, Chung WK, et al. Genetic basis for congenital heart disease: revisited: a scientific statement from the American Heart Association. *Circulation*. 2018;138(21):e653–e711, Table 5.

in situ hybridization (FISH) analysis allows rapid screening of suspected cases if a specific chromosomal abnormality is suspected. Chromosome microarray tools, including **array comparative genome hybridization** and **single nucleotide polymorphism (SNP) arrays**, have identified copy number variations (microdeletions or microduplications) or SNPs in many patients with CHD and suspicion of a congenital anomaly syndrome. These variants are submicroscopic and thus not visible on routine chromosome analysis. Comparative genome hybridization has in many cases replaced routine karyotyping in the clinical workup of newborns with CHD. Overall, 25% of cases of CHD can be associated with a gene alteration using these methodologies. Whole exome and whole genome sequencing are available for clinical genetic evaluations. The advantage of whole genome sequencing is that it allows the assessment of noncoding DNA sequences, which could participate in the regulation of gene expression of cardiac developmental gene pathways (Table 473.5).

A well-characterized genetic cause of CHD is the deletion of a large region (1.5-3 Mb) of chromosome 22q11.2, known as the **DiGeorge**

Table 473.3 Chromosomal Aneuploidies and Copy Number Variants Associated with Congenital Heart Disease

CHROMOSOME CHANGE	MAIN FEATURES	PERCENT WITH CONGENITAL HD	HEART ANOMALY
I. ANEUPLOIDES (IDENTIFIABLE BY ROUTINE KARYOTYPE)			
Trisomy 8 mosaicism	Widely spaced eyes, broad nasal bridge, small jaw, high arched palate, cryptorchidism, renal anomalies, skeletal/vertebral anomalies	25	VSD, PDA, CoA, PVS, TAPVR, TrA
Trisomy 9/mosaicism	Prenatal and postnatal growth restriction, microcephaly, deep-set eyes, low-set ears, severe intellectual disability	65	PDA, LSVC, VSD, TOF/PA, DORV
Trisomy 13 (Patau syndrome)	Cleft lip and palate, scalp defects, hypotelorism, microphthalmia or anophthalmia, colobomata of irides, holoprosencephaly, microcephaly, deafness, severe intellectual disability, rib abnormalities, polydactyly, omphalocele, renal abnormalities, hypospadias, cryptorchidism, uterine abnormalities	57–80	ASD, VSD, PDA, HLHS, laterality defects, atrial isomerism
Trisomy 18 (Edwards syndrome)	IUGR, polyhydramnios, micrognathia, short sternum, hypertonia, rocker-bottom feet, overlapping fingers and toes, TEF, CDH, omphalocele, renal anomalies, biliary atresia, severe intellectual disability	80–90	ASD, VSD, PDA, TOF, DORV, TGA, CoA, BAV, BPV, polyvalvular nodular dysplasia
Trisomy 21 (Down syndrome)	Hypotonia, hyperextensibility, epicanthal folds, up-slanting palpebral fissures, single palmar transverse crease, clinodactyly of fifth finger, brachydactyly, variable intellectual disability, premature aging	40–50	AVSD, VSD, ASD, (TOF, TGA less common)
Monosomy X (Turner syndrome, 45,X)	Lymphedema of hands and feet, widely spaced hypoplastic nipples, webbed neck, primary amenorrhea, short stature, normal intelligence, or mild learning disability	23–35	CoA, BAV, AS, HLHS, aortic dissection
II. CHROMOSOME ABNORMALITIES (IDENTIFIABLE ON KARYOTYPE AND CHROMOSOMAL MICROARRAY)			
3p25 deletion	Prenatal and postnatal growth deficiency, polydactyly, microcephaly, intellectual disability, renal anomalies	33	VSD, AVSD, tricuspid atresia
Deletion 4p16.3 (Wolf-Hirschhorn syndrome)	Microcephaly, widely spaced eyes, broad nasal bridge (Greek helmet appearance), downturned mouth, micrognathia, preauricular skin tags, severe intellectual disability, seizures, poor growth	50–65	ASD, VSD, PDA, LSVC, aortic atresia, dextrocardia, TOF, tricuspid atresia
Deletion 4q	Growth restriction, intellectual disability, cleft palate, broad nasal bridge, micrognathia, abnormal ears, genitourinary defects	50	VSD, PDA, AS, ASD, TOF, CoA
Deletion 5p (cri-du-chat)	Catlike cry, prenatal and postnatal growth restriction, round face, widely spaced eyes, epicanthal folds, single palmar transverse crease, severe intellectual disability	30–60	VSD, ASD, PDA
Deletion 9p syndrome	Craniosynostosis, trigonocephaly, up-slanting palpebral fissures, abnormal ear pinnae, scoliosis, micropenis, cryptorchidism, intellectual disability	35–50	VSD, PDA, PVS
Deletion 10p	Frontal bossing, short down-slanting palpebral fissures, small low-set ears, micrognathia, cleft palate, short neck, urinary/genital and upper-limb anomalies	42	BAV, ASD, VSD, PDA, PVS, CoA
Duplication 10q24-qter	Prenatal growth restriction, intellectual disability, camptodactyly, renal anomalies, cryptorchidism	50	AVSD, VSD
III. COPY NUMBER VARIANTS (IDENTIFIABLE BY CHROMOSOMAL MICROARRY)			
1p36 deletion	Growth deficiency, intellectual disability, microcephaly, deep-set eyes, low-set ears, hearing loss, hypotonia, seizures, CNS defects, genital anomalies	70	PDA, VSD, ASD, BAV, Ebstein anomaly, noncompaction cardiomyopathy

Continued

Table 473.3 Chromosomal Aneuploidies and Copy Number Variants Associated with Congenital Heart Disease—cont'd

CHROMOSOME CHANGE	MAIN FEATURES	PERCENT WITH CONGENITAL HD	HEART ANOMALY
1q21.1 deletion	Short stature, microcephaly, colobomas, microphthalmia, hearing loss, seizures, mild intellectual disability, autism spectrum disorder, skeletal malformations	N/A	PDA, VSD, ASD, TrA, TOF
1q21.1 duplication	Large head size, hemivertebrae, variable intellectual disability, variable autistic features, hypospadias, clubfoot	N/A	TOF, TGA, PVS
1q41q42 microdeletion	Growth restriction, intellectual disability, microcephaly, diaphragmatic hernia, seizures, short limbs	40	BAV, ASD, VSD, TGA
1q43q44 microdeletion	Prenatal and postnatal poor growth, intellectual disability, limited speech, microcephaly, deep-set eyes, microcephaly, large low-set ears, cleft palate, agenesis of corpus callosum	N/A	VSD, CoA, HLHS
2q31.1 microdeletion	Prenatal and postnatal poor growth, large ventricles, microcephaly, narrow forehead, down-slanting palpebral fissures, cleft palate/cleft lip, limb defects, hypoplastic genitalia	25	VSD, ASD, PDA
2q37 microdeletion	Short stature, obesity, intellectual disability, sparse hair, arched eyebrows, epicanthal folds, thin upper lip, small hands and feet, clinodactyly	30	VSD, ASD, CoA, hypoplastic aortic arch
Deletion 7q11.23 (Williams-Beuren syndrome)	Infantile hypercalcemia, skeletal and renal anomalies, cognitive deficits, "social" personality, elfin facies	53–85	Supravalvar AS and PS, PPS
8p23.1 deletion	Microcephaly, poor growth, deep-set eyes, malformed ears, small chin, genital anomalies in males, intellectual disability	50–75	AVSD, PVS, VSD, TOF
9q34.3 Subtelomeric deletion (Kleefstra syndrome)	Short stature, obesity, intellectual disability, microcephaly, behavior abnormalities, brain anomalies, hypertelorism, arched eyebrows, midface hypoplasia	31–44	ASD, VSD, TOF, pulmonary arterial stenosis
Deletion 11q (Jacobsen syndrome)	Growth restriction, developmental delay, thrombocytopenia, platelet dysfunction, widely spaced eyes, strabismus, broad nasal bridge, thin upper lip, prominent forehead, intellectual disability	56	HLHS, AS, VSD, CoA, Shone complex
15q24 microdeletion	Prenatal and postnatal growth restriction, intellectual disability, abnormal corpus callosum, microcephaly, high forehead, down-slanting palpebral fissures, tapered eyebrows, abnormal ear pinnae, hearing loss, hypospadias, scoliosis, coloboma, strabismus	40	PDA, pulmonary arterial stenosis, PVS
16p11.2p12.2 microdeletion	Hypotonia, intellectual disability, long narrow face, deep-set eyes, low-set malformed ears	33	TOF, BAV, pulmonary atresia
17q21 microdeletion	Abnormal hair pigmentation, up-slanting palpebral fissures, epicanthal folds, bulbous nasal tip, strabismus, ptosis, long slender fingers, hip dislocation, renal anomalies, spine deformities, cryptorchidism, global developmental delay	27	PVS, ASD, VSD, BAV
Deletion 20p12 (Alagille syndrome)	Bile duct paucity, cholestasis, skeletal or ocular anomalies, broad forehead, widely spaced eyes, underdeveloped mandible	85–94	Peripheral PA hypoplasia, TOF, PVS (left-sided heart lesions and septal defects less common)
22q11.2DS (DiGeorge, velocardiofacial, and conotruncal anomaly face syndrome)	Hypertelorism, micrognathia, low-set posteriorly rotated ears, thymic and parathyroid hypoplasia, hypocalcemia, feeding/speech/learning/behavioral disorders, immunodeficiency, palate/skeletal/renal anomalies, learning disability	75	IAA-B, TrA, isolated aortic arch anomalies, TOF, conoventricular VSD

Table 473.3 Chromosomal Aneuploidies and Copy Number Variants Associated with Congenital Heart Disease—cont'd

CHROMOSOME CHANGE	MAIN FEATURES	PERCENT WITH CONGENITAL HD	HEART ANOMALY
22q11.2 duplication	Very variable phenotype, some with velopharyngeal insufficiency, cleft palate, hearing loss, minor facial anomalies, mild learning disability to normal learning ability, hypotonia, scoliosis, frequent infections	15	TOF, HLHS, VSD, PVS, TrA
22q13 microdeletion (Phelan-McDermid syndrome)	Normal growth, intellectual disability, dolichocephaly, dysplastic ears, pointed chin, large fleshy hands, hypotonia	>25	PDA, VSD, ASD, TAPVR

22q11.2DS, 22q11.2 deletion syndrome; AS, aortic stenosis; ASD, atrial septal defect; AVSD, atrioventricular septal defect; BAV, bicuspid aortic valve; BPV, bicuspid pulmonary valve; CDH, congenital diaphragmatic hernia; CoA, coarctation of the aorta; DORV, double-outlet right ventricle; HD, heart disease; HLHS, hypoplastic left heart syndrome; IAA-B, interrupted aortic arch type B; IUGR, intrauterine growth retardation; LSVC, persistent left superior vena cava; N/A, not available; PA, pulmonary artery; PDA, patent ductus arteriosus; PPS, peripheral pulmonary stenosis; PS, pulmonary stenosis; PVS, pulmonic valve stenosis; TAPVR, total anomalous pulmonary venous return; TEF, tracheoesophageal fistula; TGA, D-transposition of the great arteries; TOF, tetralogy of Fallot; TOF/PA, tetralogy of Fallot with pulmonary atresia; TrA, truncus arteriosus; VSD, ventricular septal defect.
From Pierpont ME, Brueckner M, Chung WK, et al. Genetic basis for congenital heart disease: revisited: a scientific statement from the American Heart Association. *Circulation*. 2018;138(21):e653–e711, Appendix Table.

Table 473.4 Disease Genes for Nonsyndromic Congenital Cardiovascular Disease

GENE	CARDIOVASCULAR MALFORMATION	NONSYNDROMIC (NS) OR SYNDROMIC (S)
TRANSCRIPTION FACTORS		
CITED2	ASD, VSD	NS
GATA4	ASD, VSD, AVSD, PVS, TOF	NS
GATA6	PTA, TOF	NS
MED13L	TGA	NS
NR2F2	AVSD, AS, CoA, VSD, HLHS, TOF	NS
NKX2-5	ASD, atrioventricular conduction delay, TOF, HLHS	NS
NKX2.6	PTA	NS
TBX20	ASD, VSD, MS, DCM	NS
ZFPM2/FOG2	TOF, DORV	NS
CELL SIGNALING AND ADHESION PROTEINS		
ACVR1/ALK2	AVSD	NS
CRELD1	ASD, AVSD	NS
GJA1	HLHS, VSD, PA	S (oculodentodigital dysplasia) and NS
JAG1	TOF, PVS, PAS	S (Alagille syndrome) and NS
NOTCH1	BAV, AS, HLHS, TOF, PVS	S (Adams-Oliver syndrome) and NS
PDGFRA	TAPVR	NS
SMAD6	BAV, CoA, AS	NS
TAB2	BAV, AS, TOF	NS
STRUCTURAL PROTEINS		
ACTC1	ASD, HCM, DCM, LVNC	NS
DCHS1	MVP	NS
ELN	SVAS	S (Williams-Beuren syndrome) and NS
MYH6	ASD, HCM, DCM	NS
MYH7	Ebstein anomaly, LVNC, HCM, DCM	NS
MYH11	PDA, TAA	NS

AS, Aortic valve stenosis; ASD, atrial septal defect; AVSD, atrioventricular septal defect; BAV, bicuspid aortic valve; CoA, coarctation of aorta; DCM, dilated cardiomyopathy; DORV, double-outlet right ventricle; HCM, hypertrophic cardiomyopathy; HLHS, hypoplastic left heart syndrome; LVNC, left ventricular noncompaction cardiomyopathy; MS, mitral valve stenosis; MVP, mitral valve prolapse; NS, nonsyndromic; PA, pulmonary atresia; PAS, pulmonary artery stenosis; PDA, patent ductus arteriosus; PTA, persistent truncus arteriosus; PVS, pulmonary vein stenosis; S, syndromic; SVAS, supravalvar aortic stenosis; TAA, thoracic aortic aneurysm; TAPVR, total anomalous pulmonary venous return; TGA, transposition of great arteries; TOF, tetralogy of Fallot; and VSD, ventricular septal defect.
From Pierpont ME, Brueckner M, Chung WK, et al. Genetic basis for congenital heart disease: revisited: a scientific statement from the American Heart Association. *Circulation*. 2018;138(21):e653–e711, Table 8.

Table 473.5 Clinical Genetic Tests

	GENOMIC VS TARGETED	ANEUPLOIDIES AND CHROMOSOMAL REARRANGEMENTS	COPY NUMBER VARIATION	SNPs AND INDELs	EXAMPLE OF CLINICAL USE
Karyotype	Genomic	+++	+	–	Confirmation of trisomy 21
Array CGH	Genomic	++	+++	–	Multiple congenital anomalies without obvious syndromic association
FISH	Targeted	+	+	–	Suspected 22q11.2 deletion syndrome
Gene panel testing	Targeted	–	+	+++	Suspected monogenic disease with a small differential diagnosis
Exome sequencing	Genomic	–	–	+++	Broad genetic differential diagnosis without obvious syndromic association, or previous negative panel testing
Genome sequencing	Genomic	+	+	+++	Broad genetic differential diagnosis without obvious syndromic association, or previous negative panel testing and need for rapid turnaround time

Sensitivity of tests for the types of genetic variation are indicated as not detected (–), low (+), medium (++), or high (+++). Array CGH indicates comparative genomic hybridization using arrays; FISH, fluorescence in situ hybridization; INDEL, insertion or deletion; and SNP, single nucleotide polymorphism.
From Pierpont ME, Brueckner M, Chung WK, et al. Genetic basis for congenital heart disease: revisited: a scientific statement from the American Heart Association. *Circulation*. 2018;138(21):e653–e711, Table 1.

critical region. At least 30 genes have been mapped to the deleted region; *Tbx1,* a transcription factor involved in early outflow tract development, is one gene that has been implicated as a possible cause of DiGeorge syndrome. The estimated prevalence of 22q11.2 deletions is 1 in 4,000 live births; these occur in 2% of all patients with CHD. Cardiac lesions associated with 22q11.2 deletions are most often seen in association with either DiGeorge syndrome or **Shprintzen (velocardiofacial) syndrome**. The acronym **CATCH 22** has been used to summarize the major components of these syndromes: **C**ardiac defects, **A**bnormal facies, **T**hymic aplasia, **C**left palate, and **H**ypocalcemia. The specific cardiac anomalies are **conotruncal** defects (tetralogy of Fallot, truncus arteriosus, double-outlet right ventricle, subarterial VSD) and **branchial arch** defects (coarctation of the aorta, interrupted aortic arch, right aortic arch). Congenital airway anomalies such as tracheomalacia and bronchomalacia are sometimes present. In addition to extracardiac defects, studies in adults with repaired tetralogy of Fallot have linked the presence of a 22q11.2 microdeletion to increased all-cause mortality. Although the risk of recurrence is extremely low in the absence of a parental 22q11.2 deletion, the risk rises to 50% if one parent carries the deletion. More than 90% of patients with the clinical features of DiGeorge syndrome have a deletion at 22q11.2. A second genetic locus on the short arm of chromosome 10 (10p13p14) has also been identified, the deletion of which shares some, but not all, phenotypic characteristics with the 22q11.2 deletion; patients with del(10p) have an increased incidence of sensorineural hearing loss.

Other structural heart lesions associated with specific chromosomal abnormalities include **familial secundum atrial septal defect** (ASD) associated with **heart block** (the transcription factor Nkx2.5 on chromosome 5q35), familial ASD without heart block (the transcription factor GATA4), **Alagille syndrome** (Jagged1 on chromosome 20p12), and **Williams syndrome** (elastin on chromosome 7q11). Of interest, patients with VSDs and atrioventricular septal defects have been found to have multiple Nkx2.5 pathogenic variants in cells isolated from diseased heart tissues, but not from normal heart tissues or from circulating lymphocytes, indicating a potential role for *somatic* rather than germline changes leading to mosaicism in the pathogenesis of congenital heart defects. Tables 473.2 to 473.4 are a compilation of known genetic causes of CHD.

The most progress in identifying the genetic origin of cardiovascular disease has been made in the genetic **cardiomyopathies**, and in particular, **hypertrophic cardiomyopathy** (HCM). Over 1,000 different pathogenic variants in over a dozen genes have been implicated, most of which encode proteins of the cardiac sarcomere, either the contractile thick filament (myosin) or associated regulatory subunits (e.g., troponin or myosin binding protein C), although variants in metabolic/mitochondrial genes are also common in those presenting with HCM in infancy and early childhood. Variants of the cardiac β-**myosin heavy-chain gene *MYH7*** and the **myosin-binding protein C** gene are the most common (Table 473.6), with additional common variants including cardiac troponin T and I, α-tropomyosin, regulatory and essential myosin light chains, titin, and α-myosin heavy chain. Some patients (~15%) may carry variants in more than one sarcomeric gene. Routine clinical laboratory tests are available for most of these genes, so that patients with clinical findings of HCM or children of parents who have been diagnosed with HCM should be tested. However, not all genes causing HCM have been identified, so a negative test does not eliminate a genetic cause.

Progress has also been made in identifying the genetic basis of **dilated cardiomyopathy**, which is familial in 20–30% of cases. Autosomal dominant inheritance is most often encountered, and similar to HCM, multiple genes have been identified (see Table 473.3). X-linked inheritance accounts for 5–10% of cases of familial dilated cardiomyopathy. Pathogenic variants in the dystrophin gene are the most common in this group, causing **Duchenne or Becker muscular dystrophy**. Variants in the gene encoding tafazzin are associated with **Barth syndrome** and for some cases of isolated noncompaction of the left ventricle (LVNC). Autosomal recessive inheritance is associated with a variant in cardiac troponin I. Mitochondrial myopathies may be caused by alterations of enzymes of the electron transport chain encoded by nuclear DNA or enzymes of fatty acid oxidation encoded by mitochondrial DNA. Table 473.6 is a compilation of the most common genetic causes of cardiomyopathy.

The genetic basis of **heritable arrhythmias**, most notably the **long QT syndromes**, has been linked to pathogenic variants of genes coding for subunits of cardiac potassium and sodium channels (Table 473.7). Other heritable arrhythmias include **arrhythmogenic right ventricular dysplasia**, familial atrial fibrillation, familial complete heart block, and **Brugada syndrome**. Table 473.7 is a compilation of the most common genetic causes of arrhythmias.

Of all cases of CHD, 2–4% are associated with known environmental or adverse maternal conditions and teratogenic influences, including

Table 473.6 Genetics of Hypertrophic Cardiomyopathies

CARDIOMYOPATHY	CHROMOSOMAL LOCATION	GENE
Hypertrophic cardiomyopathy	14q1	β-Myosin heavy chain
	15q2	α-Tropomyosin
	1q31	Troponin T
	19p13.2-19q13.2	Troponin I
	11p13-q13	Myosin-binding protein C
	12q23	Cardiac slow myosin regulatory light chain
	13p21	Ventricular slow myosin essential light chain
	2q31	Titin
	3p25	Caveolin-3
	Mitochondrial DNA	tRNA-glycine
	Mitochondrial DNA	tRNA-isoleucine
Hypertrophic cardiomyopathy with Wolff-Parkinson-White syndrome	7q36.1	AMP-activated protein kinase
OTHER GENETIC DISEASES CAUSING CARDIAC HYPERTROPHY		
Familial amyloid disease	18q12.1	Transthyretin (TTR)
Noonan syndrome	12q24.1, 2p22.1, 3p25, 12p12.1	Protein tyrosine phosphatase 11 (PTPN11), son of sevenless homolog 1 (SOS1), RAF1 protooncogene, GTPase KRAS
Fabry disease	Xq22	α-Galactoside A (GLA)
Danon disease	Xq24	Lysosomal-associated membrane protein 2 (LAMP2)
Hereditary hemochromatosis	6p21.3	Hereditary hemochromatosis protein (HFE)
Pompe disease	17q25	Acid α-glucosidase (GAA)
Dilated cardiomyopathy		
X-linked	Xp21	Dystrophin
	Xp28	Tafazzin
Autosomal recessive	19p13.2-19q13.2	Troponin I

Autosomal dominant: Genes encoding multiple proteins have been identified, including cardiac actin; desmin; δ-sarcoglycan; β-myosin heavy chain; cardiac troponin C and T; α-tropomyosin; titin; metavinculin; myosin-binding protein C; muscle LIM protein; α-actinin-2; phospholamban; Cypher/LIM binding domain 3; α-myosin heavy chain; SUR2A (regulatory subunit of K_{ATP} channel); and lamin A/C.

Isolated noncompaction of the left ventricle: Autosomal dominant, autosomal recessive, X-linked, and mitochondrial inheritance patterns have been reported. Genes that have been implicated include those for α-dystrobrevin, Cypher/ZASP, lamin A/C, tafazzin, MIB1, and LIM domain-binding protein 3 (LDB3).

Partially adapted from Dunn KE, Caleshu C, Cirino AL, et al. A clinical approach to inherited hypertrophy: the use of family history in diagnosis, risk assessment, and management. *Circ Cardiovasc Genet.* 2013;6:118–131.

maternal diabetes mellitus, maternal phenylketonuria, or systemic lupus erythematosus; congenital rubella syndrome; and maternal ingestion of drugs (lithium, ethanol, warfarin, thalidomide, antimetabolites, vitamin A derivatives, anticonvulsant agents). Associated noncardiac malformations noted in identifiable syndromes may be seen in as many as 25% of patients with CHD.

Gender differences in the occurrence of specific cardiac lesions have been identified. Transposition of the great arteries and left-sided obstructive lesions are slightly more common in males (65%), whereas ASD, VSD, PDA, and pulmonic stenosis are more common in females. No ethnic differences in the occurrence of congenital heart lesions as a whole have been noted, although there are some exceptions: supracristal VSD in children of Asian background and transposition of the great arteries, which has a higher occurrence in White infants.

GENETIC COUNSELING

Parents who have a child with CHD require counseling regarding the probability of a cardiac malformation occurring in subsequent children (Table 473.8 and see Chapter 98.1). Except for syndromes caused by a pathogenic variant of a single gene, many forms of CHD, but not all, are still relegated to a multifactorial inheritance pattern, which should result in a low risk of recurrence. When more genetic etiologies are identified, these risks are constantly updated; therefore consultation with a cardiac geneticist or genetic counselor is important.

The degree of severity may vary, as may the presence of associated defects. Careful echocardiographic screening of first-degree relatives will often uncover mild forms of CHD that were clinically silent. For example, the incidence of bicuspid aortic valve is more than double (5% vs 2% in the general population) in the relatives of children with left ventricular outflow obstruction (aortic stenosis, coarctation of the aorta, HLHS). Consultation with a knowledgeable genetic counselor is the most reliable way of providing the family with up-to-date information regarding the risk of recurrence.

Fetal echocardiography improves the rate of detection of congenital heart lesions in at-risk patients (see Chapter 472.4). This type of ultrasound is much more comprehensive than the screening ultrasound performed by an obstetrician and is usually performed and interpreted by a pediatric cardiologist specializing in fetal echocardiography. The resolution and accuracy of fetal echocardiography are excellent but are not perfect; families should be counseled that a normal fetal echocardiogram does not guarantee the absence of CHD. Congenital heart lesions may evolve in the course of the pregnancy; moderate aortic

Table 473.7 Genetics of Arrhythmias

ARRHYTHMIA	CHROMOSOMAL LOCATION	GENE(S) IMPLICATED
Complete heart block	19q13	Not known
Long QT syndrome		
LQT1 (autosomal dominant)	11p15.5	*KVLQT1* (K^+ channel)
LQT2 (autosomal dominant)	7q35	*HERG* (K^+ channel)
LQT3 (autosomal dominant)	3p21	*SCN5A* (Na^+ channel)
LQT4 (autosomal dominant)	4q25-27	Not known
LQT5 (autosomal dominant)	21q22-q22	*KCNE1* (K^+ channel)
LQT6	21q22.1	*KCNE2* (K^+ channel)
LQT7	17q23	KCNJ2 (K^+ channel)
LQT8	12p13.3	CACNAIC (L type Ca^{2+} channel)
LQT9	3p25	CAV-3 (caveolin-3, Na^+ current)
LQT10	11q23	SCN4B (Na^+ channel)
LQT11	7q21	AKAP9 (A-kinase anchoring protein)
LQT12	20q11.21	SNTA1 (A1-synthrophin)
LQT13	11q24.3	KCNJ5 (K^+ channel)
Jervell and Lange-Nielsen syndrome (autosomal recessive, congenital deafness)	11p15.5 21q22.1	*KVLQT1* (K^+ channel), KCNE1 (K^+ channel)
Arrhythmogenic right ventricular dysplasia (ARVD): 11 genes are now associated with ARVD (*ARVD1* through *ARVD11*) usually with autosomal dominant inheritance, but with variable penetrance. These genes include *TGF*β_3 (transforming growth factor β), *RYR2* (ryanodine receptor), *LAMR1* (laminin receptor-1), *PTPLA* (protein tyrosine phosphatase), *DSP* (desmoplakin), *PKP2* (plakophilin-2), *DSG2* (desmoglein), and *DSC2* (desmocollin).		
Familial atrial fibrillation (autosomal dominant)	10q22-q24, 6q14-16	Not known
	11p15.5	*KVLQT1* (K^+ channel)
	11p15.5	*KCNQ1* (K^+ channel)
	21q22	*KCNE2* (K^+ channel)
	17q23.1-q24.2	*KCNJ2* (K^+ channel)
	7q35-q36	*KCNH2* (K^+ channel)
Brugada syndrome (right bundle branch block, ST segment elevation, unexpected sudden death)	3p21-p24	*SCN5A* (Na^+ channel), rarely CACNA1C, HCN4, TRPM4
	3p22-p24	*GPD1L* (glycerol-3-phosphate dehydrogenase)
Catecholaminergic polymorphic ventricular tachycardia	1q43	*RYR2* (autosomal dominant)
	1p13.1	*CASQ2* (autosomal recessive)

stenosis with a normal-sized left ventricle at 18 weeks of gestation may progress to aortic atresia with a hypoplastic left ventricle by 34 weeks because of decreased flow through the atria, ventricle, and aorta in the latter half of gestation. This progression has prompted initial clinical trials of interventional treatment, such as fetal aortic balloon valvuloplasty, for the prevention of HLHS (see Chapter 472.7). In addition to diagnosing CHD in utero and subsequent parental counseling, the benefit of fetal ultrasound is that it allows for careful planning of perinatal care, especially in cases where immediate intervention in the neonatal period is warranted.

Visit Elsevier eBooks+ at eBooks.Health.Elsevier.com for Bibliography.

Table 473.8 Recurrence Risks for Isolated (Nonsyndromic) Congenital Heart Disease

DEFECT	FATHER AFFECTED (%)	MOTHER AFFECTED (%)	ONE SIBLING AFFECTED (%)	TWO SIBLINGS AFFECTED (%)
ASD	1.5–3.5	4–6	2.5–3	8
AVSD	1–4.5	11.5–14	3–4	10
VSD	2–3.5	6–10	3	10
AS	3–4	8–18	2	6
PVS	2–3.5	4–6.5	2	6
TOF	1.5	2–2.5	2.5–3	8
CoA	2–3	4–6.5	2	6
PDA	2–2.5	3.5–4	3	10
HLHS	21†		2–9*	6
TGA	2†		1.5	5
L-TGA	3–5†		5–6	NR
EA	NR	6	1	3
TrA	NR	NR	1	3
TA	NR	NR	1	3
PA	NR	NR	1	3

*Eight percent recurrence risk for HLHS; up to 22% recurrence risk for any congenital HD.
†Recurrence when one parent is affected, irrespective of sex; used in the absence of sex-stratified risks.
AS, Aortic stenosis; ASD, atrial septal defect; AVSD, atrioventricular septal defect; CoA, coarctation of the aorta; EA, Ebstein anomaly; HLHS, hypoplastic left heart syndrome; L-TGA, congenitally corrected transposition of the great arteries; NR, not reported/insufficient data; PA, pulmonary atresia; PDA, patent ductus arteriosus; PVS, pulmonary valve stenosis; TA, tricuspid atresia; TGA, D-transposition of the great arteries; TOF, tetralogy of Fallot; TrA, truncus arteriosus; VSD, ventricular septal defect.
From Cowan JR, Ware SM. Genetics and genetic testing in congenital heart disease. *Clin Perinatol*. 2015;42(2): 373–393, Table 5.

Chapter 474

Evaluation and Screening of the Infant or Child with Congenital Heart Disease

Daniel Bernstein

The initial evaluation for suspected congenital heart disease (CHD) involves a systematic approach with two major components (Fig. 474.1). First, congenital cardiac defects can be divided into two major groups based on the presence or absence of **cyanosis**, which can be determined by physical examination aided by pulse oximetry. Second, these groups can usually be further subdivided based on whether the chest radiograph shows evidence of increased, normal, or decreased pulmonary vascular markings. Next, the electrocardiogram (ECG) can be used to determine whether right, left, or biventricular **hypertrophy** exists. The character of the heart sounds and the presence and character of any murmurs further narrow the differential diagnosis. The final diagnosis is then confirmed by echocardiography, cardiac computed tomography (CT) or magnetic resonance imaging (MRI), and/or cardiac catheterization. In a cyanotic or otherwise sick newborn, echocardiographic exam, if available, should not be delayed while awaiting these other modalities.

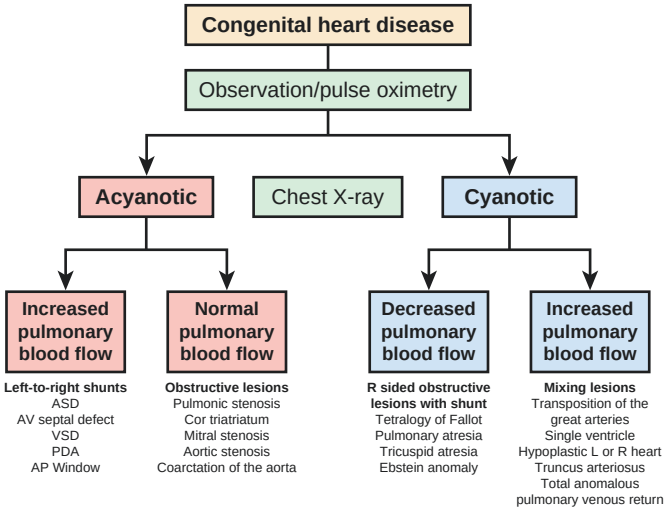

Fig. 474.1 A general algorithmic approach to the initial diagnosis of congenital heart disease, based on observation/pulse oximetry and chest x-ray, to separate patients into four major physiologic subgroups of congenital heart disease. This schematic is a broad, but useful, diagnostic overview; only the most common forms of congenital heart disease are included. A patient's initial presentation may sometimes straddle two of these physiologic groups and can evolve between them over the first week or two of life. For example, in a patient with a VSD, the pulmonary blood flow will be relatively normal in the newborn period and only increase as the pulmonary vascular resistance begins to drop. Similarly, a patient with a mixing lesion may not show pulmonary overcirculation at birth. ASD, Atrial septal defect; AV, atrioventricular; VSD, ventricular septal defect; PDA, patent ductus arteriosus, AP, aortopulmonary; L, left; R, right

Routine **pulse oximetry screening** is recommended for all newborns to detect unsuspected critical cyanotic CHD; lesions include hypoplastic left heart syndrome, pulmonary atresia, tetralogy of Fallot, total anomalous pulmonary venous return, transposition of the great arteries, tricuspid atresia, truncus arteriosus, neonatal coarctation of the aorta, and aortic arch hypoplasia/atresia. Many of these lesions are ductal dependent, and if the ductus arteriosus closes, severe cardiac decompensation will ensue. In addition, pulse oximetry may detect respiratory disorders and primary pulmonary hypertension. Screening is performed between 24 and 48 hours of life and before discharge in asymptomatic newborns. The neonate passes if the oxygen saturation is 95% or greater in the right hand or either foot AND the difference is 3% or less between the right hand and foot. The screen is failed if the saturation is less than 90% in either the right hand or foot. If it is between 90% and 94% OR there is more than a 3% difference between the right arm and foot, the screen should be repeated once in 1 hour. If the saturation is 90–94% OR there is a 3% difference after the third screen, urgent **echocardiography** is indicated. In addition, a careful reexamination of the pulses and blood pressure in the upper and lower extremity and cardiac auscultation are indicated in children with an initial positive screen.

ACYANOTIC CONGENITAL HEART LESIONS

Acyanotic congenital heart lesions can be classified according to the predominant physiologic load that they place on the heart. Although many congenital heart lesions induce more than one physiologic disturbance, it is helpful to focus on the primary load abnormality for purposes of classification. The most common lesions are those that produce a **volume load**, and the most common of these are the left-to-right shunt lesions. Atrioventricular (AV) valve regurgitation and dilated cardiomyopathies are other causes of increased volume load. The second major class of lesions causes an increase in **pressure load**, most often secondary to ventricular outflow obstruction (pulmonic or aortic valve stenosis) or narrowing of a great vessel (branch pulmonary artery stenosis or coarctation of the aorta). The chest radiograph and ECG are useful tools for differentiating between these major classes of volume- and pressure-overload lesions while awaiting confirmation with echocardiography.

Lesions Resulting in Increased Volume Load

The most common lesions resulting in increased volume load are those that cause **left-to-right shunting** (see Chapter 475): atrial septal defect (ASD), ventricular septal defect (VSD), atrioventricular septal defects (previously known as *AV canal* or *endocardial cushion defects*), and patent ductus arteriosus. The pathophysiologic common denominator in this group is the presence of a **communication** between the systemic and pulmonary sides of the circulation, which results in **shunting** of fully oxygenated blood back into the lungs for a second passage. This shunt can be quantitated by calculating the ratio of pulmonary-to-systemic blood flow (Qp:Qs). Thus a 3:1 shunt implies three times the normal pulmonary blood flow, which is a moderately large shunt likely to cause symptoms of heart failure.

The direction and magnitude of the shunt across such a communication depend on the size of the defect, the relative pulmonary and systemic pressures and vascular resistances, and the compliances of the two chambers connected by the defect. These factors are dynamic and may change dramatically with age; intracardiac defects may grow smaller with time; pulmonary vascular resistance (PVR), which is high in the immediate newborn period, decreases to normal adult levels by several weeks of life; and chronic exposure of the pulmonary circulation to high pressure and blood flow results in a gradual increase in PVR (**Eisenmenger physiology**; see Chapter 482.2). Thus a lesion such as a large VSD may be associated with little shunting and few symptoms during the initial first 2 weeks of life. When PVR declines over the next 2-4 weeks, the volume of the left-to-right shunt increases, and symptoms begin to appear.

The increased volume of blood in the lungs decreases pulmonary compliance and increases the work of breathing. Fluid leaks into the interstitial space and alveoli and causes pulmonary edema. The infant develops the symptoms we refer to as **heart failure**, such as tachypnea, tachycardia, sweating, chest retractions, nasal flaring, and wheezing. For children with large left-to-right shunts, however, the term *heart failure* is a misnomer; total left ventricular output is not decreased but is several times greater than normal, although much of this output is ineffective because it returns through the defect back to the lungs. To maintain this high level of left ventricular output, heart rate and stroke volume are increased, in part mediated by the Frank-Starling relation as the increased ventricular volume stretches the cardiac sarcomeres and in part mediated by an increase in sympathetic nervous system activity. The increase in catecholamine release, combined with the increased work of breathing, results in an elevation in total body oxygen consumption (caused by increased β-receptor stimulation), often beyond the oxygen transport ability of the circulation. Sympathetic activation leads to peripheral vasoconstriction (caused by increased α-receptor stimulation) and to the additional symptoms of sweating and irritability, and the imbalance between oxygen supply and demand leads to failure to thrive. Remodeling of the heart occurs, with predominantly chamber dilation caused by the increased volume load and a lesser degree of hypertrophy. If left untreated, the PVR eventually begins to rise, and by several years of age, the shunt volume will decrease and symptoms will appear to improve. If still uncorrected, the shunt will eventually reverse to right-to-left as the PVR rises (see Chapter 482.2). At this point, the patient may be inoperative if the pulmonary vascular resistance is elevated and fixed (unresponsive to vasodilators), and heart-lung transplant may be the only surgical option.

Additional lesions that impose a volume load on the heart include the **regurgitant lesions** (see Chapter 477) and the **dilated cardiomyopathies** (see Chapter 488.1). Regurgitation through the AV valves is most frequently encountered in patients with partial or complete AV septal defects (AV canal or endocardial cushion defects). In these lesions, the combination of a left-to-right shunt with AV valve regurgitation increases the volume load on the heart and often leads to earlier and more severe symptoms than for isolated septal defects. Regurgitation through the tricuspid valve is seen in **Ebstein anomaly** (see Chapter 479.7). Regurgitation involving one of the semilunar (aortic or pulmonary) valves also results in a volume load but is often also associated with some degree of stenosis, leading to a combined pressure and volume load. Aortic regurgitation may be encountered in patients with a VSD directly under the aortic valve **(supracristal VSD)**, leading to two sources of volume load on the left ventricle.

In contrast to left-to-right shunts, in which intrinsic cardiac muscle contractile function is generally either normal or increased, heart muscle function can be decreased in the cardiomyopathies. **Cardiomyopathies** may affect systolic contractility (dilated cardiomyopathy) or diastolic relaxation (restrictive cardiomyopathy) or both. Decreased cardiac function results in increased atrial and ventricular filling pressure, and pulmonary edema occurs secondary to increased capillary pressure. Poor cardiac output leads to decreased end-organ blood flow, sympathetic activation, and the symptoms of poor perfusion and decreased urine output. The major causes of cardiomyopathy in infants and children include viral myocarditis,

metabolic disorders, and pathogenic gene variants in sarcomeric and other cardiac structural, functional, and energy production genes (see Chapter 488).

Lesions Resulting in Increased Pressure Load

The pathophysiologic common denominator of lesions resulting in increased pressure load is an obstruction to normal blood flow. The most frequent are **obstructions to ventricular outflow**: valvular pulmonic stenosis, valvular aortic stenosis, and coarctation of the aorta (see Chapter 476). Less common are **obstructions to ventricular inflow**: tricuspid or mitral stenosis, cor triatriatum, and obstruction of the pulmonary veins. Ventricular outflow obstruction can occur at the valve, below the valve (double-chambered right ventricle, subaortic membrane), or above the valve (branch pulmonary stenosis or supravalvular aortic stenosis). Unless the obstruction is severe, cardiac output will be maintained and the clinical symptoms of heart failure will be either subtle or absent. The heart compensates for the increased afterload by increasing wall thickness (hypertrophy), but in later stages the affected chamber develops fibrosis and will begin to dilate and can progress to ventricular failure.

The clinical picture is different when obstruction to outflow is severe, which is usually encountered in the immediate newborn period. The infant may become critically ill within several hours of birth. Severe pulmonic stenosis in the newborn period **(critical pulmonic stenosis)** results in signs of right-sided heart failure (hepatomegaly, peripheral edema) and cyanosis from right-to-left shunting across the foramen ovale. Severe aortic stenosis in the newborn period **(critical aortic stenosis)** is characterized by signs of left-sided heart failure (pulmonary edema, poor perfusion), often combined with signs of right-sided failure (hepatomegaly, peripheral edema), and may progress rapidly to total circulatory collapse. In older children, severe untreated pulmonic stenosis leads to symptoms of right-sided heart failure, but usually not to cyanosis unless a pathway persists for right-to-left shunting (e.g., patency of the foramen ovale).

Coarctation of the aorta in older children and adolescents is usually manifested as upper body hypertension and diminished pulses in the lower extremities. In the immediate newborn period, presentation of coarctation can range from decreased pulses in the lower extremities to total circulatory collapse, depending on the severity of the narrowing. The clinical presentation of coarctation may be delayed because of the normally patent ductus arteriosus in the first few days of life. In these patients, even as the ductus begins to close, the open aortic end of the ductus serves as a conduit for blood flow to partially bypass the obstruction; in more severe coarctations, blood leaving the right ventricle traverses the ductus to directly supply the descending aorta (as it did in the fetus). These infants then become symptomatic, often dramatically, when the ductus finally closes, usually within the first few weeks of life. Differential cyanosis (normal saturation in the right arm and low saturation in the foot) is a hallmark sign of this condition, and if picked up on oximetry screen before hospital discharge can be lifesaving.

CYANOTIC CONGENITAL HEART LESIONS

The cyanotic group of congenital heart lesions can also be further divided according to pathophysiology. In one major subdivision, pulmonary blood flow is *decreased,* usually from an **obstruction to right ventricular outflow** (tetralogy of Fallot, tetralogy with pulmonary atresia, or pulmonary atresia with an intact septum) or to an **obstruction to right ventricular inflow** (tricuspid atresia). In the second major subdivision, pulmonary blood flow is *increased* and oxygenated and deoxygenated blood are *mixing* (transposition of the great arteries, single ventricle, truncus arteriosus, total anomalous pulmonary venous return [TAPVR] without obstruction). In the case of TAPVR with obstruction, pulmonary flow is decreased but because there is no exit from the pulmonary veins, the lungs appear to be markedly congested. The chest radiograph is a valuable tool for initial differentiation between these two categories.

Cyanotic Lesions with Decreased Pulmonary Blood Flow

For cyanosis to occur, these lesions must include both an obstruction to pulmonary blood flow (at the tricuspid valve or pulmonary valve level) *and* a pathway by which systemic venous blood can shunt from right to left and enter the systemic circulation (via a patent foramen ovale, ASD, or VSD). Common lesions in this group include tricuspid atresia, tetralogy of Fallot, tetralogy of Fallot with pulmonary atresia, pulmonary atresia with intact septum (with atrial-level shunting), and various forms of single ventricle with pulmonary stenosis or atresia (see Chapter 457). In these lesions, the degree of cyanosis depends on the degree of obstruction to pulmonary blood flow. If the obstruction is mild, cyanosis may be absent at rest. However, these patients may have hypercyanotic (tet) spells during conditions of stress. In contrast, if the obstruction is severe, pulmonary blood flow may be totally dependent on patency of the ductus arteriosus. When the ductus closes in the first few days of life, the neonate experiences profound hypoxemia.

Cyanotic Lesions with Increased Pulmonary Blood Flow

This group of lesions is not associated with obstruction to pulmonary blood flow. Cyanosis is caused by either abnormal ventricular-arterial connections or total mixing of systemic venous (deoxygenated) and pulmonary venous (oxygenated) blood within the heart (see Chapter 480). **Transposition of the great arteries** (or **vessels**) is the most common of the former group of lesions. In this condition the aorta arises from the right ventricle and the pulmonary artery arises from the left ventricle. Systemic venous blood returning to the right atrium is pumped directly back to the body, and oxygenated blood returning from the lungs to the left atrium is pumped back into the lungs. The **persistence of fetal pathways** (foramen ovale and ductus arteriosus) allows for some degree of mixing in the immediate newborn period, keeping the systemic saturation from falling until the ductus begins to close; these infants can then become extremely cyanotic quite precipitously.

Total mixing lesions include cardiac defects with a common atrium or ventricle, TAPVR, and truncus arteriosus (see Chapter 480). In this group, deoxygenated systemic venous blood and oxygenated pulmonary venous blood mix completely at some location in the heart, and as a result, the oxygen saturation is equal in the pulmonary artery and aorta. If pulmonary blood flow is not obstructed, these infants have a combination of cyanosis and pulmonary overcirculation leading to heart failure. In contrast, if pulmonary stenosis is present, these infants may have cyanosis alone, similar to patients with tetralogy of Fallot.

Visit Elsevier eBooks+ at eBooks.Health.Elsevier.com for Bibliography.

Chapter 475

Acyanotic Congenital Heart Disease: Left-to-Right Shunt Lesions

475.1 Atrial Septal Defect

Daniel Bernstein

Atrial septal defects **(ASDs)** can occur in any portion of the atrial septum—**secundum**, **primum**, or **sinus venosus**—depending on which embryonic septal structure has failed to develop normally (Fig. 475.1) (see Chapter 469). Less often, the atrial septum may be almost absent, with the creation of a functional single atrium. Isolated secundum ASDs account for approximately 7% of all congenital heart defects. The majority of cases of ASD are sporadic; autosomal dominant inheritance does occur as part of **Holt-Oram syndrome** (hypoplastic or absent thumbs, radii, triphalangism, phocomelia, first-degree heart block, ASD) or in families with both secundum ASD and heart block (see Table 473.2).

An isolated valve-incompetent **patent foramen ovale (PFO)** is a common echocardiographic finding during infancy. It is usually of no hemodynamic significance and is not considered an ASD; a PFO may play an important role if other structural heart defects are present. If another cardiac anomaly is causing increased right atrial pressure (pulmonary stenosis or atresia, tricuspid valve abnormalities, right ventricular dysfunction), venous blood may shunt across the PFO into the left atrium with resultant cyanosis. Because of the anatomic structure of the PFO, left-to-right shunting is unusual outside the immediate newborn period. In the presence of a large volume load or a hypertensive left atrium (e.g., secondary to mitral stenosis), the foramen ovale may be sufficiently dilated to result in a significant atrial left-to-right shunt. A valve-competent but probe-patent (able to be pushed opened with a catheter) PFO may be present in 15–30% of adults. An isolated PFO does not require surgical treatment, although it is a risk for paradoxical (right-to-left) systemic embolization. In adults who have had a thromboembolic stroke, echocardiographic screening for a PFO is routinely performed, and device closure of the PFO is a common treatment option.

Visit Elsevier eBooks+ at eBooks.Health.Elsevier.com for Bibliography.

475.2 Ostium Secundum Defect

Daniel Bernstein

An ostium secundum defect in the region of the fossa ovalis is the most common form of ASD and is associated with structurally normal atrioventricular (AV) valves (see Fig. 475.1). **Mitral valve prolapse** has been described in association with this defect but is rarely an important clinical consideration. Secundum ASDs may be single or multiple (fenestrated atrial septum), and openings ≥2 cm in diameter are common in symptomatic older children. Large defects may extend inferiorly toward the inferior vena cava (IVC) and ostium of the coronary sinus, superiorly toward the superior vena cava (SVC), or posteriorly. Females outnumber males 3:1 in incidence. **Partial anomalous pulmonary venous return** (PAPVR), usually of the right upper pulmonary vein, may be an associated lesion.

PATHOPHYSIOLOGY

The degree of left-to-right shunting depends on the size of the defect, the relative compliance of the right and left ventricles, and the relative vascular resistance in the pulmonary and systemic circulations. In large defects, a considerable shunt of oxygenated blood flows from the left to the right atrium (Fig. 475.2). This blood is added to the usual venous return to the right atrium and is pumped by the right ventricle to the lungs. With large defects, the ratio of pulmonary-to-systemic blood flow (Qp:Qs) is usually between 2:1 and 4:1. The paucity of symptoms in infants with ASDs is related to the structure of the right ventricle in early life, when its muscular wall is still thick and less compliant, thus limiting the left-to-right shunt. As the infant becomes older and pulmonary vascular resistance (PVR) drops, the right ventricular (RV) wall becomes thinner, and the left-to-right shunt across the ASD increases. The increased blood flow through the right side of the heart results in enlargement of the right atrium and ventricle and dilation of the pulmonary artery. The left atrium may also be enlarged as the increased pulmonary blood flow returns to the left atrium, but the left ventricle and aorta are normal in size. Despite the large pulmonary blood flow, pulmonary arterial pressure is usually initially normal

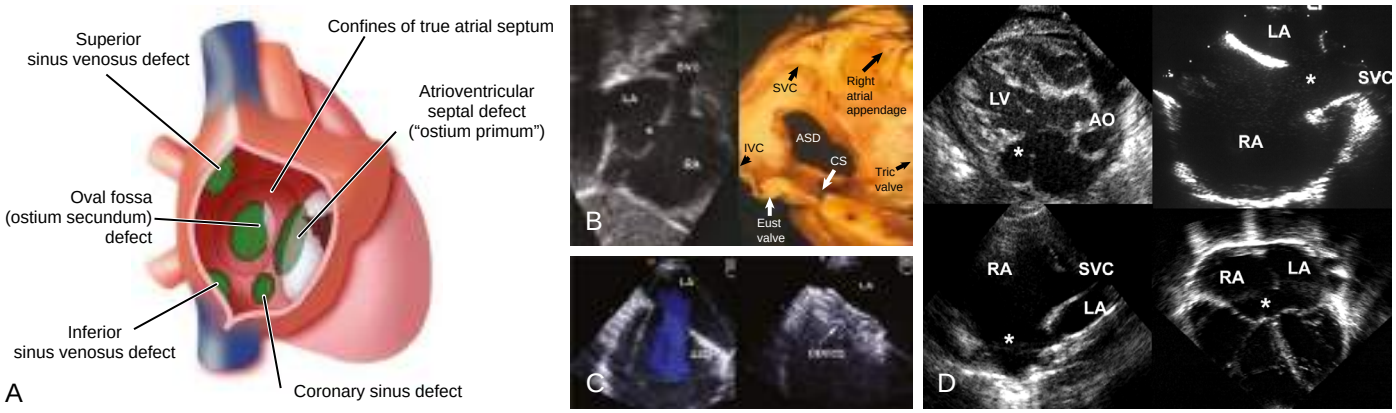

Fig. 475.1 Atrial septal defects (ASDs). **A,** Schematic diagram outlining the different types of interatrial shunting that can be encountered. Note that only the central defect is suitable for device closure. **B,** *Left,* Subcostal right anterior oblique view of a secundum ASD *(asterisk)* that is suitable for device closure. *Right,* Specimen as seen in a similar view, outlining the landmarks of the defect. **C,** *Left,* Transesophageal echocardiogram with color flow before device closure. *Right,* Taken after release of an Amplatzer device. **D,** Montage of echocardiographic interatrial communications that are not secundum ASDs *(asterisks)* and therefore not suitable for device closure. *Top left,* Coronary sinus defect caused by unroofing; *top right,* superior sinus venosus defect; *bottom left,* inferior sinus venosus defect; *bottom right,* ASD in the setting of an atrioventricular septal defect. AO, Aorta; CS, coronary sinus; Eust, eustachian; IVC, inferior vena cava; LA, left atrium; LV, left ventricle; RA, right atrium; SVC, superior vena cava; Tric, tricuspid. *(From Webb GD, Smallhorn JF, Therrien J, et al. Congenital heart disease in the adult and pediatric patient. In: Zipes DP, Libby P, Bonow RO, et al., eds. Braunwald's Heart Disease, 11th ed. Philadelphia: Elsevier; 2019, Fig 75.17, p. 1536.)*

because of the absence of a high-pressure communication between the pulmonary and systemic circulations. PVR remains low throughout childhood, although it may begin to increase in adulthood and may eventually result in reversal of the shunt and clinical cyanosis **(Eisenmenger syndrome)**.

CLINICAL MANIFESTATIONS

A child with an ostium secundum ASD is often asymptomatic; the lesion is often discovered during routine physical examination. Even an extremely large secundum ASD rarely produces clinically evident heart failure in childhood. However, on closer evaluation, younger children may show subtle signs of failure to thrive, and older children may have varying degrees of exercise intolerance. Often, the degree of limitation may go unnoticed by the family until after repair, when the child's growth or activity level greatly increases.

The physical findings of an ASD are usually characteristic but fairly subtle and require careful examination of the heart, paying special attention to the heart sounds. Examination of the chest may reveal a mild left precordial bulge. An RV systolic lift may be palpable at the left sternal border. Sometimes a pulmonic ejection click can be heard. In most patients with an ASD, the characteristic finding is that the second heart sound (S_2) is **widely split and fixed** in its splitting during all phases of respiration. Normally, the duration of RV ejection varies with respiration, with inspiration increasing RV volume and delaying closure of the pulmonary valve, widening the S_2 split. With an ASD, RV diastolic volume is constantly increased because of the shunt, and ejection time is prolonged throughout all phases of respiration. A systolic ejection murmur is heard; it is usually no greater than a grade 3/6, medium pitched, without harsh qualities, seldom accompanied by a thrill, and best heard at the left middle and upper sternal border. It is produced by the increased flow across the RV outflow tract into the pulmonary artery. Because the atria are at low pressure, flow across the ASD itself does not cause an audible murmur. A short, rumbling mid-diastolic murmur produced by the increased volume of blood flow across the tricuspid valve (see Fig. 475.2) is often audible at the lower-left sternal border. This finding, which may be subtle and is heard best with the bell of the stethoscope, usually indicates a Qp:Qs ratio of at least 2:1.

DIAGNOSIS

The chest radiograph shows varying degrees of enlargement of the right ventricle and atrium, depending on the size of the shunt. The pulmonary artery is enlarged, and pulmonary vascularity is increased. These signs vary and may not be conspicuous in mild cases. Cardiac enlargement is often best appreciated on the lateral chest radiograph because the right ventricle protrudes anteriorly as its volume increases. The **electrocardiogram** (ECG) shows RV volume overload: the QRS axis may be normal or exhibit right axis deviation, and a minor RV conduction delay (rsR′ pattern in the right precordial leads) may be present (Fig. 475.3). **Right ventricular hypertrophy** would be unusual

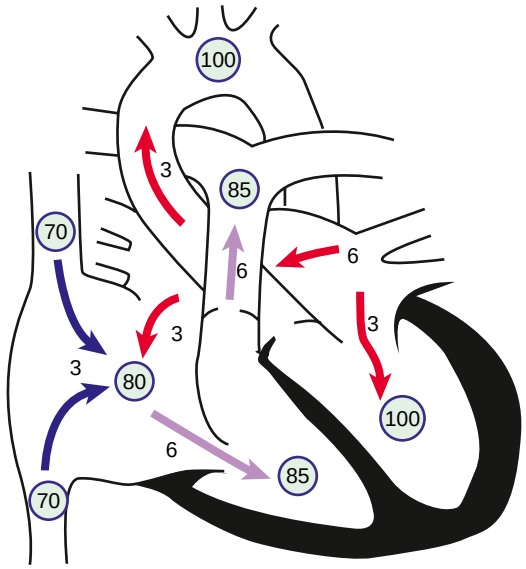

Fig. 475.2 Physiology of atrial septal defect (ASD). *Circled numbers* represent oxygen saturation (SO_2) values. The *numbers next to the arrows* represent volumes of blood flow (in L/min/m^2). This illustration shows a hypothetical patient with a pulmonary-to-systemic blood flow ratio (Qp:Qs) of 2:1. Desaturated blood enters the right atrium from the vena cava at a volume of 3 L/min/m^2 and mixes with an additional 3 L of fully saturated blood shunting left to right across the ASD; the result is an increase in SO_2 in the right atrium. Six liters of blood flow through the tricuspid valve and cause a mid-diastolic flow rumble. SO_2 may be slightly higher in the right ventricle because of incomplete mixing at the atrial level. The full 6 L flow across the right ventricular outflow tract and cause a systolic ejection flow murmur. Six liters return to the left atrium, with 3 L shunting left to right across the defect and 3 L crossing the mitral valve to be ejected by the left ventricle into the ascending aorta (normal cardiac output).

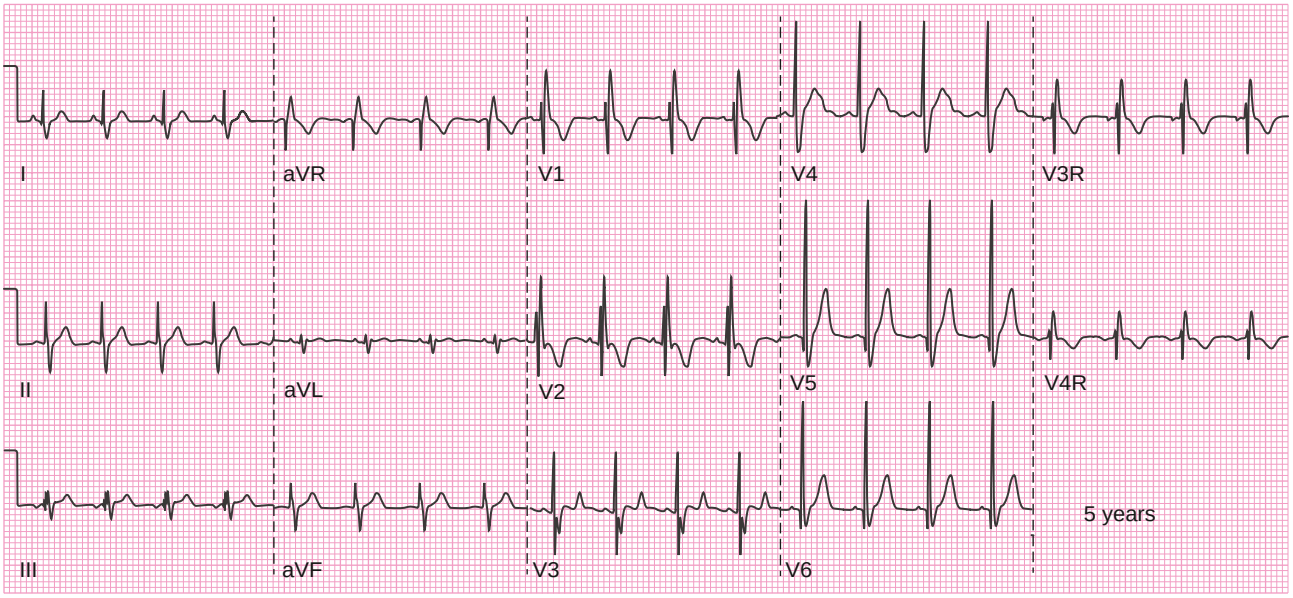

Fig. 475.3 Electrocardiogram in a child with an atrial septal defect showing rSR′ pattern (minor RV conduction delay) pattern in the right precordial leads.

in the absence of pulmonary hypertension or other lesions (e.g., valvar pulmonic stenosis).

The **echocardiogram** shows findings characteristic of RV volume overload, including an increased RV end-diastolic dimension and flattening and abnormal motion of the ventricular septum (see Fig. 475.1). A normal septum moves posteriorly during systole and anteriorly during diastole (synchronous with the left ventricular contractions). With RV overload and normal PVR, septal motion is either flattened or reversed—that is, anterior movement in systole. The location and size of the ASD are readily appreciated by two-dimensional (2D) scanning, with a characteristic brightening of the echo image seen at the edge of the defect caused by the increased reflectivity of ultrasound at the tissue-blood interface (T-artifact). The shunt is confirmed by pulsed and color flow Doppler. The normal entry of all pulmonary veins into the left atrium should be confirmed given the potential for anomalous return of the right upper pulmonary vein.

Patients with the classic features of a hemodynamically significant ASD on physical examination and chest radiography in whom echocardiographic identification of an isolated secundum ASD is made need not undergo diagnostic catheterization before repair, with the exception of an older patient, in whom PVR may be a concern. If pulmonary vascular disease is suspected, cardiac catheterization confirms the presence of the defect and allows measurement of the shunt ratio and pulmonary pressure and resistance.

If catheterization is performed, usually at the time of device closure, the oxygen content of blood from the right atrium will be much higher than that from the SVC (see Fig. 475.2). This feature is not specifically diagnostic because it may occur with PAPVR to the right atrium, with a **ventricular septal defect** (VSD) in the presence of tricuspid insufficiency, with AV septal defects associated with left ventricular–to–right atrial shunts, and with aorta–to–right atrial communications (ruptured sinus of Valsalva aneurysm). Pressure in the right side of the heart is usually normal, but small to moderate pressure gradients (<25 mm Hg) may be measured across the RV outflow tract because of functional pulmonary stenosis related to excessive blood flow. If the pressure gradient across the pulmonary valve is greater, pathologic pulmonary stenosis is likely present. In children and adolescents, PVR is almost always normal. The shunt is variable and depends on the size of the defect, but it may be of considerable volume. **Cineangiography**, performed with the catheter through the defect and in the right upper pulmonary vein, demonstrates the defect and confirms the location of the right upper pulmonary venous drainage (normal or aberrant into the SVC). **Pulmonary angiography** demonstrates the defect on the *levophase* (return of contrast to left side of the heart after passing through the lungs).

COMPLICATIONS

Secundum ASDs are usually isolated, although they may be associated with PAPVR, pulmonary valvular stenosis, VSD, pulmonary artery branch stenosis, and persistent left SVC, as well as mitral valve prolapse and insufficiency. Secundum ASDs are associated with autosomal dominant **Holt-Oram syndrome**. The gene responsible for this syndrome, situated in the region 12q21-q22 of chromosome 12, is *TBX5,* a member of the T-box transcriptional family. A **familial form of secundum ASD** associated *with* AV conduction delay has been linked to pathogenic variants in another transcription factor, Nkx2.5. Patients with **familial ASD** *without* heart block may carry a variant in the transcription factor GATA4, located on chromosome 8p22-23 (see Table 473.2).

TREATMENT

Transcatheter device or surgical closure is advised for all symptomatic patients and for asymptomatic patients with a Qp:Qs ratio of at least 2:1 and those with RV enlargement. The timing for elective closure is usually after the first year of life and before entry into school. Closure carried out at open heart surgery is associated with a mortality rate of <1%. Repair is preferred during early childhood because surgical mortality and morbidity are significantly greater in adulthood; the long-term risk of arrhythmia caused by chronic atrial dilation is also greater after ASD repair in adults. For most patients, *the procedure of choice is percutaneous catheter device closure using an atrial septal occlusion device,* implanted transvenously in the cardiac catheterization laboratory (Fig. 475.4). The results are excellent, and patients are usually discharged from the hospital the following day. The incidence of serious complications (e.g., device erosion) is very low and can be decreased by identifying high-risk patients, such as those with a deficient rim of septum in the area where the device would be anchored. Echocardiography can usually determine whether a patient is a good candidate for device closure. In patients with small secundum ASDs and minimal left-to-right shunts without RV enlargement, the consensus is that closure is usually not required. Infants with small to moderate-sized ASDs can be watched closely, because these defects will often grow smaller in the first year of life. It is unclear whether the persistence of a small ASD into adulthood increases the risk for stroke enough to warrant prophylactic closure of these defects in all patients, including those with no history of stroke.

PROGNOSIS

Small to moderate-sized ASDs detected in term infants may grow smaller or close spontaneously. Secundum ASDs are well tolerated during childhood, and significant symptoms do not usually appear until the third decade or later. Pulmonary hypertension, atrial dysrhythmias, tricuspid or mitral insufficiency, and heart failure are late manifestations; these symptoms may initially appear

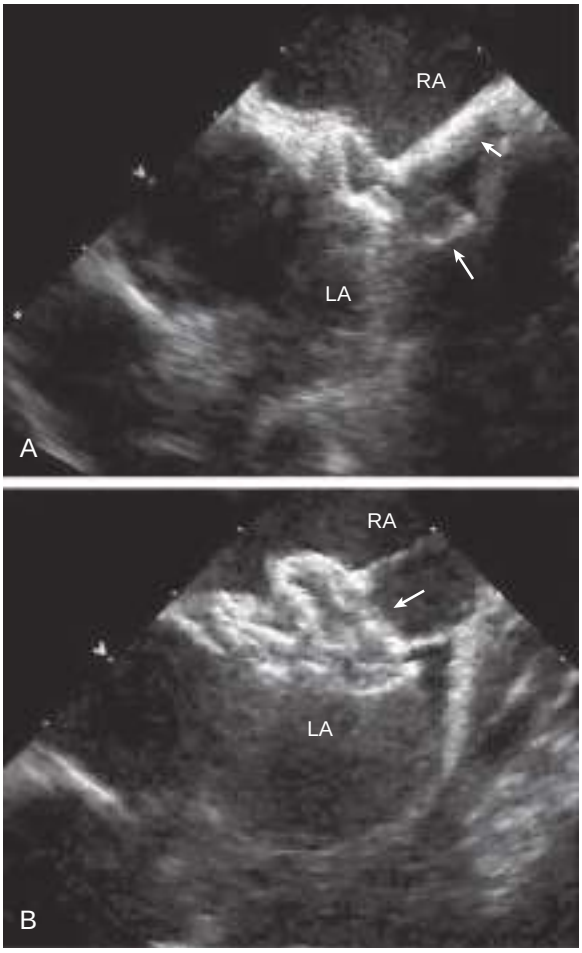

Fig. 475.4 Intravascular ultrasound imaging of transcatheter occlusion of an atrial septal defect (ASD). **A,** Catheter *(small arrow)* has been advanced across the ASD, and the left-sided disk of the device *(large arrow)* has been extruded from the sheath into the left atrium (LA). **B,** The right atrial disk *(arrow)* has now been extruded into the right atrium (RA). The two halves of the device are then locked together and the catheter detached from the occluder device and removed.

during the increased volume load of pregnancy. Infective endocarditis is extremely rare, and antibiotic prophylaxis for isolated secundum ASDs is not recommended.

The results after surgical or device closure in children with moderate-sized to large shunts are excellent. Symptoms, if present, disappear rapidly, and growth is frequently enhanced. Heart size decreases to normal, and the ECG shows decreased RV volume load. Late right-sided heart failure and arrhythmias are less common in patients who have had early repair, becoming more common in patients who undergo surgery after 20 years of age. Although early and midterm results with device closure are excellent, the long-term effects are not yet known. Reports of resolution of migraine headaches with aura in patients after device closure of an ASD or PFO suggest a possible thromboembolic etiology; however, whether to close such defects is still unclear.

475.3 Sinus Venosus Atrial Septal Defect

Daniel Bernstein

A sinus venosus ASD is situated in the upper part of the atrial septum in close relation to the entry of the superior vena cava (see Fig. 475.1). Often, one or more pulmonary veins (usually from the right lung) drain anomalously into the SVC. The SVC sometimes straddles the defect; in this case, some systemic venous blood enters the left atrium, but only rarely does it cause clinically evident cyanosis. The hemodynamic disturbance, clinical picture, ECG, and radiograph are similar to those seen in secundum ASD. The **diagnosis** can usually be made by echocardiography. If questions remain after echocardiogram regarding pulmonary venous drainage, cardiac CT or MRI is usually diagnostic. Cardiac catheterization is rarely required, except in adult patients in whom PVR assessment may be important. **Anatomic correction** generally requires surgical insertion of a patch to close the defect while incorporating the entry of any anomalous pulmonary veins into the left atrium. If the anomalous vein drains high in the SVC, the vein can be left intact and the ASD closed to incorporate the SVC mouth into the left atrium. The SVC proximal to the venous entrance is then detached and anastomosed directly to the right atrial appendage (Warden procedure). This procedure avoids direct suturing of the pulmonary vein, with less chance of future stenosis. Surgical results are generally excellent. Rarely, sinus venosus defects involve the IVC.

475.4 Partial Anomalous Pulmonary Venous Return

Daniel Bernstein

One or several pulmonary veins may return anomalously to the SVC or IVC, right atrium, or coronary sinus and produce a left-to-right shunt of oxygenated blood. *Partial* anomalous pulmonary venous return (PAPVR) usually involves some or all of the veins from only one lung, typically the right. When an associated ASD is present, it is generally of the sinus venosus type but can be secundum (see Chapters 475.2 and 475.3). When an ASD is detected by echocardiography, one must always search for associated PAPVR. The history, physical signs, and electrocardiographic and radiologic findings are indistinguishable from those of an isolated ostium secundum ASD. Occasionally, an anomalous vein draining into the IVC is visible on chest radiography as a crescentic shadow of vascular density along the right border of the cardiac silhouette **(scimitar syndrome)**; in these patients an ASD is not usually present, but **pulmonary sequestration** or **lung hypoplasia** and anomalous arterial supply to that lobe are common findings. **Total anomalous pulmonary venous return** (TAPVR) is a cyanotic lesion and is discussed in Chapter 480.7. Echocardiography generally confirms the diagnosis. MRI and CT are also useful if there is a question regarding pulmonary venous drainage or in cases of scimitar syndrome. If cardiac catheterization is performed, the presence of anomalous pulmonary veins is demonstrated by selective pulmonary arteriography, and anomalous pulmonary arterial supply to the right lung is demonstrated by descending aortography.

The prognosis for PAPVR is excellent, similar to that for ostium secundum ASDs. When a significant left-to-right shunt is present, surgical repair is performed. The associated ASD should be closed in such a way that pulmonary venous return is directed to the left atrium. A single anomalous pulmonary vein without an atrial communication may be difficult to redirect to the left atrium; if the shunt is small and the right ventricle is not enlarged, it may be left unoperated.

475.5 Atrioventricular Septal Defects (Ostium Primum and Atrioventricular Canal or Endocardial Cushion Defects)

Daniel Bernstein

The abnormalities encompassed by atrioventricular (AV) septal defects are grouped together because they represent a spectrum of a basic embryologic abnormality, a **deficiency of the AV septum**. In the normal heart, the tricuspid valve sits slightly lower (more toward the cardiac apex) than does the mitral valve, and thus a small portion of septum (the AV septum) separates the left ventricle from the right atrium. This septum is deficient in all forms of AV septal defect. When the AV septum is absent and there is also an **ostium primum** defect, the main communication is situated in the lower portion of the atrial septum and overlies the mitral and tricuspid valves. In most cases a **cleft in the anterior leaflet of the mitral valve** is also noted. The tricuspid valve is usually functionally normal, although some anatomic abnormality of the septal leaflet is present. The ventricular septum is intact.

An **AV septal defect**, formerly known as an *AV canal defect* or *endocardial cushion defect,* consists of a defect of the AV septum and contiguous atrial and ventricular septal defects with a common AV valve. The severity of the AV valve abnormality varies considerably. In a **complete AV septal defect**, a single AV valve is common to both ventricles and consists of an anterior and a posterior bridging leaflet related to the ventricular septum, with a lateral leaflet in each ventricle. The anterior bridging leaflet can be divided into right- and left-sided components or may be single and free floating over the ventricular septum. Complete AV septal defect is one of the most common forms of congenital heart disease in children with **Down syndrome**.

Transitional varieties of these defects also occur and include ostium primum defects with clefts in the anterior mitral and septal tricuspid valve leaflets and small VSDs and, less commonly, ostium primum defects with normal AV valves. In some patients the atrial septum is intact but a VSD is seen in the inlet septum, similar to that found in the complete form of AV septal defect. Sometimes, AV septal defects are associated with varying degrees of hypoplasia of one of the ventricles, known as either **left-dominant** or **right-dominant AV septal defect**. If the affected ventricular chamber is too small to establish a two-ventricle circulation, surgical palliation, aiming for an eventual Fontan procedure, is performed (see Chapters 479.4 and 480.10).

PATHOPHYSIOLOGY

In ostium primum defects, the basic abnormality is the combination of a left-to-right shunt across the atrial defect and mitral (or occasionally tricuspid) insufficiency. The shunt is usually moderate to large, the degree of mitral insufficiency is generally mild to moderate, and pulmonary artery pressure (PAP) is typically normal or only mildly increased. The physiology of this lesion is therefore similar to that of an ostium secundum ASD.

In complete AV septal defects, left-to-right shunting occurs at both the atrial and the ventricular level (Fig. 475.5). Additional shunting may occur directly from the left ventricle to the right atrium (known as a *Gerbode shunt*) because of absence of the AV septum. Pulmonary

hypertension and an early tendency to increase PVR are common. AV valvular insufficiency, which may be moderate to severe, further increases the volume load on one or both ventricles. If the defect is large enough, some right-to-left shunting may also occur at the atrial and ventricular levels and lead to mild arterial desaturation. With time, progressive pulmonary vascular disease increases the right-to-left shunt so that clinical cyanosis develops (**Eisenmenger physiology**; see Chapter 482.2). The risk for development of pulmonary vascular disease is greater in patients with Down syndrome, and therefore surgical correction is usually considered early in these patients, within the first 3-6 months of life.

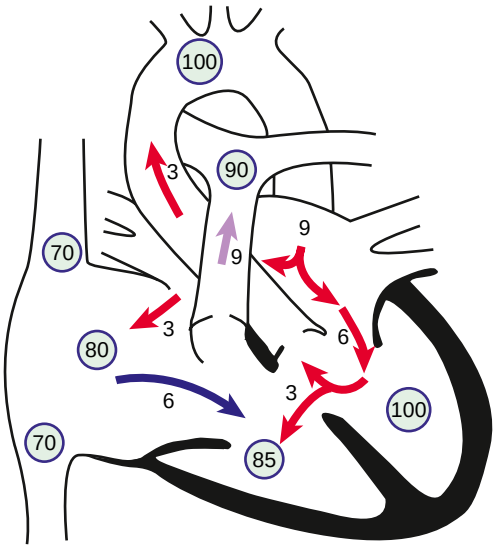

Fig. 475.5 Physiology of atrioventricular (AV) septal defect. *Circled numbers* represent oxygen saturation (SO_2) values. The *numbers next to the arrows* represent volumes of blood flow (in L/min/m^2). This illustration shows a hypothetical patient with a pulmonary-to-systemic blood flow ratio (Qp:Qs) of 3:1. Desaturated blood enters the right atrium from the vena cava at a volume of 3 L/min/m^2 and mixes with 3 L of fully saturated blood shunting left to right across the atrial septal defect; the result is an increase in SO_2 in the right atrium. Six liters of blood flow through the right side of the common AV valve, joined by an additional 3 L of saturated blood shunting left to right at the ventricular level, further increasing SO_2 in the right ventricle. The full 9 L flow across the right ventricular outflow tract into the lungs. Nine liters return to the left atrium, with 3 L shunting left to right across the defect and 6 L crossing the left side of the common AV valve and causing a mid-diastolic flow rumble. Three liters of this volume shunt left to right across the ventricular septal defect, and 3 L are ejected into the ascending aorta (normal cardiac output).

CLINICAL MANIFESTATIONS

Many children with an isolated ostium primum defect are asymptomatic, and the anomaly is discovered during a general physical examination. In patients with moderate shunts and mild mitral insufficiency, the physical signs are similar to those of the secundum ASD, but with an additional apical holosystolic murmur caused by mitral insufficiency.

A history of exercise intolerance, easy fatigability, and recurrent pneumonia may be obtained, especially in infants with large left-to-right shunts and severe mitral insufficiency. In these patients, cardiac enlargement is moderate or marked and the precordium is hyperdynamic. Auscultatory signs produced by the left-to-right shunt include a normal or accentuated first heart sound (S_1); wide, fixed splitting of S_2; a pulmonary systolic ejection murmur sometimes preceded by a click; and a low-pitched, mid-diastolic rumbling murmur at the lower-left sternal edge or apex, or both, as a result of increased flow through the AV valves. **Mitral insufficiency** may be manifested by a harsh (occasionally very high-pitched) **apical holosystolic murmur** that radiates to the left axilla.

With *complete* AV septal defects, heart failure and intercurrent pulmonary infection usually appear in infancy. The liver is enlarged, and the infant often develops respiratory symptoms, feeding intolerance, and failure to thrive. Cardiac enlargement is moderate to marked, and a systolic thrill is frequently palpable at the lower-left sternal border. A precordial bulge and lift may be present as well. S_1 is normal or accentuated. S_2 is fixed and widely split if the pulmonary flow is massive. A low-pitched, mid-diastolic rumbling murmur is audible at the lower-left sternal border, indicative of increased blood flow across the right side of the common AV valve, and a pulmonary systolic ejection murmur is produced by the large pulmonary flow. The harsh apical holosystolic murmur of mitral insufficiency may also be present.

DIAGNOSIS

Chest radiographs of children with complete AV septal defects often show moderate to severe cardiac enlargement caused by the prominence of both ventricles and atria. The pulmonary artery is large, and pulmonary vascularity is increased.

The ECG in patients with a complete AV septal defect is *distinctive* and usually diagnostic. Principal abnormalities include (1) superior and rightward orientation of the mean frontal QRS axis (−90 to −180 degrees) represented by the QRS being negative in both lead I and lead aVF, (2) counterclockwise inscription of the superiorly oriented QRS vector loop (manifested by a Q wave in leads I and aVL), (3) signs of biventricular hypertrophy or isolated RV hypertrophy, (4) RV conduction delay (rSR′ pattern in leads V_3R and V_1), (5) normal or tall P waves, and (6) occasional prolongation of the P-R interval (Fig. 475.6).

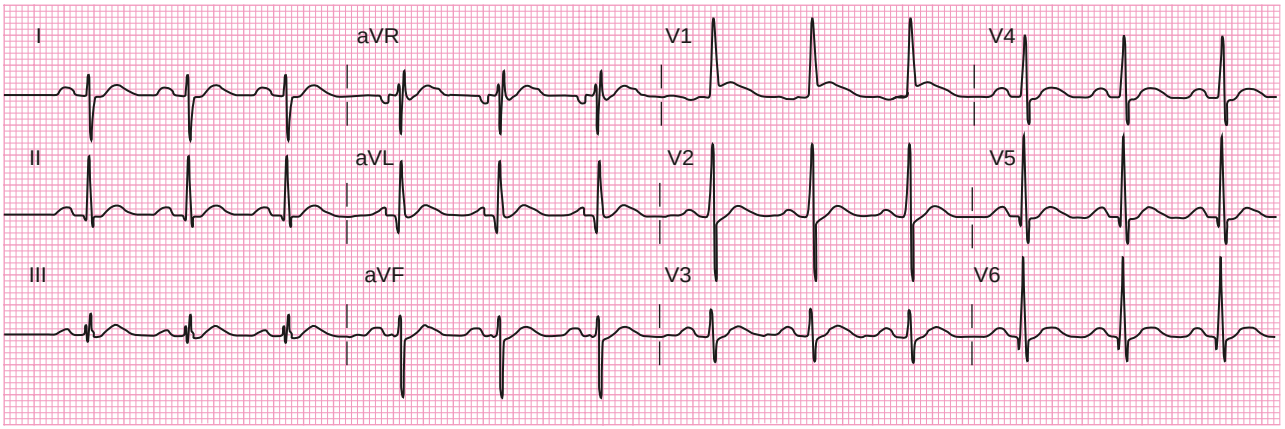

Fig. 475.6 Electrocardiogram from an infant with atrioventricular septal defect. Note that the QRS complexes are negative in both leads I and roughly equipotential in lead III, so the QRS axis is −150 degrees. There is also right ventricular hypertrophy (RVH) and a minor right ventricular conduction delay with an RSR′ pattern in aVR.

The echocardiogram is diagnostic and shows signs of RV enlargement (Fig. 475.7). There is encroachment of the mitral valve into the left ventricular outflow tract (LVOT); the abnormally low position of the AV valves results in a "gooseneck" deformity of the LVOT. In normal hearts the tricuspid valve inserts slightly more toward the apex than does the mitral valve. In AV septal defects, both valves insert at the same level because of absence of the AV septum. In complete AV septal defects, the inlet portion of the ventricular septum is also deficient, and the common AV valve is readily appreciated. Pulsed and color flow Doppler echocardiography will demonstrate left-to-right shunting at the atrial, ventricular, or left ventricular–to–right atrial levels and can be used to semiquantitate the degree of AV valve insufficiency. Echocardiography is useful for determining the insertion points of the chordae of the common AV valve, the relative size of the two ventricles, and evaluating the presence of associated lesions such as patent ductus arteriosus (PDA) or coarctation of the aorta.

Cardiac catheterization and angiocardiography are rarely required to confirm the diagnosis unless pulmonary vascular disease is suspected, as when the diagnosis has been delayed beyond early infancy, especially in patients with Down syndrome in whom the development of pulmonary vascular disease may be more rapid. Catheterization demonstrates the magnitude of the left-to-right shunt, the degree of PVR elevation, and the severity of insufficiency of the common AV valve. By oximetry, the shunt is usually demonstrable at both the atrial and the ventricular level. Arterial oxygen saturation is normal or only mildly reduced unless pulmonary vascular disease is present. Children with ostium primum defects generally have normal or only moderately elevated PAP. Conversely, complete AV septal defects are associated with RV and pulmonary arterial hypertension and, in older patients, increased PVR (see Chapter 482.2).

Selective left ventriculography will demonstrate deformity of the common AV valve and distortion of the LVOT caused by the abnormally apical position of this valve (gooseneck deformity). The abnormal anterior leaflet of the mitral valve is serrated, and insufficiency is noted. Direct shunting of blood from the left ventricle to the right atrium may also be demonstrated.

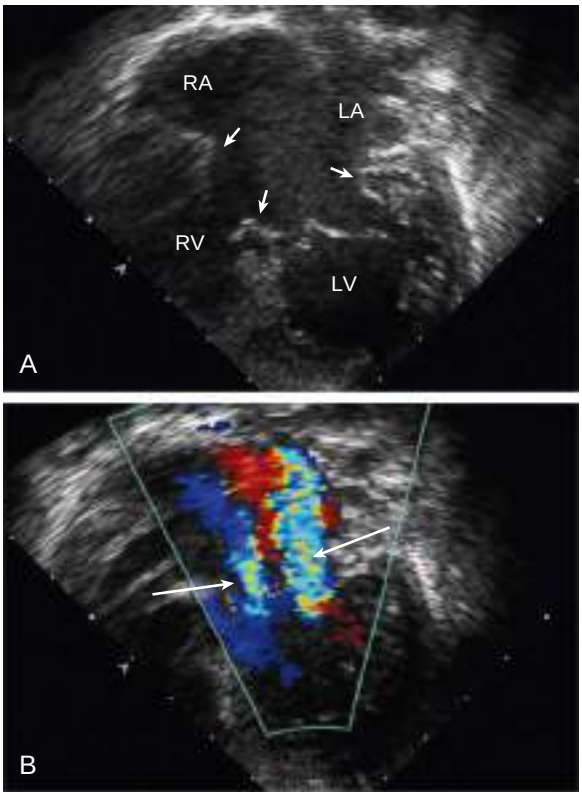

Fig. 475.7 Echocardiograms of atrioventricular (AV) septal defect. **A,** Subcostal four-chamber view demonstrating the common AV valve *(arrows)* spanning the atrial and ventricular septal defects. **B,** Doppler imaging shows two jets of regurgitation through the left side of the common AV valve *(arrows)*. LA, Left atrium; LV, left ventricle; RA, right atrium; RV, right ventricle.

TREATMENT

Ostium primum defects are approached surgically from an incision in the right atrium. The cleft in the mitral valve is located through the atrial defect and is repaired by direct suture. The defect in the atrial septum is usually closed by insertion of a patch prosthesis. The surgical mortality rate for ostium primum defects is very low.

Surgical treatment of complete AV septal defects is more complex, although highly successful. The postoperative course may be prolonged in infants with severe cardiac failure and in those with pulmonary hypertension. Because of the risk of **pulmonary vascular disease** developing as early as 6-12 months of age, surgical intervention must be performed during infancy. Full correction of these defects can be readily accomplished. Palliation with *pulmonary arterial banding* is uncommon now and reserved for the small subset of patients who have other associated lesions that make early corrective surgery too risky. However, banding may not be effective in patients with a large amount of AV valve regurgitation, as the higher pressure will only increase the regurgitation. The atrial and ventricular defects are patched, using either one or two separate patches, and the AV valves are reconstructed. Uncommon complications include surgically induced heart block requiring placement of a permanent pacemaker and excessive LVOT narrowing requiring surgical revision. More common long-term complications include residual tricuspid or mitral regurgitation, because full repair of very abnormal valves is often not possible. This requires long-term surveillance because these patients may require replacement with a prosthetic valve later in life.

PROGNOSIS

The prognosis for unrepaired complete AV septal defects depends on the magnitude of the left-to-right shunt, degree of PVR elevation, and severity of AV valve insufficiency. Before the advent of early corrective surgery, death from cardiac failure during infancy was common, and patients who survived without surgery usually developed pulmonary vascular disease. Most unoperated patients with ostium primum defects and minimal AV valve involvement are asymptomatic or have only minor, nonprogressive symptoms until they reach the third or fourth decade of life, similar to the course of patients with secundum ASDs. Today, long-term results after surgical repair are excellent. Late postoperative **complications** include atrial arrhythmias and heart block, progressive narrowing of the LVOT requiring surgical revision, and eventual worsening of AV valve regurgitation (usually on the left side) requiring reoperation or replacement with a prosthetic valve.

Visit Elsevier eBooks+ at eBooks.Health.Elsevier.com for Bibliography.

475.6 Ventricular Septal Defect

Daniel Bernstein

Ventricular septal defect is the most common cardiac malformation and accounts for 25% of cases of congenital heart disease. Defects may occur in any portion of the ventricular septum, but the most common are of the **membranous** type (Fig. 475.8). These defects are in a posteroinferior position, anterior to the septal leaflet of the tricuspid valve. VSDs between the crista supraventricularis and the papillary muscle of the conus may be associated with pulmonary stenosis and other manifestations of tetralogy of Fallot (see Chapter 479.1). VSDs superior to the crista supraventricularis **(supracristal)** are less common; these are found just beneath the pulmonary valve and may impinge on an aortic sinus and cause aortic insufficiency (see Chapter 475.7). Supracristal

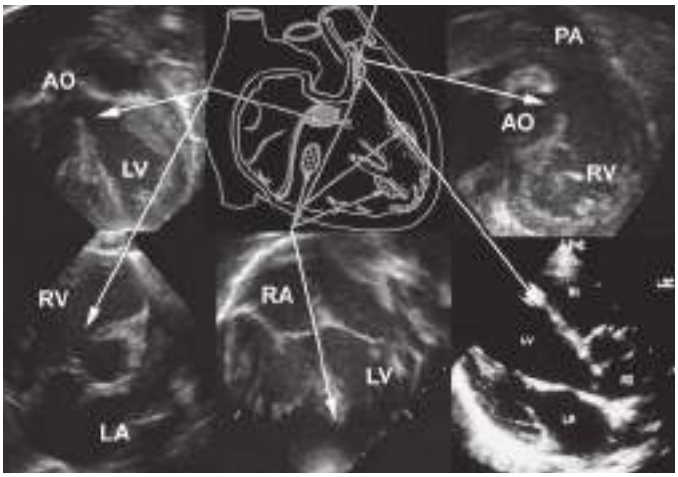

Fig. 475.8 Different types of ventricular septal defects (VSDs). The **central diagram** outlines the location of the various types of defects as seen from the right ventricle. **Two left images** show a perimembranous VSD as seen in the five-chamber and short-axis views. Note the defect is roofed by the aorta and is next to the tricuspid valve. **Bottom middle** echocardiogram shows a muscular apical defect. **Top right image** is a right anterior oblique view in a doubly committed VSD. **Bottom right image** is a short axis view showing an outlet VSD with prolapse of the right coronary cusp. AO, Aorta; LV, left ventricle; PA, pulmonary artery; RA, right atrium; RV, right ventricle. *(From Webb GD, Smallhorn JF, Therrien J, et al. Congenital heart disease in the adult and pediatric patient. In: Zipes DP, Libby P, Bonow RO, et al., eds. Braunwald's Heart Disease, 11th ed. Philadelphia: Elsevier; 2019, Fig 75.21, p. 1514.)*

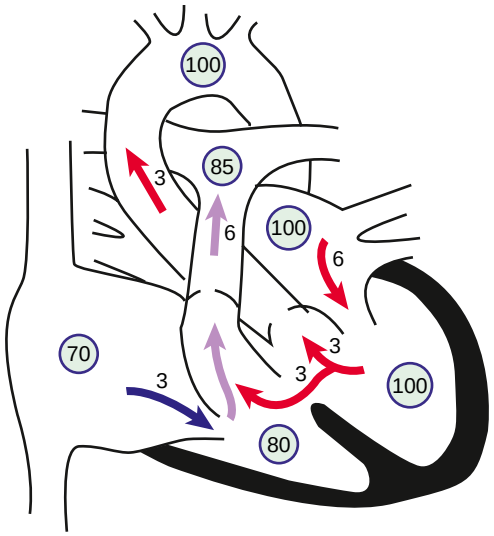

Fig. 475.9 Physiology of a moderate-to-large ventricular septal defect. *Circled numbers* represent oxygen saturation (S_{O_2}) values. The *numbers next to the arrows* represent volumes of blood flow (in L/min/m^2). This illustration shows a hypothetical patient with a pulmonary-to-systemic blood flow ratio (Qp:Qs) of 2:1. Desaturated blood enters the right atrium from the vena cava at a volume of 3 L/min/m^2 and flows across the tricuspid valve. An additional 3 L of blood shunt left to right across the VSD, resulting in increased S_{O_2} in the right ventricle. Six liters of blood are ejected into the lungs (2:1 shunt). Pulmonary arterial saturation may be further increased because of incomplete mixing at the right ventricular level. Six liters return to the left atrium, cross the mitral valve, and cause a mid-diastolic flow rumble. Three liters of this volume shunt left to right across the VSD, and 3 L are ejected into the ascending aorta (normal cardiac output).

VSDs are more common in patients of Asian descent. VSDs in the midportion or apical region of the ventricular septum are muscular in type and may be single or multiple ("Swiss cheese" septum).

PATHOPHYSIOLOGY

The physical size of the VSD is a major determinant of the size of the left-to-right shunt. When the defect is large, the level of pulmonary vascular resistance (PVR) in relation to systemic vascular resistance (SVR) is the major determinant of the shunt's magnitude, since the large defect will essentially equalize pressure between the two ventricles. When a small communication is present (usually <5 mm), the VSD is deemed to be pressure **restrictive**, meaning that right ventricular (RV) pressure is normal or only slightly elevated. The higher pressure in the left ventricle drives the shunt left to right, and the size of the defect limits the magnitude of the shunt. In larger, **nonrestrictive** VSDs (usually >10 mm), RV and left ventricular (LV) pressures are equalized. In these defects the direction of shunting and the shunt magnitude are determined by the PVR/SVR ratio (Fig. 475.9).

After birth in patients with a large VSD, PVR may remain elevated, delaying the normal postnatal decrease, and thus the size of the left-to-right shunt may initially be limited. Because of normal involution of the media of small pulmonary arterioles, PVR begins to fall in the first few weeks after birth, and the size of the left-to-right shunt then increases. Eventually, a large left-to-right shunt develops, and clinical symptoms become apparent. In most cases during early infancy, PVR is only slightly elevated, and the major contribution to pulmonary hypertension is the large communication allowing exposure of the pulmonary circulation to systemic pressure and the large pulmonary blood flow. With continued exposure of the pulmonary vascular bed to high systolic pressure and high flow, pulmonary vascular obstructive disease eventually develops. When the PVR/SVR ratio approaches 1:1, the shunt becomes bidirectional, signs of heart failure abate, and the patient begins to show signs of cyanosis (**Eisenmenger physiology**; see Chapter 482.2), intermittent at first, but then more constant. In rare infants with a large VSD, more often in those with Down syndrome, PVR never decreases after birth, and symptoms may remain minimal until Eisenmenger physiology becomes evident.

The magnitude of intracardiac shunts is usually described by the Qp:Qs ratio. If the left-to-right shunt is small (Qp:Qs <1.5:1), the cardiac chambers are not appreciably enlarged, and the pulmonary vascular bed is probably normal. If the shunt is large (Qp:Qs >2:1), left atrial and LV volume overload occurs, and RV and pulmonary arterial hypertension may be present if the defect is large. The main pulmonary artery, left atrium, and left ventricle are enlarged.

CLINICAL MANIFESTATIONS

The clinical findings of patients with a VSD vary according to the size of the defect and pulmonary blood flow and pressure. Small VSDs with trivial left-to-right shunts and normal pulmonary artery pressure (PAP) are common. These patients are asymptomatic, and the cardiac lesion is usually found during routine physical examination. Characteristically, a loud, harsh, or blowing holosystolic murmur is present and heard best over the lower-left sternal border, and it is frequently accompanied by a thrill. In a few cases the murmur ends before the second heart sound (S_2), presumably because of closure of the defect during late systole. A short, loud, harsh systolic murmur localized to the apex in a neonate is often a sign of a tiny VSD in the apical muscular septum. These tiny defects most often close during infancy. In premature infants the murmur of a VSD may be heard early because PVR decreases more rapidly.

Large VSDs with excessive pulmonary blood flow and pulmonary hypertension are responsible for signs of congestive heart failure: dyspnea, feeding difficulties, poor growth, profuse perspiration, and recurrent pulmonary infections in early infancy. Cyanosis is usually absent, but duskiness is sometimes noted during infections or crying. Prominence of the left precordium is common, as are a palpable parasternal lift, a laterally displaced apical impulse and apical thrust, and a systolic thrill. The holosystolic murmur of a large VSD is generally less harsh than that of a small VSD and more blowing in nature because of the absence of a significant pressure gradient across the defect. It is less likely to be prominent in the newborn period before PVR drops. The

pulmonic component of S_2 may be increased as a result of pulmonary hypertension. The presence of a mid-diastolic, low-pitched rumble at the apex is caused by increased blood flow across the mitral valve and usually indicates a Qp:Qs ratio ≥2:1. This murmur is best appreciated with the bell of the stethoscope.

DIAGNOSIS

In patients with small VSDs, the chest radiograph is usually normal, although minimal cardiomegaly and a borderline increase in pulmonary vasculature may be observed. The ECG is generally normal but may suggest LV hypertrophy. The presence of RV hypertrophy on ECG is worrisome and a warning that the defect is not small and that the patient has pulmonary hypertension or an associated lesion such as pulmonic stenosis. In large VSDs the chest radiograph shows gross cardiomegaly with prominence of both ventricles, the left atrium, and the pulmonary artery (Fig. 475.10). Pulmonary vascular markings are increased, and frank pulmonary edema, including pleural effusions, may be present. The ECG shows biventricular hypertrophy; the P waves may be notched (indicative of left atrial [LA] enlargement).

The 2D echocardiogram shows the position and size of the VSD (see Fig. 475.8). In small defects, especially those of the muscular septum, the defect itself may be difficult to image and is visualized only by color Doppler examination. In defects of the **membranous septum**, a thin membrane (called a **ventricular septal aneurysm** but consisting of abnormal tricuspid valve tissue) can partially cover the defect and limit the volume of the left-to-right shunt. Echocardiography is also useful for estimating shunt size by examining the degree of volume overload of the left atrium and left ventricle; in the absence of associated lesions, the extent of their increased dimensions is a good reflection of the size of the left-to-right shunt. Pulsed Doppler examination shows whether the VSD is pressure restrictive by calculating the pressure gradient across the defect. Such calculation allows an estimation of RV pressure and helps determine whether the patient is at risk for the development of early pulmonary vascular disease. The echocardiogram can also be useful to determine the presence of aortic valve insufficiency or aortic leaflet prolapse, which can be associated especially with supracristal VSDs.

The hemodynamics of a VSD can also be demonstrated by cardiac catheterization, although catheterization currently is performed only when laboratory data do not fit well with the clinical findings or when pulmonary vascular disease is suspected. Oximetry demonstrates increased oxygen content in the right ventricle; because some defects eject blood almost directly into the pulmonary artery (streaming), the full magnitude of the oxygen saturation increase may only be apparent when pulmonary arterial blood is sampled. Small, restrictive VSDs are associated with normal right-sided heart pressures and PVR. Large, nonrestrictive VSDs are associated with equal or near-equal pulmonary and systemic systolic pressure and variable elevations in PVR. Pulmonary blood flow may be 2-4 times systemic blood flow. In patients with such "hyperdynamic pulmonary hypertension," PAP is at systemic level, but PVR is only minimally elevated because of the high pulmonary blood flow (resistance is equal to the mean pressure divided by flow). However, if left untreated until Eisenmenger syndrome is present, systolic and diastolic PAP will be elevated and the degree of left-to-right shunting minimal. In these cases, desaturation of blood in the left ventricle is usually encountered. The size, location, and number of ventricular defects can be demonstrated by left ventriculography. Contrast medium passes across the defect(s) to opacify the right ventricle and pulmonary artery. Administration of 100% oxygen with and without nitric oxide can be used to determine whether PVR, if elevated, is still reactive and therefore more likely to decrease after surgical repair.

TREATMENT

The natural course of a VSD depends to a large degree on the size of the defect. A significant number (30–50%) of small defects close spontaneously, most frequently during the first 2 years of life. Small *muscular* VSDs are more likely to close (up to 80%) than *membranous* VSDs (up to 35%). Most defects that close do so before age 4 years, although spontaneous closure has been reported in adults. VSDs that close often have ventricular septal aneurysm (accessory tricuspid valve) tissue covering them that limits the magnitude of the shunt. Most children with small restrictive defects remain asymptomatic, without evidence of an increase in heart size, PAP, or PVR; a long-term risk is infective endocarditis. Some long-term studies of adults with unoperated small VSDs show an increased incidence of arrhythmia, subaortic stenosis, and exercise intolerance. It is recommended that an isolated, small, hemodynamically insignificant VSD is not an indication for surgery. However, with the declining risk of open heart surgery, whether all VSDs should be closed electively in mid-childhood is still debated.

It is less common for moderate or large VSDs to close spontaneously, although even defects large enough to result in heart failure may become smaller, and up to 8% may close completely. More frequently, infants with large defects have repeated episodes of respiratory infection and heart failure despite optimal medical management. Heart failure may be manifested in many of these infants primarily as failure to thrive. Pulmonary hypertension occurs as a result of high pulmonary blood flow. These patients are at risk for pulmonary vascular disease if the defect is not repaired during early infancy.

Patients with VSD are also at risk for the development of **aortic valve regurgitation**, the greatest risk occurring in patients with a supracristal VSD (see Chapter 475.7), where the position of the defect undermines support for the right coronary or noncoronary leaflet of the aortic valve. A small number of patients with VSD develop **acquired infundibular pulmonary stenosis**, which then protects the pulmonary circulation from the short-term effects of pulmonary overcirculation and the long-term effects of pulmonary vascular disease. In these patients the clinical picture changes from that of a VSD with a large left-to-right shunt to a VSD with pulmonary stenosis. The shunt may diminish in

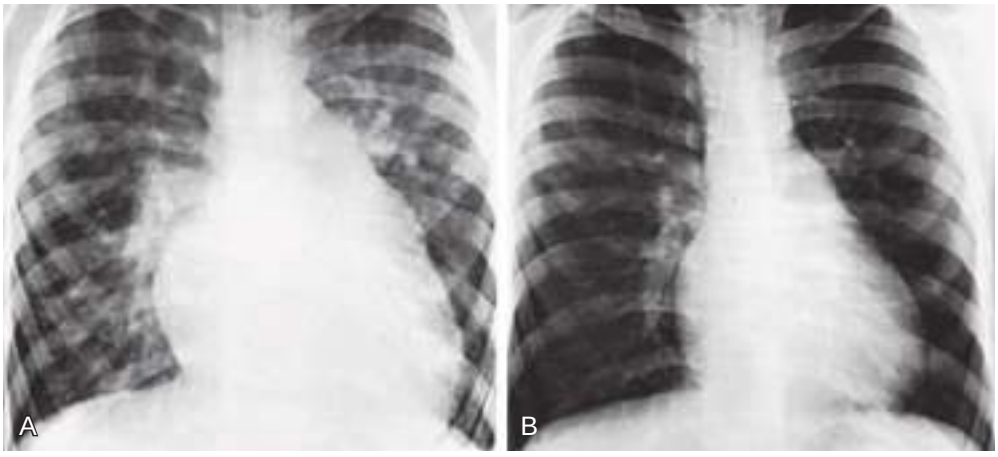

Fig. 475.10 A, Preoperative radiograph in a patient with a ventricular septal defect with a large left-to-right shunt and pulmonary hypertension. Significant cardiomegaly, prominence of the pulmonary arterial trunk, and pulmonary overcirculation are evident. B, Three years after surgical closure of the defect, heart size is greatly decreased and the pulmonary vasculature is normal.

size, become balanced, or even become a net right-to-left shunt. These patients must be carefully distinguished from those in whom an Eisenmenger physiology develops (see Chapter 482.2).

In patients with small VSDs, parents should be reassured of the relatively benign nature of the lesion, and the child should be encouraged to live a normal life, with no restrictions on physical activity. Surgical repair is not recommended; however, routine follow-up with the cardiologist is important. As protection against infective endocarditis, the integrity of primary and permanent teeth should be carefully maintained; with the latest revision of the American Heart Association (AHA) guidelines, antibiotic prophylaxis is no longer recommended for dental visits or surgical procedures (see Chapter 486). These patients can be monitored by a combination of clinical examination and noninvasive laboratory tests until the VSD has closed spontaneously. Echocardiography is used to estimate PAP, screen for the development of LVOT pathology (subaortic membrane or aortic regurgitation), and confirm spontaneous closure.

In infants with a large VSD and heart failure, management is directed at reducing symptoms and optimizing the patient's fluid status so that they are in optimal condition for surgical repair. In infants in the first year of life, if early treatment is successful, the size of the defect may sometimes diminish in size with clinical improvement. Selected patients in this group can be observed closely with echocardiographic monitoring. The clinician must be alert not to confuse clinical improvement caused by a decrease in defect size with clinical changes caused by the development of Eisenmenger physiology. Because surgical closure can be carried out at low risk in most infants, medical management should not be pursued in symptomatic infants after an initial unsuccessful trial. Because pulmonary vascular disease can usually be prevented when surgery is performed within the first year of life, even infants with well-controlled heart failure should not have surgery delayed inordinately unless there is echocardiographic evidence that the defect is becoming pressure restrictive.

Indications for surgical closure of a VSD include patients at any age with large defects in whom clinical symptoms and failure to thrive cannot be controlled medically or in whom the defect is not decreasing in size; infants between 6 and 12 months of age with moderate to large defects associated with pulmonary hypertension, even if the symptoms are controlled by medication; and patients older than 24 months with a Qp:Qs ratio greater than 2:1. Patients with a supracristal VSD of any size are usually referred for surgery because of their higher risk for developing aortic valve regurgitation (see Chapter 475.7). Severe pulmonary vascular disease nonresponsive to pulmonary vasodilators is a contraindication to closure of a VSD.

Transcatheter closure has been used successfully in treating larger muscular VSDs, which may be difficult to access by surgery. Perimembranous and intracristal VSD catheter closure is more complex because of the proximity of the defect to the tricuspid valve and conduction system; devices have been designed more specifically to address these issues and are currently being investigated. Preliminary data suggest that, for carefully selected patients (usually children beyond infancy), the results appear to be comparable to surgical repair. Hybrid methods employing a sternotomy with device placement through the anterior wall of the right ventricle under transesophageal echocardiographic and fluoroscopic visualization have also been performed in difficult-to-approach defects.

PROGNOSIS

The results of primary surgical repair are excellent, and complications leading to long-term problems (residual ventricular shunts requiring reoperation or device closure and heart block requiring a pacemaker) are rare. Surgical risks are somewhat higher for defects in the muscular septum, particularly apical defects and multiple (Swiss cheese–type) VSDs. Some of these patients may require pulmonary arterial banding if symptomatic, with subsequent debanding and repair of multiple VSDs at an older age.

After surgical closure of the left-to-right shunt, the hyperdynamic heart becomes quiet, cardiac size decreases toward normal (see Fig. 475.10), thrills and murmurs are absent, and pulmonary artery hypertension regresses. The patient's clinical status greatly improves. Most infants begin to thrive, often quite rapidly after hospital discharge, and cardiac medications are no longer required. Catch-up growth occurs in most patients within the next year. In some patients, after successful surgery, systolic ejection murmurs of low intensity persist for months. The long-term prognosis after surgery is excellent. Patients with a small VSD and those who have undergone surgical closure without residua are considered to be at standard risk for health and life insurance.

Visit Elsevier eBooks+ at eBooks.Health.Elsevier.com for Bibliography.

475.7 Supracristal Ventricular Septal Defect with Aortic Insufficiency

Daniel Bernstein

A supracristal VSD can be complicated by **prolapse of the aortic valve** into the defect and aortic insufficiency, which may eventually develop in 50–90% of these patients. Although supracristal VSD accounts for approximately 5% of all patients with VSD, the incidence is higher in Asian children and in males. The VSD, which may be small or moderate in size, is located anterior to and directly below the pulmonary valve in the outlet septum, superior to the muscular ridge known as the *crista supraventricularis,* which separates the trabecular body of the right ventricle from the smooth outflow portion. The right or, less often, the noncoronary aortic cusp prolapses into the defect and may partially or even completely occlude it. Such occlusion may limit the amount of left-to-right shunting and give the false impression that the defect is not large. Aortic insufficiency is most often not recognized until after 5 years of age, or even later. Although most common with supracristal VSDs, aortic insufficiency is occasionally associated with VSDs located in the membranous septum.

Early heart failure secondary to a large left-to-right shunt rarely occurs, but without surgery, moderate to severe aortic insufficiency and left ventricular failure may eventually ensue. The murmur of a supracristal VSD is usually heard at the mid- to upper-left sternal border, as opposed to the lower-left sternal border, and it is sometimes confused with that of pulmonic stenosis. A decrescendo diastolic murmur will be appreciated at the upper-right or mid-left sternal borders if there is aortic insufficiency. More advanced degrees of aortic insufficiency will be associated with a wide pulse pressure and a hyperdynamic precordium. These clinical findings must be distinguished from PDA or other defects associated with aortic runoff.

The clinical manifestations vary widely, from trivial aortic regurgitation and small left-to-right shunts in asymptomatic children to florid aortic insufficiency and massive cardiomegaly in symptomatic adolescents. Closure of all supracristal ventricular VSDs is usually recommended to prevent the development of aortic regurgitation, even in an asymptomatic child. Patients who already have significant aortic insufficiency require surgical intervention to prevent irreversible left ventricular dysfunction. Surgical options depend on the degree of damage to the valve, and for mild insufficiency, may include simple closure of the defect to bolster the valve apparatus without touching the valve itself, valvuloplasty for more significant degrees of involvement, and replacement with a prosthesis or homograft or aortopulmonary translocation (Ross procedure) for severe involvement.

475.8 Patent Ductus Arteriosus

Daniel Bernstein

During fetal life, most of the pulmonary arterial blood is shunted right to left through the ductus arteriosus into the aorta (see Chapter 470). Functional closure of the ductus normally occurs soon after birth, usually within the first week of life, but if the ductus remains patent when

PVR falls, aortic blood then is shunted left to right into the pulmonary artery. The aortic end of the ductus is just distal to the origin of the left subclavian artery, and the ductus enters the pulmonary artery at its bifurcation. Female patients with patent ductus arteriosus (PDA) outnumber males 2:1. PDA is also associated with maternal rubella infection during early pregnancy, an uncommon occurrence in the vaccination era. PDA is a common problem in premature infants because the smooth muscle in the wall of the preterm ductus is less responsive to high Po_2 and therefore less likely to constrict after birth. In these infants the shunt through a PDA can cause severe hemodynamic derangements and several major sequelae (see Chapter 131.3).

When a term infant is found to have a PDA, the wall of the ductus is deficient in both the mucoid endothelial layer and the muscular media, whereas in the premature infant, the PDA usually has a normal structure. Thus a PDA persisting beyond the first few weeks of life in a term infant rarely closes spontaneously or with pharmacologic intervention, whereas if early pharmacologic or surgical intervention is not required in a premature infant, spontaneous closure occurs in most instances. A PDA is seen in 10% of patients with other congenital heart lesions and often plays a critical role in providing a source of pulmonary blood flow when the right ventricular outflow tract is stenotic or atretic (see Chapter 479) or in providing systemic blood flow in the presence of aortic coarctation or interruption (see Chapters 476.6-476.8) or in hypoplastic left heart syndrome.

A PDA is a common finding (~90%) in patients with **smooth muscle dysfunction syndrome (SMDS)** caused by a heterozygous pathogenic variant in *ACTA2*. Additional features include congenital mydriasis, pulmonary hypertension, aortic and other arterial aneurysms, moyamoya-like cerebrovascular disease, and intestinal hypoperistalsis.

PATHOPHYSIOLOGY

Because of the higher aortic pressure postnatally, blood shunts left to right through the ductus, from the aorta to the pulmonary artery. The extent of the shunt depends on the size of the ductus and on the PVR/SVR ratio. If the PDA is small, pressures within the pulmonary artery, the right ventricle, and the right atrium are normal. If the PDA is large, PAP may be elevated to systemic levels during both systole and diastole. Thus patients with a large PDA are at high risk for the development of pulmonary vascular disease if left unoperated.

CLINICAL MANIFESTATIONS

A small PDA is usually asymptomatic and is usually diagnosed by the presence of a heart murmur. A large PDA will result in heart failure similar to that encountered in infants with a large VSD. Stunting of physical growth may be a major manifestation in infants with large shunts. A small PDA is associated with normal peripheral pulses, and a large PDA results in bounding peripheral arterial pulses and a *wide pulse pressure,* caused by runoff of blood into the pulmonary artery during diastole. Although normal in size when the ductus is small, the heart is moderately or grossly enlarged in cases with a large communication; in these patients the apical impulse is prominent and, with cardiac enlargement, is heaving. A **thrill**, maximal in the second left interspace, is often present and may radiate toward the left clavicle, down the left sternal border, or toward the apex. It is usually systolic but may also be palpated throughout the cardiac cycle. The classic continuous murmur is described as "machinery-like" in quality. It begins soon after onset of S_1, reaches maximal intensity at the end of systole, and wanes in late diastole. It may be localized to the second left intercostal space or radiate down the left sternal border or to beneath the left clavicle. When PVR is increased, the diastolic component of the murmur may be less prominent or absent. In patients with a large left-to-right shunt, a low-pitched mitral mid-diastolic murmur may be audible at the apex as a result of the increased volume of blood flow across the mitral valve.

DIAGNOSIS

If the left-to-right shunt is small, the ECG is normal; if the ductus is large, LV or biventricular hypertrophy is present. The diagnosis of an isolated, uncomplicated PDA is untenable when RV hypertrophy is present on the ECG.

Radiographic studies in patients with a large PDA show a prominent pulmonary artery with increased pulmonary vascular markings. Cardiac size depends on the degree of left-to-right shunting; it may be normal or moderately to greatly enlarged. The chambers involved are the left atrium and left ventricle. The aortic knob may be normal or prominent.

On echocardiogram the cardiac chambers will be normal in size if the ductus is small. With large shunts, LA and LV dimensions are increased. The ductus can easily be visualized directly and its size estimated. Color and pulsed Doppler examinations demonstrate systolic or diastolic (or both) retrograde turbulent flow in the pulmonary artery and aortic retrograde flow in diastole in the presence of a large shunt (Fig. 475.11).

The clinical signs and echocardiographic findings are sufficiently distinctive to allow an accurate diagnosis by noninvasive methods in most patients. In rare patients with atypical findings, cardiac catheterization may be indicated for confirmation of diagnosis. Cardiac catheterization will demonstrate either normal or increased pressure in the right ventricle and pulmonary artery, depending on the size of the ductus. The presence of oxygenated blood shunting into the pulmonary artery confirms the left-to-right shunt. The catheter may pass from the pulmonary artery through the ductus into the descending aorta. Injection of contrast medium into the ascending aorta shows opacification of the pulmonary artery from the aorta and identifies the ductus.

Other conditions can produce systolic and diastolic murmurs in the pulmonic area in an acyanotic patient (see Chapter 471). An **aortico-pulmonary window defect** may rarely be clinically indistinguishable from a patent ductus, although in most cases the murmur is only systolic and is loudest at the right rather than the left upper sternal border

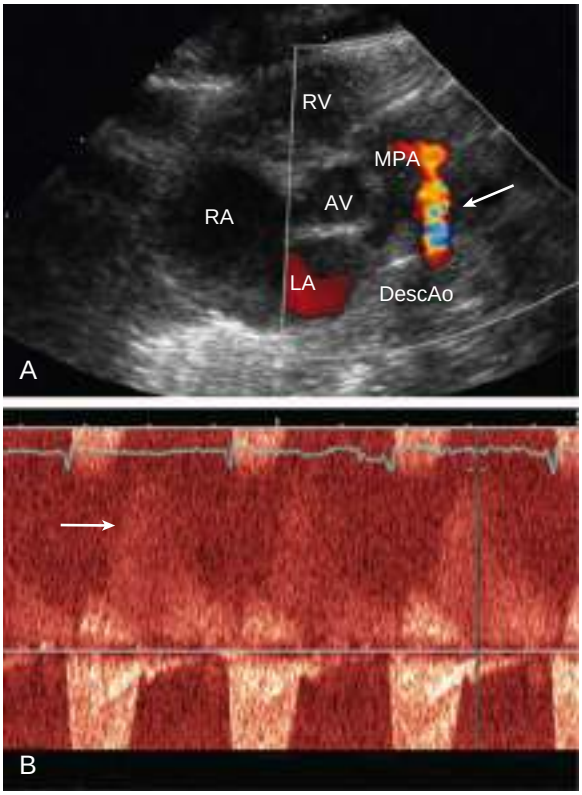

Fig. 475.11 Echocardiogram in a newborn with a small to moderate-size patent ductus arteriosus. **A,** Color Doppler evaluation in a parasternal short-axis view shows flow *(arrow)* from the aorta into the main pulmonary artery. **B,** Doppler evaluation demonstrates retrograde diastolic flow into the pulmonary artery. AV, Aortic valve; DescAo, descending aorta; LA, left atrium; MPA, main pulmonary artery; RA, right atrium; RV, right ventricle.

(see Chapter 475.9). A sinus of Valsalva aneurysm that has ruptured into the right side of the heart or pulmonary artery, a coronary AV fistula, and an aberrant left coronary artery with massive collaterals from the right coronary display dynamics similar to that of a PDA with a continuous murmur and a wide pulse pressure. Truncus arteriosus with torrential pulmonary flow also can present with aortic runoff physiology. A peripheral AV fistula also results in a wide pulse pressure, but the distinctive precordial murmur of a PDA is not present. VSD with aortic insufficiency, repaired tetralogy of Fallot, and combined aortic and mitral insufficiency (usually from rheumatic fever) may be confused with a PDA, but the murmurs should be differentiated by their to-and-fro rather than continuous nature. In a to-and-fro murmur there is a quiet segment between the systolic and diastolic components, whereas in a continuous murmur there is flow disturbance throughout the cardiac cycle (even if the murmur is louder during systole than diastole). The combination of a large VSD and a PDA result in findings more like those of an isolated VSD. Echocardiography should be able to eliminate these other diagnostic possibilities.

PROGNOSIS AND COMPLICATIONS

Spontaneous closure of the ductus after infancy is extremely rare. Patients with a small PDA may live a normal span with few or no cardiac symptoms, but late manifestations may occur. In patients with a large PDA, cardiac failure most often occurs in early infancy but may occur later in life, even with a moderate-sized communication.

Infective endarteritis may be seen at any age. Pulmonary or systemic emboli may occur. Rare complications include aneurysmal dilation of the pulmonary artery or the ductus, calcification of the ductus, noninfective thrombosis of the ductus with embolization, and paradoxical emboli. Pulmonary hypertension (Eisenmenger syndrome) usually develops in patients with a large PDA who do not undergo ductal closure (see Chapter 482.2).

TREATMENT

Irrespective of age, patients with a PDA require either catheter or surgical closure. In patients with a small PDA, the rationale for closure is prevention of bacterial endarteritis or other late complications. In patients with a moderate to large PDA, closure is accomplished to treat heart failure and prevent the development of pulmonary vascular disease. Once the diagnosis of a moderate to large PDA is made, treatment should not be unduly postponed after adequate medical therapy for cardiac failure has been instituted.

Transcatheter PDA closure is routinely performed in the cardiac catheterization laboratory (Fig. 475.12). Small PDAs are generally closed with intravascular coils. Moderate to large PDAs may be closed with an umbrella-like or pluglike device or with a catheter-introduced sac into which several coils are released. Surgical closure of a PDA can be accomplished by a standard left thoracotomy or using thoracoscopic minimally invasive techniques. The case fatality rate with interventional or surgical treatment is considerably less than 1%; thus closure of the ductus is indicated even in asymptomatic patients. Pulmonary hypertension is not a contraindication to surgery at any age if it can be demonstrated at cardiac catheterization that the shunt flow is still predominantly left to right and that severe pulmonary vascular disease is not present. After closure, symptoms of cardiac failure rapidly disappear. Infants who had failed to thrive usually have immediate improvement in physical development. The pulse and blood pressure return to normal, and the machinery-like murmur disappears. A functional systolic murmur over the pulmonary area may persist; it may represent turbulence in a persistently dilated pulmonary artery. The radiographic signs of cardiac enlargement and pulmonary overcirculation disappear over several months, and the ECG becomes normal.

PATENT DUCTUS ARTERIOSUS IN LOW BIRTHWEIGHT INFANTS

See Chapter 126.1.

Visit Elsevier eBooks+ at eBooks.Health.Elsevier.com for Bibliography.

475.9 Aortopulmonary Window Defect

Daniel Bernstein

An aortopulmonary window defect consists of a communication between the ascending aorta and the main pulmonary artery. The presence of pulmonary and aortic valves and an intact ventricular septum distinguishes this anomaly from **truncus arteriosus** (see Chapter 480.8). An aortopulmonary window is an associated lesion in patients with **smooth muscle dysfunction syndrome** (see Chapter 475.8). Symptoms of heart failure appear during early infancy; occasionally, minimal cyanosis is present. The defect is usually large, and the cardiac murmur is usually systolic with an apical mid-diastolic rumble as a result of the increased blood flow across the mitral valve. In the rare instance when the communication is smaller and pulmonary hypertension is absent, the findings on examination can mimic those of a PDA (wide pulse pressure and a continuous murmur at the upper sternal borders). The ECG shows either LV or biventricular hypertrophy. Radiographic studies demonstrate cardiac enlargement and prominence of the pulmonary artery and intrapulmonary

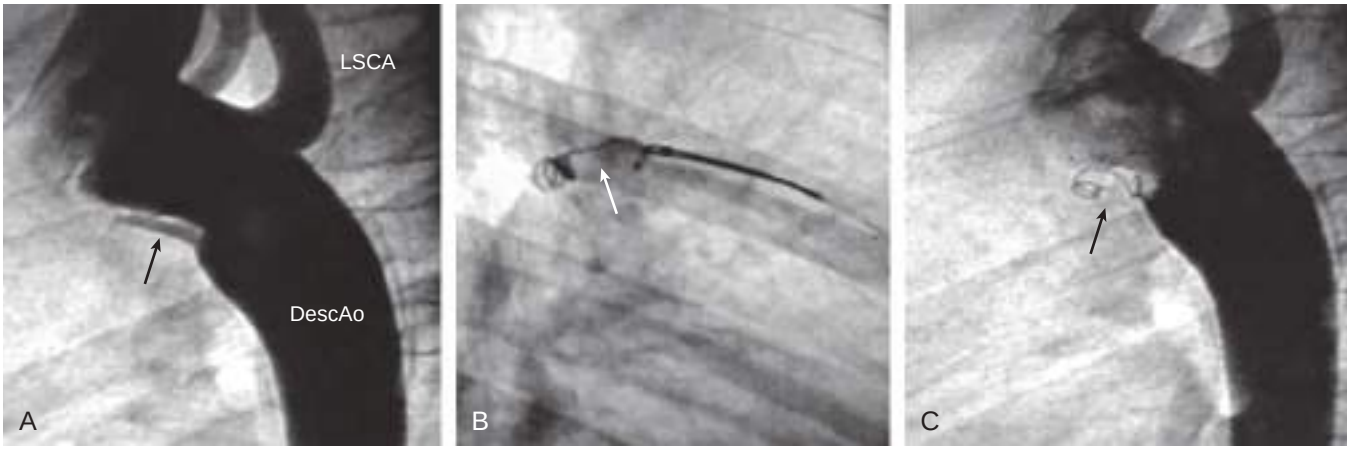

Fig. 475.12 Transcatheter closure of a small patent ductus arteriosus using a coil. **A,** Angiogram of transverse and descending aorta shows small PDA *(arrow)*. **B,** Coil *(arrow)* has been extruded from the sheath and is being positioned in the ductal lumen. **C,** Angiogram demonstrating total occlusion of PDA by coil *(arrow)*. DescAo, Descending aorta; LSCA, left subclavian artery.

vasculature. The echocardiogram shows enlarged left-sided heart chambers; the window defect can best be delineated with color flow Doppler. CT or MR angiography can also be used to visualize the defect (see Fig. 472.26).

Cardiac catheterization, usually performed in older children to evaluate pulmonary vascular resistance, reveals a left-to-right shunt at the level of the pulmonary artery, as well as hyperkinetic pulmonary hypertension, because the defect is almost always large. Selective aortography with injection of contrast medium into the ascending aorta demonstrates the lesion, and manipulation of the catheter from the main pulmonary artery directly to the ascending aorta is also diagnostic.

An aortopulmonary window defect is surgically corrected during infancy. If surgery is not carried out in infancy, survivors carry the risk of progressive pulmonary vascular obstructive disease, similar to that of other patients who have large intracardiac or great vessel communications.

475.10 Coronary Artery Fistula

Daniel Bernstein

A congenital fistula may exist between a coronary artery and an atrium, ventricle (especially the right), or pulmonary artery. Sometimes, multiple fistulas exist. Regardless of the recipient chamber, the clinical signs are similar to those of PDA, although the machinery-like murmur may be more diffuse. If the flow is substantial, the involved coronary artery may be dilated or aneurysmal. The anatomic abnormality is usually demonstrable by color flow Doppler echocardiography and, during catheterization, by contrast injection into the ascending aorta. Small fistulas may be hemodynamically insignificant and may even close spontaneously. If the shunt is large, treatment consists of either transcatheter coil embolization or, for lesions not amenable to catheter intervention, surgical closure of the fistula.

475.11 Ruptured Sinus of Valsalva Aneurysm

Daniel Bernstein

When one of the sinuses of Valsalva of the aorta is weakened by congenital or acquired disease, an aneurysm may form and eventually rupture, usually into the right atrium or ventricle. This condition is rare in childhood. The onset is usually sudden. The diagnosis should be suspected in a patient in whom symptoms of acute heart failure develop in association with a new, loud, to-and-fro murmur. Color Doppler echocardiography and cardiac catheterization demonstrate the left-to-right shunt at the atrial or ventricular level. Urgent surgical repair is generally required. This condition is often associated with infective endocarditis of the aortic valve.

Chapter 476 Acyanotic Congenital Heart Disease: Obstructive Lesions

476.1 Pulmonary Valve Stenosis with Intact Ventricular Septum

Daniel Bernstein

Of the various forms of right ventricular (RV) outflow obstruction with an intact ventricular septum, the most common is isolated **valvular pulmonary stenosis**, which accounts for 7–10% of all congenital heart defects. The valve cusps are deformed to various degrees and, as a result, the valve opens incompletely during systole. The valve may be bicuspid or tricuspid and the leaflets partially fused together with an eccentric outlet. This fusion may be so severe that only a pinhole central opening remains. If the valve is not severely thickened, it produces a domelike obstruction to RV outflow during systole. Isolated infundibular or subvalvular stenosis, supravalvular pulmonary stenosis, and branch pulmonary artery stenosis are also encountered. In cases where pulmonary valve stenosis is associated with a **ventricular septal defect** (VSD) but without anterior deviation of the infundibular septum and overriding aorta, this condition is better classified as pulmonary stenosis with VSD rather than as **tetralogy of Fallot** (see Chapter 479.1). Pulmonary stenosis and an **atrial septal defect** (ASD) are also occasionally seen as associated defects.

The clinical and laboratory findings reflect the dominant lesion, but it is important to rule out any associated anomalies. Pulmonary stenosis as a result of valve dysplasia is the most common cardiac abnormality in **Noonan syndrome** (see Chapter 101.1) and is associated, in approximately 50% of cases, with a pathogenic variant in *PTPN11,* encoding the protein tyrosine phosphatase SHP-2 on chromosome 12. *SOS1* gene variants cause an additional 10–15%, and *RAF1* and *RIT1* genes each account for about 5% of cases. These genes are components of the RAS/MAPK cell signaling pathway, important for cell division; however, the mechanism by which these gene changes cause pulmonic stenosis is unknown. Pulmonary stenosis can also be a component of **LEOPARD syndrome** (lentigines, electrocardiographic abnormalities, ocular hypertelorism, pulmonary stenosis, abnormalities of genitalia, retardation of growth, deafness syndrome), often associated with hypertrophic cardiomyopathy. Pathogenic variants in *PTPN11, RAF1, BRAF,* and *MAP2K1* have been implicated in LEOPARD syndrome. Pulmonary stenosis, of the valve or more commonly of the branch pulmonary arteries, is a common finding in patients with arteriohepatic dysplasia, also known as **Alagille syndrome** (see Chapter 404); pathogenic variants have been found in *JAGGED1* or *NOTCH2,* components of the Notch signaling pathway.

PATHOPHYSIOLOGY

The obstruction to outflow from the right ventricle to the pulmonary artery results in increased RV systolic pressure and wall stress, which lead to hypertrophy of the right ventricle (Fig. 476.1). The severity of these abnormalities depends on the size of the restricted valve opening. In severe cases, RV pressure may be higher than systemic arterial systolic pressure, whereas with milder obstruction, RV pressure is only mildly or moderately elevated. Pulmonary artery pressure (PAP, distal to the obstruction) is either normal or decreased. Arterial oxygen saturation will be normal even in cases of severe stenosis, unless an intracardiac communication such as a VSD or ASD is allowing blood to shunt from right to left. However, when severe pulmonic stenosis occurs in a neonate, decreased RV compliance often leads to cyanosis as a result of right-to-left shunting through a **patent foramen ovale** (PFO), a condition termed **critical pulmonic stenosis**.

CLINICAL MANIFESTATIONS AND LABORATORY FINDINGS

Patients with mild or moderate stenosis usually have no symptoms. Growth and development are most often normal. If the stenosis is severe, signs of RV failure such as hepatomegaly, peripheral edema, and exercise intolerance may be present. In a neonate or young infant with critical pulmonic stenosis, signs of RV failure may be more prominent; cyanosis is often present because of right-to-left shunting at the foramen ovale.

With **mild pulmonary stenosis**, central venous pressure is normal. The heart is not enlarged, the apical impulse is normal, and the RV impulse is not palpable. A sharp pulmonic ejection click (caused by doming of the valve) is heard immediately after the first heart sound (S_1) at the left upper sternal border and over the sternum, more prominently during expiration. The second heart sound (S_2) is split, with a pulmonary component of normal intensity that may be slightly

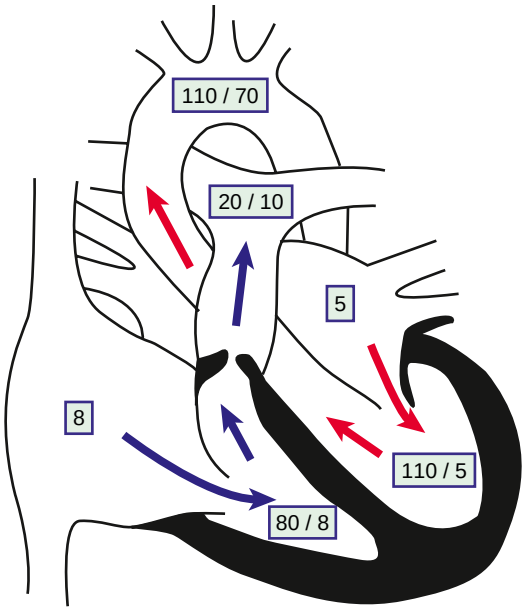

Fig. 476.1 Physiology of valvular pulmonary stenosis. *Boxed numbers* represent pressure in mm Hg. Because of the absence of right-to-left or left-to-right shunting, blood flow through all cardiac chambers is normal at 3 L/min/m^2. The pulmonary-to-systemic blood flow ratio (Qp:Qs) is 1:1. Right atrial pressure is increased slightly as a result of decreased right ventricular compliance. The right ventricle is hypertrophied, and systolic and diastolic pressures are increased. The pressure gradient across the thickened pulmonary valve is 60 mm Hg. The main pulmonary artery pressure is slightly low, and poststenotic dilation is present. Left-sided heart pressure is normal. Unless right-to-left shunting is occurring through a foramen ovale, the patient's systemic oxygen saturation will be normal.

Fig. 476.2 Radiograph of patient with valvular pulmonary stenosis and normal aortic root. The heart size is within normal limits, but poststenotic dilation of the pulmonary artery is present.

delayed. A relatively short, low- or medium-pitched systolic ejection murmur is maximally audible over the pulmonic area at the upper left sternal border and radiates minimally to the lung fields bilaterally. The electrocardiogram (ECG) is either normal or shows mild **right ventricular hypertrophy** (RVH) (e.g., slightly increased voltages in the right precordial leads); inversion of the T waves in the right precordial leads may be the only finding. Note that the T wave in lead V_1 should normally be inverted after the first week of life until at least 6-8 years of age. Therefore a positive T wave in V_1 in a young child is a sign of RVH even in the absence of voltage criteria. The only abnormality demonstrable radiographically is usually poststenotic dilation of the pulmonary artery. Two-dimensional (2D) echocardiography shows RVH and a slightly thickened pulmonic valve, which domes in systole. Doppler studies demonstrate a right ventricle–to–pulmonary artery (RV-PA) pressure gradient of ≤30 mm Hg.

In **moderate pulmonic stenosis**, central venous pressure may be slightly elevated; in older children, a prominent *a* wave may be noted in the jugular pulse. An RV lift may be palpable at the lower-left sternal border. S_2 is split, with a delayed and soft pulmonic component. As valve motion becomes more limited with more severe degrees of stenosis, both the pulmonic ejection click and the pulmonic S_2 may become inaudible. With increasing degrees of stenosis, the systolic ejection murmur becomes louder and harsher (higher frequency), the peak of the murmur is prolonged later into systole, and the murmur radiates more prominently to both lung fields, heard best over the back.

The ECG reveals RVH, sometimes with a prominent spiked P wave. Radiographically, the heart can vary from normal size to mildly enlarged with uptilting of the apex because of the prominence of the right ventricle; pulmonary vascularity is usually normal or slightly decreased. The echocardiogram shows a thickened pulmonic valve with restricted systolic motion. Doppler examination demonstrates an RV-PA pressure gradient of 30-60 mm Hg. Mild tricuspid regurgitation may be present and allows for Doppler confirmation of RV systolic pressure.

In **severe pulmonary stenosis**, mild to moderate cyanosis may be noted in patients with an interatrial communication (ASD or PFO). In the absence of any intracardiac shunt, cyanosis is absent. Hepatic enlargement and peripheral edema, if present, are an indication of RV failure. Elevation of central venous pressure is common and is identified as a large presystolic jugular *a* wave. The heart is moderately or greatly enlarged, and a conspicuous parasternal RV lift is present and frequently extends to the left midclavicular line. The pulmonic component of S_2 is usually inaudible. A loud, long, and harsh systolic ejection murmur, usually accompanied by a thrill, is maximally audible in the pulmonic area and may radiate over the entire precordium, to both lung fields, and to the back. The peak of the murmur occurs later in systole as valve opening becomes more restricted. The murmur frequently encompasses the aortic component of S_2 but is not preceded by an ejection click.

The ECG shows marked RVH, frequently accompanied by a tall, spiked P wave. Radiographic studies confirm the presence of cardiac enlargement with prominence of the right ventricle and right atrium. Prominence of the main pulmonary artery (MPA) segment may be seen as a sign of poststenotic dilation (Fig. 476.2). Intrapulmonary vascularity is decreased. The 2D echocardiogram shows severe deformity of the pulmonary valve and RVH (Fig. 476.3). In the late stages of the disease, systolic dysfunction of the right ventricle may be seen, and in these cases the ventricle becomes dilated, with prominent tricuspid regurgitation. Doppler studies demonstrate a high gradient (>60 mm Hg) across the pulmonary valve. The classic findings of severe pulmonary stenosis in older children are rarely seen today because of early intervention. In the newborn period, signs of critical pulmonic stenosis are accompanied by cyanosis.

Cardiac catheterization is not generally required for diagnostic purposes but is undertaken to perform a therapeutic **balloon valvuloplasty** procedure. Catheterization demonstrates an abrupt pressure gradient across the pulmonary valve. PAP is either normal or low. The severity of the stenosis is graded based on the ratio of RV systolic pressure to systemic systolic pressure or the RV-PA pressure gradient: 10-30 mm Hg in mild cases, 30-60 mm Hg in moderate cases, and >60 mm Hg or with RV pressure greater than systemic pressure in severe cases. If cardiac output is low or a significant right-to-left shunt exists across the atrial septum, the pressure gradient may underestimate the degree of valve stenosis. Selective right ventriculography demonstrates the

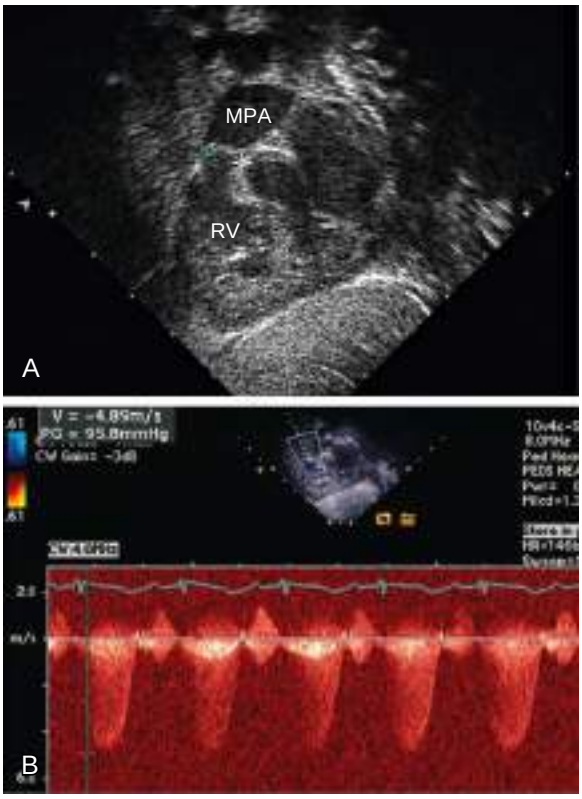

Fig. 476.3 Echocardiogram demonstrating valvar pulmonic stenosis. A, Subcostal view showing thickened pulmonary valve leaflets *(between crosshatches)*. B, Doppler study indicating a 95 mm Hg peak pressure gradient across the stenotic valve. MPA, Main pulmonary artery; RV, right ventricle.

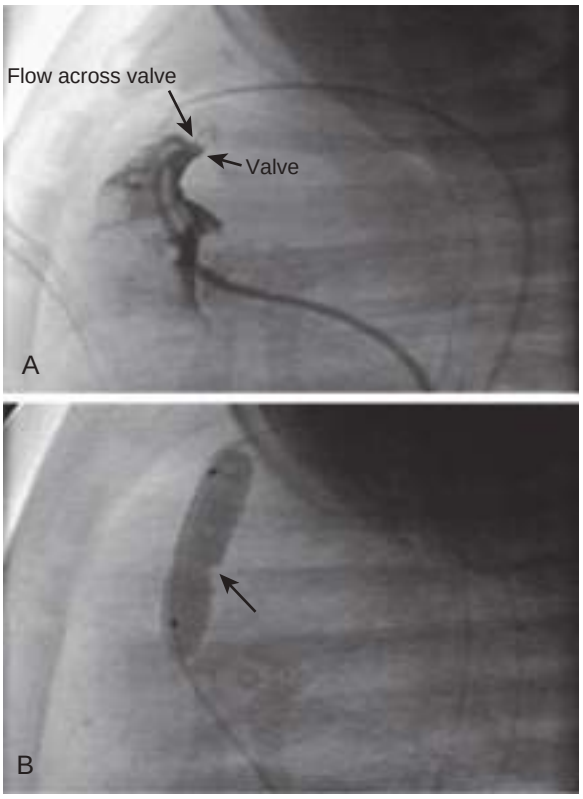

Fig. 476.4 Valvar pulmonary stenosis and balloon valvuloplasty. A, Right ventricular angiogram showing severely stenotic pulmonary valve with narrow jet of blood flowing across. B, Inflation of the balloon catheter showing the indentation *(arrow)* made on the balloon from the stenotic valve. *(Photos courtesy Dr. Jeffrey Feinstein, Stanford University, Stanford, CA.)*

thickened, poorly mobile valve. In mild to moderate stenosis, doming of the valve in systole is readily seen. Flow of contrast medium through the stenotic valve in ventricular systole produces a narrow jet of dye that fills the dilated MPA. Subvalvular hypertrophy may be present and may intensify the obstruction.

TREATMENT

Patients with moderate or severe isolated pulmonary stenosis require relief of the obstruction. Balloon valvuloplasty is the initial treatment of choice for the majority of patients (Fig. 476.4). Patients with severely thickened pulmonic valves, especially common in those with **Noonan syndrome**, may require surgical intervention. In a neonate with critical pulmonic stenosis and cyanosis, urgent treatment by either balloon valvuloplasty or surgical valvotomy is warranted.

Excellent results are obtained in most patients. The gradient across the pulmonary valve is greatly reduced or abolished. In the early period after balloon valvuloplasty, a small to moderate residual gradient may remain because of muscular infundibular narrowing; it usually resolves with time. A short, early decrescendo diastolic murmur may be heard at the midsternal to upper left sternal border as a result of pulmonary valvular insufficiency. The degree of insufficiency is usually not clinically significant, although it can occasionally worsen over time as the child grows. No difference in patient status after valvuloplasty or surgery has been noted at late follow-up; recurrence is unusual after successful treatment except in those patients with extremely dysplastic valves. In the small minority of patients where the degree of **pulmonary regurgitation** is more severe, RV dilation may ensue, and these patients require careful follow-up and may require surgical intervention (repair or valve replacement) or placement of a transcatheter stent-valve (e.g., Melody or Harmony valve).

PROGNOSIS AND COMPLICATIONS

Heart failure occurs only in severe cases and most often during the first month of life. The development of cyanosis from a right-to-left shunt across a foramen ovale is almost exclusively seen in the neonatal period when the stenosis is severe. Infective endocarditis is a risk but is not common in childhood.

Children with mild stenosis can lead a normal life, but their progress should be evaluated at regular intervals. Patients who have small gradients rarely show progression and do not need intervention, but a significant gradient is more likely to develop in children with moderate stenosis as they grow older. Worsening of obstruction over time may also be caused by the development of secondary subvalvular muscular hypertrophy. In untreated severe stenosis, the course may abruptly worsen with the development of RV dysfunction and cardiac failure. Infants with critical pulmonic stenosis require urgent catheter balloon valvuloplasty or surgical valvotomy. Development of RV failure many years after pulmonary balloon valvuloplasty is uncommon. Nonetheless, patients should be followed serially for worsening pulmonary insufficiency and RV dilation.

Visit Elsevier eBooks+ at eBooks.Health.Elsevier.com for Bibliography.

476.2 Infundibular Pulmonary Stenosis and Double-Chamber Right Ventricle

Daniel Bernstein

Infundibular pulmonary stenosis is caused by muscular or fibrous obstruction in the outflow tract of the right ventricle. The site of obstruction may be close to the pulmonary valve or well below it; an

infundibular chamber may be present between the right ventricular cavity and the pulmonary valve. In many cases, a VSD may have been present initially and later closed spontaneously. When the pulmonary valve is also stenotic, the combined defect is primarily classified as valvular stenosis with secondary infundibular hypertrophy. The hemodynamics and clinical manifestations of patients with isolated infundibular pulmonary stenosis are similar, for the most part, to those described for isolated valvular pulmonary stenosis (see Chapter 476.1).

A common variation in RV outflow obstruction below the pulmonary valve is that of a **double-chambered right ventricle**. In this condition, a muscular band is present in the mid-RV region; the band divides the chamber into two parts and creates obstruction between the inlet and outlet portions. An associated VSD is often noted, and these may close spontaneously. Obstruction is not usually seen early in life but may progress rapidly in a similar manner to the progressive infundibular obstruction observed with tetralogy of Fallot (see Chapter 479.1).

The diagnosis of isolated RV infundibular stenosis or double-chambered right ventricle is usually made by echocardiography. The ventricular septum must be evaluated carefully to determine whether an associated VSD is present. When the obstruction is moderate to severe, surgery is indicated. After surgery, the pressure gradient is abolished or greatly reduced, and the long-term outlook is excellent.

476.3 Pulmonary Stenosis in Combination with an Intracardiac Shunt

Daniel Bernstein

Valvular or infundibular pulmonary stenosis, or both, may be associated with either an ASD or a VSD. In these patients the clinical features depend on the degree of pulmonary stenosis, which determines whether the net shunt is from left to right or from right to left. Neonates with severe pulmonary stenosis (termed **critical pulmonary stenosis**) usually have right-to-left shunting through the foramen ovale (see Chapter 476.1).

The presence of a large left-to-right shunt at the atrial or ventricular level is evidence that the pulmonary stenosis is mild. These patients have symptoms similar to those of patients with an isolated ASD or VSD. With increasing age, worsening of the RV outflow obstruction may limit the shunt and result in a gradual improvement in symptoms. Eventually, particularly in patients with pulmonary stenosis and VSD, a further increase in obstruction may lead to right-to-left shunting and cyanosis. When a patient with a VSD has evidence of decreasing heart failure and increased RV forces on the ECG, one must differentiate between the development of increasing pulmonary stenosis vs the onset of pulmonary vascular disease (**Eisenmenger syndrome**; see Chapter 482.2).

These anomalies are readily repaired surgically. Defects in the atrial or ventricular septum are closed, and the pulmonary stenosis is relieved by resection of infundibular muscle or pulmonary valvotomy, or both, as indicated. Patients with a predominant right-to-left shunt can have symptoms similar to those of patients with tetralogy of Fallot (see Chapter 479.1).

476.4 Peripheral Pulmonary Stenosis

Daniel Bernstein

Single or multiple constrictions may occur anywhere along the major branches of the pulmonary arteries and may range from mild to severe and from localized to extensive. Frequently, these defects are associated with other types of congenital heart disease, including valvular pulmonic stenosis, tetralogy of Fallot, patent ductus arteriosus (PDA), VSD, ASD, and supravalvular aortic stenosis. A familial tendency has been recognized in some patients with peripheral pulmonic stenosis. Peripheral pulmonary stenosis is a common cardiac sequelae of congenital rubella syndrome. The combination of supravalvular aortic stenosis with pulmonary arterial branch stenosis, idiopathic hypercalcemia of infancy, elfin facies, and intellectual disability is known as **Williams syndrome**, a condition associated with hemizygous microdeletion of ~25-27 genes (Williams-Beuren syndrome critical region: WBSCR1), including *ELN, LIMK1, GTF21,* and *GTF21RD1* in region 7q11.23 on chromosome 7. Peripheral pulmonary stenosis is also associated with **Alagille syndrome**, which may be associated with a pathogenic variant in the *JAGGED1* or *NOTCH2* genes.

A mild constriction has little effect on the pulmonary circulation. With multiple severe constrictions, pressure is increased in the right ventricle and in the pulmonary artery proximal to the site of obstruction. When the anomaly is isolated, the diagnosis is suspected by the presence of murmurs in widespread locations over the chest, either anteriorly or posteriorly. These murmurs are usually systolic ejection in quality but may be continuous. Most often, the physical signs are dominated by the associated anomaly, such as valvar pulmonary stenosis or tetralogy of Fallot (see Chapter 479.1).

In the immediate newborn period, a mild and transient form of peripheral pulmonic stenosis may be present. Physical findings are generally limited to a soft systolic ejection murmur, which can be heard over either or both lung fields. It is the absence of other physical findings of valvular pulmonic stenosis (RV lift, soft pulmonic S_2, systolic ejection click, murmur loudest at upper left sternal border) that supports this diagnosis. This murmur usually disappears by age 1-2 months.

If the stenosis is severe, the ECG shows evidence of RVH and right atrial hypertrophy, and the chest radiograph shows cardiomegaly and prominence of the MPA. The pulmonary vasculature is usually normal; in some cases, small intrapulmonary vascular shadows are seen that represent areas of poststenotic dilation. Echocardiography is limited in its ability to visualize the distal branch pulmonary arteries. Doppler examination demonstrates the acceleration of blood flow through the stenoses and, if tricuspid regurgitation is present, allows an estimation of RV systolic pressure. MRI and CT are extremely helpful in delineating distal obstructions. If moderate to severe disease is suspected, the diagnosis is usually confirmed by cardiac catheterization.

Severe obstruction of the MPA and its primary branches can be relieved during corrective surgery for associated lesions such as the tetralogy of Fallot or valvular pulmonary stenosis. If peripheral pulmonic stenosis is isolated, it may be treated by catheter balloon dilation, sometimes with placement of an intravascular stent (see Fig. 472.31).

476.5 Aortic Stenosis

Daniel Bernstein

Congenital aortic stenosis accounts for approximately 5% of cardiac malformations recognized in childhood and is more frequent in males (3:1). A bicuspid aortic valve (BAV) is one of the most common congenital heart lesions overall, identified in 1–2% of adults. If isolated, it is not even counted in the overall incidence (0.8% of live births) of congenital heart disease. There is a high incidence of family clustering, with multiple individuals affected with BAV or other left-sided heart lesions. BAV may be encountered in conjunction with other left-sided heart lesions (coarctation of the aorta, aortopathy, mitral stenosis, **Shone complex**, and hypoplastic left heart syndrome) or in conjunction with syndromes such as Loeys-Dietz, Down, Turner, and velocardiofacial (DiGeorge). Several genes have been implicated in BAV, including *NOTCH1, GATA4, GATA5,* and *SMAD6*.

In the most common form, **valvular aortic stenosis**, the leaflets are thickened and the commissures are fused to varying degrees. Left ventricular (LV) systolic pressure is increased as a result of the obstruction to outflow. The LV wall hypertrophies in compensation; as its compliance decreases, end-diastolic pressure increases as well, impairing ventricular filling in the more severe cases.

Fig. 476.5 Williams syndrome. *(From Jones KL, Smith DW. The Williams elfin facies syndrome: a new perspective. J Pediatr. 1975;86:718.)*

Subvalvular (subaortic) stenosis with a discrete fibromuscular shelf (subaortic membrane) below the aortic valve is also an important form of left ventricular outflow tract (LVOT) obstruction. This lesion is frequently associated with other forms of congenital heart disease such as mitral stenosis and coarctation of the aorta **(Shone complex)** and may progress in severity with age, sometimes rapidly. Subvalvular aortic stenosis may also become apparent after successful surgery for other congenital heart defects (coarctation of the aorta, PDA, VSD), may develop in association with mild lesions that have not been surgically repaired, or may occur as an isolated abnormality. Subvalvular aortic stenosis may also be caused by a markedly hypertrophied ventricular septum in association with hypertrophic cardiomyopathy (see Chapter 488.2).

Supravalvular aortic stenosis, the least common type, may be sporadic, familial, or associated with **Williams syndrome**, which includes developmental delay (IQ range: 41-80), elfin facies (full face, broad forehead, flattened bridge of the nose, long upper lip, and rounded cheeks) (Fig. 476.5), and idiopathic hypercalcemia of infancy. Additional features include loquacious personality, hypersensitivity to sound, spasticity, hypoplastic nails, dental anomalies (partial anodontia, microdontia enamel hypoplasia), joint hypermobility, nephrocalcinosis, hypothyroidism, and poor weight gain. Narrowing of the coronary artery ostia can occur in patients with supravalvar aortic stenosis and should be carefully evaluated. Stenosis of other arteries, particularly the branch pulmonary arteries, may also be present. Williams syndrome is caused by hemizygous microdeletion of ~25 genes in the WBSCR1 at 7q11.23 on chromosome 7 (see Chapter 476.2).

CLINICAL MANIFESTATIONS

Symptoms in patients with aortic stenosis depend on the severity of the obstruction. Severe aortic stenosis that occurs in early infancy is termed **critical aortic stenosis** and is associated with LV failure and signs of low cardiac output. Heart failure, cardiomegaly, and pulmonary edema are severe, the pulses are weak in all extremities, and the skin may be pale or grayish. Urine output may be diminished. If cardiac output is significantly decreased, the intensity of the murmur at the right upper sternal border may be minimal. The endocardial surface may be fibrotic and stiff (endocardial fibroelastosis) in the most severe cases.

Outside of the newborn period, most infants and children with less severe forms of aortic stenosis remain asymptomatic and display normal growth and development. The murmur is usually discovered during routine physical examination. Rarely, fatigue, chest pain, dizziness, or syncope with exercise may develop in an older child with previously undiagnosed severe obstruction to LV outflow. Sudden death has been reported with aortic stenosis but usually occurs in patients with severe LVOT obstruction in whom the diagnosis and surgical relief have been delayed.

The physical findings are dependent on the degree of obstruction to LV outflow. In mild stenosis, the pulses, heart size, and apical impulse are all normal. With increasing degrees of severity, the pulses become diminished in intensity and the heart may be enlarged, with an LV apical thrust. Mild to moderate valvular aortic stenosis is usually associated with an early systolic ejection click, best heard at the left sternal border and over the sternum. Unlike the click in pulmonic stenosis, its intensity does not vary with respiration. Clicks are unusual in more severe aortic stenosis or in discrete subaortic stenosis. If the stenosis is severe, S_1 may be diminished because of decreased compliance of the thickened left ventricle. Normal splitting of S_2 is present in mild to moderate obstruction. In patients with severe obstruction, the intensity of the aortic component of S_2 is diminished, and S_2 may be split paradoxically (becoming wider in expiration). A fourth heart sound (S_4) may be audible as a result of decreased LV compliance.

The intensity, pitch, and duration of the systolic ejection murmur are other indications of severity. The louder, harsher (higher pitch), and longer the murmur, the greater the degree of obstruction. The murmur will also peak later in systole with increase severity. The typical murmur is audible maximally at the right upper sternal border and radiates to the neck and the left midsternal border. It is usually accompanied by a thrill in the suprasternal notch and, in older patients, over the carotids. In patients with subvalvular aortic stenosis, the murmur may be maximal along the left sternal border or even at the apex. A soft, decrescendo diastolic murmur is present in patients who also have aortic insufficiency, not uncommon with a bicuspid aortic valve or in patients who have had surgery or balloon valvuloplasty. Occasionally, an apical short mid-diastolic rumbling murmur is audible; this murmur should raise suspicion of associated mitral valve stenosis. Careful attention to both upper- and lower-extremity peripheral pulses is essential. Patients with mild aortic stenosis will have normal pulses; as the severity increases, the pulses will become more diminished. Discrepancy between upper- and lower-extremity pulses or a delay in femoral pulses (radio-femoral delay) suggests associated coarctation of the aorta. Discrepancy between the right and left arm pulses in the presence of normal femoral pulses is a sign of possible supravalvar aortic stenosis.

LABORATORY FINDINGS AND DIAGNOSIS

The diagnosis can usually be made on the basis of the physical examination, and the severity of obstruction confirmed by laboratory tests. If the pressure gradient across the aortic valve is mild, the ECG is likely to be normal. The ECG may occasionally be normal even with mild to moderate obstruction, but evidence of left ventricular hypertrophy (LVH) and LV strain (inverted T waves in left precordial leads) is generally present if moderate to severe stenosis is long-standing. The chest radiograph frequently shows a prominent ascending aorta. Heart size is typically normal or slightly increased. Valvular calcification is noted only in older children and adults. Echocardiography identifies both the site and the severity of the obstruction. Two-dimensional imaging shows LVH and the thickened and abnormally moving aortic valve (Fig. 476.6). The echocardiogram will also demonstrate the number of valve leaflets and their morphology, which leaflets are fused, and the presence of a subaortic membrane or supravalvar stenosis. Associated anomalies of the mitral valve or aortic arch (coarctation of the aorta) or a VSD or PDA are present in up to 20% of cases. In the absence of LV failure, the shortening fraction of the left ventricle may be increased because the ventricle is hypercontractile. In infants with critical aortic

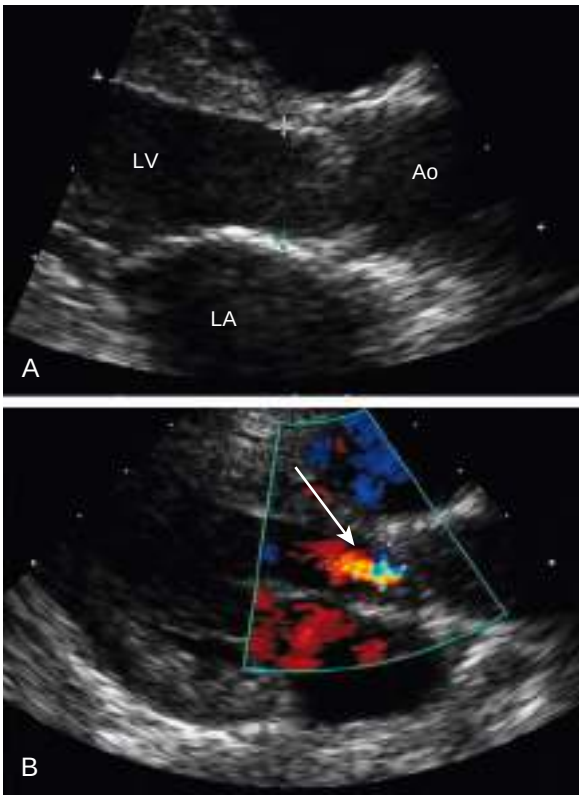

Fig. 476.6 Echocardiogram showing valvar aortic stenosis with regurgitation. **A,** In this parasternal long-axis view, the stenotic aortic valve can be seen doming in systole. The *crosshatch* marks delineate the aortic annulus. **B,** Doppler study shows the presence of aortic regurgitation *(arrow)*. Ao, Aorta; LA, left atrium; LV, left ventricle.

stenosis, the LV shortening fraction is often decreased and may be quite poor. The endocardium may appear bright, indicative of the development of endocardial fibrous scarring, known as **endocardial fibroelastosis**. Doppler studies show the specific site of obstruction and determine the peak and mean systolic LVOT gradients. When severe aortic obstruction is associated with LV dysfunction, the Doppler-derived valve gradient may greatly underestimate the severity of the obstruction because of the low cardiac output across the valve.

Cardiac catheterization is usually not required for diagnostic purposes, but it is usually performed in conjunction with aortic balloon valvuloplasty. Left heart catheterization demonstrates the magnitude of the pressure gradient from the left ventricle to the aorta. The aortic pressure curve is abnormal if the obstruction is severe. In patients with severe obstruction and decreased LV compliance, left atrial pressure is increased and pulmonary hypertension may be present. When a critically ill infant with LVOT obstruction undergoes cardiac catheterization, LV function is often greatly decreased. As with the echocardiogram, the gradient measured across the stenotic aortic valve may underestimate the degree of obstruction because of low cardiac output. Measurement of cardiac output by thermodilution and calculation of the aortic valve area may be helpful.

TREATMENT

Balloon valvuloplasty is indicated for children with moderate to severe valvular aortic stenosis to prevent progressive LV dysfunction and the risk of syncope and sudden death. Valvuloplasty should be advised when the catheter-derived peak-to-peak systolic gradient between the left ventricle and aorta exceeds 60-70 mm Hg at rest, assuming normal cardiac output, or for lesser gradients when symptoms or electrocardiographic changes are present. For more rapidly progressive subaortic obstructive lesions, a gradient of 40-50 mm Hg or the presence of aortic insufficiency is considered an indication for surgery. Balloon valvuloplasty is the procedure of choice even in the neonatal period. Surgical treatment is usually reserved for extremely dysplastic aortic valves that are not amenable to balloon therapy or in patients who also have subvalvar or *supravalvar* aortic stenosis.

Discrete subaortic stenosis can be surgically resected without damage to the aortic valve, the anterior leaflet of the mitral valve, or the conduction system. This type of obstruction is not usually amenable to catheter treatment. Relief of supravalvular stenosis is also achieved surgically, and the results are excellent if the area of obstruction is discrete and not associated with a hypoplastic aorta. In association with supravalvular aortic stenosis, one or both coronary arteries may be stenotic at their origins because of a thick supraaortic fibrous ridge. For patients who have aortic stenosis in association with severe tunnel-like subaortic obstruction, the LVOT can be enlarged by "borrowing" space anteriorly from the right ventricular outflow tract (RVOT) (the **Konno procedure**).

Regardless of whether surgical or catheter treatment has been carried out, aortic insufficiency or calcification with restenosis is likely to occur years or even decades later and eventually require reoperation and often aortic valve replacement. Thus these patients require regular follow-up with a cardiologist. When recurrence develops, it may not be associated with early symptoms. Signs of recurrent stenosis include electrocardiographic signs of LVH, an increase in the Doppler echocardiographic gradient, deterioration in echocardiographic indices of LV function, and recurrence of signs or symptoms during graded treadmill exercise. Evidence of significant aortic regurgitation includes symptoms of heart failure, cardiac enlargement on radiograph, and LV dilation on echocardiogram. The choice of reparative procedure depends on the relative degree of stenosis and regurgitation.

When **aortic valve replacement** is necessary, the choice of procedure often depends on the age of the patient. Homograft valves tend to calcify more rapidly in younger children, but they do not require chronic anticoagulation. Mechanical prosthetic valves are much longer lasting but require anticoagulation, which can be difficult to manage in young children, and they are not available in sizes appropriate for the youngest patients. In adolescent females who are nearing childbearing age, consideration of the teratogenic effects of anticoagulants may warrant the use of a homograft valve. None of these options is perfect for a younger child who requires valve replacement because neither homograft nor mechanical valves grow with the patient. An alternative operation is **aortopulmonary translocation (Ross procedure)**; it involves removing the patient's own pulmonary valve and using it to replace the abnormal aortic valve. A homograft is then placed in the pulmonary position. The potential advantage of this procedure is the possibility for growth of the translocated living "neoaortic" valve and the increased longevity of the homograft valve when placed in the lower-pressure pulmonary circulation. The long-term success of this operation, especially in young children, is still being investigated.

Transcatheter aortic valve replacement (or implantation) (TAVR) uses porcine or bovine (Melody or Sapien) valve tissue sewn into a self-expanding frame. These devices can be implanted in the cardiac catheterization laboratory using a femoral or carotid approach, or transapically through the chest wall, or in a hybrid procedure after a surgical thoracotomy. Initially used mainly in adults who were too ill to be candidates for standard surgical replacement, TAVR is gaining acceptance for carefully selected children who are not good surgical candidates. Short-term outcomes are equivalent to surgical valve replacement. Long-term complications include possible valve regurgitation or perivalvular leaks.

PROGNOSIS

Neonates with critical aortic stenosis may have severe heart failure and deteriorate rapidly to a low-output shock state. Emergency surgery or balloon valvuloplasty is lifesaving, but the mortality risk is not trivial. Neonates who die of critical aortic stenosis frequently have significant LV endocardial fibroelastosis. Those who survive may develop signs of LV diastolic dysfunction (restrictive cardiomyopathy) and eventually require cardiac transplantation (see Chapter 492).

In older infants and children with mild to moderate aortic stenosis, the prognosis is reasonably good, although disease progression over

5-10 years is common. Patients with aortic valve gradients <40-50 mm Hg are considered to have *mild* disease; those with gradients of 40-70 mm Hg have *moderate* disease. These patients usually respond well to treatment (either surgery or valvuloplasty), although reoperations on the aortic valve are often required later in childhood or in adult life, and many patients eventually require valve replacement. In unoperated patients with severe obstruction, sudden death is a significant risk and often occurs during or immediately after exercise. Subaortic stenosis secondary to hypertrophic cardiomyopathy is one of the causes of sudden cardiac death in adolescents and young adults.

Patients with moderate to severe degrees of aortic stenosis should not participate in active competitive sports. In those with milder disease, sports participation is less severely restricted. The status of each patient should be reviewed at least annually and intervention advised if progression of signs or symptoms occurs. Prophylaxis against infective endocarditis is no longer recommended unless a prosthetic or transcatheter (TAVR) valve has been inserted.

Older children and adults with isolated bicuspid aortic valve are at increased risk for developing dilation of their ascending aorta, even in the absence of significant stenosis. This risk increases with age, and the rate of increase is greatest in those with the largest aortic roots. In children, this dilation is usually mild and remains stable over many years of observation, but in young adults and older patients, the aorta can dilate substantially and progressively. Whether these patients have some undiagnosed form of connective tissue disorder remains to be determined (this form of dilation is similar to that seen in Marfan syndrome). Patients with Turner syndrome and bicuspid aortic valve also have an increased risk of aortic dilation. Although dissection and rupture are described complications of severe aortic root dilation in adults, there are not yet sufficient data to determine these risks in children, and careful monitoring with echocardiogram, CT, or MRI is warranted.

Visit Elsevier eBooks+ at eBooks.Health.Elsevier.com for Bibliography.

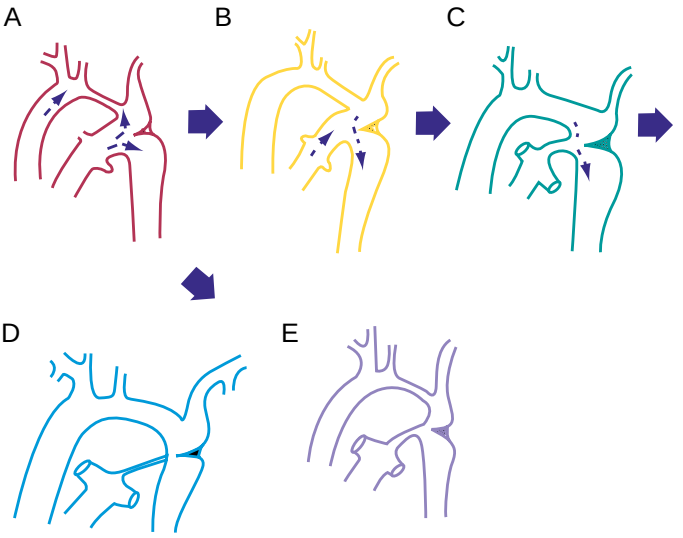

Fig. 476.7 Metamorphosis of coarctation. **A,** Fetal prototype with no flow obstruction. **B,** Late gestation. The aortic ventricle increases its output and dilates the hypoplastic segment. Antegrade aortic flow bypasses the shelf via the ductal orifice. **C,** Neonate. Ductal constriction initiates the obstruction by removing the bypass and increasing antegrade arch flow. **D,** Mature juxtaductal stenosis. The bypass is completely obliterated, and intimal hypoplasia on the edge of the shelf is aggravating the stenosis. Collaterals develop. **E,** Persistence of the infantile-type fetal prototype. An intracardiac left-sided heart obstruction precludes an increase in antegrade aortic flow before or after birth. Both isthmus hypoplasia and a contraductal shelf are present. Lower-body flow often depends on the patency of the ductus. *(From Gersony WM. Coarctation of the aorta. In: Adams FH, Emmanouilides GC, Riemenshneider T, eds. Moss Heart Disease in Infants, Children, and Adolescents, 4th ed. Baltimore: Williams & Wilkins; 1989.)*

476.6 Coarctation of the Aorta

Daniel Bernstein

Constrictions of the aorta of varying degrees may occur at any point from the transverse arch to the iliac bifurcation, but 98% occur just below the origin of the left subclavian artery at the origin of the ductus arteriosus **(juxtaductal coarctation)**. The anomaly is responsible for 5–8% of congenital heart disease and occurs twice as often in males as in females. Coarctation of the aorta is associated with a bicuspid aortic valve in >70% of patients; mitral valve abnormalities (a supravalvular mitral ring or parachute mitral valve) and subaortic stenosis are other associated lesions. When this group of left-sided obstructive lesions occurs together, they are referred to as **Shone complex**. Coarctation of the aorta is found in up to 20% of patients with **Turner syndrome** (see Chapters 99.4 and 626.1); ~5–12% of females with coarctation have Turner syndrome.

PATHOPHYSIOLOGY

Coarctation of the aorta can occur as a discrete juxtaductal obstruction or as tubular hypoplasia of the transverse aorta starting at one of the head or neck vessels and extending to the ductal area (previously referred to as *preductal* or *infantile-type coarctation;* Fig. 476.7). Often, both components are present. It is postulated that coarctation may be initiated in fetal life by the presence of a cardiac abnormality that results in decreased blood flow anterograde through the aortic valve (e.g., bicuspid aortic valve, VSD). Alternatively, it has been theorized that coarctation may be caused by abnormal extension of contractile ductal tissue into the aortic wall.

In patients with discrete juxtaductal coarctation, ascending aortic blood flows through the narrowed segment to reach the descending aorta, although LV hypertension and hypertrophy result. In the first few days of life, the PDA may serve to widen the juxtaductal area of the aorta and provide temporary relief from the obstruction. Net left-to-right ductal shunting occurs in these acyanotic infants. With more severe juxtaductal coarctation or in the presence of transverse arch hypoplasia, RV blood is ejected through the ductus to supply the descending aorta. Perfusion of the lower part of the body is then dependent on RV output. In this situation the femoral pulses are palpable, and differential blood pressures may not be helpful in making the diagnosis. However, the ductal right-to-left shunting is manifested as differential cyanosis, with the upper extremities being well oxygenated and the lower extremities cyanotic. This is one of the main reasons for performing upper- and lower-limb oxygen saturation screening in the newborn because subtle differences in saturation may not be discernable visually. Such infants may have severe pulmonary hypertension and high pulmonary vascular resistance. Signs of heart failure are prominent. Occasionally, severely hypoplastic segments of the aortic isthmus may become completely atretic and result in an interrupted aortic arch, with the left subclavian artery arising either proximal or distal to the interruption.

Blood pressure (BP) is elevated in the vessels that arise proximal to the coarctation; BP and pulse pressure are lower below the constriction. The hypertension is not caused by the mechanical obstruction alone, but also involves neurohumoral mechanisms. Unless surgically corrected in infancy, coarctation of the aorta usually results in the development of an extensive collateral circulation, chiefly from branches of the subclavian, superior intercostal, and internal mammary arteries, to create channels for arterial blood to bypass the area of coarctation. The vessels contributing to the collateral circulation may become greatly enlarged and tortuous by early adulthood.

CLINICAL MANIFESTATIONS

Coarctation of the aorta recognized after infancy may not be associated with significant symptoms, although these may be revealed on closer questioning. Some children or adolescents complain about weakness or pain/claudication (or both) in the legs after exercise, but in many cases, even patients with severe coarctation are asymptomatic. Older

children are frequently brought to the cardiologist's attention when they are found to be hypertensive on routine physical examination.

The classic sign of coarctation of the aorta is a disparity in pulsation and BP in the arms and legs. The femoral, popliteal, posterior tibial, and dorsalis pedis pulses are weak (or absent in up to 40% of patients), in contrast to bounding pulses palpated in the arms and carotid vessels. However, in patients with large numbers of collaterals, the pulse and BP may not be much diminished in the lower extremities; in these cases, diagnosis depends on palpation of the radial and femoral pulses simultaneously for the presence of a **radial-femoral delay**. Normally, the femoral pulse occurs slightly before the radial pulse. A radial-femoral delay occurs when blood flow to the descending aorta is dependent on collaterals, in which case the femoral pulse is felt after the radial pulse. In normal persons *(except neonates),* systolic BP in the legs obtained by the cuff method is usually 10-20 mm Hg higher than that in the arms. In coarctation of the aorta, BP in the legs is lower than that in the arms; frequently, it is difficult to obtain. This differential in BPs is common in patients with coarctation who are older than 1 year, approximately 90% of whom have systolic hypertension in an upper extremity >95th percentile for age. It is important to determine the BP in each arm; a BP higher in the right than the left arm suggests involvement of the left subclavian artery in the area of coarctation. Occasionally, the right subclavian may arise anomalously from below the area of coarctation and result in a left arm BP that is higher than the right. With exercise, a more prominent rise in upper arm BP occurs, and the upper- to lower-extremity pressure gradient will increase.

The precordial impulse and heart sounds are usually normal; the presence of a systolic ejection click or thrill in the suprasternal notch suggests a bicuspid aortic valve (present in 70% of cases). A short systolic murmur is often heard along the left sternal border at the third and fourth intercostal spaces. The murmur is well transmitted to the left infrascapular area and occasionally to the neck. With a bicuspid aortic valve, the typical murmur of aortic stenosis can be heard at the upper right and mid-left sternal borders. Occasionally, more significant degrees of obstruction are noted across the aortic valve. The presence of a low-pitched mid-diastolic murmur at the apex suggests mitral valve stenosis. In older patients with well-developed collateral blood flow, systolic or continuous murmurs may be heard over the left and right sides of the chest laterally and posteriorly. In these patients, a palpable thrill can sometimes be appreciated in the intercostal spaces on the back.

Neonates or infants with more severe coarctation, usually including some degree of transverse arch hypoplasia, initially have signs of lower-body hypoperfusion, acidosis, and severe heart failure. These signs may be delayed days or weeks until after closure of the ductus arteriosus. If detected before ductal closure, patients may exhibit **differential cyanosis**, best demonstrated by simultaneous oximetry of the upper and lower extremities. On physical examination the heart is large, and a systolic murmur is heard along the left sternal border.

Diagnosis

Findings on chest x-ray examination depend on the age of the patient and on the effects of hypertension and the collateral circulation. Cardiac enlargement and pulmonary congestion are noted in infants with severe coarctation. In patients with less severe forms of coarctation, the findings may not be that striking until after the first decade, when the heart tends to be mildly or moderately enlarged because of LV prominence. The enlarged left subclavian artery typically produces a prominent shadow in the left superior mediastinum. **Notching of the inferior border of the ribs** from pressure erosion by enlarged collateral vessels is common by late childhood. In most patients the descending aorta has an area of poststenotic dilation.

The ECG is usually normal in young children with milder degrees of coarctation but demonstrates LV hypertrophy in older patients. Neonates and young infants display right or biventricular hypertrophy. The segment of coarctation can generally be visualized by 2D echocardiography (Fig. 476.8); associated anomalies of the mitral and aortic valve can also be demonstrated. The descending aorta is hypopulsatile, and color Doppler demonstrates the specific site of the obstruction. Pulsed and continuous wave Doppler studies determine the pressure gradient directly at the area of coarctation; in the presence of a PDA, however, the severity of the narrowing may be underestimated. CT and MRI

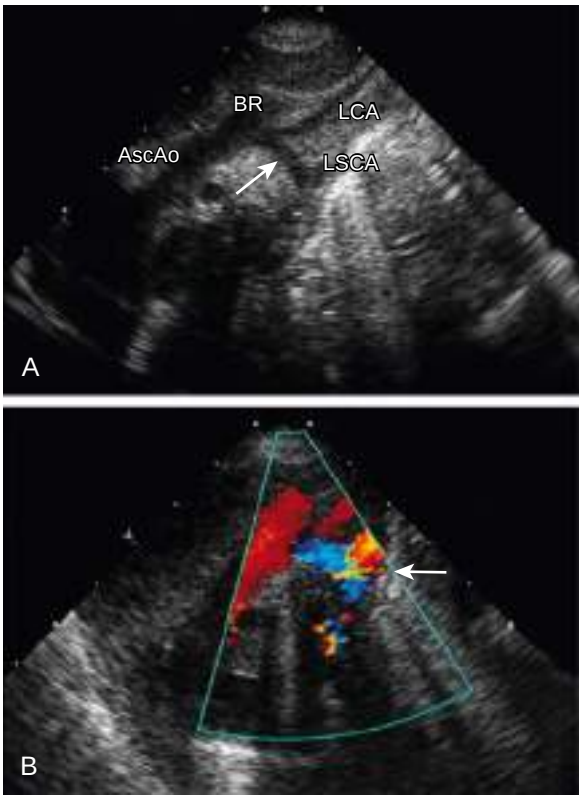

Fig. 476.8 Echocardiogram demonstrating coarctation of the aorta with hypoplastic transverse arch. **A,** Suprasternal notch 2D echocardiogram showing marked narrowing beginning just distal to the brachiocephalic artery. **B,** Color Doppler demonstrates turbulent flow in the juxtaductal area *(arrow).* AscAo, Ascending aorta; BR, brachiocephalic artery; LCA, left carotid artery; LSCA, left subclavian artery.

are valuable noninvasive tools for evaluation of coarctation when the echocardiogram is equivocal (Fig. 476.9). Cardiac catheterization with selective left ventriculography and aortography is useful in occasional patients with additional anomalies and as a means of visualizing collateral blood flow. In cases that are well defined by echocardiography, CT, or MRI, diagnostic catheterization is not usually required before surgery.

TREATMENT

In **neonates** with severe coarctation of the aorta, closure of the ductus often results in hypoperfusion, acidosis, and rapid deterioration. These patients should be given an infusion of prostaglandin E_1 to reopen the ductus and reestablish adequate lower-extremity blood flow. Once a diagnosis has been confirmed and the patient stabilized, surgical repair should be performed. **Older infants** with heart failure but good perfusion should be managed with anticongestive measures to improve their clinical status in preparation for surgical intervention. There is usually no reason to delay surgical repair waiting for patient growth; successful repairs have been performed even in small premature infants.

Older children with significant coarctation of the aorta should be treated relatively soon after diagnosis. Delay is unwarranted, especially after the second decade of life, when there may be decreased LV function and degenerative changes in the aortic wall. For patients with significant left ventricular dysfunction, relief of the obstruction can improve function as afterload on the ventricle is dramatically decreased; however, if fibrosis has occurred, patients can have residual left ventricular dysfunction. If cardiac function is normal, satisfactory repair and long-term outcome are possible well into mid-adult life.

Surgery remains the treatment of choice for isolated juxtaductal coarctation of the aorta in neonates, infants, and young children at most centers; several surgical techniques are used. The area of coarctation can be excised and a primary reanastomosis performed. Most often, the transverse aorta is opened and an "extended end-to-end" anastomosis performed to increase the effective cross-sectional area of the repair. The subclavian

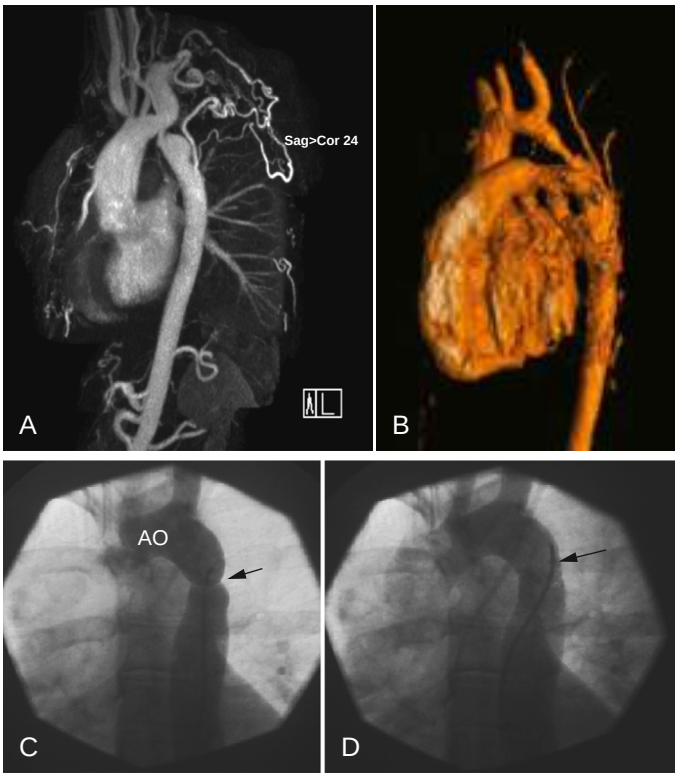

Fig. 476.9 Coarctation of the aorta. **A,** CT angiogram of coarctation. **B,** 3D reconstruction. Angiograms of the coarctation before (**C**) and after (**D**) stenting *(arrows).* AO, Aorta. *(Adapted from Webb GD, Smallhorn JF, Therrien J, et al. Congenital heart disease in the adult and pediatric patient. In: Zipes DP, Libby P, Bonow RO, et al., eds. Braunwald's Heart Disease, 11th ed. Philadelphia: Elsevier; 2019: Fig. 75.41, p. 1561.)*

flap procedure, which involves division of the left subclavian artery and its incorporation into the wall of the repaired coarctation, has fallen out of favor because of a higher degree of residual stenosis. Some centers favor a patch aortoplasty, in which the area of coarctation is enlarged with a roof of prosthetic material. The use of **primary angioplasty** for native coarctation has been effective in older children and adults. In infants ≥3 months of age, balloon angioplasty has been as effective as surgery but is associated with higher rates of recoarctation requiring intervention (repeat angioplasty or surgery) and aortic aneurysm formation. Surgery is the treatment of choice for the symptomatic neonate. Angioplasty is the treatment of choice for recoarctation. **Primary stent placement** in the catheterization laboratory is considered in older children, where the stent can be expanded if needed to keep up with patient growth and for young adults (see Fig. 476.9). For patients who present with severe LV dysfunction, where surgical intervention may be associated with increased risk, catheter-based treatments are often considered.

After surgery, a striking increase in the amplitude of the pulse in the lower extremities is noted. In the immediate postoperative course, *rebound hypertension* can occur and requires medical management. This exaggerated acute hypertension gradually subsides, and in most patients, antihypertensive medications can be discontinued. Residual murmurs are common and may result from associated cardiac anomalies, a residual flow disturbance across the repaired area, or collateral blood flow. Rare operative problems include spinal cord injury from aortic cross-clamping (if collaterals are poorly developed), chylothorax, diaphragm injury, and laryngeal nerve injury. If a left subclavian flap approach is used, the radial pulse and BP in the left arm are diminished or absent.

POSTCOARCTECTOMY SYNDROME

Postoperative **mesenteric arteritis** may be associated with acute hypertension and abdominal pain in the immediate postoperative period. The pain varies in severity and may occur in conjunction with anorexia, nausea, vomiting, leukocytosis, intestinal hemorrhage, bowel necrosis, and small bowel obstruction. Relief is usually obtained with antihypertensive drugs (e.g., nitroprusside, esmolol, captopril) and intestinal decompression; surgical exploration is rarely required for bowel obstruction or infarction.

PROGNOSIS

Although restenosis in older patients after coarctectomy is rare, a significant number of infants operated on before 1 year of age require revision later in childhood. All patients should be monitored carefully for the development of recoarctation and for aortic aneurysm at the anastomotic site. Should recoarctation occur, **balloon angioplasty** is the procedure of choice. In these patients, scar tissue from a previous surgery may make reoperation more difficult, yet it makes balloon angioplasty safer because of the lower incidence of aneurysm formation. Relief of obstruction with this technique is usually excellent. **Intravascular stents** are typically used, especially in adolescents and young adults, with generally excellent results.

Repair of coarctation in the second decade of life or beyond may be associated with a higher incidence of premature cardiovascular disease, even in the absence of residual cardiac abnormalities. Early onset of **adult-type chronic hypertension** may occur, even in patients with adequately resected coarctation.

Abnormalities of the aortic valve are present in a majority of patients. Bicuspid aortic valves are common but do not generally produce clinical signs unless the stenosis is significant. The association of a PDA with coarctation of the aorta is also common. VSDs and ASDs may be suspected by signs of a left-to-right shunt; they are exacerbated by the increased resistance to flow through the left side of the heart. Mitral valve abnormalities are also occasionally seen, as is subvalvular aortic stenosis.

Severe neurologic damage or even death may rarely occur from associated cerebrovascular disease. Subarachnoid or intracerebral hemorrhage may result from rupture of congenital aneurysms in the circle of Willis, rupture of other vessels with defective elastic and medial tissue, or rupture of normal vessels; these events are secondary to hypertension. Children with **PHACE syndrome** (posterior brain fossa anomalies, facial hemangiomas, arterial anomalies, cardiac anomalies and aortic coarctation, eye anomalies syndrome) may have strokes (see Table 691.5). Abnormalities of the subclavian arteries may include involvement of the left subclavian artery in the area of coarctation, stenosis of the orifice of the left subclavian artery, and anomalous origin of the right subclavian artery.

Untreated, the great majority of older patients with coarctation of the aorta would succumb between ages 20 and 40 years; some live well into middle life without serious disability. The common serious complications are related to systemic hypertension, which may result in premature coronary artery disease, heart failure, hypertensive encephalopathy, or intracranial hemorrhage. Heart failure may be worsened by associated anomalies. Infective endocarditis or endarteritis is a significant complication in these adult patients. Aneurysms of the descending aorta or the enlarged collateral vessels may develop.

Visit Elsevier eBooks+ at eBooks.Health.Elsevier.com for Bibliography.

476.7 Coarctation with Ventricular Septal Defect

Daniel Bernstein

In most cases, coarctation is the major anomaly causing the severe symptoms, and resection of the coarcted segment results in striking improvement. Repair of both the VSD and coarctation is usually performed at the same operation through a midline sternotomy using cardiopulmonary bypass.

476.8 Coarctation with Other Cardiac Anomalies and Interrupted Aortic Arch

Daniel Bernstein

Coarctation often occurs in infancy in association with other major cardiovascular anomalies, including hypoplastic left heart, severe mitral or aortic valve disease, transposition of the great arteries, and variations of

double-outlet or single-ventricle. The clinical manifestations depend on the effects of the associated malformations and on the coarctation itself.

Coarctation of the aorta associated with severe **mitral** and **aortic valve disease** may have to be treated within the context of hypoplastic left heart syndrome (see Chapter 480.10), even if the LV chamber is not severely hypoplastic. Such patients usually have a long segment of narrow, transverse aortic arch in addition to an isolated coarctation at the site of the ductus arteriosus. Coarctation of the aorta with **transposition of the great arteries** or **single ventricle** may be repaired alone or in combination with other corrective or palliative measures.

Complete interruption of the aortic arch is the most severe form of coarctation and is usually associated with other intracardiac pathology. Interruption may occur at any level, although it is most often seen between the left subclavian artery and the insertion of the ductus arteriosus **(type A)**, followed in frequency by those between the left subclavian and left carotid arteries **(type B)**, or between the left carotid and brachiocephalic arteries **(type C)**. In newborns with an interrupted aortic arch, the ductus arteriosus provides the sole source of blood flow to the descending aorta, and differential oxygen saturations between the right arm (normal saturation) and the legs (decreased saturation) is noted. When the ductus begins to close, severe congestive heart failure, lower-extremity hypoperfusion, and anuria usually develop, progressing to shock. Patients with an interrupted aortic arch can be supported with prostaglandin E_1 to keep the ductus open before surgical repair. As one of the **conotruncal malformations**, an interrupted aortic arch, especially type B, can be associated with **DiGeorge syndrome** (cardiac defects, abnormal facies, thymic hypoplasia, cleft palate, hypocalcemia). Cytogenetic analysis using fluorescence in situ hybridization demonstrates deletion of a segment of chromosome 22q11, known as the **DiGeorge critical region**.

476.9 Congenital Mitral Stenosis

Daniel Bernstein

Congenital mitral stenosis is a rare anomaly that can be either isolated or associated with other defects, the most common being subvalvar and valvar aortic stenosis and coarctation of the aorta **(Shone complex)**. The mitral valve may be funnel shaped, with thickened leaflets and chordae tendineae that are shortened and deformed. Other mitral valve anomalies associated with stenosis include **parachute** mitral valve, caused by a single papillary muscle, and **double-orifice** mitral valve.

If the stenosis is moderate to severe, symptoms usually appear within the first 2 years of life. These infants have failure to thrive and various degrees of dyspnea and pallor. In some patients, wheezing may be a dominant symptom, and a misdiagnosis of bronchiolitis or reactive airway disease may have been made. Heart enlargement because of dilation and hypertrophy of the right ventricle and left atrium is common. Most patients have rumbling apical diastolic murmurs, but because the pressure gradients in diastole are not very high, the auscultatory findings may be relatively obscure. S_2 is split with a loud P_2 if pulmonary hypertension is present. An opening snap of the mitral valve may be present. The ECG reveals RVH and may show bifid or spiked P waves indicative of left atrial enlargement. Radiographs usually show left atrial and RV enlargement and pulmonary congestion in a perihilar or venous pattern. The echocardiogram is diagnostic and shows thickened mitral valve leaflets, a significant reduction of the mitral valve orifice, abnormal papillary muscle structure (or a single papillary muscle), and an enlarged left atrium with a normal or small left ventricle. A **double-orifice mitral valve** is one variant that can usually be seen on echocardiogram. Doppler studies demonstrate a mean pressure gradient across the mitral orifice during diastole. Associated anomalies such as aortic stenosis and coarctation can be evaluated. Cardiac catheterization is often performed to confirm the transmitral pressure gradient before surgery. An increase in RV, pulmonary artery, and pulmonary capillary wedge pressure can be noted. Angiocardiography shows delayed emptying of the left atrium and the small mitral orifice.

The results of surgical treatment depend on the anatomy of the valve, but if the mitral orifice is significantly hypoplastic, reduction of the gradient may be difficult. In some patients, a mitral valve prosthesis is required, and if the valve orifice is too small, the prosthesis may be placed in the supramitral position. However, whatever prosthesis is used, it must be replaced serially as the child grows. These patients must be anticoagulated, usually with warfarin, and although manageable in older children, complications of excessive and insufficient anticoagulation are more common in infancy. Transcatheter balloon valvuloplasty has been used as a palliative procedure with mixed results, except in the situation of rheumatic mitral stenosis. Recent experience using the percutaneous Melody stent-valve in selected patients in the mitral position is encouraging.

Visit Elsevier eBooks+ at eBooks.Health.Elsevier.com for Bibliography.

476.10 Pulmonary Venous Hypertension

Daniel Bernstein

A variety of lesions may give rise to chronic pulmonary venous hypertension, which, when extreme, may result in pulmonary arterial hypertension and right-sided heart failure. These lesions include congenital **mitral stenosis**, **mitral insufficiency**, **total anomalous pulmonary venous return with obstruction**, **left atrial myxomas**, **cor triatriatum**, individual **pulmonary vein stenosis**, and **supravalvular mitral rings**. Early symptoms can be confused with chronic pulmonary disease such as asthma because of a lack of specific cardiac findings on physical examination. Subtle signs of pulmonary hypertension may be present. The ECG shows RVH with spiked P waves. Radiographic studies demonstrate prominence of the pulmonary veins in the hilar region and enlargement of the right ventricle and atrium and the main pulmonary artery; the left atrium is normal in size or only slightly enlarged.

The echocardiogram may demonstrate left atrial myxoma, cor triatriatum, stenosis of one or more pulmonary veins, or a mitral valve abnormality (e.g., supravalvar mitral ring). Cardiac catheterization excludes the presence of a shunt and demonstrates pulmonary hypertension with elevated pulmonary arterial wedge pressure. Left atrial pressure is normal if the lesion is at the level of the pulmonary veins, but it is elevated if the lesion is at the level of the mitral valve. Selective pulmonary arteriography usually delineates the anatomic lesion. Cor triatriatum, left atrial myxoma, and supravalvular mitral rings can all be successfully managed surgically.

The differential diagnosis includes **pulmonary venoocclusive disease**, an idiopathic process that produces obstructive lesions in one or more pulmonary veins. The cause is uncertain, and disease that begins in one vein can spread to others. Although it is usually encountered in patients after repair of obstructed total anomalous pulmonary venous return (see Chapter 480.7), it can occur sporadically or in families in the absence of congenital heart disease. Pathogenic variants in *BMPR2* may be seen in the familial or sporadic cases. The patient initially presents with symptoms similar to left-sided heart failure on the basis of congested lungs with apparent pulmonary edema. Dyspnea, fatigue, and pleural effusions are common. Left atrial pressure is normal, but pulmonary arterial wedge pressure is usually elevated. A normal wedge pressure may be encountered if collaterals have formed, or the wedge recording is performed in an uninvolved segment. Angiographically, the pulmonary veins return normally to the left atrium, but one or more pulmonary veins are narrowed, either focally or diffusely. Sporadic or familial cases present with a primary pulmonary hypertension phenotype, with dyspnea and cyanosis. However, treatment with a primary pulmonary hypertension regimen will precipitate pulmonary edema.

Studies using lung biopsy have demonstrated pulmonary venous and, occasionally, arterial involvement. Pulmonary veins and venules demonstrate fibrous narrowing or occlusion, and pulmonary artery thrombi may be present. Attempts at surgical repair, balloon dilation, and transcatheter stenting have not significantly improved the generally poor prognosis of these patients. Use of antiproliferative agents with imatinib with or without bevacizumab has demonstrated success in preliminary studies. Combined heart-lung transplantation is often the only alternative therapeutic option (see Chapter 492.2).

Visit Elsevier eBooks+ at eBooks.Health.Elsevier.com for Bibliography.

Chapter 477

Acyanotic Congenital Heart Disease: Regurgitant Lesions

477.1 Pulmonary Valvular Insufficiency and Congenital Absence of the Pulmonary Valve

Daniel Bernstein

Pulmonary valvular insufficiency most often accompanies other cardiovascular diseases (surgical repair of pulmonary valve stenosis) or may be secondary to severe **pulmonary hypertension**. Some degree of incompetence of the valve is an expected result after surgery for right ventricular outflow tract (RVOT) obstruction, including pulmonary valvotomy in patients with **valvular pulmonic stenosis** or valvotomy with infundibular resection in patients with **tetralogy of Fallot**. Isolated congenital insufficiency of the pulmonary valve is rare, and these patients are usually asymptomatic because the insufficiency is generally mild.

The prominent physical sign is a decrescendo diastolic murmur at the upper and mid-left sternal border, which has a lower pitch than the murmur of aortic insufficiency because of the lower pressure involved. Radiographs of the chest show prominence of the main pulmonary artery and, if the insufficiency is severe, right ventricular (RV) enlargement. The electrocardiogram (ECG) is normal or shows an rSR′ pattern in the right precordial leads (V_1, V_2) and minimal or no RV hypertrophy. Pulsed and color Doppler studies demonstrate retrograde flow from the pulmonary artery into the right ventricle during diastole. Echocardiography can give qualitative measures of RV volume; cardiac magnetic resonance angiography (MRA) is the best method for quantifying RV volume, the regurgitant fraction, and RV systolic function (ejection fraction). Mild pulmonary valvular insufficiency is generally well tolerated and does not require surgical treatment. When pulmonary insufficiency is moderate to severe and the right ventricle becomes significantly dilated and/or if tricuspid insufficiency has begun to develop, re-repair, replacement with a homograft valve, or transcatheter stent-valve placement may become necessary to preserve RV function.

Congenital absence of the pulmonary valve is usually associated with a ventricular septal defect (VSD), often in the context of tetralogy of Fallot (see Chapter 479.1). In many of these neonates, the pulmonary arteries become widely dilated and compress the bronchi, resulting in recurrent episodes of wheezing, pulmonary collapse, and pneumonitis. The presence and degree of cyanosis are variable. Florid pulmonary valvular incompetence may not be well tolerated, and death may occur from a combination of bronchial compression, hypoxemia, and heart failure. Correction involves plication of the massively dilated pulmonary arteries, closure of the VSD, and placement of a homograft across the RVOT.

Visit Elsevier eBooks+ at eBooks.Health.Elsevier.com for Bibliography.

477.2 Congenital Mitral Insufficiency

Daniel Bernstein

Congenital mitral insufficiency is rare as an isolated lesion and is more often associated with other anomalies. It is most frequently encountered in combination with an **atrioventricular septal defect**, either an ostium primum defect or a complete atrioventricular septal defect (see Chapter 475.5) where the insufficient jet is through a cleft in the mitral valve. Mitral insufficiency is also seen in patients with dilated cardiomyopathy (see Chapter 488.1) when the left ventricular (LV) function deteriorates, the chamber dilates, and the valve ring is stretched. In adults, mitral insufficiency can be the result of ischemic injury to a papillary muscle; this is uncommon in children. Mitral insufficiency may also be encountered in conjunction with coarctation of the aorta, VSD, corrected transposition of the great vessels, anomalous origin of the left coronary artery from the pulmonary artery, or Marfan syndrome. In the absence of other congenital heart disease, endocarditis or rheumatic fever should be suspected in a patient with isolated mitral insufficiency.

In mitral insufficiency caused by a congenitally malformed valve, the mitral valve annulus may be dilated, the chordae tendineae short and may insert anomalously, and the valve leaflets are deformed. When mitral insufficiency is severe enough to cause clinical symptoms, the left atrium enlarges as a result of the regurgitant flow, and the left ventricle becomes dilated and mildly hypertrophied. Pulmonary venous pressure is increased, and the increased pressure can ultimately result in pulmonary hypertension and RV hypertrophy and dilation. Mild lesions produce no symptoms; the only abnormal sign is an apical holosystolic murmur of mitral regurgitation. In contrast, moderate to severe regurgitation results in symptoms that can appear at any age, including poor growth, frequent respiratory infections, fatigue on exertion, and episodes of pulmonary edema or congestive heart failure. Often, a diagnosis of reactive airways disease will have been made because of the similarity in pulmonary symptoms, including wheezing, which may be a dominant finding in infants and young children. The presence of a murmur helps distinguish these two etiologies.

The typical murmur of mitral insufficiency is a moderately high-pitched, apical blowing, holosystolic murmur. The murmur radiates from the apex toward the mid-left sternal border. If the insufficiency is moderate to severe, it is usually associated with a low-pitched, apical mid-diastolic rumbling murmur indicative of increased diastolic flow across the mitral valve (physiologic mitral stenosis). The pulmonic component of the second heart sound will be accentuated if there is pulmonary hypertension. The ECG usually shows bifid P waves consistent with left atrial enlargement, signs of LV hypertrophy, and sometimes signs of RV hypertrophy. Radiographic examination shows enlargement of the left atrium, which at times can be massive. The left ventricle is also enlarged and pulmonary vascularity prominent, especially in the perihilar areas. The echocardiogram demonstrates the enlarged left atrium and left ventricle and defines the structure of the valve, the presence or absence of a cleft, and the chordal apparatus. 3D echocardiography is especially useful for this imaging. Color Doppler demonstrates the extent of the insufficiency, and pulsed Doppler of the pulmonary veins detects retrograde flow when mitral insufficiency is severe. Cardiac catheterization shows elevated left atrial pressure and left ventricular end-diastolic pressure. Pulmonary artery hypertension of varying severity may be present. Selective left ventriculography demonstrates the severity of mitral regurgitation.

Surgical **mitral valvuloplasty** can result in striking improvement in symptoms and heart size, but in some patients, installation of a prosthetic mechanical mitral valve may be necessary. Before surgery, associated anomalies must be identified, as they will need to be addressed at the time of valve repair. If the valve requires replacement, several alternatives are available, including mechanical (used mainly for older children) and bioprosthetic, as well as the use of the Melody stent-valve. These can be inserted during a **hybrid procedure** (surgery and catheterization). A cardiac catheter laboratory–inserted device (MitraClip), used mostly in adults, has been used in a few selected pediatric patients to cinch together the anterior and posterior mitral valve leaflets, reducing insufficiency by creating a double-orifice mitral valve.

477.3 Mitral Valve Prolapse

Daniel Bernstein

Mitral valve prolapse (MVP) results from an abnormal mitral valve mechanism that causes billowing of one or both mitral leaflets, especially the posterior cusp, into the left atrium toward the end of ventricular systole. The abnormality is predominantly congenital but may not be recognized until adolescence or adulthood. Primary mitral valve prolapse is common, is present in 2–3% of the population, is more common in females, and may be sporadic or inherited as an autosomal dominant trait (less often X-linked) with variable expression. Pathogenic variants in *DCHS1, LMCD1, TNS1,* and *DZIP1* are possible genes associated with nonsyndromic MVP. It is a common finding in patients with Marfan syndrome, Loeys-Dietz syndrome, mitral-aortic-skeleton-skin (MASS) phenotype, familial myxomatous valvular degeneration, fragile X syndrome, mucopolysaccharidoses, Stickler syndrome, straight back syndrome, pectus excavatum, scoliosis, Ehlers-Danlos syndrome, osteogenesis imperfecta, and pseudoxanthoma elasticum and can also be associated with hyperthyroidism. Fibromyxomatous degeneration of the valve leaflets causes them to be thickened and elongated.

The abnormal signs are auscultatory, although occasional patients may have chest pain and/or palpitations. The apical murmur is late systolic and may be preceded by a click, but these signs may vary in the same patient, and at times, only the click is audible. Sudden standing, or the strain phase of the Valsalva maneuver, decreases LV volume, so the click moves closer to S_1 and the murmur becomes longer. Squatting (or the release phase of the Valsalva maneuver) increases LV volume, so that the click moves away from S_1 and the murmur is shortened. Arrhythmias may occur, primarily unifocal or multifocal premature ventricular contractions. In young adults, MVP has been associated with sudden cardiac death secondary to ventricular arrhythmias.

The ECG is usually normal but may show biphasic T waves, especially in leads II, III, aVF, and V_6; the T-wave abnormalities may vary at different times in the same patient. The chest radiograph is normal. The echocardiogram shows a characteristic posterior movement of the posterior mitral leaflet during mid- or late ventricular systole or demonstrates pansystolic prolapse of both the anterior and posterior mitral leaflets. These echocardiographic findings must be interpreted cautiously because the appearance of minimal mitral prolapse may be a normal variant. Prolapse is more precisely defined by single or bileaflet prolapse of >2 mm beyond the long-axis annular plane of the valve with or without leaflet thickening. Prolapse with valve thickening >5 mm is "classic"; a lesser degree is "nonclassic." Two-dimensional echocardiography shows that both the free edge and the body of the mitral leaflets move posteriorly in systole toward the left atrium. Doppler is then used to assess the presence and severity of mitral regurgitation.

This lesion is not progressive in childhood, and specific therapy is not indicated. Antibiotic prophylaxis is not recommended during surgery and dental procedures (see Chapter 486). This recommendation is controversial because certain features (regurgitation, thickened redundant leaflets) may increase the risk of endocarditis.

Adults (males more often than females) with MVP are at increased risk for cardiovascular complications (sudden death, arrhythmia, cerebrovascular accident, progressive valve dilation, heart failure, and endocarditis) if they have thickened (>5 mm) and redundant mitral valve leaflets. Risk factors for morbidity also include poor LV function, moderate to severe mitral regurgitation, and left atrial enlargement. MVP with severe valve regurgitation, or heart failure, or significant arrhythmias may require initial valve repair or replacement. Beta-blocking agents have been used for patients with palpitations and some arrhythmias. Most patients are asymptomatic and require no treatment.

Visit Elsevier eBooks+ at eBooks.Health.Elsevier.com for Bibliography.

477.4 Tricuspid Regurgitation

Daniel Bernstein

Isolated congenital tricuspid regurgitation is most often associated with **Ebstein anomaly of the tricuspid valve** (see Chapter 479.7). Ebstein anomaly may occur either without cyanosis or with varying degrees of cyanosis, depending on the severity of the tricuspid regurgitation and the presence of an atrial-level communication (patent foramen ovale or atrial septal defect). Older children tend to have the acyanotic form or only develop cyanosis with exercise, whereas if detected in the newborn period, Ebstein anomaly is usually associated with severe cyanosis.

In pediatric patients, tricuspid regurgitation is most often associated with congenital heart disease and/or RV dysfunction. When the right ventricle becomes dilated because of volume overload (e.g., pulmonary insufficiency) or intrinsic myocardial disease (dilated cardiomyopathy), the tricuspid annulus also enlarges, with separation of the leaflets and resultant valve insufficiency. This form of regurgitation may improve if the cause of the RV dilation is corrected, or it may require surgical plication of the valve annulus. Tricuspid regurgitation can also be encountered in patients with congenitally corrected transposition of the great arteries (see Chapter 479) and in patients with hypoplastic left heart syndrome after surgical palliation; in both of these situations the RV is pumping at systemic pressure. Isolated tricuspid regurgitation is also encountered in newborns with perinatal asphyxia. The cause may be related to an increased susceptibility of the papillary muscles to ischemic damage and subsequent transient papillary muscle dysfunction. Lastly, tricuspid regurgitation is seen in up to 30% of children after heart transplantation, which can be a risk factor for graft dysfunction, but is also seen as a result of valve injury caused by endomyocardial biopsy.

Visit Elsevier eBooks+ at eBooks.Health.Elsevier.com for Bibliography.

Chapter 478

Cyanotic Congenital Heart Disease: Evaluation of the Critically Ill Neonate with Cyanosis and Respiratory Distress

Daniel Bernstein

See also Chapter 124.

A severely ill neonate with cardiorespiratory distress and cyanosis is a diagnostic challenge. The clinician must perform a rapid evaluation to determine whether congenital heart disease (CHD) is a cause so that potentially lifesaving measures can be instituted. The differential diagnosis of neonatal cyanosis is presented in Table 121.2.

477.3 Mitral Valve Prolapse

Daniel Bernstein

Mitral valve prolapse (MVP) results from an abnormal mitral valve mechanism that causes billowing of one or both mitral leaflets, especially the posterior cusp, into the left atrium toward the end of ventricular systole. The abnormality is predominantly congenital but may not be recognized until adolescence or adulthood. Primary mitral valve prolapse is common, is present in 2–3% of the population, is more common in females, and may be sporadic or inherited as an autosomal dominant trait (less often X-linked) with variable expression. Pathogenic variants in *DCHS1, LMCD1, TNS1,* and *DZIP1* are possible genes associated with nonsyndromic MVP. It is a common finding in patients with Marfan syndrome, Loeys-Dietz syndrome, mitral-aortic-skeleton-skin (MASS) phenotype, familial myxomatous valvular degeneration, fragile X syndrome, mucopolysaccharidoses, Stickler syndrome, straight back syndrome, pectus excavatum, scoliosis, Ehlers-Danlos syndrome, osteogenesis imperfecta, and pseudoxanthoma elasticum and can also be associated with hyperthyroidism. Fibromyxomatous degeneration of the valve leaflets causes them to be thickened and elongated.

The abnormal signs are auscultatory, although occasional patients may have chest pain and/or palpitations. The apical murmur is late systolic and may be preceded by a click, but these signs may vary in the same patient, and at times, only the click is audible. Sudden standing, or the strain phase of the Valsalva maneuver, decreases LV volume, so the click moves closer to S_1 and the murmur becomes longer. Squatting (or the release phase of the Valsalva maneuver) increases LV volume, so that the click moves away from S_1 and the murmur is shortened. Arrhythmias may occur, primarily unifocal or multifocal premature ventricular contractions. In young adults, MVP has been associated with sudden cardiac death secondary to ventricular arrhythmias.

The ECG is usually normal but may show biphasic T waves, especially in leads II, III, aVF, and V_6; the T-wave abnormalities may vary at different times in the same patient. The chest radiograph is normal. The echocardiogram shows a characteristic posterior movement of the posterior mitral leaflet during mid- or late ventricular systole or demonstrates pansystolic prolapse of both the anterior and posterior mitral leaflets. These echocardiographic findings must be interpreted cautiously because the appearance of minimal mitral prolapse may be a normal variant. Prolapse is more precisely defined by single or bileaflet prolapse of >2 mm beyond the long-axis annular plane of the valve with or without leaflet thickening. Prolapse with valve thickening >5 mm is "classic"; a lesser degree is "nonclassic." Two-dimensional echocardiography shows that both the free edge and the body of the mitral leaflets move posteriorly in systole toward the left atrium. Doppler is then used to assess the presence and severity of mitral regurgitation.

This lesion is not progressive in childhood, and specific therapy is not indicated. Antibiotic prophylaxis is not recommended during surgery and dental procedures (see Chapter 486). This recommendation is controversial because certain features (regurgitation, thickened redundant leaflets) may increase the risk of endocarditis.

Adults (males more often than females) with MVP are at increased risk for cardiovascular complications (sudden death, arrhythmia, cerebrovascular accident, progressive valve dilation, heart failure, and endocarditis) if they have thickened (>5 mm) and redundant mitral valve leaflets. Risk factors for morbidity also include poor LV function, moderate to severe mitral regurgitation, and left atrial enlargement. MVP with severe valve regurgitation, or heart failure, or significant arrhythmias may require initial valve repair or replacement. Beta-blocking agents have been used for patients with palpitations and some arrhythmias. Most patients are asymptomatic and require no treatment.

Visit Elsevier eBooks+ at eBooks.Health.Elsevier.com for Bibliography.

477.4 Tricuspid Regurgitation

Daniel Bernstein

Isolated congenital tricuspid regurgitation is most often associated with **Ebstein anomaly of the tricuspid valve** (see Chapter 479.7). Ebstein anomaly may occur either without cyanosis or with varying degrees of cyanosis, depending on the severity of the tricuspid regurgitation and the presence of an atrial-level communication (patent foramen ovale or atrial septal defect). Older children tend to have the acyanotic form or only develop cyanosis with exercise, whereas if detected in the newborn period, Ebstein anomaly is usually associated with severe cyanosis.

In pediatric patients, tricuspid regurgitation is most often associated with congenital heart disease and/or RV dysfunction. When the right ventricle becomes dilated because of volume overload (e.g., pulmonary insufficiency) or intrinsic myocardial disease (dilated cardiomyopathy), the tricuspid annulus also enlarges, with separation of the leaflets and resultant valve insufficiency. This form of regurgitation may improve if the cause of the RV dilation is corrected, or it may require surgical plication of the valve annulus. Tricuspid regurgitation can also be encountered in patients with congenitally corrected transposition of the great arteries (see Chapter 479) and in patients with hypoplastic left heart syndrome after surgical palliation; in both of these situations the RV is pumping at systemic pressure. Isolated tricuspid regurgitation is also encountered in newborns with perinatal asphyxia. The cause may be related to an increased susceptibility of the papillary muscles to ischemic damage and subsequent transient papillary muscle dysfunction. Lastly, tricuspid regurgitation is seen in up to 30% of children after heart transplantation, which can be a risk factor for graft dysfunction, but is also seen as a result of valve injury caused by endomyocardial biopsy.

Visit Elsevier eBooks+ at eBooks.Health.Elsevier.com for Bibliography.

Chapter 478

Cyanotic Congenital Heart Disease: Evaluation of the Critically Ill Neonate with Cyanosis and Respiratory Distress

Daniel Bernstein

See also Chapter 124.

A severely ill neonate with cardiorespiratory distress and cyanosis is a diagnostic challenge. The clinician must perform a rapid evaluation to determine whether congenital heart disease (CHD) is a cause so that potentially lifesaving measures can be instituted. The differential diagnosis of neonatal cyanosis is presented in Table 121.2.

CARDIAC DISEASE LEADING TO CYANOSIS

CHD produces cyanosis when obstruction to right ventricular inflow or outflow causes intracardiac right-to-left shunting or when complex anatomic defects cause an admixture of pulmonary (deoxygenated) and systemic (oxygenated) venous return somewhere in the heart. Cyanosis from pulmonary edema may also develop in patients with heart failure caused by left-to-right shunts, although the degree of desaturation is usually less severe. In general, right ventricular outflow obstruction without an intracardiac shunt (e.g., isolated valvar pulmonary stenosis) does not cause cyanosis; however, in the newborn period, cyanosis may be caused by right-to-left shunting across the foramen ovale in the presence of elevated right-sided filling pressures. **Persistent pulmonary hypertension of the newborn (PPHN)** is another cause of right-to-left shunting at the atrial level in the newborn period (see Chapter 130).

DIFFERENTIAL DIAGNOSIS

The **hyperoxia test** is one method of distinguishing cyanotic CHD from pulmonary disease. This test is based on the premise that neonates with cyanotic CHD usually are unable to significantly raise their arterial blood partial pressure of oxygen (Pa_{O_2}) during administration of 100% oxygen, whereas in infants with pulmonary disease, high levels of intraalveolar P_{O_2} will overcome at least some of the ventilation-perfusion abnormalities and reverse the hypoxia. This test is performed using a hood rather than nasal cannula or face mask to guarantee delivery of almost 100% oxygen to the patient. False-positive tests can occur if this is not done correctly. In a healthy newborn, the Pa_{O_2} should rise above 300 mm Hg; if between 150 and 300 mm Hg, noncardiac etiologies (pulmonary disease, central nervous system disorders, methemoglobinemia) are most likely. This is not 100% confirmative, however, because some patients with cyanotic CHD may be able to increase their Pa_{O_2} to >150 mm Hg because of favorable intracardiac streaming patterns. In infants with cyanosis from a central nervous system disorder, the Pa_{O_2} usually normalizes completely during artificial ventilation. If the Pa_{O_2} is between 100 and 150 mmHg, then cyanotic congenital heart lesions, increased pulmonary blood flow (mixing lesions, see Chapter 480), or PPHN are more likely. If the Pa_{O_2} is less than 100 mm Hg, then CHD with decreased pulmonary blood flow (see Chapter 479) is more likely. Another clue to etiology is that hypoxia in many heart lesions is relatively constant, whereas in respiratory disorders and in PPHN, Pa_{O_2} often varies with time or changes in ventilator management. For example, hyperventilation may improve the hypoxia in neonates with PPHN but only occasionally in those with cyanotic CHD.

Although a significant heart murmur usually suggests a cardiac basis for the cyanosis, several of the more severe cardiac defects (e.g., transposition of the great vessels) may not initially be associated with a murmur. The chest radiograph may be helpful in the differentiation of pulmonary and cardiac disease; in the latter, it also indicates whether pulmonary blood flow is increased, normal, or decreased (Fig. 478.1) as well as shows alterations in cardiac size.

Two-dimensional echocardiography with Doppler is the definitive noninvasive test to determine the presence of CHD. With today's high-quality echocardiography, cardiac catheterization is less often used for diagnostic purposes and is usually performed to examine structures that are less well visualized by echocardiography, such as distal branch pulmonary arteries and aortopulmonary collateral arteries in patients with tetralogy of Fallot with pulmonary atresia (see Chapter 479.2) or coronary arteries and right ventricular sinusoids in patients with pulmonary atresia and intact ventricular septum (see Chapter 479.3). If echocardiography is not immediately available to confirm a diagnosis of cyanotic CHD, the clinician caring for a newborn with possible cyanotic CHD should not hesitate to start a prostaglandin infusion (for a possible ductal-dependent lesion). Because of the risk of hypoventilation associated with prostaglandins, a practitioner skilled in neonatal endotracheal intubation must be available.

Fig. 478.1 Physiology of congenital heart disease delineated by chest radiography. **A,** Mild cardiomegaly with an upturned cardiac apex, a concave main pulmonary artery segment, and symmetric, severely diminished pulmonary blood flow in a 4-yr-old child with tetralogy of Fallot/pulmonary atresia. **B,** Moderate cardiomegaly and symmetric, increased pulmonary blood flow in a 3-mo-old infant with a large atrial septal defect and ventricular septal defect. **C,** Moderate cardiomegaly with interstitial edema in an 8-day-old newborn with critical aortic stenosis. *(From Frost JL, Krishnamurthy R, Sena L. Cardiac imaging. In: Walters MM, Robertson RL, eds. Pediatric Radiology—The Requisites, 4th ed. Philadelphia: Elsevier; 2017: Fig. 3.9, p. 68.)*

Chapter 479

Cyanotic Congenital Heart Disease: Lesions Associated with Decreased Pulmonary Blood Flow

479.1 Tetralogy of Fallot

Daniel Bernstein

Tetralogy of Fallot is one of the **conotruncal** family of heart lesions in which the primary defect is an anterior deviation of the *infundibular septum* (the muscular septum that separates the aortic and pulmonary outflows during division of the truncus arteriosus). The consequences of this deviation are the four components that Fallot initially described: (1) obstruction to right ventricular (RV) outflow (pulmonary stenosis); (2) a malalignment type of ventricular septal defect (VSD); (3) dextroposition of the aorta so that it overrides the ventricular septum; and (4) right ventricular hypertrophy (RVH; Fig. 479.1). Obstruction to pulmonary artery blood flow is usually at both the RV infundibulum (subpulmonic area) and the pulmonary valve. The main pulmonary artery (MPA) may also be small, and various degrees of branch pulmonary artery stenosis may be present. Complete obstruction of RV outflow (tetralogy with pulmonary atresia) is classified as an *extreme* form of tetralogy of Fallot (see Chapter 479.2) and may be associated with various degrees of hypoplasia of the branch pulmonary arteries. The degree of pulmonary outflow obstruction and whether the ductus arteriosus is open or closed determine the degree of the patient's cyanosis and the age at first presentation.

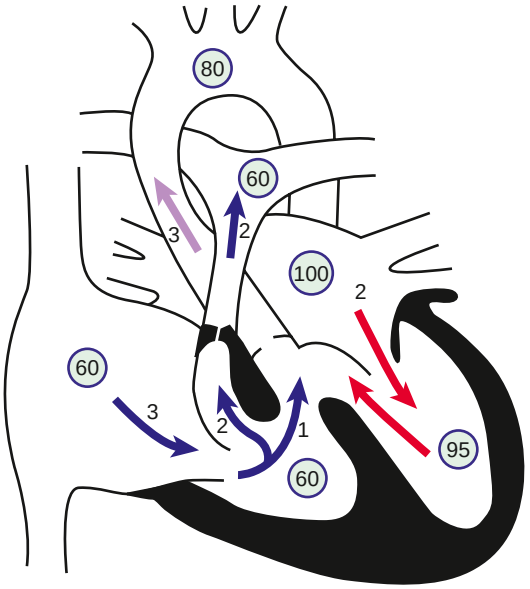

Fig. 479.1 Physiology of tetralogy of Fallot. *Circled numbers* represent oxygen saturation values. The *numbers next to the arrows* represent volumes of blood flow (in L/min/m^2). Atrial (mixed venous) oxygen saturation is decreased because of the systemic hypoxemia. A volume of 3 L/min/m^2 of desaturated blood enters the right atrium and traverses the tricuspid valve. Two liters flow through the right ventricular outflow tract into the lungs, whereas 1 L shunts right to left through the ventricular septal defect (VSD) into the ascending aorta. Thus pulmonary blood flow is two-thirds normal (Qp:Qs [pulmonary-to-systemic blood flow ratio] of 0.7:1). Blood returning to the left atrium is fully saturated. Only 2 L of blood flow across the mitral valve. Oxygen saturation in the left ventricle may be slightly decreased because of right-to-left shunting across the VSD. Two liters of saturated left ventricular blood mixing with 1 L of desaturated right ventricular blood are ejected into the ascending aorta. Aortic saturation is decreased, and cardiac output is normal.

PATHOPHYSIOLOGY

The pulmonary valve annulus may range from being nearly normal in size to being severely hypoplastic. The valve itself is often bicuspid or unicuspid and, occasionally, is the only site of stenosis. More often, the subpulmonic or infundibular muscle, known as the *crista supraventricularis,* is hypertrophic, which contributes to the subvalvar stenosis and results in an infundibular chamber of variable size and contour. When the right ventricular outflow tract (RVOT) is completely obstructed **(pulmonary atresia)**, the anatomy of the branch pulmonary arteries is extremely variable. An MPA segment may be in continuity with RV outflow, separated by a fibrous but imperforate pulmonary valve; the MPA may be moderately or severely hypoplastic but still supply part or all of the pulmonary bed; or the entire main pulmonary artery segment may be absent. Occasionally, the branch pulmonary arteries may be discontinuous. In these extreme cases, pulmonary blood flow may be supplied by a **patent ductus arteriosus** (PDA) or by multiple **major aortopulmonary collateral arteries (MAPCAs)** arising from the ascending and/or descending aorta or aortic branches and supplying various lung segments.

The VSD is usually nonrestrictive and large, is located just below the aortic valve, and is related to the posterior and right aortic cusps. Rarely, the VSD may be in the inlet portion of the ventricular septum (tetralogy with atrioventricular septal defect). The normal fibrous continuity of the mitral and aortic valves is usually maintained, and if not (because of the presence of a subaortic muscular conus), the defect is classified as a **double-outlet right ventricle** (DORV) instead of tetralogy of Fallot (see Chapter 479.5). The aortic arch is right sided in 20% of cases, and the aortic root is usually large and overrides the VSD to varying degrees. When the aorta overrides the VSD by >50% (in which case it may also be a subaortic conus), this defect is also classified as a form of DORV; however, the circulatory dynamics and the method of repair for these types of DORV are the same as for tetralogy of Fallot.

Systemic venous return to the right atrium and right ventricle is normal. When the right ventricle contracts in the presence of marked pulmonary stenosis, blood is shunted into the overriding aorta or across the VSD into the aorta. Persistent arterial desaturation and cyanosis result, with the degree of desaturation dependent on the severity of the pulmonary obstruction. Pulmonary blood flow, when severely restricted by the obstruction to RV outflow, is often supplemented by a PDA during the immediate newborn period. Peak systolic and diastolic pressures in each ventricle are similar and at the systemic level. A large pressure gradient occurs across the obstructed RVOT, and pulmonary artery pressure is either normal or lower than normal. The degree of RV outflow obstruction determines the timing of the onset of symptoms and the severity of cyanosis. When obstruction to RV outflow is mild to moderate and a balanced shunt is present across the VSD, the patient may not be visibly cyanotic (**acyanotic** or "pink" tetralogy of Fallot). When obstruction is severe, cyanosis will be present from birth and worsen dramatically when the ductus arteriosus begins to close.

CLINICAL MANIFESTATIONS

Infants with mild degrees of RV outflow obstruction may initially even have symptoms of heart failure caused by a ventricular-level left-to-right shunt. In these patients, cyanosis is not present at birth, but with increasing hypertrophy of the RV infundibulum as the patient grows, cyanosis occurs later in the first few months of life. In contrast, in infants with more severe degrees of RV outflow obstruction, neonatal cyanosis is noted immediately. In these infants, pulmonary blood flow

may be partially or almost totally dependent on flow through the ductus arteriosus. When the ductus begins to close in the first few hours or days of life, severe cyanosis and circulatory collapse may occur. All degrees of variation exist between these two clinical extremes. Older children with long-standing cyanosis who have not undergone surgery may have dusky blue skin, mucous membranes, and nailbeds (the latter two are key to diagnosing cyanosis in children with darker skin color). Patients may have gray sclerae with engorged blood vessels and (usually after 2 years of age) clubbing of the fingers and toes. Chapter 483 describes the extracardiac manifestations of long-standing cyanotic congenital heart disease.

In older children with unrepaired tetralogy, dyspnea occurs on minimal exertion. They may play actively for a short time and then sit or lie down or walk a block or so before stopping to rest. Characteristically, children assume a **squatting** position for the relief of dyspnea caused by physical effort; squatting increases venous return to the right side of the heart and also increases systemic vascular resistance, both serving to increase flow through the obstructed RV outflow. The child is usually able to resume physical activity after a few minutes of squatting.

Paroxysmal hypercyanotic attacks (hypoxic, "blue," or "tet" spells) may develop during the first year of life. The infant becomes hyperpneic and restless, cyanosis increases, gasping respirations ensue, and syncope may follow. The spells occur most frequently in the morning on initially awakening or after episodes of vigorous crying. Temporary disappearance or a decrease in intensity of the typical systolic ejection murmur occurs as flow across the RVOT diminishes during the spell. Tet spells may last from a few minutes to a few hours. Short episodes are followed by generalized weakness and sleep. Severe spells may progress to unconsciousness and occasionally to convulsions, stroke, and death. The onset of these spells is usually spontaneous and unpredictable. They are associated with reduction of an already compromised pulmonary blood flow, which, when prolonged, results in severe systemic hypoxia and metabolic acidosis. Infants who are only mildly cyanotic at rest may be more prone to the development of hypoxic spells because they have not acquired the homeostatic mechanisms that would allow them to better tolerate rapid lowering of arterial oxyhemoglobin saturation (Sa_{O_2}), such as polycythemia.

Depending on the frequency and severity of hypercyanotic attacks, one or more of the following procedures should be instituted in sequence: (1) placement of the infant on the abdomen in the knee-chest position while making certain that the infant's clothing is not constrictive; (2) administration of oxygen (although increasing inspired oxygen will not reverse cyanosis caused by intracardiac shunting); (3) injection of morphine subcutaneously or intranasal fentanyl or intranasal midazolam; (4) administer propranolol or esmolol; and (5) begin a phenylephrine intravenous infusion. Calming and holding the infant in a knee-chest position may abort progression of an early spell. Premature attempts to obtain blood samples may cause further agitation and may be counterproductive; transcutaneous oxygen saturation monitoring is helpful in these cases but is limited in not measuring the degree of acidosis if the spell is prolonged.

Because metabolic acidosis develops when arterial oxygen tension (Pa_{O_2}) is <40 mm Hg, rapid correction (within several minutes) with intravenous (IV) administration of sodium bicarbonate is necessary if the spell is unusually severe and the child shows a lack of response to the foregoing therapy. Recovery from the spell is usually rapid once the pH has returned to normal. Repeated blood pH measurements may be necessary because rapid recurrence of acidosis may ensue. For spells that are resistant to this therapy, intubation and anesthetic sedation are often sufficient to break the spell. Drugs that increase systemic vascular resistance, such as IV phenylephrine, can improve RV outflow, decrease the right-to-left shunt, and improve symptoms. β-Adrenergic blockade by the IV administration of propranolol (0.15-0.25 mg/kg/dose given slowly; can be repeated once in 15 minutes) has also been used. Spells are quite rare because most infants with tetralogy of Fallot undergo reparative surgery in early infancy.

Growth and development may be delayed in patients with severe untreated tetralogy of Fallot, particularly when their Sa_{O_2} is chronically <70%. Puberty may also be delayed in patients who have not undergone surgery.

The peripheral pulses are usually normal, as are central venous and arterial pressures. In older infants and children, the left anterior hemithorax may bulge anteriorly because of long-standing RVH. A substernal RV impulse can usually be detected. A systolic thrill may be felt along the left sternal border in the third and fourth parasternal spaces. The systolic murmur is usually loud and harsh; it may be transmitted widely, especially to the lungs, but is most intense at the mid- and upper-left sternal border. The murmur is generally ejection in quality at the upper-left sternal border, but it may sound more holosystolic toward the lower-left sternal border. It may be preceded by a click at the upper sternal border or over the sternum. The murmur is caused by turbulence through the RVOT. It tends to become louder, longer, and harsher as the severity of pulmonary stenosis increases from mild to moderate; however, it can become less prominent with severe obstruction, especially during a hypercyanotic spell, because of shunting of blood away from the RV outflow through the overriding aortic valve. Either the second heart sound (S_2) is single or the pulmonic component is soft because of the decreased excursion of the stenotic valve. Infrequently, a continuous murmur may be audible, especially if prominent MAPCAs are present.

DIAGNOSIS

The typical radiologic configuration as seen in the anteroposterior (AP) view consists of a narrow base, concavity of the left heart border in the area usually occupied by the pulmonary artery, and normal overall heart size. The hypertrophied right ventricle causes the rounded apical shadow to be uptilted so that it is situated higher above the diaphragm than normal and pointing horizontally to the left chest wall. The cardiac silhouette has been likened to that of a *boot* ("coeur en sabot") (Fig. 479.2). The hilar areas and lung fields are relatively clear because of diminished pulmonary blood flow or the small size of the pulmonary arteries, or both. The aorta is usually large, and in approximately 20% of patients it arches to the right, which results in an indentation of the leftward-positioned air-filled tracheobronchial shadow in the AP view.

The electrocardiogram (ECG) demonstrates right-axis deviation and evidence of RVH; because prominent right-sided forces are normal in the newborn period, the ECG may be technically normal at this time. A dominant R wave appears in the right precordial chest leads (V_1, V_2) or an RSR′ pattern. In some cases, the only sign of RVH may initially

Fig. 479.2 Chest radiograph of 8-yr-old child with tetralogy of Fallot. Note the normal heart size, some elevation of the cardiac apex, concavity in the region of the main pulmonary artery, right-sided aortic arch, and diminished pulmonary vascularity.

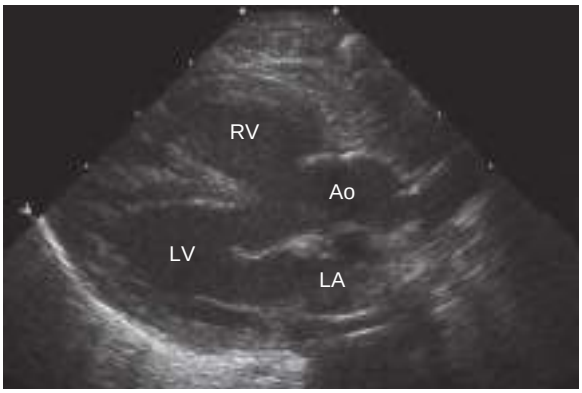

Fig. 479.3 Echocardiogram of patient with tetralogy of Fallot. This parasternal long-axis 2D view demonstrates anterior displacement of the outflow ventricular septum that resulted in stenosis of the subpulmonic right ventricular outflow tract, overriding of the aorta, and an associated ventricular septal defect. Ao, Overriding aorta; LA, left atrium; LV, left ventricle; RV, right ventricle.

be a positive T wave in leads V_3R and V_1. The P wave may be tall and peaked, suggesting right atrial enlargement (see Fig. 472.6).

Two-dimensional (2D) echocardiography with Doppler establishes the diagnosis (Fig. 479.3) and provides information about the extent of aortic override of the septum, the location and degree of the RVOT obstruction, the size of the pulmonary valve annulus and main and proximal branch pulmonary arteries, and the side of the aortic arch. The echocardiogram is also useful in determining whether a PDA is supplying a portion of the pulmonary blood flow. In a patient with tetralogy of Fallot without pulmonary atresia, echocardiography usually obviates the need for catheterization before surgical repair. However, in patients with pulmonary atresia, catheterization and CT angiography are usually necessary to image the size and source of blood supply (native pulmonary arteries or MAPCAs) to each lung vascular segment.

Cardiac catheterization demonstrates a systolic pressure in the right ventricle equal to the systemic pressure because the right ventricle is connected directly to the overriding aorta. If the pulmonary artery is entered, the pressure is greatly decreased, although crossing the RVOT, especially in severe cases, may precipitate a tet spell. Pulmonary artery pressure is usually lower than normal, in the range of 5-10 mm Hg. The Sao_2 level depends on the magnitude of the right-to-left shunt; in "pink tets," the systemic So_2 may be normal, whereas in a moderately cyanotic patient at rest, it is usually 75–85%.

Selective right ventriculography will demonstrate all the anatomic features. Contrast medium outlines the heavily trabeculated right ventricle. The infundibular stenosis varies in length, width, contour, and distensibility (Fig. 479.4). The pulmonary valve is usually thickened, and the annulus may be small. In patients with tetralogy and pulmonary atresia, echocardiography alone is not adequate to assess the anatomy of the true pulmonary arteries and collateral MAPCAs. Cardiac CT is extremely helpful, and cardiac catheterization with injection into each arterial collateral is usually indicated. Complete and accurate information regarding the size and peripheral distribution of the main pulmonary arteries and any collateral vessels (MAPCAs) is important when evaluating these children for complex reparative surgery.

Aortography or coronary arteriography outlines the course of the coronary arteries. In 5–10% of patients with the tetralogy of Fallot, coronary artery abnormalities may be present, most often an aberrant coronary artery crossing over the RVOT; care must be taken not to cut this artery during surgical repair. Verification of normal coronary arteries is important when considering surgery in young infants, who may need a patch across the pulmonary valve annulus. Echocardiography can usually delineate the coronary artery anatomy; angiography is reserved for cases in which questions remain.

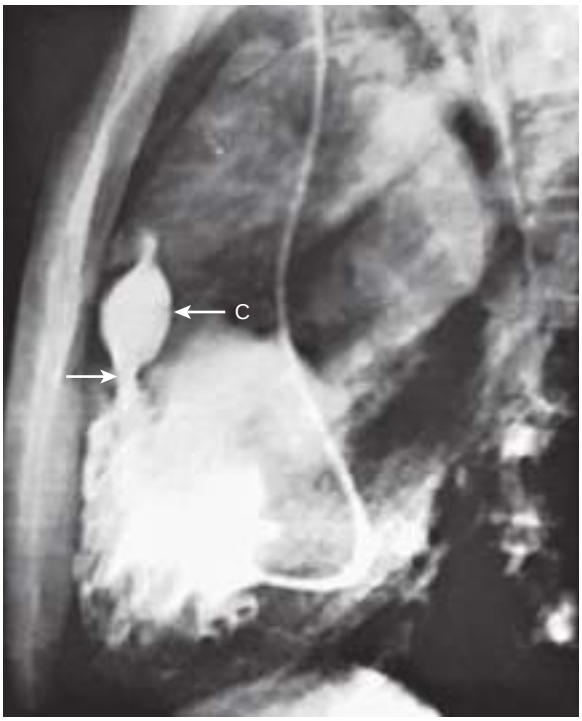

Fig. 479.4 Lateral view of selective right ventriculogram in patient with tetralogy of Fallot. The *left arrow* points to an infundibular stenosis that is below the infundibular chamber (C). The narrowed pulmonary valve orifice is seen at the distal end of the infundibular chamber.

COMPLICATIONS

Before the advent of corrective surgery, patients with tetralogy of Fallot were susceptible to several serious complications. For this reason, most children undergo complete repair (or in rare situations palliation) in the first few months of life; consequently, these complications are now rare. **Cerebral thromboses**, usually occurring in the cerebral veins or dural sinuses and occasionally in the cerebral arteries, are sequelae of extreme polycythemia and dehydration. Thromboses occur most often in patients younger than 2 years. These patients may have iron-deficiency anemia, frequently with hemoglobin and hematocrit levels in the normal range (but too low for cyanotic heart disease). Therapy consists of adequate hydration and supportive measures. Phlebotomy and volume replacement with albumin or saline are indicated in extremely polycythemic patients who are symptomatic.

Brain abscess is less common than cerebrovascular events and extremely rare today. Patients with a brain abscess are usually older than 2 years. The onset of the illness is often insidious and consists of low-grade fever or a gradual change in behavior, or both. Some patients have an acute onset of symptoms that may develop after a recent history of headache, nausea, and vomiting. Seizures may occur; localized neurologic signs depend on the site and size of the abscess and the presence of increased intracranial pressure. Head CT or MRI confirms the diagnosis. Antibiotic therapy may help keep the infection localized, but surgical drainage of the abscess is usually necessary (see Chapter 644).

Bacterial endocarditis may occur in the RV infundibulum or on the pulmonic, aortic, or rarely, tricuspid valve. Endocarditis may complicate palliative shunts or, in patients with corrective surgery, any residual pulmonic stenosis or VSD. Heart failure is not a usual feature in patients with tetralogy of Fallot, with the exception of some young infants with "pink" or acyanotic tetralogy of Fallot. When the degree of pulmonary obstruction worsens with age, the symptoms of heart failure resolve, and eventually the patient experiences cyanosis, usually by 4-6 months of age. These patients are at increased risk for hypercyanotic spells at this time.

ASSOCIATED ANOMALIES

A PDA may be present, and defects in the atrial septum are occasionally seen. A right aortic arch occurs in approximately 20% of patients, and other anomalies of the pulmonary arteries and aortic arch may also be seen. Persistence of a left superior vena cava draining into the coronary sinus is common but not a concern. Multiple VSDs are occasionally present and should be diagnosed before corrective surgery. Coronary artery anomalies are present in 5–10% and can complicate surgical repair. Tetralogy of Fallot may also occur with an atrioventricular septal defect, often associated with Down syndrome.

Congenital absence of the pulmonary valve produces a distinct syndrome that is usually marked by signs of upper airway obstruction (see Chapter 477.1). Cyanosis may be absent, mild, or moderate; the heart is large and hyperdynamic; and a loud to-and-fro murmur is present. Marked aneurysmal dilation of the main and branch pulmonary arteries results in compression of the bronchi and then produces stridulous or wheezing respirations and recurrent pneumonia. If the airway obstruction is severe, reconstruction of the trachea at the time of corrective cardiac surgery may be required to alleviate the symptoms.

Absence of a branch pulmonary artery, most often the left, should be suspected if the radiographic appearance of the pulmonary vasculature differs between the right and left sides; absence of a pulmonary artery is often associated with hypoplasia of the affected lung. It is important to recognize the absence of a pulmonary artery because occlusion of the remaining pulmonary artery during surgery seriously compromises the already reduced pulmonary blood flow.

As one of the conotruncal malformations, tetralogy of Fallot can be associated with **DiGeorge syndrome** or **velocardiofacial syndrome**, also known by the acronym **CATCH 22** (cardiac defects, abnormal facies, thymic hypoplasia, cleft palate, hypocalcemia). Cytogenetic analysis using fluorescence in situ hybridization (FISH) demonstrates deletions of a large segment of **chromosome 22q11.2** known as the **DiGeorge critical region**. Deletion or pathogenic variants in *Tbx1* have been implicated as a possible cause of DiGeorge syndrome, although several other genes have been identified as possible candidates or as modifier genes (see Chapter 473).

TREATMENT

Treatment of tetralogy of Fallot depends on the severity of the RVOT obstruction. Infants with severe tetralogy require urgent medical treatment and surgical intervention in the neonatal period. Therapy is aimed at providing an immediate increase in pulmonary blood flow to prevent the sequelae of severe hypoxia. Prolonged, severe hypoxia may lead to shock, respiratory failure, and intractable acidosis and will significantly reduce the chance of survival, even when surgically amenable lesions are present. It is critical that normal body temperature be maintained during the transfer because cold increases oxygen consumption, which places additional stress on a cyanotic infant, whose oxygen delivery is already limited. Blood glucose levels should be monitored because hypoglycemia is more likely to develop in infants with cyanotic heart disease.

Neonates with marked RVOT obstruction may deteriorate rapidly because as the ductus arteriosus begins to close, pulmonary blood flow is further compromised. The IV administration of **prostaglandin E_1** (PGE_1; 0.05-0.1 μg/kg/min), a potent and specific relaxant of ductal smooth muscle, causes dilation of the ductus arteriosus and usually provides adequate pulmonary blood flow until a surgical procedure can be performed. This agent should be administered intravenously as soon as cyanotic CHD is clinically suspected and continued through the preoperative period and during cardiac catheterization. Because prostaglandin can cause apnea, an individual skilled in neonatal intubation should be readily available.

Infants with less severe RVOT obstruction who are stable and awaiting surgical intervention require careful observation. Acyanotic patients can progress fairly quickly to having cyanotic episodes. Prevention or prompt treatment of dehydration is important to avoid hemoconcentration and possible thrombotic episodes. In the past, oral propranolol (0.5-2 mg/kg every 6 hours) was used to decrease the frequency and severity of hypercyanotic spells, but with the excellent surgical results available today, surgical treatment is indicated, usually before spells begin.

Infants with symptoms and severe cyanosis in the first month of life usually have marked obstruction of the RVOT. Two options are available in these infants. The first option is **corrective open heart surgery** performed in early infancy (or even in the newborn period in critically ill infants). This approach has widespread acceptance with excellent short- and long-term results and has supplanted palliative shunts (see later) for most cases. Early total repair carries the theoretical advantage that early physiologic correction allows for improved growth of the branch pulmonary arteries. In infants with less severe cyanosis who can be maintained with good growth and absence of hypercyanotic spells, primary repair is performed electively in the first few months.

Corrective surgical therapy consists of relief of the RVOT obstruction by resecting obstructive muscle bundles and by patch closure of the VSD. If the pulmonary valve is stenotic, as it usually is, a valvotomy is performed. If the pulmonary valve annulus is too small or the valve is extremely thickened, a valvectomy may be performed, the pulmonary valve annulus split open, and a transannular patch placed across the pulmonary valve ring. The advantage of a patch that is not circumferential is that it preserves part of the normal valve annulus and leaflets, allowing for future growth. A right ventriculotomy was once the standard approach; a transatrial-transpulmonary approach is routinely performed to reduce the long-term risks of a large right ventriculotomy. In the past, surgeons placed large transannular patches with the goal of eliminating any possibility of residual pulmonary stenosis, even if these resulted in wide-open pulmonary insufficiency. Currently, surgeons use smaller patches and are more accepting of small RVOT gradients if the degree of valve insufficiency can be minimized. In tetralogy patients, pulmonary valve insufficiency is one of the main reasons for reoperation long-term.

The second option, rarely used today, is a palliative systemic-to-pulmonary artery shunt **(Blalock-Taussig or B-T shunt)** performed to augment pulmonary artery blood flow. The B-T shunt augmented pulmonary blood flow, decreasing hypoxia, improving linear growth, and augmenting growth of the branch pulmonary arteries. Initially performed via direct anastomosis of the subclavian artery to the pulmonary artery, today, the modified B-T shunt consists of a Gore-Tex conduit anastomosed side to side from the subclavian artery to the homolateral branch of the pulmonary artery (Fig. 479.5). Sometimes the shunt is brought directly from the ascending aorta to the MPA; in this case it is called a *central shunt*. Postoperative complications after a B-T shunt include chylothorax, diaphragmatic paralysis, and Horner syndrome. Rarely, postoperative pulmonary overcirculation leading to symptoms of cardiac failure may be caused by too large a shunt. Long-term problems associated with the original B-T shunt (absent radial pulse and arm length discrepancy) are rarely seen with the current procedure.

B-T shunts are usually reserved for patients with comorbidities, such as other major congenital anomalies or prematurity, that would make full repair a higher-risk option. Many surgeons still recommend full repair in these situations, being preferable to the combined risks of a staged procedure, and successful complete repairs have been done even in small premature infants.

PROGNOSIS

After successful total correction, patients are generally asymptomatic and are able to lead unrestricted lives. Uncommon immediate postoperative problems include RV failure, transient heart block, residual VSD with left-to-right shunting, and (rarely) myocardial infarction from interruption of an aberrant coronary artery. The long-term effects of isolated, surgically induced pulmonary valvular insufficiency or of insufficiency and mild stenosis (as is more typical with modern-era smaller transannular patches) are still being defined as more patients with repaired tetralogy of Fallot reach adulthood, but pulmonary insufficiency is generally well tolerated through childhood and early adolescence. Many patients after tetralogy repair, and all those with transannular patch repairs, have a to-and-fro murmur at the left sternal border, usually indicative of mild outflow obstruction and mild

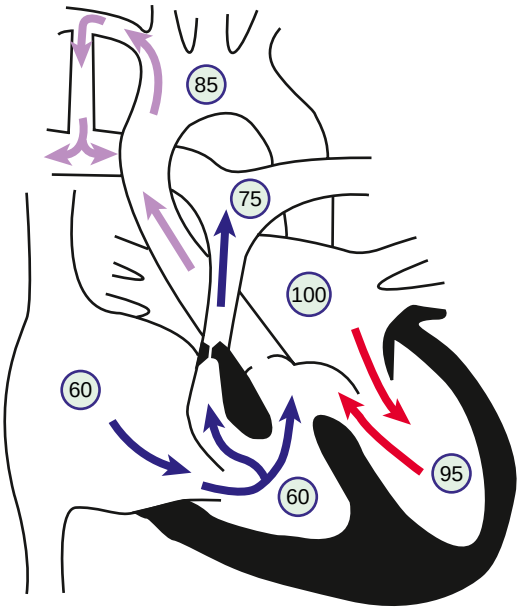

Fig. 479.5 Physiology of Blalock-Taussig shunt in patient with tetralogy of Fallot. *Circled numbers* represent oxygen saturation values. The intracardiac shunting pattern is as described for Figure 479.1. Blood shunting left to right across the shunt from the right subclavian artery to the right pulmonary artery increases total pulmonary blood flow and results in a higher oxygen saturation than would exist without the shunt.

to moderate pulmonary insufficiency. Patients with more marked or long-standing pulmonary valve insufficiency may also have moderate to more severe degrees of RV enlargement and may develop tricuspid regurgitation as the tricuspid valve annulus dilates. These patients will develop a holosystolic murmur at the lower-left and -right sternal borders. Patients with a moderate to severe residual gradient (stenosis) across the RVOT usually require balloon angioplasty or catheter placement of a stent or reoperation, but milder degrees of residual obstruction usually do not require reintervention.

Follow-up of patients 5-20 years after surgery indicates generally excellent outcomes, with minimal symptoms and good exercise tolerance. Despite being asymptomatic, many patients may have lower-than-normal exercise capacity and maximal heart rate on formal cardiopulmonary exercise testing. These abnormal findings are more common in patients who underwent placement of a transannular outflow tract patch and may be less frequent when surgery is performed at an early age. When these children move into adolescence and adulthood, some (more often those with transannular patches) will develop RV dilation as a result of long-term pulmonary regurgitation. Careful surveillance for excessive RV dilation and early signs of RV dysfunction is critical. After reaching adulthood, lifelong follow-up by a specialist in adult congenital heart disease (CHD) is important. Serial echocardiography and the more quantitative magnetic resonance angiography (MRI/MRA) are valuable tools for assessing the degree of RV dilation, identifying the presence of early stages of RV dysfunction, and quantifying the regurgitant fraction. A significant portion of patients with tetralogy of Fallot have been found to have some degree of fibrosis within the right ventricle by MRI. Valve repair or replacement is indicated for those patients with increasing RV dilation and if tricuspid regurgitation is more than mild. For patients requiring valve replacement, nonsurgical (transcatheter) options are available. Several stent-valves can be delivered in the cardiac catheterization laboratory, and these have been used successfully in patients with repaired tetralogy of Fallot. The initial versions of these devices (the Melody valve) were designed to be used predominantly in patients who have previously had a homograft or other artificial conduit placed between the RV and pulmonary arteries; often stent-valves (the Harmony valve) have been designed to be inserted into the native RVOT.

Conduction disturbances can occur after surgery. The atrioventricular node and the bundle of His and its divisions are close to the VSD and may be injured during surgery; however, permanent complete heart block after tetralogy repair is rare. When present, it should be treated by placement of a permanently implanted pacemaker. Even transient complete heart block in the immediate postoperative period is rare; it may be associated with an increased incidence of late-onset complete heart block and sudden death. In contrast, right bundle branch block is extremely common on the postoperative ECG. The duration of the QRS interval has been shown to predict both the presence of residual hemodynamic derangement and the long-term risk of arrhythmia (mainly ventricular tachycardia) and sudden death. Biventricular pacing (in which a pacemaker is used to resynchronize the activation of the right and left ventricles) has been shown to improve hemodynamics in patients with RV dysfunction and long ventricular conduction delays on ECG.

Many children have **premature ventricular beats** after repair of the tetralogy of Fallot. These beats, if isolated and infrequent, may be benign but are of particular concern in patients with residual hemodynamic abnormalities. Approximately 10% of patients with repaired tetralogy are at risk of life-threatening ventricular arrhythmias, and 30% are at risk of atrial arrhythmias as they reach adulthood. Long-duration electrocardiographic monitoring studies, such as Holter (24-48 hours) or ZioPatch (1-2 weeks), should be performed on a regular basis to ensure that occult episodes of ventricular tachycardia are not occurring. Exercise studies may be useful in provoking cardiac arrhythmias that are not apparent at rest. In the presence of complex ventricular arrhythmias or severe residual hemodynamic abnormalities, prophylactic antiarrhythmic drug therapy or an implantable defibrillator is warranted. Surgical or transcatheter intervention is indicated if significant residual RVOT obstruction or severe pulmonary insufficiency is present because arrhythmia risk may improve after hemodynamics are restored to a more normal level.

Visit Elsevier eBooks+ at eBooks.Health.Elsevier.com for Bibliography.

479.2 Tetralogy of Fallot with Pulmonary Atresia

Daniel Bernstein

Tetralogy of Fallot with pulmonary atresia is the most extreme form of the tetralogy of Fallot. The pulmonary valve is atretic (absent), and the pulmonary trunk may be hypoplastic or atretic as well. The entire RV output is ejected into the aorta. Pulmonary blood flow is then dependent on multiple **major aortopulmonary collateral arteries (MAPCAs)** arising from the ascending and/or descending aorta or aortic branches and supplying various lung segments or, rarely, on a PDA. The ultimate prognosis depends on the presence or absence of true branch pulmonary arteries and, if present, the degree of development. This is best assessed by a combination of CT and cardiac catheterization. If repair is approached early in life and performed at a center with expertise in this highly complex surgery, the mid-term outcomes are good. However, if the pulmonary arteries are severely hypoplastic and surgical intervention fails to establish low pulmonary vascular pressures, lung or heart-lung transplantation may be the only therapy (see Chapter 492.2). Tetralogy of Fallot with pulmonary atresia is also associated with the 22q11.2 deletion and DiGeorge syndrome. The association of severe **tracheomalacia** or **bronchomalacia** with these severe forms of tetralogy/pulmonary atresia may complicate postoperative recovery.

CLINICAL MANIFESTATIONS

Patients with tetralogy of Fallot/pulmonary atresia have findings similar to those in patients with severe tetralogy of Fallot. Cyanosis usually appears within the first few hours or days after birth; however, the prominent systolic murmur associated with tetralogy is usually absent. The first heart sound (S_1) may be followed by an ejection click caused

by the enlarged aortic root, S_2 is single and loud, and continuous murmurs of collateral flow may be heard over the entire precordium and over the back. Most patients are moderately cyanotic and are initially stabilized with a PGE_1 infusion pending cardiac catheterization and/or CT scan to further delineate the anatomy. Patients with several large MAPCAs may be less cyanotic and, once the diagnosis is confirmed, can be taken off prostaglandin while awaiting palliative surgical intervention. Some patients may even develop symptoms of heart failure caused by increased pulmonary blood flow via these collateral vessels.

DIAGNOSIS

The chest radiograph demonstrates a varying heart size, depending on the amount of pulmonary blood flow, a concavity at the position of the pulmonary arterial segment, and often the reticular pattern of bronchial collateral flow. The ECG shows RVH. The echocardiogram identifies aortic override, a thick RV wall, and atresia of the pulmonary valve. Pulsed and color Doppler echocardiographic studies show an absence of forward flow across the pulmonary valve, with pulmonary blood flow being supplied by MAPCAs, which can usually be seen using color Doppler arising from the descending aorta. At cardiac catheterization, right ventriculography reveals a large aorta, opacified immediately by passage of contrast medium through the VSD but with no dye entering the lungs through the RVOT. It is important in planning surgical repair to delineate carefully the often diminutive native pulmonary arteries, if present, to determine whether they are continuous or discontinuous and whether they arborize to all lung segments. The location and arborization of all MAPCAs and the presence of any localized stenosis, which become more common as the patient grows older, are determined by selective contrast injection into each vessel from its origin in the aorta. CT angiography is extremely valuable in mapping the extent of MAPCA arborization.

TREATMENT

The surgical procedure of choice depends on whether the MPA segment is present and, if so, on the size and branching pattern of the branch pulmonary arteries. If these arteries are well developed, a one-stage surgical repair with a homograft conduit inserted between the right ventricle and pulmonary arteries and closure of the VSD is usually feasible. If the pulmonary arteries are hypoplastic, extensive reconstruction may be required. This may involve several staged surgical procedures. If the native pulmonary artery is present but small, a connection made between the aorta and the hypoplastic native pulmonary artery **(aortopulmonary window)** can be performed in the newborn period to induce growth of the native pulmonary arteries. At 3-4 months of age, the multiple MAPCAs are gathered together **(unifocalization procedure)** and eventually incorporated into the final repair along with the native pulmonary arteries. This series of operations may be accomplished through successive right and left lateral thoracotomies or through a single midline sternotomy if the anatomy is favorable.

To be a candidate for full repair, the pulmonary arteries must be of adequate size to accept the full volume of RV output. Complete repair includes closure of the VSD and placement of a homograft conduit from the right ventricle to the pulmonary artery. At the time of reparative surgery, previous shunts are taken down. Because of patient growth and homograft narrowing caused by proliferation of intimal tissue and calcification, replacement of the homograft conduit replacement is usually required in later life, and multiple replacements may be needed. Some of these patients are candidates for placement of a transcatheter stent-valve in the pulmonary position. Patients with obstruction of the very distal branches of the pulmonary arteries may undergo repeat surgical procedures or transcatheter balloon dilation and stenting of the multibranch pulmonary arterial stenosis. Careful follow-up is warranted for these patients, with a combination of echocardiogram, catheterization, and CT or MRI, to ensure maximal chance of growth of all pulmonary artery segments. Serial radionuclide lung perfusion scans can be used to assess pulmonary perfusion to each lung segment and the percentage of flow to the right vs the left lung.

Visit Elsevier eBooks+ at eBooks.Health.Elsevier.com for Bibliography.

479.3 Pulmonary Atresia with Intact Ventricular Septum

Daniel Bernstein

Pulmonary atresia with an intact ventricular septum presents in the newborn period with severe cyanosis. The pulmonary valve leaflets are completely fused to form a membrane, and the RVOT is atretic. Because no VSD is present, no egress of blood from the right ventricle can occur. Any blood that enters the right ventricle will regurgitate back across the tricuspid valve into the right atrium. Right atrial pressure increases, and blood shunts via the foramen ovale into the left atrium, where it mixes with pulmonary venous blood and enters the left ventricle (Fig. 479.6). The combined left and right ventricular output is pumped solely by the left ventricle into the aorta. In a newborn with pulmonary atresia, the only source of pulmonary blood flow occurs via a PDA. The right ventricle and tricuspid valve are usually hypoplastic, although the degree of hypoplasia varies considerably. Patients who have a small RV cavity also tend to be those with the smallest tricuspid valve annulus, which limits RV inflow. Patients with pulmonary atresia and intact ventricular septum may have **coronary sinusoidal channels** within the RV wall that communicate directly with the coronary arterial circulation. The high RV pressure results in desaturated blood flowing retrograde through these channels into the coronary arteries. Sometimes there are also stenoses of the coronary arteries proximal to where the sinusoids enter, so that distal coronary artery flow is dependent on flow from the right ventricle (known as *right ventricle–dependent coronary circulation*). The prognosis in patients with these sinusoids and proximal stenosis of the coronary arteries is more guarded than in those patients without sinusoids or with sinusoids but no coronary stenoses. Rarely, the proximal coronary artery may be totally absent.

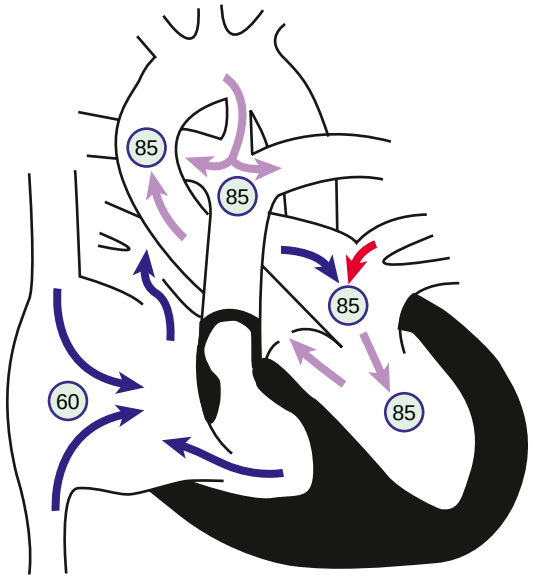

Fig. 479.6 Physiology of pulmonary atresia with intact ventricular septum. *Circled numbers* represent oxygen saturation values. Right atrial (mixed venous) oxygen saturation is decreased secondary to systemic hypoxemia. A small amount of the blood entering the right atrium may cross the tricuspid valve, which is often stenotic as well. The right ventricular cavity is hypertrophied and may be hypoplastic. No outlet from the right ventricle exists because of the atretic pulmonary valve; thus any blood entering the right ventricle returns to the right atrium via tricuspid regurgitation. Most of the desaturated blood shunts right to left via the foramen ovale into the left atrium, where it mixes with fully saturated blood returning from the lungs. The only source of pulmonary blood flow is via the patent ductus arteriosus. Aortic and pulmonary arterial oxygen saturation will be identical (definition of a total mixing lesion).

CLINICAL MANIFESTATIONS

When the ductus arteriosus closes in the first hours or days of life, infants with pulmonary atresia and an intact ventricular septum become markedly cyanotic because their only source of pulmonary blood flow is removed. Untreated, most patients die within the first week of life. Physical examination reveals severe cyanosis and respiratory distress. S_2, representing only aortic closure, is single and loud. Often, no murmurs are audible; sometimes a systolic or continuous murmur can be heard secondary to ductal blood flow. A harsh holosystolic murmur may be heard at the lower left and right sternal borders if there is significant tricuspid regurgitation.

DIAGNOSIS

The ECG shows a frontal QRS axis between 0 and +90 degrees, the amount of leftward shift reflecting the degree of RV hypoplasia. Tall, spiked P waves indicate right atrial enlargement. QRS voltages are consistent with left ventricular dominance or hypertrophy; RV forces are usually decreased in proportion to the decreased size of the RV cavity. Because the normal newborn ECG shows increased right-sided forces, if a normal "adult" ECG R-wave progression is seen, it suggests RV hypoplasia of some degree. Most patients with small right ventricles have decreased RV forces, but occasionally, patients with larger, thickened RV cavities may have evidence of RVH. The chest radiograph shows decreased pulmonary vascularity, the degree depending on the size of the branch pulmonary arteries and the patency of the ductus. Unlike in patients with pulmonary atresia and tetralogy of Fallot, the presence of MAPCAs is rare.

The 2D echocardiogram is useful in estimating RV dimensions and the size of the tricuspid valve annulus, which have been shown to be of prognostic value. Echocardiography can often suggest the presence of sinusoidal channels but cannot be used to evaluate coronary stenoses. Thus cardiac catheterization is necessary for complete evaluation. Pressure measurements reveal right atrial and RV hypertension. Ventriculography demonstrates the size of the RV cavity, the atretic RVOT, the degree of tricuspid regurgitation, and the presence or absence of intramyocardial sinusoids filling the coronary vessels. Aortography shows filling of the pulmonary arteries by the PDA and is helpful in determining the size and branching patterns of the pulmonary arterial bed. An aortogram or, if necessary, selective coronary angiography is performed to evaluate for the presence of proximal coronary artery stenosis (RV-dependent coronary circulation) or proximal coronary artery atresia.

TREATMENT

Infusion of PGE_1 (0.05-0.1 μg/kg/min) is usually effective in keeping the ductus arteriosus open before intervention, thus reducing hypoxemia and acidemia before surgery. The choice of surgical procedure depends on whether there is an RV-dependent coronary circulation and on the size of the RV cavity. In patients with only mild to moderate RV hypoplasia without sinusoids, or in patients with sinusoids but no evidence of coronary stenoses, a surgical pulmonary valvotomy is carried out to relieve outflow obstruction. Often, the RVOT is widened with a patch. To provide adequate pulmonary blood flow, an aortopulmonary (Blalock-Taussig) shunt may also be performed during the same procedure. An alternative approach uses interventional catheterization, in which the imperforate pulmonary valve is first punctured either with a wire or a radiofrequency ablation catheter, followed by a balloon valvuloplasty. If this course is taken, it may take days to weeks before the RV muscle regresses enough for the patient to be weaned from prostaglandin, and many of these patients will still require surgical intervention.

The aim of surgery or interventional catheterization is to encourage growth of the RV chamber by allowing some forward flow through the pulmonary valve while using the shunt to ensure adequate pulmonary blood flow. Later, if the tricuspid valve annulus and RV chamber grow to adequate size, the shunt is taken down and any remaining atrial-level shunt can be closed. If the RV chamber remains too small for use as a pulmonary ventricle, the patient is treated as having a single-ventricle circulation, with a **Glenn procedure** followed by a modified **Fontan procedure** (see Chapter 479.4), allowing blood to bypass the hypoplastic right ventricle by flowing to the pulmonary arteries directly from the venae cavae. When coronary artery stenoses are present and retrograde coronary perfusion occurs from the right ventricle through myocardial sinusoids, the prognosis is more guarded because of a higher risk of arrhythmias, coronary ischemia, and sudden death. It is important for these patients not to try to open the RVOT, because dropping the RV pressure rapidly will reduce coronary perfusion, leading to ischemia. These patients are usually treated with an aortopulmonary shunt, followed by the Glenn and Fontan procedure. Although at higher risk than those without coronary stenoses, recent reports show good success with this approach; however, long-term complications are higher than in other groups of single-ventricle patients. A small number of these infants (e.g., those with atresia of a proximal coronary artery) are best referred for heart transplantation.

Visit Elsevier eBooks+ at eBooks.Health.Elsevier.com for Bibliography.

479.4 Tricuspid Atresia

Daniel Bernstein

In tricuspid atresia, there is no outlet from the right atrium to the right ventricle; the entire systemic venous return leaves the right atrium and enters the left side of the heart through the foramen ovale or, most often, an atrial septal defect (ASD) (Fig. 479.7). The physiology of the circulation and the clinical presentation will depend on the presence and type of other congenital heart defects, most notably on whether the great arteries are normally related or are transposed (aorta arising from the right ventricle, pulmonary artery from the left ventricle). In patients with normally related great arteries, left ventricular (LV)

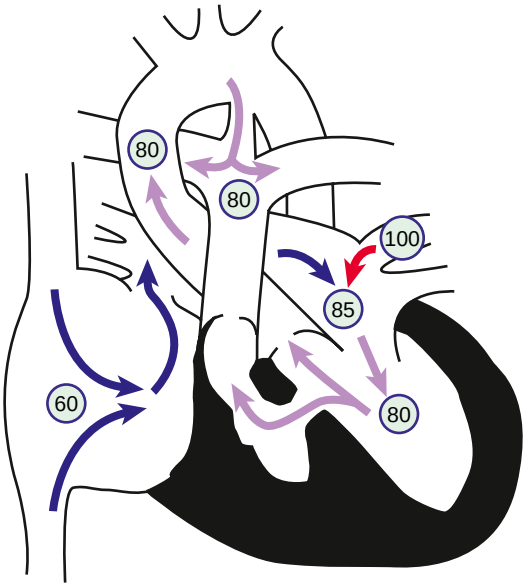

Fig. 479.7 Physiology of tricuspid atresia with normally related great vessels. *Circled numbers* represent oxygen saturation values. Right atrial (mixed venous) oxygen saturation is decreased secondary to systemic hypoxemia. The tricuspid valve is nonpatent, and the right ventricle may manifest varying degrees of hypoplasia. The only outlet from the right atrium involves shunting right to left across an atrial septal defect or patent foramen ovale to the left atrium. There, desaturated blood mixes with saturated pulmonary venous return. Blood enters the left ventricle and is ejected either through the aorta or via a ventricular septal defect (VSD) into the right ventricle. In this example, some pulmonary blood flow is derived from the right ventricle and the rest from a patent ductus arteriosus (PDA). In patients with tricuspid atresia, the PDA may close or the VSD may grow smaller and result in a marked decrease in systemic oxygen saturation.

blood supplies the systemic circulation through the aorta. Blood also flows into the right ventricle through a VSD (if the ventricular septum is intact, the right ventricle will be completely hypoplastic and pulmonary atresia will also be present [see Chapter 479.3]). *Pulmonary blood flow (and thus the degree of cyanosis) depends on the size of the VSD and the presence and severity of any associated pulmonic stenosis.* Pulmonary blood flow may be augmented by or be totally dependent on a PDA. The inflow portion of the right ventricle is always missing, but the outflow portion can be of variable size. The clinical presentation of patients with tricuspid atresia and *normally related great arteries* will depend on the degree of obstruction to pulmonary blood flow. Patients with a smaller VSD or moderate degrees of pulmonary stenosis are recognized in the early days or weeks of life by decreased pulmonary blood flow and cyanosis, especially after the PDA begins to close. Alternatively, in those with a large VSD and minimal or no RVOT obstruction, pulmonary blood flow may be normal or increased; these patients have only mild cyanosis and can present with signs of pulmonary overcirculation and heart failure.

In patients with tricuspid atresia and **transposition of the great arteries (TGA)**, LV blood flows directly into the pulmonary artery, whereas systemic blood must traverse the VSD and right ventricle to reach the aorta. In these patients, pulmonary blood flow is usually massively increased, and heart failure develops early. If the VSD is restrictive, systemic blood flow may be compromised and the patient may present with signs of decreased perfusion. **Coarctation of the aorta** is often noted in this setting.

CLINICAL MANIFESTATIONS

Some degree of cyanosis is usually evident at birth, with the extent depending on the degree of limitation to pulmonary blood flow. Unique to tricuspid atresia, an increased LV impulse may be noted, in contrast to most other causes of cyanotic heart disease, in which an increased RV impulse is usually present. Most patients have holosystolic murmurs audible along the left sternal border; S_2 is usually single. Pulses in the lower extremities may be weak or absent in the presence of transposition and with coarctation of the aorta. Patients with tricuspid atresia are at risk for spontaneous narrowing or even closure of the VSD, which can occasionally occur rapidly and lead to a marked increase in cyanosis.

DIAGNOSIS

Radiologic studies show either pulmonary undercirculation (most often in patients with normally related great arteries) or overcirculation (most often in patients with transposed great arteries). Left-axis deviation and LV hypertrophy are generally noted on the ECG (except in patients with TGA), and these unique features are a hallmark of tricuspid atresia, distinguishing it from most other cyanotic heart lesions, which are associated with right-axis deviation and RV hypertrophy. In the right precordial leads, the normally prominent R wave is replaced by an rS complex. The left precordial leads show a qR complex, followed by a normal, flat, biphasic, or inverted T wave. RV_6 is normal or tall, and SV_1 is generally deep. The P waves are usually biphasic, with the initial component tall and spiked in lead II. 2D echocardiography reveals the presence of a fibromuscular membrane in place of a tricuspid valve, a variably small right ventricle, variably sized VSD, and a slightly to moderately enlarged left ventricle (Fig. 479.8). The relationship of the great vessels (normal or transposed) can be determined. The degree of obstruction at the level of the VSD or at the RVOT can be determined by Doppler examination. Blood flow through a patent ductus can be evaluated by color flow and pulsed Doppler.

Cardiac catheterization, indicated usually only if questions remain after echocardiography, shows normal or slightly elevated right atrial pressure with a prominent *a* wave. If the right ventricle is entered through the VSD, the pressure may be lower than on the left if the VSD is restrictive in size. Right atrial angiography shows immediate opacification of the left atrium from the right atrium, followed by left ventricular filling and visualization of the aorta. Absence of direct flow to the right ventricle results in an angiographic filling defect between the right atrium and the left ventricle.

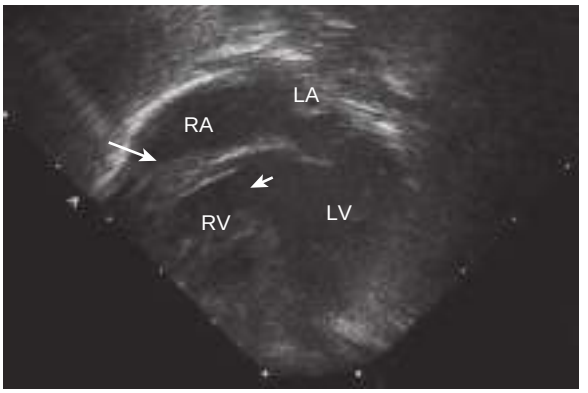

Fig. 479.8 Echocardiogram demonstrating tricuspid atresia. The floor of the right atrium consists of a fibromuscular membrane *(longer arrow)* instead of the normal tricuspid valve apparatus. The large secundum atrial septal defect can be seen between the right and left atria. The *short arrow* shows the ventricular septal defect. LA, Left atrium; LV, left ventricle; RA, right atrium; RV, right ventricle.

TREATMENT

Management of patients with tricuspid atresia depends on the adequacy of pulmonary blood flow. Moderately or severely cyanotic neonates (most often those with normally related great arteries) should be maintained on an IV infusion of PGE_1 (0.05-0.1 μg/kg/min) until a surgical aortopulmonary shunt procedure can be performed to increase pulmonary blood flow. The Blalock-Taussig procedure (see Chapter 479.1) or a variation is the preferred anastomosis. Rare patients with restrictive atrial-level communications also benefit from a Rashkind balloon atrial septostomy (see Chapter 480.2) or surgical septectomy.

Infants with increased pulmonary blood flow because of an unobstructed pulmonary outflow tract (more often patients with TGA) may require early surgery or pulmonary arterial banding (especially for patients in the first 1-2 months of life) to decrease the symptoms of heart failure and protect the pulmonary bed from the development of pulmonary vascular disease. Infants with just adequate pulmonary blood flow who are well balanced between cyanosis and pulmonary overcirculation can be watched closely for the development of increasing cyanosis, which may occur as the VSD begins to get smaller or the pulmonary outflow becomes narrower and is an indication for surgery.

The next stage of palliation for patients with tricuspid atresia involves the creation of an anastomosis between the superior vena cava and the pulmonary arteries (**bidirectional Glenn shunt**; Fig. 479.9A). This procedure is performed at usually between 2 and 6 months of age. The Glenn shunt provides a stable source of pulmonary blood flow as well as reducing the volume load on the left ventricle.

The **modified Fontan operation** is the preferred approach for longer-term palliation. It is usually performed between 2 and 3 years of age, after the patient is ambulatory. Initially, this procedure was performed by anastomosing the right atrium or atrial appendage directly to the pulmonary artery. The procedure used most often now is a modification of the Fontan procedure, known as a **cavopulmonary isolation procedure**, which involves anastomosing the inferior vena cava directly to the pulmonary arteries using a homograft or Gore-Tex tube running outside the heart (external-conduit Fontan; Fig. 479.9C). An older version of this procedure uses an internal baffle that runs along the lateral wall of the right atrium (lateral-tunnel Fontan; see Fig. 479.9B). In a completed Fontan repair, desaturated blood flows from both venae cavae directly into the pulmonary arteries. Oxygenated blood returns to the left atrium, enters the left ventricle, and is ejected into the systemic circulation. The volume load is completely removed from the left ventricle, and the right-to-left shunt is abolished. Because of the reliance on passive filling of the pulmonary circulation, the Fontan procedure is contraindicated in patients with elevated pulmonary vascular resistance, in those with pulmonary artery hypoplasia, and in patients with LV dysfunction. The patient also must not have significant mitral insufficiency. Patients who are not in normal sinus rhythm

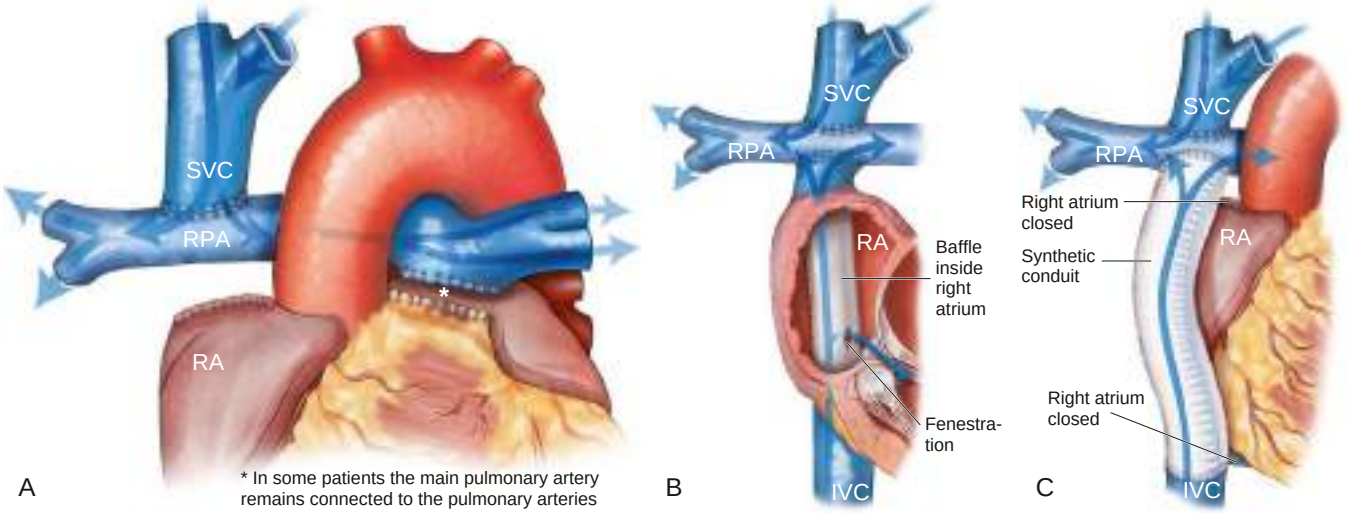

Fig. 479.9 Staged surgical approach to palliation of the patient with a single-ventricle circulation. **A,** Bidirectional Glenn shunt. The superior vena cava (SVC) is divided and detached from the right atrium (RA) and anastomosed end-to-side to the pulmonary artery, which has also been divided and detached from the right ventricle. **B,** Lateral tunnel Fontan. Inferior vena caval flow is directed upward through a synthetic or pericardial baffle sutured to the RA wall. The lower portion of the SVC (previously divided during the Glenn shunt) is now sutured directly to the right pulmonary artery. Thus blood flows from the upper body via the SVC directly into the lungs via the previous Glenn shunt and from the lower body via the baffle, through the RA but not emptying into the RA, directly into the lungs. The only remaining blood flow entering into the RA is from the coronary sinus, which represents the small amount of venous return coming directly from the left ventricle. The RA is thus excluded from the Fontan circuit. **C,** Extracardiac Fontan. The inferior vena cava (IVC) is detached from the RA, and an extracardiac synthetic conduit or homograft is used to direct that flow, outside the heart, to the inferior aspect of the right pulmonary artery (RPA). Both Fontan approaches achieve the same endpoint in isolating the venous circulation (blue blood) from the arterial circulation (red blood). The external conduit Fontan procedure is more common today because of concerns about atrial arrhythmias and/or blood clots related to the baffle in the RA. Many surgeons orient the connection from the IVC more centrally on the pulmonary arteries than shown in (**C**) to avoid a "collision" of flow from the upper and lower bodies, which in flow dynamic modeling studies has been shown to reduce the efficiency of the Fontan circulation, especially during exercise. *(Adapted from Burchill LJ, Wald RM, Mertens L. Single ventricles: echocardiographic assessment after the Fontan operation. In Otto CM, ed. The Practice of Clinical Echocardiography, 5th ed. Philadelphia: Elsevier; 2017, Figs. 49-6, 8, and 9.)*

are at increased risk, and if a pacemaker is required in these patients, dual-chamber pacing is the preferred approach.

Postoperative problems after the Fontan procedure are most often related to the increase in central venous pressure that occurs when the vena cavae are connected directly to the pulmonary arteries. Normal central venous pressure is 0-5 mm Hg, whereas after the Fontan operation, central venous pressure can rise to 10-15 mm Hg, and occasionally even more. In the immediate postoperative period, this elevation of systemic venous pressure can lead to fluid retention and pleural or pericardial effusions. The occurrence of these effusions has been markedly reduced with the cavopulmonary isolation procedure now in use, although prolonged chest tube drainage can still occur, but eventually resolves. Some centers use a fenestration at the time of the Fontan, consisting of a small communication between the inferior vena cava and the pulmonary artery conduit and the left atrium. This serves as a "pop-off" during early postoperative recovery and may hasten hospital discharge. The fenestration will result in some amount of right-to-left shunting and is therefore usually closed with a catheter closure device after the immediate postoperative period.

Late complications of the Fontan procedure include stenosis of the superior or inferior vena cava anastomosis, vena cava or pulmonary artery thromboembolism, protein-losing enteropathy, plastic bronchitis, renal dysfunction, immune deficiency, supraventricular arrhythmias (atrial flutter, paroxysmal atrial tachycardia), and hepatic injury, referred to as **Fontan-associated liver disease (FALD)**, as a result of persistently elevated central venous pressures. Rarely liver disease may predispose to the development of hepatocellular carcinoma. As more patients survive into young and middle adult years, the occurrence of these complications increases, and these patients require careful follow-up in a center skilled at caring for **adults with congenital heart disease (ACHDs)**. Oral budesonide or sildenafil has been used with varying success to treat protein-losing enteropathy associated with the Fontan procedure. MRI lymphangiography followed by thoracic duct ligation, decompression, or embolization is used to treat plastic bronchitis and other complications of a Fontan procedure. LV dysfunction may be a late occurrence, usually not until adolescence or young adulthood. Heart transplantation is a successful treatment option for pediatric patients with "failed" Fontan circuits but is a somewhat riskier procedure when performed in older adults. Patients with combined heart failure and liver dysfunction have been treated with combined heart-liver transplantation with good result.

Visit Elsevier eBooks+ at eBooks.Health.Elsevier.com for Bibliography.

479.5 Double-Outlet Right Ventricle

Daniel Bernstein

Double-outlet right ventricle **(DORV)** is characterized when both the aorta and pulmonary artery arise from the right ventricle. The only outlet from the left ventricle occurs through a VSD emptying into the right ventricle, although some degree of override of the septum may place either the aorta or pulmonary artery partially over the left ventricle. Normally, the aortic and mitral valves are in fibrous continuity; in DORV the aortic and mitral valves are separated by a smooth muscular **conus**, like that seen under the normal pulmonary valve. In DORV the great arteries may be *normally related,* with the aorta closer to (or slightly overriding) the VSD, or the great arteries may be *malposed,* with the pulmonary artery closer to (or slightly overriding) the VSD. The degree to which the great artery closest to the VSD may override the defect is variable but must be at least 50% committed to the right ventricle to be termed DORV. When the VSD is subaortic, the defect may be viewed as part of a continuum with the **tetralogy of Fallot**, and the physiology, history, physical examination, ECG, and radiography depend on the degree of pulmonary stenosis, like the situation in tetralogy of Fallot (see Chapter 479.1). If the VSD is subpulmonic, there may be subvalvar, valvar, or supravalvar aortic stenosis, and

coarctation is a possibility as well. This is known as the **Taussig-Bing malformation**. The clinical presentation of these patients will depend on the degree of aortic obstruction, but because the pulmonary artery is usually wide open, the presentation will usually include some degree of pulmonary overcirculation and heart failure. If the aortic obstruction is severe or there is a coarctation, poor pulses, hypoperfusion, and cardiovascular collapse are possible presenting signs, especially when the PDA begins to close.

The 2D echocardiogram demonstrates both great vessels arising from the right ventricle and mitral-aortic valve discontinuity. The relationships between the aorta and pulmonary artery to the VSD can be delineated, and the presence of either pulmonary obstruction or aortic obstruction can be evaluated. The aortic arch is imaged to evaluate for coarctation. Cardiac catheterization is not necessarily required if the echocardiogram is straightforward. Angiography will show that the aortic and pulmonary valves lie in the same horizontal plane and that both arise predominantly or exclusively from the right ventricle.

Surgical correction depends on the relationship of the great vessels to the VSD. If the VSD is *subaortic,* the repair will be like that used for tetralogy of Fallot with patch closure of the VSD so that the left ventricle ejects blood into the aorta. In cases where the aorta is more distant from the left ventricle, repair may consist of creating an intraventricular tunnel so that the left ventricle ejects blood through the VSD, into the tunnel, and into the aorta. The pulmonary obstruction is relieved either with an outflow patch or with a right ventricle–to–pulmonary artery homograft conduit **(Rastelli operation)**. If the VSD is *subpulmonic,* the great vessels can be switched (see Chapter 479.6) and the Rastelli operation performed. However, if there is substantial aortic obstruction or if one of the ventricles is hypoplastic, a Norwood-style single-ventricle repair may be necessary (see Chapter 480.10). In selected small infants, palliation with an aortopulmonary shunt can provide symptomatic improvement and allow for adequate growth before corrective surgery is performed.

479.6 Transposition of the Great Arteries with Ventricular Septal Defect and Pulmonary Stenosis

Daniel Bernstein

The combination of TGA with VSD and pulmonary stenosis may mimic tetralogy of Fallot in its clinical features (see Chapter 479.1). However, because of the transposed great vessels, the site of obstruction is in the left as opposed to the right ventricle. The obstruction can be either valvular or subvalvular; the latter type may be *dynamic,* related to the interventricular septum or atrioventricular valve tissue, or *acquired,* as in patients with transposition and VSD after pulmonary arterial banding.

The age at which clinical manifestations initially appear varies from soon after birth to later infancy, depending on the degree of pulmonic stenosis. Clinical findings include cyanosis, decreased exercise tolerance, and poor physical development, like those described for tetralogy of Fallot; the heart is usually more enlarged. The pulmonary vasculature as seen on radiograph depends on the degree of pulmonary obstruction. The ECG usually shows right-axis deviation, right and left ventricular hypertrophy, and sometimes tall, spiked P waves. Echocardiography confirms the diagnosis and is useful in sequential evaluation of the degree and progression of the LV outflow tract obstruction. Cardiac catheterization, if necessary, shows that pulmonary arterial pressure is low and that oxygen saturation in the pulmonary artery exceeds that in the aorta, since pulmonary blood flow is coming directly from the left ventricle. Selective right and left ventriculography demonstrates the origin of the aorta from the right ventricle, the origin of the pulmonary artery from the left ventricle, the VSD, and the site and severity of the pulmonary stenosis.

An infusion of PGE_1 (0.05-0.1 μg/kg/min) should be started in neonates who present with cyanosis. When necessary, **balloon atrial septostomy** is performed to improve atrial-level mixing and to decompress the left atrium (see Chapter 480.2). Cyanotic infants may be palliated with an aortopulmonary shunt (see Chapter 479.1), followed by a Rastelli operation when older, as the preferred corrective procedure. The Rastelli procedure achieves physiologic and anatomic correction by (1) closure of the VSD using an interventricular tunnel so that LV blood flow is directed to the aorta and (2) connection of the right ventricle to the distal pulmonary artery by an extracardiac homograft conduit (Fig. 479.10). These conduits will eventually become stenotic with patient growth and require replacement. Patients with milder degrees of pulmonary stenosis amenable to simple valvotomy may be able to undergo complete correction with an **arterial switch procedure** (see Chapter 480.2) and closure of the VSD. Surgical correction by the **Mustard or Senning operation** (see Chapter 480.2) with simultaneous closure of the VSD and relief of LV outflow obstruction may be an alternative when the position of the VSD is not suitable for a Rastelli operation; however, this procedure leaves the right ventricle as the systemic pumping chamber and has fallen out of favor.

479.7 Ebstein Anomaly of the Tricuspid Valve

Daniel Bernstein

Ebstein anomaly consists of downward displacement of an abnormal tricuspid valve into the right ventricle. The defect arises from failure of the normal process by which the tricuspid valve is separated from the RV myocardium (see Chapter 469). The anterior cusp of the valve retains some attachment to the valve ring, but the other leaflets are adherent to the wall of the right ventricle. The right ventricle is thus divided into two parts by the abnormal tricuspid valve: the first, a thin-walled "atrialized" portion, is continuous with the cavity of the right atrium; the second, often smaller, portion consists of normal ventricular myocardium. The right atrium is enlarged as a result of tricuspid valve regurgitation, although the degree is extremely variable. In more severe forms of Ebstein anomaly, the effective output from the right side of the heart is decreased because of a combination of the poorly functioning small right ventricle, tricuspid valve regurgitation, and RVOT obstruction produced by the large, sail-like, anterior tricuspid valve leaflet. The severity of tricuspid valve displacement has been grouped into four degrees (A through D), known as the *Carpentier classification.* In newborns, RV function may be so compromised that it is unable to generate enough force to open the pulmonary valve in systole, thus producing "functional" pulmonary atresia. Some infants have true anatomic pulmonary atresia. The increased volume of right atrial blood shunts through the foramen ovale (or through an associated ASD) to the left atrium and produces cyanosis (Fig. 479.11).

CLINICAL MANIFESTATIONS

The severity of symptoms and the degree of cyanosis are highly variable and depend on the extent of displacement of the tricuspid valve and the severity of RVOT obstruction. In many patients with milder forms of tricuspid valve displacement, symptoms are mild and may be delayed until the teenage years or young adult life; the patient may initially have fatigue, exercise intolerance, or palpitations as a result of cardiac dysrhythmias. The atrial right-to-left shunt is responsible for cyanosis, which may only be evident during exercise and, if long-standing, polycythemia. Jugular venous pulsations, an index of central venous pressure, may be normal or increased in those with tricuspid insufficiency. On palpation, the precordium is quiet. A holosystolic murmur caused by tricuspid regurgitation is audible over most of the anterior left side of the chest. A gallop rhythm is common and often associated with multiple clicks at the lower-left sternal border. A scratchy diastolic murmur may also be heard at the left sternal border. This murmur may mimic a pericardial friction rub.

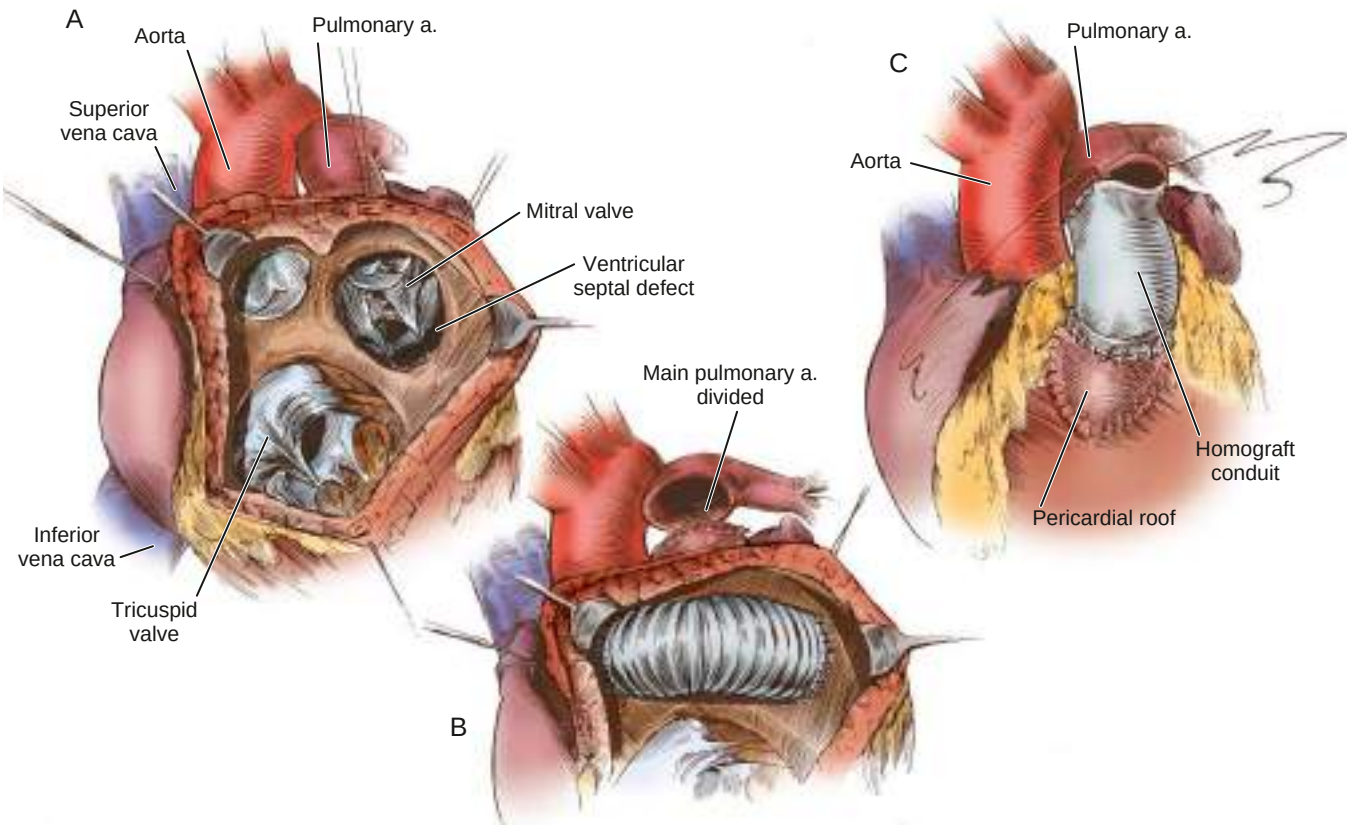

Fig. 479.10 A, Taussig-Bing type of double-outlet right ventricle with subpulmonary stenosis necessitating repair by the Rastelli technique. B, The main pulmonary artery is divided and oversewn proximally. The pulmonary valve lies within the baffle pathway. C, Completion of the Rastelli repair with a right ventricle–pulmonary artery allograft conduit. *(From Castañeda AR, Jonas RA, Mayer JE Jr, et al. Single-ventricle tricuspid atresia. In: Castañeda AR, Jonas RA. Mayer JE Jr, Hanley FL, eds. Cardiac Surgery of the Neonate and Infant. Philadelphia: Saunders; 1994.)*

Newborns with severe forms of Ebstein anomaly have marked cyanosis, massive cardiomegaly, and long holosystolic murmurs. Death may result from cardiac failure, hypoxemia, and pulmonary hypoplasia, the result of severe long-standing intrauterine right atrial enlargement. Spontaneous improvement may occur in some neonates as pulmonary vascular resistance falls and improves the ability of the right ventricle to provide pulmonary blood flow. The majority are dependent on a PDA, and thus on a prostaglandin infusion, for pulmonary blood flow. Fetuses diagnosed with Ebstein anomaly on fetal ultrasound can be particularly challenging. Severe leakage of the tricuspid valve is one of the few congenital heart lesions that cannot be bypassed by the parallel fetal circulation (see Chapter 470), and thus cardiac enlargement and fetal heart failure may supervene. When the heart enlarges, particularly the right atrium, compression of the lungs can result and the fetus is at risk for development of pulmonary hypoplasia.

DIAGNOSIS

The ECG usually shows a right bundle branch block without increased right precordial voltage, normal or tall and broad P waves, and a normal or prolonged P-R interval. **Wolff-Parkinson-White syndrome** may be present, and these patients may have episodes of supraventricular tachycardia (see Chapter 484). On radiographic examination, heart size varies from slightly enlarged to massive, box-shaped cardiomegaly caused by enlargement of the right atrium. *In newborns with severe Ebstein anomaly, the heart may be so enlarged as to totally obscure the pulmonary fields* (Fig. 479.12). Echocardiography is diagnostic and shows the degree of displacement of the tricuspid valve leaflets, a dilated right atrium, and any RVOT obstruction (Fig. 479.13). Pulsed and color Doppler examination demonstrates the degree of tricuspid regurgitation. In severe cases the pulmonary valve may appear immobile, and pulmonary blood flow may come solely from the ductus arteriosus. It may be difficult to distinguish true from functional pulmonary valve atresia. Cardiac catheterization, which is not usually necessary, confirms the presence of a large right atrium, an abnormal tricuspid valve, and any right-to-left shunt at the atrial level. The risk of arrhythmia is significant during catheterization and angiographic studies.

TREATMENT

Neonates with milder degrees of cyanosis can sometimes be managed medically, waiting to see how they do once their pulmonary vascular resistance decreases over the first few weeks of life. Those with moderate to severe hypoxia are initially treated with prostaglandins, mechanical ventilation and inhaled nitric oxide in an attempt to enhance pulmonary blood flow by reducing pulmonary vascular resistance. Surgical options for these patients include an aortopulmonary (Blalock-Taussig) shunt, tricuspid valve replacement (most often with a bioprosthetic valve), or surgical repair of the tricuspid valve (cone procedure). In the critically ill neonate, closure of the valve (creating tricuspid atresia physiology) with an aortopulmonary shunt (Starnes procedure), with eventual single-ventricle repair using the Fontan palliation (see Chapter 479.4) is

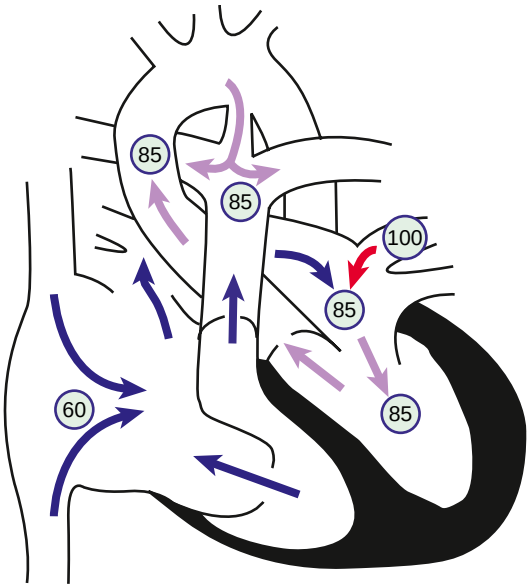

Fig. 479.11 Physiology of Ebstein anomaly of the tricuspid valve. *Circled numbers* represent oxygen saturation values. Inferior displacement of the tricuspid valve leaflets into the right ventricle has resulted in a thin-walled, low-pressure "atrialized" segment of right ventricle. The tricuspid valve is grossly insufficient. Right atrial blood flow is shunted right to left across an atrial septal defect or patent foramen ovale into the left atrium. Some blood may cross the right ventricular outflow tract and enter the pulmonary artery; however, in severe cases, the right ventricle may generate insufficient force to open the pulmonary valve, and "functional pulmonary atresia" results. In the left atrium, desaturated blood mixes with saturated pulmonary venous return. Blood enters the left ventricle and is ejected via the aorta. In this example, some pulmonary blood flow is derived from the right ventricle, the rest from a patent ductus arteriosus (PDA). Severe cyanosis will develop in neonates with a severe Ebstein anomaly when the PDA closes.

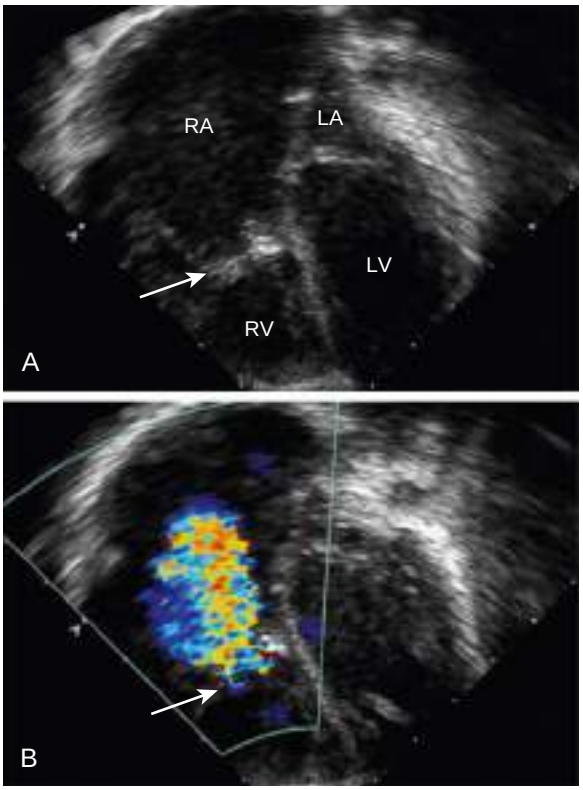

Fig. 479.13 Echocardiographic demonstration of Ebstein anomaly of the tricuspid valve. **A,** Subcostal, four-chamber, 2D view showing severe displacement of the tricuspid valve leaflets *(arrow)* inferiorly into the right ventricle. The location of the tricuspid valve annulus is outlined by the arrow. The portion of the right ventricle between the valve annulus and the valve leaflets is the "atrialized" component. **B,** Color Doppler examination showing severe regurgitation of the dysplastic tricuspid valve. Note that the regurgitant turbulent flow *(arrow)* begins halfway into the right ventricular chamber, at the location of the displaced valve leaflets. LA, Left atrium; LV, left ventricle; RA, right atrium; RV, right ventricle.

Fig. 479.12 Massive cardiomegaly in a newborn infant with severe Ebstein anomaly. The heart is so enlarged (in part because of a massive right atrium) that lung hypoplasia is a major concern.

an option. Many infants with Ebstein anomaly who have undergone valve repair will also have a bidirectional Glenn shunt performed to reduce the volume load on the right ventricle and reduce the amount of tricuspid regurgitation (see Chapter 479.4). In older children with mild or moderate disease, control of supraventricular dysrhythmias (medications or radiofrequency ablation), if present, is of primary importance; surgical treatment may not be necessary until adolescence or young adulthood. Older patients with severe tricuspid regurgitation can undergo repair or replacement of the abnormal tricuspid valve along with closure of the ASD. In some patients, a bidirectional Glenn shunt is also performed, with the superior vena cava anastomosed to the pulmonary arteries. This procedure reduces the volume of blood that the dysfunctional right side of the heart has to pump, thus creating a "one-and-one-half ventricle repair."

PROGNOSIS AND COMPLICATIONS

The prognosis in Ebstein anomaly is extremely variable and depends on the severity of the defect. The prognosis is more guarded for neonates or infants with cyanosis. Patients with milder degrees of Ebstein anomaly usually survive well into adult life. An associated form of left ventricular cardiomyopathy, **isolated left ventricular noncompaction (LVNC)**, is seen in up to 18% of patients with Ebstein anomaly, and the severity of the LV dysfunction directly affects the prognosis.

Visit Elsevier eBooks+ at eBooks.Health.Elsevier.com for Bibliography.

Chapter 480

Cyanotic Congenital Heart Disease: Lesions Associated with Increased Pulmonary Blood Flow

480.1 d-Transposition of the Great Arteries

Daniel Bernstein

d-Transposition of the great arteries or vessels (d-TGA or d-TGV) accounts for approximately 5% of all congenital heart disease. In this anomaly, the systemic veins return, as normal, to the right atrium and the pulmonary veins return to the left atrium. The connections between the atria and ventricles are also normal (i.e., **atrioventricular concordance**). The aorta arises from the right ventricle and the pulmonary artery from the left ventricle (Fig. 480.1). In normally related great vessels (i.e., in the normal heart) the aorta is posterior and to the right of the pulmonary artery. Whereas in d-TGA the aorta is anterior and to the right of the pulmonary artery (the *d* indicates a dextropositioned aorta, *transposition* indicates that the aorta arises from the right ventricle and the pulmonary artery from the left ventricle). Desaturated blood returning from the body to the right side of the heart goes inappropriately out via the aorta and back to the body again, whereas oxygenated pulmonary venous blood returning to the left side of the heart is returned directly to the lungs. Thus the systemic and pulmonary circulations exist as two parallel circuits. Survival in the immediate newborn period is provided by the foramen ovale and the ductus arteriosus, which permit some mixture of oxygenated and deoxygenated blood. Approximately 50% of patients with d-TGA also have a ventricular septal defect (VSD), which usually provides for better mixing. The clinical findings and hemodynamics vary in relation to the presence or absence of associated defects (e.g., VSD or pulmonary stenosis). d-TGA is more common in infants of diabetic mothers and in males (a ratio of 3:1). When accompanied by other cardiac defects such as pulmonic stenosis or right aortic arch, d-TGA can be associated with deletion of chromosome 22q11.2 (**DiGeorge syndrome**; see Chapter 473).

480.2 d-Transposition of the Great Arteries with Intact Ventricular Septum

Daniel Bernstein

d-TGA with an intact ventricular septum is also referred to as **simple TGA** or **isolated TGA**. Before birth, oxygenation in the upper and lower body fetal circulation is only slightly abnormal, given that oxygenated blood enters the heart from the placenta, umbilical vein, and inferior vena cava. After birth, once the ductus arteriosus begins to close, the minimal mixing of systemic and pulmonary blood by the patent foramen ovale is usually insufficient and severe hypoxemia ensues, generally within the first few days of life.

CLINICAL MANIFESTATIONS

Cyanosis and tachypnea are most often recognized within the first hours or days of postnatal life. Untreated, most of these infants would not survive the neonatal period. Hypoxemia is usually moderate to severe, depending on the degree of atrial-level shunting and whether the ductus is partially open or totally closed. This condition is a medical emergency, and only early diagnosis and appropriate intervention can avert the development of prolonged severe hypoxemia and acidosis, which lead to death. Physical findings, other than cyanosis, may be remarkably nonspecific. The precordial impulse may be normal, or a parasternal heave may be present. The second heart sound (S_2) is usually single and loud, although it may be split. Murmurs may be absent, or a soft systolic ejection murmur may be noted at the mid-left sternal border.

DIAGNOSIS

The electrocardiogram (ECG) is usually normal, showing the expected neonatal right-sided dominant pattern. Chest radiographs may show mild cardiomegaly and a narrow mediastinum (the classic "egg-shaped heart"). In the early newborn period, the pulmonary blood flow is generally normal. As pulmonary vascular resistance (PVR) drops during the first several weeks of postnatal life, evidence of increased pulmonary blood flow becomes apparent. Arterial blood partial pressure of oxygen (Pao_2) is low and does not rise appreciably after the patient breathes 100% oxygen (hyperoxia test), although this test may not be totally reliable. Echocardiography is diagnostic and confirms the transposed ventricular-arterial connections (Fig. 480.2). The size of the interatrial communication and the ductus arteriosus can be visualized and the degree of mixing assessed by pulsed and color Doppler examination. The presence of any associated lesion, such as left ventricular outflow tract obstruction or a VSD, can also be assessed. The origins of the coronary arteries can be imaged, although echocardiography is not as accurate as catheterization for

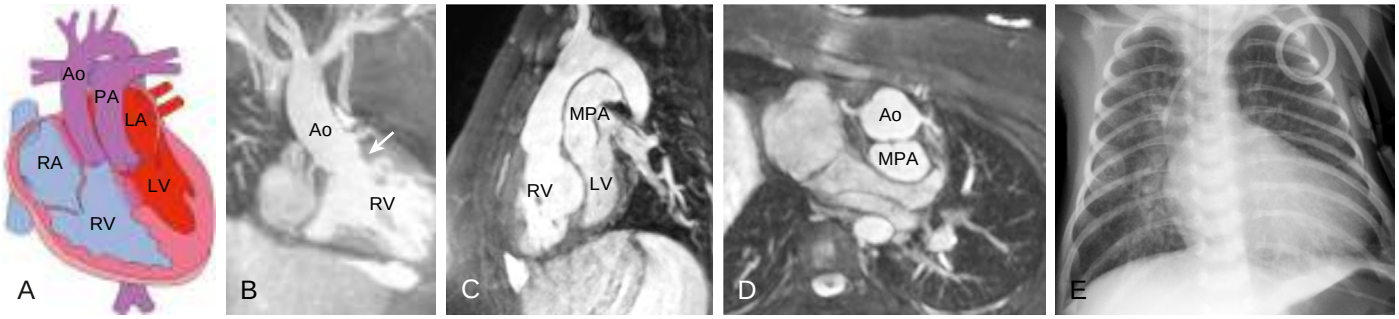

Fig. 480.1 d-Looped transposition of the great arteries (TGA). **A,** Diagram of d-TGA, with the main pulmonary artery (MPA) arising from the left ventricle (LV) and the aorta (Ao) arising from the right ventricle (RV). The degree of cyanosis is variable and depends on the presence of intracardiac shunts such as an atrial septal defect or a ventricular septal defect (VSD) to get oxygenated blood into the systemic circulation. LA, Left atrium; PA, pulmonary artery; RA, right atrium. **B** and **C,** Oblique reformatted images from a 3D steady-state free-precession sequence show (**B**) the Ao arising from the anterior RV with a subaortic conus *(arrow)*, and (**C**) the MPA arising from the posterior LV. **D,** The Ao and MPA have a parallel "back-to-front" arrangement. **E,** This parallel back-to-front arrangement contributes to the narrow mediastinum and "egg on a string" appearance seen on chest radiography. This patient has a large VSD with increased pulmonary blood flow. *(From Frost JL, Krishnamurthy R, Sena L. Cardiac imaging. In: Walters MM, Robertson RL, eds. Pediatric Radiology: The Requisites, 4th ed. Philadelphia: Elsevier; 2017, Fig 3-20, p. 75.)*

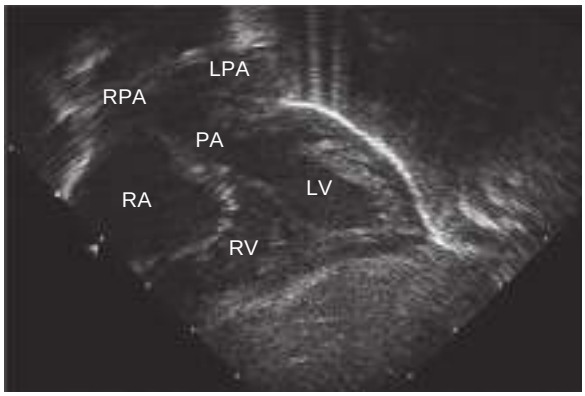

Fig. 480.2 Subcostal four-chamber 2D echocardiographic demonstration of d-transposition of the great arteries. The pulmonary artery (PA) can be seen arising directly from the left ventricle (LV). The immediate bifurcation of this great vessel into the branch pulmonary arteries differentiates it from the aorta, which branches more distally from the heart. LPA, Left pulmonary artery; RA, right atrium; RPA, right pulmonary artery; RV, right ventricle.

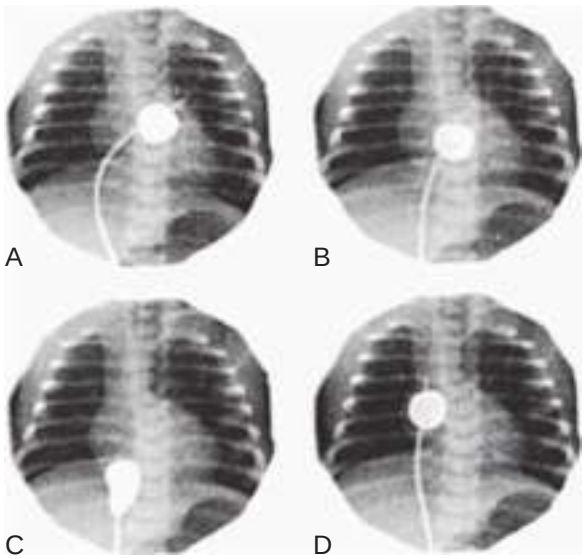

Fig. 480.3 Rashkind balloon atrial septostomy. Four frames from a continuous cineangiogram show the creation of an atrial septal defect in a hypoxemic newborn infant with transposition of the great arteries and an intact ventricular septum. **A**, Balloon inflated in the left atrium. **B**, The catheter is jerked suddenly so that the balloon ruptures the foramen ovale. **C**, Balloon in the inferior vena cava. **D**, Catheter advanced to the right atrium to deflate the balloon. The time from **A** to **C** is <1 sec.

this purpose. Cardiac catheterization may be performed in patients for whom noninvasive imaging is diagnostically inconclusive, where an unusual coronary artery anomaly is suspected, or in patients who require emergency **balloon atrial septostomy (i.e., the Rashkind procedure)**. Catheterization will show right ventricular pressure to be at a systemic level because this ventricle is supporting the systemic circulation. The blood in the left ventricle (LV) and pulmonary artery has a higher oxygen saturation than that in the aorta. Depending on the age at catheterization, LV and pulmonary artery pressure can vary from a systemic level to <50% of systemic-level pressure. Right ventriculography demonstrates the anterior and rightward aorta originating from the right ventricle (RV), as well as the intact ventricular septum. Left ventriculography shows that the pulmonary artery arises exclusively from the LV.

Anomalous coronary arteries are noted in 10–15% of patients and can be defined by an aortic root injection or by selective coronary arteriography.

TREATMENT

When transposition is suspected, an infusion of prostaglandin E_1 (PGE_1, 0.05-0.1 μg/kg/min) should be initiated immediately to maintain patency of the ductus arteriosus and improve oxygenation. Because of the risk of apnea associated with prostaglandin infusion, an individual skilled in neonatal endotracheal intubation should be available. Hypothermia intensifies the metabolic acidosis resulting from hypoxemia, and thus the patient should be kept warm. Prompt correction of acidosis and hypoglycemia is essential.

Infants who remain severely hypoxic or acidotic despite prostaglandin infusion should undergo **Rashkind balloon atrial septostomy** (Fig. 480.3). A Rashkind atrial septostomy is also usually performed in patients in whom any significant delay in surgery is expected. If surgery is planned during the first 2 weeks of life and the patient is stable, catheterization and atrial septostomy may often be avoided.

A successful Rashkind atrial septostomy should result in a rise in Pa_{O_2} to 35-50 mm Hg and elimination of any pressure gradient across the atrial septum. Some patients with TGA and VSD (see Chapter 480.3) may require balloon atrial septostomy because of poor mixing, even though the VSD is large. Others may benefit from decompression of the left atrium to alleviate the symptoms of increased pulmonary blood flow and left-sided heart failure.

The **arterial switch (Jatene) procedure** is the surgical treatment of choice for neonates with d-TGA and an intact ventricular septum and is usually performed within the first 2 weeks of life. The reason for this time frame is that as PVR declines after birth, pressure in the LV (connected to the pulmonary vascular bed) also declines. This pressure drop results in a decrease in LV mass over the first few weeks of life. If the arterial switch operation is attempted after LV pressure (and mass) has declined too far, the LV will be unable to generate adequate pressure to pump blood to the high-pressure systemic circulation. The arterial switch operation involves dividing the aorta and pulmonary artery just above the sinuses and reanastomosing them in their correct anatomic positions. The coronary arteries are removed from the old aortic root along with a button of aortic wall and reimplanted in the old pulmonary root (now called the **neoaorta**). By using a button of great vessel tissue, the surgeon avoids having to suture directly onto the coronary artery (Fig. 480.4); this is the major innovation that has allowed the arterial switch to replace previous atrial switch operations for d-TGA. Rarely, a two-stage arterial switch procedure, with initial placement of a pulmonary artery band, may be used in patients presenting late who already have had a reduction in LV muscle mass and pressure. The arterial switch procedure has a survival rate of >95% for uncomplicated d-TGA. It restores the normal physiologic relationships of systemic and pulmonary arterial blood flow and eliminates the long-term complications of the previously used atrial switch procedure.

Previous operations for d-TGA consisted of some form of **atrial switch procedure** (**Mustard** or **Senning** operation). These procedures produced excellent early survival (85–90%) but had significant long-term morbidities. Atrial switch procedures reverse blood flow at the atrial level by creating an interatrial baffle that directs systemic venous blood returning from the venae cavae to the left atrium, where it will enter the LV, the pulmonary artery, and the lungs. The same baffle also permits oxygenated pulmonary venous blood to cross over to the right atrium, RV, and aorta. Atrial switch procedures involve significant atrial surgery and have been associated with the late development of atrial conduction disturbances, sick sinus syndrome with bradyarrhythmia and tachyarrhythmia, atrial flutter, sudden death, superior or inferior vena cava syndrome, edema, ascites, and protein-losing enteropathy. The atrial switch procedure also leaves the RV as the systemic pumping chamber, and this "systemic" RV often begins to fail in young adulthood. Atrial switch operations are currently reserved for patients whose anatomy is such that they are not candidates for the arterial switch procedure.

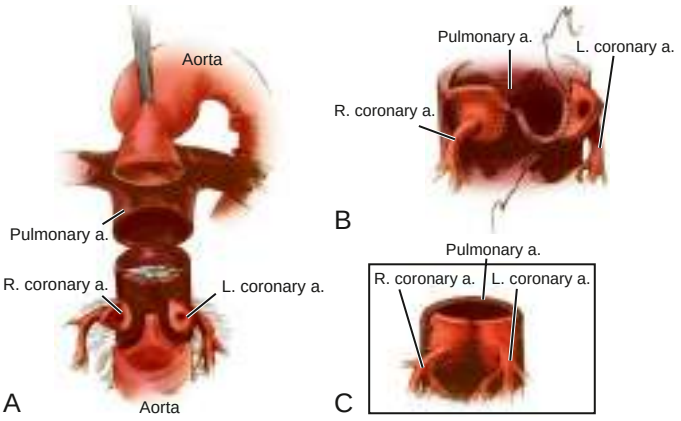

Fig. 480.4 Method for translocating the coronary arteries in the arterial switch (Jatene) procedure. **A,** The aorta (anterior) and the pulmonary artery (posterior) have been transected to allow visualization of the left and right coronary arteries. The coronaries have been excised from their respective sinuses, including a large flap (button) of arterial wall. Equivalent segments of the wall of the pulmonary artery (which will become the neoaorta) are also removed. **B,** The aortocoronary buttons are sutured into the proximal portion of the neoaorta. With this technique all sutures are placed in the button of aortic wall rather than directly on the coronary arteries. **C,** Completed anastomosis of the left and right coronary arteries to the neoaorta. *(Adapted from Castañeda AR, Jonas RA, Mayer JE Jr, et al. Cardiac Surgery of the Neonate and Infant. Philadelphia: Saunders; 1994.)*

480.3 Transposition of the Great Arteries with Ventricular Septal Defect

Daniel Bernstein

If the VSD associated with d-TGA is small, the clinical manifestations, laboratory findings, and treatment are similar to those described previously for transposition with an intact ventricular septum. A harsh systolic murmur is audible at the lower left sternal border, resulting from flow through the defect. Many of these small defects eventually close spontaneously and may not need to be addressed at the time of surgery.

When the VSD is large and not restrictive to ventricular ejection, significant mixing of oxygenated and deoxygenated blood usually occurs and clinical manifestations of cardiac failure are seen. The degree of cyanosis may be subtle and sometimes may not be recognized until an oxygen saturation measurement is performed. The murmur is holosystolic and generally indistinguishable from that produced by a large VSD in patients with normally related great arteries. The heart is usually significantly enlarged.

Cardiomegaly, a narrow mediastinal waist, and increased pulmonary vascularity are demonstrated on the chest radiograph. The ECG findings can be variable. It can show prominent P waves and isolated RV hypertrophy or biventricular hypertrophy. Occasionally, dominance of the LV is present. Usually, the QRS axis is to the right, but it can be normal or even to the left. The diagnosis is confirmed by echocardiography, and the extent of pulmonary blood flow can also be estimated by the degree of enlargement of the left atrium and ventricle. In equivocal cases, the diagnosis can be confirmed by cardiac catheterization. Right and left ventriculography indicate the presence of arterial transposition and demonstrate the site and size of the VSD. Systolic pressure is equal in the two ventricles, the aorta, and the pulmonary artery. Left atrial pressure may be much higher than right atrial pressure, a finding indicative of a restrictive communication at the atrial level. At the time of cardiac catheterization, Rashkind balloon atrial septostomy may be performed to decompress the left atrium, even when adequate mixing is occurring at the ventricular level.

Surgical treatment is advised soon after diagnosis because heart failure and failure to thrive are difficult to manage and pulmonary vascular disease can develop unusually rapidly in these patients. Preoperative management with diuretics and other anticongestive therapies (including elective intubation and positive pressure ventilation) stabilize the patient before surgery.

Patients with d-TGA and a VSD without pulmonic stenosis can be treated with an arterial switch procedure combined with VSD closure. In these patients, the arterial switch operation can be safely performed after the first 2 weeks of life because the VSD results in equal pressure in both ventricles and prevents regression of LV muscle mass. At major centers, however, there is no reason to delay repair, as results are excellent when the surgery is performed in the neonatal period.

480.4 l-Transposition of the Great Arteries (Corrected Transposition)

Daniel Bernstein

In l-transposition of the great arteries (l-TGA), both the atrioventricular and the ventriculoarterial relationships are discordant: the right atrium is connected to an LV and the left atrium to an RV, which is also known as **ventricular inversion**. The great arteries are also transposed, with the aorta arising from the RV and the pulmonary artery from the LV. In contrast to d-TGA, the aorta arises to the left of the pulmonary artery (thus the designation *l* for levo-transposition). The aorta may be anterior to the pulmonary artery, although often they are nearly side by side.

The physiology of l-TGA is quite different from that of d-TGA. Desaturated systemic venous blood returns via the vena cavae to a normal right atrium, from which it passes through a bicuspid atrioventricular (mitral) valve into a right-sided ventricle that has the architecture and smooth wall morphologic features of the normal LV (Fig. 480.5). Because transposition is also present, however, the desaturated blood ejected from this LV enters the transposed pulmonary artery and flows into the lungs, as it would in the normal circulation. Oxygenated pulmonary venous blood returns to a normal left atrium, passes through a tricuspid atrioventricular valve into a left-sided ventricle, which has the trabeculated morphologic features of a normal RV, and is then ejected into the transposed aorta. The double inversion of the atrioventricular and ventriculoarterial relationships result in desaturated right atrial blood appropriately flowing to the lungs and oxygenated pulmonary venous blood appropriately flowing to the aorta. The circulation is thus physiologically "corrected." Without other defects, the hemodynamics would be almost normal. In most patients, however, associated anomalies coexist: VSD, Ebstein-like abnormalities of the left-sided atrioventricular (tricuspid) valve, pulmonary valvular or subvalvular stenosis (or both), and atrioventricular conduction disturbances (complete heart block, accessory pathways such as Wolff-Parkinson-White syndrome).

CLINICAL MANIFESTATIONS

Symptoms and signs are widely variable and are usually determined by the associated lesions. If there is a VSD and pulmonary outflow is unobstructed, the clinical signs are similar to those of an isolated VSD. If l-TGA is associated with pulmonary stenosis and a VSD, the clinical signs are more similar to those of tetralogy of Fallot.

DIAGNOSIS

The chest radiograph may suggest the abnormal position of the great arteries; the ascending aorta occupies the upper left border of the cardiac silhouette and has a straight profile. The ECG, in addition to any atrioventricular conduction disturbances, may show abnormal P waves; absent Q waves in V_6; abnormal Q waves in leads III, aVR, aVF, and V_1; and upright T waves across the precordium. The echocardiogram is diagnostic. The characteristic echocardiographic features of the RV (moderator band, coarser trabeculations, tricuspid valve that sits more inferiorly compared with the bicuspid mitral valve, and a smooth muscular conus or infundibulum separating the atrioventricular valve

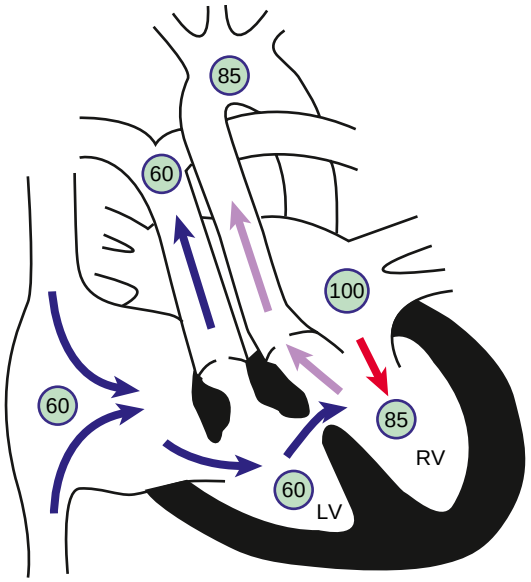

Fig. 480.5 Physiology of l-transposition or corrected transposition of the great arteries (l-TGA) with a ventricular septal defect and pulmonic stenosis (VSD + PS). *Circled numbers* represent oxygen saturation values. Right atrial (mixed venous) oxygen saturation is decreased secondary to systemic hypoxemia. Blood from the right atrium flows through the mitral valve into the "inverted" left ventricle (LV). The left ventricle is, however, attached to the transposed pulmonary artery. Therefore despite the anomalies, desaturated blood still winds up in the pulmonary circulation. Saturated blood returns to the left atrium, traverses the tricuspid valve into the "inverted" right ventricle (RV), and is pumped into the transposed aorta. This circulation would be totally "corrected" were it not for the frequent association of other congenital anomalies, in this case, VSD + PS. Because of the stenotic pulmonary valve, some left ventricular blood flow crosses the VSD and into the right ventricle and the ascending aorta, and systemic desaturation results.

from the semilunar valve) allow the echocardiographer to determine the presence of **atrioventricular discordance** (right atrium connected to LV; left atrium to RV) and ventriculoarterial discordance (RV connected to aorta; LV to pulmonary artery).

Surgical treatment of the associated anomalies, most often the VSD, is complicated by the position of the bundle of His, which can be injured at surgery and result in heart block. Identification of the usual course of the bundle in corrected transposition (running superior to the defect) has been accomplished by mapping the conduction system so that the surgeon can avoid the bundle of His during repair. Even without surgical injury, patients with l-TGA are at risk for developing heart block as they grow older.

Because simple surgical correction leaves the RV as the systemic pumping chamber, and thus vulnerable to late ventricular failure, surgeons have become more aggressive about trying operations that use the LV as the systemic pumping chamber. This is accomplished by performing an atrial switch operation (see Chapter 480.3) to reroute the systemic and pulmonary venous returns in combination with an arterial switch operation to reroute the ventricular outflows **(double switch procedure)**. The long-term benefit of this approach in preserving systemic ventricular function is still under investigation.

Visit Elsevier eBooks+ at eBooks.Health.Elsevier.com for Bibliography.

480.5 Double-Outlet Right Ventricle Without Pulmonary Stenosis

Daniel Bernstein

In double-outlet RV without pulmonary stenosis, both the aorta and the pulmonary artery arise from the RV (see Chapter 479.5). The only outlet from the LV is through a VSD. In the absence of obstruction to pulmonary blood flow, clinical manifestations are similar to those of an uncomplicated VSD with a large left-to-right shunt, although mild systemic desaturation may result from mixing of oxygenated and deoxygenated blood in the RV. The ECG usually shows biventricular hypertrophy. Echocardiography is diagnostic and shows the right ventricular origin of both great arteries, their anteroposterior relationship, and the relationship of the VSD to each of the great arteries. Surgical correction is dependent on these relationships. If the VSD is subaortic, it is accomplished by creation of an intracardiac tunnel. Blood is then ejected from the LV via the VSD into the aorta. If the VSD is subpulmonic, an arterial switch may be performed in combination with an intracardiac tunnel. If pulmonary blood flow is excessive enough to cause congestive heart failure, pulmonary arterial banding may be required in infancy, followed by surgical correction when the child is bigger. When associated pulmonary stenosis is present, cyanosis is more marked, pulmonary blood flow is decreased, and clinical presentation may be similar to that of tetralogy of Fallot.

480.6 Double-Outlet Right Ventricle with Malposition of the Great Arteries (Taussig-Bing Anomaly)

Daniel Bernstein

In double-outlet RV with malposed great arteries, the VSD is usually directly subpulmonic and the aorta distant from the LV. Sometimes both the pulmonary and the aortic valve may be located close to the VSD (**doubly committed** VSD) and sometimes neither is (**doubly uncommitted** VSD). The term *malposition* is used instead of *transposition* because both great arteries arise from the RV. Aortic obstructive lesions are common, including valvular and subvalvular aortic stenosis, coarctation of the aorta, and interruption of the aortic arch. Because pulmonary blood flow is unobstructed, patients experience cardiac failure early in infancy and are at risk for the development of pulmonary vascular disease and cyanosis. If aortic obstructive lesions are a component, patients can present with poor systemic output and cardiovascular collapse, particularly after the ductus arteriosus begins to close. Cardiomegaly is usual, and a parasternal systolic ejection murmur is audible, sometimes preceded by an ejection click and loud closure of the pulmonary valve. The ECG shows right axis deviation and right, left, or biventricular hypertrophy. The chest radiograph shows cardiomegaly and prominence of the pulmonary vasculature. The anatomic features of the anomaly and associated abnormalities are usually demonstrated by echocardiography, augmented if necessary by either cardiac catheterization, MRI, or CT. Palliation may be achieved by corrective surgery or pulmonary arterial banding in early infancy and surgical correction at a later age, which may be accomplished by an arterial switch procedure (see Chapter 480.2) combined with an intracardiac baffle or some modification of the Rastelli procedure (see Chapter 479.5).

480.7 Total Anomalous Pulmonary Venous Return

Daniel Bernstein

Abnormal development of the pulmonary veins may result in either partial or complete anomalous drainage into the systemic venous circulation. Partial anomalous pulmonary venous return (PAPVR) is usually an acyanotic lesion (see Chapter 475.4). Total anomalous pulmonary venous return (TAPVR) is associated with total mixing of systemic venous and pulmonary venous blood flow within the heart and thus produces cyanosis.

In TAPVR, there is no direct pulmonary venous connection into the left atrium (Fig. 480.6). The pulmonary veins may drain **above** the diaphragm: into the right atrium directly, into the coronary sinus, or into the superior vena cava by a "vertical vein"; or they may drain **below** the

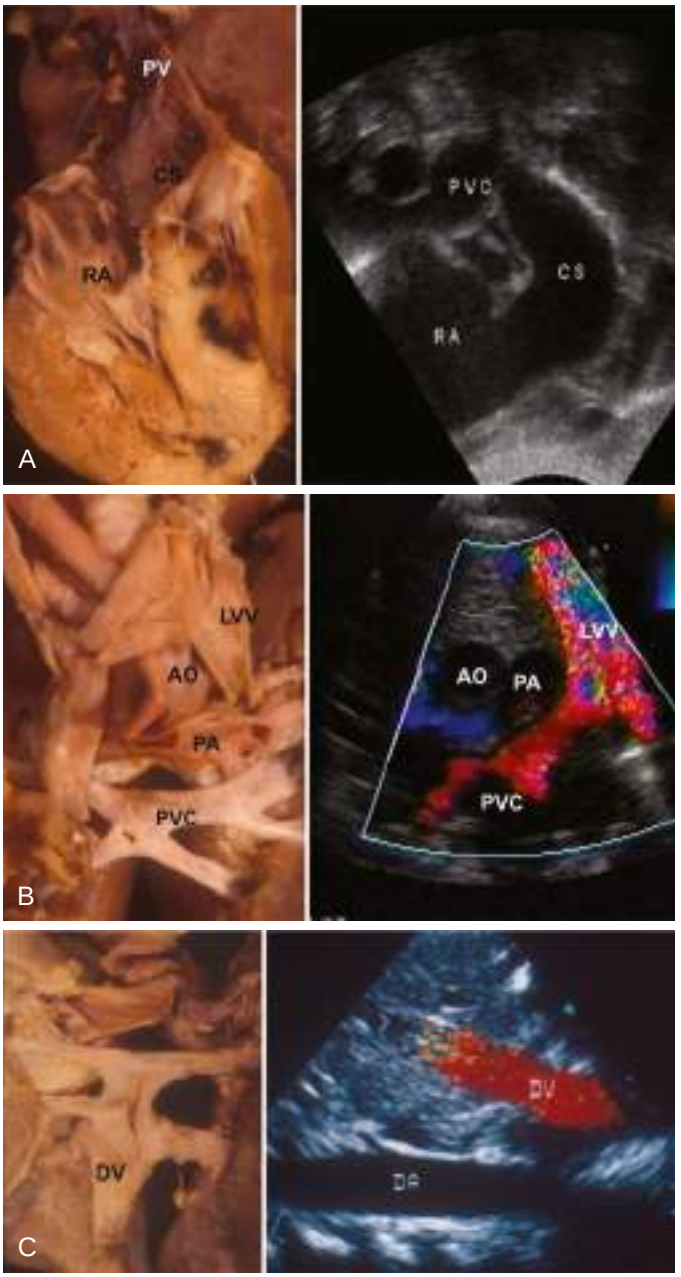

Fig. 480.6 **A,** Subcostal view demonstrating total anomalous pulmonary drainage to the coronary sinus. Note the dilated coronary sinus in both images. The echocardiogram also demonstrates an associated confluence that connects to the coronary sinus. **B,** Suprasternal view demonstrating total anomalous pulmonary venous drainage to a left vertical vein. Note the direction of flow in the vertical vein that differentiates it from a left superior vena cava. **C,** Total anomalous pulmonary venous drainage below the diaphragm. The specimen shows the pulmonary veins as they enter the confluence, whereas the echocardiogram demonstrates the descending veins as they enter the liver. Note that the direction of flow is away from the heart. AO, Aorta; CS, coronary sinus; DA, descending aorta; DV, descending vein; LVV, left vertical vein; PA, pulmonary artery; PV, pulmonary vein; PVC, pulmonary venous confluence; RA, right atrium. *(From Webb GD, Smallhorn, JF, Therrien J, et al. Congenital heart disease in the adult and pediatric patient. In: Zipes DP, Libby P, Bonow RO, et al., eds. Braunwald's Heart Disease, 11th ed. Philadelphia: Elsevier; 2019: Fig. 75-32, p. 1553.)*

diaphragm and join into a "descending vein" that enters the inferior vena cava or one of its major tributaries, often through the ductus venosus. This latter form of anomalous venous drainage is most often associated with *obstruction* to venous flow, usually as the ductus venosus closes soon after birth, although **supracardiac** anomalous veins may also become obstructed. Occasionally, the drainage may be **mixed**, with some veins draining above and others below the diaphragm.

Table 480.1 Total Anomalous Pulmonary Venous Return

SITE OF CONNECTION (% OF CASES)	% WITH SIGNIFICANT OBSTRUCTION
Supracardiac (50)	
Left superior vena cava (40)	40
Right superior vena cava (10)	75
Cardiac (25)	
Coronary sinus (20)	10
Right atrium (5)	5
Infracardiac (20)	95–100
Mixed (5)	

All forms of TAPVR involve mixing of oxygenated and deoxygenated blood before or at the level of the right atrium **(total mixing lesion)**. This mixed right atrial blood either passes into the RV and pulmonary artery or passes through an atrial septal defect (ASD) or patent foramen ovale into the left atrium, which will be the only source of oxygenated systemic blood flow. The right atrium and ventricle and the pulmonary artery are generally enlarged, whereas the left atrium and ventricle may be normal or small. The clinical manifestations of TAPVR depend on the presence or absence of *obstruction* of the venous channels (Table 480.1). If pulmonary venous return is obstructed, severe pulmonary congestion and pulmonary hypertension develop; rapid deterioration occurs without surgical intervention. *Obstructed TAPVR is a pediatric cardiac surgical emergency because prostaglandin therapy is usually not effective.*

CLINICAL MANIFESTATIONS

Two major clinical patterns of TAPVR are seen, depending on the presence or absence of obstruction. Those neonates with severe obstruction to pulmonary venous return, most prevalent in the **infracardiac** group (see Table 480.1), present with severe cyanosis and respiratory distress. Murmurs may not be present. These infants are severely ill and fail to respond to mechanical ventilation. Rapid diagnosis and surgical correction are necessary for survival. In contrast, those with mild or no obstruction to pulmonary venous return are usually characterized by the development of heart failure as the PVR falls, with mild to moderate degrees of desaturation. Systolic murmurs may be audible along the left sternal border, and a gallop rhythm may be present. Some infants may have mild obstruction in the neonatal period and develop worsening obstruction as time passes.

DIAGNOSIS

The ECG demonstrates RV hypertrophy (usually a qR pattern in V_3R and V_1, and P waves are frequently tall and spiked). In neonates with marked pulmonary venous obstruction, the chest radiograph demonstrates a very dramatic perihilar pattern of pulmonary edema and a small heart (Fig. 480.7A). This appearance can sometimes be confused with primary pulmonary disease, and the differential diagnosis includes persistent pulmonary hypertension of the newborn, respiratory distress syndrome, pneumonia, pulmonary lymphangiectasia, and other heart defects (hypoplastic left heart syndrome). In older children, if the anomalous pulmonary veins enter the innominate vein and persistent left superior vena cava (see Fig. 480.7B), a large supracardiac shadow can be seen, which together with the normal cardiac shadow forms a *snowman* appearance. In most cases without obstruction, the heart is enlarged, the pulmonary artery and RV are prominent, and pulmonary vascularity is increased.

The echocardiogram demonstrates a large RV and usually identifies the pattern of abnormal pulmonary venous connections

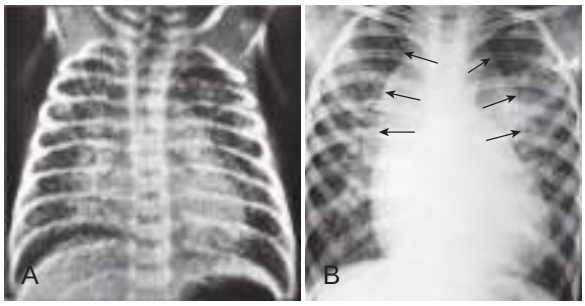

Fig. 480.7 Chest radiographs of total anomalous pulmonary venous return (TAPVR). **A,** A newborn with TAPVR to a descending vein (below the diaphragm) with obstruction, showing marked pulmonary venous congestion and normal heart size. **B,** TAPVR to the left superior vena cava (preoperative image). *Arrows* point to the supracardiac shadow, which produces the "snowman" or figure 8 configuration. Cardiomegaly and increased pulmonary vascularity are evident.

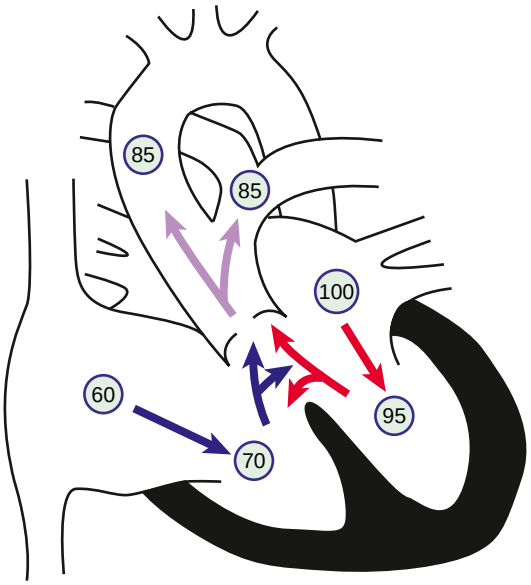

Fig. 480.8 Physiology of truncus arteriosus. *Circled numbers* represent oxygen saturation values. Right atrial (mixed venous) oxygen saturation is decreased secondary to systemic hypoxemia. Desaturated blood enters the right atrium, flows through the tricuspid valve into the right ventricle, and is ejected into the truncus. Saturated blood returning from the left atrium enters the left ventricle and is also ejected into the truncus. The common aortopulmonary trunk gives rise to the ascending aorta and to the main or branch pulmonary arteries. Oxygen saturation in the aorta and pulmonary arteries is usually the same (definition of a total mixing lesion). As pulmonary vascular resistance decreases in the first few weeks of life, pulmonary blood flow increases dramatically, and mild cyanosis and congestive heart failure result.

(see Fig. 480.6). The demonstration of any vein with Doppler flow away from the heart is pathognomonic of TAPVR because normal venous flow is usually toward the heart. Shunting occurs from right to left at the atrial level. The size of the left atrium and LV can be measured and the presence of any associated cardiac defects determined.

Echocardiography should be adequate to demonstrate TAPVR in most cases; however, if there is question about the drainage of one or more pulmonary veins, cardiac catheterization, MRI, or CTA is performed. Catheterization shows that the oxygen saturation of blood in both atria, both ventricles, and the aorta is similar, indicative of a **total mixing lesion**. An increase in systemic venous saturation occurs at the site of entry of the abnormal pulmonary venous channel, either above or below the diaphragm. In older patients without pulmonary venous obstruction, pulmonary arterial and RV pressure may be only moderately elevated, but in infants with pulmonary venous obstruction, pulmonary hypertension is usual. Selective pulmonary arteriography shows the anatomy of the pulmonary veins and their point of entry into the systemic venous circulation.

Fetal diagnosis of TAPVR is feasible in many, but not all, cases, with the main ultrasonographic signs being ventricular disproportion, increased area behind the left atrium, and the finding of a vertical vein. Color Doppler is key to making this diagnosis. Prenatal diagnosis can be helpful in planning for urgent surgical treatment after birth.

TREATMENT

Surgical correction of TAPVR is performed during early infancy, with emergent repair performed for those patients with venous obstruction. If surgery cannot be performed urgently, extracorporeal membrane oxygenation (ECMO) may be required to maintain oxygenation. Surgically, the pulmonary venous confluence is anastomosed directly to the left atrium, the ASD is closed, and any connection to the systemic venous circuit is interrupted. Early results are generally good, even for critically ill neonates. The postoperative period may be complicated by pulmonary artery hypertensive crises. In some patients, especially those in whom the diagnosis is delayed or the obstruction is severe, recurrent stenosis and development of pulmonary venoocclusive disease may occur. Attempts have been made to treat recurrent stenosis with surgery, balloon angioplasty, stents, and antiproliferative chemotherapy. The long-term prognosis in patients with recurrent obstruction is poor. In those with aggressive venoocclusive disease, **heart-lung transplantation** may be the only option (see Chapter 492.2).

Visit Elsevier eBooks+ at eBooks.Health.Elsevier.com for Bibliography.

480.8 Truncus Arteriosus

Daniel Bernstein

In truncus arteriosus, a single arterial trunk (truncus arteriosus) arises from the heart and supplies the systemic, pulmonary, and coronary circulations. A VSD is always present, with the truncus overriding the defect and receiving blood from both the RV and the LV (Fig. 480.8). The number of truncal valve cusps varies from two to as many as six, and the valve may be stenotic, regurgitant, or both. The pulmonary arteries can arise together from the posterior left side of the persistent truncus arteriosus and then divide into left and right pulmonary arteries **(type I)**. In types II and III truncus arteriosus, no main pulmonary artery is present, and the right and left pulmonary arteries arise from separate orifices on the posterior **(type II)** or lateral **(type III)** aspects of the truncus arteriosus. *Type IV truncus* is a term no longer used because, in this case, there is no identifiable connection between the heart and pulmonary arteries, and pulmonary blood flow is derived from **major aortopulmonary collateral arteries (MAPCAs)** arising from the transverse or descending aorta; this is essentially a form of pulmonary atresia (see Chapter 479.2).

Both ventricles are at systemic pressure, and both eject blood into the truncus. When PVR is relatively high immediately after birth, pulmonary blood flow may be normal; as PVR drops in the first few weeks of life, blood flow to the lungs is greatly increased and heart failure ensues. Truncus arteriosus is a **total mixing lesion** with complete admixture of pulmonary and systemic venous return. Because of the large volume of pulmonary blood flow, clinical cyanosis is usually mild. If the lesion is left untreated, PVR eventually increases, pulmonary blood flow decreases, and cyanosis becomes more prominent (**Eisenmenger physiology**; see Chapter 482.2).

CLINICAL MANIFESTATIONS

The clinical signs of truncus arteriosus vary with age and depend on the level of PVR. In the immediate newborn period, signs of heart failure are usually absent; a murmur and minimal cyanosis may be the only initial findings. If unrepaired, during the next 1-2 months of life,

pulmonary blood flow begins to become torrential and the clinical picture is dominated by heart failure, with still mild cyanosis. Runoff of blood from the truncus to the pulmonary circulation may result in a wide pulse pressure and bounding pulses. These findings will be further exaggerated if truncal valve insufficiency is present. The heart is usually enlarged, and the precordium is hyperdynamic. S_2 is loud and single. A systolic ejection murmur, sometimes accompanied by a thrill, is generally audible along the left sternal border. The murmur is frequently preceded by an early systolic ejection click caused by the abnormal truncal valve. In the presence of truncal valve insufficiency, a medium- to high-pitched early diastolic decrescendo murmur is heard at the mid-left sternal border. An apical mid-diastolic rumbling murmur caused by increased flow through the mitral valve is often audible with the bell of the stethoscope, especially as heart failure develops. Truncus arteriosus is a conotruncal malformation and may be associated with **DiGeorge syndrome**, linked to a deletion of a large region of **chromosome 22q11** (see Chapter 473).

DIAGNOSIS

The ECG shows right, left, or combined ventricular hypertrophy. The chest radiograph also shows considerable variation. Cardiac enlargement will develop over the first several weeks of life and is a result of the prominence of both ventricles. The truncus may produce a prominent shadow that follows the normal course of the ascending aorta and aortic knob; the aortic arch is right sided in 50% of patients. Sometimes a high bulge left of the aortic knob is produced by the main or left pulmonary artery. Pulmonary vascularity is increased after the first few weeks of life. Echocardiography is diagnostic and demonstrates the large truncal artery overriding the VSD and the pattern of origin of the branch pulmonary arteries (Fig. 480.9). Associated anomalies such as an interrupted aortic arch may be noted. Pulsed and color Doppler studies are used to evaluate truncal valve regurgitation. If required, cardiac catheterization shows a left-to-right shunt at the ventricular level, with right-to-left shunting into the truncus. Systolic pressure in both ventricles and the truncus is similar. Angiography reveals the large truncus arteriosus and better defines the origin of the pulmonary arteries.

TREATMENT

Most centers perform routine neonatal repair shortly after diagnosis. If surgery is delayed and PVR falls over the first several weeks of life, heart failure symptoms will worsen. Anticongestive medications can be used to better prepare these patients for surgery; however, delay of surgery much beyond this time period may increase the likelihood of developing pulmonary vascular disease. At surgery, the VSD is closed, the pulmonary arteries are separated from the truncus, and continuity is established between the RV and the pulmonary arteries with a homograft conduit. Immediate surgical results are excellent, but these conduits will develop either regurgitation or stenosis over time and must be replaced, often several times, as the child grows. If regurgitation is the primary problem, patients can now be treated with a transcatheter stent-valve (see Chapter 479.1)

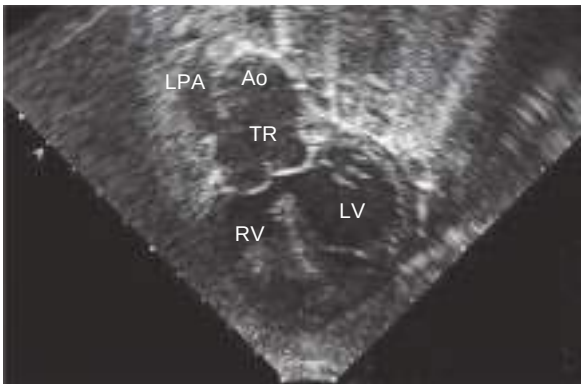

Fig. 480.9 Subcostal 2D echocardiographic demonstration of truncus arteriosus. The large truncal valve can be seen overriding the ventricular septal defect. In this case, only the left pulmonary artery (LPA) arises from the truncus (TR). The pulmonary arteries are discontinuous, and the right pulmonary artery arises from the descending aorta via the ductus arteriosus (not shown). Ao, Aorta; LV, left ventricle; RV, right ventricle.

PROGNOSIS AND COMPLICATIONS

Surgical results have been excellent, and many patients with repaired truncus are now entering mid-adulthood, with several centers reporting 30- and 40-year-old survivors. The need to replace the RV-to-pulmonary artery conduit as the child grows means that these patients will need to undergo multiple operations by the time they reach adulthood. The development of transcatheter stent-valves may reduce this in the future (see Chapter 472). When truncus arteriosus is associated with DiGeorge syndrome, the associated endocrine, immunologic, craniofacial, and airway abnormalities may complicate recovery.

Visit Elsevier eBooks+ at eBooks.Health.Elsevier.com for Bibliography.

480.9 Single Ventricle (Double-Inlet Ventricle, Univentricular Heart)

Daniel Bernstein

With a single ventricle, both atria empty through a common atrioventricular valve or through two separate valves into a single ventricular chamber, with total mixing of systemic and pulmonary venous return. This chamber may have left, right, or indeterminate (both right and left) ventricular morphologic characteristics. The aorta and pulmonary artery both arise from this single chamber, although one of the great vessels may originate from a rudimentary outflow chamber. The aorta may be posterior, anterior (malposition), or side-by-side with the pulmonary artery and either to the right or to the left. Pulmonary stenosis or atresia is common.

CLINICAL MANIFESTATIONS

The clinical picture is variable and depends on the associated intracardiac anomalies. If pulmonary outflow is obstructed, the findings are usually similar to those of tetralogy of Fallot: marked cyanosis without heart failure. If pulmonary outflow is unobstructed, the findings are similar to those of transposition with VSD: minimal cyanosis with increasing heart failure.

In patients with **pulmonary stenosis**, cyanosis is present in early infancy. Cardiomegaly is mild or moderate, a left parasternal lift is palpable, and a systolic thrill is common. The systolic ejection murmur is usually loud; an ejection click may be audible, and S_2 is single and loud. In patients with **unobstructed pulmonary flow**, as PVR drops, torrential pulmonary blood flow develops, and these patients present with tachypnea, dyspnea, failure to thrive, and recurrent pulmonary infections. Cyanosis is only mild or moderate. Cardiomegaly is generally marked, and a left parasternal lift is palpable. A systolic ejection murmur is present but is not usually loud or harsh, and S_2 is loud and closely split. A third heart sound (S_3) is common and may be followed by a short mid-diastolic rumbling murmur caused by increased flow through the atrioventricular valves. The eventual development of pulmonary vascular disease reduces pulmonary blood flow so that the cyanosis increases and signs of cardiac failure appear to improve (**Eisenmenger physiology**; see Chapter 482.2).

DIAGNOSIS

ECG findings are nonspecific. P waves are normal, spiked, or bifid. The precordial lead pattern suggests right ventricular hypertrophy, combined ventricular hypertrophy, or sometimes left ventricular dominance. The initial QRS forces are usually to the left and anterior. Radiographic examination confirms the degree of cardiomegaly. If present, a rudimentary outflow chamber may produce a bulge on the upper left border of the cardiac silhouette in the posteroanterior projection. In the absence of pulmonary stenosis, pulmonary vasculature is

increased, whereas in the presence of pulmonary stenosis, pulmonary vasculature is diminished. Echocardiography will confirm the absence or near-absence of the ventricular septum and can usually determine whether the single ventricle has right, left, or mixed morphologic features. The presence of a rudimentary outflow chamber under one of the great vessels can be identified, and pulsed Doppler can be used to determine whether flow through this communication (known as a **bulboventricular foramen**) is obstructed.

If cardiac catheterization is performed, the pressure in the single ventricular chamber is at systemic level; however, a gradient may be demonstrated across the entrance to the rudimentary outflow chamber. Pressure measurements and angiography demonstrate whether pulmonary stenosis is present.

TREATMENT

If pulmonary stenosis is severe, a **Blalock-Taussig aortopulmonary shunt** is performed to provide a reliable source of pulmonary blood flow (see Chapter 479.1). If pulmonary blood flow is unrestricted, pulmonary arterial banding is used to control heart failure and prevent progressive pulmonary vascular disease. The **bidirectional Glenn shunt** is usually performed at 2-4 months of age, followed by a **modified Fontan operation** (cavopulmonary isolation procedure; see Chapter 479.4) at 2-3 years. If subaortic stenosis is present because of a restrictive connection to a rudimentary outflow chamber (*restrictive* bulboventricular foramen), surgical relief can be provided by anastomosing the proximal pulmonary artery to the side of the ascending aorta **(Damus-Stansel-Kaye operation)**.

PROGNOSIS AND COMPLICATIONS

Unoperated, some patients succumb during infancy from heart failure. Others may survive to adolescence and early adult life but finally succumb to the effects of chronic hypoxemia or, in the absence of pulmonary stenosis, to the effects of pulmonary vascular disease. Patients with moderate pulmonary stenosis have the best prognosis because pulmonary blood flow, though restricted, is still adequate. Surgical palliation, eventually leading to Fontan-type circulatory physiology (see Chapter 479.4), has very good short- and intermediate-term results.

480.10 Hypoplastic Left Heart Syndrome

Daniel Bernstein

The term *hypoplastic left heart syndrome* (HLHS) is used to describe a related group of anomalies that include various degrees of underdevelopment of the left side of the heart: stenosis or atresia of the aortic and mitral valves and hypoplasia of the left ventricular cavity and ascending aorta. HLHS categories are based on anatomic characteristics: (1) mitral and aortic atresia (MA-AA), (2) mitral stenosis with aortic atresia (MS-AA), and (3) mitral and aortic stenosis (MS-AS). The LV may be only moderately hypoplastic, very small and nonfunctional, or totally atretic. The LV cavity may be slitlike, miniaturized, or small and thick walled with endocardial fibroelastosis. In patients with MS-AA, there may be anomalous connections between the ventricle and the coronary arteries, which some reports associate with an increased postoperative risk.

The etiology of HLHS may be the result of poor left-sided fetal blood flow (no flow–no grow hypothesis). Alternatively, there may be intrinsic defects of myogenic and endocardial programming affecting differentiation, proliferation, maturation, and apoptosis. Although no single gene is associated with all patients, multiple genes *(GJA1, NKX2-5, SAP130, PCDHA, Notch 1, MY46)* and pathways (transforming growth factor beta [TGF-β], Wnt) have been implicated.

In the immediate neonatal period, the RV maintains both the pulmonary circulation and the systemic circulation via the ductus arteriosus (Fig. 480.10). Pulmonary venous blood passes through an ASD (which may or may not be restrictive) or dilated foramen ovale from the left to the right side of the heart, where it mixes with systemic venous blood (total mixing lesion). Minimal (mitral stenosis subtypes) or no (mitral atresia subtype) blood enters the hypoplastic LV. All the RV blood is ejected into the main pulmonary artery, where it then supplies both the descending and the ascending aorta (retrograde flow) via the ductus arteriosus. The major hemodynamic abnormalities are inadequate maintenance of the systemic circulation and, depending on the size of the atrial-level communication, either pulmonary venous hypertension (restrictive foramen ovale) or pulmonary overcirculation (moderate or large ASD).

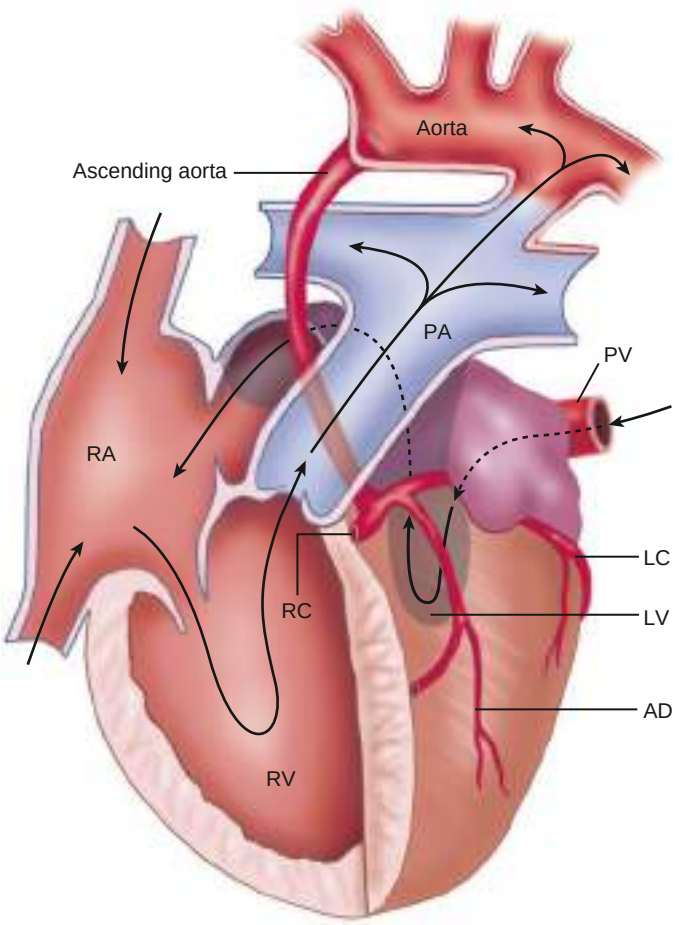

Fig. 458.10 Hypoplastic left heart with aortic hypoplasia, aortic valve atresia, and a hypoplastic mitral valve and left ventricle. AD, Anterior descending; LC, left circumflex; LV, left ventricle; PA, pulmonary artery; PV, pulmonary vein; RA, right atrium; RC, right coronary artery; RV, right ventricle. *(From Webb GD, Smallhorn, JF, Therrien J, et al. Congenital heart disease in the adult and pediatric patient. In: Zipes DP, Libby P, Bonow RO, et al., eds. Braunwald's Heart Disease, 11th ed. Philadelphia: Elsevier; 2019: Fig. 75-28, p. 1548. Adapted from historical illustrations in Neufeld HN, Adams P Jr, Edwards JE, et al. Diagnosis of aortic atresia by retrograde aortography. Circulation. 1962;25:278; and Edwards JE, Dry TJ, Parker RL, et al. An Atlas of Congenital Anomalies of the Heart and Great Vessels. Springfield: Charles C. Thomas; 1954.)*

CLINICAL MANIFESTATIONS

Although cyanosis may not always be obvious in the first 48 hours of life, a grayish-blue skin color is soon apparent and denotes a mix of cyanosis and poor perfusion. The condition is diagnosed in most infants in the first few hours or days of life. Once the ductus arteriosus begins to close, signs of poor systemic perfusion and shock predominate. All the peripheral pulses may be weak or absent. A palpable RV parasternal lift may be present along with a nondescript systolic murmur.

This lesion may be isolated or associated in 5–15% of patients with known genetic syndromes, such as Turner syndrome; trisomy 13, 18, or 21; Jacobsen syndrome (11q deletion); Holt-Oram syndrome; and Rubinstein-Taybi syndrome. In these circumstances, noncardiac

manifestations of the syndrome may be evident and influence the clinical outcomes. Occasionally, HLHS is familial and inherited as an autosomal recessive or dominant trait; there are also families with constellations of different severities of left-sided obstructive lesions, ranging from bicuspid aortic valve, to coarctation of the aorta, to Shone complex, to HLHS.

DIAGNOSIS

On chest radiograph, the heart is variable in size in the first days of life, but cardiomegaly develops rapidly and is associated with increased pulmonary vascularity. The initial ECG may show only the normal neonatal pattern of RV dominance, but later, P waves become prominent and RV hypertrophy is usual with reduced LV forces. The echocardiogram is diagnostic and demonstrates hypoplasia or atresia of the mitral valve and aortic root, a variably small left atrium and LV, and a large right atrium and RV (Fig. 480.11). The size of the atrial communication, by which pulmonary venous blood leaves the left atrium, is assessed by pulsed and color flow Doppler studies. The small ascending aorta and transverse aortic arch are identified; a discrete coarctation of the aorta in the juxtaductal area may be present, although in the presence of a large ductus, it may be difficult to identify. Doppler echocardiography demonstrates whether the mitral and aortic valves are severely stenotic or totally atretic. The presence of left ventricular–to–coronary sinusoidal connections can be identified. The diagnosis of HLHS can usually be made without the need for cardiac catheterization. If catheterization is necessary, the hypoplastic ascending aorta is demonstrated by angiography.

TREATMENT

Surgical therapy for HLHS is associated with improved survival rates, reported as high as 90–95% for the first-stage palliation in experienced centers. The first-stage repair is designed to construct a reliable source of systemic blood flow arising from the single RV using a combination of aortic and pulmonary arterial tissue and to limit pulmonary blood flow to avoid heart failure and prevent the development of pulmonary vascular disease. The surgical procedure typically used is the **Norwood procedure** (Fig. 480.12) or the **Sano procedure**. Primary heart transplantation, previously advocated by a few centers, is much less common because of the substantially improved survival rates with standard surgery and the limited supply of donor organs in this age-group.

Preoperative medical management includes maintaining ductus arteriosus patency with PGE_1 (0.05-0.1 μg/kg/min) to support systemic blood flow, avoiding excess pulmonary blood flow, and maintaining adequate flow from the left to the right atrium. Correction of acidosis and hypoglycemia and prevention of hypothermia are also key components. Excessive pulmonary blood flow, which worsens as the PVR begins to fall, can lead to both respiratory distress and systemic hypoperfusion. This can be prevented through managing ventilator settings to keep the P_{CO_2} in the 45-50 mm Hg range and avoiding supplemental oxygen (which acts as a pulmonary vasodilator) if the system arterial O_2 saturation is in the 70-80 mm Hg range. If the atrial septum is restrictive, a Rashkind balloon atrial septostomy, septal balloon dilation, or rarely, a blade septostomy of the atrial septum may be indicated.

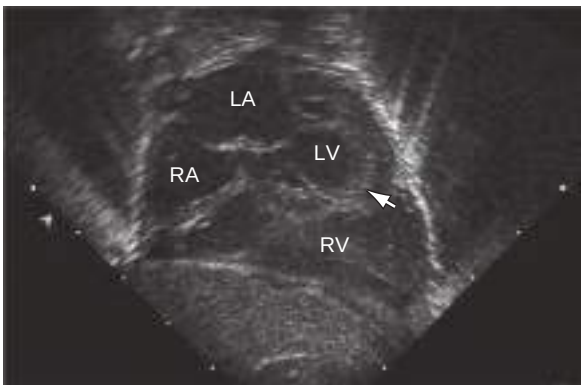

Fig. 480.11 Subcostal 2D echocardiographic diagnosis of hypoplastic left heart syndrome. The small left ventricular chamber can be seen, the apex of which *(arrowhead)* does not form the apex of the heart. The atrial septum can be seen bowing from the left to the right, indicating that the communication between the two atria is pressure restrictive. LA, Left atrium; LV, left ventricle; RA, right atrium; RV, right ventricle.

The Norwood or Sano procedure is usually performed in three stages. **Stage I** (see Fig. 480.12), usually performed in the first week of life, includes an atrial septectomy and transection and ligation of the distal main pulmonary artery; the proximal pulmonary artery is then connected to the transversely opened hypoplastic aortic arch to form a "neoaorta," extending through the coarcted segment of the juxtaductal aortic arch. In the Norwood operation, a synthetic aortopulmonary (Blalock-Taussig) shunt connects the aorta to the main pulmonary artery to provide controlled pulmonary blood flow. In the Sano modification, an RV–to–pulmonary artery conduit is used instead of an aortopulmonary shunt to provide pulmonary blood flow, temporarily creating a double-outlet RV. The operative risk for these first-stage procedures has improved dramatically in the past 2 decades, and the best reported results demonstrate a 90–95% survival rate. After the first stage, the patient's oxygen saturation usually ranges from 75% to 85% because of the continued admixture of oxygenated and deoxygenated blood in the right atrium. In the past, there was a high interstage mortality rate in infants discharged from the hospital between stages I and II. This has largely been prevented by performing careful interstage surveillance in home monitoring programs run by pediatric cardiac centers.

Stage II consists of a Glenn shunt anastomosis to connect the superior vena cava to the pulmonary arteries (see Chapter 480.4) at 2-6 months of age. **Stage III**, usually performed at 2-3 years, consists of a modified Fontan procedure (cavopulmonary isolation) to connect the inferior vena cava to the pulmonary arteries via either an intraatrial or external baffle. After stage III, all systemic venous return enters the pulmonary circulation directly. Pulmonary venous flow enters the left atrium and is directed across the atrial septum to the tricuspid valve and subsequently to the right (now the systemic) ventricle. Blood leaves the RV via the neoaorta, which supplies the systemic circulation. The old aortic root now attached to the neoaorta provides coronary blood flow. The risks associated with stages II and III are less than those of stage I; interstage mortality (usually between stages I and II) has been dramatically reduced with the use of home monitoring programs and interstage close follow-up. The short- and long-term benefits of using the Norwood vs the Sano procedure remain to be demonstrated.

An alternative therapeutic approach, initially developed for high-risk standard surgical candidates, is to perform a **hybrid procedure** for the first stage. This involves performing a Rashkind balloon atrial septostomy, cardiac catheter laboratory placement of a stent in the ductus arteriosus, and open chest surgical placement of bilateral pulmonary artery bands. After the hybrid procedure, patients can be weaned off prostaglandin and discharged from the hospital. However, after a hybrid procedure, patients need to undergo a more extensive second-stage procedure involving construction of a neoaorta and removal of the pulmonary artery bands.

Another alternative therapy is **cardiac transplantation**, either in the immediate neonatal period, thereby obviating stage I of the Norwood procedure, or after a successful stage I Norwood procedure is performed as a bridge to transplantation. After transplantation, patients usually have normal cardiac function and no symptoms of heart failure; however, these patients have the chronic risk of organ rejection and lifelong immunosuppressive therapy (see Chapter 492.1). The combination of donor shortage and improved results with standard surgical and hybrid procedures has caused most centers to stop recommending transplantation except when associated lesions make the Norwood operation an exceptionally high-risk procedure (e.g., significant coronary artery anomalies) or for patients who develop poor ventricular function at some time after the standard surgical approach.

PROGNOSIS AND COMPLICATIONS

Untreated patients most often succumb during the first few months of life, usually during the first or second week. Up to 30% of infants with HLHS

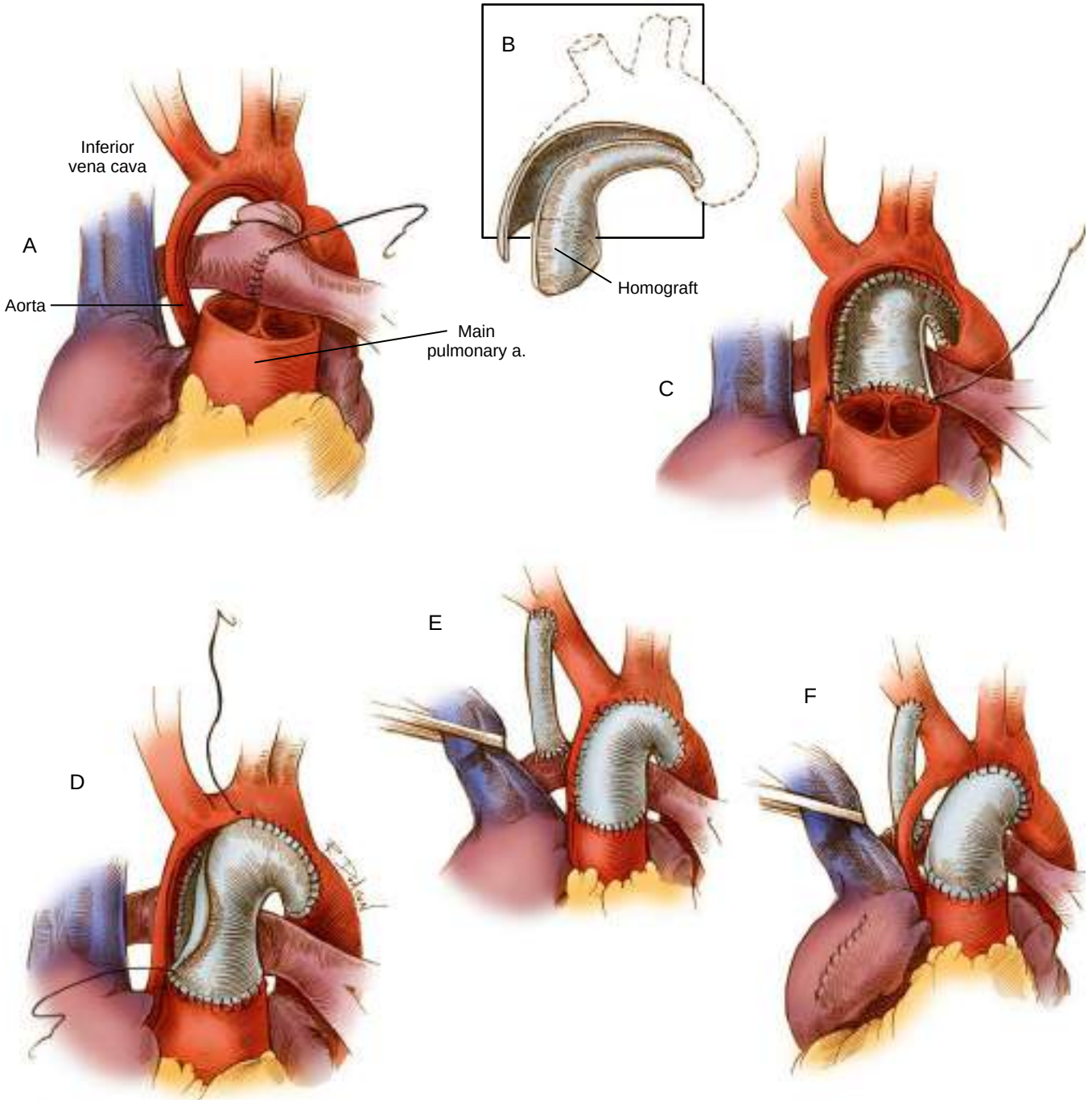

Fig. 480.12 Norwood procedure, one of the two current techniques for first-stage palliation of hypoplastic left heart syndrome. **A,** Incisions used for the procedure incorporate a cuff of arterial wall allograft. The distal divided main pulmonary artery may be closed by direct suture or with a patch. **B,** Dimensions of the cuff of the arterial wall allograft. **C,** The arterial wall allograft is used to supplement the anastomosis between the proximal divided main pulmonary artery and the ascending aorta, aortic arch, and proximal descending aorta. **D** and **E,** The procedure is completed by an atrial septectomy and a 3.5-mm modified right Blalock shunt. **F,** When the ascending aorta is particularly small, an alternative procedure involves placement of a complete tube of arterial allograft. The tiny ascending aorta may be left in situ, as indicated, or implanted into the side of the neoaorta. *(From Castañeda AR, Jonas RA, Mayer JE Jr, et al. Single-ventricle tricuspid atresia. In: Cardiac Surgery of the Neonate and Infant. Philadelphia: Saunders; 1994.)*

have evidence of either a major or a minor central nervous system abnormality. Other dysmorphic features may be found in up to 40% of patients. Thus careful preoperative evaluation (genetic, neurologic, ophthalmologic) should be performed in patients being considered for surgical therapy.

Intermediate-term follow-up after completion of all three stages of the Norwood procedure demonstrates generally good exercise capacity and long-term complications equivalent to other patients who have had the Fontan palliation (see Chapter 479.4). Some studies show that patients with HLHS have a higher risk of neurodevelopmental problems than those with other complex congenital heart lesions. Whether the poor neurodevelopmental outcome is the result of genetically associated central nervous system malformations, alteration of prenatal circulation dynamics or prenatal central nervous system injury, complications of bypass surgery, or poor preoperative and/or postoperative perfusion is unknown. Whether a specific HLHS subtype, specifically MS-AA with ventricular-coronary connections, is associated with increased postoperative mortality is still unclear, as studies have shown contradictory results.

PREVENTION

Serial fetal echocardiographic studies demonstrate that in some fetuses, HLHS may be a progressive in utero lesion, beginning with simple valvar aortic stenosis in mid-gestation. The decreased flow through the stenotic aortic valve reduces flow through the LV during development, resulting in gradual ventricular chamber hypoplasia. The potential for preventing this hypoplasia has been demonstrated by performing in utero aortic balloon valvuloplasty in mid-gestation fetuses (Fig. 480.13). Early results are encouraging, although even if the aortic valve is successfully opened, adequate ventricular growth occurs in only ~50% of patients. At present, this procedure is regarded as experimental.

Because of the high mortality of HLHS with an intact or restrictive atrial septum, in utero attempts to improve atrial mixing with either fetal atrial septoplasty or atrial stent placement are undergoing clinical investigation.

Visit Elsevier eBooks+ at eBooks.Health.Elsevier.com for Bibliography.

480.11 Abnormal Positions of the Heart and the Heterotaxy Syndromes (Asplenia, Polysplenia)

Daniel Bernstein

Classification and diagnosis of abnormal cardiac position are best performed through a *segmental* approach, with the position of the viscera and atria defined first, then the ventricles, followed by the great vessels (Fig. 480.14). Determination of **visceroatrial situs** can be made by radiographic demonstration of the position of the abdominal organs and the tracheal bifurcation for recognition of the right and left bronchi and by echocardiography. The atrial situs is usually similar to the situs of the viscera and lungs. In **situs solitus** the viscera are in their normal positions (stomach and spleen on the left, liver on the right), the three-lobed right lung is on the right, and the two-lobed left lung on the left; the right atrium is on the right, and the left atrium is on the left. When the abdominal organs and lung lobation are reversed, an arrangement known as **situs inversus** occurs: the left atrium is on the right and the right atrium on the left. If the visceroatrial situs cannot be readily determined, a condition known as **situs indeterminus** or **heterotaxia** exists. The two major heterotaxy syndromes are **asplenia syndrome** (right isomerism or bilateral right-sidedness), which is associated with a centrally located liver, absent spleen, and two morphologic right lungs (Figs. 480.15 and 480.16), and **polysplenia syndrome** (left isomerism or bilateral left-sidedness), which is associated with multiple small spleens, absence of the intrahepatic portion of the inferior vena cava, and two morphologic left lungs (Figs. 480.17 and 480.18). The heterotaxia syndromes are usually associated with severe congenital heart lesions: ASD, VSD, atrioventricular septal defect, hypoplasia of one of the ventricles, pulmonary stenosis or atresia, and anomalous systemic venous or pulmonary venous return (Table 480.2).

Human heterotaxia syndromes may be related to disorders in both motile and primary cilia function and in utero left-right axis development. Genes involved in heterotaxy syndromes, including *NODAL* (known asymmetric gene), and those influenced by *NODAL* such as the TGF-β superfamily *(LEFTY2)* and *Pitx2,* have been implicated in the

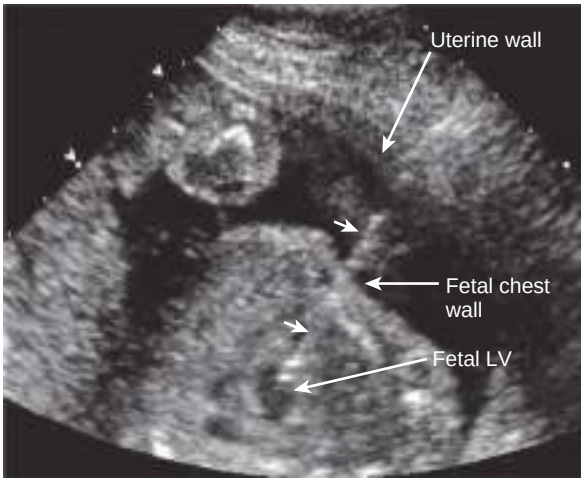

Fig. 480.13 Fetal treatment of critical aortic stenosis to prevent development of hypoplastic left heart syndrome. Fetal ultrasound showing insertion of a needle *(arrowheads)* via the maternal abdominal wall, through the uterus and the fetal chest wall, and into the fetal left ventricle (LV). A balloon catheter is next inserted via the needle into the left ventricular chamber and across the stenotic aortic valve. The balloon is inflated to dilate the valve, and the catheter and needle are removed. *(Courtesy Dr. Stanton Perry, Stanford University, Stanford, CA.)*

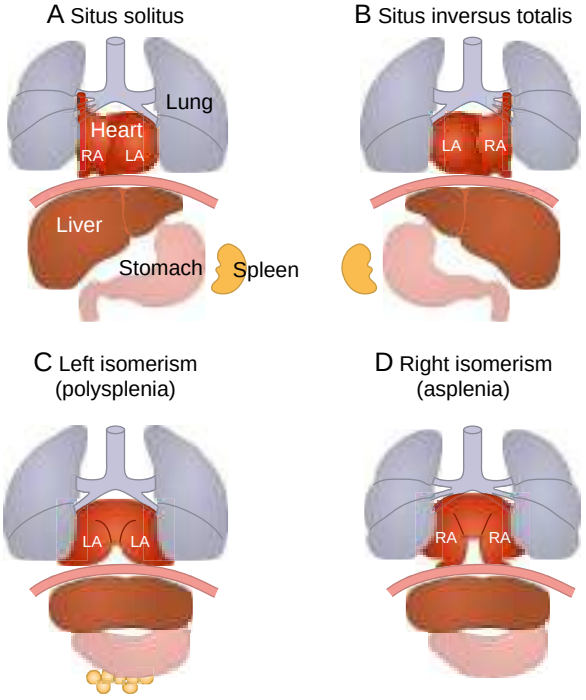

Fig. 480.14 Variations in thoracoabdominal situs in congenital heart disease. **A,** *Situs solitus:* On the right side there is a three-lobed lung, a right atrium (with superior and inferior vena cava entering), and the liver; on the left side there is a two-lobed lung, a left atrium (with pulmonary veins entering), the stomach, and the spleen. **B,** *Situs inversus totalis:* All the structures are mirror-image reversed: On the right side there is a two-lobed lung, a left atrium, the stomach, and the spleen; on the left side there is a three-lobed lung, a right atrium, and the liver. **C,** *Left isomerism (polysplenia):* There are two left sides: On the right side there is a two-lobed lung and a structure that resembles the left atrium; on the left side there is also a two-lobed lung and a structure that resembles the left atrium; there is usually a midline liver and stomach and multiple small spleens. **D,** *Right isomerism (asplenia):* There are two right sides: On the right side there is a three-lobed lung and a structure that resembles the right atrium; on the left side there is also a three-lobed lung and a structure that resembles the right atrium; there is usually a midline liver and stomach and an absent spleen. *(Adapted from Fliegauf M, Benzing T, Omran H. When cilia go bad: cilia defects and ciliopathies. Nat Rev Mol Cell Biol. 2007;8:880–893, Fig. 2.)*

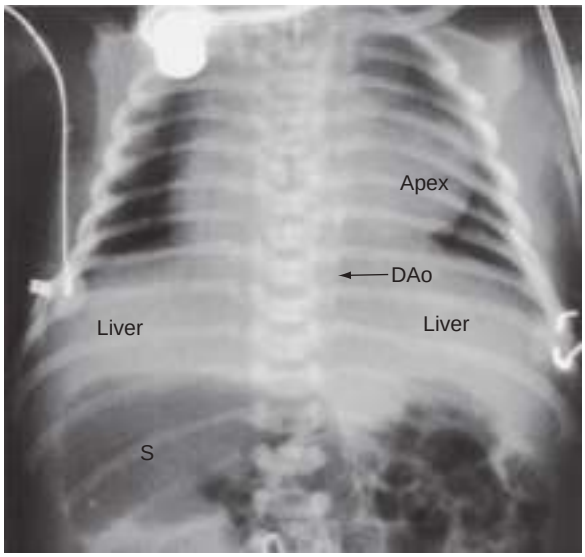

Fig. 480.15 X-ray from asplenic male neonate with right isomerism. The liver is transverse, the stomach (S) is on the right, and the heart is midline, but the base to apex axis points to the left. DAo, Descending aorta. *(Modified from Perloff JK, Marelli AJ. Perloff's Clinical Recognition of Congenital Heart Disease, 6th ed. Philadelphia: Saunders; 2012: Fig. 3-31, p. 32.)*

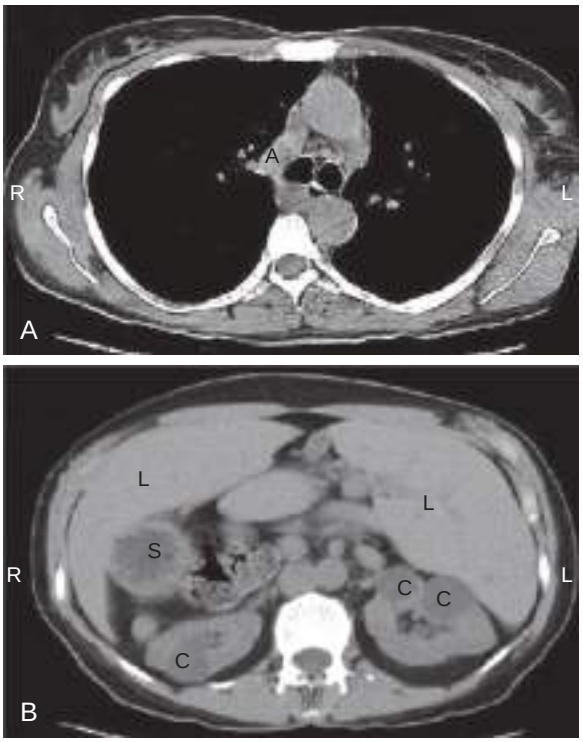

Fig. 480.16 Right isomerism with asplenia. Noncontrast-enhanced CT scan of a female with primary ciliary dyskinesia demonstrates features of right isomerism with asplenia. **A,** Large azygous vein arch is noted, which compensates for the inferior vena cava interruption. **B,** CT scan through the upper abdomen demonstrates midline liver (L), dextrogastria (s), and absent spleen. Bilateral renal cysts (C) are also noted. *(From Chmura K, Chan ED, Noone PG, Zariwala M, Winn RA, Knowles MR, Iseman MD, Gardner EM. A middle-aged woman with recurrent respiratory infections. Respiration. 2005;72(4):427–430.)*

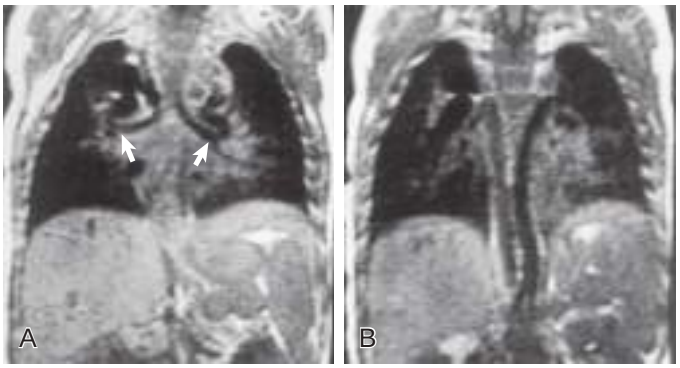

Fig. 480.17 **A,** Coronal T1-weighted MRI of a patient with heterotaxy syndrome (polysplenia) demonstrates a bilateral hyparterial bronchial branching pattern *(arrows)* and left upper quadrant spleens. **B,** More posterior coronal T1-weighted MRI shows left azygos-hemiazygos continuation to the left superior vena cava and right thoracic aorta. *(From Applegate KE, Goske MJ, Pierce G, Murphy D. Situs revisited: imaging of the heterotaxy syndrome. Radiographics. 1999;19:837–852, Fig. 4.)*

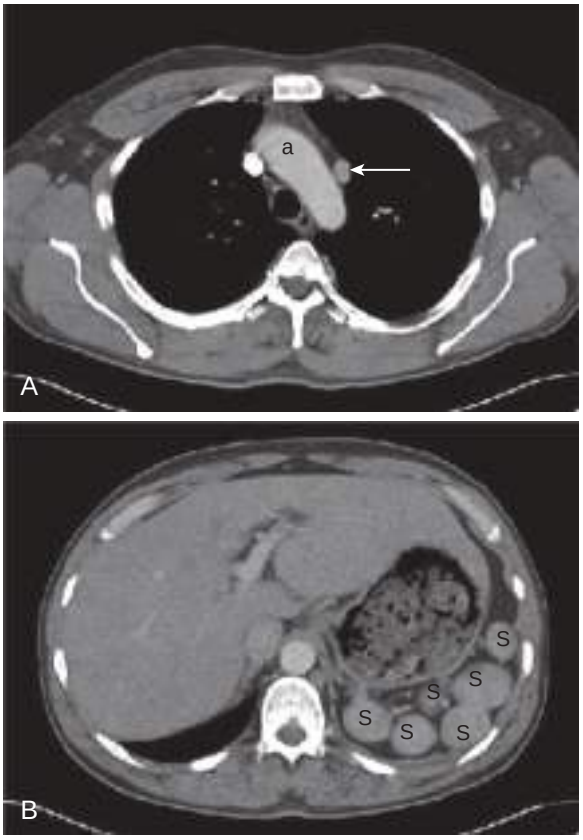

Fig. 480.18 Left isomerism with polysplenia. Contrast-enhanced computed tomography scan of a male with primary ciliary dyskinesia demonstrates features of left isomerism with polysplenia. **A,** Note bilateral superior vena cavae at the level of the aortic arch (a). The right superior vena cava is enhanced after intravenous contrast material administration through a right antecubital vein. Left-sided superior vena cava indicated by *arrow*. **B,** Upper abdomen image demonstrates left upper quadrant splenules (S). *(From Kennedy MP, Omran H, Leigh MW, et al. Congenital heart disease and other heterotaxic defects in a large cohort of patients with primary ciliary dyskinesia. Circulation. 2007;11:2814–2821, Fig. 3.)*

Table 480.2 Comparison of Cardiosplenic Heterotaxy Syndromes

FEATURE	ASPLENIA (RIGHT ISOMERISM)	POLYSPLENIA (LEFT ISOMERISM)
Spleen	Absent	Multiple
Sidedness (isomerism)	Bilateral right	Bilateral left
Lungs	Bilateral trilobar with eparterial bronchi	Bilateral bilobar with hyparterial bronchi
Sex	Male (65%)	Female ≥ male
Right-sided stomach	Yes	Less common
Symmetric liver	Yes	Yes
Partial intestinal rotation or malrotation	Yes	Yes
Risk for midgut volvulus	Yes	Yes
Dextrocardia (%)	30–40	30–40
Pulmonary blood flow	Decreased (usually)	Increased (usually)
Severe cyanosis	Yes	No
Transposition of great arteries (%)	60–75	15
Total anomalous pulmonary venous return (%)	70–80	Rare
Common atrioventricular valve (%)	80–90	20–40
Single ventricle (%)	40–50	10–15
Absent inferior vena cava with azygos continuation	No	Characteristic
Bilateral superior venae cavae	Yes	Yes
Other common defects	PA, PS, right-sided aortic arch	Partial anomalous pulmonary venous return, ventricular septal defect, double-outlet right ventricle
Risk of pneumococcal sepsis	Yes	Yes
Howell-Jolly and Heinz bodies, pitted erythrocytes	Yes	No
Risk of nosocomial infection	Yes	Yes
Absent gallbladder; biliary atresia	No	Yes

PA, Pulmonary atresia; PS, pulmonary stenosis.

development of heterotaxia syndromes (Fig. 480.19 and Table 480.3). Diagnostic gene panels are available to identify a possible genetic basis.

The next segment is localization of the **ventricles**, which depends on the direction of development of the embryonic cardiac loop. Initial protrusion of the loop to the right **(d-loop)** carries the future RV anteriorly and to the right, whereas the LV remains posterior and on the left (the normal relationship). With situs solitus, a d-loop yields normal atrioventricular connections (right atrium connecting to RV, left atrium to LV). Protrusion of the loop to the left **(l-loop)** carries the future RV to the left and the LV to the right. In this case, in the presence of situs solitus, the right atrium connects with the LV and the left atrium with the RV **(ventricular inversion)**.

The final segment is that of the **great vessels**. With each type of cardiac loop, the ventricular-arterial relationships may be regarded as either normal (RV to pulmonary artery, LV to aorta); transposed (RV to aorta, LV to pulmonary artery); or in the event of a double-outlet ventricle, either normally related or **malposed**. A further classification can be based on the position of the aorta (normally to the right and posterior) relative to the pulmonary artery. In transposition, the aorta is usually anterior and either to the right of the pulmonary artery **(d-transposition)** or to the left **(l-transposition)**.

These segmental relationships can usually be determined by echocardiographic studies demonstrating both atrioventricular and ventriculoarterial relationships. The clinical manifestations of these syndromes of abnormal cardiac position are determined primarily by their associated cardiovascular anomalies.

Dextrocardia occurs when the heart is in the right side of the chest. **Levocardia** (the normal situation) is present when the heart is in the left side of the chest. Dextrocardia without associated situs inversus or levocardia in the presence of situs inversus is most often complicated by other severe cardiac malformations. Surveys of older children and adults indicate that dextrocardia with situs inversus and normally related great arteries ("mirror-image" dextrocardia) is often associated with a functionally normal heart, although congenital heart disease of a less severe nature is common.

Anatomic or functional abnormalities of the lungs, diaphragm, and thoracic cage may result in displacement of the heart to the right **(dextroposition)**. In this case, however, the cardiac apex is pointed

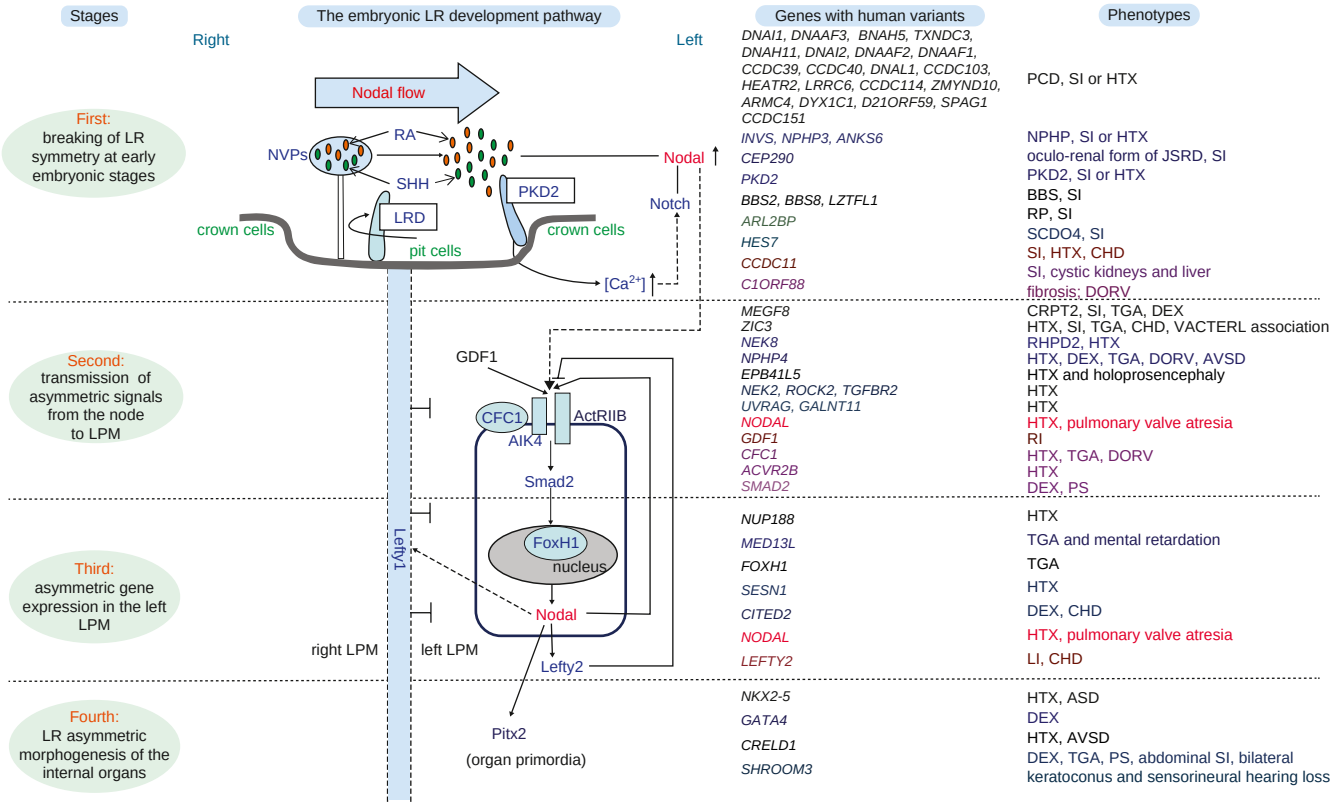

Fig. 480.19 Pathway of left-right (LR) development in the mouse embryo, list of genes associated with human LR asymmetry disorders, and corresponding phenotypes in humans. LRD-containing monocilia generate leftward nodal flow, and polycystin 2–containing cilia sense nodal flow and initiate an asymmetric calcium signal, which induces nodal expression around the node. Nodal signaling is involved in asymmetric morphogenesis by inducing expression of the nodal-responsive genes *(NODAL, LEFTY2,* and *PITX2)* in the left lateral plate mesoderm (LPM) and expression of *LEFTY1* at the midline. Pathogenic variants of genes associated with ciliopathies and nodal signal transduction pathway have been identified in human LR asymmetry disorders. *Full arrows* indicate a direct positive effect on gene expression, *dotted arrows* indicate an indirect effect, and *lines* indicate inhibition. ASD, Atrial septal defect; AVSD, atrioventricular septal defects; BBS, Bardet-Biedl syndrome; CHD, congenital heart disease; CRPT2, Carpenter syndrome 2; DEX, dextrocardia; DORV, double-outlet right ventricle; HTX, heterotaxy; JSRD, Joubert syndrome–related disorders; LI, left isomerism; NPHP, nephronophthisis; NVPs, nodal vesicular parcels; PCD, primary ciliary dyskinesia; PKD2, polycystic kidney disease 2; PS, pulmonary stenosis; RA, retinoic acid; RHPD2, renal-hepatic-pancreatic dysplasia 2; RI, right isomerism; RP, retinitis pigmentosa; SCDO4, spondylocostal dysostosis 4; SHH, sonic hedgehog; SI, situs inversus; TGA, transposition of the great arteries. *(From Deng H, Xia H, Deng S. Genetic basis of human left-right asymmetry disorders. Expert Rev Mol Med. 2014;16:e19, Fig 1.)*

Table 480.3 Ciliopathies with Heterotaxy Defects

CILIOPATHY	FEATURES	GENE(S)	CARDIAC DEFECTS
Primary ciliary dyskinesia	Bronchiectasis, sinusitis, otitis media, infertility, situs defects	*AK7, ARMC4, C21orf59, CCDC103, CCDC114, CCDC151, CCDC39, CCDC40, CCDC65, CCNO, DNAAF1, DNAAF2, DNAAF3, DNAAF5, DNAH11, DNAH5, DNAH6, DNAI2, DNAL1, DNAJB13, DRC1, DYX1C1, GAS8, HEATR2, HYDIN, LRRC6, MCIDAS, NME8, PIH1D3, RPGR, TXNDC3, RSPH1, RSPH3, RSPH4A, RSPH9, SPAG1, TTC25, ZMYND10*	Dextrocardia; heterotaxy spectrum heart defects in ~12%; heterotaxy not thought to occur with genes associated with central pair or radial spoke
Meckel-Gruber syndrome	Renal cysts, CNS anomalies (encephalocele), polydactyly, hepatic fibrosis, congenital heart defects	*MKS1, TMEM216, TMEM67, CEP290, RPGRIP1L, CC2D2A, NPHP3, TCTN2, B9D1, B9D2, TMEM231, KIF14, TMEM107*	Situs inversus; heterotaxy; HLHS
Joubert and related syndromes	Hypoplasia of the cerebellar vermis (molar tooth sign), dysregulated breathing pattern, retinal dystrophy, renal anomalies	*AH1, C5ORF42, CC2D2A, CSPP1, TMEM216, NPHP1, CEP290, TMEM67, RPGRIP1L, INPP5E, TCTN2, MKS1, CEP104, CEP120, CEP41, KIAA0556, PDE6D, PIBF1, TCTN1, TCTN3, ARL13B, CEP41, KIAA0586, TMEM237, TMEM231, TMEM138, KIAA0753, TMEM107, KIF7, OFD1, C2CD3, IFT172, ARL13B, ZNF423, TTC21B, PDE60, POC18, B9D2, B9D1*	Laterality defects; heart defects, including septal defects, aortic valve anomalies, coarctation; in some cases, associated with features of OFD

Table 480.3 Ciliopathies with Heterotaxy Defects—cont'd

CILIOPATHY	FEATURES	GENE(S)	CARDIAC DEFECTS
Short rib thoracic dysplasias, including Jeune chondrodysplasia, Saldino-Mainzer	Skeletal dysplasia; thoracic deformities; polydactyly; renal cysts; retinitis pigmentosa	*IFT80, DYNC2H1, TTC21B, WDR19, NEK1, WDR35, WDR60, IFT140, IFT172, WDR34, CEP120, KIAA0586, DYNC2LI1, IFT52, TCTEX1D2*	Rare; septal defects, laterality defects
Carpenter syndrome	Acrocephaly; polysyndactyly, hypogenitalism, obesity, congenital heart defects	*RAB23, MEGF8, RAB23*	PDA, PS, VSD, situs inversus, heterotaxy

HLHS, Hypoplastic left heart syndrome; OFD, oral-facial-digital; PDA, patent ductus arteriosus; PS, pulmonary stenosis; and VSD, ventricular septal defect.
Modified from Pierpont ME, Brueckner M, Chung WK, et al. Genetic basis for congenital heart disease: revisited: a scientific statement from the American Heart Association. *Circulation*. 2018;138(21):e653–e711, Table 6.

normally to the left, as opposed to dextrocardia, where the cardiac apex is pointed to the right or anteriorly. This anatomic position is less often associated with congenital heart lesions, although hypoplasia of a lung may be accompanied by anomalous pulmonary venous return from that lung (**scimitar syndrome**; see Chapter 475.4).

The ECG is difficult to interpret in the presence of lesions with discordant atrial, ventricular, and great vessel anatomy. Diagnosis usually requires detailed echocardiographic and sometimes MRI, CT, or cardiac catheterization studies. The **prognosis** and **treatment** of patients with one of the cardiac positional anomalies are determined by the underlying defects and are covered in their respective chapters. Asplenia increases the risk of serious infections, such as bacterial (usually pneumococcal) sepsis, and thus requires daily antibiotic prophylaxis. Patients with polysplenia frequently have poor splenic function and also require prophylaxis against bacterial sepsis. Patients with heterotaxia are also at increased risk of intestinal malrotation and volvulus and of ciliary dyskinesia and associated pulmonary complications (see Chapters 101.3 and 455).

Visit Elsevier eBooks+ at eBooks.Health.Elsevier.com for Bibliography.

Chapter 481
Other Congenital Heart and Vascular Malformations

481.1 Anomalies of the Aortic Arch

Daniel Bernstein

RIGHT AORTIC ARCH

In this abnormality, the aorta curves to the right and, if it descends on the right side of the vertebral column, is usually associated with other cardiac malformations. It is found in 20% of cases of tetralogy of Fallot and is also common in truncus arteriosus. A right aortic arch without other cardiac anomalies is not associated with symptoms. It can often be visualized on the chest radiograph. The trachea is deviated slightly to the left of the midline rather than to the right, as in the presence of a normal left arch. On a barium esophagogram, MRI, or CT scan, the esophagus is indented on its right border at the level of the aortic arch.

VASCULAR RINGS

Congenital abnormalities of the aortic arch and its major branches result in the formation of vascular rings around the trachea and esophagus with varying degrees of compression (Table 481.1). The origin of these lesions can best be appreciated by reviewing the embryology of the aortic arch (see Fig. 469.1). The most common anomalies include (1) double aortic arch (Fig. 481.1A), (2) right aortic arch with a left ligamentum arteriosum, (3) anomalous innominate artery arising farther to the left on the arch than usual, (4) anomalous left carotid artery arising farther to the right than usual and passing anterior to the trachea, (5) anomalous right subclavian artery, and (6) anomalous left pulmonary artery **(vascular sling)**. In the latter anomaly, the abnormal vessel arises from an elongated main pulmonary artery or from the right pulmonary artery. It courses between and compresses the trachea and the esophagus. Associated congenital heart disease may be present in 5–50% of patients, depending on the vascular anomaly.

Clinical Manifestations

If the vascular ring produces compression of the trachea and/or esophagus, symptoms are frequently present during infancy. Chronic wheezing is exacerbated by crying, feeding, and flexion of the neck. Extension of the neck tends to relieve the noisy respiration. Choking on solid food and vomiting may also be symptoms. Affected infants may have a brassy cough, pneumonia, or rarely, sudden death from aspiration.

Diagnosis

Standard radiographic examination is not usually helpful. In the past, performing a barium esophagogram was the standard method of diagnosis (Fig. 481.2), which has been replaced by echocardiography in combination with either MRI or CT (Fig. 481.3). Cardiac catheterization is reserved for cases with associated anomalies or in rare cases where these other modalities are not diagnostic. Bronchoscopy is helpful in more severe cases to determine the extent of airway narrowing and whether additional surgery is required on the airway.

Treatment

Surgery is advised for symptomatic patients who have evidence of tracheal compression. The anterior vessel is usually divided in patients with a double aortic arch (see Fig. 481.1B). Compression produced by a right aortic arch and left ligamentum arteriosum is relieved by division of the latter. Anomalous innominate or carotid arteries cannot be divided; attaching the adventitia of these vessels to the sternum usually relieves the tracheal compression. An anomalous left pulmonary artery is corrected by division at its origin and reanastomosis to the main pulmonary artery after it has been brought in front of the trachea. Severe tracheomalacia, if present, may require reconstruction of the trachea as well.

Visit Elsevier eBooks+ at eBooks.Health.Elsevier.com for Bibliography.

Table 481.1 Vascular Rings

LESION	SYMPTOMS	PLAIN FILM	BARIUM SWALLOW	BRONCHOSCOPY	MRI ECHO	TREATMENT
DOUBLE ARCH	Stridor Respiratory distress Swallowing dysfunction Reflex apnea	AP—wider base of heart Lat.—narrowed trachea displaced forward at C3-C4	Bilateral indentation of esophagus	Bilateral tracheal compression—both pulsatile	Diagnostic	Ligate and divide smaller arch (usually left)
RIGHT ARCH AND LIGAMENTUM/DUCTUS 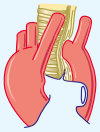	Respiratory distress Swallowing dysfunction	AP—tracheal deviation to left (right arch)	Bilateral indentation of esophagus R > L	Bilateral tracheal compression—r. pulsatile	Diagnostic	Ligate ligamentum or ductus
ANOMALOUS INNOMINATE	Cough Stridor Reflex apnea	AP—normal Lat.—anterior tracheal compression	Normal	Pulsatile anterior tracheal compression	Unnecessary	Conservative apnea, then suspend
ABERRANT RIGHT SUBCLAVIAN 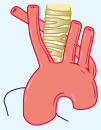	Occasional swallowing dysfunction	Normal	AP—oblique defect upward to right Lat.—small defect on right posterior wall	Usually normal	Diagnostic	Ligate artery
PULMONARY SLING 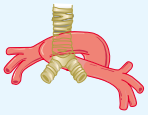	Expiratory stridor Respiratory distress	AP—low l. hilum, r. emphysema/atelectasis Lat.—anterior bowing of right bronchus and trachea	±Anterior indentation above carina between esophagus and trachea	Tracheal displacement to left Compression of right main bronchus	Diagnostic	Detach and reanastomose to main pulmonary artery in front of trachea

AP, Anteroposterior; L and l., left; Lat., lateral; MRI, magnetic resonance imaging; R and r., right.
From Kliegman RM, Greenbaum LA, Lye PS. *Practical Strategies in Pediatric Diagnosis and Therapy*, 2nd ed. Philadelphia: Elsevier; 2004:88.

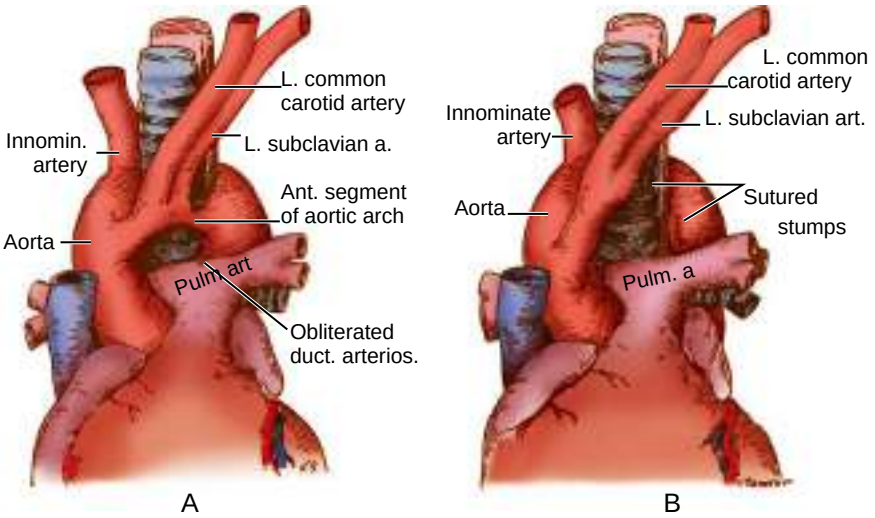

Fig. 481.1 Double aortic arch. **A,** Small anterior segment of the double aortic arch (most common type). **B,** Operative procedure for release of the vascular ring. L., Left; a. and art., artery; ant., anterior; innom., innominate; duct. arterios., ductus arteriosus; pulm., pulmonary.

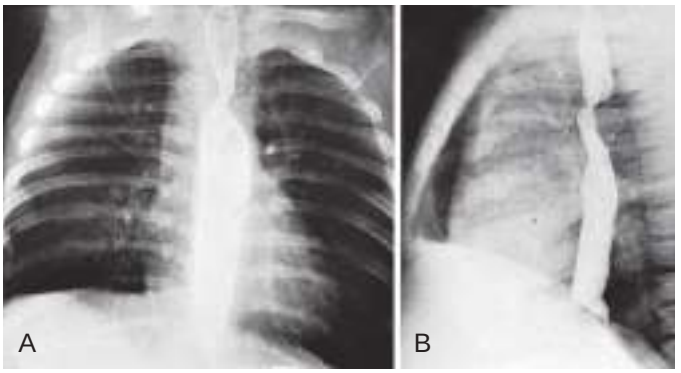

Fig. 481.2 Double aortic arch in an infant age 5 mo. **A,** Anteroposterior view. The barium-filled esophagus is constricted on both sides. **B,** Lateral view. The esophagus is displaced forward. The anterior arch was the smaller and was divided at surgery.

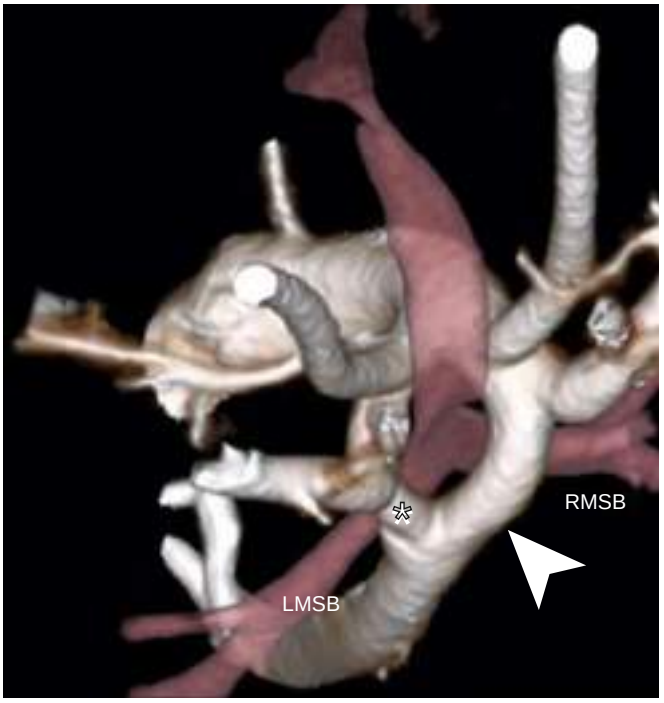

Fig. 481.3 Double aortic arch in a 12-year-old. Superior (bird's eye view) three-dimensional volume-rendered CT image shows the larger dominant arch *(arrowhead)* on the right side, coursing over the right mainstem bronchus *(RMSB)*. There is mild indentation of the trachea. The smaller left arch *(asterisk)* courses over the left mainstem bronchus *(LMSB)*. *(From Madueme PC: Computed tomography and magnetic resonance imaging of vascular rings and other things: a pictorial review. Pediatr Radiol 2022;52:1839–1848.(Fig. 2, p. 1840.)*

481.2 Anomalous Origin of the Coronary Arteries

Daniel Bernstein

Table 481.2 provides a classification system for coronary artery anomalies. Although many of these are isolated, congenital anomalies of the coronary arteries may also be seen in patients with congenital heart disease (tetralogy of Fallot, transposition of the great arteries, congenitally corrected transposition of the great arteries, single ventricle, tricuspid atresia, truncus arteriosus, quadricuspid or bicuspid aortic valves, double-outlet ventricle). In addition, acquired lesions of the coronary arteries associated with existing congenital heart disease may develop because of alterations in blood flow or postoperative stenoses, especially in patients whose surgery involves the aortic root.

Table 481.2 Congenital Anomalies of Coronary Arteries Unassociated with Congenital Heart Disease

ANOMALOUS AORTIC ORIGIN
- Eccentric ostium within an aortic sinus
- Ectopic ostium above an aortic sinus
- Conus artery from the right aortic sinus
- Circumflex coronary artery from the right aortic sinus or from the right coronary artery
- Origin of left anterior descending and circumflex coronary arteries from separate ostia in the left aortic sinus (absence of left main coronary artery)
- Atresia of the left main coronary artery
- Origin of the left anterior descending coronary artery from the right aortic sinus or from the right coronary artery
- Origin of the right coronary artery from the left aortic sinus, from posterior aortic sinus, or from left coronary artery
- Origin of a single coronary artery from the right or left aortic sinus
- Anomalous origin from a noncardiac systemic artery

ANOMALOUS AORTIC ORIGIN WITH ANOMALOUS PROXIMAL COURSE
- Acute proximal angulation
- Ectopic right coronary artery passing between aorta and pulmonary trunk
  - Ectopic left main coronary artery
  - Between aorta and pulmonary trunk
  - Anterior to the pulmonary trunk
  - Posterior to the aorta
- Within the ventricular septum (intramyocardial)
- Ectopic left anterior descending coronary artery that is anterior, posterior, or between the aorta and pulmonary trunk

ANOMALOUS ORIGIN OF A CORONARY ARTERY FROM THE PULMONARY TRUNK
- Left main coronary artery
- Left anterior descending coronary artery
- Right coronary artery
- Both right and left coronary arteries
- Circumflex coronary artery
- Accessory coronary artery

From Perloff JK, Marelli J. *Perloff's Clinical Recognition of Congenital Heart Disease*, 6th ed. Philadelphia: Saunders; 2012: Table 32-3, p. 532.

ANOMALOUS ORIGIN OF THE LEFT CORONARY ARTERY FROM THE PULMONARY ARTERY

In anomalous origin of the left coronary artery from the pulmonary artery **(ALCAPA)**, the blood supply to the left ventricular (LV) myocardium is severely compromised. Soon after birth, as pulmonary artery pressure falls, perfusion pressure to the left coronary artery (LCA) becomes inadequate; myocardial ischemia, infarction, and fibrosis result. In some cases, interarterial collateral anastomoses develop between the right coronary artery (RCA) and LCA. Blood flow in the LCA is then reversed, and it empties into the pulmonary artery, a condition known as *myocardial steal syndrome*. The LV becomes dilated, and its performance is decreased. Mitral insufficiency is a frequent complication secondary to a dilated valve ring or infarction of a papillary muscle. Localized aneurysms may also develop in the LV free wall. Rare patients have adequate myocardial blood flow during childhood and, later in life, a continuous murmur and a small left-to-right shunt via the dilated coronary system (aorta to RCA to LCA to pulmonary artery).

Clinical Manifestations

Evidence of heart failure becomes apparent within the first few months of life and may be exacerbated by respiratory infection. Recurrent attacks of discomfort, restlessness, irritability, sweating, dyspnea, and pallor occur and represent an infantile version of **angina pectoris**. Diagnosis is often made only after a chest x-ray is obtained looking for other sources of irritability and rapid breathing. Cardiac enlargement ranges from moderate to massive. A gallop rhythm is common.

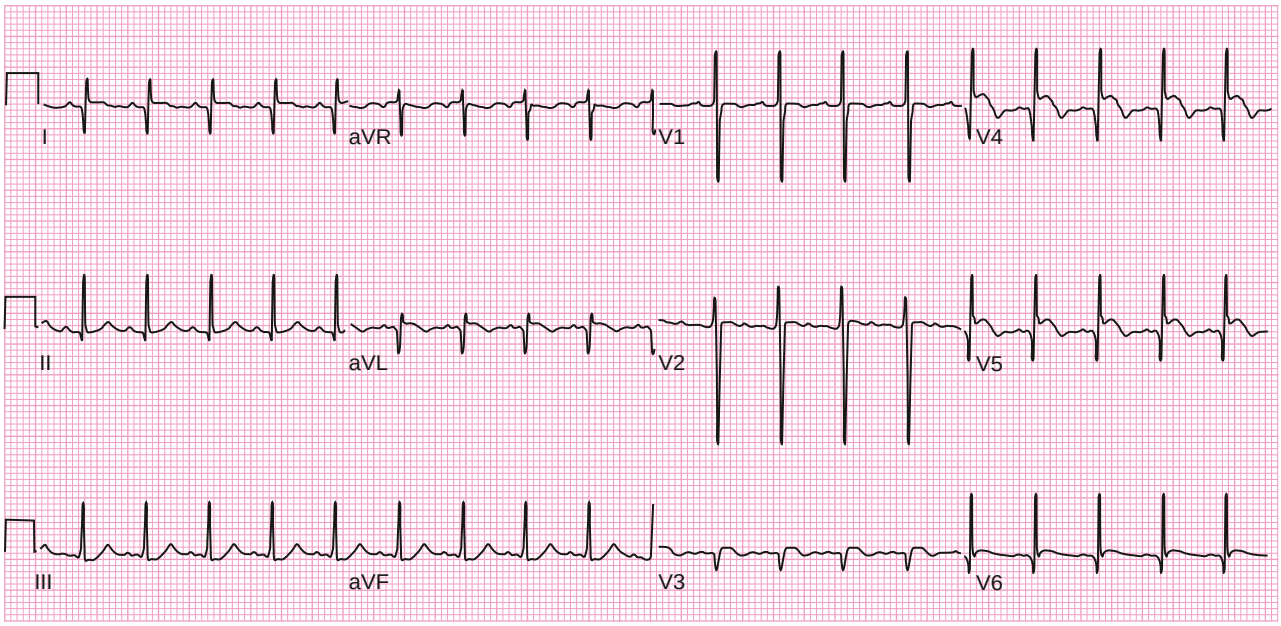

Fig. 481.4 Electrocardiogram of a 2-mo-old with anomalous origin of the left coronary artery from the pulmonary artery. Myocardial infarction is evidenced by abnormal Q waves in leads I and aVL and in the anterolateral precordial leads (V_3, V_4, V_5, V_6). There is also ST elevation in leads V_4 and V_5, a sign of ongoing ischemia. Another sign of ALCAPA is the diminution or loss of R waves in the midprecordial leads (V_2, V_3).

Murmurs may be of the nonspecific ejection type or may be holosystolic because of mitral insufficiency. Older patients with abundant intercoronary anastomoses may have continuous murmurs and less LV dysfunction. However, during older childhood and adolescence, they may experience angina during exercise. Rare patients with an anomalous RCA may also have such clinical findings, especially if the RCA supplies the inferoposterior portion of the LV (right dominant system).

Diagnosis

Radiographic examination confirms cardiomegaly. The electrocardiogram (ECG) can resemble the pattern described in anterolateral wall myocardial infarction in adults, although this pattern can vary over the first weeks of life. A QR pattern followed by flattened or inverted T waves is typically seen in leads I and aVL (Fig. 481.4). The anterolateral precordial leads (V_3-V_6) may show deep Q waves or elevated ST segments and inverted T waves (the more typical adult findings of a lateral myocardial infarction) or may be relatively normal. Decreased or absent R waves may be seen over the mid-precordial leads (V_3, V_4). Given the subtlety of these ECG findings and that an infarct pattern is not usually expected in infants, a high index of suspicion should be maintained for patients with the symptoms described earlier. Two-dimensional (2D) echocardiography with color Doppler usually confirms the diagnosis; however, in rare cases, echocardiography may not be definitive in diagnosing this condition. On 2D imaging alone, the LCA may appear as though it is arising from the aorta. Color Doppler ultrasound has improved the accuracy of diagnosis of this lesion, demonstrating the presence of retrograde flow in the LCA. If needed, CT or MRI can confirm the origin of the coronary arteries. Cardiac catheterization is also diagnostic; aortography shows immediate opacification of the RCA only. In patients who have developed collaterals, this vessel is large and tortuous. After filling of the intercoronary anastomoses, the LCA is opacified, and contrast can be seen to enter the pulmonary artery. Pulmonary arteriography should opacify the origin of the anomalous LCA. Selective left ventriculography usually demonstrates a dilated LV that empties poorly and mitral regurgitation.

Treatment and Prognosis

Untreated, death often occurs from heart failure within the first 6 months of life. Those who survive without surgery generally have abundant intercoronary collateral anastomoses. Medical management includes standard therapy for heart failure (diuretics, angiotensin-converting enzyme inhibitors, and β blockers).

Surgical treatment consists of detaching the anomalous coronary artery from the pulmonary artery and anastomosing it to the aorta to establish normal myocardial perfusion. In patients who have already sustained a significant myocardial infarction, cardiac transplantation may be the only option (see Chapter 492.1).

ANOMALOUS ORIGIN OF THE RIGHT CORONARY ARTERY FROM THE PULMONARY ARTERY

Anomalous origin of the RCA from the pulmonary artery is not usually manifested in infancy or early childhood. The LCA is enlarged, whereas the RCA is thin walled and mildly enlarged. In early infancy, perfusion of the RCA is from the pulmonary artery, whereas later, perfusion is from collaterals of the left coronary vessels. Angina and sudden death can occur in adolescence or adulthood. When recognized, this anomaly should be repaired by reanastomosis of the RCA to the aorta.

ANOMALOUS AORTIC ORIGIN OF A CORONARY ARTERY

In anomalous aortic origin of a coronary artery (AAOCA), one or both coronary arteries arise from their nonusual sinus (e.g., LCA from the right sinus of Valsalva) or high on the aorta, above the sinotubular junction. There are multiple anatomic variations, with different physiologic consequences, and therefore with different risks of coronary ischemia, arrhythmia, and potentially sudden death. Fortunately, most variants of AAOCA are benign, and the challenge for clinicians is to recognize which variants place their patient at a greater risk of a life-threatening event.

The aberrant artery may be a left, right, or major branch coronary artery. The site of origin may be the wrong sinus of Valsalva (anomalous origin of a coronary artery from the opposite sinus, **ACAOS**) or a proximal coronary artery. The ostium may be hypoplastic, slitlike, or of normal caliber. The aberrant vessel may pass anteriorly, posteriorly, or between the aorta and right ventricular outflow tract (RVOT); it may take an intramural course, tunneling in the conal or interventricular septal tissue. Obstruction resulting from hypoplasia of the ostia, tunneling between the aorta and RVOT or interventricular septum, and acute angulation produce myocardial ischemia and infarction. Although unobstructed vessels usually produce no

Table 481.3 Classification of Coronary Anomalies Based on Ischemia

ISCHEMIA	CLASSIFICATION
Absence of ischemia	Most anomalies (split RCA, ectopic RCA from right cusp; ectopic RCA from left cusp)
Episodic ischemia	Anomalous origin of a coronary artery from the opposite sinus (ACAOS); coronary artery fistulas; myocardial bridge
Typical ischemia	Anomalous left coronary artery from the pulmonary artery (ALCAPA); coronary ostial atresia or severe stenosis

RCA, Right coronary artery.
From Mehran R, Dangas GD. Coronary angiography and intravascular imaging. In: Zipes DP, Libby P, Bonow RO, et al., eds. *Braunwald's Heart Disease*, 11th ed. Philadelphia: Elsevier; 2019: Fig. 20.8, p. 385.

symptoms (Table 481.3), patients with coronary obstruction may initially present with an acute coronary event, either acute myocardial infarction, ventricular arrhythmias, angina pectoris, or syncope; sudden death may occur, especially in young athletes.

Diagnostic modalities include ECG, 2D echocardiography, CT or MRI, radionuclide perfusion scan, and cardiac catheterization with selective coronary angiography. Exercise stress testing can play an important role in assessing risk (e.g., in patients who present only with chest pain), but is usually contraindicated in those who present with a sudden cardiac arrest, documented ischemia, or ventricular arrhythmia.

Treatment is indicated for obstructed vessels, for patients with symptoms, and for those who present with a sudden cardiac event and consists of reanastomosis of the aberrant vessel to the correct aortic sinus. The management of asymptomatic patients with ectopic coronary origin without obstruction remains controversial, as the ability to predict risk is still incompletely understood. Management decisions should be based on the specific anatomy, results of laboratory investigations, and shared decision-making with patients and their families after careful explanation of risks and benefits. Surgery is not without complications and should be performed at centers experienced in AAOCA surgery.

The risk appears to be highest with anomalous LCA from the right sinus of Valsalva with interarterial course (see Table 481.3); however, there are patients with anomalous RCA who are also at risk.

Visit Elsevier eBooks+ at eBooks.Health.Elsevier.com for Bibliography.

481.3 Pulmonary Arteriovenous Fistula

Daniel Bernstein

Fistulous vascular communications in the lungs may be large and localized or multiple, scattered, and small. The most common form of this unusual condition is **Osler-Weber-Rendu syndrome** (hereditary hemorrhagic telangiectasia type I), which is also associated with angiomas of the nasal and buccal mucous membranes, gastrointestinal (GI) tract, or liver. Pathogenic variants in the endoglin gene, a cell surface component of the transforming growth factor (TGF)-β receptor complex, cause this syndrome. The usual communication is between the pulmonary artery and pulmonary vein; direct communication between the pulmonary artery and left atrium is extremely rare. Desaturated blood in the pulmonary artery is shunted through the fistula into the pulmonary vein, thus bypassing the lungs, and then enters the left side of the heart, *resulting in systemic arterial desaturation and sometimes clinically detectable cyanosis*. The shunt across the fistula is at low pressure and resistance, so pulmonary artery pressure is normal; cardiomegaly and heart failure are not present.

The clinical manifestations depend on the magnitude of the shunt. Large fistulas are associated with dyspnea, cyanosis, clubbing, a continuous murmur, and polycythemia. Hemoptysis is rare, but when it occurs, it may be massive. Features of Osler-Weber-Rendu syndrome are seen in approximately 50% of patients (or other family members) and include recurrent epistaxis and GI tract bleeding. Transitory dizziness, diplopia, aphasia, motor weakness, or convulsions may result from cerebral thrombosis, abscess, or paradoxical emboli. Soft systolic or continuous murmurs may be audible over the site of the fistula. The ECG is normal. Chest radiographs may show opacities produced by large fistulas; multiple small fistulas may be visualized by fluoroscopy (as abnormal pulsations), MRI, or CT. Selective pulmonary arteriography demonstrates the site, extent, and distribution of the fistulas.

Treatment consisting of excision of solitary or localized lesions by lobectomy or wedge resection results in complete disappearance of symptoms. In most patients, fistulas are so widespread that surgery is not possible. Any direct communication between the pulmonary artery and the left atrium can be obliterated.

Patients who have undergone a **Glenn cavopulmonary anastomosis** for cyanotic congenital heart disease (see Chapter 479.4) are also at risk for the development of pulmonary **arteriovenous malformations** (AVMs). In these patients the AVMs are usually multiple, and the risk increases over time after the Glenn procedure. Pulmonary AVMs rarely occur after full palliation by completion of the **Fontan operation**. This finding suggests that the pulmonary circulation requires an as-yet-undetermined hepatic factor to suppress the development of AVMs. The hallmark of the development of pulmonary AVMs is a gradual decrease in the patient's oxygen saturation, which is usually lower than normal to begin with. The diagnosis can often be made with contrast echocardiography; cardiac catheterization is the definitive test. Completion of the Fontan circuit, so that inferior vena cava blood flow (containing hepatic venous drainage) is routed through the lungs, usually results in improvement or resolution of the malformations.

Visit Elsevier eBooks+ at eBooks.Health.Elsevier.com for Bibliography.

481.4 Ectopia Cordis

Daniel Bernstein

In the most common thoracic form of ectopia cordis, the sternum is split and the heart protrudes outside the chest. In other forms, the heart protrudes through the diaphragm into the abdominal cavity or may be situated in the neck. Associated intracardiac anomalies are seen in 40% (tetralogy of Fallot, conotruncal lesions). **Pentalogy of Cantrell** consists of ectopia cordis, midline supraumbilical abdominal defect, deficiency of the anterior diaphragm, defect of the lower sternum, and an intracardiac defect (ventricular septal defect, tetralogy of Fallot, or diverticulum of the left ventricle). Death may occur early in life, usually from infection, cardiac failure, or hypoxemia. Surgical therapy for neonates without overwhelmingly severe cardiac anomalies consists of covering the heart with skin without compromising venous return or ventricular ejection. Repair or palliation of associated defects is also necessary.

Visit Elsevier eBooks+ at eBooks.Health.Elsevier.com for Bibliography.

481.5 Diverticulum of the Left Ventricle

Daniel Bernstein

Left ventricular diverticulum is a rare anomaly in which the diverticulum protrudes into the epigastrium. The lesion may be isolated or associated with complex cardiovascular anomalies. A pulsating mass is usually visible and palpable in the epigastrium. Systolic or systolic-diastolic murmurs produced by blood flow into and out of the diverticulum may be audible over the lower part of the sternum and the mass. The ECG shows a pattern of complete or incomplete left bundle branch block. The chest radiograph may or may not show the mass. Associated abnormalities include defects of the sternum, abdominal wall, diaphragm, and pericardium (see earlier). Surgical treatment of the diverticulum and associated cardiac defects can be performed in selected cases. Occasionally, a diverticulum may be small and not associated with clinical signs or symptoms. These small diverticula are diagnosed at echocardiographic examination for other indications.

Chapter 482
Pulmonary Hypertension

482.1 Primary Pulmonary Hypertension

Daniel Bernstein and Rachel K. Hopper

Pulmonary hypertension (PH) refers to an elevated pressure in the pulmonary arteries and is associated with significant morbidity and mortality in children. The etiologies of PH are varied, but all lead to similar symptoms and can ultimately result in right-sided heart failure (Tables 482.1 and 482.2). PH is often characterized by progressive vascular disease of the pulmonary arteries (pulmonary arterial hypertension [PAH], previously called *primary PH*). PH occurs at any age, although in pediatric patients the mean age at diagnosis is 7-10 years. In patients with idiopathic or familial PAH, females outnumber males 1.7:1; in other patients, both genders are represented equally. Pathogenic variants in the *BMPR2* gene, a member of the transforming growth factor (TGF)-β receptor family, on chromosome 2q33 have been identified in 70% of patients with **familial pulmonary arterial hypertension** and in 10–20% with idiopathic sporadic PAH (see Table 482.2). Other potential disease-causing genes include *ALK1* and *ENG* (both associated with hereditary hemorrhagic telangiectasia) and *SMAD9, CAV1, KCNK3,* and *SOX17* (associated with congenital heart disease and PAH). *TBX4* is associated with developmental lung disease and PAH. Viral infection, such as with the vasculotropic human herpesvirus 8, has been suggested as a trigger factor in some patients.

PAH is associated with precapillary obstruction of the pulmonary vascular bed as a result of hyperplasia of the muscular and elastic tissues and a thickened intima of the small pulmonary arteries and arterioles (Fig. 482.1). Secondary remodeling may be found in the larger pulmonary arteries as well. **Pulmonary venoocclusive disease**, mixed precapillary and postcapillary vascular disease, may account for some cases of PAH. Before a diagnosis of PAH can be made, other causes of elevated pulmonary artery pressure must be eliminated; these include chronic pulmonary parenchymal disease, persistent obstruction of the upper airway, congenital cardiac malformations, left-sided heart disease, recurrent pulmonary emboli, developmental lung disease, liver disease, autoimmune disease, and moyamoya disease (see Table 482.1). PAH accounts for nearly half of all pediatric PH (45%), with PAH associated with congenital heart disease being the most common in pediatric patients, followed by idiopathic or familial disease. PH associated with chronic lung disease is growing to encompass a larger portion of new cases, nearly half of all pediatric PH (49%). Bronchopulmonary dysplasia related to prematurity and other developmental lung diseases are increasingly recognized as contributing to PH in children (see Table 482.2).

PH places an afterload burden on the right ventricle, which results in right ventricular hypertrophy (RVH). Dilation of the pulmonary artery is present, and pulmonary valve insufficiency may occur. In the later stages of the disease, the right ventricle dilates, tricuspid insufficiency develops as the tricuspid valve leaflets are pulled apart, and cardiac output is decreased. Arrhythmias, syncope, and sudden death are known complications.

CLINICAL MANIFESTATIONS

The predominant symptoms include exercise intolerance (dyspnea) and fatigability; occasionally, precordial chest pain, dizziness, or headaches are noted. Syncope may be noted in approximately 30% of pediatric patients. Patients often undergo an incorrect evaluation and are treated for asthma or seizures before a proper diagnosis is made. Peripheral cyanosis may be present, especially during exercise or in patients with a patent foramen ovale or other intracardiac communication through which blood can shunt from right to left. In the late stages of disease, patients may have cold extremities and a gray appearance associated with low cardiac output. Arterial oxygen-hemoglobin saturation is usually normal unless there is an associated intracardiac shunt. If right-sided heart failure has supervened, jugular venous pressure is elevated, and hepatomegaly and edema are present. Jugular venous *a* waves are present, and in those with functional tricuspid insufficiency, a conspicuous jugular *cv* wave and systolic hepatic pulsations are manifested. The heart is moderately enlarged, and a right ventricular heave can be noted. The first heart sound is often followed by an ejection click emanating from the dilated pulmonary artery. The second heart sound (S_2) is narrowly split, with a loud pulmonic component that is sometimes booming in quality; it is frequently palpable at the upper left sternal border. A presystolic (S_4) gallop rhythm may be audible at the lower left sternal border. The systolic murmur is soft and short and is sometimes followed by a blowing decrescendo diastolic murmur caused by pulmonary insufficiency. In later stages, a holosystolic murmur of tricuspid insufficiency is appreciated at the lower left sternal border.

DIAGNOSIS

Chest radiographs reveal a prominent pulmonary artery and right ventricle (Fig. 482.2). The pulmonary vascularity in the hilar areas may be prominent, in contrast to the peripheral lung fields in which pulmonary markings are decreased. The electrocardiogram (ECG) shows RVH, often with spiked P waves. Echocardiography is used to screen for any congenital cardiac malformations and assess right ventricular size and function. Doppler evaluation of the tricuspid valve, if insufficiency is present, will allow estimation of the right ventricular (and thus pulmonary arterial) systolic pressure.

At cardiac catheterization, the presence of left-sided obstructive lesions (pulmonary venous stenosis, mitral stenosis, restrictive cardiomyopathy) that result in pulmonary venous hypertension can be evaluated (see Chapters 476.9, 480.7, and 488.3). Elevated pulmonary artery pressures with a normal pulmonary capillary wedge pressure and high vascular resistance is diagnostic of PAH. If the wedge pressure is elevated and left ventricular end-diastolic pressure (LVEDP) is normal, obstruction at the level of the pulmonary veins, left atrium, or mitral valve should be suspected. If LVEDP is also elevated, the diagnosis of restrictive cardiomyopathy should be entertained. The risks associated with cardiac catheterization are increased in severely ill patients with PAH and should occur at centers with expertise in pediatric PH.

PROGNOSIS AND TREATMENT

Many forms of PAH are progressive, and no cure is currently available. Figure 482.3 provides a general treatment approach to PH. Current medical therapies are pulmonary vasodilatory agents, which relieve symptoms, improve quality of life, and delay clinical worsening; however, they do not stop the progression of the disease. Some success has been reported with oral **calcium channel blockers (CCBs)** such as nifedipine in children who demonstrate pulmonary vasoreactivity when these agents are administered during catheterization. Continuous intravenous infusion of the arachidonic acid metabolite **prostacyclin** (epoprostenol) provides relief as long as the infusion is continued and has been shown to improve survival in children with PAH. **Treprostinil**, a prostacyclin analog with a longer half-life, has also been shown to be effective. Nebulized and oral forms of prostacyclin, as well as other oral pulmonary vasodilators, such as endothelin receptor antagonists and phosphodiesterase type 5 inhibitors, have been used with success in adults and in a small number of clinical studies in children (Table 482.3). In patients with PH secondary to left-sided heart disease or lung disease, pulmonary vasodilators should only be considered after optimization of the underlying condition and in consultation with a PH expert.

Anticoagulation may be of value in patients with previous pulmonary thromboemboli; some of these patients may respond to balloon angioplasty of narrowed pulmonary artery segments. Riociguat, a soluble guanylate cyclase stimulator, with vasorelaxation, antiproliferation, and antifibrotic properties, has proved effective in adults with chronic thromboembolic or idiopathic PH. Diuretics are often used to manage right heart failure. Despite many advances, definitive therapy is still lung transplantation (see Chapter 492.2). Palliative interventions may

Table 482.1 Classification of Pulmonary Hypertension (PH)*

1. Pulmonary arterial hypertension (PAH)
   - 1.1 Idiopathic PAH
   - 1.2 Heritable PAH
   - 1.3 Drug- and toxin-induced PAH
   - 1.4 PAH associated with:
     - 1.4.1 Connective tissue disease
     - 1.4.2 HIV infection
     - 1.4.3 Portal hypertension
     - 1.4.4 Congenital heart disease
     - 1.4.5 Schistosomiasis
   - 1.5 PAH long-term responders to calcium channel blockers
   - 1.6 PAH with overt features of venous/capillaries (PVOD/PCH) involvement
   - 1.7 Persistent PH of the newborn syndrome
2. Pulmonary hypertension due to left heart disease
   - 2.1 PH due to heart failure with preserved LVEF
   - 2.2 PH due to heart failure with reduced LVEF
   - 2.3 Valvular heart disease
   - 2.4 Congenital/acquired cardiovascular conditions leading to postcapillary PH
3. Pulmonary hypertension due to lung diseases and/or hypoxia
   - 3.1 Obstructive lung disease
   - 3.2 Restrictive lung disease
   - 3.3 Other lung disease with mixed restrictive/obstructive pattern
   - 3.4 Hypoxia without lung disease
   - 3.5 Developmental lung disorders
4. PH due to pulmonary artery obstructions
   - 4.1 Chronic thromboembolic pulmonary hypertension
   - 4.2 Other pulmonary artery obstructions
5. Pulmonary hypertension with unclear and/or multifactorial mechanisms
   - 5.1 Hematologic disorders
   - 5.2 Systemic and metabolic disorders
   - 5.3 Others
   - 5.4 Complex congenital heart disease.

*Modified as compared with the Nice 2013 classification.
HIV, Human immunodeficiency virus; PVOD, pulmonary venoocclusive disease; PCH, pulmonary capillary hemangiomatosis, LVEF, left ventricular ejection fraction.
From Simonneau G, Montani D, Celermajer DS, et al. Haemodynamic definitions and updated clinical classification of pulmonary hypertension. *Eur Respir J.* 2019;53(1):1801913.

Table 482.2 Developmental and Genetic Lung Diseases Associated with Pulmonary Hypertension

Congenital diaphragmatic hernia
Bronchopulmonary dysplasia
Down syndrome
Noonan syndrome
Alveolar capillary dysplasia (ACD) with "misalignment of veins" *(FOXF1)*
Cobalamin C deficiency
Lung hypoplasia, acinar dysplasia
Surfactant protein abnormalities
Surfactant protein B deficiency
Surfactant protein C deficiency
ATP-binding cassette A3 variants
Thyroid transcription factor 1 (TTF1)/*Nkx2.1* homeobox pathogenic variants
T-box transcription factor 4 *(TBX4)*
Pulmonary interstitial glycogenosis
Pulmonary alveolar proteinosis
Pulmonary lymphangiectasia
Other pathogenic variants (*BMPR2, ACVRL1, EIF2AK4, CAV1, ENG, KCNK3, SMAD9, SOX17*)

Adapted with data from Rosenzweig EB, Abman SH, Adatia I, et al. Paediatric pulmonary arterial hypertension: updates on definition, classification, diagnostics and management. *Eur Respir J.* 2019;53(1):1801916; and Ivy DD, Abman SH, Barst RJ et al. Pediatric pulmonary hypertension. *J Amer Coll Cardiol.* 2013;62(25):Suppl D, D118–D126, 2013.

include atrial septostomy or a surgical Potts shunt to create a right-to-left shunt as a pop-off to allow decompression of the right ventricle (see Fig. 482.3). In patients with severe PH and low cardiac output, the terminal event is often sudden and related to a lethal arrhythmia. Patients with PH diagnosed in infancy, especially those in premature infants with chronic lung disease, have a high risk of early mortality, but PH generally improves over time if lung growth and protection from infection and injury are achieved. Infants with PH caused by pulmonary vein stenosis often have rapid progression and high mortality.

482.2 Pulmonary Vascular Disease (Eisenmenger Syndrome)

Daniel Bernstein and Rachel K. Hopper

The term *Eisenmenger syndrome* refers to patients with an intracardiac defect or aortopulmonary connection through which blood is shunted

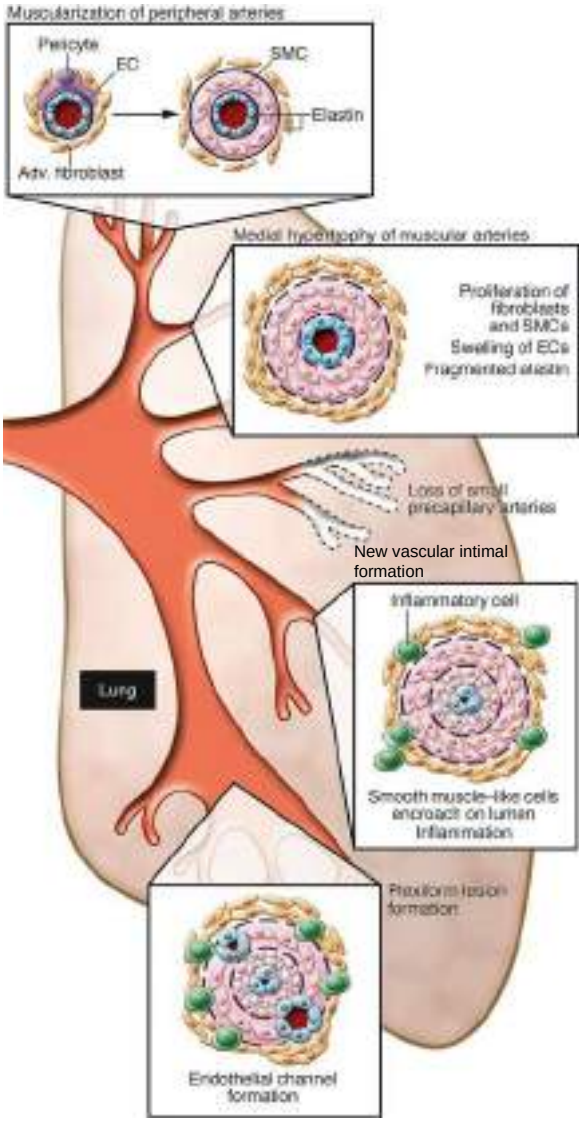

Fig. 482.1 Vascular abnormalities associated with pulmonary arterial hypertension: abnormal muscularization of distal and medial precapillary arteries, loss of precapillary arteries, thickening of large pulmonary arterioles, and new vascular intimal formation that is occlusive in vessels <500-100 μM and in plexiform lesions therein. Adv. adventitial; EC, endothelial cell; SMC, smooth muscle cell. *(From Rabinovitch M. Molecular pathogenesis of pulmonary arterial hypertension. J Clin Invest. 2012;122:4306–4313, Fig 1.)*

partially or totally from right to left as a result of the development of pulmonary vascular disease. This physiologic abnormality can occur with unrepaired ventricular or atrioventricular septal defects, patent ductus arteriosus, aortopulmonary window, or any other communication between the aorta and pulmonary artery and in many forms of complex congenital heart disease with unrestricted pulmonary blood flow. Pulmonary vascular disease with an isolated atrial septal defect can occur, but this is less common and usually does not occur until late in adulthood.

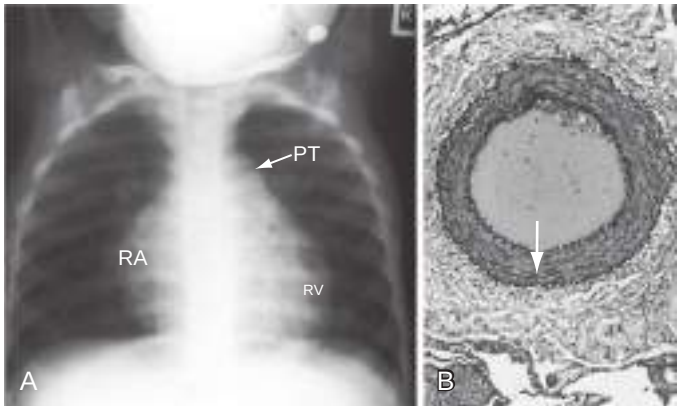

Fig. 482.2 A, Radiograph from a 3-yr-old child with pulmonary arterial hypertension. Pulmonary vascularity is reduced. The pulmonary trunk (PT), right atrium (RA), and right ventricle (RV) are considerably enlarged. B, Histology of an intrapulmonary artery at necropsy shows medial hypertrophy *(arrow). (From Perloff JK, Marelli AJ. Perloff's Clinical Recognition of Congenital Heart Disease, 6th ed. Philadelphia: Saunders; 2012: Fig. 14-17, p. 207.)*

In Eisenmenger syndrome, pulmonary vascular resistance (PVR) after birth either remains high or, after having decreased during early infancy, rises thereafter because of chronic increased shear stress on pulmonary arterioles. Factors playing a role in the rapidity of development of pulmonary vascular disease include increased pulmonary artery pressure, increased pulmonary blood flow, and the presence of hypoxia or hypercapnia. Early in the course of disease, PH is the result of markedly increased pulmonary blood flow (*hyperkinetic* PH). This form of PH decreases with the administration of pulmonary vasodilators such as nitric oxide, or oxygen, or both. With the development of Eisenmenger syndrome, PH is the result of pulmonary vascular disease (obstructive pathologic changes in the pulmonary vessels). This form of PH is usually only minimally responsive to pulmonary vasodilators or oxygen or may be totally unresponsive.

PATHOLOGY AND PATHOPHYSIOLOGY

The pathologic changes of Eisenmenger syndrome occur in the small pulmonary arterioles and muscular arteries (<300 μm) and are graded on the basis of histologic characteristics **(Heath-Edwards classification)**:

- **Grade I** change involves medial hypertrophy alone.
- **Grade II** consists of medial hypertrophy and intimal hyperplasia.
- **Grade III** involves near-obliteration of the vessel lumen.
- **Grade IV** includes arterial dilation.
- **Grades V and VI** include plexiform lesions, angiomatoid formation, and fibrinoid necrosis.

Grades IV-VI indicate irreversible pulmonary vascular obstructive disease. Eisenmenger physiology is usually defined by an absolute elevation in pulmonary arterial resistance to >12 Wood units (resistance units indexed to body surface area) or by a ratio of pulmonary-to-systemic vascular resistance of ≥1.0.

Pulmonary vascular disease occurs more rapidly in patients with trisomy 21 who have left-to-right shunts. It also complicates the natural history of patients with elevated pulmonary venous pressure secondary to mitral stenosis or left ventricular dysfunction,

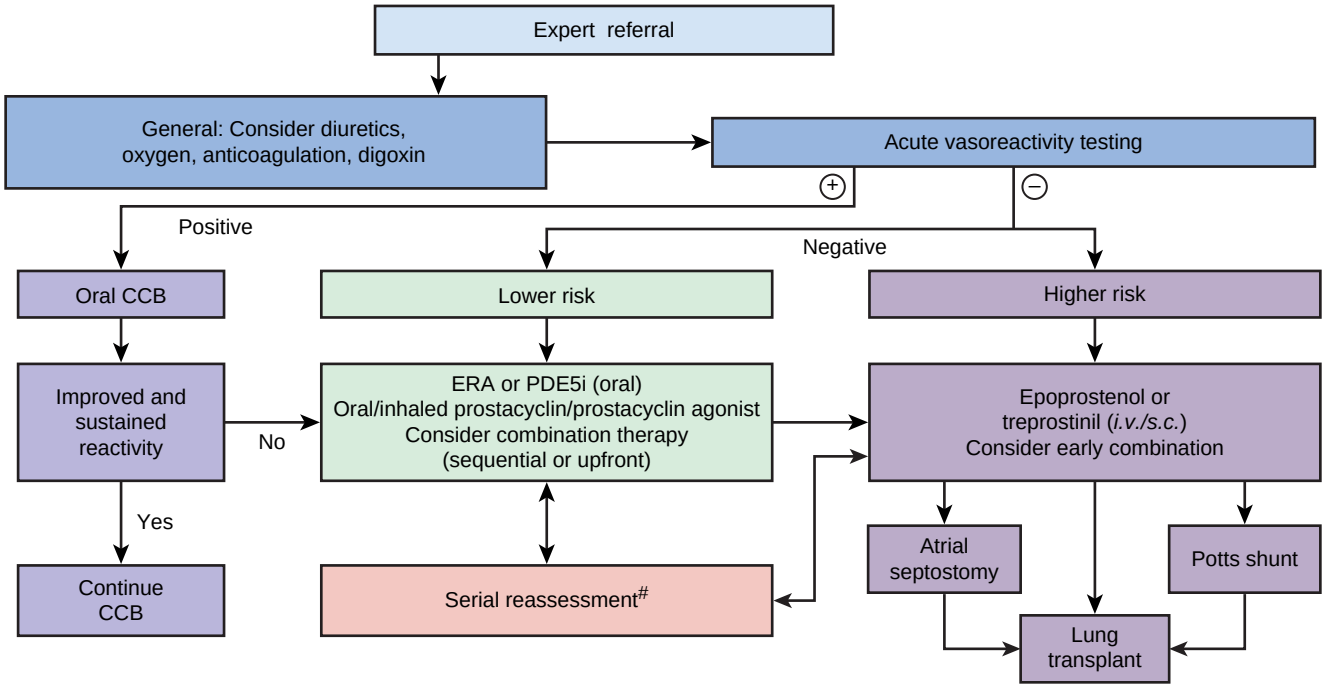

Fig. 482.3 6th World Symposium on Pulmonary Hypertension Consensus pediatric idiopathic/familial PAH treatment algorithm. Use of all agents is considered off-label in children aside from sildenafil in Europe and bosentan in age >3 yr in the United States. CCB, Calcium channel blocker; ERA, endothelin receptor antagonist; PAH, pulmonary arterial hypertension; IV, intravenous; PDE-5i, phosphodiesterase-5 inhibitor; SC, subcutaneous; PO, by mouth; #, deterioration or not meeting treatment goals. *(From Rosenzweig EB, Abman SH, Adatia I, et al. Paediatric pulmonary arterial hypertension: updates on definition, classification, diagnostics and management. Eur Respir J. 2019;53[1]:1801916.)*

Table 482.3 Summary of Drugs Used to Treat Pulmonary Hypertension*

DRUG AND MECHANISM OF ACTION	DOSES USED IN PEDIATRIC STUDIES	COMMON SIDE EFFECTS
Epoprostenol (prostacyclin [PGI_2], a potent vasodilator; also inhibits platelet aggregation)	1-2 ng/kg/min initially Increase based on clinical course and tolerance to 5-80 ng/kg/min Some patients may require even higher doses Must be given by continuous infusion that is not interrupted	Flushing, headache, nausea, diarrhea, hypotension, chest pain, jaw pain, foot and bone pain
Iloprost (synthetic analog of PGI_2)	2.5-5.0 μg 6-9 times daily (limited data in children) via inhalation	Flushing, headache, diarrhea, hypotension, jaw pain, exacerbation of pulmonary symptoms (cough, wheezing)
Treprostinil (synthetic analog of PGI_2)	1-2 ng/kg/min initially Target dose ranges from 20-80 ng/kg/min Given either IV or SC via continuous infusion Longer half-life than epoprostenol *Inhaled:* 6-54 mcg (1-9 patient activated breaths) every 6 hr *Oral:* initially 0.125 mg 3 times daily Target dose ranges from 1 to 10 mg 3 times daily	Flushing, headache, diarrhea, hypotension, jaw pain Pain at infusion site when given SC Inhaled form can exacerbate reactive airway symptoms Increased gastrointestinal side effects with oral formulation
Selexipag (prostacyclin IP receptor agonist)	50-1600 mcg PO twice daily; limited data in children	Headache, pain in jaw, joints or limbs, myalgias, nausea, vomiting, diarrhea, flushing
Ambrisentan (selective endothelin EtA receptor antagonist)	Target dose ranges from 1.25 to 10 mg daily; use ½ dose for first mo	Flushing, headache, hypotension, fluid retention/edema, nasopharyngitis/congestion, vomiting; teratogenicity risk
Bosentan (nonselective endothelin receptor EtA and EtB antagonist)	Starting dose: 0.3-1 mg/kg/dose twice daily PO for first mo For patients <10 kg: max. 2 mg/kg/dose twice daily; 10-20 kg: max. 2 mg/kg/dose twice daily (32 mg tablets); 20-40 kg: 62.5 mg/dose twice daily; >40 kg: 125 mg/dose twice daily	Flushing, headache, hypotension, nasopharyngitis/congestion, fluid retention, edema, vomiting, anemia, elevated transaminases (monthly LFTs required); teratogenicity risk. Caution in concomitant use of CYP3A4 inducers and inhibitors
Macitentan (nonselective endothelin receptor EtA and EtB antagonist)	5-10 mg daily PO; limited data in children	Flushing, headache, fluid retention/edema, anemia, nasopharyngitis/congestion; teratogenicity risk.
Sildenafil (phosphodiesterase type 5 inhibitor)	0.5-1 mg/kg/dose given 3-4 times daily PO For 10-20 kg, use 10 mg 3 times daily; >20 kg, 20 mg 3 times daily Initial dosing should be ½ final target dose to evaluate for hypotension	Flushing, headache, dyspepsia, diarrhea, hypotension, priapism, visual disturbance (blue coloration), tinnitus
Tadalafil (phosphodiesterase type 5 inhibitor)	1 mg/kg/dose given daily PO Maximum adult dose 40 mg daily Initial dosing should be ½ final target dose to evaluate for hypotension	Similar to sildenafil
Riociguat (soluble guanylate cyclase stimulator)	Limited pediatric data Starting adult dose 1 mg tid, can increase to maximum 2.5 mg tid	Hypotension, headache, dizziness, dyspepsia Use with PDE5 inhibitors contraindicated
Calcium channel blockers (amlodipine, diltiazem, nifedipine)	Previously widely used, now indicated only for patients who show a strong response to nitric oxide during cardiac catheterization	Flushing, headache, edema, arrhythmia, headache, hypotension, rash, nausea, constipation, elevated LFTs

*Modified as compared with the Nice 2013 classification.
Note: These medications should only be administered under the direction of a specialist in pulmonary hypertension.
cGMP, Cyclic guanosine monophosphate; IV, Intravenously; LFT, liver function test; SC, subcutaneously.

especially in those with restrictive cardiomyopathy (see Chapter 488.3). Pulmonary vascular disease can also occur in any patient with transmission of systemic pressure to the pulmonary circulation via a shunt at the interventricular or great vessel level and in patients chronically exposed to low partial pressure of oxygen (because of high altitude). Patients with cyanotic congenital heart lesions associated with unrestricted pulmonary blood flow are at particularly high risk.

CLINICAL MANIFESTATIONS

Symptoms do not usually develop until the second or third decade of life, although a more fulminant course may occur. Intracardiac or extracardiac communications that would normally shunt from left to right are converted to right-to-left shunting as PVR exceeds systemic vascular resistance. Cyanosis becomes apparent, and dyspnea, fatigue, and a tendency toward dysrhythmias begin to occur. In the late stages of the disease, heart failure, chest pain, headaches,

syncope, and hemoptysis may be seen. Physical examination reveals a right ventricular heave and a narrowly split S_2 with a loud pulmonic component. Palpable pulmonary artery pulsation may be present at the left upper sternal border. A holosystolic murmur of tricuspid regurgitation may be audible along the left sternal border. An early decrescendo diastolic murmur of pulmonary insufficiency may also be heard along the left sternal border. The degree of cyanosis depends on the stage of the disease. Clubbing of the distal digits may be seen in late disease as a result of chronic hypoxia.

DIAGNOSIS

On chest radiograph, the heart varies in size from normal to greatly enlarged; the latter usually occurs late in the course of the disease. The main pulmonary artery is generally prominent, similar to other causes of PAH (see Fig. 482.2A). The pulmonary vessels are enlarged in the hilar areas and taper rapidly in caliber in the peripheral branches. The right ventricle and atrium are prominent. The ECG shows marked RVH. The P wave may be tall and spiked. Cyanotic patients have various degrees of polycythemia that depend on the severity and duration of hypoxemia.

The echocardiogram shows a thick-walled right ventricle and demonstrates the underlying congenital heart lesion. 2D echocardiography assists in eliminating from consideration lesions such as obstructed pulmonary veins, supramitral membrane, mitral stenosis, and restrictive cardiomyopathy. Doppler studies demonstrate the direction of the intracardiac shunt and the presence of a typical hypertension waveform in the main pulmonary artery. Tricuspid and pulmonary regurgitation can be used in the Doppler examination to estimate pulmonary artery systolic and diastolic pressures.

Cardiac catheterization usually shows a bidirectional shunt at the site of the defect. Systolic pressure is generally equal in the systemic and pulmonary circulations. Pulmonary capillary wedge pressure is normal unless a left-sided heart obstructive lesion or left ventricular failure is the cause of the PAH. Arterial oxygen-hemoglobin saturation is decreased depending on the magnitude of the right-to-left shunt. The response to vasodilator therapy (oxygen, prostacyclin, nitric oxide) may identify patients with less severe disease. Selective pulmonary artery injections may be necessary if pulmonary venous obstruction is suspected because of high wedge pressure and low LVEDP.

TREATMENT

The best management for patients who are at risk for the development of late pulmonary vascular disease is prevention by early surgical elimination of large intracardiac or great vessel communications during infancy. Some patients may be missed because they have not shown early clinical manifestations. Rarely, PVR never decreases at birth in these infants, and therefore they never acquire enough left-to-right shunting to become clinically apparent. Such delayed recognition is a particular risk in patients with congenital heart disease who live at high altitude. It is also a risk in infants with trisomy 21, who have a propensity for earlier development of pulmonary vascular disease. Because of the high incidence of congenital heart disease associated with trisomy 21, routine echocardiography is recommended at the time of initial diagnosis, even in the absence of other clinical findings.

Medical treatment of Eisenmenger syndrome is primarily symptomatic. Many patients benefit substantially from either oral **(CCBs, endothelin antagonist**, **phosphodiesterase inhibitors)** or chronic continuous intravenous **(prostacyclin)** therapy. Combined heart-lung or bilateral lung transplantation is the only surgical option for many of these patients (see Chapter 492.2). Heart-lung transplantation may be the option if there is associated complex congenital heart disease.

Visit Elsevier eBooks+ at eBooks.Health.Elsevier.com for Bibliography.

Chapter 483

General Principles of Treatment of Congenital Heart Disease

Daniel Bernstein

Most patients who have minor congenital heart lesions do not require treatment. The parents and child should be made aware that a normal life is expected and that no restriction of the child's activities is necessary. Overprotective parents may use the presence of a minor congenital heart lesion or even a functional heart murmur as a means to exert excessive control over their child's activities. Although fears may not be expressed overtly, the child may become anxious regarding early death or debilitation, especially when an adult member of the family acquires unrelated symptomatic heart disease. The family may have an unexpressed fear of sudden death, and the rarity of this manifestation should be emphasized in discussions directed at improving their understanding of the child's congenital heart defect. General health maintenance, including a well-balanced "heart-healthy" diet, aerobic exercise, and avoidance of smoking, should be encouraged.

Even patients with moderate to severe congenital heart disease (CHD) need not be restricted from all physical activity, although many will tend to limit their own activities. Physical education should be modified appropriately to the child's capacity to participate; the extent of such modification can be guided by formal exercise testing in an appropriately equipped pediatric exercise laboratory. Although competitive sports for some patients may need to be discouraged, decisions are made on an individual basis. The influence of coach and peer pressure should be considered when recommending competitive vs noncompetitive athletics. Many cardiologists will also prohibit certain high-impact activities ("collision sports") such as tackle football or contact martial arts in patients who have had prior open heart surgery.

Routine immunizations should be given, with the inclusion of influenza vaccine during the appropriate season. Vaccination against the SARS-CoV-2 virus has been recommended for children with heart disease who are eligible based on age. Prophylaxis against respiratory syncytial virus (RSV) is recommended during RSV season in young infants with unrepaired CHD and significant hemodynamic abnormalities or in those with cardiomyopathy and heart failure. Careful consideration of the timing of administration of live-virus vaccination is required in patients who are potential candidates for heart or heart-lung transplantation, and these patients cannot receive live-virus vaccines after they have received their transplant.

Bacterial infections should be treated vigorously. **Prophylaxis against bacterial endocarditis** should be carried out during dental procedures for appropriate patients (see Chapter 486).

Cyanotic patients need to be monitored for noncardiac manifestations of oxygen deficiency (Table 483.1); however, it is rare today for a patient to remain significantly cyanotic beyond the first few years of life, although mild degrees of cyanosis may be seen in patients with a single ventricle (e.g., hypoplastic left heart) who have a fenestration in their Fontan conduits allowing right-to-left shunting. These patients should be carefully observed for excessive **polycythemia**. Cyanotic patients should avoid situations where dehydration may occur, which leads to increased viscosity and increases the risk of stroke. Diuretics may need to be decreased or temporarily discontinued during episodes of acute gastroenteritis or during excessively hot weather. High altitudes and sudden changes in the thermal environment should also be avoided. Treatment of iron deficiency is important in cyanotic patients, who

Table 483.1 Extracardiac Complications of Cyanotic Congenital Heart Disease and Eisenmenger Physiology

PROBLEM	ETIOLOGY	THERAPY
Polycythemia	Persistent hypoxia	Phlebotomy if symptomatic
Relative anemia	Nutritional deficiency	Iron replacement
CNS abscess	Right-to-left shunting	Antibiotics, drainage
CNS thromboembolic stroke	Right-to-left shunting or polycythemia	Anticoagulation, phlebotomy
Low-grade DIC, thrombocytopenia	Polycythemia	None for DIC unless bleeding, then phlebotomy
Hemoptysis	Pulmonary infarct, thrombosis, or rupture of pulmonary artery plexiform lesion	Embolization
Plastic bronchitis	Fontan procedure	Bronchoscopy, vascular coiling, lymphatic ablation
Gum disease	Polycythemia, gingivitis, bleeding	Dental hygiene
Gout	Polycythemia, diuretic agent	Allopurinol
Arthritis, clubbing	Hypoxic osteoarthropathy	None
Pregnancy complications: miscarriage, fetal growth retardation, prematurity increase, maternal illness	Poor placental perfusion, poor ability to increase cardiac output	Pregnancy prevention counseling, high-risk obstetric management
Infections	Associated asplenia, DiGeorge syndrome, endocarditis	Antibiotics
	Fatal RSV pneumonia with pulmonary hypertension	RSV monoclonal antibodies* (prevention)
Failure to thrive	Increased oxygen consumption, decreased nutrient intake	Treat heart failure; correct defect early; increase caloric intake
Protein-losing enteropathy	s/p Fontan; high right-sided pressures	Oral budesonide or sildenafil
Chylothorax	Injury to thoracic duct	Medium-chain triglyceride diet Octreotide Surgical ligation of thoracic duct
Neurodevelopmental disabilities	Chronic hypoxia, cardiac surgery, genetic	Early school-based evaluation and intervention
Psychosocial adjustment	Limited activity, cyanotic appearance, chronic disease, multiple hospitalizations	Counseling

*Palivizumab, nirsevimab.
CNS, Central nervous system; DIC, disseminated intravascular coagulation; RSV, respiratory syncytial virus; s/p, status post (after).

may have a low mean corpuscular hemoglobin concentration despite polycythemia. The risk of stroke for these patients can be reduced if the red blood cells are not microcytic. Phlebotomy with partial exchange transfusion is carried out only in symptomatic patients with severe polycythemia (usually those with hematocrit >65%).

Patients with moderate to severe forms of CHD or a history of rhythm disturbance should be carefully monitored during anesthesia for even routine surgical or dental procedures. Consultation with an anesthesiologist experienced in the care of children with CHD is recommended even if the surgical procedure is not cardiac related.

Females with unrepaired severe CHD should be counseled on the risks associated with childbearing and on the use of contraceptives and other methods to prevent pregnancy (see Chapter 483.1). Females with mild to moderate CHD and many who have had corrective surgery can have normal pregnancies, although those with residual hemodynamic derangements or with systemic right ventricles (RVs) should be followed by a high-risk perinatologist and a cardiologist with expertise in caring for adults with CHD. Pregnancy may be highly dangerous to both mother and fetus for patients with palliated (rather than repaired) complex CHD, chronic cyanosis, or pulmonary arterial hypertension; for patients with a Fontan circulation, the miscarriage rate has been reported as ranging from 27% to 50% and the rate of prematurity at 69%. Risks to the mother include heart failure, thromboembolism, and arrhythmia. Several risk stratification schemes have been developed for pregnant women with CHD, including the Cardiac Disease in Pregnancy **(CARPREG)** score, the Zwangerschap bij Aangeboren HARtAfwijkingen **(ZAHARA)** score, and the World Health Organization (WHO) classification. Based on the WHO system, patients for whom pregnancy is associated with increased risk of mortality or morbidity include those with a systemic RV (e.g., corrected transposition with good function), Fontan circulation, repaired coarctation of the aorta bicuspid aortic valve with enlarged aortic root of 45-50 mm, **Marfan syndrome** with enlarged aortic root of 40-45 mm, atrioventricular septal defects, moderate mitral stenosis, severe aortic stenosis, and mechanical valve replacement. Patients for whom pregnancy is considered contraindicated include those with pulmonary arterial hypertension, Ehlers-Danlos syndrome, severe recoarctation of the aorta, Fontan circulation with any complications, severe aortic or mitral stenosis, severe aortic dilation, and systemic ventricular dysfunction with ejection fraction <30%.

POSTOPERATIVE MANAGEMENT

After successful open heart surgery, the severity of the congenital heart defect, the age and condition (nutritional status) of the patient before surgery, the events in the operating room (OR), and the quality of the postoperative care influence the patient's course. **Intraoperative** factors that influence survival and that should be noted when a patient returns from the OR include the duration of **cardiopulmonary bypass** (CPB), duration of **aortic cross-clamping** (time the heart is not being perfused), and duration of **profound hypothermia** (used in some newborns; time the entire body is not being perfused). Surgical techniques to provide ongoing perfusion to the upper body and brain even during surgery on the aortic arch (e.g., in hypoplastic left heart syndrome [HLHS]) have eliminated the use of profound hypothermia in many centers.

Immediate postoperative care should be provided in an intensive care unit (ICU) staffed by a team of physicians, nurses, and technicians experienced with the unique problems encountered after open heart surgery in childhood. In most major centers, this occurs in a dedicated pediatric cardiovascular ICU. Preparation for postoperative monitoring begins in the OR, where the anesthesiologist or surgeon places an arterial catheter to allow direct arterial pressure measurements and arterial sampling for blood gas determination. A central venous catheter is also placed for measuring central venous pressure and for infusions of cardioactive medications. In more complex cases, right or left atrial or pulmonary artery catheters may be inserted directly into these cardiac structures and used for pressure monitoring purposes. Temporary pacing wires are placed on the atrium or ventricle, or both, in case temporary postoperative heart block occurs. Transcutaneous oximetry provides for continuous monitoring of arterial oxygen saturation. Near-infrared spectroscopy is used to monitor cerebral and other end-organ perfusion in the perioperative period.

Functional failure of one organ system may cause profound physiologic and biochemical changes in another. Respiratory insufficiency, for example, leads to hypoxia, hypercapnia, and acidosis, which in turn compromise cardiac, vascular, and renal function. The latter problems cannot be managed successfully until adequate ventilation is reestablished. Thus it is essential that the primary source of each postoperative problem be identified and treated.

Respiratory failure is a serious postoperative complication encountered after open heart surgery. CPB performed in the presence of pulmonary congestion results in decreased lung compliance, copious tracheal and bronchial secretions, atelectasis, and increased breathing effort. Because fatigue and subsequently hypoventilation and acidosis may rapidly ensue, mechanical positive pressure endotracheal ventilation is usually continued after open heart surgery for a minimum of several hours in relatively stable patients and for up to 2-3 days or longer in severely ill patients, especially infants. Protocols for early extubation have been successfully used in older children with uncomplicated intraoperative courses. Patients with certain congenital heart lesions, particularly those with **DiGeorge syndrome**, may also have airway abnormalities (micrognathia, tracheomalacia, bronchomalacia) that can make both ventilation and extubation more difficult.

The electrocardiogram (ECG) should be monitored continuously during the postoperative period. A change in heart rate, even without arrhythmia, may be the first indication of a serious complication such as hemorrhage, hypothermia, hypoventilation, or heart failure. **Cardiac rhythm disorders** must be diagnosed quickly because a prolonged untreated arrhythmia may add a severe hemodynamic burden to the heart in the critical early postoperative period (see Chapter 484). Injury to the heart's conduction system during surgery can result in postoperative complete heart block. This complication is usually temporary and is treated with surgically placed pacing wires that can later be removed. Occasionally, complete heart block is permanent. If heart block persists beyond 10-14 days postoperatively, insertion of a permanent pacemaker is required. Tachyarrhythmias are a common problem in postoperative patients. Junctional ectopic tachycardia (JET) can be a particularly troublesome rhythm to manage, although it usually responds to antiarrhythmic medications such as intravenous amiodarone.

Heart failure with poor cardiac output after cardiac surgery may be secondary to respiratory failure, serious arrhythmias, myocardial injury, blood loss, hypovolemia, a significant residual hemodynamic abnormality, or any combination of these factors. Treatment specific to the cause should be instituted. Catecholamines, phosphodiesterase inhibitors, nitroprusside and other afterload-reducing agents, and diuretics are the cardioactive agents most often used in patients with myocardial dysfunction in the early postoperative period (see Chapter 491). Postoperative pulmonary hypertension can be managed with hyperventilation and inhaled nitric oxide (iNO). In the rare patients who are unresponsive to standard pharmacologic treatment, various ventricular assist devices are available, depending on the patient's size. If pulmonary function is adequate, a **left ventricular assist device (LVAD)** may be used. If pulmonary function is inadequate, **biventricular assist devices (BVAD)** or **extracorporeal membrane oxygenation (ECMO)** may be used. These extraordinary measures are helpful in maintaining the circulation until cardiac function improves, usually within 2-5 days. They have also been used as a bridge to transplantation in patients with severe nonremitting postoperative cardiac failure.

Acidosis secondary to low cardiac output, renal failure, or hypovolemia must be prevented or, if present, promptly corrected. Serial monitoring of arterial blood gases (ABGs) and lactate concentrations is performed. A low arterial pH may be a sign of decreased perfusion, and acidosis can worsen cardiac function and may be the forerunner of arrhythmias or cardiac arrest.

Renal function may be compromised by congestive heart failure and further impaired by prolonged CPB. Blood and fluid replacement, cardiac inotropic agents, and vasodilators will usually reestablish normal urine flow in patients with hypovolemia or cardiac failure. Renal failure secondary to tubular injury contributes to postoperative fluid overload and may require temporary peritoneal or hemodialysis or hemofiltration. With attention paid to renal injury during the perioperative period, the incidence and severity of chronic renal failure can be reduced.

Neurologic abnormalities can develop after CPB, especially in the neonatal period. Seizures may occur when the patient awakens from sedation and can usually be controlled with anticonvulsant medications. In the absence of other neurologic signs, self-limited isolated seizures in the immediate postoperative period usually carry a good long-term prognosis. Thromboembolism and stroke are rarer but serious complications of open heart surgery. In the long term, both subtle and more substantial learning disabilities may develop. Patients who have undergone surgery entailing CPB, especially in the newborn period, should be watched carefully during their early school years for signs of mild to moderate learning disabilities or attention deficit disorders, which are often amenable to early remedial intervention. The risk is higher in patients who have undergone repair using hypothermic total circulatory arrest than in those where systemic blood flow is maintained using CPB. With the increased recognition of the genetic link between CHD and moderate or greater neurodevelopmental delay, many of these cases may have multifactorial etiologies.

Postpericardiotomy syndrome may occur toward the end of the first postoperative week or may sometimes be delayed until weeks or months after surgery (Table 483.2). This febrile illness is characterized by fever, decreased appetite, listlessness, nausea, and vomiting. Chest pain is not always present, so a high index of suspicion should be maintained in any recently postoperative patient. Echocardiography is diagnostic. In most instances, postpericardiotomy syndrome is self-limited; when pericardial fluid accumulates rapidly, the potential danger of cardiac tamponade should be recognized (see Chapter 489).

Table 483.2 Postpericardiotomy Syndrome (PPS) Findings

FINDING	PERCENTAGE
SYMPTOMS	
Pleuritic or pericarditic chest pain	>50
Intermittent, low-grade fever	~50
CLINICAL FINDINGS	
Pericardial friction rub	20–30
Elevated C-reactive protein (CRP)	80–90
Elevated erythrocyte sedimentation rate (ESR)	80–90
Leukocytosis	80–90
Electrocardiogram (ECG): low voltage of the QRS, T-wave inversion, ST elevation or depression	~50
IMAGING	
Chest x-ray: pleural effusion	>90
Heart echocardiography: pericardial effusion	~90
Mild (<10 mm)	~75*
Moderate (10-20 mm)	~10*
Large (>20 mm)	~5
Pleuropericardial involvement	>80

*Of all PPS patients

From Lehto J, Kiviniemi T. Postpericardiotomy syndrome after cardiac surgery. *Ann Med.* 2020;52(6):243–264, Table 1.

Rarely, arrhythmias may also occur. Symptomatic patients usually respond to salicylates, indomethacin, or colchicine and bed rest. Occasionally, corticosteroid therapy or pericardiocentesis is required. Late recurrences are rare and can lead to chronic pericarditis.

Hemolysis of mechanical origin is seen, although rarely, after repair of certain cardiac defects, for example, atrioventricular septal defects (AVSDs), or after the insertion of a mechanical prosthetic valve. It is caused by unusual turbulence of blood at increased pressure. Reoperation may be necessary in rare patients with severe and progressive hemolysis who require frequent blood transfusions, but in most cases the problem slowly regresses.

Infection is another potentially serious postoperative problem. Patients usually receive a broad-spectrum antibiotic for the initial postoperative period. Potential sites of infection include the lungs (generally related to postoperative atelectasis), the subcutaneous tissues at the incision site, the sternum, and the urinary tract (especially after an indwelling catheter has been in place). Sepsis with infective endocarditis is an infrequent complication and can be difficult to manage, especially if prosthetic material was placed at surgery (see Chapter 486). Patients who undergo CPB during a viral infection, even if mild, can develop severe complications; therefore many anesthesiologists will postpone elective surgery if a child presents with a viral infection, either upper respiratory or gastrointestinal.

INTERSTAGE MANAGEMENT

One group of infants at particularly high risk for both morbidity and mortality are those who have completed their first-stage **Norwood** or **Sano** palliation for HLHS and are awaiting the next stage **(Glenn shunt)** of their three-stage palliation. Mortality in this group of infants had been reported as high as 10–15%, motivating the National Pediatric Cardiology Quality Improvement Collaborative **(NPC-QIC)** to develop an **interstage home monitoring program** that has been successful in reducing interstage mortality by 44%.

LONG-TERM MANAGEMENT

Patients who have undergone surgery for CHD can be divided into three major categories: lesions for which total repair has been achieved; lesions for which both anatomic and physiologic corrections have been achieved; and lesions for which only palliation, although potentially long term, has been achieved. There is some disagreement among cardiologists as to exactly in which category a particular congenital heart lesion might fall, and to some degree every case should be considered individually. Many argue that only for isolated patent ductus arteriosus (PDA) is total repair really achieved, with no requirement for long-term follow-up. Patients who are able to undergo anatomic and physiologic correction include many of the left-to-right shunt lesions (atrial and ventricular septal defects) and milder forms of obstructive lesions (e.g., valvar pulmonic stenosis, some forms of valvar aortic stenosis, coarctation of aorta) and some forms of cyanotic heart disease (e.g., uncomplicated tetralogy of Fallot, simple transposition of great arteries). These patients usually have achieved total or near-total physiologic correction of their lesion; however, they are still at some risk of long-term sequelae, including late heart failure or arrhythmia, or recurrence of a significant physiologic abnormality (e.g., recoarctation of aorta, worsening mitral regurgitation in patients with AVSDs, long-standing pulmonary regurgitation in patients with tetralogy of Fallot repaired with transannular patch). These patients require regular follow-up with a pediatric cardiologist (and, when old enough, with an **adult congenital heart disease specialist**; see Chapter 483.1); however, their long-term prognosis is generally very good, although some will require repeat surgeries or catheter-based interventions. Patients with more complex lesions, such as those with single-ventricle physiology (e.g., hypoplastic left or right heart syndrome), are at much higher risk of long-term sequelae and require even closer follow-up. These patients, particularly those who have undergone the Fontan procedure, are at risk long-term for arrhythmia, thrombosis, protein-losing enteropathy, plastic bronchitis, hepatic dysfunction (Fontan-associated liver disease or FALD), renal dysfunction, and heart failure. Some may eventually require heart, heart-liver, or heart-kidney transplantation.

Physical limitations in patients with CHD are variable, ranging from minimal to none in patients with physiologic correction to mild to moderate in patients with palliative procedures. The extent to which a patient should be allowed to participate in athletics, both recreational and competitive, can best be determined by the cardiologist, often with formal cardiopulmonary exercise testing (see Chapter 472.5).

Long-term morbidities affecting neurologic function and behavior are influenced by many factors, including the effects of any genetic alterations on the developing central nervous system (CNS). There may be a greater role for prenatal CNS abnormalities (anatomic, genetic, or secondary lesions caused by alterations in fetal cerebral blood flow or oxygenation); these include microcephaly, cerebral atrophy, and altered cerebral biochemistry. Chronic hypoxemia and failure to thrive may also influence the developing brain, and there is evidence that the type of intervention required (CPB, hypothermic total circulatory arrest, catheter-based therapy) plays a substantial role. Data from the **Pediatric Cardiac Genomics Consortium** have shown that there is also a genetic component to these learning disabilities. Performing exome sequencing on patients and their parents (trios), de novo gene variants were found in 2% of patients with CHD but in 20% of patients with CHD and neurodevelopmental delay. The identity of these gene variants and their mechanism of action is under study. In general, in the absence of a significant genetic syndrome or major perioperative complication, most children function at a fairly high level after repair of congenital heart defects and are able to attend regular school. Group mean scores on standard cognitive tests are no different from the general population; however, some areas appear to be more at risk than others, including certain aspects of motor function, speech, visual-motor tracking, and phonologic awareness. Awareness of these potential issues is critical to obtaining prompt remedial assistance if a child is found to be struggling in school.

Visit Elsevier eBooks+ at eBooks.Health.Elsevier.com for Bibliography.

483.1 Congenital Heart Disease in Adults

Salil Ginde and Michael G. Earing

Approximately 90% of children with CHD survive to adulthood. More adults than children are living with CHD in the United States, with a 5% increase every year. In the past decade, 35% of hospitalizations for CHD were patients older than 18 years (mean age: 55 years).

LONG-TERM MEDICAL CONSIDERATIONS

Approximately 25% of adults with CHD have a mild form that has allowed them to survive into adulthood without surgical or interventional cardiac catheterization. The most common lesions in this category include mild aortic valve stenosis (usually in the setting of a bicuspid aortic valve), small restrictive ventricular septal defects (VSDs), mild pulmonary valve stenosis, and mitral valve prolapse (Table 483.3). These patients need less frequent follow-up to assess for progression of disease and to identify associated complications. Many adults with CHD living in the United States are patients who have had previous intervention (Table 483.4). Although most children who undergo surgical intervention will survive to adulthood, with few exceptions, *total correction is not the rule.* The few exceptions include PDA, VSDs, and atrial septal defects (ASDs); this is true only if they are closed early, before the development of irreversible pulmonary vascular changes, and if no residual lesions exist.

It has become apparent that even the simplest congenital heart lesions can be associated with long-term complications, including both cardiac and noncardiac problems (Tables 483.5 and 483.6 and Fig. 483.1). *Cardiac* complications include arrhythmias and conduction defects, ventricular dysfunction, residual shunts, valvular lesions (regurgitation and stenosis), hypertension, and aneurysms. *Noncardiac* sequelae **(comorbidities)** include pulmonary, renal, and hepatic dysfunction that is caused either directly or indirectly by the underlying CHD. Abnormal pulmonary function most often presents as restrictive lung physiology and likely results

Table 483.3 Congenital Heart Defects Associated with Survival into Adulthood Without Surgery or Interventional Cardiac Catheterization

Mild pulmonary valve stenosis
Bicuspid aortic valve
Small to moderate-sized atrial septal defect
Small ventricular septal defect
Small patent ductus arteriosus
Mitral valve prolapse
Partial atrioventricular canal (ostium primum atrial septal defect and cleft mitral valve)
Marfan syndrome
Ebstein anomaly
Congenitally corrected transposition (atrioventricular and ventriculoarterial discordance)

Table 483.4 Most Common Congenital Heart Defects in Patients Surviving to Adulthood After Surgery or Interventional Catheterization

Aortic valve disease after balloon valvuloplasty or surgical valvotomy
Pulmonary valve stenosis after balloon valvuloplasty or surgical valvotomy
Tetralogy of Fallot
Ventricular septal defect
Complete atrioventricular canal defect
Transposition of the great arteries
Coarctation of the aorta
Complex single ventricles after the modified Fontan procedure

Table 483.5 Risks in Adults Who Have Congenital Heart Disease

RHYTHM DISORDERS
Supraventricular tachycardia (including atrial fibrillation)
Right bundle branch block
Heart block
Ventricular tachycardia
Sudden death
COARCTATION OF AORTA
Essential hypertension
Recoarctation
Aneurysm formation
RESIDUAL LESIONS (SHUNTS)
Ventral septal defect
Atrial septal defect
Patent ductus arteriosus
ACQUIRED LESIONS
Subacute bacterial endocarditis
Subvalvular stenosis
Supravalvular stenosis
Valvular insufficiency
Valvular restenosis
Eisenmenger complex
PREGNANCY RISK
See Figs. 483.2 and 483.3

from prior sternotomy or thoracotomy, scoliosis, diaphragmatic dysfunction, or parenchymal lung disease. Reduced pulmonary function contributes to reduced exercise tolerance and is a risk factor for mortality in adults with CHD. Renal dysfunction may result from chronic cyanosis, multiple surgeries requiring CPB, or from other comorbid conditions, such as hypertension and diabetes mellitus. Hepatic injury from chronic liver congestion in patients with elevated central venous pressures, particularly patients palliated with the Fontan procedure, can result in hepatic fibrosis, cirrhosis, hepatic dysfunction, and rarely, hepatocellular carcinoma. Adults

Table 483.6 Adolescent Transition Issues Requiring Coordination of Patient Care Between the Cardiologist and Primary Care Physician

Antibiotic prophylaxis for endocarditis
Medications and drug interactions
Anticoagulation with prosthetic valves
Exercise and sports participation
Educational and vocational planning
Contraception and pregnancy
Drug, alcohol, and tobacco use
Noncardiac surgical planning
Anesthetic issues
New symptoms or acute illnesses
Comorbid conditions
Travel

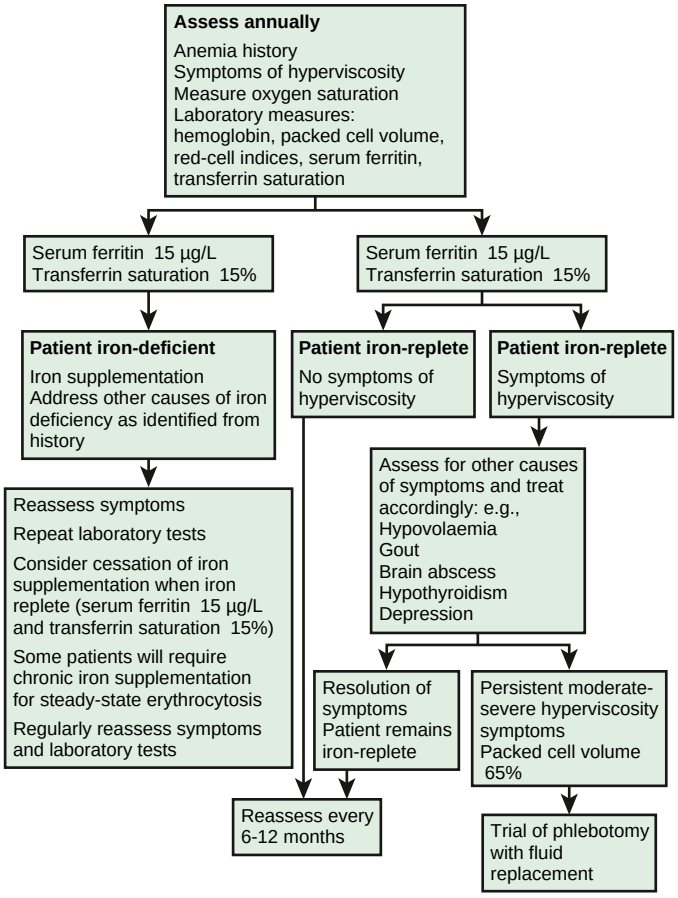

Fig. 483.1 Algorithm detailing crucial issues to address at transition to adulthood in patients with cyanotic congenital heart disease. *(From Spence MS, Balaratnam MS, Gatzoulis MA. Clinical update: cyanotic adult congenital heart disease. Lancet. 2007;370:1531.)*

with CHD are at risk for developmental abnormalities such as intellectual impairment, somatic abnormalities such as facial dysmorphism (cleft palate/lip), CNS abnormalities such as seizure disorders from previous thromboembolic events or cerebrovascular accidents, and impairments of hearing or vision loss. Psychosocial problems involving employment, life and health insurance, participation in sports, sexual activity, and contraception are common. Mental health issues, such as anxiety and depression, are common in adults with CHD and are often underrecognized and significantly affect quality of life. As a result of these long-term complications, the majority of adults with CHD need lifelong follow-up, ideally in an integrated, collaborative, and multidisciplinary program. When adults with CHD are hospitalized, it is usually for heart failure or an arrhythmia; others may require catheterization or another cardiac surgical procedure.

SPECIFIC LESIONS

Left-to-Right Shunts

In general, the long-term outcomes of adults with a history of shunt lesions that underwent repair early in life are good with near-normal life expectancy and relatively low risk for cardiac complications. However, if the initial lesion has a shunt that is large and nonrestrictive (allowing transmission of near-systemic pressure to the pulmonary arteries) and is unrepaired, irreversible pulmonary vascular changes can occur, resulting in pulmonary hypertension at systemic levels with reversed or bidirectional shunting at the level of the defect (**Eisenmenger syndrome**; see Chapter 482.2).

Atrial Septal Defects

See Chapter 475.1.

Although most individuals with an ASD are diagnosed during childhood after a murmur is noted, a minority of patients present with symptoms for the first time as adults. Most patients are asymptomatic during the first and second decades of life. In the third decade, an increasing number of patients then develop exercise intolerance, palpitations from atrial arrhythmias, and cardiac enlargement. If untreated, survival into adulthood is the rule; life expectancy is reduced, however, and there is significant long-term morbidity. After age 40 the mortality rate increases by 6% per year, and >20% of patients will have developed atrial fibrillation (AF). By age 60 the number of patients with AF increases to >60%.

Late Outcome After Closure of Atrial Septal Defect

Most patients who have undergone early ASD closure will have excellent long-term survival with low morbidity if repair is undertaken before age 25 years. Older age at repair is associated with decreased late survival with an associated increased risk for the development of atrial arrhythmias, thromboembolic events, and pulmonary hypertension. Long-term late complications and survival after transcatheter device closure remain unknown; early and intermediate results are excellent, with a high rate of ASD closure and few major complications.

Ventricular Septal Defects

See Chapter 475.6.

Although isolated VSDs are among the most common forms of CHD, the diagnosis of a VSD in an adult is rare. The primary reason is that most patients with a hemodynamically significant VSD will have undergone repair in childhood or will have died earlier in life. As result, the spectrum of isolated VSD in adults is limited to (1) those with small restrictive defects, (2) those with Eisenmenger syndrome, and (3) those who had their defects closed in childhood.

For patients with **small restrictive VSD**, long-term survival is excellent, with estimated 25-year survival of 96%. In addition, the long-term morbidity for patients with a restrictive VSD also appears to be low. Their clinical course is not completely benign. Reported long-term complications include endocarditis, progressive aortic regurgitation secondary to prolapse of the aortic valve into the defect (highest risk is with supracristal type but also can occur in setting of perimembranous defect), and the development of both right and left outflow tract obstruction from a double-chamber RV or a subaortic membrane. For patients who develop **Eisenmenger syndrome**, survival into the third decade is common. With increasing age, the long-term complications of right-sided heart failure, paradoxical emboli, and polycythemia usually result in progressive decline in survival, with death at an average age of 37 years.

Adults with **previous VSD closure**, without pulmonary hypertension or residual defects, live a normal life expectancy. Because patients with small VSDs are asymptomatic, these patients should be managed conservatively. Given the long-term risks, they do need intermittent follow-up for life to monitor for the development of late complications. The exception to this rule is patients with small supracristal or perimembranous VSD with associated prolapse of the aortic cusp into the defect resulting in progressive aortic regurgitation. These patients should be considered for surgical repair at diagnosis to prevent progressive aortic valve damage.

Complete Atrioventricular Canal

See Chapter 475.5.

The natural history for patients with complete AVSD is characterized by the early development of pulmonary vascular disease, leading to irreversible damage often by age 1 year (especially in children with Down syndrome). Thus patients who present in adulthood can be categorized into two groups: those with Eisenmenger syndrome and those who had their defects closed in childhood.

Overall, for those patients who underwent early repair before the development of pulmonary vascular disease, the long-term prognosis is good. The most common long-term complication is **left atrioventricular valve regurgitation**, with approximately 5–10% of patients requiring surgical revision for left atrioventricular valve repair or replacement during follow-up. The second most common long-term complication for this patient group is **subaortic stenosis**, occurring in up to 5% of patients after repair. Other long-term complications include residual atrial- or ventricular-level shunts, complete heart block, atrial and ventricular arrhythmias, and endocarditis.

For patients who have developed Eisenmenger syndrome, all are symptomatic with exertional dyspnea, fatigue, palpitations, edema, and syncope. Survival is similar to other forms of Eisenmenger syndrome, with a mean age at death of 37 years. Strong predictors for death include syncope, age at presentation of symptoms, poor functional class, low oxygen saturation (<85%), elevated serum creatinine and uric acid concentrations, and Down syndrome.

Patients who underwent previous repair and develop significant left atrioventricular valve regurgitation causing symptoms, atrial arrhythmias, or deterioration in ventricular function should undergo elective valve repair or replacement. Those previously repaired patients who develop significant subaortic stenosis (defined as a peak cardiac catheterization or echo gradient of >50 mm Hg) should undergo surgical repair.

Patent Ductus Arteriosus

See Chapter 475.8.

A PDA is usually an isolated lesion in the adult patient. The size of the defect is the primary determinant of clinical course in the adult patient. These clinical courses can be grouped into five main categories: silent PDAs; small, hemodynamically insignificant PDAs; moderate-size PDAs; large PDAs; and previously repaired PDAs.

A **silent** PDA is a tiny defect that cannot be heard by auscultation and is only detected by other means such as echocardiography. Life expectancy is always normal in this population, and the risk for endocarditis is extremely low.

Patients with a **small** PDA have an audible long-ejection or continuous murmur heard best at the left upper sternal border that radiates to the back. In addition, they have normal peripheral pulses. Because there is negligible left-to-right shunting these patients have normal left atrial and left ventricle (LV) size and normal pulmonary artery pressure by echocardiography and chest x-ray film. These patients, like those with silent PDAs, are asymptomatic and live a normal life expectancy. They have a higher risk for endocarditis.

Patients with **moderate-size** PDAs may present during adulthood. These patients often will have wide, bounding peripheral pulses and an audible continuous murmur. These patients all have significant volume overload and develop some degree of left atrial and LV enlargement and some degree of pulmonary hypertension. These patients are symptomatic with dyspnea, palpitations, and heart failure.

Patients with **large** PDAs typically present with signs of severe pulmonary hypertension and Eisenmenger syndrome. By adulthood, the continuous murmur is typically absent and there is differential cyanosis (lower-extremity saturations lower than the right arm saturation). These patients have a similar prognosis as other patients with Eisenmenger syndrome.

Patients who underwent **repair** of a PDA before the development of pulmonary hypertension have a normal life expectancy without restrictions.

All patients with *clinical evidence* of a PDA are at increased risk for endocarditis. As result, all PDAs except for small silent PDAs and those patients with severe irreversible pulmonary hypertension should be considered for closure. Catheter device closure is the preferred method in most centers today. Surgical closure is reserved for patients with PDA too large for device closure or when the anatomy is distorted, as in the setting of a large ductal aneurysm.

Cyanotic Heart Disease

See Chapters 478, 479, and 480.

Unlike the acyanotic forms of CHD, the majority of patients with cyanotic CHD will have had at least one and often several previous interventions before adulthood. The most frequent defects seen in the outpatient adult CHD setting are tetralogy of Fallot, complete transposition of the great arteries (TGA, also known as *d-transposition*), pulmonary valve stenosis, and various forms of functional single ventricles. Other defects include total anomalous pulmonary venous return, truncus arteriosus, and double-outlet RV.

Tetralogy of Fallot

See Chapter 479.1.

In the developed world, the unoperated adult patient with tetralogy of Fallot is a rarity because the majority of patients will have undergone palliation or, more often, repair in childhood. Only 11% of unoperated patients are alive by age 20 and only 3% by age 40.

Late survival after repair of tetralogy of Fallot is excellent. Repair is typically performed at 3-12 months of age and consists of patch closure of the VSD and relief of the pulmonary outflow tract obstruction by patch augmentation of the right ventricular outflow tract, pulmonary valve annulus, or both. Survival rates at age 32 and 35 years have been reported to be 86% and 85%, respectively, compared with 95% in age- and sex-matched controls. Most patients live an unrestricted life. Many patients do develop late symptoms that include exertional dyspnea, palpitations, syncope, and sudden cardiac death. Late complications include endocarditis, aortic regurgitation with or without aortic root dilation (typically caused by damage to the aortic valve during VSD closure or secondary to an intrinsic aortic root abnormality), left ventricular dysfunction (secondary to inadequate myocardial protection during previous repair or chronic LV volume overload caused by long-standing palliative arterial shunts), residual pulmonary valve obstruction, residual pulmonary valve regurgitation, RV dysfunction (as a result of pulmonary regurgitation or pulmonary stenosis), atrial arrhythmias (typically atrial flutter), ventricular arrhythmias, and heart block.

Reintervention is necessary in approximately 10% of patients after reparative surgery at 20-year follow-up. With longer follow-up, the incidence of reintervention continues to increase. The most common indication for reintervention is pulmonary valve replacement for severe pulmonary valve regurgitation. Pulmonary valve replacement, either surgical or transcatheter, is indicated when severe pulmonary valve regurgitation is associated with RV or LV systolic dysfunction, severe RV dilation, and/or progressive reduction in objective exercise tolerance. Although pulmonary valve replacement is associated with improved functional status, it has not been shown to improve mortality or risk for ventricular arrhythmias and sudden cardiac death in adults with tetralogy of Fallot. Implantable cardioverter defibrillators may be considered in patients with a history of recurrent ventricular arrhythmias or other risk factors such as ventricular dysfunction.

Transposition of the Great Arteries

See Chapter 480.1.

The natural history of patients with unrepaired TGA is so poor that very few patients survive past childhood without intervention. The first definitive operations for TGA was the **atrial switch** procedure, where the systemic and pulmonary venous returns are rerouted in the atrium by constructing baffles. The systemic venous return from the superior and inferior venae cavae is directed through the mitral valve and into the left ventricle (connected to the pulmonary artery). The pulmonary venous return is then directed through the tricuspid valve into the RV (connected to the aorta). The procedure results in physiologic correction and can be performed with low mortality but leave the left as the pulmonary ventricle and the right as the systemic ventricle. Long-term follow-up studies after the *atrial switch* procedure show a small but ongoing attrition rate with numerous other intermediate- and long-term complications. Two specific problems are most concerning: loss of sinus rhythm with development of atrial arrhythmias, occurring in 50% of TGA patients by age 25, and development of systemic ventricular dysfunction, occurring in 50% by age 35. Other long-term complications include endocarditis, baffle leaks, baffle obstruction, tricuspid valve regurgitation, and sinus node dysfunction requiring pacemaker placement.

The **arterial switch** operation is the procedure of choice to treat TGA. The great arteries are transected and reanastomosed to the correct ventricle (LV to aorta, RV to pulmonary artery) with coronary artery transfer. Operative survival after the arterial switch procedure in the current surgical era is very good, with a surgical mortality rate of 2–5%. Long-term data on survival and complications are not available, but intermediate results are promising. Reported intermediate complications include endocarditis, pulmonary outflow tract obstruction (at the supravalvular level or at the takeoff of the peripheral pulmonary arteries), aortic valve regurgitation, and coronary artery compromise (ranging from minor stenosis to complete occlusion).

The **Rastelli operation** represents a third type of repair for TGA, typically when there is associated VSD and pulmonary outflow tract obstruction. This operation involves the creation of an intracardiac baffle that closes the VSD in a way that directs flow from the LV to the aorta. The pulmonary valve is oversewn, and a valved conduit placed between the RV and pulmonary artery. Operative mortality is low, but patients require multiple reoperations for replacement of the pulmonary conduit during long-term follow-up. Other complications include complete heart block and left ventricular outflow tract obstruction.

Because of the high incidence of observed and potential medical problems, all patients who have had atrial, arterial, or Rastelli repair of TGA should have lifelong follow-up by a cardiologist at a center specializing in adult CHD.

Pulmonary Valve Stenosis

See Chapter 476.1.

Most patients with pulmonary valve stenosis are asymptomatic and present with a cardiac murmur. Survival into adult life and the need for intervention, however, are directly correlated to the degree of obstruction. Patients with **trivial** stenosis (defined as a peak gradient <25 mm Hg) followed for 25 years remain asymptomatic and have no significant progression of obstruction over time. For those patients with **moderate** pulmonary valve stenosis (defined as a peak gradient of 25-49 mm Hg), there is an approximately 20% chance of requiring intervention by age 25. For those patients with severe stenosis (defined as a peak gradient >50 mm Hg), the majority ultimately require an intervention, either surgery or balloon valvuloplasty, by age 25.

After surgical valvotomy for isolated pulmonary stenosis, long-term survival is excellent. With longer follow-up, the incidence of late complications and the need for reintervention do increase. The most common indication for reintervention is pulmonary valve replacement for severe pulmonary regurgitation. Other long-term complications include recurrent atrial arrhythmias, endocarditis, and residual right ventricular outflow tract obstruction.

Patients with **moderate to severe** pulmonary stenosis (defined as a peak gradient >50 mm Hg) should be considered for intervention even in the absence of symptoms. Percutaneous balloon valvuloplasty has been the accepted treatment for patients of all ages. Previously, surgical valvotomy had been the gold standard. Surgical valvotomy is reserved for patients who are unlikely to have successful results from balloon valvuloplasty, such as those with an extremely dysplastic or calcified valve.

Left-Sided Obstructive Lesions

Coarctation of the Aorta

See Chapter 476.6.

The clinical presentation of coarctation of the aorta depends on the severity of obstruction and the associated anomalies. Unrepaired coarctation typically presents with symptoms before adulthood. These symptoms include headaches related to hypertension, leg fatigue or cramps, exercise intolerance, and systemic hypertension (may be asymptomatic). Those untreated patients surviving to adulthood thus typically have only mild coarctation of the aorta. In the era before surgery, without treatment, the mean age of death was 32 years. Causes of death included left ventricular failure, intracranial hemorrhage, endocarditis, aortic rupture/dissection, and premature coronary artery disease (CAD).

After surgical repair, long-term survival is good but is directly correlated with the age at repair, with those repaired after age 14 years having a lower 20-year survival than those who were repaired earlier: 91% vs 79%. With longer follow-up, the incidence of long-term complications

continues to rise. The most common long-term complication is persistent or new systemic hypertension at rest or during exercise. Other long-term complications include aneurysms of the ascending or descending aorta, recoarctation at the site of previous repair, CAD, aortic stenosis or regurgitation (in the setting of an associated bicuspid aortic valve), rupture of an intracranial aneurysm, and endocarditis.

Patients with significant native or residual coarctation of the aorta (symptomatic patients with a peak gradient across the coarctation >20 mm Hg) should be considered for intervention, either surgery or catheter intervention with balloon angioplasty, with or without stent placement. Surgical repair in the adult patient is technically difficult and is associated with high morbidity. Catheter-based intervention is the preferred method in most experienced adult CHD centers.

Aortic Valve Stenosis

See Chapter 476.5.

The natural history of aortic valve stenosis in adults is quite variable but is characterized by progressive stenosis over time. By age 45 years, approximately 50% of bicuspid aortic valves will have some degree of stenosis.

Most patients with aortic valve stenosis are asymptomatic and are diagnosed after a murmur is detected. The severity of obstruction at diagnosis correlates with the pattern of progression. Symptoms are rare until patients have severe aortic valve stenosis (mean gradient by echocardiography >40 mm Hg). Symptoms include chest pain, exertional dyspnea, near-syncope, and syncope. When any of these symptoms is present, the risk of sudden cardiac death is quite high, so surgical intervention is mandated. For patients requiring surgical valvotomy to relieve the stenosis before adulthood, the majority of patients do well. However, at 25-year follow-up, up to 40% of patients will have required a second operation for residual stenosis or regurgitation.

Patients with symptoms and severe aortic valve stenosis should be considered for intervention. Treatment involves manipulating the valve to reduce stenosis. This can be accomplished by balloon dilation of the valve, open surgical valvotomy, or valve replacement. In absence of significant aortic regurgitation, most centers favor balloon dilation or surgical valvotomy for children and young adults who have pliable valves with fusion of commissures. In older adults, aortic valve replacement is the treatment of choice. Typically, surgery is performed for aortic valve replacement in younger adults with congenital aortic valve stenosis; however, transcatheter aortic valve replacement is increasingly commonly performed in older adults who may be higher-risk surgical candidates.

Endocarditis Prophylaxis

See Chapter 486.

Only patients with cardiac conditions associated with the highest risk for adverse outcomes should continue antibiotic prophylaxis before surgery: previous endocarditis, prosthetic valves (biological and mechanical), unrepaired cyanotic CHD, including palliative shunts and conduits, completely repaired congenital heart defects with prosthetic material or device, surgically placed or by catheter intervention during the first 6 months after the procedure, and repaired CHD with residual defects at or adjacent to the site of a prosthetic patch or prosthetic device (which inhibits endothelialization). Except for the conditions just listed, antibiotic prophylaxis is no longer recommended for other forms of CHD.

PREGNANCY AND CONGENITAL HEART DISEASE

CHD is the most common form of heart disease encountered during pregnancy in developed countries. Heart disease does not preclude a successful pregnancy but increases the risk to both the mother and the baby. During pregnancy, substantial hemodynamic changes occur. The hemodynamic changes in pregnancy result in a steady increase in cardiac output during pregnancy until the 32nd week of gestation, at which time the cardiac output reaches a plateau at 30–50% above the prepregnancy level. At delivery, with uterine contractions, an additional 300-500 mL of blood enters the circulation. This, in conjunction with increased blood pressure and heart rate during labor, increases the cardiac output at delivery to 80% of the prepregnancy level.

Despite these hemodynamic changes, the outcome of pregnancy is favorable in most women with CHD, provided that functional class and systemic ventricular function are good. The WHO modified categorization of risk stratification is shown in Figures 483.2 and 483.3. Pulmonary artery hypertension presents a serious risk during pregnancy, particularly when the pulmonary pressure exceeds 70% of systemic pressure, regardless of functional class. Other contraindications to pregnancy include severe obstructive left-sided lesions (coarctation of the aorta, aortic valve stenosis, mitral valve stenosis, hypertrophic cardiomyopathy), Marfan syndrome with coexisting dilated ascending aorta (defined as >4 cm), persistent cyanosis, and systemic ventricular dysfunction (ejection fraction of ≤40%). The need for full anticoagulation during pregnancy, although not a contraindication, poses an increased risk to both mother and fetus. The relative risks and benefits of the different anticoagulant approaches need to be discussed fully with the mother.

Pregnancy counseling should begin early in adolescence and should be part of the routine cardiac follow-up visit. Counseling should include a discussion about the risk of CHD in the offspring. In the general population, the incidence of CHD is 1%. In the offspring of a mother with CHD, the risk increases to 5–6%. Often the cardiac lesion in the offspring is not the same as that in the mother, except in the case of a syndrome with autosomal dominant inheritance (i.e., Marfan syndrome, hypertrophic cardiomyopathy). Risk stratification should include the specific CHD lesion but also needs to consider the maternal functional class. Although the specific CHD lesion is important, multiple studies demonstrate that the maternal functional class before pregnancy is highly predictive of both maternal and fetal outcomes, with those in the best functional class having the best outcomes. A cardiopulmonary exercise test performed before conception can predict maternal and neonatal outcomes in pregnant women with CHD. A blunted heart rate response to exercise is associated with a higher risk for adverse maternal and neonatal events. It is recommended that women with CHD at higher risk for pregnancy-related complications based on anatomy, functional status, and exercise testing be managed collaboratively during pregnancy by adult CHD cardiologists, obstetricians, and anesthesiologists with specialized experience in adults with CHD.

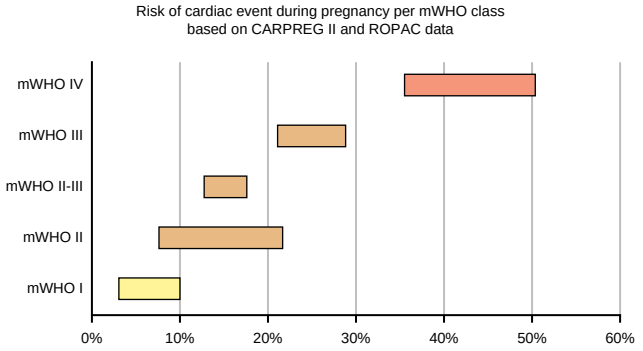

	Predictors of cardiac event during pregnancy	OR in study cohort	Event rate in study cohort
CARPREG II	Prior cardiac event or arrhythmia	5.9	33%
	NYHA III or IV or cyanosis	4.9	46%
	Mechanical valve	4.2	38%
	Ventricular dysfunction	2.3	30%
	High risk left-sided valve disease/left ventricular outflow tract obstruction	2.1	22%
	Pulmonary hypertension	3.3	32%
	Coronary artery disease	3.0	29%
	High risk aortopathy	2.7	18%
	No prior cardiac intervention	1.6	18%
	Late pregnancy assessment	1.6	20%
ZAHARA	Cardiac medication, other than anticoagulation	4.2	26%
	Atrioventricular valve regurgitation	2.0–2.3	17%
ROPAC	Atrial fibrillation at pre-pregnancy visit	5.1	52%
	Signs of heart failure at pre-pregnancy visit	3.3–4.2	63%

Fig. 483.2 Risk tools modified WHO (mWHO), CARdiac disease in PREGnancy (CARPREG), Zwangerschap bij Aangeboren HARtAfwijking (ZAHARA), Registry of Pregnancy and Cardiac disease (ROPAC). ORs and rates are derived from cohorts consisting of approximately 60% of patients with congenital heart disease (63% in CARPREG II and 58% in ROPAC). OR, Odds ratio. *(From van Hagen IM, Roos-Hesselink JW. Pregnancy in congenital heart disease: risk prediction and counselling. Heart. 2020;106:1853–1861, Fig. 1.)*

CONTRACEPTION

A critical part of caring for adults with CHD is to provide (or make available) advice on contraception. Unfortunately, data are limited on the safety of various contraceptive techniques in adult CHD patients. The estrogen-containing oral contraceptives (OCs) can be used in many adult CHD patients but are not recommended in adult CHD patients at risk for thromboembolism, such as those with cyanosis, prior Fontan procedure, AF, or pulmonary artery hypertension. In addition, OCs may disrupt anticoagulation control. Although slightly less effective than OCs containing combined estrogen/progesterone, medroxyprogesterone, the progesterone-only pills, and levonorgestrel are good options for most adult CHD patients. Medroxyprogesterone and levonorgestrel, however, can cause fluid retention and thus need to be used with caution in patients with heart failure. These medications are also associated with depression and often breakthrough bleeding. Tubal ligation, although the most secure method of contraception, can be a high-risk procedure in patients with complex CHD or those with pulmonary hypertension. Hysteroscopic sterilization (Essure) may be reasonable for high-risk patients. In the past, intrauterine devices (IUDs) were seldom used in cardiac patients because of the associated risk of bacteremia, pelvic inflammatory disease, and endocarditis. IUDs such as Mirena appear to be safe and effective and are rapidly becoming one of the most common forms of contraception in the adult CHD population.

WHO I	WHO II
Pulmonary stenosis (small/mild) Patent ductus arteriosus (small/mild) Mitral valve prolapse (small/mild) Successfully repaired simple shunt defects (ASD, VSD, PDA, APVR)	Unrepaired ASD or VSD Repaired tetralogy of Fallot Turner syndrome without aortic dilatation
Follow-up during pregnancy: Once or twice in local hospital **Delivery**: Local hospital	**Follow-up during pregnancy**: Every trimester in local hospital **Delivery**: Local hospital
WHO II-III	**WHO III**
Mild left ventricular impairment (EF>54%) Native or tissue valve disease not considered WHO I or IV Marfan or other HTAD syndrome without aortic dilatation Aorta <45mm in bicuspid aortic valve Repaired coarctation AVSD	Left ventricular impairment (30–45%) Mechanical valve Systemic right ventricle with good or mildly impaired function Fontan (if otherwise well) Unrepaired cyanotic disease Moderate mitral stenosis Severe asymptomatic aortic stenosis Moderate aortic dilatation
Follow-up during pregnancy: Bimonthly in expert center **Delivery**: Expert center	**Follow-up during pregnancy**: (Bi)monthly in expert center **Delivery**: Expert center
WHO IV: Pregnancy not recommended	
Pulmonary arterial hypertension Severe systemic ventricular dysfunction (EF<30%) Moderate systemic right ventricular dysfunction Severe mitral stenosis Severe symptomatic aortic stenosis Severe aortic dilatation Vascular Ehlers-Danlos Severe (re)coarctation Fontan with any complication	
Follow-up during pregnancy: Monthly in expert center **Delivery**: Expert center	

Fig. 483.3 Advised counseling for pregnancy in congenital heart disease. APVR, Anomalous pulmonary venous return; ASD, atrial septal defect; AVSD, atrioventricular septal defect; EF, ejection fraction; ESC, European Society of Cardiology; HTAD, hereditary thoracic aorta disease; PDA, persistent ductus arteriosus; VSD, ventricular septal defect; WHO, World Health Organization. *(From van Hagen IM, Roos-Hesselink JW. Pregnancy in congenital heart disease: risk prediction and counselling. Heart. 2020;106:1853–1861, Fig. 2.)*

ADOLESCENT TRANSITION

It is well recognized that as part of the process of obtaining independence, adolescents or young adults must develop a forward-looking, independent approach to their medical care. For children with heart disease, the transition process must begin during early adolescence and should be encouraged by both the primary care provider and the pediatric cardiologist, who must identify an appropriate adult CHD program to which transition and transfer will be made at an appropriate time (see Table 483.6).

A successful transition program includes the following elements:

- Development of a written transition plan that should begin by age 14 years
- Because adolescents and young adults are frequently unaware of the details of their cardiac diagnosis and history, a complete, concise, portable medical record, including all pertinent aspects of cardiac care, should be shared with adolescents and their family and prepared for transmittal to the eventual adult care destination.
- The primary care provider and cardiologist must address unique adolescent medical issues as they affect the cardiovascular system. In addition to medical problems, education, vocational planning, psychosocial issues, and access to medical care should be discussed with adolescents and their families.

Young adults tend to avoid medical care because of lack of education, denial, or difficulty with access to the medical care system. Thus a critical goal of the adolescent transition process is to identify an appropriate site for ongoing medical care and ensure maintenance of the medical record and continuity of care for the young adult. The site of care for a young adult with CHD may be a pediatric program or facility or a specialized center or program for the adult with CHD. The critical issues are the continuity of care, the preparation of the patient, and the patient's participation in the process.

HEART FAILURE AND TRANSPLANT

Heart failure is increasingly prevalent in adults with CHD and is associated with increased morbidity and mortality. Causes for heart failure in this population include unrepaired or residual valve dysfunction, shunts, arrhythmias, venous obstruction, and systolic and/or diastolic ventricular dysfunction. Data on medical and device therapy to treat heart failure in adults with CHD are limited because of the relatively small study populations and heterogenous heart defects. Concomitant failure of noncardiac organs, such as lung, kidney, and liver failure, is common in adult CHD patients with heart failure and further complicates the management. Currently, management of symptomatic CHD patients with systolic ventricular dysfunction is primarily extrapolated from data in adults with heart failure in the setting of acquired heart disease and includes:

- Medical therapy that includes angiotensin-converting enzyme inhibitors, angiotensin receptor blockers, β blockers, aldosterone antagonists, and diuretics
- Electrical device therapies such as implantable cardioverter defibrillators to reduce the risk for sudden cardiac death and permanent pacemaker placement for cardiac resynchronization therapy to improve symptoms of heart failure
- Mechanical circulatory support, such as ventricular assist devices, for patients with severe, refractory heart failure symptoms
- Referral to adult CHD heart failure/transplant specialist and center

Proper timing for heart transplantation in adults with CHD is unclear and may vary for individual lesions. Patients with single ventricle anatomy and complex anatomy often have lower priority with the current transplant allocation system, and therefore often have longer wait times before receiving a heart transplant. Early posttransplant mortality is higher in adults with CHD compared with adults with acquired heart disease because of increased perioperative mortality. However, once beyond the perioperative period, patients with ACHD do as well as or better than those with acquired heart disease, with expected 10-year survival equivalent to or better than that of adults without CHD.

Visit Elsevier eBooks+ at eBooks.Health.Elsevier.com for Bibliography.

Section 4

Cardiac Arrhythmias

Chapter 484

Disturbances of Rate and Rhythm of the Heart

Aarti S. Dalal and George F. Van Hare

The term *arrhythmia* refers to a disturbance in heart rate or rhythm. Such disturbances can lead to heart rates that are abnormally fast, slow, or irregular. They may be transient or incessant; congenital or acquired; or caused by infection, a toxin, or drugs. They may be associated with particular forms of congenital heart disease (CHD), may be a complication after surgical repair of CHD, may be a result of genetic causes, or may be the result of a maternal connective tissue disease. Arrhythmias, either slow or fast, may lead to acutely decreased cardiac output. If incessant, they may lead to a cardiomyopathy. Initially stable and organized arrhythmias can degenerate into a more dangerous arrhythmia such as ventricular fibrillation. Arrhythmias may lead to syncope or to sudden death (see Chapter 485). When a patient has an arrhythmia, it is important to determine whether the rhythm is likely to lead to symptoms or to deteriorate into a life-threatening condition. Rhythm abnormalities such as single premature atrial and ventricular beats are common, and in children without heart disease, usually pose no risk to the patient.

A number of **pharmacologic agents** are available for treating arrhythmias; many have not been studied extensively in children. Insufficient data are available regarding pharmacokinetics, pharmacodynamics, and efficacy in the pediatric population, and therefore the selection of an appropriate agent is based on the judgement and experience of the clinician. Fortunately, most rhythm disturbances in children can be reliably controlled with a single agent (Table 484.1). **Transcatheter ablation** is acceptable therapy not only for life-threatening or drug-resistant arrhythmias but also for the cure of arrhythmias. For patients with bradycardia, **implantable pacemakers** are small enough for use in all ages, even in premature infants. Implantable cardioverter-defibrillators are available for use in high-risk patients with malignant ventricular arrhythmias and an increased risk of sudden death.

484.1 Principles of Antiarrhythmic Therapy

Aarti S. Dalal and George F. Van Hare

Many antiarrhythmic agents are available for rhythm control. The majority are not approved by the U.S. Food and Drug Administration (FDA) for use in children; their use is therefore considered "off-label." Pediatric cardiologists have experience with these drugs, with well-recognized standards for dosing.

With the availability of potentially curative ablation procedures, medical therapy has become less important. Intolerable drug side effects, as well as the potential for an arrhythmia induced by an antiarrhythmic drug, can seriously limit medical therapy and will lead the physician and family toward a potentially curative ablation procedure.

Antiarrhythmic drugs are frequently categorized using the **Vaughan-Williams classification**. This system comprises four classes: **class I** includes agents that primarily block the sodium channel, **class II** drugs are the β blockers, **class III** includes agents that prolong repolarization by blocking potassium channels, and **class IV** drugs are the calcium channel blockers. Class I is further divided by the strength of the sodium channel blockade (see Table 484.1).

484.2 Sinus Arrhythmias and Extrasystoles

Aarti S. Dalal and George F. Van Hare

Phasic sinus arrhythmia represents a normal physiologic variation in impulse discharges from the sinus node related to respirations. The heart rate slows during expiration and accelerates during inspiration. Occasionally, if the sinus rate becomes slow enough, an **escape beat** arises from the atrioventricular (AV) junction region (Fig. 484.1). Normal phasic sinus arrhythmia is caused by the activity of the parasympathetic nervous system and can be quite prominent in healthy children. It may mimic frequent premature contractions, but the relationship to the phases of respiration can be appreciated with careful auscultation. Drugs that increase vagal tone, such as digoxin, may exaggerate sinus arrhythmia; it is usually abolished by exercise. Other irregularities in sinus rhythm, especially bradycardia associated with periodic apnea, are common in premature infants.

Sinus bradycardia is a result of slow discharge of impulses from the sinus node, the heart's "natural pacemaker." A sinus rate <90 beats/min in neonates and <60 beats/min in older children is considered sinus bradycardia. Sinus bradycardia is commonly seen in highly conditioned athletes. In healthy individuals without symptoms, it has no clinical significance. Sinus bradycardia may occur in systemic disease (hypothyroidism, anorexia nervosa), and it resolves when the disorder is under control. It may also be seen in association with conditions in which there is high vagal tone, such as gastrointestinal obstruction or intracranial processes. Low birthweight infants display great variation in sinus rate. Sinus bradycardia is common in these infants, in conjunction with apnea, and may be associated with junctional escape beats; premature atrial contractions are also frequent. These rhythm changes, especially bradycardia, appear more often during sleep and are not associated with symptoms. Usually, no therapy is necessary.

A **wandering atrial pacemaker** is defined as an intermittent shift in the pacemaker of the heart from the sinus node to another part of the atrium. It is not uncommon in childhood and usually represents a normal variant. It may also be seen in association with sinus bradycardia in which the shift in atrial focus is an escape phenomenon.

Extrasystoles are produced by the premature discharge of an ectopic focus that may be situated in the atrium, the AV junction, or the ventricle. Usually, isolated extrasystoles are of no clinical or prognostic significance. Under certain circumstances, however, premature beats may be caused by organic heart disease (inflammation, ischemia, fibrosis) or drug toxicity.

Atrial extrasystoles, also known as **premature atrial contractions** or **complexes (PACs)**, are common in childhood, usually in the absence of cardiac disease. Depending on the degree of prematurity of the beat (coupling interval) and the preceding R-R interval (cycle length), PACs may result in a normal, a prolonged (aberrancy), or an absent (blocked PAC) QRS complex. Blocked PACs occur when the premature impulse cannot conduct to the ventricle because of refractoriness of the AV node or distal conducting system (Fig. 484.2). Atrial extrasystoles must be distinguished from premature ventricular contractions. Careful scrutiny of the electrocardiogram (ECG) for a premature P wave preceding the QRS will show either a premature P wave superimposed on and deforming the preceding T wave or a P wave that is premature and has a different contour from that of the other sinus P waves. PACs usually reset the sinus node pacemaker, leading to an incomplete compensatory pause, but this feature is not always present and so is not regarded as a completely reliable means of differentiating atrial from ventricular premature complexes in children.

Ventricular extrasystoles, also known as **premature ventricular contractions** or **complexes (PVCs)**, may arise in any region of either ventricle. PVCs are characterized by premature, widened, bizarre QRS complexes that are not preceded by a premature P wave (Fig. 484.3). When all premature beats have identical contours, they are classified

Table 484.1 Antiarrhythmic Drugs Commonly Used in Pediatric Patients, by Class

DRUG	INDICATIONS	DOSING	SIDE EFFECTS	DRUG INTERACTIONS	DRUG LEVEL
CLASS IA: INHIBITS NA^+ FAST CHANNEL, PROLONGS REPOLARIZATION					
Quinidine	SVT, atrial fibrillation, atrial flutter, VT; in atrial flutter, an AV node–blocking drug (digoxin, verapamil, propranolol) must be given first to prevent 1:1 conduction	Oral: 30-60 mg/kg/24 hr divided q6h (sulfate) or q8h (gluconate) 200 mg q6 (1-1.5 g/day divided q6), sulfate; 324 mg q8-12h (1.5 g/day divided q8-12h), gluconate Max dose: 2.4 g/24 hr	Nausea, vomiting, diarrhea, fever, cinchonism, QRS and QT prolongation, AV nodal block, asystole, syncope, thrombocytopenia, hemolytic anemia, SLE, blurred vision, convulsions, allergic reactions, exacerbation of periodic paralysis	Enhances digoxin, may increase PTT when given with warfarin	2-6 μg/mL
Procainamide	SVT, atrial fibrillation, atrial flutter, VT	Oral: 15-50 mg/kg/day divided q3-6h Max dose: 4 g/24 hr IV: 10-15 mg/kg over 30-60 min load followed by 20-80 μg/kg/min Max dose: 2 g/24 hr	PR, QRS, QT interval prolongation, anorexia, nausea, vomiting, rash, fever, agranulocytosis, thrombocytopenia, Coombs-positive hemolytic anemia, SLE, hypotension, exacerbation of periodic paralysis, proarrhythmia	Toxicity increased by amiodarone and cimetidine	4-8 μg/mL With NAPA <40 μg/mL
Disopyramide	SVT, atrial fibrillation, atrial flutter	Oral (immediate release): <1 yr: 10-30 mg/kg/day divided q6h 1-4 yr: 10-20 mg/kg/day divided q6h >4-12 yr: 10-15 mg/kg/day divided q6h >12- ≤18 yr: 6-15 mg/kg/day divided q6h Max dose: 1.6 g/day Adults: <50 kg: 100 mg q6h; >50kg:150 mg q6h Long-acting dosing is 200-300 q12h	Anticholinergic effects, urinary retention, blurred vision, dry mouth, QT and QRS prolongation, hepatic toxicity, negative inotropic effects, agranulocytosis, psychosis, hypoglycemia, proarrhythmia		2-7 μg/mL
CLASS IB: INHIBITS NA^+ FAST CHANNEL, SHORTENS REPOLARIZATION					
Lidocaine	VT, VF	IV: 1 mg/kg repeat q 5 min 2 times followed by 20-50 μg/kg/min (max dose: 3 mg/kg) Adult infusion rate: 1-4 mg/min	CNS effects, confusion, convulsions, high-grade AV block, asystole, coma, paresthesias, respiratory failure	Propranolol, cimetidine, increases toxicity	1.5-5.0 μg/mL
Mexiletine	VT	Oral: 6-15 mg/kg/24 hr divided q8h Max dose: 15 mg/kg/day or 1.2 g/day. Adults: 150-300 mg q8-12h (max 1.2 g/day)	GI upset, skin rash, neurologic	Cimetidine	0.5-2 mcg/mL
Phenytoin	Digitalis intoxication	Oral: 4-8 mg/kg/24 hr divided q12h Max dose: 300-600 mg/day IV: 10-15 mg/kg over 1 hr load	Rash, gingival hyperplasia, ataxia, lethargy, vertigo, tremor, macrocytic anemia, bradycardia with rapid push	Amiodarone, oral anticoagulants, cimetidine, nifedipine, disopyramide, increase toxicity	10-20 μg/mL
CLASS IC: INHIBITS NA^+ CHANNEL					
Flecainide	SVT, atrial tachycardia, VT	BSA dosing: 50-200 mg/m^2/day divided q8-12h Weight based: 3-6 mg/kg/day divided q8h Max dosing: 8 mg/kg/day Max adult dosing: 400 mg/day	Blurred vision, nausea, decrease in contractility, proarrhythmia	Amiodarone increases toxicity	0.2-1 μg/mL

Table 484.1 Antiarrhythmic Drugs Commonly Used in Pediatric Patients, by Class—cont'd

DRUG	INDICATIONS	DOSING	SIDE EFFECTS	DRUG INTERACTIONS	DRUG LEVEL
Propafenone	SVT, atrial tachycardia, atrial fibrillation, VT	Oral: 150-300 mg/m^2/24 hr divided q8h	Hypotension, decreased contractility, hepatic toxicity, paresthesia, headache, proarrhythmia	Increases digoxin levels	0.2-1 μg/mL
CLASS II: β BLOCKERS					
Propranolol	SVT, long QT	Oral: 1-4 mg/kg/24 hr divided q6h Max dose 60 mg/24 hr IV: 0.01-0.15 mg/kg/dose SLOW over 5-10 min Max dose: 1-3 mg/dose	Bradycardia, loss of concentration, school performance problems, bronchospasm, hypoglycemia, hypotension, heart block, CHF	Co-administration with disopyramide, flecainide, or verapamil may decrease ventricular function	
Atenolol	SVT	Oral: 0.5-1 mg/kg/24 hr once daily or divided q12h	Bradycardia, loss of concentration, school performance problems	Co-administration with disopyramide, flecainide, or verapamil may decrease ventricular function	
Nadolol	SVT, long QT	Oral: 1-2 mg/kg/24 hr given once daily	Bradycardia, loss of concentration, school performance problems, bronchospasm, hypoglycemia, hypotension, heart block, CHF	Co-administration with disopyramide, flecainide, or verapamil may decrease ventricular function	
CLASS III: PROLONGS REPOLARIZATION					
Amiodarone	SVT, JET, VT	Oral: 10-15 mg/kg/day IV: 2.5-5 mg/kg over 30-60 min, may repeat 3 times, then 5-20 mg/kg/day continuous infusion Max daily dose: 2.2 g/day	Hypothyroidism or hyperthyroidism, elevated triglycerides, hepatic toxicity, pulmonary fibrosis	Digoxin (increases levels), flecainide, procainamide, quinidine, warfarin, phenytoin	1-2.5 mg/L
CLASS IV AND MISCELLANEOUS MEDICATIONS					
Digoxin	SVT (not WPW), atrial flutter, atrial fibrillation	Oral/load instructions: Premature: 20 μg/kg Newborn: 30 μg/kg >6 mo: 40 μg/kg Give 1/2 total dose followed by 1/4 q8-12h × 2 doses Maintenance: 10 μg/kg/24 hr divide q12h Max dose: 0.5 mg IV: 3/4 PO dose Max dose: 0.5 mg	PAC, PVC, bradycardia, AV block, nausea, vomiting, anorexia, prolongs PR interval	Quinidine Amiodarone, verapamil, increase digoxin levels	1-2 mg/mL
Verapamil	SVT (not WPW)	Oral: 2-8 mg/kg/day divided q8h Max dose: 480 mg/day IV: 0.1-0.3 mg/kg/dose Max dose: 5-10 mg/dose	Bradycardia, asystole, high-degree AV block, PR prolongation, hypotension, CHF	Use with β blocker or disopyramide exacerbates CHF, increases digoxin level and toxicity	
Adenosine	SVT	IV: 50-300 μg/kg by need rapid IV push Begin with 50 μg/kg and increase by 50-100 μg/kg/dose Max dose: 18 mg	Chest pain, flushing, dyspnea, bronchospasm, atrial fibrillation, bradycardia, asystole		

AV, Atrioventricular; CHF, congestive heart failure; CNS, central nervous systems; GI, gastrointestinal; IV, intravenous; JET, junctional ectopic tachycardia; NAPA, *N*-acetyl procainamide; PAC, premature atrial contraction; PTT, partial thromboplastin time; PVC, premature ventricular contraction; SLE, systemic lupus erythematosus–like illness; SVT, supraventricular tachycardia; VF, ventricular fibrillation; VT, ventricular tachycardia; WPW, Wolff-Parkinson-White syndrome.

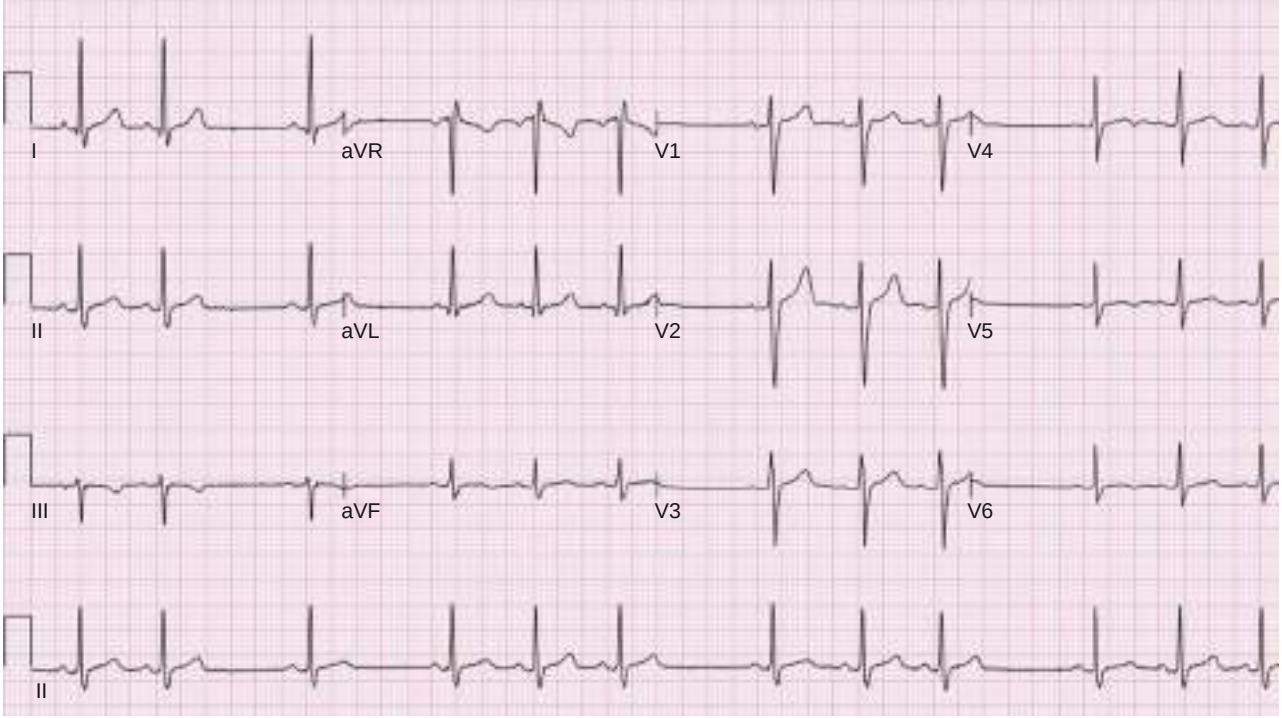

Fig. 484.1 Phasic sinus arrhythmia. Note the variation in P-P interval with no significant change in P-wave morphology or PR interval. This rhythm is normal.

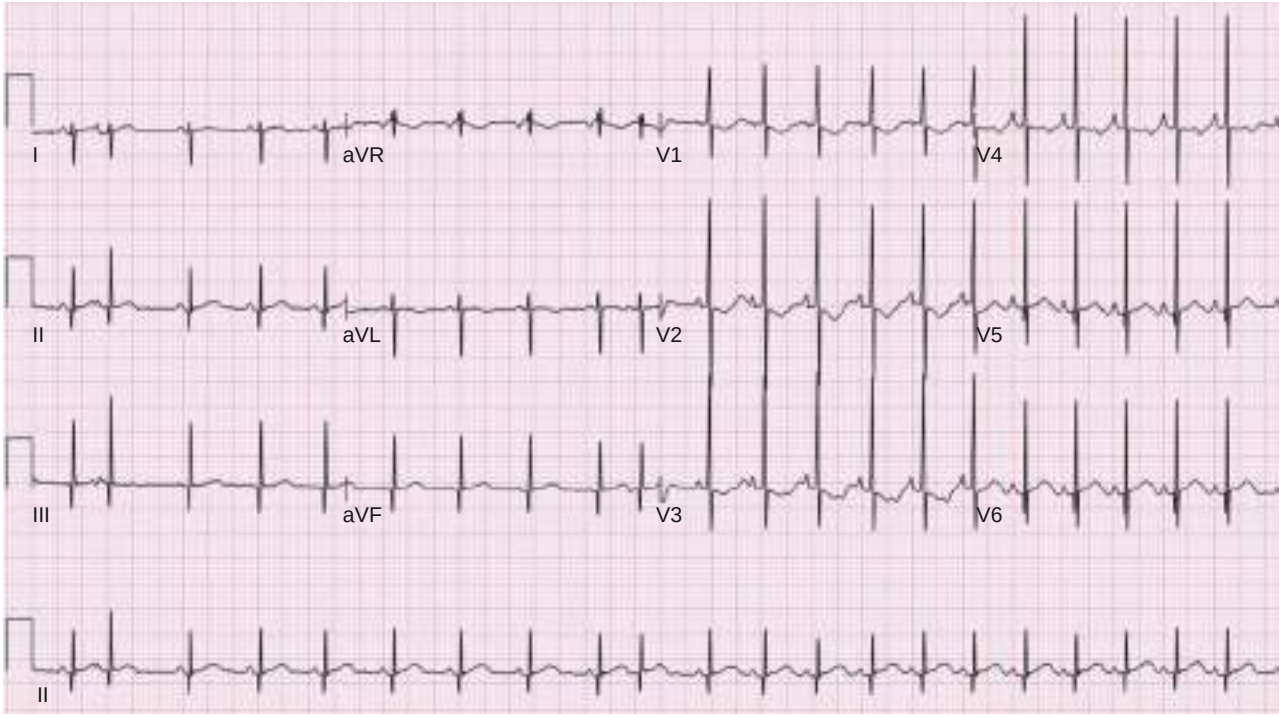

Fig. 484.2 Premature atrial contraction (PAC). The second and tenth beats are premature, and deformation of the previous T wave identifies the presence of a premature atrial contraction.

as *uniform or monomorphic,* suggesting origin from a common site. When PVCs vary in contour, they are designated as *multiform or polymorphic,* suggesting origin from more than one ventricular site. Ventricular extrasystoles are often, but not always, followed by a full compensatory pause because of a lack of resetting of the sinus node. The presence of **fusion beats**, that is, complexes with morphologic features that are intermediate between those of normal sinus beats and those of PVCs, proves the ventricular origin of the premature beat. Extrasystoles produce a smaller stroke and pulse volume than normal and, if quite premature, may not be audible with a stethoscope or palpable at the radial pulse. When frequent, extrasystoles may assume a definite rhythm, for example, alternating with normal beats **(bigeminy)** or occurring after two normal beats **(trigeminy)**. Most patients are unaware of single PVCs, although some may be aware of a "skipped beat" over the precordium. This sensation is caused by the increased stroke volume of the normal beat after a compensatory pause. Anxiety,

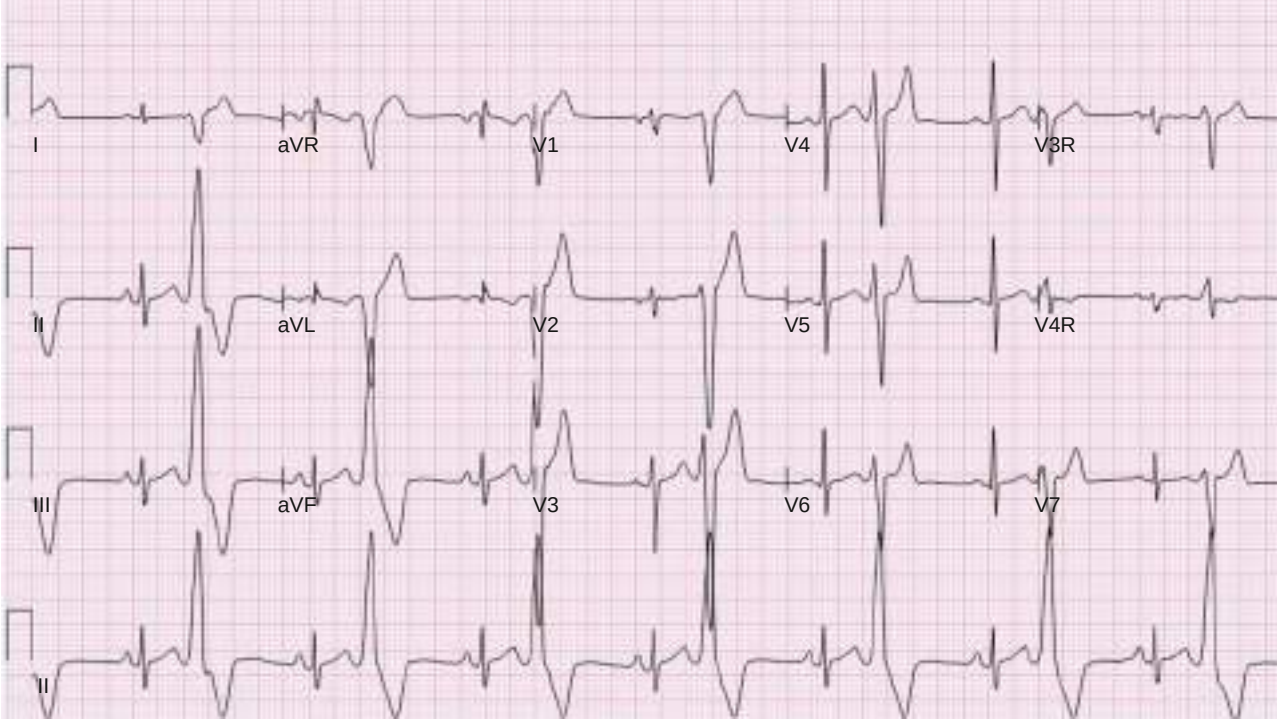

Fig. 484.3 Premature ventricular contractions in a bigeminal rhythm. Note that the premature beat is wide and has a completely different morphology from that of the sinus beat. The premature beat is not preceded by a discernible premature P wave or any appreciable deformation of the preceding T wave.

a febrile illness, or ingestion of various drugs or stimulants may make PVCs more frequent.

It is important to distinguish PVCs that are benign from those that are likely to lead to more severe arrhythmias. The former usually disappear (or are "suppressed) at higher sinus rates, as seen during exercise. If they persist or become more frequent during exercise, the arrhythmia may have greater significance. The following criteria are indications for further investigation of PVCs that could require **suppressive therapy**: (1) ≥2 PVCs in a row; (2) multiform PVCs; (3) increased ventricular ectopic activity with exercise; (4) R-on-T phenomenon (premature ventricular depolarization occurs on the T wave of the preceding beat); (5) extreme frequency of beats (e.g., >20% of total beats on Holter monitoring); and (6) most importantly, the presence of underlying heart disease, a history of heart surgery, or both. The best therapy for benign PVCs is reassurance that the arrhythmia is not life threatening, although highly symptomatic individuals may benefit from suppressive therapy.

Malignant PVCs are usually secondary to another medical problem (electrolyte imbalance, hypoxia, drug toxicity, cardiac injury, or a channelopathy). Successful treatment includes correction of the underlying abnormality if possible. An intravenous **lidocaine** bolus and drip is the first line of therapy, with more effective drugs such as **amiodarone** reserved for refractory cases or for patients with underlying ventricular dysfunction or hemodynamic compromise.

484.3 Supraventricular Tachycardia

Aarti S. Dalal and George F. Van Hare

Supraventricular tachycardia (SVT) is a general term that includes essentially all forms of paroxysmal or incessant tachycardia except ventricular tachycardia. The category of SVT can be divided into three major subcategories: reentrant tachycardias using an accessory pathway, reentrant tachycardias without an accessory pathway, and ectopic or automatic tachycardias. **Atrioventricular reciprocating tachycardia (AVRT)** involves an accessory pathway and is the most common mechanism of SVT in infants. **Atrioventricular node reentry tachycardia (AVNRT)** is rare in infancy but increases during childhood and into adolescence. **Atrial flutter** is rarely seen in children with normal hearts, whereas intraatrial reentry tachycardia (also known as *atrial flutter*) is sometimes seen in patients after cardiac surgery. Atrial and junctional ectopic tachycardias are more often associated with abnormal hearts (cardiomyopathy) and the immediate postoperative period after surgery for CHD.

CLINICAL MANIFESTATIONS

Reentrant SVT is characterized by an abrupt onset and termination; it may occur when the patient is at rest or exercising, and in infants it may be precipitated by an acute infection. Attacks may last only a few seconds or may persist for hours. The heart rate usually exceeds 180 beats/min in older children and adolescents and 220 bpm in infants and younger children. Rates of SVT are often as high as 300 beats/min in newborns and infants. The only complaint may be awareness of the rapid heart rate.

Many older children tolerate these episodes extremely well, and it is unlikely that short paroxysms are a danger to life. If heart rate is exceptionally rapid or the episode is prolonged, precordial discomfort and heart failure may occur. In children, SVT may be exacerbated by exposure to caffeine, nonprescription decongestants, or bronchodilators.

In young patients, the diagnosis may be more obscure because of their inability to communicate their symptoms. The heart rate during infancy is normally higher than in older children and increases greatly with crying. Occasionally, infants with SVT initially present with heart failure because the tachycardia may go unrecognized for a long time, **leading to tachycardia-induced cardiomyopathy**. The heart rate during SVT episodes is frequently in the range of 240-300 beats/min. If the episode lasts 6-24 hours or more, heart failure may be recognized, and the infant may present with poor feeding; an ashen color; and will be restless and irritable, with tachypnea, poor pulses, and hepatomegaly. When tachycardia occurs in the fetus, it can cause **hydrops fetalis**, the in utero manifestation of heart failure.

In neonates, SVT is usually manifested as a narrow QRS complex (<0.08 second). The P wave is visible on a standard ECG in only 50–60%

of neonates with SVT, but it is detectable with a transesophageal lead in most patients. *Differentiation from sinus tachycardia* may be difficult but is important because sinus tachycardia requires treatment of the underlying problem (e.g., sepsis, hypovolemia) rather than antiarrhythmic medication. If the rate is >230 beats/min with an abnormal P-wave axis (a normal P wave is positive in leads I and aVF), sinus tachycardia is *not* likely. The heart rate in SVT also tends to be *relatively fixed,* whereas in sinus tachycardia the heart rate *varies* with changes in parasympathetic and sympathetic tone. AVRT uses a bypass tract that may be able to conduct bidirectionally **(Wolff-Parkinson-White [WPW] syndrome)** or may be retrograde only **(concealed accessory pathway)**. Patients with WPW syndrome have a small but real risk of sudden death. If the accessory pathway rapidly conducts in antegrade fashion, the patient is at risk for atrial fibrillation begetting ventricular fibrillation. Risk stratification, including 24-hour Holter monitoring and exercise study, may help differentiate patients at higher risk for sudden death from WPW. However, it is important to note that intermittent preexcitation may not decrease a patient's risk profile. Syncope is an ominous symptom in WPW, and any patient with syncope and WPW syndrome should have an **electrophysiology study** (EPS) and consideration for catheter ablation.

The typical electrocardiographic features of WPW syndrome are seen when the patient is not having tachycardia. These features include a short P-R interval and slow upstroke of a widened QRS (delta wave) (Fig. 484.4). This may not be evident in every lead on an ECG. Although most often presenting in patients with a normal heart, WPW syndrome may also be associated with **Ebstein anomaly** of the tricuspid valve, congenitally corrected transposition of the great

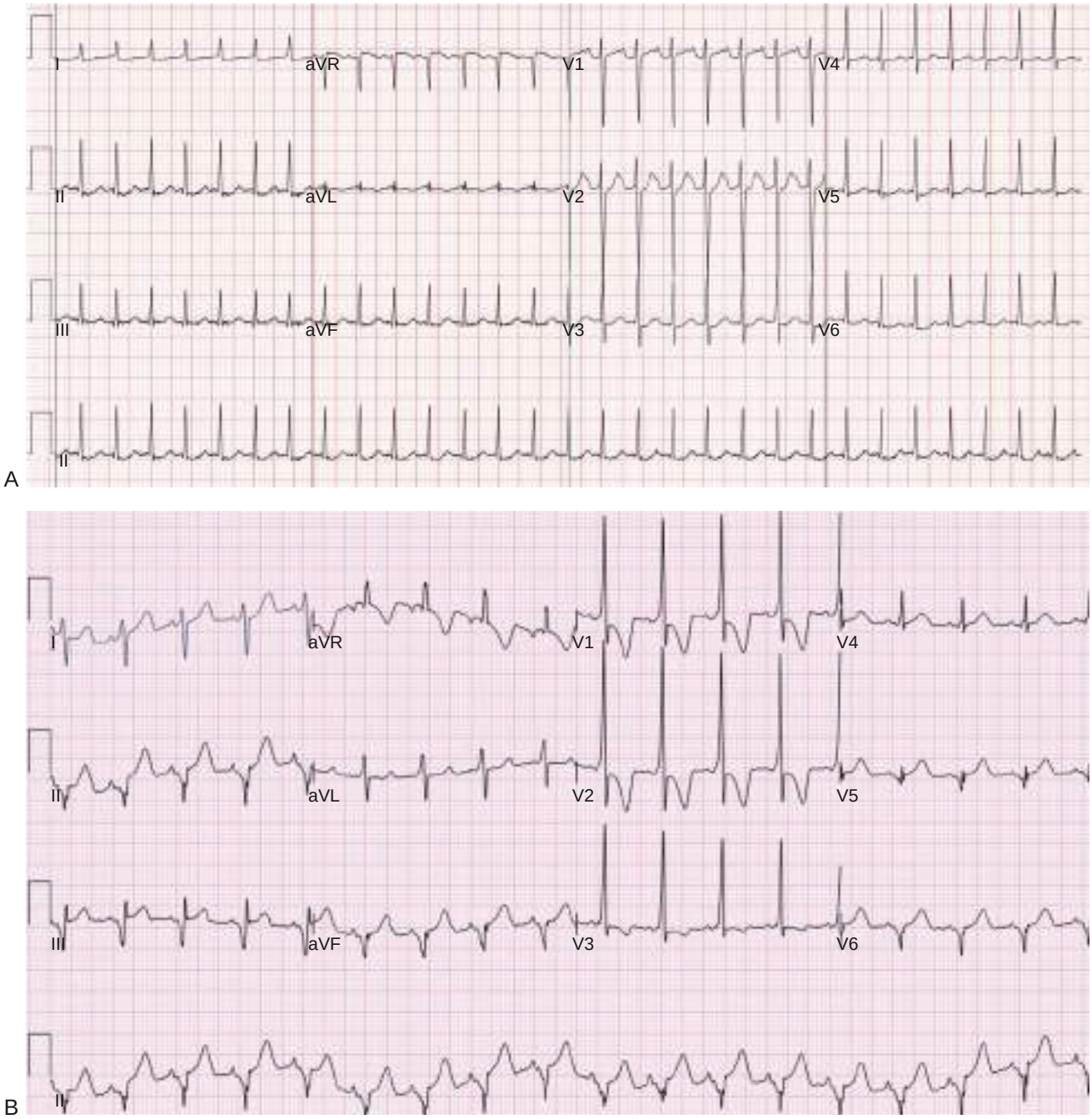

Fig. 484.4 **A,** Supraventricular tachycardia in a child with Wolff-Parkinson-White (WPW) syndrome. Note the normal QRS complexes during the tachycardia, as well as clear retrograde P waves seen on the upstroke of the T waves. **B,** Later, the typical features of WPW syndrome are apparent (short P-R interval, wide QRS with slurred upstroke known as a *delta wave*).

arteries, or certain forms of hypertrophic cardiomyopathy. WPW may also be associated with hypokalemic periodic paralysis, Danon disease, tuberous sclerosis, and rarely with pathogenic variants in *PRKAG2*.

The critical anatomic structure is an accessory pathway consisting of an electrically active myocardial fiber connecting atrium to ventricle on either the right or the left side of the AV ring (Fig. 484.5). During sinus rhythm, the impulse is carried over both the AV node and the accessory pathway; it produces some degree of fusion of the two depolarization fronts that results in an abnormal QRS complex. During AVRT, an impulse is carried in *antegrade* fashion through the AV node **(orthodromic tachycardia)**, which results in a normal QRS complex, and in *retrograde* fashion through the accessory pathway to the atrium, thereby perpetuating the tachycardia. In these cases, only after cessation of the tachycardia is the typical ECG features of WPW syndrome recognized (see Fig. 484.4). When rapid antegrade conduction occurs through the accessory pathway during tachycardia and the retrograde reentry pathway to the atrium is by the AV node **(antidromic tachycardia)**, the QRS complexes are wide and the potential for more serious arrhythmias (ventricular fibrillation) is greater, especially if atrial fibrillation occurs.

AVNRT involves the use of two functional pathways within the AV node: the *slow* and *fast* AV node pathways. This arrhythmia is more often seen in adolescence and young adulthood. It is one of the few forms of SVT that is occasionally associated with syncope. This arrhythmia is often seen in association with exercise.

TREATMENT

In infants, **vagal stimulation** can be induced by transiently placing an ice bag over the entire face to abort the attack for 15-30 seconds (this can be repeated if needed). Older children may be taught **vagal maneuvers** such as the Valsalva maneuver, straining, breath holding, or standing on their head. *Ocular pressure must never be performed, and carotid sinus massage is rarely effective*. When these measures fail, several pharmacologic alternatives are available (see Table 484.1). In stable patients, **adenosine** by rapid intravenous push is the treatment of choice (0.1 mg/kg, up to 6 mg) because of its rapid onset of action and minimal effects on cardiac contractility. The dose may need to be increased (0.2 mg/kg, up to 12 mg) if no effect on the tachycardia is seen. Because of the potential for adenosine to initiate atrial fibrillation, it should never be administered without a means for direct current **(DC) cardioversion** near at hand. Calcium channel blockers such as **verapamil** have also been used in the initial treatment of SVT in older children. Verapamil may reduce cardiac output and produce hypotension and cardiac arrest in infants younger than 1 year and therefore is contraindicated in this age-group. In urgent situations when symptoms of severe heart failure have already occurred, *synchronized* DC cardioversion (0.5-2 J/kg) is recommended as the initial management (see Chapter 79). Pace termination using esophageal pacing catheter is also an option.

Once the patient has been converted to sinus rhythm, a longer-acting agent is selected for maintenance therapy. In patients without an antegrade accessory pathway (non-WPW), the β-**adrenergic blockers** are the mainstay of drug therapy. **Digoxin** has been used for decades and may be effective in infants, but less so in older children. In children with WPW, digoxin or calcium channel blockers may *increase* the rate of antegrade conduction of impulses through the bypass tract, with the possibility of ventricular fibrillation, and are therefore contraindicated. These patients are usually managed with β blockers. In patients with resistant tachycardias, flecainide, propafenone, sotalol, and amiodarone are all acceptable next-line agents. Most antiarrhythmic agents have the potential of causing new dangerous arrhythmias (**proarrhythmia**) and decreasing heart function. Flecainide and propafenone should be limited to use in patients with hearts having otherwise normal cardiac function.

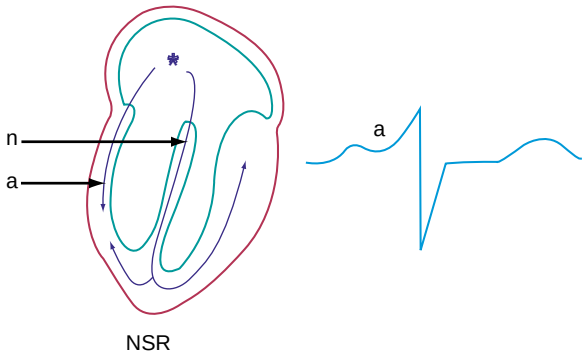

Fig. 484.5 Schematic representation of the heart with a right-sided accessory pathway (WPW syndrome). The *asterisk* indicates initiation of the sinus beat. The *arrows* indicate the direction and spread of excitation. The electrocardiographic complex shown represents a fusion beat that combines activation over the normal *(n)* and accessory *(a)* pathways. The latter inscribes the delta wave. NSR, Normal sinus rhythm.

If cardiac failure occurs because of prolonged tachycardia in an infant with a normal heart, cardiac function usually returns to normal after sinus rhythm is reinstituted, although it may take days to weeks. Infants with SVT diagnosed within the first 3-4 months of life have a lower incidence of recurrence than those initially diagnosed at a later age. These patients have up to an 80% chance of resolution by the first year of life, although approximately 30% will have recurrences later in childhood; if medical therapy is required, it can be tapered by 12-18 months and the patient watched for signs of recurrence. Parents should be taught to measure the heart rate in their infants, so that prolonged asymptomatic episodes of SVT may be detected before heart failure occurs.

The use of **24-hour electrocardiographic (Holter) monitoring** assists in following the course of therapy and detecting brief runs of asymptomatic tachycardia, particularly in younger children and infants. Direct-to-consumer heart monitoring devices ("wearables") are beginning to replace traditional monitors as newer technology allows for miniaturization and improved accuracy of at-home monitoring devices. These devices have helped identify asymptomatic tachycardia in infants and young children. Some centers use **transesophageal pacing** to evaluate the effects of therapy in infants. More detailed electrophysiology studies performed in the cardiac catheterization laboratory are often indicated in patients with refractory SVT who are candidates for catheter ablation. During an EPS, multiple electrode catheters are placed transvenously in different locations in the heart. Pacing is performed to evaluate the conduction characteristics of the accessory pathway and to initiate the tachyarrhythmia, and mapping is performed to locate the accessory pathway. **Catheter ablation** of an accessory pathway is frequently used in children and teenagers and in patients who require multiple agents or find drug side effects intolerable or for whom arrhythmia control is poor. Ablation may be performed either by **radiofrequency ablation**, which creates tissue heating, or **cryoablation**, in which tissue is frozen (Fig. 484.6). The overall initial success rate for catheter ablation in experienced pediatric laboratories ranges from 90% to 98%, depending on the location of the accessory pathway. Surgical ablation of bypass tracts is rarely done and proposed only in carefully selected patients.

The management of SVT caused by AVNRT is almost identical to that for AVRT. Children with AVNRT are not at increased risk of sudden death because they do not have a manifest accessory pathway. In practice, their episodes are more likely to be brought on by exercise or other forms of stress, and the heart rates can be quite fast, leading to chest pain, dizziness, and occasionally syncope. If chronic antiarrhythmic medication is desired, β blockers are the drugs of choice; acutely, AVNRT responds to adenosine. Less is known about the natural history, but patients with AVNRT are seen quite frequently in adulthood, so spontaneous resolution seems unlikely. Patients are quite amenable to catheter ablation, either using radiofrequency energy or cryoablation, with high success rates and low complication rates.

Atrial ectopic tachycardia is an uncommon tachycardia in childhood. It is characterized by a variable rate (seldom >200 beats/min), identifiable P waves with an abnormal axis, and either a sustained or incessant nonsustained tachycardia (Fig. 484.7). This form of atrial tachycardia has a single automatic focus. Identification of this mechanism is aided by monitoring the ECG while initiating vagal or pharmacologic therapy. Unlike reentrant tachycardias, which "break" suddenly, automatic tachycardias such as atrial tachycardia tend to

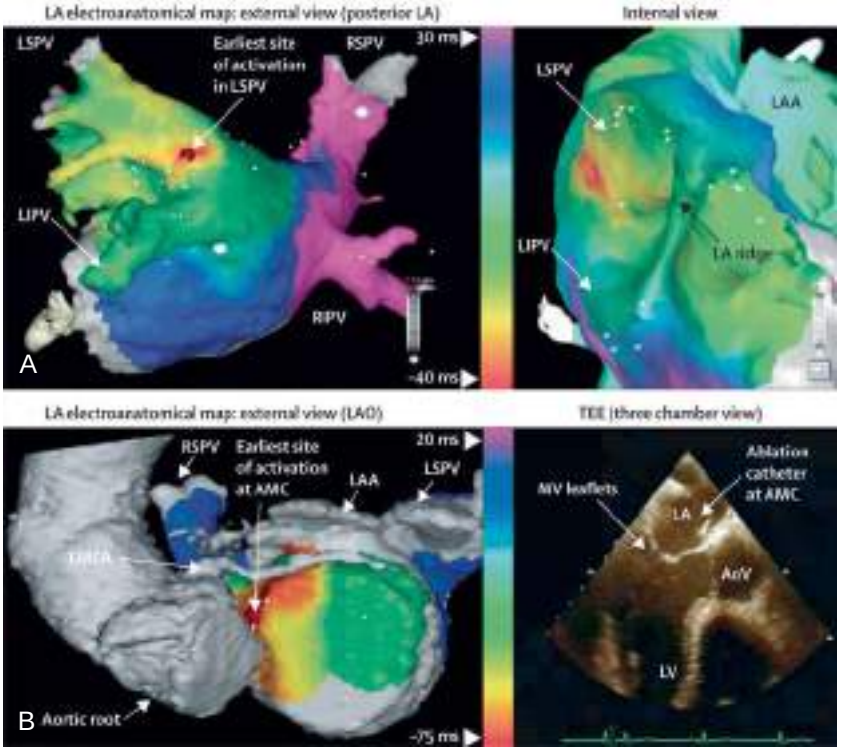

Fig. 484.6 Three-dimensional electroanatomic map of focal atrial tachycardias. Focal site of early activation *(red)* is shown, with radial propagation away from that central site. The activation map was superimposed onto the patient's cardiac CT scan, taken the day before the procedure and imported into the mapping system. This patient had two separate atrial foci. **A,** Tachycardia #1: Earliest site of activation, mapped to the posterior aspect of the LSPV ostium. Posterior external view *(left side)* and endoluminal or internal view looking posterior to anterior from within the left atrium into the mouth of the LSPV *(right side)* are shown. **B,** Tachycardia #2: Earliest site mapped to the aortomitral continuity. The anatomic relation between the mitral annulus and the aortic root can be clearly appreciated *(left side)*. The location of the ablation catheter at the site of earliest atrial activation during atrial tachycardia is shown on the TEE image *(right side)*. AMC, Aortomitral continuity; AoV, aortic valve; LA, left atrium; LAA, left atrial appendage; LAO, left anterior oblique; LIPV, left inferior pulmonary vein; LMCA, left main coronary artery; LSPV, left superior pulmonary vein; LV, left ventricle; MV, mitral valve; RIPV, right inferior pulmonary vein; RSPV, right superior pulmonary vein; TEE, transesophageal echocardiogram. *(From Lee G, Sanders P, Kalman JM. Catheter ablation of atrial arrhythmias: state of the art. Lancet. 2012;380:1509–1518, Fig 3.)*

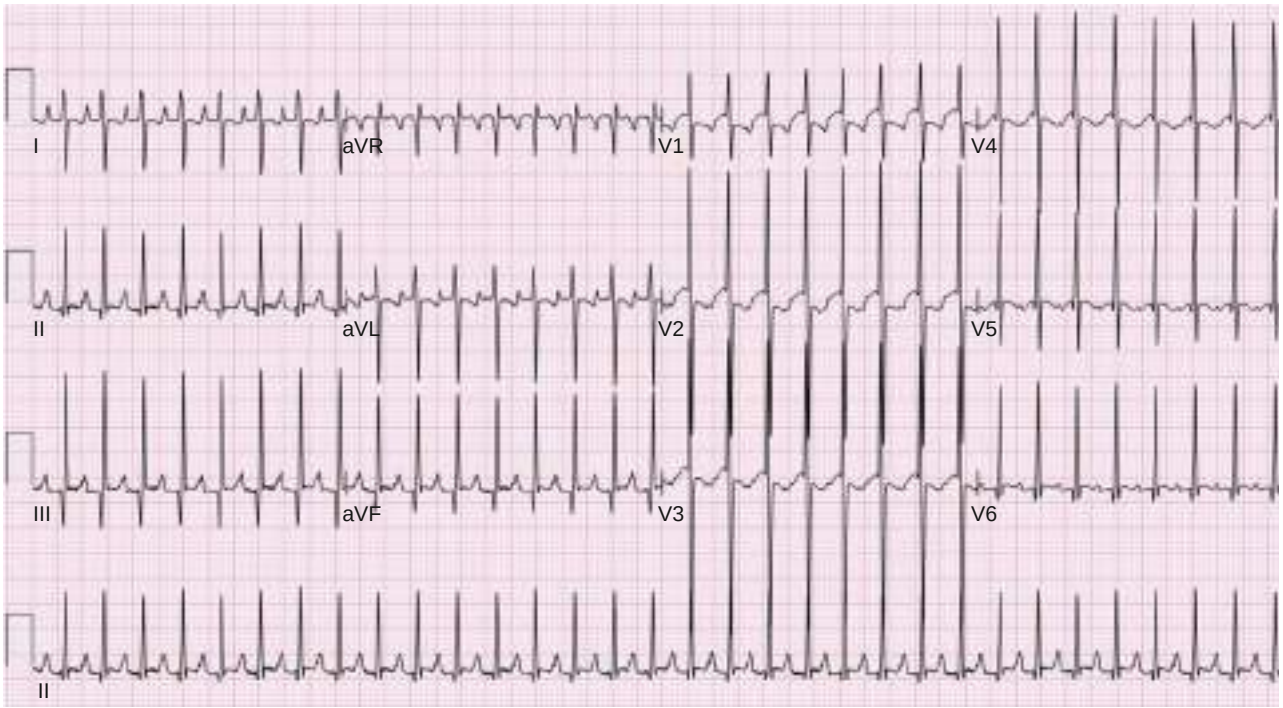

Fig. 484.7 Atrial ectopic tachycardia. Note the abnormal P waves and relative prolongation of the PR interval.

"warm up" and "cool down" (i.e., rates tend to gradually increase and decrease). Atrial ectopic tachycardias are usually more difficult to control pharmacologically than the more common reentrant tachycardias. If pharmacologic therapy with a single agent is unsuccessful, catheter ablation is suggested and has a high success rate, usually >90%. Long-term treatment or ablation may not be necessary in some cases, as atrial ectopic tachycardia may resolve spontaneously in some patients.

Chaotic or multifocal atrial tachycardia is defined as atrial tachycardia with ≥3 ectopic P-wave morphologies, frequent blocked P waves, and varying P-R intervals of conducted beats. This arrhythmia occurs most often in infants younger than 1 year of age, usually without concomitant cardiac disease, although some evidence suggests an association with viral myocarditis or pulmonary disease. The goal of drug treatment is rate control, or slowing of the ventricular rate, because conversion to sinus rhythm may not be possible. Multiple agents are often required. When this arrhythmia occurs in infancy, it usually terminates spontaneously by 3 years of age.

Accelerated junctional ectopic tachycardia (JET) is an automatic (non-reentry) arrhythmia in which the junctional rate exceeds that of the sinus node and AV dissociation may result. This arrhythmia is most often recognized in the early postoperative period after cardiac surgery and may be extremely difficult to control. Reduction of the infusion rate of exogenous catecholamines and mitigating causes of endogenous catecholamines such as fever and pain are important adjuncts to management. Intravenous amiodarone and procainamide are effective in the treatment of postoperative JET. Congenital JET may be seen in the absence of surgery. It is often incessant, can be difficult to treat, and can lead to a dilated cardiomyopathy. Patients who require chronic therapy may respond to amiodarone or sotalol. Congenital JET can be cured by catheter ablation, but long-term AV block requiring a pacemaker is an occasional important complication.

Atrial flutter, also known as *intraatrial reentrant tachycardia,* is an atrial tachycardia characterized by atrial activity at a rate of 250-300 beats/min in children and adolescents and 400-600 beats/min in neonates. The mechanism of common atrial flutter consists of a reentrant rhythm originating in the right atrium circling the tricuspid valve annulus. Because the AV node cannot transmit such rapid impulses, some degree of **AV block** is virtually always present, and the ventricles respond to every second to fourth atrial beat (Fig. 484.8). Occasionally, the response is variable, and the rhythm appears irregular.

In older children, atrial flutter usually occurs in the setting of CHD; neonates with atrial flutter frequently have normal hearts. Atrial flutter may occur during acute infectious illnesses but is most often seen in patients with large stretched atria, such as those associated with long-standing mitral or tricuspid insufficiency, tricuspid atresia, Ebstein anomaly, or rheumatic mitral stenosis. Atrial flutter can also occur after any palliative or corrective cardiac surgery involving an atriotomy. Uncontrolled atrial flutter may precipitate heart failure. Vagal maneuvers or adenosine may produce a temporary slowing of the heart rate as a result of increased AV block, allowing a diagnosis to be made. The diagnosis is confirmed by ECG, which demonstrates the rapid and regular atrial saw-toothed flutter waves. *Atrial flutter usually converts immediately to sinus rhythm by synchronized DC cardioversion, which is most often the treatment of choice.* If pacing wires or atrial pacemaker leads are present, pace termination with atrial overdriving pacing may be a treatment option. In infants, an esophageal pacing lead can also be used, but care must be taken to avoid inadvertent ventricular pacing. Patients with chronic atrial flutter in the setting of CHD may be at increased risk for thromboembolism and stroke and should thus undergo anticoagulation before elective cardioversion. β Blockers or calcium channel blockers may be used to slow the ventricular response in atrial flutter by prolonging the AV node refractory period. Other agents may be used to maintain sinus rhythm, including **class I agents** such as procainamide or propafenone or **class III** agents such as amiodarone and sotalol. **Catheter ablation** has been used in patients with normal hearts and those with CHD with moderate success. After cardioversion, neonates with normal hearts may be followed off antiarrhythmic therapy or may be treated with digoxin, propranolol, or sotalol for 6-12 months, after which the medication can usually be discontinued, because neonatal atrial flutter generally does not recur.

Atrial fibrillation is uncommon in children and is rare in infants. The atrial excitation is chaotic and more rapid (400-700 beats/min) and produces an *irregularly irregular* ventricular response and pulse (Fig. 484.9). This rhythm disorder is often associated with atrial

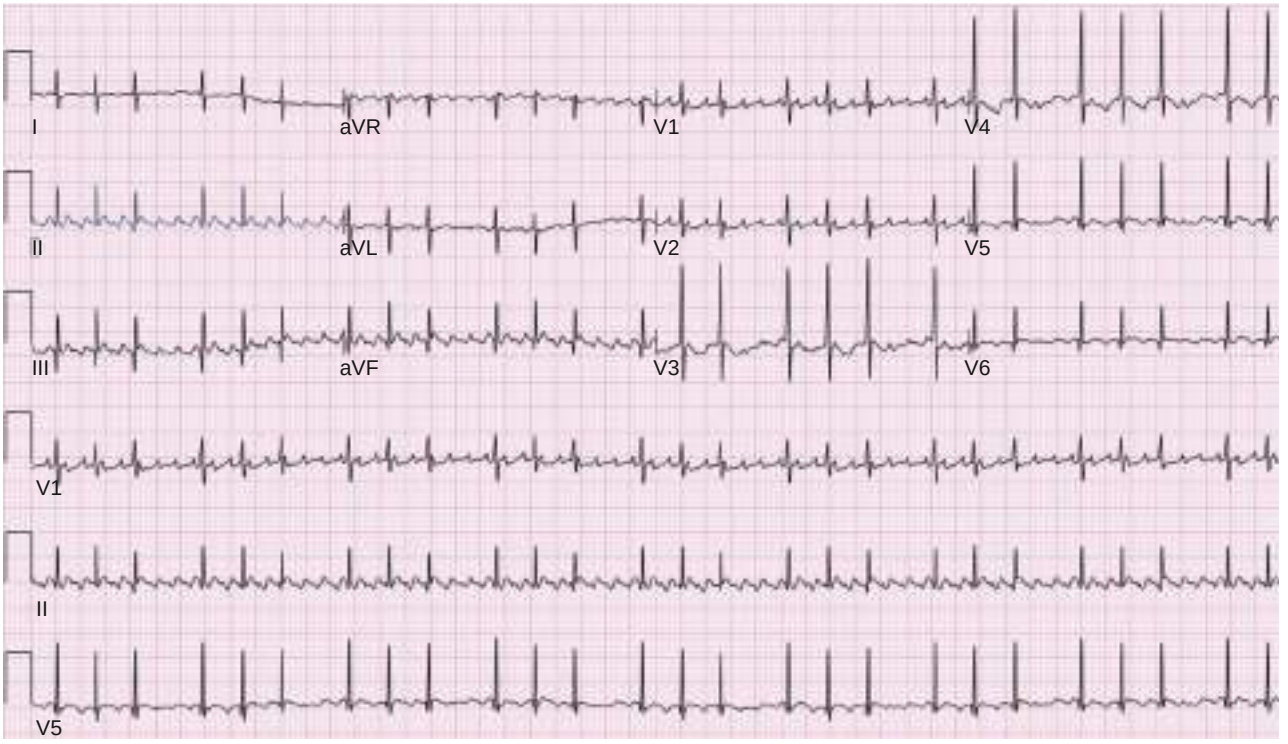

Fig. 484.8 Neonatal atrial flutter. Note that there is variable AV conduction and the flutter waves have a cycle length of 160 msec, corresponding to an atrial rate of 375 bpm.

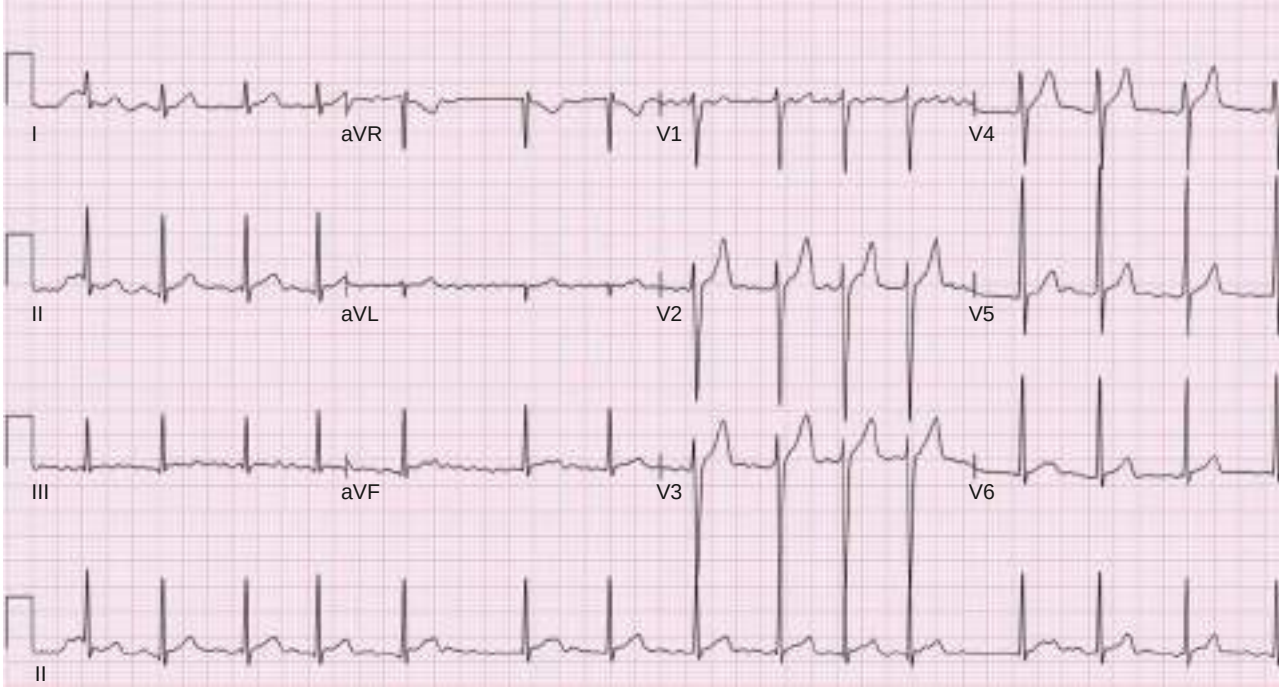

Fig. 484.9 Atrial fibrillation, characterized by the absence of clear P waves and an irregularly irregular ventricular response. One can appreciate the irregular, rapid undulations (F waves). Fibrillatory waves may not be visible in all leads and should be carefully sought in every tracing with irregular R-R intervals. Note that no two R-R intervals are the same.

enlargement or disease. Atrial fibrillation may be seen in older children with rheumatic mitral valve stenosis. It is also seen rarely as a complication of atrial surgery, in patients with left atrial enlargement secondary to left AV valve insufficiency, and in patients with WPW syndrome. Thyrotoxicosis, pulmonary embolism, pericarditis, or cardiomyopathy may be suspected in a previously normal older child or adolescent who presents with atrial fibrillation. Very rarely, atrial fibrillation may be familial and is usually an autosomal dominant disorder often affecting the potassium or sodium channel genes. The best initial treatment is **rate control**, most effectively with calcium channel blockers, to limit the ventricular rate during atrial fibrillation. Digoxin is not given if WPW syndrome is present. Normal sinus rhythm may be restored with intravenous procainamide, ibutilide, or amiodarone; DC cardioversion is the first choice in hemodynamically unstable patients. Patients with chronic atrial fibrillation are at risk for thromboembolism and stroke and should undergo anticoagulation with warfarin. Patients being treated by elective cardioversion should also undergo anticoagulation.

484.4 Ventricular Tachyarrhythmias

Aarti S. Dalal and George F. Van Hare

Ventricular tachycardia (VT) is much less common than SVT in pediatric patients. VT is defined as at least three PVCs at >120 beats/min (Fig. 484.10). It may be paroxysmal or incessant. VT can be seen in congenital or acquired heart disease, including inherited arrhythmia syndromes secondary to channelopathies, myopathies, or laminopathies. VT may be associated with structural disease such as myocarditis, anomalous origin of a coronary artery, mitral valve prolapse, primary cardiac tumors, arrhythmogenic cardiomyopathy (previously known as *arrhythmogenic right ventricular cardiomyopathy*), dilated or hypertrophic cardiomyopathy, and cardiac laminopathies (associated with lamin A/C gene pathogenic variants). Patients with laminopathies associated with a variant in the lamin A/C gene *(LMNA)*, as seen in Emery Dreifuss muscular dystrophy or 1B limb girdle muscular dystrophy are at risk of primary ventricular arrhythmias in addition to development of cardiomyopathies. VT can also be seen in patients with channelopathies such as catecholaminergic polymorphic ventricular tachycardia, Brugada syndrome, *TANGO2*-related encephalopathy and arrhythmias, and long QT syndrome. A prolonged QT interval of either congenital or acquired (proarrhythmic medication or hypokalemia, hypocalcemia, hypomagnesemia) causation can increase a patient's risk of arrhythmias. Other causes include WPW syndrome and drug use (cocaine, amphetamines). VT may develop years after intraventricular surgery (especially tetralogy of Fallot and related defects) or occur without obvious organic heart disease. VT must be distinguished from SVT with aberrancy or rapid conduction over an accessory pathway (Table 484.2). The presence of clear capture and fusion beats confirms the diagnosis of VT. Although some children tolerate rapid ventricular rates for many hours, this arrhythmia should be promptly treated because hypotension and degeneration into ventricular fibrillation may result. For patients who are hemodynamically stable, intravenous amiodarone, lidocaine, and procainamide are the initial drugs of choice. If treatment is to be successful, it is critical to search for and correct any underlying abnormalities, such as electrolyte imbalance, hypoxia, or drug toxicity. **Amiodarone** is the treatment of choice during cardiac arrest (see Chapter 79). Hemodynamically unstable patients with VT should be immediately treated with DC cardioversion. Overdrive ventricular pacing, through temporary pacing wires or a permanent pacemaker, may also be effective, although it may cause the arrhythmia to deteriorate into ventricular fibrillation. In the neonatal period, VT may be associated with an anomalous left coronary artery (see Chapter 481.2) or a myocardial tumor.

Unless a clearly reversible cause is identified, an electrophysiology study is usually indicated for patients in whom VT has developed, and depending on the findings, catheter ablation and/or implantable cardioverter-defibrillator (ICD) implantation may be indicated.

A related arrhythmia, **ventricular accelerated rhythm**, is occasionally seen in infants. It is defined the same way as VT, but the rate is only slightly faster than the coexisting sinus rate (within 10%). It is generally benign and resolves spontaneously.

Ventricular fibrillation (VF) is a chaotic rhythm that results in death unless an effective ventricular beat is rapidly reestablished. Usually, cardiopulmonary resuscitation and DC defibrillation are necessary. If defibrillation is ineffective or VF recurs, amiodarone or lidocaine may be given intravenously and defibrillation repeated (see Chapter 79). After recovery from VF, a search should be made for the

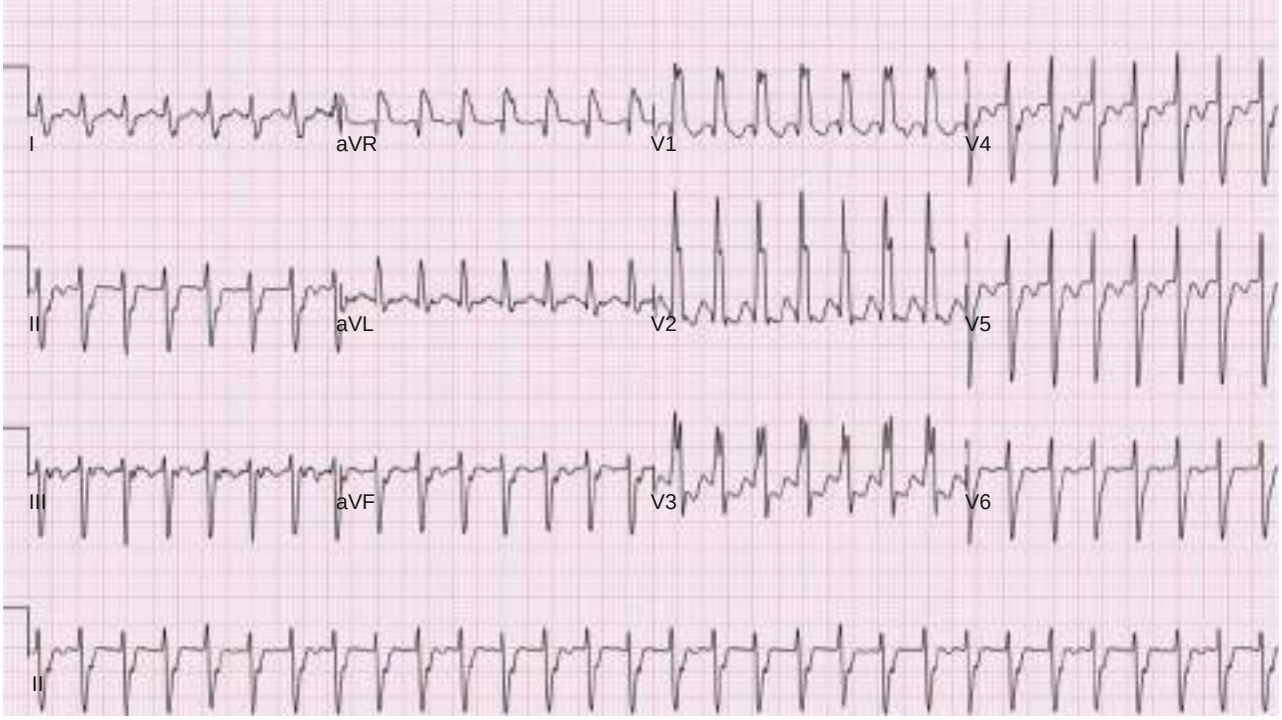

Fig. 484.10 Ventricular tachycardia. The QRS complexes are wide and abnormal. Atrioventricular dissociation can be best appreciated in the lead II rhythm strip at the bottom.

Table 484.2 Diagnosis of Tachyarrhythmias: Electrocardiographic Findings

	HEART RATE (BEATS/MIN)	P WAVE	QRS DURATION	REGULARITY
Sinus tachycardia	<230	Always present, normal axis	Normal	Rate varies with respiration
Atrial tachycardia	180-320	Present Abnormal P-wave morphology and axis	Normal or prolonged (with aberration)	Usually regular, but ventricular response may be variable because of Wenckebach conduction
Atrial fibrillation	120-180	Fibrillatory waves	Normal or prolonged (with aberration)	Irregularly irregular (no two R-R intervals alike)
Atrial flutter	Atrial: 250-400 Ventricular response variable: 100-320	Saw-tooth flutter waves	Normal or prolonged (with aberration)	Regular ventricular response (e.g., 2:1, 3:1, 3:2)
Junctional tachycardia	120-280	Atrioventricular dissociation with no fusion, and normal QRS capture beats	Normal or prolonged (with aberration)	Regular (except with capture beats)
Ventricular tachycardia	120-300	Atrioventricular dissociation with capture beats and fusion beats	Prolonged for age	Regular (except with capture beats)

underlying cause. EPS is indicated for patients who have survived VF unless a clearly reversible cause is identified. If WPW syndrome is noted, catheter ablation should be performed. For patients in whom no correctable abnormality can be found, an ICD is almost always indicated because of the high risk of sudden death.

484.5 Long QT Syndromes

Aarti S. Dalal and George F. Van Hare

Long QT syndrome is a genetic abnormality of ventricular repolarization, with an estimated incidence of about 1 per 10,000 births (Table 484.3; also includes other genetic arrhythmia syndromes). It presents as a long QT interval on the surface ECG and is associated with malignant ventricular arrhythmias (**torsades de pointes** and VF). Long QT syndrome can cause syncope and sudden death and may be the cause of some cases of sudden infant death syndrome, drowning, and intrauterine fetal demise (Fig. 484.11). In perhaps 80% of cases, there is an identifiable pathogenic variant. The distinction between dominant and recessive forms of the disease (Romano-Ward syndrome vs Jervell-Lange-Nielsen syndrome) is no longer made because the latter recessive condition is known to result from the homozygous state. **Jervell-Lange-Nielsen syndrome** is associated with congenital sensorineural deafness. Asymptomatic but at-risk patients carrying the gene variant may not all have a prolonged QT duration. QT interval prolongation may become apparent with exercise, position change or during catecholamine infusions.

Genetic studies have identified pathogenic variants in cardiac potassium and sodium channels (see Table 484.3). Additional forms (up to 13 variants) of long QT syndrome (LQTS) have been described, but these are much less common. Genotype may predict clinical manifestations;

LQTS type 1 (**LQT1**) events are usually induced by stress or exertion, whereas events in **LQT3** often occur at rest, especially during sleep (see Fig. 484.11). **LQT2** events have an intermediate pattern, often occurring in the postpartum period or with auditory triggers. LQT3 has the highest probability for sudden death, followed by LQT2 and then LQT1. Drugs may prolong the QT interval directly but more often do so when drugs such as erythromycin or ketoconazole inhibit their metabolism (Table 484.4).

The **clinical manifestation** of LQTS in children is most often a syncopal episode brought on by exercise, fright, or a sudden startle; some events occur during sleep (LQT3). Patients can initially be seen with seizures, presyncope, or palpitations; approximately 10% are initially in cardiac arrest. The diagnosis is based on electrocardiographic and clinical criteria. Not all patients with long QT intervals have LQTS, and patients with normal QT intervals on a resting ECG may have LQTS. A heart rate–corrected QT interval (QTc) of >0.47 second is highly indicative, whereas a QTc interval of >0.44 second is suggestive. Other features include notched T waves in three leads, T-wave alternans, a low heart rate for age, a history of syncope (especially with stress), and a familial history of either LQTS or unexplained sudden death. Exercise testing, provocative drug testing, and 24-hour Holter monitoring are adjuncts to the diagnosis. Genotyping is available and can identify the pathogenic variant in approximately 80% of patients known to have LQTS by clinical criteria. Genotyping is not useful in ruling out the diagnosis in individuals with suspected disease, but when positive is very useful in identifying asymptomatic affected relatives of the index case.

Short QT syndromes manifest with atrial or ventricular fibrillation and are associated with syncope and sudden death (see Table 484.3). They are often caused by a gain-of-function mutation in cardiac potassium channels.

Treatment of LQTS includes the use of β-blocking agents at doses that blunt sympathetic tone. Nonselective β blockers such as propranolol and nadolol seem to be more effective than atenolol and metoprolol for some genotypes. Some patients require a **pacemaker** because of drug-induced bradycardia. An **implantable cardiac defibrillator** (ICD) is indicated in patients with continued syncope despite treatment with β blockers and those who have experienced cardiac arrest. Genotype-phenotype correlative studies suggest that β blockers are not as effective in patients with LQT3, but these patients may respond to mexiletine with shortening of the QT interval.

484.6 Sinus Node Dysfunction

Aarti S. Dalal and George F. Van Hare

Sinus arrest and sinoatrial block may cause a sudden pause in the heartbeat. **Sinus arrest** is presumably caused by failure of impulse formation within the sinus node. **Sinoatrial block** results from a block between the sinus pacemaker complex and the surrounding atrium. These arrhythmias are rare in childhood except in patients who have had extensive atrial surgery.

Sick sinus syndrome is the result of abnormalities in the sinus node or atrial conduction pathways, or both. This syndrome may occur in the absence of CHD and has been reported in siblings, but it is most commonly seen after surgical correction of congenital heart defects,

Table 484.3 Heritable Arrhythmia Syndrome Susceptibility Genes

GENE	LOCUS	PROTEIN
LONG QT SYNDROME (LQTS)		
Major LQTS Genes		
KCNQ1 (LQT1)	11p15.5	I_{Ks} potassium channel alpha subunit (KVLQT1, K_v7.1)
KCNH2 (LQT2)	7q35-36	I_{Kr} potassium channel alpha subunit (HERG, K_v11.1)
SCN5A (LQT3)	3p21-p24	Cardiac sodium channel alpha subunit (Na_v1.5)
Minor LQTS Genes (Listed Alphabetically)		
AKAP9	7q21-q22	Yotiao
CACNA1C	12p13.3	Voltage-gated L-type calcium channel (Ca_v1.2)
CALM1	14q32.11	Calmodulin 1
CALM2	2p21	Calmodulin 2
CALM3	19q13.2-q13.3	Calmodulin 3
CAV3	3p25	Caveolin-3
KCNE1	21q22.1	Potassium channel beta subunit (MinK)
KCNE2	21q22.1	Potassium channel beta subunit (MiRP1)
KCNJ5	11q24.3	Kir3.4 subunit of I_{KACH} channel
SCN4B	11q23.3	Sodium channel $beta_4$ subunit
SNTA1	20q11.2	Syntrophin-$alpha_1$
TRIADIN KNOCKOUT (TKO) SYNDROME		
TRDN	6q22.31	Cardiac triadin
ANDERSEN-TAWIL SYNDROME (ATS)		
KCNJ2 (ATS1)	17q23	I_{K1} potassium channel (Kir2.1)
TIMOTHY SYNDROME (TS)		
CACNA1C	12p13.3	Voltage-gated L-type calcium channel (Ca_v1.2)
Cardiac-Only TS (COTS)		
CACNA1C	12p13.3	Voltage-gated L-type calcium channel (Ca_v1.2)
SHORT QT SYNDROME (SQTS)		
KCNH2 (SQT1)	7q35-36	I_{Kr} potassium channel alpha subunit (HERG, K_v11.1)
KCNQ1 (SQT2)	11p15.5	I_{Ks} potassium channel alpha subunit (KVLQT1, K_v7.1)

Continued

Table 484.3 Heritable Arrhythmia Syndrome Susceptibility Genes—cont'd

GENE	LOCUS	PROTEIN
KCNJ2 (SQT3)	17q23	I_{K1} potassium channel (Kir2.1)
CACNA1C (SQT4)	12p13.3	Voltage-gated L-type calcium channel ($Ca_v1.2$)
CACNB2 (SQT5)	10p12	Voltage-gated L-type calcium channel $beta_2$ subunit
CACN2D1 (SQT6)	7q21-q22	Voltage-gated L-type calcium channel 2 $delta_1$ subunit
CATECHOLAMINERGIC POLYMORPHIC VENTRICULAR TACHYCARDIA (CPVT)		
RYR2 (CPVT1)	1q42.1-q43	Ryanodine receptor 2
CASQ2 (CPVT2)	1p13.3	Calsequestrin 2
KCNJ2 (CPVT3)	17q23	I_{K1} potassium channel (Kir2.1)
CALM1	14q32.11	Calmodulin 1
CALM3	19q13.2-q13.3	Calmodulin 3
TRDN	6q22.31	Cardiac triadin
BRUGADA SYNDROME (BRS)		
SCN5A (BrS1)	3p21-p24	Cardiac sodium channel alpha subunit ($Na_v1.5$)
Minor Brs Genes (Listed Alphabetically)		
ABCC9	12p12.1	ATP-binding cassette, subfamily C member 9
CACNA1C	2p13.3	Voltage-gated L-type calcium channel ($Ca_v1.2$)
CACNA2D1	7q21-q22	Voltage-gated L-type calcium channel 2 $delta_1$ subunit
CACNB2	10p12	Voltage-gated L-type calcium channel $beta_2$ subunit
FGF12	3q28	Fibroblast growth factor 12
GPD1L	3p22.3	Glycerol-3-phosphate dehydrogenase 1–like
KCND3	1p13.2	Voltage-gated potassium channel (I_{to}) subunit $K_v4.3$
KCNE3	11q13.4	Potassium channel $beta_3$ subunit (MiRP2)
KCNJ8	12p12.1	Inward rectifier K^+ channel Kir6.1
HEY2	6q	Hes-related family BHLH transcription factor with YRPW motif 2
PKP2	12p11	Plakophilin-2
RANGRF	17p13.1	RAN guanine nucleotide release factor 1
SCN1B	19q13	Sodium channel $beta_1$
SCN2B	11q23	Sodium channel $beta_2$
SCN3B	11q24.1	Sodium channel $beta_3$
SCN10A	3p22.2	Sodium voltage-gated channel $alpha_{10}$ subunit ($Na_v1.8$)
SLMAP	3p14.3	Sarcolemma-associated protein
EARLY REPOLARIZATION SYNDROME (ERS)		
ABCC9	12p12.1	ATP-binding cassette, subfamily C member 9
CACNA1C	2p13.3	Voltage-gated L-type calcium channel ($Ca_v1.2$)
CACNA2D1	7q21-q22	Voltage-gated L-type calcium channel 2 $delta_1$ subunit
CACNB2	10p12	Voltage-gated L-type calcium channel $beta_2$ subunit
KCNJ8	12p12.1	Inward rectifier K^+ channel Kir6.1
SCN5A	3p21-p24	Cardiac sodium channel alpha subunit ($Na_v1.5$)
SCN10A	3p22.2	Sodium voltage-gated channel $alpha_{10}$ subunit ($Na_v1.8$)
IDIOPATHIC VENTRICULAR FIBRILLATION (IVF)		
ANK2	4q25-q27	Ankyrin B
CALM1	14q32.11	Calmodulin 1
DPP6	7q36	Dipeptidyl-peptidase-6
KCNJ8	12p12.1	Inward rectifier K^+ channel Kir6.1
RYR2	1q42.1-q43	Ryanodine receptor 2
SCN3B	11q23	Sodium channel $beta_3$ subunit

Table 484.3 Heritable Arrhythmia Syndrome Susceptibility Genes—cont'd

GENE	LOCUS	PROTEIN
SCN5A	3p21-p24	Cardiac sodium channel alpha subunit ($Na_v1.5$)
PROGRESSIVE CARDIAC CONDUCTION DISEASE/DEFECT (PCCD)		
SCN5A	3p21-p24	Cardiac sodium channel alpha subunit ($Na_v1.5$)
TRPM4	19q13.33	Transient receptor potential cation channel, subfamily M, member 4
SICK SINUS SYNDROME (SSS)		
ANK2	4q25-q27	Ankyrin B
HCN4	15q24-q25	Hyperpolarization-activated cyclic nucleotide–gated channel 4
MYH6	14q11.2	Myosin, heavy chain 6, cardiac muscle, alpha
SCN5A	3p21-p24	Cardiac sodium channel alpha subunit ($Na_v1.5$)
"ANKYRIN-B SYNDROME"		
ANK2	4q25-q27	Ankyrin B
FAMILIAL ATRIAL FIBRILLATION (FAF)		
ANK2	4q25-q27	Ankyrin B
GATA4	8p23.1-p22	GATA-binding protein 4
GATA5	20q13.33	GATA-binding protein 5
GJA5	1q21	Connexin 40
KCNA5	12p13	I_{Kur} potassium channel ($K_v1.5$)
KCNE2	21q22.1	Potassium channel beta subunit (MiRP1)
KCNH2	7q35-36	I_{Kr} potassium channel alpha subunit (HERG, $K_v11.1$)
KCNJ2	17q23	I_{K1} potassium channel (Kir2.1)
KCNQ1	11p15.5	I_{Ks} potassium channel alpha subunit (KVLQT1, $K_v7.1$)
NPPA	1p36	Atrial natriuretic peptide precursor A
NUP155	5p13	Nucleoporin 155 kD
SCN5A	3p21-p24	Cardiac sodium channel alpha subunit ($Na_v1.5$)

From Tester DJ, Ackerman MJ. Genetics of cardiac arrhythmias. In Zipes DP, Libby P, Bonow RO, et al., eds. *Braunwald's Heart Disease*, 11th ed. Philadelphia: Elsevier; 2019, Table 33.1, p. 605.

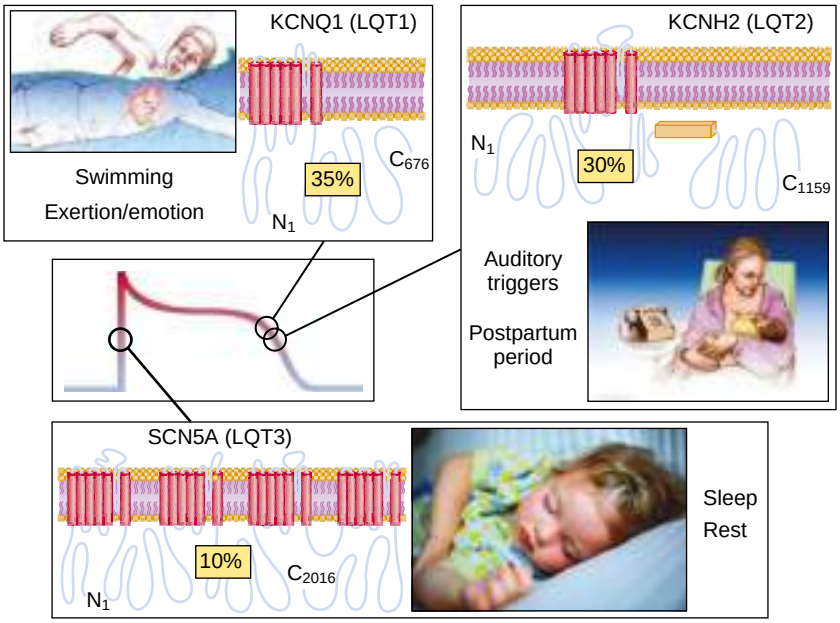

Fig. 484.11 Genotype-phenotype correlations in long QT syndrome (LQTS). About 75% of clinically strong LQTS is caused by mutations in three genes (35% *KCNQ1*, 30% *KCNH2*, and 10% *SCN5A*) encoding for ion channels that are critically responsible for the orchestration of the cardiac action potential. Observed genotype-phenotype correlations include swimming/exertion/emotion and LQT1, auditory triggers/postpartum period and LQT2, and sleep/rest and LQT3. *(From Tester DJ, Ackerman MJ. Genetics of cardiac arrhythmias. In: Zipes DP, Libby P, Bonow RO, et al., eds. Braunwald's Heart Disease, 11th ed. Philadelphia: Elsevier; 2019: Fig 33-3, p. 607.)*

Table 484.4 Acquired Causes of QT Prolongation*

DRUGS
Antibiotics—erythromycin, clarithromycin, azithromycin, telithromycin, trimethoprim/sulfamethoxazole, fluoroquinolones†
Antifungal agents†—fluconazole, itraconazole, ketoconazole
Antiprotozoal agents—pentamidine isethionate
Antihistamines—astemizole, terfenadine (Seldane; Seldane has been removed from the market for this reason)
Antidepressants—tricyclics such as imipramine (Tofranil), amitriptyline (Elavil), desipramine (Norpramin), and doxepin (Sinequan)
Antipsychotics—haloperidol, risperidone, phenothiazines such as thioridazine (Mellaril) and chlorpromazine (Thorazine), selective serotonin uptake inhibitors
Antiarrhythmic agents
Class 1A (sodium channel blockers)—quinidine, procainamide, disopyramide
Class III (prolong depolarization)—amiodarone (rare), bretylium, dofetilide, *N*-acetyl-procainamide, sotalol
Lipid-lowering agents—probucol
Antianginals—bepridil
Diuretics (through K^+ loss)—furosemide (Lasix), ethacrynic acid (bumetanide [Bumex])
Opiates—methadone, oxycodone
Oral hypoglycemic agents—glibenclamide, glyburide
Organophosphate insecticides
Motility agents—cisapride, domperidone
Vasodilators—prenylamine
Other drugs—ondansetron, HIV protease inhibitors, Chinese herbs
ELECTROLYTE DISTURBANCES
Hypokalemia—diuretics, hyperventilation
Hypocalcemia
Hypomagnesemia
UNDERLYING MEDICAL CONDITIONS
Bradycardia—complete atrioventricular block, severe bradycardia, sick sinus syndrome
Myocardial dysfunction—anthracycline cardiotoxicity, congestive heart failure, myocarditis, cardiac tumors
Endocrinopathy—hyperparathyroidism, hypothyroidism, pheochromocytoma
Neurologic—encephalitis, head trauma, stroke, subarachnoid hemorrhage
Nutritional—alcoholism, anorexia nervosa, starvation

*A more exhaustive updated list of medications that can prolong the QTc interval is available at the University of Arizona Center for Education and Research of Therapeutics website (www.crediblemeds.org).
†Combinations of quinolones plus azoles increase the risk of prolonged QT intervals.
From Park MY. *Pediatric Cardiology for Practitioners*, 5th ed. Philadelphia: Mosby; 2008: Box 24-1, p. 433.

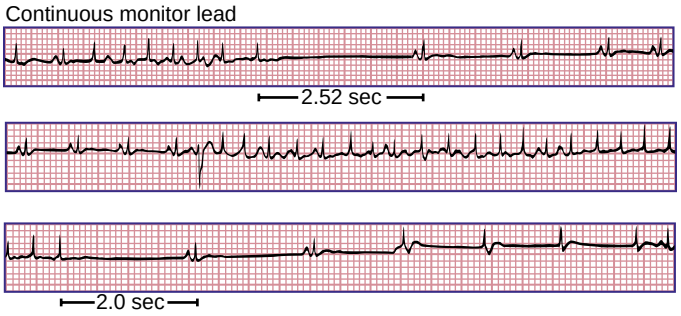

Fig. 484.12 The "tachy-brady" syndrome with sinus node dysfunction. Note the bursts of supraventricular tachycardia, probably multifocal atrial in origin, followed by long periods of sinus arrest and by sinus bradycardia. Often, symptoms are caused by the long sinus pauses after termination of tachycardia, rather than by the tachycardia itself.

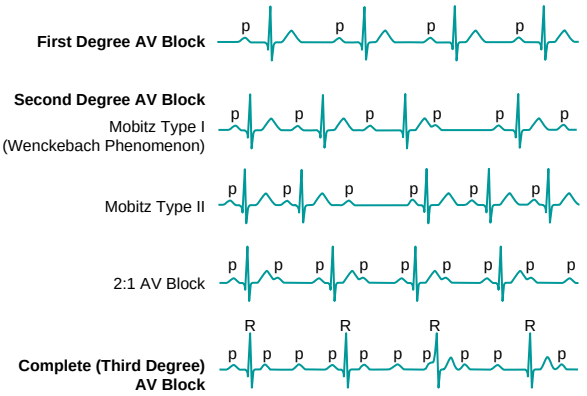

Fig. 484.13 Atrioventricular (AV) block. *(From Park MY. Pediatric Cardiology for Practitioners, 5th ed. Philadelphia: Mosby; 2008: Fig 25-1, p. 446.)*

especially the **Fontan procedure** and the **atrial switch** (Mustard or Senning) operation for transposition of the great arteries. Clinical manifestations depend on the heart rate. Most patients remain asymptomatic without treatment, but dizziness and syncope can occur during periods of marked sinus slowing with failure of junctional escape. Pacemaker therapy is indicated in patients who experience symptoms such as exercise intolerance or syncope.

Patients with sinus node dysfunction may also have episodes of SVT **("tachy-brady" syndrome)** with symptoms of palpitations, exercise intolerance, or dizziness (Fig. 484.12). Treatment must be individualized. Drug therapy to control tachyarrhythmias (propranolol, sotalol, amiodarone) may suppress sinus and AV node function to such a degree that further symptomatic bradycardia may be produced. Therefore insertion of a pacemaker in conjunction with drug therapy is usually necessary for such patients, even in the absence of symptoms ascribable to low heart rate.

484.7 Atrioventricular Block

Aarti S. Dalal and George F. Van Hare

Atrioventricular block may be divided into three forms (Fig. 484.13). In **first-degree AV block**, the PR interval is prolonged but all the atrial impulses are conducted to the ventricle. In **second-degree AV block**, not every atrial impulse is conducted to the ventricle. In the variant of second-degree block known as the **Wenckebach type** (also called **Mobitz type I**), the PR interval increases progressively until a P wave is not conducted. In the cycle following the dropped beat, the PR interval normalizes. In **Mobitz type II** there is no progressive conduction delay or subsequent shortening of the PR interval after a blocked beat. This conduction defect is less common but has more potential to cause syncope and may be progressive. A related condition is **high-grade second-degree AV block**, in which two or more P waves in a row fail to conduct. This is even more dangerous. In **third-degree AV block (complete heart block)**, no impulses from the atria reach the ventricles. An independent escape rhythm is usually present but may not be reliable, leading to syncope or even sudden death.

Congenital complete AV block in children is presumed to be caused by autoimmune injury of the fetal conduction system by maternally derived immunoglobulin G antibodies (anti-SSA/Ro, anti-SSB/La) in a mother with overt or, more often, asymptomatic systemic lupus erythematosus (SLE) or Sjögren syndrome. Autoimmune disease accounts for 60–70% of all cases of congenital complete AV block and 80% of cases in which the heart is structurally normal (Fig. 484.14). A pathogenic variant in *NKX2-5* is associated with congenital AV block and an atrial septal defect.

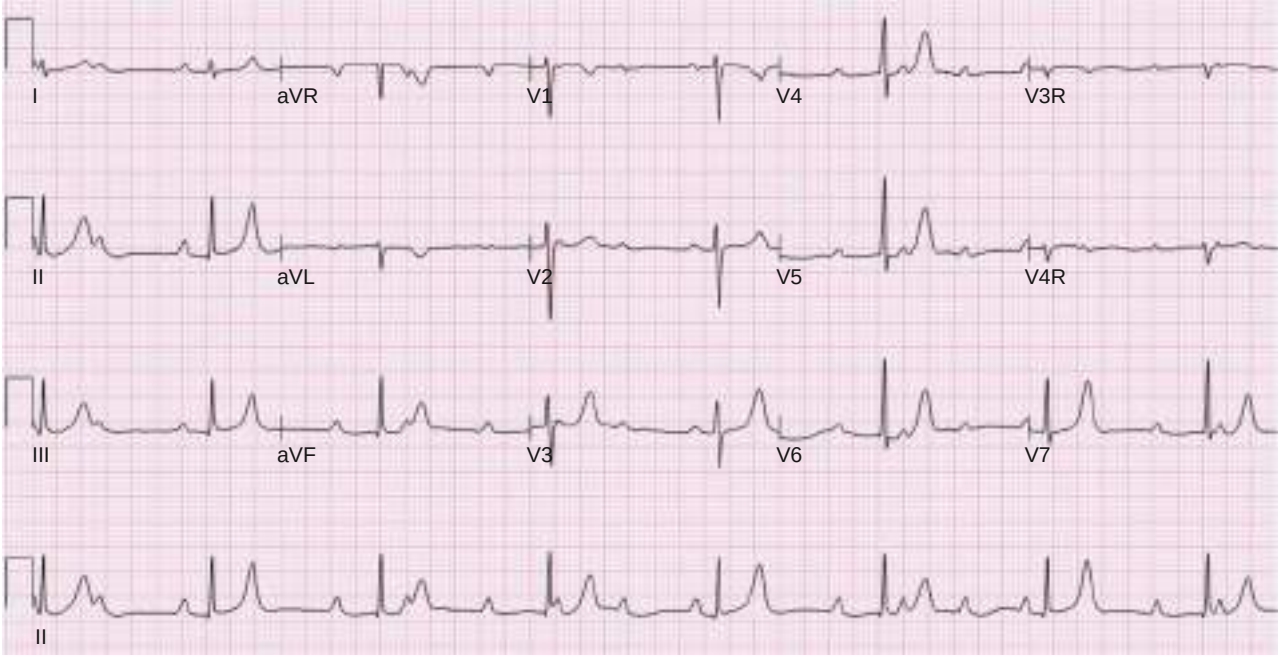

Fig. 484.14 Congenital complete atrioventricular (AV) block. The ventricular rate is regular at 44 beats/min. The atrial rate is approximately 100 beats/min and completely dissociated from the ventricle. The QRS morphology is normal, which is common in congenital complete AV block.

Complete AV block is also seen in patients with complex CHD and abnormal embryonic development of the conduction system. It has been associated with myocardial tumors and myocarditis. Acquired heart block (first, second, or third degree) is seen in Lyme disease and COVID-19–associated multisystem inflammatory syndrome. In these syndromes, first-degree heart block may progress to second- or third-degree heart block. Complete AV block is a known complication of myocardial abscess secondary to endocarditis. It is also seen in genetic conditions, including LQTS, Emery Dreifuss muscular dystrophy, and Kearns-Sayre syndrome. Postoperative AV block can be a complication of CHD repair—in particular, those repairs involving closure of a ventricular septal defect.

The incidence of congenital complete AV block is 1 per 20,000-25,000 live births; a high fetal loss rate may cause an underestimation of its true incidence. In some infants of mothers with SLE, complete AV block is not present at birth but develops within the first 3-6 months after birth. The arrhythmia is often diagnosed in the fetus (secondary to the dissociation between atrial and ventricular contractions seen on fetal echocardiography) and may produce hydrops fetalis. Maternal treatment with corticosteroids to halt progression or reverse AV block is controversial. Infants with associated CHD and heart failure have a high mortality rate.

In older children with otherwise normal hearts, complete AV block is often asymptomatic, although syncope and sudden death may occur. Infants and toddlers may have night terrors, tiredness with frequent naps, and irritability. The peripheral pulse is prominent because of the compensatory large ventricular stroke volume and peripheral vasodilation; systolic blood pressure is elevated. Jugular venous pulsations occur irregularly and may be large when the atrium contracts against a closed tricuspid valve (cannon wave). Exercise and atropine may produce an acceleration of 10-20 beats/min. Systolic murmurs are frequently audible along the left sternal border, and apical mid-diastolic murmurs are not unusual. The first heart sound is variable because of variable ventricular filing with AV dissociation. AV block may result in enlargement of the heart because of slow rates and increased diastolic ventricular filling.

The **diagnosis** is confirmed by electrocardiography; the P waves and QRS complexes have no constant relationship (see Fig. 484.14). The QRS duration may be prolonged, or it may be normal if the heartbeat is initiated high in the AV node or bundle of His.

The **prognosis** for congenital complete AV block is usually favorable; patients who have been observed to age 30-40 have lived normal, active lives. Some patients have episodes of exercise intolerance, dizziness, and syncope (Stokes-Adams attacks); syncope requires the implantation of a permanent cardiac pacemaker. Pacemaker implantation should be considered for patients who develop symptoms such as progressive cardiac dilation, prolonged pauses, or daytime average heart rates of ≤50 beats/min. In addition, prophylactic pacemaker implantation in adolescents is reasonable considering the low risk of the implant procedure and the difficulty in predicting who will develop sudden severe symptoms.

Cardiac pacing is recommended in neonates with low ventricular rates (≤55 beats/min), evidence of heart failure, wide complex rhythms, or CHD (with ventricular rates <70 beats/min). Isoproterenol, atropine, or epinephrine may be tried to increase the heart rate temporarily until pacemaker placement can be arranged. Transthoracic epicardial pacemaker implants have traditionally been used in infants; transvenous placement of pacemaker leads is available for young children. Postsurgical complete AV block can occur after any open heart procedure requiring suturing near the AV valves or crest of the ventricular septum. Postoperative heart block is initially managed with temporary pacing wires. The likelihood of a return of normal conduction after 10-14 days is low; a permanent pacemaker is recommended after that time.

Visit Elsevier eBooks+ at eBooks.Health.Elsevier.com for Bibliography.

Chapter 485

Sudden Death

Aarti S. Dalal and George F. Van Hare

Sudden death other than sudden infant death syndrome is rare in children. The causes of sudden death can be divided into traumatic versus nontraumatic in origin. *Traumatic* causes of sudden death are the most common in children; these include motor vehicle crashes, violent deaths, recreational deaths, and occupational deaths. *Nontraumatic* sudden deaths are often the result of specific cardiac causes. The incidence of sudden death varies from 0.8 to 6.2 per 100,000 per year in children and adolescents, in contrast to the higher incidence of **sudden cardiac death (SCD)** in adults of 1 per 1,000. Approximately 65% of sudden deaths are a result of heart-related problems in patients with either normal or congenitally (repaired, palliated, or unoperated) abnormal hearts. Competitive high school **sports** (basketball, soccer, football) are high-risk environmental factors. Common identifiable causes of death in competitive athletes include hypertrophic cardiomyopathy, with or without obstruction to left ventricular outflow, other cardiomyopathies, channelopathies, and anomalous coronary arteries; most are sudden *unexplained* deaths (Fig. 485.1). Table 485.1 lists other potential causes. These can be classified as *structural* abnormalities, including aortic stenosis and coronary artery abnormalities; myocardial disease, such as myocarditis; conduction system disease, including long QT syndrome; and miscellaneous causes, including seizures, pulmonary hypertension, and commotio cordis. Symptoms may be absent before the event but, if present, include syncope, chest pain, dyspnea, exercise intolerance, and palpitations. Patients may have a family history of heart disease (dilated or hypertrophic cardiomyopathy, long QT interval, arrhythmogenic [right ventricular] cardiomyopathy, Brugada or Marfan syndromes) or sudden unexplained death. Death often follows exertion or exercise. Some patients with sudden death during sports have anatomically normal hearts at autopsy; these patients should undergo genetic testing for hereditary arrhythmia syndromes.

MECHANISM OF SUDDEN DEATH

There are three recognized mechanisms of sudden death: *arrhythmic, nonarrhythmic cardiac* (circulatory and vascular causes), and *noncardiac.* **Ventricular fibrillation (VF)**, although the most common final cause of sudden death in adults, is only the final cause in 10–20% of children with SCD. More often, **bradycardia** leads either to VF or asystole (see Chapter 484).

CONGENITAL HEART DISEASE

Valvar aortic stenosis is the congenital defect most often associated with sudden death in children. Historically, approximately 5% of children with this disease die, although this has become quite rare in the modern era. A history of syncope, chest pain, and evidence of severe obstruction and left ventricular hypertrophy are risk factors (see Chapter 476.5).

Coronary artery anomalies are also frequently associated with sudden death in children and adolescents. The most common abnormality associated with sudden death is the origin of the left main coronary artery from the right sinus of Valsalva. The coronary artery takes an interarterial course between the aorta and pulmonary artery and may also have an intramural course, traveling within the ventricular myocardium. Exercise results in a rise in pulmonary and aortic pressure, and this is thought to compress the left main coronary artery and results in ischemia caused by compression or kinking. Anomalous origin of the right coronary artery from the left sinus of Valsalva is much more common, but only rarely is a cause of sudden death.

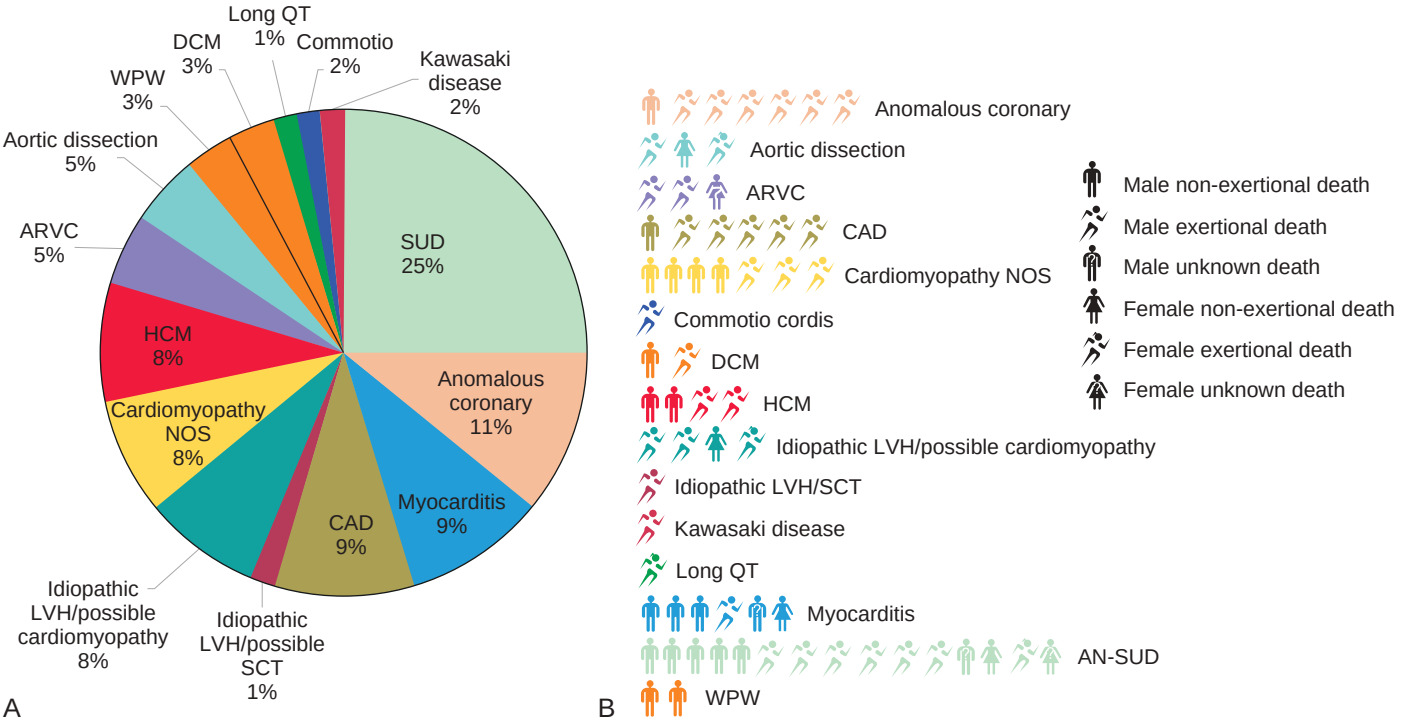

Fig. 485.1 A, Causes of sudden cardiac death in adolescent and young adult athletes. B, Cause and activity at time of death. One person figure equals one death; female figures follow male figures unless no male deaths were present. AN-SUD, Autopsy-negative sudden unexplained death; ARVC, arrhythmogenic right ventricular cardiomyopathy; CAD, coronary artery disease; DCM, dilated cardiomyopathy; HCM, hypertrophic cardiomyopathy; LVH, left ventricular hypertrophy; NOS, not otherwise specified; SCT, sickle cell trait; SUD, sudden unexplained death; WPW, Wolff-Parkinson-White syndrome. *(From Harmon KG, Asif I, Maleszewski JJ, et al. Incidence, cause, and comparative frequency of sudden cardiac death in National Collegiate Athletic Association athletes. Circulation. 2015;132:10–19, Fig. 2.)*

CARDIOMYOPATHY

All three major types of cardiomyopathy (hypertrophic, dilated, and restrictive) are associated with sudden death in the pediatric population; cardiac arrest or sudden death may be the initial manifestation of the cardiomyopathy (see Chapter 488.1).

Hypertrophic cardiomyopathy (HCM) is the most common cause of sudden death in the athletic adolescent in the United States. The annual risk of sudden death in young patients with HCM is 2% per year. Risk factors for sudden death include a history of syncope, symptoms, myocardial size, ventricular arrhythmias, and presentation at an early age. Many patients with HCM have left ventricular outflow tract obstruction (LVOTO). The mechanism of sudden death is arrhythmic and may be secondary to the development of dynamic obstruction with exercise and resultant loss of cardiac output, or may be related to cardiac ischemia. Thus patients without LVOTO are also at risk of sudden death. The **dilated cardiomyopathies** are also associated with SCD in children, although the risk is clearly lower than in adults.

Arrhythmogenic cardiomyopathy (also referred to as *arrhythmogenic right ventricular cardiomyopathy*) is a specific form of cardiomyopathy associated with exercise-induced ventricular arrhythmias and sudden death. It mainly affects the right ventricle, but the left can be involved as well. The diagnosis can be difficult; MRI, electrophysiology study, or endomyocardial biopsy is used with limited reliability. Pathologically, the disease is characterized by transmural fatty replacement of right ventricular myocardium, with patchy areas of fibrosis. Pathogenic variants are noted in ~60% of this autosomal dominant (with incomplete penetrance) disorder; associated genes include *PKP2, DSP, DSC2, DSG2, JUP, CTNNA3, PLN, TMEN43, SCN5A, CDH2,* and *DES*.

Myocarditis has often been found on pathology of patients with sudden death of unknown etiology. Symptoms before sudden death may be absent or may include overt heart failure or subtle findings such as a high heart rate. Pediatric patients with this disease may have complete atrioventricular block or ventricular arrhythmias.

Table 485.1 Potential Causes of Sudden Death in Infants, Children, and Adolescents

SIDS AND SIDS "MIMICS"
SIDS
Long QT syndromes*
Inborn errors of metabolism
Child abuse
Myocarditis
Ductal-dependent CHD
CORRECTED OR UNOPERATED CHD
Aortic stenosis
Tetralogy of Fallot
Transposition of great vessels (postoperative atrial switch)
Mitral valve prolapse
Hypoplastic left heart syndrome
Eisenmenger syndrome
CORONARY ARTERIAL DISEASE
Anomalous origin*
Anomalous tract (tunneled)
Kawasaki disease
Periarteritis
Arterial dissection
AORTOPATHIES (DISSECTION, RUPTURED AORTA)
Marfan syndrome
Loeys-Dietz syndrome
Takayasu aortitis
Smooth muscle dysfunction syndrome
Vascular Ehlers-Danlos syndrome
Familial thoracic aortic aneurysm and dissection syndrome
Mycotic aneurysm
MYOCARDIAL DISEASE
Myocarditis
Hypertrophic cardiomyopathy*
Dilated cardiomyopathy
Arrhythmogenic (right ventricular) cardiomyopathy
Lyme carditis
Takotsubo syndrome
Nonischemic left ventricular scar
Myocardial infarction
CONDUCTION SYSTEM ABNORMALITY/ARRHYTHMIA
Long QT syndromes*
Brugada syndrome
Proarrhythmic drugs
Wolff-Parkinson-White syndrome
Complete AV block
Commotio cordis
Idiopathic ventricular fibrillation
Arrhythmogenic (right ventricular) cardiomyopathy
Catecholaminergic polymorphic ventricular tachycardia
Heart tumor
MISCELLANEOUS
Seizures
Pulmonary hypertension
Pulmonary embolism
Heat stroke
Cocaine and other stimulant drugs or medications
Anorexia nervosa
Electrolyte disturbances

*Common.
CHD, Congenital heart disease; SIDS, sudden infant death syndrome.

CARDIAC ARRHYTHMIA

A primary conduction system abnormality may result in sudden death. Causes include Wolff-Parkinson-White (WPW) syndrome, long QT syndrome, short QT syndrome, and Brugada syndrome. Besides causing supraventricular tachycardia, **WPW syndrome** can result in atrial fibrillation with rapid conduction across the accessory pathway, leading to VF and sudden death (Fig. 485.2). This is unusual in pediatric patients but has an increasing incidence in adolescence. In adults, there is an incidence of sudden death in asymptomatic patients of 1 per 1,000 patient-years, but this rate may well be higher in children, who have not yet survived to adulthood. As digoxin and verapamil can augment conduction down accessory pathways, these drugs are contraindicated in WPW syndrome.

Long QT syndrome (LQTS; see Chapter 484), a group of channelopathies that affect ventricular repolarization, is also associated with sudden death (Fig. 485.3). The mechanism of sudden death is polymorphic ventricular tachycardia **(torsades de pointes)** (Fig. 485.4). An initial presentation of SCD is found in 9% of patients. Thus treatment of asymptomatic patients with a long QT interval on electrocardiogram (ECG) and positive family history is advised.

Acquired long QT interval may be seen in patients with marked electrolyte abnormalities, central nervous system injury, or starvation (including bulimia and anorexia nervosa). Medications can also result in prolongation of the QT interval (see Table 484.4). These patients are also at risk of malignant ventricular arrhythmias, and correction of the underlying problem or withdrawal of the inciting medication may be necessary to reduce the risk of sudden death.

Brugada syndrome, an autosomal dominant disorder associated with SCD, often occurs with fever, drugs, nighttime electrolyte disorders, or after a large meal (Fig. 485.5). The most common pathogenic variant is a loss of function in *SCN5A,* seen in up to 30% of patients. Typical ECG findings include *coved* ST segment elevations in leads V_1-V_3; death results from either VF or ventricular tachycardia.

MISCELLANEOUS CAUSES

Commotio cordis is an often fatal condition that follows blunt nonpenetrating trauma to the chest (e.g., from a baseball or hockey puck). Occasionally, innocent-appearing chest blows incurred at home or at a playground may be fatal. Patients experience immediate VF in the absence of identifiable cardiac trauma (contusion, hematoma, lacerated coronary artery). This risk is highest in children before adolescence. Historically, death results from VF that is unresponsive to resuscitative efforts in 85–90% of children. Immediate direct current (DC) defibrillation may be effective, if available, particularly if employed

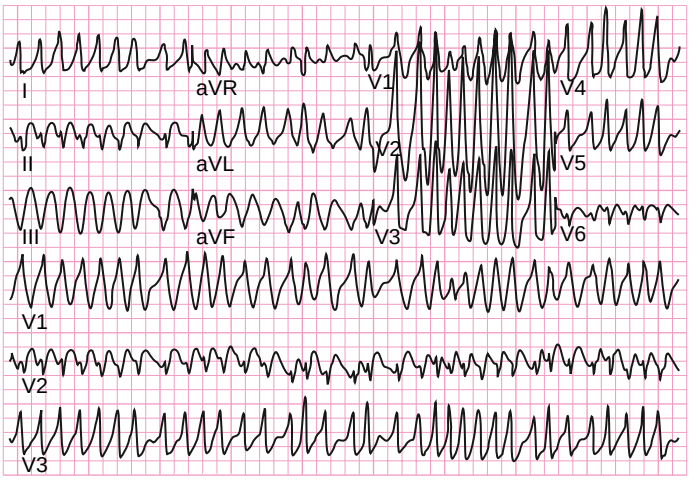

Fig. 485.2 Atrial fibrillation in a patient with Wolff-Parkinson-White syndrome and rapid conduction to the ventricle. Note the wide QRS complexes, a result of full preexcitation, and the irregularly irregular ventricular response, caused by the atrial fibrillation.

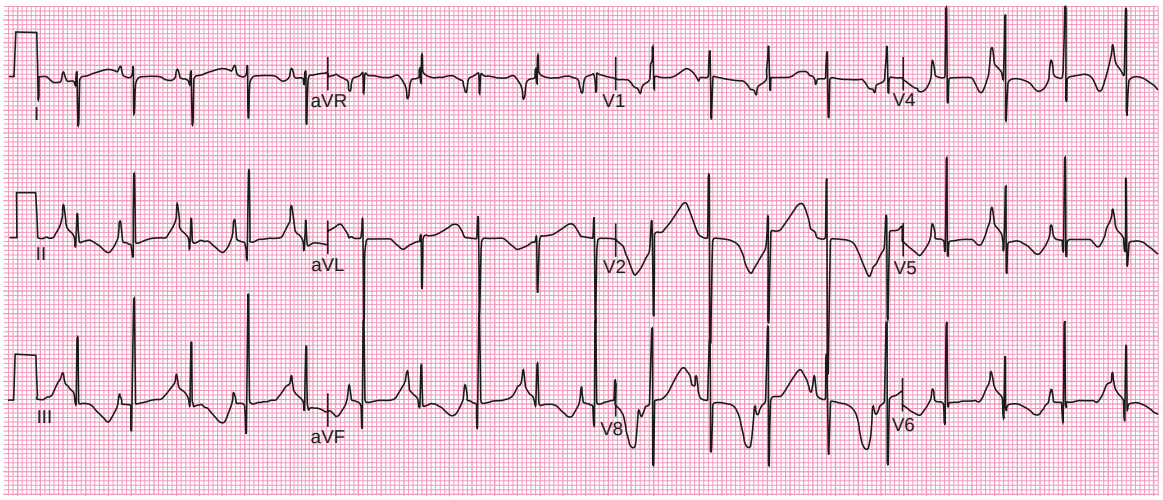

Fig. 485.3 Long QT syndrome in a neonate. QTc is markedly prolonged, and T-wave alternans is evident.

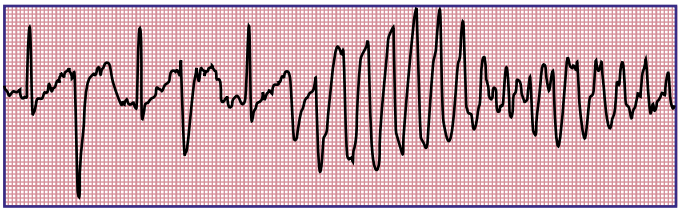

Fig. 485.4 Episode of torsades de pointes in a patient with long QT syndrome.

immediately; however, it is reported to be successful in only approximately 25% of cases.

EVALUATION AND THERAPY FOR RESUSCITATED PATIENTS

It is important to focus therapy on potentially reversible causes of sudden death. These include correction of major hemodynamic defects, pacing therapy for a patient with bradycardia, or supportive therapy for myocarditis. Unfortunately, reversible causes are not always found in young cardiac arrest survivors. Adding to this dilemma is the limited ability to predict antiarrhythmic drug response or risk of recurrence. The **implantable-cardioverter defibrillator** (ICD) is the therapy of choice for survivors of most forms of arrhythmic sudden death, with the exception of correctable causes such as WPW (see Chapter 484).

MEDICATION FOR ATTENTION-DEFICIT/HYPERACTIVITY DISORDER

Concern has been raised that stimulant medications prescribed for children with attention-deficit/hyperactivity disorder might increase the risk of sudden death (see Chapter 50). The concern arises from a limited number of reports to the U.S. Food and Drug Administration (FDA) of sudden death of unknown etiology in individuals taking stimulant medications, mostly adults. In a few cases, left ventricular hypertrophy caused by hypertension, coarctation of the aorta, or HCM has been identified at postmortem examination. No prospective studies support the notion that these medications increase the risk, and there is no evidence that ECG screening will reliably identify a subgroup at risk. Some have suggested ECG screening of children before starting these medications, but there is no consensus that such an approach is effective. The current recommendations do not support ECG screening before the initiation of stimulant medication in the absence of a positive cardiac history.

PREVENTION OF SUDDEN DEATH

The probability of survival to hospital discharge for a young patient who experiences an out-of-hospital cardiac arrest is <20%. The

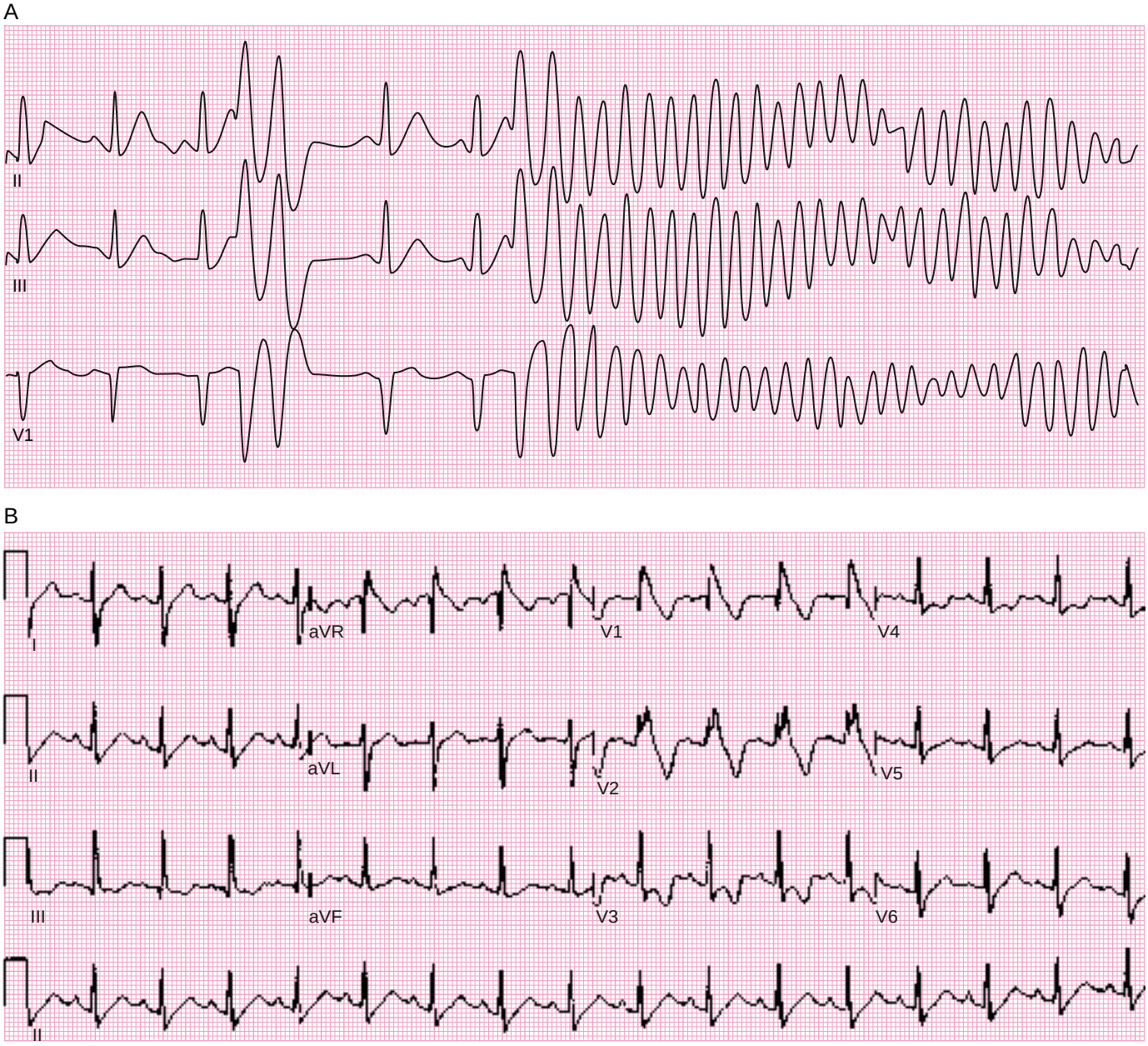

Fig. 485.5 Brugada syndrome. **A,** Frequent ventricular ectopy and sustained polymorphic ventricular tachycardia. **B,** Persistent coved-type ST segment elevation in lead V_1 and V_2 characteristic of Brugada type I. *(A from Talib S, van de Poll SE. Brugada syndrome diagnosed after Ramadan. Lancet. 2013;382:100.)*

presence of immediate **automatic external defibrillators** (AEDs), when combined with standard cardiopulmonary resuscitation (CPR) at the site of exercise (gym, track, basketball, or football arena), improves survival substantially. Thus identifying patients at risk is extremely important. The American Academy of Pediatrics Policy Statement on Sudden Death in the Young provides primary care providers with guidelines screening for life-threatening conditions, regardless of athletic status.

Some of the more common causes of sudden death in children and adolescents can be identified from the patient's history (prodromal symptoms), the family history, and physical examination. The American Heart Association (AHA) has a recommended 14-point preparticipation evaluation (PPE) that includes questions about personal and family history in addition to physical exam findings (Table 485.2). The screening for sudden cardiac arrest and SCD should be performed at the time of PPE or upon entry into middle school and high school. The AAP's Preparticipation Physical Evaluation form is available at https://www.aap.org/. Of paramount importance is the careful evaluation of any child who experiences **syncope** in association with **exercise** because this may be the last opportunity to diagnose a life-threatening condition in such a patient.

Patient avoidance of high-risk behavior (cocaine use, anorexia nervosa) and knowledge of drug side effects or drug interactions and contraindications are critical. Chest-protecting equipment has not been shown to prevent commotio cordis. Prompt bystander CPR and rapid defibrillation with an AED has the highest chance of leading to survival. Family survivors of victims of sudden death should also be evaluated for genetic etiologies of SCD (e.g., LQTS, HCM).

The 14-element screening checklist underperforms and may miss high-risk cardiac lesion. Depending on the population (elite vs recreational athletes) and the screening protocol (checklist, with ECG, with echocardiogram, with cardiac MRI), the incidence of

Table 485.2 Fourteen-Element Cardiovascular Screening Checklist for Congenital and Genetic Heart Disease

PERSONAL HISTORY
1. Chest pain/discomfort/tightness/pressure related to exertion
2. Unexplained syncope/near-syncope: Judged not to be of neurocardiogenic (vasovagal) origin; of particular concern when occurring during or after physical exertion
3. Excessive exertional and unexplained dyspnea/fatigue or palpitations, associated with exercise
4. Prior recognition of a heart murmur
5. Elevated systemic blood pressure
6. Prior restriction from participation in sports
7. Prior testing for the heart, ordered by a physician
FAMILY HISTORY
8. Premature death (sudden and unexpected, or otherwise) before age 50 attributable to heart disease in at least one relative
9. Disability from heart disease in close relative <50 yr of age
10. Hypertrophic or dilated cardiomyopathy, long QT syndrome, or other ion channelopathies, Marfan syndrome, or clinically significant arrhythmias; specific knowledge of certain cardiac conditions in family members
PHYSICAL EXAMINATION
11. Heart murmur: Refers to heart murmurs judged likely to be organic and unlikely to be innocent; auscultation should be performed with the patient in both the supine and standing positions (or with Valsalva maneuver), specifically to identify murmurs of dynamic left ventricular outflow tract obstruction
12. Femoral pulses to exclude aortic coarctation
13. Physical stigmata of Marfan syndrome
14. Brachial artery blood pressure (sitting position): Preferably taken in both arms

From American College of Cardiology: ACC/AHA release recommendations for congenital and genetic heart disease screenings in youth. https://www.acc.org/latest-in-cardiology/articles/2014/09/15/14/24/acc-aha-release-recommendations-for-congenital-and-genetic-heart-disease-screenings-in-youth

at-risk cardiac lesions varies from 0.3–0.4% to 1.4%. The use of a preparticipation ECG for the detection of those athletes at risk for sudden death has long been controversial. Because many athletes either have no pre-event symptoms or are unwilling to admit to symptoms for concern of not being able to play, some have proposed that the ECG may identify a small but at-risk group with HCM or prolonged QT, Brugada, or WPW syndromes. These ECGs would fail to identify patients with phenotype-negative LQTS or catecholaminergic polymorphic ventricular tachycardia, as well as coronary artery anomalies. In addition, many false positives may be identified, requiring further evaluation to exclude worrisome diagnoses. Preparticipation ECG testing is mandatory in several European countries but not in the United States, although many athletic groups with varsity-level or professional membership (e.g., collegiate or professional sports organizations) require such testing as part of the medical evaluation. If the ECG is abnormal, **echocardiography** is performed. Cost-effectiveness studies suggest that the cost for implementation of a national program in the United States would be prohibitive because of the low incidence of sudden death in the pediatric population, the high rate of false-positive ECGs, and the difficulty in definitively excluding cardiac disease in patients with borderline ECG findings. Although studies of regional or national screening programs have suggested some benefit (e.g., the Veneto region of Italy), others have failed to demonstrate any effect of screening on the background incidence of sudden death in young individuals.

Visit Elsevier eBooks+ at eBooks.Health.Elsevier.com for Bibliography.

Section 5

Acquired Heart Disease

Chapter 486

Infective Endocarditis*

Erin Faherty and Thomas S. Murray

Infective endocarditis includes acute and subacute *bacterial* endocarditis, as well as *nonbacterial* endocarditis, caused by viruses, fungi, and other microbiologic agents. It is a significant cause of morbidity and mortality in children and adolescents despite advances in the management and prophylaxis of the disease with antimicrobial agents. The inability to eradicate infective endocarditis by prevention or early treatment stems from several factors. The disease represents a complex interplay between a pathogen and host factors such as endothelial disruption and immune function that is still not completely understood; the nature of the infecting organism changes over time; and diagnosis may be difficult during early stages and thus is often delayed until a more serious manifestation has developed. Special risk groups include intravenous drug users; survivors of cardiac surgery, especially those with mechanical prosthesis; patients taking immunosuppressant medications; and patients who require chronic intravascular catheters. Some patients have endocarditis on a native valve previously thought to be healthy but found to have mild structural abnormalities on surgical inspection.

ETIOLOGY

Viridans-type streptococci (α-hemolytic streptococci groups such as *Streptococcus mitis, S. anginosus, S. mutans, S. salivarius, S. bovis, S. sanguinis,* and *S. mitis*) and *Staphylococcus aureus* remain the leading causative agents for endocarditis in pediatric patients. Other organisms cause endocarditis less frequently, and in approximately 6% of cases, blood cultures are negative for any organisms (Table 486.1). No relationship exists between the infecting organism and the type of congenital defect, duration of illness, or age of the child. Staphylococcal endocarditis is more common in patients with no underlying heart disease. Viridans group streptococcal infection is more common after dental procedures; enterococci are seen more often after lower bowel or genitourinary manipulation.

Pseudomonas aeruginosa or *Serratia marcescens* is seen more frequently in intravenous drug users, and fungal organisms are encountered after open heart surgery. Coagulase-negative staphylococci are common in the presence of an indwelling central venous catheter.

EPIDEMIOLOGY

Infective endocarditis is often a complication of congenital or rheumatic heart disease but can also occur in children without any abnormal valves or cardiac malformations. In developed countries, congenital heart disease (CHD) is the overwhelming predisposing factor. Endocarditis is rare in infancy; in this age-group it usually follows open heart surgery or is associated with a central venous line.

Patients with congenital heart lesions where there is turbulent blood flow because of a hole or stenotic orifice, especially if there is a high-pressure gradient across the defect, are most susceptible to

* The authors would like to thank Dr Robert S. Baltimore for his work on previous editions of this chapter.

Table 486.1 Bacterial Agents in Pediatric Infective Endocarditis

COMMON: NATIVE VALVE OR OTHER CARDIAC LESIONS
Viridans group streptococci *(S. mutans, S. sanguinis, S. mitis)*
Staphylococcus aureus
Group D streptococcus (enterococcus) *(S. bovis, S. faecalis)*
UNCOMMON: NATIVE VALVE OR OTHER CARDIAC LESIONS
Streptococcus pneumoniae
Haemophilus influenzae
Coagulase-negative staphylococci
Abiotrophia defectiva (nutritionally variant streptococcus)
*Coxiella burnetii (Q fever)**
Neisseria gonorrhoeae
*Brucella**
*Chlamydia psittaci**
*Chlamydia trachomatis**
*Chlamydia pneumoniae**
Legionella*
Bartonella*
*Tropheryma whipplei** (Whipple disease)
HACEK group†
*Streptobacillus moniliformis**
*Pasteurella multocida**
Campylobacter fetus
Culture negative (6% of cases)
PROSTHETIC VALVE
Staphylococcus epidermidis
Staphylococcus aureus
Viridans group streptococcus
Pseudomonas aeruginosa
Serratia marcescens
Diphtheroids
*Legionella spp.**
HACEK group†
Fungi‡

*These fastidious bacteria plus some fungi may produce culture-negative endocarditis. Detection may require special media, incubation for >7 days, polymerase chain reaction on blood or valve for 16SrRNA (bacteria) or 18SrRNA (fungi), or serologic tests.
†The HACEK group includes Haemophilus spp. (H. paraphrophilus, H. parainfluenzae, H. aphrophilus), Actinobacillus actinomycetemcomitans, Cardiobacterium hominis, Eikenella corrodens, and Kingella spp.
‡Candida spp., Aspergillus spp., Pseudallescheria boydii, Histoplasma capsulatum.

endocarditis. This turbulent flow traumatizes the vascular endothelium, creating a substrate for deposition of fibrin and platelets, leading to the formation of a *nonbacterial thrombotic embolus (NBTE)* that is thought to be the initiating lesion for infective endocarditis. Biofilm forms on the surface of implanted mechanical devices such as valves, catheters, or pacemaker wires, which also serves as the adhesive substrate for infection. The development of transient bacteremia then colonizes this NBTE or biofilm, leading to proliferation of bacteria within the lesion. Bacterial surface proteins, such as the FimA antigen in viridans streptococci, act as adhesion factors to the NBTE or biofilm, after which bacteria can rapidly proliferate within the vegetation. Given the heavy colonization of mucosal surfaces (the oropharynx or gastrointestinal, vaginal, or urinary tracts) by potentially pathogenic bacteria, these surfaces are thought to be the origin of this transient bacteremia. There is controversy over the extent to which daily activities (e.g., brushing or flossing the teeth) vs invasive procedures (e.g., dental cleaning or surgery) contribute to this bacteremia. Transient bacteremia is reported to occur in 20–68% of patients after tooth brushing and flossing, and even in 7–51% of patients after chewing food. The magnitude of this bacteremia is also similar to that resulting from dental procedures. Maintenance of good oral hygiene may be a more important factor in decreasing the frequency and magnitude of bacteremia. Case reports suggest that body piercing and tattoos may be additional risk factors.

Children at **highest risk** of adverse outcome after infective endocarditis include those with prosthetic cardiac valves or other prosthetic material used for cardiac valve repair, unrepaired cyanotic CHD (including those palliated with shunts and conduits), completely repaired defects with prosthetic material or device during the first 6 months after repair, repaired CHD with residual defects at or adjacent to the site of a prosthetic patch or device, valve stenosis or insufficiency occurring after heart transplantation, permanent valve disease from **rheumatic fever** (mitral stenosis, aortic regurgitation), and previous infective endocarditis. Patients with high-velocity blood flow lesions such as ventricular septal defects (VSDs) and aortic stenosis are also at high risk. In older patients, congenital bicuspid aortic valves and mitral valve prolapse with regurgitation pose additional risks for endocarditis. Surgical correction of CHD may reduce but does not eliminate the risk of endocarditis, except for the repair of a simple atrial septal defect or patent ductus arteriosus without prosthetic material.

In ~30% of patients with infective endocarditis, a predisposing factor is presumably recognized. Although a preceding dental procedure may be identified in 10–20% of patients, the time of the procedure may range from 1 to 6 months before the onset of symptoms—thus the continued controversy over the absolute risk of infective endocarditis after dental procedures. Primary bacteremia with *S. aureus* is thought to be another risk for endocarditis. The occurrence of endocarditis directly after most routine heart surgery is relatively low, but it can be an antecedent event, especially if prosthetic material is used. In the small group of patients with culture-negative endocarditis, epidemiologic or exposure factors may contribute to the diagnosis (Table 486.2).

CLINICAL MANIFESTATIONS

Table 486.3 outlines the manifestations of infective endocarditis. Early manifestations are usually mild, especially when viridans group streptococci are the infecting organisms. Prolonged fever without other manifestations (except occasionally weight loss) that persists for as long as several months may be the only symptom. Alternatively, with pathogenic organisms such as *S. aureus,* the onset may be acute and severe, with high intermittent fever and prostration. Usually, the onset and course vary between these two extremes. Fever in the absence of signs of URI in a patient with congenital heart disease must be considered as endocarditis. The symptoms are often nonspecific and consist of low-grade fever with afternoon elevations, fatigue, myalgia, arthralgia, headache, and at times chills, nausea, and vomiting. The cardiac examination often depends on the underlying heart disease and the location of infection. A new pathologic murmur or changing heart murmur may be appreciated and can be associated with heart failure. Of note, children with palliated congenital heart disease, such as those palliated with a shunt, may not present with a change in murmur. Splenomegaly and petechiae are seen in <50% of patients. Serious neurologic complications such as embolic strokes, cerebral abscesses, mycotic aneurysms, and hemorrhage are most often associated with staphylococcal disease and may be late manifestations. Meningismus, increased intracranial pressure, altered sensorium, and focal neurologic signs are manifestations of these complications. Meningitis may be seen together with pneumococcal endocarditis. Myocardial abscesses may occur with staphylococcal disease and may damage the cardiac conducting system, causing heart block, or may rupture into the pericardium and produce purulent pericarditis. Pulmonary (with right-sided endocarditis) and systemic emboli (with left-sided lesions) are infrequent, except with fungal disease.

Many of the classic **skin findings** develop late in the disease; they are seldom seen in appropriately treated patients. Such manifestations include **Osler nodes** (tender, pea-size intradermal nodules in the pads of the fingers and toes), **Janeway lesions** (painless, small,

Table 486.2 Epidemiologic Clues in the Etiologic Diagnosis of Culture-Negative Endocarditis

EPIDEMIOLOGIC FEATURE	COMMON MICROORGANISM
Injection drug use (IDU)	*Staphylococcus aureus*, including community-acquired oxacillin-resistant strains Coagulase-negative staphylococci β-Hemolytic streptococci Fungi Aerobic gram-negative bacilli, including *Pseudomonas aeruginosa* Polymicrobial
Indwelling cardiovascular medical devices	*S. aureus* Coagulase-negative staphylococci Fungi Aerobic gram-negative bacilli *Corynebacterium* spp.
Genitourinary disorders, infection, and manipulation, including pregnancy, delivery, and abortion	*Enterococcus spp.* Group B streptococci *(S. agalactiae)* *Listeria monocytogenes* Aerobic gram-negative bacilli *Neisseria gonorrhoeae*
Chronic skin disorders, including recurrent infections	*S. aureus* β-Hemolytic streptococci
Poor dental health, dental procedures	Viridans group streptococci Nutritionally variant streptococci *Abiotrophia defectiva* *Granulicatella* spp. *Gemella* spp. HACEK organisms
Alcohol use, cirrhosis	*Bartonella spp.* *Aeromonas spp.* *Listeria spp.* *Streptococcus pneumoniae* *β-Hemolytic* streptococci
Burns	*S. aureus* Aerobic gram-negative bacilli, including *P. aeruginosa* Fungi
Diabetes mellitus	*S. aureus* β-Hemolytic streptococci *S. pneumoniae*
Early (≤1 yr) prosthetic valve placement	Coagulase-negative staphylococci *S. aureus* Aerobic gram-negative bacilli Fungi *Corynebacterium* spp. *Legionella* spp.
Late (>1 yr) prosthetic valve placement	Coagulase-negative staphylococci *S. aureus* *Viridans group streptococci* *Enterococcus* spp. Fungi *Corynebacterium* spp.
Dog or cat exposure	*Bartonella spp.* *Pasteurella spp.* *Capnocytophaga spp.*
Contact with contaminated milk or infected farm animals	*Brucella spp.* *Coxiella burnetii* *Erysipelothrix spp.*
Homeless, body lice	*Bartonella spp.*
HIV/AIDS	*Salmonella spp.* *S. pneumoniae* *S. aureus*
Pneumonia, meningitis	*S. pneumoniae*
Solid-organ transplantation	*S. aureus* *Aspergillus fumigatus* *Enterococcus spp.* *Candida spp.*
Gastrointestinal lesions	*Streptococcus gallolyticus (bovis)* *Enterococcus spp.* *Clostridium septicum*

HACEK, *Haemophilus* spp., *Aggregatibacter* spp., *Cardiobacterium hominis, Eikenella corrodens,* and *Kingella* spp.; HIV/AIDS, human immunodeficiency virus infection and acquired immunodeficiency syndrome.
From Baddour LM, Wilson WR, Bayer AS, et al. Infective endocarditis in adults: diagnosis, antimicrobial therapy, and management of complications. A scientific statement for healthcare professionals from the American Heart Association. *Circulation*. 2015;132:1435–1486.

erythematous, or hemorrhagic lesions on the palms and soles), and **splinter hemorrhages** (linear lesions beneath the nails). These lesions may represent vasculitis produced by circulating antigen-antibody complexes. Retinal lesions are seen in 10–20%.

In the newborn infant the major risk factor for infective endocarditis is the presence of a central intravenous line. Thus prematurity is a risk, as are other severe congenital abnormalities. CHD is less likely to be the underlying condition than it is for older children. The clinical conditions are variable and may be indistinguishable from sepsis or congestive heart failure. Identification of infective endocarditis is most often based on a high index of suspicion during evaluation of an infection in a child with an underlying risk factor.

DIAGNOSIS

The critical information for appropriate treatment of infective endocarditis is obtained from blood cultures. All other laboratory data are secondary in importance (see Table 486.3). Blood specimens for culture should be obtained as promptly as possible, even if the child feels well and has no other physical findings. Although increased blood volume can increase the sensitivity of the blood culture, smaller volumes are reasonable in neonates and small children. When small volumes of blood are present, a single aerobic blood culture bottle should be inoculated. Ideally, for patients weighing 2-12.7 kg, the volume of the first blood culture is 4 mL (repeat culture is 2 mL); for patients 12.8-36.3 kg it is 10 mL for initial and repeat, and for patients >36.3 kg, 20-30 mL for both. Three to five separate blood collections should be obtained after careful preparation of the phlebotomy site. Contamination presents a special problem because bacteria found on the skin may cause infective endocarditis. The timing of collections is not important because bacteremia can be expected to be relatively constant. In 90% of cases of endocarditis, the causative agent is recovered from the first two blood cultures. Bacteremia is low grade in 80% (<100 colony-forming units/mL of blood). The laboratory should be notified that endocarditis is suspected so that, if necessary, the blood can be cultured on enriched media for longer than usual (>5 days) to detect nutritionally deficient and fastidious bacteria or fungi.

Table 486.3 Manifestations of Infectious Endocarditis

HISTORY
Prior congenital or rheumatic heart disease
Preceding dental, urinary tract, or intestinal procedure
Intravenous drug use
Central venous catheter
Prosthetic heart valve
SYMPTOMS
Fever
Chills
Chest and abdominal pain
Arthralgia, myalgia
Dyspnea
Malaise, weakness
Night sweats
Weight loss
CNS manifestations (stroke, seizures, headache)
SIGNS
Elevated temperature
Tachycardia
Embolic phenomena (Roth spots, petechiae, splinter nail bed hemorrhages, Osler nodes, CNS or ocular lesions)
Janeway lesions
New or changing murmur
Splenomegaly
Arthritis
Heart failure
Arrhythmias
Metastatic infection (arthritis, meningitis, mycotic arterial aneurysm, pericarditis, abscesses, septic pulmonary emboli)
Clubbing
LABORATORY STUDIES
Positive blood culture
Elevated erythrocyte sedimentation rate; may be low with heart or renal failure
Elevated C-reactive protein
Anemia
Leukocytosis
Immune complexes
Hypergammaglobulinemia
Hypocomplementemia
Cryoglobulinemia
Rheumatoid factor
Hematuria
Renal failure: azotemia, high creatinine (glomerulonephritis)
Chest radiograph: bilateral infiltrates, nodules, pleural effusions
Echocardiographic evidence of valve vegetations, prosthetic valve dysfunction or leak, myocardial abscess, or new-onset valve insufficiency

CNS, Central nervous system.

Table 486.4 Diagnostic Approach to Uncommon Pathogens Causing Endocarditis

PATHOGEN	DIAGNOSTIC PROCEDURE
Brucella spp.	Blood cultures; serology; culture, immunohistology, and mNGS of surgical material or blood/plasma
Coxiella burnetii	Serology (IgG phase I >1 in 800); tissue culture, immunohistology, and mNGS of surgical material or blood/plasma
Bartonella spp.	Blood cultures; serology; culture, immunohistology, and mNGS of surgical material or blood/plasma
Chlamydia spp.	Serology; culture, immunohistology, and mNGS of surgical material or blood/plasma
Mycoplasma spp.	Serology; culture, immunohistology, and mNGS of surgical material or blood/plasma
Legionella spp.	Blood cultures; serology; culture, immunohistology, and mNGS of surgical material or blood/plasma
Tropheryma whipplei	Histology and mNGS of surgical material or blood/plasma

IgG, Immunoglobulin G; mNGS, metagenomic next-generation sequencing; PCR, polymerase chain reaction
From Moreillon P, Que YA. Infective endocarditis *Lancet*. 2004;363:139–148.

Although bacteremia may occur in the absence of endocarditis, bacteremia secondary to *S. mutans, S. bovis I, S. mitis, S. sanguinis,* and *S. aureus* (in the absence of focal musculoskeletal infection) is highly concerning for endocarditis. Antimicrobial pretreatment of the patient reduces the yield of blood cultures by 50–60%. Other specimens that may be cultured include scrapings from cutaneous lesions, urine, synovial fluid, abscesses, and in the presence of manifestations of meningitis, cerebrospinal fluid. Serologic diagnosis or metagenomic next-generation sequencing or polymerase chain reaction for 16S and 28S ribosomal RNA (rRNA) for bacteria and fungi, respectively, of resected valve tissues is necessary in patients with unusual or fastidious microorganisms when there is suspicion of culture-negative endocarditis or if the patient has received prior antibiotics (Table 486.4 and Fig. 486.1). Metagenomic next-generation sequencing on blood and plasma may help identify pathogens in patients with culture-negative endocarditis. Suspicion should be high when evaluating infection in a child with an underlying contributing factor.

Echocardiography remains the mainstay of diagnosis. Two-dimensional echocardiography can identify the size, shape, location, and mobility of the lesion; when combined with Doppler interrogation, the presence of valve dysfunction (regurgitation, obstruction) can be determined. (Fig. 486.2). In pediatric patients, transthoracic echocardiogram is usually adequate for detection of lesions, especially for children <60 kg. Transesophageal echocardiogram should be considered in pediatric patients with limited transthoracic views; it is superior to transthoracic echocardiogram in evaluating prosthetic valves or complications of infective endocarditis, such as aortic root abscess. Intracardiac echocardiography can be useful for patients with suspicion for an infected pacemaker lead or implanted percutaneous pulmonary valve. Cardiac MRI may be useful in suspected perivalvular complications, and PET-CT may aid in the diagnosis of endocarditis for those patients with prosthetic valves.

Echocardiography may also be helpful in predicting embolic complications, given that lesions >1 cm and fungating masses are at greatest risk for embolization. The absence of vegetations does not exclude endocarditis, and vegetations are often not visualized in the early phases of the disease or in patients with complex congenital heart lesions. Electrocardiography should be part of the evaluation and can demonstrate new rhythm disorders such as **ventricular**

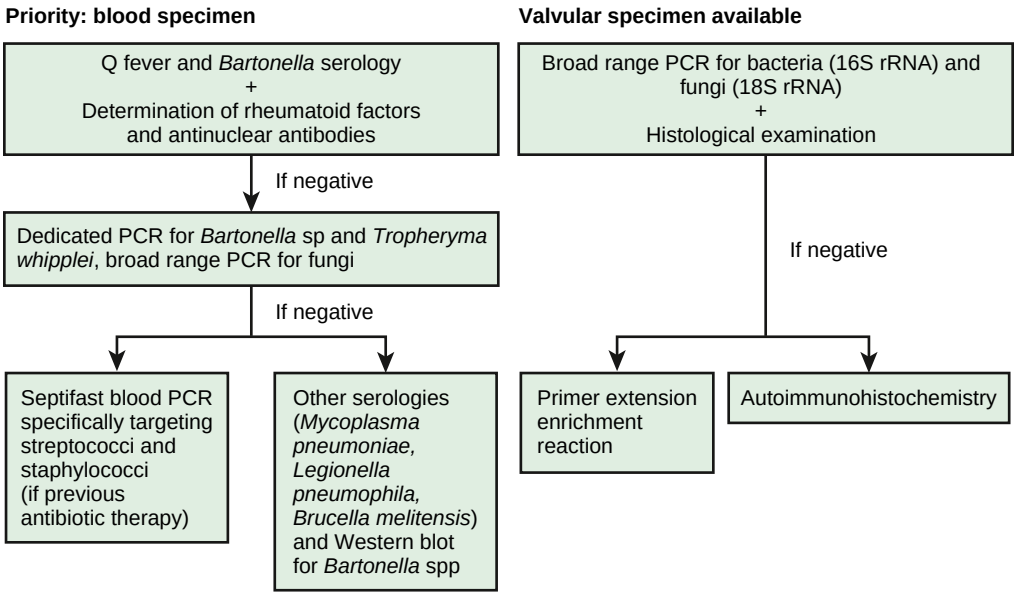

Fig. 486.1 Algorithm of diagnostic tests applied to clinical specimens for the identification of the causative agents of **blood culture–negative endocarditis**. Septifast, LightCycler SeptiFast (Roche). Serum should be considered a priority specimen, with Q fever and *Bartonella* serologic analysis routinely done. We also suggest that detection of antinuclear antibodies and rheumatoid factor be routinely done for the diagnosis of noninfective endocarditis. *(From Thuny F, Grisoli D, Collart F, et al. Management of infective endocarditis: challenges and perspectives. Lancet. 2012;379:965–975, Fig. 2.)*

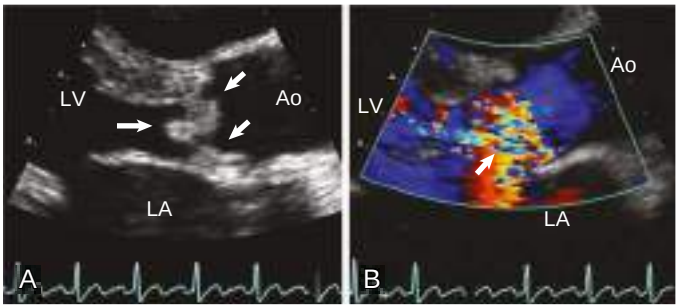

Fig. 486.2 Infective endocarditis of the native aortic valve. **A,** Transthoracic echocardiography shows vegetations *(small arrows)* attached to the left ventricular aspects of the valve cusps and prolapsing into the left ventricular outflow tract *(large arrow)* during diastole. **B,** Severe aortic regurgitation *(arrow)* is shown by color Doppler. Ao, Ascending aorta; LA, left atrium; LV, left ventricle. *(From Baddour LM, Freeman WK, Suri RM, Wilson WR. Cardiovascular infections. In: Zipes DP, Libby P, Bonow RO, et al., eds. Braunwald's Heart Disease, 11th ed. Philadelphia: Elsevier; 2019: Fig. 73-1, p. 1490.)*

ectopy and conduction disorders such as **complete heart block**. The presence of either of these findings, particularly heart block, may signal a serious or even life-threatening complication of endocarditis.

The **Duke criteria** help in the diagnosis of endocarditis (Table 486.5). Two major criteria, one major and three minor, or five minor criteria suggest definite endocarditis. Additional minor criteria to those listed include newly diagnosed clubbing, splenomegaly, splinter hemorrhages, or petechiae; high erythrocyte sedimentation rate or C-reactive protein level; presence of central nonfeeding or peripheral lines; and microscopic hematuria.

PROGNOSIS AND COMPLICATIONS

Despite the use of antibiotic agents, mortality remains high, up to 25%. Serious morbidity occurs in 50–60% of children with documented infective endocarditis; the most common is heart failure caused by worsening valvular regurgitation due to aortic or mitral valve vegetations, accompanied by ventricular dysfunction. Myocardial abscesses and toxic myocarditis may also lead to heart failure without characteristic changes in auscultatory findings and, occasionally, to life-threatening arrhythmias. Systemic emboli, often with central nervous system manifestations, are a major threat. Pulmonary emboli may occur in children with VSD or tetralogy of Fallot, although massive life-threatening pulmonary embolization is rare. Other complications include mycotic aneurysms, rupture of a sinus of Valsalva, obstruction of a valve secondary to large vegetations, acquired VSD, and heart block as a result of involvement (abscess) of the conduction system. Additional complications include meningitis, osteomyelitis, arthritis, renal abscess, purulent pericarditis, and immune complex–mediated glomerulonephritis.

TREATMENT

Antibiotic therapy should be instituted immediately once a definitive diagnosis of infectious endocarditis is made. When virulent organisms are responsible, small delays may result in progressive endocardial damage and are associated with a greater likelihood of severe complications. The choice of antibiotics, method of administration, and length of treatment should be coordinated with consultants from both cardiology and infectious diseases (Tables 486.6 and 486.7). Empirical therapy after appropriate blood cultures are drawn but before the identifiable agent is recovered may be initiated with vancomycin plus gentamicin in patients without a prosthetic valve and when there is a high risk of *S. aureus,* enterococcus, or viridans streptococci (the three most common organisms). High serum bactericidal levels must be maintained long enough to eradicate organisms that are growing in relatively inaccessible avascular vegetations. Between 5 and 20 times the in vitro minimal inhibitory concentration must be produced at the site of infection to destroy bacteria growing at the core of these lesions. Several weeks are required for a vegetation to organize completely; therapy must be continued through this period so that recrudescence can be avoided. A total of 4-6 weeks of treatment is usually recommended. Depending on the clinical and laboratory responses, antibiotic therapy may require modification, and some patients require more

Table 486.5 Definition of Infective Endocarditis (IE): Modified Duke Criteria

DEFINITE INFECTIVE ENDOCARDITIS

Pathologic Criteria

- Microorganisms demonstrated by results of cultures or histologic examination of a vegetation, a vegetation that has embolized, or an intracardiac abscess specimen; *or*
- Pathologic lesions; vegetation, or intracardiac abscess confirmed by results of histologic examination showing active endocarditis

Clinical Criteria

- Two major criteria, *or*
- One major criterion and three minor criteria, *or*
- Five minor criteria

Possible Infective Endocarditis

- One major criterion and one minor criterion, *or*
- Three minor criteria

Rejected Diagnosis of Infective Endocarditis

- Firm alternative diagnosis explaining evidence of suspected IE, *or*
- Resolution of IE syndrome with antibiotic therapy for ≤4 days, *or*
- No evidence of IE at surgery or autopsy, on antibiotic therapy for ≤4 days, *or*
- Does not meet criteria for possible IE

DEFINITION OF TERMS USED IN MODIFIED DUKE CRITERIA

Major Criteria

- Blood culture findings positive for IE
  Typical microorganisms consistent with IE from two separate blood cultures:
  - Viridans streptococci, *Streptococcus gallolyticus* (formerly known as *S. bovis*), *Staphylococcus aureus,* HACEK group, *or*
  - Community-acquired enterococci, in the absence of a primary focus, *or*

  Microorganisms consistent with IE from persistently positive blood culture findings, defined as:
  - At least two positive culture findings of blood samples drawn >12 hr apart, *or*
  - Three or most of at least four separate culture findings of blood (with first and last sample drawn ≥1 hr apart)
  - Single positive blood culture for *Coxiella burnetii* or anti–phase I IgG titer ≥1:800
- Evidence of endocardial involvement
  Echocardiographic findings positive for IE (TEE recommended in patients with prosthetic valves, rated at least *possible* IE by clinical criteria or *complicated* IE [paravalvular abscess]; TTE as first test in other patients), defined as follows:
  - Oscillating intracardiac mass on valve or supporting structures, in the path of regurgitant jets, or on implanted material in the absence of an alternative anatomic explanation, *or*
  - Abscess, *or*
  - New partial dehiscence of prosthetic valve

  New valvular regurgitation; worsening or changing of preexisting murmur not sufficient

Minor Criteria

- Predisposition, predisposing heart condition, or intravenous drug use
- Fever—temperature >38°C
- Vascular phenomena, major arterial emboli, septic pulmonary infarcts, mycotic aneurysm, intracranial hemorrhage, conjunctival hemorrhages, and Janeway lesions
- Immunologic phenomena: glomerulonephritis, Osler nodes, Roth spots, and rheumatoid factor
- Microbiologic evidence: positive blood culture finding but does not meet a major criterion as noted earlier (excludes single positive culture findings for coagulase-negative staphylococci and organisms that do not cause endocarditis) or serologic evidence of active infection with organism consistent with IE

TEE, Transesophageal echocardiography; TTE, transthoracic echocardiography.
Modified from Li JS, Sexton DJ, Mick N, et al. Proposed modifications to the Duke criteria for the diagnosis of infective endocarditis. *Clin Infect Dis.* 2000;30:633.

prolonged treatment. With highly sensitive viridans group streptococcal infections, shortened regimens that include oral penicillin for some portion have been recommended for certain adults, but effectiveness studies in children are lacking. In *nonstaphylococcal* disease, bacteremia usually resolves in 24-48 hours, whereas fever resolves in 5-6 days with appropriate antibiotic therapy. Resolution with *staphylococcal* disease takes longer.

If the infection occurs on a valve and induces or increases symptoms and signs of heart failure, appropriate therapy should be instituted, including diuretics, inotropic medications, and afterload reducing agents. Surgical intervention for infective endocarditis is indicated for severe aortic, mitral, or prosthetic valve involvement with intractable heart failure (Table 486.8). Severe heart failure may be associated with acute valve regurgitation, obstruction of conduits or shunts, or periannular extension of infection, including fistula formation. Rarely, a mycotic aneurysm, rupture of an aortic sinus, intraseptal abscess causing complete heart block, or dehiscence of an intracardiac patch requires emergency surgery. Other surgical indications include failure to sterilize the blood despite adequate antibiotic levels in 7-10 days in the absence of extracardiac infection, myocardial abscess, recurrent emboli, and increasing size of vegetations while receiving therapy. Vegetations (aortic, mitral, prosthetic valve) >10-15 mm are at high risk of embolism. Although antibiotic therapy should be administered for as long as possible before surgical intervention, active infection is not a contraindication if the patient is critically ill as a result of severe hemodynamic deterioration from infective endocarditis. Emergent surgical intervention in patients with severe heart failure may improve the likelihood of survival. Removal of vegetations and, in some instances, valve replacement may be lifesaving, and sustained antibiotic administration will most often prevent reinfection. Replacement of infected prosthetic valves carries a higher risk.

Fungal endocarditis is difficult to manage and has a poorer prognosis. It has been encountered after cardiac surgery, in severely debilitated or immunosuppressed patients, and in patients on a prolonged course of antibiotics. The drugs of choice are amphotericin B (liposomal or standard preparation) and 5-fluorocytosine. Surgery to excise infected tissue is occasionally attempted, but often with limited success. Recombinant tissue plasminogen activation may help lyse intracardiac vegetations and avoid surgery in some high-risk patients.

PREVENTION

The American Heart Association (AHA) recommendations for antimicrobial prophylaxis before dental and other surgical procedures has resulted in a substantial reduction in the number of patients who require prophylactic treatment, and the procedures requiring coverage were recommended. The primary reasons for these revised recommendations were that (1) infective endocarditis is much more likely to result from exposure to the more frequent random bacteremias associated with daily activities than from a dental or surgical procedure, (2) routine prophylaxis may prevent "an exceedingly small" number of cases, and (3) the risk of antibiotic-related adverse events exceeds the benefits of prophylactic therapy. Improving general dental hygiene was thought to be a more important factor in reducing the risk of infective endocarditis resulting from routine daily bacteremias. The current recommendations limit the use of prophylaxis to those patients with cardiac conditions associated with the greatest risk of an adverse outcome from infective endocarditis (Table 486.9). Patients with permanently damaged valves from rheumatic heart disease should also be considered for prophylaxis. Prophylaxis for these patients is recommended for "all dental procedures that involve manipulation of gingival tissue or the periapical region of teeth or perforation of the oral mucosa." Furthermore, "placement of removable prosthodontic or endodontic appliances, adjustment of orthodontic appliances, placement of orthodontic brackets, shedding of deciduous teeth and bleeding from trauma to the lips or oral mucosa" are not indications for

Table 486.6 Therapy of Pediatric Native Valve Endocarditis Caused by Highly Penicillin-Susceptible^ Viridans Group Streptococci and *Streptococcus bovis*

REGIMEN	DOSAGE*† AND ROUTE	DURATION	COMMENTS
Penicillin G	200,000-300,000 U/kg/24 hr IV given every 4 hr up to 12-24 million U/day	4 wk	Avoids nephrotoxicity of gentamicin
Or			
Ceftriaxone sodium	100 mg/kg/24 hr IV given every 12 hr **or** 80 mg/kg/24 hr given every 24 hr up to 4 g/day (If total amount is over 2 g/day then dosing should be every 12 hr)	4 wk	Avoids nephrotoxicity of gentamicin
Or			
Vancomycin hydrochloride¶	40 mg/kg/24 hr IV given every 8-12 hr up to 2g/day	4 wk	Vancomycin therapy recommended only for patients unable to tolerate penicillin or ceftriaxone; vancomycin dosage should be adjusted to obtain a trough concentration range of 10-15 μg/mL

^Defined as minimum inhibitory concentration (MIC) ≤0.10 μg/mL.
*Dosages recommended are for patients with normal renal function.
†Pediatric dose should not exceed that of a normal adult.
¶Vancomycin dosages should be infused during course of at least 1 hr to reduce risk of histamine release and facial flushing. Peak vancomycin levels should only be obtained to calculate the area under the curve to mean MIC ratio.
Data from Baltimore RS, Gewitz M, Baddour LM, et al. Infective endocarditis in childhood: 2015 update. A scientific statement from the American Heart Association. *Circulation.* 2015;132:1487–1515.

Table 486.7 Therapy for Pediatric Endocarditis Caused by Staphylococci in the Absence of Prosthetic Materials

REGIMEN	DOSAGE*§ AND ROUTE	DURATION	COMMENTS
OXACILLIN-SUSCEPTIBLE STRAINS			
Nafcillin or oxacillin† ± gentamicin‡ for first 3-5 days	200 mg/kg/24 hr IV given every 4-6 hr up to 12 g/day AND consider gentamicin 3-6 mg/kg/24 hr IV every 8 hr	4-6 wk	Clinical benefit of aminoglycosides has not been established. Gentamicin trough levels of <1-2 μg/mL should be targeted to avoid risk of toxicity. Gentamicin peak levels should be obtained 30 min after the completion of an infusion with a peak goal of 3-5 μg/mL (for synergy).
For penicillin-allergic (non-anaphylactoid-type) patients:			Consider skin testing for oxacillin-susceptible staphylococci and questionable history of immediate-type hypersensitivity to penicillin.
Cefazolin ± gentamicin‡ for first 3-5 days	100 mg/kg/24 hr IV given every 8 hr up to 12 g/day AND consider gentamicin 3-6 mg/kg/24 hr IV given every 8 hr	4-6 wk	Cephalosporins should be avoided in patients with anaphylactoid-type hypersensitivity to β-lactams; vancomycin should be used in these cases.§ Gentamicin trough levels of <1-2 μg/mL should be targeted to avoid risk of toxicity. Gentamicin peak levels should be obtained 30 min after the completion of an infusion with a peak goal of 3-5 μg/mL (for synergy).
OXACILLIN-RESISTANT STRAINS			
Vancomycin¶ ± gentamicin‡ for first 3-5 days	40 mg/kg/24 hr IV given every 8-12 hr up to 2 g/day AND consider gentamicin 3-6 mg/kg/24 hr IV given every 8 hr	6 wk	Adjust vancomycin dosage to achieve trough concentration of 10-15 μg/mL. Gentamicin trough levels of <1-2 μg/mL should be targeted to avoid risk of toxicity. Gentamicin peak levels should be obtained 30 min after the completion of an infusion with a peak goal of 3-5 μg/mL (for synergy).
Daptomycin ± gentamicin‡ for first 3-5 days	6 mg/kg/24 hr given every 24 hr <6 yr of age; 10 mg/kg/24 hr given every 24 hr AND consider gentamicin 3-6 mg/kg/24 hr IV given every 8 hr	4-6 wk	Gentamicin trough levels of <1-2 μg/mL should be targeted to avoid risk of toxicity. Gentamicin peak levels should be obtained 30 min after the completion of an infusion with a peak goal of 3-5 μg/mL (for synergy).

*Dosages recommended are for patients with normal renal function.
§Pediatric dose should not exceed that of a normal adult.
†Penicillin G 200,000-300,000 U/kg/24 hr IV given every 4 hr up to 12-24 million U/day may be used in place of nafcillin or oxacillin if strain is penicillin susceptible (minimum inhibitory concentration ≤0.1 μg/mL) and does not produce β-lactamase.
‡Gentamicin should be administered in close temporal proximity to nafcillin, or oxacillin dosing and blood levels monitored to reduce the risk of nephrotoxicity and ototoxicity.
¶For specific dosing adjustment and issues concerning vancomycin, see Table 464.6 footnotes.
IE, Infective endocarditis; IV, intravenously.
Data from Baltimore RS, Gewitz M, Baddour LM, et al. Infective endocarditis in childhood: 2015 update. A scientific statement from the American Heart Association. Circulation. 2015;132:1487–1515.

Table 486.8 Echocardiographic Features that Suggest Potential Need for Surgical Intervention

VEGETATION
Persistent vegetation after systemic embolization
Anterior mitral valve leaflet vegetation, particularly if it is highly mobile with size >10 mm*
One or more embolic events during the first 2 wk of antimicrobial therapy*
Increase in vegetation size despite appropriate antimicrobial therapy*†
VALVULAR DYSFUNCTION
Acute aortic or mitral insufficiency with signs of ventricular failure†
Heart failure unresponsive to medical therapy†
Valve perforation or rupture†
PERIVALVULAR EXTENSION
Valvular dehiscence, rupture, or fistula†
New heart block†‡
Large abscess or extension of abscess despite appropriate antimicrobial therapy†

*Surgery may be required because of risk of embolization.
†Surgery may be required because of heart failure or failure of medical therapy.
‡Echocardiography should not be the primary modality used to detect or monitor heart block.
From Baddour LM, Freeman WK, Suri RM, et al. Cardiovascular infections. In: Zipes DP, Libby P, Bonow RO, et al., eds. *Braunwald's Heart Disease*, 11th ed. Philadelphia: Elsevier, 2019: Table 73-5, p. 1492.

prophylaxis. The 2023 recommendations of the European Society of Cardiology are noted in Table 486.10. Given that many invasive respiratory tract procedures do cause bacteremia, prophylaxis for many of these procedures is considered reasonable. In contrast to prior recommendations, prophylaxis for gastrointestinal or genitourinary procedures is no longer recommended in the majority of cases. Prophylaxis for patients undergoing cardiac surgery with placement of prosthetic material is still recommended. Given the highly individual nature of these recommendations, direct consultation with the child's cardiologist is still the best method for determining a specific patient's ongoing need for prophylaxis (Table 486.11).

Continuing education regarding both oral hygiene and, in appropriate cases, the need for prophylaxis is important, especially in teenagers and young adults. Vigorous treatment of sepsis and local infections and careful asepsis during heart surgery and catheterization reduce the incidence of infective endocarditis.

Visit Elsevier eBooks+ at eBooks.Health.Elsevier.com for Bibliography.

Table 486.9 Cardiac Conditions Associated with Highest Risk of Adverse Outcome from Infective Endocarditis for Which Prophylaxis with Dental Procedures Is Reasonable (2007 AHA Statement)

Prosthetic cardiac valve or prosthetic material used for cardiac valve repair
Previous infective endocarditis
Congenital heart disease (CHD)*
• Unrepaired cyanotic CHD, including palliative shunts and conduits
• Completely repaired CHD with prosthetic material or device, whether placed by surgery or catheter intervention, during the first 6 mo after the procedure†
• Repaired CHD with residual defects at the site or adjacent to the site of a prosthetic patch or prosthetic device (which inhibits endothelialization)
• Cardiac transplantation recipients who develop cardiac valvulopathy

*Except for the conditions listed here, antibiotic prophylaxis is no longer recommended by the AHA for any other form of CHD.
†Prophylaxis is reasonable because endothelialization of prosthetic material occurs within 6 mo after the procedure.
From Wilson W, Taubert KA, Gewitz M, et al. Prevention of infective endocarditis: guidelines from the American Heart Association. *Circulation*. 2007;116:1736–1754.

Table 486-10 2023 European Recommendations for Antibiotic Prophylaxis in Patients with Cardiovascular Diseases Undergoing Oro-Dental Procedures at Increased Risk of Infective Endocarditis

- Antibiotic prophylaxis is recommended in patients with previous IE.
- Antibiotic prophylaxis is recommended in patients with surgically implanted prosthetic valves and with any material used for surgical cardiac valve repair.
- Antibiotic prophylaxis is recommended in patients with transcatheter implanted aortic and pulmonary valvular prostheses.
- Antibiotic prophylaxis should be considered in patients with transcatheter mitral and tricuspid valve repair.
- Antibiotic prophylaxis is recommended in patients with untreated cyanotic CHD, and patients treated with surgery or transcatheter procedures with post-operative palliative shunts, conduits, or other prostheses. After surgical repair, in the absence of residual defects or valve prostheses, antibiotic prophylaxis is recommended only for the first 6 months after the procedure.

From Delgado V, Marsan NA, de Waha S, et al: 2023 ESC Guidelines for the Management of endocarditis. *Eur Heart J* 2023;193:1-95 https://doi.org/10.1093/eurheartj/ehad193.

Table 486.11 Prophylactic Antibiotic Regimens for a Dental Procedure (2007 AHA Statement)

SITUATION	AGENT	ADULTS	CHILDREN
Oral	Amoxicillin	2 g	50 mg/kg
Unable to take oral medication	Ampicillin *or* Cefazolin or ceftriaxone	2 g IM or IV 1 g IM or IV	50 mg/kg IM or IV 50 mg/kg IM or IV
Allergic to penicillins or ampicillin—oral	Cephalexin*† *or* Clindamycin *or* Azithromycin or clarithromycin	2 g 600 mg 500 mg	50 mg/kg 20 mg/kg 15 mg/kg
Allergic to penicillins or ampicillin and unable to take oral medication	Cefazolin or ceftriaxone† *or* Clindamycin	1 g IM or IV 600 mg IM or IV	50 mg/kg IM or IV 20 mg/kg IM or IV

*Or other first- or second-generation oral cephalosporin in equivalent adult or pediatric dosage.
†Cephalosporins should not be used in an individual with a history of anaphylaxis, angioedema, or urticaria with penicillins or ampicillin.
IM, Intramuscularly; IV, intravenously.
From Wilson W, Taubert KA, Gewitz M, et al. Prevention of infective endocarditis: guidelines from the American Heart Association *Circulation*. 2007;116:1736–1754.

Chapter 487

Rheumatic Heart Disease

Michael R. Carr and Stanford T. Shulman

Rheumatic involvement of the cardiac valves is the most important sequela of **acute rheumatic fever (ARF)**, and the second most common major manifestation after arthritis (see Chapter 229.1). The definitions of three subgroups of rheumatic heart disease (RHD) are noted in Table 487.1. The valvular lesions begin as small verrucae composed of fibrin and blood cells along the borders of one or more of the heart valves. The mitral valve is affected most often, followed in frequency by the aortic valve. Isolated aortic valve disease is rare and generally seen with concomitant mitral valve involvement. Right-sided heart manifestations are rarer and are virtually only associated with left-sided valve disease. As the inflammation subsides, the verrucae tend to disappear and leave scar tissue. With repeated attacks of rheumatic fever, new verrucae form near the previous ones and the mural endocardium and chordae tendineae become involved. A single episode of **acute rheumatic carditis** often results in complete healing of the valvular lesions, whereas *repeated* episodes, especially involving previously affected valves, result in chronic **RHD**, which is the rationale for secondary prophylaxis. The prevalence of RHD ranges from 3 to 4 cases per 100,000 population in nonendemic countries to >1,000 cases per 100,000 in endemic countries (Fig. 487.1). On a global scale, the sequelae of RHD is significant, with up to 300,000 deaths per year related to the disease process, as well as an exponential degree of related comorbidity.

The diagnosis of ARF requires the fulfillment of the **Jones criteria** (see Chapter 229.1), with carditis being a major criterion. The diagnosis of RHD was once only based on cardiac auscultatory findings of mitral or aortic valve involvement, which was insensitive for early valve involvement/injury. This was based on valvulitis being seen more frequently in ARF compared with pericarditis or myocarditis, both of which lack more readily apparent physical examination findings. Screening large, high-risk populations with echocardiography demonstrated a substantially greater number of patients with RHD than those detected by auscultation alone. Because access to echocardiography is often available, the current version of the Jones criteria focused on the concept of **subclinical carditis (SCC)** detected by echocardiography (see Table 487.1). SCC is defined as echocardiographic evidence of mitral or aortic valvulitis in the absence of auscultatory findings and not consistent with physiologic mitral or aortic insufficiency (Table 487.2). Echocardiography with Doppler should be performed for all cases of confirmed or suspected ARF (Table 487.3). Additional recommendations are that echocardiography should be performed in moderate- to high-risk patient populations if ARF is considered likely and that echocardiography can be used to exclude cardiac findings consistent with ARF in patients with cardiac murmurs thought to be suggestive of rheumatic carditis. Additionally, serial echocardiography should be considered in patients with diagnosed or suspected ARF even if there is no evidence of valvulitis by echocardiography at diagnosis. The echocardiographic finding of SCC fulfills the major criterion for carditis. The category of latent RHD is another approach to include patients with mild asymptomatic valve changes not typically detected on physical exam but identified by screening high-risk populations with echocardiography (see Table 487.1).

PATTERNS OF VALVULAR DISEASE

Mitral Insufficiency

Mitral insufficiency is the result of structural changes that may include some loss of valvular substance and/or changes to the subvalvular apparatus, including elongation of the chordae, both of which can lead to valve dysfunction. During ARF with severe cardiac involvement, heart failure is caused by a combination of mitral insufficiency coupled with a pancarditis involving the pericardium and myocardium in addition to the endocardium/valve. Because of the increased volume load from the mitral insufficiency and the inflammatory process, the left ventricle dilates. The left atrium also enlarges to accommodate the regurgitant volume. Increased left atrial pressure results in pulmonary congestion and symptoms of left-sided heart failure. Spontaneous improvement often occurs with time, even in patients in whom mitral insufficiency is severe at the onset. The resultant chronic lesion is most often mild or moderate in severity, and the patient is often asymptomatic. More than half of patients with acute mitral insufficiency no longer have an audible mitral insufficiency murmur 1 year later, although they still may demonstrate insufficiency on echocardiography. In patients with severe chronic mitral insufficiency, pulmonary artery pressure (PAP) becomes elevated, the right ventricle and atrium become enlarged, and right-sided heart failure subsequently develops.

Clinical Manifestations

Physical signs of mitral insufficiency depend on its severity. With mild disease, signs of heart failure are not present, the precordium is quiet, and auscultation reveals a high-pitched **holosystolic murmur** at the apex that radiates to the axilla. With severe mitral insufficiency, signs of acute or chronic heart failure may be noted. The heart is enlarged, with a heaving apical left ventricular (LV) impulse and often an apical systolic **thrill**. The second heart sound (S_2) may be accentuated if pulmonary hypertension is present. A third heart sound or **gallop** is generally prominent. A holosystolic murmur is heard at the apex with radiation to the axilla. A short mid-diastolic rumbling murmur is caused by increased blood flow across the mitral valve as a result of the significant insufficiency. Therefore auscultation of a diastolic murmur, often referred to as **relative mitral stenosis (Carey-Coombs murmur)**, does not necessarily mean that true mitral stenosis is present. The latter lesion takes many years to develop and is characterized by a diastolic murmur of greater length, usually with presystolic accentuation.

The electrocardiogram and chest radiographs are normal if the mitral insufficiency is mild. With more severe insufficiency, the ECG shows a prominent, longer duration and often bifid P waves, signs of LV hypertrophy, and associated right ventricular (RV) hypertrophy if pulmonary hypertension is present. On chest radiograph, prominence of the left atrium and ventricle can be seen, the former of which is better seen on lateral projections. Congestion of the perihilar vessels, a sign of pulmonary venous hypertension, may also be evident. Calcification of the mitral valve is rare in children. Echocardiography in the acute phase may demonstrate enlargement of the left atrium and ventricle. LV systolic function can be impaired if there is also a component of myocardial inflammation. Mitral annular dilation, chordal elongation, and at times, evidence of chordal rupture resulting in a flail leaflet may be noted. The leaflet tips demonstrate a nodular appearance, and prolapse of the anterior mitral valve leaflet tip (much more often than the posterior leaflet) is seen. Doppler evaluation demonstrates the severity of the mitral regurgitation. Chronic mitral insufficiency from RHD is characterized on echocardiography by leaflet and chordal thickening, chordal fusion, and restricted leaflet motion. These changes often lead to stenosis, but poor coaptation of the abnormal leaflets can also lead to variable degrees of regurgitation. Cardiac catheterization and left ventriculography are considered only if diagnostic questions are not completely resolved by noninvasive assessment or in rare cases with a concern for significantly elevated PAP.

Complications

Severe mitral insufficiency may result in cardiac failure that may be precipitated by progression of the rheumatic process, recurrent episodes of ARF, the onset of **atrial fibrillation (AF)** or other arrhythmias, or infective endocarditis. The effects of chronic mitral insufficiency may become manifest after many years and include LV and RV failure and atrial and ventricular arrhythmias.

Treatment

In patients with mild mitral insufficiency, **prophylaxis** against recurrences of rheumatic fever is all that is required in addition to the typical treatment for ARF (Table 487.4). For more significant insufficiency, corticosteroids are added in the acute phase. Treatment of complicating heart failure (see Chapter 491), arrhythmias (see Chapter 484), and infective endocarditis (see Chapter 486) is described elsewhere. Afterload-reducing

agents—angiotensin-converting enzyme (ACE) inhibitors or angiotensin receptor blockers (ARBs)—may reduce the regurgitant volume, attenuate pathologic compensatory mechanisms, and preserve LV function, but these have not been proven to alter the natural history of the disease process. Diuretics may also provide some symptomatic and clinical benefit in select cases. In rare cases, phosphodiesterase inhibitors such as milrinone may be used in the acute stage because of their inotropic, lusitropic, and systemic vascular dilating effects. Surgical treatment is indicated for patients who, despite adequate medical therapy, have persistent heart failure, dyspnea with moderate activity, and progressive cardiomegaly, often with pulmonary hypertension. Although annuloplasty and other forms of mitral valve repair provide good results in some children and adolescents, mitral valve replacement may be required, which can be more complicated in younger children. In patients with a prosthetic mitral valve replacement, prophylaxis against bacterial endocarditis is warranted for dental procedures, as the routine antibiotics taken by these patients for rheumatic fever prophylaxis are insufficient to prevent endocarditis. Additionally, current recommendations suggest selecting a different class of antibiotic for such procedures, rather than increasing the dose of the antibiotic taken for rheumatic fever prophylaxis. Lastly, it is important to remember that all attempts should be made at maximizing medical management of severe mitral insufficiency during the acute phase of the disease process, before considering surgical intervention, because surgery carries a poorer prognosis and an increased risk for reoperation when performed during the acute phase.

Table 487.1 Proposed RHD Definitions

Latent RDH	All cases of RHD diagnosed through echocardiographic screening, to include previously unrecognized clinical RHD and subclinical RHD.
Clinical RDH	All cases of RHD that have clinical signs or symptoms, including pathologic heart murmur* diagnosed either through echocardiographic screening or clinical evaluation. Clinical RHD is typically more advanced than subclinical RHD.
Subclinical RDH	All cases of RHD that do not have clinical signs or symptoms, including heart murmur.* Subclinical RHD is only diagnosed by echocardiography and is typically less advanced than clinical RHD.

*Detection of a pathologic heart murmur without echocardiography has been shown to be poorly sensitive and specific in echocardiographic screening studies for RHD.
RHD, Rheumatic heart disease.
Modified from Beaton A, Engelman D, Mirabel M. Echocardiographic screening for rheumatic heart disease. In: Dougherty S, Carapetis J, Zühlke, Wilson N, eds. *Acute Rheumatic Fever and Rheumatic Heart Disease*. Philadelphia: Elsevier; 2021: Table 13.1.

Mitral Stenosis

Mitral stenosis of rheumatic origin results from fibrosis of the mitral ring, commissural adhesions, and contracture of the valve leaflets, chordae, and papillary muscles over time. This is a chronic process and often takes ≥10 years for the lesion to become fully established, although the process may occasionally be accelerated. In the developed world, rheumatic mitral stenosis is seldom encountered before adolescence and is not usually recognized until adult life. Significant mitral stenosis results in increased left atrial pressure and subsequent enlargement and hypertrophy of the left atrium, pulmonary venous hypertension, increased pulmonary vascular resistance, and eventually overt pulmonary hypertension (Fig. 487.2). RV hypertrophy and right atrial dilation ensue and are followed by RV dilation, tricuspid regurgitation, and clinical signs of right-sided heart failure.

Clinical Manifestations

Generally, the correlation between symptoms and the severity of obstruction is good. Patients with mild stenosis are asymptomatic. More severe degrees of obstruction are associated with exercise intolerance and dyspnea. Critical lesions can result in orthopnea, paroxysmal nocturnal dyspnea, and overt pulmonary edema, as well as atrial arrhythmias. When pulmonary hypertension has developed, RV dilation may result in functional tricuspid insufficiency, hepatomegaly, ascites, and edema. Hemoptysis caused by rupture of bronchial or pleurohilar veins and, occasionally, pulmonary infarction may occur.

Jugular venous pressure is increased in severe disease with heart failure, tricuspid valve disease/regurgitation, or severe pulmonary hypertension. In mild disease, the heart size is normal; however, moderate cardiomegaly is typical with severe mitral stenosis. Cardiac enlargement can be massive when AF and heart failure supervene. A parasternal RV lift is palpable when PAP is high. The principal auscultatory findings are a loud first heart sound, an opening snap of the mitral valve, and a long, low-pitched, rumbling mitral diastolic murmur with presystolic accentuation at the apex. The mitral diastolic murmur may be virtually absent in patients who are in significant heart failure from the elevated LV filling pressures. A holosystolic murmur secondary to tricuspid insufficiency may be audible at the left lower sternal border. In the presence of pulmonary hypertension, the pulmonic component of S_2 is accentuated. An early diastolic murmur may

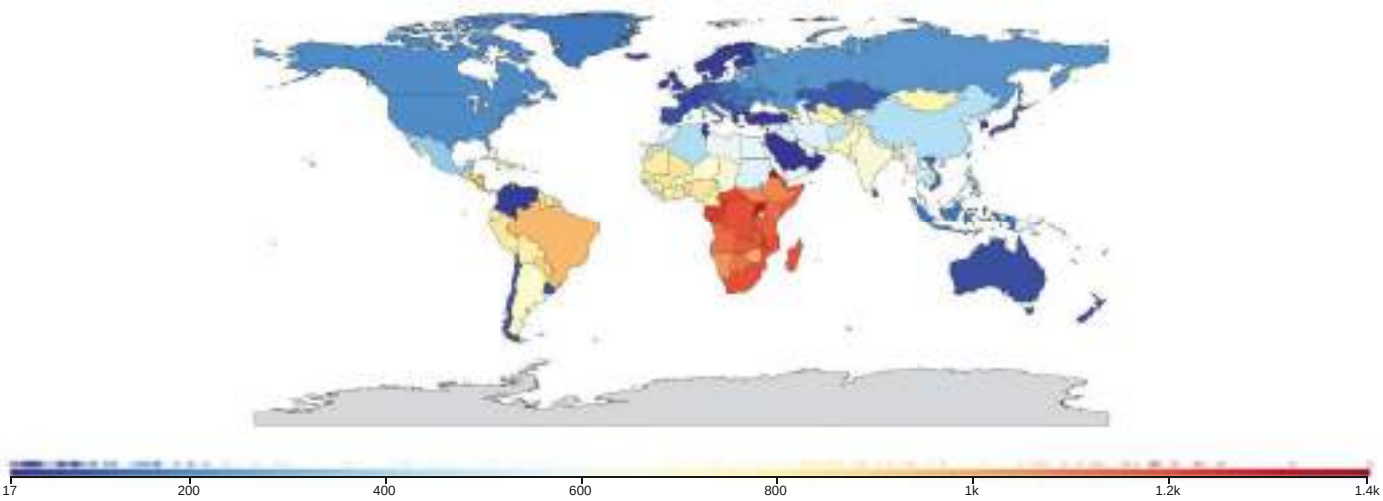

Fig. 487.1 Prevalence of rheumatic heart disease global map showing prevalence/100,000 population in 2017 by country. *(From the Institute for Health Metrics and Evaluation Global Burden of Disease 2019, Non-communicable disease data. Seattle: University of Washington IHME. https://www.healthdata.org/research-analysis/gbd.)*

be caused by associated rheumatic aortic insufficiency or pulmonary valvular insufficiency secondary to pulmonary hypertension.

ECGs and chest radiographs are normal if the stenosis is mild; as the severity increases, prominent and notched P waves and varying degrees of RV hypertrophy become evident. AF or other atrial arrhythmias are common late manifestations. Moderate to severe lesions are associated with radiographic signs of left atrial enlargement and prominence of the pulmonary artery and right-sided heart chambers; calcifications may be noted in the region of the mitral valve (see Fig. 487.2). Severe stenosis is associated with a redistribution of pulmonary blood flow so that the apices of the lung have greater perfusion (the reverse of normal). Lastly, horizontal lines in the lower lung periphery, called *Kerley B lines,* may be evident.

Echocardiography demonstrates thickening of the mitral valve and chordal apparatus, as well as restricted motion of the valve (Fig. 487.3). The typical "elbow" or "dog leg" appearance of the anterior leaflet of the mitral valve can aid in the distinction of a rheumatic valve from the various forms of congenital mitral stenosis. Left atrial dilation is common; color Doppler flow across the mitral valve shows a narrow jet with flow acceleration, and variable degrees of tricuspid insufficiency can be seen from left atrial hypertension. Doppler can estimate the transmitral pressure gradient but can underestimate the gradient if there is LV dysfunction. Estimates of the RV/PAP can be made by echocardiographic assessment of the tricuspid and pulmonary insufficiency, as well as changes in the RV size and function and the systolic septal position. Cardiac catheterization quantitates the diastolic gradient across the mitral valve well, allows for the calculation of cross-sectional valve area in older children, and assesses the degree of left atrial hypertension and PAP elevation.

Table 487.2 Echocardiographic Findings in Rheumatic Valvulitis

PATHOLOGIC MITRAL REGURGITATION*	PATHOLOGIC AORTIC REGURGITATION*
1. Seen in at least two views 2. Jet length ≥2 cm in at least one view 3. Peak velocity >3 meters/sec 4. Pan-systolic jet in at least one envelope	1. Seen in at least two views 2. Jet length ≥1 cm in at least one view 3. Peak velocity >3 meters/sec 4. Pan-diastolic jet in at least one envelope

*All four criteria need to be met.
Adapted from Gewitz MH, Baltimore RS, Tani LY, et al., On behalf of the American Heart Association Committee on Rheumatic Fever, Endocarditis and Kawasaki Disease of the Council on Cardiovascular Disease in the Young. Revision of the Jones criteria for the diagnosis of acute rheumatic fever in the era of Doppler echocardiography: a scientific statement from the American Heart Association. *Circulation.* 2015;131:1806–1818.

Table 487.3 Morphologic Findings in Echocardiogram in Rheumatic Vasculitis

ACUTE MITRAL VALVE CHANGES
Annular dilation
Chordal elongation
Chordal rupture resulting in flail leaflet with severe mitral regurgitation
Anterior (or, less commonly, posterior) leaflet tip prolapse
Beading/nodularity of leaflet tips
CHRONIC MITRAL VALVE CHANGES: NOT SEEN IN ACUTE CARDITIS
Leaflet thickening
Chordal thickening and fusion
Restricted leaflet motion
Calcification
AORTIC VALVE CHANGES IN EITHER ACUTE OR CHRONIC CARDITIS
Irregular or focal leaflet thickening
Coaptation defect
Restricted leaflet motion
Leaflet prolapse

From Kumar RK, Antunes MJ, Beaton A, et al. Contemporary diagnosis and management of rheumatic heart disease: implications for closing the gap: a scientific statement from the American Heart Association. *Circulation.* 2020;142(2):e337–e357, Supplemental Table 2.

Treatment

Intervention is indicated in patients with clinical signs and hemodynamic evidence of severe obstruction, but before the onset of severe manifestations. Pharmacologic therapy (diuretics and β blockers)

Table 487.4 Recommended Durations of Secondary Prophylaxis According to International Guidelines

GUIDELINE	SECONDARY PROPHYLAXIS DURATION RECOMMENDED
American (AHA)	ARF with carditis and residual heart disease: until age 40 yr or for 10 yr after last ARF (whichever is longer); lifetime prophylaxis may be needed
	ARF with carditis but no residual heart disease: until age 21 yr or for 10 yr after last ARF (whichever is longer)
	ARF without carditis: until age 21 yr or for 5 yr after last ARF (whichever is longer)
WHO Expert Consultation Geneva (2004)	Lifelong if severe valvular disease or after valve surgery
	For 10 yr after last ARF or until age 25 yr in patients with a previous diagnosis of carditis
	For 5 yr after last ARF or until age 18 yr in patients without proven carditis

AHA, American Heart Association; ARF, acute rheumatic fever; RHD, rheumatic heart disease; WHO, World Health Organization.
Modified from Kumar RK, Antunes MJ, Beaton A, et al. Contemporary diagnosis and management of rheumatic heart disease: implications for closing the gap: a scientific statement from the American Heart Association. *Circulation.* 2020;142(2):e337–e357, Table 2.

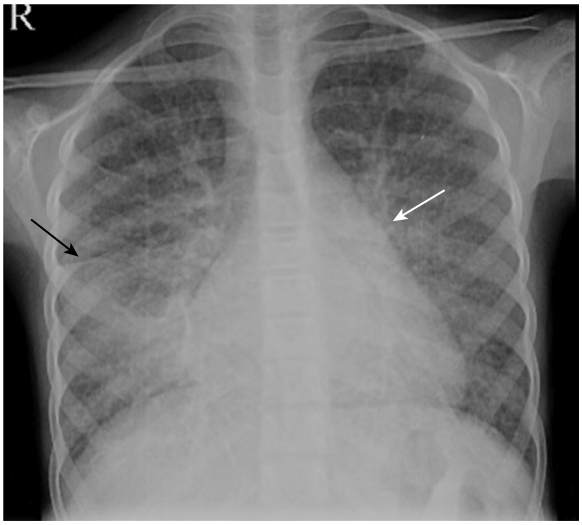

Fig. 487.2 Chest x-ray from an 8-yr-old child with advanced juvenile mitral valve stenosis. Severe pulmonary venous hypertension is shown by the prominent upper lobe vasculature, interstitial edema, and visible interlobar fissure *(black arrow).* The left heart border is straightened, indicating enlargement of the main pulmonary artery and left atrial appendage *(white arrow). (From Kumar RK, Antunes MJ, Beaton A, et al. Contemporary diagnosis and management of rheumatic heart disease: implications for closing the gap: a scientific statement from the American Heart Association. Circulation. 2020;142(2):e337–e357, Supplemental Fig. 3.)*

can be attempted but is generally used only for symptom control and much less often in children. However, it should not be considered adequate treatment in severe, symptomatic disease. Surgical valvotomy or balloon catheter mitral valvuloplasty generally yields good results (see Fig. 487.3); mitral valve replacement is avoided unless absolutely necessary. Balloon valvuloplasty is indicated for symptomatic, stenotic, pliable, noncalcified valves in patients without significant atrial arrhythmias or thrombi. Unfortunately, neither surgical nor interventional options may exist in areas of the world with high disease burden.

Aortic Insufficiency

In *acute* rheumatic aortic insufficiency, poor coaptation of the leaflets or leaflet prolapse is seen. *Chronic* rheumatic aortic insufficiency leads to sclerosis of the valve and results in distortion and retraction of the cusps. In both settings, regurgitation of blood leads to LV volume overload with dilation and hypertrophy of the left ventricle as it attempts to compensate for the excessive volume load. Concomitant mitral annular dilation accompanying LV dilation can further exacerbate mitral valve disease, specifically regurgitation. Combined mitral and aortic insufficiency in the acute phase of ARF is much more common than aortic involvement alone. However, in cases of isolated significant aortic insufficiency, RHD should not be discounted, even given the rare nature of this finding.

Clinical Manifestations

Symptoms are unusual except in severe aortic insufficiency or in the presence of significant concomitant mitral valve involvement or myocardial dysfunction. The large stroke volume and forceful LV contractions may result in palpitations. Sweating and heat intolerance are related to excessive vasodilation. Dyspnea on exertion can progress to orthopnea and pulmonary edema; angina may be precipitated by heavy exercise. Nocturnal attacks with sweating, tachycardia, chest pain, and hypertension may occur.

The pulse pressure is wide with bounding peripheral pulses (**water hammer** or **Corrigan pulse**). Systolic blood pressure is elevated, and diastolic pressure is lowered. In severe aortic insufficiency, the heart is enlarged, with an LV apical heave. A diastolic thrill may be present. The typical murmur begins immediately with S_2 and continues until late in diastole. The murmur is heard over the upper left and mid-left sternal border with radiation to the apex and upper right sternal border. Characteristically, it has a high-pitched blowing quality and is easily audible in full expiration with the diaphragm of the stethoscope placed firmly on the chest and the patient leaning forward. An aortic systolic ejection murmur is frequently heard because of the increased stroke volume. An apical presystolic murmur **(Austin Flint murmur)** resembling that of mitral stenosis is sometimes heard and is caused by the large regurgitant aortic flow in diastole preventing the mitral valve from opening fully.

Chest radiographs demonstrate enlargement of the left ventricle and aorta. The ECG may be normal, but in advanced cases it reveals signs of LV hypertrophy with a strain pattern and prominent P waves. Echocardiography shows a dilated left ventricle and diastolic mitral valve flutter or oscillations caused by aortic regurgitant flow hitting the valve leaflets. The aortic valve may demonstrate irregular or focal thickening, decreased systolic excursion, a coaptation defect, and leaflet prolapse. Doppler evaluation demonstrates the degree of aortic insufficiency. Cardiac magnetic resonance imaging/angiography (cMRI/MRA) can be useful in quantitating regurgitant volume and in assessing LV size and systolic function. Cardiac catheterization is generally only necessary when echocardiographic or axial imaging data are equivocal.

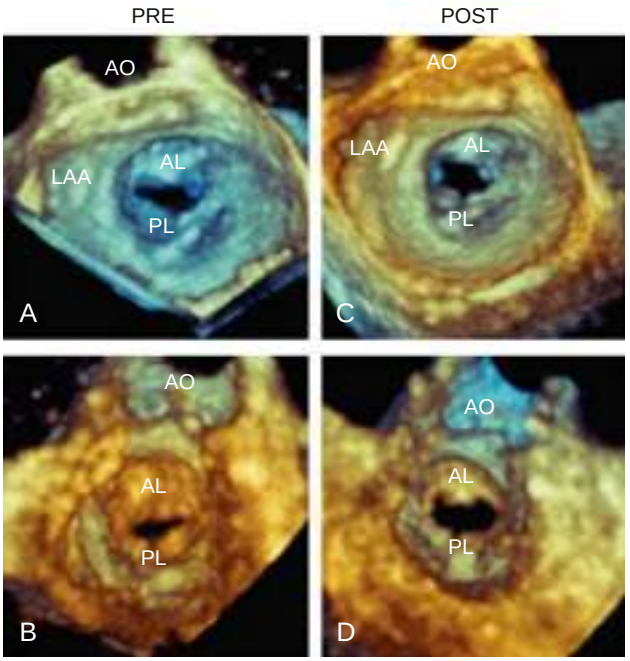

Fig. 487.3 Balloon mitral valvotomy. Real-time three-dimensional transesophageal echocardiographic images obtained before, during, and after balloon mitral valvotomy in a patient with mitral stenosis. **A** and **B** illustrate the stenotic mitral orifice as seen from the left atrium (**A**) and from the left ventricle (**B**) immediately prior to the procedure. **C** and **D**, obtained immediately after the procedure, show the commissure splitting and the larger mitral valve orifice. AL, anterior leaflet; AO, aorta; LAA, left atrial appendix; PL, posterior leaflet. *(From Salcedo EE, Carroll JD. Imaging guidance of transcatheter valve procedures. In Otto CM, Bonow RO (eds). Valvular Heart Disease: A Companion to Braunwald's Heart Disease. Philadelphia: Elsevier, 2013. Fig 16.11.)*

Prognosis and Treatment

Mild and moderate degrees of aortic insufficiency are well tolerated. Unlike mitral insufficiency, aortic insufficiency does not generally regress. Patients with combined lesions during the episode of ARF may have only aortic involvement 1-2 years later. Treatment consists of ACE inhibitors or ARBs and prophylaxis against ARF recurrence. Surgical intervention, which is typically aortic valve repair but occasionally can involve aortic valve prosthetic (biologic or mechanical) replacement, should be done well in advance of the onset of heart failure, pulmonary edema, and angina or when signs of decreasing myocardial performance become evident, as manifested by increasing LV dimensions and decreasing systolic function on echocardiography. Surgery is considered when early symptoms are present, significant ST-T wave changes are seen on the ECG, or evidence of decreasing LV ejection fraction is noted.

Tricuspid Valve Disease

Primary tricuspid valve involvement is rare during both the acute and chronic stages of rheumatic fever. Tricuspid insufficiency is more common secondary to RV dilation, resulting from significant left-sided cardiac lesions. The clinical signs of tricuspid insufficiency include prominent pulsations of the jugular veins, systolic pulsations of the liver, and a blowing holosystolic murmur at the lower left sternal border that increases in intensity during inspiration. Concomitant signs of mitral or aortic valve disease, with or without AF, are common. In these cases, signs of tricuspid insufficiency often decrease or even disappear when heart failure produced by the left-sided valvular lesions is successfully treated. Tricuspid valvuloplasty may be required in very rare cases.

Pulmonary Valve Disease

Pulmonary insufficiency secondary to ARF is rare and usually occurs on a functional basis secondary to pulmonary hypertension and is a late finding with severe mitral stenosis. The murmur **(Graham Steell murmur)** is similar to that of aortic insufficiency, but peripheral arterial signs (bounding pulses) are absent. The correct diagnosis is confirmed by two-dimensional echocardiography and Doppler studies demonstrating nonphysiologic pulmonary insufficiency, evidence of pulmonary hypertension, and the presence of mitral valve disease. Surgical intervention on the pulmonary valve is highly unusual.

Visit Elsevier eBooks+ at eBooks.Health.Elsevier.com for Bibliography.

Section 6

Diseases of the Myocardium and Pericardium

Chapter 488

Diseases of the Myocardium

John J. Parent and Stephanie M. Ware

The heterogeneous heart muscle diseases associated with structural remodeling and abnormalities of cardiac function **(cardiomyopathy)** are important causes of morbidity and mortality in the pediatric population. Several classification schemes have been formulated in an effort to provide logical, useful, and scientifically based etiologies for the cardiomyopathies. Insight into the molecular genetic basis of cardiomyopathies has increased exponentially, and etiologic classification schemes continue to evolve (Table 488.1).

Table 488.2 classifies the cardiomyopathies based on their anatomic (ventricular morphology) and functional pathophysiology. **Dilated cardiomyopathy**, the most common form of cardiomyopathy, is characterized predominantly by left ventricular (LV) dilation and decreased LV systolic function (Fig. 488.1). **Hypertrophic cardiomyopathy** demonstrates increased ventricular myocardial wall thickness, normal or increased systolic function, and often, diastolic (relaxation) abnormalities with fibrosis of varying degrees (Table 488.3 and Figs. 488.2 and 488.3). **Restrictive cardiomyopathy** is characterized by near-normal ventricular chamber size and wall thickness with preserved systolic function but dramatically impaired diastolic function leading to elevated filling pressures and atrial enlargement (Fig. 488.4). **Arrhythmogenic right ventricular (RV) cardiomyopathy** is characterized by fibrofatty infiltration and replacement of the normal RV myocardium and occasionally the left ventricle, leading to RV (and LV) systolic and diastolic dysfunction and arrhythmias. **Left ventricular noncompaction** is characterized by a hypertrabeculated LV apex and lateral wall, with a heterogeneous group of associated phenotypes (most often a dilated phenotype with LV dilation and dysfunction). Cardiomyopathies may be primary or associated with other organ involvement (Tables 488.4-488.6).

488.1 Dilated Cardiomyopathy

John J. Parent and Stephanie M. Ware

Dilated cardiomyopathy **(DCM)**, the most common form of cardiomyopathy in children, is the cause of significant morbidity and mortality and a common indication for cardiac transplantation. The etiologies are diverse. Unlike adult patients with DCM, ischemic etiologies are rare in children, although these include anomalous origin of the left coronary artery from the pulmonary artery, premature coronary atherosclerosis (homozygous familial hypercholesterolemia, rare genetic syndromic diseases such as progeria), and coronary inflammatory diseases such as Kawasaki disease. It is estimated that up to 50% of cases are **genetic** (usually autosomal dominant; some are autosomal recessive or X-linked), including some with metabolic causes (see Tables 488.1 and 488.2). Although the most common etiology of DCM remains **idiopathic**, it is likely that undiagnosed familial/genetic conditions and myocarditis predominate. The annual incidence of DCM in children younger than 18 years is 0.57 cases per 100,000 per year. The incidence is higher in males, Blacks, and infants <1 year old.

PATHOGENESIS

The pathogenesis of the ventricular dilation and altered contractility seen in DCM varies depending on the underlying etiology; systolic dysfunction and myocyte injury are common. Genetic abnormalities of several components of the cardiac muscle, including sarcomere proteins, the cytoskeleton, and the proteins that bridge the contractile apparatus to the cytoskeleton, have been identified in autosomal dominant and X-linked inherited disorders. DCM can occur after viral myocarditis. Although the primary pathogenesis varies from direct myocardial injury to viral-induced inflammatory injury, the resulting myocardial damage, ventricular enlargement, and poor function likely occur by a final common pathway similar to that in genetic disorders.

In 20–50% of cases, the DCM is familial, with autosomal dominant inheritance most common (see Table 488.3). **Duchenne and Becker muscular dystrophies** are X-linked cardiomyopathies that account for 5–10% of DCM cases (see Chapter 649.1). These dystrophinopathies result in an abnormal sarcomere-cytoskeleton connection, causing impaired myocardial force generation, myocyte damage/scarring, chamber enlargement, and altered function (see Table 488.6). Female carriers of dystrophinopathies may also manifest DCM.

Mitochondrial myopathies, as with the muscular dystrophies, may present clinically with a predominance of extracardiac findings, although in some children cardiomyopathy may be the first symptom. These are inherited in a recessive or mitochondrial pattern (see Tables 488.4 and 488.5). Disorders of **fatty acid oxidation** present with systemic derangements of metabolism (hypoketotic hypoglycemia, acidosis, and hepatic dysfunction), some with peripheral myopathy and neuropathy, and others with sudden death or life-threatening cardiac arrhythmias.

Anthracycline cardiotoxicity (doxorubicin [Adriamycin]) on rare occasion causes acute inflammatory myocardial injury, but more classically results in DCM and occurs in up to 30% of patients given a cumulative dose of doxorubicin exceeding 550 mg/m^2. The risk of toxicity appears to be exacerbated by concomitant radiation therapy.

CLINICAL MANIFESTATIONS

Although more prevalent in patients <1 year of age, all age-groups may be affected. Clinical manifestations of DCM are typically those of heart failure but can also include palpitations, syncope, and sudden death. Irritability or lethargy can be accompanied by additional nonspecific complaints of failure to thrive, nausea, vomiting, or abdominal pain. Respiratory symptoms (tachypnea, wheezing, cough, orthopnea, or dyspnea on exertion) are often present. Infrequently, patients may present acutely with pallor, altered mentation, hypotension, and shock. Patients can be tachycardic with narrow pulse pressure and may have hepatic enlargement and rales or wheezing. The precordial cardiac impulse is increased, and the heart may be enlarged to palpation or percussion. Auscultation may reveal a gallop rhythm in addition to tachycardia, and occasionally murmurs of mitral or, less often, tricuspid insufficiency may be present. The presence of hypoglycemia, acidosis, hypotonia, or signs of liver dysfunction suggests an inborn error of metabolism. Neurologic or skeletal muscle deficits are associated with mitochondrial disorders or muscular dystrophies (see Tables 488.4-488.6).

LABORATORY FINDINGS

Electrocardiographic screening reveals atrial or ventricular hypertrophy, nonspecific T-wave abnormalities, and occasionally, atrial or ventricular arrhythmias. The chest radiograph may demonstrate cardiomegaly and pulmonary vascular prominence or pleural effusions. The echocardiogram is often diagnostic, demonstrating the characteristic findings of LV enlargement, decreased ventricular contractility, and occasionally a globular (remodeled) LV contour (see Fig. 488.1).

Table 488.1 Classification of the Cardiomyopathies by Phenome and Genome

	PHENOTYPE				GENOME	
TYPE	**MORPHOLOGY**	**PHYSIOLOGY**	**PATHOLOGY**	**SYSTEMIC CONDITIONS, CLINICAL FEATURES, RISK FACTORS**	**NONSYNDROMIC, USUALLY SINGLE GENE**	**SYNDROMIC**
Dilated (DCM)	Dilation of LV and RV with minimal or no wall thickening	Reduced contractility is the primary defect; variable degree of diastolic dysfunction	Myocyte hypertrophy; scattered fibrosis	Hypertension, alcohol, thyrotoxicosis, myxedema, persistent tachycardia, toxins (e.g., chemotherapy, especially anthracyclines), radiation	Diverse gene ontology with >50 genes implicated	Diverse array of associated conditions, especially muscular dystrophies: Emery-Dreifuss, limb-girdle, Duchenne/Becker; Laing distal myopathy; Barth syndrome; Kearns-Sayre syndrome; other mitochondrial disorders; fatty acid oxidation disorders; Alstrom syndrome, others
Restrictive (RCM)	Usually normal chamber sizes; minimal wall thickening	Contractility normal or near-normal with a marked increase in end-diastolic filling pressure	Specific to type, diagnosis: amyloid, iron, glycogen storage disease, others	Endomyocardial fibrosis, amyloid, sarcoid, scleroderma, Churg-Strauss syndrome, cystinosis, lymphoma, pseudoxanthoma elasticum, hypereosinophilic syndrome, carcinoid	If not associated with systemic genetic disease, genetic cause usually from sarcomeric pathogenic gene variants	Gaucher disease, hemochromatosis, Fabry disease, familial amyloidosis, mucopolysaccharidoses, Noonan syndrome
Hypertrophic (HCM)	Usually normal or reduced internal chamber dimension; wall thickening pronounced, especially septal hypertrophy	Systolic function increased or normal	Myocyte hypertrophy, classically with disarray	Severe hypertension can confound clinical, morphologic diagnosis	Pathogenic variants of genes encoding sarcomeric proteins	Noonan syndrome, Noonan syndrome with multiple lentigines, Danon syndrome, Fabry disease, Wolff-Parkinson-White syndrome, Friedreich ataxia, MERRF, MELAS, other mitochondrial disorders, fatty acid oxidation disorders
Arrhythmogenic right ventricular cardiomyopathy (ARVC)	Scattered fibrofatty infiltration, classically of RV but also of LV; dilation of RV or LV, or both, is common but not universal	Ventricular arrhythmias (VT, VF) early or late, reduced contractility with progressive disease; can mimic DCM	Islands of fatty replacement; fibrosis	Palmoplantar keratoderma, wooly hair in Naxos syndrome	Pathogenic variants of genes encoding proteins of desmosome	Naxos syndrome
Left ventricular noncompaction (LVNC)	Ratio of noncompacted to compacted myocardium increased with normal LV or RV or any other phenotype	Normal to reduced systolic function	Myocardium normal and ranging to findings consistent with other coexisting cardiomyopathies	Phenotype observed in setting of other types of cardiomyopathy	Various cardiomyopathy genes associated, but uncertain whether genetic cause or developmental defect during organogenesis	

Continued

Downloaded for mohamed ahmed (dr.mms2020@gmail.com) at University of Southern California from ClinicalKey.com by Elsevier on April 21, 2024. For personal use only. No other uses without permission. Copyright ©2024. Elsevier Inc. All rights reserved.

Table 488.1 Classification of the Cardiomyopathies by Phenome and Genome—cont'd

	PHENOTYPE				GENOME	
TYPE	**MORPHOLOGY**	**PHYSIOLOGY**	**PATHOLOGY**	**SYSTEMIC CONDITIONS, CLINICAL FEATURES, RISK FACTORS**	**NONSYNDROMIC, USUALLY SINGLE GENE**	**SYNDROMIC**
Infiltrative	Usually thickened walls; occasional dilation	Restrictive physiology; systolic function usually mildly reduced	Specific to type, diagnosis: amyloid, iron, glycogen storage disease, others		See RCM earlier	See RCM earlier
Inflammatory	Normal or dilated without hypertrophy	Reduced systolic function	Inflammatory infiltrates	Hypereosinophilic syndrome, acute myocarditis		
Ischemic	Normal or dilated without hypertrophy	Reduced systolic function	Areas of infarcted myocardium	Hypercholesterolemia, hypertension, diabetes, cigarette smoking, family history	Familial hypercholesterolemia; other heritable lipid disorders	Familial hypercholesterolemia
Infectious	Normal or dilated without hypertrophy	Reduced systolic function	Specific to infection	Viral (especially acute myocarditis); protozoal (e.g., Chagas disease); bacterial, direct infection (e.g., Lyme disease), or from acute cellular toxicity as result of systemic toxins (e.g., *Streptococcus*, gram-negative, others)	Genetic predisposition to infection and/or variable response to infective agent	

LV, Left ventricle; MELAS, mitochondrial encephalopathy, lactic acidosis, and strokelike symptoms; MERRF, myoclonic epilepsy associated with ragged-red fibers; RV, right ventricle; VF, ventricular fibrillation; VT, ventricular tachycardia.
From Falk RH, Hershberger RE. The dilated, restrictive, and infiltrative cardiomyopathies. In: Zipes DP, Libby P, Bonow RO, et al., eds. *Braunwald's Heart Disease*, 11th ed. Philadelphia: Elsevier; 2019: Table 77.1.

Downloaded for mohamed ahmed (dr.mms2020@gmail.com) at University of Southern California from ClinicalKey.com by Elsevier on April 21, 2024. For personal use only. No other uses without permission. Copyright ©2024. Elsevier Inc. All rights reserved.

Table 488.2 Etiology of Pediatric Myocardial Disease

CARDIOMYOPATHY	
Dilated Cardiomyopathy (DCM)	
Neuromuscular diseases	Muscular dystrophies (e.g., Duchenne, Becker, limb-girdle, Emery-Dreifuss, congenital muscular dystrophy), myotonic dystrophy, myofibrillar myopathy
Inborn errors of metabolism	Fatty acid oxidation disorders (trifunctional protein, VLCAD, LCHAD), carnitine abnormalities (carnitine transport, CPTI, CPTII), mitochondrial disorders (including Kearns-Sayre syndrome), organic acidemias (propionic acidemia), Danon disease (DCM more common in females)
Genetic variants in cardiomyocyte structural apparatus	Familial or sporadic DCM
Genetic syndromes	Alström syndrome, Barth syndrome (phospholipid disorders)
Ischemic	Most common in adults
Chronic tachyarrhythmias	Atrial tachycardias (intractable reentrant supraventricular tachycardia [AVRT, AVNRT], multifocal atrial tachycardia, permanent junctional reciprocating tachycardia), ventricular tachycardia
Hypertrophic Cardiomyopathy (HCM)	
Inborn errors of metabolism	Mitochondrial disorders (including Friedreich ataxia, variants in nuclear or mitochondrial genome), storage disorders (glycogen storage disorders, especially Pompe; mucopolysaccharidoses; Fabry disease; sphingolipidoses; hemochromatosis; Danon disease); fatty acid oxidation disorders
Genetic variants in cardiomyocyte structural apparatus	Familial or sporadic HCM
Genetic syndromes	Noonan, Costello, cardiofaciocutaneous, and Beckwith-Wiedemann syndromes
Infant of a diabetic mother	Transient hypertrophy
Restrictive Cardiomyopathy (RCM)	
Neuromuscular disease	Myofibrillar myopathies
Metabolic	Storage disorders
Genetic variants in cardiomyocyte structural apparatus	Familial or sporadic RCM
Secondary	Rare in children; radiation therapy of thorax, amyloidosis, sarcoidosis, hemochromatosis, β-thalassemia
Arrhythmogenic Right Ventricular Cardiomyopathy (ARVC)	
Genetic variants in cardiomyocyte structural apparatus	Familial or sporadic ARVC
Left Ventricular Noncompaction	
Genetic variants in cardiomyocyte structural apparatus	LVNC phenotype associated with HCM or DCM
Other	X-linked (Barth syndrome), autosomal recessive, mitochondrial inheritance, 1p36 deletion syndrome, and other chromosome abnormalities or genomic disorders; associated with congenital heart defects
SECONDARY OR ACQUIRED MYOCARDIAL DISEASE	
Myocarditis (see also Table 488.7)	**Viral:** parvovirus B19, adenovirus, coxsackievirus A and B, echovirus, rubella, varicella, influenza, mumps, Epstein-Barr virus, cytomegalovirus, measles, poliomyelitis, smallpox vaccine, hepatitis C virus, human herpesvirus 6, HIV, SARS-CoV-2 (COVID-19), opportunistic infections **Rickettsial:** psittacosis, *Coxiella,* Rocky Mountain spotted fever, typhus **Bacterial:** diphtheria, mycoplasma, meningococcus, leptospirosis, Lyme disease, typhoid fever, tuberculosis, streptococcus, listeriosis **Parasitic:** Chagas disease, toxoplasmosis, *Loa loa, Toxocara canis,* schistosomiasis, cysticercosis, echinococcus, trichinosis **Fungal:** histoplasmosis, coccidioidomycosis, actinomycosis
Systemic inflammatory disease	SLE, infant of mother with SLE, scleroderma, Churg-Strauss vasculitis, rheumatoid arthritis, rheumatic fever, sarcoidosis, dermatomyositis, periarteritis nodosa, hypereosinophilic syndrome (Löffler syndrome), acute eosinophilic necrotizing myocarditis, giant cell myocarditis, Kawasaki disease, multisystem inflammatory syndrome in children (COVID-19)
Nutritional deficiency	Beriberi (thiamine deficiency), kwashiorkor, Keshan disease (selenium deficiency)
Drugs, toxins	Doxorubicin (Adriamycin), cyclophosphamide, chloroquine, ipecac (emetine), sulfonamides, mesalazine, chloramphenicol, alcohol, hypersensitivity reaction, envenomations, irradiation, herbal remedy (blue cohosh), immune checkpoint inhibitors
Coronary artery disease	Kawasaki disease, medial necrosis, anomalous left coronary artery from pulmonary artery, other congenital coronary anomalies (anomalous right coronary artery, coronary ostial stenosis), familial hypercholesterolemia
Hematology-oncology	Anemia, sickle cell disease, leukemia
Endocrine-neuroendocrine	Hyperthyroidism, carcinoid tumor, pheochromocytoma, adrenal crisis
Stress (takotsubo) cardiomyopathy	Endocrine (see earlier) Neurologic (stroke, bleed) Induction of anesthesia Fright Medications/drugs (sympathomimetic agents, venlafaxine)

CPTI/CPTII, Carnitine palmitoyltransferase 1/2; LCHAD, long-chain 3-hydroxyacyl-CoA dehydrogenase deficiency; LVNC, left ventricular noncompaction; SLE, systemic lupus erythematosus; VLCAD, very-long-chain acyl-coenzyme A dehydrogenase.

RV enlargement and depressed function are occasionally noted. Echo Doppler studies can reveal evidence of pulmonary hypertension, mitral regurgitation, or other structural cardiac or coronary abnormalities. Cardiac MRI is useful for patients with suboptimal imaging echocardiographic windows or in patients with concern of acute myocarditis where, in contrast to echocardiography, recognition of inflammation of the myocardium is possible.

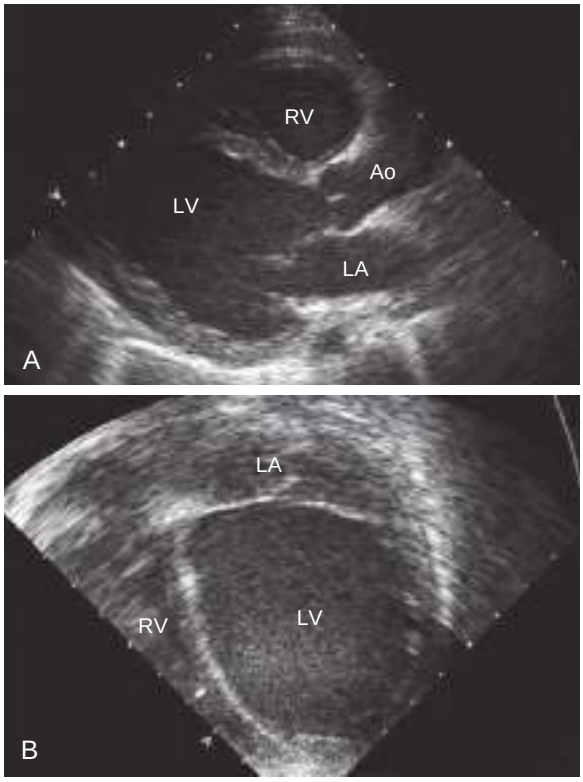

Fig. 488.1 Echocardiogram of a patient with dilated cardiomyopathy. **A,** Parasternal long-axis view showing the enlarged left ventricle. **B,** Apical four-chamber view showing the large left ventricle compressing the right ventricle. Ao, Ascending aorta; LA, left atrium; LV, left ventricle; RV, right ventricle.

Additional testing may include complete blood count, renal and liver function tests, creatine phosphokinase (CPK), cardiac troponin I, lactate, brain natriuretic peptide (BNP) and pro-BNP, plasma amino acids, urine organic acids, and an acylcarnitine profile. Additional genetic testing is typically indicated, and enzymatic testing may be useful (see Table 488.3). Cardiac catheterization and endomyocardial biopsy are not routine but may be useful in patients with acute DCM. Biopsy samples can be examined histologically for the presence of mononuclear cell infiltrates, myocardial damage, storage abnormalities, and evidence of infection. It is considered standard of care to screen first-degree family members using echocardiography and electrocardiogram (ECG) in idiopathic and familial cases of DCM.

PROGNOSIS AND MANAGEMENT

The 1- and 5-year freedom from death or transplantation in patients diagnosed with DCM is 60–70% and 50–60%, respectively. Independent risk factors at DCM diagnosis for subsequent death or transplantation include older age, heart failure, lower LV fractional shortening *z* score, and underlying etiology. DCM is the most common cause for cardiac transplantation in pediatric and adult studies.

The therapeutic approach to patients with DCM includes a careful assessment to uncover possible treatable etiologies, screening of family members, and rigorous pharmacologic therapy. **Medications** aimed at reverse remodeling (improving ventricular size and function) include angiotensin-converting enzyme (ACE) inhibitors or angiotensin receptor blockers (ARBs) plus β-adrenergic blockade with carvedilol or metoprolol. The combination medication valsartan/sacubitril, which is an ARB/neprilysin inhibitor, respectively, that is FDA approved for patients 1 year of age and older, has been readily used in this setting in pediatrics in lieu of either an ACE or ARBs alone (see Chapter 491). Each of these medications have proved independently and in combination to improve survival and symptoms and reduce hospital admissions in adults with DCM. Additionally, furosemide may be used to reduce symptoms of pulmonary or systemic venous congestion. Digoxin therapy can also be considered in some patients. Implantable cardiac defibrillators may be considered for certain select patients with a high risk of sudden cardiac arrest. **Pacemakers**, including dual-chamber and biventricular pacing therapy, can improve patients with

Table 488.3 Cardiomyopathies

	DCM	HCM	RCM	LVNC	ARVC
Prevalence	50/100,000	1/500	Unknown	Unknown	1/2,000
Causes	Sarcomeric/ cytoskeletal/ desmosomal gene variant, neuromuscular disease, inborn error of metabolism, mitochondrial disease, genetic syndrome, infection	Sarcomeric/ cytoskeletal/ desmosomal gene variant, genetic syndrome, inborn error of metabolism/ mitochondrial disease	Sarcomeric gene variant, neuromuscular disease, genetic syndrome, storage or infiltrative disease	Sarcomeric-cytoskeletal-desmosomal gene mutation, neuromuscular disease, inborn error of metabolism, mitochondrial disease, genetic syndrome	Desmosomal gene variants
Inheritance	30–50% AD, AR, X-L, Mt	50% AD, Mt	AD, up to 50%	AD, X-L, Mt, % unknown	30–50% AD, rare AR (Naxos disease; Carvajal syndrome)
Sudden death	Yes	Yes	Yes	Yes	Yes
Arrhythmias	Atrial, ventricular, and conduction disturbances	Atrial and ventricular	Atrial fibrillation	Atrial, ventricular, and conduction disturbances	Ventricular and conduction disturbances
Ventricular function	Systolic and diastolic dysfunction	Diastolic dysfunction Dynamic systolic outflow obstruction	Diastolic dysfunction Normal systolic function	Systolic or diastolic dysfunction	Normal-reduced systolic and diastolic function

ACE, Angiotensin-converting enzyme; AD, autosomal dominant inheritance; AR, autosomal recessive inheritance; ARVC, arrhythmogenic right ventricular cardiomyopathy; DCM, dilated cardiomyopathy; HCM, hypertrophic cardiomyopathy; ICD, implantable cardioverter-defibrillator; LVNC, left ventricular noncompaction; Mt, mitochondrial inheritance; RCM, restrictive cardiomyopathy; X-L, X-linked inheritance.

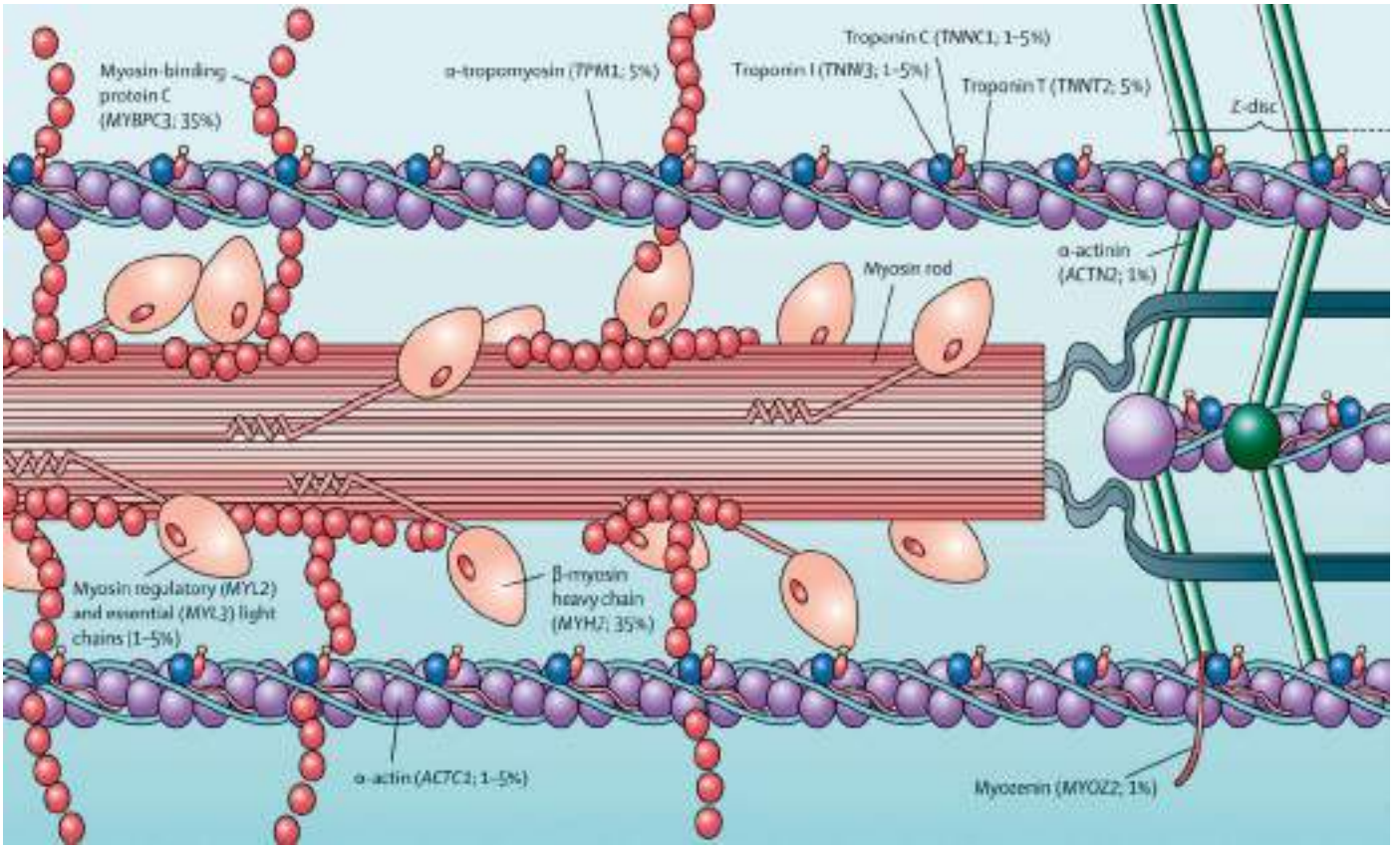

Fig. 488.2 Locations of genes within the cardiac sarcomere known to cause hypertrophic cardiomyopathy. Prevalence of every gene (derived from data of unrelated hypertrophic cardiomyopathy probands with positive genotyping) is shown in parentheses. *(From Maron BJ, Maron MS. Hypertrophic cardiomyopathy. Lancet 2013;381:242–252, Fig 1.)*

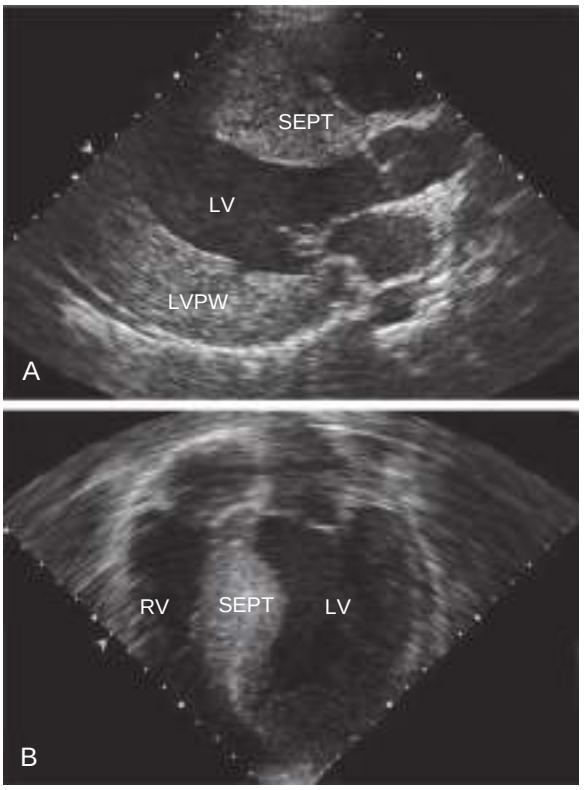

Fig. 488.3 Echocardiograms demonstrating hypertrophic cardiomyopathy. **A,** Parasternal long-axis view of a patient with severe concentric left ventricular hypertrophy. **B,** Four-chamber view of a patient with asymmetric septal hypertrophy. LV, Left ventricle; LVPW, left ventricular posterior wall; RV, right ventricle; SEPT, septum.

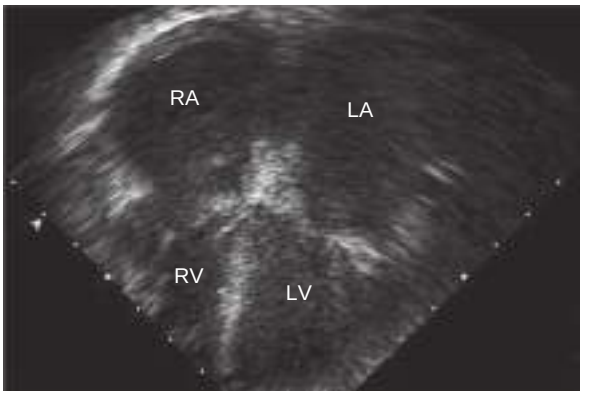

Fig. 488.4 Echocardiogram of a patient with restrictive cardiomyopathy. Apical four-chamber view shows the greatly enlarged right and left atria compared to the normal-size left and right ventricular chambers. LA, Left atrium; LV, left ventricle; RA, right atrium; RV, right ventricle.

Table 488.4 Nuclear DNA Abnormalities Associated with Cardiomyopathy and Arrhythmias or Conduction Defects*

CONDITION	GENETIC DEFECT	HEART FINDINGS	OTHER CLINICAL FEATURES
ISOLATED COMPLEX DEFICIENCIES			
Complex I deficiency	Multiple complex I subunit genes, *ACAD9, FOXRED1*	HCM, DCM, LVNC, WPW	Leigh syndrome, FILA, MELAS, leukoencephalopathy, seizures, hypotonia, pigmentary retinopathy, optic atrophy, hearing loss, liver dysfunction
Complex II deficiency	*SDHA, SDHD*	HCM, DCM, LVNC, AF, heart block	Leukoencephalopathy, cerebellar atrophy, seizures, spasticity, myopathy, liver dysfunction, kidney dysfunction
Complex III deficiency	*BCS1L*	HCM	Developmental delay, psychosis, hearing loss
Complex IV deficiency	*SCO2, SURF1, C2orf64, Cl2orf62, COX6B1*	HCM, DCM	Leigh syndrome, encephalopathy, ataxia, liver dysfunction, kidney dysfunction
MITOCHONDRIAL TRANSLATION DEFECTS			
GTP-binding protein-3 deficiency	*GTPBP3*	HCM, DCM, heart block, WPW	Leigh syndrome, encephalopathy
Mitochondrial translational activator protein deficiency	*MTOI*	HCM, heart block	Encephalopathy, hypotonia
Alanyl-tRNA synthetase deficiency	*AARS2*	HCM	Leukoencephalopathy, myopathy
Tyrosyl-tRNA synthetase deficiency	*YARS2*	HCM	MLASA syndrome
tRNA methyltransferase-5 deficiency	*TRMTS*	HCM	Developmental delay, hypotonia, peripheral neuropathy, renal tubulopathy
RNA processing defect	*ELAC2*	HCM, PSVE	Microcephaly, growth deficiency, hearing loss
Mitochondrial ribosomal subunit deficiencies	*MRPS22, MRPl3, MRPL44*	HCM, WPW	Leukoencephalopathy, seizures, liver dysfunction, renal tubulopathy
mtDNA DEPLETION SYNDROMES			
MNGIE	*TYMP*	Mild or asymptomatic HCM	Leukoencephalopathy, severe gastrointestinal dysmotility, ophthalmoplegia, hearing loss, peripheral neuropathy
F-box protein deficiency	*FBXL4*	Cardiomyopathy, unspecified	Encephalopathy, brain atrophy
Coenzyme Q_{10} biosynthesis defects	*COQ2, COQ4, COQ9*	HCM	Leigh syndrome, encephalomyopathy, retinitis pigmentosa, hearing loss, liver dysfunction, renal tubulopathy
3-METHYLGLUTACONIC ACIDURIAS			
Barth syndrome	*TAZ*	HCM, DCM, LVNC, EFE, VT, LQTS	Myopathy, short stature, neutropenia
Dilated cardiomyopathy and ataxia syndrome	*DNAJC19*	DCM, LVNC	Ataxia, optic ataxia, short stature, testicular abnormalities, liver disease
Complex V deficiency	*TMEM70*	HCM	Cataracts, leukodystrophy, ataxia, myopathy, short stature
Sengers syndrome	*AGK*	HCM	Cataracts, myopathy, exercise intolerance, short stature

*Examples of conditions that are associated with heart disease and feature abnormal nDNA are shown, along with the causative molecular defects and clinical findings. The genetic defects noted here are provided as major contributors to the various mitochondrial conditions but are not a comprehensive compilation.

AF, Atrial fibrillation; DCM, dilated cardiomyopathy; EFE, endocardial fibroelastosis; FILA, fatal infantile lactic acidosis; GTP, guanosine triphosphate; HCM, hypertrophic cardiomyopathy; LQTS, long QT syndrome; MELAS, mitochondrial encephalomyopathy, lactic acidosis, and strokelike episodes; MLASA, myopathy, lactic acidosis, sideroblastic anemia; MNGIE, mitochondrial neurogastrointestinal encephalopathy; nDNA, nuclear DNA; PSVE, paroxysmal supraventricular extrasystoles; LVNC, left ventricular noncompaction; VT, ventricular tachycardia; WPW, Wolff-Parkinson-White syndrome.

From Enns GM. Pediatric mitochondrial diseases and the heart. *Curr Opin Pediatr*. 2017;29:541–551, Table 2.

certain underlying electrical derangements. In patients presenting with extreme degrees of heart failure or circulatory collapse, intensive care measures are often required, including intravenous inotropes and diuretics, mechanic ventilatory support, and on occasion, mechanical circulatory support, which may include a ventricular assist device (VAD), total artificial heart, extracorporeal membrane oxygenation (ECMO), and ultimately cardiac transplantation. In patients with DCM and atrial or ventricular arrhythmias, specific antiarrhythmic therapy should be instituted.

Visit Elsevier eBooks+ at eBooks.Health.Elsevier.com for Bibliography.

Table 488.5 Mitochondrial DNA Abnormalities Associated with Cardiomyopathy and Arrhythmias or Conduction Defects*

CONDITION	GENETIC DEFECT	HEART FINDINGS	OTHER CLINICAL FEATURES
Kearns-Sayre syndrome	mtDNA deletion	HCM, DCM, heart block, PMVT	Progressive external ophthalmoplegia, pigmentary retinopathy, cerebellar ataxia, hearing loss, increased CSF protein, diabetes mellitus, renal tubulopathy
MELAS	$tRNA^{Lou}$ point variant	HCM, DCM, LVNC, RCM, heart block, WPW	Encephalopathy, seizures, strokelike episodes, headaches, hearing loss, myopathy
MERRF	$tRNA^{Lys}$ point variant	HCM, DCM, HiCM, WPW	Myoclonus, seizures, ataxia, optic atrophy, hearing loss, short stature
Complex I deficiency	Multiple complex I subunit genes	HCM, DCM	Leigh syndrome, leukoencephalopathy, seizures, optic atrophy
Complex III deficiency	*MTCYB*	HCM, DCM, HiCM	Exercise intolerance, myopathy, seizures, optic atrophy, short stature
Complex IV deficiency	*MT-CO1, MT-CO2, MT-CO3*	HCM, DCM, HiCM	Encephalopathy, seizures, pigmentary retinopathy, hearing loss, myopathy, liver dysfunction
Complex V deficiency	*MT-ATP6, MT-ATP8*	HCM	Ataxia, peripheral neuropathy

*Relatively common conditions that are associated with heart disease and feature abnormal mtDNA are shown, along with the most common molecular defects and clinical findings. Although the most common molecular defects are indicated in the table, in most cases, multiple genetic abnormalities can cause similar clinical presentations.
CSF, Cerebrospinal fluid; DCM, dilated cardiomyopathy; HCM, hypertrophic cardiomyopathy; HiCM, histiocytoid cardiomyopathy; LVNC, left ventricular noncompaction; MELAS, mitochondrial encephalomyopathy, lactic acidosis, and strokelike episodes; MERRF, myoclonic epilepsy with ragged red fibers; mtDNA, mitochondrial DNA; PMVT, polymorphic ventricular tachycardia; RCM, restrictive cardiomyopathy; WPW, Wolff-Parkinson-White syndrome.
From Enns GM. Pediatric mitochondrial diseases and the heart. *Curr Opin Pediatr.* 2017;29:541–551. Table 3.

Table 488.6 Gene Variants and Cardiac Manifestations of Neuromuscular Disorders

DISORDER	GENE VARIANT	CARDIOMYOPATHY	ECG	ARRHYTHMIA
Duchenne muscular dystrophy (DMD)	Dystrophin	Dilated	Short PR interval, prolonged QT interval, increased QT:PT ratio, right ventricular hypertrophy, deep Q waves II, III, aVF, V_5, V_6	Increased baseline HR, decreased rate variability, premature ventricular beats (58% of patients by 24 yr of age)
DMD—female carrier	Dystrophin	Dilated	None	Uncommon
Becker muscular dystrophy	Dystrophin	Dilated	Conduction system disease	Similar to DMD
Emery-Dreifuss autosomal dominant or proximal dominant limb-girdle muscular dystrophy IB	Lamin A/C	Dilated	Conduction abnormalities: prolonged PR interval, sinus bradycardia	Atrial fibrillation or flutter and atrial standstill; ventricular dysrhythmias
Limb-girdle muscular dystrophy	α, β, γ, δ sarcoglycans	Dilated	Incomplete right bundle branch block, tall R waves in V_1 and V_2, left anterior hemiblock	Uncommon
Congenital muscular dystrophy	Laminin α_2	Dilated	None	None
Limb-girdle muscular dystrophy 21	Fukutin	Dilated	AV node and bundle branch block; age at onset: late teens and early 20s	Atrial arrhythmias and/or ventricular arrhythmias
Emery-Dreifuss X-linked	Emerin	Rare	Conduction abnormalities: prolonged PR interval, sinus bradycardia	Atrial fibrillation or flutter and atrial standstill
Friedreich ataxia	Frataxin	Hypertrophic	T-wave inversion, left axis deviation, repolarization abnormalities	Ventricular arrhythmias
Myotonic dystrophy type 1, infantile	Myotonic dystrophy protein kinase gene	Hypertrophic	Conduction disease, prolonged PR interval, widening of QRS complex	Atrial fibrillation and flutter, complete heart block
Myotonic dystrophy type 1	Myotonic dystrophy protein kinase gene	LVNC	Conduction disease, prolonged PR interval, widening of QRS complex	Atrial fibrillation and flutter, complete heart block

AV, Atrioventricular; HR, heart rate; LVNC, left ventricular noncompaction.
From Hsu DT. Cardiac manifestations of neuromuscular disorders in children. *Pediatr Respir Rev.* 2010;11:35–38, Table 1.

488.2 Hypertrophic Cardiomyopathy

John J. Parent and Stephanie M. Ware

Hypertrophic cardiomyopathy **(HCM)** is a heterogeneous, relatively common, and potentially life-threatening form of cardiomyopathy. The causes of HCM include inborn errors of metabolism, neuromuscular disorders, syndromic conditions, and genetic abnormalities of the structural components of the cardiomyocyte (see Tables 488.1 and 488.2). Both the age of onset and the associated features are helpful in identifying the underlying etiology.

HCM is a genetic disorder and frequently occurs because of pathogenic variants in sarcomere or cytoskeletal components of the cardiomyocyte (see Fig. 488.2). Pathogenic variants of the genes encoding cardiac β-myosin heavy-chain *(MYH7)* and myosin-binding protein C *(MYBPC3)* are the most common (see Table 488.3). Pathogenic variants are inherited in an autosomal dominant pattern with a high penetrance but variable expressivity. Additional genetic causes for HCM include nonsarcomeric protein pathogenic variants, such as the γ_2-regulatory subunit of adenosine monophosphate–activated protein kinase *(PRKAG2)* and the lysosome-associated membrane protein 2α-galactosidase (**Danon disease**, a form of glycogen storage disease). Syndromic conditions, such as **Noonan syndrome**, may present with HCM at birth, and recognition of extracardiac manifestations is important in making the diagnosis. Medical therapy directed at the Ras signaling pathway is in the initial phases of use in patients with Noonan syndrome and related RASopathies.

Glycogen storage disorders such as **Pompe disease** often present in infancy with a heart murmur, abnormal ECG, systemic signs and symptoms, and occasionally heart failure. Many states have Pompe testing on the newborn screening, facilitating early diagnosis and therapy, which has improved the prognosis. The characteristic ECG in Pompe disease demonstrates prominent P waves, a *short* P-R interval, and massive QRS voltages. The echocardiogram confirms severe, often concentric, LV hypertrophy.

PATHOGENESIS

HCM is characterized by the presence of increased LV wall thickness in the absence of structural heart disease or hypertension. Often the interventricular septum is disproportionately involved, leading to the previous designation of *idiopathic hypertrophic subaortic stenosis* or the current term of **asymmetric septal hypertrophy**. In the presence of a resting or provocable outflow tract gradient, the term **hypertrophic obstructive cardiomyopathy** is used. Although the left ventricle is predominantly affected, the right ventricle may be involved, particularly in infancy. The mitral valve can demonstrate systolic anterior motion and mitral insufficiency. Left ventricular outflow tract (LVOT) obstruction occurs in 25% of patients, is dynamic in nature, and may in part be secondary to the abnormal position of the mitral valve as well as the obstructing subaortic hypertrophic cardiac muscle. The cardiac myofibrils and myofilaments demonstrate disarray and myocardial fibrosis.

Typically, systolic function is preserved or even hyperdynamic, although systolic dysfunction may occur late and is a predictor for death or need for cardiac transplant. LVOT obstruction with or without mitral insufficiency may be provoked by physiologic manipulations such as the Valsalva maneuver, positional changes, and physical activity. Frequently, the hypertrophic and fibrotic cardiac muscle demonstrates relaxation abnormalities (diminished compliance), and LV filling may be impaired (diastolic dysfunction).

CLINICAL MANIFESTATIONS

Many patients are asymptomatic; 50% of cases present with a heart murmur or during screening when another family member has been diagnosed with HCM. Symptoms of HCM may include palpitations, chest pain, easy fatigability, dyspnea, dizziness, and syncope. Sudden death is a well-recognized but uncommon manifestation that occurs during physical exertion but may also occur at rest or during sleep. Characteristic physical examination findings include an overactive precordial impulse with a lift or heave, a systolic ejection murmur in the aortic region *not* associated with an ejection click, and an apical blowing murmur of mitral insufficiency.

DIAGNOSIS

The ECG typically demonstrates LV hypertrophy with ST segment and T-wave abnormalities (particularly T-wave inversion in the left precordial leads). Intraventricular conduction delays and signs of ventricular preexcitation **(Wolff-Parkinson-White syndrome)** may be present and should raise the possibility of PRKAG2-related HCM, Danon disease, or Pompe disease. Chest radiography demonstrates normal or mildly increased heart size with a prominence of the left ventricle. Echocardiography is diagnostic in identifying, localizing, and quantifying the degree of myocardial hypertrophy (see Fig. 488.3). Doppler interrogation defines, localizes, and quantifies the degree of LVOT obstruction and demonstrates and quantifies the degree of mitral insufficiency and diastolic dysfunction.

Cardiac catheterization is rarely used in the diagnosis of HCM but may be helpful if there is concern for a **myocardial bridge** (when a coronary artery runs through vs on top of the myocardium) that may be causing intermittent coronary insufficiency during dynamic obstruction. Myocardial bridges can be seen on coronary angiography. Additionally, cardiac catheterization may occasionally be used to better define hemodynamics in patients.

Additional diagnostic studies include metabolic testing, genetic testing for specific syndromes, or genetic testing for pathogenic variants in genes known to cause isolated HCM (see Table 488.3). Clinical genetic testing panels continue to expand. Genetic diagnosis is also useful in identifying at-risk family members who require ongoing surveillance (Figs. 488.5 and 488.6).

PROGNOSIS AND MANAGEMENT

Children <1 year of age or with inborn errors of metabolism or malformation syndromes or those with a mixed HCM/DCM have a significantly poorer prognosis. The risk of sudden death in older patients is greater in those with a personal or family history of cardiac arrest, ventricular tachycardia, exercise hypotension, syncope, or excessive (>3 cm) ventricular wall thickness. Although intrafamilial variability in symptoms occurs, a family history of sudden death is a highly significant predictor of risk. Restriction from competitive sports and strenuous physical activity is highly recommended, and additional recreational exercise activities should be tailored to each individual based on their overall clinical status. β-Adrenergic blocking agents (propranolol, atenolol, metoprolol) or calcium channel blockers (verapamil) may be useful in diminishing LVOT obstruction, modifying LV hypertrophy, and improving ventricular filling. They also confer an antiarrhythmic benefit and may reduce symptoms. In patients with atrial or ventricular arrhythmias, specific antiarrhythmic therapy should be used. Patients with documented, previously aborted sudden cardiac arrest, strong family histories of sudden death, ventricular wall end-diastolic dimensions of ≥3 cm, unexplained syncope, nonsustained ventricular tachycardia, apical aneurysm, ejection fraction ≤50%, or blunted or hypotensive blood pressure response to exercise should be considered for treatment with an **implantable cardioverter-defibrillator** (ICD). Early identification of HCM, family screening/surveillance, appropriate activity restriction, and use of ICDs have greatly reduced the mortality of HCM to approximately 0.5% per year in the modern era.

Innovative interventional procedures have been used to reduce the degree of LVOT obstruction anatomically or physiologically. Dual-chamber pacing, alcohol septal ablation, surgical septal

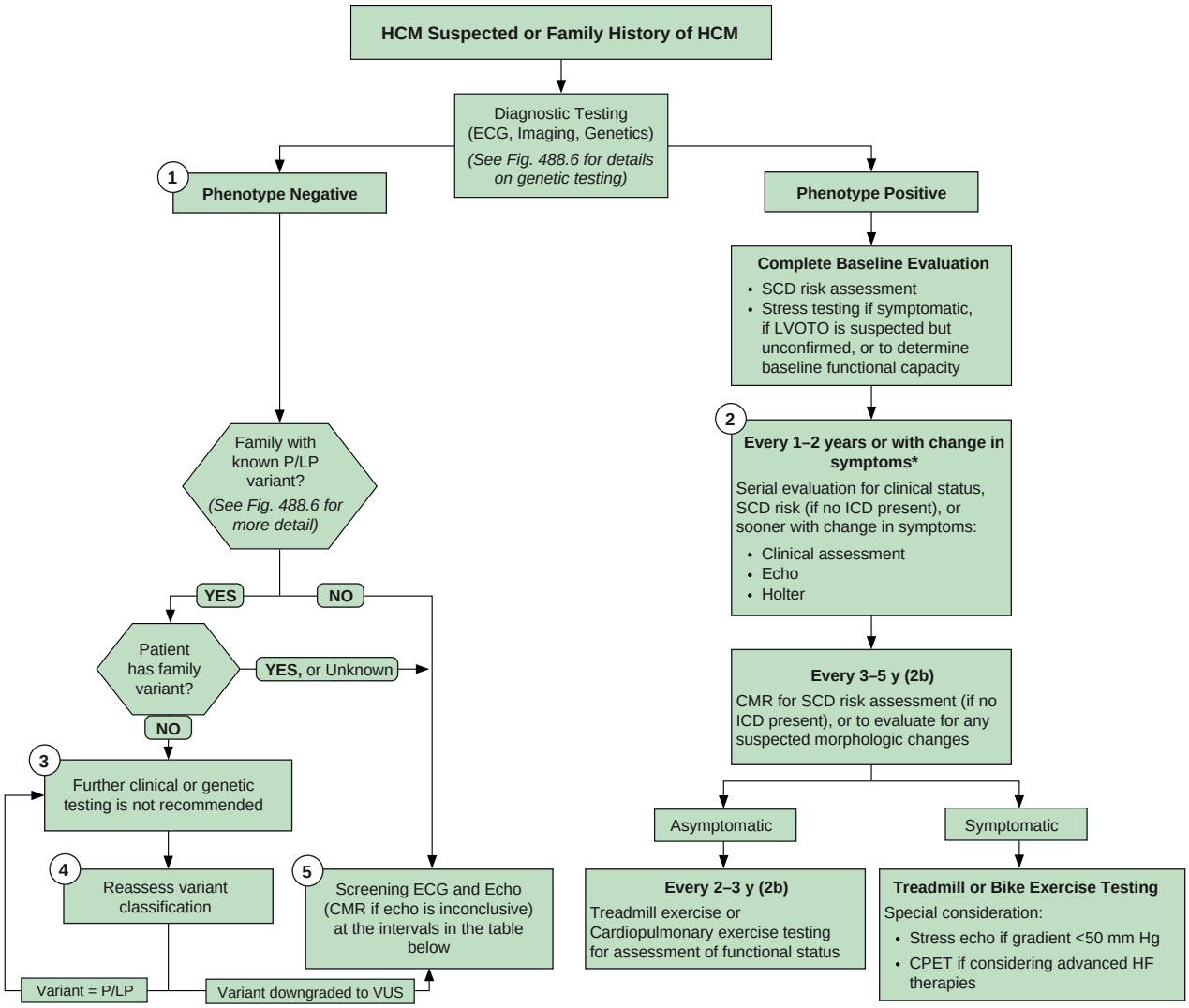

Screening Asymptomatic First-Degree Relatives of Patients With HCM		
Age of First-Degree Relative	**Initiation of Screening**	**Surveillance Interval**
Children and adolescents from genotype-positive family and/or family with early onset HCM	At the time of diagnosis in another family member	Every 1–2 y
All other children and adolescents	At any time after the diagnosis in the family, but no later than puberty	Every 2–3 y
Adults	At the time of diagnosis in another family member	Every 3–5 y

Fig. 488.5 Algorithm for recommended evaluation and testing modified for HCM. *The interval may be extended, particularly in adult patients who remain stable after multiple evaluations. CMR, Cardiovascular magnetic resonance; CPET, cardiopulmonary exercise test; ECG, electrocardiography/electrocardiogram; HCM, hypertrophic cardiomyopathy; HF, heart failure; ICD, implantable cardioverter-defibrillator; LVOTO, left ventricular outflow tract obstruction; P/LP, pathogenic or likely pathogenic variant; SCD, sudden cardiac death; VUS, variant of unknown significance. *(Modified from Ommen SR, Mital S, Burke MA, et al. 2020 AHA/ACC guideline for the diagnosis and treatment of patients with hypertrophic cardiomyopathy: executive summary. J Amer Coll Cardiol. 2020;142:e533–e557, Fig. 1.)*

myomectomy, and mitral valve replacement have all met with some success but are typically reserved for patients with significant symptoms despite medical therapy (Fig. 488.7). Mavacamten, a selective myosin inhibitor, has been an effective therapy in adults. Enzyme replacement therapy for Pompe disease is an effective therapy after birth (see Chapter 107.1). Preliminary trials of in utero enzyme replacement therapy for Pompe disease have also demonstrated efficacy.

First-degree relatives of patients identified as having HCM should be screened with ECG and echocardiogram. Genetic testing is available clinically and is of high utility. It is important first to test the affected individual in the family rather than "at-risk" individuals, because 20–50% of cases of HCM will not demonstrate pathogenic variants in currently available panels of genes. If a causative genetic variant is identified, at-risk members of the family can be effectively tested. In families with HCM without demonstrable pathogenic variants, repeat noninvasive cardiac screening with ECG and echocardiogram should be undertaken in at-risk individuals yearly until young adulthood (age 21 years) and then every 3 years if no prior evidence of HCM is present. Gene-positive but phenotype-negative pediatric patients may remain asymptomatic during childhood but require careful and frequent follow-up.

Visit Elsevier eBooks+ at eBooks.Health.Elsevier.com for Bibliography.

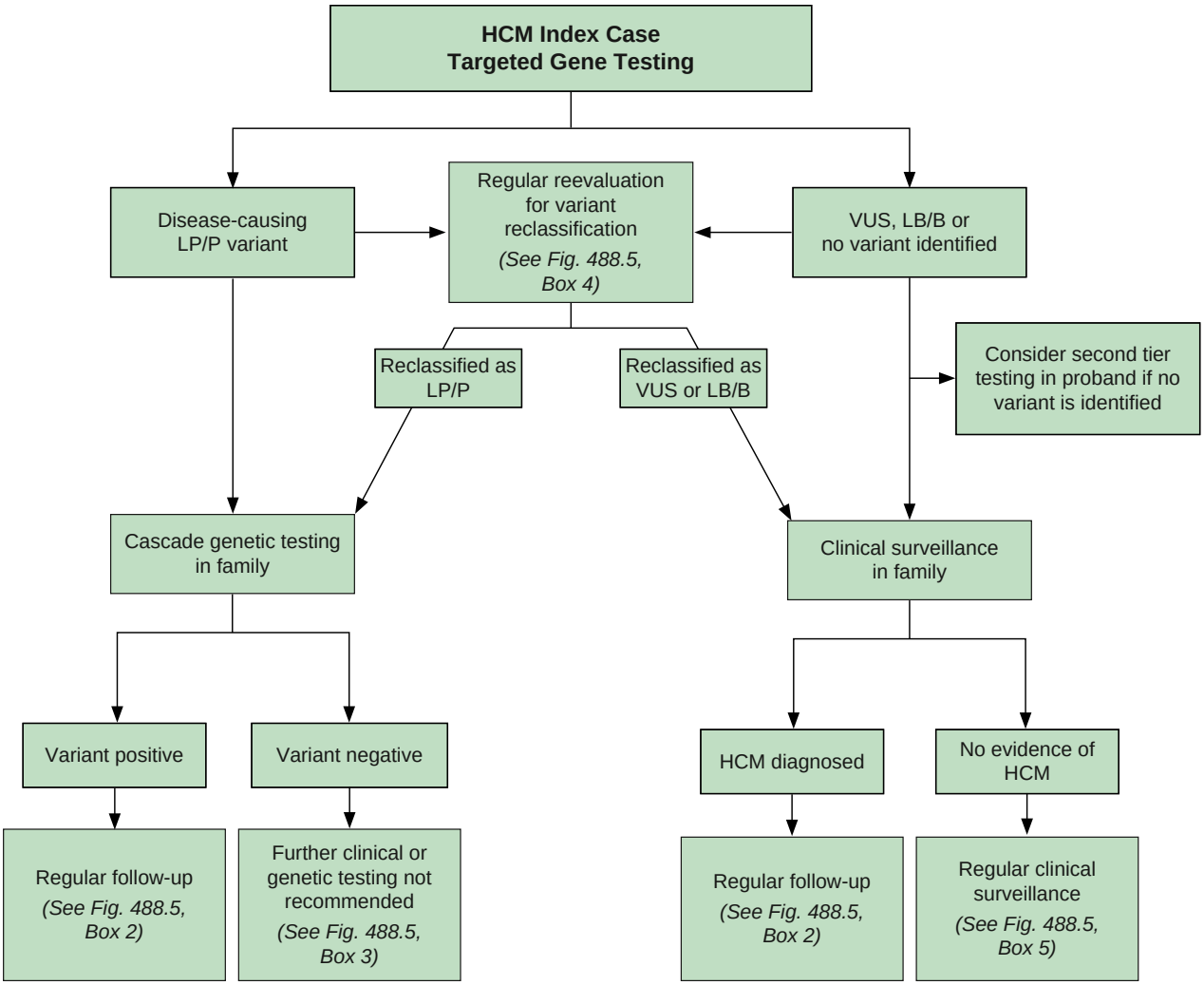

Fig. 488.6 Algorithm for genetic testing processes in HCM. HCM, Hypertrophic cardiomyopathy; LB/B, likely benign/benign; LP/P, likely pathogenic or pathogenic; VUS, variant of unknown significance. *(Modified from Ommen SR, Mital S, Burke MA, et al. 2020 AHA/ACC guideline for the diagnosis and treatment of patients with hypertrophic cardiomyopathy: executive summary. J Amer Coll Cardiol. 2020;142:e533–e557, Fig. 2.)*

488.3 Restrictive Cardiomyopathy

John J. Parent and Stephanie M. Ware

Restrictive cardiomyopathy **(RCM)** accounts for <5% of cardiomyopathy cases. Incidence increases with age and is more common in females. In equatorial Africa, RCM accounts for a large number of deaths. Infiltrative myocardial causes and storage disorders frequently result in associated LV hypertrophy and may represent HCM with restrictive physiology. Noninfiltrative causes include pathogenic variants in genes encoding sarcomeric or cytoskeletal proteins. Although there has been significant success in discovering pathogenic gene variants causing RCM, the majority of cases are considered idiopathic. Potential etiologies include sarcoidosis and Gaucher, Hurler, or Fabry diseases.

PATHOGENESIS

RCM is characterized by normal ventricular chamber dimensions, normal myocardial wall thickness, and preserved systolic function. Dramatic atrial dilation can result from the abnormal ventricular myocardial compliance and high ventricular diastolic pressure. Autosomal dominant inheritance has been demonstrated for families with pathogenic gene variants in sarcomeric and cytoskeletal genes.

CLINICAL MANIFESTATIONS

Abnormal ventricular filling, sometimes referred to as *diastolic heart failure,* is manifest in the systemic venous circulation with edema, hepatomegaly, or ascites. Elevation of left-sided filling pressures results in cough, dyspnea, or pulmonary edema. With activity, patients may experience chest pain, shortness of breath, syncope/near-syncope, or even sudden death. Pulmonary hypertension and pulmonary vascular disease develop and may progress rapidly. Heart murmurs are typically absent, but a gallop rhythm may be prominent. In the presence of pulmonary hypertension, an overactive RV impulse and pronounced pulmonary component of the second heart sound (S_2) are present in RCM.

DIAGNOSIS

The characteristic electrocardiographic finding of prominent P waves (reflective of atrial enlargement) is usually associated with normal QRS voltages and nonspecific ST and T-wave changes. RV hypertrophy occurs in patients with pulmonary hypertension. The chest radiograph may be normal or may demonstrate a prominent atrial shadow and pulmonary vascular redistribution. The echocardiogram is often diagnostic, demonstrating normal-sized ventricles with preserved systolic function and dramatic enlargement of the atria (see Fig. 488.4). Flow and tissue Doppler interrogation reveal abnormal filling parameters. It is critical to differentiate RCM from **constrictive pericarditis**, which can be treated surgically (see Chapter 489.2). MRI may be necessary to demonstrate the thickened or calcified pericardium often present in constrictive pericardial disease.

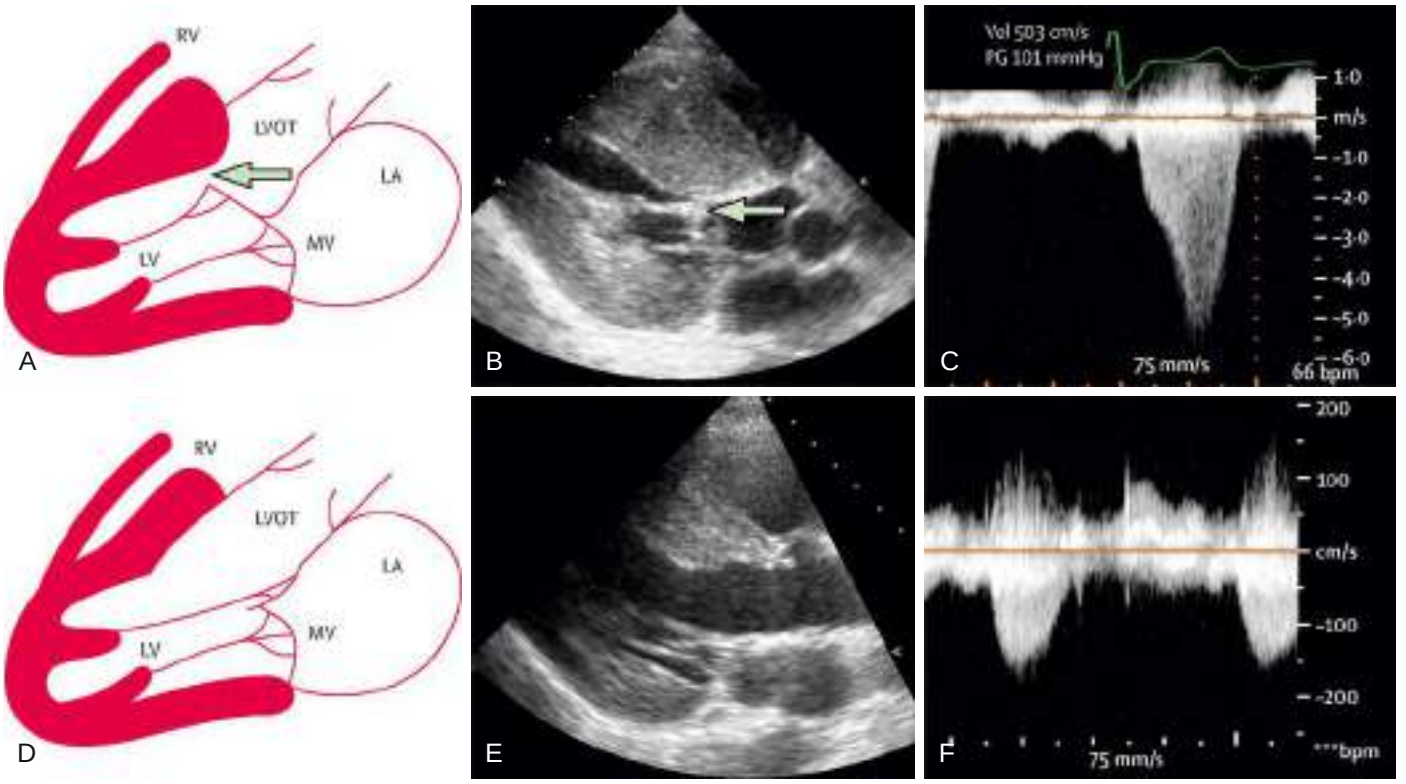

Fig. 488.7 Scheme of septal reduction therapy. **A,** Left ventricular outflow tract (LVOT) obstruction *(arrow)* created by hypertrophied basal septum and systolic anterior motion. **B,** Transthoracic echocardiography with systolic anterior motion *(arrow)*. **C,** Continuous-wave Doppler imaging of dynamic LVOT obstruction. **D,** Schematic finding after septal reduction. **E,** Transthoracic echocardiography after septal reduction procedure. **F,** Absence of LVOT obstruction in continuous-wave Doppler imaging after septal reduction therapy. LA, Left atrium; LV, left ventricle; MV, mitral valve; RV, right ventricle. *(From Veselka J, Anavekar NS, Charron P. Hypertrophic obstructive cardiomyopathy. Lancet. 2017;389:1253–1264, Fig. 5, p. 1259.)*

PROGNOSIS AND MANAGEMENT

Pharmacologic modalities are of limited use, and the prognosis of patients with RCM is generally poor, with often progressive clinical deterioration. Sudden death is a significant risk, with a 2-year survival of 50%. When signs of heart failure exist, judicious use of diuretics can result in clinical improvement. As a result of the dramatic atrial enlargement and ventricular scarring, these patients are predisposed to the development of atrial tachyarrhythmias, complete heart block, and thromboemboli. Antiarrhythmic agents may be necessary, and anticoagulation with platelet inhibitors or warfarin (Coumadin) is indicated.

Cardiac transplantation is the treatment of choice in many centers for patients with RCM, and the results are excellent in patients without pulmonary hypertension, pulmonary vascular disease, or severe congestive heart failure. Some patients may need bridging to transplant with a VAD if they have elevated pulmonary pressures or significant heart failure.

Visit Elsevier eBooks+ at eBooks.Health.Elsevier.com for Bibliography.

488.4 Left Ventricular Noncompaction, Arrhythmogenic Right Ventricular Cardiomyopathy, Endocardial Fibroelastosis, and Takotsubo Cardiomyopathy

John J. Parent and Stephanie M. Ware

Left ventricular noncompaction (LVNC) is characterized by a distinctive trabeculated or spongy-appearing left ventricle commonly associated with LV dysfunction and/or dilation and at times hypertrophy, diastolic dysfunction, and arrhythmias (Fig. 488.8). LVNC may be isolated or associated with structural congenital cardiac defects. Patients may present with signs of heart failure, arrhythmias, syncope, sudden death, or as an asymptomatic finding during screening of family members.

Imaging studies using ultrasound or MRI can demonstrate the characteristic pattern of deeply trabeculated LV myocardium, most characteristically within the apex. ECG findings are nonspecific and include chamber hypertrophy, ST and T-wave changes, or arrhythmias. In some patients, preexcitation is notable, and giant QRS voltages occur in approximately 30% of younger children. Metabolic screening should be considered, especially in young children. Elevated serum lactate and urine 3-methylglutaconic acid may be seen in **Barth syndrome**, an X-linked disorder of phospholipid metabolism caused by a pathogenic variant in the *TAZ* gene. Clinical testing for *TAZ* variants is available and should be considered, especially in males. Patients with mitochondrial disorders frequently demonstrate signs of LVNC. These children are at risk for atrial or ventricular arrhythmias and thromboembolic complications. Treatment includes anticoagulation, antiarrhythmic therapy if needed, and treatment of heart failure if present. In patients refractory to medical therapy, cardiac transplantation has been used successfully.

Arrhythmogenic right ventricular cardiomyopathy (ARVC) is relatively uncommon in North America compared with the high prevalence in Europe, especially Italy (see Chapter 484.4). Autosomal dominant inheritance is common. In addition, recessive forms associated with severe ARVC and skin manifestations are known. Comprehensive genetic screening has been reported to identify a cause in up to 50% of cases. ARVC is typically characterized by a dilated right ventricle with fibrofatty infiltration of the RV wall; increasingly, LV involvement is being recognized. Global and regional RV and LV dysfunction and ventricular tachyarrhythmias are the major clinical findings. Syncope or aborted sudden death can occur and should be treated with antiarrhythmic medications and placement of an ICD. In patients with ventricular dysfunction, heart failure management as indicated for patients with DCM may be of use.

Endocardial fibroelastosis (EFE), once an important cause of heart failure in children, is uncommon. The decline in primary EFE is likely related to the abolition of mumps virus infections by immunization practices. Rare familial cases exist, but the causative genes are unknown. Secondary EFE can occur with severe left-sided obstructive lesions such as aortic stenosis or atresia, hypoplastic left heart

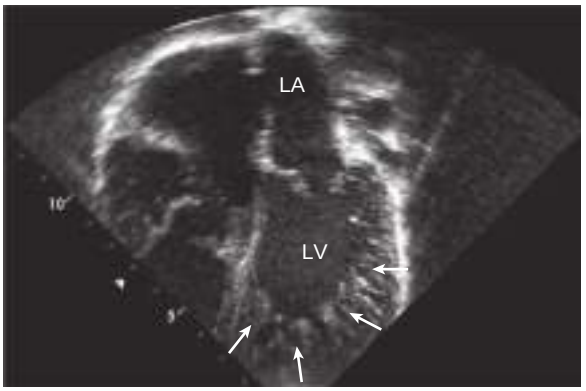

Fig. 488.8 Echocardiogram of a patient with left ventricular noncompaction cardiomyopathy. Apical view showing abnormal trabeculations of left ventricle at the apex *(arrows)*. For comparison, see the smooth-walled LV in Figure 488.2. LA, Left atrium; LV, left ventricle.

syndrome, or coarctation of the aorta. EFE is characterized by an opaque, white, fibroelastic thickening on the endocardial surface of the ventricle, which leads to systolic and/or diastolic dysfunction. Surgical removal of the endocardial fibrosis has been successfully done to improve cardiac function. Standard heart failure management, including transplantation, has been used in the management of EFE.

Takotsubo cardiomyopathy is a reversible stress-induced syndrome associated with transient systolic and diastolic dysfunction and regional ventricular wall motion abnormalities characterized by ventricular apical ballooning. Physical or emotional stress and associated etiologies (see Table 488.2) precipitate transient episodes of chest pain or heart failure. Treatment includes that for heart failure (β blockers, ACE inhibitors, diuretics) and addressing the precipitating event (thyrotoxicosis, pheochromocytoma, drug ingestion).

Visit Elsevier eBooks+ at eBooks.Health.Elsevier.com for Bibliography.

488.5 Myocarditis

John J. Parent and Stephanie M. Ware

Acute or chronic inflammation of the myocardium is characterized by inflammatory cell infiltrates, myocyte necrosis, or myocyte degeneration and may be caused by infectious, connective tissue, granulomatous, toxic, immune, or idiopathic processes. There may be associated systemic manifestations of the disease, and occasionally the endocardium or pericardium is involved. Patients may be asymptomatic, have nonspecific prodromal symptoms, or present with overt congestive heart failure, compromising arrhythmias, or sudden death. It is assumed that viral infections are the most common etiology, although myocardial toxins, drug exposures, hypersensitivity reactions, and immune disorders may also lead to myocarditis (Table 488.7).

ETIOLOGY AND EPIDEMIOLOGY

Viral Infections

Coxsackievirus and other enteroviruses, adenovirus, parvovirus B19, Epstein-Barr virus, parechovirus, influenza virus, and cytomegalovirus are the most common causative agents in children. COVID-19 infections, particularly during multisystem inflammatory syndrome in children (MIS-C) and, rarely, after mRNA COVID-19 vaccinations, have been associated with myocarditis. In Asia, hepatitis C virus appears to be significant as well. The true incidence of viral myocarditis is unknown because mild cases probably go undetected. The disease is typically sporadic but may be epidemic. Manifestations are, to some degree, age dependent: in neonates and young infants, viral myocarditis can be fulminant; in children, it often occurs as an acute, myopericarditis with heart failure; and in older children and adolescents, it may present with signs and symptoms of acute or chronic heart failure or chest pain.

Table 488.7 Etiology of Myocarditis

INFECTIOUS CAUSES
Viral: adenoviruses, echoviruses, enteroviruses (e.g., coxsackieviruses), herpesviruses (human cytomegalovirus, Epstein-Barr virus, human herpesvirus 6), hepatitis C virus, human immunodeficiency virus, influenza virus, parvovirus B19, SARS-CoV-2 (COVID-19) disease and vaccine, smallpox vaccine
Bacterial: *Borrelia burgdorferi* (Lyme disease), *Chlamydia, Corynebacterium diphtheriae, Legionella, Mycobacterium tuberculosis, Mycoplasma, Staphylococcus,* streptococcus A, *Streptococcus pneumoniae,* Whipple disease
Fungal: *Actinomyces, Aspergillus, Candida, Cryptococcus*
Helminthic: *Echinococcus granulosus, Trichinella spiralis*
Protozoal: *Toxoplasma gondii, Trypanosoma cruzi*
Rickettsial: *Coxiella burnetii, Rickettsia typhi*
Spirochetal: *Borrelia burgdorferi, Leptospira, Treponema pallidum*
AUTOIMMUNE DISEASES
Rheumatic fever, celiac disease, Churg-Strauss syndrome, Crohn disease, dermatomyositis, giant cell myocarditis, hypereosinophilic syndrome, Kawasaki disease, lupus erythematosus, lymphofollicular myocarditis, rheumatoid arthritis, sarcoidosis, scleroderma, ulcerative colitis
HYPERSENSITIVITY REACTIONS
Penicillin, ampicillin, cephalosporins, tetracyclines, sulfonamides, antiphlogistics, benzodiazepines, clozapine, loop and thiazide diuretics, methyldopa, smallpox vaccine, tetanus toxoid, tricyclic antidepressants
TOXIC REACTIONS TO DRUGS
Amphetamines, anthracyclines, catecholamines, cocaine, cyclophosphamide, 5-fluorouracil, phenytoin, trastuzumab, immune checkpoint inhibitors
TOXIC
Ethanol, snakebite, scorpion bite, electric shock, spider bite
OTHER CAUSES
Arsenic, copper, iron, radiotherapy, thyrotoxicosis, immune modulation

Adapted from Canter CE, Simpson KE. Diagnosis and treatment of myocarditis in children in the current era. *Circulation*. 2014;129:115–128, Table 1.

Bacterial Infections

Bacterial myocarditis has become much less common with the advent of advanced public health measures, which have minimized infectious causes such as diphtheria. Diphtheritic myocarditis is unique because bacterial toxin may produce circulatory collapse and toxic myocarditis characterized by atrioventricular block, bundle branch block, or ventricular ectopy (see Chapter 233). Lyme disease may present as myocarditis; rheumatic fever (poststreptococcal) may also manifest with valve, myocardium, and pericardium involvement. Any overwhelming systemic bacterial infection can manifest with circulatory collapse and shock with evidence of myocardial dysfunction, characterized by tachycardia, gallop rhythm, and low cardiac output. Additional nonviral infectious causes of myocarditis include rickettsiae, protozoa, parasitic infections, and fungal disease.

PATHOPHYSIOLOGY

Myocarditis is characterized by myocardial inflammation, injury or necrosis, and ultimately fibrosis. Cardiac enlargement and diminished systolic function are a direct result of the myocardial damage. Typical signs of congestive heart failure occur and may progress rapidly to shock, atrial or ventricular arrhythmias, and sudden death. Viral myocarditis may also become a chronic process, with persistence of viral nucleic acid in the myocardium and the perpetuation of chronic inflammation secondary to altered host immune response, including activated T lymphocytes (cytotoxic and natural killer cells) and antibody-dependent cell-mediated damage. Additionally, persistent viral infection may alter the expression of major histocompatibility complex (MHC) antigens with resultant exposure of neoantigens to the immune system. Some viral proteins share antigenic epitopes with host cells, resulting in autoimmune damage to the antigenically related myocyte. Cytokines such as tumor necrosis factor-α and interleukin-1 are inhibitors of myocyte response to adrenergic stimuli and result in diminished cardiac function. The final result of viral-associated inflammation can be DCM.

CLINICAL MANIFESTATIONS

Manifestations of myocarditis range from asymptomatic or nonspecific generalized illness to acute cardiogenic shock and sudden death. Infants and young children more often have a fulminant presentation with fever, respiratory distress, tachycardia, hypotension, gallop rhythm, and cardiac murmur. Associated findings may include a rash or evidence of end-organ involvement such as hepatitis or aseptic meningitis.

Patients with acute or chronic myocarditis may present with chest discomfort, fever, palpitations, easy fatigability, or syncope/near-syncope. Cardiac findings include overactive precordial impulse, gallop rhythm, and apical systolic murmur of mitral insufficiency. In patients with associated pericardial disease, a rub may be noted. Hepatic enlargement, peripheral edema, and pulmonary findings such as wheezes or rales may be present in patients with decompensated heart failure.

DIAGNOSIS

Electrocardiographic changes are nonspecific and may include sinus tachycardia, atrial or ventricular arrhythmias, heart block, diminished QRS voltages, and nonspecific ST and T-wave changes, often suggestive of acute ischemia. Chest radiographs in severe, symptomatic cases reveal cardiomegaly, pulmonary vascular prominence, overt pulmonary edema, or pleural effusions. Echocardiography often shows diminished ventricular systolic function, cardiac chamber enlargement, mitral insufficiency, and occasionally, evidence of pericardial infusion.

Cardiac MRI is a standard imaging modality for the diagnosis of myocarditis; information on the presence and extent of edema, gadolinium-enhanced hyperemic capillary leak, myocyte necrosis, LV dysfunction, and evidence of an associated pericardial effusion assist in the cardiac MRI diagnosis of myocarditis (Table 488.8 and Fig. 488.9).

Endomyocardial biopsy may be useful in identifying inflammatory cell infiltrates or myocyte damage and performing molecular viral analysis using polymerase chain reaction techniques. Catheterization and biopsy, although not without risk (perforation and arrhythmias), should be performed by experienced personnel in patients suspected to have myocarditis or if unusual forms of cardiomyopathy are strongly suspected, such as storage diseases or mitochondrial defects. Nonspecific tests include erythrocyte sedimentation rate, CPK isoenzymes, cardiac troponin I, and BNP levels. A novel microRNA derived from type 17 helper (Th17) cells may be another useful specific test for viral myocarditis.

DIFFERENTIAL DIAGNOSIS

The predominant diseases mimicking acute myocarditis include carnitine deficiency, other metabolic disorders of energy generation, hereditary mitochondrial defects, idiopathic DCM, pericarditis, EFE, and anomalies of the coronary arteries (see Table 488.2).

TREATMENT

Primary therapy for acute myocarditis is supportive. Acutely, the use of inotropic agents, preferably milrinone, should be considered but used with caution because of their proarrhythmic potential. Diuretics are often required as well. If in extremis, mechanical ventilatory support and mechanical circulatory support with VAD implantation or ECMO may be needed to stabilize the patient's hemodynamic status and serve as a bridge to recovery or cardiac transplantation. Diuretics, β blockers, ACE inhibitors, and ARBs are of use in patients with compensated congestive heart failure in the outpatient setting but may be contraindicated in those presenting with fulminant heart failure and cardiovascular collapse. In patients manifesting with significant atrial or ventricular arrhythmias, specific antiarrhythmic agents (e.g., amiodarone) should be administered and ICD placement considered if persistent after a period of recovery is observed.

Table 488.8 MRI Findings Suggestive of Myocarditis

- T2-weighted edema (global or regional)
- Regional hyperemia/capillary leak by early gadolinium enhancement ratio (EGEr)
- Myocardial fibrosis or necrosis on late gadolinium enhancement (LGE)
- Features often present in a midmyocardial, subepicardial, and nonvascular distribution
- Repeat MRI if no *early* MRI evidence present but clinical manifestation suggests myocarditis

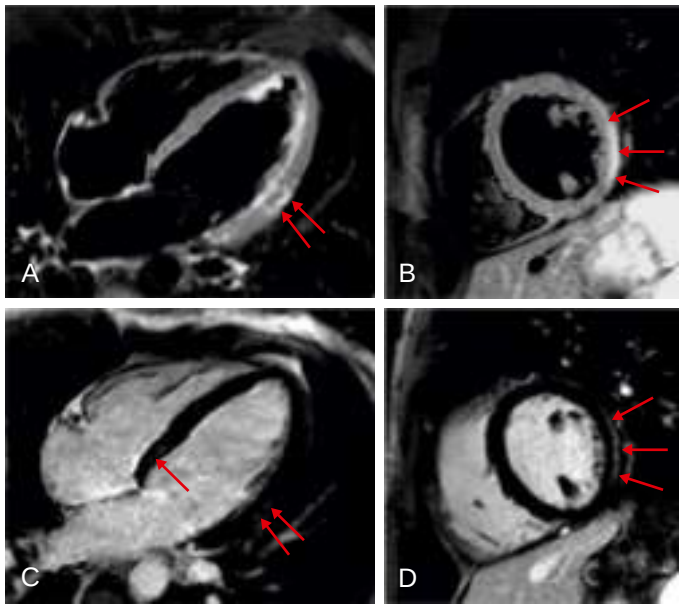

Fig. 488.9 MRI findings in patients with myocarditis. Cardiac MR images of a young patient presenting with acute chest pain syndrome caused by acute myocarditis. (**A**) Long-axis and (**B**) short-axis T2-weighted images demonstrating focal myocardial edema in subepicardium of left midventricular lateral wall *(red arrows)*. Corresponding (**C**) long-axis and (**D**) short-axis T1-weighted images demonstrate the presence of typical late gadolinium enhancement in subepicardium of left midventricular lateral wall and basal septum *(red arrows)*. *(From Kindermann I, Barth C, Mahfoud F, et al. Update on myocarditis. J Am Coll Cardiol. 2012;59:779–792, Fig. 3, p. 783.)*

Immunomodulation of patients with myocarditis is controversial. Intravenous immunoglobulin (IVIG) may have a role in the treatment of acute or fulminant myocarditis, and corticosteroids have been reported to improve cardiac function, but this remains controversial in children. Relapse has been noted in patients receiving immunosuppression who were weaned from therapy. There are no studies to recommend specific antiviral therapies for myocarditis.

If there is an identifiable and treatable condition, its specific therapy should be employed. If a medication is the etiology, it should be withdrawn and an alternative drug added if needed.

PROGNOSIS

The prognosis of symptomatic acute enteroviral myocarditis in newborns is poor, with a 75% mortality. The prognosis is better for children and adolescents, although patients who have persistent evidence of DCM often progress to the need for cardiac transplantation; recovery of ventricular function, however, has been reported in 10–50% of patients.

The prognosis for COVID-19 immunization–associated myocarditis is excellent with full recovery noted by 90 days. Patients with COVID-19 requiring intensive care unit (ICU) admission and those with MIS-C must be followed by a pediatric cardiologist (including follow-up echocardiography) and refrain from exercise for 3-6 months. Return to full activity requires clearance from a cardiologist.

Visit Elsevier eBooks+ at eBooks.Health.Elsevier.com for Bibliography.

Chapter 489

Diseases of the Pericardium

John J. Parent and Stephanie M. Ware

The heart is enveloped in a bilayer membrane, the *pericardium,* which normally contains a small amount of serous fluid. The pericardium is not vital to normal function of the heart, and primary diseases of the pericardium are uncommon. However, the pericardium may be affected by a variety of

CLINICAL MANIFESTATIONS

Manifestations of myocarditis range from asymptomatic or nonspecific generalized illness to acute cardiogenic shock and sudden death. Infants and young children more often have a fulminant presentation with fever, respiratory distress, tachycardia, hypotension, gallop rhythm, and cardiac murmur. Associated findings may include a rash or evidence of end-organ involvement such as hepatitis or aseptic meningitis.

Patients with acute or chronic myocarditis may present with chest discomfort, fever, palpitations, easy fatigability, or syncope/near-syncope. Cardiac findings include overactive precordial impulse, gallop rhythm, and apical systolic murmur of mitral insufficiency. In patients with associated pericardial disease, a rub may be noted. Hepatic enlargement, peripheral edema, and pulmonary findings such as wheezes or rales may be present in patients with decompensated heart failure.

DIAGNOSIS

Electrocardiographic changes are nonspecific and may include sinus tachycardia, atrial or ventricular arrhythmias, heart block, diminished QRS voltages, and nonspecific ST and T-wave changes, often suggestive of acute ischemia. Chest radiographs in severe, symptomatic cases reveal cardiomegaly, pulmonary vascular prominence, overt pulmonary edema, or pleural effusions. Echocardiography often shows diminished ventricular systolic function, cardiac chamber enlargement, mitral insufficiency, and occasionally, evidence of pericardial infusion.

Cardiac MRI is a standard imaging modality for the diagnosis of myocarditis; information on the presence and extent of edema, gadolinium-enhanced hyperemic capillary leak, myocyte necrosis, LV dysfunction, and evidence of an associated pericardial effusion assist in the cardiac MRI diagnosis of myocarditis (Table 488.8 and Fig. 488.9).

Endomyocardial biopsy may be useful in identifying inflammatory cell infiltrates or myocyte damage and performing molecular viral analysis using polymerase chain reaction techniques. Catheterization and biopsy, although not without risk (perforation and arrhythmias), should be performed by experienced personnel in patients suspected to have myocarditis or if unusual forms of cardiomyopathy are strongly suspected, such as storage diseases or mitochondrial defects. Nonspecific tests include erythrocyte sedimentation rate, CPK isoenzymes, cardiac troponin I, and BNP levels. A novel microRNA derived from type 17 helper (Th17) cells may be another useful specific test for viral myocarditis.

DIFFERENTIAL DIAGNOSIS

The predominant diseases mimicking acute myocarditis include carnitine deficiency, other metabolic disorders of energy generation, hereditary mitochondrial defects, idiopathic DCM, pericarditis, EFE, and anomalies of the coronary arteries (see Table 488.2).

TREATMENT

Primary therapy for acute myocarditis is supportive. Acutely, the use of inotropic agents, preferably milrinone, should be considered but used with caution because of their proarrhythmic potential. Diuretics are often required as well. If in extremis, mechanical ventilatory support and mechanical circulatory support with VAD implantation or ECMO may be needed to stabilize the patient's hemodynamic status and serve as a bridge to recovery or cardiac transplantation. Diuretics, β blockers, ACE inhibitors, and ARBs are of use in patients with compensated congestive heart failure in the outpatient setting but may be contraindicated in those presenting with fulminant heart failure and cardiovascular collapse. In patients manifesting with significant atrial or ventricular arrhythmias, specific antiarrhythmic agents (e.g., amiodarone) should be administered and ICD placement considered if persistent after a period of recovery is observed.

Table 488.8 MRI Findings Suggestive of Myocarditis

- T2-weighted edema (global or regional)
- Regional hyperemia/capillary leak by early gadolinium enhancement ratio (EGEr)
- Myocardial fibrosis or necrosis on late gadolinium enhancement (LGE)
- Features often present in a midmyocardial, subepicardial, and nonvascular distribution
- Repeat MRI if no *early* MRI evidence present but clinical manifestation suggests myocarditis

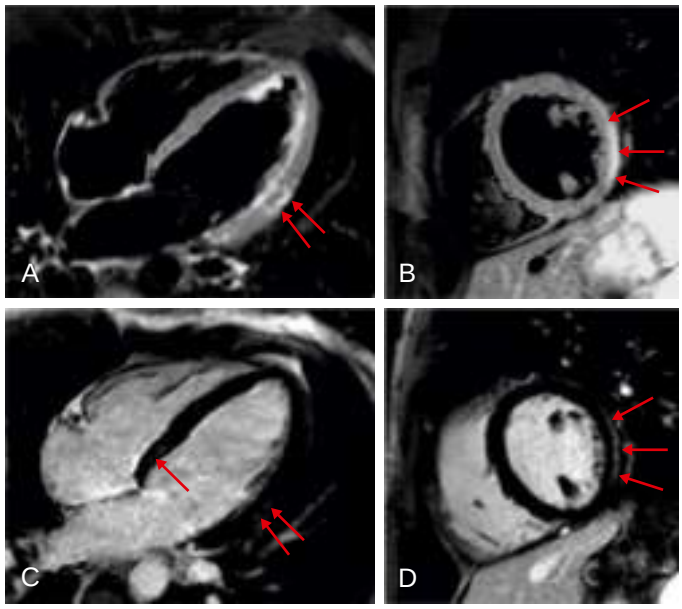

Fig. 488.9 MRI findings in patients with myocarditis. Cardiac MR images of a young patient presenting with acute chest pain syndrome caused by acute myocarditis. (**A**) Long-axis and (**B**) short-axis T2-weighted images demonstrating focal myocardial edema in subepicardium of left midventricular lateral wall *(red arrows)*. Corresponding (**C**) long-axis and (**D**) short-axis T1-weighted images demonstrate the presence of typical late gadolinium enhancement in subepicardium of left midventricular lateral wall and basal septum *(red arrows)*. *(From Kindermann I, Barth C, Mahfoud F, et al. Update on myocarditis. J Am Coll Cardiol. 2012;59:779–792, Fig. 3, p. 783.)*

Immunomodulation of patients with myocarditis is controversial. Intravenous immunoglobulin (IVIG) may have a role in the treatment of acute or fulminant myocarditis, and corticosteroids have been reported to improve cardiac function, but this remains controversial in children. Relapse has been noted in patients receiving immunosuppression who were weaned from therapy. There are no studies to recommend specific antiviral therapies for myocarditis.

If there is an identifiable and treatable condition, its specific therapy should be employed. If a medication is the etiology, it should be withdrawn and an alternative drug added if needed.

PROGNOSIS

The prognosis of symptomatic acute enteroviral myocarditis in newborns is poor, with a 75% mortality. The prognosis is better for children and adolescents, although patients who have persistent evidence of DCM often progress to the need for cardiac transplantation; recovery of ventricular function, however, has been reported in 10–50% of patients.

The prognosis for COVID-19 immunization–associated myocarditis is excellent with full recovery noted by 90 days. Patients with COVID-19 requiring intensive care unit (ICU) admission and those with MIS-C must be followed by a pediatric cardiologist (including follow-up echocardiography) and refrain from exercise for 3-6 months. Return to full activity requires clearance from a cardiologist.

Visit Elsevier eBooks+ at eBooks.Health.Elsevier.com for Bibliography.

Chapter 489

Diseases of the Pericardium

John J. Parent and Stephanie M. Ware

The heart is enveloped in a bilayer membrane, the *pericardium,* which normally contains a small amount of serous fluid. The pericardium is not vital to normal function of the heart, and primary diseases of the pericardium are uncommon. However, the pericardium may be affected by a variety of

conditions, often as a manifestation of a systemic illness, and can result in serious, even life-threatening, cardiac compromise (Table 489.1).

489.1 Acute Pericarditis

John J. Parent and Stephanie M. Ware

Inflammation of the pericardium may have only minor pathophysiologic consequences in the absence of significant fluid accumulation in the pericardial space. When the amount of fluid in the nondistensible pericardial space becomes excessive, pressure within the pericardium increases and is transmitted to the heart, resulting in impaired filling by compressing the chambers (atria or ventricles). Although small to moderate amounts of **pericardial effusion** can be well tolerated and clinically silent, once the noncompliant pericardium has been distended maximally, any further fluid accumulation causes abrupt impairment of cardiac filling, and this can impair cardiac output and is termed **cardiac tamponade**. When untreated, tamponade can lead to shock and death. Pericardial effusions may be serous/transudative, exudative/purulent, fibrinous, or hemorrhagic.

Pericarditis may present without an obvious pericardial effusion on echocardiography. In addition, pericarditis may be associated with myocarditis (**myopericarditis**), in which case either pericarditis or myocarditis may be the dominant finding.

CLINICAL MANIFESTATIONS

The most common symptom of acute pericarditis is chest pain, typically described as sharp/stabbing, positional, radiating, worse with inspiration, and relieved by sitting upright, leaning forward, or prone. Cough, fever, dyspnea, abdominal pain, and vomiting are nonspecific symptoms associated with pericarditis. Additionally, signs and symptoms of organ system involvement may occur in the presence of generalized systemic disease.

Muffled or distant heart sounds, tachycardia, narrow pulse pressure, jugular venous distention, and a pericardial friction rub provide clues to the diagnosis of acute pericarditis. Cardiac tamponade is recognized by the excessive fall of systolic blood pressure (>10 mm Hg) with inspiration. This pulsus paradoxus can be assessed by careful auscultatory blood pressure determination (automated blood pressure cuffs are inadequate), arterial pressure line waveform, or pulse oximeter tracing inspection. Doppler assessment during echocardiography can also indirectly suggest pulsus paradoxus is present. Conditions other than cardiac tamponade that may result in pulsus paradoxus include severe dyspnea, obesity, and positive pressure ventilator support.

Table 489.1 Etiology of Pericardial Disease

CONGENITAL
Absence (partial, complete)
Cysts
Mulibrey nanism (*TRIM 37* gene variant)
Camptodactyly-arthropathy–coxa vara–pericarditis syndrome (*PRG4* gene variant)
Myhre syndrome (*SMAD4* gene variant)
INFECTIOUS
Viral: coxsackievirus B, Epstein-Barr virus, influenza, adenovirus, parvovirus, HIV, mumps, COVID-19, and mRNA COVID-19 and HPV vaccines
Bacterial: *Haemophilus influenzae,* streptococcus, pneumococcus, staphylococcus, meningococcus, mycoplasma, tularemia, *Listeria,* leptospirosis, tuberculosis, Q fever, salmonella
Immune complex mediated: meningococcus, *H. influenzae*
Fungal: actinomycosis, histoplasmosis
Parasitic: toxoplasmosis, echinococcosis
NONINFECTIOUS
Idiopathic
Systemic inflammatory diseases: acute rheumatic fever, juvenile idiopathic arthritis, systemic lupus erythematosus, mixed connective tissue disorders, systemic sclerosis, Kawasaki disease, eosinophilic granulomatosis with polyangiitis, Behçet syndrome, sarcoidosis, familial Mediterranean fever and other recurrent fever syndromes, pancreatitis, granulomatosis with polyangiitis
Metabolic: uremia, hypothyroidism, Gaucher disease, very-long-chain acyl-CoA dehydrogenase deficiency
Traumatic: surgical, catheter perforation, blunt trauma
Postpericardiotomy syndrome
Oncologic: lymphomas, leukemia, radiation therapy, primary pericardial tumors

DIAGNOSIS

The electrocardiogram is often abnormal in acute pericarditis, although the findings are nonspecific. Low-voltage QRS amplitude may be seen as a result of pericardial fluid accumulation. Tachycardia and abnormalities of the ST segments (diffuse ST segment elevation), PR segments, and T waves (inversion or flattening) may be present as well. Elevated troponin levels may be present in myopericarditis.

Although the chest x-ray findings in a patient with pericarditis without effusion are usually normal in the presence of a significant effusion, cardiac enlargement will be seen and the cardiac contour may be unusual (Erlenmeyer flask or water bottle appearance) (Fig. 489.1). Echocardiography is the most sensitive technique for identifying the size and location of a pericardial effusion. Compression and collapse of the right atrium and/or right ventricle are present with cardiac tamponade (Fig. 489.2). Abnormal diastolic filling parameters have also been described in cases of tamponade. Advanced imaging modalities like computed tomography or cardiac magnetic resonance imaging are useful for diagnosis in unclear cases (Fig. 489.3).

DIFFERENTIAL DIAGNOSIS

Chest pain similar to that present in pericarditis can occur with lung diseases, especially pleuritis, and with gastroesophageal reflux or costochondritis, with the latter being reproducible on palpation. Pain related to myocardial ischemia is usually more severe and prolonged and occurs with exercise, allowing distinction from pericarditis-induced pain. The presence of pericardial effusion on echocardiography is highly suggestive of pericarditis but does not determine the etiology.

Infectious Pericarditis

A number of viral agents are known to cause pericarditis, and the clinical course of the majority of these infections is mild and spontaneously resolving. The term *acute benign pericarditis* is synonymous for viral pericarditis. Agents identified as causing pericarditis include the enteroviruses, influenza, adenovirus, respiratory syncytial virus, and parvovirus. Because the course of this illness is usually benign, symptomatic treatment with nonsteroidal antiinflammatory drugs (NSAIDs) is often sufficient. Persistent or early recurrence episodes may need courses of colchicine or, rarely, corticosteroids. Anakinra and the interleukin-1

Fig. 489.1 "Water bottle" silhouette. This chest radiograph shows marked cardiomegaly, also known as a water bottle silhouette, which is seen in the presence of large pericardial effusions. Also note the associated pulmonary edema from associated high left atrial and left ventricular filling pressures. *(Courtesy Dr. Steven M. Selbst, Wilmington, DE; from Durani Y, Giordani K, Goudie BW. Myocarditis and pericarditis in children. Pediatr Clin North Am 2010;57:1281–1303, Fig. 7.)*

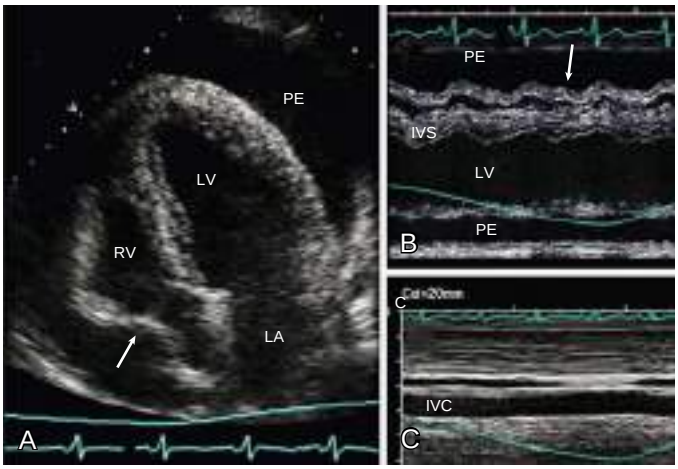

Fig. 489.2 Echocardiographic images of large pericardial effusion with features of tamponade. **A,** Apical four-chamber view of LV, LA, and RV that shows large PE with diastolic right atrial collapse *(arrow)*. **B,** M-mode image with cursor placed through RV, IVS, and LV in parasternal long axis. The view shows circumferential PE with diastolic collapse of RV free wall *(arrow)* during expiration. **C,** M-mode image from subcostal window in the same patient that shows IVC plethora without inspiratory collapse. IVC, Inferior vena cava; IVS, interventricular septum; LA, left atrium; LV, left ventricle; PE, pericardial effusion; RV, right ventricle. *(From Troughton RW, Asher CR, Klein AL. Pericarditis. Lancet. 2004;363:717–727.)*

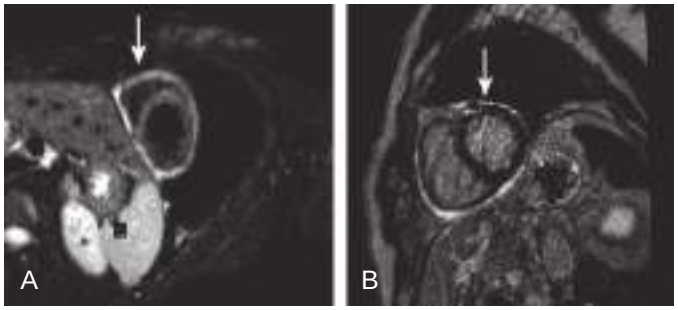

Fig. 489.3 Cardiac magnetic resonance T2 STIR (**A**) and delayed gadolinium (**B**) sequences showing enhancement of the pericardium signifying acute or active inflammation *(arrow). (Modified from Chetrit M, Xu B, Kwon DH, et al: Imaging-guided therapies for pericardial diseases. JACC: Cardiovascular Imaging. 2019;13(6):1422–1437; Fig. 1E and 1F, p. 1424.)*

cytokine trap agent rilonacept have been effective in colchicine-nonresponsive acute or recurrent pericarditis. Patients with large effusions and tamponade may require pericardiocentesis. Presumed viral but often idiopathic pericarditis may have an autoimmune component. Up to 30% of patients may have recurrences of pericarditis. Treatment *and* prevention of recurrences with colchicine improve symptoms and avoid recurrences in most of these patients. If the condition becomes chronic or relapsing, surgical pericardiectomy or creation of a pericardial window may be necessary.

Echocardiography is useful in differentiating pericarditis from *myocarditis,* which will show evidence of diminished myocardial contractility or valvular dysfunction (see Chapter 488.5). Pericarditis and myocarditis may occur together in some cases of viral infection.

Purulent pericarditis, often caused by bacterial infections, has become much less common with the advent of new immunizations for *Haemophilus influenzae* and pneumococcal disease. Historically, purulent pericarditis was seen in association with severe pneumonias, epiglottitis, meningitis, or osteomyelitis. Patients with purulent pericarditis are acutely ill. Unless the infection is recognized and treated expeditiously, the course can be fulminant, leading to tamponade and death. **Tuberculous pericarditis** is rare in developed countries but can be a relatively common complication of HIV infection in regions where tuberculosis is endemic and access to antiretroviral therapy is limited. **Immune complex–mediated pericarditis** is a rare complication that may result in a nonpurulent (sterile) effusion after systemic bacterial infections such as meningococcus or *Haemophilus.*

Noninfectious Pericarditis

Systemic inflammatory diseases such as autoimmune, rheumatologic, and connective tissue disorders may involve the pericardium and result in serous pericardial effusions. Pericardial inflammation may be a component of the type II hypersensitivity reaction seen in patients with acute rheumatic fever. It is often associated with rheumatic valvulitis and responds quickly to antiinflammatory agents, including corticosteroids. Tamponade is quite uncommon (see Chapters 229.1 and 487).

Juvenile idiopathic arthritis, usually systemic-onset disease, can manifest with pericarditis. Differentiating rheumatoid pericardial inflammation from that seen with systemic lupus erythematosus is difficult and requires careful rheumatologic evaluation. Aspirin and corticosteroids can result in rapid resolution of a pericardial effusion but may be needed on a chronic basis to prevent relapse. Many of the autoinflammatory recurrent fever syndromes present with pericarditis, usually with other manifestations of those disorders (see Chapter 204).

Patients with chronic renal failure or hypothyroidism may have pericardial effusions. Clinical suspicion warrants careful screening with physical examination and, if indicated, imaging studies during the course of their illness.

Especially common in referral centers with hematology/oncology units is the presence of pericardial effusion related to neoplastic disease. Conditions resulting in effusion include Hodgkin disease, lymphomas, and leukemia. Radiation therapy directed to the mediastinum of patients with malignancy can result in pericarditis and, later, constrictive pericardial disease.

The **postpericardiotomy syndrome** occurs in patients who have undergone cardiac surgery and is characterized by fever, lethargy, anorexia, irritability, and chest/abdominal discomfort beginning 1-4 weeks postoperatively (see Table 483.2 in Chapter 483). There can be associated pleural effusions. Postpericardiotomy syndrome is effectively treated with aspirin, NSAIDs, colchicine, and in severe cases, corticosteroids. Pericardial drainage is necessary in those patients with cardiac tamponade.

In many patients the etiology of pericarditis is not known. Approximately 30% of these patients have multiple occurrences and are treated with colchicine to reduce the risk of recurrent pericarditis. Other less frequently used treatments have included NSAIDs and corticosteroids. Refractory idiopathic recurrent pericarditis may require pericardiectomy; anakinra and rilonacept have demonstrated promise for difficult-to-treat patients.

489.2 Constrictive Pericarditis

John J. Parent and Stephanie M. Ware

Rarely, chronic pericardial inflammation can result in fibrosis, calcification, and thickening of the pericardium. Pericardial scarring may lead to impaired cardiac distensibility and filling and is termed *constrictive pericarditis.* Constrictive pericarditis can result from recurrent or chronic pericarditis, cardiac surgery, or radiation to the mediastinum as a treatment for malignancies, most often Hodgkin disease or lymphoma.

Clinical manifestations of systemic venous hypertension predominate in cases of restrictive pericarditis. Jugular venous distention, peripheral edema, hepatomegaly, and ascites may precede signs of more significant cardiac compromise, such as tachycardia, hypotension, and pulsus paradoxus. A pericardial knock, rub, and distant heart sounds might be present on auscultation. Abnormalities of liver function tests, hypoalbuminemia, hypoproteinemia, and lymphopenia may be present. On occasion, chest radiographs demonstrate calcifications of the pericardium.

Constrictive pericarditis may be difficult to distinguish clinically from restrictive cardiomyopathy because both conditions result in impaired myocardial filling (see Chapter 488.3). Echocardiography may be helpful in distinguishing constrictive pericardial disease from restrictive cardiomyopathy, but cardiac MRI and CT are more sensitive in detecting abnormalities of the pericardium. In rare cases, exploratory thoracotomy with direct examination of the pericardium may be required to confirm the diagnosis.

Although acute pericardial constriction is reported to respond to antiinflammatory agents, the more typical chronic constrictive pericarditis will respond only to pericardiectomy with extensive resection of the pericardium.

Visit Elsevier eBooks+ at eBooks.Health.Elsevier.com for Bibliography.

Chapter 490

Tumors of the Heart

John J. Parent and Stephanie M. Ware

Although cardiac tumors occur rarely in pediatric patients, they may result in serious hemodynamic or electrophysiologic abnormalities depending on tumor type and location.

The vast majority of tumors originating from the heart are benign. **Rhabdomyomas** are the most common pediatric cardiac tumors and are associated with tuberous sclerosis in 70–95% of cases (see Chapter 636.2). Rhabdomyomas may occur at any age, from fetal life through late adolescence. They are often multiple, can occur in any cardiac chamber, and originate within the myocardium, often extending into the atrial or ventricular cavities (Fig. 490.1). Depending on their location and size, rhabdomyomas can result in inflow or outflow obstruction, leading to cyanosis or cardiac failure; many are asymptomatic. Atrial and ventricular arrhythmias have been reported with rhabdomyomas, and on occasion, ventricular preexcitation (Wolff-Parkinson-White syndrome) is present on electrocardiogram (ECG).

Fibromas are the second most common pediatric cardiac tumor and, in contrast to rhabdomyomas, are usually solitary and intramyocardial. The size and location of fibromas can lead to heart failure, cyanosis, or rhythm disturbances. Loss of the tumor suppressor *PTCH1* is associated with the development of cardiac fibromas in sporadic cases. There is an increased incidence in patients with **Gorlin syndrome** (3%).

Myxomas, the most common cardiac tumor seen in adults, occur infrequently in the pediatric population. Myxomas are predominantly intraatrial, appear pedunculated, and are rather mobile (Fig. 490.2); however, they may also be ventricular (Fig. 490.3). They may cause obstruction to inflow or outflow and may present with a murmur, heart failure, or syncope. On occasion, atrial myxomas are associated with systemic symptoms of fever, malaise, and arthralgia. **Carney complex** is a familial autosomal dominant multiple neoplasia (often endocrine: pituitary adenoma, thyroid, testis, ovarian) and lentiginosis syndrome in which cardiac myxomas can occur at a young age in any or all cardiac chambers. Pathogenic variants in the *PRKAR1A* gene are causative in some families.

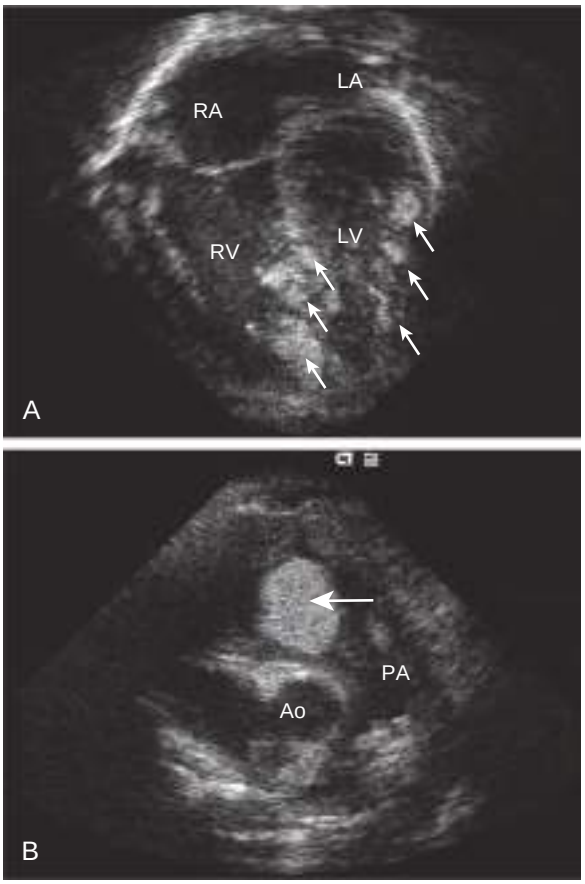

Fig. 490.1 Echocardiograms demonstrating rhabdomyomas. **A,** Apical four-chamber view showing multiple rhabdomyomas *(arrows)* within the septum and left ventricular myocardium. **B,** Short-axis view showing a large rhabdomyoma *(arrow)* extending into the right ventricular outflow tract. Ao, Ascending aorta; LA, left atrium; LV, left ventricle; PA, pulmonary artery; RA, right atrium; RV, right ventricle.

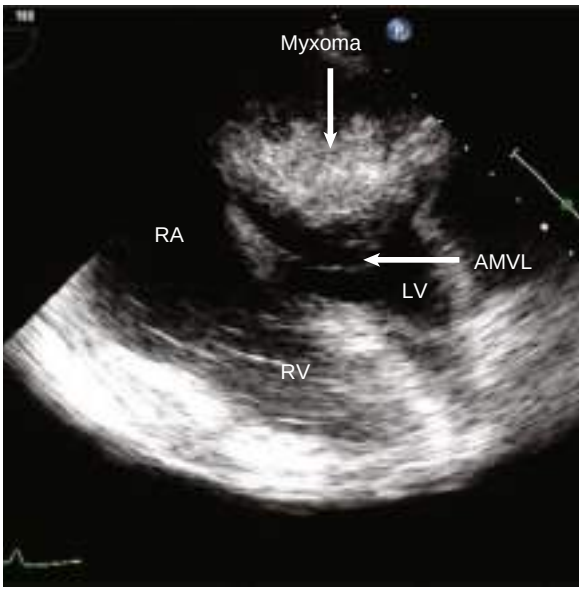

Fig. 490.2 A large left atrial myxoma prolapsing across the mitral valve, resulting in heart failure symptoms. AMVL, anterior mitral valve leaflet; LV, left ventricle; RA, right atrium; RV, right ventricle. *(From Zipes DP, Libby P, Bonow RO, et al., eds. Braunwald's Heart Disease, 11th ed. Philadelphia: Elsevier; 2019, Fig. 95.8, p. 1871.)*

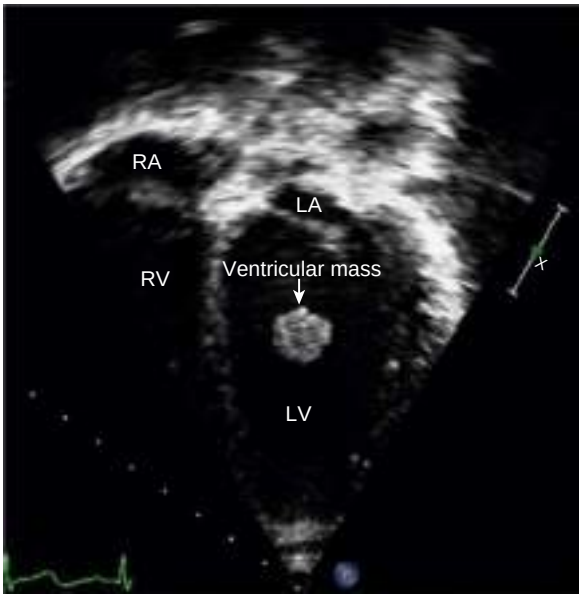

Fig. 490.3 Left ventricular myxoma. TTE apical four-chamber view of mass within the left ventricle. RA, right atrium; RV, right ventricle; LA, left atrium; LV, left ventricle. *(From Schroeder L, Zyblewski S, Forbus G, et al. Left ventricular myxoma. J Pediatr. 2016;168:249–249.e2, Fig. 1.)*

Other benign tumors include hemangiomas, Purkinje cell tumors, papillomas, lipomas, and mesotheliomas. Depending on their location, these benign tumors can result in valvular function abnormalities, myocardial dysfunction, or heart block and other arrhythmias.

Malignant pediatric cardiac tumors are much less common than benign tumors; the majority of such malignancies are sarcomas, including angiosarcomas, rhabdosarcomas, or fibrosarcomas. Lymphomas and pheochromocytomas are reported but rare. Tumors originating from noncardiac sources that invade, extend, or metastasize to the heart are more frequently seen than primary malignant cardiac tumors. In pediatric patients, Wilms tumor and lymphoma/leukemia are the most common causes of such secondary tumors.

Although the manifestations of cardiac tumors in pediatric patients are protean, when a tumor is suspected, noninvasive imaging with echocardiography and/or MRI may be diagnostic and can determine tumor type, location, extent, and hemodynamic impact. ECG and Holter studies are valuable adjuncts when rhythm abnormalities are suspected. Cardiac catheterization is rarely indicated but may be used to confirm tumor location, assess intracardiac hemodynamics, and perform biopsy for histologic assessment. Such risks as blood loss, perforation, arrhythmia, and vessel injury should be considered when discussing catheterization and biopsy.

Because the natural history of rhabdomyomas is one of spontaneous diminution or complete resolution, treatment of the majority of cardiac tumors in pediatric patients is usually unnecessary. *Everolimus,* an inhibitor of the mammalian target of rapamycin (mTOR), may enhance resolution in symptomatic patients with cardiac rhabdomyomas. Careful clinical follow-up and imaging are important. **Antiarrhythmic medications** may be prescribed to control rhythm disorders. Surgical removal of a cardiac tumor may be indicated to relieve obstruction, improve myocardial or valve function, or control arrhythmias. **Heart transplantation** has been performed in cases of unresectable tumors with significant hemodynamic compromise. Wilms tumors extending from the inferior vena cava into the atrium may require cardiopulmonary bypass support during the course of primary resection of the renal tumor. Radiation or chemotherapy can improve cardiac function in rare cases of lymphoma or leukemia compressing the heart with hemodynamic compromise.

Visit Elsevier eBooks+ at eBooks.Health.Elsevier.com for Bibliography.

Section 7

Cardiac Therapeutics

Chapter 491

Heart Failure

Danielle S. Burstein and Joseph W. Rossano

The International Society for Heart and Lung Transplantation (ISHLT) defines heart failure as follows:

> A clinical and pathological syndrome that results from ventricular dysfunction, volume, or pressure overload, alone or in combination. It leads to characteristic signs and symptoms, such as poor growth, feeding difficulties, respiratory distress, exercise intolerance, and fatigue, and is associated with circulatory, neurohormonal, and molecular abnormalities. Heart failure has numerous etiologies that are a consequence of cardiac and noncardiac disorders, either congenital or acquired.

PATHOPHYSIOLOGY

The heart can be viewed as a pump with an output proportional to its filling volume and inversely proportional to the resistance against which it pumps. As ventricular end-diastolic volume increases, a healthy heart increases cardiac output until a maximum is reached and cardiac output can no longer be augmented (the **Frank-Starling principle**; Fig. 491.1). The increased stroke volume obtained in this manner is a result of stretching of myocardial fibers, but it also results in increased wall tension, which elevates myocardial oxygen consumption. Hearts working under various types of stress function along different Frank-Starling curves. Cardiac muscle with compromised intrinsic contractility requires a greater degree of dilation to produce increased stroke volume and does not achieve the same maximal cardiac output as normal myocardium does. If a cardiac chamber is already dilated because of a lesion causing increased preload (e.g., a left-to-right shunt or valvular insufficiency), there is little room for further dilation as a means of augmenting cardiac output. The presence of lesions that result in increased afterload to the ventricle (e.g., aortic or pulmonic stenosis, coarctation of the aorta) decreases cardiac performance, thereby resulting in a depressed Frank-Starling relationship.

Systemic oxygen transport is calculated as the product of cardiac output and oxygen content of systemic blood. **Cardiac output** can be calculated as the product of heart rate and stroke volume. The primary determinants of stroke volume are the *afterload* (pressure work), *preload* (volume work), and *contractility* (intrinsic myocardial function). Abnormalities in heart rate can also compromise cardiac output; for example, tachyarrhythmias shorten the diastolic time interval for ventricular filling. Alterations in the oxygen-carrying capacity of blood (e.g., anemia or hypoxemia) also lead to a decrease in systemic oxygen transport and, if compensatory mechanisms are inadequate, can result in decreased delivery of substrate to tissues.

In some cases of heart failure, cardiac output is normal or increased, yet because of decreased systemic oxygen content (e.g., secondary to anemia) or increased oxygen demands (e.g., secondary to hyperventilation, hyperthyroidism, or hypermetabolism), an inadequate amount of oxygen is delivered to meet the body's needs. This condition, **high-output failure**, results in the development of signs and symptoms of heart failure when there is no basic abnormality in myocardial function and cardiac output is greater than normal. It is also seen with large systemic arteriovenous fistulas (e.g., vein of Galen malformation). These conditions reduce peripheral vascular resistance and cardiac afterload and increase myocardial contractility. Heart failure results when the demand for cardiac output exceeds the ability of the heart to respond.

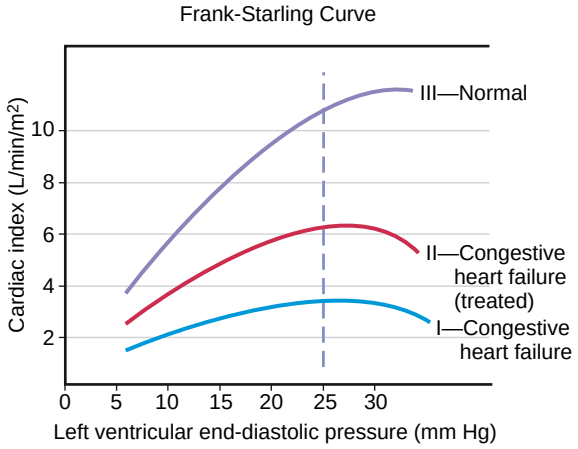

Fig. 491.1 The Frank-Starling relationship. As left ventricular end-diastolic (LVED) pressure increases, the cardiac index increases, even in the presence of congestive heart failure, until a critical level of LVED pressure is reached. Adding an inotropic agent (digoxin) shifts the curve from I to II. *(From Gersony WM, Steep CN. In: Dickerman JD, Lucey JF, eds. Smith's The Critically Ill Child: Diagnosis and Medical Management, 3rd ed. Philadelphia: Saunders; 1984.)*

Chronic severe high-output failure may eventually result in a decrease in myocardial performance as the metabolic requirements of the myocardium are not met.

Multiple systemic compensatory mechanisms are used by the body to adapt to chronic heart failure. Some are mediated at the molecular/cellular level, such as upregulation or downregulation of various metabolic pathway components leading to changes in efficiency of oxygen and other substrate utilizations. Others are mediated by neurohormones such as the renin-angiotensin system and the sympathoadrenal axis. One of the principal mechanisms for increasing cardiac output is an increase in sympathetic tone secondary to increased secretion of circulating epinephrine by the adrenals and increased release of norepinephrine at the neuromuscular junction. The *initial* beneficial effects of sympathetic stimulation include an increase in heart rate and myocardial contractility, mediated by these hormones' action on cardiac β-adrenergic receptors, increasing cardiac output. These hormones also cause vasoconstriction, mediated by their action on peripheral arterial α-adrenergic receptors. Some vascular beds may constrict more readily than others, so that blood flow is redistributed from the cutaneous, visceral, and renal beds to the heart and brain. Whereas these acute effects are beneficial, *chronically* increased sympathetic stimulation can have deleterious effects, including hypermetabolism, increased afterload, arrhythmogenesis, and increased myocardial oxygen requirements. Peripheral vasoconstriction can result in decreased renal, hepatic, and gastrointestinal tract function. Chronic exposure to circulating catecholamines leads to a decrease in the number of cardiac β-adrenergic receptors (downregulation) and also causes direct myocardial cell damage. Therapeutic agents for heart failure are directed at restoring balance to these neuroendocrine systems.

Based on these physiologic and clinical principles, heart failure has been described by different **classification** and **stage** definitions (Tables 491.1-491.3 and Fig. 491.2). These definitions help describe the degree of cardiac impairment and help direct therapy.

Table 491.1 Classification of Heart Failure Based on LVEF

HF CLASS ACCORDING TO LVEF (MUST HAVE SIGNS AND SYMPTOMS)	ACRONYM	LVEF, %
HF with reduced ejection fraction	HFrEF	≤40
HF with mildly reduced ejection fraction	HFmrEF	41–49
HF with preserved ejection fraction	HFpEF	≥50
HF with preserved ejection fraction, improved	HFpEF, improved	Prior <40, now ≥40

LVEF, Left ventricular ejection fraction.
From Kellerman RD, Rakel DP, Heidelbaugh JJ, Lee EM, eds. *Conn's Current Therapy 2023.* Philadelphia: Elsevier; 2023: Table 2, p. 117.

Table 491.2 New York Heart Association (NYHA) Functional Classification (FC)

NYHA FC	FUNCTIONAL CAPACITY
I	No limitations. Can perform high level of activity without symptoms (for example, running, cycling, weightlifting).
II	Slight limitations. Tolerate lower or moderate level activities well, may have limitations with higher-level activities (for example, regular walking causes no symptoms, but a run may cause shortness of breath).
III	Significant limitations. Symptoms with low-level activities such as with daily activities such as walking and household chores.
IV	Symptoms at rest, dyspnea with any physical activity.

From Kellerman RD, Rakel DP, Heidelbaugh JJ, Lee EM, eds. *Conn's Current Therapy 2023.* Philadelphia: Elsevier; 2023: Table 3, p. 117.

ETIOLOGY OF HEART FAILURE

There are many causes of heart failure in the pediatric population, and the etiologies of heart failure are age-dependent (Table 491.4). Pediatric heart failure can occur because of ventricular systolic or diastolic dysfunction caused by an underlying cardiomyopathy. This may be the result of a primary cardiomyopathy from an underlying genetic mutation in cardiac proteins or secondary due to conditions including metabolic and neuromuscular diseases. Ischemic cardiomyopathy caused by congenital coronary anomalies or acquired disease, such as Kawasaki disease, can also result in heart failure. Inflammatory or infectious diseases of the myocardium (e.g., myocarditis) can present with a range of heart failure severity from mild symptoms of chest pain to severe disease with fulminant cardiogenic shock. Persistent atrial and ventricular arrhythmias, particularly tachyarrhythmias, may also result in ventricular dysfunction and heart failure. High-output heart failure can occur in the setting of severe anemia or large arteriovenous malformations.

Heart failure in children can also occur in the setting of underlying congenital heart disease with outflow tract obstructive lesions, shunt lesions with overcirculation of the pulmonary vascular system (e.g., ventricular septal defect), or ventricular volume overload caused by significant valve regurgitation. Heart failure in children can also occur because of valvar heart disease resulting in significant valve regurgitation that causes ventricular volume overload and ventricular dilation with eventual systolic dysfunction. Single ventricle heart disease, including hypoplastic left heart syndrome, has increased the risk of developing heart failure due to multiple mechanisms that influence appropriate blood flow through the single ventricle palliated circulation.

CLINICAL MANIFESTATIONS

The clinical manifestations of heart failure depend in part on the degree of the child's cardiac reserve. A critically ill infant or child who has exhausted the compensatory mechanisms to the point that cardiac output is no longer sufficient to meet the basal metabolic needs of the body may present in **cardiogenic shock**. Other patients may be comfortable when quiet but are incapable of increasing cardiac output in response to even mild activity without experiencing significant symptoms. Conversely, it may take rather vigorous exercise to compromise cardiac function in children who have less severe heart disease.

A thorough **history** is extremely important in making the diagnosis of heart failure and in evaluating the possible causes. Parents or caregivers who observe their child on a daily basis may not recognize subtle changes that have occurred over the course of days or weeks. Gradually worsening perfusion or increasing respiratory effort may not be recognized as an abnormal finding, or may be misattributed to other diagnoses such as asthma. Edema, which is generally absent in infants and young children, may be passed off as normal weight gain, and exercise intolerance as lack of interest in an activity. The history of a young infant should also focus on **feeding**. An infant with heart failure often takes less volume per feeding, becomes dyspneic while sucking, and may perspire profusely. Eliciting a history of fatigue in an older child requires detailed questions about activity level and its course over several months.

In children and adolescents, the signs and symptoms of heart failure may be similar to those in adults and include fatigue, exercise intolerance, anorexia, nausea, vomiting, dyspnea, edema, wheezing, and cough. Many children, however, may have primarily abdominal symptoms (abdominal pain, nausea, vomiting, anorexia) and a surprising lack of respiratory complaints. Attention to the cardiovascular system may come only after an abdominal radiograph unexpectedly catches the lower end of an enlarged heart.

The **physical examination** for a child with suspected heart failure includes evaluation of vital signs and physical exam. Abnormal vital signs sometimes seen in pediatric heart failure include tachypnea, tachycardia, and desaturation caused by pulmonary edema. The elevation in systemic venous pressure may be gauged by clinical assessment of jugular venous pressure and liver enlargement. Orthopnea and

Table 491. 3 Classification of HF According to the American Heart Association (AHA) and American College of Cardiology (ACC)

HEART FAILURE STAGE		AHA/ACC DESCRIPTION
Stage A	At risk	Patients without identified structural or functional cardiac abnormality or ventricular function abnormality but at high risk of developing HF because of the presence of a condition (hypertension) strongly associated with the development of HF. Examples: anthracycline exposure, known pathogenic sarcomeric gene variant including dystrophinopathies.
Stage B	Pre-HF	Patients with structural heart disease or ventricular function abnormality that is strongly associated with the development of HF but without HF signs or symptoms, past or present. Examples: asymptomatic patient with CHD status postsurgical correction with residual lesion, isolated left ventricle noncompaction, elevated BNP or troponin if exposed to cardiotoxins.
Stage C	HF	Patients with current or prior symptoms of HF associated with underlying structural heart disease or ventricular function abnormality (elevated filling pressure, systolic dysfunction). Examples: acute myocarditis, dilated cardiomyopathy, mitral or aortic regurgitation.
Stage D	Advanced HF	Patients with advanced structural heart disease and refractory symptoms of HF requiring specialized interventions. Example: Inotropic dependency patient in end stage of dilated cardiomyopathy: may require VAD or transplant.

BNP, B-type natriuretic protein; CHD, congenital heart defect; VAD, ventricular assist devices; HF, heart failure
Modified from Hunt SA, Baker DW, Chin MH, Cinquegrani MP, Feldman AM, Francis GS, et al. ACC/AHA guidelines for the evaluation and management of chronic heart failure in the adult: executive summary. A report of the American college of cardiology/American heart association task force on practice guidelines (committee to revise the 1995 guidelines for the evaluation and management of heart failure). *J Am Coll Cardiol*. 2001;38:2101–13.

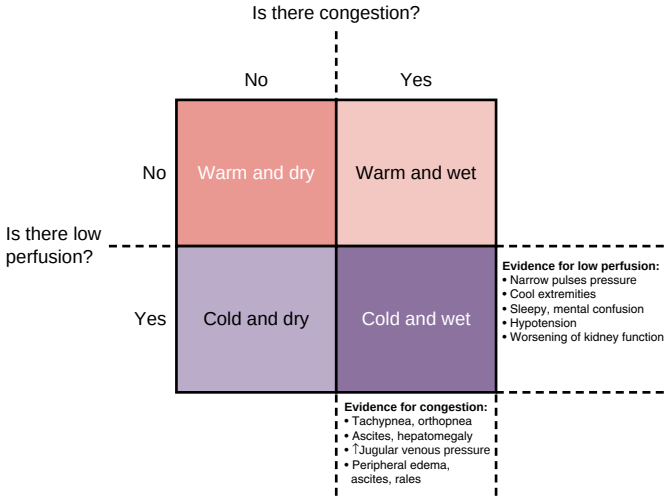

Fig. 491.2 Clinical assessment in acute decompensated heart failure should answer the two questions suggested by this diagram: First, does the patient present with significant congestion? Second, does the patient present with significant underperfusion? Using this construct, patients will segregate into one of four categories in accordance with clinical findings. Typically, patients move in a clockwise fashion through these categories, first becoming congested (warm and wet) and then vasoconstricted to maintain blood pressure (cold and wet). Once vasoactive support and diuresis are achieved, movement is generally counterclockwise, from cold and wet, to warm and wet, and then warm and dry. However, some patients will remain underperfused despite restoration of normovolemia, representing the cold and dry group, for whom mechanical support may be needed. *(Modified from Kantor PF, Mertens LL. Clinical practice: heart failure in children. Part I: clinical evaluation, diagnostic testing, and initial medical management. Eur J Pediatr. 2010;169[3]:269–279.)*

basilar rales are variably present; edema is usually discernible in dependent portions of the body, or anasarca may be present. Cardiomegaly is invariably noted based on a hyperactive precordium, ventricular heave, or displaced apical impulse. A **gallop rhythm** is common; when ventricular dilation is advanced, the **holosystolic murmur** of mitral or tricuspid valve regurgitation may be heard. **Pulsus alternans** is an ominous physical exam finding usually seeing in a state of low stroke volume with variable cardiac output with each ventricular contraction. Impaired systemic perfusion with poor capillary refill or decreased pulses is a concerning sign for cardiogenic shock.

In infants, heart failure may be difficult to distinguish from other causes of respiratory distress or gastrointestinal diseases. Prominent manifestations of heart failure include tachypnea, feeding difficulties, vomiting, poor weight gain, excessive perspiration, irritability, weak cry, and noisy, labored respirations with intercostal and subcostal retractions, as well as flaring of the alae nasi. The signs of cardiac-induced pulmonary congestion may be indistinguishable from those of bronchiolitis; wheezing is often a more prominent finding in young infants with heart failure than rales. Hepatomegaly usually occurs, and cardiomegaly is invariably present. Despite pronounced tachycardia, a gallop rhythm can frequently be recognized. The other auscultatory signs are those produced by the underlying cardiac lesion. Clinical assessment of jugular venous pressure in infants may be difficult because of the shortness of the neck and the difficulty of observing a relaxed state; palpation of an enlarged liver is a more reliable sign.

DIAGNOSIS

Chest radiograph (CXR) may be helpful in pediatric heart failure. It can assess the cardiac silhouette for cardiac enlargement. Pulmonary vascularity is variable and depends on the cause of the heart failure. Infants and children with large left-to-right shunts have exaggeration of the pulmonary arterial vessels to the periphery of the lung fields, whereas patients with cardiomyopathy may have a relatively normal pulmonary vascular bed early in the course of disease. Fluffy perihilar pulmonary markings suggestive of venous congestion and acute pulmonary edema are seen only with more severe degrees of heart failure. Pleural effusions may also be present. Cardiac enlargement as a marker of heart failure may be noted on a chest radiography performed to evaluate for a possible pulmonary infection, bronchiolitis, or asthma.

Electrocardiography (ECG) may be helpful in assessing the cause of heart failure but does not establish the diagnosis. In cardiomyopathies, exaggerated left or right ventricular voltages may be suggestive of underlying cardiomyopathy, and ischemic changes may correlate with other noninvasive parameters of ventricular function. Low-voltage QRS morphologic characteristics with ST-T–wave abnormalities may also suggest myocardial inflammatory disease (myocarditis) but can be seen with pericarditis as well. ECG is the best tool for evaluating rhythm disorders as a potential cause of heart failure, especially tachyarrhythmias. Ambulatory ECG monitoring can evaluate for occult arrhythmias that may be present in heart failure.

Echocardiography is the standard technique for assessing ventricular function (Fig. 491.3). Ventricular function can be quantitated simply and reliably with commonly used parameters such as fractional shortening (a single-dimensional variable) and an ejection fraction. The *fractional shortening* is determined as the difference between

Table 491.4 Etiology of Heart Failure

FETAL
Severe anemia (hemolysis, fetal-maternal transfusion, parvovirus B19–induced anemia, hypoplastic anemia)
Supraventricular tachycardia
Ventricular tachycardia
Complete heart block
Severe Ebstein anomaly or other severe right-sided lesions
Myocarditis
PREMATURE NEONATE
Fluid overload
Patent ductus arteriosus
Ventricular septal defect
Cor pulmonale (bronchopulmonary dysplasia)
Hypertension
Myocarditis
Genetic/metabolic cardiomyopathy
FULL-TERM NEONATE
Asphyxial cardiomyopathy
Arteriovenous malformation (vein of Galen, hepatic)
Left-sided obstructive lesions (coarctation of aorta, hypoplastic left heart syndrome)
Large mixing cardiac defects (single ventricle, truncus arteriosus)
Myocarditis
Genetic/metabolic cardiomyopathy
Pheochromocytoma
Stress cardiomyopathy (Takotsubo)
Substance misuse
INFANT/TODDLER
Left-to-right cardiac shunts (ventricular septal defect)
Hemangioma (arteriovenous malformation)
Anomalous left coronary artery
Genetic/metabolic cardiomyopathy
Acute hypertension (hemolytic-uremic syndrome)
Supraventricular tachycardia
Kawasaki disease
Myocarditis
CHILD/ADOLESCENT
Congenital heart disease (various forms, including single ventricle heart disease)
Rheumatic fever
Acute hypertension (glomerulonephritis)
Myocarditis
Thyrotoxicosis
Hemochromatosis-hemosiderosis
Cancer therapy (radiation, doxorubicin)
Sickle cell anemia
Endocarditis
Cor pulmonale (cystic fibrosis)
Genetic/metabolic cardiomyopathy (hypertrophic, dilated)

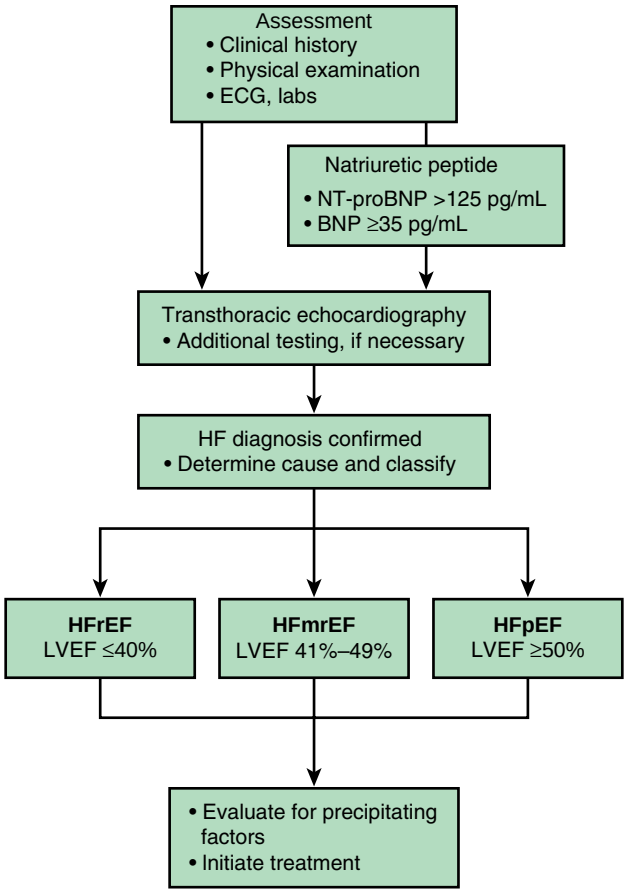

Fig. 491.3 Diagnostic algorithm for HF- and EF-based classification BNP, B-type natriuretic peptide; ECG, electrocardiogram; EF, ejection fraction; HF, heart failure; HFmrEF, heart failure with mildly reduced ejection fraction; HFpEF, heart failure with preserved ejection fraction; HFrEF, heart failure with reduced ejection fraction; LVEF, left ventricular ejection fraction; LV, left ventricular; NT-proBNP, N-terminal pro-B type natriuretic peptide. *(From Heidenreich PA, Bozkurt B, Aguilar D, et al. 2022 AHA/ACC/HFSA guideline for the management of heart failure. J Amer Coll Cardiol. 2022;79[17]:1757–1780, Fig. 4.)*

end-systolic and end-diastolic diameter divided by end-diastolic diameter. Normal fractional shortening is between approximately 28% and 42%. The *ejection fraction* uses two-dimensional data to calculate a three-dimensional volume; the normal range is 55–65%. In children with right ventricular enlargement or other cardiac pathology resulting in flattening of the interventricular septum, ejection fraction is used because fractional shortening measured in the standard echocardiographic short-axis view will not be accurate. Doppler studies can also be used to estimate cardiac output. Doppler assessment of transmitral inflow and tissue characterization can also be used as a noninvasive assessment of diastolic function.

Cardiac magnetic resonance imaging (CMR) is also useful in quantifying left and right ventricular function, volume, and mass along with coronary artery anatomy. If valvular regurgitation is present, CMR can quantify the regurgitant fraction. CMR can also provide details about tissue characterization such as fibrosis and inflammation, which is helpful for assessing conditions such as myocarditis.

Cardiac catheterization is an invasive test that can be helpful for assessing heart failure by evaluating intracardiac hemodynamics and shunt lesions. Angiography can be performed to evaluate for structural heart defects. Endomyocardial biopsy may sometimes be performed as part of an evaluation of myocarditis.

Laboratory testing is important for evaluating end-organ function and systemic perfusion. This includes evaluating renal function, liver function, lactate levels, and electrolytes. Heart failure may result in hyponatremia caused by compensatory activation of the renin-angiotensin-aldosterone pathway with renal water retention, which may be compounded by further salt wasting due to chronic diuretic treatment. When heart failure is severe, respiratory acidosis or metabolic acidosis, or both, may be present. The cardiac serum **biomarker B-type (brain) natriuretic peptide (BNP)** (or N-terminal pro-BNP) is a cardiac neurohormone released in response to increased ventricular wall tension that is elevated in patients with heart failure. In children with heart failure, BNP may be elevated as a result of systolic dysfunction (e.g., cardiomyopathy) and in children with volume overload (e.g., left-to-right shunts such as ventricular septal defect). Table 491.5 lists other causes of an elevated BNP.

TREATMENT

The underlying cause of cardiac failure must be removed or alleviated if possible. If the cause is a congenital cardiac anomaly amenable to surgery, medical treatment of the heart failure is indicated to prepare the patient for surgery. With the current excellent outcomes of primary surgical repair of congenital heart defects, even in the neonatal period,

Table 491.5 Causes of Elevated Concentrations of Natriuretic Peptides

CARDIAC
Heart failure (HFpEF, HFrEF)
Acute coronary symptoms
Pulmonary embolism
Myocarditis
Left ventricular hypertrophy
Hypertrophic or restrictive cardiomyopathy
Valvular heart disease
Congenital heart disease
Atrial and ventricular tachyarrhythmias
Heart contusion
Cardioversion ICD shock
Surgical procedures involving the heart
Pulmonary hypertension
Toxic injury (chemotherapy)
NONCARDIAC
Ischemic stroke
Subarachnoid hemorrhage
Renal dysfunction
Liver dysfunction (mainly liver cirrhosis with ascites)
Paraneoplastic syndrome
Chronic obstructive pulmonary disease
Severe infections (including pneumonia and sepsis)
Severe burns
Anemia
Severe metabolic and hormone abnormalities (e.g., thyrotoxicosis, diabetic ketosis)

HFpEF, Heart failure with preserved ejection fraction; HFrEF, heart failure with reduced ejection fraction; ICD, implantable cardioverter-defibrillator.
Adapted from McDonagh TA, Metra M, Adamo M, et al. 2021 ESC Guidelines for the diagnosis and treatment of acute and chronic heart failure [published correction appears in *Eur Heart J*. 2021 Oct 14]. *Eur Heart J*. 2021;42(36):3599–3726, Table 7.

few children require aggressive heart failure management to grow big enough for surgery. In contrast, if the cause of heart failure is cardiomyopathy, medical management provides temporary relief from symptoms and may allow the patient to recover if the insult is reversible (e.g., myocarditis). If the lesion is not reversible, heart failure management usually allows the child to return to normal activities for some period and to delay, sometimes for months or years, the need for heart transplantation.

General Measures

Heart failure management focuses on maintaining adequate cardiac output to allow for appropriate end-organ function while reducing volume overload and venous or pulmonary congestion. Encouraging regular physical activity is important for preventing acquired cardiovascular comorbidities, but it is important that the child be allowed to rest as needed and monitor for cardiac symptoms. Formal **cardiopulmonary exercise** testing can be used to assess the patient's ability to perform exercise in a controlled environment and is useful for providing exercise recommendations. Malnutrition is common in patients with heart failure because of gastrointestinal symptoms related to mesenteric venous congestion, and patients often require supplemental nutrition either with caloric fortification and/or nasogastric supplementation. For patients with pulmonary edema, positive pressure ventilation (PPV) may be required along with other drug therapies. For those in low-output heart failure, PPV can significantly reduce total body oxygen consumption by eliminating the work of breathing and help to reverse metabolic acidosis. Reverse remodeling agents, including β blockers, angiotensin-blockers, combination angiotensin receptor/neprilysin inhibitors, and aldosterone antagonists, can provide long-term myocardial reverse remodeling. Appropriate blood pressure control is important to reduce afterload and stress on the myocardium. In patients with advanced heart failure and/or cardiogenic shock, providing adequate cardiac output to meet the metabolic demands and provide adequate end-organ perfusion may require inotropic agents and, potentially, mechanical circulation support (Table 491.6).

Diet

Infants with heart failure usually fail to thrive because of a combination of increased metabolic demands and decreased caloric intake. Increasing daily calories is an important aspect of their management. Increasing the number of calories per ounce of infant formula (or supplementing breastfeeding) may be beneficial. Many infants do not tolerate an increase beyond 24 calories/oz because of diarrhea or because these formulas provide too large a solute load for compromised kidneys.

Severely ill infants and children may lack sufficient strength for effective sucking because of extreme fatigue, rapid respirations, and generalized weakness. In these circumstances, nasogastric feedings may be helpful. In many patients with cardiac enlargement, **gastroesophageal reflux** is a major problem. The use of continuous drip nasogastric feedings at night, administered by pump, may improve caloric intake while decreasing problems with reflux. Continued **malnutrition** may be an important factor in the decision to undertake earlier surgical intervention in patients who have an operable congenital heart lesion or to proceed with mechanical circulatory support and/or listing for transplantation in patients with cardiomyopathy. *Iron supplementation should be initiated in the presence of iron deficiency even in the absence of anemia.*

The use of low-sodium formulas in the routine management of infants with heart failure is not recommended because these preparations are often poorly tolerated and may exacerbate diuretic-induced hyponatremia. Human breast milk is the ideal low-sodium nutritional source. The use of more potent diuretic agents allows more palatable standard formulas to be used for nutrition while controlling salt and water balance by chronic diuretic administration. Most older children can be managed with generally heart-healthy diets that have low fat and sugar content, although caloric supplementation may be needed if there is significant malnutrition.

Diuretics

Diuretics are an important component of heart failure management by reducing volume overload and congestion. Diuretics interfere with reabsorption of water and sodium by the kidneys, which results in a reduction in circulating blood volume and thereby reduces pulmonary fluid overload and ventricular filling pressure. Diuretics are usually the first mode of therapy initiated in patients with congestive heart failure.

Loop diuretics, including Furosemide and bumetanide, are the most commonly used diuretics in pediatric patients with heart failure. It inhibits the reabsorption of sodium and chloride in the distal tubules and the loop of Henle. Patients requiring acute diuresis should be given intravenous (IV) furosemide at an initial dose of 1-2 mg/kg, which usually results in rapid diuresis and prompt improvement in clinical status, particularly if symptoms of pulmonary congestion are present. Chronic furosemide therapy is then prescribed at a dose of 1-4 mg/kg/24 hr given between 1 and 4 times a day. Careful monitoring of electrolytes is necessary with long-term furosemide therapy because of the potential for significant loss of potassium. Potassium chloride supplementation is usually required unless the potassium-sparing diuretics are given concomitantly. Chronic administration of furosemide may cause contraction of the extracellular fluid compartment and result in "contraction alkalosis" (see Chapter 73.7). Diuretic-induced hyponatremia may become difficult to manage in patients with severe heart failure.

Thiazide diuretics, including chlorothiazide, are also used for diuresis in children with heart failure. It is less immediate in action and less potent than furosemide, and it affects the reabsorption of electrolytes in the renal tubules only. The usual dose is 10-40 mg/kg/24 hr in two divided doses. Potassium supplementation is often required if chlorothiazide is used alone. **Sodium glucose cotransporter 2 (SGLT2) inhibitors** (dapagliflozin, empagliflozin) also produce a natriuresis and have other beneficial direct cardiac effects and have been recommended for some etiologies of heart failure.

Table 491.6 Dosage of Drugs Commonly Used for the Treatment of Congestive Heart Failure

DRUG	DOSAGE*
DIGOXIN	
Digitalization (1/2 initially, followed by 1/4 q12h × 2)	Premature: 20 μg/kg Full-term neonate (up to 1 mo): 20-30 μg/kg Infant or child: 25-40 μg/kg Adolescent or adult: 0.5-1 mg in divided doses *Note:* These doses are PO; IV dose is 75% of PO dose
Maintenance digoxin†	5-10 μg/kg/day, divided q12h *Note:* These doses are PO; IV dose is 75% of PO dose
DIURETICS	
Furosemide (Lasix)	IV: 0.5-2 mg/kg/dose PO: 1-4 mg/kg/day, divided qd-qid
Bumetanide (Bumex)	IV: 0.01-0.1 mg/kg/dose PO: 0.01-0.1 mg/kg/day q24-48h
Chlorothiazide (Diuril)	PO: 20-40 mg/kg/day, divided bid or tid
Spironolactone (Aldactone)	PO: 1-3 mg/kg/day, divided bid or tid
ADRENERGIC AGONISTS (ALL IV)	
Dobutamine	2-20 μg/kg/min
Dopamine	2-20 μg/kg/min
Epinephrine	0.01-1.0 μg/kg/min
PHOSPHODIESTERASE INHIBITORS (ALL IV)	
Milrinone	0.25-1.0 μg/kg/min
AFTERLOAD-REDUCING AGENTS	
Captopril (Capoten), all PO	Premature: start at 0.01 mg/kg/dose; 0.1-0.4 mg/kg/day, divided q6-24h Infant: start at 0.15-0.3 mg/kg/dose; 1.5-6 mg/kg/day, divided q6-12h Child: start at 0.3-0.5 mg/kg/dose; 2.5-6 mg/kg/day, divided q6-12h
Enalapril (Vasotec), all PO	0.08-0.5 mg/kg/day, divided q12-24h
Hydralazine (Apresoline)	IV: 0.1-0.5 mg/kg/dose (maximum: 20 mg) PO: 0.75-5 mg/kg/day, divided q6-12h
Nitroglycerin	IV: 0.25-0.5 μg/kg/min start; increase to 20 μg/kg/min maximum
Nitroprusside (Nipride)	IV: 0.5-8 μg/kg/min
β-ADRENERGIC BLOCKERS	
Carvedilol (Coreg)	PO: initial dose: 0.1 mg/kg/day (maximum: 6.25 mg) divided bid (may use tid in infants), increase gradually (usually 2-wk intervals) to maximum of 0.5-1 mg/kg/day over 8-12 wk as tolerated; adult maximum dose: 50-100 mg/day
Metoprolol (Lopressor, Toprol-XL)	PO, non–extended-release form: 0.2 mg/kg/day divided bid, increase gradually (usually 2-wk intervals) to maximum dose of 1-2 mg/kg/day PO, extended-release form (Toprol-XL): given once daily; adult initial dose: 25 mg/day, maximum: 200 mg/day

*Pediatric doses based on weight should not exceed adult doses. Because recommendations may change, these doses should always be double-checked. Doses may also need to be modified in any patient with renal or hepatic dysfunction.

†Maintenance digitalis therapy is started approximately 12 hr after full digitalization. The daily dosage, one quarter of the total digitalizing dose, is divided in two and given at 12-hr intervals. The oral maintenance dose is usually 20–25% higher than when digoxin is used parenterally. The normal daily dose of digoxin for older children (>5 yr of age) calculated by body weight should not exceed the usual adult dose of 0.125-0.5 mg/24 hr.

IV, Intravenous; PO, oral; bid, twice daily, tid, 3 times daily; qid, 4 times daily; qd, every day.

Cardiac Reverse Remodeling

Angiotensin Antagonists

The renin-angiotensin-aldosterone pathway becomes active as a compensatory response to heart failure, but these compensatory effects can result in increased afterload and adverse remodeling of the myocardium, including development of cardiac fibrosis. Angiotensin antagonists, including angiotensin-converting enzyme inhibitors (ACEIs) and aldosterone II receptor blockers (ARBs), reduce ventricular afterload by decreasing peripheral vascular resistance and thereby improving myocardial performance. Afterload reducers may be useful in children with heart failure secondary to cardiomyopathy and in patients with severe mitral or aortic insufficiency. They may also be effective in patients with heart failure caused by left-to-right shunts. ACEIs and ARBs may have additional beneficial effects on cardiac remodeling independent of their influence on afterload by directly influencing adverse cardiac intracellular signaling pathways and decreasing the formation of myocardial fibrosis. In adult patients with dilated cardiomyopathy, the addition of an ACEI to standard medical therapy reduces both morbidity and mortality.

The orally active ACEIs **captopril**, **enalapril,** and **lisinopril** produce arterial dilation by blocking the production of angiotensin II, thereby resulting in significant afterload reduction. Venodilation and consequent preload reduction also have been reported. In addition, these agents interfere with aldosterone production and therefore also help control salt and water retention. ACEIs have additional beneficial effects on cardiac structure and function that may be independent of

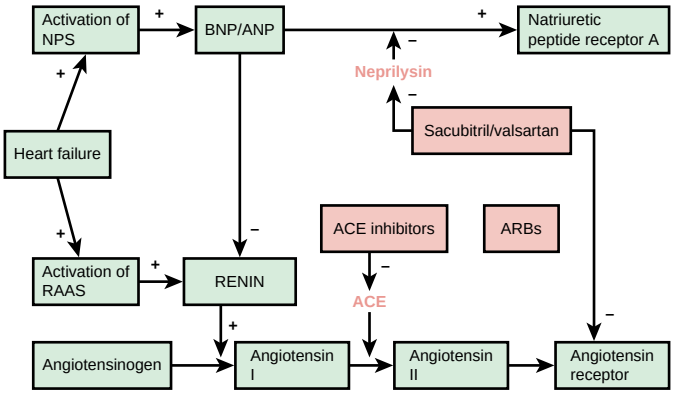

Fig. 491.4 Systems activated in heart failure and pathways blocked by angiotensin-converting enzyme inhibitors, angiotensin receptor blockers, and neprilysin inhibitors (sympathetic nervous system activation pathway is not shown in the figure). ANP, Atrial natriuretic peptide; BNP, B-type natriuretic peptide; NPS, natriuretic peptide system; RAAS, renin angiotensin aldosterone system. *(From Arya A, Azad S, Sitaraman R. Angiotensin receptor and neprilysin inhibitor: a new drug in pediatric cardiologist's armamentarium. Ann Pediatr Cardiol. 2020;13[4]:334–336, Fig. 1.)*

Table 491.7 Valsartan/Sacubitril Recommended Dose* (Twice Daily)

	STARTING	SECOND	FINAL
Pediatric patients <40 kg** (mg/kg)	1.6	2.3	3.1
Pediatric patients at least 40 kg, <50 kg (mg)	24/26	49/51	72/78#
Pediatric patients at least 50 kg (mg)	49/51	72/78#	97/103

*Available as 24/26, 49/51, and 97/103 mg tablets, where the first drug is sacubitril and the second drug is valsartan.
#Doses of 72/78 mg can be achieved using three 24/26 mg tablets. Titration: titrate dose every 2 wk and target final dose.
**An oral suspension can be substituted at the recommended tablet dosage in patients unable to swallow tablets.
From Arya A, Azad S, Sitaraman R. Angiotensin receptor and neprilysin inhibitor: a new drug in pediatric cardiologist's armamentarium. *Ann Pediatr Cardiol.* 2020;13(4):334–336, Table 1.

their effect on afterload. Adverse reactions to ACEIs include hypotension and its sequelae (weakness, dizziness, syncope) and hyperkalemia. A maculopapular pruritic rash is encountered in a small number of patients, but the drug may be continued because the rash often disappears spontaneously with time. Neutropenia, renal toxicity, and chronic cough also occur. Angioedema is a rare side effect of ACEIs and is related to inhibiting breakdown of bradykinin. If patients have had side effects related to bradykinin effect from ACEIs, including chronic cough, ARBs may be an alternative therapy and include **losartan** and **valsartan.**

An angiotensin receptor combined with neprilysin inhibition (ARNI) (valsartan/sacubitril) is approved for children 1-18 years of age with New York Heart Association class II-IV and a left ventricular ejection fraction ≤40%. The mechanism of action is noted in Figure 491.4 and the dosing in Table 491.7.

Aldosterone Antagonists

Spironolactone and **eplerenone** inhibit aldosterone and act both as a reverse remodeling agent and a weak diuretic. They also enhance potassium retention, often eliminating the need for oral potassium supplementation in patients receiving diuretics. Aldosterone antagonists blunt the adverse cardiac remodeling effects and may reduce cardiac fibrosis that results in heart failure. Spironolactone is usually given orally in two divided doses of 2 mg/kg/24 hr. Adults with heart failure have improved survival when an aldosterone inhibitor is included in the diuretic regimen, likely through multiple effects, including a favorable effect on cardiac fibrosis. Eplerenone is an alternative to spironolactone and does not have the side effect of gynecomastia.

β Blockers

Studies in adults with dilated cardiomyopathy show that β-adrenergic blocking agents, introduced gradually as part of a comprehensive heart failure treatment program, improve exercise tolerance, decrease hospitalizations, and reduce overall mortality. The agents most often used are **carvedilol**, with both α- and β-adrenergic receptor–blocking and free radical–scavenging effects, and **metoprolol**, a β_1-adrenergic receptor–selective antagonist. β Blockers are used for the chronic treatment of patients with heart failure and should not be administered when patients are still in the acute phase of heart failure (i.e., receiving IV adrenergic agonist infusions). Although highly efficacious in adults, clinical studies in children have shown mixed results, potentially from the significant heterogeneity of the populations being studied and differences in the types of β-blocking agents.

Although ACEIs/ARBs along with β-adrenergic–blocking agents and aldosterone antagonists have been shown in multiple prospective, randomized, controlled trials in adults to improve symptoms and mortality in adult heart failure patients, it is unclear if these medications improve the natural history of heart failure in children. Nonetheless, these medications are commonly used for the treatment of heart failure and are recommended by consensus guidelines from the ISHLT and Canadian Cardiovascular Society.

Afterload Reduction

Afterload reduction is an important component of heart failure management to reduce workload on the myocardium. Oral afterload-reducing agents, including ACEIs and ARBs, are often used for both cardiac reverse remodeling and afterload reduction benefits. If renal insufficiency is present, alternative oral afterload-reducing agents may be considered, including calcium channel blockers such as **amlodipine**, although they have potential side effects including peripheral edema and gingival hyperplasia.

Intravenously administered afterload-reducing agents, including **milrinone** (see later section on "Phosphodiesterase Inhibitors"), **nicardipine**, and **nitroprusside**, should be initiated only in a closely monitored clinical care setting. Nitroprusside's short IV half-life makes it ideal for titrating the dose in critically ill patients. Peripheral arterial vasodilation and afterload reduction are the major effects, but venodilation causing a decrease in venous return to the heart may also be beneficial. Blood pressure must be continuously monitored because sudden hypotension can occur. Consequently, nitroprusside is contraindicated in patients with preexisting hypotension. Because the drug is metabolized, small amounts of circulating cyanide are produced and detoxified in the liver to thiocyanate, which is excreted in urine. When high doses of nitroprusside are administered for several days, toxic symptoms related to *thiocyanate poisoning* may occur (fatigue, nausea, disorientation, acidosis, and muscular spasm). If nitroprusside use is prolonged, blood thiocyanate levels should be monitored.

Phosphodiesterase Inhibitors

Milrinone is useful in treating patients with low cardiac output who are refractory to standard therapy. It has been shown to be highly effective in managing the low-output state present in children after open heart surgery. It works by inhibiting phosphodiesterase, which prevents the degradation of intracellular cyclic adenosine monophosphate. Milrinone has both positive inotropic effects on the heart and peripheral vasodilatory effects and has generally been used as an adjunct to dopamine or dobutamine therapy in the intensive care unit. It is given by IV infusion at 0.25-1 μg/kg/min. A major side effect is **hypotension** secondary to peripheral vasodilation. The hypotension can generally be managed by the administration of IV fluids to restore adequate intravascular volume. Because of renal clearance of milrinone, caution must be used in the setting of renal insufficiency. Long-term milrinone

is often used to support patients while listed for heart transplantation, and in select patients can be used in the outpatient setting.

α- and β-Adrenergic Agonists

The α- and β-adrenergic receptor agonists may be needed for advanced heart failure with impaired cardiac output and are usually administered in an intensive care setting, where the dose can be carefully titrated to hemodynamic response. Continuous determinations of arterial blood pressure and heart rate are performed; measuring serial mixed venous oxygen saturations or cardiac output directly with a pulmonary thermodilution (Swan-Ganz) catheter may be helpful in assessing drug efficacy, although this technique is used much less in children than in adults. These agents increase myocardial oxygen consumption and are associated with increased arrhythmogenic burden and have been shown to increase morbidity and mortality in adults with heart failure; thus they are usually avoided as a long-term therapy.

Dopamine is a predominantly β-adrenergic receptor agonist, but it has α-adrenergic effects at higher doses. Dopamine has less chronotropic and arrhythmogenic effect than the pure β-agonist isoproterenol. At a dose of 2-10 μg/kg/min, dopamine results in increased contractility with little peripheral vasoconstrictive effect. If the dose is increased beyond 15 μg/kg/min, however, its peripheral α-adrenergic effects may result in vasoconstriction.

Dobutamine, a derivative of dopamine, is also useful in treating low cardiac output. It has direct inotropic effects and causes a moderate reduction in peripheral vascular resistance. Dobutamine can be used alone or as an adjunct to dopamine therapy to avoid the vasoconstrictive effects of higher-dose dopamine. Dobutamine is also less likely to cause cardiac rhythm disturbances.

Epinephrine is a mixed α- and β-adrenergic receptor agonist that is usually reserved for patients with cardiogenic shock and low arterial blood pressure. Although epinephrine can raise blood pressure effectively, it also increases systemic vascular resistance, and therefore increases the afterload against which the heart has to work and is associated with an increased risk of arrhythmia. Additionally, epinephrine is proarrhythmic and can result in direct cardiac toxicity, including myocardial necrosis and apoptosis.

Digitalis Glycosides

Digoxin, once the mainstay of heart failure management in both children and adults, is currently used less frequently as a result of the introduction of other therapies and the recognition of its potential toxicities. Some cardiologists will use digitalis as an adjunct to ACEIs and diuretics in patients with symptomatic heart failure, whereas others have stopped using it altogether. Despite multiple clinical studies, predominantly in adults, the controversy over digitalis remains. Some data suggest a beneficial effect of digoxin on reducing death among infants with single ventricle heart disease.

Digoxin is the digitalis glycoside used most often in pediatric patients. It has a half-life of 36 hours and is absorbed well by the gastrointestinal tract (60–85%), even in infants. An initial effect is seen as early as 30 minutes after administration, and the peak effect for oral digoxin occurs at 2-6 hours. When the drug is administered intravenously, the initial effect is seen in 15-30 minutes, and the peak effect occurs at 1-4 hours. The kidney eliminates digoxin, so dosing must be adjusted according to the patient's renal function. The half-life of digoxin may be up to 6 days in patients with anuria because slower hepatic excretion pathways are used in these patients.

Rapid digitalization of infants and children may be carried out intravenously. This should be done with caution in patients with severe heart failure. The dose depends on the patient's age (see Table 491.6). The recommended digitalization schedule is to give half the total digitalizing dose immediately and the succeeding two one-quarter doses at 12-hours intervals later. The ECG must be closely monitored and rhythm strips obtained before each of the three digitalizing doses. Digoxin should be discontinued if a new rhythm disturbance is noted. Prolongation of the P-R interval is not necessarily an indication to withhold digitalis, but a delay in administering the next dose or a reduction in the dosage should be considered, depending on the patient's clinical status. Minor ST segment or T-wave changes are frequently noted with digitalis administration and should not affect the digitalization regimen. Baseline serum electrolyte levels should be measured before and after digitalization. **Hypokalemia** and **hypercalcemia** exacerbate digitalis toxicity. Because hypokalemia is relatively common in patients receiving diuretics, potassium levels should be monitored closely in those receiving a potassium-wasting diuretic in combination with digitalis. In patients with active myocarditis, some cardiologists recommend avoiding digitalis altogether, and if used, maintenance digitalis should be started at half the normal dose without digitalization because of the increased risk of arrhythmia in these patients.

Patients who are not critically ill may be given digitalis initially by the oral route, and in most instances, digitalization is completed within 24 hours. When slow digitalization is desirable, for example, in the immediate postoperative period, initiation of a maintenance digoxin schedule without a previous loading dose achieves full digitalization in 7-10 days.

Measurement of serum digoxin levels is useful in the following circumstances: (1) when an unknown amount of digoxin has been administered or ingested accidently, (2) when renal function is impaired or if drug interactions are possible, (3) when questions regarding compliance are raised, and (4) when a toxic response is suspected. In suspected toxicity, elevated serum digoxin levels are not in themselves diagnostic of toxicity but must be interpreted as an adjunct to other clinical and electrocardiographic findings (rhythm and conduction disturbances). Hypokalemia, hypomagnesemia, hypercalcemia, cardiac inflammation secondary to myocarditis, and prematurity may all potentiate digitalis toxicity. A cardiac arrhythmia that develops in a child who is taking digitalis may also be related to the primary cardiac disease rather than the drug; however, any arrhythmia occurring after the institution of digitalis therapy must be considered to be drug related until proven otherwise. Many drugs interact with digoxin and may increase levels or risk of toxicity, so care should be taken when a patient receiving digoxin is being considered for any additional pharmacologic therapy.

Additional Therapies

Several medications that have shown promise in the treatment of adult patients with heart failure are being studied in pediatric patients. For chronic heart failure, **ivabradine** has been studied in patients with elevated heart rates despite optimized β blocker use. Ivabradine is a selective inhibitor of the I_f current in the sinus node and lowers heart rates without decreasing myocardial contractility. The use of ivabradine was associated with improved outcomes in adults with heart failure, and a recent study of children with heart failure caused by dilated cardiomyopathy demonstrated improved left ventricular systolic function and clinical status.

Sodium-glucose co-transporter 2 (SGLT2) inhibitors, which blocks reabsorption of glucose in the proximal renal tubule, are the newest class of adult heart failure medications and, though developed as a treatment for diabetes, have shown dramatic improvement in cardiac mortality and morbidity in adults with heart failure with reduced ejection fraction. Given the mechanism of action, which includes glucosuria, there is a risk for urinary tract infection and yeast infection. Additional possible side effects include acute kidney injury and bone fracture as well as development of diabetic ketoacidosis in patients with diabetes. Further studies are needed to determine what role, if any, these medications will have in the treatment of pediatric heart failure.

ELECTROPHYSIOLOGIC APPROACHES TO HEART FAILURE MANAGEMENT

Significant improvements in symptomatology and functional capacity have been achieved in select adult patients with cardiomyopathy using **biventricular resynchronization pacing**. This technique improves cardiac output by restoring normal synchrony between right and left ventricular contraction, which is often lost in patients with dilated cardiomyopathy (these patients usually manifest a left bundle branch block on ECG). There is growing experience with resynchronization pacing in children, but it remains uncertain which population of patients with heart failure benefit from this therapy.

Arrhythmias are a leading cause of sudden death in patients with severe cardiomyopathy (both dilated and hypertrophic). Although antiarrhythmic medications can sometimes reduce this risk, for patients at particularly high risk (e.g., those with a condition known to be associated with a high risk of ventricular arrhythmia or those who have already

Table 491.8 Treatment of Cardiogenic Shock*

	DETERMINANTS OF STROKE VOLUME		
	Preload	**Contractility**	**Afterload**
Parameters measured	CVP, PCWP, LAP, cardiac chamber size on echocardiography	CO, BP, fractional shortening or ejection fraction on echocardiography, MV O_2 saturation	BP, peripheral perfusion, SVR
Treatment to improve cardiac output	Volume expansion (crystalloid, colloid, blood)	β-Adrenergic agonists, phosphodiesterase inhibitors	Afterload-reducing agents: milrinone, nitroprusside, ACEIs

*The goal is to improve peripheral perfusion by increasing cardiac output, where cardiac output = heart rate × stroke volume.
ACEIs, Angiotensin-converting enzyme inhibitors; BP, blood pressure; CO, cardiac output (measured with a thermodilution catheter); CVP, central venous pressure; LAP, left atrial pressure (measured with an indwelling LA line); MV O_2 saturation, mixed venous oxygen saturation (measured with a central venous catheter); PCWP, pulmonary capillary wedge pressure (measured with a thermodilution catheter); SVR, systemic vascular resistance (calculated from CO and mean BP).

experienced a "missed sudden death" episode), use of an **implantable cardioverter-defibrillator** can be lifesaving (see Chapter 485).

491.1 Cardiogenic Shock

Joseph W. Rossano and Danielle S. Burstein

Cardiogenic shock may be caused by (1) severe cardiac dysfunction before or after cardiac surgery, (2) septicemia, (3) severe burns, (4) anaphylaxis, (5) cardiomyopathy, (6) myocarditis, (7) myocardial infarction or stunning, and (8) acute central nervous system (CNS) disorders. It is characterized by low cardiac output and results in inadequate tissue perfusion (see Chapter 85).

Treatment is aimed at restoring adequate cardiac output to prevent the untoward effects of prolonged ischemia on vital organs, as well as management of the underlying cause. Under normal physiologic conditions, cardiac output is increased as a result of sympathetic stimulation, which increases both contractility and heart rate. If contractility is depressed, cardiac output may be improved by increasing the heart rate, increasing ventricular filling pressure (preload) through the Frank-Starling mechanism, or decreasing systemic vascular resistance (afterload). Optimal filling pressure is variable and depends on a number of extracardiac factors, including ventilatory support and intraabdominal pressure. The increased pressure necessary to fill a relatively noncompliant ventricle should also be considered, particularly after open heart surgery or in patients with restrictive or hypertrophic cardiomyopathies. If carefully administered incremental fluid does not result in improved cardiac output, abnormal myocardial contractility or an abnormally high afterload, or both, must be implicated as the cause of the low cardiac output. Although an increase in heart rate *may* improve cardiac output, an excessive increase in heart rate may reduce cardiac output because of decreased time for diastolic filling. Additionally, high heart rates will increase myocardial oxygen demand, which may be counterproductive in a state of limited tissue oxygen supply.

Myocardial contractility usually improves when treatment of the basic cause of shock is instituted, hypoxia is eliminated, and acidosis is corrected. β-Adrenergic agonists such as dopamine, epinephrine, and dobutamine improve cardiac contractility, increase heart rate, and ultimately increase cardiac output. However, some of these agents also have α-adrenergic effects, which cause peripheral vasoconstriction and increase afterload, so careful consideration of the balance of these effects in an individual patient is important. The use of cardiac glycosides and β blockers to treat acute low-cardiac-output states should be avoided.

Patients in cardiogenic shock may have a marked increase in systemic vascular resistance (SVR) resulting in high afterload and poor peripheral perfusion. If the increased SVR is persistent and the administration of positive inotropic agents alone does not improve tissue perfusion, the use of afterload-reducing agents may be appropriate, such as nitroprusside or milrinone in combination with a β-adrenergic agonist. Milrinone, a phosphodiesterase inhibitor (see earlier), is also a positive inotropic agent, and combined with a β-adrenergic agonist, it works synergistically to increase levels of myocardial cyclic adenosine monophosphate.

Sequential evaluation and management of cardiovascular shock are mandatory (see Chapter 85). Table 491.8 outlines the general treatment principles for acute cardiac circulatory failure under most circumstances. In addition to cardiac-specific medications, other treatments aimed at improving oxygen capacity (e.g., blood transfusion for patients with anemia) and decreasing oxygen demand (e.g., intubation, mechanical ventilation, sedation, antipyretics) can be beneficial. Treatment of infants and children with low cardiac output after cardiac surgery also depends on the nature of the operative procedure, any intraoperative complications, and the physiology of the circulation after repair or palliation (see Chapter 483). If cardiogenic shock does not respond rapidly to medical therapy, consideration of mechanical support is warranted.

MECHANICAL CIRCULATORY SUPPORT

Extracorporeal membrane oxygenation (ECMO), which can provide total cardiopulmonary support, is the most common *short-term* modality to support circulatory failure in children. In experienced centers, children can be placed on ECMO rapidly, and therefore the modality can be used in multiple settings, including low cardiac output syndrome (low-output heart failure) after cardiac surgery, rapidly deteriorating hemodynamics in several scenarios (e.g., myocarditis), and as resuscitation from refractory cardiac arrest. The modality is ideal for short-term support when the underlying disease requiring ECMO is expected to resolve within days to weeks. For multiple reasons, including the relatively high complication rate and decreased mobility of many patients on ECMO, it is not an ideal support modality for long-term myocardial support.

Given the limitations of ECMO, there is a need to develop long-term support options for children with refractory heart failure. **Ventricular assist devices (VADs)** include both short-term and long-term mechanical circulatory support and can be deployed either percutaneously or surgically. In children, most of these devices are used with the intention of subsequently performing a heart transplantation, although the devices can be removed if myocardial function recovers. This is in contrast to adult patients, many of whom are placed on these devices with no plan for heart transplantation, the so-called *destination therapy.* Successfully managing patients on VAD support requires a dedicated multidisciplinary team.

For infants and small children, the most commonly used VADs are paracorporeal devices, including paracorporeal pulsatile-flow VADs (e.g., Berlin Heart EXCOR) and paracorporeal continuous-flow VADs (e.g., Pedimag). These devices can be used for left, right, or biventricular support. They are classified as a paracorporeal device because the pump sits outside the body. In older children and adolescents, intracorporeal continuous flow devices (e.g., HeartMate3) are preferred. These VADs are completely internalized except for a drive line that connects to the power source (Fig. 491.5). These VADs have fewer complications and can provide long-term durable support outside the hospital. These devices are often used in older children and adolescents, with many of these patients discharged home on VAD support. Other types of devices, including **temporary percutaneous VAD** (e.g., Impella) for short-term support and the **total artificial heart** for long-term support, have also been used in children.

Visit Elsevier eBooks+ at eBooks.Health.Elsevier.com for Bibliography.

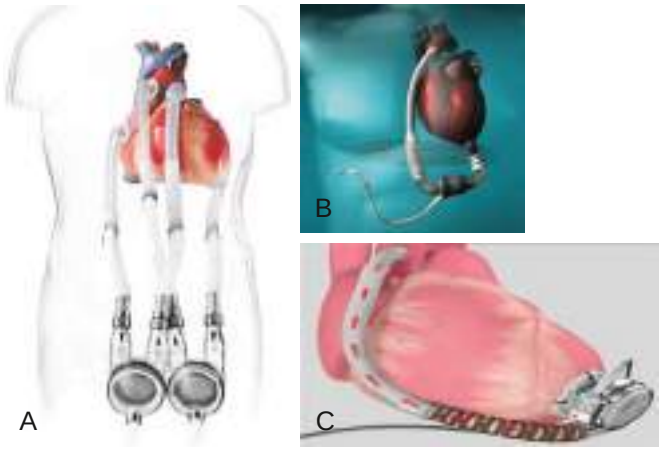

Fig. 491.5 Commonly used ventricular assist devices in children. **A,** Paracorporeal pneumatic pulsatile Berlin Heart EXCOR. **B** and **C,** Continuous flow devices: **(B)** HeartMate3; **(C)** HeartWare HVAD. *(A courtesy Berlin Heart, LLC; B from St. Jude Medical; C courtesy Medtronic, Inc.)*

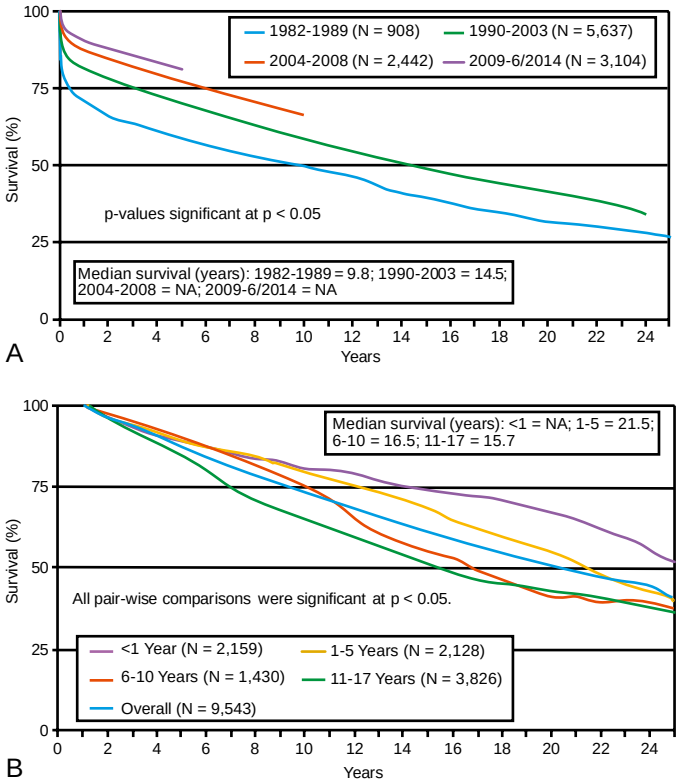

Fig. 492.1 **A,** Survival after pediatric heart transplantation comparing current and past eras. **B,** Long-term survival among patients that lived to 1-yr post-transplant. NA, Not applicable. *(From Rossano JW, Dipchand AI, Edwards LB, et al. The Registry of the International Society for Heart and Lung Transplantation: Nineteenth Pediatric Heart Transplantation Report—2016. Focus theme: primary diagnostic indications for transplant. J Heart Lung Transplant. 2016;35[10]:1185–1195, Figs. 6 and 7.)*

Chapter 492

Pediatric Heart and Heart-Lung Transplantation

492.1 Pediatric Heart Transplantation

Danielle S. Burstein and Joseph W. Rossano

Pediatric heart transplantation is considered the standard therapy that offers long-term survival for end-stage heart disease in children. In adults, ventricular assist devices (VADs) are usually employed as a long-term therapy for patients not eligible for heart transplantation, but in children the vast majority of VADs are used as a *bridge* to transplantation as opposed to an alternative to transplantation. According to the International Society for Heart and Lung Transplantation, as of January 2019, over 14,000 heart transplants had been performed on children in the world, with about 400 transplants annually—a quarter of these in children <1 year of age. Survival rates have improved significantly over time, with most of the improvement occurring in the early period after transplant. This period continues to the associated with the greatest risk of death, and many patients who survive the first year after transplant are alive 20 years later (Fig. 492.1). Indeed, a growing number of patients receiving a heart transplant in childhood are approaching their 15-, 20-, and 30-year posttransplant anniversaries. Current (2011-2023) 1-year survival is ~90% and 5-year survival ~80%.

INDICATIONS

Heart transplantation is performed (1) in infants and children with end-stage cardiomyopathy who have become refractory to medical therapy, (2) in patients with previously repaired or palliated congenital heart disease (CHD) who have developed ventricular dysfunction or other nonoperable late-term complications, and (3) less frequently in patients with complex CHD—pulmonary atresia with intact septum and coronary arterial stenoses and some forms of hypoplastic left heart syndrome (HLHS)—for whom standard surgical procedures are extremely high risk. Additionally, **retransplantation** accounts for approximately 5% of transplants annually. **Cardiomyopathies** account for >50% of heart transplants in pediatric patients older than 1 year, with the percentage of patients with previously repaired complex CHD at approximately 30%. In infants younger than 1 year, CHD previously represented >80% of transplants; this has decreased to 60% as standard surgical results for complex CHD (e.g., HLHS) have improved.

RECIPIENT AND DONOR SELECTION

Potential heart transplant recipients must be free of serious noncardiac medical problems such as neurologic disease, active systemic infection, severe hepatic or renal disease, and severe malnutrition. Many children with ventricular dysfunction are at risk for the development of **pulmonary vascular disease**, which, if severe enough, would also preclude heart transplantation. Therefore pulmonary vascular resistance (PVR) is measured at cardiac catheterization in heart transplant candidates, both at rest and, if elevated, in response to vasodilators. Patients with fixed elevated PVR above 6 index Wood units are at higher risk for heart transplantation and may be considered candidates for heart-lung transplantation (see Chapter 492.2). However, with advances in postoperative management of pulmonary hypertension (e.g., inhaled nitric oxide), many patients with moderate elevation in PVR can undergo heart transplant alone. A comprehensive social services evaluation is an important component of the recipient evaluation. Because of the complex posttransplantation medical regimen, the family must have a history of compliance. Detailed informed consent must be obtained, indicating that the family (and, if old enough, the patient) understand the lifelong commitment to immunosuppressive medication and careful monitoring.

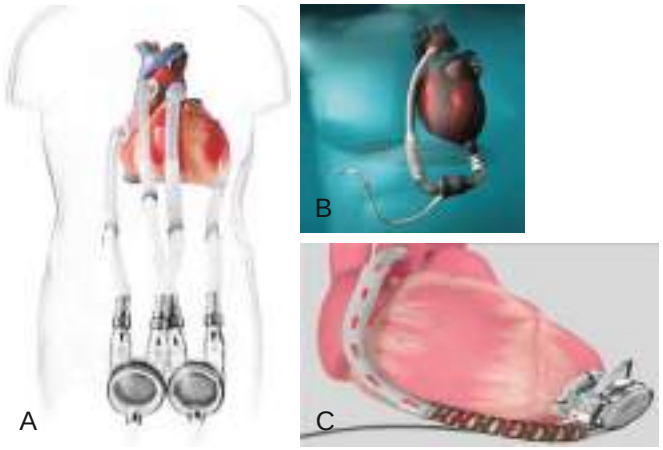

Fig. 491.5 Commonly used ventricular assist devices in children. **A,** Paracorporeal pneumatic pulsatile Berlin Heart EXCOR. **B** and **C,** Continuous flow devices: **(B)** HeartMate3; **(C)** HeartWare HVAD. *(A courtesy Berlin Heart, LLC; B from St. Jude Medical; C courtesy Medtronic, Inc.)*

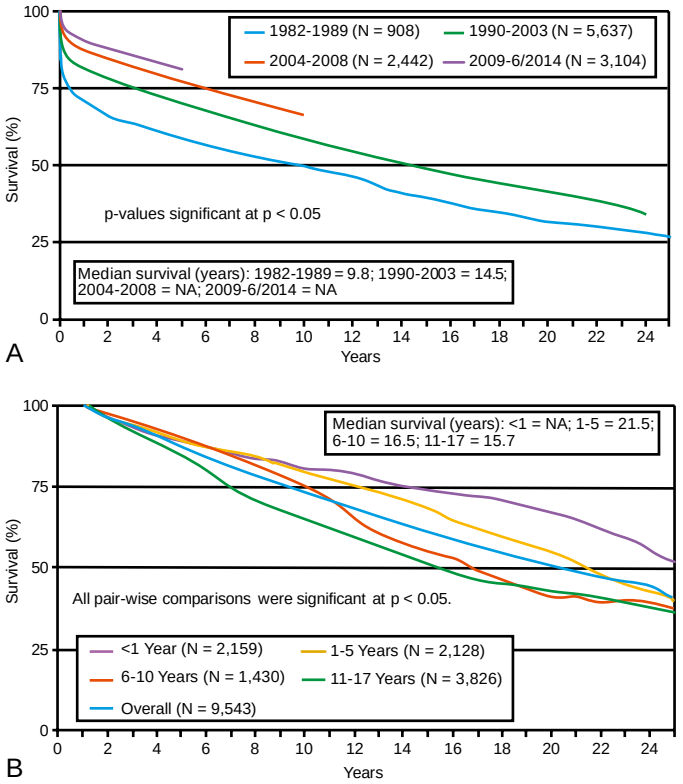

Fig. 492.1 **A,** Survival after pediatric heart transplantation comparing current and past eras. **B,** Long-term survival among patients that lived to 1-yr post-transplant. NA, Not applicable. *(From Rossano JW, Dipchand AI, Edwards LB, et al. The Registry of the International Society for Heart and Lung Transplantation: Nineteenth Pediatric Heart Transplantation Report—2016. Focus theme: primary diagnostic indications for transplant. J Heart Lung Transplant. 2016;35[10]:1185–1195, Figs. 6 and 7.)*

Chapter 492

Pediatric Heart and Heart-Lung Transplantation

492.1 Pediatric Heart Transplantation

Danielle S. Burstein and Joseph W. Rossano

Pediatric heart transplantation is considered the standard therapy that offers long-term survival for end-stage heart disease in children. In adults, ventricular assist devices (VADs) are usually employed as a long-term therapy for patients not eligible for heart transplantation, but in children the vast majority of VADs are used as a *bridge* to transplantation as opposed to an alternative to transplantation. According to the International Society for Heart and Lung Transplantation, as of January 2019, over 14,000 heart transplants had been performed on children in the world, with about 400 transplants annually—a quarter of these in children <1 year of age. Survival rates have improved significantly over time, with most of the improvement occurring in the early period after transplant. This period continues to the associated with the greatest risk of death, and many patients who survive the first year after transplant are alive 20 years later (Fig. 492.1). Indeed, a growing number of patients receiving a heart transplant in childhood are approaching their 15-, 20-, and 30-year posttransplant anniversaries. Current (2011-2023) 1-year survival is ~90% and 5-year survival ~80%.

INDICATIONS

Heart transplantation is performed (1) in infants and children with end-stage cardiomyopathy who have become refractory to medical therapy, (2) in patients with previously repaired or palliated congenital heart disease (CHD) who have developed ventricular dysfunction or other nonoperable late-term complications, and (3) less frequently in patients with complex CHD—pulmonary atresia with intact septum and coronary arterial stenoses and some forms of hypoplastic left heart syndrome (HLHS)—for whom standard surgical procedures are extremely high risk. Additionally, **retransplantation** accounts for approximately 5% of transplants annually. **Cardiomyopathies** account for >50% of heart transplants in pediatric patients older than 1 year, with the percentage of patients with previously repaired complex CHD at approximately 30%. In infants younger than 1 year, CHD previously represented >80% of transplants; this has decreased to 60% as standard surgical results for complex CHD (e.g., HLHS) have improved.

RECIPIENT AND DONOR SELECTION

Potential heart transplant recipients must be free of serious noncardiac medical problems such as neurologic disease, active systemic infection, severe hepatic or renal disease, and severe malnutrition. Many children with ventricular dysfunction are at risk for the development of **pulmonary vascular disease**, which, if severe enough, would also preclude heart transplantation. Therefore pulmonary vascular resistance (PVR) is measured at cardiac catheterization in heart transplant candidates, both at rest and, if elevated, in response to vasodilators. Patients with fixed elevated PVR above 6 index Wood units are at higher risk for heart transplantation and may be considered candidates for heart-lung transplantation (see Chapter 492.2). However, with advances in postoperative management of pulmonary hypertension (e.g., inhaled nitric oxide), many patients with moderate elevation in PVR can undergo heart transplant alone. A comprehensive social services evaluation is an important component of the recipient evaluation. Because of the complex posttransplantation medical regimen, the family must have a history of compliance. Detailed informed consent must be obtained, indicating that the family (and, if old enough, the patient) understand the lifelong commitment to immunosuppressive medication and careful monitoring.

Donor shortage is a serious problem for both adults and children. At the national registry of transplant recipients in the United States, the **United Network for Organ Sharing (UNOS)**, allografts are matched by ABO blood group and body weight. However, ABO matching may not be required for young infants less than 2 years of age because of the immaturity of the immune system. Patients, especially with a history of CHD, who have undergone prior operations may have antibodies against human leukocyte antigens (HLAs). Patients with elevated anti-HLA antibodies are at risk for a positive cross match and early graft dysfunction. These antibodies can also contribute to late graft dysfunction through antibody-mediated rejection and development of cardiac allograft vasculopathy. For patients with these elevated antibodies, there are strategies to avoid a positive cross match through a prospective cross match or a virtual cross match, although this may prolong the waiting list time. There are also desensitization therapies that may reduce circulating HLA antibody production, although they do not affect historical antibodies, and current data remain unclear how effective desensitization therapy is for reducing posttransplant rejection risk. Contraindications to organ donation include prolonged cardiac arrest with persistent moderate to severe cardiac dysfunction, ongoing systemic illness or infection, and preexisting severe cardiac disease. Physicians caring for a patient who may be a potential donor should always contact the organ donor coordinator at their institution, who can best judge the appropriateness of organ donation and has experience in interacting with potential donor families. A history of resuscitation alone or reparable CHD is not an automatic exclusion for donation.

The decision of when to place a patient on the transplant waiting list is based on many factors, including degree of ventricular function, markedly decreased exercise tolerance as determined by cardiopulmonary exercise testing (see Chapter 472.5), poor response to medical heart failure therapy, multiple hospitalizations for heart failure, arrhythmia, progressive deterioration in renal or hepatic function, early stages of pulmonary vascular disease, and poor nutritional status. Patients with severe ventricular dysfunction are often started on a regimen of anticoagulation to reduce the risk of mural thrombosis and thromboembolism. Patients with progressive heart failure resulting in decreases in end-organ (renal or hepatic) function unresponsive to standard pharmacologic treatment may be candidates for a VAD. The use of these devices has increased dramatically over the past decade, and currently over half of patients with dilated cardiomyopathy are on VAD support before transplant. VADs can improve hemodynamics and end-organ function, allow for rehabilitation, and allow some patients to be discharged home on VAD support (see Chapter 491).

PERIOPERATIVE MANAGEMENT

Heart transplantation in children can be performed either with a *biatrial* or *bicaval* anastomosis. In the *biatrial* anastomosis, both donor and recipient hearts are excised so that the posterior portions of the atria containing the venae cavae and pulmonary veins are left intact. The aorta and pulmonary artery are divided above the level of the semilunar valves. The anterior portions of the donor's atria are then connected to the remaining posterior portions of the recipient's atria, thereby avoiding the need for delicate suturing of the venae cavae or pulmonary veins. Previously, the donor and recipient great vessels were connected via end-to-end anastomoses. This has been supplanted in many centers by the *bicaval* anastomosis, with the donor right atrium (and sinus node) left intact and the suture lines at the superior and inferior vena cavae; the left atrial connection is still performed as in the *biatrial* anastomosis.

In the immediate postoperative period, **immunosuppression** is achieved with induction therapy that includes an antilymphocyte therapy for the first 5-7 days; common agents include antithymocyte globulin (ATG) and the humanized anti–interleukin-2 receptor antibodies (basiliximab). Steroids are also commonly used within the first 5-7 days and then are often weaned off or discontinued. Antiproliferative agents (mycophenolate mofetil [MMF]) are also started immediately after transplant and are transitioned to an oral compound once enteral medications are tolerated. The most common combinations of chronic immunosuppression are a *calcineurin inhibitor* (CNI; tacrolimus or cyclosporine) plus an *antiproliferative agent* (MMF or azathioprine). Mammalian target of rapamycin (mTOR) inhibitors (sirolimus or everolimus) may be added to decrease the dose of CNI if renal insufficiency occurs. Many centers do not use steroids as part of maintenance immunosuppression but do use them as bolus treatment for acute rejection episodes. Immunosuppression levels are usually reduced after the first year posttransplant if there are no significant concerns for rejection. An ongoing U.S. multicenter pediatric trial called the TEAMMATE trial is comparing conventional immunosuppression therapy (tacrolimus and mycophenolate) with low-dose tacrolimus with everolimus and mycophenolate to determine which combination of immunosuppression is better at improving long-term pediatric post–heart transplant outcomes.

Many pediatric heart transplant recipients can be extubated from endotracheal intubation and mechanical ventilation support within the first 48 hours after transplantation and are out of bed in several days. In patients with preexisting high-risk factors, postoperative recovery may be considerably prolonged. For those with preoperative pulmonary hypertension, the use of nitric oxide in the postoperative period can allow the donor right ventricle to hypertrophy in response to elevated pulmonary artery pressures. Occasionally, these patients will require extracorporeal membrane oxygenation (ECMO) for primary graft dysfunction.

DIAGNOSIS AND MANAGEMENT OF ACUTE GRAFT REJECTION

Posttransplantation management consists of adjusting medications to maintain a balance between the risk of rejection and the side effects of over-immunosuppression. **Acute graft rejection** is a leading cause of death in pediatric heart transplant recipients. The incidence of acute rejection is greatest in the first 3 months after transplantation and decreases considerably thereafter. Many pediatric patients experience at least one episode of acute rejection in the first 2 years after transplantation, although modern immunosuppressive regimens have decreased the frequency of severe rejection episodes. Because the symptoms of rejection can mimic many routine pediatric illnesses (e.g., pneumonia, gastroenteritis), the transplant center should be notified whenever a heart transplant recipient is seen in the pediatrician's office or emergency department for acute illnesses.

Clinical manifestations of acute rejection may include fatigue, fluid retention, fever, diaphoresis, abdominal symptoms, and a gallop rhythm. The electrocardiogram (ECG) may show reduced voltage, atrial or ventricular arrhythmias, or heart block but is usually nondiagnostic. X-ray examination may show an enlarged heart, effusions, or pulmonary edema but typically only in the more advanced stages of rejection. Natriuretic peptide levels are usually increased during episodes of acute rejection. Most rejection episodes occur without any detectable clinical symptoms. On echocardiography, indices of systolic left ventricular function may be decreased; however, these usually do not deteriorate until rejection is at least moderately severe. Techniques to evaluate wall thickening and left ventricular diastolic function have not fulfilled their promise as predictors of early rejection. Most transplant centers do not rely on echocardiography alone for rejection surveillance.

Myocardial biopsy is the most reliable method of monitoring patients for rejection. Biopsy specimens are taken from the right ventricular side of the interventricular septum and can be harvested relatively safely, even in small infants. In infants, surveillance biopsies are usually performed less often and may be as infrequent as once or twice per year. Children may have clinically unsuspected rejection episodes even 5-10 years after transplantation; most pediatric transplant centers continue routine surveillance biopsies, although at less frequent intervals. Cardiac MRI evaluation has been an effective noninvasive method to perform rejection surveillance and to diagnose actual rejection.

Gene expression profiling of peripheral blood mononuclear cells has been validated in adults as a highly sensitive, moderately selective method of rejection surveillance. These results have not been confirmed in children. Other promising current techniques include the profiling of donor cell–free DNA released in the serum of patients during episodes of graft injury. Progress has also been made in genetic profiling as a means to determine which patients are most at risk for rejection. Children who have single nucleotide polymorphisms (SNPs) leading to greater activity of inflammatory cytokines or decreased activity of regulatory cytokines are at increased risk of rejection.

Cardiac rejection can be classified as cellular, antibody-mediated, or mixed. Criteria for grading cellular rejection are based on a system developed by the **International Society for Heart and Lung Transplantation (ISHLT)** that considers the degree of cellular infiltration and whether myocyte necrosis is present. ISHLT rejection grade 1R is usually mild enough that it is often not treated with bolus steroids, and many of these episodes resolve spontaneously. For patients with ISHLT grade 2R rejection, treatment is instituted with either intravenous (IV) methylprednisolone or a "bump and taper" of oral prednisone. Asymptomatic patients further out from transplant with normal echocardiograms may be treated as outpatients. Patients with grade 3R, or anyone with hemodynamic instability, are admitted to the hospital for IV corticosteroid and potentially more aggressive antirejection therapy. For rejection episodes resistant to steroid therapy, additional therapeutic regimens include antilymphocyte preparation (antithymocyte globulin), methotrexate, or total lymphoid irradiation. Refractory rejection is often considered a contraindication for retransplantation because of the relatively poor outcomes compared with other indications for retransplantation.

Criteria for grading antibody-mediated rejection are based on a system developed by the ISHLT that considers histologic and immunopathologic findings. In contrast to cellular rejection, antibody-mediated rejection is mediated by circulating donor-specific antibodies (DSAs) and can be detected by immunostaining of the biopsy specimen for the complement component C4d, for macrophages expressing CD68, and for evidence of histologic damage. Antibody-mediated rejection is less responsive to standard therapies for acute cellular rejection (e.g., bolus corticosteroids) and has been treated with plasmapheresis, intravenous immunoglobulin (IVIG), the anti–CD20 monoclonal antibody rituximab, and the proteasome inhibitor bortezomib, all with mixed results. The long-term outcome of patients with persistent DSAs or antibody-mediated rejection is poor, with many having early graft failure and premature development of graft vasculopathy.

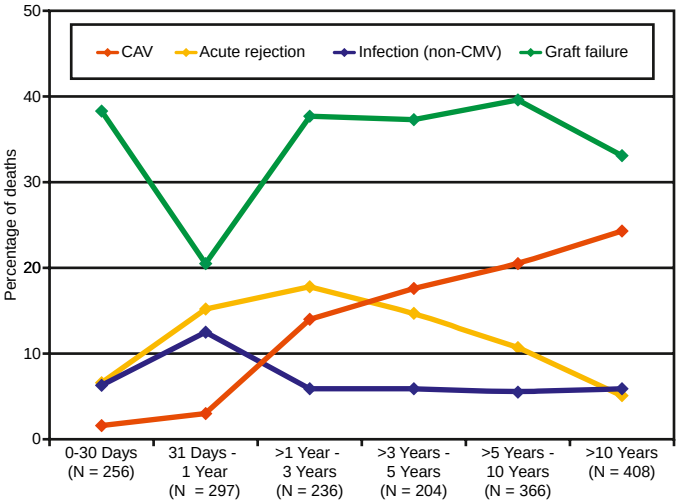

Fig. 492.2 Major causes of death after pediatric heart transplantation by time since transplant. CAV, Cardiac allograft vasculopathy; CMV, cytomegalovirus. *(From Rossano JW, Dipchand AI, Edwards LB, et al. The Registry of the International Society for Heart and Lung Transplantation: Nineteenth Pediatric Heart Transplantation Report—2016. Focus theme: primary diagnostic indications for transplant. J Heart Lung Transplant. 2016;35[10]:1185–1195, Fig. 10.)*

COMPLICATIONS OF IMMUNOSUPPRESSION

Infection

Infection is also a leading cause of death in pediatric transplant patients (Fig. 492.2). The incidence of infection is greatest in the first 3 months after transplantation, when immunosuppressive doses are highest. **Viral** infections are most common and account for as many as 25% of infectious episodes. **Cytomegalovirus (CMV)** infection was once a leading cause of morbidity and mortality and may occur as a primary infection in patients without previous exposure to the virus or as a reactivation. Severe CMV infection can be disseminated or associated with pneumonitis or gastroenteritis and may provoke an episode of acute graft rejection or graft coronary disease. Most centers use IV ganciclovir or CMV immune globulin (Cytogam), or both, as prophylaxis in any patient receiving a heart from a donor who is positive for CMV or in any recipient who has serologic evidence of previous CMV disease. Oral preparations of ganciclovir with improved absorption profiles are available for chronic therapy, usually for 3-6 months after transplant, and have largely replaced IV preparations for prophylaxis. These regimens have significantly reduced the burden of CMV disease in heart transplant patients. Polymerase chain reaction (PCR) enhances the ability to diagnose CMV infection and monitor the efficacy of therapy serially.

Most normal childhood viral illnesses are well tolerated and do not usually require special treatment. Otitis media and routine upper respiratory tract infections can be treated in the outpatient setting, although fever or symptoms that last beyond the usual course require further investigation. **Gastroenteritis**, especially with vomiting, can result in greatly reduced absorption of immunosuppressive medications and provoke a rejection episode. In this setting, drug levels should be closely monitored and use of IV medications considered. Gastroenteritis can also be a sign of rejection, so a high index of suspicion must always be maintained. Varicella is another childhood illness of concern for immunosuppressed patients. If a heart transplant recipient acquires clinical varicella infection, treatment with IV acyclovir usually attenuates the illness.

Bacterial infections occur next in frequency after viral, with the lung the most common site of infection, followed by blood, urinary tract, and less often, the sternotomy site. Other sources of posttransplantation infection include fungi and protozoa. Many centers use trimethoprim-sulfamethoxazole for prophylaxis during the first several months after transplant to prevent *Pneumocystis jiroveci* infection.

Growth Stunting

Patients requiring chronic corticosteroid therapy usually have decreased linear growth. Thus many pediatric transplant programs aim for steroid-free immunosuppression within the first year after transplant. In patients who experience rejection when steroids are withdrawn, alternate-day corticosteroid regimens may result in improved linear growth. **Total lymphoid irradiation** has also shown promise as a steroid-sparing protocol. Despite these concerns, the majority of long-term survivors of pediatric heart transplantation have normal growth.

Hypertension

Hypertension is common in patients treated with CNIs, caused by a combination of plasma volume expansion and defective renal sodium excretion. Corticosteroids usually potentiate calcineurin-induced hypertension.

Renal Function

Chronic administration of cyclosporine or tacrolimus can lead to a tubulointerstitial nephropathy in adults, but severe renal dysfunction is less common in children. Most pediatric patients gradually have an increase in serum creatinine in the first year after transplantation; if renal dysfunction occurs, it usually responds to a decrease in CNI dosage. The addition of sirolimus, an mTOR inhibitor, allows a reduction in CNI dose in patients with renal dysfunction, although it is unclear whether this strategy leads to long-term improved renal function. Infection with BK virus, a growing problem in renal transplant patients, has been described as a source of renal dysfunction in heart transplant patients. Fortunately, pediatric heart transplant patients infrequently require dialysis or renal transplantation.

Neurologic Complications

Neurologic side effects of cyclosporine and tacrolimus include tremor, myalgias, paresthesias, and, rarely, seizures. These complications can be treated with reduced doses of medication and occasionally with oral magnesium supplementation. A rare form of encephalopathy known as **posterior reversible encephalopathy syndrome** (PRES) can occur in patients taking CNIs (cyclosporine or tacrolimus). PRES presents with hypertension, headaches, and seizures, requires MRI for diagnosis, and is usually managed by changing CNI or, in rare cases, eliminating CNIs totally in favor of other immunosuppressive agents (e.g., sirolimus, MMF).

Tumors

One of the serious complications limiting long-term survival in pediatric heart transplant patients is the risk of neoplastic disease. The most common is **posttransplant lymphoproliferative disease** (PTLD), a condition associated with Epstein-Barr virus (EBV) infection. Patients who are EBV seronegative at transplant (usually infants and young children) are at increased risk of developing PTLD if they subsequently seroconvert, acquiring the virus either from the donor organ or from primary infection. Unlike true cancer, many cases of PTLD respond to a reduction in immunosuppression. A monoclonal antibody directed against the CD20 antigen on activated lymphocytes (rituximab), in conjunction with steroids and cyclophosphamide therapy, has been effective against some forms of PTLD. However, PTLD can behave more aggressively, and many patients eventually require chemotherapy. An increased risk of skin cancer requires that children use appropriate precautions when exposed to sunlight.

Cardiac Allograft Vasculopathy

Cardiac allograft vasculopathy (CAV) is a disease of the coronary arteries that occurs in approximately 20% of children 5 years after transplant. The cause is still unclear, although it is thought to be a form of immunologically mediated vessel injury. Multiple factors, including rejection episodes, infections, hypercholesterolemia, and hyperglycemia, are thought to increase the risk of CAV. Unlike native coronary atherosclerosis, CAV is a diffuse process with a high degree of distal vessel involvement. Because the transplanted heart has been denervated, patients may not experience symptoms such as angina pectoris during ischemic episodes, and the initial manifestation may be cardiovascular collapse or sudden death. Most centers perform coronary angiography annually to screen for coronary abnormalities; some also perform coronary intravascular ultrasound in larger children and adolescents. Standard coronary artery bypass procedures are usually not helpful because of the diffuse nature of the process, although transcatheter stenting can sometimes be effective for isolated lesions. For patients with severe CAV, repeat heart transplantation has been the only effective treatment. Thus prevention has been the focus of most current research. The cell-cycle inhibitors sirolimus and everolimus have been shown to decrease coronary arterial intimal thickening in adult transplant patients. Cholesterol-lowering HMG-CoA (3-hydroxy-3-methyl-coenzyme A) reductase inhibitors (e.g., pravastatin, atorvastatin) have been associated with a lower risk of CAV.

Other Complications

Corticosteroids usually result in cushingoid facies, steroid acne, and striae. Cyclosporine can cause a subtle change in facial features, such as hypertrichosis and gingival hyperplasia. These cosmetic features can be particularly disturbing to adolescents and may be the motivation for noncompliance, one of the leading risks for late morbidity and mortality. Most of these cosmetic complications are dose related and improve as immunosuppressive medications are weaned. Tacrolimus does not have the cosmetic side effects of cyclosporine. Osteoporosis and aseptic necrosis are additional reasons for reducing the steroid dosage as soon as possible. Diabetes and pancreatitis are rare but serious complications.

Rehabilitation

Despite the potential risks of immunosuppression, the prospect for rehabilitation in pediatric heart transplant recipients is excellent; most have no functional limitations in their daily lives. They can attend daycare or school and participate in competitive sports and other age-appropriate activities. Standardized measurements of ventricular function are close to normal. Because the transplanted heart is denervated, the increase in heart rate and cardiac output during exercise is slower in transplant recipients, and maximal heart rate and cardiac output responses are mildly attenuated. These subtle abnormalities are rarely noticeable by the patient.

Growth of the transplanted heart is excellent, although a mild degree of ventricular hypertrophy is often seen, even years after transplantation. The sites of atrial and great vessel anastomoses usually grow without the development of obstruction. In neonates who undergo transplantation for HLHS, however, juxtaductal aortic coarctation may recur.

A serious problem with noncompliance may occur once patients reach adolescence, and life-threatening rejection may result. Early intervention by social workers, counselors, and psychologists may be able to reduce this risk.

Visit Elsevier eBooks+ at eBooks.Health.Elsevier.com for Bibliography.

492.2 Heart-Lung and Lung Transplantation

Samuel B. Goldfarb, Danielle S. Burstein, and Joseph W. Rossano

More than 700 heart-lung and 2,500 lung (single or double) pediatric transplants have been performed and reported to ISHLT, with >100 procedures performed annually. The majority of these are lung transplantation, with only three heart-lung transplants reported in 2017. Only 16 heart-lung transplants have been performed in the United States in the past 5 years compared to over 140 lung transplants during this same time frame. Primary indications for lung transplantation include cystic fibrosis, pulmonary hypertension, interstitial lung disease, surfactant deficiencies, and retransplant. Indications for heart-lung transplant include complex CHD along with either pulmonary parenchymal or vascular disease. Patients with normal hearts are candidates for lung transplantation even in the setting of right ventricular dysfunction. This had led to the marked decline in heart-lung transplant procedures in the current era. In some patients with CHD, double-lung transplantation can be performed in combination with repair of intracardiac defects. Patients with cystic fibrosis are *not* candidates for single-lung grafts

because of the risk of infection from the diseased contralateral lung. Patients are selected according to many of the same criteria as for heart transplant recipients (see Chapter 492.1).

Posttransplant immunosuppression is usually achieved with a triple-drug regimen, combining a CNI (cyclosporine or tacrolimus) with an antiproliferative agent (MMF or azathioprine) and prednisone. Most patients receive induction therapy with an antithymocyte or anti–T-cell preparation. Unlike patients with isolated heart transplants, patients with lung or heart-lung transplants cannot be weaned totally off steroids. Prophylaxis against *P. jiroveci* infection is achieved with trimethoprim-sulfamethoxazole or aerosolized pentamidine. Ganciclovir and CMV immune globulin prophylaxis are used as in heart transplant recipients (see Chapter 492.1). Antifungal medications are used in the perioperative and posttransplant periods in patients who have pretransplant colonization.

Pulmonary rejection is common in lung or heart-lung transplant recipients, whereas heart rejection is encountered much less often than in patients with isolated heart transplants. Acute cellular rejection (ACR) occurs in approximately 10–30% of patients in the first year after transplant depending on the recipient's age. Younger recipients have a lower incidence of ACR. Antibody-mediated rejection (AMR) and chronic lung allograph dysfunction (CLAD) are other forms of rejection. Symptoms of lung rejection may include fever and fatigue, although many episodes are minimally symptomatic. Signs of rejection could include changes in lung function testing and radiographic findings. Surveillance for acute rejection is performed by monitoring pulmonary function (forced vital capacity; forced expiratory volume in 1 second [FEV_1]; forced expiratory flow, midexpiratory phase [$FEF_{25–75\%}$]), systemic arterial oxygen tension, chest radiographs, chest CT, transbronchial biopsy, and open lung biopsy. The gold standard for ACR is tissue diagnosis, generally performed with transbronchial biopsies. AMR is diagnosed based on findings of donor-specific antibodies and tissue biopsy often associated with graft dysfunction. CLAD is a form of chronic rejection. It can present as an obstructive lung disease in the form of obliterative bronchiolitis. CLAD can also present with significant pulmonary fibrosis in the form of restrictive allograft dysfunction (RAD). In heart-lung transplant recipients, hearts are assessed for rejection similar to the approach described in Chapter 492.1.

Actuarial survival rates after lung or heart-lung transplantation in children are currently 75–80% at 1 year and 50% at 5 years after transplant; improved patient selection and postoperative management are continually improving these survival statistics from prior eras. In the analysis of survival at 5 years conditional on survival at 12 months, rates significantly improve for both lung and heart-lung regardless of underlying condition. One year conditional survival rates at 5 years for both are roughly 70%. Some groups, such as patients with CHD in the absence of Eisenmenger syndrome, have particularly poor outcomes with transplant. Graft failure and infection are the leading cause of early death, whereas a form of chronic rejection in the form of CLAD or RAD accounts for almost 50% of cases of late mortality. Other causes of early morbidity and mortality include technical complications, multiorgan failure, primary graft dysfunction, and cardiovascular causes. Additional late complications include the development of late graft failure, malignancies, infection, and other side effects of chronic immunosuppression.

Postoperative indices of cardiopulmonary function and exercise capacity show significant improvement. Problems of donor availability are even more severe with lung transplantation than with isolated heart transplantation. However, significant advances in ex vivo lung perfusion have great potential to expand the number of organs available for transplantation.

Visit Elsevier eBooks+ at eBooks.Health.Elsevier.com for Bibliography.

Section 8

Diseases of the Peripheral Vascular System

Chapter 493

Diseases of the Blood Vessels (Aneurysms and Fistulas)

493.1 Aneurysms

Daniel Bernstein

See also Chapter 208.

Aneurysms of the coronaries and occasionally the systemic arteries may complicate Kawasaki disease and are the leading cause of morbidity in this disease (Figs. 493.1 and 493.2). Persistent moderate to large aneurysms carry several risks: embolism and thromboembolism (a clot developing in the aneurysm because of stagnant blood flow and obstructing flow and/or breaking off and traveling more distally down the coronary, resulting in myocardial ischemia/infarction) and stenosis (the distal end of the aneurysm tends to become narrowed over time, limiting downstream coronary blood flow). Management includes anticoagulation to prevent thrombosis and β blockers to reduce myocardial oxygen requirements (see Chapter 210).

COVID-19–associated multisystem inflammatory syndrome in children (MIS-C) typically occurs a few weeks after active SARS-CoV-2 infection and can cause coronary artery dilation and aneurysms, in addition to other significant cardiac manifestations (ventricular dysfunction, arrhythmias, and conduction abnormalities; see Chapters 311 and 449.1).

Other than in Kawasaki disease and MIS-C, aneurysms are not common in children and occur most frequently in the aorta in association with coarctation of the aorta, patent ductus arteriosus, Ehlers-Danlos syndrome type IV (vascular ecchymotic form), hyper-IgE syndrome, Marfan syndrome, and the four forms of Loeys-Dietz syndrome (see Chapter 641). Aneurysms may be seen in the arterial tortuosity syndrome and the multisystem smooth muscle dysfunction syndrome (MSMDS) (see Chapter 493.4). MSMDS is characterized by congenital mydriasis, patent ductus arteriosus, aortic and other arterial aneurysms, as well as moyamoya-like cerebrovascular disease and pulmonary hypertension. The affected gene is *ACTA2*. Aneurysms may also occur secondary to an infected embolus; infection contiguous to a blood vessel; trauma; congenital abnormalities of vessel structure, especially the medial wall; and arteritis, including polyarteritis nodosa, Behçet syndrome, and Takayasu arteritis (see Chapter 210.2).

493.2 Arteriovenous Fistulas

Daniel Bernstein

Arteriovenous fistulas may be limited and small or may be large and extensive, producing systemic complications (see Chapters 554 and 691). The most common sites in infants and children are within the

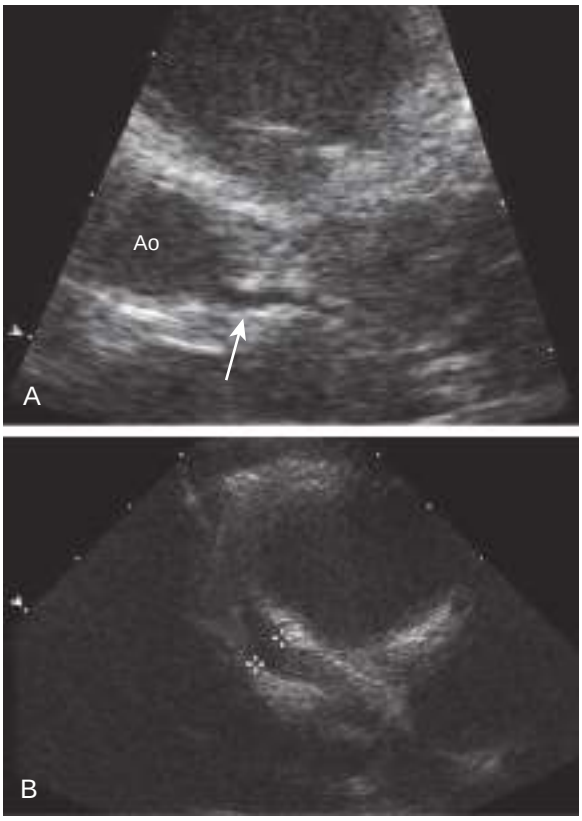

Fig. 493.1 Two-dimensional echocardiograms comparing a normal left main coronary artery (*arrow* in **A**) with a giant coronary artery aneurysm (outlined by *cross marks* in **B**) in a patient with Kawasaki disease. Ao, Aorta.

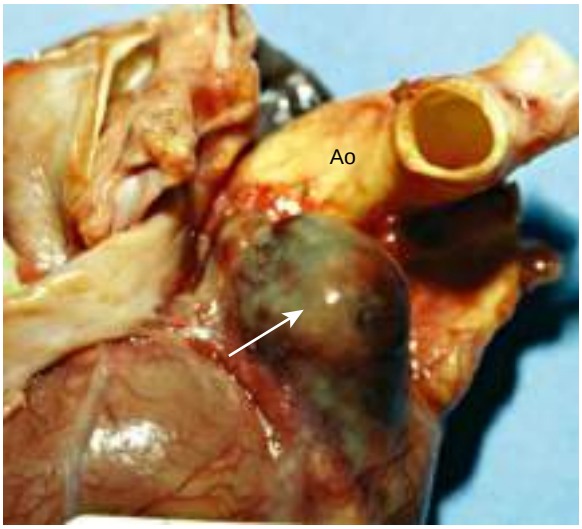

Fig. 493.2 Pathologic specimen showing giant aneurysm of left main coronary artery *(arrow)*. Ao, Ascending aorta.

cranium, in the liver, in the lung, in the extremities, and in vessels in or near the thoracic wall. These fistulas, although usually **congenital**, may follow trauma or may be a manifestation of hereditary hemorrhagic telangiectasia (Osler-Weber-Rendu disease). Femoral arteriovenous fistulas are a rare complication of percutaneous femoral catheterization.

CLINICAL MANIFESTATIONS

Clinical symptoms occur only in association with large arteriovenous communications when arterial blood flows into a low-pressure venous system without the resistance of the capillary bed; local venous pressure is increased, and arterial flow distal to the fistula is decreased. Systemic arterial resistance falls because of the runoff of blood through the fistula. Compensatory mechanisms include tachycardia and increased stroke volume so that cardiac output rises. Total blood volume is also increased. In large fistulas, left ventricular dilation, a widened pulse pressure, and high-output heart failure can occur. CT, MRI, or injection of contrast material into an artery proximal to the fistula confirms the diagnosis.

Large intracranial arteriovenous fistulas most often occur in newborn infants in association with a **vein of Galen malformation**. The large intracranial left-to-right shunt results in heart failure secondary to the demand for high cardiac output. Patients with smaller communications may not have cardiovascular manifestations but may later be disposed to hydrocephalus (see Chapter 631.9) or seizures. The diagnosis can often be made by auscultation of a continuous murmur over the cranium. Older children with more diffuse intracranial arteriovenous malformations may be recognized on the basis of intracranial calcification and high cardiac output without cardiac failure.

Coronary arteriovenous fistulas can develop between a coronary artery and any of the cardiac chambers **(coronary cameral fistula)** or great vessels. These fistulas can result in steal of blood away from the heart muscle downstream of the fistula resulting in ischemia and, in rare cases, can even cause obstruction of ventricular inflow caused by physical interference with atrioventricular valve function.

Hepatic arteriovenous fistulas may be generalized or localized in the liver and may be hemangioendotheliomas or cavernous hemangiomas. The fistula may be located between the hepatic artery and the ductus venosus or portal vein. Congenital hemorrhagic telangiectasia may also be present. Large arteriovenous fistulas are associated with increased cardiac output and heart failure. Hepatomegaly is usual, and systolic or continuous murmurs may be audible over the liver.

Peripheral arteriovenous fistulas generally involve the extremities and can be associated with disfigurement, swelling of the extremity, and visible hemangiomas. Their presence can be complicated by breathing difficulties if located near the upper airways and causing obstruction. Because only a small minority results in large arterial runoff, cardiac failure is uncommon.

TREATMENT

Medical management of heart failure is initially helpful in neonates with these conditions; with time, the size of the shunt may diminish and symptoms spontaneously regress. Hemangiomas of the liver often eventually disappear completely. Large liver hemangiomas have been treated with corticosteroids, β blockers, ε-aminocaproic acid, interferon, local compression, embolization, or local irradiation; the beneficial effects of these management options are not firmly established because individual patients display marked variation in clinical course without treatment. **Transcatheter closure** is becoming the treatment of choice for many patients with a symptomatic arteriovenous fistula. Embolic agents that have been used include detachable balloons, steel (Gianturco) coils, plugs, and liquid tissue adhesives (cyanoacrylate). Often, multiple procedures are necessary before flow is significantly reduced. **Gamma knife radiosurgery** has been used successfully in patients with cerebral arteriovenous malformations. Surgical removal of a large fistula may be attempted in patients with severe cardiac failure and lack of improvement with medical treatment. Surgical treatment may be contraindicated or unsuccessful when the lesion is extensive and diffuse or is located in a position where adjoining tissue may be injured during the surgery or related procedures. β-Adrenergic blockers such as propranolol have dramatically changed the treatment for cutaneous hemangiomas, with excellent results.

Visit Elsevier eBooks+ at eBooks.Health.Elsevier.com for Bibliography.

Fig. 493.3 Lateral radiograph of the neonate showing calcification of the descending aorta and its bifurcation *(arrows). (From Karthikeyan G. Generalized arterial calcification of infancy. J Pediatr. 2013;162:1074, Fig 3.)*

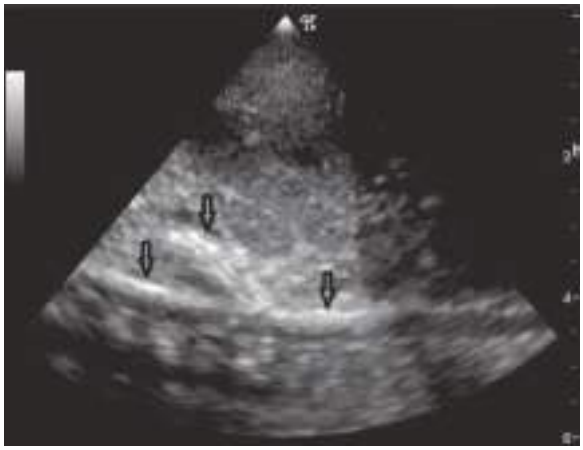

Fig. 493.4 Ultrasonography of abdominal aorta showing calcification of descending aorta and its branches *(arrows). (From Karthikeyan G. Generalized arterial calcification of infancy. J Pediatr. 2013;162:1074, Fig. 1.)*

493.3 Generalized Arterial Calcification of Infancy (Idiopathic Infantile Arterial Calcification)

Robert M. Kliegman

Generalized arterial calcification of infancy (GACI) is a rare and often lethal autosomal recessive disorder characterized by calcification of muscular arteries with fibrotic myointimal proliferation and subsequent vascular stenosis leading to tissue ischemia, poor function, or infarction. Diffuse arterial calcification may begin in utero, leading to hydrops fetalis; in the neonate, diffuse arterial calcification leads to respiratory distress and heart failure or myocardial infarction (coronary, pulmonary arteries), hypertension (renal arteries), and poor femoral pulses (aorta, femoral arteries).

Pathogenic variants in the ectonucleotide pyrophosphatase 1 gene (*ENPP1*) are noted in 75% of patients. Serum calcium, phosphate, and alkaline phosphatase levels are normal; the vascular calcification may be seen on plain x-ray films (Fig. 493.3), ultrasonography (Fig. 493.4), or CT scans (Fig. 493.5), which may reveal calcifications not visible on plain films.

A subset of patients with GACI have monoallelic or biallelic pathogenic variants in the adenosine triphosphate–binding cassette subfamily C number 6 gene (*ABCC6*), which is responsible for **pseudoxanthoma elasticum** (PXE). PXE, an autosomal recessive disorder, is classically associated with a later onset of ectopic mineralization of elastic fibers in the skin, eyes, joints, and arteries. In addition, some surviving infants with *ENPP1* variant develop PXE symptoms involving the skin and retina (angioid streaking).

Infants with GACI have been treated with bisphosphonates with variable success. In addition, some survivors with the *ENPP1* variant have developed hypophosphatemic-hyperphosphaturic rickets.

In the absence of stroke or encephalomalacia, most survivors are developmentally normal. In some survivors the vascular calcification resolves and is replaced by fibrosis. The differential diagnosis includes Singleton-Merten syndrome (aortic calcification, dental anomalies, osteopenia), hypervitaminosis D, hyperparathyroidism, congenital syphilis (aortitis), twin-twin transfusion syndrome (recipient), and idiopathic iliac artery calcification of infancy.

ARTERIAL CALCIFICATIONS CAUSED BY DEFICIENCY OF CD73

This rare autosomal recessive disorder, caused by pathogenic variants in the 5-exonucleotidase CD73 *(NT5E)*, results in joint and arterial (lower-extremity) calcification in adults. Patients present with intermittent claudication and joint pain. Onset is probably before adulthood, since patients may be undiagnosed with nonspecific findings during adolescence.

493.4 Arterial Tortuosity

Robert M. Kliegman

Arterial tortuosity may be seen in many different diseases and genes (Table 493.1). These disorders are usually recognized by their phenotype, and all may present during childhood. Tortuosity is best defined by magnetic resonance angiography (Fig. 493.6). When present, it often increases the risk for early cardiovascular morbidity for patients with Marfan or Loeys-Dietz syndrome.

Arterial tortuosity syndrome is another genetic arteriopathy caused by pathogenic variants in the *SCL2A10* gene. It has many features of other connective tissue diseases, including hyperextensible and soft velvety skin, high-arched palate, micrognathia, abdominal hernias, and joint hypermobility. The prognosis for patients with arterial tortuosity syndrome is quite variable, but the presence of vascular stenosis is associated with a poorer prognosis.

Visit Elsevier eBooks+ at eBooks.Health.Elsevier.com for Bibliography.

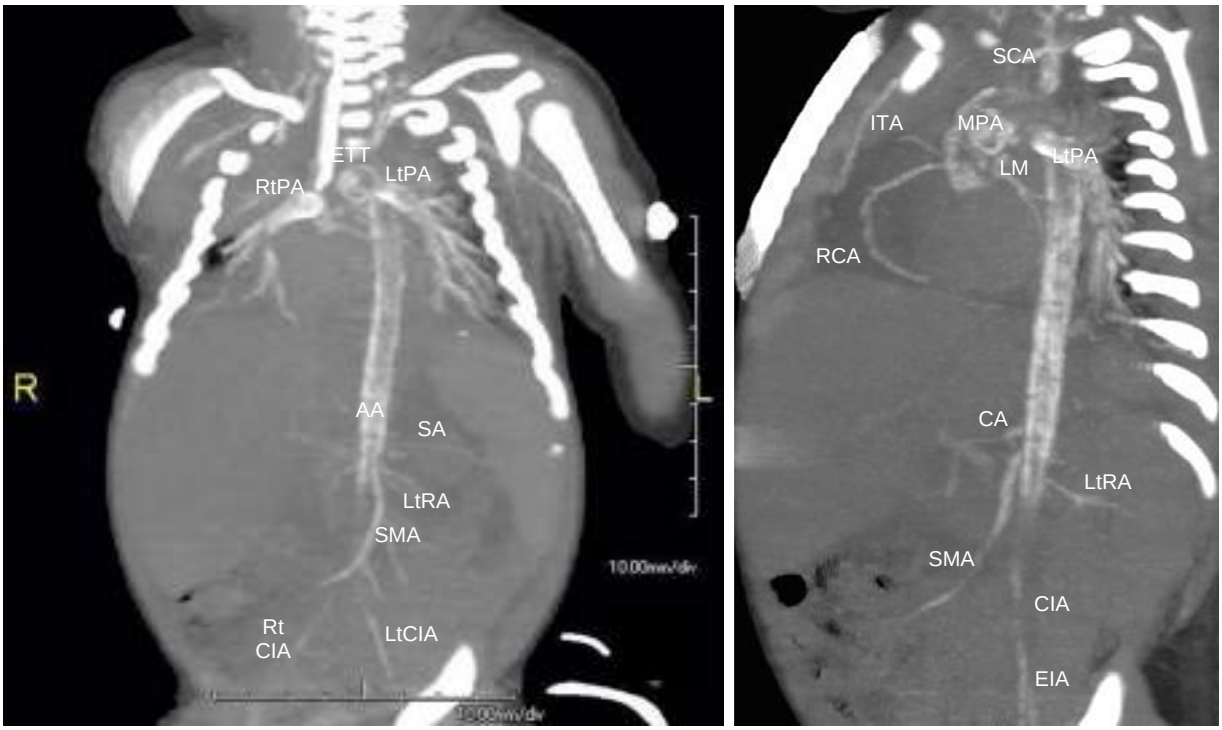

Fig. 493.5 Coronal maximum intensity projection (MIP) CT scans demonstrate an endotracheal tube (ETT) and extensive vascular calcifications. PA, Pulmonary artery; SA, splenic artery; RA, renal artery; CIA, common iliac artery; BA, brachial artery; CA, celiac axis; SMA, superior mesenteric artery; SCA, subclavian artery. *(From Bolster F, Ali Z, Southall P, et al. Generalized arterial calcification of infancy—findings at post-mortem computed tomography and autopsy. Forensic Sci Int. 2015;254:e7–e12, Fig 3.)*

Table 493.1 Genetic Disorders Associated with Aortic Disease and Arterial Tortuosity

GENE	DISORDER
TGFBR1	Loeys-Dietz syndrome, FTAAD
TGFBR2	Loeys-Dietz syndrome, FTAAD
FBN1	Marfan syndrome
SMAD3	Osteoarthritis-aneurysm syndrome, FTAAD
SLC2A10	Arterial tortuosity syndrome
TGFB2	FTAAD
PRKG1	FTAAD
FBLN4/EFEMP2	Cutis laxa
ATP7A	Occipital horn syndrome, Menkes syndrome
Monosomy X/mosaic monosomy X	Turner syndrome
FTAAD	Familial aortic aneurysm and dissection
ACTA2	Multisystem smooth muscle dysfunction syndrome

FTAAD, Familial thoracic aortic aneurysm and dissection.
Adapted from Morris SA. Arterial tortuosity in genetic arteriopathies. *Curr Opin Cardiol.* 2015;30:587–590, Table 1, p. 590.

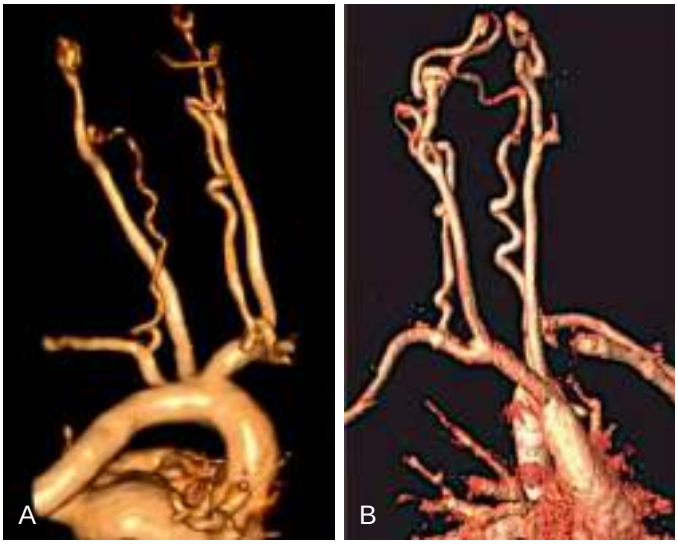

Fig. 493.6 Examples of vertebral artery tortuosity in Marfan syndrome with *FBN1* pathogenic variant (**A**) and Loeys-Dietz syndrome with a *TGFBR2* mutation (**B**). *(From Morris SA. Arterial tortuosity in genetic arteriopathies. Curr Opin Cardiol. 2015;30:587–593, Fig 1.)*

Chapter 494

Systemic Hypertension

Ian R. Macumber and Joseph T. Flynn

Hypertensive children, although frequently asymptomatic, already may manifest evidence of target organ damage. Up to 40% of hypertensive children have left ventricular hypertrophy, and hypertensive children have increased carotid intima-to-media thickness, a marker of early atherosclerosis. Primary (essential) hypertension occurring during childhood often continues into adulthood. Children with blood pressure (BP) >90th percentile exhibit a 2.4-fold greater risk of having hypertension as adults. Similarly, almost half of hypertensive adults had a BP >90th percentile as children. Adolescent hypertension is also an independent predictor of both end-stage kidney disease and left ventricular dysfunction in middle-age males.

PREVALENCE OF HYPERTENSION IN CHILDREN

In infants and young children, systemic hypertension is uncommon, with a prevalence of <1%, but, when present, often indicates an underlying disease process **(secondary hypertension)**. *Severe and symptomatic hypertension in children is usually caused by secondary hypertension.* In contrast, the prevalence of primary hypertension, mostly in older school-age children and adolescents, has increased in prevalence in parallel with the obesity epidemic. Estimates are variable, but data from the U.S. National Health and Nutrition Examination Survey (NHANES) show that approximately 9% of American youth have **elevated BP** and 3–4% have **hypertension**. A meta-analysis suggests a similar worldwide prevalence of hypertension in children. The normative data from the 2017 American Academy of Pediatrics (AAP) clinical practice guidelines have resulted in an overall trend of increased hypertension prevalence. The influence of obesity on elevated BP is evident in children as young as 2-5 years old. Approximately 20% of American youth have obesity, and up to 10% of these have hypertension.

DEFINITION OF HYPERTENSION

Normal BP in adults is <120/80 mm Hg. **Elevated** blood pressure is considered systolic BP of 120-129 *and* diastolic BP <80 mm Hg. **Stage 1** hypertension is systolic 130-139 *or* diastolic 80-89 mm Hg; **Stage 2** hypertension is systolic ≥140 *or* diastolic ≥90 mm Hg. This definition is based on potential outcomes because it relates degree of BP elevation with significant likelihood of subsequent cardiovascular events. Because hypertension-associated cardiovascular events (e.g., myocardial infarction, stroke) occur rarely in childhood, the definition of hypertension in children is statistical and based on the *distribution of BP in healthy children,* not outcomes. The AAP clinical practice guideline on childhood hypertension maintains the same statistical approach to defining and categorizing childhood BP as in previous guidelines from the **National High Blood Pressure Education Program (NHBPEP)**:

- **Normal BP:** BP <90th percentile for age, sex, and height or <120/<80 (systolic/diastolic) mm Hg for adolescents ≥13 years old
- **Elevated BP:** BP reading ≥90th percentile and <95th percentile for age, sex, and height or 120-129/<80 mm Hg for adolescents ≥13 years old
- **Hypertension:** BP >95th percentile for age, sex, and height or ≥130/80 mm Hg for adolescents ≥13 years old. Hypertensive-level BP is further staged as follows:
  - **Stage 1 hypertension:** BP >95th percentile for age, sex, and height up to the 95th percentile + 11 mm Hg or 130-139/80-89 mm Hg for adolescents ≥13 years of age
  - **Stage 2 hypertension:** BP ≥95th percentile + 12 mm Hg for age, sex, and height or >140/90 mm Hg for adolescents ≥13 years of age

The BP cut-points for adolescents ≥13 years old and use of the term *elevated BP* instead of prehypertension were chosen to align with revised BP cut-points and terminology found in the American Heart Association/American College of Cardiology (AHA/ACC) guideline for adult hypertension. The European Society of Hypertension (ESH) pediatric BP guideline also suggested that an absolute BP cutoff be used for adolescents age 16 and older, rather than using BP percentiles. For these older adolescents, the ESH guidelines define *high-normal* BP as 130-139/85-89 mm Hg and *hypertension* as ≥140/90 mm Hg.

The AAP guideline* also contains tables of normative BP values for children and adolescents based on a reanalysis of the NHBPEP database, removing all overweight and obese children. This revision results in BP values that are 2-3 mm Hg lower than the corresponding BP values in the 2004 NHBPEP Fourth Report, illustrating the impact of the childhood obesity epidemic on BP in young persons. The AAP guideline also contains a *simplified table* of BP values that may require further evaluation, which should be useful for screening (Table 494.1).

BLOOD PRESSURE MEASUREMENT IN CHILDREN

The AAP guideline recommends that children 3 years or older should have their BP measured during annual preventive visits, unless the child has risk factors such as obesity, chronic kidney disease (CKD), or diabetes, in whom it should be checked at every healthcare encounter. In contrast, the ESH pediatric guideline recommends checking BP at every healthcare encounter for all children >3 years old. Selected children <3 years old should also have their BP measured, including those with a history of prematurity, congenital heart disease, kidney disease, solid-organ transplant, cancer, treatment with drugs known to raise BP, other illnesses associated with hypertension (e.g., neurofibromatosis, tuberous sclerosis), or evidence of increased intracranial pressure. The preferred method is by auscultation using a sphygmomanometer (BP) with a cuff appropriate for the size of the child's arm.

Elevated readings should be confirmed on repeat visits before determining that a child is hypertensive. The BP should be measured with the child in the seated position after a period of quiet for at least 5 minutes, and it is recommended that the BP be checked 3 times, averaging the results. Careful attention to **cuff size** is necessary to avoid overdiagnosis, because a cuff that is too short or narrow artificially increases BP readings. An appropriate-sized cuff has an inflatable bladder whose length covers 80–100% of the upper arm circumference (measured midway between the acromion process and olecranon) and whose width is at least 40% of the arm circumference. A wide variety of cuff sizes should be available in any medical office where children are routinely seen.

Systolic blood pressure (SBP) is indicated by appearance of the *first* Korotkoff sound. Diastolic blood pressure (DBP) has been defined by consensus as the *fifth* Korotkoff sound, unless the Korotkoff sounds can be heard down to 0 mm Hg, in which case the *fourth* Korotkoff sound should be reported as the DBP. Palpation is useful for rapid assessment of SBP, although the palpated BP is generally about 10 mm Hg lower than that obtained by auscultation. Oscillometric techniques are used frequently in infants and young children, but they are susceptible to artifacts and are best for measuring mean arterial pressure (MAP). In addition, different devices use different proprietary algorithms to back-calculate SBP and DBP from the MAP, making comparison between devices difficult.

Ambulatory Blood Pressure Monitoring

Ambulatory blood pressure monitoring **(ABPM)** is frequently used as a tool to assess pediatric hypertension. The patient wears a device that records BP every 20-30 minutes throughout a 24-hour period, during usual daily activities, including sleep. This monitoring allows calculation of the mean daytime BP, sleep BP, and mean

* https://publications.aap.org/pediatrics/article/140/3/e20171904/38358/Clinical-Practice-Guideline-for-Screening-and.

BP over 24 hours. The physician can also determine the proportion of BP measurements that are in the hypertensive range (BP load) and whether there is an appropriate decrease in BP during sleep (nocturnal dip), generally considered *normal* if there is a decrease in nocturnal BP of >10% from awake values. The cuff should be placed on the patient's nondominant arm. It is recommended that the patient keep a journal of sleep and awake times, medication timing, and other events that may be relevant to BP readings. Clinicians should only perform ABPM if they have had specific training in performing and interpreting the results.

ABPM readings are more strongly correlated with target-organ damage in children than casual/office BP readings and are more sensitive for a diagnosis of hypertension than either manual or automated office blood pressures. The 2017 AAP guideline strongly recommends that ABPM be performed on all patients with elevated office readings to confirm the diagnosis of hypertension. In addition, ABPM is necessary to diagnose **white coat hypertension** (elevated office BP but normal ambulatory BP) and **masked hypertension** (normal office BP but elevated ambulatory BP). It should be noted that white coat hypertension is not a benign condition, and children with white coat hypertension may be at increased risk of developing sustained hypertension in the future. In adults, white coat hypertension has been associated with higher all-cause and cardiovascular mortality compared to normotensive individuals. ABPM is also a useful tool for evaluating effectiveness of antihypertensive therapy. ABPM is recommended to assess BP patterns in high-risk patient populations, such as children with CKD, solid-organ transplant, diabetes mellitus, and severe obesity.

ABPM is an extremely useful tool for evaluating and managing hypertension in appropriate patient populations, but it does have limitations. Not every patient will tolerate APBM, including younger children (although there are reports of successful ABPM in toddlers 18 months old) and some children with developmental delay. Nonetheless, it is usually feasible to perform ABPM in children ≥6-7 years. The most accepted normative data come from the German Working Group on Pediatric Hypertension. However, there are concerns with this dataset: (1) it includes only Central European White children and thus might not be generalizable to other ethnicities; (2) there were relatively few shorter children included, which may limit its application to patients with chronic diseases such as CKD; and (3) there was very little variability in DBP values, which is not consistent with data from other BP measurement techniques showing that DBP varies with both age and height.

Table 494.1 Simplified Table of Screening Blood Pressure Values (mm Hg) Requiring Further Evaluation

	MALES		FEMALES	
AGE (YR)	SYSTOLIC	DIASTOLIC	SYSTOLIC	DIASTOLIC
1	98	52	98	54
2	100	55	101	58
3	101	58	102	60
4	102	60	103	62
5	103	63	104	64
6	105	66	105	67
7	106	68	106	68
8	107	69	107	69
9	107	70	108	71
10	108	72	109	72
11	110	74	111	74
12	113	75	114	75
≥13	120	80	120	80

From Flynn JT, Kaelber DC, Baker-Smith CM, et al. Clinical practice guideline for screening and management of high blood pressure in children and adolescents. *Pediatrics*. 2017;140(3):e20171904, Table 6.

ETIOLOGY AND PATHOPHYSIOLOGY

Blood pressure is the product of cardiac output (CO) and peripheral vascular resistance (PVR). An increase in either CO or PVR results in an increase in BP; if either of these factors increases while the other decreases, BP may not increase. When hypertension is the result of another disease process, it is referred to as *secondary hypertension*. When no identifiable cause can be found, it is referred to as *primary hypertension*.

Secondary hypertension is most common in infants and younger children. It is most often caused by kidney abnormalities; additional etiologies include cardiovascular disease and endocrinopathies. Younger age, severely elevated BP, and symptomatic hypertension make a secondary cause of hypertension more likely. Many childhood diseases can be responsible for *chronic hypertension* (Table 494.2) or *acute/intermittent hypertension* (Table 494.3). The most likely cause varies with age. Hypertension in the premature infant is sometimes

Table 494.2 Conditions Associated with Chronic Hypertension in Children

RENAL
Recurrent pyelonephritis/renal scarring
Chronic glomerulonephritis
Prematurity
Congenital dysplastic kidney
Polycystic kidney disease
Vesicoureteral reflux nephropathy
Segmental hypoplasia (Ask-Upmark kidney)
Obstructive kidney disease
Renal tumors
Renal trauma
Systemic lupus erythematosus (other connective tissue diseases)
VASCULAR
Coarctation of thoracic or abdominal aorta
Renal artery lesions (stenosis, fibromuscular dysplasia, thrombosis, aneurysm)
Umbilical artery catheterization with thrombus formation
Neurofibromatosis (intrinsic or extrinsic narrowing for vascular lumen)
Renal vein thrombosis
Vasculitis (ANCA associated, polyarteritis nodosa, Takayasu arteritis)
Arteriovenous shunt
Williams-Beuren syndrome
Moyamoya disease
ENDOCRINE
Hyperthyroidism
Congenital adrenal hyperplasia (11β-hydroxylase and 17-hydroxylase defect)
Cushing syndrome
Primary hyperaldosteronism
Apparent mineralocorticoid excess
Glucocorticoid remedial aldosteronism (familial aldosteronism type 1)
Glucocorticoid resistance (Chrousos syndrome)
Pseudohypoaldosteronism type 2 (Gordon syndrome)
Pheochromocytoma
Other neural crest tumors (neuroblastoma, ganglioneuroblastoma, ganglioneuroma)
Liddle syndrome
Geller syndrome
CENTRAL NERVOUS SYSTEM
Intracranial mass
Hemorrhage
Residual after brain injury
Quadriplegia (dysautonomia)
Sleep disordered breathing

ANCA, Antineutrophil cytoplasmic antibody.

Table 494.3 Conditions Associated with Transient or Intermittent Hypertension in Children

RENAL
Acute postinfectious glomerulonephritis
Henoch-Schönlein purpura with nephritis
Hemolytic-uremic syndrome
Acute kidney injury
After renal transplantation (immediately and during episodes of rejection)
Hypervolemia
Pyelonephritis
Renal trauma
Leukemic infiltration of the kidney
DRUGS AND POISONS
Cocaine
Oral contraceptives
Sympathomimetic agents
Amphetamines
Phencyclidine
Corticosteroids and adrenocorticotropic hormone
Cyclosporine, sirolimus, or tacrolimus treatment after transplantation
Licorice (glycyrrhizic acid)
Lead, mercury, cadmium, thallium
Antihypertensive withdrawal (clonidine, methyldopa, propranolol)
Vitamin D intoxication
Ma-huang
CENTRAL AND AUTONOMIC NERVOUS SYSTEM
Increased intracranial pressure
Guillain-Barré syndrome
Burns
Familial dysautonomia
Stevens-Johnson syndrome
Posterior fossa lesions
Porphyria
Poliomyelitis
Encephalitis
Spinal cord injury (autonomic storm)
MISCELLANEOUS
Preeclampsia
Pain, anxiety
Hypercalcemia
After coarctation repair
White blood cell transfusion
Extracorporeal membrane oxygenation

associated with umbilical artery catheterization, renal artery thrombosis, or bronchopulmonary dysplasia. Hypertension during early childhood may be caused by kidney disease, coarctation of the aorta, endocrine disorders, or medications.

Kidney disease (e.g., acute or chronic glomerulonephritis, reflux or obstructive nephropathy, hemolytic-uremic syndrome, polycystic kidney disease, congenital anomalies of the kidney and urinary tract) and **renovascular hypertension** account for approximately 90% of children with secondary hypertension. Parenchymal kidney disease and renal artery stenosis lead to water and sodium retention thought to be, in part, secondary to increased renin secretion. **Coarctation of the aorta** must always be considered, even in adolescents. **Obstructive sleep apnea** is associated with hypertension in children, and patients with hypertension and symptoms of obstructive sleep apnea (snoring, daytime somnolence, insomnia, pauses in breathing) should be referred for polysomnography. Several **endocrinopathies** are associated with hypertension, usually those involving the thyroid, parathyroid, and adrenal glands. Systolic hypertension and tachycardia are common in hyperthyroidism; DBP is not usually elevated. **Hypercalcemia**, whether secondary to hyperparathyroidism or other causes, often results in mild elevation in BP because of an increase in vascular tone. **Adrenocortical disorders** (e.g., aldosterone-secreting tumors, sodium-retaining congenital adrenal hyperplasia, Cushing syndrome) may produce hypertension in patients with increased mineralocorticoid secretion. It is important to consider conditions associated with real or apparent **mineralocorticoid excess** and thus a *suppressed* renin level (with or without hypokalemia) form of secondary hypertension (Table 494.4 and Fig. 494.1). **Pheochromocytomas** are catecholamine-secreting tumors that give rise to hypertension because of the cardiac and peripheral vascular effects of epinephrine and norepinephrine. Children with pheochromocytoma usually have sustained rather than the intermittent or exercise-induced hypertension seen in adults. Pheochromocytoma develops in approximately 5% of patients with neurofibromatosis and can also be seen in certain genetic disorders such as von Hippel-Lindau disease. Rarely, secondary hypertension can be caused by **pseudohyperaldosteronism**, which leads to elevated BP in the face of a suppressed renin level. Such disorders include Liddle syndrome, apparent mineralocorticoid excess, and glucocorticoid-remediable aldosteronism. Altered sympathetic tone can be responsible for acute or intermittent elevation of BP in children with Guillain-Barré syndrome, poliomyelitis, burns, and Stevens-Johnson syndrome. Intracranial lesions also affect sympathetic outflow from the central nervous system.

A number of **drugs of misuse**, **therapeutic agents**, and **toxins** may cause hypertension (Table 494.5). Cocaine may provoke a rapid increase in BP and can result in seizures or intracranial hemorrhage. Phencyclidine causes transient hypertension that may become persistent in chronic abusers. Tobacco use may also increase BP. Sympathomimetic agents used as nasal decongestants, appetite suppressants, and stimulants for attention-deficit disorder produce peripheral vasoconstriction and varying degrees of cardiac stimulation. Individuals vary in their susceptibility to these effects. Oral contraceptives should be suspected as a contributor to elevated BP in adolescent girls, although the incidence is lower with the use of low-estrogen preparations. Immunosuppressant agents such as cyclosporine and tacrolimus cause hypertension in organ transplant recipients, and the effect is exacerbated by the coadministration of corticosteroids. BP may be elevated in patients with poisoning by a heavy metal (lead, cadmium, mercury).

In older school-age children and adolescents, **primary hypertension** becomes increasingly common. These patients often are overweight, have a strong family history of hypertension, and have BP values at, or only slightly above, the 95th percentile for age. Isolated systolic hypertension is also more consistent with primary hypertension, whereas diastolic hypertension may suggest a secondary cause. The cause of primary hypertension is likely to be multifactorial; obesity, genetic alterations in calcium and sodium transport, vascular smooth muscle reactivity, the renin-angiotensin-aldosterone system (RAAS), sympathetic nervous system overactivity, and insulin resistance have been implicated in this disorder. Elevated uric acid levels may play a role in the pathophysiology of primary hypertension, and elevated uric acid levels have been associated with higher SBP and DBP in children. Proof-of-concept studies have confirmed that lowering of uric acid levels results in lower BP in overweight youth with hypertension or prehypertension. Some children and adolescents demonstrate *salt-sensitive hypertension*. This is more common in children with primary hypertension and may be ameliorated by weight loss and sodium restriction.

Normotensive children of hypertensive parents may show abnormal physiologic responses that are similar to those of their parents. When subjected to stress or competitive tasks, the offspring of hypertensive adults, as a group, respond with greater increases in heart rate and BP than do children of normotensive parents. Similarly, some children of hypertensive parents may excrete higher levels of urinary catecholamine metabolites or may respond to sodium loading with greater weight gain and increases in BP than do those without a family history of hypertension. The abnormal responses in children with affected parents tend to be greater in the Black population than among White individuals.

Table 494.4 Clinical Findings in Patients with Mineralocorticoid Excess

CONDITION	INVOLVED GENE	CLINICAL PRESENTATION
CAH: 11β-hydroxylase deficiency	*CYP11B1* (autosomal recessive)	Early growth spurt initially, then short adult stature, advanced bone age, premature adrenarche, acne, precocious puberty in males, amenorrhea/hirsutism/virilism in females
CAH: 17α-hydroxylase deficiency	*CYP17A1* (autosomal recessive)	Pseudohermaphroditism (male), sexual infantilism (female)
Apparent mineralocorticoid excess	*HSD11β;* deficiency of 11β hydroxysteroid dehydrogenase (autosomal recessive)	Growth stunting/short stature, nephrocalcinosis, hypokalemia, low renin, hypoaldosteronism
Liddle syndrome	*SCNN1A* *SCNN1B* *SCNN1G* (autosomal dominant)	Severe hypertension, hypokalemia, metabolic alkalosis, muscle weakness
Geller syndrome (exacerbated by pregnancy)	GOF variant in mineralocorticoid receptor gene *NR3C2* (autosomal dominant)	Early onset of hypertension (before age 20 yr), exacerbated in pregnancy: hypokalemia, low renin
Glucocorticoid remediable aldosteronism (GRA) (familial aldosteronism type 1)	Chimeric gene with ACTH responsive promoter of 11β hydroxylase fused with aldosterone synthase gene (autosomal dominant)	Early onset of hypertension, presence of family history of mortality or morbidity from early hemorrhagic stroke
Pseudohypoaldosteronism type 2 (Gordon syndrome)	*WNK1* *WNK4* *KLHL3* *CUL3* (autosomal dominant)	Short stature, hyperkalemic and hyperchloremic metabolic acidosis, borderline blood pressure, low renin
Glucocorticoid resistance (children) (Chrousos syndrome)	*NR3C1* (autosomal dominant or sporadic)	Ambiguous genitalia, precocious puberty; women may have androgen excess: acne, excessive hair, oligo/anovulation, infertility

CAH, Congenital adrenal hyperplasia; GOF, gain of function.
Modified from Melcescu E, Phillips J, Moll G, et al. 11 Beta-hydroxylase deficiency and other syndromes of mineralocorticoid excess as a rare cause of endocrine hypertension. *Horm Metab Res.* 2012;44:867–878, Table 1.

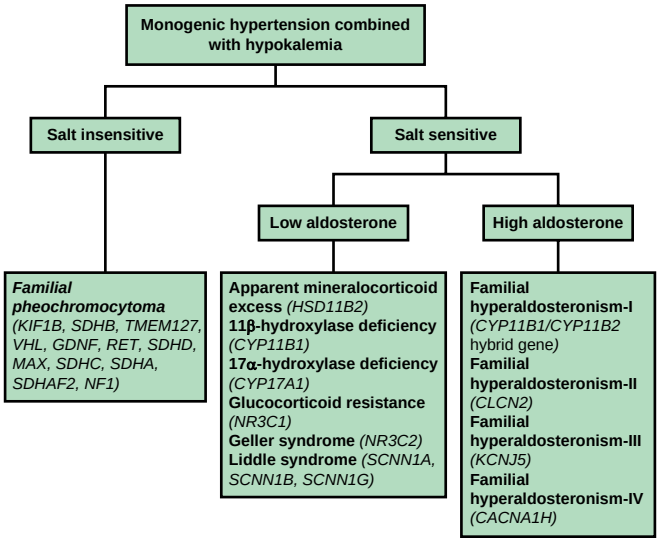

Fig. 494.1 Algorithm showing the overall categorization of monogenic hypertension combined with hypokalemia. Involved genes are italicized and in parentheses. *(From Lu YT, Fan P, Zhang D, et al. Overview of monogenic forms of hypertension combined with hypokalemia. Frontiers Pediatr. 2021;8:Article 543309, Fig. 1.)*

CLINICAL MANIFESTATIONS

Children and adolescents with primary hypertension are usually asymptomatic; the BP elevation is usually mild and is detected during a routine examination or evaluation before athletic participation. These children may also be obese. Children with secondary hypertension can have BP elevations ranging from mild to severe. Unless the BP has been sustained or is rising rapidly, hypertension does not usually produce symptoms. Therefore clinical manifestations may instead reflect the underlying disease process, such as growth failure in children with CKD. Children and adolescents with **acute severe hypertension**, in contrast, present with BP elevation well above stage 2 hypertension and severe symptoms that may represent acute target-organ injury.

Subclinical hypertensive **target-organ injury** is a common clinical manifestation in children with primary hypertension. Using echocardiography with pediatric normative data, left ventricular hypertrophy is detected in up to 40% of hypertensive children. Other markers of target-organ damage that have been demonstrated in hypertensive children include hypertensive retinopathy, increased carotid intima-to-media thickness, and increased vascular stiffness. Studies have shown that children with hypertension perform worse on tests of neurocognition than normotensive children and that these test results improve with successful treatment of hypertension. Target-organ effects of increased BP can be detected in adolescents even at BP levels below what is currently considered hypertensive.

Table 494.5 Drugs That May Elevate Blood Pressure

CLASS	DRUG
Antiinflammatory agents	COX-2 inhibitors (celecoxib) NSAIDs (ibuprofen, ketorolac)
Corticosteroids	Prednisone Hydrocortisone Dexamethasone
CNS stimulants	ADHD medications (methylphenidate, atomoxetine) Caffeine
Drugs of misuse	Amphetamines Cocaine MDMA Phencyclidine Tobacco
Estrogen- and progesterone-containing agents	HRT Oral contraceptives
Heavy metals	Cadmium Lead Mercury
Immunosuppressive agents	Cyclosporine Sirolimus Tacrolimus
Psychiatric agents	SNRI SSRI Tricyclic antidepressants
Supplements	Ephedra Guarana Ginseng Licorice St. John's wort Ma-huang
Sympathomimetic agents	Appetite suppressants Decongestants

COX-2, Cyclooxygenase-2; NSAID, nonsteroidal antiinflammatory drug; ADHD, attention-deficit/hyperactivity disorder; HRT, hormone replacement therapy; SNRI, serotonin-norepinephrine reuptake inhibitor; SSRI, selective serotonin reuptake inhibitor.

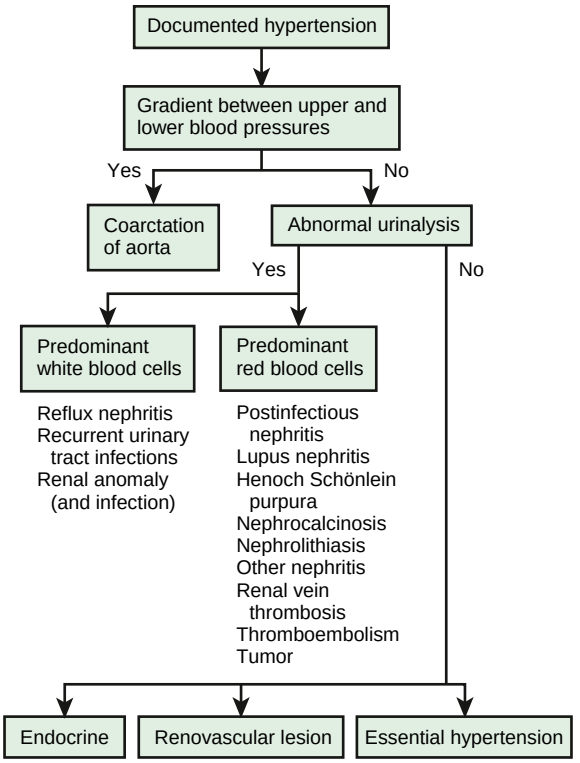

Fig. 494.2 Initial diagnostic algorithm in the evaluation of hypertension. *(From Kliegman RM, Greenbaum LA, Lye PS, eds. Practical Strategies in Pediatric Diagnosis and Therapy, 2nd ed. Philadelphia: Elsevier; 2004, p. 222.)*

DIAGNOSIS

The first step in diagnosing hypertension is recognition of elevated BP. BP readings taken in the office should be compared to normative BP tables (see 2017 AAP guidelines), indexed by height and sex, to ensure that the patient is normotensive. Multiple studies have shown substantial underrecognition of hypertension in children and adolescents, with less than half of elevated BP readings recognized, and even fewer with appropriate follow-up. This may be related to the complexity of the normative tables, although other factors such as provider experience and the presence or absence of obesity have also been shown to affect recognition of elevated BP readings. In addition to use of the simplified screening table found in the 2017 AAP guideline (see Table 494.1), this issue could also be overcome by building alerts into the electronic medical record. Elevated office BP readings should be confirmed using ABPM to identify children with white coat hypertension, who may not require further evaluation. This may require referral to an appropriate subspecialist.

Once the diagnosis of sustained hypertension is made, the evaluation should be directed toward uncovering potential underlying causes of the hypertension (Fig. 494.2), evaluating for comorbidities, and screening for evidence of target-organ damage. The extent of the evaluation for underlying causes of hypertension depends on the type of hypertension that is suspected. An extensive evaluation may be necessary when secondary hypertension is a strong consideration, such as in younger children, or in older children with severe, symptomatic hypertension. Alternatively, school-age children and adolescents with overweight/obesity and a family history of hypertension who have mild elevations of BP may only need limited testing.

In all patients, a careful **history** and **physical examination** are warranted. Birth history should be documented to screen for prematurity and other perinatal events that may affect later BP. A family history for metabolic disease, kidney disease, early cardiovascular events, and other forms of secondary hypertension should be obtained. Growth parameters should be determined to detect evidence of chronic disease. BP should be obtained in all four extremities to detect coarctation (thoracic or abdominal) of the aorta. Table 494.6 identifies other features of the physical examination that may provide evidence of an underlying cause of hypertension. Unless the history and physical examination suggest another cause, children with confirmed hypertension should have an evaluation to detect kidney disease, including urinalysis, electrolytes, blood urea nitrogen, creatinine, and complete blood count. Standard renal ultrasound should be considered in patients with a higher suspicion of secondary hypertension to assess for discrepancies in kidney size, structural abnormalities, and other potential causes of hypertension. Table 494.7 provides a more complete list of studies to consider in the clinical evaluation of a child with confirmed hypertension. Measuring serum potassium is essential because hypokalemia may be present in renovascular hypertension and many monogenic forms of hypertension (including Liddle syndrome, glucocorticoid remedial aldosteronism, and apparent mineralocorticoid excess), whereas hyperkalemia may be seen in Gordon syndrome (see Fig. 494.1). Hypokalemia may also be seen with a pheochromocytoma.

Renovascular hypertension is often associated with other diseases but may be isolated (Table 494.8). Magnetic resonance (MR) or computed tomography (CT) angiography can reveal renal artery stenosis, but formal intraarterial angiography may be needed to detect intrarenal vascular stenoses (Fig. 494.3) and in infants and young children, in whom noninvasive imaging techniques often are not helpful because of small vessel size. Doppler renal ultrasonography is of similar limited utility

Table 494.6 Physical Examination Findings in Patients with Hypertension

PHYSICAL FINDINGS	POTENTIAL RELEVANCE
GENERAL	
Pale mucous membranes, edema, growth retardation	Chronic renal disease
Elfin facies, upturned nose, short stature, cognitive impairment	Williams syndrome
Webbing of neck, low hairline, widespread nipples, wide carrying angle	Turner syndrome
Moon face, buffalo hump, hirsutism, truncal obesity, striae, acne	Cushing syndrome
HABITUS	
Thinness	Pheochromocytoma, renal disease, hyperthyroidism
Virilization	Congenital adrenal hyperplasia
Rickets	Chronic renal disease
SKIN	
Café-au-lait spots, neurofibromas	Neurofibromatosis, pheochromocytoma
Tubers, "ash-leaf" spots	Tuberous sclerosis
Rashes	Systemic lupus erythematosus, vasculitis (Henoch-Schönlein purpura), impetigo with acute nephritis
Pallor, evanescent flushing, sweating	Pheochromocytoma
Needle tracks	Illicit drug use
Bruises, striae	Cushing syndrome
Acanthosis nigricans	Type 2 diabetes, insulin resistance
EYES	
Extraocular muscle palsy	Nonspecific, chronic, severe
Fundal changes	Nonspecific, chronic, severe
Proptosis	Hyperthyroidism
HEAD AND NECK	
Goiter	Thyroid disease
Adenotonsillar hypertrophy	Sleep-disordered breathing
Webbed neck	Turner syndrome
CARDIOVASCULAR SIGNS	
Absent of diminished femoral pulses, low leg pressure relative to arm pressure	Aortic coarctation
Heart size, rate, rhythm; murmurs; respiratory difficulty, hepatomegaly	Aortic coarctation, congestive heart failure
Bruits over great vessels	Arteritis or arteriopathy
Rub	Pericardial effusion secondary to chronic renal disease
PULMONARY SIGNS	
Pulmonary edema	Congestive heart failure, acute nephritis
Picture of bronchopulmonary dysplasia	Bronchopulmonary dysplasia–associated hypertension
ABDOMEN	
Epigastric bruit	Primary renovascular disease or in association with Williams syndrome, neurofibromatosis, fibromuscular dysplasia, or arteritis
Abdominal masses	Wilms tumor, neuroblastoma, pheochromocytoma, polycystic kidneys, hydronephrosis, dysplastic kidneys
Jaundice	Alagille arteriohepatic dysplasia
NEUROLOGIC SIGNS	
Neurologic deficits	Chronic or severe acute hypertension with stroke
Muscle weakness	Hyperaldosteronism, Liddle syndrome (hypokalemic low renin hypertension)
GENITALIA	
Ambiguous, virilized	Congenital adrenal hyperplasia (11β- or 17α-hydroxylase deficiencies)
SKELETAL	
Short metacarpal (fourth, fifth) bones, short stature	Autosomal dominant hypertension with brachydactyly (Bilginturan disease)

Table 494.7 Clinical Evaluation of Confirmed Hypertension

STUDY OR PROCEDURE	PURPOSE	TARGET POPULATION
EVALUATION FOR IDENTIFIABLE CAUSES		
History, including sleep history, family history, risk factors, diet, and habits such as smoking and drinking alcohol; physical examination	History and physical examination help focus subsequent evaluation	All children with persistent BP ≥90th percentile
Blood urea nitrogen, creatinine, electrolytes, urinalysis, and urine culture	R/O renal disease and chronic pyelonephritis, mineralocorticoid excess states	All children with persistent BP ≥95th percentile
Complete blood count	R/O anemia, consistent with chronic renal disease	All children with signs of chronic kidney disease
Renal ultrasound	R/O renal scar, congenital anomaly, or disparate renal size	All children with signs or symptoms concerning for secondary cause of hypertension
EVALUATION FOR COMORBIDITY		
Fasting lipid panel, fasting glucose	Identify hyperlipidemia, identify metabolic abnormalities	Overweight patients with BP at 90th to 94th percentile; all patients with BP ≥95th percentile; family history of hypertension or cardiovascular disease; child with chronic renal disease
Drug screen	Identify substances that might cause hypertension	History suggestive of possible contribution by substances or drugs
Polysomnography	Identify sleep-disordered breathing	History of loud, frequent snoring, or daytime somnolence
EVALUATION FOR TARGET-ORGAN DAMAGE		
Echocardiogram	Identify left ventricular hypertrophy and other indications of cardiac involvement	Patients with comorbid risk factors* and BP 90th to 94th percentile; all patients with BP ≥95th percentile
Retinal exam	Identify retinal vascular changes	Patients with comorbid risk factors and BP 90th to 94th percentile; all patients with BP ≥95th percentile
ADDITIONAL EVALUATION AS INDICATED		
Ambulatory blood pressure monitoring	Identify white coat hypertension, abnormal diurnal BP pattern, BP load	All children with persistent BP ≥95th percentile
Renovascular imaging Magnetic resonance or CT angiography	Identify renovascular disease	Young children with stage 1 hypertension and any child or adolescent with stage 2 hypertension
Arteriography: digital subtraction or classic		
Plasma and urine catecholamines	Identify catecholamine-mediated hypertension	Patients with signs and symptoms concerning for pheochromocytoma

*Comorbid risk factors also include diabetes mellitus and kidney disease.
R/O, Rule out.
From National High Blood Pressure Education Program Working Group on High Blood Pressure in Children and Adolescents. The fourth report on the diagnosis, evaluation, and treatment of high blood pressure in children and adolescents. *Pediatrics*. 2004;114(2 Suppl 4th Report):562.

in children because of poor patient cooperation, imaging difficulties related to obesity, and operator inexperience. Doppler renal ultrasonography has a sensitivity of approximately 60–65% in patients with renovascular disease; specificity is 95%. CT angiography has a sensitivity and specificity of 88% and 81%, respectively, compared to 80% and 63% for MR angiography. *Doppler ultrasonography is not recommended when screening for renovascular hypertension in the 2017 AAP guideline except in selected patients.*

The presence of primary hypertension often clusters with other risk factors. All hypertensive children should be screened for comorbidities that may increase cardiovascular risk, including dyslipidemia and glucose intolerance. A nonfasting lipid panel is usually sufficient to screen for dyslipidemia but should be followed up by a fasting panel if abnormal. Similarly, a random fasting glucose level may be obtained initially but will need to be followed up with a fasting level if abnormal. In addition, a sleep history should be obtained in children with confirmed hypertension to screen for **sleep-disordered breathing**, an entity that is associated with high BP, particularly in overweight children. Patients with symptoms of sleep-disordered breathing should be referred to a sleep specialist for evaluation.

Left ventricular hypertrophy (LVH) is the most common manifestation of target-organ damage in hypertensive children. Left ventricular (LV) mass measurements should be indexed to height to account for the effect of body size and body surface area (BSA). LVH is defined as LV mass >51 g/m 2.7 in those 8 years of age and older, or LV mass >115 g/BSA for boys and >95 g/BSA for females <8 years of age. According to the 2017 AAP guideline, echocardiography should be obtained when treatment with antihypertensive medications is being considered.

PREVENTION

Prevention of high BP may be viewed as part of the prevention of cardiovascular disease and stroke, the leading cause of death in adults in the United States. Other risk factors for cardiovascular disease include

Table 494.8 Causes of Renovascular Hypertension in Children

Fibromuscular dysplasia
Syndromic causes
Neurofibromatosis type 1
Tuberous sclerosis
Williams syndrome
Marfan syndrome
Other syndromes
Vasculitis
Takayasu arteritis (disease)
Polyarteritis nodosa
Kawasaki disease
Other systemic vasculitides
Extrinsic compression
Neuroblastoma
Wilms tumor
Other tumors
Other causes
Radiation
Umbilical artery catheterization
Trauma
Congenital rubella syndrome
Transplant renal artery stenosis

From Tullus K, Brennan E, Hamilton G, et al. Renovascular hypertension in children. *Lancet*. 2008;371:1453–1463, Panel 1.

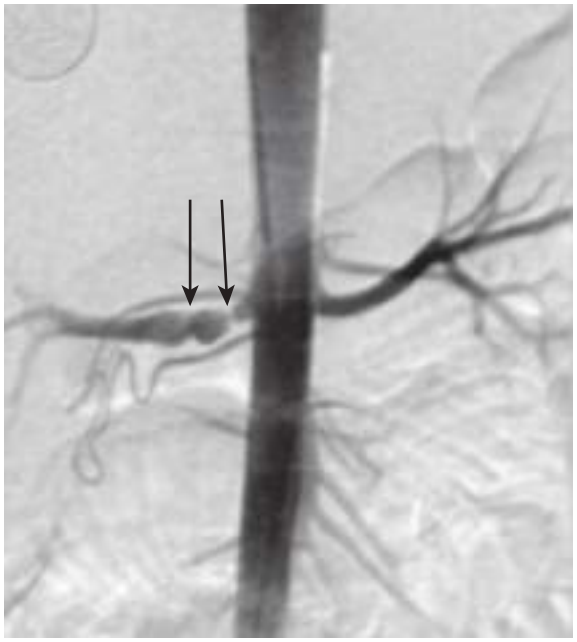

Fig. 494.3 Renal angiogram in 7-yr-old child with hypertension. Right renal artery is visible with a string-of-beads appearance characteristic of fibromuscular dysplasia *(arrows)*. The aorta and left renal artery appear normal. *(From Tullus K, Brennan E, Hamilton G, et al. Renovascular hypertension in children. Lancet. 2008;371:1453–1463, Fig 1.)*

obesity, elevated serum cholesterol levels, high dietary sodium intake, and a sedentary lifestyle, as well as alcohol and tobacco use. The increase in arterial wall rigidity and blood viscosity that is associated with exposure to the components of tobacco may exacerbate hypertension. Public health, population-based approaches to prevention of primary hypertension in both adults and children include a reduction in obesity, reduced sodium intake, avoidance of tobacco intake, and an increase in physical activity through school- and community-based programs.

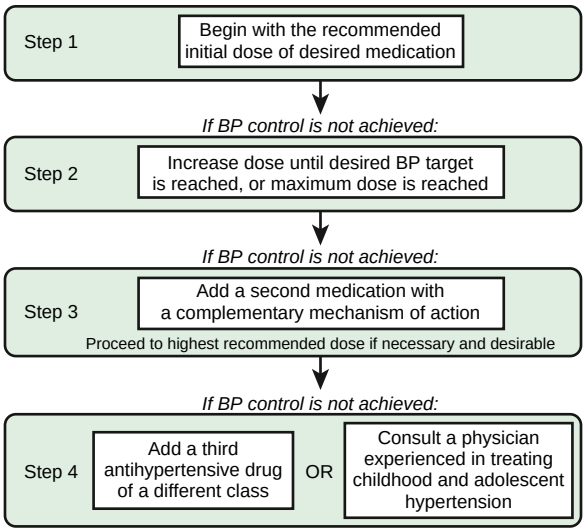

Fig. 494.4 Stepped-care approach to antihypertensive therapy in children and adolescents. BP, Blood pressure. *(From Flynn JT, Daniels SR. Pharmacologic treatment of hypertension in children and adolescents. J Pediatr. 2006;149:746–754, Fig 2.)*

TREATMENT

The mainstay of therapy for children with asymptomatic mild hypertension without evidence of target-organ damage is therapeutic **lifestyle modification** with dietary changes and regular exercise. **Weight loss** is the primary therapy in obesity-related hypertension. It is recommended that all hypertensive children have a diet increased in fresh fruits, fresh vegetables, fiber, and nonfat dairy and reduced in sodium. The **DASH** (Dietary Approaches to Stop Hypertension) diet has been suggested as a nutritional approach to prevent or treat hypertension (www.dashdiet.org). The diet focuses on lowering sodium intake and increasing potassium-, calcium-, and magnesium-containing foods, such as six to eight servings of whole grains, four to five servings of fruits, and four to five servings of vegetables per day and low-fat dairy foods. For adults, the standard DASH diet contains 2,300 mg of sodium (also recommended by the American Heart Association) and the low-sodium DASH diet recommends up to 1,500 mg of sodium per day. Studies suggest that although the DASH diet has potential beneficial effects on blood pressure, adherence to the diet remains low among adolescents. In addition, regular aerobic physical activity for at least 30-60 minutes on most days along with a reduction of sedentary activities to <2 hours a day is recommended.

Indications for **pharmacologic therapy** include symptomatic hypertension, stage 2 hypertension without a modifiable risk factor, hypertension in patients with comorbidities such as diabetes (types 1 and 2) or CKD, and persistent hypertension despite nonpharmacologic measures. When indicated, antihypertensive medication should be initiated as a single agent at a low dose (Fig. 494.4). The dose can then be increased until the goal BP is achieved. Once the highest recommended dose is reached, or if the child develops side effects, a second drug from a different class can be added.

Most classes of antihypertensive agents have been shown to reduce blood pressure in children and adolescents, although no data exist demonstrating one class to be superior. Per the 2017 AAP practice care guidelines, ACEIs, ARBs, thiazide diuretics, and calcium channel blockers are considered acceptable initial agents for use in children. The choice of antihypertensive agent for a patient should be tailored to the etiology of that patient's hypertension whenever possible. Table 494.9 gives recommended dosing information for antihypertensive agents in children and adolescents.

Table 494.9 Recommended Doses for Selected Antihypertensive Agents for Use in Hypertensive Children and Adolescents

CLASS	DRUG	STARTING DOSE	INTERVAL	MAXIMUM DOSE*
Aldosterone receptor antagonist	Eplerenone	25 mg/day	qd-bid	100 mg/day
	Spironolactone†	1 mg/kg/day	qd-bid	3.3 mg/kg/day up to 100 mg/day
Angiotensin-converting enzyme inhibitors	Benazepril†	0.2 mg/kg/day up to 10 mg/day	qd	0.6 mg/kg/day up to 40 mg/day
	Captopril†	0.5 mg/kg/dose (0.05 mg/kg/dose in infants)	tid	6 mg/kg/day up to 450 mg/day
	Enalapril†	0.08 mg/kg/day	qd	0.6 mg/kg/day up to 40 mg/day
	Fosinopril	0.1 mg/kg/day up to 10 mg/day	qd	0.6 mg/kg/day up to 40 mg/day
	Lisinopril†	0.07 mg/kg/day up to 5 mg/day	qd	0.6 mg/kg/day up to 40 mg/day
	Quinapril	5-10 mg/day	qd	80 mg/day
	Ramipril	1.6 mg/m^2/day	qd	6 mg/m^2/day up to 10 mg/day
Angiotensin receptor blockers	Candesartan	1-6 yr: 0.2 mg/kg/day 6-17 yr: <50 kg 4-8 mg qd >50 kg 8-16 mg qd	qd	1-6 yr: 0.4 mg/kg up to 4 mg/day 6-17 yr: <50 kg: 16 mg qd >50 kg: 32 mg qd
	Losartan†	0.75 mg/kg/day up to 50 mg/day	qd	1.4 mg/kg/day up to 100 mg/day
	Olmesartan	20 to <35 kg 10 mg qd; ≥35 kg 20 mg qd	qd	20 to <35 kg: 20 mg qd ≥35 kg: 40 mg qd
	Valsartan†	6-17 yr: 1.3 mg/kg/day up to 40 mg/day	qd	6-17 yr: 2.7 mg/kg/day up to 160 mg/day
α- and β-adrenergic antagonists	Labetalol†	2-3 mg/kg/day	bid	10-12 mg/kg/day up to 1.2 g/day
	Carvedilol	0.1 mg/kg/dose up to 6.25 mg bid	bid	0.5 mg/kg/dose up to 25 mg bid
β-adrenergic antagonists	Atenolol†	0.5-1 mg/kg/day	qd-bid	2 mg/kg/day up to 100 mg/day
	Bisoprolol/HCTZ	2.5/6.25 mg/day	qd	10/6.25 mg/day
	Metoprolol	1-2 mg/kg/day	bid	6 mg/kg/day up to 200 mg/day
	Propranolol	1 mg/kg/day	bid-tid	8 mg/kg/day up to 640 mg/day
Calcium channel blockers	Amlodipine†	1-5 yr: 0.1 mg/kg/day ≥6 yr: 2.5 mg/day	qd	1-5 yr: 0.6 mg/kg/day up to 5 mg/day ≥6 yr: 10 mg/day
	Felodipine	2.5 mg/day	qd	10 mg/day
	Isradipine†	0.05-0.15 mg/kg/dose	tid-qid	0.6 mg/kg/day up to 10 mg/day
	Extended-release nifedipine	0.2-0.5 mg/kg/day	qd-bid	3 mg/kg/day up to 120 mg/day
Central α-agonist	Clonidine†	5-10 μg/kg/day	bid-tid	25 μg/kg/day up to 0.9 mg/day
Diuretics	Amiloride	5-10 mg/day	qd	20 mg/day
	Chlorthalidone	0.3 mg/kg/day	qd	2 mg/kg/day up to 50 mg/day
	Chlorothiazide	10 mg/kg/day	bid	20 mg/kg/day up to 375 mg/day
	Furosemide	0.5-2.0 mg/kg/dose	qd-bid	6 mg/kg/day
	HCTZ	0.5-1 mg/kg/day	qd	3 mg/kg/day up to 37.5 mg/day
Vasodilators	Hydralazine	0.25 mg/kg/dose	tid-qid	7.5 mg/kg/day up to 200 mg/day
	Minoxidil	0.1-0.2 mg/kg/day	bid-tid	1 mg/kg/day up to 50 mg/day

*The maximum recommended adult dose should never be exceeded.
†Information on preparation of a stable extemporaneous suspension is available for these agents.
bid, Twice daily; HCTZ, hydrochlorothiazide; qd, once daily; qid, 4 times daily; tid, 3 times daily.
Adapted from Flynn JT. Management of hypertension in the young: role of antihypertensive medications. *J Cardiovasc Pharmacol*. 2011;58(2):111–120.

There have been changes in the recommended BP goals for the treatment of hypertension in children and adolescents. Data from the SPRINT (SBP intervention) trial group suggests that stricter goals (SBP goal of 120 vs 140 mm Hg) improve cardiovascular outcomes in adults. In children with CKD, the ESCAPE (Effects of Strict BP Control and Angiotensin-Converting Enzyme Inhibition on the Progress of Chronic Renal Failure in Pediatric Patients) trial group showed slower progression of CKD if the 24-hour MAP was kept below the 50th percentile on ABPM compared to the 50th to 95th percentile. It is now recommended that treatment achieve BP <90th percentile for age or <130/80 mm Hg, whichever is lower. A lower goal based on ABPM (24-hour MAP <50th percentile) is recommended for children and adolescents with CKD. ACEIs or ARBs should be used for children with diabetes and microalbuminuria or proteinuric kidney disease.

Acute severe hypertension, sometimes referred to as *accelerated hypertension* or *hypertensive crisis*, is defined as severe hypertension (often with BP values well in excess of stage 2 hypertension) accompanied by symptoms such as headache, dizziness, or nausea/

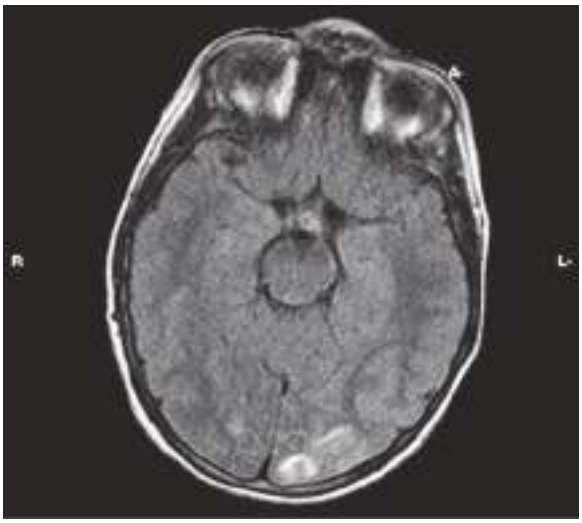

Fig. 494.5 MRI of the brain of a 6-yr-old child with end-stage kidney disease and hypertensive encephalopathy (i.e., posterior reversible leukoencephalopathy syndrome). Bilateral occipital high signal intensity is more pronounced on the left side. *(From Daroff RB, Fenichel GM, Jankovic J, et al., eds. Bradley's Neurology in Clinical Practice, 6th ed. Philadelphia: Saunders; 2012: Fig. 49B.4, p. 924.)*

vomiting, and in more severe cases, retinopathy, encephalopathy, cardiac failure, acute kidney injury, and seizures. These situations have also been described as *hypertensive urgency* and *hypertensive emergency,* respectively. This nomenclature can lead to confusion because there is often no absolute distinction between the two situations, and treatment will often depend on clinical judgment. *Hypertensive encephalopathy* (generalized or posterior reversible encephalopathy syndrome) is suggested by the presence of headache, vomiting, temperature elevation, visual disturbances, ataxia, depressed level of consciousness, imaging abnormalities, and seizures (Fig. 494.5); it is one of the more common presentations of acute severe hypertension in children and adolescents. Acute severe hypertension may also manifest with decreased vision (cortical blindness) and papilledema, congestive heart failure, or accelerated deterioration of kidney function.

For patients with acute severe hypertension and life-threatening symptoms, intensive care unit (ICU) admission and intravenous (IV) drug infusion are indicated so that decreases in BP can be carefully monitored and titrated (Table 494.10). Ideally, arterial lines should be used for continuous BP monitoring; if this is not available, oscillometric devices can be used for frequent/repeated BP measurement. Drug choices include labetalol, nicardipine, and sodium nitroprusside. Because too rapid a reduction in BP may interfere with adequate organ perfusion, a stepwise reduction in pressure should be planned. In general, BP should be reduced by

Table 494.10 Antihypertensive Drugs for Management of Severe Hypertension in Children Age 1-17 Years

DRUG	CLASS	DOSE	ROUTE	COMMENTS
USEFUL FOR SEVERELY HYPERTENSIVE PATIENTS WITH LIFE-THREATENING SYMPTOMS				
Esmolol	β-Adrenergic blocker	100-500 μg/kg/min	IV infusion	Very short acting—constant infusion preferred; may cause profound bradycardia
Hydralazine	Direct vasodilator	0.2-0.4 mg/kg/dose	IV, IM	Should be given every 4 hr when given IV bolus
Labetalol	α- and β-Adrenergic blocker	Bolus: 0.20-1.0 mg/kg/dose, up to 40 mg/dose Infusion: 0.25-3.0 mg/kg/hr	IV bolus or infusion	Asthma and overt heart failure are relative contraindications
Nicardipine	Calcium channel blocker	Bolus: 30 μg/kg up to 2 mg/dose Infusion: 0.5-4 μg/kg/min	IV bolus or infusion	May cause reflex tachycardia
Sodium nitroprusside	Direct vasodilator	0.5-10 μg/kg/min	IV infusion	Monitor cyanide levels with prolonged (>72 hr) use or in renal failure or coadminister with sodium thiosulfate
USEFUL FOR SEVERELY HYPERTENSIVE PATIENTS WITH LESS SIGNIFICANT SYMPTOMS				
Clonidine	Central α-agonist	0.05-0.1 mg/dose, may be repeated up to 0.8 mg total dose	PO	Side effects include dry mouth and drowsiness
Fenoldopam	Dopamine receptor agonist	0.2-0.8 μg/kg/min	IV infusion	Produced modest reductions in blood pressure in a pediatric clinical trial in patients up to age 12 yr
Hydralazine	Direct vasodilator	0.25 mg/kg/dose, up to 25 mg/dose	PO	Extemporaneous suspension stable for only 1 wk
Isradipine	Calcium channel blocker	0.05-0.15 mg/kg/dose, up to 5 mg/dose	PO	Stable suspension can be compounded
Minoxidil	Direct vasodilator	0.1-0.2 mg/kg/dose, up to 10 mg/dose	PO	Most potent oral vasodilator; long acting

IM, intramuscular; IV, intravenous; PO, oral.
Adapted from Flynn JT, Tullus K. Correction to severe hypertension in children and adolescents: pathophysiology and treatment. *Pediatr Nephrol.* 2012;27(3):503–504.

no more than 25% of the planned reduction over the first 8 hours, with a gradual normalization of BPs over the next 24-48 hours. For patients with less severe symptoms, such as headache or nausea/vomiting, oral medications such as clonidine or isradipine can be used if the patient can tolerate oral medications. Short-acting IV medications such as hydralazine or labetalol are acceptable if the patient cannot take oral drugs.

Treatment of secondary hypertension must also focus on the underlying disease, such as CKD, hyperthyroidism, pheochromocytoma, coarctation of the aorta, or renovascular hypertension. The treatment of renovascular hypertension includes antihypertensive medications, angioplasty, or surgery. If bilateral renovascular hypertension or renovascular disease in a solitary kidney is suspected, drugs acting on the RAAS are usually contraindicated because they may reduce glomerular filtration rate and lead to acute kidney injury.

Visit Elsevier eBooks+ at eBooks.Health.Elsevier.com for Bibliography.

Diseases of the Blood

PART XIX

Section 1

The Hematopoietic System

Chapter 495

Development of the Hematopoietic System

Stella T. Chou

HEMATOPOIESIS IN THE HUMAN EMBRYO AND FETUS

Hematopoiesis is the process by which the cellular elements of blood are formed. In the developing human embryo and fetus, hematopoiesis has three developmental waves and is conceptually divided into three anatomic stages: mesoblastic, hepatic, and myeloid. *Mesoblastic* hematopoiesis occurs in extraembryonic structures, principally in the yolk sac, and begins between the 10th and 14th days of gestation. By 6-8 weeks of gestation, the liver replaces the yolk sac as the primary site of blood cell production, and during this time, the placenta also contributes as a hematopoietic site. By 10-12 weeks, extraembryonic hematopoiesis has ceased. *Hepatic* hematopoiesis occurs through the remainder of gestation and then diminishes during the second trimester while bone marrow *(myeloid)* hematopoiesis increases. The liver is the predominant erythropoietic organ through 20-24 weeks of gestation.

Each hematopoietic organ houses distinct populations of cells. The yolk sac predominantly produces erythrocytes, megakaryocytes, and macrophages. The fetal liver is primarily an erythropoietic organ, while the bone marrow produces erythrocytes, megakaryocytes, and leukocytes. The types of leukocytes present in the fetal liver and marrow differ with gestation. Macrophages precede neutrophils in the marrow, and the ratio of macrophages to neutrophils decreases as gestation progresses. Regardless of gestational age or anatomic location, production of all hematopoietic tissues begins with multipotent cells capable of both self-renewal and clonal maturation into all blood cell lineages. Progenitor cells differentiate under the influence of transcription factors and hematopoietic growth factors.

The classical model of hematopoietic differentiation involves differentiation into increasingly lineage-specific progenitors, although there may also be alternate pathways that are used separately or in combination with classical pathways (Fig. 495.1). In the classical pathway, *long-term repopulating hematopoietic stem cells* (LTR-HSCs) are characterized by their ability to self-renew and differentiate into cells that are multipotent. *Multipotent progenitors* (MPPs) have reduced self-renewal capacity and differentiate into *common lymphoid progenitors* (CLPs) or *common myeloid progenitors* (CMPs). The CMP differentiates into all the blood lineages except for lymphoid. The commitment of hematopoietic cells to increasingly lineage-restricted cells requires cytokine stimulation and regulation by transcription factors.

Erythrocytes in the fetus are larger than in adults, and at 22-23 weeks' gestation, the mean corpuscular volume can be as high as 135 femtoliters (fL) (Fig. 495.2A). Similarly, the mean corpuscular hemoglobin is very high at 22-23 weeks and falls relatively linearly with advancing gestation (see Fig. 495.2B). In contrast, the mean corpuscular hemoglobin concentration is constant throughout gestation at 34 ±1 g/dL. While the size and quantity of hemoglobin in erythrocytes diminish during gestation, the hematocrit and blood hemoglobin concentration gradually increase (Fig. 495.3).

Platelet concentration in the blood increases gradually between 22 and 40 weeks' gestation (Fig. 495.4), but the platelet size, assessed by mean platelet volume, remains constant at 8 ±1 fL. No differences are observed between males and females in fetal and neonatal reference ranges for erythrocyte indices, hematocrit, hemoglobin, platelet counts, or mean platelet volume measurements.

FETAL GRANULOCYTOPOIESIS

Neutrophils are first observed in the human fetus about 5 weeks after conception as small clusters of cells around the aorta. The fetal bone marrow space begins to develop around the eighth week, and from 8-10 weeks, the marrow space enlarges, but no neutrophils appear there until 10.5 weeks. From 14 weeks through term, the most common granulocytic cell type in the fetal bone marrow space is the neutrophil. Neutrophils and macrophages originate from a common progenitor cell, but macrophages appear before neutrophils in the fetus, first in the yolk sac, liver, lung, and brain, all before the bone marrow cavity is formed.

Granulocyte colony-stimulating factor (G-CSF) and macrophage colony-stimulating factor (M-CSF) are expressed in developing fetal bone as early as 6 weeks after conception, and both are expressed in the fetal liver as early as 8 weeks. Granulocyte-macrophage colony-stimulating factor (GM-CSF) and stem cell factor (SCF) also are distributed widely in human fetal tissues. However, no changes in expression of any of these factors, or of their specific receptors, appear to be the signal for fetal production of neutrophils or macrophages.

Fetal blood contains few neutrophils until the third trimester. At 20 weeks' gestation, the blood neutrophil count is 0-500/mm^3. Although mature neutrophils are scarce, progenitor cells with the capacity to generate neutrophil clones are abundant in fetal blood. When cultured in vitro in the presence of recombinant G-CSF, they mature into large colonies of neutrophils. The physiologic role of G-CSF includes upregulating neutrophil production, and the low number of circulating neutrophils in the mid-trimester human fetus may be caused, in part, by low production of G-CSF. Monocytes isolated from the blood of adults produce G-CSF when stimulated with a variety of inflammatory mediators, such as bacterial lipopolysaccharide (LPS) or interleukin (IL)-1. In contrast, monocytes isolated from the blood or organs of fetuses up to 24 weeks' gestation generate only small quantities of G-CSF protein and messenger RNA (mRNA) after LPS or IL-1 stimulation. Despite this, G-CSF receptors on the surface of neutrophils of newborn infants are equal in number and affinity to those on adult neutrophils.

In the fetus, actions of the granulocytic factors (G-CSF, M-CSF, GM-CSF, and SCF) are not limited to hematopoiesis. Receptors for each of

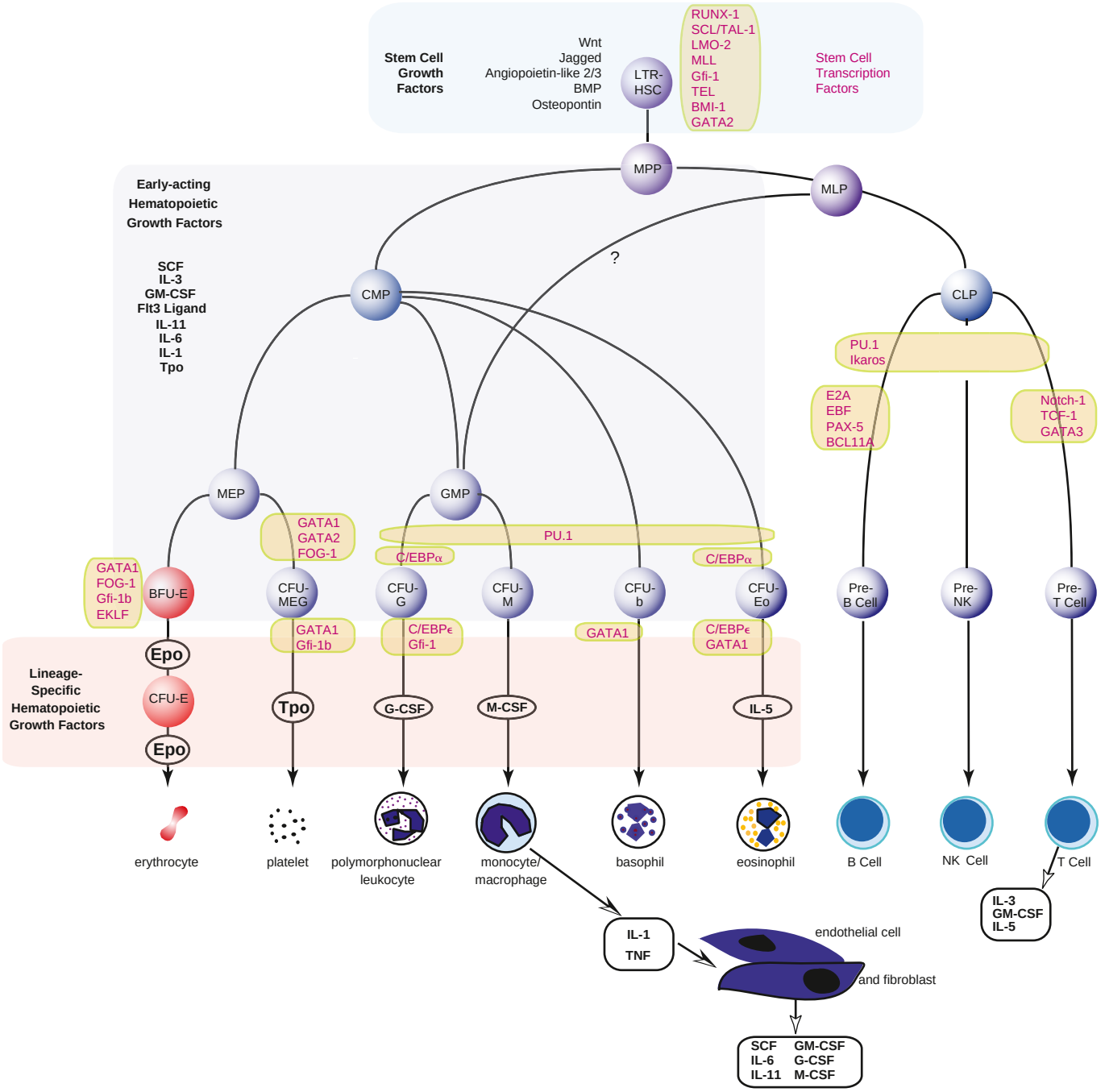

Fig. 495.1 Major cytokine sources and actions to promote hematopoiesis. Cells of the bone marrow microenvironment, such as macrophages, endothelial cells, and reticular fibroblasts, produce macrophage colony-stimulating factor (M-CSF), granulocyte-macrophage colony-stimulating factor (GM-CSF), and granulocyte colony-stimulating factor (G-CSF) after stimulation. These cytokines and others listed in the text have overlapping interactions during hematopoietic differentiation, as indicated; for all lineages, optimal development requires a combination of early- and late-acting factors. BFU, Burst-forming unit; BMP, bone morphogenic protein; CFU, colony-forming unit; CLP, common lymphoid progenitor; CMP, common myeloid progenitor; Epo, erythropoietin; GMP, granulocyte-monocyte progenitor; IL, interleukin; LTR-HSC, long-term repopulating-hematopoietic stem cell; MEP, megakaryocyte-erythroid progenitor; MLP, multipotent lymphoid progenitor; MPP, multipotent progenitor; SCF, stem cell factor; TNF, tumor necrosis factor; Tpo, thrombopoietin. *(From Sieff CA, Daley GO, Zon LI. The anatomy and physiology of hematopoiesis. In Orkin SH, Fisher DE, Ginsburg D, et al., eds. Nathan and Oski's Hematology and Oncology of Infancy and Childhood, 8th ed. Philadelphia: Elsevier, 2015.)*

these are located in areas of the fetal central nervous system and gastrointestinal tract, where their patterns of expression change with development.

FETAL THROMBOPOIESIS

Several biologic differences exist between fetal, neonatal, and adult megakaryopoiesis and thrombopoiesis. There is a developmentally unique pattern of fetal/neonatal megakaryopoiesis characterized by rapid proliferation, followed by full cytoplasmic maturation without polyploidization. Fetal and neonatal megakaryocytes are significantly smaller, exhibit lower ploidy, and produce fewer platelets. However, fetal and neonatal megakaryocytes have a higher proliferative potential than adult progenitors. These differences allow fetuses and neonates to populate their rapidly expanding bone marrow space and blood volume while maintaining normal platelet counts.

Megakaryocyte progenitors are categorized as *burst-forming unit–megakaryocytes* (BFU-MK), which are primitive megakaryocyte

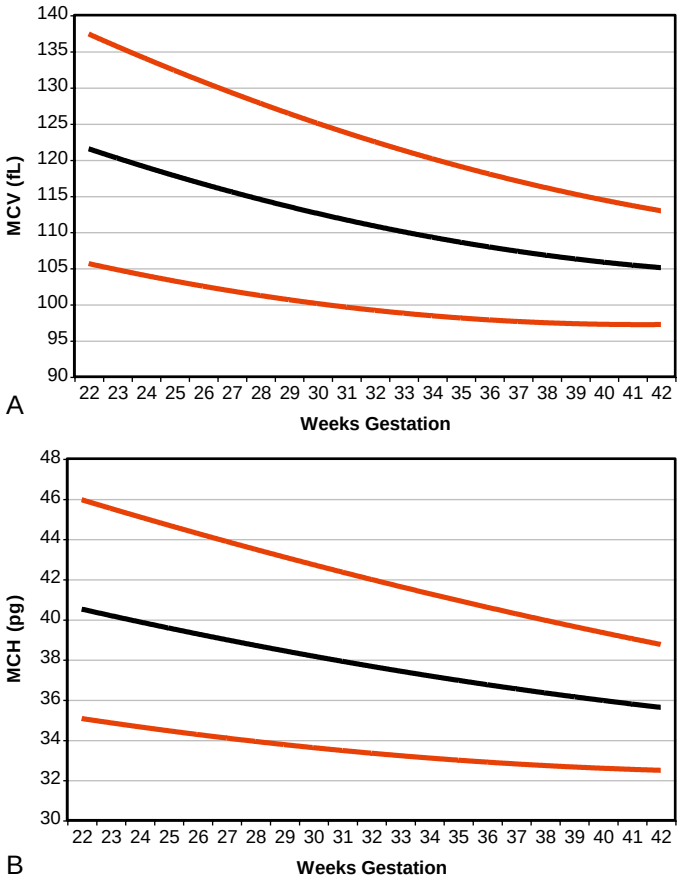

Fig. 495.2 A, Erythrocyte mean corpuscular volume (MCV), and B, mean corpuscular hemoglobin (MCH) from 22 weeks' gestation through term. The *lines* represent the 5th percentile, the mean, and the 95th percentile reference range. *(From Christensen RD, Jopling J, Henry E, et al. The erythrocyte indices of neonates, defined using data from over 12,000 patients in a multihospital healthcare system. J Perinatol 2008;28:24–28.)*

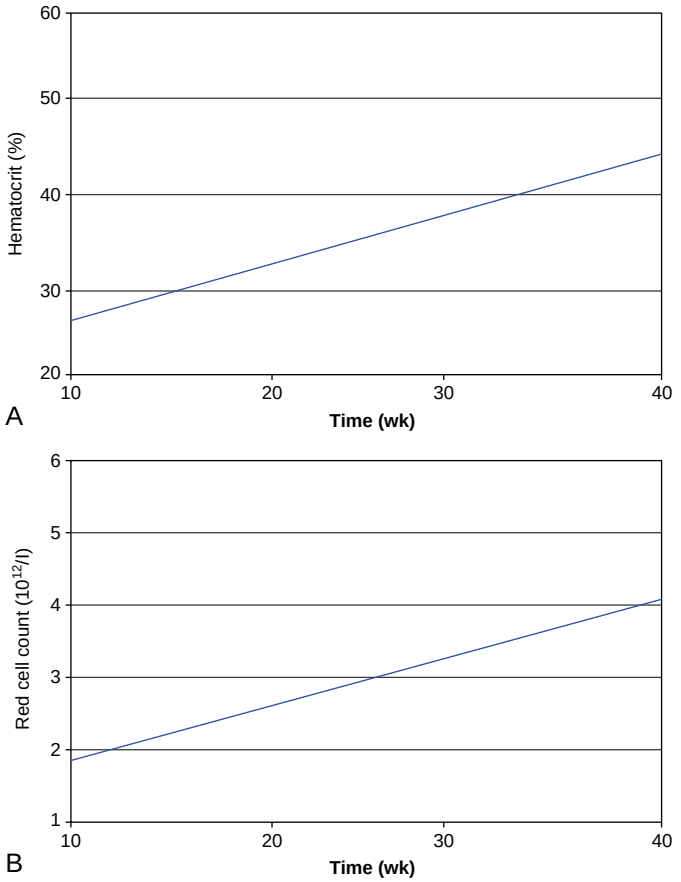

Fig. 495.3 Reference ranges of fetal hematocrit (A) and fetal red blood cell count (B) by cordocentesis throughout gestations.

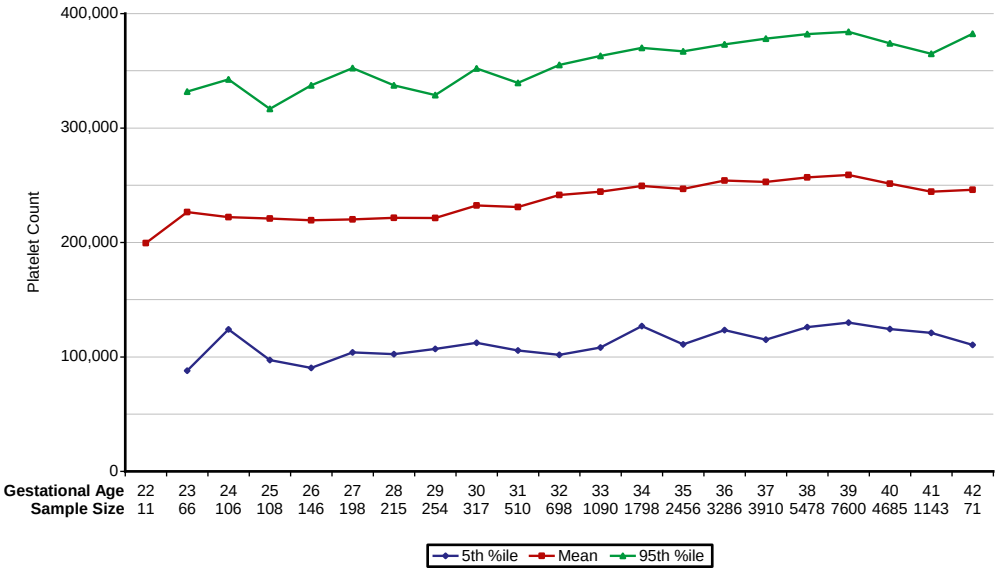

Fig. 495.4 Platelet count from 22 weeks' gestation through term. The *lines* represent the 5th percentile, the mean, and the 95th percentile reference range. *(From Wiedmeier SE, Henry E, Sola-Visner MC, et al. Platelet reference ranges for neonates, defined using data from over 47,000 patients in a multihospital healthcare system. J Perinatol 2009;29:130–136.)*

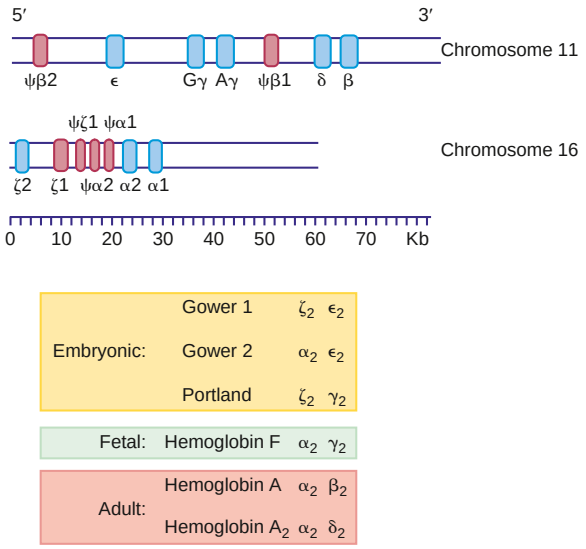

Fig. 495.5 Organization of the globin genes. The *bottom line* reflects the scale in kilobases. The *upper segment* represents the β-like globin genes on chromosome 11, and the *lower segment* the α-like genes on chromosome 16. Regions of the gene that code for primary globin proteins are shown as *blue segments*, and regions that code for pseudogenes ("ψ," nonexpressed remnants) are shown as *pink segments*. The composition of embryonic, fetal, and adult hemoglobins is listed. α, Alpha; β, beta; γ, gamma; δ, delta; ε, epsilon; ζ, zeta.

progenitors, and *colony-forming unit–megakaryocytes* (CFU-MK), which are more differentiated. BFU-MK produce large multifocal colonies containing ≥50 megakaryocytes, whereas CFU-MK generate smaller (3-50 cells/colony) unifocal colonies. Megakaryocytes are identified by their morphologic characteristics as they undergo endoreduplication, which results in large cells with polyploid nuclei. Megakaryocytes, unlike megakaryocyte progenitors, do not have the capacity to generate colonies. Rather, they undergo maturation, progressing from small mononuclear cells to large polyploid cells. The modal megakaryocyte *ploidy* (the number of sets of complete chromosomes) in normal adult marrow is 16N. In the fetus and neonate, ploidy is lower, primarily 2N and 4N, and mature megakaryocyte size is smaller. Large megakaryocytes generate more platelets than do small megakaryocytes; in vitro studies suggest that megakaryocytes of neonates produce fewer platelets than do their adult counterparts.

The exact mechanisms by which megakaryocytes release platelets into the circulation remain incompletely understood. In situ examination of this process suggests that mature megakaryocytes migrate to a perivascular site and extend a process through the endothelium, giving rise to proplatelets, which then release platelets. An alternate mechanism is that platelets are released from megakaryocytes in the lungs as a result of shear forces.

Thrombopoietin (TPO) is the dominant regulator of megakaryocyte development and platelet production. TPO is predominantly produced in the liver from early fetal to adult life but is also expressed by cells in the kidney, and, to a lesser extent, by smooth muscle and marrow cells. TPO concentrations are higher in healthy neonates of any gestational age than in healthy adults. TPO is a primary stimulator of megakaryocyte and platelet production, but SCF, IL-3, IL-11, IL-6, and erythropoietin also stimulate megakaryopoiesis and thrombopoiesis in vitro and in vivo. Importantly, TPO promotes expansion of hematopoietic stem cells (HSCs) and progenitor cells, and the TPO receptor is expressed on HSCs and erythroid progenitors in addition to megakaryocyte progenitors, megakaryocytes, and mature platelets.

FETAL ERYTHROPOIESIS

Similar to hematopoietic production of other cell lineages, fetal erythropoiesis is regulated by growth factors produced by the fetus, not by the mother. Erythropoietin (EPO) does not cross the human placenta. Stimulating maternal EPO production does not enhance fetal erythropoiesis, nor does suppressing maternal erythropoiesis by hypertransfusion.

EPO plays a central regulatory role on the proliferation and maturation of erythroid progenitors. Erythroid-committed progenitors consist of *burst-forming unit–erythroid* (BFU-E) and *colony-forming unit–erythroid* (CFU-E) cells. In colony-forming assays, human BFU-E cells are more proliferative, forming colonies of multiple clusters of erythroblasts, as compared with CFU-E cells, which form one or two clusters, with each containing 8-100 hemoglobinized erythroblasts. EPO is essential for erythrocyte production from CFU-E cells by inducing survival and proliferation of erythroblasts. EPO binds to specific receptors on the surface of committed erythroid precursors, and its expression is regulated by an oxygen-sensing mechanism through the hypoxia-inducible factor (HIF) family of proteins. HIF-1α and HIF-2α are regulated by oxygen tension, whereas HIF-1β is constitutively expressed. Together, HIF proteins maintain oxygen homeostasis and regulate erythropoiesis by inducing EPO under hypoxic conditions.

EPO is produced by monocytes and macrophages in the fetal liver during the first and second trimesters. After birth, the anatomic site of EPO production shifts to the kidney. The specific stimulus for this shift is unknown but may involve the increase in arterial oxygen tension that occurs at birth. Epigenetic modification of gene expression may also play a role because it appears that renal and hepatic EPO genes are methylated to different degrees. Although EPO mRNA and protein can be found in the human fetal kidney, it is not known whether this production is biologically relevant. It appears that renal production of EPO is not essential for normal fetal erythropoiesis, as evidenced by the normal serum EPO concentration and normal hematocrit of anephric fetuses.

Hemoglobins in the Fetus and Neonate

Hemoglobin is a tetramer of four *globin* chains with an iron-containing porphyrin ring called *heme* covalently bound to each chain. A dynamic interaction between heme and globin gives hemoglobin its unique properties in the reversible transport of oxygen. The hemoglobin molecule consists of two alpha (α)-like and two beta (β)-like polypeptide chains, with each chain having a heme group attached (Fig. 495.5). There are two β-globin genes and four α-globin genes. Within erythrocytes of an early embryo, fetus, child, and adult, six different hemoglobins may normally be detected (Fig. 495.6): the **embryonic** hemoglobins (Gower-1, Gower-2, and Portland), **fetal** hemoglobin (HbF), and the **adult** hemoglobins (HbA and HbA_2). The electrophoretic mobilities of hemoglobins vary with their chemical structures.

Expression and quantitative relationships among the hemoglobins are determined by complex developmental processes. Globin chain expression is developmental stage specific and occurs through two hemoglobin switches, mediated primarily through changes of the β-globin genes expressed. There are five functional β-like globin chain genes: embryonic *(HBE1)*, two fetal *(HBG1, HBG2)*, and two adult *(HBD, HBB)*; and three α-like globin chain genes: embryonic *(HBZ)* and two adult *(HBA1, HBA2)*. Primitive erythroid cells primarily express embryonic globins. The first β-globin switch occurs at approximately 6 weeks' gestation to fetal globin *(HBG)*, which coincides with the onset of definitive hematopoiesis. The major hemoglobin in the fetus (HbF) consists of two α and two gamma (γ) globin chains ($\alpha_2\gamma_2$). The second globin switch is responsible for the expression of the major hemoglobin of adults (HbA), consisting of two α and two β polypeptide chains ($\alpha_2\beta_2$) and is first expressed at mid-gestation. A key regulator of the fetal-to-adult hemoglobin switch is the transcription factor **BCL11A**, which binds to the β-globin gene and acts to silence γ-globin expression and thus HbF.

Embryonic Hemoglobins

The blood of early human embryos contains two slowly migrating hemoglobins, *Gower-1* and *Gower-2,* and *Hb Portland,* which has HbF-like mobility. The zeta (ζ) chains of Hb Portland and Gower-1 are structurally quite similar to α chains. Both Gower hemoglobins contain the epsilon (ε) β-like globin polypeptide chain. Hb Gower-1 has the structure $\zeta_2\varepsilon_2$, whereas Gower-2 has $\alpha_2\varepsilon_2$. Hb Portland has the structure $\zeta_2\gamma_2$. In embryos up to 6 weeks' gestation, the Gower hemoglobins predominate but are no longer detectable by 3 months of gestation.

Fetal Hemoglobin

By 6-8 weeks' gestation, HbF ($\alpha_2\gamma_2$) is the predominant hemoglobin; at 24 weeks' gestation, it constitutes 90% of the total hemoglobin. HbF

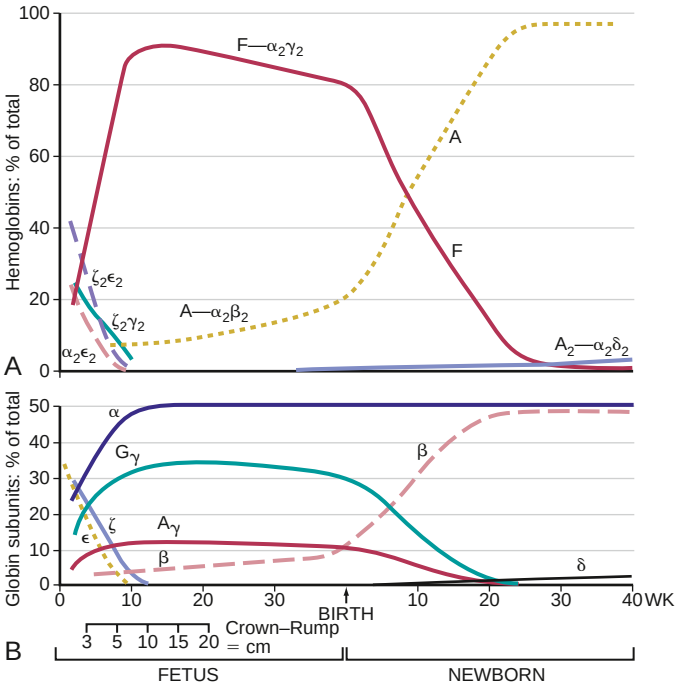

Fig. 495.6 Changes in hemoglobin tetramers (**A**) and in globin subunits (**B**) during human development from embryo to early infancy. *(From Polin RA, Fox WW. Fetal and Neonatal Physiology, 2nd ed. Philadelphia: Saunders, 1998: p. 1769.)*

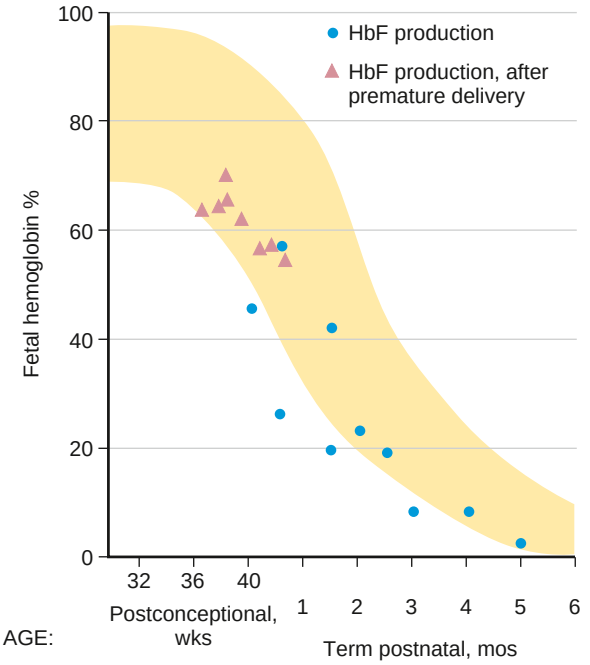

Fig. 495.7 Pre- and postnatal changes in the percentage of total hemoglobin represented by fetal hemoglobin (HbF) *(yellow)*. The *triangles* represent postnatal production by reticulocytes in premature infants, and the *circles* represent cord blood and postnatal reticulocyte production in term infants. *(From Brown MS. Fetal and neonatal erythropoiesis. In: Stockman JA, Pochedly C eds. Developmental and Neonatal Hematology. New York: Raven Press, 1988.)*

declines modestly in the third trimester, such that the HbF comprises 70–80% of the total hemoglobin. HbF production decreases rapidly postnatally (Fig. 495.7), and by 6-12 months of age declines to adult concentrations of <2%. Understanding the molecular basis of the fetal-to-adult hemoglobin switch is of interest because of the therapeutic benefits to patients with β-thalassemia and sickle cell disease, whose clinical severity is improved with modest elevation of HbF. The exact mechanisms by which BCL11A acts to repress HbF are not fully elucidated, but erythroid-specific enhancers of BCL11A have been identified and are potential targets for therapeutic HbF induction.

Adult Hemoglobins

HbA constitutes 5–10% of total hemoglobin at 24 weeks' gestation and steadily increases, so that at term, HbA averages 30% of total hemoglobin. By 6-12 months of age, individuals reach adult concentrations of HbA. The minor adult hemoglobin component, HbA_2, contains delta (δ) chains and has the structure $\alpha_2\delta_2$. At birth, <1.0% of HbA_2 is detected, but by 12 months of age the normal level is 2.0–3.4%. Throughout life, the normal ratio of HbA to HbA_2 is approximately 30:1.

Alterations of Hemoglobins

HbF levels may be elevated with hemoglobinopathies, hereditary persistence of HbF, or bone marrow failure syndromes or may be associated with stress erythropoiesis. Because the HbF level is elevated during the first years of life, knowledge of its normal pattern of decline is important (see Figs. 495.6 and 495.7). Two disorders resulting from pathogenic variants in the β-globin gene (HBB), β-thalassemia and sickle cell disease, become symptomatic postnatally as fetal γ-globin expression decreases and adult β-globin increases. In both these disorders, elevated HbF levels persist in childhood and later. In patients with the most severe type, β^0 thalassemia, except for a small amount of HbA_2, HbF is the only hemoglobin produced. At the other end of the spectrum, in individuals with β-thalassemia trait, the postnatal decrease of HbF is delayed and mildly elevated levels of HbF (>2%) may persist throughout life. Individuals with sickle cell disease, who also have a pathogenic variant in the *HBB* gene, typically demonstrate elevated levels of HbF, ranging from approximately 5% to up to 30%. In contrast, elevated HbF is not characteristic of α-thalassemia syndromes, but tetramers of γ chains (γ_4 or Hb Barts) may be found in the neonatal period. Because α-globin chains are expressed in fetal and adult hemoglobin, four α gene pathogenic variants leading to functional deletions are not compatible with life. Fetuses die in utero or shortly after birth from the severe anemia and hydrops fetalis. Inheritance of only one normal gene of the four (α –/–) results in **hemoglobin H disease**, which is usually associated with a moderate anemia. Inheritance of two or three normal α genes results in α-**thalassemia** trait or carrier status, respectively.

Hereditary persistence of HbF (HPFH) is a benign genetic condition caused by heterozygous deletions or nucleotide substitutions in regions of the β-globin locus that regulate transcription of *HBG1* and *HBG2*, causing persistent pancellular HbF expression levels of approximately 30% of total hemoglobins. Individuals with HPFH do not exhibit anemia.

Preterm infants treated with human recombinant EPO increase HbF production during active erythropoiesis. Moderate elevations of HbF may also occur in many diseases accompanied by hematologic stress, such as hemolytic anemias, leukemia, and bone marrow failure syndromes, such as Diamond Blackfan anemia.

The normal adult level of HbA_2 (2.0–3.4%) is seldom altered. Levels of HbA_2 > 3.4% are found in most persons with the β-thalassemia trait and in those with megaloblastic anemias secondary to vitamin B_{12} and folic acid deficiency. Decreased HbA_2 levels are found in those with iron-deficiency anemia (see Chapter 504) and α-thalassemia (see Chapter 511.10).

RED CELL LIFE SPAN IN THE FETUS AND NEONATE

In general, the highest hematocrit during a person's lifetime occurs at birth, and the lowest hematocrit occurs at the physiologic nadir that occurs 8-10 weeks postnatally. A shortened life span of fetal and neonatal red blood cells (RBCs) has been suggested as an important component. The average erythrocyte life span in normal adults is approximately 120 days. The life span of fetal/neonatal **erythrocytes** was once estimated to be considerably less, with an average of 60-90 days suggested by chromium (^{51}Cr)-labeled erythrocyte studies. However, newer studies indicate that the life span of fetal/neonatal RBCs is similar to that of adults. Neocytolysis is the active removal of young **erythrocytes** that were generated in relatively hypoxic conditions, after normoxic or hyperoxic conditions. This process has also been suggested as an explanation for the physiologic nadir of neonates.

Visit Elsevier eBooks+ at eBooks.Health.Elsevier.com for Bibliography.

Chapter 496

Anemias

Courtney D. Thornburg

Anemia is defined as a reduction of the hemoglobin concentration or red blood cell (RBC) volume below the range of values occurring in healthy persons. Normal ranges for hemoglobin and hematocrit (packed red cell volume) vary substantially with age and between males and females (Table 496.1) and by race and ethnicity (Table 496.2). Anemia is a significant global health problem affecting children and reproductive-age females (Figs. 496.1 and 496.2).

Physiologic responses to anemia include increased cardiac output, augmented oxygen extraction (increased arteriovenous oxygen difference), and shunting of blood flow toward vital organs and tissues. In addition, the concentration of 2,3-diphosphoglycerate increases within the RBC. The resultant "rightward shift" of the oxygen dissociation curve reduces the affinity of hemoglobin for oxygen and results in more complete transfer of oxygen to the tissues. This same shift in the oxygen dissociation curve can also occur at high altitude. Higher levels of erythropoietin (EPO) and consequent increased RBC production by the bone marrow further help the body to adapt.

HISTORY AND PHYSICAL EXAMINATION

A detailed history and thorough physical exam are essential when evaluating an anemic child. Important historical facts include demographics, diet, medications, chronic diseases, infections, travel, and exposures. A family history of anemia and associated difficulties (e.g., splenomegaly, jaundice, early-age onset of gallstones) is also important. Often, few physical symptoms or signs result solely from a low hemoglobin, particularly when the anemia develops slowly. Clinical findings generally do not become apparent until the hemoglobin level falls to <7-8 g/dL. Clinical features can include pallor, sleepiness, irritability, and decreased exercise tolerance. Pallor can involve the tongue, nail beds, conjunctiva, palms, or palmar creases. A flow murmur is often present. Ultimately, weakness, tachypnea, shortness of breath on exertion, tachycardia, cardiac dilation, and high-output heart failure results from increasingly severe anemia, regardless of its cause. Unusual physical findings linked to specific underlying disease etiologies are discussed in detail in sections describing the associated disorders and in Table 496.3.

Table 496.1 Normal Mean and Lower Limits of Normal for Hemoglobin, Hematocrit, and Mean Corpuscular Volume

	HEMOGLOBIN (g/dL)		HEMATOCRIT (%)		MEAN CORPUSCULAR VOLUME (fL)	
AGE (yr)	MEAN	LOWER LIMIT	MEAN	LOWER LIMIT	MEAN	LOWER LIMIT
0.5-1.9	12.5	11.0	37	33	77	70
2-4	12.5	11.0	38	34	79	73
5-7	13.0	11.5	39	35	81	75
8-11	13.5	12.0	40	36	83	76
12-14 female	13.5	12.0	41	36	85	78
12-14 male	14.0	12.5	43	37	84	77
15-17 female	14.0	12.0	41	36	87	79
15-17 male	15.0	13.0	46	38	86	78
18-49 female	14.0	12.0	42	37	90	80
18-49 male	16.0	14.0	47	40	90	80

From Brugnara C, Oski FJ, Nathan DG, eds. *Nathan and Oski's Hematology of Infancy and Childhood*, 7th ed. Philadelphia: Saunders, 2009: p. 456.

Table 496.2 NHANES-III Hemoglobin Values for Non-Hispanic Whites and Blacks Ages 2-18 Yr*

	WHITE NON-HISPANIC		BLACK	
AGE (yr)	MEAN	−2 SD	MEAN	−2 SD
2-5	12.21	10.8	11.95	10.37
6-10	12.87	11.31	12.40	10.74
11-15 male	13.76	11.76	13.06	10.88
11-15 female	13.32	11.5	12.61	10.85
16-18 male	15.00	13.24	14.18	12.42
16-18 female	13.39	11.61	12.37	10.37

*Sample size is 5,142 (White, 2,264; Black, 2,878).
NHANES-III, Third National Health and Nutrition Examination Survey; SD, standard deviation.
Adapted from Robbins EB, Blum S. Hematologic reference values for African American children and adolescents. *Am J Hematol* 2007;82:611–614.

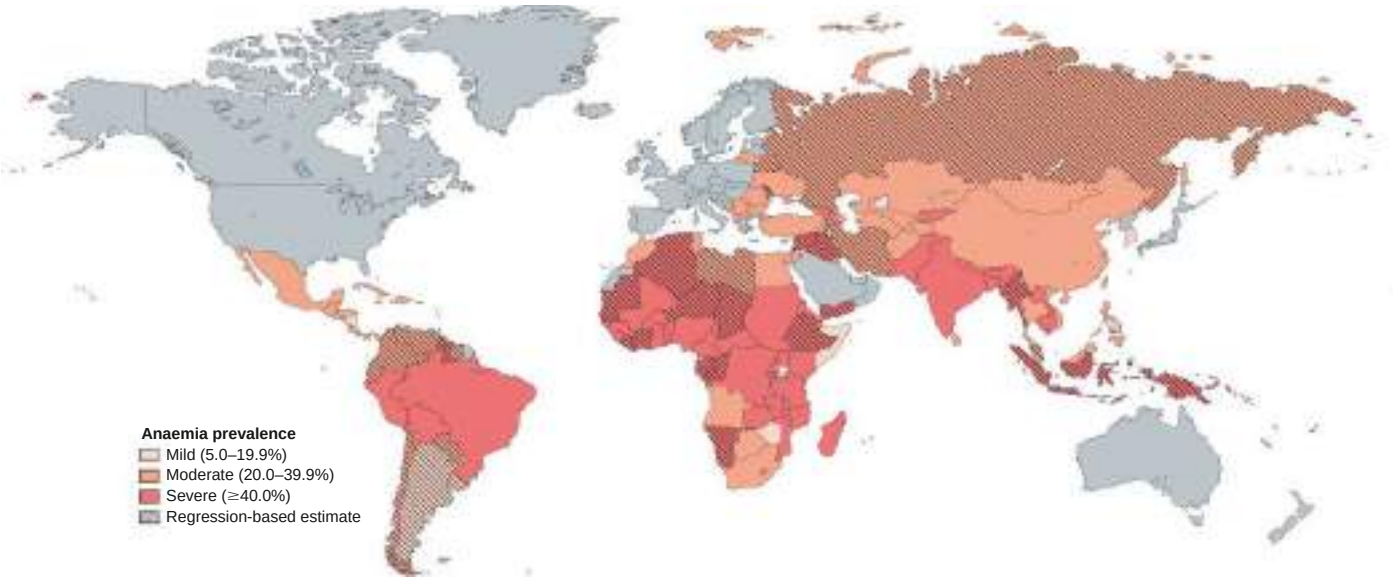

Fig. 496.1 Global prevalence of anemia in children of preschool age (0-5 yr). *(Adapted from Worldwide prevalence of anaemia 1993–2005. In WHO Global Database on Anaemia. Geneva: World Health Organization, 2008.)*

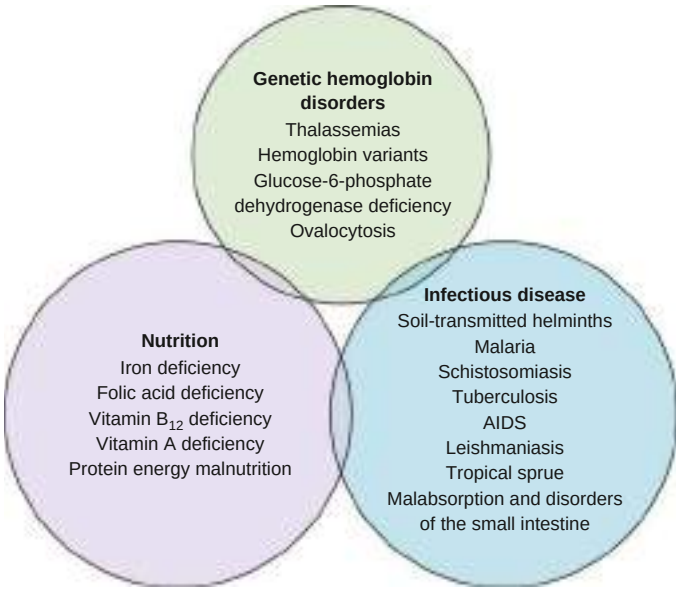

Fig. 496.2 Causes of anemia in countries with low- or middle-income populations. *(From Balarajan Y, Ramakrishnan U, Özaltin E, et al. Anaemia in low-income and middle-income countries. Lancet 2011;378:2123–2134; Fig 3.)*

LABORATORY STUDIES

Initial laboratory testing should include hemoglobin, hematocrit, RBC indices, white blood cell (WBC) count and differential, platelet count, reticulocyte count, and examination of the peripheral blood smear. The need for additional laboratory studies is dictated by the history, physical exam, and initial testing.

DIFFERENTIAL DIAGNOSIS

Anemia can result from many underlying pathologic processes. To narrow the diagnostic possibilities, anemias may be classified based on their morphology and physiology (Fig. 496.3).

Anemias may be morphologically categorized by red cell size (mean corpuscular volume [MCV]) and microscopic appearance. Anemias can be classified as *microcytic, normocytic,* or *macrocytic* based on whether the MCV is low, normal, or high, respectively (Table 496.4). RBC size also changes with age, and normal developmental changes in MCV should be accommodated before a designation is made (see Table 496.1). Examination of a peripheral blood smear often reveals changes in RBC appearance that will help to further narrow the diagnostic categories (Fig. 496.4 and Table 496.5). Details regarding morphologic changes associated with specific disorders are described in subsequent sections.

Anemias may also be further divided based on underlying pathophysiology. The two major categories are **decreased production** and **increased destruction** (or **loss**). These two groups are not always mutually exclusive. Decreased RBC production may be a consequence of either ineffective erythropoiesis or complete failure of erythropoiesis. Increased destruction or loss may be secondary to hemolysis, sequestration, or bleeding. The peripheral blood reticulocyte percentage or absolute number helps to distinguish between the two physiologic categories. The normal reticulocyte percentage of total RBCs during most of childhood is approximately 1%, with an absolute reticulocyte count of 25,000-75,000/mm^3. In the presence of anemia, EPO production and the absolute number of reticulocytes should rise. Low or normal numbers of reticulocytes generally represent an inadequate response to anemia that is associated with relative bone marrow failure or ineffective erythropoiesis. Increased numbers of reticulocytes represent a normal bone marrow response to ongoing RBC destruction (hemolysis), sequestration, or loss (bleeding).

Figure 496.3 presents a useful approach to assessing the common causes of anemia in the pediatric age group. Children with **microcytic anemia** and low or normal reticulocyte counts most often have defects in erythroid maturation or ineffective erythropoiesis. **Iron deficiency** is the most common cause (see Chapter 504). **Thalassemia trait** constitutes the primary differential diagnosis when iron deficiency is suspected (see Chapter 511). Distinctions between these entities are presented in Table 504.2. Chronic disease or inflammation (more often normocytic), lead poisoning, and sideroblastic anemias should also be considered and are discussed in other chapters. Microcytosis and elevated reticulocyte counts are associated with thalassemias and

Table 496.3 Physical Findings in the Evaluation of Anemia

SYSTEM	OBSERVATION	SIGNIFICANCE
Skin	Hyperpigmentation	Fanconi anemia, dyskeratosis congenita
	Café-au-lait spots	Fanconi anemia
	Vitiligo	Vitamin B_{12} deficiency
	Partial oculocutaneous albinism	Chédiak-Higashi syndrome
	Jaundice	Hemolysis, hepatitis
	Petechiae, purpura	Bone marrow infiltration, autoimmune hemolysis with autoimmune thrombocytopenia (Evans syndrome), hemolytic-uremic syndrome
	Erythematous rash	Parvovirus, Epstein-Barr virus
	Butterfly rash	Systemic lupus erythematosus
Head	Frontal bossing	Thalassemia major, severe iron deficiency, chronic subdural hematoma
	Microcephaly	Fanconi anemia Diamond-Blackfan anemia
Eyes	Microphthalmia	Fanconi anemia
	Retinopathy	Sickle cell disease, types SS and SC
	Optic atrophy, blindness	Osteopetrosis
	Blocked lacrimal gland	Dyskeratosis congenita
	Kayser-Fleischer ring	Wilson disease
	Blue sclera	Iron deficiency
Ears	Deafness	Osteopetrosis
Mouth	Glossitis	Vitamin B_{12} deficiency, iron deficiency
	Angular stomatitis	Iron deficiency
	Cleft lip, palate	Diamond-Blackfan anemia
	Pigmentation	Peutz-Jeghers syndrome (intestinal blood loss)
	Telangiectasia	Osler-Weber-Rendu syndrome (blood loss)
	Leukoplakia	Dyskeratosis congenital
Chest	Shield chest or widespread nipples	Diamond-Blackfan anemia
	Murmur	Endocarditis; prosthetic valve hemolysis
Abdomen	Hepatomegaly	Hemolysis, infiltrative tumor, chronic disease, hemangioma, cholecystitis
	Splenomegaly	Acquired hemolytic anemia, inherited hemolytic anemia (hereditary spherocytosis, pyruvate kinase deficiency, sickle cell disease [age of presentation varies based on phenotype]), thalassemia, malaria, leukemia/lymphoma, Epstein-Barr virus, portal hypertension, hemophagocytic syndromes
	Nephromegaly	Fanconi anemia
	Absent kidney	Fanconi anemia
Extremities	Absent thumbs	Fanconi anemia
	Thenar eminence hypoplasia: triphalangeal thumb	Diamond-Blackfan anemia
	Spoon nails	Iron deficiency
	Beau line (nails)	Heavy metal intoxication, severe illness
	Mees line (nails)	Heavy metals, severe illness, sickle cell disease
	Dystrophic nails	Dyskeratosis congenita
	Edema	Milk-induced protein-losing enteropathy with iron deficiency, renal failure
Rectal	Hemorrhoids	Portal hypertension
	Heme-positive stool	Intestinal hemorrhage
Nerves	Irritable, apathy	Iron deficiency
	Peripheral neuropathy	Deficiency of vitamins B_1 and B_{12}, lead poisoning
	Dementia	Deficiency of vitamins B_{12} and E
	Ataxia, posterior column signs	Deficiency of vitamins B_{12} and E
	Stroke	Sickle cell disease, paroxysmal nocturnal hemoglobinuria

Adapted from Scott JP. Hematology. In: Behrman RE, Kliegman RM, eds. *Nelson Essentials of Pediatrics*, 2nd ed. Philadelphia: Saunders, 1994: p. 520.

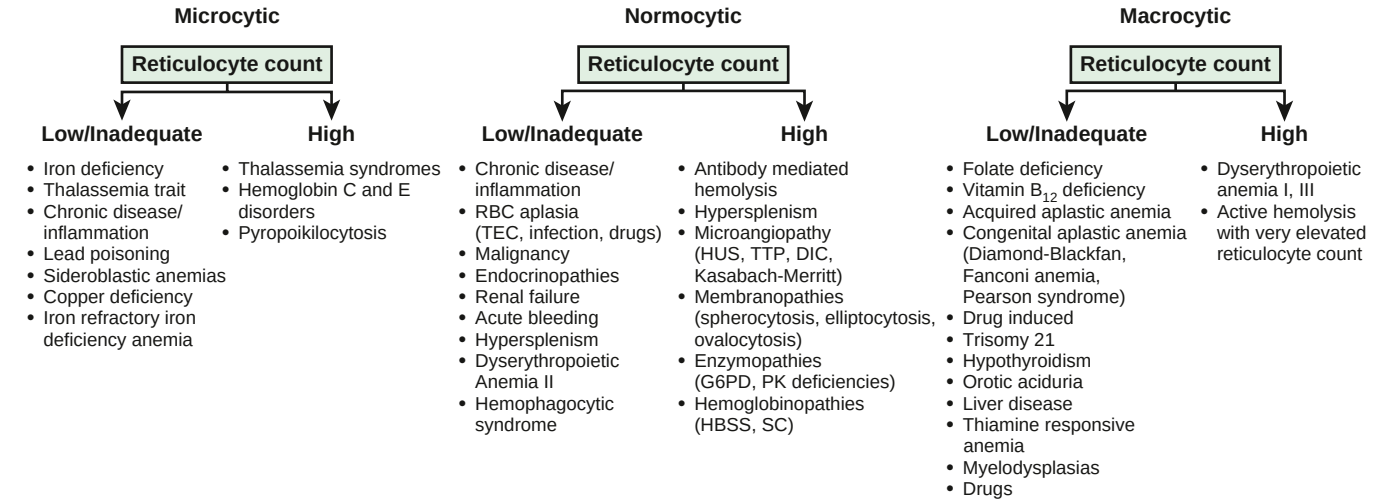

Fig. 496.3 Use of the mean corpuscular volume (MCV) and reticulocyte count in the diagnosis of anemia. *(Adapted from Brunetti M, Cohen J. The Harriet Lane Handbook, 17th ed. Philadelphia: Mosby, 2005. p. 338.)*

Table 496.4 Causes of High or Low Mean Corpuscular Volume

LOW MEAN CORPUSCULAR VOLUME
Iron deficiency
Thalassemias
Lead toxicity
Anemia of chronic disease
Copper deficiency
Sideroblastic anemia
Hemoglobin E
Hereditary pyropoikilocytosis
HIGH MEAN CORPUSCULAR VOLUME
Normal newborn
Elevated reticulocyte count
Vitamin B_{12} or folate deficiency
Diamond-Blackfan anemia (congenital hypoplastic anemia)
Fanconi anemia
Aplastic anemia
Down syndrome
Hypothyroidism (occasionally)
Orotic aciduria
Lesch-Nyhan syndrome
Drugs (zidovudine, chemotherapy)
Chronic liver disease
Paroxysmal nocturnal hemoglobinuria
Thiamine-responsive megaloblastic anemia
Myelodysplasias
Dyserythropoietic anemias

From Kliegman RM, Toth H, Bordini BJ, Basel D, eds. *Nelson Pediatric Symptom-Based Diagnosis: Common Diseases and Their Mimics.* 2nd ed. Philadelphia: Elsevier, 2023: Table 49.5, p. 910.

hemoglobin C and E (see Chapter 511). Notably, thalassemias and hemoglobinopathies are most often seen in patients of Mediterranean, Middle Eastern, African, or Asian descent.

Normocytic anemia and low reticulocyte count characterize many anemias. The **anemia of chronic disease/inflammation** is usually normocytic (see Chapter 504). The anemia associated with renal failure, primarily a result of reduced EPO production, will invariably be associated with clinical and laboratory evidence of significant kidney disease. Decreased or absent RBC production secondary to transient erythroblastopenia of childhood (see Chapter 499), infection, medications, or endocrinopathy usually results in a normocytic anemia, as does bone marrow infiltration by malignancy. Normocytic anemia in combination with leukopenia (or significant leukocytosis with blasts) and/or thrombocytopenia should raise suspicion for malignancy. See Chapters 517 and 518 to review pancytopenias. Acute bleeding, hypersplenism, and congenital dyserythropoietic anemia type II are also normocytic (see Chapter 501).

In children with normocytic anemia and an appropriate (high) reticulocyte response, the anemia is usually caused by bleeding, hypersplenism, or ongoing hemolysis. In hemolytic conditions, reticulocytosis, indirect hyperbilirubinemia, and increased serum lactate dehydrogenase are indicators of accelerated erythrocyte destruction. Many causes of hemolysis result from conditions that are extrinsic (usually acquired) or intrinsic (usually congenital) to the erythrocyte. Abnormal RBC morphology (e.g., spherocytes, dacryocytes or sickle forms, and schistocytes) identified on the peripheral smear is often helpful in ascertaining the cause.

The anemia seen in children with macrocytic blood cells is sometimes megaloblastic, resulting from impaired DNA synthesis and nuclear development (see Chapter 503). The peripheral blood smear in **megaloblastic anemias** contains large macroovalocytes, and the neutrophils often show nuclear hypersegmentation. The major causes of megaloblastic anemia include folate deficiency, vitamin B_{12} deficiency, and rare inborn errors of metabolism. Other **macrocytic anemias** with low or normal reticulocyte counts include acquired and congenital (Diamond-Blackfan anemia and Fanconi anemia) aplastic anemias and hypothyroidism. Patients with trisomy 21 have macrocytic cells, although an accompanying anemia is generally not present. High MCV and reticulocytosis is seen in congenital dyserythropoietic anemias I and III and in situations where hemolysis results in such a large outpouring of young red cells that the MCV is abnormally high.

Visit Elsevier eBooks+ at eBooks.Health.Elsevier.com for Bibliography.

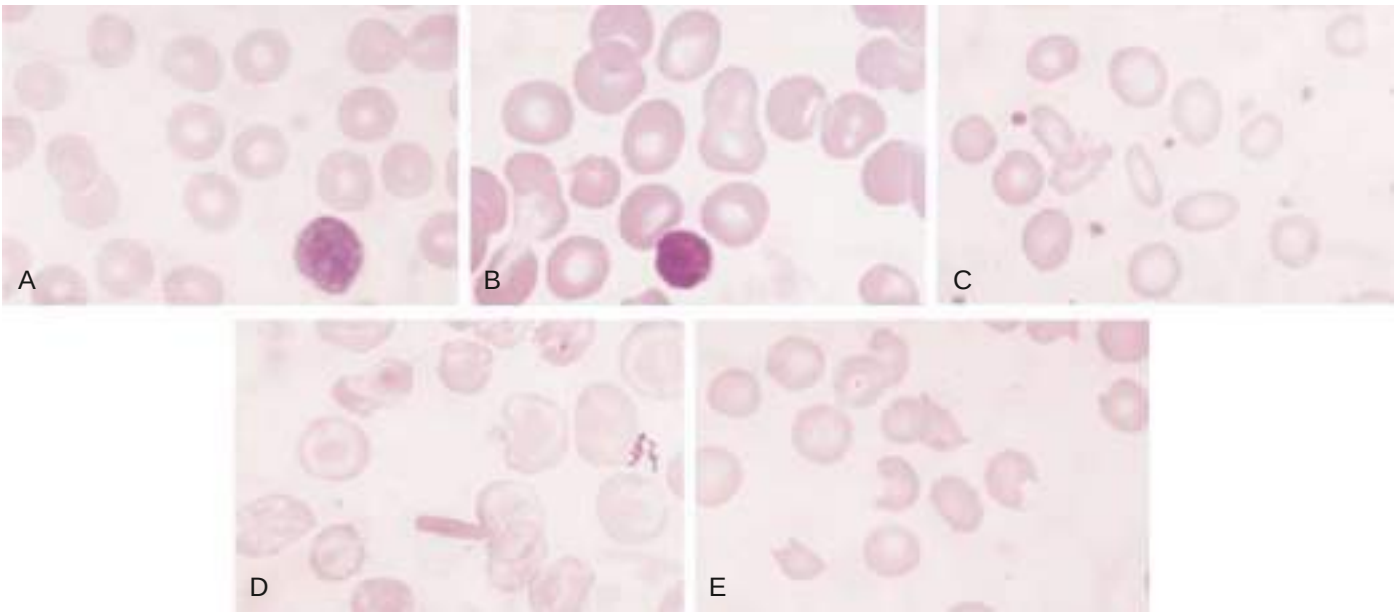

Fig. 496.4 Morphologic abnormalities of the red blood cell. **A,** Normal. **B,** Macrocytes (folic acid or vitamin B_{12} deficiency). **C,** Hypochromic microcytes (iron deficiency). **D,** Target cells (HbCC disease). **E,** Schistocyte (hemolytic-uremic syndrome). *(Courtesy Dr. Elias Schwartz, Children's Hospital of Philadelphia.)*

Table 496.5 Peripheral Blood Morphologic Findings in Various Anemias

MICROCYTES Iron deficiency Thalassemias Lead toxicity Anemia of chronic disease	**BASOPHIL STIPPLING** Thalassemia Lead intoxication Myelodysplasia
MACROCYTES Newborns Vitamin B_{12} or folate deficiency Diamond-Blackfan anemia Fanconi anemia Aplastic anemia Liver disease Down syndrome Hypothyroidism	**RED BLOOD CELL FRAGMENTS, HELMET CELLS, BURR CELLS** Disseminated intravascular coagulation Hemolytic uremic syndrome Thrombotic thrombocytopenic purpura Kasabach-Merritt syndrome Waring blender syndrome (artificial heart valve) Uremia Liver disease
SPHEROCYTES Hereditary spherocytosis Immune hemolytic anemia (newborn or acquired) Hypersplenism	**HYPERSEGMENTED NEUTROPHILS** Vitamin B_{12} or folate deficiency
SICKLED CELLS Sickle cell anemias (SS disease, SC disease, $S\beta^+$ thalassemia, $S\beta^0$ thalassemia)	**BLASTS** Leukemia (ALL or AML) Severe infection (rarely)
ELLIPTOCYTES Hereditary elliptocytosis Iron deficiency Megaloblastic anemia	**LEUKOPENIA/THROMBOCYTOPENIA** Fanconi anemia Aplastic anemia Leukemia Hemophagocytic histiocytosis
TARGET CELLS Hemoglobinopathies (especially hemoglobin C and SC and thalassemia) Liver disease Xerocytosis	**HOWELL-JOLLY BODIES** Asplenia, hyposplenia Severe iron deficiency
	DACROCYTES (TEARDROP CELLS) Myelodysplasia Leukemia Neuroblastoma

ALL, Acute lymphocytic leukemia; AML, acute myeloid leukemia; SC, sickle cell C disease; SS, sickle cell S disease.
From Kliegman RM, Toth H, Bordini BJ, Basel D, eds. *Nelson Pediatric Symptom-Based Diagnosis: Common Diseases and Their Mimics.* 2nd ed. Philadelphia: Elsevier, 2023: Table 49.7, p. 910.

Section 2

Anemias of Inadequate Production

Chapter 497

Congenital Hypoplastic Anemia (Diamond-Blackfan Anemia)

Courtney D. Thornburg

Diamond-Blackfan anemia (DBA) is a rare, congenital **bone marrow failure syndrome** that usually becomes symptomatic in early infancy. More than 90% of cases are recognized in the first year of life. The disorder is characterized by anemia, usually normochromic and macrocytic; reticulocytopenia; and insufficient or absent red blood cell (RBC) precursors in an otherwise normally cellular bone marrow. Up to 50% of affected individuals have additional, extrahematopoietic anomalies.

ETIOLOGY

The most common DBA-associated pathogenic variants are in *RPS19* (Fig. 497.1). This gene encodes a component protein of the small 40S ribosomal subunit and pathogenic variants are present in approximately 25–30% of patients with additional ribosomal protein (RP) genes, each encoding a different small (40S) or large (60S) ribosomal subunit protein, implicated as well. All of these pathogenic variants are inherited in an autosomal dominant fashion, with 40–45% of cases inherited from a parent and 55–60% with a de novo pathogenic variant. Less frequently, X-linked inherited cases of DBA involve pathologic genetic variants in *GATA1* or *TSR2*. Patients with *GATA1*-related DBA usually have no extra hematopoietic manifestations (Fig. 497.2). *TSR2*-related DBA is associated with mandibulofacial dysostosis. Approximately 20% of cases do not have an identified genetic variant. Because most causative variants are in ribosomal genes, the disorder is often referred to as a **ribosomopathy**.

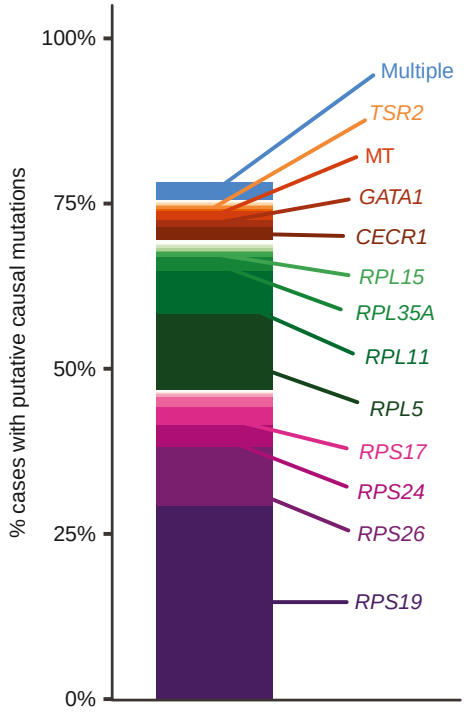

Fig. 497.1 Mutational spectrum of likely pathogenic variants in DBA. Percentage of putative causal mutations in each gene. A total of 78% of case subjects have a putative causal mutation. *(Modified from Ulirsch JC, Verboon JM, Kazerounian S, et al. The genetic landscape of Diamond-Blackfan anemia. Am J Hum Genetics 2018;103:930–947, Fig.1.)*

EPIDEMIOLOGY

DBA affects about 5-10 individuals per million live births. Notably, there is substantial phenotypic diversity in DBA, even in families whose members share the same pathologic genetic variant, suggesting that additional genetic modifiers affect phenotypic expression of the disease.

CLINICAL MANIFESTATIONS

Profound anemia usually becomes evident by 2-6 months of age, occasionally somewhat later. Approximately 25% of patients are anemic at birth, although hydrops fetalis occurs rarely; 92% are diagnosed within the first year of life. Approximately 40–50% of patients have congenital anomalies, and more than one anomaly is found in 25% of DBA patients (Table 497.1). Craniofacial abnormalities are the most common (50% of patients) and include a depressed nasal bridge and high-arched palate. Skeletal anomalies, mostly upper limb and hand, affect 30–40%. This includes thumb abnormalities, including flattening of the thenar eminence and triphalangeal thumb, that may be bilateral or unilateral. The radial pulse may be absent. Genitourinary (39%), cardiac (30%), ophthalmologic, and musculoskeletal anomalies have also been described. Short stature is common, but it is often unclear whether this characteristic results from the disease itself, related therapies, or both.

LABORATORY FINDINGS

The RBCs are usually macrocytic for age, but no hypersegmented neutrophils or other characteristics of megaloblastic anemia are appreciated on the peripheral blood smear. RBC characteristics are like those of a "fetal" RBC population, with increased expression of "i" antigen and elevated fetal hemoglobin (HbF). **Erythrocyte adenosine deaminase** (eADA) activity is increased in most patients with DBA, a finding that helps distinguish congenital RBC aplasia from acquired **transient erythroblastopenia of childhood** (TEC) (see Chapter 499). Because elevated eADA activity is not a fetal RBC feature, measurement of this enzyme may be particularly helpful when diagnosing DBA in very young infants. Thrombocytosis,

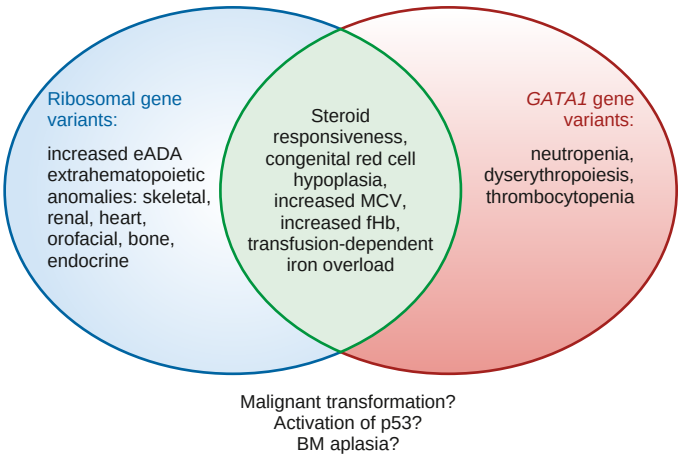

Fig. 497.2 Common and distinct phenotypes in congenital red cell aplasia caused by variants in *RP* genes and in *GATA1*. BM, Bone marrow; eADA, erythrocyte adenosine deaminase activity; fHb, fetal hemoglobin; MCV, mean corpuscular volume. *(Adapted from Weiss MJ, Mason PJ, Bessler M. What's in a name? J Clin Invest 2012;122:2346–2349.)*

or rarely thrombocytopenia, and occasionally neutropenia, may also be present. **Reticulocytopenia** is characteristic despite severe anemia. Bone marrow erythrocyte precursors are greatly reduced in most patients; other marrow elements are usually normal. Serum iron levels are elevated. Unlike Fanconi anemia, there is no increase in chromosomal breaks when lymphocytes are exposed to alkylating agents. Table 497.2 outlines suggested diagnostic criteria for "classical" DBA. Patients may be diagnosed with "nonclassical" DBA or "probable" DBA depending on their individual genetic test results, family history, and major and minor criteria.

Table 497.1 Range of Congenital Anomalies Observed in Diamond-Blackfan Anemia

TYPE/LOCATION	ANOMALIES
Craniofacial	Hypertelorism Broad, flat nasal bridge Cleft palate High-arched palate Microcephaly Micrognathia Microtia Low-set ears Low hairline Ptosis
Ophthalmologic	Congenital glaucoma Strabismus Epicanthal folds Congenital cataract
Neck	Short neck Webbed neck Sprengel deformity Klippel-Feil deformity
Thumbs	Triphalangeal Duplex or bifid Hypoplastic Flat thenar eminence Absent radial artery
Urogenital	Absent kidney Horseshoe kidney Hypospadias
Cardiac	Ventricular septal defect Atrial septal defect Coarctation of the aorta Complex cardiac anomalies
Other	Low birth weight Short stature Syndactyly Learning difficulties

Multiple anomalies, most often including craniofacial, are present in up to 25% of affected individuals. At least one anomaly is present in 40–50%.
From Vlachos A, Ball S, Dahl N, et al. Diagnosing and treating Diamond-Blackfan anaemia: Results of an international clinical consensus conference. *Br J Haematol* 2008;142: 859–876, Table IV.

DIFFERENTIAL DIAGNOSIS

DBA must be differentiated from other anemias associated with reticulocytopenia. The syndrome of TEC is often the primary alternative diagnosis. Table 499.1 shows a useful comparison of findings in these two disorders (see Chapter 499). TEC often is differentiated from DBA by its relatively late onset, although it occasionally develops in infants younger than 6 months of age. Macrocytosis, congenital anomalies, fetal RBC characteristics, and elevated eADA are generally associated with DBA and not TEC.

Other inherited macrocytic bone marrow failure syndromes, particularly **Fanconi anemia** and **Shwachman-Diamond syndrome** (see Chapter 517), should also be considered, as should myelodysplastic syndrome. **Aase syndrome** includes congenital RBC aplasia with triphalangeal thumb, congenital heart disease, and cleft palate. **Hemolytic disease of the newborn** can also mimic features of DBA because it can have a protracted course and can be coupled with greatly reduced erythropoiesis. The anemia in this disorder usually resolves spontaneously at 5-8 weeks of age. Several types of chronic hemolytic diseases may be complicated by an **aplastic crisis**, characterized by reticulocytopenia and decreased numbers of RBC precursors. This event usually occurs after the first several months of life and is often caused by **parvovirus B19 infection** (see Chapter 499). Infection with parvovirus B19 in utero is also associated with pure RBC aplasia in infancy and even with hydrops fetalis at birth (see Chapter 298). When diagnosing DBA in young infants, it is important to rule out parvovirus B19 infection using a polymerase chain reaction assay because serologic testing may be inaccurate. Other infections, including HIV, as well as drugs, immune processes, and Pearson syndrome (see Chapter 498), should also be ruled out.

TREATMENT

Corticosteroids are a mainstay of therapy, and approximately 80% of patients initially respond. Because corticosteroids impair linear growth as well as physical and neurocognitive development, many hematologists maintain infants on chronic transfusion therapy and delay the start of steroids until after age 1 year. Prednisone or prednisolone in doses totaling 2 mg/kg/day is used as an initial trial. An increase in RBC precursors is usually seen in the bone marrow 1-3 weeks after therapy is begun and is followed by peripheral reticulocytosis. The hemoglobin can reach normal levels in 4-6 weeks, although the rate of response is quite variable. Once it is established that the hemoglobin concentration is increasing, the dose of corticosteroid may be reduced gradually by tapering and then by eliminating all except a single, lowest effective daily dose. This dose may

Table 497.2 Diagnostic Criteria for Diamond-Blackfan Anemia

DIAGNOSTIC CRITERIA	SUPPORTING CRITERIA: MAJOR CRITERIA	SUPPORTING CRITERIA: MINOR CRITERIA
Age younger than 1 yr	Pathogenic variant described in "classical DBA"	Elevated red cell adenosine deaminase
Macrocytic anemia with no other significant cytopenias	Positive family history	Congenital anomalies described in "classical" DBA
Reticulocytopenia		Elevated HbF
Normal marrow cellularity with paucity of bone marrow erythroid precursors		No evidence for another inherited bone marrow failure syndrome

"Classical DBA" diagnosis is made if all the diagnostic criteria are met.
DBA, Diamond Blackfan anemia, HbF, fetal hemoglobin.
From Vlachos A, Ball S, Dahl N, et al. Diagnosing and treating Diamond-Blackfan anaemia: results of an international clinical consensus conference. *Br J Haematol* 2008;142:859–876.

then be doubled, used on alternate days, and tapered still further while maintaining the hemoglobin level at ≥9 g/dL. The target maintenance dose should not exceed 0.5 mg/kg/day or 1 mg/kg every other day. In some patients, very small amounts of prednisone, as low as 2.5 mg twice a week, may be sufficient to sustain adequate erythropoiesis. Scheduled surveillance examinations and testing for corticosteroid side effects should be pursued in all patients, regardless of dose. Appropriate *Pneumocystis jiroveci* prophylaxis should be considered after the first month of high-dose steroids and continued until the patient is on low-dose alternate-day therapy. In the setting of illness, stress steroids should be considered for children on chronic corticosteroids. Many children with DBA stop taking corticosteroids, usually because of unacceptable side effects (i.e., cushingoid features, pathologic fractures, cataracts) or the evolution of corticosteroid refractoriness.

Chronic red cell transfusions are required in approximately 35% of patients, including patients who are never steroid responsive (30%), are steroid refractory (15%), or cannot be weaned to acceptable low dose (50%). Transfusions are given at intervals of 3-5 weeks to maintain a hemoglobin level >8 g/dL. Some younger children may require hemoglobin >9 g/dL to sustain normal growth and activities. Appropriate screening and ultimately the initiation of chelation therapy are required for transfusion-related iron overload.

L-leucine (700 mg/m^2 orally three times per day) has been evaluated in a phase I/II trial patients with DBA 2 years of age and older. In 43 evaluable patients, 16% had erythroid response, 36% had increase in weight, and 44% had an increase in linear growth velocity.

Spontaneous remission of anemia with independence from steroid or red cell transfusion therapy has been reported. The likelihood of remission is 25% by age 25 years, with most of these patients experiencing remission during the first decade. Mild macrocytic anemia and increased erythrocyte ADA levels persist in these circumstances.

Hematopoietic stem cell transplantation (HSCT) can be curative. Indications for HSCT include steroid resistance or unacceptable toxicity and transfusion dependence as well as significant complications of chronic red cell transfusions including iron overload and alloimmunizations. HLA-matched sibling HSCT is recommended for transfusion-dependent children with DBA. One recommendation is for HSCT between ages 3 and 9 years, and some advocate HSCT at a younger age to avoid iron overload and allosensitization from chronic red cell transfusions. It is important that sibling donors be carefully screened, including genotype if known, to ensure that the donor does not carry the pathologic genetic variant. Overall, outcomes are improving for matched-sibling and alternative donor HSCT.

PROGNOSIS

DBA has been identified as a **cancer predisposition syndrome** because of the higher risk of myelodysplastic syndrome, acute myeloid leukemia, colon carcinoma, osteogenic sarcoma, and female genital cancers. Patients are at risk for iron overload-related endocrine abnormalities (diabetes, hypogonadism), especially if transfused. Patients who have undergone HSCT are at risk of associated late effects (see Chapters 179, 180, and 181). The overall actuarial survival of all patients with DBA is approximately 75% at age 40 years, with approximately 87% for those maintained on corticosteroids and approximately 57% for transfusion-dependent patients. Of reported deaths, 67% were treatment related and 22% were DBA related (malignancy and severe aplastic anemia).

Treatment outcome and survival data are collected through the Diamond-Blackfan Anemia Registry (https://www.dbar.org).

Visit Elsevier eBooks+ at eBooks.Health.Elsevier.com for Bibliography.

Chapter 498

Pearson Syndrome

Courtney D. Thornburg

Pearson syndrome (PS) is a rare multisystem mitochondrial disorder that presents with a hypoplastic anemia that may be initially confused with Diamond-Blackfan syndrome (anemia) or transient erythroblastopenia of childhood (see Chapter 499). The marrow failure usually appears in the neonatal period and is characterized by a *sideroblastic macrocytic anemia* and, occasionally, neutropenia and thrombocytopenia. There are vacuolated erythroblasts and myeloblasts in the bone marrow (Fig. 498.1). PS is considered a unique variant of congenital sideroblastic anemia because the marrow also contains ringed sideroblasts. The hemoglobin F level is elevated. There is multiorgan involvement manifested by failure to thrive and symptoms of exocrine pancreas dysfunction, liver and renal tubular defects, malabsorption, and myopathy. Endocrine dysfunction (type 1 diabetes, adrenal insufficiency, hypoparathyroidism, and hypothyroidism) has also been reported. Children that survive early childhood typically develop **Kearns-Sayre syndrome**, an early-onset, mitochondrial disorder with lactic acidosis, progressive external ophthalmoplegia (impaired eye movement and ptosis), pigmentary retinitis, deafness, cerebellar ataxia, and heart block. Pearson syndrome is caused by a large heteroplasmic **mitochondrial DNA (mtDNA) deletion** (see Chapter 108) that predominates in the hematopoietic lineage. Subsequently, there is heterogeneity in different tissues and between patients, accounting for the variable clinical picture. The proportion of deleted mtDNA in the bone marrow correlates with the severity of the hematologic disease, and a reduction in the percentage of deleted mtDNA over time may be associated with spontaneous improvement of red blood cell hypoproliferation. PS may be misdiagnosed as Diamond-Blackfan anemia (DBA) based on the overlapping features, including severe anemia starting at a young age. Evaluation for mtDNA deletion differentiates PS from DBA (see Chapter 497).

Therapy for the hematologic manifestations of the disease includes red cell transfusions to correct anemia and granulocyte colony-stimulating factor in the setting of severe neutropenia. The hematologic manifestations may spontaneously resolve within the first few years of life and stem cell transplantation may be considered for persistent cytopenias.

Visit Elsevier eBooks+ at eBooks.Health.Elsevier.com for Bibliography.

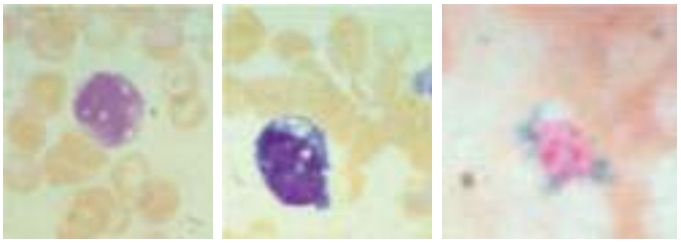

Fig. 498.1 Bone marrow morphology in Pearson syndrome. *Left,* Vacuoles in myeloid precursor. *Center,* Vacuoles in erythroid precursor. *Right,* Ringed sideroblast. (*From Shimamura A, Alter BP. Pathophysiology and management of inherited bone marrow failure syndromes. Blood Rev 2010;24:101–122; Fig 14.*)

then be doubled, used on alternate days, and tapered still further while maintaining the hemoglobin level at ≥9 g/dL. The target maintenance dose should not exceed 0.5 mg/kg/day or 1 mg/kg every other day. In some patients, very small amounts of prednisone, as low as 2.5 mg twice a week, may be sufficient to sustain adequate erythropoiesis. Scheduled surveillance examinations and testing for corticosteroid side effects should be pursued in all patients, regardless of dose. Appropriate *Pneumocystis jiroveci* prophylaxis should be considered after the first month of high-dose steroids and continued until the patient is on low-dose alternate-day therapy. In the setting of illness, stress steroids should be considered for children on chronic corticosteroids. Many children with DBA stop taking corticosteroids, usually because of unacceptable side effects (i.e., cushingoid features, pathologic fractures, cataracts) or the evolution of corticosteroid refractoriness.

Chronic red cell transfusions are required in approximately 35% of patients, including patients who are never steroid responsive (30%), are steroid refractory (15%), or cannot be weaned to acceptable low dose (50%). Transfusions are given at intervals of 3-5 weeks to maintain a hemoglobin level >8 g/dL. Some younger children may require hemoglobin >9 g/dL to sustain normal growth and activities. Appropriate screening and ultimately the initiation of chelation therapy are required for transfusion-related iron overload.

L-leucine (700 mg/m^2 orally three times per day) has been evaluated in a phase I/II trial patients with DBA 2 years of age and older. In 43 evaluable patients, 16% had erythroid response, 36% had increase in weight, and 44% had an increase in linear growth velocity.

Spontaneous remission of anemia with independence from steroid or red cell transfusion therapy has been reported. The likelihood of remission is 25% by age 25 years, with most of these patients experiencing remission during the first decade. Mild macrocytic anemia and increased erythrocyte ADA levels persist in these circumstances.

Hematopoietic stem cell transplantation (HSCT) can be curative. Indications for HSCT include steroid resistance or unacceptable toxicity and transfusion dependence as well as significant complications of chronic red cell transfusions including iron overload and alloimmunizations. HLA-matched sibling HSCT is recommended for transfusion-dependent children with DBA. One recommendation is for HSCT between ages 3 and 9 years, and some advocate HSCT at a younger age to avoid iron overload and allosensitization from chronic red cell transfusions. It is important that sibling donors be carefully screened, including genotype if known, to ensure that the donor does not carry the pathologic genetic variant. Overall, outcomes are improving for matched-sibling and alternative donor HSCT.

PROGNOSIS

DBA has been identified as a **cancer predisposition syndrome** because of the higher risk of myelodysplastic syndrome, acute myeloid leukemia, colon carcinoma, osteogenic sarcoma, and female genital cancers. Patients are at risk for iron overload-related endocrine abnormalities (diabetes, hypogonadism), especially if transfused. Patients who have undergone HSCT are at risk of associated late effects (see Chapters 179, 180, and 181). The overall actuarial survival of all patients with DBA is approximately 75% at age 40 years, with approximately 87% for those maintained on corticosteroids and approximately 57% for transfusion-dependent patients. Of reported deaths, 67% were treatment related and 22% were DBA related (malignancy and severe aplastic anemia).

Treatment outcome and survival data are collected through the Diamond-Blackfan Anemia Registry (https://www.dbar.org).

Visit Elsevier eBooks+ at eBooks.Health.Elsevier.com for Bibliography.

Chapter 498

Pearson Syndrome

Courtney D. Thornburg

Pearson syndrome (PS) is a rare multisystem mitochondrial disorder that presents with a hypoplastic anemia that may be initially confused with Diamond-Blackfan syndrome (anemia) or transient erythroblastopenia of childhood (see Chapter 499). The marrow failure usually appears in the neonatal period and is characterized by a *sideroblastic macrocytic anemia* and, occasionally, neutropenia and thrombocytopenia. There are vacuolated erythroblasts and myeloblasts in the bone marrow (Fig. 498.1). PS is considered a unique variant of congenital sideroblastic anemia because the marrow also contains ringed sideroblasts. The hemoglobin F level is elevated. There is multiorgan involvement manifested by failure to thrive and symptoms of exocrine pancreas dysfunction, liver and renal tubular defects, malabsorption, and myopathy. Endocrine dysfunction (type 1 diabetes, adrenal insufficiency, hypoparathyroidism, and hypothyroidism) has also been reported. Children that survive early childhood typically develop **Kearns-Sayre syndrome**, an early-onset, mitochondrial disorder with lactic acidosis, progressive external ophthalmoplegia (impaired eye movement and ptosis), pigmentary retinitis, deafness, cerebellar ataxia, and heart block. Pearson syndrome is caused by a large heteroplasmic **mitochondrial DNA (mtDNA) deletion** (see Chapter 108) that predominates in the hematopoietic lineage. Subsequently, there is heterogeneity in different tissues and between patients, accounting for the variable clinical picture. The proportion of deleted mtDNA in the bone marrow correlates with the severity of the hematologic disease, and a reduction in the percentage of deleted mtDNA over time may be associated with spontaneous improvement of red blood cell hypoproliferation. PS may be misdiagnosed as Diamond-Blackfan anemia (DBA) based on the overlapping features, including severe anemia starting at a young age. Evaluation for mtDNA deletion differentiates PS from DBA (see Chapter 497).

Therapy for the hematologic manifestations of the disease includes red cell transfusions to correct anemia and granulocyte colony-stimulating factor in the setting of severe neutropenia. The hematologic manifestations may spontaneously resolve within the first few years of life and stem cell transplantation may be considered for persistent cytopenias.

Visit Elsevier eBooks+ at eBooks.Health.Elsevier.com for Bibliography.

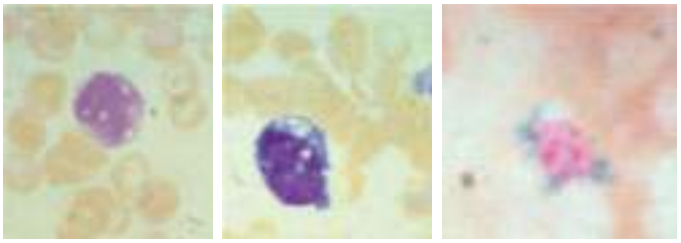

Fig. 498.1 Bone marrow morphology in Pearson syndrome. *Left,* Vacuoles in myeloid precursor. *Center,* Vacuoles in erythroid precursor. *Right,* Ringed sideroblast. (*From Shimamura A, Alter BP. Pathophysiology and management of inherited bone marrow failure syndromes. Blood Rev 2010;24:101–122; Fig 14.*)

Chapter 499

Acquired Pure Red Blood Cell Anemia

Courtney D. Thornburg

TRANSIENT ERYTHROBLASTOPENIA OF CHILDHOOD

Transient erythroblastopenia of childhood **(TEC)** is the most common *acquired red cell aplasia* occurring in children. It is more prevalent than congenital hypoplastic anemia (Diamond-Blackfan anemia [DBA]). This syndrome of severe *transient hypoplastic anemia* occurs mainly in previously healthy children between 6 months and 3 years of age. Most children are older than 12 months at onset. Only 10% of affected patients are more than 3 years of age. The annual incidence is estimated to be 4.3 cases per 100,000 children, although it is likely higher, because TEC often resolves spontaneously with many cases undiagnosed. The suppression of erythropoiesis has been linked to IgG, IgM, and cell-mediated mechanisms. Familial cases have been reported, suggesting a hereditary component. TEC often follows a viral illness, although no specific virus has been consistently implicated.

The temporary suppression of erythropoiesis results in reticulocytopenia and moderate to severe normocytic anemia. Some degree of neutropenia occurs in up to 20% of cases. Platelet numbers are normal or elevated. Like the situation observed in iron-deficiency anemia and other red blood cell (RBC) hypoplasias, thrombocytosis is presumably caused by increased erythropoietin (EPO), which has homology to thrombopoietin (TPO). Mean corpuscular volume (MCV) is characteristically normal for age, and fetal hemoglobin (HbF) levels are normal before the recovery phase. RBC adenosine deaminase levels are normal in TEC, thus contrasting with the elevation noted in most cases of congenital hypoplastic anemia (Table 499.1). Differentiation from DBA is sometimes difficult, but differences in age at onset and in age-related MCV, HbF, and adenosine deaminase are usually helpful. The peak occurrence of TEC coincides with that of iron-deficiency anemia in infants receiving milk as their main caloric source; differences in MCV should help to distinguish between TEC and DBA.

Virtually all children recover within 1-2 months. RBC transfusions may be necessary for severe anemia in the absence of signs of early recovery. The anemia develops slowly, and significant symptoms usually develop only with severe anemia. *Corticosteroid therapy is of no value in this disorder.* Any child with presumed TEC who requires more than one transfusion should be reevaluated for another possible diagnosis. In rare instances, a prolonged case of apparent TEC may be caused by parvovirus-induced RBC aplasia, occurring in children with *hemolytic anemia* or *congenital* or *acquired immunodeficiencies*.

RED CELL APLASIA ASSOCIATED WITH PARVOVIRUS B19 INFECTION

Parvovirus B19 is a common infectious agent that causes **erythema infectiosum** (fifth disease) (see Chapter 298). It is also the most clearly documented viral cause of RBC aplasia in patients with chronic hemolytic anemia or an immunocompromised state. This single-stranded virus is cytotoxic to marrow erythroid progenitor cells, interacting specifically by binding to the red cell P antigen. In addition to decreased or absent erythroid precursors, characteristic nuclear inclusions in erythroblasts and giant pronormoblasts may be seen under light microscopy in bone marrow specimens. The virus does not cause significant anemia in immunocompetent individuals with a normal RBC life span.

Because parvovirus infection usually lasts less than 2 weeks, anemia may not develop or be appreciated in otherwise normal children whose peripheral RBC life span is 100-120 days. The RBC life span is much shorter in patients with **chronic hemolysis** secondary to conditions such as hereditary spherocytosis, immune hemolytic anemia, or sickle cell disease. In these children, a brief cessation of erythropoiesis can cause severe anemia, known as **aplastic crisis**. When a definitive diagnosis is required, the workup should include

Table 499.1 Comparison of Diamond-Blackfan Anemia and Transient Erythroblastopenia of Childhood

FEATURE	DBA	TEC
Male:female	1:1	1:3
AGE AT DIAGNOSIS, MALE (MO)		
Mean	10	26
Median	2	23
Range	0-408	1-120
AGE AT DIAGNOSIS, FEMALE (MO)		
Mean	14	26
Median	3	23
Range	0-768	1-192
Males >1 yr	9%	82%
Females >1 yr	12%	80%
Etiology	Genetic	Acquired, possibly familial
Antecedent history	None	Viral illness
Physical examination abnormal (congenital anomalies present)	25%	0%
LABORATORY		
Hemoglobin (g/dL)	1.2-14.8	2.2-12.5
WBCs <5,000/μL	15%	20%
Platelets >400,000/μL	20%	45%
Adenosine deaminase	Increased	Normal
MCV increased at diagnosis	80%	5%
MCV increased during recovery	100%	90%
MCV increased in remission	100%	0%
HbF increased at diagnosis	100%	20%
HbF increased during recovery	100%	100%
HbF increased in remission	85%	0%
i Antigen increased	100%	20%
i Antigen increased during recovery	100%	60%
i Antigen increased in remission	90%	0%

DBA, Diamond-Blackfan anemia; HbF, fetal hemoglobin; MCV, mean cell volume; TEC, transient erythroblastopenia of childhood; WBC, white blood cell.

From Nathan DG, Orkin SH, Ginsburg D, et al., eds. *Nathan and Oski's Hematology of Infancy and Childhood*. 6th ed. Philadelphia: Saunders; 2003, p. 329. Adapted from Alter BP. The bone marrow failure syndromes. In: Nathan DG, Oski FA, eds. *Hematology of Infancy and Childhood*. 3rd ed. Philadelphia: Saunders; 1987. p 159; and Link MP, Alter BP. Fetal erythropoiesis during recovery from transient erythroblastopenia of childhood (TEC). *Pediatr Res* 1981;15:1036–1039.

serum parvovirus IgM and IgG titers. In young infants, a polymerase chain reaction (PCR) assay should be used since serologic testing may be inaccurate. Recovery from moderate to severe anemia is usually spontaneous, heralded by the appearance of nucleated RBCs and subsequent reticulocytosis in the peripheral blood. Nonetheless the parvovirus PCR may remain positive for months after recovery. An RBC transfusion may be necessary if the anemia is associated with significant symptoms. Parvovirus-induced aplastic crisis usually occurs only once in children with chronic hemolysis. In families with more than one child with a hemolytic disorder, parents should be warned that a similar aplastic episode can occur in the other children if they have not been previously infected. During the episode of aplastic crisis, the child is potentially contagious and should be isolated from at-risk patients.

Persistent parvovirus infection may occur in children with congenital immunodeficiency diseases, lymphoproliferative disorders, those being treated with immunosuppressive agents, and those with HIV/AIDS, because these children may be unable to mount an adequate antibody response. The resultant pure RBC aplasia may be severe, and affected children may be thought to have TEC. This type of RBC aplasia differs from TEC in that there is no spontaneous recovery, and more than one transfusion is often needed. The diagnosis of parvovirus infection is made by PCR of peripheral blood or bone marrow DNA because the usual serologic responses, reflected by parvovirus serum IgM or IgG titers, are impaired in immunodeficient children. In chronically infected patients, the disease may be treated with high doses of intravenous immunoglobulin, which contains neutralizing antibody to parvovirus and is effective in the short term.

Parvovirus infection and destruction of erythroid precursors can also occur in utero. Such events are associated with increased rates of fetal loss in the first and second trimesters. Infants may be born with **hydrops fetalis** and anemia (see Chapter 138). The presence of persistent congenital parvovirus infection is detected by PCR of peripheral blood and/or bone marrow DNA because immunologic tolerance to the virus can prevent the usual development of specific antibodies.

OTHER RED CELL APLASIAS IN CHILDREN

Acquired red cell aplasia in adults is usually mediated by a chronic antibody and often associated with disorders such as chronic lymphocytic leukemia, lymphoma, thymoma, lymphoproliferative disorders, and systemic lupus erythematosus. This chronic antibody-mediated type of RBC aplasia, often responsive to immunosuppressive therapy, is quite rare in childhood. Cases of acquired pure RBC aplasia attributable to T-cell suppression have also been described.

Infections other than parvovirus, such as cytomegalovirus, Epstein-Barr virus, and human herpes virus-6, may cause pure RBC aplasia. Certain drugs, such as chloramphenicol, also can inhibit erythropoiesis in a dose-dependent manner. Reticulocytopenia, erythroid hypoplasia, and vacuolated pronormoblasts in the bone marrow are reversible effects of this drug. These effects are distinct from the idiosyncratic and rare development of severe aplastic anemia in chloramphenicol recipients. Acquired antibody-mediated (to erythropoietin) pure RBC aplasia is a rare complication in chronic kidney disease patients treated with erythropoietin. In addition to discontinuing erythropoiesis-stimulating agents, therapy and addressing anemia with red cell transfusions, further treatment may require immunosuppression and eventually renal transplantation.

Visit Elsevier eBooks+ at eBooks.Health.Elsevier.com for Bibliography.

Chapter 500

Anemia of Chronic Disease and Renal Disease

500.1 Anemia of Chronic Disease

Courtney D. Thornburg

The anemia of chronic disease **(ACD)**, also referred to as **anemia of inflammation**, is found in conditions where there is ongoing immune activation. It occurs in a wide range of disorders, including infections, malignancies, chronic disease, autoimmunity, and graft-versus-host disease. A similar anemia is associated with chronic kidney disease. ACD is typically a mild to moderate normocytic, normochromic, hypoproliferative anemia associated with a decreased serum iron and low transferrin saturation.

ETIOLOGY

Decreased red cell life span, impaired erythropoiesis, and an increased uptake of iron in the reticuloendothelial system are important mechanisms contributing to ACD.

ACD-associated alterations in iron recycling are characterized by an accumulation of iron in reticuloendothelial macrophages despite low levels of serum iron. The diversion of iron from the circulation into the reticuloendothelial system results in *functional* iron deficiency, which causes the impaired heme synthesis and iron-restricted erythropoiesis that contribute to anemia. These alterations in iron metabolism have been attributed to inflammation-associated excess synthesis of hepcidin, a key regulatory protein that controls intestinal iron absorption and tissue distribution. Hepcidin, although mainly synthesized by hepatocytes, is expressed in other cells, including monocytes and macrophages. It functions by binding to and initiating the degradation of the iron exporter, ferroportin (Fig. 500.1).

CLINICAL MANIFESTATIONS

Although the important symptoms and signs associated with ACD are those of the underlying disease, the mild to moderate anemia can affect the patient's quality of life.

LABORATORY FINDINGS

Hemoglobin concentrations are generally 6-9 g/dL. The anemia is usually normochromic and normocytic, although some patients have modest hypochromia and microcytosis, particularly if there is concomitant iron deficiency. Absolute reticulocyte counts are normal or low, and leukocytosis is common. The serum iron level is low, without the increase in serum transferrin (the iron transport protein) that occurs in iron deficiency. This pattern of low serum iron and low-to-normal serum transferrin is a valuable diagnostic feature. *However, note that the serum ferritin level may be elevated secondary to inflammation*. Soluble transferrin receptor (sTfR) is a useful diagnostic test to distinguish ACD from iron-deficiency anemia (IDA) because sTfR levels are high in IDA and normal in ACD. A bone marrow biopsy typically shows normal cellularity with decreased or adequate red blood cell precursors; marrow hemosiderin may be increased and granulocytic hyperplasia may be present.

serum parvovirus IgM and IgG titers. In young infants, a polymerase chain reaction (PCR) assay should be used since serologic testing may be inaccurate. Recovery from moderate to severe anemia is usually spontaneous, heralded by the appearance of nucleated RBCs and subsequent reticulocytosis in the peripheral blood. Nonetheless the parvovirus PCR may remain positive for months after recovery. An RBC transfusion may be necessary if the anemia is associated with significant symptoms. Parvovirus-induced aplastic crisis usually occurs only once in children with chronic hemolysis. In families with more than one child with a hemolytic disorder, parents should be warned that a similar aplastic episode can occur in the other children if they have not been previously infected. During the episode of aplastic crisis, the child is potentially contagious and should be isolated from at-risk patients.

Persistent parvovirus infection may occur in children with congenital immunodeficiency diseases, lymphoproliferative disorders, those being treated with immunosuppressive agents, and those with HIV/AIDS, because these children may be unable to mount an adequate antibody response. The resultant pure RBC aplasia may be severe, and affected children may be thought to have TEC. This type of RBC aplasia differs from TEC in that there is no spontaneous recovery, and more than one transfusion is often needed. The diagnosis of parvovirus infection is made by PCR of peripheral blood or bone marrow DNA because the usual serologic responses, reflected by parvovirus serum IgM or IgG titers, are impaired in immunodeficient children. In chronically infected patients, the disease may be treated with high doses of intravenous immunoglobulin, which contains neutralizing antibody to parvovirus and is effective in the short term.

Parvovirus infection and destruction of erythroid precursors can also occur in utero. Such events are associated with increased rates of fetal loss in the first and second trimesters. Infants may be born with **hydrops fetalis** and anemia (see Chapter 138). The presence of persistent congenital parvovirus infection is detected by PCR of peripheral blood and/or bone marrow DNA because immunologic tolerance to the virus can prevent the usual development of specific antibodies.

OTHER RED CELL APLASIAS IN CHILDREN

Acquired red cell aplasia in adults is usually mediated by a chronic antibody and often associated with disorders such as chronic lymphocytic leukemia, lymphoma, thymoma, lymphoproliferative disorders, and systemic lupus erythematosus. This chronic antibody-mediated type of RBC aplasia, often responsive to immunosuppressive therapy, is quite rare in childhood. Cases of acquired pure RBC aplasia attributable to T-cell suppression have also been described.

Infections other than parvovirus, such as cytomegalovirus, Epstein-Barr virus, and human herpes virus-6, may cause pure RBC aplasia. Certain drugs, such as chloramphenicol, also can inhibit erythropoiesis in a dose-dependent manner. Reticulocytopenia, erythroid hypoplasia, and vacuolated pronormoblasts in the bone marrow are reversible effects of this drug. These effects are distinct from the idiosyncratic and rare development of severe aplastic anemia in chloramphenicol recipients. Acquired antibody-mediated (to erythropoietin) pure RBC aplasia is a rare complication in chronic kidney disease patients treated with erythropoietin. In addition to discontinuing erythropoiesis-stimulating agents, therapy and addressing anemia with red cell transfusions, further treatment may require immunosuppression and eventually renal transplantation.

Visit Elsevier eBooks+ at eBooks.Health.Elsevier.com for Bibliography.

Chapter 500

Anemia of Chronic Disease and Renal Disease

500.1 Anemia of Chronic Disease

Courtney D. Thornburg

The anemia of chronic disease **(ACD)**, also referred to as **anemia of inflammation**, is found in conditions where there is ongoing immune activation. It occurs in a wide range of disorders, including infections, malignancies, chronic disease, autoimmunity, and graft-versus-host disease. A similar anemia is associated with chronic kidney disease. ACD is typically a mild to moderate normocytic, normochromic, hypoproliferative anemia associated with a decreased serum iron and low transferrin saturation.

ETIOLOGY

Decreased red cell life span, impaired erythropoiesis, and an increased uptake of iron in the reticuloendothelial system are important mechanisms contributing to ACD.

ACD-associated alterations in iron recycling are characterized by an accumulation of iron in reticuloendothelial macrophages despite low levels of serum iron. The diversion of iron from the circulation into the reticuloendothelial system results in *functional* iron deficiency, which causes the impaired heme synthesis and iron-restricted erythropoiesis that contribute to anemia. These alterations in iron metabolism have been attributed to inflammation-associated excess synthesis of hepcidin, a key regulatory protein that controls intestinal iron absorption and tissue distribution. Hepcidin, although mainly synthesized by hepatocytes, is expressed in other cells, including monocytes and macrophages. It functions by binding to and initiating the degradation of the iron exporter, ferroportin (Fig. 500.1).

CLINICAL MANIFESTATIONS

Although the important symptoms and signs associated with ACD are those of the underlying disease, the mild to moderate anemia can affect the patient's quality of life.

LABORATORY FINDINGS

Hemoglobin concentrations are generally 6-9 g/dL. The anemia is usually normochromic and normocytic, although some patients have modest hypochromia and microcytosis, particularly if there is concomitant iron deficiency. Absolute reticulocyte counts are normal or low, and leukocytosis is common. The serum iron level is low, without the increase in serum transferrin (the iron transport protein) that occurs in iron deficiency. This pattern of low serum iron and low-to-normal serum transferrin is a valuable diagnostic feature. *However, note that the serum ferritin level may be elevated secondary to inflammation*. Soluble transferrin receptor (sTfR) is a useful diagnostic test to distinguish ACD from iron-deficiency anemia (IDA) because sTfR levels are high in IDA and normal in ACD. A bone marrow biopsy typically shows normal cellularity with decreased or adequate red blood cell precursors; marrow hemosiderin may be increased and granulocytic hyperplasia may be present.

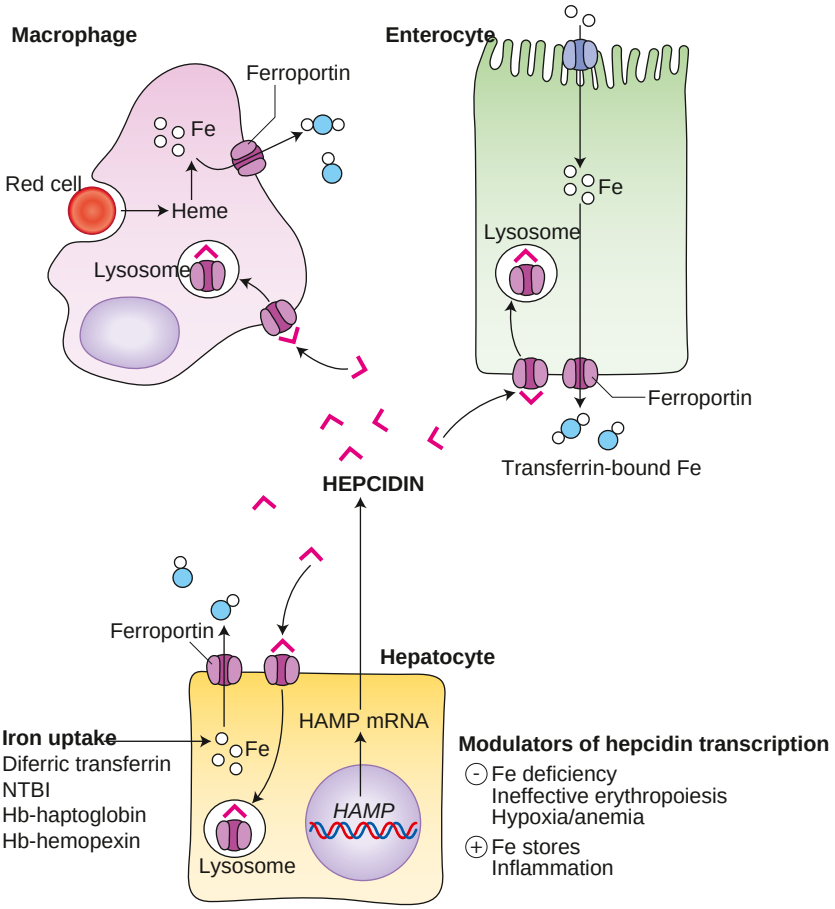

Fig. 500.1 Central role of hepcidin in iron metabolism. Hepcidin, produced by hepatocytes, downregulates iron export to circulating transferrin from iron "donor" cells (hepatocytes, macrophages, and duodenal enterocytes) by promoting the internalization and lysosomal degradation of ferroportin. Hepatocytes take up iron in several forms, whereas enterocytes obtain their iron predominantly from the gut lumen, and macrophages are specialized to deal with the high throughput of iron from senescent red cells. (*From Pippard M. Iron deficiency anemia, anemia of chronic disorders and iron overload. In Porwit A, McCullough J, Erber WN, eds. Blood and Bone Marrow Pathology, 2nd ed. London: Elsevier, 2011; Fig 11-5.*)

TREATMENT

Where possible, the best approach to ACD is the treatment of the underlying disorder. If the associated systemic disease can be controlled, the anemia typically improves or resolves. Transfusions raise the hemoglobin concentration temporarily but are rarely indicated. Erythropoiesis-stimulating agents (ESAs), such as recombinant human erythropoietin (EPO) or related extended half-life formulations, increase the hemoglobin level and improve activity and the sense of well-being. When using ESAs, *treatment with iron* is usually necessary to produce optimal effect. Response to these agents is highly variable, and poorly responsive patients may require high doses to reach target hemoglobin levels. In adults, high doses are associated with a higher incidence of adverse events, such as stroke, cardiovascular events, cancer progression, and death, leading the U.S. Food and Drug Administration (FDA) to require a "black box" warning on labels.

ACD does not respond to iron alone unless there is concomitant deficiency. Unfortunately, it is a common clinical challenge to identify iron deficiency in patients with an inflammatory disease (see Chapters 496 and 504). In this circumstance, a trial of iron therapy might be helpful, although there may be no response because persistent inflammation impairs iron absorption and utilization; intravenous iron may further increase hepcidin production.

Visit Elsevier eBooks+ at eBooks.Health.Elsevier.com for Bibliography.

500.2 Anemia of Renal Disease

Courtney D. Thornburg

Anemia is common in children with chronic kidney disease (CKD). The anemia is usually normocytic, and the absolute reticulocyte count is normal or low. Although most patients with end-stage renal disease (ESRD) are anemic, earlier stages of CKD are also associated with a lower prevalence of anemia. In adults, a lower glomerular filtration rate (GFR) has been correlated with lower hemoglobin concentration, and hemoglobin has been reported to decline below a GFR threshold of 40-60 mL/min/1.73 m^2. In children with CKD, hemoglobin levels decline as the GFR decreases below 43 mL/min/1.73 m^2.

Decreased hemoglobin values are linked to increased incidence of left ventricular hypertrophy, impaired physical activity, and a reduced quality of life in pediatric patients with CKD. In those with ESRD on dialysis, anemia is also associated with increased risk of hospitalization and mortality.

ETIOLOGY

Although the anemia of CKD shares many features with anemia of chronic disease, its predominant cause is decreased erythropoietin (EPO) production by diseased kidneys. Other important causes include absolute and/or functional iron deficiency because of chronic blood loss (from blood sampling, surgeries, and dialysis) and disturbances in iron metabolism. Higher hepcidin levels have also been implicated in the anemia of CKD. Hepcidin is filtered by the glomerulus and excreted by the kidney; serum concentrations are increased in patients with decreased GFR. Inflammation may also be a contributing factor in pediatric dialysis patients who have elevated levels of proinflammatory cytokines. Hyperparathyroidism and deficiencies of vitamin B_{12}, folate, and carnitine may also have a role in anemia of CKD.

LABORATORY FINDINGS

Anemia in children with CKD is defined by age: hemoglobin <11.0 g/dL (0.5-5 years), <11.5 g/dL (5-12 years), <12 g/dL (12-15 years), <13.0 g/dL (males >15 years), and <12.0 g/dL (females >15 years). The anemia of CKD is hypoproliferative and usually normocytic and normochromic, unless there is concomitant iron deficiency or vitamin deficiency. The EPO level and absolute reticulocyte count are usually

low. White cell and platelet counts are generally normal. Ferritin will be low if there is accompanying iron deficiency and high if there is associated inflammation.

TREATMENT

Oral iron therapy is recommended for all pediatric CKD patients with anemia. Intravenous (IV) iron therapy may be considered for those receiving maintenance hemodialysis and those who to do not respond to oral iron. Current IV iron preparations (iron-gluconate, iron-sucrose, iron-carboxymaltose, iron-isomaltoside, ferumoxytol) have iron as a core within a carbohydrate stabilizer shell, thus preventing the uncontrolled release of free iron and thus reducing serious side effects.

Erythropoiesis-stimulating agents (ESAs) are the mainstay of therapy and, particularly for children with ESRD, have greatly reduced the need for frequent transfusions, decreasing the incidence of associated iron overload and alloimmunization.

Hemoglobin levels at which ESAs are initiated may be guided by individual patient characteristics, with a goal of 11-12 g/dL for children on maintenance ESA therapy. Dosing varies with age and dialysis modality. Darbepoetin, a synthetic form of EPO, appears to be equally effective as recombinant human EPO and has the benefit of less frequent dosing because of a longer half-life. Iron therapy should be prescribed when using ESAs because treatment demands additional iron for erythropoiesis. Infants and children require higher doses of ESAs.

In the rare case in which anti-EPO antibody-mediated pure red cell aplasia develops, ESA therapy should be stopped, and immunomodulatory therapy may be indicated to suppress the antibody response.

Visit Elsevier eBooks+ at eBooks.Health.Elsevier.com for Bibliography.

Chapter 501

Congenital Dyserythropoietic Anemias

Courtney D. Thornburg

The congenital dyserythropoietic anemias **(CDAs)** are a heterogeneous class of inherited disorders resulting from abnormalities of late erythropoiesis. These rare conditions are characterized by variable degrees of anemia, ineffective erythropoiesis, hyperbilirubinemia, gallstones, splenomegaly, and secondary hemochromatosis (iron overload). They may be misdiagnosed as other congenital anemias, such as hereditary spherocytosis or thalassemia. **Dyserythropoiesis** is the major cause of anemia but a shortened half-life of circulating red blood cells (RBCs) may also contribute. The CDAs have been classified into four major types (I, II, III, and IV) and variants based on distinctive bone marrow morphology, clinical features, and genetic mutations. **Genetic testing** is now the key method for achieving a timely accurate diagnosis (Fig. 501.1).

CONGENITAL DYSERYTHROPOIETIC ANEMIA TYPE I

Pathogenesis

Type I CDA **(CDA I)** is an autosomal recessive disorder. It is caused by pathogenic variants in *CDAN1,* the first gene to be implicated, which encodes Codanin-1, a cell-cycle regulated protein. Pathogenic variants in *CDIN1* (CDAN1-interacting nuclease 1, previously *C15orf41*) also cause CDA I. Proteins encoded by *CDAN1* and *CDIN1* likely contribute to DNA repair and/or chromatin reassembly after DNA replication.

Clinical Manifestations

CDA I may be diagnosed at any age, although most cases are recognized during childhood or adolescence in the setting of moderate to severe macrocytic anemia with relative reticulocytopenia. CDA I is rarely diagnosed in utero with severe anemia resulting in hydrops fetalis. Neonates with CDA 1 may have neonatal jaundice or pulmonary hypertension related to anemia. Type I CDA has been associated with **dysmorphic features** in 4–25% of patients, primarily involving the digits (syndactyly, absence of nails or curved toenails, supernumerary toes, skin pigmentation, café-au-lait spots, macrocephaly, dolichocephaly, spinal fusion, scoliosis, and short stature). Patients have progressive iron overload even in the absence of transfusions.

Laboratory Findings

Hemoglobin concentrations generally range between 7-11 g/dL. The anemia is usually macrocytic (mean corpuscular volume: 100-120 fL), but normocytic indices may be seen during childhood. **Anisopoikilocytosis** is appreciated on the peripheral blood smear. In some cases, normoblasts and basophilic stippling of RBCs may be seen. The reticulocyte count is inadequate for the degree of anemia **(reticulocytopenia)**. Elevated serum ferritin secondary to iron overload may be present. The bone marrow aspirate shows erythroid hyperplasia. Binucleate erythroblasts make up 2.5–10% of late erythroblasts. Incompletely divided cells with thin chromatin bridges between nuclei of pairs of erythrocytes are highly specific for type I CDA. Electron microscopy is the gold standard for clinical diagnosis, revealing erythroblasts with a characteristic "Swiss cheese" heterochromatin pattern.

Treatment

Treatment of this disorder includes transfusions, especially in the neonatal period and early childhood and in association with co-inherited disorders, such as thalassemia or RBC enzymopathy. However, adolescents and adults may require episodic transfusions only during aplastic crises, infection, or pregnancy. For patients with CDAN1 mutations, treatment with PEGylated interferon-α_2 can reduce transfusion requirements. Because of potential side effects of spastic diplegia and peripheral neuropathy, treatment initiation may be reserved for patients beyond early childhood requiring frequent transfusions. Patients do not respond to erythropoietin; splenectomy is generally not recommended. Cholecystectomy is often required for management of pigmented gallstones. Allogeneic stem cell transplantation may also be considered for severe cases.

The most important long-term complication is progressive **iron overload**, caused by increased intestinal absorption of iron and ineffective erythropoiesis and transfusion therapy. Regular phlebotomies is a treatment option as long as there is not significant anemia. If this approach is untenable, chelation therapy should be employed when repeated ferritin levels exceed 1,000 μg/L or liver iron is elevated as determined by hepatic magnetic resonance imaging T2*.

CONGENITAL DYSERYTHROPOIETIC ANEMIA TYPE II

Pathogenesis

CDA type II **(CDA II)**, the most common type of CDA, is an autosomal recessive disorder caused by biallelic pathogenic variants in *SEC23B*. This gene encodes a component of the cytoplasmic coat protein II (COPII) complex that is involved in endoplasmic reticulum vesicle trafficking.

Clinical Manifestations

CDA II presents with varying degrees of normocytic anemia and no or mild reticulocytosis. Approximately 20% of patients are transfusion dependent. CDA II may be initially misdiagnosed as hereditary spherocytosis due to overlapping symptoms of anemia, jaundice, splenomegaly, or hepatomegaly. Extramedullary hematopoiesis may result in

low. White cell and platelet counts are generally normal. Ferritin will be low if there is accompanying iron deficiency and high if there is associated inflammation.

TREATMENT

Oral iron therapy is recommended for all pediatric CKD patients with anemia. Intravenous (IV) iron therapy may be considered for those receiving maintenance hemodialysis and those who to do not respond to oral iron. Current IV iron preparations (iron-gluconate, iron-sucrose, iron-carboxymaltose, iron-isomaltoside, ferumoxytol) have iron as a core within a carbohydrate stabilizer shell, thus preventing the uncontrolled release of free iron and thus reducing serious side effects.

Erythropoiesis-stimulating agents (ESAs) are the mainstay of therapy and, particularly for children with ESRD, have greatly reduced the need for frequent transfusions, decreasing the incidence of associated iron overload and alloimmunization.

Hemoglobin levels at which ESAs are initiated may be guided by individual patient characteristics, with a goal of 11-12 g/dL for children on maintenance ESA therapy. Dosing varies with age and dialysis modality. Darbepoetin, a synthetic form of EPO, appears to be equally effective as recombinant human EPO and has the benefit of less frequent dosing because of a longer half-life. Iron therapy should be prescribed when using ESAs because treatment demands additional iron for erythropoiesis. Infants and children require higher doses of ESAs.

In the rare case in which anti-EPO antibody-mediated pure red cell aplasia develops, ESA therapy should be stopped, and immunomodulatory therapy may be indicated to suppress the antibody response.

Visit Elsevier eBooks+ at eBooks.Health.Elsevier.com for Bibliography.

Chapter 501

Congenital Dyserythropoietic Anemias

Courtney D. Thornburg

The congenital dyserythropoietic anemias **(CDAs)** are a heterogeneous class of inherited disorders resulting from abnormalities of late erythropoiesis. These rare conditions are characterized by variable degrees of anemia, ineffective erythropoiesis, hyperbilirubinemia, gallstones, splenomegaly, and secondary hemochromatosis (iron overload). They may be misdiagnosed as other congenital anemias, such as hereditary spherocytosis or thalassemia. **Dyserythropoiesis** is the major cause of anemia but a shortened half-life of circulating red blood cells (RBCs) may also contribute. The CDAs have been classified into four major types (I, II, III, and IV) and variants based on distinctive bone marrow morphology, clinical features, and genetic mutations. **Genetic testing** is now the key method for achieving a timely accurate diagnosis (Fig. 501.1).

CONGENITAL DYSERYTHROPOIETIC ANEMIA TYPE I

Pathogenesis

Type I CDA **(CDA I)** is an autosomal recessive disorder. It is caused by pathogenic variants in *CDAN1,* the first gene to be implicated, which encodes Codanin-1, a cell-cycle regulated protein. Pathogenic variants in *CDIN1* (CDAN1-interacting nuclease 1, previously *C15orf41*) also cause CDA I. Proteins encoded by *CDAN1* and *CDIN1* likely contribute to DNA repair and/or chromatin reassembly after DNA replication.

Clinical Manifestations

CDA I may be diagnosed at any age, although most cases are recognized during childhood or adolescence in the setting of moderate to severe macrocytic anemia with relative reticulocytopenia. CDA I is rarely diagnosed in utero with severe anemia resulting in hydrops fetalis. Neonates with CDA 1 may have neonatal jaundice or pulmonary hypertension related to anemia. Type I CDA has been associated with **dysmorphic features** in 4–25% of patients, primarily involving the digits (syndactyly, absence of nails or curved toenails, supernumerary toes, skin pigmentation, café-au-lait spots, macrocephaly, dolichocephaly, spinal fusion, scoliosis, and short stature). Patients have progressive iron overload even in the absence of transfusions.

Laboratory Findings

Hemoglobin concentrations generally range between 7-11 g/dL. The anemia is usually macrocytic (mean corpuscular volume: 100-120 fL), but normocytic indices may be seen during childhood. **Anisopoikilocytosis** is appreciated on the peripheral blood smear. In some cases, normoblasts and basophilic stippling of RBCs may be seen. The reticulocyte count is inadequate for the degree of anemia **(reticulocytopenia)**. Elevated serum ferritin secondary to iron overload may be present. The bone marrow aspirate shows erythroid hyperplasia. Binucleate erythroblasts make up 2.5–10% of late erythroblasts. Incompletely divided cells with thin chromatin bridges between nuclei of pairs of erythrocytes are highly specific for type I CDA. Electron microscopy is the gold standard for clinical diagnosis, revealing erythroblasts with a characteristic "Swiss cheese" heterochromatin pattern.

Treatment

Treatment of this disorder includes transfusions, especially in the neonatal period and early childhood and in association with co-inherited disorders, such as thalassemia or RBC enzymopathy. However, adolescents and adults may require episodic transfusions only during aplastic crises, infection, or pregnancy. For patients with CDAN1 mutations, treatment with PEGylated interferon-α_2 can reduce transfusion requirements. Because of potential side effects of spastic diplegia and peripheral neuropathy, treatment initiation may be reserved for patients beyond early childhood requiring frequent transfusions. Patients do not respond to erythropoietin; splenectomy is generally not recommended. Cholecystectomy is often required for management of pigmented gallstones. Allogeneic stem cell transplantation may also be considered for severe cases.

The most important long-term complication is progressive **iron overload**, caused by increased intestinal absorption of iron and ineffective erythropoiesis and transfusion therapy. Regular phlebotomies is a treatment option as long as there is not significant anemia. If this approach is untenable, chelation therapy should be employed when repeated ferritin levels exceed 1,000 μg/L or liver iron is elevated as determined by hepatic magnetic resonance imaging T2*.

CONGENITAL DYSERYTHROPOIETIC ANEMIA TYPE II

Pathogenesis

CDA type II **(CDA II)**, the most common type of CDA, is an autosomal recessive disorder caused by biallelic pathogenic variants in *SEC23B*. This gene encodes a component of the cytoplasmic coat protein II (COPII) complex that is involved in endoplasmic reticulum vesicle trafficking.

Clinical Manifestations

CDA II presents with varying degrees of normocytic anemia and no or mild reticulocytosis. Approximately 20% of patients are transfusion dependent. CDA II may be initially misdiagnosed as hereditary spherocytosis due to overlapping symptoms of anemia, jaundice, splenomegaly, or hepatomegaly. Extramedullary hematopoiesis may result in

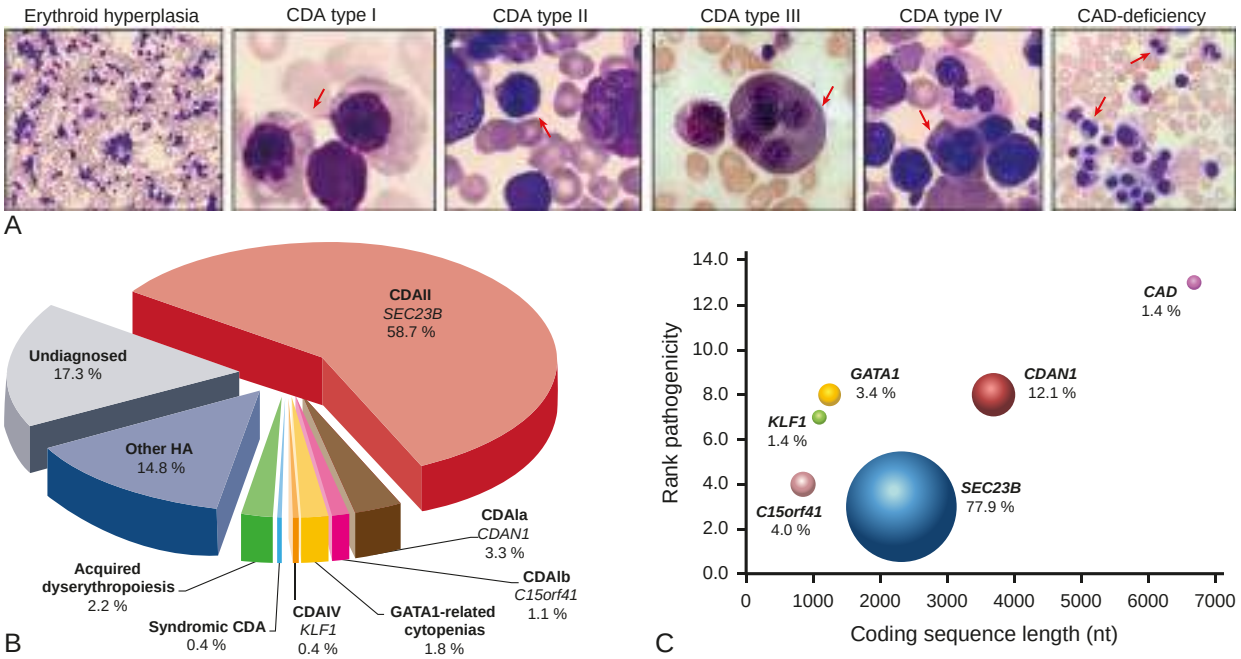

Fig. 501.1 Morphologic and molecular features of patients with congenital dyserythropoietic anemias (CDA). **A,** Light microscopy analysis of the bone marrow from patients with different CDA subtypes. CDA patients generally show erythroid hyperplasia. *Red arrows* indicate typical findings for each CDA subtype: CDAI, internuclear chromatin bridging; CDAII, binucleate erythroid precursors; CDAIII, giant multinucleated erythroblasts; CDAIV, multinucleate erythroblasts; and CAD deficiency, binucleate CDAII-like precursors. **B,** Pie chart showing the frequencies of the different CDA subtypes diagnosed after genetic testing in patients clinically suspected of having CDA. The frequency of each condition was calculated as the ratio between the number of patients in each CDA subtype and the overall count of patients tested (n = 218 patients [those included in our international registry of CDAs from 1995 to 2019]). Six patients originally suspected of CDA showed conclusive diagnosis of acquired dyserythropoiesis: two patients with liver failure, two with iron-deficiency anemia, one with erythrophagocytosis, and one with transient erythroblastopenia. Syndromic CDA refers to one patient with a mutation in the CAD gene. GATA1-related cytopenias include: X-linked thrombocytopenia with or without dyserythropoietic anemia; congenital erythropoietic porphyria; and idiopathic cytopenias of undetermined significance. Other hereditary anemias (HA) include: hereditary spherocytosis; hereditary dehydrated stomatocytosis; red cell enzymatic defects; and sideroblastic anemia. The undiagnosed cases were evaluated by analysis of the CDA gene panel, by extended targeted next-generation sequencing for hereditary anemias, or by whole-exome sequencing. **C,** Bubble chart defining the lengths of the coding sequences of each CDA-causative gene and their relative pathogenicity scores. These scores were calculated by combining the constraint metrics of each gene available at the ExAC database (http://exac.broadinstitute.org/). High pathogenicity scores identify increased constraints (intolerance to variation). The more intolerant to variation a gene is, the less likely it is to be mutated. The size of each bubble represents the frequency of the mutations in each gene, as calculated by the ratio of the number of mutated alleles for each gene and the overall count of disease alleles (n = 149, from 78 patients included in our international registry of CDAs from 2008 to 2019). (*From Iolascon A, Andolfo I, Russo R. Congenital dyserythropoietic anemias. Blood. 2020;136:1274–1281; Fig. 1.*)

posterior mediastinal or paravertebral masses. Iron overload occurs in both transfusion dependent and independent patients.

Laboratory Findings

The anemia is normocytic and is generally mild with inappropriately low reticulocytes. Hemoglobin levels are lower in children than adults and range from 8-11 g/dL. The peripheral blood smear shows anisopoikilocytosis, occasional basophilic stippling, as well as a few, sometimes binucleate, mature erythroblasts. The bone marrow aspirate is normoblastic but hypercellular, with erythroid hyperplasia. Binucleated and multinucleated erythroblasts with equal nuclei size (10–35%) and karyorrhexis (fragmentation of the nuclei) in >2% are characteristic. Electron micrographs demonstrate vesicles laden with endoplasmic reticulum proteins running beneath the plasma membrane (double membranes). Ninety-five percent of patients with CDA II have hypoglycosylated band 3, which has faster migration on the gel, and the diagnosis may be made by analyzing red blood cell membrane proteins with sodium dodecyl sulfate-polyacrylamide gel electrophoresis (SDS PAGE).

Treatment

Most patients can lead a normal life and have a normal life expectancy if complications and consequences are managed appropriately. Approximately 10% of patients will require red cell transfusions in infancy and childhood but rarely during adulthood. Splenectomy may provide hematologic improvement and is currently recommended for patients with severe anemia and/or symptomatic splenomegaly. Splenectomy does not prevent further iron overloading, even in those patients whose hemoglobin is normalized, presumably because of persistent ineffective erythropoiesis in the bone marrow. Secondary iron overload is the most prominent long-term complication and should be approached as previously outlined.

Allogeneic stem cell transplantation may also be considered for severe cases.

CONGENITAL DYSERYTHROPOIETIC ANEMIA TYPE III

CDA type III **(CDA III)** is an extremely rare, poorly defined entity characterized by mild to moderate macrocytic anemia. It is inherited in an autosomal dominant or de novo fashion, although there have been cases that might represent other inheritance patterns. CDA III is caused by pathogenic variants in *KIF23*, which encodes a ubiquitous protein, mitotic kinesin-like protein 1, which regulates daughter cell separation during mitosis. Iron overload is not clinically significant (likely due to hemolysis being predominantly intravascular), and spleen size is generally normal. Patients can present with angioid streaks with macular degeneration. An association with monoclonal gammopathy and multiple myeloma is also reported. The blood smear shows macrocytes, anisopoikilocytosis, and occasional basophilic stippling. The bone marrow is notable for giant erythroid precursors that are often multinucleated, containing up to 12 nuclei per cell. Such multinucleated erythroblasts can also be seen in myelodysplasia and erythroleukemia. Transfusions are usually not required.

TRANSCRIPTION FACTOR–RELATED CDA

Transcription factor–related CDA includes CDA type IV (CDA IV) and X-linked thrombocytopenia with or without dyserythropoietic anemia (XLTDA). CDA IV has an autosomal dominant inheritance due to pathogenic variants in *KLF1*, which encodes an erythroid transcription factor that regulates fetal hemoglobin switching and is necessary for terminal erythroid differentiation. Patients have severe hemolytic anemia with no or mild reticulocytosis and very high fetal hemoglobin. Bone marrow morphology consists of hypercellularity and binucleate or multinucleate erythroblasts. Electron micrographs show immature red cell progenitors that have atypical inclusions within the cytoplasm, nuclear membrane invaginations, and heterochromatin.

XLTDA is an X-linked condition due to pathogenic variants in *GATA1*, a DNA-binding protein with two zinc fingers and a transactivation domain that plays a key role in development and maintenance of red cell and platelet lineages. The laboratory features of this condition include mild to severe anemia and macrothrombocytopenia with poorly granulated platelets. Bone marrow morphology shows dyserythropoiesis and megakaryocytes that are abnormal and reduced in number. Patients present with bleeding and anemia, and management includes transfusion and supportive care.

Visit Elsevier eBooks+ at eBooks.Health.Elsevier.com for Bibliography.

Chapter 502

Physiologic Anemia of Infancy

Courtney D. Thornburg

At birth, normal full-term infants have higher hemoglobin (Hb) levels and larger red blood cells (RBCs) than do older children and adults. However, within the first week of life, a progressive decline in Hb level begins and then persists for 6-8 weeks. The resulting anemia is known as the **physiologic anemia of infancy**.

With the onset of respiration at birth, considerably more oxygen becomes available for binding to Hb, and as a result the Hb-oxygen saturation increases from 50–95% or more. There is also a gradual, normal developmental switch from fetal to adult Hb synthesis after birth that results in the replacement of high-oxygen-affinity fetal Hb with lower-affinity adult Hb, capable of delivering more oxygen to tissues. The increase in blood oxygen content and delivery results in the downregulation of erythropoietin (EPO) production, leading to suppression of erythropoiesis. Because there is no erythropoiesis, aged RBCs that are removed from the circulation are not replaced, and the Hb level decreases. The Hb concentration continues to decline until tissue oxygen needs become greater than oxygen delivery. Normally, this point is reached between 8-12 weeks of age, when the Hb concentration is about 11 g/dL. In healthy term infants, the nadir rarely falls below 10 g/dL. At this juncture, EPO production increases and erythropoiesis resumes. The supply of stored reticuloendothelial iron, derived from previously degraded RBCs, remains sufficient for this renewed Hb synthesis, even in the absence of dietary iron intake, until approximately 20 weeks of age. In all, this "anemia" should be viewed as a physiologic adaptation to extrauterine life, reflecting the excess oxygen delivery relative to tissue oxygen requirements. There is no hematologic problem, and no therapy is required unless physiologic anemia of infancy is exacerbated by other ongoing processes including nutritional deficiency and blood loss. The degree of anemia at birth is correlated with maternal hemoglobin.

A late **hyporegenerative anemia**, with reticulocytopenia, can occur in infants with **hemolytic disease of the newborn**. The persistence of maternally derived anti-RBC antibodies in the infant's circulation can lead to an ongoing low-grade hemolytic anemia that can exaggerate the physiologic anemia. Lower-than-expected Hb at the "physiologic" nadir has also been seen in infants after intrauterine or neonatal RBC transfusions. When infants are transfused with adult blood containing HbA, the associated shift of the oxygen dissociation curve facilitates oxygen delivery to the tissues. Accordingly, the definition of anemia and the need for transfusion should be based not only on the infant's Hb level, but also on oxygen requirements and the ability of circulating RBCs to release oxygen to the tissues.

Premature infants also develop a physiologic anemia, known as **anemia of prematurity**. The Hb decline is both more extreme and more rapid. Hb levels of 7-9 g/dL usually are reached by 3-6 weeks of age, and levels may be even lower in very small premature infants (see Chapter 139). The same physiologic factors at play in term infants are exaggerated in preterm infants. In premature infants, the physiologic Hb decline may be intensified by blood loss from repeated phlebotomies obtained to monitor ill neonates. Demands on erythropoiesis are further heightened by the premature infant's presumed shortened RBC life span (40-60 days) and the accelerated expansion of RBC mass that accompanies the premature baby's rapid rate of growth. Nonetheless, plasma EPO levels are lower than would be expected for the degree of anemia, resulting in a suboptimal erythropoietic response. The reason for diminished EPO levels is not fully understood. During fetal life, EPO synthesis is handled primarily by the liver, and the liver's oxygen sensor is less sensitive to hypoxia compared with that of the kidney. The developmental switch from liver to kidney EPO production is not accelerated by early birth, and thus the preterm infant must rely on the liver as the primary site for synthesis, leading to diminished responsiveness to anemia. An additional mechanism thought to contribute to diminished EPO levels may be accelerated EPO metabolism. Because the pronounced decline in Hb that occurs in many very low birthweight infants may be associated with abnormal clinical signs, this "anemia of prematurity" is not considered benign and usually requires transfusions when symptomatic.

TREATMENT

In the **full-term infant**, physiologic anemia requires no therapy beyond ensuring that the infant's diet contains essential nutrients for normal hematopoiesis. For infants who are exclusively breastfed, iron supplementation is indicated beginning at 4 months of age and continued until oral iron intake via food is sufficient. In **premature infants**, an optimal Hb has not been established and is usually dictated by the infant's overall clinical condition. Transfusions may be needed to maintain the Hb at what is considered safe for that child. Premature infants who are feeding well and growing normally rarely need transfusion unless iatrogenic blood loss has been significant. Although factors such as poor weight gain, respiratory difficulties, and abnormal heart rate have prompted transfusion, the beneficial effect has not been documented. Laboratory tests such as blood lactate, EPO, and mixed venous oxygen saturation have poor predictive value. A restrictive strategy does not increase infant morbidity or mortality. Long-term neurodevelopmental outcomes have been found to be poorer in liberally transfused neonates. Exposure to packed RBCs may be related to the development of necrotizing enterocolitis, and early transfusions may be associated with the risk of intraventricular hemorrhage. Iron supplementation is indicated starting at 2 to 6 weeks of age until 6 to 12 months of age; dosing depends on birth weight and infants with smaller birth weights require higher doses.

Strategies to decrease anemia include delayed cord clamping, avoiding unnecessary phlebotomy, and providing adequate iron supplementation. Delayed cord clamping at birth results in fewer transfusions and a reduction in both intraventricular hemorrhage and necrotizing enterocolitis in preterm infants. Given the impact of phlebotomy losses during monitoring in the neonatal intensive care unit, attention to reducing unnecessary blood draws also has been advocated. Iron therapy is indicated for all neonates with anemia of prematurity starting at 1 month of age and continuing until about 1 year of age. Iron is prescribed as mg of elemental iron per kg/day and depends on birthweight.

When transfusions are necessary, an RBC volume of 10-15 mL/kg is recommended. It is good practice to split units derived from a single donor to minimize donor exposure if sequential transfusions are indicated.

Visit Elsevier eBooks+ at eBooks.Health.Elsevier.com for Bibliography.

TRANSCRIPTION FACTOR–RELATED CDA

Transcription factor–related CDA includes CDA type IV (CDA IV) and X-linked thrombocytopenia with or without dyserythropoietic anemia (XLTDA). CDA IV has an autosomal dominant inheritance due to pathogenic variants in *KLF1*, which encodes an erythroid transcription factor that regulates fetal hemoglobin switching and is necessary for terminal erythroid differentiation. Patients have severe hemolytic anemia with no or mild reticulocytosis and very high fetal hemoglobin. Bone marrow morphology consists of hypercellularity and binucleate or multinucleate erythroblasts. Electron micrographs show immature red cell progenitors that have atypical inclusions within the cytoplasm, nuclear membrane invaginations, and heterochromatin.

XLTDA is an X-linked condition due to pathogenic variants in *GATA1*, a DNA-binding protein with two zinc fingers and a transactivation domain that plays a key role in development and maintenance of red cell and platelet lineages. The laboratory features of this condition include mild to severe anemia and macrothrombocytopenia with poorly granulated platelets. Bone marrow morphology shows dyserythropoiesis and megakaryocytes that are abnormal and reduced in number. Patients present with bleeding and anemia, and management includes transfusion and supportive care.

Visit Elsevier eBooks+ at eBooks.Health.Elsevier.com for Bibliography.

Chapter 502

Physiologic Anemia of Infancy

Courtney D. Thornburg

At birth, normal full-term infants have higher hemoglobin (Hb) levels and larger red blood cells (RBCs) than do older children and adults. However, within the first week of life, a progressive decline in Hb level begins and then persists for 6-8 weeks. The resulting anemia is known as the **physiologic anemia of infancy**.

With the onset of respiration at birth, considerably more oxygen becomes available for binding to Hb, and as a result the Hb-oxygen saturation increases from 50–95% or more. There is also a gradual, normal developmental switch from fetal to adult Hb synthesis after birth that results in the replacement of high-oxygen-affinity fetal Hb with lower-affinity adult Hb, capable of delivering more oxygen to tissues. The increase in blood oxygen content and delivery results in the downregulation of erythropoietin (EPO) production, leading to suppression of erythropoiesis. Because there is no erythropoiesis, aged RBCs that are removed from the circulation are not replaced, and the Hb level decreases. The Hb concentration continues to decline until tissue oxygen needs become greater than oxygen delivery. Normally, this point is reached between 8-12 weeks of age, when the Hb concentration is about 11 g/dL. In healthy term infants, the nadir rarely falls below 10 g/dL. At this juncture, EPO production increases and erythropoiesis resumes. The supply of stored reticuloendothelial iron, derived from previously degraded RBCs, remains sufficient for this renewed Hb synthesis, even in the absence of dietary iron intake, until approximately 20 weeks of age. In all, this "anemia" should be viewed as a physiologic adaptation to extrauterine life, reflecting the excess oxygen delivery relative to tissue oxygen requirements. There is no hematologic problem, and no therapy is required unless physiologic anemia of infancy is exacerbated by other ongoing processes including nutritional deficiency and blood loss. The degree of anemia at birth is correlated with maternal hemoglobin.

A late **hyporegenerative anemia**, with reticulocytopenia, can occur in infants with **hemolytic disease of the newborn**. The persistence of maternally derived anti-RBC antibodies in the infant's circulation can lead to an ongoing low-grade hemolytic anemia that can exaggerate the physiologic anemia. Lower-than-expected Hb at the "physiologic" nadir has also been seen in infants after intrauterine or neonatal RBC transfusions. When infants are transfused with adult blood containing HbA, the associated shift of the oxygen dissociation curve facilitates oxygen delivery to the tissues. Accordingly, the definition of anemia and the need for transfusion should be based not only on the infant's Hb level, but also on oxygen requirements and the ability of circulating RBCs to release oxygen to the tissues.

Premature infants also develop a physiologic anemia, known as **anemia of prematurity**. The Hb decline is both more extreme and more rapid. Hb levels of 7-9 g/dL usually are reached by 3-6 weeks of age, and levels may be even lower in very small premature infants (see Chapter 139). The same physiologic factors at play in term infants are exaggerated in preterm infants. In premature infants, the physiologic Hb decline may be intensified by blood loss from repeated phlebotomies obtained to monitor ill neonates. Demands on erythropoiesis are further heightened by the premature infant's presumed shortened RBC life span (40-60 days) and the accelerated expansion of RBC mass that accompanies the premature baby's rapid rate of growth. Nonetheless, plasma EPO levels are lower than would be expected for the degree of anemia, resulting in a suboptimal erythropoietic response. The reason for diminished EPO levels is not fully understood. During fetal life, EPO synthesis is handled primarily by the liver, and the liver's oxygen sensor is less sensitive to hypoxia compared with that of the kidney. The developmental switch from liver to kidney EPO production is not accelerated by early birth, and thus the preterm infant must rely on the liver as the primary site for synthesis, leading to diminished responsiveness to anemia. An additional mechanism thought to contribute to diminished EPO levels may be accelerated EPO metabolism. Because the pronounced decline in Hb that occurs in many very low birthweight infants may be associated with abnormal clinical signs, this "anemia of prematurity" is not considered benign and usually requires transfusions when symptomatic.

TREATMENT

In the **full-term infant**, physiologic anemia requires no therapy beyond ensuring that the infant's diet contains essential nutrients for normal hematopoiesis. For infants who are exclusively breastfed, iron supplementation is indicated beginning at 4 months of age and continued until oral iron intake via food is sufficient. In **premature infants**, an optimal Hb has not been established and is usually dictated by the infant's overall clinical condition. Transfusions may be needed to maintain the Hb at what is considered safe for that child. Premature infants who are feeding well and growing normally rarely need transfusion unless iatrogenic blood loss has been significant. Although factors such as poor weight gain, respiratory difficulties, and abnormal heart rate have prompted transfusion, the beneficial effect has not been documented. Laboratory tests such as blood lactate, EPO, and mixed venous oxygen saturation have poor predictive value. A restrictive strategy does not increase infant morbidity or mortality. Long-term neurodevelopmental outcomes have been found to be poorer in liberally transfused neonates. Exposure to packed RBCs may be related to the development of necrotizing enterocolitis, and early transfusions may be associated with the risk of intraventricular hemorrhage. Iron supplementation is indicated starting at 2 to 6 weeks of age until 6 to 12 months of age; dosing depends on birth weight and infants with smaller birth weights require higher doses.

Strategies to decrease anemia include delayed cord clamping, avoiding unnecessary phlebotomy, and providing adequate iron supplementation. Delayed cord clamping at birth results in fewer transfusions and a reduction in both intraventricular hemorrhage and necrotizing enterocolitis in preterm infants. Given the impact of phlebotomy losses during monitoring in the neonatal intensive care unit, attention to reducing unnecessary blood draws also has been advocated. Iron therapy is indicated for all neonates with anemia of prematurity starting at 1 month of age and continuing until about 1 year of age. Iron is prescribed as mg of elemental iron per kg/day and depends on birthweight.

When transfusions are necessary, an RBC volume of 10-15 mL/kg is recommended. It is good practice to split units derived from a single donor to minimize donor exposure if sequential transfusions are indicated.

Visit Elsevier eBooks+ at eBooks.Health.Elsevier.com for Bibliography.

Chapter 503

Megaloblastic Anemias

Courtney D. Thornburg

Megaloblastic anemia describes a group of disorders that are caused by impaired DNA synthesis. Red blood cells (RBCs) are larger than normal at every developmental stage, and there is maturational asynchrony between the nucleus and cytoplasm of erythrocytes. The delayed nuclear development becomes increasingly evident as cell divisions proceed. Myeloid and platelet precursors are also affected, and giant metamyelocytes and neutrophil bands are often present in the bone marrow. *There is often an associated thrombocytopenia and leukopenia*. The peripheral blood smear is notable for large, often oval RBCs with increased mean corpuscular volume (Fig. 503.1). Neutrophils are characteristically hypersegmented, with many having more than five lobes (see Fig. 503.1). Most cases of childhood megaloblastic anemia result from a deficiency of folic acid or vitamin B_{12} (cobalamin), vitamins essential for DNA synthesis (Table 503.1). Rarely, these anemias may be caused by inborn errors of metabolism. Megaloblastic anemias resulting from malnutrition are relatively uncommon in the United States but are important worldwide (see Chapters 62, 64, and 496).

503.1 Folic Acid Deficiency

Courtney D. Thornburg

Folates are essential for DNA replication and cellular proliferation. Humans cannot synthesize folate and must depend on dietary sources, including green vegetables, fruits, and animal organs (e.g., liver, kidney). Folates are heat labile and water soluble; consequently, boiling or heating folate sources leads to decreased amounts of the vitamin. Naturally occurring folates are in a polyglutamated form that is less efficiently absorbed than the monoglutamate species (i.e., folic acid). Dietary folate polyglutamates are hydrolyzed to simple folates that are absorbed primarily in the proximal small intestine by a specific carrier-mediated system. Folates travel in the bloodstream and are taken up in cells, primarily in the form of unconjugated methyltetrahydrofolate, which is subsequently reconjugated (polyglutamated) in the cell. There is an active enterohepatic circulation. Although rare, megaloblastic anemia because of folate deficiency has its peak incidence at 4-7 months of age, somewhat earlier than iron-deficiency anemia, although both conditions may be present concomitantly in infants with poor nutrition.

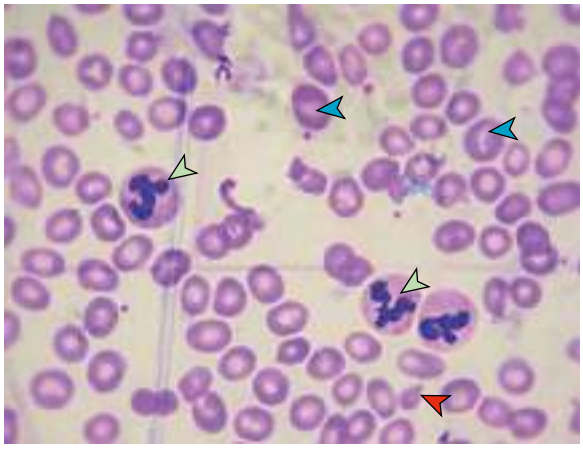

Fig. 503.1 Peripheral blood film shows hypersegmented neutrophils *(green arrowheads)*, macrocytes *(blue arrowheads)*, and a teardrop-shaped red blood cell *(red arrowhead)*. *(From Bawaskar HS, Bawaskar P, Bawaskar PH, Parekh PB. Tropical megaloblastic anemia. Lancet 2019;393:2261–2262.)*

ETIOLOGY

Folic acid deficiency can result from inadequate folate intake, decreased folate absorption, or acquired and congenital disorders of folate metabolism or transport (Table 503.2).

Inadequate Folate Intake

In the United States, anemia caused by insufficient folate intake usually occurs in the context of increased vitamin requirements associated with pregnancy, periods of accelerated growth, and chronic hemolysis (see Chapter 67.6). Folate requirements greatly increase during pregnancy, in part to meet fetal needs, and deficiencies are common in mothers, particularly those who are poor or malnourished. Folate supplementation is recommended from the start of pregnancy to prevent neural tube defects and to meet the needs of the developing fetus. Folate-deficient mothers generally do not give birth to infants with clinical folate deficiency because there is selective transfer of folate

Table 503.1 Causes of Red Blood Cell Macrocytosis

CAUSATIVE CONDITIONS	ACCOMPANYING HEMATOLOGIC FEATURES
MEGALOBLASTIC ANEMIA	
Cobalamin (vitamin B_{12}) deficiency Folate deficiency Antifolate drugs (e.g., methotrexate) Cytotoxic drugs (e.g., hydroxyurea, 5-FU) Immunosuppressive drugs (e.g., azathioprine) Thiamine-responsive anemia Hereditary orotic aciduria	Megaloblastic changes, including hypersegmented neutrophils Macrocytosis can become severe Mild reticulocytopenia Pancytopenia (when the megaloblastic process is severe)
DISORDERS OF ERYTHROID PRODUCTION	
Aplastic anemia, PRCA, Blackfan-Diamond anemia Some sideroblastic anemias CDA, non-CDA dyserythropoiesis, Fanconi anemia Myelodysplasia, myeloproliferative diseases	Nonmegaloblastic Some disorders feature dyserythropoiesis and sometimes hyposegmented neutrophils Macrocytosis can often be severe (e.g., aplastic processes) Reticulocytopenia (often severe)
RETICULOCYTOSIS	
Chronic hemolytic anemia	Nonmegaloblastic; no hypersegmented neutrophils
DRUGS AND TOXINS	
Alcohol abuse Some antiviral drugs (e.g., nucleoside RT inhibitors) Some anticonvulsant drugs	Mechanism of macrocytosis is often unknown No hypersegmented neutrophils
NONHEMATOLOGIC DISEASES	
Chronic liver diseases Hypothyroidism Copper deficiency	Nonmegaloblastic; no hypersegmented neutrophils Macrocytes are rarely oval
ARTIFACTS	
RBC clumping by cold agglutinins; some warm RBC antibodies Severe hyperglycemia Hyponatremia	Nonmegaloblastic; no hypersegmented neutrophils Disparity between high MCV and normal morphologic examination

CDA, Congenital dyserythropoietic anemia; MCV, mean corpuscular volume; PRCA, pure red cell aplasia; RBC, red blood cell; RT, reverse transcriptase; 5-FU, 5-fluorouracil.
From Orkin SH, Fisher DE, Ginsburg D, et al., eds. *Nathan and Oski's Hematology and Oncology of Infancy and Childhood*, 8th ed. Philadelphia: Elsevier, 2015; Table 10-3.

Table 503.2 Causes of Folate Deficiency* in Adults and Children

INADEQUATE NUTRITION
Poor diet†
Poor food preparation methods
Exclusive feeding with goat's milk
DEFECTS IN ABSORPTION
Gastric achlorhydria§
Diseases of the upper small intestine
Tropical sprue
Celiac disease
Dermatitis herpetiformis
Inflammatory bowel disease
Oral pancreatic replacement therapy§
Hereditary folate malabsorption
INCREASED REQUIREMENTS OR LOSSES
Pregnancy
Lactation§
Prematurity§,‖
Chronic hemolytic anemia§
Dialysis
Hyperthyroidism§
Lesch-Nyhan syndrome
DISORDERS OF TRANSPORT
Cerebral folate deficiency (genetic or acquired)¶
DISORDERS OF CELLULAR METABOLISM
Drugs inhibiting folate metabolism
Antifolates (e.g., methotrexate)
Pyrimethamine§; trimethoprim§
Sulfasalazine§
Valproic acid§,#
Inherited defects
Methylenetetrahydrofolate reductase (MTHFR) deficiency
Disorders of intracellular cobalamin metabolism
Dihydrofolate reductase deficiency
Methylenetetrahydrofolate dehydrogenase, cyclohydrolase, and formyltetrahydrofolate synthetase 1 (MTHFD1) deficiency
Others
MULTIFACTORIAL OR UNCERTAIN MECHANISMS
Alcohol use disorder‡
Anticonvulsants§
Oral contraceptives§

*Folate deficiency is often multifactorial.
†Relative dietary insufficiency (i.e., intake that is adequate under usual circumstances) is a particularly important cofactor that can convert borderline folate deficiency to clinically overt deficiency when other conditions coexist, such as increased requirements for folate or mild malabsorption.
§Megaloblastic anemia rarely results unless other limitations of folate status coexist.
‖Neonatal stores are low in premature infants.
¶Cerebral folate deficiency can occur on a genetic basis or an autoimmune basis; megaloblastic anemia does not occur because folate deficiency appears not to exist outside the central nervous system.
#Disrupts mitochondrial folate metabolism in utero.
‡Poor intake is often associated with alcoholism in adults.
From Orkin SH, Fisher DE, Ginsburg D, et al., eds. *Nathan and Oski's Hematology and Oncology of Infancy and Childhood*, 8th ed. Philadelphia: Elsevier, 2015; Box 10-2.

to the fetus via placental folate receptors. Rapid growth after birth increases demands for folic acid, and infants who are premature or ill and those with certain hemolytic disorders will have particularly high folate requirements. Human breast milk, infant formulas, and pasteurized cow's milk provide adequate amounts of folic acid. *Goat's milk is folate deficient, and supplementation must be given when it is the child's main food source.* Unless supplemented, powdered milk may also be a poor source of folic acid.

Malnutrition is the most common cause of folate deficiency in older children. In addition, children with chronic hemolytic anemias, infections, or malabsorption are at increased risk due to increased demand. Because body stores of folate are limited, deficiency can develop quickly in malnourished individuals. On a folate-free diet, megaloblastic anemia will occur after 2-3 months.

Decreased Folate Absorption

Malabsorption caused by chronic diarrheal states or diffuse inflammatory disease can lead to folate deficiency. In both situations, some of the decreased folate absorption may be caused by impaired folate conjugase activity. Chronic diarrhea also interferes with the enterohepatic circulation of folate, thereby enhancing folate losses because of rapid intestinal passage. Megaloblastic anemia caused by folic acid deficiency can occur in celiac disease or chronic infectious enteritis and in association with enteroenteric fistulas. Previous intestinal surgery is another potential cause of decreased folate absorption.

Certain anticonvulsant drugs (e.g., phenytoin, phenobarbital) can impair folic acid absorption, and many patients treated with these drugs have low serum levels. Frank megaloblastic anemia is rare and readily responds to folic acid therapy, even when administration of the offending drug is continued. Alcohol overuse also is associated with folate malabsorption.

Congenital Abnormalities in Folate Transport and Metabolism

Inborn errors of folate transport or metabolism are rare but can be life threatening. Those associated with megaloblastic anemia include hereditary folate malabsorption and certain extremely uncommon enzyme deficiencies.

Hereditary folate malabsorption (HFM) is an autosomal recessive disorder caused by loss-of-function pathogenic variants in the *SLC46A1* gene encoding the protein-coupled folate transporter. HFM is associated with an inability to absorb folic acid, 5-tetrahydrofolate, 5-methyltetrahydrofolate, or 5-formyltetrahydrofolate (folinic acid). It can become apparent at 2-6 months of age with megaloblastic anemia and other deficits, including infections and diarrhea. Neurologic abnormalities attributable to folate deficiency in the central nervous system (CNS) include seizures, developmental delay, and intellectual disability. Folate transport is impaired both in the intestine and at the brain's choroid plexus. Serum and cerebrospinal fluid (CSF) folate levels are very low, with a loss of the normal 3:1 ratio of CSF to serum folate.

Treatment for HFM involves parenteral (intramuscular) folate or high-dose oral 5-formyltetrahydrofolate (5-formylTHF), folinic acid, leucovorin, or the active isomer of 5-formylTHF (Isovorin or Fusilev) targeting normal or near normal trough levels in the CSF to ameliorate both the megaloblastic anemia and neurologic complications of folate deficiency.

Functional methionine synthase deficiency may result from pathologic genetic variants affecting the function of methionine synthase reductase or methionine synthase. These disorders are autosomal recessive and characterized not only by megaloblastic anemia but also by cerebral atrophy, nystagmus, blindness, and altered muscle tone. Both respond to hydroxocobalamin (OHCbl) plus betaine with variable clinical success. **Dihydrofolate reductase (DHFR) deficiency** is extremely rare and is associated with homozygous pathologic genetic variants in the *DHFR* gene. Clinical symptoms include megaloblastic anemia and neurologic manifestations. Although **methylenetetrahydrofolate reductase (MTHFR) deficiency** is the most common inborn error of folate metabolism, and severe cases can produce several neurologic and vascular complications, there is *no* associated megaloblastic anemia.

Drug-Induced Abnormalities in Folate Metabolism

Several drugs have anti–folic acid activity as their primary pharmacologic effect and regularly produce megaloblastic anemia. *Methotrexate* binds to dihydrofolate reductase and prevents formation of tetrahydrofolate, the active form of folate. *Pyrimethamine,* used in the therapy of toxoplasmosis, and *trimethoprim,* used for treatment of various infections, can induce folic acid deficiency and occasionally megaloblastic anemia. Therapy with folinic acid (5-formyltetrahydrofolate) is usually beneficial.

CLINICAL MANIFESTATIONS

In addition to the clinical features associated with anemia, folate-deficient infants and children may manifest irritability, chronic diarrhea, and poor weight gain. Hemorrhages from thrombocytopenia may occur in advanced cases. HFM and other rare etiologies of folate deficiency may be further associated with hypogammaglobulinemia, severe infections, failure to thrive, neurologic abnormalities, and cognitive delays.

LABORATORY FINDINGS

The anemia is macrocytic (mean corpuscular volume >100 fL). Variations in RBC shape and size are common (see Chapter 496, Fig. 496.4B). The reticulocyte count is low, and nucleated RBCs with megaloblastic morphology are often seen in the peripheral blood. Neutropenia and thrombocytopenia may be present, particularly in patients with long-standing and severe deficiencies. The neutrophils are large, some with *hypersegmented nuclei* (see Fig. 503.1). The bone marrow is hypercellular because of erythroid hyperplasia, and megaloblastic changes are prominent. Large, abnormal neutrophilic forms (giant metamyelocytes) with cytoplasmic vacuolation are also seen.

Levels of RBC folate are a better indicator of chronic deficiency than serum folic acid levels. The normal RBC folate level is 150-600 ng/mL of packed cells. Levels of iron and vitamin B_{12} in serum usually are normal or elevated. Serum activity of lactate dehydrogenase, a marker of ineffective erythropoiesis, is markedly elevated.

TREATMENT

When the diagnosis of folate deficiency is established, folic acid may be administered orally or parenterally at 0.5-1.0 mg/day. If the specific diagnosis is in doubt, smaller doses of folate (0.1 mg/day) may be used for 1 week as a diagnostic test because a hematologic response can be expected within 72 hours. Doses of folate >0.1 mg can correct the anemia of vitamin B_{12} deficiency but might aggravate any associated neurologic abnormalities. In most medical settings in developed countries, this therapeutic trial to distinguish the different causes of megaloblastic anemia is rarely necessary because vitamin B_{12} and folate blood levels are usually readily available. Folic acid therapy (0.5-1.0 mg/day) should be continued for 3-4 weeks until a definite hematologic response has occurred. Maintenance therapy with a multivitamin (containing 0.2 mg of folate) is adequate. Parenteral or high doses of specific folate formulations are required in the setting of HFM. Transfusions are indicated only when the anemia is severe, or the child is very ill.

Visit Elsevier eBooks+ at eBooks.Health.Elsevier.com for Bibliography.

503.2 Vitamin B_{12} (Cobalamin) Deficiency

Courtney D. Thornburg

Vitamin B_{12}, a generic term encompassing all biologically active cobalamins, is a water-soluble vitamin with a central, functional cobalt atom and a planar corrin ring. Methylcobalamin and adenosyl cobalamin are the metabolically active derivatives, serving as cofactors in two essential metabolic reactions: methylation of homocysteine to methionine (via methionine synthase) and conversion of methyl-malonyl-coenzyme A (CoA) to succinyl CoA (via L-methyl-malonyl-CoA mutase). The products and by-products of these enzymatic reactions are critical to DNA, RNA, and protein synthesis.

Cobalamin (Cbl) is synthesized *exclusively* by microorganisms, and humans must rely on dietary sources (animal products, including meat, eggs, fish, and milk) for their needs (see Chapter 67.7). Unlike folate, older children and adults have sufficient vitamin B_{12} stores to last 3-5 years. In young infants born to mothers with low vitamin B_{12} stores, clinical signs of Cbl deficiency can become apparent in the first 6-18 months of life.

METABOLISM

Under normal circumstances, cobalamin is released from food protein in the stomach through peptic digestion. Cbl then binds to *haptocorrin* (HC), a salivary glycoprotein. This complex moves into the duodenum, where HC is digested by pancreatic proteases and Cbl is liberated. Cbl then binds to *intrinsic factor* (IF), another glycoprotein that is produced by gastric parietal cells. The Cbl-IF complex subsequently enters mucosal cells of the distal ileum by receptor-mediated endocytosis. Through a complex series of protein interactions, Cbl is taken up into the blood stream and taken up into cells. Cobalamins are processed in the cytoplasm to a common intermediate that can be allocated to the methylcobalamin and adenosyl-cobalamin synthesis pathways to meet cellular needs.

ETIOLOGY

Vitamin B_{12} deficiency can result from inadequate dietary intake of Cbl, lack of IF, impaired intestinal absorption of IF-Cbl, inactivation, or absence of vitamin B_{12} transport protein (see Table 503.1).

Inadequate Vitamin B_{12} Intake

Vitamin B_{12} deficiency in infants is most often nutritional, resulting from low Cbl levels in the breast milk of B_{12}-deficient mothers. Associated **megaloblastic anemia** often appears during the first year of life. Maternal deficiency may be caused by **pernicious anemia** or gastrointestinal disorders such as *Helicobacter pylori* infection, celiac disease, Crohn disease, or pancreatic insufficiency. Previous gastric bypass surgery, treatment with proton pump inhibitors, and inadequate intake from a strict unsupplemented vegetarian diet have also been implicated. Fortunately, because of active placental Cbl transport in utero, most children of B_{12}-deficient mothers maintain Cbl levels sufficient to support adequate prenatal development. Such infants are born with low B_{12} stores, the depletion of which is associated with a gradual onset of clinical manifestations. *Vitamin B_{12} replacement often results in rapid improvement, but the longer the deficient period, the greater the likelihood of permanent disabilities.* Neonatal screening programs may detect maternal-neonatal nutritional B_{12} deficiency because of an increase in propionyl carnitine, but there is higher sensitivity using a measurement of methylmalonic acid. In high-income countries, dietary deficiency during childhood or adolescence is infrequent but can result from strict vegetarian or vegan diet. Daily requirements range from 0.4-2.4 μg.

Impaired Vitamin B_{12} Absorption

Gastric surgery or medications that impair gastric acid secretion may result in IF deficiency, leading to decreased vitamin B_{12} absorption. Pancreatic insufficiency can also lead to Cbl deficiency because of impaired cleavage and IF complex formation. Patients with neonatal necrotizing enterocolitis, inflammatory bowel disease, celiac disease, or surgical removal of the terminal ileum may also have impaired absorption of vitamin B_{12}. An overgrowth of intestinal bacteria within diverticula or duplications of the small intestine can cause vitamin B_{12} deficiency by consumption of (or competition for) the vitamin or by splitting of its complex with IF. In these cases, *hematologic response can follow appropriate antibiotic therapy.* In endemic areas, when the fish tapeworm *Diphyllobothrium latum* infests the upper small intestine, similar mechanisms may be operative. When megaloblastic anemia occurs in such situations, the serum vitamin B_{12} level is low, and the gastric fluid contains IF.

Hereditary intrinsic factor deficiency (HIFD) is a rare autosomal recessive disorder caused by a variety of pathologic genetic variants in the *IF* gene that produce a lack of gastric IF or a functionally abnormal IF. HIFD differs from typical adult pernicious anemia in that gastric acid is secreted normally and the stomach is histologically normal. It is not associated with antibodies or endocrine abnormalities. Unlike Imerslund-Grasbeck syndrome, described next, HIFD is only occasionally associated with proteinuria. Symptoms become prominent at an early age (6-24 months), consistent with exhaustion of vitamin B_{12} stores acquired in utero. As the anemia becomes severe, weakness, irritability, anorexia, and listlessness occur. The tongue is smooth, red, and painful. Neurologic manifestations include ataxia, paresthesias, hyporeflexia, Babinski responses, and clonus. Oral vitamin B_{12} is usually *ineffective*, and lifelong intramuscular (IM) or intranasal Cbl should be used to bypass the absorption defect. The natural form, OHCbl, is believed to be more effective than the synthetic form, cyanocobalamin (CNCbl).

Imerslund-Grasbeck syndrome is a rare, recessively inherited pediatric disorder resulting in selective vitamin B_{12} malabsorption in the ileum and consequent vitamin B_{12} deficiency. It usually becomes clinically apparent within the first 6 years of life. In addition to megaloblastic anemia, the patient may also have neurologic defects (e.g., hypotonia, developmental delay, brain atrophy, movement disorders, dementia) and/or proteinuria. Patients carry pathologic variants in genes *CUBN* or *AMN*, which encode proteins that form the cubam receptor for the ileal IF-Cbl complex. Because CUBN is also a key receptor for protein reabsorption in the kidney, impaired expression at this site results in associated proteinuria. The disease can be fatal if it remains untreated. Early diagnosis and treatment with IM or intranasal Cbl will reverse the hematologic and neurologic abnormalities. Proteinuria does not respond to therapy.

Classic pernicious anemia (autoimmune gastritis) usually occurs in older adults but can rarely affect children. This disorder **(juvenile pernicious anemia)** usually presents during adolescence. In such cases, the disease is associated with various detectable antibodies, including those against IF and the hydrogen-potassium adenosine triphosphatase proton pump in gastric parietal cells. These children can have additional immunologic abnormalities, cutaneous candidiasis, hypoparathyroidism, and other endocrine deficiencies; atrophy of the gastric mucosa and achlorhydria may occur. IM or intranasal vitamin B_{12} should be administered regularly.

Absence of Vitamin B_{12} Transport Protein Transcobalamin

Transcobalamin (TC) deficiency is a rare cause of megaloblastic anemia. A congenital deficiency is inherited as an autosomal recessive condition resulting in a failure to absorb and transport vitamin B_{12}. Most patients lack TC, but some have functionally defective forms. This disorder usually manifests in the first weeks of life. Characteristically, there is failure to thrive, diarrhea, vomiting, glossitis, neurologic abnormalities, and megaloblastic anemia. The diagnosis can be difficult given that total serum vitamin B_{12} levels are often normal because approximately 80% of serum Cbl is bound to HC. The diagnosis is suggested by the presence of severe megaloblastic anemia in the face of normal folate levels and no evidence of another inborn error of metabolism. Plasma homocysteine and methylmalonic acid levels are elevated. A definitive diagnosis is made by measuring plasma TC. The serum vitamin B_{12} levels must be kept high to force enough Cbl into cells and allow normal function using high-dose oral supplementation or IM or intranasal treatment. Symptoms and laboratory studies should be monitored, and doses adjusted as needed.

Disorders of Intracellular Cobalamin Metabolism

Disorders of intracellular cobalamin metabolism are associated with pathologic genetic variants in genes associated with lettered complementation groups. These include *MMACHC (cblC)*, *MMADHC* (*cblD*-combined and *cblD* homocystinuria), *MTRR (cblE), LMBRD1 (cblF), MTR (cblG), ABCD4 (cblJ), THAP11* (*cblX*-like), *ZNF143* (*cblX*-like), or *HCFC1* (*cblX*, which can show a cblC complementation class). The disorders present at a range of ages starting in utero and have a variable clinical presentation including complications of methylmalonic acidemia, homocystinuria, and megaloblastic anemia. Patients require care with a metabolic specialist to guide treatment with OHCbl, avoidance of agents that can cause metabolic decompensation, and surveillance for complications.

Vitamin B_{12} deficiency may develop by inactivation of vitamin B_{12}. This most often occurs in adolescents who chronically use "Whippets," which contain nitrous oxide, as a recreational agent to get high. Conversely, patients with underlying vitamin B_{12} deficiency may have an exacerbation after nitrous oxide anesthesia.

CLINICAL MANIFESTATIONS

Children with Cbl deficiency often present with nonspecific manifestations such as weakness, lethargy, feeding difficulties, failure to thrive, and irritability. Other common findings include pallor, glossitis, vomiting, diarrhea, and icterus. Hyperpigmentation is another feature that may mimic Addison disease. Neurologic symptoms can include paresthesia, sensory deficits, hypotonia, seizures, developmental delay, developmental regression, neuropsychiatric changes, and brain/spine MRI changes. Neurologic problems from vitamin B_{12} deficiency may occur in the *absence* of any hematologic abnormalities. Thrombotic microangiopathy is a rare manifestation.

LABORATORY FINDINGS

The hematologic manifestations of folate and Cbl deficiency are identical. The anemia resulting from Cbl deficiency is macrocytic, with prominent macro-ovalocytosis of the RBCs (see Chapter 496, Fig. 496.2, and Fig. 503.1). The neutrophils may be large and hypersegmented (see Fig. 503.1). In advanced cases, neutropenia and thrombocytopenia can occur, simulating aplastic anemia or leukemia. Macrocytosis may not always be present. Serum vitamin B_{12} levels are low, and the serum concentrations of methylmalonic acid and homocysteine are elevated. Concentrations of serum iron and serum folic acid are normal or elevated. Serum lactate dehydrogenase activity is markedly increased, a reflection of ineffective erythropoiesis. Moderate elevations of serum bilirubin levels (2-3 mg/dL) also may be found. Excessive excretion of methylmalonic acid in the urine (normal: 0-3.5 mg/24 hr) is a reliable and sensitive index of vitamin B_{12} deficiency and is especially helpful when the serum vitamin B_{12} level is in the low-normal range.

DIAGNOSIS

A comprehensive medical history is essential to the clinical recognition of possible Cbl deficiency. Information regarding clinical symptoms, dietary history, diseases, surgeries, or medications and drugs is likely to provide important clues. The physical examination may reveal relevant findings such as irritability, pallor, pigmentation or specific neurologic symptoms. Screening laboratory findings offer important information, but more focused testing will be required to confirm a diagnosis of vitamin B_{12} deficiency and its cause. Cbl deficiency is usually identified by measuring total or TC-bound vitamin B_{12} in the blood. Although an extremely low level is generally diagnostic, this may not be the case because false negatives and false positives are reportedly common using currently available assays. As a result, it is wise not to discount vitamin B_{12} deficiency, particularly in the face of clinical symptoms, macrocytic anemia, an abnormal blood smear, and a normal folate level. In untreated patients, methylmalonic acid and total homocysteine levels are often helpful because they are greatly elevated in the majority of those with clinical signs of B_{12} deficiency. Excessive urinary methylmalonic acid excretion is also a sensitive test of B_{12} deficiency. Although modest increases occur with renal failure, elevated methylmalonic acid is otherwise quite specific for B_{12} deficiency. Notably, however, serum homocysteine is also elevated in folate deficiency, homocystinuria, and renal failure.

If vitamin B_{12} deficiency has been confirmed and there is no evidence of inadequate dietary intake or, in the case of an infant, inadequate maternal B_{12}, malabsorption should be investigated. Anti-IF antibodies and anti–parietal cell antibodies are useful for the diagnosis of pernicious anemia. Measurement of IF and testing from more specialized laboratories may be required for less common disorders.

TREATMENT

Treatment regimens in children have not been well studied. The cause of vitamin B_{12} deficiency should ultimately dictate treatment dosage and route of administration as well as the duration of therapy. Cyanocobalamin is available as a nasal spray as an alternative to parenteral injection. Dose adjustments should be made in response to clinical status and laboratory values. The physiologic requirement for vitamin B_{12} is about 1-3 μg/day. Hematologic responses have been observed with small doses, indicating that a mini-dose may be administered as a therapeutic test when the diagnosis of vitamin B_{12} deficiency is in doubt or in circumstances where the anemia is severe and higher initial doses might result in severe metabolic disturbances.

Visit Elsevier eBooks+ at eBooks.Health.Elsevier.com for Bibliography.

503.3 Other Rare Megaloblastic Anemias

Courtney D. Thornburg

Orotic aciduria is a rare autosomal recessive disorder that usually appears in the first year of life and is characterized by growth failure, developmental delay, megaloblastic anemia, and increased urinary excretion of orotic acid (see Chapter 110). Rarely, orotic aciduria occurs without megaloblastic anemia. This defect is the most common metabolic error in the de novo synthesis of pyrimidines and therefore affects nucleic acid synthesis. The usual form of hereditary orotic aciduria is caused by a deficiency (in all body tissues) of orotic phosphoribosyl transferase and orotidine-5-phosphate decarboxylase, two sequential enzymatic steps in pyrimidine nucleotide synthesis. The diagnosis is suggested by the presence of severe megaloblastic anemia with normal serum B_{12} and folate levels and no evidence of TC deficiency. A presumptive diagnosis is made by finding increased urinary orotic acid. However, confirmation of the diagnosis requires assay of the transferase and decarboxylase enzymes in the patient's erythrocytes. Failure to thrive and intellectual disability often accompany this condition. The anemia is refractory to vitamin B_{12} or folic acid, but the anemia responds promptly to administration of uridine.

Thiamine-responsive megaloblastic anemia (Rogers syndrome) is a very rare autosomal recessive disorder characterized by megaloblastic anemia, sensorineural deafness, and diabetes mellitus. Congenital heart defects, arrhythmias, visual problems, short stature, trilineage myelodysplasia, and strokes are also described. Thiamine-responsive megaloblastic anemia usually presents in infancy but may occasionally develop in childhood and adolescence and occurs in several ethnically distinct populations. The bone marrow is characterized not only by megaloblastic changes but also by ringed sideroblasts. The defect is caused by biallelic pathologic genetic variants in *SCL19A2*, which encodes a high-affinity plasma membrane thiamine transporter. Continuous thiamine supplementation usually reverses the anemia and diabetes, but not existing hearing defects.

Visit Elsevier eBooks+ at eBooks.Health.Elsevier.com for Bibliography.

Chapter 504
Iron-Deficiency Anemia

Jennifer A. Rothman

Iron deficiency is the most widespread and common nutritional disorder in the world. It is estimated that 30–50% of the global population has iron-deficiency anemia, and most of these individuals live in developing countries. In the United States, 8–14% of children ages 12-36 months are *iron deficient*, and 30% of this group progresses to *iron-deficiency anemia*.

A full-term newborn infant contains about 0.5 grams of iron, compared with 5 grams of iron in adults. This change in quantity of iron from birth to adulthood means that an average of 0.8 mg of iron must be absorbed each day during the first 15 years of life. A small additional amount is necessary to balance normal losses of iron by shedding of cells. It is therefore necessary to absorb approximately 1 mg daily to maintain positive iron balance in childhood. Because <10% of dietary iron is usually absorbed, a dietary intake of 8-10 mg of iron daily is necessary to maintain iron levels. During infancy, when growth is most rapid, the 1 mg/L of iron in cow's and breast milk makes it difficult to maintain body iron. Although breastfed infants have an advantage because they absorb iron 2-3 times more efficiently than infants fed cow's milk, breastfed infants nonetheless are at risk of developing iron deficiency without regular intake of iron-fortified foods by 6 months of age.

ETIOLOGY

Most iron in neonates resides in circulating hemoglobin. As the relatively high hemoglobin concentration of the newborn infant falls during the first 2-3 months of life, considerable iron is recycled. These iron stores are usually sufficient for blood formation in the first 6-9 months of life in term infants. Stores are depleted sooner in premature infants, low birthweight infants, or infants with perinatal blood loss, because their iron stores are smaller. Delayed (1-3 minute) clamping of the umbilical cord can improve iron status and reduce the risk of iron deficiency, whereas early clamping (<30 seconds) puts the infant at risk for iron deficiency. Dietary sources of iron are especially important in these infants. In term infants, anemia caused solely by inadequate dietary iron usually occurs at 9-24 months of age and is less common thereafter. The usual dietary pattern observed in infants and toddlers with nutritional iron-deficiency anemia in developed countries is excessive consumption of cow's milk (low iron content, blood loss from milk protein colitis) in a child who is often overweight or bottle feeding beyond 12 months of age. Worldwide, **undernutrition** is usually responsible for iron deficiency (Table 504.1).

Blood loss must be considered as a possible cause in every case of iron-deficiency anemia. Sources of blood loss, particularly in older children and adolescents, include menstrual losses, recurrent nosebleeds, or intravascular hemolysis with hemoglobinuria, as seen in diseases such as malaria or endurance athletics such as triathletes. Chronic iron-deficiency anemia from occult bleeding may be caused by a lesion of the gastrointestinal (GI) tract, such as peptic ulcer, Meckel diverticulum, polyp, hemangioma, or inflammatory bowel disease. Infants can have chronic intestinal blood loss induced by exposure to cow's milk protein. Involved infants characteristically develop anemia that is more severe and occurs earlier than would be expected simply from an inadequate intake of iron. The ongoing loss of blood in the stools can be prevented either by breastfeeding or by delaying the introduction of whole cow's milk in the first years of life and then limiting the quantity to <24 oz/24 hours. *Infants and toddlers who have excessive raw milk intake with no iron supplementation and limited iron containing foods are at high risk of iron deficiency.* Unrecognized blood loss also can be associated with chronic diarrhea and, rarely, with pulmonary hemosiderosis. In developing countries, infections with hookworm, *Trichuris trichiura,* and *Plasmodium* often contribute to iron deficiency. Since iron is absorbed in the proximal duodenum with the assistance of gastric acid, gastric bypass procedures or *Helicobacter pylori* infection may interfere with iron absorption. Similarly, inflammation of the bowel from celiac disease and giardiasis may also interfere with iron absorption.

Approximately 2% of adolescent females have iron-deficiency anemia, largely as a result of their adolescent growth spurt and menstrual blood loss. The highest risk of iron-deficiency anemia (>30%) is among teenagers who are or have been pregnant.

CLINICAL MANIFESTATIONS

Most children with iron-deficiency anemia are asymptomatic and are identified by routine laboratory screening at 9-12 months of age. Normal hemoglobin values vary according to age, gender, ethnicity, and method of testing, such as capillary versus venous blood. Pallor is the

TREATMENT

Treatment regimens in children have not been well studied. The cause of vitamin B_{12} deficiency should ultimately dictate treatment dosage and route of administration as well as the duration of therapy. Cyanocobalamin is available as a nasal spray as an alternative to parenteral injection. Dose adjustments should be made in response to clinical status and laboratory values. The physiologic requirement for vitamin B_{12} is about 1-3 μg/day. Hematologic responses have been observed with small doses, indicating that a mini-dose may be administered as a therapeutic test when the diagnosis of vitamin B_{12} deficiency is in doubt or in circumstances where the anemia is severe and higher initial doses might result in severe metabolic disturbances.

Visit Elsevier eBooks+ at eBooks.Health.Elsevier.com for Bibliography.

503.3 Other Rare Megaloblastic Anemias

Courtney D. Thornburg

Orotic aciduria is a rare autosomal recessive disorder that usually appears in the first year of life and is characterized by growth failure, developmental delay, megaloblastic anemia, and increased urinary excretion of orotic acid (see Chapter 110). Rarely, orotic aciduria occurs without megaloblastic anemia. This defect is the most common metabolic error in the de novo synthesis of pyrimidines and therefore affects nucleic acid synthesis. The usual form of hereditary orotic aciduria is caused by a deficiency (in all body tissues) of orotic phosphoribosyl transferase and orotidine-5-phosphate decarboxylase, two sequential enzymatic steps in pyrimidine nucleotide synthesis. The diagnosis is suggested by the presence of severe megaloblastic anemia with normal serum B_{12} and folate levels and no evidence of TC deficiency. A presumptive diagnosis is made by finding increased urinary orotic acid. However, confirmation of the diagnosis requires assay of the transferase and decarboxylase enzymes in the patient's erythrocytes. Failure to thrive and intellectual disability often accompany this condition. The anemia is refractory to vitamin B_{12} or folic acid, but the anemia responds promptly to administration of uridine.

Thiamine-responsive megaloblastic anemia (Rogers syndrome) is a very rare autosomal recessive disorder characterized by megaloblastic anemia, sensorineural deafness, and diabetes mellitus. Congenital heart defects, arrhythmias, visual problems, short stature, trilineage myelodysplasia, and strokes are also described. Thiamine-responsive megaloblastic anemia usually presents in infancy but may occasionally develop in childhood and adolescence and occurs in several ethnically distinct populations. The bone marrow is characterized not only by megaloblastic changes but also by ringed sideroblasts. The defect is caused by biallelic pathologic genetic variants in *SCL19A2*, which encodes a high-affinity plasma membrane thiamine transporter. Continuous thiamine supplementation usually reverses the anemia and diabetes, but not existing hearing defects.

Visit Elsevier eBooks+ at eBooks.Health.Elsevier.com for Bibliography.

Chapter 504
Iron-Deficiency Anemia

Jennifer A. Rothman

Iron deficiency is the most widespread and common nutritional disorder in the world. It is estimated that 30–50% of the global population has iron-deficiency anemia, and most of these individuals live in developing countries. In the United States, 8–14% of children ages 12-36 months are *iron deficient*, and 30% of this group progresses to *iron-deficiency anemia*.

A full-term newborn infant contains about 0.5 grams of iron, compared with 5 grams of iron in adults. This change in quantity of iron from birth to adulthood means that an average of 0.8 mg of iron must be absorbed each day during the first 15 years of life. A small additional amount is necessary to balance normal losses of iron by shedding of cells. It is therefore necessary to absorb approximately 1 mg daily to maintain positive iron balance in childhood. Because <10% of dietary iron is usually absorbed, a dietary intake of 8-10 mg of iron daily is necessary to maintain iron levels. During infancy, when growth is most rapid, the 1 mg/L of iron in cow's and breast milk makes it difficult to maintain body iron. Although breastfed infants have an advantage because they absorb iron 2-3 times more efficiently than infants fed cow's milk, breastfed infants nonetheless are at risk of developing iron deficiency without regular intake of iron-fortified foods by 6 months of age.

ETIOLOGY

Most iron in neonates resides in circulating hemoglobin. As the relatively high hemoglobin concentration of the newborn infant falls during the first 2-3 months of life, considerable iron is recycled. These iron stores are usually sufficient for blood formation in the first 6-9 months of life in term infants. Stores are depleted sooner in premature infants, low birthweight infants, or infants with perinatal blood loss, because their iron stores are smaller. Delayed (1-3 minute) clamping of the umbilical cord can improve iron status and reduce the risk of iron deficiency, whereas early clamping (<30 seconds) puts the infant at risk for iron deficiency. Dietary sources of iron are especially important in these infants. In term infants, anemia caused solely by inadequate dietary iron usually occurs at 9-24 months of age and is less common thereafter. The usual dietary pattern observed in infants and toddlers with nutritional iron-deficiency anemia in developed countries is excessive consumption of cow's milk (low iron content, blood loss from milk protein colitis) in a child who is often overweight or bottle feeding beyond 12 months of age. Worldwide, **undernutrition** is usually responsible for iron deficiency (Table 504.1).

Blood loss must be considered as a possible cause in every case of iron-deficiency anemia. Sources of blood loss, particularly in older children and adolescents, include menstrual losses, recurrent nosebleeds, or intravascular hemolysis with hemoglobinuria, as seen in diseases such as malaria or endurance athletics such as triathletes. Chronic iron-deficiency anemia from occult bleeding may be caused by a lesion of the gastrointestinal (GI) tract, such as peptic ulcer, Meckel diverticulum, polyp, hemangioma, or inflammatory bowel disease. Infants can have chronic intestinal blood loss induced by exposure to cow's milk protein. Involved infants characteristically develop anemia that is more severe and occurs earlier than would be expected simply from an inadequate intake of iron. The ongoing loss of blood in the stools can be prevented either by breastfeeding or by delaying the introduction of whole cow's milk in the first years of life and then limiting the quantity to <24 oz/24 hours. *Infants and toddlers who have excessive raw milk intake with no iron supplementation and limited iron containing foods are at high risk of iron deficiency.* Unrecognized blood loss also can be associated with chronic diarrhea and, rarely, with pulmonary hemosiderosis. In developing countries, infections with hookworm, *Trichuris trichiura,* and *Plasmodium* often contribute to iron deficiency. Since iron is absorbed in the proximal duodenum with the assistance of gastric acid, gastric bypass procedures or *Helicobacter pylori* infection may interfere with iron absorption. Similarly, inflammation of the bowel from celiac disease and giardiasis may also interfere with iron absorption.

Approximately 2% of adolescent females have iron-deficiency anemia, largely as a result of their adolescent growth spurt and menstrual blood loss. The highest risk of iron-deficiency anemia (>30%) is among teenagers who are or have been pregnant.

CLINICAL MANIFESTATIONS

Most children with iron-deficiency anemia are asymptomatic and are identified by routine laboratory screening at 9-12 months of age. Normal hemoglobin values vary according to age, gender, ethnicity, and method of testing, such as capillary versus venous blood. Pallor is the

serum transferrin levels that are accompanied by the deposition of non–transferrin-bound iron in parenchymal tissues. Because hepcidin production is induced by inflammatory stimuli, hepcidin elevation is also a feature of the **anemia of chronic disease** (ACD). However, in contrast to patients with IRIDA, in whom the hepcidin dysregulation is congenital, patients with ACD generally retain normal to high iron stores because of the acquired nature of their hepcidin elevation (see Chapter 500.1). Rare medical causes that may mimic IRIDA include vascular malformations of the GI tract, Castleman disease (where IL-6 overproduction causes hepcidin elevation), autoimmune gastritis, and pathogenic germline variants in *KCNQ1* (which regulates gastric acid secretion).

TREATMENT

Because of the underlying pathophysiology of IRIDA, *parenteral iron supplementation* is required to correct the anemia. Although parenteral iron therapy raises body iron stores, the hematologic response is usually slow and not completely corrective. This likely results from insufficient export of the processed iron from macrophages into the circulation, an expected consequence of hepcidin elevation. Serum ferritin levels increase with parenteral iron therapy in a dose-dependent manner and may raise concerns for iron overload, which would be expected to exhibit a reticuloendothelial rather than a parenchymal pattern of iron loading. Given the limited number of IRIDA cases reported to date, the optimal formulation and dosing of parenteral iron have not yet been established. Although oral iron supplementation does not appear to have a significant role in treatment of IRIDA, the addition of ascorbic acid to a ferrous sulfate oral supplement has been associated with hematologic responses in isolated cases. Treatment with recombinant erythropoietin has not been found to produce significant clinical benefit in patients with IRIDA.

Visit Elsevier eBooks+ at eBooks.Health.Elsevier.com for Bibliography.

Chapter 505

Other Microcytic Anemias

Jennifer A. Rothman

A number of rare microcytic anemias need to be considered when children with microcytic anemia fail to respond to oral iron (Table 504.5). These anemias include thalassemia or thalassemia trait (see Chapter 511), infantile poikilocytosis and hereditary pyropoikilocytosis (Chapter 508), and anemia of chronic disease (Chapter 500.1). Additionally, rare nutritional disorders and disorders of iron metabolism can cause microcytosis.

INFANTILE POIKILOCYTOSIS AND HEREDITARY PYROPOIKILOCYTOSIS

Infants with common **hereditary elliptocytosis** (see Chapter 508) may initially present with hemolytic anemia characterized by marked poikilocytosis with budding and fragmentation of the red blood cells (RBCs). These small RBC fragments reduce the overall mean corpuscular volume (MCV), resulting in microcytosis. By 2 years of age, the findings become typical of hereditary elliptocytosis. **Hereditary pyropoikilocytosis** is a much less common variant of hereditary elliptocytosis, in which the hemolytic anemia and RBC changes are more severe.

COPPER DEFICIENCY

Copper deficiency is a rare cause of microcytic anemia and neurologic dysfunction. Copper is absorbed in the stomach and proximal duodenum. Deficiency is associated with malabsorption; severe malnutrition, often with feeding of milk alone; gastric surgery or feedings that bypass the stomach and duodenum; or parenteral nutrition with inadvertent omission of supplemental copper. Zinc and copper are competitively absorbed from the gastrointestinal (GI) tract, so zinc excess may inadvertently lead to copper deficiency. Diagnosis is made by measuring a serum copper level, serum ceruloplasmin, and possibly a zinc level. Treatment includes either oral or parenteral supplementation, depending on the underlying cause.

DEFECTS OF IRON METABOLISM

Rare microcytic anemias may be associated with defects in iron trafficking and regulation. Most are inherited and usually identified in childhood, including defects of iron absorption, transport, utilization, and recycling. A *defect of iron absorption* is **iron-refractory iron-deficiency anemia** (see Chapter 504.1). *Defects of iron recycling* include aceruloplasminemia and atransferrinemia. **Aceruloplasminemia** is an autosomal recessive disorder in the *CP* gene that encodes ceruloplasmin. Iron cannot be appropriately transported from macrophages to plasma to be available for RBC production but accumulates instead in the brain and visceral organs, which can lead to an adult-onset neurodegenerative disorder. The diagnosis is made by a combination of absence of serum ceruloplasmin, low serum copper and iron, elevated ferritin, and increased liver iron concentration. Hypotransferrinemia or **atransferrinemia** is also an autosomal recessive disorder caused by pathogenic variants in the transferrin *(TF)* gene. Diagnosis is made by low or absent serum transferrin and liver iron overload. Genetic testing can confirm the diagnosis for both disorders. Treatment includes iron chelation therapy, limiting iron supplementation and dietary iron, and possibly fresh-frozen plasma to replace ceruloplasmin and/or transferrin. Purified transferrin (apotransferrin) infusions are available.

Defects of mitochondrial iron utilization are a diverse group of acquired and inherited defects known as **sideroblastic anemias** (Table 505.1). Several genes associated with these disorders have been described. Impaired heme synthesis leads to retention of iron within the mitochondria of marrow RBCs. The perinuclear distribution of mitochondria results in a pattern of iron staining surrounding the nucleus. These are *ringed sideroblasts* (Fig. 505.1), which are distinct from the more diffuse cytoplasmic distribution of iron in normal RBC precursors. The anemia is characterized by hypochromic, microcytic RBCs mixed with normal RBCs, so the complete blood count indicates a very high RBC distribution width. The serum iron concentration usually is elevated, and the transferrin saturation of iron is increased.

Congenital sideroblastic anemia (CSA) can be *syndromic* or *nonsyndromic*. The most common type of nonsyndromic CSA is an X-linked disorder and is most often a result of pathogenic variants in *ALAS2* that encodes erythrocytic isozyme 5-aminolevulinic acid synthetase, the rate-limiting enzyme reaction in heme synthesis. An important cofactor for 5-ALA synthetase is *pyridoxal phosphate,* with several pathogenic variants occurring near its binding site. Severe anemia is recognized in infancy or early childhood, whereas milder cases might not become apparent until early adulthood or later. Clinical findings include pallor, icterus, and moderate splenomegaly and/or hepatomegaly. The severity of the anemia varies such that some patients require no therapy and others need regular RBC transfusions. A subset of patients with hereditary sideroblastic anemia manifest a hematologic response to pyridoxine doses of 50-200 mg/day. Iron overload, as manifested by elevated serum ferritin, elevated serum iron, and increased transferrin saturation, is a major complication of this disorder. Clinical evidence of iron overload (e.g., diabetes mellitus, liver dysfunction) may be found in some patients who have little or no anemia, which may require iron chelation therapy. Stem cell transplantation has been used to treat affected children who are dependent on RBC transfusions.

A unique variant of congenital sideroblastic anemia is **Pearson syndrome** (see Chapter 498), but the anemia is usually *macrocytic* and not microcytic. Another rare variant of sideroblastic anemia is caused by pathogenic variants in *TRNT1* and manifests with developmental

Table 505.1 Clinical and Genetic Features of Congenital Sideroblastic Anemias

CATEGORY	DISORDER	INHERITANCE	SYNDROMIC	GENE	FREQUENCY	AGE AT PRESENTATION	ANEMIA SEVERITY	MCV	ASSOCIATED ABNORMALITIES
Heme synthesis defects	XLSA	X-linked	No	*ALAS2*	100s	Infancy to adulthood	Mild to severe	↓ males N/↑ female	Iron overload in the absence of transfusions
	SLC25A38 deficiency	AR	No	*SLC25A38*	40	Infancy	Severe	↓	Transfusional iron overload
	EPP	AR/PSD	No	*FECH*	100s	Childhood	Mild	↓	Acute photosensitivity
Fe-S biogenesis defects	GLRX5 deficiency	AR	No	*GLRX5*	2	Adulthood	Mild to severe	↓	Iron overload
	HSPA9 deficiency	AR/PSD	No	*HSPA9*	12	Childhood	Mild to severe	N/↓	Retinitis pigmentosa
	HSCB deficiency	AR	No	*HSCB*	1	Childhood	Moderate	N	None
	XLSA/A	X-linked	Yes	*ABCB7*	5	Childhood	Mild to moderate	↓	Cerebellar ataxia and hypoplasia, delayed motor development
Mitochondrial protein synthesis defects	PMPS	SP/M	Yes	*mtDNA*	100s	Early childhood	Severe	↑	Lactic acidosis, exocrine pancreatic insufficiency, failure to thrive, hepatic/renal failure
	MLASA1	AR	Yes	*PUS1*	10	Childhood	Mild to severe	N/↑	Myopathy, lactic acidosis, facial dysmorphism
	MLASA2	AR	Yes	*YARS2*	40	Childhood	Mild to severe	N/↑	Myopathy, lactic acidosis, cardiomyopathy
	LARS2 deficiency	AR	Yes	*LARS2*	1	Infancy	Severe	↑	Lactic acidosis, cardiomyopathy, hepatopathy, seizures
	SIFD	AR	Yes	*TRNT1*	30	Infancy	Severe		Immunodeficiency (B.T), aseptic febrile episodes, developmental delay, seizures, cardiomyopathy, retinitis pigmentosa, other
Mitochondrial respiratory protein mutations	MT-ATP6-SA	SP/M	Yes	*MT-ATP6*	4	Infancy to early childhood	Moderate to severe	N/↑	Lactic acidosis, myopathy, neurologic abnormalities
	NDUFB11-SA	X-linked	Yes	*NUDFB11*	5	Early childhood	Moderate	N	Lactic acidosis, myopathy
	Multifactorial TRMA	AR	Yes	*SLC19A2*	50	Early childhood	Mild to severe	↑	Sensorineural deafness, non-type 1 diabetes mellitus, optic atrophy, strokelike episodes

↑, increased; ↓, decreased; AR, autosomal recessive; EPP, erythropoietic protoporphyria; MCV, mean red blood cell volume; MLASA, mitochondrial myopathy lactic acidosis and sideroblastic anemia;. mtDNA, mitochondrial DNA; N, normal; PMPS, Pearson marrow pancreas syndrome; PSD, Pseudodominant; SIFD, sideroblastic anemia, immunodeficiency (B cell), periodic fevers, and developmental delay; SP/M, sporadic/mitochondrial; TRMA, thiamine responsive megaloblastic anemia; XLSA, X-linked sideroblastic anemia.
Adapted from Ducamp S and Fleming D. The molecular genetics of sideroblastic anemia. *Blood* 2019:133(1):59–69.

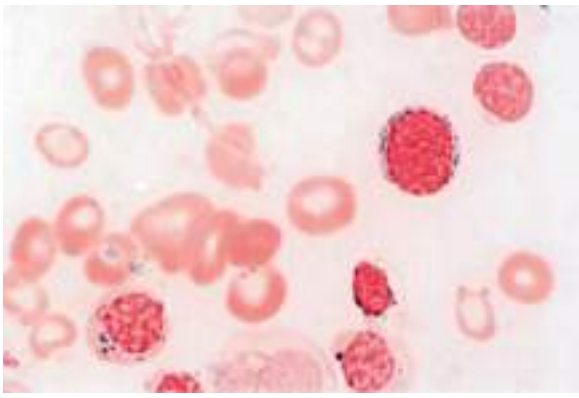

Fig. 505.1 Ring sideroblast in myelodysplastic syndrome (refractory anemia with ring sideroblasts)—iron stain. *(From Ryan DH, Cohen HJ. Bone marrow examination. In: Hoffman R, Benz EJ Jr, Shattil SJ, et al., eds. Hematology, 4th ed. Philadelphia: Churchill Livingstone, 2005.)*

delay, periodic fevers, and B-cell immunodeficiency in addition to sideroblastic anemia.

Acquired sideroblastic anemias can be triggered by copper deficiency or drugs and toxins that disturb mitochondrial iron metabolism, including lead, chloramphenicol, penicillamine, ethanol, and isoniazid. The acquired neoplastic sideroblastic syndromes (myelodysplasias) seen in adults are very rare in children.

Visit Elsevier eBooks+ at eBooks.Health.Elsevier.com for Bibliography.

Section **3**

Hemolytic Anemias

Chapter **506**

Definitions and Classification of Hemolytic Anemias

Stephanie Prozora and Patrick G. Gallagher

Hemolysis is defined as the premature destruction of red blood cells (RBCs). Anemia results when the rate of destruction exceeds the capacity of the marrow to produce additional RBCs. Normal RBC survival time is 110-120 days (half-life: 55-60 days), and thus, approximately 0.85% of the most senescent RBCs are removed and replaced each day. During hemolysis, RBC survival is shortened, the RBC count falls, erythropoietin is increased, and marrow erythropoietic activity is stimulated. This leads to compensatory erythroid hyperplasia with increased RBC production, reflected by an increase in the reticulocyte count. The marrow can increase its output twofold to threefold acutely, with a maximum of sixfold to eightfold in chronic hemolysis. The reticulocyte percentage can be corrected to measure the magnitude of marrow production in response to hemolysis as follows:

$$\text{Reticulocyte index} = \text{reticulocyte } \% \times \frac{\text{Observed hematocrit}}{\text{Normal hematocrit}} \times \frac{1}{\mu}$$

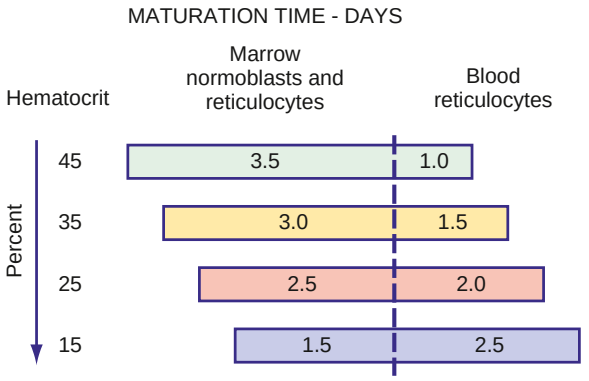

Fig. 506.1 Number of days for maturation of reticulocytes to mature erythrocytes in the marrow and blood. The duration of maturation as blood reticulocytes is taken as μ, which is used in the correction equation in this chapter. *(Modified from Hillman RS, Finch CA. Red cell manual. Philadelphia: FA Davis, 1983.)*

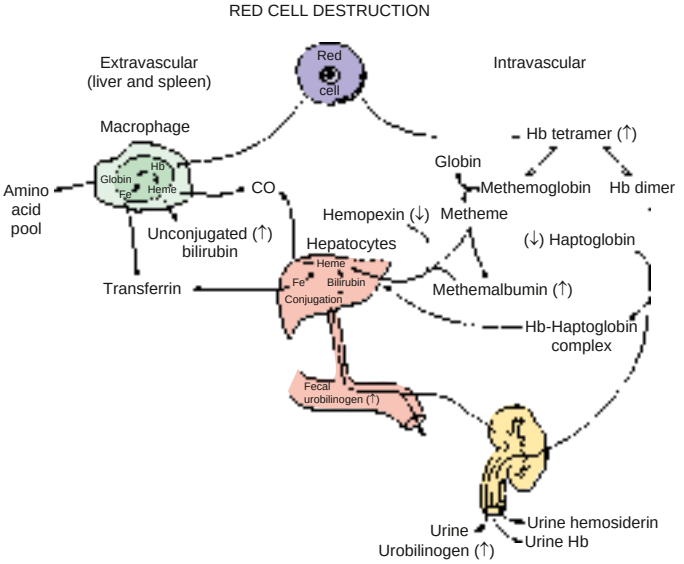

Fig. 506.2 Red cell destruction and catabolism of hemoglobin (Hb) based on the description by Hillman and Finch. Fe, Iron; CO, carbon monoxide. *(From Hillman RS, Finch CA. Red cell manual. Philadelphia: FA Davis, 1983.)*

where μ is a maturation factor of 1-3 related to the severity of the anemia (Fig. 506.1). The normal reticulocyte index is 1.0; therefore the index measures the fold increase in erythropoiesis (e.g., twofold, threefold). Because the reticulocyte index is essentially a measure of RBC production per day, the maturation factor μ provides this correction (see Fig. 506.1).

When hemolysis is chronic, compensatory erythroid hyperplasia may lead to significant expansion of the medullary spaces at the expense of cortical bone. This is particularly prominent in children with severe chronic hemolytic anemia such as thalassemia. These changes may be evident on physical examination or on radiographs of the skull and long bones. In severe cases, there is increased propensity for long bone fracture. Hemolysis also leads to increased degradation of hemoglobin. This process can result in indirect hyperbilirubinemia, increased biliary excretion of heme pigment derivatives, and formation of bilirubinate gallstones.

During hemolysis (Fig. 506.2), heme-binding proteins in the plasma are altered. Hemoglobin binds to haptoglobin and hemopexin, both of which are cleared more rapidly as heme-bound complexes. Oxidized heme binds to albumin to form methemalbumin, which is increased in the plasma during hemolysis. When the capacity of these heme-binding molecules is exceeded, free hemoglobin appears in the plasma. Free hemoglobin in the plasma is considered *prima facie* evidence of

serum transferrin levels that are accompanied by the deposition of non–transferrin-bound iron in parenchymal tissues. Because hepcidin production is induced by inflammatory stimuli, hepcidin elevation is also a feature of the **anemia of chronic disease** (ACD). However, in contrast to patients with IRIDA, in whom the hepcidin dysregulation is congenital, patients with ACD generally retain normal to high iron stores because of the acquired nature of their hepcidin elevation (see Chapter 500.1). Rare medical causes that may mimic IRIDA include vascular malformations of the GI tract, Castleman disease (where IL-6 overproduction causes hepcidin elevation), autoimmune gastritis, and pathogenic germline variants in *KCNQ1* (which regulates gastric acid secretion).

TREATMENT

Because of the underlying pathophysiology of IRIDA, *parenteral iron supplementation* is required to correct the anemia. Although parenteral iron therapy raises body iron stores, the hematologic response is usually slow and not completely corrective. This likely results from insufficient export of the processed iron from macrophages into the circulation, an expected consequence of hepcidin elevation. Serum ferritin levels increase with parenteral iron therapy in a dose-dependent manner and may raise concerns for iron overload, which would be expected to exhibit a reticuloendothelial rather than a parenchymal pattern of iron loading. Given the limited number of IRIDA cases reported to date, the optimal formulation and dosing of parenteral iron have not yet been established. Although oral iron supplementation does not appear to have a significant role in treatment of IRIDA, the addition of ascorbic acid to a ferrous sulfate oral supplement has been associated with hematologic responses in isolated cases. Treatment with recombinant erythropoietin has not been found to produce significant clinical benefit in patients with IRIDA.

Visit Elsevier eBooks+ at eBooks.Health.Elsevier.com for Bibliography.

Chapter 505

Other Microcytic Anemias

Jennifer A. Rothman

A number of rare microcytic anemias need to be considered when children with microcytic anemia fail to respond to oral iron (Table 504.5). These anemias include thalassemia or thalassemia trait (see Chapter 511), infantile poikilocytosis and hereditary pyropoikilocytosis (Chapter 508), and anemia of chronic disease (Chapter 500.1). Additionally, rare nutritional disorders and disorders of iron metabolism can cause microcytosis.

INFANTILE POIKILOCYTOSIS AND HEREDITARY PYROPOIKILOCYTOSIS

Infants with common **hereditary elliptocytosis** (see Chapter 508) may initially present with hemolytic anemia characterized by marked poikilocytosis with budding and fragmentation of the red blood cells (RBCs). These small RBC fragments reduce the overall mean corpuscular volume (MCV), resulting in microcytosis. By 2 years of age, the findings become typical of hereditary elliptocytosis. **Hereditary pyropoikilocytosis** is a much less common variant of hereditary elliptocytosis, in which the hemolytic anemia and RBC changes are more severe.

COPPER DEFICIENCY

Copper deficiency is a rare cause of microcytic anemia and neurologic dysfunction. Copper is absorbed in the stomach and proximal duodenum. Deficiency is associated with malabsorption; severe malnutrition, often with feeding of milk alone; gastric surgery or feedings that bypass the stomach and duodenum; or parenteral nutrition with inadvertent omission of supplemental copper. Zinc and copper are competitively absorbed from the gastrointestinal (GI) tract, so zinc excess may inadvertently lead to copper deficiency. Diagnosis is made by measuring a serum copper level, serum ceruloplasmin, and possibly a zinc level. Treatment includes either oral or parenteral supplementation, depending on the underlying cause.

DEFECTS OF IRON METABOLISM

Rare microcytic anemias may be associated with defects in iron trafficking and regulation. Most are inherited and usually identified in childhood, including defects of iron absorption, transport, utilization, and recycling. A *defect of iron absorption* is **iron-refractory iron-deficiency anemia** (see Chapter 504.1). *Defects of iron recycling* include aceruloplasminemia and atransferrinemia. **Aceruloplasminemia** is an autosomal recessive disorder in the *CP* gene that encodes ceruloplasmin. Iron cannot be appropriately transported from macrophages to plasma to be available for RBC production but accumulates instead in the brain and visceral organs, which can lead to an adult-onset neurodegenerative disorder. The diagnosis is made by a combination of absence of serum ceruloplasmin, low serum copper and iron, elevated ferritin, and increased liver iron concentration. Hypotransferrinemia or **atransferrinemia** is also an autosomal recessive disorder caused by pathogenic variants in the transferrin *(TF)* gene. Diagnosis is made by low or absent serum transferrin and liver iron overload. Genetic testing can confirm the diagnosis for both disorders. Treatment includes iron chelation therapy, limiting iron supplementation and dietary iron, and possibly fresh-frozen plasma to replace ceruloplasmin and/or transferrin. Purified transferrin (apotransferrin) infusions are available.

Defects of mitochondrial iron utilization are a diverse group of acquired and inherited defects known as **sideroblastic anemias** (Table 505.1). Several genes associated with these disorders have been described. Impaired heme synthesis leads to retention of iron within the mitochondria of marrow RBCs. The perinuclear distribution of mitochondria results in a pattern of iron staining surrounding the nucleus. These are *ringed sideroblasts* (Fig. 505.1), which are distinct from the more diffuse cytoplasmic distribution of iron in normal RBC precursors. The anemia is characterized by hypochromic, microcytic RBCs mixed with normal RBCs, so the complete blood count indicates a very high RBC distribution width. The serum iron concentration usually is elevated, and the transferrin saturation of iron is increased.

Congenital sideroblastic anemia (CSA) can be *syndromic* or *nonsyndromic*. The most common type of nonsyndromic CSA is an X-linked disorder and is most often a result of pathogenic variants in *ALAS2* that encodes erythrocytic isozyme 5-aminolevulinic acid synthetase, the rate-limiting enzyme reaction in heme synthesis. An important cofactor for 5-ALA synthetase is *pyridoxal phosphate,* with several pathogenic variants occurring near its binding site. Severe anemia is recognized in infancy or early childhood, whereas milder cases might not become apparent until early adulthood or later. Clinical findings include pallor, icterus, and moderate splenomegaly and/or hepatomegaly. The severity of the anemia varies such that some patients require no therapy and others need regular RBC transfusions. A subset of patients with hereditary sideroblastic anemia manifest a hematologic response to pyridoxine doses of 50-200 mg/day. Iron overload, as manifested by elevated serum ferritin, elevated serum iron, and increased transferrin saturation, is a major complication of this disorder. Clinical evidence of iron overload (e.g., diabetes mellitus, liver dysfunction) may be found in some patients who have little or no anemia, which may require iron chelation therapy. Stem cell transplantation has been used to treat affected children who are dependent on RBC transfusions.

A unique variant of congenital sideroblastic anemia is **Pearson syndrome** (see Chapter 498), but the anemia is usually *macrocytic* and not microcytic. Another rare variant of sideroblastic anemia is caused by pathogenic variants in *TRNT1* and manifests with developmental

Table 505.1 Clinical and Genetic Features of Congenital Sideroblastic Anemias

CATEGORY	DISORDER	INHERITANCE	SYNDROMIC	GENE	FREQUENCY	AGE AT PRESENTATION	ANEMIA SEVERITY	MCV	ASSOCIATED ABNORMALITIES
Heme synthesis defects	XLSA	X-linked	No	*ALAS2*	100s	Infancy to adulthood	Mild to severe	↓ males N/↑ female	Iron overload in the absence of transfusions
	SLC25A38 deficiency	AR	No	*SLC25A38*	40	Infancy	Severe	↓	Transfusional iron overload
	EPP	AR/PSD	No	*FECH*	100s	Childhood	Mild	↓	Acute photosensitivity
Fe-S biogenesis defects	GLRX5 deficiency	AR	No	*GLRX5*	2	Adulthood	Mild to severe	↓	Iron overload
	HSPA9 deficiency	AR/PSD	No	*HSPA9*	12	Childhood	Mild to severe	N/↓	Retinitis pigmentosa
	HSCB deficiency	AR	No	*HSCB*	1	Childhood	Moderate	N	None
	XLSA/A	X-linked	Yes	*ABCB7*	5	Childhood	Mild to moderate	↓	Cerebellar ataxia and hypoplasia, delayed motor development
Mitochondrial protein synthesis defects	PMPS	SP/M	Yes	*mtDNA*	100s	Early childhood	Severe	↑	Lactic acidosis, exocrine pancreatic insufficiency, failure to thrive, hepatic/renal failure
	MLASA1	AR	Yes	*PUS1*	10	Childhood	Mild to severe	N/↑	Myopathy, lactic acidosis, facial dysmorphism
	MLASA2	AR	Yes	*YARS2*	40	Childhood	Mild to severe	N/↑	Myopathy, lactic acidosis, cardiomyopathy
	LARS2 deficiency	AR	Yes	*LARS2*	1	Infancy	Severe	↑	Lactic acidosis, cardiomyopathy, hepatopathy, seizures
	SIFD	AR	Yes	*TRNT1*	30	Infancy	Severe		Immunodeficiency (B.T), aseptic febrile episodes, developmental delay, seizures, cardiomyopathy, retinitis pigmentosa, other
Mitochondrial respiratory protein mutations	MT-ATP6-SA	SP/M	Yes	*MT-ATP6*	4	Infancy to early childhood	Moderate to severe	N/↑	Lactic acidosis, myopathy, neurologic abnormalities
	NDUFB11-SA	X-linked	Yes	*NUDFB11*	5	Early childhood	Moderate	N	Lactic acidosis, myopathy
	Multifactorial TRMA	AR	Yes	*SLC19A2*	50	Early childhood	Mild to severe	↑	Sensorineural deafness, non-type 1 diabetes mellitus, optic atrophy, strokelike episodes

↑, increased; ↓, decreased; AR, autosomal recessive; EPP, erythropoietic protoporphyria; MCV, mean red blood cell volume; MLASA, mitochondrial myopathy lactic acidosis and sideroblastic anemia;. mtDNA, mitochondrial DNA; N, normal; PMPS, Pearson marrow pancreas syndrome; PSD, Pseudodominant; SIFD, sideroblastic anemia, immunodeficiency (B cell), periodic fevers, and developmental delay; SP/M, sporadic/mitochondrial; TRMA, thiamine responsive megaloblastic anemia; XLSA, X-linked sideroblastic anemia.
Adapted from Ducamp S and Fleming D. The molecular genetics of sideroblastic anemia. *Blood* 2019:133(1):59–69.

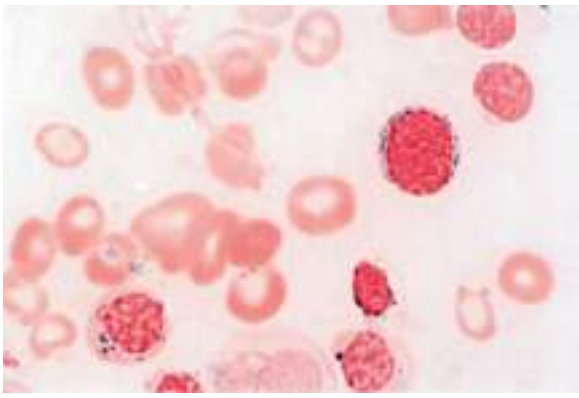

Fig. 505.1 Ring sideroblast in myelodysplastic syndrome (refractory anemia with ring sideroblasts)—iron stain. *(From Ryan DH, Cohen HJ. Bone marrow examination. In: Hoffman R, Benz EJ Jr, Shattil SJ, et al., eds. Hematology, 4th ed. Philadelphia: Churchill Livingstone, 2005.)*

delay, periodic fevers, and B-cell immunodeficiency in addition to sideroblastic anemia.

Acquired sideroblastic anemias can be triggered by copper deficiency or drugs and toxins that disturb mitochondrial iron metabolism, including lead, chloramphenicol, penicillamine, ethanol, and isoniazid. The acquired neoplastic sideroblastic syndromes (myelodysplasias) seen in adults are very rare in children.

Visit Elsevier eBooks+ at eBooks.Health.Elsevier.com for Bibliography.

Section **3**

Hemolytic Anemias

Chapter **506**

Definitions and Classification of Hemolytic Anemias

Stephanie Prozora and Patrick G. Gallagher

Hemolysis is defined as the premature destruction of red blood cells (RBCs). Anemia results when the rate of destruction exceeds the capacity of the marrow to produce additional RBCs. Normal RBC survival time is 110-120 days (half-life: 55-60 days), and thus, approximately 0.85% of the most senescent RBCs are removed and replaced each day. During hemolysis, RBC survival is shortened, the RBC count falls, erythropoietin is increased, and marrow erythropoietic activity is stimulated. This leads to compensatory erythroid hyperplasia with increased RBC production, reflected by an increase in the reticulocyte count. The marrow can increase its output twofold to threefold acutely, with a maximum of sixfold to eightfold in chronic hemolysis. The reticulocyte percentage can be corrected to measure the magnitude of marrow production in response to hemolysis as follows:

$$\text{Reticulocyte index} = \text{reticulocyte } \% \times \frac{\text{Observed hematocrit}}{\text{Normal hematocrit}} \times \frac{1}{\mu}$$

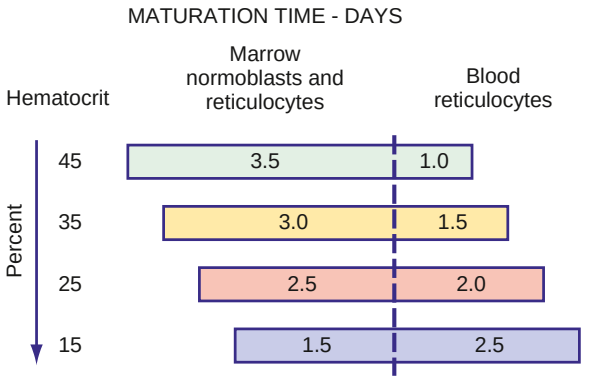

Fig. 506.1 Number of days for maturation of reticulocytes to mature erythrocytes in the marrow and blood. The duration of maturation as blood reticulocytes is taken as μ, which is used in the correction equation in this chapter. *(Modified from Hillman RS, Finch CA. Red cell manual. Philadelphia: FA Davis, 1983.)*

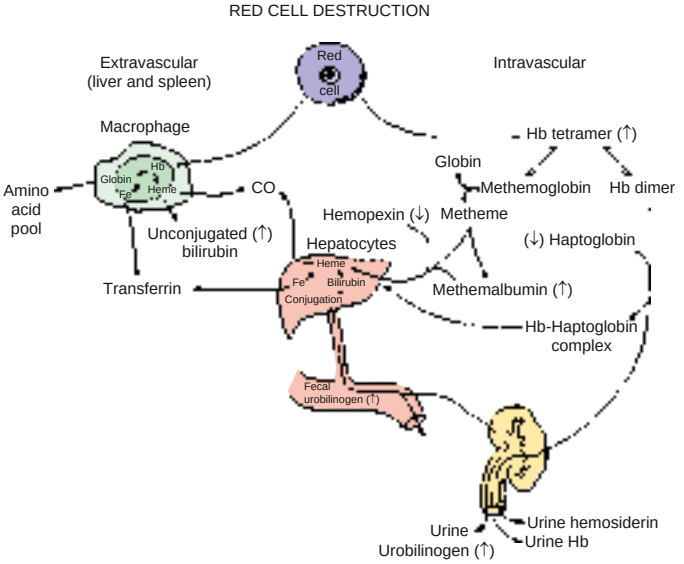

Fig. 506.2 Red cell destruction and catabolism of hemoglobin (Hb) based on the description by Hillman and Finch. Fe, Iron; CO, carbon monoxide. *(From Hillman RS, Finch CA. Red cell manual. Philadelphia: FA Davis, 1983.)*

where μ is a maturation factor of 1-3 related to the severity of the anemia (Fig. 506.1). The normal reticulocyte index is 1.0; therefore the index measures the fold increase in erythropoiesis (e.g., twofold, threefold). Because the reticulocyte index is essentially a measure of RBC production per day, the maturation factor μ provides this correction (see Fig. 506.1).

When hemolysis is chronic, compensatory erythroid hyperplasia may lead to significant expansion of the medullary spaces at the expense of cortical bone. This is particularly prominent in children with severe chronic hemolytic anemia such as thalassemia. These changes may be evident on physical examination or on radiographs of the skull and long bones. In severe cases, there is increased propensity for long bone fracture. Hemolysis also leads to increased degradation of hemoglobin. This process can result in indirect hyperbilirubinemia, increased biliary excretion of heme pigment derivatives, and formation of bilirubinate gallstones.

During hemolysis (Fig. 506.2), heme-binding proteins in the plasma are altered. Hemoglobin binds to haptoglobin and hemopexin, both of which are cleared more rapidly as heme-bound complexes. Oxidized heme binds to albumin to form methemalbumin, which is increased in the plasma during hemolysis. When the capacity of these heme-binding molecules is exceeded, free hemoglobin appears in the plasma. Free hemoglobin in the plasma is considered *prima facie* evidence of

Table 506.3 Clinical and Laboratory Features Suggestive of Hemolytic Anemia

Pallor	↑ RDW (caused by ↑ reticulocyte count)
Icterus	Abnormal RBC morphology
Splenomegaly	↑ Indirect bilirubin (normal direct bilirubin)
Gallstones	↓ Serum haptoglobin level
History of neonatal icterus	↑ Urinary urobilinogen level
Positive family history of anemia, splenectomy, cholecystectomy	Hemoglobinuria (+ dipstick test result for blood; no RBCs in urine)
↑ Reticulocyte count	↑ LDH level

LDH, Lactate dehydrogenase; RBC, red blood cell; RDW, red cell distribution width.
From Kliegman RM, Lye PS, Bordini BJ, et al., eds. *Nelson Pediatric Symptom-Based Diagnosis.* Philadelphia: Elsevier, 2018: 674; Table 37.12.

Table 506.4 Hemolytic Anemias: Diagnostic Clues Based on Red Blood Cell Shape

Sickle cells: sickle cell disease
Target cells: hemoglobinopathies (HbC, HbS, thalassemia), liver disease
Schistocytes/burr cells/helmet cells/RBC fragments: microangiopathic hemolytic anemia (DIC, HUS, TTP)
Spherocytes: hereditary spherocytosis, autoimmune hemolytic anemia
Cigar-shaped cells: hereditary elliptocytosis
"Bite" cells: G6PD deficiency
Poikilocytosis, microcytosis, fragmented erythrocytes, elliptocytes: hereditary pyropoikilocytosis

DIC, Disseminated intravascular coagulation; G6PD, glucose-6-phosphate dehydrogenase; HbC, hemoglobin C; HbS, sickle hemoglobin; HUS, hemolytic-uremic syndrome; RBC, red blood cell; TTP, thrombotic thrombocytopenia purpura.
From Kliegman RM, Lye PS, Bordini BJ, et al., eds. *Nelson Pediatric Symptom-Based Diagnosis.* Philadelphia: Elsevier, 2018: 674; Table 37.13.

Chapter 507

Hereditary Spherocytosis

Stephanie Prozora and Patrick G. Gallagher

Hereditary spherocytosis (HS) is a common cause of inherited hemolytic anemia, with a prevalence of approximately 1 in 2,000-5,000 persons. Described in patients of all ethnic groups, it is the most common inherited abnormality of the erythrocyte associated with inherited hemolytic anemia in persons of Northern European origin. HS is marked by wide variability in the associated clinical, laboratory, and genetic manifestations. Symptomatology ranges from asymptomatic patients with well-compensated anemia to severely affected patients with hemolytic anemia requiring regular blood transfusions.

ETIOLOGY

The pathophysiology underlying HS is twofold: an intrinsic defect of the erythrocyte membrane and an intact spleen that selectively retains, damages, and removes abnormal HS erythrocytes. Qualitative or quantitative defects of key membrane proteins lead to a multistep process of accelerated HS erythrocyte destruction. Abnormalities of ankyrin or spectrin are the most common molecular defects (Table 507.1). Defects in these membrane proteins result in uncoupling of the "vertical" interactions of the lipid bilayer with the underlying membrane skeleton with subsequent release of membrane microvesicles. The loss of membrane surface area without a proportional loss of cell volume causes decreased erythrocyte deformability. This impairs cell passage from the splenic cords to the splenic sinuses, leading to the trapping and premature destruction of HS erythrocytes by the spleen (Figs. 507.1 and 507.2). Splenectomy markedly improves erythrocyte life span and may be indicated in some patients with HS.

CLINICAL MANIFESTATIONS

Hereditary spherocytosis is usually transmitted as an autosomal dominant trait. However, as many as 25% of patients have no previous family history, representing either recessive inheritance or de novo gene variants.

In the neonatal period, HS is a significant cause of hemolysis and can manifest as anemia and/or hyperbilirubinemia severe enough to require phototherapy, transfusion, or exchange transfusions. Hemolysis may be more prominent in the newborn because hemoglobin F binds 2,3-diphosphoglycerate poorly, and the increased level of free 2,3-diphosphoglycerate destabilizes interactions among spectrin, actin, and protein 4.1 in the red blood cell (RBC) membrane (see Fig. 507.1). The need for transfusions in infancy is not indicative of more severe disease later in life because infants are typically slow to mount an adequate reticulocyte response for the first few months after birth.

Disease severity varies and can be used to clinically classify HS (Table 507.2). Mild cases (20–30% of all HS) are asymptomatic into adulthood and have well-compensated mild anemia where reticulocyte production and erythrocyte destruction are essentially balanced. Cases of moderate or "typical" HS (60–70%) have partially compensated hemolytic anemia with reticulocytosis, frequently with symptoms of fatigue, pallor, and intermittent jaundice. Splenomegaly is common after infancy, and it is present in almost all HS patients by young adulthood. Severe cases of HS (3–5%) have life-threatening anemia and are transfusion dependent.

Bilirubin gallstone formation is a function of age; they can form as early as 4-5 years of age and are present in most adult HS patients.

HS patients are susceptible to **aplastic crises** primarily as a result of parvovirus B19 infection, hypoplastic crises associated with other infections, and megaloblastic crises due to folate deficiency (Fig. 507.3). During these crises, high RBC turnover in the setting of erythroid marrow failure can result in profound anemia (hematocrit <10%), high-output heart failure, cardiovascular collapse, and death. Leukocyte and platelet counts may also fall.

Rare complications associated with HS include splenic sequestration crisis, gout, cardiomyopathy, priapism, leg ulcers, and neurologic or muscular abnormalities, including spinocerebellar degeneration.

Table 507.1 Common Gene Pathogenic Variants in Hereditary Spherocytosis

PROTEIN	GENE	COMMON PATHOGENIC VARIANTS	PREVALENCE	INHERITANCE	DISEASE SEVERITY
Ankyrin-1	*ANK1*	Frameshift Nonsense Splicing Missense Insertion/deletion Promoter region	50–67% 5–10% in Japan	Mostly dominant, rare recessive	Mild to moderate
Band 3	*AE1 (SLC4A1)*	Missense Nonsense	15–20%	Dominant	Mild to moderate
β-Spectrin	*SPTB*	Nonsense Missense Insertion/deletion	15–20%	Dominant	Mild to moderate
α-Spectrin	*SPTA1*	Splicing Nonsense Missense	<5%	Recessive	Severe
Protein 4.2	*EPB42*	Missense Nonsense Splicing Deletion	<5% 45–50% in Japan	Recessive	Mild to moderate

Modified from Bolton-Maggs PHB, Langer JC, Iolascon A, et al. Guidelines for the diagnosis and management of hereditary spherocytosis–2011 update. *Br J Haematol.* 2011;156:37–49.

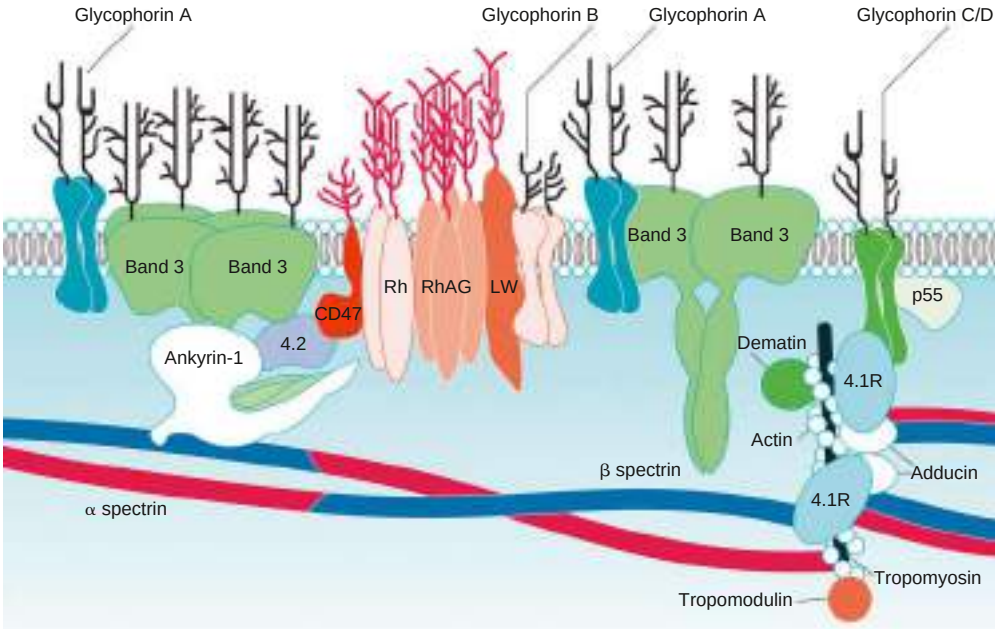

Fig. 507.1 A simplified cross-section of the red blood cell (erythrocyte) membrane. The lipid bilayer forms the equator of the cross-section with its polar heads (small circles) turned outward. 4.1R, protein; 4.2, protein 4.2; LW, Landsteiner-Wiener glycoprotein; Rh, Rhesus polypeptide; RhAG, Rh-associated glycoprotein. *(From Perrotta S, Gallagher PG, Mohandas N. Hereditary spherocytosis. Lancet 2008;372:1411–1426.)*

DIAGNOSIS

Typically, there is evidence of hemolytic anemia with reticulocytosis and indirect hyperbilirubinemia. The mean corpuscular volume (MCV) of HS erythrocytes is low normal or even slightly decreased and the mean corpuscular hemoglobin concentration (MCHC) is usually increased (>35 g/dL). An MCHC > 35.4 g/dL combined with an RBC distribution width (RDW) <14% has been suggested as a screening test for HS. Erythroid cells on peripheral blood smear vary in size and include spherocytes and polychromatophilic reticulocytes. Spherocytes are smaller in diameter, hyperchromic due to elevated hemoglobin concentration from cellular dehydration, and lacking in central pallor (Fig. 507.4). Numbers of spherocytes are variable, with increased numbers likely reflecting the severity of disease. Other markers of hemolysis include decreased haptoglobin and elevated lactic dehydrogenase.

The diagnosis of HS can be established from a positive family history and the presence of typical clinical and laboratory features of the disease: splenomegaly, spherocytes on the blood smear,

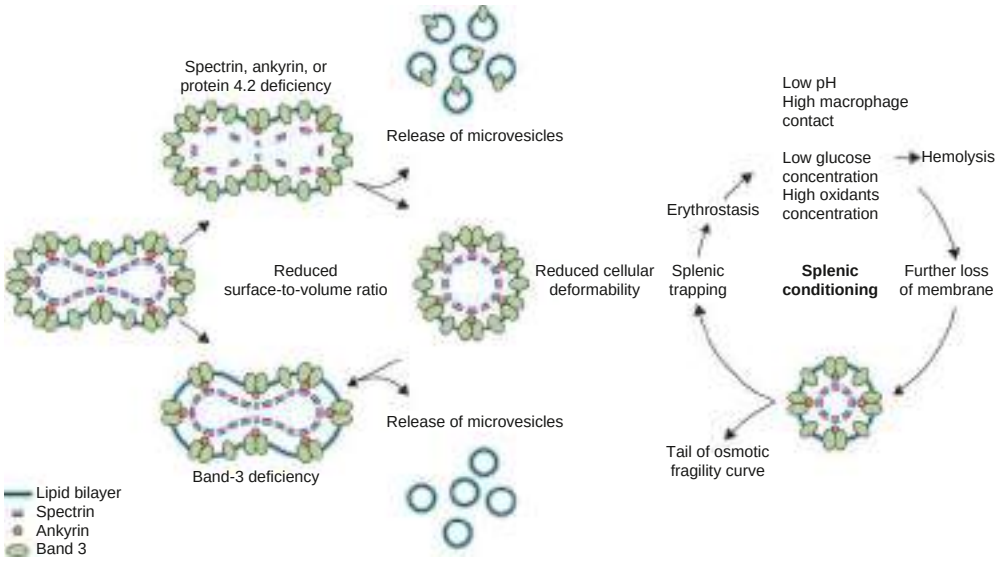

Fig. 507.2 Pathophysiologic effects of hereditary spherocytosis. *(From Perrotta S, Gallagher PG, Mohandas N. Hereditary spherocytosis. Lancet 2008;372:1411–1426.)*

reticulocytosis, and an elevated MCHC. If these are present, no additional testing is necessary to confirm the diagnosis clinically. If the diagnosis is less certain, additional testing can be performed. Binding of fluorescently labeled eosin-5-maleimide (EMA) to band 3 and other membrane proteins is decreased in HS erythrocytes. This flow cytometry–based screening test is easy to perform and has good diagnostic sensitivity and specificity. In the classic incubated osmotic fragility test, HS erythrocytes are incubated in progressive dilutions of sodium chloride causing the cells to swell and lyse, with spherocytes lysing at a lower dilution due to their lower surface area to volume ratio. This test detects the presence of spherocytes in the blood, but it is not specific to HS and may be abnormal in other anemias with prominent spherocytosis. Osmotic fragility testing has poor sensitivity and may miss cases of mild HS where the numbers of spherocytes are few. Other assays such as the cryohemolysis test, the acidified glycerol lysis test, and the osmotic gradient ektacytometry have been used for diagnosis of HS, but they are not available in many laboratories. Genetic diagnosis is widely available on a commercial basis. The precise role of molecular testing in HS diagnosis and management is evolving. Some experts suggest molecular testing before splenectomy to verify the diagnosis of HS.

Diagnosis in the neonatal period requires a high index of suspicion as the disease presents differently than in older children, particularly in de novo and recessively inherited cases where family history is not available for guidance. Jaundice is frequently observed, and kernicterus can occur. Hemolytic anemia may be severe enough to require blood transfusion. In fact, HS is the leading cause of Coombs-negative hemolytic anemia, requiring transfusion in the first months of life. Splenomegaly is uncommon in neonates.

DIFFERENTIAL DIAGNOSIS

The differential diagnosis for spherocytosis on peripheral blood smear includes isoimmune and autoimmune hemolysis. Isoimmune hemolytic disease of the newborn, particularly when there is a result of ABO incompatibility, closely mimics the appearance of HS. The detection of antibody on an infant's RBCs using a direct antiglobulin (Coombs) test should establish the diagnosis of immune hemolysis. Autoimmune hemolytic anemias also are characterized by spherocytosis, but there will typically be evidence of previously normal values for hemoglobin, hematocrit, and reticulocyte count. Rare causes of spherocytosis include thermal injury, hemolytic transfusion reaction, clostridial sepsis, severe hypophosphatemia, Wilson disease, and snake, bee, or wasp envenomation, which all may manifest as transient spherocytic hemolytic anemia.

TREATMENT

General Supportive Care

Infants born to a parent with known HS should be monitored carefully because hyperbilirubinemia may peak several days after birth. Parents should be advised of the risk of neonatal anemia and jaundice and the potential need for transfusion, phototherapy, and/or exchange transfusion to treat anemia or hyperbilirubinemia. A subset of infants will be transfusion-dependent until development of adequate erythropoiesis to compensate for the ongoing hemolysis, usually between 6-12 months of age. Transfusion dependence after this time is rare and is most likely due to recessive HS.

Once the baseline level of disease severity is reached, an annual visit to the hematologist usually is sufficient follow-up. Growth should be monitored, and exercise tolerance and spleen size documented. Vaccinations should be up to date. Screening for gallbladder disease should begin at ~4 years of age, repeated every 3-5 years, or as indicated clinically. Documentation of parvovirus B19 susceptibility or immunity should be obtained in newly diagnosed patients. Similarly, HIV and hepatitis serology should be documented in patients who have received transfusions. Folic acid supplementation is recommended in cases of moderate and severe HS due to the demands of brisk erythropoiesis. Parents should receive anticipatory guidance regarding the risk of aplastic crisis secondary to parvovirus infection and hypoplastic crises with other infections. Parents and patients should be informed of an increased risk for gallstone development.

Guidelines for Splenectomy

Because spherocytes are destroyed almost exclusively in the spleen, splenectomy is curative in most patients because hemolysis, anemia, hyperbilirubinemia, and the incidence of gallstones are significantly lessened, if not completely eradicated, after splenectomy. Thus splenectomy became routine in the care of HS patients. However, splenectomy is associated with *short-term* risks, related to the operative procedure itself, and *long-term* risks, particularly increased lifelong

Table 507.2 Clinical and Laboratory Classification of Hereditary Spherocytosis

	NORMAL	MILD SPHEROCYTOSIS	MODERATE SPHEROCYTOSIS	MODERATELY SEVERE SPHEROCYTOSIS	SEVERE SPHEROCYTOSIS*
Inheritance	—	Autosomal dominant	Autosomal dominant, de novo variant	Autosomal dominant, de novo variant	Autosomal recessive
Proportion of hereditary spherocytosis cases	—	~20–30%	~60–70%	~10%	<5%
Hemoglobin (Hb, g/dL)†	11.5-16‡	10.5-15	8-12	6-8	<6
Reticulocytes (%)†	0.5-1.5	1.5-6	≥6	≥10	≥10
Bilirubin (mg/dL)†,‖	0-1	0.5-2	≥2	≥2	≥3
Peripheral smear*	Normal	Mild spherocytosis	Spherocytosis	Spherocytosis	Spherocytosis ± poikilocytosis
Osmotic fragility (fresh)	Normal	Normal or slightly increased	Increased	Increased	Greatly increased
Osmotic fragility (incubated)	Normal	Usually increased	Increased	Increased	Greatly increased
MCHC (g/dL)§	32-36	34-37	34-38	35-39	
RDW (%)§	11-14	12-19	16-23	20-30	
Hb/MCHC*	0.38-0.41	0.35-0.40	0.29-0.33	0.18-0.28	
Hb/RDW§	0.95-1.05	0.7-1.0	0.48-0.74	0.16-0.35	
Serum transferrin receptor (nmol/L)§	18-25	30-65	80-125	100-150	
Erythropoietin (mIU/mL)§	7-16	9-30	25-90	30-300	
Membrane protein patterns (SDS-PAGE)¶	—	"Normal"# Slight ↓ spectrin Slight ↓ spectrin and ankyrin Slight ↓ band 3 and 4.2 Absent protein 4.2 and ↓ CD47	↓ Spectrin ↓ Spectrin and ankyrin ↓ Band 3 and protein 4.2 Absent protein 4.2 and ↓ CD47	↓ Spectrin ↓ Spectrin and ankyrin ↓ Band 3 and protein 4.2	↓↓ Spectrin ↓↓ Spectrin and ankyrin ↓↓ Band 3 and protein 4.2**
Transfusions	—	No	Sometimes required in infancy or with aplastic crisis	Occasionally with crises	Regular*
Splenectomy	—	Rarely, partial splenectomy††	Sometimes; consider partial splenectomy	Usually (6-9 yr)	Yes (>3 yr)

*Patients with severe disease are transfusion dependent by definition. Values are in untransfused patients or at nadir before transfusion.
†Data modified from Eber SW, Armbrust R, Schröter W. Variable clinical severity of hereditary spherocytosis: relation to erythrocytic spectrin concentration, osmotic fragility and autohemolysis. *J Pediatr*. 1990;177:409–416.
‡Varies with age.
§Ranges shown encompass the majority of individuals in each category. From Rocha S, Costa E, Rocha-Pereira P, et al. Complementary markers for the clinical severity classification of hereditary spherocytosis in unsplenectomized patients. *Blood Cells Mol Dis*. 2011;46:166–170.
‖Multiply by 17.1 to convert to μmol/L.
¶Indicates common patterns observed on SDS gels. Decreased spectrin alone is seen in α-spectrin or β-spectrin defects. Decreased spectrin and ankyrin arc observed with ankyrin defects. Decreased band 3 and protein 4.2 occur with band 3 defects. Absent protein 4.2 and decreased CD47 occur with protein 4.2 defects.
#Patients with mild spherocytosis who appear normal probably have small deficits (10–15%) that cannot be distinguished from normal findings on SDS gels.
**Rare patients with severe spherocytosis who are homozygous or compound heterozygous for band 3 defects.
††Consider in adolescents and adults who require a cholecystectomy or have disfiguring chronic jaundice.
CD, cluster of differentiation; MCHC, Mean corpuscular hemoglobin concentration; RDW, red cell distribution width (measure of variation in shape); SDS-PAGE, sodium dodecyl sulfate–polyacrylamide gel electrophoresis; ↓, decreased.
From Orkin SH, Fisher DE, Ginsburg D, et al., eds. *Nathan and Oski's Hematology and Oncology of Infancy and Childhood*. 8th ed. Philadelphia: Elsevier, 2015:518; Table 16.3.

risk for sepsis, often caused by encapsulated bacteria. This risk is not eliminated but reduced with the requisite preoperative and postoperative vaccination against pneumococcus, meningococcus, and *Haemophilus influenzae* type b. In addition, there are increasing concerns regarding the emergence of penicillin-resistant pneumococci, as well as increased risk for cardiovascular diseases including thrombosis, pulmonary hypertension, and atherosclerosis, which have tempered the practice of routine splenectomy in HS.

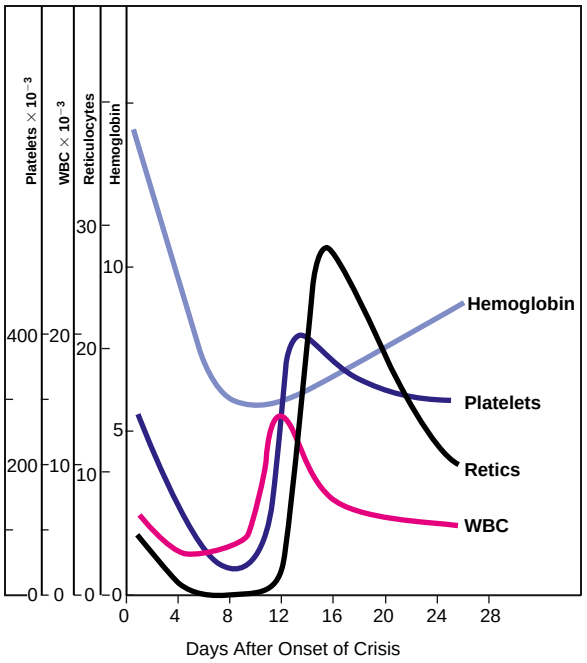

Fig. 507.3 Parvovirus-induced aplastic crisis. Progression of the changes in blood count is shown for a patient with hereditary spherocytosis and infection with parvovirus. Note that the fall in baseline reticulocytosis is associated with a rapid fall in hemoglobin. White blood cells (WBC) and platelets are also affected; Retics, reticulocytes. *(Adapted from Nathan DG, Orkin SH, Ginsburg D, et al., eds. Hematology of Infancy and Childhood, 6th ed. Philadelphia: Saunders, 2003.)*

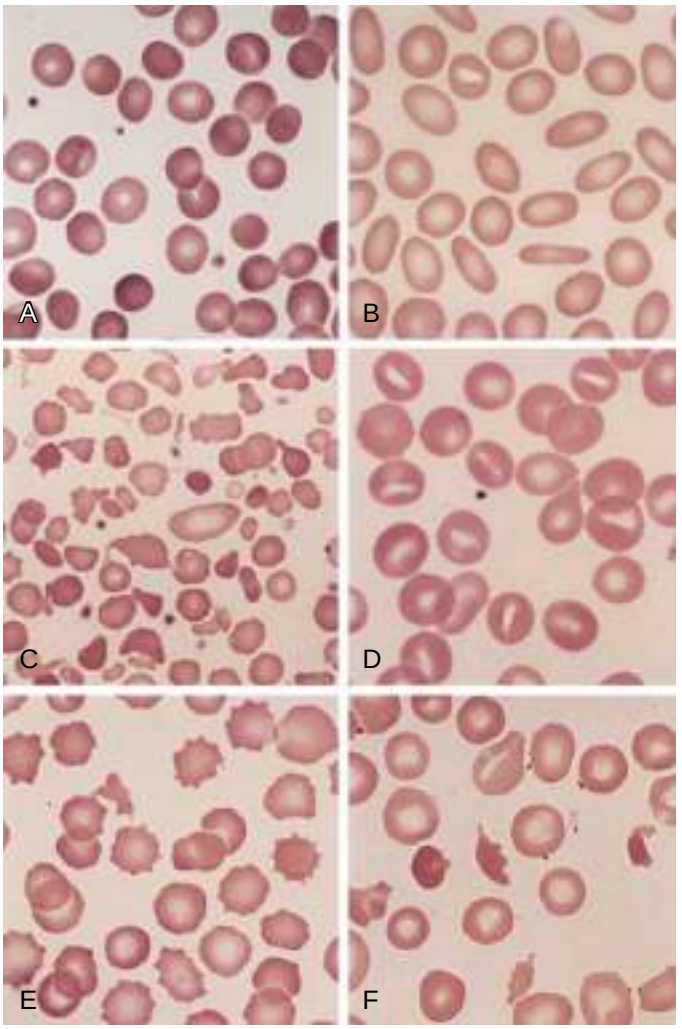

Fig. 507.4 Morphology of abnormal red cells. **A,** Hereditary spherocytosis. **B,** Hereditary elliptocytosis. **C,** Hereditary pyropoikilocytosis. **D,** Hereditary stomatocytosis. **E,** Acanthocytosis. **F,** Fragmentation hemolysis.

When considering splenectomy, the patient and the parents, together with their healthcare providers, should review and consider the risks and benefits. Individual-specific factors may confer additional risk after a splenectomy; time and distance from medical care in case of febrile illness and residence in or travel to areas where parasitic diseases such as malaria or babesiosis occur should be considered.

Most experts recommend splenectomy for patients with severe HS and believe it should be strongly considered for patients with moderate HS and frequent hypoplastic or aplastic crises, poor growth, or cardiomegaly. It is generally not recommended for patients with mild HS. When splenectomy is indicated, it should be performed after the age of 6 years, if possible, to avoid the heightened risk of postsplenectomy sepsis in younger children. The laparoscopic approach has less surgical morbidity and has become the technique of choice. Partial or subtotal splenectomy (removal of 85–95% of spleen volume) has been shown to decrease the hemolytic rate while preserving *some* splenic phagocytic function, although the decrease in hemolysis is less than that achievable with total splenectomy. Partial splenectomy is most attractive in children with severe HS requiring frequent transfusion early in childhood.

In children undergoing splenectomy, a concomitant cholecystectomy should be performed if there are gallstones. It is controversial whether to perform a concomitant splenectomy in less-severely ill patients who are undergoing cholecystectomy for gallstone disease. Postsplenectomy thrombocytosis is commonly observed but requires no treatment and usually resolves spontaneously. The patient should remain current on their vaccinations, as should household and frequent contacts. Prophylactic antibiotics are typically prescribed at least until the patient is 5 years of age or at least 2 years postsplenectomy. Folate supplementation should be continued if the hemoglobin level and reticulocyte count do not normalize.

Splenectomy failure may occur in cases of accessory spleen, accidental autotransplantation of splenic tissue into peritoneum at time of surgery, inaccurate diagnosis, or another co-inherited hemolytic anemia. Clues include return of hemolysis and disappearance of Howell-Jolly bodies on peripheral blood smear. The diagnosis can be made by radionucleotide studies.

Visit Elsevier eBooks+ at eBooks.Health.Elsevier.com for Bibliography.

Chapter 508

Hereditary Elliptocytosis, Hereditary Pyropoikilocytosis, and Related Disorders

Stephanie Prozora and Patrick G. Gallagher

Hereditary elliptocytosis (HE), hereditary pyropoikilocytosis (HPP), and related disorders are characterized by the finding of elliptocytes on peripheral blood smear (Table 508.1). Whereas hereditary spherocytosis is thought of as a disorder of the vertical interactions coupling the erythrocyte membrane skeleton to the lipid bilayer, the HE syndromes interfere with the horizontal interactions that link spectrin molecules to each other and to membrane skeleton junctional complexes (see Chapter 507, Fig. 507.1), leaving the cell vulnerable to shear stress.

HE is the prototypical member of the group, in which abnormal shear stress over time results in elliptical deformation of the cell. It is much more common than hereditary spherocytosis, but it is much less likely to cause significant clinical symptomatology. The severity of HE varies markedly, with most patients experiencing little or no symptomatology beyond the finding of elliptocytes on peripheral blood smear. About 10% of patients have hemolytic HE with ongoing hemolysis and anemia. HE is often worse during infancy, with hemolytic anemia and hyperbilirubinemia that evolves to a well-compensated state with anemia that is absent, sporadic, or chronic. Hereditary elliptocytosis occurs worldwide and in all ethnic groups, but it is more common in patients with ancestry linked to areas of endemic malaria.

HPP is a subtype of HE characterized by severe hemolytic anemia with findings on peripheral blood smear reminiscent of a thermal burn (*pyro*, fire). HE and HPP are seen co-segregating in the same families because they involve overlapping pathogenic variants in spectrin. HPP occurs predominantly in patients of African descent.

Table 508.1 Clinical Subtypes of Hereditary Elliptocytosis and Related Disorders

CLINICAL MANIFESTATIONS	LABORATORY MANIFESTATION
TYPICAL HETEROZYGOUS HE	
Asymptomatic Dominant inheritance: one parent with HE No splenomegaly *Variants:* Some neonates have moderately severe hemolytic anemia and HPP-like smear; converts to typical HE by "1 yr." Some patients with typical HE have mild to moderate chronic hemolysis and some poikilocytosis, caused by co-inheritance of the low-expression variant α-spectrin^{LELY}, coexistence of chronic disease producing splenomegaly, or unknown factors.	Blood smear: elliptocytes, rod forms, few or no poikilocytes No anemia, little or no hemolysis (reticulocytes, 1–3%) Normal osmotic fragility Usually a defect in α-spectrin or β-spectrin leading to decreased spectrin self-association, or a defect in protein 4.1 leading to partial deficiency or dysfunction
HOMOZYGOUS HE OR HPP	
Moderate to severe hemolytic anemia Splenomegaly Intermittent jaundice Aplastic crises Recessive inheritance: typically one parent with HE and one with α-spectrin mutation, or both parents with HE Good improvement after splenectomy	Blood smear: bizarre poikilocytes, fragments, ± spherocytes, ± elliptocytes Reticulocytosis Decreased MCV because of red cell fragmentation Increased osmotic fragility, positive EMA test *α-Spectrin defects:* Decreased red cell and spectrin heat stability Marked defect in spectrin self-association In the more severe variants, partial spectrin deficiency (indicated by more spherocytes on the blood smear)
SPHEROCYTIC HE	
Mild to moderate hemolytic anemia Splenomegaly Intermittent jaundice Aplastic crises Dominant inheritance pattern Excellent response to splenectomy	Blood smear: rounded elliptocytes, ± spherocytes; may see variable morphology within a kindred Reticulocytosis Increased osmotic fragility *Variable molecular defects:* C-terminal truncation of β-spectrin Protein 4.2 deficiency (some patients); variable morphology: spherocytes, ovalocytes, stomatocytes, or spiculated cells, sometimes resembling spherocytic HE Glycophorin C deficiency (rare)
SOUTHEAST ASIAN OVALOCYTOSIS	
Anemia and jaundice in neonatal period; then asymptomatic Dominant inheritance Lowland Aboriginal tribes, especially in Melanesia, Malaysia, and the Philippines Very rigid red cells that resist invasion by malarial parasites in vitro and protect against cerebral malaria in vivo	Blood smear: rounded elliptocytes, some with a transverse bar that divides the central clear space (theta cells) No hemolysis or anemia after neonatal period Normal osmotic fragility, positive EMA test Mutant band 3 that lacks anion exchange function and tends to aggregate, leading to a rigid membrane

EMA, Eosin-5′-maleimide; HE, hereditary elliptocytosis; HPP, hereditary pyropoikilocytosis; MCV, mean cell volume.
Adapted from Wilensky ID, Narla M, Lux SF. Disorders of the red cell membrane. In: Handin RI, Lux SF, Stossel TP, eds. *Blood: Principles and Practice of Hematology*. Philadelphia: Lippincott, 2003.

Southeast Asian ovalocytosis (SAO) is a disorder characterized by the presence of ovalocytes (less elongated and plumper than elliptocytes), some with one or two transverse ridges on peripheral smear. SAO is found in individuals from New Guinea, Malaysia, Indonesia, and the Philippines. Unlike HE and HPP, SAO is due to a variant in a transmembrane protein, band 3, affecting vertical skeletal interactions and leading to increased red cell rigidity. These changes may lead to protection from malaria, particularly cerebral malaria.

ETIOLOGY

Various molecular defects have been described in HE. HE is inherited as an autosomal dominant disorder with occasional de novo cases. Most commonly, there are missense pathogenic variants of α- or β-spectrin that interfere with the formation of spectrin heterodimers into tetramers, the primary structural unit of the membrane skeleton (see Fig. 507.1). Erythrocytes carrying many of these spectrin pathogenic variants are resistant to malaria in vitro, hypothesized to explain the increased prevalence of HE in malaria-endemic areas. Less commonly, elliptocytosis results from pathogenic variants in protein 4.1 or glycophorin C, proteins of the junctional complex that link spectrin tetramers to the actin cytoskeleton. These defects in horizontal membrane skeleton protein interactions leave the cell susceptible to shearing forces, leading to the characteristic elliptical deformation of the cell and potentially membrane fragmentation.

In HPP, two abnormal spectrin alleles are inherited. Frequently, an HPP patient inherits an abnormal spectrin allele carrying a self-association site missense variant from one parent, who has mild or asymptomatic HE, and a production-defective allele that leads to quantitative deficiency of spectrin from the other parent, who is otherwise clinically well.

SAO is an autosomal dominant disorder associated with an in-frame, nine amino acid deletion in band 3.

CLINICAL MANIFESTATIONS

Most HE patients do not have clinically significant hemolysis (see Fig. 507.4B). HE may be an incidental finding on a blood film examination for an unrelated indication. The diagnosis of HE is established by the findings on the peripheral blood smear, the autosomal dominant inheritance pattern, and the absence of other causes of elliptocytosis. The differential diagnosis for other causes of elliptocytosis includes deficiencies of iron, folic acid, and vitamin B_{12}, thalassemia, myelodysplastic syndromes, and pyruvate kinase deficiency.

Interestingly, elliptocytes are not always present on the peripheral blood smear in the first few months of life. Even in hemolytic HE, which may lead to neonatal jaundice and anemia, the peripheral blood smear typically shows bizarre poikilocytes and pyknocytes with rare to no elliptocytes. Hemolysis and anemia are aggravated in the newborn period because of the increased presence of hemoglobin F, which binds poorly to 2,3-diphosphoglycerate. The increased free 2,3-diphosphoglycerate tends to destabilize the spectrin–actin–protein 4.1 complex, leading to membrane instability (see Fig. 507.1). The usual features of a chronic hemolytic process due to hemolytic HE manifest as anemia, jaundice, and splenomegaly. Cholelithiasis may occur in later childhood and aplastic crises have been reported. HPP is characterized by extreme microcytosis (mean corpuscular volume [MCV], 50-65 fL/cell), extraordinary variation in cell size and shape, and microspherocytosis with occasional elliptocytosis (see Fig. 507.4C). Hemolysis is chronic and significant.

SAO is associated with neonatal hyperbilirubinemia, but it is associated with little to no hemolysis later in life.

LABORATORY FINDINGS

Examination of the peripheral blood smear is essential to establish the diagnosis of HE (see Fig. 507.4*B*). HE elliptocytes are normochromic and normocytic with varying degrees of elongation. Because some HE patients may present with relatively low numbers of elliptocytes, there is no cutoff percentage that is useful diagnostically. In hemolytic HE, other abnormal RBC shapes may be present, depending on the severity of hemolysis, including spherocytes, pyknocytes, and other poikilocytes. In HPP, microspherocytes, red cell fragments, and occasional elliptocytes are seen. SAO is suggested when ovalocytes, which in contrast to elliptocytes are less elongated, are observed.

Reticulocyte levels and other markers of hemolysis, such as total bilirubin, lactate dehydrogenase, and haptoglobin, are helpful in establishing the severity of hemolysis, if present. In hemolytic HE and HPP, additional testing may include the eosin-5-maleimide (EMA) binding test, which detects binding to band 3 by flow cytometry, or incubated osmotic fragility testing. In cases of chronic hemolysis, splenomegaly and cholelithiasis can be assessed with abdominal ultrasound.

TREATMENT

If the presentation is that of typical HE (i.e., an isolated peripheral blood smear abnormality without clinically evident hemolysis), no treatment is necessary. For chronic HE and HPP, red blood cell transfusions are occasionally required. Splenectomy decreases the hemolysis and should be considered using criteria similar to that of hereditary spherocytosis. If hemolysis continues after splenectomy, patients should receive folic acid to prevent secondary folic acid deficiency. SAO does not require treatment beyond the newborn period.

Visit Elsevier eBooks+ at eBooks.Health.Elsevier.com for Bibliography.

Chapter 509

Hereditary Stomatocytosis Syndromes

Stephanie Prozora and Patrick G. Gallagher

The hereditary stomatocytosis syndromes are a group of heterogeneous, dominantly inherited disorders in which alterations in red cell cation permeability lead to alterations in intracellular water content (Table 509.1). A net increase in sodium and potassium ions allows water to enter the erythrocyte, creating stomatocytes or hydrocytes, whereas a net loss of sodium and potassium ions leads to water loss, creating dehydrated red cells, or xerocytes (Fig. 509.1).

HEREDITARY XEROCYTOSIS

Pathophysiology

Hereditary xerocytosis, the most common type of the hereditary stomatocytosis syndromes, is a dominant disorder of erythrocyte dehydration. The underlying defect is most commonly a missense variant in *PIEZO1*, a mechanosensory transduction protein, associated with delayed channel inactivation. In a few patients, pathogenic variants in the Gardos channel, important in erythrocyte dehydration in sickle cell disease, have been observed. Typically, there is a net loss of intracellular potassium that is not accompanied by a compensatory increase in sodium. Subsequently, the gradual loss of intracellular water leads to erythrocyte dehydration. Hereditary xerocytosis may be associated with a syndrome of hydrops fetalis with perinatal anemia and ascites. These findings are transient and remain unexplained.

Clinical Features

Affected patients exhibit a mild compensated macrocytic hemolytic anemia with variable degrees of splenomegaly and intermittent jaundice. The mean corpuscular hemoglobin concentration (MCHC) and mean cell volume (MCV) are elevated, and erythrocyte osmotic fragility is decreased, as are potassium concentration and total monovalent cation content. There are small numbers of stomatocytes, target cells, and contracted red blood cells (RBCs) with hemoglobin puddled to the side on peripheral blood smear. Treatment is supportive, similar

Southeast Asian ovalocytosis (SAO) is a disorder characterized by the presence of ovalocytes (less elongated and plumper than elliptocytes), some with one or two transverse ridges on peripheral smear. SAO is found in individuals from New Guinea, Malaysia, Indonesia, and the Philippines. Unlike HE and HPP, SAO is due to a variant in a transmembrane protein, band 3, affecting vertical skeletal interactions and leading to increased red cell rigidity. These changes may lead to protection from malaria, particularly cerebral malaria.

ETIOLOGY

Various molecular defects have been described in HE. HE is inherited as an autosomal dominant disorder with occasional de novo cases. Most commonly, there are missense pathogenic variants of α- or β-spectrin that interfere with the formation of spectrin heterodimers into tetramers, the primary structural unit of the membrane skeleton (see Fig. 507.1). Erythrocytes carrying many of these spectrin pathogenic variants are resistant to malaria in vitro, hypothesized to explain the increased prevalence of HE in malaria-endemic areas. Less commonly, elliptocytosis results from pathogenic variants in protein 4.1 or glycophorin C, proteins of the junctional complex that link spectrin tetramers to the actin cytoskeleton. These defects in horizontal membrane skeleton protein interactions leave the cell susceptible to shearing forces, leading to the characteristic elliptical deformation of the cell and potentially membrane fragmentation.

In HPP, two abnormal spectrin alleles are inherited. Frequently, an HPP patient inherits an abnormal spectrin allele carrying a self-association site missense variant from one parent, who has mild or asymptomatic HE, and a production-defective allele that leads to quantitative deficiency of spectrin from the other parent, who is otherwise clinically well.

SAO is an autosomal dominant disorder associated with an in-frame, nine amino acid deletion in band 3.

CLINICAL MANIFESTATIONS

Most HE patients do not have clinically significant hemolysis (see Fig. 507.4B). HE may be an incidental finding on a blood film examination for an unrelated indication. The diagnosis of HE is established by the findings on the peripheral blood smear, the autosomal dominant inheritance pattern, and the absence of other causes of elliptocytosis. The differential diagnosis for other causes of elliptocytosis includes deficiencies of iron, folic acid, and vitamin B_{12}, thalassemia, myelodysplastic syndromes, and pyruvate kinase deficiency.

Interestingly, elliptocytes are not always present on the peripheral blood smear in the first few months of life. Even in hemolytic HE, which may lead to neonatal jaundice and anemia, the peripheral blood smear typically shows bizarre poikilocytes and pyknocytes with rare to no elliptocytes. Hemolysis and anemia are aggravated in the newborn period because of the increased presence of hemoglobin F, which binds poorly to 2,3-diphosphoglycerate. The increased free 2,3-diphosphoglycerate tends to destabilize the spectrin–actin–protein 4.1 complex, leading to membrane instability (see Fig. 507.1). The usual features of a chronic hemolytic process due to hemolytic HE manifest as anemia, jaundice, and splenomegaly. Cholelithiasis may occur in later childhood and aplastic crises have been reported. HPP is characterized by extreme microcytosis (mean corpuscular volume [MCV], 50-65 fL/cell), extraordinary variation in cell size and shape, and microspherocytosis with occasional elliptocytosis (see Fig. 507.4C). Hemolysis is chronic and significant.

SAO is associated with neonatal hyperbilirubinemia, but it is associated with little to no hemolysis later in life.

LABORATORY FINDINGS

Examination of the peripheral blood smear is essential to establish the diagnosis of HE (see Fig. 507.4*B*). HE elliptocytes are normochromic and normocytic with varying degrees of elongation. Because some HE patients may present with relatively low numbers of elliptocytes, there is no cutoff percentage that is useful diagnostically. In hemolytic HE, other abnormal RBC shapes may be present, depending on the severity of hemolysis, including spherocytes, pyknocytes, and other poikilocytes. In HPP, microspherocytes, red cell fragments, and occasional elliptocytes are seen. SAO is suggested when ovalocytes, which in contrast to elliptocytes are less elongated, are observed.

Reticulocyte levels and other markers of hemolysis, such as total bilirubin, lactate dehydrogenase, and haptoglobin, are helpful in establishing the severity of hemolysis, if present. In hemolytic HE and HPP, additional testing may include the eosin-5-maleimide (EMA) binding test, which detects binding to band 3 by flow cytometry, or incubated osmotic fragility testing. In cases of chronic hemolysis, splenomegaly and cholelithiasis can be assessed with abdominal ultrasound.

TREATMENT

If the presentation is that of typical HE (i.e., an isolated peripheral blood smear abnormality without clinically evident hemolysis), no treatment is necessary. For chronic HE and HPP, red blood cell transfusions are occasionally required. Splenectomy decreases the hemolysis and should be considered using criteria similar to that of hereditary spherocytosis. If hemolysis continues after splenectomy, patients should receive folic acid to prevent secondary folic acid deficiency. SAO does not require treatment beyond the newborn period.

Visit Elsevier eBooks+ at eBooks.Health.Elsevier.com for Bibliography.

Chapter 509

Hereditary Stomatocytosis Syndromes

Stephanie Prozora and Patrick G. Gallagher

The hereditary stomatocytosis syndromes are a group of heterogeneous, dominantly inherited disorders in which alterations in red cell cation permeability lead to alterations in intracellular water content (Table 509.1). A net increase in sodium and potassium ions allows water to enter the erythrocyte, creating stomatocytes or hydrocytes, whereas a net loss of sodium and potassium ions leads to water loss, creating dehydrated red cells, or xerocytes (Fig. 509.1).

HEREDITARY XEROCYTOSIS

Pathophysiology

Hereditary xerocytosis, the most common type of the hereditary stomatocytosis syndromes, is a dominant disorder of erythrocyte dehydration. The underlying defect is most commonly a missense variant in *PIEZO1*, a mechanosensory transduction protein, associated with delayed channel inactivation. In a few patients, pathogenic variants in the Gardos channel, important in erythrocyte dehydration in sickle cell disease, have been observed. Typically, there is a net loss of intracellular potassium that is not accompanied by a compensatory increase in sodium. Subsequently, the gradual loss of intracellular water leads to erythrocyte dehydration. Hereditary xerocytosis may be associated with a syndrome of hydrops fetalis with perinatal anemia and ascites. These findings are transient and remain unexplained.

Clinical Features

Affected patients exhibit a mild compensated macrocytic hemolytic anemia with variable degrees of splenomegaly and intermittent jaundice. The mean corpuscular hemoglobin concentration (MCHC) and mean cell volume (MCV) are elevated, and erythrocyte osmotic fragility is decreased, as are potassium concentration and total monovalent cation content. There are small numbers of stomatocytes, target cells, and contracted red blood cells (RBCs) with hemoglobin puddled to the side on peripheral blood smear. Treatment is supportive, similar

Table 509.1 Features of Hereditary Stomatocytosis-Xerocytosis Syndromes

FEATURE (NORMAL VALUE)	OTHER HEREDITARY STOMATOCYTOSIS SYNDROMES			SOUTHEAST ASIAN OVALOCYTOSIS	HEREDITARY XEROCYTOSIS (DEHYDRATED STOMATOCYTOSIS)	
	OVERHYDRATED HEREDITARY STOMATOCYTOSIS	MILD HEREDITARY STOMATOCYTOSIS	HEREDITARY CRYOHYDROCYTOSIS		TYPICAL	PSEUDO-HYPERKALEMIA
Hemolysis	Severe	Mild to moderate	Mild to moderate	Mild (neonatal only)	Moderate	Mild or none
Anemia	Moderate to severe	Mild to moderate	Mild to moderate to completely compensated	Mild (neonatal only)	Mild to moderate to completely compensated	None
Blood smear	Stomatocytes; ± spherocytes	Stomatocytes; ± spherocytes	Stomatocytes, sometimes with curved or offset stoma; ± spherocytes; ± target cells	Rounded elliptocytes, some with a double central clearing and a theta (θ) shape; ± stomatocytes	Target cells; sometimes small numbers of echinocytes or stomatocytes	Target cells; few stomatocytes
MCV	Increased	Normal to increased	Normal to increased		High normal to increased	Normal to increased
MCHC	Decreased	Normal to decreased	Normal to increased		Normal to increased	Normal to increased
Unincubated osmotic fragility	Very increased	Variable	Variable	Unknown	Decreased to very decreased	Slightly decreased
RBC Na^+ (5-12 mEq/L)*	60-150	30-60	15-100	Normal	5-30	10-30
RBC K^+ (90-105 mEq/L)*	20-55	40-85	30-100	Normal	60-90	75-100
RBC $Na^+ + K^+$ (95-110 mEq/L)*	110-170	115-145	70-130	Normal	70-100	85-110
RBC passive membrane leak*†	20-40	~3-10	1-6	2-4	2-4	1-2
Cold hemolysis	No	Unknown	Yes	Yes	No	No
Pseudohyperkalemia	Sometimes	Unknown	Yes	Unknown	Sometimes	Yes
Perinatal ascites	No	Unknown	No	No	Sometimes	No
Stomatin markedly decreased	Yes	No	No (type 1) Yes (type 2)	No	No	No
Effect of splenectomy on hemolysis	Some benefit	Some benefit	Minimal or no effect	No significant hemolysis	No effect	No significant hemolysis
Thromboembolism risk after splenectomy	Yes	Unknown	?Yes	Unknown	Yes	Unknown
Genetics	Autosomal dominant	Autosomal dominant	Autosomal dominant	Autosomal dominant	Autosomal dominant	Autosomal dominant
Defective gene(s)	*KHAG*	Band 3 *(SLC4A1)*	Type 1: Band 3 *(SLC4A1)* Type 2: Glut 1 *(SLC2A1)*	Band 3 *(SLC4A1)* in-frame deletion	*PIEZO1*	*PIEZO1, ABCR6*

*Based on a relatively small number of measurements reported in the literature.
†Times normal. Defined as the ouabain- and bumetanide-resistant $^{86}Rb^+$ influx at 37°C, and expressed as the ratio of patient residual leak to normal residual leak (normal: 0.06-0.10 mmol/L RBC/hr).
MCHC, Mean corpuscular hemoglobin concentration; MCV, mean cell volume; RBC, red blood cell.
From Orkin SH, Fisher DE, Ginsburg D, et al., eds. *Nathan and Oski's Hematology and Oncology of Infancy and Childhood*, 8th ed. Philadelphia: Elsevier, 2015: 561; Table 16.12.

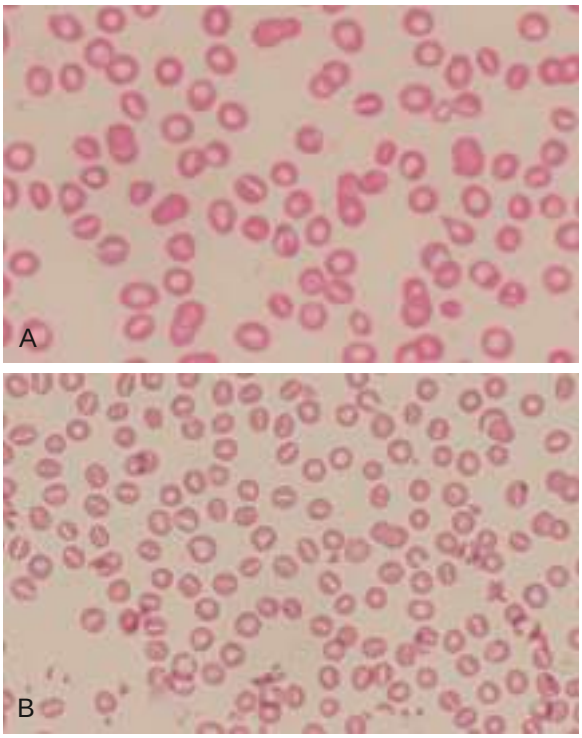

Fig. 509.1 Peripheral blood smears. **A,** Hereditary xerocytosis. **B,** Hereditary hydrocytosis.

to other disorders with congenital hemolytic anemia. Because of the apparent predisposition to major thromboses postsplenectomy, *splenectomy is not recommended in hereditary xerocytosis and related disorders.* Another unusual manifestation of hereditary xerocytosis is the propensity for iron overload, independent of transfusion history. Thus iron indices should be monitored at regular intervals.

HEREDITARY HYDROCYTOSIS

Pathophysiology

Hereditary hydrocytosis is a very rare, dominant disorder associated with large, swollen stomatocytic erythrocytes. The principal defect is an increase in Na^+ and K^+ permeability, leading to markedly increased intracellular sodium and water content. The molecular defect is unknown in most cases. In a subset of cases, missense variants in the Rh-associated glycoprotein (RhAG) have been identified.

Clinical Features

Hereditary hydrocytosis is the most clinically severe disorder of altered erythrocyte volume regulation. It is characterized by moderate to severe hemolysis and macrocytosis (110-150 fL), with a low MCHC (24–30%), elevated erythrocyte sodium concentration, reduced potassium concentration, increased total Na^+ and K^+ content, and increased erythrocyte osmotic fragility. There are large numbers (10–30%) of stomatocytes on peripheral blood smear. Patients typically develop jaundice, splenomegaly, and cholelithiasis.

Treatment is supportive. RBC transfusions are occasionally required. Patients should be followed for evidence of hematologic decompensation during acute illness. Interval ultrasonography to detect cholelithiasis should be obtained. When there is significant hemolysis, folate should be prescribed daily. Similar to hereditary xerocytosis, significant postsplenectomy major thromboses have been observed; thus splenectomy is not recommended in hereditary hydrocytosis.

INTERMEDIATE SYNDROMES AND OTHER VARIANTS

Hereditary xerocytosis and hereditary hydrocytosis are at the extremes of disorders with alterations in erythrocyte permeability. Patients with intermediate defects have been described with varying degrees of hemolysis and anemia. One of these intermediate syndromes is **cryohydrocytosis** in which affected patients typically suffer from mild anemia associated with stomatocytes, spherocytes, and sphero-stomatocytes on peripheral blood smear. Cryohydrocytosis erythrocytes are deficient in band 3 and demonstrate a significant cation leak upon cooling to low temperature (*kyros* = cold). This disorder is due to missense variants in band 3 that likely convert band 3 from an anion exchanger to a nonselective cation leak channel.

Rh deficiency syndrome, also known as Rh_{null} syndrome, is mild to moderate hemolytic anemia associated with markedly decreased (Rh_{mod}) or absent (Rh_{null}) Rh antigens on the erythrocyte membrane. Rh_{null} erythrocytes, which lack all Rh antigens, LW, and Fy5 antigens and have decreased reduced expression of Ss, U, and Duclos antigens, are dehydrated with decreased cell cation and water content. Findings on blood smear include reticulocytes, stomatocytes, and spherocytes. In response to immunization during pregnancy or after blood transfusion, Rh_{null} patients produce antibodies varying in specificity from reacting to anti-e or anti-C to reacting with all erythrocytes tested, an antibody called "anti-total Rh."

Familial deficiency of high-density lipoproteins (Tangier disease) is a rare recessive disorder that results from pathogenic variants in the cholesterol and phospholipid transport protein ABCA1, which lead to perturbations of cellular cholesterol transport and result in the accumulation of cholesterol esters in many tissues. Hematologic manifestations include a mild to moderate stomatocytic hemolytic anemia and thrombocytopenia. Affected patients can also have large orange tonsils, hepatosplenomegaly, lymphadenopathy, cloudy corneas, peripheral neuropathy, and premature atherosclerosis.

Sitosterolemia, also known as phytosterolemia, is a recessive disorder in which the absorption of sterols, both cholesterol and its plant-derived relatives (e.g., sitosterol), is unlimited and unselective. Clinical manifestations include early-onset xanthomatosis, short stature, and premature coronary artery disease. Hematologic abnormalities include macrothrombocytopenia and stomatocytic hemolytic anemia. The plasma cholesterol may or may not be abnormal, but mass spectrometry always shows a massive increase in plant sterol levels in the plasma and in the membranes of platelets and erythrocytes. Pathogenic variants in *ABCG5* or *ABCG8*, transporters that actively pump plant sterols out of intestinal cells back into the intestine and out of liver cells into bile ducts, lead to gastrointestinal hyperabsorption and decreased biliary elimination of plant sterols, as well as altered cholesterol metabolism. Treatment involves dietary restriction of cholesterol and plant sterols and prescription of ezetimibe, a sterol absorption inhibitor, and cholestyramine and other related bile acid–sequestering agents.

OTHER DISORDERS ASSOCIATED WITH STOMATOCYTOSIS

Acquired stomatocytosis may be seen with liver disease, alcoholism, malignancy, and cardiovascular disease and after vinca alkaloid administration. Stomatocytes can be seen as a blood smear–processing artifact.

Visit Elsevier eBooks+ at eBooks.Health.Elsevier.com for Bibliography.

Chapter 510

Paroxysmal Nocturnal Hemoglobinuria and Acanthocytosis

Stephanie Prozora and Patrick G. Gallagher

PAROXYSMAL NOCTURNAL HEMOGLOBINURIA

Etiology

Paroxysmal nocturnal hemoglobinuria (PNH) is an acquired disorder of the cell membranes of multipotent bone marrow stem cells. The underlying somatic pathogenic variant propagates into a clonal population of stem cells so that all blood cells derived from these variant clonal progenitors, especially red blood cells (RBCs), are susceptible to complement-mediated destruction (Fig. 510.1). The pathogenic variant causes cell membranes to be deficient (either partially or completely) in proteins that impede complement-mediated lysis via the constitutively active alternative pathway. These complement regulating proteins include decay-accelerating factor (CD55), the membrane inhibitor of reactive lysis (CD59), and the C8 binding protein. The underlying defect involves the glycolipid anchor that maintains these protective proteins on the cell surface. Various pathogenic variants in the *PIGA* gene that encodes the glycosylphosphatidylinositol anchor protein have been identified in patients with PNH.

Clinical Manifestations

PNH is a rare disorder in children. Approximately 60% of pediatric patients have marrow failure, and the remainder have either intermittent or chronic anemia, often with prominent intravascular hemolysis (Tables 510.1 and 510.2). Nocturnal and morning hemoglobinuria is the classic finding in adults, but only a minority of PNH patients experience this. Most patients experience chronic hemolysis, often with thrombocytopenia and leukopenia. Hemoglobinuria is rarely seen in children compared with adults with PNH. *Thrombosis and thromboembolic phenomena* are serious complications that may be related to altered glycoproteins on the platelet surface and resultant platelet activation and production of procoagulant microparticles. Abdominal venous thrombosis presents as recurrent episodes of abdominal pain, Budd-Chiari syndrome (hepatic veins), or splenomegaly (splenic vein). Released free hemoglobin results in depletion of nitric oxide, fostering vasoconstriction, thrombosis, and pain. Back and head pain may also be prominent. Hypoplastic or aplastic pancytopenia can precede or follow the diagnosis of PNH; rarely, PNH may progress to acute myelogenous leukemia. At the time of presentation, more than 90% of patients with PNH have some blood abnormality (including ~35% with anemia alone, ~15% with anemia and thrombocytopenia, ~7% with anemia and neutropenia, and ~30% with pancytopenia), >10% have abdominal pain, and >5% have thrombosis. The mortality in PNH is related primarily to the development of aplastic anemia or thrombotic complications. The predicted survival rate for children before the development of eculizumab was 80% at 5 years, 60% at 10 years, and 28% at 20 years.

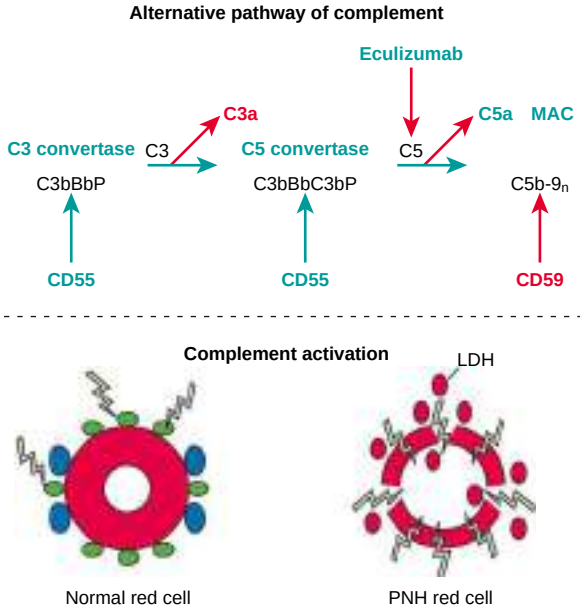

Fig. 510.1 Complement-mediated lysis in paroxysmal nocturnal hemoglobinuria (PNH). *Red circles* are hemoglobin. *Blue circles* are decay accelerating factor (CD55). *Green circles* are membrane inhibitor of reactive lysis (CD59). Bb, activated factor B; C3b, activated C3; C5b, activated C5; MAC, membrane attack complex (consisting of C5b, C6, C7, C8, and several molecules of C9 [9n]). *(From Parker C. Eculizumab for paroxysmal nocturnal haemoglobinuria. Lancet 2009;373:759–767.)*

Laboratory Findings

Hemoglobin levels can range from normal to markedly decreased. Common findings reflect chronic intravascular hemolysis and include hemosiderinuria, an elevated reticulocyte percentage, a low serum haptoglobin, and increased lactic dehydrogenase. Initially, the anemia is normocytic, but if iron deficiency develops, it becomes microcytic. On the blood smear, poikilocytosis and anisocytosis may be present. Markedly reduced levels of RBC acetylcholinesterase activity and decay-accelerating factor are also found. *Flow cytometry is the diagnostic test of choice for PNH*. With the use of anti-CD59 for RBCs and anti-CD55 and anti-CD59 for granulocytes, flow cytometry is more sensitive than the classic RBC lysis (Ham or sucrose) tests in detecting these reduced glycolipid-bound membrane proteins. Fluorescently labeled aerolysin testing can heighten the sensitivity of detection by binding selectively to glycosylphosphatidylinositol anchors.

Treatment

Eculizumab therapy has resulted in sustained survival in the majority of patients. Eculizumab is a monoclonal antibody against complement component C5 that interrupts formation of the membrane attack complex, blocking downstream complement destruction of RBCs and activation of platelets. It decreases the rate of hemolysis, stabilizes hemoglobin levels, reduces the number of transfusions, reduces the risk of thrombosis, and improves quality of life. Eculizumab is an approved and effective treatment for PNH in adults. A recent phase I/II trial demonstrated safety and efficacy in patients 11-17 years of age. Because of the cost and duration of treatment (i.e., lifelong) required, particularly in children, it may be most useful in preventing thrombosis, anemia, and other symptoms while stem cell transplant is considered. Survival in adults with PNH treated with eculizumab may not be different from sex- and age-matched control patients from the general population. However, the medication does not improve the hematopoietic clonal expansion or prevent marrow failure. Before beginning eculizumab, it is recommended to immunize patients with the meningococcal vaccine if the patient hasn't already received this vaccine because a very serious risk of complement inhibition is increased susceptibility to *Neisseria* infections. If eculizumab therapy is desired to begin immediately for clinical reasons, the vaccine can be given at the same time, and prophylactic antibiotics can be given for a 2-week bridge. Headache is a common adverse effect after the first few doses but disappears subsequently. A poor response to eculizumab may be due to polymorphisms in the C5 gene that produce resistance to

Table 510.1 Suggested Criteria as Indications for PNH Testing

CATCH CRITERION	INDICATIONS FOR TESTING	SUPPORTING INFORMATION
Cytopenias	Patients for whom a bone marrow examination is considered for otherwise unexplained cytopenia(s)	Additional features such as elevated LDH, DAT-negative hemolysis, history of unexplained TE, and hemoglobinuria
AA/MDS	All patients with a diagnosis or suspicion of AA Testing should be done at diagnosis and monitored at least q6 months Low or intermediate-1 risk MDS, and especially if hypoplastic	Additional features such as elevated LDH, DAT-negative hemolysis, history of unexplained TE, and hemoglobinuria
Thrombosis	Unprovoked and/or unusual site TE (e.g.,, splenic, hepatic, CNS), especially if recurrent and/or despite anticoagulation	Additional features such as elevated LDH, DAT-negative hemolysis, otherwise-unexplained cytopenias, especially including anemia
Coombs-negative hemolysis	Hemolysis or hemolytic anemia (i.e., elevated LDH and indirect bilirubin, reduced haptoglobin, DAT/Coombs test negative) without other clear cause	Test in all patients unless a clear alternate explanation exists Supportive information may be helpful but is not necessary
Hemoglobinuria	Otherwise-unexplained hemoglobinuria or cases where "hematuria" has been identified without evidence of erythrocytes on microscopy	Test in all patients unless a clear alternate explanation exists Supportive information may be helpful but is not necessary

AA, Aplastic anemia; CNS, central nervous system; DAT, direct antiglobulin test (aka Coombs test); LDH, lactate dehydrogenase; MDS, myelodysplastic syndromes; TE, thromboembolic event.
From Patriquin CJ, Kiss T, Caplan S, et al. How we treat paroxysmal nocturnal hemoglobinuria: A consensus statement of the Canadian PNH Network and review of the national registry. *Eur J Haematol*. 2019;102:36–52: Table 2, p. 39.

Table 510.2 Classification of Paroxysmal Nocturnal Hemoglobinuria

CATEGORY	RATE OF INTRAVASCULAR HEMOLYSIS*	BONE MARROW	FLOW CYTOMETRY	BENEFIT FROM ECULIZUMAB
Classic clinical PNH	Florid (markedly abnormal LDH, often with episodic macroscopic hemoglobinuria)	Cellular marrow caused by erythroid hyperplasia and normal or near-normal morphology†	Large population (>50%) of GPI-AP– PMNs§	Yes
Clinical PNH in the setting of another bone marrow failure syndrome‡	Mild (often with minimal abnormalities of biochemical markers of hemolysis)	Evidence of a concomitant bone marrow failure syndrome‡	Although variable, the percentage of GPI-AP– PMNs is usually relatively small (<50%)	Typically no, but some patients have relatively large clones and clinically significant hemolysis and may benefit from treatment
Subclinical PNH	No clinical or biochemical evidence of intravascular hemolysis	Evidence of a concomitant bone marrow failure syndrome‡	Small (<1%) population of GPI-AP– PMNs detected by high-resolution flow cytometry	No

*Based on macroscopic hemoglobinuria, serum LDH concentration and reticulocyte count.
†Karyotypic abnormalities are uncommon.
‡Aplastic anemia or low-risk myelodysplastic syndrome.
§Analysis of PMNs is more informative than analysis of red blood cells because of selective destruction GPI-AP– RBCs.
GPI-AP–, Glycosylphosphatidylinositol–anchored protein–deficient; LDH, lactate dehydrogenase; PMNs, polymorphonuclear leukocytes.
From Parker CJ, Ware RE. Paroxysmal nocturnal hemoglobinuria. In: Orkin SH, Fisher DE, Ginsburg D, et al., eds. *Nathan and Oski's Hematology and Oncology of Infancy and Childhood*, 8th ed. Philadelphia: Elsevier, 2015: Table 14-1.

eculizumab blockades. Patients on eculizumab therapy require regular monitoring, including complete blood counts with reticulocytes, lactate dehydrogenase, total bilirubin, and repeat flow cytometry every 6-12 months.

Hematopoietic stem cell transplantation (HSCT) is a key therapeutic consideration if a suitable donor exists, particularly in children. Severe aplastic anemia is a strong indication for transplant in PNH (Fig. 510.2). HSCT is the only potentially curative therapy available for PNH. Nonmyeloablative transplantation (with reduced intensity conditioning regimens) are often used to reduce transplant-related mortality and morbidity; because eradication of only the PNH clones is sought, total myeloablation is not necessary.

Glucocorticoids such as prednisone can be used for acute hemolytic episodes; the dosage should be tapered as soon as the hemolysis abates. Prolonged anticoagulation (heparin or low molecular weight heparin) therapy may be of benefit when thromboses occur. Because of chronic urinary loss of iron as hemosiderin, iron therapy may be necessary. Androgens (e.g., fluoxymesterone), antithymocyte globulin, cyclosporine, and growth factors (e.g., erythropoietin and granulocyte colony-stimulating factor) have been used to treat marrow failure.

ACANTHOCYTOSIS

Acanthocytosis is characterized by RBCs with irregular circumferential pointed projections (also known as spur cells) (see Fig. 507.4E).

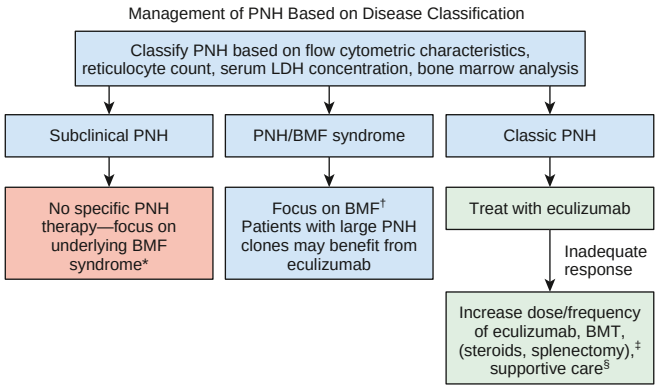

*Some, but not all, studies suggest a favorable response to immunosuppressive therapy (IST).
† BMT eradicates the PNH clone, and typically, treatment with IST does not affect PNH clone size.
‡ Consider for patients with clinically significant extravascular hemolysis.
§ Transfusion.

Fig. 510.2 Management algorithm for paroxysmal nocturnal hemoglobinuria (PNH). A management scheme based on classification of PNH into two categories: subclinical, PNH in the setting of another bone marrow failure syndrome (PNH/BMF), and classic PNH (see Table 510.2 for characteristics of each category.) *LDH*, Lactic dehydrogenase; *BMF*, bone marrow failure (aplastic anemia and low risk MDS); *BMT*, bone marrow transplant. *(From Orkin SH, Fisher DE, Ginsburg D, et al., eds. Nathan and Oski's Hematology and Oncology of Infancy and Childhood, 8th ed. Philadelphia: Elsevier, 2015. Fig 14-9.)*

Table 510.3 Hereditary Acanthocytosis Syndromes

SYNDROME	INHERITANCE	GENES
Chorea-acanthocytosis	Autosomal recessive	*VPS13A*
McLeod syndrome	X-linked recessive	*XK*
Huntington disease–like 2	Autosomal dominant	*JPH3*
Pantothenate kinase-associated neurodegeneration	Autosomal recessive	*PANK2*
Abetalipoproteinemia	Autosomal recessive	*MTTP*
Hereditary hypobetalipoproteinemia	Autosomal recessive	*APOB, MTP, PCSK9*
Aceruloplasminemia	Autosomal recessive	*CP*

This morphologic finding results from alterations in the membrane ratio of cholesterol to phospholipid, with the morphology attributed to an excess of lipid in the outer layer relative to the inner layer of the membrane bilayer. In liver disease, acanthocytes develop because of increased abundance of free cholesterol, as patients develop splenic congestion, hemolytic anemia, and jaundice. **Abetalipoproteinemia** is an inherited autosomal recessive disease in which acanthocytosis is associated with fat malabsorption, progressive ataxia, and retinitis pigmentosa. The fat malabsorption may become apparent in the first year of life, whereas the ataxia develops at school-age. The anemia is usually mild. **Hypobetalipoproteinemia** is a recessive familial disease that has a similar clinical spectrum, but with milder findings. Aceruloplasminemia leads to anemia, diabetes, ocular problems, tremors, chorea, ataxia, and facial abnormalities due to increased iron in the brain and other organs.

There are four genetically diverse **neuroacanthocytosis syndromes** (Table 510.3). *Chorea-acanthocytosis* is an adult-onset disease without anemia, variable numbers of acanthocytes on peripheral blood smear, with multiple neurologic findings such as limb chorea, tics, and hypotonia. The rare *X-linked McLeod syndrome* (marked by absence of the Kell antigen) presents with mild hemolytic anemia, late-onset myopathy, peripheral neuropathy, chorea, and splenomegaly. There are usually >3% acanthocytes on peripheral smear and caudate atrophy noted on MRI. McLeod syndrome is the only neuroacanthocytosis syndrome likely to present in childhood. Acanthocytes also are seen in *pantothenate kinase-associated neurodegeneration* (with dystonia, rigidity, chorea, dysarthria, spasticity, retinopathy) and *Huntington disease–like 2*.

In contrast to acanthocytes, echinocytes or "burr cells" have a more regular distribution of projections or serrations along the surface of the RBCs and will tend to a more spheroidal cell contour as they age. They are seen often as artifacts (e.g., due to elevated pH, contact with glass, or blood storage) and infrequently in end-stage renal disease, liver disease, uremia, pyruvate-kinase deficiency, long-distance runners, and patients with hypomagnesemia and hypophosphatemia.

Visit Elsevier eBooks+ at eBooks.Health.Elsevier.com for Bibliography.

Chapter 511

Hemoglobinopathies

Kim Smith-Whitley and Janet L. Kwiatkowski

HEMOGLOBIN DISORDERS

Hemoglobin is a tetramer consisting of two pairs of globin chains. Abnormalities in these proteins are referred to as **hemoglobinopathies**.

More than 800 variant hemoglobins have been described. The most common and useful clinical classification of hemoglobinopathies is based on nomenclature associated with alteration of the involved *globin chain*. Two hemoglobin (Hb) gene clusters are involved in Hb production and are located at the end of the short arms of chromosomes 16 and 11. Their control is complex, including an upstream locus control region on each respective chromosome and an X-linked control site. On chromosome 16, there are three genes within the alpha (α) gene cluster: zeta (ζ), alpha 1 (α_1), and alpha 2 (α_2). On chromosome 11, there are five genes within the beta (β) gene cluster: epsilon (ε), gamma 1 (γ_1), gamma 2 (γ_2), delta (δ), and beta (β).

The order of gene expression within each cluster roughly follows the order of expression during the embryonic period, fetal period, and eventually childhood. After 8 weeks of fetal life, the embryonic hemoglobins, Gower-1 ($\zeta_2\varepsilon_2$), Gower-2 ($\alpha_2\varepsilon_2$), and Portland ($\zeta_2\gamma_2$), are formed. At 9 weeks of fetal life, the major hemoglobin is hemoglobin F (HbF; $\alpha_2\gamma_2$). Hemoglobin A (HbA; $\alpha_2\beta_2$) first appears at approximately 1 month of fetal life but does not become the dominant hemoglobin until after birth, when HbF levels start to decline. HbA_2 ($\alpha_2\delta_2$) is a minor hemoglobin that appears shortly before birth and remains at a low level after birth. The final hemoglobin distribution pattern that occurs in childhood is not achieved until at least 6 months of age and sometimes later. The normal hemoglobin pattern is ≥95% HbA, ≤3.5% HbA_2, and <2.5% HbF.

511.1 Sickle Cell Disease

Kim Smith-Whitley and Janet L. Kwiatkowski

Children with sickle cell disease should be followed by experts in the management of this disease, most often by pediatric hematologists. Children who receive disease-specific care that focuses on prevention of infectious complications and end-organ damage should have a

higher likelihood of survival to adult age. Medical care provided by a pediatric hematologist is also associated with a decreased frequency of emergency department (ED) visits and length of hospitalization compared to patients who were not seen by a hematologist within the last year.

PATHOPHYSIOLOGY

Hemoglobin S (HbS) is the result of a single base-pair change, thymine for adenine, at the 6th codon of the β-globin gene. This change encodes valine instead of glutamine in the sixth residue in the β-globin molecule. Sickle cell anemia (HbSS), homozygous HbSS, occurs when both β-globin alleles have the sickle cell pathogenic variant (βs). Sickle cell disease refers not only to patients with sickle cell anemia but also to compound heterozygotes where one β-globin allele includes the sickle cell pathogenic variant and the second β-globin allele includes a gene pathogenic variant other than the sickle cell pathogenic variant, such as HbC, β-thalassemia, HbD, and HbO^{Arab}. In sickle cell anemia, HbS is typically as high as 90% of the total hemoglobin, whereas in sickle cell disease, HbS is >50% of all hemoglobin.

In red blood cells (RBCs), the hemoglobin molecule has a highly specified conformation allowing for the transport of oxygen in the body. In the absence of globin-chain pathogenic variants, hemoglobin molecules do not interact with one another. However, the presence of HbS results in a conformational change in the Hb tetramer, and in the deoxygenated state, HbS molecules interact with each other, forming rigid polymers that give the RBC its characteristic "sickled" shape. Intraerythrocytic changes lead to a shortened RBC life span and hemolysis. Hemolysis leads to multiple changes, including altered nitric oxide metabolism and oxidant stress, which contribute to endothelial dysfunction. Intravascular sickling primarily occurs in the postcapillary venules and is a function of both mechanical obstruction by sickled erythrocytes, platelets, and leukocytes and increased adhesion between these elements and the vascular endothelium. Sickle cell disease is also an inflammatory disease based on nonspecific markers of inflammation, including, but not limited to, elevated baseline white blood cell (WBC) count and cytokines.

DIAGNOSIS AND EPIDEMIOLOGY

Every state in the United States has instituted a mandatory newborn screening program for sickle cell disease. Such programs identify newborns with the disease and provide prompt diagnosis and referral to providers with expertise in sickle cell disease for anticipatory guidance and the initiation of penicillin prophylaxis before 4 months of age.

The most commonly used procedures for newborn diagnosis include thin-layer/isoelectric focusing (IEF) and high-performance liquid chromatography (HPLC). Some laboratories perform genetic testing on specimens demonstrating abnormal hemoglobins. A confirmatory step is recommended, with all patients who have initial abnormal screens being retested during the first clinical visit, which helps to account for potential administrative errors in specimen handling. In addition, a complete blood cell count (CBC) and Hb phenotype determination is recommended for both parents to provide an opportunity for genetic counseling and to better characterize disease genotype in the affected offspring if necessary. Infants who may have **HbS-hereditary persistence fetal hemoglobin (HbSHPFH)** but do not have full parental studies should have molecular testing for β-globin genotype before 12 months of age (or sooner if hydroxyurea is initiated). Table 511.1 correlates the initial hemoglobin phenotype at birth with the type of hemoglobinopathy.

In newborn screening programs, the hemoglobin with the greatest quantity is reported first, followed by other hemoglobins in order of decreasing quantity. Some states perform IEF initially on newborn blood samples, then use DNA probes to confirm abnormal hemoglobins found on IEF. In newborns with a hemoglobin analysis result of **HbFS**, the pattern supports HbSS, HbSHPFH, or $HbS\beta^0$-thalassemia. In certain situations, a newborn with a hemoglobin analysis of HbFS may have $HbS\beta^+$-thalassemia and the hemoglobin A may not be demonstrating on the electrophoresis in quantities high enough for detection. In a newborn with a hemoglobin analysis of **FSA**, the pattern is supportive of the diagnosis of $HbS\beta^+$-thalassemia. The diagnosis of $HbS\beta^+$-thalassemia is confirmed if at least 50% of the hemoglobin is HbS, HbA is present, and the amount of HbA_2 is elevated (typically >3.5%), although HbA_2 is not elevated in the newborn period. In newborns with a hemoglobin analysis of **FSC**, the pattern supports a diagnosis of HbSC. In newborns with a hemoglobin analysis of **FAS**, the pattern supports a diagnosis of HbAS (sickle cell trait); however, in this circumstance, care must be taken to confirm that the newborn has not received an RBC transfusion before testing.

A newborn with a hemoglobin analysis of **AFS** either has been transfused with RBCs before collection of the newborn screen to account for the greater amount of HbA than HbF, or there has been an error. The patient may have either sickle cell disease or sickle cell trait and

Table 511.1 Various Newborn Sickle Cell Disease Screening Results with Baseline Hemoglobin

NEWBORN SCREENING RESULTS: SICKLE CELL DISEASE*	POSSIBLE HEMOGLOBIN PHENOTYPE†	BASELINE HEMOGLOBIN RANGE AFTER AGE 5 YR
FS	SCD-SS	6-11 g/dL
	SCD-S β^0 thal	6-10 g/dL
	SCD-S β^+ thal	9-12 g/dL
	SCD-S $\delta\beta^-$ thal	10-12 g/dL
	S HPFH	12-14 g/dL
FSC	SCD-SC	10-15 g/dL
FSA‡	SCD-S β^+ thal	9-12 g/dL
FS other	SCD-S β^0 thal	6-10 g/dL
	SCD-SD, SO^{Arab}, SC^{Harlem}, S^{Lepore}	Variable
AFS‡§	SCD-SS	6-10 g/dL
	SCD-S β^+ thal	6-9 g/dL
	SCD-S β^0 thal	7-13 g/dL variable

*Hemoglobins are reported in order of quantity.
†Requires confirmatory hemoglobin analysis after at least 6 mo of age and, if possible, β-globin gene testing or hemoglobin analysis from both parents for accurate diagnosis of hemoglobin phenotype.
‡Sickle cell trait is another possible diagnosis.
§Impossible to determine the diagnosis because the infant most likely received a blood transfusion before testing.
A, Normal hemoglobin A; C, hemoglobin C; F, fetal hemoglobin; HPFH, hereditary persistence of fetal hemoglobin; O^{Arab}, hemoglobin O^{Arab}; S, sickle hemoglobin; SC, sickle-hemoglobin C; SCD, sickle cell disease; SS, homozygous sickle cell disease; thal, thalassemia.

should be started on penicillin prophylaxis until the final diagnosis can be determined.

Given the implications of a diagnosis of sickle cell disease versus sickle cell trait in a newborn, the importance of repeating the Hb identification analysis in the patient and obtaining a Hb identification analysis and CBC to evaluate the peripheral blood smear and RBC parameters in the parents cannot be overemphasized. Unintended mistakes do occur in state newborn screening programs. Newborns who have the initial phenotype of HbFS but whose final true phenotype is HbSβ^+-thalassemia have been described as one of the more common errors identified in newborn screening hemoglobinopathy programs. Determining an accurate phenotype is important for appropriate genetic counseling for the parents. In addition, distinguishing HbSS from HbSHPFH in the newborn period usually requires parental or genetic testing. Infants who maintain HbF percentages above 25% after 12 months of age without evidence of hemolysis should have testing for β-globin gene deletions consistent with HPFH. These children have a much milder clinical course and do not require penicillin prophylaxis or hydroxyurea therapy.

If the parents are tested for sickle cell trait or hemoglobinopathy trait, full disclosure to the parent tested should be provided privately, and in some circumstances, the issue of paternity may be disclosed. For this reason and because of healthcare privacy, common practice is to always seek permission for the genetic testing and to report the hemoglobinopathy trait results back to each parent separately.

In the United States, sickle cell disease is the most common genetic disorder identified through the state-mandated newborn screening program, occurring in 1:2,647 births. The sickle hemoglobin gene is more prevalent in communities of color because descendants of people where malaria has been endemic are more likely to have been protected from the severe manifestations of malaria. Regarding ethnicity in the United States, sickle cell disease occurs in Black persons at a rate of 1:396 births and in Hispanics at a rate of 1:36,000 births. In the United States, an estimated 100,000 people have sickle cell disease, with an ethnic distribution of 90% Black and 10% Hispanic. The U.S. sickle cell disease population represents a fraction of the worldwide burden of the disease, with global estimates of 312,000 neonates born annually with HbSS disease.

CLINICAL MANIFESTATIONS AND TREATMENT OF SICKLE CELL ANEMIA

For a comprehensive discussion of the clinical management of children and adolescents with sickle cell disease, refer to the National Heart, Lung, and Blood Institute (NHLBI) 2014 Expert Panel Report on the Evidence-Based Management of Sickle Cell Disease (https://www.nhlbi.nih.gov/sites/www.nhlbi.nih.gov/files/sickle-cell-disease-report.pdf).

Fever and Bacteremia

Fever in a child with sickle cell anemia is a medical emergency, requiring prompt medical evaluation and delivery of antibiotics because of the increased risk of serious bacterial infection and subsequent high mortality rate. As early as 6 months of age, infants with sickle cell anemia develop abnormal immune function because of splenic dysfunction. By 5 years of age, most children with sickle cell anemia have complete functional asplenia. Regardless of age, all patients with sickle cell anemia are at increased risk of infection and death from bacterial infection, particularly encapsulated organisms such as *Streptococcus pneumoniae*, *Haemophilus influenzae* type b, and *Neisseria meningitidis,* as well as *Salmonella* spp.

Several clinical strategies have been developed to manage children with sickle cell disease who present with fever. These strategies range from hospital admission for intravenous (IV) antimicrobial therapy to administering a third-generation cephalosporin in an ED or outpatient setting to patients without established risk factors for occult bacteremia (Table 511.2). Given the observation that the average time for a positive blood culture is <20 hours in children with sickle cell anemia, admission for 24 hours is probably the most prudent strategy for children and families who live out of town or who are identified as high risk for poor follow-up.

Table 511.2 Clinical Factors Associated with Increased Risk of Acute Complications in Febrile Children with Sickle Cell Disease

Seriously ill appearance
Hypotension: systolic blood pressure <70 mm Hg at 1 yr of age or <70 mm Hg + 2 × age (yr) for older children
Poor perfusion: capillary refill time >4 sec
Temperature >40.0°C (104°F)
Hypoxia
Corrected white blood cell count >30,000/mm^3 or <5,000/mm^3
Platelet count <100,000/mm^3
History of pneumococcal sepsis*
Severe pain
Dehydration: poor skin turgor, dry mucous membranes, history of poor fluid intake, or decreased output of urine
Presence of acute chest syndrome (new infiltrate on chest radiograph)
Hemoglobin level <5.0 g/dL
No prophylactic antibiotics
Not immunized

*Or other serious infection requiring hospital admission.
Adapted from Williams JA, Flynn PM, Harris S et al. A randomized study of outpatient treatment with ceftriaxone for selected febrile children with sickle cell disease. *N Engl J Med* 1993;329:472–476.

Outpatient management of fever without a source should be considered in children with the lowest risk of bacteremia and after appropriate cultures are obtained and IV ceftriaxone or another cephalosporin is given. Observation after antibiotic administration is important because children treated with ceftriaxone can develop severe, rapid, and life-threatening immune hemolysis. In the event that *Salmonella* spp. or *Staphylococcus aureus* bacteremia occurs, strong consideration should be given to an evaluation for osteomyelitis with an MRI, given the increased risk of osteomyelitis in children with sickle cell anemia compared to the general population. Screening laboratory and radiologic studies are strongly recommended to identify those at risk for transient red cell aplasia, acute splenic sequestration, and acute chest syndrome (ACS), because many children with these diagnoses present to acute care settings with isolated fever. Screening children and caregivers for psychosocial factors that could impede their return to the hospital in the case of a positive blood culture is essential.

Aplastic Crisis

Human parvovirus B19 infection poses a unique threat for patients with sickle cell disease because this infection results in temporary **red cell aplasia**, limiting the production of reticulocytes and causing profound anemia (see Fig. 507.3 in Chapter 507). Any child with sickle cell disease, fever, and *reticulocytopenia* should be presumed to have parvovirus B19 infection until proven otherwise. However, reticulocytopenia is not a requirement for the diagnosis of a recent parvovirus B19 infection because reticulocytosis and increased nucleated RBCs may be seen in the recovery phase. Diagnostic testing for the presence of human parvovirus B19 with polymerase chain reaction (PCR) testing is superior to using immunoglobulin M (IgM) and IgG titers. The acute exacerbation of anemia is treated conservatively using red cell transfusion when the patient becomes hemodynamically symptomatic or has a concurrent illness, such as ACS or acute splenic sequestration. Children with suspected aplastic crisis should be closely monitored because acute infection with parvovirus B19 is associated with pain, splenic sequestration, ACS, glomerulonephritis, arthropathy, and stroke. Patients with parvovirus-associated aplastic crisis are contagious, and infection precautions should be taken to avoid nosocomial spread of the infection and to avoid exposure of pregnant caregivers who may be at risk for adverse fetal outcomes with acute infection.

Splenic Sequestration

Acute splenic sequestration is a life-threatening complication occurring primarily in infants and young children with sickle cell anemia.

The incidence of splenic sequestration has declined from an estimated 30% to 12.6% with early identification by newborn screening and improved parental education. Sequestration can occur as early as 5 weeks of age but most often occurs in children between ages 6 months and 2 years. Patients with the SC and Sβ$^+$-thalassemia types of sickle cell disease can have acute splenic sequestration events throughout adolescence and adulthood.

Splenic sequestration is associated with rapid spleen enlargement causing left-sided abdominal pain and Hb decline from the patient's baseline. Sequestration may lead to signs of hypovolemia as a result of the trapping of blood in the spleen and profound anemia, with total Hb falling below 3 g/dL. A decrease in WBC and platelet count may also be present. Sequestration may be spontaneous or triggered by fever, bacteremia, or viral infections.

Treatment includes early intervention and maintenance of hemodynamic stability using isotonic fluid or transfusions. Careful blood transfusions with RBCs are recommended to treat both the sequestration and the resultant anemia. Blood transfusion aborts the RBC trapping in the spleen and allows release of the patient's blood cells that have become sequestered, often raising Hb above baseline values. A reasonable approach is to provide only 5 mL/kg of RBCs and/or a posttransfusion Hb target of 8 g/dL, keeping in mind that the goal of transfusion is to prevent hypovolemia. Blood transfusion that results in Hb levels >10 g/dL may put the patient at risk for **hyperviscosity syndrome** because RBCs may be released from the spleen after transfusion.

Repeated episodes of splenic sequestration are common, occurring in 65% of patients. Most recurrent episodes develop within 6 months of the previous episode. Prophylactic splenectomy performed after an acute episode has resolved is the only effective strategy for preventing future life-threatening episodes. Although blood transfusion therapy has been used with the goal of preventing subsequent episodes, evidence strongly suggests that this strategy does not reduce the risk of recurrent splenic sequestration compared to no transfusion therapy. However, a short course of regular RBC transfusions can be used until splenectomy is arranged. Children should be appropriately immunized with meningococcal and pneumococcal vaccines before surgery. Penicillin prophylaxis should be prescribed after splenectomy.

Hepatic and Gallbladder Involvement

See Chapters 408 and 414.

Sickle Cell Pain

Dactylitis, referred to as **hand-foot syndrome**, is often the first manifestation of pain in infants and young children with sickle cell anemia, occurring in 50% of children by their second year of life (Fig. 511.1). Dactylitis often manifests with symmetric or less often unilateral swelling of the hands and/or feet. Unilateral dactylitis can be confused with osteomyelitis, and careful evaluation to distinguish the two is important because treatment differs significantly. Dactylitis requires palliation with pain medications, whereas osteomyelitis requires at least 4-6 weeks of IV antibiotics. Feedback from the parents is needed to determine if pain therapy is successful in relieving pain.

The cardinal clinical feature of sickle cell disease is **acute vasoocclusive pain**. Acute sickle cell pain is characterized as unremitting discomfort that can occur in any part of the body but most often occurs in the chest, abdomen, or extremities. These painful episodes are often abrupt and cause disruption of daily life activities and significant stress for children and their caregivers. A patient with sickle cell anemia has approximately one painful episode per year that requires medical attention, but the frequency is extremely variable. The pattern of symptoms with subsequent episodes may resemble that of previous episodes.

The exact etiology of pain is unknown, but the pathogenesis may be initiated when blood flow is disrupted in the microvasculature by sickled RBCs and other cellular elements, resulting in tissue ischemia. Acute sickle cell pain may be precipitated by physical stress, infection, dehydration, hypoxia, local or systemic acidosis, exposure to cold, and swimming for prolonged periods. However, most pain episodes occur without an identifiable trigger. Successful treatment of these episodes requires education of both caregivers and patients regarding the recognition of symptoms and the optimal management strategy. Given the absence of any reliable objective laboratory or clinical parameter associated with pain, trust between the patient and the treating physician is paramount to successful clinical management. Specific therapy for pain varies greatly but generally includes the use of acetaminophen or a nonsteroidal antiinflammatory drug (NSAID) early in the course of pain, followed by escalation to a combination analgesic regimen using a single-agent short-acting oral opioid, long-acting oral opioid, and continued nonopioid agent.

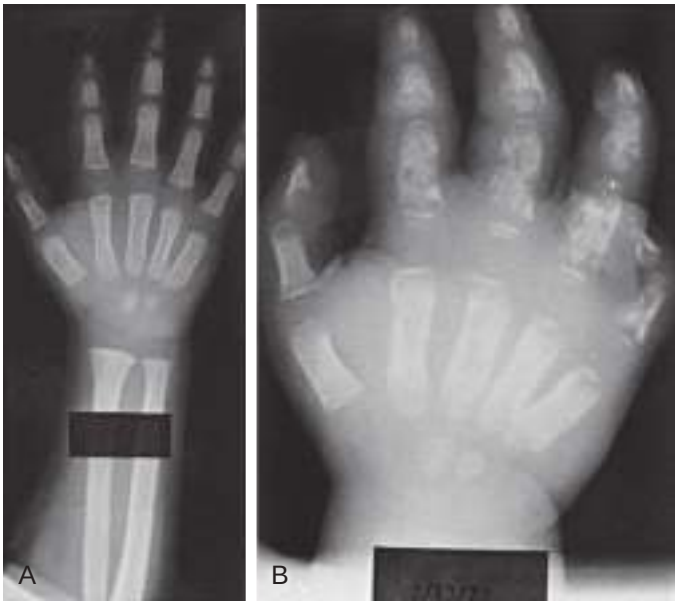

Fig. 511.1 Radiographs of an infant with sickle cell anemia and acute dactylitis. **A,** The bones appear normal at the onset of the episode. **B,** Destructive changes and periosteal reaction are evident 2 weeks later.

The majority of painful episodes in patients with sickle cell disease are managed at home with comfort measures, such as heating pad, relaxation techniques, massage, and oral pain medication. Some patients require treatment in an acute care setting with IV morphine or derivatives of morphine. The primary goal of treatment in these settings is timely administration of analgesics to provide relief of pain. The incremental increase and decrease in the use of the medication to relieve pain roughly parallels the eight phases associated with a chronology of pain and comfort in children (Table 511.3). When pain requires continued parenteral analgesic administration, hospitalization or prolonged stays in day hospitals are required. The average hospital length of stay for children admitted in pain is 4.4 days. The American Society of Hematology and NHLBI clinical guidelines for treating acute and chronic pain in children and adults with sickle cell disease are comprehensive and represent a starting point for treating pain.

The only measure for degree of pain is the patient. Healthcare providers working with children in pain should use a consistent, validated pain scale (e.g., Wong-Baker FACES Scale) for assessing pain. Although pain scales have proved useful for some children, other forms of pain assessment may be required to determine when opioid therapy should be initiated and decreased. Individualized pain plans provide important information for assessment and treatment that address patient preferences.

Several myths have been propagated regarding the treatment of pain in sickle cell disease. The concept that all painful episodes in children should be managed without opioids is without foundation and results in unwarranted suffering on the part of the patient. Blood transfusion therapy during an existing painful episode does not decrease the intensity or duration of the painful episode. Aggressive IV hydration does

Table 511.3 Phases of a Painful Episode in Patients with Sickle Cell Disease

PHASE	DESCRIPTION AND COMFORT MEASURES
DATA FROM CHILDREN	
I	*Baseline* No pain and no comfort measures
II	*Prepain phase* No evidence of pain Child begins to display some prodromal signs and symptoms of VOE (yellow eyes, fatigue) No comfort measures used Caregivers encouraged child to increase fluids to prevent the pain event from occurring
III	*Pain starting point* Child complained of mild "ache-ish" pain in one specific area, which gradually or rapidly increased or "waxed" Mild analgesics (ibuprofen and acetaminophen) given Child maintained normal activities and continued to attend school Caregivers hoped to prevent an increase in pain intensity
IV	*Pain acceleration* Pain continued to escalate; intensity increased from mild to moderate; pain appeared in more areas of the body; child was kept home from school; decreased level of activity; differences in behaviors, appearance, and mood Stronger oral analgesics may be combined with rest, rubbing, heat, distraction, and psychologic comfort
V	*Peak pain experience* Pain continued to escalate Some children were incapacitated and unable to obtain pain relief Pain described as "stabbing," "drilling," "pounding," "banging," "excruciating," "unbearable," or "throbbing" Caregivers sometimes decide to seek help from ED for stronger analgesics and protection from complications such as fever or respiratory distress Caregivers may be exhausted from caring for the child for several days with little or no rest All methods of comfort were used around the clock to reduce the pain and avoid going to the hospital Pain increased despite all efforts Decision is made to take the child to ED
VI	*Pain decrease starting point* Pain begins to resolve after the use of IV fluids and analgesics Analgesics sedate the child and allow the child to sleep for longer periods Pain described as "slowly decreasing" Pain is still sharp and throbbing
VII	*Steady pain decline* Pain decreased slowly or rapidly Child takes more interest in surroundings, roommates, and visitors Child is less irritable Level of activity increased—child may be taken to tub room for warm bath, may watch television, may play games with other children or hospital volunteers Mobility has improved Pain levels reported as "just a little" More animation in behaviors evident
VIII	*Pain resolution* Pain is at a tolerable level Child may be discharged from the hospital on mild oral analgesics; child is at or close to baseline conditions, with behavior, appearance, and mood more normal Caregiver and child attempt to regain, recapture, and catch up with life as it was before the pain event
DATA FROM ADULTS	
I	*Evolving/infarctive phase* 3 days ↓ RBC deformability ↓ Hemoglobin ↑ % of dense RBCs ↑ RDW, ↑ HDW S/S: fear, anorexia, anxiety, ↑ pain

Table 511.3 Phases of a Painful Episode in Patients with Sickle Cell Disease—cont'd

PHASE	DESCRIPTION AND COMFORT MEASURES
II	*Postinfarctive/inflammatory phase* 4-5 days ↓ Hemoglobin ↑ White blood cells (leukocytosis) ↑ Acute-phase reactants C-reactive protein ↑ Reticulocytes, ↑ LDH, ↑ CPK ↑ % dense RBCs ↑ RDW, ↑ HDW S/S: fever, severe steady pain, swelling, tenderness, joint stiffness, joint effusions
III	*Resolving/healing/recovery/postcrisis phase* ↑ RBC deformability Hemoglobin returns to precrisis level Retics return to precrisis levels ↓ % of dense RBCs ↓ RDW, ↓ HDW ↓ ISC Precursors to relapse that happens in phase III: ↑ platelets, ↑ acute-phase reactants (fibrinogen, α_1-acid glycoprotein, osmomucoid), ↑ viscosity, ↑ ESR ↑ Retics expressing the ↑ $\alpha_4\beta_1$-integrin complex ICAM-1

CPK, Creatinine phosphokinase; ED, emergency department; ESR, erythrocyte sedimentation rate; HDW, hemoglobin distribution width; ICAM, intracellular adhesion molecule; ISC, irreversibly sickled cells; IV, intravenous; LDH, lactate dehydrogenase; RBC, red blood cell; RDW, red cell distribution width; S/S, signs and symptoms; VOE, vasoocclusive episode.
Adapted from Jacob E. The pain experience of patients with sickle cell anemia. *Pain Manage Nurs* 2001;2:74–83; with data from Ballas SK, Smith ED. Red blood cell changes during the evolution of the sickle cell painful crisis. *Blood* 1992;79:2154–2163; and Beyer JE, Simmons L, Woods GM, Woods PM. A chronology of pain and comfort in children with sickle cell disease. *Arch Pediatr Adolesc Med* 1999;153:913–920.

not relieve or prevent pain and is appropriate when the patient is dehydrated or unable to drink as a result of the severe pain. *Opioid dependency in children with sickle cell disease is rare and should never be used as a reason to withhold pain medication.* However, patients with multiple painful episodes requiring hospitalization within 1 year or with pain episodes that require hospitalization for >7 days should be evaluated for comorbidities and environmental stressors that are contributing to the frequency or duration of pain. Children with chronic pain should be evaluated for other disease-related complications, including, but not limited to, presence of avascular necrosis, leg ulcers, and vertebral body compression fractures. A careful history is warranted to distinguish chronic pain that often is not relieved by opioids versus recurrent acute prolonged vasoocclusive pain episodes.

Skeletal pain (bone or bone marrow infarction) with or without fever must be differentiated from **osteomyelitis**. Both *Salmonella* spp. and *S. aureus* cause osteomyelitis in children with sickle cell disease, often involving the diaphysis of long bones (in contrast to children without sickle cell anemia, in whom osteomyelitis is in the metaphyseal region of the bone). Differentiating osteomyelitis from a vasoocclusive crisis is often difficult. Clinical signs and symptoms can be consistent with both osteomyelitis and vasoocclusive crises because low-grade fever pain, swelling of the affected area, high WBC counts, and elevated C-reactive protein levels can be present in both. Blood, fluid, and tissue cultures, when positive, are helpful. MRI may be useful for locating an area to obtain fluid for culture. Ultimately, aspiration with or with or without biopsy and culture will be needed to differentiate the two processes (see Chapter 725).

Avascular Necrosis

Avascular necrosis **(AVN)** occurs at a higher rate among children with sickle cell disease than in the general population and is a source of both acute and chronic pain. Most often, the femoral head is affected. AVN of the hip may cause limp and leg-length discrepancy. Other sites affected include the humeral head and mandible. Risk factors for AVN include HbSS disease with α-thalassemia trait, frequent vasoocclusive episodes, and elevated hematocrit (for patients with sickle cell anemia). Optimal treatment of AVN has not been determined, and individual management requires consultation with a sickle cell specialist, orthopedic surgeon, physical therapist, and primary care physician. Initial management should include referral to a pediatric orthopedist and a physical therapist to address strategies to increase strength and decrease weight-bearing daily activities that may exacerbate the pain associated with AVN as well as to determine whether surgical approaches may be beneficial. Opioids are often used but usually can be tapered after the acute pain has subsided. Regular blood transfusion therapy has not been demonstrated as an effective therapy to abate the acute and chronic pain associated with AVN.

Priapism

Priapism, defined as an unwanted painful erection of the penis, affects males of all sickle genotypes but most frequently affects males with sickle cell anemia. The mean age of first episode is 15 years, although priapism has been reported in children as young as 3 years. The actuarial probability of a patient experiencing priapism is approximately 90% by 20 years of age.

Priapism occurs in two patterns: *prolonged*, lasting >4 hours, or *stuttering*, with brief episodes that resolve spontaneously but may occur in clusters and herald a prolonged event. Both types occur from early childhood to adulthood. Most episodes occur between 3 AM and 9 AM. Priapism in sickle cell disease represents a low-flow state caused by venous stasis from RBC sickling in the corpora cavernosa. Recurrent prolonged episodes of priapism are associated with erectile dysfunction (impotence).

The optimal treatment for acute priapism is unknown. Supportive therapy, such as a hot shower, short aerobic exercise, or pain medication, is often used by patients at home. A prolonged episode lasting >4 hours should be treated by aspiration of blood from the corpora cavernosa, followed by irrigation with dilute epinephrine to produce immediate and sustained *detumescence*. Urology consultation is required to initiate this procedure, with appropriate input from a hematologist. Simple blood transfusion with exchange transfusion has been proposed for the acute treatment of priapism, but limited evidence supports this strategy as the initial management. If no benefit is obtained from surgical management, transfusion therapy should be considered. However, detumescence may not occur for up to 24 hours (much longer than with urologic aspiration) after transfusion, and transfusion for priapism has been associated with acute neurologic events. Consultation with a hematologist and urologist will help identify therapies to prevent recurrences.

Neurologic Complications

Neurologic complications associated with sickle cell disease are varied and complex, ranging from acute ischemic stroke with focal neurologic deficit to clinically *silent* abnormalities found on imaging. Before the development of transcranial Doppler ultrasonography to screen for stroke risk among children with sickle cell anemia, approximately 11% experienced an overt stroke before age 20. A functional definition of *overt stroke* is the presence of a focal neurologic deficit lasting for >24 hours and/or abnormal neuroimaging of the brain indicating a cerebral infarct on T2-weighted MRI corresponding to the focal neurologic deficit (Figs. 511.2 and 511.3). A *silent cerebral infarct* lacks focal neurologic findings and is diagnosed by abnormal imaging on T2-weighted MRI. The prevalence of silent infarct among children with HbSS is around 35%. Children with other types of sickle cell disease, such as HbSC or HbSβ^+-thalassemia, develop overt or silent cerebral infarcts as well, but at a lower frequency than children with HbSS and HbSβ^0-thalassemia. Other neurologic complications include transient ischemic attacks, headaches that may or may not correlate to degree of anemia, seizures, cerebral venous thrombosis, cerebral vasculopathy, and **posterior reversible encephalopathy syndrome (PRES)**. Chiari I malformations can occur in older children with sickle cell disease. **Fat embolism syndrome** (associated with bone marrow infarction) is a rapidly progressive, potentially fatal complication involving pain, respiratory distress, changes in mental status, and multiorgan system failure. When this syndrome is identified early, exchange transfusion therapy has improved patient survival in small case series. Skull infarction can lead to a subgaleal hematoma or epidural bleed, which may present as altered mental status.

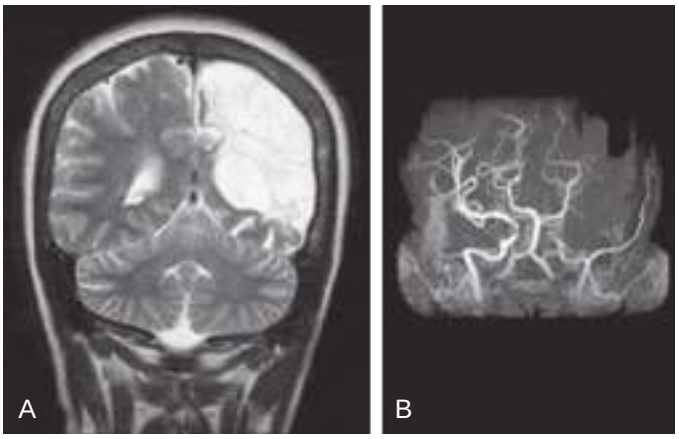

Fig. 511.2 MRI and magnetic resonance angiography (MRA) of the brain. **A,** T2-weighted MRI shows remote infarction of the territories of the left anterior cerebral artery and middle cerebral artery. **B,** MRA shows occlusion of the left internal carotid artery siphon distal to the takeoff of the ophthalmic artery.

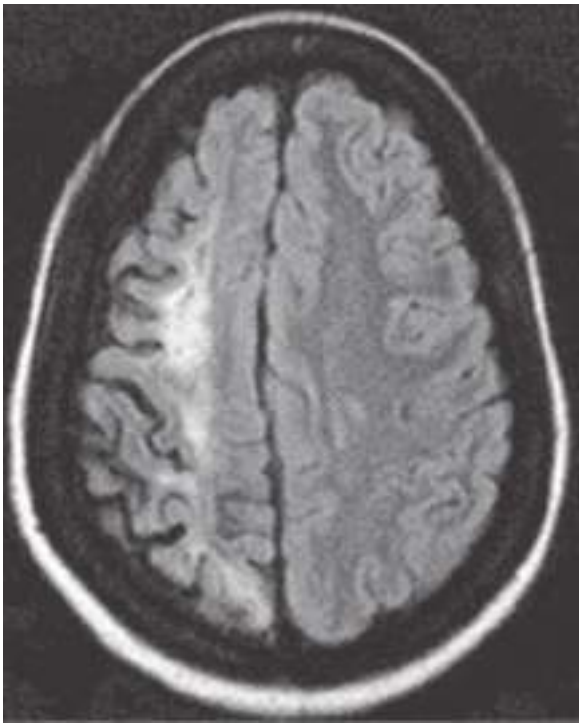

Fig. 511.3 Fast fluid-attenuated inversion recovery sequence MRI of the brain showing a right hemisphere border-zone cerebral infarction in a child with sickle cell anemia. *(From Switzer JA, Hess DC, Nichols F, et al. Pathophysiology and treatment of stroke in sickle-cell disease: present and future. Lancet Neurol 2006;5:501–512.)*

For patients presenting with acute focal neurologic deficit, a prompt pediatric neurologic evaluation and consultation with a pediatric hematologist is recommended. In addition, oxygen administration to keep oxygen saturation (So_2) >96% and blood transfusion within 2 hours of presentation, with a goal of increasing Hb to a maximum of 10 g/dL, is warranted. A timely simple blood transfusion is important because this is the most efficient strategy to dramatically increase oxygen content of the blood, particularly when exchange transfusion is not readily available. However, greatly exceeding this posttransfusion Hb limits oxygen delivery to the brain as a result of hyperviscosity by increasing the Hb significantly over the patient's baseline values. Subsequently, prompt treatment with an exchange transfusion is recommended, either manually or with automated erythrocytapheresis, to reduce the HbS percentage to <30%. Exchange transfusion at the time of acute stroke is associated with a decreased risk of second stroke compared to simple transfusion alone. CT of the head to exclude cerebral hemorrhage should be performed as soon as possible, and, if available, MRI of the brain with diffusion-weighted imaging to distinguish between ischemic infarcts and PRES. MR venography is useful to evaluate the possibility of **cerebral venous thrombosis**, a rare but potential cause of focal neurologic deficit in children with sickle cell disease. MR angiography may identify evidence of cerebral vasculopathy; these images are not critical in the initial time management of a child with sickle cell disease presenting with a focal neurologic deficit but are important for long-term management.

The clinical presentation of PRES or central venous thrombosis can mimic a stroke but would require a different treatment course. For both PRES and cerebral venous thrombosis, the optimal management has not been defined in patients with sickle cell disease, resulting in the need for consultation with both a pediatric neurologist and a pediatric hematologist. The primary approach for **prevention** of recurrent overt stroke is blood transfusion therapy aimed at keeping the maximum HbS concentration <30%. Despite regular blood transfusion therapy, approximately 20% of patients will have a second stroke and 30% of this group will have a third.

Transcranial Doppler Ultrasonography

Primary prevention of overt stroke can be accomplished using screening transcranial Doppler ultrasonography (TCD) assessment of the blood velocity in the terminal portion of the internal carotid and the proximal portion of the middle cerebral artery. Children with sickle cell anemia with an elevated *time-averaged mean maximum* (TAMM) blood flow velocity ≥200 cm/sec (abnormal study) are at increased risk for a cerebrovascular event. A repeat study should be performed within a week to confirm the result. However, a single value ≥220 cm/sec is concerning and does not require repeating before recommending an intervention. A TAMM measurement of <200 but ≥170 cm/sec represents a conditional threshold. A repeat measurement is suggested within a few months because of the high rate of conversion to a TCD velocity >200 cm/sec in this group of patients.

Two distinct methods of measuring TCD velocity are a nonimaging technique and an imaging technique. The *nonimaging* technique was the method used in the stroke prevention trial sponsored by the

National Institutes of Health, whereas most pediatric radiologists in practice use the *imaging* technique. When compared to each other, the imaging technique produces values that are 10–15% below those of the nonimaging technique. The imaging technique uses the *time-averaged mean of the maximum velocity* (TAMX), and this measure is believed to be equivalent to the nonimaging calculation of TAMM. A downward adjustment for the transfusion threshold is appropriate for centers using the imaging method to assess TCD velocity. The magnitude of the transfusion threshold in the imaging technique has not been settled, but a transfusion threshold of a TAMX of 185 cm/sec and a conditional threshold of TAMX of 165 cm/sec seem reasonable. Alternatively, some experts recommend using the same thresholds regardless of technique.

Children with abnormal TCD studies should begin chronic blood transfusion therapy to maintain HbS levels <30% to decrease the risk of first stroke. This strategy results in an over 90% reduction in the rate of overt strokes. Once transfusion therapy is initiated, a subset of patients at low risk for the development of increased TCD values, such as those without MRA-confirmed cerebral vasculopathy, may be able to transition from chronic transfusions to long-term hydroxyurea therapy. Acute stroke risk is decreased when hydroxyurea use and chronic transfusions overlap until a robust therapeutic response to hydroxyurea is achieved.

Pulmonary Complications

Lung disease in children with sickle cell disease is the second most common reason for hospital admission and is associated with significant mortality. **ACS** refers to a life-threatening pulmonary complication of sickle cell disease defined as a new radiodensity on chest radiography. Other clinical definitions include clinical features such as fever, respiratory distress, hypoxia, cough, and chest pain (Fig. 511.4). Even in the absence of respiratory symptoms, very young children with fever should receive a chest radiograph to identify evolving ACS because clinical examination alone is insufficient to identify patients with a new radiographic density. Early detection of ACS may alter clinical management. The radiographic findings in ACS are variable but may include single-lobe involvement, predominantly left lower lobe; multiple lobes, most often both lower lobes; and pleural effusions, either unilateral or bilateral. *ACS may progress rapidly from a simple infiltrate to extensive infiltrates and a pleural effusion.* Therefore continuous pulse oximetry and frequent clinical exams are required, and repeat chest x-ray films may be indicated for progressive hypoxia, dyspnea, tachypnea, and other signs of respiratory distress.

Most patients with ACS do not have a single identifiable cause. Infection is the most well-known etiology, yet only 30% of ACS episodes will have positive sputum or bronchoalveolar culture, and the most common bacterial pathogens are *S. pneumoniae*, *Mycoplasma pneumoniae*, and *Chlamydia* spp. The most frequent event preceding ACS is a painful episode requiring systemic opioid treatment. **Fat emboli** have also been implicated as a cause of ACS, arising from infarcted bone marrow, and can be life-threatening if large amounts are released to the lungs. Fat emboli can be difficult to diagnose but should be considered in any patient with sickle cell disease presenting with rapid onset of respiratory distress and altered mental status changes. Petechial rash may also occur but may be difficult to detect if not carefully sought.

Given that the causes of ACS are varied, recommended management is also multimodal (Table 511.4). The type of opioid, with overuse of morphine being more likely to cause ACS than nalbuphine

Table 511.4 Overall Strategies for the Management of Acute Chest Syndrome

PREVENTION
Incentive spirometry and periodic ambulation in patients admitted for sickle cell pain, surgery, or febrile episodes
Watchful waiting in any hospitalized child or adult with sickle cell disease (pulse oximetry monitoring and frequent respiratory assessments)
Cautious use of intravenous fluids
Intense education and optimum care of patients who have sickle cell anemia and asthma
DIAGNOSTIC TESTING AND LABORATORY MONITORING
Blood cultures, if febrile
Nasopharyngeal samples for viral culture (respiratory syncytial virus, influenza), depending on clinical setting
Complete blood counts every day and appropriate chemistries
Continuous pulse oximetry
Chest radiographs, for persistent or progressive illness
TREATMENT
Blood transfusion (simple or exchange), depending on clinical features; consider maintaining an active type and cross match
Supplemental O_2 for drop in pulse oximetry by 4% over baseline, or values <90%
Empirical antibiotics (third-generation cephalosporin and macrolide)
Continued respiratory therapy (incentive spirometry and chest physiotherapy as necessary)
Bronchodilators and corticosteroids for patients with asthma
Optimum pain control and fluid management

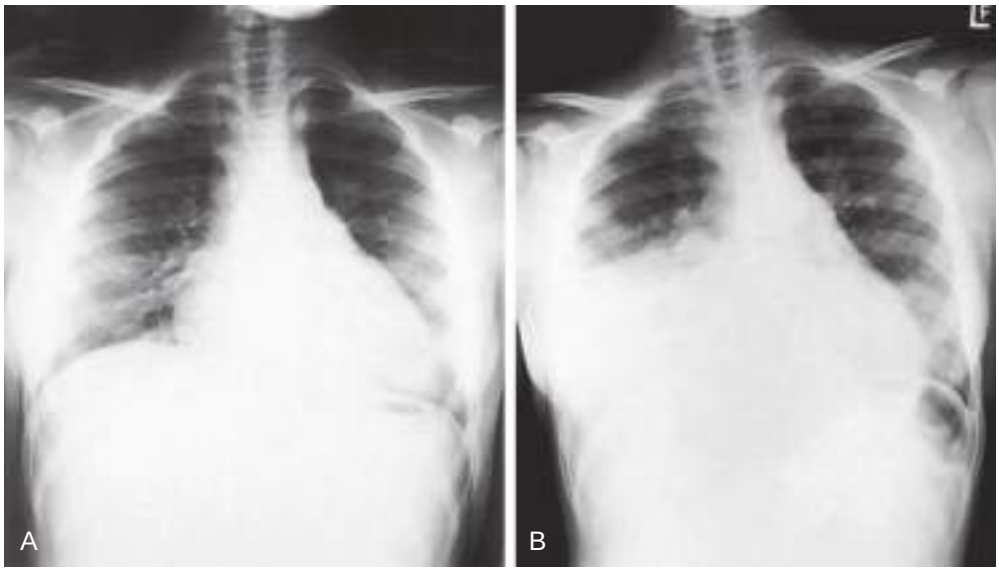

Fig. 511.4 Probable pulmonary infarction in a 15-year-old patient with HbSS. **A,** Frontal radiograph shows consolidation and a small pleural effusion posteriorly in the right lower lobe. **B,** Radiograph obtained <24 hr later shows massive right middle and lower lobe consolidation and effusion. No organisms could be cultured. The diagnosis of "probably pulmonary infarction" was established clinically. *(Courtesy Dr. Thomas L. Stovis, Children's Hospital of Michigan, Detroit. From Kuhn JP, Stovis TL, Haller JO: Caffey's Pediatric Diagnostic Imaging, 10th ed. Philadelphia: Mosby, 2004. p. 1087.)*

hydrochloride, is associated with an increase in the risk of ACS, in part because of sedation and hypoventilation. However, under no circumstance should opioid administration be limited to prevent ACS; rather, other measures must be taken to prevent ACS from developing. In patients with pain, regular use of an **incentive spirometer** at 10-12 breaths every 2 hours can significantly reduce the frequency of subsequent ACS episodes. Because of the clinical overlap between pneumonia and ACS, all episodes should be treated promptly with antimicrobial therapy, including at least a macrolide and a third-generation cephalosporin. A previous diagnosis of asthma or wheezing with ACS should prompt treatment following standard of care for an asthma exacerbation with bronchodilators. The diagnosis of ACS does not negate the recommended management of a patient with asthma exacerbation. Oxygen should be administered for patients who demonstrate hypoxia. Blood transfusion therapy using either simple or exchange (manual or automated) transfusion is the only method to abort a rapidly progressing ACS episode. The decision when to give blood and whether the transfusion should be a simple or exchange transfusion is less clearly defined. Usually, blood transfusions are given when at least one of the following clinical features are present: decreasing So_2, increasing work of breathing, rapidly changing respiratory effort either with or without a worsening chest radiograph, a dropping Hb of 2 g/dL below the patient's baseline, or previous history of severe ACS requiring admission to the intensive care unit.

Pulmonary hypertension has been identified as a major long time risk factor for death in adults with sickle cell anemia. The natural history of pulmonary hypertension in children with sickle cell anemia is unknown. Asymptomatic patients do not require screening for pulmonary hypertension. The initial diagnostic test is an echocardiogram and, depending on the severity of those findings, the echocardiogram should be followed by right-sided heart catheterization. Clinical findings suggestive of pulmonary hypertension include hypoxia or dyspnea at rest or with exertion, comorbid vascular complications (leg ulcers, priapism), elevated N-terminal, pro-B-type natriuretic peptide, or an abnormal 6-minute walk distance.

Renal Disease and Enuresis

Renal disease among patients with sickle cell disease is a major comorbid condition that can lead to premature death. Seven sickle cell disease nephropathies have been identified: gross hematuria, papillary necrosis, nephrotic syndrome, renal infarction, hyposthenuria, pyelonephritis, and renal medullary carcinoma. The presentation of these entities is varied but may include hematuria, proteinuria, renal insufficiency, concentrating defects, or hypertension.

The common presence of **nocturnal enuresis** occurring in children with sickle cell disease is not well defined but is troublesome for affected children and their parents. The overall prevalence of enuresis was 33% in the Cooperative Study of Sickle Cell Disease, with the highest prevalence (42%) among children 6-8 years old. Furthermore, enuresis may still occur in approximately 9% of older adolescents. Patients with sickle cell disease and nocturnal enuresis should have a systematic evaluation for recurrent urinary tract infections, kidney function, and possibly obstructive sleep apnea syndrome. Unfortunately, most children with nocturnal enuresis do not have an etiology, and targeted therapeutic interventions have been of limited success.

Cognitive and Psychologic Complications

Ongoing evaluation of the family unit and identification of the resources available to cope with a chronic illness are critical for optimal management. Children and adolescents with sickle cell disease have decreased quality of life, as measured on standardized assessments, compared to their siblings and children with other chronic diseases. Furthermore, children with sickle cell disease are at great risk for academic failure and have a 20% high school graduation rate, possibly because, among other reasons, approximately one third of children with sickle cell anemia have had a cerebral infarct, either silent or an overt stroke. Early school-age children with sickle cell anemia should have MRI without sedation to screen for silent cerebral ischemia. Children with cerebral infarcts require ongoing cognitive and school performance assessment so that education resources can be focused to optimize educational attainment. Participation in relevant support groups and group activities, such as camps for children with sickle cell disease, may be of direct benefit by improving self-esteem and establishing peer relationships.

Other Complications

In addition to the previous organ dysfunctions, patients with sickle cell disease can have other significant complications. These complications include, but are not limited to, sickle cell retinopathy, delayed onset of puberty, leg ulcers, and complications associated with pregnancy. Optimal treatment for each of these entities has not been determined, and individual management requires consultation with the hematologist and primary care physician. Reproductive health issues are prevalent in children and adolescents with sickle cell disease; therefore hematologists, adolescent medicine teams, and obstetrics/gynecology teams should co-manage patients to provide optimal care.

THERAPEUTIC CONSIDERATIONS

Hydroxyurea

Hydroxyurea is a well-established drug proven effective in reducing the frequency of acute pain episodes. In adults with sickle cell anemia, hydroxyurea decreases the rate of hospitalization for painful episodes by 50% and the rate of ACS and blood transfusion by almost 50%. In addition, adults taking hydroxyurea have shorter hospitalizations and require less analgesic medication during hospitalization.

In children with sickle cell anemia, hydroxyurea is safe and well tolerated. The primary toxicities are limited to myelosuppression that reverses on cessation of the drug. Infants treated with hydroxyurea experience fewer episodes of pain, dactylitis, and ACS; are hospitalized less frequently; and less often require a blood transfusion. Infants treated with hydroxyurea do not experience increased rates of bacteremia or serious infection.

Current recommendations are that all children with sickle cell anemia should be offered hydroxyurea beginning at 9 months of age. Hydroxyurea may be indicated for other sickle cell–related complications, especially in patients who are unable to tolerate other treatments. For patients who either will not or cannot continue blood transfusion therapy to prevent recurrent stroke, hydroxyurea therapy may be a reasonable alternative. The trial assessing the efficacy of hydroxyurea as an alternative to transfusions to prevent a *second* stroke was terminated early after the data safety and monitoring process found an increased stroke rate in the hydroxyurea arm compared to the transfusion arm. Hydroxyurea alone is inferior to transfusion therapy for secondary stroke prevention in patients who do not have contraindications to ongoing transfusions.

The long-term toxicity associated with initiating hydroxyurea in very young children has not yet been established. However, all evidence to date suggests that the benefits far outweigh the risks. For these reasons, very young children starting hydroxyurea require well-informed parents and medical care by pediatric hematologists, or at least co-management by a physician with expertise in immunosuppressive medications. The typical starting dose of hydroxyurea is 15-20 mg/kg once daily, with an incremental dosage increase every 8 weeks of 5 mg/kg, and if no toxicities occur, up to a maximum of 35 mg/kg per day. The infant hydroxyurea study found young children could safely be started at 20 mg/kg/day without increased toxicity. Achievement of the therapeutic effect of hydroxyurea can require several months, and for this reason, initiating hydroxyurea to address short-term symptom relief is not optimal. We prefer to introduce the concept to parents within the first year of life, preferably by 9 months; provide literature that describes both the pros and cons of starting hydroxyurea in children with severe symptoms of sickle cell disease; and educate parents on starting hydroxyurea in asymptomatic children as a preventive therapy for repetitive pain and ACS events. Other effects of hydroxyurea that may vary include an increase in the total Hb level and a decrease in the TCD velocity.

Other medications are available for long-term use in children and adults with sickle cell disease. **Oral L-glutamine** reduces hospitalizations and sickle cell crisis in children age 5 years and older. In addition, **crizanlizumab**, a humanized P-selectin inhibitor administered

monthly IV, is indicated for reducing acute pain in adults and children age 16 years and older. **Voxelotor**, a sickle hemoglobin polymerization inhibitor, is FDA-approved for adults and children 4 years and older. In clinical trials, Voxelotor demonstrated reduced hemolysis in patients with sickle cell disease.

Gene Therapy

The FDA (2023) has approved two different gene therapy approaches to ex vivo gene modification of autologous hematopoietic stem and progenitor cells following myeloablative conditioning. Both therapies are approved for patients ≥12 years of age with recurrent vasoocclusive crises.

Casgevy (exagamglogene autotemcel: exa-cel), involves *gene editing* with CRISPR/Cas9 (clustered regularly interspaced short palindromic repeats / CRISPR associated nuclease 9). Exa-cel specifically targets and inactivates the red cell precursor *BCL11A* gene (a suppressor of fetal hemoglobin expression), which results in increased production of fetal hemoglobin (which does not sickle), resulting in decreased polymerization of sickle hemoglobin.

Lyfgenia (lovotibeglogene autotemcel: lovo-cel) is a *gene addition* approach using a lentiviral vector carrying a modified beta globin gene (beta-A-T87Q globin), thus increasing the levels of hemoglobin A.

Both have been successful in reducing or eliminating vasoocclusive crises after therapy. Lyfgenia has a black box warning for the risk of off target editing /insertional mutagenesis and the possibility of acute myeloid leukemia.

Hematopoietic Stem Cell Transplantation

The only currently approved cure for sickle cell anemia is transplantation with human leukocyte antigen (HLA)–matched hematopoietic stem cells from a sibling donor (allogenic) without sickle cell disease. Because of the limited availability of appropriate sibling donors, research is exploring a wide variety of curative regimens. Clinical trials are underway to explore unrelated and partially matched related donor stem cell transplants.

The most common indications for allogenic transplant are recurrent ACS, stroke, and abnormal TCD. Sibling-matched stem cell transplantation has a lower risk for graft-versus-host disease than unrelated donors. Surveys suggest that younger children may have lower morbidity and mortality. The decision to consider unrelated transplantation should involve appropriate consultation and counseling from physicians with expertise in sickle cell transplantation.

Stem cell transplantation for children with sickle cell disease who have a genetically matched sibling and *few complications* is less commonly performed. The use of hydroxyurea has dramatically decreased the disease burden for the patient and family, with far fewer hospitalizations for pain or ACS episodes and less use of blood transfusions. The field of stem cell transplantation is also progressing such that larger studies involving nonsibling donor and haploidentical donor transplantation. Transplant-related complications caused by conditioning regimens may be decreased by using low-intensity, nonmyeloablative HLA-matched sibling, allogenic stem cell transplantation.

Red Blood Cell Transfusions

RBC transfusions are used frequently both in the treatment of acute complications and to prevent acute or recurrent complications. Typically, short-term transfusions are used to prevent progression of acute complications such as ACS, aplastic crisis, splenic sequestration, and acute stroke, as well as to prevent surgery-related ACS. RBC transfusions are not recommended for uncomplicated acute pain events. Select RBC volumes judiciously to avoid high posttransfusion Hb levels and hyperviscosity. Long-term or chronic transfusion therapy is used to prevent first stroke in patients with abnormal TCD or MRI findings (silent stroke), recurrent stroke, or recurrent ACS. Patients with sickle cell disease are at increased risk of developing *alloantibodies* to less common RBC surface antigens after receiving even a single transfusion. In addition to standard cross matching for major blood group antigens (A, B, O, RhD), more *extended matching* should be performed to identify donor units that are C-, E-, and Kell-antigen matched. Full RBC antigen phenotyping or genotyping for all patients with sickle cell disease should be performed before RBC transfusion whenever possible to have the RBC units least likely to result in alloimmunization available for these patients.

Three methods of **blood transfusion therapy** are used in the management of acute and chronic complications associated with sickle cell disease: automated erythrocytapheresis, manual exchange transfusion (phlebotomy of a set amount of patient's blood followed by rapid administration of donated packed RBCs), and simple transfusion. The decision on which method to use depends on the patient's pretransfusion Hb level, the clinical indication, RBC alloimmunization, and transfusional iron overload. Exchange transfusion, manual or automated, is preferable for patients with new neurologic symptoms. *Automated erythrocytapheresis* is the preferred method for patients requiring chronic blood transfusion therapy because there is a minimum net iron balance after the procedure, followed by manual exchange transfusion. However, this method requires technical expertise, special machines, and good patient venous access. *Manual exchange* is more accessible. However, both methods may expose the patient to more RBC units and possible alloimmunization. *Simple transfusion* therapy may lower donor exposure and be more readily available but may result in higher net iron burden when compared to erythrocytapheresis or exchange transfusion.

Preparation for surgery for children with sickle cell disease requires a coordinated effort from the hematologist, surgeon, anesthesiologist, and primary care provider. Historically, ACS was associated with general anesthesia in patients with sickle cell disease. Blood transfusion before surgery for children with sickle cell disease is recommended to raise Hb level preoperatively to no more than 10 g/dL, to avoid ACS development. Because of better general perioperative care and the use of long-term therapies such as hydroxyurea and chronic transfusions, the decision to transfuse before general anesthesia should be made in conjunction with the medical team who provides sickle cell disease–related care for the patient. When preparing a child with sickle cell disease for surgery with a simple blood transfusion, caution must be used not to elevate Hb level beyond 10 g/dL because of the risk of hyperviscosity syndrome. For children with milder forms of sickle cell disease, such as HbSC or HbSβ-thalassemia, a decision must be made on a case-by-case basis as to whether an exchange transfusion is warranted because a simple transfusion may raise the hemoglobin to an unacceptable level.

Iron Overload

The primary toxic effect of blood transfusion therapy relates to excessive iron stores or iron overload, which can result in organ damage and premature death. Excessive iron stores develop after 100 mL/kg of RBC transfusion, or about 10 transfusions. The assessment of iron overload in children receiving regular blood transfusions is difficult. *The most common and least invasive method of estimating total body iron involves serum ferritin levels*. Ferritin measurements have significant limitations in their ability to estimate iron stores for several reasons, including, but not limited to, elevation during acute inflammation and poor correlation with excessive iron in specific organs, such as the heart and endocrine glands. MRI of the liver has proved to the most effective approach for assessment of iron stores. MRI T2* and MRI R2 and R2* sequences are used to estimate iron levels in the heart and liver. These imaging strategies are more accurate than serum ferritin in estimating heart and liver iron content. The standard for iron assessment previously was liver biopsy, which is an invasive procedure exposing children to the risk of general anesthesia, bleeding, and pain. Liver biopsy alone does not accurately estimate total body iron because iron deposition in the liver is not homogeneous and does not always correlate with iron levels in the heart and other organs. The major advantage of a liver biopsy is that histologic assessment of the parenchyma can be ascertained along with appropriate staging of suspected pathology, particularly cirrhosis.

The primary **treatment** of transfusion-related iron overload requires iron chelation using medical therapy. In the United States, three chelating agents are approved for use in transfusional iron overload. *Deferoxamine* is administered subcutaneously 5 of 7 nights/week over 8 to 12 hours a night. *Deferasirox* is taken by mouth daily, and *deferiprone* is available in tablet forms taken orally twice or three times a day and an oral solution taken three times a day. The FDA approved *deferasirox* for use in patients

age ≥2 years. A pill formulation of deferasirox is available that does not require mixing before oral administration. A sprinkle formulation that is mixed with a soft food such as applesauce also is available for young children who are unable to swallow pills. *Deferiprone* is an older oral chelator that has been widely used outside the United States for many years and was also approved as a first-line agent (see Table 511.8). Because of a 1–2% risk of agranulocytosis, weekly CBC monitoring is recommended, particularly in the first 6 months of treatment and with any febrile illness. Transfusion-related excessive iron stores in children with sickle cell disease should be managed by a physician with expertise in chelation therapy because of the need for close monitoring and due to the risk of significant toxicity from available chelation therapies.

OTHER SICKLE CELL SYNDROMES

The most common sickle cell syndromes besides HbSS are HbSC, HbSβ^0-thalassemia, and HbSβ^+-thalassemia. The other syndromes—HbSD, HbSO^{Arab}, HbSHPFH, HbSE, and other variants—are much less common. Patients with HbSβ^0-thalassemia have a clinical phenotype similar to those with HbSS. In the RBCs of patients with HbSC, crystals of HbC interact with membrane ion transport, dehydrating RBCs and inducing sickling. Children who have HbSC disease can experience the same symptoms and complications as those with severe HbSS disease, but less frequently. Children with HbSC have increased incidence of retinopathy, chronic hypersplenism, and acute splenic sequestration over the life span. The natural history of the other sickle cell syndromes is variable and difficult to predict because of the lack of systematic evaluation.

There is no validated model that can predict the clinical course of an individual with sickle cell disease. A patient with HbSC can have a more severe clinical course than a patient with HbSS. Management of end-organ dysfunction in children with sickle cell syndromes requires the same general principles as managing patients with sickle cell anemia; however, each situation should be managed on a case-by-case basis and requires consultation with a pediatric hematologist.

ANTICIPATORY GUIDANCE

Children with sickle cell disease should receive general health maintenance as recommended for all children, with special attention to disease-specific guidance and infection prevention education. In addition to counseling regarding adherence to penicillin and a vaccination schedule, patients, parents, and caregivers should be instructed to seek immediate medical attention for all febrile illness. In addition, early detection of acute splenic sequestration has been shown to decrease mortality. Therefore parents and caregivers should be educated early and repeatedly about the importance of daily penicillin administration and correct palpation of the spleen.

Prophylactic Penicillin

Children with sickle cell anemia should receive prophylactic oral penicillin VK until at least 5 years of age (125 mg twice daily up to age 3 years, then 250 mg twice daily thereafter). No established guidelines exist for penicillin prophylaxis beyond 5 years of age; some clinicians continue penicillin prophylaxis, and others recommend discontinuation. Penicillin prophylaxis should be continued beyond 5 years in children with a history of pneumococcal infection because of the increased risk of a recurrent infection. An alternative for children who are allergic to penicillin is erythromycin ethylsuccinate.

Immunizations

In addition to penicillin prophylaxis, routine childhood immunizations, as well as the annual administration of influenza vaccine, are highly recommended. Children with sickle cell disease develop functional asplenia and also require immunizations to protect against encapsulated organisms, including additional pneumococcal and meningococcal vaccinations. The U.S. Centers for Disease Control and Prevention (CDC) provides vaccination guidelines at https://www.cdc.gov/vaccines/hcp/acip-recs/index.html.

Spleen Palpation

Splenomegaly is a common complication of sickle cell disease, and splenic sequestration can be life threatening. Parents and primary caregivers should be taught how to palpate the spleen to determine if the spleen is enlarging starting at the first visit, with reinforcement at subsequent visits. Parents should also demonstrate spleen palpation to the provider.

Transcranial Doppler Ultrasound

Primary stroke prevention using TCD has resulted in a decrease in the prevalence of overt stroke among children with sickle cell anemia. Children with HbSS or HbSβ^0-thalassemia should be screened annually with TCD starting at age 2 years. TCD is best performed when the child is quietly awake and in their usual state of health. TCD measurements may be falsely elevated or decreased in the settings of acute anemia, sedation, pain, fever, or immediately after blood transfusions. Screening should occur annually from ages 2-16 years. Abnormal values should be repeated within a week to identify patients at greatest risk of overt stroke. Conditional values should be repeated within at least 3 months, and normal values should be repeated annually. Routine neuroimaging with MRI in asymptomatic patients requires consultation with a pediatric hematologist or neurologist with expertise in sickle cell disease.

Hydroxyurea

Recommendations include offering hydroxyurea therapy to all children with sickle cell anemia starting at 9 months of age regardless of clinical symptoms. Monitoring children receiving hydroxyurea is labor intensive. Hydroxyurea is a chemotherapeutic agent, and patients receiving this agent require the same level of nursing and physician oversight as any child with cancer receiving chemotherapy. The parents must be educated about the consequences of therapy, and when ill, children should be promptly evaluated. Starting doses should be approximately 20 mg/kg/day. CBC with differential and reticulocyte count should be checked within 4 weeks after initiation of therapy or any dose change to monitor for hematologic toxicity, then every 8-12 weeks. Dose escalation should be based on clinical and laboratory parameters. If appropriate, dose increases should be in 5 mg/kg/day increments to a maximum of 35 mg/kg/day.

While receiving hydroxyurea, steady-state absolute neutrophil count should be approximately 2,000/μL or higher and platelet count should be 80,000/μL or higher. However, children may tolerate lower absolute neutrophil counts while receiving hydroxyurea. Holding hydroxyurea and adjusting to lower doses may be required for neutropenia and thrombocytopenia. Hydroxyurea is a pregnancy class D medication, and adolescents should be counseled regarding methods to prevent pregnancy while taking this medication. Close monitoring of the patient requires a commitment by the parents and the patient as well as diligence by a physician to identify toxicity early. Information is scarce regarding the impact of hydroxyurea on fertility, although hydroxyurea has been shown to further reduce sperm count in males with sickle cell disease in several case reports; this effect may be reversible once hydroxyurea is discontinued.

Red Cell Transfusion Therapy

At the initiation of blood transfusion therapy, children with sickle cell disease should have testing to identify the presence of alloantibodies and RBC phenotyping or genotyping, which is performed to identify the best matched blood. RBC units selected should be extended antigen-matched for C, E, and K, when feasible. Goals of transfusion for acute events should be established before initiating therapy, including target posttransfusion Hb level and HbS percentage, or both. For children receiving chronic transfusion therapy, pretransfusion HbS goals should be defined; the most common goal is <30%. Posttransfusion Hb values should be targeted to avoid hyperviscosity. Children, parents, and caregivers should be educated about the symptoms of delayed hemolytic transfusion reactions. Any child with sickle cell disease with a recent history of RBC transfusion who presents with pain, dark urine, increased scleral icterus, or symptoms of worsening anemia should be screened for a delayed hemolytic transfusion reaction after consultation with the blood bank. Children meeting criteria for chronic transfusion therapy should receive annual evaluation for transfusion-transmitted infections, including hepatitis B, hepatitis C, and HIV. After receiving 100 mL/kg RBC transfusions, regular assessments of iron overload should begin, usually including measurements of serum ferritin and MRI assessments for hepatic iron every 1-2 years. Cardiac iron assessments should be

performed in children over 10 years old, especially if there is a history of poor adherence with iron chelation and/or liver iron concentration of 15 mg/g dry weight or higher. For children requiring chelation therapy, audiology and ophthalmology exams should be performed annually and monitoring of liver function and pituitary function performed regularly because of iron deposition.

Pulmonary and Asthma Screening

Pulmonary complications of sickle cell disease are common and life threatening. Asthma is common in children with sickle cell disease, and thus evaluation for asthma symptoms and asthma risk factors should be performed routinely, particularly given the high morbidity and mortality. All children should receive annual screening for signs and symptoms of lower airway disease, such as nighttime cough and exercise-induced cough. In children with symptoms consistent with lower airway disease, consultation with an asthma specialist should be considered. Pulse oximetry readings should be performed during well visits to identify children with abnormally low daytime oxygen saturation. For children with snoring, daytime somnolence, and symptoms associated with obstructive sleep apnea syndrome (OSAS), sleep studies should be performed as necessary.

Retinopathy

Effective therapy is available for retinopathy associated with sickle cell disease. Although all patients are at risk for development of retinopathy, those with sickle cell disease, type SC, are at very high risk. Patients should receive annual screening by an ophthalmologist to identify vascular changes that would benefit from laser therapy. Although changes may occur earlier, children with sickle cell disease should begin annual screenings no later than age 10 years.

Renal Disease

Sickle cell–associated renal disease starts in infancy and may not become clinically evident until adulthood. Chronic kidney disease is common in adults with sickle cell disease, with high morbidity and mortality. Screening protocols for early signs of sickle nephropathy in children have not been adopted due to lack of data. However, when creatinine elevation, microalbuminuria, or macroalbuminuria is detected, a nephrologist should be consulted to determine next steps for further evaluation and possible treatment. The age to begin screening for proteinuria has not been defined, but some experts recommend screening annually after at least 10 years, if not sooner. If proteinuria is detected, urine studies should be repeated with an early-morning urine collection; if the protein remains elevated, the patient should be referred to a pediatric nephrologist. Males with sickle cell disease should also receive counseling regarding the diagnosis and treatment of priapism. Because of the high frequency of enuresis beyond early childhood, approximately 9% between 18 and 20 years of age, parents and caregivers should be educated about the prolonged nature of enuresis in this disease. OSAS is associated with an increased prevalence of enuresis in sickle cell disease. Unfortunately, no evidence-based therapies have been developed to treat enuresis in children and young adults with sickle cell disease. In children with enuresis who have symptoms and clinical features of OSAS, referral to specialists for evaluation is recommended.

Echocardiography

Echocardiography is a screening tool to identify individuals with sickle cell disease who have pulmonary artery hypertension (see the section on "Pulmonary Hypertension"). Studies in adults with sickle cell disease have found that echocardiography is insensitive at identifying individuals truly at risk for pulmonary hypertension, although an elevated tricuspid velocity measurement may still be a risk factor for premature death in adults with sickle cell disease. Routine echocardiograms for pulmonary hypertension screening are not recommended in asymptomatic children; however, they are recommended in patients with leg ulcers, priapism, and connective tissue disease, as well as referral to a pulmonary hypertension specialist for patients with new steady-state cardiorespiratory symptoms, heart failure, or pulmonary embolus.

Additional Screening

Patients with sickle cell disease are at increased risk for behavioral health issues, including anxiety and depression. Screening should be performed at routine and acute visits. AVN of the hips and shoulders is increased in patients with sickle cell disease and may be identified early on routine physical exam. Plain radiographs may not detect early disease; thus, when AVN is suspected and plain films are normal, MRI should be obtained. When AVN is confirmed, patients should be referred promptly to orthopedics and physical therapy.

Visit Elsevier eBooks+ at eBooks.Health.Elsevier.com for Bibliography.

511.2 Sickle Cell Trait (Hemoglobin AS)

Kim Smith-Whitley and Janet L. Kwiatkowski

The prevalence of sickle cell trait varies throughout the world; in the United States, the incidence is 7–10% of the Black population. Because all state newborn screening programs include sickle cell disease, for most children, sickle cell trait is first identified on their newborn screen. Communication of sickle cell trait status from infancy to young adulthood for the affected individual, family, and healthcare providers is often inconsistent, and many young adults are unaware of their sickle cell trait status.

By definition, among individuals with sickle cell trait, the HbS level is <50%. The life span of people with sickle cell trait is normal, and serious complications are extremely rare. The CBC is within the normal range (Fig. 511.5B). Hemoglobin analysis is diagnostic, revealing a predominance of HbA, typically >50%, and HbS <50%. Rare complications of sickle cell trait may exist. Sickle cell trait is reported to be associated with exertional rhabdomyolysis in military recruits, and possibly with sudden death during rigorous exercise. However, whether these reports establish sickle cell trait as a risk factor that is nonmodifiable by other genetic factors remains unclear. Other complications reported with sickle cell trait include splenic infarction at high altitude, hematuria, hyposthenuria, deep vein thrombosis, and susceptibility to progressive eye injury after hyphema (Table 511.5). Renal medullary carcinoma has been reported almost exclusively in individuals with sickle cell trait and occurs predominantly in young people.

Children with sickle cell trait do not require limitations on physical activities as long as provisions are made for frequent rest and oral hydration, particularly when participating in physical conditioning or competitive sports. **Sudden death** in persons with sickle cell trait while exercising under extreme conditions is most likely associated with a second genetic factor and/or environmental factors and not the presence of sickle cell trait itself. However, if **exertional rhabdomyolysis** is identified, evaluation by neurology and cardiology should be considered. No causal pathway has been implicated for the presence of sickle cell trait and sudden death. All patients with sickle cell trait who participate in rigorous athletic activities should receive maximum hydration and appropriate rest during exertion, as would be the precautionary steps for all athletes, particularly when participating in hot, humid conditions. The presence of sickle cell trait should never be a reason to exclude a person from athletic participation but rather should serve as an indication that prudent surveillance is necessary to ensure appropriate hydration and prevention of exhaustion from heat or other strenuous exercise. If athletes are to be screened for sickle cell trait, the appropriate procedure is testing using a hemoglobin electrophoresis followed by genetic counseling, along with the knowledge that genetic information may provide opportunities to challenge paternity. Such situations are typically handled by a pediatrician or hematologist accustomed to providing both a balanced approach to genetic counseling and addressing the challenges about paternity.

Visit Elsevier eBooks+ at eBooks.Health.Elsevier.com for Bibliography.

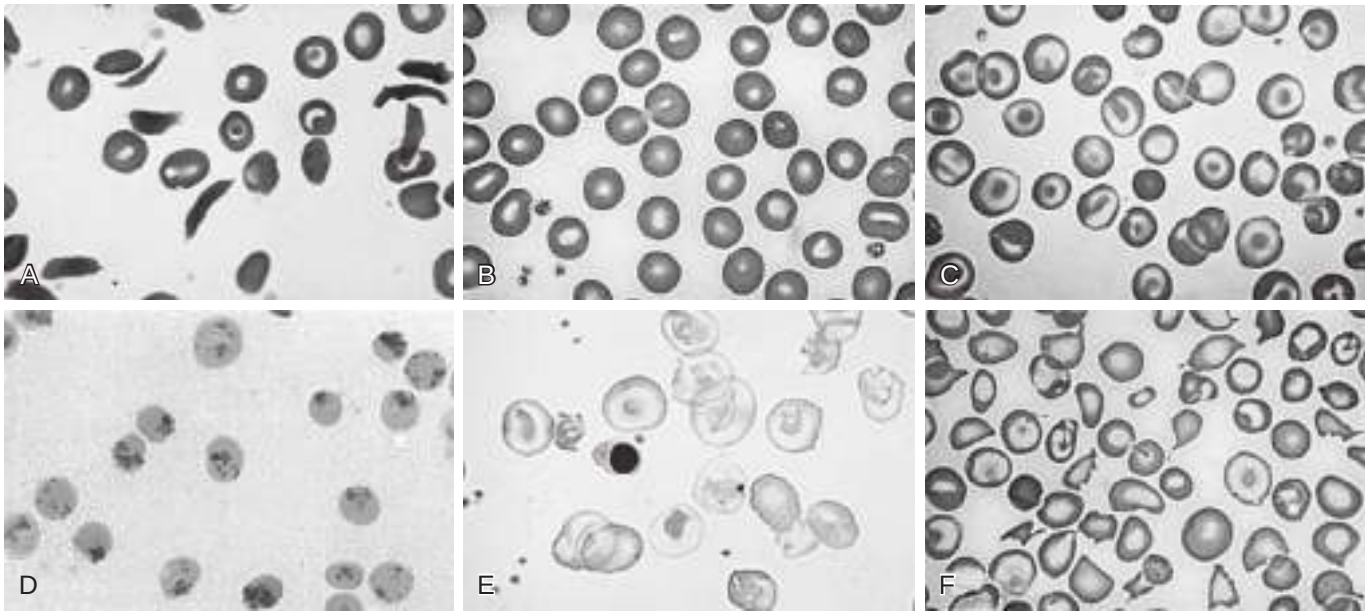

Fig. 511.5 Red blood cell morphology associated with hemoglobin disorders. **A,** Sickle cell anemia (HbSS): target cells and fixed (irreversibly sickled) cells. **B,** Sickle cell trait (HbAS): normal red blood cell (RBC) morphology. **C,** Hemoglobin CC: target cells and occasional spherocytes. **D,** Congenital Heinz body anemia (unstable hemoglobin): RBCs stained with supravital stain (brilliant cresyl blue) reveal intracellular inclusions. **E,** Homozygous β^0-thalassemia: severe hypochromia with deformed RBCs and normoblasts. **F,** Hemoglobin H disease (α-thalassemia): anisopoikilocytosis with target cells. *(Courtesy Dr. John Bolles, The ASH Collection, University of Washington, Seattle.)*

Table 511.5 Complications Reported with Sickle Cell Trait

Renal medullary cancer
Hematuria
Renal papillary necrosis
Hyposthenuria
Splenic infarction at high altitudes
Exertional rhabdomyolysis
Protection against severe complications of falciparum malaria
Microalbuminuria (adults)

From Tsaras G, Owusu-Ansah A, Boateng O, et al. Complications associated with sickle cell trait: a brief narrative review. *Am J Med* 2009;122:507–512.

511.3 Other Hemoglobinopathies

Kim Smith-Whitley and Janet L. Kwiatkowski

HEMOGLOBIN C

The pathogenic variant for HbC is at the same site as in HbS, with substitution of lysine instead of valine for glutamine. In the United States, hemoglobin C trait **(HbAC)** occurs in 1:40 and homozygous hemoglobin C disease **(HbCC)** occurs in 1:5,000 of the Black population. HbAC is asymptomatic. HbCC can result in mild anemia, splenomegaly, and cholelithiasis; rare cases of spontaneous splenic rupture have been reported. Splenic dysfunction does not occur. This condition is usually diagnosed through newborn screening programs. HbC crystallizes, disrupting the red cell membrane, and HbC crystals may be visible on peripheral smear (see Fig. 511.5C).

HEMOGLOBIN E

Hemoglobin E is an abnormal hemoglobin resulting from a qualitative pathogenic variant in the β-globin gene and is the second most common globin pathogenic variant worldwide. Patients may have asymptomatic hemoglobin E trait **(HbAE)** or benign homozygous hemoglobin E disease **(HbEE)**. Compound heterozygous hemoglobin E/β-thalassemia produces clinical phenotypes ranging from moderate to severe anemia, depending on the β-thalassemia pathogenic variant. In California, HbE/β-thalassemia is found almost exclusively in persons of Southeast Asian descent, with a prevalence of 1:2,600 births.

HEMOGLOBIN D

At least 16 variants of hemoglobin exist. HbD-Punjab (Los Angeles) is a rare hemoglobin that is seen in 1–3% of Western Indians and in some Europeans with Asian-Indian ancestry and produces symptoms of sickle cell disease when present in combination with HbS. Heterozygous HbD or hemoglobin D trait **(HbAD)** is clinically silent. Homozygous hemoglobin D disease **(HbDD)** produces a mild to moderate anemia with splenomegaly.

511.4 Unstable Hemoglobin Disorders

Kim Smith-Whitley and Janet L. Kwiatkowski

At least 200 rare unstable hemoglobins have been identified; the most common is **Hb Köln**. Most patients seem to have de novo pathogenic variants rather than inherited hemoglobin disorders. The best-studied unstable hemoglobins are the ones leading to hemoglobin denaturation from pathogenic variants affecting heme binding. The denatured hemoglobin can be visualized during severe hemolysis or after splenectomy as **Heinz bodies**. Unlike the Heinz bodies seen after toxic exposure, in unstable hemoglobins, Heinz bodies are present in reticulocytes and older RBCs (see Fig. 511.5D). Heterozygotes are asymptomatic.

Children with homozygous gene pathogenic variants can present in early childhood with anemia and splenomegaly or with unexplained hemolytic anemia. Hemolysis is increased with febrile illness and with the ingestion of oxidant medications (similar to glucose-6-phosphate dehydrogenase [G6PD] deficiency [see Chapter 512.3]) with some unstable hemoglobins. If the spleen is functional, the blood smear can appear almost normal or have only hypochromasia and basophilic stippling. A diagnosis may be made by demonstrating Heinz bodies, Hb instability, or an abnormal Hb analysis (although some unstable hemoglobins have normal mobility and are not detected on Hb analysis).

Treatment is supportive. Transfusion may be required during hemolytic episodes in severe cases. Oxidative drugs should be avoided, and folate supplementation may be helpful if dietary deficiency is a concern. Splenectomy may be considered in patients requiring recurrent transfusion or demonstrating poor growth, but the complications of splenectomy, including bacterial sepsis, risk of thrombosis, and risk of developing pulmonary hypertension, should be considered before surgery.

511.5 Abnormal Hemoglobins with Increased Oxygen Affinity

Kim Smith-Whitley and Janet L. Kwiatkowski

More than 110 high-affinity hemoglobins have been characterized. These pathogenic variants affect the state of Hb configuration during oxygenation and deoxygenation. Hemoglobin changes structure when in the oxygenated versus the deoxygenated state. The deoxygenated state is termed the **T (tense) state** and is stabilized by 2,3-diphosphoglycerate. When fully oxygenated, hemoglobin assumes the **R (relaxed) state**. The exact molecular interactions between these two states are unknown. High-affinity hemoglobins contain pathogenic variants that either stabilize the R form or destabilize the T form. The interactions between the R and T forms are complex, and the mechanisms of the pathogenic variants are not known. In most cases, the high-affinity hemoglobins can be identified by Hb analysis; approximately 20% must be characterized under controlled conditions where measurements are obtained with the P_{50} lowered to 9-21 mm Hg (normal: 23-29 mm Hg). The decreased P_{50} in these hemoglobins leads to an erythrocytosis with Hb levels of 17-20 g/dL. Levels of erythropoietin and 2,3-DPG are normal. Patients are usually asymptomatic and do not need phlebotomy. If phlebotomy is performed, oxygen delivery could be problematic because of the reduced number of Hb molecules to carry oxygen.

511.6 Abnormal Hemoglobins Causing Cyanosis

Kim Smith-Whitley

Abnormal hemoglobins causing cyanosis, also called **structural methemoglobinemias**, are rare. They are referred to as **M hemoglobins** and represent a group of hemoglobin variants that result from point pathogenic variants in one of the globin chains, α, β, or γ, located in the heme pocket; 13 known variants exist. These unstable hemoglobins lead to hemolytic anemia, most pronounced when the β-globin gene is affected. Clinically, these children are cyanotic from birth, without other signs or symptoms of disease, if the pathogenic variant is in the α-**globin** gene (HbM Boston, HbM Iwate, Hb Auckland). Infants with β-**globin** pathogenic variants become cyanotic later in infancy after the fetal hemoglobin switch (HbM Saskatoon, HbM Chile, HbM Milwaukee 1 and 2). The γ-**chain** pathogenic variants (HbF-M Fort Ripley, HbF-M Osaka, HbF Cincinnati, HbF Circleville, HbF Toms River, HbF Viseu) are all transient, presenting with cyanosis at birth, which resolves during the neonatal period after HbF production discontinues.

The abnormal M hemoglobins exhibit autosomal dominant inheritance and are diagnosed by Hb analysis. HbM variants may not be isolated reliably using Hb analysis (HPLC or IEF); consequently, diagnostic confirmation may require DNA sequencing or mass spectrometry. There is no specific treatment and affected patients do not respond to treatments used for *enzyme-deficient methemoglobinemia*. Beyond cyanosis, individuals are otherwise asymptomatic and do not require additional monitoring. Children with the β-globin form should avoid oxidant drugs. Individuals with all forms have a normal life expectancy and pregnancy course.

Low-affinity hemoglobins have less cyanosis than the M hemoglobins. The amino acid substitutions destabilize the oxyhemoglobin and lead to decreased oxygen saturation. The best characterized are Hb Kansas, Hb Beth Israel, and Hb Denver. Hb analysis (IEF and HPLC techniques) may be normal in affected individuals. When clinically suspected, oxygen affinity studies reveal a right-shifted dissociation curve, and heat testing demonstrates unstable hemoglobin. Children present with mild cyanosis only.

511.7 Hereditary Methemoglobinemia

Kim Smith-Whitley and Janet L. Kwiatkowski

Hereditary methemoglobinemia is a clinical syndrome caused by an increase in the serum concentration of methemoglobin either because of congenital changes in hemoglobin synthesis or of metabolism leading to imbalances in reduction and oxidation of hemoglobin. The iron molecule in hemoglobin is normally in the ferrous state (Fe^{2+}), which is essential for oxygen transport. Under physiologic conditions, there is a slow, constant loss of electrons to released oxygen, and the ferric (Fe^{3+}) form combines with water, producing **methemoglobin (MetHb)**. The newly formed MetHb has a reduced ability to bind oxygen.

Two pathways for MetHb reduction exist. The physiologic and predominant pathway is a reduced form of nicotinamide adenine dinucleotide (NADH)–dependent reaction catalyzed by cytochrome b5 reductase. This mechanism is >100-fold more efficient than the production of MetHb. The alternate pathway uses NAD phosphate generated by G6PD in the hexose monophosphate shunt and requires an extrinsic electron acceptor to be activated (i.e., methylene blue, ascorbic acid, riboflavin). In normal individuals, oxidation of hemoglobin to MetHb occurs at a slow rate, 0.5–3%, which is countered by MetHb reduction to maintain a steady state of 1% MetHb.

MetHb may be increased in the RBC because of exposure to toxic substances or to absence of reductive pathways, such as NADH-cytochrome b5 reductase deficiency. **Toxic methemoglobinemia** is much more common than hereditary methemoglobinemia (Table 511.6). Infants are exceptionally vulnerable to hemoglobin oxidation because their erythrocytes have half the amount of cytochrome b5 reductase seen in adults, hemoglobin F is more susceptible to oxidation than hemoglobin A, and the more alkaline infant gastrointestinal (GI) tract promotes the growth of nitrite-producing gram-negative bacteria. When MetHb levels are >1.5 g/24 hours, cyanosis is visible (15% MetHb); a level of 70% MetHb is lethal. The MetHb level is usually reported as a percentage of normal hemoglobin, and the toxic level is lower at a lower Hb level. Methemoglobinemia has been described in infants who ingested foods and water high in **nitrates**, who were exposed to aniline teething gels or other chemicals, and in some infants with severe gastroenteritis and acidosis. Methemoglobin can color the blood brown (Fig. 511.6). A patient with significant methemoglobinemia is cyanotic and does not respond to 100% oxygen. Arterial oxygen tension will be normal or elevated (if on high FiO_2) despite cyanosis, but blood oxygen saturation determined by multiwavelength co-oximetry will be low. Oxygen saturation calculated from arterial blood gas or pulse oximetry is misleading and inaccurate. Although pulse oximetry is usually lower than normal, it does not reflect the true degree of desaturation.

511.8 Hereditary Methemoglobinemia with Deficiency of NADH Cytochrome b5 Reductase

Kim Smith-Whitley

The first reported inherited disorder causing methemoglobinemia resulted from an enzymatic deficiency of NADH cytochrome b5

Table 511.6 Known Etiologies of Acquired Methemoglobinemia

MEDICATIONS
Benzocaine
Chloroquine
Dapsone
Doxycycline
EMLA (eutectic mixture of local anesthetics) topical anesthetic (lidocaine 2.5% and prilocaine 2.5%)
Flutamide
Lidocaine
Metoclopramide
Nitrates
Nitric oxide
Nitroglycerin
Nitroprusside
Nitrous oxide
Phenazopyridine
Prilocaine
Primaquine
Riluzole
Silver nitrate
Sodium nitrate
Sulfonamides
MEDICAL CONDITIONS
Pediatric gastrointestinal infection, sepsis
Recreational drug overdose with amyl nitrate ("poppers")
Sickle cell disease–related painful episode
MISCELLANEOUS
Aniline dyes
Fume inhalation (automobile exhaust, burning of wood and plastics)
Herbicides
Industrial chemicals: nitrobenzene, nitroethane (found in nail polish, resins, rubber adhesives)
Pesticides
Gasoline octane booster
Nitrate rich vegetables (beets, borage, chard)
Well water

From Ash-Bernal R, Wise R, Wright SM. Acquired methemoglobinemia. *Medicine (Baltimore)* 2004;83:265–273.

reductase, which was classified into two distinct phenotypes. **In type I**, the most common form, the deficiency of NADH cytochrome b5 activity is found only in erythrocytes, with other cell types unaffected. In **type II,** the enzyme deficiency is present in all tissues and results in more significant symptoms beginning in infancy with encephalopathy, intellectual impairment, spasticity, microcephaly, and growth retardation, with death most often by 2 years of age. Both types exhibit an autosomal recessive inheritance pattern.

Cyanosis varies in intensity with season and diet. The time of cyanosis onset also varies, appearing in some patients at birth and others as late as adolescence. Although as much as 50% of the total circulating hemoglobin may be in the form of nonfunctional MetHb, little or no cardiorespiratory distress occurs in these patients, except on exertion.

Daily oral treatment with *ascorbic acid* (200-500 mg/day in divided doses) gradually reduces the MetHb to approximately 10% of the total pigment and alleviates the cyanosis as long as therapy is continued. Chronic high doses of ascorbic acid have been associated with hyperoxaluria and renal stone formation. Ascorbic acid should not be used to treat *acute toxic methemoglobinemia*. When immediately available, poison control should be contacted to verify the most up-to-date therapeutic strategies. As with ascorbic acid, *riboflavin* uses the alternate pathway of MetHb reduction and is most effective when given in high doses. *Methylene blue*, administered via IV (1-2 mg/kg initially), is used to treat toxic methemoglobinemia. An oral dose can be administered (100-300 mg/day) as maintenance therapy.

Fig. 511.6 Normal arterial blood vs methemoglobinemia. Arterial whole blood with 1% methemoglobin *(left)* vs arterial whole blood with 72% methemoglobin *(right)*. Note the characteristic chocolate-brown color of the sample with an elevated methemoglobin level. Both samples were briefly exposed to 100% oxygen and shaken. This quick analysis is a good bedside test for methemoglobinemia. The sample on the *left* turned bright red, whereas the sample on the *right* remained chocolate-brown. *Methods:* Whole blood samples were drawn at the same time from the same person. The measured hemoglobin concentration was 11.7 g/dL. Calculated concentration of methemoglobin: 11.7 g/dL × 0.01 = 0.117 g/dL *(left)* and 11.7 g/dL × 0.72 = 8.42 g/dL *(right)*. An elevated methemoglobin level was made in vitro by adding 0.1 mL of a 0.144 molar solution of sodium nitrate *(right)*, and 0.1 mL of normal saline was added as a control *(left)*. Co-oximetry measurements were taken on both samples shortly after the blood was drawn and 20 min after the addition of sodium nitrate solution. Both blood samples were exposed to 100% oxygen before the second measurement. *(Protocol based on personal communication with Dr. Ali Mansouri, December 2002.)*

Methylene blue should not be used in patients with G6PD deficiency. This treatment is ineffective and can cause severe oxidative hemolysis. If methylene blue is given to a patient with G6PD deficiency, symptoms will not improve, and marked hemolysis can develop within 24 hours of administration. Because G6PD deficiency status is rarely known at the time of treatment, a careful history should be elicited. When the history is negative for symptoms of G6PD deficiency, treatment with methylene blue should be initiated judiciously, and the patient should be closely monitored for improvement.

511.9 Syndromes of Hereditary Persistence of Fetal Hemoglobin

Kim Smith-Whitley and Janet L. Kwiatkowski

Hereditary persistence of HbF **(HPFH)** syndromes are a form of thalassemia; pathogenic variants are associated with a decrease in the production of either or both β- and δ-globins. There is an imbalance in the α:non-α synthetic ratio characteristic of thalassemia. More than 20 variants of HPFH have been described. They are deletional, $\delta\beta^0$ (Black, Ghanaian, Italian), nondeletional (Tunisian, Japanese, Australian), linked to the β-globin–gene cluster (British, Italian-Chinese, Black), or unlinked to the β-globin–gene cluster (Atlanta, Czech, Seattle). The $\delta\beta^0$ forms have deletions of the entire δ- and β-globin gene sequences, and the most common form in the United States is the Black **(HPFH 1)** variant. As a result of the δ and β gene deletions, there is production only of γ-globin and formation of HbF. In the homozygous form, no manifestations of thalassemia are present. There is only HbF with very mild anemia and slight microcytosis. When inherited with other variant hemoglobins, HbF is elevated into the 20–30% range; when inherited with HbS, sickle cell disease is ameliorated, with fewer complications.

Visit Elsevier eBooks+ at eBooks.Health.Elsevier.com for Bibliography.

511.10 Thalassemia Syndromes

Janet L. Kwiatkowski

Thalassemia refers to a group of genetic disorders of globin-chain production in which there is an imbalance between the α-globin and β-globin chain production. β-**thalassemia** syndromes result from a decrease in β-globin chains, which results in a relative excess of α-globin chains. There are >300 β-thalassemia pathogenic variants that have been characterized. These pathogenic variants can affect any step in the transcription of β-globin genes. β^0**-thalassemia** refers to the absence of production of the β-globin. When patients are homozygous for the β0-thalassemia gene, they cannot make any normal β-globin chains (HbA). β+**-thalassemia** indicates a pathogenic variant that makes decreased amounts of normal β-globin (HbA). Some β-thalassemia pathogenic variants have structural changes such as HbE. Others, such as δβ-thalassemia or HPFH, are variants of β-thalassemia that have decreased production of β-globin gene with increased compensatory production of HbF. β^0-thalassemia syndromes are generally more severe than β^+-thalassemia syndromes, but there is significant variability between the genotype and phenotype. β-thalassemia *major*, commonly called transfusion-dependent thalassemia, refers to severe β-thalassemia that requires early transfusion therapy. β-thalassemia *intermedia* (also known as non–transfusion-dependent thalassemia) is a clinical diagnosis of a patient with a less severe clinical phenotype that usually does not require regular transfusion therapy in childhood. Many of these patients have at least one β^+-thalassemia pathogenic variant. β-thalassemia syndromes usually require a β-thalassemia pathogenic variant in both β-globin genes. Carriers with a single β-globin pathogenic variant are generally asymptomatic, except for microcytosis and mild anemia.

In α-**thalassemia**, there is an absence or reduction in α-globin production usually due to deletions of α-globin genes. Normal individuals have four α-globin genes; the more genes affected, the more severe the disease. α^0**-thalassemia** indicates no α-chains produced from that chromosome (– –/). α^+**-thalassemia** produces a decreased amount of α-globin chain from that chromosome (-alpha/).

The primary pathology in the thalassemia syndromes stems from the *quantity* of globin produced, whereas the primary pathology in sickle cell disease is related to the *quality* of β-globin produced.

EPIDEMIOLOGY

There are >300 different pathogenic variants resulting in absent or decreased globin production. Although most are rare, the 20 most common abnormal alleles constitute 80% of the known thalassemias worldwide; 1.5% of the world's population carries alleles for β-thalassemia, and in Southeast Asia 5–10% of the population carry alleles for α-thalassemia. In the United States, an estimated 2,000 persons have β-thalassemia major.

PATHOPHYSIOLOGY

Two related features contribute to the sequelae of β-**thalassemia syndromes**: inadequate β-globin gene production leading to decreased levels of normal hemoglobin (HbA) and unbalanced α- and β-globin chain production leading to ineffective erythropoiesis. In β-thalassemia α-globin chains are in excess to non–α-globin chains, and α-globin tetramers (α_4) are formed and appear as RBC inclusions. The free α-globin chains and inclusions are very unstable, precipitate in RBC precursors, damage the RBC membrane, and shorten RBC survival, leading to anemia and increased erythroid production (Table 511.7). This results in a marked increase in erythropoiesis, with early erythroid precursor death in the bone marrow. Clinically, this is characterized by a lack of maturation of erythrocytes and an inappropriately low reticulocyte count. This ineffective erythropoiesis and the compensatory massive marrow expansion with erythroid hyperactivity characterize β-thalassemia. Because of the low or absent production of β-globin, the α-chains combine with γ-chains, resulting in HbF ($\alpha_2\gamma_2$) being the dominant hemoglobin. In addition to the natural survival effect, the γ-globin chains may be produced in increased amounts, regulated by genetic polymorphisms. The δ-chain synthesis is not usually affected in β-thalassemia or β-thalassemia trait, and therefore patients have a relative or absolute increase in HbA_2 production ($\alpha_2\delta_2$).

In the α-**thalassemia syndromes**, there is a reduction in α-globin production. Normally, there are four α-globin genes (two from each parent) that control α-globin production. α-thalassemia syndromes vary from complete absence (hydrops fetalis) to only slightly reduced (α-thalassemia silent carrier) α-globin production. In the α-thalassemia syndromes, an excess of β- and γ-globin chains are produced. These excess chains form **hemoglobin Bart's (γ_4)** in fetal life and **HbH** (β_4) after birth. These abnormal tetramers are nonfunctional hemoglobins with very high oxygen affinity. They do not transport oxygen and result in extravascular hemolysis. A fetus with the most severe form of α-thalassemia **(hydrops fetalis)** develops in utero anemia and, without therapeutic intervention, the pregnancy usually results in fetal loss because HbF production requires sufficient amounts of α-globin. In contrast, infants with β-thalassemia major become symptomatic only after birth when HbA predominates and insufficient β-globin production manifests in clinical symptoms.

HOMOZYGOUS β-THALASSEMIA (TRANSFUSION-DEPENDENT BETA THALASSEMIA, BETA THALASSEMIA MAJOR, COOLEY ANEMIA)

Clinical Manifestations

If not treated, children with homozygous β^0-thalassemia usually become symptomatic from progressive anemia, with weakness, poor growth, and cardiac decompensation during the second 6 months of life. Depending on the pathogenic variant and degree of HbF production, regular transfusions are necessary beginning in the second month to second year of life, but rarely later. The decision to transfuse is multifactorial but is not determined solely by the degree of anemia. Persistent hemoglobin level below 7 g/dL in the absence of acute illness is an indication to start transfusions. In addition, the presence of signs of ineffective erythropoiesis, such as growth failure, bone deformities secondary to marrow expansion, and hepatosplenomegaly, are important variables in determining transfusion initiation.

The classic presentation of children with severe disease includes *thalassemic facies* (maxilla hyperplasia, flat nasal bridge, frontal bossing), pathologic bone fractures, marked hepatosplenomegaly, and cachexia and is primarily seen in countries without access to chronic transfusion therapy. Occasionally, patients with moderate anemia develop these features because of severe compensatory, ineffective erythropoiesis.

In nontransfused patients with severe ineffective erythropoiesis, marked **splenomegaly** can develop with hypersplenism and abdominal symptoms. The features of ineffective erythropoiesis include expanded medullary spaces (with massive expansion of the marrow of the face and skull), extramedullary hematopoiesis, and higher metabolic needs (Fig. 511.7). The chronic anemia and increased erythroid drive produce an increase in iron absorption from the GI tract and secondary hemosiderosis-induced organ injury.

Chronic transfusion therapy dramatically improves the quality of life and reduces the complications of severe thalassemia. Transfusion-induced **hemosiderosis** becomes the major clinical complication of transfusion-dependent thalassemia. Each mL of pure packed RBCs contains approximately 1 mg of iron. Physiologically, there is no mechanism to eliminate excess body iron. Iron is initially deposited in the liver and is followed by deposition in the endocrine organs and the heart. This leads to a high rate of hypothyroidism, hypogonadotropic gonadism, growth hormone deficiency, hypoparathyroidism, and diabetes mellitus. Iron deposition in the heart causes heart failure and arrhythmias, and heart disease is the leading cause of death in inadequately chelated patients. Eventually, most patients not receiving adequate iron chelation therapy die from cardiac failure or cardiac arrhythmias secondary to hemosiderosis. Hemosiderosis-induced morbidity can be prevented by adequate iron chelation therapy.

Laboratory Findings

In the United States, some children with β-thalassemia major will be identified on newborn screening because of the detection of only HbF on hemoglobin electrophoresis. However, infants with β^+ pathogenic variants might be missed on newborn screen if small amounts of hemoglobin

Table 511.7 The Thalassemias

THALASSEMIA	GLOBIN GENOTYPE	RED BLOOD CELL FEATURES	CLINICAL FEATURES	HEMOGLOBIN ANALYSIS
α-THALASSEMIA				
1 Gene deletion	−,α/α,α	Normal	Normal	Newborn: Bart's: 1–2%
2 Gene deletion (α-thalassemia trait)	−,α/−,α −, −/α,α	Microcytosis, mild hypochromasia	Normal, mild anemia	Newborn: Bart's: 5–10%
3 Gene deletion hemoglobin H	−,−/−,α	Microcytosis, hypochromic	Mild anemia, transfusions not required	Newborn: Bart's: 20–30%
2 Gene deletion + Constant Spring	$-,-/\alpha,\alpha^{\text{Constant Spring}}$	Microcytosis, hypochromic	Moderate to severe anemia, transfusion, splenectomy.	2–3% Constant Spring, 10–15% HbH
4 Gene deletion	−,−/−,−	Anisocytosis, poikilocytosis	Hydrops fetalis	Newborn: 89–90% Bart's with Gower-1, Gower-2, and Portland
Nondeletional	$\alpha,\alpha/\alpha,\alpha^{\text{variant}}$	Microcytosis, mild anemia	Normal	1–2% variant hemoglobin
β-THALASSEMIA				
β^0 or β^+ heterozygote: trait	β^0/A, β^+/A	Variable microcytosis, mild anemia	Normal	Elevated A_2, variable elevation of F
β^0 or β^+- homozygote or compound heterozygote Thalassemia severe	β^0/β^0, β^+/β^0, $\beta^+\beta^+$, E/β^0, E/β^+	Microcytosis, nucleated RBC	Transfusion dependent	F 98% and A_2 2%, E 30–40% (E/β^0); variably low HbA with β^+
β^0 or β^+ homozygote or compound heterozygote Thalassemia intermedia	β^0/β^0, β^+/β^0, $\beta^+\beta^+$, E/β^0, E/β^+	Hypochromic, microcytosis	Mild to moderate anemia, intermittent transfusions	A_2 2–5%, F 10–30%, HbA variably low levels
Dominant (rare)	B^0/A	Microcytosis, abnormal RBCs	Moderately severe anemia, splenomegaly	Elevated F and A_2
δ-Thalassemia	A/A	Normal	Normal	A_2 absent
$(\delta\beta)^0$-Thalassemia	$(\delta\beta)^0$/A	Hypochromic	Mild anemia	F 5–20%
$(\delta\beta)^+$-Thalassemia Lepore	β^{Lepore}/A	Microcytosis	Mild anemia	Lepore 8–20%
Homozygous Hb Lepore	$\beta^{\text{Lepore}}/\beta^{\text{Lepore}}$	Microcytic, hypochromic	Thalassemia intermedia	F 80%, Lepore 20%
γδβ-Thalassemia	$(\gamma^A\delta\beta)^0$/A	Microcytosis, microcytic, hypochromic	Moderate anemia, splenomegaly, homozygote: thalassemia intermedia	Decreased F and A_2 compared with δβ-thalassemia
γ-Thalassemia	$(\gamma^A\gamma^G)^0$/A	Microcytosis	Insignificant unless homozygote	Decreased F

A are present. An HbFE pattern can be consistent with hemoglobin E β^0-thalassemia, or the more benign hemoglobin EE disease, and needs to be followed up. The lack of standardized neonatal diagnosis of thalassemia disorders requires close follow-up of newborns with unclear thalassemia pathogenic variants and babies from high-risk ethnic groups.

Infants with serious β-thalassemia disorders have a progressive anemia after the newborn period. Microcytosis, hypochromia, and targeting characterize the RBCs. Nucleated RBCs, marked anisopoikilocytosis, and a relative reticulocytopenia are typically seen (see Fig. 511.5E). The Hb level falls progressively often to <6 g/dL unless transfusions are given. The reticulocyte count is commonly <8% and is inappropriately low compared to the degree of anemia caused by ineffective erythropoiesis. The unconjugated serum bilirubin level is usually elevated, but other chemistries may be initially normal. Even if the child does not receive transfusions, iron eventually accumulates with elevated serum ferritin and transferrin saturation. Evidence of bone marrow hyperplasia can be seen on radiographs (see Fig. 511.7).

Early definitive diagnosis is recommended. Newborn screening techniques such as hemoglobin electrophoresis are not definitive. DNA diagnosis of the β-thalassemia pathogenic variants, along with testing for common genetic modifiers of the clinical phenotype, is recommended. Co-inheritance of one or more α-thalassemia deletions is common, and it decreases the severity of the β-thalassemia disease as it improves the α:β chain imbalance. Some patients' pathogenic variants cannot be diagnosed by standard electrophoresis or common DNA probes. Referral of the samples to a tertiary laboratory is indicated, along with parental and family testing. After the definitive diagnosis, families should undergo detailed counseling.

Management and Treatment of Thalassemia

See Figure 511.8.

Transfusion Therapy

β-thalassemia major is a clinical diagnosis that requires the integration of laboratory findings and clinical features. Of patients with homozygous β^0-thalassemia (the most severe pathogenic variants), 15–20% may have a clinical course that is phenotypically consistent with thalassemia intermedia. In contrast, 25% of patients with homozygous β^+-thalassemia, typically a more benign genotype, may have transfusion-dependent thalassemia. Transient clinical events, such as a sudden fall in hemoglobin secondary to an episode of parvovirus requiring transfusion, do not necessarily indicate a transfusion-dependent patient. The long-term observation of the clinical characteristics, such as growth, bony changes, and hemoglobin, are necessary to determine chronic transfusion therapy.

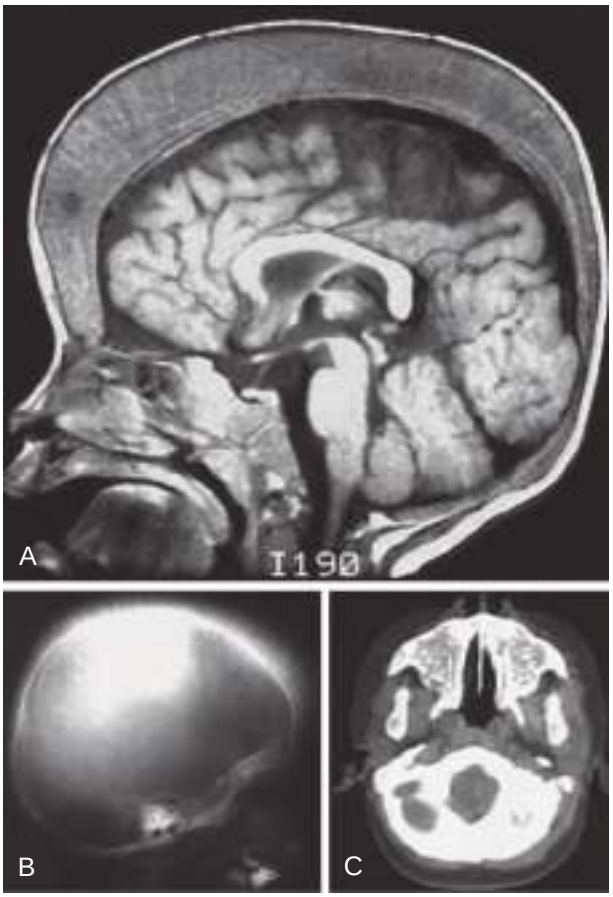

Fig. 511.7 Ineffective erythropoiesis in a 3-yr-old patient who has β-thalassemia major and has not received a transfusion. **A,** Massive widening of the diploic spaces of the skull as seen on MRI. **B,** Radiographic appearance of the trabeculae as seen on plain radiograph. **C,** Obliteration of the maxillary sinuses with hematopoietic tissue as seen on CT scan.

Guidelines for Transfusion Therapy. Patients who require transfusion therapy should have an extended RBC phenotype and/or genotype. Patients should receive RBCs depleted of leukocytes and matched for D, C, c, E, e, and Kell antigens at a minimum. Cytomegalovirus-safe units are indicated in stem cell transplantation candidates. Transfusions should generally be given at intervals of 3-4 weeks, with the goal being to maintain a pretransfusion Hb level of 9.5-10.5 g/dL. Ongoing monitoring for transfusion-associated transmitted infections (hepatitis A, B, and C, HIV), alloimmunization, annual blood transfusion requirements, and transfusion reactions is essential.

Iron Overload Monitoring

Excessive iron stores from transfusion cause many of the complications of β-thalassemia major. Accurate assessment of excessive iron stores is essential to optimal therapy. Serial serum ferritin levels provide a useful screening technique in assessing iron balance trends, but results may not accurately predict quantitative iron stores. Undertreatment or overtreatment of presumed excessive iron stores can occur in managing a patient based on serum ferritin alone. Quantitative measurements of liver iron and cardiac iron by MRI are standard noninvasive methods to assess tissue iron overload; estimation of pancreatic and gonadal iron is being studied. This technology, along with access to multiple chelators, enables targeted chelation therapy for patients with organ-specific hemosiderosis before the onset of overt organ failure. Integration of these imaging technologies with chelation therapy may prevent heart failure, diabetes, and other organ dysfunction.

Quantitative liver iron by approved R2 or R2* MRI is the best indicator of total body iron stores and should be obtained in patients after chronic transfusion therapy has been initiated. The liver iron results will help guide the chelation regimen. Cardiac iron estimation by T2* MRI, is usually obtained starting at 10 years old, but should be obtained earlier in the setting of severe iron overload or if the transfusion and chelation history is not known. There may be a discrepancy between the liver iron and the heart iron because of different rates of tissue loading and unloading and the differential effects of iron chelators on organ-specific iron removal.

Chelation Therapy

Iron-chelation therapy should start as soon as the patient becomes significantly iron-overloaded. In general, this occurs after 1 year of transfusion therapy and correlates with the serum ferritin >1,000 ng/mL and/or a liver iron concentration of >5,000 μg/g dry weight. Iron chelation is not currently labeled for use in children <2 years.

There are three available iron chelators (deferoxamine, deferasirox, and deferiprone); each varies in its route of administration, pharmacokinetics, adverse events, and efficacy (Table 511.8). Combination chelation therapy may be required for high iron burden. The overall goal is to prevent hemosiderosis-induced tissue injury and avoid chelation toxicity. This requires close monitoring of the patients. In general, chelation toxicity increases as iron stores decrease.

Deferoxamine (Desferal) is the most studied iron chelator; it has an excellent safety and efficacy profile. It requires subcutaneous or IV administration because of its poor oral bioavailability and short half-life of <30 minutes, necessitating administration as a continuous infusion over at least 8 hours daily, 5-7 days/week. Deferoxamine is initially started at 25 mg/kg and can be increased to 60 mg/kg in heavily iron-overloaded patients. The major problem with deferoxamine is poor adherence because of the difficult, time-consuming route of administration. Adverse side effects include local skin reactions, ototoxicity, retinal changes, and bone dysplasia with truncal shortening. Maintaining the therapeutic index (deferoxamine dose in mg/kg divided by the serum ferritin) below 0.025 limits these adverse effects.

The *oral* iron chelator **deferasirox** is commercially available in the United States. Of patients treated with deferoxamine, 70% have switched to deferasirox because it is orally available. Deferasirox has a half-life of >16 hours and requires once-daily administration. The drug was initially available as a dispersible tablet that is dissolved in water or juice. Subsequently, a film coated tablet that is swallowed whole and a granule form that is sprinkled on soft food and ingested became available. Dosing is different for the different deferasirox formulations. For the dispersible tablet form, the initial dose typically is 20 mg/kg/day and can be escalated to as high as 40 mg/kg/day based on the iron burden. The dosing for the film-coated tablet and granule forms is 30% lower than the dispersible tablet, with a starting dose of 14 mg/kg/day, which can be escalated to a maximum of 28 mg/kg/day. The most common side effects are GI symptoms, which may be lessened with the film-coated tablet and granule formulations because they do not contain lactose and sodium laureate, which are found in the dispersible tablet and are thought to be responsible for some of the GI symptoms. The most serious side effect of deferasirox is potential kidney damage. Up to 30% of patients have transient increases in creatinine that may require temporary modifications of dosing. This toxicity may occur more commonly in the setting of dehydration. Proteinuria also can develop and, less commonly, a renal Fanconi syndrome may occur. Long-term studies in thousands of patients have not demonstrated progressive renal dysfunction, but isolated cases of renal failure in patients have occurred. In addition, hepatic transaminitis may occur, with an increase to >5 times the upper limit of normal in approximately 8% of patients. All patients require monthly chemistry panels and ongoing monitoring for proteinuria.

Deferiprone, an oral iron chelator, is approved in the United States for use in individuals with transfusional iron overload 3 years and older. Deferiprone has a half-life of approximately 3 hours and requires dosing 3 times daily; a new longer-acting tablet form is available that is

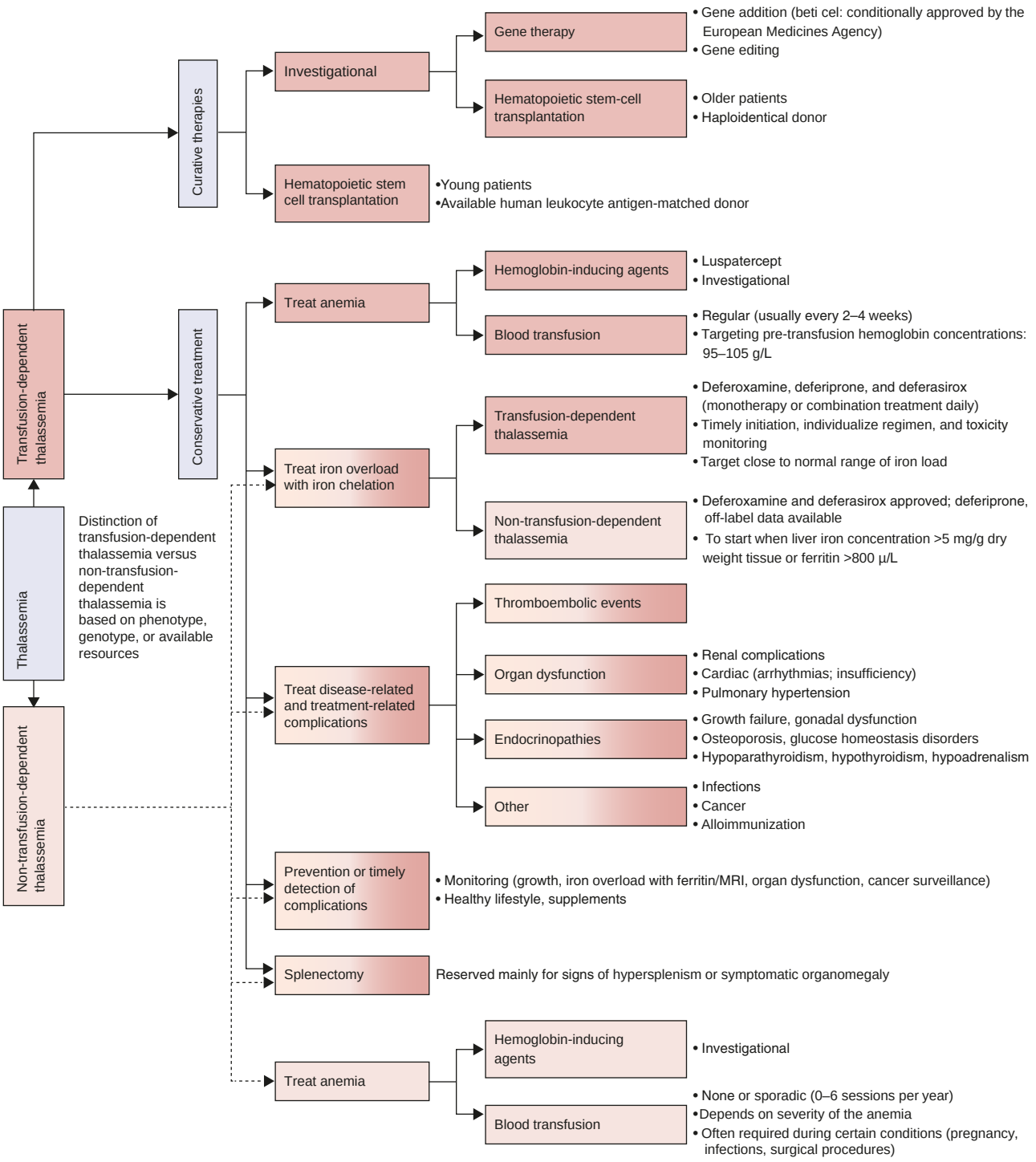

Fig. 511.8 Algorithm for the therapeutic management of thalassemia. *(From Kattamis A, Kwiatkowski JL, Aydinok Y. Thalassemia. Lancet. 2022;399:2310–2322; Fig. 3.)*

dosed twice daily. The starting dose is 75 mg/kg/day and can be escalated to 99 mg/kg/day based on the degree of iron overload. Deferiprone, a small molecule, effectively enters cardiac tissue and may be more effective than other chelators in reducing cardiac hemosiderosis. The most serious side effect of deferiprone is transient agranulocytosis, which occurs in 1-2% of patients and usually in the first year of treatment. It has been associated with rare deaths where patients were not adequately monitored. The use of deferiprone requires frequent CBC monitoring, typically weekly for at least the first 6 months of therapy. Most importantly, the drug should be held and the neutrophil count checked immediately with all febrile illnesses.

As thalassemia patients live longer, the iron chelation goals have changed. Aggressive treatment with combination chelation therapy is often used in heavily iron-overloaded patients to prevent or reverse organ dysfunction. Deferoxamine, in combination with deferiprone, is routinely used in patients with increased cardiac iron. Combination therapy of deferoxamine and deferasirox or with deferasirox and deferiprone may also be efficacious in patients with severe iron overload.

Luspatercept

Luspatercept is a recombinant fusion protein that binds TGFβ family ligands and thus blocks a signaling pathway involved in ineffective

Table 511.8 Properties of Iron Chelators

	DEFEROXAMINE	DEFERASIROX	DEFERIPRONE
Prototype trade name	Desferal	Exjade; Jadenu	Ferriprox
Route of administration	Subcutaneous; intravenous	Oral dispersible tablet; film-coated tablet; granules	Oral solution; oral tablet (3 times per day); oral tablet (twice per day)
Usual dose	Standard, 25–40 mg/kg per day over 8–12 h; low cardiac T2* or heart failure, 50–60 mg/kg per day over 12–24 h	Oral dispersible tablet, 20–40 mg/kg per day once daily; film-coated tablet and granules, 14–28 mg/kg per day once daily	75–100 mg/kg per day divided into 3 doses (oral solution or oral tablet, 3 times per day); 75–100 mg/kg per day divided into 2 doses (oral tablet, twice per day)
Excretion	Urinary (60%), defecation (40%)	Defecation (~90%)	Urinary (~75–90%)
Ability to remove liver iron	High	High	Moderate*
Ability to remove cardiac iron	Moderate†	Moderate‡	High
Adverse events	Local reactions, auditory, ophthalmologic, allergic reactions, bone defects, Yersinia or Klebsiella infections; high doses: pulmonary, neurologic, renal failure	Gastrointestinal, rash, renal impairment (increase in creatinine, proteinuria, proximal renal tubular dysfunction, renal insufficiency), elevated hepatic enzymes, gastrointestinal bleeding or ulcers, hepatic failure, auditory, ophthalmologic	Gastrointestinal, elevated hepatic enzymes, arthropathy, neutropenia or agranulocytosis
EU licensure	Licensed	Patients age 6 years and older with transfusion-dependent thalassemia; patients age 10 years and older with non-transfusion-dependent thalassemia (as a first-line treatment); patients age 2 years and older with transfusion-dependent thalassemia (as a second-line treatment)	Patients with thalassemia major when current chelation therapy is contraindicated or inadequate
USA licensure	Licensed	Patients age 2 years and older with transfusion-dependent thalassemia; patients age 10 years and older with nontransfusion-dependent thalassemia	Patients age 8 years and older with transfusional iron overload and thalassemia syndromes

*Reports of insufficient liver iron removal in some patients at doses of 75 mg/kg per day, but higher dosages, especially for patients with high transfusional iron burden, might be more effective.
†With continuous infusion.
‡Limited data show faster cardiac iron removal with modest hepatic iron loading, but this removal might be less effective in patients with more severe hepatic siderosis.
From Kattamis A, Kwiatkowski JL, Aydinok Y. Thalassemia. Lancet 2022;399:2310–2322; Table 1.

erythropoiesis and results in improved erythroid maturation. The drug is given by subcutaneous injection every 3 weeks at a starting dose of 1 mg/kg/dose, which can be escalated to 1.25 mg/kg/dose if no response after 6 weeks of treatment. In patients with transfusion-dependent β-thalassemia, use of luspatercept was associated with a reduction in RBC requirements in about 70% of treated patients. Luspatercept is approved by the FDA for use in adults with transfusion-dependent β-thalassemia. Adverse effects include bone pain, arthralgia, dizziness, hypertension, and hyperuricemia. The drug also is being studied in nontransfusion dependent thalassemia, where a 1 to 1.5 g/dL rise in hemoglobin has been seen.

Hydroxyurea

Hydroxyurea, a DNA antimetabolite, increases HbF production. It has been most successfully used in sickle cell disease and in some patients with β-thalassemia intermedia. Studies in β-thalassemia major are limited. In many parts of the world, hydroxyurea therapy is used in β-thalassemia intermedia patients. Even though increases in HbF levels are observed, they do not predictively correlate with increase in total Hb in these patients. In general, there appears to be a mean increase in Hb of 1 g/dL (range: 0.1-2.5 g/dL). Hydroxyurea therapy in thalassemia intermedia is associated with a reduced risk of leg ulcers, pulmonary hypertension, and extramedullary hematopoiesis. The initial starting dose for thalassemia intermedia is 10 mg/kg and may be escalated to 20 mg/kg/day. Patients with β-thalassemia are at increased risk of developing cytopenias with hydroxyurea use, which may prevent dose escalation. Close monitoring of the CBC with differential is required.

Hematopoietic Stem Cell Transplantation and Gene Therapy

Hematopoietic stem cell transplantation has cured >3,000 patients who had β-thalassemia major. In low-risk HLA-matched sibling patients, there is at least a 90% survival and an 80% event-free survival. In general, myeloablative conditioning regimens have been used to prevent graft rejection and thalassemia recurrence. Most success has been in children <14 years old without excessive iron stores and hepatomegaly who undergo sibling HLA-matched allogeneic transplantation. All children who have an HLA-matched sibling should be offered the option of bone marrow transplantation. Outcomes of hematopoietic stem cell transplantation with a matched *unrelated donor* using molecular techniques for HLA typing have significantly improved, approaching outcomes with matched sibling donors, but with an increased risk of graft versus host disease. Alternative transplantation regimens for patients without appropriate donors are experimental and have variable success.

Gene therapy using gene addition or gene editing approaches are FDA approved for transfusion-dependent patients with β-thalassemia. Results with gene addition using lentiviral vectors containing a functional β-globin gene have been promising. **Betibeglogene autotemcel** is a rare gene-based, FDA- approved therapy for adults and pediatric patients (≥4 years) with transfusion dependent β-thalassemia. This one-time therapy transduces harvested autologous CD34+ cells with a replicant incompetent vector containing a modified β-globin gene. Approximately 90% of treated patients achieve transfusion independence.

A second approved approach to gene therapy involves gene editing to increase hemoglobin F levels. The first patient treated with transfusion-dependent thalassemia treated with a CRISPR-Cas9 gene editing approach was able to discontinue RBC transfusions while maintaining a normal hemoglobin level, mostly consisting of HbF. This gene approach is indicated for transfusion-dependent β-thalassemia patients ≥12 years of age.

Splenectomy

Splenectomy may be required in thalassemia patients who develop hypersplenism. These patients have a falling steady-state Hb level and/or a rising transfusion requirement. However, splenectomy is less frequently used as a therapeutic option; serious adverse effects of splenectomy are increasingly recognized beyond infection risk. In thalassemia intermedia, splenectomized patients have a marked increased risk of venous thrombosis, pulmonary hypertension, leg ulcers, and silent cerebral infarction compared to nonsplenectomized patients. All patients should be fully immunized against encapsulated bacteria and receive appropriate instructions regarding fever management. Prophylactic penicillin should be administered after splenectomy to prevent sepsis, and families need to be educated on the risk of fever and sepsis.

Preventive Monitoring of Thalassemia Patients

See Table 511.9.

Cardiac Disease

Cardiac disease is the major cause of death in thalassemia. Serial echocardiograms should be monitored to evaluate cardiac function and pulmonary artery pressure. Pulmonary hypertension frequently occurs in nontransfusion dependent thalassemia patients and may be an indication for transfusion therapy. After approximately 8 years of chronic transfusion therapy, cardiac hemosiderosis may occur; consequently, cardiac T2* MRI imaging studies are recommended, typically beginning at 10 years of age. Patients with cardiac hemosiderosis and decreasing cardiac ejection fraction require intensive combination chelation therapy. Periodic electrocardiogram studies also are obtained after age 10 years because of the risk of arrhythmia from cardiac iron overload.

Endocrine Disease

Endocrine function progressively declines with age secondary to hemosiderosis and nutritional deficiencies. Iron deposition in the pituitary and endocrine organs can result in multiple endocrinopathies, including hypothyroidism, growth hormone deficiency, delayed puberty, hypoparathyroidism, diabetes mellitus, osteoporosis, and adrenal insufficiency. Monitoring for endocrine dysfunction starts early, about 5 years of age, or after at least 3 years of chronic transfusions. All children require monitoring of their height, weight, pubertal assessment, and sitting height semiannually. Bone density scans should be obtained starting in the second decade of life given the high rate of osteopenia. Nutritional assessments are required. Most patients need vitamin D, vitamin C, and zinc replacement. Fertility is a growing concern among patients and should be assessed routinely.

Psychosocial Support

Thalassemia imposes major disruption in the family unit and significant obstacles to normal development. Culturally sensitive anticipatory counseling is necessary, and the early use of child life services decreases psychologic trauma of therapy. Early social service consultation to address financial and social issues is mandatory.

Table 511.9 Risk Factors of Thalassemia Comorbidities

CARDIOVASCULAR	
Left ventricle dysfunction	Anemia; cardiac iron overload
Pulmonary hypertension	Chronic hypoxia; splenectomy hypercoagulability; advanced age; nontransfusion-dependent thalassemia
Arrhythmia	Anemia; cardiac iron overload; thyroid disturbances
Thromboembolic events	Splenectomy; hypercoagulability; iron-induced endothelial damage
HEPATOBILIARY	
Viral hepatitis	Red cell transfusions
Fibrosis or cirrhosis	Liver iron overload
Gallstones	Chronic hemolysis
ENDOCRINOPATHIES	
Growth retardation; delayed puberty; hypogonadism	Pituitary iron deposition (thyroid hormone, hypothalamus-pituitary-gonadal axis, growth hormone-insulin like growth factor disturbances); nutrition; anemia
Glucose intolerance; diabetes	Liver iron overload; pancreatic iron deposition; family predisposition
Thyroid dysfunction	Anemia; thyroid iron deposition; hypopituitarism
Adrenal insufficiency	Anemia; adrenal iron deposition; hypopituitarism
Bone disease	Ineffective erythropoiesis, iron predisposition and chelator toxicity; hypogonadism; hypoparathyroidism
NEOPLASIA	
Hepatocellular carcinoma	Chronic hepatitis B or hepatitis C virus infections; liver iron overload
Thyroid cancer; renal cancer; gastrointestinal cancer; breast cancer; hematologic malignancies	Iron toxicity; chronic anemia; advanced age
OTHER	
Renal dysfunction; tubular dysfunction; nephrolithiasis	Anemia; renal iron deposition; and chelator (especially deferasirox) toxicity
Extramedullary hematopoiesis	Ineffective erythropoiesis
Leg ulcers	Anemia; hypercoagulability
Auditory disturbances	Chelator toxicity
Ophthalmologic disturbances	Chelator toxicity
Infectious complications	Splenic dysfunction; transfusion-related infections; iron overload; use of iron chelation therapy (especially deferoxamine)
Spleen (splenomegaly, hypersplenism)	Ineffective erythropoiesis; extramedullary hematopoiesis

From Kattamis A, Kwiatkowski JL, Aydinok Y. *Thalassemia*. Lancet 2022;399:2310–2322. Table 2.

OTHER β-THALASSEMIA SYNDROMES

Non–Transfusion-Dependent Thalassemia: β-Thalassemia Intermedia

Non–transfusion-dependent thalassemia (thalassemia intermedia) includes a spectrum of patients who initially are not chronically transfused in infancy but may be sporadically transfused throughout their lifetime. The major determining characteristic of these patients is less α-β–globin chain imbalance than observed in thalassemia major. Sometimes, genetic modifiers alter the primary pathogenic variant severity and improve the globin-chain imbalance. Co-inheritance of α-thalassemia trait or polymorphisms of globin promoters such as BCL11A may lessen disease severity and result in a nontransfusion dependent thalassemia. HbE β-thalassemia is a common cause of both transfusion-dependent and non–transfusion-dependent thalassemia. These secondary

genetic modifiers play a role in altering the severity of this disorder. Occasionally, patients with a single β-thalassemia pathogenic variant or autosomal dominant β-thalassemia trait have clinical features of thalassemia intermedia, or non–transfusion-dependent thalassemia. Genetic studies of these patients often uncover co-inheritance of genetic modifiers that worsens the condition, such as α-gene triplication or an unstable β-globin variant.

Individuals with thalassemia intermedia have significant ineffective erythropoiesis that leads to microcytic anemia with hemoglobin of approximately 7 g/dL (range: 6-10 g/dL). These patients have some of the complications characterized in untransfused thalassemia major patients, but the severity varies depending on the degree of ineffective erythropoiesis. They can develop medullary hyperplasia, hepatosplenomegaly, hematopoietic pseudotumors, pulmonary hypertension, leg ulcers, thrombotic events, and growth failure. Many patients develop hemosiderosis secondary to increased GI absorption of iron requiring chelation. Extramedullary hematopoiesis can occur in the vertebral canal, compressing the spinal cord and causing neurologic symptoms; the latter is a medical emergency requiring immediate local radiation therapy to halt erythropoiesis. Transfusions are indicated in thalassemia intermedia patients with significant clinical morbidity.

Thalassemia trait is often misdiagnosed as iron deficiency in children because the two diagnoses produce similar hematologic abnormalities on CBC. However, *iron deficiency is much more prevalent.* A short course of iron and reevaluation is all that is required to identify children who will need further evaluation. Children who have β-thalassemia trait have a persistently normal RBC distribution width and low mean corpuscular volume (MCV), whereas patients with iron deficiency develop an elevated red cell distribution width (RDW) with treatment. On Hb analysis, patients with β-thalassemia trait have elevated levels of HbA_2 and variably increased HbF. There are "silent" forms of β-thalassemia trait, and if the family history is suggestive, further studies may be indicated.

α-THALASSEMIA SYNDROMES

The same evolutionary pressures that produced β-thalassemia and sickle cell disease produced α-thalassemia. Infants are identified in the newborn period by the increased production of hemoglobin Bart's (γ_4) during fetal life and its presence at birth. The α-thalassemia syndromes occur most frequently in Southeast Asia. Deletions are most common in α-thalassemia. In addition to deletional pathogenic variants, there are nondeletional α-globin gene pathogenic variants, the most common being Constant Spring ($\alpha^{CS}\alpha$); these variants cause a more severe anemia and clinical course than the deletional variants. Normally, there are four α-globin genes. The different phenotypes in α-thalassemia largely result from whether one (α^+-thalassemia) or both (α^0-thalassemia) α-globin genes are deleted in each of the two loci.

The deletion of one α-globin gene (silent carrier) is not identifiable hematologically. Specifically, no alterations are noted in the MCV and mean corpuscular hemoglobin (MCH). Persons with this deletion are usually diagnosed after the birth of a child with a two-gene deletion or HbH (β_4), but some newborn screening programs report even low concentrations of Hb Bart's. During the newborn period, <3% Hb Bart's is observed. The deletion of one α-globin gene is common in Black persons.

The deletion of two α-globin genes results in α-thalassemia trait. The α-globin alleles can be lost in a *trans* (–α/–α) or *cis* ($\alpha,\alpha/^{-SEA}$) configuration. The *trans* or *cis* pathogenic variants can combine with other pathogenic variants or deletions and lead to HbH or α-thalassemia major. In persons from Africa or of African descent, the most common α-globin deletions are in the *trans* configuration, whereas in persons from or descended from Asia or the Mediterranean region, *cis* deletions are most common.

α-**Thalassemia trait** (two missing α-globin genes) manifests as a microcytic anemia that can be mistaken for iron-deficiency anemia (see Fig. 511.5F). The Hb analysis is normal, except during the newborn period, when Hb Bart's is typically <8% but >3%. Children with a deletion of two α-globin genes are commonly mistaken to have iron deficiency, given the presence of both low MCV and MCH. The simplest approach to distinguish between iron deficiency and α-thalassemia trait is with a good dietary history. Children with iron-deficiency anemia often have a diet that is low in iron and drink a significant amount of cow's milk. Alternatively, a brief course of iron supplementation along with monitoring of erythrocyte parameters might confirm the diagnosis of iron deficiency. If both parents of a child diagnosed with α-thalassemia trait are carriers in the *cis* conformation, they are at risk for a future hydrops fetalis pregnancy. Thus family screening and genetic counseling are indicated.

The deletion of three α-globin genes leads to the diagnosis of HbH disease. A more severe form of HbH disease may be caused by a nondeletional α-globin pathogenic variant in combination with two gene deletions. HbH Constant Spring ($-\alpha/\alpha,\alpha^{CS}$) is the most common type of nondeletional HbH disease.

In California, where a large population of persons of Asian descent resides, approximately 1:10,000 of all newborns have HbH disease. The simplest manner of diagnosing HbH disease is during the newborn period, when excess in γ-tetramers are present and Hb Bart's is commonly >25%. Obtaining supporting evidence from the parents is helpful. Later in childhood, there is an excess of β-globin chain tetramers that results in HbH. A definitive diagnosis of HbH disease requires DNA analysis. Brilliant cresyl blue can stain HbH, but it is rarely used for diagnosis. Patients with HbH disease have a marked microcytosis, anemia, mild splenomegaly, and, occasionally, scleral icterus or cholelithiasis. Chronic transfusion is not usually required for therapy because the Hb range is 7-11 g/dL, with MCV 51-73 fL, but intermittent transfusions for worsening anemia, particularly in the setting of acute infection, may be needed. Individuals with nondeletional HbH disease are more likely to require transfusions than individuals with deletional HbH disease.

The deletion of all four α-globin gene alleles causes profound anemia during fetal life, resulting in **hydrops fetalis**; the ζ-globin gene must be present for fetal survival. There are no normal hemoglobins present at birth (primarily Hb Bart's, with Hb Gower-1, Gower-2, and Portland). Intrauterine transfusions may rescue the fetus, but congenital abnormalities and neurodevelopmental delay often result. Infants with severe α-thalassemia will have lifelong transfusion dependence, and hematopoietic stem cell transplantation is the only cure.

Treatment of HbH disease requires ongoing monitoring of growth and organ dysfunction. Dietary supplement with folate and multivitamins without iron is indicated. Older patients may develop decreased bone density with calcium and vitamin D deficiency. Vitamin D supplementation is indicated if the level is low, and adequate dietary calcium intake should be encouraged to promote bone health. Iron supplementation should be avoided as patients are at risk of developing iron overload. Intermittent transfusion requirements during intercurrent infection may occur, particularly in nondeletional HbH. Splenectomy is occasionally indicated, and because of the high risk of postsplenectomy thrombosis, aspirin or other anticoagulant therapy after splenectomy should be considered. Hemosiderosis, secondary to GI iron absorption or transfusion exposure, may develop in older patients and require chelation therapy. Because HbH is an unstable hemoglobin sensitive to oxidative injury, oxidative medications should be avoided. At-risk couples for hydrops fetalis should be identified and offered molecular diagnosis on fetal tissue obtained early in pregnancy. Later in pregnancy, intrauterine transfusion can improve fetal survival, but chronic transfusion therapy or bone marrow transplantation for survivors will be required.

Visit Elsevier eBooks+ at eBooks.Health.Elsevier.com for Bibliography.

Chapter 512
Enzymatic Defects

512.1 Pyruvate Kinase Deficiency

Allison S. Remiker and Amanda M. Brandow

Congenital nonspherocytic hemolytic anemia occurs in persons homozygous or compound heterozygous for autosomal recessive genes that cause either a marked reduction in red blood cell (RBC) pyruvate kinase (PK) or production of an abnormal enzyme with decreased catalytic activity resulting in impaired conversion of phosphoenolpyruvate to pyruvate. Generation of adenosine triphosphate (ATP) within RBCs at this step is impaired, and low levels of ATP, pyruvate, and the oxidized form of nicotinamide adenine dinucleotide (NAD^+) are found (Fig. 512.1). The concentration of 2,3-diphosphoglycerate is increased; this isomer is beneficial in facilitating oxygen release from hemoglobin but detrimental in inhibiting hexokinase and enzymes of the hexose monophosphate shunt. This decrease of hemoglobin oxygen affinity leads to a rightward shift of the hemoglobin-oxygen dissociation curve and therefore improved oxygen delivery manifesting as tolerance of anemia more than expected for the degree of severity. In addition, an unexplained decrease occurs in the sum of the adenine (ATP, adenosine diphosphate, and adenosine monophosphate) and pyridine (NAD^+ and reduced form of NAD) nucleotides, further impairing glycolysis. Because of decreased ATP, RBCs cannot maintain their potassium and water content; the cells become rigid, and their life span is considerably reduced with precipitous destruction in the liver and/or spleen. This is more pronounced in reticulocytes, which require higher levels of ATP.

ETIOLOGY

There are two mammalian PK genes, but only the *PKLR* gene is expressed in RBCs. More than 300 pathogenic variants are reported in this structural gene, which codes for a 574–amino acid protein that forms a functional tetramer. There is some correlation of the type, location, and amino acid substitution with disease severity. The majority of patients have at least one missense pathogenic variant. Most affected patients are compound heterozygotes for two different PK gene defects. The many possible combinations likely account for the variability in clinical severity. The pathogenic variants 1456 C to T and 1529 G to A are the most common pathogenic variants in the White population.

CLINICAL MANIFESTATIONS AND LABORATORY FINDINGS

The clinical manifestations of **PK deficiency** vary from severe neonatal hemolytic anemia to mild, well-compensated hemolysis first noted in adulthood (Table 512.1). Perinatal complications include premature birth, prenatal anemia or fetal hydrops requiring transfusions, and preterm labor. Severe hyperbilirubinemia, anemia, and, in rare cases, hepatic failure may occur in the neonatal period, and kernicterus has been reported. The hemolysis in older children and adults varies in severity, with hemoglobin values ranging from 2-14 g/dL in various reports and associated pallor, jaundice, scleral icterus, splenomegaly, bone deformities due to extramedullary hematopoiesis, and hyperpigmentation. Reticulocyte counts are often extremely elevated, reflecting the severe ongoing hemolysis. Associated serum chemistries consistent with nonimmune hemolytic anemia are present, including an elevated indirect bilirubin, decreased haptoglobin, increased lactate dehydrogenase (LDH), negative direct antiglobulin test (DAT), and

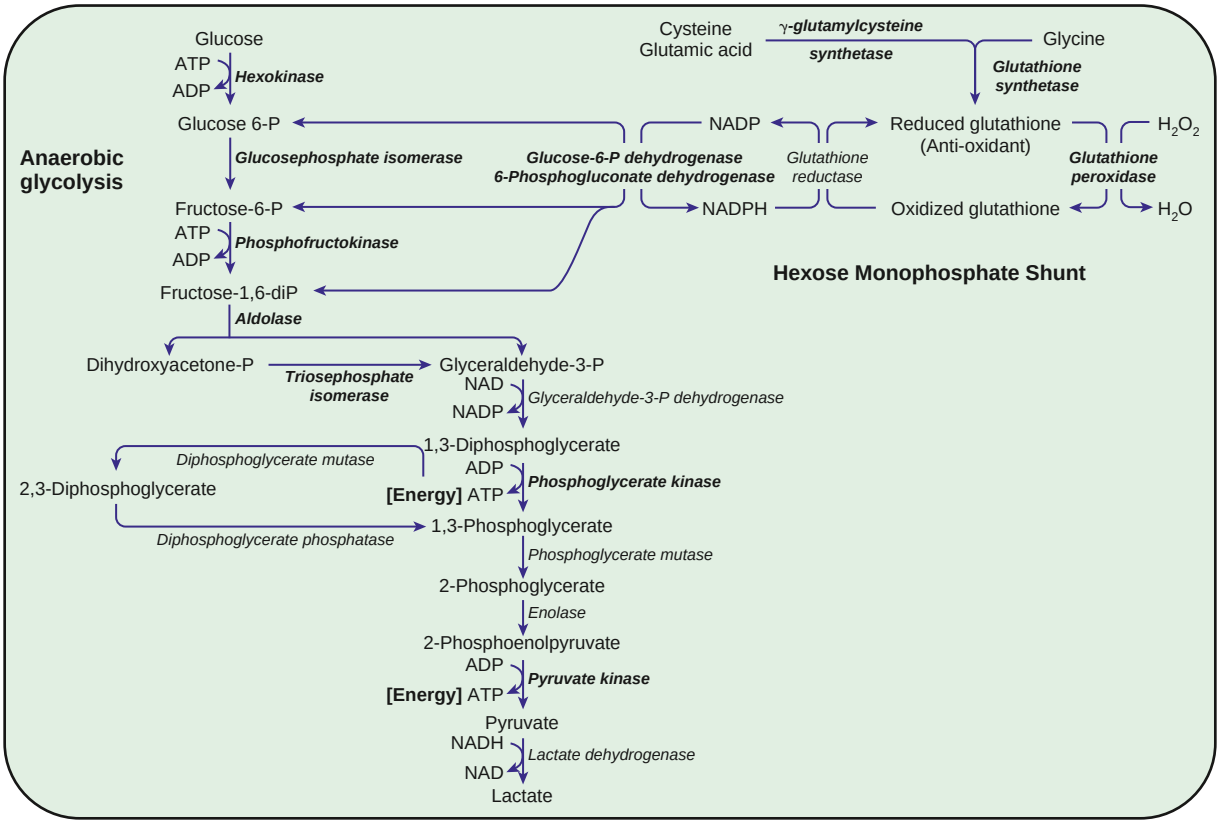

Fig. 512.1 Red blood cell metabolism: glycolysis and hexose monophosphate pathway. The enzyme deficiencies clearly associated with hemolysis are shown in **bold**. ATP, Adenosine triphosphate; ADP, adenosine diphosphate; NADP, nicotinamide adenine dinucleotide phosphate; NADPH, reduced form of NADP.

Table 512.1 Hexokinase Variants Associated with Hemolytic Anemia

CLINICAL FEATURES			PROPERTIES OF RBC HEXOKINASE			
INHERITANCE	ANEMIA	OTHER	ACTIVITY	KINETIC ABNORMALITIES	STABILITY	MOBILITY
—	+	Congenital malformations	13-24*	0	—	—
Recessive	++		15-20*	+	Normal	Abnormal
Recessive	++		16*	0	—	Abnormal
Recessive	+++	Hydrops fetalis	17			
Recessive	+		20*	0	Normal	Normal
Recessive	++	Low platelet and fibroblast HK activity	20*	0	Low	Normal
Recessive	++	Low platelet HK activity	25*	+	Normal	Abnormal
Recessive	+		25*	0	Low	Normal
Dominant	+	Spherocytes, ovalocytes	30*	0	Low	Normal
Recessive	+	Developmental and cognitive delays	45†	+	Normal	Normal
Recessive	+		50*	0	Normal	Normal
—	+	Congenital malformations	33*	+	—	—
Recessive	+		40-53*	+	Low	Normal
—	+		50*	+	—	—
			53			
Dominant	+		45-91†	+	Normal	Abnormal
Dominant	++	WBC HK activity low	75*	+	Normal	Abnormal
Recessive	±		77†			

*Maximal enzyme activity (V_{max}) compared to reticulocytosis controls.
†Maximal enzyme activity (V_{max}) compared to normal red cells.
HK, Hexokinase; RBC, red blood cell; WBC, white blood cell.
From Orkin SH, Fisher DE, Ginsburg D, et al., eds. *Nathan and Oski's Hematology and Oncology of Infancy and Childhood.* 8th ed. Philadelphia: Elsevier, 2015: 583; Table 17.2.

negative indirect antiglobulin test. A severe form of the disease has a relatively high incidence among the Amish of the Midwestern United States (homozygous splicing pathogenic variant R479H). PK deficiency may possibly provide protection against falciparum malaria. There are long-term effects of chronic hemolysis, including folate deficiency, skin ulcers, gallstones, increased risk of bone fractures, and risk of transient bone marrow aplasia associated with certain viral infections.

Polychromatophilia and **mild macrocytosis** reflect the elevated reticulocyte count. Spherocytes are uncommon, but a few spiculated pyknocytes may be found. Diagnosis relies on demonstration of a marked reduction of RBC PK activity or an increase in the Michaelis-Menten dissociation constant (K_m) for its substrate, phosphoenolpyruvate (high K_m variant). Other RBC enzyme activity is normal or elevated, reflecting the reticulocytosis. No abnormalities of hemoglobin are noted. The white blood cells (WBCs) and platelets have normal PK activity and must be rigorously excluded from the RBC hemolysates used to measure PK activity. Fructose 1,6-disphosphate (FDP) must also be removed because it is an allosteric activator of PK. Heterozygous carriers usually have moderately reduced levels of PK activity. Molecular testing provides additional evidence for the disease. However, due to genotype-phenotype variability with unclear pathogenicity regarding variants, it is recommended to perform initial biochemical testing.

TREATMENT

Intrauterine RBC transfusions are performed in the setting of severe anemia associated with fetal hydrops. Phototherapy and exchange transfusions may be indicated for hyperbilirubinemia in newborns. Transfusions of packed RBCs are necessary for severe anemia or for aplastic crises. If the anemia is consistently severe and frequent transfusions are required, iron chelation may be necessary. Splenectomy should be considered after the child is 5-6 years of age to decrease the need for transfusions and minimize iron overload. Although not curative, splenectomy may be followed by higher Hb levels and by strikingly high (30–60%) reticulocyte counts. Death resulting from overwhelming pneumococcal sepsis has followed splenectomy; thus immunization with vaccines for encapsulated organisms should be given before splenectomy and prophylactic penicillin administered after the procedure. Splenectomy has also been associated with thrombosis and pulmonary hypertension. There is currently no standard curative therapy, although the role of gene therapy and hematopoietic cell transplant are actively being investigated. An oral allosteric PK activator (mitapivat) is being studied in clinical trials involving adults and is under review by the US Food and Drug Administration (FDA). The natural history of the disease is limited and is currently being studied through an international registry.

512.2 Other Glycolytic Enzyme Deficiencies

Allison S. Remiker and Amanda M. Brandow

Chronic nonspherocytic hemolytic anemias of varying severity have been associated with deficiencies of other enzymes in the glycolytic pathway, including hexokinase, glucose phosphate isomerase, and aldolase, which are inherited as autosomal recessive disorders. **Phosphofructokinase deficiency,** which occurs primarily in Ashkenazi Jews in the United States, results in hemolysis associated with a myopathy classified as **glycogen storage disease type VII** (see Chapter 107.1). Clinically, hemolytic anemia is complicated by

muscle weakness, exercise intolerance, cramps, and myoglobinuria. Erythrocyte production is increased to compensate for hemolysis. Enzyme assays for phosphofructokinase yield low values for RBCs and muscle.

Triose phosphate isomerase deficiency is an autosomal recessive disorder affecting many systems. Affected patients have hemolytic anemia, cardiac abnormalities, and lower motor neuron and pyramidal tract impairment, with or without evidence of cerebral impairment. They usually die in early childhood. The gene for triose phosphate isomerase has been cloned and sequenced and is located on chromosome 12.

Phosphoglycerate kinase (PGK) is the first ATP-generating step in glycolysis. At least 23 kindreds with PGK deficiency have been described. PGK is the only glycolytic enzyme inherited on the X chromosome. PGK is important in erythrocytes, the central nervous system (CNS), and skeletal muscle. The phenotype is quite variable and may affect one isolated tissue or a combination of all three. Affected males may present with dysfunction of the CNS with seizures, intellectual disability, and nonspherocytic hemolytic anemia; hemolytic anemia without CNS involvement; or myopathy, myoglobinuria, and progressive weakness. Some patients present with parkinsonism. Female heterozygotes have been shown to have partial symptoms depending on their degree of enzymatic activity, including signs of hemolysis. The gene for PGK is particularly large, spanning 23 kb, and various genetic abnormalities, including nucleotide substitutions, gene deletions, missense, and splicing pathogenic variants, result in PGK deficiency.

DEFICIENCIES OF ENZYMES OF HEXOSE MONOPHOSPHATE PATHWAY

The most important function of the hexose monophosphate pathway is to maintain glutathione in its reduced state (GSH) as protection against the oxidation of RBCs (see Fig. 512.1). Approximately 10% of the glucose taken up by RBCs passes through this pathway to provide the reduced form of NAD phosphate (NADPH) necessary for the conversion of oxidized glutathione to GSH. Maintenance of GSH is essential for the physiologic inactivation of oxidant compounds, such as hydrogen peroxide, that are generated within RBCs. If glutathione, or any compound or enzyme necessary for maintaining it in the reduced state, is decreased, the SH groups of the RBC membrane are oxidized, and the Hb becomes denatured and may precipitate into RBC inclusions called **Heinz bodies**. Once Heinz bodies have formed, an acute hemolytic process results from damage to the RBC membrane by the precipitated Hb, the oxidant agent, and the action of the spleen. The damaged RBCs then are rapidly removed from the circulation.

512.3 Glucose-6-Phosphate Dehydrogenase Deficiency and Related Deficiencies

Allison S. Remiker and Amanda M. Brandow

Glucose-6-phosphate dehydrogenase (G6PD) deficiency, the most frequent disease involving enzymes of the hexose monophosphate pathway, is responsible for two clinical syndromes: episodic *acute* hemolytic anemia and *chronic* nonspherocytic hemolytic anemia. The most common manifestations are neonatal jaundice and episodic acute hemolytic anemia, which is induced by infections, certain drugs, and, rarely, fava beans. This X-linked deficiency affects >400 million people worldwide, representing an overall 4.9% global prevalence. The global distribution of this disorder parallels that of malaria, representing an example of "balanced polymorphism," in which there is an evolutionary advantage of resistance to falciparum malaria in heterozygous females that outweighs the small negative effect of affected hemizygous males.

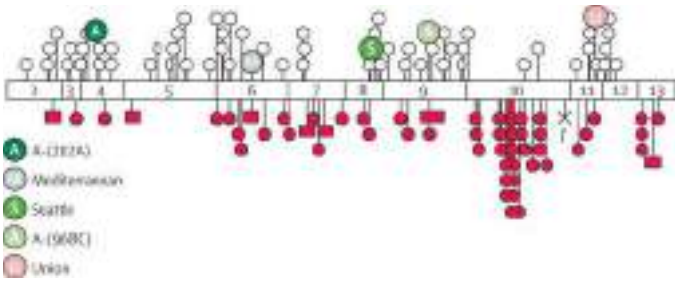

Fig. 512.2 Most common pathogenic variants along coding sequence of *G6PD* gene. Exons are shown as *open numbered boxes*. *Open circles* are pathogenic variants causing classes II and III variants. *Filled circles* represent sporadic pathogenic variants giving rise to severe variants (class I). *Open ellipses* are pathogenic variants causing class IV variants. X is a nonsense pathogenic variant; *f*, a splice site pathogenic variant; *filled squares*, small deletions. 202A and 968C are the two sites of base substitution in G6PD-A. *(From Cappellini MD, Fiorelli G. Glucose-6-phosphate dehydrogenase deficiency. Lancet. 2008;371:64–74.)*

The deficiency is caused by inheritance of any of a large number of abnormal alleles of the gene responsible for the synthesis of the G6PD protein. Over 200 pathogenic variants have been described in the gene responsible for the synthesis of the G6PD protein. Many of these pathogenic variants are missense point pathogenic variants leading to amino acid substitutions and destabilization of the G6PD enzyme. Figure 512.2 shows some of the pathogenic variants that cause episodic versus chronic hemolysis. Milder disease is associated with pathogenic variants near the *amino* terminus of the G6PD molecule, and chronic nonspherocytic hemolytic anemia is associated with pathogenic variants clustered near the *carboxyl* terminus near the G6P and NADP-binding sites. The normal enzyme found in most populations is designated G6PD B+. A normal variant, designated G6PD A+, is common in Americans of African descent.

EPISODIC OR INDUCED ACUTE HEMOLYTIC ANEMIA

Etiology

G6PD catalyzes the conversion of glucose 6-phosphate to 6-phosphogluconic acid. This reaction produces NADPH, which maintains GSH (glutathione in its reduced, functional state; see Fig. 512.1). GSH provides protection against **oxidant threats** from certain drugs and infections that would otherwise cause precipitation of hemoglobin (Heinz bodies) or damage the RBC membrane.

Synthesis of RBC G6PD is determined by a gene on the X chromosome. Thus heterozygous females have intermediate enzymatic activity and have two populations of RBCs: one is normal, and the other is deficient in G6PD activity. Because they have fewer susceptible cells, most heterozygous females do not have clinically evident hemolysis after exposure to oxidant drugs. Rarely, the majority of RBCs is G6PD deficient in heterozygous females because the inactivation of the normal X chromosome is random and sometimes exaggerated.

Disease involving this enzyme therefore occurs more frequently in males than in females. Approximately 13% of male Americans of African descent have a variant enzyme **(G6PD A–)** that results in a deficiency of RBC G6PD activity (5–15% of normal). Italians, Greeks, and other Mediterranean, Middle Eastern, African, and Asian ethnic groups also have a high incidence, ranging from 5–40%, of a variant designated **G6PD B– (G6PD Mediterranean)**. In these variants, the G6PD activity of homozygous females or hemizygous males is <5% of normal. Therefore the defect in Americans of African descent is *less severe* than that in Americans of European descent. A third variant enzyme with greatly reduced activity **(G6PD Canton)** occurs in approximately 5% of the Chinese population.

Clinical Manifestations

Most individuals with G6PD deficiency are asymptomatic, with no clinical manifestations of illness unless triggered by infection, drugs, or ingestion of fava beans. Typically, hemolysis ensues in about 24-96 hours after a patient has ingested a substance with **oxidant properties**. In severe cases, hemoglobinuria and jaundice result, and the Hb concentration may fall precipitously. Drugs that elicit hemolysis in these individuals include fluoroquinolones, methylene blue, sulfonylureas, rasburicase, and antimalarials, such as primaquine and dapsone (Table 512.2). There is mixed evidence regarding the safety data of aspirin and sulfa-containing medications, which are generally thought to be safe. Chemical exposures to henna compounds and naphthalene (e.g., mothballs and deodorant) have also been implicated. The degree of hemolysis varies with the inciting agent, amount ingested, and severity of the enzyme deficiency. In some individuals, ingestion of fava beans also produces an acute, severe hemolytic syndrome, known as **favism**. Fava beans contain divicine, isouramil, and convicine, which ultimately lead to production of hydrogen peroxide and other reactive oxygen products. Favism is thought to be more frequently associated with the G6PD Mediterranean and G6PD Canton variants.

In the G6PD A– variant, the stability of the folded protein dimer is impaired, and this defect is accentuated as the RBCs age. Thus hemolysis decreases as older RBCs are destroyed, even if administration of the drug is continued. This recovery results from the *age-labile enzyme*, which is abundant and more stable in younger RBCs (Fig. 512.3). The associated reticulocytosis produces a compensated hemolytic process in which the blood hemoglobin may be only slightly decreased, despite continued exposure to the offending agent.

G6PD deficiency can produce hemolysis in the neonatal period. In G6PD A–, spontaneous hemolysis and hyperbilirubinemia have been observed in preterm infants. In newborns with the G6PD B– and G6PD Canton varieties, hyperbilirubinemia and even kernicterus may occur. Neonates with co-inheritance of G6PD deficiency and a pathogenic variant of the promoter of uridine-diphosphate-glucuronyl transferase (UGT1A1), seen in **Gilbert syndrome**, have more severe neonatal jaundice. When a pregnant woman ingests oxidant drugs, they may be transmitted to her G6PD-deficient fetus, and hemolytic anemia and jaundice may be apparent at birth. Similarly, medications may be transmitted to a neonate through breast milk.

Laboratory Findings

The onset of acute hemolysis usually results in a precipitous fall in hemoglobin and hematocrit. If the episode is severe, the Hb-binding proteins, such as haptoglobin, are saturated, and free hemoglobin may appear in the plasma and subsequently in the urine. Hemolysis is intravascular and extravascular. Unstained or supravital preparations of RBCs reveal precipitated hemoglobin, or Heinz bodies. The RBC inclusions are not visible on the Wright-stained blood film. Cells that contain these inclusions are seen only within the first 3-4 days of illness because they are rapidly cleared from the blood. Also, the blood film may contain RBCs with what appears to be a bite taken from their periphery ("bite cells") and **polychromasia** (evidence of bluish, larger RBCs), representing reticulocytosis (Fig. 512.4).

Diagnosis

The diagnosis depends on direct or indirect demonstration of reduced G6PD activity in RBCs. By direct measurement, enzyme activity in affected persons is ≤10% of normal, and the reduction of enzyme activity is more extreme in Americans of European descent and in Asians than in Americans of African descent. Satisfactory screening tests are based on decolorization of methylene blue, reduction of methemoglobin, or fluorescence of NADPH. Confirmatory testing is available using quantitative NADPH formation measured spectrophotometrically. Immediately after a hemolytic episode, reticulocytes and young RBCs predominate. These young cells have significantly higher enzyme activity than do older cells in the A– variety (African). *Testing may therefore have to be deferred for a few weeks before a diagnostically low*

Table 512.2 Agents Precipitating Hemolysis in Glucose-6-Phosphate Dehydrogenase Deficiency

DEFINITE RISK OF AHA	"POSSIBLE" RISK OF AHA	POSSIBLE ASSOCIATION (LESS LIKELY)
ANTIMALARIAL DRUGS		
Dapsone	Chloroquine	
Pamaquine	Quinidine	
Primaquine	Quinine	
Tafenoquine		
OTHER DRUGS		
Ciprofloxacin	Aspirin*	Chloramphenicol
Glibenclamide	Menadiol sodium phosphate	Dimercaptosuccinic acid
Methylene blue	Sulfadiazine	Glibenclamide
Moxifloxacin	Sulfasalazine	Mepacrine
Nalidixic acid	Sulfonylureas	Vitamin K analogs
Nitrofurantoin	Tolonium chloride	
Norfloxacin		
Ofloxacin		
Phenazopyridine		
Rasburicase and pegloticase		
Sulfamethoxazole/cotrimoxazole		
Henna (cosmetic use)		

*Hemolysis is dose related. Typical 75 to 100 mg per day, widely used for prophylaxis of cardiovascular events, is safe for G6PD-deficient persons.
AHA, acute hemolytic anemia.
From Luzzatto L, Ally M, Notaro R. Glucose-6-phosphate dehydrogenase deficiency. *Blood*. 2020;136:1225–1240; Table 1.

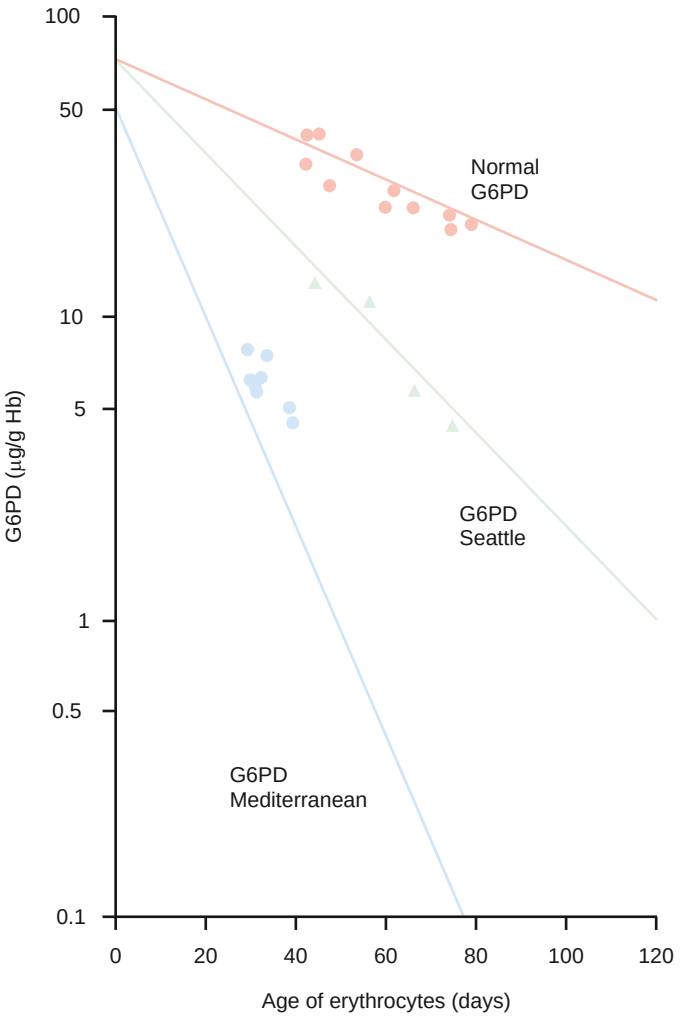

Fig. 512.3 Main mechanism of G6PD of RBCs is in vivo instability of mutant enzyme. For many G6PD variants, such as the two studied here, this is essentially acceleration of a process that takes place normally with the aging of RBCs in the circulation. Hb, Hemoglobin. *(Adapted from Morelli A, Benatti U, Gaetani GF, et al. Biochemical mechanisms of glucose-6-phosphate dehydrogenase deficiency. Proc Natl Acad Sci USA. 1978;75:1979–1983.)*

level of enzyme can be shown. The diagnosis can be suspected when G6PD activity is within the low-normal range in the presence of a high reticulocyte count. G6PD variants also can be detected by electrophoretic and molecular analysis. G6PD deficiency should be considered in any neonatal patients with hyperbilirubinemia and borderline low G6PD activity.

Prevention and Treatment

Prevention of hemolysis constitutes the most important therapeutic measure. When possible, males belonging to ethnic groups with a significant incidence of G6PD deficiency (e.g., Greeks, southern Italians, Sephardic Jews, Filipinos, southern Chinese, Black Americans, Thais) should be tested for the defect before known oxidant drugs are given.

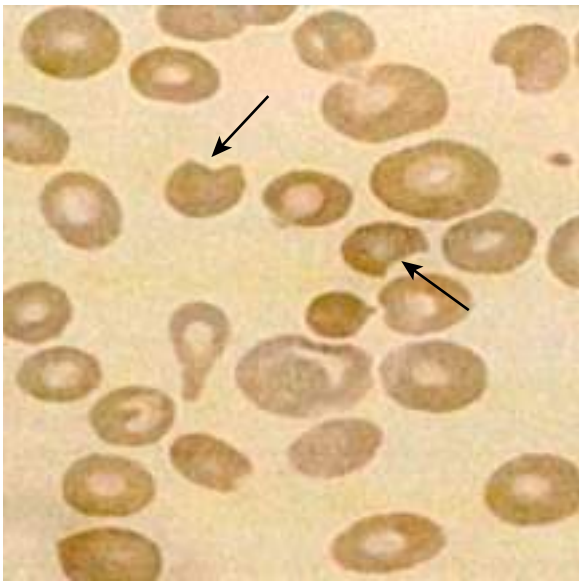

Fig. 512.4 Morphologic erythrocyte changes (anisopoikilocytosis, bite cells) during acute hemolysis in a G6PD-deficient patient. *Arrows* show bite cells. *Anisopoikilocytosis* is abnormality in the shape or size of erythrocytes. *(From Cappellini MD, Fiorelli G. Glucose-6-phosphate dehydrogenase deficiency. Lancet. 2008;371:64–74.)*

The usual doses of aspirin and trimethoprim-sulfamethoxazole do not cause clinically relevant hemolysis in the A– variety. Aspirin administered in doses used for acute rheumatic fever (50-100 mg/kg/24 hr) may produce a severe hemolytic episode. Infants with severe neonatal jaundice who belong to these ethnic groups also require testing for G6PD deficiency because of their heightened risk for this defect. If severe hemolysis has occurred, supportive therapy may require blood transfusions, although recovery is the rule when the oxidant agent is discontinued.

CHRONIC HEMOLYTIC ANEMIAS ASSOCIATED WITH DEFICIENCY OF G6PD OR RELATED FACTORS

Chronic **nonspherocytic hemolytic anemia** has been associated with profound deficiency of G6PD caused by enzyme variants, particularly those defective in quantity, activity, or stability. The gene defects leading to chronic hemolysis are located primarily in the region of the NADP-binding site near the carboxyl terminus of the protein (see Fig. 512.2). These include the Loma Linda, Tomah, Iowa, Beverly Hills, Nashville, Riverside, Santiago de Cuba, and Andalus variants. Persons with G6PD B– enzyme deficiency occasionally have chronic hemolysis, and the hemolytic process may worsen after ingestion of oxidant drugs. Splenectomy is of little value in these types of chronic hemolysis.

Other enzyme defects may impair the regeneration of GSH as an oxidant "sump" (see Fig. 512.1). Mild, chronic nonspherocytic anemia has been reported in association with decreased RBC GSH, resulting from γ-glutamylcysteine or GSH synthetase deficiencies. Deficiency of 6-phosphogluconate dehydrogenase has been associated primarily with drug-induced hemolysis, and hemolysis with hyperbilirubinemia has been related to a deficiency of GSH peroxidase in newborn infants.

Visit Elsevier eBooks+ at eBooks.Health.Elsevier.com for Bibliography.

Chapter 513

Hemolytic Anemias Resulting from Extracellular Factors—Immune Hemolytic Anemias

Allison S. Remiker and Amanda M. Brandow

IMMUNE HEMOLYTIC ANEMIAS

A number of extrinsic agents and disorders may lead to premature destruction of red blood cells (RBCs) at a rate where hemolysis exceeds hematopoietic replacement. Among the most clearly defined are antibodies associated with immune hemolytic anemias. The hallmark of this group of diseases is the positive result of the direct antiglobulin **(Coombs)** test (DAT), which detects a coating of immunoglobulin or components of complement on the RBC surface. The most important immune hemolytic disorder in pediatric practice is hemolytic disease of the newborn (erythroblastosis fetalis), caused by transplacental transfer of maternal antibody active against the RBCs of the fetus, that is, isoimmune hemolytic anemia (see Chapter 140).

Various other immune hemolytic anemias are **autoimmune** (Table 513.1). Often, no underlying cause can be found; this is the *primary* or idiopathic type. If the autoimmune hemolysis is associated with an underlying disease, including various infections (Epstein-Barr virus [EBV], rarely HIV, cytomegalovirus, and mycoplasma), autoimmune or inflammatory diseases (autoimmune lymphoproliferative disease [ALPS], systemic lupus erythematosus [SLE], rheumatoid arthritis, type 1 diabetes mellitus, ulcerative colitis), primary immunodeficiency diseases (common variable immunodeficiency [CVID], Wiskott-Aldrich syndrome), neoplasms (lymphoproliferative, solid tumors), or posttransplant (solid organ or allogeneic stem cell), it is considered *secondary* (Table 513.2). As many as 20% of episodes of autoimmune hemolysis are drug-induced (e.g.,

Table 513.1 Diseases Characterized by Immune-Mediated Red Blood Cell Destruction

AUTOIMMUNE HEMOLYTIC ANEMIA CAUSED BY WARM-REACTIVE AUTOANTIBODIES
Primary (idiopathic)
Secondary
Lymphoproliferative disorders
Connective tissue disorders (especially systemic lupus erythematosus)
Nonlymphoid neoplasms (e.g., ovarian tumors)
Chronic inflammatory diseases (e.g., ulcerative colitis)
Immunodeficiency disorders
AUTOIMMUNE HEMOLYTIC ANEMIA CAUSED BY COLD-REACTIVE AUTOANTIBODIES (CRYOPATHIC HEMOLYTIC SYNDROMES)
Primary (idiopathic) cold agglutinin disease
Secondary cold agglutinin disease
Lymphoproliferative disorders
Infections (*Mycoplasma pneumoniae*, Epstein-Barr virus)
Paroxysmal cold hemoglobinuria
Primary (idiopathic)
Viral syndromes (most common)
Congenital or tertiary syphilis
DRUG-INDUCED IMMUNE HEMOLYTIC ANEMIA (SEE TABLE 513.2)
Hapten/drug adsorption (e.g., penicillin)
Ternary (immune) complex (e.g., quinine, quinidine)
True autoantibody induction (e.g., methyldopa)

Adapted from Packman CH. Autoimmune hemolytic anemias. In Rakel R (ed). *Conn's Current Therapy*. Philadelphia: Saunders, 1995: 305.

Table 513.2 Secondary Etiologies Causing Autoimmune Cytopenias in Children

DISEASES ASSOCIATED WITH AUTOIMMUNE CYTOPENIAS IN CHILDREN
Lymphoproliferative Disorders
Autoimmune lymphoproliferative syndrome (ALPS)*
Rosai-Dorfman disease
Castleman disease
Ras-associated leukoproliferative disorder
Immune Deficiencies
Common variable immune deficiency (CVID)*
Selective IgA deficiency
Chromosome 22q11.2 deletion (DiGeorge or velocardiofacial syndrome)
Severe combined immunodeficiency syndromes
IPEX syndrome
Rheumatologic Conditions
Systemic lupus erythematosus (SLE)*
Antiphospholipid antibody syndrome*
Juvenile idiopathic arthritis
Sjögren syndrome
Sarcoid
Malignancies
Non-Hodgkin lymphoma
Acute lymphoblastic leukemia
Myelodysplastic syndrome
Hodgkin lymphoma
Chronic Infections
EBV
HIV**
Helicobacter pylori
CMV
HCV
Other
Celiac disease
Inflammatory bowel disease
RECOMMENDED EVALUATION FOR CHILDREN WITH CHRONIC SINGLE LINEAGE AUTOIMMUNE CYTOPENIAS OR MULTI-LINEAGE AUTOIMMUNE CYTOPENIAS*
Flow cytometry for double negative T cells (ALPS)
ANA (SLE)
Anti-phospholipid antibodies
Quantitative immunoglobulins (CVID)
Specific antibody titers (CVID)
T cells subsets (CD3/CD4, CD3/CD8)
Ferritin
HIV**
FOXP3 testing (IPEX)
Exome or specific gene panels

*Consider screening for these conditions in children with chronic single lineage autoimmune cytopenias or multi-lineage autoimmune cytopenias.

**Consider also screening for HIV in adolescents with chronic single lineage or multi-lineage autoimmune cytopenias. Other diseases should be considered if the history or physical are suggestive of the underlying condition. It is extremely rare for the other conditions to present with autoimmune cytopenias and no other signs or symptoms suggestive of the underlying disease. Thus, the utility of routine screening is low.

EBV, Epstein-Barr virus; CMV, cytomegalovirus; HCV, hepatitis C virus; ANA, antinuclear antibody; IPEX, immune dysregulation, polyendocrinopathy, enteropathy X-linked.

Modified from Teachey DT, Lambert MP. Diagnosis and management of autoimmune cytopenias in childhood. *Pediatr Clin North Am*. 2013;60:1489–1511; Table 2.

methyldopa, L-dopa, checkpoint inhibitors). Other drugs (penicillins, cephalosporins) cause hemolysis by means of "drug-dependent antibodies"—antibodies directed toward the drug and in some cases toward an RBC membrane antigen as well.

Etiology

Autoimmune hemolytic anemia (AIHA) is caused by the production of anti-RBC autoantibodies generated by tissue and self-reactive B lymphocytes circulating in the periphery supported by T helper lymphocytes. The complement system induces sequential activation of the membrane attack complex (MAC) leading to erythrocyte lysis typically in the liver and circulation. RBCs are opsonized by the autoantibodies or complement then phagocytosed primarily in the spleen and lymph tissue. Antibody-dependent cell-mediated cytotoxicity (ADCC) induced by cytotoxic $CD8^+$ T lymphocytes and natural killer (NK) cells are an additional important mechanism contributing to AIHA also predominantly in lymphoid organs and the spleen.

The underlying cause of autoimmunity is loss of central self-tolerance in the early stages of lymphocyte differentiation, as well as loss of peripheral self-tolerance driven by Tregs and $CD8^+$ suppressor T lymphocytes. Loss of tolerance allows for autoreactive cells to avoid negative selection, and/or suppression of autoantibodies fails to occur appropriately in the periphery. It is theorized patients who develop AIHA have an underlying predisposition to losing such self-tolerance, which is stimulated by environmental factors.

The autoantibody may be produced as an inappropriate immune response to an RBC antigen or to another antigenic epitope similar to an RBC antigen, known as *molecular mimicry.* Alternatively, an infectious agent may alter the RBC membrane so that it becomes "foreign" or antigenic to the host.

The autoantibodies that form in AIHA have antibody class, antigenic reactivity, and thermal characteristics associated with binding and/or destroying erythrocytes. The temperature predilection is associated with corresponding nomenclature, including warm (wAIHA), cold (cold agglutinin disease [CAD]), paroxysmal cold hemoglobinuria (PCH), and rare mixed forms.

AUTOIMMUNE HEMOLYTIC ANEMIAS ASSOCIATED WITH "WARM" ANTIBODIES

Etiology

Warm autoimmune hemolytic anemia (wAIHA) is the most common form in children found in as many as 90% of cases. Autoantibodies are "warm-reactive" meaning they preferentially bind to erythrocytes at 37°C. Extravascular hemolysis occurs in the spleen. Typically, the antibodies are immunoglobulin (Ig) G, and react to epitopes (antigens) that are "public" or common to all human RBCs, such as Rh proteins. When IgG is present in exceptional quantity, it can fix complement, which results in intravascular hemolysis.

Clinical Manifestations

Patients with wAIHA present with symptoms consistent with anemia and nonspecific signs of hemolysis. Onset may be acute, with pallor, jaundice, icterus, hemoglobinuria, abdominal pain, fever, shortness of breath, and dizziness, or more gradual with primarily fatigue and pallor. Cardiovascular compromise is rare. The spleen is usually enlarged and is the primary site of destruction of IgG-coated RBCs.

Laboratory Findings

In many cases, anemia is profound with hemoglobin (Hb) levels <6 g/dL. Considerable spherocytosis and polychromasia (reflecting the reticulocyte response) are present. More than 50% of the circulating RBCs may be reticulocytes, and nucleated RBCs usually are present. In some cases, a *low reticulocyte count* may be found, particularly early in the episode due to similar epitopes on RBC precursors in the marrow, marrow suppression if there is concurrent infection, and/or a "shocked" marrow after a severe hemolytic event. Leukocytosis is common. The platelet count is usually normal, but concomitant immune thrombocytopenic purpura sometimes occurs (**Evans syndrome**). Patients with Evans syndrome often have or eventually develop a chronic disease, including SLE, an immunodeficiency syndrome (common variable immunodeficiency), or autoimmune lymphoproliferative syndrome.

Results of the **DAT (Coombs test)** are strongly positive, and free antibody can sometimes be demonstrated in the serum **(indirect Coombs test)**. These antibodies are active at 35–40°C (95–104°F) ("warm" antibodies) and most often belong to the IgG class. They do not require complement for activity. Antibodies from the serum and those eluted from the RBCs react with the RBCs of many persons in addition to those of the patient. They often have been regarded as nonspecific panagglutinins, but careful studies have revealed specificity for RBC antigens of the Rh system in 70% of patients (50% of adult patients). Complement, particularly fragments of C3b, may be detected on the RBCs in conjunction with IgG. The Coombs test result is *rarely* negative because of the sensitivity of the Coombs reaction. A minimum of 260-400 molecules of IgG per cell is necessary on the RBC membrane to produce a positive reaction. Special tests are required to detect the antibody in cases of "Coombs-negative" autoimmune hemolytic anemia. In warm antibody hemolytic anemia, the direct Coombs test may detect IgG alone, both IgG and complement fragments, or solely complement fragments if the level of RBC-bound IgG is below the detection limit of the anti-IgG Coombs reagent.

Treatment

Transfusions may provide only transient benefit but may be lifesaving in cases of severe anemia until the effects of other treatments are observed. All tested units for transfusion are serologically incompatible. It is important to identify the patient's ABO blood group to avoid a hemolytic transfusion reaction mediated by anti-A or anti-B. The blood bank should also test for the presence of an underlying alloantibody, which could cause rapid hemolysis of transfused RBCs. Patients who have been neither previously transfused nor pregnant are unlikely to harbor an alloantibody. Early consultation between the clinician and the blood bank physician is essential. Failure to transfuse a profoundly anemic infant or child may lead to serious morbidity and even death.

Patients with mild disease and compensated hemolysis may not require treatment. *If the hemolysis is severe and results in significant anemia or symptoms, treatment with glucocorticoids is initiated.* Glucocorticoids decrease the rate of hemolysis by blocking macrophage function through downregulating Fcγ receptor expression, decreasing the production of the autoantibody, and perhaps enhancing the elution of antibody from the RBCs. Initial dosing is dependent on the degree of anemia and symptoms. In patients who present with Hb <6 to 7 g/dL or severe symptoms, initial treatment with intravenous (IV) methylprednisolone 0.5-1 mg/kg every 6 to 8 hours in the first 24-72 hours is typically indicated. With rapid deterioration or severity of anemia, high-dose methylprednisolone 30 mg/kg with maximum 1 g daily for 3 days may be required. When hemolytic anemia remains severe despite glucocorticoid therapy, or if very large doses are necessary to maintain a reasonable Hb level, intravenous immunoglobulin (IVIG) may be tried. Long-term use of IVIG has not been shown to be effective in the majority of children. In children who present with mild to moderate anemia with Hg ≥7 to 8 g/dL and an appropriate reticulocyte count, oral prednisone 2 mg/kg/day may be started. Response is typically seen within 2-4 weeks after initiation of steroids and considered adequate with Hb concentration >9 to 10 g/dL. Hb, reticulocyte count, lactate dehydrogenase, and DAT should be monitored for response. Treatment should be continued until the rate of hemolysis decreases, with the dose then gradually reduced, typically over at least 4 months. The Coombs test result may remain positive even after the Hb level returns to normal. It is usually safe to discontinue prednisone once the direct Coombs test result becomes negative.

The majority of patients (approximately 80%) have an initial response to glucocorticoids within the first month of treatment; however, it is common to require prolonged or multimodal therapies over time. If a patient is unable to taper prednisone effectively within 1-2 months after diagnosis, addition of a second-line therapy should be considered.

Relapse occurs in 15–40% of patients with wAIHA, typically within the first 6-12 months after initial response to treatment. If this occurs, resumption of the lowest dose of prednisone that was effective in treating the patient is recommended. Because of the adverse effects of long-term steroid use, alternative agents could be considered if relapse continues to occur.

There are limited data in second-line therapies for wAIHA in children. **Rituximab**, a monoclonal antibody that targets B lymphocytes, the source of antibody production, *is useful in chronic cases refractory to conventional therapy.* Plasmapheresis has been used in refractory cases but generally is not helpful because most hemolysis is in the extravascular space. Splenectomy may be beneficial but is complicated by a heightened risk of infection with encapsulated organisms, particularly in patients <6 years old. Prophylaxis is indicated with appropriate vaccines (pneumococcal, meningococcal, and *Haemophilus influenzae* type b) before splenectomy and with oral penicillin after splenectomy. Thrombosis and pulmonary hypertension are also increasingly recognized problems after splenectomy. In refractory disease, several immunomodulating agents have been used in small case series or reports including azathioprine, 6-mercaptopurine, cyclosporine, mycophenolate mofetil, tacrolimus, sirolimus, and monoclonal antibodies (e.g., obinutuzumab, daratumumab, alemtuzumab, bortezomib).

Prognosis

Acute idiopathic autoimmune hemolytic disease in childhood varies in severity but is self-limited; death from untreatable anemia is rare. Approximately 30% of patients have chronic hemolysis, often associated with an underlying disease, such as SLE, immunodeficiency, or lymphoma. The presence of antiphospholipid antibodies in adult patients with immune hemolysis predisposes to thrombosis. Mortality in chronic cases depends on the primary disorder.

AUTOIMMUNE HEMOLYTIC ANEMIAS ASSOCIATED WITH "COLD" ANTIBODIES OR COLD AGGLUTININ DISEASE

"Cold" antibodies agglutinate RBCs at temperatures <37°C (98.6°F). They are primarily of the IgM class and require complement for hemolytic activity. The highest temperature at which RBC agglutination occurs is called the thermal amplitude. A higher thermal amplitude antibody—that is, one that can bind to RBCs at temperatures achievable in the body—results in hemolysis with exposure to a cold environment. High antibody titers are associated with high thermal amplitude.

Cold antibodies usually have specificity for the oligosaccharide antigens of the I/i system. They may occur in primary or idiopathic cold agglutinin disease, secondary to infections such as those from *Mycoplasma pneumoniae* and EBV, or secondary to lymphoproliferative disorders. After *M. pneumoniae* infection, the anti-I levels may increase considerably, and occasionally, enormous increases may occur to titers ≥1/30,000. The antibody has specificity for the I antigen and thus reacts poorly with human cord RBCs, which possess the i antigen but exhibit low levels of I. Patients with infectious mononucleosis occasionally have CAD, and the antibodies in these patients often have anti-i specificity. This antibody causes less hemolysis in adults than in children because adults have fewer i molecules on their RBCs. Spontaneous RBC agglutination is observed in the cold and in vitro, and RBC aggregates are seen on the blood film (rouleaux formation). Mean corpuscular volume (MCV) may be spuriously elevated because of RBC agglutination and reticulocytosis. The severity of the hemolysis is related to the thermal amplitude of the antibody, which itself partly depends on the IgM antibody titer.

When very high titers of cold antibodies are present and active near body temperature, severe intravascular hemolysis with hemoglobinemia and hemoglobinuria may occur and may be heightened on a patient's exposure to cold (external temperature or ingested foods). Each IgM molecule has the potential to activate a C1 molecule, so that large amounts of complement are found on the RBCs in CAD. These sensitized RBCs may undergo intravascular complement-mediated lysis or may be destroyed in the liver and spleen. Only complement, not IgM, is detected on RBCs because the IgM is removed during the washing steps of the DAT.

CAD is less common in children than in adults and more frequently results in an acute, self-limited episode of hemolysis. RBC transfusion is indicated based on symptoms and severity of anemia. If transfusion is required, blood should be warmed before administration. Glucocorticoids are much less effective in CAD than in hemolytic disease with warm antibodies. Patients should avoid exposure to cold and should be treated for any underlying disease. In the uncommon patient with severe hemolytic disease, immunosuppression and plasmapheresis can be used. Successful treatment of CAD has been reported with rituximab, which effectively depletes B lymphocytes. Splenectomy is not useful in CAD.

Paroxysmal Cold Hemoglobinuria

Paroxysmal cold hemoglobinuria is mediated by the Donath-Landsteiner (D-L) hemolysin, which is an IgG cold-reactive autoantibody with anti-P specificity. In vitro, the D-L antibody binds to RBCs in the cold, and the RBCs are lysed by complement as the temperature is increased to 37°C. A similar sequence is thought to occur in vivo as RBCs move from the cooler extremities to warmer parts of the circulation. Most reported cases are self-limited; many patients experience only one paroxysm of hemolysis. Congenital or acquired syphilis was once the most common underlying cause of paroxysmal cold hemoglobinuria, but currently, most cases are associated with nonspecific viral infections. Treatment includes transfusion for severe anemia and avoidance of cold ambient temperatures.

Drug-Induced Hemolytic Anemia

Drugs (penicillin or sometimes cephalosporins) that cause hemolysis through the "hapten" mechanism (immune but not autoimmune) bind tightly to the RBC membrane. Antibodies to the drug, either newly or previously formed, bind to the drug molecules on RBCs, mediating their destruction in the spleen. In other cases, certain drugs, such as quinine and quinidine, do not bind to RBCs, but rather form part of a "ternary complex," consisting of the drug, an RBC membrane antigen, and an antibody that recognizes both (see Table 513.3). Methyldopa and sometimes cephalosporins may, by unknown mechanisms, incite true autoantibodies to RBC membrane antigens, so that the presence of the drug is not required to cause hemolysis. Cephalosporins are the most common cause of drug-induced immune hemolytic anemia.

Visit Elsevier eBooks+ at eBooks.Health.Elsevier.com for Bibliography.

Table 513.3 Selected Drugs That Cause Immune-Mediated Hemolysis

MECHANISM	DRUG ADSORPTION (HAPTEN)	TERNARY (IMMUNE) COMPLEX	AUTOANTIBODY INDUCTION
Direct antiglobulin test	Positive (anti-IgG)	Positive (anti-C3)	Positive (anti-IgG)
Site of hemolysis	Extravascular	Intravascular	Extravascular
Medications	Penicillins Cephalosporins 6-Mercaptopurine Tetracycline Oxaliplatin Hydrocortisone	Cephalosporins Quinidine Amphotericin B Hydrocortisone Rifampin (Rifadin) Metformin Quinine Probenecid Chlorpromazine Oxaliplatin	α-Methyldopa Cephalosporins Oxaliplatin L-Dopa Procainamide Ibuprofen Diclofenac (Voltaren) Interferon alfa

Adapted from Packman CH. Hemolytic anemia resulting from immune injury. In Kaushansky K, Lichtman MA, Beutler E, et al, (eds): *Williams Hematology*. 8th ed. New York: McGraw-Hill, 2010.

Chapter 514

Hemolytic Anemias Secondary to Other Extracellular Factors

Allison S. Remiker and Amanda M. Brandow

FRAGMENTATION HEMOLYSIS

See Table 506.2 in Chapter 506.

Red blood cell (RBC) destruction may occur in hemolytic anemias because of **mechanical injury** as the cells traverse a damaged vascular bed. Damage may be microvascular when RBCs are sheared by fibrin in the capillaries during intravascular coagulation or when renovascular disease accompanies the **hemolytic-uremic syndrome (HUS)** (see Chapter 560.5) or **thrombotic thrombocytopenic purpura (TTP)** (see Chapter 533.5). Larger vessels may be involved in **Kasabach-Merritt syndrome** (giant hemangioma and thrombocytopenia; see Chapter 554) or when a replacement heart valve is poorly epithelialized. The blood film shows many *schistocytes,* or fragmented cells, as well as polychromatophilia, reflecting the reticulocytosis (see Fig. 507.4F in Chapter 507 on Castleman disease). Secondary iron deficiency may complicate the intravascular hemolysis because of urinary hemoglobin and hemosiderin iron loss (see Fig. 506.2 in Chapter 506). **Treatment should be directed toward the underlying condition**, and the prognosis depends on the effectiveness of this treatment. The benefit of transfusion may be transient because the transfused cells are destroyed as quickly as those produced by the patient.

It is critical to determine the precise etiology of the fragmentation hemolysis because the treatment depends on the underlying problem (Table 514.1). **Acquired TTP** results from an antibody to an enzyme (ADAMTS13) that regulates the size of von Willebrand multimers. The lack of this enzyme results in a marked increase in multimer size and a resultant *thrombotic microangiopathy*. **Congenital TTP** can result in the inability to produce adequate amounts of the enzyme ADAMTS13 and results in the same pathophysiology. The treatment for acquired TTP involves plasma exchange (PEX) to remove the antibody and replace the ADAMTS13, in addition to immunosuppressive therapy with glucocorticoids. Treatment should be initiated as soon as possible when there is a high index of suspicion, even before confirmation of the diagnosis because of high morbidity and mortality. Once diagnosis has been confirmed, rituximab is suggested. Use of caplacizumab, an anti-von Willebrand factor monoclonal antibody, is used in adult patients with severe disease, although it has not been approved by the US Food and Drug Administration (FDA) in children. The treatment for congenital TTP involves scheduled plasma infusions to replace the ADAMTS13. Recombinant ADAMTS13 is under investigation for use in acquired and congenital TTP. In contrast, HUS results from *Shiga* toxin produced by *Escherichia coli* 0157 and may not be helped by plasmapheresis, and treatment is largely based on supportive measures. **Atypical HUS** involves activation of the alternative complement pathway and can be treated with *eculizumab* (anti-C5), an inhibitor of the complement pathway. Plasmapheresis may reduce the RBC fragmentation and improve the platelet count but has little effect on the tissue (kidney) vasculopathy, and thus is not usually recommended. **Pneumococcal-induced HUS** results from neuraminidase produced by the bacteria, which damages the membranes of the RBCs and the kidney, exposing the **T-antigen**. Plasma contains natural antibody to the T-antigen, producing hemolysis, renal damage, and a thrombotic microangiopathy. Thus, patients with T-antigen activation from suspected pneumococcal-induced HUS should not be given plasma infusions because this will significantly exacerbate the RBC hemolysis and can lead to life-threatening anemia.

THERMAL INJURY

Extensive burns may directly damage the RBCs and cause hemolysis that results in the formation of *spherocytes.* Blood loss and marrow suppression may contribute to anemia and require blood transfusion. Erythropoietin (EPO) has been used as treatment for diminished RBC production. There may be a role of early use of propranolol, which has been shown to restore erythrocyte progenitors.

Table 514.1 Thrombotic Microangiopathies

DISEASE*	PATHOPHYSIOLOGY	LAB FINDINGS	MANAGEMENT
Thrombotic thrombocytopenic purpura (TTP)	*Acquired:* Ab to ADAMTS13 *Congenital:* Inadequate ADAMTS13 production	Ab to ADAMTS13 ADAMTS13 <10%	*Acquired:* Plasma exchange (PEX) Glucocorticoids +/- Rituximab *Congenital:* Scheduled plasma infusions, recombinant ADAMTS13
Hemolytic-uremic syndrome (HUS)	*Escherichia coli* 0157, *Shiga* toxin	*E. coli* 0157, *Shiga* toxin	Supportive ? Value of plasmapheresis
Atypical HUS	Complement-mediated alternative pathway	ADAMTS13 >10% Decreased factors H and I (inhibitors of complement)†	Eculizumab (Ab to C5) Plasmapheresis not indicated
Pneumococcal-induced HUS	Neuraminidase-induced RBC, platelet, and kidney damage Exposure of T-antigen on RBC and kidney	Pneumococcal infection ADAMTS13 >10%	Plasmapheresis with albumin for neuraminidase and endogenous T Ab removal Avoid plasma infusions, which will exacerbate RBC hemolysis
Disseminated intravascular coagulation (DIC)	Sepsis, shock, endotoxin	Decreased fibrinogen, increased fibrin split products, decreased clotting factors and platelets	Treat underlying condition; replace factors and platelets if bleeding

*All show fragmentation hemolytic anemia, thrombocytopenia, and potential renal and other organ damage. An elevated lactate dehydrogenase and reduced haptoglobin usually are present secondary to hemolysis.
†May be related to inherited defect in factor H or I.
Ab, Antibody; RBC, red blood cell.

RENAL DISEASE

The anemia of uremia is multifactorial in origin. EPO production may be decreased, and the marrow suppressed by toxic metabolites. Furthermore, the RBC life span often is shortened because of retention of metabolites and organic acidemia. The use of EPO in chronic renal disease can decrease the need for blood transfusion. Abnormalities in the hepcidin-ferroportin pathway provide an additional pathway contributing to anemia associated with chronic kidney disease. Investigative use of medications targeting this pathway are being evaluated in patients. Hemodialysis is also implicated in causing fragmentation of erythrocytes.

LIVER DISEASE

A change in the ratio of cholesterol to phospholipids in the plasma may result in changes in the composition of the RBC membrane and shortening of the RBC life span. Some patients with liver disease have many target RBCs on the blood film, whereas others have a preponderance of *spiculated cells.* These morphologic changes reflect the alterations in the plasma lipid composition.

TOXINS AND VENOMS

Bacterial sepsis caused by *Haemophilus influenzae,* staphylococci, or streptococci may be complicated by accompanying hemolysis. Particularly severe hemolytic anemia has been observed in clostridial infections and results from a hemolytic clostridial toxin. Large numbers of spherocytes may be seen on the blood film. **Spherocytic hemolysis** also may be noted after bites by various snakes, including cobras, vipers, and rattlesnakes, which have phospholipases in their venom. Large numbers of bites by insects, such as bees, wasps, and yellow jackets, also may cause spherocytic hemolysis by a similar mechanism (see Chapter 768).

WILSON DISEASE

See Chapter 405.2.

An acute and self-limited episode of hemolytic anemia may precede by years the onset of hepatic or neurologic symptoms in Wilson disease. This event appears to result from the toxic effects of free copper on the RBC membrane. The blood film often (but not always) shows large numbers of spherocytes, and the Coombs test result is negative. Because early diagnosis of Wilson disease permits prophylactic treatment with penicillamine and prevention of hepatic and neurologic disease, correct assessment of this rare type of hemolysis is important.

Visit Elsevier eBooks+ at eBooks.Health.Elsevier.com for Bibliography.

Section 4

Polycythemia (Erythrocytosis)

Chapter 515

Polycythemia

Allison S. Remiker and Amanda M. Brandow

Polycythemia exists when the hemoglobin concentration and/or hematocrit and total red blood cell (RBC) volume exceed the upper limits of normal in peripheral blood. In postpubertal individuals, an RBC mass >25% above the mean normal value (based on body surface area) or a hemoglobin level >16.5 g/dL (in males) or >16.0 g/dL (in females) and/or hematocrit >49% (in males) or >48% (in females) indicate **absolute erythrocytosis**. A decrease in plasma volume, such as occurs in acute dehydration and burns, may result in a high hemoglobin value. These situations are more accurately designated as **hemoconcentration** or **relative polycythemia** because the RBC mass is not increased, and normalization of the plasma volume restores hemoglobin to normal levels. Once the diagnosis of true polycythemia is made, sequential studies should be done to determine the underlying etiology (Fig. 515.1).

CLONAL POLYCYTHEMIA (POLYCYTHEMIA VERA)

Pathogenesis

Polycythemia vera is an acquired clonal myeloproliferative neoplastic disorder, which is rare in children and adolescents. The median age of diagnosis is >60 years. Although primarily manifesting as erythrocytosis, thrombocytosis and leukocytosis can also be seen. When isolated severe thrombocytosis exists in the absence of erythrocytosis, the myeloproliferative disorder is called **essential thrombocythemia**. A gain-of-function pathogenic variant involving exon 12 or 14 (V617F) of *JAK2,* a cytoplasmic tyrosine kinase, is found in >90% of adult patients with polycythemia vera, but in <30% of children with this condition. The erythropoietin receptor is normal, and serum erythropoietin levels are low. Patients without *JAK* pathogenic variants may have variants in the calreticulin or thrombopoietin receptor genes. Risk factors for development of polycythemia vera include a family history of polycythemia vera and presence of an autoimmune disorder.

Clinical Manifestations

Patients with polycythemia vera usually have splenomegaly. Erythrocytosis may cause hypertension, headache, early satiety, or neurologic symptoms and increases the risk of thrombosis. Granulocytosis may cause diarrhea or pruritus from histamine release. Thrombocytosis (with or without platelet dysfunction) may cause thrombosis or hemorrhage. Bleeding or acquired von Willebrand disease with extreme thrombocytosis, and complications of pregnancy may occur. Long-term effects include progression to myelofibrosis, myelodysplasia, and/or acute leukemia. These events are rare in children. Table 515.1 lists the diagnostic criteria for polycythemia vera.

Treatment

Phlebotomy and low-dose aspirin are the initial treatments of choice to alleviate symptoms of hyperviscosity and decrease the risk of thrombosis. Iron supplementation should be given to prevent viscosity problems from iron-deficient microcytosis or thrombocytosis. If these treatments are unsuccessful, the patient has progressive splenomegaly, thrombocytosis, or leukocytosis, or has high-risk features (i.e., age >60 or history of thrombosis), antiproliferative treatments (hydroxyurea, pegylated interferon, or busulfan) may be helpful. The use of ruxolitinib (a JAK2 inhibitor) is approved in hydroxyurea-resistant or hydroxyurea-intolerant adult patients, but the long-term effectiveness remains under investigation. There are limited data in the treatment of children, given the rarity of the condition. Often only phlebotomy is required. Transformation of the disease into myelofibrosis or acute leukemia is rare in children.

Visit Elsevier eBooks+ at eBooks.Health.Elsevier.com for Bibliography.

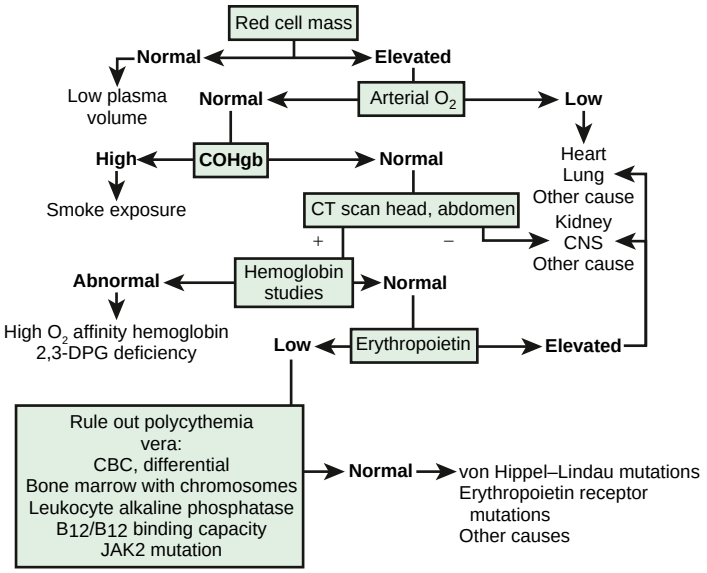

Fig. 515.1 Algorithm showing sequential studies in the evaluation of polycythemia. CBC, Complete blood count; CNS, central nervous system; COHgb, carboxyhemoglobin; 2,3-DPG, 2,3-diphosphoglycerate.

Table 515.1 World Health Organization (WHO) Diagnostic Criteria for Polycythemia Vera

MAJOR CRITERIA
1. Hb >16.5 g/dL (males) or Hb >16.0 g/dL (females)
or
Hct >49% (males) or >48% (females)
or
Elevated red cell mass >25% above mean normal predicted value
2. Bone marrow (BM) biopsy showing hypercellularity for age with trilineage growth (panmyelosis) including prominent erythroid, granulocytic, and megakaryocytic proliferation with pleomorphic mature megakaryocytes (difference in sizes)
3. Presence of *JAK2* or JAK2 exon 12 mutation
MINOR CRITERIA
1. Subnormal serum erythropoietin level
DIAGNOSIS
All three major criteria
or
First two major criteria and the minor criterion*

*Criterion number 2 (BM biopsy) may not be required in cases with sustained absolute erythrocytosis: hemoglobin levels >18.5 g/dL in males (hematocrit, 55.5%) or 16.5 g/dL in females (hematocrit >49.5%) if major criterion 3 and the minor criterion are present. However, initial myelofibrosis (present in up to 20% of patients) can only be detected by performing a BM biopsy; this finding may predict a more rapid progression to overt myelofibrosis (post-PV MF).

Hb, Hemoglobin; Hct, hematocrit.

Modified from Arber DA, Orazi A, Hasserjian R, et al. The 2016 revision to the World Health Organization classification of myeloid neoplasms and acute leukemia. *Blood.* 2016;127: 2391–405.

Table 516.1 Differential Diagnosis of Polycythemia

CLONAL (PRIMARY)
Polycythemia vera
NONCLONAL
Congenital
High–oxygen affinity hemoglobinopathy (e.g., hemoglobin Chesapeake, Malmo, San Diego)
Erythropoietin receptor mutations (primary familial and congenital polycythemia [PFCP])
Methemoglobin reductase deficiency
Hemoglobin M disease
2,3-Diphosphoglycerate deficiency
Acquired
Hormonal
Adrenal disease: virilizing hyperplasia, Cushing syndrome
Athletic performance enhancing substances (e.g., anabolic steroids, androgens, recombinant erythropoiesis stimulating agents)
Malignant tumors: adrenal, cerebellar, hepatic, other
Renal disease: cysts, hydronephrosis, renal artery stenosis
Hypoxia
Altitude
Cardiac disease
Lung disease
Sleep apnea
Central hypoventilation
Chronic carbon monoxide exposure including smoking
Neonatal: delayed cord clamping (placental-fetal transfusion)
Normal intrauterine environment
Placental insufficiency (preeclampsia, maternal chronic hypertension, placental abruption)
Twin-twin or maternal-fetal hemorrhage
Perinatal asphyxia
Infants of diabetic mothers
Intrauterine growth restriction
Trisomy 13, 18, or 21
Adrenal hyperplasia
Maternal-congenital hyperthyroidism
Spurious
Plasma volume decrease

Chapter 516

Nonclonal Polycythemia

Allison S. Remiker and Amanda M. Brandow

PATHOGENESIS

Nonclonal polycythemia is diagnosed when polycythemia is caused by a physiologic process that is not derived from a single cell (Table 516.1). Nonclonal polycythemia can be congenital or acquired (secondary).

Congenital Polycythemia

Lifelong or familial polycythemia should trigger a search for a congenital problem. These inherited conditions may be transmitted as dominant or recessive disorders instigating erythrocytosis

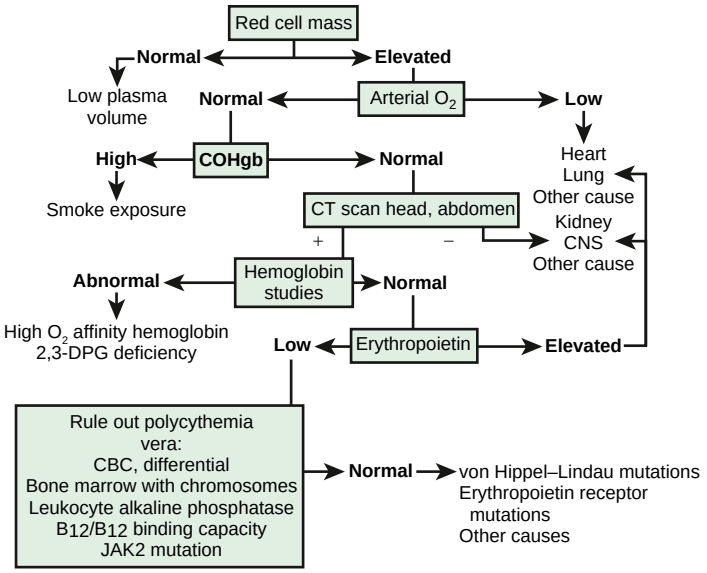

Fig. 515.1 Algorithm showing sequential studies in the evaluation of polycythemia. CBC, Complete blood count; CNS, central nervous system; COHgb, carboxyhemoglobin; 2,3-DPG, 2,3-diphosphoglycerate.

Table 515.1 World Health Organization (WHO) Diagnostic Criteria for Polycythemia Vera

MAJOR CRITERIA
1. Hb >16.5 g/dL (males) or Hb >16.0 g/dL (females)
or
Hct >49% (males) or >48% (females)
or
Elevated red cell mass >25% above mean normal predicted value
2. Bone marrow (BM) biopsy showing hypercellularity for age with trilineage growth (panmyelosis) including prominent erythroid, granulocytic, and megakaryocytic proliferation with pleomorphic mature megakaryocytes (difference in sizes)
3. Presence of *JAK2* or JAK2 exon 12 mutation
MINOR CRITERIA
1. Subnormal serum erythropoietin level
DIAGNOSIS
All three major criteria
or
First two major criteria and the minor criterion*

*Criterion number 2 (BM biopsy) may not be required in cases with sustained absolute erythrocytosis: hemoglobin levels >18.5 g/dL in males (hematocrit, 55.5%) or 16.5 g/dL in females (hematocrit >49.5%) if major criterion 3 and the minor criterion are present. However, initial myelofibrosis (present in up to 20% of patients) can only be detected by performing a BM biopsy; this finding may predict a more rapid progression to overt myelofibrosis (post-PV MF).

Hb, Hemoglobin; Hct, hematocrit.

Modified from Arber DA, Orazi A, Hasserjian R, et al. The 2016 revision to the World Health Organization classification of myeloid neoplasms and acute leukemia. *Blood.* 2016;127: 2391–405.

Table 516.1 Differential Diagnosis of Polycythemia

CLONAL (PRIMARY)
Polycythemia vera
NONCLONAL
Congenital
High–oxygen affinity hemoglobinopathy (e.g., hemoglobin Chesapeake, Malmo, San Diego)
Erythropoietin receptor mutations (primary familial and congenital polycythemia [PFCP])
Methemoglobin reductase deficiency
Hemoglobin M disease
2,3-Diphosphoglycerate deficiency
Acquired
Hormonal
Adrenal disease: virilizing hyperplasia, Cushing syndrome
Athletic performance enhancing substances (e.g., anabolic steroids, androgens, recombinant erythropoiesis stimulating agents)
Malignant tumors: adrenal, cerebellar, hepatic, other
Renal disease: cysts, hydronephrosis, renal artery stenosis
Hypoxia
Altitude
Cardiac disease
Lung disease
Sleep apnea
Central hypoventilation
Chronic carbon monoxide exposure including smoking
Neonatal: delayed cord clamping (placental-fetal transfusion)
Normal intrauterine environment
Placental insufficiency (preeclampsia, maternal chronic hypertension, placental abruption)
Twin-twin or maternal-fetal hemorrhage
Perinatal asphyxia
Infants of diabetic mothers
Intrauterine growth restriction
Trisomy 13, 18, or 21
Adrenal hyperplasia
Maternal-congenital hyperthyroidism
Spurious
Plasma volume decrease

Chapter 516

Nonclonal Polycythemia

Allison S. Remiker and Amanda M. Brandow

PATHOGENESIS

Nonclonal polycythemia is diagnosed when polycythemia is caused by a physiologic process that is not derived from a single cell (Table 516.1). Nonclonal polycythemia can be congenital or acquired (secondary).

Congenital Polycythemia

Lifelong or familial polycythemia should trigger a search for a congenital problem. These inherited conditions may be transmitted as dominant or recessive disorders instigating erythrocytosis

by augmenting hypoxia sensing or abnormalities in oxygen sensing. Autosomal dominant causes include hemoglobins that have increased oxygen affinity (P_{50} [partial pressure of oxygen in the blood at which the hemoglobin is 50% saturated] <20 mm Hg), erythropoietin receptor pathogenic variants resulting in an enhanced effect of erythropoietin, or variants in the von Hippel–Lindau *(VHL), EGLN1*, or *EPAS1* genes that result in altered intracellular oxygen sensing. Another rare cause is autosomal recessive 2,3-diphosphoglyceric acid deficiency, which leads to a left shift of the oxygen dissociation curve, increased oxygen affinity, and consequent polycythemia.

Subtle decreases in oxygen delivery to tissues may cause polycythemia. Congenital **methemoglobinemia** resulting from an autosomal recessive deficiency of cytochrome b5 reductase may cause cyanosis and polycythemia (see Chapter 511.7). Most affected individuals are asymptomatic. Neurologic abnormalities may be present in patients whose enzyme deficits are not limited to hematopoietic cells. Hemoglobin M disease (autosomal dominant) causes methemoglobinemia and can lead to polycythemia. Cyanosis may occur in the presence of as little as 1.5 g/dL of methemoglobin but is uncommon in other hemoglobin variants unless hyperviscosity results in localized hypoxemia.

In rare cases, there is an undefined inherited lesion causing primary familial and congenital polycythemia (PFCP), which is described as an elevation of erythrocyte mass and hemoglobin, hypersensitivity to EPO, and low serum EPO in the setting of a normal hemoglobin-oxygen dissociation curve.

Acquired (Secondary) Polycythemia

Polycythemia may be present in clinical situations associated with chronic arterial oxygen desaturation. Cardiovascular defects involving right-to-left shunts and pulmonary diseases interfering with proper oxygenation are the most common causes of hypoxic polycythemia. Clinical findings usually include cyanosis, hyperemia of the sclerae and mucous membranes, and clubbing of the fingers. As the hematocrit rises to >65%, clinical manifestations of hyperviscosity, such as headache and hypertension, may require phlebotomy. Living at high altitudes also causes hypoxic polycythemia; the hemoglobin level increases approximately 4% for each rise of 1,000 m (~3,300 ft) in altitude. Smoking has been associated with polycythemia secondary to tissue hypoxia, elevation of carbon monoxide, and volume contraction. Partial obstruction of a renal artery rarely results in polycythemia. Polycythemia has also been associated with benign and malignant tumors that secrete paraneoplastic erythropoietin. Exogenous or endogenous excess of anabolic steroids also may cause polycythemia. A common spurious cause is a decrease in plasma volume, as occurs in moderate to severe dehydration.

DIAGNOSIS

See Chapter 515; Figure 515.1 outlines sequential studies to evaluate polycythemia.

TREATMENT

For mild disease, observation is sufficient. When the hematocrit is >65–70% (hemoglobin >23 g/dL), blood viscosity greatly increases. Periodic phlebotomy may prevent or decrease symptoms such as headache, dizziness, or exertional dyspnea. Apheresed blood should be replaced with plasma or saline to prevent hypovolemia in patients accustomed to a chronically elevated total blood volume. Increased demand for red blood cell production may cause iron deficiency. Iron-deficient microcytic red cells are more rigid, further increasing the risk of intracranial and other thromboses in patients with polycythemia. Periodic assessment of iron status should be performed, and iron deficiency should be treated.

Visit Elsevier eBooks+ at eBooks.Health.Elsevier.com for Bibliography.

Section 5

The Pancytopenias

Chapter 517

Inherited Bone Marrow Failure Syndromes with Pancytopenia

Yigal Dror and Michaela Cada

Pancytopenia refers to a reduction below normal values of all three peripheral blood lineages: leukocytes, platelets, and erythrocytes. Identifying the etiology of pancytopenia usually requires microscopic examination of the peripheral blood smear, as well as bone marrow biopsy and aspirate specimens to assess overall cellularity and morphology. The three general categories of pancytopenia are related to bone marrow pathologies and can frequently be differentiated based on bone marrow findings.

Pancytopenia with hypocellular bone marrow on biopsy is seen with *inherited bone marrow failure syndromes* (IBMFSs) with pancytopenia, *acquired* aplastic anemia of varied etiologies, and the *hypoplastic* variant of *myelodysplastic syndrome* (MDS). **Pancytopenia with cellular bone marrow** is seen with primary bone marrow disease (e.g., acute leukemia, myelodysplasia) and secondary to autoimmune disorders (e.g., autoimmune lymphoproliferative syndrome, systemic lupus erythematosus), vitamin B_{12} or folate deficiency, storage diseases (e.g., Gaucher, Niemann-Pick), overwhelming infection, sarcoidosis, and hypersplenism. **Pancytopenia with bone marrow infiltration** can be seen in metastatic solid tumors, myelofibrosis, hemophagocytic lymphohistiocytosis, and osteopetrosis. It is important to note that exceptions exist with regard to this classification; IBMFSs can manifest as normocellular or hypercellular bone marrow at early stages of presentation or in cases where MDS develops.

Inherited pancytopenias with hypocellular bone marrow are IBMFSs that feature decreased bone marrow production of the three major hematopoietic lineages occurring on an inherited basis and resulting in anemia, neutropenia, and thrombocytopenia. Patients may have single-lineage or bi-lineage cytopenia at presentation and gradually develop pancytopenia over time. All disorders for which a genetic basis has been deciphered have thus far been shown to be monogenic. Transmission of pathogenic variant genes is mendelian and in an autosomal dominant, autosomal recessive, or X-linked manner (Table 517.1). Modifying genes and acquired factors may also be operative. Inherited pancytopenias account for approximately 30% of cases of pediatric bone marrow failure. Clinical features may help differentiate the IBMFS disorders (Table 517.2), but whole exome sequencing (WES) or specific bone marrow failure syndrome gene panels help to confirm the diagnosis.

FANCONI ANEMIA

Etiology and Epidemiology

Fanconi anemia (FA) is a rare multisystem hereditary disorder resulting in the development of bone marrow failure in those affected and a predisposition to malignancy, including myelodysplasia (MDS), acute myeloid leukemia (AML), and epithelial cancers. Individuals with FA

Table 517.1 Inherited Bone Marrow Failure Syndromes with Multilineage Cytopenia and Familial MDS/AML: Inheritance, Variant Genes, and Affected Pathways

DISORDER	INHERITANCE	GENE	AFFECTED PATHWAYS
Fanconi anemia	AR	*FANCA, FANCC, FANCD1/BRCA2, FANCD2, FANCE, FANCF, FANCG/XRCC9, FANCI, FANCJ/BRIP1, FANCL/PHF9, FANCM, FANCN/PALB2, FANCO/RAD51C, FANCP/SLX4, FANCQ/ERCC4, FANCR/RAD51, FANCS/BRCA1, FANCT/UBE2T, FANCU/XRCC2, FANCV/REV7, FANCW/RFWD3*	DNA repair, homologous recombination, ribosome biogenesis *(FANCI)*
	XLR	*FANCB*	DNA repair, homologous recombination
Mixed Fanconi anemia/xeroderma pigmentosa/Cockayne syndrome	AR	*ERCC1/XPF*	DNA repair
Shwachman-Diamond syndrome	AR	*SBDS, DNAJC21, EFL1*	Ribosome biogenesis
	AD	*SRP54*	Co-translational protein modification
Dyskeratosis congenita	XLR	*DKC1*	Telomere maintenance, ribosome biogenesis
	AD	*TINF2, TERC, TERT, RTEL1, ACD(TPP1), PARN*	Telomere maintenance, RNA processing
	AR	*TERT, RTEL1, ACD(TPP1), WRAP53(TCAB1), CTC1, POT1, RPA1, PARN, NOP10, NHP2*	Telomere maintenance, RNA processing, ribosome biogenesis
Congenital amegakaryocytic thrombocytopenia	AR	*MPL*	Hematopoietic cytokine receptor
SRP72-associated hereditary aplastic anemia/MDS	AD	*SRP72*	Co-translational protein modification
ERCC6L2-associated hereditary aplastic anemia/MDS	AR	*ERCC6L2*	Transcription
THPO-associated hereditary aplastic anemia/MDS	AR/AD	*THPO*	Hematopoietic cytokine
Reticular dysgenesis	AR	*AK2*	Nucleotide metabolism
Cartilage-hair hypoplasia	AR	*RMRP, POP1, NEPRO*	rRNA and mitochondrial RNA processing
Pearson's syndrome	Maternal	*mDNA*	Mitochondrial DNA genes
Familial thrombocytopenia with predisposition to AML	AD	*RUNX1/CBFA2*	Hematopoietic cytokines
	AD	*ETV6*	Transcription repression
GATA2-associated disorders (MonoMac syndrome, Emberger syndrome, familial MDS syndrome)	AD	*GATA2*	Transcription
Bone marrow failure and diabetes		*DUT*	Nucleotide metabolism
Familial MDS/AML (others)		*CEBPA*	Transcription
Familial MDS/AML (others)		*DDX41*	RNA helicase
Seckel syndrome	AR	*CEP152, CENPJ, CEP63, NIN, PLK4, CDK5RAP2;* *ATR, RBBP8, ATRIP, DNA2*	Centriole/Centrosome duplication and function; DNA damage sensing and repair, and checkpoint signaling activation
Schimke immunoosseous dysplasia	AR	*SMARCAL1*	Chromatin remodeling
Dubowitz syndrome	AR	*NSUN2;* *LIG4*	Cytosine methylation in various RNA types; DNA non-homologous end joining repair
	AD	-14q32, -17q24, -19q13	
Rothmund-Thomson syndrome	AR	*RECQL4*	Chromosome segregation
Nijmegen breakage syndrome	AR	*NBN*	DNA repair

AD, Autosomal dominant; AML, acute myeloid leukemia AR, autosomal recessive; MDS, myelodysplastic syndrome; UK, unknown; XLR, X-linked recessive.

Table 517.2 Clinical Manifestations and Laboratory Findings in Inherited Bone Marrow Failure Syndrome

SYNDROME	NONHEMATOLOGICAL CLINICAL MANIFESTATIONS	LABORATORY FINDINGS
Fanconi anemia	Short stature, low birth weight, microcephaly, microphthalmia, hearing loss, triangular face, micrognathia, cardiac anomalies, tracheoesophageal fistula, esophageal atresia, kidney anomalies, hypoplastic thenar eminence, clinodactyly, café-au-lait spots	Pancytopenia, macrocytosis, elevated Hb F, increased chromosome breakage in clastogenic assay
Dyskeratosis congenita	Mucocutaneous triad (skin pigmentation, nail dysplasia, oral leukoplakia), short stature, low birth weight, failure to thrive, pulmonary fibrosis, stenosis of the esophagus, liver fibrosis	Pancytopenia, macrocytosis, elevated Hb F, very short telomeres
Diamond-Blackfan anemia	Low birth weight, short stature, developmental delay, anomalies in craniofacial skeleton, eyes, heart, visceral organs, and limbs	Anemia, elevated red blood cell adenosine deaminase, macrocytosis, elevated Hb F
Shwachman-Diamond syndrome	Exocrine pancreatic insufficiency, failure to thrive, malabsorption, short stature, neurodevelopment and skeletal abnormalities	Neutropenia, low serum isoamylase, low serum trypsinogen
Severe congenital neutropenia	Recurrent infection	Neutropenia
Congenital amegakaryocytic thrombocytopenia	Nonsyndromic (occasionally, growth retardation, cardiac anomalies, psychomotor developmental delay)	Thrombocytopenia, reduced megakaryocytes
GATA2 deficiency	Lymphedema, immunodeficiency, atypical mycobacterial infections	Neutropenia, anemia, thrombocytopenia
SAMD9/SAMD9L disorders	MIRAGE (SAMD9): MDS, infection, restriction of growth, adrenal hypoplasia, genital phenotypes, and enteropathy	Transient or permanent cytopenia
	Ataxia–pancytopenia syndrome (SAMD9L): cerebellar atrophy and white matter hyperintensities, gait disturbance, nystagmus	
MECOM-associated syndromes	Radioulnar synostosis, clinodactyly, hearing loss, cardiac/renal malformation	Thrombocytopenia
Pearson syndrome	Pancreatic insufficiency, failure to thrive, microcephaly, ptosis, Kearns-Sayre syndrome	Neutropenia, anemia, pancytopenia, lactic acidosis, hyperglycemia

Hb F, Hemoglobin F; MDS, myelodysplastic syndrome.
Modified from Park M. Overview of inherited bone marrow failure syndromes. *Blood Res.* 2022;57(S1):49–54. Table 1.

often have congenital malformations and high sensitivity to alkylating agents and radiation. The estimated frequency of FA is 1 in 200,000 in most populations but is higher in Ashkenazi Jews (1:30,000) and Afrikaners (1:22,000). Carrier frequency is approximately 1:200-300 in most populations. Pathogenic variants in 22 genes, designated *FANC* genes, have been reported to cause FA or FA-like disease. All pathogenic variants except for one are inherited in an autosomal recessive manner. One uncommon form of FA is X-linked recessive. FA occurs in all ethnic groups. At presentation, patients may have typical physical anomalies and abnormal hematologic findings (majority of patients), normal physical features but abnormal hematologic findings (about one third of patients), or physical anomalies and normal hematologic findings (unknown percentage of patients). There can be sibling discordance in clinical and hematologic manifestations, even in affected monozygotic twins.

Pathology

All FA genes code for proteins that play roles in various cellular pathways and most prominently in DNA cross linking and repair. Patients with FA have faulty DNA repair and increased chromosomal fragility caused by DNA interstrand cross-linking agents such as diepoxybutane (DEB) and mitomycin C (MMC). Cell fusion of FA cells with normal cells or with cells from some unrelated patients with FA produces a corrective effect on chromosomal fragility, a process called *complementation.* The classic FA phenotype that clearly defines the FA-associated genes *(FANCA, FANCB, FANCC, FANCD1/BRCA2, FANCD2, FANCE, FANCF, FANCG, FANCI, FANCJ/BACH1/BRIP1, FANCL, FANCM, FANCN/PALB2, FANCP/SLX4, FANCQ/ERCC4, UBE2T, REV7, RFWD3)* includes the triad of **bone marrow failure**, **congenital anomalies**, and **elevated chromosome fragility**. These genes can be mutated in patients who have one or all of the components of the triad. Genes that were found to be associated with one or two but not all three of the components are **FA-like genes** *(FANCO/RAD51C, RAD51, FANCS/BRCA1, FANCR/EXCC2). FANCA* accounts for approximately 64% of FA cases, *FANCC* for 14%, and *FANG* for 9%. *FANCB*, *FANCD1/BRCA2*, *FANCD2*, *FANCE,* and *FANCF* are collectively mutated in almost 13% of FA patients. The remaining genes are pathogenic variants in rare cases.

The proteins encoded by wild-type *FANC* genes are involved in the DNA damage recognition and repair biochemical pathway. Therefore aberrant proteins lead to genomic instability and chromosome fragility. FANC proteins are involved in other cellular activities, such as reactive oxygen species detoxification, energetic metabolism, and cytokine signaling. Thus FANC pathogenic variants likely affect several cellular and biochemical roles of the respective proteins, which eventually leads to the FA phenotype. The observed disease complexity and heterogeneity is likely caused by the involvement of multiple cellular and biochemical pathways both in unrelated individuals and in family members with the same genetic pathogenic variant.

Clinical Manifestations

The most common congenital anomalies in FA are skeletal and include absence of radii and/or thumbs that are hypoplastic, supernumerary, bifid, or absent. Anomalies of the feet, congenital hip dislocation, and leg abnormalities can also be seen (Fig. 517.1 and Table 517.3). Skin hyperpigmentation of the trunk, neck, and intertriginous areas;

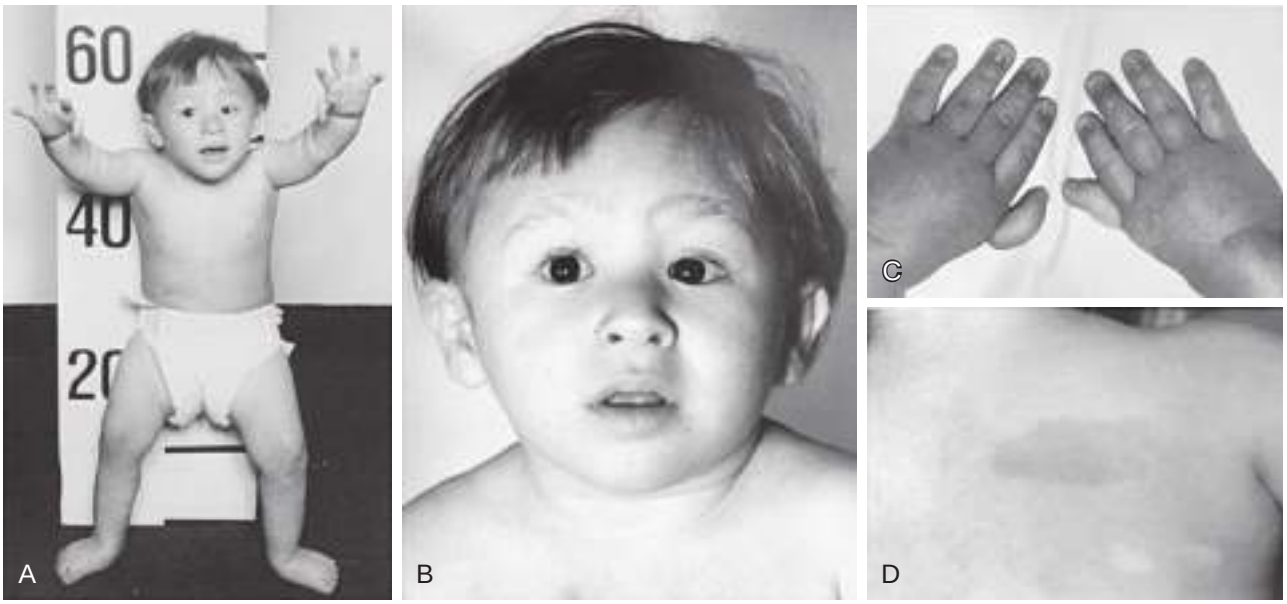

Fig. 517.1 A 3-year-old boy with Fanconi anemia who exhibits several classic phenotypic features. **A,** Front view. **B,** Face. **C,** Hands. **D,** Back right shoulder. The features to be noted include short stature, dislocated hips, microcephaly, a broad nasal base, epicanthal folds, micrognathia, thumbs attached by a thread, and café-au-lait spots with hypopigmented areas beneath. *(From Nathan DC, Orkin SH, Ginsburg D, et al, eds: Nathan and Oski's Hematology of Infancy and Childhood, 6th ed. Philadelphia: Saunders, 2003. p. 285.)*

Table 517.3 Specific Types of Anomalies in Fanconi Anemia

SKIN (40%) Generalized hyperpigmentation on the trunk, neck, and intertriginous areas; café-au-lait spots; hypopigmented areas	EYES (20%) Small eyes, strabismus, epicanthal folds, short or almond-shaped palpebral fissures, hypertelorism, ptosis, slanting, cataracts, astigmatism, blindness, epiphora, nystagmus, proptosis, small iris
BODY (40%) Short stature, delicate features, small size, underweight	EARS (10%) Deafness (usually conductive); abnormal shape; atresia; dysplasia; low set, large, or small; infections; abnormal middle ear; absent eardrum; dimples; rotated; canal stenosis
UPPER LIMBS (35%) *Thumbs (35%):* absent or hypoplastic; supernumerary, bifid, or duplicated; rudimentary; short, low set, attached by a thread; triphalangeal, tubular, stiff, hyperextensible *Radii (7%):* absent or hypoplastic (only with abnormal thumbs); absent or weak pulse *Hands (5%):* clinodactyly; hypoplastic thenar eminence; six fingers; absent first metacarpal; enlarged, abnormal fingers; short fingers; transverse crease *Ulnae (1%):* dysplastic or absent	KIDNEY (20%) Ectopic or pelvic; abnormal, horseshoe, hypoplastic, or dysplastic; absent; hydronephrosis or hydroureter; infections; duplicated; rotated; reflux; hyperplasia; no function; abnormal artery
LOWER LIMBS (5%) *Feet:* toe syndactyly, abnormal toes, flat feet, short toes, clubfeet, six toes, supernumerary toe *Legs:* congenital hip dislocation, Perthes disease, coxa vara, abnormal femur, thigh osteoma, abnormal legs	GASTROINTESTINAL SYSTEM (5%) High-arched palate, atresia (esophagus, duodenum, jejunum), imperforate anus, tracheoesophageal fistula, Meckel diverticulum, umbilical hernia, hypoplastic uvula, abnormal biliary ducts, megacolon, abdominal diastasis, Budd-Chiari syndrome
GONADS *Males (25%):* hypogenitalia, undescended testes, hypospadias, abnormal genitalia, absent testis, atrophic testes, azoospermia, phimosis, abnormal urethra, micropenis, delayed development *Females (2%):* hypogenitalia; bicornuate uterus; abnormal genitalia; aplasia of uterus and vagina; atresia of uterus, vagina, and ovary	UROGENITAL *Males (25%):* micropenis, penile-scrotal fusion, undescended or atrophic or absent testes, hypospadias, chordae, phimosis, azoospermia *Females (2%):* bicornuate uterus, aplasia or hypoplasia of vagina and uterus, atresia of vagina, hypoplastic uterus, hypoplastic or absent ovary, hypoplastic fused labia
OTHER SKELETAL ANOMALIES *Head (20%) and face (2%):* microcephaly, hydrocephalus, micrognathia, peculiar face, birdlike face, flat head, frontal bossing, scaphocephaly, sloped forehead, choanal atresia, dental abnormalities *Neck (1%):* Sprengel deformity; short, low hairline; webbed *Spine (2%):* spina bifida (thoracic, lumbar, cervical, occult sacral), scoliosis, abnormal ribs, sacral agenesis, sacrococcygeal sinus, Klippel-Feil syndrome, vertebral anomalies, extra vertebrae	CARDIOPULMONARY SYSTEM (6%) Patent ductus arteriosus, ventricular septal defect, abnormal heart, peripheral pulmonic stenosis, aortic stenosis, coarctation, absent lung lobes, vascular malformation, aortic atheromas, atrial septal defect, tetralogy of Fallot, pseudotruncus, hypoplastic aorta, abnormal pulmonary drainage, double aortic arch, cardiac myopathy
	CENTRAL NERVOUS SYSTEM (3%) Hyperreflexia, Bell palsy, central nervous system arterial malformation, moyamoya syndrome, Arnold-Chiari malformation, stenosis of internal carotid artery, small pituitary gland, absent corpus callosum
	Slow development (10%)

Abnormalities are listed in the approximate order of frequency within each category.
Adapted from Shimamura A, Alter BP. Pathophysiology and management of inherited bone marrow failure syndromes. *Blood Rev.* 2010;24:101–122.

café-au-lait spots; and vitiligo, alone or in combination, occur with similar frequency. Short stature is common and in some patients is aggravated by subnormal growth hormone (GH) secretion or hypothyroidism. Male patients with FA may have an underdeveloped penis; undescended, atrophic, or absent testes; and hypospadias or phimosis, and all are infertile. Females can have malformations of the vagina, uterus, and ovary, and all have reduced fertility. Many patients have characteristic facial dysmorphisms, including microcephaly, small eyes, epicanthal folds, and abnormal shape, size, or positioning of the ears (see Fig. 517.1). Kidneys may be ectopic, pelvic, horseshoe-shaped, hypoplastic, dysplastic, or absent. Cardiovascular (CV) and gastrointestinal (GI) malformations also occur. Approximately 10% of patients with FA are cognitively delayed. Neonates with FA usually have intrauterine growth restriction (IUGR) and low birthweight and may show malformations consistent with VACTERL/VACTERL-H association (vertebral anomalies, anal atresia, cardiac malformations, tracheoesophageal fistula with esophageal atresia, renal and limb structural abnormalities with hydrocephalus).

Bone marrow failure usually appears within the first decade of life. Thrombocytopenia, red blood cell (RBC) macrocytosis, and increased fetal hemoglobin (Hb F), as a result of bone marrow stress, often appear first. At these stages, bone marrow aspirate and biopsy often show a hypocellular specimen. Subsequently, patients develop neutropenia and then anemia. Severe aplasia develops in most cases, usually over a few years.

Cancer Risk and Other Complications

In addition to the low blood counts and physical anomalies, patients with FA have a high risk of developing cancer. The most frequent solid tumors are *squamous cell carcinomas* (SCCs) of the head and neck (600-fold higher risk than the general population) and carcinoma of the upper esophagus (2,000-fold higher risk), the vulva (3,000-fold higher risk), and/or anus, cervix, and lower esophagus. Onset of solid-tumor malignancy is much sooner than that seen in the general population, with median age of onset of SCC in the FA population occurring at 33 years vs 60–70 years in the general population. Human papillomavirus (HPV) is suspected in the pathogenesis of SCC. Benign and malignant liver tumors can occur (adenomas, hepatomas) and are usually associated with androgen therapy for aplastic anemia. Androgens are also implicated in the etiology of peliosis hepatis (blood-filled hepatic sinusoids), which is reversible when androgen therapy is discontinued. Clonal bone marrow cytogenetic abnormalities are common in FA and on follow-up can either be stable, intermittently detected, or progressive. The cumulative incidence of clonal and malignant myeloid transformation by age 18 years, which includes clonal cytogenetic marrow abnormalities, MDS, and AML, is approximately 75%. One study indicated that by age 40 years, the cumulative incidence of leukemia is 33%.

Diagnosis

FA should be considered in all children and young adults with unexplained cytopenias. Abnormal hematologic findings and characteristic physical anomalies suggest the diagnosis, which can be confirmed with a lymphocyte chromosomal breakage study done with and without the addition of cross-linking agents such as DEB and MMC. Increased chromosome fragility is indicated by spontaneously occurring chromatid breaks, rearrangements, gaps, endoreduplications, and chromatid exchanges in blood lymphocytes cultured with phytohemagglutinin, as well as in cultured skin fibroblasts, underscoring the constitutional nature of FA. With the addition of DEB or MMC, fragility is strikingly enhanced in lymphocyte cultures of patients with FA compared with those of controls. Abnormal chromosome breakage analysis and genetic testing for prenatal diagnosis can be performed on amniotic fluid cells or on tissue from a chorionic villus biopsy. No other inherited pancytopenia is associated with a prominent in vitro hypersensitivity to DEB or MMC by the chromosomal breakage study. However, 10–15% of patients with suspected FA have *somatic mosaicism* and may not show the characteristically high degree of chromosomal fragility in their lymphocytes, reflecting the presence of mixed populations of somatic cells, some with two abnormal alleles and some with only one. The latter population of lymphocytes derives from a portion of hematopoietic stem cells (HSCs) that underwent spontaneous somatic gene correction on one allele. Testing of skin fibroblasts should be performed if the suspicion of FA is high despite negative testing on peripheral blood lymphocytes.

Next-generation sequencing (NGS) gene panels and WES are the tests of choice for FA. NGS is an efficient and accurate method for diagnosing FA but can occasionally be limited by difficulties in interpreting previously unreported variants or in unraveling pathogenic variants due to reversion variants or technical matters. When no definite causative point pathogenic variants are found, high-resolution copy number variation analysis techniques are employed, followed by a genome-wide search for pathogenic variants in novel associated genes. Pathogenic variants in one of the 22 FA genes are found in over 95% of FA cases.

Extensive screening for potential medical problems is necessary after the diagnosis of FA is established. Imaging using radiation should be minimized as much as possible because of the carcinogenic risk inherent to this genetic instability disease; MRI should replace CT whenever possible. In addition to detailed review of the past medical history and thorough physical examination, the screen should include ultrasonographic examination of the abdomen and echocardiography to rule out internal congenital anomalies. Other imaging may be done as necessary and based on the initial screen. Subspecialty consultations for anomalies and disabilities that have been identified can be arranged during this interval. If growth velocity is below expectations, endocrine evaluation is needed to assess for GH and thyroid deficiency. Blood work should include evaluation of renal, liver, thyroid, metabolic, and immune systems.

Treatment

A hematologist, preferably one who specializes in IBMFSs, with a multidisciplinary team should manage patients with FA. At diagnosis, a detailed assessment of the patient's blood counts, bone marrow function, growth, development, and other organ function should be carried out.

If hematologic abnormalities are mild to moderate and stable and there is no transfusion requirement, patients can be observed closely with peripheral blood counts every 3 months and bone marrow aspiration surveillance every year for clonal cytogenetic abnormalities, MDS, and AML. Bone marrow biopsy might also be intermittently done during bone marrow testing to evaluate changes in percentage of cellularity and fibrosis. More frequent monitoring can be applied when deemed necessary, as when a decline in blood counts occurs. Glucose levels should be performed annually or biannually, depending on the degree of hyperglycemia found on initial testing. Screening for hypothyroidism should be performed yearly. Patients should be assessed for solid tumors at least annually, with a careful physical examination that includes comprehensive inspection of the skin, oral cavity, and other organs for unusual masses. After a certain age (e.g., 10 years) or after HSC transplant (HSCT), fluoroscopic examination of the orolaryngeal cavity and occult fecal blood testing are also recommended. Beginning at menarche, female patients should be screened annually for gynecologic cancer. Administration of HPV quadrivalent vaccine to decrease the risk of SCC is advised.

Chromosome fragility (and/or targeted genetic testing) should be offered to siblings and parents of affected patients for identification of other affected individuals. It is noteworthy that heterozygosity for several FA genes (e.g., *FANCN*, *FANCD1*, *FANCS*) is associated with cancer development. Human leukocyte antigen (HLA) typing of patients, biological parents, and full siblings for future HSCT should also occur early.

HSCT is the only curative therapy for the hematologic abnormalities observed in FA patients. Outcomes have improved because of modified reduced-intensity regimens that include fludarabine, low dose cyclophosphamide, and antithymocyte globulin with or without low-dose busulfan. Most regimens do not use radiation. These regimens have decreased the toxicities experienced by FA patients, who have high sensitivity to DNA-damaging agents such as alkylating drugs and irradiation. Those who undergo transplant using an HLA-identical sibling

donor without irradiation in the preparative regimen have an overall 3-5-year survival rate of >90%.

Traditionally, HSCT of FA patients with matched unrelated donors (MUD) or mismatched related donors have been a challenge because of the high degree of HSCT-related toxicity and death. However, major progress has been made in this regard. Several reports of radiation-free HSCT with in vivo or ex-vivo T-cell depleted, peripheral blood $CD34^+$ selected MUD graft and conditioning with fludarabine, rabbit antithymocyte globulin (ATG), low-dose cyclophosphamide, and low-dose busulfan demonstrated 80% or higher probabilities of overall and disease-free survival 1–5 years post HSCT. Improvement in high-resolution HLA typing contributes to better selection of unrelated-donor selection and a better outcome. Transplantation using haploidentical donors is on the rise and is showing promising outcomes, similar to those seen with unrelated donors.

Those transplanted before they receive multiple transfusions or develop clonal and malignant myeloid transformation (MDS or AML) do better. Survival rates are higher for patients who undergo transplant at <10 years of age. Molecular technology has led to preimplantation genetic diagnosis on parent-derived blastomeres, allowing for the unaffected ones to be implanted and resulting in the creation of an HLA-matched sibling donor without FA.

Androgens produce a response in approximately 70% of patients, heralded by reticulocytosis and a rise in hemoglobin within 1-2 months. White blood cell (WBC) counts may increase next, followed by platelet counts. After the initial response is seen, counts may continue to improve over many months until a maximum response is achieved. If a low dose is initially employed, the androgen dose can be increased every 3-4 weeks as long as no major side effects are seen and until the desired response is achieved. If a high dose is initially employed, androgen dosage can be slowly reduced to the minimum dose that maintains the required blood counts. Oral danazol and oxymetholone are currently the two most commonly used androgenic drugs. Patients typically stop responding to androgens after several months or years, as their bone marrow failure progresses or as they develop MDS or AML. Thus androgen therapy is not curative but is used rather as a bridge while waiting for a suitable donor for HSCT or while weighing the risks and benefits of transplant. Side effects of androgens include masculinization, increased linear growth, increased mood swings or aggressiveness, elevated hepatic enzymes, cholestasis, peliosis hepatis, and liver tumors. Screenings for these should be performed regularly.

The potential for recombinant growth factor (cytokine) therapy for FA has not been defined. Granulocyte colony-stimulating factor (G-CSF) can usually induce an increase in the absolute neutrophil count; however, there may be a heightened risk of expansion of bone marrow cells with clonal cytogenetic abnormalities such as monosomy 7. In one study, combination therapy consisting of G-CSF given subcutaneously daily or every 2 days along with erythropoietin given subcutaneously or intravenously 3 times per week resulted in improved neutrophil counts in most patients and a sustained rise in hemoglobin and platelet levels in approximately one third of patients. Most patients lost the response because of progression of bone marrow disease.

Prognosis

Improvements in supportive care, careful surveillance of known complications, prompt intervention, and improved transplant techniques have resulted in patients with FA surviving into their 30s. Unfortunately, there is an increased risk of solid tumors after HSCT. For example, head and neck cancer risk is increased 4.4-fold and is accelerated by approximately 15 years compared with nontransplanted patients. The cumulative incidence of malignancy 20 years after transplant is 35–40%. Some of the increased risk might be attributed to the use of DNA-damaging agents or the occurrence of graft-versus-host disease (GVHD).

SHWACHMAN-DIAMOND SYNDROME

Etiology and Epidemiology

Shwachman-Diamond syndrome (SDS) is an inherited disorder caused by pathogenic variants in one of four genes. It occurs in all racial and ethnic groups. SDS is a multisystem disorder. However, the nonhematologic manifestations of SDS are substantially different and usually include exocrine pancreatic insufficiency and skeletal abnormalities such as metaphyseal dysplasia (Table 517.4). SDS is a **ribosomopathy**, and the underlying defect is in ribosome assembly.

Table 517.4 Major Clinical Features of Shwachman-Diamond Syndrome

CLINICAL FEATURE	TOTAL/AVERAGE
Number of patients	225
Neutropenia	90%
Severe (≤500/μL)	46%
Anemia	46%
Thrombocytopenia	42%
Pancytopenia	21%
Exocrine pancreatic insufficiency	98%
Liver (elevated transaminases)	61%
Skeletal abnormalities	70%
Metaphyseal dysostosis	53%
Rib cage abnormalities	35%
Short stature (<3rd percentile)	66%

Data from Ginzberg H, Shin J, Ellis L, et al. Shwachman syndrome: phenotypic manifestations of sibling sets and isolated cases in a large patient cohort are similar. *J Pediatr*. 1999;135:81–88; Cipolli M, D'Orazio C, Delmarco A, et al. Shwachman's syndrome: pathomorphosis and long-term outcome. *J Pediatr Gastroenterol Nutr*. 1999;29:265–272; and Kuijpers TW, Alders M, Tool AT, et al. Hematologic abnormalities in Shwachman-Diamond syndrome: lack of genotype-phenotype relationship. *Blood*. 2005;106:356–361.

Pathology

Four genes have been linked to SDS. *SBDS* is the first gene that was described to have biallelic variants in SDS in 2003. *SBDS* maps to chromosome 7q11 and accounts for 80–90% of SDS cases. *SBDS* plays a role in the late stage of the pre-60S ribosome subunit maturation, binding to the *EFL1* GTPase and facilitating the release of eIF6 to enable 80S monosome formation. *DNAJC21* is the second reported SDS gene. The function of the human *DNAJC21* is required for the release and recycling of the Arx1/Alb1 heterodimer from the pre-60S biogenesis factors. The third SDS gene discovered is *EFL1*. *DNAJC21* and *EFL1*-associated SDS are autosomal recessive. Monoallelic pathogenic variants in *SRP54*, a protein involved in co-translational protein modification, mainly cause severe congenital neutropenia phenotype. Nevertheless, a small proportion of the patients have partial or classical SDS phenotype. The underlying genetic defects of SDS indicate that the last step in ribosome biogenesis is associated with pancytopenia (most often neutropenia) and a hypoplastic bone marrow. Defects in ribosomal proteins that are involved in earlier stages of ribosome subunit maturation and are structural components of the ribosome are associated with predominantly anemia and pure red cell aplasia.

Exocrine pancreatic insufficiency is caused by failure of exocrine pancreatic acinar development in SDS, and fatty replacement of pancreatic tissue is prominent. **Bone marrow failure** is characterized by dysfunctional HSCs, accelerated apoptosis of bone marrow progenitors, and a defective bone marrow microenvironment that does not support and maintain normal hematopoiesis.

Clinical Manifestations

Most patients with SDS have symptoms of fat malabsorption from birth that are caused by pancreatic insufficiency, but steatorrhea is not always obvious. Approximately 50% of patients appear to exhibit an improvement in pancreatic enzyme secretion as they age. The clinical picture can be dominated by complications from neutropenia, anemia,

or thrombocytopenia. Bacterial and fungal infections secondary to neutropenia, neutrophil dysfunction, and immunodeficiency can occur. A major concern is the development of MDS and acute leukemia, most often AML.

Short stature is a consistent feature of SDS. Most patients show normal growth velocity yet remain consistently below the 3rd percentile for height and weight. The occasional SDS adult achieves the 25th percentile for height. Although skeletal abnormalities are variable, classic findings are metaphyseal dysplasia, osteopenia, delayed appearance of secondary ossification centers, short or flared ribs, and thoracic dystrophy.

Some patients have hepatomegaly and elevations of liver enzymes. Most patients have dental abnormalities and poor oral health. Many have neurocognitive problems and poor social skills.

Laboratory Findings

Exocrine pancreatic insufficiency in SDS is associated with reduced age-adjusted serum trypsinogen and pancreatic isoamylase levels. Because serum pancreatic isoamylase is physiologically low in the first 3 years of life, and because reduced serum trypsinogen is typically seen in young infants and often improves with age, testing both enzymes is helpful. Fecal elastase is often reduced in SDS patients. Fat-soluble vitamin (A, D, E, and K) absorption is impaired, and thus measurement of vitamin A, D, and E levels, as well as prothrombin time (or international normalized ratio [INR]), is helpful to assess the consequences of fat malabsorption. Ultrasound or CT scan can visualize fatty replacement of pancreatic tissue. Fat malabsorption can be proven by assay on a 72-hour stool collection.

Neutropenia is observed in about 70% of patients with SDS at presentation and is seen in close to 100% of patients on follow-up. It is chronic but can be persistent or intermittent and mild, moderate, or severe. It has been identified in some neonates during an episode of sepsis. Neutrophils may have a defect in mobility, migration, and chemotaxis because of alterations in neutrophil cytoskeletal or microtubular function. Anemia, thrombocytopenia, and pancytopenia are seen in 40–66%, 40–60%, and 21–44% of cases, respectively. Pancytopenia can be severe as a result of full-blown aplastic anemia. Bone marrow aspirate and biopsy specimens show varying degrees of bone marrow hypoplasia and fat infiltration. However, at a young age or when patients develop MDS or leukemia, the bone marrow can be normocellular or even hypercellular.

Patients may also have B-cell defects with one or more of the following: low immunoglobulin G (IgG) or IgG subclasses, low percentage of circulating B lymphocytes, decreased in vitro B-cell proliferation, and lack of specific antibody production. Patients may have a low percentage of circulating T cells, subsets, or natural killer cells and decreased in vitro T-cell proliferation.

Diagnosis

The clinical diagnosis of SDS relies on having evidence of two of the following: bone marrow dysfunction, exocrine pancreatic insufficiency, and metaphyseal dysplasia. However, atypical presentations have been identified, such as MDS without previous documentation of low blood counts. Up to 20% of patients lack clear evidence of exocrine pancreatic defects at diagnosis. Furthermore, 20–60% lack metaphyseal dysplasia at diagnosis because this bony anomaly often develops with age. Therefore it is recommended that all patients with either hypoplastic/aplastic bone marrow or exocrine pancreatic insufficiency or metaphyseal dysplasia of unknown etiology be considered for SDS genetic testing. Genetic analysis for *SBDS*, *DNAJC21*, and *EFL1* are definitive in all or almost all cases of SDS. A patient with neutropenia and an *SRP54* pathogenic variant who does not have exocrine pancreatic insufficiency or metaphyseal dysplasia should be considered as having severe congenital neutropenia.

Pearson syndrome, consisting of refractory sideroblastic anemia, cytoplasmic vacuolization of bone marrow precursors, metabolic acidosis, exocrine pancreatic insufficiency, and a diagnostic mitochondrial DNA pathogenic variant, is similar to SDS, but the clinical course, morphologic features of the bone marrow, and gene pathogenic variant are different. Severe anemia requiring transfusion, rather than neutropenia, is present in Pearson syndrome from birth to 1 year of age. SDS shares some manifestations with **Fanconi anemia**, such as bone marrow dysfunction and growth failure, but patients with SDS are readily distinguished because of pancreatic insufficiency with fat malabsorption, fatty changes within the pancreatic body visualized by imaging, characteristic skeletal abnormalities not seen in FA, and a normal chromosomal breakage study with DEB and MMC. Distinguishing SDS from **dyskeratosis congenita (DC)** may not be possible based solely on clinical findings and pancreatic enzyme levels; telomere length measurement may facilitate a correct diagnosis. *In difficult cases of IBMFSs that cannot be easily classified, comprehensive genetic testing using an NGS panel of all known IBMFS genes or unbiased testing using WES/genome sequencing is likely to assist in establishing a diagnosis.*

Predisposition to Cancer

Patients with SDS are predisposed to MDS and leukemic transformation. Approximately 25% of patients develop clonal marrow cytogenetic abnormalities, MDS, or leukemia by age 18 years. About one third of patients have been reported to develop leukemia by age 30 years. Isochromosome 7q [i(7q)] is particularly common and is rarely seen in other conditions. i(7q) might be related to the presence of pathogenic variant *SBDS* on 7q11 and likely confers a compensatory effect by increasing *SBDS* transcribing alleles (although they remain variant). Other clonal chromosome abnormalities include monosomy 7, i(7q) combined with monosomy 7, deletions or translocations involving part of 7q, and deletions of 20q [Del(20q)]. The i(7q) and del(20q) are associated with relatively low risk and very slow progression to MDS or leukemic transformation.

Treatment

Fat malabsorption responds to oral pancreatic enzyme replacement and supplemental fat-soluble vitamins, administered according to guidelines similar to those for cystic fibrosis. A long-term plan should be initiated to periodically monitor changes in peripheral blood counts that require corrective action and to look for early evidence of malignant myeloid transformation. The latter also requires periodic bone marrow aspirations for smears and cytogenetic testing, as well as bone marrow biopsy. A common recommendation is to perform bone marrow testing every 1-3 years and complete blood counts every 3 months.

Daily *subcutaneous G-CSF* for profound neutropenia is effective in inducing a sustained increase in neutrophils. Some patients require transfusion support for management of severe anemia or thrombocytopenia. Experience with erythropoietin is limited. Androgens have been used in few published cases (with and without steroids); some patients showed response, and some did not.

The only curative option for severe bone marrow failure and advanced MDS or leukemia in SDS is allogeneic HSCT. Traditional myeloablative HSCT results in treatment-related mortality in 35–50% of patients. Reduced-intensity conditioning regimens that incorporate *fludarabine* appear to be safer and have been shown to be effective in SDS. Graft failure poses a challenge, possibly due to a stromal cell defect that is not corrected by HSCT. Results of treatment for advanced MDS and AML are generally limited, and outcome is typically poor.

Prognosis

The accurate life expectancy of SDS patients is unknown; analysis of published cases revealed a median survival of 35 years. Because the number of undiagnosed patients with mild or asymptomatic disease is unknown, the overall prognosis may be better than previously thought.

Although all patients have some degree of hematologic cytopenia at diagnosis, the changes in most patients are mild to moderate and do not require therapeutic intervention. Severe neutropenia responds well to G-CSF, but there is a concern that G-CSF may promote the growth of evolving MDS or leukemia clones because of the agent's powerful

growth stimulus on bone marrow cells. HSCT for severe bone marrow failure has produced a 50–70% survival rate, but safer protocols need to be introduced. Malignant bone marrow transformation remains ominous.

Approximately 50% of patients experience spontaneous conversion from exocrine pancreatic insufficiency to pancreatic sufficiency as a result of improvement in pancreatic enzyme secretion.

DYSKERATOSIS CONGENITA

Etiology and Epidemiology

DC is an inherited multisystem telomere disorder. A diagnostic triad of mucocutaneous features was proposed when the disorder was first described and included **dysplastic nails**, lacy **reticular pigmentation** of the upper chest and/or neck, and **oral leukoplakia** (Fig. 517.2). *However, this triad is not present in all individuals.* If it occurs, skin and nail findings usually become apparent in the first 10 years of life, whereas oral leukoplakia may be noticed later. Manifestations tend to progress as patients age. Hematological manifestations are actually the most common features in this disease. Varying degrees of bone marrow failure are seen in approximately 90% of patients. Severe aplastic anemia occurs in approximately 50% of cases, with the age of onset varying according to the genetic group. In some genetic groups, the disease usually starts in the first decade of life (e.g., *DKC1*, *TINF2, PARN*), whereas in others, it typically starts after the first decade (e.g., *TERT, TERC*). In addition to progressive bone marrow failure, patients with DC are also at high risk for pulmonary and hepatic fibrosis, other congenital anomalies, and a predisposition to solid tumors and MDS or AML. DC is rare, with an incidence in childhood of approximately 4 cases per 1 million population per year.

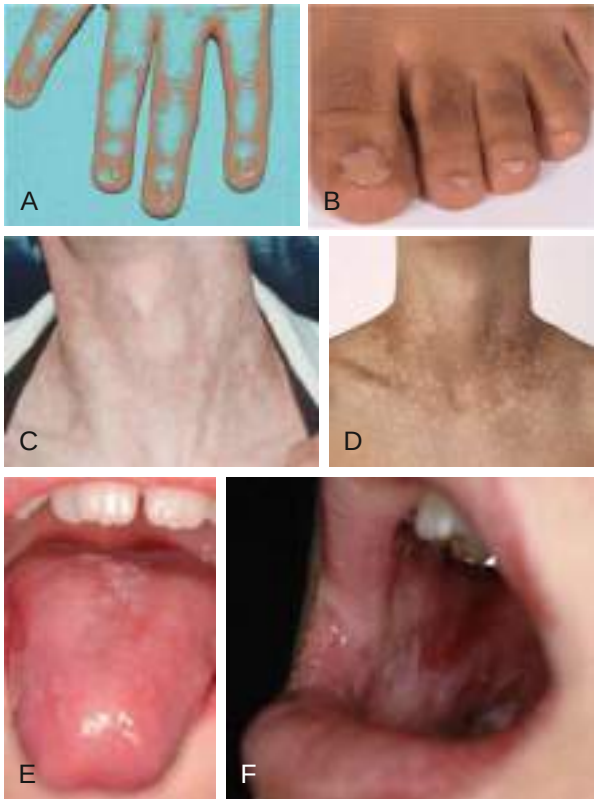

Fig. 517.2 Features of the diagnostic triad in dyskeratosis congenita. **A** and **B**, Dystrophic nails on hands and feet. **C** and **D**, Lacy reticular pigmentation on neck and upper thorax. **E** and **F**, Oral leukoplakia on tongue and buccal mucosa. *(**A-C** and **E** from Shimamura A, Alter BP. Pathophysiology and management of inherited bone marrow failure syndromes. Blood Rev. 2010;24:101–122, Fig. 8; **D** and **F** from Savage SA, Alter BP. Dyskeratosis congenital. Hematol Oncol Clin North Am. 2009;23:215–231)*

Pathology

DC is genetically heterogeneous, and patients have pathogenic variants in genes that encode components of the telomerase complex *(TERT, TERC)*, telomere-capping complex *(CTC1, STN1)*, T-loop unwinding and telomere replication *(RTEL1, RPA1)*, telomerase trafficking *(WRAP53*/TCAB1*)*, TERC-associated factors that stimulate telomerase activity *(DKC1, NOP10, NHP2, NAF1)*, TERC-maturation factors *(PARN)*, and telomere-shelterin complex *(TINF2, POT1, ACD)*.

All components are critical for telomere maintenance. The **X-linked recessive** form of DC maps to Xq28, and many pathogenic variants have been identified in the *DKC1* gene, which codes for the nuclear protein dyskerin. The **autosomal dominant** form of disease is caused by pathogenic variants in *TINF2, TERC, TERT, RTEL1, ACD, NAF1,* and *RPA1*. **Autosomal recessive** DC is linked to pathogenic variants in *NOP10, NHP2, TCAB1/WRAP53, CTC1,* and *STN1,* as well as *TERT, TERC, RTEL1, PARN*, and *ACD*. Because of impaired telomere maintenance in all three inherited forms of DC, extremely short telomeres (<1st percentile for age) are demonstrated in the peripheral blood cells of all patients. Finding extremely short telomeres in lymphocytes performed by automated multicolor flow fluorescence in situ hybridization (FISH) has 97% sensitivity and 91% specificity for DC. Approximately 70% of individuals who meet clinical diagnostic criteria of DC have a pathogenic variant in one of the known DC-related genes. Pathogenic variants in *DKC1* are most common (20–25% of individuals), followed by *TINF2* (12–20% of individuals), *TERC* (5–10% of individuals), *RTEL1*, *TERT,* and *CTC1*. The remainder of the genetic pathogenic variants have been described in only a few families. Bone marrow failure is likely caused by progressive attrition and depletion of HSCs because of premature senescence, apoptosis, or chromosome instability, which manifests as pancytopenia.

Clinical Manifestations

The clinical criteria for classic DC include the presence of at least two of the four major features—abnormal skin pigmentation, nail dystrophy, leukoplakia, and bone marrow failure—and two or more of the other somatic features known to occur in DC. However, making a diagnosis continues to be challenging because individuals develop clinical features of DC at variable rates and ages, even within the same family. Further, some of the patients have only one complication (e.g., isolated bone marrow failure or isolated pulmonary fibrosis). In about one quarter of individuals with DC, pathogenic variants in the known DC-related genes cannot be identified. The spectrum ranges from individuals who develop bone marrow failure first, then years later develop other classic findings such as nail abnormalities, to others who have severe nail problems and abnormalities of skin pigmentation at presentation but normal bone marrow function. In classic disease, skin pigmentation and nail changes typically appear first, usually in the first decade of life. Bone marrow failure usually develops within the first two decades, with 80% of patients developing bone marrow failure by age 30 years and almost 90% of patients having bone marrow failure at some point in their life.

Lacy reticulated **skin pigmentation** affecting the face, neck, chest, and arms is a common finding (89%). The degree of pigmentation increases with age and can involve the entire skin surface. There may also be a telangiectatic erythematous component. Nail dystrophy of both hands and feet is the next most common finding (88%). It usually starts with longitudinal ridging, splitting, or pterygium formation and may progress to complete nail loss. **Leukoplakia** usually involves the oral mucosa (78%), especially the tongue, but may also be seen in the conjunctiva and the anal, urethral, or genital mucosa. Excessive tearing **(epiphora)** secondary to nasolacrimal duct obstruction is common and observed in about 30% of individuals. Approximately 25% of individuals have learning difficulties and/or developmental delay. Hyperhidrosis of the palms and soles, hair loss and graying, dental caries or loss, esophageal stricture, pulmonary disease with reduced diffusion capacity and/or a restrictive defect due to pulmonary fibrosis and abnormalities in pulmonary vasculature, and short stature are each seen in approximately 15–20% of individuals.

Ocular abnormalities include conjunctivitis, blepharitis, loss of eyelashes, strabismus, cataracts, and optic atrophy. **Skeletal** abnormalities include osteoporosis, avascular necrosis of the hips or shoulders, abnormal bone trabeculation, scoliosis, and mandibular hypoplasia. **Genitourinary** abnormalities include hypoplastic testes, hypospadias, phimosis, urethral stenosis, and horseshoe kidney. **GI** findings, such as vascular lesions causing bleeding, hepatomegaly, peptic ulceration, and fibrosis, are seen in 10% of cases.

Laboratory Findings

The initial hematologic change in DC is usually thrombocytopenia, anemia, or both, followed by pancytopenia and aplastic anemia. The red cells are often macrocytic, and the Hb F is elevated. Initial bone marrow specimens may be normocellular or hypercellular, but with time, a symmetric depletion of all hematopoietic lineages ensues. Some patients have immunologic abnormalities, including reduced or elevated immunoglobulin values, decreased B- and/or T-lymphocyte counts, and reduction or absence of lymphocyte proliferative responses to phytohemagglutinin. This is particularly common and severe in the *DKC1*-associated disease. Primary skin fibroblasts in culture have abnormal morphologic features and doubling rate and show numerous unbalanced chromosome rearrangements, such as dicentrics, tricentrics, and translocations, in the absence of DEB or MMC. These findings provide evidence of a defect that predisposes patient cells to chromosomal rearrangements and possibly to DNA damage.

The hallmark of DC is very short telomeres, below the first percentile for age. However, some patients do not have short telomeres. Further, adult patients tend to have telomere length at the low range of normal rather than below the first percentile.

Diagnosis

The diagnosis of DC can often be made based on medical and family history and physical examination. The following abnormalities are seen in patients with DC but not in those with FA: nail dystrophy, early-onset leukoplakia, tooth abnormalities, hyperhidrosis of the palms and soles, and hair loss. There are several relatively more severe forms of DC. **Hoyeraal-Hreidarsson syndrome** is a multisystem disorder that presents in early childhood, which requires the features of DC along with **cerebellar hypoplasia** to establish the diagnosis. Patients have the classic diagnostic DC triad, in addition to developmental delay, IUGR, and bone marrow failure. Hoyeraal-Hreidarsson syndrome is genetically heterogeneous and caused by X-linked recessive pathogenic variants in *DKC1*. Some patients may also have severe immunodeficiency. **Revesz syndrome** has many of the features of DC and presents in early childhood. Bilateral exudative retinopathy is required to establish a diagnosis. Patients may also have intracranial calcifications, IUGR, developmental delay, and bone marrow failure. Pathogenic variants of *TINF2* are involved in Revesz syndrome, making it mostly an autosomal dominant condition, but a few patients have been described without an identified pathogenic variant. Individuals with these severe forms of DC have even shorter telomere lengths than those with classic DC. **Coats plus syndrome** is caused by compound heterozygous pathogenic variants in the *CTC1* gene or the *STN1* gene and has overlapping features with DC, including sparse and graying hair, dystrophic nails, and anemia. Telomeres can be very short, but patients display variable telomere length. Coats plus syndrome is characterized by retinal telangiectasia and exudates, intracranial calcification, leukodystrophy, brain cysts, osteopenia, GI bleeding, and portal hypertension caused by the development of vasculature ectasias in the stomach, small intestine, and liver.

Laboratory testing and imaging are an important part in establishing a diagnosis but also evaluate the spectrum of patient organ involvement. These tests include, but are not limited to, the laboratory tests described in the section "Laboratory Findings," as well as ultrasound of the abdomen, pulmonary function tests, liver enzymes, and nutritional elements (such as ferritin, folic acid, and vitamin B12). MRI of the head is useful when the patient has developmental delay and ataxia. Baseline bone marrow testing is critical. Annual evaluation of the bone marrow and complete blood counts every 3 months are common practice.

Because of genomic instability, imaging involving radiation should be limited to those that may affect management.

Cancer Risk and Other Complications

Patients with DC are predisposed to MDS and AML, as well as to solid tumors. Cancer usually develops in the third and fourth decades of life. The cumulative incidence of solid cancers and leukemia by the age of 65–70 years were estimated as 20% and 5–10%, respectively. The cumulative incidence of MDS was predicted to be 20% by the age of 50 years. The actuarial risk of clonal and malignant myeloid disease is 25% by age 18 years.

Forty percent of the cancers in such patients are SCCs of the head and neck (tongue, mouth, pharynx). SCCs of the skin and GI tract (esophagus, stomach, colon), as well as anorectal adenocarcinoma, are common. Patients may develop multiple separate primaries in different sites involving the tongue and nasopharynx.

Other life-threatening complications include pulmonary fibrosis, liver fibrosis, and severe GI bleeding.

Treatment

Androgens can induce improvement of bone marrow function in approximately 70% of patients, and in some, this treatment can result in normal trilineage blood counts for a number of years. Patients with DC become refractory to androgens as aplastic anemia progresses due to HSC depletion. They also tend to be more sensitive to the side effects of androgens than FA patients, making it important to start with lower doses and to monitor for side effects frequently. When the response is maximal, the androgen dose can be slowly reduced to the minimum dose required to maintain desired and safe blood cell counts but cannot be stopped.

Cytokine therapy with granulocyte-macrophage colony stimulating factor (GM-CSF) or with G-CSF alone or combined with erythropoietin appears to offer potential benefit, at least in the short term. Use of cytokines needs to be balanced with a potential growth-promoting effect of these medications on as-yet undetected MDS or AML cells.

Allogeneic HSCT is the only curative option for severe bone marrow failure, MDS, and AML. Long-term survival, even with sibling HLA-matched HSC donors, has traditionally been poor at about 50%. Morbidity and mortality result from transplant-related complications such as graft failure, GVHD, sepsis, or venoocclusive disease or from emergence of DC-related complications, such as pulmonary fibrosis and GI bleeding related to vascular anomalies. The high morbidity and mortality rate after HSCT is likely caused by ongoing tissue sensitivity and aging because of the telomere maintenance defect.

Prognosis

Considerable heterogeneity exists in DC, and some data about genotype-phenotype correlations are available. Patients with certain genetic groups (e.g., monoallelic *TERC, TERT*) may develop severe aplastic anemia or fibrosis of the liver and lungs, but these complications may appear later on in life and may not be accompanied by multisystem involvement. Patients with other genetic groups (e.g., monoallelic pathogenic variants in *DKC1* or *TINF2 and biallelic pathogenic variants in PARN, ACD, RTEL1, TERC or TERT*) appear to have more physical anomalies and a higher incidence and earlier onset of aplastic anemia and cancer. The mean age of death for patients with DC who are diagnosed in childhood is approximately 30 years. However, patients who are diagnosed during adulthood may have a mild disease or be completely asymptomatic. The main causes of death are bone marrow failure, complications of HSCT, cancer, fatal pulmonary problems, and GI bleeding.

CONGENITAL AMEGAKARYOCYTIC THROMBOCYTOPENIA

Etiology and Epidemiology

Congenital amegakaryocytic thrombocytopenia **(CAMT)** is less common than FA, SDS, and DC. It is transmitted in an autosomal recessive manner. CAMT typically manifests in infancy as isolated thrombocytopenia caused by reduction or absence of bone marrow megakaryocytes

with initial preservation of granulopoietic and erythroid lineages. Pancytopenia due to aplastic anemia often ensues in the first few years of life. Development of MDS and AML was reported in patients with CAMT, as well as persistent aplastic anemia.

The defect in CAMT is directly related to pathogenic variants in *MPL,* the gene for the receptor of thrombopoietin (THPO). *THPO* is a growth factor that promotes HSC survival and stimulates megakaryocyte proliferation and maturation. Heterozygotes of the pathogenic variant gene have normal hematology, whereas affected individuals have pathogenic variants in both alleles. Genotype-phenotype correlations predict disease course and prognosis. **Nonsense pathogenic variants** cause a complete loss of function of the THPO receptor, resulting in persistently low platelet counts in early infancy due to absence of megakaryocytes and a fast progression to pancytopenia and aplastic anemia **(CAMT type I)**. Impaired stem cell survival with *MPL* nonsense pathogenic variants explains the evolution of CAMT into aplastic anemia because THPO also has an antiapoptotic and cell survival effect on HSCs. **Missense pathogenic variants** of *MPL* are associated with a milder disease course, a later presentation, a partial and transient increase in platelets during the first year of life after presentation, and a delayed onset, if any, of pancytopenia, indicating residual receptor function **(CAMT type II)**. Biologically active plasma THPO is consistently elevated in all patients with CAMT. A small proportion of patients with the clinical picture of CAMT have no pathogenic variants in *MPL*, but more recently have been found to have homozygous pathogenic variants in *THPO.*

Clinical Manifestations

Intracranial hemorrhage is a major risk; about 25% of the patients develop this complication either in utero (13%), at birth (4%), or within the first 4 weeks of life (7%). Patients with CAMT commonly have a petechial rash, bruising, or bleeding. Onset of symptoms may depend on the severity of pathogenic variants and ranges from birth to the first year of life. Most patients with CAMT have normal physical and imaging features. About 10–20% of published phenotypic CAMT cases involved physical anomalies. The most common anomalies are neurologic. Findings related to cerebellar and cerebral atrophy are frequent, and developmental delay is a prominent feature. Congenital heart disease is rare but includes atrial and ventricular septal defects, patent ductus arteriosus, tetralogy of Fallot, and coarctation of the aorta. Some of these occur in combinations. Other anomalies include abnormal hips or feet, kidney malformations, eye anomalies, and cleft or high-arched palate. Some patients have microcephaly and abnormal facies.

Laboratory Findings

Thrombocytopenia is the major laboratory finding in CAMT. At birth, most patients present with thrombocytopenia but not all. Typically, at first, thrombocytopenia appears with normal hemoglobin levels and WBC counts. Peripheral blood platelets are reduced or totally absent. As in other IBMFSs, RBCs may be macrocytic. Hemoglobin F may be elevated, and there may be increased expression of i antigen. Initial bone marrow aspirates and biopsy specimens show normal cellularity with marked reduction or absence of megakaryocytes. Most patients develop pancytopenia between 6 months to 2 years of age. In patients in whom aplastic anemia develops, bone marrow cellularity is decreased, with fatty replacement; erythropoietic and granulopoietic lineages are also symmetrically reduced.

Diagnosis

If thrombocytopenia persists beyond the neonatal period or is associated with adequate platelet transfusion response and no obvious precipitating cause such as infections or immunologic reactions, a bone marrow aspirate and biopsy are indicated. Deficient megakaryocytes in such cases suggest the diagnosis, and genetic analysis will confirm it. If CAMT occurs at birth or shortly after, it must be distinguished from other causes of inherited and acquired neonatal thrombocytopenia. Thrombocytopenia with absent radii **(TAR syndrome)** is distinguished from CAMT because radii are absent in TAR. The distinction from DC may be evident by a lack of mucocutaneous, neurologic, and immunologic findings that are characteristic of the early-onset forms of DC. Telomere lengths below the first percentile matched for age to healthy controls is characteristic of DC and not CAMT. CAMT blood lymphocytes do not show increased chromosomal breakage when exposed to DEB, distinguishing the disease from FA.

Cancer Predisposition

CAMT can evolve into MDS and AML, but the true risk cannot be defined because most patients undergo early transplantation. Typical course in patients with transformation includes thrombocytopenia, aplastic anemia, followed by MDS (e.g., with monosomy 7 or trisomy 8) and leukemia.

Therapy and Prognosis

The mortality rate from thrombocytopenic bleeding, complications of aplastic anemia, or leukemic transformation in patients with *MPL* **nonsense** pathogenic variants is close to 100% if bone marrow function is not improved. Patients with **missense** pathogenic variants have a milder course but may still have serious complications. HSCT is the only curative option. The majority of patients with CAMT who undergo HSCT are cured, especially if the procedure is performed with HLA-matched sibling donors. Before transplantation, platelet transfusion should be used carefully. Platelet count should not always be the sole indication for treatment, but symptoms such as clinical bleeding are an appropriate trigger. Single-donor, leuko-reduced platelets are preferred to minimize sensitization. In a patient who is a candidate for HSCT, all blood products should be irradiated and cytomegalovirus safe. The role of thrombomimetic agents such as eltrombopag or romiplostim might be suitable for some patients (CAMT type II) and need to be studied further. However, the promotion of fibrosis by these agents and the risk of MDS and leukemia in CAMT render HSCT the preferred treatment for patients with severe cytopenia. Romiplostim has shown good and sustained response in those with pathogenic variants in *THPO*, and there have been no reports of acute leukemia or MDS in this subgroup of CMPL patients, but the numbers of patients with pathogenic variants in *THPO* are small.

GATA2-RELATED DISORDERS

The *GATA2* gene codes for a hematopoietic transcription factor that is crucial for the proliferation and maintenance of early hematopoietic cells. Heterozygous germline pathogenic variants, inherited in an autosomal dominant fashion and that are spontaneous in the majority of cases, result in various phenotypes that range from mild cytopenia to severe immunodeficiency and myeloid neoplasia. Approximately two thirds of pathogenic variants in *GATA2* are null, and one third are missense substitutions. Germline pathogenic variants in *GATA2* have been recognized as a major MDS and AML predisposition syndrome. Approximately 150 unique *GATA2* germline pathogenic variants have been identified in about 550 patients.

Clinical manifestations include monocytopenia and *Mycobacterium avium* complex (MonoMAC syndrome) infections, MDS with lymphedema (Emberger syndrome), familial MDS/AML, primary MDS, and chronic neutropenia and dendritic cell, monocyte, and B and NK lymphoid deficiency (DCML deficiency). Hematologic presentation is variable. Some patients present with cytopenia, a hypocellular marrow and monocytopenia, whereas others have severe immunodeficiency, and others still present with MDS/AML and no preexisting relevant medical history or cytopenia. Immune deficiency results in HPV-related infections such as warts or generalized verrucosis, disseminated nontuberculous mycobacterial, and systemic bacterial and fungal infections. Recurrent respiratory tract infections can result in lung disease, such as pulmonary alveolar proteinosis. Few patients have autoimmune dysregulation manifesting as autoimmune cytopenia, arthritis, lupus, and others. Constitutional abnormalities, such as lymphedema, hydrocele, and congenital deafness, as well as abnormalities in pulmonary, CV, urogenital, and neurological systems have been observed in approximately 50% of patients (Fig. 517.3).

In children and adolescents with primary MDS, pathogenic variants in *GATA2* are a predominant germline predisposition accounting for 7% of all MDS cases, 15% of patients with advanced MDS, and 37% of patients

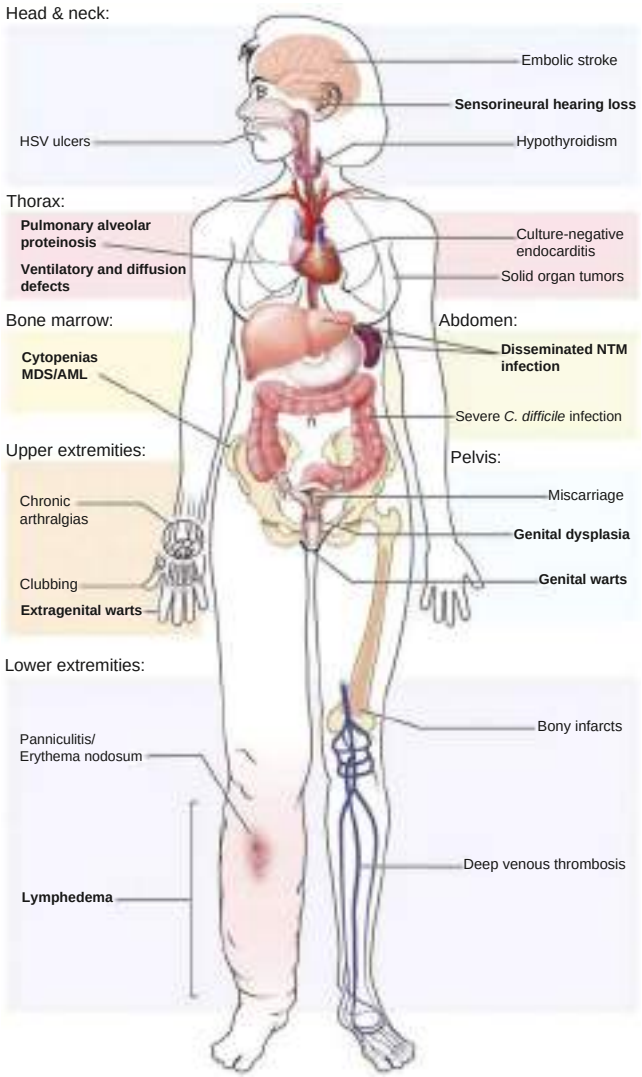

Fig. 517.3 Clinical features of GATA2 deficiency by organ system. Common clinical problems are indicated in bold. AML, acute myelogenous leukemia; MDS, myelodysplastic syndrome; NTM, non-tuberculous mycobacterium. *(From National Institute of Allergy and Infectious Diseases [NIAID] Health Information Fact Sheet.* https://www.niaid.nih.gov/sites/default/files/GATA2-Factsheet.pdf.*)*

with MDS and monosomy 7. Among children with MDS, the prevalence of *GATA2* pathogenic variants increases with age; 66% of adolescents with MDS and monosomy 7 carry germline *GATA2* pathogenic variants. Median age of diagnosis with *GATA2*-related MDS is approximately 10 years.

Patients should be followed by a hematologist with expertise in bone marrow failure/MDS and by an immunologist. Blood counts should be done every 3 months, and bone marrow aspirate and biopsy with cytogenetics should be carried out annually. HSCT is the only curative option for MDS and carries an overall survival ranging from 60–85% depending on donor type and MDS disease severity.

SAMD9/9L-RELATED DISORDER

Sterile alpha motif domain-containing protein 9 *(SAMD9)* and the paralogue gene *SAMD9*-like *(SAMD9L)* are located side-by-side on chromosome 7q21. They are interferon and tumor necrosis factor (TNF)-α responsive proteins that play a role in antiviral response, tumor suppression, inflammation, development, and endosomal fusion. Gain of function pathogenic variants, mostly missense, in these genes have variable penetrance. Thirty-eight pathogenic variants have been identified in approximately 110 patients.

Multiple organs can be affected in those with germline *SAMD9/9L* pathogenic variants, including the hematologic, immunologic, endocrine, and neurologic systems (see Table 517.2). The term **MIRAGE syndrome** was given to a constellation of abnormalities that include MDS, infection, restriction of growth (starting in utero), adrenal hypoplasia/insufficiency (with early onset), genital phenotypes (such as 46XY females and testicular dysgenesis), and enteropathy (often with reflux). Thrombocytopenia and anemia are often present at birth. In some patients, the anemia and thrombocytopenia resolve during infancy. Patients with *SAMD9L* pathogenic variants might show disease-specific neurological findings with very variable age of onset. Severe cerebellar ataxia is observed in some, whereas others have cerebellar atrophy, dysmetria, nystagmus, white matter abnormalities, and loss of Purkinje cells. The majority of patients in both syndromes have hematologic manifestations which range from single lineage cytopenia to pancytopenia with hypocellular marrow, MDS with monosomy 7, or deletion 7q. Some patients have nonsyndromic *SAMD9/9L* related MDS.

SAMD9/9L pathogenic variants are seen in 8–17% of pediatric MDS. The median age of presentation with SAMD9/9L related MDS is approximately 10 years. Ninety percent of children present in the early stage of MDS (refractory cytopenia of childhood), and another 10% present with advanced MDS. Transient monosomy 7 syndrome, the disappearance of monosomy 7 clones from the bone marrow, has been described in a few young children. It was hypothesized that pathogenic variants in the growth inhibitory genes, *SAMD9*/9L, confer gain of function that further suppress cell growth. Hence, monosomy 7, which depletes one allele of *SAMD9*/9L, reduces the growth inhibitory effect of the pathogenic variants. Somatic revertant mosaicism with expansion of benign, corrected hematopoiesis, has also been reported with normalization of blood counts and marrow cellularity for up to 20 years from diagnosis.

Monitoring and treatment depend on the degree of blood count abnormalities, the presence of MDS, and the presence of syndromic disease. Children who received HSCT for *SAMD9*/9L–related MDS showed an overall survival of 85% in one study.

OTHER INHERITED APLASTIC ANEMIAS

A substantial number of genes that are associated with bone marrow failure with pancytopenia have been identified with the emergence of whole genome screening methods (see Table 517.1). The specific gene-associated disorders may vary by phenotype but frequently include physical malformations, familial distribution, early age of disease onset, pancytopenia, and a risk of MDS and AML. Significant overlap exists between inherited pancytopenia syndromes and familial MDS and AML syndromes.

SRP72-Related Disorder

This autosomal dominant disorder is characterized by familial aplastic anemia and MDS. Some patients also have deafness. *SRP72* encodes for a signal recognition particle 72 protein. SRP72 is part of a ribonucleoprotein complex that mediates targeting of secretory proteins to the endoplasmic reticulum.

ERCC6L2-Related Disorder

This autosomal recessive disorder features multilineage cytopenia, MDS, and physical malformations. Neurological and cranial abnormalities are common in *ERCC6L2*-related disorder and include developmental delay, microcephaly, ataxia, dysmetria, generalized brain volume loss, retinal dystrophy, and low-set ears. ERCC6L2 regulates transcription by RNA Pol II through an interaction with DNA-PK; thereby, it promotes resolution of R loops and minimizes transcription-associated genome instability. The inherited BMF syndrome caused by biallelic pathogenic variants in ERCC6L2 is thus a primary transcription deficiency and may not cause a DNA repair defect.

Dubowitz Syndrome

Dubowitz syndrome is characterized by a peculiar facies, infantile eczema, small stature, and mild microcephaly. The face is small, with a shallow supraorbital ridge, a nasal bridge at the same level as the forehead, short palpebral fissures, variable ptosis, and micrognathia. There

is a predisposition to cancer in these patients. Approximately 10% of patients have hematopoietic disorders, including moderate pancytopenia, hypoplastic anemia, bone marrow hypoplasia, and full-blown aplastic anemia. Patients also have an increased risk of lymphoma and neuroblastoma. In about one third of patients, a genetic cause can be identified and includes biallelic pathogenic variants in *NSUN2* (an RNA methyltransferase), biallelic pathogenic variants in *LIG4* (a nuclear DNA ligase), or one copy deletion in several chromosome sites including 14q32, 17q24, -14q32, -17q24, and -19q13.

Seckel Syndrome

Seckel syndrome, sometimes called "bird-headed dwarfism," is a developmental disorder characterized by marked growth failure and mental deficiency, microcephaly, a hypoplastic face with a prominent nose, and low-set and/or malformed ears. Approximately 25% of patients have aplastic anemia or malignancies. The syndrome is genetically heterogeneous and is associated with biallelic pathogenic variants in *ATR*, *RBBP8*, *CENPJ*, *CEP152*, *CEP63*, *NIN,* or *ATRIP.* A deletion at the14q21-q22 locus has also been described.

Reticular Dysgenesis

Reticular dysgenesis is a severe form of immunodeficiency. It is mainly characterized by severe lymphopenia and neutropenia. Patients typically present with severe infections at birth or shortly thereafter. On physical examination, lymph nodes and tonsils are absent, and a thymic shadow on radiographs cannot be seen. Laboratory tests show absence of cellular and humoral immunity. Anemia, thrombocytopenia, and aplastic anemia may be evident. Bone marrow specimens show markedly reduced myeloid and lymphoid elements. Clonogenic assays of hematopoietic progenitors consistently show reduced to absent colony growth, suggesting that the disorder has its origins at the HSC level. The disease is inherited in an autosomal recessive fashion and is caused by biallelic pathogenic variants in mitochondrial *AK2*. The only curative therapy is HSCT.

Schimke Immunoosseous Dysplasia

Schimke immunoosseous dysplasia is an autosomal recessive disorder caused by pathogenic variants in the chromatin remodeling gene *SMARCAL1*. Patients have spondyloepiphyseal dysplasia with exaggerated lumbar lordosis and a protruding abdomen. There are pigmentary skin changes and abnormally discolored and configured teeth. T-cell immunodeficiency, progressive renal insufficiency, nephrotic syndrome, and early atherosclerosis are common causes of morbidity and mortality. Approximately 50% of patients have hypothyroidism; 50% have cerebral ischemia; 10% have bone marrow failure with neutropenia, thrombocytopenia, and anemia; and about 5% are predisposed to non-Hodgkin lymphoma. Eighty percent of patients have lymphopenia and altered cellular immunity. Bone marrow transplantation has been successfully applied to patients with bone marrow failure or immunodeficiency.

Cartilage Hair Hypoplasia

Cartilage-hair hypoplasia features metaphyseal dysostosis, short-limbed dwarfism, and fine sparse hair. Skeletal abnormalities may also include scoliosis, lordosis, chest deformity and varus lower limbs. GI abnormalities such as aganglionic megacolon have been reported. Most reported cases are of Finnish or Amish descent. In over 80% of patients, biallelic causal pathogenic variants in the noncoding RNA gene *RMRP* (RNA Component of Mitochondrial RNA Processing Endoribonuclease) can be found. Recently, biallelic pathogenic variants in *POP1* and in *NEPRO* have also been found to be associated with the disease. POP1 is a component of the RNAse-MRP endoribonuclease complex. NEPRO is a nucleolar and neural progenitor protein that interacts with multiple subunits of the RNase MRP complex. The complex plays a role in rRNA and in mitochondrial RNA processing by cleavage at a priming site during replication.

The hematological abnormalities include macrocytic anemia. In most cases the anemia is mild and self-limited, but a proportion of patients have severe and persistent anemia that requires regular RBC transfusions. Lymphopenia occurs in 65% of patients. Severe immunodeficiency can occur, often with severe anemia. Neutropenia has been reported in 25% of patients. HSCT has been used successfully to reconstitute the hemato/immunological system. Lymphomas and basal cell carcinoma occur at an increased frequency among these patients.

Pearson Syndrome

Pearson syndrome is a mitochondrial metabolic disorder with various bone marrow impairments. Insufficiency of the exocrine pancreas, caused by acinar cell atrophy and fibrosis, develops in 30% of cases. The syndrome is caused by a maternally inherited deletion of mitochondrial DNA (mtDNA) that encodes enzymes that are critical to oxidative phosphorylation. Severe macrocytic anemia requiring transfusions is commonly present within the first year of life, sometimes at birth. Bone marrow aspirate typically shows ringed sideroblasts and prominent vacuolization of erythroid and myeloid precursors. However, cases with pure red cell aplasia mimicking Diamond Blackfan anemia have been reported. Pancytopenia may occur alone or in association with hepatic failure, renal tubulopathy, and lactic acidosis. In such cases, platelet transfusions may also be required. Erythropoietin has been used for the anemia of renal failure. G-CSF is indicated to prevent infections in patients with severe neutropenia. HSCT is traditionally not recommended for the hematopoietic complications of Pearson syndrome due to their tendency to improve spontaneously in most cases; nonetheless, HSCT has been used in rare cases with Pearson syndrome, and engraftment was achieved. Interestingly, HSCT was associated not only with improved hematopoiesis but also with resolution of lactacidemia and acidosis. Patients may need pancreatic enzyme replacement if they develop malabsorption due to exocrine pancreatic insufficiency.

Immune-Related Pancytopenias

Primary immunodeficiency, autoimmune, lymphoproliferative, and hemophagocytic disorders can be associated with pancytopenia. Autoantibodies, hypersplenism, and bone marrow involvement are potential mechanisms. Recognizable disorders include common variable immunodeficiency syndrome (Chapter 165), hemophagocytic lymphohistiocytosis (Chapter 556.2), autoimmune lymphoproliferative syndrome (Chapter 174.7), and other lymphoproliferative disorders.

UNCLASSIFIED INHERITED BONE MARROW FAILURE SYNDROMES

Unclassified IBMFSs are heterogeneous disorders that in many cases were shown to present as new syndromes. In other cases, they may be atypical presentations of already characterized diseases. Unbiased approaches, such as study of comprehensive genetic panels of all known IBMFS genes regardless of the specific hematologic (e.g., isolated neutropenia or pancytopenia) or nonhematologic manifestations, or WES/genome sequencing, have proved this to be true. These disorders do not fit into classic genetic bone marrow failure diseases because all features of any one disease may not be evident at presentation. All are characterized by various cytopenias caused by underproductive bone marrow with or without physical manifestations. Compared with patients with classical disorders who present at a median age of 1 month, patients with unclassified disorders present later, at a median age of 9 months. Patients with unclassified IBMFSs can manifest single or multilineage cytopenia, aplastic anemia, MDS, or malignancy with variable expression of malformations. Table 517.5 lists criteria for the diagnosis, which include evidence of chronic bone marrow failure, in addition to factors that indicate a high likelihood of inherited disease (e.g., family history, congenital anomalies, young age at presentation).

When patients present later and without physical malformations, an acquired etiology cannot be ruled out. Detailed genetic testing for known IBMFS genes followed by approaches to discover novel genes and novel syndromes by WES/genome sequencing may identify an inherited etiology and define the disease.

Determining the actual genetic cause helps group patients according to diseases and guides counseling and proper medical care. Implementing a treatment plan is urgent in many cases. In such patients, the management should be according to the type of complications that the patient has at presentation and the lessons that can be learned from published experience on unclassified cases in the literature.

Visit Elsevier eBooks+ at eBooks.Health.Elsevier.com for Bibliography.

Table 517.5 The Canadian Inherited Marrow Failure Registry Criteria for Unclassified Inherited Bone Marrow Failure Syndromes

FULFILLS CRITERIA 1 AND 2: 1. Does not fulfill criteria for any categorized inherited bone marrow failure syndrome* 2. Fulfills both of the following:
FULFILLS AT LEAST TWO OF THE FOLLOWING: a. Chronic cytopenia(s) detected on at least two occasions over at least 3 months† b. Reduced marrow progenitors or reduced clonogenic potential of hematopoietic progenitor cells or evidence of ineffective hematopoiesis‡ c. High fetal hemoglobin for age‡ d. Red blood cell macrocytosis (not caused by hemolysis or a nutritional deficiency)
FULFILLS AT LEAST ONE OF THE FOLLOWING: a. Family history of bone marrow failure b. Presentation at age <1 year c. Anomalies involving multiple systems to suggest an inherited syndrome

*The criteria for most common syndromes are described in Tsangaris E, Klaasen R, Fernandez CV, et al. Genetic analysis of inherited bone marrow failure syndromes from one prospective, comprehensive, and population-based cohort and identification of novel mutations. *J Med Genet*. 2011;48:618–628.

†Cytopenia is defined according to the affected cell: neutropenia, neutrophil count of $<1.5 \times 10^9$/L; thrombocytopenia, platelet count of $<150 \times 10^9$/L; anemia, hemoglobin concentration of >2 standard deviations below mean, adjusted for age.

‡Hemoglobinopathies with ineffective erythropoiesis and high fetal hemoglobin should be excluded by clinical or laboratory testing.

Modified from Teo JT, Klaassen R, Fernandez CV, et al. Clinical and genetic analysis of unclassifiable inherited bone marrow failure syndromes. *Pediatrics*. 2008;22:e139–e148.

Table 518.1 Etiology of Acquired Aplastic Anemia

Radiation, Drug, and Chemicals
Predictable: chemotherapy, benzene
Idiosyncratic: chloramphenicol, antiepileptics, gold, 3,4-methylenedioxymethamphetamine, nonsteroidal antiinflammatory drugs (NSAIDs), antibiotics
See also Table 518.2
Viruses
Cytomegalovirus
Epstein-Barr
Hepatitis B
Hepatitis C
Hepatitis non-A, non-B, non-C (seronegative hepatitis)
HIV
COVID-19
Immune Diseases
Eosinophilic fasciitis
Hypoimmunoglobulinemia
Thymoma
Common variable immunodeficiency syndrome *(NFKB1)*
Pregnancy
Paroxysmal Nocturnal Hemoglobinuria
Marrow Replacement
Leukemia
Myelodysplasia
Myelofibrosis
Autoimmune
Nutritional
Vitamin B_{12}
Folate
Copper
Other
Cryptic dyskeratosis congenita (no physical stigmata)
Telomerase reverse transcriptase haploinsufficiency
Atypical presentation of genetic marrow failure syndromes
Leishmaniasis

Chapter 518

Acquired Pancytopenias

John H. Fargo and Jeffrey D. Hord

ETIOLOGY AND EPIDEMIOLOGY

Therapeutic and recreational drugs, environmental toxins, infectious agents, radiation, and immune disorders can result in pancytopenia by direct destruction of hematopoietic progenitors, disruption of the marrow microenvironment, or immune-mediated suppression of marrow elements (Tables 518.1 and 518.2). A careful history of exposure to known risk factors should be obtained for every child presenting with pancytopenia. Even in the absence of the classic associated physical findings, the possibility of a genetic predisposition to bone marrow failure must also be considered (see Chapter 517). Many cases of acquired marrow failure in childhood are idiopathic, in that no causative agent is identified. Many are probably immune mediated through cytotoxic T lymphocytes and cytokine destruction of marrow stem and progenitor cells. Patients with an initial diagnosis of acquired aplastic anemia may have developed somatic pathogenic variants in genes associated with myelodysplastic syndromes (MDS) and acute myeloid leukemia (AML). Clonal hematopoiesis resulting from these acquired somatic genetic variants may over time lead to the development of MDS or AML. The overall incidence of **acquired aplastic anemia** is relatively low, with an approximate incidence in both children and adults in the United States and Europe of 2–6 cases per 1 million population per year. The incidence is higher in Asia, with as many as 14 cases per 1 million per year in Japan.

Severe bone marrow suppression can develop after exposure to many different therapeutic drugs and environmental chemicals, including certain chemotherapeutic agents, insecticides, antibiotics, anticonvulsants, nonsteroidal antiinflammatory drugs (NSAIDs), and recreational drugs. Some of the most notable agents are benzene, chloramphenicol, gold, and 3,4-methylenedioxymethamphetamine (MDMA, or "ecstasy").

A number of viruses can either directly or indirectly result in bone marrow failure. Parvovirus B19 is classically associated with isolated red blood cell (RBC) aplasia, but in patients with sickle cell disease or immunodeficiency, it can result in transient pancytopenia (see Chapter 298). Prolonged pancytopenia can occur after infection with many of the hepatitis viruses, herpesviruses, Epstein-Barr virus (see Chapter 301), cytomegalovirus (see Chapter 302), and HIV (see Chapter 322).

Immune-mediated acquired pancytopenia is also found to be prominent among acute, sporadic cases of aplastic anemia. Immunologic conditions, such as seronegative hepatitis, eosinophilic fasciitis, and thymoma, have been implicated in aplastic anemia.

Patients with evidence of bone marrow failure should also be evaluated for inherited forms of marrow failure, **paroxysmal nocturnal hemoglobinuria** (PNH; see Chapter 510), and collagen vascular diseases. Pancytopenia without peripheral blasts may be caused by bone marrow replacement by malignant cells including leukemia and solid tumor cells, such as neuroblastoma.

Table 518.2 Drugs and Toxins Associated with Aplastic Anemia

DOSE DEPENDENT
Antineoplastic Agents
Antimetabolites: fluorouracil, mercaptopurine, 6-thioguanine, methotrexate, cytosine arabinoside, gemcitabine, fludarabine, cladribine, pentostatin, hydroxyurea
Alkylating and cross-linking agents: busulfan, cyclophosphamide, chlorambucil, nitrogen mustard, melphalan, cisplatin, carboplatin, ifosfamide, nitrosoureas (BCNU and CCNU), mitomycin C
Cytotoxic antibiotics: daunorubicin, doxorubicin, mitoxantrone
Plant alkaloids: vinblastine, paclitaxel
Topoisomerase inhibitors: etoposide
Antimicrobial Agents
Chloramphenicol, dapsone, fluorocytosine
Antiinflammatory and Antirheumatic Agent
Colchicine
Insecticides
Chlordane, chlorophenothane (DDT), lindane, parathion
Other Chemicals
Benzene
Benzene-containing chemicals: kerosene, chlorophenols, carbon tetrachloride
DOSE INDEPENDENT*
Idiosyncratic, likely immune mediated
Antimicrobial Agents
Chloramphenicol, dapsone, sulfonamides, tetracycline, methicillin, amphotericin, quinacrine, chloroquine, pyrimethamine
Anticonvulsants
Hydantoins, carbamazepine, phenacemide, primidone, ethosuximide
Antiinflammatory Agents
Phenylbutazone, indomethacin, ibuprofen, oxyphenbutazone, sulindac, naproxen
Antiarrhythmic Drugs
Quinidine, tocainide, procainamide
Metals
Gold, arsenic, mercury, bismuth
Antihistamines
Cimetidine, ranitidine, chlorpheniramine, pyrilamine, tripelennamine
Diuretics
Acetazolamide, furosemide, chlorothiazide, methazolamide
Hypoglycemic Agents
Chlorpropamide, tolbutamide
Antithyroid Drugs
Propylthiouracil, potassium perchlorate, methylthiouracil, methimazole, carbimazole
Antihypertensive Agents
Methyldopa, enalapril, captopril
Sedatives
Chlordiazepoxide, chlorpromazine, meprobamate, prochlorperazine

*Most agents listed in this group should be considered to be possibly associated with aplastic anemia.

From Bagby GC. Aplastic anemia and related bone marrow failure states. In: Goldman L, Schafer AI, eds. *Goldman-Cecil Medicine*, 26th ed. Philadelphia: Elsevier, 2020: Table 156.2.

PATHOLOGY AND PATHOGENESIS

The hallmark of aplastic anemia is peripheral pancytopenia, coupled with hypoplastic or aplastic bone marrow. The severity of the clinical course is related to the degree of myelosuppression. **Severe aplastic anemia** is defined as a condition in which ≥2 cell components have become seriously compromised (absolute neutrophil count <500/mm^3, platelet count <20,000/mm^3, reticulocyte count <1% after correction for hematocrit) in a patient whose bone marrow biopsy material has <30% cellularity. Approximately 65% of patients who first present with **moderate aplastic anemia** (absolute neutrophil count 500–1,500/mm^3, platelet count 20,000–100,000/mm^3, reticulocyte count <1%) eventually progress to meet the criteria for severe disease if they are simply observed. Bone marrow failure may be a consequence of a direct cytotoxic effect on hematopoietic stem cells (HSCs) from a drug or chemical or may result from either cell-mediated or antibody-dependent cytotoxicity. There is strong evidence that many cases of idiopathic aplastic anemia are caused by an immune-mediated process, with increased circulating cytotoxic T lymphocytes producing cytokines (interferon-γ) that suppress hematopoiesis. Abnormal telomere length and telomerase activity in granulocytic precursors of patients with aplastic anemia suggest that early apoptosis of hematopoietic progenitors may play a role in the pathogenesis of this disease.

Cytogenetic abnormalities associated with aplastic anemia include uniparental disomy of 6p, monosomy 7/deletion of 7q, and trisomy 8, 6, or 15. Genes associated with aplastic anemia include telomere complex genes *(TERT, TERC)* and *BCOR/BCORL, PIGA, DNMT3A,* and *ASXL1*.

CLINICAL MANIFESTATIONS, LABORATORY FINDINGS, AND DIFFERENTIAL DIAGNOSIS

Pancytopenia results in increased risks of cardiac failure, fatigue, infection, and bleeding. Acquired pancytopenia is typically characterized by anemia, leukopenia, and thrombocytopenia in the setting of elevated serum cytokine values. Other treatable disorders, such as cancer, collagen vascular disorders, PNH, and infections, that may respond to specific therapies (IV immunoglobulin for parvovirus), should be considered in the differential diagnosis. Careful examination of the peripheral blood smear for RBC, leukocyte, and platelet morphologic features is important. A reticulocyte count should be performed to assess erythropoietic activity. In children, the possibility of *congenital* pancytopenia must always be considered, and chromosomal breakage analysis should be performed to evaluate for **Fanconi anemia** (see Chapter 517) and telomere length to evaluate for telomeropathies. The presence of fetal hemoglobin suggests congenital pancytopenia but is not diagnostic. To assess for possible PNH, flow cytometric analysis of erythrocytes and granulocytes for CD55 and CD59 is the most sensitive test. Bone marrow examination should include both aspiration and biopsy, and the marrow should be carefully evaluated for morphologic features, cellularity, and cytogenetic abnormalities.

TREATMENT

The treatment of children with acquired pancytopenia requires comprehensive supportive care coupled with an attempt to treat the underlying etiology for marrow failure. For patients with a human leukocyte antigen (HLA)–matched family member donor, **allogeneic hematopoietic stem cell transplantation (HSCT)** offers a 90% chance of long-term survival. Preparative regimens vary but typically consist of cyclophosphamide, fludarabine, and horse antithymocyte globulin (ATG). Preliminary data also suggest that children with severe aplastic anemia can be successfully transplanted using *alemtuzumab* (humanized monoclonal antibody against CD52 on lymphocytes)–based conditioning. The risks associated with bone marrow transplantation include the immediate complications of transplantation, graft failure, and graft-versus-host disease. Late adverse effects associated with transplantation may include secondary cancers, cataracts, short stature, hypothyroidism, and gonadal dysfunction (see Chapters 179 and 180). Only approximately 20% of patients have an HLA-matched family member donor, so matched-related HSCT is not an option for the majority of patients.

For patients without a sibling donor, the major form of therapy is **immunosuppression** with horse ATG and cyclosporine, with a response rate of 60–70%. The median time to response is 6 months. As many as 30–60% of patient responders experience relapse after discontinuation of immunosuppression, and some patients must continue cyclosporine for several years to maintain a hematologic

response. Among those who relapse after immunosuppression, approximately 50% show response to a second course of ATG and cyclosporine. To accelerate neutrophil recovery, a hematopoietic colony-stimulating factor (e.g., granulocyte CSF, granulocyte-macrophage CSF) is sometimes added to ATG and cyclosporine for treatment of patients with very severe neutropenia (absolute neutrophil count <200/mm^3), but there is no clear evidence that this treatment influences response rate or survival. Higher baseline reticulocyte count correlates with a higher probability of response to immunosuppression and survival. There is an inverse correlation between telomere length and the probability of relapse after immunosuppression.

For patients who show no response to immunosuppression or who experience relapse after immunosuppression, **matched-unrelated HSCT and T-cell–depleted haploidentical family member–donor HSCT** are treatment options, with a response rate approaching 90%. Cord blood transplants have been performed in this refractory group of pediatric patients, with survival approximating 90%. Ongoing studies using **eltrombopag** (an oral thrombopoietin mimetic agent) have shown promise in patients ≥15 years of age (mostly adults) with refractory disease. The use of eltrombopag resulted in a hematologic response with improvements in platelet and neutrophil counts and hemoglobin levels in over half the patients. In patients who responded, bone marrow biopsies demonstrated trilineage normalization of hematopoiesis, with some showing a durable response. **High-dose cyclophosphamide** has been used successfully in the treatment of patients who are not good candidates for HSCT and have not had an adequate response to immunosuppression. This therapy leads to prolonged severe pancytopenia, increasing the risk of life-threatening infection, especially fungal infections. Other therapies that have been used in the past with inconsistent results include androgens, corticosteroids, and plasmapheresis. **Alemtuzumab** as monotherapy in relapsed disease showed improved response rates and 3-year survival compared to additional courses of ATG and cyclosporine.

COMPLICATIONS

The major complications of severe pancytopenia are predominantly related to the risk of life-threatening bleeding from prolonged thrombocytopenia or to infection secondary to protracted neutropenia. Patients with protracted neutropenia as a result of bone marrow failure are at risk not only for serious bacterial infections but also for invasive mycoses. Patients who have been transfused with RBCs regularly over a long period are at increased risk of developing alloantibodies to RBC antigens and may require iron chelation therapy for transfusional iron overload. The general principles of supportive care that have evolved from the use of chemotherapy-related myelosuppression to treat patients with cancer should be fully extended to the care of patients with acquired pancytopenia.

PROGNOSIS

Spontaneous recovery from pancytopenia rarely occurs. If left untreated, severe pancytopenia has an overall mortality rate of approximately 50% within 6 months of diagnosis and of >75% overall, with infection and hemorrhage being the major causes of morbidity and mortality. The majority of children with acquired severe aplastic anemia show response to allogeneic marrow transplantation or immunosuppression, leaving them with normal or near-normal blood cell counts.

PANCYTOPENIA CAUSED BY MARROW REPLACEMENT

Processes that either infiltrate or replace the bone marrow can manifest as acquired pancytopenia. Infiltration can be caused by malignancy (classically, neuroblastoma or leukemia) or result from myelofibrosis, MDS, or osteopetrosis. Although uncommon, evidence of hypoplastic anemia can precede the onset of acute leukemia, generally by a few months. This relationship is important to appreciate in evaluating and monitoring children who present with what appears to be acquired aplastic anemia. Morphologic examination of the peripheral blood and bone marrow and marrow cytogenetic studies are critically important in making the diagnoses of leukemia, myelofibrosis, and MDS.

Myelodysplasia is very rare in children, but when it occurs, its clinical course is more aggressive than the same category of MDS in adults. Pediatric MDS can be subdivided into **refractory cytopenia of childhood** (peripheral blasts <2% and marrow blasts <5%) and **MDS with excess blasts** (peripheral blasts 2–19% and/or marrow blasts 5–19%). Disease in children with >20% blasts is usually defined as AML.

Myelodysplastic syndromes are a heterogeneous group of bone marrow failure disorders that have in common ineffective hematopoiesis that leads to pancytopenia over time. In one group, there are somatic variants (in >25 genes) leading to MDS. In another group, usually in younger patients (<55 years), there is autoimmune suppression of hematopoiesis by clonal expansion of T lymphocytes, particularly in those patients who look similar to patients with idiopathic aplastic anemia. In all patients, other causes of MDS (medications and vitamin B_{12}, folate, or copper deficiencies) must be ruled out.

A number of inherited conditions are associated with an increased risk for development of MDS, including Down syndrome, severe congenital neutropenia, Noonan syndrome, Fanconi anemia, trisomy 8 mosaicism, neurofibromatosis, Shwachman-Diamond syndrome, and some familial MDS syndromes caused by pathogenic variants in *ANKRD26, CEBPA, DDX41, ETV6, GATA2, RUNX1,* and *SRP72* genes. Significant clonal abnormalities are found within the marrow of approximately 50% of patients with MDS, with monosomy 7 being most common but prognostically neutral. Those with a structurally complex karyotype have a very poor outcome (see Chapter 517).

The transition time from pediatric MDS to acute leukemia is relatively short, 14–26 months, so aggressive treatment such as HSCT must be considered shortly after diagnosis. With allogeneic HSCT, the survival rate is approximately 60%. One exception to such an aggressive therapeutic approach is MDS and AML in children with Down syndrome because these diseases in this specific population are very responsive to conventional chemotherapy, with long-term survival rates >80%.

The decision on how to treat a child with MDS who lacks a suitable HSC donor should be made with the specific clonal abnormality found within the child's marrow taken into consideration. Lenalidomide produces the best responses among patients who have the chromosomal abnormality 5q−. Immunosuppressive therapy with ATG and cyclosporine is most effective in patients with trisomy 8, especially in the presence of a PNH clone. Imatinib mesylate targets mutations in the tyrosine kinase receptor family of genes found in patients with t(5;12) and del(4q12). The DNA hypomethylating agents azacitidine and decitabine have also been used in treating MDS without a known molecular target and have some effect.

Visit Elsevier eBooks+ at eBooks.Health.Elsevier.com for Bibliography.

Section 6

Blood Component Transfusions

Chapter 519

Red Blood Cell Transfusions and Erythropoietin Therapy

Patricia E. Zerra and Cassandra D. Josephson

Red blood cells (RBCs) are transfused to increase the oxygen-carrying capacity of the blood, with the goal to increase or maintain satisfactory tissue oxygenation. This goal may not be achieved simply by increasing the hemoglobin (Hb) concentration or hematocrit (Hct) by an RBC transfusion because tissue oxygenation depends on several additional factors, including oxygen off-loading from RBCs, microvascular blood flow, and diffusion of oxygen into tissue cells. Although some attempts have been made to accurately relate posttransfusion Hb or Hct values to changes in posttransfusion tissue oxygenation (e.g., improvements in the ratio of cerebral vs mesenteric oxygenation patterns assessed by serial near-infrared spectroscopy measurements), decisions to transfuse RBCs per physiologic indications, rather than degree of anemia, remain investigational. This information can be applied to approaches for transfusion in both preterm infants/neonates and children/adolescents. However, neonates, especially extremely low birthweight infants (≤1,000 g), are not "small" children (i.e., RBC physiology and pathophysiology of anemia of prematurity are unique); thus RBC transfusions for neonates and children are considered separately.

RBC TRANSFUSION IN CHILDREN AND ADOLESCENTS

Guidelines for RBC transfusions in children and adolescents are based on maintaining a specified Hb or Hct level considered to be optimal (per the best evidence available) for the clinical condition present at the time of transfusion. The guidelines are similar to those for adults (Table 519.1). Transfusions may be given more stringently to children because normal Hb levels are lower in healthy children than in adults and, as is often the case, most children do not have the underlying multiorgan, cardiorespiratory, and vascular diseases that develop with aging in adults to suggest a need for RBC transfusions. As a result, children may compensate better for RBC loss than elderly adults, thus requiring less RBC transfusion support. In general, there is increasing enthusiasm for applying patient blood management strategies, encompassing conservative transfusion practices (i.e., accepting lower pretransfusion Hct values to "trigger" an RBC transfusion) to all patient ages with evidence-based support.

In the **perioperative period,** it is unnecessary for most children to maintain Hb of ≥8 g/dL, a level frequently desired for adults. Instead, Hb of ≥7 g/dL is an acceptable level, although the optimal value for individual patients is based on clinical and laboratory circumstances, as influenced by the following factors. The desired preoperative Hb level should consider the estimated blood loss for the surgical procedure planned and the rate of bleeding. There should be a compelling reason to prescribe any postoperative RBC transfusion, such as continued bleeding with hemodynamic instability because most children (without continued bleeding) can restore their RBC mass with iron therapy (in a relatively short time).

Table 519.1 Guidelines for Pediatric Red Blood Cell Transfusions*†

CHILDREN AND ADOLESCENTS
1. Maintain stable status with acute loss of >25% of circulating blood volume.
2. Maintain hemoglobin >7.0 g/dL† in the perioperative period.
3. Maintain hemoglobin >12.0 g/dL with *severe* cardiopulmonary disease.
4. Maintain hemoglobin >12.0 g/dL during extracorporeal membrane oxygenation.
5. Maintain hemoglobin >7.0 g/dL with *symptomatic* chronic anemia.
6. Maintain hemoglobin >7.0 g/dL with *marrow failure*.
INFANTS ≤4 MO OLD
1. Maintain hemoglobin >12.0 g/dL with *severe* pulmonary disease.
2. Maintain hemoglobin >12.0 g/dL during extracorporeal membrane oxygenation.
3. Maintain hemoglobin >10.0 g/dL with *moderate* pulmonary disease.
4. Maintain hemoglobin >12.0 g/dL with *severe* cardiac disease.
5. Maintain hemoglobin >10.0 g/dL preoperatively and during *major* surgery.
6. Maintain hemoglobin >7.0 g/dL postoperatively.
7. Maintain hemoglobin >7.0 g/dL with *symptomatic* anemia.

*Words in *italics* must be defined for local transfusion guidelines.
†Pretransfusion blood hemoglobin (Hb) level (convert to hematocrit values if preferred by multiplying Hb values by 3) "triggering" an RBC transfusion. Hb values to maintain vary among published reports, and the guideline values to maintain should be determined locally to fit the practices judged to be optimal by local physicians.

The most important measures in the treatment of **acute hemorrhage** are to control the hemorrhage and, if blood loss is modest, to restore the circulating blood volume and tissue perfusion with crystalloid or, less often, colloid solutions. If the estimated blood loss is >25% of the circulating blood volume (>15 mL/kg of an estimated 60 mL/kg total estimated blood volume) *and* the patient's condition is unstable despite initial intravenous (IV) fluids, RBC transfusions should be given without undue hesitation, along with plasma transfusions at a 1:1 ratio of RBC/plasma volumes. Some experts recommend transfusing platelets early if bleeding is sustained or "massive" (i.e., approximating one blood volume or 60 mL/kg, which may occur very quickly in infants and small pediatric patients). Details of combined RBC and plasma transfusions, the volume ratio transfused, and considerations for adding platelet transfusions to treat bleeding patients are controversial. Accordingly, each hospital should develop and follow a "massive transfusion" protocol to ensure consistent practices.

In critically ill children with severe cardiac or pulmonary disease requiring assisted ventilation, it is common practice to maintain the Hb level close to the normal range, although the efficacy of this practice has not been well documented. A similar approach is used for children with acute cardiac, pulmonary, or cardiopulmonary disorders managed with extracorporeal membrane oxygenation (ECMO).

The pretransfusion Hb level or Hct that should "trigger" an RBC transfusion remains controversial (i.e., restrictive or a low pretransfusion level vs liberal or a high pretransfusion level) despite a substantial amount of published information, including randomized clinical trials. The current trend in critical care settings is to transfuse RBCs conservatively, following restrictive guidelines, and to permit modest anemia because there appears to be no disadvantage to conservative/restrictive transfusion practices, and some patients with Hb levels maintained close to the normal range by RBC transfusions (i.e., liberal guidelines) have poorer outcomes. Studies in critically ill adults demonstrated better outcomes when Hb level was maintained at 7–9 g/dL vs 10–12 g/dL. Anemic adults with *significant cardiac disease* did better with Hb level maintained at 13 g/dL rather than 10 g/dL. A similar study in children admitted to intensive care units found no inferiority when RBC

transfusions were given by restrictive guidelines *(transfusion threshold of 7 g/dL)*. It must be remembered that the children studied were in stable clinical status and needed few transfusions. Therefore, results of the trial cannot be automatically generalized to all patients admitted to ICUs because unstable critically ill children (who were not included in the study) may need more liberal RBC transfusion approaches.

With **chronic anemia,** the decision to transfuse RBCs should not be based solely on blood Hb levels because children compensate well and may be asymptomatic despite low Hb levels. Patients with iron-deficiency anemia are often treated successfully with oral iron alone, even at Hb levels <5 g/dL. Factors other than Hb concentration to be considered in the decision to transfuse RBCs include (1) the patient's symptoms, signs, and compensatory capacities; (2) the presence of underlying cardiorespiratory, vascular, and central nervous system disease; (3) the cause and anticipated course of the anemia; and (4) alternative therapies, such as recombinant human erythropoietin (EPO) therapy, which is known to reduce the need for RBC transfusions and to improve the overall condition of children with chronic renal insufficiency (see Chapter 572.2). In anemias that are likely to be permanent, it is also important to balance the detrimental effects of the degree of long-standing anemia on growth and development against the potential toxicity associated with repeated transfusions (i.e., iron overload and risks of transfusion-transmitted diseases) given to maintain the Hb concentration at a specified level. RBC transfusions for disorders such as sickle cell anemia and thalassemia are discussed in Chapters 511.1 and 511.10.

RBC TRANSFUSION IN PRETERM INFANTS AND NEONATES

For neonates, almost all aspects of RBC transfusions remain controversial—the accepted indications for RBC transfusions, restrictive vs liberal pretransfusion Hb/Hct levels, optimal RBC product to be transfused, and fresh vs stored RBC units—and clinical practices vary greatly. Generally, RBCs are given to maintain an Hb value believed to be the most desirable for each neonate's clinical status. Restrictive guidelines (i.e., lower pretransfusion Hb/Hct levels) have been compared to more liberal transfusion practices, but both short-term and long-term results and outcomes have been inconsistent and controversial, particularly as to neurodevelopmental status. Two multicenter randomized controlled trials showed no difference in survival or neurodevelopmental outcome in premature infants receiving RBC transfusion based on liberal versus restrictive Hb thresholds. Importantly, a lower Hb threshold was *not inferior* to a higher threshold for RBC transfusion. However, these studies had limitations, and accordingly, conventional guidelines are recommended to avoid problems caused by undertransfusion or overtransfusion (see Table 519.1).

During the first few weeks of life, all neonates experience a decline in circulating RBC mass caused by physiologic factors and, in sick premature infants, by phlebotomy blood losses. In healthy term infants, the nadir Hb value rarely falls to <11 g/dL at age 10-12 weeks. This benign drop in Hb does not require transfusions. In contrast, the decline occurs earlier and is more pronounced in premature infants, in whom the mean Hb concentration falls to approximately 7 g/dL in infants weighing <1 kg at birth, resulting in the **anemia of prematurity**, for which there often is need for RBC transfusions, particularly when the anemia is worsened by blood draws for laboratory testing.

A key reason that the nadir Hb values of premature infants are lower than those of term infants is the premature infant's relatively diminished plasma EPO level in response to anemia (see Chapters 139 and 496). Another factor is the rapid disappearance of EPO from infant plasma (i.e., accelerated metabolism). Low plasma EPO levels provide a rationale for the possible use of recombinant EPO in the treatment of anemia of prematurity; treatment with EPO and iron effectively stimulate neonatal erythropoiesis. Recombinant EPO has not been widely accepted as a treatment for anemia of prematurity (see Chapter 139).

Many low birthweight preterm infants need RBC transfusions (see Table 519.1). Although the practice to maintain a very high Hb level >13 g/dL (or Hct >40%) was once widely recommended, currently more restrictive guidelines have been suggested. However, one prospective, observational, multisite, birth cohort study of very low birthweight infants (≤1500 g) found a sixfold increased risk of necrotizing enterocolitis (NEC) when an infant's hemoglobin was ≤8 g/dL. Importantly, RBC transfusion in a given week did not significantly increase the rate of NEC in this population. Consistent with the rationale for oxygen delivery in neonates with severe respiratory disease, it also seems appropriate to keep the Hb value relatively high in neonates with *severe cardiac disease* leading to either cyanosis or congestive heart failure, but convincing and consistent data are lacking.

The optimal Hb level for neonates facing major surgery has not been established. However, it seems reasonable to begin surgery in neonates with the Hb level no lower than 10 g/dL (hematocrit >30%) and to maintain that value during major surgery because even modest blood loss will have a relatively large effect on the small blood volume of the neonate. Neonates with underlying pulmonary problems have limited ability to compensate for anemia due to the inability to increase ventilation and the inferior off-loading of oxygen because of the diminished interaction between fetal Hb and 2,3-diphosphoglycerate. Postoperatively, a lower pretransfusion Hb value should be followed to "trigger" a transfusion.

Stable neonates do not require RBC transfusion, regardless of their blood Hb levels, unless they exhibit clinical symptoms attributable to anemia. Proponents of RBC transfusions for symptomatic anemia in preterm neonates believe that the low RBC mass contributes to tachypnea, dyspnea, tachycardia, apnea and bradycardia, feeding difficulties, and lethargy, which can be alleviated by transfusion of RBCs. However, anemia is only one of several possible causes of these problems, and RBC transfusions should only be given when clinical benefit seems likely.

RBC PRODUCT AND DOSE

The RBC product of choice to transfuse neonates, infants, children, and adolescents is prestorage *leukocyte-reduced* RBCs suspended in an anticoagulant/preservative storage solution at Hct of approximately 60–70% for storage up to 35–42 days. For those infants with birthweight <1,500 g, *irradiation* is recommended to prevent transfusion-associated graft-versus-host disease. Additionally, both leukoreduction and cytomegalovirus-seronegative RBC units have been recommended by some (estimated risk of *transfusion-transmission cytomegalovirus* [TT-CMV] infection: 0–0.3% per unit) as first-line therapy to prevent TT-CMV. However, given the low risks of TT-CMV with improvements in modern leukoreduction techniques, others have recommended use of leukoreduced blood without need for CMV antibody testing as an acceptably safe and low-risk alternative. RBC transfusion should not be delayed if CMV-negative blood is unavailable, and CMV-untested leukoreduced blood should be used because the risk of TT-CMV is relatively low, with possibly more harm to the patient if transfusion is withheld or delayed. The usual dose is 10–15 mL/kg, but transfusion volumes vary greatly depending on clinical circumstances (continued vs arrested bleeding, hemolysis). For neonates, some prefer a centrifuged RBC concentrate (Hct 70–90%). Unless transfusions are being given to treat rapid bleeding, RBCs are infused slowly (over 2–4 hours) at a dose of approximately 10–15 mL/kg. In this small-volume setting, because of the small quantity of extracellular fluid transfused and the slow rate of infusion, the type of RBC anticoagulant/preservative solution does not pose any risk for premature infants when the dose does not exceed 20 mL/kg. However, the additive solutions (e.g., AS-1, AS-3, AS-5) have not been studied by comparative randomized clinical trials in the setting of >20 mL/kg dosing or massive transfusion settings such as cardiopulmonary bypass, ECMO, or massive transfusion for trauma. Although a few anecdotal reports suggest RBCs in additive solutions are safe for large-volume transfusions while awaiting more definitive information, some hospitals that manage these complex neonates and children maintain separate inventories of different RBC products earmarked either for neonates and infants (e.g., citrate-phosphate-dextrose or citrate-phosphate-dextrose-adenine) or for older children (e.g., additive solutions).

STORAGE AGE OF RBC UNITS

The historical practice of transfusing fresh RBCs (<7 days of storage) for the small-volume (15 mL/kg) transfusions commonly given was supplanted several years ago in most centers by reserving a single unit of RBCs for an infant, from which multiple aliquots were obtained for transfusions as needed throughout the 42 days of storage. Concerns about high concentrations of extracellular potassium, loss of 2,3-diphosphoglycerate, altered RBC shape and deformability, and nitric oxide quenching were found not to pose clinically significant problems. Preterm neonates allocated to "fresh RBC" (<7 days' storage) transfusions vs "stored RBC" (up to 42 days' storage) transfusions have no advantage for fresh RBC transfusions in altering the composite clinical outcome of mortality, plus NEC, retinopathy of prematurity, bronchopulmonary dysplasia, and intraventricular hemorrhage, or of the individual disorders.

For children weighing >30 kg who are to undergo elective surgery for whom RBC transfusions are likely to be needed, autologous RBC transfusions offer an alternative to donor allogeneic RBCs. **Preoperative autologous** blood collections from the patient occur up to 6 weeks before the surgery and require careful considerations for the volume to be drawn, vascular access, and use of EPO and iron to help restore the donated RBCs. **Acute normovolemic hemodilution** occurs in the preoperative period, in which blood is withdrawn from the patient and replaced with saline, a task often difficult in centers without experience in the process. **Salvaged autologous blood** is collected from blood loss during the operation but is impractical unless the volume of blood salvaged is fairly large to permit washing and transfusion of a significant number of RBCs. Because of all these difficulties, plus the relative safety of the usual allogeneic blood supply, autologous RBC transfusions are not typically used in the pediatric setting.

Visit Elsevier eBooks+ at eBooks.Health.Elsevier.com for Bibliography.

Chapter 520

Platelet Transfusions

Patricia E. Zerra and Cassandra D. Josephson

CHILDREN AND ADOLESCENTS

Guidelines for platelet (PLT) support of children and adolescents with quantitative and qualitative PLT disorders are similar to those for adults, in whom the risk of life-threatening bleeding occurring after injury or spontaneously can be related to the severity of thrombocytopenia, although somewhat imprecisely (Table 520.1).

For children and adolescents with overt bleeding, therapeutic PLT transfusions should be given when the blood PLT count falls below 50×10^9/L and repeated as needed to maintain the PLT count $>50 \times 10^9$/L during bleeding and for 48 hours after bleeding ceases to allow the clot to "stabilize." Similarly, for a major invasive procedure (e.g., surgical), the PLT count should be maintained $>50 \times 10^9$/L until any bleeding that occurs ceases and the patient is stable. For minor invasive procedures (e.g., lumbar puncture, intravascular catheter placement), practices vary. It is reasonable to maintain the PLT count $>25 \times 10^9$/L, although these procedures often are performed in children with cancer or recent transplants, and it is important to be mindful of possible clotting abnormalities and anemia that may affect hemostasis beyond the effects of thrombocytopenia. Historical studies of patients with thrombocytopenia resulting from bone marrow failure suggest that the risk of spontaneous bleeding increases when blood PLT levels fall to $<20 \times 10^9$/L, particularly when hemorrhagic risk factors (infection, organ failure, clotting abnormalities, minor skin/mucosal bleeding, mucosal lesions, severe graft-versus-host disease [GVHD], anemia) are present. In this high-risk setting, prophylactic PLT transfusions are given to maintain a PLT count $>20 \times 10^9$/L. This threshold has been challenged by several studies of adult patients, who in many instances were carefully selected to be in relatively good clinical condition *without* hemorrhagic risk factors. Consequently, a lower PLT transfusion trigger of 10×10^9/L is recommended for stable (i.e., low-risk) patients.

Table 520.1 Guidelines for Pediatric Platelet (PLT) Transfusion*

CHILDREN AND ADOLESCENTS
1. Maintain PLT count $>50 \times 10^9$/L with bleeding.
2. Maintain PLT count $>50 \times 10^9$/L with *major invasive* procedure; $>25 \times 10^9$/L with minor.
3. Maintain PLT count $>20 \times 10^9$/L and *marrow failure* WITH hemorrhagic risk factors.
4. Maintain PLT count $>10 \times 10^9$/L and *marrow failure* WITHOUT hemorrhagic risk factors.
5. Maintain PLT count at any level with PLT dysfunction PLUS bleeding or invasive procedure.
INFANTS ≤4 MO OLD
1. Maintain PLT count $>100 \times 10^9$/L with bleeding or during extracorporeal membrane oxygenation.
2. Maintain PLT count $>50 \times 10^9$/L and an invasive procedure.
3. Maintain PLT count $>20 \times 10^9$/L and *clinically stable.*
4. Maintain PLT count $>50 \times 10^9$/L and *clinically unstable and/or bleeding or not when on indomethacin, nitric oxide, antibiotics, etc., affecting PLT function.*
5. Maintain PLT count at any level with PLT dysfunction PLUS bleeding invasive procedure.

*Words in *italics* must be defined for local transfusion guidelines.

In practice, severe thrombocytopenia that is prolonged beyond 1 week usually becomes complicated by the development of risk factors, including fever, antimicrobial therapy, GVHD, active bleeding, need for an invasive procedure, disseminated intravascular coagulation, and liver or kidney dysfunction with clotting abnormalities. In these situations, prophylactic PLT transfusions are given to maintain relatively high PLT counts (e.g., at least $>30 \times 10^9$/L). Despite the desire by some physicians to elevate the blood PLT count to 80×10^9/L or 100×10^9/L, there are no definitive data to justify a true benefit of PLT transfusions given at a PLT count $>50 \times 10^9$/L, unless bleeding is ongoing despite a PLT count between 50 and 100×10^9/L *and* thrombocytopenia seems to be the only cause for the bleeding.

Qualitative PLT disorders may be *inherited* or *acquired,* as in advanced hepatic or renal insufficiency or when blood flows through an extracorporeal circuit, such as during extracorporeal membrane oxygenation (ECMO) or cardiopulmonary bypass. In patients with inherited disorders, PLT transfusions are justified only if the risk of significant bleeding is quite high or if bleeding is overt because inherited PLT dysfunction often is lifelong and repeated transfusions may lead to alloimmunization and refractoriness (i.e., poor response to PLT transfusions). Accordingly, prophylactic PLT transfusions are rarely justified unless an invasive procedure is planned, and therapeutic PLT transfusions must be given judiciously.

When managing patients with PLT dysfunction, it is important to remember that an abnormal test result with a modern PLT function device or, historically, a bleeding time more than twice the upper limit of normal provides diagnostic evidence of PLT dysfunction. However, an abnormal bleeding time or any other abnormal laboratory test is poorly predictive of hemorrhagic risk or the need to transfuse PLTs. Alternative therapies, particularly desmopressin acetate, should be considered to avoid PLT transfusions. Antiplatelet medications (nonsteroidal antiinflammatory drugs) should also be avoided.

INFANTS AND NEONATES

In neonates, thrombopoiesis and the risks of bleeding are substantially different from that in older children; the approach to thrombocytopenia and PLT transfusions likewise differs (see Table 520.1). **Thrombopoietin** (TPO) levels are higher in healthy neonates than in older individuals. Relative to adult PLT progenitors, *megakaryocyte* progenitors of neonates are more sensitive to TPO, have higher proliferative potential, and give rise to larger megakaryocyte colonies. Fetal/neonatal megakaryocytes are smaller in size and have lower ploidy than do their adult counterparts; this

information is important because small megakaryocytes of low ploidy produce fewer PLTs than do larger megakaryocytes of higher ploidy. Presumably, this allows the expanding marrow of the growing fetus and neonate to be supplied with sufficient numbers of megakaryocytes, yet not allowing blood PLT counts to become excessively high during proliferation because of the lower numbers of PLTs produced by each megakaryocyte.

An important contrasting point is that older children and adults respond to situations of increased demand for PLTs by first increasing megakaryocyte size and ploidy, which is followed in 3–5 days by increased megakaryocyte number. In thrombocytopenic neonates, megakaryocyte numbers but not size increase. Moreover, although cytoplasmic maturation is achieved per TPO stimulation, increases in ploidy are relatively diminished and actually appear to be inhibited by TPO, resulting in large numbers of small megakaryocytes that are cytoplasmically mature but with low ploidy and, consequently, lower PLT production.

PLT counts ≥150 × 10^9/L are present after 17 weeks' gestational age, and it is accepted that neonates have PLT counts in the same range as older children and adults (150,000–450,000/μL). However, other data suggest a lower limit of 120,000/μL for extremely small preterm infants. Approximately 1% of term infants demonstrate PLT counts <150 × 10^9/L, but bleeding in such infants is rare. In contrast, 18–35% of preterm neonates treated in intensive care units (ICUs) exhibit PLT counts <150 × 10^9/L at some time during admission, with approximately 4% overall receiving PLT transfusions. Notably, when only extremely low birthweight preterm infants (<1 kg) were considered in one report, 70% had PLT counts <150 × 10^9/L, and 5–9% of infants received platelet transfusions.

Debate continues in the United States as to the appropriate prophylactic platelet transfusion threshold for neonates, with a wide range in practice patterns. Multiple pathogenetic mechanisms underlie thrombocytopenia in these sick neonates, including predominantly accelerated PLT destruction plus diminished PLT production, as evidenced by decreased numbers of megakaryocyte progenitors and relatively low upregulation of TPO levels during thrombocytopenia, when compared with thrombocytopenic children and adults.

PLT counts <100 × 10^9/L pose significant clinical risks for premature neonates. Bleeding time may be prolonged at PLT counts <100 × 10^9/L in infants with birthweight <1,500 g, and PLT dysfunction is suggested by bleeding times (a test no longer performed) that are disproportionately long for the degree of thrombocytopenia. The risk of hemorrhage may be increased in thrombocytopenic infants. However, in a randomized trial, transfusing PLTs prophylactically whenever the PLT count fell to <150 × 10^9/L (i.e., at the lower limit of normal range) to maintain the average PLT count at >200 × 10^9/L, compared to not transfusing PLTs until the PLT count fell to <50 × 10^9/L to maintain the average PLT count at approximately 100 × 10^9/L, *did not result* in a lower incidence of intracranial hemorrhage (28% vs 26%, respectively). A U.S. multicenter observational study of very low birthweight infants in six neonatal ICUs found wide variation in PLT thresholds for transfusion, ranging from 10,000 to 139,000/μL in the first week of life and <10,000/μL to >50,000/μL after the first week. The most common thresholds were 80,000–89,000/μL in the first 7 days of life and 40,000–49,000/μL after the first 7 days. Furthermore, after controlling for severity of thrombocytopenia, the authors found PLT transfusions were not associated with a lower risk of intraventricular hemorrhage. Thus, there is no documented benefit for prophylactic PLT transfusions to maintain PLT counts within the normal range or to correct moderate thrombocytopenia (PLT count >50 × 10^9/L). As an exception, infants with inherited PLT dysfunction disorders *and* bleeding, as well as infants at high risk of bleeding because of acquired PLT dysfunction, such as during ECMO, typically receive transfusions to keep their PLT counts >100 × 10^9/L.

One randomized clinical trial reported a significantly higher rate of new major hemorrhage or death within 28 days of randomization in very low birthweight neonates given prophylactic PLT transfusions at a pretransfusion PLT count of 50,000/μL (26%) vs a pretransfusion PLT count of 25,000/μL (19%), irrespective of their baseline risk of bleeding. Results are too preliminary to permit changes in practice but support other published findings indicating no need to maintain normal PLT counts and add to the belief that a PLT count of 50,000/μL is too high to serve as the pretransfusion PLT count for transfusions in stable low birthweight neonates.

Table 520.1 lists pediatric PLT transfusion guidelines that are acceptable to many neonatologists. One particularly contentious issue is how to manage critically ill neonates receiving agents known to adversely affect PLT function (e.g., indomethacin, nitric oxide, antibiotics). Some reports suggest increased risk of bleeding for these neonates, but the efficacy of PLT transfusions has not been convincingly proven, particularly when given prophylactically. For optimal PLT transfusion practices, each hospital should modify their guidelines to comply with local practices, with audits and reviews done to avoid violations of the recommended practices.

PLATELET PRODUCTS AND DOSING

In the United States, two types/sources of PLT units are available, although any one blood bank or hospital may stock only one of these types. Whole blood–derived PLT units **(PLT concentrates)** and PLT units collected by apheresis **(apheresis PLTs)** differ in their PLT content and plasma volume. Although a PLT concentrate contains approximately 5.5-10 × 10^{10} PLTs in approximately 50 mL, and 1 apheresis PLT unit contains at least 3 × 10^{11} PLTs in 300–600 mL, the PLT content may vary considerably among different blood suppliers. Accordingly, it is prudent for hospital blood banks to confirm the composition of the PLT units they issue for transfusion, at the very least by contacting their blood supplier. It is often easier to use PLT concentrates for infants and small children because apheresis PLTs usually need to be prepared as *aliquots* to provide the correct dose (10–15 mL/kg). However, many blood centers exclusively provide only one type of PLT component. Platelet products generally have a 5-day expiration time, although 7-day storage has been approved for apheresis platelet units within certain stipulations to reduce the risk of bacterial contamination and are stored at room temperature with constant agitation.

The posttransfusion goal of most PLT transfusions is to raise the PLT count well above 50 × 10^9/L, hopefully to ≥100 × 10^9/L. These increases can be achieved consistently in children weighing up to 30 kg by infusion of 5–10 mL/kg of standard (unmodified) PLT concentrates, obtained either from PLT concentrates or apheresis PLTs. For larger children, the appropriate dose is 4-8 pooled PLT concentrates or 1 apheresis unit. Because PLT concentration/quantity varies in different PLT products made available for transfusion, each hospital should monitor posttransfusion PLT counts to determine the dose that works best locally. PLT concentrates may be transfused as rapidly as the patient's overall condition permits, certainly within 2 hours, but not longer than 4 hours. Neonates/infants requiring repeated PLT transfusions should receive leukocyte-reduced blood products to diminish HLA alloimmunization and PLT refractoriness and to reduce the risk of transfusion-transmission cytomegalovirus infection (TT-CMV). For those infants weighing <1,500 g at birth, *irradiation* is recommended to prevent transfusion associated GVHD. Additionally, some recommend both leukoreduction and CMV-seronegative RBC units (estimated risk of TT-CMV infection: 0–0.3% per unit) as first-line therapy to prevent TT-CMV. However, given the low risks of TT-CMV with improvements in modern leukoreduction techniques, others have recommended use of leukoreduced blood from CMV-untested donors as an acceptably safe and low-risk alternative. PLT transfusion should not be delayed if CMV-negative units are unavailable; CMV-untested leukoreduced units should be used because the risk of TT-CMV is relatively low and more harm may come to the patient if transfusion is withheld or delayed.

Routinely reducing the volume of PLT concentrates for infants and small children by additional centrifugation steps is both unnecessary and unwise. Transfusion of 10–15 mL/kg of an unmodified PLT concentrate is adequate because it adds approximately 10 × 10^9 PLTs to 70 mL of blood (estimated intravascular blood volume of 1 kg neonate), a dose/volume calculated to increase the PLT count by 100 × 10^9/L. This calculated increment is consistent with actual posttransfusion increment reported in patients. Moreover, 10–15 mL/kg is not an excessive transfusion volume, provided that the intake of other IV fluids, medications, and nutrients is monitored and adjusted.

It is important to select PLT units for transfusion with the donor ABO group identical to that of the neonate/infant and to avoid repeated transfusion of group O PLTs to group A or B recipients, because passive transfusion anti-A or anti-B in group O plasma can occasionally lead to intravascular hemolysis.

Visit Elsevier eBooks+ at eBooks.Health.Elsevier.com for Bibliography.

Chapter 521

Neutrophil (Granulocyte) Transfusions

Patricia E. Zerra and Cassandra D. Josephson

Table 521.1 lists guidelines for granulocyte transfusion (GTX). GTX has been used sparingly in older infants and children. The current ability to collect markedly higher numbers of neutrophils from donors stimulated with combined recombinant granulocyte colony-stimulating factor (G-CSF) plus dexamethasone has led to renewed interest for patients with neutropenic infections, particularly when severe neutropenia is prolonged (e.g., in the setting of placental/cord blood hematopoietic progenitor cell transplantation). As a result, higher neutrophil yields are collected with this approach, making the addition of GTX to antibiotics a therapeutic consideration. This is especially true at institutions where neutropenic patients continue to die of progressive bacterial and fungal infections or to suffer substantial morbidity despite optimal antiinfection measures, including antibiotics and recombinant myeloid growth factors.

GRANULOCYTE TRANSFUSIONS FOR CHILDREN

The use of GTX added to antibiotics for children with **severe neutropenia** (neutrophil count <0.5 × 10^9/L) because of bone marrow failure is similar to that for adults. Unfortunately, two randomized clinical trials comparing antibiotics plus GTX from donors stimulated with G-CSF plus dexamethasone vs antibiotics without GTX to treat neutropenic infections in children have not provided definitive guidelines. However, in practice, neutropenic patients with bacterial infections usually show response to antibiotics alone, provided bone marrow function recovers within the first 7–10 days of infection onset, so that severe neutropenia is relatively brief. Children with newly diagnosed acute lymphoblastic leukemia show rapid response to induction chemotherapy and are rarely candidates for GTX. In contrast, infected children with more sustained bone marrow failure and consequent severe neutropenia (e.g., acute myeloblastic leukemia, malignant neoplasms resistant to treatment, severe aplastic anemia, placental/cord blood hematopoietic progenitor cell transplant recipients) may benefit when GTX is added to antibiotics.

Currently, the efficacy of GTX obtained from G-CSF plus dexamethasone–stimulated donors for bacterial sepsis unresponsive to antibiotics in patients with severe neutropenia (neutrophil count <0.5 × 10^9/L) *is not well supported* by trials in children. Furthermore, GTX efficacy for yeast and fungal infections remains unproven, despite transfusing GTX with relatively large numbers of neutrophils.

Children with **qualitative neutrophil defects (neutrophil dysfunction)** usually have adequate or even increased numbers of blood neutrophils but develop serious infections because their neutrophils kill pathogenic microorganisms inefficiently. Neutrophil dysfunction syndromes are rare; accordingly, no definitive studies have established GTX efficacy. However, several patients with progressive life-threatening infections have shown striking improvement with the addition of GTX, often given for long periods, to antimicrobial therapy. These disorders are chronic and thus associated with an increased risk of alloimmunization to leukocyte antigens, specifically to Kell system antigens on the red blood cells in some patients with chronic granulomatous disease, and GTX is recommended only when serious infections are clearly unresponsive to antimicrobial drugs.

Table 521.1 Guidelines for Pediatric Granulocyte Transfusions*

CHILDREN AND ADOLESCENTS
1. Severe neutropenia (blood neutrophil count <0.5 × 10^9/L) and infection (bacterial, yeast, or fungal) *unresponsive or progressive* despite appropriate antimicrobial therapy.
2. Qualitative neutrophil defect, neutropenia not required, and infection (bacterial or fungal) *unresponsive or progressive* to appropriate antimicrobial therapy.
INFANTS ≤4 MO OLD†
Blood neutrophil count <3.0 × 10^9/L in first week of life or <1.0 × 10^9/L thereafter and *fulminant* bacterial infection.

*Words in *italics* must be defined for local transfusion guidelines.
†No longer commonly used.

GRANULOCYTE TRANSFUSION FOR NEONATES

Neonates are unusually susceptible to severe bacterial infections, and a number of defects of neonatal defenses contribute to this susceptibility, including actual or "relative" neutropenia. Neonates with fulminant sepsis who exhibit *relative neutropenia* (blood neutrophil count <3.0 × 10^9/L during the first week of life and <1.0 × 10^9/L thereafter) and a severely diminished neutrophil marrow storage pool (with <10% of nucleated marrow cells being postmitotic neutrophils) are at risk of dying if treated only with antibiotics. Despite this risk, GTX has not provided the solution. GTX is rarely used in neonates because the results of clinical trials are mixed and not uniformly convincing, and it is difficult to obtain neutrophil apheresis concentrates in a timely fashion.

Current data are insufficient to conclude that recombinant myeloid growth factors have a role in treating septic neonates, despite demonstration that both G-CSF and granulocyte-macrophage CSF enhance myelopoiesis and raise neutrophil counts in infants. In contrast to the uncertain role of G-CSF and GM-CSF to treat infections in many clinical settings, it is important to remember that G-CSF is efficacious for the long-term treatment of several types of severe **congenital neutropenias**.

GRANULOCYTE PRODUCT

If the decision to provide a GTX has been made, an adequate dose of neutrophils/granulocytes collected by leukapheresis must be transfused as shortly after collection as possible. To facilitate this goal, experienced donors with recently performed negative testing for HIV and hepatitis (usually within the past 30 days) are selected. Granulocyte donors should be documented to be cytomegalovirus antibody negative (seronegative). These donors should also be ABO/Rh crossmatch compatible with the recipient because there is a large volume of red blood cells in the granulocyte product.

Granulocyte Product Dosing

Neonates and **infants** weighing <10 kg should receive 1-2 × 10^9/kg neutrophils per each GTX. **Larger infants** and **small children** should receive a minimal total dose of 1 × 10^{10} neutrophils per each GTX. The preferred dose for **adolescents** is 5-8 × 10^{10} neutrophils per each GTX, a dose requiring donors to be stimulated with G-CSF plus dexamethasone. GTX should be given daily until either the infection resolves or the blood neutrophil count is sustained above 1.5 × 10^9/L for a few days. Because neutrophils transfused through the GTX often passively increase the blood neutrophil count, it may be necessary to skip 1-2 days of GTXs to accurately assess whether endogenous myelopoiesis and neutrophil production have recovered.

Visit Elsevier eBooks+ at eBooks.Health.Elsevier.com for Bibliography.

Chapter 522

Plasma Transfusions

Patricia E. Zerra and Cassandra D. Josephson

Guidelines for plasma transfusion in pediatric patients are similar to those for adults but with the understanding that plasma levels of coagulant and anticoagulant proteins can be developmentally low in preterm infants (Table 522.1). Therefore transfusions of plasma and plasma-derived commercial concentrates should be determined by actual bleeding or a significant risk of bleeding, not simply by prolonged clotting time results. Plasma is transfused to replace clinically significant congenital or acquired deficiencies of plasma proteins for which more highly purified protein concentrates, treated to reduce infectious disease risks, or recombinant products are not available. Plasma and plasma derivatives are required to provide clotting proteins when bleeding is actually occurring or in settings when prevention of bleeding is deemed critical.

PLASMA PRODUCTS AND PATIENT TESTING

Two interchangeable plasma products are available for transfusion, plasma frozen within 8 hours of collection **(fresh-frozen plasma [FFP])** and plasma frozen within 24 hours of collection **(F24)**. Although levels of factors V and VIII are modestly reduced in F24 (generally, not more than 25% lower), they are equally efficacious for all indications for which plasma is transfused in infants and children (see Table 522.1). Recommendations for the volume of plasma to be transfused vary with the specific protein being replaced and the severity of the deficiency, but a starting dose of 15 mL/kg is usually sufficient to elevate plasma levels satisfactorily.

Transfusion of plasma is efficacious for the treatment of deficiencies of clotting factors II, V, X, and XI. Deficiencies of factor XIII and fibrinogen are treated either with cryoprecipitate or specific commercial concentrates; for patients being given large doses of plasma (e.g., in massive transfusion settings or to treat bleeding in liver failure), however, additional sources of fibrinogen may not be necessary because plasma contains large amounts of fibrinogen. It is always useful to include a measurement of plasma fibrinogen (a separate test) when performing clotting assays, including prothrombin time (PT)/international normalized ratio (INR) and activated partial thromboplastin time (aPTT).

PLASMA TRANSFUSION IN CHILDREN

Transfusion of plasma is not recommended for the treatment of patients with severe hemophilia A or B, von Willebrand disease, or factor VII deficiency because safer plasma-derived and recombinant factor products for VII, VIII, IX, and von Willebrand factor are available. Moreover, mild to moderate hemophilia A and certain types of von Willebrand disease can be treated with intranasal or intravenous desmopressin (see Chapter 526). An important use of plasma is for rapid reversal of the effects of warfarin in patients who are actively bleeding or who require emergency surgery (in whom functional deficiencies of vitamin K–dependent factors II, VII, IX, and X cannot be rapidly reversed by vitamin K administration). Plasma-derived and virally inactivated prothrombin "complex" concentrates can also be used for this purpose.

Results of screening coagulation tests (PT/INR, aPTT, thrombin time, and plasma fibrinogen level) should not be assumed to reflect the integrity of the coagulation system or be regarded as indications for plasma transfusions. This is particularly true for neonates. To justify plasma transfusions, coagulation test results must be related to the patient's clinical condition in regard to bleeding and the risk of bleeding. Transfusion of plasma in patients with chronic liver disease and prolonged clotting times is not recommended unless bleeding is present, or an invasive procedure is planned because prophylactic correction of the clotting factor deficiencies is brief and of questionable benefit.

Plasma also contains several anticoagulant proteins (antithrombin III, protein C, and protein S) whose deficiencies have been associated with thrombosis. In select situations, plasma as replacement therapy along with anticoagulant treatment may be appropriate in patients with these disorders; when available, purified concentrates are preferred. Other indications for plasma include replacement fluid during plasma exchange in patients with **thrombotic thrombocytopenic purpura** (i.e., thrombotic microangiopathies) or other disorders for which plasma is likely to be beneficial. This includes plasma exchange in a patient with overt bleeding caused by the underlying disorder (e.g., Goodpasture syndrome, vasculitis) or disorders with significant severe coagulopathy that would substantially worsen with replacement by albumin solutions only. *Plasma is not indicated for correction of hypovolemia or as immunoglobulin replacement therapy because safer alternatives exist (albumin or crystalloid solutions and IV immunoglobulin, respectively).*

Table 522.1 Guidelines for Children and Infants for Plasma Transfusions*

1. *Severe* clotting factor deficiency AND bleeding.
2. *Severe* clotting factor deficiency AND an invasive procedure.
3. *Emergency reversal* of warfarin effects.
4. Dilutional coagulopathy and bleeding (e.g., massive transfusion).
5. Anticoagulant protein (antithrombin III, proteins C and S) replacement.
6. Plasma exchange replacement fluid for thrombotic thrombocytopenic purpura or for disorders with overt bleeding or in which there is risk of bleeding because of clotting protein abnormalities (e.g., liver failure).

*Words in *italics* must be defined for local transfusion guidelines.

PLASMA TRANSFUSION IN NEONATES

In neonates, clotting times are "physiologically" prolonged because of developmental deficiency of clotting proteins; plasma should be transfused only after reference to normal values is adjusted for the birthweight and age of the infant (*not* to normal ranges for older children and adults). The indications for plasma in neonates include (1) reconstitution of red blood cell (RBC) concentrates to simulate whole blood for use in massive transfusions (exchange transfusion, cardiac bypass surgery, and extracorporeal membrane oxygenation), (2) hemorrhage secondary to vitamin K deficiency, (3) disseminated intravascular coagulation *with* bleeding, and (4) bleeding in congenital coagulation factor deficiency when more specific treatment is either unavailable or inappropriate. The use of prophylactic plasma transfusion to prevent intraventricular hemorrhage in premature infants is not recommended. Plasma should not be used as a suspending agent to adjust the hematocrit values of RBC concentrates before small-volume RBC transfusions to neonates because it offers no apparent medical benefit over the use of sterile solutions such as crystalloid and albumin. Similarly, the use of plasma in partial exchange transfusion for the treatment of neonatal hyperviscosity syndrome is unnecessary because safer crystalloid or colloid solutions are available.

In the treatment of bleeding infants, *cryoprecipitate* is often considered because of its small infusion volume. However, cryoprecipitate contains significant quantities of only fibrinogen, von Willebrand factor, and factors VIII and XIII. Thus it is not effective for treating the usual clinical situation in bleeding infants with multiple clotting factor deficiencies. However, cryoprecipitate is an excellent source of fibrinogen (much more concentrated than frozen plasma), and with a dose of 1–2 units/kg, the patient's fibrinogen level can be quickly raised by 60–100 mg/dL.

In preliminary studies, infusions of very small volumes of recombinant activated factor VII have been lifesaving in patients with hemorrhage caused by several mechanisms. Because the efficacy and toxicity of factor VIIa have not been fully defined in these "off-label" uses (not approved by the U.S. Food and Drug Administration), it must be considered "experimental" therapy at this time.

Visit Elsevier eBooks+ at eBooks.Health.Elsevier.com for Bibliography.

Chapter 523

Risks of Blood Transfusions

Patricia E. Zerra and Cassandra D. Josephson

The greatest risk of a blood transfusion is mistakenly receiving a transfusion intended for another patient. *Misidentification* is usually a result of mistakes made in labeling the patient's blood sample sent to the blood bank or not accurately matching the unit with the patient at the bedside when the blood is transfused. This risk is particularly high for infants, especially if ABO type-specific or type-compatible blood is transfused, because (1) identification bands may not be attached directly to their bodies, (2) difficulties in drawing blood samples for pretransfusion compatibility testing may lead to deviations from usual policies, and (3) infants cannot speak to identify themselves. Thus particular care must be taken to ensure accurate patient and blood sample identification.

INFECTIOUS RISKS OF TRANSFUSION

Although the infectious disease risks of allogeneic blood transfusions are extremely low, transfusions must be given judiciously because "emerging infections," such as Ebola or Zika virus, when they first arise, pose a potential threat until they are studied definitively and, accordingly, are of constant concern, and testing is not done for every microorganism possibly transmitted by blood transfusions (Table 523.1 and Fig. 523.1). Taking nucleic acid amplification testing (NAT) and all other donor-screening activities (antibody and epidemiology screening) into account, a current estimate of the risk of transfusion-associated **HIV** infection is approximately 1 per every 2 million donor exposures. Similarly, with NAT, the risk of hepatitis C virus **(HCV)** infection is 1 per every 1.5-2 million donor exposures (see Table 523.1). NAT identifies circulating microbial nucleic acids that appear in the window before antibodies develop, and NAT is used routinely to detect HIV, HCV, West Nile virus, hepatitis B virus, *Trypanosoma cruzi, Babesia microti,* and Zika virus.

Transfusion-associated cytomegalovirus **(CMV)** has been nearly eliminated by transfusion of leukocyte-reduced cellular blood products or by selection of blood collected from donors who are seronegative for antibody to CMV. Although it is logical to hypothesize that first collecting blood components from CMV-seronegative donors and then removing the white blood cells (WBCs) might further improve safety, little data are available to document the superior efficacy of this combined approach. However, in a recent prospective birth cohort study of premature infants with birthweight ≤1,500 g, a combined approach of leukoreduction and CMV-seronegative cellular blood components yielded 0% transfusion transmission of CMV (15.3% cumulative incidence at 12 weeks of maternal breast milk transmission from CMV-seropositive mothers) in >300 transfused infants studied. Similar uncontrolled reports of hematopoietic stem cell transplant patients found 0% transmission of CMV from leukoreduced blood products from donors of unknown CMV antibody status. Therefore considerable care must be taken not to place children at risk of delayed or missed transfusions while awaiting/searching for blood from CMV-seronegative donors, then to leukoreduce (i.e., risks must not be taken for practices with no established benefits).

Further data on these two mitigation strategies revealed that large quantities of CMV viral material are present "free" in the plasma of healthy-appearing donors during the early phase of primary infection (while CMV antibodies are either absent ["window" phase] or are newly emerging and at low, inconsistently detected levels in plasma), rather than being leukocyte associated, as occurs with CMV as substantial quantities of IgG antibodies appear. As a result of this biology of CMV primary infection, plasma "free" virus will not be removed by leukoreduction during early infection, and CMV-seronegative donors who may be asymptomatic or deny symptoms of infection during blood donor screening will be misclassified as being CMV safe. They are not necessarily as safe because antibody is below the limits of detection, while plasma "free" CMV is plentiful during early infection. Because almost all plasma "free" CMV disappears and becomes almost exclusively cell associated, once donors are CMV seropositive with antibody present for several months, some propose that the best method to reduce CMV risk may be leukoreduction of blood from donors known to be CMV seropositive for at least 1 year. However, data to prove the efficacy of this proposal are lacking, and in practice, several studies have shown that the most efficacious method currently available to prevent transfusion-transmitted CMV is to perform leukoreduction in the

Table 523.1 Estimated Risks in Transfusion per Unit Transfused in the United States

ADVERSE EFFECT (INFECTIOUS)	ESTIMATED RISK
Human immunodeficiency virus (HIV)-1 and HIV-2	1:2 million
Hepatitis B	1:2 million
Hepatitis C	1:2 million
Human T-cell lymphotropic virus (HTLV) I and II	1:3 million
Bacterial contamination (usually platelets)	1:100,000
Malaria	<1:3 million
Hepatitis A	Unknown
Parvovirus	Unknown
Dengue fever	Unknown
Cytomegalovirus	<1:3 million
Babesiosis	Unknown
West Nile virus	<1:3 million
Trypanosoma cruzi	<1:3 million
Leishmania spp.	Unknown
Variant Creutzfeldt-Jakob prion disease	Unknown
Zika virus	<1:3 million
Syphilis	Unknown
ADVERSE EFFECT (NONINFECTIOUS)	**ESTIMATED RISK**
Febrile nonhemolytic reaction	1:800
Mild-moderate allergic reaction	1:1,000
Severe allergic reactions	1:40,000
Transfusion-associated circulatory overload (TACO)	1:8,500
Hypotensive	1:11,000
Acute hemolytic transfusion reaction	1:95,000
Transfusion-associated dyspnea	1:15,000
Transfusion-related acute lung injury (TRALI)	1:70,000
Delayed hemolytic transfusion reaction	1:20,000
Transfusion-associated graft-versus-host disease	Uncommon
Immunomodulation	Unknown
Posttransfusion purpura	1:30,000
Life-threatening reactions, requiring major medical intervention	1:20,000

Adapted from Busch MP, Bloch EM, Kleinman S. Prevention of transfusion-transmitted infections. *Blood* 2019;133:1854–1864; and Savinkina AA, Haass KA, Sapiano MRP, et al. Transfusion-associated adverse events and implementation of blood safety measures – findings from the 2017 National Blood Collection and Utilization Survey. *Transfusion* 2020;60:S10–S16.

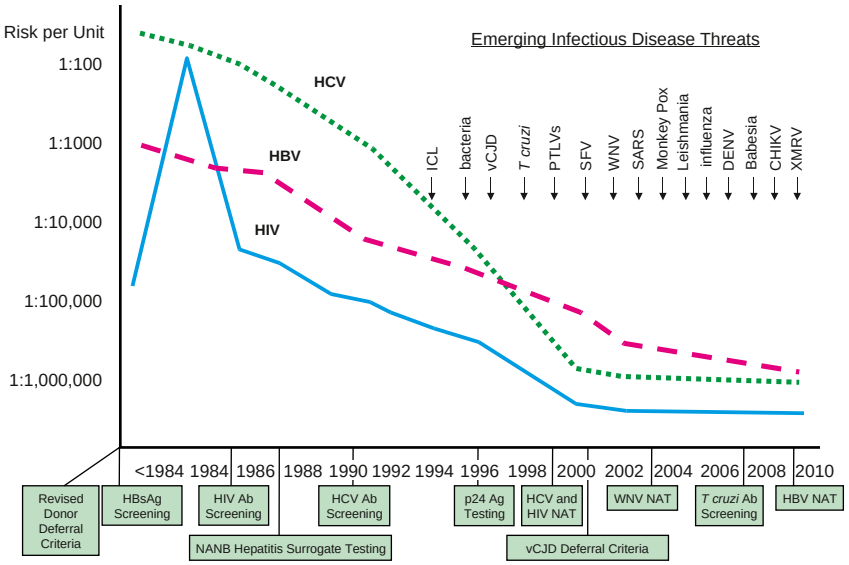

Fig. 523.1 Risks of major transfusion-transmitted viruses related to interventions and accelerating rate of emerging infectious diseases of concern to blood safety. Evolution of the risks of transmission by blood transfusion for human immunodeficiency virus (HIV), hepatitis B virus (HBV), and hepatitis C virus (HCV). Major interventions to reduce risks are shown below the timeline on the *x* axis. Emerging infectious disease threats in the past 20 years are shown above in the *top right quadrant* of the figure. Ab, Antibody; Ag, antigen; CHIKV, chikungunya virus; DENV, dengue virus; HBsAg, hepatitis B surface antigen; ICL, idiopathic CD4 T-lymphocytopenia; NANB, non-A, non-B hepatitis; NAT, nucleic acid amplification testing; PTLVs, primate T-lymphotropic viruses; SARS, severe acute respiratory syndrome; SFV, simian foamy virus; vCJD, variant Creutzfeldt-Jakob disease; WNV, West Nile virus; XMRV, xenotropic murine leukemia virus–related virus. *(From Busch MP. Transfusion-transmitted viral infections: Building bridges to transfusion medicine to reduce risks and understand epidemiology and pathogenesis. 2005 Emily Cooley Award Lecture. Transfusion. 2006;46:1624–1640.)*

blood center/bank without regard for the CMV antibody status of the donor/unit (i.e., leukoreduction alone performed by the blood center/bank, not at the bedside, is sufficient in most cases).

Additional infectious risks include other types of **hepatitis** (A, B, E) and **retroviruses** (human T-cell lymphotropic virus types I and II, HIV-2), syphilis, parvovirus B19, Epstein-Barr virus, human herpesvirus 8, West Nile virus, yellow fever vaccine virus, malaria, babesiosis, *Anaplasma phagocytophilum*, Chagas disease, and Zika virus. Variant Creutzfeldt-Jacob disease has also been transmitted by blood transfusions in humans. All are reported very infrequently, but nonetheless provide the rationale to transfuse only when true benefits are likely.

NONINFECTIOUS RISKS OF TRANSFUSION

Transfusion-associated risks of a noninfectious nature that may occur include hemolytic and nonhemolytic transfusion reactions, circulatory fluid overload, **graft-versus-host disease** (GVHD), electrolyte and acid-base imbalances, iron overload if repeated red blood cell (RBC) transfusions are needed long term, increased susceptibility to oxidant damage, exposure to plasticizers, hemolysis with T-antigen activation of RBCs, posttransfusion purpura, **transfusion-related acute lung injury** (TRALI), posttransfusion immunosuppression and immunomodulation, and alloimmunization (Fig. 523.2; see Table 523.1). The risk of TRALI may be reduced by avoiding transfusion of plasma or platelets from female donors, who were possibly alloimmunized to leukocyte antigens during pregnancy or by selecting donors (e.g., males) who are likely to be negative for human leukocyte antigen (HLA) antibodies.

Immunologic adverse effects, including immunosuppression, immunomodulation, and alloimmunization, may be reduced by leukoreduction. Transfusion reactions and alloimmunization to RBC and leukocyte antigens seem to be uncommon in infants, perhaps because of developmental immaturity of the immune system or deficient cytokine production. When they do occur, adverse effects are seen primarily in massive transfusion settings, such as exchange transfusions and trauma or surgery, in which relatively large quantities of blood components are needed but are rare when small-volume transfusions are usually given.

Premature infants are known to have immune dysfunction, but their relative risk of posttransfusion GVHD is controversial. The postnatal age of the infant, the number of immunocompetent lymphocytes in the transfusion product, the degree of HLA compatibility between donor and recipient, and other, poorly described phenomena determine which infants are truly at risk for GVHD. Regardless, many centers caring for preterm infants transfuse exclusively irradiated cellular products. As an alternative, pathogen-reduction technology has been documented to prevent GVHD and can substitute for irradiation. Directed donations with blood drawn from blood relatives must always be irradiated because of the risk of engraftment with transfused HLA-homozygous, haploidentical lymphocytes. Cellular blood products given as intrauterine or exchange transfusions should be irradiated, as should transfusions for patients with severe congenital immunodeficiency disorders (severe combined immunodeficiency syndrome and DiGeorge syndrome requiring heart surgery) and transfusions for recipients of hematopoietic progenitor cell transplants. Other groups who are potentially at risk but for whom no conclusive data are available include patients given T-cell antibody therapy (antithymocyte globulin or OKT3), those with organ allografts, those receiving immunosuppressive drug regimens, and those infected with HIV.

As an alternative, pathogen-reduction technology has been documented to prevent T-cell proliferation, and thus TA-GVHD may be used as a substitute for irradiation. Current practice uses **irradiation** from a cesium, cobalt, or linear acceleration source at doses ranging from 1,500 to 2,500 centigray (cGy); a maximum dose of 2,500 cGy is required to hit the center of the irradiation field and a minimum of 1,500 cGy delivered to any other portion of the cannister. All cellular blood components should be irradiated, except those frozen without a cryoprotectant agent and to be rendered as "acellular" products, such as plasma and cryoprecipitate, which do not require irradiation. Leukocyte reduction cannot be substituted for irradiation to prevent GVHD. However, as mentioned, pathogen-reduction technologies have been demonstrated to be efficacious.

Visit Elsevier eBooks+ at eBooks.Health.Elsevier.com for Bibliography.

All transfusions must be stopped when a patient is experiencing a reaction and assessed by a provider
Provide supportive therapy to support vital organ function (cardiac, pulmonary, renal)
For questions regarding transfusion reaction diagnosis or management, call the transfusion service, or other appropriate physician

Reaction	Symptoms	Interventions
Increase in temperature		
Possible febrile non-hemolytic reaction	Incremental increase <1°C above baseline and no other new symptoms	• Close observation, frequent vital signs • If stable and no other new symptoms then continue with transfusion
Possible bacterial contamination Possible hemolysis	Incremental increase ≥1°C above baseline, or incremental increase <1°C with any other new symptoms (chills or rigors, hypotension, nausea or vomiting)	• Stop transfusion, keep intravenous line open, assess patient, check patient ID and unit ID and compatibility • Antipyretic drug • Consider blood cultures (patient); empirical antibiotics if neutropenic • Do not resume transfusion • Strongly consider culturing blood product if ≥2°C increase in temperature or if high clinical suspicion of sepsis • Notify blood transfusion laboratory; return unit (with administration set) plus post-transfusion patient sample to blood transfusion laboratory
	For consistently febrile patient due to underlying disease or treatment, when possible: • Avoid starting transfusion if patient's temperature is increasing • Treat fever with antipyretic drug before starting transfusion • If incremental increase in temperature ≥1°C above baseline treat as per above (stop and do not resume transfusion, cultures if indicated) • Notify blood transfusion laboratory, return unit (with administration set) plus post-transfusion patient sample to blood transfusion laboratory	
Allergic symptoms		
Urticaria	Mild hives, rash, or skin itching only	• Stop transfusion, keep intravenous line open, and assess patient • Antihistamines • Notify patient clinician and blood transfusion laboratory; sample not required • If symptoms resolve, then can resume transfusion • If symptoms do not improve or worsen or recur then discontinue transfusion; return unit (with administration set) to blood transfusion laboratory
Possible allergic reaction	Hives, rash, itching, and or any other new symptoms (throat, eye, and tongue swelling, etc)	• Stop transfusion, keep intravenous line open, assess patient, check patient ID and unit ID and compatibility • Antihistamines • Do not resume transfusion • Notify blood transfusion laboratory; return unit (with administration set) plus post-transfusion patient sample to blood transfusion laboratory
Respiratory symptoms		
Possible anaphylaxis, transfusion-associated circulatory overload, septic transfusion reaction, or transfusion-related acute lung injury	Bronchospasm, dyspnea, tachypnoea and hypoxemia, copious frothy pink-tinged fluid (from endotracheal tube)	• Stop transfusion, keep intravenous line open, assess patient, check patient ID and unit ID and patient compatibility • Treat symptoms as indicated (adrenaline, antihistamines, steroids; oxygen and respiratory support, diuretics; fluid, blood pressure, and renal support) • Chest radiograph for presence of bilateral interstitial infiltrate, if suggestive of transfusion-related acute lung injury • Blood cultures (patient and product), if high clinical suspicion of sepsis • Do not resume transfusion • Notify blood transfusion laboratory; return unit with administration set, plus post-transfusion patient sample. Associated products can be quarantined
All other symptoms		
Possible anaphylaxis, hemolytic transfusion reaction, fluid overload, or transfusion-related acute lung injury	Chills, rigors, hypotension, nausea or vomiting, feeling of impending doom, back or chest pain, intravenous site pain, cough, dyspnea, hypoxia	• Stop transfusion, keep intravenous line open, assess unit, check patient ID and unit ID and patient compatibility • Treat symptoms as indicated (adrenaline, antihistamines, steroids; oxygen and respiratory support, diuretics; fluid, blood pressure, and renal support) • Blood cultures (patient and product) if high clinical suspicion of sepsis • Do not resume transfusion • Notify blood transfusion laboratory; return unit with administration set, plus post-transfusion patient sample. Associated products can be quarantined

Fig. 523.2 Transfusion reaction decision tree. Algorithm to guide assessment and actions to take when a transfusion reaction is initially identified. Actions should proceed from left to right. *(From Delaney M, Wendel S, Bercovitz RS. Transfusion reactions: prevention, diagnosis, and treatment. Lancet 2016;388:2825–2836. Fig 2.)*

Section 7

Hemorrhagic and Thrombotic Diseases

Chapter 524

Hemostasis

Brian R. Branchford, Benjamin J. Samelson-Jones, Leslie J. Raffini, and Veronica H. Flood

Hemostasis is the biological process that limits hemorrhage after blood vessel injury. An initial platelet plug (primary hemostasis) is bolstered by the product of the coagulation cascade: a factor XIII-cross-linked fibrin clot (secondary hemostasis). Extraneous fibrin is lysed by plasmin (fibrinolysis), and normal blood flow is restored through the previously damaged vessel. If hemostasis is impaired, varying degrees of bleeding may occur depending on the hemostatic defect and the site of injury. Excess coagulation activity can lead to thrombotic complications. The hemostatic response therefore needs to be rapid and locally regulated, such that trauma neither results in hemorrhage nor triggers a systemic thrombotic reaction. When a platelet adheres to a site of vascular injury, the activated platelet surface provides a phospholipid reaction surface where clotting factors bind and create a "thrombin burst." Active clotting is controlled by negative feedback loops that inhibit the clotting process when procoagulant products come in contact with intact endothelium. The main components of the hemostatic process are the **vessel wall, platelets, coagulation factors, anticoagulant proteins,** and **fibrinolytic system.** Many components of the hemostasis system are multifunctional. Fibrinogen serves as the ligand between platelets during platelet aggregation and as the substrate for thrombin to produce fibrin. Platelets provide the reaction surface on which clotting reactions occur, form the plug at the site of vessel injury, release procoagulant compounds from their granules, and contract to constrict and limit clot size.

THE HEMOSTATIC PROCESS

The intact vascular endothelium is the primary barrier against hemorrhage and thrombosis. The endothelial cells that line the vessel wall normally inhibit coagulation and provide a smooth surface that permits rapid blood flow.

After vascular injury, vasoconstriction occurs, and flowing blood comes in contact with the subendothelial matrix. **Von Willebrand factor (VWF)** tethers platelets to the site of injury by binding subendothelial matrix components such as collagen and platelets, via the glycoprotein Ib complex on platelet membranes. Platelet binding of VWF initiates complex cellular signaling, activating the platelets and triggering secretion of storage granules containing adenosine diphosphate (ADP), serotonin, and stored plasma and platelet membrane proteins. On activation, the platelet receptor for fibrinogen, $\alpha IIb\beta_3$, is switched on ("inside out" signaling) to bind fibrinogen and triggers the aggregation and recruitment of other platelets to form the platelet plug. Multiple physiologic agonists can trigger platelet activation and aggregation, including ADP, collagen, thrombin, and arachidonic acid. Aggregation involves the interaction of specific receptors on the platelet surface with plasma hemostatic proteins, primarily fibrinogen.

One of the subendothelial matrix proteins that is exposed after vascular injury is *tissue factor*. Exposed tissue factor binds to factor VII and activates the *clotting cascade* (Fig. 524.1). The activated clotting factor then initiates the activation of the next sequential clotting factor in a systematic manner. During the process of platelet activation, internalized platelet phospholipids (primarily phosphatidylserine) become externalized supporting membrane binding of the principal enzyme complexes of coagulation: the extrinsic and intrinsic Xase complexes and the prothrombinase complex. These complexes are localized to the platelet surface and bring together the active proteolytic enzyme, an activated cofactor, and the zymogen substrate that will form the next active enzyme in the cascade. This sequence of the coagulation cascade serves as a biochemical amplifier where a small amount of activated proteolytic enzyme can rapidly produce a large amount of downstream components, in a temporally and spatially controlled manner. In vivo, small amounts of activated factor VII (VIIa) are present, so the system is always poised to act. Near the bottom of the cascade, the multipotent enzyme *thrombin* is formed. Thrombin converts fibrinogen into fibrin, activates factors V, VIII, and XI, and aggregates platelets. Activation of factor XI by thrombin amplifies further thrombin generation and contributes to inhibition of fibrinolysis. Thrombin also activates factor XIII. The stable fibrin-platelet plug is ultimately formed through clot retraction and cross linking of the fibrin clot by factor XIIIa.

Virtually all procoagulant proteins are balanced by anticoagulant proteins that regulate or inhibit procoagulant function. Four clinically important, naturally occurring anticoagulants regulate the extension of the clotting process: antithrombin **(AT)**, protein C, protein S, and tissue factor pathway inhibitor **(TFPI)**. AT is a serine protease inhibitor (SERPIN) that regulates primarily factor Xa and thrombin and to a lesser extent, factors IXa, XIa, and XIIa. When thrombin encounters intact endothelium, thrombin binds to *thrombomodulin,* its endothelial receptor. The thrombin-thrombomodulin complex then converts **protein C** into activated protein C. In the presence of the cofactor **protein S**, activated protein C proteolyzes and inactivates factor Va and factor VIIIa. Inactivated factor Va is also a functional anticoagulant that inhibits clotting. TFPI limits activation of factor X by factor VIIa and tissue factor and shifts the activation site of tissue factor and factor VIIa to that of factor IX (Fig. 524.2).

Once a stable fibrin-platelet plug is formed, the fibrinolytic system limits its extension and proteolyzes the clot **(fibrinolysis)** to reestablish vascular integrity. Plasmin, generated from plasminogen by either urokinase-like or tissue-type plasminogen activator, degrades the fibrin clot. In the process of dissolving the fibrin clot, fibrin degradation products are produced. The fibrinolytic pathway is regulated by plasminogen activator inhibitors and α_2-antiplasmin, as well as by the thrombin-activatable fibrinolysis inhibitor (TAFI).

PATHOLOGY

Congenital deficiency of an individual procoagulant protein leads to a bleeding disorder, whereas deficiency of an anticoagulant (clotting factor inhibitor) predisposes the patient to thrombosis. In acquired hemostatic disorders, there are frequently multiple problems with homeostasis that perturb and dysregulate hemostasis. A primary illness (sepsis) and its secondary effects (shock and acidosis) activate coagulation and fibrinolysis and impair the host's ability to restore normal hemostatic function. When sepsis triggers **disseminated intravascular coagulation,** platelets, procoagulant clotting factors, and anticoagulant proteins are consumed, leaving the hemostatic system unbalanced and prone to bleeding or clotting (see Chapter 532). Similarly, newborn infants and patients with severe liver disease have synthetic deficiencies of both procoagulant and anticoagulant proteins. Such dysregulation causes the patient to be predisposed to both hemorrhage and thrombosis with mild or moderate triggers that result in major alterations in the hemostatic process.

In the laboratory evaluation of hemostasis, parameters are manipulated to allow assessment of isolated aspects of hemostasis and limit the multifunctionality of some of its components. The coagulation process is studied in plasma anticoagulated with citrate to bind calcium, with added phospholipid to mimic the reaction surface normally provided by the platelet membrane and with a stimulus to trigger clotting. Calcium is added to restart the clotting process. This process does not necessarily reflect the in vivo pathways of clot formation.

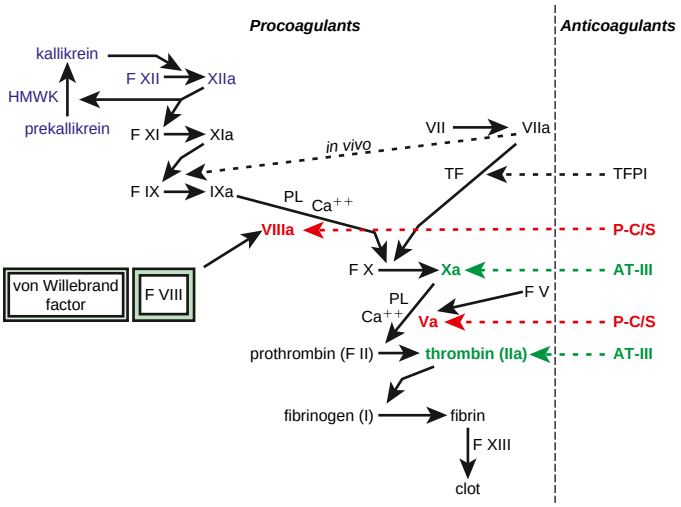

Fig. 524.1 The clotting cascade, with sequential activation and amplification of clot formation. Many of the factors (F) are activated by the clotting factors shown above them in the cascade. The activated factors are designated by the addition of an *a*. On the *right side*, the major anticoagulants and the sites that they regulate are shown. Tissue factor pathway inhibitor (TFPI) regulates tissue factor (TF); factor VIIa, protein C, and protein S (P-C/S) regulate factors VIII and V; and antithrombin III (AT-III) regulates factor Xa and thrombin (factor IIa). The *dotted line* shows that, in vivo, TF and factor VIIa activate both factors IX and X, but that, in vitro, only the activation of factor X is measured. Unactivated factor VIII, when bound to its carrier protein, von Willebrand factor (VWF), is protected from protein C inactivation. When thrombin, or factor Xa activates factor VIII, it becomes unbound from VWF, at which point it can participate with factor IXa in the activation of factor X in the presence of phospholipid (PL) and Ca^{++} (the "tenase" complex). Factor XIIIa cross-links the fibrin clot and thereby makes it more stable. Prekallikrein, high-molecular-weight kininogen (HMWK), and factor XII are shown in *purple* because they do not have a physiologic role in coagulation, although they contribute to the clotting time in partial thromboplastin time (PTT).

524.1 Clinical and Laboratory Evaluation of Hemostasis

Brian R. Branchford, Benjamin J. Samelson-Jones, Leslie J. Raffini, and Veronica H. Flood

CLINICAL HISTORY

For most hemostatic disorders, the clinical history provides the most useful information. To evaluate for a bleeding disorder, the history should determine the sites of bleeding, the severity and duration of hemorrhage, and the age at onset. Was the bleeding spontaneous, or did it occur after trauma? Was there a previous personal or family history of similar problems? Did the symptoms correlate with the degree of injury or trauma? Does bruising occur spontaneously? Are there lumps with bruises for which there is minimal trauma? If the patient had previous surgery or significant dental procedures, was there any increased bleeding? If a child or adolescent has had surgery that affects the mucosal surfaces, such as a tonsillectomy or major dental extractions, the absence of bleeding usually rules out a hereditary bleeding disorder. Delayed or slow healing of superficial injuries may suggest a hereditary bleeding disorder. In postpubertal females, it is important to take a careful menstrual history. Because some common bleeding disorders, such as **von Willebrand disease (VWD)**, have a fairly high prevalence, mothers and family members may have the same mild bleeding disorder and may not be cognizant that the child's menstrual history is abnormal. Females with mild VWD who have a moderate history of bruising frequently have a reduction in symptoms during pregnancy or after administration of oral contraceptives. Some medications, such as aspirin and other nonsteroidal antiinflammatory drugs (NSAIDs), inhibit platelet function and increase bleeding symptoms in patients with a low platelet count or abnormal hemostasis. Standardized bleeding scores have been developed but have not been widely adopted in pediatrics.

Outside the neonatal period, thrombotic disorders are relatively rare until adulthood. In the neonate, physiologic deficiencies of procoagulants and anticoagulants place the hemostatic mechanism at greater risk for imbalance, and clinical events can lead to either hemorrhage or thrombosis. If a child or teenager presents with deep vein thrombosis

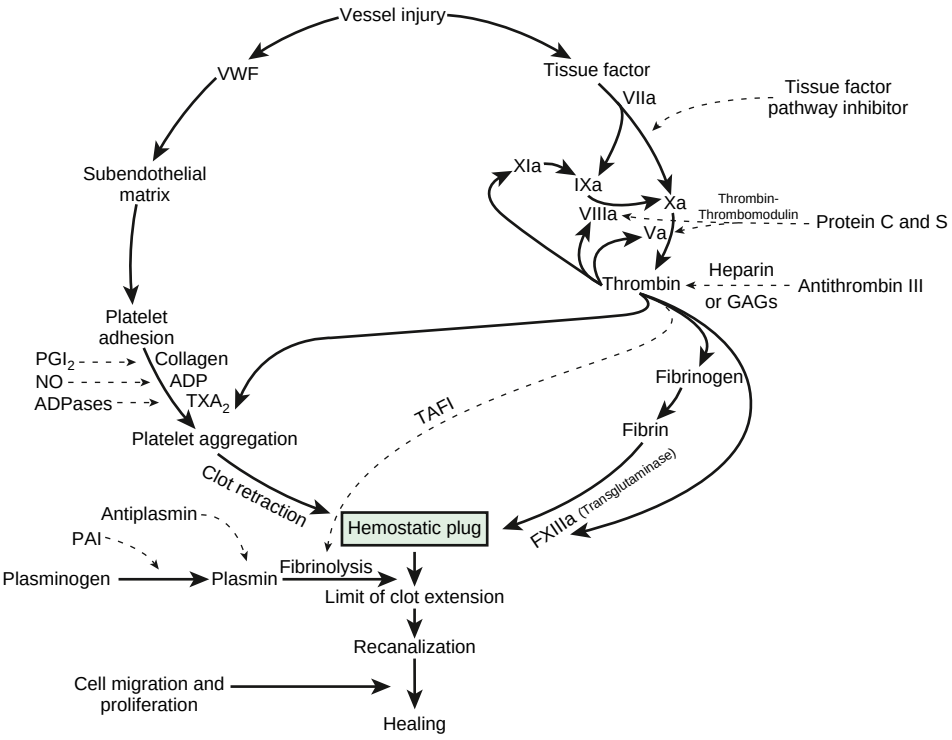

Fig. 524.2 The hemostatic mechanism. ADP, Adenosine diphosphate; GAGs, glycosaminoglycans; NO, nitric oxide; PGI_2, prostacyclin (prostaglandin I_2); PAI, plasminogen activator inhibitor; TAFI, thrombin-activated fibrinolytic inhibitor; TXA_2, thromboxane A_2; VWF, von Willebrand factor.

(DVT) or pulmonary embolism (PE), a detailed family history must be obtained to evaluate for DVT, PE, myocardial infarction (MI), or cerebrovascular accident (stroke) in other family members. The presence of **thrombosis**, especially in the absence of a provoking agent in the child or teenager, should induce the clinician to take a careful family history and consider an evaluation for a hereditary or acquired predisposition to thrombosis.

PHYSICAL EXAMINATION

The physical examination should focus on whether bleeding symptoms are associated primarily with the mucous membranes or skin (*mucocutaneous* bleeding) or with the muscles and joints (*deep* bleeding). The examination should determine the presence of petechiae, ecchymoses, hematomas, hemarthroses, or mucous membrane bleeding. Patients with defects in platelet–blood vessel wall interaction (VWD or platelet function defects) usually have mucocutaneous bleeding, which may include epistaxis, menorrhagia, petechiae, ecchymoses, occasional hematomas, and less frequently, hematuria and gastrointestinal bleeding. Individuals with a clotting deficiency of factor VIII or IX (hemophilia A or B) have symptoms of deep bleeding into muscles and joints, with much more extensive ecchymoses and hematoma formation. Patients with mild VWD or other mild bleeding disorders may have no abnormal findings on physical examination. Individuals with disorders of the collagen matrix and vessel wall may have loose joints and lax skin associated with easy bruising **(Ehlers-Danlos syndrome)**.

Patients undergoing evaluation for thrombotic disorders should be asked about swollen, warm, tender extremities (venous thrombosis), unexplained dyspnea or persistent "pneumonia," especially in the absence of fever (PE), and skin changes suggestive of chronic thrombosis (dilated collateral veins). Arterial thrombi usually cause an acute, dramatic impairment of organ function, such as stroke, MI, or a painful, white, cold extremity (Table 524.1).

LABORATORY TESTS

In patients who have a positive bleeding history or who are actively hemorrhaging, a platelet count, prothrombin time (PT), and partial thromboplastin time (PTT) should be performed as screening tests (Fig. 524.3). In individuals with abnormal screening tests, further evaluation should be based on those results (Table 524.2). In a patient with an abnormal bleeding history and a positive family history, normal screening tests should not preclude further laboratory evaluation, which may include a thrombin time, VWF testing, and platelet function studies. Historically, bleeding time and platelet function analysis **(PFA-100)** have been used as screening tests, but neither has proved to be useful in diagnosis of mild bleeding disorders.

There are no useful routine screening tests for *hereditary* thrombotic disorders. If the family history is positive or clinical thrombosis is unexplained, specific thrombophilia assays should be performed. Thrombosis is rare in children, and when it is present, the possibility of a hereditary predisposition should be considered (see Chapter 527).

Platelet Count

Platelet count is essential in the evaluation of the child with a positive bleeding history because thrombocytopenia is the most common acquired cause of a bleeding diathesis in children. Patients with a platelet count of $>50 \times 10^9$/L rarely have significant clinical bleeding. **Thrombocytosis** in children is usually reactive and is not associated with bleeding complications. Persistent, severe thrombocytosis in the absence of an underlying illness may require evaluation for the very rare pediatric presentation of essential thrombocythemia or polycythemia vera.

Prothrombin Time and Activated Partial Thromboplastin Time

Because clotting (coagulation) factors were named in the order of discovery, they do not necessarily reflect the sequential order of activation (Table 524.3; see also Table 524.2). Only two factors have commonly used names: fibrinogen (factor I) and prothrombin (factor II). The dual mechanisms of activating clotting have been termed the **intrinsic** (surface activation) and **extrinsic** (tissue factor–mediated) pathways. PT measures the activation of clotting by tissue factor (thromboplastin) in the presence of calcium. The tissue factor–factor VIIa complex activates factor X. Whether factor X is activated by the intrinsic or the extrinsic pathway, factor Xa on the platelet phospholipid surface complexes with factor Va and calcium (the "prothrombinase" complex) to activate prothrombin to thrombin (also referred to as *factor IIa*). Once thrombin is generated, fibrinogen is converted to a fibrin clot, the endpoint of the reaction (see Fig. 524.2). PT is not prolonged with deficiencies of factors VIII, IX, XI, and XII. In most laboratories, the normal PT value is 10-13 seconds. PT has been standardized using the international normalized ratio **(INR)** so that values can be compared from one laboratory or instrument to another. This ratio is used to determine similar degrees of anticoagulation with vitamin K antagonists, such as warfarin.

Partial Thromboplastin Time

The intrinsic pathway involves the initial activation of factor XII, which is accelerated by two other plasma proteins, prekallikrein and high-molecular-weight kininogen. In the clinical laboratory, factor XII is activated using a surface (silica or glass) or a contact activator, such as ellagic acid. Factor XIIa, in turn, activates factor XI to factor XIa, which then catalyzes factor IX to factor IXa. On the platelet phospholipid surface, factor IXa complexes with factor VIIIa and calcium to activate factor X ("tenase" complex).

This process is accelerated by interaction with phospholipid and calcium at the steps involving factors V and VIII. An isolated deficiency of

Table 524.1 Signs and Symptoms of Thrombosis

LOCATION OF CLOT	PRESENTING SYMPTOMS	RADIOGRAPHIC DIAGNOSIS
Venous thrombus in limbs	Swelling, pain, and/or redness	Venous ultrasonography with Doppler
Arterial thrombus in limbs	Cool limbs, diminished or absent pulse	Arterial ultrasonography with Doppler
Cerebral venous sinus thrombosis	Headache, nausea and/or vomiting, lethargy, change in mental status	CT venography or MR venography of head/brain
Pulmonary embolism	Chest pain, shortness of breath, pleuritis	CT angiography
Thrombus in the heart	Chest pain, shortness of breath, pleuritis	Echocardiogram
Portal vein thrombosis	Abdominal pain, nausea and/or vomiting, anorexia	Right upper quadrant ultrasonography with Doppler
Renal vein thrombosis	Hematuria, abdominal mass, abdominal pain, thrombocytopenia	Renal ultrasonography with Doppler or CT abdomen/pelvis with IV contrast

CT, Computed tomography; IV, intravenous; MR, magnetic resonance.
Modified from Han H, Hensch L, Hui SKR, Teruya J. Evaluation and management of coagulopathies and thrombophilias in pediatric patients. *Clin Lab Med.* 2021;41:83–100. Table 5.

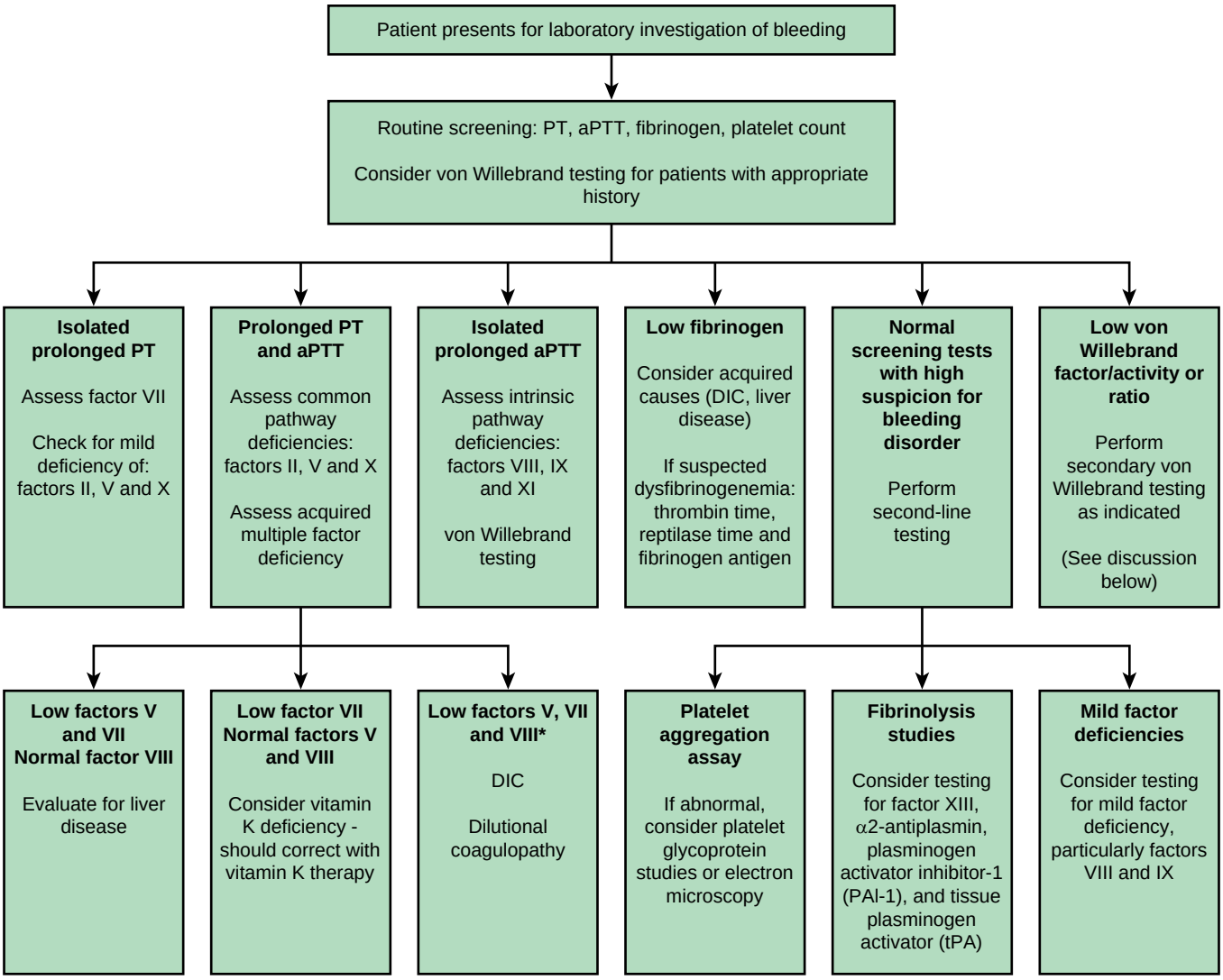

Fig. 524.3 Testing algorithm based on the screening tests (PT, aPTT, fibrinogen, and platelet count). DIC, disseminated intravascular coagulation. *Note: Factor VIII can be normal or increased in these settings secondary to the acute phase response. *(From Han H, Hensch L, Hui SKR, Teruya J. Evaluation and management of coagulopathies and thrombophilias in pediatric patients. Clin Lab Med. 2021;41:83–100. Fig. 1.)*

a single clotting factor may result in isolated prolongation of PT, PTT, or both, depending on the location of the factor in the clotting cascade. This approach is useful in determining hereditary clotting factor deficiencies; however, in acquired hemostatic disorders encountered in clinical practice, more than one clotting factor is frequently deficient, so the relative prolongation of PT and PTT must be assessed.

Measurement of PTT as performed in the clinical laboratory is actually "activated" PTT; most refer to it as **PTT**. This test measures the initiation of clotting at the level of factor XII through sequential steps to the final clot endpoint. It does not measure factor VII, factor XIII, or anticoagulants. PTT uses a contact activator (silica, kaolin, or ellagic acid) in the presence of calcium and phospholipid. Because of differences in reagents and laboratory instruments, the normal range for PTT varies among hospital laboratories. Normal ranges for PTT have much more interlaboratory variability than those for PT.

Thus the mechanisms studied by PT and PTT allow the evaluation of clotting factor deficiencies, even though these pathways may not be the same as those occurring physiologically. The PTT can be prolonged by deficiencies of factor XII, prekallikrein, and high-molecular-weight kininogen, yet these deficiencies do not result in bleeding,

Thrombin Time

Thrombin time (TT) measures the final step in the clotting cascade, in which fibrinogen is converted to fibrin. The normal TT varies between laboratories but is usually 11-15 seconds. Prolongation of TT occurs with reduced fibrinogen levels (*hypofibrinogenemia* or *afibrinogenemia*), with dysfunctional fibrinogen *(dysfibrinogenemia)*, or in the presence of substances that interfere with fibrin polymerization, such as heparin and fibrin split products. If heparin contamination is a potential cause of prolonged TT, a reptilase time can be ordered.

Reptilase Time

Reptilase time uses snake venom to clot fibrinogen. Unlike thrombin time, reptilase time is not sensitive to heparin and is prolonged only by reduced or dysfunctional fibrinogen and fibrin split products. Therefore, if TT is prolonged but reptilase time is normal, the prolonged TT is caused by heparin and does not indicate the presence of fibrin split products or reduced concentration or function of fibrinogen.

Mixing Studies

If there is unexplained prolongation of PT or PTT, a mixing study is usually performed. Normal plasma is added to the patient's plasma, and the PT or PTT is repeated. Correction of PT or PTT by 1:1 mixing with normal plasma suggests deficiency of a clotting factor because a 50% level of individual clotting proteins is sufficient to produce normal PT or PTT. If the clotting time is not corrected or only partially corrected, an **inhibitor** is usually present. An inhibitor of clotting may be either a chemical similar to heparin that delays coagulation or an

Table 524.2 Causes of Bleeding Associated with Prolonged Prothrombin Time and Activated Partial Thromboplastin Time

ISOLATED PROLONGED PT	ISOLATED PROLONGED aPTT	PROLONGED PT AND aPTT	CAUSES OF BLEEDING WITHOUT PT/aPTT PROLONGATION
FVII deficiency	Hemophilia A (FVIII deficiency)	Disseminated intravascular coagulation	FXIII deficiency
Mild common pathway factor deficiency (II, V, and X), fibrinogen deficiency	Hemophilia B (FIX deficiency)	Dilutional coagulopathy	von Willebrand disease
Early vitamin K deficiency	Hemophilia C (FXI deficiency)	Liver synthetic dysfunction	Platelet dysfunction
Early liver synthetic dysfunction	von Willebrand disease	Marked vitamin K deficiency	Mild deficiency of FVIII, FIX, and FXI
Direct Xa inhibitor	Acquired FVIII, FIX, or FXI inhibitors	Common pathway factor deficiency (FII, FV, and FX), severe fibrinogen deficiency	α_2-antiplasmin deficiency and other causes of hyperfibrinolysis
—	Heparin	Warfarin or direct thrombin inhibitor, DOAC (not always)	Collagen vascular diseases (i.e., Ehlers-Danlos syndrome)
—	—	Increased tissue factor pathway inhibitor, FV Amsterdam or East Texas bleeding disorder	DOAC

DOAC, Direct oral anticoagulant.
From Han H, Hensch L, Hui SKR, Teruya J. Evaluation and management of coagulopathies and thrombophilias in pediatric patients. *Clin Lab Med.* 2021;41:83–100. Table 1.

Table 524.3 Coagulation (Clotting) Factors

CLOTTING FACTOR	SYNONYM	DISORDER
I	Fibrinogen	Congenital deficiency (afibrinogenemia) or dysfunction (dysfibrinogenemia)
II	Prothrombin	Congenital deficiency or dysfunction
V	Labile factor, proaccelerin	Congenital deficiency (parahemophilia)
VII	Stable factor or proconvertin	Congenital deficiency
VIII	Antihemophilic factor	Congenital deficiency is hemophilia A (classic hemophilia)
IX	Christmas factor	Congenital deficiency is hemophilia B (sometimes referred to as Christmas disease)
X	Stuart-Prower factor	Congenital deficiency
XI	Plasma thromboplastin antecedent	Congenital deficiency (sometimes referred to as hemophilia C)
XII	Hageman factor	Congenital deficiency is not associated with clinical symptoms
XIII	Fibrin-stabilizing factor	Congenital deficiency

antibody directed against a specific clotting factor or the phospholipid used in clotting tests. In the inpatient setting the most common cause of a prolonged PTT is **heparin contamination** of the sample. The presence of heparin in the sample can be ruled in or out by adding *heparinase* to the sample and repeating the PTT. If the mixing study is not corrected or if its result becomes more prolonged and the patient has clinical bleeding, an inhibitor of a specific clotting factor (antibody directed against the factor), most often factor VIII, factor IX, or factor XI, may be present. If the patient has no bleeding symptoms and both PTT and the mixing study are prolonged, a **lupus-like anticoagulant** (see Chapter 531) is often present. Patients with these findings usually have a long PTT but do not bleed.

Platelet Aggregation

When a qualitative platelet function defect is suspected, platelet aggregation testing is usually ordered. Platelet-rich plasma from the patient is activated with a series of agonists (ADP, epinephrine, collagen, thrombin or thrombin-receptor peptide, and ristocetin). Some platelet aggregometers measure specific adenosine triphosphate release from the platelets, as measured by the generation of luminescence via lumiaggregometry, and are more sensitive in detecting abnormalities of the platelet release reaction from storage granules. Repeat testing or testing of other symptomatic family members can help to determine the hereditary nature of the defect. Many medications, especially aspirin, other NSAIDs, and valproic acid, alter platelet function testing. Figure 524.1 provides an approach to the differential diagnosis of many common bleeding disorders based on screening tests.

Factor XIII

The PT and PTT reflect only fibrin formation and do not measure cross-linking by factor XIII. Therefore specific testing is required to identify factor XIII deficiency. Clot solubility testing can be performed but only identifies the most severely affected individuals. Quantitative measurement of factor XIII levels can also be performed.

Testing for Thrombotic Predisposition

Hereditary predisposition to thrombosis is associated with a reduction of anticoagulant function (protein C, protein S, AT III); the presence of

Table 524.4 Reference Values for Coagulation Tests in Healthy Children

PARAMETER	15 D-4 WK	1-5 MO	6-11 MO	1-5 YR	6-10 YR	11-17 YR	ADULT RANGES
SCREENING TESTS							
PT (sec)	11.2 (9.5-12.6)	11.0 (9.7-12.8)	11.0 (9.8-13.0)	11.3 (9.9-13.4)	11.7 (10.0-14.6)	11.8 (10.0-14.1)	10.9 (9.2-12.2)
PTT (sec)	35.4 (27.6-45.6)	33.5 (24.8-40.7)	32.4 (25.1-40.7)	31.6 (24.0-39.2)	31.6 (26.9-38.7)	31.0 (24.6-38.4)	31.7 (27.8-36.3)
COAGULATION PROTEINS							
Fibrinogen (g/L)	2.54 (1.43-4.02)	2.26 (1.50-3.76)	2.33 (1.57-3.60)	2.73 (1.88-4.13)	2.78 (1.89-4.75)	2.66 (1.77-4.20)	2.75 (2.17-3.42)
FII (IU/mL)	56 (45-74)	75 (47-111)	92 (74-117)	99 (49-130)	90 (68-132)	94 (48-119)	101 (75-132)
FV (IU/mL)	100 (69-124)	100 (60-147)	102 (59-160)	111 (73-188)	101 (82-141)	97 (62-125)	99 (61-142)
FVII (IU/mL)	76 (55-108)	88 (43-141)	88 (52-128)	82 (48-124)	77 (55-135)	82 (55-133)	95 (59-151)
FVIII (IU/mL)	96 (65-153)	85 (50-187)	75 (53-132)	95 (59-167)	87 (61-154)	93 (43-155)	97 (56-146)
FIX (IU/mL)	44 (30-77)	53 (29-105)	77 (51-107)	84 (53-129)	80 (55-156)	97 (60-138)	112 (70-131)
FX (IU/mL)	85 (66-92)	89 (68-122)	100 (76-134)	99 (60-153)	99 (71-162)	93 (64-131)	106 (73-150)
FXI IU/mL)	56 (33-75)	64 (28-126)	86 (61-126)	92 (58-154)	83 (32-154)	84 (55-139)	105 (49-139)
FXII (U/mL)	69 (25-81)	76 (38-137)	109 (48-156)	107 (50-175)	84 (49-154)	92 (49-154)	108 (47-157)
FXIII (IU/mL)	86 (78-100)	83 (55-133)	92 (51-137)	97 (49-137)	97 (54-142)	106 (64-133)	100 (68-138)
Von Willebrand antigen (IU/mL)	163 (46-220)	102 (36-217)	79 (48-199)	89 (41-186)	80 (45-141)	92 (56-123)	91 (43-144)
ANTICOAGULANT PROTEINS							
Antithrombin (IU/mL)	41 (33-63)	80 (29-120)	96 (63-122)	67 (61-128)	97 (64-136)	97 (64-136)	112 (83-126)
Protein C (IU/mL)	38 (30-115)	82 (28-128)	85 (44-151)	86 (61-144)	91 (39-170)	95 (66-127)	119 (69-149)
Protein S (IU/mL)	90 (29-115)	82 (33-154)	88 (52-1138)	97 (60-149)	105 (67-162)	99 (53-147)	102 (58-138)
Plasminogen (U/mL)	53 (41-83)	69 (38-110)	81 (49-126)	92 (60-178)	92 (52-158)	92 (58-131)	94 (63-135)
D-dimer (ng/mL)	530 (445-1200)	515 (90-878)	270 (133-844)	280 (88-780)	275 (60-567)	245 (69-580)	277 (109-560)

PT, Prothrombin time; PTT, partial thromboplastin time.
Data expressed as median (95% confidence interval).
Data adapted from Toulon P, Berruyer M, Brionne-François M, et al. Age dependency for coagulation parameters in paediatric populations. Results of a multicentre study aimed at defining the age-specific reference ranges. *Thromb Haemost.* 2016;116:9–16.

a factor V molecule that is resistant to inactivation by protein C (factor V Leiden); elevated levels of procoagulants (a pathogenic variant of the prothrombin gene); or a deficiency of fibrinolysis (plasminogen deficiency); and the rare metabolic disease homocystinuria (see Chapter 527).

Tests of the Fibrinolytic System

Euglobulin clot lysis time is a screening test used in some laboratories to assess fibrinolysis. More specific tests are available in most laboratories to determine the levels of plasminogen, plasminogen activator, and inhibitors of fibrinolysis. An increase in fibrinolysis may be associated with hemorrhagic symptoms, and a delay in fibrinolysis is associated with thrombosis.

DEVELOPMENTAL HEMOSTASIS

The normal newborn infant has reduced plasma concentrations of several procoagulants and anticoagulants compared to adults (see Table 524.4), and this is even more pronounced in preterm infants. During gestation, there is progressive maturation and increase of the clotting factors synthesized by the liver. The extremely premature infant has prolonged PT and PTT values, as well as a marked reduction in anticoagulant protein levels (protein C, protein S, and AT). Levels of fibrinogen, factors V and VIII, VWF, and platelets are near-normal throughout the later stages of gestation (see Chapter 142). Because protein C and protein S are physiologically reduced, factors V and VIII, which are present at normal levels at birth, are not balanced with their regulatory proteins. In contrast, the physiologic deficiency of vitamin K–dependent procoagulant proteins (factors II, VII, IX, and X) is partially balanced by the physiologic reduction of AT. The net effect is that newborns (especially premature infants) are at increased risk for complications of bleeding, clotting, or both. Establishing absolute cutoff values for normal ranges of coagulation proteins in newborn and preterm infants is challenging because of the age-dependent variation and heterogeneity among laboratory instruments and reagents. Repeat testing (or testing parents) may be necessary to confirm a diagnosis of an inherited deficiency.

Visit Elsevier eBooks+ at eBooks.Health.Elsevier.com for Bibliography.

Chapter 525

Hereditary Clotting Factor Deficiencies (Bleeding Disorders)

Benjamin J. Samelson-Jones, Brian R. Branchford, and Veronica H. Flood

Inherited deficiencies in the coagulation factors responsible for forming cross-linked fibrin clots (as detailed in Chapter 524) can result in bleeding disorders. **Hemophilia A** (factor VIII deficiency) and **hemophilia B** (factor IX deficiency) are the most common and serious congenital coagulation factor deficiencies. The clinical findings in hemophilia A and hemophilia B are virtually identical. Factor XI deficiency is a rare autosomal bleeding disorder discussed in Chapter 525.2. Reduced levels of the *contact factors* (factor XII, high molecular weight kininogen, and prekallikrein) are associated with significant prolongation of *activated partial thromboplastin time* (aPTT; also referred to as **PTT**) but are not associated with clinical bleeding, as discussed in Chapter 525.3.

525.1 Factor VIII or Factor IX Deficiency (Hemophilia A or B)

Benjamin J. Samelson-Jones, Brian R. Branchford, and Veronica H. Flood

Hemophilia A (factor VIII deficiency) and hemophilia B (factor IX deficiency) are the most common severe inherited bleeding disorders.

PATHOPHYSIOLOGY

The activated forms of factors VIII and IX participate in the enzyme complex responsible for the sustained proteolytic activation of factor X during coagulation. Together with phospholipids and calcium, they form the intrinsic tenase (or factor X activating) complex. Hemophilia A and hemophilia B have similar clinical manifestations because, molecularly, both disorders result in a deficiency of factor X activation, which, in turn, results in insufficient thrombin generation (see Fig. 524.1 in Chapter 524 for a depiction of the in vitro clotting process as it occurs in the test tube). In hemostatically normal individuals, hemorrhage after an injury is constrained by the initial formation of the platelet plug, which is stabilized by the generation of a cross-linked fibrin clot. In people with hemophilia A or B, clot formation is delayed and ineffectual. Inadequate thrombin production leads to failure to form a tightly cross-linked fibrin to support the platelet plug. When untreated bleeding occurs in a closed space, such as a joint, bleeding may stop as the result of **tamponade**. With open wounds, in which tamponade cannot occur, even minor injuries may result in significant blood loss, with a highly friable clot forming slowly; rebleeding occurs during physiologic thrombolysis or with minimal new traumas.

CLINICAL MANIFESTATIONS

The severity of the bleeding phenotype in hemophilia A and B is strongly associated with the amount of residual factor VIII or factor IX, respectively. **Severe hemophilia** is characterized by having <1% normal factor activity, and bleeding is frequent and often spontaneous. Patients with **moderate hemophilia** have factor levels of 1–5% normal and bleed excessively with mild trauma. Individuals with **mild hemophilia** have factor levels 5–40% normal and usually only bleed abnormally after major trauma or surgery; people with mild hemophilia may go many years before the condition is diagnosed.

Because neither factor VIII nor factor IX crosses the placenta, bleeding symptoms may be present at birth. Between 1% and 4% of neonates with hemophilia have intracranial hemorrhages, mostly from birth trauma. However, about 35% and 70% of male infants with severe and nonsevere hemophilia, respectively, *do not bleed* with circumcision. Thus, in the absence of a positive family history (50% of cases), hemophilia may go undiagnosed in the newborn period. Obvious symptoms, such as easy bruising, intramuscular hematomas, and hemarthroses, begin when the child starts to cruise. Bleeding from minor traumatic lacerations of the mouth (torn frenulum) may persist for hours or days and may cause the parents to seek medical evaluation. Even in patients with severe hemophilia, only 90% have evidence of increased bleeding by a year of age.

Although bleeding may occur in any area of the body, the hallmark of hemophilia bleeding is **hemarthrosis**, which can occur spontaneously or after minor trauma. The earliest joint hemorrhages appear most often in the ankles. In the older child and adolescent, hemarthroses of the knees and elbows are also common. Whereas the child's early joint hemorrhages are recognized only after major swelling and fluid accumulation in the joint space, older children are frequently able to recognize bleeding before the physician does: patients report a warm, tingling sensation in the affected joint as the first sign of a joint hemorrhage. Repeated bleeding episodes into the same joint may result in a "target" joint, which becomes more susceptible to recurrent bleeding because of the pathologic changes (see "Chronic Complications").

Although most **muscular hemorrhages** are clinically evident because of localized pain or swelling, bleeding into the iliopsoas muscle requires specific mention. A patient may lose large volumes of blood into the iliopsoas muscle, verging on hypovolemic shock, with only a vague area of referred pain in the groin. The hip is held in a flexed, internally rotated position because of irritation of the iliopsoas. The diagnosis is made clinically from the inability to extend the hip but should be confirmed with ultrasonography, CT, or MRI (Fig. 525.1).

Life-threatening bleeding in the patient with hemophilia is caused by bleeding into vital structures (central nervous system [CNS], upper airway) or by exsanguination (external trauma, gastrointestinal [GI] or iliopsoas hemorrhage). Prompt treatment with clotting factor concentrate for these life-threatening hemorrhages is imperative. If head trauma is of sufficient concern to suggest radiologic evaluation, factor replacement should *precede* radiologic evaluation. Life-threatening hemorrhages require replacement therapy to achieve a level equal to that of normal plasma (100 IU/dL or 100%; see section below on "Treatment").

LABORATORY FINDINGS AND DIAGNOSIS

A reduced level of factor VIII or factor IX will often result in a *prolonged PTT*. In severe hemophilia, the PTT value is usually 2-3 times the upper limit of normal. However, depending on the PTT reagents, people with mild hemophilia can have a PTT in the normal range. Results of the other screening tests of the hemostatic mechanism (platelet count, bleeding time, prothrombin time [PT]) are normal. The specific activity assays for factors VIII and IX confirm the diagnosis of hemophilia. One IU of each factor activity is defined as that amount in 1 mL of normal plasma, referenced against a standard established by the World Health Organization (WHO). Thus 100 mL of normal plasma has 100 IU/dL (100% normal activity) of each factor. The term *% activity* refers to the percentage found in normal plasma (100% activity). Factor concentrates are also referenced against an international WHO standard, so treatment doses are usually referred to in IU.

In the newborn period, factor VIII activity values may be artificially elevated because of the acute-phase response elicited by the birth process. This artificial elevation may cause an infant with mild hemophilia A to have a normal or near-normal measured level. Patients with severe hemophilia A do not have detectable levels of factor VIII. In contrast, factor IX levels are physiologically low in all newborns and only reach adult values at about 6 months of age. If severe hemophilia is present in the family, an undetectable level of factor IX is diagnostic of severe hemophilia B. In some patients with mild factor IX deficiency, the presence of low factor IX activity can be confirmed only after several months of life.

Fig. 525.1 Massive hematoma into the iliopsoas muscle in a patient with hemophilia B. A male with severe deficiency of factor IX (hemophilia B) was admitted for right lower abdominal pain of progressively increasing severity and tenderness. He had had a common cold with severe cough and loss of appetite for approximately 1 week. **A,** Abdominal radiograph shows presence of the psoas sign on the right side and left-shifted colon gas. **B,** CT scan shows massive hematoma in the right iliopsoas muscle, resulting in anterior translocation of the right kidney. **C,** Reconstructed 3-dimensional image shows more clearly the kidney translocation and the extended, but intact, large vessels. These are useful findings for the diagnostic procedures because progressive right lower abdominal pain may closely simulate acute appendicitis. The hemorrhage was successfully managed by replacement of factor IX for 1 week without any recurrence. The patient did not have any inhibitors to factor IX. *(From Miyazaki K, Higashihara M. Massive hemorrhage into the iliopsoas muscle. Intern Med. 2005;44:158–159.)*

The mixing of normal plasma with hemophilia plasma usually corrects PTT value, unless the patient has an inhibitor, as discussed later. An inhibitor titer can be quantified by the Bethesda assay, where 1 Bethesda Unit (BU) neutralizes 1 IU/mL of factor.

DIFFERENTIAL DIAGNOSIS

In young infants with severe bleeding manifestations, the differential diagnosis includes severe thrombocytopenia; severe platelet function disorders, such as Bernard-Soulier syndrome and Glanzmann thrombasthenia; type 3 (severe) von Willebrand disease; and vitamin K deficiency.

GENETICS

The genes for factor VIII and IX (*F8* and *F9*, respectively) are carried near the terminus of the long arm of the X chromosome, making hemophilia an X-linked disorder. It occurs in approximately 1/5,000 males, with 80% having factor VIII deficiency and 20% having factor IX deficiency. Hemophilia appears in all ethnic groups. A third of cases are estimated to be the result of a spontaneous pathogenic variant. Approximately 50% of cases of severe hemophilia A have a specific *F8* change, in which there is an internal inversion within the factor VIII gene (intron 22 inversion). Meanwhile, 98% of hemophilia patients have an identified genetic cause of their hemophilia, which can facilitate diagnosis, prenatal testing, and identification of female carriers.

Some **female carriers** (heterozygotes) have sufficiently low factor level to have abnormal bleeding. Factor levels should be determined in all known or potential carriers to assess the need for treatment in the event of surgery or clinical bleeding. Female carriers with factor levels <40% normal are considered to have hemophilia and should be treated as such. Notably, about 0.2% of people with severe and moderate hemophilia are female, mostly because of skewed lyonization or Turner syndrome. Female carriers with factor levels >40% normal can also have abnormal bleeding and are termed *symptomatic hemophilia carriers*. Historically, female carriers were thought to be asymptomatic, but newer data prove these individuals can also have significant bleeding.

TREATMENT

Disease-specific therapy started early in life is the hallmark of excellent hemophilia care (Table 525.1). Treatment can be divided into on-demand therapy (hemostatic interventions to stop bleeding) and prophylaxis therapy to prevent bleeding. *Prophylaxis is the standard of care for children with severe hemophilia* in countries with sufficient medical resources. Prophylaxis decreases catastrophic bleeding, prevents hemarthrosis, and preserves joint health. The types of hemostatic agents available for hemophilia A and hemophilia B are rapidly expanding, with several new classes of medications receiving regulatory approval (Table 525.2).

On-Demand Treatment

To treat acute bleeding, nothing works better than replacing the deficient coagulation factor. When mild to moderate bleeding occurs, values of factor VIII or factor IX must be raised to hemostatic levels, approximately 50% of normal activity. For life-threatening or major hemorrhages, the dose should aim to achieve levels of 100% activity. Both plasma-derived and recombinant factor VIII and factor IX concentrates are available. Replacement therapy requires intravenous administration, which patients and families often learn to do themselves. The half-lives of standard factor VIII and factor IX are 8-12 hours and 18-24 hours, respectively, although there is wide variability between patients with younger children often having shorter half-lives. There are also bioengineered factor VIII and factor IX products designed to have longer half-lives (termed *extended half-life products*), which reduce the frequency of intravenous administrations necessary to treat bleeds and provide prophylaxis.

Table 525.1 summarizes the treatment recommendations of some common types of hemorrhage in a patient with hemophilia. The calculation of the factor replacement dose is as follows, with the difference between factor VIII and factor IX being because of their different volumes of distribution:

$$\text{Factor VIII dose (IU)} = [\%\ \text{desired raise}] \times [\text{weight (kg)}] \times 0.5$$

$$\text{Factor IX dose (IU)} = [\%\ \text{desired raise}] \times [\text{weight (kg)}] \times 1.3$$

Therefore emergency dosing for factor VIII deficiency is approximately 50 units per kg and emergency dosing for factor IX deficiency is approximately 100-130 units/kg.

It is important to note that patients can have variable recoveries, and different factor products also have slightly different recoveries. Many patients will carry dosing cards detailing their recommended treatments. In general, doses are rounded up to vial size so as not to waste product.

For some patients with *mild* factor VIII deficiency, **desmopressin acetate** can be used to stimulate the cellular release of endogenously

Table 525.1 Treatment of Hemophilia *Without* Inhibitors

TYPE OF HEMORRHAGE	HEMOPHILIA A	HEMOPHILIA B
Hemarthrosis*	50-60 IU/kg factor VIII concentrate† on day 1, then 20 IU/kg the following day. Consider every other day until joint function is normal or back to baseline. Consider prophylaxis.	80-100 IU/kg factor IX concentrate‡ on day 1; then 40 IU/kg the following day. Consider every other day until joint function is normal or back to baseline. Consider prophylaxis.
Muscle or significant subcutaneous hematoma	50 IU/kg factor VIII concentrate; 20 IU/kg every other day treatment may be needed until resolved.	80 IU/kg factor IX concentrate‡; 40 IU/kg every 2-3 days may be needed until resolved.
Mouth, deciduous tooth, or tooth extraction	20 IU/kg factor VIII concentrate†; antifibrinolytic therapy§; remove loose deciduous tooth.	40 IU/kg factor IX concentrate‡; antifibrinolytic therapy§; remove loose deciduous tooth.
Epistaxis	Apply pressure for 15-20 min; pack with petrolatum gauze; give antifibrinolytic therapy§; 20 IU/kg factor VIII concentrate† if this treatment fails.‖	Apply pressure for 15-20 min; pack with petrolatum gauze; antifibrinolytic therapy§; 30 IU/kg factor IX concentrate‡ if this treatment fails.#
Major surgery, life-threatening hemorrhage	50-75 IU/kg factor VIII concentrate; then initiate 25 IU/kg q8-12h to maintain trough level >50 IU/dL for 5-7 days; then 50 IU/kg q24h to maintain trough >25 IU/dL for 7 days; monitor factor VIII levels.	80-120 IU/kg factor IX concentrate‡, then 50-60 IU/kg q12-24h to maintain factor IX at >40 IU/dL for 5-7 days, and then at >30 IU/dL for 7 days; monitor factor IX levels.
Iliopsoas hemorrhage	50 IU/kg factor VIII concentrate; then 25 IU/kg q12h until asymptomatic; then 20 IU/kg every other day, for a total of 10-14 days.**	100 IU/kg factor IX concentrate‡; then 50-60 IU/kg q12-24h to maintain factor IX at >40 IU/dL until patient is asymptomatic; then 40-50 IU every other day, for a total of 10-14 days.**
Hematuria	Bed rest; 1.5× maintenance fluids; if not controlled in 1-2 days, 20 IU/kg factor VIII concentrate; if not controlled, give prednisone (unless patient is HIV-infected).	Bed rest; 1.5× maintenance fluids; if not controlled in 1-2 days, 40 IU/kg factor IX concentrate‡; if not controlled, give prednisone (unless patient is HIV-infected).

*For hip hemarthrosis, orthopedic evaluation for possible aspiration is advisable to prevent avascular necrosis of the femoral head.
†For mild or moderate hemophilia, desmopressin 0.3 μg/kg can be used instead of factor VIII concentrate if the patient is known to respond with a hemostatic level of factor VIII; if repeated doses are given, monitor factor VIII levels for tachyphylaxis.
‡Stated doses apply for recombinant factor IX concentrate; different dosing may apply for long-acting recombinant factor IX concentrates or plasma-derived factor IX.
§Do not give antifibrinolytic therapy until 4-6 hr after a dose of prothrombin complex concentrate.
#Nonprescription coagulation-promoting products may be helpful.
**Repeat radiologic assessment should be performed before discontinuation of therapy.
HIV, Human immunodeficiency virus; IU, international units; q12-24h, every 12 to 24 hours.
Adapted from Di Paola J, Montgomery RR, Gill JC, Flood VH. Hemophilia and von Willebrand disease. In: Orkin SH, Fisher DE, Ginsburg D, et al., eds. *Nathan and Oski's Hematology and Oncology of Infancy and Childhood*, 8th ed. Philadelphia: Elsevier, 2015: pp. 1028–1054.

Table 525.2 Strengths and Weaknesses of the Old and New Therapeutic Options for Hemophilia

	STRENGTHS	WEAKNESSES
Standard half-life clotting factor concentrates	Effective for both bleeding control and prevention; well established safety and effectiveness profile for decades; measurable FVIII and FIX concentrations as surrogate marker of effectiveness; can result in normal concentrations of FVIII and FIX	Frequent intravenous injections; inhibitor development
Extended half-life clotting factor concentrates	Effective for both bleeding control and prevention; a reduced number of injections; higher trough concentrations; measurable FVIII and FIX concentrations as surrogate markers of effectiveness; can result in normal concentrations of FVIII and FIX	Intravenous route; inhibitor development
Nonreplacement therapies (emicizumab, fitusiran, anti-tissue factor pathway inhibitor antibodies, SerpinPC)	Subcutaneous route; infrequent injections; standard doses for all patients	Need for adjunctive hemostatic treatment; steady state of coagulation activity not within the normal range; thrombotic risk
Gene therapy	Single intravenous injection; restoration of endogenous FVIII and FIX production	Preexisting immunity against adeno-associated viral vectors; immune response against vectors and transfected cells; unknown durability of transduction; need for immunosuppressive therapy; unknown long-term safety

FVIII, factor VIII; FIX, factor IX.
From Mancuso ME, Mahlangu JN, Pipe SW. The changing treatment landscape in haemophilia: from standard half-life clotting factor concentrates to gene editing. *Lancet*. 2021;397:630–640. Table 5.

produced factor VIII to increase its plasma levels. In patients with moderate or severe factor VIII deficiency, the stored levels of factor VIII are inadequate, and desmopressin treatment is ineffective. Desmopressin can be administered intravenously or intranasally, with the latter facilitating home treatment. The intranasal formulation is a higher concentration of desmopressin than that used to treat enuresis or hypopituitarism; the dose is 150 μg (1 spray) for children weighing <50 kg and 300 μg (2 sprays) for children and young adults weighing >50 kg. Most centers administer a trial of desmopressin to determine if the factor VIII levels increase sufficiently for hemostasis. Because desmopressin triggers the release of cellularly stored factor VIII, usually it can only be given twice in a 1-2 day period. The most serious complication is hyponatremia, which can be mitigated by fluid restrictions for the 24 hours after administration. Desmopressin is not effective in the treatment of factor IX deficiency.

Mucosal bleeding often benefits from antifibrinolytic agents such as aminocaproic acid or tranexamic acid that can be given orally or intravenously.

PROPHYLAXIS

Many patients are given lifelong prophylaxis to prevent spontaneous joint bleeding. The World Federation of Hemophilia recommends prophylaxis for children with severe hemophilia and for adults with joint disease. Usually, such programs are initiated at the time of the first or second joint hemorrhage. Young children often require the insertion of a central catheter to ensure venous access for factor replacements. Such regimens are expensive but highly effective in preventing or greatly limiting the degree of joint pathology; complications include central line infection and thrombosis.

The goal of prophylaxis is generally to maintain a measurable plasma factor level (1–2%), when assayed just before the next infusion (trough level); this converts patients from severe to moderate hemophilia. For standard half-life products, this typically requires intravenous administration 2-4 times per week; this frequency is reduced with prophylaxis with extended half-life products.

Another class of hemophilia drugs that promotes hemostasis without factor VIII or factor IX is termed **nonfactor therapies**. Emicizumab is approved for prophylaxis for hemophilia A. Emicizumab is a bispecific, humanized monoclonal antibody that can bridge activated factor IX and factor X to restore factor X activation. It is administered subcutaneously and is given only 1-4 times per month after four weekly loading doses. Because emicizumab mimics some of the biochemistry of activated factor VIII, it dramatically shortens PTT times. It is not used to treat acute bleeds.

Efanesoctocog alfa, a modified extended half-life single recombinant factor VIII protein that decouples recombinant factor VIII from endogenous von Willebrand factor, has demonstrated efficacy in patients with severe hemophilia A. **Fitusiran**, a small interfering RNA molecule that reduces antithrombin synthesis, has been used successfully for prophylaxis in patients with hemophilia A or B with or without inhibitors. **Gene therapy** (valoctocogene roxaparvovec for hemophilia A; etranacogene dezaparvovec for hemophilia B) has demonstrated efficacy in reducing bleeding in adult patients with severe hemophilia.

SUPPORTIVE CARE

Effective measures to avoid trauma include anticipatory guidance, including the use of car seats, seatbelts, and bike helmets and the avoidance of high-risk behaviors. Older males should be counseled to avoid violent contact sports, but this issue is admittedly a challenge; however, active lifestyles are also encouraged to limit obesity. Early psychosocial intervention helps the family achieve a balance between overprotection and permissiveness. Patients with hemophilia should avoid aspirin and other nonsteroidal antiinflammatory drugs (NSAIDs) that affect platelet function.

Inhibitor Formation

The formation of neutralizing antibodies, termed *inhibitors*, is the major complication of factor VIII or factor IX replacement therapy. They develop in 20–30% of severe hemophilia A patients and 3–10% of severe hemophilia B patients that receive factor therapy, usually within 20 exposures to factor. Inhibitors may be identified during routine laboratory surveillance or become clinically apparent when bleeding episodes fail to respond to appropriate replacement therapy. There are both patient and product risk factors for inhibitor development, with the underlying hemophilia-causing gene pathogenic variant being the most important with the majority of people with large-gene deletions developing inhibitors. Prophylaxis with plasma-derived factor VIII products decreases the risk of inhibitor development about 1.7-fold compared to recombinant factor VIII products. Intensive early factor exposure during surgery or major trauma increases the risk of inhibitor development, likely through initiating immunologic danger signaling. Patients with inhibitors always require referral to a center that cares for many such patients and has a comprehensive hemophilia program.

Clinically, inhibitor titers are demarcated as low-titer (≤5 BU) and high-titer (>5 BU). Low-titer inhibitors can often be overcome by large amounts of factor, while high-titers necessitate the use of bypassing agents, which can circumvent the inhibitor to promote hemostasis. The two bypassing agents available that can treat acute bleeds are activated prothrombin complex concentrates and recombinant activated factor VII, both of which are administered intravenously. Prophylaxis regimens for bypassing agents have been described, but most hemophilia A patients with inhibitors currently use emicizumab prophylaxis because of its efficacy and ease of administration.

Inhibitor eradication has been prioritized, and it is still recommended since the advent of emicizumab. Low-titer or transient inhibitors often disappear with continued regular factor infusions. Higher titer inhibitors often require immune tolerance induction regimens, in which high doses of factor are administered to attempt to develop immune tolerance. This procedure is successful in about two-thirds of severe hemophilia A patients. Immune tolerance induction with factor IX products is complicated by allergic reactions and the development of nephrotic syndrome in some patients. Rituximab, corticosteroids, and other immunosuppressives have been used in patients with high-titer inhibitors in whom immune tolerance programs have failed, although the use of immunosuppressive therapy has declined with the use of emicizumab prophylaxis for factor VIII deficiency inhibitor patients.

CHRONIC COMPLICATIONS

Long-term complications of hemophilia A and B include chronic arthropathy and the risk of transfusion-transmitted infectious diseases, although both complications have been substantially mitigated with modern hemophilia care, including early initiation of prophylaxis and the use of recombinant protein products or plasma-derived products with advanced donor screening and highly active viricidal procedures.

Chronic arthropathy is the major long-term disability associated with hemophilia. The natural history of severe hemophilia without prophylaxis is one of cyclic recurrent hemorrhages into specific joints, including hemorrhages into the same (target) joint. In young children, the joint distends easily, and a large volume of blood may fill the joint until tamponade ensues or therapy intervenes. After joint hemorrhage, proteolytic enzymes are released by white blood cells into the joint space, and heme iron induces macrophage proliferation, leading to inflammation of the synovium. The synovium thickens and develops frondlike projections into the joint that are susceptible to being pinched and may induce further hemorrhage. The cartilaginous surface becomes eroded and ultimately may even expose raw bone, leaving the joint susceptible to articular fusion. In the older patient with advanced arthropathy, bleeding into the target joint, with its thickened synovium, causes severe pain, because the joint has little space to accommodate blood. Once a target joint develops, the patient is usually given short- or long-term prophylaxis to prevent progression of the arthropathy and reduce inflammation.

In the past, plasma-derived products tragically transmitted hepatitis B virus, hepatitis C virus, and HIV to large numbers of people with hemophilia. Modern plasma-derived products pose a very low risk of spreading identified bloodborne pathogens, but the risk of transmitting unidentified pathogens or emerging agents such as prions remains largely undefined.

COMPREHENSIVE CARE

Patients with hemophilia are best managed through comprehensive hemophilia care centers. Such centers are dedicated to patient and family education and the prevention and treatment of the complications of

hemophilia, including chronic joint disease and inhibitor development. Such centers involve a team that includes physicians, nurses, orthopedists, physical therapists, and psychosocial workers, all focused on hemophilia care. Education remains crucial in hemophilia care because patients who are receiving prophylaxis may be less experienced in recognizing bleeding episodes than affected children from previous eras.

Visit Elsevier eBooks+ at eBooks.Health.Elsevier.com for Bibliography.

525.2 Factor XI Deficiency

Benjamin J. Samelson-Jones, Brian R. Branchford, and Veronica H. Flood

Factor XI deficiency (previously known as hemophilia C) is an autosomal disorder associated with mild to moderate bleeding symptoms. Bleeding is usually after trauma and surgery, with bleeding most commonly occurring at sites of high fibrinolytic activity, such as the oropharynx and urogenital tract. This focality is likely secondary to the role of factor XI in augmenting thrombin generation for the subsequent activation of *thrombin-activatable fibrinolysis inhibitor* (TAFI). Heavy menstrual bleeding is also common in females with factor XI deficiency. Factor XI deficiency can occur in any ethnic group but is frequently encountered in Ashkenazi Jews with a heterozygous frequency of 1 in 11 individuals. Factor XI deficiency usually (but not always) results in a prolonged PTT; specific factor XI activity assays are diagnostic.

The bleeding phenotype is poorly predicted by the measured factor XI activity. Some patients with severe deficiency (<20% normal activity) may have minimal or no symptoms, whereas other individuals with higher levels experience excessive surgical bleeding. Because spontaneous bleeding is very rare, treatment is focused on perioperative management. Although factor XI concentrates are available in other countries, in the United States, factor XI has to be replaced with fresh-frozen plasma (FFP). For minor surgeries or bleeds, antifibrinolytics such as aminocaproic acid or tranexamic acid are frequently used. For major surgeries, 15-25 mL/kg of FFP in combination with antifibrinolytics is recommended. The factor XI half-life is 50 hours.

Visit Elsevier eBooks+ at eBooks.Health.Elsevier.com for Bibliography.

525.3 Deficiencies of the Contact Factors (Nonbleeding Disorders)

Benjamin J. Samelson-Jones, Brian R. Branchford, and Veronica H. Flood

Deficiency of the "contact factors"—factor XII, prekallikrein, and high molecular weight kininogen—causes a prolonged PTT but no bleeding symptoms. Because these contact factors function at the step of initiation of the intrinsic clotting system by the reagent used to determine PTT, the PTT is markedly prolonged when these factors are absent. Thus there is the paradoxical situation in which PTT is extremely prolonged with no evidence of clinical bleeding. It is important that individuals with these findings be well informed about the meaning of their clotting factor deficiency because they do not need treatment, even for major surgery.

525.4 Factor VII Deficiency

Benjamin J. Samelson-Jones, Brian R. Branchford, and Veronica H. Flood

Factor VII deficiency is a rare autosomal bleeding disorder that ranges in its presentation from mild to severe bleeding. There is a poor correlation between the clinical severity and the measured factor VII level, although major bleeding is more frequent in patients with <1% activity. Epistaxis and menorrhagia are the most common symptoms, although hemarthroses and intracranial hemorrhages also occur, with the latter reported in 1% of symptomatic cases.

Patients with this deficiency have greatly prolonged PT but normal PTT. Specific factor VII assays are diagnostic. Some recombinant factor VIIa products are approved for the treatment of factor VII deficiency at a dose of 15-30 mcg/kg, which is lower than the dose approved for hemophilia with inhibitors. The plasma half-life of factor VII is 2-6 hours and usually at least three doses at this frequency are required for major bleeding or surgery. Prophylaxis regimens with 2-3 administrations per week have been described in patients with severe bleeding.

Visit Elsevier eBooks+ at eBooks.Health.Elsevier.com for Bibliography.

525.5 Factor X Deficiency

Benjamin J. Samelson-Jones, Brian R. Branchford, and Veronica H. Flood

Factor X deficiency is a rare autosomal recessive disorder with variable severity. Mild deficiency results in mucocutaneous and posttraumatic bleeding, whereas severe deficiency (<1–10% normal activity) is associated with joint, GI, and intracranial hemorrhages. Intracranial and umbilical bleeding can be the presenting symptom for neonates. Heterozygous carriers usually have activity >50% normal and are asymptomatic.

A reduced factor X level is associated with prolongation of both PT and PTT; factor X specific assays are diagnostic. Replacement treatment is with FFP or prothrombin complex concentrate (PCC) or plasma-derived factor X concentrates. The plasma half-life of factor X is approximately 40-60 hours, and prophylaxis regimens with PCC or factor X concentrates administered 1-2 times per week are described for patients with severe bleeding.

Although it is rarely a problem in pediatric patients, about 10% of cases of **light-chain amyloidosis** are associated with factor X deficiency, resulting from the adsorption of factor X on the amyloid protein. In the setting of amyloidosis, replacement therapy often is not successful because of the rapid clearance of factor X.

Visit Elsevier eBooks+ at eBooks.Health.Elsevier.com for Bibliography.

525.6 Prothrombin (Factor II) Deficiency

Benjamin J. Samelson-Jones, Brian R. Branchford, and Veronica H. Flood

Prothrombin (factor II) deficiency is caused either by a markedly reduced prothrombin level (hypoprothrombinemia) or by functionally abnormal prothrombin (dysprothrombinemia). Laboratory testing in homozygous patients shows prolonged PT and PTT; specific prothrombin assays are diagnostic. Mucocutaneous bleeding in infancy and posttraumatic bleeding later are common. Patients are treated with either FFP or PCC at doses of 15-25 mL/kg or 20-40 U/kg, respectively. The half-life of prothrombin is 3-4 days, and once weekly prophylaxis regimens with PCC are reported.

Acquired factor II deficiency can be seen with a small percentage of patients with a lupus anticoagulant and is usually associated with significant bleeding. It is distinguished from inherited prothrombin deficiency by clinical history and the laboratory identification of antiphospholipid antibodies and abnormal PTT mixing studies.

Visit Elsevier eBooks+ at eBooks.Health.Elsevier.com for Bibliography.

525.7 Factor V Deficiency

Benjamin J. Samelson-Jones, Brian R. Branchford, and Veronica H. Flood

Deficiency of factor V is an autosomal recessive, mild to moderate bleeding disorder. Factor V circulates with 80% in plasma and 20% in platelet α-granules; this platelet factor V pool has been suggested to ameliorate the bleeding that might be expected from low plasma factor V levels. The most common symptoms are epistaxis, oral cavity bleeding, heavy menstrual periods, and postoperative bleeding; joint, muscle, and intracranial hemorrhages occur rarely.

Laboratory evaluation shows prolonged PT and PTT. Specific assays for factor V show a reduction in factor V levels. FFP is the only currently available therapeutic product that contains factor V. Factor V is lost rapidly from stored FFP. Treatment for major surgery or bleeding is usually 15-25 mL/kg FFP followed by additional doses of 10 mL/kg every 12 hours. Twice weekly FFP prophylaxis regimens are sometimes used for patients with severe bleeding. Platelet transfusions are also an option for acute or prophylactic treatment. Rarely, a patient with a negative family history of bleeding has an *acquired antibody* to factor V, which can be identified in laboratory mixing studies.

Visit Elsevier eBooks+ at eBooks.Health.Elsevier.com for Bibliography.

525.8 Combined Deficiency of Factors V and VIII

Benjamin J. Samelson-Jones, Brian R. Branchford, and Veronica H. Flood

Combined deficiency of factors V and VIII is an autosomal recessive bleeding disorder that occurs secondary to the absence of intracellular transporters responsible for the shuttling of factors V and VIII from the endoplasmic reticulum to the Golgi compartments, as the result of pathogenic variants in the genes *LMAN1* or *MCFD2*. Factor V and VIII levels are usually between 5–20% of normal. Bleeding symptoms are often mild and most commonly mucocutaneous, traumatic, surgical bleeding. Treatment for major bleeding or surgery is 15-25 mL/kg of FFP.

Visit Elsevier eBooks+ at eBooks.Health.Elsevier.com for Bibliography.

525.9 Congenital Fibrinogen Disorders

Benjamin J. Samelson-Jones, Brian R. Branchford, and Veronica H. Flood

Congenital fibrinogen disorders are a heterogenous group of rare autosomal recessive or dominant diseases because of qualitative (**dysfibrinogenemia**) or quantitative (**hypofibrinogenemia** or **afibrinogenemia**) reductions in functional fibrinogen. Fibrinogen cleavage by thrombin into fibrin is the final step of the coagulation cascade: polymerization follows cleavage and results in fibrin clot formation. Fibrinogen is also the major integrin ligand during platelet aggregation. Conversely, fibrin also sequesters thrombin to the site of clot formation and supports fibrinolysis by enhancing the activation of plasminogen. The multiple roles of fibrinogen and fibrin in hemostasis underlie the phenotypes of inherited fibrinogen disorders, which can have bleeding and clotting clinical manifestations, sometimes in the same patient. The most common bleeding symptoms are mucocutaneous, soft-tissue, joint, genitourinary, traumatic, surgical bleeding, and heavy menstrual periods. Both venous and arterial thrombosis are rare in the quantitative defects but occur in about 20% of cases of dysfibrinogenemia. Some congenital fibrinogen disorders also have nonhematologic manifestations, including liver disease due to retention of misfolded protein, poor wound healing, and splenic rupture.

Diagnosis is based on a decreased fibrinogen activity. Patients usually will also have a prolonged PT and PTT. Dysfibrinogenemia is defined as a decreased ratio of fibrinogen activity compared to fibrinogen antigen. Treatment for bleeding or major surgery is with FFP, cryoprecipitate, or fibrinogen concentrates, depending on local availability. Because of the variable clinical manifestations, including both bleeding and clotting complications, treatment is tailored to the personal and family history. The half-life of fibrinogen is 2-4 days.

Visit Elsevier eBooks+ at eBooks.Health.Elsevier.com for Bibliography.

525.10 Factor XIII Deficiency (Fibrin-Stabilizing Factor or Transglutaminase Deficiency)

Benjamin J. Samelson-Jones, Brian R. Branchford, and Veronica H. Flood

Factor XIII deficiency is a rare autosomal bleeding disorder. Factor XIII is a heterotetramer composed of two catalytic A subunits and two carrier B subunits; activation of factor XIII by thrombin frees the activated A subunits, which covalently crosslink fibrin to increase clot strength and constrain fibrinolysis. The different biochemical roles of the A and B subunits result in distinct clinical manifestations. Inherited deficiencies in the factor XIII A-subunit results in soft tissue, umbilical, surgical, joint, and intracranial bleeding; the latter occurs in about a third of cases. Deficiencies in the B-subunit are associated with mild mucocutaneous and surgical bleeding. Because of its role in stabilizing the fibrin clot, factor XIII deficiency often presents with *delayed* abnormal bleeding or bruising symptoms where patients may have mild trauma and then present with an excessive hematoma on the following day. Extrahematologic clinical manifestation of factor XIII deficiency includes delayed umbilical cord separation, poor wound healing, and recurrent miscarriages.

Unlike the other severe inherited coagulation deficiencies, factor XIII deficiency will have normal PTT and PT. Specific activity assays are diagnostic and should be considered in infants with delayed umbilical cord separation, delayed bleeding symptoms, or unexplained intracranial hemorrhage. Treatment for bleeding or major surgery is 20-40 U/kg of factor XIII concentrate. Recombinant A-subunit protein is also available for A-subunit deficiencies. If specific factor XIII replacement therapies are not available, cryoprecipitate is preferred over FFP because of the substantially higher factor XIII content. The half-life of factor XIII is 9-12 days, which facilitates prophylaxis. Because of the high prevalence of intracranial hemorrhage, prophylaxis of 20-40 U/kg factor XIII concentrate every 4 weeks is recommended for patients with <10% normal activity. *Autoimmune acquired* factor XIII deficiency can be differentiated using specific mixing studies or activity assays of platelet lysates.

Visit Elsevier eBooks+ at eBooks.Health.Elsevier.com for Bibliography.

525.11 Antiplasmin or Plasminogen Activator Inhibitor Deficiency

Benjamin J. Samelson-Jones, Brian R. Branchford, and Veronica H. Flood

Deficiency of either antiplasmin or plasminogen activator inhibitor, both of which are antifibrinolytic proteins, results in increased plasmin generation and premature lysis of fibrin clots. Affected patients have a mild-to-moderate bleeding disorder characterized by delayed bleeding symptoms, typically associated with trauma or surgery. Mucocutaneous bleeding and heavy menstrual bleeding are the most described symptoms, with rare reports of joint or intracranial hemorrhages.

Because results of the usual hemostatic tests are normal, further workup of a patient with a positive bleeding history (especially delayed bleeding) should include *euglobulin clot lysis time*, which measures fibrinolytic activity and yields a shortened result in the presence of these deficiencies. Specific assays for α_2-antiplasmin and plasminogen activator inhibitor are available, although the lower limit of normative values of these assays are not well defined. Antifibrinolytic therapies such as aminocaproic acid or tranexamic acid are the mainstay of treatments for controlling or preventing bleeding because they mitigate the hyperfibrinolysis. FFP can also be used to replace the deficient proteins.

Visit Elsevier eBooks+ at eBooks.Health.Elsevier.com for Bibliography.

Chapter 526

Von Willebrand Disease

Brian R. Branchford and Veronica H. Flood

Von Willebrand disease (VWD) is the most common inherited bleeding disorder, with an estimated prevalence cited at 1:100 to 1:10,000 depending on the criteria used for diagnosis. Patients with VWD typically present with mucosal bleeding. A family history of either VWD or bleeding symptoms and confirmatory laboratory testing are also required for the diagnosis of VWD.

PATHOPHYSIOLOGY

VWD is caused by a defect in, or deficiency of, von Willebrand factor (VWF). VWF has several functions in coagulation. VWF serves to tether platelets to injured subendothelium via binding sites for platelets and for collagen. VWF also serves as a chaperone, or carrier protein, for factor VIII (FVIII), protecting it from degradation in plasma. VWF is stored in endothelial cell Weibel-Palade bodies and platelet dense granules and circulates as a large, multimeric glycoprotein. Shear stress induces a conformational change in VWF that facilitates its ability to bind platelets through an exposed binding site on platelet glycoprotein Ib (GPIb). This enables VWF to recruit platelets to the site of clot formation, a function dependent on the high molecular weight (HMW) multimer forms of VWF.

VWD typically presents with mucocutaneous bleeding, similar to that seen with other platelet defects. **Epistaxis, easy bruising,** and **menorrhagia** in females are common complaints. However, symptoms are variable and do not necessarily correlate well with VWF levels. **Surgical bleeding**, particularly with dental extractions or adenotonsillectomy, is another common presentation. Severe type 3 VWD may present with joint and/or muscle bleeds. Most patients will have a family history of bleeding, but the VWD genetic variant demonstrates incomplete penetrance (not all carriers of the variant express bleeding symptoms) and variable expressivity (different VWF levels can be found in individuals with the same gene variant). Females are more likely to be diagnosed with VWD because of the potential for symptoms with menorrhagia, but males and females are equally likely to have VWD. However, diagnosis based on symptoms may be difficult, since minor bruising and epistaxis are not uncommon in childhood. Significant unexplained bruising, or bruising in unusual areas (stomach, back, face), in infants and toddlers is more often from nonaccidental trauma than from an underlying bleeding disorder. Gastrointestinal bleeding due to VWD may be complicated by associated angiodysplastic lesions anywhere in the gastrointestinal tract.

CLASSIFICATION

VWD may be caused by quantitative or qualitative defects in VWF. Mild to moderate quantitative defects are classified as type 1 VWD, whereas severe quantitative defects, in which there is no detectable VWF protein, are classified as type 3 VWD. The qualitative defects are grouped together as type 2 VWD.

Type 1 VWD is by far the most common type, accounting for 60–80% of all VWD patients. Typical symptoms include mucosal bleeding, such as epistaxis and menorrhagia, as well as easy bruising and potentially surgical bleeding. Diagnostic guidelines use a VWF level, as measured by the VWF antigen assay **(VWF:Ag)**, of <30 IU/dL for a clear diagnosis of VWD. Antigen and activity are usually symmetrically depressed in type 1 VWD. Patients with VWF:Ag <30 IU/dL are most likely to have a genetic defect in VWF. Patients with VWF:Ag between 30 and 50 IU/dL are said to have "low VWF." Whether or not this category truly represents VWD is a subject of some debate, and the joint guidelines suggest that the resolution should be based on presence or absence of bleeding symptoms. Because some patients with VWF levels in this range do experience bleeding, many physicians elect to treat them, especially perioperatively, for surgical procedures such as tonsillectomy.

Patients with type 1 VWD may have low VWF as a result of increased clearance of their VWF, known as **type 1C VWD**. Diagnosis of this subtype is important *because treatment of these patients with desmopressin is likely to be ineffective, necessitating administration of VWF-containing products instead.*

VWF levels can be influenced by external factors. Blood type has long been known to affect VWF, with lower VWF levels seen in people with blood group O. Stress, inflammation, exercise, menstrual cycle, and pregnancy all increase VWF levels; therefore a single normal VWF level does not necessarily rule out the presence of VWD. Certain diseases, such as **hypothyroidism** (see Chapter 603), and medications, such as valproic acid, can lower VWF levels in affected patients. Repeat testing is often required to confidently rule out or confirm a diagnosis of VWD.

Type 3 VWD is the most severe form and presents with symptoms similar to those seen in *mild hemophilia.* In type 3 VWD the VWF protein is completely absent, and the activity and antigen are both essentially zero. Type 3 VWD is seen at a frequency of approximately 1/1,000,000 members of the general population. In addition to mucosal bleeding, patients may experience joint bleeds, muscle bleeds, or central nervous system (CNS) hemorrhage. Some physicians elect to treat patients with prophylaxis, or modified prophylaxis, after injury, given that these patients typically have very low FVIII (<10 IU/dL). Because type 3 VWD is caused by a complete lack of VWF, *desmopressin is ineffective and treatment with VWF-containing concentrates is required.*

Type 2 VWD is often suspected when a discrepancy exists between the VWF antigen level (often normal) and the VWF activity (often low) because this type represents a qualitative defect, in which an abnormal protein is produced in normal amounts. A ratio of activity to antigen of less than 0.7 may raise concern for type 2 VWD, which itself has multiple subtypes. Multimer evaluation or other specialized testing can be used to discriminate the type 2 subtypes.

Type 2A VWD is characterized by a defect in VWF multimerization and decreased VWF activity in terms of platelet binding. It is the most common of the type 2 variants, accounting for approximately 10% of VWD cases. Type 2A VWD can result from variants that affect multimer assembly and processing, or variants that result in increased proteolysis of secreted VWF. Some variants affect both secretion and clearance of the VWF. Regardless of the mechanism, all type 2A VWD patients lack the HMW multimers, and therefore have reduced VWF activity, which results in bleeding. Symptoms are typically more severe than those seen in type 1 VWD. *Desmopressin may have clinical efficacy for treatment of minor bleeding, but significant surgical challenges or major bleeding symptoms generally require a VWF-containing concentrate for treatment.*

Type 2B VWD results from gain-of-function variants that increase the ability of VWF to bind platelets. This leads to increased clearance of both VWF and platelets from circulation and results in the loss of HMW multimers and decreased VWF activity, similar to that seen in type 2A VWD. Special testing is therefore required to diagnose type 2B VWD, either by direct measurement of the increased platelet binding or by an increased response to low dose ristocetin on platelet aggregation testing. Thrombocytopenia is not always present and may be more prominent during times of stress such as surgery or pregnancy. *Desmopressin is relatively contraindicated in type 2B VWD because it may accelerate VWF-platelet binding and clearance, so treatment with VWF-containing product is necessary.*

Platelet-type pseudo-VWD occurs when a variant in platelet GPIb causes spontaneous binding to VWF and also presents with decreased VWF activity, loss of HMW multimers, and thrombocytopenia similar to type 2B VWD. Specific testing is required to distinguish the two conditions. Because the defect involves platelets, treatment generally requires platelet transfusion.

Type 2M VWD includes those patients with decreased VWF activity but normal (or near normal) multimer distribution. This is generally caused by a defect in the ability of VWF to bind platelet GPIb, but this category also includes patients with defects in VWF-collagen interactions. *Some minor bleeding in type 2M VWD may respond to desmopressin, but because type 2M VWD is a functional defect, treatment with VWF-containing concentrates is usually required.*

Table 526.1 Laboratory Testing for von Willebrand Disease (VWD)

TEST	ABBREVIATION	PURPOSE
VWF antigen	VWF:Ag	Measures total amount of VWF protein present.
VWF activity	VWF:RCo*	Assesses interaction of VWF and platelets as mediated by ristocetin.
VWF activity/antigen ratio	VWF:RCo/VWF:Ag	A decreased ratio (<0.7) is found in type 2A, type 2B, and type 2M VWD.
Factor VIII activity	FVIII	Measures circulating FVIII, which will be very low in type 2N and type 3 VWD.
Multimer distribution	VWF multimers	Allows visualization of VWF multimers, used to identify high molecular weight multimers, which will be absent in types 2A and 2B VWD.

*In some laboratories a GPIb-binding assay, the VWF:GPIbM, is available.
VWF, Von Willebrand factor; GPIb, glycoprotein Ib; RCo, ristocetin cofactor.

Table 526.2 Classification of von Willebrand Disease

	TYPE 1	TYPE 3	TYPE 2A	TYPE 2B*	TYPE 2M	TYPE 2N
VWF:Ag	↓	Absent	↓	↓	↓	Normal or ↓
VWF:RCo	↓	Absent	⇊	⇊	⇊	Normal or ↓
FVIII	Normal	⇊	Normal or ↓	Normal or ↓	Normal or ↓	⇊
Multimer distribution	Normal	Absent	Loss of HMWM	Loss of HMWM	Normal	Normal

*Platelet count is also usually decreased in type 2B VWD.
FVIII, factor VIII; HMWM, high molecular weight multimers; VWF:Ag, von Willebrand factor antigen; VWF:RCo, VWF ristocetin cofactor activity.

Type 2N VWD is characterized by a defect in the ability of VWF to bind FVIII. Some patients with type 2N VWD may be misdiagnosed as mild hemophilia; therefore a high index of suspicion for this diagnosis is required in patients with low FVIII and an absent family history of FVIII deficiency. *Because the VWF in this case is dysfunctional, desmopressin is not usually helpful, and VWF-containing product infusion is typically required.*

LABORATORY DIAGNOSIS

There are no reliable screening tests for VWD. Patients with significant bleeding may present with anemia, and some patients with type 2B VWD or platelet-type pseudo-VWD may have thrombocytopenia. The partial thromboplastin time (PTT) may be prolonged if FVIII is low but especially in type 1 VWD it is often normal, precluding use of the PTT as a screening test. Platelet function analysis has been considered as a screening test for VWD, but suboptimal sensitivity and specificity render results difficult to interpret. Bleeding times are similarly unreliable in diagnosis of VWD.

Unfortunately, no single test can reliably diagnose VWD; therefore a panel of tests is usually required (Table 526.1). These include VWF:Ag, which measures the total amount of VWF protein present, and VWF activity test, typically using the *ristocetin cofactor* activity assay **(VWF:RCo)**, which provides a measure of the amount of functional VWF. FVIII activity is also usually included in the workup. Another test measures VWF binding to platelet GPIb without ristocetin **(VWF:GPIbM)**. This test is now FDA approved and its use is increasing. Collagen binding measures an additional function of VWF. Multimer distribution provides an assessment of HMW multimers (Table 526.2; Fig. 526.1).

Additional specialized testing may be employed to help determine the correct diagnosis. Specific testing for type 1C (clearance defects), type 2B, and type 2N VWD can confirm these diagnoses. Genetic diagnosis is not typically performed, partly because of the large size of the VWF gene and the high number of benign sequence variations. Large gene deletions are responsible for some cases of VWD and will not be detected on routine DNA sequencing. However, use of genetic diagnosis is increasing, particularly for types 2A, 2B, 2M, and 2N VWD.

TREATMENT

Treatment of VWD depends on the type of VWD present and the reason for treatment (Table 526.3). In general, type 1 VWD patients may be treated with **desmopressin**, which increases the amount of circulating VWF (and FVIII) by release from storage in endothelial cells. The exceptions are the rare type 1 patient who lacks a response to desmopressin and patients with type 1C VWD who do respond with an increase in VWF levels, but whose rapid clearance of circulating endogenous VWF results in a rapid return to baseline levels. Treatment of types 2 and 3 VWD requires **VWF-containing concentrates,** similar to the treatment of hemophilia. Dosing depends on the type of VWD and the reason for treatment. Careful monitoring of VWF and FVIII levels is recommended to tailor treatment for surgeries and major trauma. For all types of VWD, adjunct therapy should be considered when possible, such as the use of antifibrinolytics for oral surgery or hormonal treatment for menorrhagia.

Alternate treatment strategies should also be considered, particularly for difficult symptoms or severe VWD. Hormonal therapy for females with menorrhagia, although not specific to VWD, can be very helpful in managing symptoms and improving quality of life. Local treatment of epistaxis, such as nasal cautery or packing, may be helpful in some circumstances. Iron therapy for patients with iron-deficiency anemia may also be required.

Visit Elsevier eBooks+ at eBooks.Health.Elsevier.com for Bibliography.

	Normal	Type 1	Type 1C (Vicenza)	Type 3	Type 2A	Type 2B	Type 2N	Type 2M	PT-VWD
VWF:Ag	N	↓	↓↓	absent	↓	↓	N or ↓	↓ or N	↓
VWF:RCo	N	↓	↓↓	absent	↓↓↓	↓↓	N or ↓	↓↓	↓↓
FVIII:C	N	N or ↓	↓	2-10 IU/dL	N or ↓	N or ↓	↓↓	N	N or ↓
VWFpp/VWF:Ag ratio	N	N	↑↑	absent	N or ↑	↑	N	N	↑
RIPA	N	often N	↓	absent	↓	often N	N	N or ↓	often N
LD-RIPA	absent	absent	absent	absent	absent	↑↑↑	absent	absent	↑↑↑
PFA'	N	N or ↑	↑	↑↑↑	↑	↑	N	↑	↑
BT'	N	N or ↑	↑	↑↑↑	↑	↑	N	↑	↑
Platelet count	N	N	N	N	N	↓ or N	N	N	↓
VWF multimers	N	N but ↓	N but ↓	absent	abnormal	abnormal	N but ↓	N but ↓	abnormal



Fig. 526.1 Specialized laboratory testing for von Willebrand disease (VWD). ↓, ↓↓, ↓↓↓, Relative decrease; ↑, ↑↑, ↑↑↑, relative increase; BT, bleeding time; FVIII:C, factor VIII coagulant activity; LD-RIPA, low-dose ristocetin-induced platelet aggregation; N, normal; N but ↓, normal but decreased in intensity; PFA, platelet function analysis; PT-VWD, platelet-type VWD; RIPA, ristocetin-induced platelet aggregation; VWF:Ag, von Willebrand factor antigen; VWF:RCo, VWF activity by ristocetin cofactor; VWF pp, VWF propeptide. *(Courtesy Dr. Robert R. Montgomery.)*

Table 526.3 Treatment of Von Willebrand Disease

TREATMENT	VWD TYPES	ROUTE	DOSING
Desmopressin*	Type 1 VWD Some type 2 VWD (use with caution)	IV or IN	0.3 μg/kg IV† 1 spray IN (<50 kg) 2 sprays IN (>50 kg)
Von Willebrand factor (VWF) concentrates‡	Type 3 VWD Type 2 VWD Severe type 1 VWD (or type 1 clearance defects)	IV	40-60 ristocetin cofactor activity units/kg (adjust dose depending on baseline VWF level and desired peak VWF level). If recombinant VWF used, may need to administer additional recombinant FVIII for emergency treatment.
Antifibrinolytics	Mucosal bleeding, all types of VWD	PO or IV	Aminocaproic acid: 100 mg/kg PO loading dose followed by 50 mg/kg every 6 hr§ Tranexamic acid: 1,300 mg PO 3 times daily for 5 days

*Recommended treatment with Stimate brand nasal spray because this form is concentrated to give 150 μg/spray. Other forms are much more dilute and will not result in desired increase in VWF.
†Maximum recommended dose is 20-30 μg/day.
‡Currently both Humate-P and Wilate are approved for treatment of VWD. Vonvendi is a recombinant VWF that is also approved for treatment of VWD but does not contain FVIII.
§Maximum recommended dose is 24 g/day.
IN, Intranasal; IV, intravenous; PO, oral administration.

Chapter 527

Hereditary Predisposition to Thrombosis

Benjamin J. Samelson-Jones and Leslie J. Raffini

Most children that develop clots have multiple risk factors, which may include inherited predispositions to thrombosis. The strength of the inherited prothrombotic risk factors varies. An estimated 30–60% of individuals with *strong* thrombophilias, such as antithrombin deficiency, protein C deficiency, and protein S deficiency, develop thromboembolic disease by age 60; in contrast, less than 10% of individuals with *weak* thrombophilias, such as heterozygous factor V Leiden variant or prothrombin *G20210A* gene variant, develop thromboembolic disease. The inherited thrombophilias with the best understood pathogenesis, population prevalence, and prothrombotic risks are listed in Table 527.1. Some of these disorders may also be acquired or mixed acquired and genetic (Table 527.2).

The inheritance of other thrombophilias is less well understood. Elevated levels of factor VIII (FVIII) and homocysteine are associated with thrombosis, but their levels are not necessarily genetically determined. Additional alterations in plasma proteins have also been associated with increased thrombotic risk, such as elevated concentrations of factors IX and XI, heparin cofactor II deficiency, elevated lipoprotein (a), and dysfibrinogenemia; however, these abnormalities have not gained widespread acceptance in routine testing of children for inherited thrombophilia.

In general, the prothrombotic tendency conferred by these defects is either a result of an increased procoagulant effect (prothrombin gene pathogenic variant, elevated FVIII, hyperhomocysteinemia) or a decreased anticoagulant effect (factor V Leiden, deficiency of protein C, protein S, or antithrombin). Although numerous inherited risk factors for thrombosis have been identified, the majority of individuals who inherit one of these risk factors, even strong thrombophilias, do not necessarily develop thrombosis during childhood. Before evaluating for these disorders, both the limitations of the testing and potential benefits need to be considered.

The **factor V Leiden pathogenic variant** is the result of a single base pair change at nucleotide 1765 within the factor V gene causing an R506Q amino acid substitution in the encoded protein. This pathogenic variant causes activated factor V to become resistant to inactivation by activated protein C. It is the most common inherited risk factor for thrombosis, although its prevalence varies across ethnicities. Individuals who are heterozygous have a 5-7–fold increased relative risk of venous thrombosis, whereas homozygous individuals have an even higher risk. There appears to be a synergistic prothrombotic risk enhancement with the inherited risk of factor V Leiden and the acquired risk of estrogen-containing contraceptives. The baseline annual risk of thrombosis for females of reproductive age is approximately 1/10,000 and increases to 1/2,500 for those taking estrogen-containing contraceptives. For young females who are heterozygous for the factor V Leiden pathogenic variant and on estrogen-containing contraceptives, the annual risk of venous thromboembolism (VTE) increases to 1 in 200. The **prothrombin 20210 gene pathogenic variant** is a G-to-A transition in the 3' untranslated region of the gene that results in increased levels of prothrombin. It is a weaker risk factor for venous thrombosis than factor V Leiden.

Deficiencies of the natural anticoagulation proteins (protein C, protein S, and antithrombin) are less common than the specific genetic pathogenic variants mentioned previously but are associated with a stronger risk of thrombosis. Although heterozygous deficiencies do not often present during childhood, homozygous defects may be embryonically lethal or result in significant symptoms in infancy. Neonates with *homozygous* deficiencies of protein C or protein S may present with **purpura fulminans**. This rare condition is characterized by rapidly spreading purpuric skin lesions resulting from thromboses of the small dermal vessels, followed by bleeding into the skin. In addition, these infants may also develop cerebral thrombosis, ophthalmic thrombosis, disseminated intravascular coagulation, and large-vessel thrombosis. An infant with purpuric skin lesions of unknown cause should receive empiric replacement with fresh-frozen plasma. Definitive diagnosis can be difficult in the sick premature neonate, who may have undetectable levels of these factors but not have a true genetic deficiency. Protein C and antithrombin concentrates are also available and have been demonstrated to be effective.

Elevated levels of homocysteine have been associated with venous *and* arterial thromboses, although the pathogenic mechanisms for thrombosis in homocystinemia are poorly understood. Thromboembolic complications are well described in children with **homocystinuria,** a rare inborn error of metabolism caused by deficiency of cystathione β-synthase that results in plasma levels of homocysteine

Table 527.1 Clinically Relevant Inherited Thrombophilias and Accompanying Diagnostic Laboratory Studies

THROMBOPHILIA	GENERAL POPULATION PREVALENCE (%)	VTE ADULT PATIENT PREVALENCE (%)	ANNUAL INCIDENCE OF VTE (%)	ODDS RATIO FOR FIRST VTE EPISODE IN CHILDHOOD	ODDS RATIO FOR RECURRENT VTE EPISODE IN CHILDHOOD	LABORATORY STUDIES
Antithrombin deficiency	0.02-0.04	1	1.8	9.4	3.4	Functional coagulation testing‡
Protein C deficiency	0.2	3	1.5	7.7	2.5	Functional coagulation testing‡
Protein S deficiency	0.03-0.13	2	1.9	5.8	3.8	Functional coagulation testing‡
Factor V Leiden variant*	3-7	20	0.5	3.8	0.8	Gene testing
Prothrombin 20210 variant*	1-4	5	0.3	2.6	2.2	Gene testing

*Values refer to heterozygous changes.
‡May be impacted by anticoagulation therapies.
VTE, Venous thromboembolism.

Table 527.2 Classification of Hypercoagulable States

HEREDITARY	MIXED	ACQUIRED
LOSS OF FUNCTION		
Antithrombin deficiency	Hyperhomocysteinemia	Previous venous thromboembolism Hepatic cirrhosis Severe liver disease Nephrotic syndrome L-asparaginase
Protein C deficiency	Obesity	Pregnancy, puerperium
Protein S deficiency	Cancer	
		Drug-induced: Heparin-induced thrombocytopenia Prothrombin complex concentrates L-asparaginase Hormonal therapy
GAIN OF FUNCTION		
Factor V Leiden	Postoperative	
Prothrombin FII G20210A	Myeloproliferative disorders	
Elevated factor VIII, IX, or XI		

Modified from Hoffman R, Benz Jr. EJ, Silberstein LE, et al., eds. *Hematology Basic Principles and Practice*, 7th ed. Philadelphia: Elsevier, 2018: Table 140.1, p. 2077.

that exceed 100 μmol/L. Much more common are mild to moderate elevations of homocysteine, which may be acquired or associated with a polymorphism in the methylenetetrahydrofolate reductase *(MTHFR)* gene. Although moderate elevations of homocysteine have been associated with both venous and arterial thrombotic events, testing for polymorphisms in the *MTHFR* gene is not indicated because these polymorphisms are common and by themselves (without homocystinemia) are not associated with thromboembolism.

Increased plasma concentrations of FVIII appear to be regulated by both genetic and environmental factors and are associated with an increased risk of thrombosis. High FVIII levels are usually polygenic, although rarely specific changes in the FVIII gene have been identified. FVIII is also an acute-phase reactant and may increase during periods of inflammation.

Although interpretation of gene testing is fairly straightforward, several challenges in interpretation of thrombophilia studies are unique to pediatric patients. Neonates have decreased concentrations of protein C, protein S, and antithrombin that increase rapidly over the first 6 months of life; protein C concentrations remain below adult levels throughout much of childhood. It is important to use pediatric normal ranges when evaluating these values and recognize that often the normal range overlaps with heterozygous defects and that retesting may be required, particularly in young children. Several nongenetic factors may also influence the results of inherited thrombophilia testing, including acute thrombosis, infection, inflammation, hepatic dysfunction, nephrotic syndrome, medication, and vitamin K deficiency. In some patients the hereditary nature may be confirmed by testing the parents.

Thrombophilia testing is considered during childhood when a child develops thrombosis or if a child has relatives with thrombosis or thrombophilia. Thrombophilia testing rarely influences the acute management of a child with a thrombotic event. The majority of children who develop thrombosis have multiple, coexistent *acquired* risk factors (see Table 528.1 in Chapter 528). More than 90% of thromboses in children are associated with indwelling intravascular catheters; inherited thrombophilias are uncommon in this scenario, and testing is generally not warranted. However, inherited thrombophilia is more common in an otherwise healthy child or adolescent who develops a blood clot or in a child who develops unusual or recurrent thrombosis. Thrombophilia testing may be useful in these situations because it may help explain why the child developed a blood clot and inform on the duration of therapy. However, current treatment recommendations do not differ based on the presence or absence of an inherited thrombophilia. The identification of an inherited anticoagulant protein defect, such as antithrombin or protein C deficiency, may allow for replacement therapies while off anticoagulation, such as in the perioperative setting.

The decision to perform thrombophilia testing in an otherwise healthy child with a **family history** of thrombosis or thrombophilia should be carefully considered, weighing the potential advantages and limitations of such an approach. Given that the absolute risk of thrombosis in children is extremely low (0.07/100,000), it is unlikely that an inherited thrombophilia will have any impact on clinical decision-making for a young child. The risk of thrombosis increases with age, so identification of a thrombophilic defect in an adolescent may guide primary thromboprophylaxis in high-risk situations (lower-extremity casting or prolonged immobility), inform the discussion about estrogen-based contraceptives, and promote lifestyle modification to avoid behavioral risk factors (sedentary lifestyle, dehydration, obesity, and smoking). Limitations of such testing include the cost as well as the potential for causing unnecessary anxiety or false reassurance.

In most patients with inherited thrombophilia, the treatment is the same as for patients with no inherited disorders (see Chapter 528). In neonates with purpura fulminans caused by homozygous protein C or S deficiency or in patients with warfarin-induced skin necrosis, heparin-induced thrombocytopenias and severe antithrombin deficiency often require factor replacement (protein C, S or antithrombin concentrates or plasma) in addition to unfractionated heparin or low molecular weight heparin. In less severe antithrombin deficiency, higher than usual doses of heparin may be needed.

Visit Elsevier eBooks+ at eBooks.Health.Elsevier.com for Bibliography.

Chapter 528

Thrombotic Disorders in Children

Leslie J. Raffini and Brian R. Branchford

Thromboembolic events (TEs) are seen in pediatric tertiary care centers and may result in significant acute and chronic morbidity. TEs in children are rare. Diagnosis and treatment are often extrapolated from adult data because of a current lack of high-quality data in the pediatric setting.

EPIDEMIOLOGY

Although the overall incidence of thrombosis in the general pediatric population is quite low (0.07/100,000), the rate of **venous thromboembolism (VTE)** in hospitalized children is 60/10,000 admissions. Infants <1 year old account for the largest proportion of pediatric VTEs, with a second peak during adolescence.

Most children who develop a TE have multiple risk factors that may be acquired, inherited, or anatomic (Table 528.1). The presence of a central venous catheter (CVC) or peripherally inserted central venous catheter (PICC) is the most important risk factor for VTE in pediatric patients, associated with approximately 90% of neonatal VTE and 60% of childhood VTE. PICC lines may be among the highest-risk CVC subtypes. CVCs are often necessary for the care of premature neonates and children with acute and chronic diseases and are used for intravenous (IV) hyperalimentation, chemotherapy, dialysis, antibiotics, or supportive therapy. CVCs may damage the endothelial lining and/or cause blood flow disruption, increasing the risk of thrombosis. Many other acquired risk factors are associated with thrombosis, including trauma, surgery, infection, inflammation, chronic medical conditions, and certain medications. Cancer, congenital heart disease, and prematurity are the most common medical conditions associated with TEs.

Antiphospholipid antibody syndrome (APS) is characterized by recurrent fetal loss and/or thrombosis (Table 528.2). Antiphospholipid antibodies are associated with venous and, less often, arterial thrombosis. The autoantibodies in APS include lupus anticoagulant, anticardiolipin antibodies, and anti-β_2 glycoprotein I. If all three antibodies are positive **(triple positive)**, the risk of thrombosis is increased. The mechanism by which these antibodies cause thrombosis is not well understood. A diagnosis of APS requires the presence of both clinical and laboratory abnormalities (see "Laboratory Testing"). The laboratory abnormalities must be identified on two separate occasions, at least 12 weeks apart. Because of the high risk of VTE recurrence, patients with APS often require long-term anticoagulation, at least until the antibodies have resolved; the type of antibodies and the presence of arterial thrombosis may have important implications for the type of anticoagulant therapy chosen. Up to 20% of healthy children may have a *transient* lupus anticoagulant, often diagnosed because of a prolonged partial thromboplastin time (PTT) on routine preoperative testing. In this setting, transient antibodies may be associated with a recent viral infection and are not a risk factor for thrombosis. APS is also noted in patients with **systemic lupus erythematosus** (see Chapter 199) and may also be associated with livedo reticularis, neuropsychiatric complications, thrombocytopenia, or anemia; these patients are often persistently positive for the antiphospholipid antibody. **Catastrophic antiphospholipid syndrome** is a rare and potentially fatal disorder characterized by rapid onset of multiorgan thrombosis and/or thrombotic microangiopathies (Table 528.3).

Anatomic abnormalities that impede blood flow also predispose patients to thrombosis at an earlier age. Atresia of the inferior vena cava has been described in association with acute and chronic lower-extremity deep vein thrombosis **(DVT)**. Compression of the left iliac vein by the overlying right iliac artery **(May-Thurner syndrome)** should be considered in patients who present spontaneously with left iliofemoral thrombosis, and thoracic outlet obstruction **(Paget-Schroetter syndrome)** frequently presents with effort-related axillary-subclavian vein thrombosis.

CLINICAL MANIFESTATIONS

Extremity Deep Vein Thrombosis

Children with acute DVT often present with extremity pain, swelling, and discoloration (see Table 524.1). A history of a current or recent CVC in that extremity should be very suggestive. Many times, symptoms of CVC-associated thrombosis are more subtle and chronic, including repeated CVC occlusion (potentially requiring clearance with tissue plasminogen activator [tPA]) or sepsis, or prominent venous collaterals on the chest, face, and neck.

Pulmonary Embolism

Signs and symptoms classically include shortness of breath, pleuritic chest pain, cough, hemoptysis, fever, tachypnea, tachycardia, and/or, in the case of massive pulmonary embolism (PE), hypotension and right-sided heart failure. Based on autopsy studies in pediatric centers, PE is often undiagnosed because young children are unable to describe their symptoms accurately, and their respiratory deterioration may be masked by other conditions (see Chapter 458.1).

Cerebral Sinovenous Thrombosis

Signs and symptoms of cerebral sinovenous thrombosis (CSVT) may be subtle and may develop over many hours or days (see Table 524.1). Neonates with CSVT often present with seizures, whereas older children often complain of headache, vomiting, seizures, visual changes, and/or focal neurologic signs. They may also have papilledema and abducens palsy. Older patients may have a concurrent sinusitis or mastoiditis that has contributed to the thrombosis. Other risk factors may include trauma, meningitis, or dehydration.

Renal Vein Thrombosis

Renal vein thrombosis (RVT) is the most common spontaneous VTE in neonates (see Table 524.1). Affected infants may present with hematuria, an abdominal mass, and thrombocytopenia. Infants of diabetic mothers are at increased risk for RVT, although the mechanism for the increased risk is unknown. Approximately 25% of cases are bilateral.

Portal Vein Thrombosis

Portal vein thrombosis (PVT) often occurs during the neonatal period and is often asymptomatic, only manifesting in those patients who develop symptomatic portal hypertension (e.g., gastrointestinal [GI] bleeding, splenomegaly) after the initial thrombotic event (see Table 524.1). The most common risk factor associated with PVT is an umbilical venous catheter, although sepsis, pancreatitis, cirrhosis, liver transplant, splenectomy, and sickle cell disease are also notable risk factors. A known complication of PVT is cavernous transformation, which confers a risk for variceal bleeding.

Peripheral Arterial Thrombosis

The majority of arterial TEs in children are associated with catheters, often related to umbilical artery lines in neonates or cardiac catheterization via the femoral artery (see Table 524.1). Less common etiologies of arterial thrombosis include homocystinuria and APS. Patients with an arterial thrombosis affecting blood flow to an extremity will present with a cold, pale extremity with poor or absent pulses, which can signify a limb-threatening emergency.

Acute Ischemic Stroke

Acute ischemic stroke (AIS) typically presents with hemiparesis, slurred speech, altered consciousness, or seizures. This condition may occur secondary to pathology that affects the intracranial arteries (e.g., sickle cell disease, vasculitis, vasculopathy, traumatic arterial dissection, or paradoxical embolism across a patent foramen ovale) or may result from venous thrombi that embolize to the arterial circulation (placental

Table 528.1 Risk Factors for Thrombosis

GENERAL
Indwelling catheter, especially PICC lines
Infection
Trauma
Surgery
Cancer
Immobility
Cardiac disease/prosthetic valve
Systemic lupus
Rheumatoid arthritis
Inflammatory bowel disease
Celiac disease
Polycythemia/dehydration
Nephrotic syndrome
Diabetes
Pregnancy
Obesity
Prematurity
Paroxysmal nocturnal hemoglobinuria
Thrombotic thrombocytopenic purpura (acquired)
COVID-19
Antiphospholipid antibody syndrome
INHERITED THROMBOPHILIA
Factor V Leiden pathogenic variant
Prothrombin pathogenic variant
Antithrombin deficiency
Protein C deficiency
Protein S deficiency
Homocystinuria
Elevated factor VIII
Dysfibrinogenemia
GATA-2 deficiency
Hereditary thrombotic thrombocytopenic purpura
ANATOMIC
Thoracic outlet obstruction (Paget-Schroetter syndrome)
Iliac vein compression syndrome (May-Thurner syndrome)
Absence of inferior vena cava
MEDICATIONS
Estrogen-containing contraceptives
Asparaginase
Heparin (heparin-induced thrombocytopenia)
Corticosteroids
Immune checkpoint inhibitors
Hemophilia bypassing agents

PICC, Peripherally inserted central venous catheter.

thrombi, children with congenital heart disease, or patent foramen ovale allowing right-to-left shunting of an embolic venous thrombosis).

Rapidly Progressive Thrombosis (Thrombotic Storm)

Rapid progression or multifocal thrombosis is a rare complication of APS (**catastrophic antiphospholipid syndrome**), or heparin-induced thrombocytopenia with thrombosis (see Table 528.3). Multiorgan dysfunction develops in the presence of small vessel occlusion and elevated D-dimer levels, and this may progress to disseminated intravascular coagulation. Treatment includes aggressive anticoagulation, often with direct thrombin inhibitors or fondaparinux, followed by prolonged warfarin therapy. In rare cases, plasmapheresis and/or immunosuppression and/or antiinflammatory therapy may be warranted.

DIAGNOSIS

Compression ultrasound with Doppler flow is the most common imaging study for the diagnosis of extremity DVT and chest CT is used most frequently for the diagnosis of PE (Fig. 528.1). Echocardiogram is often used to detect and follow right atrial clots, most often detected in patients with central catheter tips in the right atrium. Other diagnostic imaging options include CT and MR venography, which are noninvasive, although the sensitivity and specificity of these studies is not known. These studies may be particularly helpful in evaluating proximal or abdominal thrombosis. For the diagnosis of CSVT and AIS, the most sensitive imaging study is brain MRI with venography or diffusion-weighted imaging.

Table 528.2 Sydney Investigational Criteria for the Diagnosis of the Antiphospholipid Syndrome

CLINICAL
• Vascular thrombosis (one or more episodes of arterial, venous, or small-vessel thrombosis). For histopathologic diagnosis, there should be no evidence of inflammation in the vessel wall.
• Pregnancy morbidities attributable to placental insufficiency, including: (a) three or more otherwise unexplained recurrent spontaneous miscarriages before 10 weeks of gestation, (b) one or more fetal losses after the 10th week of gestation, (c) stillbirth, and (d) episode of preeclampsia, preterm labor, placental abruption, intrauterine growth restriction, or oligohydramnios that are otherwise unexplained.
LABORATORY
• Medium- or high-titer aCL or anti-β_2GPI IgG and/or IgM antibody present on two or more occasions, at least 12 weeks apart, measured by standard ELISA.
• Lupus anticoagulant in plasma, on two or more occasions, at least 12 weeks apart, detected according to the guidelines of the ISTH SSC Subcommittee on Lupus Anticoagulants and Phospholipid-Dependent Antibodies.
"Definite APS" is considered present if at least one of the clinical criteria and one of the laboratory criteria are met.

aCL, Anticardiolipin; aPL, antiphospholipid; β_2GPI, β_2-glycoprotein I; ELISA, enzyme-linked immunosorbent assay; Ig, immunoglobulin.
Modified from Miyakis S, Lockshin MD, Atsumi T, et al. International consensus statement on an update of the classification criteria for definite antiphospholipid syndrome (APS). *Thromb Haemost.* 2006;4:295–306. Table 2.

Table 528.3 Proposed Criteria for the Classification of Catastrophic Antiphospholipid Syndrome

1. Evidence of involvement of three or more organs, systems and/or tissues*
2. Development of manifestations simultaneously or in less than a week
3. Confirmation by histopathology of small vessel occlusion in at least one organ or tissue†
4. Laboratory confirmation of the presence of antiphospholipid antibodies (lupus anticoagulant and/or anticardiolipin antibodies)‡
DEFINITE CATASTROPHIC APS
• All four criteria
PROBABLE CATASTROPHIC APS
• All four criteria, except for only involvement of two organs, systems, and/or tissues
• All four criteria, except for the absence of laboratory confirmation at least 6 weeks apart because of the early death of a patient never previously tested for aPL before the catastrophic APS event
• Criteria 1, 2, and 4
• Criteria 1, 3, and 4 and the development of a third event in more than a week but less than a month, despite anticoagulation

*Usually, clinical evidence of vessel occlusions, confirmed by imaging techniques when appropriate. Renal involvement is defined by a 50% rise in serum creatinine, severe systemic hypertension (≥180/100 mm Hg) and/or proteinuria (≥500 mg/24 h).
†For histopathologic confirmation, significant evidence of thrombosis must be present, although, in contrast with Sydney criteria, vasculitis may coexist occasionally.
‡If the patient had not been previously diagnosed as having an APS, the laboratory confirmation requires that the presence of antiphospholipid antibodies must be detected on two or more occasions at least 6 weeks apart (not necessarily at the time of the event), according to the proposed preliminary criteria for the classification of definite APS.
aPL, Antiphospholipid; APS, antiphospholipid syndrome
Modified from Asherson RA, Cevera R, de Groot PG et al. Catastrophic antiphospholipid syndrome: international consensus statement on classification criteria and treatment guidelines. *Lupus* 2003;12:530–534.

LABORATORY TESTING

All children with a VTE should have a complete blood count and a baseline prothrombin time (PT) and PTT to assess their coagulation status in

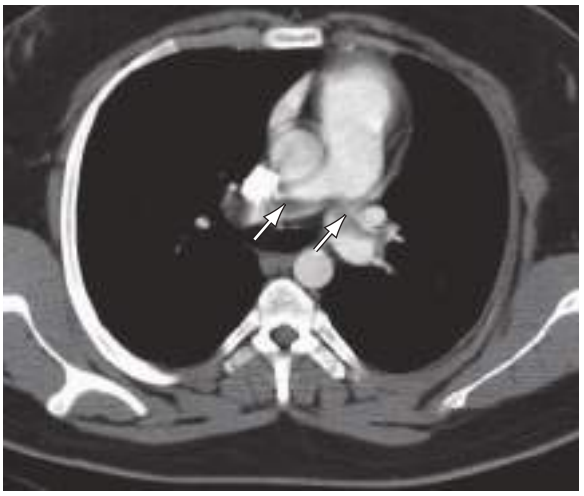

Fig. 528.1 Chest CT scan from a 15-yr-old male with a large pulmonary embolism. Large filling defects are present in the right and left main pulmonary arteries *(arrows)*.

anticipation of anticoagulation treatment. In adults with suspected DVT, the D-dimer level has a high negative predictive value, but the predictive value is not as well established for children. The D-dimer is a fragment produced when fibrin is degraded by plasmin and is a measure of both clot formation and subsequent fibrinolysis. Based on the clinical scenario, other laboratory studies, such as renal and hepatic function, may be indicated. Testing for APS includes evaluation for the lupus anticoagulant as well as anticardiolipin and anti–β_2-glycoprotein antibodies and should be considered in patients with inflammatory disorders, recent trauma, surgery, or infection, and those who present with thrombosis and no other obvious risk factors.

There is debate regarding which patients should have testing for inherited risk factors. Thrombophilia testing rarely influences the acute management of a child with a thrombotic event, and natural anticoagulants like protein C and S or antithrombin (AT) may appear to have low levels due to consumption during the acute phase of thrombosis, even if the patient does not have an existing deficiency of these proteins (see Chapter 527). Identification of an inherited thrombophilia may influence the duration of treatment, particularly for those with a *strong* thrombophilia, and may aid in counseling patients about their risk of recurrence. **Unprovoked** (absence of risk factors) thrombosis and a family history of thrombotic events may be a clue to an inherited thrombophilia, although they may coincide with a known risk factor.

The evaluation and interpretation of coagulation studies in pediatric patients may be complicated by the developing hemostatic system and the differences in normal ranges between infants and adults (see Chapter 527).

TREATMENT

Therapeutic options for children with thrombosis may include observation, anticoagulation, thrombolysis, and surgery. In premature neonates and critically ill children who are at high risk of bleeding, the potential benefits must be weighed against the risks, and close observation with repeat imaging may be an option. The majority of nonneonates with symptomatic thrombosis are treated with anticoagulant therapy. The goal of anticoagulation is to reduce the risk of embolism, halt clot extension, and prevent recurrence (see Chapter 528.1). Systemic or endovascular thrombolysis may be indicated for organ- or limb-threatening thrombosis. Surgery may be necessary for life- or limb-threatening thrombosis when there is a contraindication to thrombolysis. The optimal treatment for a child with AIS depends on the likely etiology and the size of the infarct and may include either anticoagulation or antiplatelet therapy such as aspirin. Children with sickle cell disease who develop stroke are treated acutely with erythrocytapheresis to rapidly lower the percentage of hemoglobin S and may also receive ongoing chronic red blood cell transfusions (or erythrocytapheresis) to reduce recurrence risk.

A summary of management recommendations for various types of VTE can be found in (Tables 528.4 and 528.5)

COMPLICATIONS

Complications of VTE include recurrent thrombosis (local or distant), and development of post-thrombotic syndrome (PTS). Over time, due to venous hypertension or damaged endovascular valves, patients may develop pain, swelling, edema, discoloration, and ulceration of the affected limb. Several prospective studies in adults have shown PTS to be present in 17–50% of patients with a history of thrombosis. The likelihood of developing PTS has been shown to increase with age, thrombus burden, and delay in anticoagulation therapy.

528.1 Anticoagulant and Thrombolytic Therapy

Leslie J. Raffini and Brian R. Branchford

Initial options for anticoagulation in children have generally included unfractionated heparin (UFH) or low molecular weight heparin (LMWH), followed by LMWH or warfarin for outpatient management (see Tables 528.4 and 528.5). Clinical trials of several direct oral anticoagulants (DOACs) have demonstrated the safety and efficacy of these drugs to treat VTE in children, and the landscape of treatment options for children with thrombosis is changing rapidly as these drugs gain regulatory approval. DOACs act by inhibiting factor Xa or thrombin (Table 528.6).

The optimal duration of anticoagulation for children with TEs is not well established. American Society of Hematology (ASH) guidelines recommend that pediatric patients with provoked DVT or PE receive ≤3 months of anticoagulation and those with unprovoked DVT or PE receive 6-12 months of therapy. Patients with strong inherited thrombophilia, recurrent thrombosis, and APS (or other nonmitigatable risk factors) may require indefinite anticoagulation.

UNFRACTIONATED HEPARIN

Both UFH and LMWH act by catalyzing the action of AT. UFH consists of large molecular weight polysaccharide chains that interact with AT, supporting the inhibition of factor Xa and thrombin, as well as other serine proteases.

Heparin Dosing

A therapeutic heparin dose achieves a prolongation of the PTT of 1.5-2.5 the upper limit of normal. A bolus dose of 75-100 units/kg results in a therapeutic PTT in the majority of children. This bolus should be followed by a continuous infusion. Initial dosing is based on age, with infants having the highest requirements. It is important to continue to monitor the PTT closely. In some situations, such as patients with a lupus anticoagulant, those with elevated factor VIII, or neonates, the PTT may not accurately reflect the degree of anticoagulation, and heparin can be monitored using a heparin anti-Xa level of 0.35-0.7 units/mL.

Heparin Complications

Maintaining the PTT in the therapeutic range can be difficult in young children. The bioavailability of heparin is difficult to predict and may be influenced by plasma proteins, including AT level. In many patients, this results in multiple dose adjustments requiring close monitoring with frequent venipuncture. UFH also requires continuous IV access, which may be difficult to maintain in young children.

The most common adverse effect related to heparin therapy is bleeding. There are case reports of life-threatening bleeding in children treated with heparin. The true frequency of bleeding in pediatric patients receiving heparin has not been well established and is reported as 1–24%. If the anticoagulant effect of heparin must be reversed immediately, protamine sulfate may be administered to neutralize the heparin. With an elimination half-life of approximately 30 minutes, the anticoagulant effect of this drug typically wears off in approximately 2-3 hours after stopping the infusion. UFH is cleared by the liver and kidney.

Other adverse effects include osteoporosis (with long-term use) and **heparin-induced thrombocytopenia (HIT)**. Although rare in pediatric populations, HIT is a prothrombotic, immune-mediated

Table 528.4 Management Considerations for Pediatric Thromboembolic Events

VTE	MANAGEMENT RECOMMENDATION	COMMENTS
Symptomatic DVT	Anticoagulation Provoked—treat <3 months (or until provoking factor is resolved) Unprovoked—treat 6-12 months, or longer based on risk/benefit analysis Thrombolysis considered if life- or limb-threatening VTE IVC filter considered if absolute contraindication to anticoagulation	Observation may be necessary or reasonable for premature neonates or critically ill children at high risk of bleeding Recommendations vary regarding utility of radiographic follow-up
Asymptomatic DVT	Anticoagulation or observation	Natural history is unclear, decision may vary based on VTE- and patient-specific factors
Massive PE (hemodynamic compromise)	Thrombolysis followed by anticoagulation	
Submassive PE (no hemodynamic compromise)	Anticoagulation alone	
CVC-related	Anticoagulation Removal of CVC if not functioning or no longer needed	Duration of anticoagulation needed before CVC removal is still being investigated, and recommendations vary
Renal vein thrombosis (RVT)	Unilateral: Anticoagulation alone Bilateral: Consider thrombolysis for bilateral RVT (life- or organ-threatening)	
Portal vein thrombosis (PVT)	Occlusive: Anticoagulation Nonocclusive: Observation (close radiologic follow-up)	Observe for cavernous transformation. Bleeding risk with anticoagulation increases in the setting of portal hypertension (and associated esophageal varices)
Cerebral Sinovenous Thrombosis (CSVT)	Anticoagulation (radiologic follow-up recommended) Acetazolamide if concomitant increased intracranial pressure	Decision in patients with intracranial hemorrhage needs to be individualized, but some patients may benefit from anticoagulation

CVC, Central venous catheter; DVT, deep vein thrombosis; IVC, inferior vena cava; PE pulmonary embolism; VTE, venous thromboembolism

Table 528.5 Comparison of Antithrombotic Agents

	rTPA	UNFRACTIONATED HEPARIN	WARFARIN	LMW HEPARIN (ENOXAPARIN)
Indication	Recent onset of life- or limb-threatening thrombus	Acute or chronic thrombus, prophylaxis	Subacute or chronic thrombosis, thromboprophylaxis for cardiac valves	Acute or chronic thrombus, prophylaxis
Administration	IV continuous infusion	IV continuous infusion	PO once daily	SC injection twice daily
Monitoring	"Lytic state": FDP or D-dimer	PTT	INR	Anti–factor Xa activity
Other	Higher risk of bleeding	Difficult to titrate; requires frequent dose adjustments; higher dose required in newborns	Heavily influenced by other drugs and diet	More stable and easy to titrate; concern of osteopenia with long-term use

FDP, Fibrin degradation products; INR, international normalized ratio; IV, intravenous; LMW, low-molecular-weight; PO, oral; PTT, partial thromboplastin time; rTPA, recombinant tissue-type plasminogen activator; SC, subcutaneous.

complication in which antibodies develop to a complex of heparin and platelet factor-4. These antibodies result in platelet activation, stimulation of coagulation, thrombocytopenia, and in some cases, life-threatening thrombosis. If HIT is strongly suspected, heparin must be discontinued immediately. An alternative parenteral anticoagulant, including the direct thrombin inhibitors argatroban or bivalirudin, may be used in this situation.

LOW MOLECULAR WEIGHT HEPARIN

In contrast to UFH, LMWH contains smaller molecular weight polysaccharide chains. The interaction of the smaller chains with AT results primarily in the inhibition of factor Xa, with less of an effect on thrombin. The several LMWHs available have variable inhibitory effects on thrombin. For this reason, the PTT is not a reliable measure of the anticoagulant effect of LMWH, and the anti–factor Xa activity is used instead. Because of the ease of dosing and need for less monitoring, *LMWH is the most frequently used anticoagulant in pediatric patients*. Although dalteparin was the first (and currently only) LMWH approved by the Food and Drug Administration (FDA) for use in children (older than 1 month of age), enoxaparin is the LMWH that has been studied and used more often in pediatric patients.

Enoxaparin Dosing

The recommended standard starting dose of enoxaparin for infants <2 months old is 1.5 mg/kg/dose subcutaneously every 12 hours and for patients >2 months old, 1 mg/kg every 12 hours, although many

Table 528.6 Pharmacologic Properties of Direct Oral Anticoagulants

	DABIGATRAN	APIXABAN	BETRIXABAN	EDOXABAN	RIVAROXABAN
Target	Thrombin	Factor Xa	Factor Xa	Factor Xa	Factor Xa
Bioavailability, %	6–7%	50%	34%	62%	66%*
Protein binding, %	35%	87%	60%	40–59%	92–95%
Time to maximum concentration, hr	2	1–3	3–4	1–2	2–4
Half-life, hr	12–14	8–15	19–27	9–14	9–13
Renal elimination, %	>80%	25%	6–13%	50%	33%
Metabolism via cytochrome P450 enzymes, %	<2%	<32%	<1%	<5%	57%
Drug interactions	Inhibitors and inducers of P-gp	Dual inhibitors and inducers of CYP3A4 and P-gp	Inhibitors and inducers of P-gp	Inhibitors and inducers of P-gp	Dual inhibitors and inducers of CYP3A4 and P-gp
Specific reversal agents	Idarucizumab	Andexanet alfa	Andexanet alfa†	Andexanet alfa†	Andexanet alfa

*Applies to the 15 mg and 20 mg doses given once a day without food; bioavailability is 80–100% when these doses are given with food.
†Expected to be effective on the basis of its mechanism of action, although not approved for these agents.
P-gp, P-glycoprotein.
From Chan N, Sobieraj-Teague M, Eikelboom JW. Direct oral anticoagulants: evidence and unresolved issues. Lancet 2020;396:1767–1776. Table 1.

centers use slightly higher doses for children <2 years old. In general, peak levels are achieved 3-6 hours after injection. A therapeutic anti–factor Xa level, drawn 4 hours after the second or third dose, should be 0.5-1.0 IU/mL; the dose can be titrated to achieve this range. The elimination half-life of enoxaparin is 4-6 hours. Enoxaparin is cleared by the kidney and should be used with caution in patients with renal insufficiency. It should be avoided in patients with renal failure.

After an initial period of anticoagulation with heparin or LMWH, patients may continue to receive LMWH as an outpatient for the duration of therapy or may be transitioned to an oral anticoagulant such as warfarin.

Direct Thrombin Inhibitors

Argatroban and bivalirudin are IV direct thrombin inhibitors that are used in the setting of HIT, complex heart disease/failure cases with ventricular assist devices, or other relatively uncommon situations in pediatrics. They have short half-lives but cannot be fully reversed. Dosing has not been well established in children.

WARFARIN

Warfarin is an oral anticoagulant that competitively interferes with vitamin K metabolism, exerting its action by decreasing concentrations of the vitamin K–dependent coagulation factors II, VII, IX, and X, as well as protein C and protein S. Therapy should be started while a patient is anticoagulated with heparin or LMWH because of the risk of warfarin-induced skin necrosis. This transient hypercoagulable condition may occur when levels of protein C drop more rapidly than the procoagulant factors.

Dosing

Warfarin therapy is often initiated with a weight-based loading dose, with subsequent dose adjustments made according to a nomogram. When initiating warfarin therapy, UFH or LMWH should be continued until the international normalized ratio (INR) is therapeutic for 2 days. In most patients, this takes 5-7 days. The PT is used to monitor the anticoagulant effect of warfarin. Because the thromboplastin reagents used in PT assays have widely varying sensitivities, the PT performed in one laboratory cannot be compared with that performed in another laboratory. As a result, the INR was developed as a mechanism to standardize the variation in the thromboplastin reagent. The target INR range depends on the clinical situation. In general, a range of 2.0-3.0 is the target for the treatment of VTE. High-risk patients, such as those with mechanical heart valves, APS, or recurrent thrombosis, may require a higher target range.

Polymorphisms in *CYP2C9* and *VKORC1* affect the pharmacokinetics and pharmacodynamics of warfarin. Pharmacogenetic testing can identify wild-type responders, as well as those who are more sensitive (increased risk of bleeding). Genotyping in adults may help select warfarin dose, monitor for bleeding, or choose a DOAC instead of warfarin for patients highly sensitive and at risk for hemorrhage.

Complications

Bleeding is the most common adverse effect of warfarin. The risk of serious bleeding in children receiving warfarin for the treatment of VTE has been reported at 0.5% per year. Children who have supratherapeutic INR are at higher risk. There is considerable interpatient variation in dose. Diet, medications, and illness may influence the metabolism of warfarin, requiring frequent dose adjustments and laboratory studies. Numerous medications can affect the pharmacokinetics of warfarin by altering its clearance or rate of absorption. These effects can have a profound impact on the INR and must be considered when monitoring a patient receiving warfarin.

The strategies used to reverse warfarin therapy depend on the clinical situation and whether there is bleeding. Vitamin K can be administered to reverse the effect of warfarin but takes some time to have an effect. If the patient is having significant bleeding, a nonactivated plasma-derived 4-factor prothrombin complex concentrate (PCC) or fresh-frozen plasma (FFP, 15 mL/kg) should be given along with the vitamin K. PCCs have not been well investigated in children.

Nonhemorrhagic complications are uncommon in children, although hair loss has been reported. Warfarin is a teratogen, particularly in the first trimester. **Warfarin embryopathy** is characterized by bone and cartilage abnormalities known as *chondrodysplasia punctata*. Affected infants may have nasal hypoplasia and excessive calcifications in the epiphyses and vertebrae.

DIRECT ORAL ANTICOAGULANTS

Oral direct thrombin inhibitors (dabigatran) or inhibitors of factor Xa (apixaban, rivaroxaban, edoxaban) are approved for the prevention or treatment of thrombosis in patients >18 years old (see Table 528.6), and dabigatran is FDA-approved for children older than 3 months of age. Fixed dosing, oral administration, no dietary interference with vitamin

Table 528.7 Guidelines for Therapeutic Anticoagulation Treatment Duration

INDICATION	RISK FACTOR	THERAPEUTIC ANTICOAGULATION TREATMENT DURATION
First VTE episode	Provoked, reversible	3 mo
	Provoked, chronic	3 mo, then continue anticoagulation with either therapeutic or prophylaxis regimens until the risk factor is resolved
	Unprovoked	6–12 mo
Recurrent VTE	Reversible	3 mo
	Chronic	If recurrence occurs while the patient was on prophylaxis regimen, after first VTE episode, restart therapeutic regimen until risk factor is resolved
	Unprovoked	Restart therapeutic regimen for at least 3 mo and then switch to lifelong VTE prophylaxis regimen

VTE, Venous thromboembolism.
From Shoag J, Davis JA, Corrales-Medina FF. Venous thromboembolism in pediatrics. *Pediatr Rev.* 2021;42:78–87.

K, and no need to monitor laboratory tests, as well as initial results suggesting noninferiority to warfarin and fewer bleeding episodes, have favored the use of DOACs. Clinical trials have demonstrated the safety and efficacy of dabigatran and rivaroxaban in children. Drugs are available to *reverse* the effects of DOACs if indicated. DOACs should be avoided in patients with APS in the presence of arterial thrombosis.

THROMBOLYTIC THERAPY

Although anticoagulation alone is often effective at managing thrombosis while awaiting natural fibrinolysis, more rapid clot resolution may sometimes be necessary or desirable. In these situations, a thrombolytic agent that can activate the fibrinolytic system is of potential benefit. The pharmacologic activity of thrombolytic agents depends on the conversion of endogenous plasminogen to plasmin. Plasmin is then able to degrade several plasma proteins, including fibrin and fibrinogen. Because of the high risk of bleeding, thrombolytic therapy is generally reserved for patients with life- or limb-threatening thrombosis.

tPA is available as a recombinant product and has become the primary agent used for thrombolysis in children, although proper dose finding studies have not been performed. Depending on the situation, tPA may be used systemically or locally with catheter-directed thrombolysis, sometimes with the addition of mechanical clot lysis devices operated by interventional radiologists.

Dosing

An extremely wide range of doses of tPA has been used for systemic therapy, and no consensus exists as to the optimal dose. Systemic tPA doses of 0.1-0.6 mg/kg/hr were previously recommended, although recent reports indicate successful therapy with fewer bleeding complications using prolonged infusions with very low doses—0.01-0.06 mg/kg/hr.

Monitoring

There is no specific laboratory test to document a "therapeutic range" for thrombolytic therapy. It is important to maintain the fibrinogen >100 mg/dL and the platelet count >75,000 × 10^9/L during treatment. Supplementation of plasminogen using FFP is generally recommended in neonates before initiating thrombolysis because of their low baseline levels.

The clinical and radiologic response to thrombolysis should be closely monitored. The duration of therapy depends on the clinical response. Invasive procedures, including urinary catheterization, arterial puncture, and rectal temperatures, should be avoided.

The role of adjuvant UFH during thrombolytic therapy is controversial. Animal models have demonstrated that thrombolytic therapy can induce a procoagulant state with activation of the coagulation system, generation of thrombin, and extension or reocclusion of the thrombosis. In pediatric patients thought to be at low risk for bleeding, adjuvant UFH should be considered using doses of 10-20 units/kg/hr. The recommended duration of therapy is noted in Table 528.7.

Complications

The most serious complication from thrombolysis is bleeding, which has been reported in 0–40% of patients. Absolute contraindications to thrombolysis include major surgery within 7 days, history of significant bleeding (intracranial, pulmonary, or GI), peripartum asphyxia with brain damage, uncontrolled hypertension, and severe thrombocytopenia. In the event of serious bleeding, thrombolysis should be stopped, and cryoprecipitate should be given to replace fibrinogen.

THROMBOPROPHYLAXIS

There have been no formal trials of VTE prevention in children, although many institutions are starting to develop and use risk-guided algorithms to identify children who may benefit from mechanical (sequential compression devices) or pharmacologic (low-dose anticoagulant) prevention strategies in the absence of concomitant bleeding risk. Hospitalized adolescents with multiple risk factors for thrombosis who are immobilized for a prolonged period are a group that expert consensus would suggest may benefit from prophylactic treatment with enoxaparin, 0.5 mg/kg every 12 hours (maximum 30 mg).

ANTIPLATELET THERAPY

Inhibition of platelet function using agents such as aspirin is more likely to be protective against arterial TEs than VTEs. Aspirin, or acetylsalicylic acid (ASA), exerts its antiplatelet effect by irreversibly inhibiting cyclooxygenase, preventing platelet thromboxane A_2 production. Aspirin is used routinely in children with Kawasaki disease and may also be useful in children with stroke, ventricular assist devices, and single-ventricle cardiac defects. The recommended dose of aspirin to achieve an antiplatelet effect in children is 1-5 mg/kg/day.

Visit Elsevier eBooks+ at eBooks.Health.Elsevier.com for Bibliography.

Chapter 529

Postneonatal Vitamin K Deficiency

Brian R. Branchford, Benjamin J. Samelson-Jones, and Veronica H. Flood

Vitamin K deficiency occurring after the neonatal period is usually secondary to insufficient vitamin K intake, malabsorption, or alterations in the intestinal flora as a consequence of antibiotics. The biologic activity of the "vitamin K–dependent factors" (coagulation factors II, VII, IX, and X, as well as the natural anticoagulants protein C and protein S) requires vitamin K for their posttranslational carboxylation. In the absence of vitamin K, only nonfunctional forms of these proteins are synthesized, which are ineffective for hemostasis. Severe vitamin K deficiency will result in a prolonged prothrombin time (PT) and partial thromboplastin time (PTT), although early deficiency may only demonstrate a prolonged PT because of the short half-life of factor VII. Plasma levels of uncarboxylated factor II are measured in the PIVKA-II (proteins induced by vitamin K absence) test and elevated levels are diagnostic of vitamin K deficiency, although clinical history and basic coagulation labs are usually sufficient to make the diagnosis. It can often be clinically helpful to distinguish between deficiencies of the vitamin K–dependent factors and deficiencies in the clotting factors synthesized by hepatocytes due to liver disease (see Chapter 530), which includes the vitamin K–dependent factors as well as factors V and XI.

Intestinal malabsorption of fats may accompany cystic fibrosis, biliary atresia, or other liver diseases and results in a deficiency of fat-soluble dietary vitamins including vitamin K.

Prophylactic administration of water-soluble vitamin K orally is indicated in these patients (2-5 mg/24 hr for children and 5-10 mg/24 hr for adolescents and adults). Vitamin K may also be administered at 1-2 mg intravenously. Broad-spectrum antibiotics can alter the intestinal flora, reducing the vitamin K that is produced in the gastrointestinal tract. Patients have only a few weeks of vitamin K stores. The anticoagulant properties of warfarin (Coumadin) depend on interference with vitamin K, with a concomitant reduction of the vitamin K–dependent clotting factors. **Rat poison** (superwarfarin) produces a similar deficiency that should be considered in young children presenting with bleeding and bruising with a history compatible with ingestion. There are also cases of illicit drugs being adulterated with vitamin K antagonists. Vitamin K is a specific antidote for these substances. Four factor prothrombin complex concentrates contain all the vitamin K–dependent clotting factors; they are available for warfarin reversal and have been used to rapidly replace vitamin K–dependent clotting factors in urgent scenarios. Dosing is based on the international normalized ratio (INR), and vitamin K should also be administered.

Visit Elsevier eBooks+ at eBooks.Health.Elsevier.com for Bibliography.

Chapter 530

Coagulopathy in Liver Disease

Brian R. Branchford and Veronica H. Flood

Because all the clotting factors *except* factor VIII (which is synthesized in liver sinusoids and extrahepatic endothelium) are produced exclusively in hepatocytes, coagulation abnormalities are very common in patients with severe liver disease (Table 530.1). Only 15% of such patients have significant clinical bleeding states, possibly because of concomitant reduction in anticoagulation proteins (protein C and S). The severity of the coagulation abnormality appears to be directly proportional to the extent of hepatocellular damage. The most common mechanism causing the hemostasis defect is decreased synthesis of coagulation factors. Patients with severe liver disease characteristically have normal to increased (not reduced) levels of factor VIII activity in plasma. In some instances, **disseminated intravascular coagulation** (DIC; see Chapter 510), hypofibrinogenemia, or hyperfibrinolysis may complicate liver disease, making laboratory differentiation of severe liver disease from DIC-related clotting factor consumption difficult. These entities, as well as vitamin K deficiency (see Chapter 529), may be distinguished by comparing levels of a hepatically synthesized factor (such as factor V), a hepatically synthesized vitamin K–dependent factor (such as factor VII), and a nonhepatically synthesized factor that could be subject to consumption (such as factor VIII).

Treatment of the coagulopathy of liver disease should be reserved for patients with clinical bleeding rather than used to normalize the lab values. Because a reduction in vitamin K–dependent coagulation factors is common in those with acute or chronic liver disease, a trial of vitamin K supplementation can be given. Vitamin K can be given orally, subcutaneously, or preferably intravenously (not intramuscularly) at a dose of 1 mg/24 hr for infants, 2-5 mg/24 hr for children, and 5-10 mg/24 hr for adolescents and adults. Inability to correct coagulopathy with vitamin K indicates that the coagulopathy may be caused by reduced levels of clotting factors that are not vitamin K–dependent and/or by inadequate production of precursor vitamin K proteins. Treatment for bleeding consists of factor replacement with **fresh-frozen plasma** (FFP) or **cryoprecipitate**. FFP (10-15 mL/kg) contains all clotting factors, but replacement of fibrinogen for severe hypofibrinogenemia may require cryoprecipitate at a dose of 1 unit per 5-10 kg body weight, or a fibrinogen concentrate if a patient is unable to tolerate excess fluid volume. In severe liver disease, it is often difficult to attain correction of abnormal clotting studies despite vigorous therapy with FFP and cryoprecipitate, and such attempts are often complicated by volume overload concerns. Some patients with bleeding as a result of liver disease have responded to therapy with desmopressin (DDAVP), whereas others have responded to treatment with recombinant factor VIIa, albeit at a dose lower than typically given for hemophilia. Recombinant factor VIIa is contraindicated in DIC.

Desmopressin (0.3 μg/kg intravenously) is effective in shortening bleeding time, prompts endothelial cell release of von Willebrand factor and factor VIII, promotes platelet activation, and is therefore used effectively to augment hemostasis before diagnostic liver biopsy in the setting of hepatic insufficiency/failure. In clinical trials of adults, recombinant factor VIIa has not been shown to be effective for the treatment of bleeding caused by severe liver disease, possibly because of its short half-life (3-6 hours). Frequently, severe liver disease is associated with moderate prolongation of coagulation disorder screening tests (partial thromboplastin time [PTT]; prothrombin time [PT]) that is not corrected by vitamin K or plasma replacement. Another diagnostic clue may be a low serum albumin level because this protein is also synthesized in the liver.

Visit Elsevier eBooks+ at eBooks.Health.Elsevier.com for Bibliography.

Table 530.1 Coagulation Changes in Liver Disease

CHANGES IN PROCOAGULANT PROTEINS	CHANGES IN ANTICOAGULANT PROTEINS	CHANGES IN ANTIFIBRINOLYTIC PROTEINS
Decreased fibrinogen and factors FII, FV, FVII, FIX, FX, and FXI	Decreased protein C	Decreased α_2-antiplasmin and thrombin-activatable fibrinolysis inhibitor
Increased FVIII	Decreased protein S	FXIII decreased in some patients
Increased VWF, decreased ADAMTS-13	Decreased antithrombin	Increased tissue plasminogen activator

ADAMTS-13, A disintegrin and metalloproteinase with a thrombospondin type 1 motif, member 13.
From Han H, Hensch L, Hui SKR, Teruya J. Evaluation and management of coagulopathies and thrombophilias in pediatric patients. *Clin Lab Med.* 2021;41:83–100. Table 4.

Chapter 531

Acquired Inhibitors of Coagulation

Brian R. Branchford and Veronica H. Flood

Acquired circulating anticoagulants **(inhibitors)** are antibodies that react, or cross-react, with clotting factors or components used in coagulation screening tests (phospholipids), thereby prolonging screening tests, such as prothrombin time (PT) and partial thromboplastin time (PTT), although not all of them result in a clinical bleeding state. Some of these anticoagulants are autoantibodies that react with phospholipid and thereby interfere with clotting in vitro *but not in vivo.* This group comprises anticardiolipin and anti-beta(2)-glycoprotein-Ib antibodies, but the most common subtype of these **antiphospholipid antibodies** has been referred to as the *lupus anticoagulant* (see Chapter 528.1). This unfortunately named antibody is neither found exclusively in patients with systemic lupus erythematosus (SLE; see Chapter 199), nor does its presence consistently signify the concomitant presence of SLE in a patient. It can also be seen in those with other collagen vascular diseases and in association with HIV infection. In otherwise healthy children, spontaneous lupus-like inhibitors have developed transiently after incidental viral infection and can be seen in up to 26% of screening tests in asymptomatic subjects. These transient inhibitors are usually not associated with either bleeding or thrombosis.

Although the classic lupus anticoagulant is more often associated with a predisposition to thrombosis than with bleeding symptoms, bleeding symptoms in a patient with the lupus anticoagulant may be caused by **thrombocytopenia**, which may be a manifestation of the antiphospholipid syndrome or of lupus itself (alone or occasionally in context with Evans syndrome), or, rarely, by a coexistent specific autoantibody against prothrombin (factor II). The antiprothrombin antibody does not inactivate prothrombin but rather causes accelerated clearance of the protein, resulting in low levels of prothrombin and subsequent inadequate hemostasis.

Rarely, antibodies may arise spontaneously against a specific clotting factor, such as *factor VIII* or *von Willebrand factor*, leading to acquired hemophilia A or von Willebrand disease (VWD), but this is usually seen more frequently in adult patients. These patients are prone to excessive hemorrhage and may require specific treatment. In patients with a hereditary deficiency of a clotting factor (factor VIII or factor IX), antibodies may develop after exposure to transfused factor concentrates. These hemophilic inhibitory antibodies are discussed in Chapter 525.1.

LABORATORY FINDINGS

Inhibitors against specific coagulation factors usually affect factors VIII, IX, and XI, or, rarely, prothrombin (factor II). Depending on the target of the antibody and the target's participation in the intrinsic, extrinsic, or common coagulation cascade pathway, the PT and/or PTT may be prolonged. The mechanism by which the inhibitory antibody functions determines whether mixing patient plasma with normal plasma will normalize (correct) the clotting time. Patient plasma that contains antibodies directed against the active site of a clotting factor (factor VIII or factor IX) will not correct on 1:1 mixing with normal plasma, whereas antibodies that lead to increased clearance of the factor (such as antiprothrombin antibodies) will correct on such mixing studies. Specific factor assays are used to determine which factor is involved, and the pattern of abnormalities in PT, PTT, and/or thrombin time (TT) is used to guide initial investigation.

TREATMENT

Management of the bleeding patient with an acquired inhibitory autoantibody against factor VIII or IX is the same as for the patient with congenital hemophilia who has an alloantibody against factor VIII or factor IX. Infusions of recombinant factor VIIa or activated prothrombin complex concentrate may be needed to control significant bleeding. Occasionally, high-dose coagulation factor VIII or IX concentrates may be effective. Immunosuppressive agents have been used "off label" to treat the inhibitor or reduce titers. Acute bleeding caused by an antiprothrombin antibody can often be treated with a plasma infusion and may resolve with a short course of corticosteroid therapy.

Asymptomatic spontaneous inhibitors that arise after a viral infection tend to disappear within a few weeks to months. Inhibitors seen with an underlying disease, such as those associated with SLE, often resolve during the treatment of the underlying disease.

Visit Elsevier eBooks+ at eBooks.Health.Elsevier.com for Bibliography.

Chapter 532

Disseminated Intravascular Coagulation

Benjamin J. Samelson-Jones and Leslie J. Raffini

Disseminated intravascular coagulation (DIC) is an acquired clinicopathologic syndrome characterized by the widespread pathologic activation of the coagulation system, which results in both microvascular thrombi and the consumption of clotting factors, anticoagulant proteins, and platelets. Microvasculature injury can contribute to organ dysfunction, while hemorrhage can be life-threatening in a minority of cases. The diagnosis of DIC is based on the laboratory findings and clinical manifestations within the appropriate clinical context. The

simultaneous occurrence of bleeding and clotting is clinically challenging, with management starting from appropriately recognizing this syndrome.

ETIOLOGY

DIC is always a secondary complication of an underlying disorder (Table 532.1) and never an isolated diagnosis. The complex pathogenesis involves the loss of localization and excessive activation of coagulation leading to unregulated thrombin generation and microvascular fibrin deposition. Dysfunction of the vascular endothelium can both precipitate and amplify this process. The excessive activation consumes platelets, procoagulant clotting factors (factor V, factor VIII, prothrombin, and fibrinogen), and anticoagulant proteins (protein C, protein S, and antithrombin). The fibrinolytic system can also become dysregulated with endothelial injury and plasma protein consumption.

Table 532.1 Causes of Disseminated Intravascular Coagulation in Children

INFECTIONS
Meningococcemia (purpura fulminans)
Bacterial sepsis (staphylococcal, streptococcal, *Escherichia coli*, *Salmonella*)
Rickettsia (Rocky Mountain spotted fever)
Viruses (cytomegalovirus, herpes simplex, hemorrhagic fevers)
Malaria
Fungi
TISSUE INJURY
Central nervous system trauma (massive head injury)
Fat embolism
Crush injury
Profound shock or asphyxia
Hypothermia or hyperthermia (heat shock)
Massive burns
MALIGNANCY
Acute promyelocytic leukemia
Acute monoblastic leukemia
Disseminated solid tumors (rhabdomyosarcoma, neuroblastoma)
VENOM OR TOXINS
Toxic shock syndrome
Snakebites
Spider bites
MICROANGIOPATHIC DISORDERS
Severe thrombotic thrombocytopenic purpura or hemolytic-uremic syndrome
Vascular malformations
GASTROINTESTINAL DISORDERS
Fulminant hepatitis
Ischemic bowel
Pancreatitis
HEREDITARY THROMBOTIC DISORDERS
Homozygous/compound heterozygous protein C, protein S, or antithrombin deficiency
PERINATAL
Maternal toxemia
Abruptio placentae
Severe respiratory distress syndrome
Meconium aspiration syndrome
Necrotizing enterocolitis
Erythroblastosis fetalis
Fetal demise of a twin
MISCELLANEOUS
Severe acute graft rejection
Acute hemolytic transfusion reaction
Severe collagen-vascular disease
Kawasaki disease
Heparin-induced thrombosis
Infusion of activated prothrombin complex concentrates
Hyperpyrexia/encephalopathy, hemorrhagic shock syndrome

Adapted from Montgomery RR, Scott IP. Hemostasis: diseases of the fluid phase. In Nathan DG, Oski FA, eds. *Hematology of Infancy and Childhood*, 4th ed. Philadelphia: Saunders, 1993.

LABORATORY FINDINGS

Although DIC is characterized by a number of abnormal laboratory findings, none are specific for the diagnosis. The consumption of coagulation factors and platelets often results in a prolonged prothrombin time (PT), an increased partial thromboplastin time (PTT), and low platelet counts. Low fibrinogen is seen in severe disease, but as an acute-phase reactant, fibrinogen may be high or normal early in the disease process; declining fibrinogen levels, even within the normal range, can suggest DIC. Fibrinogen degradation products and D-dimer levels are frequently highly elevated. Factors V and VIII are usually both reduced in DIC, whereas in acute hepatic disease, factor VIII may be normal or elevated. Thrombi in the microvasculature can lead to red blood cell fragmentation and a **microangiopathic hemolytic anemia** with elevated lactate dehydrogenase and characteristic blood smear morphology, including schistocytes, helmet cells, and microspherocytes.

CLINICAL MANIFESTATIONS

DIC may be subclinical with only laboratory abnormalities, termed *nonovert DIC*. Clinical manifestations include thrombotic and hemorrhagic complications, as well as organ dysfunction. Bleeding frequently first occurs from sites of venipuncture or surgical incision, and the skin may show petechiae, purpura, and ecchymoses. Localized large-vessel arterial or venous thromboembolic events can occur. Tissue necrosis may involve many organs and can be most spectacularly seen as infarction of large areas of skin and subcutaneous tissue. A compromised blood supply can lead to organ dysfunction including organ failure, especially to the lungs, kidneys, liver, and brain.

MANAGEMENT

The primary treatment of DIC is resolving the underlying triggering disease process. Blood components support is recommended for active hemorrhage or in patients requiring invasive procedures; this may consist of platelet infusions (for thrombocytopenia), cryoprecipitate (for hypofibrinogenemia), and fresh-frozen plasma (for replacement of other coagulation factors and anticoagulant proteins). Blood product support in the absence of bleeding should not be based solely on laboratory abnormalities, but clinical practice varies on the importance of minor bleeding symptoms. Hemostatic products with activated clotting factors such as recombinant factor VIIa (FVIIa) and activated prothrombin complex concentrate (aPCC) theoretically may worsen the widespread and unregulated generation of thrombin. Likewise, systemic antifibrinolytics are generally contraindicated except in clinical scenarios associated with hyperfibrinolysis such as acute promyelocytic leukemia and early trauma.

DIC patients with overt thromboembolic complications should receive therapeutic anticoagulation, usually with unfractionated heparin, as outlined in Chapter 528.1; stringent attention to replacement therapy is warranted to maintain an adequate platelet count to limit bleeding. Prophylactic anticoagulation may be carefully used in patients with DIC at high risk of thromboembolic events that are not actively bleeding. Most patients should receive mechanical thromboprophylaxis such as sequential compression devices.

The prognosis of patients with DIC is primarily dependent on the outcome of the treatment of the primary disease and prevention of end-organ damage.

Visit Elsevier eBooks+ at eBooks.Health.Elsevier.com for Bibliography.

Chapter 533

Platelet and Blood Vessel Disorders

Brian R. Branchford, Benjamin J. Samelson-Jones, and Veronica H. Flood

MEGAKARYOPOIESIS

Platelets are anuclear cellular fragments produced by megakaryocytes (large polyploid cells) within the bone marrow, lung, and other tissues. When the megakaryocyte approaches maturity, budding of the cytoplasm occurs, and large numbers of platelets are liberated. Platelets circulate with a life span of 7-10 days. **Thrombopoietin (TPO)** is the primary growth factor that controls platelet production (Fig. 533.1). Levels of TPO appear to correlate inversely with platelet number and megakaryocyte mass, with highest expression in the thrombocytopenic states associated with decreased marrow megakaryopoiesis, and may be variable in states of increased platelet production.

The platelet plays multiple hemostatic roles. The platelet surface possesses a number of important receptors for adhesive proteins, including **von Willebrand factor (VWF)** and fibrinogen, as well as receptors for agonists that trigger platelet aggregation, such as thrombin, collagen, and adenosine diphosphate (ADP). After injury to the blood vessel wall, the extracellular matrix containing adhesive and procoagulant proteins is exposed. Subendothelial collagen binds VWF, which then undergoes a conformational change that induces binding of the platelet glycoprotein Ib (GPIb) complex, the VWF receptor. This process is called *platelet adhesion.* Platelets then undergo activation. During the process of activation, the platelets generate thromboxane A_2 from arachidonic acid via the enzyme cyclooxygenase. After activation, platelets release agonists, such as ADP, adenosine triphosphate (ATP), calcium ions (Ca^{2+}), serotonin, and coagulation factors, into the surrounding milieu from dense and alpha granules. Binding of VWF to the GPIb complex triggers a complex signaling cascade that results in activation of the fibrinogen receptor, the major platelet integrin glycoprotein αIIb-β_3 (GPIIb-IIIa). Circulating fibrinogen binds to this receptor on activated platelets, linking platelets in a process called *aggregation.* This series of events forms a hemostatic plug at the site of vascular injury. The serotonin and histamine that are liberated during activation increase local vasoconstriction. In addition to acting in concert with the vessel wall to form the platelet plug, the platelet provides the catalytic phospholipid surface on which coagulation factors assemble and eventually generate thrombin through a sequential series of enzymatic cleavages. Lastly, the platelet contractile proteins and cytoskeleton mediate clot retraction.

THROMBOCYTOPENIA

The normal platelet count is 150-450 × 10^9/L. *Thrombocytopenia* refers to a reduction in platelet count to <150 × 10^9/L, although clinically significant bleeding is not seen until counts drop well below 50 × 10^9/L. Causes of thrombocytopenia include decreased production on either a congenital or an acquired basis, sequestration of the platelets within an enlarged spleen or other organ, and increased destruction of normally synthesized platelets on either an immune or a nonimmune basis (Tables 533.1-533.3, Fig. 533.2, and Chapter 524).

533.1 Immune Thrombocytopenia

Brian R. Branchford and Veronica H. Flood

The most common cause of acute onset of thrombocytopenia in an otherwise-well child is immune thrombocytopenia **(ITP)** (also called immune or idiopathic thrombocytopenic purpura).

EPIDEMIOLOGY

In a small number of children, estimated at 1/20,000, 1-4 weeks after exposure to a common viral infection, an autoantibody directed against the platelet surface develops with resultant sudden onset of thrombocytopenia. A recent history of viral illness is described in 50–65% of children with ITP. The peak age is 1-4 years, although the age ranges from early in infancy to elderly. In childhood, males and females are equally affected. ITP seems to occur more often in late winter and spring after the peak season of viral respiratory illness. Approximately 5–10% of ITP may recur more than 3 months after initial disease resolution.

PATHOGENESIS

The exact antigenic target for most such antibodies in most cases of childhood acute ITP remains undetermined, although in chronic ITP, many patients demonstrate antibodies against αIIb-β_3 and GPIb. After binding of the antibody to the platelet surface, circulating antibody-coated platelets are recognized by the Fc receptor on splenic macrophages, ingested, and destroyed. The most common identifiable viruses that have been described in association with ITP include Epstein-Barr

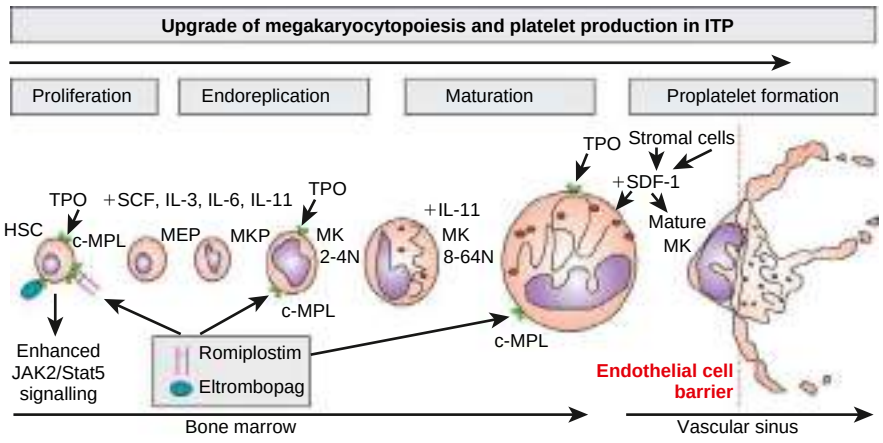

Fig. 533.1 Scheme of megakaryocytopoiesis and platelet production in immune thrombocytopenia (ITP). Hematopoietic stem cells (HSC) are mobilized, and megakaryocyte (MK) and erythroid progenitors (MEP) accumulate with MK-committed progenitors (MKP), giving rise to mature MKs under control of thrombopoietin (TPO) working with chemokines, cytokines, and growth factors, including stem cell factor (SCF) and interleukin (IL)-3, IL-6, and IL-11. Endoreplication results in ploidy changes in MKs and increased chromosome number (up to 64N). Mature MKs migrate to the endothelial cell barrier delimiting the vascular sinus and, under the influence of stromal-derived factor-1 (SDF-1), give rise to proplatelets that protrude into the circulation and produce large numbers of platelets under hemodynamic determinants. Therapeutically given romiplostim and eltrombopag enter the marrow and join with TPO to stimulate megakaryocytopoiesis and platelet production. *(From Nurden AT, Viallard JF, Nurden P. New-generation drugs that stimulate platelet production in chronic immune thrombocytopenic purpura. Lancet 2009;373:1563–1569.)*

Table 533.1 Differential Diagnosis of Thrombocytopenia in Children and Adolescents

DESTRUCTIVE THROMBOCYTOPENIAS
Primary Platelet Consumption Syndromes
Immune thrombocytopenias
- Acute and chronic ITP
- Autoimmune diseases with chronic ITP as a manifestation
  - Cyclic thrombocytopenia
  - Autoimmune lymphoproliferative syndrome and its variants
  - Systemic lupus erythematosus
  - Evans syndrome
  - Antiphospholipid antibody syndrome
  - Neoplasia-associated immune thrombocytopenia
- Thrombocytopenia associated with HIV
- Neonatal immune thrombocytopenia
  - Alloimmune
  - Autoimmune (e.g., maternal ITP)
- Drug-induced immune thrombocytopenia (including heparin-induced thrombocytopenia)
- Posttransfusion purpura
- Allergy and anaphylaxis
- Posttransplant thrombocytopenia

Nonimmune thrombocytopenias
- Thrombocytopenia of infection
  - Bacteremia or fungemia
  - Viral infection
  - Protozoan
- Thrombotic microangiopathic disorders
  - Hemolytic-uremic syndrome
  - Eclampsia, HELLP syndrome
  - Thrombotic thrombocytopenic purpura
  - Bone marrow transplantation–associated microangiopathy
  - Drug induced (quinine, etc.)
- Platelets in contact with foreign material
- Congenital heart disease
- Drug-induced via direct platelet effects (ristocetin, protamine)
- Type 2B VWD or platelet-type VWD

Combined Platelet and Fibrinogen Consumption Syndromes
Disseminated intravascular coagulation
Kasabach-Merritt syndrome
Hemophagocytic lymphohistiocytosis (inherited or acquired)

IMPAIRED PLATELET PRODUCTION
Hereditary disorders (see Table 533.2)
Acquired disorders
- Aplastic anemia
- Myelodysplastic syndrome
- Marrow infiltrative process—neoplasia
- Osteopetrosis
- Nutritional deficiency states (iron, folate, vitamin B12, anorexia nervosa)
- Drug- or radiation-induced thrombocytopenia
- Neonatal hypoxia or placental insufficiency

SEQUESTRATION
Hypersplenism
Hypothermia
Burns

ASSOCIATION WITH OTHER DISEASES
Fanconi anemia
Congenital amegakaryocytic thrombocytopenia
Shwachman-Diamond syndrome
Hemophagocytic lymphohistiocytosis
TAFRO syndrome

HELLP, Hemolysis, elevated liver enzymes, and low platelets; HIV, human immunodeficiency virus; ITP, immune thrombocytopenic purpura; TAFRO, thrombocytopenia, ascites, myelofibrosis renal dysfunction, organomegaly (a variant of multicentric Castleman disease); VWD, von Willebrand disease.
From Wilson DB. Acquired platelet defects. In: Orkin SH, Fisher DE, Ginsburg D, et al., eds. *Nathan and Oski's Hematology and Oncology of Infancy and Childhood*, 8th ed. Philadelphia: Elsevier, 2015: Box 34.1, p. 1077.

virus (EBV; see Chapter 301) and HIV (see Chapter 322), and ITP is also noted as a rare occurrence after measles, mumps, and rubella (MMR) vaccination. EBV-related ITP is usually of short duration and follows the course of infectious mononucleosis. HIV-associated ITP is usually chronic. In some patients, ITP appears to arise in children infected with *Helicobacter pylori* or rarely after vaccines. The SARS-CoV-2 virus responsible for the COVID-19 infection has been associated with development of ITP, as have some of the vaccines for this virus.

CLINICAL MANIFESTATIONS

The classic presentation of ITP is a previously healthy 1–4-year-old child who has sudden onset of generalized petechiae and purpura. The parents often state that the child was fine the previous day but is now covered with bruises and purple dots. There may be bleeding from the gums and mucous membranes, particularly with *profound thrombocytopenia* (platelet count $<10 \times 10^9$/L). There is a history of a preceding viral infection 1-4 weeks before the onset of thrombocytopenia. Findings on physical examination are typically normal, other than petechiae and purpura. *Splenomegaly, lymphadenopathy, bone pain, and pallor are rare.* A simple classification system to characterize the severity of bleeding in ITP on the basis of symptoms and signs rather than platelet count includes:

1. No symptoms
2. Mild symptoms: Bruising and petechiae, occasional minor epistaxis, very little interference with daily living
3. Moderate symptoms: More severe skin and mucosal lesions, more troublesome epistaxis, and menorrhagia
4. Severe symptoms: Bleeding episodes—menorrhagia, epistaxis, melena—requiring transfusion or hospitalization, symptoms interfering seriously with the quality of life

The presence of abnormal findings such as hepatosplenomegaly, bone or joint pain, remarkable lymphadenopathy, other cytopenias, or congenital anomalies suggests other diagnoses (e.g., leukemia, genetic syndromes). When the onset is insidious, especially in an adolescent, chronic ITP or the possibility of a systemic illness, such as **systemic lupus erythematosus** (SLE), is more likely. In addition, presentation at an atypical age (neonates, adolescents) should suggest an underlying disease.

OUTCOME

Severe bleeding is rare (<3% of cases in one large international study). In 70–80% of children who present with acute ITP, spontaneous resolution occurs within 6 months. Therapy does not appear to affect the natural history of the illness. Fewer than 1% of patients develop an **intracranial hemorrhage** (ICH). Proponents of interventional therapy argue that the objective of early therapy is to raise the platelet count to $>20 \times 10^9$/L and prevent the rare development of ICH. There is no evidence that therapy prevents serious bleeding. Approximately 20% of children who present with acute ITP go on to have chronic ITP. The outcome/prognosis may be related more to age; ITP in younger children is more likely to resolve, whereas development of chronic ITP in adolescents approaches 50%.

LABORATORY FINDINGS

Severe thrombocytopenia (platelet count $<20 \times 10^9$/L) is common, and platelet size is normal or increased, reflective of increased platelet turnover (Fig. 533.3). In acute ITP, the hemoglobin value, white blood cell (WBC) count, and differential count are usually normal. Hemoglobin may be decreased in the context of profuse nosebleeds (epistaxis) or menorrhagia. Bone marrow examination, *which is not routinely indicated in this disease*, shows normal granulocytic and erythrocytic series, with characteristically normal or increased numbers of megakaryocytes. Some of the megakaryocytes may appear to be immature and reflect increased platelet turnover. *Indications for bone marrow aspiration/biopsy* include an abnormal WBC count or differential or unexplained anemia, as well as history and physical examination findings suggestive of a bone marrow failure syndrome or malignancy. Other laboratory tests should be performed as indicated by the history and examination. HIV studies should be done in at-risk populations, especially sexually active teens. Platelet antibody testing is seldom useful in acute ITP. A direct antiglobulin test (Coombs) should be done if there is unexplained anemia to rule out **Evans syndrome** (autoimmune hemolytic anemia and thrombocytopenia; see Chapter 506). Evans syndrome may be idiopathic or an early sign of SLE, autoimmune lymphoproliferative syndrome, or common variable immunodeficiency

Table 533.2 Inherited Platelet Disorders

PLATELET DEFECT	GENE DEFECT (CHROMOSOMAL LOCATION)	CLINICAL AND LABORATORY CHARACTERISTICS	BLEEDING TREATMENT
DEFECTS IN PLATELET ADHESION			
Bernard-Soulier syndrome (BSS)	Autosomal recessive: *GP1BA* (17p13) *GP1BB* (22q11) *GP9* (3q21) Autosomal dominant: Ala156Val, GP1BA - Bolzano variant	• Often severe bleeding phenotype • Thrombocytopenia • Large platelets • Platelet aggregation: absent ristocetin-induced response • Flow cytometry: reduced or absent CD42a (GPIX)/CD42b (GP1bα) • *GP1BA* & *GP1BB* gene sequencing	• Supportive care • Platelet transfusion (risk of alloantibodies) • Antifibrinolytics • rFVIIa
Velocardiofacial/DiGeorge syndrome (VCFS)	22q11.2 deletion including *GP1BB*	• Thrombocytopenia • Large platelets and α-granules • Cardiac, thymus, parathyroid, facial, and cognitive abnormalities	• Supportive care
Platelet-type von Willebrand disease (PT-VWD)	Autosomal dominant: gain of function variants in *GP1BA*	• Thrombocytopenia • Large platelets • Platelet clumping • Decreased VWF:Ag, VWF multimers • Platelet aggregation: low dose ristocetin-induced platelet agglutination • *GP1BA* gene sequencing	• Supportive care • Platelet transfusion • Antifibrinolytics • rFVIIa
DEFECTS OF PLATELET AGGREGATION			
Glanzmann thrombasthenia (GT)	Autosomal recessive: *ITGA2B* (17Q21.32) *ITGB3* (17q21.32)	• Often severe bleeding phenotype • Normal platelet count and morphology • Platelet aggregation: absent response to all agonists except ristocetin • Flow cytometry: absent or reduced CD41 and CD61	• Supportive care • rFVIIa (considered the first line) • Platelet transfusion (risk of HPA alloantibodies) • Antifibrinolytics
DEFECTS IN AGONISTS RECEPTORS			
Thromboxane-prostanoid (TP) receptor defects	Autosomal recessive *TBXA2R* (19p13.3)	• Mild bleeding phenotype • Platelet aggregation: abnormal response to arachidonic acid and U46619 • *TBXA2R* gene sequencing	• Supportive care
ADP receptor defects P2Y12	Autosomal recessive *P2RY12* (3q23–25)	• Mild bleeding phenotype • Platelet aggregation: abnormal response to ADP • *P2RY12* gene sequencing	• Supportive care
Collagen receptor defects GPVI	Autosomal recessive *GP6* (19q13.4)	• Mild bleeding phenotype • Platelet aggregation: abnormal response to collagen • *GP6* gene sequencing	• Supportive care
PLATELET GRANULES DEFECTS (α-GRANULES)			
Gray platelet syndrome (GPS)	Autosomal recessive *NBEAL2* (3p21)	• Progressive myelofibrosis • Thrombocytopenia • Large pale platelets on blood smears • Absent α-granules on TEM • *NBEAL2* gene sequencing	• Supportive care • Antifibrinolytics • DDVAP • Platelet transfusion • Splenectomy
Arthrogryposis, renal dysfunction, and cholestasis syndrome (ARC syndrome)	Autosomal dominant *VPS33B* (15q26) *VIPAS39* (14q24)	• Thrombocytopenia • Large pale platelets on blood smears • Absent α-granules on TEM • Lethal early in life • *VPS33B* & *VIPAS39* sequencing	• Supportive care • Platelet transfusion • Antifibrinolytics

Continued

Table 533.2 Inherited Platelet Disorders—cont'd

PLATELET DEFECT	GENE DEFECT (CHROMOSOMAL LOCATION)	CLINICAL AND LABORATORY CHARACTERISTICS	BLEEDING TREATMENT
Quebec platelet disorder (QPD)	Autosomal recessive Tandem duplication of *PLAU* (10q22.2)	• Delayed-onset bleeding not responding to platelet transfusion • Variable thrombocytopenia • Abnormal urokinase in platelets detected with immunoblot or ELISA • *PLAU* duplication testing	• Supportive care • Antifibrinolytics
Paris-Trousseau/Jacobsen syndrome (PTS)	Autosomal dominant Deletion of chromosome 11q23–24 Hemizygous deletion of *FLI1* (11q24.1 – q24.3)	• Thrombocytopenia • Large platelets • Giant α-granules on TEM • Immature megakaryocytes in the bone marrow • Cognitive, cardiac, and facial abnormalities	• Supportive care • Antifibrinolytics • Platelet transfusion
PLATELET GRANULES DEFECTS (δ-GRANULES)			
Hermansky-Pudlak syndrome (HPS)	Autosomal recessive HPS1–10 (*HPS1, AP3B1, HPS3, HPS4, HPS5, HPS6, DTNBP1, BLOC1S3, BLOC1S6,* and *AP3D1*)	• Decreased to absent δ-granules • Lumiaggregometry: decreased/absent ATP release • Whole-mount EM • Gene sequencing of 10 candidate genes • Oculocutaneous albinism	• Supportive care • Antifibrinolytics • Platelet transfusion • DDAVP
Chediak-Higashi syndrome (CHS)	Autosomal recessive *LYST* (1q42 – 1q42.2)	• Giant eosinophilic inclusions in neutrophils • Decreased to absent δ-granules • Lumiaggregometry: decreased/absent ATP release • Hypopigmentation and immunodeficiency	• Supportive care
PLATELET CYTOSKELETAL DEFECTS			
Wiskott-Aldrich syndrome (WAS) / X-linked thrombocytopenia	X-linked *WAS* (Xp11.23 – p11.22) encoding WAS protein	• Thrombocytopenia • Small platelets • Recurrent infections and eczema • Decreased/absent intracellular • WASp per immunoblot/ELISA • *WAS* gene sequencing	• Supportive care • Platelet transfusion • Antifibrinolytics • Splenectomy (not recommended)
ARPC1B deficiency	Autosomal recessive *ARPC1B* (7q22.1)	• Small platelets • Inflammatory disease, recurrent infections, small vessel vasculitis, abnormal platelet function • Decreased/absent intracellular • ARPC1B per immunoblot • *ARPC1B* gene sequencing	• Supportive care • Antifibrinolytics • Platelet transfusion
MYH9-related disease (MYH9-RD)	Autosomal dominant *MYH9* (22q12–13) encoding nonmuscle myosin heavy chain IIA	• Thrombocytopenia • Large platelets • Döhle-like inclusions in neutrophils • Myosin IIA aggregates in neutrophils - immunofluorescence microscopy • Variable degree of renal disease, sensorineural hearing loss, presenile cataract	• Supportive care • Platelet transfusion • Antifibrinolytics • THPO receptor agonists

VWF, Von Willebrand factor; HPA, human platelet antigen; ADP, adenosine diphosphate; TEM, transmission electron microscopy; EM, electron microscopy; ELISA, enzyme-linked immunosorbent assay; DDAVP, desmopressin; THPO, thrombopoietin.
Modified from Al-Huniti A, Kahr WHA. Inherited platelet disorders: diagnosis and management. *Transfu Med Rev* 2020;34:277–285. Table 1.

syndrome. An antinuclear antibody should be considered in adolescents, especially with other features of SLE (see Chapter 199).

DIAGNOSIS AND DIFFERENTIAL DIAGNOSIS

The well-appearing child with moderate to severe thrombocytopenia, an otherwise normal complete blood cell count (CBC), and normal exam findings has a limited differential diagnosis that includes exposure to medication inducing drug-dependent antibodies, splenic sequestration because of previously unappreciated portal hypertension, and, rarely, early aplastic processes, such as Fanconi anemia (see Chapter 517). Other than congenital thrombocytopenia syndromes (see Chapter 533.8), such as thrombocytopenia–absent radius (TAR) syndrome and MYH9-related thrombocytopenia, most marrow processes that interfere with platelet production eventually cause abnormal synthesis of red blood cells (RBCs) and WBCs and therefore manifest diverse abnormalities on the CBC. Disorders that cause increased platelet destruction on a nonimmune basis are usually serious systemic illnesses with obvious clinical findings such as **hemolytic-uremic syndrome** (HUS) and **disseminated intravascular**

Table 533.3 Classification of Fetal and Neonatal Thrombocytopenias*

Fetal	**Alloimmune thrombocytopenia**
	Congenital infection (CMV, toxoplasma, rubella, HIV, syphilis)
	Aneuploidy (trisomy 18, 13, or 21, triploidy, Turner syndrome)
	Autoimmune condition (maternal ITP, SLE)
	Severe Rh hemolytic disease
	Congenital/inherited (Wiskott-Aldrich, Noonan, Cornelia deLange, Jacobsen syndromes)
Early-onset neonatal (<72 hr)	**Placental insufficiency** (PET, IUGR, diabetes)
	Perinatal asphyxia
	Perinatal infection (*Escherichia coli*, GBS, herpes simplex)
	DIC
	Alloimmune thrombocytopenia
	Autoimmune condition (maternal ITP, SLE)
	Congenital infection (CMV, toxoplasma, rubella, HIV)
	Thrombosis (aortic, renal vein)
	Bone marrow disease (congenital leukemia, HLH)
	Kasabach-Merritt syndrome
	Metabolic disease (propionic and methylmalonic acidemia)
	Congenital/inherited (TAR, CAMT)
Late-onset neonatal (>72 hr)	**Late-onset sepsis**
	NEC
	Congenital infection (CMV, toxoplasma, rubella, HIV)
	Autoimmune
	Kasabach-Merritt syndrome
	Metabolic disease (propionic and methylmalonic acidemia)
	Congenital/inherited (TAR, CAMT)

*The most common conditions are shown in **bold**.
CAMT, Congenital amegakaryocytic thrombocytopenia; CMV, cytomegalovirus; DIC, disseminated intravascular coagulation; GBS, group B streptococcus; HIV, human immunodeficiency virus; HLH, hemophagocytic lymphohistiocytosis; ITP, immune thrombocytopenic purpura; IUGR, intrauterine growth restriction; NEC, necrotizing enterocolitis; PET, preeclampsia; SLE, systemic lupus erythematosus; TAR, thrombocytopenia with absent radii.
From Roberts I, Murray NA. Neonatal thrombocytopenia: causes and management. *Arch Dis Child Fetal Neonatal Ed* 2003;88:F359–F364.

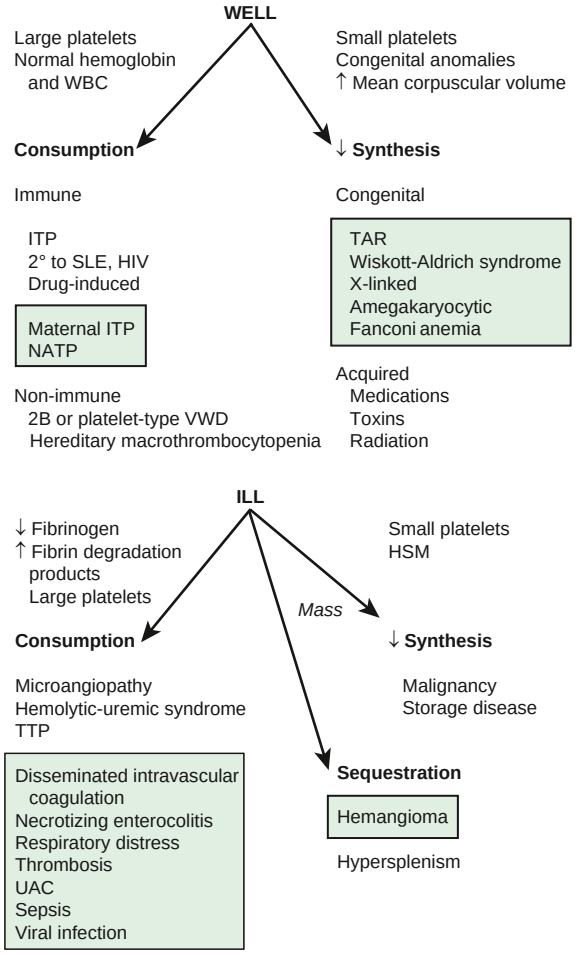

Fig. 533.2 Differential diagnostic algorithm of childhood thrombocytopenic syndromes. The syndromes initially are separated by their clinical appearance. Clues leading to the diagnosis are shown in *italics*. The mechanisms and common disorders leading to these findings are shown in the *lower part* of the figure. Disorders that commonly affect neonates are listed in the *shaded boxes*. HSM, Hepatosplenomegaly; ITP, immune thrombocytopenia; NATP, neonatal alloimmune thrombocytopenic purpura; SLE, systemic lupus erythematosus; TAR, thrombocytopenia–absent radius; TTP, thrombotic thrombocytopenic purpura; UAC, umbilical artery catheter; VWD, von Willebrand disease; WBC, white blood cell. *(From Scott JP. Bleeding and thrombosis. In Kliegman RM, ed. Practical Strategies in Pediatric Diagnosis and Therapy. Philadelphia: Saunders, 1996. p. 849; and Kliegman RM, Marcdante KJ, Jenson HB, et al., eds. Nelson Essentials of Pediatrics, 5th ed. Philadelphia: Saunders, 2006. p. 716.)*

coagulation (DIC) (see Fig. 533.2, and Table 532.1 in Chapter 532). Patients receiving heparin may develop heparin-induced thrombocytopenia. Isolated enlargement of the spleen suggests the potential for hypersplenism caused by liver disease or portal vein thrombosis. Autoimmune thrombocytopenia may be an initial manifestation of SLE, HIV infection, common variable immunodeficiency, and, rarely, lymphoma or autoimmune lymphoproliferative syndrome. Wiskott-Aldrich syndrome (WAS) must be considered in young males found to have thrombocytopenia with *small* platelets, particularly if there is a history of eczema and recurrent infection (see Chapter 165.2). Bernard-Soulier syndrome, on the other hand, involves a macrothrombocytopenia. Gray platelet syndrome is usually associated with splenomegaly and pale-colored platelets on peripheral smear.

TREATMENT

A number of treatment options exist (Table 533.4), but there are no current high-quality data showing that treatment affects either short- or long-term clinical outcome of ITP in children. Many patients with new-onset ITP have mild symptoms, with findings limited to petechiae and purpura on the skin, despite severe thrombocytopenia. Compared with untreated controls, treatment appears to be capable of inducing a more rapid rise in platelet count to the presumed safe level of >20 $\times 10^9$/L, although no data indicate that early therapy prevents ICH.

Antiplatelet antibodies bind to transfused platelets as well as they do to autologous platelets. Thus platelet transfusion in ITP is usually contraindicated unless life-threatening bleeding is present. Management guidelines for ITP in children and adults reinforce existing emphasis on prioritizing watchful waiting for spontaneous resolution or outpatient therapy in the uncommon cases for which treatment is needed. Initial approaches to the management of pediatric ITP include the following:

1. No therapy other than education and counseling of the family and patient for patients with minimal, mild, and moderate symptoms, as defined earlier. This approach emphasizes the usually benign nature of ITP and avoids the therapeutic roller coaster that ensues once interventional therapy is begun. This approach is much less costly, and side effects are minimal. Observation is recommended for children with no bleeding or *only* mild bleeding symptoms such as bruising or petechiae.
2. Treatment with either intravenous immunoglobulin (IVIG) or corticosteroids, particularly for children who present with *mucocutaneous* bleeding. IVIG at a dose of 0.8-1.0 g/kg/day for 1-2 days induces a rapid rise in platelet count (usually >20 × 10^9/L) in 95% of patients within 48 hours. IVIG appears to induce a response by downregulating Fc-mediated phagocytosis of antibody-coated platelets. IVIG therapy is both expensive and time-consuming and typically requires inpatient admission. Additionally, after infusion, there is a risk of headaches and vomiting, suggestive of IVIG-induced aseptic meningitis.
3. Corticosteroid therapy has been used for many years to treat acute and chronic ITP in adults and children. Doses of prednisone at 1-4 mg/kg/day appear to induce a more rapid rise in platelet count than in untreated patients with ITP. Corticosteroid therapy is usually continued for a short course (approximately 5 days) until a rise in platelet count to >20 × 10^9/L has been achieved to avoid the long-term side effects of corticosteroid therapy, especially growth failure, diabetes mellitus, and osteoporosis.

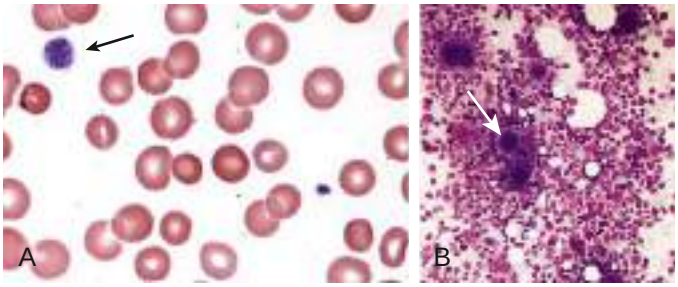

Fig. 533.3 Blood and marrow aspirate from child with immune thrombocytopenia. **A,** Blood smear shows large platelets. **B,** Bone marrow aspirate shows increased numbers of megakaryocytes, many of which appear immature. *(From Blanchette V, Bolton-Maggs P: Childhood immune thrombocytopenic purpura: diagnosis and management. Pediatr Clin North Am 2008;55:393–420. Fig 4.)*

Each of these medications may also be used to treat subsequent ITP exacerbations/recurrences, which usually occur several weeks after an initial course of therapy in 5–10% of patients. In the special case of ICH, multiple modalities should be used, including platelet transfusion (although not recommended in other bleeding manifestations), IVIG, high-dose corticosteroids, and prompt consultation by neurosurgery and general surgery (splenectomy).

Patients who are bleeding significantly (<5% of children with ITP) should be treated. ICH remains rare, and there are no data showing that treatment actually reduces its incidence. *Mucosal bleeding* in particular is the most significant in terms of predicting severe bleeding, but specific predictive indices, such as positive or negative predictive values, are not currently well established.

The role of **splenectomy** in ITP should be reserved for one of two circumstances: (1) the older child (≥4 years) with severe ITP that has lasted >1 year **(chronic ITP)** and whose symptoms are not easily controlled with therapy and/or (2) when life-threatening hemorrhage (e.g., ICH) complicates acute ITP if the platelet count cannot be corrected rapidly with transfusion of platelets and administration of IVIG and corticosteroids. Splenectomy is associated with a lifelong risk of overwhelming postsplenectomy infection caused by encapsulated organisms, increased risk of thrombosis, and the potential development of pulmonary hypertension in adulthood. As an alternative to splenectomy**, rituximab** has been used in children to treat chronic ITP. In 30–40% of children, rituximab has induced a partial or complete remission. TPO receptor agonists have also been used to increase platelet count and are approved for pediatric use.

CHRONIC AUTOIMMUNE THROMBOCYTOPENIC PURPURA

Approximately 20% of patients who present with acute ITP have persistent thrombocytopenia for >12 months and are said to have *chronic* ITP. At that time, a careful reevaluation for associated disorders should be performed, especially for autoimmune disease (e.g., SLE), chronic infectious disorders (e.g., HIV), and nonimmune causes of chronic thrombocytopenia, such as type 2B and platelet-type von Willebrand disease (VWD), X-linked thrombocytopenia, autoimmune lymphoproliferative syndrome, common variable immunodeficiency syndrome, autosomal macrothrombocytopenia, and WAS. The presence of coexisting *H. pylori* and hepatitis C infection should be considered and, if found, treated. Therapy should be aimed at controlling symptoms and

Table 533.4 Treatment Options for Immune Thrombocytopenia (ITP)

	PROS	CONS	COST
Observation	Does not expose patient to unnecessary medications	May increase parent and physician anxiety	Relatively inexpensive
IVIG	Rapid response in most cases	IV administration, side effects	Expensive
Corticosteroids	Oral, effective in 70–80% of patients, minimal side effects with short courses	Side effects, may not affect long term outcome	Inexpensive
Rituximab	Long-term remission in 40–60% of patients	IV administration, immune suppression, potential for reactivation of hepatitis	Very expensive
Splenectomy	Curative in 80% of patients	Requires surgery and anesthesia, lifelong risk of infection	Expensive
Thrombopoietin receptor agonists	Potential for oral administration, 40–60% of patients respond	Not curative, usually required long term, can cause elevated liver enzymes	Very expensive

IV, Intravenous; IVIG, intravenous immunoglobulin.
Adapted from Flood VH, Scott JP. Bleeding and thrombosis. In: Kliegman R, Lye P, Bordini B, et al. eds. *Nelson Pediatric Symptom-Based Diagnosis.* Philadelphia: Elsevier, 2017.

preventing serious bleeding. In ITP, the spleen is the primary site of both antiplatelet antibody synthesis and platelet destruction. Splenectomy is successful in inducing complete remission in 64–88% of children with chronic ITP. This effect must be balanced against the lifelong risk of overwhelming postsplenectomy infection and/or thrombosis. This decision is often affected by quality-of-life issues, as well as the ease with which the child can be managed using medical therapy, such as IVIG, corticosteroids, IV anti-D, or rituximab. Two effective agents that act to stimulate thrombopoiesis, **romiplostim** and **eltrombopag** (see Fig. 533.1), are approved to treat adults and children with chronic ITP. Although these do not address the mechanism of action of ITP, the increase in platelet count may be enough to compensate for the increased destruction and allow the patient to have resolution of bleeding and maintain a platelet count >50 × 10^9/L.

Visit Elsevier eBooks+ at eBooks.Health.Elsevier.com for Bibliography.

533.2 Drug-Induced Thrombocytopenia

Brian R. Branchford and Veronica H. Flood

A number of drugs are associated with immune thrombocytopenia as the result of either an immune process or megakaryocyte injury. Some common drugs used in pediatrics that cause thrombocytopenia include valproic acid, phenytoin, carbamazepine, sulfonamides, vancomycin, and trimethoprim-sulfamethoxazole. Most of these drugs may affect platelet function as well as the count itself. Heparin-induced thrombocytopenia (and rarely an associated thrombosis) is seldom seen in pediatrics, but it occurs when, after exposure to heparin, the patient has an antibody directed against the heparin–platelet factor 4 complex. Recommended treatment for heparin-induced thrombocytopenia includes direct thrombin inhibitors such as argatroban or bivalirudin and removal of all sources of heparin, including central venous catheter line flushes.

Visit Elsevier eBooks+ at eBooks.Health.Elsevier.com for Bibliography.

533.3 Nonimmune Platelet Destruction

Brian R. Branchford and Veronica H. Flood

The syndromes of DIC (see Chapter 532), HUS (see Chapter 560.5), and thrombotic thrombocytopenic purpura (see Chapter 533.5) share the hematologic picture of a thrombotic microangiopathy in which there exists RBC destruction and consumptive thrombocytopenia caused by platelet and fibrin deposition in the microvasculature. The microangiopathic hemolytic anemia is characterized by the presence of RBC fragments, including helmet cells, schistocytes, spherocytes, and burr cells.

533.4 Hemolytic-Uremic Syndrome

See Chapter 560.5.

533.5 Thrombotic Thrombocytopenic Purpura

Brian R. Branchford and Veronica H. Flood

Thrombotic thrombocytopenic purpura (TTP) is a rare thrombotic microangiopathy characterized by the pentad of fever, microangiopathic hemolytic anemia, thrombocytopenia, abnormal renal function, and central nervous system (CNS) changes; TTP is clinically similar to HUS (Table 533.5). Although TTP can be congenital, the acquired form is more common and usually presents in adults and occasionally in adolescents. Microvascular thrombi within the CNS cause subtle, shifting neurologic signs that vary from changes in affect and orientation to aphasia, blindness, and seizures. Initial manifestations are often nonspecific (weakness, pain, emesis), and prompt recognition of this disorder is critical. Laboratory findings provide important clues to the diagnosis and show microangiopathic hemolytic anemia characterized by morphologically abnormal RBCs, with schistocytes, spherocytes, helmet cells, and an elevated reticulocyte count in association with thrombocytopenia. Coagulation studies are usually nondiagnostic. Blood urea nitrogen and creatinine are sometimes elevated. The **treatment** of acquired TTP is plasmapheresis (plasma exchange), which is effective in 80–95% of patients. Treatment with plasmapheresis should be instituted on the basis of thrombocytopenia and microangiopathic hemolytic anemia even if other symptoms are not yet present because of the high mortality (80–90%) in patients without timely intervention. Rituximab, corticosteroids, and splenectomy are reserved for refractory cases. *Caplacizumab,* an anti-VWF humanized immunoglobulin, blocks the interaction of ultralarge (i.e., most likely to bind platelets) VWF multimers with platelets, and many result in rapid resolution of acute TTP.

The majority of cases of TTP are acquired, caused by an autoantibody-mediated **deficiency of ADAMTS13** (a disintegrin and metalloproteinase with a thrombospondin type 1 motif member 13) that is responsible for cleaving the high-molecular-weight multimers of VWF and appears to play a pivotal role in the evolution of the thrombotic microangiopathy (Fig. 533.4) that results in a preponderance of ultralarge multimers that more adeptly bind platelets, triggering the microangiopathy. In contrast, levels of ADAMTS13 in HUS are usually normal.

Congenital ADAMTS13 deficiency causes rare familial cases of TTP/HUS, usually manifested as recurrent episodes of thrombocytopenia, hemolytic anemia, jaundice, and renal involvement, with or without neurologic changes, that often present in infancy in the context of an intercurrent illness. Treatment of hereditary TTP with recombinant ADAMTS13 has been successful when patients are refractory to fresh frozen plasma therapy. Abnormalities of the complement system have now also been implicated in rare cases of familial TTP. ADAMTS13 deficiency can be treated by repeated infusions of fresh-frozen plasma.

Visit Elsevier eBooks+ at eBooks.Health.Elsevier.com for Bibliography.

533.6 Kasabach-Merritt Syndrome

Brian R. Branchford and Veronica H. Flood

See also Chapter 691.

The association of a giant hemangioma with localized intravascular coagulation causing consumptive thrombocytopenia and hypofibrinogenemia is called Kasabach-Merritt syndrome. In most patients, the site of the hemangioma is obvious, but retroperitoneal and intra-abdominal hemangiomas may require body imaging for detection. Platelet trapping and activation of coagulation occurs inside the hemangioma, with fibrinogen consumption and generation of fibrin(ogen) degradation products. Arteriovenous malformation within the lesions can cause heart failure. Pathologically, Kasabach-Merritt syndrome appears to develop more often as a result of a kaposiform hemangioendothelioma or tufted hemangioma rather than a simple hemangioma. The peripheral blood smear shows microangiopathic changes.

Multiple modalities have been used to treat Kasabach-Merritt syndrome, including propranolol, surgical excision (if possible), laser photocoagulation, high-dose corticosteroids, local radiation therapy, antiangiogenic agents such as interferon-α_2, and vincristine. Over time, most patients who present in infancy have regression of the hemangioma. Treatment of the associated coagulopathy may benefit from a trial of antifibrinolytic therapy with ε-aminocaproic acid (Amicar) or anticoagulation with low molecular weight heparin.

Visit Elsevier eBooks+ at eBooks.Health.Elsevier.com for Bibliography.

Table 533.5 ADAMTS13 Deficiency and Thrombotic Thrombocytopenic Purpura

DISEASE	PATHOPHYSIOLOGY	LAB FINDINGS	MANAGEMENT
Thrombotic thrombocytopenic purpura (TTP)	*Acquired*: Ab to ADAMTS13 *Congenital*: Inadequate ADAMTS13 production	Ab to ADAMTS13 ADAMTS13 <10%	*Acquired*: Plasmapheresis with plasma *Congenital*: Scheduled plasma infusions

Autoimmune TTP may be transient, recurrent, drug (ticlopidine, clopidogrel) associated, or seen in some pregnancy-associated cases of TTP.
ADAMTS13 pathogenic variants are often familial and chronic-relapsing RRP.

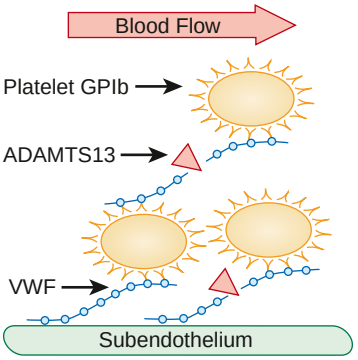

Fig. 533.4 Pathogenesis of thrombotic thrombocytopenic purpura (TTP). The von Willebrand factor (VWF) multimers facilitate platelet adhesion to the subendothelium by binding to exposed connective tissue and then to platelet glycoprotein Ib (GPIb). In flowing blood shear stress unfolds ultralarge VWF multimers in the platelet-rich thrombus and enables ADAMTS13 to cleave a specific Tyr-Met bond in the second of the three A domains in VWF subunits. Cleavage reduces VWF multimer size and limits thrombus growth. In the absence of ADAMTS13, VWF-dependent platelet accumulation continues and eventually results in microvascular thrombosis and TTP. *(Courtesy Dr. J. Evan Sadler, Washington University.)*

533.7 Sequestration

Brian R. Branchford and Veronica H. Flood

Thrombocytopenia develops in individuals with massive splenomegaly, such as those with portal vein thrombosis or liver disease, because the spleen acts as a reservoir for platelets and may sequester a large number of them. Most such patients also have mild leukopenia and anemia on CBC. Individuals who have thrombocytopenia caused by splenic sequestration should undergo a workup to diagnose the etiology of splenomegaly, including infectious, inflammatory, infiltrative, neoplastic, obstructive, and hemolytic causes.

533.8 Congenital Thrombocytopenic Syndromes

Brian R. Branchford and Veronica H. Flood

See Table 533.2.

Congenital amegakaryocytic thrombocytopenia (CAMT) usually manifests within the first few days to week of life, when the child presents with petechiae and purpura caused by profound thrombocytopenia. CAMT is caused by a rare defect in hematopoiesis as a result of pathogenic variants in the *MPL* gene that encodes the stem cell TPO receptor. Other than skin and mucous membrane abnormalities, findings on physical examination are normal. Examination of the bone marrow shows an absence of megakaryocytes. These patients often progress to marrow failure (aplasia). Hematopoietic stem cell transplantation (HSCT) is curative.

Thrombocytopenia–absent radius (TAR) syndrome consists of thrombocytopenia (absence or hypoplasia of megakaryocytes) that presents in early infancy with bilateral radial anomalies of variable severity, ranging from mild changes to marked limb shortening (Fig. 533.5). Many such individuals also have other skeletal abnormalities of the ulna, radius, and lower extremities. *Present thumbs help to differentiate this disorder from Fanconi anemia*. Intolerance to cow's milk formula (present in 50%) may complicate management by triggering gastrointestinal (GI) bleeding, increased thrombocytopenia, eosinophilia, and a leukemoid reaction. The thrombocytopenia of TAR syndrome frequently remits over the first few years of life. The molecular basis of TAR syndrome is linked to *RBM8A*. A few patients have been reported to have a syndrome of **amegakaryocytic thrombocytopenia with radioulnar synostosis** caused by a pathogenic variant in the *HOXA11* gene. In contrast to TAR syndrome, this clinical disorder presents with marrow aplasia.

WAS is characterized by microthrombocytopenia, with tiny platelets, eczema, and recurrent infection as a consequence of immune deficiency (see Chapter 165.2). WAS is inherited as an X-linked disorder, and the gene implicated in WAS has been identified. The WAS protein appears to play an integral role in regulating the cytoskeletal architecture of both platelets and T lymphocytes in response to receptor-mediated cell signaling. The WAS protein is common to all cells of hematopoietic lineage. Molecular analysis of families with X-linked thrombocytopenia has shown that many affected members have a single nucleotide pathogenic variant within the WAS gene, whereas individuals with the full manifestation of WAS have large gene deletions. Examination of the bone marrow in WAS shows the normal number of megakaryocytes, although they may have bizarre morphologic features. Transfused platelets have a normal life span in these patients. Splenectomy often corrects the thrombocytopenia, suggesting that the platelets formed in WAS have accelerated destruction. After splenectomy, these patients are at increased risk for overwhelming infection and require lifelong antibiotic prophylaxis against encapsulated organisms. Approximately 5–15% of patients with WAS develop lymphoreticular malignancies (involving mostly leukemias and lymphomas). Successful HSCT from an unaffected donor cures WAS. **X-linked macrothrombocytopenia** and **dyserythropoiesis** have been linked to pathogenic variants in *GATA1*, which encodes an erythroid and megakaryocytic transcription factor.

MYH9-related thrombocytopenias include a number of diverse hereditary thrombocytopenia syndromes (e.g., Sebastian, Epstein, May-Hegglin, Fechtner) characterized by autosomal dominant macrothrombocytopenia, neutrophil inclusion bodies, and a variety of physical anomalies, including sensorineural deafness, renal disease, and eye disease. These have all been shown to be caused by different pathogenic variants in the *MYH9* gene (nonmuscle myosin-IIa heavy chain 9). The thrombocytopenia is usually mild and not progressive. Some other individuals with recessively inherited macrothrombocytopenia have abnormalities in chromosome 22q11. Pathogenic variants in the gene for glycoprotein Ibβ, an essential component of the platelet VWF receptor, can result in **Bernard-Soulier syndrome** (see Chapter 533.13), a macrothrombocytopenic disease. A diagnostic approach to genetic platelet disorders is noted in Figure 533.6.

Visit Elsevier eBooks+ at eBooks.Health.Elsevier.com for Bibliography.

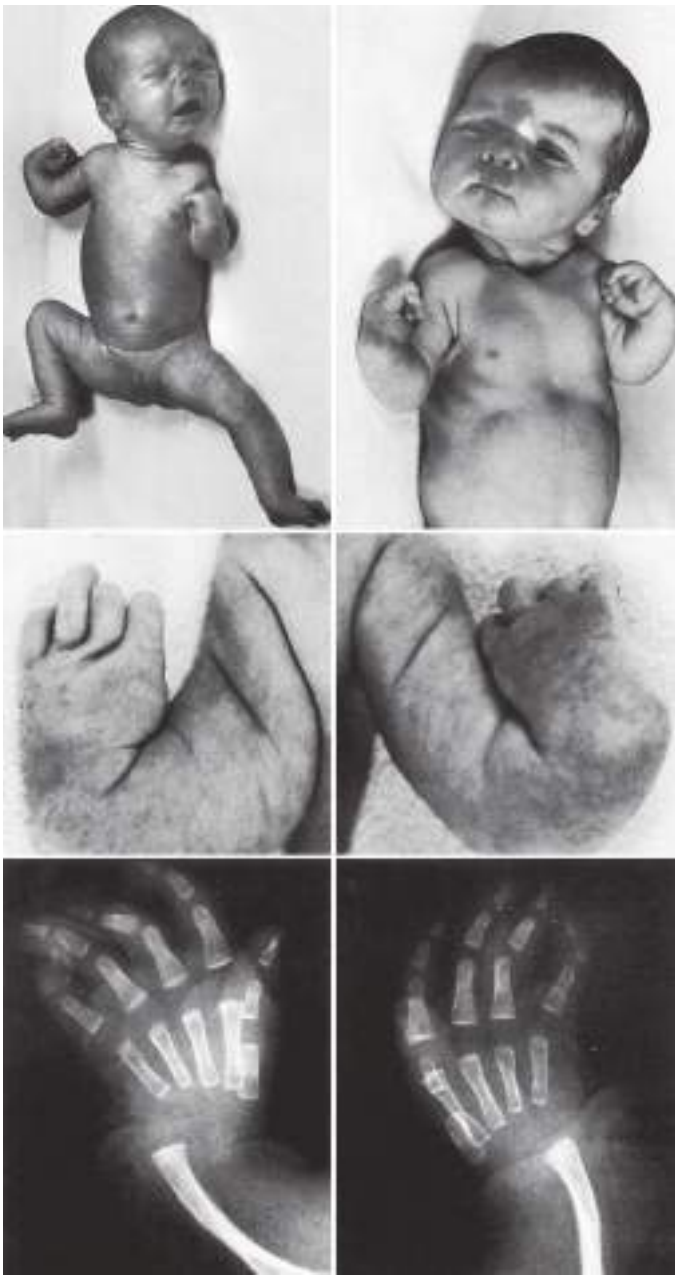

Fig. 533.5 A newborn, the first child of young, healthy parents, with fully expressed thrombocytopenia–absent radius (TAR) syndrome, including hypereosinophilia and anemia. Hypoplasia of the distal humeri and the shoulder girdles, bilateral hip dysplasia, mild talipes calcaneus, and clinodactyly of both little fingers are seen. This patient had a pronounced allergy to cow's milk, with exposure followed by diarrhea, vomiting, and decreased weight and platelet count, making a cow's milk–free diet mandatory. A persistent depressed nasal bridge and development of pronounced bowed legs are seen. *(From Wiedemann H-R, Kunze J, Grosse F-R, eds. Clinical Syndromes, 3rd ed. [English translation]. London: Mosby-Wolfe, 1997. p. 430.)*

533.9 Neonatal Thrombocytopenia

Brian R. Branchford and Veronica H. Flood

Thrombocytopenia in the newborn rarely is indicative of a primary disorder of megakaryopoiesis. It is usually the result of systemic illness or transfer of maternal antibodies directed against fetal platelets (see Table 533.3). Neonatal thrombocytopenia often occurs in association with congenital viral infections, especially rubella, cytomegalovirus, protozoal infection (e.g., toxoplasmosis), and syphilis, and perinatal bacterial infections, especially those caused by gram-negative bacilli. Thrombocytopenia associated with DIC may be responsible for severe spontaneous bleeding. The constellation of marked thrombocytopenia and abnormal abdominal findings is common in necrotizing enterocolitis and other causes of necrotic bowel. Thrombocytopenia in an ill child requires a prompt search for viral and bacterial pathogens.

Antibody-mediated thrombocytopenia in the newborn occurs because of transplacental transfer of maternal antibodies directed against fetal platelets. **Neonatal alloimmune thrombocytopenia (NAIT)** is caused by the development of maternal antibodies against paternally inherited antigens present on fetal platelets that are recognized as foreign by the maternal immune system. The incidence of NATP is 1/4,000-5,000 live births. The clinical manifestations of NAIT are those of an apparently well child who, within the first few days after delivery, has generalized petechiae and purpura. Laboratory studies show a normal maternal platelet count but moderate to severe thrombocytopenia in the newborn. Detailed review of the history should show no evidence of maternal thrombocytopenia. Up to 30% of infants with severe NAIT may have ICH, either prenatally or in the perinatal period. Unlike Rh disease, first pregnancies may be severely affected. Subsequent pregnancies are often more severely affected than the first.

The **diagnosis** of NAIT is made by checking for the presence of maternal alloantibodies directed against the father's platelets. Specific studies can be done to identify the target alloantigen. The most common cause is incompatibility for the platelet alloantigen HPA-1a. Specific DNA sequence polymorphisms have been identified that permit informative prenatal testing to identify at-risk pregnancies. The differential diagnosis of NAIT includes transplacental transfer of maternal IgG antiplatelet autoantibodies (maternal ITP), and, more commonly, viral or bacterial infection.

Treatment of NAIT requires the administration of IVIG prenatally to the mother if the status is known before birth. Therapy usually begins in the second trimester and is continued throughout the pregnancy. Fetal platelet count can be monitored by percutaneous umbilical blood sampling. Delivery should be performed by cesarean section to reduce risk for ICH from vaginal delivery. After delivery, if severe thrombocytopenia persists, transfusion of platelets that share the maternal alloantigens (e.g., washed maternal platelets) will cause a rise in platelet counts to provide effective hemostasis. However, a random donor platelet transfusion is more likely to be readily available. Some centers have units available that may lack the antigens most often involved. After there has been one affected child, genetic counseling is critical to inform the parents of the high risk of thrombocytopenia in subsequent pregnancies.

Children born to mothers with immune thrombocytopenic purpura **(maternal ITP)** appear to have a lower risk of serious hemorrhage than infants born with NAIT, although severe thrombocytopenia may occur. The mother's preexisting platelet count may have some predictive value in that severe maternal thrombocytopenia before delivery appears to predict a higher risk of fetal thrombocytopenia. In mothers who have had splenectomy for ITP, the maternal platelet count may be normal and is not predictive of fetal thrombocytopenia.

Treatment includes prenatal administration of corticosteroids to the mother and IVIG and sometimes corticosteroids to the infant after delivery. Thrombocytopenia in an infant, whether a result of NAIT or maternal ITP, usually resolves within 2-4 months after delivery. The period of highest risk is the immediate perinatal period.

Two syndromes of congenital failure of platelet production often present in the newborn period. In **CAMT** the newborn manifests petechiae and purpura shortly after birth. Findings on physical examination are otherwise normal. Megakaryocytes are absent from the bone marrow. This syndrome is caused by a pathogenic variant in the megakaryocyte TPO receptor that is essential for development of all hematopoietic cell lines. Pancytopenia eventually develops, and HSCT is curative. **TAR syndrome** consists of thrombocytopenia that presents in early infancy, with bilateral radial anomalies of variable severity, ranging from mild changes to marked limb shortening. It frequently remits over the first few years of life (see Chapter 533.8 and Fig. 533.5).

Visit Elsevier eBooks+ at eBooks.Health.Elsevier.com for Bibliography.

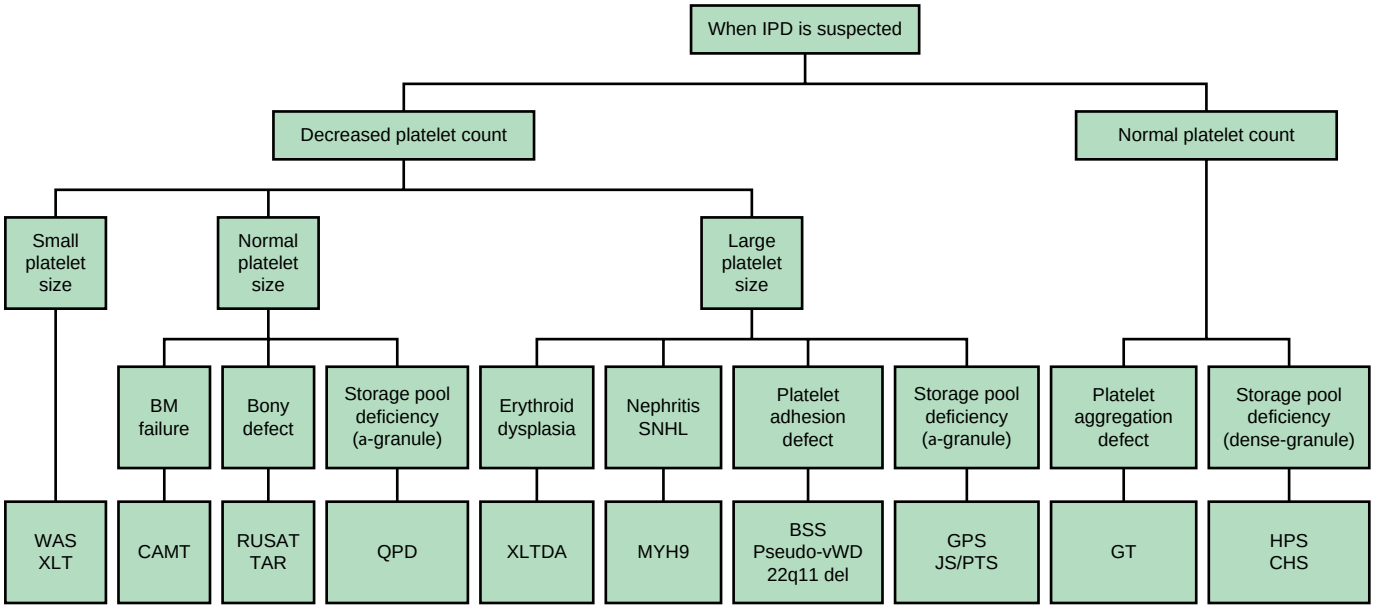

Fig. 533.6 Diagnostic algorithm for sequence and flow in inherited platelet disorders (IPDs). BM, bone marrow; WAS, Wiskott-Aldrich syndrome; XLT, X-linked thrombocytopenia; CAMT, congenital amegakaryocytic thrombocytopenia; RUSAT, radioulnar synostosis with amegakaryocytic thrombocytopenia; TAR, thrombocytopenia-absent radius; QPD, Quebec platelet disorder; XLTDA, X-linked thrombocytopenia with or without dyserythropoietic anemia; MYH9, MYH9-related disorders; BSS, Bernard-Soulier syndrome; vWD, von Willebrand disease; 22q11 del, 22q11 deletion syndrome; GPS, gray platelet syndrome; JS, Jacobsen syndrome; PTS, Paris-Trousseau syndrome; GT, Glanzmann thrombasthenia; HPS, Hermansky-Pudlak syndrome; CHS, Chediak-Higashi syndrome. *(From Shim YJ. Genetic classification and confirmation of inherited platelet disorders: current status in Korea. CEP 2020;63:79–87. Fig. 2.)*

533.10 Thrombocytopenia From Acquired Disorders Causing Decreased Production

Brian R. Branchford and Veronica H. Flood

Disorders of the bone marrow that inhibit megakaryopoiesis usually affect RBC and WBC production. Infiltrative disorders, including malignancies, such as acute lymphocytic leukemia, histiocytosis, lymphomas, and storage disease, usually cause either abnormalities on physical examination (lymphadenopathy, hepatosplenomegaly, or masses), abnormalities of the WBC count, or anemia. Aplastic processes may present as isolated thrombocytopenia, although there are usually clues on the CBC (leukopenia, neutropenia, anemia, or macrocytosis). Children with constitutional aplastic anemia (Fanconi anemia) often (but not always) have abnormalities on examination, including radial and/or thumb anomalies, other skeletal anomalies, short stature, microcephaly, and hyperpigmentation. Bone marrow examination should be performed when thrombocytopenia is associated with abnormalities found on physical examination or on examination of the other blood cell lines.

533.11 Platelet Function Disorders

Brian R. Branchford and Veronica H. Flood

There is no simple and reliable test to screen for abnormal platelet function. Bleeding time and the platelet function analyzer (PFA-100) have been used, but neither has sufficient sensitivity or specificity to rule in or rule out a platelet defect, especially one with mild-moderate phenotypic expression. Bleeding time measures the interaction of platelets with the blood vessel wall and thus is affected by both platelet count and platelet function. The predictive value of bleeding time is problematic because bleeding time is dependent on other factors, including the technician's skill and the patient's cooperation, often a challenge in the infant or young child; it is not recommended in high resource settings. The PFA-100 measures platelet adhesion and aggregation in whole blood at high shear when the blood is exposed to either collagen-epinephrine or collagen-ADP. Results are reported as the closure time in seconds. The use of the PFA-100 as a screening test remains controversial. For patients with a positive history of bleeding suggestive of VWD or platelet dysfunction, specific VWF testing and platelet function studies should be done, irrespective of the results of the bleeding time or PFA-100.

Platelet function in the clinical laboratory is measured using platelet aggregometry. In the aggregometer, agonists, such as collagen, ADP, ristocetin, epinephrine, arachidonic acid, and thrombin (or the thrombin receptor peptide), are added to platelet-rich plasma, and the clumping of platelets over time is measured by an automated machine through either light transmission or electric impedance. At the same time, other instruments measure the release of granular contents, such as ATP, from the platelets after activation. The ability of platelets to aggregate and their metabolic activity can thus be assessed simultaneously. When a patient is being evaluated for possible platelet dysfunction, it is critically important to exclude the presence of other exogenous agents and to study the patient, if possible, off all medications for 2 weeks, especially those with any potential antiplatelet effects. Further evaluation using flow cytometric analysis of surface receptors or molecular and/or genetic testing is often necessary to make a more definitive diagnosis.

Visit Elsevier eBooks+ at eBooks.Health.Elsevier.com for Bibliography.

533.12 Acquired Disorders of Platelet Function

Brian R. Branchford and Veronica H. Flood

A number of systemic illnesses are associated with platelet dysfunction, most frequently liver disease, kidney disease (uremia), and disorders that trigger increased amounts of fibrin degradation products. These disorders frequently cause prolonged bleeding time and are often associated with other abnormalities of the coagulation mechanism. *The most important element of management is to treat the primary illness.* If treatment of the primary process is not feasible, infusions of

desmopressin have been helpful in augmenting hemostasis and correcting bleeding time. In some patients, transfusions of platelets and cryoprecipitate have also been helpful in improving hemostasis.

Many medications alter platelet function. The most common drug in adults that alters platelet function is acetylsalicylic acid *(aspirin)*. Aspirin irreversibly acetylates the enzyme cyclooxygenase, which is critical in the formation of thromboxane A_2. Aspirin usually causes moderate platelet dysfunction that becomes more prominent if there is another abnormality of the hemostatic mechanism. In children, common drugs that reversibly inhibit platelet function include other nonsteroidal anti-inflammatory drugs (NSAIDs), valproic acid, and high-dose penicillin. Specific agents to inhibit platelet function therapeutically include those that block the platelet ADP receptor (clopidogrel) and αIIb-β_3 receptor antagonists, as well as aspirin.

Visit Elsevier eBooks+ at eBooks.Health.Elsevier.com for Bibliography.

533.13 Congenital Abnormalities of Platelet Function

Brian R. Branchford and Veronica H. Flood

Severe platelet function defects usually present with petechiae and purpura shortly after birth, especially after vaginal delivery (see Table 533.2). Defects in the platelet GPIb complex (the VWF receptor) or the αIIb-β_3 complex (the fibrinogen receptor) cause severe congenital platelet dysfunction. Although laboratory tests of platelet function are available, molecular characterization by genetic testing is rapidly progressing for platelet disorders.

Bernard-Soulier syndrome, a severe congenital platelet function disorder, is caused by absence or severe deficiency of the GPIb complex (VWF receptor) on the platelet membrane. This syndrome is characterized by a macrothrombocytopenia, with giant platelets and greatly prolonged bleeding time (>20 min) or PFA-100 closure time. Patients may have significant mucocutaneous and GI bleeding. Platelet aggregation tests classically demonstrate absent ristocetin-induced platelet aggregation but normal aggregation to all other agonists. Ristocetin induces the binding of VWF to platelets and agglutinates platelets. Results of studies of VWF antigen and activity are normal. The GPIb complex interacts with the platelet cytoskeleton; a defect in this interaction is believed to be the cause of the large platelet size. This receptor deficiency can also be detected by flow cytometry. Bernard-Soulier syndrome is inherited as an autosomal recessive disorder. Causative pathogenic variants are usually identified in the genes encoding the GPIb complex of glycoproteins Ibα, Ibβ, V, and IX.

Glanzmann thrombasthenia is a congenital disorder associated with severe platelet dysfunction that yields prolonged bleeding time and a normal platelet count. Platelets have normal size and morphologic features on the peripheral blood smear, and closure times for PFA-100 or bleeding time are extremely abnormal. Aggregation studies classically demonstrate abnormal or absent aggregation with all agonists used except ristocetin because ristocetin agglutinates platelets and does not require a metabolically active platelet. This disorder is caused by deficiency of the platelet fibrinogen receptor αIIb-β_3, the major integrin complex on the platelet surface that undergoes conformational changes by inside-out signaling when platelets are activated. This receptor deficiency can also be detected by flow cytometry. Fibrinogen binds to this complex when the platelet is activated and causes platelets to aggregate. Glanzmann thrombasthenia is caused by pathogenic variants in the genes for αIIb or β_3 and is inherited in an autosomal recessive manner. For both Bernard-Soulier syndrome and Glanzmann thrombasthenia, the **diagnosis** is confirmed by flow cytometry of the patient's platelet glycoproteins. Bleeding in Glanzmann thrombasthenia may be quite severe and is typically mucocutaneous, including epistaxis, gingival, and GI bleeding. There are reports of curative therapy using stem cell transplant.

Hereditary deficiency of platelet storage granules occurs in two well-characterized but rare syndromes that involve deficiency of intracytoplasmic granules. **Dense granule deficiency** is characterized by absence of the granules that contain ADP, ATP, Ca^{2+}, and serotonin. This disorder is diagnosed by the finding that ATP is not released on platelet aggregation studies and ideally is characterized by transmission electron microscopic studies. **Hermansky-Pudlak syndrome** (with nine subtypes) is a dense granule deficiency caused by defects in lysosomal storage. Affected patients present with oculocutaneous albinism and hemorrhage caused by the platelet defect; some patients also develop granulomatous colitis resembling

Table 533.6 Comparison of Nine Types of Hermansky-Pudlak Syndrome

	1	2	3	4	5	6	7	8	9
Oculocutaneous albinism	Variable, mild-moderate: brown to white hair	Severe: lack of hair and iris pigment	Mild-moderate: light skin pigment	Severe: blonde hair, gray iris	Variable: light-brown hair, brown iris	Variable: iris heterochromia	Variable	Variable: tan skin, silver hair, brown iris	Pale skin, silver-blonde hair, pale-blue iris
Platelet defect/bruising	+	+	+	+	+	+	+	+	+
Granulomatous colitis	+	–	–	+	–	+	+	–	–
Pulmonary fibrosis/ILD	+	+	–	+	–	–	–	–	–
Other symptoms		Neutropenia Failure to thrive Hypothyroidism CAH		Depression	High cholesterol				Cutaneous infections

+, Present; –, absent; CAH, congenital adrenal hyperplasia; ILD, interstitial lung disease.

Crohn disease or pulmonary fibrosis/interstitial lung disease (Table 533.6). **Chédiak-Higashi syndrome** also presents with a dense granule defect, immune dysfunction, and albinism. **Gray platelet syndrome** is caused by the absence of platelet α granules, resulting in large platelets that are large and appear gray on Wright stain of peripheral blood. In this rare syndrome, aggregation and release are absent with most agonists other than thrombin and ristocetin. Transmission electron microscopic studies are diagnostic. Autosomal recessive gray platelet syndrome is caused by defects in the *NBEAL2* gene, while autosomal dominant disease is associated with a pathogenic variant in *GFI1B*. This disorder may also be associated with familial leukemia. **Quebec platelet syndrome** is caused by degradation of platelet α granules caused by defects in *PLAU*, which encodes a urokinase-type plasminogen activator. Treatment usually involves antifibrinolytic therapy.

OTHER HEREDITARY DISORDERS OF PLATELET FUNCTION

Abnormalities in the pathways of platelet signaling/activation and release of granular contents cause a heterogeneous group of platelet function defects that are usually manifested as increased bruising, epistaxis, and menorrhagia. Symptoms may be subtle and are often made more obvious by high-risk surgery, such as tonsillectomy or adenoidectomy, or by administration of NSAIDs. In the laboratory, bleeding time is variable, and closure time as measured by the PFA-100 is frequently, but not always, prolonged. Platelet aggregation studies show deficient aggregation with one or two agonists and/or abnormal release of granular contents.

The formation of thromboxane from arachidonic acid (AA) after the activation of phospholipase is critical to normal platelet function. Deficiency or dysfunction of enzymes, such as cyclooxygenase and thromboxane synthase, which metabolize AA, causes abnormal platelet function. In the aggregometer, platelets from such patients do not aggregate in response to AA.

The most common platelet function defects are those characterized by variable bleeding time/PFA closure times and abnormal aggregation with one or two agonists, usually ADP and/or collagen. Some of these individuals have only decreased release of ATP from intracytoplasmic granules; the significance of this finding is debated.

TREATMENT OF PATIENTS WITH PLATELET DYSFUNCTION

Successful treatment depends on the severity of both the diagnosis and the hemorrhagic event. In all but severe platelet function defects, desmopressin, 0.3 μg/kg intravenously, may be used for mild to moderate bleeding episodes. In addition to its effect on stimulating levels of VWF and factor VIII, desmopressin corrects bleeding time and augments hemostasis in many individuals with mild to moderate platelet function defects. Antifibrinolytic therapy may be useful for mucosal bleeds. For individuals with Bernard-Soulier syndrome or Glanzmann thrombasthenia, platelet transfusions of 0.5-1 unit single donor platelets correct the defect in hemostasis and may be lifesaving. Rarely, alloantibodies develop to the deficient platelet protein, rendering the patient refractory to the transfused platelets. In such patients, the use of recombinant factor VIIa has been effective, and this treatment was recently approved for platelet-refractory Glanzmann's thrombasthenia. In both conditions, HSCT has been curative.

Visit Elsevier eBooks+ at eBooks.Health.Elsevier.com for Bibliography.

533.14 Disorders of the Blood Vessels

Brian R. Branchford and Veronica H. Flood

Disorders of the vessel walls or supporting structures mimic the findings of a bleeding disorder, although coagulation studies are usually normal. The findings of petechiae and purpuric lesions in such patients are often attributable to an underlying vasculitis or vasculopathy. Skin biopsy can be particularly helpful in elucidating the type of vascular pathology.

IgA VASCULITIS (HENOCH-SCHÖNLEIN PURPURA)

See Chapter 210.1.

EHLERS-DANLOS SYNDROME

See Chapter 744.

OTHER ACQUIRED DISORDERS

Scurvy, chronic corticosteroid therapy, and severe malnutrition are associated with "weakening" of the collagen matrix that supports the blood vessels. Therefore these factors are associated with easy bruising, and, particularly in the case of scurvy, bleeding gums and loosening of the teeth. Lesions of the skin that initially appear to be petechiae and purpura may be seen in vasculitic syndromes, such as SLE. Leukocytoclastic vasculitis may present with nonthrombocytopenic purpura (see Chapter 210). A unique variant of leukocytoclastic vasculitis is associated with exercise.

Visit Elsevier eBooks+ at eBooks.Health.Elsevier.com for Bibliography.

Section 8
The Spleen

Chapter 534
Anatomy and Function of the Spleen

Allison S. Remiker and Amanda M. Brandow

ANATOMY

The splenic precursor is recognizable by 5 weeks of gestation. At birth, the spleen weighs approximately 11 g. Thereafter, it enlarges until puberty, reaching an average weight of 150 g, and then diminishes in size during adulthood. Approximately 15% of patients will have an accessory spleen. The major splenic components are a lymphoid compartment *(white pulp)* and a filtering system *(red pulp)*. The white pulp consists of periarterial lymphatic sheaths (PALS; T-zone) of T lymphocytes with embedded germinal centers containing B lymphocytes. The red pulp has a skeleton of fixed reticular cells, mobile macrophages, partially collapsed endothelial passages (cords of Billroth), and splenic sinuses. A *perifollicular zone (PFZ)* (known as the marginal zone in murine models) is rich in dendritic (antigen-presenting) cells and natural killer cells and separates the red pulp from the white pulp. The splenic capsule contains smooth muscle and contracts in response to epinephrine. Approximately 10% of the blood delivered to the spleen flows rapidly through a closed vascular network. The other 90% flows more slowly through an open system (the *splenic cords*), where it is filtered through 1-5 μm slits before entering the splenic sinuses.

FUNCTION

The unique anatomy and blood flow of the spleen enable it to perform reservoir, filtering, and immunologic functions. The spleen

Crohn disease or pulmonary fibrosis/interstitial lung disease (Table 533.6). **Chédiak-Higashi syndrome** also presents with a dense granule defect, immune dysfunction, and albinism. **Gray platelet syndrome** is caused by the absence of platelet α granules, resulting in large platelets that are large and appear gray on Wright stain of peripheral blood. In this rare syndrome, aggregation and release are absent with most agonists other than thrombin and ristocetin. Transmission electron microscopic studies are diagnostic. Autosomal recessive gray platelet syndrome is caused by defects in the *NBEAL2* gene, while autosomal dominant disease is associated with a pathogenic variant in *GFI1B*. This disorder may also be associated with familial leukemia. **Quebec platelet syndrome** is caused by degradation of platelet α granules caused by defects in *PLAU*, which encodes a urokinase-type plasminogen activator. Treatment usually involves antifibrinolytic therapy.

OTHER HEREDITARY DISORDERS OF PLATELET FUNCTION

Abnormalities in the pathways of platelet signaling/activation and release of granular contents cause a heterogeneous group of platelet function defects that are usually manifested as increased bruising, epistaxis, and menorrhagia. Symptoms may be subtle and are often made more obvious by high-risk surgery, such as tonsillectomy or adenoidectomy, or by administration of NSAIDs. In the laboratory, bleeding time is variable, and closure time as measured by the PFA-100 is frequently, but not always, prolonged. Platelet aggregation studies show deficient aggregation with one or two agonists and/or abnormal release of granular contents.

The formation of thromboxane from arachidonic acid (AA) after the activation of phospholipase is critical to normal platelet function. Deficiency or dysfunction of enzymes, such as cyclooxygenase and thromboxane synthase, which metabolize AA, causes abnormal platelet function. In the aggregometer, platelets from such patients do not aggregate in response to AA.

The most common platelet function defects are those characterized by variable bleeding time/PFA closure times and abnormal aggregation with one or two agonists, usually ADP and/or collagen. Some of these individuals have only decreased release of ATP from intracytoplasmic granules; the significance of this finding is debated.

TREATMENT OF PATIENTS WITH PLATELET DYSFUNCTION

Successful treatment depends on the severity of both the diagnosis and the hemorrhagic event. In all but severe platelet function defects, desmopressin, 0.3 μg/kg intravenously, may be used for mild to moderate bleeding episodes. In addition to its effect on stimulating levels of VWF and factor VIII, desmopressin corrects bleeding time and augments hemostasis in many individuals with mild to moderate platelet function defects. Antifibrinolytic therapy may be useful for mucosal bleeds. For individuals with Bernard-Soulier syndrome or Glanzmann thrombasthenia, platelet transfusions of 0.5-1 unit single donor platelets correct the defect in hemostasis and may be lifesaving. Rarely, alloantibodies develop to the deficient platelet protein, rendering the patient refractory to the transfused platelets. In such patients, the use of recombinant factor VIIa has been effective, and this treatment was recently approved for platelet-refractory Glanzmann's thrombasthenia. In both conditions, HSCT has been curative.

Visit Elsevier eBooks+ at eBooks.Health.Elsevier.com for Bibliography.

533.14 Disorders of the Blood Vessels

Brian R. Branchford and Veronica H. Flood

Disorders of the vessel walls or supporting structures mimic the findings of a bleeding disorder, although coagulation studies are usually normal. The findings of petechiae and purpuric lesions in such patients are often attributable to an underlying vasculitis or vasculopathy. Skin biopsy can be particularly helpful in elucidating the type of vascular pathology.

IgA VASCULITIS (HENOCH-SCHÖNLEIN PURPURA)

See Chapter 210.1.

EHLERS-DANLOS SYNDROME

See Chapter 744.

OTHER ACQUIRED DISORDERS

Scurvy, chronic corticosteroid therapy, and severe malnutrition are associated with "weakening" of the collagen matrix that supports the blood vessels. Therefore these factors are associated with easy bruising, and, particularly in the case of scurvy, bleeding gums and loosening of the teeth. Lesions of the skin that initially appear to be petechiae and purpura may be seen in vasculitic syndromes, such as SLE. Leukocytoclastic vasculitis may present with nonthrombocytopenic purpura (see Chapter 210). A unique variant of leukocytoclastic vasculitis is associated with exercise.

Visit Elsevier eBooks+ at eBooks.Health.Elsevier.com for Bibliography.

Section 8
The Spleen

Chapter 534
Anatomy and Function of the Spleen

Allison S. Remiker and Amanda M. Brandow

ANATOMY

The splenic precursor is recognizable by 5 weeks of gestation. At birth, the spleen weighs approximately 11 g. Thereafter, it enlarges until puberty, reaching an average weight of 150 g, and then diminishes in size during adulthood. Approximately 15% of patients will have an accessory spleen. The major splenic components are a lymphoid compartment *(white pulp)* and a filtering system *(red pulp)*. The white pulp consists of periarterial lymphatic sheaths (PALS; T-zone) of T lymphocytes with embedded germinal centers containing B lymphocytes. The red pulp has a skeleton of fixed reticular cells, mobile macrophages, partially collapsed endothelial passages (cords of Billroth), and splenic sinuses. A *perifollicular zone (PFZ)* (known as the marginal zone in murine models) is rich in dendritic (antigen-presenting) cells and natural killer cells and separates the red pulp from the white pulp. The splenic capsule contains smooth muscle and contracts in response to epinephrine. Approximately 10% of the blood delivered to the spleen flows rapidly through a closed vascular network. The other 90% flows more slowly through an open system (the *splenic cords*), where it is filtered through 1-5 μm slits before entering the splenic sinuses.

FUNCTION

The unique anatomy and blood flow of the spleen enable it to perform reservoir, filtering, and immunologic functions. The spleen

receives 5–6% of the cardiac output but normally contains only 25 mL of blood. It can retain much more when it enlarges, leading to **cytopenias**. Hematopoiesis in the red pulp is a major splenic function at 3-6 months of fetal life but subsequently disappears. *Splenic hematopoiesis* can be resumed in patients with myelofibrosis or severe hemolytic anemia. Factor VIII, iron, plasmablasts, plasma cells, and one third of the circulating platelet mass are sequestered in the spleen and can be released by stress or epinephrine stimulation. **Thrombocytosis** and **leukocytosis** occur with loss of the splenic reservoir function. A high platelet count after the loss of splenic function or splenectomy is not associated with an increased risk of thrombosis in children.

Slow blood flow past macrophages and through small openings in the sinus walls facilitates the filtering functions of the spleen removing any particles >1 micron in size from the circulation. Excess membrane is removed from young red blood cells (RBCs) and loss of this function is characterized by target cells, poikilocytosis, and decreased osmotic fragility. The spleen is the primary site for destruction of old RBCs, and this function is assumed by other reticuloendothelial cells after splenectomy. The spleen also removes damaged/abnormal RBCs (e.g., spherocytes, antibody-coated RBCs) and damaged/senescent platelets. Intracytoplasmic inclusions may be removed from RBCs without cell lysis. Functional or anatomic hyposplenia is characterized by continued circulation of cells containing nuclear remnants **(Howell-Jolly bodies)**, denatured hemoglobin **(Heinz bodies)**, and other debris in RBCs. This debris may appear as "pits" on indirect microscopy.

The spleen plays a large role in host defense against infection. Mechanical filtration occurs removing parasitized erythrocytes, as well as unopsonized bacteria. The spleen is the largest lymphoid organ in the body and contains almost half the body's total immunoglobulin-producing B lymphocytes. The spleen processes foreign material to stimulate production of opsonizing antibody. Upon antigenic challenge, B and T cells are developed in the spleen, with subsequent release of immunoglobulins. Production of immune-mediating proteins important in bacterial clearance occurs in the spleen including complement, opsonins, properdin, and tuftsin. Thus young (nonimmune) or hyposplenic individuals are at increased risk for **sepsis** caused by pneumococci and other encapsulated bacteria. The spleen can also use phagocytosis to trap and destroy intracellular parasites. The spleen has a minor role in antibody response to intramuscularly or subcutaneously injected antigens but is required for early antibody production after exposure to intravenous antigens. Additionally, the spleen is important in the pathogenesis of immune-mediated cytopenias (IMCs). Antibody-coated platelets or erythrocytes are phagocytosed via mechanisms associated with splenic macrophages. The spleen also serves as a reservoir for antibody producing plasma cells involved in IMCs.

Visit Elsevier eBooks+ at eBooks.Health.Elsevier.com for Bibliography.

Chapter 535

Splenomegaly

Allison S. Remiker and Amanda M. Brandow

CLINICAL MANIFESTATIONS

A soft, thin spleen is palpable in 15% of neonates, 10% of normal children, and 5% of adolescents. In most individuals, the spleen must be 2-3 times its normal size before it is palpable. The spleen is best examined when standing on the right side of a supine patient by palpating across the abdomen as the patient inspires deeply or with the patient in the right lateral decubitus position. A splenic edge felt more than 2 cm below the left costal margin is abnormal. An enlarged spleen might descend into the pelvis; when splenomegaly is suspected, the abdominal examination should begin at a lower starting point. Superficial abdominal venous distention may be present when splenomegaly is a result of portal hypertension. Patients may also complain of left upper quadrant pain as the spleen enlarges. Radiologic detection or confirmation of splenic enlargement is done with ultrasonography, CT, MRI, positron emission tomography, or technetium-99m sulfur colloid scan. The latter also assesses splenic function.

DIFFERENTIAL DIAGNOSIS

Table 535.1 lists specific causes of splenomegaly. A thorough history with a focus on systemic complaints (e.g., fever, night sweats, malaise, weight loss) and a complete physical examination (with special attention to lymphadenopathy, jaundice, hepatomegaly, rashes, joint swelling, petechiae, ecchymoses), in combination with a complete blood count and careful review of the peripheral smear, can help guide diagnosis.

Pseudosplenomegaly

Abnormally long mesenteric connections may produce a *wandering* or ptotic spleen. An enlarged left lobe of the liver, a left upper quadrant mass, or a splenic hematoma may be mistaken for splenomegaly. Splenic **cysts** may contribute to splenomegaly or mimic it; these may be congenital (epidermoid) or acquired (pseudocyst) after trauma or infarction. Cysts are usually asymptomatic and are found on radiologic evaluation. **Splenosis** after splenic rupture or an accessory spleen (present in 15% of normal individuals) may also mimic splenomegaly; most are not palpable. The syndrome of **congenital polysplenism** includes cardiac defects, left-sided organ anomalies, bilobed lungs, biliary atresia, and pseudosplenomegaly (see Chapter 480.11).

Hypersplenism

Increased splenic function (sequestration or destruction of circulating cells) can result in peripheral blood **cytopenias** (thrombocytopenia, neutropenia, anemia), increased bone marrow activity, and splenomegaly. It is usually secondary to another disease and may be cured by treatment of the underlying condition or, if absolutely necessary, may be moderated by splenectomy. Table 535.1 lists the most common diseases associated with massive splenomegaly.

Congestive Splenomegaly

Splenomegaly may result from obstruction in the hepatic, portal, or splenic veins leading to hypersplenism. Wilson disease (see Chapter 405.2), galactosemia (see Chapter 107.2), biliary atresia (see Chapter 404.1), and α_1-antitrypsin deficiency (see Chapter 405) may result in hepatic inflammation, fibrosis, and vascular obstruction. Congenital abnormalities (absence or hypoplasia) of the portal or splenic veins may cause vascular obstruction. Septic omphalitis or thrombophlebitis (spontaneous or as a result of umbilical venous catheterization in neonates) may result in secondary obliteration of these vessels. Splenic venous flow may be obstructed by masses of sickled erythrocytes leading to infarction. When the spleen is the site of vascular obstruction, splenectomy cures hypersplenism. However, because obstruction usually is in the hepatic or portal systems, **portacaval shunting** may be more helpful since both portal hypertension and thrombocytopenia contribute to variceal bleeding.

Visit Elsevier eBooks+ at eBooks.Health.Elsevier.com for Bibliography.

Table 535.1 Differential Diagnosis of Splenomegaly by Pathophysiology

ANATOMIC LESIONS
Cysts, pseudocysts
Hamartomas
Polysplenia syndrome
Hemangiomas and lymphangiomas
Hematoma or rupture (traumatic)
Peliosis

HYPERPLASIA CAUSED BY HEMATOLOGIC DISORDERS
*Acute and Chronic Hemolysis**
Hemoglobinopathies (sickle cell disease in infancy with or without sequestration crisis and sickle variants, thalassemia major, unstable hemoglobins)‡
Erythrocyte membrane disorders (hereditary spherocytosis, elliptocytosis, pyropoikilocytosis)
Erythrocyte enzyme deficiencies (severe G6PD deficiency, pyruvate kinase deficiency)
Immune hemolysis (autoimmune and isoimmune hemolysis)
Paroxysmal nocturnal hemoglobinuria
Chronic Iron Deficiency
Extramedullary Hematopoiesis
Myeloproliferative diseases: CML, juvenile CML, myelofibrosis with myeloid metaplasia, polycythemia vera
Osteopetrosis
Patients receiving granulocyte and granulocyte-macrophage colony-stimulating factors

INFECTIONS†
Bacterial
Acute sepsis: *Salmonella typhi*, *Streptococcus pneumoniae*, *Haemophilus influenzae* type b, *Staphylococcus aureus*
Chronic infections: infective endocarditis, chronic meningococcemia, brucellosis, tularemia, cat-scratch disease
Local infections: splenic abscess (*S. aureus*, streptococci, less often *Salmonella* spp., polymicrobial infection), pyogenic liver abscess (anaerobic bacteria, gram-negative enteric bacteria), cholangitis

*Viral**
Acute viral infections
Congenital CMV, herpes simplex, rubella
Hepatitis A, B, and C; CMV
EBV
Viral hemophagocytic syndromes: CMV, EBV, HHV-6
HIV‡

Spirochetal
Syphilis, especially congenital syphilis
Leptospirosis

Rickettsial
Rocky Mountain spotted fever
Q fever
Typhus

Fungal/Mycobacterial
Miliary tuberculosis
Disseminated histoplasmosis
South American blastomycosis
Systemic candidiasis (in immunosuppressed patients)

Parasitic
Malaria‡
Toxoplasmosis, especially congenital
Toxocara canis, *Toxocara cati* (visceral larva migrans)
Leishmaniasis (kala-azar)‡
Schistosomiasis (hepatic-portal involvement)
Trypanosomiasis
Fascioliasis
Babesiosis

IMMUNOLOGIC AND INFLAMMATORY PROCESSES*
Systemic lupus erythematosus
Juvenile idiopathic arthritis
Mixed connective tissue disease
Systemic vasculitis
Serum sickness
Drug hypersensitivity, especially to phenytoin
Graft-versus-host disease
Sjögren syndrome
Cryoglobulinemia
Amyloidosis
Sarcoidosis
Autoimmune lymphoproliferative syndrome‡
Castleman disease‡
Posttransplant lymphoproliferative disease
Large granular lymphocytosis and neutropenia
Histiocytosis syndromes‡
Macrophage activation syndrome
Hemophagocytic lymphohistiocytosis (genetic, acquired)‡

MALIGNANCIES
Primary: leukemia (acute, chronic)‡, lymphoma‡, angiosarcoma, mastocytosis
Metastatic

STORAGE DISEASES
Lipidosis (Gaucher disease‡, Niemann-Pick disease, infantile GM1 gangliosidosis)
Mucopolysaccharidoses (Hurler, Hunter-type)
Mucolipidosis (I-cell disease, sialidosis, multiple sulfatase deficiency, fucosidosis)
Defects in carbohydrate metabolism: galactosemia, fructose intolerance, glycogen storage disease IV
Sea-blue histiocyte syndrome
Tangier disease
Wolman disease
Hyperchylomicronemia type I, IV

CONGESTIVE DISEASE*
Heart failure
Intrahepatic cirrhosis or fibrosis
Extrahepatic portal (thrombosis), splenic, and hepatic vein obstruction (thrombosis, Budd-Chiari syndrome)

*Common.
†Chronic or recurrent infection suggests underlying immunodeficiency.
‡Associated with hypersplenomegaly.
CML, Chronic myelogenous leukemia; CMV, cytomegalovirus; EBV, Epstein-Barr virus; G6PD, glucose-6-phosphate dehydrogenase; HHV-6, human herpesvirus 6; HIV, human immunodeficiency virus.

Chapter 536

Hyposplenism, Splenic Trauma, and Splenectomy

Allison S. Remiker and Amanda M. Brandow

HYPOSPLENISM

Congenital absence (asplenia) or underdevelopment (hyposplenia) of the spleen is associated with complex cyanotic heart defects, dextrocardia, bilateral trilobed lungs, and heterotopic abdominal organs (**Ivemark syndrome**; see Chapter 480.11). Patients with isolated congenital asplenia have pathogenic variants in *RPSA* in ~40% of cases. Right atrial isomerism (Ivemark syndrome), a form of heterotaxy, may have asplenia associated with pathogenic variants of *GDF1*. Splenic function is usually normal in children with congenital polysplenia. **Functional hyposplenism** may occur in normal neonates, especially premature infants. Children with sickle cell hemoglobinopathies (see Chapter 511.1) may have splenic hypofunction as early as 6 months of age. In this setting, the spleen eventually autoinfarcts and becomes fibrotic and permanently nonfunctional. Functional hyposplenism may also occur in malaria (see Chapter 334), after irradiation to the left upper quadrant, and when the reticuloendothelial function of the spleen is overwhelmed (as in severe hemolytic anemia or metabolic storage disease). Thrombosis of the splenic/celiac arteries or splenic vein is associated with functional hyposplenism. Splenic hypofunction has been reported occasionally in patients with autoimmune diseases (i.e., juvenile idiopathic arthritis, lupus, sarcoidosis), nephritis, inflammatory bowel disease, celiac disease, chronic hepatitis, Pearson syndrome, Fanconi anemia, those with use of high-dose corticosteroids, and graft-versus-host disease (Table 536.1).

Splenic hypofunction is characterized by **red blood cell (RBC) inclusions** in peripheral blood smears (Howell-Jolly or Heinz bodies), "pits" on interference microscopy, and poor uptake of technetium or other spleen scans (Table 536.2 and Fig. 536.1). Reduced immunoglobulin M memory B cells may also be detected and is a risk factor for overwhelming **sepsis**. Patients with functional hyposplenism or asplenia are at increased risk for sepsis from **encapsulated bacteria** and benefit from antibiotic prophylaxis and urgent evaluation when febrile.

Table 536.1 Diseases Associated with Hyposplenism or Splenic Atrophy

CONGENITAL FORMS Normal and premature neonates Isolated congenital hypoplasia Ivemark syndrome Autoimmune polyendocrinopathy–candidiasis–ectodermal dystrophy (APECED) syndrome Hypoparathyroidism syndrome Stormorken syndrome Heterotaxia syndromes	**AUTOIMMUNE DISORDERS** Systemic lupus erythematosus Juvenile idiopathic arthritis Glomerulonephritis Granulomatosis with polyangiitis Goodpasture syndrome Sjögren syndrome Polyarteritis nodosa Thyroiditis Sarcoidosis
GASTROINTESTINAL DISORDERS Celiac disease Inflammatory bowel disease Whipple disease Dermatitis herpetiformis Intestinal lymphangiectasia Idiopathic chronic ulcerative enteritis	**INFECTIOUS DISEASES** Pneumococcal meningitis HIV/AIDS Malaria **IATROGENIC FORMS** Exposure to methyldopa High-dose steroids Total parenteral nutrition Splenic irradiation
HEPATIC DISORDERS Active chronic hepatitis Primary biliary cirrhosis Hepatic cirrhosis and portal hypertension Alcoholism and alcoholic hepatopathy	**ALTERATION IN SPLENIC CIRCULATION** Thrombosis of splenic artery Thrombosis of splenic vein Thrombosis of celiac artery **MISCELLANEOUS** Amyloidosis
HEMATOLOGIC AND ONCOLOGIC DISORDERS Sickle cell disease (all genotypes) Bone marrow transplantation Chronic graft-versus-host disease Acute leukemia Chronic myeloproliferative disorders Fanconi syndrome Splenic tumors Mastocytosis	

From Di Sabatino A, Carsetti R, Corazza GR. Post-splenectomy and hyposplenic states. *Lancet* 2011;378:86–97.

SPLENIC TRAUMA

Injury to the spleen may occur with abdominal trauma. Small splenic capsular tears may cause abdominal or referred left shoulder pain as a result of diaphragmatic irritation by blood. Larger tears result in more severe blood loss, with similar pain and signs of **hypovolemic shock**. Previously enlarged spleens (as in patients with infectious mononucleosis) are more likely to rupture with minor trauma. *Patients with splenomegaly should avoid contact sports and other activities that increase the risk of splenic trauma.* CT scan with intravenous contrast is the best imaging modality to assess splenic trauma in a hemodynamically stable patient. In emergent situations extended focused assessment with sonography in trauma (E-FAST) should be considered as an initial evaluation, although the sensitivity and specificity in children is variable.

Treatment of a small capsular injury should include careful observation with attention to changes in vital signs or abdominal findings, serial hemoglobin determinations, and the availability of prompt surgical intervention if a patient's condition deteriorates (see Chapter 80). RBC transfusion requirements should be minimal (<25 mL/kg/48 hr). These patients are usually hospitalized for 10-14 days and have their activities restricted for months. Laparotomy, with or without splenectomy, is indicated for more marked abdominal bleeding, in patients who have clinical instability or deterioration, or when other organ damage is suspected. Partial splenectomy and splenic repair should be substituted for total splenectomy when feasible to maintain some splenic immune function. Nonoperative management is typically possible in >90% of patients. Delayed splenic rupture is quite rare in children.

SPLENECTOMY

Splenectomy should be limited to specific indications where medical therapy is (or has been) ineffective. These include traumatic splenic rupture, anatomic defects, splenic malignancy (i.e., splenic marginal zone lymphoma [SMZL]), severe transfusion-dependent hemolytic anemia, refractory and severe immune-mediated cytopenias, metabolic storage diseases, and secondary hypersplenism. There are certain conditions where splenectomy should be avoided because of increased risk of complications and/or better alternative treatments. These include autoimmune lymphoproliferative syndrome (ALPS), hereditary stomatocytosis (HSt), hereditary xerocytosis (HX), cold agglutinin disease (CAD), paroxysmal cold hemoglobinuria (PCH), Gaucher disease, and thrombocytopenia in hepatic cirrhosis. *The major long-term risk of splenectomy is sudden, overwhelming postsplenectomy infections (sepsis or meningitis).* This risk is especially high in children <5 years old at surgery. The risk of sepsis is less when splenectomy is performed for trauma, RBC membrane defects, and immune thrombocytopenia (2–4%) than when there is sickle cell anemia, thalassemia, or a preexisting immune deficiency (Wiskott-Aldrich syndrome, Hodgkin disease) or reticuloendothelial blockade (storage disease, severe hemolytic anemia) (8–30%). The overall risk is 2-5 per 1,000 asplenic patient-years,

Table 536.2 Diagnostic Techniques for and Features of Spleen Dysfunction

	DESCRIPTION	COMMENTS
Immunoglobulin M memory B cells	Cells dependent on spleen for survival. Produced in marginal zone.	Special tests required.
Technetium-99m–labeled sulfur colloidal scintiscan	Quantitation of splenic uptake of colloidal sulfur particles enables a fairly accurate static assessment of spleen function.	Hypertrophy of the left hepatic lobe might be a limiting factor (this technique does not clearly show whether the mass originated in the liver or the spleen in the presence of an overlapping hypertrophic left hepatic lobe).
Technetium-99m–labeled or rubidium-81–labeled heat-damaged autologous erythrocyte clearance	Measurement of clearance time allows a dynamic evaluation of spleen function.	Preexisting erythrocyte defects, difficult erythrocyte incorporation of the radioisotope, and false-positive or false-negative results in relation to excessive or insufficient heat damage make the test not suitable for clinical practice.
Detection of Howell-Jolly bodies by staining	Erythrocytes with nuclear remnants Flow cytometry	No need for special equipment; inaccurate in the quantitation of splenic hypofunction.
Detection of pitted erythrocytes by phase-interference microscopy	Erythrocytes with membrane indentations (4% upper limit of the normal range)	Need for phase-interference microscopy; counts enable a wide range of measurements and correlate with radioisotopic methods.

From Di Sabatino A, Carsetti R, Corazza GR. Post-splenectomy and hyposplenic states. *Lancet* 2011;378:86–97. Table 1.

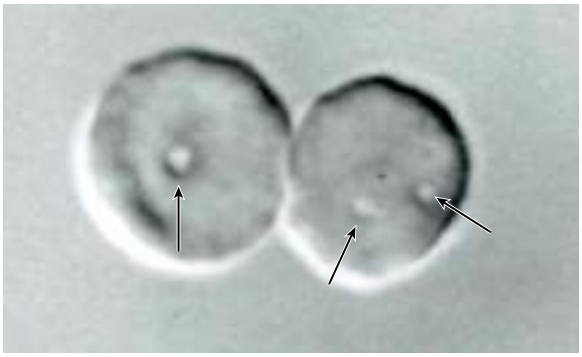

Fig. 536.1 Characteristic pitted erythrocytes in hyposplenism. A pitted erythrocyte is recognizable on phase-interference microscopy by the characteristic "pit" on the cell membrane *(arrows). (From Di Sabatino A, Carsetti R, Corazza GR. Post-splenectomy and hyposplenic states. Lancet. 2011;378:86–97. Fig 2.)*

with a lifelong risk of overwhelming postsplenectomy infections of 5%; more than half occur within 2 years after splenectomy, although the risk remains lifelong. The use of laparoscopic splenectomy has decreased surgical morbidity and hospitalization time.

Encapsulated bacteria, such as *Streptococcus pneumoniae* (>60% of cases), *Haemophilus influenzae,* and *Neisseria meningitidis,* account for >80% of cases of postsplenectomy sepsis. Because the spleen is responsible for filtering the blood and for early antibody responses, sepsis (with or without meningitis) can progress rapidly, leading to death within 12-24 hours of onset. Febrile splenectomized patients should be evaluated and treated promptly with antibiotics to cover the organisms previously mentioned. This treatment should be initiated at home if access to definitive medical care will be delayed. Common empiric antibiotics include amoxicillin-clavulanate or cefdinir. A broad-spectrum cephalosporin (cefotaxime or ceftriaxone) is recommended until specific antibiotic susceptibility and presence, or absence of meningitis is known. Vancomycin (to cover penicillin-resistant pneumococci) should be initiated, depending on the illness severity and susceptibilities of pneumococci at the institution. Splenectomized patients are also at increased risk for contracting protozoal infections, such as malaria and babesiosis. Serious infections may occur after an animal bite or lick (particularly dogs) and is caused by *Capnocytophaga canimorsus* or *C. cynodegmi*. Prophylactic antibiotics should be given after a bite potentially to prevent sepsis caused by these organisms (see Chapter 765).

Preoperative, intraoperative, and postoperative management may decrease the risk of postsplenectomy infection. It is important to be certain of the need for splenectomy and, if possible, to postpone the operation until the patient is ≥5 years of age. *Pneumococcal, meningococcal, and H. influenzae conjugate vaccines given at least 14 days before splenectomy may reduce postsplenectomy sepsis.* The 7-valent (PCV7) was replaced by the 13-valent pneumococcal polysaccharide-protein conjugate vaccine (PCV13). Thus, depending on what primary pneumococcal vaccine was given, a single dose of PCV13 may be recommended. In addition, the 23-valent pneumococcal polysaccharide vaccine (Pneumovax) should be given at age ≥2 years and a second dose 5 years later. Yearly influenza vaccine should also be given because influenza infection is a risk factor for secondary pneumococcal infections. Prophylaxis with oral penicillin VK (125 mg twice daily for children <5 years old; 250 mg twice daily for children ≥5 years) should be given until at least 5 years of age and for at least 2 years after splenectomy. Although the greatest risk is in the immediate postoperative period, reports of deaths occurring years after splenectomy suggest that the risk (and the need for prophylaxis) may be lifelong. Lifelong prophylaxis should be strongly considered in patients who have had an invasive pneumococcal infection or who have an underlying immune deficiency. In children with sickle cell disease, penicillin prophylaxis should be started as soon as the diagnosis is made. Prophylaxis may be continued into adulthood for higher-risk patients, including those with a history of pneumococcal sepsis, but effectiveness in this older group has not been well documented.

In patients with traumatic injury, splenic repair or partial splenectomy should be considered in an attempt to preserve splenic function. Partial splenectomy or partial *splenic embolization* may be sufficient to ameliorate some forms of hemolytic anemia. Up to 50% of children whose spleen is removed because of trauma have spontaneous splenosis; *surgical splenosis* (distributing small pieces of spleen throughout the abdomen) may decrease the risk of sepsis in patients whose splenectomy is necessitated by trauma. However, in both these settings, the splenic tissue that regrows frequently has poor function.

In addition to postsplenectomy sepsis, splenectomized patients may be at risk for **thromboembolic complications**, including arterial and venous thrombosis and pulmonary hypertension. These findings have been reported regardless of the underlying reason for splenectomy and the postsplenectomy platelet count. Proposed mechanisms include loss of filtering function of the spleen, allowing abnormal RBCs to remain in the circulation and activate the coagulation cascade. Portal vein thrombosis has been reported as a complication of laparoscopic splenectomy. The etiology of pulmonary hypertension is not well understood. It has been described in chronic hemolytic conditions including thalassemia, sickle cell disease, and hereditary spherocytosis, indicating there may be a relation to ongoing chronic hemolysis postsplenectomy.

Visit Elsevier eBooks+ at eBooks.Health.Elsevier.com for Bibliography.

Section 9

The Lymphatic System

Chapter 537

Anatomy and Function of the Lymphatic System

Michael E. Kelly and Richard L. Tower

The lymphatic system participates in many biologic processes, including fluid homeostasis, absorption of dietary fat, and initiation of specific immune responses. Besides these well-known, classical functions, several novel and unexpected physiologic and pathophysiologic functions of the lymphatics have been recently discovered, including blood pressure regulation, reverse cholesterol transport, association with metabolic diseases and obesity, and an important role in the preparation for neonatal respiration. This system includes circulating lymphocytes, lymphatic vessels, lymph nodes, spleen, tonsils, adenoids, Peyer patches, and thymus. **Lymph** is an ultrafiltrate of blood and is collected by lymphatic capillaries that are present in all organs where blood flows except the bone marrow and retina. Lymphatic capillaries form progressively larger vessels that drain regions of the body. The lymphatic vessels carry lymph to the lymph nodes, where it is filtered through sinuses, particulate matter and infectious organisms are phagocytosed, and antigens are presented to surrounding lymphocytes. These actions stimulate antibody production, T-cell responses, and cytokine secretion (see Chapter 165). Lymph is ultimately returned to the intravascular circulation.

The composition of lymph can vary with the site of lymph drainage. It is usually clear, but lymph drained from the intestinal tract may be milky **(chylous)** because of the presence of fats. The protein content is intermediate between an exudate and a transudate. The protein level may be increased with inflammation and in lymph drained from the liver or intestines. Lymph also contains variable numbers of lymphocytes and antigen-presenting cells.

Embryonic lymphatic development is a stepwise process that starts in the embryonic veins, where lymphatic endothelial cell (LEC) progenitors are initially specified. The differentiation and maturation of these progenitors continues as they bud from the veins to produce scattered primitive lymph sacs, from which most of the lymphatic vasculature is derived. *PROX1* gene expression is important to LEC specification, and studies have shown the critical importance of bone morphogenetic protein (BMP), Wnt, Notch, and vascular endothelial growth factor (VEGF) signaling pathways in lymphatic system development.

Little is known about the establishment of organ-specific lymphatics at later stages. Studies using lineage-tracing technology suggest a venous and nonvenous origin of LECs giving rise to organ-specific lymphatics in the mesentery, skin, and heart. Lymphatic vessels also run parallel to the dural sinuses in the central nervous system. The embryonic origin of the meningeal lymphatics has not been determined.

Visit Elsevier eBooks+ at eBooks.Health.Elsevier.com for Bibliography.

Chapter 538

Abnormalities of Lymphatic Vessels

Michael E. Kelly and Richard L. Tower

LYMPHATIC MALFORMATIONS

Developmental lymphatic anomalies including **lymphatic malformations (LMs) and complex lymphatic anomalies (CLAs)** manifest as localized or multifocal lesions of the lymphatic vasculature, respectively (see International Society for the Study of Vascular Anomalies [**ISSVA**] classification; www.issva.org).

Cystic LMs are the most common *congenital* lymphatic anomalies. They occur as solitary lesions of variable size that are classified as macrocystic, microcystic, or mixed cystic LM. LMs commonly infiltrate soft tissues and can be found anywhere on the body, although they occur more frequently on the head, neck, and axilla.

CLAs are multifocal lymphatic vascular lesions involving both soft tissue and bone and often result in disruption of central collecting lymphatic channels. They include **generalized lymphatic anomaly (GLA), Gorham-Stout disease (GSD)** (Fig. 538.1), **kaposiform lymphangiomatosis (KLA), and central conducting lymphatic anomalies (CCLA)** (Fig. 538.2). CLAs are rare diseases with overlapping and variable clinical features. Common features include bone involvement, lymphatic leakage into the thoracic (chylous effusion) and abdominal (chylous ascites) cavities and mesenteric involvement leading to protein losing enteropathy. In addition to common features, GSD is uniquely associated with progressive cortical bone loss (see Fig. 538.1). KLA can be distinguished by the presence of spindle cells on histology, an aggressive clinical course, and evidence of consumptive coagulopathy and hemorrhage. CCLA, or channel type anomaly is characterized by dilation, malformation, and dysfunction of the major abdominal or thoracic lymphatic vessels.

LMs can also occur as combined malformations with other blood vessel types like capillaries (capillary-lymphatic malformation) or veins (lymphatic-venous malformation). LMs are commonly associated with **PIK3CA-related overgrowth spectrum (PROS) disorders**, which include **Klippel-Trenaunay syndrome (KTS), CLOVES (congenital lipomatous overgrowth, vascular malformations, epidermal nevi, and scoliosis/skeletal/spinal anomalies) and Proteus syndrome** (Fig. 538.3).

Genetics

Somatic, activating variants in the *PIK3CA* gene that encodes the p110α catalytic subunit of PI3K are present at variable frequencies in most (80%) isolated LMs and LMs associated with PROS. These activating *PIK3CA* variants are identical to those found in venous malformations and in many human cancers. The genetics of CLAs are far more diverse. Activating *PIK3CA* gene variants have been identified in several patients diagnosed with GLA. In addition, pathologic genetic variants in genes involved in the RAS-MAPK signaling pathway have been implicated in other CLAs. Activating *NRAS* gene variants are associated with KLA while two patients with GSD were found to have activating gene variants in *KRAS*. Somatic, pathologic genetic variants in both the *ARAF* and *CBL* genes have been found in patients diagnosed with CCLA as have inactivating germline pathogenic variants in *EPHB4*. The role of RAS/MAPK pathway activation in CLAs is further reinforced by the observation that patients with known RASopathies, including Noonan and Noonan-like syndrome, can present with central conducting lymphatic anomalies.

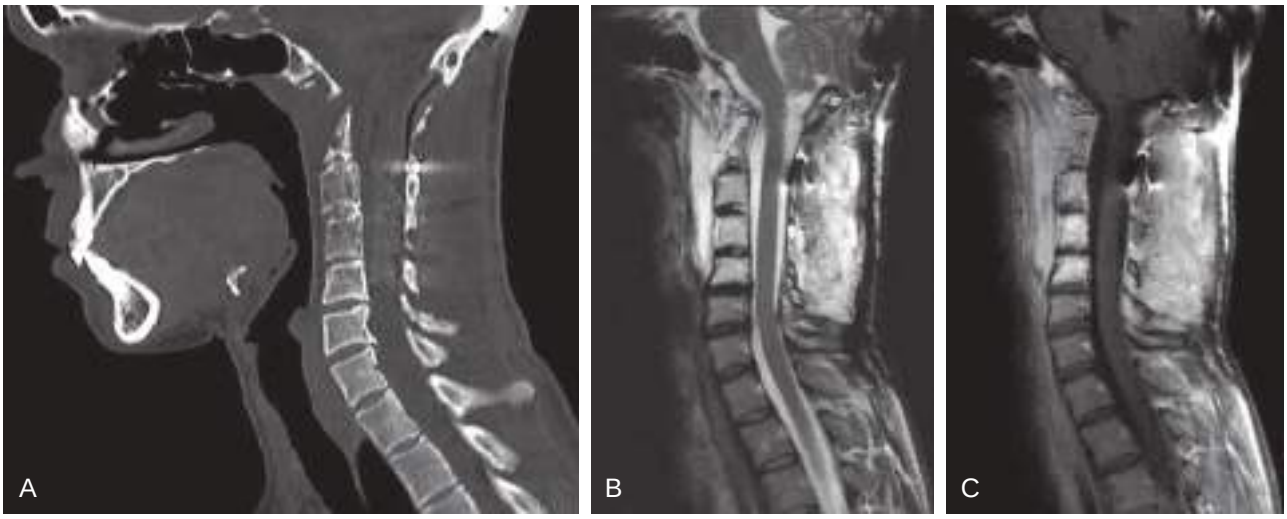

Fig. 538.1 Gorham–Stout disease. **A,** CT sagittal reformat. Multiple erosive changes in the occiput, clivus, and the cervical spine. (**B**) Sagittal T2-weighted fat-saturated (FS) MRI sequence. High signal is seen in the clivus and C 1–5 vertebral and the surrounding soft tissue. **C,** Postgadolinium T1 FS MRI. Enhancement is seen in the areas of osseous and soft tissue abnormalities. *(From Trenor III CC, Chaudry G. Complex lymphatic anomalies. Sem Pediatr Surg 2014;23:186–190. Fig. 3.)*

Fig. 538.2 Intranodal lymphangiogram in 15-year-old male with central conducting lymphatic anomaly and recurrent pericardial effusions. Stagnant flow is seen in the patulous superior portion of the thoracic duct. Direct puncture of the terminal portion demonstrates marked dilation with no spontaneous emptying.

Treatment

A decision to treat an LM depends on the anatomic location, involvement of local structures, and symptoms. Referral to a specialized vascular anomalies clinic with the expertise to guide appropriate imaging and treatment decisions is recommended. For localized macrocystic LMs, **interventional radiology (IR) administration of sclerosing agents** (OK432, ethanol, bleomycin) is most effective. For lesions involving skin and mucosa, **laser treatments** may be used.

Most patients with CLAs have extensive and invasive disease, necessitating systemic therapeutic approaches. The mTOR inhibitor **sirolimus** has had excellent effects in patients with vascular anomalies, including those patients with CLAs. A majority of CLA patients showed improvements in functional impairment and quality of life measures, whereas fewer showed evidence of decreased disease burden by imaging. **Combining sirolimus with bisphosphonates** may be even more effective in CLA patients with significant bone disease. **Alpelisib,** a *PIK3CA* inhibitor, has been used with success in patients with PROS and in a growing number of GLA patients with a known *PIK3CA* pathologic variant. Small numbers of patients with KLA who were known to have pathogenic variants in either NRAS or CBL experienced clinical improvement with **trametinib**, a MEK inhibitor. Trametinib also induced remodeling of the central lymphatics and induced symptom resolution in a patient with CCLA who had an *ARAF* pathogenic variant, as well a patient with Noonan syndrome and a *SOS1* pathogenic variant with severe lymphatic abnormalities.

LYMPHEDEMA

Lymphedema is a localized swelling caused by impaired lymphatic flow and can be primary (congenital) or acquired. **Primary lymphedemas** are grouped as LMs because they result from dysgenesis of lymphatic networks during early development. Primary lymphedema may be found in Turner syndrome, Noonan syndrome, autosomal dominantly inherited Milroy disease, and other chromosomal abnormalities. Pathologic variants in multiple genes, including the vascular endothelial growth factor receptor–3 gene *(VEGFR3), GJC2*, *PTPN14*, and *GATA2,* are associated with primary lymphedema (www.issva.org) (Table 538.1). Autosomal recessive, dominant or de novo pathogenic variants of *VEGFR3* produce Milroy disease. Pathologic variants in other genes are associated with specific syndromes: *CCBE1* (Hennekam), *FOXC2* (lymphedema distichiasis), *SOX18* (hypotrichosis-telangiectasia-lymphedema), *KMT2D/MLL2,* and *KDM6A* (Kabuki). Unilateral or bilateral lower extremity lymphedema in an adolescent may be Meige disease.

Acquired obstruction of the lymphatics is much more common than primary disorders and result from tumor, postirradiation fibrosis, and postinflammatory scarring. **Filariasis** is an important cause of lymphedema in Africa, Asia, and Latin America. One third of the 120 million infected persons (primarily older adolescents and adults) have lymphedema or a hydrocele. Injury to the major lymphatic vessels can cause

Fig. 538.3 Photographs and MRIs of participants with isolated LM, CLOVES, KTS, and FAVA. **A,** An 8-month-old male with isolated LM. Note swelling in deltoid region without cutaneous vascular signs. Coronal and sagittal fat-saturated T2-weighted MRI demonstrates macrocystic LM (a multilocular cystic mass) involving the anterolateral aspects of the right shoulder without muscular infiltration *(arrows)*; humeral head *star*. **B,** A 19-month-old female with CLOVES syndrome. Note asymmetric distribution of truncal lipomatous masses and bilateral lower extremity involvement. Coronal fat-saturated T1-weighted MRI after contrast administration demonstrates moderate heterogeneous enhancement of the bilateral truncal masses *(arrows)*. Axial T1-weighted MRI without contrast depicts truncal lipomatous overgrowth *(arrows)*; segment VI of the liver *(asterisk)*.

Continued

Fig. 538.3, cont'd **C,** A 3-yr-old male (KT4) with KTS. Note capillary-lymphatic malformation and overgrowth involving right lower extremity. Coronal and axial fat-saturated T2-weighted MRI shows the persistent marginal vein system *(bent arrows)* and marked enlargement of the subcutaneous tissues because of a combination of lymphatic fluid and fat *(straight arrow)*. There are also intramuscular venous malformations. **D,** A 9-yr-old male (F8) with FAVA of the left gastrocnemius muscle; note absence of overgrowth and cutaneous vascular anomalies. Sagittal fat-saturated T1-weighted MRI after contrast administration demonstrates the longitudinal distribution of the diffuse, fibro-adipose vascular anomaly *(arrows)*. Axial fat-saturated T2-weighted MRI with (upper) and without (lower) contrast. Note right head of the gastrocnemius muscle is diffusely replaced by a contrast enhancing heterogeneous soft tissue lesion *(arrows)*. CLOVES, congenital lipomatous overgrowth, vascular malformations, epidermal nevis, spinal/skeletal anomalies/scoliosis; FAVA, fibro-adipose vascular anomaly; KTS, Klippel-Trenaunay syndrome; LM, lymphatic malformations. *(From Luks VL, Kamitaki N, Vivero MP, et al. Lymphatic and other vascular malformative/overgrowth disorders are caused by somatic mutations in PIK3CA. J Pediatr. 2015;166:1048–1054.)*

Table 538.1 Chromosomal, Gene, and Syndromes Associated with Lymphedema

	SYNDROMES	KNOWN GENES, CHROMOSOMAL LOCI, INHERITANCE PATTERN
Primary lymphedema	Milroy disease Meige disease	*VEGFR3* AR, AD Familial lymphedema No known gene
Chromosomal aneuploidy	Turner syndrome Klinefelter syndrome Trisomy 21 Trisomy 13 Trisomy 18	45,X 47,XXY 47,XX+21; 47,XY+21 47,XX+13; 47,XY+13 47,XX+18; 47,XY+18
Other genetic and syndromic disorders	Emberger syndrome (primary lymphedema with myelodysplasia) Lymphedema-distichiasis syndrome Hennekam lymphangiectasia-lymphedema syndrome 1 (HKLLS1) Hennekam lymphangiectasia-lymphedema syndrome 2 (HKLLS2) Hypotrichosis-lymphedema-telangiectasia ± renal defect syndrome (HLTRS) Microcephaly with or without chorioretinopathy, lymphedema, or mental retardation (MCLMR) Microcephaly and chorioretinopathy, 1 (MCCRP1) Noonan syndrome Cholestasis-lymphedema syndrome (Aagenaes syndrome) Ectodermal dysplasia, hypo/anhidrotic, lymphedema and immunodeficiency; immunodeficiency 33	*GATA2*(3q21.3), AD *FOXC2*(16q24.1), AD *CCBE1*(18q21.32), AR *FAT4*(4q28.1), AR *SOX18*(20q13.33), AR/AD *KIF11*(10q23.33), AD *TUBGCP6*(22q13.33), AR *PTPN11*, *SOS1*, *RAF1*, *RIT1*, *KRAS*, AD *LSC1*, AR *IKBKG*, (Xq28), XLR

AD, Autosomal dominant; AR, Autosomal recessive; XLR, X-linked recessive.
Modified from Unolt M, Barry J, Digilio MC, et al. Primary lymphedema and other lymphatic anomalies are associated with 22q11.2 deletion syndrome. *Eur J Med Genetics.* 2018;61:411–415. Table 1.

collection of lymph fluid in the abdomen (chylous ascites) or chest (chylothorax).

Untreated lymphedema can be disabling and is associated with immune dysfunction, inflammation, fibrosis, adipose tissue overgrowth, and lymphangiosarcoma. Treatment modalities attempt to reduce localized swelling through massage, exercise, and compression. Lymphatic reconstructive procedures, including lymphovenous bypass and lymphatico-lymphatic anastomosis are increasingly used to achieve lymphatic decongestion, especially in the early stages of disease.

LYMPHANGIOLEIOMYOMATOSIS

Lymphangioleiomyomatosis **(LAM)** is characterized by proliferation of lymphatic endothelial cells and smooth muscle cells in the lungs, leading to airway and lymphatic obstruction, cyst formation, pneumothorax, and respiratory failure. It may initially be mistaken for asthma. LAM occurs in young females and is associated with pathogenic variants in the tuberous sclerosis tumor-suppressor gene *TSC2* in one third of cases. **Sirolimus** stabilizes lung function, reduces symptoms, and improves life quality. Lung transplantation may be required.

LYMPHANGITIS

Lymphangitis is an inflammation of the lymphatics that drain an area of infection. Tender, erythematous streaks extend proximally from the infected area. Regional nodes may also be tender. Group A streptococci and *Staphylococcus aureus* are the most common pathogens, and therapy should include antibiotics that treat these organisms.

Visit Elsevier eBooks+ at eBooks.Health.Elsevier.com for Bibliography.

Bibliography

Adams DM, et al. Efficacy and Safety of Sirolimus in the Treatment of Complicated Vascular Anomalies. *Pediatrics*. 2016;137:e20153257.

Chang DW, Dayan J, Greene AK, et al. Surgical treatment of lymphedema: a systematic review and meta-analysis of controlled trials. Results of a consensus conference. *Plast Reconstr Surg*. 2021;1(4):975–993. 147.

Dentici ML, Di Pede A, Lepri FR, et al. Kabuki syndrome: clinical and molecular diagnosis in the first year of life. *Arch Dis Child*. 2015;100:158–164.

Frosk P, Chodirker B, Simard L, et al. A novel *CCBE1* pathogenic variant leading to a mild form of hennekam syndrome: case report and review of the literature. *BMC Med Genet*. 2015;16:28.

Iacobas I, et al. Multidisciplinary guidelines for initial evaluation of complicated lymphatic anomalies—expert opinion consensus. *Pediatric Blood & Cancer*. 2020;67:e28036.

Kuentz P, et al. Molecular diagnosis of PIK3CA-related overgrowth spectrum (PROS) in 162 patients and recommendations for genetic testing. *Genet Med*. 2017;19:989–997.

Li D, et al. ARAF recurrent pathogenic variant causes central conducting lymphatic anomaly treatable with a MEK inhibitor. *Nature Medicine*. 2019;25:1116–1122.

Mäkinen T, Boon LM, Vikkula M, Alitalo K. Lymphatic Malformations: Genetics, Mechanisms and Therapeutic Strategies. *Circ Res*. 2021;129(1):136–154.

Ricci KW, et al. Efficacy of systemic sirolimus in the treatment of generalized lymphatic anomaly and Gorham–Stout disease. *Pediatric Blood & Cancer*. 2019;66:e27614.

Rodriguez-Laguna L, et al. Somatic activating pathogenic variants in PIK3CA cause generalized lymphatic anomaly. *J Exper Med*. 2018;216:407–418.

Trenor II CC, Chaudry G. Complex lymphatic anomalies. *Semin Pediatr Surg*. 2014;23:186–190.

Section 9

The Lymphatic System

Chapter 537

Anatomy and Function of the Lymphatic System

Michael E. Kelly and Richard L. Tower

The lymphatic system participates in many biologic processes, including fluid homeostasis, absorption of dietary fat, and initiation of specific immune responses. Besides these well-known, classical functions, several novel and unexpected physiologic and pathophysiologic functions of the lymphatics have been recently discovered, including blood pressure regulation, reverse cholesterol transport, association with metabolic diseases and obesity, and an important role in the preparation for neonatal respiration. This system includes circulating lymphocytes, lymphatic vessels, lymph nodes, spleen, tonsils, adenoids, Peyer patches, and thymus. **Lymph** is an ultrafiltrate of blood and is collected by lymphatic capillaries that are present in all organs where blood flows except the bone marrow and retina. Lymphatic capillaries form progressively larger vessels that drain regions of the body. The lymphatic vessels carry lymph to the lymph nodes, where it is filtered through sinuses, particulate matter and infectious organisms are phagocytosed, and antigens are presented to surrounding lymphocytes. These actions stimulate antibody production, T-cell responses, and cytokine secretion (see Chapter 165). Lymph is ultimately returned to the intravascular circulation.

The composition of lymph can vary with the site of lymph drainage. It is usually clear, but lymph drained from the intestinal tract may be milky **(chylous)** because of the presence of fats. The protein content is intermediate between an exudate and a transudate. The protein level may be increased with inflammation and in lymph drained from the liver or intestines. Lymph also contains variable numbers of lymphocytes and antigen-presenting cells.

Embryonic lymphatic development is a stepwise process that starts in the embryonic veins, where lymphatic endothelial cell (LEC) progenitors are initially specified. The differentiation and maturation of these progenitors continues as they bud from the veins to produce scattered primitive lymph sacs, from which most of the lymphatic vasculature is derived. *PROX1* gene expression is important to LEC specification, and studies have shown the critical importance of bone morphogenetic protein (BMP), Wnt, Notch, and vascular endothelial growth factor (VEGF) signaling pathways in lymphatic system development.

Little is known about the establishment of organ-specific lymphatics at later stages. Studies using lineage-tracing technology suggest a venous and nonvenous origin of LECs giving rise to organ-specific lymphatics in the mesentery, skin, and heart. Lymphatic vessels also run parallel to the dural sinuses in the central nervous system. The embryonic origin of the meningeal lymphatics has not been determined.

Visit Elsevier eBooks+ at eBooks.Health.Elsevier.com for Bibliography.

Chapter 538

Abnormalities of Lymphatic Vessels

Michael E. Kelly and Richard L. Tower

LYMPHATIC MALFORMATIONS

Developmental lymphatic anomalies including **lymphatic malformations (LMs) and complex lymphatic anomalies (CLAs)** manifest as localized or multifocal lesions of the lymphatic vasculature, respectively (see International Society for the Study of Vascular Anomalies [**ISSVA**] classification; www.issva.org).

Cystic LMs are the most common *congenital* lymphatic anomalies. They occur as solitary lesions of variable size that are classified as macrocystic, microcystic, or mixed cystic LM. LMs commonly infiltrate soft tissues and can be found anywhere on the body, although they occur more frequently on the head, neck, and axilla.

CLAs are multifocal lymphatic vascular lesions involving both soft tissue and bone and often result in disruption of central collecting lymphatic channels. They include **generalized lymphatic anomaly (GLA), Gorham-Stout disease (GSD)** (Fig. 538.1), **kaposiform lymphangiomatosis (KLA), and central conducting lymphatic anomalies (CCLA)** (Fig. 538.2). CLAs are rare diseases with overlapping and variable clinical features. Common features include bone involvement, lymphatic leakage into the thoracic (chylous effusion) and abdominal (chylous ascites) cavities and mesenteric involvement leading to protein losing enteropathy. In addition to common features, GSD is uniquely associated with progressive cortical bone loss (see Fig. 538.1). KLA can be distinguished by the presence of spindle cells on histology, an aggressive clinical course, and evidence of consumptive coagulopathy and hemorrhage. CCLA, or channel type anomaly is characterized by dilation, malformation, and dysfunction of the major abdominal or thoracic lymphatic vessels.

LMs can also occur as combined malformations with other blood vessel types like capillaries (capillary-lymphatic malformation) or veins (lymphatic-venous malformation). LMs are commonly associated with **PIK3CA-related overgrowth spectrum (PROS) disorders**, which include **Klippel-Trenaunay syndrome (KTS), CLOVES (congenital lipomatous overgrowth, vascular malformations, epidermal nevi, and scoliosis/skeletal/spinal anomalies) and Proteus syndrome** (Fig. 538.3).

Genetics

Somatic, activating variants in the *PIK3CA* gene that encodes the p110α catalytic subunit of PI3K are present at variable frequencies in most (80%) isolated LMs and LMs associated with PROS. These activating *PIK3CA* variants are identical to those found in venous malformations and in many human cancers. The genetics of CLAs are far more diverse. Activating *PIK3CA* gene variants have been identified in several patients diagnosed with GLA. In addition, pathologic genetic variants in genes involved in the RAS-MAPK signaling pathway have been implicated in other CLAs. Activating *NRAS* gene variants are associated with KLA while two patients with GSD were found to have activating gene variants in *KRAS*. Somatic, pathologic genetic variants in both the *ARAF* and *CBL* genes have been found in patients diagnosed with CCLA as have inactivating germline pathogenic variants in *EPHB4*. The role of RAS/MAPK pathway activation in CLAs is further reinforced by the observation that patients with known RASopathies, including Noonan and Noonan-like syndrome, can present with central conducting lymphatic anomalies.

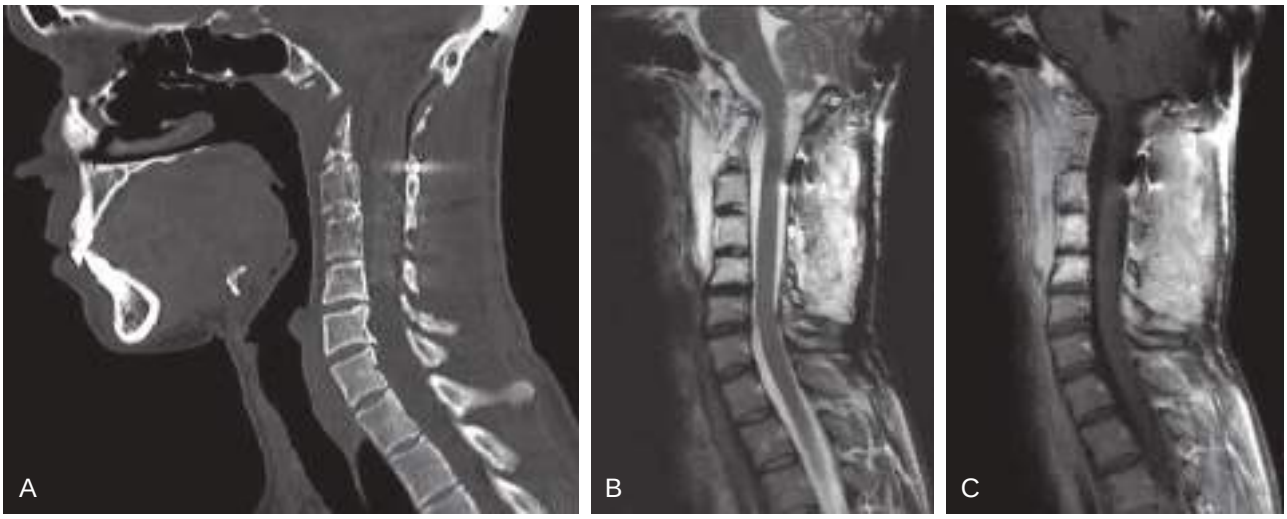

Fig. 538.1 Gorham–Stout disease. **A,** CT sagittal reformat. Multiple erosive changes in the occiput, clivus, and the cervical spine. (**B**) Sagittal T2-weighted fat-saturated (FS) MRI sequence. High signal is seen in the clivus and C 1–5 vertebral and the surrounding soft tissue. **C,** Postgadolinium T1 FS MRI. Enhancement is seen in the areas of osseous and soft tissue abnormalities. *(From Trenor III CC, Chaudry G. Complex lymphatic anomalies. Sem Pediatr Surg 2014;23:186–190. Fig. 3.)*

Fig. 538.2 Intranodal lymphangiogram in 15-year-old male with central conducting lymphatic anomaly and recurrent pericardial effusions. Stagnant flow is seen in the patulous superior portion of the thoracic duct. Direct puncture of the terminal portion demonstrates marked dilation with no spontaneous emptying.

Treatment

A decision to treat an LM depends on the anatomic location, involvement of local structures, and symptoms. Referral to a specialized vascular anomalies clinic with the expertise to guide appropriate imaging and treatment decisions is recommended. For localized macrocystic LMs, **interventional radiology (IR) administration of sclerosing agents** (OK432, ethanol, bleomycin) is most effective. For lesions involving skin and mucosa, **laser treatments** may be used.

Most patients with CLAs have extensive and invasive disease, necessitating systemic therapeutic approaches. The mTOR inhibitor **sirolimus** has had excellent effects in patients with vascular anomalies, including those patients with CLAs. A majority of CLA patients showed improvements in functional impairment and quality of life measures, whereas fewer showed evidence of decreased disease burden by imaging. **Combining sirolimus with bisphosphonates** may be even more effective in CLA patients with significant bone disease. **Alpelisib,** a *PIK3CA* inhibitor, has been used with success in patients with PROS and in a growing number of GLA patients with a known *PIK3CA* pathologic variant. Small numbers of patients with KLA who were known to have pathogenic variants in either NRAS or CBL experienced clinical improvement with **trametinib**, a MEK inhibitor. Trametinib also induced remodeling of the central lymphatics and induced symptom resolution in a patient with CCLA who had an *ARAF* pathogenic variant, as well a patient with Noonan syndrome and a *SOS1* pathogenic variant with severe lymphatic abnormalities.

LYMPHEDEMA

Lymphedema is a localized swelling caused by impaired lymphatic flow and can be primary (congenital) or acquired. **Primary lymphedemas** are grouped as LMs because they result from dysgenesis of lymphatic networks during early development. Primary lymphedema may be found in Turner syndrome, Noonan syndrome, autosomal dominantly inherited Milroy disease, and other chromosomal abnormalities. Pathologic variants in multiple genes, including the vascular endothelial growth factor receptor–3 gene *(VEGFR3), GJC2*, *PTPN14*, and *GATA2,* are associated with primary lymphedema (www.issva.org) (Table 538.1). Autosomal recessive, dominant or de novo pathogenic variants of *VEGFR3* produce Milroy disease. Pathologic variants in other genes are associated with specific syndromes: *CCBE1* (Hennekam), *FOXC2* (lymphedema distichiasis), *SOX18* (hypotrichosis-telangiectasia-lymphedema), *KMT2D/MLL2,* and *KDM6A* (Kabuki). Unilateral or bilateral lower extremity lymphedema in an adolescent may be Meige disease.

Acquired obstruction of the lymphatics is much more common than primary disorders and result from tumor, postirradiation fibrosis, and postinflammatory scarring. **Filariasis** is an important cause of lymphedema in Africa, Asia, and Latin America. One third of the 120 million infected persons (primarily older adolescents and adults) have lymphedema or a hydrocele. Injury to the major lymphatic vessels can cause

Fig. 538.3 Photographs and MRIs of participants with isolated LM, CLOVES, KTS, and FAVA. **A,** An 8-month-old male with isolated LM. Note swelling in deltoid region without cutaneous vascular signs. Coronal and sagittal fat-saturated T2-weighted MRI demonstrates macrocystic LM (a multilocular cystic mass) involving the anterolateral aspects of the right shoulder without muscular infiltration *(arrows)*; humeral head *star*. **B,** A 19-month-old female with CLOVES syndrome. Note asymmetric distribution of truncal lipomatous masses and bilateral lower extremity involvement. Coronal fat-saturated T1-weighted MRI after contrast administration demonstrates moderate heterogeneous enhancement of the bilateral truncal masses *(arrows)*. Axial T1-weighted MRI without contrast depicts truncal lipomatous overgrowth *(arrows)*; segment VI of the liver *(asterisk)*.

Continued

Fig. 538.3, cont'd **C,** A 3-yr-old male (KT4) with KTS. Note capillary-lymphatic malformation and overgrowth involving right lower extremity. Coronal and axial fat-saturated T2-weighted MRI shows the persistent marginal vein system *(bent arrows)* and marked enlargement of the subcutaneous tissues because of a combination of lymphatic fluid and fat *(straight arrow)*. There are also intramuscular venous malformations. **D,** A 9-yr-old male (F8) with FAVA of the left gastrocnemius muscle; note absence of overgrowth and cutaneous vascular anomalies. Sagittal fat-saturated T1-weighted MRI after contrast administration demonstrates the longitudinal distribution of the diffuse, fibro-adipose vascular anomaly *(arrows)*. Axial fat-saturated T2-weighted MRI with (upper) and without (lower) contrast. Note right head of the gastrocnemius muscle is diffusely replaced by a contrast enhancing heterogeneous soft tissue lesion *(arrows)*. CLOVES, congenital lipomatous overgrowth, vascular malformations, epidermal nevis, spinal/skeletal anomalies/scoliosis; FAVA, fibro-adipose vascular anomaly; KTS, Klippel-Trenaunay syndrome; LM, lymphatic malformations. *(From Luks VL, Kamitaki N, Vivero MP, et al. Lymphatic and other vascular malformative/overgrowth disorders are caused by somatic mutations in PIK3CA. J Pediatr. 2015;166:1048–1054.)*

Table 538.1 Chromosomal, Gene, and Syndromes Associated with Lymphedema

	SYNDROMES	KNOWN GENES, CHROMOSOMAL LOCI, INHERITANCE PATTERN
Primary lymphedema	Milroy disease Meige disease	*VEGFR3* AR, AD Familial lymphedema No known gene
Chromosomal aneuploidy	Turner syndrome Klinefelter syndrome Trisomy 21 Trisomy 13 Trisomy 18	45,X 47,XXY 47,XX+21; 47,XY+21 47,XX+13; 47,XY+13 47,XX+18; 47,XY+18
Other genetic and syndromic disorders	Emberger syndrome (primary lymphedema with myelodysplasia) Lymphedema-distichiasis syndrome Hennekam lymphangiectasia-lymphedema syndrome 1 (HKLLS1) Hennekam lymphangiectasia-lymphedema syndrome 2 (HKLLS2) Hypotrichosis-lymphedema-telangiectasia ± renal defect syndrome (HLTRS) Microcephaly with or without chorioretinopathy, lymphedema, or mental retardation (MCLMR) Microcephaly and chorioretinopathy, 1 (MCCRP1) Noonan syndrome Cholestasis-lymphedema syndrome (Aagenaes syndrome) Ectodermal dysplasia, hypo/anhidrotic, lymphedema and immunodeficiency; immunodeficiency 33	*GATA2*(3q21.3), AD *FOXC2*(16q24.1), AD *CCBE1*(18q21.32), AR *FAT4*(4q28.1), AR *SOX18*(20q13.33), AR/AD *KIF11*(10q23.33), AD *TUBGCP6*(22q13.33), AR *PTPN11*, *SOS1*, *RAF1*, *RIT1*, *KRAS*, AD *LSC1*, AR *IKBKG*, (Xq28), XLR

AD, Autosomal dominant; AR, Autosomal recessive; XLR, X-linked recessive.
Modified from Unolt M, Barry J, Digilio MC, et al. Primary lymphedema and other lymphatic anomalies are associated with 22q11.2 deletion syndrome. *Eur J Med Genetics.* 2018;61:411–415. Table 1.

collection of lymph fluid in the abdomen (chylous ascites) or chest (chylothorax).

Untreated lymphedema can be disabling and is associated with immune dysfunction, inflammation, fibrosis, adipose tissue overgrowth, and lymphangiosarcoma. Treatment modalities attempt to reduce localized swelling through massage, exercise, and compression. Lymphatic reconstructive procedures, including lymphovenous bypass and lymphatico-lymphatic anastomosis are increasingly used to achieve lymphatic decongestion, especially in the early stages of disease.

LYMPHANGIOLEIOMYOMATOSIS

Lymphangioleiomyomatosis **(LAM)** is characterized by proliferation of lymphatic endothelial cells and smooth muscle cells in the lungs, leading to airway and lymphatic obstruction, cyst formation, pneumothorax, and respiratory failure. It may initially be mistaken for asthma. LAM occurs in young females and is associated with pathogenic variants in the tuberous sclerosis tumor-suppressor gene *TSC2* in one third of cases. **Sirolimus** stabilizes lung function, reduces symptoms, and improves life quality. Lung transplantation may be required.

LYMPHANGITIS

Lymphangitis is an inflammation of the lymphatics that drain an area of infection. Tender, erythematous streaks extend proximally from the infected area. Regional nodes may also be tender. Group A streptococci and *Staphylococcus aureus* are the most common pathogens, and therapy should include antibiotics that treat these organisms.

Visit Elsevier eBooks+ at eBooks.Health.Elsevier.com for Bibliography.

Chapter 539

Lymphadenopathy

Zachary T. Graff and Richard L. Tower

Palpable lymph nodes are common in pediatrics and often pose a diagnostic challenge. Lymph node enlargement can be caused by proliferation of normal lymphoid elements or by infiltration with malignant or other phagocytic cells. In most patients, a careful history and a complete physical examination suggest the proper diagnosis.

DIAGNOSIS

What Is the Site of the Mass?

The differential diagnosis of a mass varies greatly based on anatomic location. Although pathologic masses can occur in any site, masses occurring in the supraclavicular and lower half of the neck are more likely to reflect pathologic lymphadenopathy than in other sites of the body.

Is the Mass a Lymph Node?

Nonlymphoid masses (cervical rib, thyroglossal cyst, branchial cleft cyst or infected sinus, cystic hygroma, goiter, thyroiditis, sternomastoid muscle tumor of infancy, neurofibroma) occur frequently in the neck and less often in other areas.

Is the Node Enlarged?

Lymph nodes are not usually palpable in the newborn. With antigenic exposure, lymphoid tissue increases in volume. They are not considered enlarged until their diameter exceeds 1 cm for cervical and axillary nodes, 1.5 cm for inguinal nodes, and epitrochlear >0.5 cm. Other lymph nodes usually are not palpable or visualized with plain radiographs.

What are the Characteristics of the Node?

Acutely infected nodes are usually tender. There may also be erythema and warmth of the overlying skin. Fluctuance suggests abscess formation. *Tuberculous* nodes may be matted. With chronic infection, many of these signs are not present. A firm, fixed, nonmobile (to adjacent or underlying tissues), nontender node should always raise the question of malignancy, regardless of the presence or absence of systemic symptoms or other abnormal physical findings. Tumors or tumor-involved nodes are often present for >2 weeks and may be associated with local extension (voice change, dysphagia, otalgia) or systemic signs (fever, weight loss, night sweats).

Is the Lymphadenopathy Localized or Generalized?

Generalized adenopathy (enlargement of >2 noncontiguous node regions) is caused by systemic disease (Table 539.1) and is often accompanied by abnormal physical findings in other systems. In contrast, *regional adenopathy* is most frequently the result of infection in the involved node and/or its drainage area (Table 539.2). When caused by infectious agents other than bacteria, adenopathy may be characterized by atypical anatomic areas, a prolonged course, a draining sinus, lack of prior pyogenic infection, and unusual clues in the history (cat scratches, tuberculosis exposure, venereal disease). The histopathologic pattern may also help with a differential diagnosis (Table 539.3).

Table 539.1 Differential Diagnosis of Generalized Lymphadenopathy

NEONATE	CHILD	ADOLESCENT
COMMON CAUSES		
CMV	Nonspecific viral infections	Viral infections
HIV	EBV	EBV
Syphilis	CMV	CMV
Toxoplasmosis	HIV	HIV
	Toxoplasmosis	Measles
	Measles	Toxoplasmosis
		Syphilis
RARE CAUSES		
Chagas disease (congenital)	Serum sickness	Serum sickness
Congenital leukemia	SLE, JIA	SLE, JIA
Congenital tuberculosis	Leukemia/lymphoma	Leukemia/lymphoma
Reticuloendotheliosis	Tuberculosis (miliary)	Tuberculosis
Metabolic storage disease	Sarcoidosis	Sarcoidosis
Histiocytic disorders	DRESS	DRESS
Listeria sepsis	Fungal infections	Fungal infections
	Plague	Plague
	Leptospirosis	Leptospirosis
	Brucellosis	Brucellosis
	Langerhans cell histiocytosis	Drug reaction (immune)
	Macrophage activation syndrome	Castleman disease
	Hemophagocytic lymphohistiocytosis	Rickettsial infection
	Castleman disease (very rare in this age group)	
	Chronic granulomatous disease	
	Sinus histiocytosis (Rosai-Dorfman disease)	
	Kikuchi-Fujimoto disease	
	Autoimmune lymphoproliferative disease (ALP)	
	Rickettsial infection	

CMV, Cytomegalovirus; DRESS, drug reaction, eosinophilia, systemic symptoms; EBV, Epstein-Barr virus; JIA, juvenile idiopathic arthritis (as Still disease); SLE, systemic lupus erythematosus.

From Kliegman RM, Toth H, Bordini BJ, Basel D, eds. *Nelson Pediatric Symptom-Based Diagnosis: Common Diseases and Their Mimics*, 2nd ed. Philadelphia: Elsevier, 2023: Table 48.3, p. 891.

TREATMENT

Evaluation and treatment of lymphadenopathy is guided by the probable etiologic factor, as determined from the history and physical examination. Many patients with **cervical adenopathy** have a history compatible with viral infection and are observed without intervention. If bacterial infection is suspected, antibiotic treatment covering at least streptococci and staphylococci is indicated. Those who do not respond to oral antibiotics, as demonstrated by persistent swelling and fever, require intravenous (IV) antistaphylococcal antibiotics. If there is no response in 1-2 days, or if there are signs of airway obstruction or significant toxicity, ultrasound, CT, or MRI of the neck with contrast should be obtained. If *pus* is present, it may be aspirated, or if it is extensive, it may require incision and drainage. Gram stain and culture of the pus should be obtained. The sizes of involved nodes should be documented before treatment. Failure to decrease in size within 14 days also suggests the need for further evaluation. This evaluation may include a complete blood cell count (CBC) with differential; Epstein-Barr virus, cytomegalovirus, *Toxoplasma,* and *Bartonella henselae* titers; anti–streptolysin O or anti-DNase B serologic tests; tuberculin skin test or gamma interferon assay; and chest radiograph to evaluate for mediastinal adenopathy. If these are not diagnostic, consultation with an infectious diseases or oncology specialist may be helpful. Biopsy should be considered if there is persistent or unexplained fever, weight loss, night sweats, supraclavicular location, mediastinal mass, hard nodes, or fixation of the nodes to surrounding tissues. Biopsy may also be indicated if there is an increase in size over baseline in 2 weeks, no decrease in size in 4-6 weeks, no regression to "normal" in 8-12 weeks, or if new signs and symptoms develop.

Table 539.2 Sites of Regional Lymphadenopathy and Associated Diseases

CERVICAL
Oropharyngeal infection (viral, group A streptococcal, staphylococcal, or fusobacterial)
Scalp infection (tinea)
Mycobacterial lymphadenitis (tuberculous and nontuberculous mycobacteria)
Viral infection (EBV, CMV, HHV-6, measles)
Cat-scratch disease
Kawasaki disease
Multisystem inflammatory syndrome in children (MIS-C) associated with COVID-19
Thyroid disease
Kimura disease
Rosai-Dorfman (sinus histiocytosis)
Periodic fever, aphthous stomatitis, pharyngitis, cervical adenopathy (PFAPA) syndrome
Kikuchi-Fujimoto disease
Unicentric Castleman disease
ANTERIOR AURICULAR
Conjunctivitis or other eye infections
Oculoglandular tularemia, cat-scratch disease, EBV, adenovirus
POSTERIOR AURICULAR
Otitis media
Viral infection (especially rubella, parvovirus)
SUPRACLAVICULAR
Malignancy or infection in the mediastinum (right)
Metastatic malignancy from abdomen (left)
Lymphoma
Tuberculosis
EPITROCHLEAR
Hand infection, arm infection*
Lymphoma†
Sarcoidosis
Syphilis
EBV
HIV
INGUINAL
Urinary tract infection
Sexually transmitted infection (especially syphilis or lymphogranuloma venereum)
Lower extremity suppurative infection
Plague
HILAR (NOT PALPABLE, FOUND ON CHEST RADIOGRAPH OR CT) (SEE TABLE 539.1)
Tuberculosis†
Histoplasmosis†
Blastomycosis†
Coccidioidomycosis†
Leukemia/lymphoma†
Hodgkin disease†
Metastatic malignancy*
Sarcoidosis†
Castleman disease
AXILLARY
Cat-scratch disease
Arm infection
Malignancy of chest wall
Leukemia/lymphoma
Brucellosis

*Unilateral.
†Bilateral.
CMV, Cytomegalovirus; EBV, Epstein-Barr virus; HHV-6, human herpesvirus 6.
From Kliegman RM, Toth H, Bordini BJ, Basel D, eds. *Nelson Pediatric Symptom-Based Diagnosis: Common Diseases and Their Mimics*, 2nd ed. Philadelphia: Elsevier, 2023: Table 48.2, p. 890.

Differentiating benign disorders from a malignancy may initially be difficult. Hard, nontender, nonerythematous nodes involving multiple regions (including mediastinum and abdomen), hepatic or splenic enlargement, fever, night sweats, and weight loss suggest malignancy or a granulomatous process. Persistence of symptoms and lymphadenopathy >2 weeks and certain locations (supraclavicular, mediastinal, abdominal) also suggest malignancy. Cytopenias and elevated blood lactate dehydrogenase are associated with malignancy and certain infectious and inflammatory disorders. Ultrasound is useful in distinguishing malignancy from reactive nodes. CT with contrast is helpful in identifying other affected nodes and organs. Although fine needle aspiration (FNA) is sometimes used as an initial approach to diagnosis, excisional biopsies are often needed and are the preferred diagnostic approach to fully appreciate the lymph node architecture and genomic profiling when malignant conditions are being considered.

Visit Elsevier eBooks+ at eBooks.Health.Elsevier.com for Bibliography.

539.1 Kikuchi-Fujimoto Disease (Histiocytic Necrotizing Lymphadenitis)

Zachary T. Graff and Richard L. Tower

Kikuchi-Fujimoto disease is a rare, usually self-limiting disease that is seen in all ethnic groups; children and adults may be affected. Familial cases have been reported. The etiology is unknown, although infectious and autoimmune diseases such as systemic lupus erythematosus (SLE) have been associated. The differential diagnosis includes infectious lymphadenitis, lymphoma, tuberculosis, and SLE.

Presentation is varied but most often presents as firm, painful unilateral posterior cervical adenopathy evolving over several weeks. Fever is frequently reported. Labs are often normal; however, elevated erythrocyte sedimentation rate (ESR), elevated CRP, atypical lymphocytosis, and leukopenia can be seen. Nodes range in size from 0.5-6.0 cm, are painful or tender in only 50% of cases, may be multiple, and must be differentiated from lymphoma. Node involvement may occasionally be bilateral or rarely present in axillary, supraclavicular, or intraabdominal lymph nodes. Ultrasound usually shows multiple conglomerated, unilateral cervical lymphadenopathy with perinodal fat swelling and even size distribution. Aseptic meningitis is an uncommon associated feature.

The diagnosis is made by lymph node biopsy. Histologic features include paracortical lymph node expansion with patchy, well-circumscribed areas of necrosis showing karyorrhexis, an absence of neutrophils and eosinophils, a CD68+/MPO+ histiocytic infiltrate, and CD123+/TCL1+ plasmacytoid dendritic cells. Kikuchi-Fujimoto disease usually resolves within 6 months, although relapses have occurred up to 16 years later. Treatment is typically symptomatic including rest and analgesics. Therapy with systemic steroids is reserved for patients with severe symptoms. Recurrences occur in ~5-20% depending on site (higher recurrences with bone, CNS, or skin involvement). Patients should be followed for the possible development of systemic lupus erythematosus. Rarely, the disease has been fatal.

Visit Elsevier eBooks+ at eBooks.Health.Elsevier.com for Bibliography.

539.2 Sinus Histiocytosis with Massive Lymphadenopathy (Rosai-Dorfman Disease)

Zachary T. Graff and Richard L. Tower

The uncommon, benign, and usually self-limited Rosai-Dorfman disease (RDD) is a non-Langerhans cell histiocytosis that has a worldwide distribution but is more common in individuals of African descent. The etiology is unknown, but immune dysfunction is suspected. Lesional histiocytes are $S100^+$, $CD68^+$, and $CD1a^-$. It is not a single entity, but a

Table 539.3 Differential Diagnosis for the Histologic Patterns Seen in Pediatric Lymphadenopathies

HISTOLOGIC PATTERN	DIFFERENTIAL DIAGNOSIS	KEY FEATURES
Isolated follicular hyperplasia	Nonspecific reactive pattern Viral infections HIV lymphadenitis Measles Follicular lymphoma Primary immunodeficiencies	Multinucleated Warthin-Finkeldey cells seen in both HIV and measles Expansile irregular follicles in acute HIV Normal polarization of germinal center cells and phenotyping helpful to rule out follicular lymphoma
Follicular hyperplasia with PTGC	Nonspecific reactive pattern Nodular lymphocyte predominant Hodgkin lymphoma	Cytologically atypical cells seen in nodular lymphocyte predominant Hodgkin lymphoma are absent in PTGC
Paracortical hyperplasia	EBV infectious mononucleosis HSV1/2 CMV Varicella Measles Classic Hodgkin lymphoma Drug-induced lymphadenopathy Primary immunodeficiencies Non-Hodgkin B-cell and T-cell lymphoma	Polymorphic with numerous immunoblasts RS-like cells express CD20, unlike RS cells of classic Hodgkin lymphoma Warthin-Finkeldey cells may be seen in measles and HSV lymphadenitis Well-delineated necrosis in HSV Intranuclear inclusions may be seen in CMV, HSV, and varicella Associated monocytoid B-cell hyperplasia seen in CMV lymphadenitis
Suppurative	Bacterial lymphadenitis, Staphylococcus, Streptococcus, Haemophilus, Yersinia, *Francisella tularensis*, Brucella HSV lymphadenitis Kawasaki	Poorly formed granulomas also may be seen in bacterial infections Necrotic foci beneath the capsule seen in Kawasaki
Necrotizing granulomas	Mycobacteria, tuberculous, and nontuberculous Fungal infections CSD Kikuchi-Fujimoto lymphadenitis/SLE	Acellular (caseating) necrosis with numerous giant cells seen in mycobacterial and fungal infections CSD palisading histiocytes with neutrophilic microabscesses Kikuchi-Fujimoto lymphadenitis/SLE necrosis with nuclear debris and absence of neutrophils; C-shaped histiocytes; clusters of immunoblasts and plasmacytoid dendritic cells
Nonnecrotizing granulomas	Sarcoidosis; infections; nonspecific	
Histiocytoses	HLH, Rosai-Dorfman disease	
Miscellaneous	Toxoplasmosis • Triad: follicular hyperplasia, monocytoid B-cell hyperplasia, epithelioid histiocytes extend into lymphoid follicles • Kimura • Follicular hyperplasia and interfollicular eosinophils	

CMV, cytomegalovirus; CSD, cat-scratch disease; EBV, Epstein Barr virus; HLH, hemophagocytic lymphohistiocytosis; HSV, herpes simplex virus; PTGC, progressive transformation of germinal centers; SLE, systemic lupus erythematosus.
From Faraz M, Rosando FGN. Reactive lymphadenopathies. *Clin Lab Med.* 2021;41:433–451. Table 1.

pattern, and can be associated with neoplasia or autoimmune disease. It can be sporadic or associated with inherited conditions. Some patients have somatic pathogenic variants in *NRAS*, *KRAS*, and *MAP2K1*. Familial RDD has been noted in patients with pathogenic variants in *SLC29A3*. RDD may coexist with SLE, JIA, and autoimmune hemolytic anemia.

Patients can be classified as classical (nodal) RDD or extranodal RDD. **Classical RDD** patients present with massive *bilateral*, painless, mobile cervical adenopathy with or without fever, night sweats, and weight loss. Other lymph node involvement can include mediastinal, axillary, and inguinal, although retroperitoneal involvement is rare. **Extranodal RDD** occurs in 43% of cases. Soft tissue involvement has been reported in many organ systems. The most common sites are the skin, followed by the nasal cavity and sinuses, palate, orbit, bone, and central nervous system. Lab abnormalities can include normocytic anemia, leukocytosis (typically neutrophilia), elevated ESR, and polyclonal elevation of immunoglobulin G (hypergammaglobulinemia). Initial imaging studies are determined by symptoms and sites of suspected disease.

A biopsy that demonstrates histiocytes with hypochromatic nuclei with pale cytoplasm containing engulfed erythrocytes, plasma cells, and lymphocytes (emperipolesis), and immunoreactivity to S100 protein, in conjunction with expected clinical features, is diagnostic. IgG4-positive cells are often abundant. Occasionally, autoantibodies to erythrocytes or synovium may be present. The differential diagnosis includes Langerhans cell histiocytosis, myeloproliferative disorders, lymphoma, and hyper-IgG4 syndrome. After diagnosis, whole-body imaging with MRI or PET scan is recommended to evaluate for extranodal RDD.

Observation alone is a reasonable treatment choice for patients with uncomplicated nodal/cutaneous disease, as spontaneous remissions are seen in 20–50% of these patients. Symptomatic patients may benefit from surgical resection or debulking with the presence of single-site disease. Systemic therapy is typically reserved for severe, refractory, multifocal, or unresectable disease. Steroids are helpful in reducing nodal size; however, durable responses are often not seen with steroids alone. Various immunomodulatory (sirolimus) and chemotherapy regimens have been used successfully in severe disease, with treatment courses ranging from 6-12 months followed by close observation. Targeted therapies, including MEK inhibitors, have shown promising early results with studies ongoing. Radiation therapy has modest efficacy in RDD but has been used successfully in emergent therapy with visual or airway compromise. RDD may recur for many years with an unpredictable clinical course.

Visit Elsevier eBooks+ at eBooks.Health.Elsevier.com for Bibliography.

539.3 Castleman Disease (Angiofollicular Lymph Node Hyperplasia)

Zachary T. Graff and Richard L. Tower

Castleman disease (CD) is an uncommon nonmalignant B-cell lymphoproliferative disorder and is also called **angiofollicular lymph node hyperplasia**. CD causes lymph node enlargement and is classified as either unicentric (involving a single lymph node or lymph node region) or multicentric (involving multiple lymph node regions). **Unicentric CD** typically presents with enlargement of a single bulky lymph node, most often in the mediastinum, neck, or abdomen, which can be asymptomatic or present with locally compressive symptoms. Patients may have fever, night sweats, weight loss, and fatigue. Diagnosis is made by an excisional lymph node biopsy. Staging imaging is performed with CT scan of chest/abdomen/pelvis or PET-CT scan to evaluate for multicentric disease. Management includes surgical resection when possible and is associated with a benign course, although patients should be educated on an increased risk of lymphoma.

Multicentric CD is subclassified based on the etiologic driver of the disease, either human herpes virus-8 (HHV-8), peripheral neuropathy, organomegaly, endocrinopathy, monoclonal plasma cell disorder, skin changes (POEMS) syndrome, or idiopathic. An underlying immunocompromised state is the primary risk factor for HHV-8 CD, particularly patients with HIV. Other forms of multicentric CD have no known risk factors. HHV-8 and idiopathic multicentric CD are driven by the excessive production of interleukin-6 (IL-6). Lymphadenopathy is often small volume and is present in peripheral and central lymph node chains. Constitutional symptoms such as fever, night sweats, and weight loss are more common at presentation compared to unicentric CD. Fluid collections including ascites, cytopenias, and liver/kidney dysfunction are also seen and indicate more aggressive disease. Diagnosis is again made by excisional lymph node biopsy as well as consistent clinical features. To determine type of multicentric CD, testing for HIV, HHV-8, and evaluation for POEMS (polyneuropathy, organomegaly, edema/endocrinopathy, monoclonal-protein, skin) syndrome is needed. Serum inflammatory markers are often tested at baseline and used to track disease. The differential diagnosis is broad even after lymph node biopsy, including infection, autoimmune disease, and malignancy. There is no standard treatment for multicentric Castleman disease. For symptomatic HHV-8+ multicentric CD, rituximab +/- etoposide with antiretroviral therapy for HIV+ patients have achieved excellent relapse-free survival. Idiopathic multicentric CD is managed with anti-IL-6 directed therapy (siltuximab) and steroids. Even after initial responses, symptoms can return after stopping therapy. Rituximab, steroids, and additional immunomodulatory medications (particularly the mTOR inhibitor sirolimus) are used next in patients that have had an inadequate response to therapy. Cytotoxic chemotherapy can be used for severe disease with organ dysfunction after failure of first-line therapy.

TAFRO (thrombocytopenia, anasarca, fever, reticulum fibrosis, organomegaly) syndrome is thought to be a subtype of multicentric Castleman disease based on the histologic appearance of the lymph node. Although there are overlapping features, TAFRO may be a distinct entity (Fig. 539.1).

Visit Elsevier eBooks+ at eBooks.Health.Elsevier.com for Bibliography.

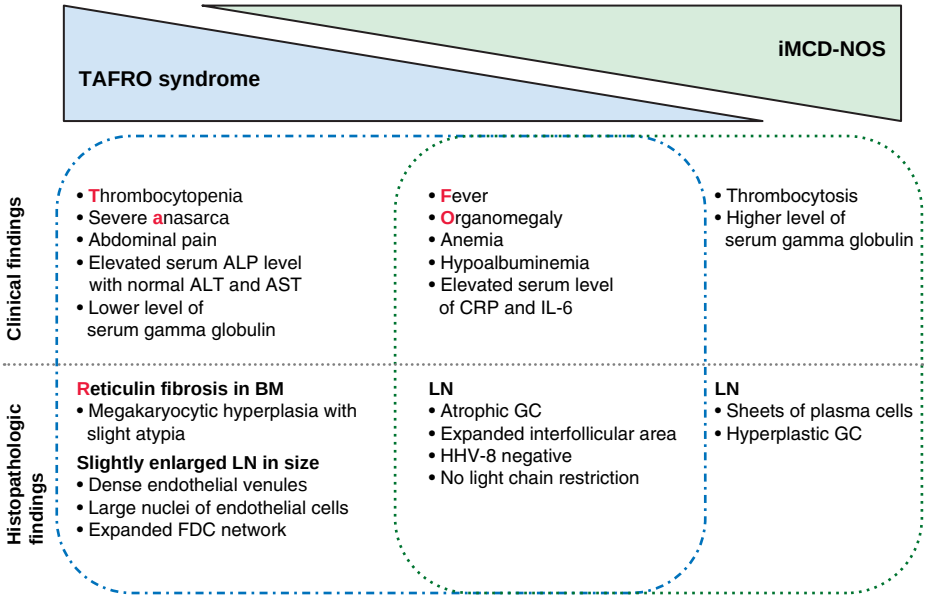

Fig. 539.1 Summary of the clinical and histopathologic features of TAFRO syndrome and iMCD-NOS. Although TAFRO syndrome and iMCD-NOS have clinicopathologic features in common, TAFRO syndrome has unique characteristics that can distinguish it from iMCD-NOS. ALP, alkaline phosphatase; ALT, Alanine transaminase; AST, aspartate transaminase; BM, bone marrow; CRP, C-reactive protein; FDC, follicular dendritic cell; GC, germinal center; HHV, human herpes virus; LN, lymph node; iMCD, idiopathic multicentric Castleman disease; NOS, not otherwise specified; TAFRO, thrombocytopenia, anasarca, fever, reticulin fibrosis, organomegaly. *(From Igawa T, Sato Y. TAFRO syndrome. Hematol Oncol Clin N Am. 2018;32:107–118. Fig. 4.)*

Cancer and Benign Tumors

PART XX

Chapter 540

Epidemiology of Childhood and Adolescent Cancer

Barbara L. Asselin

Cancer in patients younger than 20 years is uncommon, with an age-adjusted annual incidence of 19.6 per 100,000 children age 0-19 years, representing only approximately 1% of all new cancer cases in a year in the United States, or an estimated 16,000 new cases in 2021. This translates to nearly a 1 in 300 chance of developing cancer by age 20 years. Although the relative 5-year survival rates have improved from 61% in 1975–1977 to 85.1% in 2011–2017 in all age-groups 0-19 years (Fig. 540.1), **malignant neoplasms** remain the leading cause of disease-related (noninjury) mortality (9%) among persons 1-19 years of age, with 1,800-1,900 cancer-related deaths annually in the United States among children and adolescents 0-19 years of age. The relative contribution of cancer to the overall mortality in infants 0-1 year old and adolescents 15-19 years old is lower than for children age 1-14 years. The impressive improvements in survival over the last four decades are attributed primarily to advances in treatment, supportive care, and enrollment in clinical trials for the majority of patients. Ongoing multi-institutional cooperative clinical trials are investigating novel therapies and ways to improve survival rates further while decreasing treatment-related long-term complications. Because increasingly more patients survive their disease, clinical investigations also are focusing on the quality of life among survivors and the late outcomes of therapy for pediatric and adult survivors of childhood cancer. The **National Cancer Institute** (NCI; https://www.cancer.gov/types/childhood-cancers/) estimated that as of January 1, 2018, there were approximately 483,000 persons alive (in all age-groups) who had survived childhood cancer (diagnosed at ages 0-19 years). Given the overall improvement in survival rates coupled with the increased incidence of childhood cancer observed in recent decades, the number of survivors will continue to increase.

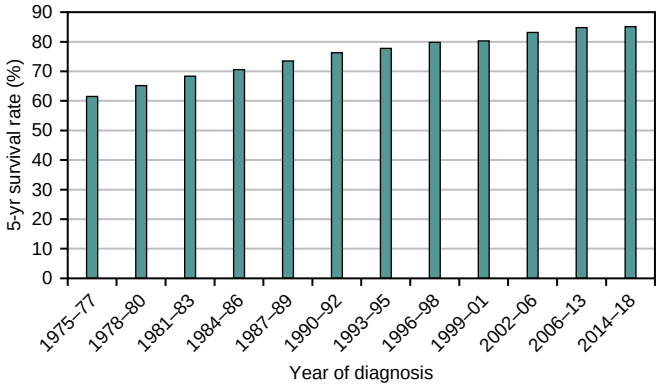

Fig. 540.1 The 5-year relative survival rates (%) by year of diagnosis of all cancers in children ≤19 years old. The difference between the periods 1975–1977 and 2014–2018 is statistically significant ($p < .05$). Rates based on follow-up of patients into 2018 from Surveillance, Epidemiology, and End Results (SEER) database. *(Data compiled from Howlader N, Noone AM, Krapcho M, et al., eds. SEER Cancer Statistics Review, 1975-2018. Bethesda, MD: National Cancer Institute. https://seer.cancer.gov/csr/1975_2018/. Based on November 2020 SEER data submission, posted to the SEER website, April 2021.)*

Pediatric malignancies differ greatly from adult malignancies in both prognosis and distribution by histology and tumor site. **Lymphohematopoietic cancers** (i.e., acute lymphoblastic leukemia, myeloid leukemia, Hodgkin and non-Hodgkin lymphomas) account for approximately 40%, **central nervous system cancers** for approximately 30%, and **embryonal tumors** and **sarcomas** for approximately 10% among the broad categories of childhood cancers (Table 540.1). In contrast, the **epithelial tumors** (or **adenocarcinomas**) of organs such as lung, colon, breast, and prostate often seen among adults, are rare malignancies in children. Incidence patterns in the pediatric age-group show two peaks, in early childhood and in adolescence (Fig. 540.2). During the first year of life, *embryonal tumors* such as neuroblastoma, nephroblastoma (Wilms tumor), retinoblastoma, rhabdomyosarcoma, hepatoblastoma, and medulloblastoma are most common (Figs. 540.3 and 540.4). These tumors are much less common in older children and adults after cell differentiation processes have slowed considerably. Embryonal tumors, acute leukemias, non-Hodgkin lymphomas, and gliomas peak in incidence from 2-5 years of age. As children age, bone malignancies, Hodgkin disease, gonadal germ cell malignancies (testicular and ovarian carcinomas), and other carcinomas increase in incidence. Adolescence is a transitional period between the common early childhood malignancies and characteristic carcinomas of adulthood (see Fig. 540.4).

Incidence rates also vary by *gender* (generally higher in males vs females), *ethnicity* (leukemia more common in Hispanic children than White or Black children; brain tumors more common in White children), and between countries (data assembled by the International Agency for Research in Cancer in Lyon, France, http://www.iarc.who.int/). These variations are not fully understood but likely reflect differences in genetic susceptibility and environmental exposures related to both known and unknown causes and risk factors for cancer (Table 540.2). Over the past four decades, 1975–2018, the U.S. Surveillance, Epidemiology, and End Results Program (SEER) data show some increases in the incidence of children and adolescents diagnosed with cancer (annual percent change about 1%), particularly in occurrence of leukemia, brain, and lymphoma and among adolescents. Interestingly, a similar increased incidence of malignancies diagnosed in childhood was observed between 1980 and 2010 in an international population-based registry study involving 62 countries. Reasons postulated to explain these increases include, but are not limited to, improved diagnosis, better record keeping, and development of data registries. Further analysis of trends among subpopulations, geographic variations, and incidence rates in high-income vs low-income countries are needed to clarify the role of *genetic ancestry, environmental factors,* and *technology* as explanations of these time trends in cancer in children.

Table 540.1 Age-Adjusted Incidence and Survival Rates of Malignant Neoplasms by Tumor Type in U.S. Children

	ANNUAL INCIDENCE RATES PER 1 MILLION CHILDREN, 2014–2018					5-YR SURVIVAL (%), AGE ≤19 YR AT DIAGNOSIS, 2011–2017
	AGE <1 YR	AGE 1-4 YR	AGE 5-9 YR	AGE 10-14 YR	AGE 15-19 YR	
All malignancies combined	265	227	137	164	252	85.1
All Leukemias (ALL/AML)	51 (18/20)	93 (78/11)	4.5 (37/4)	36 (24/8)	37 (19.5/10)	85 (89/68)
Lymphoma (Hodgkin)	— (—)	9 (1)	17 (3.5)	28 (13)	54 (33)	94 (98)
CNS tumors	46	54	50	52	64	74
Neuroblastoma	56	21	4	1	1	82
Nephroblastoma/Wilms (renal cell carcinoma)	16 (—)	19 (—)	6 (—)	1 (1)	— (1.5)	93
Bone	—	2	7	16	15	71
Soft tissue sarcomas	14	11	9	13	17	74
Retinoblastoma	31.5	8	—	—	—	96
Hepatoblastoma (hepatic carcinoma)	14 (—)	6 (—)	0.8 (—)	0.4 (0.7)	— (1.5)	82
Germ cell tumors	20	4	3	9	29	92
Malignant epithelial cancer	2.5	2	6	24	68.5	94
Thyroid / melanoma	–*/–†	–*/1†	2*/2†	11*/3†	35*/9†	(99*/94†)

*Thyroid carcinoma.
†Malignant melanoma.
—, Indicates that the rate could not be calculated with <16 cases for the time interval.
ALL, Acute lymphoid leukemia; AML, acute myeloid leukemia; CNS, central nervous system.
Data compiled from Howlader N, Noone AM, Krapcho M, et al., eds. SEER cancer statistics review, 1975-2018. Bethesda, MD: National Cancer Institute, 2020. Based on November 2020 SEER data submission, posted to SEER website, April 2021.
Based on the International Classification of Childhood Cancer (ICCC). Rates are per 1 million children and are age-adjusted to the 2000 U.S. standard population.

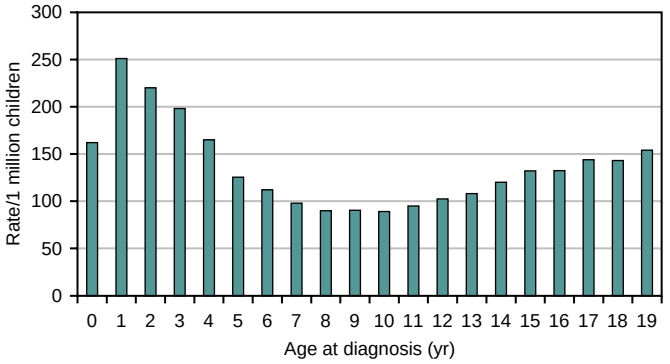

Fig. 540.2 Age-specific cancer incidence rates per 1 million children within the United States. *(Rates based on data from 2000–2017 from Surveillance, Epidemiology, and End Results [SEER] database http://seer.cancer.gov/csr/1975_2018/ and data compiled from Marcotte EL, Domingues AM, Sample JM, et al. Racial and ethnic disparities in pediatric cancer incidence among children and young adults in the United States by single year of age. Cancer 2021;127[19]:3651–3663. http://seer.cancer.gov/csr/1975_2018/.)*

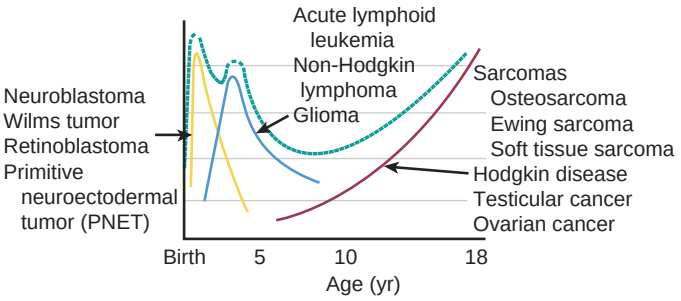

Fig. 540.3 Generalized incidence of the most common types of cancer in children by age. The cumulative incidence of all cancers is shown as a *dashed green line. (Courtesy Archie Bleyer, MD.)*

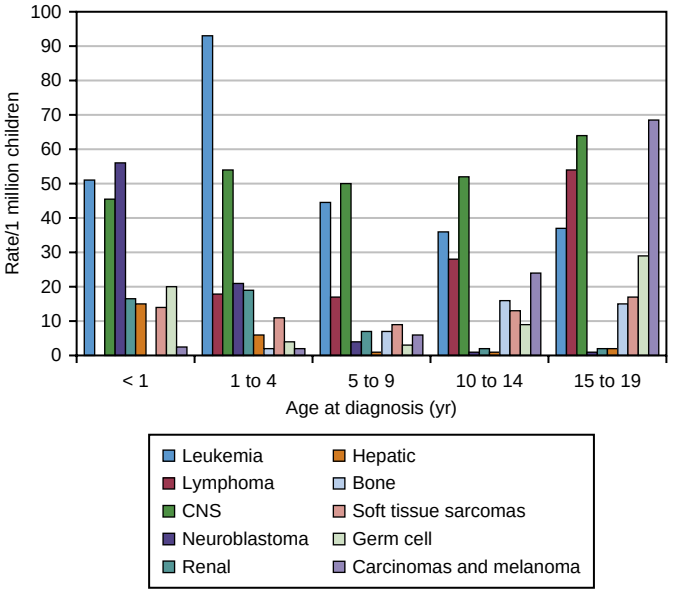

Fig. 540.4 Surveillance, Epidemiology, and End Results (SEER) cancer incidence rates per 1 million children by International Classification of Childhood Cancer (ICCC) and age <20 years. CNS, Central nervous system. *(Data compiled from Howlader N, Noone AM, Krapcho M, et al., eds. SEER cancer statistics review, 1975-2018. Bethesda, MD: National Cancer Institute, 2020. http://seer.cancer.gov/csr/1975_2018/. Based on November 2020 SEER data submission, posted to the SEER website, April 2021.)*

Table 540.2 Known Risk Factors for Selected Childhood Cancers

CANCER TYPE	RISK FACTOR	COMMENTS
Acute lymphoid leukemia	Ionizing radiation	Therapeutic irradiation for cancer treatment
	Ethnicity	Hispanic children have higher incidence compared with White or Black children White children have a higher rate than Black children
	Immunodeficiency	SCID, Wiskott-Aldrich syndrome
	Genetic factors*	Down syndrome is associated with an estimated 10-20–fold increased risk NF1 Li-Fraumeni syndrome (*TP53* pathogenic variants) Noonan syndrome Chromosome breakage syndromes Bloom syndrome Ataxia-telangiectasia
Acute myeloid leukemias/ myelodysplastic syndrome	Chemotherapeutic agents	Alkylating agents and epipodophyllotoxins associated with risk of secondary leukemia
	Genetic factors*	Down syndrome (particularly acute megakaryocytic leukemia) NF1 Fanconi anemia and other inherited marrow failure syndromes Li-Fraumeni syndrome GATA2 deficiency Noonan syndrome Familial monosomy 7 and other chromosomal pathogenic variants
Brain cancers	Therapeutic ionizing radiation to the head	Radiation therapy as part of cancer treatment
	Genetic factors*	NF1 is strongly associated with optic gliomas, and, to a lesser extent, with other central nervous system tumors Li-Fraumeni syndrome Tuberous sclerosis Noonan syndrome Von Hippel-Landau syndrome FAP syndrome
Hodgkin disease	Family history	Monozygotic twins and siblings of cases are at increased risk
	Infections	EBV is associated with increased risk
Non-Hodgkin lymphoma	Immunodeficiency	Congenital immunodeficiency disorders (e.g., SCID and Wiskott-Aldrich syndrome) Immunosuppressive therapy for other conditions associated with increased risk
	Infections	EBV is associated with Burkitt lymphoma PTLD-EBV plays role in development of B-cell lymphoproliferative disease seen in immunocompromised hosts, especially those on immunosuppression following organ transplantation
Osteosarcoma	Ionizing radiation	Cancer radiation therapy
	Chemotherapy	Alkylating agents increase risk
	Genetic factors*	Li-Fraumeni syndrome Second malignancy in hereditary retinoblastoma with *RB1* pathogenic variant
Ewing sarcoma	Ethnicity	White children have about a ninefold higher incidence rate than Black children in the United States
Neuroblastoma		Beckwith-Wiedemann syndrome Li-Fraumeni
Retinoblastoma	Genetic factors*	Familial; pathogenic variant of *RB1* without other syndromic features—also with high risk of second malignancies
Wilms tumor	Genetic factors*	WAGR syndrome *WT1* germline pathogenic variant Beckwith-Wiedemann syndrome Li-Fraumeni syndrome
	Ethnicity	Asian children reportedly have about half the rates of White and Black children
Rhabdomyosarcoma	Genetic factors*	Li-Fraumeni syndrome NF1 Beckwith-Wiedemann syndrome DICER1 syndrome Gorlin syndrome

Continued

Table 540.2 Known Risk Factors for Selected Childhood Cancers—cont'd

CANCER TYPE	RISK FACTOR	COMMENTS
Hepatoblastoma	Genetic factors*	Beckwith-Wiedemann syndrome Gardner syndrome; FAP
Malignant germ cell tumors	Cryptorchidism	Cryptorchidism is a risk factor for testicular germ cell tumors

*See Chapter 541 for additional information.
SCID, Severe combined immunodeficiency syndrome; NF1, neurofibromatosis type1; FAP, familial adenomatous polyposis; EBV, Epstein-Barr virus; PTLD, posttransplant lymphoproliferative disorder; WAGR, Wilms, aniridia, genitourinary anomalies, and retardation syndrome.
From Ripperger T, Bielack SS, Borkhardt A, et al. Childhood cancer predisposition syndromes – a concise review and recommendations by the Cancer Predisposition Working Group of the Society for Pediatric Oncology and Hematology. *Am J Med Genet.* 2017;173:1017–1037, with data compiled from Porter CC, Druley TE, Erez A, et al. Recommendations for surveillance for children with leukemia-predisposing conditions. *Clin Cancer Res.* 2017;23(11):e14–e22.

Childhood cancer includes a diverse array of malignant tumors, termed "cancers," and nonmalignant tumors arising from disorders of genetic processes involved in control of cellular growth and development. Although many genetic conditions are associated with increased risks for childhood cancer, such conditions are believed to account for 8–10% of all occurrences (see Chapter 541). The most notable germline genetic conditions that impart susceptibility to childhood cancer are Li-Fraumeni *(P53)* syndrome, neurofibromatosis types 1 and 2, Down syndrome, Beckwith-Wiedemann syndrome, tuberous sclerosis, von Hippel-Landau disease, Noonan syndrome, ataxia-telangiectasia, and familial adenomatous polyposis syndrome and associated conditions (see Table 540.2). Consensus guidelines for surveillance screening in pediatric cancer predisposition syndromes were developed during a workshop of the Pediatric Cancer Working Group of the **American Association for Cancer Research** (AACR) and are available online through the AACR Open Access journal website (http://clincancerres.aacrjournals.org/content/23/11).

Compared with adult epithelial tumors, an extremely small fraction of pediatric cancers appears to be explained by known **environmental exposures** (see Table 540.2). Ionizing radiation exposure and several chemotherapeutic agents explain only a small number of pediatric cases (see Chapter 758). The association between fetal exposures and pediatric cancer is largely not established, with the exception of maternal diethylstilbestrol intake during pregnancy and subsequent vaginal adenocarcinoma in adolescent daughters. Environmental exposures that have been studied without convincing evidence for a causal role include nonionizing power frequency electromagnetic fields, pesticides, parental occupational chemical exposures, dietary factors, in vitro fertilization, and tobacco smoke exposure. Viruses associated with certain pediatric cancers include **polyomaviruses** (BK, JC, SV40) associated with brain cancer and **Epstein-Barr virus** (EBV) associated with certain subtypes of non-Hodgkin lymphoma.

The etiology of cancer in children still is poorly understood, and epidemiology studies demonstrate that the likely mechanisms are multifactorial, possibly resulting from potential interactions between genetic susceptibility traits and environmental exposures. Ongoing studies are investigating the role of **polymorphisms** of genes encoding enzymes, which function in the activation or metabolism of xenobiotics, protection of cells against oxidative stress, DNA repair, and/or immune modulation.

Curative therapy with chemotherapy, radiation, and/or surgery can adversely affect a child's development and result in serious long-term medical and psychosocial effects in childhood and adulthood. Potential adverse late effects include subsequent second malignancy, early mortality, infertility, reduced stature, cardiomyopathy, pulmonary fibrosis, osteoporosis, neurocognitive impairment, affective disorders, and altered social functioning (see Chapter 542). Much has been learned about the incidence of late effects from large, multisite cohort studies such as the **Childhood Cancer Survivor Study**, an ongoing study of medical and psychosocial outcomes in survivors, which has provided data for the development of clinical care guidelines for survivors (http://www.survivorshipguidelines.org).

Given the relative rarity of specific types of childhood cancer and the sophisticated technology and expertise required for diagnosis, treatment, and monitoring of late effects, all children with cancer should be treated with standardized clinical protocols in pediatric clinical research settings whenever possible. Promoting such treatment, the **Children's Oncology Group** is an international multi-institutional research consortium that facilitates cooperative clinical, biologic, and epidemiologic research in more than 200 affiliated institutions in the United States, Canada, and other countries (http://childrensoncologygroup.org/). Coordinated participation in such research trials has been a major factor in the increased survival for many children with cancer.

INFLUENCING THE INCIDENCE OF CANCER

There are only a few recognized environmental causes of childhood cancer that can be avoided or counteracted. One example is immunization against **hepatitis B**, which decreases the risk of hepatocellular carcinoma in adolescence and adulthood, and **human papillomavirus** vaccination, which prevents cervical cancer and HPV-positive oropharyngeal cancers and anal cancers. Associations between cumulative radiation exposure from common diagnostic radiologic tests such as CT scans and an increased risk of malignancy later in life are of great concern for pediatricians. Guidelines to ensure the safe clinical use of diagnostic imaging are being evaluated (http://www.imagegently.org/). An objective of pediatric medicine is *to teach children how to adopt healthy lifestyles to reduce their risk of cancer during adulthood,* such as avoiding tobacco, alcohol, high-fat diets, and obesity.

Visit Elsevier eBooks+ at eBooks.Health.Elsevier.com for Bibliography.

Chapter 541

Molecular and Cellular Biology of Cancer

Kristopher R. Bosse and Stephen P. Hunger

Cancer is a complex of diseases arising from alterations that can occur in a wide variety of genes. Multiple pathogenic gene variants and other genetic aberrations, some germline but most acquired (somatic), are required for cells to become fully malignant. These genetic changes lead to alterations in normal cellular processes that control cell proliferation and survival, including signal transduction, cell-cycle control, DNA repair, cellular growth and differentiation, translational regulation, senescence, and apoptosis (programmed cell death).

GENES INVOLVED IN ONCOGENESIS

Two major classes of genes are implicated in the development of cancer: oncogenes and tumor-suppressor genes. **Protooncogenes** are cellular genes that are important for normal cellular function and code for various proteins, including transcription factors, growth factors, and growth factor receptors. These proteins are vital components in the networks of signal transduction that regulate cell growth, division, and differentiation. Protooncogenes can be altered to form **oncogenes**—genes that, when translated, can contribute to malignant transformation of a cell.

Oncogenes can be divided into five different classes based on their mechanisms of action. Changes in any of these normal cellular components can result in unchecked cell growth. Some oncogenes code for **growth factors** that bind to a receptor and stimulate the production of a protein. Other oncogenes code for **growth factor receptors**, which are proteins on the cell surface. When growth factors bind to a growth factor receptor, they can turn the receptor on or off. Pathogenic genetic variants or posttranslational modifications of the receptor can result in it being permanently turned on, with consequent unregulated growth. **Signal transducers** or effectors make up another class. Signal transducers are responsible for taking the signal from the cell surface receptor to the cell nucleus. **Transcription factors** are molecules that bind to specific areas of the DNA and control transcription. **MYC** and **MYCN** are examples of transcription factors that when activated by pathogenic variants or amplification cause overstimulation of cell division. The final class of oncogenes **interferes with apoptosis**, or programmed cell death. Cells that no longer respond to the signal to die can lead to uncontrolled cell proliferation.

The three main mechanisms by which protooncogenes are activated are **amplification**, **pathogenic variants**, and **translocation** or **interstitial deletion** (Table 541.1). *MYC* or *MYCN,* which code for proteins that regulate transcription, are examples of protooncogenes that are activated by amplification. Patients with neuroblastoma in which the *MYCN* gene is amplified 10-300–fold have a poorer clinical outcome. Point pathogenic genetic variants can also activate protooncogenes. The *NOTCH1* protooncogene codes for a membrane-bound receptor integral to cell fate and differentiation pathways during normal development that undergoes proteolytic cleavage on ligand-induced activation, so that the protein can enter the nucleus and activate target gene transcription. *NOTCH1* has pathogenic variants in approximately 75% of **T-cell acute lymphoblastic leukemias** (ALLs), resulting in a *constitutively activated* protein important in leukemogenesis.

The third mechanism by which protooncogenes become activated is chromosomal translocation or interstitial deletion. In some leukemias and lymphomas, transcription factor–controlling sequences are relocated adjacent to transcriptionally active T-cell receptors or immunoglobulin genes, resulting in dysregulated transcription of these genes and leukemogenesis. A prominent example are translocations that bring *c-MYC* under control of the immunoglobulin heavy-chain gene *(IGH)* or kappa *(IGκ)* or lambda *(IGλ)* light-chain genes in **Burkitt lymphoma**. Chromosomal translocations that join genes from two different chromosomes or interstitial deletions or inversions within a chromosome can also result in **fusion genes**; transcription of the fusion gene results in production of a chimeric protein with new and potentially oncogenic activity. Examples of cancers associated with fusion genes include the childhood solid tumors **Ewing sarcoma** [**t(11;22)**] and **alveolar rhabdomyosarcoma** [**t(2;13)** or **t(1;13)**]. These translocations result in novel messenger RNA transcripts that are useful as diagnostic markers. The best-described translocation in leukemia is the **Philadelphia chromosome t(9;22)**, which produces the BCR-ABL1 protein found in **chronic myelogenous leukemia** and specific subtypes of **ALL**. BCR-ABL1 is a constitutively active tyrosine kinase. In addition, the protein is localized to the cytoplasm instead of the nucleus, exposing the kinase to a new spectrum of substrates.

Alteration in the regulation of **tumor-suppressor genes** is another mechanism involved in oncogenesis. Tumor-suppressor genes are important regulators of cellular growth and apoptosis. They have been called *recessive* oncogenes because the inactivation of both alleles of a tumor-suppressor gene is typically required for expression of a malignant phenotype.

Knudson's "2-hit" model of cancer development was based on the eye tumor **retinoblastoma** developing at a significantly younger age in children with the familial versus the sporadic form of the disease, and that tumors were often multifocal in familial cases but were almost always unifocal in sporadic cases. Knudson postulated that sporadic cases of retinoblastoma required somatic pathogenic variants to inactivate both copies of a gene, whereas in familial cases, children must inherit an inactivated allele from one parent and consequently only require the somatic inactivation of the remaining normal allele. This hypothesis was confirmed 15 years later following the discovery of the ***RB*** tumor-suppressor gene.

Another major tumor-suppressor protein is **TP53**, which is known as the "guardian of the genome" because it detects the presence of chromosomal damage and prevents the cell from dividing until repairs have been made. In the presence of damage beyond repair, TP53 initiates apoptosis and the cell dies. More than 50% of all tumors have abnormal TP53 proteins. Pathogenic variants in the *TP53* gene are important in many cancers, including breast, colorectal, lung, esophageal, stomach, ovarian, and prostatic carcinomas, as well as gliomas, sarcomas, and some leukemias.

SYNDROMES PREDISPOSING TO CANCER

Several syndromes are associated with an increased risk of developing malignancies, which can be characterized by different mechanisms (Table 541.2). One mechanism involves the *inactivation of tumor-suppressor genes* such as *RB* in **familial retinoblastoma**. Interestingly, patients with retinoblastoma in which one of the alleles is inactivated throughout the patient's body are also at a very high risk for developing osteosarcoma. A familial syndrome, **Li-Fraumeni syndrome**, in which one *TP53* pathogenic variant allele is inherited, also has been described in patients who develop sarcomas, leukemias, adrenocortical carcinoma, and cancers of the breast, bone, lung, and brain. **Neurofibromatosis** (NF) is a condition characterized by the proliferation of cells of neural crest origin. NF patients are at a higher risk of developing nervous system tumors, breast cancer, leukemia, pheochromocytomas, and other tumors. NF is inherited in an autosomal dominant manner, although 50% of cases present without a family history and occur secondary to the high rate of spontaneous pathogenic variants of the *NF1* gene.

A second mechanism responsible for an inherited predisposition to develop cancer involves *defects in DNA repair.* Syndromes associated with an excessive number of broken chromosomes caused by repair defects include **Bloom syndrome** (short stature, photosensitive telangiectatic erythema), **ataxia-telangiectasia** (childhood ataxia with progressive neuromotor degeneration, ocular telangiectasias), and **Fanconi anemia** (short stature, skeletal and renal anomalies, pancytopenia). As a result of the decreased ability to repair chromosomal defects, cells accumulate

Table 541.1 Oncogene Activators of Pediatric Tumors

MECHANISM	CHROMOSOME	GENES	PROTEIN FUNCTION	TUMOR
Chromosomal translocation	t(9;22)	*BCR::ABL1*	Chimeric tyrosine kinase	CML, ALL
	t(1;19)	*TCF3 (E2A)::PBX1*	Chimeric transcription factor	ALL
	t(8;14)	*MYC::IGH*	Transcription factor	Burkitt lymphoma
	t(15;17)	*PML::RARA*	Chimeric transcription factor	APML
	11q23 and others (over 50 fusions partners)	*KMT2A (MLL)*	Regulation of gene expression	Infant leukemia, ALL, AML, treatment-related leukemias
	t(12;21)	*ETV6::RUNX1*	Chimeric protein	ALL
	t(2;13) or t(1;13)	*PAX3* or *PAX7::FOXO1*	Transcription factor	Rhabdomyosarcoma
	t(11;22)	*EWS::FLI1*	Transcription factor	Ewing sarcoma
Gene amplification	2p	*MYCN*	Transcription factor	Neuroblastoma
	7p	*EGFR*	Growth factor receptor, tyrosine kinase	Glioblastoma, lung cancer
Point pathogenic gene variant	1p or 12p	*NRAS* or *KRAS*	Guanosine triphosphatase	AML, ALL, JMML, rhabdomyosarcoma, neuroblastoma
	10q	*RET*	Tyrosine kinase	MEN2
	2p	*ALK*	Tyrosine kinase	Neuroblastoma
	9q	*NOTCH1*	Transmembrane receptor	ALL

ALL, Acute lymphoblastic leukemia; AML, acute myeloid leukemia; APML, acute promyelocytic leukemia; CML, chronic myelogenous leukemia; JMML, juvenile myelomonocytic leukemia; MEN2, multiple endocrine neoplasia, type 2.

Table 541.2 Familial or Genetic Susceptibility to Malignancy

DISORDER	TUMOR/CANCER	COMMENT
CHROMOSOMAL DELETION/ANEUPLOIDY SYNDROMES		
Chromosome 11p13 deletion syndrome	Wilms tumor	Also known as WAGR syndrome (Wilms tumor, aniridia, genitourinary abnormalities, mental retardation); deletion typically includes *WT1* gene
Chromosome 13q14 deletion syndrome	Retinoblastoma, sarcoma	Associated with intellectual disability, characteristic craniofacial abnormalities; deletion typically includes *RB1* gene
Trisomy 21	ALL, AML, AMKL, TMD	Risk of ALL is increased 20-fold, risk of AMKL is increased 500-fold; high cure rates; more prone to chemotherapy toxicity; AMKL associated with *GATA1* pathogenic variants
Klinefelter syndrome (47,XXY)	Breast cancer, extragonadal germ cell tumors	
Trisomy 8	Myeloid neoplasms	Most commonly mosaic trisomy 8
Monosomy 5 or 7	AML, MDS	
CHROMOSOMAL INSTABILITY SYNDROMES		
Xeroderma pigmentosum	Basal cell and squamous cell carcinomas, melanoma	Autosomal recessive; failure to repair UV-damaged DNA; *XP/POLH* pathogenic variants
Fanconi anemia	AML, MDS, rare head, neck, and skin tumors, GI and GU cancers	Autosomal recessive; chromosome fragility; positive diepoxybutane (DEB) test result; pathogenic variants in *FANCX* gene family (includes at least 21 members)
Bloom syndrome	AML, MDS, ALL, lymphoma, and solid tumors	Associated with growth deficiency, malar rash; autosomal recessive; increase sister chromatid exchange (SCE); pathogenic variants in *BLM* gene; member of the RecQ helicase gene (unwinds DNA)
Ataxia-telangiectasia	Lymphoma, leukemia, less often central nervous system and other solid tumors	Associated with progressive ataxia, oculocutaneous telangiectasias; autosomal recessive; sensitive to radiation-induced DNA damage; increased risk of treatment-related morbidity; biallelic pathogenic variant in *ATM* tumor-suppressor gene
Nijmegen breakage syndrome	Leukemia, lymphoma	Associated with microcephaly, characteristic facies, immunodeficiency; biallelic pathogenic variants in *NBN* gene
Werner syndrome (progeria)	Soft tissue sarcomas, osteosarcoma, melanoma	Associated with accelerated aging; autosomal recessive; pathogenic variants in *WRN* gene

Table 541.2 Familial or Genetic Susceptibility to Malignancy—cont'd

DISORDER	TUMOR/CANCER	COMMENT
IMMUNODEFICIENCY SYNDROMES		
Wiskott-Aldrich syndrome	Lymphoma, leukemia	Associated with thrombocytopenia, eczema, and recurrent infections; X-linked recessive; *WASP* pathogenic variants
X-linked lymphoproliferative syndrome (XLP)	B-cell lymphoproliferative disease, lymphomas, HLH	Associated with fulminant and often fatal EBV infection; X-linked; pathogenic variants in the *SH2D1A* gene
X-linked agammaglobulinemia (XLA)	Lymphoproliferative disorders, colorectal cancer	Associated with absence of B cells; X-linked; pathogenic variants in *BTK* gene
Severe combined immunodeficiency (SCID)	Leukemia, lymphoma	X-linked or autosomal recessive; pathogenic variants in *IL2RG* and *ADA* genes
SYNDROMES ARISING FROM PATHOGENIC VARIANTS IN TUMOR SUPRESSORS OR ONCOGENES		
Neurofibromatosis 1	Neurofibroma, optic glioma, acoustic neuroma, astrocytoma, meningioma, pheochromocytoma, rhabdomyosarcoma, MPNST, neuroblastoma, leukemias	Associated with café-au-lait macules, axillary/inguinal freckling, Lisch nodules; autosomal dominant; pathogenic variants in tumor-suppressor gene *NF1*
Neurofibromatosis 2	Bilateral acoustic neuromas, meningiomas	Autosomal dominant; pathogenic variants in tumor-suppressor gene *NF2*
Tuberous sclerosis	Facial angiofibromas, renal cell carcinoma, renal angiomyolipomas, myocardial rhabdomyoma	Autosomal dominant; pathogenic variants in tumor-suppressor gene *TSC1* or *TSC2*
Noonan syndrome	JMML, ALL, neuroblastoma, brain tumors	Associated with distinct facial features, short stature, and heart defects; autosomal dominant; caused by RAS/MAPK pathway pathogenic variants (most frequently *PTPN11*)
Gorlin-Goltz syndrome (nevoid basal cell carcinoma syndrome)	Multiple basal cell carcinomas, medulloblastoma	Associated with odontogenic keratocysts, skeletal and skin anomalies; autosomal dominant; pathogenic variants in *PTCH1 or SUFU* gene
Li-Fraumeni syndrome	Osteosarcoma, soft tissue sarcoma, acute leukemias, breast and brain cancer, adrenal cortical tumors	Autosomal dominant; pathogenic variants in *TP53* tumor-suppressor gene
Beckwith-Wiedemann syndrome (BWS)	Wilms tumor, hepatoblastoma, neuroblastoma, rhabdomyosarcoma	Associated with macrosomia, macroglossia, hemihypertrophy, omphalocele; epigenetic/genomic alterations of chromosome 11p15
Von Hippel-Landau syndrome	Hemangioblastomas of the brain and retina, pheochromocytoma, renal cell carcinoma	Autosomal dominant; pathogenic variants of tumor-suppressor *VHL* gene
Multiple endocrine neoplasia, type 1 (Wermer syndrome)	Parathyroid, pancreatic islet cell and pituitary tumors	Associated with hyperparathyroidism, ZES; autosomal dominant; pathogenic variants in *MEN1* tumor-suppressor gene
Multiple endocrine neoplasia syndrome, type 2A (Sipple syndrome)	Medullary thyroid carcinoma, parathyroid tumors, pheochromocytoma	Associated with hyperparathyroidism; autosomal dominant; pathogenic variants in *RET* gene
Multiple endocrine neoplasia type 2B (multiple mucosal neuroma syndrome)	Mucosal neuromas, pheochromocytoma, medullary thyroid carcinoma	Associated with Marfan habitus, neuropathy; autosomal dominant; pathogenic variants in *RET* gene
Familial adenomatous polyposis (FAP)	Colorectal, thyroid, stomach and small intestinal cancer, hepatoblastoma	Associated with multiple colon polyps; autosomal dominant; pathogenic variants in *APC* gene
Juvenile polyposis syndrome	Colorectal, stomach, small intestinal and rectal cancer	Autosomal dominant; pathogenic variants in *BMPR1A* and *SMAD4* gene
Hereditary nonpolyposis colorectal cancer (HNPCC, Lynch syndrome)	Colorectal cancer, endometrial and stomach cancer, many other cancers	Autosomal dominant; pathogenic variants in DNA mismatch repair genes *MSH2, MLH1, PMS1, PMS2,* and *MSH6*
Turcot syndrome	Colorectal cancer, brain tumors (glioblastoma, medulloblastoma)	Autosomal dominant; pathogenic variants in *APC* or *MLH1* gene
Gardner syndrome	Colorectal cancer, other tumors similar to FAP	Subtype of FAP; autosomal dominant; pathogenic variants in *APC* gene
Constitutional mismatch repair deficiency syndrome (CMMRD)	Many different types of hematologic malignancies and brain and CNS tumors, colorectal carcinomas, and several other rare tumors	Autosomal recessive; homozygous germline pathogenic variants in the *MLH1, MSH2, MSH6,* or *PMS2* genes; tumors with very high variant burden, pathogenic variants of only one allele of the same genes results in Lynch syndrome
Peutz-Jeghers syndrome	Breast cancer, colorectal cancer, pancreatic cancer	Associated with hamartomatous polyps of GI tract; freckling of mouth, lips, fingers, and toes; autosomal dominant; pathogenic variants in *STK11* gene

Continued

Table 541.2 Familial or Genetic Susceptibility to Malignancy—cont'd

DISORDER	TUMOR/CANCER	COMMENT
Hereditary hemochromatosis	Hepatocellular carcinoma	Autosomal dominant; pathogenic variants in the *HFE* gene; malignancy associated with cirrhotic liver
Glycogen storage disease type 1 (von Gierke disease)	Hepatocellular carcinoma, liver adenomas	Autosomal recessive; pathogenic variants in *G6PC* or *SLC37A4* gene
Diamond-Blackfan anemia (DBA)	Colorectal and other GI cancers, AML, MDS, osteogenic sarcoma	Autosomal dominant; pathogenic variants in the small or large subunit-associated ribosomal protein genes (most often *RPS19*)
Shwachman-Diamond syndrome	AML, MDS	Associated with neutropenia, diarrhea, and failure to thrive; autosomal recessive; pathogenic variants in *SBDS* gene
DICER1 syndrome	Pleuropulmonary blastoma (PPB), cystic nephromas, ovarian Sertoli-Leydig tumors, multinodular goiter	Autosomal dominant; associated with pathogenic variants in *DICER1* gene
Familial neuroblastoma	Neuroblastoma	Autosomal dominant; pathogenic variants in *ALK* or *PHOX2B* gene
Hereditary paraganglioma-pheochromocytoma syndrome (PGL/PCC)	PGL, PCCs	Autosomal dominant; pathogenic variants in the mitochondrial enzyme succinate dehydrogenase protein family (*SDHA, B, C,* or *D*)
Severe congenital or cyclic neutropenia	AML, MDS	Associated with increased bacterial infections; typically autosomal dominant; pathogenic variants in *ELANE* or *HAX1* (Kostmann syndrome) gene
Rhabdoid predisposition syndrome 1 and 2	Atypical teratoid rhabdoid tumors, rhabdoid tumor of kidney, medulloblastoma, choroid plexus tumor	*SMARCB1/SMARCA4* tumor suppression genes
Predisposition to medulloblastoma	Medulloblastoma	*SUFU,* tumor suppression gene
Rothmund-Thomson syndrome	Skin, bone	*ANAPC1/RECQL4* stability gene
Multiple exostosis	Chondrosarcoma	*EXT1/EXT2,* tumor suppression gene
PTEN Hamartoma tumor syndromes: Cowden, Bannayan-Riley-Ruvalcaba, proteus, proteus-like syndromes	Breast, thyroid, renal, colon, melanoma	*PTEN, AKT1, PIK3CA, AKT3, PIK3R2, WWP1* germline or somatic pathogenic variants
BRCA1/2	Brain, solid tumors in children	Heterozygous pathogenic variants increase risk

ALL, Acute lymphoblastic leukemia; AML, acute myeloid leukemia; AMKL, acute megakaryocytic leukemia; CNS, central nervous system; EBV, Epstein-Barr virus; GI, gastrointestinal; GU, genitourinary; HLH, hemophagocytic lymphohistiocytosis; JMML, juvenile myelomonocytic leukemia; MAPK, mitogen-activated protein kinase; MDS, myelodysplastic syndrome; MPNST, malignant peripheral nerve sheath tumor; PTEN, phosphatase and tensin homolog; TMD, transient myeloproliferative disorder; UV, ultraviolet; ZES, Zollinger-Ellison syndrome.

abnormal DNA that results in significantly increased rates of cancer, especially leukemia. **Xeroderma pigmentosum** likewise increases the risk of skin cancer because of defects in repair to DNA damaged by ultraviolet light. **Constitutional mismatch repair deficiency syndrome** (CMMRD) is a disorder that results from the loss of both alleles of genes integral in repairing errors that occur during DNA replication, leading to the accumulation of multiple potentially pathogenic genetic alterations. These disorders display an autosomal recessive pattern.

The third category of inherited cancer predisposition is characterized by *defects in immune surveillance.* This group includes patients with **Wiskott-Aldrich syndrome**, severe combined immunodeficiency, common variable immunodeficiency, and the X-linked lymphoproliferative syndrome. The most common types of malignancy in these patients are lymphoma and leukemia. Cure rates for immunodeficient children with cancer are much poorer than for immunocompetent children with similar malignancies, suggesting a role for the immune system in cancer treatment as well as in cancer prevention.

Genome-wide association studies (GWAS) in a diverse array of childhood tumors, including ALL and neuroblastoma, have defined common **single nucleotide polymorphisms (SNPs)** in genes that are associated with cancer predisposition and collectively define regions of the genome that are critical in tumorigenesis. These alterations may occur in the coding or noncoding regions of the genome and typically lead to a relatively modest increase in cancer risk (2-10–fold over background) compared to the cancer susceptibility syndromes previously discussed, which may be associated with a lifetime risk of 50–100% of developing cancer. Furthermore, **whole genome sequencing** efforts across diverse pediatric cancers have identified that at least 8% of children who develop malignancy have a germline cancer-predisposing gene pathogenic variant. Many of these predisposing pathogenic variants occur in children without a family history of cancer or a known cancer predisposition syndrome.

OTHER FACTORS ASSOCIATED WITH ONCOGENESIS

Viruses

Several viruses have been implicated in the pathogenesis of malignancy. The association of the **Epstein-Barr virus (EBV)** with Burkitt lymphoma and nasopharyngeal carcinoma was identified more than 40 years ago, although EBV infection alone is not sufficient for malignant transformation. EBV is also associated with mixed cellularity and lymphocyte-depleted Hodgkin disease, as well as some T-cell lymphomas, which is particularly intriguing because EBV normally does not infect T lymphocytes. The most conclusive evidence for a role of EBV in lymphogenesis is the direct causal role of EBV for **B-cell lymphoproliferative disease** in immunocompromised persons, especially those with HIV infection or those receiving immunosuppression after organ

transplantation. **Human herpesvirus 8 (HHV-8)** is associated with the development of Kaposi sarcoma.

Children who are chronically infected with **hepatitis B virus** (hepatitis B surface antigen positive) have a 100-fold increased risk of developing **hepatocellular carcinoma**. In adults the latency period between viral infection and development of hepatocellular carcinoma approaches 20 years. However, in children who acquire the viral infection through perinatal transmission, the latency period can be as short as 6-7 years. The additional factors that are required for the malignant transformation of virally infected hepatocytes are not clear. **Hepatitis C virus** infection is another risk factor for hepatocellular carcinoma and is also associated with a subset of B-cell non-Hodgkin lymphomas such as splenic lymphoma.

Almost all cervical carcinomas are caused by **human papillomaviruses (HPVs)**. High-risk HPVs include types 16 and 18 but also types 31, 33, 34, 45, 52, and 58, which together cause >90% of cervical cancers. Vaccines against the major oncogenic subtypes are now available and are likely to save hundreds of millions of lives worldwide. The low-risk HPVs, including 6 and 11, which are commonly found in genital warts, are almost never associated with malignancies. Like other virus-associated cancers, the presence of HPV alone is not sufficient to cause malignant transformation. The mechanism by which the HPV-associated **oncoproteins HPV E6** and **E7** induce malignant transformation is thought to involve both the TP53 and the RB tumor-suppressor proteins, as well as other pathways that are critical in cell cycle progression, maintenance of telomerase and genomic stability, and apoptosis.

Radiation

Children who are exposed to ionizing radiation, either via environmental factors or from medical diagnostics or treatment, are also at an increased of developing cancer over their lifetime, especially leukemias, brain, breast, skin, or thyroid malignancies. This increased pediatric cancer risk is likely due both to the enhanced radiosensitivity of the developing organs of children and their longer postexposure life expectancy. Diagnostic imaging (e.g., CT scans) and therapeutic radiation for children with cancer are a major source of childhood radiation exposure. However, CT scan dose-reduction strategies, the increased use of MRI in pediatric medical centers, and the shift in therapeutic practice in oncology to proton radiotherapy all have been integral in lowering the exposure of children to ionizing radiation.

Genomic Imprinting

The development of cancer has also been linked to *genomic imprinting,* which is the selective inactivation of one of two alleles of certain genes depending on parental origin. **Beckwith-Wiedemann syndrome (BWS)** (see Chapter 113), the most commonly identified imprinting disorder, is an overgrowth syndrome characterized by macrosomia, macroglossia, hemihypertrophy, omphalocele, and renal anomalies that is also associated with an increased risk of Wilms tumor, hepatoblastoma, rhabdomyosarcoma, neuroblastoma, and adrenocortical carcinoma. This increased risk in developing cancer is directly associated with changes in the promoter methylation patterns (or loss of heterozygosity) of imprinted genes on chromosome 11p15.5. Normally, the maternally derived *IGF2* (insulin-like growth factor receptor 2) allele at this genomic locus is inactivated, thus suppressing *IGF2* expression. However, children with BWS show a gain of methylation in this promoter region, which allows for expression from both maternal and paternal *IGF2* alleles, leading to growth factor overexpression. Concurrently, the neighboring maternal *H19* gene (which encodes ncRNA and miRNA critical in growth suppression) is silenced by this hypermethylation, ultimately resulting in a progrowth phenotype and predisposition to tumor development.

Telomerase

Telomeres are a series of tens to thousands of TTAGGG DNA sequence repeats at the ends of chromosomes that are important for stabilizing the chromosomal ends and limiting breakage, translocation, and loss of DNA material. With DNA replication there is a progressive shortening of telomere length, which is a hallmark of cellular aging and acts as a replicative senescence signal. In a majority of cancers, **telomerase** (encoded by the *TERT* gene), an enzyme that adds telomeres to the ends of chromosomes, becomes activated, usually through pathologic variants in the *TERT* promoter. The telomerase-driven maintenance of telomere length in tumors enables unrestrained cellular proliferation by relieving a main checkpoint to cellular life span.

Visit Elsevier eBooks+ at eBooks.Health.Elsevier.com for Bibliography.

Chapter 542

Principles of Cancer Diagnosis

Julia C. Meade, Erika D. Friehling, and A. Kim Ritchey

Childhood cancer is uncommon and can manifest with symptoms seen with nonmalignant illnesses. The challenge for the pediatrician is to be alert to the clues suggesting a diagnosis of cancer. In addition to the classic manifestations, any persistent, unexplained symptom or sign should be evaluated as potentially emanating from a cancerous or precancerous condition.

SIGNS AND SYMPTOMS

The symptoms and signs of cancer are variable and nonspecific in pediatric patients. The types of cancer that occur during the first 20 years of life vary dramatically as a function of age—more so than at any other comparable age range (see Chapter 540). Unlike cancers in adults, childhood cancers usually originate from the deeper, visceral structures and from the parenchyma of organs rather than from the epithelial layers that line the ducts and glands of organs and compose the skin. In children, dissemination of disease at diagnosis is common, and presenting symptoms or signs are often caused by systemic involvement. **Pain was one of the initial presenting symptoms in >50% of children with cancer in one study.** Infants and young children cannot express or localize their symptoms well.

Solid tumors may produce **mass effects** that are nonspecific, such as compression of the thoracic airways or superior vena cava (lymphoma), the optic chiasm and hypothalamic-pituitary region (craniopharyngioma), and the fourth ventricle (cerebellar astrocytoma). Another factor is the variability in the physiology and biology of the host related to growth and development during infancy, childhood, and adolescence.

The signs of cancer in children are often attributed to other causes before the malignancy is recognized. Delays in diagnosis are particularly problematic during late adolescence and are the result of a variety of factors prominent in this age-group, including historic lack and complexity of health insurance coverage.

Although there is no clearly established set of warning signs of cancer in young people, the most common cancers in children suggest some guidelines that may be helpful in early recognition of signs and symptoms of cancer (Table 542.1). Most of the symptoms and signs are not specific and might represent other possibilities in a differential diagnosis. Nonetheless, these clues encompass the common cancers of childhood and have been very useful in early detection.

PHYSICAL EXAMINATION

Physical examination findings in a child with malignancy are dependent on whether the cancer is systemic or localized. The cancers most common in children involve the lymphoid and hematopoietic system. When the bone marrow is compromised by malignancy (e.g., leukemia, disseminated neuroblastoma), typical findings include pallor from anemia; bleeding, petechiae, or purpura from thrombocytopenia or coagulopathy; cellulitis or other localized infection from leukopenia; and skin nodules (especially in infants) and hepatosplenomegaly

Table 542.1 Common Manifestations of Childhood Malignancies

	SIGNS AND SYMPTOMS	POTENTIAL ETIOLOGY AND POSSIBLE DIAGNOSIS
Constitutional/ systemic	Fever, persistent or recurrent infection, neutropenia	Bone marrow infiltration from leukemia, neuroblastoma
	Fever of unknown origin, weight loss, night sweats	Hodgkin and non-Hodgkin lymphoma
	Painless, persistent lymphadenopathy	Leukemia, Hodgkin lymphoma, non-Hodgkin lymphoma, Burkitt lymphoma, thyroid carcinoma
	Hypertension	Renal or adrenal tumor such as neuroblastoma, pheochromocytoma, or Wilms tumor
	Soft tissue mass	Ewing sarcoma, osteosarcoma, neuroblastoma, thyroid carcinoma, rhabdomyosarcoma, Langerhans cell histiocytosis
	Pain	Bone marrow involvement (ALL) or metastatic disease (neuroblastoma), primary bone tumors, Langerhans cell histiocytosis
Neurologic/ ophthalmologic	Headache with emesis, visual disturbances, ataxia, papilledema, cranial nerve palsies	Increased intracranial pressure from primary brain tumor or metastasis
	Leukocoria (white pupil)	Retinoblastoma
	Periorbital ecchymosis	Neuroblastoma
	Miosis, ptosis, heterochromia	Horner syndrome: compression of cervical sympathetic nerves from neuroblastoma
	Opsoclonus myoclonus, ataxia	Paraneoplastic syndrome from neuroblastoma
	Exophthalmos, proptosis	Mass effect from rhabdomyosarcoma, lymphoma, or Langerhans cell histiocytosis
Respiratory/ thoracic	Cough, stridor, pneumonia, tracheal-bronchial compression; superior vena cava syndrome	Anterior mediastinal mass due to germ cell tumor, non-Hodgkin lymphoma, or Hodgkin lymphoma
	Vertebral or nerve root compression; dysphagia	Posterior mediastinal mass from neuroblastoma or Ewing sarcoma
Gastrointestinal	Abdominal mass	Neuroblastoma, Wilms tumor, lymphoma
	Diarrhea	Vasoactive intestinal peptide secretion from neuroblastoma, ganglioneuroma
Hematologic	Pallor, anemia	Bone marrow infiltration from leukemia, neuroblastoma
	Petechiae, thrombocytopenia	Bone marrow infiltration from leukemia, neuroblastoma
Musculoskeletal	Bone pain, limp, arthralgia	Osteosarcoma, Ewing sarcoma, leukemia, metastatic neuroblastoma
Endocrine	Diabetes insipidus	Pituitary tumor, Langerhans cell histiocytosis
	Poor growth	Diencephalic syndrome from hypothalamic tumor
	Galactorrhea	Pituitary tumor/prolactinoma
	Precocious puberty	Germ cell tumor (cranial or extracranial), adrenocortical carcinoma, hepatoblastoma

ALL, Acute lymphoblastic leukemia
Adapted from Marcdante KJ, Kliegman RM, Jenson HB, et al., eds. *Nelson Essentials of Pediatrics*. 6th ed. Philadelphia: Saunders; 2011. p. 588.

from malignant leukocytosis. Abnormalities found in lymphatic malignancies include peripheral **adenopathy** (Fig. 542.1) and signs of superior vena cava syndrome from an anterior **mediastinal mass** (Fig. 542.2), including respiratory distress, and facial and neck plethora and edema. Enlargement of cervical lymph nodes is common in children, but when persistent, progressive, and painless, it often suggests **lymphoma**. Supraclavicular adenopathy suggests underlying malignancy.

Abnormalities of the central nervous system (CNS) that can indicate cancer include headaches, vomiting, cranial nerve palsies, ataxia, afebrile seizures, ptosis, decreased visual activity, neuroendocrine deficits, and increased intracranial pressure, which may be diagnosed by the presence of papilledema (Fig. 542.3). Any focal neurologic deficit in the motor or sensory system, especially a decrease in cranial nerve function, should prompt further investigation for malignancy.

Ophthalmologic presentation of malignancy includes a **white pupillary reflex** (Fig. 542.4) rather than the usual red reflection from incident light. A white pupillary reflex is essentially pathognomonic for retinoblastoma, although some benign conditions can mimic this finding. **Proptosis** can be produced by rhabdomyosarcoma, neuroblastoma, lymphoma, and Langerhans cell histiocytosis. In the few first years of life, Horner syndrome, periorbital ecchymosis, iris heterochromia, and opsoclonus-myoclonus all suggest a diagnosis of neuroblastoma.

Abdominal masses can be divided into upper and lower locations. Malignancies in the upper abdomen include Wilms tumor, neuroblastoma, and hepatoblastoma. Enlargement of the liver or spleen

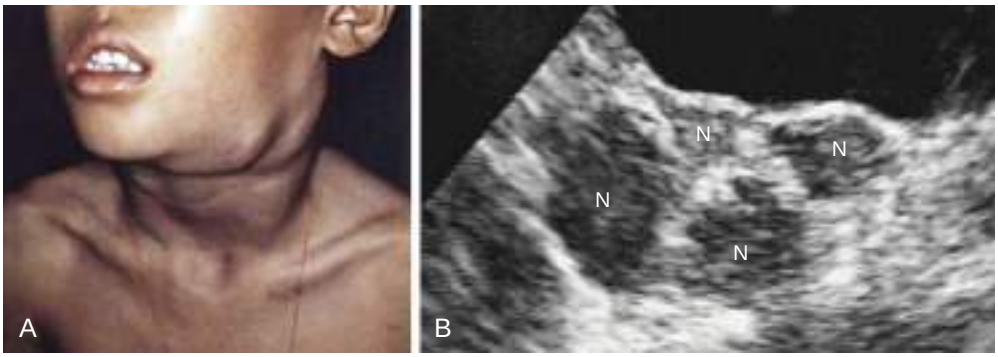

Fig. 542.1 Cervical lymphadenopathy. Manifestations on physical examination (**A**), and ultrasound examination (**B**). N, Abnormally enlarged lymph nodes. *(From Sinniah D, D'Angio GJ, Chatten J, et al. Atlas of Pediatric Oncology. London: Arnold; 1996.)*

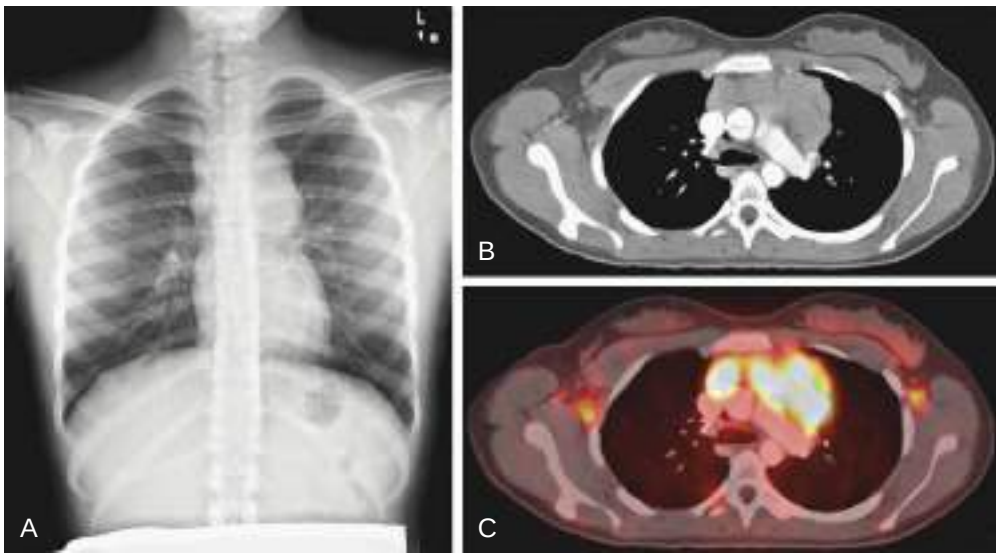

Fig. 542.2 Anterior upper mediastinal mass from non-Hodgkin lymphoma. **A**, Plain chest radiograph. **B**, CT scan. **C**, PET scan.

Fig. 542.3 Papilledema on fundoscopic examination. *(From Sinniah D, D'Angio GJ, Chatten J, et al. Atlas of Pediatric Oncology. London: Arnold; 1996.)*

Fig 542.4 White pupillary reflex in the left eye. *(From Sinniah D, D'Angio GJ, Chatten J, et al. Atlas of Pediatric Oncology. London: Arnold; 1996.)*

from leukemia can be mistaken for an upper abdominal mass. Lower abdominal masses non-Hodgkin lymphoma, neuroblastoma, germ cell tumors (ovarian), and sarcomas.

Rhabdomyosarcoma can occur as an extremity mass, particularly in adolescents, but also as a mass in the head and neck region (e.g., orbit, nasopharynx, and others). These tumors can be deceptively benign in

appearance, but as with all unexplained masses, require immediate attention. Sacrococcygeal masses in neonates are usually **teratomas**, which are usually benign but can undergo malignant transformation if not removed promptly. **Neuroblastoma** can present as "blueberry muffin" spots on the skin of neonates or as periorbital ecchymosis in older children.

AGE-RELATED MANIFESTATIONS

Because various types of cancer in children occur at specific ages, the physician should tailor the history and physical examination based on the age of the child. The **embryonal tumors**, including neuroblastoma, retinoblastoma, and hepatoblastoma usually occur during the first 2 years of life (see Fig. 540.4). The peak age for presentation of **Wilms tumor** is 3-4 years. Two thirds of patients with **rhabdomyosarcoma** present before age 6 with another smaller peak in adolescence. From 1-4 years of age, **acute lymphoblastic leukemia** peaks in incidence. **Brain tumors** have a peak incidence in the first decade of life. **Non-Hodgkin lymphomas** are uncommon earlier than 5 years of age but steadily increase thereafter. During adolescence, bone tumors, Hodgkin lymphoma, and gonadal and soft tissue sarcomas predominate. Hence, for infants and toddlers, special attention should be paid to the possibility of embryonal and intraabdominal tumors. Preschool-age and early school-age children showing compatible signs and symptoms should be specifically evaluated for **leukemia**. School-age children might present with lymphoma or with brain tumors. Adolescents require assessment for bone and soft tissue sarcomas and gonadal malignancies, as well as for Hodgkin lymphoma.

EARLY DETECTION

The prognosis of malignancy in children depends primarily on tumor type, extent of disease at diagnosis, and rapidity of response to treatment. Early diagnosis helps to ensure that appropriate therapy is given in a timely manner and thus optimizes the chances of cure. Because most physicians in general practice rarely encounter children with undiagnosed cancer, they should remember to investigate the possibility of malignancy, especially when they encounter an atypical course of a common childhood condition, unusual manifestations that do not fit common conditions, and any persistent symptom that defies diagnosis. It is also good practice to obtain a three-generation family pedigree with specific attention to a family history of cancer. A strong family history of cancer would suggest a referral for a cancer predisposition evaluation.

Delays in diagnosis are particularly likely in certain clinical situations. The cardinal symptom of both **osteosarcoma** and **Ewing sarcoma** is localized and usually persistent pain. Because these tumors occur during the second decade of life, a time of increased physical activity, patients often assume the pain results from trauma. Prompt radiologic evaluation can help confirm the diagnosis. **Lymphoma**, especially during adolescence, often manifests as an anterior mediastinal mass. Symptoms such as chronic cough, unexplained shortness of breath, or "new-onset asthma" are typical with this presentation and are often overlooked. Tumors of the nasopharynx or middle ear can mimic infection. Prolonged, unexplained ear pain, nasal discharge, retropharyngeal swelling, and trismus should be investigated as possible signs of malignancy.

Early symptoms of **leukemia** may be limited to prolonged or unexplained low-grade fever. Bone and joint pain may present with refusal to walk. Blood counts with abnormalities in two or more cell lines might indicate the need for bone marrow examination, even when leukemic blast cells are not seen in the blood smear (see Table 542.1).

Mass screening for children with malignancy is not feasible. A screening program to detect early-stage neuroblastoma was successful in documenting more cases of the disease but had no impact on overall outcome. However, certain children are at increased risk for cancer and require an individualized plan to ensure early detection of malignancy. Select examples include children with certain chromosome abnormalities, such as Down syndrome, Klinefelter syndrome, and WAGR syndrome (Wilms tumor, *a*niridia, *g*enital abnormalities, mental *r*etardation); children with overgrowth syndromes, such as Beckwith-Wiedemann syndrome or hemihypertrophy; and children with certain inherited single-gene disorders, including hereditary retinoblastoma, Li-Fraumeni syndrome, familial adenomatous polyposis, and neurofibromatosis (see Table 541.2).

ENSURING THE DIAGNOSIS

When a malignant neoplasm is suspected, the immediate goal is to confirm the diagnosis. A tentative diagnosis can often be established based on the patient's age, symptoms, and location of masses. Selected imaging techniques and tumor markers can facilitate the diagnostic approach (Table 542.2 and Fig. 542.5). Especially when a solid tumor is present, the pediatric oncologist, surgeon, and pathologist should work as a team to determine the site of biopsy, amount of tissue required, and whether percutaneous image-guided biopsy, incisional biopsy, or excisional biopsy and tumor resection are indicated. For select situations, at the time of the initial diagnostic procedure, plans for bone marrow aspiration and biopsy and placement of central venous access may be appropriate.

Pathologic evaluation of pediatric malignancies requires appropriate handling of tissue so that multiple different techniques can be used to obtain a diagnosis. It is important that some fresh tissue not be placed in formalin. Along with routine light microscopy, pathologic evaluation may include immunochemistry, flow cytometry, cytogenetics, molecular genetic studies (e.g., fluorescence in situ hybridization, tumor whole exome sequencing, and evaluation of circulating tumor genes with cell-free DNA detection in blood). Additional technologies include DNA microarray analysis and cancer genome sequencing that can identify specific gene expression patterns and sequences in tumors, which can facilitate more accurate classification and treatment.

STAGING

Once a specific diagnosis is confirmed, studies to define the extent of the malignancy are necessary to determine prognosis and treatment. Table 542.2 outlines the minimum evaluation required for common pediatric malignancies. In addition, for many tumors (e.g., Wilms tumor, neuroblastoma, rhabdomyosarcoma), a surgical staging system is used. Surgical stage can be determined at the time of the initial diagnostic procedure or subsequently. For example, a patient who has abdominal surgery for possible Wilms tumor should have careful evaluation and biopsy of all adjacent lymph nodes. A child with rhabdomyosarcoma can require a subsequent biopsy of sentinel lymph nodes as determined by scintigraphy or dye injection adjacent to the primary tumor. The pathologist facilitates staging by examining margins of the specimen to determine residual tumor.

Visit Elsevier eBooks+ at eBooks.Health.Elsevier.com for Bibliography.

Table 542.2 Workup of Common Pediatric Malignancies to Assess Primary Tumor and Potential Metastases

MALIGNANCY	BONE MARROW ASPIRATE OR BIOPSY	CHEST X-RAY FILM	CT SCAN	MRI	PET SCAN	BONE SCAN	CSF ANALYSIS	SPECIFIC MARKERS	OTHER TESTS
Leukemia	Yes (includes flow cytometry, cytogenetics, molecular studies)	Yes	—	—	—	—	Yes	—	—
Non-Hodgkin lymphoma	Yes (includes flow cytometry, cytogenetics, molecular studies)	Yes	Yes	—	Yes	Yes (selected cases)	Yes	—	—
Hodgkin lymphoma	Yes (in advanced stage)	Yes	Yes	—	Yes	—	—	—	—
CNS tumors	—	—	—	Yes	—	—	Yes (selected cases)	Yes (selected cases)	—
Neuroblastoma	Yes (includes cytogenetics, molecular studies)	—	Yes	Yes	—	—	—	Urine VMA, HVA	MIBG or PET scan; bone x-rays
Wilms tumor	—	Yes	Yes	—	—	—	—	—	—
Rhabdomyo-sarcoma	Yes	Yes	Yes	Yes (select sites)	—	Yes (selected cases)	Yes (for paramenin-geal tumors only)	—	—
Osteosarcoma	—	Yes	Yes (of chest)	Yes (for primary tumors)	—	Yes (selected cases)	—	—	—
Ewing sarcoma	Yes (selected cases)	Yes	Yes (of chest)	Yes (for primary tumors)	Yes	Yes (selected cases)	—	—	—
Germ cell tumors	—	Yes	Yes	Consider MRI of brain	—	—	—	AFP, HCG	—
Liver tumors	—	Yes	Yes	—	—	—	—	AFP, HCG	—
Retinoblastoma	Selected cases	—	Yes	Yes (includes brain)	—	Yes (selected cases)	Selected cases	—	—

AFP, α-Fetoprotein; CNS, central nervous system; CSF, cerebrospinal fluid; HCG, human chorionic gonadotropin; HVA, homovanillic acid; MIBG, metaiodobenzylguanidine; VMA, vanillylmandelic acid.
Modified from Marcdante KJ, Kliegman RM, Jenson HB, et al., eds. *Nelson Essentials of Pediatrics*. 6th ed. Philadelphia: Saunders; 2011. p. 589.

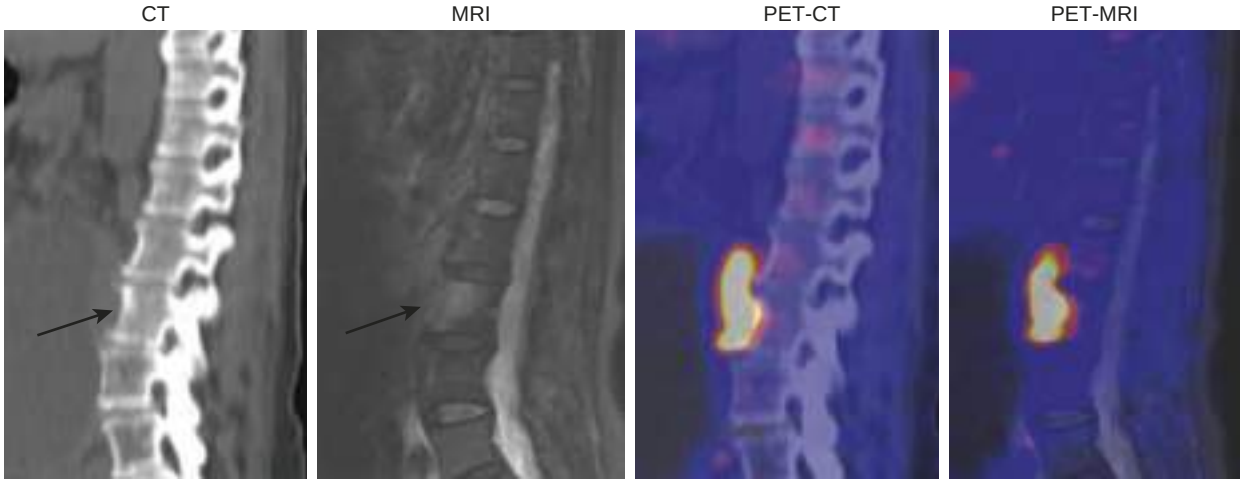

Fig. 542.5 Neuroblastoma PET/CT sagittal fused image demonstrated partial mis-registration of avid disease, occult on the low-dose noncontrast CT. PET/MRI sagittal fused image demonstrated correct image co-registration with corresponding T2-weighted hyperintensity in L3 vertebra, confirming L3 marrow involvement, delineated on the MR and not on the CT *(arrow). (From Sepehrizadeh T, Jong I, DeVeer M, Malhotra A. PET/MRI in paediatric disease. Eur J Radiol. 2021;144:109987. Fig. 2.)*

Chapter 543

Principles of Cancer Treatment

Erika D. Friehling, Julia C. Meade, Archie Bleyer, and A. Kim Ritchey

Treatment of children with cancer begins with an absolute requirement for the *correct diagnosis* (including subtype), proceeds through accurate and thorough *staging* of the extent of disease and determination of *prognostic subgroup*, provides appropriate multidisciplinary and usually multimodal therapy, and requires assiduous evaluation for possible recurrent disease and late effects of the disease and the therapies rendered. Throughout treatment, every child with cancer should have the benefit of the expertise of specialized teams of providers of pediatric cancer care, including pediatric oncologists, pathologists, radiologists, surgeons, radiation oncologists, nurses, and support staff, including nutritionists, social workers, psychologists, pharmacists, other medical specialists, and teachers trained to work with seriously ill children.

The best chance for cure of cancer is during the initial course of treatment; the cure rates for patients with recurrent disease are much lower than those for patients with primary disease. All patients with cancer should be referred to an appropriate specialized center as soon as possible when the diagnosis of cancer is suspected. All such centers in North America are identified on the **Children's Oncology Group** website (http://www.childrensoncologygroup.org) and on the **National Cancer Institute** (NCI) cancer trials website (http://www.clinicaltrials.gov). In the United States, the NCI's Clinical Trials Cooperative Groups Program is associated with a >80% reduction in the incidence of mortality from childhood cancer over 40 years despite an overall increase in cancer incidence during this interval (Fig. 543.1). After what appeared to be a plateau in the rate of decline in mortality in the early 2000s, there is evidence that the mortality rate continues to decline. Notably, a greater decline in mortality has been seen in the adolescent and young adult population when compared with children <15 years old, reversing prior trends (Fig. 543.2). The most current information on treatment of all types of childhood cancer is available in the PDQ (Physician Data Query) on the NCI website (http://www.cancer.gov/cancertopics/pdq/pediatrictreatment).

DIAGNOSIS AND STAGING

Accurate diagnosis and staging of the extent of disease are imperative because the nature of therapy depends strongly on the type of cancer. In addition, **prognostic subgroups** based on the stage of disease have been established for most cancers that occur in children. Accordingly, children with a better prognosis are treated with less intensive therapy, including lower doses of chemotherapy or radiation therapy, a shorter duration of treatment, or elimination of at least one treatment modality (radiation therapy, chemotherapy, surgery). Accurate staging thus reduces the risk of excessive acute toxicity and long-term effects of therapy in patients whose prognosis indicates that less therapy is required for cure. **Overtreatment** of patients with a more favorable prognosis is a definite risk if the patient is not referred to a cancer treatment center. Conversely, **undertreatment** also is a clear risk if the diagnosis and stage are not correct, resulting in a compromise of an otherwise high potential for cure.

Diagnostic imaging is a critical phase of evaluation in most children with solid tumors. MRI, CT, ultrasonography, scintigraphy (nuclear medicine scans), positron emission tomography (PET), and spectroscopy, as appropriate, all serve a clear purpose in the evaluation of children with cancer, not only before treatment to determine the extent of disease and the appropriate therapy but also during follow-up to determine whether the therapy was effective (see Chapter 542). In addition, response to treatment as determined by imaging techniques is being increasingly used to guide changes in the therapy.

Expertise in pathology and laboratory medicine provides critical diagnostic support and guides therapy in most children with cancer. Relatively noninvasive methods of obtaining tumor tissue such as percutaneous image-guided biopsy can be performed in pediatric centers with appropriate expertise in diagnostic imaging, interventional radiology, cytology, and anesthesia support. Sentinel node mapping is helpful in the staging of some children's cancers. Determining the adequacy of surgery by evaluating frozen sections of the surgical margins for tumor cells is essential in many tumor operations.

A MULTIMODAL, MULTIDISCIPLINARY APPROACH

Many pediatric subspecialists are involved in the evaluation, treatment, and management of children with cancer, including provision of primary therapy and supportive care services (Fig. 543.3). More than two of the primary modalities are often used together, with chemotherapy the most widely used, followed in order of use by surgery, radiation therapy, and biologic agent therapy (Fig. 543.4).

The **leukemias** that occur in childhood usually are managed with chemotherapy alone, with a small proportion of patients receiving cranial radiation therapy to prevent or treat overt central nervous system (CNS) leukemia. Children with **non-Hodgkin lymphoma** also are treated with chemotherapy alone, except for radiation therapy for CNS involvement. Localized therapy with surgery or irradiation, or both, is an important component of treatment of most solid tumors, including **Hodgkin lymphoma**, but systemic multiagent chemotherapy usually is necessary because tumor dissemination generally is present even if undetectable. Chemotherapy alone usually is not adequate to eradicate gross residual tumors. Therefore it is not unusual for children with malignant tumors to require treatment with all three modalities (see Fig. 543.4). Unfortunately, most treatments that are effective in children with cancer have a narrow therapeutic index (a low ratio of efficacy to toxicity). The acute and late effects of these treatments can be minimized but not entirely avoided.

Biologic agent therapy is an important modality in a few childhood cancers (see Fig. 543.4). This type of treatment generally refers to immunotherapy, biologic response modifiers, or endogenously occurring molecules that have therapeutic effects in supraphysiologic doses. Examples are retinoic acid therapy in acute promyelocytic leukemia, monoclonal antibody therapy for neuroblastoma and certain non-Hodgkin lymphomas, tyrosine kinase inhibitors such as imatinib mesylate for chronic myelogenous and Philadelphia chromosome–positive leukemias, and radioactive metaiodobenzylguanidine (MIBG) therapy for neuroblastoma. In addition, immune therapy directed at tumor cell antigens with modification of T-cell receptors (TCRs) or chimeric antigen receptors (CARs) have improved survival in patients with chemotherapy-resistant diseases (leukemia, lymphoma) and have shown promise in solid tumors and brain tumors.

Chemotherapy is used more widely in children than in adults because children better tolerate the acute adverse effects, and the malignant diseases that occur in childhood are more responsive to chemotherapy than are malignant diseases of adults. **Radiation therapy** is used sparingly in children because of its association with growth impairment and with the development of second malignant neoplasms.

Whenever possible, treatment is given on an outpatient basis. Children should remain living at home and in school as much as possible throughout treatment. Increasingly, pediatric cancer therapies are being administered to ambulatory patients, with the advent of such innovations as programmable infusion pumps, oral chemotherapeutic regimens, early discharge from hospital with intensive outpatient supportive care, and home healthcare services. Some patients miss a considerable amount of school in the first year after diagnosis because of the intensity of therapy or its adverse effects and the ensuing complications of the disease or therapy. Tutoring should be encouraged so that children do not fall behind in their schooling; counseling should be provided as appropriate. In-hospital school services should be provided for patients who must spend much of their time as inpatients receiving therapy for disease or for managing adverse effects. Upon completion of therapy, referral for pediatric neuropsychiatric testing in a specialized center is often recommended to ensure they are well supported in their education.

De novo or acquired resistance to chemotherapy and radiation therapy remains an obstacle to cure. Ongoing discoveries of molecular and cellular

mechanisms that explain the cancer process have led to increasingly specific antineoplastic therapies, generally referred to as **molecularly targeted therapies**. Their most prominent feature is a relative lack of normal tissue toxicity, such that the additional therapeutic benefit occurs with minimum additional toxicity. Many biologic agent therapies, such as imatinib and selumetinib, fall into this category (Table 543.1). **Complementary** and **alternative** therapies are increasingly being provided by parents to their children with cancer, with or without knowledge of the medical professionals entrusted with the child's care (see Chapter 7). Collaboration with the family and a pharmacist specializing in chemotherapy can minimize unwanted interactions from supplements.

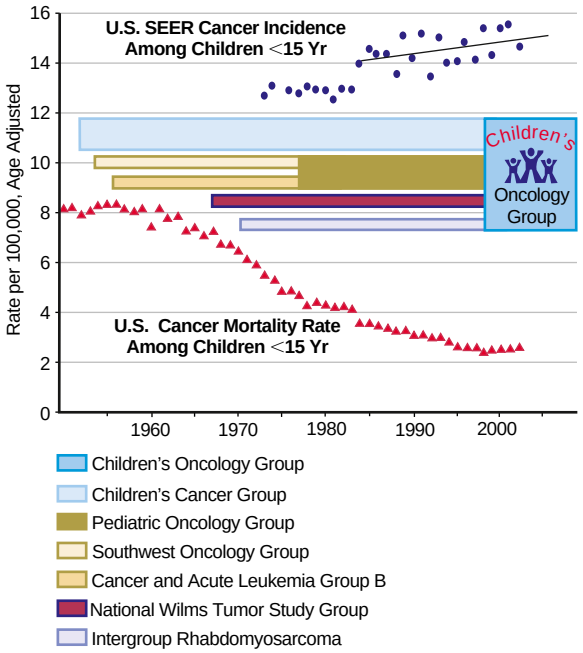

Fig. 543.1 Reduction in the national cancer mortality rate among children younger than 15 years of age *(triangles)* in the United States as a direct consequence of the National Cooperative Group Program sponsored by the National Cancer Institute and compared with the rising incidence of cancer before age 15 *(circles)*. The *horizontal bars* indicate the duration of the existence of the national pediatric cancer cooperative groups, beginning with the Children's Cancer Group in 1955. Other groups are the Pediatric Oncology Group, which was derived from the Pediatrics Divisions of the Southwest Oncology Group and the Cancer and Acute Leukemia Group B; the National Wilms Tumor Study Group; and the Intergroup Rhabdomyosarcoma Study Group. In 2000 the four pediatric cooperative groups merged into the Children's Oncology Group. *(Incidence and mortality rate data from Ries LAG, Eisner MP, Kosary CL, et al., eds. SEER Cancer Statistics Review, 1975–2002. Bethesda, MD: National Cancer Institute; http://seer.cancer.gov/csr/1975_2002/, based on November 2004 SEER [Surveillance, Epidemiology, and End Results] data submission. The mortality rate data are national rates, and the incidence data are derived from the SEER program, representing approximately 15% of the United States. The most current information on treatment of all types of childhood cancer is available in the PDQ [Physician Data Query] on the NCI website, http://www.cancer.gov/cancertopics/pdq/pediatrictreatment.)*

DISCUSSING THE TREATMENT PLAN WITH THE PATIENT AND FAMILY

The diagnostic and treatment plan must be carefully explained to parents and, if the child is old enough to understand, to the patient. Children should be given as much information as they can understand and would be useful to them. All questions should be answered openly and honestly. Effects of treatment, such as loss of hair during chemotherapy, the possible need to amputate a limb, and possible temporary or permanent functional impairment, must be anticipated and fully discussed. The possibility and probability of death from cancer should be covered in an age-appropriate manner. It usually is necessary to repeat explanations several times before

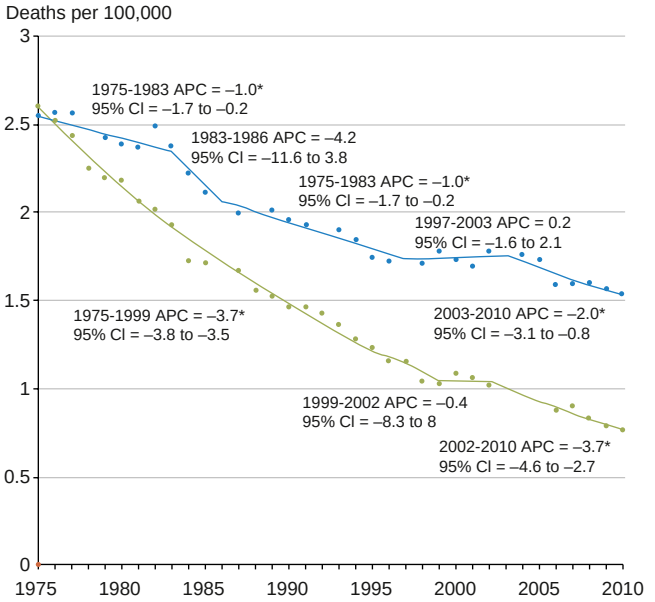

Fig. 543.2 Age-adjusted mortality trends for all malignant cancers among children <20 yr old in the United States from 1975 through 2010, along with annual percentage changes (APCs) for join point segments. *Asterisk* indicates that the slope of the join point segment is statistically different from zero ($p < .05$). The *green line* indicates leukemias and lymphomas, and the *blue line* indicates all other cancer sites; CI, confidence interval. *(From Smith MA, Altekruse SF, Adamson PC, et al. Declining childhood and adolescent cancer mortality. Cancer. 2014;120:2497–2506.)*

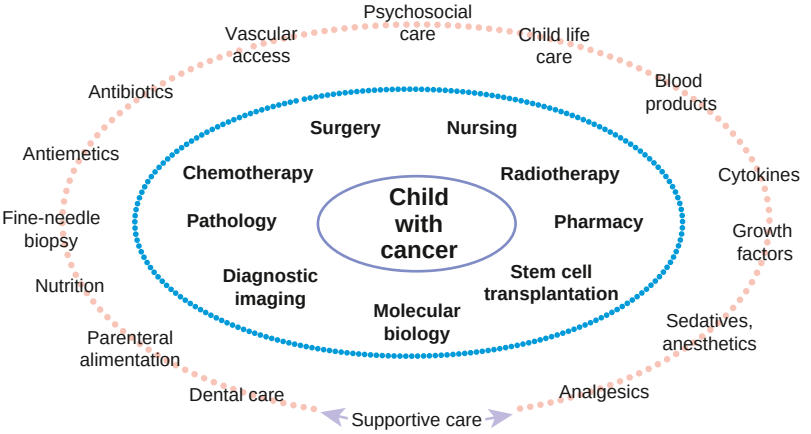

Fig. 543.3 Multidisciplinary care of children with cancer. The *inner circle* designates primary modalities, and the *outer ring* identifies supportive care elements to which all children with cancer have access.

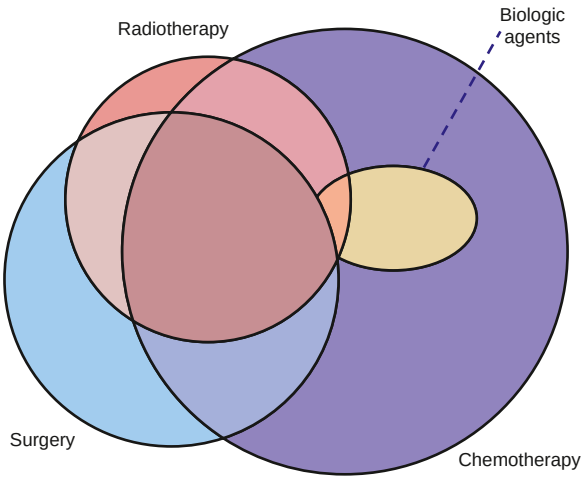

Fig. 543.4 The primary modalities of therapy used in the treatment of children with cancer. The relative sizes of the circles designate the approximate proportion of overall role in the management of pediatric cancers.

Table 543.1 Tyrosine Kinase Inhibitors and Monoclonal Antibodies for Pediatric Cancers

AGENT	TARGET	MALIGNANCY
Imatinib	BCR-ABL	CML Philadelphia chromosome–positive ALL
	PDGFRα cKIT	Hypereosinophilic syndrome Gastrointestinal stromal tumor
Dasatinib, nilotinib	BCR-ABL	CML Philadelphia chromosome–positive ALL
Brentuximab	CD30	Hodgkin lymphoma
Rituximab	CD20	Non-Hodgkin lymphoma
Selumetinib	MAPK/MEK	Plexiform neurofibroma Low-grade glioma
Bevacizumab	VEGFR-1, -2	Low-grade glioma
Crizotinib, lorlatinib	ALK/ROS	Neuroblastoma Anaplastic large cell lymphoma Inflammatory myofibroblastic tumor
Dinutuximab	GD2	Neuroblastoma
Blinatumomab	CD19	Leukemia Lymphoma

ALL, Acute lymphoblastic leukemia; CML, chronic myelogenous leukemia.

distraught family members fully understand. Throughout treatment, parents, patients, siblings, and medical staff will all need help in expressing feelings of anxiety, depression, guilt, and anger. The pediatrician, pediatric oncologist, and nurses should call on experienced professionals, including pediatric social workers, child psychologists and psychiatrists, child life specialists, and teachers with special expertise in managing students with cancer, to assist when needed.

TREATMENTS

Chemotherapy

The most widely used modality in pediatric cancer therapy is chemotherapy (see Fig. 543.4). Therapy usually involves a combination of drugs with different mechanisms of action and nonoverlapping toxicities. Sequential single-drug therapy rarely results in complete responses, and partial responses usually are infrequent, transient, and grow progressively shorter in duration with each drug used. Most of the cytotoxic drugs for childhood cancer are selected from several classes of agents, including alkylating agents, antimetabolites, antibiotics, hormones, plant alkaloids, and topoisomerase inhibitors (Table 543.2). The increased metabolic and cell cycle activity of malignant cells makes them more susceptible to the cytotoxic effects of these types of agents (Fig. 543.5).

Because most antineoplastic agents are cell cycle dependent, their adverse effects usually are related to the proliferation kinetics of individual cell populations. Most susceptible are tissues or organs with high rates of cell turnover: bone marrow, oral and intestinal mucosa, epidermis, liver, and spermatogonia. The most common acute adverse effects are **myelosuppression** (with neutropenia and thrombocytopenia the most problematic), immunosuppression, nausea and vomiting, hepatic dysfunction, upper and lower gastrointestinal mucositis, dermatitis, and alopecia. Fortunately, the tissues affected also recover relatively quickly, so that the acute adverse effects are usually reversible. Life-threatening effects of many chemotherapy agents include severe neutropenia with infection, fungemia, or fungal pneumonia as a result of immunosuppression, and septicemia, not infrequently linked to indwelling intravascular devices (Table 543.3; see Chapters 223 and 224). **Cardiomyopathy** caused by anthracyclines (e.g., doxorubicin, daunorubicin) and **renal failure** from platinum-containing agents also may be life-threatening or disabling. Assistance from a supportive care team can also provide safe and effective support for toxicities associated with chemotherapy, such as pain and nausea.

Least susceptible to chemotherapy and radiation therapy are cells that do not replicate or that replicate slowly, such as neurons, muscle cells, connective tissue, and bone. Children are not exempt from toxicities of these tissues, probably because they are still undergoing proliferation, although at a slower pace than other tissues, during growth and growth spurts.

Physically, children can endure the acute adverse effects of chemotherapy better than adults can in many ways. The maximum tolerated dosage in children, when expressed based on body surface area or body weight, typically is greater than that in adults. A comparison of anticancer drugs tested in phase I trials in both adult and pediatric patients showed that the maximum tolerated dosage in children was greater than that in adults for 70% of the agents, equal to that in adults for 15%, and less than the adult dose for only 15% of the agents. For all the drugs that were compared, the mean pediatric maximum tolerated dosage was greater than the adult mean.

Pharmacogenomics

Interindividual variability in the response to similar doses of a given medication is an inherent characteristic of both adult and pediatric populations. Variations in the germline genome can lead to differences in drug response at the level of individual patients. **Pharmacogenomics** represents the combination of pharmacology and genomics and is defined as the broader application of genetic testing strategies to identify factors predictive of drug efficacy and risk of adverse drug reactions.

Thiopurine *S*-methyltransferase **(TPMT)** is an enzyme that catalyzes the methylation of the chemotherapy 6-mercaptopurine (6MP) used in the treatment of acute lymphoblastic leukemia (ALL). To exert its cytotoxic effects, 6MP requires metabolism to thioguanine nucleotides, and this reaction is prevented by TPMT. Of the general population, 89% has normal TPMT activity, 11% has intermediate activity, and 0.3% has low activity. In patients with low or intermediate activity variants of TPMT, there is accumulation of cytotoxic thioguanine nucleotides (Fig. 543.6). These patients are at increased risk for **severe myelosuppression** if treated with routine doses of thiopurines and require a 10-15–fold reduction in dose to minimize this risk.

TPMT genotype is not the only determinant of intolerance to thiopurines; genetic variation in *NUDT15,* a nucleotide diphosphatase that reduces the incorporation of thioguanine into DNA, may also be involved. Reduction or loss of *NUDT15* activity results in increased cytotoxicity. Patients who have inherited reduced-function *NUDT15* alleles tolerate thiopurine doses that are much lower (10%) than normal. It is reasonable to expect that both *TPMT* and *NUDT15* genotypes will need to be considered for individualized thiopurine treatment, identifying patients who will benefit from specific dosing regimens and those who will be at risk for short-term and long-term toxicities.

Immunotherapy

Tumor-directed immune therapies employ and enhance the patient's immune system to kill malignant cells. Tumor antigen–specific monoclonal antibodies have been incorporated into the standard therapy of

Table 543.2 Common Chemotherapeutic Agents Used in Pediatric Cancer

DRUG	MECHANISM OF ACTION OR CLASSIFICATION	INDICATION(S)	ADVERSE REACTIONS (PARTIAL LIST)	COMMENTS
Methotrexate	Folic acid antagonist; inhibits dihydrofolate reductase	ALL, non-Hodgkin lymphoma, osteosarcoma, Hodgkin lymphoma, medulloblastoma	Myelosuppression, mucositis, stomatitis, dermatitis, hepatitis With long-term administration, osteopenia and bone fractures With high-dose administration, renal and CNS toxicity With intrathecal administration, arachnoiditis, leukoencephalopathy, and leukomyelopathy	Systemic administration may be PO, IM, or IV; also may be administered intrathecally Plasma methotrexate levels must be monitored with high-dose therapy and when low doses are administered to patients with renal dysfunction, and leucovorin rescue applied accordingly
6-Mercaptopurine (Purinethol)	Purine analog; inhibits purine synthesis	ALL	Myelosuppression, hepatic necrosis, mucositis; allopurinol increases toxicity	Allopurinol inhibits metabolism
Cytarabine (cytosine arabinoside; Ara-C)	Pyrimidine analog; inhibits DNA polymerase	ALL, AML, non-Hodgkin lymphoma, Hodgkin lymphoma	Nausea, vomiting, myelosuppression, conjunctivitis, mucositis, CNS dysfunction With intrathecal administration, arachnoiditis, leukoencephalopathy, and leukomyelopathy	Systemic administration may be PO, IM, or IV; may also be administered intrathecally
Cyclophosphamide (Cytoxan)	Alkylates guanine; inhibits DNA synthesis	ALL, non-Hodgkin lymphoma, Hodgkin lymphoma, soft tissue sarcoma, Ewing sarcoma, Wilms tumor, neuroblastoma	Nausea, vomiting, myelosuppression, hemorrhagic cystitis, pulmonary fibrosis, inappropriate ADH secretion, bladder cancer, anaphylaxis	Requires hepatic activation and thus is less effective in presence of liver dysfunction Mesna prevents hemorrhagic cystitis
Ifosfamide (IFEX)	Alkylates guanine; inhibits DNA synthesis	Non-Hodgkin lymphoma, Wilms tumor, soft tissue sarcoma	Nausea, vomiting, myelosuppression, hemorrhagic cystitis, pulmonary fibrosis, inappropriate ADH secretion, CNS dysfunction, cardiac toxicity, anaphylaxis	Mesna prevents hemorrhagic cystitis
Doxorubicin (Adriamycin), daunorubicin (Cerubidine), and idarubicin (Idamycin)	Binds to DNA, intercalation	ALL, AML, osteosarcoma, Ewing sarcoma, Hodgkin lymphoma, non-Hodgkin lymphoma, neuroblastoma	Nausea, vomiting, cardiomyopathy, red urine, tissue necrosis on extravasation, myelosuppression, conjunctivitis, radiation dermatitis, arrhythmia	Dexrazoxane reduces risk of cardiotoxicity
Dactinomycin	Binds to DNA, inhibits transcription	Wilms tumor, rhabdomyosarcoma, Ewing sarcoma	Nausea, vomiting tissue necrosis on extravasation, myelosuppression, radiation dermatitis, mucosal ulceration	
Bleomycin (Blenoxane)	Binds to DNA, cleaves DNA strands	Hodgkin disease, non-Hodgkin lymphoma, germ cell tumors	Nausea, vomiting, pneumonitis, stomatitis, Raynaud phenomenon, pulmonary fibrosis, dermatitis	
Vincristine (Oncovin)	Inhibits microtubule formation	ALL, non-Hodgkin lymphoma, Hodgkin disease, Wilms tumor, Ewing sarcoma, neuroblastoma, rhabdomyosarcoma	Local cellulitis, peripheral neuropathy, constipation, ileus, jaw pain, inappropriate ADH secretion, seizures, ptosis, minimal myelosuppression	IV administration only; must not be allowed to extravasate
Vinblastine (Velban)	Inhibits microtubule formation	Hodgkin lymphoma, non-Hodgkin lymphoma, Langerhans cell histiocytosis, CNS tumors	Local cellulitis, leukopenia	IV administration only; must not be allowed to extravasate
L-Asparaginase	Depletion of L-asparagine	ALL; AML, when used in combination with cytarabine	Allergic reaction pancreatitis, hyperglycemia, platelet dysfunction and coagulopathy, encephalopathy	Pegaspargase now preferred to L-asparaginase
Pegaspargase (Oncaspar) Calaspargase-pegol-mknl (Asparlas)	Polyethylene glycol conjugate of L-asparagine	ALL	Indicated for prolonged asparagine depletion and for patients with allergy to L-asparaginase	

Continued

Table 543.2 Common Chemotherapeutic Agents Used in Pediatric Cancer—cont'd

DRUG	MECHANISM OF ACTION OR CLASSIFICATION	INDICATION(S)	ADVERSE REACTIONS (PARTIAL LIST)	COMMENTS
Prednisone and dexamethasone (Decadron)	Lymphatic cell lysis	ALL; Hodgkin lymphoma, non-Hodgkin lymphoma	Cushing syndrome, cataracts, diabetes, hypertension, myopathy, osteoporosis, avascular necrosis, infection, peptic ulceration, psychosis	
Carmustine (BiCNU)	Carbamylation of DNA; inhibits DNA synthesis	CNS tumors, non-Hodgkin lymphoma, Hodgkin lymphoma	Nausea, vomiting, delayed myelosuppression (4-6 wk); pulmonary fibrosis, carcinogenic stomatitis	Phenobarbital increases metabolism, decreases activity
Carboplatin and cisplatin (Platinol)	Inhibits DNA synthesis	Osteosarcoma, neuroblastoma, CNS tumors, germ cell tumors	Nausea, vomiting, renal dysfunction, myelosuppression, ototoxicity, tetany, neurotoxicity, hemolytic-uremic syndrome, anaphylaxis	Aminoglycosides may increase nephrotoxicity
Etoposide (Vepesid)	Topoisomerase inhibitor	ALL, non-Hodgkin lymphoma, germ cell tumor, Ewing sarcoma	Nausea, vomiting, myelosuppression, secondary leukemia	
Tretinoin (all *trans*-retinoic acid) and isotretinoin (*cis*-retinoic acid; Accutane)	Enhances normal differentiation	Acute promyelocytic leukemia; neuroblastoma	Dry mouth, hair loss, pseudotumor cerebri, premature epiphyseal closure, birth defects	

ADH, Antidiuretic hormone; ALL, acute lymphoblastic leukemia; AML, acute myelogenous leukemia; CNS, central nervous system; IM, intramuscular; IV, intravenous; PO, oral.

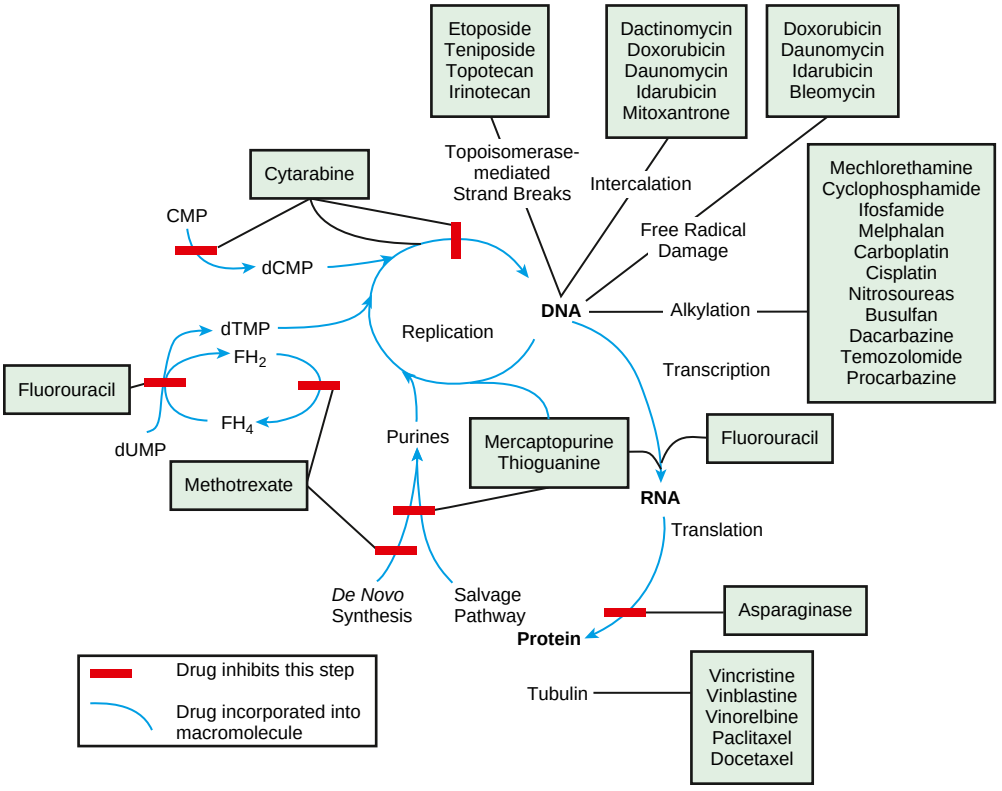

Fig. 543.5 Site of action of the commonly used anticancer drugs. CMP, Cytidine monophosphate; dCMP, deoxycytidine monophosphate; dTMP, deoxythymidine monophosphate; dUMP, deoxyuridine monophosphate; FH_2, dihydrofolate; FH_4, tetrahydrofolate. *(Redrawn from Adamson PC, Balis FM, Blaney SM. General principles of chemotherapy. In: Pizzo PA, Poplack DG, eds. Principles and Practice of Pediatric Oncology. 6th ed. Philadelphia: Lippincott Williams & Wilkins; 2011: p. 283.)*

neuroblastoma (anti–ganglioside GD_2). The antiangiogenic agent bevacizumab (monoclonal antibody against vascular endothelial growth factor A) is used in the treatment of low-grade gliomas.

Chimeric antigen receptor T cells (CAR-T cells) are genetically engineered to make new TCRs that can recognize and attach to an antigen on the tumor cell. This results in T-cell proliferation, cytolysis, and cytokine release with subsequent tumor cell death (Fig. 543.7). The B-cell antigen CD19 is the antigen targeted in children with ALL and some adults with lymphoma. The response to therapy in children with chemotherapy-resistant ALL is dramatic. Other antigens may be targeted, including CD22, CD30 (lymphomas), CD171, GD2 (neuroblastoma), EGFR, and HER2 (glioblastoma).

Side effects of CAR-T therapy are common and potentially serious and are caused by the **cytokine release syndrome (CRS)**. Manifestations

Table 543.3 Infectious Complications of Malignancy

PREDISPOSING FACTOR	ETIOLOGY	SITE OF INFECTION	INFECTIOUS AGENTS
Neutropenia	Chemotherapy, bone marrow infiltration	Sepsis, shock, pneumonia, soft tissue, proctitis, mucositis	Viridans group streptococcus, *Staphylococcus aureus, Staphylococcus epidermidis, Escherichia coli, Pseudomonas aeruginosa, Candida, Aspergillus,* anaerobic oral and rectal bacteria
Immunosuppression, lymphopenia, lymphocyte-monocyte dysfunction	Chemotherapy, corticosteroid	Pneumonia, meningitis, disseminated viral infection	*Pneumocystis jiroveci, Cryptococcus neoformans, Mycobacterium, Nocardia, Listeria monocytogenes, Candida, Aspergillus, Strongyloides, Toxoplasma,* varicella-zoster virus, cytomegalovirus, herpes simplex
Indwelling central venous catheter	Nutrition, administration of chemotherapy	Line sepsis, tract of tunnel, exit site	*S. epidermidis, S. aureus, Candida albicans, P. aeruginosa, Aspergillus, Corynebacterium, Enterococcus faecalis, Mycobacterium fortuitum, Propionibacterium acnes*

Modified from Kliegman RM, Marcdante KJ, Jenson HB, et al., eds. *Nelson Essentials of Pediatrics*. 6th ed. Philadelphia: Saunders; 2011.

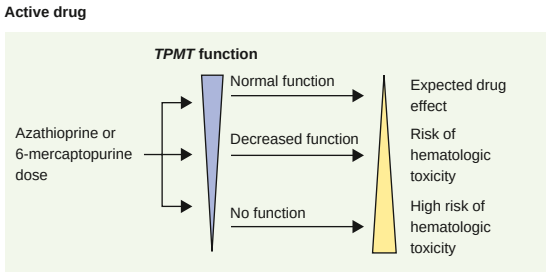

Fig. 543.6 The impact of variable pharmacokinetic gene function on the effect of bioactivation of prodrug versus inactivation of an active drug. *(From Roden DM, McLeod HL, Relling MV, et al. Pharmacogenomics. Lancet. 2019;394[10197]:521–532. Fig. 2)*

of CRS include hypotension, vascular leak, myalgias, cerebral edema, seizures, and confusion. Symptoms correlate with the extent of the tumor burden and require supportive care. Tocilizumab, an anti–interleukin-6 receptor monoclonal antibody, is the treatment of choice for CRS. B-cell aplasia may also develop and requires immune globulin replacement.

Immune checkpoint inhibitors are drugs (monoclonal antibodies) which enhance the ability of T-cells to attack cancer cells. Checkpoints on T-cells and cancer cells include PD-1/PD-L1 (programed death protein and programed death ligand-1), which normally dampen the T-cell response. CTLA-4 and LAG-3 are additional immune checkpoint molecules. Thus checkpoint inhibitors allow the T-cell to kill the cancer cells more effectively. Immune-related adverse events (irAEs) due to activated T cells include autoimmune-like disorders affecting many tissues including skin, liver, lung, CNS, and gastrointestinal and endocrine organs.

Surgery

Superb pediatric surgical and anesthesia services are indispensable for children with cancer. The pediatric surgeon's role varies depending on the type of tumor. For **solid tumors**, complete resection with documented evidence of negative margins often is required for cure or long-term control. Considerable prolongation of life usually depends on the tumor's resectability and the actual extent of resection.

Except for pontine gliomas and retinoblastoma, all solid tumors in children require a tissue diagnosis; therefore biopsy of the suspected neoplasm is paramount. Staging with sentinel node biopsies has become the standard of care for several pediatric malignancies. Surgical expertise is essential for implantation of vascular access devices and removal and replacement of such devices when infection or thrombosis supervenes (see Chapter 224).

Minimally invasive endoscopic surgical techniques are being used when indicated and, if the patient's condition permits, for biopsy and resection of tumor, direct ascertainment of residual disease and assessment of response, lysis of adhesions, and splenectomy.

Radiation Therapy

Radiation therapy is used sparingly in children, who are more susceptible than adults to the adverse delayed effects of ionizing radiation. A major advance in pediatric radiation therapy is the application of **conformal radiation** to children with cancer. This technique, most often applied as **intensity-modulated radiation therapy**, spares normal tissue by conforming the radiation volume to the shape of the tumor, thereby enabling delivery of higher doses to the tumor with lower exposure of normal tissue adjacent to the tumor or in the path of the radiation beam. Another example is **proton-beam radiotherapy**. With more focused beams and better sedation and immobilization techniques, radiation therapy is becoming more common in children. Acute adverse effects from radiation therapy depend on which part of the body is irradiated and the means of administration. **Dermatitis** is the most common general adverse effect because skin is always in the treatment field. Nausea and diarrhea are common subacute adverse effects with abdominal radiation therapy. **Mucositis** typically occurs to some extent whenever oral or intestinal mucosa is in the treatment volume. **Somnolence** is common with cranial irradiation. **Alopecia** occurs where hair is in the radiation field.

Most radiation therapy schedules require treatment 5 days per week for 4-7 weeks, depending on the dose needed to control the tumor and the amount and nature of normal tissue in the field. Most adverse effects are not noted until the second half of the course of irradiation. Late effects can occur months to years after radiation therapy and usually are dose-dependent manifestations. The type of delayed toxicity also depends on the site of irradiation. Examples are impaired growth resulting from cranial or vertebral irradiation, endocrine dysfunction from hypothalamic irradiation, pulmonary or cardiac insufficiency from chest irradiation, strictures and adhesions from abdominal irradiation, and infertility from pelvic irradiation. Second malignancy can also develop in the radiation field, such as breast cancer from chest irradiation and brain tumors from CNS irradiation.

ACUTE TOXIC EFFECTS AND SUPPORTIVE CARE

Adverse treatment effects that occur early in therapy can result in oncologic emergencies. These include metabolic disorders, bone marrow suppression, and compression by tumors on vital structures (Table 543.4). In **tumor lysis syndrome (TLS)**, uric acid, phosphate, and potassium are released in the circulation in large quantities from death of tumor cells. Hyperuricemia can lead to impairment of renal function, which further exacerbates the metabolic abnormalities. TLS can occur before therapy in patients with a large tumor burden (e.g., Burkitt lymphoma, lymphoblastic lymphoma, and leukemia presenting with a high white blood cell count), but it is usually seen within 12-48 hours of initiating chemotherapy. TLS is infrequently reported in other tumors (Hodgkin lymphoma, neuroblastoma, hepatoblastoma). Before therapy is initiated, the serum levels of uric acid, electrolytes, calcium, phosphorus, and creatinine should be measured, and adequate hydration ensured. Allopurinol (a xanthine oxidase inhibitor) should be started to prevent further accumulation of uric acid. In patients with established TLS with high uric acid levels or those at high risk for TLS, rasburicase (an enzyme that degrades uric acid) should be given. Symptomatic hyperkalemia and hyperphosphatemia with subsequent hypocalcemia can develop in the setting of inadequate renal function.

Virtually all chemotherapy regimens can produce **myelosuppression**, as can malignancies that invade and replace bone marrow. **Anemia** can

Fig. 543.7 Chimeric antigen receptor (CAR) T-cell therapy. CAR T-cell therapy is a type of treatment in which a patient's T cells are genetically engineered in the laboratory so they will bind to specific proteins (antigens) on cancer cells and kill them. *(1)* A patient's T cells are removed from their blood. Then *(2)* the gene for a special receptor called a chimeric antigen receptor is inserted into the T cells in the laboratory. The gene encodes the engineered CAR protein that is expressed on the surface of the patient's T cells, creating a CAR T cell. *(3)* Millions of CAR T cells are grown in the laboratory. *(4)* They are then given to the patient by intravenous infusion. *(5)* The CAR T cells bind to antigens on the cancer cells and kill them. *(Courtesy National Institutes of Health, National Cancer Institute, Bethesda, Maryland. https://www.cancer.gov/about-cancer/treatment/research/car-t-cell-therapy-infographic)*

Table 543.4 Oncologic Emergencies

CONDITION	MANIFESTATIONS	ETIOLOGY	MALIGNANCY	TREATMENT
METABOLIC				
Hyperuricemia	Uric acid nephropathy	Tumor lysis syndrome	Lymphoma, leukemia	Allopurinol, hydration, rasburicase
Hyperkalemia	Arrhythmias, cardiac arrest	Tumor lysis syndrome	Lymphoma, leukemia	Kayexalate, sodium bicarbonate, calcium gluconate, glucose, and insulin; check for pseudohyperkalemia from leukemic cell lysis in test tube
Hyperphosphatemia	Hypocalcemic tetany; metastatic calcification, photophobia, pruritus	Tumor lysis syndrome	Lymphoma, leukemia	Hydration, forced diuresis; stop alkalinization; oral aluminum hydroxide to bind phosphate
Hyponatremia	Seizure, lethargy (may also be asymptomatic)	SIADH; fluid, sodium losses in vomiting	Leukemia, CNS tumor	Restrict free water for SIADH; replace sodium if depleted
Hypercalcemia	Anorexia, nausea, polyuria, pancreatitis, gastric ulcers; prolonged PR, shortened QT interval	Bone resorption; ectopic parathormone, vitamin D, or prostaglandins	Metastasis to bone, rhabdomyosarcoma, leukemia	Hydration and furosemide diuresis; corticosteroids; calcitonin, bisphosphonates
HEMATOLOGIC				
Anemia	Pallor, weakness, heart failure	Bone marrow suppression or infiltration; blood loss	Any with chemotherapy	Packed red blood cell transfusion
Thrombocytopenia	Petechiae, hemorrhage	Bone marrow suppression or infiltration	Any with chemotherapy	Platelet transfusion
Disseminated intravascular coagulation	Shock, hemorrhage	Sepsis, hypotension, tumor factors	Promyelocytic leukemia, others	Fresh-frozen plasma; platelets, cryoprecipitate, treat underlying disorder
Neutropenia	Infection	Bone marrow suppression or infiltration	Any with chemotherapy	If febrile, administer broad-spectrum antibiotics, and filgrastim (G-CSF) if appropriate

Table 543.4 Oncologic Emergencies—cont'd

CONDITION	MANIFESTATIONS	ETIOLOGY	MALIGNANCY	TREATMENT
Hyperleukocytosis (>100,000/mm^3)	Hemorrhage, thrombosis; pulmonary infiltrates, hypoxia; tumor lysis syndrome	Leukostasis; vascular occlusion	Leukemia	Leukapheresis; chemotherapy; hydroxyurea
Graft versus host disease	Dermatitis, diarrhea, hepatitis	Immunosuppression and nonirradiated blood products; bone marrow transplantation	Any with immunosuppression	Corticosteroids; cyclosporine; tacrolimus; antithymocyte globulin
SPACE-OCCUPYING LESIONS				
Spinal cord compression	Back pain ± radicular *Cord above T10:* symmetric weakness, increased deep tendon reflex; sensory level present; toes up *Conus medullaris (T10-L2):* symmetric weakness, increased knee reflexes; decreased ankle reflexes; saddle sensory loss; toes up or down *Cauda equina (below L2):* asymmetric weakness; loss of deep tendon reflex and sensory deficit; toes down	Metastasis to vertebra and extramedullary space	Neuroblastoma, ewing, glioma	Corticosteroids, surgery, chemotherapy, radiotherapy
Increased intracranial pressure	Confusion, coma, emesis, headache, hypertension, bradycardia, seizures, papilledema, hydrocephalus; cranial nerve III and VI palsies	Primary or metastatic brain tumor	Medulloblastoma, glioma	Corticosteroids, ventriculostomy, radiotherapy, chemotherapy
Superior vena cava syndrome	Distended neck veins, plethora, edema of head and neck, cyanosis, Horner syndrome	Superior mediastinal mass	Lymphoma Germ cell tumor	Chemotherapy, radiotherapy
Tracheal compression	Respiratory distress	Mediastinal mass compressing trachea	Lymphoma Neuroblastoma	Radiation, corticosteroids

CNS, Central nervous system; G-CSF, granulocyte colony-stimulating factor; SIADH, syndrome of inappropriate antidiuretic hormone secretion.
Adapted from Kliegman RM, Marcdante KJ, Jenson HB, et al., eds. *Nelson Essentials of Pediatrics*. 6th ed. Philadelphia: Saunders; 2011. p. 590.

be corrected by transfusions of packed erythrocytes, and **thrombocytopenia** can be corrected by platelet infusions. Patients receiving immunosuppressive therapy should receive irradiated blood products to prevent graft-versus-host disease and leukoreduced blood products to prevent transfusion-associated reactions and infections. **Neutropenia** (neutrophil counts <500/μL) poses a risk of life-threatening infection. Patients with febrile neutropenia should be hospitalized and treated with empirical broad-spectrum intravenous antimicrobial therapy pending the results of appropriate cultures of blood, urine, or any obvious sites of infection (see Chapter 223). Treatment is continued until fever resolves and the neutrophil count rises. If fever persists for more than 3-5 days while the patient is receiving broad-spectrum antibiotics, the possibility of fungal infection must be considered. Fungal infections caused by *Candida* and *Aspergillus* are common in immunosuppressed patients. Opportunistic organisms such as *Pneumocystis jiroveci* can produce fatal pneumonia. Prophylactic treatment with trimethoprim-sulfamethoxazole is given when severe or prolonged immunosuppression is anticipated.

Viruses of low pathogenicity can produce serious disease in the setting of immunosuppression caused by malignancy or its treatment. Patients should not be given live-virus vaccines. Children who are receiving chemotherapy and who are exposed to chickenpox should receive varicella-zoster immunoglobulin, or if varicella-zoster immunoglobulin is not available, oral acyclovir should be considered. If clinical disease develops, the child should be hospitalized and treated with intravenous acyclovir.

Depending on the type of cancer therapy, patients can lose >10% body weight. Patients sometimes reduce their food intake because of temporary, treatment-associated nausea, stomatitis, and vomiting. Appetite loss is not a cause for alarm. **Malnutrition** is a particular risk in patients receiving radiation therapy involving the abdomen or the head and neck, intensive chemotherapy, or total body irradiation and high-dose chemotherapy before marrow transplantation. If oral supplementation proves inadequate, such patients may require enteral tube feedings or parenteral hyperalimentation.

Adequate **pain management** is critical. The World Health Organization (WHO) guidelines are particularly useful in the management of pain associated with cancer and cancer therapy (see Chapter 93). Assistance from a **supportive care** team can provide safe and effective support for toxicities associated with chemotherapy, such as pain and nausea.

LATE EFFECTS

Late effects of therapy can cause substantial morbidity (Table 543.5). The type of late effects depends on the child's age at treatment, the location(s) of the cancer, and the therapy administered. These effects can be either from the tumor or its treatment. For example, a brain or spinal tumor can leave the child with a permanent paresis or autonomic dysfunction; anthracycline-induced cardiomyopathy usually produces refractory cardiac dysfunction; and the leukoencephalopathy caused by intrathecal methotrexate and CNS radiation therapy often is only partially reversible.

Successful surgical resection can result in loss of important functional structures. Irradiation can produce irreversible organ damage, with symptoms and functional limitations depending on the organ involved and the severity of the damage. Many problems related to radiation therapy do not become obvious until the patient is fully grown, such as asymmetry between irradiated and nonirradiated areas or extremities. Irradiation of fields that include endocrine organs can cause hypothyroidism, pituitary dysfunction, or infertility. In sufficient doses, cranial irradiation can produce neurologic dysfunction, and spinal irradiation can produce growth deficiency.

Chemotherapy also carries the risk of long-lasting organ damage. Of particular concern are **leukoencephalopathy** after high-dose

methotrexate therapy; **infertility** in patients treated with alkylating agents (e.g., cyclophosphamide); **myocardial damage** caused by anthracyclines; **pulmonary fibrosis** caused by bleomycin; **renal dysfunction** caused by ifosfamide, nitrosourea, or platinum agents; and **hearing loss** from cisplatin. Development of these sequelae may be dose related and usually is irreversible. Appropriate baseline and intermittent testing should be performed before these drugs are administered to ensure that there is no preexisting damage to the organs likely to be affected and to permit monitoring of the effects of treatment-induced changes.

Perhaps the most serious late effect is the occurrence of **second cancers** in patients successfully cured of a first malignancy. The risk

Table 543.5 Late Effects and High-Risk Features of Childhood Cancer and Its Treatment

LATE EFFECTS	EXPOSURE	SELECTED HIGH-RISK FACTORS	AT-RISK DIAGNOSTIC GROUPS
NEUROCOGNITIVE			
Neurocognitive deficits Functional deficits in: • Executive function • Sustained attention • Memory • Processing speed • Visual-motor integration Learning deficits Diminished IQ Behavioral change	Chemotherapy: • Methotrexate Radiation affecting brain: • Cranial • Ear/infratemporal • Total body irradiation (TBI)	Age <3 yr old at time of treatment Female Supratentorial tumor Premorbid or family history of learning or attention problems Radiation doses >24 Gy Whole-brain irradiation	Acute lymphoblastic leukemia Brain tumor Sarcoma (head and neck or osteosarcoma)
NEUROSENSORY			
Hearing loss, sensorineural	Chemotherapy: • Cisplatin • Carboplatin Radiation affecting hearing: • Cranial • Infratemporal • Nasopharyngeal	Higher cisplatin dose (360 mg/m^2) Higher radiation dose impacting ear (>30 Gy) Concurrent radiation and cisplatin	Brain tumor Germ cell tumor Sarcoma (head and neck) Neuroblastoma Hepatoblastoma
Hearing loss, conductive Tympanosclerosis Otosclerosis Eustachian tube dysfunction	Radiation affecting hearing: • Cranial • Infratemporal • Nasopharyngeal	Higher radiation dose affecting ear (>30 Gy)	Brain tumor Sarcoma (head and neck)
Visual impairment Cataracts Lacrimal duct atrophy Xerophthalmia Retinopathy Glaucoma	Chemotherapy: • Busulfan • Glucocorticoids Radiation affecting eye: • Cranial • Orbital/eye • TBI	Higher radiation dose impacting eye (≥15 Gy for cataracts; >45 Gy for retinopathy and visual impairment)	Brain tumor Acute lymphoblastic leukemia Retinoblastoma Rhabdomyosarcoma (orbital) Allogeneic HSCT
Peripheral neuropathy, sensory	Chemotherapy: • Vincristine • Vinblastine • Cisplatin • Carboplatin Brentuximab vedotin	Higher cisplatin dose (≥300 mg/m^2)	Acute lymphoblastic leukemia Brain tumor Hodgkin lymphoma Germ cell tumor Non-Hodgkin lymphoma Sarcoma Neuroblastoma Wilms tumor Carcinoma
NEUROMOTOR			
Peripheral neuropathy, motor	Chemotherapy: • Vincristine • Vinblastine Brentuximab vedotin		Acute lymphoblastic leukemia Hodgkin lymphoma Non-Hodgkin lymphoma Sarcoma Brain tumor Neuroblastoma Wilms tumor
ENDOCRINE			
GH deficiency Precocious puberty	Radiation affecting HPA: • Cranial • Orbital/eye	Female Radiation dose to HPA >18 Gy	Acute lymphoblastic leukemia Sarcoma (facial) Carcinoma (nasopharyngeal)
Obesity	Ear/infratemporal Nasopharyngeal	Female Younger age (<4 yr)	Acute lymphoblastic leukemia
Hypothyroidism, central Gonadotropin deficiency Adrenal insufficiency, central	TBI	Radiation dose to HPA >18 Gy	Brain tumor Sarcoma (facial) Carcinoma (nasopharyngeal)
Hypothyroidism, primary	Neck, mantle irradiation	Radiation dose to thyroid >20 Gy	Hodgkin lymphoma

Table 543.5 Late Effects and High-Risk Features of Childhood Cancer and Its Treatment—cont'd

LATE EFFECTS	EXPOSURE	SELECTED HIGH-RISK FACTORS	AT-RISK DIAGNOSTIC GROUPS
REPRODUCTIVE			
Gonadal dysfunction Delayed or arrested puberty Premature menopause Germ cell dysfunction or failure Infertility	Chemotherapy, alkylating: • Busulfan • Carmustine (BiCNU) • Chlorambucil • Cyclophosphamide • Ifosfamide • Lomustine (CCNU) • Mechlorethamine • Melphalan • Procarbazine Radiation affecting reproductive system: • Whole abdomen (females) • Pelvic • Lumbar/sacral spine (females) • Testicular (males) • TBI	Higher alkylating agent dose Alkylating agent conditioning for HSCT Radiation dose ≥15 Gy in prepubertal females Radiation dose ≥10 Gy in pubertal females For germ cell failure in males, any pelvic irradiation For androgen insufficiency, gonadal irradiation, ≥20-30 Gy in males	Acute lymphoblastic leukemia, high risk Brain tumor Hodgkin lymphoma, advanced or unfavorable Non-Hodgkin lymphoma, advanced or unfavorable Sarcoma Neuroblastoma Wilms tumor, advanced Autologous or allogeneic HSCT
CARDIAC			
Cardiomyopathy Arrhythmias	Chemotherapy: • Daunorubicin • Doxorubicin • Idarubicin	Female Age <5 yr old at time of treatment Higher doses of chemotherapy (≥300 mg/m^2) Higher doses of cardiac radiation (≥30 Gy) Combined-modality therapy with cardiotoxic chemotherapy and irradiation	Hodgkin lymphoma Leukemia Non-Hodgkin lymphoma Sarcoma Wilms tumor Neuroblastoma
Cardiomyopathy Arrhythmias Pericardial fibrosis Valvular disease Myocardial infarction Atherosclerotic heart disease	Radiation affecting heart: • Chest • Mantle • Mediastinum • Axilla • Spine • Upper abdomen		
PULMONARY			
Pulmonary fibrosis Interstitial pneumonitis Restrictive lung disease Obstructive lung disease	Chemotherapy: • Bleomycin • Busulfan • Carmustine (BiCNU) • Lomustine (CCNU) Radiation impacting lungs: • Mantle • Mediastinum • Whole lung • TBI	Higher doses of chemotherapy Combined modality therapy with pulmonary toxic chemotherapy and irradiation	Brain tumor Germ cell tumor Hodgkin lymphoma Sarcoma (chest wall or intrathoracic) Autologous or allogeneic HCST
GASTROINTESTINAL			
Chronic enterocolitis Strictures Bowel obstruction	Radiation affecting GI tract (≥30 Gy) Abdominal surgery	Higher radiation dose to bowel (≥45 Gy) Combined modality therapy with abdominal irradiation and radiomimetic chemotherapy (dactinomycin or anthracyclines) Combined modality therapy with abdominal surgery and irradiation	Sarcoma (retroperitoneal or pelvic primary)
HEPATIC			
Hepatic fibrosis Cirrhosis	Radiation affecting liver	Higher radiation dose or treatment volume (20-30 Gy to entire liver or ≥40 Gy to at least one third of liver)	Sarcoma Neuroblastoma
RENAL			
Renal insufficiency Hypertension Glomerular injury Tubular injury	Chemotherapy: • Ifosfamide • Cisplatin • Carboplatin Radiation affecting kidneys: • Whole abdomen • Upper abdominal fields • TBI	Higher ifosfamide dose (≥60 g/m^2) Higher cisplatin dose (≥200 mg/m^2) Renal radiation dose (≥15 Gy) Combined modality therapy with above agents	Brain tumor Germ cell tumor Sarcoma Wilms tumor Neuroblastoma Hepatoblastoma Carcinoma Autologous or allogeneic HSCT

GH, Growth hormone; HPA, hypothalamic-pituitary-adrenal axis; HSCT, hematopoietic stem cell transplantation; IQ, intelligence quotient.
From Kurt BA, Armstrong GT, Cash DK, et al. Primary care management of the childhood cancer survivor. *J Pediatr.* 2008;152:458–466.

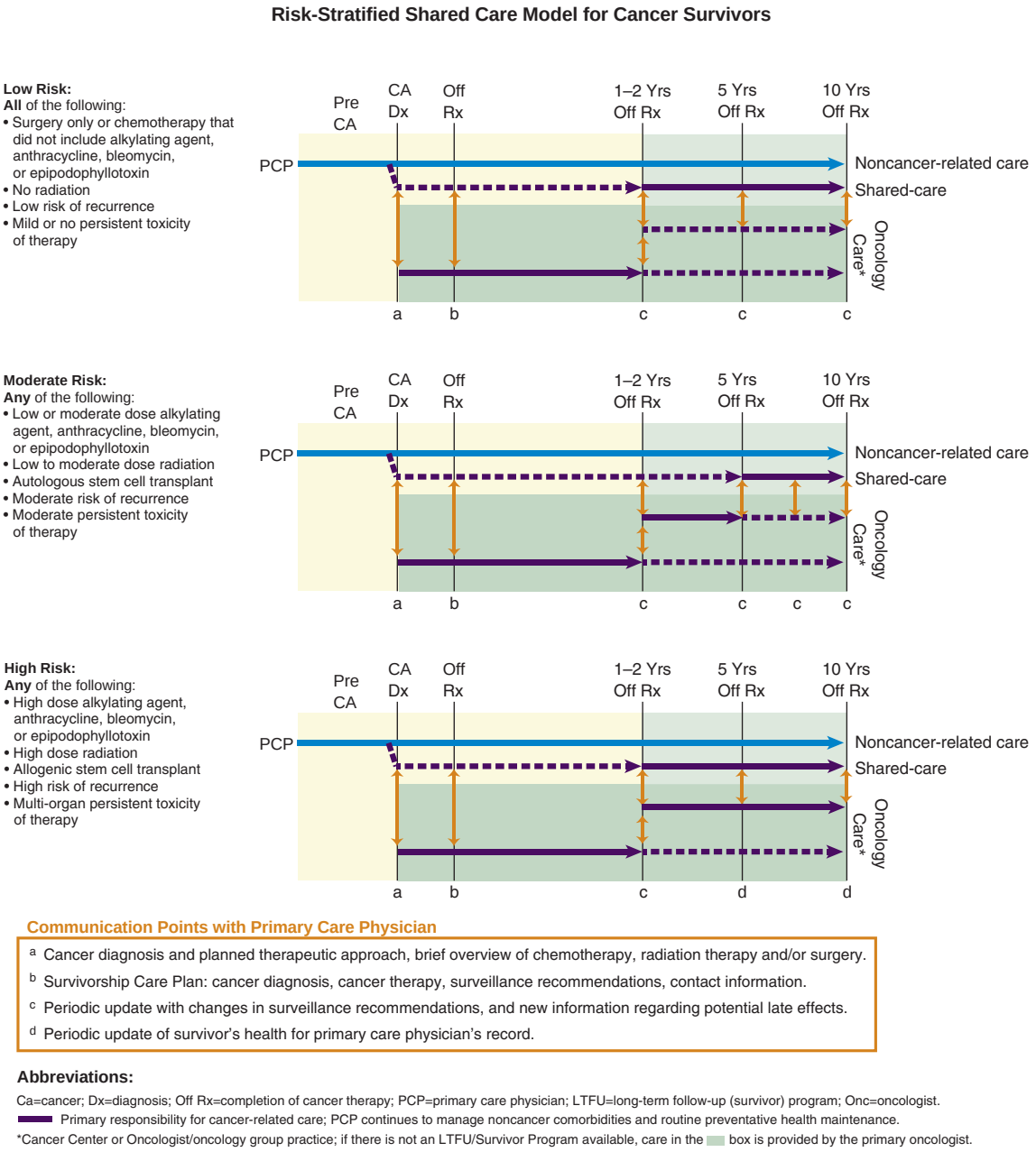

Fig. 543.8 Proposed risk-stratified shared care model for childhood cancer survivors. *Purple solid line* denotes primary responsibility cancer-related care; risk stratification is based on determination of the long-term follow-up staff. *(Adapted from McCabe MS, Partridge A, Grunfeld, E, Hudson MM. Risk-based health care, the cancer survivor, the oncologist, and the primary care physician. Semin Oncol. 2013;40:804–812; with data from Oeffinger KC, McCabe MS. Models for delivering survivorship care. J Clin Oncol. 2006;24:5117–5124.)*

appears to be cumulative, increasing by approximately 0.5% per year, resulting in approximately a 12% incidence at 25 years after treatment. Patients who have been treated for childhood cancer should be examined annually with particular attention to possible late effects of therapy, including second malignancies (Fig. 543.8).

Risk-stratified therapy over the past few decades has been shown to reduce late morbidity and mortality. A good resource for the pediatrician, patient, and family who must anticipate the possibilities is available at http://www.survivorshipguidelines.org.

PALLIATIVE CARE

At all stages of caring for children with cancer, principles of palliative care should be applied to relieve pain and suffering and to provide comfort (see Chapter 8). Early involvement of palliative or supportive care teams is beneficial. **Pain** is a serious cause of suffering among patients with cancer. It may be the result of organ obstruction or compression or bone metastasis, or it may be neuropathic. Pain should be managed in a stepwise manner, as recommended by the WHO, in accordance with the principles of selecting the appropriate analgesic, prescribing the appropriate dosage, administering the drug by the appropriate route, and choosing an appropriate dosing schedule to prevent persistent pain and to relieve breakthrough pain (see Chapter 93). In addition, the dosage should be titrated aggressively while attempts are made to prevent, anticipate, and manage side effects. Adjuvant drugs and sequential trials of analgesic drugs should be considered.

The goals in the care of dying patients are to avoid distress for the patient, family, and caregivers; to provide care consistent with the patient's and family's wishes; and to comply with and advocate for clinical, cultural, and ethical standards.

Visit Elsevier eBooks+ at eBooks.Health.Elsevier.com for Bibliography.

Chapter 544

The Leukemias

A. Kim Ritchey, Erika D. Friehling, Julia C. Meade, David G. Tubergen, and Archie Bleyer

INTRODUCTION

The leukemias are the most common malignant neoplasms in childhood, accounting for approximately 31% of all malignancies that occur in children younger than 15 years old. Each year, leukemia is diagnosed in approximately 3,100 children and adolescents <20 years old in the United States, an annual incidence of 4.8 cases per 100,000 children. Acute lymphoblastic leukemia (ALL) accounts for approximately 77% of cases of childhood leukemia, acute myelogenous leukemia (AML) for approximately 11%, chronic myelogenous leukemia (CML) for 2–3%, and juvenile myelomonocytic leukemia (JMML) for 1–2%. The remaining cases consist of a variety of acute and chronic leukemias that do not fit classic definitions for ALL, AML, CML, or JMML.

The leukemias may be defined as a group of malignant diseases in which genetic abnormalities in a hematopoietic cell give rise to an unregulated clonal proliferation of cells. The progeny of these cells have a growth advantage over normal cellular elements because of their increased rate of proliferation and a decreased rate of spontaneous apoptosis. The result is a disruption of normal marrow function and, ultimately, marrow failure. The clinical features, laboratory findings, and responses to therapy vary depending on the type of leukemia.

544.1 Acute Lymphoblastic Leukemia

Erika D. Friehling, A. Kim Ritchey, Julia C. Meade, and Archie Bleyer

Leukemia (ALL) was the first disseminated cancer shown to be curable. It is a heterogeneous group of malignancies with distinctive genetic abnormalities that result in varying clinical behaviors and responses to therapy.

EPIDEMIOLOGY

Acute lymphoblastic leukemia is diagnosed in approximately 3,100 children and adolescents <20 years old in the United States each year. It has a striking peak incidence at 2-3 years of age and occurs more in males than in females at all ages. The disease is more common in children with certain chromosomal abnormalities, such as Down syndrome, Li-Fraumeni, Bloom syndrome, and ataxia-telangiectasia. Among identical twins, the risk to the second twin if one twin develops leukemia is greater than that in the general population. The risk is >70% if ALL is diagnosed in the first twin during the first year of life and the twins shared the same (monochorionic) placenta. If the first twin develops ALL by 5-7 years of age, the risk to the second twin is at least twice that of the general population, regardless of zygosity.

ETIOLOGY

In virtually all cases, the etiology of ALL is unknown, although several genetic and environmental factors are associated with childhood leukemia (Table 544.1). Most cases of ALL are thought to be caused by post-conception somatic pathogenic gene variants in lymphoid cells. However, the identification of the leukemia-specific fusion-gene sequences in archived neonatal blood spots of some children who develop ALL at a later date indicates the importance of in utero events in the initiation of the malignant process in some cases. The long lag period before the onset of the disease in some children, reported to be as long as 14 years, supports the concept that additional genetic modifications are required for disease expression. Moreover, those same pathogenic variants have been found in neonatal blood spots of children who *never* go on to develop leukemia.

Exposure to medical diagnostic radiation both in utero and in childhood is associated with an increased incidence of ALL (see Chapter 758). In addition, published descriptions and investigations of geographic clusters of cases have raised concern that environmental factors can increase the incidence of ALL. Thus far, no such factors other than radiation have been identified in the United States. In certain developing countries, there is an association between B-cell ALL (B-ALL) and Epstein-Barr virus (EBV) infections.

CELLULAR CLASSIFICATION

The classification of ALL depends on characterizing the malignant cells in the bone marrow to determine the morphology, phenotype as measured by cell membrane markers, and cytogenetic and molecular genetic features. **Morphology** is usually adequate alone to establish a diagnosis, but the other studies are essential for disease classification, which can have a major influence on the prognosis and the choice of appropriate therapy. The current system used is the World Health Organization (WHO) classification of leukemias. Phenotypically, surface markers show that approximately 85% of cases of ALL are classified as **B-lymphoblastic leukemia** (previously termed precursor B-ALL or pre–B-ALL), approximately 15% are **T-lymphoblastic leukemia**, and approximately 1% are derived from mature B cells. The rare leukemia of mature B cells is termed **Burkitt leukemia** and is one of the most rapidly growing cancers in humans, requiring a different therapeutic approach than other subtypes of ALL. A small percentage of children with leukemia have a disease characterized by surface markers of both lymphoid and myeloid derivation.

Chromosomal abnormalities are used to subclassify ALL into prognostic groups (Table 544.2). Many genetic alterations, including inactivation of tumor-suppressor genes and pathogenic gene variants that activate the *JAK-STAT* or *RAS* pathways, have been discovered (Fig. 544.1).

The polymerase chain reaction (PCR) and fluorescence in situ hybridization (FISH) techniques offer the ability to pinpoint molecular genetic abnormalities and can be used to detect small numbers of malignant cells at diagnosis as well as during follow-up (**minimal residual disease [MRD]**, see later) and are of proven clinical utility. DNA microarray and whole genome sequencing make it possible to analyze the expression of thousands of genes in the leukemic cell.

Table 544.1 Predisposing Factors of Acute Lymphoblastic Leukemia

GENETIC SUSCEPTIBILITY
Congenital syndromes: Down syndrome, Fanconi anemia, ataxia telangiectasia, Bloom syndrome, Nijmegen breakage syndrome
Inherited gene variants: *ARID5B, IKZF1, CEBPE, CDKN2A,* or *CDKN2B, PIP4K2A, ETV6*
Constitutional Robertsonian translocation between chromosomes 15 and 21, rob(15;21)(q10;q10)
Single nucleotide polymorphisms: rs12402181 in miR-3117 and rs62571442 in miR-3689d2
ENVIRONMENTAL FACTORS
Pesticide exposure
Ionizing radiation
Childhood infections

From Malard F, Mohty M. Acute lymphoblastic leukaemia. *Lancet.* 2020;395:1146–1158. Panel, p. 1147.

CLINICAL MANIFESTATIONS

The initial presentation of ALL usually is nonspecific and relatively brief. Anorexia, fatigue, malaise, irritability, and intermittent low-grade fever are often present. Bone or joint pain, particularly in the lower extremities, may be present. Less often, symptoms may be of several months' duration, may be localized predominantly to the bones or joints, and may include joint swelling. Bone pain is severe and can wake the patient at night. As the disease progresses, signs and symptoms of **bone marrow failure** become more obvious with the occurrence of pallor, fatigue, exercise intolerance, bruising, oral mucosal bleeding or epistaxis, and fever, which may be caused by infection or the leukemia. Organ infiltration can cause lymphadenopathy, hepatosplenomegaly, testicular enlargement, or central nervous system (CNS) involvement (cranial neuropathies, headache, seizures). Respiratory distress may be caused by severe anemia or mediastinal node compression of the airways.

On **physical examination,** findings of pallor, listlessness, purpuric and petechial skin lesions, or mucous membrane hemorrhage can reflect bone marrow failure (see Chapter 542). The proliferative nature of the disease may be manifested as lymphadenopathy, splenomegaly, or, less often, hepatomegaly. Patients with bone or joint pain may have exquisite tenderness over the bone or objective evidence of joint swelling and effusion. Nonetheless, with marrow involvement, deep bone pain may be present, but tenderness will not be elicited. Rarely, patients show signs of increased intracranial pressure that indicate leukemic involvement of the CNS. These include papilledema (see Fig. 542.3), retinal hemorrhages, and cranial nerve palsies. Respiratory distress usually is related to anemia but can occur in patients as the result of a large anterior mediastinal mass (e.g., in the thymus or nodes). This problem is most frequently seen in adolescent males with T-cell ALL (T-ALL). **T-ALL** also usually has a higher leukocyte count.

B-lymphoblastic leukemia is the most common immunophenotype, with onset at 1-10 years of age. The median leukocyte count at presentation is 33,000/μL, although 75% of patients have counts <20,000/μL; thrombocytopenia is seen in 75% of patients and hepatosplenomegaly in 30–40% of patients. In all types of leukemia, CNS symptoms are seen at presentation in 5% of patients. Leukemia cells can be seen in the cerebrospinal fluid (CSF) of 10–15% of patients, but only 3–5% are diagnosed with CNS leukemia, defined as >5 WBCs/μL with blasts present. Testicular involvement is rarely evident at diagnosis, but prior studies indicate occult involvement in 25% of males. There is no indication for testicular biopsy.

DIAGNOSIS

The diagnosis of ALL is strongly suggested by peripheral blood findings that indicate bone marrow failure. Anemia and thrombocytopenia are seen in most patients. Leukemic cells might not be reported in the peripheral blood in routine laboratory examinations. Many patients with ALL present with total leukocyte counts of <10,000/μL. In such cases, the leukemic cells often are reported initially to be "atypical lymphocytes," and it is only on further evaluation that the cells are

Table 544.2 Main Genetic Subtypes of B-Cell Acute Lymphoblastic Leukemia

	FREQUENCY	PATHOGENIC VARIANTS	PROGNOSIS
High hyperdiploid (gain of ≥5 chromosomes)	25% children; 3% AYAs and adults	RTK-RAS signaling pathway, histone modifiers	Favorable
Near-haploid (24-31 chromosomes)	2% children; <1% AYAs and adults	RAS-activating, *IKZF3*	Poor
Low-hypodiploid (32-39 chromosomes)	<1% children; 5% AYAs; >10% adults	*TP53, IKZF2, RB1*	Very poor
MLL (KMT2A) rearrangements	>80% infants; <1% children; 4% AYAs; 15% adults	*MLL (KMT2A)* rearrangement, few additional pathogenic variants (PI3K-RAS signaling pathway)	Very poor
ETV6-RUNX1 translocation, t(12;21)(q13;q22)	30% children; <5% AYAs and adults	*ETV6-RUNX1*	Favorable
TCF3-PBX1 translocation, t(1;19)(q23;p13)	5% children, AYAs and adults	*TCF3-PBX1*	Favorable
TCF3-HLF variant of t(1;19)(q23;p13)	<1% acute lymphoblastic leukemia	*TCF3-HLF*	Poor
BCR-ABL1 Philadelphia chromosome, t(9;22)(q34;q11)	2–5% children, 6% AYAs; >25% adults	*BCR-ABL1* fusion gene, common deletions of *IKZF1, CDKN2A, CDKN2B,* and *PAX5*	Poor (improved with tyrosine kinase inhibitors)
Philadelphia chromosome-like acute lymphoblastic leukemia	10% children; 25–30% AYAs; 20% adults	Rearrangements of *CRLF2* (about 50%), *ABL*-class tyrosine kinase genes (12%) and *JAK2* (10%); pathogenic variants of *EPOR* (3–10%); pathogenic variants activating JAK-STAT (10%) and RAS (2–8%) signaling pathways	Poor
DUX4 and *ERG*-deregulated acute lymphoblastic leukemia	5–10% acute lymphoblastic leukemia	*DUX4* rearrangement and overexpression, *ERG* deletions	Favorable, including if coexistence of *IKZF1* pathogenic variants (about 40% of patients)
MEF2D-rearranged acute lymphoblastic leukemia	4% children; 7% AYAs and adults	*MEF2D* is fused to *BCL9* (most frequent fusion event), *HNRNPUL1, SS18, FOXJ2, CSF1R,* or *DAZAP1*	Poor
ZNF384-rearranged acute lymphoblastic leukemia	5% children; 10% AYAs and adults	*ZNF384* rearranged with a transcriptional regulator or chromatin modifier (*EP300, CREBBP, TAF15, SYNRG,* EWSR1, *TCF3, ARID1B, BMP2K,* or *SMARCA2*)	Intermediate

AYAs, Adolescents and young adults.
From Malard F, Mohty M. Acute lymphoblastic leukaemia. *Lancet.* 2020;395:1146–1158. Table 1, p. 1148.

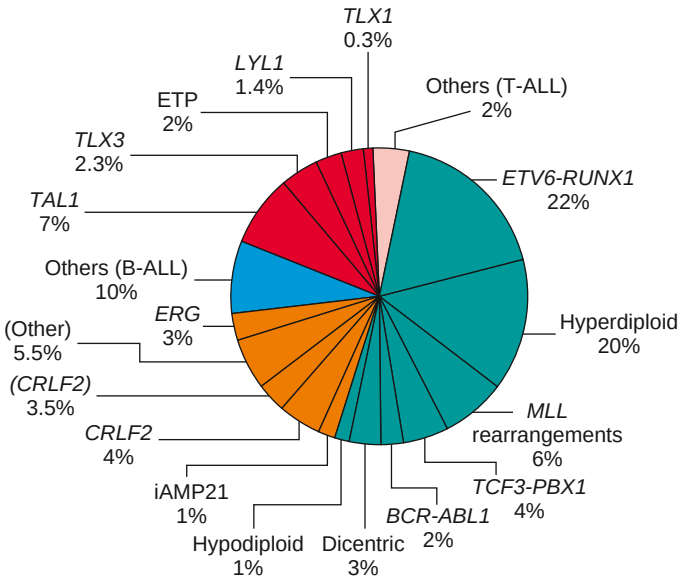

Fig. 544.1 Estimated frequency of specific genotypes in childhood acute lymphoblastic leukemia (ALL). *Teal wedges* refer to B-cell ALL (B-ALL), *orange* to recently identified subtypes of B-ALL, and *red wedges* to T-cell ALL (T-ALL). *(From Mullighan CG. Genomic characterization of childhood acute lymphoblastic leukemia. Semin Hematol. 2013;50:314–324.)*

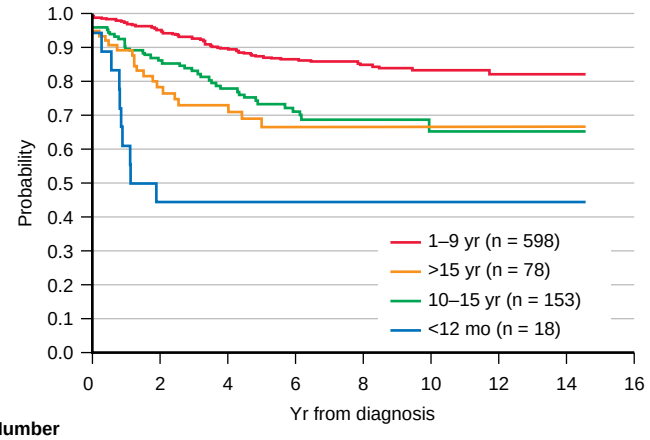

Number at risk									
<12 mo	18	11	8	8	6	1	1	0	0
1–9 yr	598	528	378	295	213	149	85	31	4
10–15 yr	153	130	100	77	50	26	11	6	1
>15 yr	78	60	40	29	20	7	1	0	0

Fig. 544.2 Kaplan-Meier estimates of event-free survival according to age at diagnosis of acute lymphoblastic leukemia. *(From Pui CH, Robinson LL, Look AT. Acute lymphoblastic leukaemia. Lancet. 2008;371:1030–1042.)*

found to be part of a malignant clone. When the results of an analysis of peripheral blood suggest the possibility of leukemia, flow cytometry can rapidly facilitate the diagnosis. The bone marrow should be examined promptly to confirm the diagnosis. It is important that all studies necessary to confirm a diagnosis and adequately classify the type of leukemia be performed, including bone marrow aspiration and biopsy, flow cytometry, cytogenetics, and molecular studies.

ALL is diagnosed by a bone marrow evaluation that demonstrates >25% of the bone marrow cells as a homogeneous population of lymphoblasts. Initial evaluation also includes CSF examination. If lymphoblasts are found and the CSF leukocyte count is elevated, overt CNS or

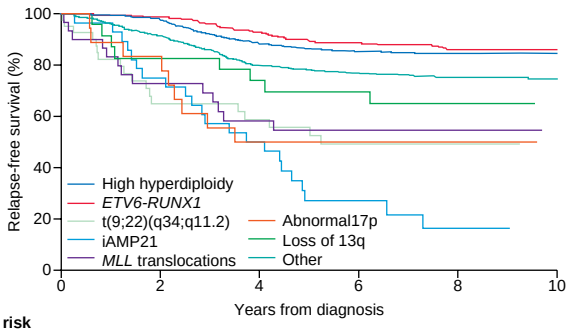

Number at risk						
High hyperdiploidy	551	529	470	434	249	98
ETV6-RUNX1	365	355	331	301	167	47
t(9;22)(q34;q11.2)	42	22	19	14	8	2
iAMP21	28	21	14	6	1	0
MLL translocations	30	20	16	14	9	1
Abnormal17p	18	15	9	8	7	2
Loss of 13q	24	19	17	15	9	4
Other	644	567	483	440	258	105

Fig. 544.3 Kaplan-Meier analysis of relapse-free survival according to biologic subtype of leukemia. *(From Moorman AV, Ensor HM, Richards SM, et al. Prognostic effect of chromosomal abnormalities in childhood B-cell precursor acute lymphoblastic leukaemia: Results from the UK Medical Research Council ALL97/99 randomised trial. Lancet Oncol. 2010;11:429–438.)*

meningeal leukemia is present. This finding reflects a poorer stage and indicates the need for additional CNS and systemic therapies. The staging lumbar puncture (LP) may be performed in conjunction with the first dose of intrathecal chemotherapy, if the diagnosis of leukemia was previously established from bone marrow evaluation. An experienced proceduralist should perform the initial LP, because a traumatic LP is associated with an increased risk of CNS relapse.

DIFFERENTIAL DIAGNOSIS

The diagnosis of leukemia is readily made in the patient with typical signs and symptoms, anemia, thrombocytopenia, and elevated WBC count with blasts present on smear. Elevation of the lactate dehydrogenase (LDH) is often a clue to the diagnosis of ALL. When pancytopenia is present without peripheral blasts, aplastic anemia (congenital or acquired), marrow infiltration from metastatic disease, and hemophagocytic lymphohistiocytosis should be considered. Failure of a single cell line, as seen in transient erythroblastopenia of childhood, immune thrombocytopenia, and congenital or acquired neutropenia, is rarely the presenting feature of ALL. A high index of suspicion is required to differentiate ALL from infectious mononucleosis in patients with acute onset of fever and lymphadenopathy and from juvenile idiopathic arthritis in patients with fever, bone pain but often no tenderness, and joint swelling. These presentations also can require bone marrow examination.

ALL must be differentiated from AML and other malignant diseases that invade the bone marrow and can have clinical and laboratory findings similar to ALL, including neuroblastoma, rhabdomyosarcoma, Ewing sarcoma, and retinoblastoma.

TREATMENT

The single most important prognostic factor in ALL is the treatment: without effective therapy, the disease is fatal. Considerable progress has been made in overall survival for children with ALL through use of multiagent chemotherapeutic regimens, intensification of therapy, and selection of treatment based on relapse risk. Survival is also related to age (Fig. 544.2) and biologic subtype (Fig. 544.3).

Risk-stratified therapy is the standard of current ALL treatment and accounts for age at diagnosis, initial WBC count, immunophenotypic and cytogenetic characteristics of blast populations, rapidity of early treatment response (i.e., how quickly the leukemic cells can be cleared from the marrow or peripheral blood), and assessment of MRD at the end of induction therapy (Table 544.3). Different

Table 544.3 Prognostic Factors for Acute Lymphoblastic Leukemia

	FAVORABLE FACTOR	ADVERSE FACTOR
DEMOGRAPHIC AND CLINICAL FEATURES		
Age	1 year to <10 years	<1 year or ≥10 years
Sex	Female	Male
Ethnicity	White, Asian	Black, Hispanic
CLINICAL, BIOLOGIC, OR GENETIC FEATURES OF LEUKEMIA		
CNS involvement	No	Yes
Blood count at diagnosis	Low blood count; $<50 \times 10^9$ cells/L for B-cell acute lymphoblastic leukemia and $<100 \times 10^9$ cells/L for T-cell acute lymphoblastic leukemia	High blood count; $\geq 50 \times 10^9$/L for B-cell acute lymphoblastic leukemia and $\geq 100 \times 10^9$ cells/L for T-cell acute lymphoblastic leukemia
Immunophenotype	B-cell lineage	T-cell lineage
Cytogenetic features	Hyperdiploidy, *ETV6-RUNX*, *TCF3-PBX1*, and trisomy of chromosomes 4, 10, or 17	Hypodiploidy, *BCR-ABL1* Philadelphia chromosome-positive, *MLL* rearrangements, *TCF3-HLF*, and complex karyotype (≥5 chromosomal abnormalities)
Genomic features	*DUX4*-rearrangement (*ERG* deletion)	*IKZF1* deletions or pathogenic variants, Philadelphia chromosome-like, *MEF2D*-rearrangement
RESPONSE TO TREATMENT		
Minimal residual disease at specified time points	Low minimal residual disease $<10^{-3}$ nucleated cells or undetectable	Persistence of minimal residual disease $\geq 10^{-3}$ nucleated cells, the higher this value the worse the prognosis

From Malard F, Mohty M. Acute lymphoblastic leukaemia. *Lancet*. 2020;395:1146–1158. Table 2, p. 1150.

study groups use various factors to define risk, but age 1-10 years and a leukocyte count <50,000/μL are used by the National Cancer Institute (NCI) to define standard risk. Children who are younger than 1 year or older than 10 years or who have an initial leukocyte count of >50,000/μL are considered to be high risk. Additional characteristics that adversely affect outcome include T-cell immunophenotype or a slow response to initial therapy. Chromosomal abnormalities, including hypodiploidy, the Philadelphia chromosome, and *KMT2A (MLL)* gene rearrangements, portend a poorer outcome. Other genetic pathogenic variants, such as in the *IKZF1* gene, have been shown to be associated with a poor prognosis and may become important in treatment algorithms in the future. More favorable characteristics include a rapid response to therapy, hyperdiploidy, trisomy of specific chromosomes (4, 10, and 17), and rearrangements of the *ETV6-RUNX1* (formerly *TEL-AML1*) genes.

The outcome for patients at higher risk can be improved by administration of more intensive therapy despite the greater toxicity of such therapy. Infants with ALL, along with patients who present with specific chromosomal abnormalities, such as t(4;11), have an even higher risk of relapse despite intensive therapy. However, the poor outcome of Philadelphia chromosome–positive ALL with t(9;22) has been dramatically changed by the addition of imatinib to an intensive chemotherapy backbone. **Imatinib** is an agent specifically designed to inhibit the BCR-ABL kinase resulting from the translocation. With this approach, the event-free survival has improved from 30% to 70%. Clinical trials demonstrate that the prognosis for patients with a slower response to initial therapy may be improved by therapy that is more intensive than the therapy considered necessary for patients who respond more rapidly.

Most children with ALL are treated in clinical trials conducted by national or international cooperative groups. Standard treatment involves chemotherapy for 2-3 years, and most achieve remission at the end of the induction phase. Patients in clinical remission can have MRD that can only be detected with specific molecular probes to translocations and other DNA markers contained in leukemic cells or specialized flow cytometry. MRD can be quantitative and can provide an estimate of the burden of leukemic cells present in the marrow. Higher levels of MRD present at the end of induction suggest a poorer prognosis and higher risk of subsequent relapse. MRD of >0.01% on the marrow on day 29 of induction is a significant risk factor for shorter event-free survival for all risk categories, compared with patients with negative MRD. Therapy for ALL intensifies treatment in patients with evidence of MRD at the end of induction.

Initial therapy, termed **remission induction**, is designed to eradicate the leukemic cells from the bone marrow. During this phase, therapy is given for 4 weeks and consists of vincristine weekly, a corticosteroid such as dexamethasone or prednisone, and usually a single dose of a long-acting, pegylated asparaginase preparation. Patients at higher risk also receive daunorubicin at weekly intervals. With this approach, 98% of patients are in remission, as defined by <5% blasts in the marrow and a return of neutrophil and platelet counts to near-normal levels after 4-5 weeks of treatment. Intrathecal chemotherapy is always given at the start of treatment and at least once more during induction.

The second phase of treatment, **consolidation**, focuses on intensive CNS therapy in combination with continued intensive systemic therapy to prevent later CNS relapses. Intrathecal chemotherapy is given repeatedly by LP. The likelihood of later CNS relapse is thereby reduced to <5%, from historical incidence as high as 60%. A small percentage of patients with features that predict a high risk of CNS relapse may receive irradiation to the brain in later phases of therapy. This includes patients who at diagnosis have lymphoblasts in the CSF and either an elevated CSF leukocyte count or physical signs of CNS leukemia, such as cranial nerve palsy.

Subsequently, many regimens provide 14-28 weeks of therapy, with the drugs and schedules used varying depending on the risk group of the patient. This period of treatment is often termed **intensification** and includes phases of aggressive treatment **(delayed intensification)** as well as relatively less toxic phases of treatment **(interim maintenance)**. Multiagent chemotherapy, including such medications as cytarabine, methotrexate, asparaginase, and vincristine, is used during these phases to eradicate residual disease.

Finally, patients enter the **maintenance** phase of therapy, which lasts for 2-3 years, depending on the protocol used. Patients are given daily mercaptopurine and weekly oral methotrexate, usually with intermittent doses of vincristine and a corticosteroid.

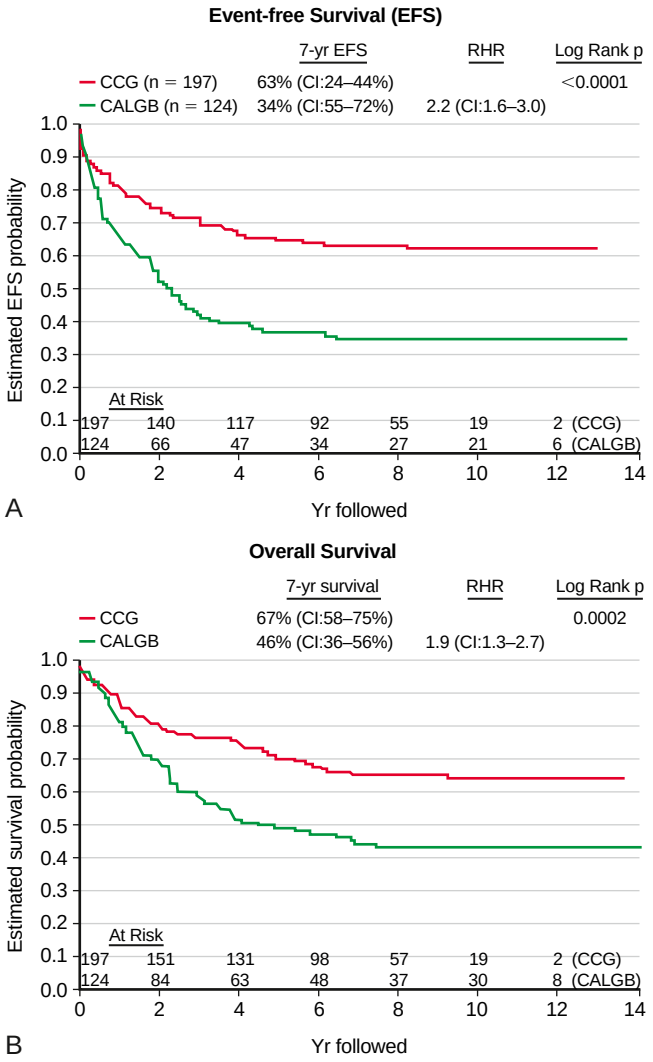

Fig. 544.4 Comparison of event-free survival (A) and overall survival (B) among Cancer and Leukemia Group B (CALGB) (adult protocol, *green line*) and Children's Cancer Group (CCG) (pediatric protocol, *red line*) patients. CI, Confidence interval; EFS, event-free survival; RHR, relative hazard rate. *(From Stock W, La M, Sanford B, et al. What determines the outcomes for adolescents and young adults with acute lymphoblastic leukemia treated on cooperative group protocols? A comparison of Children's Cancer Group and Cancer and Leukemia Group B studies. Blood. 2008;112:1646–1654.)*

A small number of patients with particularly poor prognostic features, such as those with induction failure or extreme hypodiploidy, may undergo bone marrow transplantation during the first remission.

Adolescents and **young adults** with ALL have a poor prognosis compared to children <15 years old. They often have adverse prognostic factors and require more intensive therapy. Patients in this age-group have a superior outcome when treated with pediatric rather than adult treatment protocols (Fig. 544.4). Although the explanation for these findings may be multifactorial, it is important that these patients be treated with pediatric treatment protocols, ideally in a pediatric cancer center.

Genetic polymorphisms of enzymes important in drug metabolism may impact both the efficacy and the toxicity of chemotherapeutic medications. **Pharmacogenetic testing** of the thiopurine *S*-methyltransferase *(TPMT)* gene, which encodes one of the metabolizing enzymes of mercaptopurine, can identify patients with varying levels of TPMT enzyme activity. Decreased TPMT enzyme activity results in accumulation of a toxic metabolite of mercaptopurine and severe myelosuppression, requiring dose reductions of the chemotherapy (see Chapter 543).

Treatment of Relapse

The major impediment to a successful outcome is **relapse** of the disease. Outcomes remain poor among those who relapse, with the most important prognostic indicators being time from diagnosis and site of relapsed disease. In addition, other factors, such as immunophenotype (T-ALL worse than B-ALL) and age at initial diagnosis, have prognostic significance.

Relapse occurs in the bone marrow in 15–20% of patients with ALL and has the most serious implications, especially if it occurs during or shortly after completion of therapy. Intensive chemotherapy with agents not previously used in the patient followed by allogeneic stem cell transplantation can result in long-term survival for some patients with bone marrow relapse (see Chapter 177). **Chimeric antigen receptor** (CAR) T-cell technology will have an increasing role in the treatment of patients who have experienced a relapse of ALL (see Chapter 543). In addition, therapy targeted to the possible underlying pathogenic pathways (tyrosine kinase inhibitors) or cell receptors (blinatumomab) have demonstrated promising results in patients with relapsed or refractory disease (Fig. 544.5)

The incidence of **CNS relapse** has decreased to <5% since introduction of preventive CNS therapy. CNS relapse may be discovered at a routine LP in the asymptomatic patient. Symptomatic patients with relapse in the CNS usually present with signs and symptoms of increased intracranial pressure and can present with isolated cranial nerve palsies. The diagnosis is confirmed by demonstrating the presence of leukemic cells in the CSF. The treatment includes intrathecal medication and cranial or craniospinal irradiation. Systemic chemotherapy also must be used, because these patients are at high risk for subsequent bone marrow relapse. Most patients with leukemic relapse confined to the CNS do well, especially those in whom the CNS relapse occurs longer than 18 months after initiation of chemotherapy.

Testicular relapse occurs in <2% of males with ALL, usually after completion of therapy. Such relapse occurs as painless swelling of one or both testes. The diagnosis is confirmed by biopsy of the affected testis. Treatment includes systemic chemotherapy and possibly local irradiation. A high proportion of males with a testicular relapse can be successfully retreated, and the survival rate of these patients is good.

The most current information on treatment of childhood ALL is available in the PDQ (Physician Data Query) on the NCI website (http://www.cancer.gov/cancertopics/pdq/treatment/childALL/healthprofessional/).

SUPPORTIVE CARE

Close attention to the medical supportive care needs of the patients is essential in successfully administering aggressive chemotherapeutic programs. Patients with high WBC counts are especially prone to **tumor lysis syndrome** as therapy is initiated. The kidney failure associated with very high levels of serum uric acid can be prevented or treated with allopurinol or urate oxidase. Chemotherapy often produces severe myelosuppression, which can require erythrocyte and platelet transfusion and always requires a high index of suspicion and aggressive empirical antimicrobial therapy for sepsis in febrile children with neutropenia. Patients must receive prophylactic treatment for *Pneumocystis jiroveci* pneumonia during chemotherapy and for several months after completing treatment.

The successful therapy of ALL is a direct result of intensive and often toxic treatment. However, such intensive therapy can incur substantial academic, developmental, and psychosocial costs for children with ALL and considerable financial costs and stress for their families. Both long-term and acute toxicity effects can occur. An array of cancer care professionals with training and experience in addressing the myriad of problems that can arise is essential to minimize the complications and achieve an optimal outcome.

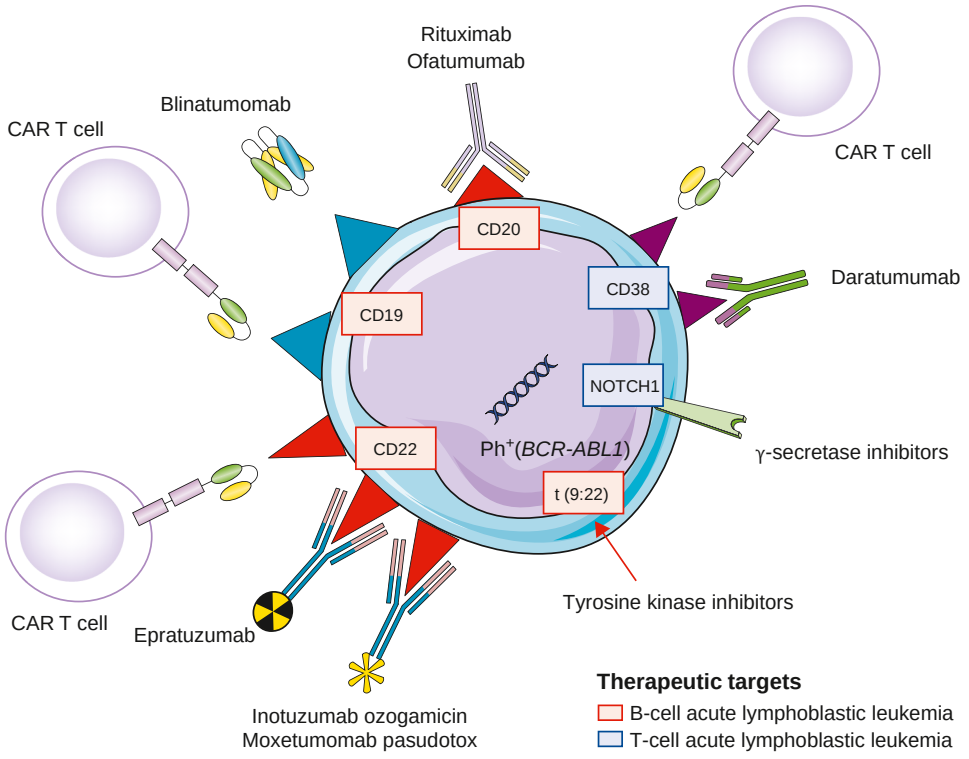

Fig. 544.5 New targeted therapy for acute lymphoblastic leukemia. CAR, Chimeric antigen receptor. *(From Malard F, Mohty M. Acute lymphoblastic leukaemia. Lancet. 2020;395:1146–1158. Fig. 2, p. 1153.)*

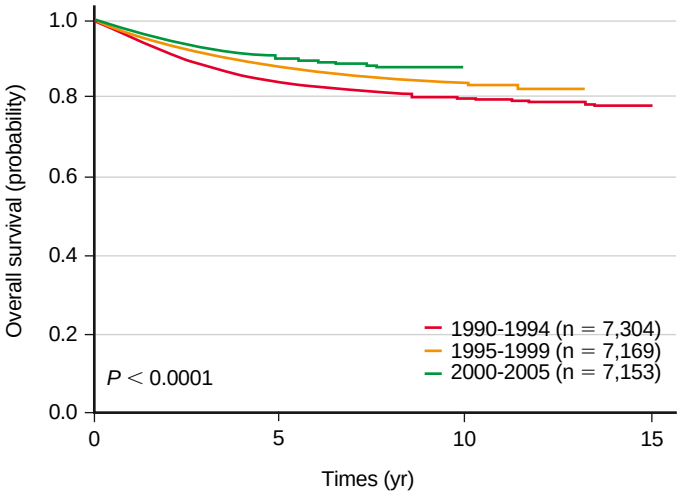

Fig. 544.6 Overall survival probabilities by treatment era for patients with acute lymphoblastic leukemia (ALL) in Children's Oncology Group trials in 1990–1994, 1995–1999, and 2000–2005. *(From Hunger SP, Lu X, Devidas M, et al. Improved survival for children and adolescents with acute lymphoblastic leukemia between 1990 and 2005: a report from the Children's Oncology Group. J Clin Oncol. 2012;30:1663–1669.)*

PROGNOSIS

Improvements in therapy and risk stratification have resulted in significant increases in survival rates, with current data showing overall 5-year survival of approximately 90% (Fig. 544.6). Although survivors are more likely to experience significant chronic medical conditions compared with siblings, including musculoskeletal, cardiac, and neurologic conditions, risk-adapted therapy has resulted in a decrease in late effects. Overall, long-term management following ALL should be conducted in a clinic where children and adolescents can be followed by a variety of specialists to address the challenges of these unique patients.

Visit Elsevier eBooks+ at eBooks.Health.Elsevier.com for Bibliography.

544.2 Acute Myelogenous Leukemia

Julia C. Meade, Erika D. Friehling, A. Kim Ritchey, David G. Tubergen, and Archie Bleyer

EPIDEMIOLOGY

AML accounts for 11% of the cases of childhood leukemia in the United States; it is diagnosed in approximately 370 children annually. The relative frequency of AML increases in adolescence, representing 36% of cases of leukemia in 15-19 year olds. **Acute promyelocytic leukemia (APL)** is a subtype that is more common in certain regions of the world, but the incidence of the other types is generally uniform. Environmental risk factors have been identified, including ionizing radiation, chemotherapeutic agents (e.g., alkylating agents, epipodophyllotoxin), and organic solvents (benzene). Approximately 10% of children with AML are found to have a germline pathogenic variant predisposing them to leukemia. Certain syndromes are also known to increase the risk of leukemia: Down syndrome, Fanconi anemia, Bloom syndrome, Kostmann syndrome, Shwachman-Diamond syndrome, Diamond-Blackfan syndrome, Li-Fraumeni syndrome, and neurofibromatosis type 1 (see Table 544.1).

CELLULAR CLASSIFICATION

The characteristic feature of AML is that >20% of bone marrow cells on bone marrow aspiration or biopsy touch preparations constitute a fairly homogeneous population of blast cells, with features similar to those that characterize early differentiation states of the myeloid-monocyte-megakaryocyte series of blood cells. Current practice requires the use of flow cytometry to identify cell surface antigens and use of chromosomal and molecular genetic techniques for additional diagnostic precision and to aid the choice of therapy. The WHO has proposed a new classification system that incorporates morphology, chromosome abnormalities, and specific gene pathogenic variants. This system provides significant biologic and prognostic information (Table 544.4).

CLINICAL MANIFESTATIONS

The production of symptoms and signs of AML is a result of replacement of bone marrow by malignant cells and caused by secondary bone

marrow failure. Patients with AML can present with any or all of the findings associated with marrow failure in ALL. In addition, patients with AML may present with signs and symptoms that are uncommon in ALL, including **subcutaneous nodules** or "blueberry muffin" lesions (especially in infants), infiltration of the gingiva (especially in monocytic subtypes), signs and laboratory findings of **disseminated intravascular coagulation** (especially indicative of APL), and discrete masses, known as **chloromas** or **granulocytic sarcomas**. These masses can occur in the absence of apparent bone marrow involvement and typically are associated with a t(8;21) translocation. Chloromas also may be seen in the orbit and epidural space.

DIAGNOSIS

Analysis of bone marrow aspiration and biopsy specimens of patients with AML typically reveals the features of a hypercellular marrow consisting of a monotonous pattern of cells. Flow cytometry and special stains assist in identifying myeloperoxidase-containing cells, thus confirming both the myelogenous origin of the leukemia and the diagnosis. Some chromosomal abnormalities and molecular genetic markers are characteristic of specific subtypes of disease (Table 544.5).

Table 544.4 WHO Classification of Acute Myeloid Neoplasms

Acute myeloid leukemia with recurrent genetic abnormalities
- AML with t(8;21)(q22;q22.1); *RUNX1-RUNX1T1*
- AML with inv(16)(p13.1q22) or t(16;16)(p13.1;q22); *CBFB-MYH11*
- APL with *PML-RARA*
- AML with t(9;11)(p21.3;q23.3); *MLLT3-KMT2A*
- AML with t(6;9)(p23;q34.1); *DEK-NUP214*
- AML with inv(3)(q21.3q26.2) or t(3;3)(q21.3;q26.2); *GATA2, MECOM*
- AML (megakaryoblastic) with t(1;22)(p13.3;q13.3); *RBM15-MKL1*
- *Provisional entity: AML with BCR-ABL1*
- AML with variant NPM1
- AML with biallelic pathogenic variants of CEBPA
- *Provisional entity: AML with variant RUNX1*

AML with myelodysplasia-related changes
Therapy-related myeloid neoplasms
Acute myeloid leukemia, not otherwise specified
- AML with minimal differentiation
- AML without maturation
- AML with maturation
- Acute myelomonocytic leukemia
- Acute monoblastic/monocytic leukemia
- Pure erythroid leukemia
- Acute megakaryoblastic leukemia
- Acute basophilic leukemia
- Acute panmyelosis with myelofibrosis

Myeloid sarcoma
Myeloid proliferations related to Down syndrome
- Transient abnormal myelopoiesis
- Myeloid leukemia associated with Down syndrome

Blastic plasmacytoid dendritic cell neoplasm

AML, Acute myelogenous leukemia; APL, acute promyelocytic leukemia.
Adapted from Arber DA, Orazi A, Hasserjian R, et al. The 2016 revision to the World Health Organization classification of myeloid neoplasms and acute leukemia. *Blood*. 2016;127:2391–2405.

PROGNOSIS AND TREATMENT

Aggressive multiagent chemotherapy is successful in inducing remission in approximately 85–90% of patients. Survival has increased dramatically since the 1970s, when only 15% of newly diagnosed patients survived, compared with a current survival rate of 60–70% with modern therapy (Fig. 544.7). Various induction chemotherapy regimens exist, typically including an anthracycline in combination with high-dose cytarabine. Targeting therapy to genetic markers may be beneficial (see Table 544.5). Up to 5% of patients die of either infection or bleeding before a remission can be achieved. Post-remission therapy is chosen based on a combination of cytogenetic and molecular markers of the leukemia as well as the response to induction chemotherapy (MRD assessment). Selected patients with favorable prognostic features [t(8;21); t(15;17); inv(16); *NPM1* pathogenic variants] and robust response to induction chemotherapy have improved outcomes with chemotherapy alone, with stem cell transplantation only recommended after a relapse. However, patients with unfavorable prognostic features (e.g., monosomies 7 and 5, 5q−, and 11q23 abnormalities) who have inferior outcomes with chemotherapy might benefit from stem cell transplant in first remission. With improvements in supportive care, there is no longer a substantial difference in mortality when comparing matched-related stem cell transplants to matched-unrelated stem cell transplants for AML.

Acute promyelocytic leukemia, characterized by a gene rearrangement involving the retinoic acid receptor [t(15;17); PML-RARA], is very responsive to **all-*trans*-retinoic acid (ATRA, tretinoin)** combined with anthracyclines and cytarabine. The success of this therapy makes marrow transplantation in first remission unnecessary for patients with this disease. Arsenic trioxide is an effective noncytotoxic therapy for APL. Data from trials in adults and children show that the use of combined ATRA and arsenic without cytotoxic drugs for initial therapy for selected patients is feasible and highly effective.

Increased **supportive care** is needed in patients with AML because the intensive therapy they receive produces prolonged bone marrow suppression with a very high incidence of serious infections, especially viridans streptococcal sepsis and fungal infection. These patients require prolonged hospitalization and prophylactic antimicrobials.

The most current information on treatment of AML is available in the PDQ (Physician Data Query) on the NCI website (http://www.cancer.gov/cancertopics/pdq/treatment/childAML/healthprofessional/).

Visit Elsevier eBooks+ at eBooks.Health.Elsevier.com for Bibliography.

Table 544.5 Prognostic Implications of Common Chromosomal Abnormalities in Pediatric Acute Myelogenous Leukemia

CHROMOSOMAL ABNORMALITY	GENETIC ALTERATION	USUAL MORPHOLOGY	PROGNOSIS
t(8;21)	*RUNX1-RUNX1T1*	Myeloblasts with differentiation	Favorable
inv(16)	*CBFB-MYHII*	Myeloblasts plus abnormal eosinophils with dysplastic basophilic granules	Favorable
t(15;17)	*PML-RARA*	Promyelocytic	Favorable
11q23 abnormalities	*KMT2A(MLL)* rearrangements	Monocytic	Unfavorable
FLT3 alterations	*FLT3*-ITD	Any	Unfavorable
del(7q), −7	Unknown	Myeloblasts without differentiation	Unfavorable

Adapted from Nathan DG, Orkin SH, Ginsburg D, et al., eds. *Nathan and Oski's Hematology of Infancy and Childhood*. 6th ed. Philadelphia: Saunders; 2003: p. 1177.

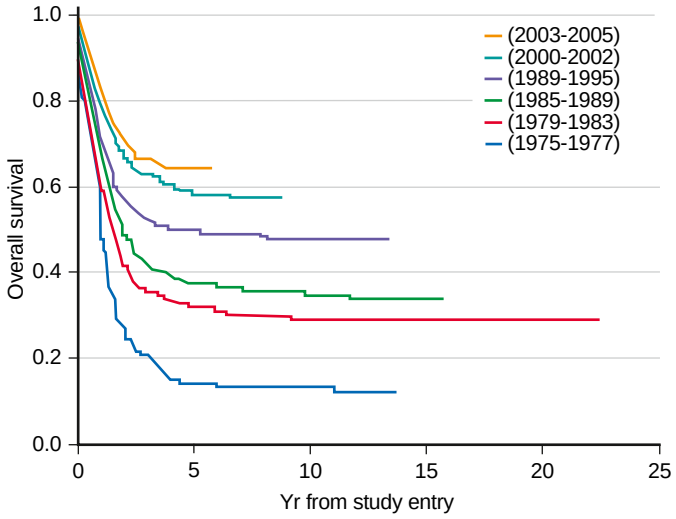

Fig. 544.7 Overall survival showing incremental improvements over the last 40 years in Children's Oncology Group and legacy trials in childhood acute myelogenous leukemia (AML). *(From Gamis AS, Alonzo TA, Perentesis JP, Meshinchi S. On behalf of the COG Acute Myeloid Leukemia Committee: Children's Oncology Group's 2013 blueprint for research: acute myeloid leukemia. Pediatr Blood Cancer. 2013;60:964–971.)*

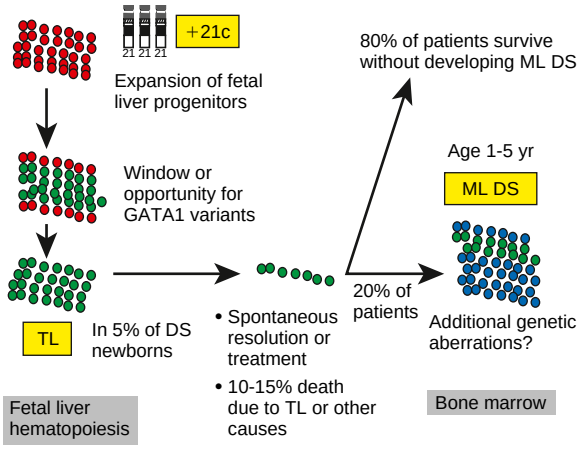

Fig. 544.8 Stepwise development of myeloid leukemia in Down syndrome (ML DS) following transient leukemia (TL). TL arises from expanded fetal liver progenitors as a result of constitutional trisomy 21, providing a window of opportunity for the occurrence of acquired mutations in the hematopoietic transcription factor GATA1. In most cases, TL spontaneously disappears, but some children need treatment because of severe TL-related symptoms. Approximately 20% of children with TL subsequently develop ML DS, which requires additional hits. *(From Zwaan MC, Reinhardt D, Hitzler J, Vyas P. Acute leukemias in children with Down syndrome. Pediatr Clin North Am. 2008;55:53–70.)*

544.3 Down Syndrome and Acute Leukemia and Transient Abnormal Myelopoiesis

A. Kim Ritchey, Julia C. Meade, Erika D. Friehling, David G. Tubergen, and Archie Bleyer

Acute leukemia occurs about 15-20 times more frequently in children with Down syndrome than in the general population (see Chapters 57 and 541). The ratio of ALL to AML in patients with Down syndrome is the same as that in the general population. The exception is during the first 3 years of life, when AML is more common. In children with Down syndrome who have ALL, the expected outcome of treatment has been slightly inferior to that for other children, a difference that can be partially explained by a lack of good prognostic characteristics, such as *ETV6-RUNX1* and trisomies, as well as the presence of genetic abnormalities associated with an inferior prognosis, such as *IKZF1*. However, studies of patients with Down syndrome and standard risk ALL show a 94% 10-year event-free survival. Patients with Down syndrome demonstrate a remarkable sensitivity to methotrexate and other antimetabolites, resulting in substantial toxicity if standard doses are administered. However, in the case of AML, patients with Down syndrome have much better outcomes than children without Down syndrome, with a >90% long-term survival rate. After induction therapy, these patients receive therapy that is less intensive to decrease toxicity while maintaining excellent cure rates.

Approximately 10% of neonates with Down syndrome develop a **transient abnormal myelopoiesis (TAM)**, a unique myeloproliferative disorder characterized by high leukocyte counts, blast cells in the peripheral blood, and associated anemia, thrombocytopenia, jaundice, and hepatosplenomegaly. Hydrops fetalis is an uncommon manifestation of TAM and is associated with pleural effusions, ascites, cardiac infiltration, hepatic dysfunction, and anemia. Mortality is rare from TAM but is associated with hyperleukocytosis, prematurity, ascites, coagulopathy, and renal or hepatic dysfunction. These features usually resolve within the first 3 months of life. Although these neonates can require temporary transfusion support, they usually do not require chemotherapy. Low-dose cytarabine has been used to decrease mortality in patients with high WBC counts and life-threatening complications. Patients who have Down syndrome and who develop TAM require close follow-up, because 20–30% will develop typical leukemia (often **acute megakaryocytic leukemia**) by 3 years of age (mean onset, 16 months). *GATA1* variants (a transcription factor that controls megakaryopoiesis) are present in blasts from patients with Down syndrome who have TAM and also in those with leukemia (Fig. 544.8). The presence of flow cytometry minimal residual disease at 3 months after a diagnosis of TAM is a risk factor for the development of myeloid leukemia.

Visit Elsevier eBooks+ at eBooks.Health.Elsevier.com for Bibliography.

544.4 Chronic Myelogenous Leukemia

Erika D. Friehling, Julia C. Meade, A. Kim Ritchey, David G. Tubergen, and Archie Bleyer

Chronic myelogenous leukemia (**CML**) is a clonal disorder of the hematopoietic tissue that accounts for 2–3% of all cases of childhood leukemia. Approximately 99% of the cases are characterized by a specific translocation, t(9;22)(q34;q11), known as the **Philadelphia chromosome**, resulting in a *BCR-ABL* fusion protein.

The presenting symptoms of CML are nonspecific and can include fever, fatigue, weight loss, and anorexia. Splenomegaly also may be present, resulting in pain in the left upper quadrant of the

abdomen. The diagnosis is suggested by a high WBC count with myeloid cells at all stages of differentiation in the peripheral blood and bone marrow. It is confirmed by cytogenetic and molecular studies that demonstrate the presence of the characteristic Philadelphia chromosome and the *BCR-ABL* gene rearrangement. This translocation, although characteristic of CML, is also found in a small percentage of patients with ALL.

The disease is characterized by an initial **chronic phase** in which the malignant clone produces an elevated leukocyte count with a predominance of mature forms but with increased numbers of immature granulocytes. In addition to leukocytosis, blood counts can reveal mild anemia and thrombocytosis. Typically, the chronic phase terminates 3-4 years after onset, when the CML moves into the **accelerated** or "blast crisis" **phase**. At this point, the blood counts rise dramatically, and the clinical picture is indistinguishable from acute leukemia. Additional manifestations can occur, including neurologic symptoms from hyperleukocytosis, which causes increased blood viscosity with decreased CNS perfusion.

Imatinib (Gleevec), an agent designed specifically to inhibit the *BCR-ABL* tyrosine kinase, has been used in adults and children and has shown an ability to produce major cytogenetic responses in >70% of patients (see Table 542.1). Experience in children suggests it can be used safely with results comparable to those seen in adults. Second-generation tyrosine kinase inhibitors, such as **dasatinib and nilotinib**, have improved remission rates in adults and are now included in the first-line therapy in that population. Both agents have been studied in children and have been found to be effective and safe. While waiting for a response to the tyrosine kinase inhibitor, disabling or threatening signs and symptoms of CML can be controlled during the chronic phase with hydroxyurea, which gradually returns the leukocyte count to normal. **Treatment with a tyrosine kinase inhibitor is the current standard for pediatric CML.** Although not considered curative at this time, prolonged responses can be seen, and studies in adults have shown that, in select cases, treatment with the tyrosine kinase inhibitor can be stopped. The role of potentially curative human leukocyte antigen (HLA)-matched family donor stem cell transplant in management of pediatric CML is debated.

Visit Elsevier eBooks+ at eBooks.Health.Elsevier.com for Bibliography.

544.5 Juvenile Myelomonocytic Leukemia

Julia C. Meade, Erika D. Friehling, A. Kim Ritchey, David G. Tubergen, and Archie Bleyer

JMML, formerly termed **juvenile chronic myelogenous leukemia,** is a clonal proliferation of hematopoietic stem cells that typically affects children <2 years old. JMML is rare, constituting <1% of all cases of childhood leukemia. Patients with this disease do not have the Philadelphia chromosome characteristic of CML. Patients with JMML present with rashes, lymphadenopathy, splenomegaly, and hemorrhagic manifestations. Analysis of the peripheral blood often shows an elevated leukocyte count with increased monocytes, thrombocytopenia, and anemia with the presence of erythroblasts. The bone marrow shows a myelodysplastic pattern, with blasts accounting for <20% of cells. Most patients with JMML have been found to have pathogenic variants that lead to activation of the ***RAS* oncogene pathway**. About 90% have molecular changes in *NRAS, KRAS, NF1, CBL,* and *PTPN11*. Patients with **neurofibromatosis type 1** and **Noonan syndrome** have a predilection for this type of leukemia because they have germline mutations involved in *RAS* signaling. JMML in the setting of Noonan syndrome and CBL syndrome is unique, with most patients having a spontaneous resolution. However, for other patients with JMML, stem cell transplantation offers the best opportunity for cure, although outcomes are still poor.

Visit Elsevier eBooks+ at eBooks.Health.Elsevier.com for Bibliography.

544.6 Infant Leukemia

A. Kim Ritchey, Erika D. Friehling, Julia C. Meade, David G. Tubergen, and Archie Bleyer

The incidence of infant acute leukemia is about 40 cases per million, or about 160 cases per year in the United States. Approximately 2% of cases of childhood leukemia occur before age 1 year. In contrast to the situation in older children, the ratio of ALL in infants to AML is 2:1. Leukemic clones have been noted in cord blood at birth before symptoms appear, and in one case, the same clone was noted in maternal cells (maternal-to-fetal transmission). Chromosome translocations can also occur in utero during fetal hematopoiesis, leading to malignant clone formation.

Several unique biologic features and a particularly poor prognosis are characteristic of ALL during infancy. Almost all are B cell with infrequent T cell. Seventy to 80% of the cases demonstrate rearrangements of the *KMT2A (MLL)* gene, found at the site of the 11q23 band translocation, the majority of which are the t(4;11). This subset of patients largely accounts for the very high relapse rate. These patients often present with hyperleukocytosis and extensive tissue infiltration producing organomegaly, including CNS disease. Subcutaneous nodules, known as **leukemia cutis**, and tachypnea caused by diffuse pulmonary infiltration by leukemic cells are observed more often in infants than in older children. The leukemic cell morphology is usually that of large, irregular lymphoblasts, with a phenotype negative for the CD10 (common ALL antigen) marker (pro-B), unlike most older children with B-ALL, who are $CD10^+$.

Very intensive chemotherapy programs, including stem cell transplantation, are being explored in infants with *KMT2A (MLL)* gene rearrangements, but none has yet proved satisfactory. Infants defined as high risk (*KMT2A*, age <6 months and WBC ≥300,000) have survival of only 30%, whereas infants with the *KMT2A* without other high-risk features have survival of 58%. Infants with leukemia who lack the *KMT2A* rearrangement have a prognosis somewhat inferior to that of older children with ALL.

Infants with AML often present with CNS or skin involvement and have a subtype known as **acute myelomonocytic leukemia.** The treatment may be the same as that for older children with AML, with similar outcome. Meticulous supportive care is necessary because of the young age and aggressive therapy needed in these patients.

Visit Elsevier eBooks+ at eBooks.Health.Elsevier.com for Bibliography.

Chapter 545

Lymphoma

Jessica Hochberg, Stanton C. Goldman, and Mitchell S. Cairo

INTRODUCTION

Lymphoma is the third most common cancer among U.S. children (≤14 years old), with an annual incidence of 15 cases per 1 million children. It is the most common cancer in adolescents, accounting for >25% of newly diagnosed cancers in those 15-19 years old. The two broad categories of lymphoma, Hodgkin lymphoma (HL) and non-Hodgkin lymphoma (NHL), have different clinical manifestations and treatments.*

545.1 Hodgkin Lymphoma

Stanton C. Goldman, Jessica Hochberg, and Mitchell S. Cairo

Hodgkin lymphoma (HL) is a malignant process involving the lymphoreticular system that accounts for 6% of childhood cancers. In the United States, HL accounts for approximately 5% of cancers in children ≤14 years old; it accounts for approximately 15% of cancers in adolescents (15-19 years), making HL the most common malignancy in this age-group.

EPIDEMIOLOGY

The worldwide incidence of HL is approximately 2-4 new cases per 100,000 population per year. There is a bimodal age distribution, with peaks at 15-35 years of age and again after 50 years. HL is the most common cancer seen in adolescents and young adults and the third most common in children <15 years old. In developing countries, the early peak tends to occur before adolescence. A male predominance is found among young children but lessens with age. Infectious agents may be involved, such as human herpesvirus 6, cytomegalovirus, and Epstein-Barr virus (EBV). The role of EBV is supported by prospective serologic studies. Infection with EBV confers a fourfold higher risk of developing HL and may precede the diagnosis by years. EBV antigens have been demonstrated in HL tissues, particularly type II latent membrane proteins 1 and 2. Some studies have suggested that elevated copies of EBV by polymerase chain reaction correspond to worse prognosis. The EBV antigens latent membrane protein 1 and 2 have been used as targets for cytotoxic T-lymphocyte therapy in patients with relapsed/refractory HL.

PATHOGENESIS

The **Reed-Sternberg (RS) cell,** a pathognomonic feature of HL, is a large cell (15-45 μm in diameter) with multiple or multilobulated nuclei. This cell type is considered the hallmark of HL, although similar cells are seen in infectious mononucleosis, NHL, and other conditions. The RS cell is clonal in origin and arises from the germinal center B cells but typically has lost most B-cell gene expression and function. There is no single simple genetic aberration that leads to malignant transformation of the RS cell; rather, a combination of somatic pathogenic variants, chromosomal instability, and complex chromosomal rearrangements has been reported with no particular pattern or frequency. This typically leads to cell regulation defects such as constitutive activation of the nuclear factor (NF)-κB pathway or abnormal regulation of the Bcl-2 family of proteins. HL is characterized by a variable number of RS cells surrounded by an inflammatory infiltrate of lymphocytes, macrophages, plasma cells, and eosinophils in different proportions, depending on the HL histologic subtype. The interaction between the RS cell and these background inflammatory cells with their associated cytokine release is important in the development and progression of HL. Reactive infiltration of eosinophils and $CD68^+$ macrophages and increased concentrations of cytokines, such as interleukin (IL)-1 and IL-6 and tumor necrosis factor, are all associated with an unfavorable prognosis. Other factors associated with a worse prognosis include advanced stage, the presence of systemic symptoms, decreased response to therapy, and slow response to therapy. In addition, evidence of $CD8^+$ T cells surrounding the RS cell offers evidence of an important role in T-cell promotion of malignant cell survival, perhaps through the CD30 and CD40 ligands found on RS cells as well as immune checkpoint inhibition pathways. Other features that distinguish the histologic subtypes include various degrees of fibrosis and the presence of collagen bands, necrosis, or malignant reticular cells (Fig. 545.1). The distribution of subtypes varies with age.

The **Revised World Health Organization Classification of Lymphoid Neoplasms** includes two modifications of the older Rye system. HL appears to arise in lymphoid tissue and spread to adjacent lymph node areas in a relatively orderly manner (Table 545.1). Hematogenous spread also occurs, leading to involvement of the liver, spleen, bone, bone marrow (BM), or brain, and is usually associated with systemic symptoms.

CLINICAL MANIFESTATIONS

Patients typically present with painless, nontender, firm, rubbery cervical or supraclavicular lymphadenopathy and usually some degree of mediastinal involvement. Clinically detectable hepatosplenomegaly may be encountered. Depending on the extent and location of nodal and extranodal disease, patients may present with symptoms and signs of airway obstruction (dyspnea, hypoxia, cough), pleural or pericardial effusion, hepatocellular dysfunction, or BM infiltration (anemia, neutropenia, or thrombocytopenia). Systemic symptoms, classified as **B symptoms**, that are considered important in staging are unexplained fever >38°C (100.4°F), weight loss >10% total body weight over 6 months, and drenching night sweats. Less common and not considered of prognostic significance are symptoms of pruritus, lethargy, anorexia, or pain. Patients also exhibit immune system deficiencies that often persist during and after therapy.

DIAGNOSIS

Any patient with persistent, unexplained lymphadenopathy unassociated with an obvious underlying inflammatory or infectious process should undergo chest radiography to identify the presence of a large mediastinal mass before undergoing lymph node biopsy (Fig. 545.2). Formal excisional biopsy is preferred over needle biopsy to ensure that adequate tissue is obtained, both for light microscopy and for appropriate immunohistochemical and molecular studies. Once the diagnosis of HL is established, extent of disease (stage) should be determined to allow selection of appropriate therapy (Table 545.2). Evaluation includes history, physical examination, and imaging studies, including chest radiograph; CT scans of the neck, chest, abdomen, and pelvis; and PET scan (Fig. 545.3). Laboratory studies should include a CBC to identify abnormalities that might suggest marrow involvement, ESR, and measurement of serum ferritin, which is of some prognostic significance and, if abnormal at diagnosis, serves as a baseline to evaluate the effects of treatment. A chest radiograph is particularly important for measuring the size of the mediastinal mass in relation to the maximal diameter of the thorax (see Fig. 545.2). This determines "bulk" disease and becomes prognostically significant. Chest CT more clearly defines the extent of a mediastinal mass if present and identifies hilar nodes and pulmonary parenchymal involvement, which may not be evident on chest radiographs (see Fig. 545.3). BM aspiration and biopsy should be performed to rule out advanced disease. Bone scans are performed in patients with bone pain and/or elevation of alkaline phosphatase. Fluorodeoxyglucose (FDG) PET imaging has advantages over traditional gallium scanning, with higher resolution, better dosimetry, less intestinal activity, and the potential to quantify disease (Table 545.3).

* The views expressed are the result of independent work and do not necessarily represent the views or findings of the U.S. Food and Drug Administration or the United States.

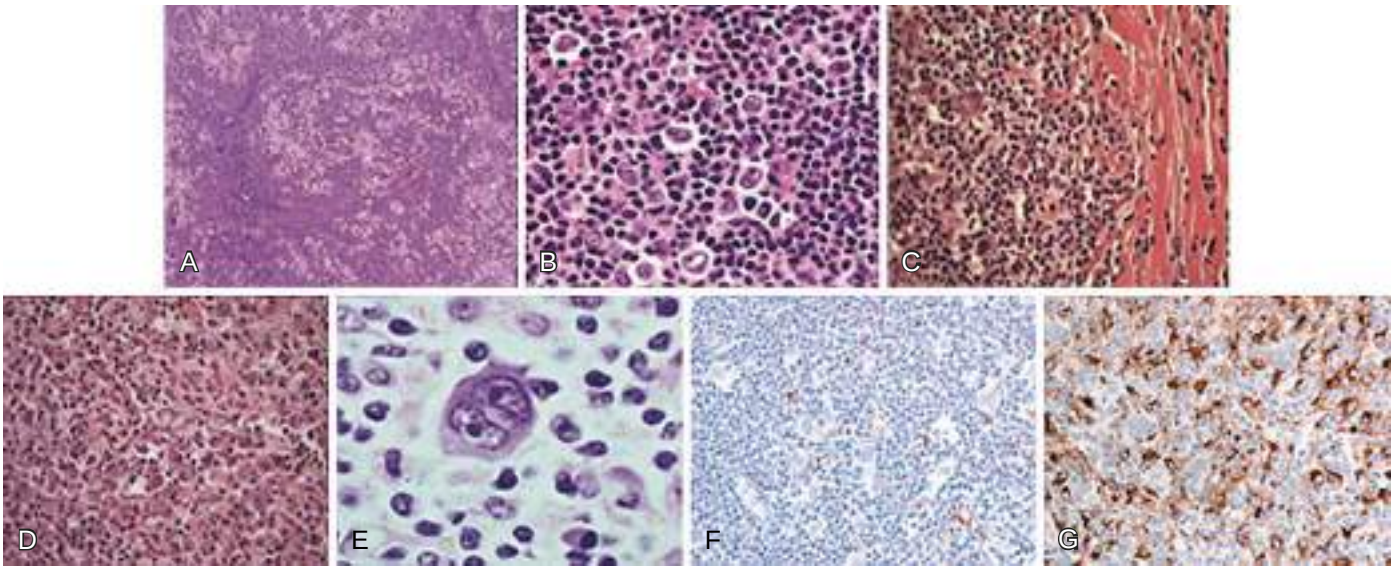

Fig. 545.1 Histologic subtypes of Hodgkin lymphoma. **A,** Hematoxylin and eosin (H&E) stains of nodular lymphocyte–predominant Hodgkin lymphoma (NLPHL) demonstrating a nodular proliferation with a moth-eaten appearance. **B,** High-power view demonstrating the neoplastic L and H cells found in NLPHL. **C,** Classic Hodgkin lymphoma, nodular sclerosis subtype. Large mononuclear and binucleate Reed-Sternberg cells are seen admixed in the inflammatory cell background. **D,** Classic Hodgkin lymphoma, mixed cellularity subtype, demonstrating increased numbers of Reed-Sternberg cells in a mixed inflammatory background without sclerotic changes. **E,** High-power view of a classic Reed-Sternberg cell showing binucleate cells with prominent eosinophilic nucleoli and relatively abundant cytoplasm. **F,** Few CD68$^+$ macrophages in a patient with successful treatment. **G,** Many CD68$^+$ macrophages in a treatment failure patient.

Table 545.1 New World Health Organization/Revised European–American Classification of Lymphoid Neoplasms for Hodgkin Lymphoma

Nodular lymphocyte predominance
Classical Hodgkin lymphoma
Lymphocyte rich
Mixed cellularity
Nodular sclerosis
Lymphocyte depletion

From Harris NL, Jaffe ES, Diebold J, et al. The World Health Organization classification of neoplastic diseases of the haematopoietic and lymphoid tissues: report of the Clinical Advisory Committee Meeting, Airlie House, Virginia, November 1997. *Histopathology*. 2000;36:69–87.

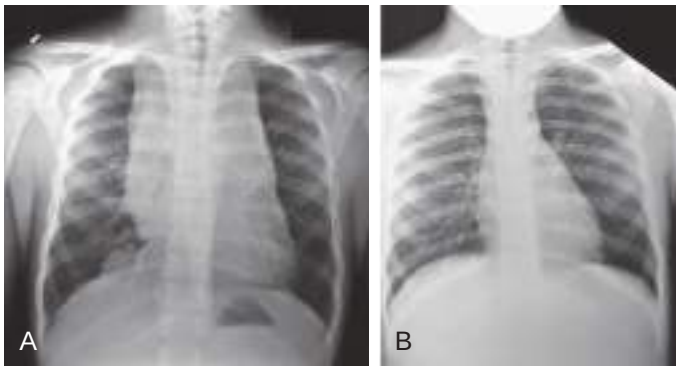

Fig. 545.2 **A,** Anterior mediastinal mass in a patient with Hodgkin disease before therapy. **B,** After 2 months of chemotherapy, the mediastinal mass has disappeared.

PET scans are essential as a prognostic tool in HL, enabling therapy to be reduced in those predicted to have a good outcome and identifying those at risk of relapse.

The staging classification currently used for HL was initially adopted at the **Ann Arbor Conference** in 1971 and was revised in 1989. The **Lugano classification** was developed in 2014 and incorporates standardized staging and response criteria for FDG-PET–avid lymphomas (see Table 545.2). HL can be subclassified into A or B categories: *A* is used to identify asymptomatic patients, and *B* is used for patients who exhibit any B symptoms. Extralymphatic disease resulting from direct extension of an involved lymph node region is designated by category *E*. A *complete response* in HL is defined as the complete resolution of disease on clinical examination and imaging studies, or at least 70–80% reduction of disease and a change from initial positivity to negativity on PET scanning, reflecting residual fibrosis, which is common.

Table 545.2 Lugano Classification for Hodgkin Lymphoma*

STAGE	INVOLVEMENT	EXTRANODAL STATUS
I	One node or group of adjacent nodes	Single extranodal lesions without nodal involvement
II	Two or more nodal groups on the same side of the diaphragm	Stage I or II by nodal extent with limited contiguous extranodal involvement
II bulky	II as above with "bulky" disease	Not applicable
III	Nodes on both sides of the diaphragm; nodes above the diaphragm with spleen involvement	Not applicable
IV	Additional noncontiguous extralymphatic involvement	Lung, liver, bone marrow, bone marrow, bone

*The absence or presence of fever >38°C (100.4°F) for 3 (some suggest 7) consecutive days, drenching night sweats, or unexplained loss of >10% of body weight in the 6 months preceding admission are to be denoted in all cases by the suffix letter A or B, respectively.

From *Cheson* BD, Fisher RI, Barrington SF, et al. Recommendations for initial evaluation, staging and response assessment of Hodgkin and non-Hodgkin lymphoma: the Lugano classification. *J Clin Oncol*. 2014;32(27):3059–3067.

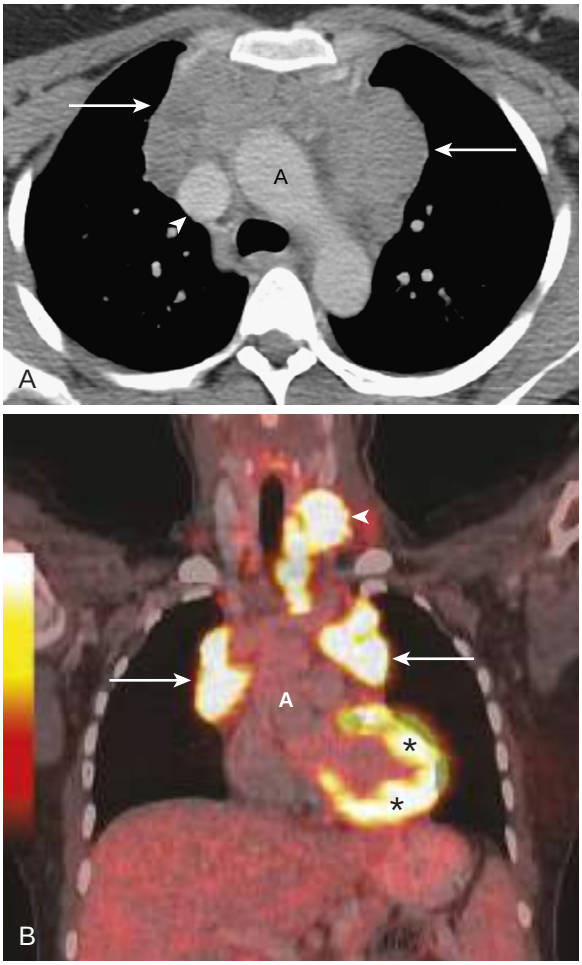

Fig. 545.3 Hodgkin lymphoma in a young individual. **A,** CT shows a homogeneous anterior mediastinal mass *(arrows)*. The *arrowhead* points to the superior vena cava. **B,** PET/CT in the coronal plane. The mass shows marked fluorodeoxyglucose (FDG) activity *(arrows)*. Note the associated left neck mass *(arrowhead)*. The left ventricle activity *(asterisks)* is normal. A, Ascending aorta. *(From Haaga JR, Boll DT, et al., eds. CT and MRI of the Whole Body [Vol, 1]. Philadelphia: Elsevier; 2017: Fig. 38-89, p. 1065.)*

Table 545.3	TEP Evaluation After Two Chemotherapy Cycles Using Deauville Criteria 5-Point Scale
	^{18}F-FDG UPTAKE
1	No uptake
2	Uptake lower than or equal to that of mediastinal blood pool
3	Uptake higher than that of mediastinum and lower than or equal to that of the liver
4	Uptake moderately higher than that of the liver at any site
5	Uptake markedly higher than that of the liver at any site or at new sites of disease, or both
X	New areas of uptake unlikely to be related to lymphoma

^{18}F-FDG, fluorodeoxyglucose F^{18}; TEP, technical expert panel.
From Brice P, de *Kerviler* E, Friedberg JW. Classical Hodgkin lymphoma. *Lancet.* 2021;398:1518–1526. Table 2.

TREATMENT

Multiple agents allow different mechanisms of action to have nonoverlapping toxicities so that full doses can be given to each patient. Chemotherapy and radiation therapy are both effective in the treatment of HL. Treatment of HL in pediatric patients is **risk adapted** and involves the use of combined chemotherapy with or without low-dose involved-field radiation therapy based on response. Treatment is determined largely by disease stage, presence or absence of B symptoms, and the presence of *bulky nodal disease*. The development of effective multiagent combination **chemotherapy** and **immunotherapy** is a major milestone in the treatment of HL, resulting in a complete response rate of 70–80% and cure rate of 40–50% in patients with advanced-stage disease. However, this regimen also led to significant acute and long-term toxicity. The desire to reduce side effects and morbidity has stimulated attempts to reduce the intensity of chemotherapy, as well as radiation dose and volume. Combinations of chemotherapy have reduced the risk of secondary cancers. Also, current radiation therapy uses lower amounts of overall radiation in addition to narrowing the radiation treatment field to either involved-field or even involved-node irradiation. The current **Children's Oncology Group** and other trials are investigating whether radiation therapy can be eliminated altogether in patients who have a very good rapid early response to induction chemotherapy.

Chemotherapy agents used to treat children and adolescents with HL include cyclophosphamide, procarbazine, vincristine or vinblastine, prednisone or dexamethasone, doxorubicin, bleomycin, dacarbazine, etoposide, methotrexate, and cytosine arabinoside. The combination chemotherapy regimens in current use are based on **COPP** (cyclophosphamide, vincristine [Oncovin], procarbazine, and prednisone) or **ABVD** (doxorubicin [Adriamycin], bleomycin, vinblastine, and dacarbazine), with the addition of prednisone, cyclophosphamide, and etoposide (**ABVE-PC** and **BEACOPP**) or **BAVD** (brentuximab vedotin, doxorubicin [Adriamycin], vincristine, dacarbazine) in various combinations for intermediate- and high-risk groups (Table 545.4). *Risk-adapted protocols* are based on both staging criteria and rapidity of response to initial chemotherapy. The aim is to reduce total drug doses and treatment duration and to eliminate radiation therapy, if possible.

Agents such as those that disrupt the NF-κB pathway or monoclonal antibodies (mAbs) that target RS tumor cells, as well as the benign reactive cells that surround them, are being investigated. Ongoing clinical trials report encouraging results with anti-CD20 antibody **(rituximab)**, particularly in nodular lymphocyte-predominant HL, for which trials in relapsed disease have shown an overall response rate of 94%. In addition, anti-CD30 agents are being used that target the RS cells themselves, where CD30 is abundantly expressed. **Brentuximab vedotin** is an antibody–drug conjugate approved by the U.S. Food and Drug Administration to treat HL. It combines the chimeric anti-CD30 antibody brentuximab linked to the antimitotic agent monomethyl auristatin E. This agent shows impressive efficacy as single-agent therapy in refractory HL and is being tested as part of up-front therapy combined with chemotherapy in patients with newly diagnosed disease where pediatric trials incorporating brentuximab to replace vincristine in the OEPA/COPDac backbone have demonstrated overall safety, tolerability, and efficacy with 97% event-free survival (EFS) and the ability to limit radiation to involved node radiation sites only. Furthermore, the combination of both brentuximab and rituximab, together with **AVD** chemotherapy in newly diagnosed patients, has shown 100% efficacy while allowing for the elimination of toxic alkylator agents, topoisomerase inhibitors, bleomycin, and any radiation in the majority of patients. **EBV-specific cytotoxic T lymphocytes (CTLs)** can also be generated from allogeneic donors for patients with advanced HL. In clinical trials, these cells show promising results, with enhanced antiviral activity and stabilization of disease. EBV-CTLs have been developed and are currently being investigated. These enhanced EBV-CTLs are designed to be latent membrane protein 1 and 2 specific and can be generated from second-party (in the case of BM transplant recipients) or even third-party donors for patients with refractory disease. These approaches represent an exciting direction in adoptive cellular tumor

Table 545.4 Chemotherapy Regimens for Children, Adolescents, and Young Adults with Hodgkin Lymphoma

CHEMOTHERAPY REGIMEN	CORRESPONDING AGENTS
ABVD	Doxorubicin (Adriamycin), bleomycin, vinblastine, dacarbazine
ABVD-Rituxan	Doxorubicin (Adriamycin), bleomycin, vinblastine, dacarbazine, rituximab
ABvVD	Doxorubicin (Adriamycin), brentuximab, vinblastine, dacarbazine
ABvVD-R	Doxorubicin (Adriamycin), brentuximab, vinblastine, dacarbazine, rituximab
AEPA/CAPDac	Brentuximab, etoposide, prednisone, and doxorubicin/cyclophosphamide, brentuximab, prednisone, and dacarbazine
ABVE (DBVE)	Doxorubicin (Adriamycin), bleomycin, vincristine, etoposide
VAMP	Vincristine, doxorubicin (Adriamycin), methotrexate, prednisone
OPPA ± COPP (females)	Vincristine (Oncovin), prednisone, procarbazine, doxorubicin (Adriamycin), cyclophosphamide, vincristine (Oncovin), prednisone, procarbazine
OEPA ± COPP (males)	Vincristine (Oncovin), etoposide, prednisone, doxorubicin (Adriamycin), cyclophosphamide, vincristine (Oncovin), prednisone, procarbazine
COPP/ABV	Cyclophosphamide, vincristine (Oncovin), prednisone, procarbazine, doxorubicin (Adriamycin), bleomycin, vinblastine
BEACOPP (advanced stage)	Bleomycin, etoposide, doxorubicin (Adriamycin), cyclophosphamide, vincristine (Oncovin), prednisone, procarbazine
COPP	Cyclophosphamide, vincristine (Oncovin), prednisone, procarbazine
CHOP	Cyclophosphamide, doxorubicin (Adriamycin), vincristine (Oncovin), prednisone
ABVE-PC (DBVE-PC)	Doxorubicin (Adriamycin), bleomycin, vincristine, etoposide, prednisone, cyclophosphamide
ICE ± (Brentuximab)	Ifosfamide, carboplatin, etoposide ± brentuximab
Ifos/Vino ± (Brentuximab)	Ifosfamide, vinorelbine ± brentuximab

immunology, and it remains to be determined whether CTLs will have improved cytotoxicity that can overcome inhibitory signals.

RELAPSE

Most relapses occur within the first 3 years after diagnosis, but relapses as late as 10 years have been reported. Relapse cannot be predicted accurately with this disease. Poor prognostic features include tumor bulk, stage at diagnosis, extralymphatic disease, and presence of B symptoms. Patients who achieve an initial chemosensitive response but relapse or progress before 12 months from diagnosis are candidates for myeloablative chemotherapy and autologous stem cell transplantation (SCT), with or without radiation therapy. Retrospective studies show a significant decrease in relapse in patients with HL following allogeneic vs autologous SCT. Reduced-intensity conditioning or nonmyeloablative regimens are successful at reducing regimen-related morbidity and mortality associated with myeloablative allogeneic SCT while still achieving a strong graft versus HL effect. For more difficult-to-treat refractory cases, radioimmunotherapy agents such as Zevalin and Bexxar are being trialed, often in combination with SCT strategies. Both are monoclonal anti-CD20 antibodies to which a radioactive isotope is directly linked. Clinical trials show each to be more effective than rituximab in NHL patients, and there is some interest in studying their use in the CD20 subpopulation of HL patients. Tumors can evade the host immune system by exploiting immune checkpoint pathways, such as the CTL-associated protein four (CTLA-4) and **programmed-death protein 1 (PD-1)** pathways. PD-1 is a negative co-stimulatory receptor with increased expression reported on T cells. PD-1 is critical for suppression of T-cell activation, with binding of **programmed-death ligand 1 (PD-L1)** resulting in "T-cell exhaustion." Blockade of this interaction renders previously anergic T cells responsive to antigen. Evidence has shown that antitumor immune responses can be improved by blocking immune checkpoint inhibitors in the tumor microenvironment. Phase I trials of the PD-1 blocking mAbs **nivolumab** and **pembrolizumab** have shown significant promise in refractory patients. Phase II clinical trials suggest that combining immunotherapy such as rituximab or brentuximab with PD-1 checkpoint blockade will be highly effective against relapsed lymphomas and well tolerated, without treatment-related adverse events. With the success seen in relapsed or refractory patients, PD-1 blockade likely will have a role in frontline therapy as well where studies have shown promise in combination with chemotherapy in adults, with pediatric trials currently under investigation.

PROGNOSIS

With the use of current therapeutic regimens, patients with favorable prognostic factors and early-stage disease have an EFS of 85–90% and an overall survival (OS) at 5 years of >95%. Patients with advanced-stage disease have slightly lower EFS (80–85%) and OS (90%), respectively, although OS has approached 100% with dose-intense chemotherapy (Table 545.5). Prognosis after relapse depends on the time from completion of treatment to recurrence, site of relapse (nodal vs extranodal), and presence of B symptoms at relapse. Patients whose disease relapses >12 months after chemotherapy alone or combined-modality therapy have the best prognosis, and their relapses usually respond to additional standard therapy, resulting in a long-term survival of 60–70%. A myeloablative autologous SCT in patients with refractory disease or relapse within 12 months of therapy results in a long-term survival rate of only 40–50%. Allogeneic SCT has shown promise in patients with poor-risk features at relapse/progression.

Visit Elsevier eBooks+ at eBooks.Health.Elsevier.com for Bibliography.

545.2 Non-Hodgkin Lymphoma

Stanton C. Goldman, Jessica Hochberg, and Mitchell S. Cairo

Non-Hodgkin lymphoma (**NHL**) accounts for approximately 60% of lymphomas in children and is the second most common malignancy between ages 15 and 35 years. The annual incidence of pediatric NHL in the United States is 750-800 cases per year. In contrast to adult NHL, which is predominantly indolent, pediatric NHL is usually *high grade*. Although >70% of patients present with advanced disease, the prognosis has improved dramatically, with survival rates of 90–95% for localized disease and 80–95% for advanced disease.

EPIDEMIOLOGY

Although most children and adolescents with NHL present with de novo disease, a small number of patients have NHL secondary to specific etiologies, including inherited or acquired immunodeficiencies (e.g., severe combined immunodeficiency syndrome, Wiskott-Aldrich syndrome), virus-associated malignancy (e.g., HIV, EBV), and as part of genetic syndromes (e.g., ataxia-telangiectasia, Bloom syndrome).

Table 545.5 Treatment Regimens and Outcome by Disease Staging

		LOCALIZED/LOW STAGE	INTERMEDIATE	ADVANCED
Hodgkin lymphoma	Treatment	*POG study 9426/GPOH-HD 95:* ABVD-type therapy ± IFRT (risk adapted based on early response to chemotherapy)	*Stanford/DAL-HD-90:* COPP-based or dose-intense multiagent chemotherapy + low-dose RT *POG 9426/CCG 5942:* ABVD-type therapy ± IFRT (risk adapted) *ABvVD-R*	*POG 8725/DAL-HD-90:* Dose-intense multiagent chemotherapy + low-dose RT *HD9/HD12/CCG 59704:* Dose-intense BEACOPP ± IFRT *AEPA/CAPDac* *ABvVD-R*
	Prognosis	5-yr EFS: 85–90% 5-yr OS: 95%	*Stanford/DAL-HD-90:* 5-yr EFS: 89–92% *POG 9426/CCG 5942:* 5-yr EFS: 84% 5-yr OS: 91% *ABvVD-R:* 5-yr EFS/OS: 100%	*POG 8725:* 5-yr EFS: 72–89% (age-based) *DAL-HD-90:* 5-yr EFS: 86% 5-yr OS: 85–90% *HD9/HD12/CCG 59704:* 5-yr EFS/OS: 88-93/~100% *AEPA/CAPDac:* 3 yr EFS/OS: 97.4%/98.7% *ABvVD-R:* 5-yr EFS/OS: 100%
Burkitt lymphoma and diffuse large B-cell lymphoma	Treatment	*FAB/LMB 96 Group A therapy:* Complete surgical resection followed by two cycles of chemotherapy	*FAB/LMB 96 Group B therapy:* Reduced cyclophosphamide and no maintenance therapy *COG ANHL01P1:* FAB/LMB Group B therapy + rituximab	*FAB/LMB 96 standard-intensity Group C therapy:* Reduction, induction, intensification, and maintenance therapy *COG ANHL01P1:* FAB/LMB Group C therapy + rituximab
	Prognosis	4-yr EFS: 98% (CI_{95} 94-99.5%) 4-yr OS: 99% (CI_{95} 96-99.9%)	*FAB/LMB96:* 4-yr EFS: 92% (CI_{95} 90–94%) 4-yr OS: 95% (CI_{95} 93–96%) *PMB DLBCL has worse prognosis (EFS/OS: 66/73%) *COG ANHL01P1:* 3-yr EFS 93% (CI_{95} 79-98%) 3-yr OS 95% (CI_{95} 83–99%)	*FAB/LMB96:* 4-yr FS:BM−/CNS−: 91% ± 3%BMCNS+: 85% ± 6%BM+/CNS+: 66% ± 7% *COG ANHL01P1:* 3-yr EFS/OS:BM+ or CNS+: 90% (CI_{95} 75–96%) CNS+: 93% (CI_{95} 61–99%)
Lymphoblastic lymphoma	Treatment	*NHL-BFM86/90/95:* Two cycles of ALL-type therapy *COG A5971:* ALL-type therapy × 2 yr without prophylactic cranial RT	No intermediate group; disease classified as localized (stages I/II) or advanced (stages III/IV)	*NHL-BFM86/90/95:* ALL-type therapy × 2 yr ± px CRT *CCG 5941:* Intensive chemotherapy × 1 yr + cranial RT if CNS + at diagnosis
	Prognosis	*COG A5971:* 5-yr EFS: 90 (CI_{95} 78–96%) 5-yr OS: 96 (CI_{95} 84–99%)	No intermediate group; see above	*NHL-BFM95:* 5-yr EFS: 90% ± 3% (III), 95 ± 5% (IV) *CCG 5941:* 5-yr EFS/OS: 78% ± 5%/85% ± 4%
Anaplastic large cell lymphoma	Treatment	*EICHNL ALCL 99:* Short intensive chemotherapy + HD MTX Completely resected stage I disease may be treated with surgery alone	No intermediate group; disease classified as standard risk (no skin, visceral, or mediastinal involvement) or high risk (presence of skin, mediastinal, or visceral involvement)	*ALCL 99, CCG 5941:* Short intensive chemotherapy + HD MTX *COG ANHL0131*: APO (doxorubicin, prednisone, vincristine) ± vinblastine
	Prognosis	*EICHNL database:* 5-yr PFS: 89% (CI_{95} 82–96%) 5-yr OS: 94% (CI_{95} 89–99%)	No intermediate group; see above	*ALCL 99:* 2-yr EFS: 71% (CI_{95} 75–77%) 2-yr OS: 94% (CI_{95} 89-95%) *COG 5941:* 5-yr EFS 68% (CI_{95} 57–78%) 5-yr OS: 80% (CI_{95} 69–87%) *COG ANHL0131:* 2-yr EFS 79% (CI_{95} 71–88%) 2-yr OS 89% (CI_{95} 83–95%)

ABVD, Doxorubicin (Adriamycin), bleomycin, vinblastine, dacarbazine; ABvVD-R, doxorubicin (adriamycin), bleomycin, vinblastine, dacarbazine rituximab; AEPA/CAPDac, Adcetris (brentuximab vedotin), etoposide, prednisone, doxorubicin (adriamycin), cyclophosphamide, adcetris (brentuximab vedotin), prednisone, cacarbazine; ALCL, anaplastic large cell lymphoma; ALL, acute lymphoblastic leukemia; ANHL, Children's Oncology Group non-hodgkin lymphoma study; BEACOPP, bleomycin, etoposide, doxorubicin (Adriamycin), cyclophosphamide, vincristine (Oncovin), prednisone, procarbazine; BM, bone marrow (involvement); CCG, Children's Cancer Group; CI_{95}, 95% confidence interval; CNS, central nervous system (involvement); COG, Children's Oncology Group; COPP, cyclophosphamide, vincristine (Oncovin), prednisone, procarbazine; CRT, chemoradiotherapy; DAL-HD, German-Austrian Lymphoma Froup Hodgkin 90 Study; EFS, event-free survival; EICHNL, European Intergroup for Childhood Non-Hodgkin Lymphoma; FAB, French-American-British; HD MTX, high-dose methotrexate; IFRT, involved-field radiation therapy; LMB, Lymphome Malins de Burkitt; MTX, methotrexate; NHL-BFM, non-Hodgkin lymphoma Berlin-Frankfurt-Munster; OS, overall survival; PFS, progression-free survival; PMB DLBCL, primary mediastinal B-cell diffuse large B-cell lymphoma; POG, Pediatric Oncology Group; px, prophylactic; RT, radiation therapy.

However, most children in North America and Europe in whom NHL develops have no obvious genetic or environmental etiology.

PATHOGENESIS

Three most prevalent subtypes of childhood and adolescent NHL with different treatment approaches are **lymphoblastic lymphoma (LBL), mature B-cell lymphoma**, and **anaplastic large cell lymphoma** (**ALCL**; Figs. 545.4 and 545.5). LBL arises from precursor T lymphocytes and less often from precursor B lymphocytes, with biology and treatment approaches similar to acute lymphoblastic leukemia. Mature B-cell lymphomas comprise two main pathologies, **Burkitt lymphoma (BL)** and **diffuse large B-cell lymphoma (DLBCL)**. DLBCL is further divided into several subtypes: the *germinal center B-cell–like* subtype, which carries a favorable prognosis and accounts for most pediatric cases of DLBCL, and the subtypes with poorer prognosis, including *activated B-cell–like* and *primary mediastinal B-cell* subtypes. Primary mediastinal B-cell subtype of DLBCL shares molecular signature more akin to HL then germinal center–derived DLBCL. Most cases of ALCL are of mature T-cell origin, with a smaller percentage of null-cell and B-cell origin. Cellular surface markers can aid in differentiating NHL subtypes and present opportunities for specific antibody-targeted treatments. BL and DLBCL express the mature B-cell antigens CD20 (the target of rituximab) and CD22, whereas ALCL expresses the CD30 antigen (the target of the antibody conjugate brentuximab vedotin). Some pathologic subtypes have specific cytogenetic aberrations. Children with BL frequently have a driver genetic change involving the *MYC* gene juxtaposed to an immunoglobulin chain in the form of translocations: t(8;14) (90%) or, less often, a t(2;8) or t(8;22) translocation (10%). Children with BL who have additional chromosomal aberrations such as 13q deletion or complex karyotype have a poorer prognosis. Unlike adult DLBCL, a higher proportion of pediatric DLBCL may also have c-myc dysregulation with t(8;14) translocation (30%) and often have a complex (80%) and aneuploid (80%) karyotype. In recent years a Burkitt morphology lymphoma (Burkitt-like) that lacks a c-myc driver has been categorized by findings of 11q aberrations and several target genes such as chromatin remodeling complex pathogenic variants (INO80) that likely contribute to lymphomagenesis (Fig. 545.6). Patients with ALCL usually have a driver t(2;5) translocation (90%), which results in the formation of a fusion gene encoding the constitutively active nucleophosmin–anaplastic lymphoma kinase (ALK) tyrosine kinase and can be targeted by the oral agent, crizotinib. T-cell LBL harbors many of the same cytogenetic abnormalities as T-cell acute lymphoblastic leukemia (T-ALL), including rearrangements with breakpoints at 14q11.2 involving the T-cell receptor and multiple other rearranged genes. Loss of heterozygosity at chromosome 6q defines a poor-risk subgroup of T-LBL patients.

Genomic studies have offered insights into NHL pathogenesis as well as elucidated potential targets for novel therapies. Gene expression profiling of T-LBL and T-ALL has implicated the activation of oncogenic transcription factors as a result of aberrant T-cell receptor gene rearrangement. One of the most frequently activated signaling pathways is NOTCH1, which may be amenable to therapeutic targeting with γ-secretase inhibitors. In BL and DLBCL, extensive genomic work has identified unique gene expression signatures that

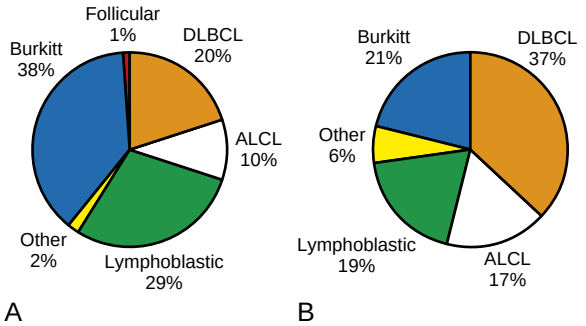

Fig. 545.4 Incidence of non-Hodgkin lymphoma subtypes. **A,** In 0- to 14-yr-old children. **B,** In 15- to 19-yr-old adolescents. ALCL, Anaplastic large cell lymphoma; DLBCL, diffuse large B-cell lymphoma. *(Adapted from Hochberg J, Waxman IM, Kelly KM, et al. Adolescent non-Hodgkin lymphoma and Hodgkin lymphoma: state of the science. Br J Haematol. 2008;144:24–40.)*

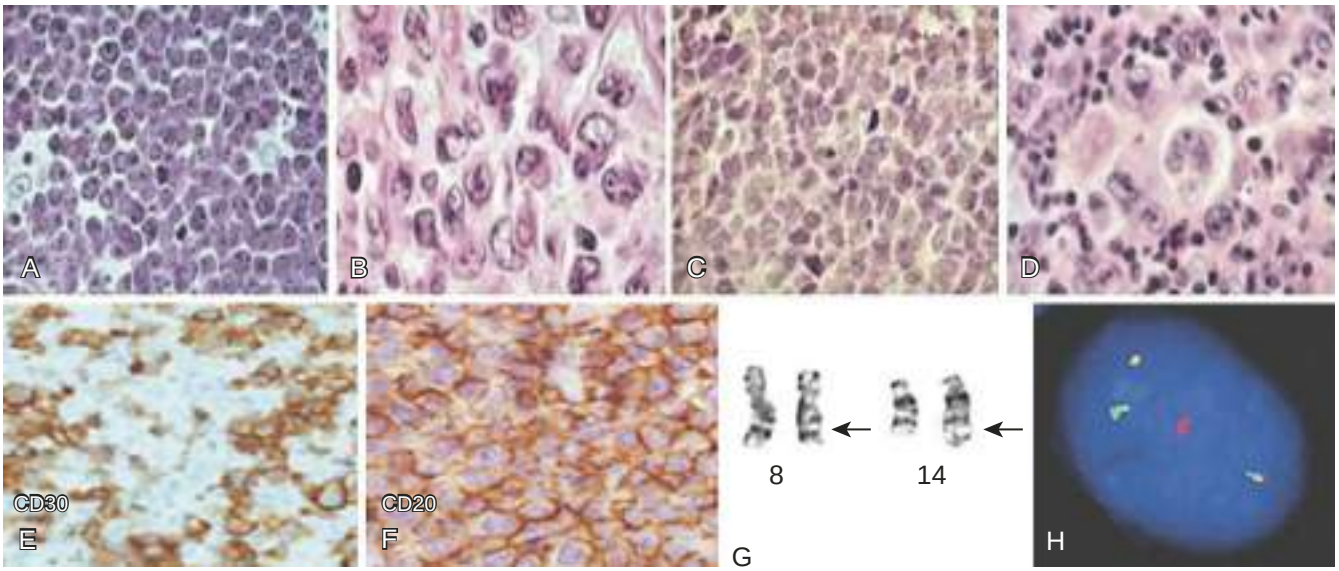

Fig. 545.5 Histologic subtypes of childhood and adolescent non-Hodgkin lymphoma. **A-D,** Hematoxylin and eosin (H&E) stains showing morphology of Burkitt lymphoma (**A,** high power), diffuse large B-cell lymphoma (**B,** high power), precursor T-lymphoblastic lymphoma (**C,** high power), and anaplastic large cell lymphoma (**D,** high power). **E** and **F,** Characteristic surface markers for anaplastic large cell lymphoma (ALCL) (CD30; **E**) and BL (CD20; **F**). **G** and **H,** Cytogenetic analysis of Burkitt lymphoma (BL) demonstrating t(8;14). **G,** Karyotype showing the conventional t(8;14)(q24;q32). **H,** Interphase fluorescence in situ hybridization showing a balanced translocation involving MYC and immunoglobulin (Ig) H loci. The chromosome eight centromere is labeled with spectrum aqua, MYC probe is labeled with spectrum orange, and IgH is labeled with spectrum green. Two fusion signals are seen, as well as one red and one green, representing the normal chromosomes. *(**A-D** from Cairo MS, Raetz E, Lim MS, et al. Childhood and adolescent non-Hodgkin lymphoma: new insights in biology and critical challenges for the future. Pediatr Blood Cancer. 2005;45:753–769; **E-H** from Giulino-Roth, Cesarman E. Molecular biology of Burkitt lymphoma. In Robertson ES, ed. Burkitt's Lymphoma. New York: Springer; 2012.)*

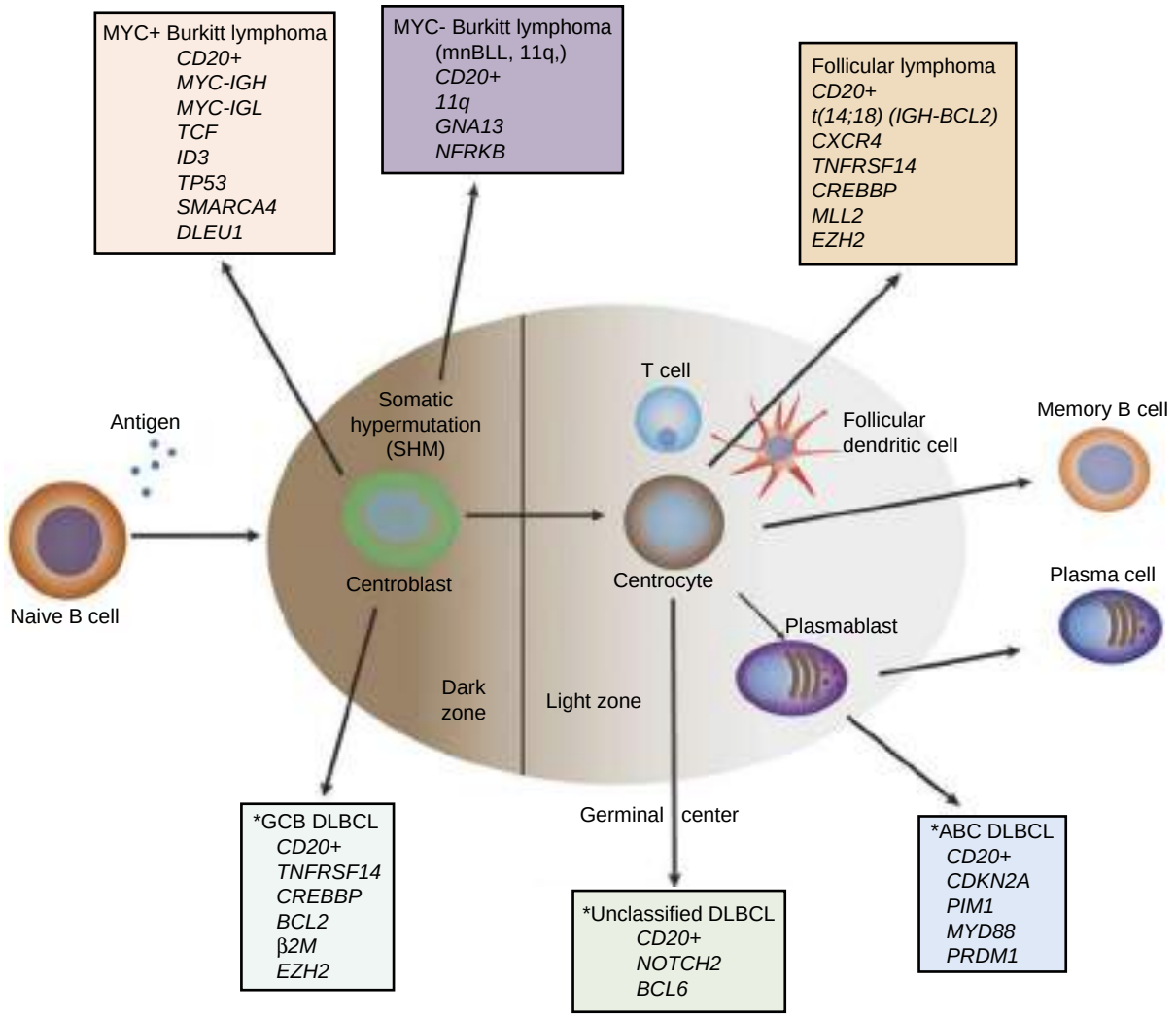

Fig. 545.6 Germinal center–derived B-cell lymphomagenesis. *Diffuse large B-cell lymphoma (DLBCL), recently subclassified as MCD, BNS, N1, and EZB subgroups. *(From Cairo, MS. A new Burkitt "look-alike" lymphoma. Blood. 2019;133[9]:889–891.)*

differentiate these two mature B-cell neoplasms. In addition, next-generation sequencing of BL has identified genetic lesions in *TCF3* and *ID3,* which lead to activation of the AKT/PI3 kinase pathway. Other genetic lesions that have been described in BL include loss of function of the chromatin remodeling genes *ARID1A* and *SMARCA4.* Importantly, many of these alterations are potentially targetable by agents that are in development.

CLINICAL MANIFESTATIONS

The clinical manifestations of childhood and adolescent NHL depend primarily on pathologic subtype and sites of involvement. The current revised staging system used for NHL is the **International Pediatric Non-Hodgkin Lymphoma Staging System (IPNHLSS),** which reflects our increasing ability to diagnose lower levels of organ involvement with disease. For instance, the older staging system (St. Jude/Murphy classification) did not account for molecular or flow cytometry involvement of BM, which is now reflected in the new system (Tables 545.6 and 545.7). Patients are further classified based on risk categories according to pediatric international cooperative group trials. Approximately 70% of patients with NHL present with advanced disease (stage III or IV), including extranodal disease with BM and CNS involvement. B symptoms of fever, weight loss, and night sweats can be seen, particularly in ALCL, but unlike HL, are not prognostic.

The primary site of tumor involvement and the pattern of metastasis vary by pathologic subtype. LBL typically manifests as a symptomatic mediastinal mass and also has a predilection for spreading to the BM, CNS, and testes in males. BL commonly manifests as a diffuse leukemia presentation or massive abdominal (*sporadic* type) or head and neck (*endemic* type) tumor and can metastasize to the BM or CNS. DLBCL usually manifests as either an abdominal or a mediastinal primary tumor and, rarely, disseminates to the BM or CNS. ALCL manifests either as a primary cutaneous manifestation (10%) or as systemic disease (90%) with dissemination to liver, spleen, lung, or mediastinum. BM or CNS disease is rare in ALCL. Site-specific manifestations of NHL include painless, rapid lymph node enlargement; cough or dyspnea with thoracic involvement; superior mediastinal syndrome; ascites, increased abdominal girth or intestinal obstruction with an abdominal mass; nasal congestion, earache, hearing loss, or tonsil enlargement with Waldeyer ring involvement; and localized bone pain.

NHL can present as a life-threatening **oncologic emergency**. These manifestations are important to recognize because these patients require intensive supportive care and, in some cases, alternative treatment. **Superior mediastinal syndrome** can occur as a consequence of a large mediastinal mass causing obstruction of blood flow or respiratory airways. Spinal cord tumors can cause cord compression and acute paraplegias requiring emergent radiation therapy. **Tumor lysis syndrome** (TLS) can occur from rapid cell turnover, which is especially common in BL. TLS can result in severe metabolic abnormalities, including hyperuricemia, hyperphosphatemia, hyperkalemia, and

Table 545.6 International Pediatric Non-Hodgkin Lymphoma Staging System (IPNHLSS)*

STAGE I
- A single tumor with the exclusion of the mediastinum and abdomen (N: nodal; EN: extranodal; bone (B) or skin (S): EN-B, EN-S)

STAGE II
- A single extranodal tumor with regional node involvement
- Two or more nodal areas on the same side of the diaphragm
- A primary gastrointestinal tract tumor (usually in the ileocecal area), with or without involvement of associated mesenteric nodes, that is completely resectable (if malignant ascites or extension of the tumor to adjacent organs, it should be regarded as stage III)

STAGE III
- Two or more extranodal tumor(s) (including bone or skin: EN-B, EN-S) above and/or below the diaphragm
- Two or more nodal areas above and below the diaphragm
- Any intrathoracic tumor (mediastinal, hilar, pulmonary, pleural, or thymic)
- Intraabdominal and retroperitoneal disease, including liver, spleen, kidney, and/or ovary localizations, regardless of degree of resection (except a primary gastrointestinal tract tumor [usually in the ileocecal region], with or without involvement of associated mesenteric nodes, that is completely resectable)
- Any paraspinal or epidural tumor, whether or not other sites are involved
- Single bone lesion with concomitant involvement of extranodal and/or nonregional nodal sites

STAGE IV
- Any of the previous findings with initial involvement of the central nervous system (stage IV CNS), bone marrow (stage IV BM), or both (stage IV combined) based on conventional methods, see Table 545.7
- For each stage, type of examination and degree of BM and CNS involvement should be specified, using the abbreviations listed in Table 545.7 to identify involvement

*Based on the classification proposed by Murphy (Murphy SB. Classification, staging and end results of treatment of childhood non-Hodgkin's lymphomas: dissimilarities from lymphomas in adults. *Semin Oncol*. 7:332–339, 1980.)

From Rosolen A, Perkins SL, Pinkerton CR, et al. Revised International Pediatric Non-Hodgkin Lymphoma Staging System. *J Clin Oncol*. 2015;33(18):2112–2118.

Table 545.7 Additional IPNHLSS Information*

BONE MARROW (BM) INVOLVEMENT

Stage IV disease, caused by BM involvement, is currently defined by morphologic evidence of ≥5% blasts or lymphoma cells by bone marrow aspiration. This applies to any histologic subtype and will be maintained in the IPNHLSS.

However, for each stage, type and degree of BM involvement (by bone marrow aspiration) should be specified, using the abbreviations below to identify involvement:

BMm = BM positive by morphology (specify % lymphoma cells).
BMi = BM positive by immunophenotypic methods (immunohistochemical/flow cytometry analysis) (specify % lymphoma cells).
BMc = BM positive by cytogenetic/FISH analysis (specify % lymphoma cells).
BMmol = BM positive by molecular techniques (PCR based) (specify level of involvement).

Same approach should be used for peripheral blood (PB) involvement (i.e., PBm, PBi, PBc, PBmol).

Note: Definition of BM involvement should be obtained from analysis of bilateral BM aspirates and BM biopsy.

CENTRAL NERVOUS SYSTEM (CNS) INVOLVEMENT

CNS is considered involved in case of:
1. Any CNS tumor mass (identified by imaging techniques; i.e., CT, MRI).
2. In case of cranial nerve palsy that cannot be explained by extradural lesions.
3. In case of blasts morphologically identified in the cerebrospinal fluid (CSF).

Condition that defines CNS positivity should be specified: CNS positive/mass; CNS positive/palsy; CNS positive/blasts.

CSF status: CSF positivity is based on morphologic evidence of lymphoma cells.

CSF should be considered positive when any number of blasts is detected.

CSF unknown (e.g., not performed, technical difficulties).

Similar to BM, type of CSF involvement should be described whenever possible:

CSFm = CSF positive by morphology (specify the number of blasts per microliter).
CSFi = CSF positive by immunophenotype methods (immunohistochemical/flow cytometry analysis) (specify % lymphoma cells).
CSFc = CSF positive by cytogenetic/FISH analysis (specify % lymphoma cells).
CSFmol = CSF positive by molecular techniques (PCR based) (specify level of involvement).

*Until sufficient data are available, PET should be used with caution for staging, and PET results should be compared and discussed in light of other, more consolidated imaging approaches.

IPNHLSS, International Pediatric Non-Hodgkin Lymphoma Staging System Information; FISH, fluorescence in situ hybridization; PCR, polymerase chain reaction.

From Rosolen A, Perkins SL, Pinkerton CR, et al. Revised International Pediatric Non-Hodgkin Lymphoma Staging System. *J Clin Oncol*. 2015;33(18):2112–2118.

hypocalcemia. This can rapidly lead to renal insufficiency/failure, as well as cardiac abnormalities, if not aggressively treated.

LABORATORY FINDINGS

Recommended laboratory and radiologic testing includes CBC; measurements of electrolytes, lactate dehydrogenase, uric acid, calcium, phosphorus, BUN, creatinine, bilirubin, alanine aminotransferase, and aspartate aminotransferase; BM aspiration and biopsy; lumbar puncture with cerebrospinal fluid cytology, cell count, and protein; chest radiographs; and abdominal ultrasound for initial diagnosis. Staging relies on more detailed anatomic imaging, with CT for neck, chest, abdomen, and pelvic imaging and MRI the preferred modality for suspected CNS disease of brain and spine (Fig. 545.7). PET scan, usually with radioactive FDG for functional imaging, is more sensitive and has replaced gallium imaging. It is also an excellent modality for judging treatment response to therapy. Tumor tissue (i.e., biopsy, BM, cerebrospinal fluid, pleurocentesis/paracentesis fluid) should be tested by flow cytometry for immunophenotypic origin (T, B, or null) and cytogenetics (karyotype). Additional tests might include fluorescent in situ hybridization (FISH) or quantitative reverse-transcription polymerase chain reaction (RT-PCR) for specific genetic translocations, T- and B-cell gene rearrangement studies, and molecular profiling by oligonucleotide microarray or next-generation sequencing.

TREATMENT

The primary modality of treatment for childhood and adolescent NHL is *multiagent systemic chemotherapy and/or immunotherapy with intrathecal chemotherapy* (see Table 545.5). An international pediatric NHL response classification has been developed (IPNHLRC) (Tables 545.8 and 545.9). Surgery is used mainly for diagnosis. Radiation therapy is used only in special circumstances, such as CNS involvement in LBL or the presence of acute superior mediastinal syndrome or paraplegias. Newly diagnosed patients, especially those with BL or LBL, are at high risk for TLS. These patients require vigorous hydration, frequent electrolyte monitoring, and either a xanthine oxidase inhibitor (e.g., allopurinol, 10 mg/kg/day orally in three divided doses daily) or a recombinant urate oxidase (e.g., rasburicase, 0.2 mg/kg/day intravenously once daily for up to 5 days). Recombinant urate oxidase is preferred in patients with a high risk of tumor lysis but is *contraindicated* in patients with a history of G6PD deficiency.

Burkitt Lymphoma and Diffuse Large B-Cell Lymphoma

Pediatric BL and DLBCL (except mediastinal primary B cell) are treated with the same mature B-cell NHL chemoimmunotherapy regimens

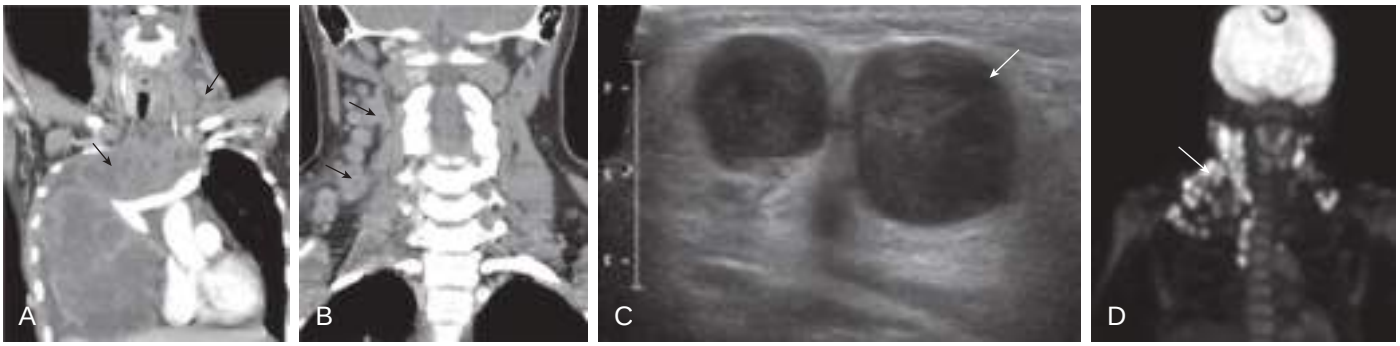

Fig. 545.7 Lymphoma. Coronal postcontrast CT images demonstrate extensive cervical (**A**) and mediastinal (**B**) lymphadenopathy *(arrows)*. **C,** Sonographic image demonstrates two enlarged lymph nodes with abnormal internal morphology *(arrow)*. **D,** PET scan demonstrates metabolically active conglomeration of right-sided cervical lymph nodes *(arrow)*. *(From Haaga JR, Boll DT, et al., eds. CT and MRI of the Whole Body (Vol. 1). Philadelphia: Elsevier; 2017: Fig. 26-15, p. 768.)*

Table 545.8 International Pediatric Non-Hodgkin Lymphoma Response Criteria (IPNHLRC)

Complete Response (CR): disappearance of all disease (three designations)

1. Complete (CR):
   a. CT or MRI reveals no residual disease or new lesions.
   b. Resected residual mass that is pathologically (morphologically) negative for disease (detection of disease with more sensitive techniques, as described in "supporting data," Table 545.9).
   c. Bone marrow (BM) and cerebrospinal fluid (CSF) morphologically free of disease (detection of disease with more sensitive techniques, as described in Table 545.9).
2. Complete Response, biopsy negative (CRb):
   a. Residual mass has no morphologic evidence of disease from limited or core biopsy (detection of disease with more sensitive techniques, as described in Table 545.9) with no new lesions by imaging examination.
   b. BM and CSF morphologically free of disease (detection of disease with more sensitive techniques, as described in Table 545.9).
   c. No new and/or progressive disease elsewhere.
3. Complete Response, unconfirmed (CRu):
   a. Residual mass is negative by FDG-PET; no new lesions by imaging examination.
   b. BM and CSF morphologically free of disease (detection of disease with more sensitive techniques, as described in Table 545.9).
   c. No new and/or progressive disease elsewhere.

Partial Response (PR): 50% decrease in the sum of the product of the greatest perpendicular diameters (SPD) on CT or MRI. FDG-PET may be positive (Deauville score of 4 or 5 with reduced lesional uptake compared with baseline). No new and/or PD. Morphologic evidence of disease may be present in the BM or CSF if present at diagnosis (detection of disease with more sensitive techniques, as described in Table 545.9); however, there should be a 50% reduction in the percentage of lymphoma cells.

Minor Response (MR): Decrease in SPD is >25% but <50% on CT or MRI. No new and/or PD. Morphologic evidence of disease may be present in the BM or CSF if present at diagnosis (detection of disease with more sensitive techniques, as described in Table 545.9); however, there should be a 25–50% reduction in the percentage of lymphoma cells.

No Response (NR): For those who do not meet CR, PR, MR, or PD criteria.

Progressive Disease (PD): For those with >25% increase in the SPD on CT or MRI, Deauville score 4 or 5 on FDG-PET with an increase in lesional uptake from baseline, or the development of new morphologic evidence of disease in the BM or CSF.

FDG-PET, Fluorodeoxyglucose positron emission tomography.
From Sandlund JT, Guillerman RP, Perkins SL, et al. International Pediatric Non-Hodgkin Lymphoma Response Criteria. *J Clin Oncol.* 2015;33(18):2106–2111.

Table 545.9 Supporting IPNHLRC Data

BONE MARROW (BM) INVOLVEMENT

BM involvement is currently defined by morphologic evidence of lymphoma cells. This applies to any histologic subtypes.

Type and degree of BM involvement should be specified, using the following abbreviations:
- BMm = BM positive by morphology (specify % lymphoma cells).
- BMi = BM positive by immunophenotypic methods (histochemical/flow cytometry analysis) (specify % lymphoma cells).
- BMc = BM positive by cytogenetic/FISH analysis (specify % lymphoma cells).
- BMmol= BM positive by molecular techniques.

Same approach should be used for peripheral blood (PB) involvement (i.e., PBm, PBi, PBc, PBmol).

CENTRAL NERVOUS SYSTEM (CNS) INVOLVEMENT

Cerebrospinal fluid (CSF) status: CSF positivity is based on morphologic evidence of lymphoma cells.

CSF should be considered positive when any number of blasts is detected.

CSF unknown (e.g., not performed, technical difficulties).

Similar to BM, type of CSF involvement should be described whenever possible:
- CSFm = CSF positive by morphology (specify the number of blasts/μL).
- CSFi = CSF positive by immunophenotypic methods (histochemical/flow cytometry analysis) (specify % lymphoma cells).
- CSFc = BM positive by cytogenetic/FISH analysis (specify % lymphoma cells).
- CSFmol = CSF positive by molecular techniques.

RESIDUAL MASS (RM)

RMm = Tumor detected by standard morphologic evaluation.
RMi = Tumor detected by immunophenotypic methods (immunohistochemical or flow cytometry analysis).
RMc = Tumor detected by cytogenetic/FISH analysis.
RMmol = Tumor detected by molecular techniques.

FISH, Fluorescence in situ hybridization.
From Sandlund JT, Guillerman RP, Perkins SL, et al. International Pediatric Non-Hodgkin Lymphoma Response Criteria. *J Clin Oncol.* 2015;33(18):2106–2111.

based on stage and risk stratification. For patients with localized disease, multiagent chemotherapy is given over 6 weeks, and the prognosis is excellent. In the international French-American-British Lymphoma, mature B cell [FAB/LMB 96] trial, patients with localized, completely resected disease received two cycles of COPAD (cyclophosphamide, vincristine, prednisone, and doxorubicin), resulting in a 4-year OS of 99%. Advanced disease is usually treated with a 4- to 6-month regimen of multiagent chemoimmunotherapy, such as FAB/LMB 96 protocol therapy or

NHL-Berlin-Frankfurt-Mulnster-95 (BFM 95) protocol therapy with the addition of rituximab, with an OS of 79–90%. A subset of patients who likely require a different treatment approach have **primary mediastinal B-cell lymphoma (PMBCL)**. PMBCL is a histologic subtype that represents 2% of mature B-NHLs. Pediatric patients with PMBCL had an inferior outcome when treated with standard mature B-NHL protocols (EFS of only 66%). Alternative treatment strategies, including prolonged infusional chemotherapy, rituximab, and chimeric antigen receptor T cells expressing anti-CD19 mAbs, may benefit this group (see Chapter 543).

Rituximab is a mAb directed at CD20 that, when combined with standard chemotherapy, improves outcomes in adult patients with aggressive B-NHL (usually DLBCL). A window study of rituximab given to pediatric patients with newly diagnosed BL and DLBCL demonstrated its activity as a single agent with a response rate of 41%. Additionally, a Children's Oncology Group study examined the safety and pharmacokinetics of rituximab when added to standard chemotherapy for intermediate-risk patients. Rituximab was found to be safe, and survival in this cohort was the best reported to date (3-year OS of 95%). In a similar cohort of CNS-positive patients, the addition of rituximab to the chemotherapy backbone resulted in a 93% EFS. Based on this pilot data, an international randomized study of rituximab added to standard multiagent chemotherapy in advanced-stage pediatric patients enrolled over 300 patients. The randomized trial demonstrated that the addition of rituximab markedly prolonged EFS and OS. The EFS at 3 years was 94% compared to 82% in patients who received chemotherapy alone. As expected with an antibody to a protein on the surface of normal mature B cells, there was a higher incidence of low immunoglobulin levels in rituximab-treated patients up to 1 year poststudy entry. Rituximab is standard-of-care therapy for pediatric mature B-NHL with advanced disease at presentation. These patients make up roughly ~30% of all mature B-NHL. A study of dose substitution of anthracycline (doxorubicin) intensity with rituximab in children and adolescents with good-risk mature B-cell lymphoma noted reduction of anthracycline dramatically reduced mucositis and febrile admissions during the intensive induction phases of therapy and was associated with 100% EFS and OS. With the success of rituximab in pediatric mature B-NHL and the poor outcome of recurrent or refractory disease, there is interest in improving immunotherapy in up-front patients. Polatuzumab vedotin is a CD79b-directed antibody conjugated to an antimitotic agent. The therapy has been approved in conjunction with rituximab and chemotherapy for adult refractory DLBCL. A study to determine the feasibility and safety of the addition of polatuzumab vedotin in combination with rituximab and FAB chemotherapy in patients with intermediate and high-risk mature B-NHL is in progress.

Lymphoblastic Lymphoma

Localized or advanced LBL requires 12-24 months of therapy, including chemotherapy, intrathecal therapy, and cranial radiation in CNS-positive lymphomas. The best results in advanced LBL have been obtained using therapeutic approaches mirroring those for childhood acute leukemia, including induction, consolidation, interim maintenance, and reinduction (advanced disease only) phases, as well as a year-long maintenance phase with 6-mercaptopurine and methotrexate. For patients with relapsed disease, the outcome is poor (OS of 10%), and novel treatments are needed. *Nelarabine,* a purine analog with significant T-lymphocyte toxicity, has completed testing in primary therapy for T-LBL in conjunction with a much larger cohort of T-ALL patients. Nelarabine was demonstrated in the trial to improve disease-free survival at 4 years and to reduce the risk of CNS relapses. The smaller subset of patients with advanced LBL did not have a benefit demonstrated to nelarabine, but this subset was underpowered, and most U.S. centers are now including nelarabine in the up-front treatment of all T-LBL patients.

Anaplastic Large Cell Lymphoma

For patients who present with localized disease, surgical resection alone is sufficient. The majority of patients, however, have advanced disease, which requires multiagent chemotherapy. Various chemotherapy regimens have been studied, with similar outcomes and survival of 70–79%. CNS prophylaxis consists of intrathecal chemotherapy, although this may be omitted with the substitution of high-dose methotrexate.

Two novel targeted agents have shown substantial promise in early-phase trials in ALCL. The CD30 antibody–drug conjugate **brentuximab vedotin** and the ALK inhibitor **crizotinib** both have impressive activity and minimal toxicity in patients with relapsed ALCL. A trial piloted the addition of brentuximab vedotin in newly diagnosed advanced ALCL patients with impressive 2-year EFS of 79% and OS of 97% among ~70 patients. There were no toxic deaths with combination brentuximab and chemotherapy and no severe neurotoxicity.

Relapsed Non-Hodgkin Lymphoma

Patients with NHL in whom progressive or relapsed disease develops require reinduction chemotherapy and may require either allogeneic or autologous SCT. A notable exception is ALCL, where low-dose approaches such as prolonged vinblastine have been efficacious for some patients. The specific reinduction regimen or transplantation type depends on the pathologic subtype, previous therapy, site of reoccurrence, and stem cell donor availability. Novel reinduction approaches are being investigated, including a type II CD20 antibody, *obinutuzumab,* alone and in combination with chemotherapy, *ibrutinib,* a BTK inhibitor alone and in combination with chemotherapy, and *idelalisib,* a PI3K delta inhibitor alone and in combination with chemotherapy. Although there are no randomized trials examining autologous versus allogeneic SCT for relapsed NHL, data from retrospective studies suggest that outcomes are similar, with the exception of LBL and ALCL, for which allogeneic SCT is superior, perhaps because of a graft versus lymphoma effect.

Native (autologous) patient T cells have been genetically manipulated to produce a T-cell vs leukemia or lymphoma response. Tisagenlecleucel (Kymriah) is a CD19-directed genetically modified autologous T-cell immunotherapy first approved for patients under 25 years with precursor B-ALL. The immunotherapy has been approved in adults with relapsed mature DLBCL after two prior lines of systemic therapy. An additional CD19-directed immunotherapy, axicabtagene ciloleucel, has been approved for recurrent adult mature B-NHL. The responses have been less impressive in adult DLBL to those seen in childhood adolescent and young adult ALL, but continued work with different target antigens and genetic manipulation of the constructs is ongoing. These T-cell–modified products, although autologous, can lead to a cytokine release syndrome and CNS toxicities that can be severe.

Because relapsed NHL can be difficult to treat, efforts have been made to identify patients at higher risk of relapse to tailor initial therapy. The measurement of **minimal residual disease** may serve as a prognostic marker and aid in risk stratification. Minimal residual disease is prognostic in ALCL and LBL. In ALCL, there is also evidence that a humoral response to the ALK kinase can be used to predict outcome, with a superior outcome in patients who mount an antibody titer to ALK.

COMPLICATIONS

Patients receiving multiagent chemotherapy for advanced disease are at acute risk for mucositis, infections, cytopenias that require red blood cell and platelet blood product transfusions, electrolyte imbalances, and poor nutrition. Long-term complications include the risk of growth retardation, cardiac toxicity, gonadal toxicity with infertility, and secondary malignancies.

PROGNOSIS

The prognosis is excellent for most forms of childhood and adolescent NHL (see Table 545.5). Patients with localized disease have a 90–100% survival rate, and those with advanced disease have an 80–95% survival rate. Because outcomes for pediatric patients with NHL have improved substantially, the focus has now shifted to minimizing the *long-term toxicity of therapy.* Novel targeted agents are desirable because they have the potential to improve outcomes and decrease the reliance on toxic conventional chemotherapy. An ongoing multi-institutional study is testing the reduction of anthracycline to decrease short-term (mucositis) and long-term (cardiac health) complications of therapy by incorporation of immunotherapy in mature B-NHL, with promising results to date.

Visit Elsevier eBooks+ at eBooks.Health.Elsevier.com for Bibliography.

545.3 Late Effects in Children and Adolescents with Lymphoma

Jessica Hochberg, Stanton C. Goldman, and Mitchell S. Cairo

The majority of patients with newly diagnosed HL and NHL have OS rates >90%. There are approximately 270,000 survivors of childhood cancer in the United States, or about one of every 640 adults between ages 20 and 40. However, this survival has often been achieved at the expense of an increased relative risk of long-term complications, including solid tumors, leukemia, cardiac disease, pulmonary complications, thyroid disease, and infertility. An analysis of >1,000 long-term childhood NHL survivors found increased rates of death >20 years after treatment. A review of the National Cancer Institute Surveillance, Epidemiology, and End Results data over a 25-year follow-up demonstrates that the relative survival curves do not plateau after 10 years following diagnosis of HL, but rather accelerate. This finding highlights the importance of late morbidity and mortality among survivors of lymphoma. The incidence of Grade 3-5 adverse health conditions is >15% in adult survivors of childhood HL treated with chemoradiotherapy regimens. Radiation therapy has been shown to further compound the risk for late mortality, obesity, and organ dysfunction with worsening effects on cardiovascular, pulmonary, and thyroid function. The first **Childhood Cancer Survivor Study**, a retrospective cohort study of 10,397 cancer survivors, shows that 62.3% of survivors report at least one chronic condition, with 27.5% reporting severe or life-threatening conditions. The survivor's adjusted relative risk of a severe or life-threatening chronic condition, compared with that of a sibling, was 8.2 (95% confidence interval, 6.9-9.7). Studying disease-specific health outcomes, both HL and NHL were found to be associated with a cumulative incidence of chronic health conditions **approaching 70–80%, with severe conditions reported in ~50% of HL survivors** (Fig. 545.8).

Visit Elsevier eBooks+ at eBooks.Health.Elsevier.com for Bibliography.

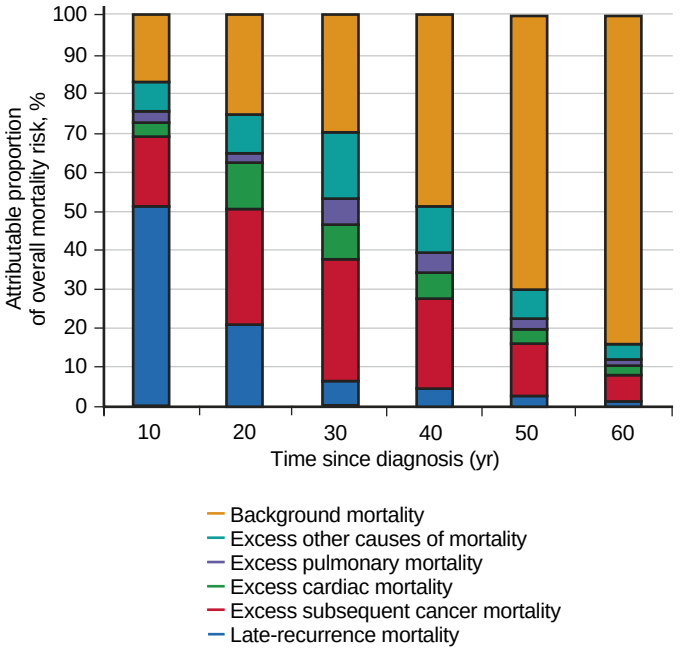

Fig. 545.8 Percentage of attributable proportions of overall mortality risk in survivors of childhood cancer. *(Adapted from Yeh JM, Nekhlyudov L, Goldie SJ, et al. A model-based estimate of cumulative excess mortality in survivors of childhood cancer. Ann Intern Med. 2010;152[7]:409– 417.)*

Chapter 546

Central Nervous System Tumors in Childhood

Wafik Zaky

Primary central nervous system (CNS) tumors are a heterogeneous group of diseases that are, collectively, the most common malignancy in childhood and adolescence. The overall mortality among this group approaches 30%. Patients with CNS tumors have the highest morbidity, primarily neurologic, of all children with malignancies. Outcomes have improved with innovations in neurosurgery, imaging, and radiation therapy as well as the introduction of chemotherapy and biologic agents as a therapeutic modality. The treatment approach for the majority of these tumors is multimodal. Surgery with complete resection, if feasible, is the foundation, with radiation therapy and chemotherapy utilized according to the diagnosis, patient age, and other factors.

ETIOLOGY

The etiology of pediatric CNS tumors is not well defined. An overall female predominance exists in the incidence of CNS tumors, but male predominance is noted in the incidence of high-grade tumors like glioblastoma multiforme, medulloblastoma, and ependymoma. Familial syndromes associated with an increased incidence of brain tumors account for approximately 5% of cases (Table 546.1). Cranial exposure to ionizing radiation also is associated with a higher incidence of CNS tumors. There are sporadic reports of CNS tumors within families without evidence of a heritable syndrome.

EPIDEMIOLOGY

Approximately 5,550 primary brain tumors are diagnosed each year in children and adolescents in the United States, with an average annual age adjusted incidence rate of 5.65 per 100,000 population. It is the most common cancer in patients 0-14 years of age and the leading cause of cancer-related death in this age-group.

PATHOGENESIS

More than 100 histologic categories and subtypes of primary brain tumors are described in the World Health Organization (WHO) classification of tumors of the CNS. In children 0-14 years of age, the most common tumors are pilocytic astrocytomas (PAs) and embryonal tumors (i.e., medulloblastoma/primitive neuroectodermal tumors [PNETs]). In adolescents (15-19 years), the most common tumors are pituitary/craniopharyngeal tumors and PAs (Fig. 546.1).

There is a slight predominance of infratentorial tumor location (43.2%), followed by the supratentorial region (40.9%), spinal cord (4.9%), and multiple sites (11%) (Fig. 546.2, Table 546.2). There are age-related differences in the primary location of tumor. During the first year of life, supratentorial tumors predominate and include, most commonly, choroid plexus complex tumors and germ cell tumors. In children 1-10 years of age, infratentorial tumors predominate, due to the high incidence of juvenile PA and medulloblastoma. After 10 years of age, supratentorial tumors predominate, with diffuse astrocytomas (DAs) most common. Tumors of the optic pathway and hypothalamus region, the brainstem, and the pineal–midbrain region are more common in children and adolescents than in adults. Additionally, some tumors are more common in males (astrocytic and germ cell tumors), whereas meningioma and craniopharyngiomas are more common in females. Malignant tumors are more common in White children (embryonal and astrocytic neoplasms), whereas low-grade tumors are more common in Black children (meningiomas and craniopharyngiomas).

545.3 Late Effects in Children and Adolescents with Lymphoma

Jessica Hochberg, Stanton C. Goldman, and Mitchell S. Cairo

The majority of patients with newly diagnosed HL and NHL have OS rates >90%. There are approximately 270,000 survivors of childhood cancer in the United States, or about one of every 640 adults between ages 20 and 40. However, this survival has often been achieved at the expense of an increased relative risk of long-term complications, including solid tumors, leukemia, cardiac disease, pulmonary complications, thyroid disease, and infertility. An analysis of >1,000 long-term childhood NHL survivors found increased rates of death >20 years after treatment. A review of the National Cancer Institute Surveillance, Epidemiology, and End Results data over a 25-year follow-up demonstrates that the relative survival curves do not plateau after 10 years following diagnosis of HL, but rather accelerate. This finding highlights the importance of late morbidity and mortality among survivors of lymphoma. The incidence of Grade 3-5 adverse health conditions is >15% in adult survivors of childhood HL treated with chemoradiotherapy regimens. Radiation therapy has been shown to further compound the risk for late mortality, obesity, and organ dysfunction with worsening effects on cardiovascular, pulmonary, and thyroid function. The first **Childhood Cancer Survivor Study**, a retrospective cohort study of 10,397 cancer survivors, shows that 62.3% of survivors report at least one chronic condition, with 27.5% reporting severe or life-threatening conditions. The survivor's adjusted relative risk of a severe or life-threatening chronic condition, compared with that of a sibling, was 8.2 (95% confidence interval, 6.9-9.7). Studying disease-specific health outcomes, both HL and NHL were found to be associated with a cumulative incidence of chronic health conditions **approaching 70–80%, with severe conditions reported in ~50% of HL survivors** (Fig. 545.8).

Visit Elsevier eBooks+ at eBooks.Health.Elsevier.com for Bibliography.

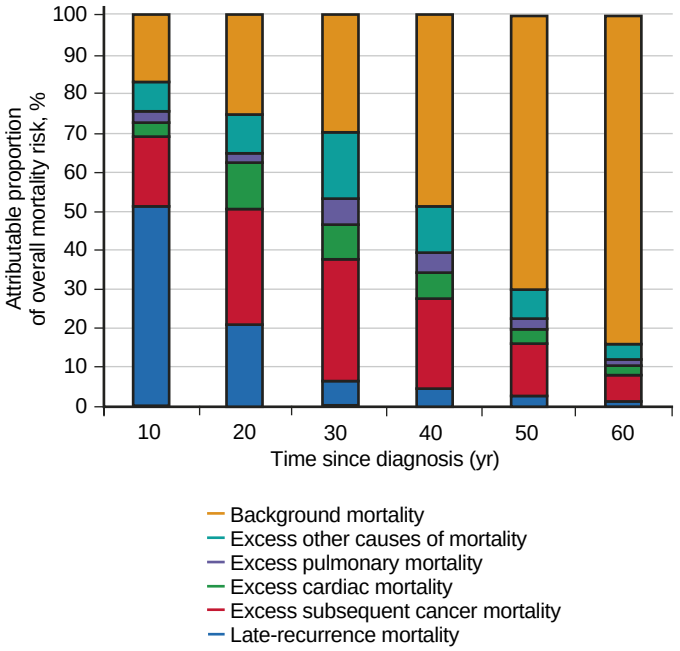

Fig. 545.8 Percentage of attributable proportions of overall mortality risk in survivors of childhood cancer. *(Adapted from Yeh JM, Nekhlyudov L, Goldie SJ, et al. A model-based estimate of cumulative excess mortality in survivors of childhood cancer. Ann Intern Med. 2010;152[7]:409– 417.)*

Chapter 546

Central Nervous System Tumors in Childhood

Wafik Zaky

Primary central nervous system (CNS) tumors are a heterogeneous group of diseases that are, collectively, the most common malignancy in childhood and adolescence. The overall mortality among this group approaches 30%. Patients with CNS tumors have the highest morbidity, primarily neurologic, of all children with malignancies. Outcomes have improved with innovations in neurosurgery, imaging, and radiation therapy as well as the introduction of chemotherapy and biologic agents as a therapeutic modality. The treatment approach for the majority of these tumors is multimodal. Surgery with complete resection, if feasible, is the foundation, with radiation therapy and chemotherapy utilized according to the diagnosis, patient age, and other factors.

ETIOLOGY

The etiology of pediatric CNS tumors is not well defined. An overall female predominance exists in the incidence of CNS tumors, but male predominance is noted in the incidence of high-grade tumors like glioblastoma multiforme, medulloblastoma, and ependymoma. Familial syndromes associated with an increased incidence of brain tumors account for approximately 5% of cases (Table 546.1). Cranial exposure to ionizing radiation also is associated with a higher incidence of CNS tumors. There are sporadic reports of CNS tumors within families without evidence of a heritable syndrome.

EPIDEMIOLOGY

Approximately 5,550 primary brain tumors are diagnosed each year in children and adolescents in the United States, with an average annual age adjusted incidence rate of 5.65 per 100,000 population. It is the most common cancer in patients 0-14 years of age and the leading cause of cancer-related death in this age-group.

PATHOGENESIS

More than 100 histologic categories and subtypes of primary brain tumors are described in the World Health Organization (WHO) classification of tumors of the CNS. In children 0-14 years of age, the most common tumors are pilocytic astrocytomas (PAs) and embryonal tumors (i.e., medulloblastoma/primitive neuroectodermal tumors [PNETs]). In adolescents (15-19 years), the most common tumors are pituitary/craniopharyngeal tumors and PAs (Fig. 546.1).

There is a slight predominance of infratentorial tumor location (43.2%), followed by the supratentorial region (40.9%), spinal cord (4.9%), and multiple sites (11%) (Fig. 546.2, Table 546.2). There are age-related differences in the primary location of tumor. During the first year of life, supratentorial tumors predominate and include, most commonly, choroid plexus complex tumors and germ cell tumors. In children 1-10 years of age, infratentorial tumors predominate, due to the high incidence of juvenile PA and medulloblastoma. After 10 years of age, supratentorial tumors predominate, with diffuse astrocytomas (DAs) most common. Tumors of the optic pathway and hypothalamus region, the brainstem, and the pineal–midbrain region are more common in children and adolescents than in adults. Additionally, some tumors are more common in males (astrocytic and germ cell tumors), whereas meningioma and craniopharyngiomas are more common in females. Malignant tumors are more common in White children (embryonal and astrocytic neoplasms), whereas low-grade tumors are more common in Black children (meningiomas and craniopharyngiomas).

Table 546.1 Familial Syndromes Associated with Pediatric Brain Tumors

SYNDROME	CENTRAL NERVOUS SYSTEM MANIFESTATIONS	CHROMOSOME	GENE
Neurofibromatosis type 1 (autosomal dominant)	Optic pathway gliomas, astrocytoma, malignant peripheral nerve sheath tumors, neurofibromas	17q11	*NF1*
Neurofibromatosis type 2 (autosomal dominant)	Vestibular schwannomas, meningiomas, spinal cord ependymoma, spinal cord astrocytoma, hamartomas	22q12	*NF2*
von Hippel-Lindau (autosomal dominant)	Hemangioblastoma	3p25-26	*VHL*
Tuberous sclerosis (autosomal dominant)	Subependymal giant cell astrocytoma, cortical tubers	9q34	*TSC1*
		16q13	*TSC2*
Li-Fraumeni (autosomal dominant)	Astrocytoma, primitive neuroectodermal tumor	17q13	*TP53*
Cowden (autosomal dominant)	Dysplastic gangliocytoma of the cerebellum (Lhermitte-Duclos disease)	10q23	*PTEN*
Turcot (autosomal dominant)	Medulloblastoma	5q21	*APC*
	Glioblastoma	3p21	*hMLH1*
		7p22	*hPSM2*
Nevoid basal cell carcinoma Gorlin (autosomal dominant)	Medulloblastoma	9q31	*PTCH1*

Modified from Kleihues P, Cavenee WK. *World Health Organization Classification of Tumors: Pathology and Genetics of Tumors of the Nervous System*. Lyon: IARC Press, 2000.

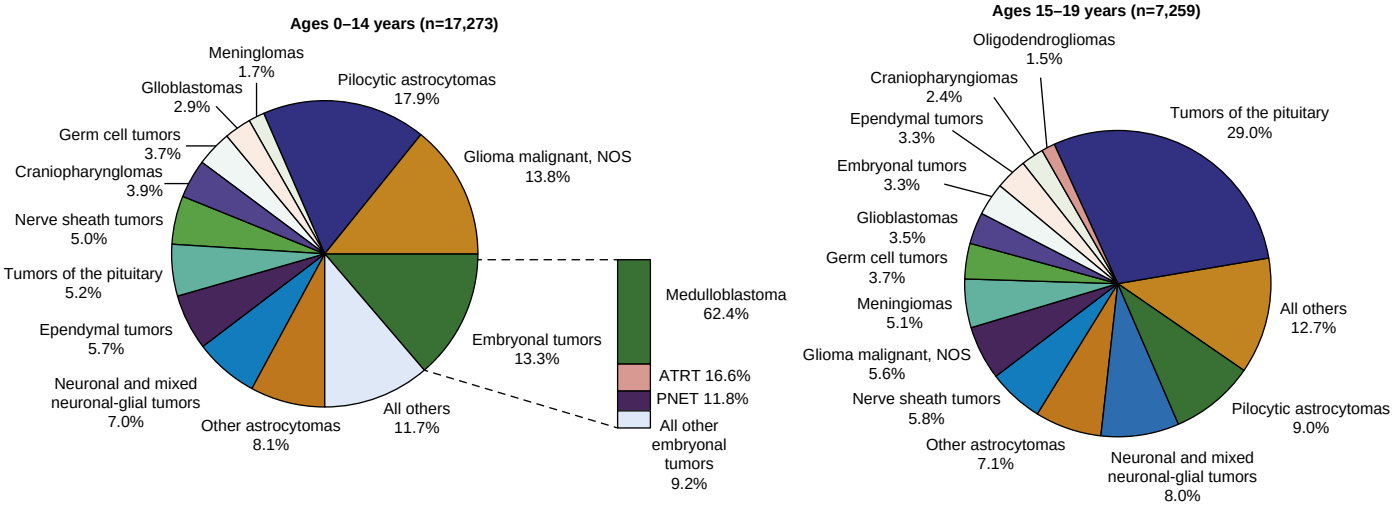

Fig. 546.1 Distribution of childhood primary brain and central nervous system (CNS) tumors by histology. ATRT, Atypical teratoid rhabdoid tumor; NOS, not otherwise specified; PNET, primitive neuroectodermal tumor. *(From Ostrom QT, Patil N, Cioffi G, et al. CBTRUS Statistical Report: Primary Brain and Other Central Nervous System Tumors Diagnosed in the United States in 2013-2017. Neuro Oncol. 2020;30;22:iv1–iv96.)*

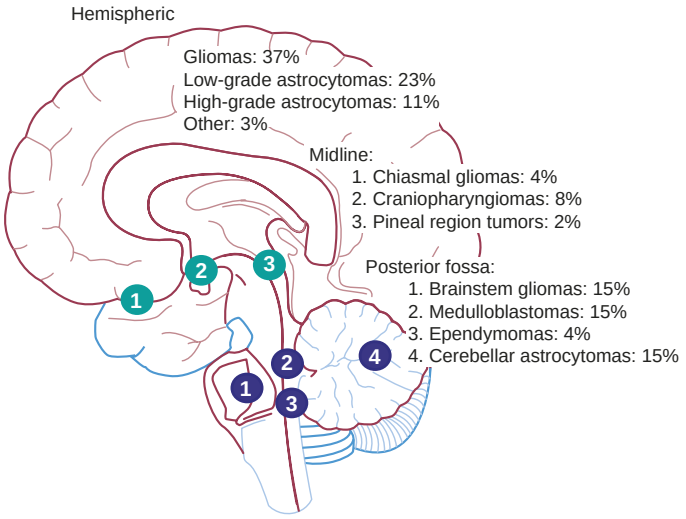

Fig. 546.2 Childhood brain tumors occur at any location within the central nervous system. The relative frequency of brain tumor histologic types and the anatomic distribution are shown. *(Redrawn from Albright AL. Pediatric brain tumors. CA Cancer J Clin 1993;43:272–288.)*

CLINICAL MANIFESTATIONS

The clinical presentation of the patient with a brain tumor depends on the tumor location, the tumor type, and the age of the child. Signs and symptoms are related to obstruction of cerebrospinal fluid (CSF) drainage paths by the tumor, leading to **increased intracranial pressure (ICP)** or causing focal brain dysfunction. In young children, the diagnosis of a brain tumor may be delayed because the symptoms are similar to those of more common illnesses, such as gastrointestinal disorders, with associated vomiting. Infants with open cranial sutures may present with signs of increased ICP, such as vomiting, lethargy, and irritability, as well as the later finding of macrocephaly. The **classic triad** of headache, nausea, and vomiting as well as papilledema is associated with midline or infratentorial tumors. Disorders of equilibrium, gait, and coordination occur with infratentorial tumors. **Torticollis** may occur in cases of cerebellar tonsil herniation. Blurred vision, diplopia, and nystagmus also are associated with infratentorial tumors. Tumors of the brainstem region may be associated with gaze palsy, multiple cranial nerve palsies, and upper motor neuron deficits (e.g., hemiparesis, hyperreflexia, and clonus). **Supratentorial tumors** are more commonly associated with focal motor weakness, focal sensory changes, language disorders, focal seizures, and reflex asymmetry. Infants with supratentorial tumors may present

Table 546.2 Posterior Fossa Tumors of Childhood

TUMOR	RELATIVE INCIDENCE (%)	PRESENTATION	DIAGNOSIS	PROGNOSIS
Medulloblastoma	35-40	2-3 mo of headaches, vomiting, truncal ataxia	Heterogeneously or homogeneously enhancing fourth ventricular mass; may be disseminated	65–85% survival; dependent on stage/type; poorer (20–70%) in infants
Cerebellar astrocytoma	35-40	3-6 mo of limb ataxia; secondary headaches, vomiting	Cerebellar hemisphere mass, usually with cystic and solid (mural nodule) components	90–100% survival in totally resected pilocytic type
Brainstem glioma	10-15	1-4 mo of double vision, unsteadiness, weakness, and cranial nerve dysfunction, including facial weakness, swallowing dysfunction, and oculomotor abnormalities	Diffusely expanded, minimally or partially enhancing mass in 80%; 20% more focal tectal or cervicomedullary lesion	>90% mortality in diffuse tumors; better in localized
Ependymoma	10-15	2-5 mo of unsteadiness, headaches, double vision, and facial asymmetry	Usually enhancing, fourth ventricular mass with cerebellopontine predilection	>75% survival in totally resected lesions
Atypical teratoid/rhabdoid	5–10% of infantile malignant tumors	As in medulloblastoma, but primarily in infants; often associated facial weakness and strabismus	As in medulloblastoma, but often more laterally extended	≤20% survival in infants

Modified from Packer RJ, MacDonald T, Vezina G. Central nervous system tumors. *Pediatr Clin North Am*. 2008;55:121–145.

with premature hand preference. **Optic pathway tumors** manifest as visual and/or afferent oculomotor disturbances, such as decreased visual acuity, Marcus Gunn pupil (afferent pupillary defect), nystagmus, and/or visual field defects. Suprasellar region tumors and third ventricular region tumors may manifest initially as **neuroendocrine deficits,** such as subacute development of obesity, abnormal linear growth velocity, diabetes insipidus, galactorrhea, precocious puberty, delayed puberty, and hypothyroidism. In fact, signs of endocrine dysfunction preceded symptoms of neuroophthalmologic dysfunction by an average of 1.9 years, and their recognition as a possible sign of hypothalamic or pituitary neoplasm can hasten diagnosis and improve outcome. The **diencephalic syndrome,** which manifests as failure to thrive but normal linear growth, emaciation despite normal caloric intake, and inappropriately normal or happy (euphoric) affect, occurs in infants and young children with tumors (most often low-grade hypothalamic or thalamic glioma). **Parinaud syndrome** is seen with pineal region tumors and is manifested by paresis of upward gaze, pupillary caliber reactive to accommodation but not to light (pseudo-Argyll Robertson pupil), nystagmus to convergence or retraction, and eyelid retraction. **Spinal cord tumors** and spinal cord dissemination of brain tumors may manifest as long nerve tract motor and/or sensory deficits often localized to below a specific spinal level, bowel and bladder deficits, resistance to back flexion, scoliosis, bowel and bladder dysfunction, and back or radicular pain. The signs and symptoms of meningeal metastatic disease from brain tumors or leukemia include head or back pain and symptoms referable to compression of cranial nerves or spinal nerve roots.

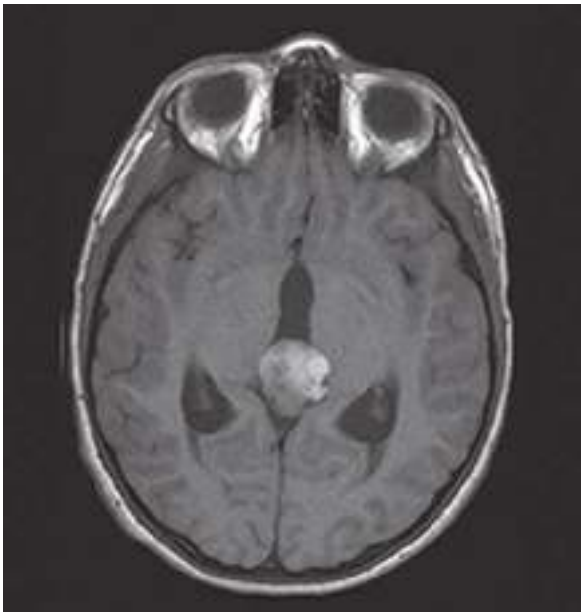

Fig. 546.3 Axillary T1 weighted MR image with gadolinium of a 10-yr-old male presenting with **mixed germ cell tumor** of the pineal region, with early onset of puberty, headaches, and elevated α-fetoprotein and β-human chorionic gonadotropin in the spinal fluid and serum.

DIAGNOSIS

The evaluation of a patient when a CNS tumor is suspected is an emergency. Initial evaluation should include a complete history (including endocrine), physical (including ophthalmic) examination, and full neurologic assessment with neuroimaging. For primary brain tumors, **MRI** with and without gadolinium is the neuroimaging standard. Tumors in the pituitary/suprasellar region, optic pathway, and infratentorium are better delineated with MRI than with CT. Patients with tumors of the midline and the pituitary/suprasellar/optic chiasmal region should undergo evaluation for **neuroendocrine dysfunction.** Formal ophthalmologic examination is beneficial in patients with optic path region tumors to document the impact of the disease on oculomotor function, visual acuity, and fields of vision. The suprasellar and pineal regions are preferential sites for germ cell tumors (Fig. 546.3). Both serum and CSF measurements of β-**human chorionic gonadotropin** and α-**fetoprotein** can assist in the diagnosis of germ cell tumors. In tumors with a propensity for spreading to the leptomeninges, such as medulloblastoma/PNET, ependymoma, and germ cell tumors, lumbar puncture with cytologic analysis of the CSF is indicated; lumbar puncture is contraindicated in individuals with newly diagnosed hydrocephalus secondary to CSF flow obstruction, in tumors that cause supratentorial midline shift, and in individuals with

infratentorial tumors. Lumbar puncture in these individuals may lead to brain herniation, resulting in neurologic compromise and death. Therefore, in children with newly diagnosed intracranial tumors and signs of increased ICP, the lumbar puncture usually is delayed until surgery or shunt placement.

SPECIFIC TUMORS

Astrocytoma

Astrocytomas are a heterogeneous group of tumors that account for approximately 40% of pediatric CNS malignancies. These tumors occur throughout the CNS.

Low-grade astrocytomas (LGAs), the predominant group of astrocytomas in childhood, are characterized by an indolent clinical course. **PA** is the most common astrocytoma in children, accounting for approximately 15.2% of all brain tumors (Fig. 546.4). Based on clinicopathologic features using the WHO Classification System, PA is classified as a WHO grade I tumor. Although PA can occur anywhere in the CNS, the classic sites are the **cerebellum followed by the optic pathway region** (Fig. 546.5A-B). The classic but not exclusive neuroradiologic finding in PA is the presence of a contrast-enhancing nodule within the wall of a cystic mass (Fig. 546.5A). The microscopic findings include the biphasic appearance of bundles of compact fibrillary tissue interspersed with loose microcystic, spongy areas. The presence of **Rosenthal fibers,** which are condensed masses of glial filaments occurring in the compact areas, with low mitotic potentials helps establish the diagnosis. A small proportion of these tumors can progress and develop leptomeningeal spread, particularly in the optic path region and very rarely transform to higher grade aggressive type. A PA of the optic nerve and chiasmal region is a relatively common finding in patients with neurofibromatosis type 1 (15% incidence). Molecularly, PA has activation of the **MAPK** pathway in the form of **BRAF** fusion or duplication and less commonly BRAF pathogenic variant (V600E) (see Fig. 546.4). Other low-grade tumors occurring in the pediatric age-group with clinic pathologic characteristics similar to PA include pleomorphic xanthoastrocytoma, pilomyxoid astrocytoma, and subependymal giant cell astrocytoma.

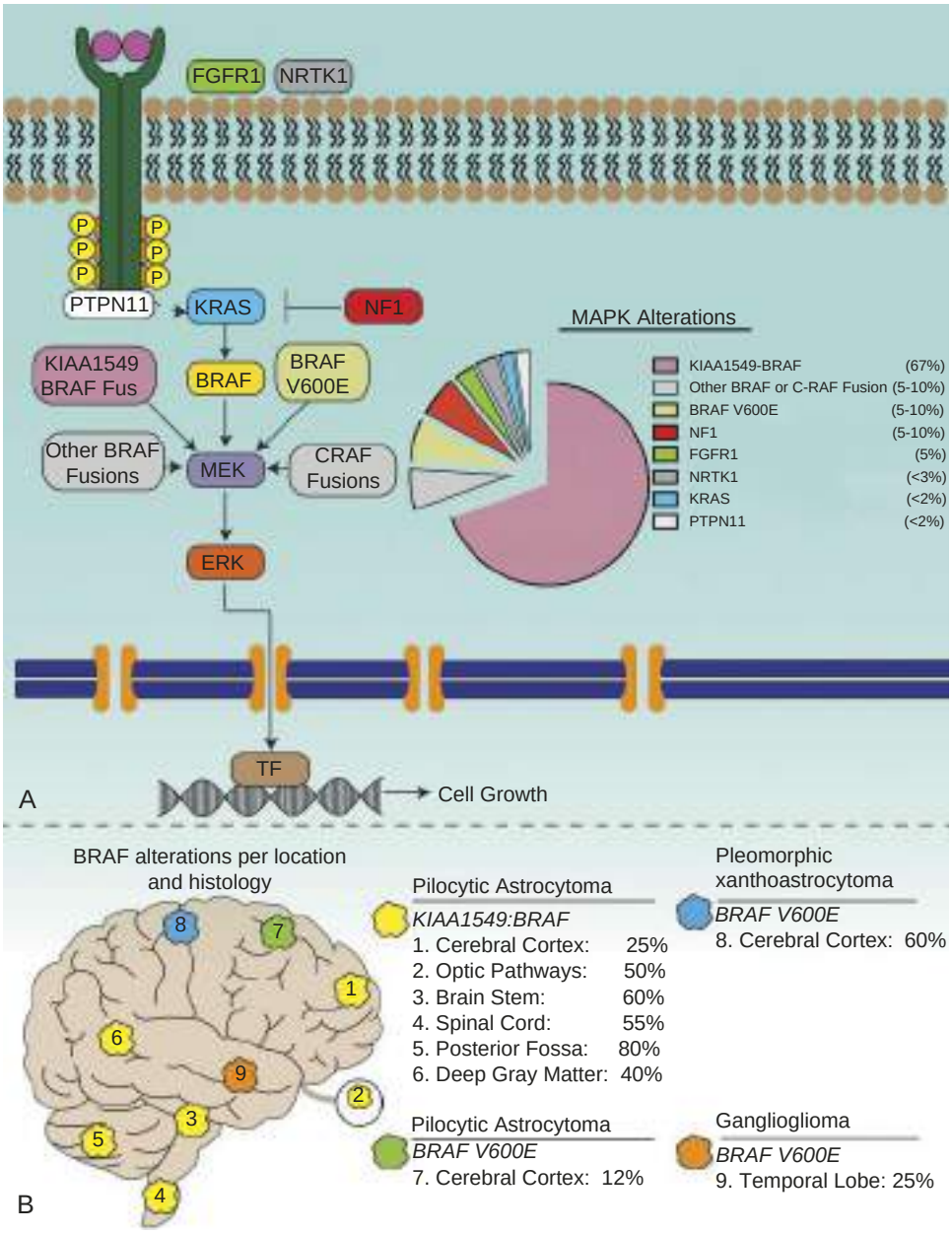

Fig. 546.4 A, Schematic of the frequency of MAPK pathway alterations detected by biopsy of pilocytic astrocytomas. This underestimates the frequency of NF1 pathogenic variants among children with low-grade gliomas (LGGs) because the tumors in patients affected by NF1 often do not undergo biopsy. Although BRAF fusions (BRAF Fus) constitute the majority of alterations in pilocytic astrocytoma, BRAF pathogenic variants are more commonly observed in pleomorphic xanthoastrocytomas and gangliogliomas. B, Frequency of the different BRAF abnormalities as a function of tumor location and histological diagnosis. *(From Pollack IF, Agnihotri S, Broniscer A. Childhood brain tumors: current management, biological insights, and future directions. J Neurosurg Pediatr. 2019;23:261–273. Fig. 1.)*

The second most common astrocytoma is **DA,** which consists of a group of tumors characterized by a pattern of diffuse infiltration of tumor cells amidst normal neural tissue. Histologically, these low-grade tumors demonstrate greater cellularity, with few mitotic figures, nuclear pleomorphism, and microcysts. They occur anywhere in the CNS with predilection to supratentorial location. The characteristic MRI finding is a lack of enhancement after contrast agent infusion. Molecular genetic abnormalities found in DA include pathogenic variants of *P53* and overexpression of platelet-derived growth factor receptor-α. Evolution of DA into malignant astrocytoma is associated with cumulative acquisition of multiple molecular abnormalities. Overactivation of the MAPK pathway has been detected in DA in the form of the ***BRAF V600E*** pathogenic variant and **FGFR1** duplication.

Pilomyxoid astrocytoma occurs most commonly in the hypothalamic/optic chiasmic region and carries a high risk of local as well as cerebrospinal spread. This astrocytoma affects young children and infants. It is classified as a WHO grade II tumor.

The clinical management of LGAs focuses on a multimodal approach incorporating surgery if feasible as the primary treatment as well as radiation therapy and chemotherapy. With complete surgical resection, the overall survival approaches 80–100%. In patients with partial resection, overall survival varies from 50–95%, depending on the anatomic location of the tumor. In the patient who has undergone partial tumor resection and has stable neurologic status, the current approach is to follow the patient closely by examination and imaging. With evidence of progression, a second surgical resection should be considered. In patients in whom a second procedure was less than complete or is not feasible, radiation therapy is beneficial. Radiation therapy is delivered to the tumor bed at a total cumulative dose ranging from 50-55 Gy. Modern surgical techniques and innovative radiation therapy methodology, *including proton-beam radiation,* may have a positive impact on the survival and clinical outcome of these patients. Chemotherapy for LGAs has become the standard of care for progressive LGAs. Because of concerns regarding morbidity from radiation therapy in young children, several chemotherapy approaches have been evaluated, especially in children younger than 10 years of age. Complete response to chemotherapy is uncommon; however, these approaches have yielded durable control of disease in 70–100% of patients with clinical improvement. Patients with midline tumors in the hypothalamic/optic chiasmatic region (see Fig. 546.5B) have tended to do less well. The chemotherapy approaches have permitted delay and, potentially, avoidance of radiation therapy. Chemotherapy agents given singly or in combination for LGA include carboplatin, vincristine, lomustine, procarbazine, temozolomide, and vinblastine. Observation is the primary approach in clinical management of selected patients with LGAs that are biologically indolent (neurofibromatosis type 1 and tectal gliomas and indolent LGA variants like angiocentric gliomas). *Astrocytomas associated with tuberous sclerosis have responded to everolimus, a mammalian target of rapamycin inhibitor.*

Malignant astrocytomas are less common in children and adolescents than in adults, accounting for 7–10% of all childhood brain tumors. Among this group, **anaplastic astrocytoma** (WHO grade III; Fig. 546.6) is more common than **glioblastoma multiforme** (WHO grade IV). The histopathology of anaplastic astrocytomas demonstrates greater cellularity than that of LGA, with cellular and nuclear atypia, and the presence of mitoses. Characteristic histopathologic findings in glioblastoma multiforme include dense cellularity, high mitotic index, microvascular proliferation, and foci of tumor necrosis with pseudopalisading. Genome-wide DNA methylation patterns have identified five molecular subgroups of pediatric high-grade glioma. These subgroups appear to have distinct cellular origins and biological drivers. Common genetic alterations include gene pathogenic variants in ***histone H3.3*** or ***H3.1, p53,*** and ***BRAF*** in addition to focal amplifications of oncogene (***PDGFRA*** and ***EGFR***) and deletions of tumor-suppressor genes ***(CDKN2A, CDKN2B, PTEN).***

Optimal therapeutic approaches for malignant astrocytomas have yet to be defined. Standard therapy continues to be surgical resection followed by involved-field radiation therapy with evolving role of maintenance alkylator chemotherapy (temozolomide ± lomustine). A study of adult glioblastoma showed significantly better survival with temozolomide during and after irradiation than with irradiation alone. Current therapeutic approaches incorporate novel chemotherapeutic agents with radiation therapy.

Oligodendrogliomas are uncommon tumors of childhood. These infiltrating tumors occur predominantly in the cerebral cortex and originate in the white matter. Histologically, oligodendrogliomas consist of rounded cells with little cytoplasm and microcalcifications. Observation of a **calcified cortical mass** on CT in a patient presenting with a seizure is suggestive of oligodendroglioma. The definition of oligodendroglioma requires two diagnostic genotypic features: pathogenic gene variants in isocitrate dehydrogenase (IDH) and the co-deletions of the short arm of chromosome 1 (1p) and the long arm of chromosome 19 (19q). Treatment approaches are similar to those for infiltrating astrocytomas.

Ependymal Tumors

Ependymal tumors are derived from the ependymal lining of the ventricular system. Cellular ependymoma (WHO grade II) is the most common of these neoplasms, accounting for 5% of childhood CNS tumors. Approximately 70% of ependymomas in childhood occur in the posterior fossa. The mean age of patients is 6 years, with approximately

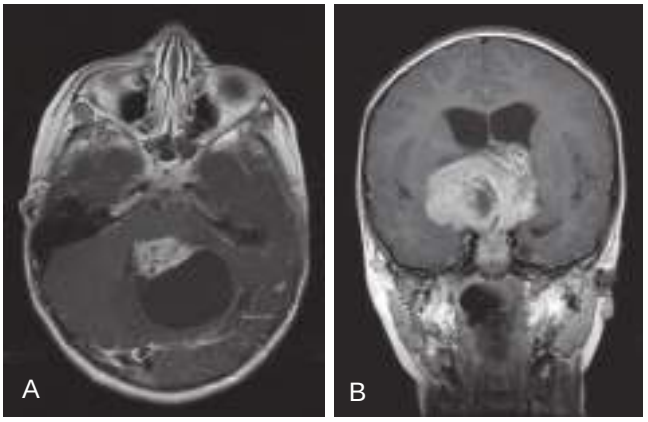

Fig. 546.5 A, Gadolinium-enhanced axial T1-weighted MR image in a 4-yr-old child with cerebellar **pilocytic astrocytoma** presenting with headaches, emesis, and ataxia demonstrates a predominantly cystic mass with enhancement of the solid component and enhancement of the capsule. B, Gadolinium-enhanced coronal view of a cystic juvenile pilocytic astrocytoma of the suprasellar region from a 4-yr-old child presenting with visual loss and headaches.

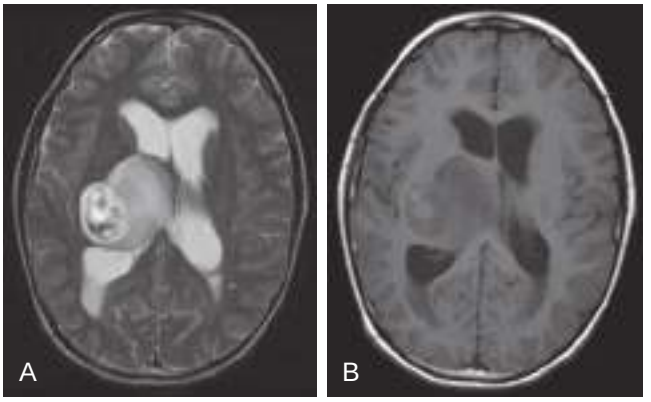

Fig. 546.6 A, Nonenhanced axial T2-weighted MR image of **grade III astrocytoma** of the right thalamus demonstrating diffuse hyperintensity and area of necrotic cyst formation. B, Gadolinium-enhanced sagittal T1-weighted MR image showing slight enhancement and hypodensity of **grade III astrocytoma** of the thalamus. This 14-yr-old child presented with left arm and leg numbness and weakness and right-sided headaches.

40% of cases occurring in children younger than 4 years of age. The incidence of leptomeningeal spread approaches 10% overall. Clinical presentation can be insidious and often depends on the anatomic location of the tumor. MRI demonstrates a well-circumscribed tumor with variable and complex patterns of gadolinium enhancement, with or without cystic structures (Fig. 546.7). These tumors usually are noninvasive, extending into the ventricular lumen and/or displacing normal structures, sometimes leading to significant obstructive hydrocephalus. Histologic characteristics include perivascular pseudorosettes, ependymal rosettes, monomorphic nuclear morphology, and occasional nonpalisading foci of necrosis. Other histologic subtypes include **anaplastic ependymoma** (WHO grade III), which is much less common in childhood and is characterized by a high mitotic index and histologic features of microvascular proliferation and pseudopalisading necrosis. **Myxopapillary ependymoma** (WHO grade II) is a slow-growing tumor arising from the filum terminale and conus medullaris and appears to be a biologically different subtype. Preliminary studies suggest that there are genetically distinct subtypes of ependymoma, exemplified by an association between alterations in the ***NF2*** gene and spinal ependymoma. Surgery is the primary treatment modality, with extent of surgical resection a major prognostic factor. Two other major prognostic factors are age, with younger children having poorer outcomes, and tumor location, with localization in the posterior fossa, which often is seen in young children, associated with poorer outcomes. Surgery alone is rarely curative. Multimodal therapy incorporating irradiation with surgery has resulted in long-term survival in approximately 40% of patients with ependymoma undergoing gross total resection. Recurrence is predominantly local. The role of chemotherapy in multimodal therapy of ependymoma is still unclear. Current investigations are directed toward identification of optimal radiation dose, surgical questions addressing the use of second-look procedures after chemotherapy, and further evaluation of classic as well as novel chemotherapeutic agents. Genome-wide DNA methylation patterns have identified nine molecular subgroups in these tumors across three anatomic compartments including supratentorial (ST), posterior fossa (PF), and the spinal locations (Fig. 548.8). Two subgroups (group A and B) of PF ependymoma have been identified with distinct molecular and clinical characteristics, and the use of targeted chemotherapy against these subtypes is being evaluated.

Choroid Plexus Tumors

Choroid plexus tumors account for 2–4% of childhood CNS tumors. They are the most common CNS tumors in children younger than 1 year of age and account for 10–20% of CNS tumors in infants. These tumors are intraventricular epithelial neoplasms arising from the choroid plexus. Children present with signs and symptoms of increased ICP. Infants may present with macrocephaly and focal neurologic deficits. In children, these tumors predominantly occur supratentorially in the lateral ventricles. The group of choroid plexus tumors is made up of **choroid plexus papillomas** (WHO grade I), **atypical choroid plexus papillomas** (WHO grade II), and **choroid plexus carcinomas** (WHO grade III). Choroid plexus papilloma, the *most common of this group*, is a well-circumscribed lesion with focal calcification on neuroimaging. *Choroid plexus carcinoma* is a malignant tumor with metastatic potential to seed into the CSF pathways. This malignancy has the following histologic characteristics: nuclear pleomorphism, high mitotic index, necrosis, and increased cell density. MRI typically demonstrates a large, hyperdense, contrast-enhancing, intraventricular mass with peritumoral edema, hemorrhage, and hydrocephalus. The tumor suppressor p53 is crucially involved in the biology of this cancer and may contribute to aggressive tumor behavior. Molecular data subclassify choroid plexus tumors into three distinct subgroups with different molecular aberrations and clinical outcomes. These tumors are associated with the Li-Fraumeni syndrome. After complete surgical resection, the frequency of cure for choroid plexus *papilloma* approaches 100%, whereas the frequency of cure for choroid plexus *carcinoma* approaches 20–40%. Reports suggest that radiation therapy and/or chemotherapy may lead to better disease control for choroid plexus carcinoma.

Embryonal Tumors

Embryonal tumors or **primitive neuroectodermal tumors (PNETs)** are one of the most common groups of *malignant* CNS tumors of childhood, accounting for approximately 9% of pediatric CNS tumors. They have the potential to metastasize to the neuraxis and extracranial tissues. The group includes medulloblastoma, supratentorial PNET, atypical teratoid/rhabdoid tumor, and other rare embryonal tumors, all of which are histologically classified as WHO grade IV tumors.

Medulloblastoma, which accounts for ~62% of embryonal CNS tumors, is a cerebellar tumor occurring predominantly in males and at a median age of 5-7 years. CT and MRI demonstrate a solid, homogeneous, contrast medium–enhancing mass in the PF causing fourth ventricular obstruction and hydrocephalus (Fig. 546.9). Up to 30% of patients with medulloblastoma present with neuroimaging evidence of leptomeningeal spread. Among a variety of diverse histologic patterns of this tumor, the most common is a monomorphic sheet of undifferentiated cells classically noted as small, blue round cells. Neuronal differentiation is more common among these tumors and is characterized

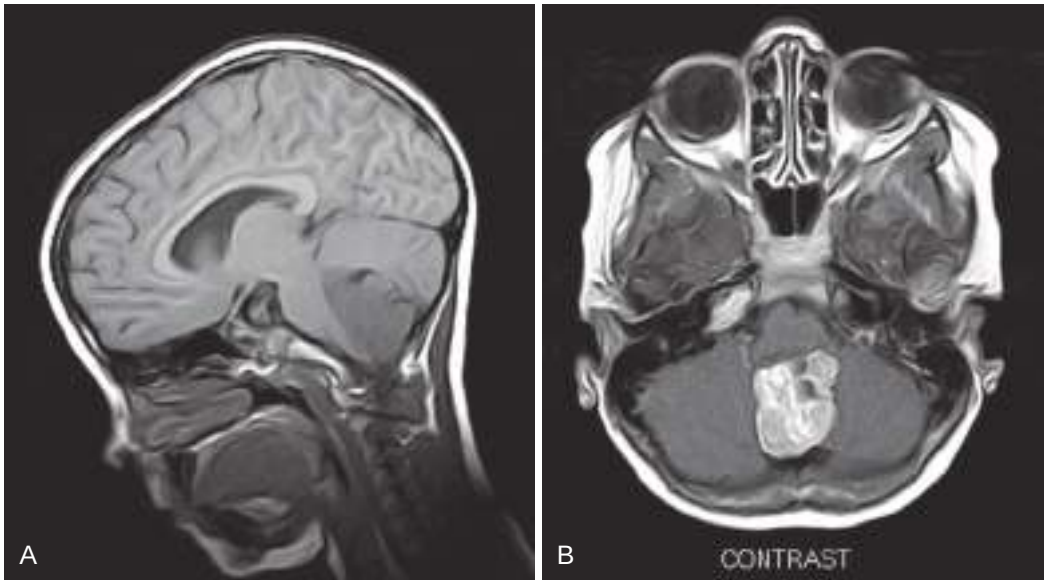

Fig. 546.7 A, Sagittal T1-weighted MR image of a 6-yr-old patient with **ependymoma**, demonstrating a hypointense mass within the fourth ventricle compressing the brainstem. B, Gadolinium-enhanced axial T1-weighted image of an ependymoma showing an enhancing mass within the fourth ventricle.

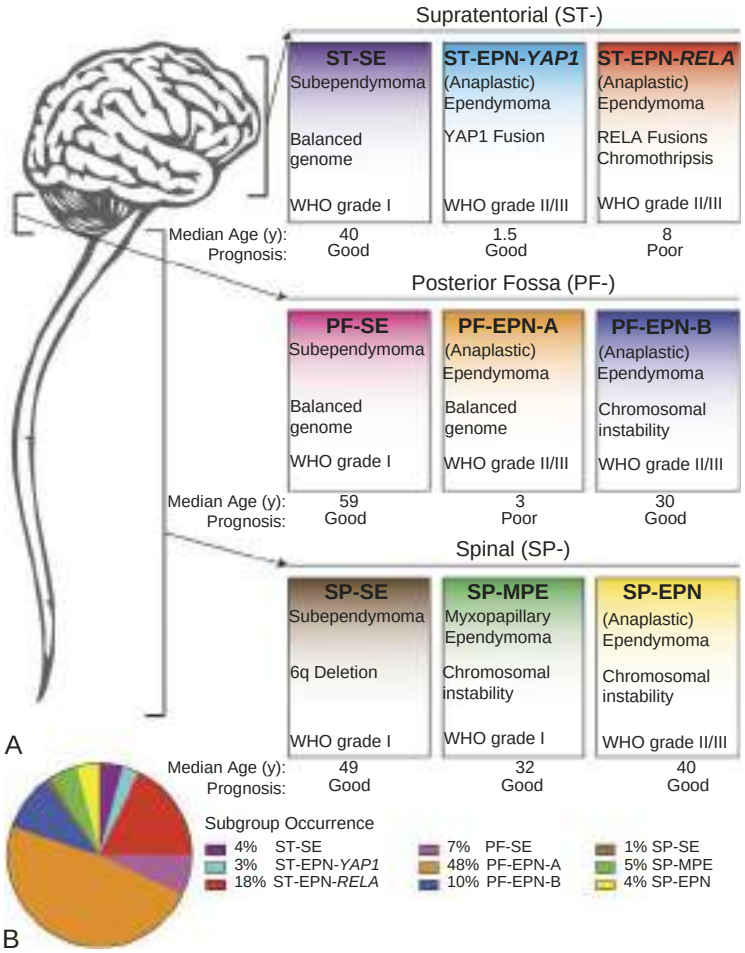

Fig. 546.8 **A,** Illustration of the nine recognized subsets of **ependymomas**. Only four of these subsets (ST-EPN-YAP1, ST-EPN-RELA, PF-EPN-A, and PF-EPN-B) typically occur during the childhood years. The subependymoma (SE) groups typically affect middle-age or older adults, and the spinal lesions, although occasionally encountered in children, are largely seen in adults. **B,** Estimate of the overall frequency of the different subtypes of ependymomas. *(From Pollack IF, Agnihotri S, Broniscer A. Childhood brain tumors: current management, biological insights, and future directions. J Neurosurg Pediatr. 2019;23:261–273. Fig. 3.)*

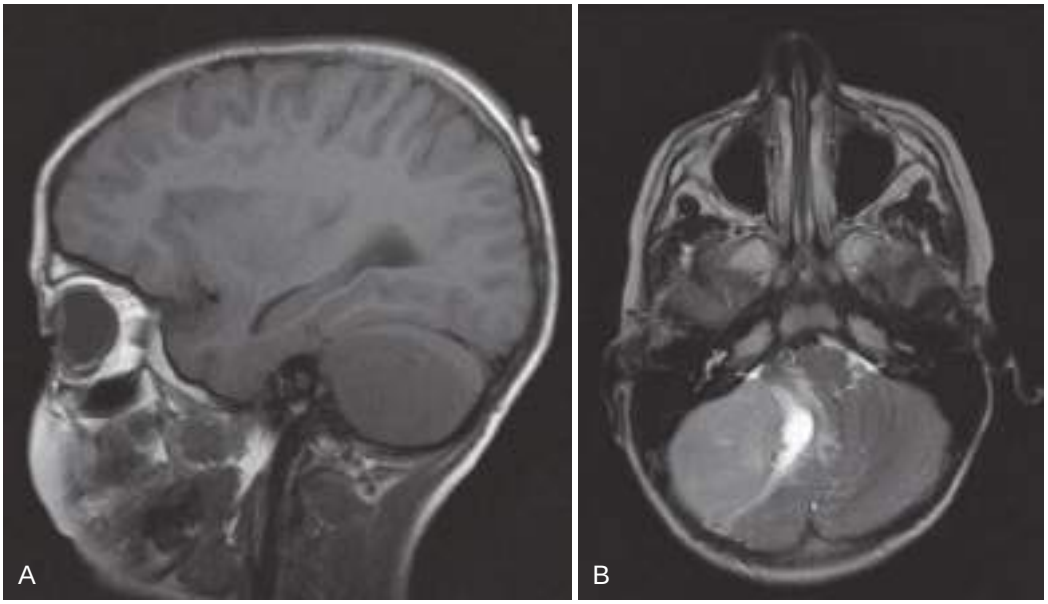

Fig. 546.9 **A,** Sagittal T1-weighted MR image shows hypointense mass involving the cerebellar hemisphere in a 6-yr-old child with desmoplastic variant of **medulloblastoma**. **B,** Axial T2-weighted image of the same child shows hyperintense mass involving the cerebellar hemisphere.

histologically by the presence of Homer Wright rosettes and by immunopositivity for synaptophysin. An anaplastic variant is often more aggressive and may be associated with poorer prognosis. Patients present with signs and symptoms of increased ICP (i.e., headache, nausea, vomiting, blurring of vision, mental status changes, and hypertension) and cerebellar dysfunction (i.e., ataxia, poor balance, dysmetria, dysarthria). Clinical staging evaluation includes MRI of the brain and spine, both preoperatively and postoperatively, as well as lumbar puncture after the increased ICP has resolved. Clinical features that have consistently demonstrated prognostic significance include age at diagnosis,

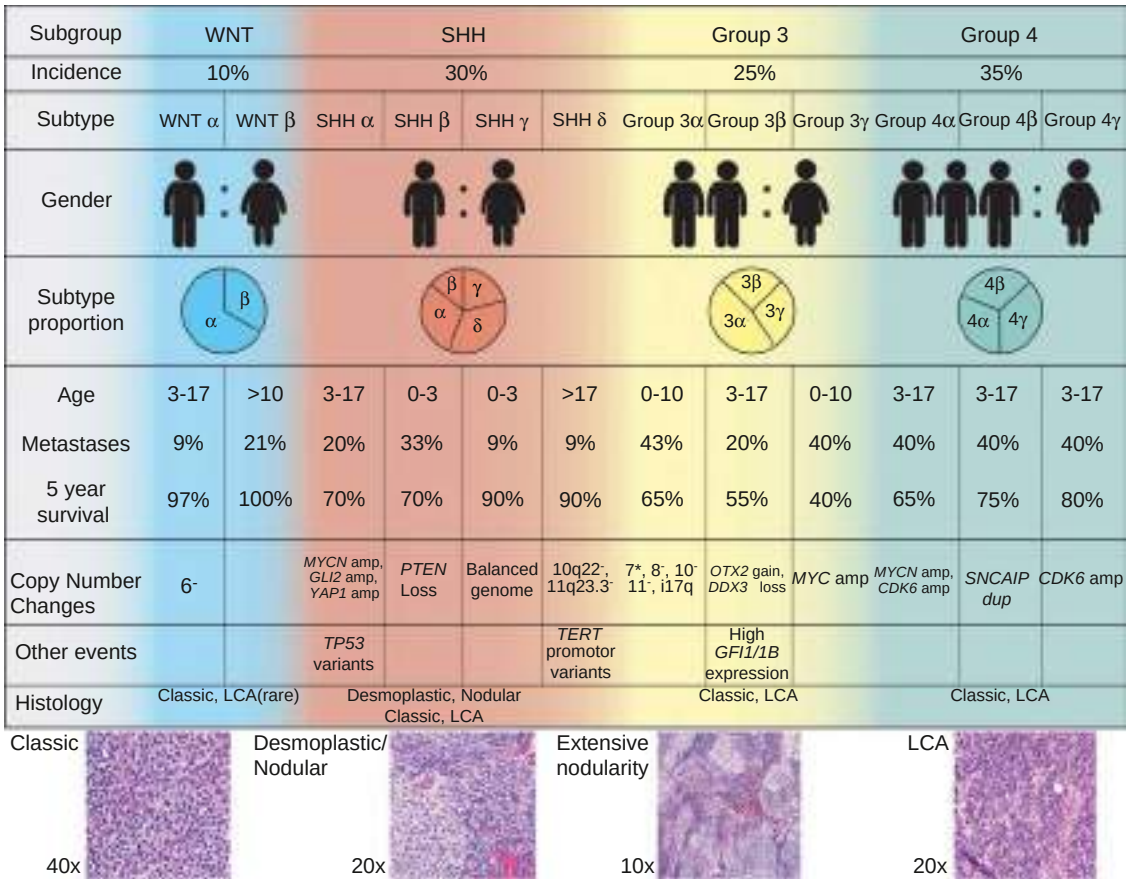

Fig. 546.10 Schematic *(upper)* depicting the four WHO-recognized subgroups of medulloblastoma, as well as the additional subtypes noted more recently and their distinguishing characteristics in terms of amplifications (amp) and duplications (dup). The figure *(lower)* also depicts the histological diversity of medulloblastomas: WNT tumors most commonly have a classic histology, whereas SHH tumors have desmoplastic histology with varying degrees of nodularity. Large cell/anaplastic (LCA) histology is most commonly seen in group 3 and less commonly in group 4 tumors. *(From Pollack IF, Agnihotri S, Broniscer A. Childhood brain tumors: current management, biological insights, and future directions. J Neurosurg Pediatr. 2019;23:261–273. Fig. 2.)*

extent of disease, and extent of surgical resection. Patients younger than 4 years of age have a poor outcome, partly as the result of a higher incidence of disseminated disease on presentation and past therapeutic approaches that have used less intense therapies. Patients with disseminated disease at diagnosis (M > 0), including positive CSF cytologic result alone (M1), have a markedly poorer outcome than those patients with no dissemination (M0). Similarly, patients with gross residual disease after surgery have poorer outcomes than those in whom surgery achieved gross total resection of disease.

Cytogenetic and molecular genetic studies have demonstrated multiple abnormalities in medulloblastoma (Fig. 546.10). The most common abnormality involves chromosome 17p deletions, which occur in 30–40% of all cases. Several signaling pathways have been shown to be active in medulloblastomas, including the sonic hedgehog **(SHH)** pathway, predominately associated with the desmoplastic variants, and the **WNT** pathway, which can occur in up to 15% of cases and has been associated with improved survival. Integrative genomic studies have identified at least four distinct molecular subgroups of medulloblastoma—**WNT**, **SHH**, **group 3**, and **group 4**—that exhibit highly discriminate transcriptional, cytogenetic, and mutational spectra, in addition to divergent patient demographics and clinical behavior (see Fig. 546.10). These prognostic groups still must be validated in larger prospective studies, though the WNT subgroup is known to have the most favorable outcome. A multimodal treatment approach is pursued in medulloblastoma, with surgery as the starting point of treatment. Medulloblastoma is sensitive to both chemotherapy and radiation therapy. With technologic advances in neurosurgery, neuroradiology, and radiation therapy, as well as identification of chemotherapy as an effective modality, the overall outcome among all patients approaches 60–70%. Standard radiation treatment in standard risk medulloblastoma incorporates craniospinal radiation at a total cumulative dose of 24 Gy, with a cumulative dose of 50-55 Gy to the tumor bed. Craniospinal radiation at this dose in children younger than 3 years of age results in severe late neurologic sequelae, including microcephaly, learning disabilities, cognitive impairment, neuroendocrine dysfunction (growth failure, hypothyroidism, hypogonadism, and absence/delay of puberty), and/or second malignancies. Similarly, in older children, late sequelae, such as learning disabilities, neuroendocrine dysfunction, and/or second malignancies, can occur. These observations have resulted in stratification of treatment approaches into the following three strata: (1) patients younger than 3 years of age, (2) standard-risk patients older than 3 years of age with surgical total resection and no disease dissemination (M0), and (3) high-risk patients older than 3 years of age with disease dissemination (M > 0) and/or bulky residual disease after surgery. With the risk-based approach to treatment, children with high-risk medulloblastoma receive high-dose cranial–spinal radiation (36 Gy) with chemotherapy during and after radiation therapy. As the dose of radiation depends on the risk stratification, complete staging with MRI of the spine before starting treatment is essential for the best chance of survival. Approaches in young children (usually younger than 3 years of age) incorporate high-dose chemotherapy with peripheral stem cell reinfusion to avoid radiation therapy.

Overall survival in children with nonmetastatic medulloblastoma and gross total tumor resection approaches 85%. The presence of bulky residual tumor (56% survival) or metastases (38% survival) confers a poor prognosis. The molecular classification is being evaluated to stratify risk groups and tailor therapy accordingly. The WNT subgroup and nonmetastatic group 4 tumors are recognized as low-risk tumors that may qualify for reduced therapy. High-risk groups were defined as patients with metastatic SHH or group 4 tumors, where intensification of therapy is being profiled.

Supratentorial primitive neuroectodermal tumors (SPNETs) account for approximately 1% of childhood CNS tumors, primarily in children within the first decade of life. These tumors are similar histologically to medulloblastoma and are composed of undifferentiated or poorly differentiated neuroepithelial cells. Historically, patients with SPNETs have had poorer outcomes than those with medulloblastoma after combined-modality therapy. Children with SPNETs are considered among the high-risk group and receive dose-intense chemotherapy with craniospinal radiation therapy.

Atypical teratoid/rhabdoid tumor is a very aggressive embryonal malignancy that occurs predominantly in children younger than 5 years of age and can occur at any location in the neuraxis. The histology demonstrates a heterogeneous pattern of cells, including rhabdoid cells that express epithelial membrane antigen and neurofilament antigen. The characteristic cytogenetic pattern is partial or complete deletion of chromosome 22q11.2 that is associated with pathogenic variants in the *INI1* gene. The relation between this variant and tumorigenesis is unclear. Though the overall prognosis remains poor, intensive chemotherapy, focal radiation, and high-dose chemotherapy with stem cell rescue have shown a trend toward improved survival. This is noted more in patients who undergo complete resection of tumor and focal radiation.

Pineal Parenchymal Tumors

The pineal parenchymal tumors are the most common malignancies after germ cell tumors that occur in the pineal region. These include **pineoblastoma**, occurring predominantly in childhood, **pineocytoma**, and the **mixed pineal parenchymal tumors**. The therapeutic approach in this group of diseases is multimodal. There was significant concern regarding the location of these masses and the potential complications of surgical intervention. With developments in neurosurgical technique and surgical technology, the morbidity and mortality associated with these approaches have markedly decreased. Stereotactic biopsy of these tumors may be adequate to establish diagnosis; however, consideration should be given to total resection of the lesion before institution of additional therapy. Pineoblastoma, the more malignant variant, is considered a subgroup of childhood PNETs. Chemotherapy regimens incorporate cisplatin, cyclophosphamide (Cytoxan), etoposide (VP-16), and vincristine and/or lomustine. The survival outcome of combined chemotherapy and radiation therapy in pineal-region PNETs approaches 70% at 5 years. Pineocytoma usually is approached with surgical resection.

Craniopharyngioma

Craniopharyngioma (WHO grade I) is a common tumor of childhood, accounting for 3–10% of all CNS childhood tumors. Two histological subtypes have been identified, adamantinomatous and papillary craniopharyngiomas (CP), each with specific origin and genetic alterations. ***BRAFV600E*** pathogenic variants are solely found in the papillary CP subgroup, which is the common type in adults, whereas ***CTNNB1*** pathogenic variants are exclusively detected in adamantinomatous CP, which is common in children. Children with CP often present with endocrinologic abnormalities (growth failure and delayed sexual maturation) and/or visual changes (decreased acuity or visual field abnormalities). These tumors are often large and heterogeneous, displaying both solid and cystic components, and occur within the suprasellar region. They are minimally invasive, adhere to adjacent brain parenchyma, and engulf normal brain structures. MRI demonstrates the solid tumor with cystic structures containing fluid of intermediate density, and CT may show calcifications. Surgery is the primary treatment modality, with gross total resection being curative. Controversy exists regarding the relative roles of surgery and radiation therapy in large, complex tumors. Significant morbidity (panhypopituitarism, growth failure, visual loss) is associated with these tumors and their therapy, owing to the anatomic location.

Germ Cell Tumors

Germ cell tumors of the CNS are a heterogeneous group of tumors that are primarily tumors of childhood, arising predominantly in midline structures of the pineal and suprasellar regions (see Fig. 546.3). They account for 3–5% of pediatric CNS tumors. The peak incidence of these tumors is in children 10-12 yr of age. Overall, there is a male preponderance, although there is a female preponderance for suprasellar tumors. Germ cell tumors occur multifocally in 5–10% of cases. This group of tumors is much more prevalent in Asian populations than European populations. Delays in diagnosis can occur because these tumors have a particularly insidious course; the initial presenting symptoms may be subtle. Similar to peripheral germ cell tumors, the analysis of protein markers, **α-fetoprotein,** and **β-human chorionic gonadotropin** may be useful in establishing the diagnosis and monitoring treatment response. Surgical biopsy is recommended to establish the diagnosis; however, secreting **germinomas** and **nongerminomatous germ cell tumors** may be diagnosed based on protein marker elevations. Therapeutic approaches to germinomas and nongerminomatous germ cell tumors are different. The survival proportion among patients with pure germinoma exceeds 90%. The postsurgical treatment of pure germinomas is somewhat controversial in defining the relative roles of chemotherapy and radiation therapy. Clinical trials have investigated the use of chemotherapy and reduced-dose radiation and field after surgery in pure germinomas. The therapeutic approach to nongerminomatous germ cell tumors is more aggressive, combining more intense chemotherapy regimens with craniospinal radiation therapy. Survival rates among patients with these tumors are markedly lower than those noted in patients with germinoma, ranging from 70–80% at 5 years. Trials have shown the benefit of the use of high doses of chemotherapy with peripheral blood stem cell rescue specially at metastatic and relapse groups.

Tumors of the Brainstem

Tumors of the brainstem are a heterogeneous group of tumors that account for 10.9% of childhood primary CNS tumors. Outcome depends on tumor location, imaging characteristics, and the patient's clinical status. Patients with these tumors may present with motor weakness, cranial nerve dysfunction, cerebellar dysfunction, and/or signs of increased ICP. On the basis of MRI evaluation and clinical findings, tumors of the brainstem can be classified into four types: focal (5–10% of patients), dorsally exophytic (5–10%), cervicomedullary (5–10%), and diffuse intrinsic pontine glioma **(DIPG)** (70–85%) (Fig. 546.11). Surgical resection is the primary treatment approach for focal and dorsally exophytic tumors and leads to a favorable outcome. Histologically, these two groups usually are low-grade gliomas. *Cervicomedullary tumors, because of their location, may not be amenable to surgical resection but are sensitive to radiation therapy*. DIPG, characterized by the diffuse infiltrating grade II-IV glioma, is associated with a very poor outcome independent of histologic diagnosis. These tumors are not amenable to surgical resection. Biopsy in children in whom MRI shows DIPG is controversial and is not recommended unless there are atypical radiographic findings suspicious for another diagnosis, such as infection, vascular malformation, myelination disorder, or metastatic tumor. Studies have identified the unique genetic makeup of this fatal brain cancer, with nearly 80% found to harbor pathogenic variants in histone ***H3.3*** or ***H3.1 (H3-K27M)*** and 20% pathogenic variants affecting the activin receptor gene ***(ACVR1);*** three molecularly distinct subgroups have been identified (H3-K27M, silent and MYCN).

The standard treatment approach has been palliative radiation therapy, and median survival with this treatment is 12 months, at best. Use

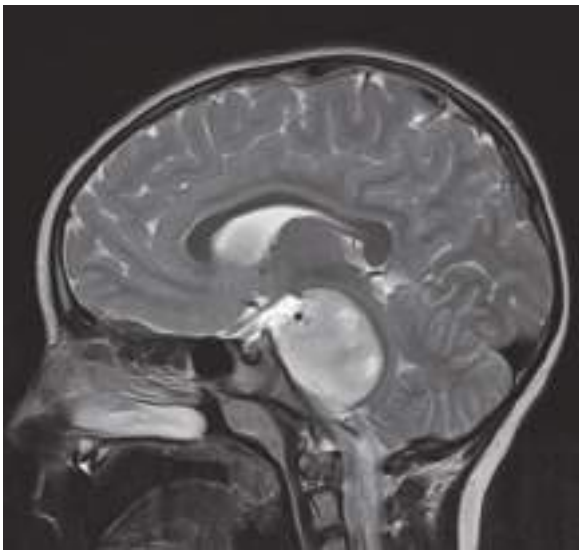

Fig. 546.11 T2-weighted sagittal MR image of a diffuse infiltrating **pontine glioma** in a 5-yr-old child presenting with headaches, left facial droop, and lethargy.

of chemotherapy, including high-dose chemotherapy with peripheral blood stem cell rescue, has not yet been of survival benefit in this group of patients. Experimental approaches have included the use of immunotherapy with oncolytic herpes simplex virus (HSV) or adenoviruses.

Metastatic Tumors

Metastatic spread of other childhood malignancies to the brain is uncommon. Childhood acute lymphoblastic leukemia and non-Hodgkin lymphoma can spread to the leptomeninges, causing symptoms of communicating hydrocephalus. **Chloromas,** which are collections of myeloid leukemia cells, can occur throughout the neuraxis. Rarely, brain parenchymal metastases occur from lymphoma, neuroblastoma, rhabdomyosarcoma, Ewing sarcoma, osteosarcoma, and clear cell sarcoma of the kidney. Therapeutic approaches are based on the specific histologic diagnosis and may incorporate radiation therapy, intrathecal administration of chemotherapy, and/or systemic administration of chemotherapy. Medulloblastoma is the childhood brain tumor that most commonly metastasizes extraneurally. Less commonly, extraneural metastases from malignant glioma, PNET, and ependymoma can occur. Ventriculoperitoneal shunts have been known to allow extraneural metastases, primarily within the peritoneal cavity but also systemically.

COMPLICATIONS AND LONG-TERM MANAGEMENT

Data from the National Cancer Institute Surveillance, Epidemiology, and End Results Program indicate that more than 70% of patients with childhood brain tumors will be long-term survivors. At least 50% of these survivors will experience chronic problems as a direct result of their tumors and treatment. These problems include chronic neurologic deficits such as focal motor and sensory abnormalities, seizure disorders, neurocognitive deficits (e.g., developmental delays, learning disabilities), and neuroendocrine deficiencies (e.g., hypothyroidism, growth failure, delay or absence of puberty). These patients are also at significant risk for secondary malignancies, hearing deficit, and early cataract from radiation therapy. Supportive multidisciplinary interventions for children with brain tumors both during and after therapy may help improve the ultimate outcome. Optimal seizure management, physical therapy, endocrine management with timely growth hormone and thyroid replacement therapy, tailored educational programs, and vocational interventions may enhance the childhood brain tumor survivor's quality of life.

Visit Elsevier eBooks+ at eBooks.Health.Elsevier.com for Bibliography.

Chapter 547

Neuroblastoma

Fiorela N. Hernandez Tejada and Douglas J. Harrison

Neuroblastomas are embryonal cancers of the peripheral sympathetic nervous system with heterogeneous clinical presentation and course, ranging from tumors that undergo spontaneous regression to very aggressive tumors unresponsive to very intensive multimodal therapy. The causes of most cases remain unknown. Advances have been made in the treatment of children with these tumors, which have improved outcomes, although many with aggressive forms of neuroblastoma still succumb to their disease despite intensive therapy.

EPIDEMIOLOGY

Neuroblastoma is the most common extracranial solid tumor in children and is the most commonly diagnosed malignancy in the first year of life. Approximately 600 new cases are diagnosed each year in the United States, accounting for 8–10% of childhood malignancies and one-third of cancers in infants. Neuroblastoma accounts for >15% of the mortality from cancer in children. The median age of children at diagnosis of neuroblastoma is 18 months, and 90% of cases are diagnosed in children who are <10 years of age. The incidence is slightly higher in males and in the White population.

PATHOLOGY

Neuroblastoma tumors, which are derived from primordial neural crest cells, form a spectrum with variable degrees of neural differentiation, ranging from tumors with primarily undifferentiated small round cells (neuroblastoma) to tumors consisting of mature and maturing Schwannian stroma with ganglion cells (ganglioneuroblastoma or ganglioneuroma). The tumors may resemble other **small, round blue cell tumors,** such as rhabdomyosarcoma, Ewing sarcoma, and non-Hodgkin lymphoma. The prognosis of children with neuroblastoma varies with the histologic features of the tumor as dictated by the presence and amount of Schwannian stroma, the degree of tumor cell differentiation, and the mitosis-karyorrhexis index.

PATHOGENESIS

The etiology of neuroblastoma in most cases remains unknown. Familial neuroblastoma is rare but accounts for 1–2% of all cases, is associated with a younger age at diagnosis, and is linked to germline gain-of-function pathogenic variants in the *ALK* gene. The *BARD1* gene has also been identified as a major genetic contributor to neuroblastoma risk. Germline gain-of-function pathogenic variants in *PHOX2B* predisposes to most of the syndromic neuroblastoma cases, including Hirschsprung disease and central congenital hypoventilation syndrome. Neuroblastoma is associated with other neural crest disorders, such as neurofibromatosis type 1, and potentially congenital cardiovascular malformations (Table 547.1). Children with Beckwith-Wiedemann syndrome and hemihypertrophy also have a higher incidence of neuroblastoma. Increased incidence of neuroblastoma is associated with some maternal and paternal occupational chemical exposures, maternal drug use, farming, and work related to electronics, although no single environmental exposure has been shown to directly cause neuroblastoma.

Genetic characteristics of neuroblastoma tumors that are of prognostic importance include amplification of the *MYCN (N-myc)* proto-oncogene and tumor cell DNA content, or ploidy (Tables 547.2-547.4). Amplification of *MYCN* is strongly associated with advanced tumor stage and poor outcomes. Other genetic alterations have been identified

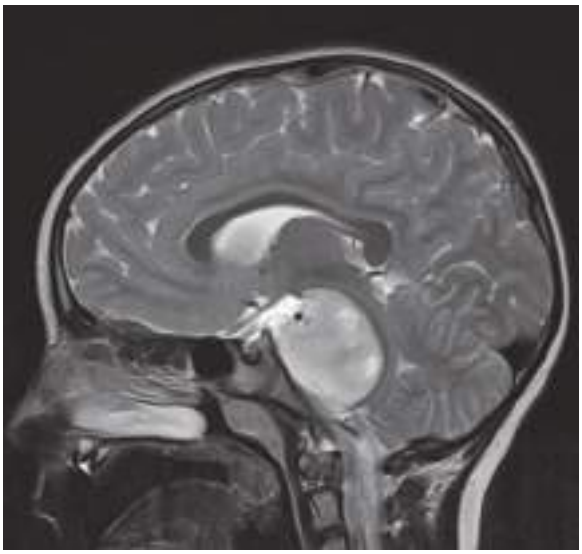

Fig. 546.11 T2-weighted sagittal MR image of a diffuse infiltrating **pontine glioma** in a 5-yr-old child presenting with headaches, left facial droop, and lethargy.

of chemotherapy, including high-dose chemotherapy with peripheral blood stem cell rescue, has not yet been of survival benefit in this group of patients. Experimental approaches have included the use of immunotherapy with oncolytic herpes simplex virus (HSV) or adenoviruses.

Metastatic Tumors

Metastatic spread of other childhood malignancies to the brain is uncommon. Childhood acute lymphoblastic leukemia and non-Hodgkin lymphoma can spread to the leptomeninges, causing symptoms of communicating hydrocephalus. **Chloromas,** which are collections of myeloid leukemia cells, can occur throughout the neuraxis. Rarely, brain parenchymal metastases occur from lymphoma, neuroblastoma, rhabdomyosarcoma, Ewing sarcoma, osteosarcoma, and clear cell sarcoma of the kidney. Therapeutic approaches are based on the specific histologic diagnosis and may incorporate radiation therapy, intrathecal administration of chemotherapy, and/or systemic administration of chemotherapy. Medulloblastoma is the childhood brain tumor that most commonly metastasizes extraneurally. Less commonly, extraneural metastases from malignant glioma, PNET, and ependymoma can occur. Ventriculoperitoneal shunts have been known to allow extraneural metastases, primarily within the peritoneal cavity but also systemically.

COMPLICATIONS AND LONG-TERM MANAGEMENT

Data from the National Cancer Institute Surveillance, Epidemiology, and End Results Program indicate that more than 70% of patients with childhood brain tumors will be long-term survivors. At least 50% of these survivors will experience chronic problems as a direct result of their tumors and treatment. These problems include chronic neurologic deficits such as focal motor and sensory abnormalities, seizure disorders, neurocognitive deficits (e.g., developmental delays, learning disabilities), and neuroendocrine deficiencies (e.g., hypothyroidism, growth failure, delay or absence of puberty). These patients are also at significant risk for secondary malignancies, hearing deficit, and early cataract from radiation therapy. Supportive multidisciplinary interventions for children with brain tumors both during and after therapy may help improve the ultimate outcome. Optimal seizure management, physical therapy, endocrine management with timely growth hormone and thyroid replacement therapy, tailored educational programs, and vocational interventions may enhance the childhood brain tumor survivor's quality of life.

Visit Elsevier eBooks+ at eBooks.Health.Elsevier.com for Bibliography.

Chapter 547

Neuroblastoma

Fiorela N. Hernandez Tejada and Douglas J. Harrison

Neuroblastomas are embryonal cancers of the peripheral sympathetic nervous system with heterogeneous clinical presentation and course, ranging from tumors that undergo spontaneous regression to very aggressive tumors unresponsive to very intensive multimodal therapy. The causes of most cases remain unknown. Advances have been made in the treatment of children with these tumors, which have improved outcomes, although many with aggressive forms of neuroblastoma still succumb to their disease despite intensive therapy.

EPIDEMIOLOGY

Neuroblastoma is the most common extracranial solid tumor in children and is the most commonly diagnosed malignancy in the first year of life. Approximately 600 new cases are diagnosed each year in the United States, accounting for 8–10% of childhood malignancies and one-third of cancers in infants. Neuroblastoma accounts for >15% of the mortality from cancer in children. The median age of children at diagnosis of neuroblastoma is 18 months, and 90% of cases are diagnosed in children who are <10 years of age. The incidence is slightly higher in males and in the White population.

PATHOLOGY

Neuroblastoma tumors, which are derived from primordial neural crest cells, form a spectrum with variable degrees of neural differentiation, ranging from tumors with primarily undifferentiated small round cells (neuroblastoma) to tumors consisting of mature and maturing Schwannian stroma with ganglion cells (ganglioneuroblastoma or ganglioneuroma). The tumors may resemble other **small, round blue cell tumors,** such as rhabdomyosarcoma, Ewing sarcoma, and non-Hodgkin lymphoma. The prognosis of children with neuroblastoma varies with the histologic features of the tumor as dictated by the presence and amount of Schwannian stroma, the degree of tumor cell differentiation, and the mitosis-karyorrhexis index.

PATHOGENESIS

The etiology of neuroblastoma in most cases remains unknown. Familial neuroblastoma is rare but accounts for 1–2% of all cases, is associated with a younger age at diagnosis, and is linked to germline gain-of-function pathogenic variants in the *ALK* gene. The *BARD1* gene has also been identified as a major genetic contributor to neuroblastoma risk. Germline gain-of-function pathogenic variants in *PHOX2B* predisposes to most of the syndromic neuroblastoma cases, including Hirschsprung disease and central congenital hypoventilation syndrome. Neuroblastoma is associated with other neural crest disorders, such as neurofibromatosis type 1, and potentially congenital cardiovascular malformations (Table 547.1). Children with Beckwith-Wiedemann syndrome and hemihypertrophy also have a higher incidence of neuroblastoma. Increased incidence of neuroblastoma is associated with some maternal and paternal occupational chemical exposures, maternal drug use, farming, and work related to electronics, although no single environmental exposure has been shown to directly cause neuroblastoma.

Genetic characteristics of neuroblastoma tumors that are of prognostic importance include amplification of the *MYCN (N-myc)* proto-oncogene and tumor cell DNA content, or ploidy (Tables 547.2-547.4). Amplification of *MYCN* is strongly associated with advanced tumor stage and poor outcomes. Other genetic alterations have been identified

Table 547.1 Syndromes Due to or Associated with Neuroblastoma

EPONYM	FEATURES
SYNDROMES CAUSED BY NEUROBLASTOMA	
Pepper syndrome	Massive involvement of the liver with metastatic disease with or without respiratory distress
Horner syndrome	Unilateral ptosis, myosis, and anhidrosis associated with a thoracic or cervical primary tumor; symptoms do not resolve with tumor resection
Hutchinson syndrome	Limping and irritability in young child associated with bone and bone marrow metastases
Opsoclonus-myoclonus-ataxia syndrome	Myoclonic jerking and random conjugate eye movements with or without cerebellar ataxia; often associated with a biologically favorable and differentiated tumor; the condition is likely immune mediated, may not resolve with tumor removal, and often exhibits progressive neuropsychologic sequelae
Kerner-Morrison syndrome	Intractable secretory watery diarrhea due to tumor secretion of vasointestinal peptides; tumors are generally biologically favorable
ROHHAD	Approximately 40% may have neural crest-derived tumors. Obesity and neurologic issues may be part of a paraneoplastic syndrome
SYNDROMES PREDISPOSING TO NEUROBLASTOMA	
Neurocristopathy syndrome	Neuroblastoma associated with other neural crest disorders, including congenital hypoventilation syndrome or Hirschsprung disease; germline pathogenic variants in the paired homeobox gene *PHOX2B* have been identified in a subset of patients with this disease
Beckwith-Wiedemann syndrome	Macrosomia, hyperinsulinemic hypoglycemia, omphalocele
Costello syndrome (faciocutaneo-skeletal syndrome)	Autosomal dominant, pathogenic variant in *HRAS*, intellectual disability, delayed development, cardiomyopathy
Familial pheochromocytoma/paraganglioma syndrome	Autosomal dominant, pathogenic variant in *MAX* and other genes
Fanconi anemia	Autosomal recessive, congenital anomalies, aplastic anemia, pathogenic variants in *FANCA*, *FANCC*, *FANCG*
Neurofibromatosis type 1	*NF1* pathogenic variants
Noonan syndrome	Ras-MAPK pathway (RASopathies) pathogenic variant
Turner syndrome	Partial or complete deletion of X chromosome, short-webbed neck, short stature

ROHHAD, Rapid-onset obesity, hypothalamic dysfunction, hypoventilation, autonomic dysregulation.
Modified from Park JR, Eggert A, Caron H. *Neuroblastoma*: biology, prognosis, and treatment. *Pediatr Clin North Am*. 2008;55:97–120.

Table 547.2 Children's Oncology Group Neuroblastoma Risk Stratification

RISK GROUP	STAGE	AGE	*MYCN* AMPLIFICATION STATUS	PLOIDY	SHIMADA
Low	1	Any	Any	Any	Any
Low	2A/2B	Any	Not amplified	Any	Any
High	2A/2B	Any	Amplified	Any	Any
Intermediate	3	<547 days	Not amplified	Any	Any
Intermediate	3	≥547 days	Not amplified	Any	FH
High	3	Any	Amplified	Any	Any
High	3	≥547 days	Not amplified	Any	UH
High	4	<365 days	Amplified	Any	Any
Intermediate	4	<365 days	Not amplified	Any	Any
High	4	365 to <547 days	Amplified	Any	Any
High	4	365 to <547 days	Any	DNA index = 1	Any
High	4	365 to <547 days	Any	Any	UH
Intermediate	4	365 to <547 days	Not amplified	DNA index > 1	FH
High	4	≥547 days	Any	Any	Any
Low	4S	<365 days	Not amplified	DNA index > 1	FH
Intermediate	4S	<365 days	Not amplified	DNA index = 1	Any
Intermediate	4S	<365 days	Not amplified	Any	UH
High	4S	<365 days	Amplified	Any	Any

FH, Favorable histology; UH, unfavorable histology.
Data from Irwin MS, Naranjo A, Zhang FF, et al. Revised neuroblastoma risk classification system: a report From the Children's Oncology Group. *J Clin Oncol*. 2021;39(29):3229–3241.

Table 547.3 International Neuroblastoma Staging System

STAGE	DEFINITION	INCIDENCE (%)	SURVIVAL AT 5 YR* (%)
1	Localized tumor with complete gross excision, with or without microscopic residual disease; representative ipsilateral lymph nodes negative for tumor microscopically (nodes attached to and removed with the primary tumor may be positive)	5	≥90
2A	Localized tumor with incomplete gross excision; representative ipsilateral nonadherent lymph nodes negative for tumor microscopically	10	70-80
2B	Localized tumor with or without complete gross excision, with ipsilateral nonadherent lymph nodes positive for tumor; enlarged contralateral lymph nodes must be negative microscopically	10	70-80
3	Unresectable unilateral tumor infiltrating across the midline,† with or without regional lymph node involvement; *or* localized unilateral tumor with contralateral regional lymph node involvement; *or* midline tumor with bilateral extension by infiltration (resectable) or by lymph node involvement	25	40-70
4	Any primary tumor with dissemination to distant lymph nodes; bone, bone marrow, liver, skin, and other organs (except as defined for stage 4S)	60	85-90¶ 30-40#
4S	Localized primary tumor (as defined for stage 1, 2A, or 2B), with dissemination limited to skin, liver, and bone marrow‡ (limited to infants <1 yr of age)	5	>80

*Survival is influenced by other characteristics, such as *MYCN* amplification. Percentages are approximate.
†The *midline* is defined as the vertebral column. Tumors originating on one side and crossing the midline must infiltrate to or beyond the other side of the vertebral column.
‡Marrow involvement in stage 4S should be minimal (i.e., <10% of total nucleated cells identified as malignant on bone marrow biopsy or on marrow aspirate). More extensive marrow involvement would be considered stage 4. Results of the metaiodobenzylguanidine (MIBG) scan (if performed) should be negative in the marrow.
¶If age at diagnosis is <18 mo.
#If age at diagnosis is >18 mo.
Modified from Kliegman RM, Marcdante KJ, Jenson HB, et al., eds. *Nelson Essentials of Pediatrics*. 5th ed. Philadelphia: WB Saunders; 2006. p 746; and Brodeur GM, Pritchard J, Berthold F, et al. Revisions of the international criteria for neuroblastoma diagnosis, staging, and response to treatment. *J Clin Oncol*. 1993;11:1466–1477.

Table 547.4 Phenotypic and Genetic Features of Neuroblastoma, Treatment, and Survival According to Prognostic Category

	PROGNOSTIC CATEGORY*			
VARIABLE	LOW RISK	INTERMEDIATE RISK	HIGH RISK	TUMOR STAGE 4S
Pattern of disease	Localized tumor	Localized tumor with loco-regional lymph node extension; metastases to bone marrow and bone in infants	Metastases to bone marrow and bone (except in infants)	Metastases to liver and skin (with minimal bone marrow involvement) in infants
Tumor genomics	Whole-chromosome gains	Whole-chromosome gains	Segmental chromosomal aberrations	Whole-chromosome gains
Treatment	Surgery†	Moderate-intensity chemotherapy; surgery†	Dose-intensive chemotherapy, surgery, and external-beam radiotherapy to primary tumor and resistant metastatic sites; myeloablative chemotherapy with autologous hematopoietic stem cell rescue; isotretinoin with anti-ganglioside GD2 immunotherapy	Supportive care‡
Survival rate	>98%	90–95%	40–50%	>90%

*Patients are assigned to prognostic groups according to risk, as described by the Children's Oncology Group, with the level of risk defining the likelihood of death from disease. Stage 4S disease is considered separately here because of the unique phenotype of favorable biologic features and relentless early progression but ultimately full and complete regression of the disease.
†The goal of surgery is to safely debulk the tumor mass and avoid damage to surrounding normal structures while obtaining sufficient material for molecular diagnostic studies. Some localized tumors may spontaneously regress without surgery.
‡Low-dose chemotherapy or radiation therapy, or both, is used in patients with life-threatening hepatic involvement, especially in infants <2 mo of age, who are at much higher risk for life-threatening complications from massive hepatomegaly.
From Maris JM. Recent advances in neuroblastoma. *N Engl J Med*. 2010;362:2202–2210.

in patients with neuroblastoma using whole genome sequencing such as loss of function in *ATRX* and *TERT*. Hyperdiploidy confers better prognosis if the child is younger than 18 months of age at diagnosis if amplification of *MYCN* is not present. Other chromosomal abnormalities, including loss of heterozygosity of 1p, 11q, and 14q, and gain of 17q, may be found in neuroblastoma tumors and have been associated with worse outcomes. In addition, many other biologic factors are associated with neuroblastoma outcomes, including tumor vascularity and the expression levels of nerve growth factor receptors (TrkA, TrkB), ferritin, lactate dehydrogenase, ganglioside GD2, neuropeptide Y, chromogranin A, CD44, multidrug resistance–associated protein, and telomerase.

CLINICAL MANIFESTATIONS

Neuroblastoma may develop at any site of sympathetic nervous system tissue. Approximately half of neuroblastoma tumors arise in the adrenal glands, and most of the remainder originate in the paraspinal sympathetic ganglia. Metastatic spread, which is more common in children older than 1 year of age at diagnosis, occurs via local invasion or distant hematogenous or lymphatic routes. The most common sites

of metastasis are the regional or distant lymph nodes, long bones and skull, bone marrow, liver, and skin. Lung and brain metastases are rare, occurring in less than 3% of cases.

The signs and symptoms of neuroblastoma reflect the tumor site and extent of disease and may mimic other disorders, which can result in a delayed diagnosis. Metastatic disease can cause a variety of signs and symptoms, including fever, irritability, failure to thrive, bone pain, cytopenias, bluish subcutaneous nodules, orbital proptosis, and periorbital ecchymoses (Fig. 547.1). Localized disease can manifest as an asymptomatic mass or can cause symptoms due to mass effect, which can in certain cases result in spinal cord compression, bowel obstruction, and superior vena cava syndrome.

Children with neuroblastoma can also present with associated neurologic signs and symptoms (see Table 547.1). Neuroblastoma originating in the superior cervical ganglion can result in **Horner syndrome.** Paraspinal neuroblastoma tumors can invade the neural foramina, causing spinal cord and nerve root compression. Neuroblastoma can also be associated with a paraneoplastic syndrome of autoimmune origin, termed **opsoclonus-myoclonus-ataxia syndrome**, in which patients experience rapid, uncontrollable jerking eye and body movements, poor coordination, and cognitive dysfunction. Some tumors produce catecholamines that can cause increased sweating and hypertension, and some release vasoactive intestinal peptide, causing a profound secretory diarrhea. Children with extensive tumors can also experience tumor lysis syndrome and disseminated intravascular coagulation. Infants younger than 18 months of age also can present in unique fashion, termed *stage MS* (previously 4S; see later), with widespread subcutaneous tumor nodules, massive liver involvement, limited bone marrow disease, and a small primary tumor without bone involvement or other metastases. The stage MS disease can spontaneously regress. The enigmatic characteristics of neuroblastoma with paraneoplastic syndromes and spontaneous regression under some circumstances have led some researchers to suggest that neuroblastoma may originate as a neurodevelopmental disorder.

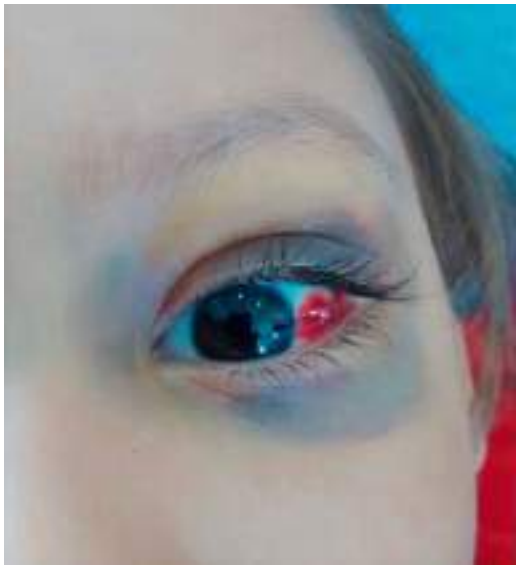

Fig. 547.1 Neuroblastoma. Periorbital ecchymosis, proptosis, and subconjunctival hemorrhage of the left eye. *(From Mota EB, Penna CRR, Marchiori E. Metastatic dissemination of a neuroblastoma. J Pediatr. 2017;189:232–232.e1. Fig. 1.)*

DIAGNOSIS

Neuroblastoma is usually discovered as a mass or multiple masses on plain radiography, CT, or MRI (Fig. 547.2A). The mass often contains calcification and hemorrhage that can allow it to be appreciated on plain radiography or CT (Fig. 547.3). Prenatal diagnosis of perinatal neuroblastoma on maternal ultrasound scans is sometimes possible. Tumor markers, including catecholamine metabolites homovanillic acid and vanillylmandelic acid, are elevated in the urine of approximately 95% of cases and help to confirm the diagnosis. A pathologic diagnosis is established from tumor tissue obtained by biopsy. Neuroblastoma can be confirmed without a primary tumor biopsy if small, round, blue tumor cells are observed in bone marrow samples (Fig. 547.4) and the levels of vanillylmandelic acid or homovanillic acid are elevated in the urine.

Evaluations for metastatic disease should include CT or MRI of the chest and abdomen, bone scans to detect cortical bone involvement, and at least two independent bone marrow aspirations and biopsies to evaluate for marrow disease. **Iodine-123 metaiodobenzylguanidine (^{123}I-MIBG)** studies should be used when available to better define the extent of disease. Some centers use gallium-68 dotatate PET/MRI or CT scans, especially if the MIBG scan is negative (Fig. 547.5). MRI of the spine should be performed in cases with suspected or potential spinal cord compression, but imaging of the brain with

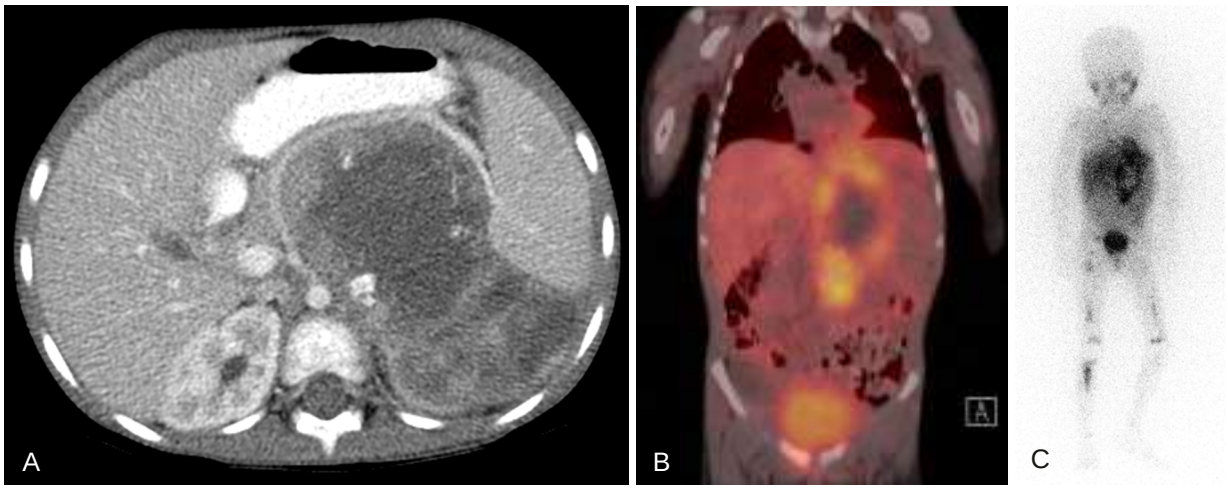

Fig. 547.2 A, CT scan of an abdominal neuroblastoma with central necrosis at diagnosis. B, Coronal fused CT and metaiodobenzylguanidine (MIBG) image of the same child with extensive retroperitoneal mass and central necrosis, probably an adrenal primary with extensive lymph node involvement. C, MIBG avid neuroblastoma with increased uptake of radiolabeled tracer can be detected in multiple sites of disease, including bone and soft tissue.

either CT or MRI is not routinely performed unless dictated by the clinical presentation.

The **International Neuroblastoma Risk Group (INRG) Staging System (INSS)** is currently used to stage patients with neuroblastoma and is based on the extent of disease as determined by imaging at diagnosis. Extent of locoregional disease is based on specific local image-defined risk factors (IDRFs) (see Table 547.3). L1 tumors (previously classified as INSS stage 1) are localized and confined to one body compartment without any IDRFs. L2 tumors (previously classified as INSS stages 2 and 3) refer to localized tumors with the presence of IDRFs. Disseminated tumors with metastases to bones, bone marrow, liver, distant lymph nodes, and/or other organs are staged as M (previously classified as INSS stage 4). Stage MS (previously stage 4S) refers to neuroblastoma in children younger than 18 months of age with dissemination to liver, skin, and/or bone marrow without bone involvement and with a primary tumor that would otherwise be staged as L1 or L2. This new INSS was recently developed to allow for more effective comparisons of treatments and outcomes worldwide.

TREATMENT

Treatment strategies for neuroblastoma have changed with significant reduction in treatment intensity for children who have localized low-risk tumors and with continued increased treatment intensity and the addition of novel agents for treatment of children who have high risk or recurrent disease. The patient's age and tumor stage are combined with cytogenetic and molecular features of the tumor to determine the treatment risk group and estimated prognosis for each patient (see

Fig. 547.3 Neuroblastoma. CT images of the abdomen with coronal (**A**) and sagittal (**B**) reconstructions showing a large low-density tumor in the right suprarenal region *(arrowheads)*. Note the neoplastic calcifications inside the mass. *(From Mota EB, Penna CRR, Marchiori E. Metastatic dissemination of a neuroblastoma. J Pediatr. 2017;189:232–232.e1. Fig. 3.)*

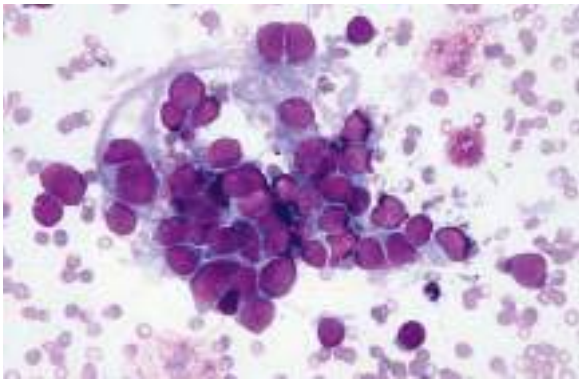

Fig. 547.4 Neuroblastoma cells aspirated from the bone marrow. Clumps of cells often contain ≥3 cells with or without evidence of rosette formation. Rosettes of cells surrounding an inner mass of fibrillary material are characteristic of neuroblastoma.

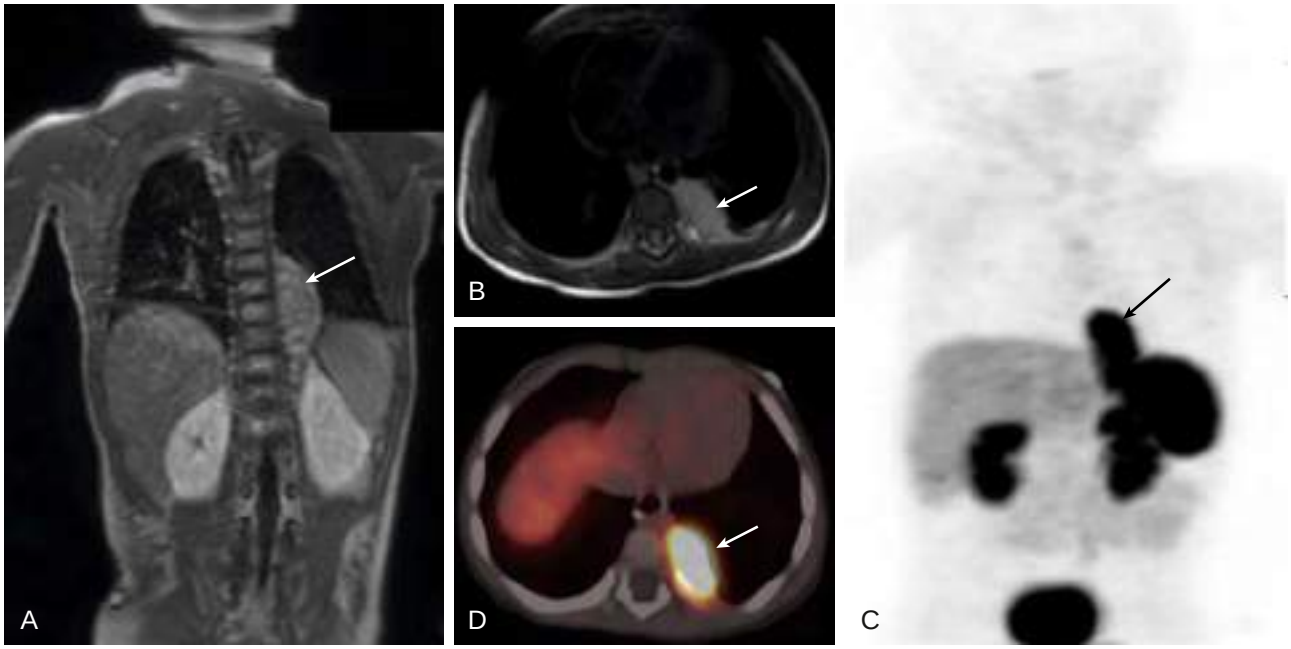

Fig. 547.5 Neuroblastoma. MRI and gallium-68 DOTANOC PET/CT scan of chest and abdomen reveal a mass in left posterior mediastinum (likely neuroblastoma). **A**, Coronal T1-weighted postcontrast image (**A**) and axial T2-weighted image (**B**) reveal a well-defined isointense lesion (42 × 26 × 27 mm) in the left posterior mediastinum extending from D7-D11 vertebrae. **C**, PET/CT maximum intensity projection image shows increased uptake in left lower thoracic paraspinal region. **D**, Axial fused PET-CT image shows somatostatin-receptor expressing mass (maximum standardized uptake value, 21; *arrow in A–D*) in the same location. *(From Kaur A, Bhagwat C, Madaan P, et al. Dancing eyes. J Pediatr. 2019;214:231.)*

Tables 547.2-547.4). Treatment for children with low-risk neuroblastoma typically includes surgery for stages L1 and L2 and observation for asymptomatic stage MS with cure rates generally >90% without further therapy. Treatment with chemotherapy or radiation for the rare child with local recurrence can still be curative. Children with spinal cord compression at diagnosis may require urgent treatment with chemotherapy, surgery, or radiation to avoid neurologic damage. Stage MS neuroblastomas have a very favorable prognosis, and many regress spontaneously without therapy. Chemotherapy or resection of the primary tumor does not improve survival rates, but for infants with massive liver involvement and respiratory compromise, chemotherapy or radiation is used to alleviate symptoms. For children with stage 4S neuroblastoma who require treatment for symptoms, the survival rate is 81%.

Treatment of intermediate-risk neuroblastoma includes surgery, chemotherapy, and, in some cases, radiation therapy. The chemotherapy usually includes moderate doses of cisplatin or carboplatin, cyclophosphamide, etoposide, and doxorubicin given over several months. Radiation therapy is used for tumors with incomplete response to chemotherapy. Children with intermediate-risk neuroblastoma, including children with L2 disease and infants with M disease both with favorable characteristics, have an excellent prognosis and >90% survival with this moderate treatment. In this intermediate-risk group, obtaining adequate diagnostic material for determination of the underlying biologic features of the tumor, such as the Shimada pathologic classification and *MYCN* gene amplification, is critical, so that children with unfavorable characteristics can receive more-aggressive treatment and those with favorable features can be spared excessive toxic therapy.

Children with high-risk neuroblastoma historically have had poor long-term survival rates of 25–35% despite intensive treatment consisting of induction chemotherapy, high-dose chemotherapy with autologous stem cell rescue, surgery, radiation, and 13-*cis*-retinoic acid. Induction chemotherapy for children with high-risk neuroblastoma includes combinations of cyclophosphamide, topotecan, doxorubicin, vincristine, cisplatin, and etoposide. After completion of induction chemotherapy, resection of the residual primary tumor is followed by high-dose chemotherapy with autologous stem cell rescue and focal radiation therapy to tumor sites. A national cooperative group trial demonstrated significantly better survival with chemotherapy plus autologous stem cell rescue than with chemotherapy alone. The further addition of the differentiating agent, 13-*cis*-retinoic acid, following autologous stem cell transplantation, resulted in further improvements in survival rates. In addition, a national clinical trial has demonstrated an increase in short-term survival rates with the addition of the monoclonal antibody ch14.18 **(dinutuximab)** to 13-*cis*-retinoic acid therapy. This monoclonal antibody targets a disialoganglioside, GD2, which has ubiquitous expression on neuroblastoma cells. In this large, randomized, clinical trial of high-risk neuroblastoma patients sponsored by the Children's Oncology Group, incorporation of the antibody into consolidative therapy following autologous stem cell transplant improved the 2-year event-free survival from 46.5–66.5%. The incorporation of tandem autologous stem cell transplant (two separate autologous stem cell transplants with differing conditioning regimens) may further improve outcomes for patients with high-risk disease.

Cases of high-risk neuroblastoma are associated with frequent relapses, and children with recurrent neuroblastoma have a <50% response rate to alternative chemotherapy regimens. New treatment strategies and agents are needed for children with both high-risk and recurrent neuroblastoma. Therapies currently under investigation include new chemotherapeutic agents as well as novel therapies directed against critical intracellular signaling pathways, radiolabeled targeted agents (such as *therapeutic* ^{131}I-MIBG), immunotherapy, and antitumor vaccines.

Visit Elsevier eBooks+ at eBooks.Health.Elsevier.com for Bibliography.

Chapter 548

Neoplasms of the Kidney

548.1 Wilms Tumor

Najat C. Daw and Dristhi S. Ragoonanan

Wilms tumor **(nephroblastoma)** is the most common primary malignant *renal* tumor of childhood. It is the second most common malignant abdominal tumor in childhood after neuroblastoma. The most common sites of metastases are the lungs, regional lymph nodes, and liver. Histologically, the classic Wilms tumor is made up of varying proportions of blastemal, stromal, and epithelial cells, recapitulating stages of normal renal development. The use of multimodality treatment and multi-institutional cooperative group trials has dramatically improved the cure rate of Wilms tumor from <30% to >90% (Table 548.1).

EPIDEMIOLOGY

Wilms tumor accounts for 6% of pediatric malignancies and >95% of kidney tumors in children. In the United States, incidence of Wilms tumor is approximately 7 cases per 1 million children <15 years of age per year, and about 650 new cases are diagnosed each year. Approximately 75% of the cases occur in children <5 years old, with a peak incidence at 2-3 years. It can arise in one or both kidneys; the incidence of bilateral Wilms tumors is 7%. The male/female ratio is 0.92 to 1 in unilateral disease and 0.6 to 1 in bilateral disease. Most cases are sporadic, but approximately 2% of patients have a family history. In 8–10% of patients, Wilms tumor is observed in the context of hemihypertrophy, aniridia, genitourinary anomalies, and a variety of rare syndromes, including **Beckwith-Wiedemann syndrome (BWS)** and **Denys-Drash syndrome** (Table 548.2). An earlier age at diagnosis and an increased incidence of bilateral disease are generally observed in syndromic and familial cases.

ETIOLOGY: GENETICS AND MOLECULAR BIOLOGY

Wilms tumor is thought to be derived from incompletely differentiated renal mesenchyme, and tumors are typically composed of cells reminiscent of the undifferentiated and partially differentiated cells that normally arise from renal mesenchyme. Foci of benign, undifferentiated mesenchyme **(nephrogenic rests)** that persist abnormally in the kidney into postnatal life are observed in approximately 1% of children in the general population but are present in up to 90% of children who have a family history of Wilms tumor, develop bilateral tumors, or display features of Wilms tumor–related syndromes. Nephrogenic rests usually regress or differentiate, but those that persist can become malignant.

Wilms tumor has been associated with genetic abnormalities. The first identified Wilms tumor gene, *WT1*, located at 11p13, is a homozygous gene variant in 10–15% of tumors, resulting in loss of function of the encoded zinc finger transcription factor. The majority of *WT1* pathogenic variants are somatic; however, *WT1* pathogenic variants can also be germline. The type of WT1 pathogenic variant affects the disease phenotype. Germline truncating variants are usually associated with Wilms tumor in the context of genitourinary anomalies or the **WAGR syndrome** (Wilms tumor, aniridia, genitourinary anomalies, mental retardation) as it involves the deletion of several contiguous genes at 11p13. Missense germline variants are usually observed in children with Denys-Drash syndrome, resulting in early-onset renal failure. In instances of germline variant, the wild-type allele present in the germline is altered or lost in the tumor, resulting in loss of *WT1* function.

Tables 547.2-547.4). Treatment for children with low-risk neuroblastoma typically includes surgery for stages L1 and L2 and observation for asymptomatic stage MS with cure rates generally >90% without further therapy. Treatment with chemotherapy or radiation for the rare child with local recurrence can still be curative. Children with spinal cord compression at diagnosis may require urgent treatment with chemotherapy, surgery, or radiation to avoid neurologic damage. Stage MS neuroblastomas have a very favorable prognosis, and many regress spontaneously without therapy. Chemotherapy or resection of the primary tumor does not improve survival rates, but for infants with massive liver involvement and respiratory compromise, chemotherapy or radiation is used to alleviate symptoms. For children with stage 4S neuroblastoma who require treatment for symptoms, the survival rate is 81%.

Treatment of intermediate-risk neuroblastoma includes surgery, chemotherapy, and, in some cases, radiation therapy. The chemotherapy usually includes moderate doses of cisplatin or carboplatin, cyclophosphamide, etoposide, and doxorubicin given over several months. Radiation therapy is used for tumors with incomplete response to chemotherapy. Children with intermediate-risk neuroblastoma, including children with L2 disease and infants with M disease both with favorable characteristics, have an excellent prognosis and >90% survival with this moderate treatment. In this intermediate-risk group, obtaining adequate diagnostic material for determination of the underlying biologic features of the tumor, such as the Shimada pathologic classification and *MYCN* gene amplification, is critical, so that children with unfavorable characteristics can receive more-aggressive treatment and those with favorable features can be spared excessive toxic therapy.

Children with high-risk neuroblastoma historically have had poor long-term survival rates of 25–35% despite intensive treatment consisting of induction chemotherapy, high-dose chemotherapy with autologous stem cell rescue, surgery, radiation, and 13-*cis*-retinoic acid. Induction chemotherapy for children with high-risk neuroblastoma includes combinations of cyclophosphamide, topotecan, doxorubicin, vincristine, cisplatin, and etoposide. After completion of induction chemotherapy, resection of the residual primary tumor is followed by high-dose chemotherapy with autologous stem cell rescue and focal radiation therapy to tumor sites. A national cooperative group trial demonstrated significantly better survival with chemotherapy plus autologous stem cell rescue than with chemotherapy alone. The further addition of the differentiating agent, 13-*cis*-retinoic acid, following autologous stem cell transplantation, resulted in further improvements in survival rates. In addition, a national clinical trial has demonstrated an increase in short-term survival rates with the addition of the monoclonal antibody ch14.18 **(dinutuximab)** to 13-*cis*-retinoic acid therapy. This monoclonal antibody targets a disialoganglioside, GD2, which has ubiquitous expression on neuroblastoma cells. In this large, randomized, clinical trial of high-risk neuroblastoma patients sponsored by the Children's Oncology Group, incorporation of the antibody into consolidative therapy following autologous stem cell transplant improved the 2-year event-free survival from 46.5–66.5%. The incorporation of tandem autologous stem cell transplant (two separate autologous stem cell transplants with differing conditioning regimens) may further improve outcomes for patients with high-risk disease.

Cases of high-risk neuroblastoma are associated with frequent relapses, and children with recurrent neuroblastoma have a <50% response rate to alternative chemotherapy regimens. New treatment strategies and agents are needed for children with both high-risk and recurrent neuroblastoma. Therapies currently under investigation include new chemotherapeutic agents as well as novel therapies directed against critical intracellular signaling pathways, radiolabeled targeted agents (such as *therapeutic* ^{131}I-MIBG), immunotherapy, and antitumor vaccines.

Visit Elsevier eBooks+ at eBooks.Health.Elsevier.com for Bibliography.

Chapter 548

Neoplasms of the Kidney

548.1 Wilms Tumor

Najat C. Daw and Dristhi S. Ragoonanan

Wilms tumor **(nephroblastoma)** is the most common primary malignant *renal* tumor of childhood. It is the second most common malignant abdominal tumor in childhood after neuroblastoma. The most common sites of metastases are the lungs, regional lymph nodes, and liver. Histologically, the classic Wilms tumor is made up of varying proportions of blastemal, stromal, and epithelial cells, recapitulating stages of normal renal development. The use of multimodality treatment and multi-institutional cooperative group trials has dramatically improved the cure rate of Wilms tumor from <30% to >90% (Table 548.1).

EPIDEMIOLOGY

Wilms tumor accounts for 6% of pediatric malignancies and >95% of kidney tumors in children. In the United States, incidence of Wilms tumor is approximately 7 cases per 1 million children <15 years of age per year, and about 650 new cases are diagnosed each year. Approximately 75% of the cases occur in children <5 years old, with a peak incidence at 2-3 years. It can arise in one or both kidneys; the incidence of bilateral Wilms tumors is 7%. The male/female ratio is 0.92 to 1 in unilateral disease and 0.6 to 1 in bilateral disease. Most cases are sporadic, but approximately 2% of patients have a family history. In 8–10% of patients, Wilms tumor is observed in the context of hemihypertrophy, aniridia, genitourinary anomalies, and a variety of rare syndromes, including **Beckwith-Wiedemann syndrome (BWS)** and **Denys-Drash syndrome** (Table 548.2). An earlier age at diagnosis and an increased incidence of bilateral disease are generally observed in syndromic and familial cases.

ETIOLOGY: GENETICS AND MOLECULAR BIOLOGY

Wilms tumor is thought to be derived from incompletely differentiated renal mesenchyme, and tumors are typically composed of cells reminiscent of the undifferentiated and partially differentiated cells that normally arise from renal mesenchyme. Foci of benign, undifferentiated mesenchyme **(nephrogenic rests)** that persist abnormally in the kidney into postnatal life are observed in approximately 1% of children in the general population but are present in up to 90% of children who have a family history of Wilms tumor, develop bilateral tumors, or display features of Wilms tumor–related syndromes. Nephrogenic rests usually regress or differentiate, but those that persist can become malignant.

Wilms tumor has been associated with genetic abnormalities. The first identified Wilms tumor gene, *WT1*, located at 11p13, is a homozygous gene variant in 10–15% of tumors, resulting in loss of function of the encoded zinc finger transcription factor. The majority of *WT1* pathogenic variants are somatic; however, *WT1* pathogenic variants can also be germline. The type of WT1 pathogenic variant affects the disease phenotype. Germline truncating variants are usually associated with Wilms tumor in the context of genitourinary anomalies or the **WAGR syndrome** (Wilms tumor, aniridia, genitourinary anomalies, mental retardation) as it involves the deletion of several contiguous genes at 11p13. Missense germline variants are usually observed in children with Denys-Drash syndrome, resulting in early-onset renal failure. In instances of germline variant, the wild-type allele present in the germline is altered or lost in the tumor, resulting in loss of *WT1* function.

Table 548.1 Treatment and Four-Year Outcomes for Patients with Wilms Tumor

STUDY	STAGE/HISTOLOGY	TREATMENT	EFS (%)	OS (%)
NWTS-5	Stage I or II FH; no LOH	Regimen EE4A	91	98
COG AREN0532	Stage I FH (age <24 mo, tumor weight <550 g)	Nephrectomy alone	90	100
	Stage I or II FH; +LOH	Regimen DD4A	87	100
	Stage III FH; no LOH	Regimen DD4A Flank radiation*	88	97
COG AREN0533	Stage III or IV FH; +LOH	Regimen M Radiation to flank per local stage Radiation to metastatic sites	90	96
	Stage IV FH with lung metastases only and complete response at 6 weeks; no LOH	Regimen DD4A Radiation to flank per local stage Omit radiation to whole lung	80	96
	Stage IV FH with lung metastases only and incomplete response at 6 weeks; no LOH	Regimen M Radiation to flank per local stage Radiation to whole lung	89	95
COG AREN0534	Stage V FH	Chemotherapy Radiation per local stage	82	95
COG AREN0321	Stage I FA + DA	Regimen DD4A Radiation to flank	100	100
	Stage II DA	Regimen UH-1 Radiation to flank	87	86
	Stage III DA	Regimen UH-1 Radiation to flank*	81	89
	Stage IV DA	Regimen UH-1/UH-2 Radiation to flank per local stage Radiation to metastatic sites	42	49
COG AREN0534	Stage V DA	Chemotherapy Radiation to flank per local stage Radiation to metastatic sites	58	68
	Unilateral Wilms tumor with bilateral predisposition	EE4A followed by treatment per stage/histology Radiation to flank per local stage	94	100

*Whole-abdomen radiation therapy indicated for patients with diffuse intraperitoneal tumor rupture, peritoneal tumor seeding, and cytology-positive ascites

NWTS-5, National Wilms Tumor Study-5; COG, Children's Oncology Group; EFS, event-free survival; OS, overall survival; FH, favorable histology; LOH, loss of heterozygosity at both 1p and 16q; FA, focal anaplasia; DA, diffuse anaplasia; EE4A, vincristine/dactinomycin × 19 weeks; DD4A, vincristine/dactinomycin/doxorubicin × 25 weeks; M, vincristine/dactinomycin/doxorubicin/cyclophosphamide/etoposide × 31 weeks; revised UH-1, vincristine/doxorubicin/cyclophosphamide/carboplatin/etoposide × 30 weeks; revised UH-2, revised UH-1 with vincristine/irinotecan × 36 weeks.

Table 548.2 Wilms Tumor Predisposing Conditions

SYNDROME	GENETIC LESION	ESTIMATED WT RISK	PHENOTYPE
WT1-ASSOCIATED WILMS TUMOR PREDISPOSITION SYNDROMES			
Denys-Drash syndrome (DDS)	*WT1* pathogenic variant affecting exon 8 or 9	~75%	Ambiguous genitalia, diffuse mesangial sclerosis
Frasier syndrome	*WT1* pathogenic variant affecting intron 9 donor splice site	Low; 1 case reported	Ambiguous genitalia, streak gonads, focal segmental glomerulosclerosis
WAGR syndrome (Wilms tumor, aniridia, genital anomalies, retardation)	Deletion of 11p13 containing *WT1*	~50%	Aniridia, genitourinary anomalies, delayed-onset renal failure
WT1-associated WT predisposition	*WT1* pathogenic variant	~30%	Median age at WT diagnosis is 1.3 yr (range: 0.6-4.5)
OTHER SYNDROMES THAT PREDISPOSE TO WILMS TUMOR			
Beckwith-Wiedemann syndrome (BWS)	LOM at maternal IC2 at 11p15.5 GOM at maternal IC1 at 11p15.5 Paternal UPD at 11p15.5 Pathogenic variant in *CDKN1C* Negative molecular test	~0.2% ~24% ~8% ~1.4% ~4%	Organomegaly, large birth weight, macroglossia, omphalocele, hemihypertrophy, ear pits and creases, neonatal hypoglycemia
Bloom syndrome	Biallelic *BLM* pathogenic variants	~3%	Short stature, microcephaly, growth deficiency, immune abnormalities, sensitivity to sunlight

Continued

Table 548.2 Wilms Tumor Predisposing Conditions—cont'd

SYNDROME	GENETIC LESION	ESTIMATED WT RISK	PHENOTYPE
Fanconi anemia	Biallelic *BRCA2* or *PALB2* pathogenic variants	20–40%	Short stature, abnormal skin pigmentation, skeletal malformations, microcephaly, bone marrow failure
Hyperparathyroid-jaw tumor syndrome	*CDC73* pathogenic variant	~3%	Primary hyperparathyroidism, ossifying fibroma of the maxilla and/or mandible
Mosaic variegated aneuploidy	Biallelic *BUB1B* or *TRIP13* pathogenic variants	>85%	Microcephaly, growth deficiency, developmental delay, eye anomalies, mild dysmorphism
Perlman syndrome	Biallelic *DIS3L2* pathogenic variants	~65%	Organomegaly, large birth weight, developmental delay
Simpson-Golabi-Behmel syndrome	*GPC3* pathogenic variant	4–9%	Overgrowth, congenital heart defects
CLOVES syndrome	*PIK3CA* pathogenic variant	<5%	Congenital lipomatous overgrowth, vascular malformations, epidermal nevi, scoliosis/skeletal/spine anomalies
Sotos syndrome	*NSD1* pathogenic variant	<5%	Cerebral giantism, macrocephaly, intellectual disability, advanced bone age, poor coordination
Trisomy 18	Trisomy 18	<5%	Cognitive impairment, hypertonia, overlapping fingers, congenital heart disease, micrognathia
GENETIC VARIANTS THAT PREDISPOSE TO NONSYNDROMIC WILMS TUMOR			
CTR9-associated WT predisposition	*CTR9* pathogenic variant	4 families reported; 9/14 individuals with a pathogenic *CTR9* variant developed WT	Median age at WT diagnosis is 1.3 yr (range: 0.6-3.3). All reported variants are paternally inherited
DICER1 syndrome	*DICER1* pathogenic variant	Low; 5 families in which 6/22 individuals with a pathogenic *DICER1* variant developed WT	Lung cysts, cystic nephroma, nodular hyperplasia of the thyroid, nasal chondromesenchymal hamartoma, ciliary body medulloepithelioma and increased cancer risks including pleuropulmonary blastoma (PPB), ovarian sex cord-stromal tumors, pineoblastoma, and pituitary blastoma
Li-Fraumeni syndrome (LFS)	*TP53* pathogenic variant	Low; 12 cases reported	Around 50% of individuals with LFS develop cancer by the age of 30 yr, with a lifetime risk of >70% The tumors most closely associated with LFS include soft tissue sarcomas, osteosarcoma, premenopausal breast cancer, brain tumors, and adrenocortical carcinoma
REST-associated WT predisposition	*REST* pathogenic variant	4 families reported; 7/14 individuals with a pathogenic *REST* variant developed WT Ten presumed sporadic cases reported	Median age at WT diagnosis is 3 yr (range: 0.5-6) Other clinical features reported include primary ovarian failure, café-au-lait macules, and mild developmental delay
TRIM28-associated WT predisposition	*TRIM28* pathogenic variant	9 families reported; 18/24 individuals with a pathogenic *TRIM28* variant developed WT; however, few unaffected family members were tested 17 presumed sporadic cases reported	Median age at WT diagnosis is 1.1 yr (range: 0.4-9.8) All reported variants are maternally inherited Histology is frequently epithelial type

GOM, Gain of methylation; IC, imprinting center; LOM, loss of methylation; UPD, uniparental disomy; WT, Wilms tumor.
Modified from Maciaszek JL, Oak N, Nichols KE. Recent advances in Wilms' tumor predisposition. *Hum Mole Genetics.* 2020;29(R2):R138–R149. Table 1, p. R139–R140.

Consistent with the etiology of Wilms tumor being grounded in aberrant kidney development, genes that regulate the proliferation and differentiation of kidney progenitors have been identified to be mutated in tumors. One class of genes that encodes proteins essential for the biogenesis of mature miRNAs are altered in one fifth to one third of Wilms tumors. These include *DROSHA* missense variants that occur in approximately 10% of tumors, and *DICER, DGCR8, XPO5*, and *TARBP2* variants. Of note, germline *DICER1* variants are observed, albeit infrequently, in Wilms tumor families and, more frequently, in families with pleuropulmonary blastoma (see Table 548.2).

The **Wnt signaling pathway** plays a critical role in regulating the differentiation of the fetal kidney. Somatic pathogenic variants in *CTNNB1* and *WTX*, both of which play a role in the Wnt pathway regulation, are observed in approximately 15% and 20% of Wilms tumors,

Table 548.3 Differential Diagnosis of Abdominal and Pelvic Tumors in Children

TUMOR	PATIENT AGE	CLINICAL SIGNS	LABORATORY FINDINGS
Wilms tumor	Preschool	Unilateral flank mass, aniridia, hemihypertrophy	Hematuria, polycythemia, thrombocytosis, elevated partial thromboplastin time
Neuroblastoma	Preschool	Gastrointestinal/genitourinary obstruction, raccoon eyes, myoclonus-opsoclonus, diarrhea, skin nodules	Increased urinary vanillylmandelic acid, homovanillic acid, or ferritin; stippled calcification in the mass
Non-Hodgkin lymphoma	>1 yr	Intussusception in >2 yr old	Increased lactate dehydrogenase; blood cytopenia caused by bone marrow involvement
Rhabdomyosarcoma	All	Gastrointestinal/genitourinary obstruction, abdominal pain, vaginal bleeding, paratesticular mass	Hypercalcemia; blood cytopenia caused by bone marrow involvement
Germ cell tumor/ teratoma	Preschool, teenage	*Females:* Abdominal pain, vaginal bleeding *Males:* Testicular mass, new-onset hydrocele, sacrococcygeal mass/dimple	Increased β-human chorionic gonadotropin, increased α-fetoprotein
Hepatoblastoma	Birth-3 yr	Right upper quadrant mass, jaundice Early puberty in males	Increased α-fetoprotein
Hepatocellular carcinoma	School age, teenage	Right upper quadrant mass, jaundice, hepatitis B, cirrhosis	Increased α-fetoprotein

respectively. Somatic variants in genes that are critical for regulating progenitor proliferation and differentiation (*MYCN, SIX1,* and *SIX2*) are observed in approximately 10% of tumors. Other somatic variants, including *MLLT1, ARID1A,* and *SMARCA4,* occur at a frequency of approximately 4–5% each. Importantly a somatic variant of the p53 gene, *TP53*, is observed in approximately 5% of tumors and is associated with **anaplastic tumor** histology, a poor prognostic feature of Wilms tumor.

Loss of heterozygosity (LOH; usually copy number neutral) or loss of imprinting at imprinted loci at 11p15 is observed in approximately 70% of Wilms tumors. This epigenetic alteration often results in biallelic expression of *IGF2,* a normally imprinted gene that encodes insulin-like growth factor 2, in addition to the loss of imprinting of other 11p15 genes. BWS, a somatic overgrowth syndrome with predisposition to embryonal tumors (including Wilms tumor), has been linked to 11p15, and microdeletions within the *IGF2* imprinting control region are present in BWS families in whom Wilms tumor is observed.

Allelic imbalances have been identified in Wilms tumors, particularly LOH at 1p and 16q, which has been associated with increased risk of recurrence. Gain of chromosome 1q was found to be associated with inferior survival in unilateral favorable-histology Wilms tumor.

In patients with a family history of Wilms tumor, predisposition is inherited as an autosomal dominant trait with incomplete penetrance. Predisposition to other tumor types or other phenotypes is not observed in most of these families. Germline pathogenic variants have been identified in a minority of families, and each of those genes identified (e.g., *WT1, DICER1, MYCN, REST, BRCA2*) is altered in <5% of Wilms tumor families.

CLINICAL PRESENTATION

The most common initial clinical presentation for Wilms tumor is the incidental discovery of an asymptomatic **abdominal mass** by parents while bathing or clothing an affected child or by a physician during a routine physical examination (Table 548.3). At presentation, the mass can be quite large, because retroperitoneal masses can grow unhampered by strict anatomic boundaries. Functional defects in paired organs such as the kidney, with good functional reserve, are also unlikely to be detected early. Physical exam findings include a firm, nontender, smooth abdominal mass that rarely crosses the midline. Care should be taken to avoid vigorous palpation to prevent the risk of renal capsule rupture. Children with direct access to pediatricians vs generalists as primary caregivers are more likely to be diagnosed early and to have smaller tumors and less advanced stage at diagnosis. Hypertension is present in about 25% of patients at presentation and has been attributed to increased renin activity. Abdominal pain (40%), gross painless hematuria (18%), and constitutional symptoms such as fever, anorexia, and weight loss are other findings at diagnosis. Occasionally, rapid abdominal enlargement and anemia occur because of bleeding into the renal parenchyma or pelvis. Wilms tumor thrombus extends into the inferior vena cava (IVC) in 4–10% of patients and rarely into the right atrium; dislodgment of the intravascular tumor may produce a fatal occlusive **pulmonary embolism**. Patients might also have microcytic anemia from iron deficiency or anemia of chronic disease, polycythemia, elevated platelet count, and acquired deficiency of von Willebrand factor or factor VII deficiency.

DIAGNOSIS AND DIFFERENTIAL DIAGNOSIS

An abdominal mass in a child should be considered malignant until diagnostic imaging, laboratory findings, and pathology can define its true nature (see Table 548.3). Imaging studies include plain abdominal radiography, abdominal ultrasonography (US), and CT of the abdomen to define the intrarenal origin of the mass and differentiate it from adrenal masses (e.g., neuroblastoma) and other masses in the abdomen. Abdominal US helps differentiate solid from cystic masses. Wilms tumor might show focal areas of necrosis or hemorrhage and hydronephrosis because of obstruction of the renal pelvis by the tumor. US with Doppler imaging of renal veins and the IVC is a useful first study to identify Wilms tumor, evaluate the collecting system, and demonstrate tumor thrombi in the renal veins and IVC. However, its routine use after CT has been performed is not required.

CT is useful to define the extent of the disease, integrity of the contralateral kidney, and metastasis (Figs. 548.1 and 548.2). MRI requires sedation in young children and is not routinely used. However, MRI may be helpful in defining an extensive tumor thrombus that extends up to the level of the hepatic veins, or even into the right atrium, and to distinguish Wilms tumor from nephrogenic rests. Chest CT is more sensitive than chest radiography to screen for pulmonary metastasis and is preferably performed before surgery because effusions and atelectasis can confound the interpretation of postoperative imaging studies. A bone scan is performed if the histologic diagnosis confirms clear cell sarcoma of the kidney (CCSK) or rhabdoid tumor of the kidney, to look for bone metastasis. Brain imaging with CT or MRI is also obtained in cases of clear cell sarcoma or rhabdoid tumor of the kidney because these tumors can spread to the brain.

Wilms tumor lesions are metabolically active and concentrate fluorodeoxyglucose (FDG). Regional spread and metastatic lesions can

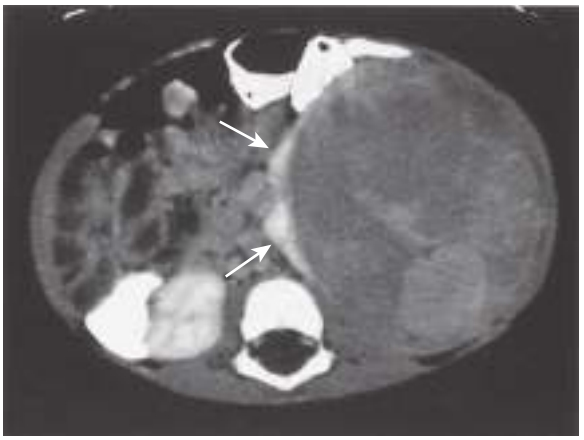

Fig. 548.1 Large heterogeneous Wilms tumor in left kidney. The residual renal parenchyma is displaced medially *(arrows). (From Haaga JR, Boll DT, eds. CT and MRI of the Whole Body. 6th ed. Philadelphia: Elsevier; 2017: Fig. 54-84, p. 1816.)*

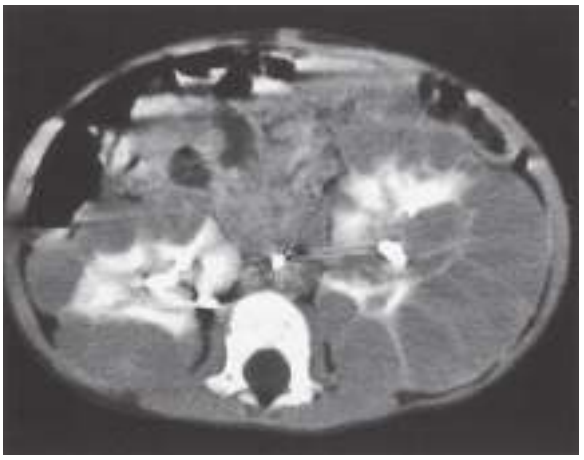

Fig. 548.2 Multicentric and bilateral Wilms tumors. The tumors have a low density and compress residual enhancing renal tissue. *(From Haaga JR, Boll DT, eds. CT and MRI of the Whole Body. 6th ed. Philadelphia: Elsevier; 2017: Fig. 54-86, p. 1817.)*

be visualized on PET/CT scanning. The diagnosis is usually made by imaging studies and confirmed by histology at the time of nephrectomy. Although biopsy is a reliable diagnostic tool, it is discouraged because it results in disease upstaging according to the Children's Oncology Group (COG) staging system. A core needle biopsy obtained through a posterior approach (to limit contamination of the peritoneal cavity) should be performed in cases of unusual presentation (>10 years old, signs of infection, inflammation) or unusual imaging findings (significant adenopathy, no renal parenchyma seen, intratumoral calcification).

Patients with Wilms tumor associated syndromes should undergo routine screening with serial abdominal US to allow for early detection and treatment.

TREATMENT

The COG protocols and the **International Society of Pediatric Oncology (SIOP)** protocols differ in their initial treatment approach. *COG advocates upfront surgery* prior to initiating treatment, whereas *SIOP recommends preoperative chemotherapy.* Each approach has advantages and limitations, but they have similar outcomes. Early surgery provides accurate diagnosis and staging and can facilitate *risk-adapted therapy*. Preoperative chemotherapy can make surgery easier and reduces the risk of intraoperative tumor rupture and hemorrhage. Surgery entails a radical nephrectomy, with meticulous dissection to avoid rupture of the tumor capsule, and lymph node sampling despite the absence of abnormal nodes on preoperative imaging studies or intraoperative assessment. Partial nephrectomy is performed in patients with bilateral disease or those with unilateral Wilms tumor and predisposing syndrome such as the Denys-Drash and WAGR syndromes to minimize the risk of future renal failure.

Table 548.4 Children's Oncology Group Staging of Wilms Tumor

STAGE	DESCRIPTION
I	Tumor *confined to the kidney* and completely resected Renal capsule or sinus vessels not involved Tumor not ruptured or biopsied Regional lymph nodes examined and negative
II	Tumor extends *beyond the kidney* but is completely resected with negative margins and lymph nodes At least one of the following has occurred: (a) penetration of renal capsule, (b) invasion of renal sinus vessels
III	*Residual tumor* present following surgery confined to the abdomen, including gross or microscopic tumor; spillage of tumor preoperatively or intraoperatively; biopsy prior to nephrectomy, regional lymph node metastases; tumor implants on the peritoneal surface; extension of tumor thrombus into the inferior vena cava, including thoracic vena cava and heart
IV	*Hematogenous metastases* (lung, liver, bone, brain, etc.) or lymph node metastases outside the abdominopelvic region
V	*Bilateral* renal involvement by tumor

Prognostic factors for risk-adapted therapy include age, stage, histology, tumor weight, LOH at chromosomes 1p and 16q, and metastatic lung nodule response (Table 548.4). Histology plays a major role in risk stratification of Wilms tumor. Absence of anaplasia is considered a favorable histologic finding. Presence of anaplasia is further classified as focal or diffuse, both of which are unfavorable histologic findings.

The COG has very specific drug dose and schedule recommendations for risk-adapted treatment of Wilms tumor. Patients with *favorable-histology* Wilms tumor have a good outcome and are generally treated in the outpatient setting. Nephrectomy alone is sufficient for patients with very low risk disease (<2 years old with stage I disease and a tumor weight <550 g), resulting in a 4-year event-free survival of 90% and a 4-year overall survival of 100%. Patients with stage I and II disease receive chemotherapy with two drugs, vincristine and actinomycin D (also called dactinomycin), every 1-3 weeks for a total of 18 weeks (regimen **EE4A**). Patients with stage III or stage IV disease receive chemotherapy with three drugs (vincristine, doxorubicin, and actinomycin D) every 1-3 weeks for a total of 24 weeks (regimen **DD4A**) and radiation therapy. Patients with regional lymph node metastases, residual disease after surgery, or tumor rupture receive radiation therapy to the flank or abdomen, and those with lung metastases receive radiation therapy to the lungs. Rapid response of lung metastases to chemotherapy may eliminate the need for lung radiation. In patients with stage III or stage IV disease and LOH at both 1p and 16q or in those with lung metastases only who have incomplete response at 6 weeks of DD4A, therapy is augmented by adding cyclophosphamide/etoposide to DD4A (Regimen M). The LOH of both 1p and 16q and gain of 1q confers an adverse prognosis and deserves treatment intensification.

For patients with bilateral Wilms tumor, three-drug preoperative chemotherapy, surgical resection within 12 weeks of diagnosis, and histology-based postoperative therapy improves survival outcomes and feasibility of nephron-sparing surgery.

Anaplastic histology (focal and diffuse) accounts for approximately 11% of Wilms tumor cases. Patients with *diffuse anaplasia* have worse outcome than patients with favorable histology and receive more

intensive therapy. Patients with stage 1 anaplastic Wilms tumor treated with regimen DD4A and flank radiation had excellent survival outcomes. Patients with stage II-IV disease are treated more intensively with multiagent chemotherapy including vincristine, cyclophosphamide, doxorubicin, etoposide, carboplatin, and irinotecan, in addition to radiotherapy. Despite some improvement in survival outcomes, patients with stage IV disease continue to fare poorly.

RECURRENT DISEASE

Approximately 15% of favorable-histology and 50% of anaplastic-histology Wilms tumors relapse; most relapses occur early (within 2 years of diagnosis). Factors associated with a favorable outcome after relapse include low stage (I/II) at diagnosis, treatment with vincristine and actinomycin D only, no prior radiotherapy, favorable histology, relapse to lung only, and interval from nephrectomy to relapse ≥12 months. Patients with recurrent Wilms tumor who previously received only vincristine and actinomycin D had a 4-year survival of approximately 80%, whereas those who previously received the three-drug regimen of vincristine, actinomycin D, and doxorubicin had a 4-year survival of only 50%. Other agents used to treat recurrent Wilms tumor include doxorubicin, carboplatin, cyclophosphamide, ifosfamide, etoposide, irinotecan, and topotecan. *Metachronous* Wilms tumor may not represent tumor relapse but development of a new tumor in the opposite kidney.

PROGNOSIS

Despite some adverse risk factors that decrease prognosis (presence of metastasis, unfavorable histology, recurrent disease, incomplete lung nodule response at 6 weeks of chemotherapy, LOH of both 1p and 16q and gain of 1q), most children with Wilms tumor have a very favorable prognosis. Overall survival of children with Wilms tumor exceeds 90%, with some prognostic factors (low stage, favorable histology, young age, low tumor weight) conferring even better outcomes. Wilms tumor tops the list of common pediatric solid tumors in terms of favorable outcome.

LATE EFFECTS

Current strategies are successful with relatively few long-term effects of therapy. Generally, late complications are a consequence of treatment type and intensity; the use of radiotherapy and anthracyclines increase the risk of these complications. Clinically significant late sequelae include musculoskeletal effects, cardiac toxicity, pulmonary disease, reproductive problems, renal dysfunction, and development of second malignant neoplasms such as leukemia and cancer of the digestive organs and breast (in females).

548.2 Other Pediatric Renal Tumors

Najat C. Daw and Dristhi S. Ragoonanan

MESOBLASTIC NEPHROMA

Mesoblastic nephroma is the most common solid renal tumor identified in the *neonatal period* and the most frequent benign renal tumor in childhood. It represents approximately 5% of all pediatric renal tumors. ETV6-NTRK3 fusion pathogenic variant is the most common molecular alteration seen in these tumors. Many cases are diagnosed with prenatal US and can manifest as polyhydramnios, hydrops, and premature delivery. Most patients are diagnosed before 3 months of age, whereas Wilms tumor is *rarely diagnosed* before 6 months. Male/female ratio is 1.5:1. Radical nephrectomy is the treatment of choice and may be sufficient by itself. Local recurrence is uncommon. Although rare, malignant variants do occur, marked by metastases to the lung, liver, heart, and brain.

CLEAR CELL SARCOMA OF THE KIDNEY

CCSK is an uncommon renal neoplasm of childhood, with approximately 20 new cases diagnosed each year in North America. Peak incidence is between 1 and 4 years of age with a male/female ratio of 2:1. It usually presents with abdominal distention, abdominal mass, or gross hematuria. Gene expression profiles of CCSK suggest the cell of origin to be a renal mesenchymal cell with neural markers, and *BCOR* gene duplication is the most common molecular alteration seen. Bone is the most common site of distant metastasis, followed by lung, abdomen, retroperitoneum, brain, and liver. Therefore the staging workup should include a bone scan. With modern therapy, patients with stage I and II disease have an excellent prognosis (4-year overall survival of 97–100%), whereas those with stage III and IV disease have a 4-year overall survival of 89% and 45%, respectively.

RHABDOID TUMOR OF THE KIDNEY

Malignant rhabdoid tumor of the kidney **(MRTK)** has rhabdomyoblast-like morphology and is a rare but aggressive cancer. The median age of presentation is 11 months, and hematuria is a common presenting feature. Both rhabdoid tumor of the kidney and central nervous system (CNS) atypical teratoid/rhabdoid tumors have deletions and pathogenic variants of the *SMARCB1/hSNF5/INI1* gene and are considered related. Germline pathogenic variants in *SMARCA4* or *SMARCB1* have been linked to rhabdoid tumor predisposition syndrome, an autosomal dominant disorder that results in the increased risk of developing rhabdoid tumors predominantly in infants and children younger than 3 years of age. MRTKs tend to metastasize to the lungs and brain. Prognosis is poor with current therapeutic protocols. Younger age at diagnosis, advanced-stage disease, and CNS involvement are associated with a worse prognosis. The outcome of patients with MRTK is poor. Both the 4-year relapse-free survival and overall survival for patients treated on the National Wilms Tumor Study-5 (NWTS-5) were 50% for stage I, 33% for stages II and III, and 21% for stage IV.

RENAL CELL CARCINOMA

Although renal cell carcinoma **(RCC)** is the most prevalent renal tumor in adults, it is extremely rare in children, accounting for <10% of pediatric renal tumors. The annual incidence rate is approximately four cases per 1 million children. Although Wilms tumor is the predominant renal tumor in childhood, it is rare past early childhood, and RCC is the most prevalent renal malignancy during the second decade of life. Several **genetic disorders** are associated with a predisposition to RCC, including von Hippel-Lindau disease, tuberous sclerosis, and hereditary leiomyomatosis. The most common subtype of RCC in children, the **translocation-type RCC**, is characterized by translocations most frequently involving the *TFE3* gene on chromosome Xp11.2 or the *TFEB* gene on chromosome 6p21. *Renal medullary carcinoma is seen typically in young patients with sickle cell trait.*

Children with RCC may present with frank hematuria, flank pain, and/or a palpable mass, although RCC can be asymptomatic and detected incidentally. RCC has a propensity to metastasize to the lungs, liver, and bone. Although local lymph node involvement is a poor prognostic indicator in adult RCC, the importance of nodal status in pediatric RCC is controversial. Nephrectomy alone may be adequate for early-stage RCC. Along with surgery, there is no established optimal treatment for childhood RCC; neither chemotherapy nor radiation therapy has demonstrated significant activity. Localized pediatric RCC has an excellent outcome without adjuvant therapy; however, the outcomes remain poor for metastatic RCC and renal medullary carcinoma.

Visit Elsevier eBooks+ at eBooks.Health.Elsevier.com for Bibliography.

Chapter 549

Soft Tissue Sarcomas

Wendy A. Allen-Rhoades and Carola A.S. Arndt

The annual incidence of soft tissue sarcomas is 11 cases per 1 million children younger than 14 years of age and 17.4 cases per 1 million adolescents age 15-19 years. Rhabdomyosarcoma accounts for more than 50% of soft tissue sarcomas. The prognosis most strongly correlates with age and extent of disease at diagnosis, primary tumor site and histology, and presence of translocations involving the *FOXO1* and *PAX* genes.

RHABDOMYOSARCOMA

Epidemiology

The most common pediatric soft tissue sarcoma, rhabdomyosarcoma, accounts for approximately 3.5% of childhood cancers. These tumors may occur at any anatomic site (Table 549.1) including the head and neck, orbit, genitourinary tract, and extremities; retroperitoneal and other sites account for the remainder of primary sites. The incidence at each anatomic site is related to both patient age and tumor type. Extremity lesions are more likely to occur in older children and to have alveolar histology and harbor a fusion oncoprotein. Rhabdomyosarcoma occurs with increased frequency in patients with neurofibromatosis, Costello syndrome, and other family cancer predisposition syndromes such as Li-Fraumeni syndrome (Table 549.2).

Table 549.1 Common Presenting Signs and Symptoms by Primary Site

PRIMARY SITE (%)	SYMPTOMS AND SIGNS
Head and neck (40%)	Painless or painful swelling Proptosis Ptosis Ophthalmoplegia Headache Vomiting Cranial nerve palsy Other cranial nerve palsies Nasal discharge Nasal/sinus congestion Trismus Systemic hypertension
Limbs/trunk (30%)	Asymptomatic swelling
Genitourinary tract/pelvis (20%)	Painless scrotal lesions Hematuria Urinary retention/dribbling Vulval nodule Polypoid vaginal lesions Vaginal bleeding/discharge Constipation
Abdomen/liver/biliary (~10%)	Asymptomatic swelling Abdominal pain Intestinal obstruction Jaundice Cholangitis
Metastatic disease (20% at diagnosis) Bone Bone marrow Lung Lymph nodes	Otherwise unexplained: Poor feeding Seizures Pain Irritability Pancytopenia

Modified from Rogers TN, Dasgupta R. Management of rhabdomyosarcoma in pediatric patients. *Surg Oncol Clin N Am.* 2021;30(2):339–353. Table 2.

Pathogenesis

Rhabdomyosarcoma is thought to arise from the same embryonic mesenchyme as striated skeletal muscle although a large percentage of these tumors arise in areas lacking skeletal muscle (e.g., bladder, prostate, vagina). On the basis of light microscopic appearance, it belongs to the general category of small, round, blue cell tumors that includes Ewing sarcoma, neuroblastoma, and non-Hodgkin lymphoma. Definitive diagnosis of a pathologic specimen requires immunohistochemical studies using antibodies to skeletal muscle (desmin, muscle-specific actin, myogenin) and reverse transcription polymerase chain reaction, next generation sequencing, or fluorescent in situ hybridization for *FOXO1* rearrangements.

Determination of the specific histologic subtype and fusion status is important in treatment planning and assessment of prognosis. There are four recognized histologic subtypes. The **embryonal type** accounts for approximately 60% of all cases and does not typically harbor a genetic translocation. The rare **spindle/sclerosing** subtype that accounts for approximately 3–4% of all children with rhabdomyosarcoma. It is characterized by a sclerosing (microalveolar) pattern that can mimic the alveolar subtype, but it does not harbor the characteristic PAX/FOXO translocation seen in the alveolar subtype. The **alveolar type** accounts for approximately 25–40% of cases and is characterized by the presence of a chromosomal translocation. Over 80% of *FOXO1* translocations in the alveolar subtype involve a translocation between *FOXO1* and *PAX3*, but other rare variants exist such as *PAX3-NCOA2*. The tumor cells tend to grow in nests that often have cleft-like spaces resembling alveoli. Alveolar tumors occur most often in the trunk and extremities and carry the poorest prognosis. The **pleomorphic type** (adult form) is rare in childhood, accounting for <1% of cases.

Table 549.2 Genetic Disorders Associated with Rhabdomyosarcoma

DISORDER	GENETIC VARIANTS
Beckwith-Wiedemann syndrome	Deletions and loss of heterozygosity at chromosome 11p15, particularly affecting *IGF2*, *CDKAIC*, *H19*, and/or *LIT1*
Gorlin syndrome (basal cell nevus syndrome)	*PTCH*
Costello syndrome	*H-RAS*
Neurofibromatosis 1	*NF1*
Li-Fraumeni syndrome	*TP53*
Mosaic variegated aneuploidy syndrome	*BUB1B*
Nijmegen breakage syndrome (ataxia-telangiectasis syndrome variant 1)	*NBS*
Rubinstein-Taybi syndrome	*CREBBP*
Constitutional mismatch-repair/deficiency syndrome	*PSM2*
Adenomatous polyposis coli	*APC*
Hereditary retinoblastoma	*RB1*
Familial pleuropulmonary blastoma syndrome	*DICER1*
Noonan syndrome	*PTPN11*
Werner syndrome	*RECOL2*

From Parham DM, Alaggio R, Coffin CM. Myogenic tumors in children and adolescents. *Pediatr Dev Pathol.* 2012;15(1):S211–S236. Table 3.

Clinical Manifestations

The most common presenting feature of rhabdomyosarcoma is a mass that may or may not be painful. Symptoms are caused by displacement or obstruction of normal structures. Origin in the **nasopharynx** may be associated with nasal congestion, mouth breathing, epistaxis, and difficulty with swallowing and chewing. Regional extension into the cranium can produce cranial nerve paralysis, blindness, and signs of increased intracranial pressure with headache and vomiting. When the tumor develops in the face or cheek, there may be swelling, pain, trismus, and, as extension occurs, paralysis of cranial nerves. Tumors in the **neck** can produce progressive swelling with neurologic symptoms after regional extension. **Orbital** primary tumors are usually diagnosed early in their course because of associated proptosis, periorbital edema, ptosis, change in visual acuity, and local pain. When the tumor arises in the **middle ear**, the most common early signs are pain, hearing loss, chronic otorrhea, or a mass in the ear canal; extensions of the tumor produce cranial nerve paralysis and signs of an intracranial mass on the involved side. An unremitting croupy cough and progressive stridor can accompany rhabdomyosarcoma of the **larynx**. Because most of these signs and symptoms also are associated with common childhood conditions, clinicians must be alert to the possibility of tumor.

Rhabdomyosarcoma of the trunk or extremities often is first noticed after trauma and initially may be regarded as a hematoma. If the swelling does not resolve or increases, malignancy should be suspected. Involvement of the genitourinary tract can produce hematuria, obstruction of the lower urinary tract, recurrent urinary tract infections, incontinence, or a mass detectable on abdominal or rectal examination. Paratesticular tumor usually manifests as a painless, rapidly growing mass in the scrotum. Vaginal rhabdomyosarcoma may manifest as a grapelike mass of tumor tissue bulging through the vaginal orifice, known as **sarcoma botryoides**, and can cause urinary tract or large bowel symptoms. Vaginal bleeding or obstruction of the urethra or rectum may occur. Similar findings can be noted with tumors arising from the uterus.

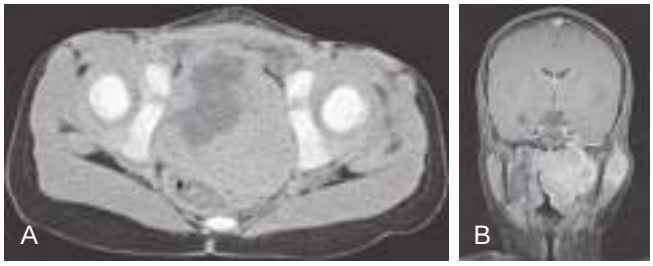

Fig. 549.1 A, Pelvic CT scan of a child with a bladder rhabdomyosarcoma. B, MR image of a child with a parameningeal rhabdomyosarcoma.

Tumors in any location may disseminate early and cause symptoms of pain or respiratory distress associated with pulmonary metastases. Extensive bone involvement can produce symptomatic hypercalcemia or bony pain. In such cases, it may be difficult to identify the primary lesion.

Diagnosis

Early diagnosis of rhabdomyosarcoma requires a high index of suspicion. The microscopic appearance is that of a small, round blue cell tumor. Neuroblastoma, lymphoma, and Ewing sarcoma also are **small, round blue cell tumors** from which suspected rhabdomyosarcomas must be differentiated. The differential diagnosis depends on the site of presentation. Definitive diagnosis is established by biopsy, microscopic appearance, and results of immunohistochemical stains and analysis of *PAX/FOXO1* expression. A lesion in an extremity may be thought to be a hematoma or hemangioma, an orbital lesion resulting in proptosis may be treated as an orbital cellulitis, or bladder-obstructive symptoms may be missed. Adolescents may ignore or be embarrassed to mention paratesticular lesions for a long time. Unfortunately, several months often elapse between initial symptoms and biopsy. Diagnostic procedures are determined mainly by the area of involvement. CT or MRI is necessary for evaluation of the primary tumor site. With signs and symptoms in the head and neck area, MRI should be performed to identify intracranial extension or meningeal involvement and also to reveal bony involvement or erosion at the base of the skull. For abdominal and pelvic tumors, CT with a contrast agent or MRI can help delineate the tumor (Figs. 549.1 and 549.2). A radionuclide bone or fluorodeoxyglucose PET (FDG-PET) scan, chest CT, and bilateral bone marrow aspiration and biopsy should be performed to evaluate the patient for the presence of metastatic disease and to plan treatment. Some low-risk patients may not need bone marrow evaluation. The most critical element of the diagnostic workup is examination of tumor tissue by an experienced sarcoma pathologist, which includes the use of special histochemical stains and immunostains along with molecular genetics to detect fusion transcripts as described earlier. Lymph nodes also should be sampled for the presence of disease spread, especially in tumors of the extremities and in males older than 10 years of age with paratesticular tumors.

Treatment

Treatment is multidisciplinary and includes the pediatric oncologist, pediatric surgeon or other surgical subspecialist, and often a radiation oncologist. Only if the tumor is able to be completely resected, with negative margins, without loss of function or major cosmetic deformity, should this be attempted initially. Unfortunately, most rhabdomyosarcomas are not completely resectable at initial diagnosis. Treatment is based on risk classification of the tumor, which is determined by the stage of tumor, the tumor histology and/or fusion status, and the amount of tumor that was surgically resected prior to chemotherapy ("surgical group"). Stage is dependent on primary site

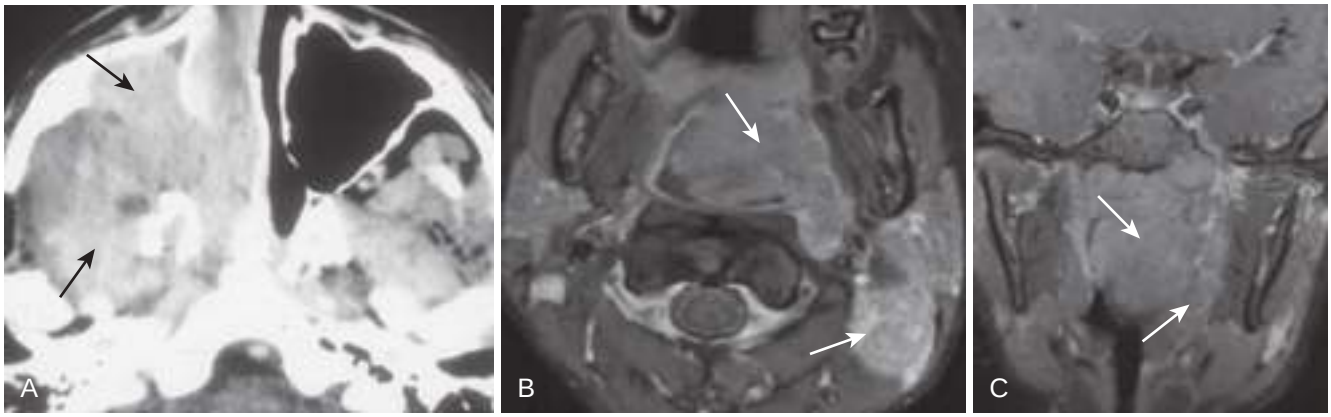

Fig. 549.2 Rhabdomyosarcoma. A, Axial contrast-enhanced CT scan at the level of the nasal cavity demonstrates a large, enhancing aggressive soft tissue mass involving the right maxillary sinus and the infratemporal fossa *(arrows)*. Axial MR image (B) and coronal contrast-enhanced T1-weighted MR image (C) demonstrate an infiltrative mass involving the pharyngeal mucosal space, left infratemporal masticator space, skull base, and sphenoid sinus *(arrows)*. *(From Haaga JR, Boll DT, eds. CT and MRI of the Whole Body. 6th ed. Philadelphia: Elsevier; 2017: Fig. 26-16, p. 769.)*

(favorable vs unfavorable), tumor invasiveness (T1 or T2), lymph node status, tumor size, and presence of metastasis. Favorable sites include female genital, paratesticular, and head and neck (nonparameningeal) regions; all other sites are considered unfavorable. Table 549.3 shows the Children's Oncology Group staging system for rhabdomyosarcoma.

Patients should be offered enrollment in clinical trials. Table 549.4 shows current risk stratification and outcome based on results of recent studies. Patients with low-risk disease can be cured with minimal therapy consisting of vincristine and actinomycin with or without lower doses of cyclophosphamide; radiation therapy can be used in the case of residual disease after initial surgery. Treatment for patients with intermediate-risk disease consists of vincristine, actinomycin, and cyclophosphamide along with radiation. The addition of irinotecan has recently been studied in intermediate risk rhabdomyosarcoma, and the current trial for patients with intermediate risk disease is exploring the role of maintenance chemotherapy. For patients with high-risk disease, approaches using intensive multiagent chemotherapy have not improved the outcome and new approaches are being investigated.

Prognosis

Prognostic factors include age, stage, histology/fusion status, and primary site. Among patients with resectable tumor and favorable histology, 80–90% have prolonged disease-free survival. Unresectable tumor localized to certain favorable sites, such as the orbit, also has a high likelihood of cure. Approximately 65–70% of patients with incompletely resected tumor also achieve long-term disease-free survival. Patients with disseminated disease have a poor prognosis; only approximately 50% achieve remission, and fewer than 50% of these are cured. Older children have a poorer prognosis than younger children. For all patients, surveillance for late effects of cancer treatment is extremely important. Some examples of late effects include infertility from cyclophosphamide, late effects in the radiation field such as bladder dysfunction, infertility, cataracts, impaired bone growth, and secondary malignancies.

OTHER SOFT TISSUE SARCOMAS

The nonrhabdomyosarcoma soft tissue sarcomas constitute a heterogeneous group of tumors that account for 3% of all childhood malignancies (Table 549.5). Because they are relatively rare in children, much of the information about their natural history and treatment has been derived from studies in adult patients. In children, the median age at diagnosis is 12 years, with a male:female ratio of 2.3:1. These tumors commonly arise in the trunk or lower extremities. The most common histologic types are synovial sarcoma (42%), fibrosarcoma (13%), malignant fibrous histiocytoma (12%), and neurogenic tumors (10%). Molecular genetic studies often prove useful in diagnosis, because several of these tumors have characteristic chromosomal translocations. Tumor size, stage (clinical group), invasiveness, and histologic grade correlate with survival.

Surgery remains the mainstay of therapy, but a careful search for lung and bone metastases should be undertaken before surgical excision. Chemotherapy and radiation therapy should be considered for large, high-grade, and/or unresectable tumors. The role of chemotherapy for nonrhabdomyosarcoma soft tissue sarcomas is not as well defined as for rhabdomyosarcoma. Patients with large (>5 cm) high-grade, or unresectable or metastatic disease are treated with multiagent chemotherapy in addition to irradiation and/or surgery. Patients with completely resected small (<5 cm) tumors are generally treated with surgery alone and can be expected to have an excellent outcome regardless of whether the tumor is high or low grade.

Visit Elsevier eBooks+ at eBooks.Health.Elsevier.com for Bibliography.

Table 549.3 Staging System for Rhabdomyosarcoma

STAGE	SITE	T STAGE	SIZE	NODE STATUS	METASTASIS
1	Favorable	T1 or T2	a or b	N0 or N1 or Nx	M0
2	Unfavorable	T1 or T2	a	N0 or Nx	M0
3	Unfavorable	T1 or T2	a b	N1 N0 or N1 or Nx	M0
4	Any	T1 or T2	a or b	N0 or N1 or Nx	M1

T1, confined to anatomic site of origin; T2, extension and/or fixative to surrounding tissue.
Size: a, <5 cm in diameter; b, ≥5 cm in diameter.
Nodes: N0, regional nodes not involved; N1, regional nodes involved; Nx, regional node status unknown.
Metastases: M0, no distant metastases; M1, metastases present (includes positive cytology in cerebrospinal, pleural, or peritoneal fluid).

Table 549.4 Risk Groups and Outcome for Rhabdomyosarcoma, Children's Oncology Group

RISK GROUP	STAGE	CLINICAL GROUP	MOLECULAR FINDINGS	AGE	LONG-TERM EFS (%)*
Very Low	1	I	FOXO1 -, wildtype P53, wildtype MYOD1	Any	92
Low	1	II, III (orbit only)	FOXO1-, wildtype P53, wildtype MYOD1	Any	87
Low	2	I, II	FOXO1 -, wildtype P53, wildtype MYOD1	Any	87
Intermediate	1	III (non orbit)	FOXO1-	Any	70-85
Intermediate	1, 2, 3	I, II, III	FOXO1+	Any	63-93
Intermediate	2, 3	III	FOXO1 -	Any	63-93
Intermediate	3	I, II	FOXO1-	Any	63-93
Intermediate	4	IV	FOXO1-	<10 yr	60-64
High	4	IV	FOXO1-	≥10 yr	35
High	4	IV	FOXO1+	Any	9†

*4–5-year EFS based on D9602, D9803, ARST0331, ARST0431, and ARST0531 studies.
†From Rudzinski ER, Anderson JR, Chi YY, et al. Histology, fusion status, and outcome in metastatic rhabdomyosarcoma: A report from the Children's Oncology Group. *Pediatr Blood Cancer*. 2017;64(12):10.1002/pbc.26645.
EFS, event-free survival,
Modified from Oberoi, S, Crane, JN, Haduong, JH, et al. Children's Oncology Group's 2023 blueprint for research: Soft tissue sarcomas. *Pediatr Blood Cancer*. 2023;70(Suppl. 6):e30556. https://doi.org/10.1002/pbc.30556.

Table 549.5 Clinical and Biological Features of the Nonrhabdomyosarcoma Soft Tissue Sarcomas

TUMOR*	CELL ORIGIN AND CYTOGENETICS/ PRODUCT	COMMON SITES	COMMON AGES	GOOD PROGNOSTIC FACTORS†	OUTCOME	THERAPY
Synovial sarcoma	Mesenchymal cells/t(X;18)(p11q11)/*SSX1–SYT* (seen in biphasic tumors) *SSX2–SYT* (seen in monophasic tumors)/translocation present in >90%, MYCN overexpression	Extremities (lower twice as common as upper extremity)	Adolescence/young adulthood, accounts for 30% of pediatric NRSTS	Age ≤14 years, size <5 cm, calcification, chemosensitive	Stages I and II, 70%; stages III and IV, poor	WLE with/without RT chemo: ifosfamide/doxorubicin
Dermatofibrosarcoma protuberans (DFSP)	Dermis/t(17;22)(q21;q13) ring chromosome/*COL1A1–PDGFB*	Trunk and proximal limbs, rare head and neck	20-50 years, rare in childhood	Complete excision, local recurrence 60% with incomplete resection		WLE (3 cm) margin pseudopod-like projections with Mohs micrographic surgery; RT has been used when WLE not possible, imatinib for unresectable; locally advanced, recurrent, or metastatic disease
MFH aka undifferentiated pleomorphic sarcoma	Unknown/19p+, complex abnormalities	Lower extremity, trunk, head and neck	In children, 10-20 years, 40-60 years common radiation-induced sarcoma	Extremity site	5-year survival, 27–53%	WLE chemo: ifosfamide/doxorubicin
Angiomatoid fibrous histiocytoma	Fibroblast/t(2;22)(q34;q12) t(12;16)(q13;p11) t(12;22)(q13;q12)/*EWSR1–CREB1 TLS–ATF1 EWSR1–ATF1*	Extremity, trunk and head and neck (subcutis may infiltrate dermis or muscle)	Young children and young adults	Much less aggressive than MFH	Excellent with surgery alone	WLE
MPNST	Schwann cell or fibroblast/17q;22q loss or rearrangement, complex abnormalities in high-grade tumors	Extremity, retroperitoneum trunk	Younger patients with neurofibromatosis (NF1) develop in 10% patients with *NF1* and 20–60% cases of MPNST occur in association with *NF1*	Size <5 cm, no *NF1*	53% survival without NF, 16% with NF	WLE with/without RT chemo: neoadjuvant role, ifosfamide/doxorubicin
Fibrosarcoma	Fibroblast/t(X;18), t(2;5), t(7;22)	Truncal/proximal site	Adolescence		5-year survival 34–60%	WLE with/without RT chemo: no established role
Infantile fibrosarcoma	Fibroblast/t(12;15)(p13;q25)/*ETV6–NTRK3*	Distal extremity	Most <2 years	<5 years	5-year survival 84%	WLE, RT/chemo if WLE not possible historically, neoadjuvant chemotherapy (with VA ± C). However, the use of molecular targeting with NTRK inhibitor for up to 26 cycles has had dramatic results and should be considered first-line therapy

Table 549.5 Clinical and Biological Features of the Nonrhabdomyosarcoma Soft Tissue Sarcomas—cont'd

TUMOR*	CELL ORIGIN AND CYTOGENETICS/ PRODUCT	COMMON SITES	COMMON AGES	GOOD PROGNOSTIC FACTORS†	OUTCOME	THERAPY
Leiomyosarcoma	Deletion 1p, other complex abnormalities, smooth muscle-uterine t(12;14)(q15;q24); *HMGA2* rearrangement	Retroperitoneum GI tract, any soft-tissue or vascular area	40-70 years, when in children, any age, associated with human immunodeficiency virus related to EBV infection, reported in patients who received RT for retinoblastoma and Carney triad‡	<5 cm	33% disease-free survival at 1-5 years	WLE chemo: ifosfamide/doxorubicin or gemcitabine/docetaxel
Alveolar soft part sarcoma	der(17)t(X;17)(p11;25)/*ASPSCR1–TFE3*	Orbit, head and neck, lower extremity	15-35 years	Young age, orbital site, <5 cm	5-year survival 27–59% (indolent; death from disease after 10-20 years) 79% metastatic disease, including brain	WLE chemo or RT only after recurrence chemo: no clear role Possible role of vascular endothelial growth factor inhibitors being explored
Hemangiopericytoma infantile form (<1 year of age)	Pericytes/t(12;19)(q13;q13)/t(13;22)(q22;q11)	Extremity, retroperitoneum head and neck extremity, trunk	20-70 years, when in children, 10-20 years rare, but typically 1 year	Low stage, <5 cm, infantile form	Stages I and II, 30–70% 5-year survival with adjuvant therapy stages III and IV, poor infantile—excellent with surgery alone	WLE, with/without RT chemo: no established role but can be chemoresponsive, infantile form responds more favorably to chemotherapy
Liposarcoma (myxoid)	Primitive mesenchyme/t(12;16)(q13p11)/*FUS–DDIT3*	Extremity, retroperitoneum	0-2 years and second decade; sixth decade most common	Child, myxoid type	Very good with WLE, rarely metastasizes	WLE, with/without RT RT important in retroperitoneal lesion chemo: no established role
Clear cell sarcoma	Mesoderm, melanin deposits t(12;22)(p13;q12)/*EWSR1–ATF1*	Tendons and aponeuroses of lower extremity	Young adults, females	<5 cm, no necrosis, nonmetastatic	Adverse prognosis; 5-year survival rates of 60–70%. However, only 30–40% are long-term survivors due to late recurrences	WLE with sentinel node biopsy no clear role for adjuvant chemotherapy Potential role for immunotherapy (e.g., translocation-targeted vaccines, interferon, GM-CSF-secreting vaccine)
Epithelioid sarcoma	Inactivation of INI1 (hSNF5/SMAR CB1) located on chromosome 22q11.2	Distal extremities (especially hands)	Young adult	Younger age, distal tumor location, no necrosis or vascular invasion, negative nodal status, and microscopic complete resection	Tumor is highly aggressive and has a propensity for lymph node metastases Localized smaller tumors have better prognosis	WLE with sentinel lymph node biopsy ± RT and/or chemo: ifosfamide/doxorubicin Clinical trial for use of tazemetostat recently completed Approval for patients with metastatic or locally advanced epithelioid sarcoma not eligible for complete resection

*Listed in order of decreasing incidence.
†Low histologic grade and low stage are good prognostic factors.
‡Carney triad: A condition consisting of gastric epithelioid leiomyosarcoma, pulmonary chondroma, functioning extraadrenal paraganglioma.
NRST, Nonrhabdomyosarcoma soft tissue sarcoma; GI, gastrointestinal; EBV, Epstein-Barr virus; MFH, malignant fibrous histiocytoma; MPNST, malignant peripheral nerve sheath tumor; NF, neurofibromatosis; V, vincristine; C, cyclophosphamide; NTRK, neurotrophic tyrosine receptor kinase; RT, radiation therapy; WLE, wide local excision; GM-CSF, granulocyte-macrophage colony-stimulating factor.
From Amin S, Levy CF. Rhabdomyosarcoma and other soft-tissue sarcomas. In: Fish JD, Lipton JM, Lanzkowsky P, eds. *Lanzowsky's Manual of Pediatric Hematology and Oncology*. 7th ed. London: Elsevier; 2022: Table 25.1, p. 543–544.

Chapter 550
Neoplasms of Bone

550.1 Malignant Tumors of Bone

Wendy A. Allen-Rhoades and Carola A.S. Arndt

The annual incidence of malignant bone tumors in the United States is approximately 8.2 cases per 1 million children younger than 14 years and 14.7 per 1 million for adolescents age 15-19. **Osteosarcoma** is the most common primary malignant bone tumor in children and adolescents, followed by **Ewing sarcoma** (Table 550.1, Fig. 550.1). In children <10 years old, Ewing sarcoma is more common than osteosarcoma. Both tumor types are most likely to occur in the second decade of life.

OSTEOSARCOMA

Epidemiology

The annual incidence of osteosarcoma in the United States is 5.7 cases per 1 million children 0-19 years old. The highest risk period for development of osteosarcoma is during the adolescent growth spurt, suggesting an association between rapid bone growth and malignant transformation. Patients with osteosarcoma are taller than their peers of similar age.

Pathogenesis

Although the cause of osteosarcoma is unknown, certain genetic or acquired conditions predispose patients to development of osteosarcoma. Patients with **hereditary retinoblastoma** have a significantly increased risk for development of osteosarcoma. The sites of osteosarcoma in these patients include previously irradiated areas but also sites far from the original retinoblastoma radiation field. Predisposition to development of osteosarcoma in these patients may be related to loss of heterozygosity of the *RB* gene. Osteosarcoma also occurs in **Li-Fraumeni syndrome**, which is a familial cancer syndrome associated with germline pathogenic variants of the *P53* gene. Kindreds with Li-Fraumeni syndrome have a spectrum of malignancies in first-degree relatives, including carcinoma of the breast, soft tissue sarcomas, brain tumors, leukemia, adrenocortical carcinoma, and other malignancies. **Rothmund-Thomson syndrome** is a rare condition associated with short stature, skin telangiectasia, small hands and feet, hypoplasticity or absence of the thumbs, and a high risk of osteosarcoma. **Diamond-Blackfan anemia** is also a risk factor for osteosarcoma. Osteosarcoma can also be induced by irradiation for Ewing sarcoma, craniospinal irradiation for brain tumors, or high-dose irradiation for other malignancies. Other benign conditions that can be associated with malignant transformation to osteosarcoma include Paget disease, enchondromatosis, multiple hereditary exostoses, and fibrous dysplasia (see Chapter 550.2).

The pathologic diagnosis of osteosarcoma is made by demonstration of a highly malignant, pleomorphic, spindle cell neoplasm associated with the formation of malignant osteoid and bone. There are four pathologic subtypes of conventional high-grade osteosarcoma: osteoblastic, fibroblastic, chondroblastic, and telangiectatic. No significant differences in outcome are associated with the various subtypes, although the chondroblastic component of that subtype may not respond as well to chemotherapy.

Telangiectatic osteosarcoma may be confused with aneurysmal bone cyst (ABC) because of its lytic appearance on radiography. High-grade osteosarcoma typically arises in the diaphyseal region of long bones and invades the medullary cavity. It also may be associated with a soft tissue mass. Two variants of osteosarcoma, parosteal and periosteal, should be distinguished from conventional osteosarcoma because of their characteristic clinical features. **Parosteal osteosarcoma** is a low-grade, well-differentiated tumor that does not invade the medullary cavity and most frequently is found in the posterior aspect of the distal femur. Surgical resection alone often is curative in this lesion, which has a low propensity for metastatic spread. **Periosteal osteosarcoma** is a rare variant that arises on the surface of the bone but has a higher rate of metastatic spread than the parosteal type and an intermediate prognosis.

Clinical Manifestations

Pain, limp, and swelling are the most common presenting manifestations of osteosarcoma. Because these tumors occur most often in active

Table 550.1 Comparison of Features of Osteosarcoma and the Ewing Family of Tumors

FEATURE	OSTEOSARCOMA	EWING FAMILY OF TUMORS*
Age	Second decade	Second decade
Ethnicity	All	Primarily Whites
Sex (M:F)	1.5:1	1.5:1
Predisposition	Retinoblastoma, Li-Fraumeni syndrome, Rothmund-Thomson syndrome, Paget disease, radiotherapy	None known
Site	Metaphyses of long bones	Diaphyses of long bones, flat bones, soft tissues
Presentation	Local pain and swelling; often history of injury; pathologic fracture	Local pain and swelling; fever, palpable mass, pathologic fracture
Radiographic findings	Sclerotic destruction (less often lytic); sunburst pattern, Codman triangle	Primarily lytic, multilaminar periosteal reaction ("onion-skinning"), "moth-eaten," Codman triangle
Differential diagnosis	Ewing sarcoma, osteomyelitis, hematoma	Osteomyelitis, eosinophilic granuloma, lymphoma, neuroblastoma, rhabdomyosarcoma, FUO
Metastasis	Lungs, bones	Lungs, bones, bone marrow
Treatment	Chemotherapy	Chemotherapy
	Ablative surgery of primary tumor	Radiotherapy and/or surgery of primary tumor
Outcome	Without metastases, 70% cured; with metastases at diagnosis, ≤20% survival	Without metastases, 65–75% cured; with metastases at diagnosis, 20–30% survival

FUO, Fever of unknown origin.
*Ewing family of tumors includes: (1) Ewing sarcoma of bone; (2) extraosseous (extraskeletal) Ewing tumor; (3) peripheral primitive neuroectodermal tumor (PPNET). A PPNET arising from the chest wall is an Askin tumor.

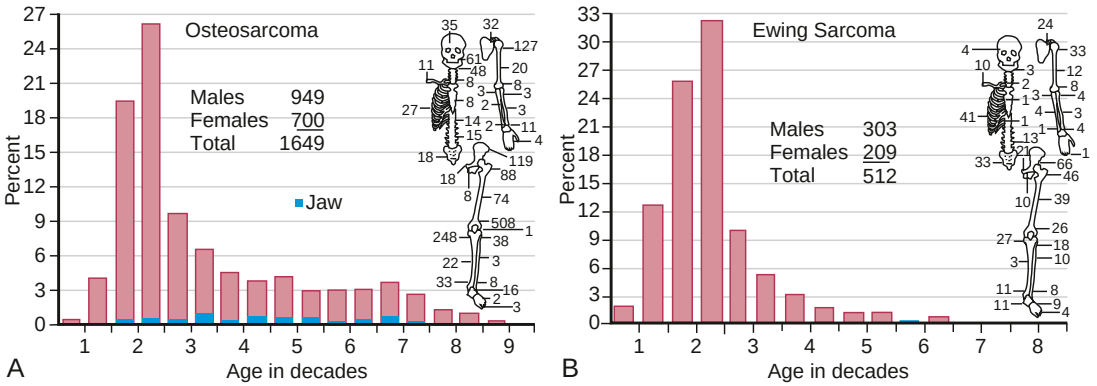

Fig. 550.1 **A,** Age and skeletal distribution of 1,649 cases of osteosarcoma in the Mayo Clinic files. **B,** Age and skeletal distribution of 512 cases of Ewing sarcoma in the Mayo Clinic files. *(From Unni KK, ed. Dahlin's Bone Tumors: General Aspects and Data on 11,087 Cases. 5th ed. Philadelphia: Lippincott-Raven; 1996. Reprinted by permission of the Mayo Foundation.)*

adolescents, initial complaints may be attributed to a sports injury or sprain; any bone or joint pain not responding to conservative therapy within a reasonable time should be investigated thoroughly. Additional clinical findings may include limitation of motion, joint effusion, tenderness, and warmth. Results of routine laboratory tests, such as a complete blood cell count and chemistry panel, are usually normal, although alkaline phosphatase or lactate dehydrogenase values may be elevated.

Diagnosis

Bone tumor should be suspected in a patient who presents with deep bone pain, often causing nighttime awakening, and has a palpable mass with radiographs that demonstrate a lesion. The lesion may be mixed lytic and blastic in appearance, but new bone formation is usually visible. The classic radiographic appearance of osteosarcoma is the *sunburst pattern* (Fig. 550.2). When osteosarcoma is suspected, the patient should be referred to a center with experience in managing bone tumors. The biopsy and the surgery should be performed by the same surgeon so that the incisional biopsy site can be placed in a manner that will not compromise the definitive surgical procedure. Tissue usually is obtained for molecular and biologic studies at the time of the initial biopsy. Before biopsy, MRI of the primary lesion and the entire bone should be performed to evaluate the tumor for its proximity to nerves and blood vessels, soft tissue and joint extension, and skip lesions. The metastatic workup includes CT of the chest and radionuclide bone scanning or positron emission tomography (PET) scan to evaluate for lung and bone or soft tissue metastases, respectively. The **differential diagnosis** of a lytic bone lesion includes histiocytosis, Ewing sarcoma, lymphoma, and bone cyst.

Fig. 550.2 Radiograph of an osteosarcoma of the femur with typical sunburst appearance of bone formation.

Treatment

With chemotherapy and surgery, 5-year disease-free survival of patients with nonmetastatic extremity osteosarcoma is 65–75%. Complete surgical resection of the tumor is important for cure. The current approach is to treat patients with preoperative chemotherapy in an attempt to facilitate limb salvage operations and to treat micrometastatic disease immediately. Up to 80% of patients are able to undergo limb salvage operations after initial chemotherapy. It is important to resume chemotherapy as soon as possible after surgery. Lung metastases present at diagnosis should be resected by thoracotomies at some time during treatment. Active agents in use in multidrug chemotherapy regimens for conventional osteosarcoma include doxorubicin, cisplatin, methotrexate, and ifosfamide.

One of the most important prognostic factors in osteosarcoma is the *histologic response to chemotherapy;* a poor histologic response is ≥10% viable tumor (<90% necrosis in resected tissue). **MAP** (methotrexate, doxorubicin, cisplatin) is the standard chemotherapy regimen for osteosarcoma. After limb salvage surgery, intensive rehabilitation and physical therapy are necessary to ensure maximal functional outcome. Intensification of therapy by addition of ifosfamide and etoposide in patients with poor histologic response after induction chemotherapy with MAP has not improved outcome.

For patients who require amputation, early prosthetic fitting and gait training are essential to enable patients to resume normal activities as soon as possible. Before definitive surgery, patients with tumors on weight-bearing bones should be instructed to use crutches to avoid stressing the weakened bones and causing pathologic fracture. The role of chemotherapy in parosteal and periosteal osteosarcomas is not well defined, and chemotherapy is generally reserved for use in patients with tumors that have a high-grade microscopic appearance.

Prognosis

Surgical resection alone is curative only for patients with low-grade parosteal osteosarcoma. Conventional high-grade osteosarcoma requires multiagent chemotherapy. Up to 75% of patients with nonmetastatic extremity osteosarcoma are cured with current multiagent treatment protocols. The prognosis is not as favorable for patients with pelvic tumors as for those with primary tumors in the extremities. From 20–30% of patients who have limited numbers of pulmonary metastases also can be cured with aggressive chemotherapy and resection of lung nodules. Patients with bone metastases and those with widespread lung metastases have an extremely poor prognosis. Long-term follow-up of patients with osteosarcoma is important to monitor for late effects of chemotherapy, such as cardiotoxicity from anthracycline and hearing loss from cisplatin. Patients in whom late, isolated lung metastases develop may be cured with surgical resection of the metastatic lesions alone.

EWING SARCOMA

Epidemiology

The incidence of Ewing sarcoma in the United States is 3.1 cases per 1 million children ages 0-19 years. It is rare among Black children. Ewing sarcoma, an undifferentiated sarcoma of bone, also may arise from soft tissue. Treatment protocols for these tumors are the same whether the tumors arise in bone or soft tissue. Anatomic sites of primary tumors arising in bone are distributed evenly between the extremities and the central axis (pelvis, spine, and chest wall). Primary tumors arising in the chest wall are often referred to as **Askin tumors**.

Pathogenesis

Immunohistochemical staining assists in the diagnosis of Ewing sarcoma to differentiate it from **small, round, blue cell tumors** such as lymphoma, rhabdomyosarcoma, and neuroblastoma. Histochemical stains may react positively with certain neural markers on tumor cells (neuron-specific enolase and S-100), especially in peripheral primitive neuroectodermal tumors. Reactivity with muscle markers (e.g., desmin, actin) is absent. Additionally, MIC-2 (CD99) staining is usually positive. A specific chromosomal translocation, t(11;22) (q24;q12), or a variant is found in most of the Ewing sarcoma family of tumors. Analysis for the translocation by next generation sequencing, fluorescence in situ hybridization (FISH), or polymerase chain reaction (PCR) analysis for the chimeric fusion gene products *EWS/FLI1* or *EWS/ERG* (or other variants) are used routinely in diagnosis.

Clinical Manifestations

Symptoms of Ewing sarcoma are similar to those of osteosarcoma. Pain, swelling, limitation of motion, and tenderness over the involved bone or soft tissue are common presenting symptoms. Patients with large chest wall primary tumors may present with respiratory distress. Patients with paraspinal or vertebral primary tumors may present with symptoms of cord compression. Ewing sarcoma often is associated with **systemic manifestations**, such as fever and weight loss, and may be accompanied by elevated inflammatory markers; patients may have undergone treatment for a presumptive diagnosis of osteomyelitis or a fever of unknown origin. Patients also may have a delay in diagnosis when their pain or swelling is attributed to a sports injury. Biopsy and tissue diagnosis should be considered for patients presenting with suspicious bone lesions, because even the gross appearance of Ewing sarcoma can appear similar to infection and the time course can be rapid. Surgical procedures for treatment of infection can contaminate the surgical field and impact treatment outcomes.

Diagnosis

The diagnosis of Ewing sarcoma should be suspected in a patient who presents with pain and swelling, with or without systemic symptoms, and with a radiographic appearance of a primarily lytic bone lesion with periosteal reaction, the characteristic **onion-skinning** (Fig. 550.3). A large, associated soft tissue mass often is visualized on MRI or CT (Fig. 550.4). The **differential diagnosis** includes osteosarcoma,

Fig. 550.3 Radiograph of tibial Ewing sarcoma showing periosteal elevation or "onion-skinning."

Fig. 550.4 MR image of tibial Ewing sarcoma showing a large associated soft tissue mass.

osteomyelitis, Langerhans cell histiocytosis, primary lymphoma of bone, metastatic neuroblastoma, or rhabdomyosarcoma in the case of a pure soft tissue lesion. Patients should be referred to a center with experience in managing bone tumors for evaluation and biopsy. Thorough evaluation for metastatic disease includes CT of the chest, radionuclide bone scan, or PET scan. Bone marrow aspiration and biopsy specimens from at least two sites are generally required but can be omitted for certain lower risk patients. MRI of the tumor and the entire length of involved bone should be performed to determine the exact extension of the soft tissue and bony mass and the proximity of tumor to neurovascular structures. Studies are also using fluorodeoxyglucose (FDG) PET to evaluate response to therapy.

To avoid compromising an ultimate potential for limb salvage by a poorly planned biopsy incision, the same surgeon should perform the biopsy and the surgical procedure. CT-guided biopsy of the lesion often provides diagnostic tissue. It is important to obtain adequate tissue for special stains and molecular studies.

Treatment

Tumors of the Ewing sarcoma family are best managed with a comprehensive multidisciplinary approach in which the surgeon, chemotherapist, and radiation oncologist plan therapy. Multiagent chemotherapy is important because it can shrink the tumor rapidly and is usually given before local control is attempted. In North America, standard **chemotherapy** for nonmetastatic Ewing sarcoma includes vincristine, doxorubicin, cyclophosphamide, etoposide, and ifosfamide. Chemotherapy usually causes dramatic shrinkage of the soft tissue mass and rapid, significant pain relief. Patients with nonmetastatic Ewing sarcoma have a better outcome when treated on a 14-day rather than on a 21-day schedule. An international cooperative group trial found that myeloablative chemotherapy and stem cell rescue was not superior to chemotherapy with lung irradiation for patients with pulmonary metastases.

Ewing sarcoma is considered a radiosensitive tumor, and local control may be achieved with **irradiation** or **surgery**. Radiation therapy is associated with a risk of radiation-induced second malignancies, especially osteosarcoma, as well as failure of bone growth in skeletally immature patients. It is important to provide the patient with crutches if the tumor is in a weight-bearing bone to avoid a pathologic fracture before definitive local control. Many centers prefer surgical resection, if possible, to achieve local control. Chemotherapy should be resumed as soon as possible after surgery.

Prognosis

Patients with small, nonmetastatic, distally located extremity tumors have the best prognosis, with a cure rate of up to 75%. Patients with pelvic tumors have, until recently, had a much worse outcome. Patients with metastatic disease at diagnosis, especially bone or bone marrow metastases, have a poor prognosis, with <30% surviving long term.

Long-term follow-up of patients with Ewing sarcoma is important because of the potential for late effects of treatment, such as anthracycline-induced cardiotoxicity, infertility, and second malignancies, especially in the radiation field, and late relapses, even as long as 10 years after initial diagnosis.

Visit Elsevier eBooks+ at eBooks.Health.Elsevier.com for Bibliography.

550.2 Benign Tumors and Tumor-Like Processes of Bone

Carola A.S. Arndt and A. Noelle Larson

Benign bone lesions in children are common compared with the relatively rare malignant neoplasms of bone. A broad range of diagnostic possibilities must be considered when the physician is confronted with an undiagnosed bone lesion (Table 550.2). Some, although histologically benign, can be life-threatening, while others can be locally destructive to bone. Many represent an incidental finding that, if asymptomatic, can be observed. A group of benign characteristic lesions including osteochondroma, nonossifying fibroma, unicameral bone cyst, and enchondroma may occur in 19% of children in a historic cohort of children and can readily be diagnosed on standard radiographs without additional imaging studies. Other conditions require further study to determine a diagnosis where no single element in the history or diagnostic test is sufficient to rule out malignancy. Benign lesions are usually painless but may be painful, especially if the lesion is causing local bone destruction or there is an impending pathologic fracture. Night pain that awakens a child suggests malignancy, but relief of such pain with aspirin is common with osteoid osteomas. Rapidly enlarging lesions usually are associated with malignancy, but several benign lesions, such as ABCs, can enlarge faster than most malignancies. Several conditions, such as osteomyelitis, can simulate the appearance of bone tumors.

Many benign bone tumors are diagnosed incidentally or after pathologic fracture. Initial management of these fractures is similar to that of nonpathologic fractures in the same location. It is unusual for benign bone tumors to interfere with fracture healing, but the area of weakness typically remains, and refracture is common. Fractures rarely result in resolution of the tumor, which usually is treated after the fracture has healed. Fractures around the hip, however, frequently require immediate treatment to stabilize the femoral neck and restore anatomic alignment.

Radiographs of any suspected bone lesion should always be obtained in two planes. Additional studies may be necessary to help arrive at the correct diagnosis and to guide treatment. Although these lesions are benign, selected lesions require intervention. If biopsy is performed, both microbiology and pathology evaluations should always be obtained.

Osteochondroma (exostosis) is one of the most common benign bone tumors in children. Because many are completely asymptomatic and unrecognized, the true incidence of this lesion is unknown. Osteochondromas develop in childhood, arising from the metaphysis of a long bone, particularly the distal femur, proximal humerus, and proximal tibia. The lesion enlarges with the child until skeletal maturity. Children commonly present at 5-15 years of age, when the child or parent notices a bony, nonpainful mass. Some are discovered because they are irritated by soft tissues rubbing over the lesion during athletic or other activities. Fracture is rare. Osteochondromas appear radiographically as stalks or broad-based projections from the surface of the bone, usually in a direction away from the adjacent joint (Fig. 550.5A). The bone is in continuity with the medullary canal. Invariably, the lesion is radiographically smaller than suggested by palpation because the cartilage cap covering the lesion is not seen. This cartilage cap may be up to 1 cm thick. Both the cortex of the bone and the marrow space of the involved bone are continuous with the lesion. Malignant degeneration of a chondrosarcoma is rare in children but occurs in as many as 1% of adults. Routine removal is not performed unless the lesion is large enough to cause symptoms, such as pain or nerve compression, most commonly presenting as foot drop. Osteochondromas can be diagnosed by radiographs alone, and unless patients present with unusual symptoms such as night pain, further studies such as CT or MRI are not typically indicated. Patients should be referred to an orthopedic practice for counseling, but routine radiographic follow-up and treatment should be based on symptoms.

Multiple hereditary osteochondrosis (exostoses) is a related but rare condition characterized by the presence of multiple osteochondromas (see Fig. 550.5B). This is an autosomal dominant disorder due to pathogenic variants in *EXT1* or *EXT2*. Severely involved children can have short stature, limb-length inequality, premature partial physeal arrests, deformity of both the upper and lower extremities including genu valgum, dislocation of the radial head at the elbow, and neurovascular impingement or entrapment in areas adjacent to the tumor and neurovascular compartments. These children must be monitored carefully during growth by a pediatric orthopedist. Malignant transformation may occur but is rare. Screening MRI of the entire spine is recommended during childhood to detect bony lesions growing into the

Table 550.2 Features of Pediatric Benign Bone Tumors

LESION	TYPICAL COURSE	MOST COMMON WORKUP TO CONFIRM DIAGNOSIS
Fibroma (nonossifying fibroma, fibrous cortical defect, metaphyseal fibrous defect)	Observation; surgery to treat fracture/impending fracture (rare, large lesions)	Radiographs
Enchondroma	Observation; treat if symptomatic	Radiographs, occasionally MRI
Osteochondroma	Observation; excise if symptomatic	Radiographs
Subungual exostosis	Symptoms warrant excision for most patients	Radiographs
Unicameral/simple bone cyst	Observation; treat if fracture occurs to prevent further fractures	Radiographs, occasionally MRI
Osteoid osteoma	NSAIDs; but symptoms warrant percutaneous ablation for most patients	Radiographs, CT
Heterotopic ossification	Observation; if symptomatic, excise after bone is mature (>6 mo)	Radiographs, ± MRI, CT
Fibrous dysplasia	Observation; treat if pain or bony deformities	Radiographs, ± MRI, ± biopsy
Chronic regional multifocal osteomyelitis (reactive bone condition)	Observation; medical treatment available if symptomatic; pathology is identical to osteomyelitis	Radiographs, MRI; bone scan to look for other lesions; antibiotics to rule out osteomyelitis; biopsy
Langerhans cell histiocytosis	Variable; depends on extent of disease	Skeletal survey, MRI, biopsy, workup to rule out systemic disease
Infection	Treat with prolonged antibiotics, typically some intravenously; surgery for joint/growth plate involvement, abscess, and chronic disease	CRP, sedimentation rate, CBC with differential, blood cultures, radiographs, ± MRI, ± biopsy
Osteoblastoma	Locally aggressive, treat	Radiographs, CT, MRI, biopsy
Aneurysmal bone cyst	Locally aggressive, treat	Radiographs, MRI, biopsy
Chondroblastoma	Locally aggressive, treat	Radiographs, MRI, biopsy
Chondromyxoid fibroma	Locally aggressive, treat	Radiographs, MRI, biopsy
Osteofibrous dysplasia	Possibly locally aggressive; variable	Radiographs, MRI, biopsy
Adamantinoma	Malignant, treat	Radiographs, MRI, biopsy

CBC, Complete blood count; CRP, C-reactive protein; CT, computed tomography; MRI, magnetic resonance imaging; NSAIDs, nonsteroidal antiinflammatory drugs.

canal, which can result in spinal cord compression which may occur in up to 20–30% of patients (see Fig. 550.5C).

SUBUNGUAL EXOSTOSIS

This lesion is an osteochondroma that forms underneath the nailbed in an otherwise healthy child. The nailbed may become discolored or raised, and the condition is typically painful (Fig. 550.6). It can be differentiated from a paronychia or ingrown toenail by findings of an osteochondroma on radiographs. Radiographs should be taken, which will show a bony protuberance under the nailbed. Treatment should be nailbed removal and surgical excision with nailbed repair. Despite surgical excision, recurrence can occur up to 5% of the time.

Enchondroma is a benign lesion of hyaline cartilage that occurs centrally in the bone. These lesions are asymptomatic and frequently occur in the hands. Most are discovered incidentally, although pathologic fractures often lead to the diagnosis. Radiographically, the lesions occupy the medullary canal, are radiolucent, and are sharply marginated. Punctate or stippled calcification may be present within the lesion, but this is much more common in adults than in children. Almost all enchondromas in children are solitary and small. Most can simply be observed, with curettage and bone grafting reserved for lesions that are symptomatic or large enough to weaken the bone structurally. Large lesions with extensive involvement may represent low-grade chondrosarcoma. Multifocal involvement is referred to as **Ollier disease** and can result in bone dysplasia, short stature, limb-length inequality, and joint deformity. Surgery may be necessary to correct or prevent such deformities. When multiple enchondromas are associated with angiomas of the soft tissue, the condition is referred to as **Maffucci syndrome**. A high rate of malignant transformation has been reported in both of these multifocal conditions.

Chondromyxoid fibroma is an uncommon benign bone tumor in children. This metaphyseal lesion usually causes pain and local tenderness. The lesion occasionally is asymptomatic. Chondromyxoid fibroma appears radiographically as eccentric, lobular metaphyseal radiolucency with sharp, sclerotic, and scalloped margins. The lower extremity is involved most often. Treatment usually consists of curettage and bone grafting or en bloc resection.

Osteoid osteoma is a small benign bone tumor typically found in the proximal tibia and femur and the posterior elements of the spine. Most of these tumors are diagnosed between 5 and 20 years of age. The clinical pattern is characteristic, consisting of unremitting and gradually increasing pain that often is worst at night and is relieved by NSAIDs. Boys are affected more often than girls. Vertebral lesions can cause scoliosis or symptoms that mimic a neurologic disorder. Examination can reveal a limp, atrophy, and weakness when the lower extremity is involved. Palpation and range of motion do not alter the discomfort. Radiographs may show cortical thickening, and CT shows distinctive findings, with a round or oval metaphyseal or diaphyseal lucency (0.5-1.0 cm in diameter) surrounded by dense sclerotic bone (Fig. 550.7). The central lucency, or nidus, shows intense uptake on bone scan. Approximately 25% of osteoid osteomas are not visualized on plain radiographs but can be identified with CT. Because of the small size of the lesion and its location adjacent to thick cortical bone, MRI is poor at diagnosing osteoid osteomas, revealing only extensive T2

Fig. 550.5 A, Lateral radiograph of the right humerus showing isolated osteochondroma. Bone lesion is in continuity with the medullary canal and points away from the growth plate. B, Hip-to-ankle radiograph in a child with multiple hereditary exostoses (MHE) showing many osteochondromas about the knees and ankles. C, Sagittal T2 weighted MR image of the cervical spine in a 15-yr-old female with MHE who underwent routine cervical screening MRI, which detected asymptomatic spinal stenosis caused by C6 osteochondroma. She underwent urgent decompression.

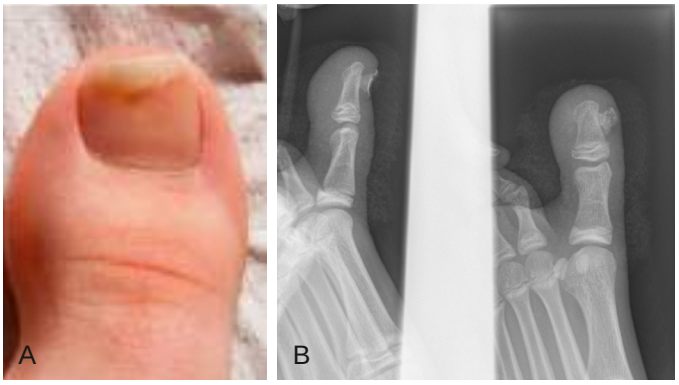

Fig. 550.6 A, Photograph of the great toe showing nailbed abnormality. B, Lateral and oblique views of the left great toe showing subungual exostosis. These lesions are typically painful and require surgical removal.

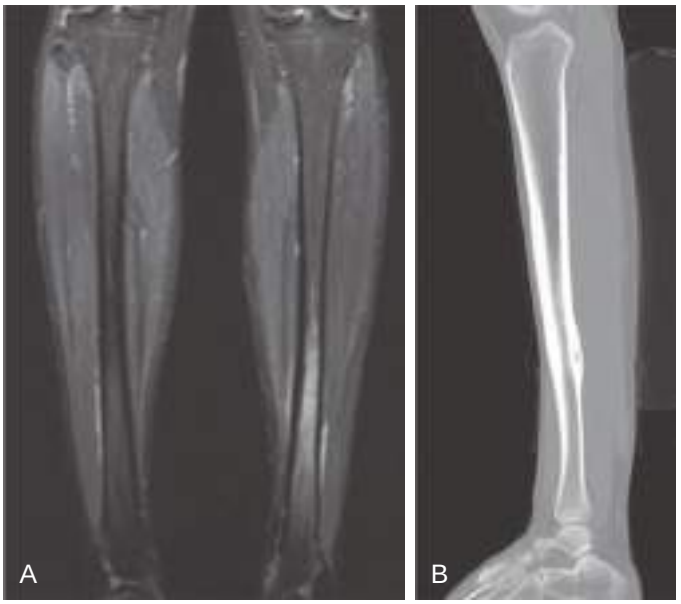

Fig. 550.7 MRI and CT in 15-yr-old female with left tibial night pain. A, Coronal T2 weighted MR of the bilateral tibias shows increased T2 signal change in the left tibia diaphysis. B, Sagittal CT scan shows cortically based lesion <1 cm typical for osteoid osteoma. Patient was treated with percutaneous radiofrequency ablation.

signal change throughout the region. Treatment is directed at removing the lesion. Patients may be treated with NSAIDs, and the symptoms typically resolve within 1-2 years. Most patients and families elect for treatment. Percutaneous treatments such as radiofrequency ablation and cryoablation have become the standard of care for routine lesions. There is still an occasional role for open surgical resection, if there is concern for osteomyelitis (Brodie's abscess), or the lesion is in close proximity to articular cartilage or neurovascular structures.

Osteoblastoma is a locally destructive, progressively growing lesion of bone with a predilection for the vertebrae, although almost any bone may be involved. Most patients note the insidious onset of dull aching pain, which may be present for months before patients seek medical attention. Spinal lesions can cause neurologic symptoms or deficits. The radiographic appearance is variable and less distinctive than that of other benign bone tumors. CT or MRI is indicated. Approximately 25% show features suggesting a malignant neoplasm, making biopsy necessary in many cases. Expansile spinal lesions often involve the posterior elements. Treatment involves curettage and bone grafting or en bloc excision; care must be taken to preserve nerve roots when treating spinal lesions. Surgical stabilization of the spine may be necessary.

Fibromas (nonossifying fibroma, fibrous cortical defect, metaphyseal fibrous defect) are fibrous lesions of bone that occur in up to 40% of children older than 2 years of age. They most likely represent a defect in ossification rather than a neoplasm and usually are asymptomatic. Most are discovered incidentally when radiographs are taken for other reasons, usually to rule out a fracture after trauma. Occasional pathologic fractures can occur through large lesions. Physical examination usually is unrevealing. Radiographs show a sharply marginated eccentric lucency in the metaphysis or metaphyseal cortex (Fig. 550.8). Lesions may be multilocular and expansile, with extension from the cortex into the medullary bone. The long axis of the lesion runs parallel to that of the bone. Approximately 50% are bilateral or multiple. Because of the characteristic radiographic appearance, most lesions do not require axial imaging, biopsy, or treatment. If the child is asymptomatic, no further monitoring is needed for characteristic lesions. Spontaneous regression can be expected after skeletal maturity. Curettage and bone grafting may be considered for symptomatic lesions or lesions occupying >50% of the bone diameter due to the risk of a pathologic fracture.

Fig. 550.8 Anteroposterior radiograph of the knee showing nonossifying fibroma, which was discovered incidentally.

Fig. 550.9 External rotation view of the left humerus in a 9-yr-old female who presented with pain after falling off her bicycle. Imaging is consistent with simple bone cyst.

Unicameral bone cysts can occur at any age in childhood but are rare in children younger than 3 years of age and after skeletal maturity. The cause of these fluid-filled lesions is unknown. Spontaneous resolution after skeletal maturity is expected, although pathologic fracture can be a significant problem in the interim. Diagnosis usually follows a pathologic fracture (Fig. 550.9). Such fractures can occur with relatively minor trauma, such as with throwing or catching a ball. Unicameral bone cysts appear radiographically as solitary, centrally located lesions within the medullary portion of the bone. These cysts are most common in the proximal humerus or femur. They often extend to (but not through) the physis and are sharply marginated. The cortex expands, but that does not exceed the width of the adjacent physis. Treatment involves allowing the pathologic fracture to heal. Subsequently, humerus lesions can be observed or treated. Proximal femoral lesions are typically treated due to the risk of pathologic fracture. Treatments include aspiration and injection with methylprednisolone or calcium phosphate. A randomized controlled trial (RCT) showed 42% healing rate with steroid injections (1-3, mean 1.7 injections) compared with injection of bone marrow aspirate (23% healing rate, 1-3 injections, 2.1 mean). Open biopsy and bone grafting with or without internal fixation can also be performed. Recurrence is common despite surgical treatment. Repeat injections are frequently necessary to treat recurrent lesions. Healing rates are higher with injection or surgical treatment compared with observation, and internal fixation is recommended for proximal femoral lesions given the high risk of fracture.

Fibrous dysplasia is a developmental abnormality characterized by fibrous replacement of cancellous bone. Lesions may be solitary or multifocal (polyostotic). Lesions may progress over time or may be stable. Some children are asymptomatic, although others have bone pain. Those with skull involvement might have swelling or exophthalmos. Pain and limp are characteristic of proximal femoral involvement, which also may indicate impending pathologic fracture. Limb-length discrepancy, bowing of the tibia or femur, and pathologic fractures may be presenting complaints. The triad of polyostotic disease, precocious puberty, and cutaneous pigmentation is known as McCune-Albright syndrome. Radiographic features of fibrous dysplasia include a lytic or ground-glass expansile lesion of the metaphysis or diaphysis. The lesion is sharply marginated and often is surrounded by a thick rim of sclerotic bone. Bowing, especially of the proximal femur, may be present. Treatment usually involves observation for asymptomatic lesions. Surgery is indicated for patients with progressive deformity, pain, or impending pathologic fractures. Bone grafting is not as successful in the treatment of fibrous dysplasia, because the lesion recurs within the grafted bone. Reconstructive surgical techniques with metal implants often are necessary to provide stability and treat pain, particularly in the proximal femur. In addition to surgical stabilization, bisphosphonate therapy has been used to treat bone pain, although a recent RCT showed improvement in regional bone mineral density but no change in pain scores.

LOCALLY AGGRESSIVE LESIONS

Aneurysmal bone cyst (ABC) is a reactive lesion of bone seen in persons younger than 20 years of age. The lesion is characterized by cavernous spaces filled with blood and solid aggregates of tissue. Although the femur, tibia, and spine are commonly involved, this progressively growing, expansile lesion can develop in any bone. Radiographs show eccentric lytic destruction and expansion of the metaphysis surrounded by a thin sclerotic rim of bone. Expansion of the bone frequently extends beyond the diameter of the physis. Pain and swelling are common. Spinal involvement can lead to cord or nerve root compression and associated neurologic symptoms, including paralysis. Posterior elements of the spine are involved more commonly than the vertebral body. Unlike most other benign bone tumors, which usually are confined to a single bone, ABCs can involve adjacent vertebrae. Spinal lesions can require stabilization after excision. As with other benign tumors, attempts are made to preserve nerve roots and other vital structures. Rapid growth is characteristic and can lead to confusion with malignant neoplasms (Fig. 550.10). ABCs can occur with concomitantly with neoplasms, confounding pathology results from biopsy. Treatment consists of percutaneous injection, curettage and bone grafting, or excision. Recurrence after surgical treatment occurs in 20–30% of patients, is more common in younger than older children, and usually occurs in the first 1-2 years after treatment. Treatment approaches also include percutaneously treatment with polidocanol or doxycycline, which targets the specific matrix metalloproteinase upregulation pathway seen in ABCs and has shown promising results.

CHARACTERISTIC LESIONS OF THE TIBIA

Osteofibrous dysplasia affects the tibia in children. Most children present with anterior swelling or enlargement of the leg. Radiographs show solitary or multiple lucent cortical diaphyseal lesions surrounded by sclerosis. Anterior bowing of the tibia often is present, and pathologic fracture can occur. The radiographic appearance closely resembles that

Fig. 550.10 Aneurysmal bone cyst. **A**, A 10-yr-old female presents with right tibia pain after playing softball. PA radiograph of the right proximal tibia reveals an eccentric, lytic lesion. **B**, Repeat imaging 4 months later shows rapid expansion. **C**, Coronal T2 MR image. **D**, Sagittal T2 MR image shows fluid-fluid levels classically seen with aneurysmal bone cysts. **E**, The patient was treated with curettage, bone grafting, and plate fixation to prevent fracture.

Table 550.3 Summary of Prognosis and Treatment of Vascular Bone Tumors

CLASSIFICATION	ENTITY	PROGNOSIS	TREATMENT
Benign	Hemangioma	100% survival, 0% metastasis	Treat symptoms
Intermediate	Epithelioid hemangioma	100% survival, 2% metastases, 9% local recurrence	Curettage or marginal excision
	Pseudomyogenic hemangioendothelioma	Limited follow-up, stable or progressive osseous disease	
Malignant	Epithelioid hemangioendothelioma	85% survival, 25% metastases	Wide resection
	Angiosarcoma	30% survival	Wide resection, consider systemic therapy

From van IJzendoorn DGP, Bovee JVMG. Vascular tumors of bone: the evolvement of a classification based on molecular developments. *Surg Pathol Clin.* 2017;10:621–635. Table 1.

of adamantinoma, a malignant neoplasm, making biopsy more common than with other benign bone tumors. Some believe osteofibrous dysplasia is a precursor lesion to adamantinoma. Treatment options include observation, excision and bone grafting, or wide resection.

Adamantinoma is a rare malignancy, typically found in adults, but occasionally in children. In contrast to osteofibrous dysplasia, the lesion involves the medullary canal. Resection is indicated, as there are no known benefits to radiation or chemotherapy for this slow-growing tumor.

Langerhans cell histiocytosis is a monostotic or polyostotic disease that can also involve the skin, liver, or other organs. Single-site disease should be distinguished from the other forms of Langerhans cell histiocytosis (Hand-Schüller-Christian or Letterer-Siwe variants), which can have a less favorable prognosis (see Chapter 556.1). Langerhans cell histiocytosis usually occurs during the first 3 decades of life and is most common in males 5-10 years of age. The skull is commonly affected, but any bone may be involved. Patients usually present with local pain and swelling. Marked tenderness and warmth often are present in the area of the involved bone. Spinal lesions can cause pain, stiffness, and occasional neurologic symptoms. Vertebra plana with uniform compression or flattening of the vertebral body is commonly but not always associated with Langerhans cell histiocytosis. The radiographic appearance of the skeletal lesions is similar in all forms of Langerhans cell histiocytosis but is variable enough to mimic many other benign and malignant lesions of bone as well as infection. The radiolucent lesions have well-defined or irregular margins with expansion of the involved bone and periosteal new bone formation. A skeletal survey is warranted as lesions may not be apparent on bone scan. Polyostotic involvement and the typical skull lesions strongly suggest the diagnosis of eosinophilic granuloma. Biopsy often is necessary to confirm the diagnosis because of the broad radiographic differential diagnosis. Treatment for isolated bone lesions includes curettage and bone grafting, or observation for asymptomatic lesions because most osseous lesions heal spontaneously and do not recur. All children with bone lesions should be evaluated for visceral involvement because multisystem organ disease may exist with the bone lesion and may not be obvious. Treatment of multisystem disease is more complex and often systemic and may require chemotherapy. For multisystem disease, bone lesions frequently improve with systemic chemotherapy, and operative treatment may not be necessary.

VASCULAR TUMORS OF BONE

There is a wide spectrum of vascular bone tumors (Table 550.3), which, depending on severity, may produce local sclerosis or osteopenia (see also Chapter 554). More severe lesions are locally aggressive and result in cortical destruction.

Visit Elsevier eBooks+ at eBooks.Health.Elsevier.com for Bibliography.

Chapter 551

Retinoblastoma

Cynthia E. Herzog

Retinoblastoma is an embryonal malignancy of the retina and the most common intraocular tumor in children. Although the survival rate of children with retinoblastoma in the United States and developed countries is extremely high, retinoblastoma progresses to metastatic disease and death in >40% of children in low income countries. Furthermore, the associated loss of vision and side effects of therapy are significant problems that remain to be addressed.

EPIDEMIOLOGY

Approximately 200-300 new cases of retinoblastoma are diagnosed each year in the United States, with no known racial or gender predilection. The cumulative lifetime incidence of retinoblastoma is approximately 1 in 20,000 live births, and retinoblastoma accounts for 2% of all pediatric malignancies. The median age at diagnosis is approximately 2 years, and >90% of cases are diagnosed in children <5 years old. Overall, 66–75% of children with retinoblastoma have unilateral tumors, with the remainder having bilateral retinoblastoma. Bilateral involvement is more common in younger children, particularly in those diagnosed before age 1 year, and is always heritable. Risk of retinoblastoma may be increased in children conceived by in vitro fertilization.

Retinoblastoma can be either hereditary or sporadic. **Hereditary** cases usually are diagnosed at a younger age and are multifocal and bilateral, whereas **sporadic** cases are usually diagnosed in older children who tend to have unilateral, unifocal involvement. The hereditary form is associated with loss of function of the **retinoblastoma gene *(RB1)*** via a pathogenic variant or deletion. *RB1* is located on chromosome 13q14 and encodes the retinoblastoma protein, a tumor-suppressor protein that controls cell cycle phase transition and has roles in apoptosis and cell differentiation. Children with **13q deletion syndrome** are at increased risk to develop retinoblastoma. Many different causative pathogenic variants have been identified, including translocations, deletions, insertions, point pathogenic variants, and epigenetic modifications such as gene methylation. The nature of the predisposing pathogenic variant can affect the penetrance and expressivity of retinoblastoma development.

According to Knudson's "2-hit" model of oncogenesis, two pathogenic variant events are required for retinoblastoma tumor development (see Chapter 541). In the hereditary form of retinoblastoma, the first pathogenic variant in *RB1* is inherited through germinal cells, and a pathogenic variant occurs subsequently in somatic retinal cells. Second pathogenic variants that lead to retinoblastoma often result in the loss of the normal allele and concomitant loss of heterozygosity. Parents and siblings of a child with a germline pathologic genetic variant should be referred to a genetic specialist for testing; most children with hereditary retinoblastoma have spontaneous new germinal pathogenic variants, and both parents have wild-type retinoblastoma genes. All first-degree relatives of children with known or suspected hereditary retinoblastoma should have retinal examinations to identify retinomas or retinal scars, which may suggest hereditary retinoblastoma even though malignant retinoblastoma did not develop. In the sporadic form of retinoblastoma, the two pathogenic variants occur in somatic retinal cells. Heterozygous carriers of oncogenic *RB1* pathogenic variants demonstrate variable phenotypic expression.

PATHOGENESIS

Histologically, retinoblastoma appears as a small, round blue cell tumor with rosette formation **(Flexner-Wintersteiner rosettes)**. It may arise in any of the nucleated layers of the retina and exhibit various degrees of differentiation. Retinoblastoma tumors tend to outgrow their blood supply, resulting in necrosis and calcification.

Endophytic tumors arise from the inner surface of the retina and grow into the vitreous and can also grow as tumors suspended within the vitreous itself, known as **vitreous seeding**. *Exophytic* tumors grow from the outer retinal layer and can cause retinal detachment. Diffuse infiltrating tumors grow intraretinally and remain flat; these are less common and can cause iris neovascularization. Tumors can also be both endophytic and exophytic. These tumors can also spread by direct extension to the choroid or along the optic nerve beyond the lamina cribrosa to the central nervous system, or by hematogenous or lymphatic spread to distant sites, including bones, bone marrow, and lungs.

SCREENING

Children with a positive family history of retinoblastoma should undergo a dilated eye examination under general anesthesia early in life and at regular intervals until genetic testing is performed and results are available. Infants with a negative genetic test require no further screening; infants with a positive genetic test require regular screening ophthalmologic examinations until age 7 years.

CLINICAL MANIFESTATIONS

Retinoblastoma classically presents with **leukocoria,** a *white pupillary reflex*, which often is first noticed when a red reflex is not present at a routine newborn or well-child examination or in a flash photograph of the child (Fig. 551.1). Strabismus often is an initial presenting complaint. Decreased vision, orbital inflammation, hyphema, and pupil irregularity can occur with advancing disease. Pain can occur if secondary glaucoma is present. Only about 10% of retinoblastoma cases are detected by routine ophthalmologic screening in the context of a positive family history.

DIAGNOSIS

The diagnosis is established by the characteristic ophthalmologic findings of a chalky, white-gray retinal mass with a soft, friable consistency. Imaging studies are not diagnostic, and biopsies are contraindicated. Indirect ophthalmoscopy with slit-lamp evaluation can detect retinoblastoma tumors, but a complete evaluation requires an examination

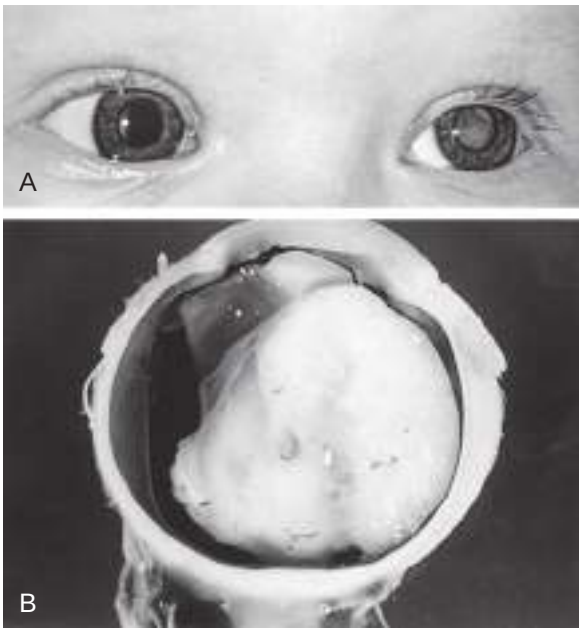

Fig. 551.1 A, Leukocoria noted in the left eye of a child presenting with retinoblastoma. B, A large white tumor mass noted within the posterior chamber of the enucleated eye. *(From Shields JA, Shields CL. Current management of retinoblastoma. Mayo Clin Proc. 1994;69:50–56.)*

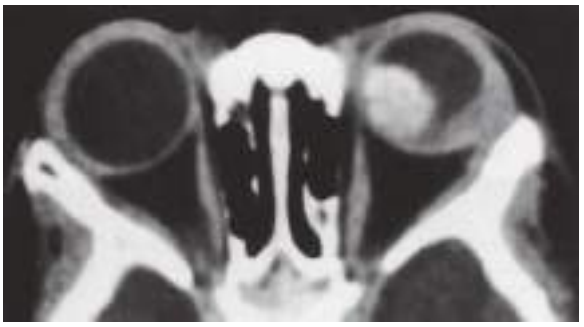

Fig. 551.2 Axial contrast-enhanced CT scan shows calcified retinoblastoma of the left eye. *(From Haaga JR, Boll DT, eds. CT and MRI of the Whole Body. 6th ed. Philadelphia: Elsevier; 2017. Fig. 20-32.)*

under general anesthesia by an experienced ophthalmologist to obtain complete visualization of both eyes, which also facilitates photographing and mapping of the tumors. Retinal detachment or vitreous hemorrhage can complicate the evaluation.

Orbital ultrasonography, CT, or MRI is used to evaluate the extent of intraocular disease and extraocular spread (Fig. 551.2). In approximately 5% of cases, a pineal area (primitive neuroectodermal) tumor is detected in a child with hereditary and bilateral retinoblastoma, a phenomenon known as **trilateral retinoblastoma**. MRI allows for better evaluation of optic nerve involvement. Metastatic disease is rarely present at diagnosis; evaluation of the cerebrospinal fluid and bone marrow for tumor metastasis and radionuclide bone scan are required only if indicated by other clinical, laboratory, or imaging findings.

The **differential diagnosis** of retinoblastoma includes other causes of leukocoria, including persistent hyperplastic primary vitreous, Coats disease, vitreous hemorrhage, cataract, endophthalmitis from *Toxocara canis*, choroidal coloboma, retinopathy of prematurity, and familial exudative vitreoretinopathy.

TREATMENT

Treatment is determined by the size and location of the tumors, if the disease is localized to the eye or has spread either to the brain or to the rest of the body, and whether the child has hereditary or sporadic disease. The primary goal of treatment is always cure; the secondary goals include preserving vision and the eye itself and decreasing the risk of late side effects, mainly secondary malignancies. With current modalities for local control of intraocular tumors and more effective systemic chemotherapy, primary enucleation is being performed less often.

Most unilateral disease presents with a solitary, large tumor. **Enucleation** is performed if useful vision cannot be salvaged. With bilateral disease, chemoreduction in combination with **focal therapy** (laser photocoagulation or cryotherapy) has replaced the traditional approach of enucleation of the more severely affected eye and irradiation of the remaining eye. If feasible, small tumors can be treated with focal therapy with careful follow-up for recurrence or new tumor growth. Larger tumors often respond to multiagent **chemotherapy**, including carboplatin, vincristine, and etoposide given intravenously. However, systemic therapy is generally reserved for patients with unilateral disease when high-risk features are noted after enucleation, or in very young patients with bilateral disease that are at higher risk of complications with intraarterial chemotherapy. The delivery of chemotherapy via the ophthalmic artery is becoming more common, as is delivery of intravitreal chemotherapy. If these approaches fail, **external-beam irradiation** should be considered, although this approach may result in significant orbital deformity and increased incidence of second malignancies in patients with germline *RB1* pathologic genetic variants. **Brachytherapy**, or *episcleral plaque radiotherapy,* is an alternative with less morbidity. Enucleation may be required for unresponsive or recurrent tumors. Intense multiagent chemotherapy with autologous stem cell rescue may be used for patients with metastatic disease.

PROGNOSIS

Approximately 95% of U.S. children with retinoblastoma are cured with modern treatment. Current efforts using chemotherapy in combination with focal therapy are intended to preserve useful vision and avoid external-beam radiation or enucleation. Unfortunately, the diagnosis of retinoblastoma in many children from resource-poor countries is delayed, resulting in spread of the tumor outside the orbit. The prognosis for children with retinoblastoma that has spread outside the eye is poor. Trilateral retinoblastoma, disease involving both eyes and the pineal region, is almost universally fatal.

Children with germline *RB1* pathologic genetic variants are at significant risk for development of *second malignancies*, especially osteosarcoma, as well as soft tissue sarcomas and malignant melanoma. The risk of second malignancies is further increased by the use of radiation therapy. Other radiation-related late adverse effects include cataracts, orbital growth deformities, lacrimal dysfunction, and late retinal vascular injury.

Visit Elsevier eBooks+ at eBooks.Health.Elsevier.com for Bibliography.

Chapter 552

Gonadal and Germ Cell Neoplasms

Cynthia E. Herzog and Winston W. Huh

EPIDEMIOLOGY

Malignant **germ cell tumors (GCTs)** and gonadal tumors are rare, with an incidence of 12 cases per 1 million persons younger than 20 years. Most malignant tumors of the gonads in children are GCTs. The incidence varies according to age and sex, although the incidence of GCTs in adolescent males has increased over time. **Sacrococcygeal** tumors occur predominantly in infant females. **Testicular** GCTs occur predominantly before age 4 years and after puberty. Klinefelter syndrome is associated with an increased risk of **mediastinal** GCTs. Trisomy 21, undescended testes, infertility, testicular atrophy, testicular microlithiasis, testicular dysgenesis syndrome, and inguinal hernias are associated with an increased risk of **testicular cancer**. The risk of testicular cancer in patients with cryptorchidism is reduced but not eliminated if orchiopexy is performed before 13 years of age. The risk of testicular GCT is increased in first-degree relatives and is highest among monozygotic twins.

PATHOGENESIS

The GCTs and non-GCTs arise from primordial germ cells and coelomic epithelium, respectively. Testicular and sacrococcygeal GCTs arising during early childhood characteristically have deletions at chromosome arms 1p and 6q and gains at 1q, and they lack the isochromosome 12p that is highly characteristic of malignant GCTs of adults. Testicular GCTs also may demonstrate loss of imprinting. Ovarian GCTs from older females characteristically have deletions at 1p and gains at 1q and 21. Dysregulation of microRNAs have been linked to GCTs. Because GCTs may contain benign and mixed malignant elements in different areas of the tumor, extensive sectioning is essential to confirm the correct diagnosis. The many histologically distinct subtypes of GCTs include **teratoma** (mature and immature), endodermal sinus tumor, and embryonal carcinoma (Fig. 552.1). Non-GCTs of the

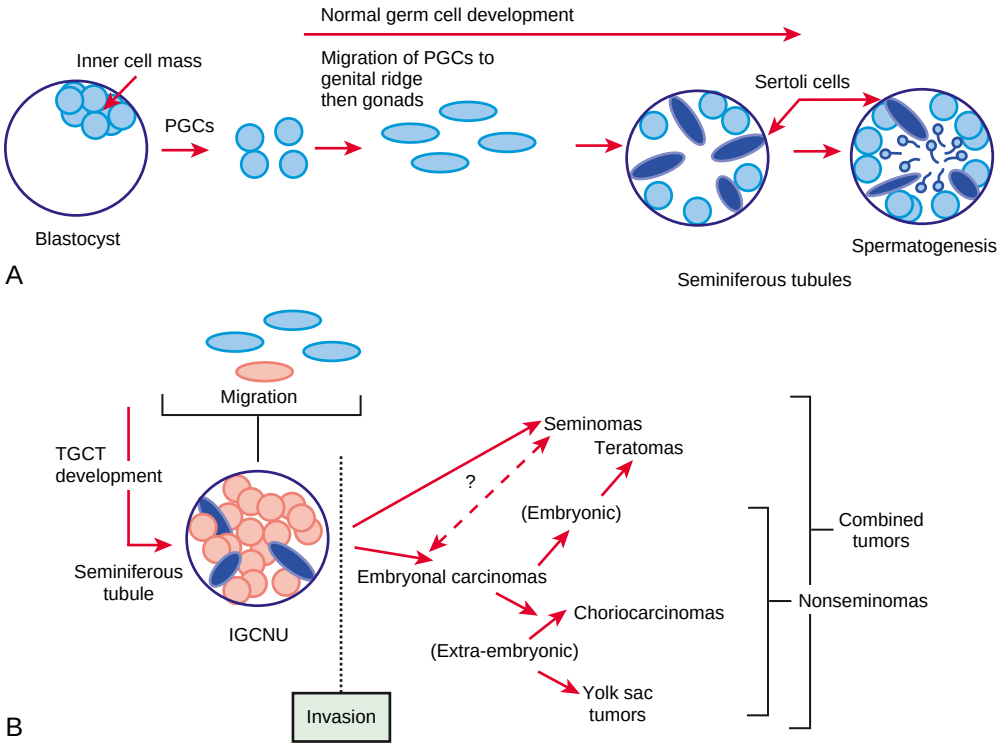

Fig. 552.1 A, Normal germ cell development. B, Model for the origin and histogenesis of different subtypes of testicular germ cell tumors. IGCNU, Intratubular germ cell neoplasia unclassified; PGCs, primary germ cells; TGCT, testicular germ cell tumor.

Table 552.1 Main Histologic Types of Testicular Germ Cell Tumors*

NONINVASIVE GERM CELL NEOPLASIA
Germ cell neoplasia in situ (GCNIS; previous synonyms: carcinoma in situ testis, intratubular germ cell neoplasia unclassified)
Gonadoblastoma (in patients with disorders of sex development; tumor also contains sex cord–stromal elements)
GERM CELL TUMORS DERIVED FROM GCNIS
Seminoma
Nonseminoma (nonseminomatous germ cell tumors)
Embryonal carcinoma
Teratoma (postpubertal type)
Yolk sac tumor (postpubertal type)
Choriocarcinoma and other trophoblastic tumors
GERM CELL TUMORS UNRELATED TO GCNIS
Childhood tumors
Teratoma (prepubertal type)
Yolk sac tumor (prepubertal type)
Spermatocytic tumor (median age at diagnosis: approximately 50 yr)

*Based on updated WHO classification of tumors of the testis and paratesticular tissue. Adapted from Raypert-De Meyts E, McGlynn KA, Okamoto, et al. Testicular germ cell tumours, *Lancet* 2016;387:1762–1770.

ovary include epithelial (serous and mucinous) and sex cord–stromal tumors; non-GCTs of the testicle include sex cord–stromal (e.g., Leydig cell, Sertoli cell) tumors. *DICER1* pathogenic variants have been observed in nonepithelial ovarian cancers, especially in Sertoli-Leydig tumors. Table 552.1 provides a histologic classification of testicular GCTs.

CLINICAL MANIFESTATIONS AND DIAGNOSIS

The clinical presentation of germ cell neoplasms depends on location (Table 552.2). Ovarian tumors often are quite large by the time they are diagnosed (Fig. 552.2). Extragonadal GCTs occur in the midline, including the suprasellar region, pineal region, neck, mediastinum, and retroperitoneal and sacrococcygeal areas (Fig. 552.3). Symptoms relate to mass effect, but the intracranial GCTs often present with anterior and posterior pituitary deficits (see Chapter 546).

The serum α-fetoprotein **(AFP)** level is elevated with endodermal sinus tumors and may be minimally elevated with teratomas (Table 552.3). Infants normally have higher levels of AFP, which usually falls to normal adult levels by about age 8 months; consequently, high AFP levels must be interpreted with caution in this age-group. Elevation of the β subunit of human chorionic gonadotropin (β-**hCG**), which is secreted by syncytiotrophoblasts, is seen with choriocarcinoma and germinomas. Lactate dehydrogenase, although nonspecific, may be a useful marker. If elevated, these markers provide important confirmation of the diagnosis and provide a means for risk stratification and to monitor the patient for tumor response and recurrence. Both serum and cerebrospinal fluid (CSF) should be assayed for these markers in patients with intracranial lesions. MicroRNA-371 is a superior tumor marker in GCT, but its use is still limited.

Diagnosis begins with physical examination and imaging studies, including plain radiographs of the chest and ultrasonography of the abdomen. CT or MRI can further delineate the primary tumor. If germ cell malignancy is strongly suggested, preoperative staging with CT of the chest and bone scan is appropriate. Primary surgical resection is indicated for tumors deemed resectable. For older patients with testicular tumors, ipsilateral retroperitoneal lymph node sampling may be required to determine extent of the disease and aid in treatment planning. Ovarian tumors also require detailed surgical evaluation, including lymph node removal and pelvic washings for cytologic analysis for peritoneal spread. Diagnosis of intracranial lesions can be established with imaging and AFP or β-hCG determinations of serum and CSF.

Gonadoblastomas often occur in patients with gonadal dysgenesis and all or parts of a Y chromosome. **Gonadal dysgenesis** is characterized by failure to fully masculinize the external genitalia. If this syndrome is diagnosed, imaging of the gonad with ultrasonography or CT is performed, and surgical resection of the tumor usually is curative. Prophylactic resection of dysgenetic gonads at the time of diagnosis is recommended, because gonadoblastomas, some of which contain malignant GCT elements, often develop. Gonadoblastomas may produce abnormal amounts of estrogen.

Table 552.2 Clinical Features of Germ Cell Tumors

	CLINICAL FEATURES	
TUMOR TYPE	**FEMALE**	**MALE**
Mature/immature teratoma	Abdominal pain, abdominal mass 10% bilateral Gliomatosis peritonei does not affect prognosis	Nontender scrotal mass Excellent survival with surgery alone in prepubertal males
Dysgerminoma/seminoma	Rapidly developed intraabdominal mass 20% bilateral 14–25% mixed with other germ cell elements	Virtually not seen in children, most common testicular tumor in adult males. Most patients present in their 30s
YST	Most common malignant histology 75% stage I	Most common malignant histology, most pediatric tumors are pure YST 85% stage I
Embryonal carcinoma	Associated with precocious puberty, amenorrhea, and hirsutism	Higher incidence of metastatic disease at presentation, patients can present with retroperitoneal mass
Choriocarcinoma	Rare in children, when present in infants related to maternal metastatic disease	Frequent pulmonary metastatic disease at presentation, patients can present with hemoptysis due to hemorrhage of metastases
Gonadoblastoma	Associated with gonadal dysgenesis Presents mostly in phenotypical females with a Y chromosome	Very rare

YST, Yolk sac tumor.
Modified from Fonseca A, Olson TA. Extracranial germ cell tumors. In: Fish JD, Liptin JM, Lanzkowsky P, eds. *Lanzkowsky's Manual of Pediatric Hematology and Oncology*. 7th ed. London: Elsevier; 2022: Table 28.2, p. 600.

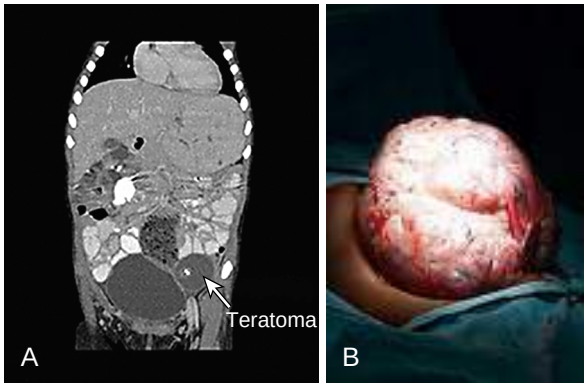

Fig. 552.2 A, Postnatal MR image showing a left ovarian teratoma with bony calcification. B, Massive ovarian teratoma. *(From Lakhoo K. Neonatal teratomas. Early Hum Dev. 2010;86:643–647.)*

Table 552.3 Serum Tumor Marker Levels for Pediatric GCTs

GCT TYPE	AFP	β-hCG	LDH
MT	-	-	-
IT	+/–	-	+/–
Seminoma/dysgerminoma	-	-	+
Yolk sac tumor	+	-	-
Choriocarcinoma	-	+	-
Embryonal carcinoma	+	+	+/–

+, Usually elevated; +/–, may be elevated; -, usually not elevated.
GCT, Germ cell tumor; AFP, α-fetoprotein; hCG, human chorionic gonadotropin; LDH, lactate dehydrogenase; MT, mature teratoma; IT, immature teratoma.
From Weil BR, Billmire DF. Management of germ cell tumors in pediatric patients. *Surg Oncol Clin N Am*. 2021;30:325–338. Table 1.

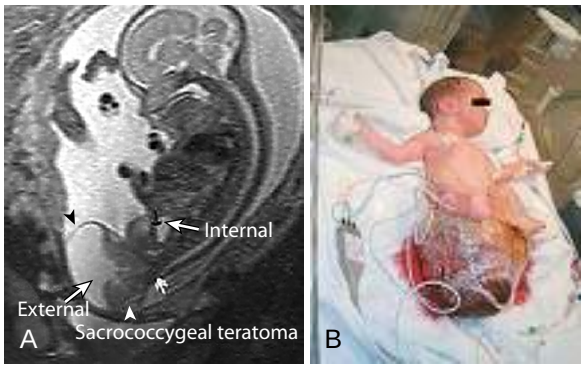

Fig. 552.3 A, Prenatal MR image showing sacrococcygeal teratoma with a small internal and large external component. B, Postnatal large, bleeding sacrococcygeal teratoma. *(From Lakhoo K. Neonatal teratomas. Early Hum Dev. 2010;86:643–647.)*

Teratomas occur in many locations, presenting as masses. They are not associated with elevated markers unless malignancy is present. The sacrococcygeal region is the most common site for teratomas. Sacrococcygeal teratomas occur most commonly in infants and may be diagnosed in utero or at birth, with most found in girls. The rate of malignancy in this location varies, ranging from <10% in children younger than 2 months to >50% in children older than 4 months.

Germinomas occur intracranially, in the mediastinum, and in the gonads. In the ovary, they are called **dysgerminomas,** and in the testis, they are called **seminomas.** They usually are tumor-marker–negative masses despite being malignant. Endodermal sinus or yolk sac tumor and choriocarcinoma appear highly malignant by histologic criteria. Both occur at gonadal and extragonadal sites. Embryonal carcinoma most often occurs in the testes. Choriocarcinoma and embryonal carcinoma rarely occur in the pure form and are usually found as part of a mixed malignant GCT.

Non–germ cell gonadal tumors are very uncommon in pediatrics and occur predominantly in the ovary. Epithelial carcinomas (usually an adult tumor), Sertoli-Leydig cell tumors, and granulosa cell

tumors may occur in children. Carcinomas account for ~30% of ovarian tumors in females <20 years old; most of these occur in older teens and are of the serous or mucinous subtype. **Sertoli-Leydig cell tumors** and **granulosa cell tumors** produce hormones that can cause virilization, feminization, or precocious puberty, depending on pubertal stage and the balance between Sertoli cells (estrogen production) and Leydig cells (androgen production). Diagnostic evaluation usually focuses on the chief complaint of inappropriate sex steroid effect and includes hormone measurements, which reflect gonadotropin-independent sex steroid production. Appropriate imaging also is performed to rule out a functioning gonadal tumor. Surgery usually is curative. No effective therapy for nonresectable disease has been found.

TREATMENT

Complete surgical excision of the tumor usually is indicated, except for patients with intracranial tumors, for whom the primary therapy consists of radiation therapy and chemotherapy. For testicular tumors, an inguinal approach is indicated, and complete resection should include the entire spermatic cord. When complete excision cannot be accomplished, preoperative chemotherapy is indicated, with second-look surgery, especially if retroperitoneal lymph node enlargement persists. For teratomas, both mature and immature, and completely resected malignant tumors of the testes and ovary, surgery alone is the treatment. For ovarian tumors, unless the contralateral ovary is obviously also involved by tumor, a fertility-sparing surgery should be performed. Cisplatin-based chemotherapy regimens usually are curative in GCTs that cannot be completely resected, even if metastases are present. However, sex cord–stromal tumors tend to be refractory to chemotherapy. Except for GCTs of the central nervous system, radiation therapy is limited to those tumors that are not amenable to complete excision and are refractory to chemotherapy. High-dose chemotherapy followed by autologous stem cell rescue is an option in those with refractory disease.

PROGNOSIS

The overall cure rate for children with GCTs is >80%. Age is the most predictive factor of survival for extragonadal GCTs. Children >12 years old have a fourfold higher risk of death and a sixfold higher risk if the tumor is thoracic. Histology has minimal effect on prognosis. Patients with nonresected extragonadal GCTs have a slightly worse prognosis.

Visit Elsevier eBooks+ at eBooks.Health.Elsevier.com for Bibliography.

Chapter 553

Neoplasms of the Liver

Fiorela N. Hernandez Tejada and Cynthia E. Herzog

Hepatic tumors are rare in children. Primary tumors of the liver account for approximately 1% of malignancies in children younger than 15 years, with an annual incidence of 1.5 cases per 1 million children in the United States (Table 553.1). Between 50% and 60% of hepatic tumors in children are malignant, with >65% of these malignancies being **hepatoblastomas** and most of the remainder being **hepatocellular carcinomas (HCCs)**. Rare **hepatic malignancies** include embryonal sarcoma, angiosarcoma, malignant germ cell tumor, rhabdomyosarcoma of the liver, and undifferentiated sarcoma. More common childhood malignancies, such as neuroblastoma, Wilms tumor, and lymphoma, can metastasize to the liver. **Benign liver tumors**, which usually present in the first 6 months of life, include hemangiomas, hamartomas, and hemangioendotheliomas.

Table 553.1 Pediatric Liver Tumors Consensus Classification

Epithelial tumors Hepatocellular	**Benign:** Hepatocellular adenoma, focal nodular hyperplasia (FNH), regenerative nodules, and dysplastic nodules **Malignant:** Hepatoblastoma (various types), hepatocellular carcinoma (classic HCC and fibrolamellar HCC), hepatocellular malignant neoplasm not otherwise specified (NOS)
Biliary	**Benign:** Bile duct adenoma, biliary hamartoma **Malignant:** Cholangiocarcinoma, combined HCC-cholangiocarcinoma
Mesenchymal tumors	**Benign:** Hemangioma, mesenchymal hamartoma **Malignant:** Embryonal sarcoma, rhabdomyosarcoma, malignant vascular tumors (epithelioid hemangioendothelioma, angiosarcoma)
Other rare malignancies	Malignant rhabdoid tumor, germ cell tumors, desmoplastic small round cell tumor, peripheral primitive neuroectodermal tumor
Metastases (and secondary)	From solid tumors: neuroblastoma, Wilms, acute myeloid leukemia, Langerhans cell histiocytosis, hemophagocytic lymphohistiocytosis

Modified from Chavhan GB, Siddiqui I, Ingley KM, Gupta AA. Rare malignant liver tumors in children. *Pediatr Radiol*. 2019;49:1404–1421. Table 1.

HEPATOBLASTOMA

Epidemiology

Approximately 100 new cases of hepatoblastoma are diagnosed each year in the United States. The incidence of hepatoblastoma has increased over the last 30 years by as much as 2.7% per year, probably related to increasing survival of very low birthweight premature infants. Hepatoblastoma occurs predominantly in children <3 years old, and the median age of diagnosis is 1 year. The etiology is unknown. Hepatoblastomas are associated with **familial adenomatous polyposis**. Alterations in the antigen-presenting cell/β-catenin pathway have been found in most of the tumors evaluated. Hepatoblastomas are also associated with **Beckwith-Wiedemann syndrome** (BWS), **hemihyperplasia**, and other somatic overgrowth syndromes. Increased expression of insulin-like growth factor 2 secondary to genetic pathogenic variants or epigenetic changes is implicated in hepatoblastoma development in patients with BWS. All children with BWS or hemihyperplasia should be routinely screened with α-fetoprotein (AFP) levels and abdominal ultrasounds. Prematurity/low birthweight is associated with increased incidence of hepatoblastoma, with the risk increasing as birthweight decreases. Aicardi syndrome, trisomy 18, other trisomies, Li-Fraumeni syndrome, Prader-Willi syndrome, Alagille syndrome, glycogen storage disease (type 1), Simpson-Golabi-Behmel syndrome, and fetal alcohol syndrome have also been associated with increased risk of hepatoblastoma.

Pathogenesis

Hepatoblastoma arises from precursors of hepatocytes and is histologically classified as *whole epithelial* type, containing fetal or embryonal malignant cells (either as a mixture or as pure elements), and *mixed* type, containing both epithelial and mesenchymal elements. Histologic classification has a direct correlation with clinical outcome. *Pure fetal histology* and low mitotic activity predicts the best outcome, and the *small cell undifferentiated* subtype associated with normal AFP levels predicts the worse outcome.

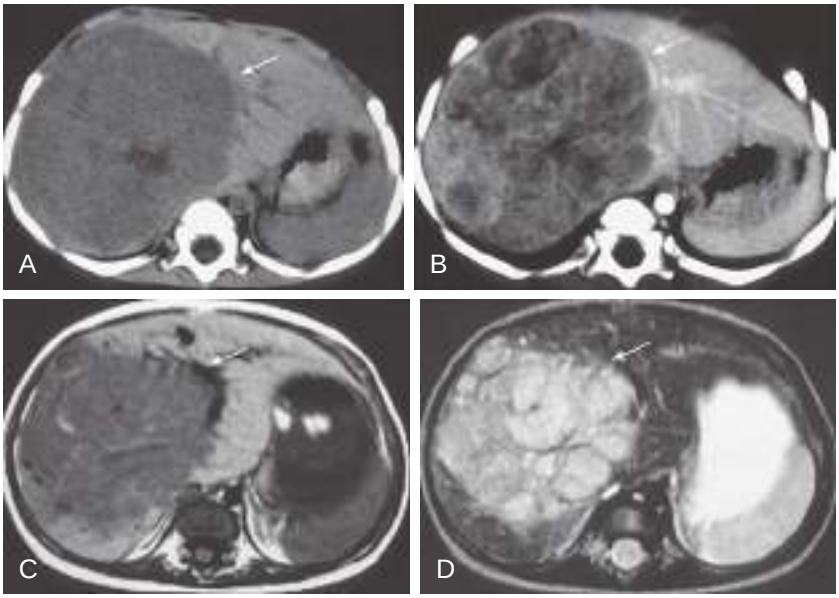

Fig. 553.1 Hepatoblastoma in a 3-yr-old child. **A**, Precontrast CT scan shows well-demarcated, heterogeneous hypodense mass *(arrow)*. **B**, Postcontrast CT scan shows heterogeneous internal enhancement *(arrow)*. **C** and **D**, The mass *(arrow)* demonstrates heterogeneous hypointensity on T1-weighted (**C**) and hyperintensity on T2-weighted (**D**) MR images.

Clinical Manifestations

Hepatoblastoma usually presents as a large, asymptomatic abdominal mass, with no associated systemic symptoms. Jaundice is uncommon. It arises from the right lobe three times more often than the left and usually is unifocal. When the disease progresses, fatigue, fever, weight loss, anorexia, vomiting, and abdominal pain may ensue. Rarely, hepatoblastoma presents with hemorrhage secondary to trauma or spontaneous rupture. Metastatic spread of hepatoblastoma most often involves regional lymph nodes and the lungs.

Diagnosis

A biopsy of liver tumors is necessary to establish the diagnosis. A valuable serum tumor marker, AFP, is used in the diagnosis and monitoring of hepatic tumors. AFP is normally elevated in the newborn period and then declines to <10 ng/mL by 1 year of age. The AFP levels are elevated in almost all hepatoblastomas. Bilirubin and liver enzymes usually are normal. Anemia is common, and thrombocytosis occurs in approximately 30% of patients. Serologic testing for hepatitides B and C should be performed, but the results usually are negative in hepatoblastoma.

Diagnostic imaging should include plain radiographs and ultrasonography of the abdomen to characterize the hepatic mass. US can differentiate malignant hepatic masses from benign vascular lesions. Either CT or MRI is an accurate method of defining the extent of intrahepatic tumor involvement and the potential for surgical resection. Evaluation for metastatic disease should include CT of the chest (Fig. 553.1).

Treatment

Treatment is guided by the degree of local tumor burden determined by the pre- and posttreatment extent of disease. In general, the cure of malignant hepatic tumors in children depends on complete resection of the primary tumor (Fig. 553.2); as much as 85% of the liver can be resected, with hepatic regeneration noted within 3-4 months after surgery. Treatment of hepatoblastoma is based on surgery and **systemic chemotherapy** using cisplatin in combination with vincristine and 5-fluorouracil (5-FU), and for intermediate- and high-risk patients, doxorubicin is also used. The role of **radiation therapy** is questionable, because the effective antitumor dose exceeds the hepatic tolerance. Radiation therapy may have a role in shrinking unresectable disease or managing incompletely resected tumors. In 30% of cases, tumors are resectable at diagnosis; a safe attempt for initial gross total resection should be made, followed by adjuvant chemotherapy. Unresectable tumors with or without metastatic disease at presentation usually respond to chemotherapy; preresection chemotherapy is indicated, and excision of the primary tumor and

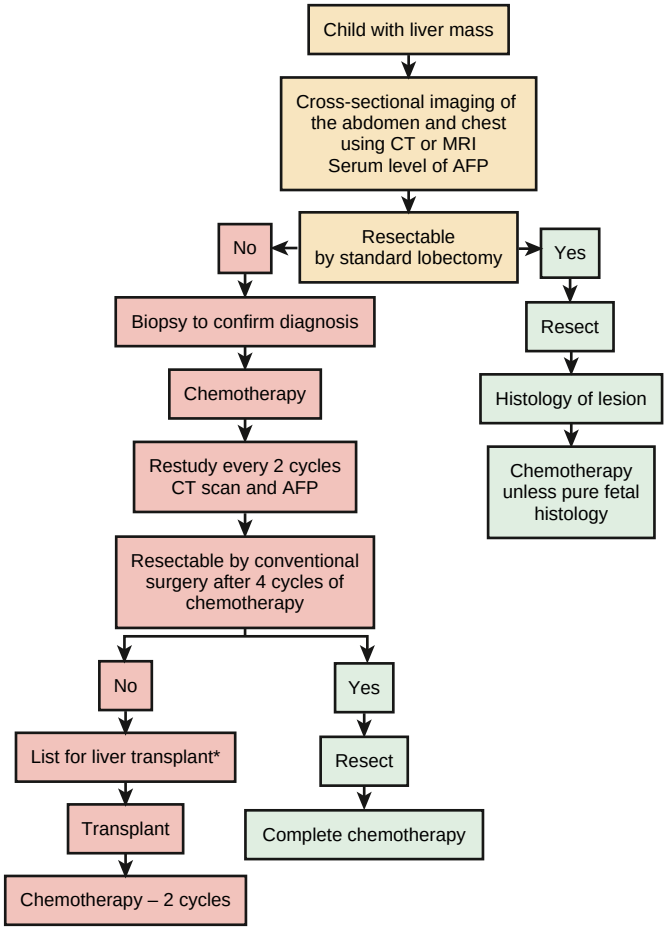

Fig. 553.2 Algorithm for the management of a child who presents with a hepatoblastoma. AFP, α-Fetoprotein. *(From Tiao GM, Bobey N, Allen S, et al. The current management of hepatoblastoma: a combination of chemotherapy, conventional resection, and liver transplantation. J Pediatr. 2005;146:204–211.)*

extrahepatic disease should be attempted as soon as it becomes feasible, followed by additional chemotherapy. Orthotopic **liver transplant** is a viable option for unresectable primary hepatic malignancies and results in good long-term survival. The pretransplant medical condition is an important predictor of outcome, and thus transplant is much more effective as the primary surgery than as salvage therapy. Alternative treatment options currently under investigation include other systemic chemotherapy agents such as carboplatin, ifosfamide, etoposide, irinotecan, and temsirolimus. Other treatment approaches include transarterial chemoembolization, cryoablation, and radiofrequency ablation (RFA).

Prognosis

In low-stage tumors, survival rates >90% can be achieved with multimodal treatment, including surgery and adjuvant chemotherapy. With tumors unresectable at diagnosis, survival rates of approximately 60% can be obtained. Metastatic disease further reduces survival, but complete regression of disease often can be obtained with chemotherapy and surgical resection of the primary tumor and isolated pulmonary metastatic disease, resulting in survival rates of approximately 25%. Treatment-related long-term adverse effects include cardiac toxicity with doxorubicin and renal and ototoxicity with cisplatin.

HEPATOCELLULAR CARCINOMA

Epidemiology

HCC occurs mostly in adolescents and often is associated with perinatal acquired hepatitis B infection and tyrosinemia. It is more common in East Asia and other areas where hepatitis B is endemic; the incidence has decreased following the introduction of hepatitis B vaccination. In these areas, HCC also tends to occur in a bimodal pattern, with the younger age peak overlapping the age of hepatoblastoma presentation. HCC also occurs in the chronic form of glycogen storage disease, α_1-antitrypsin deficiency, biliary atresia, progressive familial intrahepatic cholestasis, Alagille syndrome, congenital portosystemic shunts, Budd-Chiari syndrome, status postirradiation for liver metastatic Wilms tumor, and with other liver diseases producing chronic inflammation or cirrhosis (Fig. 553.3).

Pathogenesis

Pediatric HCC arises in cirrhotic and noncirrhotic backgrounds and presents as a multicentric, invasive tumor consisting of large pleomorphic cells of epithelial origin. Compared to adults, cirrhosis in children is less common, and congenital liver disorders are more common. HCCs are classified as **classical** or **fibrolamellar**. The fibrolamellar variant occurs more often in adolescent and young adult patients, is not associated with cirrhosis, and represents one fourth of the pediatric

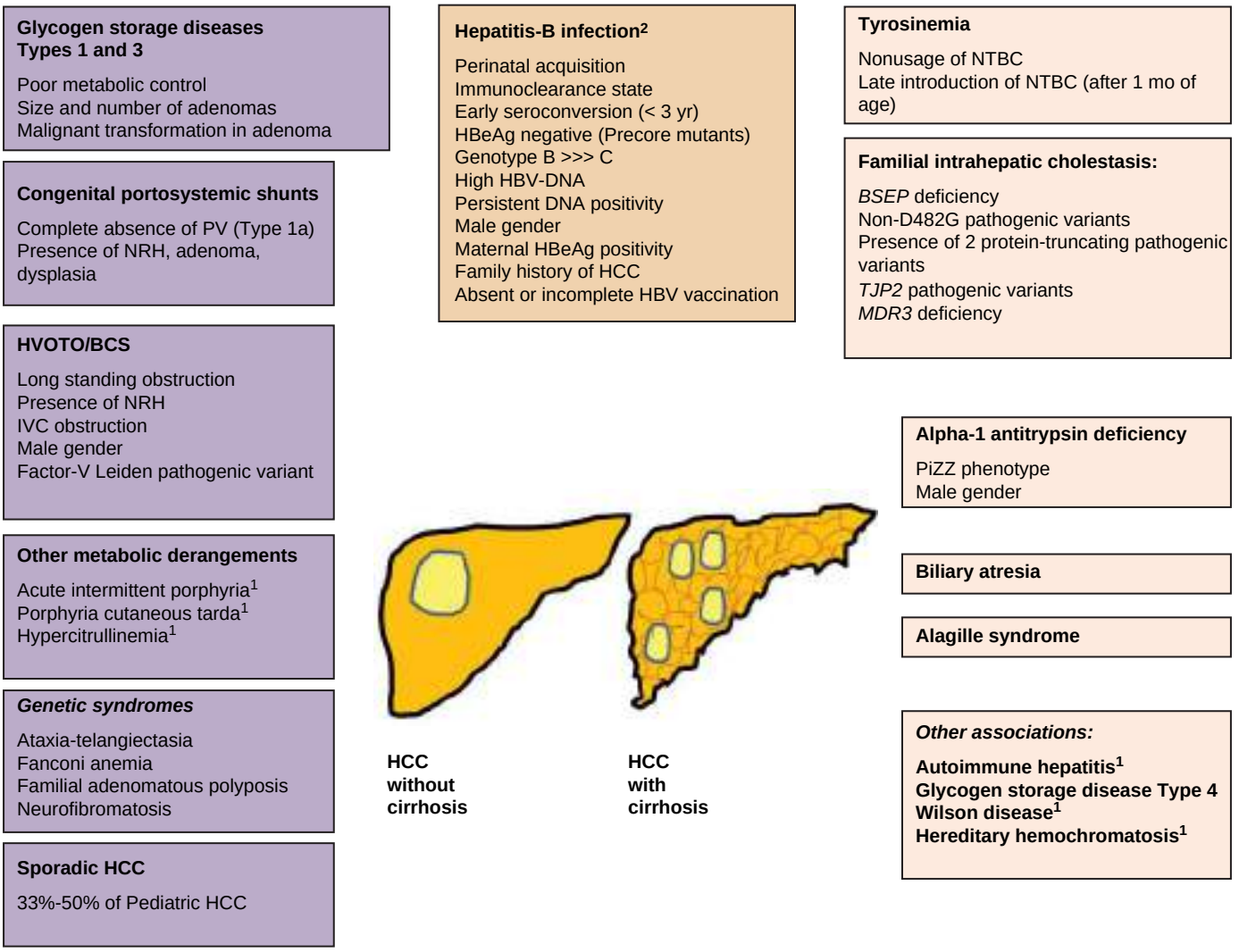

Fig. 553.3 Risk factors for pediatric hepatocellular carcinoma (HCC). [1]Conditions cause HCC in adults, and very rarely in children; [2]Hepatitis B virus (HBV)-related HCC may occur in the presence or absence of cirrhosis. BCS, Budd-Chiari syndrome; HVOTO, hepatic venous outflow tract obstruction; IVC, inferior vena cava; NRH, nodular regenerative hyperplasia; BSEP, bile salt export pump; MDR3, multidrug resistance protein-3; NTBC, [2-(2-nitro4-trifluoromethylbenzoyl)-1,3-cyclohexanedione (Nitisinone); PiZZ, homozygous PiZ phenotype of α_1-antitrypsin; PV, Portal vein; TJP: tight junction protein. *(From Khanna R, Verma SK. Pediatric hepatocellular carcinoma. World J Gastroenterol. 2018;24[35]:3980–3999. Fig. 1.)*

HCC cases. This variant has been reported to have a distinct translocation, *DNAJB1-PRKACA*. A rare subtype called **transitional liver tumor** occurs in older children and has clinical and histopathologic findings of both hepatoblastoma and HCC.

Clinical Manifestations

HCC usually presents as a hepatic mass with abdominal distention and symptoms of anorexia, weight loss, jaundice, and abdominal pain. HCC can present as an acute abdominal crisis with rupture of the tumor and hemoperitoneum. Metastatic spread usually involves regional lymph nodes and the lungs. The AFP level is elevated in approximately 60% of children with conventional HCC, but not in the fibrolamellar variant. Evidence of hepatitis B usually is found in endemic areas but not in Western countries or with the fibrolamellar type. Liver enzymes may be abnormal.

Diagnostic imaging should include plain radiographs and US of the abdomen to characterize the hepatic mass. US can differentiate malignant hepatic masses from benign vascular lesions. Either CT or MRI is an accurate method of defining the extent of intrahepatic tumor involvement and the potential for surgical resection. Evaluation for metastatic disease should include CT of the chest.

Treatment

Complete tumor resection is crucial for curative treatment. Because of the multicentric origin of HCC and underlying liver disease, complete resection is accomplished in only 20–30% of cases. A gross total resection should be attempted at diagnosis when possible; if not, neoadjuvant chemotherapy should be given to convert nonresectable tumors into resectable ones. Combination chemotherapy following surgery is necessary. For unresectable tumors, **chemotherapy** followed by surgical assessment is essential, and **liver transplant** should be decided individually for each patient with HCC. Chemotherapy, including cisplatin, carboplatin, doxorubicin, and etoposide, has shown activity against this tumor, but improved long-term outcome has been difficult to achieve if tumor is not completed resected. **Sorafenib**, a small inhibitor of several tyrosine protein kinase showed antitumoral activity in adult patients with HCC, and initial studies have been published in the pediatric population with encouraging results. Other techniques are under study in adults, including cryosurgery, RFA, transarterial chemoembolization, and radiation therapy.

Visit Elsevier eBooks+ at eBooks.Health.Elsevier.com for Bibliography.

Chapter 554

Complex Vascular Anomalies

Alexandra J. Borst and Denise M. Adams

Vascular anomalies in children encompass a spectrum of disorders that may be divided into **vascular malformations** and vascular tumors (Tables 554.1-554.4; see Chapter 691). **Vascular malformations** are developmental disorders of blood vessel formation. Malformations do not regress; rather, they slowly enlarge. They should be named after the predominant vessel(s) forming the lesion: arterial, capillary, lymphatic, or venous, or combinations of these (see Table 554.1). Vascular tumors exhibit endothelial cell hyperplasia and proliferation. The International Society for the Study of Vascular Anomalies (ISSVA) continues to update the classification structure for vascular disorders as new disorders are identified and as the biology and genetic causes for established disorders are found. The complete classification, associated syndromes, and causative pathogenic variants can be found at www.issva.org. The discovery of the molecular basis of many **vascular malformations** and tumors has allowed for improved understanding of the etiology of these disorders as well as new **targeted therapeutic approaches** for management.

GENETIC BASIS FOR VASCULAR ANOMALIES

Two key intracellular signaling pathways have been implicated in the pathogenesis of most **vascular malformations**, syndromes, and tumors. The RAS/MAPK and PI3K/AKT/mTOR pathways are crucial for cell cycle regulation, proliferation, and migration (Fig. 554.1). Pathogenic, *somatic* variants in the *PIK3CA* gene have been identified in patients with **venous malformations**, **lymphatic malformations**, and several vascular anomalies and overgrowth syndromes (see Table 554.4). Pathogenic variants in the RAS/MAPK pathway have been identified in **capillary and arteriovenous malformations (AVMs)**, central conducting lymphatic anomalies, as well as many of the vascular tumors.

Discovery of the molecular basis for **vascular malformations** and tumors has led to the ability to find **targeted therapies** for management of these conditions. **Sirolimus** has been utilized successfully in vascular malformations and tumors. The identification of the crucial role of *PIK3CA* pathogenic variants in vascular anomalies has led to the investigation of **PI3K inhibitors** as important targeted therapies. Agents that target the RAS/MAPK pathway, such as **MEK inhibitors**, have also been trialed in complicated AVMs as well as Kaposiform lymphangiomatosis (KLA).

COMPLEX LYMPHATIC ANOMALIES

Lymphatic anomalies represent a rare disease entity, with an estimated incidence of 1:10,000 for the most common form of lymphatic malformations, but with only a few hundred case reports in the literature for *complex* lymphatic anomalies. Lymphatic anomalies arise from developmental defects in lymphangiogenesis. They carry significant risk for comorbidities, including pain, infection, disfigurement, and life-threatening organ dysfunction. Lymphatic anomalies encompass a broad range of developmental and functional defects in lymphatic vessels that range from discrete malformations to complex anomalies (generalized lymphatic anomaly [GLA], KLA, and Gorham-Stout disease [GSD]) and primary lymphedema syndromes.

Most lymphatic anomalies are thought to arise from *somatic* pathogenic variants in genes involved in lymphangiogenesis, but germline predispositions also exist. Pathogenic variants in the PIK3CA/AKT/mTOR and VEGFC/VEGFR3 pathways have been found in many isolated lymphatic malformations; variants in the RAS/MAPK pathway have been identified in patients with *complex lymphatic anomalies* (Fig. 554.2). However, most patients remain without a genetic diagnosis.

Generalized Lymphatic Anomaly

Previously known as lymphangiomatosis, GLA is characterized by a nonneoplastic, multicentric proliferation of dilated lymphatic vessels, with multiple sites resembling common lymphatic malformations (Fig. 554.3). The lesions are present since birth but generally become clinically apparent within the first 2 decades of life. The lesions can affect the bones, liver, spleen, mediastinum, lung, and soft tissues. Bone involvement is typically osteolytic, with punched out lesions and intact cortex. Clinical response depends on location and extent of disease, with thoracic involvement having the poorest prognosis. Patients with GLA most commonly have pathogenic somatic variants in *PIK3CA* leading to overactivity in the PI3K/AKT/mTOR pathway and disrupted lymphatic development and growth. Many patients have been successfully managed with sirolimus.

Gorham-Stout Disease

GSD (also known as *vanishing bone disease*) has significant clinical overlap with GLA but tends to involve a single site or adjacent sites. Patients may present with adjacent soft tissue mass or small areas of

Table 554.1 Overview of Vascular Anomalies

VASCULAR TUMORS	VASCULAR MALFORMATIONS			
	SIMPLE	COMBINED*	OF MAJOR NAMED VESSELS	ASSOCIATED WITH OTHER ANOMALIES
Benign	Capillary malformations Lymphatic malformations	CMV, CLM LVM, CLVM	See Table 554.2	See Table 554.3
Locally aggressive or borderline	Venous malformations Arteriovenous malformations†	CAVM† CLAVM†		
Malignant	Arteriovenous fistula†	Others		

*Defined as two or more vascular malformations found in one lesion.
†High-flow lesions.
A list of casual genes and related vascular anomalies is available in Tables 554.3 and 554.4
CVM, Capillary venous malformation; CLM, capillary lymphatic malformation, LVM, lymphatic venous malformation, CLVM, capillary lymphatic venous malformation, CAVM, capillary arteriovenous malformation; CLAVM, capillary lymphatic arteriovenous malformation.
From ISSVA Classification for Vascular Anomalies (Approved at the 20th ISSVA Workshop, Melbourne, April 2014, last revision May 2018) https://www.issva.org/UserFiles/file/ISSVA-Classification-2018.pdf

Table 554.2 Anomalies of Major Named Vessels (Also Known as "Channel Type" or "Truncal" Vascular Malformations)

Affect
Lymphatics
Veins
Arteries
Anomalies of
Origin
Course
Number
Length
Diameter (aplasia, hypoplasia, stenosis, ectasia / aneurysm)
Valves
Communication (AVF)
Persistence (of embryonal vessel)

AVF, Arteriovenous fistula.
From ISSVA Classification for Vascular Anomalies (Approved at the 20th ISSVA Workshop, Melbourne, April 2014, last revision May 2018) https://www.issva.org/UserFiles/file/ISSVA-Classification-2018.pdf

microcystic lymphatic malformation. The upper axial skeleton is commonly affected, and there is osteolysis of both the medullary and cortical bone (Fig. 554.4). This osteolysis can be profound and result in significant morbidity, including dysfunction of an appendage or even spinal column instability. Some molecular findings in patients with GSD have suggested that somatic activating variants in *KRAS* and dysfunction of the RAS/MAPK signaling pathway drive the pathogenesis of GSD. Many patients have been treated with sirolimus with adjunctive bisphosphonate therapy.

Kaposiform Lymphangiomatosis

KLA has been considered an aggressive subtype of GLA but is histologically and molecularly distinct. Many patients with KLA harbor *somatic* activation variants in the RAS pathway, rather than the PI3K/AKT/mTOR pathway identified as causative in GLA. KLA presents with distinct foci of spindled endothelial cells on a background of malformed lymphatic vessels. KLA can affect multiple organs and sites but primarily affects the thoracic cavity with patients presenting with life-threatening, and frequently hemorrhagic, pleural effusions (Fig. 554.5). Patients often have a coagulopathy at presentation due to the same **Kasabach-Merritt phenomenon (KMP)** seen in patients with **Kaposiform hemangioendothelioma**. Patients typically present at a younger age than those with GLA or GSD; the mortality has been reported as high as 50–60% prior to the introduction of sirolimus.

Central Conducting Lymphatic Anomaly

Central conducting lymphatic anomaly (CCLA), also known as *lymphangiectasia*, is classified as a channel-type lymphatic anomaly. CCLA is caused by lymphatic channel dysmotility and distal obstruction/malformation affecting lymphatic drainage and leading to recurrent effusions (Fig. 554.6). Patients with other complex lymphatic anomalies may have a component of CCLA. Pathogenic variants in *EPHB4* and *ARAF* have been identified in patients with CCLA and both mTOR and MEK inhibition have been used in its management with mixed success. Patients frequently needed targeted interventional procedures to embolize abnormal lymphatic vessels.

Treatment of Complex Lymphatic Anomalies

Management of complex lymphatic anomalies is principally aimed at control, not cure. This can include a variety of medical, surgical, and interventional procedures to control symptoms and prevent morbidity. Sirolimus, an mTOR inhibitor, has been shown to decrease symptoms of lymphatic leak such as lymphatic blebs, decrease the size of macrocystic and microcystic malformations, decrease chylous production, and may slow the pathologic dissolution of bone by lymphatic malformation. MEK inhibition has shown promise in the management of KLA and CCLA, both found to be driven more by perturbations affecting RAS/MAPK signaling. Adjunctive therapy with bisphosphonates is often used in GSD and in patients with GLA and KLA with bony vertebral lesions.

COMPLEX VENOUS ANOMALIES

Venous anomalies are slow-flow lesions that represent abnormal or excessive growth of venous structures. **Venous malformations** are the most common vascular malformations with an incidence of 1 in 5,000 to 10,000. Due to the slow and sometimes turbulent flow, they commonly are associated with pain, swelling, and intralesional thrombosis. Venous malformations have been found to have *somatic* pathogenic variants in both *PIK3CA* and *TIE2/TEK*, an endothelial cell–specific tyrosine kinase receptor that functions through the PI3K/AKT/mTOR pathway (see Fig. 554.1).

Blue Rubber Bleb Nevus Syndrome

Blue rubber bleb nevus syndrome (BRBNS) is characterized by multiple cutaneous and internal venous malformations, primarily hepatic and intestinal (Fig. 554.7). Many cases have been found to be due to gain-of-function

Table 554.3 Vascular Malformations Associated with Other Anomalies

SYNDROME	LESIONS	GENES
Klippel-Trenaunay syndrome*:	CM + VM +/− LM + limb overgrowth	*PIK3CA*
Parkes-Weber syndrome:	CM + AVF + limb overgrowth	*RASA1*
Servelle-Martorell syndrome:	limb VM + bone undergrowth	
Sturge-Weber syndrome:	facial + leptomeningeal CM + eye anomalies +/− bone and/or soft tissue overgrowth	*GNAQ*
Limb CM + congenital nonprogressive limb overgrowth		*GNA11*
Maffucci syndrome:	VM +/− spindle-cell hemangioma + enchondroma	*IDH1/IDH2*
Macrocephaly-CM (M-CM/MCAP)*		*PIK3CA*
Microcephaly-CM (MICCAP)		*STAMBP*
CLOVES syndrome*:	LM + VM + CM +/− AVM + lipomatous overgrowth	*PICK3CA*
Proteus syndrome:	CM, VM, and/or LM + asymmetrical somatic overgrowth	*AKT1*
Bannayan-Riley-Ruvalcaba syndrome:	AVM + VM + macrocephaly, lipomatous overgrowth	*PTEN*
CLAPO syndrome*:	lower lip CM + face and neck LM + asymmetry and partial/generalized overgrowth	*PIK3CA*

*These lesions belong to the PIK3CA-related overgrowth spectrum (PROS)
CM, Capillary malformation; VM, venous malformation; LM, lymphatic malformation; AVF, arteriovenous fistula; M-CM, macrocephaly-capillary malformation; MCAP, megalocephaly-capillary-malformation-polymicrogyria; MICCAP, microcephaly-capillary malformation; CLOVES, congenital lipomatous overgrowth, vascular malformations, epidermal nevi, skeletal/scoliosis/spinal anomalies; CLAPO, lower lip CM + face and neck LM + asymmetry and partial/generalized overgrowth.
From ISSVA Classification for Vascular Anomalies (Approved at the 20th ISSVA Workshop, Melbourne, April 2014, last revision May 2018) https://www.issva.org/UserFiles/file/ISSVA-Classification-2018.pdf

Table 554.4 PIK3CA-Related Overgrowth Spectrum

PIK3CA-related overgrowth spectrum (PROS) group lesions with heterogeneous segmental overgrowth phenotypes with or without vascular anomalies due to somatic PIK3CA activating variants.

This spectrum includes:

- Fibroadipose hyperplasia or overgrowth (FAO)
- Hemihyperplasia multiple lipomatosis (HHML)
- Congenital lipomatous overgrowth, vascular malformations, epidermal nevi, scoliosis/skeletal, and spinal (CLOVES) syndrome
- Macrodactyly
- Fibroadipose infiltrating lipomatosis/facial infiltrative lipomatosis
- Megalencephaly-capillary malformation (MCAP or M-CM)
- Dysplastic megalencephaly (DMEG)
- Klippel-Trenaunay syndrome

From ISSVA Classification for Vascular Anomalies (Approved at the 20th ISSVA Workshop, Melbourne, April 2014, last revision May 2018) https://www.issva.org/UserFiles/file/ISSVA-Classification-2018.pdf

TIE2/TEK pathogenic variants; both sporadic and autosomal dominant inheritance have been described. Significant morbidity can arise due to intestinal venous malformations, which can lead to severe bleeding and secondary iron deficiency anemia. Patients must be monitored closely for signs and symptoms of bleeding. The mainstay of management is control of disease with sirolimus and supportive care for anemia.

Glomuvenous Malformation (Glomangioma)

Glomuvenous malformations, also known as *glomangiomas* or *glomus tumors*, are one of the rare germline conditions in vascular anomalies. Glomuvenous malformations result from an autosomal dominant loss-of-function variant in the *GLMN* gene, which encodes a protein essential for normal vascular development. Patients present with multiple superficial cutaneous lesions with a cobblestone appearance (Fig. 554.8). There is 100% penetrance but variable expressivity. Painful lesions can be treated with surgical resection, laser, or sclerotherapy.

SYNDROMES ASSOCIATED WITH VASCULAR ANOMALIES

PIK3CA-Related Overgrowth Spectrum Disorders

PIK3CA-related overgrowth spectrum (PROS) encompasses a group of disorders caused by somatic mosaic mutations in the PI3K/AKT/mTOR pathway (see Table 554.4). The *PIK3CA* (phosphatidylinositol-4,5-bisphosphate 3-kinase catalytic subunit α) gene encodes a group of lipid kinases (PI3 kinases) that are key to regulating cell proliferation and survival via the PI3K/AKT/mTOR pathway. Patients with PROS present with a wide spectrum of clinical phenotypes, but progressive segmental overgrowth and vascular malformations are key components.

Klippel-Trenaunay Syndrome

Klippel-Trenaunay syndrome (KTS) is characterized by overgrowth of one lower extremity in combination with combined slow-flow vascular malformation (capillary, venous, and/or lymphatic). Complications include lymphatic overgrowth, infection, oozing and/or bleeding from lymphatic blebs, and thromboembolism (Fig. 554.9). Patients with KTS have an anomalous venous return system composed of dilated and incompetent veins, often with a larger marginal vein. The deep venous system may also be poorly developed. Patients can have lymphatic involvement of the skin, musculature, and intestinal tract. Venous malformation may affect the bladder and urethra. Due to variability in diagnostic criteria and identification of KTS over the years, the genetic etiology of KTS is not completely confirmed, but many patients have been identified to have a *somatic* variants in *PIK3CA*; KTS is considered part of PROS disorders. Surgical and interventional procedures may be important for some patients with KTS. Medical management currently includes sirolimus and anticoagulation therapy.

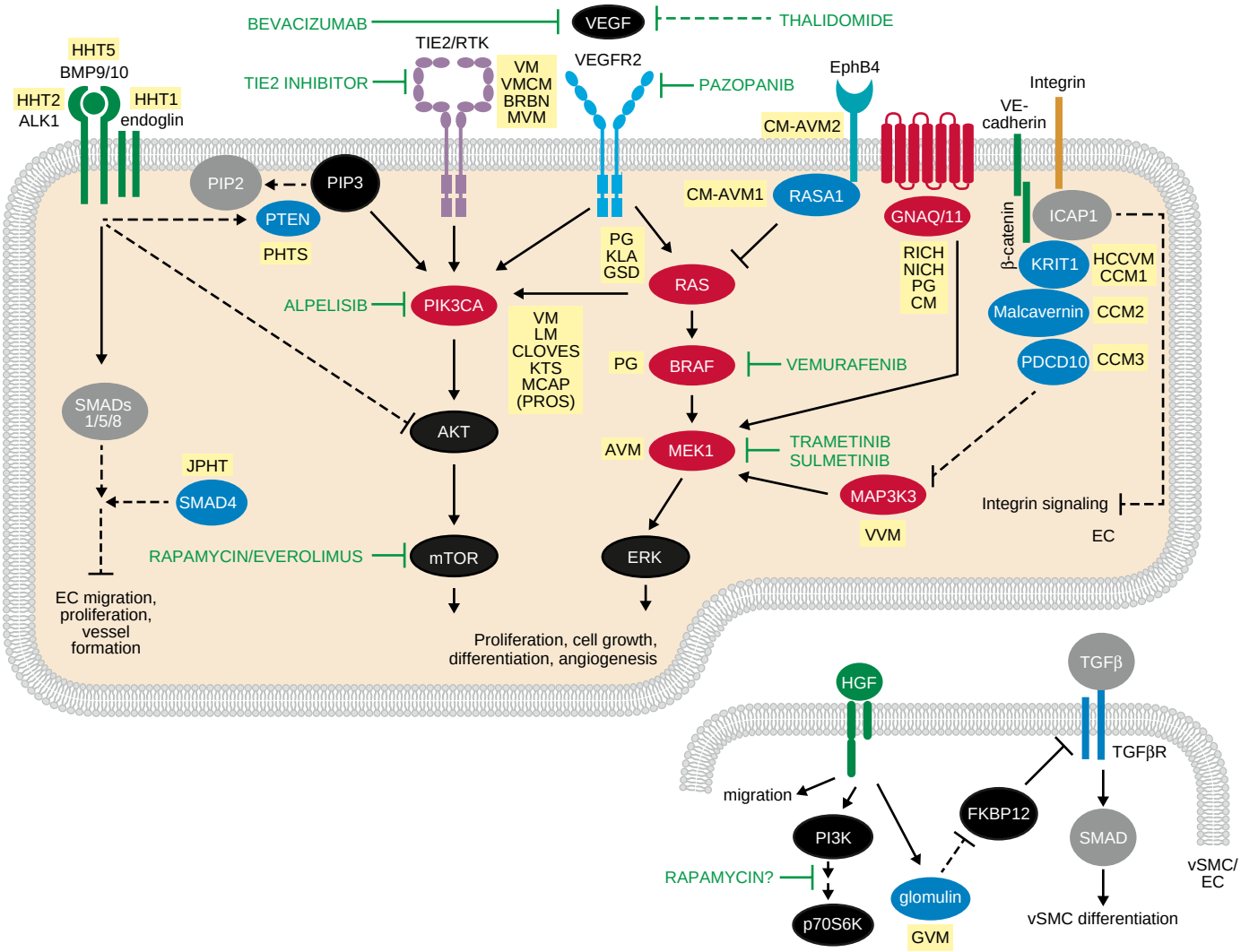

Fig. 554.1 PI3K/AKT/mTOR signaling and RAS/MAPK signaling in vascular anomalies. Red, gain of function; blue, loss of function; black, enhanced signaling; gray, decreased signaling. *(From Queisser A, Seront E, Boon LM, Vikkula M. Genetic basis and therapies for vascular anomalies. Circ Res. 2021;129[1]:155–173. Fig. 3.)*

CLOVES

CLOVES, or congenital lipomatous overgrowth, vascular malformations, epidermal nevi, and scoliosis/spinal/skeletal anomalies, is a disorder that results from an early embryonic pathogenic variant in *PIK3CA*. In addition to extremity hypertrophy, patients can have significant fatty lipomatous overgrowth (Fig. 554.10). Spinal involvement is common. Patients with vascular malformations usually have a combination of capillary, venous, and lymphatic malformations. AVMs are less common but have been reported with spinal involvement. Deep venous anomalies increase the risk for venous thromboembolism. Patients with CLOVES have an increased risk of Wilms tumor and require serial monitoring with abdominal ultrasonography in early childhood. Patients may require sclerotherapy, surgery, and other interventional procedures depending on symptoms. Patients have also been successfully managed with sirolimus.

Macrocephaly-Capillary Malformation

Macrocephaly-capillary malformation (M-CM) syndrome is a PROS disorder characterized by macrocephaly, brain abnormalities, CM (often in a reticular pattern), overgrowth, and developmental delays (Fig. 554.11). Neurologic manifestations can include hydrocephalus, cortical dysplasia, polymicrogyria, and posterior fossa crowding with cerebellar tonsillar herniation. Patients require supportive care for overgrowth and other vascular anomalies, as well as close monitoring of brain growth and development.

AKT-RELATED OVERGROWTH SPECTRUM

Proteus Syndrome

Proteus is an overgrowth disorder caused by a *somatic* mosaic pathogenic variant in the PI3K/AKT/mTOR pathway. Clinical features include overgrowth (including lipomatous), bony abnormalities, cerebriform connective tissue nevus, vascular malformations (capillary, venous, lymphatic), epidermal nevi, cerebral abnormalities and accompanying intellectual disability, and increased risk for secondary neoplasms and venous thromboembolism. Management of proteus disorders has primarily been supportive, although use of AKT1 inhibition is currently being evaluated.

RASopathies

RASopathies refers to a group of medical conditions caused by pathogenic variants in the RAS/MAPK pathway. It includes both germline conditions, as well as *somatic* variants. The RAS/MAPK pathway is important in cell cycle regulation, proliferation, migration, and stress response. RAS/MAPK pathway pathogenic variants have been identified in patients with solitary CMs and AVMs, GLA, KLA, verrucous venous malformation, cerebral CM, pyogenic granuloma (PG), and congenital hemangiomas.

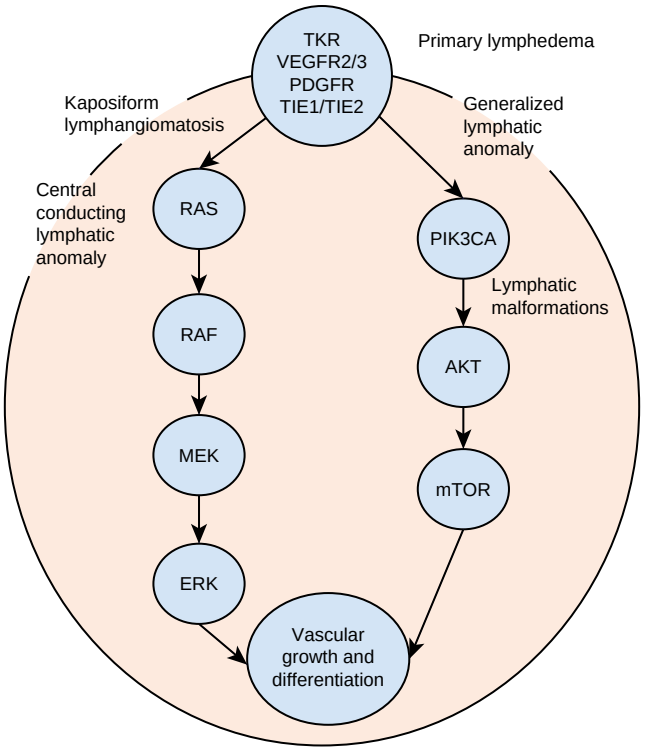

Fig. 554.2 Molecular pathways identified in lymphatic anomalies.

Capillary Malformation-Arteriovenous Malformation Syndrome

Capillary malformation-arteriovenous malformation (CM-AVM) is an autosomal dominant disorder characterized by diffuse, circumscribed CMs and increased risk for intra- or extracranial AVMs. AVMs are found in ~80% of patients. The CMs have a distinct appearance with a round or ovoid shape and surrounding pale halo. Most cases of CM-AVM are caused by a loss-of-function pathogenic variant in *RASA1*, but variants in *EPHB4* have also been reported (CM-AVM type 2). Familial penetrance is high, and screening is important due to the high risk for life-threatening complications from AVMs. AVMs may require treatment with a combination of interventional and surgical procedures.

Parkes-Weber Syndrome

Parkes-Weber syndrome (PKWS) is associated with pathogenic variants in *RASA1*. The syndrome includes multiple microscopic arteriovenous fistulae in association with a CM. PKWS is also associated with soft tissue and bony overgrowth of an extremity.

KAPOSIFORM HEMANGIOENDOTHELIOMA

Kaposiform hemangioendothelioma (KHE) is a rare and potentially life-threatening vascular tumor. KHE classically presents as a red to purple firm plaque on the lateral neck, axilla, trunk, or extremities. Visceral tumors occur as well. Lesions may occasionally get smaller over time but rarely resolve completely. **Tufted angioma,** once thought to be a separate tumor on the same clinical spectrum as KHE, is considered under the umbrella term of KHE (Fig. 554.12). The main complication of these tumors is the development of **KMP**, which may be fatal; therefore early diagnosis and treatment is important. Retroperitoneal or intrathoracic lesions in the absence of cutaneous lesions are uncommon but are often associated with KMP.

Kasabach-Merritt Phenomenon

KMP is a life-threatening combination of a rapidly enlarging KHE, thrombocytopenia, microangiopathic hemolytic anemia, and an acute or chronic consumption coagulopathy. The clinical manifestations are usually evident during early infancy. The vascular lesion is usually cutaneous and is only

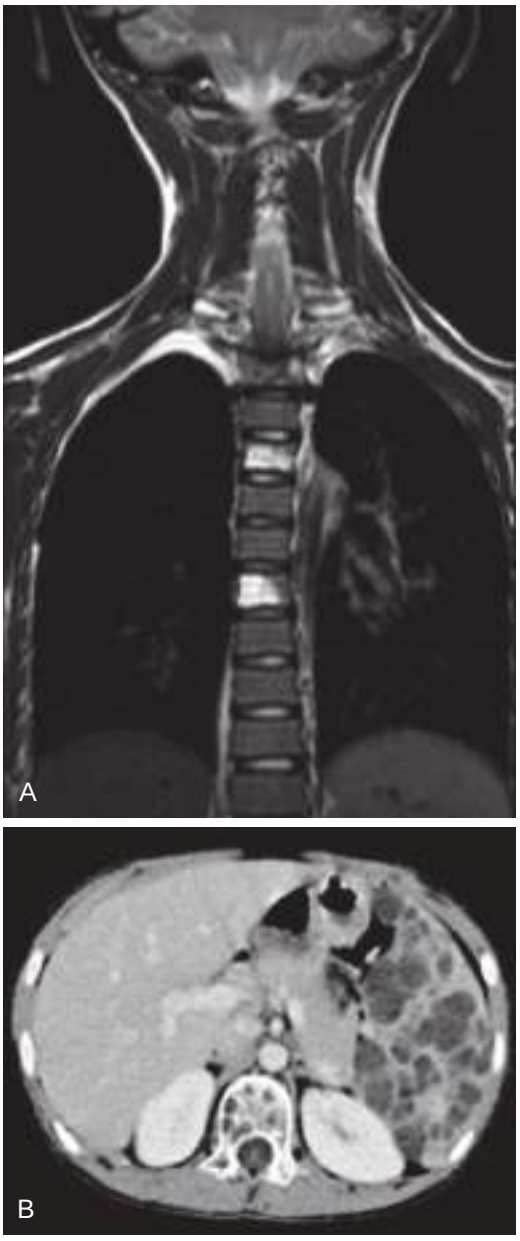

Fig. 554.3 **A,** MRI imaging of vertebral body **lymphatic malformations** in a patient with generalized lymphatic anomaly (GLA). **B,** Splenic and vertebral body lesions in a patient with GLA. (***B*** *from Joshi M, Phansalkar DS. Simple lymphangioma to generalized lymphatic anomaly: role of imaging in disclosure of a rare and morbid disease. Case Rep Radiol. 2015;2015:603859.)*

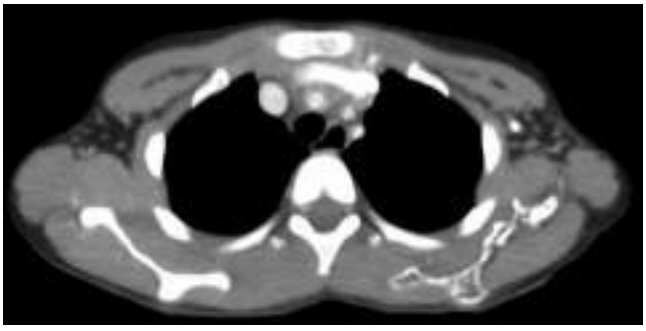

Fig. 554.4 Osteolytic destruction of the left scapula in a patient with Gorham-Stout disease (GSD). Axial CT image of the left scapula demonstrates intramedullary lucent lesions with cortical thinning.

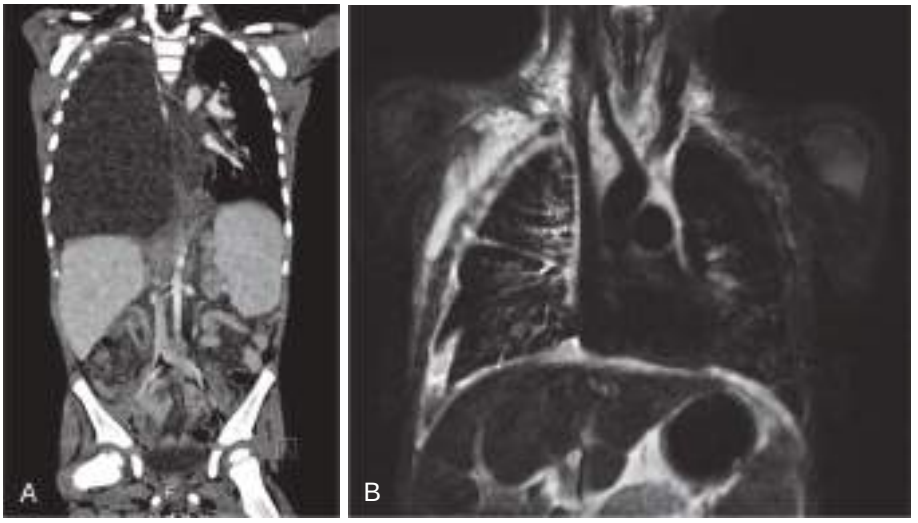

Fig. 554.5 **A,** Large hemorrhagic pleural effusion in a patient with Kaposiform lymphangiomatosis (KLA). **B,** Abnormal lymphatic fluid distribution and central lymphatic drainage in a patient with KLA.

Fig. 554.6 MR lymphangiography study showing a dilated and malformed thoracic duct and central lymphatics with retrograde flow into the mediastinum and pericardium *(arrows)* in a patient with central conducting lymphatic anomaly (CCLA).

Fig. 554.7 Multiple **venous malformations** on the tongue **(A)** and subcutaneous tissues of the foot **(B)** in a patient with blue rubber bleb nevus syndrome (BRBNS).

rarely located in viscera. The associated thrombocytopenia may lead to precipitous hemorrhage accompanied by ecchymoses, petechiae, and a rapid increase in the size of the vascular lesion. Severe anemia from hemorrhage or microangiopathic hemolysis may ensue. The thrombocytopenia has been attributed to sequestration or increased destruction of platelets within the lesion. Hypofibrinogenemia and decreased levels of consumable clotting factors are relatively common (see Chapter 533.6). KMP is seen in KHE or tufted angioma, as well as to a milder extent in very large congenital and hepatic hemangiomas *but not* in infantile hemangiomas.

Treatment includes surgical excision of small lesions, although this is often difficult because of coagulopathy and the infiltrative nature of the tumor. Additional pharmacologic treatments include systemic steroids with or without vincristine as first-line therapy in most cases. mTOR inhibition with sirolimus has been found to be successful as an alternative first-line treatment for KHE. The optimal initial combination of medical therapies is not yet known. Antiplatelet, antifibrinolytic, and other chemotherapeutic agents have been used with mixed results. The mortality rate overall once patients have KMP is high.

OTHER RARE VASCULAR TUMORS

Benign Tumors (Other Than Infantile Hemangiomas) (see Chapter 691)

Epithelioid Hemangiomas

Epithelioid hemangioma (EH) is a very rare vascular tumor, usually occurring in the skin or subcutaneous tissues, but occasionally occurring

Fig. 554.8 Cobblestoned appearance of a patient with a glomangioma, or glomuvenous malformation, caused by a germline pathogenic variant in the glomulin gene *(GLMN)*. Family members all with similar appearing lesions.

Fig. 554.9 Overgrown right lower extremity with **capillary-venous-lymphatic malformation** in a patient with Klippel-Trenaunay syndrome.

in other sites such as bone. They may be mistaken for infantile hemangiomas or PGs and can be reactive due to trauma or infection. EHs are well-circumscribed proliferations of capillaries that stain for endothelial cell and lymphatic markers but are without any cytologic atypia or mitoses. Primary treatment is with surgical excision, though they can recur locally. *FOS* gene rearrangements have been identified in some EHs.

Pyogenic Granuloma (Lobular Capillary Hemangioma)

A PG is a small red, glistening, sessile, or pedunculated papule that often has a discernible epithelial collarette (see Fig. 691.16). The surface may be weeping and crusted or completely epithelialized. PGs initially grow rapidly, may ulcerate, and bleed easily when traumatized because they consist of exuberant granulation tissue. They are relatively common in children, particularly on the face, arms, and hands. Such a lesion located on a finger or hand may appear as a subcutaneous nodule. PGs may arise at sites of injury, but a history of trauma often cannot be elicited.

PGs are benign but a nuisance because they bleed easily with trauma and may recur if incompletely removed. Numerous satellite papules have developed after surgical excision of PGs from the back, particularly in the interscapular region. Small lesions may regress after cauterization with silver nitrate; larger lesions require excision and electrodesiccation of the base of the granuloma. Small (<5 mm) lesions may be treated successfully with **pulsed dye laser** therapy.

Spider Angioma

A vascular spider (nevus araneus) consists of a central feeder artery with many dilated radiating vessels and a surrounding erythematous flush, varying from a few millimeters to several centimeters in diameter (see Fig. 691.17). Pressure over the central vessel causes blanching; pulsations visible in larger nevi are evidence for the arterial source of the lesion. Spider angiomas are associated with conditions in which there are increased levels of circulating estrogens, such as cirrhosis and pregnancy, but they also occur in up to 15% of normal preschool-age children and 45% of school-age children. Sites of predilection in children are the dorsum of the hand, forearm, nose, infraocular region, lips, and ears. Lesions often regress spontaneously after puberty. If removal is desired, pulsed dye laser therapy is the mode of choice; resolution is achieved in 90% of cases with a single treatment.

Maffucci Syndrome

The association of spindle cell hemangiomas with nodular enchondromas in the metaphyseal or diaphyseal cartilaginous portion of long bones is known as Maffucci syndrome. Maffucci syndrome is caused by *somatic* mosaic pathogenic variants in the *IDH1* and *IDH2* genes. Vascular lesions are typically soft, compressible, asymptomatic blue to purple subcutaneous masses that grow in proportion to a child's growth and stabilize by adulthood. Mucous membranes or viscera may also be involved. Onset occurs during childhood. Bone lesions may produce limb deformities and pathologic fractures. Malignant transformation of enchondromas (chondrosarcoma, angiosarcoma) or primary malignancies (ovarian, fibrosarcoma, glioma, pancreatic) may be a complication (see Chapter 550).

LOCALLY AGGRESSIVE RARE VASCULAR TUMORS

Retiform Hemangioendothelioma

Retiform hemangioendothelioma (RHE) is an intermediate, or rarely metastasizing, vascular tumor. They usually present as a slow-growing mass with plaque-like or nodular appearance. They can involve the entire dermis and extend into the subcutaneous tissue. Histologically, hobnail endothelial cells are found, but only variably lymphatic endothelial cell markers. Treatment is with surgical excision, though local recurrence is common and regional lymph node metastases have been reported.

Papillary Intralymphatic Angioendothelioma

Papillary intralymphatic angioendothelioma (PILA), also referred to as *Dabska tumor,* is a locally aggressive hemangioendothelioma. PILA occur within the dermis and superficial soft tissues of the head, neck, trunk, or extremities. On occasion they have been reported to arise from preexisting lymphatic or venolymphatic malformations, or within an extremity affected by lymphedema. They appear as violaceous nodules similar to RHE but histologically appear similar to lymphatic malformations and contain hobnail endothelial cells. Primary treatment is with excision, but regional lymph node metastasis and even death due to distant metastasis have been reported. Systemic chemotherapy based on sarcoma treatment may be used in recurrent or refractory cases.

Composite Hemangioendothelioma

Composite hemangioendotheliomas (CHE) contain overlapping histologic features with epithelioid, retiform, and spindle-cell hemangioendotheliomas. Some also contain angiosarcoma-like features within the same tumor. Fewer than 40 cases have been reported in the literature, and they can present at any age and in association with other vascular anomalies. Treatment options include surgical excision, chemotherapy, and radiation therapy.

Fig. 554.10 **A,** Soft tissue and bony overgrowth of the digits of the bilateral hands in a patient with CLOVES. Also noted is overlying capillary malformation (CM). **B,** Overgrowth of digits of the feet and right sandal-toe gap deformity in a patient with CLOVES. Also noted are CM and dilated venous pattern from underlying bilateral **venous malformation** of the lower extremities.

Fig. 554.11 Infant with macrocephaly, prominent forehead, depressed nasal bridge, short neck, bluish white iris, and reticulated port-wine stains over body, consistent with macrocephaly-capillary malformation (M-CM). *(From Panigrahi I, Bhushan M, Yadav M, Khandelwal N, Singhi P. Macrocephaly-capillary malformation syndrome: three new cases. J Neurol Sci. 2012;313:178–181. Fig. 5.)*

Pseudomyogenic Hemangioendothelioma (Epithelioid Sarcoma-Like Hemangioendothelioma)

Pseudomyogenic hemangioendothelioma (PMH) is a rare vascular tumor that presents more commonly in males than females (4:1 predominance) and usually in young adulthood (<40 years). The typical presentation is multifocal presentation within one extremity, and it does frequently have bony involvement. Histologically, it shares some features with epithelioid sarcoma, with myoid-appearing spindle cells, but has very low metastatic potential. Primary treatment is with surgical resection, but local recurrence is common, and mTOR inhibition with sirolimus has shown promise in its management.

MALIGNANT TUMORS

Epithelioid Hemangioendothelioma

Epithelioid hemangioendothelioma (EHE) is variant of *angiosarcoma,* which is locally aggressive and has metastatic potential. It usually occurs in middle-age adults and presents as a solitary mass in the soft tissues, viscera, or bone, with liver as the most common site. Thirty

Fig. 554.12 **A,** Patient with **Kaposiform hemangioendothelioma** (KHE) of the thigh who presented with **Kasabach-Merritt phenomenon** (KMP) with thrombocytopenia and hypofibrinogenemia unresponsive to all therapy until introduction of sirolimus. **B,** Premature infant with KHE of the arm who presented with KMP.

percent present with metastases, and occasionally patients present with hemolytic anemia or consumptive coagulopathy. EHE is characterized by the WWTR1/CAMTA1 translocation, with some also expressing a *YAP1-TFE3* gene fusion. Histologically, EHE are epithelioid tumors arranged in nests or cords. They may contain spindle endothelial cells and express Fli-1 and CD31. Treatment depends on location and metastatic pattern but includes surgery, radiotherapy, and chemotherapy. Overall survival for those with progressive disease is quite poor.

Angiosarcoma

Angiosarcomas account for ~2% of all soft tissue sarcomas, occur mostly in adults, and very rarely affect children. In children, they may be cutaneous or in the deep tissues or viscera. Angiosarcomas present as rapidly enlarging purplish plaques or nodules that ulcerate and can leak serosanguinous fluid. Necrosis and hemorrhage within the tumor are common. Due to risk for rapid progression and metastasis, multimodal therapy including resection and intensive chemotherapy is generally pursued. Combined treatment with mTOR and MEK inhibition has shown some promise, but progression-free and overall survival remain very poor.

Hepatic angiosarcomas appear to be a distinct subtype of angiosarcoma, presenting in earlier childhood, usually between age 1 and 5 years (Fig. 554.13). There is sometimes a history of infantile hepatic hemangioma, although cutaneous infantile hemangiomas do not appear to progress to angiosarcoma. Patients can present with anemia and thrombocytopenia due to intratumoral bleeding. Liver function tests may be abnormal, but α-fetoprotein is normal or only minimally elevated. Risk of local invasion and metastasis is quite high, so rapid diagnosis, surgical resection, and initiation of sarcoma-based chemotherapy is important. Unfortunately, complete cure is very rare.

Lymphangiosarcoma is a distinct subtype of angiosarcoma arising from the lymphatic endothelium of a site of lymphedema. Lymphangioma resembles angiosarcoma both clinically and histologically and appears to harbor the same c-myc amplification seen in postradiation angiosarcoma of the breast. Similar to the "hemangiosarcoma" form of angiosarcoma, lymphangiosarcomas are managed similarly and have similar overall poor prognosis.

Visit Elsevier eBooks+ at eBooks.Health.Elsevier.com for Bibliography.

Fig. 554.13 Angiosarcoma of the liver. *(From Potanos KM, Hodgkinson N, Fullington NM, et al. Long-term survival in pediatric hepatic angiosarcoma (PHAS): a case report and review of the literature. J Pediatr Surg Case Rep. 2015;3:410–413. Fig. 1.)*

Chapter 555
Rare Tumors

555.1 Thyroid Tumors

Jonathan D. Wasserman

See Chapter 607.

BENIGN THYROID TUMORS

Benign thyroid tumors represent approximately 75% of all thyroid nodules presenting in the pediatric population and generally require no treatment unless they result in compressive symptoms or thyroid hormone hypersecretion. The workup of a suspected thyroid nodule includes the laboratory assessment of thyroid function (thyroid-stimulating hormone [TSH]), ultrasound (US) to assess characteristics of the nodule(s) and regional lymph nodes, and US-guided fine-needle aspiration biopsy (of the primary nodule and suspicious lymph nodes) for cytopathologic diagnosis if imaging is suspicious for malignancy. Nuclear scintigraphy using radioactive iodine (^{123}I) or technetium 99m (^{99m}Tc)-pertechnetate are not recommended in the initial diagnostic evaluation, except in the event of a suppressed TSH level.

MALIGNANT THYROID TUMORS

Pediatric thyroid malignancies are rare tumors that include medullary thyroid carcinoma (MTC) and the differentiated thyroid carcinomas (DTCs), namely, papillary thyroid carcinoma (PTC) and follicular thyroid carcinoma. Findings suggestive of a thyroid malignancy are noted in Table 555.1.

PTC represents the majority of thyroid cancers in children. The incidence of pediatric thyroid cancer has been rising, with the highest rate in adolescence, and a female predominance emerges around the time of puberty. With few exceptions, children with PTC have a highly favorable prognosis, with anticipated survival over decades, even in the presence of distally metastatic disease at diagnosis. *The major established risk factor for development of PTC is exposure to ionizing radiation, typically in the context of antineoplastic therapy.*

MTC is an uncommon disease in childhood that usually occurs in the context of **multiple endocrine neoplasia type 2a (MEN2A) or type 2b (MEN2B),** autosomal dominant, hereditary endocrine tumor syndromes that arise secondary to activating variants in the *RET* proto-oncogene. In addition to the almost complete penetrance of MTC in patients with the most common *RET* variants, patients with MEN2A and MEN2B have up to a 50% lifetime risk of developing pheochromocytomas (PHEOs). Up to 20% of MEN2A patients also develop primary hyperparathyroidism. Patients with MEN2B do not develop hyperparathyroidism but have a distinct clinical phenotype that includes a characteristic facial appearance, marfanoid body habitus, aerodigestive tract ganglioneuromatosis, and **oral and ocular mucosal neuromas** (Fig. 555.1). The diagnosis of MEN2B is often delayed (usually after the MTC has already metastasized) because its pathognomonic features are not apparent in very early childhood, although an inability to cry tears (alacrimia) and constipation represent the earliest clues to diagnosis. MTC may be sporadic or familial without features of MEN 2A or 2B; it may also be associated with **Hirschsprung disease**.

Children with sporadic **DTC** typically present with an asymptomatic thyroid mass and/or cervical lymphadenopathy. Lymph node metastases are present in most PTC cases, and lung metastases are identified in up to 20% of patients, primarily in those children with a high burden of neck disease. In contrast, children with MEN2-related **MTC** are often diagnosed only after a positive genetic test result or, in the case of MEN2B, after the clinical phenotype is recognized. When

Table 555.1	Clinical Findings Associated with Malignant Thyroid Nodules
HISTORIC FEATURES	
Neck irradiation during childhood or adolescence	
Rapid growth	
Recent, persistent changes in speaking, breathing, or swallowing	
Family history of multiple endocrine neoplasia type 2	
PHYSICAL EXAMINATION	
Firm, fixed, and irregular consistency of nodule	
Vocal cord paralysis or hoarseness	
Persistent regional lymph adenopathy	

Modified from Melmed S, Auchus RJ, Goldfine AB, et al., eds. *Williams Textbook of Endocrinology*. 14th ed. Philadelphia: Elsevier; 2020: Table 14.3, p. 439.

Fig. 555.1 Classic appearance of oral mucosal neuromas on the tongue in a boy with multiple endocrine neoplasia type 2b (MEN2B) secondary to the typical M918T variant in the *RET* protooncogene.

a family history is known, presymptomatic surveillance may identify MTC at earlier stages. As with PTC, MTC also frequently metastasizes to cervical lymph nodes.

There are well-documented genotype-phenotype correlations in MEN2, and the biologic aggressiveness of MTC depends on the hereditary setting in which it develops. With the availability of genetic testing for *RET* variants, MTC has become one of the few malignancies that can be prevented by *prophylactic thyroidectomy*.

The age at which prophylactic thyroidectomy is recommended is determined based on the specific *RET* variant, serum calcitonin levels, and parent and child preference.

The **primary therapy** for thyroid cancer, regardless of histologic type, is thyroidectomy and, if there is evidence of lymph node metastasis, a compartment-oriented lymph node dissection performed by a highly experienced thyroid cancer surgeon. In **DTC**, adjuvant radioactive iodine (^{131}I) may be used postoperatively to treat iodine-avid distant metastasis and unresectable residual neck disease. The use of ^{131}I is limited to children at higher risk for residual or recurrent disease who are most likely to benefit from treatment. Children with **MTC** do not require ^{131}I therapy.

In children with DTC, the TSH level is initially suppressed by giving supraphysiologic levothyroxine, because TSH may stimulate DTC tumor growth; the TSH level is kept normal in MTC.

Oral multikinase inhibitors and oncogene-targeted therapy (for children with tumors driven by *BRAF*, *RET*, or *NTRK* substitutions or oncogenic fusions) have demonstrated benefit for the treatment of advanced MTC and DTC in adults. These are rarely indicated in pediatric patients but may be considered for symptomatic and/or progressive disease.

Long-term follow-up of thyroid cancer survivors involves monitoring of tumor markers (thyroglobulin/thyroglobulin antibody in DTC, calcitonin/carcinogenic embryonic antigen in MTC) and routine imaging, primarily neck US.

Visit Elsevier eBooks+ at eBooks.Health.Elsevier.com for Bibliography.

555.2 Nasopharyngeal Carcinoma

Cynthia E. Herzog

Nasopharyngeal carcinoma is rare in the pediatric population, but it is one of the most common nasopharyngeal tumors in pediatric patients. In adults, the incidence is highest in South China, but it is also high among the Inuit people and in North Africa and Northeast India. In China, this diagnosis is rare in the pediatric population, but in other populations, a substantial proportion of cases occur in the pediatric age-group, primarily in adolescents. It occurs in males twice as often as in females and is more common in Black people. In the pediatric population, the tumors are more frequently of undifferentiated histology and associated with **Epstein-Barr virus (EBV)**. Nasopharyngeal carcinoma is associated with specific human leukocyte antigen (HLA) types; other genetic factors may play a role, especially in low-incidence populations.

Most pediatric patients present with advanced locoregional disease manifesting as cervical lymphadenopathy. Epistaxis, trismus, and cranial nerve deficits also may be present. The diagnosis is established from biopsy of the nasopharynx or cervical lymph nodes. In most cases the lactate dehydrogenase level is elevated, but this finding is nonspecific. CT or MRI evaluation of the head and neck is performed to determine the extent of locoregional disease. Chest radiography, CT, bone scan, and liver scan are used to evaluate for metastatic disease. PET scans appear to be useful for monitoring primary disease and looking for metastases. EBV DNA levels correlate with disease stage, have prognostic value, and can be used to monitor for recurrence.

Treatment is a combination of chemotherapy and irradiation. Cisplatin, given concurrently with radiation, with either neoadjuvant or adjuvant cisplatin-based chemotherapy, is the standard treatment. The outcome depends on the extent of disease; patients with distant metastases have a very poor prognosis. Using intensity-modulated radiation therapy improves local control and reduces the late adverse effects associated with radiation therapy, including hormonal dysfunction, dental caries, fibrosis, and second malignancies. Use of proton therapy may result in further reduction of adverse effects.

Visit Elsevier eBooks+ at eBooks.Health.Elsevier.com for Bibliography.

555.3 Adenocarcinoma of the Colon and Rectum

Cynthia E. Herzog and Winston W. Huh

Colorectal carcinoma (CRC) is rare in the pediatric population, with an estimated incidence rate of approximately one case per 1 million. Even in patients with predisposing conditions, CRC usually does not present until late adolescence or adulthood; only 35–40% of CRC in this age-group are association with a known predisposition factor. **Hereditary nonpolyposis colon cancer (HNPCC) (Lynch Syndrome)** is an autosomal dominant disorder, with germline pathogenic variants in DNA mismatch repair genes *(MMR)* causing DNA repair errors and microsatellite instability (MSI). *MYH*-associated polyposis, Peutz-Jeghers syndrome, and juvenile polyposis also predispose to CRC.

Genetic testing is available, and screening for cancer in HNPCC and familial adenomatous polyposis (FAP) should begin during childhood or adolescence. Likewise, genetic evaluation for these conditions should be pursued in young patients presenting with colon cancer, even when there is no history of predisposing genetic conditions.

Presenting symptoms include bloody stools or melena, abdominal pain, weight loss, and changes in bowel patterns. In many cases, signs are vague, often resulting in a delay in diagnosis, sometimes not until the disease has reached an advanced stage. The histologic subtype differs from that seen in adults, with most pediatric tumors being either mucinous adenocarcinoma or signet ring cell carcinoma. Pediatric patients tend to have tumors with MSI and tend to present with more advanced disease. Treatment is based on guidelines used in adults with CRC and consists of surgical resection when possible with chemotherapy for unresectable tumors. Adequate lymph node removal should be performed at surgical resection of primary tumor. Radiation therapy is useful in select cases. Pediatric patients have a worse overall prognosis compared with adult patients, but the reasons for this discrepancy are not clear.

Visit Elsevier eBooks+ at eBooks.Health.Elsevier.com for Bibliography.

555.4 Adrenal Tumors

Jonathan D. Wasserman

See Chapters 617-621.

The adrenal gland is comprised of two embryologically distinct layers, the steroid-secreting outer cortex and the catecholamine-secreting inner medulla. **Adrenocortical tumors (ACTs)** arise from the cortex, whereas pheochromocytomas (**PHEOs**) derive from the chromaffin cells of the adrenal medulla. Additionally, catecholaminergic tumors arising from the parasympathetic and sympathetic ganglia *outside* the adrenal medulla are called **paragangliomas (PGLs)**. Both ACTs and PHEOs are strongly associated with hereditary tumor predisposition syndromes, and thus diagnosis of either in childhood should initiate a thorough family history and referral to an expert in cancer genetics for counseling and germline testing.

ACTs are very rare and, in children, tend to present before age 10 years. They have a female predominance and are functional (hormone secreting) in >90% of cases, primarily producing androgens and/or glucocorticoids and causing clinically apparent **virilization** with or without **Cushing syndrome** (see Chapter 619). ACTs may also present as an abdominal mass or pain. In children, ACTs are most frequently associated with **Li-Fraumeni syndrome** (germline inactivating variants in the *TP53* tumor-suppressor gene) and **Beckwith-Wiedemann syndrome** (BWS), but they can also be seen in hemihyperplasia other than that seen as part of BWS, MEN1, McCune-Albright syndrome, FAP, and very rarely, congenital adrenal hyperplasia. Unusual causes of bilateral nodular adrenocortical disease, which also typically present with Cushing syndrome, include the Carney complex and macronodular adrenocortical hyperplasia.

PHEOs/PGLs are rare tumors that are more likely to be bilateral, malignant, and secondary to a heritable tumor syndrome when diagnosed in childhood compared with adulthood (see Chapter 621). **Von Hippel-Lindau disease** is the most common genetic association in the pediatric population, followed by the **familial PGL syndromes (1, 2, 3, 4)** caused by variants in the succinate dehydrogenase *(SDHx)* genes. MEN2 (types 2A and 2B) and neurofibromatosis type 1 *(NF1)* are also included in the differential diagnosis but are more often associated with a PHEO diagnosis during adulthood (Table 555.2). Overall, germline pathogenic variants in at least 16 different genes have been associated with predisposition to PHEO/PGL. PHEO/PGL is also associated with congenital cyanotic heart disorders (somatic gain-of-function variant in *EPAS1*). *Hypertension is usually sustained* in pediatric patients with PHEO/PGL, who may also lack the triad of intermittent headache, palpitations, and diaphoresis typically seen in adults. Nonetheless, PHEO/PGL accounts for <1% of pediatric hypertension. Additional manifestations may include chest pain, pallor, tremor, fever, cardiomyopathy, or exacerbations with exercise; flushing is not typical of PHEO/PGL. The differential diagnosis is noted in Table 555.3. The most appropriate screening test for PHEO/PGL is measurement of fractionated plasma and/or urine **metanephrine** levels. Initial imaging studies, when metanephrine levels are elevated, include CT or MRI. When indicated, to confirm abnormal biochemistry and/or cross-sectional imaging, ^{18}F-DOPA and ^{68}Ga-DOTATATE (DOTA-octreotate) PET/MRIs are the functional imaging modalities of choice given greater sensitivity and specificity than earlier radioisotopes (Fig. 555.2). ^{131}I-Metaiodobenzyguanidine (MIBG) imaging may also be considered in such circumstances.

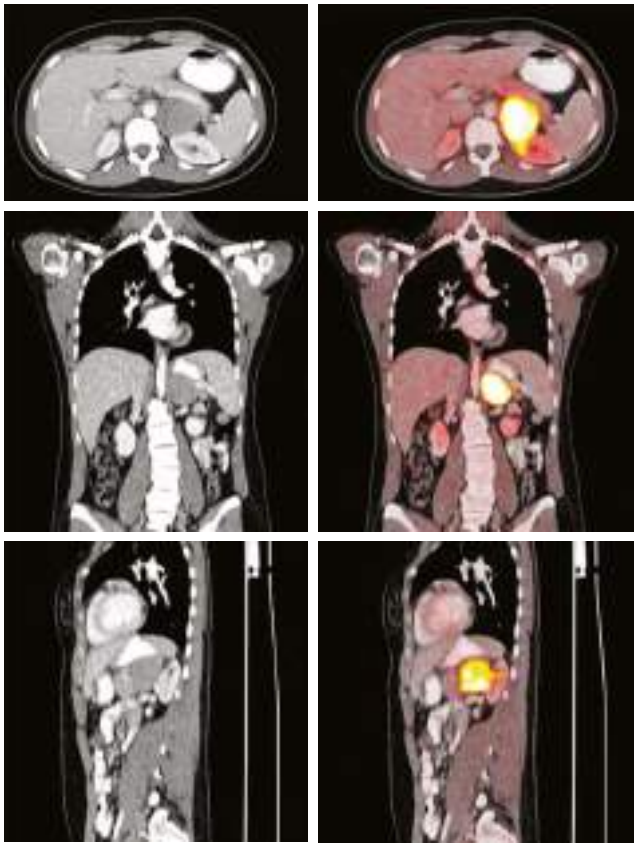

Fig. 555.2 Appearance of pheochromocytoma on functional imaging (^{18}F-I -dihydroxyphenylalanine [^{18}F-DOPA] PET/CT). Focal uptake is seen in the left suprarenal fossa. *(From Duh QY, Livhits M, Yeh MW. The adrenal glands. In: Mattox KL, Townsend CM, Beauchamp RD, Evers BM, eds. Sabiston Textbook of Surgery. 21st ed. Philadelphia: Elsevier; 2022. Fig. 40.18A.)*

Table 555.2 Germline Pathogenic Variants Associated with Pheochromocytoma and Paraganglioma

SYNDROME/NAME	GENE	TYPICAL TUMOR LOCATION AND OTHER ASSOCIATIONS
HYPOXIC PATHWAY: CLUSTER 1*		
SDHD (familial paraganglioma type 1)†	*SDHD*	Primarily skull base and neck; occasionally adrenal medulla, mediastinum, abdomen, pelvis; GIST; possible pituitary adenoma
SDHAF2 (familial paraganglioma type 2)†	*SDHAF2*	Primarily skull base and neck; occasionally abdomen and pelvis
SDHC (familial paraganglioma type 3)	*SDHC*	Primarily skull base and neck; occasionally abdomen, pelvis, or chest; GIST; possible pituitary adenoma
SDHB (familial paraganglioma type 4)	*SDHB*	Abdomen, pelvis, and mediastinum; rarely adrenal medulla, skull base, and neck; GIST; renal cell carcinoma; possible pituitary adenoma
SDHA	*SDHA*	Primarily skull base and neck; occasionally abdomen and pelvis; GIST; possible pituitary adenoma
VHL disease	*VHL*	Adrenal medulla, frequently bilateral; occasionally paraganglioma that may be localized from skull base to pelvis
Hereditary leiomyomatosis and renal cell carcinoma (Reed syndrome)—fumarate hydratase variant	*FH*	Multifocal and metastatic; associated with hereditary leiomyomatosis, uterine fibroids, and renal cell cancer
Hypoxia-inducible factor (HIF) 2α	*HIF2A*	Paraganglioma, polycythemia, and rarely somatostatinoma
Familial erythrocytosis associated with pathogenic variant in prolyl hydroxylase isoform 1 (PDH1)	*EGLN2*	Polycythemia associated with pheochromocytoma and paraganglioma
Familial erythrocytosis associated with pathogenic variant in prolyl hydroxylase isoform 2 (PDH2)	*EGLN1*	Polycythemia associated with pheochromocytoma and paraganglioma
KIF1B	*KIF1B*	Neuroblastoma
KINASE SIGNALING PATHWAY: CLUSTER 2‡		
MEN2A and MEN2B	*RET*	Adrenal medulla, frequently bilateral
Neurofibromatosis type 1 (NF1)	*NF1*	Adrenal or periadrenal
MAX†	*MAX*	Adrenal medulla
Familial pheochromocytoma	*TMEM127*	Adrenal medulla; possible renal cell carcinoma

*Cluster 1 tumors are mostly extraadrenal paragangliomas (except in VHL, where most tumors are localized to the adrenal) and nearly all have a noradrenergic biochemical phenotype.
†Associated with maternal imprinting.
‡Cluster 2 tumors are usually adrenal pheochromocytomas with an adrenergic biochemical phenotype.
GIST, Gastrointestinal stromal tumor; MEN, multiple endocrine neoplasia; SDH, succinate dehydrogenase; VHL, von Hippel-Lindau disease.
Modified from Melmed S, Auchus RJ, Goldfine AB, et al., eds. *Williams Textbook of Endocrinology*. 14th ed. Philadelphia: Elsevier; 2020: Table 16.4, p. 550.

Table 555.3 Differential Diagnosis of Pheochromocytoma-Type Spells

ENDOCRINE CAUSES
Carbohydrate intolerance
Hyperadrenergic spells
Hypoglycemia
Pancreatic tumors (e.g., insulinoma)
Pheochromocytoma
Thyrotoxicosis
CARDIOVASCULAR CAUSES
Orthostatic hypotension
Paroxysmal cardiac arrhythmia
Pulmonary edema
Renovascular disease
Syncope (e.g., vasovagal reaction)
PSYCHOLOGIC CAUSES
Factitious (e.g., drugs, Valsalva maneuver)
Hyperventilation
Severe anxiety and panic disorders
Somatization disorder
PHARMACOLOGIC CAUSES
Chlorpropamide-alcohol flush
Combination of a monoamine oxidase inhibitor and a decongestant
Illegal drug ingestion (cocaine, phencyclidine, lysergic acid diethylamide)
Sympathomimetic drug ingestion
Vancomycin (red man syndrome)
Withdrawal of adrenergic inhibitor
NEUROLOGIC CAUSES
Autonomic neuropathy
Diencephalic epilepsy (autonomic seizures)
Migraine headache
Postural orthostatic tachycardia syndrome
Stroke
OTHER CAUSES
Carcinoid syndrome
Mast cell disease
Recurrent idiopathic anaphylaxis
Unexplained flushing spells

Modified from Melmed S, Auchus RJ, Goldfine AB, et al., eds. *Williams Textbook of Endocrinology*. 14th ed. Philadelphia: Elsevier; 2020: Table 16.3, p. 547.

The initial treatment of ACT and PHEO/PGL is *resection by a surgeon experienced in the management of these tumors.* Children with suspected or confirmed PHEO/PGL require preoperative medical management with α-adrenergic blockade (and sometimes β-blockade) to mitigate risk of hypertensive crisis.

Medical therapy for metastatic ACT includes mitotane and chemotherapy with cisplatin, etoposide, and doxorubicin. Endocrine therapy targeting hormonal overproduction may also be needed to palliate symptoms and improve quality of life. Metastatic PHEO/PGL has historically been poorly responsive to cytotoxic chemotherapy. Kinase inhibitor therapy and peptide-receptor radiotherapy (such as ^{177}Lu-DOTATATE) have demonstrated promise in some studies.

Long-term follow-up is warranted for both ACTs and PHEOs to monitor for recurrence, particularly in the context of hereditary tumor predisposition syndromes.

Visit Elsevier eBooks+ at eBooks.Health.Elsevier.com for Bibliography.

555.5 Desmoplastic Small Round Cell Tumor

Cynthia E. Herzog

Desmoplastic small round cell tumor **(DSRCT)** is a very rare and aggressive mesenchymal tumor that occurs predominantly in adolescent and young adult males. It is associated with a diagnostic chromosomal translocation between the Ewing tumor gene and the Wilms tumor gene, t(11;22) (p13;q12), creating a chimeric gene *(EWS-WT1)* that encodes a chimeric protein with oncogenic properties. Patients typically present at advanced stage with a bulky abdominal mass, multiple peritoneal and omental implants, and symptoms of abdominal sarcomatosis, including pain, ascites, intestinal obstruction, hydronephrosis, and weight loss. DSRCT mainly involves the abdominal cavity but can spread to the lymph nodes, liver, lungs, and bones, and in ~10% of cases, arise outside of the abdomen. There is no standard treatment approach. Aggressive treatment with combination chemotherapy, debulking surgery, and whole abdominopelvic irradiation results almost universally in a poor outcome. Median survival ranges between 17 and 25 months, and the 5-year overall survival remains <20%. Hyperthermic intraperitoneal chemotherapy may be of benefit but requires further study. Novel targeted agents and radioimmunotherapy with monoclonal antibodies targeting different surface antigens on tumor cells are being studied.

Visit Elsevier eBooks+ at eBooks.Health.Elsevier.com for Bibliography.

Chapter 556
Histiocytosis Syndromes of Childhood

Stephan Ladisch

INTRODUCTION

Childhood histiocytoses constitute a diverse group of disorders that are frequently severe in their clinical expression. These disorders are individually rare and are grouped together because they have in common a prominent proliferation or accumulation of cells of the monocyte-macrophage system of bone marrow (myeloid) origin. Although these disorders sometimes are difficult to distinguish clinically, accurate diagnosis is essential for facilitating progress in treatment. A current systematic classification of histiocytoses is based on histopathologic, clinical, and genetic findings (Tables 556.1-556.3) A thorough, comprehensive evaluation of a biopsy specimen obtained at diagnosis is critical. This evaluation includes studies such as immunostaining, molecular genetic analyses, and electron microscopy that may require special sample processing.

CLASSIFICATION AND PATHOLOGY

Three classes of childhood histiocytosis are defined, based on histopathologic findings. The first and best known is **Langerhans cell histiocytosis (LCH)**, previously called *histiocytosis X.* LCH includes the clinical entities of bone or skin limited disease (**eosinophilic granuloma)**, **Hand-Schüller-Christian disease,** and **Letterer-Siwe disease.** The normal Langerhans cell is an antigen-presenting cell (APC) of the skin. The hallmark of LCH in all forms is the presence of a clonal proliferation of cells of the monocyte–dendritic cell lineage containing the characteristic electron microscopic findings of a Langerhans cell, the **Birbeck granule**. This tennis racket–shaped bilamellar granule, when seen in the cytoplasm of lesional cells in LCH, is diagnostic of the disease. The Birbeck granule expresses a newly characterized antigen, *langerin* (CD207), which itself is involved in antigen presentation to T lymphocytes. CD207 expression has been established to be uniformly present in LCH lesions and thus becomes an additional reliable diagnostic marker. However, it is now clear that the LCH cell is not actually a (differentiated) Langerhans cell but rather an immature cell of myeloid origin, possibly in an arrested state of development. The definitive diagnosis of LCH is established by demonstrating CD1a positivity of lesional cells, which can be done using fixed tissue (Fig. 556.1). Lesional cells must be distinguished from normal Langerhans cells of the skin, which are also CD1a positive but are only sparsely distributed and are not diagnostic of LCH. The peripheral lesions usually leading to the diagnosis of LCH (e.g., skin, lymph node, bone) contain various proportions of Birbeck granule–containing CD1a-positive cells, lymphocytes, granulocytes, monocytes, and eosinophils.

Clonality of individual lesions exists in some cases of LCH. Importantly, an activating *somatic* pathogenic variant of the *BRAF* gene *(V600E)* (part of the mitogen-activated protein kinase [MAPK] cell signaling pathway: Fig. 556.2) has been identified in many patients with LCH. Studies in patients negative for *BRAFV600E* have revealed pathogenic variants in other genes of the MAPK pathway, including *MAP2K1* and *ARAF.* With the majority of LCH patients having one or another of these activating variants in the MAPK pathway (see Fig. 556.2), it has been suggested that LCH is driven by a disorder in MAPK signaling affecting cell migration and resulting in an accumulation of LCH cells in the lesions.

In contrast to the prominence of an APC in LCH, the other common form of histiocytosis is characterized by accumulation of activated macrophages and lymphocytes and is known as **hemophagocytic lymphohistiocytosis (HLH)**. This diagnosis is the result of uncontrolled hemophagocytosis and uncontrolled activation (upregulation) of inflammatory cytokines driven by an abnormality of T cells. It has some similarities to the **macrophage activation syndrome**. Tissue infiltration by activated CD8 T lymphocytes, activated macrophages, and hypercytokinemia are classic features (Fig. 556.3). With the characteristic morphology of normal macrophages by light microscopy, these phagocytic cells (see Fig. 556.1) are CD163 positive but negative for the markers that are characteristic of LCH cells (Birbeck granules, CD1a, CD207).

The two major forms of HLH, primary and secondary, have indistinguishable pathologic findings but are important to differentiate because of implications for treatment and prognosis. **Primary HLH**, originally named *familial erythrophagocytic lymphohistiocytosis,* is now known as **familial hemophagocytic lymphohistiocytosis (FHLH)**. This disease is an autosomal recessive disorder and represents approximately 25% of patients with HLH (see Table 556.3).

Table 556.1 Main Types of Histiocytosis Disease

DISEASE	HISTIOCYTOSIS CLASSIFICATION GROUP
LANGERHANS CELL HISTIOCYTOSIS	L
Single system	L
Pulmonary	L
Multisystem with no risk organ involvement	L
Multisystem with risk organ involvement	L
ERDHEIM-CHESTER DISEASE	L
Mixed H	L
Indeterminate H	L
Extracutaneous/disseminated JXG with MAPK pathogenic variant (including LALK + H. and other genetic alterations)	L
ROSAI-DORFMAN-DESTOMBES DISEASE	R
Familial	R
Sporadic classical with or without IgG4 infiltration	R
Sporadic extranodal with or without IgG4 infiltration	R
MALIGNANCY HISTIOCYTOSES	M
Primary, phenotypic subtypes	M
Secondary, phenotypic subtypes	M
Histiocytoses with cutaneous or mucosal involvement	C
LYMPHOHISTIOCYTOSES	M
Primary	M
Sporadic	M
Unknown	M

L, Langerhans; R, Rosai-Dorfman-Destombes; M, Malignant, C, cutaneous; H, hemophagocytic; JXG, juvenile xanthogranuloma; MAPK: mitogen-activated kinase.
From Emile JF, Cohen-Aubart F, Collin M, et al. Histiocytosis. *Lancet*. 2021;398:157–168. Supplementary Appendix, Table 1.

Genes are known for four of five familial HLH syndromes and other hereditary causes of HLH; these pathogenic variants affect the ability of T lymphocytes and natural killer (NK) cells to synthesize and release perforin and granzymes, thus reducing cytotoxic granule formation (Fig. 556.4). **Secondary HLH** includes other forms of the syndrome triggered by a separate pathologic process, such as infection *(infection-associated hemophagocytic syndrome),* tumor *(malignancy-associated HLH),* or primary immunodeficiency diseases and metabolic disorders (Tables 556.4 and 556.5). Both primary and secondary HLH affect multiple organs and are characterized by massive infiltrates of hyperactivated lymphocytes and activated phagocytic macrophages in the involved organs, with the lymphocytes serving as the driver of the resulting disease process.

In primary HLH, genetic pathogenic variants in multiple different steps in granule formation and release by cytotoxic T cells have been identified (Fig. 556.5, *bottom*). Pathogenic variants in the *PRF1* perforin gene or the *MUNC13-4* gene are the most common causes of defective function of the cytotoxic lymphocytes whose activity is inhibited in primary HLH. In an analogous way, a trigger can result in secondary HLH (see Fig. 556.5, *top*). A myriad of both infectious and noninfectious processes can trigger secondary HLH (Fig. 556.6; see Table 556.4 and Fig. 556.11). Examples of noninfectious triggers include drugs (e.g., phenytoin, Lamictal, highly active antiretroviral therapy), hematopoietic stem cell transplantation, chemotherapy, autoimmune diseases, inflammatory bowel disease, cancer, and immunodeficiency states (e.g., DiGeorge syndrome, Bruton agammaglobulinemia, severe combined immunodeficiency syndrome, chronic granulomatous disease). A complicating factor in diagnosis is the realization that there are also both mixed genetic variants causing primary HLH and heterozygotic variants (therefore not strictly primary HLH) also causing disease, particularly triggered by infection.

In addition to these two most common forms of childhood histiocytosis (LCH and HLH), rarer diseases are included under this rubric (see Table 556.2). **Juvenile xanthogranuloma (JXG)** is characterized by vacuolated histiocytes with foamy cytoplasm in lesions that evolve into mixed granulomas also containing eosinophils, lymphocytes, and other cells. **Erdheim-Chester disease (ECD)** predominantly affects adults. Surface markers suggest a link among LCH, JXG, and ECD; all three are dendritic cell diseases, and represent a spectrum, or continuum, of differentiation stages of the abnormal dendritic cell precursors, frequently with *BRAFV600E* pathogenic variants in the affected cells. Another rare form of histiocytosis is **Rosai-Dorfman disease**, also known as **sinus histiocytosis** with massive lymphadenopathy. Rosai-Dorfman disease is characterized by packing of sinusoids of the lymph nodes with hemophagocytic histiocytes, although extranodal involvement may also be present. Last, there is a group of unequivocal **malignancies** of cells of monocyte–macrophage lineage. By this definition, acute monocytic leukemia and true malignant histiocytosis are included among the class III histiocytoses (see Chapter 544). True neoplasms of Langerhans cells have been reported but are extremely rare.

556.1 Langerhans Cell Histiocytosis

Stephan Ladisch

CLINICAL MANIFESTATIONS

LCH has an extremely variable presentation. The skeleton is involved in 80% of patients and may be the only affected site, especially in children >5 years old. **Bone lesions (eosinophilic granuloma)** may be single or multiple and are seen most often in the skull (Fig. 556.7). Other sites include the pelvis, femur, vertebra, maxilla, and mandible. Lesions may be asymptomatic or associated with pain and local swelling. Involvement of the spine may result in collapse of the vertebral body, which can be seen radiographically and may cause secondary compression of the spinal cord. In flat and long bones, osteolytic lesions with sharp borders occur, and no evidence exists of reactive new bone formation until the lesions begin to heal. Lesions that involve weight-bearing long bones may result in pathologic fractures. Chronically draining, infected ears are usually associated with destruction in the mastoid area. Bone destruction in the mandible and maxilla may result in teeth that appear to be free floating on radiographs. With response to therapy, healing of bone lesions is usually complete.

Approximately 50% of patients experience **skin involvement** (isolated or part of multisystem disease) at some time during the course of disease. This is a frequently difficult-to-treat scaly, papular, seborrheic dermatitis of the scalp, diaper, axillary, or posterior auricular regions (see Fig. 556.7; Figs. 556.8 and 556.9). The lesions may spread to involve the back, palms, and soles. The exanthem may be petechial or hemorrhagic, even in the absence of thrombocytopenia. Localized or disseminated **lymphadenopathy** is present in approximately 33% of patients. **Hepatosplenomegaly** occurs in approximately 20% of patients. Various degrees of hepatic malfunction may occur, including jaundice and ascites.

Gastrointestinal involvement, more common than previously appreciated, can present as vomiting, abdominal pain, bloody diarrhea, and/or failure to thrive.

Exophthalmos, when present, may be bilateral and is caused by retroorbital accumulation of granulomatous tissue. Gingival mucous membranes may be involved with infiltrative lesions that appear superficially like candidiasis. Otitis media is present in 30–40% of patients; deafness may follow

Table 556.2 Clinical Features, Investigations, and Treatment of Langerhans Cell Histiocytosis, Erdheim-Chester Disease, and Rosai-Dorfman-Destombes Disease

	MOST FREQUENT REVEALING CLINICAL FEATURES	INITIAL INVESTIGATIONS* WHEN DIAGNOSIS IS CONFIRMED BY BIOPSY	MOST FREQUENT FIRST-LINE SYSTEMIC THERAPIES FOR MULTIORGAN OR DISSEMINATED FORMS	MOST FREQUENT SYSTEMIC SECOND-LINE AND SALVAGE THERAPIES
Childhood Langerhans cell histiocytosis	Bone pain or fracture; vertebra plana†; skin papules; lymphadenomegaly; palpable tumor; diabetes insipidus†; exophthalmos†; deafness or chronic otorrhea; systemic symptoms with fever, hepatosplenomegaly, or hematologic cytopenia (risk organs); pneumothorax	For all patients: blood tests (full blood count, erythrocyte sedimentation rate or CRP, albumin, renal function tests, liver function tests, coagulation tests); chest and skeletal radiographs According to initial investigations: CT scan or MRI focused on involved area; brain MRI when diabetes insipidus or any sign of CNS involvement or visual or hearing dysfunction; chest high-resolution CT scan when signs of lung involvement	Vinblastine combined with corticosteroids	Should be decided according to initial extension and risk-organ involvement status, as assessed by a trained team With risk organ involvement: BRAF or MEK inhibitors‡ Without risk organ involvement: monotherapy or combined chemotherapies with cladribine, and, in less documented approaches, cytarabine or clofarabine
Adult Langerhans cell histiocytosis	Bone pain or fracture; skin papules; lymphadenopathy; palpable tumor; diabetes insipidus†; exophthalmos†; repeated dental loss; pneumothorax; dyspnea, dry cough	^{18}F-FDG-PET (full body); chest, abdomen, and pelvis CT scan; brain MRI; blood tests (full blood count, CRP, albumin, renal function tests, liver function tests)	Cytarabine, alone or combined with methotrexate; vinblastine combined with corticosteroids; cladribine	BRAF or MEK inhibitors
Erdheim-Chester disease	Lower limb pain; general symptoms (fatigue, weight loss, fever); xanthelasma; diabetes insipidus†; exophthalmos†; dyspnea, dry cough; signs of cardiac involvement (e.g., tamponade); signs of CNS involvement (degenerative or tumoral)	^{18}F-FDG-PET (full body); chest, abdomen, and pelvis CT scan; brain MRI; cardiac MRI; blood tests (full blood count, CRP, albumin, renal function tests, liver function tests)	Interferon alfa-2a or pegylated interferon alfa-2a; other potential options are anakinra, infliximab, or sirolimus plus corticosteroids; BRAF or MEK inhibitors for life-threatening cases (e.g., CNS or heart involvement)	BRAF or MEK inhibitors
Rosai-Dorfman-Destombes disease	Lymphadenopathy; skin nodules; nasal obstruction, epistaxis, nasal dorsum deformity; dyspnea, dry cough; signs of CNS or nerve root involvement; testicular enlargement	Children: chest x-ray with neck and abdominal ultrasound scans Adults: neck, chest, abdomen, and pelvis CT scan; ^{18}F-FDG-PET is recommended by some experts All patients: brain MRI when signs of orbital or CNS involvement; blood tests (full blood count, CRP, albumin, renal function tests, liver function tests)	Corticosteroids; sirolimus; methotrexate; azathioprine	Several drugs or combined chemotherapies or MEK inhibitors reported to be active in case reports or small case series

^{18}F-FDG-PET, ^{18}F-fluorodeoxyglucose PET; CNS, central nervous system..

*Aimed to determine the extent of the disease; thus each clinical feature drives specific investigation of the potentially involved organ(s), including for any signs of endocrine dysfunction or autoimmunity.

†Features that are suggestive of the disease.

‡BRAF inhibitors: vemurafenib, dabrafenib, encorafenib. MEK inhibitors: cobimetinib, trametinib, binimetinib, selumetinib.

From Emile JF, Cohen-Aubart F, Collin M, et al. Histiocytosis. *Lancet*. 2021;398:157–168. Fig. 1, p. 158.

destructive lesions of the middle ear. In 10–15% of patients, **pulmonary infiltrates** are found on radiography. The lesions may range from diffuse fibrosis and disseminated nodular infiltrates to diffuse cystic changes (Fig. 556.10). Rarely, pneumothorax is a complication. If the lungs are severely involved, tachypnea and progressive respiratory failure may result.

Pituitary dysfunction or hypothalamic involvement in patients often presents as diabetes insipidus and may also cause growth retardation. Patients suspected of having LCH should demonstrate the ability to concentrate their urine before going to the operating room for a biopsy. Rarely, panhypopituitarism may occur, as may primary hypothyroidism as a result of thyroid gland infiltration.

Patients with multisystem disease who are affected more severely are those who have systemic manifestations, including fever, weight loss, malaise, irritability, and failure to thrive. These systemic manifestations will distinguish patients at high risk of mortality (i.e., risk organ–positive, or RO+, patients) from patients at low risk of mortality (i.e., without systemic

Table 556.3 Hemophagocytic Lymphohistiocytosis

DISEASE	GENE	PROTEIN	PERCENTAGE OF FHLH	IMMUNE IMPAIRMENT	UNIQUE CLINICAL CHARACTERISTICS
FHLH-1	Unknown		Rare	Cytotoxicity	
FHLH-2	*PRF1*	Perforin	~20–37, 50delT mainly in African American/ African descent	Cytotoxicity; forms pores in APCs	
FHLH-3	*UNC13D*	Munc13–4	20–33	Cytotoxicity; vesicle priming	Increased incidence of CNS HLH
FHLH-4	*STX11*	Syntaxin	<5	Cytotoxicity; vesicle fusion	Mild recurrent HLH, colitis
FHLH-5	*STXBP2*	Syntaxin-binding protein 2	5–20	Cytotoxicity; vesicle fusion	Colitis, hypogammaglobulinemia
SYNDROMES WITH PARTIAL OCULOCUTANEOUS ALBINISM					
Griscelli syndrome	*RAB27A*	Rab27A	~5	Cytotoxicity; vesicle docking	Partial albinism, silver-gray hair
Chédiak-Higashi syndrome	*LYST*	Lyst	~2	Cytotoxicity; heterogeneous defects in NK cells	Partial albinism, bleeding tendency, recurrent infections
Hermansky-Pudlak syndrome type II	*AP3B1*	AP-3 complex subunit β_1	Rare	Cytotoxicity; vesicle trafficking	Partial albinism, bleeding tendency
EBV-DRIVEN AND RARE CAUSES					
XLP1	*SH2D1A*	SAP	~7	Signaling in cytotoxic NK and T cells	Hypogammaglobulinemia, lymphoma
XLP2	*BIRC4*	XIAP	~2	NK T-cell survival and NF-κB signaling	Mild recurrent HLH, colitis
ITK deficiency	*ITK*	ITK	Rare	IL-2 signaling in T cells	Hypogammaglobulinemia, autoimmunity, Hodgkin lymphoma
CD27 deficiency	*CD27*	CD27	Rare	Signal transduction in lymphocytes	Combined immunodeficiency, lymphoma
XMEN syndrome	*MAGT1*	MAGT1	Rare	Magnesium transporter, induced by TCR stimulation	Lymphoma, recurrent infections, CD4 T-cell lymphopenia
NLRC4 GOF	*NLRC4* Somatic or germline variants	NLRC4 inflammasome	Rare	↑ IL-18	Responds to recombinant IL-18BP
CDC42	*CDC42*	CDC42	Rare	↑ IL-18, variants interfere with binding and localization of CDC42	Neonatal cytopenias, hepatosplenomegaly, fevers, urticaria-like rashes, facial dysmorphisms
CD70	*CD70*	CD70 interaction with CD27	Rare	↓ expression and ↓ cytotoxicity of T cells	EBV susceptibility to HLH
CTPS1	*CTPS1*	Cytidine nucleotide triphosphate synthesis	Rare	Impaired proliferation of NKT cells	EBV susceptibility
RASGRP1	*RASGRP1*	RASGRP1	Rare	Activates RAS; defects in T-cell activation, migration, proliferation ↓ cytotoxicity ↓ NKT cells	EBV susceptibility to HLH

APCs, Antigen-presenting cells; CNS, central nervous system; EBV, Epstein-Barr virus; FHLH, familial hemophagocytic lymphohistiocytosis; GOF, gain of function; HLH, hemophagocytic lymphohistiocytosis; ITK, interleukin (IL)-2–inducible T-cell kinase; NF-κB, nuclear factor–kappa B; NK, natural killer; TCR, T-cell receptor; XLP-1, 2-X-linked lymphoproliferative diseases.

Adapted from Erker C, Harker-Murray, Talano JA. Usual and unusual manifestations of familial hemophagocytic lymphohistiocytosis and Langerhans cell histiocytosis. *Pediatr Clin North Am.* 2017;64:91–109. Table 1.

manifestations; risk organ–negative patients). The **risk organs** are liver, spleen, and the hematopoietic (bone marrow) system. The lung is not considered a risk organ. The distinction of risk-organ involvement is important for deciding the intensity of the treatment approach and has been addressed in standard treatment approaches for LCH, as delineated in the Histiocyte Society protocols. Bone marrow involvement may cause anemia and thrombocytopenia. Two uncommon but serious manifestations of LCH are hepatic involvement (leading to fibrosis and cirrhosis) and a peculiar central nervous system (CNS) involvement characterized by ataxia, dysarthria, and other neurologic symptoms. **Hepatic involvement** is associated with multisystem disease that is often already present at diagnosis. In contrast, neurodegenerative **CNS involvement**, which is progressive and

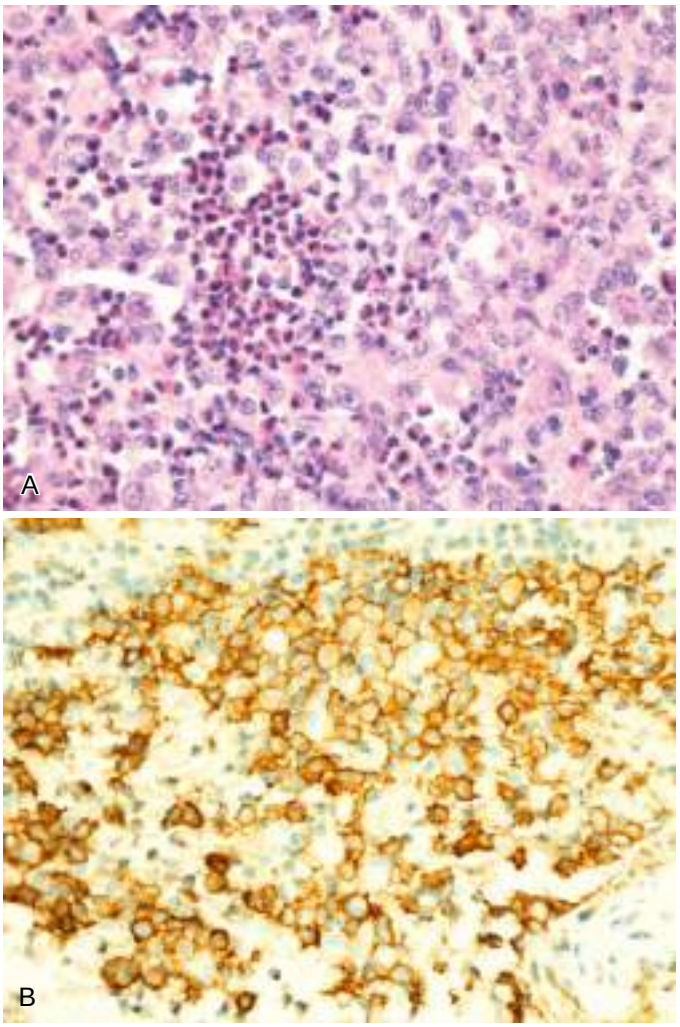

Fig. 556.1 A, Histopathology of Langerhans cell histiocytosis (LCH) shows eosinophilic granuloma of a lytic bone lesion of the femoral head. Multiple LCH cells with characteristic grooved nuclei, as well as numerous eosinophils, are visible in this mixed infiltrate. B, CD1a staining, characteristic and diagnostic of lesions with LCH cells.

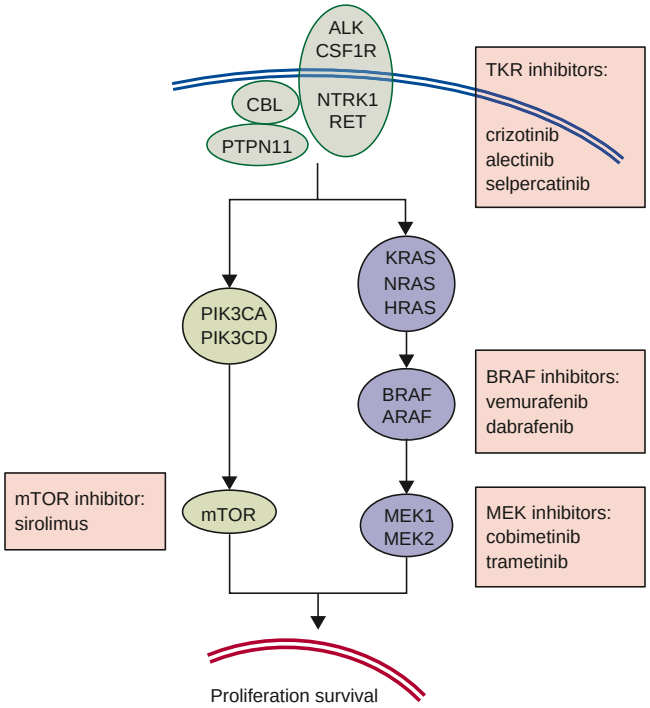

Fig. 556.2 Proteins of the MAP kinase cell-signaling pathway involved by activating pathogenic variants, and inhibitors already reported to benefit patients with histiocytosis. *(From Emile JF, Cohen-Aubart F, Collin M, et al. Histiocytosis. Lancet. 2021;398:157–168. Fig. 1.)*

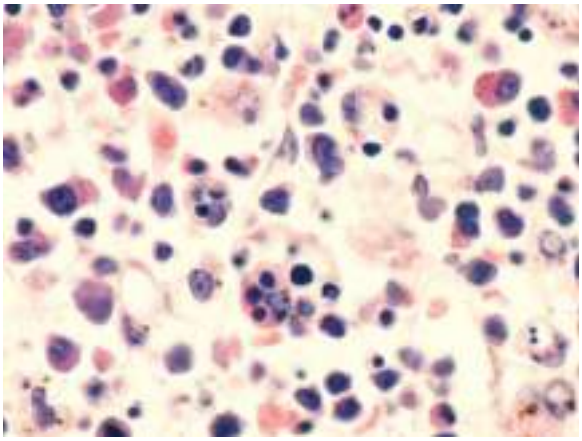

Fig. 556.3 Bone marrow aspirate of a child with familial (genetically confirmed) hemophagocytic lymphohistiocytosis. Numerous characteristic hemophagocytic cells (which are CD163-positive macrophages) are seen ingesting various blood elements.

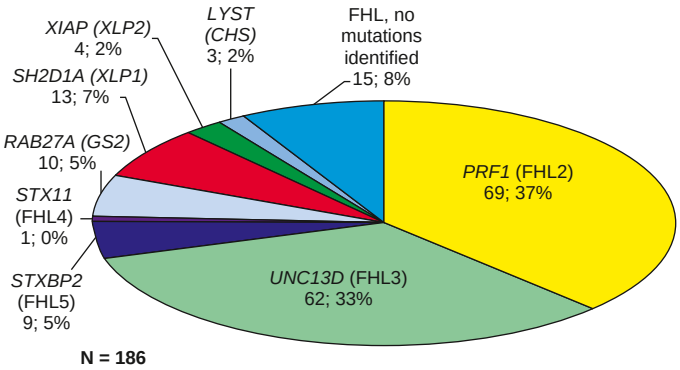

Fig. 556.4 Different genetic subtypes in 171 patients with familial hemophagocytic lymphohistiocytosis (FHL) or FHL-related disease. For each subtype, the name of the gene, the abbreviation of the disease subtype, the absolute number, and the percentage are shown. Furthermore, we include as FHL one subgroup of 15 patients with either familial recurrence or refractory/recurrent disease despite specific therapy and/or repeatedly documented severe functional defect in degranulation or cytotoxicity assays. *(From Cetica V, Sieni E, Pende D, et al. Genetic predisposition to hemophagocytic lymphohistiocytosis: Report on 500 patients from the Italian registry. J Allergy Clin Immunol. 2016;137:188–196. Fig. 2, p. 191.)*

histopathologically characterized by gliosis and has no definitive treatment, may be observed only many years after the initial diagnosis of LCH. These manifestations are not known to be associated with LCH cells, Birbeck granules, CD1a positivity, or any other indication of LCH cell infiltration, raising questions about their pathogenesis and the suggestion that they may be cytokine-mediated.

After tissue biopsy, which is diagnostic of LCH and is easiest to perform on skin or bone lesions, a comprehensive clinical and laboratory evaluation is essential and should be undertaken. This should include a series of studies in all patients: CBC, liver function tests, coagulation studies, skeletal survey, chest radiograph, and measurement of urine osmolality. In addition, detailed evaluation of any organ system shown to be involved by physical examination or by these studies should be performed to establish the extent of disease before initiation of treatment.

TREATMENT AND PROGNOSIS

The clinical course of **single-system disease** (usually bone, lymph node, or skin) generally is benign, with a high chance of spontaneous remission. Therefore treatment should be minimal and should be directed at arresting the progression of a bone lesion that could result in permanent damage before it resolves spontaneously. Curettage or, less often but especially

Table 556.4 Infections Associated with Hemophagocytic Syndrome

VIRAL
Adenovirus
Cytomegalovirus (CMV)
Dengue virus
Epstein-Barr virus (EBV)
Enteroviruses
Herpes simplex viruses (HSV1, HSV2)
Human herpesviruses (HHV6, HHV8)
HIV
Influenza viruses
Parvovirus B19
Varicella-zoster virus (VZV)
Hepatitis viruses
Measles
Parechovirus
BACTERIAL
Babesia microti
Brucella abortus
Enteric gram-negative rods
Haemophilus influenzae
Mycoplasma pneumoniae
Staphylococcus aureus
Streptococcus pneumoniae
Ehrlichia chaffeensis
FUNGAL
Candida albicans
Cryptococcus neoformans
Histoplasma capsulatum
Fusarium
MYCOBACTERIAL
Mycobacterium tuberculosis
RICKETTSIAL
Coxiella burnetii
Other rickettsial diseases
PARASITIC
Leishmania donovani
Plasmodium

From Nathan DG, Orkin SH, Ginsburg D, et al., eds. *Nathan and Oski's Hematology of Infancy and Childhood*. 6th ed. Philadelphia: Saunders; 2003, p. 1381.

Table 556.5 Other Primary Immunodeficiency and Inherited Metabolic Diseases That May Be Complicated (Rarely) by Hemophagocytic Lymphohistiocytosis

PRIMARY IMMUNODEFICENCY DISEASES
SCID
CIDs
DiGeorge syndrome
Wiskott-Aldrich syndrome
Ataxia telangiectasia
Dyskeratosis congenita
ORAI-1 deficiency
Chronic granulomatous disease
Other PIDs
X-linked agammaglobulinemia
Autoimmune lymphoproliferative syndrome
STAT1 gain of function
CTLA4
GATA2
TRAPS
FMF
NEMO
TIM3
DOCK8
STAT2
STAT3
PIK3CD
INBORN ERRORS OF METABOLISM
Lysinuric protein intolerance
Multiple sulfatase deficiency
Biotinidase deficiency
Lysosomal acid lipase deficiency/Wolman disease
Methylmalonic acidemia
Galactosemia
Gaucher disease
Pearson syndrome
Galactosialidosis
Propionic acidemia
Cobalamin C disease
Niemann-Pick disease
LCHAD deficiency
CONGENITAL DISORDERS OF GLYCOSYLATION
COG6

From Canna SW, March RA. Pediatric hemophagocytic lymphohistiocytosis. *Blood*. 2020;135(16):1332–1343. Table 5.

when a weight-bearing bone is involved, corticosteroid injection or low-dose local radiation therapy (5-6 Gy) may accomplish this goal.

In contrast, **multisystem disease** requires treatment with systemic multiagent chemotherapy. Several different regimens have been proposed, but central elements are the inclusion of vinblastine and corticosteroids, both of which have been found to be very effective in treating LCH. Etoposide has been excluded from the standard treatment of multisystem LCH, which is treated with multiple agents, designed to reduce mortality, reactivation of disease, and long-term consequences. The response rate to therapy is quite high, and mortality in severe LCH has been substantially reduced by multiagent chemotherapy, especially if the diagnosis is made accurately and expeditiously. The most recent treatment results associated with lengthened continuation therapy (HS LCH-III) show a greater than 85% survival rate in severe (RO+) multisystem disease and a reduced rate of reactivation.

Experimental therapies are suggested only for unresponsive disease (often in very young children with multisystem disease and organ dysfunction who have not responded to multiagent initial treatment) and reactivation of RO+ disease in risk organs but not in reactivation of mild disease (any risk organ–negative reactivations) (see Fig. 556.2). The approaches include immunosuppressive therapy with cyclosporine/antithymocyte globulin and possibly imatinib, 2-chlorodeoxyadenosine, and clofarabine. With the discovery of the *BRAFV600E* pathogenic variant causing hyperactivation of the MAPK pathway in LCH cells, pharmacologic inhibition of BRAF and pharmacologic inhibition of MEK are currently the subject of clinical trials as therapeutic approaches for resistant disease.

Late (fibrotic) complications, whether hepatic or pulmonary, are irreversible and require organ transplantation to be definitively treated. Current treatment approaches and experimental protocols for both LCH and HLH can be obtained at the Histiocyte Society website (http://www.histiocytesociety.org). An unresolved problem is treatment of the (usually late-onset) severe, progressive, and intractable LCH-associated **neurodegenerative** syndrome. This is also under investigation for response to experimental therapies, including the pharmacologic inhibitors of the MAPK pathway. Regarding current treatment recommendations for LCH as well as HLH, the continuing rapid advances in understanding of their pathogeneses is likely to result in further rapid development and validation of new therapeutic approaches.

Visit Elsevier eBooks+ at eBooks.Health.Elsevier.com for Bibliography.

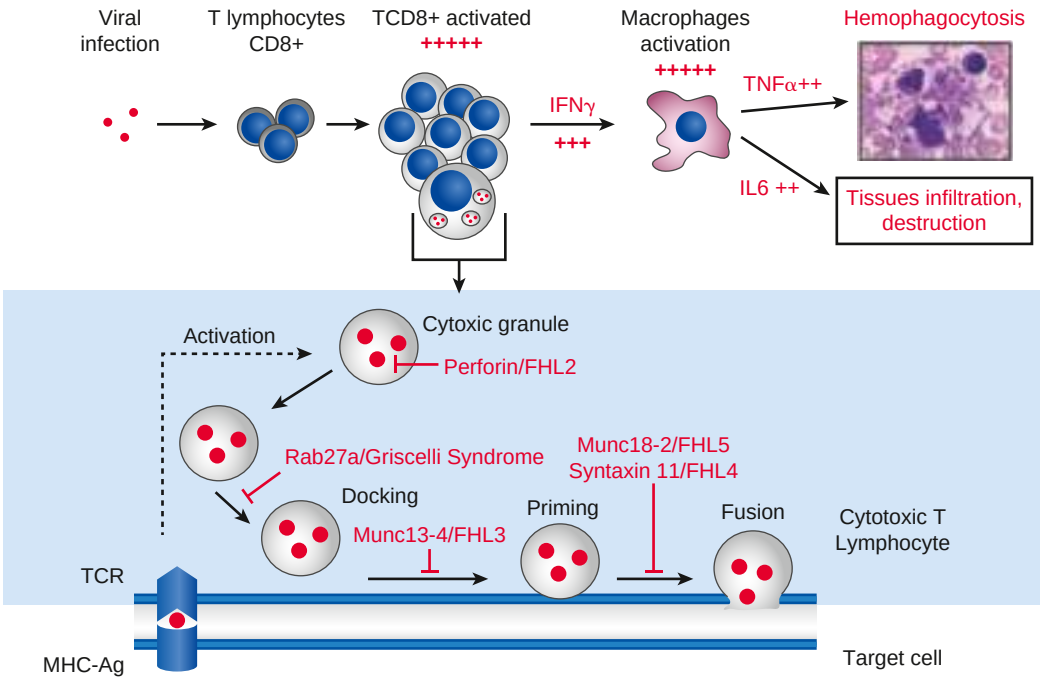

Fig. 556.5 Inborn errors in the cytotoxic activity of lymphocytes. **Top,** Immune mechanisms leading to the occurrence of a hemophagocytic syndrome. Following a viral infection, antigen-specific CD8+ T lymphocytes undergo massive expansion and activation and secrete high levels of interferon (IFN)-γ. The overwhelming activated effector cells induce excessive macrophage activation and proinflammatory cytokine production, including tumor necrosis factor (TNF)-α and interleukin-6 (IL-6). Macrophages spontaneously phagocytose blood elements (platelets, red blood cells, and a polymorphonuclear cell shown here). Activated lymphocytes and macrophages infiltrate various organs, resulting in massive tissue necrosis and organ failure. **Bottom,** Genetic variants causing hemophagocytic lymphohistiocytic syndrome (HLH) affect a precise step of the cytotoxic machinery: granule content, docking, priming, or fusion. Only the defects causing Griscelli syndrome and familial hemophagocytic lymphohistiocytosis (FHL) are shown. MHC-Ag, Major histocompatibility complex antigen; TCR, T-cell receptor. *(From Pachlopnik Schmid J, Cote M, Menager MM, et al. Inherited defects in cytotoxic lymphocyte activity. Immunol Rev. 2010;235:10–23.)*

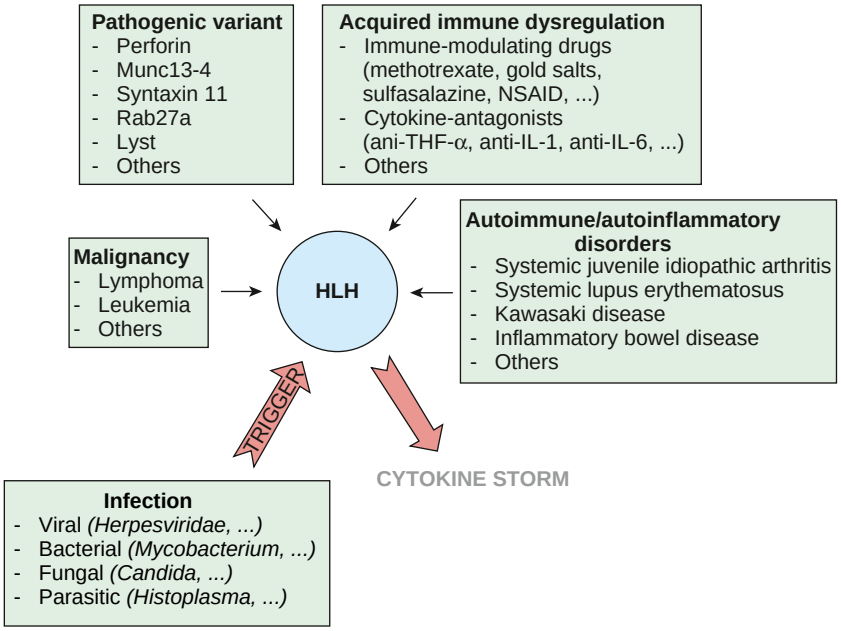

Fig. 556.6 Hemophagocytic lymphohistiocytosis (HLH) comprises a heterogeneous spectrum of disorders that all present with severe cytokine storm and life-threatening immunopathology. HLH can be caused by pathogenic variants in genes involved in granule-mediated cytotoxicity but can also be acquired on a multitude of underlying autoimmune/autoinflammatory diseases or malignancies, with possible facilitation by immunomodulating therapies. Clinical manifestations of HLH are generally precipitated by an infection. IL, Interleukin; NSAID, nonsteroidal antiinflammatory drugs. *(From Brisse E, Wouters CH, Matthys P. Hemophagocytic lymphohistiocytosis (HLH): a heterogeneous spectrum of cytokine-driven immune disorders. Cytokine Growth Factor Rev. 2015;26:263–280. Fig. 2, p. 267.)*

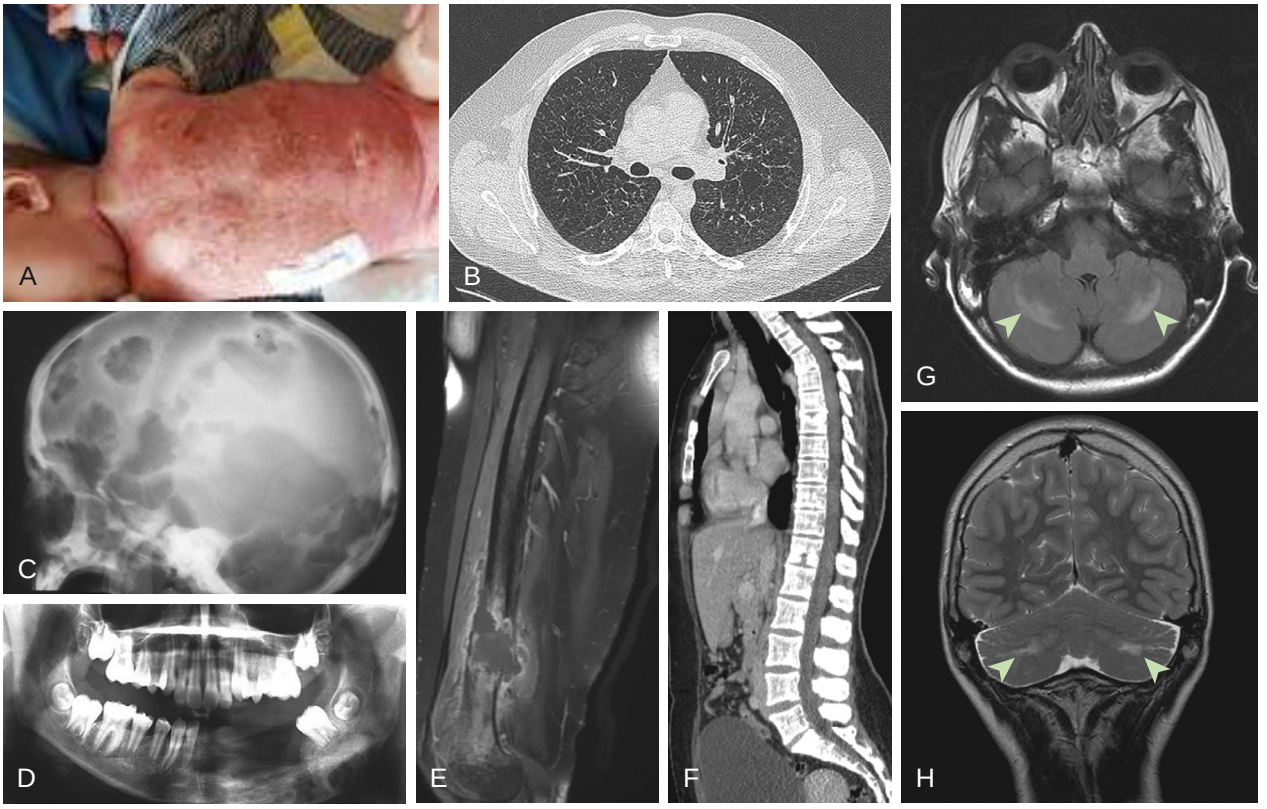

Fig. 556.7 Langerhans cell histiocytosis. **A,** Young child with disseminated Langerhans cell histiocytosis (LCH) skin lesions. **B,** Chest CT scan showing multiple cysts. **C,** X-rays showing LCH involvement of the skull. **D,** X-rays showing LCH involvement of the mandible, as revealed by so-called floating teeth. **E,** MRI showing a femoral lesion revealed by a fracture. **F,** CT scan showing the spinal column. **G and H,** MRI showing degenerative neuro-LCH on axial T2 spin echo-weighted images, which reveal symmetrical hyperintensities within the cerebellar corpus medullare *(arrows). (From Emile JF, Cohen-Aubart F, Collin M, et al. Histiocytosis. Lancet. 2021;398:157–168. Fig. 2.)*

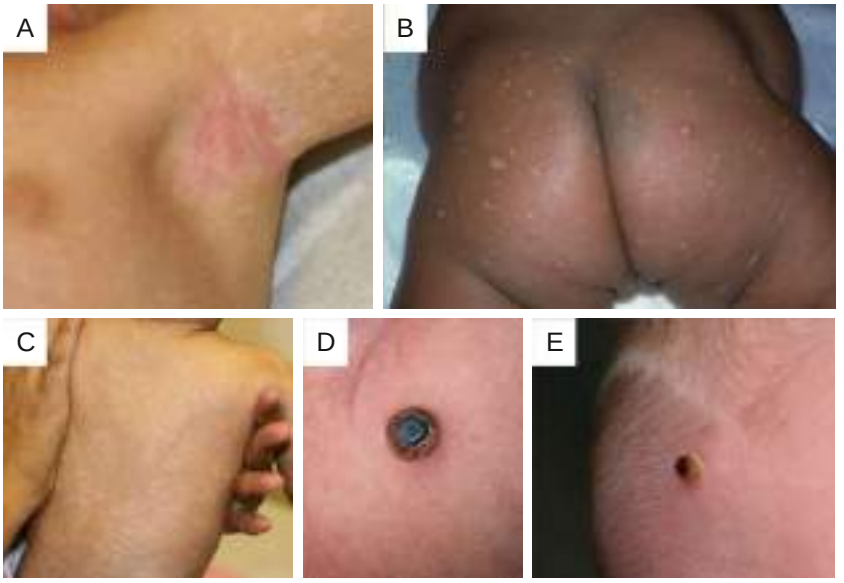

Fig. 556.8 Variable appearance of Langerhans cell histiocytosis of skin. **A,** Eczematous dermatitis. **B,** Hypopigmented, eroded papules. **C,** Hypopigmented macules. **D** and **E,** Crusted papulonodules. Presentation does not reflect presence or absence of multisystem disease. Despite similar appearance, the patient in **D** had a single lesion, whereas the patient in **E** had organ involvement. *(From Simko SJ, Garmezy B, Abhyankar H, et al. Differentiating skin-limited and multisystem Langerhans cell histiocytosis. J Pediatr. 2014;165:990–996. Fig. 3.)*

Fig. 556.9 Langerhans cell histiocytosis presenting as "blueberry muffin" rash in neonate. Multiple firm, nonblanching, purple papules affecting the head and neck (A) and the body (B). *(From Schmitt AR, Wetter DA, Camilleri MJ, et al. Langerhans cell histiocytosis presenting as a blueberry muffin rash. Lancet. 2017;390:155.)*

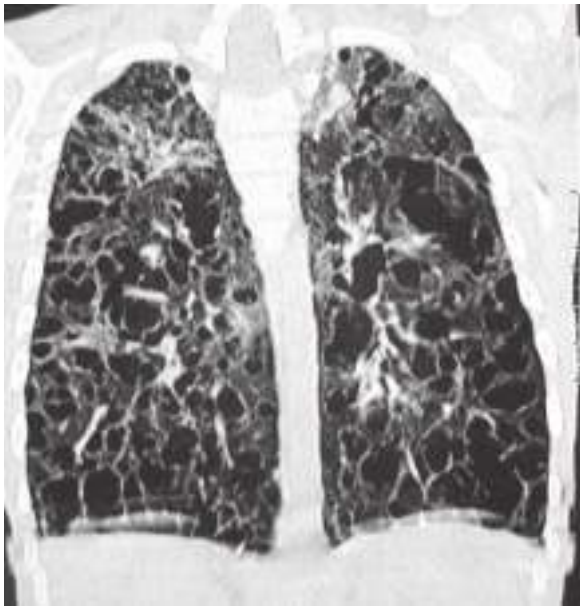

Fig. 556.10 High-resolution coronal CT image (lung window) reveals diffuse lung cysts with parenchymal destruction in bilateral lung fields. *(From Chauhan L, Aggarwal N. Honey-comb Langerhans cell histiocytosis. J Pediatr. 2016;168:248. Fig. 2.)*

556.2 Hemophagocytic Lymphohistiocytosis

Stephan Ladisch

See the previous section on "Classification and Pathology," Table 556.3, and Chapter 174.

CLINICAL MANIFESTATIONS

Primary FHLH and secondary HLH have a remarkably similar, clinically indistinguishable presentation (Fig. 556.11). It consists of a generalized disease process, most often with fever (90–100%), maculopapular and/or petechial rash (10–60%), weight loss, and irritability. The initial clinical presentation can vary but is usually severe. In the case of secondary HLH, onset may be camouflaged by a primary disease process. Acute presentations of HLH include a hyperferritinemic septic shock–like picture, acute respiratory distress, seizures, ataxia, focal lesions, or coma (because of CNS infiltration). Other features that are frequently present result from bone marrow involvement and pancytopenia or hepatic dysfunction.

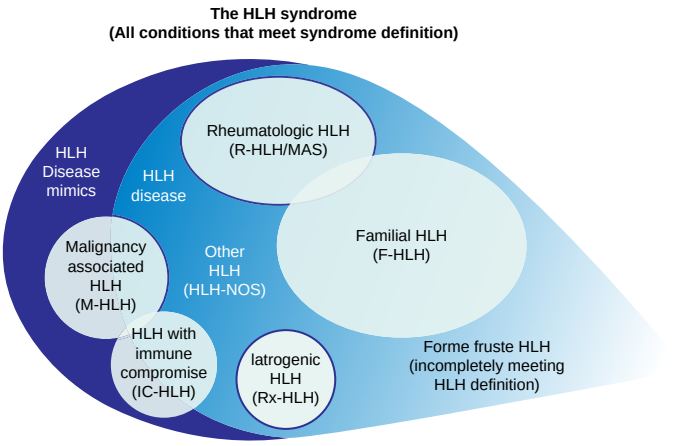

Fig. 556.11 Spectrum of the hemophagocytic lymphohistiocytosis (HLH) syndrome. The HLH syndrome includes all conditions meeting consensus diagnostic criteria. This syndrome includes conditions that would benefit from HLH-directed immunosuppressive therapies, which are termed "HLH disease," and those conditions that would not benefit from such therapy or require entirely different treatments, termed "HLH disease mimics." HLH disease includes recognizable subgroups: familial HLH with clear genetic etiology, HLH associated with malignancy, HLH associated with rheumatologic conditions (also called MAS), HLH observed after immune-activating therapies (iatrogenic HLH, also called cytokine release syndrome), HLH associated with immune compromise (either primary immune deficiency or treatment-related immune suppression), and HLH not associated with other specific conditions. Recognition of these subcategories is valuable as this may alter treatment. *(From Jordan MB, Allen CE, Greenberg J, et al. Challenges in the diagnosis of hemophagocytic lymphohistiocytosis: Recommendations from the North American Consortium (NACHO). Pediatr Blood Cancer. 2019;66:e27929.)*

Children with primary HLH are generally <1-2 years old, and children with secondary HLH typically present at an older age, but both forms may present at any age. **Physical examination** often reveals hepatosplenomegaly (70–100%), lymphadenopathy (20–50%), respiratory distress (40–90%), jaundice, and symptoms of CNS involvement (50%) that are not unlike those of aseptic meningitis, CNS vasculitis, or acute demyelinating encephalomyelitis. MRI may demonstrate systemic T2 weighted/fluid-attenuated inversion recovery (FLAIR) hyperintensities in gray and white matter and in supratentorial and infratentorial regions (Fig. 556.12). The cerebrospinal fluid (CSF) pleocytosis (50–90%) associated with CNS involvement in primary HLH is characterized by cells that are the same phagocytic macrophages found in the peripheral blood or bone marrow. HLH may initially or only manifest CNS symptoms. Isolated neuroinflammation may be present in the absence of cytopenias, splenomegaly, or other systemic features. Approximately 35% will eventually develop diagnostic features of HLH (Table 556.6). The interval from neurologic onset to eventual diagnosis often exceeds 2 years. In CNS isolated disease, the diagnosis of familial HLH is often made by whole exome sequencing for other diseases.

The **diagnosis** of HLH is arrived at in two stages. The first stage is based on a set of eight clinical and laboratory findings, with the presence of five of the eight being diagnostic of HLH. The eight findings, formulated by the Histiocyte Society, are fever, splenomegaly, cytopenia of two cell lines (in 90–100%), hypertriglyceridemia (80–100%) or hypofibrinogenemia (65–85%), hyperferritinemia (≥500 but often >10,000), extremely elevated soluble CD25 (interleukin-2 receptor), reduced or absent NK cell activity, and bone marrow, CSF, or lymph node evidence of hemophagocytosis (see Table 556.6). The second stage involves genetic analysis and is undertaken as quickly as possible but generally requires ~2 weeks to complete and should not interfere with initiation of treatment (Fig. 556.13). The genetic findings and family history will determine whether the diagnosis is (autosomal

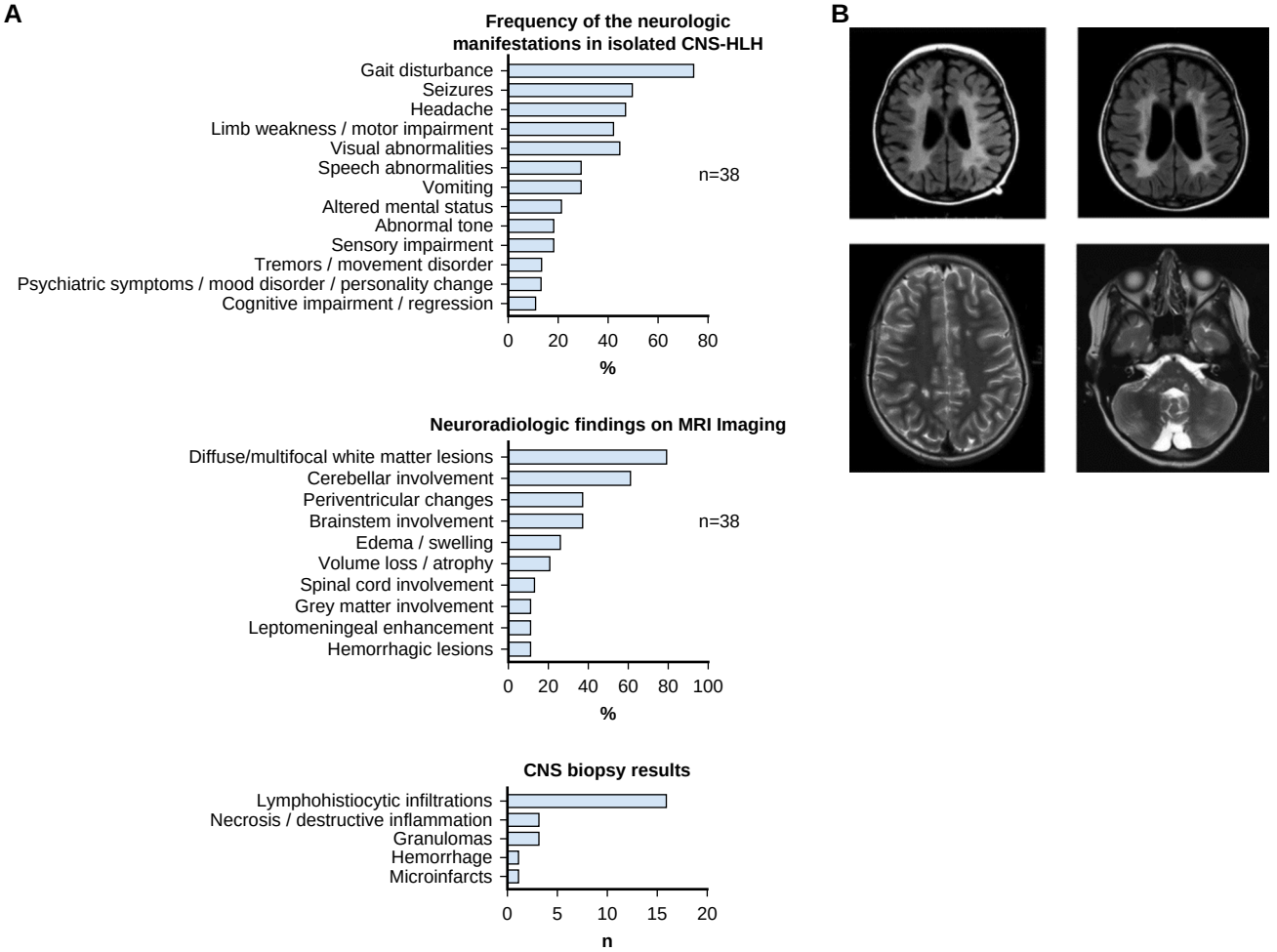

Fig. 556.12 A, Frequencies of neurologic manifestations, neuroradiologic findings, and histopathologic central nervous system (CNS) biopsy results in 38 patients with isolated CNS hemophagocytic lymphohistiocytosis (HLH). B, Examples of CNS MRI imaging in patients with isolated CNS-HLH. *Upper panels*, T2 images in one patient from 2016 *(left)* and 2017 *(right)* demonstrate cerebral atrophy with diffuse white matter involvement. Neuroradiologic findings on MRI show imaging abnormalities. *Lower panels*, T2 images from another patient reveal multiple nodular lesions in the pons, cerebellum, and white matter. *(From Blincoe A, Heeg M, Campbell PK, et al. Neuroinflammatory disease as an isolated manifestation of hemophagocytic lymphohistiocytosis. J Clin Immunol. 2020;40:901–916. Fig. 1.)*

recessive) primary HLH, secondary HLH, or a genetic hybrid form of HLH.

Hemophagocytosis is not specific for HLH and should be considered only in the context of the diagnostic criteria. No absolute clinical or laboratory distinction can be made between primary HLH and secondary HLH. In some subgroups of HLH, perforin assays may be normal. Similarly, some patients with primary FHLH have no known identifiable pathogenic variant, while new genetic variants associated with HLH continue to be discovered.

In the absence of either (1) a documented genetic defect coupled with defective NK cell cytotoxicity or (2) frank hemophagocytosis, care should be taken in making the diagnosis of secondary HLH, given the implication to use cytotoxic chemotherapy. The nonspecific criteria (indicative of inflammation) used to diagnose HLH can also be seen in diseases that are not always associated with hemophagocytosis (e.g., overwhelming acute viral infection with appropriate T-cell activation), in which the cytotoxic and immunosuppressive therapy used in treating HLH might be contraindicated.

Macrophage activation syndrome, particularly in the context of systemic-onset juvenile idiopathic arthritis (JIA) or infection, has many similarities to HLH (see Chapter 196). Indeed, whole exome sequencing of patients with systemic-onset JIA or those with fatal influenza has revealed a higher than expected incidence of HLH genes.

TREATMENT AND PROGNOSIS

Therapy for **primary HLH** (autosomal recessive genetic disease or familial occurrence) consists of a combination of etoposide, dexamethasone, cyclosporine, and intrathecal methotrexate. It should be stressed that pancytopenia and the presence of an infection are *not* contraindications to cytotoxic or immunosuppressive therapy (etoposide and steroid, cyclosporine or antithymocyte globulin for maintenance therapy). Paradoxically they ameliorate the HLH. Emapalumab, a monoclonal antibody against interferon-γ, is approved for recurrent, refractory, or progressive familial HLH or for patients who cannot tolerate chemotherapy. The goal for all therapies is to reach the point of initiating **stem cell transplantation,** to date the only known potentially curative treatment for primary HLH, effective in achieving cure in >60% of patients. Chemotherapy is inadequate for sustained cure of primary HLH, which is ultimately fatal without transplantation.

In **secondary HLH**, it is critical that the underlying disease (e.g., infection, malignancy) be identified and successfully treated. The diagnostic distinction between primary HLH and secondary HLH sometimes can be based on the acute onset of secondary HLH in the presence of an already documented infection or cancer, including leukemia, and certain autoimmune or immunodeficiency disorders. In this case, treatment of the underlying infection is coupled with supportive care. If the diagnosis is made in the setting of iatrogenic immunodeficiency, immunosuppressive

Table 556.6 Diagnostic Criteria for the HLH-2004 Trial and Their Relevance for Clinical Diagnosis

HLH2004 ENTRY CRITERIA	COMMENT
A. Molecular diagnosis consistent with HLH: Pathogenic variants of *PRF1*, *UNC13D*, *STXBP2*, Rab27a, *STX11*, *SH2D1A*, or *XIAP* or	In a patient with known variants, treatment before full development of HLH may be appropriate, but genetic studies usually just help to define HLH recurrence risk, not the presence of an active disease state.
B. Five of the eight criteria listed below are fulfilled	
1. Fever ≥38.3°C	Nearly universal in untreated HLH.
2. Splenomegaly	Although splenomegaly and hepatomegaly are very common in HLH, adenopathy is not.
3. Cytopenias (affecting at least two of three lineages in the peripheral blood): Hemoglobin <9 g/dL (in infants <4 wk: hemoglobin <10 g/dL), platelets <100 × 10^3/mL, neutrophils < 1 × 10^3/mL	Cytopenias are ubiquitous in HLH. Lack of cytopenias should make one doubt a diagnosis of HLH, except in the special case of isolated, CNS-only disease.
4. Hypertriglyceridemia (>265 mg/dL) and/or hypofibrinogenemia (<150 mg/dL)	Low fibrinogen in the context of inflammation is paradoxical and one of the more distinctive features of HLH.
5. Hemophagocytosis in bone marrow or spleen or lymph nodes or liver	Not specific to HLH, or essential for the diagnosis, but helpful as a disease marker. Of note, it is often not evident early after disease onset.
6. Low or absent NK-cell activity	More modern and robust assays measuring perforin levels and its degranulation should replace this assay for reliable diagnosis of HLH. This assay is not specific for primary HLH.
7. Ferritin >500 ng/mL	Most patients have much higher levels than this threshold suggests.
8. Elevated soluble CD25 (soluble IL-2 receptor α)	As HLH is a T-cell driven disease, this assay is extremely informative for diagnosis and response to therapy.

HLH, Hemophagocytic lymphohistiocytosis; NK, natural killer; IL, interleukin; CNS, central nervous system.
From Jordan MB, Allen CE, Greenberg J, et al. Challenges in the diagnosis of hemophagocytic lymphohistiocytosis: Recommendations from the North American Consortium (NACHO). *Pediatr Blood Cancer*. 2019;66(11):e27929. Table 1.

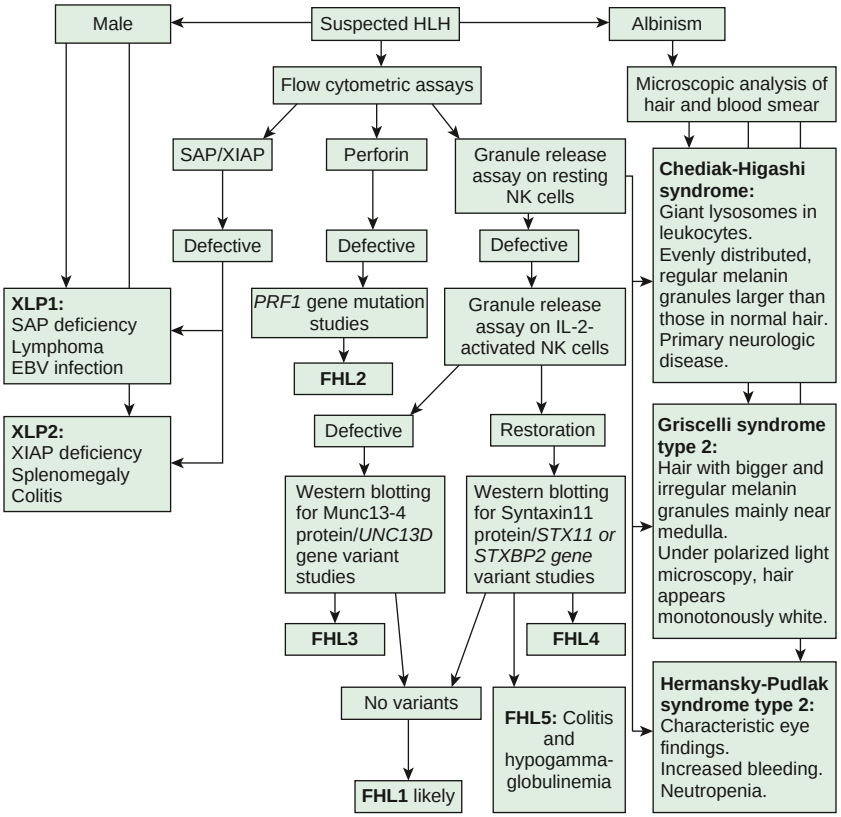

Fig. 556.13 Algorithm for identification of genetic causes of hemophagocytic lymphohistiocytosis (HLH). The HLH algorithm is based on flow cytometry assays: all the patients fitting into HLH criteria, irrespective of age and clinical presentations, should be screened for perforin expression and granule release assay. All male patients should be screened for signaling lymphocyte activation molecule–associated protein (SAP) and X-linked inhibitor of apoptosis protein (XIAP) expression. For patients clinically presenting with albinism, microscopic analysis of hair and blood smear is essential for differential diagnosis of Chédiak-Higashi syndrome, Griscelli syndrome, and Hermansky-Pudlak syndrome. Based on the defect in expression of a particular protein identified, molecular characterization for the respective gene should be performed for confirmation of diagnosis. EBV, Epstein-Barr virus; FHL, familial hemophagocytic lymphohistiocytosis; IL, interleukin; NK, natural killer. *(Adapted from Madkaikar M, Shabrish S, Desai M. Current updates on classification, diagnosis and treatment of hemophagocytic lymphohistiocytosis (HLH). Indian J Pediatr. 2016;83:434–443.)*

treatment should be withdrawn and supportive care instituted along with specific therapy for the underlying infection. In many patients the prognosis is excellent without additional specific treatment other than treating the triggering infection. However, when a treatable infection or other cause cannot be documented, and when the clinical presentation is severe, the prognosis for secondary HLH is as poor as for primary HLH. These patients should receive the identical initial 8-week chemotherapeutic approach, including etoposide, even in the face of cytopenias. In both primary and secondary HLH, the cytotoxic effect of etoposide on macrophages interrupts cytokine production and the consequent cytokine storm, the hemophagocytic process, and the accumulation of macrophages, all of which may contribute to the pathogenesis of **infection-associated hemophagocytic syndrome**. A broad spectrum of infectious agents, including viruses (e.g., cytomegalovirus, Epstein-Barr virus, human herpesvirus 6), fungi, protozoa, and bacteria, may trigger secondary HLH, often in the setting of immunodeficiency (see Table 556.3). A thorough evaluation for infection should be undertaken in immunodeficient patients with hemophagocytosis. The same syndrome may be identified in conjunction with a rheumatologic disorder (e.g., systemic lupus erythematosus, Kawasaki disease) or a neoplasm (e.g., leukemia). In these patients, effective treatment of the underlying disease (e.g., infection, cancer) is critical and may itself lead to ultimate resolution of the hemophagocytosis. In addition anakinra or ruxolitinib (JAK inhibitors) has been used in patients with secondary HLH.

Visit Elsevier eBooks+ at eBooks.Health.Elsevier.com for Bibliography.

556.3 Other Histiocytoses

Stephan Ladisch

Other rare histiocytoses that have been named for their clinical presentation include xanthogranuloma in JXG, ECD, and striking lymphadenopathy in Rosai-Dorfman disease (sinus histiocytosis with massive lymphadenopathy). JXG and ECD may require systemic treatment with cytotoxic chemotherapy or potentially MAPK pathway inhibitors, reflecting the presence of a *BRAF* pathogenic variant. Rosai-Dorfman disease usually is not treated, although the massive lymphadenopathy may require intervention because of its tendency to cause physical obstruction.

Rare histiocytic malignancies include acute monocytic leukemia, true malignant histiocytosis, and histiocytic sarcoma. Also included is the more recently identified histiocytic malignancy, ALK+ histiocytosis, which is a systemic histiocytic proliferation presenting as disseminated disease in infants. The cells bear histiocytic markers (CD68, CD163) but not those of LCH (CD1a, BRAF V600E). Whereas all these rare histiocytic malignancies are referred to as histiocytoses because of their monocyte-macrophage lineage, they are better considered under the rubric of true proliferative malignancies of the monocyte–macrophage lineage.

Visit Elsevier eBooks+ at eBooks.Health.Elsevier.com for Bibliography.

Nephrology

PART XXI

Section 1

Glomerular Disease

Chapter 557

Introduction to Glomerular Diseases

557.1 Anatomy of the Glomerulus

Edward J. Nehus

The kidneys lie in the retroperitoneal space slightly above the level of the umbilicus. They range in length and weight, respectively, from approximately 6 cm and 24 g in a full-term newborn to ≥12 cm and 150 g in an adult. The kidney (Fig. 557.1) has an outer layer, **the cortex,** which contains the glomeruli, proximal and distal convoluted tubules, and collecting ducts, and an inner layer, **the medulla,** which contains the straight portions of the tubules, the loops of Henle, the vasa recta, and the terminal collecting ducts (Fig. 557.2).

The blood supply to each kidney usually consists of a main renal artery that arises from the aorta, although multiple renal arteries can occur. The main artery divides into segmental branches within the medulla, becoming the interlobar arteries that pass through the medulla to the corticomedullary junction. At this point, the interlobar arteries branch to form the arcuate arteries, which run parallel to the surface of the kidney. Interlobular arteries originate from the arcuate arteries and give rise to the afferent arterioles of the glomeruli. Specialized muscle cells in the wall of the afferent arteriole and specialized distal tubular cells adjacent to the glomerulus (macula densa) form the juxtaglomerular apparatus that controls the secretion of renin. The afferent arteriole divides into the glomerular capillary network, which then recombines into the efferent arteriole (see Fig. 557.2). The juxtamedullary efferent arterioles are larger than those in the outer cortex and provide the blood supply, as the vasa recta, to the tubules and medulla.

Each kidney contains approximately one million **nephrons** (each consisting of a glomerulus and associated tubules). There is a large distribution of normal nephron numbers in humans, ranging from 200,000 to 1.8 million nephrons per kidney. This variation can have major pathophysiologic significance as a risk factor for the later development of hypertension and progressive renal dysfunction. In humans, the formation of nephrons is complete at 34-36 weeks of gestation, but functional maturation with tubular growth and elongation continues during the first decade of life. Because new nephrons cannot be formed after birth, any disease that results in progressive loss of nephrons can lead to renal insufficiency. A decreased number of nephrons secondary to low birthweight, prematurity, and/or unknown genetic or environmental factors has been implicated as a significant risk factor for the development of primary hypertension and progressive renal dysfunction in adulthood. A low nephron number presumably results in hyperfiltration and eventual sclerosis of *overworked* nephron units.

The glomerular network of specialized capillaries serves as the filtering mechanism of the kidney. The glomerular capillaries are lined by endothelial cells (Fig. 557.3) and have very thin cytoplasm that contains many holes (fenestrations). The **glomerular basement membrane** (GBM) forms a continuous layer between the endothelial and mesangial cells on one side and the epithelial cells on the other. The membrane has three layers: a central electron-dense lamina densa; the lamina rara interna, which lies between the lamina densa and the endothelial cells; and the lamina rara externa, which lies between the

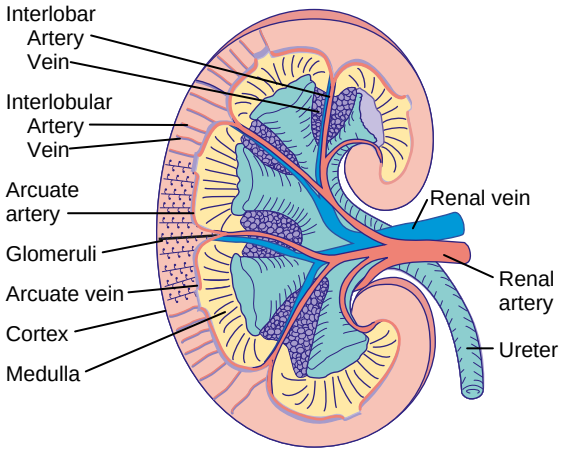

Fig. 557.1 Gross morphology of the renal circulation. *(From Pitts RF. Physiology of the Kidney and Body Fluids, 3rd ed. Chicago: Year Book Medical Publishers; 1974.)*

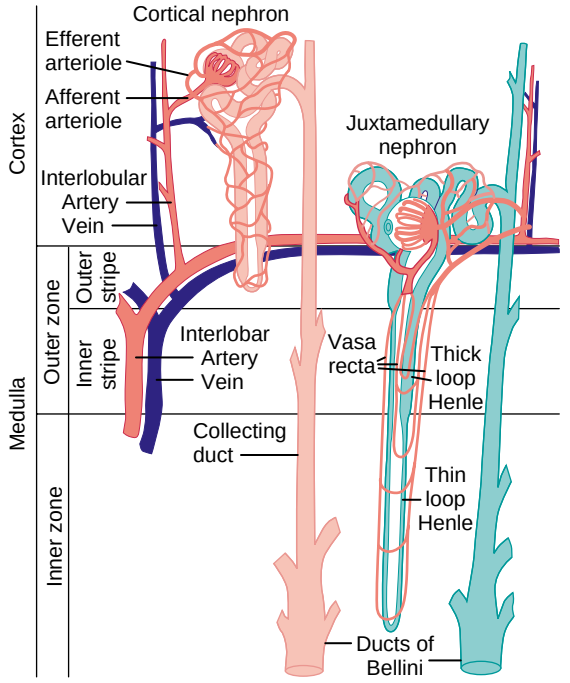

Fig. 557.2 Comparison of the blood supplies of cortical and juxtamedullary nephrons. *(From Pitts RF. Physiology of the Kidney and Body Fluids, 3rd ed. Chicago: Year Book Medical Publishers; 1974.)*

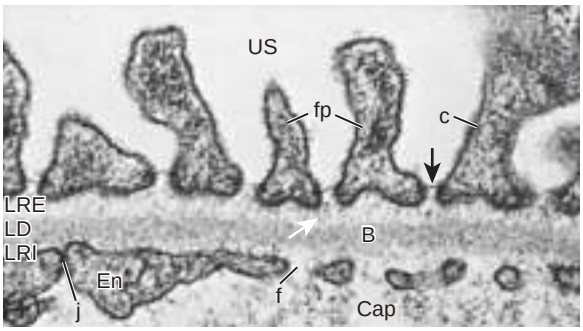

Fig. 557.3 Electron micrograph of the normal glomerular capillary *(Cap)* wall demonstrating the endothelium *(En)* with its fenestrations *(f)*; the glomerular basement membrane *(B)* with its central dense layer, the lamina densa *(LD)*, and adjoining lamina rara interna *(LRI)* and externa *(LRE) (white arrow)*; and the epithelial cell foot processes *(fp)* with their thick cell coat *(c)*. The glomerular filtrate passes through the endothelial fenestrae, crosses the basement membrane, and passes through the filtration slits *(black arrow)* between the epithelial cell foot processes to reach the urinary space *(US)* (×60,000). *j*, Junction between two endothelial cells. *(From Farquhar MG, Kanwar YS. Functional organization of the glomerulus: state of the science in 1979. In: Cummings NB, Michael AF, Wilson CB, eds. Immune Mechanisms in Renal Disease. New York: Plenum; 1982.)*

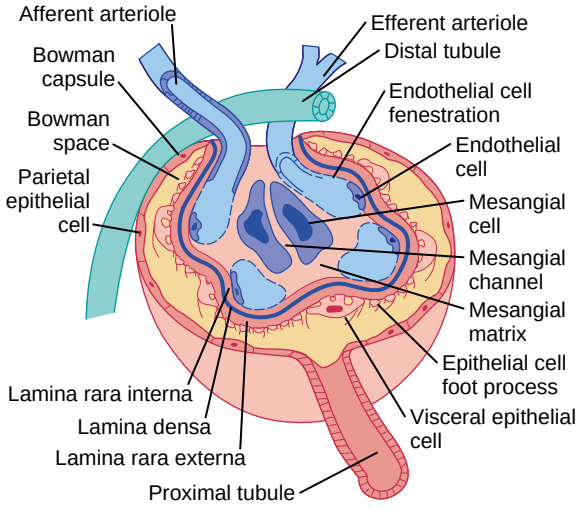

Fig. 557.4 Schematic depiction of the glomerulus and surrounding structures.

lamina densa and the epithelial cells. The visceral epithelial cells cover the capillary and project cytoplasmic foot processes, which attach to the lamina rara externa. Between the foot processes are spaces or filtration slits. The **mesangium** (mesangial cells and matrix) lies between the glomerular capillaries on the endothelial cell side of the GBM and forms the medial part of the capillary wall. The mesangium may serve as a supporting, stalk-like structure for the glomerular capillaries and probably has a role in the regulation of glomerular blood flow, filtration, and the removal of macromolecules (such as immune complexes) from the glomerulus. The Bowman's capsule, which surrounds the glomerulus, is composed of a basement membrane, which is continuous with the basement membranes of the glomerular capillaries and the proximal tubules, and the parietal epithelial cells, which are adjacent to the visceral epithelium (Fig. 557.4).

Visit Elsevier eBooks+ at eBooks.Health.Elsevier.com for Bibliography.

557.2 Glomerular Filtration

Edward J. Nehus

Kidney function is best measured as the **glomerular filtration rate (GFR)**. As the blood passes through the glomerular capillaries, the plasma is filtered through the glomerular capillary walls. Small plasma molecules filter freely (e.g., electrolytes, glucose, phosphate, urea, creatinine, peptides, low molecular weight proteins), whereas larger molecules are retained in the circulation (such as albumin and globulins). The filtrate is collected in Bowman's space and enters the tubules. There its composition is modified by tightly regulated secretion and absorption of solute and fluid by the multiple tubular segments of the nephron and the ductal system, until it exits the kidney, via the ureter, as urine.

Glomerular filtration is the net result of opposing forces applied across the capillary wall. The force for ultrafiltration (glomerular capillary hydrostatic pressure) is a result of systemic arterial pressure, modified by the tone of the afferent and efferent arterioles. The major force opposing ultrafiltration is glomerular capillary oncotic pressure, created by the gradient between the high concentration of plasma proteins within the capillary and the almost protein-free ultrafiltrate in Bowman's space. Filtration may be modified by the rate of glomerular plasma flow, the hydrostatic pressure within Bowman's space, and/or the permeability of the glomerular capillary wall.

Although glomerular filtration begins at approximately the sixth week of fetal life, kidney function is not necessary for normal intrauterine homeostasis because the placenta serves as the major fetal excretory organ. After birth, the GFR increases until renal growth ceases (by age ~18-20 years in most people). To compare GFRs of children and adults, the GFR is standardized to the body surface area (1.73 m^2) of an "ideal" 70-kg adult. Even after correction for surface area, the GFR of a child does not approximate adult values until the second to third year of life (Fig. 557.5). The GFR may be estimated by measurement of the serum creatinine level. Creatinine is derived from muscle metabolism. Its production is typically constant, and its excretion is primarily through glomerular filtration, although tubular secretion can become important as the serum creatinine rises in renal insufficiency. In contrast to the concentration of blood urea nitrogen, which is affected by the state of hydration and nitrogen balance, the serum creatinine level is primarily influenced by muscle mass and the level of glomerular function.

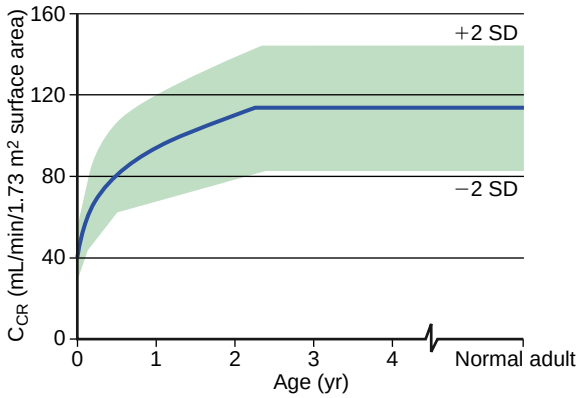

Fig. 557.5 Changes in the normal value of the glomerular filtration rate, as measured by the creatinine clearance *(Ccr)*, when standardized to mL/min/1.73 m^2 of body surface area. The *solid line* depicts the mean, and the *shaded area* includes 2 standard deviations (SDs). *(From McCrory W. Developmental Nephrology. Cambridge, MA: Harvard University Press; 1972.)*

The serum creatinine is of value only in estimating the GFR under steady-state conditions. A patient can have a normal serum creatinine level with decreased renal function very shortly after the onset of acute kidney injury. In this clinical setting, serum creatinine may take days to reach the steady state. Furthermore, kidney function may fall significantly before a noticeable rise in serum creatinine occurs.

The precise measurement of the GFR is accomplished by quantitating the clearance of a substance that is freely filtered across the capillary wall and is neither reabsorbed nor secreted by the tubules. The clearance (C_s) of such a substance is the volume of plasma that, when completely cleared of the contained substance, would yield an equal quantity of that substance excreted in the urine over a specified time. Renal clearance is calculated by the following formula:

$$C_s\left(\text{mL/min}\right) = U_s\left(\text{mg/mL}\right) \times \left(V\left(\text{mL/min}\right) / P_s\left(\text{mg/mL}\right)\right)$$

where C_s equals the clearance of substance s, U_s reflects the urinary concentration of s, V represents the urinary flow rate, and P_s equals the plasma concentration of s. To correct the clearance for individual body surface area, the formula is:

$$\text{Corrected clearance}\left(\text{mL/min}/1.73\,\text{m}^2\right) = C_s(\text{mL/min}) \times \frac{1.73}{\text{Surface area}\left(\text{m}^2\right)}$$

The GFR is optimally measured by the clearance of inulin, a fructose polymer having a molecular weight of approximately 5.7 kDa. Because the inulin clearance technique is cumbersome, radioisotopes are commonly used to measure GFR in clinical practice. GFR can be accurately determined by a single intravenous injection of a radioisotope, most commonly ^{99m}TC-DTPA, followed by timed monitoring of serum samples.

Because true measurement of the GFR is expensive and time-consuming, the GFR is commonly estimated (eGFR) by the clearance of endogenous creatinine. Formulas that estimate creatinine clearance accurately in clinical settings have been useful tools in patient care. The "bedside" Schwartz formula is the most widely used pediatric formula and is based on the serum creatinine (S_{cr}), patient height, and an empirical constant:

$$\text{eGFR} = 0.413\,\text{height}\left(\text{cm}\right)/S_{cr}\left(\text{mg/dL}\right)$$

The accuracy of GFR-estimating equations can be further improved utilizing an additional endogenous marker, cystatin C, in addition to serum creatinine. Cystatin C is a 13.6-kDa protease inhibitor produced by nucleated cells that is freely filtered by the kidney. It continues to gain popularity as a clinical tool to provide an alternative to creatinine-based formulas because it has distinct advantages in estimating the GFR. Unlike creatinine, cystatin C is not secreted by the renal tubules under any conditions. Furthermore, it is less affected by sex, age, and muscle mass than serum creatinine. Several cystatin C-based formulas have been developed, including a multivariable eGFR equation that combines both cystatin C and creatinine in addition to height, BUN, and gender:

$$\text{eGFR} = 39.8 \times \left[\text{height}\left(\text{m}\right)/S_{cr}\left(\text{mg/dl}\right)\right]^{0.456} \times \left[1.8/\text{cystatin C}\left(\text{mg/L}\right)\right]^{0.418} \times \left[30/\text{BUN}\left(\text{mg/dl}\right)\right]^{0.079} \times \left[1.076\right]^{\text{male}} \times \left[\text{ht}\left(\text{m}\right)/1.4\right]^{0.179}$$

However, cystatin C assays are not available in many laboratories and lack standardization. Therefore the creatinine-based bedside Schwartz equation remains the most widely used assessment of kidney function in children.

Visit Elsevier eBooks+ at eBooks.Health.Elsevier.com for a Bibliography.

557.3 Glomerular Diseases

Edward J. Nehus

PATHOGENESIS

Glomerular injury may be the result of a genetic, immunologic, perfusion, or coagulation disorder. Genetic disorders of the glomerulus may result from pathogenic variants in genes encoding proteins located within the glomerulus, interstitium, or tubular epithelium; pathogenic variants in regulatory genes controlling DNA transcription; abnormal posttranscriptional modification of RNA transcripts; or abnormal posttranslational modification of proteins. Immunologic injury to the glomerulus results in **glomerulonephritis,** which is a generic term for several diseases but more precisely is a histopathologic term defining inflammation of the glomerular capillaries. Evidence that glomerulonephritis is caused by immunologic injury includes morphologic and immunopathologic similarities to experimental immune-mediated glomerulonephritis, the demonstration of immune reactants (immunoglobulin, complement) in glomeruli, abnormalities in serum complement, and the finding of autoantibodies (anti-GBM) in some of these diseases (Fig. 557.6). There appear to be two major mechanisms of immunologic injury: glomerular deposition of circulating antigen-antibody immune complexes and direct interaction of antibody with specific glomerular antigens in situ. In the former, antibody is produced against and combines with a circulating antigen that is usually unrelated to the kidney (see Fig. 557.6). The immune complexes accumulate in GBMs and activate the complement system, leading to immune injury. Immunofluorescence microscopy often demonstrates granular or irregular deposits containing immunoglobulin and complement in the glomerular capillary wall. Electron microscopic studies may show these deposits in the GBM and in the mesangium. Examples of circulating immune complex–mediated glomerulonephritis include postinfectious glomerulonephritis, IgA nephropathy, membranoproliferative glomerulonephritis, and lupus nephritis. In situ immune complex formation occurs when an antibody reacts with antigen(s) of the GBM. Immunopathologic studies reveal linear deposition of immunoglobulin and complement along the GBM. This type of immune complex injury occurs in Goodpasture syndrome and membranous nephropathy.

The inflammatory reaction that follows immunologic injury results from activation of one or more mediator pathways. The most important of these is the complement system, which has two initiating sequences: the classic pathway, which is activated by antigen-antibody immune complexes, and the alternative or properdin pathway, which occurs by autoactivation of C3 by a process known as C3 tick over. These pathways converge at C3; from that point on, the same sequence leads to lysis of cell membranes (see Chapter 173). The major noxious products of complement activation are produced after activation of C3 and include anaphylatoxin (which stimulates contractile proteins within vascular walls and increases vascular permeability) and chemotactic factors (C5a) that recruit neutrophils and perhaps macrophages to the site of complement activation, leading to consequent damage to vascular cells and basement membranes.

PATHOLOGY

The glomerulus may be injured by several mechanisms, but it has only a limited number of histopathologic responses; different disease states can produce similar microscopic changes.

Proliferation of glomerular cells occurs in most forms of glomerulonephritis and may be generalized (involving all glomeruli) or focal (involving only some glomeruli and sparing others). Within a single glomerulus, proliferation may be diffuse (involving all parts of the glomerulus) or segmental (involving only one or more tufts, but not others). Proliferation commonly involves the endothelial and mesangial cells and is often associated with an increase in the mesangial matrix (see Fig. 557.6). Mesangial proliferation can result from deposition of

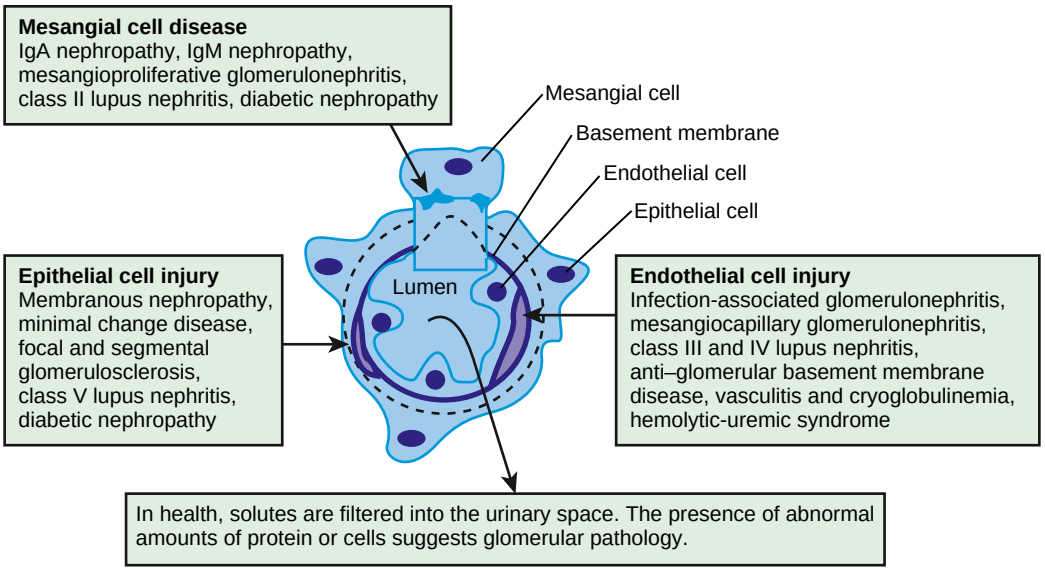

Fig. 557.6 Cellular location of injury during glomerulonephritis. Mesangial cells are directly exposed to the circulation. Deposition of immune complexes within these cells is typically seen in disorders such as immunoglobulin A *(IgA)* nephropathy; it results in proliferation and expansion of the cells, leading to hematuria, proteinuria, and renal impairment. Epithelial cells, in conjunction with basement membrane, allow filtration of plasma solutes but retard passage of cells and plasma proteins. Disease related to these cells is typified by the presence of subepithelial deposits and flattening of the foot processes that engage the basement membrane, resulting in disruption of the filtration barrier and proteinuria. Endothelial cell disease can result from deposition of immune complex (as occurs in mesangiocapillary glomerulonephritis), attachment of antibody to the basement membrane (Goodpasture disease), or trauma and activation of coagulation (hemolytic-uremic syndrome). Endothelial cell proliferation and necrosis are accompanied by leukocyte accumulation; rupture of the basement membrane, crescent formation, and disruption of glomerular architecture can develop. A nephritic or rapidly progressive presentation ensues. *(From Chadban SJ, Atkins RC. Glomerulonephritis. Lancet. 2005;365:1797–1806.)*

immune complex within the mesangium. The resultant increase in cell size and number, and production of mesangial matrix, can increase the glomerular size and narrow the lumens of glomerular capillaries, leading to renal insufficiency.

Crescent formation in Bowman's space (capsule) is a result of proliferation of parietal epithelial cells and is often associated with clinical signs of renal dysfunction. Crescents develop in several forms of glomerulonephritis (termed **rapidly progressive** or **crescentic;** see Chapter 559.7) and are a characteristic response to deposition of fibrin in Bowman's space. Newly formed crescents contain fibrin, the proliferating epithelial cells of Bowman's space, basement membrane–like material produced by these cells, and macrophages that might have a role in the genesis of glomerular injury. Over subsequent days to weeks, the crescent is invaded by connective tissue and becomes a fibroepithelial crescent. This process generally results in glomerular obsolescence and the clinical development of chronic renal failure. Crescent formation is often associated with glomerular cell death. The necrotic glomerulus has a characteristic eosinophilic appearance and usually contains nuclear remnants. Crescent formation is usually associated with generalized proliferation of the mesangial cells and with either immune complex or anti-GBM antibody deposition in the glomerular capillary wall.

Certain forms of acute glomerulonephritis show glomerular exudation of blood cells, including neutrophils, eosinophils, basophils, and mononuclear cells. The thickened appearance of GBM can result from a true increase in the width of the membrane (as seen in membranous glomerulopathy; see Chapter 559.5), from massive deposition of immune complexes that have staining characteristics similar to the membrane (as seen in systemic lupus erythematosus; see Chapter 560.2), or from the interposition of mesangial cells and matrix into the subendothelial space between the endothelial cells and the GBM. The last can give the basement membrane a split appearance, as seen in membranoproliferative glomerulonephritis (see Chapter 559.6) and other diseases.

Sclerosis refers to obliteration of capillary loops within the glomerulus caused by increased mesangial matrix. Glomerulosclerosis may be caused by a putative circulating factor, as occurs in primary focal segmental glomerulosclerosis (FSGS), or it may be secondary to a variety of conditions including pathogenic variants, obesity, infection, certain medications, or any condition that results in reduced renal mass.

Tubulointerstitial fibrosis is present in all patients who have glomerular disease and who develop progressive renal injury. This fibrosis is initiated by injury to either the glomeruli, which, if severe, may secondarily involve the tubules, or direct injury to the tubules themselves. Tubular injury recruits mononuclear cell infiltrate, which releases a variety of soluble factors that have fibrosis-promoting effects. Matrix proteins of the renal interstitium begin to accumulate, leading to eventual destruction of renal tubules and peritubular capillaries.

Visit Elsevier eBooks+ at eBooks.Health.Elsevier.com for Bibliography.

Section 2

Conditions Particularly Associated with Hematuria

Chapter 558

Clinical Evaluation of the Child with Hematuria

Francisco X. Flores

Hematuria, defined as the persistent presence of more than five red blood cells (RBCs)/high-power field (hpf) in uncentrifuged urine, occurs in 4–6% of urine samples from school-aged children. Quantitative studies demonstrate that normal children can excrete more than 500,000 RBCs per 12-hour period; this increases with fever and/or exercise. In the clinical setting, qualitative estimates are provided by a urinary dipstick that uses a very sensitive peroxidase chemical reaction between hemoglobin (or myoglobin) and a colorimetric chemical indicator impregnated on the dipstick. Chemstrip (Boehringer Mannheim), a common commercially available dipstick, is very sensitive and capable of detecting 3-5 RBCs/hpf of unspun urine. The presence of 10-50 RBCs/μL may suggest underlying pathology, but significant hematuria is generally considered as >50 RBCs/hpf. False-negative results can occur in the presence of formalin (used as a urine preservative) or high urinary concentrations of ascorbic acid (i.e., in patients with vitamin C intake >2,000 mg/day). False-positive results may be seen in a child with an alkaline urine (pH >8), or more commonly following contamination with oxidizing agents such as hydrogen peroxide used to clean the perineum before obtaining a specimen. Microscopic analysis of 10-15 mL of freshly voided and centrifuged urine is essential in confirming the presence of RBCs suggested by >10 RBCs/hpf, or a 1+ positive urinary dipstick reading.

Red urine *without* RBCs is seen in a number of conditions (Table 558.1). Clinically significant heme-positive urine without RBCs may be caused by the presence of either hemoglobin or myoglobin. **Hemoglobinuria** without hematuria can occur in the presence of acute or chronic hemolysis. **Myoglobinuria** without hematuria occurs in the presence of rhabdomyolysis resulting from skeletal muscle injury and is generally associated with a fivefold increase in the plasma concentration of creatine kinase. Clinically innocuous heme-negative urine can appear red, cola colored, or burgundy, due to ingestion of various drugs, foods (blackberries, beets), or dyes used in food and candy, whereas dark brown (or black) urine can result from various urinary metabolites.

Evaluation of the child with hematuria begins with a careful history, physical examination, and microscopic urinalysis. This information is used to determine the level of hematuria (upper vs lower urinary tract) and to determine the urgency of the evaluation based on symptomatology. Special consideration needs to be given to the family history, identification of anatomic abnormalities and malformation syndromes, presence of gross hematuria, and manifestations of hypertension, edema, or heart failure.

Table 558.2 lists causes of hematuria. Upper urinary tract sources of hematuria originate within the nephron (glomerulus, tubular system, or interstitium). Lower urinary tract sources of hematuria originate from the pelvicalyceal system, ureter, bladder, or urethra. Hematuria from within the glomerulus is often associated with brown, cola- or tea-colored, or burgundy urine, proteinuria >100 mg/dL via dipstick, urinary microscopic findings of RBC casts, and deformed urinary RBCs (particularly acanthocytes). Hematuria originating within the tubular system may be associated with the presence of leukocytes or renal tubular casts. Lower urinary tract sources of hematuria may be associated with gross hematuria that is bright red or pink, terminal hematuria (gross hematuria occurring at the end of the urine stream), blood clots, normal urinary RBC morphology, and minimal proteinuria on dipstick (<100 mg/dL).

Patients with hematuria can present with a number of symptoms suggesting specific disorders. Tea- or cola-colored urine, facial or body edema, hypertension, and oliguria are classic symptoms of **glomerulonephritis.** Diseases commonly manifesting as glomerulonephritis include postinfectious glomerulonephritis, immunoglobulin A (IgA) nephropathy, membranoproliferative glomerulonephritis (MPGN), IgA vasculitis nephritis (formerly Henoch-Schönlein purpura nephritis), systemic lupus erythematosus (SLE) nephritis, granulomatosis with polyangiitis (formerly Wegener granulomatosis), microscopic polyangiitis, Goodpasture syndrome, and hemolytic-uremic syndrome. A history of recent upper respiratory, skin, or gastrointestinal infection suggests postinfectious glomerulonephritis, hemolytic-uremic syndrome, or IgA vasculitis nephritis. Rash and joint complaints suggest IgA vasculitis or SLE nephritis.

Hematuria associated with glomerulonephritis is typically painless but can be associated with flank pain when acute or unusually severe. Frequency, dysuria, and unexplained fevers suggest a urinary tract infection, whereas renal colic suggests nephrolithiasis. A flank mass can suggest hydronephrosis, renal cystic diseases, renal vein thrombosis, or tumor. Hematuria associated with headache, mental status changes, visual changes (diplopia), epistaxis, or heart failure suggests associated severe hypertension. Patients with hematuria and a history of trauma require immediate evaluation (see Chapter 80). Child abuse must always be suspected in the child presenting with unexplained perineal bruising and hematuria.

A careful family history is critical in the initial assessment of the child with hematuria given the numerous genetic causes of renal disorders. Hereditary glomerular diseases include hereditary nephritis (isolated Alport syndrome or with leiomyomatosis or macrothrombocytopenia); thin glomerular basement membrane disease; SLE nephritis; hereditary angiopathy with nephropathy, aneurysms, and muscle cramps (HANAC); and IgA nephropathy (Berger disease). Other hematuric renal disorders with a hereditary component include both autosomal recessive and autosomal dominant polycystic kidney diseases, atypical hemolytic-uremic syndrome, urolithiasis, and sickle cell disease/trait.

Physical examination may also suggest possible causes of hematuria. The presence of hypertension, edema, or signs of heart failure suggests acute glomerulonephritis. Several malformation syndromes are associated with renal disease, including VATER (*v*ertebral body anomalies, *a*nal atresia, *t*racheo*e*sophageal fistula, and *r*enal dysplasia) syndrome. Abdominal masses may be caused by bladder distention in posterior urethral valves, hydronephrosis in ureteropelvic or ureterovesical junction obstruction, polycystic kidney disease, or Wilms tumor. Hematuria seen in patients with neurologic or cutaneous abnormalities may be the result of a number of syndromic renal disorders, including tuberous sclerosis, von Hippel-Lindau syndrome, and Zellweger (cerebrohepatorenal) syndrome. Anatomic abnormalities of the external genitalia may be associated with hematuria and/or renal disease.

Patients with gross hematuria present additional challenges because of the associated parental anxiety. The most common cause of gross hematuria is bacterial or viral urinary tract infection. **Urethrorrhagia,** which is urethral bleeding in the absence of urine, is associated with

Table 558.1 Other Causes of Red Urine

HEME POSITIVE
Hemoglobin
Myoglobin
HEME NEGATIVE
Drugs
Adriamycin
Chloroquine
Deferoxamine
Hydroxocobalamin
Ibuprofen
Iron sorbitol
Levodopa
Metronidazole
Nitrofurantoin
Phenazopyridine (Pyridium)
Phenolphthalein
Phenothiazines
Phenytoin
Quinine
Rifampin
Salicylates
Sulfasalazine
Dyes (Vegetable/Fruit)
Beets
Blackberries
Blueberries
Food and candy coloring
Paprika
Rhubarb
Metabolites
Homogentisic acid
Melanin
Methemoglobin
Porphyrin
Tyrosinosis
Urates

Table 558.2 Causes of Hematuria in Children

UPPER URINARY TRACT DISEASE
Isolated Renal Disease
Immunoglobulin (Ig) A nephropathy (Berger disease)
Alport syndrome (hereditary nephritis)
Thin glomerular basement membrane nephropathy
Postinfectious GN (poststreptococcal GN)*
Membranous nephropathy
Membranoproliferative GN*
Rapidly progressive GN
Focal segmental glomerulosclerosis
Anti–glomerular basement membrane disease
Hereditary angiopathy with nephropathy, aneurysms, muscle cramps (HANAC)
Multisystem Disease
Systemic lupus erythematosus nephritis*
IgA vasculitis nephritis†
Granulomatosis with polyangiitis‡
Microscopic polyangiitis
Goodpasture syndrome
Hemolytic-uremic syndrome
Sickle cell glomerulopathy
HIV nephropathy
Tubulointerstitial Disease
Pyelonephritis
Interstitial nephritis
Papillary necrosis
Acute tubular necrosis
Vascular Disorders
Arterial or venous thrombosis
Malformations (aneurysms, hemangiomas)
Nutcracker syndrome
Hemoglobinopathy (sickle cell trait/disease)
Crystalluria
Anatomic Disorders
Hydronephrosis
Cystic-syndromic kidney disease
Polycystic kidney disease
Multicystic dysplasia
Tumor (Wilms tumor, rhabdomyosarcoma, angiomyolipoma, medullary carcinoma)
Trauma
LOWER URINARY TRACT DISEASE
Inflammation (infectious and noninfectious)
Cystitis
Urethritis
Urolithiasis
Trauma
Coagulopathy
Heavy exercise
Bladder tumor
Factitious syndrome, factitious syndrome by proxy§

*Denotes glomerulonephritides presenting with hypocomplementemia.
†Formerly Henoch-Schönlein purpura.
‡Formerly Wegener granulomatosis.
§Formerly Munchausen syndrome and Munchausen syndrome by proxy.
GN, Glomerulonephritis.

dysuria and blood spots on underwear after voiding. This condition, which often occurs in prepubertal boys at intervals several months apart, has a benign self-limited course. Less than 10% of patients have evidence of glomerulonephritis. Recurrent episodes of gross hematuria suggest IgA nephropathy, Alport syndrome, or thin glomerular basement membrane disease. Dysuria and abdominal or flank pain are symptoms of idiopathic hypercalciuria, or urolithiasis. Table 558.3 lists common causes of gross hematuria; Figure 558.1 outlines a general approach to the laboratory and radiologic evaluation of the patient with glomerular or nonglomerular hematuria. Asymptomatic patients with isolated microscopic hematuria should not undergo extensive diagnostic evaluation, because such hematuria is often transient and benign.

The child with completely asymptomatic isolated microscopic hematuria that persists on at least three urinalyses observed over a minimum of a 2-week period poses a dilemma in regard to the degree of further diagnostic testing that should be performed. Significant disease of the urinary tract is uncommon with this clinical presentation. The initial evaluation of these children should include a urine culture followed by a spot urine for hypercalciuria with a calcium:creatinine ratio in culture-negative patients. In Black patients, a sickle cell screen should be included. If these studies are normal, urinalysis of all first-degree relatives is indicated. Renal and bladder ultrasonography should be considered to rule out structural lesions such as tumor, cystic disease, hydronephrosis, or urolithiasis. Ultrasonography of the urinary tract is most informative in patients presenting with gross hematuria, abdominal pain, flank pain, or trauma. If these initial studies are normal, assessment of serum creatinine and electrolytes is recommended.

The finding of certain hematologic abnormalities can narrow the differential diagnosis. **Anemia** in this setting may be caused by

Table 558.3 Common Causes of Gross Hematuria

Urinary tract infection
Meatal stenosis with ulcer
Perineal irritation
Trauma
Urolithiasis
Hypercalciuria
Obstruction
Coagulopathy
Tumor
Glomerular disease
Postinfectious glomerulonephritis
IgA vasculitis nephritis*
IgA nephropathy
Alport syndrome (hereditary nephritis)
Thin glomerular basement membrane disease
Systemic lupus erythematosus nephritis

*Formerly Henoch-Schönlein purpura.

hypervolemia with dilution associated with acute kidney injury; decreased RBC production in chronic kidney disease; hemolysis from hemolytic-uremic syndrome, a chronic hemolytic anemia, or SLE; blood loss from pulmonary hemorrhage, as seen in Goodpasture syndrome; or melena in patients with IgA vasculitis or hemolytic-uremic syndrome. Inspection of the peripheral blood smear might reveal a **microangiopathic** process consistent with the hemolytic-uremic syndrome. The presence of autoantibodies in SLE can result in a positive Coombs test, the presence of antinuclear antibody, leukopenia, and multisystem disease. **Thrombocytopenia** can result from decreased platelet production (malignancies) or increased platelet consumption (SLE, idiopathic thrombocytopenic purpura, hemolytic-uremic syndrome, renal vein thrombosis, or congenital hepatic fibrosis with portal hypertension secondary to autosomal recessive polycystic kidney disease). Although urinary RBC morphology may be normal with lower tract bleeding and dysmorphic from glomerular bleeding, it is not sensitive enough to unequivocally delineate the site of hematuria. A bleeding diathesis is an unusual cause of hematuria, and coagulation studies are not routinely obtained unless a personal or family history suggests a bleeding tendency.

A voiding cystourethrogram is only required in patients with a urinary tract infection, renal scarring, hydroureter, or pyelocaliectasis. Cystoscopy is an unnecessary and costly procedure in most pediatric patients with hematuria and carries the associated risks of anesthesia. This procedure should be reserved for evaluating the rare child with a bladder mass noted on ultrasound, urethral abnormalities caused by trauma, posterior urethral valves, or tumor. The finding of unilateral gross hematuria localized by cystoscopy is rare, but it can indicate a vascular malformation or another anatomic abnormality.

Children with persistent asymptomatic isolated hematuria and a completely normal evaluation should have their blood pressure and urine checked every 3 months until the hematuria resolves. Referral to a pediatric nephrologist should be considered for patients with persistent asymptomatic hematuria greater than 1 year in duration and is recommended for patients with nephritis (glomerulonephritis, tubulointerstitial nephritis), hypertension, renal dysfunction, urolithiasis or nephrocalcinosis, or a family history of renal disease such as polycystic kidney disease or hereditary nephritis. Renal biopsy is indicated for some children with persistent microscopic hematuria and for most children with recurrent gross hematuria associated with decreased renal function, proteinuria, or hypertension.

Visit Elsevier eBooks+ at eBooks.Health.Elsevier.com for Bibliography.

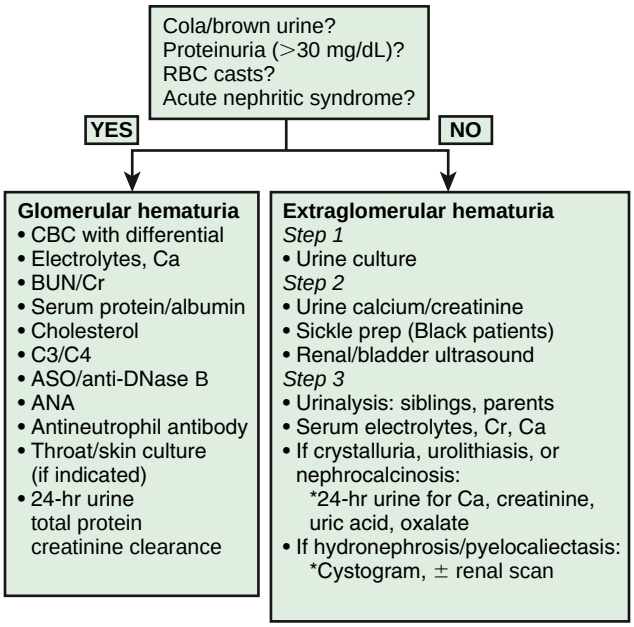

Fig. 558.1 Diagnostic algorithm of the general approach to the laboratory and radiologic evaluation of the patient with glomerular or extraglomerular hematuria. ANA, Antinuclear antibody; ASO, antistreptolysin O; BUN, blood urea nitrogen; C3/C4, complement; CBC, complete blood cell count; Cr, creatinine; RBC, red blood cell.

Chapter 559

Isolated Glomerular Diseases Associated with Recurrent Gross Hematuria

Francisco X. Flores

INTRODUCTION

Approximately 10% of children with gross hematuria have an acute or a chronic form of glomerulonephritis that may be associated with a systemic illness. The gross hematuria, which is usually characterized by brown or cola-colored urine, may be painless or associated with vague flank or abdominal pain. A presentation with gross hematuria is common within 1-2 days after the onset of an apparent viral upper respiratory tract infection in immunoglobulin (Ig) A nephropathy and typically resolves within 5 days. This relatively short period contrasts with a latency period of 7-21 days occurring between the onset of a streptococcal pharyngitis or impetiginous skin infection and the development of postinfectious acute glomerulonephritis. Gross hematuria in these circumstances can last as long as 4-6 weeks. Gross hematuria can also be seen in children with glomerular basement membrane (GBM) disorders such as hereditary nephritis (Alport syndrome [AS]) and thin GBM disease. These glomerular diseases can also manifest as microscopic hematuria and/or proteinuria without gross hematuria.

Visit Elsevier eBooks+ at eBooks.Health.Elsevier.com for Bibliography.

559.1 Immunoglobulin A Nephropathy (Berger Nephropathy)

Francisco X. Flores

IgA nephropathy is the most common chronic glomerular disease in children. It is characterized by a predominance of IgA within mesangial glomerular deposits in the absence of systemic disease. Its diagnosis requires a renal biopsy, which is performed when clinical features warrant confirmation of the diagnosis or characterization of the histologic severity, which might affect therapeutic decisions.

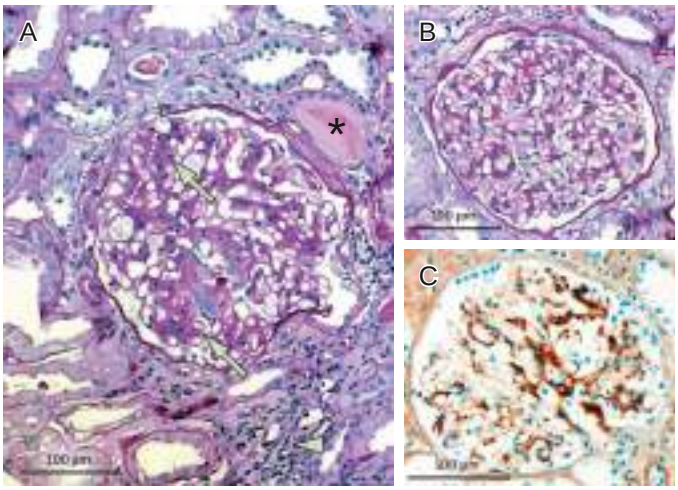

Fig. 559.1 IgA nephropathy. **A,** In IgA nephropathy, segmental areas *(arrows)* of mesangial hypercellularity and matrix expansion occur, characteristic of mesangioproliferative glomerulonephritis. Part of the glomerular tuft adheres to Bowman's capsule *(white dashed oval)*, constituting the starting point of a secondary focal segmental glomerulosclerosis lesion. Tubulointerstitial damage with leukocyte infiltrates, tubular atrophy and fibrosis *(arrowhead)*, and tubular protein casts *(asterisk)* is also present. Periodic acid–Schiff (PAS) stain. **B,** Other glomeruli in the same patient exhibit few pathologic abnormalities on light microscopy (PAS stain), but the characteristic mesangial granular IgA deposition (**C**) can be found in these glomeruli as well. *(From Floege J, Amann K. Primary glomerulonephritides. Lancet. 2016;387:2036–2046. Fig. 2.)*

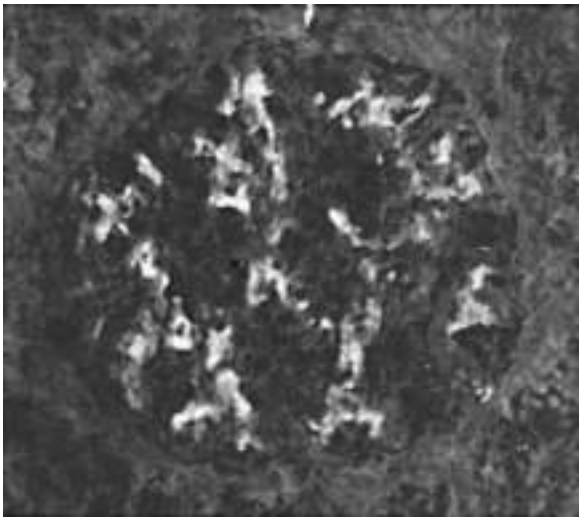

Fig. 559.2 Immunofluorescence microscopy of the biopsy specimen from a child with episodes of gross hematuria demonstrating mesangial deposition of IgA (×150).

PATHOLOGY AND PATHOLOGIC DIAGNOSIS

Focal and segmental mesangial proliferation and an increased mesangial matrix are seen in the glomerulus (Fig. 559.1). Renal histology demonstrates mesangial proliferation that may be associated with epithelial cell crescent formation and sclerosis. IgA deposits in the mesangium are often accompanied by C3 complement (Fig. 559.2).

IgA nephropathy is an immune complex disease initiated by excessive amounts of poorly galactosylated IgA_1 in the serum, causing the production of IgG and IgA autoantibodies. The abnormalities identified in the IgA system have also been observed in patients with IgA vasculitis (formerly known as Henoch-Schönlein purpura), and this finding lends support to the hypothesis that these two diseases are part of the same disease spectrum. Familial clustering of IgA nephropathy cases suggests the importance of genetic factors. Genome-wide linkage analysis suggests the linkage of IgA nephropathy to 6q22-23 in multiplex IgA nephropathy kindreds. Additional genomic studies demonstrate a high predisposition to IgA nephropathy in Southeast Asia.

CLINICAL AND LABORATORY MANIFESTATIONS

IgA nephropathy is seen more often in male than in female patients. Although there are rare cases of rapidly progressive forms of the disease, the clinical presentation of childhood IgA nephropathy is often benign compared with that of adults. IgA nephropathy is an uncommon cause of end-stage renal failure during childhood. A majority of children with IgA nephropathy in the United States and Europe present with gross hematuria, whereas microscopic hematuria and/or proteinuria is a more common presentation in Japan. Other presentations include acute nephritic syndrome, nephrotic syndrome, or a combined nephritic-nephrotic picture. Gross hematuria often occurs within 1-2 days of onset of an upper respiratory or gastrointestinal infection, in contrast with the longer latency period observed in acute postinfectious glomerulonephritis and may be associated with loin pain. Proteinuria is often <1,000 mg/24 hr in patients with asymptomatic microscopic hematuria. Mild to moderate hypertension is most often seen in patients with nephritic or nephrotic syndrome but is rarely severe enough to result in hypertensive emergencies. Normal serum levels of C3 in IgA nephropathy help to distinguish this disorder from postinfectious glomerulonephritis. Serum IgA levels have limited diagnostic value because they are elevated in only 50% of pediatric patients.

PROGNOSIS AND TREATMENT

Although IgA nephropathy does not lead to significant kidney damage in most children, progressive disease develops in 20–30% of adult patients 15-20 years after disease onset. Therefore most children with IgA nephropathy do not display progressive renal dysfunction until adulthood, prompting the need for careful long-term follow-up. Poor

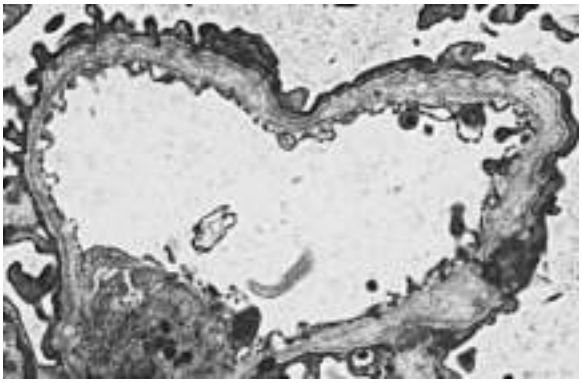

Fig. 559.3 Electron micrograph of a biopsy specimen from a child with Alport syndrome depicting thickening, thinning, splitting, and layering of the glomerular basement membrane (GBM; ×1,650). *(From Yum M, Bergstein JM. Basement membrane nephropathy. Hum Pathol. 1983;14:996–1003.)*

prognostic indicators at presentation or follow-up include persistent hypertension, diminished renal function, and significant, increasing, or persistent proteinuria. A more severe prognosis is correlated with histologic evidence of diffuse mesangial proliferation, extensive glomerular crescents, glomerulosclerosis, and diffuse tubulointerstitial changes, including inflammation and fibrosis.

The primary treatment of IgA nephropathy is appropriate blood pressure control and management of significant proteinuria. Angiotensin-converting enzyme inhibitors and angiotensin II receptor antagonists are effective in reducing proteinuria and slowing the rate of disease progression when used individually or in combination. Fish oil, which contains antiinflammatory omega-3 polyunsaturated fatty acids, may decrease the rate of disease progression in adults. If a renin-angiotensin system (RAS) blockade proves ineffective and significant proteinuria persists, then addition of immunosuppressive therapy with corticosteroids is recommended. Corticosteroids reduce proteinuria and improve renal function in those patients with a glomerular filtration rate >60 mL/min/m^2. It remains unclear if the effects of glucocorticoids deter progression to end-stage renal failure to a degree to offset their significant side effects. Additional immunosuppression with cyclophosphamide or azathioprine has not appeared to be effective. Tonsillectomy has been used as a treatment for IgA nephropathy in many countries, including Japan. Performing a tonsillectomy in the absence of significant tonsillitis in association with IgA nephropathy is currently not recommended. Targeted-release oral budesonide is approved by the FDA to reduce proteinuria in adult patients with IgA nephropathy. Patients with IgA nephropathy may undergo successful kidney transplantation. Although recurrent disease is frequent, allograft loss caused by IgA nephropathy occurs in only 15–30% of patients.

Visit Elsevier eBooks+ at eBooks.Health.Elsevier.com for Bibliography.

559.2 Alport Syndrome

Francisco X. Flores

Alport syndrome (AS), or hereditary nephritis, is a genetically heterogeneous disease caused by pathogenic variants in the genes coding for type IV collagen, a major component of basement membranes. These genetic alterations are associated with marked variability in the clinical presentation, natural history, and histologic abnormalities.

GENETICS

Approximately 70–80% of patients have X-linked inheritance caused by a mutation in the *COL4A5* gene encoding the α5 chain of type IV collagen. Patients with a subtype of X-linked AS and diffuse **leiomyomatosis** demonstrate a contiguous pathogenic variant within the *COL4A5* and *COL4A6* genes that encodes the α5 and α6 chains, respectively, of type IV collagen. Autosomal recessive forms of AS in approximately 5% of patients are caused by pathogenic variants in the *COL4A3* and *COL4A4* genes on chromosome 2 encoding the α3 and α4 chains, respectively, of type IV collagen. An autosomal dominant form of AS linked to the *COL4A3-COL4A4* gene locus occurs in 19–31% of cases.

Fechtner syndrome (AS with macrothrombocytopenia) and **Epstein syndrome** are autosomal dominant disorders due to pathogenic variants in *MYH9*. **Hereditary angiopathy with nephropathy, aneurysms, and muscle cramps (HANAC)** may initially resemble AS. HANAC is due to pathogenic variants in the *COL4A1* gene.

PATHOLOGY

Kidney biopsy specimens during the first decade of life will show only a few changes on light microscopy. Later, the glomeruli may develop mesangial proliferation and capillary wall thickening, leading to progressive glomerular sclerosis. Tubular atrophy, interstitial inflammation and fibrosis, and lipid-containing tubular or interstitial cells, called *foam cells,* develop as the disease progresses. Immunopathologic studies are usually nondiagnostic.

In most patients, electron microscopy reveals diffuse thickening, thinning, splitting, and layering of the glomerular and tubular basement membranes (Fig. 559.3). To confound the diagnosis, the ultrastructural analysis of the GBM in all genetic forms of AS may be completely normal, display nonspecific alterations, or demonstrate only uniform thinning.

CLINICAL MANIFESTATIONS

All patients with AS have *asymptomatic* microscopic hematuria, which may be *intermittent* in females and younger males. Single or recurrent episodes of gross hematuria commonly occurring 1-2 days after an upper respiratory infection are seen in approximately 50% of patients. Proteinuria is often seen in males but may be absent, mild, or intermittent in females. Progressive proteinuria, often exceeding 1 g/24 hours, is common by the second decade of life and can be severe enough to cause nephrotic syndrome.

Bilateral **sensorineural hearing loss,** which is never congenital, develops in 90% of hemizygous males with X-linked AS, 20% of heterozygous females with X-linked AS, and 67% of patients with autosomal recessive AS. This deficit begins in the high-frequency range but progresses to involve the hearing associated with normal speech, prompting the need for hearing aids. This progression of hearing loss seems to run parallel to the loss of renal function. **Ocular abnormalities**, which occur in 30–40% of patients with X-linked AS, include anterior lenticonus (extrusion of the central portion of the lens into the anterior chamber), macular flecks, and corneal erosions. **Leiomyomatosis** of the esophagus, tracheobronchial tree, and female genitals has been reported but is rare.

DIAGNOSIS

A combination of a thorough family history, a screening urinalysis of first-degree relatives, an audiogram, and an ophthalmologic examination are critical in making the diagnosis of AS. The presence of anterior lenticonus is pathognomonic. AS is highly likely in the patient who has hematuria and at least two of the following characteristic clinical features: macular flecks, recurrent corneal erosions, GBM thickening and thinning, or sensorineural deafness. The absence of epidermal basement membrane staining for the α5 chain of type IV collagen in male hemizygotes and discontinuous epidermal basement membrane staining in female heterozygotes on skin biopsy is pathognomonic for X-linked AS and can preclude a diagnostic renal biopsy. Genetic testing is clinically available for X-linked AS and *COL4A5* pathogenic variants. Prenatal diagnosis is available for families with members who have X-linked AS and who carry an identified pathogenic variant.

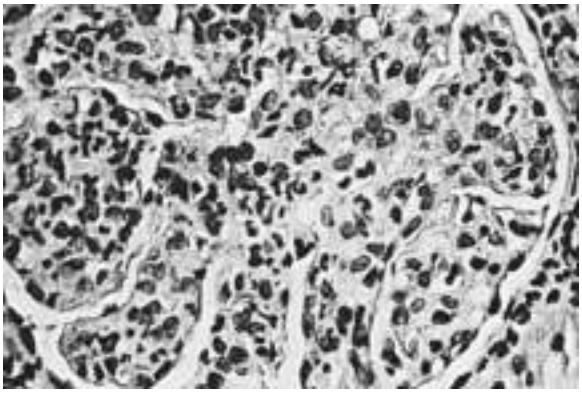

Fig. 559.4 Glomerulus from a patient with poststreptococcal glomerulonephritis appears enlarged and relatively bloodless and shows mesangial proliferation and exudation of neutrophils (×400).

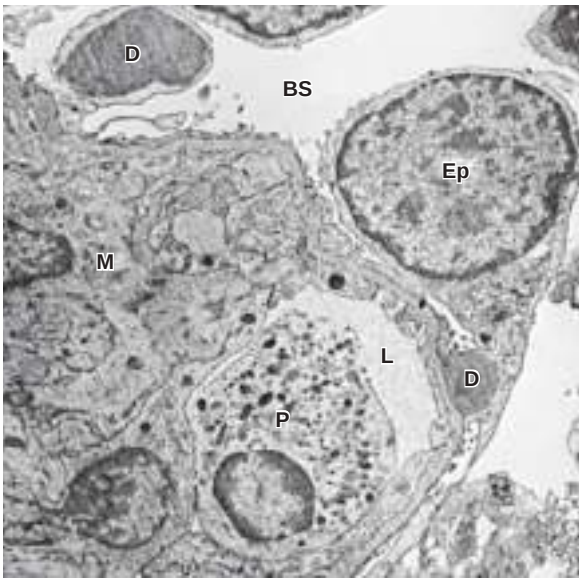

Fig. 559.5 Electron micrograph in poststreptococcal glomerulonephritis demonstrating electron-dense deposits *(D)* on the epithelial cell *(Ep)* side of the glomerular basement membrane. A polymorphonuclear leukocyte *(P)* is present within the lumen *(L)* of the capillary. BS, Bowman's space; M, mesangium.

PROGNOSIS AND TREATMENT

The risk of progressive renal dysfunction leading to end-stage kidney disease (ESKD) is highest among hemizygotes and autosomal recessive homozygotes. ESKD occurs before age 30 years in approximately 75% of hemizygotes with X-linked AS. The risk of ESKD in X-linked heterozygotes is 12% by age 40 years and 30% by age 60 years. Risk factors for progression are gross hematuria during childhood, nephrotic syndrome, and prominent GBM thickening. An intrafamilial variation in phenotypic expression results in significant differences in the age of ESKD among family members. No specific therapy is available to treat AS, although angiotensin-converting enzyme inhibitors (and possibly angiotensin II receptor inhibitors) can slow the rate of progression. Careful management of renal failure complications, such as hypertension, anemia, and electrolyte imbalance, is critical. Patients with ESKD are treated with dialysis and kidney transplantation (see Chapter 573). Approximately 5% of kidney transplantation recipients develop anti-GBM nephritis, which occurs primarily in males with X-linked AS who develop ESKD before age 30 years.

Pharmacologic treatment of proteinuria with angiotensin-converting enzyme inhibition or angiotensin II receptor blockade has proven effective in other glomerular diseases and has also shown promise in AS. Screening of heterozygote carriers for significant renal disease in later adulthood and possible treatment of significant proteinuria is also recommended.

Visit Elsevier eBooks+ at eBooks.Health.Elsevier.com for Bibliography.

559.3 Thin Basement Membrane Disease

Francisco X. Flores

Thin basement membrane disease (TBMD) is defined by the presence of persistent microscopic hematuria and isolated thinning of the GBM (and, occasionally, tubular basement membranes) on electron microscopy. Microscopic hematuria is often initially observed during childhood and may be intermittent. Episodic gross hematuria can also be present, particularly after a respiratory illness. Isolated hematuria in multiple family members without renal dysfunction is referred to as **benign familial hematuria.** Although most of these patients will not undergo renal biopsy, it is often presumed that the underlying pathology is TBMD. TBMD may be sporadic or transmitted as an autosomal dominant trait. Heterozygous pathogenic variants in the *COL4A3* and *COL4A4* genes, which encode the α3 and α4 chains of type IV collagen present in the GBM, result in TBMD. Rare cases of TBMD progress, and such patients develop significant proteinuria, hypertension, or renal insufficiency. Homozygous pathogenic variants in these same genes result in autosomal recessive AS. Therefore in these rare cases, the absence of a positive family history for renal insufficiency or deafness would not necessarily predict a benign outcome. Consequently, monitoring patients with benign familial hematuria for progressive proteinuria, hypertension, or renal dysfunction is important throughout childhood and young adulthood.

Visit Elsevier eBooks+ at eBooks.Health.Elsevier.com for Bibliography.

559.4 Acute Poststreptococcal Glomerulonephritis

Francisco X. Flores

Group A β-hemolytic streptococcal infections are common in children and can lead to the postinfectious complication of acute GN. Acute poststreptococcal glomerulonephritis (APSGN) is a classic example of the **acute nephritic syndrome** characterized by the sudden onset of gross hematuria, edema, hypertension, and renal dysfunction. It is one of the most common glomerular causes of gross hematuria in children and is a major cause of morbidity in group A β-hemolytic streptococcal infections.

ETIOLOGY AND EPIDEMIOLOGY

APSGN follows infection of the throat or skin by certain *nephritogenic* strains of group A β-hemolytic streptococci. Epidemics and clusters of household (camps, military) cases occur throughout the world, and 97% of cases occur in less-developed countries. The overall incidence has decreased in industrialized nations, presumably as a result of improved hygienic conditions and the near eradication of streptococcal pyoderma. Poststreptococcal GN commonly follows streptococcal pharyngitis during cold-weather months and streptococcal skin infections or pyoderma during warm-weather months. Although epidemics of nephritis have been described in association with throat (serotypes M1, M4, M25, and some strains of M12) and skin (serotype M49) infections, this disease is most commonly sporadic.

PATHOLOGY

Glomeruli appear enlarged and relatively bloodless and show a diffuse mesangial cell proliferation, with an increase in mesangial matrix (Fig. 559.4). Polymorphonuclear leukocyte infiltration is common in glomeruli during the early stage of the disease. Crescents and interstitial inflammation may be seen in severe cases, but these changes are not specific for poststreptococcal GN. Immunofluorescence microscopy reveals a pattern of "lumpy-bumpy" deposits of immunoglobulin and complement on the glomerular basement membrane and in the mesangium. On electron microscopy, electron-dense deposits, or "humps," are observed on the epithelial side of the glomerular basement membrane (Fig. 559.5).

PATHOGENESIS

Morphologic studies and a depression in the serum complement (C3) level provide strong evidence that ASPGN is mediated by immune complexes. Circulating immune complex formation with streptococcal antigens and subsequent glomerular deposition is thought less likely to be a pathogenic mechanism. Molecular mimicry, whereby circulating antibodies elicited by streptococcal antigens react with normal glomerular antigens, in situ immune complex formation of antistreptococcal

Table 559.1 Summary of Primary Renal Diseases that Manifest as Acute Glomerulonephritis

DISEASES	POSTSTREPTOCOCCAL GLOMERULONEPHRITIS	IGA NEPHROPATHY	GOODPASTURE SYNDROME	IDIOPATHIC RAPIDLY PROGRESSIVE GLOMERULONEPHRITIS
CLINICAL MANIFESTATIONS				
Age and sex	All ages, mean 7 yr, 2:1 male	10-35 yr, 2:1 male	15-30 yr, 6:1 male	Adults, 2:1 male
Acute nephritic syndrome	90%	50%	90%	90%
Asymptomatic hematuria	Occasionally	50%	Rare	Rare
Nephrotic syndrome	5–10%	Rare	Rare	10–20%
Hypertension	60%	30–50%	Rare	25%
Acute renal failure	50% (transient)	Very rare	50%	60%
Other	Latent period of 1-3 wk	Follows viral syndromes	Pulmonary hemorrhage; iron deficiency anemia	None
Laboratory findings	↑ ASO titers (70%) Positive Streptozyme (95%) ↓ C3-C9; normal C1, C4	↑ Serum IgA (50%) IgA in dermal capillaries	Positive anti-GBM antibody	Positive ANCA in some
Immunogenetics	HLA-B12, D "EN" (9)*	HLA-Bw 35, DR4 (4)*	HLA-DR2 (16)*	None established
RENAL PATHOLOGY				
Light microscopy	Diffuse proliferation	Focal proliferation	Focal → diffuse proliferation with crescents	Crescentic GN
Immunofluorescence	Granular IgG, C3	Diffuse mesangial IgA	Linear IgG, C3	No immune deposits
Electron microscopy	Subepithelial humps	Mesangial deposits	No deposits	No deposits
Prognosis	95% resolve spontaneously 5% RPGN or slowly progressive	Slow progression in 25–50%	75% stabilize or improve if treated early	75% stabilize or improve if treated early
Treatment	Monitor for oliguria, hypertension; treat appropriately	Uncertain (options include steroids, and ACE inhibitors); sparsentan (adults)	Plasma exchange, steroids, cyclophosphamide	Steroid pulse therapy

*Relative risk.
ACE, Angiotensin-converting enzyme; ANCA, antineutrophil cytoplasmic antibody; ASO, antistreptolysin O; GBM, glomerular basement membrane; GN, glomerulonephritis; HLA, human leukocyte antigen; Ig, immunoglobulin; RPGN, idiopathic rapidly progressive glomerulonephritis.
From Kliegman RM, Greenbaum LA, Lye PS, eds. *Practical Strategies in Pediatric Diagnosis and Therapy,* 2nd ed. Philadelphia: Elsevier; 2004.

antibodies with glomerular deposited antigen, and complement activation by directly deposited streptococcal antigens, continues to be considered as a probable mechanism of immunologic injury.

Group A streptococci possesses M proteins, and nephritogenic strains are related to the M protein serotype. The search for the precise nephritogenic antigen(s) that cause disease suggests that streptococcal pyogenic exotoxin (SPE) B and nephritis-associated streptococcal plasmin receptor are promising candidates. Both have been identified in glomeruli of affected patients, and in one study, circulating antibodies to SPE B were found in all patients. Cross reactivity of SPE B and other M proteins with various components of the glomerular basement membrane also give evidence for molecular mimicry.

CLINICAL MANIFESTATIONS

Poststreptococcal GN is most common in children ages 5-12 years and uncommon before the age of 3 years. The typical patient develops an acute nephritic syndrome 1-2 weeks after an antecedent streptococcal pharyngitis or 3-6 weeks after a streptococcal pyoderma. The history of a specific infection may be absent because symptoms may have been mild or have resolved without patients receiving specific treatment or seeking the care of a medical provider.

The severity of kidney involvement varies from asymptomatic microscopic hematuria with normal renal function to gross hematuria with acute renal failure. Depending on the severity of renal involvement, patients can develop various degrees of edema, hypertension, and oliguria. Patients are at risk for developing encephalopathy and/or heart failure secondary to hypertension or hypervolemia. Hypertensive encephalopathy must be considered in patients with blurred vision, severe headaches, altered mental status, or new seizures. The effects of acute hypertension not only depend on the severity of hypertension but also the absolute change in comparison with the patient's baseline blood pressure and the rate at which it has risen. Respiratory distress, orthopnea, and cough may be symptoms of pulmonary edema and heart failure. Peripheral edema typically results from salt and water retention and is common; nephrotic syndrome develops in a minority (<5%) of childhood cases. Atypical presentations of APSGN include those with subclinical disease and those with severe symptoms but an absence of initial urinary abnormalities; in individuals who present with a purpuric rash, it is difficult to distinguish APSGN from IgA vasculitis without a renal biopsy.

The acute phase generally resolves within 6-8 weeks. Although urinary protein excretion and hypertension usually normalize by 4-6 weeks after onset, persistent microscopic hematuria can persist for 1-2 years after the initial presentation.

DIAGNOSIS

Urinalysis demonstrates red blood cells, often in association with red blood cell casts, proteinuria, and polymorphonuclear leukocytes. A mild normochromic anemia may be present from hemodilution and low-grade hemolysis. The serum C3 level is significantly reduced in >90% of patients in the acute phase and returns to normal 8-10 weeks

Table 559.2 Secondary Causes of Membranoproliferative Glomerulonephritis

ASSOCIATED WITH INFECTION
Hepatitis B and C
Visceral abscesses
Infective endocarditis
Shunt nephritis
Quartan malaria
Schistosoma nephropathy
Mycoplasma infection
ASSOCIATED WITH RHEUMATOLOGIC DISEASE
Systemic lupus erythematosus
Scleroderma
Sjögren syndrome
Sarcoidosis
Mixed essential cryoglobulinemia with or without hepatitis C infection
Anti–smooth muscle syndrome
ASSOCIATED WITH MALIGNANCY
Carcinoma
Lymphoma
Leukemia
ASSOCIATED WITH AN INHERITED DISORDER
α_1-Antitrypsin deficiency
Complement deficiency (C2 or C3), with or without partial lipodystrophy

From Saha MK, Pendergraft WF III, Jennette JC, et al. Primary glomerular disease. In: Yu AS, Chertow GM, Luyckx VA, et al., eds. *Brenner & Rector's The Kidney,* 11th ed. Philadelphia: Elsevier; 2020: Box 31.7.

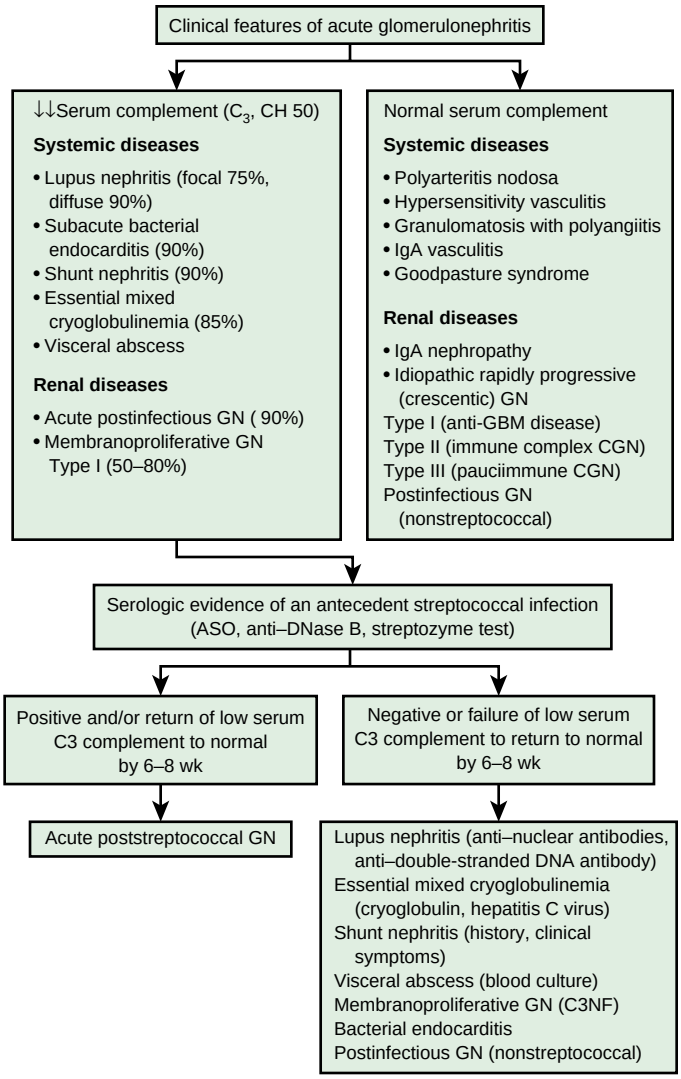

Fig. 559.6 Differential diagnostic algorithm of acute glomerulonephritis *(GN).* ASO, Anti–streptolysin O; CGN, crescentic glomerulonephritis; GBM, glomerular basement membrane; NF, nuclear factor. *(Adapted from Sulyok E. Acute proliferative glomerulonephritis. In: Avner ED, Harmon WE, Niaudet P, eds. Pediatric Nephrology, 5th ed. Philadelphia: Lippincott Williams & Wilkins; 2004: Fig. 30-4.)*

after the onset. Although serum CH_{50} is commonly depressed, *C4 is most often normal in APSGN,* or only mildly depressed.

Confirmation of the diagnosis requires clear evidence of a prior streptococcal infection. A positive throat culture report might support the diagnosis or might represent the carrier state. A rising antibody titer to streptococcal antigen(s) confirms a recent streptococcal infection. The antistreptolysin O titer is commonly elevated after a pharyngeal infection but rarely increases after streptococcal skin infections. The best single antibody titer to document cutaneous streptococcal infection is the antideoxyribonuclease B level. If available, a positive Streptozyme screen (which measures multiple antibodies to different streptococcal antigens) is a valuable diagnostic tool. Serologic evidence for streptococcal infections is more sensitive than the history of recent infections and far more sensitive than positive bacterial cultures obtained at the time of onset of acute nephritis.

MRI of the brain is indicated in patients with severe neurologic symptoms and can demonstrate **posterior reversible encephalopathy syndrome** in the parietooccipital areas on T2 weighted images. Chest x-ray is indicated in those with signs of heart failure or respiratory distress, or physical exam findings of a heart gallop, decreased breath sounds, rales, or hypoxemia.

The clinical diagnosis of poststreptococcal GN is quite likely in a child presenting with acute nephritic syndrome, evidence of recent streptococcal infection, and a low C3 level. However, it is important to consider other diagnoses such as systemic lupus erythematosus, endocarditis, membranoproliferative GN, and an acute exacerbation of chronic GN. Renal biopsy should be considered only in the presence of acute renal failure, nephrotic syndrome, absence of evidence of streptococcal infection, or normal complement levels. In addition, renal biopsy is considered when hematuria and proteinuria, diminished renal function, and/or a low C3 level persist more than 2 months after onset. Persistent hypocomplementemia can indicate a chronic form of postinfectious GN or another disease such as membranoproliferative GN.

The differential diagnosis of poststreptococcal GN includes many of the causes of hematuria listed in Table 559.1 and Table 558.2, and algorithms to help with the diagnosis are presented in Figs. 559.6 and 559.7. Acute postinfectious GN can also follow other infections with coagulase-positive and coagulase-negative staphylococci, *Streptococcus pneumoniae,* and gram-negative bacteria. The clinical course, histopathology, and laboratory features are similar to those described for APSGN. For some, the terms APSGN and acute postinfectious GN are used synonymously. Acute GN can occur after certain fungal, rickettsial, protozoan, parasitic, or viral diseases. Among the latter, influenza and parvovirus infections are particularly notable.

COMPLICATIONS

Acute complications result from hypertension and acute renal dysfunction. Hypertension is seen in 60% of patients and is associated with hypertensive encephalopathy in 10% of cases. Although the

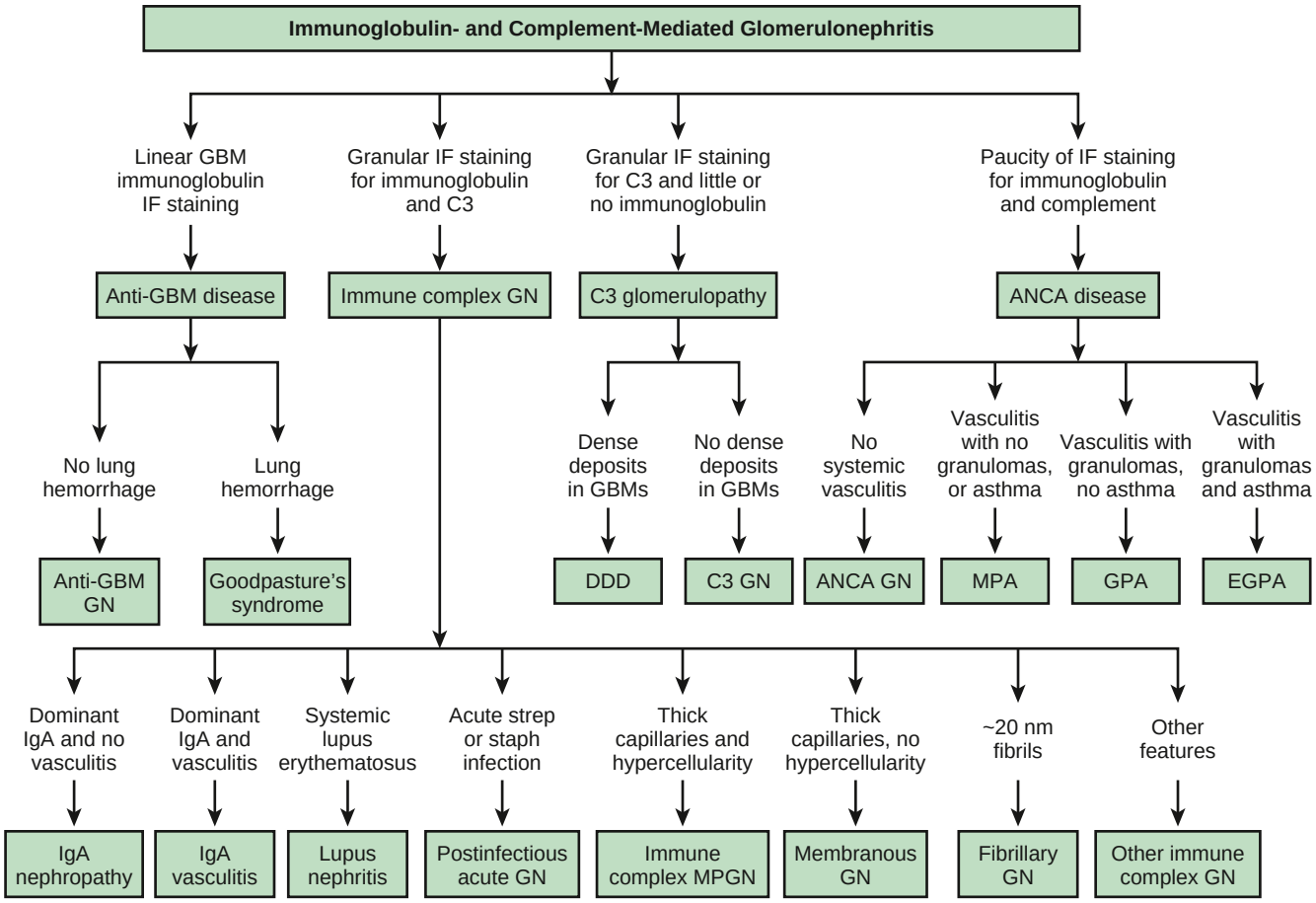

Fig. 559.7 Algorithm for diagnostic classification of glomerulonephritis *(GN)* that is known or suspected of being mediated by antibodies and complement. Note that the integration of light microscopy, immunofluorescence *(IF)* microscopy, electron microscopy, laboratory data, and clinical manifestations is required to precisely diagnose GN. ANCA, Anti–neutrophil cytoplasmic autoantibody; DDD, dense deposit disease; EGPA, eosinophilic granulomatosis with polyangiitis; GBM, glomerular basement membrane; GPA, granulomatosis with polyangiitis; IgA, immunoglobulin A; MPA, microscopic polyangiitis; MPGN, membranoproliferative glomerulonephritis. *(From Saha MK, Pendergraft WF III, Jennette JC, et al. Primary glomerular disease. In Yu AS, BChir GM, Chertow GM, et al., eds. Brenner & Rector's The Kidney, 11th ed. Philadelphia: Elsevier; 2020: Fig. 31-35.)*

neurologic sequelae are often reversible with appropriate management, severe prolonged hypertension can lead to intracranial bleeding. Other potential complications include heart failure, hyperkalemia, hyperphosphatemia, hypocalcemia, acidosis, seizures, and uremia. Acute renal failure can require treatment with dialysis.

PREVENTION

Early systemic antibiotic therapy for streptococcal throat and skin infections does not eliminate the risk of GN. Family members of patients with acute GN, especially young children, should be considered at risk and be cultured for group A β-hemolytic streptococci and treated if positive. Family pets, particularly dogs, have also been reported as carriers.

TREATMENT

Management is directed at treating the acute effects of renal dysfunction and hypertension (see Chapter 572.1). Although a 10-day course of systemic antibiotic therapy with penicillin is recommended to limit the spread of the nephritogenic organisms, antibiotic therapy does not affect the natural history of APSGN. This is unlike the GN seen in the context of ongoing or chronic infections, as noted in Chapter 560.1. Sodium and fluid restriction, diuretics, and pharmacotherapy with calcium channel antagonists, vasodilators, or angiotensin-converting enzyme inhibitors are standard therapies used to treat hypertension.

PROGNOSIS

Complete recovery occurs in >95% of children with APSGN. Recurrences are extremely rare. Mortality in the acute stage can be avoided by appropriate management of acute renal failure, cardiac failure, and hypertension. Infrequently, the acute phase is severe and leads to glomerulosclerosis and chronic renal disease in <2% of affected children.

Visit Elsevier eBooks+ at eBooks.Health.Elsevier.com for Bibliography.

559.5 Membranous Nephropathy

Francisco X. Flores

Membranous nephropathy (MN), among the most common causes of nephrotic syndrome in adults, is a rare cause of nephrotic syndrome in children. MN is classified as the primary, idiopathic form, where there is isolated renal disease, or secondary MN, where nephropathy is associated with other identifiable systemic diseases or medications. In children, *secondary* MN is far more common than primary, idiopathic MN. The most common etiologies of secondary

MN are systemic lupus erythematosus or chronic infections. Among the latter, chronic hepatitis B infection and congenital syphilis are the best characterized and recognized causes of MN. Other chronic infections have also been associated with MN, including malaria, which is likely the most common cause of nephrotic syndrome worldwide. Certain medications, such as penicillamine and gold, or chronic factor replacement in patients with hemophilia, can also cause MN. Rare causes associated with MN include tumors, such as neuroblastoma, or other idiopathic systemic diseases. Identification of secondary causes of MN is critical, because removal of the offending agent or treatment of the causative disease often leads to resolution of the associated nephropathy and improves patient outcome.

PATHOLOGY

Glomeruli have diffuse thickening of the glomerular basement membrane (GBM), without significant cell proliferative changes. Immunofluorescence and electron microscopy typically demonstrate granular deposits of IgG and C3 located on the epithelial side of the GBM. The GBM thickening presumably results from the production of membrane-like material in response to deposition of immune complexes (Fig. 559.8).

PATHOGENESIS

MN is believed to be caused by in situ immune complex formation. Therefore antigens from the infectious agents or medications associated with secondary MN directly contribute to the pathogenesis of the renal disease. The causative antigen in idiopathic MN is not established, but the podocyte phospholipase A2 receptor (PLA2R), present on normal podocytes, may be a target antigen in idiopathic MN. Antigen from this receptor is found in immune deposits extracted from glomeruli in patients with idiopathic MN. The majority of idiopathic MN patients have circulating antibody against this podocyte membrane antigen, as well as against several podocyte cytoplasmic antigens. Childhood MN may be associated with anticationic bovine serum albumin antibodies. In addition, neutral endopeptidase antigen may be the antigen in neonatal onset MN.

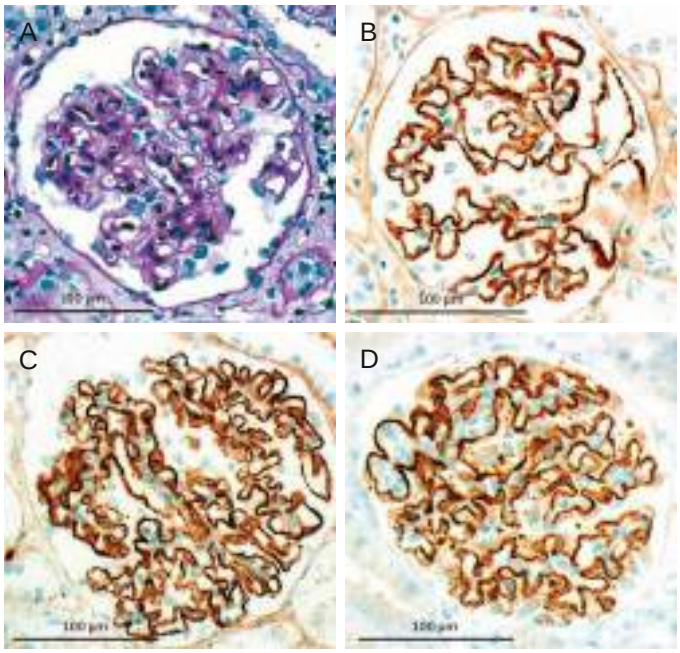

Fig. 559.8 Membranous glomerulonephritis. The periodic acid–Schiff (PAS) stain (**A**) shows slightly thickened glomerular basement membranes and prominent podocytes. On immunohistology, granular deposits of IgG (**B**) and C3c (**C**) can be found along the glomerular basement membrane, and pronounced de novo expression of phospholipase A2 receptor (PLA2R) (**D**) is present on the podocytes. *(From Floege J, Amann K. Primary glomerulonephritides. Lancet. 2016;387:2036–2046. Fig. 3.)*

CLINICAL MANIFESTATIONS

In children, MN is most common in the second decade of life, but it can occur at any age, including infancy. The disease usually manifests as nephrotic syndrome and accounts for 2–6% of all cases of childhood nephrotic syndrome. Most patients also have microscopic hematuria and only rarely present with gross hematuria. Approximately 20–30% of children have hypertension at presentation. A subset of patients with MN present with a major venous thrombosis, commonly **renal vein thrombosis**. This complication of nephrotic syndrome (see Chapter 567) is particularly common in patients with MN. Serum C3 and CH_{50} levels are normal, except in secondary forms such as in systemic lupus erythematosus, where levels may be depressed (see Fig. 559.6).

DIAGNOSIS

MN might be suspected on clinical grounds, particularly in the setting of known risk factors for secondary forms of the disease. In the past, the diagnosis could be established only by renal biopsy, but testing for PLA2R antibodies has allowed a noninvasive way to make the diagnosis, to differentiate primary vs secondary MN, and to guide treatment decisions. Common indications for renal biopsy leading to the diagnosis of MN include presentation with nephrotic syndrome in a child >10 years old or unexplained persistent hematuria with significant proteinuria.

PROGNOSIS AND TREATMENT

The clinical course of idiopathic membranous glomerulopathy is variable. Children presenting with asymptomatic, low-grade proteinuria can enter remission spontaneously. Retrospective reports of children 1-15 years after diagnosis treated with a variety of regimens indicate that 20% progress to chronic renal failure, 40% continue with active disease, and 40% achieve complete remission. Poor prognostic factors include male gender, high levels of proteinuria, reduced kidney function, and findings of glomerulosclerosis and tubular damage in the renal biopsy. Although no controlled trials have been performed in children, immunosuppressive therapy with an extended course of prednisone can be effective in promoting complete resolution of symptoms. The addition of chlorambucil or cyclophosphamide provides further benefit to those not responding to steroids alone. Rituximab has shown significant promise in adults and has been proposed by some as the first-line treatment but has yet to be studied in a randomized controlled trial in any age-group. For those unresponsive to immunosuppression, or with mild clinical features, proteinuria can be reduced with angiotensin-converting enzyme inhibitors and angiotensin II receptor blockers.

Visit Elsevier eBooks+ at eBooks.Health.Elsevier.com for Bibliography.

559.6 Membranoproliferative Glomerulonephritis

Francisco X. Flores

Membranoproliferative glomerulonephritis (MPGN), also known as **mesangiocapillary glomerulonephritis**, most commonly occurs in older children or young adults. MPGN can be classified into *primary* (idiopathic) and *secondary* forms of glomerular disease. Secondary forms of MPGN are most commonly associated with subacute and chronic infection, including hepatitis B and C, syphilis, endocarditis, and infected shunts, especially ventriculoatrial

shunts (shunt nephritis) (Table 559.2). MPGN can also be one of the glomerular lesions seen in lupus nephritis (see Chapter 560.2).

PATHOLOGY

Primary MPGN is defined by the histologic pattern of glomeruli as seen by light, immunofluorescence, and electron microscopy. Two subtypes have been defined on histologic criteria and are associated with different clinical phenotypes. **Type I MPGN** is most common. Glomeruli have an accentuated lobular pattern from diffuse mesangial expansion, endocapillary proliferation, and an increase in mesangial cells and matrix. The glomerular capillary walls are thickened, often with splitting from interposition of the mesangium. Crescents, if present, indicate a poor prognosis. Immunofluorescence microscopy reveals C3 and lesser amounts of immunoglobulin in the mesangium and along the peripheral capillary walls in a lobular pattern. Electron microscopy confirms numerous deposits in the mesangial and subendothelial regions.

Far less common is **type II MPGN,** also called **dense deposit disease,** which has similar light microscopic findings as type I MPGN. Differentiation from type I disease is by immunofluorescence and electron microscopy. In type II disease, C3 immunofluorescence typically is prominent, without concomitant immunoglobulin. By electron microscopy, the lamina densa in the GBM undergoes a very dense transformation, without evident immune complex–type deposits.

C3 glomerulonephritis (C3GN) is a related but separate diagnostic category. By light and electron microscopy C3GN usually has features indistinguishable from classic MPGN. Immunofluorescence studies distinguish between the two, with C3GN having only C3 deposition and MPGN having both C3 and immunoglobulin fluorescence.

PATHOGENESIS

Although the histology of type I MPGN produced by primary and secondary forms is indistinguishable, it appears that type I disease occurs when circulating immune complexes become trapped in the glomerular subendothelial space, which then causes injury, resulting in the characteristic proliferative response and mesangial expansion. Further evidence confirming this pathway to glomerular injury is the finding of complement activation through the classic pathway in as many as 50% of affected patients.

Type II MPGN appears *not* to be mediated by immune complexes. The pathogenesis of the disease is not known, but the characteristic finding of severely depressed serum complement levels suggests that deranged complement regulation might play a major role in the disease. A typical finding is markedly depressed serum C3 complement levels, with normal levels of other complement components. In many patients with type II MPGN, **C3 nephritic factor** (ant–C3 convertase antibody) is present. This factor activates the alternative complement pathway. In unusual cases, patients with type II MPGN demonstrate an associated systemic disease called **partial lipodystrophy,** where there is diffuse loss of adipose tissue and decreased complement in the presence of C3 nephritic factor. The correlation between the presence of C3 nephritic factor, complement levels, and disease presence or severity is not strong, indicating that the complement abnormalities alone are not sufficient to cause the disease.

Type II MPGN (dense deposit disease) is considered part of the broader spectrum of C3GN. The latter, as defined previously pathologically, appears to be caused by primary dysregulation of the alternative or terminal cascade complement pathways.

CLINICAL MANIFESTATIONS

MPGN is most common in the second decade of life, equally affects males and females, and is more common in White individuals. Systemic features may provide clues to which type of MPGN may be present, but the two histologic types of idiopathic MPGN are indistinguishable in terms of their renal manifestations. Patients present in equal proportions with nephrotic syndrome, acute nephritic syndrome (hematuria, hypertension, and some level of renal dysfunction), or persistent asymptomatic microscopic hematuria and proteinuria. Serum C3 complement levels are low in the majority of cases (see Fig. 559.6).

DIFFERENTIAL DIAGNOSIS

The differential diagnosis includes all forms of acute and chronic glomerulonephritis, including idiopathic and secondary forms, along with postinfectious glomerulonephritis. Postinfectious glomerulonephritis, far more common than MPGN, usually does not have nephrotic features but typically has hematuria, hypertension, renal dysfunction, and transiently low C3 complement, all features that may be seen with MPGN or C3GN. In contrast to MPGN and C3GN, where C3 levels usually remain persistently low, C3 returns to normal within 8-10 weeks after the onset of postinfectious glomerulonephritis (see Chapter 559.4). The diagnosis of MPGN is made by renal biopsy. Indications for biopsy include nephrotic syndrome in an older child, significant proteinuria with microscopic hematuria, and hypocomplementemia lasting >2 months in a child with acute nephritis. If C3 but no immunoglobulin deposition is found in glomeruli with MPGN, genetic testing and functional assays to define defects of complement cascade regulation should be pursued.

PROGNOSIS AND TREATMENT

It is important to determine whether MPGN is idiopathic or secondary to a systemic disease, particularly lupus or chronic infection, because treatment of the causative disease can result in resolution of the MPGN. Untreated, idiopathic MPGN, regardless of type, has a poor prognosis. By 10 years following onset, 50% of patients with MPGN have progressed to end-stage renal disease. By 20 years following onset, up to 90% have lost renal function. Those with nephrotic syndrome and hypertension at the time of presentation progress to renal failure more rapidly. No definitive therapy exists, but several reports, including a randomized controlled trial, indicate that extended courses of alternate-day prednisone (for years) provide benefit. Some patients treated with steroids enter a complete clinical remission of their disease, but many have ongoing disease activity. Nevertheless, an extended course of prednisone is associated with significant preservation of renal function when compared with patients receiving no such treatment.

The prognosis of C3GN, separate from dense deposit disease (considered a part of C3GN by some) and other forms of classically defined MPGN, is as yet hard to define because reports of the outcome of such patients previously had been grouped in studies of all forms of MPGN (types I and II, and even a poorly characterized type III form not considered earlier). The apparent pathophysiology of C3GN promises that treatments targeting the interruption of complement activation pathways, such as complement factor H replacement or shutting down the terminal complement cascade by blocking C5 activation with eculizumab (anti–C5 antibody), could be beneficial in preventing the progression of renal disease.

Visit Elsevier eBooks+ at eBooks.Health.Elsevier.com for Bibliography.

559.7 Rapidly Progressive (Crescentic) Glomerulonephritis

Francisco X. Flores

Rapidly progressive describes the clinical course of several forms of glomerulonephritis (GN) that have the unifying feature of a histopathologic finding of crescents in the majority of glomeruli (Fig. 559.9). The terms *rapidly progressive glomerulonephritis* (RPGN) and *crescentic glomerulonephritis* (CGN) are synonymous. The natural history of most forms of CGN is the rapid loss of the renal function.

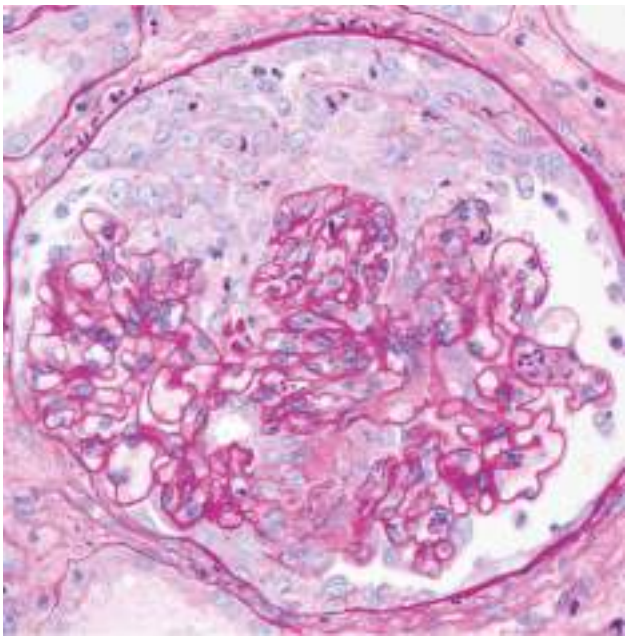

Fig. 559.9 Light micrograph showing a cellular crescent in Bowman's space. The underlying glomerular tuft is delineated by the glomerular basement membranes. (Periodic acid-Schiff stain, x500.) *(From Saha MK, Pendergraft WF, Jennette JC, Falk RJ. Primary glomerular dsease. In Yu AS, Chertow, G, et al, eds. Brenner and Rector's The Kidney, 11th edition. Philadelphia: Elsevier; 2020: Fig. 31.34.)*

CLASSIFICATION

CGN can be a severe manifestation of essentially every defined primary and secondary GN, but particular forms of GN are more likely to present as, or evolve into, RPGN (Table 559.3). If no underlying cause is identified by systemic features, serologic testing, or histologic examination, the disease is classified as idiopathic CGN. The incidence of specific etiologies of CGN in children varies widely; certain common themes are shared in all such reports. Patients with systemic vasculitis appear to be particularly prone to develop CGN. Patients with IgA vasculitis, antineutrophil cytoplasmic antibody (ANCA)-mediated GN (microscopic polyangiitis and granulomatosis with polyangiitis), and systemic lupus erythematosus account for the majority of patients with CGN. Postinfectious GN or endocarditis rarely progresses to CGN, but because it is the most common form of GN in childhood, it accounts for a significant percentage of patients with CGN in most reports. MPGN and idiopathic disease make up most of the remaining cases of CGN. IgA nephropathy, a common GN, only rarely is rapidly progressive. Goodpasture disease often has rapidly progressive GN as a component of the syndrome, but its rarity in childhood results in only a small percentage of children with CGN.

PATHOLOGY AND PATHOGENESIS

The hallmark of CGN is the histopathologic finding of epithelial crescents involving 50% or more glomeruli (see Fig. 559.9). Crescent formation, through proliferation of parietal epithelial cells in Bowman's space, may be the final pathway of any severe inflammatory glomerular injury. Podocytes and renal progenitor cells are involved in the pathogenesis of CGN. Fibrous crescents, in which proliferative cellular crescents are replaced by collagen, are a late finding. The immunofluorescence findings, as well as the pattern of any deposits by electron microscopy, can delineate the underlying glomerulopathy in CGN secondary to lupus, IgA vasculitis nephritis, MPGN, postinfectious GN, IgA nephropathy, or Goodpasture disease. Rare or absent findings by immunofluorescence and electron microscopy typify pauciimmune GN (granulomatosis with polyangiitis and microscopic polyangiitis) and idiopathic crescentic GN.

Table 559.3 Classification of Rapidly Progressive (Crescentic) Glomerulonephritis

PRIMARY
Anti–glomerular basement membrane antibody disease
Goodpasture syndrome (with pulmonary disease)
Immune complex mediated
Pauci-immune (usually antineutrophil cytoplasmic antibody positive)
SECONDARY
Membranoproliferative glomerulonephritis
Immunoglobulin A nephropathy, IgA vasculitis
Poststreptococcal glomerulonephritis
Systemic lupus erythematosus

Light micrograph showing a cellular crescent in Bowman's space. The underlying glomerular tuft is delineated by the glomerular basement membranes. (Periodic acid-Schiff stain, x500.) (From Saha MK, Pendergraft WF, Jennette JC, Falk RJ. Primary glomerular dsease. In Yu AS, Chertow, G, et al, eds. *Brenner and Rector's The Kidney*, 11th edition. Philadelphia: Elsevier; 2020: Fig. 31.34.)

CLINICAL MANIFESTATIONS

Most children present with acute nephritis (hematuria, various degrees of renal dysfunction, and hypertension) and usually have concomitant proteinuria, often with nephrotic syndrome. Occasional patients present late in the course of disease with oliguric renal failure. Extrarenal manifestations, such as pulmonary involvement, joint symptoms, or skin lesions, can help lead to the diagnosis of the underlying systemic disease causing the CGN.

DIAGNOSIS AND DIFFERENTIAL DIAGNOSIS

The diagnosis of CGN is made by obtaining a kidney biopsy. Delineation of the underlying etiology is reached by a combination of additional biopsy findings (described earlier), extrarenal symptoms and signs, and serologic testing, including the evaluation of antinuclear and anti-DS DNA antibodies, serum complement levels, anti-GBM antibodies, and ANCA titers. If the patient has no extrarenal manifestations and a negative serologic evaluation, and if the biopsy has no immune or electron microscopy deposits, the diagnosis is idiopathic, rapidly progressive CGN.

PROGNOSIS AND TREATMENT

The natural course of CGN is far more severe in the setting of other etiologies, including the idiopathic category, and progression to end-stage kidney disease within weeks to months from the onset is common. Having a majority of fibrous crescents on a renal biopsy portends a poor prognosis, because the disease usually has progressed to irreversible damage. Although there are few controlled data, the consensus of most nephrologists is that the combination of high-dose corticosteroids and cyclophosphamide may be effective in preventing progressive renal failure in patients with systemic lupus erythematosus, IgA vasculitis nephritis, granulomatosis with polyangiitis, and IgA nephropathy if given early in the course when acute cellular crescents predominate. Although such therapy can also be effective in the other diseases causing RPGN, renal outcomes in those settings are less favorable. Progression to end-stage kidney disease often occurs despite aggressive immunosuppressive therapy. In combination with immunosuppression, plasmapheresis has been reported to benefit patients with Goodpasture disease. Plasmapheresis may also benefit patients with ANCA-associated CGN, in particular those with the most severe renal dysfunction and pulmonary hemorrhage at presentation. The possible benefits of plasmapheresis in other forms of RPGN are unclear.

Visit Elsevier eBooks+ at eBooks.Health.Elsevier.com for Bibliography.

Chapter 560

Multisystem Disease Associated with Hematuria

Prasad Devarajan

Gross or microscopic hematuria may be associated with several multisystem disorders, including chronic systemic infections, systemic lupus erythematosus (SLE), IgA vasculitis nephritis (formerly known as Henoch-Schönlein purpura nephritis), Goodpasture disease, hemolytic uremic syndrome (HUS), nephrotoxicity, and renal cortical necrosis. In most of these conditions, the presenting complaints pertain primarily to the underlying systemic illness, and hematuria often heralds or portends renal involvement (see Chapters 560.1-560.8).

560.1 Chronic Infections

Prasad Devarajan

Glomerulonephritis (GN) with hematuria is a recognized complication of various chronic infections. Examples include bacterial endocarditis caused by viridans group streptococci and other organisms, and ventriculoatrial shunts infected with *Staphylococcus epidermidis*. Other infections, observed less commonly in children than in adults, include those due to HIV, hepatitis B virus (HBV), or hepatitis C virus; syphilis; and renal candidiasis. Parasitic infections associated with glomerular disease include malaria, schistosomiasis, leishmaniasis, filariasis, hydatid disease, trypanosomiasis, and toxoplasmosis. In each condition, the infecting organism has a low virulence, and the host is chronically infected with a microbial antigen. In the presence of high levels of circulating antigen, the host's antibody response leads to the formation of **immune complexes** that are deposited in the kidneys and initiate glomerular inflammation. Foreign antigens can also stimulate an autoimmune response through the production of antibodies that cross react with such antigens incorrectly recognized as glomerular structural components.

The kidney histopathology in GN due to chronic infections can resemble poststreptococcal GN, membranous GN, or membranoproliferative GN. The clinical manifestations are generally those of an acute nephritic syndrome (active urinary sediment with hematuria, proteinuria, and granular and/or red blood cell (RBC) casts, edema, hypertension) or nephrotic syndrome (proteinuria, edema, hypoalbuminemia). *The serum C3 and CH_{50} complement levels are often decreased due to activation of the classic complement pathway.*

In **HIV-associated nephropathy,** direct viral infection of nephrons occurs because renal cells express a variety of lymphocyte chemokine receptors that are essential for and facilitate viral invasion. The kidney expression of HIV infection is quite variable and includes an immune complex injury and a direct cytopathic effect. The classic histopathologic lesion of HIV-associated nephropathy is *focal segmental glomerulosclerosis.* In the era of antiretroviral therapy, the decline in mortality from HIV disease has led to the increased recognition of renal disorders as an important long-term complication in children who survive perinatal HIV infection.

HBV infection is a global public health problem. It is estimated that there are more than 350 million HBV carriers in the world.

Prompt eradication of any infection before severe glomerular injury occurs usually results in resolution of the GN associated with chronic infections. Progression to end-stage kidney disease has been described but is uncommon. Spontaneous resolution of hepatitis B infection is common in children (30–50%) and results in remission of the glomerulopathy. Widespread use of hepatitis B vaccines has decreased the incidence of HBV-related renal diseases. Also, with the new availability of direct-acting antivirals for hepatitis C virus, a sustained virologic response, successful remission, and even regression of glomerular lesions can be achieved if treatment is initiated at an early stage. Similarly, in patients with HIV-associated nephropathy, several clinical studies have demonstrated the overall improvement in kidney function with early initiation of antiretroviral therapy. Particularly in children, modern antiretroviral therapy has improved the outcome and decreased the prevalence of childhood HIV-associated nephropathy.

Visit Elsevier eBooks+ at eBooks.Health.Elsevier.com for Bibliography.

560.2 Glomerulonephritis Associated with Systemic Lupus Erythematosus

Prasad Devarajan

Systemic lupus erythematosus (SLE) is a chronic autoimmune disease characterized by fever, weight loss, dermatitis, hematologic abnormalities, arthritis, and involvement of the heart, lungs, central nervous system (CNS), and kidneys (see Chapter 199). Although SLE is less frequent in children, kidney involvement (lupus nephritis) is more common and is more severe than that seen in adults. Lupus nephritis is the most important cause of morbidity and mortality in SLE.

PATHOGENESIS AND PATHOLOGY

The hallmark of SLE is the abnormal production of pathogenic autoantibodies to self-antigens such as DNA (anti–double stranded DNA antibody [anti-dsDNA]) and nuclear proteins (antinuclear antibodies [ANA]), driven by immune dysregulation and loss of self-tolerance. The antigen-antibody complexes accumulate in small vessels of many organs, where they incite a local inflammatory response by activating complement pathways and by binding to Fc receptors. Lupus nephritis is a result of the deposition of circulating immune complexes, as well as the direct binding of autoantibodies to glomerular components with resultant complement stimulation.

Kidney biopsy and evaluation of kidney histopathology remain the gold standard for establishing the diagnosis of SLE nephritis and determining specific therapeutic regimens. The World Health Organization (WHO) classification of lupus nephritis has been employed in clinical trials and is based on a combination of features, including light microscopy, immunofluorescence, and electron microscopy. In patients with **WHO class I nephritis** (minimal mesangial lupus nephritis), no histologic abnormalities are detected on light microscopy, but mesangial immune deposits are present on immunofluorescence or electron microscopy. In **WHO class II nephritis** (mesangial proliferative nephritis), light microscopy shows both mesangial hypercellularity and an increased matrix, along with mesangial deposits containing immunoglobulin and complement.

WHO class III nephritis and **WHO class IV nephritis** are interrelated lesions characterized by both mesangial and endocapillary lesions. Class III nephritis is defined by <50% glomeruli with involvement, and class IV has ≥50% glomerular involvement. Immune deposits are present in both the mesangium and subendothelial areas. A **subclassification** scheme helps grade the severity of the proliferative lesion based on whether the glomerular lesions are segmental (<50% glomerular tuft involved) or global (≥50% glomerular tuft involved). The WHO classification scheme also delineates whether there is a predominance of chronic disease versus active disease. Chronic injury results in glomerular sclerosis and is felt to be the consequence of significant proliferative disease seen in classes III and IV. Other signs of active disease include capillary walls that are thickened secondary to subendothelial deposits (creating the characteristic wire-loop lesion), necrosis, and crescent formation. WHO class IV nephritis is associated with poorer outcomes but can be successfully treated with aggressive immunosuppressive therapy.

WHO class V nephritis (membranous lupus nephritis) is less commonly seen as an isolated lesion and resembles idiopathic membranous nephropathy with subepithelial immune deposits. This lesion is often seen in combination with class III or IV proliferative nephritis, and if the membranous lesion is present in >50% glomeruli, both classes are noted in the designation. This classification scheme also identifies cases with combinations of mixed classes III, IV, and V lesions, directing appropriate treatment for such patients.

Another classification scheme proposed by both the International Society of Nephrology and the Renal Pathology Society differs mainly in its subclassification of class IV into diffuse global and diffuse segmental lesions (Table 560.1). Although this classification is widely preferred, it should be noted that most available results of clinical trials are based on the WHO classification.

Transformation of the histologic lesions of lupus nephritis from one class to another is common. This is more likely to occur among inadequately treated patients and usually results in progression to a more severe histologic lesion.

Immunofluorescence microscopy is an essential component of the pathologic evaluation. Lupus nephritis is characterized by the granular deposition of all immunoglobulin isotypes (IgG, IgM, and IgA—also referred to as "full house"), as well as complements (C3, C4, and C1q) in the glomerular mesangium and capillary walls. This pattern of extensive glomerular immune deposition is referred to as full-house immune staining and is diagnostic of lupus nephritis.

CLINICAL MANIFESTATIONS

Most children with SLE are adolescent females (female-to-male ratio of 5:1) and present with extrarenal manifestations. The relative risk of SLE is three- to sevenfold higher in Asian, Black, and Hispanic females compared with White females. Lupus nephritis in Black and Hispanic populations also typically displays an increased severity and worse prognosis. Lupus nephritis affects 80% of pediatric patients with SLE, and although it commonly presents within the first year of diagnosis, may occur at any time during the disease. The clinical findings in patients having milder forms of lupus nephritis (all class I and II, some class III) include hematuria, normal renal function, and proteinuria <1 g/24 hr. Some patients with class III and all patients with class IV nephritis have hematuria and proteinuria, active urinary sediment with cellular casts, hypertension, reduced kidney function, nephrotic syndrome, or acute kidney injury. The urinalysis may be normal on rare occasions in patients with proliferative lupus nephritis. Patients with class V nephritis commonly present with nephrotic syndrome.

Table 560.1 Classification of Lupus Nephritis

CLASS	CLINICAL FEATURES
I. Minimal mesangial LN	No renal findings
II. Mesangial proliferative LN	Mild clinical renal disease; minimally active urinary sediment; mild to moderate proteinuria (never nephrotic) but may have active serology
III. Focal proliferative LN (<50% glomeruli involved) A. Active A/C. Active and chronic C. Chronic	More active sediment changes; often active serology; increased proteinuria (>25% nephrotic); hypertension may be present; some evolve into class IV pattern; active lesions require treatment; chronic do not
IV. Diffuse proliferative LN (>50% glomeruli involved); all may be with segmental or global involvement (S or G) A. Active A/C. Active and chronic C. Chronic	Most severe renal involvement with active sediment, hypertension, heavy proteinuria (frequent nephrotic syndrome), often reduced glomerular filtration rate; serology very active; active lesions require treatment
V. Membranous LN glomerulonephritis	Significant proteinuria (often nephrotic) with less active lupus serology
VI. Advanced sclerosing LN	More than 90% glomerulosclerosis; no treatment prevents renal failure

LN, Lupus nephritis.
From Radhakrishnan J, Appel GB. Glomerular disorders and nephrotic syndromes. In: Goldman L, Schafer AI, eds. *Goldman's Cecil Medicine*. 26th ed. Philadelphia: Elsevier; 2020: Table 113.7.

DIAGNOSIS

The diagnosis of SLE is confirmed by the detection of circulating ANA and by demonstrating antibodies that react with native anti-dsDNA. In most patients with active disease, C3 and C4 levels are depressed. In view of the lack of a clear correlation between the clinical manifestations and the severity of the kidney involvement, kidney biopsy should be performed in all patients with SLE who display even minor urinary abnormalities or other clinical evidence for renal disease. Histopathologic findings are used to determine the classification, severity, prognosis, and selection of specific immunosuppressive therapies.

TREATMENT

Current therapies are largely based on the histology, clinical severity, and lessons learned from clinical trials of adults with lupus nephritis. Immunosuppression remains the cornerstone of therapy. The goal of immunosuppressive therapy in lupus nephritis is to produce both a clinical remission, defined as normalization of renal function and proteinuria, and a serologic remission, defined as normalization of anti-DNA antibody, C3, and C4 levels. Therapy is initiated in all patients with prednisone at a dose of 1-2 mg/kg/day in divided doses, followed by a slow steroid taper over 4-6 months beginning 4-6 weeks after achieving a serologic remission.

For patients with more severe forms of nephritis (WHO classes III and IV), more aggressive immunosuppressive regimens are required because corticosteroid therapy alone is insufficient to induce a remission. In general, such regimens are separated into two phases, namely, induction and maintenance. The most commonly employed induction therapy has been six consecutive monthly intravenous infusions of cyclophosphamide at a dose of 500-1,000 mg/m^2. Pulse intravenous methylprednisolone (1,000 mg/m^2) is also used in addition to oral corticosteroids. Maintenance therapy previously consisted of additional cyclophosphamide infusions every 3 months for 18 months, which reduced the risk of progressive renal dysfunction. Serious side effects of cyclophosphamide have included infections, hair loss, hemorrhagic cystitis, and gonadal failure.

As an alternative induction therapy, in adult and pediatric clinical trials, mycophenolate mofetil was as efficacious as, or even superior to, cyclophosphamide, and is increasingly considered for use in children at a dosage of 600 mg/m^2 per dose twice daily. Maintenance therapy using mycophenolate mofetil or azathioprine is also as efficacious as intravenous cyclophosphamide and results in less serious side effects. Mycophenolate mofetil is particularly more efficacious than cyclophosphamide in Black patients. Major side effects of mycophenolate mofetil have included diarrhea, leukopenia, and teratogenicity. Azathioprine, at a single daily dose of 1.5-2.0 mg/kg, may be used as a steroid-sparing agent in patients with WHO class I or II lupus nephritis.

Rituximab, a chimeric monoclonal antibody specific for human CD20, is an alternative that has been shown to induce a remission in adults and children with proliferative lupus nephritis refractory to steroids and other immunosuppressants. Rituximab is used in cases where resistance to conventional treatment is demonstrated. Plasmapheresis is ineffective in lupus nephritis unless there is accompanying thrombotic thrombocytopenic purpura (TTP) or antineutrophilic cytoplasmic antibody (ANCA)-associated disease. Other therapies include belimumab, a fully humanized monoclonal antibody against a type II transmembrane protein that functions in the normal survival and differentiation of B cells; it has been approved by the FDA for use

in SLE. Its role in lupus nephritis, either in combination with current therapies or to replace them, requires further study.

The optimal treatment for class V lupus nephritis remains unclear. On the one hand, the low risk of progression to end-stage kidney disease when compared with proliferative forms of lupus nephritis has encouraged a less aggressive approach. On the other hand, patients with uncontrolled nephrotic syndrome due to class V lupus nephritis are at a high risk of morbidity and may require more aggressive immunosuppression.

Hydroxychloroquine is prescribed for most patients with SLE for extrarenal manifestations but is thought to have a beneficial effect in maintaining the remission in lupus nephritis. It is a rational choice given its low side effect profile. Use of antihypertensive drugs to aggressively treat hypertension, as well as the specific use of drugs that block the renin-angiotensin system (angiotensin-converting enzyme inhibitors and angiotensin-receptor blockers) to reduce proteinuria, are also important adjuvant therapies that appear to decrease the long-term progression of renal disease.

PROGNOSIS

Overall, kidney survival (defined as chronic kidney disease without progression to end-stage kidney disease therapy) is seen in 80% of patients 10 years after the diagnosis of SLE nephritis. Patients with diffuse proliferative WHO class IV lupus nephritis, poor kidney function at presentation, or persistent nephrotic-range proteinuria exhibit the highest risk for progression to end-stage kidney disease. Concerns regarding the side effects of chronic immunosuppressive therapy and the risk of recurrent disease are lifelong. Close monitoring for the relapse of disease is critical to ensure maximally successful renal outcomes. Special care must be taken to minimize the risks of infection, osteoporosis, obesity, poor growth, hypertension, and diabetes mellitus associated with chronic corticosteroid therapy. Patients require counseling regarding the risk of malignancy or infertility, which may be increased in those receiving a cumulative dose of >20 g of cyclophosphamide or other immunosuppressant therapies.

Visit Elsevier eBooks+ at eBooks.Health.Elsevier.com for Bibliography.

560.3 IgA Vasculitis Nephritis

Prasad Devarajan

IgA vasculitis (formerly known as Henoch-Schönlein purpura) is an idiopathic systemic immune complex–mediated vasculitis associated with IgA deposition within small-vessel walls. It is the most common small-vessel vasculitis in children, with a peak incidence in early childhood (4-6 years of age). Ninety percent of cases occur in children, with about half the cases preceded by an upper respiratory infection. It is characterized by a purpuric rash and commonly accompanied by arthritis and abdominal pain (see Chapter 210.1). Approximately 50% of patients with IgA vasculitis develop kidney manifestations, which vary from asymptomatic microscopic hematuria to severe, progressive GN. IgA vasculitis nephritis shares a similar pathogenesis and nearly identical kidney histology with IgA nephropathy. Although the two are considered as distinct entities, many consider IgA vasculitis nephritis and IgA nephropathy as part of the same clinical spectrum and IgA nephropathy as one of the sequelae of IgA vasculitis nephritis.

PATHOGENESIS AND PATHOLOGY

The pathogenesis of IgA vasculitis nephritis appears to be mediated by the deposition of **polymeric IgA** in glomeruli. This is analogous to the same type of IgA deposits seen in systemic small vessels in IgA vasculitis, primarily those of the skin and intestine. Studies have identified defective glycosylation of the hinge region of IgA1 in patients with both IgA vasculitis nephritis and IgA nephropathy. Recognition of the exposed hinge region of IgA1 by naturally occurring autoantibodies leads to formation of immune complexes that are deposited in the glomerular mesangium. Any mucosal infection or food antigen may trigger the increased production of pathogenic IgA1. IgA immune complexes are deposited throughout the body and activate pathways leading to necrotizing vasculitis. A skin biopsy characteristically shows leukocytoclastic vasculitis with IgA, C3, and fibrin deposition. The glomerular findings can be indistinguishable from those of IgA nephropathy. Pathognomonic IgA deposits are detected by immunofluorescence as the dominant immunoglobulin in the glomerular mesangium. Histologically, a broad spectrum of glomerular lesions that can range from mild mesangial and endocapillary proliferation to necrotic and crescentic changes from extracapillary proliferation can be seen.

CLINICAL AND LABORATORY MANIFESTATIONS

The classic tetrad of IgA vasculitis nephritis includes a palpable purpura, arthritis or arthralgia, abdominal pain, and evidence for kidney disease. *These may develop over a period of days to weeks and may vary in their order of presentation.* Notably, not all of the tetrad are present in all patients. The nephritis associated with IgA vasculitis usually *follows* the onset of the rash, often presenting weeks or even months after the initial nonkidney manifestations have resolved. Nephritis can be manifest at the initial presentation but only rarely before onset of the rash. Some degree of kidney involvement occurs in approximately 50% of IgA vasculitis cases, more commonly in older children (age >8 years confers a threefold greater risk for kidney involvement). Most patients (80%) initially display only mild renal involvement, principally isolated microscopic hematuria without significant proteinuria. About 20% of patients can present with a more severe kidney involvement, including a combined acute nephritic and nephrotic picture (hematuria, hypertension, renal insufficiency, significant proteinuria, and nephrotic syndrome). Older children (and adults) have a greater risk for more severe involvement. Initial mild kidney involvement can also occasionally progress to more severe nephritis despite resolution of all other features of IgA vasculitis. The severity of the systemic manifestations is not correlated with the severity of the nephritis. *Most patients who develop nephritis have urinary abnormalities by 1 month, and nearly all have abnormalities by 3-6 months after the onset of IgA vasculitis.* Therefore a urinalysis (and blood pressure checks) should be performed weekly in patients with IgA vasculitis during the period of active clinical disease (usually during the first 4 weeks). Thereafter, a urinalysis (and blood pressure checks) should be performed once a month for up to 6 months. If all urinalyses and blood pressures are normal during this follow-up interval, nephritis is unlikely to develop. If proteinuria, kidney insufficiency, or hypertension develops along with hematuria, consultation with a pediatric nephrologist is indicated. Indications for a kidney biopsy in children with IgA vasculitis nephritis include significant proteinuria (urine protein >1 g/day or urine protein/creatinine ratio >1.0), significant hypertension, or elevated serum creatinine.

Mimics of IgA vasculitis include endocarditis (skin, renal) and granulomatosis with polyangiitis (skin, renal).

PROGNOSIS AND TREATMENT

The prognosis of IgA vasculitis nephritis for most patients is excellent. Spontaneous and complete resolution of the nephritis typically occurs in many patients with mild initial manifestations (isolated hematuria with insignificant proteinuria). However, such patients uncommonly can progress to severe kidney involvement, including development of chronic kidney disease. Patients with acute nephritic or nephrotic syndrome at presentation have a guarded kidney prognosis, particularly if they are found to have concomitant necrosis or substantial crescentic changes on kidney biopsy. Untreated, the risk of developing chronic kidney disease, including end-stage kidney disease, is 2–5% in all patients with IgA vasculitis, but almost 50% in those with the most severe early kidney clinical and histologic features.

No controlled studies have demonstrated any efficacy of short courses (weeks) of oral corticosteroids administered promptly after the onset of IgA vasculitis in either preventing the development of nephritis or decreasing the severity of subsequent kidney involvement. Tonsillectomy has been proposed as an intervention for IgA vasculitis nephritis, but it also does not appear to have any measurable effect on

the renal outcome. Mild IgA vasculitis nephritis does not require treatment because it usually resolves spontaneously.

The efficacy of treatment for moderate or severe IgA vasculitis nephritis, which is far more likely to progress to chronic kidney disease, is more difficult to assess. Several uncontrolled studies have reported a significant benefit from aggressive immunosuppression (high-dose and extended courses of corticosteroids with azathioprine, mycophenolate mofetil, or cyclophosphamide) in patients with poor prognostic features on kidney biopsy; such patients are at high risk of progressing to chronic kidney disease. Reports of the treatment of high-risk patients with either plasmapheresis or rituximab have also indicated a potential benefit. Balancing the absence of controlled data with the severe side effects of aggressive therapies in patients with poor renal prognostic factors is difficult. Aggressive therapy with careful monitoring may be reasonable in those with the most severe IgA vasculitis nephritis (>50% crescents on biopsy). One common approach in children with severe clinical kidney involvement (nephrotic range proteinuria, elevated serum creatinine, hypertension) is the use of oral prednisone (1 mg/kg/day for 3 months), along with angiotensin-converting enzyme inhibitors, followed by azathioprine or mycophenolate mofetil if severe clinical involvement persists. For children with severe histologic manifestations (>50% glomerular crescents), treatment with intravenous methylprednisolone pulses for 3 days, followed by a combination of oral prednisone (for 3 months) and azathioprine or mycophenolate mofetil (extended course) may be considered. For children with the most severe histology (>75% glomerular crescents) and progressive kidney disease, intravenous steroids plus plasmapheresis may be considered. If progression to end-stage kidney disease occurs, renal transplantation is the treatment of choice. Deposition of IgA in the transplanted kidney is common, but most cases are subclinical, and the overall graft survival is similar to that for other renal transplant recipients.

Visit Elsevier eBooks+ at eBooks.Health.Elsevier.com for Bibliography.

560.4 Goodpasture Disease

Prasad Devarajan

Goodpasture disease is an autoimmune disease characterized by pulmonary hemorrhage, **rapidly progressive glomerulonephritis**, and elevated **anti–glomerular basement membrane (anti-GBM) antibody** titers. The disease results from an attack on these organs by antibodies directed against certain epitopes of type IV collagen, located within the alveolar basement membrane in the lung and glomerular basement membrane (GBM) in the kidney. An acquired conformational change in the noncollagenous 1 domain of the alpha 3-chain of type IV collagen leads to the production of pathologic autoantibodies. The high affinity of these antibodies to the GBM results in the characteristic rapidly progressive kidney disease. Infusion of human anti-GBM antibodies into animals reproduces the rapidly aggressive glomerulonephritis, confirming the high pathogenicity of these antibodies.

PATHOLOGY

Kidney biopsy shows proliferative crescentic glomerulonephritis in most patients. Immunofluorescence microscopy demonstrates the pathognomonic continuous linear deposition of immunoglobulin G along the GBM (Fig. 560.1).

CLINICAL MANIFESTATIONS

Goodpasture disease is rare in childhood. Patients usually present with hemoptysis from pulmonary hemorrhage that can be life-threatening. Concomitant renal manifestations include acute glomerulonephritis with hematuria, nephritic urinary sediment with cellular casts, proteinuria, and hypertension, which usually follow a rapidly progressive course. Kidney failure commonly develops within days to weeks of the clinical presentation. Although fever may be present, other systemic complaints such as malaise or arthralgia are usually

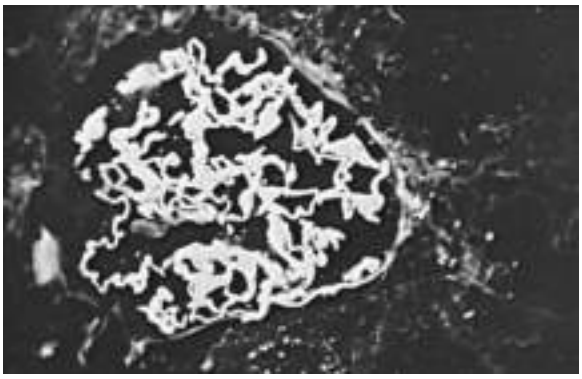

Fig. 560.1 Immunofluorescence micrograph demonstrating the continuous linear staining of immunoglobulin G along the glomerular basement membrane in Goodpasture disease (×250).

absent; their presence should raise suspicion for a systemic vasculitis. *Less commonly, patients can have anti-GBM nephritis manifesting as isolated, rapidly progressive glomerulonephritis without pulmonary hemorrhage.* In essentially all cases, anti-GBM antibody is present in the serum and/or the kidney, and the serum complement C3 level is normal. **Antineutrophilic cytoplasmic antibody (ANCA)** levels can be found to be elevated in 10–40% of patients, along with the anti-GBM antibody; such patients doubly positive for these autoantibodies have more severe disease at presentation. In general, anti-GBM antibody titers are correlated with the severity of the renal involvement. However, a kidney biopsy should be performed (unless contraindicated) because the accuracy of anti-GBM serology is variable, and renal biopsy provides additional histologic information that can guide therapy.

DIAGNOSIS AND DIFFERENTIAL DIAGNOSIS

The diagnosis is made by a combination of the clinical presentation of pulmonary hemorrhage with acute glomerulonephritis, the presence of serum antibodies directed against GBM (anti–type IV collagen in GBM), and characteristic renal biopsy findings. Other diseases that can cause a **pulmonary-renal syndrome** need to be considered and include SLE, IgA vasculitis, nephrotic syndrome–associated pulmonary embolism, and ANCA-associated vasculitis (such as granulomatosis with polyangiitis and microscopic polyangiitis). These diseases are ruled out by the absence of other characteristic clinical features, kidney biopsy findings, and negative serologic studies for antibodies against nuclear (ANA), DNA (anti-dsDNA), and neutrophil cytoplasmic components (ANCA antibody).

PROGNOSIS AND TREATMENT

Untreated, the prognosis of Goodpasture disease is poor. Treatment must be initiated emergently as soon as the diagnosis is suspected. The prompt institution of plasmapheresis, high-dose intravenous methylprednisolone, and cyclophosphamide often induces remission and improves survival times. Initial therapy with plasmapheresis removes circulating anti-GBM antibodies, and initial immunosuppression with steroids and cyclophosphamide inhibits ongoing antibody production. Rituximab may be used as a substitute in cases where cyclophosphamide toxicity is encountered. Initial treatment is guided by the clinical response and serial anti-GBM antibody titers. Retrospective cohort studies suggest that when this combination of treatments is started early, most patients will have a good kidney outcome. However, an initial presentation with oligoanuria, a high proportion of glomerular crescents, or kidney failure requiring dialysis predicts worse kidney and patient survival rates. After the induction of remission, maintenance therapy with lower doses of prednisone and azathioprine (or mycophenolate mofetil) is continued for 6-9 months. However, patients who survive the acute pulmonary hemorrhage and rapidly progressive glomerulonephritis can still progress to end-stage kidney disease despite ongoing immunosuppressive therapy. For patients who

progress, kidney transplantation is the treatment of choice. Relapse and recurrent disease after kidney transplantation are both uncommon.

Visit Elsevier eBooks+ at eBooks.Health.Elsevier.com for Bibliography.

560.5 Hemolytic-Uremic Syndrome

Prasad Devarajan

Hemolytic-uremic syndrome (HUS) is a common cause of community-acquired acute kidney injury in young children. It is the most common form of **thrombotic microangiopathy (TMA)** in children (Fig. 560.2). Like all TMAs, HUS is characterized by the triad of microangiopathic hemolytic anemia, thrombocytopenia, and kidney insufficiency. HUS has clinical features in common with thrombotic thrombocytopenic purpura (TTP) (see Chapter 533.5). The etiology and pathophysiology of the more common forms of HUS clearly delineate typical childhood HUS as separate from idiopathic TTP.

ETIOLOGY

The various etiologies of HUS and other related thrombotic microangiopathies allow classification into infection-induced, genetic, drug-induced, and HUS associated with systemic diseases characterized by microvascular injury (Table 560.2; see Fig. 560.2). The most common form of HUS is caused by **Shiga toxin–producing *Escherichia coli* (STEC)**, which causes prodromal acute enteritis and is commonly termed STEC-HUS or *diarrhea-associated HUS*. In the subcontinent of Asia and in southern Africa, the toxin of *Shigella dysenteriae* type 1 is causative, whereas in Western countries, verotoxin or STEC is the usual cause. STEC-HUS accounts for about 90% of all HUS cases in childhood.

Several serotypes of *E. coli* can produce the toxin. O157:H7 is most common in Europe and the Americas; other serotypes include O26, O111, O121, O145, O91, O103, O104, and O80. The reservoir of STEC is the intestinal tract of domestic animals, usually cows. Disease commonly is transmitted by undercooked meat or unpasteurized (raw) milk and apple cider. Local outbreaks have followed the ingestion of undercooked, contaminated hamburger or other foods cross-contaminated on unwashed cutting boards at fast food restaurants; contaminated municipal water supplies; petting farms; and swimming in contaminated ponds, lakes, or pools. With broad food distribution, wider epidemics have been traced to lettuce, raw spinach, and bean sprouts contaminated with STEC. Less often, STEC has been spread by person-to-person contact within families or childcare centers.

A rare but distinct entity of infection-triggered HUS is related to neuraminidase-producing *Streptococcus pneumoniae* (Sp-HUS). Sp-HUS, typically severe, develops during acute infection with this organism, typically manifesting as pneumonia with empyema. Compared with the prevaccine era, Sp-HUS incidence seems to be decreasing after the introduction of 7-serotype valent and 13-serotype valent pneumococcal vaccines. However, severe Sp-HUS cases continue to occur secondary to vaccine failure and emergence of nonvaccine/replacement serotypes. A TMA, similar to HUS or TTP, also can occur in patients with untreated HIV infection and influenza infection.

Genetic forms of HUS (atypical, nondiarrheal) compose the second major category of the disease (see Table 560.2 and Fig. 560.2). Inherited deficiencies of either von Willebrand factor–cleaving protease (ADAMTS13) or complement factor H, I, or B can cause HUS. A specific genetic defect has not been identified in approximately 50% of familial cases transmitted in classic Mendelian autosomal dominant or

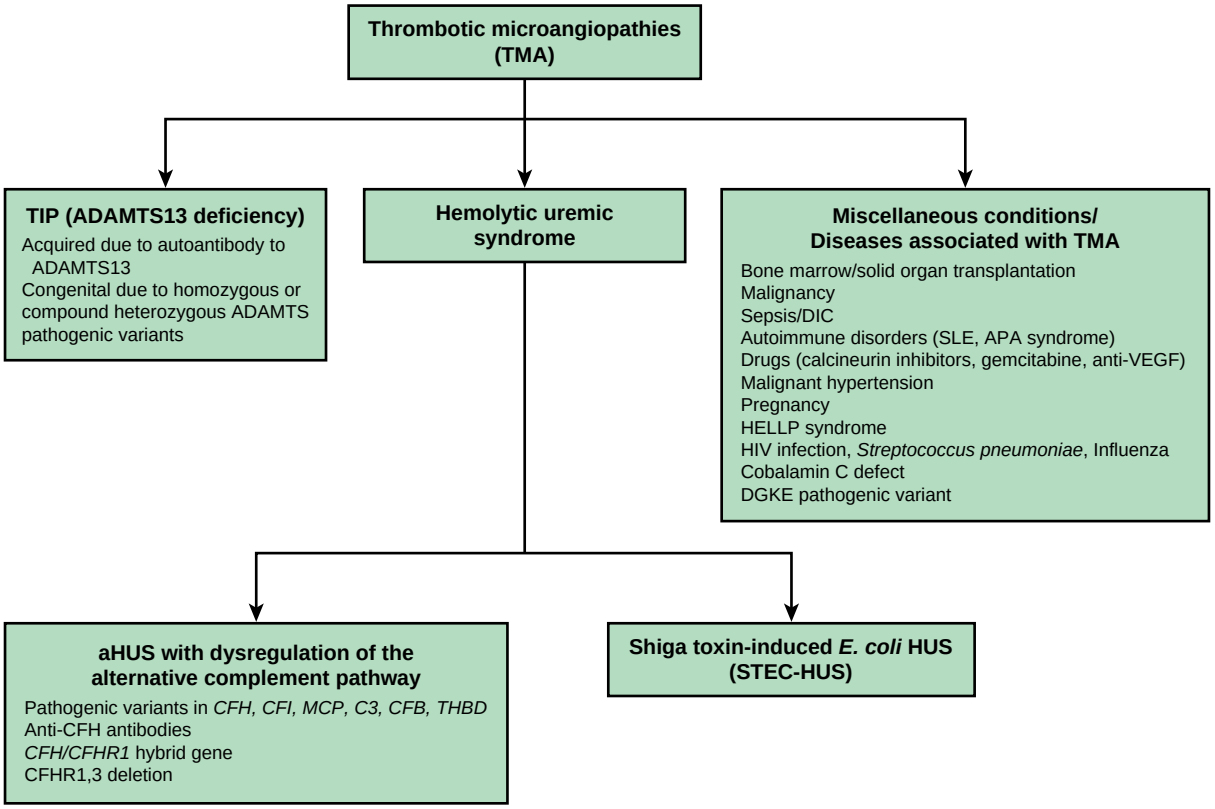

Fig. 560.2 Classification algorithm for the thrombotic microangiopathies based on etiology. ADAMTS13, A disintegrin and metalloproteinase with a thrombospondin type 1 motif, member 13; aHUS, atypical hemolytic uremic syndrome; APA, antiphospholipid antibody syndrome; CFB, complement Factor B; CFH, complement Factor H; CFI, complement Factor I; DGKE, diacylglycerol kinase ε; DIC, disseminated intravascular coagulation; HELLP syndrome, hemolysis, elevated liver enzymes and low platelet count syndrome; MCP, membrane cofactor protein (CD46); SLE, systemic lupus erythematosus; THBD, thrombomodulin gene; VEGF, vascular endothelial growth factor. *(From Dixon BP, Gruppo RA. Atypical hemolytic uremic syndrome. Pediatr Clin N Am. 2018;65:509–525. Fig. 2.)*

Table 560.2 Current Classification of Hemolytic Uremic Syndromes and Thrombotic Microangiopathies

DIARRHEA-ASSOCIATED HUS
STEC (*Escherichia coli* O157:H7)
STEC (*E .coli* 0121 and 0104:H4)
Non-STEC (*Shigella dysenteriae* type 1)
HUS SECONDARY TO SYSTEMIC INFECTIONS
Neuraminidase (*Streptococcus pneumoniae*)
HIV
Influenza
Human herpes virus 6
Parvovirus B19
Malaria
ATYPICAL HUS DUE TO COMPLEMENT DYSREGULATION
Factor H deficiency (pathogenic variants, autoantibodies)
Factor I deficiency (pathogenic variants)
Factor B (gain-of-function pathogenic variants)
Membrane cofactor (MCP) deficiency (pathogenic variants)
C3 deficiency (pathogenic variants, autoantibodies)
Thrombomodulin deficiency (pathogenic variants)
Anti–complement factor H antibody
Unknown
THROMBOTIC THROMBOCYTOPENIC PURPURA (TTP)
Inherited ADAMTS13 deficiency (pathogenic variants)
Acquired ADAMTS13 deficiency (antibody-mediated)
Pregnancy-associated
Vitamin B_{12} deficiency
DRUG INDUCED
Cyclosporine
Tacrolimus
Bleomycin
Mithramycin
Cisplatin
Quinine
Cocaine
Anti–vascular endothelial growth factor (anti-VEGF) drugs
SYSTEMIC DISEASE ASSOCIATED
Systemic lupus erythematosus
Coexisting nephropathies
Malignant hypertension
Malignancies
Cobalamin C defect
Diacylglycerol kinase epsilon pathogenic variant
TRANSPLANT ASSOCIATED
Stem cell transplant
Bone marrow transplant
Renal
Heart
Intestinal

recessive patterns. Some of these may be due to cobalamin C pathogenic variants. A major feature characteristic of genetic forms of HUS is the *absence* of a preceding diarrheal prodrome, although the presence of a diarrheal prodrome does not rule out atypical HUS. Genetic forms of HUS can be indolent and unremitting once they become manifest, or they can have a relapsing pattern precipitated by an infectious illness. The latter feature likely explains the association of many infectious agents with HUS, particularly in reports published before the recognition of the unique pathophysiology of STEC and neuraminidase-producing pneumococci in causing HUS.

HUS can be superimposed on any disease associated with microvascular injury, including malignant hypertension, SLE, and antiphospholipid syndrome. It can also occur after bone marrow or solid organ transplantation and may be triggered by the use of the calcineurin inhibitors cyclosporine and tacrolimus in that setting. Several other medications also can induce HUS (see Table 560.2 and Fig. 560.2).

PATHOLOGY

Kidney biopsies are only rarely performed in HUS because the diagnosis is usually established by clinical criteria, and the risks of biopsy are significant during the active phase of the disease. Early glomerular changes include thickening of the capillary walls caused by swelling of endothelial cells and accumulation of fibrillar material between endothelial cells and the underlying basement membrane, causing narrowing of the capillary lumens. Platelet-fibrin thrombi are often seen in glomerular capillaries. Thrombi are also seen in afferent arterioles and small arteries with fibrinoid necrosis of the arterial wall, leading to kidney cortical necrosis from vascular occlusion. Late findings include glomerular sclerosis and obsolescence secondary to either severe direct glomerular involvement or glomerular ischemia from arteriolar involvement.

PATHOGENESIS

Microvascular injury with endothelial cell damage is characteristic of all forms of TMA, including HUS. In the diarrhea-associated form of HUS, enteropathic organisms produce either Shiga toxin or the highly homologous Shiga-like verotoxin. These toxins are easily absorbed from the colonic mucosa into the systemic circulation, bind to endothelial cells in the glomerulus and elsewhere, and directly cause endothelial cell damage. Shiga toxin can also directly activate platelets to promote their aggregation. Mechanical injury to RBCs passing through the thrombotic microvasculature results in a severe nonimmune anemia with a negative direct Coombs test. In pneumococcal-associated HUS, neuraminidase cleaves sialic acid on membranes of endothelial cells, red cells, and platelets to expose the underlying cryptic Thomsen-Friedenreich (T) antigen. Endogenous IgM antibodies recognize and react with the T antigen to trigger hemolysis and anemia with a positive direct Coombs test.

The *familial* recessive and dominant forms of HUS, including the inherited deficiencies of ADAMTS13 and regulators of the complement cascade, probably predispose patients to developing HUS but do not cause the disease per se because these patients might not develop HUS until later childhood or even adulthood. In such cases, HUS is often triggered by an inciting event such as an infectious disease. The absence of ADAMTS13 impairs cleavage of von Willebrand factor multimers, which enhances platelet aggregation. Factor H plays a central role in complement regulation, primarily arresting the amplification and propagation of complement activation. It is possible that mild endothelial injury that would normally resolve instead evolves to an aggressive microangiopathy because of the inherited deficiencies of these factors.

In each form of HUS, capillary and arteriolar endothelial injury in the kidney leads to localized thrombosis, particularly in glomeruli, causing a direct decrease in glomerular filtration. Progressive platelet aggregation in the areas of microvascular injury results in consumptive thrombocytopenia. Microangiopathic hemolytic anemia results from mechanical damage to RBCs as they pass through the damaged and thrombotic microvasculature.

CLINICAL MANIFESTATIONS

Typical HUS (diarrhea form) is most common in preschool- and school-age children, but it can occur in adolescents and adults. In HUS caused by toxigenic *E. coli,* the onset of HUS occurs 5-7 days after the onset of gastroenteritis with fever, vomiting, abdominal pain, and diarrhea. The prodromal intestinal symptoms may be severe and require hospitalization, but they can also be relatively mild and considered trivial. Not all infected patients will develop HUS. The diarrhea is often bloody but not necessarily so. After the prodromal illness, the sudden onset of pallor, weakness, and lethargy heralds the onset of HUS, and it reflects the development of microangiopathic hemolytic anemia. Oliguria can be present in early stages but may be masked by ongoing diarrhea because the prodromal enteritis often overlaps the onset of HUS, particularly with ingestion of large doses of toxin. Thus patients with HUS can present with either significant dehydration or volume overload, depending on whether the enteritis or kidney insufficiency from HUS predominates and the amount of fluid that has been administered.

Patients with pneumococci-associated HUS usually are quite ill with pneumonia, empyema, and bacteremia when they develop HUS. The onset can be insidious in patients with the genetic forms of HUS, with HUS triggered by a variety of illnesses, including mild, nonspecific gastroenteritis or respiratory tract infections.

HUS can be relatively mild or can progress to a severe and fatal multisystem disease. Leukocytosis, severe prodromal enteritis, hyponatremia, and antibiotic use portend a severe course, but no presenting features reliably predict the severity of HUS in any given patient. Patients with HUS who appear mildly affected at presentation can rapidly develop severe, multisystem, life-threatening complications. Kidney insufficiency can be mild but also can rapidly evolve into severe oliguric or anuric kidney failure. The combination of rapidly developing kidney failure and severe hemolysis can result in life-threatening hyperkalemia. Severe acute kidney injury requiring dialysis develops in about 50% of patients with STEC-HUS. The duration of the dialysis requirement is usually about 2 weeks. Volume overload, hypertension, and severe anemia can all develop soon after the onset of HUS and together can precipitate heart failure. Direct **cardiac involvement** is rare, but pericarditis, myocardial dysfunction, or arrhythmias can occur without predisposing features of hypertension, volume overload, or electrolyte abnormalities.

The majority of patients with HUS have some **CNS involvement**. Most have mild manifestations, with significant irritability, lethargy, or nonspecific encephalopathic features. Severe CNS involvement occurs in ≤20% of cases. Seizures and significant encephalopathy are the most common manifestations in those with severe CNS involvement, resulting from focal ischemia secondary to microvascular CNS thrombosis. Small infarctions in the basal ganglion and cerebral cortex have also been reported, but large strokes and intracranial hemorrhage are rare. Hypertension may produce an encephalopathy and seizures. Intestinal complications can be protean and include severe inflammatory colitis, ischemic enteritis, bowel perforation, intussusception, and pancreatitis. Patients can develop petechiae, but significant or severe bleeding is rare despite very low platelet counts.

DIAGNOSIS AND DIFFERENTIAL DIAGNOSIS

The diagnosis is made by the combination of microangiopathic hemolytic anemia with schistocytes, thrombocytopenia, and some degree of kidney involvement. The anemia can be mild at presentation, but it rapidly progresses. Thrombocytopenia is an invariable finding in the acute phase, with platelet counts usually 20,000-100,000/mm^3. Partial thromboplastin and prothrombin times are usually normal. The Coombs test is negative, except in pneumococci-induced HUS, where the Coombs test is usually positive. Leukocytosis is often present and significant. Urinalysis typically shows microscopic hematuria and low-grade proteinuria. The kidney insufficiency can vary from mild elevations in serum BUN and creatinine to acute, anuric kidney failure.

The etiology of HUS is often clear with the presence of a diarrheal prodrome or pneumococcal infection. The presence or absence of toxigenic organisms on stool culture has little role in making the diagnosis of diarrhea-associated STEC-HUS. Only a minority (~10%) of patients infected with those organisms develops HUS, and the organisms that cause HUS may be rapidly cleared. Therefore the stool culture may be negative in patients who have diarrhea-associated HUS. If no history of diarrheal prodrome or pneumococcal infection is obtained, then evaluation for genetic forms of HUS should be considered because those patients are at risk for recurrence, have a severe prognosis, and can benefit from specific therapy. Other causes of acute kidney injury associated with a microangiopathic hemolytic anemia and thrombocytopenia should be considered and excluded, such as SLE, malignant hypertension, and bilateral renal vein thrombosis. A kidney biopsy is rarely indicated to diagnose HUS.

PROGNOSIS AND TREATMENT

With early recognition and intensive supportive care, the mortality rate for diarrhea-associated HUS is <5%. Up to half of patients may require dialysis support during the acute phase of the disease. Recovery of platelet counts usually occurs first, followed by kidney recovery about 5 days later, and finally by resolution of anemia. Most recover kidney function completely, but of surviving patients, 5% remain dependent on dialysis, and up to 30% are left with some degree of chronic kidney disease. The prognosis for HUS not associated with diarrhea is more severe. Pneumococci-associated HUS causes increased patient morbidity (>80% require dialysis), with the mortality rate reported as 20%. The familial, genetic forms of HUS can be insidiously progressive or relapsing diseases and have a poor prognosis. Identification of specific factor deficiencies in some of these genetic forms provides an opportunity for directed therapy to improve the outcome.

The primary approach that has substantially improved an acute outcome in HUS is early recognition of the disease, monitoring for potential complications, and meticulous supportive care. Supportive care includes careful management of fluid and electrolytes, including prompt correction of a volume deficit, control of hypertension, and early institution of dialysis if the patient becomes significantly oliguric or anuric, particularly with hyperkalemia. Early intravenous volume expansion before the onset of oliguria or anuria may be nephroprotective in diarrhea-associated HUS. Red cell transfusions are usually required because hemolysis can be brisk and recurrent until the active phase of the disease has resolved. In pneumococci-associated HUS, it is critical that any administered red cells be washed before transfusion to remove residual plasma, because endogenous IgM directed against the revealed T antigen can play a role in accelerating the pathogenesis of the disease. Platelets should generally not be administered, regardless of the platelet count, to patients with HUS because they are rapidly consumed by the active coagulation and theoretically can worsen the clinical course. Despite low platelet counts, serious bleeding is very rare in patients with HUS.

There is no evidence that any therapy directed at arresting the disease process of the most common, diarrhea-associated STEC-HUS provides benefit, and some can cause harm. Attempts have been made using anticoagulants, antiplatelet agents, fibrinolytic therapy, plasma therapy, immune globulin, and antibiotics. Anticoagulation, antiplatelet, and fibrinolytic therapies are specifically contraindicated because they increase the risk of serious hemorrhage. Antibiotic therapy to clear enteric toxigenic organisms (STEC) can result in increased toxin release, potentially exacerbating the disease; therefore it is not recommended. However, prompt treatment of causative pneumococcal infection is important. The European experience with *E. coli* O104:H4 in adults who were treated with azithromycin demonstrated more rapid elimination of the organism. Furthermore, in vitro evidence suggests that meropenem, rifaximin, and azithromycin downregulate the release and expression of Shiga toxin. Nonetheless, *in children with E. coli O157:H7–associated HUS, antibiotics are still considered contraindicated.*

Plasma infusion or plasmapheresis has been proposed for patients suffering severe manifestations of HUS with serious CNS involvement. There are no controlled data demonstrating the effectiveness of this approach, and it is specifically contraindicated in those with pneumococcal-associated HUS because it could exacerbate the disease. The use of plasma therapy in STEC-HUS was one of many treatment strategies during one of the largest reported outbreaks of STEC-HUS. This outbreak was caused by an uncommon serotype (O104:H4) that had unique virulence factors. Thought initially to cause more severe disease, it differed epidemiologically from other STEC-HUS serotypes by affecting primarily healthy adults, rather than the usual pattern of affecting children and the elderly. Treatment in this epidemic included plasma exchange in most of the adult patients, as well as the use of eculizumab.

Eculizumab is an anti-C5 antibody that inhibits complement activation, a pathway that contributes to active disease in some forms of atypical familial HUS; this pathway may also contribute to the process in STEC-HUS. Eculizumab is approved by the FDA for the treatment of *atypical HUS*. Because of the risk of meningococcal disease in patients with defects in terminal complement components, it is recommended to give the meningococcal vaccine before giving eculizumab (if the patient has not been primarily immunized). Although initial reports suggested that eculizumab provided benefit in patients with

diarrhea-associated HUS, subsequent systematic analysis showed no benefit from either plasma exchange or eculizumab.

Plasma therapy can be of substantial benefit to patients with identified deficits of ADAMTS13 or factor H. It may also be considered in patients with other genetic forms of HUS, such as the undefined familial (recessive or dominant) form or sporadic but recurrent HUS. In contrast to its use in STEC-HUS, eculizumab shows great promise in the treatment of atypical HUS, including HUS occurring following renal transplantation. Whether it should be combined with plasma therapy or used as a primary treatment of atypical HUS is still undetermined.

Most patients with diarrhea-associated HUS recover completely, with little risk of long-term sequelae. Patients with hypertension, any level of kidney insufficiency, or residual urinary abnormalities persisting a year after an episode of diarrhea-positive HUS (particularly significant proteinuria) require careful follow-up. Patients who have recovered completely with no residual urinary abnormalities after 1 year are less likely but may still manifest long-term sequelae. In a multicenter pooled analysis of 3,476 children with hemolytic uremic syndrome followed up for a mean of 4.4 years, the combined average death and end-stage kidney disease rate was 12%, and the combined average kidney sequelae rate (chronic kidney disease, proteinuria, hypertension) was 25%. Because of reports of late sequelae in such patients, annual examinations with a primary physician are still warranted.

Visit Elsevier eBooks+ at eBooks.Health.Elsevier.com for Bibliography.

560.6 Toxic Nephropathy

Prasad Devarajan

Aberrant renal function often results from purposeful or accidental exposure to any number of diagnostic, biologic, or therapeutic agents that are potential or actual nephrotoxins. Among diagnostic agents, **contrast-induced nephropathy** is a common and generally reversible form of **acute kidney injury** that results from administration of radiocontrast media in predisposed individuals. Iodinated radiocontrast agents are generally well tolerated by most patients without significant adverse consequences. In volume-depleted patients or patients with underlying chronic kidney disease, their use poses a risk for the development of acute kidney injury with significant attendant morbidity and mortality. Contrast agents can lead to renal vasoconstriction as well as direct tubule cell injury. Contrast-induced nephropathy usually manifests as an increase in serum creatinine 1-2 days following exposure; most patients are not oliguric. In most cases, the serum creatinine normalizes in the next 3-7 days, and treatment is supportive. The overall risk of radiocontrast agents to cause acute kidney injury remains controversial but appears to be low in children with normal kidney function and with the dominant current practice of using low osmolar contrast agents. Biologic nephrotoxins include venomous exposures from insects, reptiles, amphibians, and a wide variety of sea-dwelling animals. The most common forms of toxic nephropathy unfortunately relate to the exposure of children to pharmacologic agents, accounting for close to 20% of episodes of acute kidney injury occurring in children and adolescents. Age, underlying medical condition, genetics, exposure dose, and the concomitant use of other drugs all influence the likelihood of developing acute kidney injury. One common scenario is the use of nonsteroidal antiinflammatory agents (NSAIDs) in febrile children with concomitant dehydration. In this situation, NSAIDs can inhibit the production of intrarenal vasodilatory prostaglandins, thereby leading to decreased renal perfusion and acute kidney injury.

Table 560.3 summarizes the agents that commonly cause acute kidney injury and some of their clinical manifestations. A combination of multiple drugs amplifies the risk. Mechanisms of injury often help to explain the presentation; however, multiple toxic exposures in patients with complicated clinical histories often limit the ability to clearly establish clinical cause and effect. For example, diminished urine output may be the clinical hallmark of tubular obstruction caused by agents such as methotrexate or agents that cause acute tubular necrosis, such as amphotericin B or pentamidine. Alternatively, nephrogenic

Table 560.3 Renal Syndromes Produced by Nephrotoxins

NEPHROTIC SYNDROME	**OBSTRUCTIVE UROPATHY**
Angiotensin-converting enzyme inhibitors	Sulfonamides
Gold salts	Acyclovir
Interferon	Methotrexate
Mercury compounds	Protease inhibitors
Nonsteroidal antiinflammatory drugs	Ethylene glycol
Penicillamine	Methoxyflurane
NEPHROGENIC DIABETES INSIPIDUS	**FANCONI SYNDROME**
Amphotericin B	Aminoglycosides
Cisplatin	Chinese herbs (aristolochic)
Colchicine	Cisplatin
Demeclocycline	Heavy metals (cadmium, lead, mercury, and uranium)
Lithium	Ifosfamide
Methoxyflurane	Lysol
Propoxyphene	Outdated tetracycline
Vinblastine	**RENAL TUBULAR ACIDOSIS**
RENAL VASCULITIS	Amphotericin B
Hydralazine	Lead
Isoniazid	Lithium
Penicillins	Toluene
Propylthiouracil	**INTERSTITIAL NEPHRITIS**
Sulfonamides	Amidopyrine
Numerous other drugs that can cause a hypersensitivity reaction	*p*-Aminosalicylate
THROMBOTIC MICROANGIOPATHY	Carbon tetrachloride
Cyclosporine A	Cephalosporins
Oral contraceptive agents	Cimetidine
Mitomycin C	Cisplatin
NEPHROCALCINOSIS OR NEPHROLITHIASIS	Colistin
Allopurinol	Copper
Bumetanide	Cyclosporine
Ethylene glycol	Ethylene glycol
Furosemide	Foscarnet
Melamine	Gentamicin
Methoxyflurane	Gold salts
Topiramate	Indomethacin
Vitamin D	Interferon-α
ACUTE KIDNEY INJURY	Iron
Acetaminophen	Kanamycin
Acyclovir	Lithium
Aminoglycosides	Mannitol
Amphotericin B	Mercury salts
Angiotensin-converting enzyme inhibitors	Mitomycin C
Biologic toxins (snake, spider, bee, wasp)	Neomycin
Cisplatin	Nonsteroidal antiinflammatory drugs
Cyclosporine	Penicillins (especially methicillin)
Ethylene glycol	Pentamidine
Halothane	Phenacetin
Heavy metals	Phenylbutazone
Ifosfamide	Poisonous mushrooms
Lithium	Polymyxin B
Methoxyflurane	Radiocontrast agents
Nonsteroidal antiinflammatory drugs	Rifampin
Radiocontrast agents	Salicylate
Tacrolimus	Streptomycin
Vancomycin with or without piperacillin-tazobactam	Sulfonamides
	Tacrolimus
	Tetrachloroethylene
	Trimethoprim-sulfamethoxazole

STEC, Shiga toxin–producing *Escherichia coli*.

diabetes insipidus may be the critical clinical manifestation of agents that cause interstitial nephritis, such as lithium or cisplatin. Acute kidney injury due to nephrotoxins is frequently polyuric. Nephrotoxicity is often reversible if the noxious agent is promptly removed.

Clinical use of potential nephrotoxins should be judicious. Necessity of exposure, dosing parameters, and the use of drug levels or pharmacogenomic data, when available, should always be considered. Caution is particularly mandated for patients with complex medical conditions that include preexisting renal disease, cardiac disease, diabetes, and/or complicated surgeries. Alternative approaches to imaging or the use of different pharmacologic options should be considered when possible. Imaging modalities such as ultrasonography, radionuclide scanning, or MRI may be preferable to contrast studies in some patients. Alternatively, a judicious volume expansion with or without the administration of *N*-acetylcysteine might offer renoprotection when radioiodinated contrast studies are critical, especially in children with chronic kidney disease or those who are already on other nephrotoxic agents. Pharmacologic agents with no known kidney effects can often be substituted for known nephrotoxins with equal clinical efficacy. In all cases, simultaneous use of known nephrotoxins should be avoided whenever possible. The use of nephrotoxic agents represents one of the few modifiable risk factors for acute kidney injury, and promising new biomarkers for the early detection and modification of nephrotoxic injuries are currently becoming available. Use of the electronic health record for systematic surveillance for nephrotoxic medication exposure and acute kidney injury can also lead to sustained reductions in avoidable kidney injury.

Visit Elsevier eBooks+ at eBooks.Health.Elsevier.com for Bibliography.

560.7 Cortical Necrosis

Prasad Devarajan

BACKGROUND

Renal cortical necrosis is a rare cause of severe acute kidney injury occurring secondary to extensive ischemic damage of the renal cortex. Ischemic necrosis is due to markedly decreased renal arterial perfusion as a result of vascular spasm, microvascular injury, or intravascular coagulation. Renal cortical necrosis is usually bilateral and extensive, although focal and patchy forms have also been described. The medulla, the juxtamedullary cortex, and a thin rim of subcapsular cortex are usually spared. It occurs most commonly in neonates and in adolescents of childbearing age.

ETIOLOGY

In newborns, cortical necrosis is most associated with hypoxic or ischemic insults caused by perinatal asphyxia, placental abruption, and twin–twin or fetal–maternal transfusion. Other causes include renal vascular thrombosis and severe congenital heart disease. After the neonatal period, cortical necrosis is most commonly seen in children with septic shock or severe hemolytic-uremic syndrome. In adolescents and women, cortical necrosis occurs in association with obstetric complications, including prolonged intrauterine fetal death, placental abruption, septic abortion, or amniotic fluid embolism.

Less common causes of cortical necrosis include malaria, extensive burns, snakebites, infectious endocarditis, and medications (e.g., nonsteroidal antiinflammatory agents). Acute renal cortical necrosis has also been reported to occur in SLE-associated antiphospholipid antibody syndrome.

PATHOGENESIS

The presumed initiating factor in many cases is intense vasospasm of the small vessels. When prolonged, this leads to necrosis and thrombosis of the distal arterioles and glomeruli, with ensuing cortical necrosis. In hemolytic-uremic syndrome and septic abortion, endotoxin-mediated endothelial damage contributes to worsening vascular thrombosis.

CLINICAL MANIFESTATIONS

Cortical necrosis clinically presents as severe acute kidney injury in patients with predisposing causes. Urine output is diminished and gross, and/or microscopic hematuria may be present. Hypertension is common, and thrombocytopenia may be present because of renal microvascular injury.

LABORATORY AND RADIOLOGIC FINDINGS

Laboratory results are consistent with acute kidney injury: an elevated BUN and creatinine, hyperkalemia, and metabolic acidosis. Anemia and thrombocytopenia are common. Urinalysis reveals hematuria with red cell or granular casts, and proteinuria.

Ultrasound examination with Doppler flow studies demonstrates decreased perfusion to both kidneys. Kidneys are enlarged in the initial stages, but cortical tissue becomes shrunken in the later stages. Thin cortical shells of calcification (tram lines) are a radiologic hallmark, but they develop only 4-5 weeks after the initial insult.

CT scanning with contrast is the most sensitive imaging modality in renal cortical necrosis. Diagnostic features include absent opacification of the renal cortex and enhancement of subcapsular and juxtamedullary regions and of the medulla with absent excretion of contrast medium.

A radionuclide renal scan shows decreased uptake with significantly delayed or absent function. Renal scanning is the imaging technique of choice if contrast-enhanced CT scanning is not available or is contraindicated.

TREATMENT

The cornerstones of therapy for renal cortical necrosis are to restore hemodynamic stability, institute early dialysis, and treat the underlying cause. Most cases of renal cortical necrosis require initial treatment in an intensive care setting. It is important to prevent or treat the underlying cause of acute cortical necrosis, when possible. Therapy involves medical management of acute renal failure, often with the initiation of dialysis as indicated. Management is otherwise supportive and involves volume repletion, correction of asphyxia, and treatment of sepsis.

PROGNOSIS

The most important prognostic factors include the extent of necrosis, duration of oligoanuria, and severity of the overall associated conditions. Untreated, renal cortical necrosis has a high mortality rate, exceeding 50%. Early initiation of dialysis significantly diminishes the mortality rate. Most patients require dialysis for variable but extended periods of time. Twenty to 40% of patients have partial recovery of renal function, the extent of which depends on the amount of preserved cortical tissue. All patients require long-term follow-up for chronic kidney disease.

Visit Elsevier eBooks+ at eBooks.Health.Elsevier.com for Bibliography.

560.8 Coagulopathies and Thrombocytopenia

Prasad Devarajan

Gross or microscopic hematuria may be associated with inherited or acquired disorders of coagulation (hemophilia, disseminated intravascular coagulation, thrombocytopenia). In these cases, however, hematuria is not usually the presenting complaint or a major factor affecting the clinical management or outcome (see Chapters 524-533).

Chapter 561

Tubulointerstitial Disease Associated with Hematuria

Prasad Devarajan

Gross or microscopic hematuria may be associated with several disorders of the renal tubules and the interstitium (pyelonephritis, tubulointerstitial nephritis, papillary necrosis, acute tubular necrosis). However, except for papillary necrosis, hematuria is not usually the presenting complaint or a major factor affecting the clinical management or outcome (see Chapters 561.2-561.4).

561.1 Pyelonephritis

See Chapter 575, Urinary Tract Infections.

561.2 Tubulointerstitial Nephritis

Prasad Devarajan

Tubulointerstitial nephritis (TIN, also called interstitial nephritis) is the term applied to conditions characterized by tubulointerstitial inflammation and damage with relative sparing of glomeruli and vessels. Both acute and chronic primary forms exist. **Acute TIN** is characterized by an acute extensive lymphocytic inflammatory response and a rapid decline in renal function. **Chronic TIN** usually displays a protracted onset and a chronic patchy lymphocytic infiltrate, interstitial fibrosis, and a slow deterioration in renal function. Secondary forms of interstitial nephritis can be associated with primary glomerular diseases, as well as systemic diseases affecting the kidney.

ACUTE TUBULOINTERSTITIAL NEPHRITIS

The hallmarks of acute TIN are an extensive lymphocytic infiltration of the tubulointerstitium, interstitial edema, and varying degrees of tubular necrosis and regeneration. Eosinophils may be present, particularly in drug-induced TIN; occasionally, interstitial granulomas with giant cells occur. Glomeruli are usually normal in primary TIN. The pathogenesis is not fully understood, but a T-cell–mediated immune mechanism has been postulated. *Drugs are the most common cause of acute TIN in children.* Many medications, especially antimicrobials, anticonvulsants, and analgesics, have been implicated as etiologic agents (Table 561.1). Nonsteroidal antiinflammatory drugs (NSAIDs), penicillins, and sulfonamides account for most cases. Drug-induced TIN is an idiosyncratic reaction that occurs in only a very small subset of patients who ingest the medication, typically with repeated exposure. Drugs of abuse (including synthetic cannabinoids, bath salts, ecstasy, anabolic steroids, inhaled solvents, heroin, and cocaine) are an increasingly common problem in certain populations. Other causes of acute TIN include infections, primary glomerular diseases, and systemic diseases such as systemic lupus erythematosus.

Clinical Manifestations

The classic presentation of acute TIN is fever, rash, and arthralgia in the setting of a rising serum creatinine. Acute TIN accounts for about 5% of pediatric acute kidney injury cases. Although the full clinical triad may be noted in drug-induced TIN, most patients with acute TIN do not demonstrate all the typical features. The rash can vary from maculopapular to urticarial and is often transient. Patients often have nonspecific constitutional symptoms of nausea, vomiting, fatigue, and weight loss. Flank pain may be present, presumably secondary to stretching of the renal capsule from acute inflammatory enlargement of the kidney. If acute TIN is caused by a systemic disease such as systemic lupus erythematosus, the clinical presentation will be consistent with specific signs and symptoms of the underlying disease. Unlike the typical presentation of oliguric **acute kidney injury (AKI)** seen with glomerular diseases, 30–40% of patients with acute TIN are nonoliguric, and hypertension is less common. Peripheral eosinophilia can occur, especially with drug-induced TIN. Microscopic hematuria is invariably present, but significant hematuria or proteinuria >1.5 g/day is uncommon. One exception is patients whose TIN is caused by NSAIDs, who can present with nephrotic syndrome. Urinalysis can reveal white blood cell, granular, or hyaline casts, but red blood cell casts (a characteristic of glomerular disease) are absent. The presence of urine eosinophils is neither sensitive nor specific, being detected in only 25% of cases. Because of pyuria, the initial diagnosis may be a urinary tract infection.

Diagnosis

The diagnosis is usually based on the clinical presentation and laboratory findings. A renal biopsy will establish the correct diagnosis in cases where the etiology or clinical course confounds the diagnosis. A careful history of the timing of disease onset in relation to drug exposure is essential in suspected drug-induced TIN. Because of the immune-mediated nature of TIN, signs or symptoms generally appear within 1-2 weeks following exposure. In children, antimicrobials are a common inciting agent. NSAIDs are an important cause of acute TIN in children, and volume depletion or underlying chronic kidney disease can increase the risk of occurrence. Urinalysis and serial measurements of serum creatinine and electrolytes should be monitored. Renal ultrasonography, though not diagnostic, can demonstrate enlarged, echogenic kidneys. Removal of a suspected offending agent followed by spontaneous improvement in kidney function is highly suggestive of the diagnosis, and additional testing is generally not performed in this setting. In more severe cases, in which the cause is unclear, or the patient's kidney function deteriorates rapidly, a renal biopsy is indicated.

Treatment and Prognosis

Treatment of acute TIN starts with eliminating the suspected causative drug or agent. Most patients with mild ATN recover kidney function when the inciting agent is discontinued. Other treatment includes supportive care directed at addressing complications of AKI, such as hyperkalemia or volume overload (see Chapter 572.1). Corticosteroid administration within 2 weeks of the discontinuation of certain offending agents (e.g., NSAIDs or antibiotics) can hasten the recovery and improve the long-term prognosis in drug-induced TIN. Current recommendations favor the use of oral prednisone in children whose kidney function fails to improve soon after stopping the suspected agent. IV methylprednisolone is used in severe cases. Mycophenolate mofetil has been found to be beneficial in steroid-unresponsive cases. Whether such therapies are indicated in other causes of TIN is not clear. For patients with prolonged kidney insufficiency, the prognosis remains guarded, and severe acute TIN from any cause can progress to chronic TIN.

CHRONIC TUBULOINTERSTITIAL NEPHRITIS

In children, chronic TIN most commonly occurs in the context of (1) an underlying congenital urologic kidney disease, such as obstructive uropathy or vesicoureteral reflux, or (2) an underlying metabolic disorder affecting the kidneys (see Table 561.1). Some commonly used drugs such as cyclosporine and tacrolimus also cause chronic TIN. Chronic TIN can occur as an idiopathic disease, although this is more common in adults.

The **juvenile nephronophthisis (JN)–medullary cystic kidney disease complex (MCKD)** is a group of inherited, genetically determined cystic renal diseases that share the common histologic finding of chronic TIN. At least 20 different genes are associated with JN, usually

Table 561.1 Etiology of Interstitial Nephritis

ACUTE INTERSTITIAL NEPHRITIS

Drugs
- Antimicrobials
  - Penicillin derivatives
  - Cephalosporins
  - Sulfonamides
  - Trimethoprim-sulfamethoxazole
  - Ciprofloxacin
  - Tetracyclines
  - Vancomycin
  - Erythromycin derivatives
  - Rifampin
  - Amphotericin B
  - Acyclovir
- Anticonvulsants
  - Carbamazepine
  - Phenobarbital
  - Phenytoin
  - Sodium valproate

Drugs of Abuse
- Synthetic cannabinoids
- Bath salts
- Ecstasy
- Anabolic steroids
- Inhaled solvents
- Heroin
- Cocaine

Other Drugs
- Allopurinol
- All-trans-retinoic acid
- 5-Aminosalicylic acid
- Cimetidine
- Cyclosporine
- Diuretics
- Escitalopram
- Interferon
- Mesalazine
- Quetiapine
- Olanzapine
- Nonsteroidal antiinflammatory drugs
- Protease inhibitors
- Proton pump inhibitors
- Aristolochic acid (traditional Chinese herb)

Infections
- Adenovirus
- Bacteria associated with acute pyelonephritis
- BK virus
- *Brucella*
- Streptococcal species
- Cytomegalovirus
- Epstein-Barr virus
- Hepatitis B virus
- Histoplasmosis
- Human immunodeficiency virus
- Hantavirus
- Leptospirosis
- *Toxoplasma gondii*

Disease-Associated
- Glomerulonephritis (e.g., systemic lupus erythematosus)
- Acute allograft rejection
- Tubulointerstitial nephritis and uveitis (TINU) syndrome

Idiopathic

CHRONIC INTERSTITIAL NEPHRITIS

Drugs and Toxins
- Analgesics
- Cyclosporine
- Lithium
- Heavy metals (including lead)

Infections (See Acute Interstitial Nephritis)
- Disease-associated causes
  - Metabolic and hereditary
  - Cystinosis
  - Oxalosis
  - Fabry disease
  - Wilson disease
  - Sickle cell nephropathy
  - Alport syndrome
  - Juvenile nephronophthisis, medullary cystic disease

Immunologic
- Systemic lupus erythematosus
- Crohn disease
- Chronic allograft rejection
- Tubulointerstitial nephritis and uveitis (TINU) syndrome
- Anti-tubular basement disease

Urologic
- Posterior urethral valves
- Eagle-Barrett syndrome
- Ureteropelvic junction obstruction
- Vesicoureteral reflux

Miscellaneous
- Balkan nephropathy
- Radiation
- Sarcoidosis
- Neoplasm

Idiopathic

inherited as an autosomal recessive disease (Table 561.2). These genes only define 30% of cases, and new genes are being identified at a rapid pace. Although uncommon in the United States, JN causes 10–20% of pediatric cases of end-stage kidney disease (ESKD) in Europe. Patients with JN typically present with polyuria, growth failure, unexplained anemia, and chronic kidney disease in late childhood or adolescence. JN is a **ciliopathy** and is often associated with extrarenal features such as retinal degeneration, hepatobiliary disease, cerebellar vermis hypoplasia, laterality defects, intellectual disability, and shortening of bones (see Chapter 101.3). These features are represented in several syndromes, such as **Senior-Løken syndrome (retinitis pigmentosa), Joubert syndrome (cerebellar vermis hypoplasia;** 22 subtypes),

Table 561.2 Juvenile Nephronophthisis: Summary of the *NPHP1* to *NPHP18*, *NHPH1L*, and *NPHP2L* Genes, Gene Products, Chromosomal Localization, Phenotypes, Extrarenal Symptoms, and Interaction Partners

GENE (PROTEIN)	CHROMOSOME	PHENOTYPE (MEDIAN AGE AT ESRD)	EXTRARENAL SYMPTOMS	INTERACTION PARTNERS
NPHP1 (nephrocystin-1)	2q13	NPHP (13 yr)	RP (10%), OMA (2%), JBTS (rarely)	Inversin, nephrocystin-3, nephrocystin-4, filamin A and B, tensin, β-tubulin, PTK2B
NPHP2/INVS (inversin)	9q31	Infantile NPHP (<4 yr)	RP (10%), LF, situs inversus, CHD	Nephrocystin-1, calmodulin, catenins, β-tubulin, APC2
NPHP3 (nephrocystin-3)	3q22	Infantile and adolescent NPHP	LF, RP (10%), situs inversus, MKS, CHD	Nephrocystin-1
NPHP4 (nephrocystin-4)	1p36	NPHP (21 yr)	RP (10%), OMA, LF	Nephrocystin-1, BCAR1, PTK2B
NPHP5/IQCB1 (nephrocystin-5)	3q21	NPHP (13 yr)	Early-onset RP	Calmodulin, RPGR, nephrocystin-6
NPHP6/CEP290 (nephrocystin-6/CEP290)	12q21	NPHP	JBTS, MKS	ATF4, nephrocystin-5, CC2D2A
NPHP7/GLIS2 (nephrocystin-7/GLIS2)	16p	NPHP	—	—
NPHP8/RPGRIP1L (nephrocystin-8/RPGRIP1L)	16q	NPHP	JBTS, MKS	Nephrocystin-1
NPHP9/NEK8 (nephrocystin-9/NEK8)	17q11	Infantile NPHP	—	—
NPHP10/SDCCAG8 (nephrocystin-10/SDCCAG8)	1q43	Juvenile NPHP	RP (SLS), BBS-like	OFD1
TMEM67/MKS3/NPHP11 (nephrocystin-11/meckelin)	8q22.1	NPHP	JBTS, MKS, LF	MKS1, nephrocystin-1, nephrocystin-4, nephrocystin-6, nesprin-2, TMEM216
TTC21B//JBTS11/NPHP12 (nephrocystin-12/IFT139)	2q24.3	Early-onset NPHP, juvenile NPHP	JATD, MKS, JBTS, BBS-like	Ciliopathy modifier
WDR19/NPHP13 (nephrocystin-13/IFT144)	4p14	NPHP	JATD, SBS, CED, RP, Caroli, BBS-like	—
ZNF423/NPHP14 (nephrocystin-14/ZNF423)	16q12.1	Infantile NPHP, PKD	JBTS, situs inversus	PARP1, nephrocystin-6,
CEP164/NPHP15 (nephrocystin-15 centrosomal protein 164 kDa)	11q23.3	NPHP (8 years)	RP, JBTS, LF, obesity	ATRIP, CCDC92, TTBK2, nephrocystin-3, nephrocystin-4, Dvl3
ANKS6/NPHP16 (nephrocystin-16/ANKS6)	9q22.33	NPHP, PKD	LF, situs inversus, cardiovascular abnormalities	INVS, nephrocystin-3, NEK8, HIF1AN, NEK7, BICC1
IFT172/NPHP17 (nephrocystin-17/IFT172)	2p23.3	NPHP	JATD, MZSDS, JBTS	IFT140, IFT80
CEP83/NPHP18 (nephrocystin-18/centrosomal protein 83 kDa)	12q22	Early-onset NPHP (3 yr)	Learning disability, hydrocephalus, LF	CEP164, IFT20
NPHP1L/XPNPEP3 (nephrocystin-1L/XPNPEP3)	22q13	NPHP	Cardiomyopathy, seizures	Cleaves LRRC50, ALMS1, nephrocystin-6
NPHP2L/SLC41A1 (nephrocystin-2L/SLC41A1)	1q32.1	NPHP	Bronchiectasis	—

ATF4, Activating transcription factor 4; APC2, anaphase-promoting complex 2; BBS, Bardet-Biedl syndrome; BCAR1, breast cancer antiestrogen resistance 1; CC2D2A, coiled-coil and C2 domain containing 2A; CED, cranioectodermal dysplasia; CHD, congenital heart disease; JATD, Jeune asphyxiating thoracic dysplasia; JBTS, Joubert syndrome; LF, liver fibrosis; MKS, Meckel-Gruber syndrome; MZSDS, Mainzer-Saldino syndrome; NPHP, nephronophthisis; OMA, oculomotor apraxia; PKD, polycystic kidney disease; PTK2B, protein tyrosine kinase 2B; RP, retinitis pigmentosa; RPGR, retinitis pigmentosa GTPase regulator; SBS, Sensenbrenner syndrome; SLS, Senior-Løken syndrome.

From Wolf MTF. Nephronophthisis and related syndromes. *Curr Opin Pediatr*. 2015;27:201–211. Table 1.

Bardet-Biedl syndrome (intellectual disability, obesity; 17 subtypes), **Jeune asphyxiating thoracic dystrophy** (shortening of the long bones, narrow rib cage; 11 subtypes), and many others. **MCKD** is an autosomal dominant disease that typically manifests in adulthood, characterized by tubulointerstitial sclerosis leading to ESKD. Because at least four different gene pathogenic variants may give rise to the condition, the name **autosomal dominant tubulointerstitial kidney disease (ADTKD)** has been proposed for this condition. The two best known forms of ADTKD include mucin-1 kidney disease 1 (MKD1) and mucin-2 kidney disease/uromodulin kidney disease (MKD2), based on the pathogenic variant identified. **TIN with uveitis (TINU syndrome)** is a rare autoimmune syndrome of chronic TIN with bilateral anterior uveitis and bone marrow granulomas that occurs primarily in adolescent girls. Clinical manifestations include photophobia, ocular pain and redness, and visual impairment. Chronic TIN is seen in all forms of progressive kidney disease, regardless of the underlying cause, and the severity of interstitial disease is the single most important factor predicting progression to ESKD.

Pathogenesis and Pathology

The pathophysiology of chronic TIN is undefined, but data suggest that, other than the abnormal cilia structure and function in JN and MCKD, in other cases it is immune mediated. Cells making up the interstitial infiltrate appear to be a combination of native interstitial cells, inflammatory cells recruited from the circulation, and resident tubular cells that undergo epithelial-mesenchymal transformation. Grossly, kidneys can appear pale and small for age. Microscopically, tubular atrophy and "dropout" with interstitial fibrosis and a patchy lymphocytic interstitial inflammation are seen. Patients with JN often have characteristic small cysts in the corticomedullary region. In primary chronic TIN, glomeruli are relatively spared until late in the disease course. Patients with chronic TIN secondary to a primary glomerular disease have histologic evidence of the primary disease. Chronic TIN due to cyclosporine or tacrolimus use is characterized by tubular atrophy, "stripe" interstitial fibrosis, and vascular sclerosis.

Clinical Manifestations

The clinical features of chronic TIN are often nonspecific and can reflect signs and symptoms of slowly progressive chronic kidney disease (see Chapter 572). Fatigue, growth failure, polyuria, polydipsia, and enuresis are often present. Anemia that is seemingly disproportionate to the degree of kidney insufficiency is common and is a particularly prominent feature in JN. Because tubular damage often leads to salt wasting by the kidney, significant hypertension is unusual. Fanconi syndrome, proximal renal tubular acidosis, distal renal tubular acidosis, and hyperkalemic distal renal tubular acidosis can occur.

Extrarenal manifestations of **nephronophthisis** include ophthalmic, neurologic, hepatic, and skeletal disorders (Table 561.3).

Table 561.3 Extrarenal Manifestations Associated with Nephronophthisis and Resulting Syndromes Associated with *NPHP* Pathogenic Variants

DISORDER	SYNDROME
OPHTHALMOLOGIC	
Retinitis pigmentosa	Senior-Løken syndrome (SLSN)
	Arima syndrome (cerebro-oculo-hepato-renal syndrome)
	Alstrom (RP, obesity, DM type 2, hearing impairment)
	RHYNS (RP, hypopituitarism, skeletal dysplasia)
Oculomotor apraxia	Cogan syndrome
Nystagmus	Joubert syndrome/Joubert syndrome–related disorders
Coloboma	Joubert syndrome/Joubert syndrome–related disorders
NEUROLOGIC	
Encephalocele	Meckel-Gruber syndrome (occipital encephalocele, NPHP)
Vermis aplasia	Joubert syndrome/Joubert syndrome–related disorders
Hypopituitarism	RHYNS
HEPATIC	
Liver fibrosis	Boichis syndrome
	Meckel-Gruber syndrome (occipital encephalocele, NPHP)
	Arima syndrome (cerebro-oculo-hepato-renal syndrome)
	Joubert syndrome/Joubert syndrome–related disorders
SKELETAL	
Short ribs	Jeune syndrome/asphyxiating thoracic dystrophy
Cone-shaped epiphysis	Mainzer-Saldino syndrome
Postaxial polydactyly	Joubert syndrome/Joubert syndrome–related disorders
	Bardet-Biedl syndrome (NPHP, RP, obesity, deafness)
	Ellis van Creveld
Skeletal abnormalities	Sensenbrenner syndrome/cranioectodermal dysplasia
	Ellis van Creveld
OTHERS	
Situs inversus	
Cardiac malformation	
Bronchiectasis	
Ulcerative colitis	

RP, Retinitis pigmentosa; DM, diabetes mellitus; NPHP, nephronophthisis.
From Wolf MT, Hildebrandt F. Nephronophthisis. *Pediatr Nephrol*. 2011;26:181–194.

Diagnosis

The diagnosis is suggested by signs or symptoms of kidney tubular damage such as polyuria and an elevated serum creatinine value, coupled with a history suggestive of a chronic disease, such as longstanding enuresis or the presence of anemia resistant to iron therapy. Radiographic studies, in particular ultrasonography, can give additional evidence of chronicity, such as small, echogenic kidneys, corticomedullary microcysts suggesting JN, or findings of obstructive uropathy. A voiding cystourethrogram can demonstrate the presence of vesicoureteral reflux or bladder abnormalities. If JN is suspected, a specific genetic diagnosis is available. In instances in which the cause is unclear, a kidney biopsy may be performed. In cases of advanced disease, a kidney biopsy might not be diagnostic. Many ESKDs display a common histologic appearance of tubular fibrosis and inflammation.

Treatment and Prognosis

Therapy is directed at maintaining the fluid and electrolyte balance and avoiding further exposure to nephrotoxic agents. Patients with obstructive uropathies can require salt supplementation and treatment with potassium-binding resin. Prevention of infection by antibiotic prophylaxis can slow the progression of renal damage in appropriate patients. The prognosis in patients with chronic TIN depends in large part on the nature of the underlying disease. Patients with obstructive uropathy or vesicoureteral reflux can have a variable degree of kidney damage and thus a variable course. ESKD can develop over months to years. Patients with JN uniformly progress to ESKD by adolescence. Patients with metabolic disorders can benefit from treatment when available.

Visit Elsevier eBooks+ at eBooks.Health.Elsevier.com for Bibliography.

561.3 Papillary Necrosis

Prasad Devarajan

Renal papillary necrosis (RPN) is a descriptive term applied to conditions that result in necrosis of the kidney medullary pyramids and papillae. The hypoxic and hypertonic environment that normally prevails in the kidney medullary region renders it especially vulnerable to ischemic necrosis. Common precipitating factors in children include shock, hypovolemia, hypoxia, pyelonephritis, urinary tract obstruction, and sickle cell hemoglobinopathies, Analgesic abuse and diabetes mellitus are additional important causes in adults. RPN can result in secondary infection, deposition of stones, and sloughing of papillae with resultant urinary tract obstruction. Both an acute progressive clinical course and a more chronic protracted form have been described. Patients most commonly present with flank pain and hematuria. Radiologic studies are key to establishing the diagnosis. Management is directed toward treating the underlying cause, ameliorating kidney ischemia with hydration, and surgical relief of obstruction.

PATHOGENESIS AND PATHOLOGY

RPN may be focal (involving only the papillary tips) or diffuse (involving the whole papilla and the innermost areas of the medulla). RPN may affect a single papilla or multiple papillae. Histologically, the tissue typically reveals classic coagulative necrosis, surrounded by an inflammatory response.

Under normal conditions, the medullary region of the kidney subsists on a hypoxic precipice due to low blood flow and countercurrent exchange of oxygen, although paradoxically housing nephron segments with very high energy requirements. The blood flow decreases even further as one approaches the innermost regions of the medulla and becomes marginal toward the apex and tips of the papillae. The already compromised blood supply is further attenuated in several pathophysiologic states, including the hypoxia from shock and dehydration, the intraluminal stasis of sickle cell nephropathy, the inflammation of pyelonephritis, the increased pressure of urinary tract obstruction, the microvascular changes of diabetes, and the direct damage from analgesics (including NSAIDs). Approximately 15–30% of patients with sickle cell disease will encounter episodes of RPN during their lifetime.

CLINICAL MANIFESTATIONS

The classic presentation of acute RPN is flank pain and renal colic, gross hematuria with clots and tissue debris, and fever with chills. AKI, an increase in the serum creatinine, and oliguria are not common but may accompany the rapidly progressive form. Patients with the chronic indolent form may be asymptomatic and may first present with the passage of sloughed papillae in the urine.

DIAGNOSIS

The diagnosis of RPN is usually based on the history, clinical presentation, laboratory findings, and radiologic investigations. Contrast-enhanced CT scanning is the imaging modality of choice. In the acute phase, this method depicts several typical features, including clefts in the medulla, pelvic filling defects, nonenhanced lesions surrounded by rings of excreted material, medullary calcifications, and the presence of obstruction. If IV contrast is contraindicated, CT scanning without contrast or renal ultrasonography may be performed. These modalities are now replacing IV urography, which was the imaging method of choice in the past.

TREATMENT AND PROGNOSIS

Treatment of acute RPN starts with ameliorating the kidney ischemia with IV hydration. In addition, it is important to treat the underlying cause, including appropriate medical management of shock, sepsis, pyelonephritis, or sickle cell disease. Cessation of any analgesics (including NSAIDs) is critical. Patients with acute obstruction may require surgical intervention for relief.

Visit Elsevier eBooks+ at eBooks.Health.Elsevier.com for Bibliography

561.4 Acute Tubular Necrosis

Prasad Devarajan

Acute tubular necrosis (ATN) is a descriptive term applied to conditions that result in necrosis of the renal tubular epithelial cells. The hypoxic environment that normally prevails in the kidney medullary region renders its nephron segments especially vulnerable to necrotic cell death. ATN frequently coexists with other forms of cell death, as well as cellular regeneration. Common precipitating factors in children include prolonged renal ischemia, sepsis, shock, hypovolemia, and nephrotoxic medications. ATN is the most common cause of *intrinsic* **acute kidney injury (AKI)** (see Chapter 572). ATN is clinically characterized by a rapid (within hours to days) decline in kidney function that leads to retention of waste products such as BUN and creatinine, fluid overload, and reduced urine output in many cases. Patients with hospital-acquired ATN frequently have no specific symptoms, and the diagnosis requires a high index of suspicion in predisposed individuals. Laboratory tests and radiologic studies are the key to establishing the diagnosis. Management is directed toward treating the underlying or precipitating cause, correction of imbalances in fluid, electrolyte, and acid-base status, avoidance of nephrotoxic medications, and treatment of complications.

PATHOGENESIS AND PATHOLOGY

The pathologic findings are highly variable, depending on the etiology and the region of the kidney affected. In children with predominantly ischemic ATN, necrosis is relatively inconspicuous, whereas it is more widespread in nephrotoxic ATN. Because the medullary region of the kidney (including the straight segment of the proximal tubule and the medullary thick ascending limb of the loop of Henle) normally subsists in a hypoxic environment due to low blood flow and countercurrent exchange of oxygen, these nephron segments are usually the most severely affected. Typical findings include patchy areas of tubule cell necrosis with resultant loss of tubule epithelial cells and exposure of denuded basement membrane. Other forms of cell death, including apoptosis, necroptosis, and ferroptosis, occur simultaneously. Surviving proximal tubule cells show diffuse effacement and loss of the brush border and apical blebs. The distal nephron segments exhibit tubular dilatation with intraluminal casts. There is concomitant evidence for cellular regeneration and repair among freshly damaged tubule epithelial cells. Injury is aggravated by several pathophysiologic states, including the ischemia from sepsis, shock, and dehydration and the direct damage from nephrotoxic medications.

The significant decline in kidney function is often out of proportion to the observed patchy histologic changes. In addition to tubule cell necrosis, several other factors contribute to the decline in the glomerular filtration rate (GFR). First, a single collecting tubule drains multiple nephrons, such that obstruction of even a small number of collecting tubules results in failure of filtration from several nephrons. Second, obstruction aggravates the backflow of filtered tubular fluid into the vascular space across the denuded epithelium. Third, loss of the proximal tubular reabsorptive capacity results in increased delivery of sodium chloride to the macula densa, with activation of the tubuloglomerular feedback mechanisms that worsens the afferent arteriolar constriction. Fourth, many additional factors contribute to the pathogenesis of ATN, including changes in the microvascular blood flow, endothelial damage, and the activation of inflammatory pathways.

The pathophysiology and clinical course of ATN may be divided into three sequential phases, namely, initiation, maintenance, and recovery. The *initiation* phase occurs during the initial exposure to ischemia or nephrotoxins. Tubule cell damage begins to evolve, and the sloughed tubular cell debris results in obstruction of the tubular lumen. The combination of hypoperfusion and obstruction to the tubular fluid flow results in a fall in the GFR and urine output and a rise in serum creatinine levels. During the *maintenance* phase of ATN, renal tubule injury is established at its highest severity, the GFR and urine output become stabilized at a very low level, and the BUN and serum creatinine peak. It should be noted that ATN due to nephrotoxic

medications is typically nonoliguric. This phase typically lasts for 1-2 weeks but may extend to several weeks. Complications (e.g., metabolic, fluid, and electrolyte imbalances) typically occur during this phase. The *recovery* phase, also called the diuretic phase, is characterized by regeneration of lost tubule epithelial cells, repair of sub-lethally injured cells, and removal of intratubular casts by reestablishment of tubular fluid flow. It is clinically heralded by polyuria and a slow recovery of the GFR. Diuresis occurs because the rapidly increasing GFR precedes the complete recovery of the tubule cell structure and function and can result in volume depletion if not recognized and treated promptly.

The most prevalent causes of ATN in neonates and older children are shown in Tables 561.4 and 561.5, respectively.

CLINICAL MANIFESTATIONS

ATN is largely asymptomatic, and the clinical diagnosis depends on having a high index of suspicion in children with etiologic risk factors. ATN most frequently manifests with a progressive accumulation of fluid, a serial elevation in the BUN and serum creatinine, and a reduction in urine output, in a predisposed patient who has been exposed to either ischemic or nephrotoxic injury. The evaluation requires a complete history directed toward the known causes of ATN, physical examination, laboratory testing, and renal imaging. A detailed history of all ingested drugs and medications is especially important. Although ATN is technically a histologic diagnosis, kidney biopsies are only rarely performed in children with this condition.

Signs of ATN on physical examination include edema, hypertension, and evidence of heart failure. Children with intravascular volume depletion exhibit tachycardia, hypotension, decreased skin turgor, and dry mucous membranes.

Table 561.4 Prevalent Causes of Acute Tubular Necrosis in Neonates

MECHANISM	CAUSES
Ischemia	Perinatal asphyxia, respiratory distress syndrome, hemorrhage, congenital heart disease, sepsis, shock
Exogenous toxins	Aminoglycosides, maternal ingestion of angiotensin-converting enzyme inhibitors or nonsteroidal antiinflammatory drugs
Endogenous toxins	Hemoglobin (hemolysis), myoglobin (seizures)
Primary kidney disease	Renal vein thrombosis, renal artery thrombosis, polycystic kidney disease

Table 561.5 Prevalent Causes of Acute Tubular Necrosis in Older Children

MECHANISM	CAUSES
Ischemia	Severe dehydration, hemorrhage, shock, sepsis, burns, major surgery, severe cardiac disease, prolonged cold ischemia time in kidney transplant
Exogenous toxins	Aminoglycosides, cisplatin, contrast agents, cyclosporine, tacrolimus, angiotensin-converting enzyme inhibitors, nonsteroidal antiinflammatory drugs
Endogenous toxins	Hemoglobin (hemolysis, extracorporeal circulation), myoglobin (crush injuries, seizures, influenza)
Primary kidney disease	Hemolytic uremic syndrome, crescentic glomerulonephritis

DIAGNOSIS

The diagnosis of ATN is aided by laboratory findings and radiologic investigations. A freshly voided urine is typically positive for blood and protein, and microscopy reveals red blood cells and broad, muddy-brown granular casts. Heme-positive urine in the absence of red blood cells in the sediment should raise the suspicion for hemolysis or rhabdomyolysis. In ATN, the impaired kidney reabsorptive and concentrating capacity typically results in a low urine specific gravity and a high urinary sodium and fractional excretion of sodium. The hallmark of ATN is a progressive increase in the serum creatinine and BUN. Urine biomarkers, such as neutrophil gelatinase associated lipocalm (NGAL) and cystatin C, usually increase before creatinine levels and are helpful in predicting acute tubular injury. A mild to moderate anemia is common due to dilution and decreased erythropoiesis. A high anion gap metabolic acidosis results from impaired renal excretion of acids and decreased tubular reabsorption of bicarbonate. Several electrolyte disturbances may be encountered, including hyponatremia (usually dilutional), hyperkalemia, hyperphosphatemia, hypocalcemia, and hypomagnesemia. If rhabdomyolysis is suspected, the diagnosis can be confirmed by the detection of urine myoglobin and elevated levels of serum creatine kinase. The diagnosis of nephrotoxicity may be aided by the determination of serum drug levels. Renal ultrasonography in ATN typically reveals enlarged echogenic kidneys. Prolonged severe ATN results in renal cortical necrosis and a reduction in kidney size.

TREATMENT AND PROGNOSIS

See Chapter 572.1

Treatment of ATN starts with ameliorating the kidney ischemia by restoring and maintaining the intravascular volume with IV hydration. In addition, it is important to treat the underlying cause, including with appropriate medical management of shock, sepsis, or cardiac disease. Cessation of any potential nephrotoxic agent (including NSAIDs) is critical. Dosages of all medications should be chosen based on the estimated GFR. Children with oliguria and volume overload may require fluid restriction and the judicious use of furosemide. Although furosemide can convert the clinical picture from an oliguric to a nonoliguric one (which can facilitate medical management), there is little evidence that it changes the clinical course of ATN. Children with established ATN may not respond to furosemide and are at higher risk for ototoxicity. Common indications for dialysis in ATN include fluid overload that is unresponsive to diuretics or is a hindrance to the provision of adequate nutrition, hyperkalemia unresponsive to medical management, symptomatic acid-base imbalances, and refractory hypertension.

In the absence of multiorgan failure, most children with ATN eventually regain renal function to a large extent. In the context of severe multiorgan dysfunction, renal recovery is limited, and morbidity and mortality rates remain high. Patients who recover from severe ATN remain at risk for subsequently developing chronic kidney disease.

Visit Elsevier eBooks+ at eBooks.Health.Elsevier.com for a Bibliography.

Chapter 562
Vascular Diseases Associated with Hematuria

562.1 Vascular Abnormalities

Prasad Devarajan

Hemangiomas, hemangiolymphangiomas, angiomyomas, and arteriovenous malformations of the kidneys and lower urinary tract are rare causes of hematuria. They can present clinically with microscopic hematuria or gross hematuria with clots. When associated cutaneous vascular malformations are present, they can offer a clue to these underlying causes of hematuria. **Angiomyolipomas,** the most common benign solid tumors of the kidney, are composed of vascular, smooth muscle, and fatty tissue elements. They can rupture on occasion to cause severe hemorrhage. Angiomyolipomas are an important component of the **tuberous sclerosis complex** (see Chapter 636.2), which includes developmental delay, facial angiofibromas, and lung cysts. Renal colic can develop with any upper tract vascular abnormality that obstructs urinary drainage, induces an inflammatory response, or distends the renal capsule. The diagnosis may be confirmed by angiography or endoscopy.

Unilateral bleeding of varicose veins of the left ureter, resulting from compression of the left renal vein between the aorta and superior mesenteric artery (mesoaortic compression), is referred to as the **nutcracker syndrome.** Patients with this syndrome typically present with persistent microscopic hematuria (and, occasionally, recurrent gross hematuria) that may be accompanied by proteinuria, left lower abdominal pain, left flank pain, or orthostatic hypotension. The diagnosis requires a high degree of suspicion and is confirmed by Doppler ultrasonography, CT scanning, phlebography of the left renal vein, or MRI.

Visit Elsevier eBooks+ at eBooks.Health.Elsevier.com for Bibliography.

562.2 Renal Vein Thrombosis

Prasad Devarajan

EPIDEMIOLOGY

Renal vein thrombosis (RVT) occurs in two distinct clinical settings: (1) In newborns and infants, RVT is commonly associated with asphyxia, dehydration, shock, sepsis, congenital hypercoagulable states, central venous catheters, and maternal diabetes or preeclampsia. (2) In older children, RVT is seen in patients with nephrotic syndrome, cyanotic heart disease, inherited hypercoagulable states, sepsis, sickle cell nephropathy, Behcet syndrome, antiphospholipid syndrome following kidney transplantation, and following exposure to angiographic contrast agents.

PATHOGENESIS

RVT begins in the intrarenal venous circulation and can then extend to the main renal vein and even the inferior vena cava. Thrombus formation is mediated by endothelial cell injury resulting from hypoxia, endotoxin, or contrast media. Other contributing factors include hypercoagulability from either nephrotic syndrome or pathogenic variants in genes that encode clotting factors (e.g., deficiencies of protein C, protein S, antithrombin, and factor V Leiden); hypovolemia and decreased venous blood flow associated with septic shock, dehydration, or nephrotic syndrome; and intravascular sludging caused by polycythemia.

CLINICAL MANIFESTATIONS

The development of RVT is classically heralded by the sudden onset of gross hematuria and unilateral or bilateral flank masses. However, patients can also present with any combination of microscopic hematuria, flank pain, hypertension, or a microangiopathic hemolytic anemia with thrombocytopenia or oliguria. RVT is usually unilateral. Bilateral RVT results in acute kidney injury.

DIAGNOSIS

The diagnosis of RVT is suggested by the development of hematuria and flank masses in patients seen in the high-risk clinical settings or with the predisposing clinical features noted previously. Ultrasonography shows marked renal enlargement, and radionuclide studies reveal little or no renal function in the affected kidney(s). Doppler flow studies of the inferior vena cava and renal vein are essential to confirm the diagnosis. Contrast studies should be avoided to minimize the risk of further vascular damage.

DIFFERENTIAL DIAGNOSIS

The differential diagnosis of RVT includes other causes of hematuria that are associated with rapid development of microangiopathic hemolytic anemia or enlargement of the kidney(s). These include hemolytic uremic syndrome, hydronephrosis, polycystic kidney disease, Wilms tumor, and intrarenal abscess or hematoma. All patients with RVT should be evaluated for congenital and acquired hypercoagulable states.

TREATMENT

The primary treatment of RVT starts with aggressive supportive intensive care, including correction of fluid and electrolyte imbalance and treatment of renal insufficiency. Recommendations include additional initial treatment of bilateral RVT with tissue plasminogen activator and unfractionated heparin followed by continued anticoagulation with unfractionated or low molecular weight heparin. Treatment recommendations for unilateral RVT with inferior vena cava extension include either unfractionated or low molecular weight heparin. There is no consensus as to whether unilateral RVT without extension should be managed with heparin or with supportive therapy alone. Aggressive treatment with thrombolytic agents in all these clinical settings, as well as antithrombotic prevention of patients with documented thrombotic risk, remains controversial despite such recommendations given the significant risks of bleeding. Evidence-based data, particularly in children, do not exist despite such best practice recommendations. Children with severe hypertension secondary to RVT who are refractory to antihypertensive medications may require nephrectomy.

PROGNOSIS

Perinatal mortality rates from RVT have decreased significantly over the past 20 years. Partial or complete renal atrophy is a common sequela of RVT in the neonate, leading to an increased risk of chronic kidney disease, renal tubular dysfunction, and systemic hypertension. These complications are also seen in older children. However, recovery of kidney function is not uncommon in older children with RVT resulting from nephrotic syndrome or cyanotic heart disease with correction of the underlying etiology. Long-term follow-up of infants and children with RVT by pediatric nephrologists is recommended for the monitoring of kidney function and the early detection of hypertension and chronic kidney disease

Visit Elsevier eBooks+ at eBooks.Health.Elsevier.com for Bibliography.

562.3 Sickle Cell Nephropathy

Prasad Devarajan

Gross or microscopic hematuria may be seen in children with sickle cell disease or sickle trait. Hematuria tends to resolve spontaneously in most children. Clinically apparent kidney involvement occurs more commonly in patients with sickle cell disease than in those with sickle

cell trait with the exception of an association with **renal cell carcinoma**, which is more common in patients with sickle cell trait.

ETIOLOGY

The kidney manifestations of sickle cell nephropathy (SCN) are generally related to microthrombosis secondary to sickling in the relatively hypoxic, acidic, hypertonic kidney medulla, where vascular stasis is normally present. Analgesic use, volume depletion with consequent prerenal acute kidney injury, infection, and iron-related hepatic disease are independent contributing factors. Glomerular hyperfiltration, mediated by the intrarenal production of prostaglandins and synthesis of nitric oxide, is involved in the pathogenesis of proteinuria and kidney injury in SCN.

PATHOLOGY

Ischemia, papillary necrosis, and interstitial fibrosis are common pathologic findings in SCN. The specific sickle cell glomerular lesion consists of glomerular hypertrophy, with glomerulomegaly and distended capillaries. In addition, a variety of glomerular lesions are also found in SCN; most commonly these include focal segmental glomerulosclerosis, membranoproliferative glomerulonephritis, and thrombotic microangiopathy. The pathophysiology of these specific glomerulonephritic lesions in SCN is poorly understood.

CLINICAL MANIFESTATIONS

Clinical manifestations of SCN include polyuria caused by a urinary concentrating defect, renal tubular acidosis, and proteinuria associated with the glomerular lesions noted previously.

Approximately 20–30% of patients with sickle cell disease develop proteinuria. Nephrotic-range proteinuria with or without clinically apparent nephrotic syndrome occurs in up to 30% of patients with SCN, and when present, generally heralds progressive kidney disease.

TREATMENT

Tubular manifestations have no specific treatment other than those recommended generally for patients with sickle cell disease. However, angiotensin-converting enzyme inhibitors and/or angiotensin II receptor inhibitors can be used to reduce the urine protein excretion in patients with daily amounts exceeding 500 mg and may slow the progression of chronic kidney disease. Gross hematuria secondary to papillary necrosis may respond to treatment with ε-aminocaproic acid or desmopressin acetate. Hydroxyurea and newer treatments for sickle cell disease (see Chapter 511.1) have decreased the manifestations of SCN in proportion to the other complications of the primary hemoglobinopathy.

PROGNOSIS

SCN can eventually lead to hypertension, chronic kidney disease, and progressive kidney failure. Dialysis and eventual kidney transplantation are successful treatment modalities when kidney failure is irreversible.

Visit Elsevier eBooks+ at eBooks.Health.Elsevier.com for Bibliography.

562.4 Idiopathic Hypercalciuria

Prasad Devarajan

Idiopathic hypercalciuria, which may be inherited as an autosomal dominant disorder, can clinically present as recurrent *gross* hematuria, persistent microscopic hematuria, dysuria, crystalluria, or abdominal pain with or without **kidney stone** formation. Hypercalciuria can also accompany conditions resulting in hypercalcemia, such as hyperparathyroidism (see Chapter 613), vitamin D intoxication, immobilization, and sarcoidosis (see Chapter 209). Hypercalciuria may be associated with Cushing syndrome (see Chapter 619), corticosteroid therapy, tubular dysfunction secondary to Fanconi syndrome as occurs with Wilson disease (see Chapter 405.2), oculocerebrorenal (Lowe) syndrome, William syndrome, distal renal tubular acidosis, or Bartter syndrome (see Chapter 571.1). Hypercalciuria may also be seen in patients with Dent disease, which is an X-linked form of nephrolithiasis associated with hypophosphatemic rickets. Although microcrystal formation with consequent tissue irritation is believed to mediate symptoms, the precise mechanism by which hypercalciuria causes hematuria or dysuria is unknown.

DIAGNOSIS

Hypercalciuria is diagnosed by a 24-hour urinary calcium excretion >4 mg/kg. A screening test for hypercalciuria may be performed on a random urine specimen by measuring the calcium and creatinine concentrations. A spot urine calcium:creatinine ratio (mg/dL:mg/dL) >0.2 suggests hypercalciuria in an older child. Normal ratios may be as high as 0.8 in infants <7 months of age.

TREATMENT

Left untreated, hypercalciuria leads to nephrolithiasis in approximately 15% of cases. Hypercalciuria has also been associated with an increased risk for development of low bone mineral density, as well as an increased incidence of urinary tract infections. Idiopathic hypercalciuria has been identified as a risk factor in 40% of children with kidney stones, and a low urinary citrate level has been associated as a risk factor in approximately 38% of this group. Oral thiazide diuretics can normalize urinary calcium excretion by stimulating calcium reabsorption in the proximal and distal tubules. Such therapy can lead to the resolution of gross hematuria or dysuria and can prevent nephrolithiasis. The precise indications for thiazide treatment (including its duration if initiated) remain controversial.

In patients with persistent gross hematuria or dysuria, therapy is initiated with hydrochlorothiazide at a dose of 1-2 mg/kg/24 hours as a single morning dose. The dose is titrated upward until the 24-hour urinary calcium excretion is <4 mg/kg and clinical manifestations resolve. After 1 year of treatment, hydrochlorothiazide is usually discontinued, but it may be resumed if gross hematuria, nephrolithiasis, or dysuria recurs. During hydrochlorothiazide therapy, the serum potassium level should be monitored periodically to avoid hypokalemia. Potassium citrate at a dose of 1 mEq/kg/24 hours may also be beneficial, particularly in patients with low urinary citrate excretion, a low urine pH, and symptomatic dysuria or crystalluria.

Sodium restriction is important because urinary calcium excretion parallels sodium excretion. Importantly, *dietary calcium restriction is not recommended* (except in children with a massive calcium intake >250% of the recommended dietary allowance by dietary history) because calcium is a critical requirement for growth, and no evidence supports a relationship between decreased calcium intake and decreased urinary calcium levels. This is particularly important given the association of hypercalciuria in some patients with reduced bone mineral density. A number of uncontrolled, small-scale studies support a role for bisphosphonate therapy, which leads to a reduction in urinary calcium excretion and improvement in bone mineral density. Controlled studies are necessary to establish a clear role for such therapy in children with hypercalciuria.

Visit Elsevier eBooks+ at eBooks.Health.Elsevier.com for Bibliography.

562.5 Nephrocalcinosis

See Chapter 584.

Chapter 563

Anatomic Abnormalities Associated with Hematuria

563.1 Congenital Anomalies

Prasad Devarajan

Gross or microscopic hematuria may be associated with many different types of malformations of the urinary tract. The sudden onset of gross hematuria after minor trauma to the flank is often associated with ureteropelvic junction obstruction, cystic kidneys, or enlarged kidneys from any cause (see Chapter 577).

563.2 Autosomal Recessive Polycystic Kidney Disease

Prasad Devarajan

Autosomal recessive polycystic kidney disease (ARPKD) (also known as ARPKD-congenital hepatic fibrosis [CHF]) is an autosomal recessive disorder occurring with an incidence of 1:20,000 and a gene carrier rate in the general population of 1/70. The gene for ARPKD ***(PKHD1** [polycystic kidney and hepatic disease 1])* encodes **fibrocystin**, a large protein (>4,000 amino acids) with multiple isoforms.

PATHOLOGY

Both kidneys are markedly enlarged and grossly show innumerable small cysts throughout the cortex and medulla. Microscopic studies demonstrate dilated, ectatic collecting ducts radiating from the medulla to the cortex. The development of progressive interstitial fibrosis and tubular atrophy during the advanced stages of the disease eventually leads to end-stage kidney disease (ESKD). ARPKD causes dual-organ disease, hence, the term *ARPKD/CHF*. Liver involvement is characterized by a basic ductal plate abnormality that leads to bile duct proliferation and ectasia, as well as progressive hepatic fibrosis.

PATHOGENESIS

Fibrocystin may form a multimeric complex with proteins of other primary genetic cystic diseases. Altered intracellular signaling from these complexes, located at epithelial apical cell surfaces, intercellular junctions, and basolateral cell surfaces in association with the focal adhesion complex, is a critical feature of the disease pathophysiology.

Over 300 pathogenic variants in *PKHD1* (without identified specific hot spots) cause disease, and the same pathogenic variant can give variable degrees of disease severity in the same family. This clinical observation is consistent with preclinical data demonstrating many environmental and unknown genetic factors affecting disease expression. The false-negative rate for genetic diagnosis is approximately 10%. Limited available information suggests only a gross genotype–phenotype correlation: pathogenic variants that modify fibrocystin appear to cause less severe disease than those that truncate fibrocystin.

CLINICAL MANIFESTATIONS

The diagnosis of ARPKD is often made antenatally by the demonstration of oligohydramnios and bilateral enlarged kidneys on prenatal ultrasound. The typical infant presents with bilateral flank masses during the neonatal period or in early infancy. ARPKD may be associated with respiratory distress and spontaneous pneumothorax in the neonatal period. Perinatal demise (25–30%) appears to be associated with truncating pathogenic variants. Severe bilateral cases often result in the **oligohydramnios complex (Potter syndrome),** which is marked by low-set ears, micrognathia, flattened nose, limb-positioning defects, intrauterine growth restriction, and pulmonary hypoplasia (see Chapter 574). Respiratory distress may also be secondary to large kidneys that compromise the diaphragm function. Hypertension is usually noted within the first few weeks of life, is often severe, and requires aggressive multidrug therapy for control. Oliguria and acute kidney injury are uncommon, but transient hyponatremia may be seen, which often responds to diuresis. Kidney function is usually impaired but may be initially normal in 20–30% of patients. Approximately 50% of patients with a neonatal-perinatal presentation develop ESKD by age 10 years.

ARPKD is increasingly recognized in infants (and, rarely, in adolescents and young adults) with a mixed renal-hepatic clinical picture. Such children and young adults often present with predominantly hepatic manifestations in combination with variable degrees of kidney disease. **Hepatic fibrosis** manifests as portal hypertension, hepatosplenomegaly, gastroesophageal varices, episodes of ascending cholangitis, prominent cutaneous periumbilical veins, reversal of portal vein flow, and thrombocytopenia. CHF may manifest with cholangiodysplastic changes or a frank **Caroli type** with marked intrahepatic bile duct dilation, affecting the whole liver or just one segment; biliary tract disease increases the risk of ascending cholangitis. Kidney findings in patients with a hepatic presentation may range from asymptomatic abnormal renal ultrasonography to systemic hypertension and chronic kidney disease. In the newborn, clinical evidence of liver disease by radiologic or clinical laboratory assessment is present in approximately 50% of children and believed to be universal by microscopic evaluation. Natural history studies of ARPKD patients presenting as infants and young children have classified this group in terms of the severity of their dual-organ phenotype: 40% have the severe kidney/severe liver phenotype, and 20% each have the severe kidney/mild liver, severe liver/mild kidney, and mild kidney/mild liver phenotype.

DIAGNOSIS

The diagnosis of ARPKD is strongly suggested by bilateral palpable flank masses in an infant with pulmonary hypoplasia, oligohydramnios, hypertension, and the absence of renal cysts by sonography of the parents (Fig. 563.1). Markedly enlarged and uniformly hyperechogenic kidneys with poor corticomedullary differentiation are commonly seen on ultrasonography (Fig. 563.2). The diagnosis is supported by clinical and laboratory signs of hepatic fibrosis, pathologic findings of ductal plate abnormalities seen on liver biopsy, anatomic and pathologic proof of ARPKD in a sibling, or parental consanguinity. The diagnosis can be confirmed by genetic testing. The differential diagnosis includes other causes of bilateral renal enlargement and/or cysts, such as multicystic dysplasia, hydronephrosis, Wilms tumor, and bilateral renal vein thrombosis (Tables 563.1 and 563.2).

Nephronophthisis, an autosomal recessive disorder with kidney fibrosis, tubular atrophy, and cyst formation, is a common cause of ESKD in children and adolescents (see Tables 563.1 and 563.2) (see also Chapter 561). Associated external findings include retinal degeneration (Senior-Løken syndrome), cerebellar ataxia (Joubert syndrome), and hepatic fibrosis (Boichis disease). Symptoms include polyuria (salt wasting, poor concentrating ability), failure to thrive, and anemia. Hypertension and edema are seen later when ESKD develops. Prenatal diagnostic testing using genetic linkage analysis or direct pathogenic variant analysis is available in families with a previously affected child.

Preimplantation genetic diagnosis with in vitro fertilization is available for families with a child affected with ARPKD.

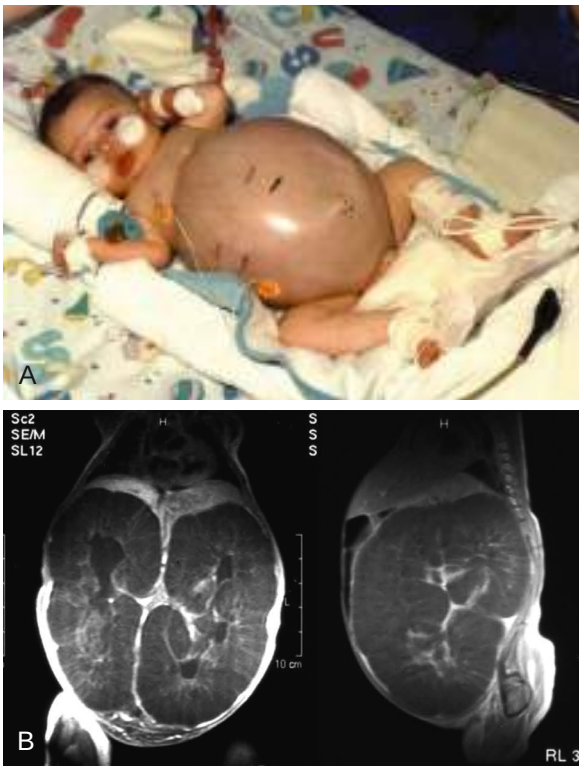

Fig. 563.1 A, Severe nephromegaly in a 3-mo-old infant with autosomal recessive polycystic kidney disease, with x-rays (B). *(From Bakkaloglu SA, Schaefer F. Disease of the kidney and urinary tract in children. In: Skorecki K, Chertow GM, Marsden PA, et al., eds. Brenner & Rector's The Kidney. 10th ed. Philadelphia: Elsevier; 2016: Fig. 74-6, p. 2320.)*

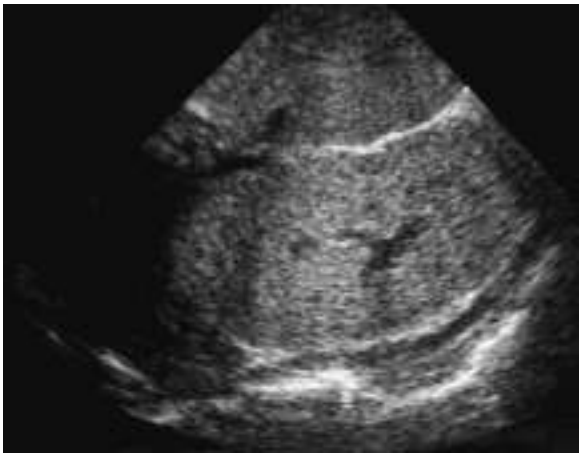

Fig. 563.2 Ultrasound examination of a neonate with autosomal recessive polycystic kidney disease demonstrating renal enlargement (9 cm) and increased diffuse echogenicity with complete loss of corticomedullary differentiation resulting from multiple small cystic interfaces.

TREATMENT

The treatment of ARPKD is supportive. Aggressive ventilatory support is often necessary in the neonatal period secondary to pulmonary hypoplasia, hypoventilation, and the respiratory illnesses of prematurity. Careful management of hypertension (angiotensin-converting enzyme inhibitors, and other antihypertensive medications as needed), fluid and electrolyte abnormalities, osteopenia, and clinical manifestations of kidney insufficiency are essential. Children with severe respiratory failure or feeding intolerance from enlarged kidneys can require unilateral or, more commonly, bilateral nephrectomies, prompting the need for renal replacement therapy. For many children approaching ESKD therapy, significant portal hypertension is present. This in combination with the dramatic improvement in liver transplantation survival has led to consideration of dual kidney and liver transplantation in a carefully selected group of patients. Dual transplantation thus avoids the later development of end-stage liver disease despite successful kidney transplantation.

PROGNOSIS

Mortality rates have improved dramatically, although approximately 30% of patients die in the neonatal period from complications of pulmonary hypoplasia. Neonatal respiratory support and renal replacement therapies have increased the 10-year survival of children surviving beyond the first year of life to >80%. The 15-year survival rate is currently estimated at 70–80%. Consideration of dual kidney and liver transplantation and the development of disease-specific therapies for pediatric clinical trials will further positively impact the natural history of ARPKD. An important resource for families of patients is the ARPKD/CHF Alliance (www.arpkdchf.org).

Visit Elsevier eBooks+ at eBooks.Health.Elsevier.com for Bibliography.

563.3 Autosomal Dominant Polycystic Kidney Disease

Prasad Devarajan

Autosomal dominant polycystic kidney disease (ADPKD), also known as adult-onset polycystic kidney disease, is the most common hereditary human kidney disease, with an incidence of 1/400 to 1/1,000. It is a systemic disorder with possible cyst formation in multiple organs (liver, pancreas, spleen, brain) and the possible development of saccular cerebral aneurysms.

PATHOLOGY

Both kidneys are enlarged and show large cortical and medullary cysts originating from all regions of the nephron.

PATHOGENESIS

Approximately 85% of patients with ADPKD have pathogenic variants that map to the *PKD1* gene on the short arm of chromosome 16, which encodes polycystin, a transmembrane glycoprotein. Another 10–15% of ADPKD pathogenic variants map to the *PKD2* gene on the long arm of chromosome 4, which encodes polycystin 2, a proposed nonselective cation channel. The majority of pathogenic variants appear to be unique to a given family. At present, a pathogenic variant can be found in 85% of patients with well-characterized disease.

Approximately 8–10% of patients will have de novo, disease-causing pathogenic variants. Pathogenic variants of *PKD1* are associated with more severe renal disease than pathogenic variants of *PKD2*. The pathophysiology of the disease appears to be related to the disruption of normal multimeric cystoprotein complexes, with consequent abnormal intracellular signaling resulting in abnormal proliferation, tubular secretion, and cyst formation. Abnormal growth factor expression, coupled with low intracellular calcium and elevated cyclic adenosine monophosphate, appear to be important features leading to formation of cysts and progressive enlargement. Pathogenic variants in *GANAB* have been reported in *PKD1*- and *PKD2*-negative patients.

CLINICAL PRESENTATION

The severity of renal disease and the clinical manifestations of ADPKD are highly variable. Symptomatic ADPKD most commonly occurs in the fourth or fifth decade of life. However, symptoms, including gross

Table 563.1 Differential Diagnosis in ARPKD and ADPKD Genotypes

	ASSOCIATED DISEASE	RENAL PHENOTYPE	EXTRARENAL PHENOTYPE
CLASSIC ARPKD			
	PKHD1, possibly *DZIP1L*	Bilateral nephromegaly, heterogenous parenchymal echogenicity with salt and pepper pattern Prenatal onset: bilateral nephromegaly, oligohydramnios, Potter-like syndrome	Progressive hepatic fibrosis, Caroli syndrome, portal hypertension
CLASSIC ADPKD			
PKD1	ADPKD-*PKD1* with truncating variant	Innumerable bilateral kidney cysts causing progressive kidney enlargement and reduction in eGFR; median age at ESKD about 55 years	Polycystic liver disease, mild to severe, SAH-CNS aneurysms*
PKD1	ADPKD-*PKD1* with nontruncating variant	Innumerable bilateral kidney cysts causing progressive kidney enlargement and reduction in eGFR; median age at ESKD about 67 years	Polycystic liver disease, mild to severe, SAH-CNS aneurysms*
PKD2	ADPKD-*PKD2*	Innumerable bilateral kidney cysts causing progressive kidney enlargement and reduction in eGFR; median age at ESKD about 79 years	Polycystic liver disease, mild to severe, SAH-CNS aneurysms*
ADPKD-LIKE PHENOTYPE			
GANAB	ADPKD-*GANAB*	Bilateral renal cysts, preserved kidney function	Polycystic liver disease, mild to severe
DNAJB11	ADPKD-*DNAJB11*	Normal or small-sized kidneys with multiple small renal cysts; possible evolution to ESKD after 60 years	Polycystic liver disease, absent to moderate
ADTKD-ASSOCIATED GENES			
HNF1B	ADTKD-*HNF1B*	Bilateral renal cysts in about 45% of affected individuals, occasionally mimics ADPKD imaging presentation; evolution to ESKD is highly variable, from childhood-onset ESKD to preserved kidney function throughout life	Diabetes, gout, hyperuricemia, hypomagnesaemia, elevated liver enzymes, bicornate uterus, solitary kidney
MUC1	ADTKD-*MUC1*	Normal or small-sized kidneys, few small renal cysts in half of patients; evolution to ESKD highly variable, age 20-70 years	Gout
SEC61A1	ADTKD-*SEC61A1*	Normal or small-sized kidneys, bilateral small renal cysts in about 50% of individuals	Congenital anemia, intrauterine growth retardation, neutropenia
UMOD	ADTKD-*UMOD*	Normal or small-sized kidneys, few small renal cysts in a third of patients, unilateral or bilateral; evolution to ESKD highly variable, age 20-70 years	Gout
ADPLD-ASSOCIATED GENES			
PRKCSH	ADPLD	Few renal cysts occasionally reported	Polycystic liver disease, mild to severe
SEC63	ADPLD	Few renal cysts occasionally reported	Polycystic liver disease, mild to severe
ALG8	ADPLD	Few renal cysts occasionally reported	Polycystic liver disease, mild to moderate
SEC61B	ADPLD	No renal cysts observed to date in the two families reported with a pathogenic variant in this gene	Polycystic liver disease, mild to moderate
LRP5	ADPLD	Few renal cysts occasionally reported	Polycystic liver disease, mild to moderate
RECESSIVE INHERITANCE			
PKHD1	ARPKD	Antenatally enlarged hyperechogenic kidneys; multiple bilateral millimeter-sized cysts; ESKD in the first decade of life in about 50% of individuals but milder renal presentation with diagnosis in adulthood possible	Congenital hepatic fibrosis, Caroli syndrome, small liver cysts in heterozygous patients
DZIP1L	ARPKD	Antenatal enlarged hyperechogenic kidneys; multiple bilateral millimeter-sized cysts; progression to ESKD variable (second and third decade of life)	No obvious extrarenal manifestations reported in the seven patients identified to date

Continued

Table 563.1 Differential Diagnosis in ARPKD and ADPKD Genotypes—cont'd

	ASSOCIATED DISEASE	RENAL PHENOTYPE	EXTRARENAL PHENOTYPE
PMM2	Hyperinsulinemic hypoglycemia with PKD	Antenatal enlarged hyperechogenic kidneys, enlarged kidneys with multiple cysts; progression to ESKD variable, from infancy to early adulthood	Hyperinsulinemic hypoglycemia; small liver cysts in some patients
SYNDROMIC FORMS OF PKD			
TSC1 or *TSC2*	Tuberous sclerosis	Multiple and bilateral angiomyolipomas and renal cysts; kidney function usually preserved; possible evolution to ESKD, either by destruction of the renal parenchyma by multiple angiomyolipomas or following nephrectomies for hemorrhagic angiomyolipomas; if there is contiguous gene deletion of *TSC2* and *PKD1*, severe PKD with evolution to ESKD occurs before age 30 years	CNS (cortical tubers, astrocytomas, epilepsy, and intellectual disabilities); skin lesions (facial angiofibromas and hypopigmented spots); pulmonary lymphangioleiomyomatosis; cardiac rhabdomyoma and retinal hamartoma; polycystic liver disease if contiguous deletion of both *PKD1* and *TSC2*
VHL	Von Hippel-Lindau disease	Bilateral renal cysts, renal cell carcinoma	Hemangioblastomas of the retina, spine, or brain; pheochromocytoma; neuroendocrine tumor of the pancreas
COL4A1	HANAC syndrome or *COL4A1*-related disease	Bilateral renal cysts occasionally reported; patients can develop renal insufficiency after about age 50-60 years	Microscopic hematuria, aneurysms, muscle cramps, elevated creatine phosphokinase, tortuosity of the retinal arteries
OFD1	Oro-facial-digital syndrome type 1	X-linked, embryonically lethal in males, PKD in females	Cleft palate, facial dysmorphy; syndactyly, clinodactyly, or polydactyly; intellectual disabilities; polycystic liver disease

*Intracranial aneurysms in 9–12% of patients with ADPKD.
ADPKD, Autosomal dominant PKD; ADPLD, autosomal dominant polycystic liver disease; ADTKD, autosomal dominant tubulointerstitial kidney disease; ARPKD, autosomal recessive polycystic kidney disease; CNS, central nervous system; eGFR, estimate glomerular filtration rate; ESKD, end-stage kidney disease; HANAC, hereditary angiopathy with nephropathy, aneurysms, and muscle cramps; PKD, polycystic kidney disease; SAH, subarachnoid hemorrhage.
From Cornec-Le Gall E, Alam A, Perrone RD. Autosomal dominant polycystic kidney disease. *Lancet*. 2019;393:919–932. Table 1.

Table 563.2 Autosomal Recessive Polycystic Kidney Disease and Hepatorenal Fibrocystic Disease Phenocopies

DISEASE	GENE(S)	RENAL DISEASE	HEPATIC DISEASE	SYSTEMIC FEATURES
ARPKD	*PKHD1*	Collecting duct dilation	CHF; Caroli disease	No
ADPKD	*PKD1; PKD2*	Cysts along entire nephron	Biliary cysts; CHF (rare)	Yes: adults
NPHP	*NPHP1-NPHP16*	Cysts at the corticomedullary junction	CHF	+/–
Joubert syndrome and related disorders	*JBTS1-JBTS20*	Cystic dysplasia; NPHP	CHF; Caroli disease	Yes
Bardet-Biedl syndrome	*BBS1-BBS18*	Cystic dysplasia; NPHP	CHF	Yes
Meckel-Gruber syndrome	*MKS1-MKS10*	Cystic dysplasia	CHF	Yes
Oral-facial-digital syndrome, type I	*OFD1*	Glomerular cysts	CHF (rare)	Yes
Glomerulocystic disease	*PKD1; HNF1B; UMOD*	Enlarged; normal or hypoplastic kidneys	CHF (with PKD1 pathogenic variants)	+/–
Jeune syndrome (asphyxiating thoracic dystrophy)	*IFT80 (ATD2) DYNC2H1 (ADT3) ADT1, ADT4, ADT5*	Cystic dysplasia	CHF; Caroli disease	Yes
Renal-hepatic-pancreatic dysplasia (Ivemark II)	*NPHP3, NEK8*	Cystic dysplasia	Intrahepatic biliary dysgenesis	Yes
Zellweger syndrome	*PEX1-3;5-6;10-11;13;14;16;19;26*	Renal cortical microcysts	Intrahepatic biliary dysgenesis	Yes

ADPKD, Autosomal dominant PKD; ARPKD, autosomal recessive polycystic kidney disease; CHF, congenital hepatic fibrosis; NPHP, nephronophthisis.
Modified from Guay-Woodford LM, Bissler JJ, Braun MC, et al. Consensus expert recommendations for the diagnosis and management of autosomal recessive polycystic kidney disease: report of an international conference. *J Pediatr*. 2014;165:611–617.

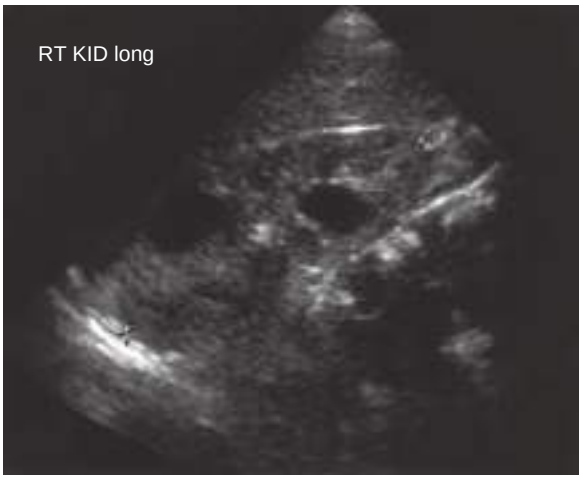

Fig. 563.3 Ultrasound examination of an 18-mo-old male with autosomal dominant polycystic kidney disease demonstrating renal enlargement (10 cm) and two large cysts.

or microscopic hematuria, bilateral flank pain, abdominal masses, hypertension, and urinary tract infection, may be seen in neonates, children, and adolescents. With the increased utilization of abdominal sonography in the pediatric population, as well as ADPKD families requesting possible screening in their asymptomatic, at-risk offspring, most children with ADPKD are diagnosed by abnormal renal sonography in the absence of symptoms. Renal ultrasonography usually demonstrates multiple bilateral macrocysts in enlarged kidneys (Fig. 563.3), although normal kidney size and unilateral disease may be seen in the early phase of the disease in children.

ADPKD is a multiorgan disorder affecting many tissue types. Cysts may be asymptomatic but present within the liver, pancreas, spleen, and ovaries and, when present, help confirm the diagnosis in childhood. **Intracranial aneurysms,** which appear to segregate within certain families, have an overall prevalence of 15% and are an important cause of mortality in adults but only occasionally occur in children. Mitral valve prolapse is seen in approximately 12% of children; aortic and coronary artery aneurysms and aortic valve insufficiency are noted in affected adults. Hernias, bronchiectasis, and intestinal diverticula can also occur in these children.

DIAGNOSIS

ADPKD is confirmed by the presence of enlarged kidneys with bilateral macrocysts in a patient with an affected first-degree relative. De novo pathogenic variants occur in 8–10% of patients with newly diagnosed disease. The diagnosis might be made in children before their affected parent, making parental renal sonography an important diagnostic test to be performed in families with no apparent family history. Among patients with genetically defined ADPKD, screening renal ultrasonography results may be normal in ≤20% by 20 years of age and <5% by 30 years of age.

Prenatal diagnosis is suggested from the presence of enlarged kidneys with or without cysts on ultrasonography in families with known ADPKD. Prenatal DNA testing is available in families with affected members whose disease is caused by identified pathogenic variants in the *PKD1* or *PKD2* genes.

The differential diagnosis includes renal cysts associated with glomerulocystic kidney disease, tuberous sclerosis, and von Hippel-Lindau disease, which may be inherited in an autosomal dominant pattern (see Table 563.1). The neonatal manifestations of ADPKD and ARPKD may rarely be indistinguishable.

TREATMENT AND PROGNOSIS

Treatment of ADPKD is primarily supportive. Control of blood pressure is critical because the rate of disease progression in ADPKD correlates with the presence of hypertension. Angiotensin-converting enzyme inhibitors and/or angiotensin II receptor antagonists are agents of choice. Obesity, dietary salt and protein excess, caffeine ingestion, smoking, multiple pregnancies, and male gender appear to accelerate the disease progression. Older patients with a family history of intracranial aneurysm rupture should be screened for cerebral aneurysms. Although the approach remains controversial, most nephrologists now recommend initial screening for cerebral aneurysms with an MR angiogram around 18 years of age in asymptomatic patients with a family history of ADPKD and associated aneurysms.

Although neonatal ADPKD may be fatal, long-term survival of the patient and the kidneys is possible for children surviving the neonatal period. ADPKD that occurs initially in older children has a favorable prognosis, with normal kidney function during childhood seen in >80% of children. Pain may be a manifestation of infection, hemorrhage, cyst rupture, stones, or tumors and should be managed appropriately with pain medications and specifically based on its etiology.

Although disease-specific therapy is not yet available, clinical trials are in progress based on promising preclinical laboratory investigations. These potential therapies include renin-angiotensin blockade, vasopressin V_2 receptor antagonism (tolvaptan), statins (to reduce pain), and somatostatin analogues. Tolvaptan has been effective in adults in slowing the progression of renal impairment. A valuable resource for patients and their families is the Polycystic Kidney Disease Foundation (www.pkdcure.org).

Visit Elsevier eBooks+ at eBooks.Health.Elsevier.com for Bibliography.

563.4 Trauma

Prasad Devarajan

Infants and children are more susceptible to kidney injury following blunt or penetrating injury to the back or abdomen because of their decreased muscle mass "protecting" the kidney. Gross or microscopic hematuria, flank pain, and abdominal rigidity can occur; associated injuries may be present (see Chapter 80). In the absence of hemodynamic instability, most kidney trauma can be managed nonoperatively. Urethral trauma can result from crush injury, often associated with a fractured pelvis or from direct injury. Such injury is suspected in the appropriate clinical setting when gross blood appears at the external urethral meatus. Rhabdomyolysis and consequent acute kidney injury is another complication of crush injury that can be ameliorated by vigorous fluid resuscitation. There may be a relationship between microscopic hematuria and recreational accidents in individuals >16 years of age, none of whom exhibited hypotension or required surgical intervention.

Visit Elsevier eBooks+ at eBooks.Health.Elsevier.com for Bibliography.

563.5 Renal Tumors

See Chapters 547 and 548.

Chapter 564

Lower Urinary Tract Causes of Hematuria

564.1 Infectious Causes of Cystitis and Urethritis

Prasad Devarajan

Gross or microscopic hematuria may be associated with bacterial, mycobacterial, or viral infections of the bladder (see Chapter 575).

564.2 Hemorrhagic Cystitis

Prasad Devarajan

Hemorrhagic cystitis is defined as the presence of sustained hematuria and lower urinary tract symptoms (e.g., dysuria, frequency, urgency) in the absence of other bleeding conditions such as vaginal bleeding, a generalized bleeding condition, or a bacterial urinary tract infection. Depending on the severity, patients can present with microscopic or gross hematuria, often with clots. In severe forms, bleeding can lead to a significant decrease in blood hemoglobin levels and symptoms of lower urinary tract obstruction.

Hemorrhagic cystitis can occur in response to chemical toxins (cyclophosphamide, penicillins, busulfan, thiotepa, dyes, insecticides), viruses (adenovirus types 11 and 21 [see Chapter 309] and influenza A [see Chapter 305]), radiation, and amyloidosis. The polyoma **BK virus** (see Chapter 321), present latently in immunocompetent hosts, is associated with the development of drug-induced cystitis in immunosuppressed patients. The pediatric bone marrow transplantation population is particularly susceptible to hemorrhagic cystitis.

For chemical irritation related to the use of cyclophosphamide, hydration, bladder washes, and the use of mesna disulfide, which inactivates urinary cyclophosphamide metabolites, helps to protect the bladder. Administration of oral cyclophosphamide in the morning followed by aggressive oral hydration throughout the remainder of the day is very effective in minimizing the risk of hemorrhagic cystitis. Treatment of hemorrhagic cystitis consists of a combination of intensive intravenous hydration, forced diuresis, analgesia, and spasmolytic drugs. Consultation with a urologist is recommended for more invasive measures if the cystitis does not respond to conservative measures. Gross hematuria associated with viral hemorrhagic cystitis usually resolves within 1 week.

Visit Elsevier eBooks+ at eBooks.Health.Elsevier.com for Bibliography.

564.3 Vigorous Exercise

Prasad Devarajan

Gross or microscopic hematuria can follow vigorous exercise. **Exercise-induced hematuria** is less common in females and can be associated with dysuria. Approximately 30–60% of runners completing marathons have dipstick-positive urine for blood. In limited follow-up, none appeared to have any significant kidney or urinary tract abnormalities. The color of the urine following vigorous exercise can vary from red to black. Blood clots may be rarely present in the urine. Findings on urine culture, intravenous pyelography, voiding cystourethrography, and cystoscopy are normal in most patients. This seems to be a benign condition, and the hematuria generally resolves within 48 hours after cessation of exercise. The absence of red blood cell casts or evidence of renal disease and the presence of dysuria and blood clots in some patients suggest that the source of bleeding lies in the lower urinary tract. **Rhabdomyolysis** with **myoglobinuria** or hemoglobinuria must be considered in the differential diagnosis when the condition is associated with symptoms in the appropriate clinical context. Hydronephrosis or other anatomic abnormalities must be considered in any child who presents with hematuria (particularly gross hematuria) after mild exercise or following mild trauma. Appropriate imaging studies are indicated in this setting.

Visit Elsevier eBooks+ at eBooks.Health.Elsevier.com for Bibliography.

Section 3

Conditions Particularly Associated With Proteinuria

Chapter 565

Clinical Evaluation of the Child with Proteinuria

Francisco X. Flores

NORMAL PHYSIOLOGY

The charge and size selective properties of the glomerular capillary wall prevent significant amounts of albumin, globulin, and other large plasma proteins from entering the urinary space (see Chapter 557). Smaller proteins (low molecular weight proteins) do cross the capillary wall but are reabsorbed by the proximal tubule. A very small amount of protein that normally appears in the urine is the result of normal tubular secretion. The normally excreted protein mostly consists of **Tamm-Horsfall protein (uromodulin)**, a protective glycoprotein secreted by the tubules that inactivates cytokines.

PATHOPHYSIOLOGY OF PROTEINURIA

Abnormal amounts of protein may appear in the urine from three possible mechanisms: *glomerular proteinuria,* which occurs as a result of disruption of the glomerular capillary wall; *tubular proteinuria,* a tubular injury or dysfunction that leads to ineffective reabsorption of mostly low molecular weight proteins; and *increased production of plasma proteins* (in multiple myeloma, rhabdomyolysis, or hemolysis), which may cause the production or release of very large amounts of protein that are filtered at the glomerulus and overwhelm the absorptive capacity of the proximal tubule.

MEASUREMENT OF URINE PROTEIN

Urine protein can be measured in random collected samples or in timed (e.g., 24-hour or overnight) samples. Tests to accurately quantify the urine protein concentration rely on precipitation with sulfosalicylic acid and measurement of turbidity (Table 565.1).

Table 565.1 Quantification of Proteinuria in Children

METHOD	INDICATIONS	NORMAL RANGE	COMMENTS
Dipstick testing	Routine screening for proteinuria performed in the office	Negative or trace in a concentrated urine specimen (specific gravity: ≥1.020) Test interpretation: 1+ ~30 mg/dL 2+ ~100 mg/dL 3+ ~300 mg/dL	False-positive test can occur if urine is very alkaline (pH >8.0) or very concentrated (specific gravity: >1.025), or when there is pus, vaginal secretions, or semen present
24-hr urine for protein and creatinine*excretion	Quantitation of proteinuria (as well as creatinine clearances)	<150 mg/m²/24 hr	More accurate than spot urine analysis; inconvenient for patient; the creatinine content should be measured to determine whether the specimen is truly a 24-hr collection. The amount of creatinine in a 24-hr specimen can be estimated as follows: females, 15-20 mg/kg; males, 20-25 mg/kg
Spot urine for protein/creatinine ratio, preferably on first morning urine specimen	Semiquantitative assessment of proteinuria	<0.2 mg protein/mg creatinine in children older than 2 yr old <0.5 mg protein/mg creatinine in those 6-24 mo old	Simplest method to quantitate proteinuria; less accurate than measuring 24-hr proteinuria
Microalbuminuria	Assess risk of progressive glomerulopathy in patients with diabetes mellitus	<30 mg urine albumin per gram of creatinine on first morning urine	Therapy should be intensified in diabetics with microalbuminuria

*Note that in a 24-hr urine specimen, the creatinine content should be measured to determine whether the specimen is truly a 24-hr collection. The amount of creatinine in a 24-hr specimen can be estimated as follows: females, 15-20 mg/kg and males, 20-25 mg/kg.

Adapted from Hogg RJ, Portman RJ, Milliner D, et al. Evaluation and management of proteinuria and nephrotic syndrome in children: recommendations from a Pediatric Nephrology Panel Established at the National Kidney Foundation Conference on Proteinuria, Albuminuria, Risk Assessment, Detection, and Elimination (PARADE). *Pediatrics*. 2000;105(6):1242–1249.

Urine Dipstick Measurement of Protein

The total protein concentration in urine can be estimated with chemically impregnated plastic strips that contain a pH-sensitive colorimetric indicator that changes color when negatively charged proteins, such as albumin, bind to it. Dipsticks primarily detect albuminuria and are less sensitive for other forms of proteins (low molecular weight proteins, Bence-Jones protein, gamma globulins). Visual changes in the color of the dipstick are a semiquantitative measure of urinary protein concentration. The dipstick is reported as negative, trace (10-29 mg/dL), 1+ (30-100 mg/dL), 2+ (100-300 mg/dL), 3+ (300-1,000 mg/dL), and 4+ (>1,000 mg/dL). False-positive results can occur with a very high urine pH (>7.0), a highly concentrated urine specimen, contamination of the urine with blood, and the presence of pyuria or prolonged dipstick immersion. False-negative test results can occur in patients with a low urine pH (<4.5), dilute urine or a large volume of urine output, or in disease states in which the predominant urinary protein is not albumin.

Positive urine dipstick test for protein is considered to be present if there is more than a trace (10-29 mg/dL) in a urine sample in which the specific gravity is <1.010. If the specific gravity is >1.015, the dipstick must read ≥1+ (>30 mg/dL) to be considered clinically significant.

Because the dipstick reaction offers only a qualitative measurement of urinary protein excretion, children with persistent proteinuria should have proteinuria quantitated more precisely. **Timed (24-hour) urine collections** offer more precise information regarding urine protein excretion than a randomly performed dipstick test. Urinary protein excretion in the normal child is <100 mg/m²/day or a total of 150 mg/day. In neonates, normal urinary protein excretion is higher, up to 300 mg/m², because of reduced reabsorption of filtered proteins. A reasonable upper limit of normal protein excretion in healthy children is 150 mg/24 hr. More specifically, normal protein excretion in children is defined as ≤4 mg/m²/hr, abnormal proteinuria is defined as excretion of 4-40 mg/m²/hr, and nephrotic-range proteinuria is defined as > 40 mg/m²/hr.

Timed urine collections are cumbersome to obtain, and the sensitivity and specificity of the test can be influenced by fluid intake, the volume of urine output, and the importance of including a complete collection without missed voids.

Urine Protein-to-Creatinine Ratio Measurement

Urine protein-to-creatinine ratio measurement of an untimed (spot) urine specimen has largely replaced timed urine collection. In children, urine protein-to-creatinine ratios have been shown to be significantly correlated with measurements of 24-hour urine protein and are useful to screen for proteinuria and to longitudinally monitor urine protein levels.

This ratio is calculated by dividing the urine protein concentration (mg/dL) by the urine creatinine concentration (mg/dL) to provide a simple measure. It should be ideally performed on a first morning voided urine specimen to eliminate the possibility of orthostatic (postural) proteinuria (see Chapter 566.2). A ratio of <0.5 in children <2 years of age and <0.2 in children >2 years of age suggests normal urinary protein excretion. A ratio >2 suggests nephrotic-range proteinuria.

CLINICAL CONSIDERATIONS

The finding of proteinuria in children and adolescents in a single, non–first morning urine specimen is common, varying between 5% and 15%. The prevalence of persistent proteinuria on repeated testing is much less common. The challenge is to differentiate the child with proteinuria related to renal disease from the otherwise healthy child with transient or other benign forms of proteinuria. When proteinuria is detected, it is important to determine whether it is transient, orthostatic, or fixed in nature.

Microalbuminuria is defined as the presence of albumin in the urine above the normal level but below the detectable range of conventional urine dipstick methods. In adults, persistent microalbuminuria (defined as a urinary albumin excretion of 30-300 mg/g creatinine on at least two to three samples) is accepted as evidence of diabetic nephropathy and also a predictor of cardiovascular and renal disease. The mean level of urinary albumin excretion falls between 8 and 10 mg/g of creatinine in children >6 years of age. Similar to adults, microalbuminuria in children has been found to be associated with obesity and to predict, with reasonable specificity, the development of diabetic nephropathy in type 1 diabetes mellitus.

Visit Elsevier eBooks+ at eBooks.Health.Elsevier.com for Bibliography.

Chapter 566 Conditions Associated with Proteinuria

566.1 Transient Proteinuria

Francisco X. Flores

The majority of children found to have positive tests for protein on urinary dipsticks will have negative evaluations on repeated dipsticks and normal urinary protein if formally quantitated. Approximately 10% of children who undergo random urinalysis have proteinuria by a single dipstick measurement. Across the school-age spectrum, this finding occurs more commonly in adolescents than in younger children. In most cases, serial testing of the patient's urine demonstrates resolution of the abnormality. This phenomenon defines **transient proteinuria,** and its cause remains elusive. Defined contributing factors include a temperature >38.3°C (101°F), exercise, dehydration, cold exposure, heart failure, recent use of epinephrine, seizures, or stress. Transient proteinuria usually does not exceed 1-2+ on the dipstick. No evaluation or therapy is needed for children with this benign condition, and it resolves spontaneously or as the cause resolves. Persistence of proteinuria, even if low grade, is not consistent with the diagnosis and suggests the need for additional evaluation (Fig. 566.1).

Visit Elsevier eBooks+ at eBooks.Health.Elsevier.com for Bibliography.

566.2 Orthostatic (Postural) Proteinuria

Francisco X. Flores

Orthostatic proteinuria is the most common cause of *persistent* proteinuria in school-age children and adolescents, occurring in up to 60% of children with persistent proteinuria. Children with this condition are usually asymptomatic, and the condition is discovered by routine urinalysis. Patients with orthostatic proteinuria excrete normal or minimally increased amounts of protein in the supine position. In the upright position, urinary protein excretion may be increased 10-fold, up to 1,000 mg/24 hr (1 g/24 hr). *Hematuria, hypertension, hypoalbuminemia, edema, and renal dysfunction are absent.*

In a child with persistent asymptomatic proteinuria, the initial evaluation should include an assessment for orthostatic proteinuria. It begins with the collection of a first morning urine sample, with subsequent testing of any urinary abnormalities by a complete urinalysis and determination of a spot urine protein-to-creatinine ratio (see Fig. 566.1). The correct collection of the first morning urine sample is critical. The child must fully empty the bladder before going to bed and then collect the first voided urine sample immediately upon arising in the morning. The absence of proteinuria (dipstick negative or trace for protein; and a normal ratio of urinary protein [uPr; mg/dL] to urinary creatinine [uCr; mg/dL] = [uPr/uCr] <0.2) on the first morning urine sample for 3 consecutive days confirms the diagnosis of orthostatic proteinuria. No further evaluation is necessary, and the patient and family should be reassured of the benign nature of this condition. However, if there are other abnormalities of the urinalysis (e.g., hematuria), or if the urine uPr:uCr ratio is >0.2, the patient should be referred to a pediatric nephrologist for a complete evaluation.

The cause of orthostatic proteinuria is unknown, although altered renal hemodynamics and partial left renal vein obstruction in the upright, lordotic position have been proposed as possible causes. An increased body mass index is recognized as a strong correlate of orthostatic proteinuria. Long-term follow-up studies in young adults suggest that orthostatic proteinuria is a benign process, but similar data are not available for children. Therefore long-term follow-up of children is prudent. Patients should be monitored for the development of nonorthostatic proteinuria, particularly in the presence of hematuria, hypertension, or edema. Such findings may herald underlying kidney disease.

Visit Elsevier eBooks+ at eBooks.Health.Elsevier.com for Bibliography.

566.3 Fixed Proteinuria

Francisco X. Flores

Children found to have fixed proteinuria on a first morning urine sample on three separate occasions should be further investigated. Fixed proteinuria is defined as a first morning urine sample that is ≥1+ on dipstick testing with a urine specific gravity >1.015 or with a urine protein-to-creatinine ratio of ≥0.2. Fixed proteinuria indicates a potential kidney disease caused by either glomerular or tubular disorders.

GLOMERULAR PROTEINURIA

The glomerular capillary wall consists of three layers: the fenestrated capillary endothelium, the glomerular basement membrane, and the podocytes (with foot processes and intercalated slit diaphragms) (Fig. 566.2). Glomerular proteinuria results from alterations in the permeability of any of the layers of the glomerular capillary wall to normally filtered proteins and occurs in a variety of renal diseases (Table 566.1). Glomerular proteinuria can range widely from <1 g to >30 g of protein in a 24-hour period. The podocyte is the predominant cell of injury in most glomerular diseases characterized by heavy proteinuria.

Glomerular proteinuria should be suspected in any patient with a first morning urine protein-to-creatinine ratio >1.0, or significant proteinuria of any degree, accompanied by hypertension, hematuria with active urine sediment, edema, or renal dysfunction. Disorders characterized primarily by proteinuria include idiopathic (minimal change disease) nephrotic syndrome, secondary causes of nephrotic syndrome, focal segmental glomerulosclerosis, mesangial proliferative glomerulonephritis, membranous nephropathy, membranoproliferative glomerulonephritis, diabetic nephropathy, and obesity-related glomerulopathy. Other renal disorders that can include proteinuria as a prominent feature include acute postinfectious glomerulonephritis, immunoglobulin A nephropathy, systemic lupus erythematosus nephritis, IgA vasculitis (formerly Henoch-Schönlein purpura) nephritis, and Alport syndrome.

The initial evaluation of a child with fixed proteinuria should include the measurement of serum creatinine and an electrolyte panel, first morning urine protein-to-creatinine ratio, serum albumin level, complement levels, and antinuclear antibodies (ANA). The child should be referred to a pediatric nephrologist for further evaluation and management. Renal biopsy is often necessary to establish a diagnosis and guide therapy.

In asymptomatic patients with low-grade proteinuria (urine protein-to-creatinine ratio between 0.2 and 1.0) in whom all other findings are normal, renal biopsy might not be indicated, because the underlying process may be transient or resolving or because specific pathologic

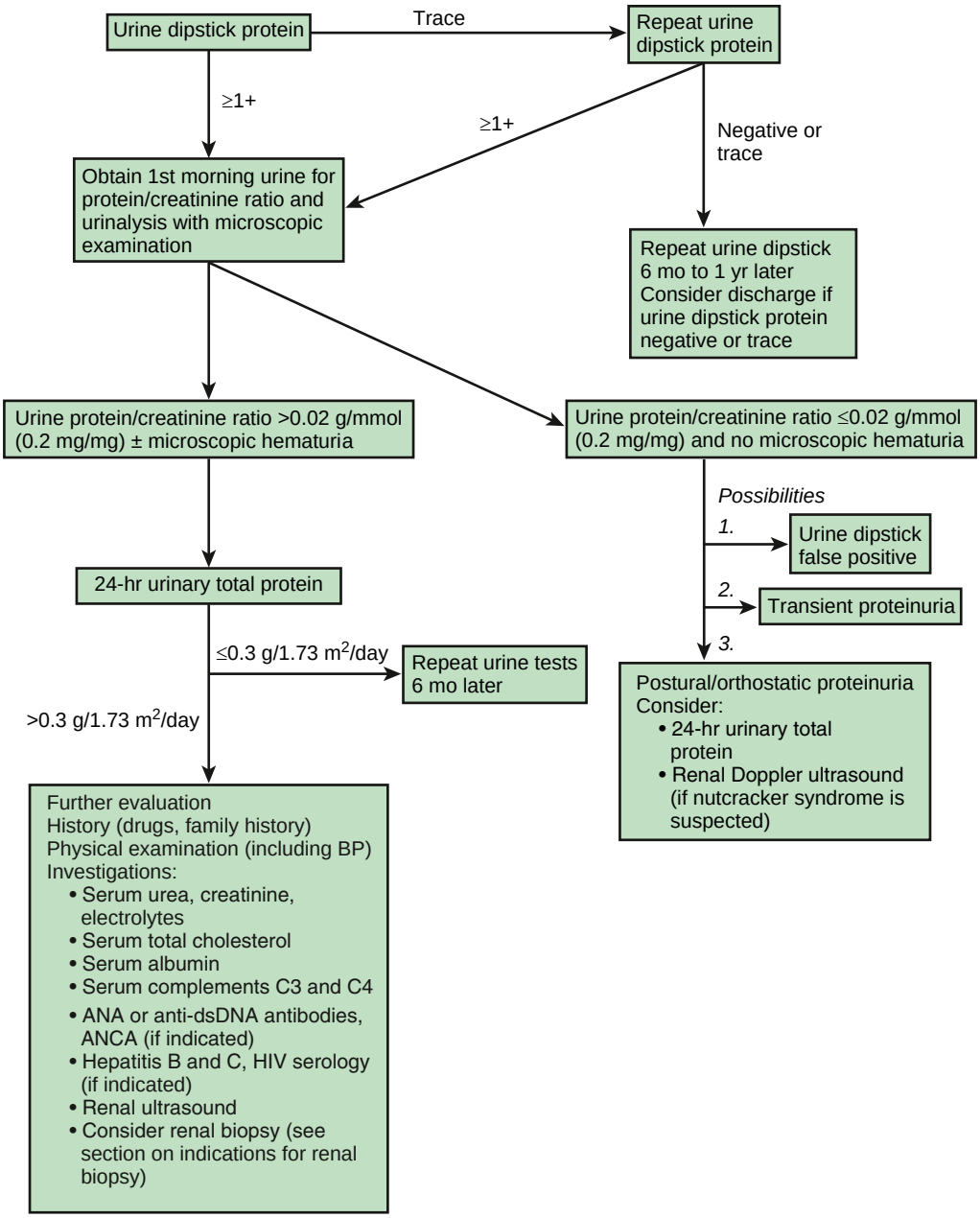

Fig 566.1 Algorithm for investigating proteinuria. ANA, Antinuclear antibody; ANCA, antinuclear cytoplasmic antibody; anti-dsDNA, anti–double-stranded DNA; BP, blood pressure. *(From Yap HK, Lau PYW. Hematuria and proteinuria. In: Geary DF, Scharfer F, eds. Comprehensive Pediatric Nephrology. Philadelphia: Elsevier; 2008: p. 190.)*

features of a chronic kidney disease might not yet be apparent. Such patients should have periodic reevaluation (ideally every 4-6 months unless the patient is or becomes symptomatic). The evaluation should consist of a physical examination with accurate blood pressure measurement, urinalysis, measurement of serum creatinine, and a repeat first morning urine protein-to-creatinine ratio. Indications for renal biopsy include increasing proteinuria (urine protein-to-creatinine ratio >1.0) or the development of hematuria with active urine sediment, hypertension, or reduced renal function.

TUBULAR PROTEINURIA

A variety of renal disorders that primarily involve the tubulointerstitial compartment of the kidney can cause low-grade fixed proteinuria (urine protein-to-creatinine ratio 0.2:1.0). In the healthy state, large amounts of proteins of lower molecular weight than albumin are filtered by the glomerulus and reabsorbed in the proximal tubule. Injury to the proximal tubules can result in diminished reabsorptive capacity and the loss of these low molecular weight proteins in the urine.

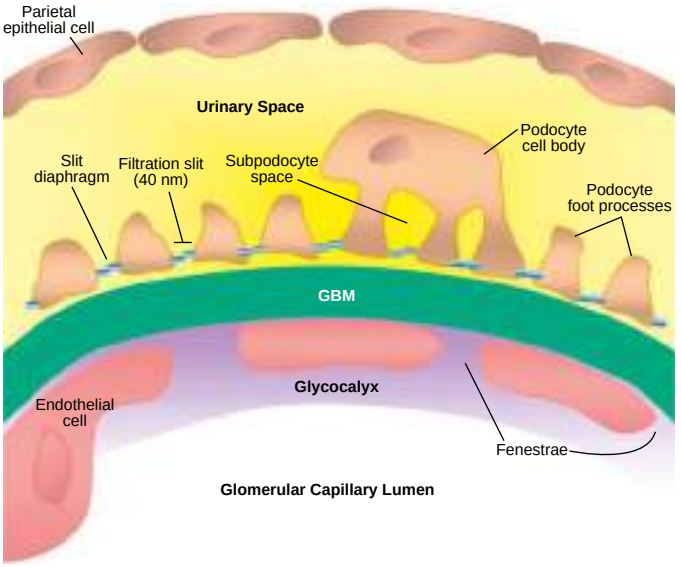

Fig. 566.2 Glomerular capillary wall. The three layers of the capillary wall (glomerular endothelial cell, glomerular basement membrane [GBM], and podocyte) act as the glomerular filtration barrier (GFB), preventing proteins and large molecules from passing from the capillary lumen into the urinary space. The podocyte cell body lies within the urinary space, and the cell is attached to the GBM through foot processes. Adjacent foot processes are separated by the filtration slit, bridged by the slit diaphragm. Disruption of the GFB leads the passage of protein across the capillary wall, leading to proteinuria. *(From Jefferson JA, Nelson PJ, Najafian B, et al. Podocyte disorders: core curriculum 2011. Am J Kidney Dis. 2011;58:666–677. Fig. 1.)*

Tubular proteinuria (see Table 566.1) may be seen in acquired and inherited disorders and may be associated with other defects of proximal tubular function, such as Fanconi syndrome (glycosuria, phosphaturia, bicarbonate wasting, and aminoaciduria). Tubular proteinuria is a consistent finding among patients with the X-linked tubular syndrome, Dent disease, caused by pathogenic variants of the renal chloride channel.

Asymptomatic patients having persistent proteinuria generally have glomerular rather than tubular proteinuria. In occult cases, glomerular and tubular proteinuria can be distinguished by protein electrophoresis of the urine. In tubular proteinuria, little or no albumin is detected, whereas in glomerular proteinuria, the major protein is albumin.

Visit Elsevier eBooks+ at eBooks.Health.Elsevier.com for Bibliography.

Table 566.1 Causes of Proteinuria

TRANSIENT PROTEINURIA
Fever
Exercise
Dehydration
Cold exposure
Congestive heart failure
Seizure
Stress
Recent use of epinephrine
ORTHOSTATIC (POSTURAL) PROTEINURIA
GLOMERULAR DISEASES CHARACTERIZED BY ISOLATED PROTEINURIA
Idiopathic (minimal change) nephrotic syndrome
Focal segmental glomerulosclerosis
Secondary causes of nephrotic syndrome (see Chapter 567)
Mesangial proliferative glomerulonephritis
Membranous nephropathy
Membranoproliferative glomerulonephritis
Amyloidosis
Diabetic nephropathy
Sickle cell nephropathy
GLOMERULAR DISEASES WITH PROTEINURIA AS A PROMINENT FEATURE
Acute postinfectious glomerulonephritis (streptococcal, endocarditis, hepatitis B or C virus, HIV)
Immunoglobulin A nephropathy
IgA vasculitis nephritis
Lupus nephritis
Serum sickness
Alport syndrome
Vasculitic disorders
Reflux nephropathy
TUBULAR DISEASES
Cystinosis
Fanconi syndrome
Wilson disease
Lowe syndrome
Dent disease (X-linked recessive nephrolithiasis)
Galactosemia
Tubulointerstitial nephritis
Acute tubular necrosis
Renal dysplasia
Polycystic kidney disease
Reflux nephropathy
Renal transplant rejection
Drugs (aminoglycosides, cisplatin, penicillamine, lithium, nonsteroidal antiinflammatory drugs, cyclosporine)
Heavy metals (lead, gold, mercury)

Chapter 567

Nephrotic Syndrome

Elif Erkan

Nephrotic syndrome is the clinical manifestation of glomerular diseases associated with heavy (nephrotic range) proteinuria. Nephrotic-range proteinuria is defined as proteinuria >3.5 g/24 hr or a urine protein:creatinine ratio >2. The triad of clinical findings associated with nephrotic syndrome arising from the large urinary losses of protein are hypoalbuminemia (≤2.5 g/dL), edema, and hyperlipidemia (cholesterol >200 mg/dL).

Nephrotic syndrome affects 1-3 per 100,000 children <16 years of age. Without treatment, nephrotic syndrome in children is associated with a high risk of death, most commonly from infections. Fortunately, 80% of children with nephrotic syndrome respond to corticosteroid therapy. Although glucocorticoid therapy is standard therapy for nephrotic syndrome, neither the target cell nor the mechanism of action of steroids has been determined. Early referral to a pediatric nephrologist is recommended for initial management

of nephrotic syndrome. However, continued care of these children is always a collaborative effort between the nephrologist and the primary care physician.

ETIOLOGY

Most children with nephrotic syndrome have a form of **primary** or idiopathic nephrotic syndrome (Table 567.1). Glomerular lesions associated with idiopathic nephrotic syndrome include minimal change disease (most common), focal segmental glomerulosclerosis (FSGS), membranoproliferative glomerulonephritis, C3 glomerulopathy, and membranous nephropathy (Table 567.2). These etiologies have different age distributions (Fig. 567.1). Nephrotic syndrome may also be **secondary** to systemic diseases such as systemic lupus erythematosus, IgA vasculitis (formerly Henoch-Schönlein purpura), malignancy (lymphoma and leukemia), and infections (hepatitis, HIV, and malaria) (see Table 567.1). A number of **hereditary** proteinuria syndromes are caused by pathogenic variants in genes that encode critical protein components of the glomerular filtration apparatus (Table 567.3).

PATHOGENESIS

Role of the Podocyte

The underlying abnormality in nephrotic syndrome is an increased permeability of the glomerular capillary wall, which leads to massive proteinuria and hypoalbuminemia. The podocyte plays a crucial role in the development of proteinuria and the progression of glomerulosclerosis (Fig. 567.2). The podocyte is a highly differentiated epithelial cell located on the outside of the glomerular capillary loop. Foot processes are extensions of the podocyte that terminate on the glomerular basement membrane. The foot processes of a podocyte interdigitate with those from adjacent podocytes and are connected by a slit called the slit diaphragm. The podocyte functions as structural support of the capillary loop, is a major component of the glomerular filtration barrier to proteins, and is involved in synthesis and repair of the glomerular basement membrane. The slit diaphragm is one of the major impediments to protein permeability across the glomerular capillary wall. Slit diaphragms are not simple passive filters; they consist of numerous proteins that contribute to complex signaling pathways and play an important role in podocyte function. Important component proteins of the slit diaphragm include nephrin, podocin, CD2AP, and α-actinin 4. Podocyte injury or pathogenic variants of genes producing podocyte proteins may cause nephrotic-range proteinuria (see Table 567.3). Genetic screening of 1,655 patients with steroid-resistant nephrotic syndrome and congenital nephrotic syndrome in the European PodoNet Registry Cohort has shown that pathogenic variants in *NPHS1, WT1,* and *NPHS2* were the most common. The proportion of patients with pathogenic variants of podocyte genes decreased by age; it was 66% in patients with congenital nephrotic syndrome and 15–16% in school-age patients and adolescents.

In idiopathic, hereditary, and secondary forms of nephrotic syndrome, there are immune and nonimmune insults to the podocyte that lead to foot process effacement of the podocyte, a decrease in number of functional podocytes, and altered slit diaphragm integrity. The end result is increased protein leakiness across the glomerular capillary wall into the urinary space.

Role of the Immune System

Minimal change nephrotic syndrome (MCNS) may occur after viral infections and allergen challenges. MCNS has also been found to occur in children with Hodgkin lymphoma and T-cell lymphoma. That immunosuppression occurs with drugs such as corticosteroids and cyclosporine and provides indirect additional evidence that the immune system contributes to the overall pathogenesis of the nephrotic syndrome.

Considering the recurrence rate of 30% after kidney transplantation, a permeability factor was implicated in pathophysiology of FSGS. Rat glomeruli exposed to patient sera with FSGS has demonstrated increased permeability to albumin. A subset of adult and pediatric patients was found to have circulating nephrin autoantibodies, suggesting the role of circulating antibodies in the pathogenesis of MCNS.

CLINICAL CONSEQUENCES OF NEPHROTIC SYNDROME

Edema

Edema is the most common presenting symptom of children with nephrotic syndrome. Despite its almost universal presence, there is uncertainty as to the exact mechanism of edema formation. There are two opposing theories, the *underfill hypothesis* and the *overfill hypothesis,* that have been proposed as mechanisms causing nephrotic edema.

The *underfill hypothesis* is based on nephrotic-range proteinuria that leads to a fall in the plasma protein level with a corresponding decrease in intravascular oncotic pressure. This leads to leakage of plasma water into the interstitium, generating edema. As a result of reduced intravascular volume, there is increased secretion of vasopressin and atrial natriuretic factor, which, along with aldosterone, results in increased sodium and water retention by the tubules. Sodium and water retention therefore occur as a consequence of intravascular volume depletion.

This hypothesis does not fit the clinical picture of some patients with edema caused by nephrotic syndrome who have clinical signs of intravascular volume overload, not volume depletion. Treating these patients with albumin alone may not be sufficient to induce a diuresis without the concomitant use of diuretics. Also, reducing the renin-aldosterone axis with mineralocorticoid receptor antagonists does not result in a marked increase in sodium excretion. With the onset of remission of MCNS, many children will have increased urine output before their urinary protein excretion is measurably reduced.

The *overfill hypothesis* postulates that nephrotic syndrome is associated with primary sodium retention, with subsequent volume expansion and leakage of excess fluid into the interstitium. There is accumulating evidence that the epithelial sodium channel in the distal tubule may play a key role in sodium reabsorption in nephrotic syndrome. The clinical weaknesses of this hypothesis are evidenced by the numerous nephrotic patients who present with an obvious clinical picture of intravascular volume depletion: low blood pressure, tachycardia, and elevated hemoconcentration. Furthermore, amiloride, an epithelial sodium channel blocker, used alone is not sufficient to induce adequate diuresis.

The goal of therapy should be a gradual reduction of edema with judicious use of diuretics, sodium restriction, and cautious use of IV albumin infusions, if indicated.

Hyperlipidemia

There are several alterations in the lipid profile in children with nephrotic syndrome, including an increase in cholesterol, triglycerides, low-density lipoproteins, and very low-density lipoproteins. The high-density lipoprotein level remains unchanged or is low. In adults, this results in an increase in the adverse cardiovascular risk ratio, although the implications for children are not as serious, especially those with steroid-responsive nephrotic syndrome. Hyperlipidemia is thought to be the result of increased synthesis as well as decreased catabolism of lipids. Although commonplace in adults, the use of lipid-lowering agents in children is uncommon.

Increased Susceptibility to Infections

Children with nephrotic syndrome are especially susceptible to infections such as cellulitis, spontaneous bacterial peritonitis, and

Table 567.1 Causes of Childhood Nephrotic Syndrome

IDIOPATHIC NEPHROTIC SYNDROME
Minimal change disease
Focal segmental glomerulosclerosis
Membranous nephropathy
Glomerulonephritis associated with nephrotic syndrome–membranoproliferative glomerulonephritis, crescentic glomerulonephritis, immunoglobulin A nephropathy

GENETIC DISORDERS ASSOCIATED WITH PROTEINURIA OR NEPHROTIC SYNDROME (SEE ALSO TABLE 567.3)

Nephrotic Syndrome (Typical)
Finnish-type congenital nephrotic syndrome (absence of nephrin)
Focal segmental glomerulosclerosis (pathogenic variants in nephrin, podocin, *MYO1E*, α-actinin 4, TRPC6)
Diffuse mesangial sclerosis (pathogenic variants in laminin β_2 chain)
Denys-Drash syndrome (pathogenic variants in WT1 transcription factor)
Congenital nephrotic syndrome with lung and skin involvement (integrin α-3 pathogenic variant)
Mitochondrial disorders

Proteinuria With or Without Nephrotic Syndrome
Nail–patella syndrome (pathogenic variant in LMX1B transcription factor)
Alport syndrome (pathogenic variant in collagen biosynthesis genes)

Multisystem Syndromes With or Without Nephrotic Syndrome
Galloway-Mowat syndrome
Charcot-Marie-Tooth disease
Jeune syndrome
Cockayne syndrome
Laurence-Moon-Biedl-Bardet syndrome

Metabolic Disorders With or Without Nephrotic Syndrome
Alagille syndrome
α_1-Antitrypsin deficiency
Fabry disease
Glutaric acidemia
Glycogen storage disease
Hurler syndrome
Partial lipodystrophy
Mitochondrial cytopathies
Sickle cell disease

SECONDARY CAUSES OF NEPHROTIC SYNDROME

Infections
Endocarditis
Post-streptococcal
Hepatitides B, C
HIV-1
Infectious mononucleosis
Cytomegalovirus
Malaria
Syphilis (congenital and secondary)
Toxoplasmosis
Tuberculosis
Schistosomiasis
Filariasis

Drugs
Captopril
Penicillamine
Gold
Nonsteroidal antiinflammatory drugs
Pamidronate, other bisphosphonates
Interferon
Mercury
Heroin
Lithium
Rifampicin
Sulfasalazine

Immunologic or Allergic Disorders
Vasculitis syndromes
Castleman disease
Kimura disease
Bee sting
Snake venom
Food allergens
Serum sickness
Poison ivy, poison oak

ASSOCIATED WITH MALIGNANT DISEASE

Wilms Tumor
Lymphoma
Pheochromocytoma
Leukemia
Thymoma
Solid tumors

Glomerular Hyperfiltration
Oligomeganephronia
Morbid obesity
Adaptation to nephron reduction

Adapted from Eddy AA, Symons JM. Nephrotic syndrome in childhood. *Lancet*. 2003;362:629–638.

Table 567.2 Summary of Primary Renal Diseases That Manifest as Idiopathic Nephrotic Syndrome

FEATURES	MINIMAL CHANGE NEPHROTIC SYNDROME	FOCAL SEGMENTAL GLOMERULOSCLEROSIS	MEMBRANOUS NEPHROPATHY	MEMBRANOPROLIFERATIVE GLOMERULONEPHRITIS	
				TYPE I	TYPE II
DEMOGRAPHICS					
Age (years)	2-6, some adults	2-10, some adults	40-50	5-15	5-15
Sex (male:female)	2:1	1.3:1	2:1	1:1	1:1
CLINICAL MANIFESTATIONS					
Nephrotic syndrome	100%	90%	80%	60%*	60%*
Asymptomatic proteinuria	0	10%	20%	40%	40%
Hematuria (microscopic or gross)	10–20%	60–80%	60%	80%	80%
Hypertension	10%	20% early	Infrequent	35%	35%

Table 567.2 Summary of Primary Renal Diseases That Manifest as Idiopathic Nephrotic Syndrome—cont'd

FEATURES	MINIMAL CHANGE NEPHROTIC SYNDROME	FOCAL SEGMENTAL GLOMERULOSCLEROSIS	MEMBRANOUS NEPHROPATHY	MEMBRANOPROLIFERATIVE GLOMERULONEPHRITIS	
				TYPE I	TYPE II
Rate of progression to renal failure	Does not progress	10 years	50% in 10-20 years	10-20 years	5-15 years
Associated conditions	Usually none	HIV, heroin use, sickle cell disease, reflux nephropathy	Renal vein thrombosis; medications; SLE; hepatitides B, C; lymphoma; tumors	None	Partial lipodystrophy
GENETICS	None except in congenital nephrotic syndrome (see Table 567.3)	Podocin, α-actinin 4, TRPC6 channel, INF-2, MYH-9	None	None	None
LABORATORY FINDINGS	Manifestations of nephrotic syndrome ↑ BUN in 15–30% Normal complement levels	Manifestations of nephrotic syndrome ↑ BUN in 20–40% Normal complement levels	Manifestations of nephrotic syndrome Normal complement levels	Low complement levels: C1, C4, C3-C9	Normal complement levels: C1, C4, low C3-C9
RENAL PATHOLOGY					
Light microscopy	Normal	Focal sclerotic lesions	Thickened GBM, spikes	Thickened GBM, proliferation	Lobulation
Immunofluorescence	Negative	IgM, C3 in lesions	Fine granular IgG, C3	Granular IgG, C3	C3 only
Electron microscopy	Foot process fusion	Foot process fusion	Subepithelial deposits	Mesangial and subendothelial deposits	Dense deposits
REMISSION ACHIEVED AFTER 8 WK OF ORAL CORTICOSTEROID THERAPY	90%	15–20%	Resistant	Not established/ resistant	Not established/ resistant

*Approximate frequency as a cause of idiopathic nephrotic syndrome. Approximately 10% of cases of adult nephrotic syndrome are a result of various diseases that usually manifest as acute glomerulonephritis.
↑, Elevated; C, complement; GBM, glomerular basement membrane; Ig, immunoglobulin; SLE, systemic lupus erythematosus.
Modified from Couser WG. Glomerular disorders. In: Wyngaarden JB, Smith LH, Bennett JC, eds. *Cecil Textbook of Medicine*, 19th ed. Philadelphia: WB Saunders; 1992. p. 560.

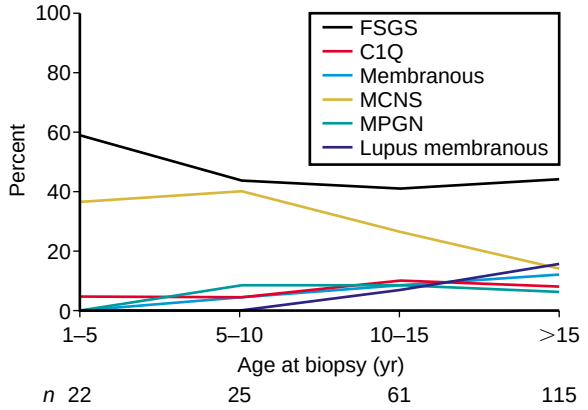

Fig. 567.1 Kidney biopsy results from 223 children with proteinuria referred for diagnostic kidney biopsy (Glomerular Disease Collaborative Network, J. Charles Jennette, MD, Hyunsook Chin, MS, and D.S. Gipson, 2007). C1Q, Nephropathy; FSGS, focal segmental glomerulosclerosis; MCNS, minimal change nephrotic syndrome; MPGN, membranoproliferative glomerulonephritis; *n*, number of patients. *(From Gipson DS, Massengill SF, Yao L, et al. Management of childhood onset nephrotic syndrome. Pediatrics. 2009;124:747–757.)*

bacteremia. This occurs as a result of many factors, particularly hypoglobulinemia, as a result of the urinary losses of immunoglobulin (Ig) G. In addition, defects in the complement cascade from urinary loss of complement factors (predominantly C3 and C5), as well as alternative pathway factors B and D, lead to impaired opsonization of microorganisms. Children with nephrotic syndrome are at significantly increased risk for infection with encapsulated bacteria and, in particular, pneumococcal disease. **Spontaneous bacterial peritonitis** presents with fever, abdominal pain, and peritoneal signs. Although pneumococcus is the most frequent cause of peritonitis, gram-negative bacteria also are associated with a significant number of cases. Children with nephrotic syndrome and fever or other signs of infection must be evaluated aggressively, with appropriate cultures drawn, and should be treated promptly and empirically with antibiotics. Peritoneal leukocyte counts >250 cells/μL are highly suggestive of spontaneous bacterial peritonitis.

Hypercoagulability

Nephrotic syndrome is a hypercoagulable state resulting from multiple factors: vascular stasis from hemoconcentration and intravascular volume depletion, increased platelet number and aggregability, and changes in coagulation factor levels. There is an increase in hepatic production of fibrinogen along with urinary losses of antithrombotic factors such as antithrombin III and protein S. Deep venous thrombosis may occur in any venous bed, including the cerebral venous sinus, renal vein, and pulmonary veins. The clinical risk is low in children (2–5%) compared with adults but has the potential for serious consequences.

Visit Elsevier eBooks+ at eBooks.Health.Elsevier.com for Bibliography.

Table 567.3 Causative Genes and Histologic Patterns of Nephrotic Syndrome by Time of Disease Onset

	CAUSE	INHERITANCE/ LOCUS	GENE/PROTEIN	HISTOLOGIC FEATURES
CONGENITAL ONSET (0-3 MO)				
Isolated	Congenital nephrotic syndrome of the Finnish type (CNF)	AR	*NPHS1*/nephrin	Radial dilation of proximal tubule
	Recessive SRNS, type 2	AR	*NPHS2*/podocin	FSGS/MGC
	Recessive SRNS, type 3	AR	*NPHS3*/PLCE1	DMS
	Isolated DMS	AR	WT1	DMS
	Recessive SRNS	AR	COQ2	FSGS, collapsing
	Recessive SRNS + deafness	AR	COQ6	FSGS
	Dominant SRNS + deafness	AD/11q24	Unknown	FSGS
	DMS + neurologic findings	AR	ARHGDIA/Rho GDP dissociation inhibitor (GDI) alpha	DMS
	NS + lung and skin disease	AR	*ITGA3*/integrin alpha 3	DMS
	Steroid-sensitive nephrotic syndrome	AR/2p12-13.2	Unknown	MGC/FSGS
Syndromic	Denys-Drash syndrome	AD	WT1	DMS
	Pierson syndrome	AR	*LAMB2*/laminin-β2	FSGS
	Nail–patella syndrome	AD	*LMX1B*/LIM homeobox transcription factor-1β	
	Frasier syndrome	AD	WT1	FSGS
	Schimke immunoosseous dysplasia	AR	SMARCAL1	FSGS
	Epidermolysis bullosa + FSGS	AR	*ITGB4*/integrin-β4	FSGS
	Galloway-Mowat syndrome	AR	Unknown	MGC to FSGS
INFANCY-CHILDHOOD ONSET				
Genetic	Recessive SSNS	AR	*EMP2*/epithelial membrane protein 2	
	Recessive SRNS	AR	*NPHS2*/podocin	FSGS/MGC
	Recessive SRNS	AR	*NPHS1*/nephrin	FSGS/MGC
	Recessive SRNS	AR	*NPHS3*/PLCE1	DMS
	Isolated DMS	AD	WT1	DMS
	Recessive SRNS + deafness or intellectual disability	AR	ARHGDIA	DMS
	SRNS	AR	*MYOE1*/nonmuscle class I myosin E	FSGS
	SRNS	AR	*PTPRO/GLEPP1* protein tyrosine phosphatase receptor type O/glomerular epithelial protein-1	FSGS
JUVENILE-ADULT ONSET				
Genetic	SRNS	AR or sporadic	*NPHS2* (p.R229Q)	FSGS
	Familial SRNS	AD	*INF2*/formin family of actin-regulating proteins	FSGS
	FSGS, type 1	AD/19q13	*ACTN4*/α-actinin-4	FSGS
	FSGS, type 2	AD/11q21-22	*TRPC6*/transient receptor potential cation channel, subfamily C, member 6	FSGS
	FSGS, type 3	AR-AD/6p12	*CD2AP*/CD2-associated protein	FSGS
	SRNS	AR	*PTPRO/GLEPP1* protein tyrosine phosphatase receptor type O/glomerular epithelial protein-1	FSGS
	SRNS	AR	*ADCK4*/aarF domain-containing kinase 4	FSGS
	SRNS (no extrarenal symptoms)	AD or sporadic	*LMX1B* encodes homeodomain-containing transcription factor	FSGS

AD, Autosomal dominant; AR, autosomal recessive; DMS, diffuse mesangial sclerosis; FSGS, focal segmental glomerulosclerosis; MGC, minimal glomerular changes; NS, nephrotic syndrome; SRNS, steroid-resistant nephrotic syndrome.
From Bakkaloglu SA, Schaefer F. Diseases of the kidney and urinary tract in children. In: Skorecki K, Chertow GM, Marsden PA, et al., eds. *Brenner & Rector's The Kidney*, 10th ed. Philadelphia: Elsevier; 2016: Table 74-2.

567.1 Idiopathic Nephrotic Syndrome

Elif Erkan

Approximately 90% of children with nephrotic syndrome have idiopathic nephrotic syndrome. Idiopathic nephrotic syndrome is associated with primary glomerular disease without an identifiable causative disease or drug. Idiopathic nephrotic syndrome includes multiple histologic types: minimal change disease, mesangial proliferation, focal segmental glomerulosclerosis, membranous nephropathy, and membranoproliferative glomerulonephritis.

PATHOLOGY

In **minimal change nephrotic syndrome (MCNS)** (approximately 85% of total cases of nephrotic syndrome in children), the glomeruli appear normal or show a minimal increase in mesangial cells and matrix. Findings on immunofluorescence microscopy are typically negative, and electron microscopy simply reveals effacement of the

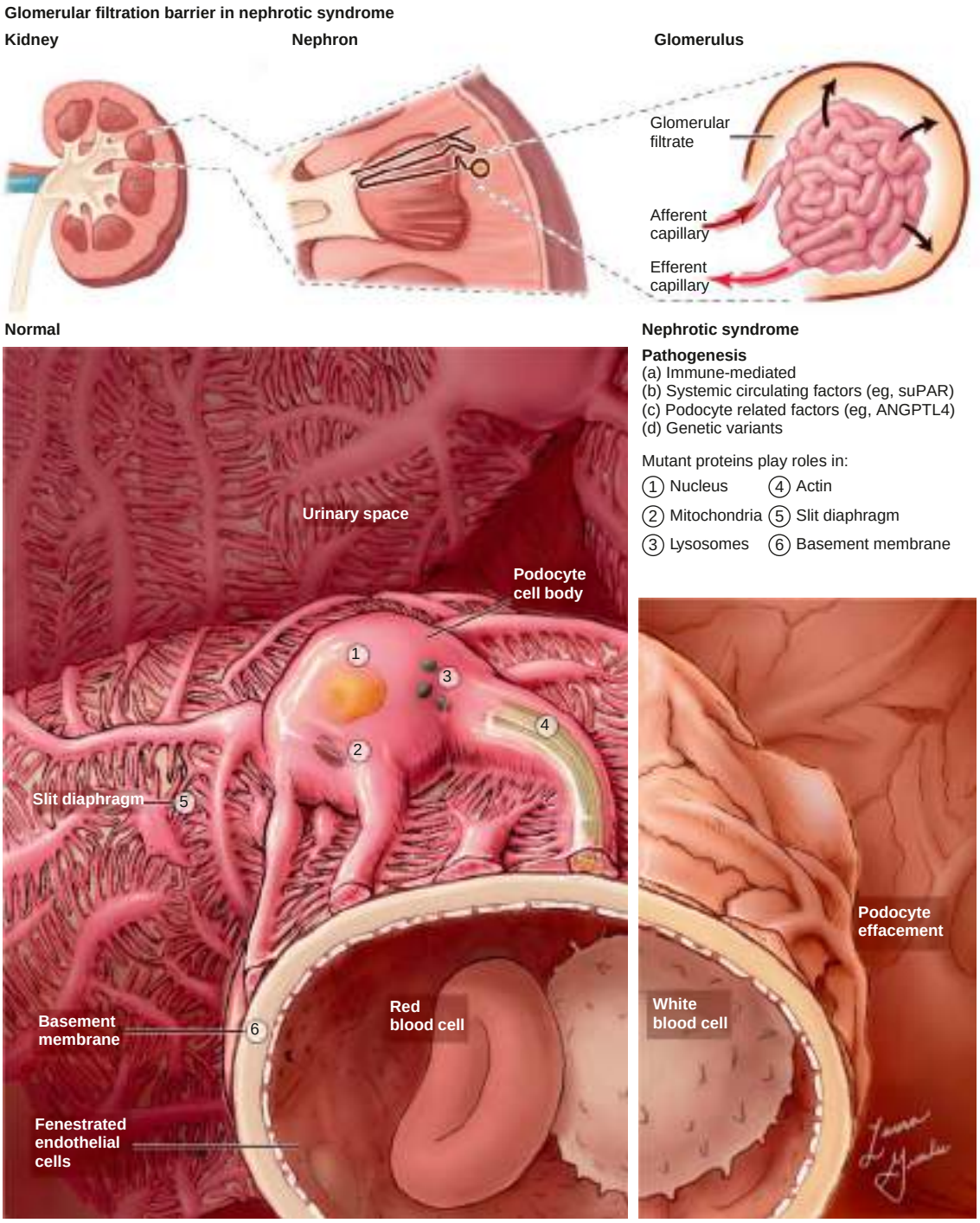

Fig. 567.2 The glomerular filtration barrier and pathogenesis of idiopathic nephrotic syndrome. Within the kidney is the glomerulus, a capillary tuft that filters the blood. The podocyte, glomerular basement membrane, and fenestrated glomerular endothelium form the glomerular filtration barrier, allowing the ultrafiltrate to enter the urinary space. The podocyte has extensive cellular extensions that interdigitate, and these foot processes are connected by the slit diaphragm. In nephrotic syndrome, there is extensive effacement of the podocytes and loss of this barrier to protein, allowing excessive serum albumin to leak into the urine. The pathogenesis of idiopathic nephrotic syndrome is hypothesized to be either immune mediated, due to a systemic podocyte-derived circulating factor, or, in rarer or familial forms, a genetic variant. Numerous pathogenic variants are associated with steroid-resistant nephrotic syndrome that affect various parts of the podocyte itself or the other constituents of the glomerular basement membrane. These include pathogenic variants affecting the podocyte nucleus, mitochondria or lysosomes, the slit diaphragm or actin cytoskeleton, and the glomerular basement membrane. Nephrin, podocin, and CD2AP, for example, are essential components of a zipper-like structure spanning the interdigitating foot processes of the podocyte and the slit diaphragm and link directly with the podocyte actin cytoskeleton. The actin cytoskeleton is further supported by microfilaments that maintain structural stability and facilitate the dynamic nature of the podocyte structure and function. The importance of these microfilaments is evident because pathogenic variants in both α-actinin 4 and INF2, which are involved in actin regulation and polymerization, lead to FSGS. *(From Noone DG, Iijima K, Parekh R. Idiopathic nephrotic syndrome in children. Lancet. 2018;392:61–72. Fig. 2.)*

epithelial cell foot processes. More than 95% of children with minimal change disease respond to corticosteroid therapy.

Mesangial proliferation is characterized by a diffuse increase in mesangial cells and matrix on light microscopy. Immunofluorescence microscopy might reveal trace to 1+ mesangial IgM and/or IgA staining. Electron microscopy reveals increased numbers of mesangial cells and matrix as well as effacement of the epithelial cell foot processes. Approximately 50% of patients with this histologic lesion respond to corticosteroid therapy.

In **focal segmental glomerulosclerosis (FSGS),** glomeruli show lesions that are both focal (present only in a proportion of glomeruli) and segmental (localized to ≥1 intraglomerular tufts). The lesions consist of mesangial cell proliferation and segmental scarring on light microscopy (Fig. 567.3; see Table 567.2). Immunofluorescence microscopy is positive for IgM and C3 staining in the areas of segmental sclerosis. Electron microscopy demonstrates segmental scarring of the glomerular tuft with obliteration of the glomerular capillary lumen. The tip variant of FSGS is more common in Caucasians and is associated with better renal survival; by contrast, the collapsing variant of FSGS has a faster progression rate to end-stage kidney disease and is more common in Black patients.

Lesions consistent with FSGS may be seen secondary to HIV infection, vesicoureteral reflux, and IV use of heroin and other drugs of abuse. Only 20% of patients with FSGS respond to prednisone. The disease is often progressive, ultimately involving all glomeruli with end-stage kidney disease in most patients.

MINIMAL CHANGE NEPHROTIC SYNDROME

Clinical Manifestations

Idiopathic nephrotic syndrome is more common in males than in females (2:1) and most commonly appears between the ages of 2 and 6 years (see Fig. 567.1). However, it has been reported as early as 6 months of age and throughout adulthood. MCNS is present in 85–90% of patients <6 years of age. In contrast, only 20–30% of adolescents who present for the first time with nephrotic syndrome have MCNS. The more common cause of idiopathic nephrotic syndrome in this older age group is FSGS. The incidence of FSGS is increasing; it may be more common in Black, Hispanic, and Asian patients. FSGS is the most common cause of end-stage kidney disease in adolescents.

The initial episode of idiopathic nephrotic syndrome, as well as subsequent relapses, usually follows minor infections and, uncommonly, reactions to insect bites, bee stings, or poison ivy.

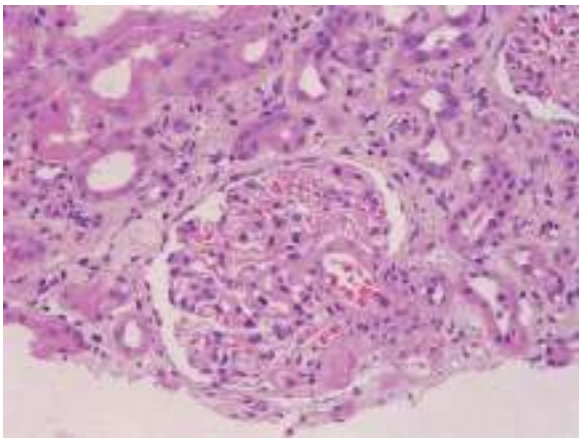

Fig. 567.3 Steroid-resistant nephrotic syndrome (SRNS). Kidney biopsy image of patient with SRNS shows focal segmental glomerulosclerosis. Segmental sclerosis is noted in a perihilar location with hyalinosis. Evidence of tubular atrophy and interstitial fibrosis is also present. H&E magnification 20×. *(From Tullus K, Webb H, Bagga A. Management of steroid-resistant nephrotic syndrome in children and adolescents. Lancet Child Adolesc Health. 2018;2:880–888. Fig. 1B, p. 881.)*

Children usually present with mild edema, which is initially noted around the eyes and in the lower extremities. Nephrotic syndrome can initially be misdiagnosed as an allergic disorder because of the periorbital swelling that decreases throughout the day. With time, the edema becomes generalized, with the development of ascites, pleural effusions, and genital edema. Anorexia, irritability, abdominal pain, and diarrhea are common. Important features of MCNS are the absence of hypertension and gross hematuria (the so-called nephritic features).

The differential diagnosis of the child with marked edema includes protein-losing enteropathy, hepatic failure, heart failure, acute or chronic glomerulonephritis, and protein malnutrition. A diagnosis other than MCNS should be considered in children <1 year of age, with a positive family history of nephrotic syndrome, and/or the presence of extrarenal findings (e.g., arthritis, rash, anemia), hypertension or pulmonary edema, acute or chronic renal insufficiency, and gross hematuria.

Diagnosis

Recommendations for the Initial Evaluation of Children with Nephrotic Syndrome

Confirming the Diagnosis of Nephrotic Syndrome. The initial workup for a child with nephrotic syndrome is shown in Table 567.4. Labs should be obtained including urinalysis with the first morning urine protein:creatinine ratio, CBC, serum electrolytes, BUN, creatinine, glomerular filtration rate, albumin, complement C3 and C4 levels, antinuclear and anti-streptococcal antibodies, and antineutrophil cytoplastic antibodies.

The urinalysis reveals 3+ or 4+ proteinuria, and microscopic hematuria is present in 20% of children. A spot urine protein:creatinine ratio should be >2.0. The serum creatinine value is usually normal, but it may be abnormally elevated if there is diminished renal perfusion from contraction of the intravascular volume. The serum albumin level is <2.5 g/dL, and serum cholesterol and triglyceride levels are elevated. Serum complement levels are normal. Kidney ultrasound may be considered to exclude renal malformations and venous thrombosis but is not mandatory. A renal biopsy is not routinely performed if the patient fits the standard clinical picture of MCNS.

Treatment

Children with their first episode of nephrotic syndrome and mild to moderate edema may be managed as outpatients. Such outpatient management is not practiced in all major centers, because the time required for successful education of the family regarding all aspects of the condition can require a short period of hospitalization. The child's parents must be able to recognize the signs and symptoms of the complications of the disease and may be taught how to use a dipstick and interpret the results to monitor for the degree of proteinuria. Tuberculosis must be ruled out before starting immunosuppressive therapy with corticosteroids by placing a purified protein derivative skin test or obtaining an interferon-gamma release assay and confirming a negative result.

Children with onset of uncomplicated nephrotic syndrome between 1 and 12 years of age are likely to have steroid-responsive MCNS, and steroid therapy may be initiated without a diagnostic renal biopsy. Children with features that make MCNS less likely (gross hematuria, sustained hypertension, acute kidney injury, low C3 levels, arthritis and/or rash to suggest glomerulonephritis, or age <1 year or >12 years) should be considered for renal biopsy before treatment.

Use of Corticosteroids to Treat Minimal Change Nephrotic Syndrome

Corticosteroids are the mainstay of therapy for MCNS. The treatment guidelines for corticosteroid use presented in the following sections are adapted from and based on the 2021 Kidney Disease: Improving

Table 567.4 Investigations in a Child with Nephrotic Syndrome (NS)

BASELINE INVESTIGATIONS
1. Urinalysis and urine microscopy
2. Urine albumin or protein:creatinine ratio
3. 24-hr timed collection of urine for protein quantification
4. Serum electrolytes, albumin, total protein, renal function, and cholesterol
ADDITIONAL TESTING IF THERE IS A SUSPICION OF A GLOMERULONEPHRITIS
1. Serum complement C3 and C4 concentrations
2. Serum immunoglobulins
3. Antistreptolysin titers
4. Anti-DNase B antibodies
5. Antinuclear antigen antibodies
6. Anti–double-stranded DNA antibodies
7. Anti-neutrophil cytoplasmic antibodies
INFECTIOUS WORKUP DEPENDING ON CLINICAL CONTEXT
1. Hepatitis B and C, HIV, syphilis, or tuberculosis can also be considered depending on the clinical context
CONSIDERATION OF GENETIC TESTING
1. A positive family history of NS
2. Congenital NS
3. Failure to respond to steroid therapy
4. Persistent kidney dysfunction
5. Features suggestive of a known syndrome (appendix)
RENAL BIOPSY CONSIDERED IN THE FOLLOWING SITUATIONS
1. Age <1 or >12 years
2. Persistent or sustained elevation in creatinine
3. Significant hematuria or gross hematuria
4. Hypocomplementemia
5. Findings indicative of another autoimmune disease
6. Infection with hepatitis B or C, HIV, or tuberculosis
7. Hypertension
8. Glucocorticoid resistance

From Noone DG, Iijima K, Parekh R. Idiopathic nephrotic syndrome in children. *Lancet*. 2018;392:61–72. Panel 3.

Global Outcomes (KDIGO) clinical practice guidelines on glomerulonephritis (Fig. 567.4).

Treatment of the Initial Episode of Nephrotic Syndrome

In children with presumed MCNS, prednisone or prednisolone should be administered as a single daily dose of 60 mg/m^2/day or 2 mg/kg/day to a maximum of 60 mg daily for 4-6 weeks followed by alternate-day prednisone (starting at 40 mg/m^2 every other day or 1.5 mg/kg every other day) for a period ranging from 4-6 weeks. The issue of the duration of steroid treatment has been controversial, but current evidence suggests that prolonged (>12 weeks) glucocorticoid treatment increases the risk of adverse effects without further improving clinical outcomes. Approximately 80–90% of children respond to steroid therapy.

Response is defined as the attainment of remission within the initial 4 weeks of corticosteroid therapy. **Remission** consists of a urine protein:creatinine ratio of <0.2 or <1+ protein on urine dipstick testing for 3 consecutive days. Most children who respond to prednisone therapy do so within the first 5 weeks of treatment.

Managing the Clinical Sequelae of Nephrotic Syndrome

Edema. Children with severe symptomatic edema, including large pleural effusions, ascites, or severe genital edema, should be hospitalized. In addition to sodium restriction (<1,500 mg daily), water/fluid restriction may be necessary if the child is hyponatremic. A swollen scrotum may be elevated with pillows to enhance fluid removal by gravity. Diuresis may be augmented by the administration of loop diuretics (furosemide), orally or intravenously, *although extreme caution should be exercised.* Aggressive diuresis can lead to intravascular volume depletion and an increased risk for acute renal failure and intravascular thrombosis.

When a patient has severe generalized edema with evidence of intravascular volume depletion (e.g., hemoconcentration, hypotension, tachycardia), IV administration of 25% albumin (0.5-1.0 g albumin/kg) as a slow infusion followed by furosemide (1-2 mg/kg/dose IV) is sometimes necessary. Such therapy should be used only in collaboration with a pediatric nephrologist and mandates close monitoring of volume status, blood pressure, serum electrolyte balance, and renal function. Symptomatic volume overload, with hypertension, heart failure, and pulmonary edema, is a potential complication of parenteral albumin therapy, particularly when it is administered as a rapid infusion.

Dyslipidemia. Dyslipidemia should be managed with a low-fat diet. Dietary fat intake should be limited to <30% of calories with a saturated fat intake of <10% calories. Dietary cholesterol intake should be <300 mg/day. There are insufficient data to recommend the use of 3-hydroxy-3-methylgluataryl coenzyme A (HMG-CoA) reductase inhibitors routinely in children with dyslipidemia.

Infections. Families of children with nephrotic syndrome should be counseled regarding the signs and symptoms of infections such as cellulitis, peritonitis, and bacteremia. If there is a suspicion of infection, a blood culture should be drawn before starting empiric antibiotic therapy. In the case of spontaneous bacterial peritonitis, peritoneal fluid should be collected if there is sufficient fluid to perform a paracentesis and sent for cell count, Gram stain, and culture. The antibiotic provided must be of broad enough coverage to include pneumococcus and gram-negative bacteria. A third-generation cephalosporin is a common choice of IV antibiotic.

Thromboembolism. Children who present with the clinical signs of thromboembolism should be evaluated with appropriate imaging studies to confirm the presence of a clot. Studies to delineate a specific underlying hypercoagulable state are recommended. In children with thrombotic events, anticoagulation therapy including heparin, low molecular weight heparin, and warfarin are therapeutic options that appear to be effective.

Obesity and Growth. Glucocorticoids may increase the body mass index in children who are overweight when steroid therapy is initiated, and these children are more likely to remain overweight. Anticipatory dietary counseling is recommended. Growth may be affected in children who require long-term corticosteroid therapy. Steroid-sparing strategies may improve linear growth in children who require prolonged courses of steroids.

Relapse of Nephrotic Syndrome. Relapse of nephrotic syndrome is defined as a urine protein:creatinine ratio of >2 or ≥3+ protein on urine dipstick testing for 3 consecutive days. Relapses are common, especially in younger children, and are often triggered by upper respiratory or gastrointestinal infections. Relapses are usually treated similar to the initial episode, except that daily prednisone courses are shortened. Daily high-dose prednisone is given until the child has achieved remission, and the regimen is then switched to alternate-day therapy. The duration of alternate-day therapy varies depending on the frequency of relapses of the individual child. Children are classified as infrequent relapsers or frequent relapsers, and as being steroid dependent, based on the number of relapses in a 12-month period or their inability to remain in remission following discontinuation of steroid therapy.

Steroid Resistance. Steroid resistance is defined as the failure to achieve remission after 4 weeks of corticosteroid therapy. Children with steroid-resistant nephrotic syndrome require further evaluation, including a diagnostic kidney biopsy and genetic testing. Steroid-resistant nephrotic syndrome is usually caused by FSGS (80%), MCNS, or membranoproliferative glomerulonephritis.

Implications of Steroid-Resistant Nephrotic Syndrome. Steroid-resistant nephrotic syndrome, and specifically FSGS, is associated with a 50% risk for end-stage kidney disease within 5 years of diagnosis if patients do not achieve a partial or complete remission. Persistent nephrotic syndrome is associated with a poor

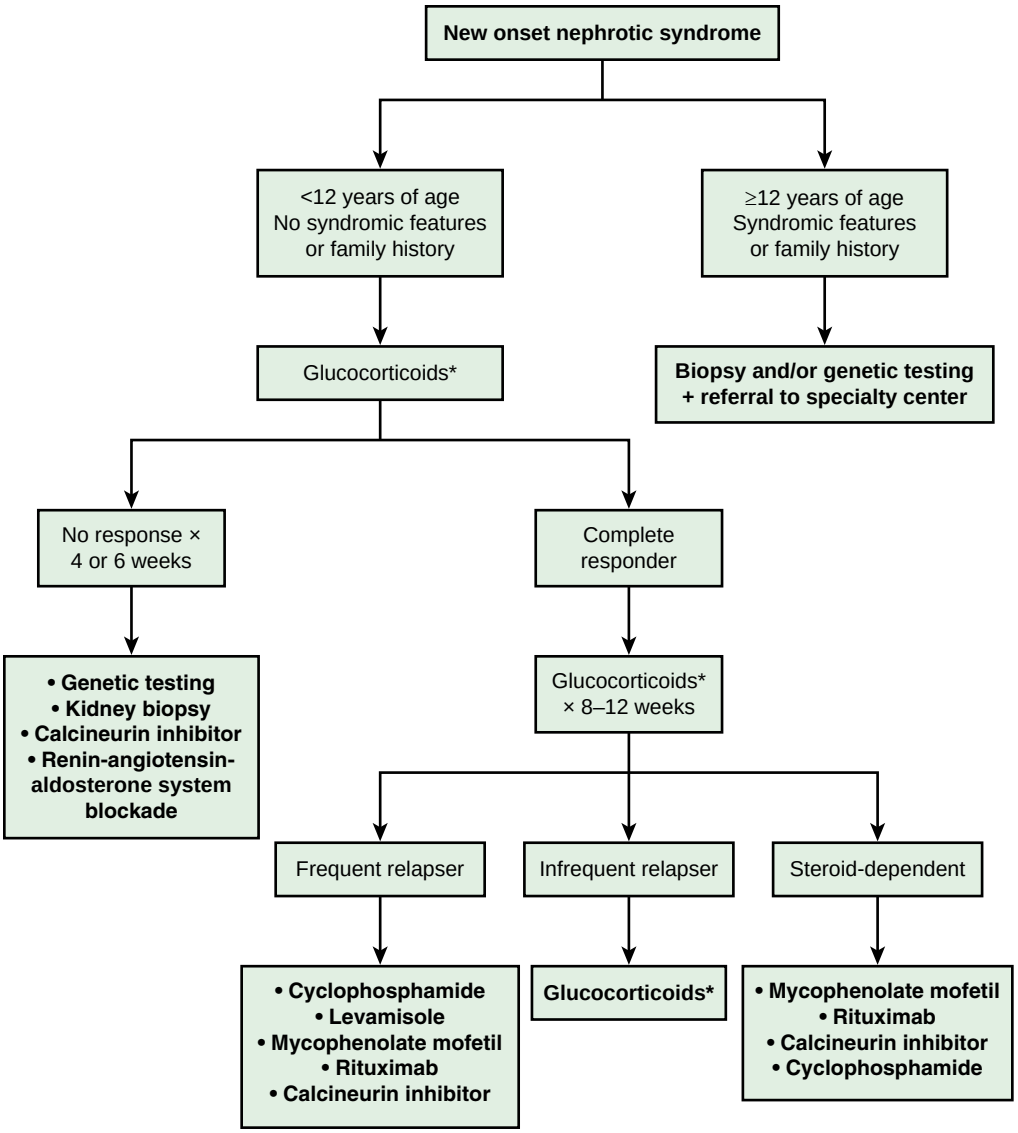

Fig. 567.4 Treatment algorithm for new-onset nephrotic syndrome (NS). Therapeutic approach to NS in children from onset. *Glucocorticoids include PO prednisone or prednisolone. NS, Nephrotic syndrome. *(From Kidney Disease: Improving Global Outcomes (KDIGO) Glomerular Diseases Work Group. KDIGO 2021 Clinical Practice Guideline for the Management of Glomerular Diseases. Kidney Int. 2021;100[4S]:S1–S276. Fig. 40.)*

patient-reported quality of life, hypertension, serious infections, and thromboembolic events. Children reaching end-stage kidney disease have a greatly reduced life expectancy compared with their peers.

Alternative Therapies to Corticosteroids in the Treatment of Nephrotic Syndrome. Steroid-dependent patients, frequent relapsers, and steroid-resistant patients are candidates for alternative therapies, particularly if they have severe corticosteroid toxicity (cushingoid appearance, hypertension, cataracts, and/or growth failure). **Cyclophosphamide** prolongs the duration of remission and reduces the number of relapses in children with **frequently relapsing** and **steroid-dependent** nephrotic syndrome. The potential side effects of the drug (neutropenia, disseminated varicella, hemorrhagic cystitis, alopecia, sterility, increased risk of future malignancy) should be carefully reviewed with the family before initiating treatment. Cyclophosphamide (2 mg/kg) is given as a single oral dose for a total duration of 8-12 weeks. Alternate-day prednisone therapy is often continued during cyclophosphamide administration. During cyclophosphamide therapy, the white blood cell count must be monitored weekly, and the drug should be withheld if the count falls below 5,000/mm^3. The cumulative threshold dose above which oligospermia or azoospermia occurs in males is >250 mg/kg.

Calcineurin inhibitors (cyclosporine or tacrolimus) are recommended as initial therapy for children with **steroid-resistant** nephrotic syndrome. Children must be monitored for side effects, including hypertension, nephrotoxicity, hirsutism, and gingival hyperplasia. **Mycophenolate** can maintain remission in children with steroid-dependent or frequently relapsing nephrotic syndrome. **Levamisole**, an anthelmintic agent with immunomodulating effects that has been shown to reduce the risk of relapse when compared with prednisone, is not available in the United States.

Rituximab, the chimeric monoclonal antibody against CD20-targeting B cells, was found to be effective in children by maintaining remission and decreasing the number of relapses in steroid-dependent and/or steroid-resistant nephrotic syndrome. Randomized trials with rituximab have shown promising results of an up to 80% drug-free remission rate at 1 year in patients with steroid-dependent nephrotic syndrome. However, rituximab is less effective in patients treated with calcineurin inhibitors and steroids and with multidrug-resistant nephrotic syndrome.

Most children who respond to cyclosporine, tacrolimus, or mycophenolate therapy tend to relapse when the medication is discontinued. Angiotensin-converting enzyme inhibitors and angiotensin II receptor blockers may be helpful as adjunct therapy to reduce proteinuria in steroid-resistant patients.

Immunizations in Children with Nephrotic Syndrome. To reduce the risk of serious infections in children with nephrotic syndrome, give the full pneumococcal vaccination (with the 13-valent conjugant vaccine and 23-valent polysaccharide vaccine) and influenza vaccination annually to the child and their household contacts; defer vaccination with live vaccines until the prednisone dose is below either 1 mg/kg daily or 2 mg/kg on alternate days. Live virus vaccines are contraindicated in children receiving corticosteroid-sparing agents such as cyclophosphamide or cyclosporine. Following close contact with varicella infection, give immunocompromised children taking immunosuppressive agents varicella-zoster immune globulin if available; immunize healthy household contacts with live vaccines to minimize the risk of transfer of infection to the immunosuppressed child, but avoid direct exposure of the child to gastrointestinal or respiratory secretions of vaccinated contacts for 3-6 weeks after vaccination.

Table 567.5 provides monitoring recommendations for children with nephrotic syndrome.

Prognosis

Most children with steroid-responsive nephrotic syndrome have repeated relapses, which generally decrease in frequency as the child grows older. Although there is no proven way to predict an individual child's course, children who respond rapidly to steroids and those who have no relapses during the first 6 months after diagnosis are likely to follow an infrequently relapsing course. It is important to indicate to the family that the child with steroid-responsive nephrotic syndrome is unlikely to develop chronic kidney disease, that the disease is rarely hereditary, and that the child (in the absence of prolonged cyclophosphamide therapy) will remain fertile. To minimize the psychologic effects of the condition and its therapy, children with idiopathic nephrotic syndrome should not be considered chronically ill and should participate in all age-appropriate childhood activities and maintain an unrestricted diet when in remission.

Children with steroid-resistant nephrotic syndrome, most often caused by FSGS, generally have a much poorer prognosis. These children develop progressive renal insufficiency, ultimately leading to end-stage kidney disease requiring dialysis or kidney transplantation. Recurrent nephrotic syndrome develops in 30–50% of transplant recipients with FSGS.

Visit Elsevier eBooks+ at eBooks.Health.Elsevier.com for Bibliography.

567.2 Secondary Nephrotic Syndrome

Elif Erkan

Nephrotic syndrome can occur as a secondary feature of many forms of glomerular disease. Membranous nephropathy, membranoproliferative glomerulonephritis, postinfectious glomerulonephritis, lupus nephritis, and IgA vasculitis nephritis (formerly Henoch-Schönlein purpura nephritis) can all have a nephrotic component (see Tables 567.1 and 567.3). Secondary nephrotic syndrome should be suspected in patients >12 years and those with sustained hypertension, hematuria, renal dysfunction, extrarenal symptoms (e.g., rash, arthralgias, fever), or depressed serum complement levels. In certain areas of the world, malaria and schistosomiasis are the leading causes of nephrotic syndrome. Other infectious agents associated with nephrotic syndrome include hepatitis B virus, hepatitis C virus, filaria, leprosy, and HIV.

Nephrotic syndrome has been associated with malignancy, particularly in the adult population. In patients with solid tumors, such as carcinomas of the lung and gastrointestinal tract, the renal pathology often resembles membranous glomerulopathy. Immune complexes composed of tumor antigens and tumor-specific antibodies presumably mediate the renal involvement. In patients with lymphomas, particularly Hodgkin lymphoma, the renal pathology most often resembles MCNS. The proposed mechanism of

Table 567.5 Monitoring Recommendations for Children with Nephrotic Syndrome

DISEASE AND TREATMENT	HOME URINE PROTEIN	WEIGHT, GROWTH, BMI	BP	CR	ELEC-TRO-LYTES	SERUM GLU-COSE	CBC	LIPID PRO-FILE	DRUG LEVELS	LFTS	UA	CPK
DISEASE TYPE												
Mild (steroid responsive)	•	•	•								•	
Moderate (frequent relapsing, steroid dependent)	•	•	•	•				•			•	
Severe (steroid resistant)	•	•	•	•				•			•	
THERAPY												
Corticosteroids		•	•			•		•				
Cyclophosphamide				•			•				•	
Mycophenolate mofetil							•			•		
Calcineurin inhibitors			•	•	•	•		•	•			
ACEIs/ARBs			•	•	•		•					
HMG-CoA reductase inhibitors								•		•		•

ACEI, Angiotensin-converting enzyme inhibitor; ARB, angiotensin II receptor blocker; BMI, body mass index; BP, blood pressure; CPK, creatine phosphokinase; Cr, creatinine; HMG-CoA, 3-hydroxy-3-methylglutaryl coenzyme A; LFTs, liver function tests; UA, urinalysis.

From Gipson DS, Massengill SF, Yao L, et al. Management of childhood onset nephrotic syndrome. *Pediatrics*. 2009;124:747–757.

the nephrotic syndrome is that the lymphoma produces a lymphokine that increases permeability of the glomerular capillary wall. Nephrotic syndrome can develop before or after the malignancy is detected, resolve as the tumor regresses, and return if the tumor recurs.

Nephrotic syndrome has also developed during therapy with numerous drugs and chemicals. The histologic picture can resemble membranous glomerulopathy (penicillamine, captopril, gold, nonsteroidal antiinflammatory drugs, mercury compounds), MCNS (probenecid, ethosuximide, methimazole, lithium), or proliferative glomerulonephritis (procainamide, chlorpropamide, phenytoin, trimethadione, paramethadione).

Visit Elsevier eBooks+ at eBooks.Health.Elsevier.com for Bibliography.

567.3 Congenital Nephrotic Syndrome

Elif Erkan

Nephrotic syndrome (massive proteinuria, hypoalbuminemia, edema, and hypercholesterolemia) has a poorer prognosis when it occurs in the first year of life, when compared with nephrotic syndrome manifesting in childhood. **Congenital nephrotic syndrome** is defined as nephrotic syndrome manifesting at birth or within the *first 3 months of life*. Congenital nephrotic syndrome may be classified as primary or as secondary to a number of etiologies such as in utero infections (cytomegalovirus, toxoplasmosis, syphilis, hepatitides B and C, HIV), infantile systemic lupus erythematosus, or mercury exposure.

Primary congenital nephrotic syndrome is due to a variety of syndromes inherited as autosomal recessive disorders (see Table 567.3). A number of structural and functional abnormalities of the glomerular filtration barrier causing congenital nephrotic syndrome have been elucidated. In a large European cohort of children with congenital nephrotic syndrome, 85% carried pathogenic variants in four genes *(NPHS1, NPHS2, WT1,* and *LAMB2),* the first three of which encode components of the glomerular filtration barrier. The Finnish type of congenital nephrotic syndrome is caused by pathogenic variants in the *NPHS1* or *NPHS2* gene, which encodes nephrin and podocin, critical components of the slit diaphragm. Affected infants most commonly present at birth with edema caused by massive proteinuria, and they are typically delivered with an enlarged placenta (>25% of the infant's weight). Severe hypoalbuminemia, hyperlipidemia, and hypogammaglobulinemia result from loss of filtering selectivity at the glomerular filtration barrier. Prenatal diagnosis can be made by the presence of elevated maternal and amniotic α-fetoprotein levels.

Denys-Drash syndrome is caused by pathogenic variants in the *WT1* gene, which results in abnormal podocyte function. Patients present with early-onset nephrotic syndrome, progressive renal insufficiency, ambiguous genitalia, and Wilms tumor.

Pathogenic variants in the *LAMB2* gene, seen in **Pierson syndrome,** lead to abnormalities of β_2-laminin, a critical component of the glomerular and ocular basement membranes. In addition to congenital nephrotic syndrome, affected infants display bilateral microcoria (fixed narrowing of the pupil).

Galloway-Mowat syndrome is characterized by microcephaly with hiatal hernia and congenital nephrotic syndrome. Patients have distinctive kidney biopsy findings with loss of or poor basement membrane formation or permeation of their basement membranes with fibrils.

Regardless of the etiology of congenital nephrotic syndrome, the diagnosis is made clinically in newborns or infants who demonstrate severe generalized edema, poor growth and nutrition with hypoalbuminemia, increased susceptibility to infections, hypothyroidism (from urinary loss of thyroxin-binding globulin), and an increased risk of thrombotic events (urinary loss of antithrombin). Most infants have progressive renal insufficiency.

Albumin and diuretic infusions, providing high amounts of protein (3-4 g/kg), lipids, and a high caloric intake to maintain nutrition, along with vitamin and thyroid hormone replacement, have been the mainstream therapy for congenital nephrotic syndrome. Treatment of the congenital syndrome also consists of unilateral nephrectomy and use of angiotensin-converting enzyme inhibitors and/or indomethacin to decrease the proteinuria and glomerular filtration rate. Some centers prefer more aggressive therapy, including bilateral nephrectomy at 1-2 years of age, weight >7 kg, and initiation of peritoneal dialysis with subsequent kidney transplantation.

Secondary congenital nephrotic syndrome can resolve with treatment of the underlying cause, such as syphilis (Table 567.6). The management of primary congenital nephrotic syndrome includes intensive supportive care with IV albumin and diuretics, regular administration of IV γ-globulin, and aggressive nutritional support (often parenteral), while attempting to pharmacologically decrease urinary protein loss with angiotensin-converting enzyme inhibitors, angiotensin II receptor inhibitors, and prostaglandin synthesis inhibitors, or even unilateral nephrectomy. If conservative management fails and patients suffer from persistent anasarca or repeated severe infections, bilateral nephrectomies are performed, and chronic dialysis is initiated. Renal transplantation is the definitive treatment of congenital nephrotic syndrome, though recurrence of the nephrotic syndrome has been reported to occur after transplantation.

Visit Elsevier eBooks+ at eBooks.Health.Elsevier.com for Bibliography.

Table 567.6 Causes of Nephrotic Syndrome in Infants Younger Than 1 Year of Age

SECONDARY CAUSES
Infections
Syphilis
Cytomegalovirus
Toxoplasmosis
Rubella
Hepatitis B or C
HIV
Malaria
Drug Reactions
Toxins
Mercury
Syndromes with Associated Renal Disease
Nail–patella syndrome
Lowe syndrome
Nephropathy associated with congenital brain malformation
Denys-Drash syndrome: Wilms tumor
Hemolytic uremic syndrome
Systemic lupus erythematosus
PRIMARY CAUSES (SEE TABLE 567.3)
Congenital nephrotic syndrome
Diffuse mesangial sclerosis
Minimal change disease
Focal segmental sclerosis
Membranous nephropathy

From Kliegman RM, Greenbaum LA, Lye PS, eds. *Practical Strategies in Pediatric Diagnosis and Therapy,* 2nd ed. Philadelphia: Elsevier; 2004: p. 418.

Section 4

Tubular Disorders

Chapter 568

Tubular Function

Eliza Blanchette and Bradley P. Dixon

Water and electrolytes are freely filtered at the level of the glomerulus. Thus the electrolyte content of ultrafiltrate at the beginning of the proximal tubule is similar to that of plasma. Carefully regulated processes of tubular reabsorption and/or tubular secretion determine the final water content and electrolyte composition of urine. Bulk movement of solute tends to occur in the proximal portions of the nephron, and fine adjustments tend to occur distally (see Chapter 73).

SODIUM

Sodium is essential in maintaining extracellular fluid balance and, thus, volume status. The kidney is capable of effecting large changes in sodium excretion in a variety of normal and pathologic states.

There are four main sites of sodium transport. Approximately 60% of sodium is absorbed in the proximal tubule by coupled transport with glucose, amino acids, and phosphate; 25% in the ascending loop of Henle (mediated by NKCC2, the loop diuretic-sensitive sodium-potassium-2 chloride transporter); and 15% in the distal tubule (mediated by NCCT, the thiazide-sensitive sodium chloride co-transporter) and collecting tubule (mediated by ENaC, the epithelial sodium channel).

The urinary excretion of sodium normally approximates the sodium intake of 2-6 mEq/kg/24 hr for a child consuming a typical American diet, minus 1-2 mEq/kg/24 hr required for normal metabolic processes. However, in states of volume depletion (dehydration, blood loss) or decreased effective circulating blood volume (septic shock, hypoalbuminemic states, heart failure), there may be a dramatic decrease in urinary sodium excretion to as low as 1 mEq/L. Changes in systemic volume status are detected by (1) baroreceptors in the atria, afferent arteriole, and carotid sinus and (2) by the macula densa, which detects changes in chloride delivery.

The major hormonal mechanisms mediating sodium balance include the renin-angiotensin-aldosterone axis, atrial natriuretic factor, and norepinephrine. Angiotensin II and aldosterone increase sodium reabsorption in the proximal tubule and distal tubule, respectively. Norepinephrine, released in response to volume depletion, does not directly act on tubular transport mechanisms but affects sodium balance by decreasing renal blood flow, thus decreasing the filtered load of sodium as well as stimulating renin release. With more severe volume depletion, antidiuretic hormone is also released (see Chapter 570). Sodium excretion is promoted by atrial natriuretic factor and suppression of renin.

POTASSIUM

Extracellular potassium homeostasis is regulated because small changes in plasma potassium concentrations have dramatic effects on cardiac, neural, and neuromuscular function (see Chapter 73.4). Essentially, all filtered potassium is fully reabsorbed in the proximal tubule and ascending loop of Henle. Therefore urinary excretion of potassium is completely dependent on tubular secretion by potassium channels (renal outer medullary potassium [ROMK] and big potassium [BK] channels) present in the principal cells of the collecting tubule. Factors that promote potassium secretion include aldosterone, increased sodium delivery to the distal nephron, and increased urine flow rate.

CALCIUM

A significant portion of filtered calcium (70%) is reabsorbed in the proximal tubule. Additional calcium is reabsorbed in the ascending loop of Henle (20%) and the distal tubule and collecting duct (5–10%). Calcium is reabsorbed by passive movement between cells (paracellular absorption) in a process driven by sodium chloride reabsorption and potassium recycling into the lumen. In addition, calcium uptake is actively regulated by calcium receptors, specific transporters, and calcium channels. Factors that promote calcium reabsorption include parathyroid hormone (released in response to hypocalcemia), calcitonin, vitamin D, thiazide diuretics, and volume depletion (see Chapter 610). Factors that promote calcium excretion include volume expansion, increased sodium intake, and diuretics such as mannitol and furosemide.

PHOSPHATE

The majority of filtered phosphate is reabsorbed in the proximal tubule by active transport coupled with sodium through the NaPi2a, NaPi2c, and PiT-2 channels. Reabsorption is increased by dietary phosphorus restriction, volume contraction, and growth hormone. Fibroblast growth factor 23 (FGF-23), parathyroid hormone, and volume expansion increase phosphate excretion.

MAGNESIUM

Approximately 25% of filtered magnesium is reabsorbed in the proximal tubule. Modulation of renal magnesium excretion occurs primarily in the ascending loop of Henle, with some contribution of the distal convoluted tubule. Magnesium is transported by the paracellular route similar to calcium, as well as through the transcellular route. Although specific magnesium transporters for transcellular absorption have been identified such as TRPM6, the precise mechanisms by which they are regulated remain unclear.

ACIDIFICATION AND CONCENTRATING MECHANISMS

Acidification and concentration are addressed in the sections on renal tubular acidosis and nephrogenic diabetes insipidus, respectively (see Chapters 569 and 570).

DEVELOPMENTAL CONSIDERATIONS

The tubular transport capabilities of neonates (especially premature infants) and young infants are less than those of adults. Although nephrogenesis (the formation of new glomerular/tubular units) is complete by about 36 weeks of gestation, significant tubular maturation occurs during infancy. Renal tubular immaturity, a reduced glomerular filtration rate, a decreased concentrating gradient, and a diminished responsiveness to antidiuretic hormone are characteristic of young infants. These factors can contribute to impaired regulation of water, solute, and electrolyte and acid-base homeostasis, particularly during times of acute illness.

Visit Elsevier eBooks+ at eBooks.Health.Elsevier.com for Bibliography.

Chapter 569

Renal Tubular Acidosis

Melisha G. Hanna and Bradley P. Dixon

Renal tubular acidosis (RTA) is a disease state characterized by a non–anion gap (hyperchloremic) metabolic acidosis in the setting of a normal or near-normal glomerular filtration rate. There are four main types of RTA: proximal (type II), classic distal (type I), hyperkalemic (type IV), and a combined proximal and distal (type III). Proximal RTA (pRTA) results from impaired bicarbonate reabsorption and distal RTA (dRTA) from failure to secrete acid. These defects may be inherited and persistent from birth or acquired, as is seen more commonly in clinical practice.

NORMAL URINARY ACIDIFICATION

Kidneys contribute to the acid-base balance by reabsorption of filtered bicarbonate (HCO_3^-) and excretion of hydrogen ion (H^+) produced every day. Hydrogen ion secretion from tubule cells into the lumen is key in the reabsorption of HCO_3^- and the formation of titratable acid (H^+ bound to buffers such as HPO_4^{2-}) and ammonium ions (NH_4^+). Because loss of filtered HCO_3^- is equivalent to the addition of H^+ to the body, all filtered bicarbonate should be absorbed before dietary H^+ can be excreted. Approximately 90% of filtered bicarbonate is absorbed in the proximal tubule and the remaining 10% in the distal segments, mostly the thick ascending limb and outer medullary collecting tubule (Fig. 569.1). In the proximal tubule and thick ascending limb of the loop of Henle, H^+ from water is secreted by the Na^+-H^+ exchanger on the luminal membrane. H^+ combines with filtered bicarbonate, resulting in the formation of H_2CO_3, which decomposes into water and CO_2 in the presence of carbonic anhydrase IV. CO_2 diffuses freely back into the cell, combines with OH^- (from H_2O) to form HCO_3^- in the presence of carbonic anhydrase II, and returns to the systemic circulation via a Na^+-HCO_3^- co-transporter situated at the basolateral membrane of the cell. In the collecting tubule, H^+ is secreted into the lumen by H^+ATPase (adenosine triphosphatase), and HCO_3^- is returned to the systemic circulation by the HCO_3^--Cl^- exchanger located on the basolateral membrane. The H^+ secreted proximally and distally in excess of the filtered HCO_3^- is excreted in the urine either as titratable acid ($H_2PO_4^-$) or as NH_4^+.

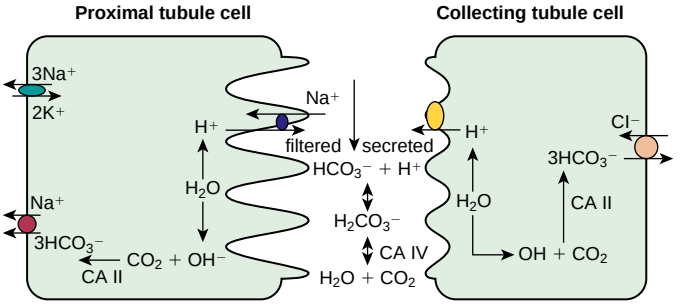

Fig. 569.1 Major cellular luminal events in acid-base regulation in the proximal and collecting tubule cells. In the proximal tubule, H^+, split from H_2O, is secreted into the lumen via the Na^+/H^+ exchanger, and HCO_3^-, formed by a combination of OH^- (split from H_2O) with CO_2 in the presence of carbonic anhydrase (CA) II, is returned to the systemic circulation by an Na^+-$3HCO_3^-$ co-transporter. Similarly, in the collecting tubule, H^+ is secreted into the lumen by an active H^+-ATPase (adenosine triphosphatase), and HCO_3^- is returned to the systemic circulation via an HCO_3^--Cl^- exchanger. H^+ secreted into the lumen combines with filtered HCO_3^- to form carbonic acid (H_2CO_3) and then CO_2 and H_2O in the presence of CA IV, which can be passively reabsorbed. *(Modified from Rose BD, Post TW. Clinical Physiology of Acid-Base and Electrolyte Disorders, 5th ed. New York: McGraw-Hill; 2001.)*

569.1 Proximal (Type II) Renal Tubular Acidosis

Melisha G. Hanna and Bradley P. Dixon

pRTA can be inherited and persistent from birth or occur as a transient phenomenon during infancy. Although rare, it may be primary and isolated. Typically, however, pRTA occurs as a component of global proximal tubular dysfunction or **Fanconi syndrome,** which is characterized by low molecular weight proteinuria, glycosuria, phosphaturia, aminoaciduria, and pRTA. Table 569.1 outlines the causes of pRTA and Fanconi syndrome. Many of these causes are inherited disorders. In addition to **cystinosis** and **Lowe syndrome,** autosomal recessive and dominant pRTA are addressed further in this section. Other inherited forms of Fanconi syndrome include galactosemia (see Chapter 107.2), hereditary fructose intolerance (see Chapter 107.3), tyrosinemia (see Chapter 105.2), and Wilson disease (see Chapter 405.2). Dent disease, or X-linked nephrolithiasis, is discussed in Chapter 571.3. In children, an important form of secondary Fanconi syndrome is exposure to medications such as the chemotherapy agents ifosfamide and cisplatin.

AUTOSOMAL RECESSIVE DISEASE

Isolated autosomal recessive pRTA is caused by pathogenic variants in *SLC4A4* encoding the sodium bicarbonate co-transporter NBC1. It manifests with ocular abnormalities (band keratopathy, cataracts, and glaucoma, often leading to blindness), short stature, enamel defects of the teeth, intellectual impairment, and occasionally basal ganglia calcification along with pRTA. An autosomal dominant pattern of inheritance has also been identified but is rare; these patients present with hyperchloremic metabolic acidosis, a normal ability to acidify urine, normal renal function, and growth retardation.

CLINICAL MANIFESTATIONS OF PROXIMAL RTA AND FANCONI SYNDROME

Patients with isolated, sporadic, or inherited pRTA present with growth failure in the first year of life. Additional symptoms can include polyuria, dehydration (from sodium loss), anorexia, vomiting, constipation, and hypotonia. Patients with primary Fanconi syndrome have additional symptoms, secondary to phosphate wasting, such as rickets. Those with systemic diseases present with additional signs and symptoms specific to their underlying disease. Urinalysis in patients with isolated pRTA is generally unremarkable. The urine pH is acidic (<5.5) because distal acidification mechanisms are intact in these patients. Urinary studies in patients with Fanconi syndrome demonstrate varying degrees of phosphaturia, aminoaciduria, glycosuria, uricosuria, and elevated urinary sodium or potassium. Depending on the nature of the underlying disorder, laboratory evidence of chronic kidney disease (CKD), including elevated serum creatinine, may be present.

Cystinosis

Cystinosis is an autosomal recessive, systemic lysosomal storage disease caused by a defect in the transport of cystine out of lysosomes resulting in the accumulation of cystine crystals in most of the major organs of the body, notably the kidney, liver, eye, and brain. It occurs at an incidence of 1:100,000 to 1:200,000. At least three clinical patterns have been described. The most severe form of the disease, infantile or nephropathic cystinosis, presents in the first or second

Table 569.1 Disorders with Dysfunction of Renal Acidification—Defective HCO_3^- Reclamation: Proximal Renal Tubular Acidosis

ISOLATED PURE BICARBONATE WASTING (UNASSOCIATED WITH FANCONI SYNDROME)
Primary
Autosomal recessive with ocular abnormalities (pathogenic variant of *SLC4A4*/NBC1)
Autosomal dominant with short stature (pathogenic variant of *SLC9A3*/ NHE3)
Carbonic anhydrase deficiency, inhibition, or alteration
Drugs
Acetazolamide
Topiramate
Sulfanilamide
Mafenide acetate
Carbonic anhydrase II deficiency with osteopetrosis (mixed proximal and distal RTA type III)
GENERALIZED (ASSOCIATED WITH FANCONI SYNDROME)
Primary (Without Associated Systemic Disease)
Genetic
Sporadic
Genetically Transmitted Systemic Diseases
Cystinosis
Lowe syndrome
Wilson syndrome
Fanconi-Bickel syndrome
Tyrosinemia
Galactosemia
Hereditary fructose intolerance (during fructose ingestion)
Metachromatic leukodystrophy
Pyruvate carboxylase deficiency
Methylmalonic acidemia
Dysproteinemic States
Multiple myeloma
Monoclonal gammopathy
Secondary Hyperparathyroidism with Chronic Hypocalcemia
Vitamin D deficiency or resistance
Vitamin D dependency
Drugs or Toxins
Ifosfamide
Cisplatin
Outdated tetracycline
3-Methylchromone
Streptozotocin
Valproate
Topiramate
Lead
Mercury
Amphotericin B (historical)
Tubulointerstitial Diseases
Sjögren syndrome
Medullary cystic disease
Renal transplantation
Other Renal and Miscellaneous Diseases
Nephrotic syndrome
Amyloidosis
Paroxysmal nocturnal hemoglobinuria

From DuBose TD Jr. Disorders of acid-base balance. In: Skorecki K, Chertow GM, Marsden PA, et al., eds. *Brenner & Rector's The Kidney,* 10th ed. Philadelphia: Elsevier; 2016: Table 17-7.

year of life with severe tubular dysfunction and growth failure. If the disease is not treated, the children develop end-stage kidney disease by the end of their first decade. A milder form of the disease manifests by adolescence called juvenile or intermediate nephropathic cystinosis, and it is characterized by less severe tubular abnormalities and a slower progression to renal failure. A nonnephropathic adult form also exists called ocular cystinosis and has isolated ocular involvement.

Cystinosis is caused by pathogenic variants in *CTNS,* which encodes the protein cystinosin, a lysosomal cystine transporter. Genotype-phenotype studies demonstrate that patients with severe nephropathic cystinosis carry variants that lead to complete loss of cystinosin function. Patients with milder clinical disease have variants that lead to the expression of partially functional protein. Patients with nephropathic cystinosis present with clinical manifestations reflecting their pronounced tubular dysfunction and Fanconi syndrome, including polyuria and polydipsia, growth failure, and rickets. Fever, caused by dehydration or diminished sweat production, is common. Patients are typically fair skinned and blond because of diminished pigmentation. Ocular presentations include photophobia, retinopathy, and impaired visual acuity. Patients also can develop hypothyroidism, hepatosplenomegaly, and delayed sexual maturation. With progressive tubulointerstitial fibrosis, CKD is invariant.

The diagnosis of cystinosis is suggested by the detection of cystine crystals in the cornea and confirmed by measurement of increased leukocyte cystine content and genetic testing for biallelic pathogenic variants in the *CTNS* gene. Prenatal testing is available for at-risk families.

Treatment of cystinosis is directed at correcting the metabolic abnormalities associated with Fanconi syndrome. In addition, lifelong therapy is required with cysteamine, a therapy which converts cystine to cysteine and a cysteine-cysteamine heterodimer. This facilitates lysosomal transport and decreases tissue cystine. Oral cysteamine does not achieve adequate levels in ocular tissues, so additional therapy with cysteamine eyedrops is required. Early initiation of cysteamine can prevent or delay deterioration of renal function and the need for renal replacement therapy. Patients with growth failure that does not improve with cysteamine may benefit from treatment with growth hormone. Kidney transplantation is a viable option in patients with renal failure. With prolonged survival, additional complications may become evident, including central nervous system abnormalities, muscle weakness, swallowing dysfunction, and pancreatic insufficiency. It is unclear whether long-term cysteamine therapy will decrease these complications.

Lowe Syndrome

Lowe syndrome (oculocerebrorenal syndrome of Lowe) is a rare X-linked disorder characterized by congenital cataracts, developmental delay, and Fanconi syndrome. The disease is caused by pathogenic variants in *OCRL1,* which encodes the phosphatidylinositol polyphosphate 5-phosphatase protein. The abnormalities seen in Lowe syndrome are thought to be caused by abnormal transport of vesicles within the Golgi apparatus. Kidneys show nonspecific tubulointerstitial changes. Thickening of glomerular basement membrane and changes in proximal tubule mitochondria are also seen.

Patients with Lowe syndrome typically present in infancy with cataracts, progressive growth failure, hypotonia, and Fanconi syndrome. Significant low molecular weight proteinuria is common. Blindness and CKD often develop. Characteristic behavioral abnormalities are also seen, including tantrums, stubbornness, stereotypy (repetitive behaviors), and obsessions. There is no specific therapy for the renal disease or neurologic deficits. Cataract removal is generally required.

569.2 Distal (Type I) Renal Tubular Acidosis

Melisha G. Hanna and Bradley P. Dixon

dRTA can be sporadic or inherited. It can also occur as a complication of inherited or acquired diseases of the distal tubules. Primary or secondary causes of dRTA can result from damaged or impaired

functioning of one or more transporters or proteins involved in the acidification process, including the H^+/ATPase, the HCO_3^-/Cl^- anion exchangers, or the components of the aldosterone pathway. Because of impaired hydrogen ion excretion, the urine pH cannot be reduced to <5.5, despite the presence of severe metabolic acidosis. Loss of sodium bicarbonate distally, due to lack of H^+ to bind to in the tubular lumen (see Fig. 569.1), results in increased chloride absorption and hyperchloremia. Inability to secrete H^+ is compensated for by increased K^+ secretion distally, leading to hypokalemia. **Hypercalciuria** is usually present and can lead to nephrocalcinosis or nephrolithiasis. Chronic metabolic acidosis also impairs urinary citrate excretion. **Hypocitraturia** further increases the risk of calcium deposition in the tubules. Bone disease is common, resulting from mobilization of organic components from bone to serve as buffers to chronic acidosis.

CLINICAL MANIFESTATIONS OF DISTAL RTA

dRTA shares features with those of pRTA, including non–anion gap metabolic acidosis and growth failure; distinguishing features of dRTA include nephrocalcinosis and hypercalciuria. The phosphate and massive bicarbonate wasting characteristic of pRTA is generally absent. Table 569.2 lists the causes of primary and secondary dRTA. Although inherited forms are rare, three specific inherited forms of dRTA have been identified, including an autosomal recessive form associated with sensorineural deafness.

Medullary sponge kidney is a relatively rare sporadic disorder in children, although not uncommon in adults. *HNF1B* pathogenic variants have been implicated in some patients. It is characterized by cystic dilation of the terminal portions of the collecting ducts as they enter the renal pyramids. On ultrasound studies, patients often have medullary nephrocalcinosis. Although patients with this condition typically maintain normal renal function through adulthood, complications include nephrolithiasis, pyelonephritis, hyposthenuria (inability to concentrate urine), and dRTA. Associations of medullary sponge kidney with Beckwith-Wiedemann syndrome or hemihypertrophy have been reported.

569.3 Hyperkalemic (Type IV) Renal Tubular Acidosis

Melisha G. Hanna and Bradley P. Dixon

Type IV RTA occurs as the result of impaired aldosterone production *(hypoaldosteronism)* or impaired renal responsiveness to aldosterone *(pseudohypoaldosteronism)*. Acidosis results because aldosterone has a direct effect on the H^+/ATPase responsible for hydrogen secretion. In addition, aldosterone is a potent stimulant for potassium secretion in the collecting tubule; consequently, lack of aldosterone results in hyperkalemia. This further affects the acid-base status by inhibiting ammoniagenesis and, thus, H^+ excretion. Aldosterone deficiency typically occurs as a result of adrenal gland disorders such as Addison disease or some forms of congenital adrenal hyperplasia. In children, aldosterone unresponsiveness is a more common cause of type IV RTA. This can occur transiently, during an episode of acute pyelonephritis or acute urinary obstruction, or chronically, particularly in infants and children with a history of obstructive uropathy. The latter patients can have significant hyperkalemia, even in instances when renal function is normal or only mildly impaired. Rare examples of inherited forms of type IV RTA have been identified (Table 569.3).

CLINICAL MANIFESTATIONS OF TYPE IV RTA

Patients with type IV RTA can present with growth failure in the first few years of life. Polyuria and dehydration (from salt wasting) are common. Rarely, patients (especially those with pseudohypoaldosteronism type 1) present with life-threatening hyperkalemia.

Table 569.2 Disorders with Dysfunction of Renal Acidification—Selective Defect in Net Acid Excretion: Classic Distal Renal Tubular Acidosis

PRIMARY DISORDERS
Familial
Autosomal dominant
SLC4A1 gene
Autosomal recessive
With deafness (*rdRTA1* or *ATP6V1B1* gene)
Without deafness (*rdRTA2* or *ATP6V0A4*)
Sporadic
ENDEMIC DISORDERS
Northeastern Thailand
DISORDERS SECONDARY TO SYSTEMIC DISORDERS
Autoimmune Diseases
Hyperglobulinemic purpura
Fibrosing alveolitis
Cryoglobulinemia
Chronic active hepatitis
Sjögren syndrome
Primary biliary cirrhosis
Thyroiditis
Polyarteritis nodosa
HIV nephropathy
Hypercalciuria and Nephrocalcinosis
Primary hyperparathyroidism
Hyperthyroidism
Medullary sponge kidney
Fabry disease
X-linked hypophosphatemia
Vitamin D intoxication
Idiopathic hypercalciuria
Wilson disease
Hereditary fructose intolerance
DRUG- AND TOXIN-INDUCED DISEASE
Amphotericin B
Toluene
Cyclamate
Mercury
Hepatic cirrhosis
Vanadate
Ifosfamide
Lithium
Foscarnet
Classic analgesic nephropathy
TUBULOINTERSTITIAL DISEASES
Balkan nephropathy
Kidney transplantation
Chronic pyelonephritis
Leprosy
Obstructive uropathy
Vesicoureteral reflux
Jejunoileal bypass with hyperoxaluria
DISORDERS ASSOCIATED WITH GENETICALLY TRANSMITTED DISEASES
Ehlers-Danlos syndrome
Hereditary elliptocytosis
Sickle cell anemia
Marfan syndrome
Medullary cystic disease
Hereditary sensorineural deafness
Jejunal bypass with hyperoxaluria
Osteopetrosis with carbonic anhydrase II deficiency (mixed proximal and distal RTA type III)
Carnitine palmitoyltransferase deficiency

From Hamm LL, DuBose TD Jr. Disorders of acid-base balance. In: Yu AS, Chertow GM, Luyckx VA, et. Al., eds. *Brenner & Rector's The Kidney,* 11th ed. Philadelphia: Elsevier; 2020: Table 16.9.

Table 569.3 Disorders with Dysfunction of Renal Acidification: Generalized Abnormality of Distal Nephron with Hyperkalemia

MINERALOCORTICOID DEFICIENCY

Primary Mineralocorticoid Deficiency

- Combined deficiency of aldosterone, desoxycorticosterone, and cortisol
  - Addison disease
  - Bilateral adrenalectomy
  - Bilateral adrenal destruction
  - Hemorrhage or carcinoma
- Congenital enzymatic defects
  - 21-Hydroxylase deficiency
  - 3β-Hydroxydehydrogenase deficiency
  - Desmolase deficiency
- Isolated (selective) aldosterone deficiency
  - Chronic idiopathic hypoaldosteronism
  - Heparin (low molecular weight or unfractionated) administration in critically ill patient
  - Familial hypoaldosteronism
  - Corticosterone methyl oxidase deficiency types 1 and 2
  - Primary zona glomerulosa defect
  - Transient hypoaldosteronism of infancy
  - Persistent hypotension and/or hypoxemia
- Angiotensin-converting enzyme inhibition
  - Endogenous
  - Angiotensin-converting enzyme inhibitors and angiotensin receptor blockers

Secondary Mineralocorticoid Deficiency

- Hyporeninemic hypoaldosteronism
  - Diabetic nephropathy
  - Tubulointerstitial nephropathies
  - Nephrosclerosis
  - Nonsteroidal antiinflammatory agents
  - Acquired immunodeficiency syndrome
  - Immunoglobulin M monoclonal gammopathy
  - Obstructive uropathy

MINERALOCORTICOID RESISTANCE

- PHA I: autosomal dominant (human mineralocorticoid receptor defect)

Renal Tubular Dysfunction (Voltage Defect)

- PHA I: autosomal recessive
- PHA II: autosomal dominant
- Drugs that interfere with Na^+ channel function in the CCT
  - Amiloride
  - Triamterene
  - Trimethoprim
  - Pentamidine
- Drugs that interfere with Na^+-K^+-ATPase in the CCT
  - Cyclosporine
  - Tacrolimus
- Drugs that inhibit aldosterone effect on the CCT
  - Spironolactone
  - Eplerenone
- Disorders associated with tubulointerstitial nephritis and renal insufficiency
  - Lupus nephritis
  - Methicillin nephrotoxicity
  - Obstructive nephropathy
  - Kidney transplant rejection
  - Sickle cell disease
  - Williams syndrome with uric acid nephrolithiasis

ATPase, Adenosine triphosphatase; CCT, cortical collecting tubule; PHA I, PHA II, pseudohypoaldosteronism types 1 and 2.

From Hamm LL, DuBose TD Jr. Disorders of acid-base balance. In: Yu AS, Chertow GM, Luyckx VA, et al., eds. *Brenner & Rector's The Kidney,* 11th ed. Philadelphia: Elsevier; 2020: Table 16.11.

Patients with obstructive uropathies can present acutely with signs and symptoms of pyelonephritis, such as fever, vomiting, and foul-smelling urine. Laboratory tests reveal a hyperkalemic non–anion gap metabolic acidosis. Urine may be alkaline or acidic. Elevated urinary sodium levels with inappropriately low urinary potassium levels reflect the absence of aldosterone effect.

DIAGNOSTIC APPROACH TO RENAL TUBULAR ACIDOSIS

The first step in the evaluation of a patient with suspected RTA is to confirm the presence of a normal anion gap metabolic acidosis, identify electrolyte abnormalities, assess renal function, and rule out other causes of bicarbonate loss such as diarrhea (Table 569.4). Metabolic acidosis associated with diarrheal dehydration is extremely common, and acidosis generally improves with correction of volume depletion. Patients with protracted diarrhea can deplete their total-body bicarbonate stores and can have persistent acidosis despite apparent restoration of volume status. In instances where a patient has a recent history of severe diarrhea, full evaluation for RTA should be delayed for several days to permit adequate time for reconstitution of total-body bicarbonate stores. If acidosis persists beyond a few days in this setting, additional studies are indicated.

Serum electrolytes, BUN, calcium, phosphorus, creatinine, and venous blood gas for pH should be obtained by venipuncture. Traumatic blood draws (such as heel-stick specimens), small volumes of blood in adult-size specimen collection tubes, or a prolonged specimen transport time at room temperature can lead to falsely low bicarbonate levels, often in association with an elevated serum potassium value. True hyperkalemic acidosis is consistent with type IV RTA, whereas the finding of normal or low potassium suggests type I or II RTA. The **blood anion gap** should be calculated using the formula $[Na^+] - [Cl^- + HCO_3^-]$. Typically, values of <12 demonstrate the absence of an anion gap. Values of >20 indicate the presence of an anion gap and other diagnoses (lactic acidosis, diabetic ketoacidosis, inborn errors of metabolism, ingested toxins) should be investigated. If tachypnea is noted, evaluation of an arterial blood gas may be appropriate to evaluate the possibility of a mixed acid-base disorder primarily involving respiratory and metabolic components. A detailed history, with particular attention to growth and development, recent or recurrent diarrheal illnesses, a family history of developmental delay, failure to thrive, end-stage kidney disease, infant deaths, or miscarriages is essential. The physical examination should determine growth parameters and volume status as well as the presence of any dysmorphic features suggesting an underlying syndrome.

Once the presence of a non–anion gap metabolic acidosis is confirmed, the urine pH can help distinguish distal from proximal causes. A urine pH <5.5 in the presence of acidosis suggests pRTA, whereas patients with dRTA typically have a urine pH >6.0. The **urine anion gap** ($[\text{urine } Na^+ + \text{urine } K^+] - \text{urine } Cl^-$) is sometimes calculated to confirm the diagnosis of dRTA. A positive gap suggests a deficiency of ammoniagenesis and, thus, the possibility of a dRTA. A negative gap is consistent with proximal tubule bicarbonate wasting (or gastrointestinal bicarbonate wasting). A urinalysis should also be obtained to determine the presence of glycosuria, proteinuria, or hematuria, suggesting more global tubular damage or dysfunction. Random or 24-hour urine calcium and creatinine measurements will identify hypercalciuria. Renal ultrasonography should be performed to identify underlying structural abnormalities such as obstructive uropathies, as well as to determine the presence of nephrolithiasis or nephrocalcinosis (Fig. 569.2).

TREATMENT AND PROGNOSIS

The mainstay of therapy in all forms of RTA is bicarbonate replacement. Patients with pRTA often require large quantities of bicarbonate, up to 20 mEq/kg/24 hr, in the form of sodium bicarbonate or sodium citrate solution (Bicitra or Shohl solution). The base requirement for dRTA is generally in the range of 2-4 mEq/kg/24 hr, although individual patient requirements can vary. Patients with Fanconi syndrome usually require phosphate supplementation. Patients with dRTA should be monitored for the development of hypercalciuria. Those with symptomatic hypercalciuria (recurrent episodes of gross hematuria), nephrocalcinosis, or nephrolithiasis may require

Table 569.4 Contrasting Features and Diagnostic Studies in Renal Tubular Acidosis

	TYPE OF RENAL TUBULAR ACIDOSIS		
FINDING	**PROXIMAL**	**CLASSIC DISTAL**	**GENERALIZED DISTAL DYSFUNCTION**
Plasma [K^+]	Low	Low	High
Urine pH with acidosis	<5.5	>5.5	<5.5 or >5.5
Urine net charge	Negative	Positive	Positive
Fractional bicarbonate excretion	>10–15% during alkali therapy	2–5%	5–10%
U−BP_{CO_2}	Normal	Low	Low
Response to therapy	Least responsive	Responsive	Less responsive
Associated features	Fanconi syndrome	Nephrocalcinosis/ hyperglobulinemia	Renal insufficiency

U−BP_{CO_2}, urine minus blood CO_2 pressure.
Modified from DuBose TD Jr. Disorders of acid-base balance. In: Skorecki K, Chertow GM, Marsden PA, et al., eds. *Brenner & Rector's The Kidney,* 10th ed. Philadelphia: Elsevier; 2016: Table 17-17.

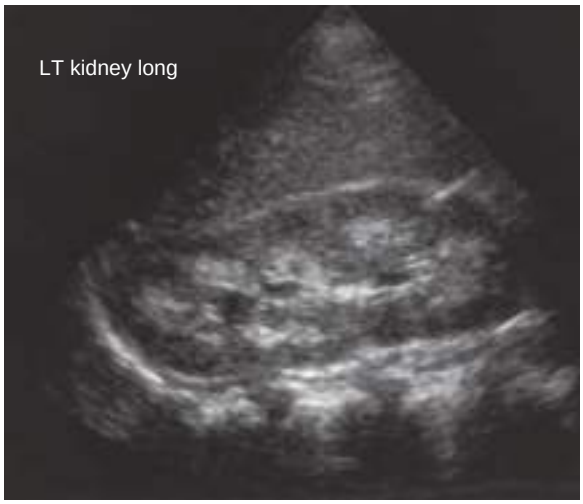

Fig. 569.2 Ultrasound examination of a child with distal RTA, demonstrating medullary nephrocalcinosis.

thiazide diuretics to decrease urine calcium excretion. Patients with type IV RTA can require chronic treatment for hyperkalemia with a sodium-potassium exchange resin (i.e., sodium polystyrene sulfonate or patiromer).

The prognosis of RTA depends to a large extent on the nature of any existing underlying disease. Patients with treated isolated proximal or dRTA generally demonstrate improvement in growth, provided serum bicarbonate levels can be maintained in the normal range. Patients with systemic illness and Fanconi syndrome can have ongoing morbidity with growth failure, rickets, and signs and symptoms related to their underlying disease.

Visit Elsevier eBooks+ at eBooks.Health.Elsevier.com for Bibliography.

569.4 Rickets Associated with Renal Tubular Acidosis

Melisha G. Hanna and Bradley P. Dixon

Rickets may be present in primary RTA, *particularly in pRTA,* due to the added features of hypophosphatemia and phosphaturia from generalized proximal tubular dysfunction. Bone demineralization without overt rickets usually is detected in distal (type I) RTA. This metabolic bone disease may be characterized by bone pain, growth retardation, osteopenia, and, occasionally, pathologic fractures. Bone demineralization in dRTA probably relates to dissolution of bone because the calcium carbonate in bone serves as a buffer against the metabolic acidosis due to the hydrogen ions retained by patients with RTA.

Administration of sufficient bicarbonate to reverse acidosis reverses bone dissolution and the hypercalciuria that is common in dRTA. pRTA is treated with both bicarbonate and oral phosphate supplements to heal rickets. Doses of phosphate similar to those used in familial hypophosphatemia or Fanconi syndrome may be indicated. Vitamin D is required to offset the secondary hyperparathyroidism that complicates oral phosphate therapy. Following therapy, growth in patients with type II (proximal) RTA is greater than in patients with primary Fanconi syndrome.

Chapter 570

Nephrogenic Diabetes Insipidus

Margret E. Bock and Bradley P. Dixon

Nephrogenic diabetes insipidus (NDI) is a rare congenital or, more commonly, acquired, disorder of water metabolism characterized by an inability of the kidneys to concentrate urine, even in the presence of antidiuretic hormone (ADH). The most common pattern of inheritance in congenital NDI is as an X-linked recessive disorder (90% of cases of congenital NDI). Rarely, affected females are seen, presumably secondary to nonrandom X-chromosome inactivation. Approximately 10% of cases of congenital NDI are inherited as autosomal dominant or recessive disorders, with males and females affected equally. The clinical phenotype of autosomal recessive forms is similar to that of the X-linked form. Secondary (acquired) forms of NDI, either partial or complete, are not uncommon. They may be seen in many disorders affecting renal tubular function, including obstructive uropathies, acute kidney injury or chronic kidney disease, cystic kidney diseases, interstitial nephritis,

nephrocalcinosis, or toxic nephropathy caused by hypokalemia, hypercalcemia, lithium, or amphotericin B.

PATHOGENESIS

The ability to concentrate urine (and thus absorb water) requires three components: (1) the delivery of urine to the collecting tubule, (2) an intact concentrating gradient in the renal medulla, and (3) the ability to modulate water permeability in the collecting tubule by ADH. ADH (also called arginine vasopressin [AVP]) is synthesized in the hypothalamus and stored in the posterior pituitary. Under basal situations, the collecting tubule is impermeable to water. However, in response to increased serum osmolality (as detected by osmoreceptors in the hypothalamus) and/or severe volume depletion, ADH is released into the systemic circulation. It then binds to its receptor, vasopressin V2R (AVPR2), on the basolateral membrane of the collecting tubule cell. Binding of the hormone to its receptor activates a cyclic adenosine monophosphate–dependent cascade that results in insertion of preformed water channels (aquaporin 2 [AQP2]) into the luminal membrane of the collecting duct, rendering it permeable to water.

Pathogenic variants in *AVPR2* cause the more common X-linked form of NDI. Pathogenic variants in *AQP2* have been identified in patients with the rarer autosomal dominant and recessive forms. Pathogenic variants in *STIM1* (stromal interaction molecular 1) have also been identified in a mouse model exhibiting partial NDI, due to abnormalities in intracellular calcium regulation by the endoplasmic reticulum. Prenatal testing is available for families at risk for X-linked NDI. Patients with secondary forms of NDI can have ADH resistance due to defective aquaporin expression (as seen in lithium intoxication). Most often, secondary ADH resistance occurs as the result of loss of the hypertonic medullary gradient as a result of solute diuresis or tubular damage, resulting in the inability to absorb sodium or urea.

CLINICAL MANIFESTATIONS

Patients with congenital NDI typically present in the newborn period with massive polyuria, volume depletion, hypernatremia, and hyperthermia. Irritability and inconsolability are common features. Constipation and poor weight gain are also seen. After multiple episodes of **hypernatremic dehydration** in infancy, patients may develop intellectual disabilities, although this has become less common with cautious fluid resuscitation and gradual correction of hypernatremia. Toddlers and older children often display a marked thirst and a preference particularly for cold water. Mediated by the intact thirst mechanism, the need to consume large volumes of water during the day is profound, and patients often have diminished appetite and poor food intake, which may contribute to failure to thrive. However, even with adequate caloric supplementation, patients still exhibit growth abnormalities. Daytime and nighttime enuresis, caused by large urine volumes, is common. Patients with congenital NDI also may exhibit behavioral problems, including hyperactivity and short-term memory problems. Patients with the secondary form generally present later in life, primarily with hypernatremia and polyuria. Associated symptoms such as developmental delay and behavioral abnormalities are less common in this latter group.

DIAGNOSIS

The diagnosis is suggested in a male infant with polyuria, hypernatremia, and dilute urine. Simultaneous serum and urine osmolality measurements should be obtained. *If the serum osmolality value is ≥290 mOsm/kg with a simultaneous urine osmolality value of <290 mOsm/kg, a formal water-deprivation test is not necessary.* Because the differential diagnosis includes causes of **central diabetes insipidus,** the inability to respond to ADH (and thus the presence of NDI) should be confirmed by the administration of vasopressin (10-20 μg intranasally) followed by serial urine and serum osmolality measurements hourly for 4 hours. In patients with possible "partial" or secondary diabetes insipidus, in whom the initial serum osmolality value may be <290 mOsm/kg, a water-deprivation test should be considered. Fluids should be withheld and urine and serum osmolalities measured periodically until the serum osmolality value is >290 mOsm/kg; vasopressin is then given as before. Criteria for premature termination of a water-deprivation test include a decrease in body weight of >3%. These evaluations typically require an inpatient admission, given the need for serial laboratory monitoring and prompt intervention/response to results. If NDI is confirmed or suspected, an additional evaluation should include a detailed history to assess possible toxic exposures, determination of renal function by serum creatinine and BUN levels, and renal ultrasonography to identify obstructive uropathies or cystic kidney disease. Because of the massive urine output, patients with congenital NDI can have *nonobstructive hydronephrosis* of varying severity.

TREATMENT AND PROGNOSIS

Treatment of NDI includes maintenance of adequate fluid intake and access to free water, minimizing the urine output by limiting the solute load with a low-osmolar, low-sodium diet, and administering medications directed at decreasing the urine output. For infants, human milk or a low-solute formula, such as Similac PM 60/40, is preferred. Most infants with congenital NDI require gastrostomy or nasogastric feedings to ensure adequate fluid administration throughout the day and night. Sodium intake in older patients should be <0.7 mEq/kg/24 hr**.** Thiazide diuretics (2-3 mg/kg/24 hr of hydrochlorothiazide) effectively induce sodium loss and stimulate proximal tubule reabsorption of water. Potassium-sparing diuretics, in particular, amiloride (0.3 mg/kg/24 hr in three divided doses), are often additionally indicated. Patients who have an inadequate response to diuretics alone might benefit from the addition of prostaglandin synthetase inhibitors such as indomethacin (2 mg/kg/24 hr), which has an additive effect in reducing water excretion in some patients. Renal function must be monitored closely in such patients because indomethacin can cause deterioration in renal function over time. Patients with secondary NDI may not require medications but should have access to free water. Such patients should have the serum electrolytes and volume status monitored closely, particularly during periods of superimposed acute illnesses. Amiloride may also play a role in managing lithium-induced NDI by blocking entry of lithium into the tubular cell through the epithelial sodium channel (ENaC).

Prevention of recurrent dehydration and hypernatremia in patients with congenital NDI has significantly improved the neurodevelopmental outcome of these patients. However, behavioral issues remain a significant problem. In addition, chronic use of nonsteroidal antiinflammatory drugs can predispose patients to chronic kidney disease. The prognosis of patients with secondary NDI generally depends on the nature of the underlying disease.

Visit Elsevier eBooks+ at eBooks.Health.Elsevier.com for Bibliography.

Chapter 571

Inherited Tubular Transport Abnormalities

571.1 Bartter Syndrome

Danielle E. Soranno and Bradley P. Dixon

Bartter syndrome is a group of disorders characterized by hypokalemic hypochloremic metabolic alkalosis with hypercalciuria and salt wasting (see Chapter 73). These disorders are currently classified by the anatomic site affected by the pathogenic variant (Tables 571.1 and 571.2). **Antenatal Bartter syndrome** (types I, II, and IV; also called hyperprostaglandin E syndrome) typically manifests in infancy and has a more severe phenotype than **classic Bartter syndrome** (type III). The perinatal onset includes maternal polyhydramnios, neonatal salt wasting, and severe episodes of recurrent dehydration. The milder phenotype, classic Bartter syndrome, manifests in childhood with failure to thrive and a history of recurrent episodes of dehydration. A phenotypically related disease, **Gitelman syndrome**, has a distinct genetic defect and is discussed in Chapter 571.2 (see Table 571.1). One distinct variant of antenatal Bartter syndrome is associated with sensorineural deafness (type IV). Bartter-like phenotypes have been noted in other diseases such as Kearns-Sayre syndrome.

PATHOGENESIS

The biochemical features of Bartter syndrome, such as hypokalemic hypochloremic metabolic alkalosis with hypercalciuria, resemble those seen with chronic use of loop diuretics and reflect a defect in sodium, chloride, and potassium transport in the ascending loop of Henle. The urinary loss of sodium and chloride, with resultant volume contraction, stimulates the renin-angiotensin II-aldosterone axis. Aldosterone promotes distal sodium uptake and potassium secretion, exacerbating the hypokalemia. It also stimulates hydrogen ion secretion distally, worsening the metabolic alkalosis. Hypokalemia stimulates prostaglandin synthesis, which further activates the renin-angiotensin II-aldosterone axis. Bartter syndrome has been associated with at least five distinct genetic defects in transporters along the loop of Henle (see Table 571.1). Each contributes, in some manner, to sodium and chloride transport. Pathogenic variants in the genes that encode the $Na^+/K^+/2Cl^-$ transporter (NKCC2, the site of action of furosemide), the luminal potassium channel (ROMK), combined chloride channel (CLC-Ka, CLC-Kb), or subunit of chloride channels (barttin) cause neonatal Bartter syndrome. Isolated defects in the genes that produce a specific basolateral chloride channel (ClC-Kb) cause classic Bartter syndrome.

CLINICAL MANIFESTATIONS

A history of maternal polyhydramnios with or without prematurity may be elicited. Dysmorphic features, including triangular facies, protruding ears, large eyes with strabismus, and drooping mouth may be present on physical examination. Consanguinity suggests the presence of an autosomal recessive disorder. Older children can have a history of recurrent episodes of polyuria with dehydration, failure to thrive, nonspecific fatigue, dizziness, and chronic constipation. Older children may also present with muscle cramps and weakness secondary

Table 571.1 Types of Bartter Syndrome, Gitelman Syndrome, and Related Conditions

DISORDER	OMIM, GENE	GENE PRODUCT	INHERITANCE	FEATURES
BS VARIANTS				
BS I (ABS, HPES)	601678, *SLC12A1*	NKCC2	AR	Polyhydramnios, prematurity, hypokalemic hypochloremic alkalosis, nephrocalcinosis, with or without concentrating defect
BS II (ABS with transient hyperkalemia and acidosis, HPES)	241200, *KCNJ1*	ROMK1	AR	Polyhydramnios, prematurity, transient hyperkalemia and acidosis, then hypokalemic hypochloremic alkalosis, nephrocalcinosis, with or without concentrating defect
BS III (CBS)	607364, *CLCNKB*	ClC-Kb	AR; many sporadic	Variable age at presentation with severity corresponding to type of gene pathogenic variant; hypokalemic hypochloremic alkalosis
BS IVa and BS IVb (ABS or HPES with sensorineural deafness)	602522, *BSND* *CLCNKA*, *CLCNKB*	Bartter ClC-Ka and ClC-Kb	AR	Polyhydramnios, prematurity, hypokalemic hypochloremic alkalosis, sensorineural deafness, with or without concentrating defect
BS V (transient ABS)	300971, *MAGED2*	MAGED2	XR	Severe polyhydramnios, hypokalemic hypochloremic alkalosis with symptoms resolving within the first few months of life
AD hypocalcemic hypercalciuria	601199, *L125P*	CaSR	AD	Hypocalcemic hypocalciuria, hypokalemic hypochloremic alkalosis, suppressed PTH
GS VARIANTS				
GS	263800, *SLC12A3*	NCC	AR	Present in later childhood or adulthood with weakness, lethargy, carpopedal spasm, hypokalemic alkalosis, hypomagnesemia, hypermagnesuria and hypocalciuria
EAST syndrome (SeSAME)	612780, *Kir4.1*	KCNJ10	AR	Epilepsy, ataxia, sensorineural deafness, hypokalemic hypochloremic alkalosis
OTHER VARIANTS				
CLDN10 pathogenic variants	617579, *CLDN10*	Claudin-10	AR	Hypokalemic metabolic alkalosis with hypocalciuria but normal to elevated magnesium

ABS, Antenatal Bartter syndrome; AD, autosomal dominant; AR, autosomal recessive; BS, Bartter syndrome; CaSR, calcium-sensing receptor; CBS, classic Bartter syndrome; ClC-Ka, chloride channel-Ka; ClC-Kb, chloride channel-Kb; GS, Gitelman syndrome; HPES, hyperprostaglandin E syndrome; MAGED, melanoma-associated antigen-D2; NCC, thiazide-sensitive NaCl cotransporter; NKCC2, furosemide-sensitive Na-K-2Cl cotransporter; OMIM, Online Mendelian Inheritance in Man; PTH, parathyroid hormone; ROMK, renal outer medullary K channel; SeSAME, seizures, sensorineural deafness, ataxia, mental retardation, and electrolyte imbalances; XR, X-linked recessive.

From Fulchiero R, Seo-Mayer P. Bartter syndrome and Gitelman syndrome. *Pediatr Clin North Am*. 2019;66:121–134. Box 1.

Table 571.2 Features That Distinguish Bartter and Gitelman Syndrome Variants

VARIANT	AGE OF ONSET	SERUM K	SERUM CL	SERUM MG	SERUM RENIN, ALDOSTERONE	URINE CA/CR	OTHER DISTINCT FEATURES
BS I	AN	Low	Low	Normal	High, high	High	—
BS II	AN	High, then low	Low	Normal	High, high	High	Transient hyperkalemia
BS III	N, C, A	Low	Very low	Normal	High, high	Low, normal, or high	—
BS IVa, IVb	AN	Low	Low	Normal	High, high	Normal or high	Sensorineural deafness
BS V	AN	Low	Low	Normal	High, high	—	Transient features
Hypocalcemic hypercalciuria	—	Low	Low	Normal	High, high	High	Family history, hypocalcemia, suppressed PTH
GS	C, A	Low	Low	Low	High, high	Low	—
EAST syndrome	—	Low	Low	Low	High, high	Low	Epilepsy, ataxia, sensorineural deafness

A, Adult; AN, antenatal; BS, Bartter syndrome; C, child; Ca/Cr, spot calcium to creatinine ratio; GS, Gitelman syndrome; Mg, magnesium; N, neonate; PTH, parathyroid hormone.
From Fulchiero R, Seo-Mayer P. Bartter syndrome and Gitelman syndrome. *Pediatr Clin North Am*. 2019;66:121–134. Box 3.

to chronic hypokalemia. Blood pressure is usually preserved, although patients with the antenatal form can have severe salt wasting, resulting in dehydration and hypotension. Serum chemistry reveals the classic biochemical abnormalities of a **hypokalemic hypochloremic metabolic alkalosis.** Renal function is typically normal. Urinary calcium levels are typically elevated, as are urinary potassium and sodium levels. Serum renin, aldosterone, and prostaglandin E levels are often markedly elevated, particularly in the more severe antenatal form. Nephrocalcinosis, resulting from hypercalciuria, may be seen on ultrasound examination (types I and II).

DIAGNOSIS

The diagnosis is usually made based on the clinical presentation and laboratory findings. The diagnosis in the neonate or infant is suggested by severe hypokalemia, usually <2.5 mmol/L, with metabolic alkalosis. Hypercalciuria is typical; hypomagnesemia is seen in a minority of patients but is more common in Gitelman syndrome. Because features of Bartter syndrome resemble the chronic use of loop diuretics, diuretic abuse should be considered in the differential diagnosis, even in young children. Chronic vomiting and cystic fibrosis can also present a similar clinical picture but can be distinguished by the measurement of **urinary chloride,** which is elevated in Bartter syndrome and low in patients with chronic vomiting and cystic fibrosis. Kidneys demonstrate hyperplasia of the juxtaglomerular apparatus, although renal biopsy is rarely performed to diagnose this condition.

TREATMENT AND PROGNOSIS

Treatment of Bartter syndrome is directed at preventing dehydration, maintaining nutritional status, and correcting hypokalemia. Potassium supplementation, usually in the form of potassium chloride to correct the concomitant chloride depletion and often at very high doses, is required. Potassium-sparing diuretics (such as spironolactone) are also often used to inhibit distal potassium secretion. Even with appropriate therapy, serum potassium values might not normalize, particularly in patients with the neonatal form. Infants and young children require a high-sodium diet and, at times, sodium supplementation. Indomethacin, a prostaglandin inhibitor, can also be effective. If hypomagnesemia is present, magnesium supplementation is required. With close attention to electrolyte balance, volume status, and growth, the long-term prognosis is generally good. Routine monitoring is necessary, particularly during periods of growth, to ensure that electrolytes are maintained in a safe range. Strict return/call precautions are needed in times of illness with extrarenal volume loss such as vomiting or diarrhea. In a minority of patients, chronic hypokalemia, nephrocalcinosis, and chronic indomethacin therapy can lead to chronic interstitial nephritis and chronic renal failure.

571.2 Gitelman Syndrome

Danielle E. Soranno and Bradley P. Dixon

Gitelman syndrome (often called a *Bartter syndrome variant*) is a rare autosomal recessive cause of hypokalemic hypochloremic metabolic alkalosis, with distinct features of **hypocalciuria** and **hypomagnesemia.** Patients with Gitelman syndrome are typically diagnosed incidentally in late childhood or early adulthood (see Tables 571.1 and 571.2).

PATHOGENESIS

The biochemical features of Gitelman syndrome resemble those of chronic use of thiazide diuretics. Thiazides act on the sodium chloride cotransporter NCCT, present in the distal convoluted tubule. Through linkage analysis and mutational studies, defects in the gene encoding NCCT have been demonstrated in patients with Gitelman syndrome.

CLINICAL MANIFESTATIONS

Patients with Gitelman syndrome typically present at a later age than those with Bartter syndrome and may have symptoms similar to older children with Bartter syndrome (see Chapter 571.1). Patients often have a history of salt craving, recurrent muscle cramps and spasms, presumably caused by low serum magnesium levels, nocturia, polyuria, and occasional hypotension. They usually do not have a history of recurrent episodes of dehydration. Biochemical abnormalities include hypokalemia, metabolic alkalosis, and hypomagnesemia. The urinary calcium level is usually very low (in contrast to the elevated urinary calcium level often seen in Bartter syndrome), and the urinary magnesium level is elevated. Renin and aldosterone levels are usually normal, and prostaglandin E secretion is not elevated. Growth failure is less prominent in Gitelman syndrome than in Bartter syndrome.

DIAGNOSIS

The diagnosis of Gitelman syndrome is suggested in an adolescent or adult presenting with hypokalemic hypochloremic metabolic alkalosis, hypomagnesemia, and hypocalciuria. The diagnosis is often made incidentally after hypokalemia is noted on bloodwork, spurring further evaluation.

TREATMENT

Therapy is directed at correcting hypokalemia and hypomagnesemia with supplemental potassium and magnesium. Sodium supplementation or treatment with prostaglandin inhibitors is generally not necessary because patients typically do not have episodes of volume

depletion or elevated prostaglandin E excretion. Recently, SGLT2 inhibitors have begun to be utilized in adults with refractory hypomagnesemia; however, further studies are needed to investigate their utility in the treatment of Gitelman syndrome.

571.3 Other Inherited Tubular Transport Abnormalities

Danielle E. Soranno and Bradley P. Dixon

Inherited abnormalities in distinct transporters in each segment of the nephron have now been identified and the molecular defects have been characterized. Renal tubular acidosis and nephrogenic diabetes insipidus are discussed in detail in Chapters 569 and 570, respectively. **Cystinuria** is an autosomal recessive disorder seen primarily in patients of Middle Eastern descent and is characterized by recurrent stone formation. The disease is caused by a defective high-affinity transporter for L-cystine and dibasic amino acids present in the proximal tubule; affected females form fewer stones than males. Treatment focuses on stone prevention via hydration, sodium restriction, urine alkalinization, and cystine-binding therapy.

Dent disease is an X-linked proximal tubulopathy with characteristic abnormalities that include low molecular weight proteinuria, hypercalciuria, and variably other features of Fanconi syndrome, such as glycosuria, aminoaciduria, and phosphaturia. Although some patients develop nephrocalcinosis, nephrolithiasis, progressive renal failure, and hypophosphatemic rickets, patients with Dent disease typically do not have proximal renal tubular acidosis or extrarenal manifestations. Loss-of-function pathogenic variants of *CLCN5,* which encodes a renal Cl^-/H^+ antiporter (ClC-5), are reported in ~50–60% of patients with Dent disease. The genetic heterogeneity of Dent disease in some patients who exhibit pathogenic variants in the gene for OCRL1 (responsible for Lowe syndrome) also meet the criteria for Dent disease (~15% of patients) called Dent 2 disease. Dent disease includes X-linked recessive nephrolithiasis with renal failure, X-linked recessive hypophosphatemic rickets, and idiopathic low molecular weight proteinuria seen in Japanese children.

Pathogenic variants in an extracellular basolateral calcium-sensing receptor, normally present in the loop of Henle, can cause a **dominant Bartter syndrome–like picture** (also known as Bartter syndrome type V). These patients' predominant symptoms are hypocalcemia and suppressed parathyroid hormone function, which differentiates them from patients with Bartter syndrome.

In the distal convoluted tubule, gain-of-function pathogenic variants in *WNK1* and loss-of-function pathogenic variants in *WNK4,* both serine threonine kinases, lead to excessive NCCT-mediated salt reabsorption with the clinical picture of pseudohypoaldosteronism type 2 (familial hyperkalemic hypertension, or **Gordon syndrome**), including volume expansion with hypertension, hyperkalemia, hyperchloremic metabolic acidosis, and hypercalciuria. Due to the excessive activation of the thiazide-sensitive NCCT, this disorder can be effectively treated with thiazide diuretics.

In the collecting duct, gain-of-function pathogenic variants of the gene that encodes the epithelial sodium channel (ENaC) cause an inherited form of hypertension, **Liddle syndrome.** Patients with this disorder have constitutive sodium uptake in the collecting duct, with hypokalemia and suppressed aldosterone. Due to the excessive activation of ENaC, potassium-sparing diuretics (specifically amiloride) are an effective treatment for Liddle syndrome. Conversely, loss-of-function pathogenic variants cause **pseudohypoaldosteronism,** characterized by severe sodium wasting and hyperkalemia as well as a distal (type IV) RTA (also discussed in Chapter 569.3). A variant of the latter disorder is associated with systemic abnormalities, including defects in sweat chloride, and can resemble cystic fibrosis.

Renal hypouricemia, a defect in *SLC22A12,* presents with low serum uric acid levels and is complicated by exercise-induced acute kidney injury. Patients have elevated urine uric acid levels and present with loin pain, nausea, and vomiting after exercise. Treatment is for acute kidney injury and reducing the intensity of exercise.

Visit Elsevier eBooks+ at eBooks.Health.Elsevier.com for Bibliography.

Chapter 572 Renal Failure

572.1 Acute Kidney Injury

Prasad Devarajan

Acute kidney injury (AKI) has been traditionally defined as an abrupt loss of kidney function leading to a rapid decline in the glomerular filtration rate (GFR), accumulation of waste products such as blood urea nitrogen (BUN) and creatinine, and dysregulation of extracellular volume and electrolyte homeostasis. The term AKI has replaced acute renal failure (ARF); AKI embodies a continuum of renal dysfunction that ranges from a small increase in serum creatinine to complete anuric renal failure. The incidence of AKI varies from 5–10% of all hospitalizations to >25% in critically ill infants and children. The etiology of AKI varies widely according to age, geographic region, and clinical setting. Functional AKI induced by dehydration is usually reversible with early fluid therapy. However, the prognosis for patients with structural AKI in the intensive care setting with multiorgan failure remains guarded.

A classification system proposed by the Kidney Disease Improving Global Outcomes (KDIGO) AKI Consensus Conference takes both serum creatinine and urine output criteria into account to define and stage AKI (Table 572.1). Thus AKI is defined as

Increase in serum creatinine by ≥0.3 mg/dL from baseline within 48 hours, *or*

Increase in serum creatinine to ≥1.5 times baseline within the prior 7 days, *or*

Urine volume ≤0.5 mL/kg/hr for 6 hours

PATHOGENESIS

AKI has been conventionally classified into three categories: prerenal, intrinsic renal, and postrenal (Table 572.2 and Fig. 572.1).

Prerenal AKI, also called *prerenal azotemia,* is characterized by a diminished effective circulating arterial volume, which leads to inadequate kidney perfusion and a decreased GFR. Evidence of structural kidney damage is largely absent. Common causes of prerenal AKI include dehydration, sepsis, hemorrhage, severe hypoalbuminemia, and cardiac failure. If the underlying cause of the kidney hypoperfusion is reversed promptly, kidney function returns to normal. If hypoperfusion is sustained, intrinsic kidney parenchymal damage can develop.

Intrinsic renal AKI includes a variety of disorders characterized by kidney parenchymal damage, including sustained hypoperfusion and ischemia. Ischemic/hypoxic injury and nephrotoxic insults are the most common causes of intrinsic AKI in high-resource countries and are more common with an underlying comorbid condition; most are associated with cardiac, oncologic, urologic, kidney, and genetic disorders or prematurity (Table 572.3). Many forms of **glomerulonephritis,**

Table 572.1 Kidney Disease Improving Global Outcomes Staging of Acute Kidney Injury

STAGE	SERUM CREATININE	URINE OUTPUT
1	1.5-1.9 times baseline, OR ≥0.3 mg/dL increase	<0.5 mL/kg/hr for 6-12 hr
2	2.0-2.9 times baseline	<0.5 mL/kg/hr for ≥12 hr
3	3.0 times baseline, OR SCr ≥4.0 mg/dL, OR Initiation of renal replacement therapy, OR eGFR <35 mL/min per 1.73 m^2 (<18 yr)	<0.3 mL/kg/hr for ≥24 hr, OR Anuria for ≥12 hr

SCr, Serum creatinine; eGFR, estimated glomerular filtration rate.

Table 572.2 Common Causes of Acute Kidney Injury

PRERENAL
Dehydration (hypovolemia)
Gastroenteritis (hypovolemia)
Hemorrhage (hypovolemia)
Burns
Sepsis
Shock
Capillary leak/systemic inflammatory response syndrome
Hypoalbuminemia
Cirrhosis
Abdominal compartment syndrome
Cardiac failure
Anaphylaxis
INTRINSIC RENAL
Glomerulonephritis
Postinfectious/poststreptococcal
Lupus erythematosus
IgA vasculitis
Membranoproliferative
Anti–glomerular basement membrane
Hemolytic uremic syndrome
Thrombotic thrombocytopenic purpura
Acute tubular necrosis
Cortical necrosis
Renal vein thrombosis
Infarction
Rhabdomyolysis
Acute interstitial nephritis
Tumor infiltration
Toxin and drugs (see Table 572.3)
Tumor lysis syndrome
Vasculitis
POSTRENAL
Posterior urethral valves
Ureteropelvic junction obstruction
Ureterovesical junction obstruction
Ureterocele
Tumors
Urolithiasis
Urethral strictures
Hemorrhagic cystitis (blood clots)
Neurogenic bladder
Anticholinergic drugs

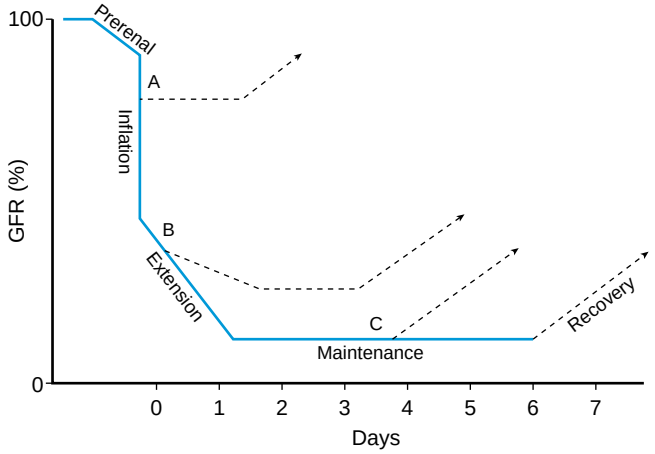

Fig. 572.1 Phases of acute kidney injury. GFR, Glomerular filtration rate. *(From Sutton TA, Fisher CJ, Molitoris BA. Microvascular endothelial injury and dysfunction during ischemic acute renal failure. Kidney Int. 2002;62:1539–1549.)*

Table 572.3 Major Endogenous and Exogenous Toxins Causing Acute Tubular Injury

ENDOGENOUS TOXINS	EXOGENOUS TOXINS
MYOGLOBULINURIA	**ANTIBIOTICS**
Muscle breakdown: trauma, compression, electric shock, hypothermia, hyperthermia, seizures, exercise, burns *Metabolic:* hypokalemia, hypophosphatemia *Infections:* tetanus, influenza *Toxins:* isopropyl alcohol, ethanol, ethylene glycol, toluene, snake and insect bites, cocaine, heroin *Drugs:* HMG-CoA reductase inhibitors (statins), amphetamines, fibrates *Inherited disease:* deficiency of myophosphorylase, phosphofructokinase, carnitine palmitoyltransferase *Autoimmune:* polymyositis, dermatomyositis	Aminoglycosides Amphotericin B Antiviral agents: acyclovir, cidofovir, indinavir, foscarnet, tenofovir Pentamidine Piperacillin tazobactam** Vancomycin **CHEMOTHERAPY** Cisplatin CAR-T cell therapy* Ifosfamide Plicamycin 5-Fluorouracil Cytarabine 6-Thioguanine Methotrexate Immune checkpoint inhibitors **CALCINEURIN INHIBITORS** Cyclosporine Tacrolimus
HEMOGLOBINURIA	**ORGANIC SOLVENTS**
Mechanical: prosthetic valves, microangiopathic hemolytic anemia, extracorporeal circulation *Drugs:* hydralazine, methyldopa *Chemicals:* benzene, arsine, fava beans, glycerol, phenol *Immunologic:* transfusion reaction *Genetic:* G6PD deficiency, PNH	Toluene Ethylene glycol Mannitol **POISONS** Snake venom Paraquat **MISCELLANEOUS** Radiocontrast media Intravenous immune globulin ACE inhibitors Nonsteroidal antiinflammatory drugs Allopurinol Oral phosphate bowel preparations Synthetic cannabinoids
INTRATUBULAR OBSTRUCTION FROM CRYSTALLURIA OR PARAPROTEINS	
Tumor lysis syndrome HGPRT deficiency Multiple myeloma Oxalate (ethylene glycol)	

*Associated cytokine release syndrome, tumor lysis syndrome.
**Controversial
ACE, Angiotensin-converting enzyme; CAR-T, chimeric antigen receptor T cells; G6PD, glucose-6-phosphate dehydrogenase; HGPRT, hypoxanthine-guanine phosphoribosyltransferase; HMG-CoA, 3-hydroxy-3-methylglutaryl coenzyme A; PNH, paroxysmal nocturnal hemoglobinuria.
Modified from Weisbord SD, Palevsky PM. Acute kidney injury. In: Yu AS, Chertow GM, Luyckx VA, et al, eds. *Brenner & Rector's The Kidney,* 11th ed. Philadelphia: Elsevier; 2020: Table 29.3.

including postinfectious glomerulonephritis, lupus nephritis, IgA vasculitis nephritis (formerly Henoch-Schönlein purpura nephritis), membranoproliferative glomerulonephritis, and anti–glomerular basement membrane nephritis, can also cause intrinsic AKI. Severe and prolonged ischemic/hypoxic injury and nephrotoxic insult lead to **acute tubular**

necrosis (ATN), seen most often in critically ill infants and children. Mechanisms leading to ischemic AKI include hypotension/intravascular volume depletion (hemorrhage, third-space fluid losses, diarrhea), decreased effective intravascular volume (heart failure, cirrhosis, hepatorenal syndrome, peritonitis, abdominal compartment syndrome), vasodilation/vasoconstriction (sepsis, hepatorenal syndrome), renal artery obstruction (thrombosis, embolization, stenosis), intrarenal artery disease (vasculitis, hemolytic uremic syndrome [HUS], sickle cell anemia, transplant rejection), and impaired renal blood flow (cyclosporine, tacrolimus, angiotensin-converting enzyme [ACE] inhibitors, angiotensin-receptor blocking agents, radiocontrast agents).

The typical pathologic feature of ATN is tubular cell necrosis, although significant histologic changes are not consistently seen in patients with clinical ATN. The mechanisms of injury in ATN can include alterations in intrarenal hemodynamics, tubular obstruction, and passive back leak of the glomerular filtrate across injured tubular cells into the peritubular capillaries.

Tumor lysis syndrome is a specific form of AKI related to spontaneous or chemotherapy-induced cell lysis in patients with lymphoproliferative malignancies. This disorder is primarily caused by obstruction of the tubules by uric acid crystals (see Chapters 544 and 545). **Acute interstitial nephritis** is another common cause of AKI and is usually a result of a hypersensitivity reaction to a therapeutic agent or various infectious agents (see Chapter 561.2).

Postrenal AKI includes a variety of disorders characterized by obstruction of the urinary tract. In neonates and infants, congenital conditions, such as posterior urethral valves and bilateral ureteropelvic junction obstruction, account for most cases of AKI. Other conditions, such as urolithiasis, tumor (intraabdominal lesion or within the urinary tract), hemorrhagic cystitis, and neurogenic bladder, can cause AKI in older children and adolescents. In a patient with two functioning kidneys, obstruction must be bilateral to result in AKI. Relief of the obstruction usually results in recovery of renal function, except in patients with associated renal dysplasia or prolonged urinary tract obstruction.

CLINICAL MANIFESTATIONS AND DIAGNOSIS

A carefully taken history is critical in defining the cause of AKI. An infant with a three day history of vomiting and diarrhea most likely has prerenal AKI caused by volume depletion, but hemolytic-uremic syndrome (HUS) must also be a consideration. A 6-year-old child with a recent pharyngitis who presents with periorbital edema, hypertension, and gross hematuria most likely has intrinsic AKI related to acute postinfectious glomerulonephritis. A critically ill child with a history of protracted hypotension or with exposure to nephrotoxic medications most likely has ATN. A neonate with a history of hydronephrosis seen on prenatal ultrasound studies and a palpable bladder most likely has congenital urinary tract obstruction, probably related to posterior urethral valves.

The physical examination must be thorough, with careful attention to volume status. Tachycardia, dry mucous membranes, and poor peripheral perfusion suggest an inadequate circulating volume and the possibility of prerenal AKI. Hypertension, peripheral edema, rales, and a cardiac gallop suggest volume overload and the possibility of intrinsic AKI from glomerulonephritis or ATN. The presence of a rash and arthritis might indicate systemic lupus erythematosus (SLE) or IgA vasculitis nephritis. Palpable flank masses may be seen with renal vein thrombosis, tumors, cystic disease, or urinary tract obstruction.

LABORATORY FINDINGS

Laboratory abnormalities can include anemia (the anemia is usually dilutional or hemolytic, as in SLE, renal vein thrombosis, HUS); leukopenia (SLE, sepsis); thrombocytopenia (SLE, renal vein thrombosis, sepsis, HUS); hyponatremia (dilutional); metabolic acidosis; elevated serum concentrations of blood urea nitrogen (BUN), creatinine, uric acid, potassium, and phosphate (diminished kidney function); and hypocalcemia (hyperphosphatemia).

The serum C3 level may be depressed (postinfectious glomerulonephritis, SLE, or membranoproliferative glomerulonephritis), and antibodies may be detected in the serum to streptococcal (poststreptococcal glomerulonephritis), nuclear (SLE), neutrophil cytoplasmic (granulomatosis with polyangiitis, microscopic polyarteritis), or glomerular basement membrane (Goodpasture disease) antigens.

The presence of hematuria, proteinuria, and red blood cell or granular urinary casts suggests intrinsic AKI, in particular glomerular disease and ATN. The presence of white blood cells and white blood cell casts with low-grade hematuria and proteinuria suggests tubulointerstitial disease. Urinary eosinophils may be present in some children with drug-induced tubulointerstitial nephritis.

Urinary indices may be useful in differentiating prerenal AKI from intrinsic AKI (Table 572.4). Patients whose urine shows an elevated specific gravity (>1.020), elevated urine osmolality (UOsm >500 mOsm/kg), low urine sodium (UNa <20 mEq/L), and fractional excretion of sodium <1% (<2.5% in neonates) most likely have prerenal AKI. Those with a specific gravity of <1.010, low urine osmolality (UOsm <350 mOsm/kg), high urine sodium (UNa >40 mEq/L), and fractional excretion of sodium >2% (>10% in neonates) most likely have intrinsic AKI.

Table 572.4 Urinalysis, Urine Chemistries, and Osmolality in Acute Kidney Injury

	HYPOVOLEMIA	ACUTE TUBULAR NECROSIS	ACUTE INTERSTITIAL NEPHRITIS	GLOMERULONEPHRITIS	OBSTRUCTION
Sediment	Bland, may have hyaline casts	Broad, brownish granular casts	White blood cells, eosinophils, cellular casts	Red blood cells, red blood cell casts	Bland or bloody
Protein	None or low	None or low	Minimal but may be increased with NSAIDs	Increased, >100 mg/dL	Low
Urine sodium (mEq/L)*	<20	>40	>30	<20	<20 (acute) >40 (few days)
Urine osmolality (mOsm/kg)	>400	<350	<350	>400	<350
Fractional excretion of sodium %†	<1	>2‡	Varies	<1	<1 (acute) >1 (few days)

*The sensitivity and specificity of urine sodium of <20 mEq/L in differentiating prerenal azotemia from acute tubular necrosis are 90% and 82%, respectively.
†Fractional excretion of sodium is the urine:plasma (U:P) ratio of sodium divided by U:P of creatinine × 100. The sensitivity and specificity of fractional excretion of sodium of <1% in differentiating prerenal azotemia from acute tubular necrosis are 96% and 95%, respectively.
‡The fractional excretion of sodium may be <1% in acute tubular necrosis secondary to radiocontrast material or rhabdomyolysis.
NSAIDs, Nonsteroidal antiinflammatory drugs.
From Singri N, Ahya SN, Levin ML. Acute renal failure. *JAMA*. 2003;289:747–751.

Chest radiography may reveal cardiomegaly, pulmonary congestion (fluid overload), or pleural effusions. Renal ultrasonography can reveal hydronephrosis and/or hydroureter, which suggest urinary tract obstruction, or nephromegaly, consistent with intrinsic renal disease. Renal biopsy may ultimately be required to determine the precise cause of AKI in patients who do not have clearly defined prerenal or postrenal AKI.

Although serum creatinine is used to measure kidney function, it is an insensitive and delayed measure of decreased kidney function following AKI. Tissue inhibitor of metallopritinase-2 (TIMP2) and insulin-like growth factor binding protein-7 (IGFBP7) are biomarkers for early tubular injury and the risk for the development of AKI used mostly in critically ill adult patients.

TREATMENT

Medical Management

Complications of AKI are noted in Table 572.5. In infants and children with urinary tract obstruction, such as in a newborn with suspected posterior ureteral valves, a bladder catheter should be placed immediately to ensure adequate drainage of the urinary tract. The placement of a bladder catheter may also be considered in nonambulatory older children and adolescents to accurately monitor urine output during AKI; however, precautions to prevent iatrogenic infection should be taken.

Determination of the volume status is of critical importance when initially evaluating a patient with AKI. If there is no evidence of volume overload or cardiac failure, the intravascular volume should be expanded by intravenous (IV) administration of isotonic saline, 20 mL/kg over 30 minutes. In the absence of blood loss or hypoproteinemia, colloid-containing solutions are not required for volume expansion. Severe hypovolemia may require additional fluid boluses (see Chapters 74, 75, and 85). Determination of the central venous pressure may be helpful if adequacy of the blood volume is difficult to determine. After volume resuscitation, hypovolemic patients generally void within 2 hours; failure to do so suggests intrinsic or postrenal AKI. Hypotension caused by sepsis requires vigorous fluid resuscitation followed by a continuous infusion of vasopressors.

Diuretic therapy should be considered only after the adequacy of the circulating blood volume has been established. Furosemide (2-4 mg/kg) may be administered as a single IV dose. Bumetanide (0.1 mg/kg) may be given as an alternative to furosemide. If urine output is not improved, then a continuous diuretic infusion may be considered. To increase renal cortical blood flow, many clinicians administer dopamine (2-3 μg/kg/min) in conjunction with diuretic therapy, although no controlled data support this practice. *There is little evidence that diuretics or dopamine can prevent AKI or hasten recovery*. Mannitol may be effective in the prevention of pigment (myoglobin, hemoglobin)-induced renal failure. Atrial natriuretic peptide may be of value in preventing or treating AKI, although there is little pediatric evidence to support its use.

If there is no response to a diuretic challenge, diuretics should be discontinued and fluid restriction is essential. Patients with a relatively normal intravascular volume should initially be limited to 400 mL/m^2/24 hr (insensible losses) plus an amount of fluid equal to the urine output for that day. Extrarenal (blood, GI tract) fluid losses should be replaced, milliliter for milliliter, with appropriate fluids. Markedly hypervolemic patients can require further fluid restriction, omitting the replacement of insensible fluid losses, urine output, and extrarenal losses to diminish the expanded intravascular volume. Fluid intake, urine and stool output, body weight, and serum chemistries should be monitored daily.

In AKI, rapid development of **hyperkalemia** (serum potassium level >6 mEq/L) can lead to cardiac arrhythmia, cardiac arrest, and death. The earliest electrocardiographic change seen in patients with developing hyperkalemia is the appearance of peaked T waves. This may be followed by widening of the QRS intervals, ST segment depression, ventricular arrhythmias, and cardiac arrest (see Chapter 472.2). Procedures to deplete body potassium stores should be initiated when the serum potassium value rises to >6.0 mEq/L. Exogenous sources of potassium (dietary, IV fluids, total parenteral nutrition) should be eliminated. Sodium polystyrene sulfonate (SPS) resin (Kayexalate), 1 g/kg, should be given orally or by retention enema. This resin exchanges sodium for potassium and can take several hours to take effect. A single dose of 1 g/kg can be expected to lower the serum potassium level by about 1 mEq/L. Resin therapy may be repeated every 2 hours, the frequency being limited primarily by the risk of sodium overload.

More severe elevations in serum potassium (>7 mEq/L), especially if accompanied by electrocardiographic changes, require emergency measures in addition to Kayexalate. The following agents should be administered:

- Calcium gluconate 10% solution, 100 mg/kg/dose (maximum 3,000 mg/dose)
- Sodium bicarbonate, 1-2 mEq/kg IV, over 5-10 minutes
- Regular insulin, 0.1 units/kg, with glucose 50% solution, 1 mL/kg, over 1 hour

Calcium gluconate counteracts the potassium-induced increase in myocardial irritability but does not lower the serum potassium level. Administration of sodium bicarbonate, insulin, or glucose lowers the serum potassium level by shifting potassium from the extracellular to the intracellular compartment. A similar effect has been reported with the acute administration of β-adrenergic agonists in adults, but there are no controlled data in pediatric patients. Because the duration of action of these emergency measures is just a few hours, persistent hyperkalemia should be managed by dialysis.

Mild **metabolic acidosis** is common in AKI because of the retention of hydrogen ions, phosphate, and sulfate, but it rarely requires treatment. If acidosis is severe (arterial pH <7.15; serum bicarbonate <8 mEq/L) or contributes to significant hyperkalemia, treatment is indicated. The acidosis should be corrected partially by the IV route, generally by giving enough bicarbonate to raise the arterial pH to 7.20 (which approximates a serum bicarbonate level of 12 mEq/L). The remainder of the correction may be accomplished by oral administration of sodium bicarbonate after normalization of the serum calcium and phosphorus levels. Correction of metabolic acidosis with IV bicarbonate can precipitate tetany in patients with renal failure because rapid correction of acidosis reduces the ionized calcium concentration.

Hypocalcemia is primarily treated by lowering the serum phosphorus level. Calcium should not be given IV, except in cases of tetany, to avoid deposition of calcium salts into tissues. Patients should

Table 572.5 Common Complications of Acute Kidney Injury

METABOLIC	CARDIOPULMONARY	GASTROINTESTINAL	NEUROLOGIC	HEMATOLOGIC	INFECTIOUS	OTHER
Hyperkalemia Metabolic acidosis Hyponatremia Hypocalcemia Hyperphosphatemia Hypermagnesemia Hyperuricemia	Pulmonary edema Arrhythmias Pericarditis Pericardial effusion Hypertension Myocardial infarction Pulmonary embolism	Nausea Vomiting Malnutrition Hemorrhage	Neuromuscular irritability Asterixis Seizures Mental status changes	Anemia Bleeding	Pneumonia Septicemia Urinary tract infection	Hiccups Elevated parathyroid hormone level Low total triiodothyronine and thyroxine levels Normal thyroxine level

From Weisbord SD, Palevsky PM. Acute kidney injury. In: Yu AS, Chertow GM, Luyckx VA, et al, eds. *Brenner & Rector's The Kidney*, 11th ed. Philadelphia: Elsevier; 2020: Table 29.6.

be instructed to follow a low-phosphorus diet, and phosphate binders should be orally administered to bind any ingested phosphate and increase the GI phosphate excretion. Common agents include sevelamer (Renagel), calcium carbonate (Tums tablets or Titralac suspension), and calcium acetate (PhosLo). Aluminum-based binders, commonly employed in the past, should be avoided because of the risk of aluminum toxicity.

Hyponatremia is most commonly a dilutional disturbance that must be corrected by fluid restriction rather than sodium chloride administration. Administration of hypertonic (3%) saline should be limited to patients with symptomatic hyponatremia (seizures, lethargy) or those with a serum sodium level <120 mEq/L. Acute correction of the serum sodium to 125 mEq/L (mmol/L) should be accomplished using the following formula:

$$\text{mEq sodium required} = 0.6 \times \text{weight in kg} \times (125 - \text{serum sodium in mEq/L}).$$

AKI patients are predisposed to **GI bleeding** because of uremic platelet dysfunction, increased stress, and heparin exposure if treated with hemodialysis (HD) or continuous renal replacement therapy (CRRT). Oral or IV H_2 blockers such as ranitidine are commonly administered to prevent this complication.

Hypertension can result from hyperreninemia associated with the primary disease process and/or expansion of the extracellular fluid volume and is most common in AKI patients with acute glomerulonephritis or HUS. Salt and water restriction is critical, and diuretic administration may be useful (see Chapter 494). Isradipine (0.05-0.15 mg/kg/dose, maximum dose 5 mg 4 times per day) may be administered for a relatively rapid reduction in blood pressure (BP). Longer-acting oral agents such as calcium channel blockers (amlodipine, 0.1-0.6 mg/kg/24 hr daily or divided twice daily) or β blockers (labetalol, 4-40 mg/kg/24 hr divided 2 or 3 times daily) may be helpful in maintaining control of the BP. Children with severe symptomatic hypertension (hypertensive urgency or emergency) should be treated with continuous infusions of nicardipine (0.5-5.0 μg/kg/min), sodium nitroprusside (0.5-10.0 μg/kg/min), labetalol (0.25-3.0 mg/kg/hr), or esmolol (150-300 μg/kg/min) and converted to intermittently dosed antihypertensives when more stable.

Neurologic symptoms in AKI can include headache, seizures, lethargy, and confusion (encephalopathy). Potential etiologic factors include hypertensive encephalopathy, hyponatremia, hypocalcemia, cerebral hemorrhage, cerebral vasculitis, and the uremic state. Benzodiazepines are the most effective agents in acutely controlling seizures, and subsequent therapy should be directed toward the precipitating cause.

The **anemia** of AKI is generally mild (hemoglobin 9-10 g/dL) and primarily results from volume expansion (hemodilution). Children with HUS, SLE, active bleeding, or prolonged AKI can require transfusion of packed red blood cells if their hemoglobin level falls below 7 g/dL. In hypervolemic patients, blood transfusion carries the risk of further volume expansion, which can precipitate hypertension, heart failure, and pulmonary edema. Slow (4- to 6-hour) transfusion with packed red blood cells (10 mL/kg) diminishes the risk of hypervolemia. The use of fresh, washed red blood cells minimizes the acute risk of hyperkalemia, and the chronic risk of sensitization if the patient becomes a future candidate for renal replacement therapy. In the presence of severe hypervolemia or hyperkalemia, blood transfusions are most safely administered during dialysis or ultrafiltration.

Nutrition is of critical importance in children who develop AKI. In most cases, sodium, potassium, and phosphorus should be restricted. Protein intake should be moderately restricted while maximizing the caloric intake to minimize the accumulation of nitrogenous wastes. In critically ill patients with AKI, parenteral hyperalimentation with essential amino acids should be considered.

Dialysis

Indications for dialysis in AKI include the following:

- Anuria/oliguria with fluid overload
- Volume overload with evidence of hypertension and/or pulmonary edema refractory to diuretic therapy
- Persistent hyperkalemia
- Severe metabolic acidosis unresponsive to medical management
- Uremia (encephalopathy, pericarditis, neuropathy)
- Calcium:phosphorus imbalance, with hypocalcemic tetany that cannot be controlled by other measures

An additional important practical indication for dialysis is the inability to provide adequate nutritional intake because of the need for severe fluid restriction. In patients with AKI, dialysis support may be necessary for days or for up to 12 weeks. Many patients with AKI require dialysis support for 1-3 weeks. Table 572.6 lists the advantages and disadvantages of the three types of dialysis.

Intermittent HD is useful in patients with a relatively stable hemodynamic status. This highly efficient process accomplishes both fluid and electrolyte removal in sessions of 3-4 hours using a pump-driven extracorporeal circuit and large central venous catheter. Intermittent HD may be performed 3-7 times per week based on the patient's fluid and electrolyte balance.

Peritoneal dialysis (PD) is most employed in neonates and infants with AKI, although this modality may be used in children and adolescents of all ages. Hyperosmolar dialysate is infused into the peritoneal cavity via a surgically or percutaneously placed PD catheter. The fluid is allowed to dwell for 45-60 minutes and is then drained from the patient by gravity (manually or with the use of machine-driven cycling), accomplishing fluid and electrolyte removal. Cycles are repeated for 8-24 hours per day based on the patient's fluid and electrolyte balance. Anticoagulation is not necessary. PD is contraindicated in patients with significant abdominal pathology.

Continuous renal replacement therapy (CRRT) is useful in patients with an unstable hemodynamic status, increased intracranial pressure, cerebral edema, concomitant sepsis, or multiorgan failure (including

Table 572.6 Comparison of Peritoneal Dialysis, Intermittent Hemodialysis, and Continual Renal Replacement Therapy

	PD	IHD	CRRT
BENEFITS			
Fluid removal	+	++	++
Urea and creatinine clearance	+	++	+
Potassium clearance	++	++	+
Toxin clearance	+	++	+
COMPLICATIONS			
Abdominal pain	+	−	−
Bleeding	−	+	+
Dysequilibrium	−	+	−
Electrolyte imbalance	+	+	+
Need for heparinization	−	+	+/−
Hyperglycemia	+	−	−
Hypotension	+	++	+
Hypothermia	−	−	+
Central line infection	−	+	+
Inguinal or abdominal hernia	+	−	−
Peritonitis	+	−	−
Protein loss	+	−	−
Respiratory compromise	+	−	−
Vessel thrombosis	−	+	+

PD, Peritoneal dialysis; IHD, intermittent hemodialysis; CRRT, continual renal replacement therapy.

Adapted from Rogers MC. *Textbook of Pediatric Intensive Care*. Baltimore: Williams & Wilkins; 1992.

hepatic failure) in the intensive care setting. CRRT is an extracorporeal therapy in which fluid, electrolytes, and small- and medium-size solutes are continuously removed from the blood (24 hours/day) using a specialized pump-driven machine. Usually, a double-lumen catheter is placed into the internal jugular or femoral vein. The patient is then connected to the pump-driven CRRT circuit, which continuously passes the patient's blood across a highly permeable filter.

CRRT may be performed in three basic fashions. In continuous venovenous **hemofiltration**, a large volume of fluid is driven by systemic or pump-assisted pressure across the filter, bringing with it by *convection* other molecules, such as urea, creatinine, phosphorus, and uric acid. The blood volume is reconstituted by an IV infusion of a replacement fluid having a desirable electrolyte composition similar to that of blood. Continuous venovenous **HD** uses the principle of diffusion by circulating dialysate in a countercurrent direction on the ultrafiltrate side of the membrane. No replacement fluid is used. Continuous **hemodiafiltration** employs both replacement fluid and dialysate, offering the most effective solute removal of all forms of CRRT.

Table 572.6 compares the relative risks and benefits of the various renal replacement therapies. CRRT has similar outcomes for recovery of renal function when compared with intermittent HD.

PROGNOSIS

The mortality rate in children with AKI is variable and depends entirely on the nature of the underlying disease process rather than on the renal failure itself. Children with AKI caused by a kidney-limited condition such as postinfectious glomerulonephritis have a very low mortality rate (<1%); those with AKI related to multiorgan failure have a very high mortality rate (>50%).

The prognosis for recovery of kidney function depends on the disorder that precipitated AKI. Recovery is likely after AKI resulting from prerenal causes, ATN, acute interstitial nephritis, or tumor lysis syndrome. Complete recovery of renal function is unusual when AKI results from most types of rapidly progressive glomerulonephritis, bilateral renal vein thrombosis, or bilateral cortical necrosis. Medical management may be necessary for a prolonged period to treat the sequelae of AKI, including chronic renal insufficiency, hypertension, renal tubular acidosis, and urinary concentrating defect.

Visit Elsevier eBooks+ at eBooks.Health.Elsevier.com for Bibliography.

572.2 Chronic Kidney Disease

Donna J. Claes

Chronic kidney disease (CKD) is determined by the presence of kidney damage and level (or severity) of kidney function (GFR; Tables 572.7 and 572.8). **End-stage kidney disease (ESKD)** is an administrative term in the United States; it is used to define patients who are treated with dialysis or kidney transplantation and is a subset of patients with stage 5 CKD.

Table 572.7 Criteria for Definition of Chronic Kidney Disease (NKF KDOQI Guidelines)

Patient has chronic kidney disease (CKD) if either of the following criteria are present:

1. Kidney damage for ≥3 mo, as defined by structural or functional abnormalities of the kidney, with or without decreased GFR, manifested by one or more of the following features:
   - Abnormalities in the composition of the blood or urine
   - Abnormalities in imaging tests
   - Abnormalities on kidney biopsy
2. GFR < 60 mL/min/1.73 m^2 for ≥3 mo, with or without the other signs of kidney damage described previously

GFR, Glomerular filtration rate; NKF KDOQI, National Kidney Foundation Kidney Disease Outcomes Quality Initiative.

Table 572.8 Standardized Terminology for Stages of Chronic Kidney Disease (NKF KDOQI Guidelines)

STAGE	DESCRIPTION	GFR (ML/MIN/1.73 M^2)
1	Kidney damage with normal or increased GFR	≥90
2	Kidney damage with mild decrease in GFR	60-89
3	Moderate decrease in GFR	30-59
4	Severe decrease in GFR	15-29
5	Kidney failure	<15 or on dialysis

GFR, Glomerular filtration rate; NKF KDOQI, National Kidney Foundation Kidney Disease Outcomes Quality Initiative.

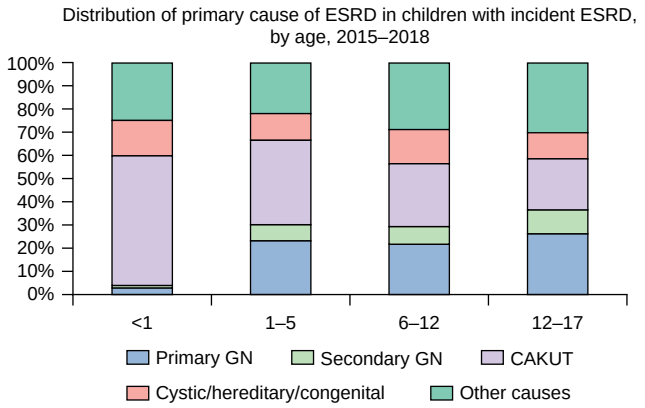

Fig. 572.2 Distribution of primary cause of end-stage renal disease (ESRD), by age, in incident pediatric dialysis patients reported to United States Renal Data System (USRDS) in 2016–2020. CAKUT, Congenital anomalies of the kidney and urinary tract; GN, glomerulonephritis. *(Adapted from the United States Renal Data System. 2022 USRDS Annual Data Report: Epidemiology of kidney disease in the United States. National Institutes of Health, National Institute of Diabetes and Digestive and Kidney Diseases, Bethesda, MD, 2022. Fig. 8.4. https://usrds-adr.niddk.nih.gov/2022/end-stage-renal-disease/8-esrd-among-children-and-adolescents)*

Pediatric CKD prevalence is approximately 18 per 1 million children. The prognosis for the infant, child, or adolescent with CKD has improved secondary to improved medical management, dialysis techniques, and kidney transplantation. Childhood-onset ESKD still carries significant morbidity and a 30-fold increased mortality rate as compared with healthy peers.

ETIOLOGY

The etiology of pediatric CKD may be the result of congenital, acquired, inherited, or metabolic renal disease; however, the common etiology is having a reduction in nephron mass (Fig. 572.2). Causes of kidney disease in children are typically subdivided as being non-glomerular vs glomerular in origin (Table 572.9). The underlying cause correlates with the age at the time of diagnosis. **Congenital anomalies of the kidney and urinary tract** (CAKUT; i.e., renal hypoplasia, dysplasia, obstructive uropathy) are predominantly diagnosed in children less than 5 years of age; in many cases, CAKUT is diagnosed with prenatal ultrasonography. Cystic kidney disease (due to single gene pathogenic variants associated with cilia function, or ciliopathies) can be diagnosed prenatally, during childhood, or as a young adult depending on the underlying genetic variant and disease phenotype. After 5 years of age, acquired or inherited forms of glomerulonephritis predominate.

Table 572.9 Etiologies of Pediatric Chronic Kidney Disease

NONGLOMERULAR	GLOMERULAR
Aplastic, hypoplastic, and dysplastic kidneys	Chronic glomerulonephritis (including focal segmental glomerulonephritis [FSGS])
Cystinosis	Congenital nephrotic syndrome (CNS)
Medullary cystic kidney disease/juvenile nephronophthisis	Hemolytic uremic syndrome (HUS)
Obstructive uropathy (e.g., PUV, cloaca, neurogenic bladder)	Idiopathic crescentic glomerulonephritis
Oxalosis	IgA nephritis
Autosomal dominant and autosomal recessive polycystic kidney disease (ADPKD, ARPDK)	IgA nephropathy (IGAN)
Pyelonephritis/interstitial nephritis/reflux nephropathy	Membranoproliferative glomerulonephritis (MPGN)
Renal infarct	Membranous nephropathy
Syndrome of agenesis of abdominal musculature (Eagle-Barrett syndrome)	Sickle cell nephropathy
Wilms tumor	Systemic immunologic disease (e.g., SLE, granulomatosis with polyangiitis)
	Hereditary nephritis (Alport syndrome)

PUV, Posterior urethral valve; SLE, systemic lupus erythematosus.

PATHOGENESIS

In addition to progressive injury with ongoing structural or metabolic genetic diseases, renal injury can progress despite removal of the original insult.

Hyperfiltration injury may be an important final common pathway of glomerular destruction, independent of the underlying cause of renal injury. As nephrons are lost, the remaining nephrons undergo structural and functional hypertrophy characterized by an increase in glomerular blood flow. The driving force for glomerular filtration is thereby increased in the surviving nephrons. Although this compensatory hyperfiltration temporarily preserves total renal function, it can cause progressive damage to the surviving glomeruli, possibly by a direct effect of the elevated hydrostatic pressure on the integrity of the capillary wall and/or the toxic effect of increased protein traffic across the capillary wall. Over time, the remaining nephrons suffer an increased excretory burden, resulting in a vicious cycle of increasing glomerular blood flow and hyperfiltration injury.

Other pathologic etiologies of CKD include proteinuria, hypertension, hyperphosphatemia, and hyperlipidemia. **Proteinuria**, secondary to either damage to the glomerular capillary wall and/or decreased tubular reabsorption, contributes to renal functional decline. Proteinuria can exert a direct toxic effect on tubular cells and initiate many inflammatory and pro-fibrotic cellular pathways that recruit monocytes and macrophages, enhancing the process of glomerular sclerosis and tubulointerstitial fibrosis. Podocyte injury can also result from proteinuria, although the mechanism is less understood. Uncontrolled **hypertension** can exacerbate disease progression by causing arteriolar nephrosclerosis and by increasing the hyperfiltration injury. **Hyperphosphatemia** can increase progression of disease by leading to calcium phosphate deposition in the renal interstitium and blood vessels. **Hyperlipidemia,** a common condition in CKD patients, can adversely affect glomerular function through oxidant-mediated injury.

CKD is viewed as a continuum of disease, with increasing biochemical and clinical manifestations as renal function deteriorates (Fig. 572.3). Regardless of etiology, the progression of tubulointerstitial fibrosis is the primary determinant of CKD progression.

CLINICAL MANIFESTATIONS

Table 572.10 outlines the pathophysiologic manifestations of CKD. The clinical presentation of CKD is varied and depends on the underlying etiology and CKD stage (Fig. 572.4). CAKUT and some genetic forms of renal disease (i.e., familial nephronophthisis) demonstrate growth failure, vomiting, and polyuria with associated polydipsia. Patients with cystic kidney disease due to a ciliopathy can have a wide range of extrarenal anomalies of the kidneys, liver, pancreas, skeletal system, eyes, central nervous system, and/or cardiac system that can assist with disease diagnosis. Urinary tract infection can also be common in those with urologic abnormalities. Glomerular forms of CKD often present with edema, hypertension, hematuria, and proteinuria; in severe forms of glomerulonephritis, malnutrition can be seen. As renal deterioration advances in severity, patients can develop uremic symptoms (i.e., worsening fatigue, weakness, nausea, vomiting, anorexia, and poor sleep patterns) and edema, hypertension, and other findings of fluid overload, regardless of CKD etiology.

Physical examination in CKD should focus on overall growth and development, with special attention and/or evaluation of BP, as well as the skin (pallor) and the extremities (edema; bony abnormalities of rickets seen in untreated renal osteodystrophy).

LABORATORY FINDINGS

Laboratory findings can include elevations in BUN and serum creatinine in addition to hyperkalemia, hyponatremia (secondary to either renal salt wasting vs volume overload), hypernatremia (loss of free water), acidosis, hypocalcemia, hyperphosphatemia, and an elevation in uric acid. Patients with heavy proteinuria can have hypoalbuminemia. A complete blood cell count may show a normochromic, normocytic anemia. Dyslipidemia is commonly seen. In children with glomerulonephritis, the urinalysis (UA) shows hematuria and proteinuria, whereas, in children with congenital lesions such as renal dysplasia, the UA often has a low specific gravity with minimal other abnormalities.

Renal function can be measured or estimated by GFR. Inulin clearance is the gold standard to measure GFR, but it is no longer readily available. Other methods to measure GFR in clinical practice include using iohexol or various radioisotopes (^{99m}Tc-DTPA, ^{51}Cr-EDTA, or ^{125}Iothalamate). However, estimating GFR by endogenous markers (such as creatinine and/or cystatin C) is the most utilized method to understand severity of renal disease. A "bedside" creatinine-based estimating equation [estimated GFR (mL/min/1.73 m^2) = 0.413 × height (cm)/serum creatinine (mg/dL)] has been validated in a pediatric CKD population of children age 1-16 years whose GFR was between 15 and 90 mL/min/1.73 m^2; however, this formula has less accuracy in the very young (<5 years of age) and young adults (18-25 years of age). Newer estimation formulas ("Chronic Kidney Disease in Children [CKID] study under 25," or U25) have been developed that allow for age- and gender-based corrections of creatinine and cystatin C with improved accuracy of GFR estimation. Although these newer formulas are more complex in regard to the mathematical corrections of age and gender for both creatinine and cystatin C, they are accessible by an online calculator, which allows for ease in their clinical use.

TREATMENT/MANAGEMENT

CKD treatment is supportive, with an aim to screen for and treat various metabolic complications of CKD in hopes of improving quality of life and potentially slowing the progression of renal dysfunction. Children with CKD should be treated at a pediatric center capable of supplying multidisciplinary services, including medical, nursing, social service, nutritional, and psychologic support.

CKD management requires close monitoring of blood studies, urine studies (including quantitative measurement for proteinuria using either a spot urine protein/urine creatinine ratio or 24-hour urine collection), and overall clinical symptomatology. Ambulatory blood pressure monitoring (ABPM) over 24 hours, the gold standard of BP evaluation, is recommended in patients with renal disease to diagnose and treat hypertension, especially masked hypertension. **Masked hypertension** (defined as a normal office BP but abnormal ABPM) is seen in up to 35% of pediatric predialysis CKD patients and carries a fourfold increased risk of having left ventricular hypertrophy (LVH).

Nutrition

Nutritional management by a dietician experienced in pediatric renal patients is recommended by the National Kidney Foundation Kidney Disease Outcomes Quality Initiative (NKF KDOQI). Patients should

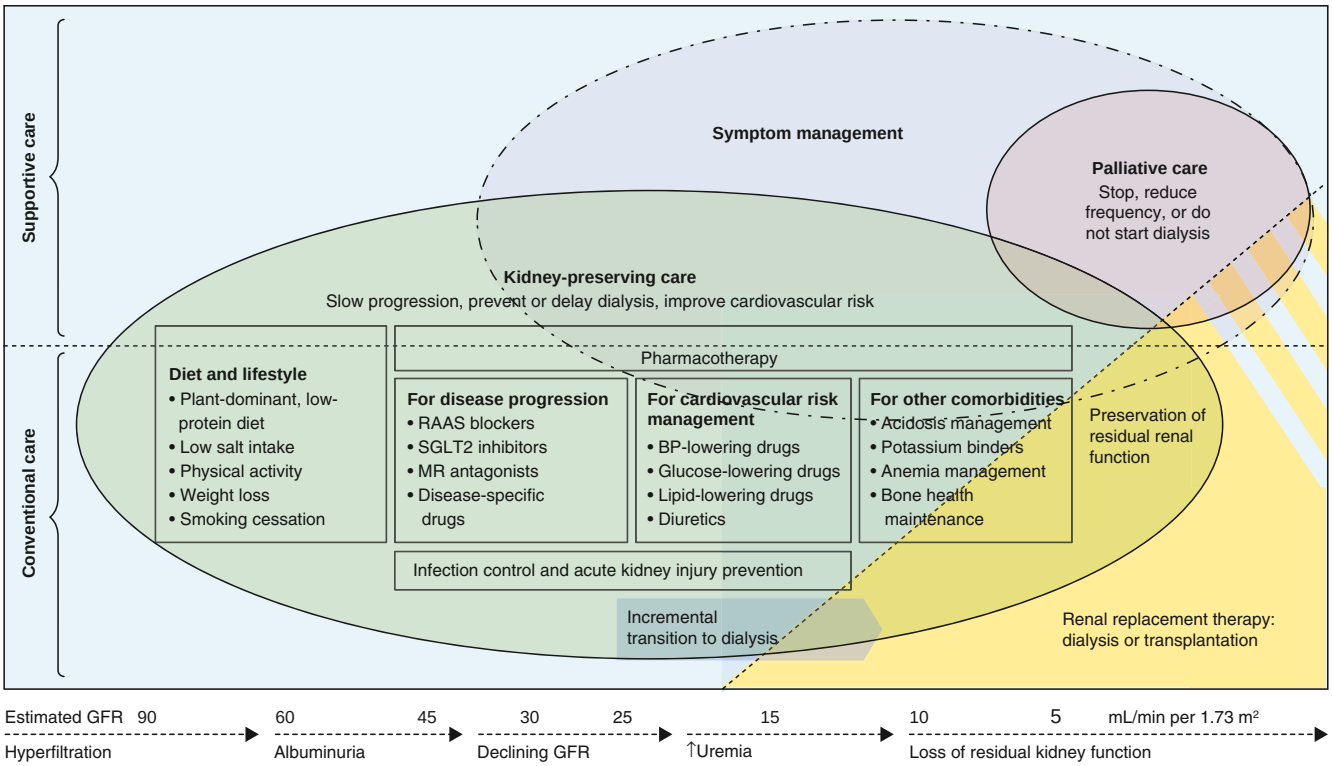

Fig. 572.3 Conservative and preservative management of chronic kidney disease without dialysis or renal transplantation. This chart highlights the role of preservative management and its goals *(green domain)* within the overall conservative management of chronic kidney disease without dialysis *(blue zone)*, juxtaposing renal replacement therapy including dialysis and kidney transplantation *(yellow zone)*. The X-axis (showing chronic kidney disease progression) should be read exclusively from left to right. The bottom half of the chart represents conventional (life-prolonging and kidney-prolonging) strategies, whereas the top half represents supportive care, including palliative and hospice care, in which dialysis is often avoided or withdrawn *(violet domain)*. The *oblique dotted line* between the two main zones (conservative management vs renal replacement therapy) suggests that there is variability in transitioning to dialysis therapy (moving from bottom left to top right), including timing (early vs late vs never), level of care (life-prolonging vs supportive care), and type of dialysis (conventional vs incremental). The symptom management *(purple)* domain provides wide ranges of interventions to encompass the goals of care under both kidney-preserving care and palliative and hospice care. Preservative management can preserve residual kidney function for longer, especially after incremental transition to dialysis. BP, Blood pressure; GFR, glomerular filtration rate; MR, mineralocorticoid receptor; RAAS, renin-angiotensin-aldosterone system. *(From Kalantar-Zadeh K, Jafar TH, Nitsch D, et al. Chronic kidney disease. Lancet. 2021;398:786–798. Fig. 1, p. 787.)*

receive 100% of estimated energy requirement for age, individually adjusted for physical activity level, body mass index, and response in the rate of weight gain or loss. When oral supplemental nutrition with increased calories or fluid volume is insufficient, tube feeding (by nasogastric tubes or gastrostomy tubes) should be considered. Calories should be balanced between carbohydrate, unsaturated fat in physiologic ranges (per dietary reference intake [DRI]), and protein. Dietary protein restriction is not suggested for children with CKD because of the concern about adverse effects on growth and development; in fact, recommended protein intake is often 100% (or more for those receiving dialysis) of the DRI for ideal weight for children. Children with CKD stages 2-5 should receive 100% of DRI of vitamins and trace elements; water-soluble vitamin supplements are often required for patients receiving dialysis.

CKD Mineral and Bone Disorder (CKD-MBD)

CKD is characterized by systemic disorders of calcium, phosphorus, parathyroid hormone (PTH), and vitamin D metabolism that can lead to bone disorders (**renal osteodystrophy**) but also *vascular and soft tissue calcification* (Fig. 572.5). Efforts have focused on the role of the hormone fibroblast growth factor 23 (FGF-23) and its cofactor, Klotho, in CKD-mineral and bone disorder (MBD). Elevated FGF-23 results in increased urinary phosphate excretion and suppression of 1-α-hydroxylase activity, leading to reduced 1,25-dihydroxycholecalciferol (1,25OH_2D) values and increased PTH secretion. Elevated FGF-23 is the first sign of altered osteocyte function in pediatric and adult CKD, is seen as early as CKD stage 2 (GFR 60-90 mL/min/1.73 m^2), and occurs despite normal calcium, phosphorus, PTH, and 1,25OH_2D levels. With continued loss of renal function, further FGF-23 elevation results in the development of secondary hyperparathyroidism (low 1,25OH_2D with hypocalcemia, hyperphosphatemia, and elevated PTH values).

Renal osteodystrophy is characterized by abnormalities in *bone turnover* (high vs low), *mineralization,* and *bone volume.* High-turnover bone disease, or **osteitis fibrosa cystica**, is the most common condition seen in advanced pediatric CKD, with characteristic laboratory (hypocalcemia, hyperphosphatemia, and elevated alkaline phosphatase and PTH values) and radiographic (subperiosteal bone resorption, metaphyseal widening) findings. Clinical manifestations may include bone pain, fractures with minor trauma, and various bony abnormalities (rachitic changes, varus and valgus deformities of the long bones, and slipped capital femoral epiphyses [SCFE]). In contrast, low-turnover bone disease **(adynamic renal osteodystrophy)** is associated with PTH over-suppression, hypercalcemia, and low alkaline phosphatase activity; it is more commonly seen in pediatric dialysis patients receiving treatment for secondary hyperparathyroidism. Defective bone mineralization occurs in states of either high bone turnover (mixed lesion) or low to normal bone turnover (osteomalacia). In terms of bone volume, most pediatric CKD patients have normal to high bone volume on bone histomorphometry unless they were exposed to prolonged corticosteroid use.

Vascular calcification in CKD-MBD typically occurs within the vascular media, which is in contrast to the atherosclerotic plaques that form within the vascular intima in patients with traditional cardiovascular risk factors (hypertension, diabetes/obesity, cigarette smoking,

Table 572.10 Pathophysiology of Chronic Kidney Disease

MANIFESTATION	MECHANISMS
Accumulation of nitrogenous waste products	Decrease in glomerular filtration rate
Acidosis	Decreased ammonia synthesis Impaired bicarbonate reabsorption Decreased net acid excretion
Sodium wasting	Solute diuresis Tubular damage
Urinary concentrating defect	Solute diuresis Tubular damage
Hyperkalemia	Decrease in glomerular filtration rate Metabolic acidosis Excessive potassium intake Hyporeninemic hypoaldosteronism
Renal osteodystrophy	Impaired renal production of 1,25-dihydroxycholecalciferol (1,25OH$_2$D) Hyperphosphatemia Hypocalcemia Secondary hyperparathyroidism
Growth retardation	Inadequate caloric intake Renal osteodystrophy Metabolic acidosis Anemia Growth hormone resistance
Anemia	Decreased erythropoietin production Iron, folate, and/or vitamin B_{12} deficiency Decreased erythrocyte survival
Bleeding tendency	Defective platelet function
Infection	Defective granulocyte function Impaired cellular immune functions Indwelling dialysis catheters
Decreased academic achievement, attention regulation, or executive functioning	Hypertension Low birth weight
Gastrointestinal symptoms (feeding intolerance, abdominal pain)	Gastroesophageal reflux Decreased gastrointestinal motility
Hypertension	Volume overload Excessive renin production
Hyperlipidemia	Decreased plasma lipoprotein lipase activity Abnormal HDL-C
Cardiomyopathy	Hypertension Anemia Fluid overload
Glucose intolerance	Tissue insulin resistance

HDL-C, High-density lipoprotein cholesterol.

and dyslipidemia). Vascular calcification in CKD has been associated with hypercalcemia, hyperphosphatemia, and an elevated calcium-phosphorus product (Ca × PO_4); yet, studies of adult and pediatric patients with mild to moderate CKD have noted findings of vascular calcification despite normal serum calcium and phosphorus values. The cause of vascular calcification in CKD is not completely understood and is being actively studied. The proposed pathophysiologic etiology involves the transition of vascular smooth muscle cells to osteoblast-like cells in response to trigger(s) that are currently unknown.

Treatment for CKD-MBD is guided by clinical assessment of calcium, phosphorus, 25OH vitamin D, and PTH. The goals of treatment are to normalize mineral metabolism with the goal of improving growth, reducing bone deformities and fragility, and reducing vascular and other soft tissue calcification. This is typically accomplished with reduced phosphorus intake, normalization of 25OH vitamin D, and use of active vitamin D sterols.

CKD patients of all ages should typically follow a low-phosphorus diet with the goal to maintain age-appropriate serum phosphorus values. Infants should be provided with a low-phosphorus formula (Similac PM 60/40). **Phosphate binders** (given with meals) are used to enhance GI phosphate excretion, and at present are recommended to be started at the onset of hyperphosphatemia. Phosphate binders should be adjusted to maintain normal serum calcium and phosphorus levels and to ensure that the recommended total daily intake of calcium is not exceeded. Phosphate binders can be either calcium based (calcium carbonate, calcium acetate) or non–calcium based (sevelamer). Because aluminum may be absorbed from the GI tract and can lead to aluminum toxicity (manifested by anemia, various bony abnormalities, and neurologic abnormalities including seizures), aluminum-based binders should be avoided.

Correcting 25OH vitamin D insufficiency can delay the onset of secondary hyperparathyroidism in predialysis CKD patients and improves bone mineralization. 25OH vitamin D provides a substrate for the formation of 1,25OH$_2$D and has been shown to directly suppress PTH production at the level of the parathyroid gland. U.S.-based pediatric CKD treatment guidelines define 25OH vitamin D sufficiency as a serum value of ≥30 ng/mL; **ergocalciferol** or **cholecalciferol** are typically recommended to treat insufficient 25OH vitamin D.

Active vitamin D sterols have been traditionally indicated when (1) 1,25OH$_2$D levels fall below the established goal range for the child's particular stage of CKD, (2) PTH levels increase above the established goal range for CKD stage (after correcting for insufficient 25OH vitamin D), or (3) patients have elevated PTH levels and hypocalcemia. Vitamin D sterols increase calcium and phosphorus absorption from the GI tract and are effective in reducing PTH values. Calcitriol is the most well-known and studied active vitamin D sterol; other agents such as paricalcitol and doxercalciferol have less intestinal calcium and phosphorus reabsorption and are used in CKD patients predisposed to hypercalcemia. The ideal PTH target to initiate and monitor active vitamin D sterol therapy is debated, particularly in the predialysis CKD population.

Fluid and Electrolyte Management

Infants and children with renal dysplasia may be polyuric with significant urinary sodium and free water losses. These children benefit from high-volume, low-caloric-density feedings with sodium supplementation. Children with high BP or edema benefit from sodium restriction and diuretic therapy. Fluid restriction is necessary in severe cases of nephrotic syndrome or when renal function worsens to the point of requiring dialysis.

Hyperkalemia can develop with severe deterioration in renal function, as well as in patients with moderate renal insufficiency who have excessive dietary potassium intake, severe acidosis, or hyporeninemic hypoaldosteronism (related to destruction of the renin-secreting juxtaglomerular apparatus). Hyperkalemia may be treated by restriction of dietary potassium intake, administration of oral alkalinizing agents, and/or use of **cation exchange resins**. The most commonly utilized cation exchange resin, SPS (Kayexalate) has many severe adverse drug events, including but not limited to GI abnormalities (including intestinal necrosis), hypernatremia, hypocalcemia, and hypomagnesemia, that can limit its use or result in significant morbidity. Newer cation exchange resins (such as sodium zirconium cyclosilicate and patiromer) are more selective for potassium ion exchange and have a more favorable side effect profile compared with SPS. Patiromer is approved for ages ≥12 years in the United States, and sodium cyclosilicate is currently approved for adults; pediatric studies are ongoing.

Metabolic acidosis develops as a result of decreased net acid excretion by the failing kidneys. Either Bicitra (1 mEq sodium citrate/mL) or sodium bicarbonate tablets (650 mg = 7.7 mEq of sodium and 7.7 mEq of bicarbonate) may be used to maintain the serum bicarbonate level ≥22 mEq/L.

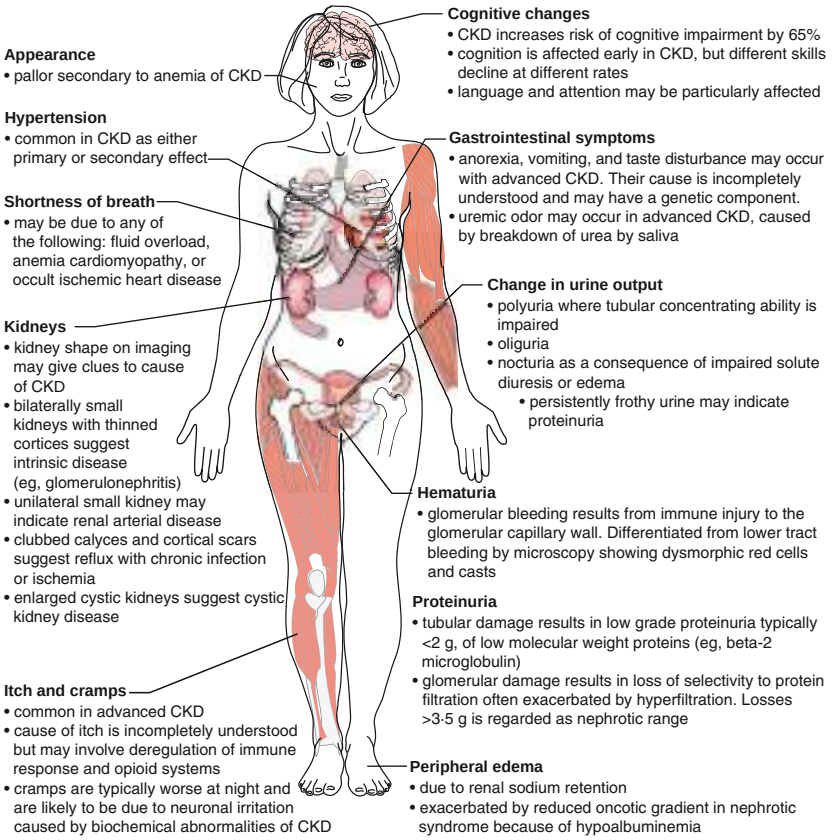

Fig. 572.4 Symptoms and signs of CKD. *(From Webster AC, Navler EV, Morton RL, et al. Chronic kidney disease. Lancet. 2017;389:1238–1252. Fig. 2.)*

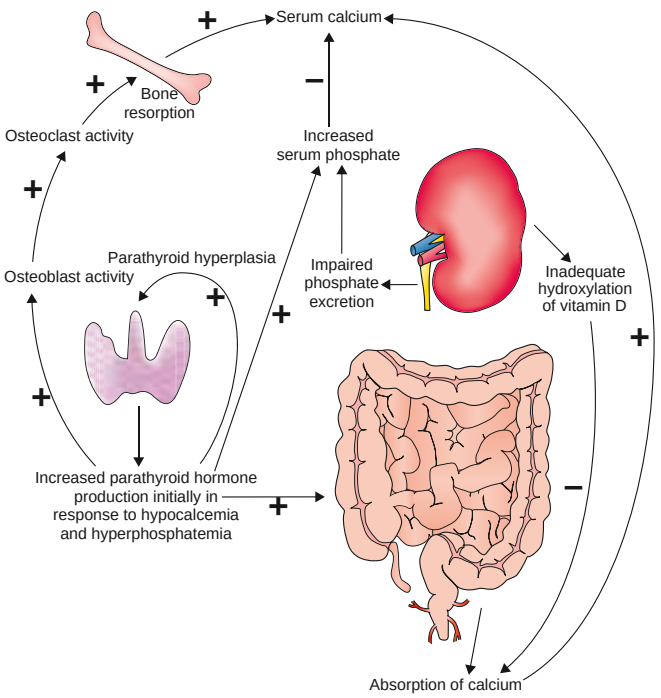

Fig, 572.5 Pathophysiology of CKD mineral bone disease. *(From Webster AC, Navler EV, Morton RL, et al. Chronic kidney disease. Lancet. 2017;389:1238–1252. Fig. 4.)*

Linear Growth

Short stature is a significant long-term sequela of childhood CKD. CKD results in an apparent growth hormone–resistant state, with elevated growth hormone levels but decreased insulin-like growth factor-1 levels and abnormalities of insulin-like growth factor–binding proteins.

Children with CKD who remain less than −2 SD for height and/or have a growth velocity of <25% over a minimum of 6 months despite optimal medical support (adequate caloric intake and effective treatment of renal osteodystrophy, anemia, and metabolic acidosis) may benefit from treatment with recombinant human growth hormone (rHuGH). rHuGH is given by daily, subcutaneous injections and continues until the patient reaches the 50th percentile for mid-parental height, achieves a final adult height, or undergoes kidney transplantation (with the caveat that rHuGH can be restarted 1 year after kidney transplantation if there are concerns for ongoing short stature despite kidney transplantation). Long-term rHuGH treatment significantly improves final adult height and induces persistent catch-up growth; some patients are able to achieve normal adult height.

Anemia

Anemia in patients with CKD is primarily the result of inadequate erythropoietin production by the peritubular interstitial cells of the kidneys and typically manifests when renal function falls below 40 mL/min/1.73 m^2. Other contributory factors for anemia in CKD include iron, folic acid, and/or vitamin B_{12} deficiency, and decreased erythrocyte survival secondary to uremia.

Anemia in pediatric CKD patients is defined when the hemoglobin falls to <5% for age and gender; alternatively, anemia can also be defined when the hemoglobin falls to <11g/dL (ages 0.5-5 years of age), <11.5 g/dL (5-12 years of age), <12 g/dL (females >12 years of age, males 12-15 years of age), and <13 g/dL (males >15 years of age). Once anemia is diagnosed, the recommendation is to investigate for deficiencies in iron and/or other vitamins (i.e., vitamin B_{12}, folate). Iron supplementation (oral or IV) is recommended for patients who demonstrate a transferrin saturation (TSAT) ≤20% and ferritin ≤100 ng/mL.

Erythropoiesis-stimulating agents (ESAs) have decreased the need for transfusions in CKD patients, especially those receiving HD. Erythropoietin and darbepoetin alfa are commonly prescribed ESAs. All patients receiving ESA therapy should be provided with either oral or IV iron supplementation. Patients who appear to be resistant to ESA should be evaluated for iron deficiency, occult blood loss, a chronic infection or inflammatory state, vitamin B_{12} or folate deficiency, or bone marrow fibrosis related to secondary hyperparathyroidism.

Emerging therapies for anemia of CKD are being directed toward the hypoxia-inducible signaling factor (HIF) pathway. HIF stabilizers prevent degradation of the HIF alpha subunit and allow for erythropoietin production. These agents are currently being studied for clinical use in adult CKD patients.

Hypertension and Proteinuria

Hypertension in pediatric CKD can be secondary to volume overload and/or excessive renin production due to glomerular disease. Both hypertension and proteinuria have been independently associated with more rapid CKD progression in various pediatric CKD observational studies. The ESCAPE trial demonstrated that more aggressive BP control delays CKD progression. In this study, participants with 24-hour mean arterial pressure (MAP) <50th percentile for age and sex by ABPM had a 35% lower risk of reaching the composite outcome (doubling of serum creatinine, estimated GFR (eGFR) of <10 mL/min/1.73 m^2, or need for dialysis or kidney transplant) compared with those randomized to a conventional BP target (MAP of 50–95% by ABPM); this effect was more notable in those with significant proteinuria.

Therapy for hypertension involves both dietary interventions and often pharmacologic agents. **Dietary sodium restriction** (<2 g of sodium/24 hr) and lifestyle modifications that promote achieving a healthy weight are both important aspects of achieving good BP control. Treatment guidelines recommend initiating pharmacologic antihypertensive therapy when systolic or diastolic BPs are >90% for age, gender, and height. Once therapy is started, it is recommended to titrate medications to achieve a systolic and diastolic BP <50% for age, gender, and height, especially in those patients with proteinuria. **ACE inhibitors** (such as enalapril, lisinopril) and **angiotensin II receptor blockers** (ARBs; such as losartan) are the antihypertensive medications of choice in all children with pediatric CKD, irrespective of the level of proteinuric renal disease, because of their potential ability to slow CKD and their superiority in controlling BP as noted in various observational and research studies. It is important to closely monitor renal function and electrolyte balance while using ACE inhibitors or ARBs, particularly in those with advanced CKD. **Thiazide** (hydrochlorothiazide, chlorothiazide, metolazone, and chlorthalidone) or **loop diuretics** (furosemide) can be helpful to control hypertension related to salt and fluid retention. Historical guidelines recommend the cessation of thiazide diuretics when a patient's eGFR falls below 30 mL/min/1.73 m^2 due to concerns of decreased efficacy; however, many adult studies support continued thiazide use either alone or in conjunction with loop diuretics for BP control in advanced (non-ESKD) CKD. Calcium channel blockers (amlodipine), β blockers (propranolol, atenolol), and centrally acting agents (clonidine) may be useful as adjunctive agents in children with CKD whose BP cannot be controlled using dietary sodium restriction, ACE inhibitors, and diuretics.

Immunizations

Children with CKD should receive all standard immunizations according to the schedule used for healthy children, with an exception to withhold live virus vaccines (such as measles, mumps, rubella, varicella) from those receiving immunosuppressive medications (i.e., kidney transplant recipients, and in some patients with glomerulonephritis). It is critical to make every attempt to administer live virus vaccines before kidney transplantation. All children with CKD should receive a yearly influenza vaccine; children with CKD are also eligible for pneumococcal vaccination with PPSV-23. Data from a number of studies suggest that children with CKD might respond suboptimally to immunizations.

Adjustment in Drug Dose

Drugs excreted by the kidneys may need to be dose adjusted in CKD patients to maximize effectiveness and minimize the risk of toxicity. Strategies in dosage adjustment include lengthening of the interval between doses, decreasing the absolute dose, or both.

Progression of Disease

The timing of CKD progression from minimal renal injury to onset of ESKD is variable. The median loss of GFR in children enrolled in the CKID study is 1.5 (non-glomerular CKD etiology) vs 4.3 (glomerular CKD etiology) mL/min/1.73 m^2/year. Nonmodifiable risk factors associated with more rapid CKD progression include older age, glomerular etiology of renal disease, CKD severity, and onset of puberty. In terms of potential modifiable risk factors, in addition to elevated BP, persistent nephrotic range proteinuria, anemia, dyslipidemia, and no ACE inhibitor/ARB use were important predictors of CKD progression.

In addition to addressing and treating the risk factors as noted previously, prompt treatment of infectious complications (especially urinary tract infection [UTI]) and episodes of dehydration can minimize additional loss of renal parenchyma. Other potentially beneficial recommendations include tobacco avoidance; prevention of obesity; and avoidance of potential nephrotoxic medications, which includes over-the-counter medications (such as nonsteroidal antiinflammatory medicines), pharmacologic agents, various illegal street drugs, and herbal and/or homeopathic medications or supplements.

Visit Elsevier eBooks+ at eBooks.Health.Elsevier.com for Bibliography.

572.3 End-Stage Kidney Disease

Donna J. Claes

Kidney failure, also termed end-stage kidney disease (ESKD), represents the state in which a patient's kidney dysfunction has progressed to the point at which homeostasis and survival can no longer be sustained despite maximal medical management. At this point, kidney replacement therapy (KRT; which is either dialysis or kidney transplantation) becomes necessary. The ultimate goal for children with ESKD is successful kidney transplantation (see Chapter 573) because it provides the most normal lifestyle and improved mortality and morbidity.

In the United States, 75% of children with ESKD require dialysis before transplantation. It is recommended discussions and plans for eventual KRT be initiated when a child reaches stage 4 CKD (GFR <30 mL/min/1.73 m^2). Indications for initiating maintenance dialysis include diuretic-resistant fluid overload, severe fluid restrictions that inhibit the ability to provide appropriate nutrition sufficient for linear growth, uncontrolled electrolyte abnormalities (hyperkalemia, hyperphosphatemia, metabolic acidosis), and subjective findings of uremia (fatigue, weakness, nausea, vomiting, anorexia, and poor sleep patterns), especially if these symptoms are negatively affecting academic performance. Although dialysis initiation should be considered as the GFR approaches 10-15 mL/min/1.73m^2, multiple adult and pediatric studies have indicated increased risk of mortality in those who start dialysis with a higher GFR compared to a lower GFR. Thus it is recommended to maximize medical management of CKD for as long as possible until concerns of severe fluid and electrolyte abnormalities, malnutrition, and uremic symptoms make medical management unsafe and/or impossible. Dialysis modality selection must be individualized to fit the needs of each child.

In the United States, peritoneal dialysis (PD) is still the most utilized dialysis modality (55.7%) compared to hemodialysis (44.3%); however, there is a temporal trend toward greater use of hemodialysis (HD) as the initial maintenance dialysis therapy. Age is a defining factor in dialysis modality selection: 85% of infants and children from birth to 5 years of age initiate maintenance dialysis treatment using PD, whereas 50% of children ≥13 years of age initiate maintenance dialysis treatment with HD.

Peritoneal dialysis utilizes the patient's peritoneal membrane to transport fluid and solutes. Excess body water is removed by an osmotic gradient created by the relatively high dextrose concentration in the dialysis fluid; wastes are removed by diffusion from the peritoneal capillaries into the dialysis fluid. Access to the peritoneal cavity is achieved by a surgically inserted tunneled catheter. PD may be provided either as continuous ambulatory peritoneal dialysis (CAPD) or as an automated therapy using a cycler (APD), which allows exchanges of peritoneal fluid to be performed automatically during sleep by a cycler machine. APD is the PD modality of choice in countries without cost restraints. Cycler-driven PD therapy allows the child and family an

uninterrupted day of activities (including decreased school interruption), a reduction in the number of dialysis catheter connections and disconnections (which decreases the risk of peritonitis), often less strict fluid and dietary restrictions, and a reduction in the time required by patients and parents to perform dialysis, reducing the risk of caregiver fatigue and burnout. Because PD is not as efficient as HD, it must often be performed 6-7 days per week. Contraindications to PD use include anatomic abnormalities (e.g., significant surgical adhesions, omphalocele, gastroschisis, or bladder exstrophy), peritoneal injury (including injury secondary to previous severe peritoneal infections), or lack of an appropriate caregiver who can reliably perform PD in the home.

Hemodialysis, unlike PD, is usually performed in a hospital or outpatient clinic setting; home pediatric HD programs or programs that provide intensified HD are available but uncommon. Access to the child's circulation is achieved by a surgically created arteriovenous fistula (AVF), arteriovenous graft (AVG), or tunneled dual lumen catheter. The internal jugular vein is the preferred catheter site because indwelling subclavian catheters can cause subclavian stenosis that limits that ability to utilize future AVF and AVG in the ipsilateral arm. Each HD treatment is typically prescribed to provide appropriate solute clearance and fluid removal. HD has historically been provided 3 times per week; however, more frequent dialysis treatments (up to 4-5 times per week) are seen in the United States. Intensified HD programs (such as short daily HD, intermittent nocturnal HD, and daily nocturnal HD) have demonstrated improved control of BP, fluid overload, phosphorus, anemia, and improved growth. Contraindications to HD include inadequate vascular access.

Pediatric patients on dialysis have a death rate 30 times higher than the general pediatric population, with cardiovascular disease and infections as the leading causes of mortality. Dialysis-associated infections (peritonitis, HD-related bloodstream infections) are also the leading causes of hospitalization in pediatric dialysis patients.

Visit Elsevier eBooks+ at eBooks.Health.Elsevier.com for Bibliography.

Chapter 573

Renal Transplantation

David K. Hooper and Charles D. Varnell Jr.

Kidney transplantation is the optimal therapy for children with end-stage kidney disease (ESKD). The life expectancy in children who receive a kidney transplant has steadily increased and is substantially better than for those who remain on dialysis (Fig. 573.1). Children and adolescents with ESKD have special needs that differ from adults, including the need to achieve normal growth and cognitive development. Successful transplantation leads to accelerated linear growth, allows for regular school attendance, and often eliminates the need for dietary restrictions. Improvements in surgical techniques and a reduction in the early complications such as thrombosis have given young children the best long-term outcomes of all age-groups among transplant recipients. Following kidney transplantation, the most commonly encountered complications include acute or chronic allograft rejection, an increased risk for infections with both community-acquired and opportunistic organisms, and cardiovascular disease (hypertension, obesity, dyslipidemia). Providers must also be aware of the risks for malignancy and sequelae of chronic kidney disease (CKD).

INCIDENCE AND ETIOLOGY OF ESKD

The incidence of ESKD in pediatric patients in the United States varies by age-group (Table 573.1), with an adjusted incident rate of 11 per million population in 2020. The etiology of ESKD in children also varies by age (Table 573.2; see Fig. 572.2 in Chapter 572). **Cystic or hereditary diseases** account for more than 24% of children wait-listed for a kidney transplant, whereas **congenital anomalies of the kidney and urinary tract (CAKUT)** account for 18% of such children. In 2020, there were 710 kidney transplants performed in children <18 years of age in the United States, with 184 performed in children ≤5 years old, 129 in children ages 6-10 years, and 397 in children ages 11-17 years. That same year, of the 6,177 children in the United States with ESKD, 4,577 (74.1%) had a functioning kidney transplant.

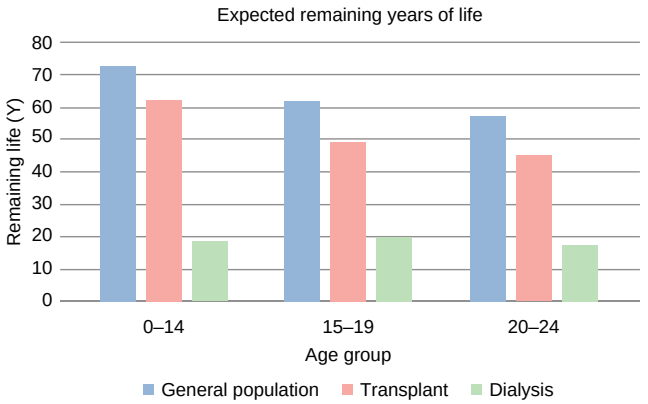

Fig. 573.1 Expected remaining years of life by end-stage renal disease treatment modality. Patients on dialysis or with a kidney transplant are compared to healthy children by age. *(Adapted from United States Renal Data System. 2020 USRDS annual data report: epidemiology of kidney disease in the United States. National Institutes of Health, National Institute of Diabetes and Digestive and Kidney Diseases, Bethesda, MD, 2020.)*

Table 573.1 Incident Rates of Reported ESKD in the United States

AGE RANGE (YEAR)	ADJUSTED INCIDENT RATES PER MILLION POPULATION
<1	26
1-5	7
6-12	8
13-17	16

Data from United States Renal Data System. 2022 USRDS annual data report: epidemiology of kidney disease in the United States. National Institutes of Health, National Institute of Diabetes and Digestive and Kidney Diseases, Bethesda, MD, 2022. Fig. 8.2. https://usrds-adr.niddk.nih.gov/2022/end-stage-renal-disease/8-esrd-among-children-and-adolescents.

INDICATIONS FOR RENAL TRANSPLANTATION

Renal transplantation is generally considered for any child when chronic renal replacement therapy is indicated. There are few absolute contraindications for pediatric kidney transplantation, yet relative contraindications arise when the combined risks of the transplant procedure itself and lifelong immunosuppression outweigh the benefits of improved health, longevity, and/or quality of life. Such relative contraindications include preexisting malignancy, primary or secondary immunodeficiency, chronic severe infection, inability to receive appropriate posttransplant care, or severe neurologic dysfunction where improvement in the quality of life and/or longevity is unlikely. In each scenario, the multidisciplinary team must weigh the risks and benefits of transplantation while accounting for the values of patients and caregivers. For instance, patients who have remission of malignancy for a minimum of 1-2 years may be considered on an individual basis for kidney transplantation. Similarly, patients with autoimmune diseases resulting in ESKD (e.g., systemic lupus erythematosus) are candidates for transplantation after a period of immunologic quiescence of the primary disease.

Table 573.2 Characteristics of Children with Incident End-Stage Kidney Disease, by Primary Cause of End-Stage Kidney Disease, 2016–2020

PRIMARY CAUSES OF ESKD	%
All Etiologies	100
Primary Glomerular Disease	21.5
Glomerulonephritis (GN) (histologically not examined)	5.4
Focal glomerulosclerosis, focal sclerosing	11.4
Membranous nephropathy	0.4
Membranoproliferative GN (MPGN) type 1, diffuse MPGN	0.4
Dense deposit disease, MPGN type 2	0.3
IgA nephropathy, Berger's disease (proven by immunofluorescence)	0.5
With lesion of rapidly progressive GN	0.8
Other proliferative GN	2.5
Secondary Glomerular Disease	8.3
Systemic lupus erythematosus (SLE nephritis)	2.6
Hemolytic uremic syndrome	1.9
Polyarteritis and other vasculitis	1.5
Associated vasculitis	1.8
CAKUT1	28.1
Congenital obstructive uropathies	10.1
Renal hypoplasia, dysplasia, oligonephronia	15.0
Chronic pyelonephritis, reflux nephropathy	3.0
Cystic/Hereditary/Congenital Diseases	11.9
Polycystic kidneys, adult type (dominant)	0.5
Polycystic, infantile (recessive)	3.0
Medullary cystic disease, including nephronophthisis	1.7
Hereditary nephritis, Alport syndrome	1.2
Cystinosis	1.0
Primary oxalosis	0.4
Congenital nephrotic syndrome	2.0
Other (congenital malformation syndromes)	1.9
Tubulointerstitial Diseases	4.9
Chronic interstitial nephritis	2.3
Acute interstitial nephritis	0.4
Tubular necrosis	2.1
Transplant Complications	1.5
Other transplant complication	1.4
Diabetes	0.6
Neoplasms/Tumors	0.8
Renal tumor	0.7
Hypertensive/Large Vessel Disease	1.6
Renal artery stenosis	0.3
Renal artery occlusion	1.2
Miscellaneous Conditions	14.0
Acquired obstructive uropathy	4.5
Unspecified with renal failure	2.3
Traumatic or surgical loss of kidney(s)	1.1
Other renal disorders	5.1
Nephropathy caused by other agents	0.9
Etiology Uncertain	4.0
Etiology Missing	2.9

IgA, Immunoglobulin A; CAKUT, congenital anomalies of the kidney and urinary tract. Modified from the United States Renal Data System. 2022 *USRDS* Annual Data Report: Epidemiology of kidney disease in the United States. National Institutes of Health, National Institute of Diabetes and Digestive and Kidney Diseases, Bethesda, MD, 2022. Table 8.1. https://usrds-adr.niddk.nih.gov/2022/end-stage-renal-disease/8-esrd-among-children-and-adolescents.

In children, dialysis may be required before transplantation to optimize the nutritional and metabolic conditions, allow for quiescence of an underlying autoimmune disorder, achieve an appropriate size, or keep a patient stable until a suitable donor is available. Although successful transplantation with an adult-sized kidney has occurred in children <10 kg and <6 months of age, recipients usually must weigh at least 8-10 kg to minimize the risk for vascular thrombosis and accommodate an adult-size kidney. This may require a period of dialysis support until the child is 12-18 months of age.

Preemptive transplantation (i.e., transplantation without prior dialysis) accounts for ~25% of all pediatric renal transplants. It is the preferred approach when possible because of a small but incremental decrease in patient and allograft survival for every year spent on dialysis before transplant. Preemptive renal transplantation can and should therefore be considered in any child with stage 4 or 5 CKD who is likely to require dialysis within 6-12 months and/or has evidence of the adverse effects of CKD on their health or neurocognitive development. This requires early referral to a transplant center for evaluation of the candidate and potential donors. The transplant team must work with the recipient and caregivers to determine the optimal time for transplantation considering the risks and benefits posed to the recipient.

CHARACTERISTICS OF KIDNEY DONORS AND RECIPIENTS

Approximately 30–40% of pediatric kidney transplants come from **living donors.** Because the Organ Procurement and Transplantation Network (OPTN) gives preference to children waiting for a **deceased-donor** renal transplant, children have a higher rate of transplantation than adults. In 2020, children less than 17 years of age on dialysis were transplanted at a rate of 43.7 transplants per 100 patient-years (29.9 deceased donor, 13.8 living donor), whereas adults were transplanted at a rate of 8.3 transplant per 100 patient-years. The current allocation policy was implemented to allocate priority to children based on projected organ survival using the **Kidney Donor Profile Index (KDPI),** which computes the projected allograft survival from 12 important donor characteristics. Under this system, the top 35% of kidneys (KDPI <35%) are preferentially allocated to children. Additional factors that determine the allocation include the time on dialysis or since listing (whichever is longest), a zero human leukocyte antigen (HLA)-antigen mismatch, calculated panel-reactive antibody (cPRA), prior living donor, and 0 or 1 HLA-DR (HLA–antigen D–related) mismatch. In 2021, a new allocation system was implemented based on a 250-nautical mile radius rather than allocation based on local organ procurement organizations, and children were given even higher priority on the wait-list. Because of such policies, the time on the wait-list for children is shorter than that for adults. Median wait time is approximately 7-8 months for children nationally compared with 4-5 years or more for adults.

EVALUATION AND PREPARING FOR KIDNEY TRANSPLANTATION

A comprehensive transplant evaluation includes a transplant surgeon, nephrologist, dietitian, social worker, psychologist, pharmacist, financial counselor, pretransplant nurse coordinator, and anesthesiologist. A urologist familiar with transplantation is also essential for patients with lower urinary tract anomalies. Important considerations for the transplant evaluation include considering the primary diagnosis and risk of recurrence; ensuring an adequate lower urinary tract for drainage of the transplanted kidney; diagnosing and treating infections; the presence of cardiovascular disease, anemia, and other sequelae of ESKD; and preparing the patient with immunizations before starting lifelong immunosuppression.

Understanding the primary renal disease is essential before kidney transplantation. For instance, a number of primary renal diseases can recur in a transplanted kidney, but this is not a contraindication to transplantation. Recurrent disease accounts for graft loss in almost 7% of primary transplantations and 10% of repeat transplants. **Primary focal segmental glomerulosclerosis (FSGS)** is known to recur in 30–60% of cases and substantially decreases allograft survival. Because **primary hyperoxaluria** is caused by enzymatic defects in the liver, traditionally kidney transplantation has been accompanied by liver transplantation to prevent recurrent disease in the kidney allograft. However, advancements in pharmacotherapy have led to development of **lumasiran**, the first medication approved by the U.S.

Food and Drug Administration (FDA) to treat primary hyperoxaluria. It is not yet known how these medications will affect progression to ESKD in children and/or the need for liver transplantation. Primary **membranoproliferative glomerulonephritis (MPGN)** carries a high risk of disease recurrence (>50%) and decreased allograft survival. Attempts to classify MPGN into immune vs complement-mediated disease may facilitate research that provides insight into prognosis and options for prevention and treatment, but data are still limited. Histologic recurrence with mesangial immunoglobulin (Ig) A deposits is common and occurs in about half of the patients with **IgA nephropathy** and in approximately 30% of patients with **IgA vasculitis** (formerly Henoch-Schönlein purpura), yet it may not necessarily lead to premature allograft failure. **Congenital nephrotic syndrome** rarely recurs after transplantation, although patients can develop **antinephrin antibodies** and present with nephrotic syndrome. **Membranous nephropathy** occurs very rarely in children. The recurrence rate after kidney transplantation for patients who have been treated for **Wilms tumor** is approximately 13%. Although **Alport syndrome** does not recur following transplantation, approximately 3–4% of patients with Alport syndrome can develop de novo **anti–glomerular basement membrane (anti-GBM) glomerulonephritis** that may lead to graft loss. Certain forms of **complement-mediated thrombotic microangiopathy (TMA)** (commonly referred to as **atypical hemolytic uremic syndrome**) caused by inherited defects in complement regulation can recur posttransplant with devastating consequences for the new allograft. These conditions must be evaluated with genetic testing and analysis of the complement system before transplant so appropriate monitoring and therapy with complement inhibition can be applied to prevent recurrent disease.

Due to the high risk of developing Wilms tumor, patients with **Denys-Drash syndrome** should undergo bilateral nephrectomy before transplantation. Other indications for unilateral or bilateral native nephrectomies include hyposthenuria with polyuria, significant proteinuria leading to coagulopathy, recurrent infection of the native kidneys, and severe hypertension resistant to medical management. Nephrectomies are also indicated in cases such as **polycystic kidney disease,** where the native kidneys may become so large that they cause feeding intolerability in infants or prevent space for a transplanted kidney. Finally, it is important to perform bilateral native nephrectomy or ureteral ligation in patients with **primary FSGS** who produce significant amounts of urine protein to allow for surveillance of proteinuria and early identification and treatment of **recurrent FSGS.**

Urologic problems, such as **vesicoureteral reflux, posterior urethral valves,** and/or abnormal bladders as seen in **Eagle-Barrett syndrome**, should be addressed before surgery. Malformations and voiding abnormalities (e.g., neurogenic bladder, bladder dyssynergia, remnant posterior urethral valves, and urethral strictures) should be identified and repaired if possible. Children with urologic disease and renal dysplasia often require multiple operations to optimize the urinary tract anatomy and function. Such procedures include ureteric reimplantation to correct vesicoureteral reflux, bladder augmentation or reconstruction, urinary diversion (vesicostomy, ureterostomy, ileal conduit, continent appendicovesicostomy), and excision of ureteroceles. Good outcomes have been achieved in posterior urethral valve bladders by following a staged procedure of initial valve resection and bladder rehabilitation by a process of regimented double voiding and/or bladder cycling before transplantation. Following transplantation, bladder function in these patients should be followed for the long term because they can become less compliant over time and lead to premature failure of the transplanted allograft.

A comprehensive nutritional assessment should be performed to ensure that an optimal nutritional status is achieved before transplant. Many children with ESKD require nutritional supplements to provide them with sufficient protein and calories. Infants and young children on dialysis often require nasogastric or gastrostomy tube feedings to overcome decreased oral intake from nausea and anorexia due to uremia.

Bone disease should be evaluated for and bone health optimized before transplantation. Uncontrolled secondary hyperparathyroidism may lead to urinary phosphate wasting, hypercalcemia, hypercalciuria, and/or nephrolithiasis posttransplant. A high calcium phosphorus product before transplantation leads to vascular stiffness and calcifications, increasing the risk for cardiovascular disease and difficult-to-control hypertension in the perioperative and posttransplant period.

In the United States, >25% of the deaths in children on maintenance dialysis are a result of cardiovascular disease. Cardiac death is the leading cause of mortality in young adults after transplant in childhood. Therefore evaluation of cardiac function, including echocardiography and electrocardiography, is required before kidney transplantation to ensure sufficient cardiac function to tolerate the large fluid load that accompanies kidney transplantation. Hypertension is common in ESKD and should be treated before transplant. If medical management is insufficient, bilateral nephrectomy may be considered to control the hyperreninemic response from the failing kidneys. Finally, patients with a history of obstructive uropathy and oligohydramnios in utero who survive to kidney transplant may have undiagnosed/unrecognized pulmonary hypertension, which should be evaluated before transplantation.

Anemia needs to be treated before transplantation. Most patients receive erythropoietin, folate, and iron to maintain goals for hemoglobin levels between 11 and 13 g/dL. Blood transfusions should be avoided if possible due to concerns about sensitizing the patient to HLAs before transplant. If a blood transfusion is required, patients should receive leukoreduced red blood cells.

Evaluation for hypercoagulable states is important before renal transplantation because venous thrombosis is an important cause of graft failure. Risk factors for graft thrombosis include history of prior thrombosis, surgical technique, perfusion and reperfusion injury of the graft, young donor age (<6 years), young recipient (<5 years), cold ischemia time >24 hours, arterial hypotension, prior history of peritoneal dialysis, and/or hypoperfusion of an adult allograft transplanted into a small child. Particularly in the young recipient, there must be an evaluation for thrombosis of the iliac vessels and inferior vena cava, especially if there is a history of previous surgery or central line placement. Children who have large protein losses, such as from nephrotic syndrome and/or peritoneal dialysis, can be at an increased risk for thrombosis because of protein loss, such as protein S, protein C, and antithrombin III. Doppler ultrasound, CT angiography, and MR angiography have all been used to evaluate vessels. To minimize the risk of contrast-induced nephropathy associated with CT contrast, patients with advanced CKD or ESKD not yet on dialysis should receive intravenous hydration before and after the study and acidosis should be corrected before giving contrast medium. While MR angiography has traditionally been avoided in patients with CKD or ESKD because of the risk of nephrogenic systemic fibrosis from early forms of gadolinium, the more recent broad availability of newer, more stable gadolinium preparations makes contrast-enhanced MRI a valid and reasonably safe option. Collaboration between radiology and nephrology is important when determining which gadolinium agents to use and when contrast MRI is appropriate in children with CKD and ESKD.

Infections must be identified, prevented, and treated before transplantation. Infectious disease screening includes obtaining a complete history of the following: current or previous infections, all vaccinations, any occupational risks among family members (e.g., healthcare worker), household or other contacts with treatment for tuberculosis, travel within the past 2 years or significant time spent in another country, bacille Calmette-Guérin administration, animal and/or insect exposure, sexual activity, and consumption of high-risk foods such as unpasteurized products. Screening includes a tuberculosis skin test (purified protein derivative) or interferon gamma release assay, cytomegalovirus IgG, Epstein-Barr virus (EBV) antibody panel, varicella titer, measles antibody, hepatitis B serologies, hepatitis C antibody, HIV, and toxoplasmosis. Additional testing for patients who live in or have visited endemic areas might include *Coccidioides* immunodiffusion, serology for *Strongyloides,* and/or antibody for *Histoplasma* antibody. Sexually active patients should also be screened for syphilis, gonorrhea, and *Chlamydia.*

It is recommended that all immunizations be current before transplantation. All live vaccines (measles, mumps, rubella [MMR] and varicella) should be given before transplantation, and antibody titers should be checked for a response because these vaccines should not be given to immunosuppressed patients. MMR may be given as early as 6 months of age. Inhaled (live-attenuated virus) influenza vaccine should not be given to transplant patients, family members, or healthcare providers.

Psychiatric evaluation should be performed before transplantation to evaluate the ability of patients and families to cope with the substantial stressors that accompany caring for a child with a kidney transplant. This evaluation should include screening for depression, substance abuse, and adherence so that problems can be identified and managed before kidney transplantation. If nonadherence is identified or anticipated, interventions should be in place before transplantation.

The ABO blood type must be confirmed twice before a patient is listed for kidney transplantation. Donors and recipients are currently matched for HLA-A, HLA-B, and HLA-DR antigens. In general, better matched organs have improved survival times following kidney transplantation. Matching at the DR locus appears to be especially advantageous, though in the modern era of immunosuppression, successful six-antigen mismatched transplants are performed routinely. All patients must be screened for preformed anti-HLA antibodies before kidney transplantation. The most common, sensitive, and specific method uses flow cytometry and single HLA-antigen beads. In this manner, a patient's PRA can be assessed and is reported as the percentage of the population against which a recipient has anti-HLA antibodies. Patients can become sensitized by a prior transplant, blood transfusions, and/or pregnancy. Highly sensitized patients (PRA >80%) may undergo desensitization with plasmapheresis, anti-CD 20 antibody, and/or proteasome inhibitors to expand the donor pool from which they can safely receive an organ.

IMMUNOSUPPRESSION

Most pediatric kidney transplant centers employ induction immunosuppression at the time of transplant followed by lifelong maintenance immunosuppression with a calcineurin inhibitor and an antiproliferative agent with or without steroids.

Induction Therapy

Induction therapy is used in nearly all pediatric renal transplants to prevent early acute rejection. The OPTN Scientific Registry of Transplant Recipients (OPTN/SRTR) 2020 Annual Report indicates that 60% of patients receive T-cell–depleting induction therapy (rabbit antithymocyte globulin). Use of an interleukin (IL)-2 receptor antagonist (basiliximab) has been stable at between 30% and 40% for the past 5 years, and the rates of no induction therapy have declined to below 10%.

T-Cell Antibodies

Antithymocyte globulin is comprised of rabbit- or horse-derived polyclonal antibodies against human T-lymphocyte antigens that results in a rapid depletion of T lymphocytes. The infusion is generally started in the operating room before reperfusion of the transplant kidney. Most centers use this for standard induction therapy, but some limit its use to induction of sensitized high-risk patients or patients who have concerns for delayed graft function and want to avoid high calcineurin inhibitor levels in the early postoperative period. The standard dosage is 1.5 mg/kg/dose for three to five doses, with daily monitoring of lymphocyte, neutrophil, and platelet counts. Some centers monitor $CD3^+$ subsets and hold the dose if the $CD3^+$ count is below 20 cells/mm^3.

Interleukin-2 Receptor Antibodies

Basiliximab is currently the only monoclonal anti-CD25 antibody on the market. This chimeric (murine/human) anti-CD25 antibody prevents T-cell proliferation but does not cause T-cell depletion. Basiliximab is given in two doses of 10 mg for patients <35 kg and 20 mg for patients ≥35 kg. The first dose should be given within 2 hours before the transplant surgery and the second dose on day 4. Patients tend to tolerate IL-2 receptor antagonists well with few side effects.

Other Induction Therapies

Alemtuzumab (Campath-1H) is a monoclonal antibody against CD52 present on T and B cells, monocytes, and natural killer cells. Some centers have used this induction antibody in steroid and calcineurin inhibitor-sparing protocols, but pediatric data are limited as has been its use.

Other induction therapies for highly sensitized patients include targeting B cells and/or removing neutralizing antibodies by using rituximab against the CD20 epitope on early-lineage and intermediate-lineage B cells, proteasome inhibitors, and plasmapheresis and/or high-dose intravenous immunoglobulin for removing donor-specific antibodies.

Maintenance Immunosuppression

Lifelong maintenance immunosuppression is required in nearly all patients following kidney transplantation. The most common regimens include a calcineurin inhibitor (predominantly tacrolimus vs cyclosporine) and an antiproliferative agent (predominantly mycophenolate mofetil [MMF] vs azathioprine) with or without corticosteroids. The mammalian target of rapamycin (mTOR) inhibitors sirolimus and everolimus are sometimes used in place of the calcineurin inhibitor or antiproliferative agent. The rationale for combination therapy in children is to provide effective immunosuppression while minimizing the toxicity of any single drug.

Calcineurin Inhibitors

Despite the search for immunosuppression regimens that minimize calcineurin inhibitor exposure, **tacrolimus** remains the centerpiece of maintenance immunosuppression for most pediatric patients in North America. According to OPTN/SRTR in 2020, >90% of children in the United States were placed on tacrolimus-based immunosuppression at the time of transplant. The increasing use of tacrolimus in place of **cyclosporine** can be attributed to studies demonstrating better efficacy (fewer rejections and less reliance on steroids) and less severe cosmetic side effects, such as hypertrichosis, gingival hyperplasia, and coarsening of facial features. This is especially relevant for adolescents for whom unwanted cosmetic side effects can become a barrier to immunosuppression adherence. Tacrolimus also appears to cause less dyslipidemia, though other side effects such as **new-onset diabetes after transplant (NODAT),** tremor, seizure, alopecia, and sleep disturbance seem to be more common in patients treated with tacrolimus. Despite the nearly complete replacement of cyclosporine with tacrolimus, there are select cases when cyclosporine is the preferred agent (e.g., to treat posttransplant recurrence of FSGS or conversion therapy in patients who develop NODAT).

Unfortunately, both calcineurin inhibitors have a narrow therapeutic index and can cause acute and chronic kidney injury. Additionally, many foods and drugs interact with the calcineurin inhibitor metabolism, requiring frequent therapeutic drug monitoring. A usual starting dose of tacrolimus is 0.1-0.15 mg/kg twice a day on the day of the transplant, targeting trough levels above 10 ng/mL for the first month and then tapering down to trough levels of 4-8 ng/mL by 6 months. Patients with CYP3A5 expression (80–90% of patients from African descent vs 20–30% of patients with Caucasian ancestry) often require doses nearly twice as high. Pharmacogenetic testing of CYP3A5 polymorphisms is available and may assist with personalized dosing. The recent development of long-acting tacrolimus preparations (Envarsus XR and Astagraf XL) have provided the opportunity for a simplified, once daily medication regimen. Most long-term immunosuppressive regimens attempt to limit calcineurin inhibitor dosing as much as possible, and the search for calcineurin inhibitor–sparing drug regimens remains an area of intense research.

Antiproliferative Agents

Most immunosuppression regimens for children following kidney transplantation include an antiproliferative agent. **MMF** is the

morpholinoethyl ester prodrug of mycophenolic acid, an inhibitor of de novo purine synthesis, and is part of the initial maintenance immunosuppression regimen in at least two thirds of U.S. pediatric renal transplant recipients. The absence of nephrotoxicity, cardiovascular risk (hypertension, dyslipidemia), and hepatotoxicity make it an attractive option for immunosuppression, and the fact that it has greater efficacy than azathioprine has enabled the use of lower doses of corticosteroids and/or calcineurin inhibitors. Primary toxicities include diarrhea and upset stomach, as well as leukopenia and anemia, affecting up to 40% of patients. These side effects are often transient and can be treated with a temporary dosage reduction, but persistent dose reductions have been associated with an increased risk of rejection. MMF is also associated with a high risk for birth defects, so its use in adolescent females necessitates two forms of birth control and regular pregnancy screening. The usual dose of MMF is 600 mg/m^2 in patients treated with cyclosporine. MMF metabolism is slower in patients treated concomitantly with tacrolimus, allowing for lower doses (450 mg/m^2) to be used.

Azathioprine, an analog of **6-mercaptopurine**, is an alternative to MMF that also inhibits de novo purine synthesis and contributes to cell cycle arrest. It was the first medication approved for immunosuppression in kidney transplantation, yet in the past 2 decades, its use has declined because of the advent of newer immunosuppressive medications with purported greater efficacy. It is inexpensive and, unlike MMF, it can be administered once daily, so it is an attractive alternative for patients who struggle to take twice-daily medications. Usual dosage is 1.5-3 mg/kg once daily. Bone marrow suppression is the primary toxicity, but gastrointestinal side effects are less common than with MMF, with the exception of pancreatitis, which has rarely been reported. Unlike MMF, it is not associated with birth defects and is an important alternative in pregnant patients. Enteric-coated mycophenolic acid is another alternative to MMF that may decrease upper gastrointestinal side effects in some patients.

Mammalian Target of Rapamycin (mTOR) Inhibitors

mTOR inhibitors (sirolimus more commonly than everolimus) are used primarily as adjunctive immunosuppression in combination with MMF to avoid tacrolimus toxicity or with tacrolimus and MMF to spare steroids. However, they are used in only 5–10% of pediatric kidney transplant recipients 1 year posttransplant, perhaps due to evidence suggesting a high rate of donor-specific antibodies and antibody-mediated rejection (AMR) in patients taking mTOR inhibitors. Other toxicities, including a high rate of aphthous ulcers, dyslipidemia, poor wound healing, proteinuria, and diarrhea, have limited their use.

Corticosteroids

Corticosteroids remain integral to most immunosuppressive protocols despite their multifaceted toxicities. According to the 2020 OPTN/SRTR report, 54% of patients are treated with steroids at the time of transplant. The adverse effects of steroids are especially pronounced in children, for whom retarded skeletal growth, hypertension, obesity, diabetes mellitus, hyperlipidemia, osteopenia, and aseptic necrosis of bone (particularly the femoral heads) can have dire long-term consequences. Cosmetic side effects, such as cushingoid facies and acne, also become barriers to adolescents taking their medication. For these reasons, steroid-based regimens in children seek to minimize steroid exposure by starting with high-dose steroids as induction therapy and tapering down over several months to a lowest dose of 5-10 mg or 0.1 mg/kg daily. Other protocols call for a more rapid steroid taper lasting from 1 week to several months before stopping them altogether.

Several well-designed randomized controlled trials in children and adults have demonstrated that complete steroid avoidance can be safely achieved in patients with a low immunologic risk by using induction therapy with dual-maintenance immunosuppression comprised of tacrolimus and MMF. In general, steroid avoidance is associated with higher rates of rejection but also carries significant benefits for growth, hypertension, and dyslipidemia with no decrease in long-term allograft survival. Importantly, this approach appears to be safe and without increases in the generation of donor-specific antibody or histologic injury. Despite this evidence, data from the OPTN network suggest that steroid use is largely dependent on the center where the transplant is performed rather than the characteristics of the patient.

Other Agents

Belatacept is a fusion protein composed of the Fc fragment of a human IgG_1 linked to the extracellular domain of CTLA-4 (a molecule crucial for T-cell costimulation), which selectively blocks the process of T-cell activation. Belatacept is attractive for maintenance immunosuppression because it is a quick monthly infusion rather than a daily oral medication, and it does not have many of the untoward side effects associated with calcineurin inhibitors, including and especially nephrotoxicity. Adult studies of belatacept have demonstrated similar rejection rates but significantly improved kidney function up to 10 years following kidney transplantation compared with cyclosporine. Unfortunately, there is an unacceptably high rate of **posttransplant lymphoproliferative disorder (PTLD)** in EBV-naïve patients, which are most of the children receiving a kidney transplant.

FLUID MANAGEMENT IN INFANTS AND SMALL CHILDREN AFTER KIDNEY TRANSPLANTATION

Maintenance of adequate blood flow to an adult-sized kidney in an infant or small child is crucial to avoid acute tubular necrosis (ATN) and graft loss from vascular thrombosis. The recipient aortic blood flow early after transplantation of an adult-size kidney more than doubles from the pretransplantation aortic blood flow. The maximum blood flow that can be obtained in an adult-size kidney transplanted into a small child is approximately 65% of what was in the donor. Low blood flow states, such as those with hypovolemia or hypotension, increase the risk for ATN, graft thrombosis, and graft nonfunction. Thus, in the postoperative period, patients are maintained on high fluid volumes.

Close attention is paid to the blood pressure and hydration status in the operating room in an attempt to reduce the incidence of delayed graft function. Typically, a central venous catheter is inserted to monitor the central venous pressure throughout the operation. A central venous pressure of 12-15 cm H_2O should be achieved before removing the vascular clamps; a higher central venous pressure may be desirable in the case of a small infant receiving an adult-size kidney. Dopamine may be started in the operating room and continued for 24-48 hours postoperatively to maintain a mean arterial blood pressure (MAP) >55 mm Hg. A blood transfusion with packed red blood cells may be required in very small recipients because the hemoglobin can drop as a result of sequestration of approximately 150-250 mL of blood in the transplanted kidney. Because an adult kidney transplanted into a small child can produce enormous amounts of urine, a fluid strategy that provides a constant rate for insensible losses (D10W at a rate of 400 mL/m^2/day) and urine replacements helps to ensure adequate hydration of the adult kidney. Some transplant centers continue to provide infants with aggressive fluid management by nasogastric or gastrostomy tube feedings of at least 2,500 mL/m^2/day for up to 6 months following transplant if the child is unable to take in sufficient volume by mouth.

REJECTION OF KIDNEY TRANSPLANT

Hyperacute rejection, caused by preformed antibodies against the donor HLA, ABO, or other antigens, occurs immediately on reperfusion of the allograft. The practice of prospective cross matching using complement-dependent cytotoxicity has virtually eliminated hyperacute rejection.

Acute T-cell-mediated rejection (TCMR) must be identified and treated promptly, although this may not be straightforward in the very young transplant recipient. Because most small children receive adult-size kidneys with a large renal reserve compared with their body mass, significant allograft dysfunction may be present with little or no increase in serum creatinine. Therefore even subtle findings such as hypertension or new proteinuria can indicate acute TCMR and must be investigated. Late diagnosis and treatment of rejection are associated with a higher incidence of resistant rejections and graft loss. Most cases of acute TCMR can be treated if detected early by using a short course (3-5 days) of high-dose intravenous steroids

(10-30 mg/kg) followed by an oral steroid taper over the next several weeks and either increased maintenance immunosuppression or improved adherence, whichever is most appropriate. Steroid-resistant or high-grade rejection can be treated with thymoglobulin (1.5 mg/kg/day) for 7-14 days, high-dose tacrolimus (trough levels >20 ng/dL for 1-2 weeks), or local allograft irradiation. Following treatment for rejection, it is important to consider 3-12 months of prophylaxis with trimethoprim/sulfamethoxazole to prevent *Pneumocystis jirovecii* pneumonia (PJP pneumonia), valganciclovir/valacyclovir to prevent cytomegalovirus/herpes reactivation, and nystatin or fluconazole to prevent oral candidiasis.

Active AMR consisting of anti-HLA donor-specific antibodies is an important cause of kidney function decline and allograft loss. It can present acutely in the few weeks following transplantation in previously sensitized patients or may develop chronically due to inadequate immunosuppression or poor adherence. Unlike acute TCMR, acute AMR is much more difficult to treat and may require plasmapheresis, intravenous immunoglobulin (IVIG), anti-CD20 antibody infusions, and/or proteasome inhibitors. Treatment is most likely to be successful if initiated within a few months of identifying new donor-specific antibodies.

Chronic rejection (T-cell mediated or antibody mediated) is the leading cause of graft loss. Children often have a gradual decline in their renal function and often have fixed proteinuria and hypertension. Despite initial excitement about the potential of MMF and sirolimus mitigating chronic graft injury, this has not translated readily into observable clinical benefits. Chronic TCMR, chronic AMR, and the impact of non-HLA antibodies are areas of active investigation.

Kidney Biopsy

Kidney biopsy is the gold standard for the diagnosis of TCMR or AMR. Despite attempts to develop noninvasive biomarker panels, none has proven sensitive enough to rule out rejection. Many centers perform **surveillance biopsies** at specific time points following transplantation to detect **subclinical rejection**, which has been reported in <10% of such surveillance biopsies.

GRAFT SURVIVAL OF KIDNEYS

Survival rates for live-donor kidney allografts are superior to those for deceased-donor allografts. Living-donor kidneys generally have fewer HLA mismatches, lower cold ischemia time, and require less immunosuppression than deceased-donor kidneys. Furthermore, deceased-donor transplant requires children to wait several weeks to a few years on the deceased-donor wait-list before receiving an organ. The OPTN/SRTR 2021 annual report showed that the death-censored, 5-year allograft survival rate was 85.2% for deceased-donor kidney transplants performed in 2014–2016, whereas the death-censored, 5-year allograft survival rate for living-donor transplants was 93.1% over the same time period. For these reasons and because it expands the donor pool, living donation should be advocated at every opportunity.

Children <10 years of age have the best long-term graft and patient survival rates of all age-groups, and adolescents and young adults have the worst. Among patients with at least 1 year of graft function, graft failure rates are stable at around 1.4 per 100 person-years until 10 years of age, when rates increase, peaking at a maximum of 6.3 per 100 person-years at age 19 years, regardless of the age at transplantation. A variety of factors likely account for such poor outcomes in adolescents and young adults, including the patient's changing physiology, a transition from pediatric to adult care, and a greater number of barriers to taking immunosuppressives.

COMPLICATIONS OF IMMUNOSUPPRESSION

Since the mid-1990s, the incidence of acute rejection has decreased, but the incidence of infection after transplantation has increased.

Pneumonia and urinary tract infection are the most common posttransplant bacterial infections. Urinary tract infections can progress rapidly to urosepsis and may be confused with episodes of acute rejection. Trimethoprim-sulfamethoxazole is used for urinary tract infection antibiotic prophylaxis as well as PJP prophylaxis for 3-6 months after transplant (see Chapter 290).

The herpesviruses (cytomegalovirus, herpesvirus, varicella-zoster virus, and EBV) pose a special problem in view of their common occurrences in childhood (see Chapters 299-302). Many young children have not yet been exposed to these viruses, and because they lack protective immunity, their predisposition to serious primary infection is high. The incidence of cytomegalovirus seropositivity is approximately 30% in children >5 years of age and rises to approximately 60% in teenagers. Thus the younger child is at a greater potential risk for serious infection when a cytomegalovirus-positive donor kidney is transplanted. About half of children are seronegative for EBV; most of them will become infected shortly after transplant. Most EBV infections are clinically silent but put transplant recipients at risk for PTLD in the presence of immunosuppression. The incidence of these infections is higher in children who receive antibody induction therapy and after treatment of acute rejection. Antiviral prophylaxis with ganciclovir or valganciclovir for 3-12 months after transplantation, especially in the higher-risk groups (recipient-negative, donor-positive), has been effective in reducing the incidence of clinical cytomegalovirus disease. Serial surveillance for these viruses by quantitative polymerase chain reaction (PCR) for the viral load in the peripheral blood has also allowed educated minimization of immunosuppression with a resultant reduction in the viral burden. It is important to monitor for PTLD with routine examinations for lymphadenopathy, hepatosplenomegaly, and EBV screening.

Polyomavirus nephropathy is an important cause of allograft dysfunction; almost 30% of children have BK viruria (see Chapter 321), although allograft dysfunction occurs only in a small subset of patients (~5%). Early protocols focusing on screening for BK virus in the urine have proven ineffective at distinguishing patients who will develop BK nephropathy; rather, plasma BK monitoring has become the standard of care. Ultimately, a renal biopsy, with identification of BK virus by immunoperoxidase staining, is required to make the diagnosis of BK virus nephropathy with certainty. Reducing immunosuppression when plasma BK PCR levels start to rise is the main form of therapy. Cidofovir, leflunomide, and IVIG have all been used as adjunctive therapies.

Oral candidiasis is another important infection following kidney transplantation and can be prevented with oral nystatin 4 times daily or fluconazole once daily for the first 3 months after transplant. Careful monitoring of calcineurin inhibitor levels is important when starting or stopping treatment with fluconazole as it interferes with calcineurin inhibitor metabolism.

Pediatric solid organ transplant patients are generally considered to be at increased risk for infections and worse outcomes compared with their nonimmunosuppressed peers. This concern was brought to the forefront during the global COVID-19 pandemic. Despite their immunosuppressed state, studies have not shown that children with a solid organ transplant are at increased risk for complications from COVID-19 infection. Early studies indicate that short-term outcomes from COVID-19 in pediatric kidney transplant recipients are generally favorable, without increased risk of graft loss, respiratory failure, or death compared with nonimmunosuppressed peers. Nonetheless, COVID-19 vaccination is recommended before transplantation to minimize risk of complications and spread.

Hypertension, dyslipidemia, obesity, and posttransplant diabetes mellitus are other complications of immunosuppression and kidney transplantation that have been underrecognized and undertreated. Cardiovascular disease is the primary cause of premature death in young adults who had a kidney transplant in childhood, and uncontrolled blood pressure leads to premature allograft failure. Up to 80% of children have hypertension and up to 60% are uncontrolled despite multiple available therapies. The 24-hour ambulatory blood pressure monitoring (ABPM) is the gold standard for assessing blood pressure control because isolated nocturnal hypertension and masked hypertension are common following kidney transplantation and can only be diagnosed with ABPM. Guidelines for CKD recommend treating blood pressure to achieve a MAP below the 50th percentile for age, gender, and height on ABPM, though recommendations for children with a kidney transplant have not been as aggressive. Blood pressure

should be treated to at least below the 90th percentile for age, gender, and height and below 130/80 mm Hg. Angiotensin-converting enzyme (ACE) inhibitors are the preferred first-line agents in patients with proteinuria; otherwise, either calcium channel blockers or ACE inhibitors can be used with other agents added as needed to achieve blood pressure control.

Although growth improves after transplantation, chronic steroid use does not allow a child to reach their full potential height. The use of recombinant human growth hormone in pediatric renal transplant recipients significantly improves the growth velocity and standard deviation score (SDS). Steroid minimization and withdrawal protocols have demonstrated growth benefits, and the steroid-avoidance data in children show significant catch-up growth at 5 years after transplantation. It is thus likely that with a well-functioning kidney and no maintenance steroids, children might now be able to realize their full height potential.

Malignancy is an important problem following kidney transplantation for children. Lifelong immunosuppression confers at least a twofold lifetime risk of developing cancer for solid-organ transplant recipients compared with the general population. The most common cancer to develop within 10 years following kidney transplantation in children is **PTLD.** It occurs in 1–5% of pediatric kidney transplant recipients and is the most likely cancer to be encountered in childhood. Over the long term, skin cancers (basal cell carcinoma, cutaneous squamous cell carcinoma) are the most common malignancies, with an incidence of close to 15% by 15 years posttransplant and increasing from there. Carcinomas other than skin carcinomas also arise at a rate far higher than in the general population. The prognosis is generally good for most of these malignancies when they are diagnosed early and treated appropriately. Any kidney transplant recipient must be assessed regularly for signs of malignancy and practice preventative measures such as using appropriate sunscreen products.

Developing good adherence behaviors with immunosuppressive medications is one of the most important challenges facing children and adolescents following kidney transplantation. Up to 43% of adolescents display some decreased adherence to their immunosuppressive regimen, which is thought to contribute to decreased allograft survival rates compared with other age-groups. A child's normal development, which includes establishing more independence, spending more time away from home, feeling invincible, and being vulnerable to cosmetic medication side effects, increases the barriers to taking immunosuppression medications. Systems-based approaches, in which clinicians partner with patients to identify and address adherence barriers, are most likely to improve adherence over the long term.

LONG-TERM OUTCOME OF KIDNEY TRANSPLANTATION

With advances in transplant care and treatment modalities and with diligent attention to the pediatric patient's psychosocial, educational, vocational, and developmental rehabilitation, the social and emotional functioning of the child and the child's family appears to return to the same level as before the illness within 1 year of successful transplantation. Renal transplantation leads to improvement in linear growth in children. School function tests improve after renal transplantation. Most patients can reenter school and social activities after a short recovery time of 6-12 weeks following surgery. Surveys of 10-year survivors of pediatric kidney transplants report that most patients consider their health to be good, and they engage in appropriate social, educational, and sexual activities while experiencing a very good to excellent quality of life.

Visit Elsevier eBooks+ at eBooks.Health.Elsevier.com for Bibliography.

Urologic Disorders in Infants and Children

PART XXII

Chapter 574

Congenital Anomalies and Dysgenesis of the Kidneys

Heather N. Di Carlo and Chad B. Crigger

EMBRYONIC AND FETAL DEVELOPMENT

The kidney is derived from reciprocal interaction between the ureteral bud and the metanephric blastema. During the fifth week of gestation, the ureteral bud arises from the mesonephric (Wolffian) duct and penetrates the metanephric blastema, which is an area of undifferentiated mesenchyme on the nephrogenic ridge. The ureteral bud undergoes a series of approximately 15 generations of divisions and by the 20th week of gestation forms the entire collecting system, including the ureter, renal pelvis, calyces, papillary ducts, and collecting tubules. Signals from the mesenchymal cells induce ureteric bud formation from the Wolffian duct as well as ureteric bud branching. Reciprocal signals from the ureteric bud and, later, from its branching tips induce mesenchymal cells to condense, proliferate, and convert into epithelial cells. Under the inductive influence of the ureteral bud, nephron differentiation begins during the seventh week of gestation.

By the 20th week of gestation, when the collecting system is developed, approximately 30% of the nephrons are present. Nephrogenesis continues at a nearly exponential rate and is complete by the 36th week of gestation. During nephrogenesis, the kidneys ascend to a lumbar site just below the adrenal glands. At least 16 signaling agents have been identified that regulate renal development. Defects in any of the signaling activities could cause a kidney not to form **(renal agenesis)** or to differentiate abnormally **(renal dysgenesis)**. Dysgenesis of the kidney includes **aplasia, dysplasia, hypoplasia,** and certain forms of **renal cystic disease.**

The fetal kidneys play a minor role in the maintenance of fetal salt and water homeostasis. The rate of urine production increases throughout gestation; at term, volumes have been reported to be 50 mL/hr. The glomerular filtration rate is 25 mL/min/1.73 m^2 at term and triples by 3 months postpartum. The increase in the glomerular filtration rate is caused by a reduction in intrarenal vascular resistance and redistribution of intrarenal blood flow to the cortex, where more nephrons are located.

RENAL AGENESIS

Renal agenesis, or absent kidney development, can occur secondary to a defect of the Wolffian duct, ureteric bud, or metanephric blastema. Unilateral renal agenesis has an incidence of 1 in 450-1,000 births. Unilateral renal agenesis often is discovered during the course of an evaluation for other congenital anomalies such as VACTERL association (vertebral defects, anal atresia, congenital heart disease, tracheoesophageal fistula, renal and limb defects; see Chapter 100.1). Its incidence is increased in newborns with a single umbilical artery. In true agenesis, the ureter and the ipsilateral bladder hemitrigone are absent. The contralateral kidney undergoes compensatory hypertrophy to some degree prenatally, but primarily after birth. Approximately 15% of these children have contralateral vesicoureteral reflux, and most males have an ipsilateral absent vas deferens because the Wolffian duct is absent. Because the Wolffian and müllerian ducts are contiguous, müllerian abnormalities in females also are common.

The **Mayer-Rokitansky-Küster-Hauser (MRKH) syndrome** (1 in 4,000 to 1 in 5,000 female births) is a group of associated findings that may include vaginal aplasia, uterine maldevelopment, and normal ovaries. Two types are described. In **type I**, only müllerian aplasia occurs, whereas in **type II**, there are associated anomalies, most commonly unilateral renal agenesis, or a horseshoe kidney, with skeletal anomalies present in 10% (see Chapter 591). **Zinner syndrome** is considered the male counterpart of MRKH syndrome (Fig. 574.1). In this condition, males with unilateral renal agenesis (or a regressed **multicystic dysplastic kidney** [MCDK]) have an ipsilateral seminal vesicle cyst and a possible epididymal cyst and dilated distal ureteral segment. These patients typically present in adolescence. Expectant management is usually followed with interim ultrasonography unless symptoms develop, including hematuria, hematospermia, or dysuria.

Renal agenesis is distinguished from aplasia, in which a nubbin of nonfunctioning tissue is seen capping a normal or abnormal ureter. This distinction may be difficult but usually is clinically insignificant. Unilateral renal agenesis is diagnosed in some patients based on the finding of an absent kidney on ultrasonography or renal scintigraphy (renal scan). Some of these patients were born with a hypoplastic kidney or a MCDK that underwent complete cyst regression. Although the specific diagnosis is not critical, if the finding of an absent kidney is based on an ultrasound, a functional imaging study such as a renal scan should be considered because some of these patients have an ectopic kidney in the pelvis. If there is a normal contralateral kidney, long-term renal function usually remains normal.

Bilateral renal agenesis is incompatible with extrauterine life and produces **Potter syndrome.** Death occurs shortly after birth from pulmonary hypoplasia. The newborn has a characteristic facial appearance, termed **Potter facies** (Fig. 574.2). The eyes are widely separated with epicanthal folds, the ears are low set, the nose is broad and compressed flat, the chin is receding, and there are limb anomalies. Bilateral renal agenesis should be suspected when maternal ultrasonography demonstrates **oligohydramnios,** nonvisualization of the bladder, and absent kidneys. The incidence of this

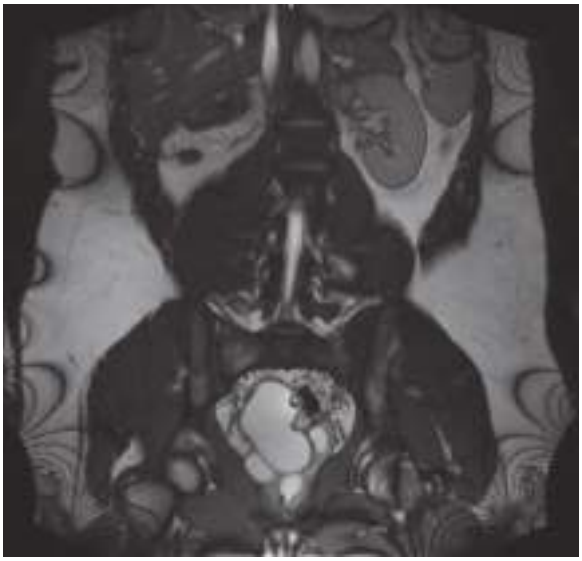

Fig. 574.1 Zinner syndrome. A 17-yr-old male with regressed right multicystic dysplastic kidney and dilated ectopic distal ureter draining into seminal vesicle cyst.

Fig. 574.2 Stillborn infant with renal agenesis exhibiting characteristic Potter facies.

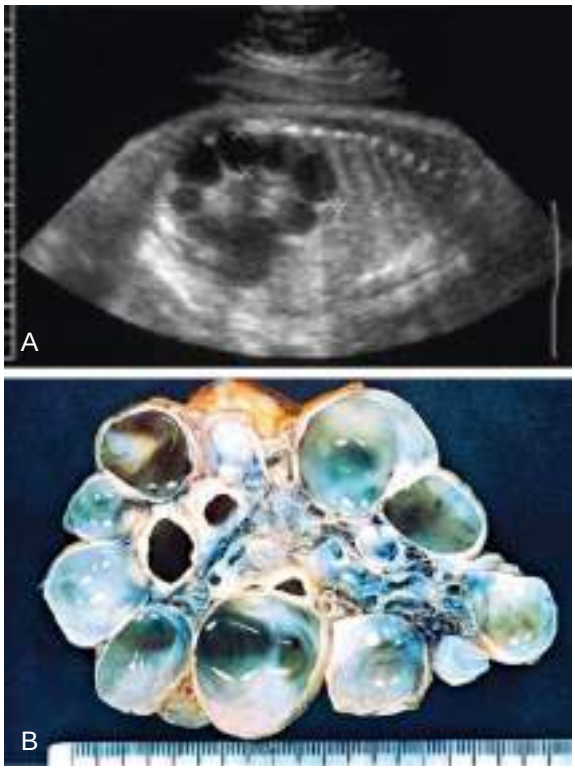

Fig. 574.3 A, Prenatal sonogram demonstrating multicystic dysplastic kidney. B, Surgical specimen.

disorder is 1 in 5,000 births, with a male predominance, and represents 20% of newborns with the Potter phenotype. Other common causes of neonatal renal failure associated with the Potter phenotype include cystic renal dysplasia and obstructive uropathy. Less common causes are autosomal recessive polycystic kidney disease (infantile), renal hypoplasia, and medullary dysplasia. Neonates with bilateral renal agenesis die of pulmonary insufficiency from pulmonary hypoplasia rather than renal failure (see Chapter 444).

The term **familial renal adysplasia** describes families in which renal agenesis, renal dysplasia, multicystic kidney (dysplasia), or a combination occurs in a single family. This disorder has an autosomal dominant inheritance pattern with a penetrance of 50–90% and variable expression. Because of this association, many clinicians advise screening first-degree relatives of persons who have renal agenesis or dysplasia.

The American Academy of Pediatrics recommends that children with a single kidney or single functioning kidney be allowed to play most sports. In fact, sports are less likely to cause kidney injury than motor vehicle crashes, horseback riding, or bicycle accidents. Children with one kidney are not at higher risk for renal injury during contact sports. Despite this, families should be made aware of the potential complications of injury to the patient's single kidney including potential need for dialysis or a renal transplant. Protective padding may be worn during sports, but there is no evidence that this prevents renal injury.

RENAL DYSGENESIS: DYSPLASIA, HYPOPLASIA, AND CYSTIC ANOMALIES

Renal dysgenesis refers to maldevelopment of the kidney that affects its size, shape, or structure. The three principal types of dysgeneses are dysplastic, hypoplastic, and cystic. Although dysplasia always is accompanied by a decreased number of nephrons (hypoplasia), the converse is not true: hypoplasia can occur in isolation. When both conditions are present, the term **hypodysplasia** is preferred. The term **dysplasia** is technically a histologic diagnosis and refers to focal, diffuse, or segmentally arranged primitive structures, specifically primitive ductal structures, resulting from abnormal metanephric differentiation. Nonrenal elements, such as cartilage, may also be present. The condition can affect all or only part of the kidney. If cysts are present, the condition is termed **cystic dysplasia.** If the entire kidney is dysplastic with a preponderance of cysts, the kidney is referred to as a **MCDK** (Fig. 574.3).

The pathogenesis of dysplasia is multifactorial. The "bud" theory proposes that if the ureteral bud arises in an abnormal location, such as an ectopic ureter, there is abnormal penetration and induction of the metanephric blastema, which causes abnormal kidney differentiation, resulting in dysplasia. Renal dysplasia also can occur with severe obstructive uropathy early in gestation, as with the most severe cases of posterior urethral valves or in a MCDK, in which a portion of the ureter is absent or atretic.

MCDK is a congenital condition in which the kidney is replaced by cysts and does not function; it can result from ureteral atresia. Kidney size is highly variable. The incidence is approximately 1 in 2,000. Some clinicians incorrectly use the terms *multicystic kidney* and *polycystic kidney* interchangeably. However, polycystic kidney disease is an inherited disorder that may be autosomal recessive or autosomal dominant and affects both kidneys (see Chapter 563). MCDK usually is unilateral and generally is not inherited. Bilateral MCDKs are incompatible with life.

MCDK is the most common cause of an abdominal mass in the newborn, but the vast majority are nonpalpable at birth. In most cases, it is discovered incidentally during prenatal ultrasound. In some patients, the cysts are identified prenatally, but the cysts regress in utero, and no kidney is identified on imaging at birth. Contralateral hydronephrosis is present in 5–10% of patients. Sonography shows the characteristic appearance of a kidney replaced by multiple cysts of varying sizes that do not communicate, and no identifiable parenchyma is present. In some patients, usually males, a small nonobstructing ureterocele is present in the bladder (see Chapter 577). Although 15% have contralateral vesicoureteral reflux, it is

usually low grade, and obtaining a voiding cystourethrogram is unnecessary unless there is significant contralateral hydronephrosis or the child develops an upper urinary tract infection. *Management is controversial.* Complete cyst regression occurs in nearly half of MCDKs by age 7 years. The risk of associated hypertension is 0.2–1.2%, and the risk of Wilms tumor arising from a MCDK is approximately 1 in 1,200. Because neoplasms arise from the stromal rather than the cystic component, even if the cysts regress completely, the likelihood that the kidney could develop a neoplasm is not altered.

Because of the occult nature of these potential problems, many clinicians advise follow-up with ultrasound and blood pressure measurement every 6 months to a year. The most important aspect of follow-up is being certain that the solitary kidney is functioning normally. *If there is an abdominal mass, the cysts enlarge, the stromal core increases in size, or hypertension develops, nephrectomy is recommended.* In lieu of follow-up screening, laparoscopic nephrectomy may be performed.

Renal hypoplasia refers to a small nondysplastic kidney that has fewer than the normal number of calyces and nephrons. The term encompasses a group of conditions with an abnormally small kidney and should be distinguished from aplasia, in which the kidney is rudimentary. If the condition is unilateral, the diagnosis usually is made incidentally during evaluation for another urinary tract problem or hypertension. Bilateral hypoplasia usually manifests with signs and symptoms of chronic renal failure and is a leading cause of end-stage renal disease during the first decade of life. A history of polyuria and polydipsia is common. Urinalysis results may be normal. In a rare form of bilateral hypoplasia called **oligomeganephronia,** the number of nephrons is markedly reduced, and those present are markedly hypertrophied.

The **Ask-Upmark kidney,** also termed **segmental hypoplasia,** refers to small kidneys, usually weighing less than 35 g, with one or more deep grooves on the lateral convexity, underneath which the parenchyma consists of tubules resembling those in the thyroid gland. It is unclear whether the lesion is congenital or acquired. Most patients are 10 years or older at diagnosis and have severe hypertension. *Nephrectomy usually controls the hypertension.*

Table 574.1 Cystic Diseases of the Kidney

INHERITABLE
Autosomal recessive (infantile) polycystic kidney disease (ARPKD)
Autosomal dominant (adult) polycystic kidney disease (ADPKD)
Juvenile nephronophthisis and medullary cystic disease complex
Juvenile nephronophthisis (autosomal recessive)
Medullary cystic disease (autosomal dominant)
Congenital nephrosis (familial nephrotic syndrome) (autosomal recessive)
Familial hypoplastic glomerulocystic disease (autosomal dominant)
Multiple malformation syndromes with renal cysts (e.g., tuberous sclerosis, von Hippel-Lindau disease)
Glomerulocystic kidney disease
Familial
Meckel-Gruber syndrome
Tuberous sclerosis
Zellweger syndrome
Trisomy 13
Jeune syndrome
Lissencephaly
Nephronophthisis
Orofacialdigital syndrome
NONHERITABLE
Multicystic kidney (multicystic dysplastic kidney)
Benign multilocular cyst (cystic nephroma)
Simple cysts
Medullary sponge kidney
Sporadic glomerulocystic kidney disease
Acquired renal cystic disease
Calyceal diverticulum (pyelogenic cyst)

Modified from Glassberg KI, Stephens FD, Lebowitz RL, et al. Renal dysgenesis and cystic disease of the kidney: a Report of the Committee on Terminology, Nomenclature and Classification, Section on Urology, American Academy of Pediatrics. *J Urol.* 1987;138:1085–1092. Table 2.

RENAL CYSTS IN CHILDREN

Although rare, there are many renal cystic disorders in children (Table 574.1). The most common is the **simple renal cyst** with a mean incidence of 0.22%. They are usually discovered incidentally during urinary tract imaging. Most are small and asymptomatic and do not require treatment, although follow-up imaging is recommended. If there are septations, irregular margins, calcifications, or a cluster of cysts, further evaluation may be indicated. The **Bosniak classification** of simple and complex renal cysts places various cystic lesions into four risk categories and helps guide a decision on whether removal of a lesion is necessary. A **calyceal diverticulum** is an outpouching of the collecting system into the corticomedullary region of the kidney, and it usually arises from the fornix of a calyx, usually in the upper or lower pole. Typically, the infundibulum between the diverticulum and renal pelvis is narrow. Occasionally, calculi form within the lesion, or it causes symptoms of flank pain, necessitating removal of the diverticulum.

A **multilocular cyst (multilocular cystic nephroma)** is a lesion in the kidney that falls in a spectrum of diseases, along with multilocular cyst with partially differentiated Wilms tumor, multilocular cyst with nodules of Wilms tumor, or cystic Wilms tumor. The multilocular cyst is considered benign and is unrelated to the MCDK. More than 95% occur in children <4 years, and most are discovered during evaluation for an abdominal or flank mass. The lesion should be removed.

ANOMALIES IN SHAPE AND POSITION

During renal development, the kidneys normally ascend from the pelvis into their normal position within the retroperitoneum. The normal process of ascent and rotation of the kidney may be incomplete,

Fig. 574.4 Crossed renal ectopia. Intravenous urography shows both renal collecting systems to the left of the spine. Segmentation anomalies of the sacrum, which are subtle in this child, are one of the skeletal anomalies associated with renal ectopia. *(From Slovis T, ed. Caffey's Pediatric Diagnostic Imaging, 11th ed. Philadelphia: Elsevier; 2008. Fig. 145-23A, p. 2244.)*

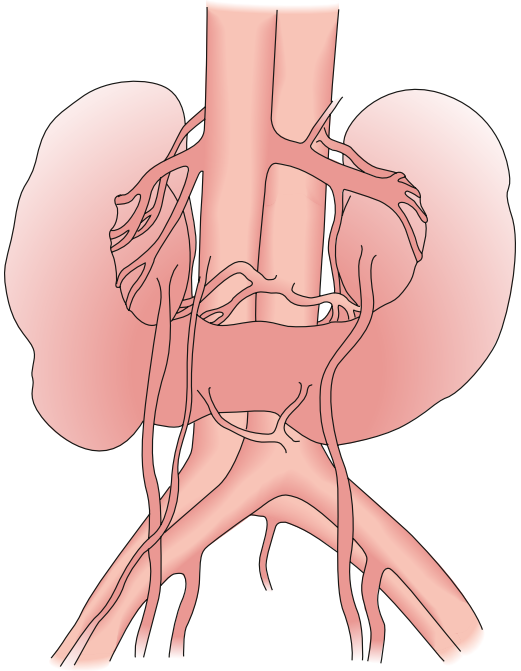

Fig. 574.5 Horseshoe kidney.

resulting in renal ectopia or malrotation. The ectopic kidney may be in a pelvic, iliac, thoracic, or contralateral position. Ectopia may be bilateral; the kidneys fuse in 90% of these cases. The incidence of renal ectopia is approximately 1 in 900 (Fig. 574.4).

Renal fusion anomalies are more common. The lower poles of the kidneys can fuse in the midline, resulting in a horseshoe kidney (Fig. 574.5); the fused portion is termed the *isthmus* and may be thick functioning parenchyma or a thin fibrous strand. Horseshoe kidneys occur in 1 in 400-500 births and are seen in 14–20% of patients with Turner syndrome (see Chapter 626); horseshoe kidneys are also associated with VACTERL and caudal regression syndromes, as well as trisomies 18 and 21. Wilms tumors are four times more common in children with horseshoe kidneys than in the general population. Stone disease, hydronephrosis secondary to ureteropelvic junction obstruction, and vesicoureteral reflux are other potential complications. The incidence of MCDK affecting one of the two sides of a horseshoe kidney also is increased. With crossed fused ectopia, one kidney crosses over to the other side, and the parenchyma of the two kidneys is fused. Renal function usually is normal. Most commonly, the left kidney crosses over and fuses with the lower pole of the right kidney. The insertion of the ureter to the bladder does not change, and the adrenal glands remain in their normal positions. The clinical significance of this anomaly is that if renal surgery is necessary, the blood supply is variable and can make partial nephrectomy more difficult.

ASSOCIATED PHYSICAL FINDINGS

Upper urinary tract anomalies are more common in children with certain physical findings. The incidence of renal anomalies is increased if there is a single umbilical artery and an abnormality of another organ system (e.g., congenital heart disease). External ear anomalies, imperforate anus, and scoliosis are also associated with renal anomalies. Infants with these physical findings should undergo a renal ultrasound.

Visit Elsevier eBooks+ at eBooks.Health.Elsevier.com for Bibliography.

Chapter 575

Urinary Tract Infections

Marie E. Wang and Pearl W. Chang

PREVALENCE AND ETIOLOGY

Urinary tract infections (UTIs) commonly occur in children of all ages, though the prevalence varies with age. UTIs are most common in children under 1 year of age. The prevalence in *febrile* infants and children less than 24 months is 7%, and the prevalence in older children less than 19 years presenting with urinary symptoms and/or fever is 8%. During the first 3 months of life, UTIs are most common in uncircumcised febrile males with a prevalence of 20%, which is eight times higher than circumcised males and 2-3 times higher than females. After 6 months of age, UTIs are much more likely in females, with peaks during infancy, toilet training, and onset of sexual activity.

UTIs are caused primarily by colonic bacteria. *Escherichia coli* (see Chapter 246) causes the majority of UTIs, followed by *Klebsiella* spp. and *Proteus* spp., *Enterococcus,* and *Pseudomonas* (see Chapter 148). Other bacteria known to cause UTIs include *Staphylococcus saprophyticus,* group B streptococcus, and, less commonly, *Staphylococcus aureus, Candida* spp., and *Salmonella* spp.

CLINICAL MANIFESTATIONS AND CLASSIFICATION

The two basic forms of UTIs are **pyelonephritis** and **cystitis.** Focal pyelonephritis (lobar nephronia) and renal abscesses are less common.

Pyelonephritis

Pyelonephritis is characterized by any or all of the following: abdominal, back, or flank pain; fever; malaise; nausea; vomiting; and, occasionally, diarrhea. *Fever may be the only manifestation, especially in young children; particular consideration should occur for a temperature ≥39°C (102.2°F) without another source lasting more than 48 hours in infants*. Newborns can also show nonspecific symptoms, such as poor feeding, irritability, jaundice, or weight loss. Pyelonephritis is the most common bacterial infection in infants younger than 24 months of age who have fever without an obvious focus (see Chapters 220 and 221). Involvement of the renal parenchyma is termed acute pyelonephritis (Figs. 575.1 and 575.2), whereas if there is no parenchymal involvement, the condition may be termed **pyelitis**. Acute pyelonephritis can result in renal injury, termed **pyelonephritic scarring**.

Acute lobar nephronia (acute focal bacterial nephritis) is a localized renal parenchymal mass caused by acute focal infection without liquefaction; it more commonly occurs in older children. It may be an early stage in the development of a renal abscess (Fig. 575.3). Manifestations are identical to those of pyelonephritis and include fever and flank pain. The epidemiology of the causative organism is also similar to that of pyelonephritis. **Renal abscess** can occur following a pyelonephritic infection caused by the usual uropathogens or less commonly following hematogenous spread with *S. aureus.* Most abscesses are unilateral and right-sided and can affect children of all ages (Fig. 575.4). Both acute lobar nephronia and renal abscess are associated with an increased risk of renal scarring. **Perinephric abscess** can occur secondary to contiguous infection in the perirenal area (e.g., vertebral osteomyelitis, psoas abscess) or pyelonephritis that dissects to the renal capsule. It differs from renal abscess in that it is diffuse throughout the capsule and is not walled off, although it can develop septations. As with renal abscesses, the most common organisms are *S. aureus* and *E. coli.* A perinephric abscess may not communicate with the collecting system, and, thus, abnormal findings may not be seen on urinalysis or culture.

Xanthogranulomatous pyelonephritis is a rare type of chronic renal infection characterized by granulomatous inflammation with

Fig. 575.1 Acute pyelonephritis seen as an area of decreased perfusion by CT scan done for abdominal pain and fever in a child who subsequently was shown to have no reflux by VCUG.

Fig. 575.2 Acute pyelonephritis with focal mass formation. The kidney shows a rounded heterogeneous mass *(arrow)* with a poorly defined margin. Inflammatory changes in the adjacent perinephric fat and renal fascial thickening *(arrowheads)* are also present. *(From Haaga JR, Boll DT, eds. CT and MRI of the Whole Body, 6th ed. Philadelphia: Elsevier; 2017. Fig. 54-131, p. 1833.)*

giant cells and foamy histiocytes. It can manifest clinically with a renal mass and nonspecific symptoms including fever, flank pain, weight loss, and malaise. Dysuria and other urinary symptoms are less common. Renal calculi, obstruction, and infection with *Proteus* spp. or *E. coli* contribute to the development of this lesion, which usually requires total or partial nephrectomy.

Alkaline encrusted pyelitis/cystitis is a rare chronic obstruction UTI caused by *Corynebacterium urealyticum*. The organism creates an alkaline urine (converting urea to ammonia), precipitating struvite and calcium phosphate resulting in stone formation and pyuria with

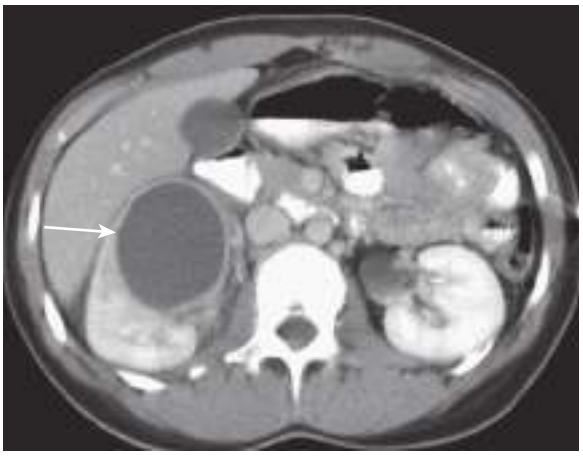

Fig. 575.3 Right renal abscess *(arrow)* shows a thick wall and low density (30 HU). Inflammatory stranding is present in the perinephric fat. *(From Haaga JR, Boll DT, eds. CT and MRI of the Whole Body, 6th ed. Philadelphia: Elsevier; 2017. Fig. 55.3, p. 1834.)*

hematuria. Risk factors include urinary tract instrumentation, congenital uropathies/anomalies, chronic illness, and immune suppression.

Cystitis

Cystitis indicates that there is only bladder involvement; symptoms include dysuria, urgency, frequency, suprapubic pain, incontinence, and possibly malodorous urine. Cystitis does not cause high fever and does not result in renal injury. Malodorous urine is suggestive but not specific for a UTI.

Acute hemorrhagic cystitis, though uncommon in immunocompetent children, is often caused by *E. coli;* it also has been attributed to adenovirus types 11 and 21. It is self-limiting, with hematuria lasting approximately 4 days. Patients receiving immunosuppressive therapy (e.g., solid-organ or bone marrow transplantation) are at higher risk for hemorrhagic cystitis; adenoviruses and polyomaviruses (i.e., JC virus and BK virus) are important causes in immunocompromised populations (see Chapter 321). Other rare types of cystitis that may be confused with infection include *eosinophilic cystitis* or *interstitial cystitis.* Eosinophilic cystitis may present with hematuria, whereas interstitial cystitis may present with irritative voiding symptoms but a negative urine culture.

PATHOGENESIS AND PATHOLOGY

Nearly all UTIs are ascending infections. The bacteria arise from the fecal flora, colonize the perineum, and enter the bladder via the urethra. In uncircumcised males, the bacterial pathogens arise from the flora beneath the prepuce. In some cases, the bacteria causing cystitis ascend to the kidney to cause pyelonephritis. Rarely, renal infection occurs by hematogenous spread, as in endocarditis or in bacteremic neonates.

If bacteria ascend from the bladder to the kidney, acute pyelonephritis can occur. Normally, the simple and compound papillae in the kidney have an antireflux mechanism that prevents urine in the renal pelvis from entering the collecting tubules. However, some compound papillae, typically in the upper and lower poles of the kidney, allow intrarenal reflux. Infected urine stimulates an immunologic and inflammatory response that can cause renal injury and scarring (Figs. 575.5 and 575.6).

Table 575.1 and Figure 575.7 outline the host risk factors for UTI. Vesicoureteral reflux (VUR) is discussed in Chapter 576. If there is grade III, IV, or V VUR and a febrile UTI, 90% of patients have evidence of acute pyelonephritis on renal scintigraphy or other imaging studies. In females, UTIs often occur at the onset of toilet training because of bowel-bladder dysfunction that occurs at that age. The child is trying to retain urine to stay dry, yet the bladder may have uninhibited contractions forcing urine out. The resulting high-pressure, turbulent urine flow and incomplete bladder emptying both increase

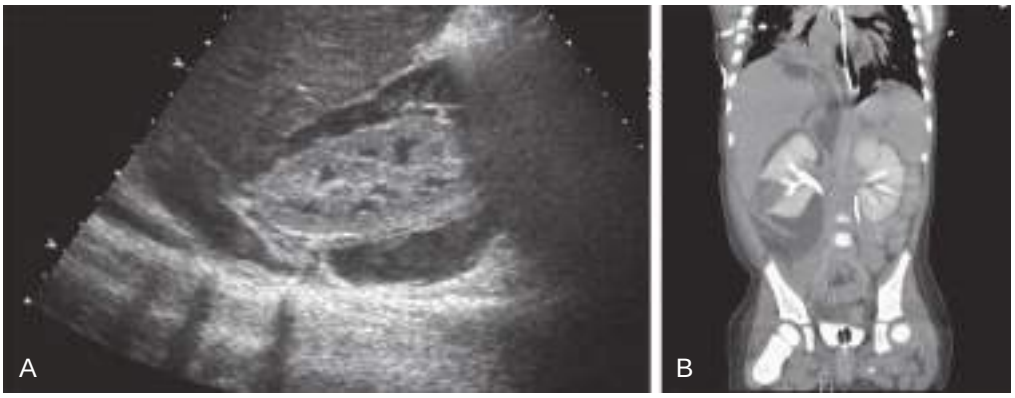

Fig. 575.4 A, Renal sonogram, 19-mo-old infant with perirenal abscess secondary to methicillin-resistant *Staphylococcus aureus*. B, CT scan demonstrates extensive perinephric and focal intrarenal abscess. Patient underwent incision and drainage.

Fig. 575.5 Scarred kidney from recurrent pyelonephritis.

Fig. 575.6 CT scan showing an area of parenchymal thinning corresponding to an underlying calyx, characteristic of pyelonephritic scarring or reflux nephropathy.

Table 575.1 Risk Factors for Urinary Tract Infection

Female anatomy	Obstructive uropathy
Uncircumcised male	Urethral instrumentation
Age ≤1 years	Constipation
Vesicoureteral reflux	Anatomic abnormality (labial adhesion)
Toilet training	Neurogenic bladder
Voiding dysfunction	Sexual activity
Sources of external irritation (such as tight clothing, pinworm infestation)	Pregnancy

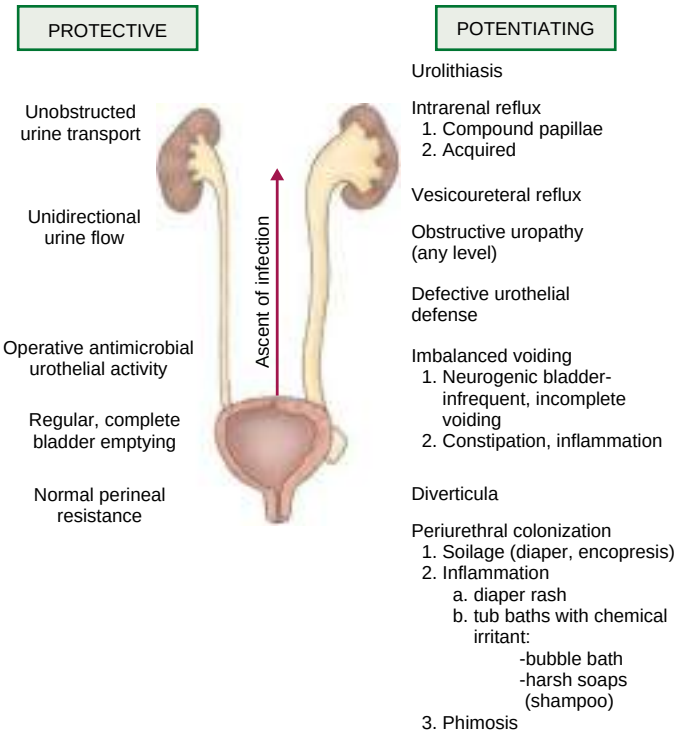

Fig. 575.7 Host factors that protect the urinary tract from infection and abnormalities that potentiate the establishment of invasive bacterial infection. *(From Holcomb III GW, Murphy JP, Ostlie DJ, eds. Holcomb and Ashcraft's Pediatric Surgery, 7th ed. Philadelphia: Elsevier; 2020. Fig. 55-3, p. 855.)*

Table 575.2 Sensitivity and Specificity of Components of Urinalysis, Alone and in Combination

TEST	SENSITIVITY (RANGE) %	SPECIFICITY (RANGE) %
Leukocyte esterase test	83 (67–94)	78 (64–92)
Nitrite test	53 (15–82)	98 (90–100)
Leukocyte esterase or nitrite positive	93 (90–100)	72 (58–91)
Microscopy (white blood cells)	73 (32–100)	81 (45–98)
Microscopy (bacteria)	81 (16–99)	83 (11–100)
Leukocyte esterase test, nitrite, or microscopy positive	99.8 (99–100)	70 (60–92)

From Finnell SM, Carroll AE, Downs SM, Subcommittee on Urinary Tract Infection. Technical report—diagnosis and management of an initial UTI in febrile infants and young children. *Pediatrics*. 2011;128:e749–e770.

the likelihood of bacteriuria. *Bowel-bladder dysfunction* can arise in school-age children who refuse to use the school bathroom, creating a state of urinary retention. Obstructive uropathy resulting in hydronephrosis increases the risk of UTI because of urinary stasis. Constipation with fecal impaction can increase the risk of UTI because it can cause bladder dysfunction.

Other host factors for UTI include anatomic abnormalities precluding normal micturition, such as a labial adhesion. This lesion acts as a barrier and causes vaginal voiding. A neurogenic bladder can predispose to UTI if there is incomplete bladder emptying and/or detrusor-sphincter dyssynergia or a resultant need for frequent catheterization. Sexual activity is associated with UTI in females due to introduction of bacteria near the urinary tract, which can be exacerbated in part because of urethral irritation and incomplete bladder emptying following intercourse.

The pathogenesis of UTI is based in part on the presence of bacterial pili or fimbriae on the bacterial surface, which allow for attachment to the uroepithelial cells. For *E. coli,* this attachment occurs through the type 1 fimbriae and P-fimbriae, which may result in bacterial uptake and replication and formation of intracellular bacterial communities. These intracellular organisms may evade the immune response, form quiescent reservoirs protected from antibiotics, and be a source of recurrent infections. Current research is attempting to prevent the initial attachment of bacteria to the bladder wall that can lead to intracellular bacterial communities and quiescent reservoirs.

DIAGNOSIS

Among children 2-24 months of age, risk factors for UTI include age younger than 12 months, being a female or uncircumcised male, temperature ≥39°C (102.2°F), fever for at least 2 days, and absence of another source of infection. Urine testing is recommended when the pretest probability of a UTI is ≥2%, and an online UTI calculator can provide probability estimates (https://uticalc.pitt.edu/). In older verbal children, urine testing should be considered when there are UTI symptoms. A positive urinalysis suggestive of infection (i.e., presence of pyuria) plus a urine culture with ≥50,000 colony-forming units (CFU)/mL of a single uropathogen are recommended for diagnosis of a UTI in a symptomatic child. In the appropriate clinical context, ≥10,000 CFU/mL may be sufficient for diagnosis, especially if the laboratory does not categorize counts between 10,000 and 100,000 CFU/mL.

There are several ways to obtain a urine sample; some are more accurate than others. In toilet-trained children, a midstream urine sample usually is satisfactory; the introitus should be cleaned before obtaining the specimen. In uncircumcised males, the prepuce must be retracted; if the prepuce is not retractable, a voided sample may be unreliable and contaminated with skin flora. For children 2-24 months who are not toilet trained, a catheterized urine sample should be obtained. Alternatively, the application of an adhesive, sealed, sterile collection bag after disinfection of the skin of the genitals can be useful only if the urinalysis and culture are negative; the negative predictive value for urinalysis from a "bag" specimen is 99%. However, a positive culture can result from skin contamination, particularly in females and uncircumcised males. If treatment is planned immediately after obtaining the urine sample, a bagged specimen *should not* be the method because of a high rate of contamination, often with mixed organisms. A suprapubic aspirate generally is unnecessary.

Inclusion of pyuria in the diagnostic criteria along with a positive urine culture helps to distinguish true UTI from asymptomatic bacteriuria or contamination. **Pyuria** is defined as ≥5 white blood cells (WBCs)/high-power field on a centrifuged specimen, ≥10 WBC/mm^3 on an enhanced urinalysis, or any **leukocyte esterase** on a dipstick. Additional urinalysis findings that support a UTI diagnosis include presence of **nitrites**. Bacteria generally require 4 hours for metabolism of nitrates to nitrites. Thus nitrites may not be detected in cases of UTI where the organism does not convert nitrates to nitrites (most notably *Enterococcus*) or if the child has urinary frequency, where there may not be enough time for the conversion to nitrites. Findings of leukocyte esterase, WBC on microscopy, or nitrites has a high sensitivity for UTI, including in febrile infants <60 days of age (Table 575.2). Microscopic hematuria is common in acute cystitis, but microhematuria alone does not suggest UTI. WBC casts in the urinary sediment suggest renal involvement, but in practice these are rarely seen.

Sterile pyuria (positive leukocytes, negative culture) may occur in partially treated bacterial UTI, viral infections, urolithiasis, renal tuberculosis, renal abscess, UTI in the presence of urinary obstruction, urethritis as a consequence of a sexually transmitted infection (see Chapter 163), inflammation near the ureter or bladder (appendicitis, Crohn disease), Kawasaki disease (see Chapter 493.1), COVID-19–associated multisystem inflammatory syndrome in children (MIS-C; see Chapter 311), schistosomiasis, neoplasm, renal transplant rejection, or interstitial nephritis (eosinophils). Prompt plating of the urine sample for culture is important, because if the urine sits at room temperature for more than 60 minutes, overgrowth of a minor contaminant can suggest a UTI when the urine might not be infected. Refrigeration is a reliable method of storing the urine until it can be cultured.

With acute renal infection, leukocytosis and neutrophilia are noted on the CBC; an elevated ESR, procalcitonin level, and CRP are common. However, these are all nonspecific markers of inflammation; thus their elevation does not prove that the child has acute pyelonephritis, and they do not need to be routinely obtained. Bacteremia in the setting of pyelonephritis is reported to occur in 3–20% of patients and is most common in infants <60 days old (with rates decreasing with increasing age in the first 60 days). For infants <60 days old or ill-appearing patients at presentation, blood cultures should be drawn before starting antibiotics, if possible.

IMAGING FINDINGS

Imaging is not needed to make the diagnosis of UTI. If there is concern about acute lobar nephronia or renal abscess (e.g., patient not responding to appropriate antibiotics), imaging should be considered. Ultrasound is the first-line imaging for screening and will likely demonstrate an enlarged kidney with a possible mass in the case of acute lobar nephronia or renal abscess. CT scan is more sensitive and specific for lobar nephronia and will typically show a wedge-shaped, lower-density area after contrast administration.

TREATMENT

Acute cystitis should be treated promptly to prevent possible progression to pyelonephritis. If the symptoms are severe, and the urinalysis shows pyuria, presumptive treatment should be started while awaiting urine culture results. If the symptoms are mild or the diagnosis is doubtful, treatment can be delayed until the results of culture are known, and the urinalysis and culture can be repeated if the results are uncertain. In **acute febrile UTI**, the clinical symptoms of cystitis and pyelonephritis are difficult to differentiate. Given the presence of systemic symptoms, it is reasonable to consider that the infection has likely progressed to the kidneys and treat for pyelonephritis. A UTI can be treated safely and effectively with oral antibiotics in the outpatient setting, including in younger children. Thus route of therapy should be based on practical considerations. Parenteral therapy should be used in children who are dehydrated, are vomiting, are unable to drink fluids, have complicated infection, or in whom urosepsis is a possibility. Infants less than 1 month of age with suspected febrile UTI are typically hospitalized and started on parenteral antibiotics while awaiting results of a sepsis evaluation and can be converted to oral therapy if there is no concern for meningitis and they are otherwise clinically well. Infants 1-2 months of age can be managed as an outpatient unless hospitalization is indicated for other reasons (e.g., emesis, dehydration). Although infants with bacteremic UTI are often treated with longer parenteral courses, duration of therapy has not been associated with UTI relapse.

Local antimicrobial sensitivity patterns should be considered when selecting empiric antibiotic treatment. For oral treatment, cephalexin is a commonly used narrow-spectrum empiric option, as overall rates of *E. coli* resistance to first-generation cephalosporins are low. In areas with high rates of *E. coli* resistance to first-generation cephalosporins, oral third-generation cephalosporins such as cefixime can be appropriate empiric options and are effective against a variety of gram-negative organisms. Trimethoprim-sulfamethoxazole (TMP-SMX) may also be used, though resistance is increasing in some areas. Nitrofurantoin can be used for cystitis but should not be used routinely in children with a febrile UTI, because it does not achieve significant renal tissue levels. The oral fluoroquinolone ciprofloxacin can be considered for UTI caused by *P. aeruginosa* or resistant microorganisms when there are no other oral antibiotic options. However, clinical treatment with fluoroquinolones in young children should be used with caution because of potential cartilage damage. For parenteral treatment in hospitalized children 1 month and older, ceftriaxone is a reasonable choice until culture results are available to determine whether a narrower-spectrum antibiotic can be used. Ampicillin plus either gentamicin or a third-generation cephalosporin are often used empirically in neonates. If prior urine culture results have grown resistant or atypical organisms, other antibiotic choices may be prudent on a case-by-case basis.

A repeat urine culture after the termination of UTI treatment is not routinely needed. Urine cultures are typically negative within 24 hours of initiation of antibiotic therapy; therefore a urine culture during treatment is almost invariably negative. Most children exhibit clinical improvement (afebrile) within 48-72 hours of antibiotic initiation. Recommended duration of therapy is generally 3-5 days for cystitis and 7-10 days for uncomplicated pyelonephritis. Atypical features include failure to respond within 48-72 hours of appropriate antibiotics; poor urine flow; an abdominal, flank, or suprapubic mass; sepsis; or an elevated creatinine level. Atypical features should prompt further evaluation.

Acute Lobar Nephronia, Renal Abscess, and Perinephric Abscess

Acute lobar nephronia is treated with the same antibiotics as pyelonephritis. The recommended duration of treatment is 14-21 days; one study suggested higher treatment failure in the group treated for shorter duration. Children with a renal or perirenal abscess or with infection in obstructed urinary tracts can require percutaneous or surgical drainage in addition to antibiotic therapy and other supportive measures (see Fig. 575.4). Percutaneous drainage is typically attempted prior to surgical intervention. Medical management alone has been successful in treating small-to-moderate renal abscesses. Although some studies have commented that resolution with antibiotics alone are more likely in abscesses 3 cm or less, some patients with abscesses >3 cm have been managed successfully with IV antibiotics only. Thus a 48-hour trial of IV antibiotics prior to percutaneous drainage may be warranted in otherwise stable children. Few studies address the role of oral antibiotic therapy for renal abscess. Traditionally, patients received 10-14 days of IV antibiotics, followed by 2-4 weeks of oral antibiotic therapy targeted against the known organism (or the likely causes of *E. coli* and *S. aureus* if the organism was unknown). The increasing use of oral antibiotics for other serious infections (e.g., osteomyelitis) suggests that an earlier transition to oral therapy for renal abscess is likely feasible. Kidney loss is reported to occur in 10–20% of cases of renal abscess. Perinephric abscesses may be managed with IV antibiotics alone or with percutaneous drainage if the area is large or causing impaired kidney function. Identification of a causative organism can be an additional advantage of percutaneous drainage of a perinephric abscess because the infection may remain isolated from the collecting system based on the location.

Other Potential Treatment or Prevention Options

There is interest in probiotic therapy as well as cranberry juice to *prevent* UTIs. Studies are ongoing and a probiotic containing a nonuropathogenic *E. coli* called Nissle 1917 is available in Europe and other parts of the world. These bacteria may inhibit growth of other bacteria. Cranberry juice may prevent bacterial adhesion and biofilm formation, hypothesized to be via proanthocyanidin (PAC). Currently there is insufficient evidence regarding the use of these therapies in children to reduce UTIs.

The main consequences of chronic renal damage caused by pyelonephritis are arterial hypertension and end-stage renal insufficiency; when they are found, they should be treated appropriately (see Chapters 494 and 572). Even without chronic renal damage, the consequences of infections include lost days from school and work, uncomfortable symptoms, and exposure to antibiotics that change the healthy microbiome.

IMAGING STUDIES IN CHILDREN WITH A FEBRILE UTI

The primary goal of imaging studies in children with a febrile UTI is to identify anatomic abnormalities that predispose to future infection, such as high-grade VUR, posterior urethral valves, or other obstructive uropathy. Imaging is usually unnecessary in children with afebrile cystitis. Historically, children either underwent a renal sonogram plus a voiding cystourethrogram (VCUG) in a "bottom-up" approach, or a dimercaptosuccinic acid (DMSA) renal scan first to identify areas of acute pyelonephritis (Fig. 575.8) in a "top-down" approach. If the DMSA scan was positive, then a VCUG was performed (Fig. 575.9) because up to 90% of children with dilating reflux have a positive DMSA scan. In the past decade, with increasing evidence that most children with first-time UTI have normal genitourinary tracts and the unclear benefit of early detection of VUR, most national guidelines recommend selective imaging for children with UTI. Though the sensitivity of renal-bladder ultrasounds for detecting VUR is poor, there is no established harm of nondetection of VUR after a first UTI.

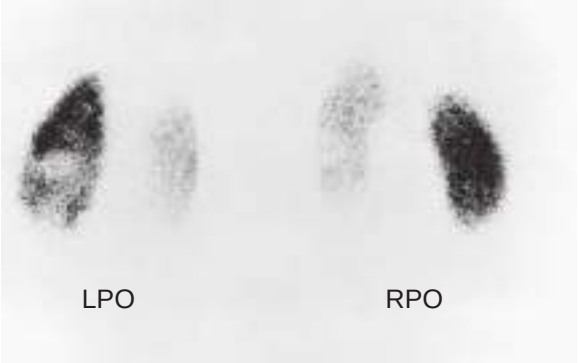

Fig. 575.8 DMSA renal scan showing bilateral photopenic areas indicating acute pyelonephritis and renal scarring. LPO, left posterior oblique; RPO, right posterior oblique.

Fig. 575.9 Intrarenal reflux. VCUG in an infant boy with a history of a UTI. Note the right VUR with ureteral dilation, with opacification of the renal parenchyma representing intrarenal reflux.

Most experts still recommend initial ultrasound of the kidneys, ureters, and bladder for children 2-24 months with a first febrile UTI. VCUG should be obtained if the ultrasound study indicates hydronephrosis, scarring, or other findings suggestive of high-grade (e.g., grades IV-V) reflux or obstructive uropathy, or if the patient has other atypical complex features. Further, a VCUG should be obtained if the child has a recurrent febrile UTI (Table 575.3). The rate of renal scarring increases between days 2 and 3 of fever; this makes the prompt evaluation and appropriate treatment of a recurrent UTI important. The risk of scarring also increases with the number of episodes of pyelonephritis and with higher grades of reflux.

The NICE (National Institute for Health and Care Excellence, UK) guidelines for diagnosis, management, and imaging after UTI were released in 2022 (Table 575.4). These recommendations divided children into those younger than 6 months, 6 months to younger than 3 years, and 3 years and older. An initial renal-bladder ultrasound is recommended for all children younger than 6 months, and a VCUG only if atypical features (including non–*E. coli* infection, sepsis or bacteremia, failure to respond to antibiotics within 48 hours), recurrent UTI, or abnormal ultrasound findings. For children age 6 months to younger than 3 years who have a UTI with atypical features or recurrent UTI, an ultrasound is recommended, and if risk factors are present, then also a VCUG should also be obtained (see Table 575.4). No imaging is suggested for otherwise first-time, typical UTI in this age group. When ultrasound is recommended, the optimal timing for obtaining it is unclear. Most national guidelines recommend an ultrasound during the acute infection if there is concern for obstruction (e.g., not responding to antibiotics, elevated creatinine, poor urine flow) but otherwise nonurgently within 2-6 weeks after the UTI as routine ultrasound during the acute infection rarely changes management.

PREVENTION OF RECURRENCES

In a child with recurrent UTIs, identification of predisposing factors is beneficial. Bowel and bladder dysfunction is a very important contributor to recurrent UTIs and is one of the main reasons for an increase in UTIs around the time of toilet training. Bladder dysfunction is manifested by urgency, wetting, and especially "Vincent's curtsy" (children squat on their heels in response to an uninhibited bladder contraction) (see Chapter 580). In toilet-trained children, a thorough history and use of urodynamic studies and measurement of postvoid residual volumes may be helpful in

Table 575.3 Guideline Recommendations for Diagnostic Evaluation Following a Febrile Urinary Tract Infection in Infants

GUIDELINE	ULTRASONOGRAPHY	VCUG	LATE DMSA SCAN
National Institute for Health and Care Excellence (NICE)	See Table 575.4		
American Academy of Pediatrics (retired)	Yes	If abnormal ultrasonogram or febrile recurrence	No
Italian Society for Paediatric Nephrology (ISPN)	Yes	If abnormal ultrasonogram, non-*Escherichia coli* infection, or febrile recurrence	If grade IV-V VUR
Spanish Association of Paediatrics	Yes, if age <6 months, atypical infection,* or recurrence	If abnormal ultrasonogram, atypical infection,* or recurrence	If atypical infection* or recurrence
Swiss consensus recommendations	Yes	If abnormal ultrasonogram, atypical infection,† or febrile recurrence	No

*Defined as fever >48 hours after appropriate antibiotics, sepsis, non–*E. coli* infection, acute kidney injury, or abdominal or vesical mass.
†Defined as failure to respond to appropriate antibiotics within 48 hours, non–*E. coli* infection, increased creatinine, abnormal electrolytes, hypertension, or poor urine flow.
VCUG, Voiding cystourethrogram; DMSA, dimercaptosuccinic acid; VUR, vesicoureteral reflux.

Table 575.4 NICE Recommended Imaging Schedule for Children with Urinary Tract Infection

CHILD AGE AND TESTS	TYPE OF INFECTION		
	RESPONDS WELL TO TREATMENT WITHIN 48 HR	ATYPICAL INFECTION*	RECURRENT INFECTION
CHILDREN YOUNGER THAN 6 MO OLD			
Ultrasound scan during acute infection	No	Yes	Yes
Ultrasound scan within 6 wk of infection	Yes	No	No
DMSA scan 4-6 mo after acute infection	No	Yes	Yes
VCUG	Consider if ultrasound scan abnormal	Yes	Yes
CHILDREN 6 MO TO YOUNGER THAN 3 YR OLD			
Ultrasound scan during acute infection	No	Yes	No
Ultrasound scan within 6 wk of infection	No	No	Yes
DMSA scan 4-6 mo after acute infection	No	Yes	Yes
VCUG	No	Not routine; consider if dilation on ultrasound, poor urine flow, non–*E. coli* infection, or family history of vesicoureteral reflux	
CHILDREN 3 YR OR OLDER			
Ultrasound scan during acute infection	No	Yes	No
Ultrasound scan within 6 wk of infection	No	No	Yes
DMSA scan 4-6 mo after acute infection	No	No	Yes
VCUG	No	No	No

*Defined as seriously ill, poor urine flow, abdominal or bladder mass, raised creatinine, sepsis or bacteriemia, failure to respond to appropriate antibiotics within 48 hours, or infection with non–*E. coli* organisms.
NICE, National Institute for Health and Care Excellence; DMSA, Dimercaptosuccinic acid; VCUG, voiding cystourethrogram.
Adapted from National Institute for Health and Clinical Excellence. Urinary tract infection in children: Diagnosis, treatment, and long-term management. NICE clinical guidelines, no. 224. London: RCOG Press; 2022. Tables 4–6.

identifying children with bladder dysfunction that may contribute to UTI. Tightening the pelvic floor during urination can sometimes be seen on a VCUG as a **spinning-top urethra** (Fig. 575.10). An ultrasound may document residual urine and possibly a thick bladder wall. Urodynamics may show an intermittent stream with increased activity in the pelvic floor muscles. Some children with UTI may also have constipation (see Chapter 378.3). Behavioral modification, with treatment of constipation as described in Chapter 580, often is effective at reducing recurrent UTI from constipation.

Routine use of antibiotic prophylaxis is not recommended for children with a first episode of pyelonephritis and an otherwise anatomically normal urinary tract. Urologic conditions that can cause recurrent UTIs that might benefit from long-term antibiotic prophylaxis include neurogenic bladder, urinary tract stasis and obstruction, severe VUR (see Chapter 576), and urinary calculi. The RIVUR study was a randomized trial of TMP-SMX prophylaxis for patients with a history of UTI and diagnosed grades I-IV VUR. Although the UTI recurrence rate was decreased by half from 30% in the group not receiving prophylaxis to 15% in those receiving prophylaxis, rates of renal scarring were the same in both groups. Additionally, the rates of UTI caused by resistant organisms increased in the group receiving prophylaxis. Although the use of prophylaxis can decrease rates of recurrence, routine prophylaxis is not recommended for children with VUR (especially lower-grade VUR) due to the increase in antibiotic resistance, need for daily medication in children, and lack of change in renal scarring.

Visit Elsevier eBooks+ at eBooks.Health.Elsevier.com for Bibliography.

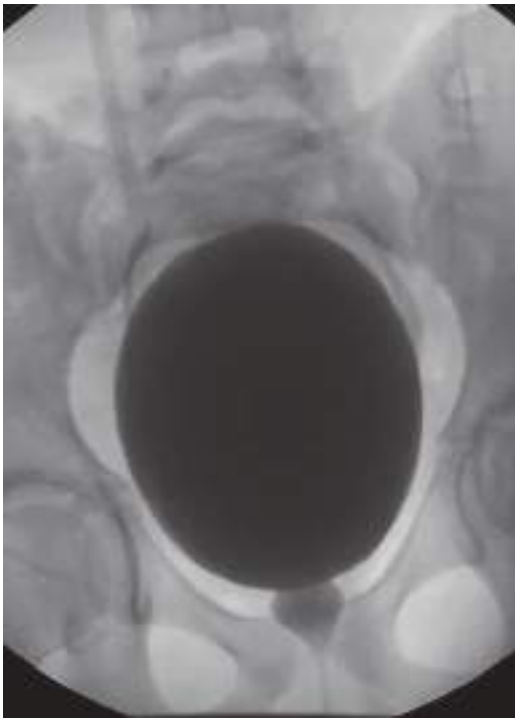

Fig. 575.10 VCUG shows contraction of the pelvic floor and external sphincter during voiding, leading to a dilated posterior urethra and bilateral reflux.

Chapter 576

Vesicoureteral Reflux

Heather N. Di Carlo and Chad B. Crigger

Vesicoureteral reflux (VUR) describes the retrograde flow of urine from the bladder to the ureter and kidney. The ureteral attachment to the bladder normally is oblique, between the bladder mucosa and detrusor muscle, creating a flap-valve mechanism that prevents VUR (Fig. 576.1). VUR occurs when the submucosal tunnel between the mucosa and detrusor muscle is short or absent. Affecting 1–2% of children, VUR usually is congenital and often is familial. VUR is present in approximately 30% of females who had a urinary tract infection and in 5–15% of infants with antenatal hydronephrosis.

VUR predisposes to kidney infection **(pyelonephritis)** by facilitating the transport of bacteria from the bladder to the upper urinary tract (see Chapter 575). The inflammatory reaction caused by pyelonephritis can result in renal injury or scarring, also termed **reflux-related renal injury** or **reflux nephropathy.** In children with a febrile urinary tract infection, those with VUR are three times more likely to develop renal injury compared with those without VUR. Extensive **renal scarring** impairs renal function and can result in renin-mediated hypertension (see Chapter 494), renal insufficiency or end-stage renal disease (see Chapter 572), impaired somatic growth, and morbidity during pregnancy. Scarring associated with reflux may be present at birth or develop in the absence of infection if there is significant bladder-sphincter discoordination during voiding.

In the past, reflux nephropathy accounted for as much as 15–20% of end-stage renal disease in children and young adults. With greater attention to the management of UTIs and a better understanding of VUR, end-stage renal disease secondary to reflux nephropathy is uncommon. Reflux nephropathy remains a common cause of hypertension in children. VUR in the absence of infection or elevated bladder pressure (e.g., neuropathic bladder, posterior urethral valves) rarely causes renal injury.

CLASSIFICATION

VUR severity is graded using the International Reflux Study (IRS) classification of I-V and is based on the appearance of the urinary tract on a contrast **voiding cystourethrogra**m (VCUG) (Figs. 576.2 and 576.3). The higher the VUR grade the greater the likelihood of renal injury. VUR severity is an indirect indication of the degree of abnormality of the ureterovesical junction.

VUR may be primary or secondary (Table 576.1). **Bladder-bowel dysfunction (BBD)** can worsen preexisting VUR if there is a marginally competent ureterovesical junction. In the most severe cases, there is such massive VUR into the upper tracts that the bladder becomes overdistended. This condition, the **megacystis-megaureter syndrome,** occurs primarily in males and may be unilateral or bilateral (Fig. 576.4). Reimplantation of the ureters into the bladder to correct VUR corrects the condition.

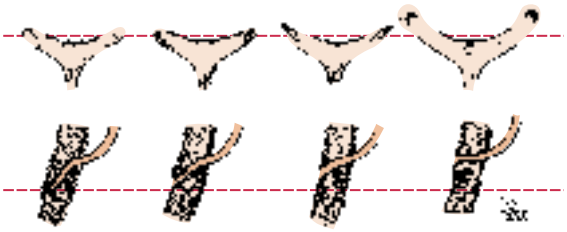

Fig. 576.1 Normal and abnormal configuration of the ureteral orifices. Shown from *left* to *right*, progressive lateral displacement of the ureteral orifices and shortening of the intramural tunnels. *Top*, Endoscopic appearance. *Bottom*, Sagittal view through the intramural ureter.

Primary VUR appears to be an autosomal dominant inherited trait with variable penetrance. Approximately 35% of siblings of children with VUR also have VUR, and VUR is found in nearly half of newborn siblings. The likelihood of a sibling having VUR is independent of the grade of VUR or sex of the index child. Approximately 12% of asymptomatic siblings with VUR have evidence of renal scarring. In addition, 50% of children born to women with a history of VUR also have VUR. The American Urological Association Vesicoureteral Reflux Guidelines Panel stated that, *in siblings of individuals with VUR, a VCUG or radionuclide cystogram is recommended if there is evidence of a renal cortical abnormality or renal size asymmetry on sonography, or if the sibling has a history of febrile UTI*. Otherwise, screening is optional. VUR may be suggested on a prenatal ultrasound that demonstrates hydronephrosis or hydroureteronephrosis.

Approximately 1 in 125 children has a **duplication** of the upper urinary tract, in which two ureters rather than one drain the kidney. Duplication may be partial or complete. In partial duplication, the

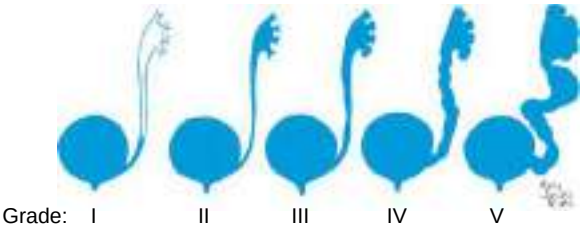

Fig. 576.2 Grading of VUR. Grade I: VUR into a nondilated ureter. Grade II: VUR into the upper collecting system without dilation. Grade III: VUR into a dilated ureter and/or blunting of the calyceal fornices. Grade IV: VUR into a grossly dilated ureter. Grade V: massive VUR, with significant ureteral dilation and tortuosity and loss of the papillary impression.

Fig. 576.3 VCUG showing grade IV right VUR.

Table 576.1 Classification of Vesicoureteral Reflux

TYPE	CAUSE
Primary	Congenital incompetence of the valvular mechanism of the vesicoureteral junction
Primary associated with other malformations of the ureterovesical junction	Ureteral duplication Ureterocele with duplication Ureteral ectopia Paraureteral diverticula
Secondary to increased intravesical pressure	Neuropathic bladder Nonneuropathic bladder dysfunction Bladder outlet obstruction
Secondary to inflammatory processes	Severe bacterial cystitis Foreign bodies Vesical calculi Clinical cystitis
Secondary to surgical procedures involving the ureterovesical junction	Surgery

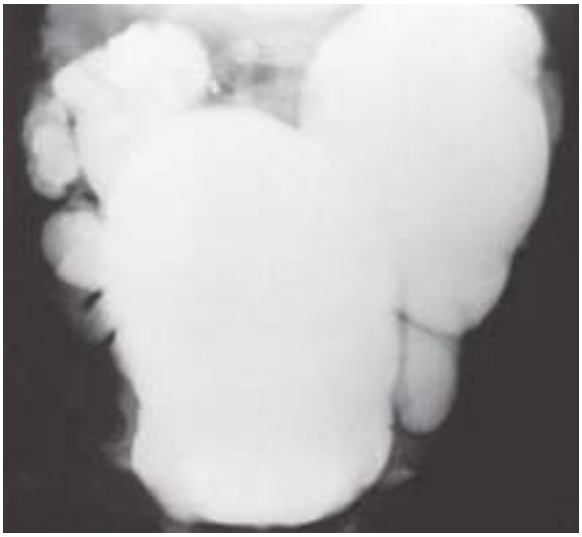

Fig. 576.4 VCUG in a newborn with megacystis-megaureter syndrome. Note the massive ureteral dilation caused by high-grade VUR. The bladder is very distended. There was no urethral obstruction or neuropathic dysfunction.

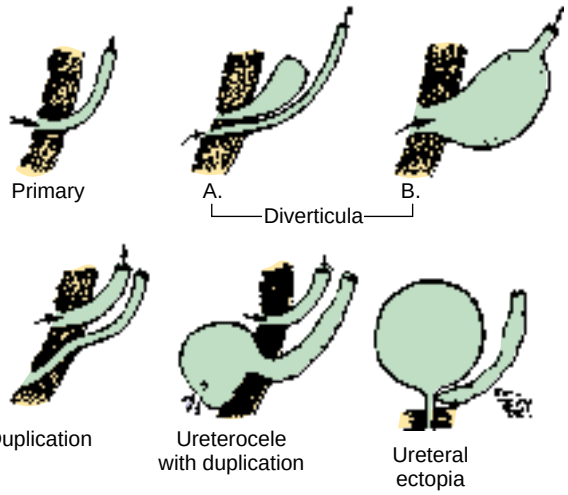

Fig. 576.5 Various anatomic defects of the ureterovesical junction associated with VUR.

Fig. 576.6 VUR and bladder diverticulum. The VCUG demonstrates left VUR and a paraureteral diverticulum.

ureters join above the bladder, and there is one ureteral orifice. In complete duplication, the attachment of the lower pole ureter to the bladder is superior and lateral to the upper pole ureter. The valvelike mechanism for the lower pole ureter often is marginal, and VUR into the lower ureter occurs in as many as 50% of cases (Fig. 576.5). VUR occurs into both the lower and upper systems in some persons. With a duplication anomaly, some patients have an **ectopic ureter**, in which the upper pole ureter drains outside the bladder (see Chapter 577 and Figs. 577.6 and 577.7). If the ectopic ureter drains into the bladder neck, typically it is obstructed and refluxes. Duplication anomalies also are common in children with a **ureterocele**, which is a cystic swelling of the intramural portion of the distal ureter. These patients often have VUR into the associated lower pole ureter or the contralateral ureter. In addition, generally VUR is present when the ureter enters a bladder diverticulum (Fig. 576.6).

VUR is present at birth in 25% of children with **neuropathic bladder,** as occurs in myelomeningocele (see Chapters 579 and 631.4), sacral agenesis, and many cases of high imperforate anus. VUR is seen in 50% of males with posterior urethral valves. VUR with increased intravesical pressure (as in detrusor-sphincter discoordination or bladder outlet obstruction) can result in renal injury because of increased intravesical pressure transmitted to the upper urinary tract, even in the absence of infection.

Primary VUR occurs in association with several congenital urinary tract abnormalities. Of children with a multicystic dysplastic kidney or renal agenesis (see Chapter 574), 15% have VUR into the contralateral kidney, and 10–15% of children with a ureteropelvic junction obstruction have VUR into either the hydronephrotic kidney or the contralateral kidney. As such, a diagnosis of VUR should prompt complete investigation to rule out concomitant pathology contralaterally.

CLINICAL MANIFESTATIONS

VUR usually is discovered during evaluation for a UTI (see Chapter 575). Among these children, 80% are female, with an average age at diagnosis of 2-3 years. In other children, a VCUG is performed during evaluation of BBD, renal insufficiency, hypertension, or other suspected pathologic process of the urinary tract. Primary VUR also may be discovered during evaluation for antenatal hydronephrosis. In this select population, 80% of affected children are male, and the VUR

grade usually is higher than in females whose VUR is diagnosed following a UTI. The UTI may be symptomatic, an isolated febrile event, or more often both febrile and symptomatic (abdominal pain, dysuria). BBD (constipation) may be present in 50% of children with reflux and a UTI.

DIAGNOSIS

Diagnosis of VUR requires catheterization of the bladder, instillation of a solution containing iodinated contrast or a radiopharmaceutical, and radiologic imaging of the lower and upper urinary tract (a contrast VCUG or radionuclide cystogram, respectively). The bladder and upper urinary tracts are imaged during bladder filling and voiding. VUR occurring during bladder filling is termed *low-pressure* VUR; VUR during voiding is termed *high-pressure* VUR. *VUR in children with low-pressure VUR is significantly less likely to resolve spontaneously than in children who exhibit only high-pressure VUR.* Radiation exposure during a radionuclide cystogram is significantly less than that from a contrast VCUG. Low-dose radiation contrast VCUG provides more anatomic information, such as demonstration of a duplex collecting system, ectopic ureter, paraureteral (bladder) diverticulum, bladder outlet obstruction in males, upper urinary tract stasis, and signs of voiding dysfunction, such as a **spinning-top** urethra in females. The VUR grading system is based on the appearance on contrast VCUG, and the grade reported is the maximum grade observed during the study. For follow-up evaluation, some prefer the radionuclide cystogram because of the lower radiation exposure (Fig. 576.7), although it is difficult to determine whether the VUR severity has changed and the grading system for the radionuclide study is different than the standard IRS grading system.

Fig. 576.7 Radionuclide cystogram shows bilateral VUR.

Children undergoing cystography may be psychologically traumatized by the catheterization. Careful preparation by caregivers, use of Child Life specialists, or administration of oral or nasal midazolam (for sedation and amnesia) or propofol before the study can result in a less-distressing experience.

Indirect cystography is a technique of detecting VUR without catheterization that involves injecting an intravenous radiopharmaceutical that is excreted by the kidneys, waiting for it to be excreted into the bladder, and imaging the lower urinary tract while the patient voids. This technique detects only 75% of VUR cases. Another technique, which avoids radiation exposure, involves instilling sonographic contrast medium through a urethral catheter. The kidneys are imaged sonographically to determine whether any of the material refluxes. This technique is currently investigational only.

After VUR is diagnosed, assessment of the upper urinary tract is important. The goal of upper tract imaging is to assess whether renal scarring and associated urinary tract anomalies are present. Renal imaging typically is performed with a renal sonogram and/or renal scintigraphy (Fig. 576.8; see Chapter 575).

The child should be evaluated for BBD, including urgency, frequency, diurnal incontinence, infrequent voiding, or a combination of these (see Chapter 575). Children with an overactive bladder often undergo a regimen of behavioral modification with timed voiding, treatment of constipation, and, on occasion, anticholinergic therapy.

After diagnosis, the child's height, weight, and blood pressure should be measured and monitored. If upper tract imaging shows renal scarring, a serum creatinine measurement should be obtained. The urine should be assessed for infection and proteinuria.

NATURAL HISTORY

The incidence of reflux-related renal scarring increases with VUR grade. With bladder growth and maturation, the VUR grade often resolves or improves. *Lower grades of VUR are much more likely to resolve than are higher grades.* For grade I and II VUR, the likelihood of resolution is similar regardless of age at diagnosis and whether it is unilateral or bilateral. For grade III, a younger age at diagnosis and unilateral VUR usually are associated with a higher rate of spontaneous resolution (Fig. 576.9). Bilateral grade IV VUR is much less likely to resolve than is unilateral grade IV VUR. Grade V VUR rarely resolves. The mean age at VUR resolution is 6 years. *BBD and grade III-V VUR are the most common risk factors for recurrent febrile UTI and new renal scarring.*

Sterile VUR does not usually cause renal injury in the absence of infection, but in situations with high-pressure VUR, as in children with posterior urethral valves, neuropathic bladder, and nonneurogenic neurogenic bladder (i.e., **Hinman syndrome**), sterile VUR can cause significant renal damage. Children with high-grade VUR who acquire

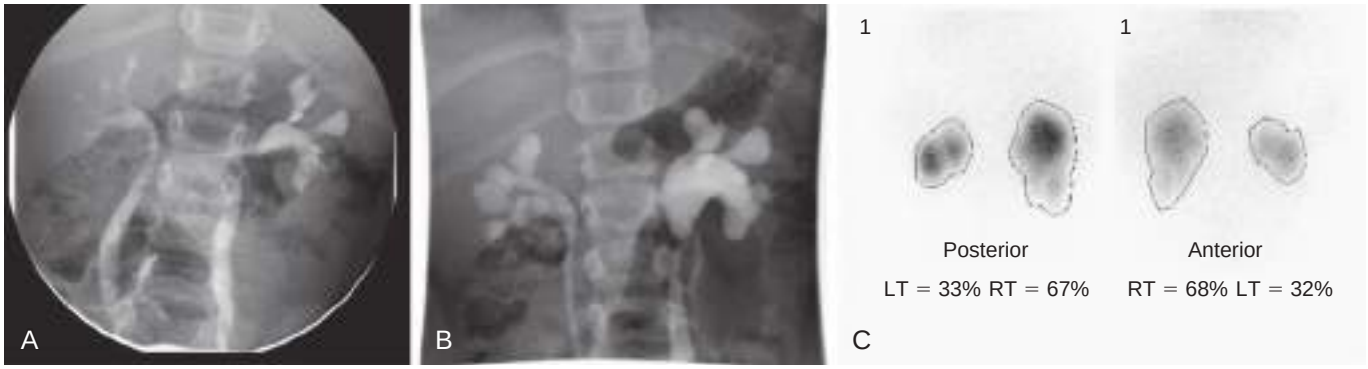

Fig. 576.8 **A,** VCUG in a 3-yr-old child with two febrile UTIs shows bilateral grade III VUR. **B,** At 5 years, repeat VCUG shows worsening VUR and calyceal clubbing, indicating renal scarring. **C,** At 11 years, renin-mediated hypertension has developed. Dimercaptosuccinic acid (DMSA) renal scan shows significant VUR-related renal scarring.

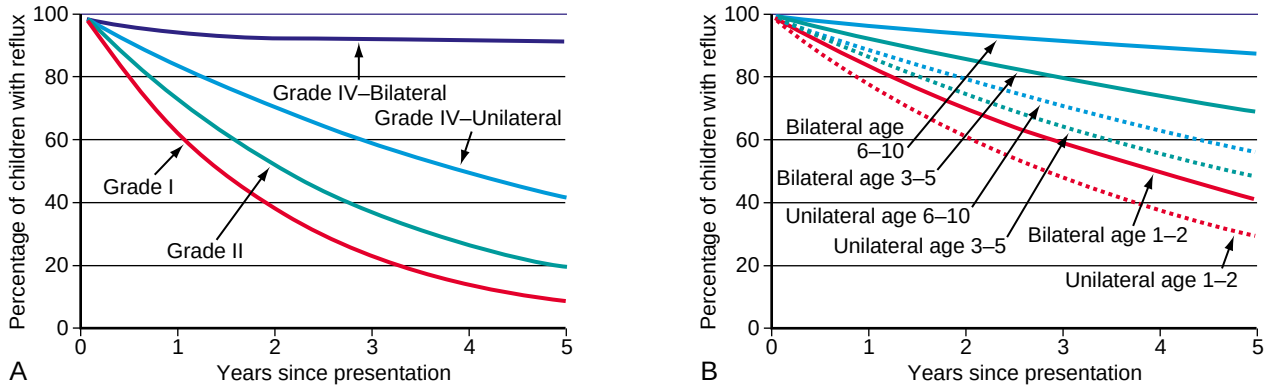

Fig. 576.9 A, Percentage chance of VUR persistence, grades I, II, and IV, for 1-5 years after presentation. B, Percentage chance of VUR persistence by age at presentation, grade III, for 1-5 years after presentation. *(From Elder JS, Peters CA, Arant BS Jr, et al. Pediatric Vesicoureteral Reflux Guidelines Panel summary report on the management of primary vesicoureteral reflux in children. J Urol. 1997;157:1846–1851.)*

a UTI are at significant risk for acute and recurrent pyelonephritis and new renal scarring (see Fig. 576.8).

TREATMENT

The goals of treatment are to prevent pyelonephritis, VUR-related renal injury, and other complications of VUR. Medical therapy is based on the principle that VUR often resolves over time and that if UTIs can be prevented, the morbidity or complications of VUR may be avoided without surgery. Medical therapy includes observation with behavioral modification or behavioral modification with antimicrobial prophylaxis in some patients. The basis for surgical therapy is that in selected children, ongoing VUR has caused or has significant potential for causing renal injury or other VUR-related complications, and that elimination of VUR minimizes the risk of these problems. Therapy for VUR should be individualized based on a particular patient's risk factors.

Observation

In children undergoing observation, therapeutic emphasis is directed at minimizing the risk of UTI by behavioral modification. These methods include timed voiding during the day, ensuring regular fecal elimination, increased fluid intake, periodic assessment of satisfactory bladder emptying, and prompt assessment and treatment of UTIs, particularly febrile UTIs. This approach is most appropriate for children with grade I and II VUR, and perhaps older children with persistent VUR and normal kidneys who have not experienced clinical pyelonephritis.

Antimicrobial Prophylaxis

In the past, daily antimicrobial prophylaxis was recommended as an initial approach to most children with VUR. However, several prospective clinical trials question the benefit of prophylaxis in children with VUR. The risk of recurrent UTI is highest in patients with grade III or IV reflux, those with BBD, and those whose first reflux-associated UTI was *febrile* rather than just symptomatic without fever. Antibiotic prophylaxis after a reflux-associated UTI decreases the risk of recurrent UTI but may increase the risk of developing resistant bacteria. In one study, antibiotic prophylaxis reduced the risk of new renal scars in children with grade III or IV reflux, while in another larger study, antibiotic prophylaxis did not affect the incidence of new renal scars in those with severe reflux (approximately 10% developed new scars regardless of prophylaxis).

Surgery

The purpose of surgical therapy is to minimize the risk of febrile UTI from ongoing VUR and nonsurgical therapy (observation or prophylaxis with follow-up testing). VUR can be corrected through a lower abdominal or inguinal incision (open), laparoscopically (with or without robotic assistance), or endoscopically with subureteral injection of a bulking agent.

Surgical management involves modifying the abnormal ureterovesical attachment. The operation can be performed from either outside (extravesical) or inside the bladder (intravesical). When VUR is associated with severe ureteral dilation (i.e., megaureter), the ureter must be tailored or narrowed to a more normal size to allow a smaller length:width ratio for the intramural tunnel, and a corner of the bladder is attached to the psoas tendon, forming a *psoas hitch.* Most children can be discharged 1-2 days following the surgical procedure. If the refluxing kidney is poorly functioning, nephrectomy or nephroureterectomy is indicated. Minimally invasive approaches with **laparoscopic** and **robotic-assisted laparoscopic ureteral reimplantation** offer alternatives to open surgical management; as experience with these procedures grows, success rates are approaching that of open surgery.

The success rate of conventional open ureteral reimplantation in children with primary VUR is >95–98% for grades I-IV, with 2% experiencing persistent VUR and 1% having ureteral obstruction that requires correction. The success rate is so high that many pediatric urologists do not perform a postoperative VCUG unless the child develops clinical pyelonephritis. For grade V VUR, the success rate is approximately 80%. In lower grades of VUR, a failed reimplantation is most likely to occur in children with undiagnosed BBD. In children with secondary VUR (posterior urethral valves, neuropathic bladder), the success rate is slightly lower than with primary VUR. The risk of pyelonephritis in children with grade III and IV VUR is significantly lower following open surgical correction compared with medical management. *Surgical repair will not reverse renal scarring or lead to improvement in renal function.*

Endoscopic repair of VUR involves injection of a bulking agent through a cystoscope just beneath the ureteral orifice, creating an effective flap-valve (Figs. 576.10 and 576.11). In 2001, the US Food and Drug Administration (FDA) approved the use of a biodegradable material, dextranomer microspheres suspended in hyaluronic acid (Dx-HA) (Deflux), for subureteral injection. The advantage of subureteral injection is that it is a noninvasive outpatient procedure (performed under general anesthesia) with no recovery time. The success rate is 70–80% and is highest for lower grades of VUR. If the first injection is unsuccessful, one or two repeat injections can be performed. The VUR recurrence rate is approximately 10–20%. In other areas of the world, a polyacrylamide hydrogel is used for endoscopic injection. The success rate with this product, which is not approved in the United States, is similar to Dx-HA, but the risk of reflux recurrence is significantly less.

CURRENT VESICOURETERAL REFLUX GUIDELINES

The long-standing belief regarding the benefit of antibiotic prophylaxis in children with VUR has been questioned. Multiple randomized, controlled prospective trials suggested that the risk of UTI in children with VUR is not reduced by prophylaxis. Most of the children in these trials had grade I-III VUR, and few younger than 1 year of age were studied.

In contrast, the PRIVENT (Prevention of Recurrent Urinary Tract Infection in Children with Vesicoureteric Reflux and Normal Renal Tracts) trial from Australia showed significant benefit to prophylaxis in children with VUR. The Swedish VUR Trial in Children studied children younger than 2 years of age with grades III and IV VUR; they compared antibiotic prophylaxis (nitrofurantoin) with observation and endoscopic injection therapy. Females in the surveillance group had a significantly higher incidence of febrile UTI and new renal scarring compared with the other treatment groups. The largest randomized trial (RIVUR [Randomized Intervention for Children with Vesicoureteral Reflux]) enrolled more than 600 children and demonstrated a reduction in the recurrence rate of UTIs with no reduction in the occurrence of renal scarring with antibiotic prophylaxis, but the prevalence of renal scarring at study entry was low.

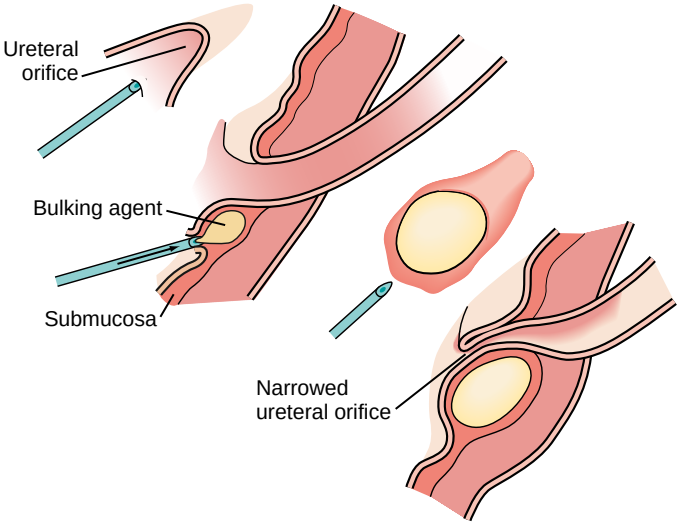

Fig. 576.10 Endoscopic correction of VUR. Through a cystoscope, a needle is inserted into the submucosal plane deep to the ureteral orifice, and a bulking agent is injected, creating a flap-valve to prevent VUR. *(Adapted from Ortenberg J. Endoscopic treatment of vesicoureteral reflux in children. Urol Clin North Am. 1998;25:151–156.)*

Prophylaxis is recommended by the American Urologic Association (AUA) in children at greatest risk for VUR-related renal injury (i.e., those <1 year of age). In addition, evaluation for bladder and bowel dysfunction is considered a standard part of initial and ongoing patient evaluation in children with VUR. Because children with BBD and VUR are much more likely to have recurrent UTIs and renal scarring, prophylaxis is recommended for these children. In children with VUR who are being managed by surveillance, if a febrile UTI occurs, prophylaxis is recommended. The decision whether to recommend observation, medical therapy, or surgery is based on the risk of VUR to the patient, the likelihood of spontaneous resolution, and the parents' and patient's preferences; the family should understand the risks and benefits of each treatment approach.

Another aspect of VUR management pertains to screening. VUR is known to be a familial disorder with autosomal dominant transmission with variable penetrance. The advantage of early VUR detection is to implement treatment before a potentially damaging episode of clinical pyelonephritis. In siblings of an index patient with VUR, optional management includes screening of asymptomatic siblings or offspring with a renal ultrasound or VCUG. The AUA recommends that a VCUG should be obtained if a screening ultrasound demonstrated a renal abnormality or if the sibling had a UTI.

The AUA also determined that female newborns with renal pelvic dilation were more likely than male newborns to have VUR. The AUA recommends that a VCUG be performed in neonates with grade III-IV *antenatal* hydronephrosis (moderate to severe pelvicalyceal dilation), hydroureter, or an abnormal bladder. In children with less severe renal pelvic dilation, an observational approach without screening for VUR, with prompt treatment of any UTI, is appropriate. However, the AUA also indicated that obtaining a VCUG is considered an appropriate option for neonates with lesser grades of hydronephrosis.

Visit Elsevier eBooks+ at eBooks.Health.Elsevier.com for Bibliography.

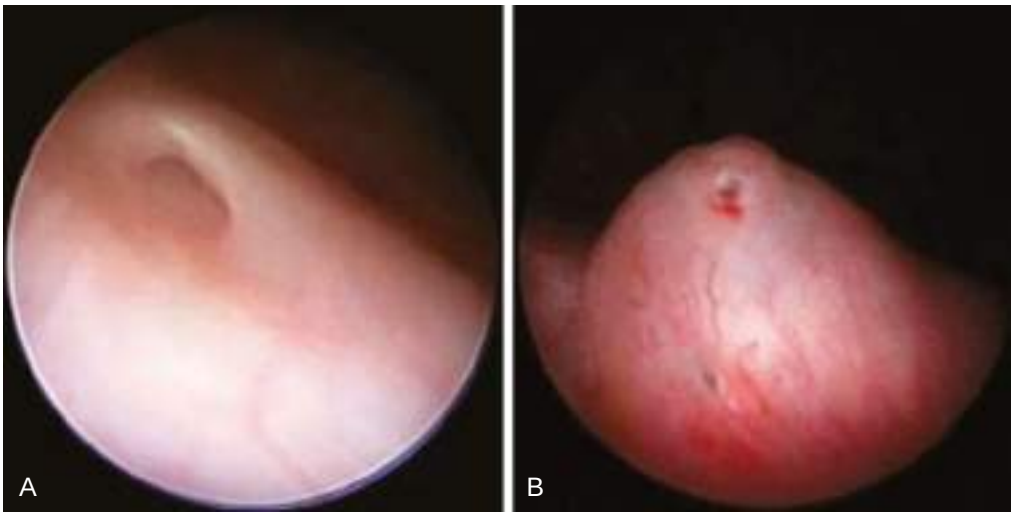

Fig. 576.11 **A,** Endoscopic view of right vesicoureteral refluxing ureter. **B,** The same ureter after subureteral injection of dextranomer microspheres.

Chapter 577

Obstruction of the Urinary Tract

Heather N. Di Carlo and Chad B. Crigger

Most childhood obstructive lesions are congenital, although urinary tract obstruction can be caused by trauma, neoplasia, calculi, inflammatory processes, or surgical procedures. Obstructive lesions occur at any level from the urethral meatus to the calyceal infundibula (Table 577.1). The pathophysiologic effects of obstruction depend on its level, the extent of involvement, the child's age at onset, and whether it is acute or chronic.

ETIOLOGY

Severe ureteral obstruction early in fetal life results in renal dysplasia, ranging from multicystic kidney, which is associated with ureteral or ureteropelvic junction (UPJ) atresia (see Fig. 574.3), to various degrees of histologic renal cortical dysplasia that are seen with less severe obstruction. **Chronic ureteral obstruction** in late fetal life or after birth results in dilation of the ureter, renal pelvis, and calyces with alterations of renal parenchyma ranging from minimal tubular changes to dilation of Bowman's space, glomerular fibrosis, and interstitial fibrosis. After birth, infection can complicate obstruction and worsen renal damage.

Prenatal screening with ultrasonography (US) may detect **antenatal hydronephrosis** (ANH), which is graded by the trimester and the anterior-posterior diameter of the renal pelvis (Table 577.2); most are mild. Table 577.3 notes the eventual etiology. Risk stratification for prenatal (Fig. 577.1) and postnatal (Fig. 577.2) urinary tract dilation (UTD) helps plan for further evaluation and treatment.

CLINICAL MANIFESTATIONS

Obstruction of the urinary tract generally causes **hydronephrosis,** which typically is asymptomatic in its early phases. An obstructed kidney secondary to a **ureteropelvic junction (UPJ) obstruction** or **ureterovesical junction obstruction** can manifest as a unilateral mass or cause upper abdominal or flank pain on the affected side. Pyelonephritis can occur because of urinary stasis. An upper urinary tract stone can occur, causing abdominal and flank pain and hematuria. With bladder outlet obstruction, the urinary stream may be weak; urinary tract infection (UTI; see Chapter 575) is common. Many of these lesions are identified by antenatal US; an abnormality involving the genitourinary tract is suspected in as many as 1 in 50 fetuses (see Table 577.3).

Obstructive renal insufficiency can manifest itself by failure to thrive, vomiting, diarrhea, or other nonspecific signs and symptoms. In older children, **infravesical obstruction** can be associated with overflow urinary incontinence or a poor urine stream. **Acute ureteral obstruction** causes flank or abdominal pain; there may be nausea and vomiting. Chronic ureteral obstruction can be silent or can cause vague abdominal or typical flank pain with increased fluid intake (such as in Dietl's crisis).

DIAGNOSIS

Urinary tract obstruction may be diagnosed prenatally by US, which typically shows hydronephrosis and occasionally a distended bladder. More complete evaluation, including imaging studies, should be undertaken in these children in the neonatal period.

A multidisciplinary consensus group has standardized the fetal evaluation and early postnatal management of babies with ANH. The US parameters include the anterior-posterior renal pelvic diameter (APRPD), **calyceal dilation,** whether the ANH involves the major and/or minor calyces, the parenchymal thickness and appearance, whether the ureter is normal or abnormal, and whether the bladder is normal or abnormal. Normal values for UTD are based on the APRPD:

Antenatal	16-27 weeks	<4 mm
	≥28 weeks	<7 mm
Postnatal	(>48 hours)	<10 mm

Assuming there is no calyceal dilation, the kidneys have a normal appearance, and the ureter and bladder are normal, the study is considered normal.

The consensus group then categorized ANH into antenatal and postnatal risk groups. For antenatal ANH, there are two risk groups: low and high (see Fig. 577.1). For postnatal ANH, there are three risk groups: low,

Table 577.1 Types and Causes of Urinary Tract Obstruction

LOCATION	CAUSE
Infundibula	Congenital Calculi Inflammatory (tuberculosis) Traumatic Postsurgical Neoplastic
Renal pelvis	Congenital (infundibulopelvic stenosis) Inflammatory (tuberculosis) Calculi Neoplasia (Wilms tumor, neuroblastoma)
Ureteropelvic junction	Congenital stenosis Calculi Neoplasia Inflammatory Postsurgical Traumatic
Ureter	Congenital obstructive megaureter Midureteral structure Ureteral ectopia Ureterocele Retrocaval ureter Ureteral fibroepithelial polyps Ureteral valves Calculi Postsurgical Extrinsic compression Neoplasia (neuroblastoma, lymphoma, and other retroperitoneal or pelvic tumors) Inflammatory (Crohn disease, chronic granulomatous disease) Hematoma, urinoma Lymphocele Retroperitoneal fibrosis
Bladder outlet and urethra	Neurogenic bladder dysfunction (functional obstruction) Posterior urethral valves Anterior urethral valves Diverticula Urethral strictures (congenital, traumatic, or iatrogenic) Urethral atresia Ectopic ureterocele Meatal stenosis (males) Calculi Foreign bodies Phimosis Extrinsic compression by tumors Urogenital sinus anomalies

Table 577.2 Definition of Antenatal Hydronephrosis by Anterior-Posterior Diameter

DEGREE OF ANTENATAL HYDRONEPHROSIS	SECOND TRIMESTER	THIRD TRIMESTER
Mild	4–6 mm	7 to 9 mm
Moderate	7–10 mm	10–15 mm
Severe	>10 mm	>15 mm

From Nguyen HT, Herndon CDA, Cooper C, et al. The Society for Fetal Urology consensus statement on the evaluation and management of antenatal hydronephrosis. *J Pediatr Urol*. 2010;6:212–231. Table 2.

Table 577.3 Etiology of Antenatal Hydronephrosis

ETIOLOGY	INCIDENCE
Transient hydronephrosis	41–88%
Ureteropelvic junction obstruction	10–30%
Vesicoureteral reflux	10–20%
Ureterovesical junction obstruction/ megaureters	5–10%
Multicystic dysplastic kidney	4–6%
Posterior urethral valve/urethral atresia	1–2%
Ureterocele/ectopic ureter/duplex system	5–7%
Others: prune-belly syndrome, cystic kidney disease, congenital ureteric strictures, megalourethra	Uncommon

From Nguyen HT, Herndon CDA, Cooper C, et al. The Society for Fetal Urology consensus statement on the evaluation and management of antenatal hydronephrosis. *J Pediatr Urol*. 2010;6:212–231. Table 5.

intermediate, and high (see Fig. 577.2). The panel recommended that all seven urinary tract parameters be described in a written report.

For antenatal presentation, if the APRPD is 4-7 mm at 16-27 weeks or 7-10 mm at ≥28 weeks and there is central or no calyceal dilation, the fetus is categorized as having **UTD A1, Low Risk**. In follow-up for UTD A1, the panel suggested one additional antenatal US at ≥32 weeks, and after birth, a renal US at >48 hours to 1 month of age and a second renal US 6 months later. Genetic screening is not indicated unless there are associated congenital malformations.

If the APRPD is ≥7 mm at 16-27 weeks or ≥10 mm at ≥28 weeks, with any peripheral calyceal dilation or any other upper urinary tract abnormality, the fetus is classified as having **UTD A2-3,** or **Increased Risk**. The assigned risk is based on the most concerning feature. For UTD A2-3, the panel recommends a follow-up US in 4-6 weeks, although with suspected **posterior urethral valves** (PUVs) or severe bilateral hydronephrosis, more frequent follow-up was recommended until delivery. Following delivery, a renal US after 48 hours but before 1 month is suggested, again with more immediate evaluation if PUV is suspected or there is significant bilateral hydronephrosis. In addition, specialist consultation with pediatric urology or nephrology is recommended.

For postnatal presentation, at >48 hours an APRPD <10 mm is **Normal.** If the APRPD is 10-15 mm and there is central calyceal dilation, but all other parameters are normal, the infant is classified as having **UTD P1, Low Risk**. Society of Fetal Urology (SFU) hydronephrosis grades 1 and 2 correspond to UTD P1. The panel recommends a follow-up renal US in 1-6 months. *A voiding cystourethrogram (VCUG) and antibiotic prophylaxis are optional and at the discretion of the clinician. A renal scan is not recommended.*

If the postnatal APRPD is ≥15 mm and there is peripheral calyceal dilation and/or abnormal ureters, the infant is classified as having **UTD P2, Intermediate Risk**. SFU hydronephrosis grade 3 corresponds to UTD P2. The panel recommends a follow-up renal US in 1-3 months. *VCUG, antibiotic prophylaxis, and a functional renal scan are optional and at the discretion of the clinician.*

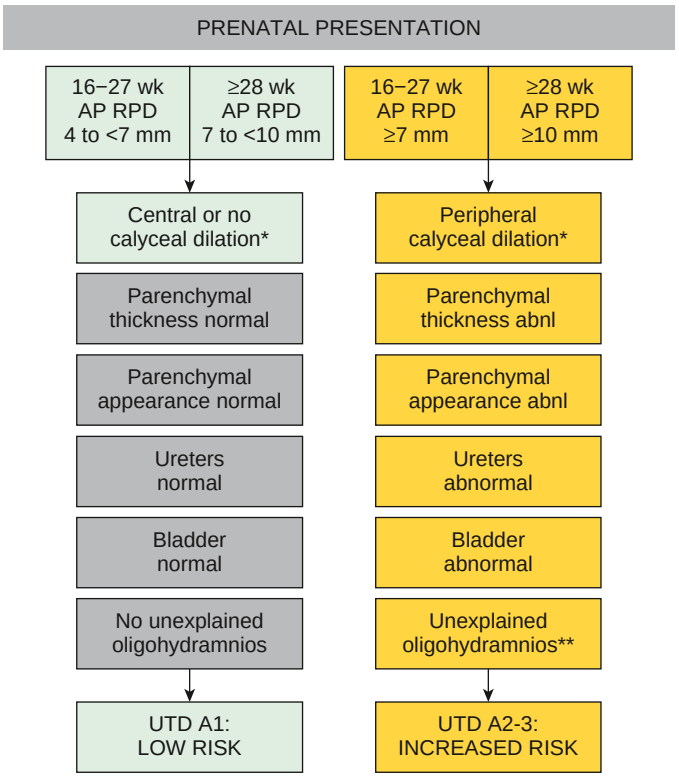

*Central and peripheral calyceal dilation may be difficult to evaluate early in gestation

**Oligohydramnios is suspected to result from a GU cause

Fig. 577.1 Urinary tract dilation (UTD) risk stratification: prenatal presentation for UTD A1 (low risk) and UTD A2-3 (increased risk). Note: Classification is based on the presence of the most concerning feature. For example, a fetus with an APRPD within the UTD A1 range but with peripheral calyceal dilation would be classified as UTD A2-3. GU, Genitourinary. *(From Nguyen HT, Benson CB, Bromley B, et al. Multidisciplinary consensus on the classification of prenatal and postnatal urinary tract dilation [UTD classification system]. J Pediatr Urol. 2014;10:982–998. Fig. 3.)*

If the APRPD is ≥15 mm and there is peripheral calyceal dilation, abnormal parenchymal thickness, abnormal parenchymal appearance, abnormal ureters, and/or abnormal bladder, the infant is classified as having **UTD P3, High Risk**. SFU hydronephrosis grade 4 corresponds to UTD P3. The panel recommends a follow-up renal US in 1 month. *A VCUG and antibiotic prophylaxis are recommended. A functional renal scan is optional and at the discretion of the clinician (but is virtually always recommended).*

PHYSICAL FINDINGS

Urinary tract obstruction is often silent. In the newborn infant, a palpable abdominal mass most commonly is a hydronephrotic or multicystic dysplastic kidney. With PUVs, which constitute an infravesical obstructive lesion in males, a walnut-sized mass representing the bladder is palpable just above the pubic symphysis. A **patent draining urachus** also can suggest urethral obstruction. **Urinary ascites** in the newborn usually is caused by renal or bladder urinary extravasation secondary to PUVs. Infection and sepsis may be the first indications of an obstructive lesion of the urinary tract. The combination of infection and obstruction poses a serious threat to infants and children and generally requires parenteral administration of antibiotics and drainage of the obstructed kidney. Renal US should be performed in all children during the acute stage of an initial febrile UTI.

IMAGING STUDIES

Renal Ultrasound

Hydronephrosis is the most common characteristic of obstruction (Fig. 577.3). Upper UTD is not diagnostic of obstruction and often

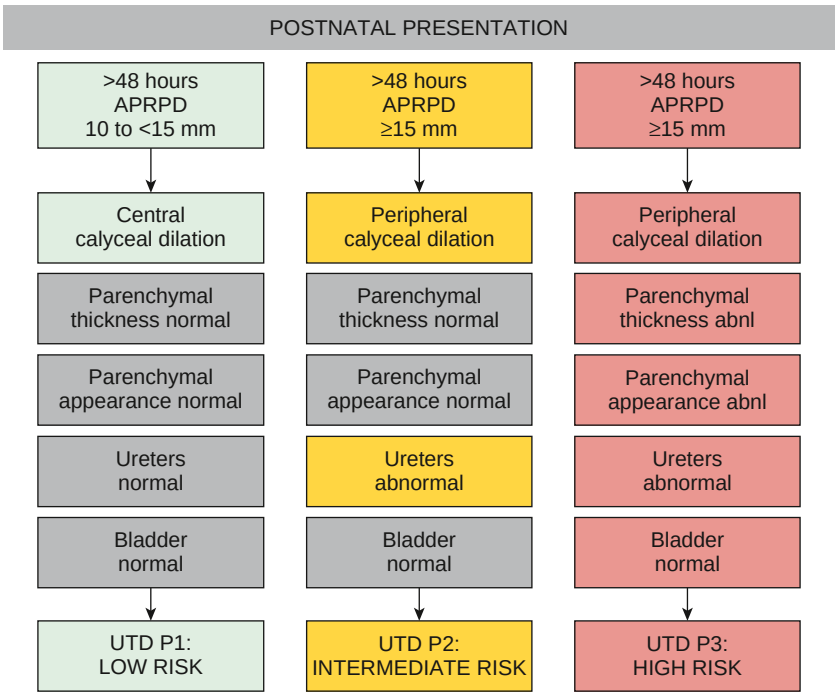

Fig. 577.2 Urinary tract dilation (UTD) risk stratification: postnatal presentation for UTD P1 (low risk), UTD P2 (intermediate risk), and UTD P3 (high risk). Note: Stratification is based on the most concerning ultrasound finding. For example, if the APRPD is in the UTD P1 range but there is peripheral calyceal dilation, the classification is UTD P2. Similarly, the presence of parenchymal abnormalities (abnl) denotes a UTD P3 classification, regardless of APRPD measurement. *(From Nguyen HT, Benson CB, Bromley B, et al. Multidisciplinary consensus on the classification of prenatal and postnatal urinary tract dilation [UTD classification system]. J Pediatr Urol. 2014;10:982–998. Fig. 6.)*

Fig. 577.3 US image of the left kidney with marked pelvic and calyceal dilation (grade 4 hydronephrosis) in a newborn with ureteropelvic junction obstruction.

Table 577.4 Society for Fetal Urology Grading System for Hydronephrosis

	RENAL IMAGE	
GRADE OF HYDRONEPHROSIS	**CENTRAL RENAL COMPLEX**	**RENAL PARENCHYMAL THICKNESS**
0	Intact	Normal
1	Slight splitting	Normal
2	Evident splitting, complex confined within renal border	Normal
3	Wide splitting, pelvis dilated outside renal border, calyces uniformly dilated	Normal
4	Further dilation of pelvis and calyces (calyces may appear convex)	Thin

After Maizels M, Mitchell B, Kass E, et al. Outcome of nonspecific hydronephrosis in the infant: a report from the registry of the Society for Fetal Urology. *J Urol.* 1994;152:2324–2327.

persists after surgical correction of a significant obstructive lesion. Dilation can result from vesicoureteral reflux (VUR), or it may be a manifestation of abnormal development of the urinary tract, even when there is no obstruction. Renal length, degree of caliectasis and parenchymal thickness, and presence or absence of ureteral dilation should be assessed. In addition to the UTD system, most pediatric urologists also grade the severity of hydronephrosis from 1-4 using the SFU grading scale (Table 577.4). The clinician should ascertain that the contralateral kidney is normal, and the bladder should be imaged to see whether the bladder wall is thickened, the lower ureter is dilated, and bladder emptying is complete. In acute or intermittent obstruction, the dilation of the collecting system may be minimal, and US may be misleading.

Voiding Cystourethrogram

In neonates and infants with congenital grade 3 or 4 hydronephrosis and in any child with ureteral dilation, a **contrast VCUG** should be obtained, because the dilation is secondary to VUR in 15% of cases. In males, the VCUG also is performed to rule out urethral obstruction, particularly in cases of suspected PUVs. In older children, the urinary flow rate can be measured noninvasively with a urinary flowmeter. Decreased flow with a normal bladder contraction suggests infravesical obstruction (e.g., PUVs, urethral stricture). When the urethra cannot be catheterized to obtain a VCUG, the clinician should suspect a urethral stricture or an obstructive urethral lesion. Retrograde urethrography with contrast medium injected into the urethral meatus helps delineate the anatomy of the urethral obstruction.

Radioisotope Studies

Renal scintigraphy is used to assess renal anatomy and function. The two most commonly used radiopharmaceuticals are mercaptoacetyl triglycine (MAG-3) and technetium-99m–labeled dimercaptosuccinic acid (DMSA). MAG-3, which is excreted by renal tubular secretion, is used to assess differential renal function, and when furosemide is administered, drainage also can be measured. DMSA is a renal cortical imaging agent and is used to assess differential renal function and to demonstrate whether renal scarring is present. It is used infrequently in children with obstructive uropathy.

In a MAG-3 diuretic renogram, a small dose of technetium-labeled MAG-3 is injected intravenously (Figs. 577.4 and 577.5). During the first 2-3 minutes, renal parenchymal uptake is analyzed and compared, allowing computation of differential renal function.

Subsequently, excretion is evaluated. After 20 minutes, furosemide 1 mg/kg is injected intravenously, and the rapidity and pattern of drainage from the kidneys to the bladder are analyzed. If no obstruction is present, half of the radionuclide should be cleared from the renal pelvis within 10-15 minutes, termed the half-time ($t_{1/2}$). If there is significant upper tract obstruction, the $t_{1/2}$ usually is longer than 20 minutes. A $t_{1/2}$ of 15-20 minutes is indeterminate. An elevated $t_{1/2}$ is suggestive but not diagnostic of obstruction. The images generated usually provide an accurate assessment of the site of obstruction. Numerous variables affect the outcome of the diuretic renogram. Newborn kidneys are functionally immature, and, in the first month of life, normal kidneys might not demonstrate normal drainage after diuretic administration. Patient dehydration prolongs parenchymal transit and can blunt the diuretic response. As such, renal scintigraphy is usually performed after 8 weeks of life in an appropriately hydrated infant. Giving an insufficient dose of furosemide can result in slow drainage. If VUR is present, continuous bladder drainage is mandatory to prevent the radionuclide from refluxing from the bladder into the dilated upper tract, which would prolong the washout phase.

Magnetic Resonance Urography

Magnetic resonance (MR) urography is also used to evaluate suspected upper urinary tract pathology. The child is hydrated and given intravenous furosemide. Gadolinium-diethylene tetrapentaacetic acid is injected, and routine T1 weighted and fat-suppressed fast spin-echo T2 weighted imaging is performed through the kidneys, ureters, and bladder. This study provides superb images of the pathology, and methodology permits assessment of differential renal function and drainage (Fig. 577.6). There is no radiation exposure; however, young children need sedation or anesthesia. It is used primarily when renal US and radionuclide imaging fail to delineate complex pathology.

Computed Tomography

In children with a suspected ureteral calculus (see Chapter 584), noncontrast, low-dose spiral CT of the abdomen and pelvis is a standard method of demonstrating whether a calculus is present, its location, and whether there is significant proximal hydronephrosis. This study may be ordered when a renal/bladder US is inconclusive. The disadvantage of CT is the significant radiation exposure, and it should be used only when the results will direct management decisions.

Ancillary Studies

In unusual cases, an **antegrade pyelogram** (insertion of a percutaneous nephrostomy tube and injection of contrast agent) can be performed to assess the anatomy of the upper urinary tract. This procedure usually requires general anesthesia. In addition, an **antegrade pressure-perfusion flow study** (Whitaker test) may be performed, in which fluid is infused at a measured rate, usually 10 mL/min. The pressures

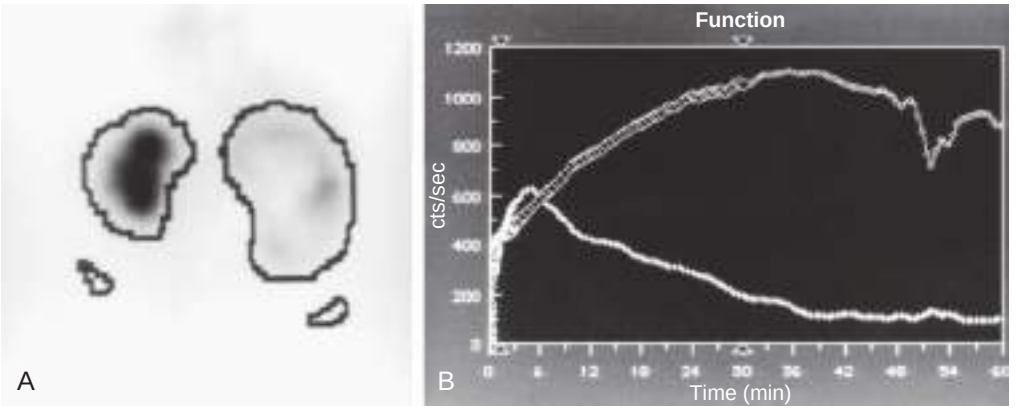

Fig. 577.4 MAG-3 diuretic renogram of a 6-wk-old infant with severe right hydronephrosis. The right kidney is on the *right* side of the image. **A,** Differential renal function: left kidney 70%, right kidney 30%. **B,** After administration of furosemide, drainage from the left kidney was normal and drainage from the right kidney was slow, consistent with right UPJ obstruction. Pyeloplasty was performed on the right kidney.

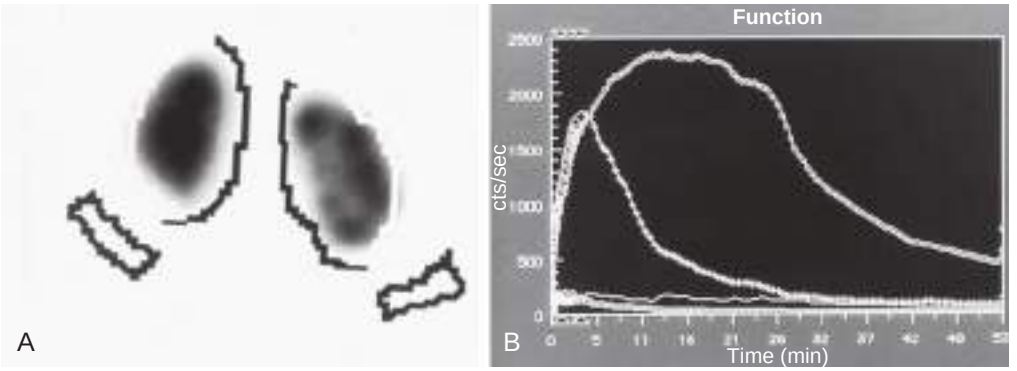

Fig. 577.5 **A,** MAG-3 diuretic renogram at 14 mo of age shows equal function in the two kidneys. **B,** Prompt drainage after the administration of furosemide.

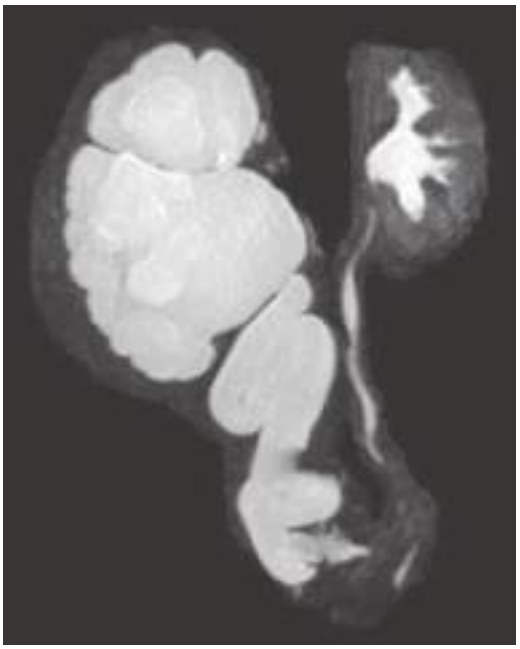

Fig. 577.6 MR urogram in boy with distal ureterovesical obstruction.

in the renal pelvis and the bladder are monitored during this infusion, and pressure differences exceeding 20 cm H_2O suggest obstruction. In other cases, cystoscopy with retrograde pyelography provides excellent images of the upper urinary tract (Fig. 577.7).

Fig. 577.7 Retrograde pyelogram showing medial deviation of a dilated upper ureter to the level of the third lumbar vertebra *(arrow)*, characteristic of a retrocaval ureter.

SPECIFIC TYPES OF URINARY TRACT OBSTRUCTION AND THEIR TREATMENT

Hydrocalycosis

Hydrocalycosis refers to a localized dilation of the calyx caused by obstruction of its infundibulum, termed **infundibular stenosis.** This condition can be developmental in origin or secondary to inflammatory processes, such as UTI. It usually is discovered during evaluation for pain or UTI. The diagnosis of infundibular stenosis is usually established by sonograph and CT scan or MR urography.

Ureteropelvic Junction Obstruction

UPJ obstruction is the most common obstructive lesion in childhood and usually is caused by intrinsic stenosis (see Figs. 577.3-577.5). An accessory artery to the lower pole of the kidney can also cause extrinsic obstruction. The typical appearance on US is grade 3 or 4 hydronephrosis without a dilated ureter and a clear transition point. UPJ obstruction may present on antenatal sonography revealing fetal hydronephrosis; as a palpable renal mass in a newborn or infant; as abdominal, flank, or back pain; as a febrile UTI; or as hematuria after minimal trauma. Approximately 60% of cases occur on the left side; the male:female ratio is 2:1. *UPJ obstruction is bilateral in only 10% of cases*. In kidneys with UPJ obstruction, renal function may be significantly impaired from pressure atrophy, but approximately half of affected kidneys have relatively normal glomerular function. The anomaly is corrected by performing a **pyeloplasty**, in which the stenotic segment is excised, and the normal ureter and renal pelvis are reattached. Success rates are 91–98%. Pyeloplasty can be performed using laparoscopic techniques, often robotic assisted using the da Vinci robot.

Lesser degrees of UPJ narrowing might cause mild hydronephrosis, which usually is nonobstructive, and typically these kidneys function normally. The spectrum of UPJ abnormalities has been referred to as **anomalous UPJ**. Another cause of mild hydronephrosis is fetal folds of the upper ureter, which also are nonobstructive.

The diagnosis can be difficult to establish in an asymptomatic infant in whom dilation of the renal pelvis is found incidentally in a prenatal US. After birth, the sonographic study is repeated to confirm the prenatal finding. A VCUG is necessary because 10–15% of patients have ipsilateral vesicoureteral reflux. Because neonatal oliguria can cause temporary decompression of a dilated renal pelvis, it is ideal to perform the first postnatal US after the third day of life. Delaying the US may be impractical. *If no dilation is found on the initial US, a repeat study should be performed at 1 month of age*. If the kidney shows grade 1 or 2 hydronephrosis and the renal parenchyma appears normal, a period of observation usually is appropriate, with sequential renal US studies to monitor the severity of hydronephrosis, and the hydronephrosis usually disappears. Antibiotic prophylaxis is *not* indicated for children with mild hydronephrosis. If the hydronephrosis is grade 3 or 4, spontaneous resolution is less likely, and obstruction is more likely to be present, particularly if the renal pelvic diameter is 3 cm. A diuretic renogram with MAG-3 is performed at 4-6 weeks of age. If there is poor upper tract drainage or the differential renal function is poor, pyeloplasty is recommended. After pyeloplasty the differential renal function often improves, and improved drainage with furosemide stimulation is expected.

If the differential function on renography is normal and drainage is satisfactory, the infant can be followed with serial US studies, even with grade 4 hydronephrosis. If the hydronephrosis remains severe with no improvement, a repeat diuretic renogram after 6-12 months can help in the decision between continued observation and surgical repair. Prompt surgical repair is indicated in infants with an abdominal mass, bilateral severe hydronephrosis, a solitary kidney, or diminished function in the involved kidney. In unusual cases in which the differential renal function is <10% but the kidney has some function, insertion of a percutaneous nephrostomy tube allows drainage of the hydronephrotic kidney for a few weeks to allow reassessment of renal function. In older children who present with symptoms, the diagnosis of UPJ obstruction usually is established by US and diuretic renography.

The differential diagnosis includes megacalycosis, a congenital nonobstructive dilation of the calyces without pelvic or ureteric dilation; VUR with marked dilation and kinking of the ureter; midureteral or

distal ureteral obstruction when the ureter is not well visualized on the urogram; and retrocaval ureter.

Midureteral Obstruction

Congenital ureteral stenosis or a ureteral valve in the midureter is rare. It is corrected by excision of the strictured segment and reanastomosis of the normal upper and lower ureteral segments. A **retrocaval ureter** is an anomaly in which the upper right ureter travels posterior to the inferior vena cava. In this anomaly, the vena cava can cause extrinsic compression and obstruction. A retrograde pyelogram or MR urogram shows the right ureter to be medially deviated at the level of the third lumbar vertebra (see Fig. 577.7). Surgical treatment consists of transection of the upper ureter, moving it anterior to the vena cava, and reanastomosing the upper and lower segments. Repair is necessary only when obstruction is present. Retroperitoneal tumors, fibrosis caused by surgical procedures, inflammatory processes (as in chronic granulomatous disease), and radiation therapy can cause acquired midureteral obstruction.

Ectopic Ureter

A ureter that drains outside the bladder is referred to as an ectopic ureter. This anomaly is three times as common in females as in males and usually is detected prenatally. The ectopic ureter typically drains the upper pole of a duplex collecting system (two ureters).

In females, approximately 35% of these ureters enter the urethra at the bladder neck; 35% enter the urethrovaginal septum; 25% enter the vagina; and a few drain into the cervix, uterus, Gartner duct, or a urethral diverticulum. Often the terminal aspect of the ureter is narrowed, causing **hydroureteronephrosis**. Apart from the ectopic ureter entering the bladder neck, in females an ectopic ureter causes continuous urinary incontinence from the affected renal moiety. UTI is common because of urinary stasis.

In males, ectopic ureters enter the posterior urethra (above the external sphincter) in 47%, the prostatic utricle in 10%, the seminal vesicle in 33%, the ejaculatory duct in 5%, and the vas deferens in 5%. Consequently, in males, an ectopic ureter does not cause incontinence, and most patients present with a UTI or epididymitis.

Evaluation includes a renal US, VCUG, and renal scan, which demonstrates whether the affected segment has significant function. The US shows the affected hydronephrotic kidney or dilated upper pole and ureter down to the bladder (Fig. 577.8). If the ectopic ureter drains into the bladder neck (female), a VCUG usually shows reflux into the ureter. Otherwise, there is no reflux into the ectopic ureter, but there may be reflux into the ipsilateral lower pole ureter or contralateral collecting system.

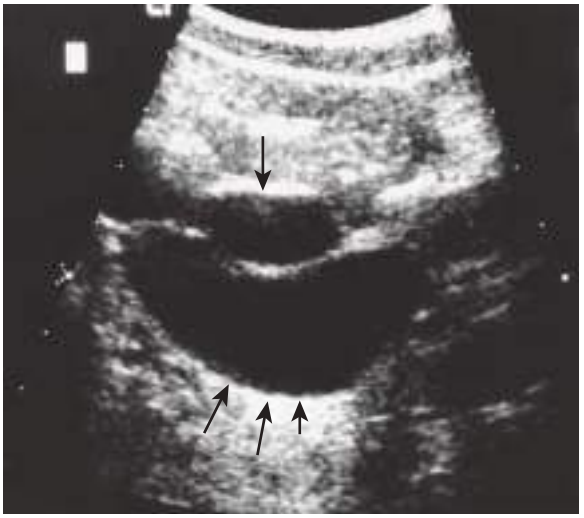

Fig. 577.8 US image of the right dilated ureter *(bottom arrows)* extending behind and caudal to a nearly empty bladder *(top arrow)* in a female with urinary incontinence and ectopic ureter draining into the vagina.

Treatment depends on the status of the renal unit drained by the ectopic ureter. If there is satisfactory function, ureteral reimplantation into the bladder or **ureteroureterostomy** (anastomosing the ectopic upper pole ureter into the normally inserting lower pole ureter) is indicated. If function is poor, partial or total nephrectomy is indicated. In many centers this procedure is done laparoscopically, often with robotic assistance.

Ureterocele

A ureterocele is a cystic dilation of the terminal ureter and is obstructive because of a pinpoint ureteral orifice. Ureteroceles are much more common in females than in males. Affected children usually are discovered by prenatal US, but some present with a febrile UTI. Ureteroceles may be ectopic, in which case the cystic swelling extends through the bladder neck into the urethra, or orthotopic, in which case the ureterocele is entirely within the bladder. Both orthotopic and ectopic ureteroceles can be bilateral.

In females, ureteroceles nearly always are associated with ureteral duplication (Fig. 577.9), whereas in 50% of affected males there is only one ureter. When associated with a duplication anomaly, the ureterocele drains the upper renal moiety, which commonly functions poorly or is dysplastic because of congenital obstruction. The lower pole ureter drains into the bladder superior and lateral to the upper pole ureter and may reflux.

An **ectopic ureterocele** extends submucosally through the bladder neck into the urethra. Rarely, large ectopic ureteroceles can cause bladder outlet obstruction and retention of urine with bilateral hydronephrosis. In females, the ureterocele can prolapse from the urethral meatus. US is effective in demonstrating the ureterocele and whether the associated obstructed system is duplicated or single. VCUG usually shows a filling defect in the bladder, sometimes large, corresponding to the ureterocele, and it often shows reflux into the adjacent lower pole collecting system with typical findings of a "drooping lily" appearance to the kidney. Nuclear renal scintigraphy is most accurate in demonstrating whether the affected renal moiety has significant function.

Treatment of ectopic ureteroceles depends on whether the upper pole functions on renal scan and whether there is reflux into the lower pole ureter. If there is nonfunction of the upper pole of the kidney and there is no reflux, treatment usually involves laparoscopic, robotic, or open excision of the obstructed upper pole and most of the associated ureter. If there is function in the upper pole or significant reflux into the lower pole ureter, or if the patient is septic from infection of the hydronephrotic kidney, then transurethral incision with cautery is appropriate initial therapy to decompress the ureterocele. Reflux into the incised ureterocele is common, and subsequent excision of the ureterocele and ureteral reimplantation usually is necessary. An alternative method is to perform an upper-to-lower ureteroureterostomy, allowing the obstructed upper pole ureter to drain through the normal lower ureter; this procedure often is performed with minimally invasive laparoscopic (robotic) technique or through a small incision.

Orthotopic ureteroceles are associated with duplicated or single collecting systems, and the orifice is in the expected location in the bladder (Fig. 577.10). These anomalies usually are discovered during an investigation for prenatal hydronephrosis or a UTI. US is sensitive for detecting the ureterocele in the bladder and hydroureteronephrosis. Transurethral incision of the ureterocele effectively relieves the obstruction, but it can result in VUR, necessitating ureteral reimplantation later. Some prefer open excision of the ureterocele and reimplantation as the initial form of treatment. Small, simple ureteroceles discovered incidentally without upper tract dilation generally do not require treatment. Rarely, a large ureterocele occupying much of the bladder lumen can result in bilateral hydronephrosis by obstructing drainage of the contralateral ureteral orifice.

Megaureter

Table 577.5 presents a classification of megaureters (dilated ureter). Numerous disorders can cause ureteral dilation, and many are nonobstructive.

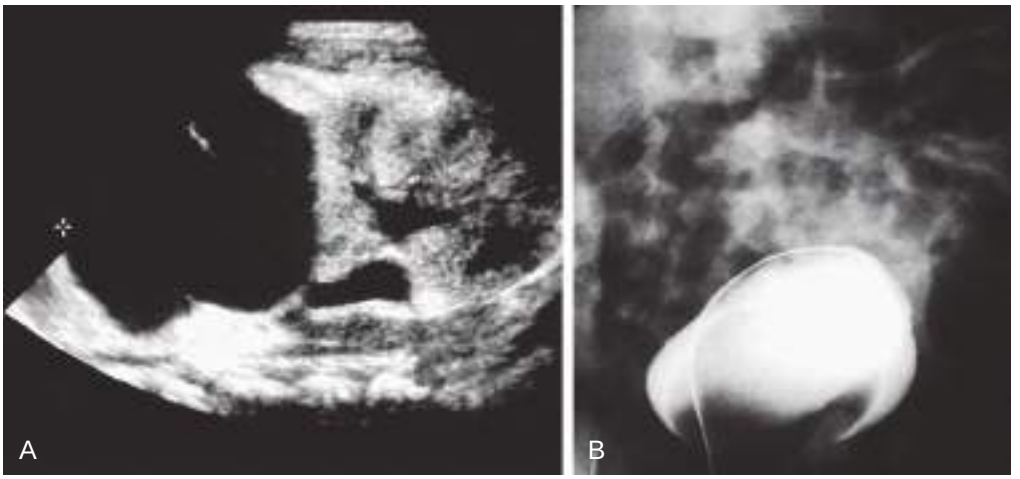

Fig. 577.9 A, Infant with ectopic ureterocele. US of the left kidney shows massive dilation of the upper pole and a normal lower pole. B, VCUG shows large ureterocele, draining the left upper pole, in the bladder. No reflux is present.

Fig. 577.10 Simple intravesical ureterocele. The excretory urogram shows left hydronephrosis and a round filling defect *(arrows)* on the left side of the bladder corresponding to a simple ureterocele causing left ureteral obstruction. This lesion was treated by transurethral incision and drainage of the ureterocele.

Megaureters usually are discovered during antenatal US or during workup for postnatal UTI, hematuria, or abdominal pain. A careful history, physical examination, and VCUG identify causes of secondary megaureters and refluxing megaureters, as well as the prune-belly syndrome. Primary obstructed megaureters and nonobstructed megaureters represent varying degrees of severity of the same anomaly.

The **primary obstructed nonrefluxing megaureter** results from abnormal development of the distal ureter, with collagenous tissue replacing the muscle layer. Normal ureteral peristalsis is disrupted, and the proximal ureter widens. In most cases there is not a true stricture. On intravenous pyelogram or an MR urogram, the distal ureter is more dilated in its distal segment and tapers abruptly at or above the junction of the bladder (Fig. 577.11). The lesion may be unilateral or bilateral. Significant hydroureteronephrosis suggests obstruction. Megaureter predisposes to UTI, urinary stones, hematuria, and flank pain because of urinary stasis. In most cases, diuretic renography and sequential sonographic studies can reliably differentiate obstructed from nonobstructed megaureters. In most nonobstructed megaureters, the hydroureteronephrosis diminishes gradually (Fig. 577.12). Truly obstructed megaureters require surgical treatment, with excision of the narrowed segment, ureteral tapering, and reimplantation of the ureter. The results of surgical reconstruction usually are good, but the prognosis depends on preexisting renal function and whether complications develop.

If differential renal function is normal (>45%) and the child is asymptomatic, it is safe to manage the patient with observation with serial US and periodic diuretic renography to monitor renal function and drainage. In children with grade 4 hydroureteronephrosis, prophylactic antimicrobial therapy should be prescribed, as these children are prone to upper UTI. If renal function deteriorates, upper urinary tract drainage slows, or UTI occurs, ureteral reimplantation is recommended. Approximately 25% of children with a nonrefluxing megaureter undergo ureteral reimplantation.

Prune-Belly Syndrome

Prune-belly syndrome, also called **triad syndrome** (lax abdominal wall muscles, urinary tract distention, intrabdominal testis) or **Eagle-Barrett syndrome,** occurs in approximately 1 in 40,000 births; 95% of affected children are male. The characteristic association occurs in a wide spectrum with deficient (hypoplastic) abdominal muscles, undescended testes, and urinary tract abnormalities (Fig. 577.13 and Table 577.6). Oligohydramnios and pulmonary hypoplasia are common complications in the perinatal period. Urinary tract abnormalities include massive (usually unobstructed) dilation of the ureters and upper tracts and a very large hypotonic bladder, with a patent urachus or a urachal diverticulum. Most patients have VUR. The prostatic urethra is usually dilated, and the prostate is hypoplastic. The anterior urethra may be dilated, resulting in a **megalourethra**. In severe cases, there is urethral stenosis or atresia. The kidneys show various degrees of dysplasia, and the testes are typically intraabdominal. Malrotation of the bowel is often present. Cardiac abnormalities occur in 10% of cases; >50% have abnormalities of the musculoskeletal system, including limb abnormalities and scoliosis. In the females, rare anomalies of the urethra, uterus, and vagina usually are present. Pathogenic variants in *FLNA* and possibly *MYOCD* or *HNF1β* have been reported; the disorder is usually sporadic, although rare instances of familial cases occur.

Many neonates with prune-belly syndrome have difficulty with effective bladder emptying because the bladder musculature is poorly

Table 577.5 Classification of Megaureter

REFLUXING		OBSTRUCTED		NONREFLUXING AND NONOBSTRUCTED	
PRIMARY	**SECONDARY**	**PRIMARY**	**SECONDARY**	**PRIMARY**	**SECONDARY**
Primary reflux	Neuropathic bladder	Intrinsic (primary obstructed megaureter)	Neuropathic bladder	Nonrefluxing, nonobstructive	Diabetes insipidus
Megacystic-megaureter syndrome	Hinman syndrome	Ureteral valve	Hinman syndrome		Infection
Ectopic ureter	Posterior urethral valves	Ectopic ureter	Posterior urethral valves		Persistent after relief of obstruction
Prune-belly syndrome	Bladder diverticulum Postoperative	Ectopic ureterocele	Ureteral calculus Extrinsic Postoperative		

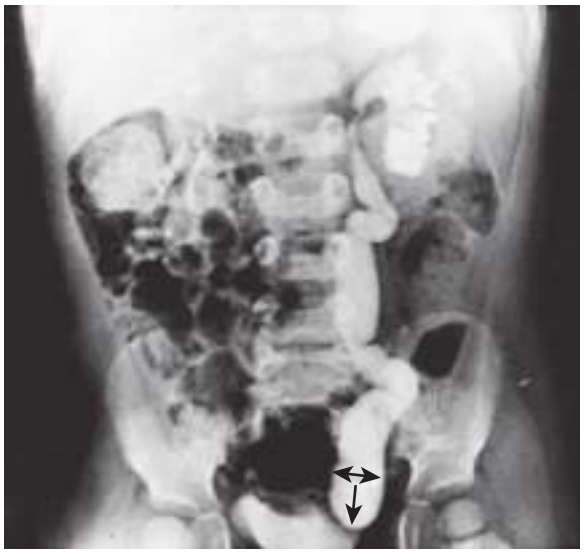

Fig. 577.11 Obstructed nonrefluxing megaureter. Excretory urogram in a female with a history of a febrile UTI. The right side is normal. The left side reveals hydroureteronephrosis with predominant dilation of the distal ureter. Note the characteristic appearance of the distal ureter. There was no vesicoureteral reflux. The diagnosis of obstruction was confirmed by diuretic renography.

developed, and the urethra may be narrowed. When no obstruction is present, the goal of treatment is the prevention of UTI with antibiotic prophylaxis. When obstruction of the ureters or urethra is demonstrated, temporary drainage procedures, such as a vesicostomy, can help to preserve renal function until the child is old enough for surgical reconstruction. Some children with prune-belly syndrome have been found to have classic or atypical PUVs. UTIs occur often and should be treated promptly. Correction of the undescended testes by orchidopexy can be difficult in these children because the testes are located high in the abdomen and surgery is best accomplished in the first 6 months of life. Reconstruction of the abdominal wall offers cosmetic and functional benefits.

The prognosis depends on the degree of pulmonary hypoplasia and renal dysplasia. One third of children with prune-belly syndrome are stillborn or die in the first few months of life because of pulmonary hypoplasia. As many as 30% of the long-term survivors develop end-stage renal disease from dysplasia or complications of infection or reflux and eventually require renal transplantation. Renal transplantation in these children offers good results.

Megacystis-microcolon-intestinal hypoperistalsis syndrome manifests with a dilated unobstructed bladder in the context of the more dominant gastrointestinal manifestations of intestinal pseudoobstruction (see Table 378.11 and Figs. 378.6 and 378.7). The abdominal muscles are normal, but abdominal distention is prominent. Associated pathogenic gene variants include *ACTG2* (~45%) as well as *MYH11*, *LOMD1*, *MYL9*, and *MYLK*; ~20% are unknown. Hydronephrosis is common, and most patients are female.

Bladder Neck Obstruction

Bladder neck obstruction usually is secondary to ectopic ureterocele, bladder calculi, or a tumor of the prostate (rhabdomyosarcoma). The manifestations include difficulty voiding, urinary retention, UTI, and bladder distention with overflow incontinence. Apparent bladder neck obstruction is common in cases of PUVs, but it seldom has any functional significance. Primary bladder neck obstruction is extremely rare.

Posterior Urethral Valves

The most common cause of severe obstructive uropathy in children is PUVs, affecting 1 in 8,000 males. The urethral valves are tissue leaflets fanning distally from the prostatic urethra to the external urinary sphincter. A slitlike opening usually separates the leaflets. Valves are of unclear embryologic origin and cause varying degrees of obstruction. Approximately 30% of patients experience end-stage renal disease or chronic renal insufficiency. The prostatic urethra dilates, and the bladder muscle undergoes hypertrophy. VUR occurs in 50% of patients, and distal ureteral obstruction can result from a chronically distended bladder or bladder muscle hypertrophy. Renal changes range from mild hydronephrosis to severe renal dysplasia; their severity depends on the severity of the obstruction and its time of onset during fetal development. As in other cases of obstruction or renal dysplasia, there may be oligohydramnios and pulmonary hypoplasia.

Affected males with PUVs often are discovered prenatally when maternal US reveals bilateral hydronephrosis, a distended bladder, and, if the obstruction is severe, oligohydramnios. Prenatal bladder decompression by percutaneous vesicoamniotic shunt or open fetal surgery has been reported. Experimental and clinical evidence of the possible benefits of fetal intervention is lacking, and few affected fetuses are candidates. Prenatally diagnosed PUVs, particularly when discovered in the second trimester, carry a poorer prognosis than those detected in the third trimester following a normal second-trimester fetal US. In the male neonate, PUVs are suspected when there is a palpably distended bladder and the urinary stream is weak. If the obstruction is severe and goes unrecognized during the neonatal period, infants can present later in childhood with failure to thrive because of uremia or sepsis caused by infection in the obstructed urinary tract. With lesser degrees of obstruction, children present later in life with difficulty in achieving diurnal urinary continence or with UTI. The diagnosis is established with a VCUG (Fig. 577.14) or by perineal US.

After the diagnosis is established, renal function and the anatomy of the upper urinary tract should be carefully evaluated. In the healthy neonate, a small polyethylene feeding tube (No. 5 or No. 8 French) is inserted in the bladder and left for several days. Passing the feeding tube may be difficult because the tip of the tube can coil in the prostatic

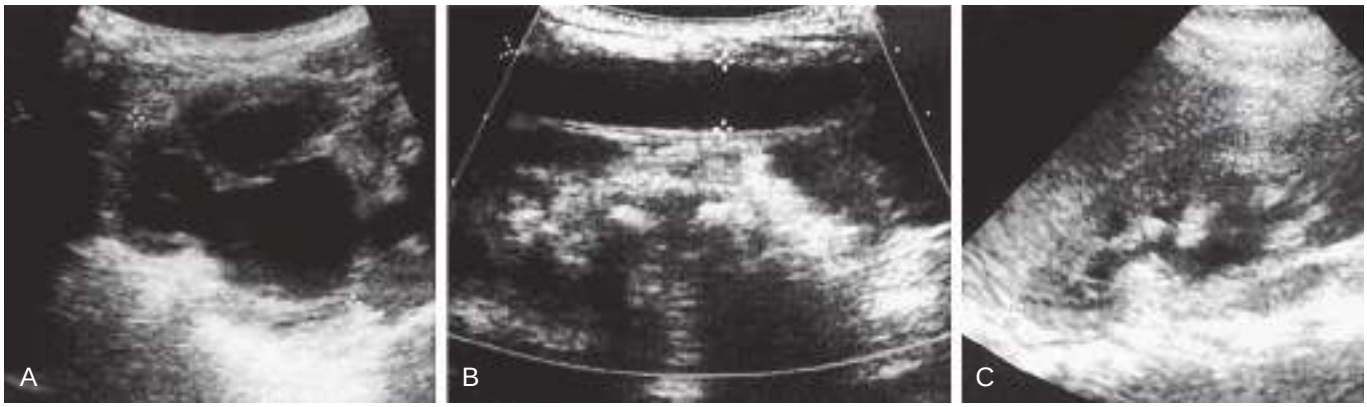

Fig. 577.12 Neonate with primary nonrefluxing megaureter. **A,** Renal US shows grade 4 hydronephrosis. **B,** Dilated ureter. Renal scan showed equal function with the contralateral kidney and satisfactory drainage with diuresis stimulation. **C,** Follow-up US at 10 mo shows complete resolution of hydronephrosis.

Fig. 577.13 Abdominal wall features of prune-belly syndrome, with increasing flaccidity and cutaneous wrinkles, including pot-belly appearance in older age. *(From Lopes RI, Baker LA, Dénes FT. Modern management of and update on prune belly syndrome. J Pediatr Urol. 2021;17:548–554. Fig. 1.)*

urethra. A sign of this problem is that urine drains around the catheter rather than through it. A Foley (balloon) catheter *should not be used*, because the balloon can cause severe bladder spasm, which can produce severe ureteral obstruction.

If the serum creatinine level remains normal or returns to normal, treatment consists of transurethral ablation of the valve leaflets, which is performed endoscopically under general anesthesia. If the urethra is too small for transurethral ablation, temporary vesicostomy is preferred, in which the dome of the bladder is exteriorized on the lower abdominal wall. When the child is older, the valves may be ablated and the vesicostomy closed.

If the serum creatinine level remains high or increases despite bladder drainage by a small catheter, secondary ureteral obstruction, irreversible renal damage, or renal dysplasia should be suspected. In such cases, a vesicostomy should be considered. Cutaneous pyelostomy rarely affords better drainage compared with cutaneous vesicostomy, and the latter also allows continued bladder growth and gradual improvement in bladder wall compliance.

In the septic and uremic infant, lifesaving measures must include prompt correction of the electrolyte imbalance and control of the infection by appropriate antibiotics. Drainage of the upper tracts by percutaneous nephrostomy and hemodialysis may be necessary. After the patient's condition becomes stable, evaluation and treatment may be undertaken. PUVs are diagnosed in some older males because of a poor stream, diurnal incontinence, or a UTI; these males are treated by primary valve ablation.

Favorable prognostic factors include a normal prenatal US between 18 and 24 weeks of gestation, a serum creatinine level <0.8-1.0 mg/dL after bladder decompression, and visualization of the corticomedullary junction on renal sonography. In several situations, a "popoff valve" can occur during urinary tract development, which preserves the integrity of one or both kidneys. For example, 15% of males with PUVs have unilateral reflux into a nonfunctioning dysplastic kidney, termed the **VURD syndrome** (valves, unilateral reflux, dysplasia). In these males, the high bladder pressure is dissipated into the nonfunctioning kidney, allowing normal development of the contralateral kidney. In newborn males with urinary ascites, the urine leaks out from the obstructed collecting system through the renal fornices, allowing normal development of the kidneys. Unfavorable prognostic factors include the presence of oligohydramnios in utero, identification of hydronephrosis before 24 weeks of gestation, a serum creatinine level >1.0 mg/dL after bladder decompression, identification of cortical cysts in both kidneys, and persistence of diurnal incontinence beyond 5 years of age.

The prognosis in the newborn is related to the child's degree of pulmonary hypoplasia and potential for recovery of renal function. Severely affected infants often are stillborn. Of those who survive the neonatal period, approximately 30% eventually require kidney transplantation, and 15% have renal insufficiency. In some series, kidney transplantation in children with PUVs has a lower success rate than does transplantation in children with normal bladders, presumably because of the adverse influence of altered bladder function on graft function and survival.

After valve ablation, antimicrobial prophylaxis is beneficial in preventing UTI, because hydronephrosis to some degree often persists for many years. These males should be evaluated annually with a renal US, physical examination including assessment of somatic growth and blood pressure, urinalysis, and determination of serum levels of electrolytes. Many individuals have significant polyuria resulting from a concentrating defect secondary to prolonged obstructive uropathy. If these children acquire a systemic illness with vomiting and/or diarrhea, urine output cannot be used to assess their hydration status. They

Table 577.6 The PBS RUBACE Severity Scoring Rubric

Eagle-Barrett syndrome PBS triad ("RUBAC") Max score: 16					Extra-genitourinary manifestations ("E") Max score: 15				
No subcategory points are awarded for normal anatomy with absent pathology					No subcategory points are awarded for normal anatomy with absent pathology				
Renal Max score: 6	**Ureteral Max score: 3**	**Bladder/outlet Max score: 3**	**Abdominal wall Max score: 2**	**Cryptorchidism Max score: 2**	**Neurologic Max score: 3**	**Cardiac Max score: 3**	**Gastrointestinal Max score: 3**	**Musculoskeletal Max score: 3**	**Respiratory Max score: 2**
1 pt: G1-G2: Structural damage (dilation, dysplasia, scarring) with preserved GFR ≥ 60	**1 pt**: Low grade or absent VUR, or distal ureter 4–10mm	**1 pt**: Urotherapy required to empty bladder, or bladder size is 100–200% of normal	**1 pt**: Can do "sit-up" exercise before or after abdomino-plasty, musculature mostly intact, minimal laxity, or mild/nonconvincing prune appearance	**1 pt**: History of or current unilateral or palpable undescended testicle(s), or patient is female		**1 pt**: Congenital septal defects (PDA, ASD, VSD) which are spontaneously resolved	**1 pt**: Mild to moderate constipation, managed with diet or laxatives	**1 pt**: Mild facies, abnormally shaped fingers or toes (no loss of function), or rib flaring	**1 pt**: Minimal respiratory support at birth, some difficulty coughing, mild intermittent asthma, or mild reactive airway disease
2 pts: G3a-b: Kidney damage with decreased GFR 30–59 **3 pts**: G4: Severe loss of kidney function with GFR 15–29	**2 pts**: Persistent high grade VUR (no surgery), s/p lower tract ureteral reconstruction, or distal ureter 1–2 cm	**2 pts**: Urethral-catheterization or pharm required to empty, bladder size >200% normal, or patient takes antibiotic prophylaxis for recurrent UTI	**2 pts**: Severe abdominal laxity with obvious thinning of abdominal wall, classic prune appearance, or s/p abdominoplasty + cannot do a "sit-up"	**2 pts**: History of or current bilateral nonpalpable testes		**2 pts**: Small septal defects which are not spontaneously resolved, minimal L to R shunting, or PDA requiring surgical management	**2 pts**: MACE/cecostomy required, or malrotation s/p Ladd's	**2 pts**: Scoliosis, hip dysplasia, club or rockerbottom foot, genu valgum, pectus excavatum or carinum	**2 pts**: Persistent/ moderate asthma, frequent respiratory tract infections (≥3/year), or ≥2 hospitalizations for pneumonia
					PBS-plus or congenital/genetic syndrome or association				
4 pts: Renal failure with GFR <15, or on dialysis or s/p renal transplant **Additional points for young age:** If patient is <2 years, add +2 pts and if patient is <13 years, add +1 pt	**3 pts**: Persistent high grade VUR despite surgery, distal ureter 2+ cm girth, or current diverting ureterostomy or nephrostomy	**3 pts**: Current surgical diversion (e.g., s/p tube, vesicostomy, APV), urethral atresia, or megalourethra requiring repair			**3 pts**: Seizures, tethered cord, spina bifida, hearing loss, intellectual delay, autism, or severe neurologic condition not otherwise specified	**3 pts**: Severe congenital or cyanotic heart disease-Tetralogy of Fallot, left-sided obstructive lesions, reversed shunt, CHF or severe cardiologic conditions not otherwise specified	**3 pts**: Required surgical bowel diversion (e.g., imperforate anus, anal atresia), gastrointestinal malignancy (e.g., hepatoblastoma), or severe GI condition not otherwise specified	**3 pts**: Arthrogryposis, muscular dystrophy, or severe musculoskeletal malformation not otherwise specified	**3 pts**: Ventilator-dependent >1 week, tracheostomy, history of pneumothorax, or severe asthma
Total triad RUBAC score: _____					**Total E score:** _____				
Total triad RUBAC score _____ **+ Total E score** _____ **= Total RUBACE score** _____									

PBS, Prune-belly syndrome; RUBACE, renal-ureter-bladder-abdominal wall-cryptorchidism-extra GU anomalies.
From Wong DG, Arevalo MK, Passoni NM, et al. Phenotypic severity scoring system and categorization for prune belly syndrome: application to a pilot cohort of 50 living patients. *BJU Int.* 2019;123:130–139. Table 1.

Fig. 577.14 VCUG in an infant with posterior urethral values. Note the dilation of the prostatic urethra and the transverse linear filling defect corresponding to the valves *(arrows)*.

can become dehydrated quickly, and there should be a low threshold for hospital admission for intravenous rehydration. Some of these patients have renal tubular acidosis, requiring oral bicarbonate therapy. If there is any significant degree of renal dysfunction, growth impairment, or hypertension, the child should be followed closely by a pediatric nephrologist. When VUR is present, expectant treatment and prophylactic doses of antibacterial drugs are advisable. If breakthrough UTI occurs, surgical correction should be undertaken.

After treatment, males with PUVs often do not achieve diurnal urinary continence as early as other males. Incontinence can result from a combination of factors, including uninhibited bladder contractions, poor bladder compliance, bladder atonia, bladder neck dyssynergia, or polyuria. Often these males require urodynamic evaluation with urodynamics or videourodynamics to plan therapy. Individuals with a poorly compliant bladder are at significant risk for ongoing renal damage, even in the absence of infection. Overnight catheter drainage has been shown to be beneficial in males with polyuria and can help preserve renal function. Urinary incontinence usually improves with age, particularly after puberty. Meticulous attention to bladder compliance, emptying, and infection can improve results in the future.

Urethral Atresia

The most severe form of obstructive uropathy in males is urethral atresia, a rare condition. In utero there is a distended bladder, bilateral hydroureteronephrosis, and oligohydramnios. In most cases, these infants are stillborn or succumb to pulmonary hypoplasia. Rare males with prune-belly syndrome also have urethral atresia. If the urachus is patent, oligohydramnios is unlikely, and the infant usually survives.

Urethral reconstruction is difficult, and most patients are managed with continent urinary diversion.

Urethral Hypoplasia

Urethral hypoplasia is a rare form of obstructive uropathy in males that is less severe than urethral atresia. In urethral hypoplasia, the urethral lumen is extremely small. Neonates with urethral hypoplasia typically have bilateral hydronephrosis and a distended bladder. Passage of a small pediatric feeding tube through the urethra is difficult or impossible. Usually a cutaneous vesicostomy must be performed to relieve upper urinary tract obstruction, and the severity of renal insufficiency is variable. The most severely affected males have end-stage renal disease. Treatment includes urethral reconstruction, gradual urethral dilation, or continent urinary diversion.

Urethral Stricture

Urethral strictures in males usually result from urethral trauma, either iatrogenic (catheterization, endoscopic procedures, previous urethral reconstruction) or accidental (straddle injuries, pelvic fractures). Because these lesions can develop gradually, the decrease in force of the urinary stream is seldom noticed by the child or the parents. More commonly, the obstruction causes symptoms of bladder instability, hematuria, or dysuria. Catheterization of the bladder usually is impossible. The diagnosis is made by a **retrograde urethrogram,** in which contrast is injected toward the bladder through a catheter inserted into the distal urethra. US also has been used to diagnose urethral strictures. Endoscopy is confirmatory. Endoscopic treatment of short strictures by direct vision urethrotomy is often successful initially and results in a profoundly improved urinary stream, but strictures are prone to recur. Longer strictures surrounded by periurethral fibrosis often require urethroplasty. Repeated endoscopic procedures should be avoided as they cause additional urethral damage. Noninvasive measurement of the urinary flow rate and pattern is useful for diagnosis and follow-up.

In females, true urethral strictures are rare because the female urethra is protected from trauma, particularly in childhood.

Anterior Urethral Valves and Urethral Diverticula in the Male

Anterior urethral valves are rare. The obstruction is not obstructing valve leaflets, as occurs in the posterior urethra. Rather, it is a urethral diverticulum in the penile urethra that expands during voiding. Distal extension of the diverticulum causes extrinsic compression of the distal penile urethra, causing urethral obstruction. There is usually a soft mass on the ventral surface of the penis at the penoscrotal junction. In addition, the urinary stream is typically weak, and the physical findings associated with PUVs are often present. The diverticulum may be small and minimally obstructive or, in other cases, may be severely obstructive and cause renal insufficiency. The diagnosis is suspected on physical examination and is confirmed by VCUG. Treatment involves open excision of the diverticulum or transurethral excision of the distal urethral cusp. Urethral diverticula occasionally occur after extensive hypospadias repair.

Fusiform dilation of the urethra or megalourethra can result from underdevelopment of the corpus spongiosum and support structures of the urethra. This condition is commonly associated with prune-belly syndrome.

Male Urethral Meatal Stenosis

See Chapter 581 for information on urethral meatal stenosis in males.

Visit Elsevier eBooks+ at eBooks.Health.Elsevier.com for Bibliography.

Chapter 578

Anomalies of the Bladder

Heather N. Di Carlo and Chad B. Crigger

BLADDER EXSTROPHY

Exstrophy of the urinary bladder occurs in approximately 1 in 35,000-40,000 births with a male:female ratio of 2:1. The severity ranges from simple **epispadias** (in males) to complete exstrophy of the cloaca involving exposure of the entire hindgut and the bladder **(cloacal exstrophy)**.

Considering the range of defects associated with exstrophy, prenatal diagnosis is challenging. Accurately diagnosing exstrophy (and its subtypes) is paramount in properly counseling families. Proper prenatal diagnosis allows for planning that may optimize postnatal medical and surgical management. Classically, the diagnosis was suspected on prenatal ultrasound. For instances in which the diagnosis remains uncertain, as for midline abdominal defects such as exstrophy versus gastroschisis or omphalocele, fetal magnetic resonance imaging (fMRI) may help elucidate the correct diagnosis.

Clinical Manifestations

Anomalies of the bladder are hypothesized to result when the mesoderm fails to invade the cephalad extension of the cloacal membrane; the timing and extent of this failure determines the degree of the anomaly. In classic bladder exstrophy (Fig. 578.1), the bladder protrudes from the abdominal wall, and its mucosa is exposed. The umbilicus is displaced downward, the pubic rami are widely separated in the midline, and the rectus muscles are separated. In males, there is complete epispadias with dorsal chordee, and the overall penile length is approximately half that of unaffected males. The scrotum typically is separated slightly from the penis and is wide and shallow. Undescended testes and inguinal hernias are common. Females may also have epispadias, with separation of the two halves of the clitoris and wide separation of the labia. The anus is displaced anteriorly in both sexes, and there may be rectal prolapse. The pubic rami are widely separated.

The consequences of untreated bladder exstrophy are total urinary incontinence and an increased incidence of bladder cancer, usually adenocarcinoma. The external and internal genital deformities cause sexual disability in both sexes, particularly in males. The wide separation of the pubic rami causes a characteristic broad-based gait but no significant lasting disability. In classic bladder exstrophy, the upper urinary tracts usually are normal at birth.

Fig. 578.1 Classic bladder exstrophy in a newborn male. The bladder is exposed in the midline, the umbilical cord is displaced caudad, the penis is epispadiac, and the scrotum is broad.

Treatment

Management of bladder exstrophy should start at birth. The bladder should be covered with plastic wrap to keep the bladder mucosa moist. Saline may be gently irrigated as needed to moisten the bladder template. *Application of gauze or petroleum-gauze to the bladder mucosa should be avoided, because significant inflammation will result.* The infant should be transferred promptly to a center with pediatric urology and pediatric anesthetic support for newborns with complex anomalies. These children are prone to *latex allergy,* and latex precautions should be practiced from birth, both in the nursery and in the operating room.

There are two surgical approaches: staged reconstruction and total single-stage reconstruction. Most babies also undergo bilateral iliac osteotomy, which allows the pubic symphysis to be approximated, which supports the bladder closure. In a staged reconstruction, the initial stage is bladder closure, the second stage (in males) is epispadias repair, and the final stage is bladder neck reconstruction. The single-stage reconstruction attempts to reconstruct the entire malformation in a single procedure. When this operation is performed in the newborn, there is an increased risk of intraoperative penile injury and postoperative hydronephrosis compared with the staged reconstruction. The complication rate is high with both approaches, and there is no consensus on which is better.

Although bladder closure within the first 48 hours of life has been the historical standard, many centers of excellence now defer the procedure until 1-2 weeks of life to ensure that the appropriate multidisciplinary surgical and anesthetic teams are available. During bladder exstrophy closure, the abdominal wall is mobilized and the pubic rami are brought together in the midline following pelvic osteotomy. Early bladder closure can be performed in almost all neonates with classic bladder exstrophy. Treatment should be deferred in select situations including when surgical therapy would be excessively risky or complex, such as a premature baby, or if performed by inexperienced surgeons. In the staged approach, in males, epispadias repair usually is performed around age 1 or 2 years. At this point the child has total urinary incontinence because there is no functional external urinary sphincter. Most infants with bladder exstrophy have vesicoureteral reflux and should receive antibiotic prophylaxis. Typically, the bladder capacity is monitored every 12-24 months using cystoscopy with cystogram under anesthesia. The final stage of reconstruction involves creation of a sphincter muscle for bladder control and correction of vesicoureteral reflux. This is usually performed when the child is 3-6 years old with a bladder capacity of at least 80-90 mL, and the child must have gained rectal sphincter control.

Total single-stage reconstruction includes newborn closure of the bladder and bladder neck narrowing, abdominal wall closure, and, in males, correction of epispadias using a technique of penile disassembly. This involves separating the two corpora cavernosa and the midline urethra into three parts via radical mobilization. Postoperatively, the infant's upper urinary tract is monitored closely for possible development of hydronephrosis and infection. Comparison of outcomes between the multistage and single-stage approaches is ongoing.

At puberty pubic hair is often distributed to the sides of the external genitals. A monsplasty can be performed during adolescence to provide a normal escutcheon.

Long-Term Prognosis

Long-term management of individuals born with bladder exstrophy includes monitoring the upper urinary tract appearance and function for any deterioration and infection, as well as assessing continence. As these patients age, erectile function is assessed in males, and, later on in adults, sexual function and fertility are evaluated.

The previously described plan of treatment has yielded a continence rate of 60–70% in a few centers, with <15% risk of deterioration of the upper urinary tract. This continence rate reflects not only successful reconstruction but also the quality and size of the bladder. From a functional standpoint, the reconstructed bladder neck does not relax during voiding as in a normal child; instead the patient must void by assisted techniques such as the Valsalva maneuver or Credé maneuver.

Children who remain incontinent for more than 1 year after bladder neck reconstruction or those who are ineligible for bladder neck reconstruction because of small bladder capacity are candidates for an alternative reconstructive procedure to achieve dryness. In select cases, cystoscopic injection of bulking agents such as dextranomer or polydimethylsiloxane microspheres into the bladder neck can provide sufficient bladder neck coaptation and resistance to establish continence. Alternatively, if the child is not a candidate for endoscopic therapy, options include:

- Augmentation cystoplasty, in which the bladder is enlarged with a patch of small or large bowel to increase its capacity.
- Creation of a neobladder out of a small or large bowel segment with placement of a continent abdominal stoma through which clean, intermittent catheterization can be performed.
- Placement of an artificial urinary sphincter, with possible combined augmentation cystoplasty.
- Ureterosigmoidostomy, in which the ureters are detached from the bladder and sutured to the sigmoid colon; individuals void urine and stool from the rectum and rely on their anal sphincter for continence. This approach does not require many resources in surgical technique or long-term care (such as ostomy supplies).
- Mainz II procedure, in which the sigmoid colon is reconfigured into a "bladder" into which the ureters are connected; the patient voids 3-6 times daily through the rectum, and the stool tends to be more solid.

Ureterosigmoidostomy carries a significant risk of chronic pyelonephritis (see Chapter 575), upper urinary tract damage, metabolic acidosis resulting from absorption of hydrogen ion and chloride in the intestine, and at least a 15–22% long-term risk of colon carcinoma. Patients from less-developed countries often undergo the Mainz II procedure because the continence rate is high and pyelonephritis and upper tract changes are relatively uncommon.

Late follow-up has shown that although adult males with exstrophy have a penis that is half the normal length, they usually experience satisfactory sexual function. Fertility has been low, possibly because of iatrogenic injury to the secondary sexual organs during reconstruction. With artificial reproductive technology, nearly all affected men can be fertile. In adult females, fertility is not affected, but uterine prolapse during pregnancy is a problem. In adult females who have undergone a continent urinary diversion, delivery by cesarean section is usually necessary.

OTHER EXSTROPHY ANOMALIES

More rarely, children have a more severe form of exstrophy, cloacal exstrophy, which occurs in 1 in 400,000 live births. In addition to an exposed bladder, gastrointestinal manifestations typically include omphalocele, an imperforate anus, and a short bowel, resulting in short bowel syndrome (see Chapter 385.6). It is the most devastating anomaly managed by pediatric urologists. Approximately 50% of patients have an upper urinary tract anomaly, and 50% have spina bifida (see Chapter 631.2). Children with cloacal exstrophy do not achieve normal urine or stool continence. Reconstructive techniques result in a satisfactory outcome in most patients with permanent urinary diversion (either ileal conduit or continent urinary diversion) and a colostomy. Because the penis in males with cloacal exstrophy usually is diminutive, genital reconstruction in males with cloacal exstrophy has been unsatisfactory. Until recently, many specialists recommended assigning a female gender to such infants, but currently there is debate as to whether these children, who have a 46,XY karyotype and brain androgen imprinting in utero, can have a satisfactory female gender identity (see Chapter 153). Decisions regarding gender assignment should be made jointly by the physicians caring for the infant (surgical team, pediatric endocrinologist, child psychiatrist, and ethicist) and the family. Current practice by pediatric urologists is to reconstruct genitalia in a manner congruent with the genotype when at all possible, and after extensive counseling with the patient's family.

Epispadias is at the less severe end of the spectrum of exstrophy anomalies, affecting approximately 1 in 117,000 males and 1 in 480,000 females. In males, the diagnosis is obvious because the prepuce is distributed primarily on the ventral aspect of the penile shaft and the urethral meatus is on the dorsum of the penis. Distal epispadias in males (Fig. 578.2) usually is associated with normal urinary control and normal upper urinary tracts and should be repaired by 6-12 months of age. In females, the clitoris is bifid, and the urethra is split dorsally (Fig. 578.3). In more severely affected males and in all females with

Fig. 578.2 Adolescent male with penopubic epispadias.

Fig. 578.3 Female with complete epispadias. *(From Gearhart JP, Rink RC, Mouriquand PDE, eds. Pediatric Urology, 2nd ed. Philadelphia: Saunders; 2010.)*

epispadias, there is total urinary incontinence because the sphincter is incompletely formed along with a wide separation of the pubic rami. These children require surgical reconstruction of the bladder neck, similar to the final management stage in children with classic bladder exstrophy.

BLADDER DIVERTICULA

Bladder diverticula develop as herniations of the bladder mucosa between defects of bladder smooth muscle fibers. Primary bladder diverticula usually develop at the ureterovesical junction and may be associated with vesicoureteral reflux, because the diverticulum interferes with the normal flap-valve attachment between the ureter and bladder. In rare circumstances, the diverticulum is so large that it interferes with normal micturition by obstructing the bladder neck. Bladder diverticula also commonly are associated with distal urethral obstructions such as posterior urethral valves or neurogenic bladder dysfunction. They occur commonly in children with connective tissue disorders, including Williams syndrome, Ehlers-Danlos syndrome, and Menkes syndrome (Fig. 578.4). Small diverticula require no treatment other than that of the primary disease, whereas large diverticula can contribute to inefficient voiding, residual urine, urinary stasis, and urinary tract infections and should be excised.

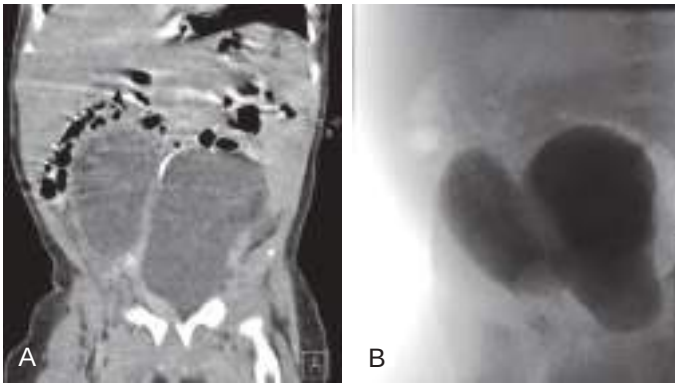

Fig. 578.4 Six-mo-old male with abdominal mass. Ultrasound showed a large fluid-filled mass and normal kidneys. **A,** CT scan shows large bladder diverticulum on right side with ureter coursing between the diverticulum and the bladder. **B,** Voiding cystourethrogram demonstrates no reflux and large diverticulum on left side. Managed with diverticulectomy.

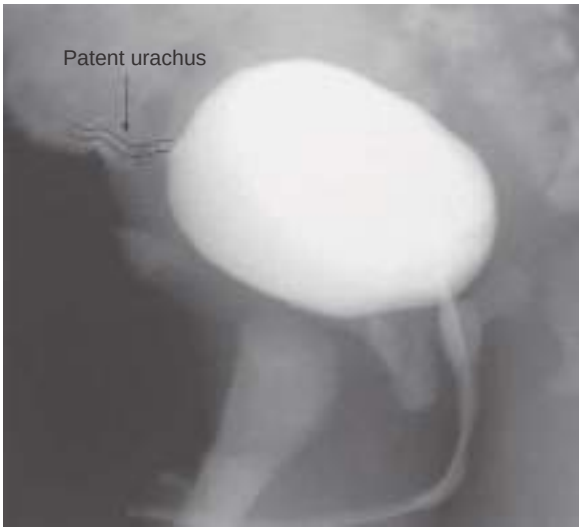

Fig. 578.5 Patent urachus. Vesicourethrogram image of patent urachus in a newborn. Retrograde contrast filling of patent canal with contrast pooling in umbilicus. *(From Partin AW, Dmochowski RR, Kavoussi LR, Peters C., eds. Campbell-Walsh Urology, 12th ed. Philadelphia: Elsevier; 2021. Fig. 30-7.)*

URACHAL ANOMALIES

The urachus is an embryologic canal connecting the dome of the fetal bladder with the allantois, a structure that contributes to the formation of the umbilical cord. The lumen of the urachus is normally obliterated during embryonic development, transforming the urachus into a solid cord. Urachal abnormalities are more common in males than in females. A **patent urachus** can occur as an isolated anomaly, or it may be associated with prune-belly syndrome or posterior urethral valves (see Chapter 577; Fig. 578.5). A patent urachus results in continuous urinary drainage from the umbilicus and treatment involves excising the tract. Another urachal anomaly is the **urachal cyst,** which can become infected. Typical symptoms and physical findings include suprapubic pain, fever, irritative voiding symptoms, and an infraumbilical mass, which can be erythematous. Diagnosis is made by ultrasonography or CT (Fig. 578.6). Treatment is intravenous antibiotic therapy and drainage and excision. Other urachal anomalies include the **vesicourachal diverticulum,** which is a diverticulum of the bladder dome, and **umbilical-urachal sinus,** which is a blind external sinus that opens at the umbilicus. These lesions should be excised.

Visit Elsevier eBooks+ at eBooks.Health.Elsevier.com for Bibliography.

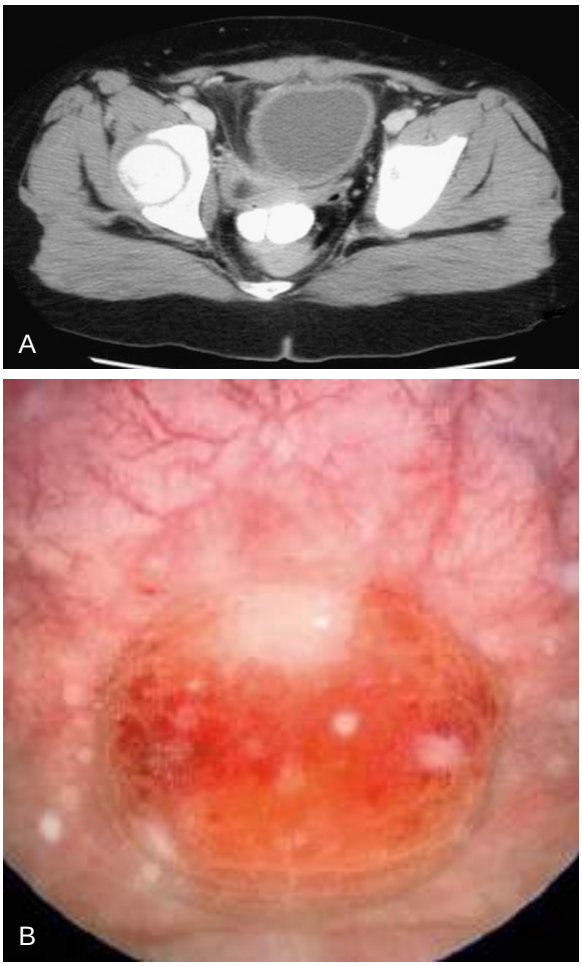

Fig. 578.6 A, CT scan demonstrating infected urachal abscess in an 8-yr-old child. The condition was managed by drainage and excision. B, Cystoscopic view of 10-yr-old child with new-onset daytime frequency and incontinence secondary to infected urachal cyst.

Chapter 579

Neuropathic Bladder

Heather N. Di Carlo and Chad B. Crigger

Neuropathic bladder dysfunction in children is usually congenital, generally resulting from neural tube defects or other spinal abnormalities (see Chapter 754). Acquired diseases and traumatic lesions of the spinal cord are less common (see Chapter 751). Central nervous system tumors, sacrococcygeal teratoma, spinal abnormalities associated with imperforate anus (see Chapter 392), and spinal cord trauma also can result in abnormal innervation of the bladder and/or sphincter (Table 579.1).

NEURAL TUBE DEFECTS

Neural tube defects, resulting from failure of the neural tube to close spontaneously between the third and fourth week in utero, result in abnormalities of the vertebral column that affect spinal cord function, including **spina bifida occulta**, **myelomeningocele,** and **meningocele** (see Chapters 631.2, 631.3, and 631.4). Specialized medical centers in the United States have performed antenatal myelomeningocele closure. Long-term results from one large clinical trial of **in utero closure** have not shown a definite improvement in lower urinary tract function, although some children have demonstrated nearly normal bladder function. Overall, this trial has demonstrated a significant reduction in the need for ventriculoperitoneal shunting and improved performance on measures of self-care, motor function, and mobility.

Table 579.1 Causes of Neuromuscular Dysfunction of the Lower Urinary Tract

CONGENITAL
Neural tube defect
Occult forms of neural tube defect (lipomeningocele and other spinal dysraphisms)
Sacral agenesis
Anorectal malformations
ACQUIRED
Extensive pelvic surgery
Central nervous system disorders
Cerebral palsy
Conditions of the brain (tumors, infarcts, encephalopathies)
Spinal cord insults
Trauma
Transverse myelitis

From Partin AW, Dmochowski RR, Kavoussi LR, Peters CW, eds. *Campbell-Walsh Urology*, 12th ed. Philadelphia: Elsevier; 2021: Box 34-1.

Clinical Manifestations and Diagnosis

The most important urologic consequences of neuropathic bladder dysfunction associated with neural tube defects are urinary incontinence (see Chapter 580), urinary tract infections (UTIs; see Chapter 575), and hydronephrosis from vesicoureteral reflux (see Chapter 576) or detrusor-sphincter dyssynergia (see Chapter 580). Pyelonephritis and renal functional deterioration (see Chapter 575) are common causes of premature death in affected patients.

In the neonate, renal ultrasonography, assessment of postvoiding residual urine volumes, and a voiding cystourethrogram are performed after closure of the myelomeningocele as approximately 10–15% of newborns with myelomeningocele have hydronephrosis, and renal malformations are common; 25% have vesicoureteral reflux. A **urodynamic** study also should be performed. In this study, the bladder is filled with saline, and the bladder volume, bladder pressure, abdominal pressure, and sphincter tone are measured until the patient voids. During bladder filling, the bladder might show (1) uninhibited (premature) contractions (termed hyperreflexia) at low volumes, (2) normal bladder volume with contraction at an appropriate volume, or (3) atonia (lack of bladder contraction). Bladder compliance or elasticity also may be abnormal (i.e., abnormally high bladder pressure during bladder filling). The sphincter can show (1) normal tonicity with relaxation during bladder contraction, (2) reduced or absent tonicity, or (3) normal or increased tonicity that increases significantly during a bladder contraction (termed **detrusor-sphincter dyssynergia**; Fig. 579.1).

Renal Damage

Renal damage usually results from detrusor-sphincter dyssynergia. This dyssynergia causes functional obstruction of the bladder outlet, leading to bladder muscle hypertrophy and trabeculation, high intravesical pressure, and transmission of this high pressure into the upper urinary tracts, causing hydronephrosis (Fig. 579.2). Vesicoureteral reflux and UTI compound this problem, but severe hydronephrosis can result without reflux. Treatment includes reduction of bladder pressure with anticholinergic drugs (e.g., oxybutynin, 0.2 mg/kg/dose up to three times per day) and **clean intermittent catheterization** every 3-4 hours. If the child has vesicoureteral reflux or UTI, antimicrobial prophylaxis also is prescribed.

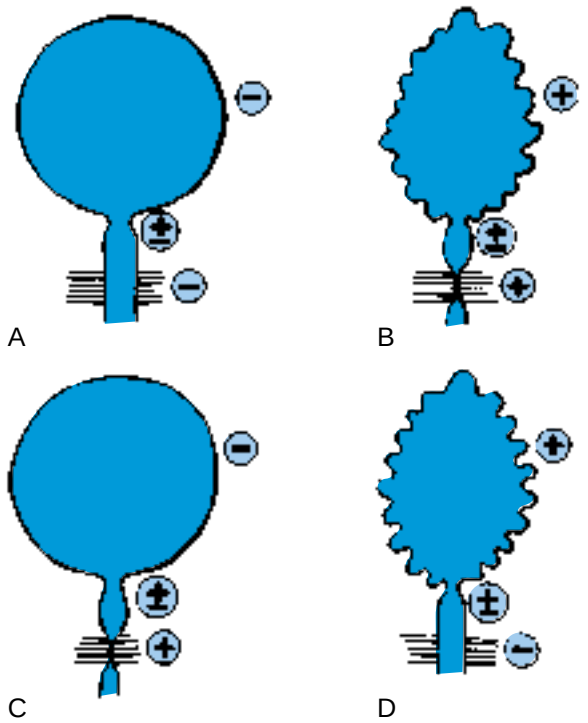

Fig. 579.1 Grouping of neuropathic bladder dysfunction according to the innervation, tonicity, and coordination of the detrusor and sphincters described by Guzman. This grouping is based on data from imaging studies, cystometrography, and electromyography of the sphincters. Patients in group B are at risk of developing reflux and hydronephrosis. For guidance in the treatment of incontinence, group A patients benefit from procedures that increase outlet resistance, group B patients from anticholinergics or bladder augmentation surgery, and group C patients from intermittent catheterization. Group D patients require both increased outlet resistance and pharmacologic or surgical bladder enlargement. Most patients require intermittent catheterization to empty. *(Modified from Gonzalez R. Urinary incontinence. In Kelalis PK, King LR, Belman AB, eds. Clinical Pediatric Urology. Philadelphia: Saunders; 1992. p. 387.)*

Fig. 579.2 Voiding cystourethrogram in an infant with myelodysplasia shows a severely trabeculated bladder with multiple diverticula and grade V (out of V) right vesicoureteral reflux. Evaluation showed severe detrusor-sphincter dyssynergia.

Temporary urinary diversion by cutaneous vesicostomy is an alternative in the newborn or infant with severe reflux, if intermittent catheterization is difficult, or if anticholinergic medications are not well tolerated. Another option for treating the severely trabeculated bladder is transurethral injection of botulinum toxin (Botox) into the detrusor muscle, which reduces bladder hypertonicity for approximately 6 months and often needs to be repeated. A different approach in these children is to temporarily inactivate the tight sphincter by urethral overdilation or transurethral injection of botulinum toxin into the sphincter. In children with upper tract changes, continuous overnight bladder drainage allows significant bladder relaxation and can reduce bladder wall thickening and lessen hydronephrosis.

Clean intermittent catheterization and anticholinergic therapy cure reflux in up to 80% of children with grade I or II reflux. Children with more severe reflux often require subureteral endoscopic injection therapy (see Chapter 576) or open antireflux surgery followed by intermittent catheterization and anticholinergic drugs. In older children with myelomeningocele with high-grade reflux, UTI, and hydronephrosis, augmentation enterocystoplasty (enlarging the bladder with a patch of intestine) with intermittent catheterization may be necessary. This intervention allows a normal-capacity bladder with low bladder pressure and effective drainage of the bladder.

Urinary Incontinence

Incontinence in the child with neuropathic bladder can result from total or partial denervation of the sphincter, bladder hyperreflexia, poor bladder compliance, chronic urinary retention, or a combination of these factors.

Incontinence is often addressed at 4-5 years of age and is tailored to the individual child. Nearly all children require clean intermittent catheterization to stay dry. This technique allows efficient bladder emptying with minimal risk of symptomatic UTI. *The urinary tract should be reevaluated with renal ultrasonography, a voiding cystourethrogram, and a urodynamic study (including bladder capacity) prior to initiation of an intermittent catheterization regimen*. If the external sphincter tone is sufficient and the bladder has adequate compliance, intermittent catheterization every 3-4 hours is often successful in keeping the child socially dry. If there are unstable bladder contractions, an anticholinergic medication such as oxybutynin chloride, hyoscyamine, or tolterodine is prescribed to increase bladder capacity. If there is sphincteric incompetence, α-adrenergic medications are prescribed to enhance outlet resistance. Bacteriuria is seen in up to 50% of children using intermittent self-catheterization, but it seldom causes symptoms. In the absence of reflux, there seems to be little cause for concern. Performing intermittent catheterization with a new catheter (hydrophilic or standard silicone) each time is also quite effective in preventing bacteriuria and avoids the need for antibiotic prophylaxis. With this treatment plan, 40–85% of patients are dry, depending on the definition of continence; some children wear a pad in their underwear or a diaper for security but feel that they are dry.

If there is persistent incontinence despite medical therapy, reconstructive urinary tract surgery nearly always provides complete or satisfactory continence. If urethral resistance is low, bladder neck reconstructive procedures such as a periurethral sling are often successful. Alternatively, implantation of an artificial sphincter is usually successful. This sphincter consists of an inflatable cuff that is placed around the bladder neck, a pressure-regulating balloon implanted in the extraperitoneal space, and a pump mechanism that is implanted in the scrotum of boys and in the labia majora of girls. Squeezing the pump 3-4 times moves the fluid out of the inflatable urethral cuff, and then the cuff slowly refills over the next 2-3 minutes.

If the bladder capacity or bladder compliance is low, or if there are persistent uninhibited contractions despite anticholinergic therapy, enlargement of the bladder with a patch of small or large intestine,

termed augmentation cystoplasty or **enterocystoplasty**, is effective. These patients still need to perform clean intermittent catheterization. If urethral catheterization is difficult, a continent urinary stoma may be incorporated into the urinary tract reconstruction. A common method is the **Mitrofanoff procedure** (appendicovesicostomy), in which the appendix is isolated from the cecum on its vascular pedicle and is interposed between the bladder and abdominal wall to allow intermittent catheterization through a dry stoma. An ileal conduit with a bag on the abdominal wall is rarely used.

Complications of Augmentation Cystoplasty

Urinary Tract Infection

The urine may be colonized with gram-negative bacteria, and attempts to sterilize the urine for prolonged periods usually fail. There is no evidence that chronic bacteriuria in patients who have had enterocystoplasty is associated with renal damage; therefore only symptomatic UTIs should be treated.

Metabolic Acidosis

The enteric mucosal surface in contact with the urine absorbs ammonium, chloride, and hydrogen ions and loses potassium. *Hyperchloremic metabolic acidosis can result, possibly requiring medical treatment* (see Chapter 73). Chronic acidosis can compromise skeletal growth. This condition is common with colocystoplasty but is uncommon with ileocystoplasty. Metabolic acidosis is also common in patients with compromised renal function. To overcome this limitation of enterocystoplasty in patients with chronic renal insufficiency, a composite augmentation using the stomach and a small or large bowel gastric segment can be used. The stomach secretes chloride and hydrogen ions; thus preexisting metabolic acidosis remains stable or improves. However, augmentation with a gastric segment remains rare.

Spontaneous Perforation

Perforation of the augmented bladder is a life-threatening complication that results most often from acute or chronic overdistention of the augmented bladder. Patients with this complication typically present with severe abdominal pain and signs of peritonitis. Prompt diagnosis and treatment with exploratory laparotomy and bladder closure are necessary. Meticulous adherence to the prescribed program of intermittent catheterization to avoid bladder overdistention is important.

Bladder Calculi

Bladder calculi have developed in as many as 70% of children followed for 10 years after enterocystoplasty. The calculi develop in response to mucus that accumulates in the bladder and serves as a nidus for stone formation. This complication can be prevented by daily irrigation of the bladder with sterile saline.

Malignant Neoplasm

Invasive transitional cell carcinoma has been reported in nearly 4.6% of patients undergoing enterocystoplasty (compared with a 2.6% risk in spina bifida patients without enterocystoplasty). The pathogenesis is uncertain, but there is speculation that it is related to bacteriuria and the bowel-bladder contact. The risk is highest following gastrocystoplasty. The risk increases 10 years following enterocystoplasty. Although there are no formal guidelines or recommendations regarding screening, it seems appropriate to advise yearly endoscopic examinations or urine cytologic studies beginning in the tenth postoperative year.

ASSOCIATED DISORDERS

Constipation

Many patients with spina bifida also have bowel problems with constipation, and a vigorous bowel regimen is important. Some benefit from the **Malone antegrade continence enema (MACE) procedure**, in which the appendix is brought out to the skin to allow a catheter to be inserted into the cecum for antegrade enema. The stoma is continent, and an antegrade enema can be performed with tap water each day. This form of management allows the patient to be continent of stool and be more self-sufficient. An alternative to the MACE procedure is a percutaneous cecostomy, in which a button is placed into the cecum to allow an antegrade flush. The MACE and percutaneous cecostomy procedures can be performed laparoscopically.

Latex Allergy

Latex allergy is a very serious problem encountered by as many as half of patients with spina bifida and other urologic conditions who require clean intermittent catheterization and urinary tract reconstructive procedures. This immunoglobulin E–mediated allergy is acquired and is secondary to repeated exposure to the latex allergen. Latex allergy can manifest as watery eyes, sneezing, itching, hives, or anaphylaxis when blowing up a balloon or if an examiner is using latex gloves. Intraoperatively, a sensitized patient can experience anaphylactic shock. A latex-free environment should be provided for all children with spina bifida in the office, during hospitalization, and during operative procedures. Affected children also should wear a medical alert bracelet.

Occult Spinal Dysraphism

Approximately 1 in 4,000 patients have occult spinal dysraphism, a category that includes lipomeningocele, intradural lipoma, diastematomyelia, tight filum terminale, dermoid cyst-sinus, aberrant nerve roots, anterior sacral meningocele, and cauda equina tumor. More than 90% of patients have a cutaneous abnormality overlying the lower spine, including a **sacral dimple**, tuft of hair, dermal vascular malformation, or subcutaneous lipoma (Fig. 579.3). Often these children have high-arched feet, discrepancy in muscle size and strength between the legs,

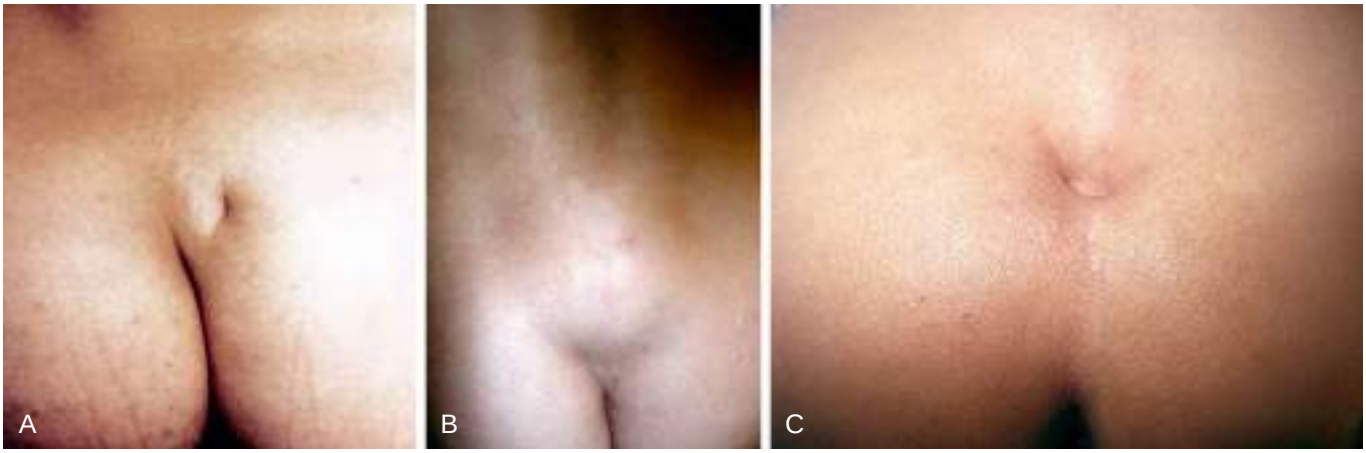

Fig. 579.3 A, Buttocks of teenage boy with tethered cord secondary to lipomeningocele. Note sacral dimple and deviation of gluteal fold to the left. B, Fat deposit over sacrum in girl with tethered cord secondary to lipomeningocele. C, Deep sacral pit in child with neuropathic bladder.

and a gait abnormality. Newborns and young infants often have a normal neurologic examination. Older children often have absent perineal sensation and back pain. Lower urinary tract function is abnormal in 40% of patients, including incontinence, recurrent UTI, and fecal soiling. The likelihood of a normal examination is inversely related to the child's age at surgical correction of the spinal lesion. In infants with abnormal urodynamics, 60% revert to normal; in older children, only 27% become normal. Management of the urinary tract in other children is similar to that described earlier for neural tube defects.

Sacral Agenesis

Sacral agenesis is defined as the absence of part or all of two or more lower vertebral bodies. *This condition is more common in the offspring of women with diabetes.* These children have a flattened buttock and a low, short gluteal cleft but usually have no orthopedic deformity, although some have high-arched feet. Palpation of the coccygeal area detects the absent vertebrae. Approximately 20% of cases are undetected until the age of 3-4 years; many are diagnosed after unsuccessful toilet training. Urodynamic studies in these children show a variety of patterns, and most need clean intermittent catheterization and pharmacotherapy to stay dry.

Imperforate Anus

Approximately 30–45% of children with a high imperforate anus have a neuropathic bladder, often because of sacral agenesis. Newborns with imperforate anus should undergo a spinal ultrasound during their initial evaluation, and if these children have difficulty with toilet training, complete urologic evaluation with upper and lower urinary tract imaging and urodynamics should be performed (see Chapter 392).

Cerebral Palsy

Children with cerebral palsy (see Chapter 638.1) often have reasonable bladder control. However, they achieve continence at a later age than unaffected children. Overall, 25–50% are incontinent, and the risk is directly related to the severity of physical impairment. Their upper urinary tracts are usually normal. Urodynamic studies have shown that most have uninhibited bladder contractions. Timed voiding and anticholinergic therapy are usually effective. Upper urinary tract deterioration is uncommon, and clean intermittent catheterization is rarely necessary.

Visit Elsevier eBooks+ at eBooks.Health.Elsevier.com for Bibliography.

Chapter 580

Enuresis and Voiding Dysfunction

Heather N. Di Carlo and Chad B. Crigger

NORMAL VOIDING AND TOILET TRAINING

Fetal voiding occurs by reflex bladder contraction in concert with simultaneous contraction of the bladder and relaxation of the sphincter. Urine storage results from sympathetic and pudendal nerve-mediated inhibition of detrusor contractile activity accompanied by closure of the bladder neck and proximal urethra with increased activity of the external sphincter. The infant has coordinated reflex voiding as often as 15-20 times/day. Over time, bladder capacity increases. In children up to the age of 14 years, the mean bladder capacity in milliliters is equal to the ([age (in years) + 2] times 30) (e.g., the bladder capacity of a 6 year old should be [6 + 2] × 30 or 240 mL).

At 2-4 years, the child is developmentally ready to begin toilet training. To achieve conscious bladder control, several conditions must be present: awareness of bladder filling, cortical inhibition (suprapontine modulation) of reflex (unstable) bladder contractions, ability to consciously tighten the external sphincter to prevent incontinence, normal bladder growth, and motivation by the child to stay dry. The transitional phase of voiding refers to the period when children are acquiring bladder control. *Females typically acquire bladder control before males, and bowel control typically is achieved before bladder control.*

DIURNAL INCONTINENCE

Daytime incontinence not secondary to neurologic abnormalities is common in children. At 5 years of age, 95% have been dry during the day at some time and 92% are dry consistently. At 7 years of age, 96% are dry, although 15% have significant **urgency** at times. At 12 years, 99% are dry consistently during the day. The most common causes of daytime incontinence are **overactive bladder (urge incontinence)** and bladder-bowel dysfunction (BBD). Table 580.1 lists the causes of diurnal incontinence in children; Table 580.2 categorizes four types of voiding dysfunction.

The patient history should assess the pattern of incontinence, including the frequency of voiding, frequency of day and night urinary leakage, volume of urine lost during incontinent episodes, whether the incontinence is associated with urgency or giggling, whether it occurs after voiding, and whether the incontinence is continuous. In addition, whether the patient has a strong continuous urinary stream and sensation of incomplete bladder emptying should be assessed. A diary of when the child voids and whether the child is wet or dry is helpful. Other urologic problems, such as urinary tract infections (UTIs), vesicoureteral reflux, neurologic disorders, or a family history of renal duplication anomalies, should be assessed. Bowel habits also should be evaluated because incontinence is common in children with constipation and/or encopresis. Diurnal incontinence can occur in children with a history of sexual abuse or following bullying. Physical examination is directed at identifying signs of organic causes of incontinence. Short stature, hypertension, enlarged kidneys and/or bladder, constipation, labial adhesion, ureteral ectopy, back or sacral anomalies (see Fig. 579.4), and neurologic abnormalities should be documented.

Assessment tools include urinalysis, with culture if indicated; bladder diary (recorded times and volumes voided, whether wet or dry); postvoid residual urine volume (generally obtained by bladder scan); and the **Dysfunctional Voiding Symptom Score** (Fig. 580.1). An alternative to the Dysfunctional Voiding Symptom Score is the **Vancouver Nonneurogenic Lower Urinary Tract Dysfunction/Dysfunctional Elimination Syndrome** questionnaire. This questionnaire is a validated tool that consists of 14 questions scored on a 5-point Likert scale to assess lower urinary tract and bowel dysfunction. In most cases, a

Table 580.1 Causes of Urinary Incontinence in Childhood

Overactive bladder (urge incontinence or diurnal urge syndrome)
Infrequent voiding (underactive bladder)
Voiding postponement
Detrusor-sphincter discoordination
Nonneurogenic neurogenic bladder (Hinman syndrome)
Vaginal voiding
Giggle incontinence
Cystitis
Bladder outlet obstruction (posterior urethral valves)
Ectopic ureter and fistula
Sphincter abnormality (epispadias, exstrophy; urogenital sinus abnormality)
Neuropathic
Overflow incontinence
Traumatic
Iatrogenic
Behavioral
Combinations

Table 580.2 Symptoms and Signs of Four Main Subtypes of Lower Urinary Tract Dysfunction

	SYMPTOMS	SIGNS
Overactive bladder	(Cystometric) detrusor overactivity, frequency, voiding urgency, incontinence, constipation, enuresis	Holding maneuvers, normal flow pattern, thick bladder wall, low-volume voids
Dysfunctional voiding	Failure to relax the sphincter during voiding, normal micturition frequency, incontinence, constipation, urinary tract infections, enuresis	Post-void residue, staccato or interrupted flow pattern, normal frequency of voids
Underactive bladder	(Cystometric) weak detrusor contractions, low micturition frequency incontinence, constipation, urinary tract infections	Post-void residue, staccato or interrupted flow pattern, frequent large volume voids
Voiding postponement	Low micturition frequency, incontinence	Normal flow pattern

Classification of daytime lower urinary tract dysfunction, assessment, and documentation should be based on the following parameters: incontinence (presence or absence and symptom frequency), voiding frequency, voiding urgency, voided volumes, and fluid intake.
From Nieuwhof-Leppink AJ, Schroeder RPJ, van de Putte EM, et al. Daytime urinary incontinence in children and adolescents. *Lancet Child Adolesc Health.* 2019;3:492–500.

Patient name:
Hospital number:
Reason for referral:
Date:

Over the last month	Almost never	Less than half the time	About half the time	Almost every time	Not available
1. I have had wet clothes or wet underwear during the day.	0	1	2	3	NA
2. When I wet myself, my underwear is soaked.	0	1	2	3	NA
3. I miss having a bowel movement every day.	0	1	2	3	NA
4. I have to push for my bowel movements to come out.	0	1	2	3	NA
5. I only go to the bathroom one or two times each day.	0	1	2	3	NA
6. I can hold onto my pee by crossing my legs, squatting or doing the "pee dance."	0	1	2	3	NA
7. When I have to pee, I cannot wait.	0	1	2	3	NA
8. I have to push to pee.	0	1	2	3	NA
9. When I pee it hurts.	0	1	2	3	NA
10. Parents to answer. Has your child experienced something stressful like the example below?	No (0)			Yes (3)	
Total*					

- New baby.
- New home.
- New school.
- School problems.
- Abuse (sexual/physical).
- Home problems (divorce/death).
- Special events (birthday).
- Accident/injury.
- Others.

*Females with a score ≥6 and males with a score ≥9 are most likely to have dysfunctional voiding.

Fig. 580.1 Dysfunctional Voiding Symptom Score questionnaire. *(From Farhat W, Bagli DJ, Capolicchio G, et al. The dysfunctional voiding scoring system: quantitative standardization of dysfunctional voiding symptoms in children. J Urol. 2000;164:1011–1015.)*

uroflow study with electromyography (noninvasive assessment of urinary flow pattern and measurement of external sphincter activity) is indicated. Another item that may be useful in children older than age 5 years is the **Pediatric Symptom Checklist (PSC)**, a brief screening questionnaire that may reveal psychosocial stressors contributing to incontinence (see Chapter 32).

Bowel function should also be assessed. The **Bristol Stool Form Score** (Fig. 580.2) should be recorded. In addition, the clinician should utilize the Rome III diagnostic criteria, which classify functional gastrointestinal disorders that do not have underlying structural or tissue-based causes. Children 4 years of age or older are diagnosed as being constipated if they fulfill two or more of the following criteria over a period of 2 months: two or fewer defecations in the toilet per week, at least one episode of fecal incontinence per week, a history of retentive posturing or excessive volitional stool retention, a history of painful or hard bowel movements, the presence of a large fecal mass in the rectum, and a history of large-diameter stools that obstruct the toilet.

Imaging (renal-bladder ultrasound with or without a voiding cystourethrogram) is indicated in children with diurnal incontinence who have significant physical findings, those who have a family history of urinary tract anomalies or UTIs, and those who do not respond to therapy appropriately. Urodynamics should be performed if there is evidence of neurologic disease and may be helpful if empirical therapy is ineffective. *If there is any evidence of a neurologic disorder or if there is a sacral abnormality on physical examination, an MRI of the lower spine should be obtained.*



Fig. 580.2 Bristol Stool Chart for evaluating bowel function.

Fig. 580.3 Spinning-top deformity. Voiding cystourethrogram demonstrating dilation of the urethra with distal urethral narrowing and contraction of the bladder neck.

OVERACTIVE BLADDER (DIURNAL URGE SYNDROME)

Children with an overactive bladder typically exhibit urinary frequency, urgency, and urge incontinence. Often a female will squat down on her foot to try to prevent incontinence (termed *Vincent's curtsy*). The bladder in these children is functionally, but not anatomically, smaller than normal and exhibits strong uninhibited contractions. Approximately 25% of children with nocturnal enuresis also have symptoms of an overactive bladder. Many children indicate they do not feel the need to urinate, even just before they are incontinent. In females, a history of recurrent UTI is common, but incontinence can persist long after infections are brought under control. It is unclear if the voiding dysfunction is a sequela of the UTIs or if the voiding dysfunction predisposes to recurrent UTIs. In some females, voiding cystourethrography shows a dilated urethra (**spinning-top deformity**; Fig. 580.3) and narrowed bladder neck with bladder wall hypertrophy. The urethral finding results from inadequate relaxation of the external urinary sphincter.

The overactive bladder nearly always resolves, but the time to resolution is highly variable, occasionally not until the teenage years. Initial therapy is timed voiding, every 1.5-2 hours. Treatment of constipation and UTIs is important. Another treatment is **biofeedback**, in which children are taught pelvic floor exercises **(Kegel exercises),** because daily performance of these exercises can reduce or eliminate unstable bladder contractions. Biofeedback often consists of 8-10 1-hour sessions and may include participation with animated computer games. Biofeedback also may include periodic uroflow studies with sphincter electromyography to be certain that the pelvic floor relaxes during voiding, and assessment of postvoid residual urine volume by sonography. **Anticholinergic** therapy often is helpful if bowel function is normal. **Oxybutynin chloride** and **tolterodine** are the only U.S. Food and Drug Administration (FDA)-approved medications in children, but hyoscyamine, trospium, solifenacin, and mirabegron have also demonstrated safety in this population; these medications reduce bladder overactivity and may help the child achieve dryness. Adequate hydration should be emphasized to combat constipation as oxybutynin can induce constipation in some patients. Treatment with an α-adrenergic blocker such as terazosin or doxazosin can aid in bladder emptying by promoting bladder neck relaxation; these medications also have mild anticholinergic properties. If pharmacologic therapy is successful, the dosage should be tapered periodically to determine its continued need. Children who do not respond to therapy should be evaluated with urodynamic studies to rule out other possible forms of bladder or sphincter dysfunction. In refractory cases, other procedures such as **sacral neuromodulation** (InterStim), percutaneous tibial nerve stimulation, and intravesical botulinum toxin injection have been effective in children.

If the child has constipation based on the criteria described earlier, treatment generally is initiated with polyethylene glycol powder, which has been shown to be safe in children and is generally more effective than other laxative preparations (see Chapter 378.3).

NONNEUROGENIC NEUROGENIC BLADDER (HINMAN SYNDROME)

Hinman syndrome is a very serious but uncommon disorder involving failure of the external sphincter to relax during voiding in children without neurologic abnormalities. Children with this syndrome, also called **nonneurogenic neurogenic bladder**, typically exhibit a staccato stream, day and night wetting, recurrent UTIs, constipation, and encopresis. Evaluation of affected children often reveals vesicoureteral reflux, a trabeculated bladder, and a decreased urinary flow rate with an intermittent pattern (Fig. 580.4). In severe cases, hydronephrosis, renal insufficiency, and end-stage renal disease can occur. The pathogenesis of this syndrome is thought to involve learning abnormal voiding habits during toilet training; the syndrome is rarely seen in infants. Urodynamic studies and MRI of the spine are indicated to rule out a neurologic cause for the bladder dysfunction.

The treatment usually is complex and can include anticholinergic and α-adrenergic blocker therapy, timed voiding, treatment of constipation, behavioral modification, and encouragement of relaxation during voiding. Biofeedback has been used successfully in older children to teach relaxation of the external sphincter. Botulinum toxin injection into the external sphincter can provide temporary sphincteric paralysis and thereby reduce outlet resistance. In severe cases, intermittent catheterization is necessary to ensure bladder emptying. In selected patients, external urinary diversion is necessary to protect the upper urinary tract. These children require long-term treatment and careful follow-up.

Fig. 580.4 Voiding cystourethrogram demonstrating severe bladder trabeculation and vesicoureteral reflux in a 12-yr-old male with Hinman syndrome. The patient presented with day and night incontinence, had chronic renal failure, and underwent kidney transplantation.

INFREQUENT VOIDING (UNDERACTIVE BLADDER)

Infrequent voiding is a common disorder of micturition. Affected children, usually females, often void only 1-2 times a day rather than the normal 4-7 times. Poor detrusor contraction strength and/or duration lead to bladder overdistention and prolonged retention of urine and ultimately bacterial growth that can lead to recurrent UTIs. Some of these children are constipated. Some also have occasional episodes of incontinence from overflow or urgency. The disorder is behavioral. If the child has UTIs, treatment includes antibacterial prophylaxis and encouragement of frequent voiding and complete emptying of the bladder by double voiding until a normal pattern of micturition is reestablished.

VAGINAL VOIDING

In females with vaginal voiding, incontinence typically occurs after urination after the female stands up. The volume is usually minimal, about 5-10 mL, and characterized as dribbling. One of the most common causes is **labial adhesion** (Fig. 580.5). This lesion, typically seen in young females, can be managed either by topical application of estrogen or steroid cream to the adhesion or manual separation (this should only be done after ensuring adequate anesthesia and potentially sedation; see Chapter 586). Some females experience vaginal voiding because they do not separate their legs widely during urination. These females typically are overweight and/or do not pull their underwear down to their ankles when they urinate. Management involves encouraging the female to separate the legs as widely as possible during urination. The most effective way to do this is to have the child sit backward on the toilet seat during micturition.

OTHER CAUSES OF INCONTINENCE IN FEMALES

Ureteral ectopia, usually associated with a duplicated collecting system in females, refers to a ureter that drains outside the bladder, often into the vagina or distal urethra. It can produce urinary incontinence characterized by constant urinary dribbling all day, even though the child voids regularly. Sometimes the urine production from the renal segment drained by the ectopic ureter is small, and urinary drainage is confused with watery vaginal discharge. Children with a history of vaginal discharge or incontinence and an abnormal voiding pattern require careful study. The ectopic orifice is usually difficult to find. On ultrasonography or intravenous urography, one may suspect duplication of the collecting system (Fig. 580.6), but the upper collecting system drained by the ectopic ureter usually has poor or delayed function.

Fig. 580.5 A, Labial adhesion. Note the inability to visualize the urethral meatus and vagina. B, Normal female external genitals following lysis of labial adhesion.

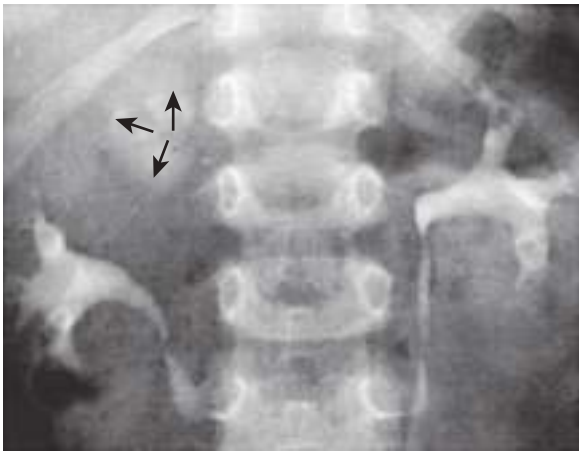

Fig. 580.6 Duplication of the right collecting system with ectopic ureter. Excretory urogram in a female presenting with a normal voiding pattern and constant urinary dribbling. The left kidney is normal, and the right side, well visualized, is the lower collecting system of a duplicated kidney. On the upper pole opposite the first and second vertebral bodies, note the accumulation of contrast material *(arrows)* corresponding with a poorly functioning upper pole drained by a ureter opening in the vestibule.

CT scanning of the kidneys or an MR urogram should demonstrate subtle duplication anomalies. Examination under anesthesia for an ectopic ureteral orifice in the vestibule or the vagina may be necessary (Fig. 580.7). Treatment in these cases is either partial nephrectomy, with removal of the upper pole segment of the duplicated kidney and its ureter down to the pelvic brim, or ipsilateral ureteroureterostomy, in which the upper pole ectopic ureter is anastomosed to the normally positioned lower pole ureter. These procedures often are performed by minimally invasive laparoscopy with or without robotic assistance.

Giggle incontinence typically affects females 7-15 years of age. The incontinence occurs suddenly during giggling, and the entire bladder volume is lost. The pathogenesis is thought to be sudden relaxation of the urinary sphincter. Anticholinergic medication and timed voiding occasionally are effective. The most effective treatment is low-dose methylphenidate, which seems to stabilize the external sphincter.

Total incontinence in females may be secondary to **epispadias** (see Fig. 578.2). This condition, which affects only 1 in 480,000 females, is characterized by separation of the pubic symphysis, separation of the right and left sides of the clitoris, and a patulous urethra. Treatment is bladder neck reconstruction; an alternative surgical therapy is

Fig. 580.7 An ectopic ureter entering the vestibule next to the urethral meatus. The thin ureteral catheter with transverse marks has been introduced into this ectopic ureter. This female had a normal voiding pattern and constant urinary dribbling.

Table 580.3 Nocturnal Enuresis

CAUSES
Delayed maturation of the cortical mechanisms that allow voluntary control of the micturition reflex
Defective sleep arousal
Reduced antidiuretic hormone production at night, resulting in an increased urine output (nocturnal polyuria)
Genetic factors, with chromosomes 12 and 13q the likely sites of the gene for enuresis
Bladder factors (lack of inhibition, reduced capacity, overactive)
Constipation
Organic factors, such as urinary tract infection, obstructive uropathy, or sickle cell anemia nephropathy
Sleep disorders
Sleep-disordered breathing secondary to enlarged adenoids
Psychologic factors more often implicated in secondary enuresis
OTHER FEATURES
Enuresis can occur in any stage of sleep (but usually non–rapid eye movement sleep)
All children are most difficult to arouse in the first third of the night and easiest to awaken in the last third, but enuretic children are more difficult to arouse than those with normal bladder control
Enuretic children often are described as "soaking the bed"
Family history in enuretic children often positive for enuresis
Risk increased with developmental delay, attention-deficit/hyperactivity disorder, autism spectrum disorders

placement of an artificial urinary sphincter to repair the incompetent urethra.

A short, incompetent urethra may be associated with certain urogenital sinus malformations. The diagnosis of these malformations requires a high index of suspicion and a careful physical examination of all incontinent females. In these cases, urethral and vaginal reconstruction often restores continence.

VOIDING DISORDERS WITHOUT INCONTINENCE

Some children have abrupt onset of severe urinary frequency, voiding as often as every 10-15 minutes during the day, without dysuria, UTI, daytime incontinence, or nocturia. The most common age for these symptoms to occur is 4-6 years, after the child is toilet trained; males are more often affected. This condition is termed the **daytime frequency syndrome of childhood,** or **pollakiuria**. The condition is functional without associated anatomic problems. Often the symptoms occur just before a child starts kindergarten or if the child is having emotional family stress-related problems. These children should be checked for UTIs, and the clinician should ascertain that the child is emptying the bladder satisfactorily. Another contributing cause is constipation. Occasionally, pinworms cause these symptoms. The condition is self-limited, and symptoms generally resolve within 2-3 months. Anticholinergic therapy is rarely effective.

Some children have **dysuria-hematuria syndrome,** in which the child has dysuria without UTI but with microscopic or total gross hematuria (blood throughout the stream). This condition affects children who are toilet-trained and is often secondary to hypercalciuria. A 24-hour urine sample should be obtained and calcium and creatinine excretion assessed. A 24-hour calcium excretion of >4 mg/kg is abnormal and deserves treatment with thiazides, because some of these children are at risk for urolithiasis. **Terminal hematuria** (blood at the end of the stream) occurs in males and typically is secondary to BBD or urethral meatal stenosis. Cystoscopy is not indicated, and the condition usually resolves with treatment for constipation.

NOCTURNAL ENURESIS

By 5 years of age, 90–95% of children are nearly completely continent during the day, and 80–85% are continent at night. Nocturnal enuresis refers to the occurrence of involuntary voiding at night after 5 years old, the age when volitional control of micturition is expected. Enuresis may be **primary** (estimated 75–90% of children with enuresis; nocturnal urinary control never achieved) or **secondary** (10–25%; the child was dry at night for at least a few months and then enuresis developed). Overall, 75% of children with enuresis are wet only at night, and 25% are incontinent day and night. This distinction is important, because children with both forms are more likely to have an abnormality of the urinary tract. *Monosymptomatic enuresis* is more common than *polysymptomatic enuresis* (associated urgency, hesitancy, frequency, daytime incontinence).

Epidemiology

Approximately 60% of children with nocturnal enuresis are males. The family history is positive in 50% of cases. Although primary nocturnal enuresis may be polygenetic, candidate genes have been localized to chromosomes 6, 12, and 13. If one parent was enuretic, each child has a 44% risk of enuresis; if both parents were enuretic, each child has a 77% likelihood of enuresis. Nocturnal enuresis without overt daytime voiding symptoms affects up to 20% of children at the age of 5 years; it ceases spontaneously in approximately 15% of involved children every year thereafter. Its frequency among adults is <1%.

Pathogenesis

The pathogenesis of primary nocturnal enuresis (normal daytime voiding habits) is multifactorial (Table 580.3).

Clinical Manifestations and Diagnosis

A careful history should be obtained, especially with respect to fluid intake at night and the pattern of nocturnal enuresis. Children with diabetes insipidus (see Chapter 596), diabetes mellitus (see Chapter 629), and chronic renal disease (see Chapter 572) can have a high obligatory urinary output and a compensatory polydipsia. The family should be asked whether the child snores loudly at night. Many children with enuresis sleepwalk or talk in their sleep. A complete physical examination should include palpation of the abdomen and possibly a rectal examination after voiding to assess the possibility of a chronically distended bladder and constipation. The child with nocturnal enuresis should be examined carefully for neurologic and spinal abnormalities. There is an increased incidence of bacteriuria in enuretic females, and, if found, it should be investigated and treated (see Chapter 575), although this does not always lead to resolution of bed-wetting. A urine sample should be obtained after an overnight fast and evaluated

for specific gravity or osmolality to exclude polyuria as a cause of frequency and incontinence and to ascertain that the concentrating ability is normal. The absence of glycosuria should be confirmed. If there are no daytime symptoms, the physical examination and urinalysis are normal, and the urine culture is negative, further evaluation for urinary tract pathology generally is not warranted. A renal ultrasound is reasonable in an older child with enuresis or in children who do not respond appropriately to therapy.

Treatment

The best approach to treatment is to reassure the child and parents that the condition is self-limited and to avoid punitive measures that can affect the child's psychologic development adversely. Fluid intake should be restricted to 2 oz after 6 or 7 PM. The parents should be certain that the child voids at bedtime. Avoiding extraneous sugar and caffeine after 5 PM is also beneficial. If the child snores and the adenoids are enlarged, referral to an otolaryngologist should be considered, because adenoidectomy can cure the enuresis in some cases.

Active treatment should be avoided in children younger than 6 years of age, because enuresis is extremely common in younger children. Treatment is more likely to be successful in children approaching puberty compared with younger children. In addition, treatment is most likely to be effective in children who are motivated to stay dry and is less successful in children who are overweight. Treatment should be viewed as a facilitator that requires active participation by the child (e.g., a coach and an athlete).

The simplest initial measure is **motivational therapy** and includes a star chart for dry nights. Waking children a few hours after they go to sleep to have them void often allows them to awaken dry, although this measure is not curative. Some have recommended that children try holding their urine for longer periods during the day, but there is no evidence that this approach is beneficial. **Conditioning therapy** involves use of a loud auditory or vibratory alarm attached to a moisture sensor in the underwear. The alarm activates when voiding occurs and is intended to awaken children and alert them to void. This form of therapy has a reported success of 30–60%, although the relapse rate is significant. Often the auditory alarm wakes up other family members and not the enuretic child; persistent use of the alarm for several months often is necessary to determine whether this treatment is effective. Conditioning therapy tends to be most effective in older children. Another form of therapy to which some children respond is self-hypnosis. The primary role of psychologic therapy is to help the child deal with enuresis psychologically and help motivate the child to void at night if he or she awakens with a full bladder.

Pharmacologic therapy is intended to treat the symptom of enuresis and thus is regarded as second line and is not curative. Direct comparisons of the moisture alarm with pharmacologic therapy favor the former because of lower relapse rates, although initial response rates are equivalent.

One form of pharmacologic treatment is **desmopressin acetate,** a synthetic analog of antidiuretic hormone that reduces urine production overnight. This medication is FDA-approved in children and is available as a tablet, with a dosage of 0.2-0.6 mg orally 2 hours before bedtime. A nasal spray formulation is available but is no longer recommended for nocturnal enuresis due to increased risk of hyponatremia and convulsions. Hyponatremia has not been reported in children using oral tablets. Fluid restriction at night is important, and the drug should not be used if the child has a systemic illness with vomiting or diarrhea or if the child has polydipsia. Desmopressin acetate is effective in as many as 40% of children and is most effective in those approaching puberty. If effective, it should be used for 3-6 months, and then an attempt should be made to taper the dosage. Some families use it intermittently (sleepovers, school trips, vacations) with success. If tapering results in recurrent enuresis, the child should return to the higher dosage. Few adverse events have been reported with the long-term use of desmopressin acetate.

For therapy-resistant enuresis or children with symptoms of an overactive bladder, anticholinergic therapy is indicated. Oxybutynin 5 mg or tolterodine 2 mg at bedtime is often prescribed. If the medication is ineffective, the dosage may be doubled. The clinician should monitor constipation as a potential side effect.

A third-line treatment is **imipramine,** which is a tricyclic antidepressant. This medication has mild anticholinergic and α-adrenergic effects, reduces the urine output slightly, and might alter the sleep pattern. The dosage of imipramine is 25 mg in children age 6-8 years, 50 mg in children age 9-12 years, and 75 mg in teenagers. Reported success rates are 30–60%. Side effects include anxiety, insomnia, dry mouth, and heart rhythm changes. If there is any history of palpitations or syncope in the child, or sudden cardiac death or unstable arrhythmia in the family, long QT syndrome in the patient needs to be excluded prior to prescribing imipramine. The drug is one of the most common causes of poisoning by prescription medication, so it is also important to emphasize safe storage.

In unsuccessful cases, combining therapies often is effective. Alarm therapy plus desmopressin is more successful than either alone. The combination of oxybutynin chloride and desmopressin is more successful than a single agent. Desmopressin and imipramine also may be combined.

Visit Elsevier eBooks+ at eBooks.Health.Elsevier.com for Bibliography.

Chapter 581

Anomalies of the Penis and Urethra

Heather N. Di Carlo and Chad B. Crigger

HYPOSPADIAS

Hypospadias is a urethral opening on the ventral surface of the penile shaft affecting 1 in 200 male newborns. Typically an isolated defect, its incidence is increased in many males with chromosomal abnormalities, anorectal malformation, and congenital heart disease. Usually, there is incomplete development of the prepuce, called a **dorsal hood,** in which the foreskin is on the sides and dorsal aspect of the penile shaft and deficient or absent ventrally. Some males with hypospadias, particularly those with proximal hypospadias, have **chordee,** in which there is ventral penile curvature during erection. The incidence of hypospadias appears to be increasing, possibly because of in utero exposure to estrogenic or antiandrogenic endocrine-disrupting chemicals (e.g., polychlorobiphenyls, phytoestrogens).

Clinical Manifestations

Hypospadias is classified according to the position of the urethral meatus after considering whether chordee is present (Fig. 581.1). The deformity is described as distal (further broken down into glanular [on the glans penis], coronal, or subcoronal), midpenile (distal penile, midshaft, or proximal penile), or proximal (penoscrotal, scrotal, or perineal). Approximately 65% of cases are distal, 25% are subcoronal or midpenile, and 10% are proximal. In the most severe cases, the scrotum is bifid, and sometimes there is moderate **penoscrotal transposition.** As many as 10% of affected males have a **megameatal variant of hypospadias** in which the foreskin is developed normally (megameatus intact prepuce variant), and there is either glanular or subcoronal hypospadias with a "fish mouth" meatus. These cases might not be diagnosed until after a circumcision is performed.

Fig. 581.1 Varying forms of hypospadias. **A,** Glanular hypospadias. **B,** Subcoronal hypospadias. Note the dorsal hood of foreskin. **C,** Penoscrotal hypospadias with chordee. **D,** Perineal hypospadias with chordee and partial penoscrotal transposition. **E,** Megameatal variant of hypospadias diagnosed following circumcision; note absence of hooded foreskin. **F,** Complete penoscrotal transposition with scrotal hypospadias.

Approximately 10% of males with hypospadias have an undescended testis; inguinal hernia(s) also are common. In the newborn, the differential diagnosis of midpenile or proximal hypospadias associated with an undescended testis should include forms of a **disorder of sex development,** particularly mixed gonadal dysgenesis, partial androgen insensitivity, true hermaphroditism, and congenital adrenal hyperplasia in a female (see Chapter 616). In the latter condition, neither gonad is palpable. *A karyotype should be obtained in patients with midpenile or proximal hypospadias and cryptorchidism* (see Chapter 628). In males with proximal hypospadias, a voiding cystourethrogram should be considered because 5–10% of these children have a dilated **prostatic utricle,** which is a remnant of the müllerian system (see Chapter 591). The incidence of upper urinary tract abnormalities is low unless there are abnormalities of other organ systems.

Complications of untreated hypospadias include deformity of the urinary stream, typically ventral deflection or severe splaying; sexual dysfunction secondary to penile curvature; infertility if the urethral meatus is proximal; meatal stenosis (congenital), which is uncommon; and cosmetic appearance. The goal of hypospadias surgery is to correct the functional and cosmetic deformities. Whereas hypospadias repair is recommended for all males with midpenile and proximal hypospadias, some males with distal hypospadias have no functional abnormality and do not need surgical correction.

Treatment

Management begins in the newborn period. *Circumcision should be avoided because the foreskin often is used in the repair in most cases.* The ideal age for repair in a healthy infant is 6-12 months because the risk of general anesthesia at this age is similar to older children; penile growth over the next several years is slow; the child does not remember the surgical procedure; and postoperative analgesic needs are less than in older children. With the exception of proximal hypospadias, virtually all cases are repaired in a single operation on an ambulatory basis. The most common repair involves tubularization of the urethral plate distal to the urethral meatus, with coverage by a vascularized flap from the foreskin, termed a tubularized incised plate repair. Proximal cases might require a two-stage repair.

The complication rate parallels severity: 5% for distal hypospadias, 10% for midpenile hypospadias, and 40% for proximal hypospadias. The most common complications include urethrocutaneous fistula and meatal stenosis. Other complications include a deformed urinary stream, persistent or recurrent penile curvature, and dehiscence of the hypospadias repair. Treatment of these complications generally is straightforward. In complex cases, a buccal mucosa graft from the mouth is used to create urethral mucosa. Repair of hypospadias is a technically demanding operation and should be performed by a surgeon with specialty training in pediatric urology and extensive experience.

CHORDEE WITHOUT HYPOSPADIAS

In some males, there is mild or moderate ventral penile curvature **(chordee)** and incomplete development of the foreskin **(dorsal hood),** but the urethral meatus is at the tip of the glans (Fig. 581.2). In most of these males, the urethra is normal, but there is insufficient ventral penile skin or prominent, inelastic ventral bands of dartos fascia that prevent a straight erection. In some cases, the urethra is hypoplastic, and a formal urethroplasty is necessary for repair. The only sign of this anomaly in the neonate may be the hooded foreskin, and delayed repair under general anesthesia after 6 months of age is recommended. **Lateral penile curvature** usually is caused by overgrowth or hypoplasia of a corporal (erectile) body and usually is congenital. Surgical repair is also recommended at age 6-12 months.

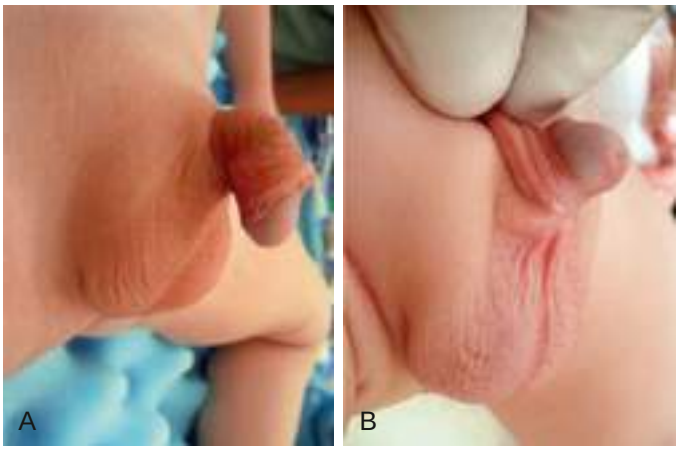

Fig. 581.2 **A** and **B,** Two examples of chordee without hypospadias. Note hooded foreskin and normal location of urethral meatus.

PHIMOSIS AND PARAPHIMOSIS

Phimosis refers to the inability to retract the prepuce. At birth, phimosis is physiologic. Over time, the adhesions between the prepuce and glans lyse and the distal phimotic ring loosens. In 80% of uncircumcised males, the prepuce becomes retractable by 3 years of age. Accumulation of epithelial debris under the infant's prepuce is physiologic and does not mandate circumcision. In older males, phimosis may be physiologic or may be pathologic from **lichen sclerosus (balanitis xerotica obliterans)** at the tip of the foreskin (Fig. 581.3A) and can also affect the meatus (see Fig. 581.3B). The prepuce might have been retracted forcefully on one or two occasions in the past, which can result in a cicatricial scar that prevents subsequent retraction of the foreskin. In males with persistent physiologic or pathologic phimosis, application of corticosteroid ointment to the tip of the foreskin twice daily for 1 month loosens the phimotic ring in two thirds of cases. *If there is ballooning of the foreskin during voiding or phimosis beyond 10 years of age and topical corticosteroid therapy is ineffective, circumcision is recommended.*

Paraphimosis occurs when the foreskin is retracted proximal to the coronal sulcus and the prepuce cannot be pulled back over the glans (Fig. 581.4). Painful venous stasis in the retracted foreskin results, with

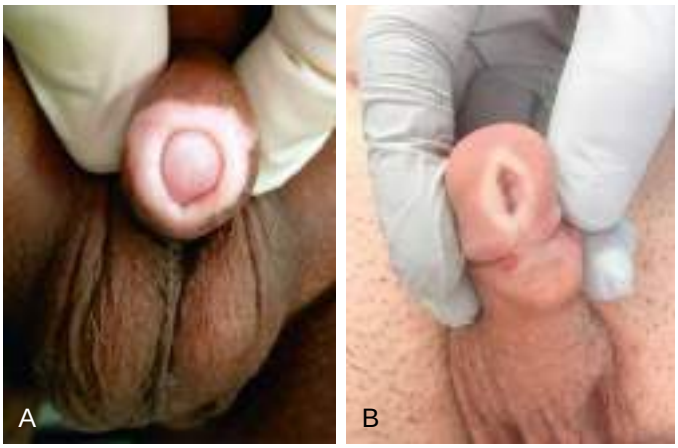

Fig. 581.3 A, Balanitis xerotica obliterans. Note whitish cicatricial plaque. B, Involvement of the urethral meatus necessitated a meatoplasty.

Fig. 581.4 Paraphimosis. The foreskin has been retracted proximal to the glans penis and is markedly swollen secondary to venous congestion.

edema leading to severe pain and inability to reduce the foreskin (pull it back over the glans). Treatment includes lubricating the foreskin and glans and then simultaneously compressing the glans and placing distal traction on the foreskin to try to push the phimotic ring past the coronal sulcus. Topical application of granulated sugar has been reported to aid in reduction of edema by creation of an osmotic gradient, facilitating reduction of paraphimosis. In addition, injection of hyaluronidase into the edematous skin has been reported to result in immediate reduction in swelling. In rare cases, emergency circumcision under general anesthesia is necessary.

CIRCUMCISION

In the United States, circumcision usually is performed for cultural reasons, but several health benefits have been identified that may outweigh the risks of the procedure. Specific benefits include prevention of urinary tract infections (UTIs) and penile cancer and reducing the risk and transmission of some sexually transmitted infections, including HIV.

UTIs are 10-15 times more common in uncircumcised *infant* males than in circumcised infants, with the urinary pathogens arising from bacteria that colonize the space between the prepuce and glans. The risk of febrile UTI (see Chapter 575) is highest between birth and 6 months, but there is an increased risk of UTI until at least 5 years of age, or age of completion of toilet training. Many recommend circumcision in infants who are predisposed to UTI, such as those with congenital hydronephrosis and vesicoureteral reflux. Circumcision reduces the risk of sexually transmitted infections in adults (see Chapter 163), in particular HIV (see Chapter 322). There have been only a handful of reports of adult males who were circumcised at birth and subsequently acquired penile carcinoma, but in Scandinavian countries, where few males are circumcised and hygiene is good, the incidence of penile cancer is low.

Circumcision should be performed by trained providers under sterile conditions. When performing a neonatal circumcision, local analgesia, such as a dorsal or penile ring block or application of EMLA (eutectic mixture of local anesthetics) cream (lidocaine 2.5% and prilocaine 2.5%) is recommended. Early and late complications after neonatal circumcision include bleeding, wound infection, meatal stenosis, secondary phimosis, removal of insufficient foreskin, and fibrous penile adhesions (skin bridge; Fig. 581.5); 0.2–3.0% of patients undergo a subsequent operative procedure. Males with a large hydrocele or hernia are at particular risk for secondary phimosis because the scrotal swelling tends to displace the penile shaft skin over the glans. Serious complications of newborn circumcision include sepsis, amputation of the distal part of the glans, removal of an excessive amount of foreskin, and urethrocutaneous fistula. Circumcision should not be performed in neonates with hypospadias, chordee without hypospadias, or a dorsal hood deformity (relative contraindication) or in those with a small penis (Fig. 581.6). In males with a "wandering raphe," in which the median raphe deviates to one side, there may be underlying penile torsion or hypospadias, and evaluation by a pediatric urologist is suggested before performing a circumcision.

PENILE TORSION

Penile torsion, a rotational defect of the penile shaft, usually occurs in a counterclockwise direction, usually to the left side (see Fig. 581.6D). In most cases, penile development is normal, and the condition is unrecognized until circumcision is performed or the foreskin is retractable. In many cases, the midline raphe of the penile shaft is deviated. Penile torsion also occurs in some males with hypospadias. The defect has primarily cosmetic significance, and correction is unnecessary if the rotation is <60 degrees from the midline. The severity of penile torsion may lessen during infancy.

INCONSPICUOUS PENIS

The term *inconspicuous penis* refers to a penis that appears to be small. A **webbed penis** is a condition in which the scrotal skin extends onto the ventral penile shaft. This deformity represents an abnormality of the attachment between the penis and scrotum. Although the deformity might appear mild, if a routine circumcision is performed, the penis can retract into the scrotum, resulting in secondary phimosis **(trapped penis).** The concealed **(hidden or buried)** penis is a normally developed penis that is camouflaged by the suprapubic fat pad (Fig. 581.7). This anomaly may be congenital, iatrogenic after circumcision, or a result of obesity. Surgical correction is indicated for cosmetic reasons or if there is a functional abnormality with a splayed stream.

A **trapped penis** is an acquired form of inconspicuous penis and refers to a phallus that becomes embedded in the suprapubic fat pad after circumcision (Fig. 581.8). This deformity can occur after neonatal circumcision in an infant who has significant scrotal swelling from a large hydrocele or inguinal hernia or after routine circumcision in an infant with a webbed penis. This complication can predispose to UTIs and can cause urinary retention. Initial treatment of a trapped penis should include topical corticosteroid cream, which often loosens the phimotic ring. In some cases, secondary repair is necessary at 6-9 months.

MICROPENIS

Micropenis is defined as a normally formed penis that is at least 2.5 standard deviations (SD) below the mean in size (Fig. 581.9). Typically, the ratio of the length of the penile shaft to its circumference is normal.

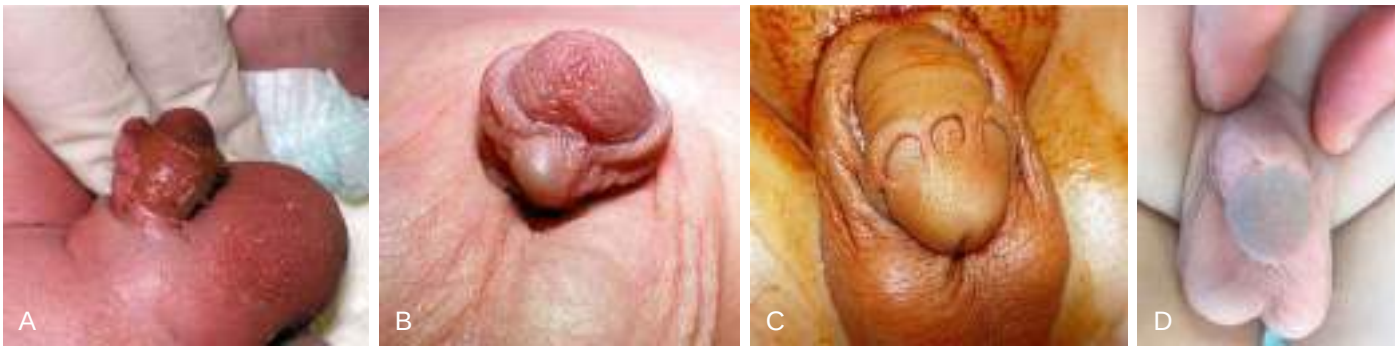

Fig. 581.5 Complications of circumcision. **A,** Denuded penile shaft. With local care, the penis healed and appeared normal. **B,** Midline epithelial inclusion cyst. **C** and **D,** Fibrous penile skin bridges.

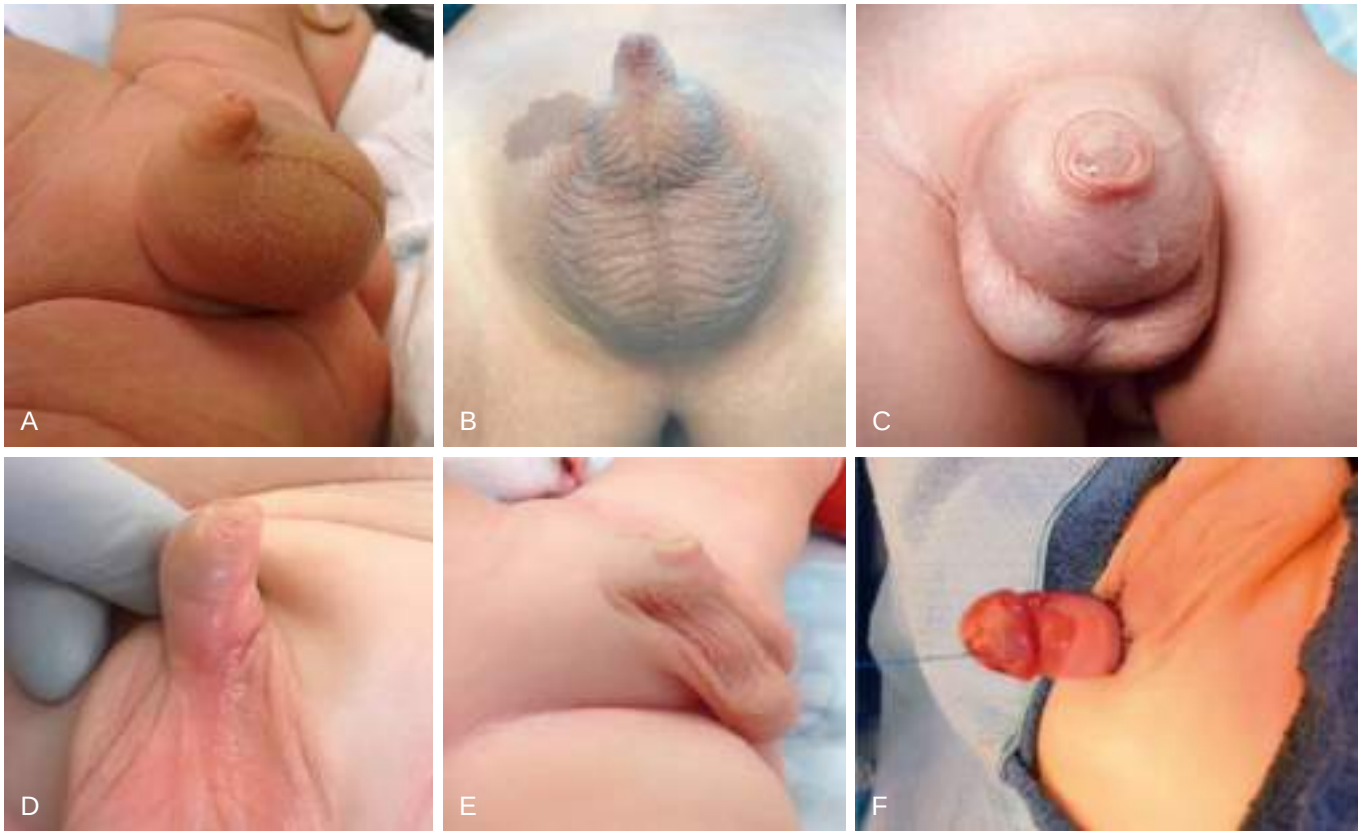

Fig. 581.6 Examples of congenital deformities in which neonatal circumcision is contraindicated. **A** and **B,** Hidden penis. **C,** Megaprepuce. **D,** Penile torsion to left side; note "wandering raphe." **E,** Webbed penis; note scrotal attachment to penile shaft. **F,** Same patient as in **E** following reconstruction at 6 mo.

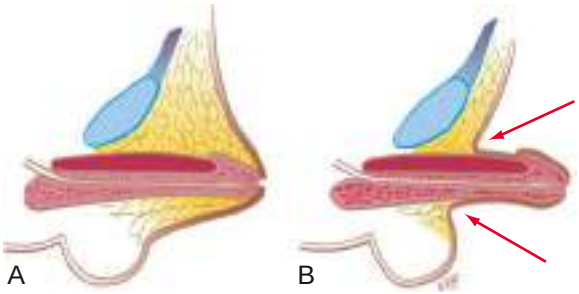

Fig. 581.7 Concealed penis **(A)**, which may be visualized by retracting skin lateral to penile shaft **(B)**. *(From Wein AJ, Kavoussi LR, Novick AC, et al., eds. Campbell-Walsh Urology, 9th ed. Philadelphia: WB Saunders; 2007: Fig. 126-4, p. 2339.)*

The pertinent measurement is the **stretched penile length**, which is measured by stretching the penis and measuring the distance from the penile base under the pubic symphysis to the tip of the glans. The mean length of the term newborn penis is 3.5 ± 0.7 cm and the diameter is 1.1 ± 0.2 cm. The diagnosis of micropenis in a male newborn is if the stretched length is <1.9 cm.

Micropenis usually results from a hormonal abnormality that occurs after the 14th week of gestation. Common causes include hypogonadotropic hypogonadism, hypergonadotropic hypogonadism (primary testicular failure), and idiopathic micropenis. If growth hormone deficiency is also present, neonatal hypoglycemia can occur. The most common cause of micropenis is failure of the hypothalamus to produce an adequate amount of gonadotropin-releasing hormone, as typically occurs in Kallmann syndrome (see Chapter 623), Prader-Willi syndrome (see Chapter 99), and Lawrence-Moon-Bardet-Biedl

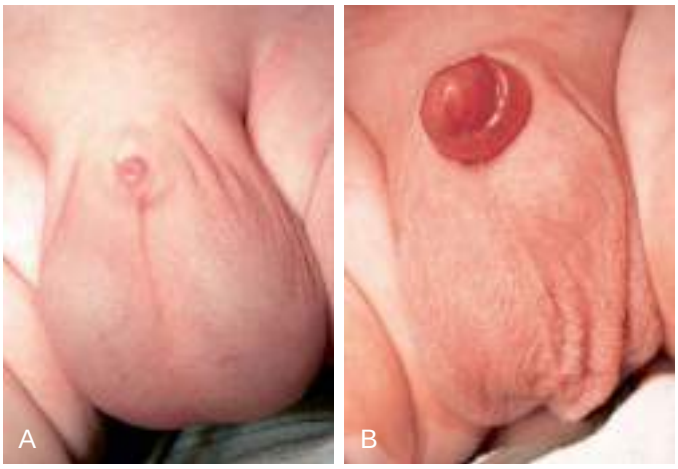

Fig. 581.8 **A,** Trapped (concealed) penis resulting from circumcision. **B,** Same patient after revision of circumcision. *(From Wein AJ, Kavoussi LR, Novick AC, et al., eds. Campbell-Walsh Urology, 9th ed. Philadelphia: WB Saunders; 2007: Fig. 126-2, p. 2340.)*

Fig. 581.9 Micropenis secondary to hypopituitarism in an 8-yr-old male. *(From Wein AJ, Kavoussi LR, Novick AC, et al., eds. Campbell-Walsh Urology, 9th ed. Philadelphia: WB Saunders; 2007: Fig. 126-5a, p. 2341.)*

syndrome. In some cases, there is growth hormone deficiency. Primary testicular failure can result from gonadal dysgenesis or rudimentary testes syndrome and also occurs in **Robinow syndrome** (characterized by hypoplastic genitals, shortening of the forearms, frontal bossing, hypertelorism, wide palpebral fissures, short broad nose, long philtrum, small chin, brachydactyly, and a normal karyotype).

A pediatric endocrinologist, geneticist, and pediatric urologist should examine all children with these syndromes, with participation by medical ethics. *Evaluation includes a karyotype, assessment of anterior pituitary function and testicular function, and MRI* to determine the anatomic integrity of the hypothalamus and the anterior pituitary gland as well as the midline structure of the brain. One of the difficult questions is whether androgen therapy is essential during childhood, because androgenic stimulation of penile growth in a prepubertal male can limit the growth potential of the penis in puberty. Studies of small groups of men with micropenis suggest that many, although not all, have satisfactory sexual function. Consequently, a decision for gender surgery in infancy is infrequently made.

PRIAPISM

Priapism is a persistent penile erection at least 4 hours in duration that continues beyond, or is unrelated to, sexual stimulation. Typically, only the corpora cavernosa is affected. There are three subtypes:

- Ischemic (venoocclusive, low-flow) priapism is characterized by little or no cavernous blood flow, and cavernous blood gases are hypoxic, hypercapnic, and acidotic. The corpora are rigid and tender to palpation. Immediate intervention is warranted.
- Nonischemic (arterial, high-flow) priapism is caused by unregulated cavernous arterial inflow. Typically, the penis is neither fully rigid nor painful. There is often a history of antecedent trauma resulting in a cavernous artery–corpora cavernosa fistula. Most cases resolve without intervention and expectant management is typical.
- Stuttering (intermittent) priapism is a recurrent form of ischemic priapism with painful erections with intervening periods of detumescence.

The most common cause of priapism in children is sickle cell disease, which is characterized by a predominance of sickle cell hemoglobin (see Chapter 511.1). As many as 29% of male patients with sickle cell disease develop priapism. The priapism is generally related to a low-flow state, secondary to sickling of red blood cells within the sinusoids of the corpora cavernosa during normal erection, resulting in venous stasis. This situation results in decreased local oxygen tension and pH, which potentiates further stasis and sickling. Priapism typically occurs during sleep, when mild hypoventilatory acidosis depresses oxygen tension and pH in the corpora. There is typically significant corporal engorgement with sparing of the glans penis. If the spongiosum is involved, voiding may be impaired. Evaluation may include a complete blood count. If the sickle cell status is unknown, hemoglobin electrophoresis should be performed. Corporal blood gas can help distinguish between a high-flow and low-flow state; ultrasound may also be used to differentiate these diagnoses. Other causes of low-flow priapism include sildenafil ingestion and leukemia.

In priapism secondary to sickle cell disease, medical therapy includes intravenous hydration, oxygen, alkalinization, and pain management with morphine. The American Urological Association guideline on priapism recommends concurrent intracavernous treatment beginning with corporal aspiration and irrigation with a sympathomimetic agent, such as phenylephrine. For patients with sickle cell disease, exchange transfusion may be considered but often takes several hours to arrange; therefore it is used when intracavernous treatment is not successful. If priapism has been present for >48 hours, ischemia and acidosis impair the intracavernous smooth muscle response to sympathomimetics. If irrigation and medical therapy are unsuccessful, a corporoglanular shunt should be considered. For stuttering priapism, administration of an oral α-adrenergic agent (pseudoephedrine) once or twice daily is first-line therapy. If this treatment is unsuccessful, an oral β-agonist (terbutaline) is recommended; a gonadotropin-releasing hormone analog plus flutamide is recommended as third-line therapy. Long-term follow-up of adults treated for sickle cell disease as children shows that satisfactory erectile function is inversely related to the patient's age at the onset of priapism and duration of priapism.

Nonischemic (high-flow) priapism most commonly follows perineal trauma, such as a straddle injury, that results in laceration of the cavernous artery. Typically, the aspirated blood is bright red, and the aspirate is similar to arterial blood. Color Doppler ultrasonography often demonstrates the fistula. The priapism spontaneously resolves in most cases. If it does not, angiographic embolization is indicated.

OTHER PENILE ANOMALIES

Aphallia (agenesis of the penis) affects approximately 1 in 10 million males. The karyotype is almost always 46, XY, and the usual appearance is that of a well-developed scrotum with descended testes and an absent penile shaft. Upper urinary tract abnormalities are common. In most cases, gender assignment surgery is recommended in the newborn period. **Diphallia** (duplication of the penis) ranges from a small accessory penis to complete duplication.

MEATAL STENOSIS

Meatal stenosis is a condition that almost always is acquired and occurs after neonatal circumcision. It most likely results from inflammation of

the denuded glans and is difficult to prevent. If the meatus is pinpoint, males void with a forceful, fine stream that goes a great distance. These males can experience dysuria, frequency, hematuria, or a combination of these conditions, typically around age 3-8 years. UTI is uncommon. Other males have dorsal deflection of the urinary stream. Although the meatus may be small, hydronephrosis or voiding difficulty is extremely rare unless there is associated balanitis xerotica obliterans (see Fig. 581.3; chronic dermatitis of unknown etiology, generally involving the glans and prepuce, occasionally extending into the urethra). Treatment is meatoplasty, in which the urethral meatus is opened surgically; this procedure can be performed either under anesthesia as an outpatient or in the office using local anesthesia (EMLA cream) with or without sedation. Routine cystoscopy is unnecessary.

OTHER MALE URETHRAL ANOMALIES

Parameatal urethral cyst manifests as an asymptomatic small cyst on one side of the urethral meatus. Treatment is excision under anesthesia. **Congenital urethral fistula** is a rare deformity in which a fistula is present from the penile urethra. It usually is an isolated abnormality. Treatment is fistula closure. **Megalourethra** is a large urethra that usually is associated with abnormal development of the corpus spongiosum. This condition is most commonly associated with prune-belly syndrome (see Chapter 577). **Urethral duplication** is a rare condition in which the two urethral channels lie in the same sagittal plane. There are many variations with complete and incomplete urethral duplication. These males often have a double stream. Most commonly, the dorsal urethra is small, and the ventral urethra is of normal caliber. Treatment involves excision of the small urethra. **Urethral hypoplasia** is a rare condition in which the entire male urethra is extremely small but patent. In some cases, a temporary cutaneous vesicostomy is necessary for satisfactory urinary drainage. Either gradual enlargement of the urethra or major urethroplasty is necessary. **Urethral atresia** refers to maldevelopment of the urethra and nearly always is fatal unless the urachus remains patent throughout gestation.

URETHRAL PROLAPSE (FEMALE)

Urethral prolapse occurs predominantly in females 1-9 years of age. The most common signs are bloody spotting on the underwear or diaper, although dysuria or perineal discomfort also can occur (Fig. 581.10). An inexperienced examiner can mistake the finding for sexual abuse. Initial therapy consists of application of estrogen cream 2-3 times daily for 3-4 weeks and sitz baths. Surgical repair is recommended for females that fail medical therapy and is curative. In some cases, this can be performed in the office under local anesthesia.

Fig. 581.10 Urethral prolapse in a 4-yr-old female who had bloody spotting on her underwear.

Fig. 581.11 Paraurethral cyst in a newborn female.

Fig. 581.12 Prolapsed ectopic ureterocele in a female infant. She had a nonfunctioning upper pole collecting system connected to the ureterocele.

OTHER FEMALE URETHRAL LESIONS

Paraurethral cyst results from retained secretions in the Skene glands secondary to ductal obstruction (Fig. 581.11). These lesions are present at birth, and most regress in size during the first 4-8 weeks, although occasionally incision and drainage is necessary. A **prolapsed ectopic ureterocele** appears as a cystic mass protruding from the urethra and is a presenting symptom in 10% of females with a ureterocele, which is a cystic swelling of the terminal ureter (Fig. 581.12). Ultrasonography should be performed to visualize the upper urinary tracts to confirm the diagnosis. Usually, either the ureterocele is incised or an upper urinary tract reconstructive procedure is necessary.

Visit Elsevier eBooks+ at eBooks.Health.Elsevier.com for Bibliography.

Chapter 582

Disorders and Anomalies of the Scrotal Contents

Heather N. Di Carlo and Chad B. Crigger

UNDESCENDED TESTIS (CRYPTORCHIDISM)

The absence of a palpable testis in the scrotum indicates that the testis is undescended, absent, atrophic, or retractile.

Epidemiology

An undescended **(cryptorchid)** testis is the most common congenital genitourinary tract disorder in males. At birth, approximately 4.5% of males have an **undescended testis.** Because testicular descent occurs at 7-8 months of gestation, 30% of premature male infants have an undescended testis; the incidence is 3.4% at term. As many as 50% of congenital undescended testes descend spontaneously during the first 3 months of life, and by 6 months the incidence decreases to 1.5%. Spontaneous descent occurs secondary to a temporary testosterone surge (termed a *minipuberty*) during the first 2 months, which also results in significant penile growth. If the testis has not descended by 4 months, it will remain undescended. Cryptorchidism is bilateral in 10% of cases. There is some evidence that the incidence of cryptorchidism is increasing; this is attributed to increase in utero exposure to endocrine disrupting chemicals. Although cryptorchidism usually is considered to be congenital, some older males have a scrotal testis that "ascends" to a low inguinal position and therefore requires an orchiopexy. In addition, 1–2% of neonatal and young males undergoing hernia repair develop secondary cryptorchidism from scar tissue along the spermatic cord.

Pathogenesis

The process of testicular descent is regulated by an interaction among genetic, hormonal, and mechanical factors, including testosterone, dihydrotestosterone, müllerian-inhibiting factor, the gubernaculum, intraabdominal pressure, and the genitofemoral nerve (Table 582.1). The testis develops in the abdomen at 7-8 weeks of gestation. Insulin-like factor 3 controls the transabdominal phase. At 10-11 weeks, the Leydig cells produce testosterone, which stimulates differentiation of the Wolffian (mesonephric) duct into the epididymis, vas deferens, seminal vesicle, and ejaculatory duct. At 32-36 weeks, the testis, which is anchored at the internal inguinal ring by the gubernaculum, begins its process of descent and is controlled in part by a calcium gene-related peptide produced by the genitofemoral nerve. The gubernaculum descends the inguinal canal and guides the testis into the scrotum. Following testicular descent, the patent processus vaginalis (hernia sac) normally closes.

Clinical Manifestations

Undescended testes are classified as **abdominal** (which are nonpalpable), **peeping** (abdominal but can be pushed into the upper part of the inguinal canal), **inguinal, gliding** (can be pushed into the scrotum but retracts immediately to the pubic tubercle), and **ectopic** (superficial inguinal pouch or, rarely, perineal). Most undescended testes are palpable just distal to the inguinal canal over the pubic tubercle.

A **disorder of sex development** should be suspected in a newborn phenotypic male with bilateral nonpalpable testes, as the child could be a virilized female with congenital adrenal hyperplasia (see Chapter 616). *In a male with midpenile or proximal hypospadias and a palpable undescended testis, the risk of a disorder of sexual development is 15%; the risk is 50% if the testis is nonpalpable.*

The potential **consequences of cryptorchidism** include poor testicular growth, infertility, testicular malignancy, associated hernia, torsion of the cryptorchid testis, and the possible psychologic effects of an empty scrotum.

The undescended testis is normal at birth histologically with a plethora of germ cells, but pathologic changes occur by 6-12 months of age. Delayed germ cell maturation, germ cell depletion, hyalinization of the seminiferous tubules, and reduced Leydig cell number are typical; these changes are progressive over time if the testis remains undescended. At puberty, an undescended testis has no viable sperm components. Although less severe, changes may occur in the contralateral descended testis after 4-7 years. After treatment for a unilateral undescended testis, 85% of patients are fertile, which is slightly less than the 90% rate of fertility in an unaffected population of adult males. In contrast, following bilateral orchiopexy, only 50–65% of patients are fertile.

The risk of a **germ cell malignancy** (see Chapter 552) developing in an undescended testis is four times higher than in the general population and is approximately 1 in 80 with a unilateral undescended testis and 1 in 40-50 for bilateral undescended testes. Testicular tumors are less common if orchiopexy is performed before 10 years of age, but they still occur, and adolescents should be instructed in testicular self-examination. The peak age for developing a malignant testis tumor is 15-45 years of age. The most common tumor developing in an undescended testis in an adolescent or adult is a **seminoma** (65%); after orchiopexy, nonseminomatous tumors represent 65% of testis tumors. Orchiopexy seems to reduce the risk of testicular cancer; it is uncommon for testis tumors to occur if the orchiopexy was performed before the age of 2 years. The contralateral scrotal testis may also be at a slightly increased risk for malignancy.

An indirect inguinal hernia usually accompanies a congenital undescended testis but rarely is symptomatic. Torsion and infarction of the cryptorchid testis also are uncommon but can occur because of excessive mobility of undescended testes. Consequently, inguinal pain and/or swelling in a male with an undescended testis should raise the suspicion of an inguinal hernia or torsion of the undescended testis.

An *acquired* or **ascending undescended testis** occurs when a male has a descended testis at birth, but during childhood, usually between ages 4-10 years, the testis does not remain in the scrotum. Such males often have a history of a retractile testis. With testicular ascent on physical examination, the testis can often be manipulated into the upper scrotum, but there is obvious tension on the spermatic cord. This condition is speculated to result from incomplete involution of the processus vaginalis, restricting spermatic cord growth and resulting in the testis gradually moving out of its scrotal position during a male's somatic growth.

On physical examination of the scrotum, the child should be encouraged to relax. Careful consideration of a hypoplastic ipsilateral scrotum may clue the examiner in to a diagnosis of an undescended testicle. The examiner should examine the patient's scrotum and inguinal canal using their dominant hand. The nondominant hand is positioned over the pubic tubercle and is pushed inferiorly toward the scrotum. The examiner's dominant hand is used to try to palpate the testis. If the testis is nonpalpable, the *soap test* often is useful; soap is applied to the inguinal canal and the examiner's hand, significantly reducing friction and facilitating identification of an inguinal testis. In addition, pulling on the scrotum can pull a high inguinal testis into a palpable position. One soft sign that a testis is absent is contralateral testicular hypertrophy, but this finding is not 100% diagnostic.

Retractile testes may be misdiagnosed as undescended testes. Males older than 1 year of age often have a brisk cremasteric reflex, and if the child is anxious or ticklish during scrotal examination, the testis may be difficult to manipulate into the scrotum. Males should be examined with their legs in a relaxed frog-leg position, and if the testis can be manipulated into the scrotum comfortably, it is probably retractile. It should be monitored every 6-12 months with follow-up physical examinations, because it can become an acquired undescended testis. Overall, as many as one third of males with a retractile testis develop an acquired undescended testis requiring orchiopexy, and males younger than 7 years of age at diagnosis of a retractile testis are at greatest risk. Although definitive data are not available, it is generally thought that males with a retractile testis are not at increased risk for infertility or malignancy.

Approximately 10% of undescended testes are **nonpalpable testes.** Of these, 50% are viable testes in the abdomen or high in the inguinal canal, and 50% are atrophic or absent, almost always in the scrotum,

Table 582.1 Conditions Associated with Cryptorchidism

DISEASES OR SYNDROMES ASSOCIATED WITH DECREASED ANDROGEN LEVELS *Disorders of Sex Development (DSD)* Sex chromosome DSD 47,XXY (Klinefelter syndrome and variants) 45,X/46,XY (mixed gonadal dysgenesis) 46,XX/46,XY (chimerism)
46,XY DSD
Disorders of testicular development Complete or partial gonadal dysgenesis Variations in *ARX, ATRX, CBX2, DAX1 (NROB1), DHH, DHX37, DMRT1, EMX2, ESR2, FGFR2, GATA4, HHAT, MAP3K1, NR5A1, SF1, SOX9, SRY, TSPYL1, WNT4, WT1*(WAGR syndrome, Denys-Drash syndrome, Frasier syndrome), *ZFPM2*, and *ZNRF3* genes
Disorders in androgen synthesis or action Androgen biosynthetic defect • Abnormal LH (*LHB*) • Steroidogenic acute regulatory protein (StAR deficiency) (*STAR*) • 7-Dehydro-cholesterol desmolase deficiency (Smith-Lemli-Opitz syndrome) • Cholesterol desmolase deficiency (*CYP11A1*) • 3β -hydroxysteroid dehydrogenase type 2 deficiency (*HSD3B2*) • 17,20-lyase deficiency or combined 17 hydroxylase/17,20-lyase deficiency (*CYP17A1*) • P450-oxidoreductase deficiency (*POR*) • 17β -Hydroxysteroid-dehydrogenase type 3 (*HSD17B3*) • 5-α reductase type 2 enzyme deficiency (*SRD5A2*) • Cytochrome b5 deficiency (*CYB5A*) • Backdoor steroidogenetic enzyme deficiency (*AKR1C2, AKR1C4*) Defect in androgen action • Partial androgen insensitivity (*AR*) • Infantile onset X-linked spinal muscular atrophy LH receptor defects • Inactivating mutation of LH receptor gene (*LHCGR*) (Leydig cell hypoplasia, aplasia)
46,XX DSD Ovotesticular DSD Testicular DSD (e.g. *SRY*+, dup *SOX9*, *RSP01*) 46,XX male
Congenital Hypogonadotropic Hypogonadism in 46,XY Isolated hypogonadotropic hypogonadism with anosmia (Kallmann syndrome) *KAL1, FGFR1/FGF8, PROK2/PROKR2, KAL1, NELF, HS6ST1, WDR11*, and *SEMA3A* gene variants *CHD7* gene variant (CHARGE syndrome)
Normosmic isolated hypogonadotropic hypogonadism Variants in *KISS1, GPR54, LEP, LEPR, TAC3/TACR3*, and *GNRH1/GNRHR* genes (also reported variants in *FGFR1/FGF8, PROKR2, CHD7*, and *WDR11* genes)
Multiple pituitary hormone deficiencies Variants in *PROP1* genes, *HESX1* gene (septo-optic dysplasia)
Congenital Hypergonadotropic Hypogonadism Down syndrome Noonan syndrome
Syndromes Associated with Both Primary and Secondary Hypogonadism Prader-Willi syndrome Bardet-Biedl syndrome
CONDITIONS ASSOCIATED WITH DECREASED INSL3 OR AMH LEVELS OR ACTIONS *INSL3* or *RXFP2* variants Persistent Müllerian duct syndrome: AMH and AMH receptor (*AMH, AMHR2*)
OTHER CONDITIONS RELATED WITH CRYPTORCHIDISM Multiple syndromes not specifically involving pituitary-gonadal development or function

AMH, anti-Müllerian hormone; CHARGE, coloboma, heart defects, atresia choanal, growth restriction, genital abnormalities, ear abnormalities; INSL3, insulin like peptide 3;.LH, luteinizing hormone.

Modified from Rodprasert W, Virtanen HE, Mäkekä JA, Toppari J: Hypogonadism and cryptorchidism. *Front Endocrinol (Lausanne)*. 2020;10:906.

secondary to spermatic cord torsion in utero **(vanishing testis).** If the nonpalpable testis is abdominal, it will not descend after 3 months of age. *Although sonography often is performed to try to identify whether the testis is present, it rarely changes clinical management, because the abdominal testis and atrophic testis are not identified on sonography.* Inguinal/scrotal sonography might be beneficial in obese males with a nonpalpable testis; in this clinical setting, the undescended testis often is nonpalpable, and an inguinal/scrotal sonogram can be beneficial in surgical planning. Computed tomographic imaging is relatively accurate in demonstrating the presence of the testis, but the radiation exposure is significant. MRI is even more accurate, but the disadvantage is that general anesthesia or sedation is necessary in most young children.

None of these imaging studies are 100% accurate and in general do not add significantly to clinical decision-making by the pediatric urologist or pediatric surgeon. Consequently, routine use of imaging is discouraged. A diagnostic approach is noted in Figure 582.1.

Treatment

The congenital undescended testis that does not descend by 6 months (corrected for gestational age) should be treated surgically within the next 12 months. Most testes can be brought down to the scrotum with an orchiopexy, which involves an inguinal incision, mobilization of the testis and spermatic cord, and correction of an indirect inguinal hernia. The procedure is typically performed on an outpatient basis and has a success rate of 98%. In some males with a testis that is close to the scrotum, a prescrotal orchiopexy can be performed. In this procedure, the entire operation is performed through a high scrotal incision. Often the associated inguinal hernia also can be corrected through this incision. Advantages of this approach over the inguinal approach include shorter operative time and less postoperative discomfort.

In males with a nonpalpable testis, an exam under anesthesia should be done to reassess for palpability; if testes are still nonpalpable, diagnostic laparoscopy is performed in most centers. This procedure allows safe and rapid assessment of whether the testis is intraabdominal. In most cases, orchiopexy of the intraabdominal testis located adjacent to the internal inguinal ring is successful, but orchiectomy should be considered in more difficult cases or when the testis appears to be atrophic. A two-stage orchiopexy sometimes is needed in males with a high abdominal testis. Males with abdominal testes are managed with laparoscopic techniques at many institutions. Testicular prostheses are available for older children and adolescents when the absence of the gonad in the scrotum might have an undesirable psychologic effect. The FDA has approved a saline testicular implant. Solid silicone "carving block" implants also are used (Fig. 582.2). Placement of testicular prostheses early in childhood is recommended for males with anorchia (absence of both testes).

The American Urological Association guidelines for the evaluation and treatment of males with an undescended testis are summarized in Table 582.2.

SCROTAL SWELLING

Scrotal swelling may be acute or chronic and painful or painless (Table 582.3). Abrupt onset of painful scrotal swelling necessitates prompt evaluation because some conditions, such as testicular torsion and incarcerated inguinal hernia, require emergency surgical management. Tables 582.4 and 582.5 show the differential diagnosis.

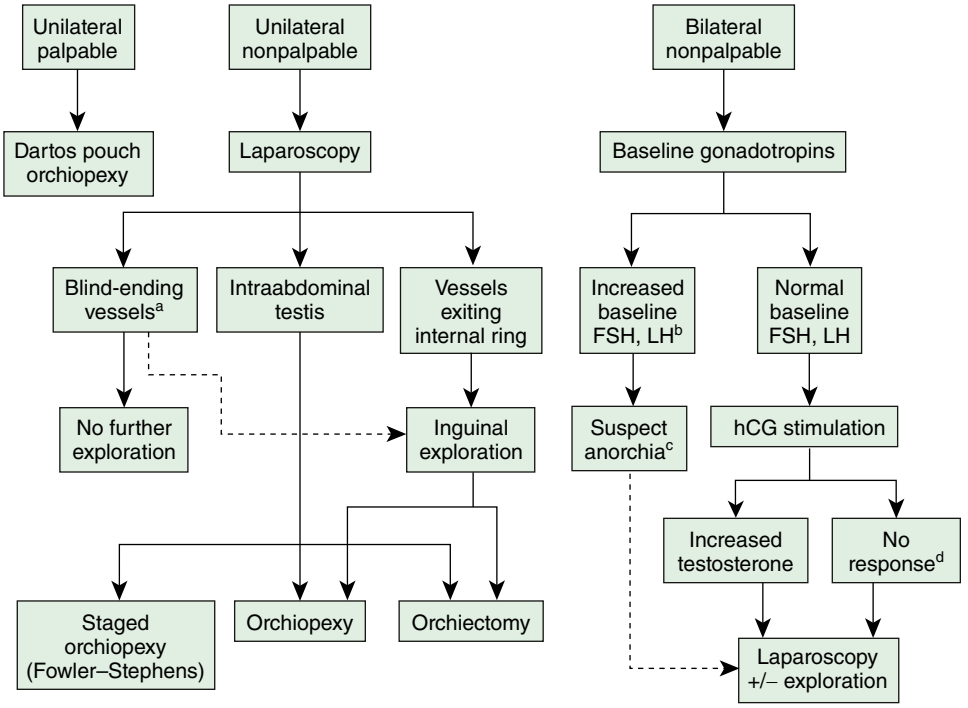

Fig. 582.1 Management algorithm for undescended testis. [a]If blind-ending vas deferens vessels are unequivocally identified, then there is no need for further exploration. [b]Baseline FSH and LH levels are elevated if values are 3 SD above the mean. *c*, Increased suspicion of anorchia with elevated baseline FSH and LH levels; however, exploration is still warranted. *d*, Testicular remnant tissue may be present despite a negative hCG stimulation test; therefore exploration for testicular remnant tissue should still be performed. *(From Bowlin PR, Lorenzo AJ. Undescended testes and testicular tumors. In: Holcomb III GW, Murphy JP, St. Peter SD, eds. Holcomb and Ashcraft's Pediatric Surgery, 7th ed. Philadelphia: Elsevier; 2020: Fig. 51-2, p. 808.)*

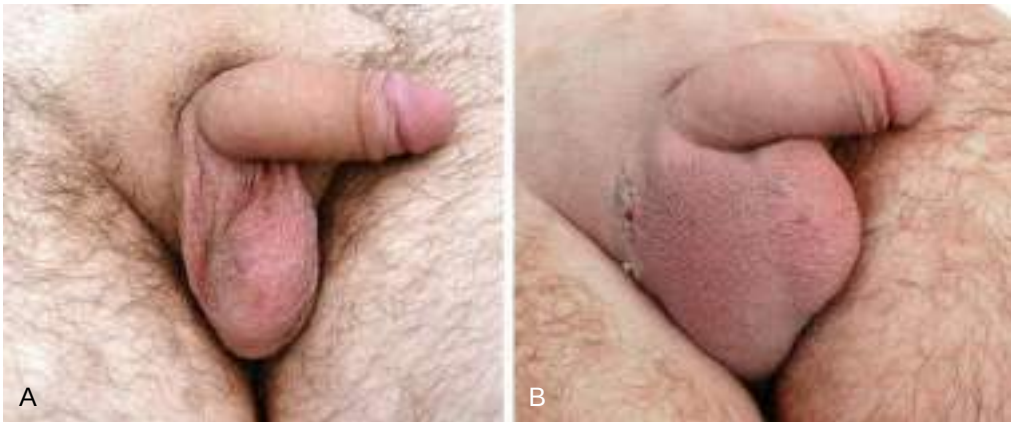

Fig. 582.2 A, Adolescent with solitary left testis. B, Appearance following implantation of right testicular prosthesis.

Table 582.2 American Urological Association Guidelines for Evaluation and Treatment of Males with an Undescended Testis

DIAGNOSIS

- Providers should obtain gestational history at initial evaluation of males with suspected cryptorchidism. *(Standard)*
- Primary care providers should palpate testes for quality and position at each recommended well-child visit. *(Standard)*
- Providers should refer infants with a history of cryptorchidism (detected at birth) who do not have spontaneous testicular descent by 6 months (corrected for gestational age) to an appropriate surgical specialist for timely evaluation. *(Standard)*
- Providers should refer males with the possibility of newly diagnosed (acquired) cryptorchidism after 6 months (corrected for gestational age) to an appropriate surgical specialist. *(Standard)*
- Providers must immediately consult an appropriate specialist for all phenotypic male newborns with bilateral, nonpalpable testes for evaluation of a possible disorder of sex development (DSD). *(Standard)*
- Providers should not perform ultrasound (US) or other imaging modalities in the evaluation of males with cryptorchidism before referral because these studies rarely assist in decision making. *(Standard)*
- Providers should assess the possibility of a disorder of sex development (DSD) when there is increasing severity of hypospadias with cryptorchidism. *(Recommendation)*
- In males with bilateral, nonpalpable testes who do not have congenital adrenal hyperplasia (CAH), providers should measure Mullerian Inhibiting Substance (MIS or Anti-Mullerian Hormone [AMH] level), and consider additional hormone testing, to evaluate for anorchia. *(Option)*
- In males with retractile testes, providers should monitor the position of the testes at least annually to monitor for secondary ascent. *(Standard)*

TREATMENT

- Providers should not use hormonal therapy to induce testicular descent because evidence shows low response rates and lack of evidence for long-term efficacy. *(Standard)*
- In the absence of spontaneous testicular descent by 6 months (corrected for gestational age), specialists should perform surgery within the next year. *(Standard)*
- In prepubertal males with palpable, cryptorchid testes, surgical specialists should perform scrotal or inguinal orchidopexy. *(Standard)*
- In prepubertal males with nonpalpable testes, surgical specialists should perform examination under anesthesia to reassess for palpability of testes. If nonpalpable, surgical exploration and, if indicated, abdominal orchidopexy should be performed. *(Standard)*
- At the time of exploration for a nonpalpable testis in boys, surgical specialists should identify the status of the testicular vessels to help determine the next course of action. *(Clinical Principle)*
- In males with a normal contralateral testis, surgical specialists may perform an orchiectomy (removal of the undescended testis) if a male has a normal contralateral testis and either very short testicular vessels and vas deferens, dysmorphic or very hypoplastic testis, or postpubertal age. *(Clinical Principle)*
- Providers should counsel males with a history of cryptorchidism and/or monorchidism and their parents regarding potential long-term risks and provide education on infertility and cancer risk. *(Clinical Principle)*

Adapted from Kolon TF, Herndon CDA, Baker LA, et al. Evaluation and treatment of cryptorchidism (2018): AUA Guideline. https://www.auanet.org/guidelines-and-quality/guidelines/cryptorchidism-guideline

Clinical Manifestations

A detailed history is helpful in determining the cause of the swelling and includes the rapidity of onset of pain. With testicular torsion, the pain often is sudden in onset and may be associated with exercise or minor genital trauma, duration of pain, and radiation of pain. Inguinal discomfort is common with testicular torsion, inguinal hernia, or epididymitis, and associated flank pain can occur with passage of a ureteral calculus; previous episodes of similar pain, which are common in males with intermittent testicular torsion or inguinal hernia; nausea and vomiting, which

Table 582.3 Differential Diagnosis of Pediatric Adolescent Acute Scrotal Pain

- Appendage torsion
  - Appendix testis
  - Other appendage (epididymis, paradidymis, vas aberrans)
- Spermatic cord torsion
  - Intravaginal, acute or intermittent
  - Extravaginal
- Epididymitis
  - Infectious
    - Urinary tract infection
    - Sexually transmitted infection
    - Viral including COVID-19
  - Sterile or traumatic
- Scrotal edema or erythema
  - Diaper dermatitis, insect bite, or other skin lesions
  - Idiopathic scrotal edema
  - IgA vasculitis (Henoch-Schönlein purpura)
- Orchitis
  - Associated with epididymitis with or without abscess
  - Vasculitis (e.g., IgA vasculitis)
  - Viral illness (mumps, COVID-19)
- Trauma
  - Hematocele or scrotal contusion or testis rupture
- Hernia or hydrocele
  - Inguinal hernia with or without incarceration
  - Communicating hydrocele
  - Encysted hydrocele with or without torsion
  - Associated with acute abdominal pathology (e.g., appendicitis, peritonitis)
- Varicocele
- Intrascrotal mass
  - Cystic dysplasia or tumor of testis
  - Epididymal cyst, spermatocele or tumor
  - Other paratesticular tumors
- Musculoskeletal pain from inguinal tendinitis or muscle strain
- Ilioinguinal neuropathy
- Genitofemoral nerve entrapment
- Referred pain (e.g., ureteral calculus or anomaly)

Modified from Palmer LS, Palmer JS. Management of abnormalities of the external genitalia in boys. In: Partin AW, Dmochowski RR, Kavoussi LR, Peters CW, eds. *Campbell-Walsh Urology*, 12th ed. Philadelphia: Elsevier; 2021: Box 44-2.

Table 582.4 Differential Diagnosis of Scrotal Masses in Male Children and Adolescents

PAINFUL	PAINLESS
Testicular torsion	Hydrocele
Torsion of appendix testis	Inguinal hernia*
Epididymitis	Varicocele*
Trauma: ruptured testis, hematocele	Spermatocele*
Inguinal hernia (incarcerated)	Testicular tumor*
Mumps orchitis	IgA vasculitis*
Testicular vasculitis	Idiopathic scrotal edema

*May be associated with discomfort.

Table 582.5 Differential Diagnosis of Scrotal Swelling in Newborn Males

- Hydrocele
- Inguinal hernia (reducible)
- Inguinal hernia (incarcerated)*
- Testicular torsion*
- Scrotal hematoma
- Testicular tumor
- Meconium peritonitis
- Epididymitis*

*May be associated with discomfort.

are associated with testicular torsion and inguinal hernia; and irritative urinary symptoms, such as dysuria, urgency, and frequency, which indicate a urinary tract infection that can cause epididymitis. Some males report a recent history of scrotal trauma. There are multiple reports of familial testicular torsion related to inheritance of bell clapper deformity (discussed later). Males with lower urinary tract pathology such as urethral stricture or neuropathic bladder may be prone to epididymitis.

Physical examination may be difficult in males with a painful scrotum. Some have advocated performing a spermatic cord block or administering intravenous analgesia to facilitate the examination, but such measures are often unnecessary. Scrotal wall erythema is common in testicular torsion, epididymitis, torsion of the appendix testis, and an incarcerated hernia. In males with a normal cremasteric reflex, testicular torsion is unlikely. Absence of a cremasteric reflex is nondiagnostic.

Laboratory Findings and Diagnosis

Pertinent laboratory studies include urinalysis and culture. A positive urinalysis suggests bacterial epididymitis (uncommon before adolescence). Serum studies are not helpful in establishing a diagnosis unless a testicular malignancy is suspected. After initial evaluation in males with testicular pain, color Doppler ultrasonography often is helpful in establishing the diagnosis because it assesses whether testicular blood flow is normal, reduced, or increased (Fig. 582.3). If a hydrocele is present and the testis is nonpalpable, or if an abnormality of the testis is found, sonography also is indicated. *Imaging studies are not 100% accurate; they should not be used to decide whether a male with testicular pain should be referred for urologic evaluation.* As such, torsion is a clinical diagnosis.

Color Doppler ultrasonography allows assessment of testicular blood flow and testicular morphologic features. Accuracy is >95% if the ultrasonographer is experienced and the patient is older than 2 years of age. The "whirlpool" sign is pathognomonic. A false-negative study (demonstrates normal testicular blood flow) can occur in a male with testicular torsion if the degree of torsion is <360 degrees and the duration of torsion is short, because there may be continued testicular perfusion. In males <1 year of age, including neonates, blood flow may be difficult to demonstrate in 15% of normal testes.

TESTICULAR (SPERMATIC CORD) TORSION

Etiology

Testicular torsion requires prompt diagnosis and treatment to salvage the testis. Torsion is the most common cause of severe testicular pain in males 12 years of age and older and is uncommon before age 10. It is caused by inadequate fixation of the testis within the scrotum, resulting from a redundant tunica vaginalis and abnormal gubernacular attachment, allowing excessive mobility of the testis. The abnormal attachment is termed a **bell clapper deformity** and may be bilateral. Following spermatic cord torsion, venous congestion occurs, and subsequently arterial flow is interrupted. The likelihood of testis survival depends on the duration and severity of torsion. After 6 hours of absent blood flow to the testis, irreversible loss of spermatogenesis can occur. Torsion is familial in 10% of males.

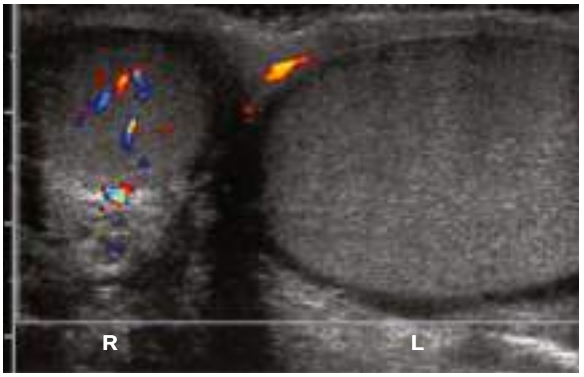

Fig. 582.3 Testicular torsion and axis change. A color Doppler ultrasound in the transverse plane shows color flow in the right testicle. The right testicle is oval to circular because it has been evaluated in the transverse plane. The left testicle is elongated as if it is in the longitudinal plane, indicating an abnormal lie within the scrotum worrisome for torsion. Lack of color Doppler flow in the left testicle confirms left testicular torsion. *(From Coley BD, ed. Caffey's Pediatric Diagnostic Imaging, 13th ed. Philadelphia: Elsevier; 2019: Fig. 125-13, p. 1195.)*

Diagnosis

Testicular torsion produces acute pain and swelling of the scrotum. On examination, the scrotum is swollen, and the testis is exquisitely tender and often difficult to examine. The cremasteric reflex is nearly always absent, though this may be absent at baseline in a proportion of males. The position (lie) of the testis is abnormal, and the testis is often located high in the scrotum. In addition, nausea and vomiting often occur. The condition can be differentiated from an incarcerated hernia because swelling in the inguinal area typically is absent with torsion. The Testicular Workup for Ischemia and Suspected Torsion (TWIST) score is a clinical tool that can be used determine the likelihood of testicular torsion. The score consists of testicular swelling (2 points), hard testis (2 points), high-riding testis (1 point), absent cremasteric reflex (1 point), and nausea/vomiting (1 point). Patients can then be stratified into low (0 points), intermediate (1-5), and high risk (6-7), which aids in determining further imaging and/or surgical consultation.

For patients who are high risk or meet the clinical diagnosis of testicular torsion, prompt surgical consultation should be obtained. If the pain duration is <4-6 hours, manual detorsion may be attempted. In 65% of cases the torsed testis rotates inward, so detorsion should be attempted in the opposite direction (e.g., the left testis is rotated clockwise). Successful manual detorsion results in dramatic pain relief. In the emergency department, patients with an intermediate risk TWIST score should undergo immediate scrotal ultrasound. In some centers, this is performed as a point of care procedure by the emergency department staff.

Some adolescents experience **intermittent testicular torsion**. These males report episodes of severe unilateral testicular pain that resolves spontaneously after 30-60 minutes. Treatment is elective bilateral scrotal orchiopexy. Close follow-up and clear return instructions are requisite in such cases until elective orchiopexy is performed.

Treatment

Treatment is prompt surgical exploration and detorsion. If the testis is explored within 6 hours of torsion, up to 90% will survive. Testicular salvage decreases rapidly with a delay of more than 6 hours. If the degree of torsion is 360 degrees or less, the testis might have sufficient arterial flow to allow the gonad to survive, even after 24-48 hours. Following detorsion, the testis is fixed in the scrotum with nonabsorbable sutures, termed **scrotal orchiopexy,** to prevent torsion in the future. The contralateral testis also should be fixed in the scrotum because the predisposing anatomic condition (bell clapper deformity) often is bilateral. If the testis appears nonviable, orchiectomy is performed (Fig. 582.4A). The detorsed testis may undergo compartment syndrome,

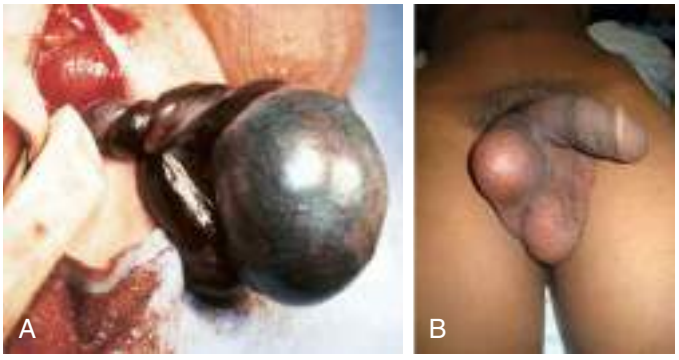

Fig. 582.4 A, Left testicular torsion in adolescent with acute scrotum; the testis is necrotic. B, "Late-phase torsion" in an adolescent with severe testicular pain 1 month prior. Note absence of inflammation and high position of testis in scrotum.

and following detorsion, despite blood flow to the testis, high intratesticular pressure may cause ischemia and necrosis. This condition has been treated intraoperatively by incising the tunica vaginalis (similar to a blunt testicular rupture) and placing a tunica vaginalis flap over the exposed tunica. Some adolescents do not undergo prompt evaluation and treatment and present with *late phase testicular torsion,* in which there is delayed diagnosis of torsion. Often the testis is high in the scrotum and nontender (see Fig. 582.4B). While males with torsion of longer duration prior to treatment may exhibit reduced spermatogenesis, current evidence shows pregnancy rates of couples in which the male has a history of acute testicular torsion to be similar to the general population.

*Spermatic cord torsion can also occur in the fetus or neonate***.** This condition results from incomplete attachment of the tunica vaginalis to the scrotal wall and is "extravaginal." When torsion occurs just before delivery, the baby usually is born with a large, firm, nontender testis. Usually the ipsilateral hemiscrotum is ecchymotic (Fig. 582.5). In these cases, the testis rarely is viable because torsion was a remote event. However, the contralateral testis is at increased risk for torsion until 1-2 months beyond term. The pediatric urology community is divided regarding whether immediate exploration is necessary in a male newborn who has suspected testicular torsion at birth, but if observation is recommended, the family needs to be counseled regarding the risk of contralateral spermatic cord torsion. If the initial exam is normal and the newborn subsequently develops scrotal swelling and erythema, and imaging is consistent with spermatic cord torsion, emergency scrotal exploration is indicated.

TORSION OF THE APPENDIX TESTIS/EPIDIDYMIS

Torsion of the appendix testis is the most common cause of testicular pain in males age 4-10 years but is uncommon in adolescents. The appendix testis is a stalklike structure that is a vestigial embryonic remnant of the müllerian (paramesonephric) ductal system that is attached to the upper pole of the testis. When it undergoes torsion, progressive inflammation and swelling of the testis and epididymis occurs, resulting in testicular pain and scrotal erythema. The onset of pain is typically gradual. Palpation of the testis usually reveals a 3-5 mm tender indurated mass on the upper pole (Fig. 582.6A). In some cases, the appendage that has undergone torsion may be visible through the scrotal skin, termed the **"blue dot"** sign. In some males, distinguishing torsion of the appendix from testicular torsion is difficult. In such cases, color Doppler ultrasonography is useful because testicular blood flow is normal and shows hyperemia to the upper pole of the testis. In such cases, the radiologist often recognizes epididymal enlargement and makes the diagnosis of epididymitis, reflecting the inflammatory reaction (see Fig. 582.6B).

The natural history of torsion of the appendix testis is for the inflammation to resolve in 3-10 days. Nonoperative treatment is recommended, including bed rest for 24 hours and analgesia with nonsteroidal antiinflammatory medication for several days. If the diagnosis is uncertain, scrotal exploration is recommended.

Fig. 582.5 A and B, Right testicular torsion in a newborn. The right hemiscrotum is darker, and the testis was indurated and enlarged.

EPIDIDYMITIS

Acute bacterial inflammation of the epididymis is an ascending retrograde infection from the urethra, through the vas deferens into the epididymis. This condition causes acute scrotal pain, erythema, and swelling. It is rare before puberty and should raise the question of a congenital abnormality of the Wolffian duct, such as an ectopic ureter entering the vas. In younger males, the responsible organism is often *Escherichia coli* (see Chapter 246). After puberty, bacterial epididymitis becomes progressively more common and can cause acute painful scrotal swelling in young sexually active males. Urinalysis usually reveals pyuria. Epididymitis can be bacterial (usually gonococcus or *Chlamydia*; see Chapters 238 and 272) or viral (mumps, enterovirus, or adenovirus; see Chapters 295, 297, and 309), but often the organism remains undetermined. Familial Mediterranean fever is another cause. Treatment consists of bed rest and antibiotics as indicated. Differentiation from torsion is straightforward with scrotal ultrasonography.

IgA vasculitis, previously known as Henoch-Schönlein purpura, (see Chapter 210.1) is a systemic vasculitis that involves multiple organ systems and that can involve the kidney and spermatic cord. When the spermatic cord is involved, typically there is bilateral painful scrotal swelling with purpuric lesions involving the scrotum. Scrotal sonography should show normal testicular blood flow. Treatment is directed toward systemic treatment of the IgA vasculitis. Isolated testicular vasculitis is less common in IgA vasculitis and, in such cases, polyarteritis nodosa should be suspected.

VARICOCELE

A **varicocele** is a congenital condition in which there is abnormal dilation of the pampiniform plexus in the scrotum, often described as a "bag of worms" (Fig. 582.7). Dilation of the pampiniform venous plexus results from valvular incompetence of the internal spermatic vein. Approximately 15% of adult males have a varicocele; of these, approximately 10–15% are subfertile. Varicocele is the most common (and virtually the only) surgically correctable cause of infertility in males. A varicocele is found in 10–15% of adolescent males, but it rarely is diagnosed in males younger than 10 years old, because the varicocele becomes distended only after the increased blood flow associated with

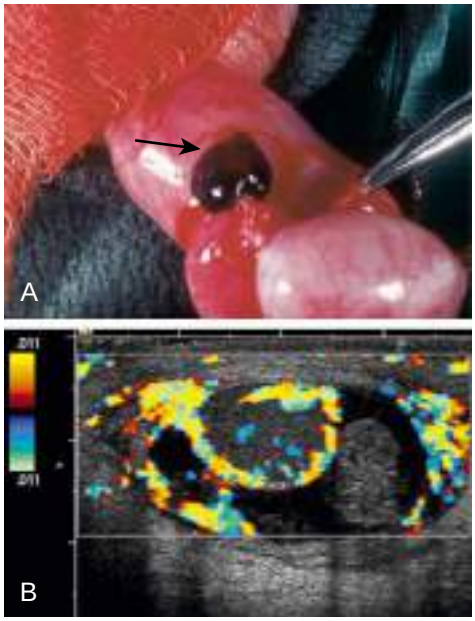

Fig. 582.6 A, Torsion of the appendix testis; the appendix testis is necrotic *(arrow)*. B, Color Doppler scrotal sonogram showing hyperemia to the testis and absent flow to the appendix testis *(right side)*. Symptoms resolved with medical therapy.

puberty occurs. Varicoceles occur predominantly on the left side, are bilateral in 2% of cases, and rarely involve the right side only. A varicocele in a male younger than 10 years or on the right side might indicate an abdominal or retroperitoneal mass; an abdominal ultrasound or CT scan should be performed in such cases.

A varicocele typically is a painless paratesticular mass. Occasionally patients describe a dull ache in the affected testis. Usually the varicocele is not apparent when the patient is supine because it is decompressed; in contrast, the varicocele becomes prominent when the patient is standing and enlarges with a Valsalva maneuver. Many pediatricians do not routinely screen adolescents for a varicocele. Varicoceles typically are graded from 1-3 with the male standing: **grade 1** is palpable only with Valsalva (clinically insignificant); **grade 2** is palpable without Valsalva but is not visible on inspection; and **grade 3** is visible with inspection. Males with a grade 3 varicocele are at greatest risk for testicular growth arrest, particularly if the varicocele is larger than the testis. Testicular size should be documented with calipers, an orchidometer, or scrotal sonography, because if the affected left testis is significantly smaller than the right testis, spermatogenesis probably has been adversely affected. A **semen analysis** should be considered in sexually mature adolescents who are Tanner stage V.

The goal of varicocelectomy is to maximize future fertility. Surgical treatment of varicoceles is indicated in males with a significant disparity in testicular size, with pain in the affected testis, if the contralateral testis is diseased or absent, or with oligospermia on semen analysis. Following treatment, typically the involved testis enlarges and catches up with the normal testis over the following 1-2 years. Varicocelectomy should also be considered in males with a large grade 3 varicocele, even if there is no disparity in testicular size. Surgical repair is accomplished with a variety of techniques by ligation of the veins of the pampiniform plexus laparoscopically or through an inguinal or subinguinal incision (with or without an operating microscope) or by ligating the internal spermatic vein in the retroperitoneum. The operation is performed on an ambulatory basis.

SPERMATOCELE

A **spermatocele** is a cystic lesion that contains sperm and is attached to the upper pole of the sexually mature testis. Spermatoceles usually are painless and are incidental findings on physical examination. Enlargement of the spermatocele or significant pain is an indication for removal.

Fig. 582.7 Left varicocele in an adolescent male.

HYDROCELE

Etiology

A hydrocele is an accumulation of fluid in the tunica vaginalis (Fig. 582.8). Between 1% and 2% of neonates have a hydrocele. In most cases, the hydrocele is noncommunicating (the processus vaginalis was obliterated during development). In such cases, the hydrocele fluid disappears by 1 year of age. If there is a persistently patent processus vaginalis, the hydrocele persists. It is typically small in the morning and may become larger during the day due to upright positioning. A rare variant of a hydrocele is the **abdominoscrotal hydrocele,** in which there is a large, tense hydrocele that extends into the lower abdominal cavity. In some older males, a noncommunicating hydrocele can result from an inflammatory condition within the scrotum, such as testicular torsion, torsion of the appendix testis, epididymitis, or testicular tumor. The long-term risk of a communicating hydrocele is the development of an inguinal hernia. Some older males and adolescents also develop a hydrocele. In some cases, hydroceles develop acutely after an episode of scrotal trauma or epididymoorchitis, whereas others develop more insidiously.

Diagnosis

On examination, hydroceles are smooth and nontender. Transillumination of the scrotum confirms the fluid-filled nature of the mass. It is important to palpate the testis, because some young males develop a hydrocele in association with a testis tumor. If the testis is nonpalpable, a scrotal ultrasound should be performed to confirm that the testis is present and normal. If compression of the fluid-filled mass completely reduces the hydrocele, an inguinal hernia/hydrocele is the likely diagnosis.

Treatment

Most congenital hydroceles resolve by 12 months of age following reabsorption of the hydrocele fluid. If the hydrocele is large and tense, however, early surgical correction should be considered, because it is difficult to verify that the child does not have a hernia, and large hydroceles rarely disappear spontaneously. Hydroceles persisting beyond 12-18 months often are communicating and should be repaired. Surgical correction is similar to a herniorrhaphy (see Chapter 394). Through an inguinal incision, the spermatic cord is identified, the hydrocele fluid is drained, and a high ligation of the processus vaginalis is performed. If an older male has a large hydrocele, often diagnostic laparoscopy can be performed to determine whether there is a patent processus vaginalis, and if the internal ring is closed, then the hydrocele may be corrected with a scrotal incision.

Fig. 582.8 Newborn with large right hydrocele.

INGUINAL HERNIA

Inguinal hernia is discussed in Chapter 394.

TESTICULAR MICROLITHIASIS

Approximately 2–3% of pediatric scrotal ultrasound examinations demonstrate calcific depositions in the testis, termed testicular microlithiasis. Typically, it is found in males undergoing an examination for testicular pain, varicocele, or scrotal swelling. In adults, it is a common finding in males with infertility and with a germ cell tumor of the testis. In pediatric patients with microlithiasis, there are no guidelines for monitoring, but the condition should be monitored for changes in testicular size or induration, with follow-up ultrasound studies as indicated.

TESTICULAR TUMOR

Testicular and paratesticular tumors can occur at any age, even in the newborn. Approximately 35% of prepubertal testis tumors are malignant; most commonly they are yolk sac tumors, although rhabdomyosarcoma and leukemia also can occur in this age group. In adolescents, 98% of painless solid testicular masses are malignant (see Chapter 552). Most manifest as a painless, hard testicular mass that does not transilluminate. Scrotal ultrasonography should be performed to confirm the finding of a testicular mass, and it can help to delineate the type of testis tumor. Serum tumor markers, including *α-fetoprotein* and *β-human chorionic gonadotropin,* should be drawn. Definitive therapy includes surgical exploration through an inguinal incision. In most cases, a radical orchiectomy, consisting of removal of the entire testis and spermatic cord, is performed. In a prepubertal male, if the ultrasonographic study or surgical exploration suggests that the tumor is localized and benign, such as a teratoma or an epidermoid cyst, testis-sparing surgery with removal only of the mass may be appropriate.

Visit Elsevier eBooks+ at eBooks.Health.Elsevier.com for Bibliography.

Chapter 583

Trauma to the Genitourinary Tract

Heather N. Di Carlo and Chad B. Crigger

Most injuries to the genitourinary tract in children result from blunt trauma during falls, athletic activities, or motor vehicle crashes (see Chapter 80). *Children are at greater risk of blunt renal injury than adults, because they have less body fat and because the kidneys are not located directly behind the ribs.* Children with a preexisting renal anomaly, such as hydronephrosis secondary to a ureteropelvic junction obstruction, horseshoe kidney, or renal ectopia, also are at increased risk for renal injury. Blunt abdominal or flank trauma often causes a renal injury. Falling can cause a deceleration injury that results in an injury to the renal pedicle, interrupting blood flow to the kidney. If the bladder is full, blunt lower abdominal trauma can cause a bladder rupture. Rupture of the membranous urethra occurs in 5% of pelvic fractures. Straddle injuries usually are associated with trauma to the bulbous urethra.

Symptoms and signs of urinary tract injury include gross or microscopic hematuria, bleeding from the urethral meatus, abdominal or flank pain, a flank mass, fractured lower ribs or lumbar transverse processes, and a perineal or scrotal hematoma.

In more than 50% of cases, there also are major injuries to the brain, spinal cord, skeleton, lungs, or abdominal organs.

DIAGNOSIS

Evaluation of the patient begins after an adequate airway has been established and the patient is hemodynamically stable (see Chapters 78 and 79). With significant abdominal injury, gross hematuria or >50 red blood cells per high-power field, or suspicion of renal injury (deceleration injury, flank pain, or bruise), renal imaging is indicated (Fig. 583.1). The bladder should be catheterized unless blood is dripping from the urethral meatus, which is an indication of potential urethral injury. Passing the catheter in the presence of a urethral injury can increase the extent of the damage and convert a partial membranous urethral tear into a total disruption. In these patients, a retrograde urethrogram should be performed by injecting radiopaque contrast medium into the urethral meatus under fluoroscopy. Oblique radiographs demonstrate the extent of the injury and whether urethral continuity is preserved or has been disrupted.

A three-phase spiral CT scan should be performed to evaluate the kidneys, ureters, and bladder. The delayed images are important to detect renal extravasation of blood or urine. Prompt function of both kidneys without extravasation usually excludes significant renal injury. Renal injuries are classified according to the grading scale presented in Table 583.1. Minor renal injuries are most common; these include contusion of the renal parenchyma and shallow cortical lacerations not involving the collecting system. Major renal injuries include deep lacerations involving the collecting system, shattered kidney, and renal pedicle injuries (Fig. 583.2). Complete absence of function of one kidney without contralateral compensatory hypertrophy (indicating congenital absence) should be regarded as an indication of major injury to the renal pedicle. Renal angiography, once used for further evaluation of renal injuries, particularly if a renal pedicle injury is suspected, now is rarely used because such patients are often hemodynamically unstable, and management is not significantly affected by the findings. In some cases, a preexisting renal anomaly is demonstrated on the study. A ruptured ureteropelvic junction obstruction may be apparent if the kidney is intact, but the distal ureter is not visualized.

If there is a pelvic fracture, a urethral transection injury should be suspected, particularly in males. The risk is directly related to the number of broken pubic rami and whether there is separation of the pubic symphysis or displacement of the posterior pubic arch. Radiographic evaluation with retrograde urethrography should be performed if there is blood at the urethral or vaginal meatus, inability to void, and a perineal or penile hematoma.

TREATMENT

Minor renal injuries such as contusions are managed by bed rest and monitoring of vital signs until abdominal or flank discomfort and gross hematuria have resolved. Children with a major renal injury usually are admitted to an intensive care unit for continuous monitoring of vital signs and urine output. Intravenous antibiotics are also administered. These injuries also are managed nonoperatively, because Gerota's fascia often causes tamponade of bleeding from the kidney, and dramatic healing of the injured parenchyma can occur even with significant urinary extravasation.

Approximately 10% of children with a major renal injury undergo surgical exploration because of associated abdominal injuries, hemodynamic instability, persistent extravasation, or persistent hematuria or to correct a congenital renal deformity. It can be difficult to identify normal and devitalized parenchyma, and the likelihood of having to remove the kidney is significant. If the child is undergoing exploration for other abdominal injuries, the injured kidney is examined. If there is persistent extravasation because of intermittent ureteral obstruction from a blood clot, passage of a temporary double-J stent endoscopically between the bladder and kidney might allow resolution. If the renal pedicle is injured, nephrectomy is necessary. The kidney can be salvaged by

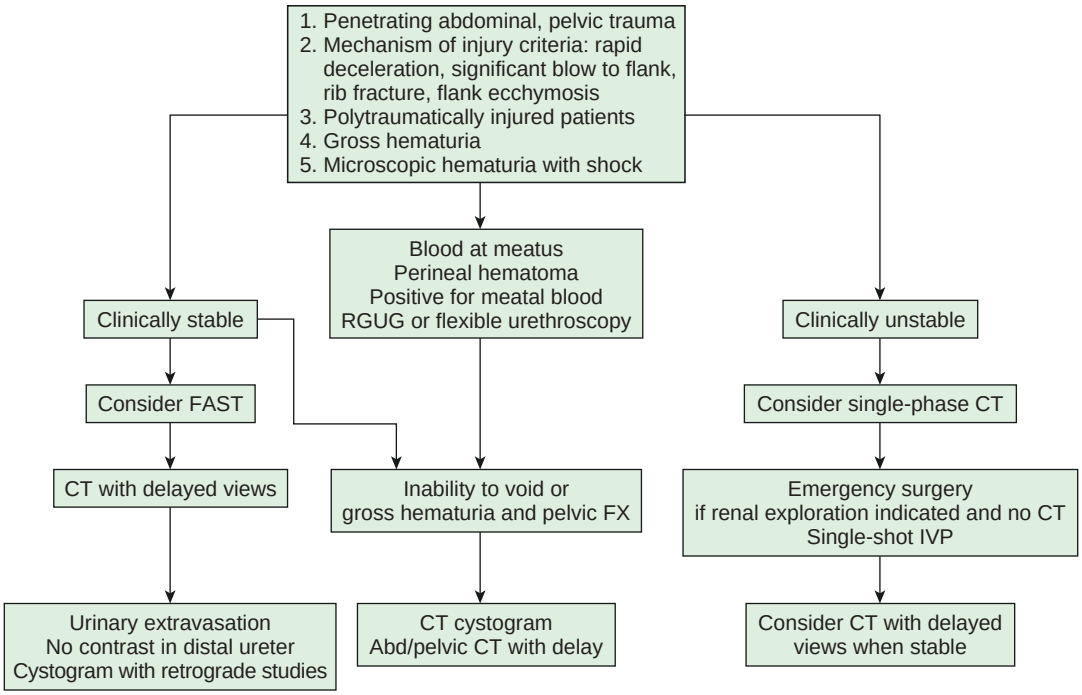

Fig. 583.1 Algorithm showing the recommended evaluation protocol for patients with a medical history or physical findings consistent with possible genitourinary injury. Abd, Abdominal; FAST, focused assessment with sonography for trauma; FX, fracture; IVP, intravenous pyelography; RGUG, retrograde urethrogram. *(From Husmann DA. Pediatric genitourinary trauma. Modified from Wein AJ, Kavoussi LR, Partin AW, Peters CA, eds. Campbell-Walsh Urology. 11th ed. Philadelphia: Elsevier; 2016: Fig. 154-6, p. 3546.)*

Table 583.1 Grading of Renal Injuries

GRADE	DESCRIPTION
1	Renal contusion or subcapsular hematoma
2	Nonexpanding perirenal hematoma, <1 cm parenchymal laceration, no urinary extravasation; all renal fragments viable; confined to renal retroperitoneum
3	Nonexpanding perirenal hematoma, >1 cm parenchymal laceration, no urinary extravasation; renal fragments may be viable or devitalized
4	Laceration extending into the collecting system with urinary extravasation; renal fragments may be vital or devitalized *or* Injury to the main renal vasculature with contained hemorrhage
5	Completely shattered kidney; by definition, multiple major lacerations >1 cm associated with multiple devitalized fragments *or* Injury to the main renal vasculature with uncontrolled hemorrhage, renal hilar avulsion

emergency renal revascularization only if the kidney is explored within 2-3 hours of the injury. Virtually all penetrating injuries of the kidneys should be explored.

In addition to loss of renal function, the main long-term complication of renal injury is renin-mediated hypertension. Children who sustain significant renal injuries should have periodic measurement of blood pressure if they have any residual renal abnormality.

Ureteral injuries usually are iatrogenic. Injuries of the ureter by blunt or penetrating trauma require immediate surgical attention.

When the bladder can be catheterized, a static cystogram is obtained, infusing a contrast solution through the catheter by gravity, ideally using fluoroscopy. Flat and oblique views are often obtained; a postvoid film also should be obtained because, in some cases, extravasation may be hidden by the full bladder. An alternative is a CT cystogram, which is highly accurate in demonstrating a bladder injury.

Bladder ruptures can be intraperitoneal or extraperitoneal. All intraperitoneal ruptures require surgical repair. Minor extraperitoneal near-ruptures might be treated by catheter drainage but generally require surgical treatment.

Treatment of a **membranous urethral injury** is controversial. Erectile dysfunction, urethral stricture, and urinary incontinence are the major late complications of rupture of the membranous urethra, and therapy is directed at minimizing the risk of these problems. A large pelvic hematoma with tamponade often is present, and an immediate attempt to repair the injury can be technically difficult and result in significant hemorrhage. Many such injuries are managed initially by temporary suprapubic cystostomy, with continuous bladder drainage for 3-6 months. Subsequently, open or endoscopic urethroplasty can be performed. Alternatively, some try to achieve urethral continuity under anesthesia and leave a urethral catheter for several months. These patients typically require subsequent open urethroplasty.

Penile injury is uncommon. Partial or complete glans amputation is a risk of newborn circumcision with a Mogen clamp. With immediate surgical repair, often the excised glans tissue can be replaced as a free graft. Some males who are in the process of toilet training sustain an injury to the glans penis if the lid of the toilet falls while they are urinating. These males often have a hematoma covering the distal half of the glans. Typically, they have no difficulty urinating and do not need extensive evaluation. Some male infants develop an inadvertent **hair tourniquet** or strangulation injury. Typically,

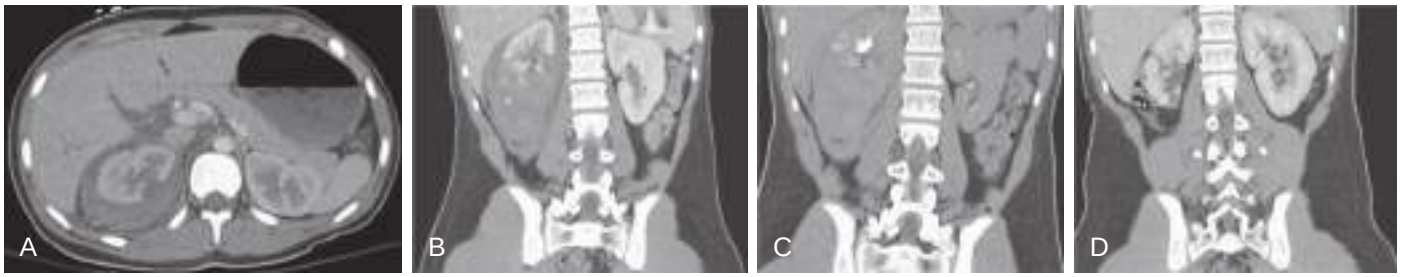

Fig. 583.2 CT images of grade 3 right renal trauma: acute, delayed, and at 3-month follow-up. **A,** Acute CT image of grade 3 renal trauma showing laceration of more than 1 cm of midrenal pole with perinephric hematoma. **B,** Acute CT image coronal reconstruction of grade 3 renal trauma, with possible devitalization of the entire lower pole of the kidney. **C,** Two-hour delayed CT image coronal reconstruction of grade 3 renal trauma, with no urinary extravasation noted and lower pole with questionable devitalization versus contusion. **D,** CT image coronal reconstruction 3 months after traumatic injury revealing parenchymal scarring at site of laceration with scarred but functional lower pole consistent with healed parenchyma following severe renal contusion. Scarring of lower pole was believed to have occurred with impoverished blood supply because of severe contusion. *(From Husmann DA. Pediatric genitourinary trauma. In: Wein AJ, Kavoussi LR, Partin AW, Peters CA, eds. Campbell-Walsh Urology. 11th ed. Philadelphia: Elsevier; 2016: Fig. 154-3, p. 3542.)*

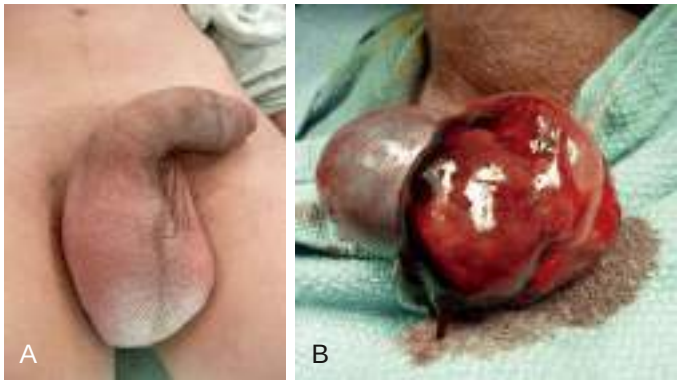

Fig. 583.3 **A,** Adolescent male with blunt right testicular injury. **B,** Tunica albuginea of testis is ruptured; the patient underwent debridement and closure of testicular capsule.

a very narrow constriction is noted with severe distal penile swelling and pain. Identification and incision of the hair allows prompt resolution of the edema. The urethra and penile vascularity should be assessed after release of the hair tourniquet. Adolescent males who indulge in extremely vigorous sexual intercourse may sustain rupture of one of the corporal bodies, resulting in penile fracture. These males have severe swelling of the penile shaft and require emergency exploration and repair. Males with penetrating injuries of the penis also require emergency debridement and repair.

Testicular injuries are relatively uncommon in children because of the small size of the testes and their mobility within the scrotum. Such injuries usually result from blunt trauma during athletic activity. Typically, these males have significant scrotal swelling, testicular pain, and tenderness (Fig. 583.3A). Ultrasonography demonstrates rupture of the tunica albuginea, which is the capsule of the testis, and surrounding hemorrhage. Prompt surgical treatment of testicular injuries increases the salvage rate (see Fig. 583.3B). An uncommon injury is the **zipper injury,** which can affect either the scrotum or foreskin. This problem generally occurs in males who do not wear underwear. The zipper can be cut with bone cutters or metal cutters. Sedation generally is unnecessary.

Visit Elsevier eBooks+ at eBooks.Health.Elsevier.com for Bibliography.

Chapter **584**

Urinary Lithiasis

Heather N. Di Carlo and Chad B. Crigger

Urinary lithiasis in children is related to genetic, climatic, dietary, and socioeconomic factors. The incidence increased steadily over the past several decades. Adolescents are 10 times more likely to have a symptomatic calculus compared with children age 0-3 years. The increase in stone disease in the United States is attributed to obesity and changes in dietary habits, such as increased sodium and fructose intake, and decreased calcium and water intake.

Urolithiasis is less common in the United States than in other parts of the world. In the United States, 1 in 685 pediatric hospital admissions is for stone disease. Approximately 7% of urinary calculi occur in children younger than 16 years of age. In the United States, many children with stone disease have a metabolic abnormality. The exceptions are patients with a neuropathic bladder (see Chapter 579), who are prone to infection-initiated renal stones, and those who have urinary tract reconstruction with small or large intestine, which predisposes to bladder calculi. The incidence of metabolic stones is similar in males and females; they are most common in the southeastern United States. Racial and ethnic differences have been noted, with the highest prevalence among Whites. In Southeast Asia, urinary calculi are endemic and are related to dietary factors.

STONE FORMATION

Nearly 90% of urinary stones contain calcium as a major constituent, and 60% are composed of calcium oxalate. Most *spontaneous* stones are composed of calcium oxalate, or calcium phosphate crystals; others are caused by uric acid, cystine, ammonium crystals, or phosphate crystals, or a combination of these substances (Table 584.1). The risk of stone formation increases in the presence of increasing concentrations of these crystals and is reduced with increasing concentrations of urinary inhibitors. Renal calculi develop from crystals that form on the calyx and aggregate to form a calculus. Bladder calculi may be stones that formed in the kidney and traveled down the ureter, or they can form primarily in the bladder.

Table 584.1 Classification of Urolithiasis

CALCIUM STONES (CALCIUM OXALATE AND CALCIUM PHOSPHATE)*
Hypercalciuria
Absorptive: increased Ca absorption from gut; types I and II
Renal leak: decreased tubular reabsorption of Ca
Resorptive
Primary hyperparathyroidism (rare in children)
Iatrogenic
Loop diuretics
Ketogenic diet
Corticosteroids
Adrenocorticotropic hormone administration
Methylxanthines (theophylline, aminophylline)
Distal renal tubular acidosis, type 1 (calcium phosphate)
Hypocitraturia—citrate most important inhibitor of Ca crystallization
Vitamin D excess
Immobilization
Sarcoidosis
Cushing disease
Hyperuricosuria
Heterozygous cystinuria
Hyperoxaluria (calcium oxalate)
Primary hyperoxaluria, types 1 and 2
Secondary hyperoxaluria
Enteric hyperoxaluria
CYSTINE STONES
Cystinuria
STRUVITE STONES (MAGNESIUM AMMONIUM PHOSPHATE)
Urinary tract infection (urea-splitting organism)
Foreign body
Urinary stasis
URIC ACID STONES
Hyperuricosuria
Lesch-Nyhan syndrome
Myeloproliferative disorders
After chemotherapy
Inflammatory bowel disease
OTHER
Indinavir stones
Melamine
Nephrocalcinosis

*Most common.

Low urine volume, low urine pH, calcium, sodium, oxalate, and urate are known to promote stone formation. Many inorganic (e.g., citrate, magnesium) and organic (e.g., glycosaminoglycans, osteopontin) substances are known to inhibit stone formation. Organic inhibitory compounds adsorb to the surface of the crystal, thereby inhibiting crystal growth and nucleation.

Stone formation depends on four factors: matrix, precipitation-crystallization, epitaxy, and the absence of inhibitors of stone formation in the urine. **Matrix** is a mixture of protein, nonamino sugars, glucosamine, water, and organic ash that makes up 2–9% of the dry weight of urinary stones and is arranged within the stones in organized concentric laminations. **Precipitation-crystallization** refers to supersaturation of the urine with specific ions composing the crystal. Crystals aggregate by chemical and electrical forces. Increasing the saturation of urine with respect to the ions increases the rate of nucleation, crystal growth, and aggregation and increases the likelihood of stone formation and growth. **Epitaxy** refers to the aggregation of crystals of different composition but similar lattice structure, thus forming stones of a heterogeneous nature. The lattice structures of calcium oxalate and monosodium urate have similar structures, and calcium oxalate crystals can aggregate on a nucleus of monosodium urate crystals. Urine also contains **inhibitors of stone formation,** including citrate, diphosphonate, and magnesium ion.

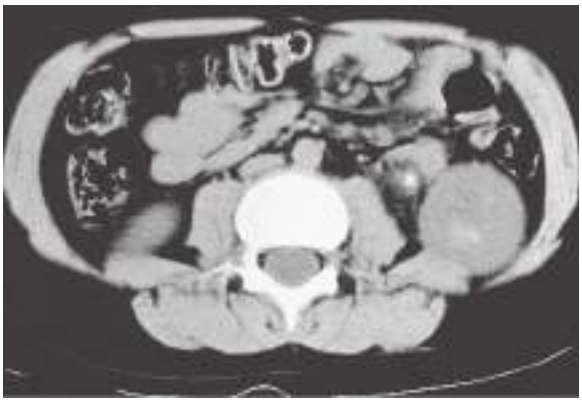

Fig. 584.1 Noncontrast CT scan of the midabdomen in a male infant with cystinuria shows a left-sided calculus at the ureteropelvic junction with proximal hydronephrosis.

CLINICAL MANIFESTATIONS

Children with urolithiasis usually have gross or microscopic hematuria. If the calculus causes ureteral or renal pelvic obstruction, then severe flank pain (renal colic) or abdominal pain occurs. The calculus typically causes obstruction at areas of narrowing of the urinary tract—the ureteropelvic junction, where the ureter crosses the iliac vessels, and the ureterovesical junction. The ureter progressively narrows distally, and its most narrow segment is the ureterovesical junction. The pain typically radiates anteriorly to the scrotum or labia. Often the pain is intermittent, corresponding to periods of obstruction of urine flow, which increases the pressure in the collecting system. If the calculus is in the distal ureter, the child can have irritative symptoms of dysuria, urgency, and frequency. If the stone passes into the bladder, the child usually becomes asymptomatic. If the stone is in the urethra, dysuria and difficulty voiding can result, particularly in males. Some children pass small amounts of gravel-like material. Stones can also be asymptomatic, although it is uncommon to pass a ureteral calculus without symptoms.

DIAGNOSIS

Approximately 90% of urinary calculi are calcified to some degree and are radiopaque on a plain abdominal film. However, many calculi are only a few millimeters in diameter and are difficult to see, particularly if they are in the ureter. Struvite (magnesium ammonium phosphate) stones are radiopaque. Cystine, xanthine, and uric acid calculi may be radiolucent but often are slightly opacified. Some children have **nephrocalcinosis,** which is calcification of the renal tissue itself. Nephrocalcinosis is seen most commonly in premature neonates receiving furosemide, which causes **hypercalciuria**, and in children with medullary sponge kidney.

In a child with suspected renal colic, there are multiple imaging options, including ultrasound, CT, and plain radiographs. The American Urological Association recommends ultrasound as the *initial* imaging modality in children as it avoids radiation. Ultrasound has high specificity (97%) but only moderate sensitivity (67%) in the diagnosis of urolithiasis; thus CT should be considered when clinical suspicion for stones is high, but ultrasound is negative. CT scan of the abdomen and pelvis is the most accurate study in diagnosis of stones with both sensitivity and specificity exceeding 96% (Fig. 584.1). This study takes only a few minutes to perform, is useful in delineating the number and location of calculi, and demonstrates whether the involved kidney is hydronephrotic. *Most pediatric imaging centers use low-dose CT to reduce radiation exposure.* A plain radiograph of the abdomen and pelvis is sometimes used to detect radiopaque stones but cannot identify obstruction and rarely visualizes renal calculi <3 mm.

In a child with a previously diagnosed calculus, renal ultrasonography can be used to follow the status of the calculus, such as whether it has grown or diminished in size or has moved. If a child has a renal pelvic calculus, a ureteropelvic junction obstruction should be suspected.

Table 584.2 Laboratory Tests Suggested for Evaluation of Urolithiasis

SERUM
Calcium
Phosphorus
Magnesium
Uric acid
Electrolytes and anion gap
Creatinine
Alkaline phosphatase
URINE
Urinalysis
Urine culture
Spot test for cystinuria
Stone analysis
If toilet-trained, 24 hour collection for:
Creatinine clearance
Calcium
Phosphate
Oxalate
Uric acid
Dibasic amino acids (if cystine spot test result is positive)
If not toilet-trained, random urine sample for:
Calcium
Creatinine
Oxalate
Citrate

In some cases, it can be difficult to determine whether hydronephrosis in such a child is secondary to an obstructing stone, ureteropelvic junction obstruction, or both.

Any material that resembles a calculus should be sent for analysis by a laboratory that specializes in identifying the components of urinary calculi.

METABOLIC EVALUATION

A metabolic evaluation for the most common predisposing factors should be undertaken in all children with urolithiasis, bearing in mind that structural, infectious and metabolic factors often coexist. This evaluation should not be undertaken in a child who is in the process of passing a stone, because the altered diet and hydration status, as well as the effect of obstruction on the kidney, can alter the results of the study. Table 584.2 lists the basic laboratory studies required, and Table 584.3 shows the normal values for 24-hour urine collections. In children with hypercalciuria, further studies of calcium excretion with dietary calcium restriction and calcium loading are necessary.

PATHOGENESIS OF SPECIFIC RENAL CALCULI

Calcium Oxalate and Calcium Phosphate Calculi

Most urinary calculi in children in the United States are composed of calcium oxalate and/or calcium phosphate. The most common metabolic abnormality in these patients is **normocalcemic hypercalciuria.** Between 30% and 60% of children with calcium stones have hypercalciuria without hypercalcemia. Other metabolic aberrations that predispose to stone disease include hyperoxaluria, hyperuricosuria, hypocitraturia, heterozygous cystinuria, hypomagnesuria, hyperparathyroidism, and **renal tubular acidosis** (RTA; see Chapter 569).

Hypercalciuria may be absorptive, renal, or resorptive. The primary disturbance in *absorptive hypercalciuria* is intestinal hyperabsorption of calcium. In some children, an increase in 1,25-dihydroxyvitamin D is associated with the increased calcium absorption, whereas in others, the process is independent of vitamin D. *Renal hypercalciuria* refers to impaired renal tubular reabsorption of calcium (see Chapter 562.4). Renal leak of calcium causes mild hypocalcemia, which triggers an increased production of parathyroid hormone, with increased intestinal absorption of calcium and increased mobilization of calcium stores. *Resorptive hypercalciuria* is uncommon and is found in patients with primary hyperparathyroidism. Excess parathyroid hormone secretion stimulates intestinal absorption of calcium and mobilization of calcium stores. Table 584.4 summarizes the metabolic evaluation of children with hypercalciuria.

Hyperoxaluria is another potentially important cause of calcium stones. Oxalate increases the solubility of calcium oxalate crystallization 7-10 times more than calcium. Consequently, hyperoxaluria significantly increases the likelihood of calcium oxalate precipitation. Oxalate is found in high concentrations in tea, coffee, spinach, and rhubarb. Primary hyperoxaluria is a rare autosomal recessive disorder that can be subclassified into glycolic aciduria and L-glyceric aciduria. Most patients with primary hyperoxaluria have glycolic aciduria; oxalic and glycolic acids are increased in the urine of affected persons. Both defects cause increased endogenous production of oxalate, with hyperoxaluria, urolithiasis, nephrocalcinosis, and injury to the kidneys. Death from renal failure occurs by age 20 in untreated patients. **Oxalosis,** defined as extrarenal deposition of calcium oxalate, occurs when renal insufficiency is present with elevated plasma oxalate. Calcium oxalate deposits appear first in blood vessels and bone marrow, and with time they appear throughout the body. Secondary hyperoxaluria is more common and can occur in patients with increased intake of oxalate and oxalate precursors such as vitamin C, in those with pyridoxine deficiency, and in children with intestinal malabsorption.

Enteric hyperoxaluria refers to disorders such as inflammatory bowel disease (see Chapter 382), pancreatic insufficiency (see Chapter 398), and biliary disease (see Chapter 404), in which there is gastrointestinal malabsorption of fatty acids, which bind intraluminal calcium and form salts that are excreted in the feces. Normally, calcium forms a complex with oxalate to reduce oxalate absorption, but if calcium is unavailable, there is increased absorption of unbound oxalate.

Hypocitraturia refers to a low excretion of citrate, which is an important inhibitor of calcium stone formation. Citrate acts as an inhibitor of calcium urolithiasis by forming complexes with calcium, increasing the solubility of calcium in the urine, and inhibiting the aggregation of calcium phosphate and calcium oxalate crystals. Disorders such as chronic diarrhea, intestinal malabsorption, and RTA can cause hypocitraturia. It may also be idiopathic.

Renal tubular acidosis (RTA) is a syndrome involving a disturbance of acid-base balance within the kidney that can be classified into three types, one of which predisposes to renal calculi that typically are calcium phosphate (see Chapter 569). In type 1 RTA, the distal nephron does not secrete hydrogen ion into the distal tubule. The urine pH is never <5.8, and hyperchloremic hypokalemic acidosis results. Patients acquire nephrolithiasis, nephrocalcinosis, muscle weakness, and osteomalacia. Type 1 RTA can be an autosomal dominant disorder, but more often it is acquired and associated with systemic diseases such as Sjögren syndrome, Wilson disease, primary biliary cirrhosis, and lymphocytic thyroiditis, or it results from amphotericin B, lithium, or toluene (an organic solvent associated with glue sniffing).

From 5–8% of patients with **cystic fibrosis** (see Chapter 454) have urolithiasis. Typically, the stones are calcium, and they often manifest in adolescence or young adulthood. Microscopic nephrocalcinosis also occurs in younger children with the disease. These patients do not have hypercalciuria, and the propensity for urolithiasis has been speculated to result from an inability to excrete a sodium chloride load or from intestinal malabsorption.

Other disorders can play a role in causing calcium stones. **Hyperuricosuria** may be related to the epitactic growth of calcium oxalate crystals around a nucleus of uric acid crystals or to the action of uric acid, which counteracts urinary mucopolysaccharides that then inhibit calcium oxalate crystallization. Heterozygous **cystinuria** is found in some patients with calcium stones. The mechanism is unknown but may be similar to that of uric acid. Sarcoidosis (see Chapter 209) causes an increased sensitivity to vitamin D_3 and thus an increased absorption of calcium from the gastrointestinal tract. In Lesch-Nyhan syndrome (see Chapter 110), there is excessive uric acid synthesis. These patients are more likely to form uric acid stones, but some of these stones may be calcified. **Immobility** can cause hypercalciuria by mobilization of calcium stores. High-dose

Table 584.3 Urine Chemistry: Normal Values

URINE CONSTITUENT	AGE	RANDOM	TIMED	COMMENTS
Calcium	0-6 mo	<0.8 mg/mg creat	<4 mg/kg/24 hours	Prandial variation
	7-12 mo	<0.6 mg/mg creat		Sodium-dependent
	≥2 yr	<0.21 mg/mg creat		
Oxalate*	<1 yr	0.15-0.26 mmol/mmol creat	≥2 yr: <0.5 mmol/ 1.73 m^2/24 hr	Random urine mmol/mmol highly age dependent
	1-<5 yr	0.11-0.12 mmol/mmol creat		Excretion rate/1.73 m^2 constant through childhood and adulthood
	5-12 yr	0.006-0.15 mmol/mmol creat		
	>12 yr	0.002-0.083 mmol/mmol creat		
Uric acid	Term infant	3.3 mg/dL GFR†	<815 mg/1.73 m^2/24 hr	Excretion rate/1.73 m^2 from >1 yr age; constant through childhood
	>3 yr	<0.53 mg/dL GFR		
Magnesium	>2 yr	<0.12 mg/mg creat	<88 mg/1.73 m^2/24 hr	Excretion rate/1.73 m^2 constant through childhood
Citrate		>400 mg/g creat		Limited data available for children
Cystine		<75 mg/g creat	<60 mg/1.73 m^2/24 hr	Cystine >250 mg/g creat suggests homozygous cystinuria

*Oxalate oxidase assay.
†(mg/dL uric acid) (serum creatinine concentration/urine creatinine concentration).
creat, Creatinine; GFR, glomerular filtration rate.
From Milliner DS. Urolithiasis. In: Avner ED, Harmon WE, Naiudet P, eds. Pediatric Nephrology. 6th ed. Berlin: Springer-Verlag; 2009: p. 1409, with permission.

Table 584.4 Metabolic Evaluation of Children with Hypercalciuria

TYPE	SERUM CALCIUM	RESTRICTED CALCIUM (URINE)	FASTING CALCIUM (URINE)	CALCIUM LOAD (URINE)	PARATHYROID HORMONE (SERUM)
Absorptive	N or I	N or I	N	I	D or N
Renal	N	I	I	I	I
Resorptive	I	I	I	I	I

I, Increased; N, normal; D, decreased

corticosteroids can cause hypercalciuria and calcium oxalate precipitation. Furosemide, which is often administered in the neonatal intensive care unit, also can cause severe hypercalciuria, urolithiasis, and nephrocalcinosis.

In some children, calcium calculi are idiopathic. A complete metabolic evaluation must be performed before this diagnosis is made.

Cystine Calculi

Cystinuria accounts for 1% of renal calculi in children. The condition is a rare autosomal recessive disorder of the epithelial cells of the renal tubule that prevents absorption of the four dibasic amino acids (cystine, ornithine, arginine, lysine) and results in excessive urinary excretion of these products. The only known complication of this familial disease is the formation of calculi, because of the low solubility of cystine. The patients usually have acidic urine, which leads to a higher rate of precipitation. In the homozygous patient, the daily excretion of cystine usually exceeds 500 mg, and stone formation occurs at an early age. Heterozygotes excrete 100-300 mg/day and typically do not have clinical urolithiasis. The sulfur content of cystine gives these stones their faint radiopaque appearance.

Struvite Calculi

Urinary tract infections (see Chapter 575) caused by urea-splitting organisms (most often *Proteus* spp., and occasionally *Klebsiella* spp., *Escherichia coli, Pseudomonas* spp., and others) result in urinary alkalinization and excessive production of ammonia, which can lead to the precipitation of magnesium ammonium phosphate (struvite) and calcium phosphate. In the kidney, these calculi often have a staghorn configuration, filling the calyces. The calculi act as foreign bodies, causing obstruction, perpetuating infection, and causing gradual kidney damage. Patients with struvite stones also can have metabolic abnormalities that predispose to stone formation. These stones often are seen in children with neuropathic bladder, particularly those who have undergone a urinary tract reconstructive procedure (see Chapter 579). Struvite stones also can form in the reconstructed bladder of children who have undergone augmentation cystoplasty or continent urinary diversion.

Uric Acid Calculi

Calculi containing uric acid represent <5% of all cases of lithiasis in children in the United States but are more common in less-developed areas of the world. Hyperuricosuria with or without hyperuricemia is the common underlying factor in most cases. The stones are radiolucent on x-ray. The diagnosis should be suspected in a patient with persistently acidic urine and urate crystalluria.

Hyperuricosuria can result from various inborn errors of purine metabolism that lead to overproduction of uric acid, the end product of purine metabolism in humans. Children with Lesch-Nyhan syndrome and patients with glucose-6-phosphatase deficiency (see Chapter 107) form urate calculi as well. In children with short-bowel syndrome (see Chapter 385.7), and particularly those with ileostomies, chronic dehydration and acidosis sometimes are complicated by uric acid lithiasis.

One of the most common causes of uric acid lithiasis is the rapid turnover of purine with some tumors and myeloproliferative diseases. The risk of uric acid lithiasis is especially great when treatment of these diseases causes rapid breakdown of nucleoproteins. Uric acid calculi or "sludge" can fill the entire upper collecting system and cause renal failure and even anuria. Urate is also present within calcium-containing stones. In these cases, more than one predisposing factor for stone formation can exist.

Indinavir Calculi

Indinavir sulfate is a protease inhibitor approved for treating HIV infection (see Chapter 322). Up to 4% of patients acquire symptomatic nephrolithiasis. Most of the calculi are radiolucent and are composed of indinavir-based monohydrate, although calcium oxalate and/or phosphate have been present in some. After each dose, 12% of the drug is excreted unchanged in the urine. The urine in these patients often contains crystals of characteristic rectangles and fan-shaped or starburst crystals. Indinavir is soluble at a pH of <5.5. Consequently, dissolution therapy by urinary acidification with ammonium chloride or ascorbic acid should be considered.

Nephrocalcinosis

Nephrocalcinosis refers to calcium deposition within the renal tissue. Often nephrocalcinosis is associated with urolithiasis. The most common causes are furosemide (administered to premature neonates), distal RTA, hyperparathyroidism, medullary sponge kidney, hypophosphatemic rickets, sarcoidosis, cortical necrosis, hyperoxaluria, prolonged immobilization, Cushing syndrome, hyperuricosuria, monogenetic causes of hypertension, and renal candidiasis.

TREATMENT

In a child or adolescent with a renal or ureteral calculus, the decision whether to remove the stone depends on its location, size, and composition (if known) and whether obstruction and/or infection is present. Pain is managed with nonsteroidal antiinflammatory drugs or, less often, opiates. Small ureteral calculi often pass spontaneously, although the child might experience severe renal colic. The narrowest segment of the ureter is the ureterovesical junction. Calculi <5 mm will pass 80–90% of the time. An α-adrenergic blocker, such as tamsulosin, 0.4 mg at bedtime, may facilitate stone passage by decreasing ureteral pressure below the stone and decreasing the frequency of the peristaltic contractions of the obstructed ureter. This intervention is termed **medical expulsive therapy**. In many cases, passage of a ureteral stent past the stone endoscopically relieves pain and dilates the ureter sufficiently to allow the calculus to pass. In cases such as children with a uric acid calculus or an infant with a furosemide-associated calculus, dissolution alkaline therapy may be effective. Fluid management with a forced diuresis is controversial and may not improve stone passage. Nonetheless, dehydration (from anorexia or emesis) must be corrected, and intravenous fluids may offset contrast-induced renal injury if CT contrast imaging is anticipated.

If the calculus does not pass or seems unlikely to pass or if there is associated urinary tract infection, removal is necessary (Table 584.5). Lithotripsy of bladder, ureteral, and small renal pelvic calculi using the holmium laser through a flexible or rigid ureteroscope is quite effective. Extracorporeal shock wave lithotripsy has been successfully applied to children with renal and ureteral stones, with a success rate of >75%. Another alternative is percutaneous nephrostolithotomy, in which access to the renal collecting system is obtained percutaneously and the calculi are broken down by ultrasonic lithotripsy. In cases in which these modalities are unsuccessful, an alternative is laparoscopic removal; this procedure can be performed using the da Vinci robot.

STONE PREVENTION

In children with urolithiasis, the underlying metabolic disorder should be addressed (Table 584.6). Because lithiasis results from elevated concentrations of specific substances in the urine, maintaining a continuous high urine output by maintaining a high fluid intake often is an effective method of preventing further stones. The high fluid intake should be continued at night, and usually it is necessary for the child to get up at least once at night to urinate and drink more water. A daily fluid intake of 2-2.5 L in adolescent stone formers is recommended, with greater intake during summer months.

Dietary sodium intake in children has increased significantly because of increased consumption of salty, processed foods. High sodium intake increases urinary excretion of calcium and may result in hypocitraturia. In addition, increased salt intake induces metabolic acidosis. To compensate for the acid load, the kidneys conserve anions, including urinary citrate, which contributes to hypocitraturia. Reduction in dietary intake of sodium and increased potassium intake is indicated.

Although counterintuitive, low-calcium diets are less effective in the treatment of calcium stones than diets containing normal amounts of calcium and limited amounts of sodium and animal protein. Low-sodium, low-protein diets reduce urinary calcium and oxalate excretion. Children with stone disease should avoid excess calcium intake. However, children require calcium for bone development, and

Table 584.5 Primary Surgical Treatment Options vs Stone Size and Location

STONES	SHOCK WAVE LITHOTRIPSY	URETEROSCOPY	PERCUTANEOUS NEPHROLITHOTOMY
RENAL			
<1 cm	Most common	Optional	Optional
1-2 cm	Most common	Optional	Optional
>2 cm	Optional	Rare	Most common
LOWER POLE			
<1 cm	Most common	Optional	Optional
>1 cm	Optional	Optional	Most common
URETERAL			
Proximal	Most common	Optional	Occasional
Distal	Optional	Most common	Rare

From Durkee CT, Balcom A. Surgical management of urolithiasis. Pediatr Clin North Am. 2006;53:465–477.

Table 584.6 Suggested Therapy for Urolithiasis Caused by Metabolic Abnormalities

METABOLIC ABNORMALITY	INITIAL TREATMENT	SECOND-LINE TREATMENT
Hypercalciuria	Reduction of dietary Na^+	Potassium citrate
	Dietary calcium at RDA	Thiazides
	Thiazides*	Neutral phosphate
Hyperoxaluria	Reduce dietary oxalate	Neutral phosphate†
	Potassium citrate	Magnesium
		Pyridoxine†
Hypocitric aciduria	Potassium citrate	Bicarbonate
Hyperuricosuria	Alkalinization	Allopurinol
Cystinuria	Alkalinization	Tiopronin (Thiola)
	Reduction of dietary Na^+	D-Penicillamine
		Captopril

*If hypercalciuria is severe or there is osteopenia.
†Initial therapy in primary hyperoxaluria.
RDA, Recommended dietary allowance.
From Milliner DS. Urolithiasis. In: Avner ED, Harmon WE, Naiudet P, eds. Pediatric Nephrology. 6th ed. Berlin: Springer-Verlag; 2009: p. 1412, with permission.

recommendations for daily calcium intake vary by age. *Consequently, calcium restriction in children should be avoided.* Thiazide diuretics also reduce renal calcium excretion. The addition of potassium citrate, an inhibitor of calcium stones, with a dosage of 1-2 mEq/kg/24 hours is beneficial. An excellent source of citrate is lemonade, because 4 oz of lemon juice contains 84 mEq of citric acid. A daily mixture of 4 oz of reconstituted lemon juice in 2 L of water and sweetened to taste should significantly increase the urinary citrate level. In difficult cases, neutral orthophosphate should be given, although it is poorly tolerated.

In patients with uric acid stones, allopurinol is effective. Allopurinol is an inhibitor of xanthine oxidase and is effective in reducing the production of both uric acid and 2,8-dihydroxyadenine and can help control the recurrence of both types of stones. In addition, urinary alkalinization with sodium bicarbonate or sodium citrate is beneficial. The urine pH should be ≥6.5 and can be monitored at home by the family.

Maintaining a high urine pH can also prevent the recurrence of cystine calculi. Cystine is much more soluble when the urinary pH is >7.5, and alkalinization of urine with sodium bicarbonate or sodium citrate is effective. Another important medication is D-penicillamine, which is a chelating agent that binds to cysteine or homocysteine, increasing the solubility of the product. Although poorly tolerated by many patients, it has been reported to be effective in dissolving cystine stones and in preventing recurrences when hydration and urinary alkalinization fail. *N*-Acetylcysteine appears to have low toxicity and may be effective in controlling cystinuria, but long-term experience with it is lacking.

Treatment of type 1 RTA involves correcting the metabolic acidosis and replacing lost potassium and sodium. Sodium or potassium citrate therapy, or both, is necessary. When the metabolic acidosis is corrected, the urinary citrate excretion returns to normal.

Treatment of primary hyperoxaluria involves liver transplantation because the defective enzymes are hepatic. Ideally, this procedure is performed before renal failure occurs. In the most severe cases, kidney transplantation is also necessary. A U.S. Food and Drug Administration (FDA)-approved agent (lumasiran) greatly decreases oxalate production in children with primary hyperoxaluria type 1. It is hoped that it will prevent end-stage renal disease in this disorder.

Visit Elsevier eBooks+ at eBooks.Health.Elsevier.com for Bibliography.

Gynecologic Problems of Childhood

PART XXIII

Chapter 585

Gynecologic History and Physical Examination

Kathryn C. Stambough and Alla Vash-Margita

HISTORY

For the young patient, developmentally appropriate social questions directed to the patient can put them at ease and help to develop cooperation and rapport that will facilitate a subsequent examination. Specific patient, caregiver, or provider concerns about vaginal discharge or bleeding, pruritus, external genital lesions, or abnormalities should direct a problem-focused history. In a patient presenting with vaginal bleeding, questions should focus on recent growth and development, signs of pubertal progression, trauma, vaginal discharge, medication exposure, and any history of foreign objects in the vagina. For complaints of vulvovaginal irritation, pruritus, or discharge, questions should concentrate on perineal hygiene, the onset and duration of symptoms, the presence and quality of discharge, exposure to skin irritants, recent antibiotic use, travel, presence of medical comorbidities or infections in the patient and their family members, and other systemic symptoms of illness or skin conditions. Throughout the history, the patient should be encouraged to ask their own questions. Occasionally, the child is brought to the clinician because they or their parents have concerns about anatomic findings, developmental changes, or congenital anomalies. It helps to understand the family's concerns and if a specific reason, event, or family history raised the need for a gynecologic consultation.

GYNECOLOGIC EXAMINATION

The physical examination of the patient should be tailored to the child's age, complaint, and any other concerns elicited in the history. The date of onset of the last menstrual period should be included with an assessment of other vital signs as age appropriate.

Neonates

At the time of delivery, a brief examination of the external genitalia of female infants to visually confirm the patency of the vagina and assess the presence of any obvious genital anomalies should be performed. The newborn examination should note any abnormal findings, such as ambiguous genitalia, imperforate hymen, urogenital abnormalities, abdominal mass, or inguinal hernia, that might herald a gynecologic problem.

Placing the infant in the supine position with thighs flexed against the abdomen allows visualization of the neonate's external genitalia. Estrogenic effects commonly notable in neonates include prominence of the labia majora and a white vaginal discharge. The labia minora and hymen may protrude slightly from the vestibule. A small amount of neonatal vaginal bleeding from endometrial sloughing after maternal hormone withdrawal might occur. Bleeding that is excessive or persistent beyond the first month of life requires further evaluation. Breast buds may be palpable at the time of the neonatal examination but should regress in the first 3 months of life; occasionally, nipple discharge occurs.

The vaginal orifice may be difficult to see. Gentle lateral traction on the labia majora usually allows complete visualization of the hymen and vaginal orifice. The hymen should be evaluated for patency. Most hymenal variations—imperforate, microperforate, septate—do not require treatment during the neonatal period (Fig. 585.1). Variations should be noted and readdressed in subsequent visits. The hymen originates from the urogenital sinus. The uterus and upper vagina originate from the Müllerian ducts. The concomitant renal malformations seen with Müllerian anomalies are not associated with hymenal anomalies because of different embryologic origin of the two structures. Similarly, uterine anomalies are typically not observed with hymenal anomalies (see Chapter 591). Hymenal polyps seen in newborns typically regress in size as the maternal estrogen effects subside. Cervicovaginal mucus secretions can accumulate behind the blocked outflow tract of an imperforate hymen and manifest as a mucocolpos. *In this instance and if urinary obstruction occurs, correction of the imperforate hymen in the neonatal period is indicated*. In the absence of any concern for urinary obstruction, the imperforate hymen and associated mucocolpos can be observed for resolution, and the imperforate hymen is ideally repaired surgically after onset of puberty, specifically thelarche. This allows for improved healing of tissue in the presence of endogenous estrogen production.

The clitoris may appear large in proportion to the other genital structures, especially in premature infants. If the clitoris appears enlarged, the clitoral width and length should be measured; width values >6 mm or length values >6.5 mm in a newborn indicate a need for further evaluation. *If clitoromegaly and ambiguous genitalia are present, the provider should immediately obtain expert (endocrine) consultation for evaluation of the infant and to counsel the parents.* Congenital adrenal hyperplasia is the most common cause of ambiguous genitalia (accounting for >90% of cases), and the salt-wasting forms can lead to rapid dehydration with subsequent fluid and electrolyte imbalance (see Chapter 616). Delay in the diagnosis and treatment of congenital adrenal hyperplasia may be life-threatening.

In the neonate, the ovaries are <1 cm in diameter and average 1 cm^3 in volume. Antenatal or postnatal abdominopelvic ultrasound might reveal small simple ovarian cysts, which represent normal follicles. Because of the abdominal location of ovaries in the neonate, ovarian enlargement can manifest as a palpable abdominal mass. Large cysts (>4-5 cm) or those of a complex nature pose the risk of ovarian torsion, hemorrhage into the cyst, or, uncommonly, an ovarian tumor. A nonresolving or enlarging neonatal ovarian cyst warrants pediatric surgery or pediatric gynecology consultation. Percutaneous decompression has been described in cases where benign nature can be reliably ascertained. Cyst aspiration can provide temporary relief but is not recommended if cystectomy can safely be performed because the aspirated fluid may not be reliable for diagnosis and may reaccumulate. If a cystectomy is done for appropriate clinical indications, the cyst wall should be surgically excised to prevent reaccumulation of fluid and to provide a pathologic diagnosis, the remaining ovarian tissue should be left in situ, and the contralateral ovary should be inspected. Preservation of normal ovarian tissue is recommended for all benign lesions, and salpingo-oophorectomy should not be performed unless clinically indicated.

Infants and Prepubertal Girls

When the maternal estrogen effect subsides, the genitalia of the female infant change in appearance. The labia begin to flatten. The hymenal membrane loses its redundancy and becomes translucent. The hypoestrogenic prepubertal vaginal epithelium appears thin, red, and sensitive to the touch. The vaginal mucosa of young children can have longitudinal ridges running along the axis of the vagina at 3 o'clock, 6 o'clock, and 9 o'clock, which can cause small protrusions on the hymen at these locations. The cervix usually appears flat and flush with the vaginal vault. During infancy, the uterus regresses in size and does not return to its birth size until the child is 5-6 years old. The prepubertal cervix:fundus ratio is 2:1.

When puberty approaches, the child experiences increasing endocrine activity of the hypothalamus, pituitary gland, adrenal

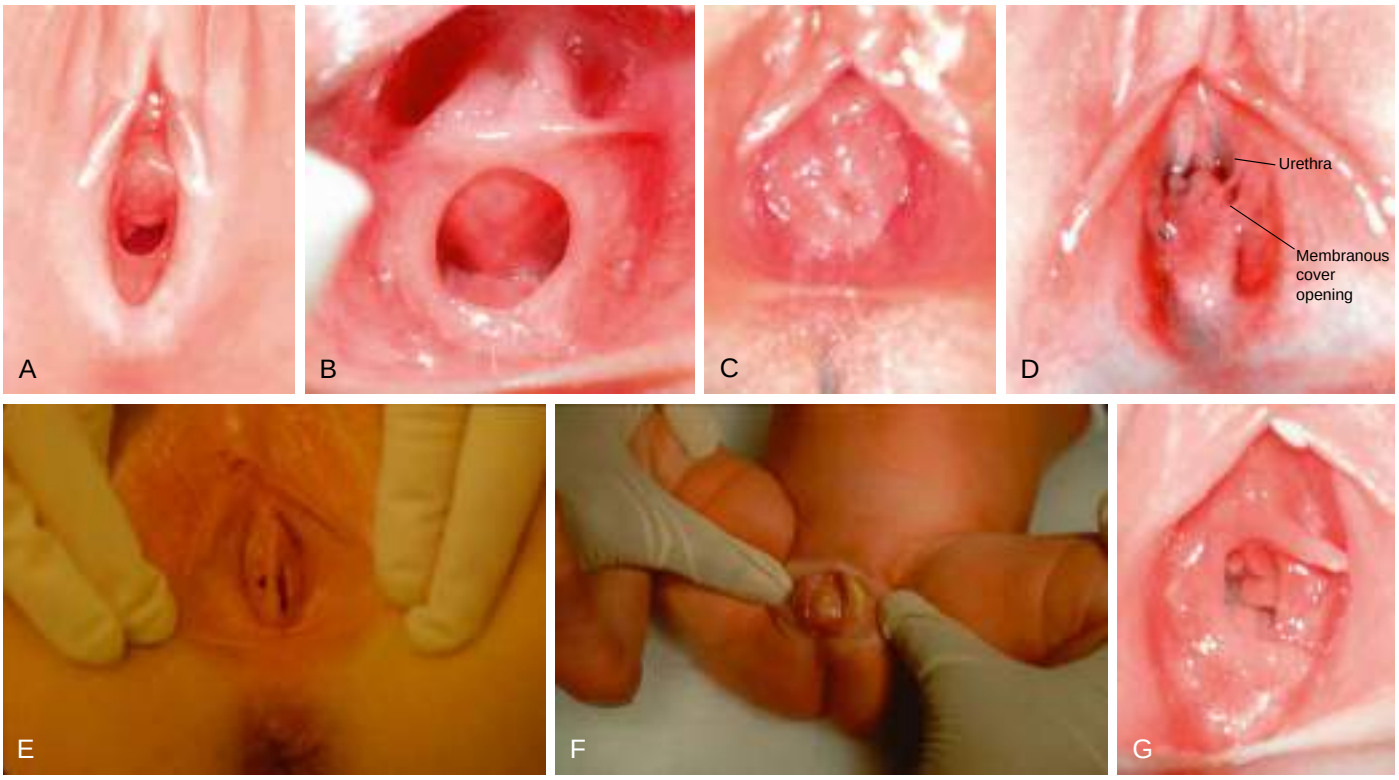

Fig. 585.1 Types of hymens. **A,** Crescentic. **B,** Annular. **C,** Redundant. **D,** Microperforate. **E,** Septated. **F,** Imperforate. **G,** Hymeneal tags. *(**A–F** from Perlman SE, Nakajima ST, Hertweck SP, eds: Clinical Protocols in Pediatric Adolescent Gynecology. Parthenon Publishing Group, 2004; **G,** from McCann JJ, Kerns DL [eds]: The Child Abuse Atlas. St Louis: Evidentia Learning, 2021, www.childabuseatlas.com.)*

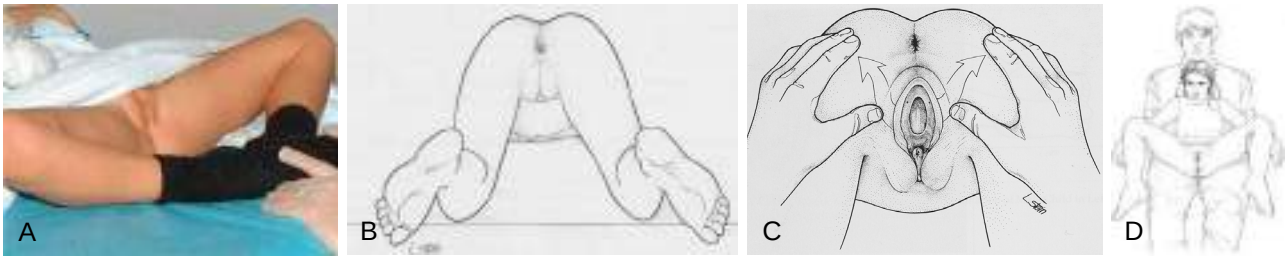

Fig. 585.2 Different exam positions for performing a gynecologic exam on a child. **A,** Frog-leg position. **B,** Knee-chest position. **C,** Prone position. **D,** Sitting on caregiver's lap. *(**A** from McCann JJ, Kerns DL, eds : The Child Abuse Atlas. St Louis: Evidentia Learning, 2021, www.childabuseatlas.com; **B–D** from Finkel MA, Giardino AP [eds]: Medical Examination of Child Sexual Abuse: A Practical Guide. Elk Grove Village, Illinois: American Academy of Pediatrics Publications, 2009;46–64.)*

gland, and ovaries (see Chapter 599). The labia majora begin to fill out, and the labia minora thicken and elongate as a result of increased estrogen levels. The hymen thickens and becomes more redundant. Clear or white physiologic secretions may be present. Breast buds begin to appear, either bilateral or initially unilateral with subsequent development of the contralateral breast. Pubic hair begins to appear.

Indications for Genital Examination

Genitourinary complaints or suspected genitourinary pathology warrants assessment of the external and internal genitalia of pediatric patients, specifically in cases of vaginal bleeding, vaginal discharge, vulvar trauma, presence of a foreign body, perineal or pelvic masses, vulvovaginal ulcerative or inflammatory lesions, congenital anomalies, or suspected sexual abuse.

Preparation

An examination of the external genitalia in prepubertal females requires a gentle, patient approach to maximize cooperation and minimize fear and embarrassment. A clear, simple explanation of what the examination involves can facilitate the child's comfort and cooperation. The presence of a parent or caregiver during the entire examination provides reassurance for most children. For the older prepubertal patient, the physician may discuss whether the patient wishes to have a family member present during the examination. Even in the presence of the caregiver, the examiner should speak directly to the child. Before initiating any part of the examination, the provider should explicitly verify with both the patient and their caregiver that the caregiver has given permission for the examination. This provides an opportunity to explain to the child the privacy of body parts and who may examine or touch those areas. It is useful to educate the patient and caregiver about the basic anatomy and hygiene of the external genital area. Before each step of the examination, the physician should explain what will occur. Allowing an older child the option of watching their examination with a handheld mirror may contribute to their comfort and understanding. Forcible restraint is never indicated; if optimal evaluation is not possible, the clinician must assess the acuity of the complaint and pathology and determine the potential need for multiple visits to complete the examination or an examination under anesthesia.

Positioning

A variety of techniques and positions can facilitate the genital examination in prepubertal patients. Children younger than 4 years of age can be placed on the parent or caregiver's lap with the child's legs straddling the caregiver's thighs (Fig. 585.2). If the child permits, they may be positioned on the table in the supine position with the hips fully abducted and the feet together in the frog-leg (diamond or butterfly) position. Older children may prefer to use the stirrups. The head of the examination table should be raised so that eye contact can be maintained with the patient throughout the examination. When the child is supine, grasping the labia majora along the inferior portion between the thumb and index finger and gently pulling outward and posteriorly (labial traction) allows visualization of the vaginal introitus. Alternatively, the child may be placed in the knee-chest position with elevation of the buttocks and hips (see Fig. 585.2). This position provides exposure of the inferior portion of the hymen, the lower vagina, and possibly the upper vagina and cervix but has the disadvantage of having the child face away from the examiner.

Some extremely cooperative children tolerate a vaginoscopic examination in an outpatient office setting for better intravaginal assessment. The endoscope (either a cystoscope or a hysteroscope) is placed in the vagina, and the labia are gently opposed, allowing the vagina to distend with water. This technique permits visualization of the vagina and cervix, allowing for the evaluation of an injury, lesion, and anatomic variant or for the presence of a foreign body. Application of 2% lidocaine gel at the introitus makes the insertion easier and less irritating for the patient. If a more complete examination is indicated or if the child is too young, frightened, or unable to cooperate, an examination under anesthesia is recommended.

Documentation

Clinicians should thoroughly and accurately document the genital examination findings in the medical record, reserving conclusions and diagnostic terms for the impression and plan portion of the documentation rather than in the description of exam findings. Each structure visualized should be noted (e.g., clitoris, labia majora, labia minora, urethra, vestibule, and rectum) with attention to describing normal appearance and any anatomic variations (e.g., the configuration of the hymen as annular, crescentic, and so forth). Describing any findings or lesions using a clock-face method provides a consistent reference point; a sketch or magnified photograph may also be helpful. Future examiners will rely on this documentation as a record with which they compare their findings and note any variances. Changes should be noted in any follow-up examinations.

Adolescents

Some teens prefer to initially meet and discuss the reason for their visit with the provider without their parent or guardian present, and this request should be honored (see Chapter 151). Obtaining a history from an adolescent usually begins with meeting the patient and parent or caregiver together to review their history and the reason for the visit and to explain the concepts of confidentiality and privacy. Care should be taken to ask the patient their preferred name and pronouns when addressing them. Familiarity with local laws governing limitations to confidential services should guide the protection of the adolescent and their parents' rights to information access and privacy. The Guttmacher Institute provides an up-to-date listing of state and federal laws in the United States affecting access to medical care (https://www.guttmacher.org/geography/united-states). Brief discussions of normal pubertal development and menstruation can reassure both patients and their parents or guardians and provide valuable education on appropriate menstrual flow, menstrual hygiene, and the duration and frequency of bleeding. Introducing the menstrual diary as an invaluable tool for the teen can help patients, parents, and clinicians identify abnormal bleeding patterns that might require further evaluation. Many applications are available for tracking menstrual periods on a smart phone or computer.

After the initial interview with the teen and their parent or caregiver, the confidential and sensitive portion of the history, particularly sexual history and alcohol, tobacco, and drug use, is taken with the teen alone. Such a request could be phrased as follows: "I would like to give your child an opportunity to ask any questions they might have privately, so would you mind stepping out of the room for a moment?" After obtaining the teen's assent for the confidential interview, questions regarding gender identity, sexual orientation, mental health, safety, and use of illicit substances should be asked. Any concerns regarding parent or caregiver access to personal electronic health records should be addressed. Concerns for the presence of vaginal discharge, the potential for sexually transmitted infections, pregnancy, or menstrual aberration should be explored. Teens and their parents should be informed of the proper use and accessibility of condoms, all contraceptive methods, and emergency contraception.

Resources for educating adolescents regarding their first pelvic examination and in-depth sexual history and psychosocial screening tools are available. These include the North American Society for Pediatric and Adolescent Gynecology (http://www.naspag.org), the American Academy of Pediatrics (http://www.aap.org), the Society for Adolescent Health and Medicine (http://www.adolescenthealth.org), and the American College of Obstetricians and Gynecologists (http://acog.org/Patients).

Individuals with Special Needs

Special care should be taken in the approach to individuals with both physical and cognitive disabilities (see Chapter 592). The assistance of Child Life services can be beneficial in decreasing patient anxiety.

Pelvic Examination

Table 585.1 presents the indications for the first pelvic examination in adolescents. If an adolescent does not meet one of the criteria listed in Table 585.1, the American College of Obstetricians and Gynecologists (ACOG) recommends that the first gynecologic encounter occur between the ages of 13-15 years (Table 585.2), with attention toward anticipatory guidance focusing on normal pubertal development and menstruation. All sexually active patients age

Table 585.1 Suggested Indications for Pelvic Examination in Adolescents

Age 21 yr of age for initial Papanicolaou test (Pap smear)
Unexplained menstrual irregularities, including pubertal aberrations (especially delayed puberty)
Severe dysmenorrhea
Unexplained abdominal or pelvic pain
Unexplained dysuria
Abnormal vaginal discharge
Concern for pelvic inflammatory disease
Placement of intrauterine device
Removal of foreign body
Inability to place tampons

Data from American College of Obstetricians and Gynecologists' Committee on Adolescent Health Care. The initial reproductive health visit: ACOG Committee Opinion, Number 811. *Obstet Gynecol.* 2020;136: e70–e80.

Table 585.2 Recommendations for First Gynecologic Evaluation

Occurs between 13 and 15yr of age
Focuses on patient education
Increases comfort with issues regarding adolescent sexuality
Ensures opportunity for adolescent to speak 1-on-1 with the provider
Makes the adolescent aware of limitations of confidentiality (including issues related to mandatory reporting, insurance billing, electronic health record notifications, and legal requirements)
Pelvic examination with Papanicolaou test (Pap smear) is generally not indicated until 21 yr of age, unless otherwise indicated by Table 585.1

Data from American College of Obstetricians and Gynecologists' Committee on Adolescent Health Care. The initial reproductive health visit: ACOG Committee Opinion, Number 811. *Obstet Gynecol.* 2020;136: e70–e80.

<25 years should undergo annual screening for sexually transmitted infections (STIs). This testing can also be obtained 3 months after treatment of a positive screening, with new symptoms, or with each new sexual partner. With the availability of urine and vaginal swab nucleic acid amplification testing for chlamydia, gonorrhea, and trichomoniasis, STI screening does not necessitate a speculum exam. Extragenital (rectal or pharyngeal) chlamydia and gonorrhea testing can be considered for patients based on self-reported sexual behaviors through shared clinical decision-making between the patient and the provider. Expedited partner treatment may be used according to the state law.

Before the initiation of a physical examination, all patients should be offered the choice of having a medical attendant, family member, or friend present during their examination. Presence of the chaperone is advised based on the laws of the state and the policies of the institution. At the initial gynecologic exam, the physician should explain the process in understandable terms. A thorough evaluation begins with an assessment of body mass index, blood pressure, menstruation status, thyroid, lymph nodes, breast development, abdominal exam, and skin. The external genitalia should be examined with the patient in the dorsal lithotomy position while communication is maintained between the physician and patient. Elevating the head of the examination table allows the teen and their examiner to maintain eye contact. The teen can hold a mirror to follow along with the examination, and they should be encouraged to ask questions. Inspection of the vulva is followed by inspection of the Bartholin, urethral, and Skene glands. The clitoris, normally 2-4 mm in width, is then assessed; a clitoris wider than 10 mm, especially in the presence of other signs of virilization, suggests a need for further evaluation. The hymenal anatomy should also be evaluated. Throughout the examination, the proper nomenclature for genital anatomy should be emphasized with the teen to empower them to use proper wordage with the avoidance of slang when referring to their body.

Because the initial Papanicolaou (Pap) test is deferred until 21 years of age except in certain immunocompromised patients and cultures for STIs can be obtained from urine or vaginal swabs, the need for a speculum exam is decreasing in this age group. If a speculum exam is indicated, use an appropriately sized speculum, such as the Huffman (½ in wide × 4 in long) or Pedersen (⅞ in wide × 4 in long) speculum. Shorter speculums will not allow visualization of the entire vaginal canal. The adolescent patient should be reassured that the exam may be uncomfortable but should not be painful and that their request to stop or wait will be honored. Encouraging the patient to watch with a handheld mirror facilitates patient education and can be empowering. They may be told before the insertion of the speculum that they will experience a pressure sensation. Before touching the introitus, it may be useful to touch the inner thigh with the speculum. Compression of the urethra anteriorly should be avoided. Gentle pressure with a finger for displacement of the fourchette posteriorly further facilitates proper speculum placement. After visualization of the vagina and cervix, specimens should be obtained as indicated. A bimanual examination, sometimes with a single digit, allows palpation of the vaginal walls and cervix and bimanual assessment of the uterus and adnexa. Reassurance of normal findings throughout the examination should be provided, and normal variants to anatomy should be pointed out to the teen as they are encountered (e.g., asymmetric labia minora).

After the examination, it is appropriate to review the exam findings with the teen (and parents or caregivers as appropriate) and initiate a collaborative discussion of the management plan. Encouraging the adolescent to participate in decision-making empowers them to undertake responsibility for their health, may strengthen compliance with the medical plan, and will acknowledge them as a unique individual.

Visit Elsevier eBooks+ at eBooks.Health.Elsevier.com for Bibliography.

Chapter 586

Vulvovaginitis

Helen M. Oquendo Del Toro and Holly R. Hoefgen

Vulvovaginitis is the most common gynecologic-based problem for prepubertal children, with a reported incidence of 17–50%. It is most typically caused by either inadequate or excessive hygiene or chemical irritants. The age of presentation peaks at 4-8 years of age. The condition is usually improved by hygiene measures and education of the caregivers and child.

ETIOLOGY

Vulvitis refers to external genital pruritus, burning, redness, or rash. **Vaginitis** denotes inflammation of the vagina, which can manifest as a discharge with or without an odor or bleeding. If these occur simultaneously, the term vulvovaginitis is used. When a child presents with vulvovaginitis, the history should include questions on hygiene (wiping from front to back) and information about possible exposure to chemical irritants (bath soaps, bubble bath, bath bombs, laundry detergents, swimming pools, or hot tubs). A detailed history of recent diarrhea, perianal itching, or nighttime itching is important. The possibility of foreign objects being placed into the vagina should also be asked, although the young child is unlikely to recall. Approximately 75% of cases of vulvovaginitis in children are nonspecific for a variety of reasons, including their lack of vaginal estrogenization and resulting atrophy and alkalinic pH, poor perianal hygiene, and the proximity of the anus to the vagina, which is without geographic barriers given the flattened labia and lack of pubic hair. Table 586.1 lists other vulvovaginal disorders commonly seen in children.

EPIDEMIOLOGY

Infectious vulvovaginitis, where a specific pathogen is isolated as the cause of symptoms, is commonly associated with fecal or respiratory pathogens, and cultures may reveal *Escherichia coli* (see Chapter 246), *Streptococcus pyogenes* (Chapter 229), *Staphylococcus aureus* (see Chapter 227), *Haemophilus influenzae* (see Chapter 240), *Enterobius vermicularis* (see Chapter 340), and, rarely, *Candida spp*. (see Chapter 280). These organisms may be transmitted by the child using improper toilet hygiene or manually from the nasopharynx to the vagina. Typical presentation includes perianal redness, introital inflammation, and often a yellow-green or mildly bloody discharge. Children may be observed to be grabbing their genital area or "digging" in their underwear, which is usually stained with yellow-brown discharge. Attempts to treat these bacterial etiologies with antifungal medication will fail, and often the antifungal product will lead to more irritation. Table 586.2 gives specific treatment recommendations based on the bacteria identified.

Neisseria gonorrhoeae or *Chlamydia trachomatis* are also causes of specific infectious vulvovaginitis (see Chapter 163). If acquired after the neonatal period, some diseases (e.g., gonorrhea, syphilis, and chlamydia) are virtually 100% indicative of sexual contact. Management of prepubertal children who have **sexually transmitted infections** requires close cooperation between clinicians and child-protection authorities. Official investigations for sexual abuse, when indicated, should be initiated promptly (see Chapter 17). For some diseases (e.g., human papillomavirus infection and herpes simplex virus), the association with sexual contact is not as clear. Presumptive treatment for prepubertal children who have been sexually assaulted or abused is not recommended, because (1) the incidence of most sexually transmitted infections in children is low after abuse/assault, (2) prepubertal females appear to be at lower risk for ascending infection than adolescent or adult women, and (3) regular follow-up of children usually can be ensured. Although *Trichomonas vaginalis* can be transmitted vertically

Table 586.1 Specific Vulvar Disorders in Children

CONDITION	PRESENTATION	DIAGNOSIS	TREATMENT
Molluscum contagiosum (Fig. 586.8)	1- to 5-mm discrete, skin-colored, dome-shaped, umbilicated lesions with a central cheesy plug	Diagnosis usually made by visual inspection	• Disease is generally self-limited and the lesions can resolve spontaneously. • Treatment choices in children may include cryosurgery, laser, application of topical anesthetic and curettage, podophyllotoxin, and topical silver nitrate. • Use of topical 5% imiquimod cream and 10% potassium hydroxide has been reported with similar effects.
Condyloma acuminata	Skin-colored papules, some with a shaggy, cauliflower-like appearance	• Diagnosis is usually made by visual inspection. • Biopsy should be reserved for when the diagnosis is in question. • Human papillomavirus DNA testing is not helpful.	• Many lesions in children resolve spontaneously, with "wait and see" often used in children (60 days). • Topical treatment with imiquimod cream (3 times/wk at bedtime × 16 wk, wash 6-10 hr after application) and podophyllotoxin (bid × 3 days followed by 4 day break; typical treatment duration is 4 wk) is the most studied. • General anesthesia is usually required for surgical/ablative procedures (cryotherapy, laser therapy, electrocautery); reserve for symptomatic or large lesions. • Other treatments have been used in adults, including trichloroacetic acid, 5-fluorouracil, sine catechins, topical cidofovir, and cimetidine. • The efficacy and safety of these treatments in children has not been established.
Herpes simplex	Blisters that break, leaving tender ulcers	Visual inspection confirmed by culture from lesion	• *Infants*: Acyclovir 20 mg/kg body weight IV q8 hr × 21 days for disseminated and central nervous system disease or × 14 days for disease limited to the skin and mucous membranes. • *Genital/mucocutaneous disease:* • *Age 3 mo-2 yr:* 15 mg/kg/day IV divided q8h × 5-7 days. • *Age 2-12 yr (first episode):* Same as above or 40-80 mg/kg/day PO divided tid-qid × 7-10 days (max 1,000-1,200 mg/day). • *Age 2-12 yr (recurrence):* 1,000 mg/day PO in 5 divided doses × 5 days or 1,600 mg/day PO divided bid × 5 days or 2400 mg PO divided q8 × 2 days.
Labial adhesions (see Fig. 586.1)	May be asymptomatic or can cause vulvitis, urinary dribbling, urinary tract infection, or urethritis	Diagnosis made by visual inspection of the adherent labia, often with a central semitranslucent line.	• Does not require treatment if the patient is asymptomatic. • Symptomatic patients: Topical estrogen cream or betamethasone ointment applied alone or in combination daily for 6 wk directly to the line of adhesion, using a cotton swab while applying gentle labial traction. • Estrogen should be interrupted if breast budding occurs. • Mechanical or surgical separation of the adhesions is rarely indicated. • The adhesions usually resolve in 6-12 wk; unless good hygiene measures are followed, recurrence is common. • To decrease the risk of recurrence, an emollient (petroleum jelly, A and D ointment) should be applied to the inner labia for 1 mo or longer at bedtime.
Lichen sclerosus (see Fig. 586.4)	A sclerotic, atrophic, parchment-like plaque with an hourglass or keyhole appearance of vulvar, perianal, or perineal skin; subepithelial hemorrhages may be misinterpreted as sexual abuse or trauma. The patient can experience perineal itching, soreness, or dysuria.	Diagnosis usually is made by visual inspection. Biopsy should be reserved for when the diagnosis is in question.	• Ultrapotent topical corticosteroids are the first-line therapy (clobetasol propionate ointment 0.05%) once or twice a day for 4-8 wk. • Once symptoms are under control, the patient should be tapered off the drug unless therapy is required for a flare-up. • In many females, the condition resolves with puberty; however, this is not always the case and patients may require long-term follow-up. • Immunomodulators can be used: tacrolimus 1% (applied once daily) and pimecrolimus 1% (applied twice daily for 3 mo, then every other day).
Psoriasis	Children are more likely than adults to have vulvar psoriasis noted as pruritic, well-demarcated, nonscaly, brightly erythematous, symmetric plaques. The classic extragenital lesions are similar but with a silver scaly appearance.	Diagnosis may be confirmed by locating other affected areas on the scalp or in nasolabial folds or behind the ears.	Vulvar lesions may be treated with low- to medium-potency topical corticosteroids, increasing strength as necessary.
Atopic dermatitis	Chronic cases can result in crusty, weepy lesions that are accompanied by intense pruritus and erythema. Scratching often results in excoriation of the lesions and secondary bacterial or candidal infection.	May be seen in vulvar area but characteristically affects the face, neck, chest, and extremities	Children with this condition should avoid common irritants and use topical corticosteroids (such as 1% hydrocortisone) for flare-ups. If dry skin is present, lotion or bath oil can be used to seal in moisture after bathing.

Continued

Table 586.1 Specific Vulvar Disorders in Children—cont'd

CONDITION	PRESENTATION	DIAGNOSIS	TREATMENT
Contact dermatitis	Erythematous, edematous, or weepy vulvar vesicles or pustules can result, but more often the skin appears inflamed	Associated with exposure to an irritant, such as perfumed soaps, bubble bath, talcum powder, lotions, elastic bands of undergarments, or disposable diaper components	Avoidance of irritant; topical corticosteroids for flare-ups
Seborrheic dermatitis	Erythematous and greasy, yellowish scaling on vulva and labial crural folds associated with greasy dandruff-type rash of scalp, behind ears and face	Diagnosis usually made by visual inspection	Gentle cleaning, topical clotrimazole with 1% hydrocortisone added
Vitiligo (see Fig. 586.6)	Sharply demarcated hypo-pigmented patches, often symmetric in vaginal and anal regions; may be present in periphery at body orifices and extensor surfaces	Clinical. Test for associated illness if clinically warranted (thyroid disease, Addison disease, pernicious anemia, diabetes mellitus).	If desired, treat limited lesions with low-potency corticosteroids or tacrolimus. See dermatologist for extensive lesions.

Table 586.2 Antibiotic Recommendations for Specific Vulvovaginal Infections

ETIOLOGY	TREATMENT
Streptococcus pyogenes *Streptococcus pneumoniae*	• Penicillin V, 250 mg PO bid-tid for children < 27 kg, and 500 mg bid-tid for children > 27 kg × 10 days • Amoxicillin, 50 mg/kg/day (max: 500 mg/dose) PO divided tid × 10 days • Erythromycin ethyl succinate, 30-50 mg/kg/day (max: 400 mg/dose) PO divided qid • TMP-SMX, 6-10 mg/kg/day (TMP component) PO divided bid × 10 days • Clarithromycin, 7.5 mg/kg bid (max: 1 g/day) PO × 5-10 days • Recurrence most likely from asymptomatic pharyngeal carriage in child or family member; however, failure of penicillin regimens can occur • For penicillin resistance: Rifampin 10 mg/kg PO every 12 hr × 2 days
Staphylococcus aureus	• Topical mupirocin 2% tid to the affected skin area • If systemic therapy required: Amoxicillin-clavulanate, 45 mg/kg/day (amoxicillin) PO divided bid-tid × 7 days (first-line treatment because of high penicillin resistance) • Extensive resistance to common antibiotics noted; recommend susceptibility testing for further antibiotic use • MRSA: TMP-SMX double-strength 8-10 mg/kg/day; culture abscesses, incision and drainage
Haemophilus influenzae	• Amoxicillin, 40 mg/kg/day PO divided tid × 7 days • For cases of treatment failure or nonencapsulated *H. influenzae*, amoxicillin–clavulanate is recommended.
Yersinia	• TMP-SMX 6 mg/kg (TMP component) daily for 3 days
Shigella	• TMP-SMX 10/50 mg/kg/day (max: 160/600) PO divided bid × 5 days • Ampicillin 50-100 mg/kg/day PO divided qid (adult max: 4 g/day) × 5 days • Azithromycin 12 mg/kg (max: 500) PO × 1 day, then 6 mg/kg/day (max: 250 mg) × 4 days (in areas of high resistance to above regimens or when sensitivities are unknown) • For resistant organisms: Ceftriaxone 50-75 mg/kg/day IV or IM divided into 1 or 2 doses (max: 2 g/day) × 2-5 days

Chlamydia trachomatis	• Children weighing < 45 kg: Erythromycin base or ethylsuccinate 50 mg/kg/day PO divided qid × 14 days
	• Children weighing > 45 kg but age younger than 8 yr: Azithromycin 1 g PO in a single dose
	• Children age older than 8 yr: Azithromycin 1 g PO in a single dose or Doxycycline 100 mg PO bid × 7 days
	• Adolescents and Adults:
	  • *Preferred*: Doxycycline 100 mg PO bid × 7 days
	  • *Alternative*: Azithromycin 1 g PO in single dose or Levofloxacin 500 mg PO once daily × 7 days

Neisseria gonorrhoeae	• Children weighing < 45 kg: Ceftriaxone, 25-50 mg/kg body weight IV or IM in a single dose (max 250 mg IM) • Children weighing ≥ 45 kg: Treat with adult regimen of 500 mg IM in a single dose; add azithromycin 1 g PO in a single dose if chlamydia has not been excluded. In persons > 150 kg, provide 1 g ceftriaxone.
Trichomonas	• Metronidazole, 15-30 mg/kg/day PO bid (max: 500 mg/dose) × 7 days or Tinidazole 50 mg/kg (max 2 g) PO as a single dose for children older than 3 yr
Pinworms (*Enterobius vermicularis*)	• Mebendazole, 100 mg chewable tablet once, repeated in 2 wk or Albendazole, 200 mg PO for child younger than age 2 yr or 400 mg PO for older child once, repeated in 2 wk • Pyrantel pamoate 11 mg/kg PO once (max 1 g), repeated in 2 wk

MRSA, Methicillin-resistant *Staphylococcus aureus*; TMP-SMX, trimethoprim-sulfamethoxazole.

and can be seen in children up to 1 year of age, it is an uncommon cause of specific infectious vulvovaginitis in the unestrogenized prepubertal female.

Other causes of specific infectious vulvovaginitis include *Shigella* (see Chapter 245), which often manifests with a blood-tinged purulent discharge, and *Yersinia enterocolitica* (see Chapter 249). Candida infections (yeast) commonly cause diaper rash (diaper dermatitis), but they are unlikely to cause vaginitis in children because the alkaline pH of the prepubertal vagina does not support fungal infections. Diabetic or immunocompromised children and children taking prolonged antibiotics may be at increased risk for fungal vaginitis. Pinworms are the most common helminthic infestation in the United States, with the highest rates in school-age and preschool children. Perianal itching can lead to excoriation and, rarely, bleeding.

CLINICAL MANIFESTATIONS

Diaper Dermatitis

Diaper dermatitis is the most common dermatologic problem in infancy and occurs in half of all diaper-wearing infants and children. The moisture and contact with urine and feces irritates the skin, and colonization with *Candida spp*. increases the severity of the dermatitis. First-line treatment includes hygiene measures such as increasing the frequency of diaper changes, allowing the infant to be diaper free, frequent bathing, and application of water-repellant barriers such as zinc oxide. If diaper dermatitis persists after these conservative measures, or if the classic satellite lesions of *Candida* are present, treatment with a topical antifungal can decrease the inflammation.

Physiologic Leukorrhea

Neonates and peripubertal children can present with a white, clear, or mucus discharge, which is physiologic in nature and secondary to exposure to estrogen. Some patients may complain of the moisture and mucus. Hygiene measures, including plain warm water baths, may help decrease symptomatology, but education should also be provided to reassure the patient and their parents.

Labial Agglutination

Labial agglutination (**labial adhesions**) are described most frequently in infants and young children (Fig. 586.1). This phenomenon is thought to be secondary to an inflammatory response in the labia minora in combination with a hypoestrogenic state. Diagnosis is made on routine genital examination. Asymptomatic patients usually require no intervention. Most common symptoms include urinary frequency, vaginitis, and postvoidal dribbling; labial adhesions also increase a patient's susceptibility to urinary tract infections. First-line therapy in symptomatic patients includes topical estrogen (estradiol cream 0.01%) or a topical steroid (betamethasone dipropionate 0.05% ointment) applied twice daily to the midline raphe under gentle traction. Surgical correction is rarely necessary, but recurrence is common until the age of puberty. Liberal use of bland emollients for 6-12 months after resolution of adhesions can limit recurrences.

Genital Ulcers

Acute genital ulceration of the vulva (Fig. 586.2) is described in young adolescents who are not sexually active and can occur in association with oral aphthous ulcers. Although linked to infectious causes such as Epstein-Barr virus, cytomegalovirus, mycoplasma, mumps, and influenza A, these ulcers may also be idiopathic vulvar aphthoses. Other potential etiologies include Crohn disease, Behçet disease, pemphigoid, Stevens-Johnson syndrome, fixed drug eruption, or mouth and genital ulcers with inflamed cartilage (MAGIC) syndrome, which has combined features of relapsing polychondritis and Behçet disease.

These lesions usually appear on the mucosal surfaces of the introitus as painful red or white lesions that evolve into sharply demarcated, red-rimmed ulcers with a necrotic or eschar-like base. The time course is generally 10-14 days until remission occurs. The lesions are painful; dysuria and vulvar pain are common complaints as well. Patients with acute genital ulcers show a fairly consistent picture of flulike prodromal symptoms, including fever, nausea, and abdominal pain. One

Fig. 586.1 Labial adhesions. *(Photo courtesy Diane F. Merritt, MD.)*

Fig. 586.2 Aphthous ulcers. *(Photo courtesy Diane F. Merritt, MD.)*

third of patients present with a history of or develop oral ulcerations. Evaluation includes culture or polymerase chain reaction (PCR) test for herpes simplex virus to exclude this etiology. Special testing for systemic disease depends on the history. Biopsies are usually nondiagnostic because they yield acute and chronic inflammatory changes. Figure 586.3 outlines the suggested evaluation and management of initial and recurrent disease. Evaluation for Behçet disease (see Chapter 202) using the International Study Group diagnostic guidelines should be considered with recurrent or severe cases (see Table 586.1 for other common etiologies). Treatment of acute genital ulcers should include topical lidocaine 2% jelly, sitz baths, good hygiene, and acetaminophen. Nonsteroidal antiinflammatory drug *avoidance* is suggested because of a possible causative link. Hospitalization may be required for pain management not controlled with oral narcotics or urinary retention requiring Foley catheterization, or for whirlpool debridement should hygiene become difficult. Antibiotic treatment is not required, unless evidence of bacterial superinfection exists or the patient is immunocompromised. Insufficient evidence exists to recommend whether oral steroid treatment is effective, but this may be helpful in the setting of recurrent outbreaks and extensive disease. Ultrapotent topical steroids (clobetasol 0.05% ointment) are beneficial in oral aphthous ulcers and may prove helpful in acute genital ulcers as well.

Dermatoses

Dermatologic conditions often affect the vulvar area in children; it is important to determine if the child presenting with vulvar irritation has a skin condition elsewhere on the body. **Lichen sclerosus** is commonly seen in the anogenital region and has a characteristic appearance of thinning and whitened skin changes associated with areas of erosion, ulceration, and petechiae. This disease can cause severe discomfort and most commonly presents with vulvar or perianal pruritus, dysuria, and constipation. Patients may also present without any symptoms, which may lead to underrecognition and undertreatment. If untreated, lichen sclerosus can lead to destruction and scarring of

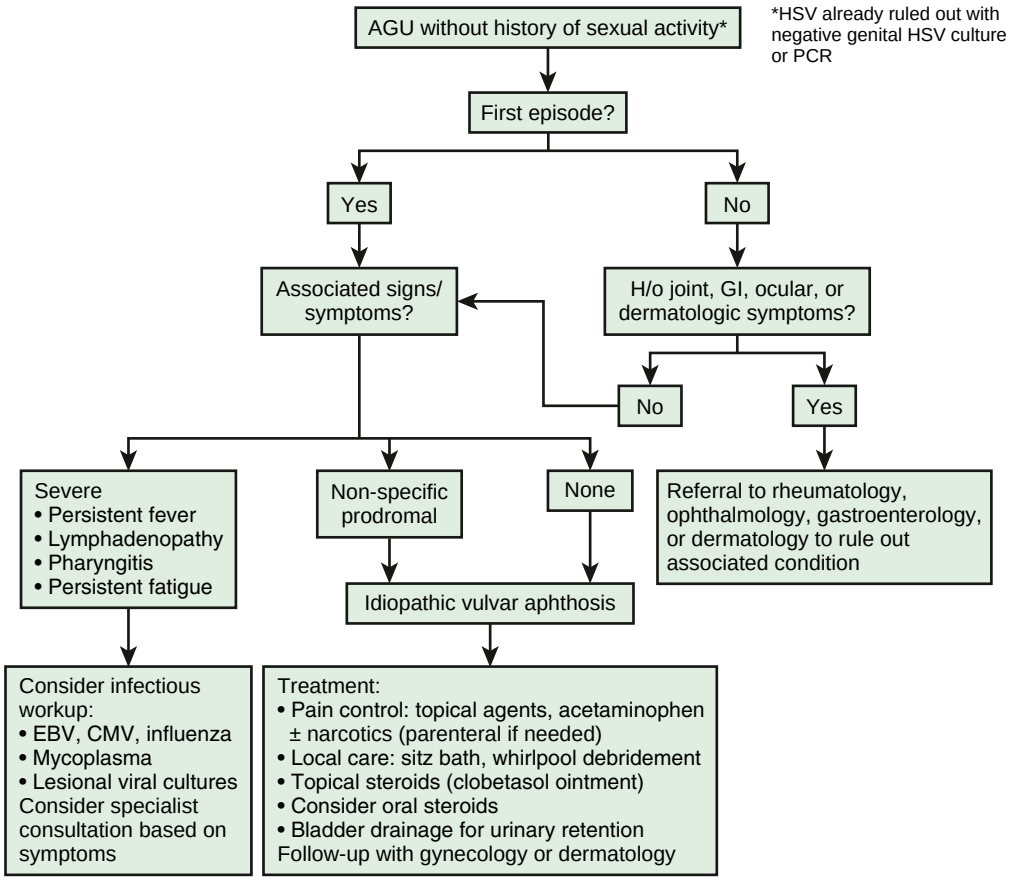

Fig. 586.3 Algorithm for evaluation and management of acute genital ulcers in non–sexually active young girls. AGU, Acute genital ulcer; CMV, cytomegalovirus; EBV, Epstein-Barr virus; GI, gastrointestinal; HSV, herpes simplex virus; PCR, polymerase chain reaction. *(From Rosman IS, Berk DR, Bayliss SJ, et al. Acute genital ulcers in nonsexually active young girls: Case series, review of the literature, and evaluation and management recommendations. Pediatr Dermatol. 2012;29[2];147-153.)*

Fig. 586.4 Lichen sclerosus. *(Photo courtesy Diane F. Merritt, MD.)*

normal genital architecture, including labial resorption, obliteration of the clitoris, narrowing of the introitus, and painful fissures that may become secondarily infected. Once thought to resolve with puberty, this theory is now controversial, and many postmenarchal adolescents still suffer from disease (Fig. 586.4). Lichen sclerosus may be treated with potent topical steroids, such as clobetasol propionate 0.05% applied once or twice daily until the symptoms resolve, and then tapered down through lower-dose topical steroids. Topical calcineurin inhibitors such as tacrolimus and pimecrolimus have been used in the treatment of lichen sclerosus. Patients should be followed every 6-12 months to evaluate for recurrence (Fig. 586.5).

Vitiligo is an acquired skin depigmentation resulting from an autoimmune process directed at epidermal melanocytes. Lesions appear as sharply demarcated patches of pigment loss, often symmetrically located around the vagina and anal area. Similar lesions of hypopigmentation can be found surrounding body orifices and extensor surfaces (Fig. 586.6). Although the diagnosis is clinical, there is an association with other autoimmune or endocrine disorders (hypothyroidism, Graves disease, Addison disease, pernicious anemia, insulin-dependent diabetes mellitus), and the workup should include evaluation for thyroid dysfunction. Mild topical corticosteroid cream or ointment may be prescribed for children. Dermatologists may offer immunomodulators (tacrolimus) and phototherapy.

Vulvar psoriasis presents as pruritic, well-demarcated, erythematous, symmetric plaques that involve the vulva, perineum, and/or gluteal folds. Lesions on the mons pubis may have the more characteristic scaly appearance. The classic signs of psoriasis may also be appreciated with pitting nailbeds, posterior auricular erythema, or a silvery scaling rash found elsewhere on the body. Many of the treatments used in adults may not be appropriate in children. Psoriasis may be treated with moisturizers, topical steroids, and light therapy. Teens may be treated with coal tar, retinoids, tacrolimus, and calcipotriene, which is a derivative of vitamin D_3.

DIAGNOSIS AND DIFFERENTIAL DIAGNOSIS

Children with symptoms of vulvovaginitis often have had previous evaluations and treatment failures. Cultures with sensitivities to test for specific pathogens may be obtained with cotton swabs or urethral (Calgiswab) swabs moistened with nonbacteriostatic saline. Use of a swab can cause discomfort or, rarely, minimal bleeding. The

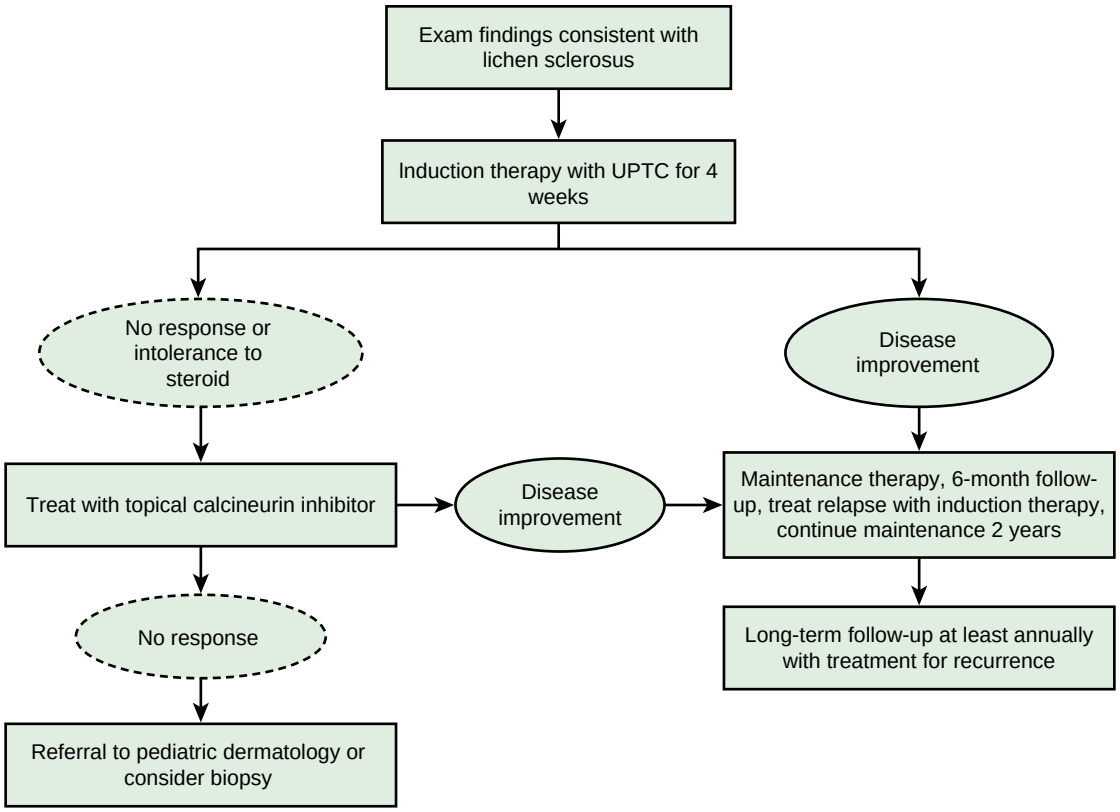

Fig. 586.5 Management algorithm for lichen sclerosus. UPTC, Ultrapotent topical corticosteroids. *(From Simms-Cendan J, Hoover K, Marathe K, Tyler K. NASPAG clinical opinion: Diagnosis and management of lichen sclerosis in pediatric and adolescent patients. J Pediatr Adolesc Gynecol. 2022;35[2]:112-120; Fig. 6.)*

Fig. 586.6 Vitiligo. *(Photo courtesy Diane F. Merritt, MD.)*

premoistened swab can be placed vertically between the labia minora to collect secretions, as it is not necessary to place the swab into the vagina. Testing for gonorrhea and chlamydia may be done by culture or by nucleic acid amplification testing, depending on institutional or state and Centers for Disease Control and Prevention guidelines. Tests for *Shigella* and *H. influenzae* might require special media and collection procedures.

If pinworms (see Chapter 340) are suspected, transparent adhesive tape or an anal swab should be applied to the anal region in the morning before defecation or bathing and then placed on a slide. Eggs seen on microscopic examination confirm the diagnosis, and sometimes the pinworms can be seen at the anal verge. Clinical history is often more indicative of disease than physical examination, and a negative tape test does not rule out this pathogen as a cause.

If the vaginal discharge is serosanguineous, if a foul odor is present, or if the discharge fails to respond to hygiene measures, presence of a vaginal foreign body (Fig. 586.7) should be considered. If inspection suggests the presence of a foreign body, the vagina can be irrigated, or an examination under anesthesia may reveal the foreign body. Vaginal irrigation may occasionally lead to expulsion of the foreign body; in cases where this does not occur, vaginoscopy is an excellent diagnostic tool and can be performed in an unsedated cooperative patient in an outpatient setting, or under general anesthesia if necessary. Using a cystoscope with saline or water irrigation to gravity, insert the endoscopic device into the vagina and gently oppose the labia; the vagina will distend, and the entire vaginal cavity and cervix may be easily assessed.

TREATMENT AND PREVENTION

The treatment of specific vulvovaginitis should be directed at the disorder or organism causing the symptoms (see Tables 586.1 and 586.2). Treatment of nonspecific vulvovaginitis includes sitz baths

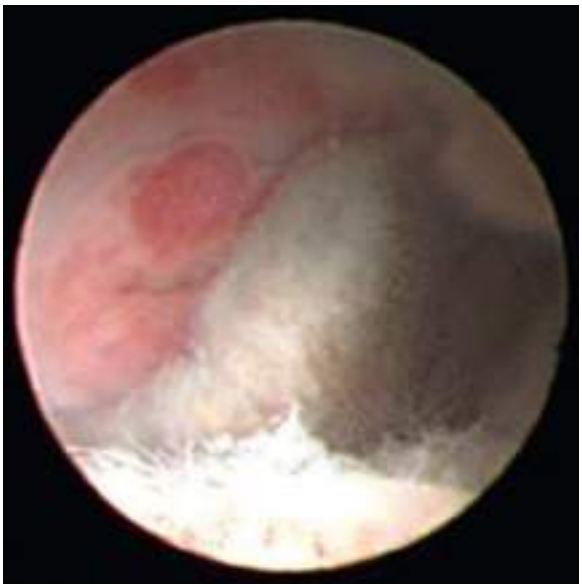

Fig. 586.7 Vaginal foreign body as seen through vaginoscope. *(Photo courtesy Diane F. Merritt, MD.)*

Fig. 586.8 Molluscum contagiosum. *(Photo courtesy Diane F. Merritt, MD.)*

and avoidance of irritating or harsh soaps and chemicals and tight clothing that abrades the perineum. External application of bland emollient barriers such as nonprescription diaper rash medications and petroleum jelly may be helpful. Proper perineal hygiene is critical for long-term improvement. Younger children need supervised perineal hygiene, and caregivers should be advised to wipe the genital area from front to back. Use of a warm moistened washcloth or diaper wipe is helpful after initially wiping with toilet tissue. Children should wear cotton underwear and limit time spent in tights, leotards, leggings, tight jeans, and wet swimsuits. Soaking in warm clean bathwater for 15-minute intervals (no shampoo or bubble bath) is soothing and helps with cleaning the area. Parents should be counseled to avoid all scented, antiseptic, and deodorant-based soaps, and to eliminate the use of fabric softeners or dryer sheets when laundering undergarments.

Visit Elsevier eBooks+ at eBooks.Health.Elsevier.com for Bibliography.

Chapter 587

Vaginal Bleeding in the Prepubertal Child

Kathryn C. Stambough and Christina Davis-Kankanamge

Newborn females may experience physiologic bleeding (**neonatal withdrawal bleeding**) in the first week of life secondary to diminished circulating maternal estrogen and stimulation of endometrial sloughing; this bleeding resolves in 3-4 days. Vaginal bleeding in infants lasting longer than a few days and all other vaginal bleeding in prepubescent children should be promptly evaluated because there are many pathologic etiologies that require expeditious workup. Common causes include vulvovaginitis, dermatologic conditions, vaginal foreign bodies, and urethral prolapse; less common are the effects of endogenous or exogenous estrogen; and the least common but most worrisome sources include neoplasms and trauma.

Although many cases of pediatric vaginal bleeding are idiopathic, many can be attributed to **vulvovaginitis** (see Chapter 586) stemming from transmission of respiratory, oral, fecal, or sexually communicated pathogens. Vulvovaginitis may present with serosanguineous vaginal drainage (e.g., *Streptococcus, Shigella*) or vulvar irritation. Age-appropriate anatomic and physiologic factors put prepubertal females at higher risk of developing vulvovaginitis. The protective barrier of fully developed labia is absent, leaving the vaginal introitus exposed to the external environment. The hypo-estrogenized vagina is marked by an alkaline milieu prone to infection because of lack of the protective acidic pH afforded by the lactobacilli colonization that occurs with puberty. Routine handwashing, improved perineal hygiene (e.g., wiping from front to back, use of wet wipes after bowel movements, proper cleansing of genitalia during baths), and avoidance of topical irritants, chemicals, and perfumed or deodorant soaps and bubble baths reduces nonspecific vulvovaginitis. Topical application of bland emollient barriers (e.g., over-the-counter diaper rash ointments, petroleum jelly) may be protective against and mitigate symptoms of external irritation. Antibiotics should be employed in the event of recurrent or persistent infections where a specific pathogen has been identified (see Table 586.2).

Vulvar dermatoses may initially present with bleeding. **Lichen sclerosus** (see Table 586.1 and Fig. 586.4) is characterized by chronic inflammation, intense pruritus, loss of normal architecture, and thinning and whitening of vulvar and perianal skin, often in a butterfly or keyhole distribution. Petechiae or blood blisters can complicate the classic clinical picture, leading to a mistaken assumption of sexual trauma. A tissue biopsy can provide a definitive diagnosis but is not usually necessary in prepubertal children and, if needed, is most appropriately performed under anesthesia. The first-line treatment is ultrapotent topical steroids (e.g., clobetasol propionate 0.05%). Appropriate timing and duration of application is practitioner dependent, but guidelines suggest treating children similarly to adults by starting with once or twice daily application for 4 weeks. Tapering of topical corticosteroid use can then occur with symptom control and include a decrease in the frequency of corticosteroid application, potency of the corticosteroid used, or both. Follow-up evaluations for response should start at 1 month after initiation of treatment. In the event of flare-ups, long-term maintenance therapy with a lower potency steroid may be initiated with appropriate counseling because side effects are rare.

Vaginal foreign bodies are a common finding in children presenting with blood-tinged and foul-smelling discharge. Quick identification and removal of the foreign body avoids potential complications, including recurrent urinary tract infections, dermatologic

abnormalities, vaginal perforation, or fistula formation. The most common object found in the prepubertal vagina is retained toilet paper. If physical exam in knee-chest or frog-leg position reveals the object, an attempt at removal in the office can be made using warm water flushes through a small feeding tube. If the object is not visible, irrigation is unlikely to remove it, and examination under anesthesia and vaginoscopy are often required. Direct visualization via vaginoscopy facilitates extraction of an object, as well as evaluation for potential sites of injury or unrelated sources of bleeding. In-office vaginoscopy may also be a possibility in the appropriate patient (see Chapter 585).

Several urologic conditions may have a mixed clinical picture suspicious for vaginal bleeding, including **gross hematuria** (see Chapter 558) and **urethral prolapse** (see Chapter 581) (Fig. 587.1). Prolapse involves protrusion of urethral mucosa through the external meatus, resulting in a friable hemorrhagic mass that often obscures the adjacent vaginal introitus. Predisposing factors include hypoestrogenic state, neuromuscular diseases, urethral anomalies, fascial defects, trauma, and chronic increases in intraabdominal pressure (e.g., recurrent Valsalva related to constipation or forceful coughing). Treatment of prolapse is conservative, involving twice-daily sitz baths followed by topical application of estrogen cream (e.g., Estradiol 0.01%) at the affected area for 2 weeks. If on reevaluation the prolapse remains, application should be continued until complete resolution is achieved. Surgical excision is rarely necessary and reserved primarily for management of necrotic tissue.

Vaginal bleeding may be a presenting sign of **precocious puberty** (see Chapter 600), defined as premature pubertal development occurring 2.0-2.5 standard deviations earlier than the average age in the general population. A formal evaluation should be conducted if pubic hair or breast development occurs rapidly or initiates before age 8 years in a female child. The most common source of premature development is **gonadotropin-dependent** or **central precocious puberty** (see Chapter 600.1), resulting in early enhancement of pulsatile release of hypothalamic gonadotropic-releasing hormone (GnRH) that stimulates ovarian follicular growth and subsequent estrogen production. **Gonadotropin-independent** or **peripheral precocious puberty** occurs less commonly and in the absence of hypothalamic influence, with estrogen being a product of ovarian or adrenal tumors, or McCune-Albright syndrome (see Chapter 600.6). In both instances, elevated estrogen levels lead to a thickened endometrium capable of shedding as in menses.

Fig. 587.1 Prepubertal urethral prolapse with high crescent-shaped hymen. *(From Lara-Torre E, Valea FA. Pediatric and adolescent gynecology: Gynecologic examination, infections, trauma, pelvic mass, precocious puberty. In Lobo RA, Gershenson DM, Lentz GM, Valea FA [eds]: Comprehensive Gynecology. Elsevier, 2022: 227; Fig. 12.6.)*

Evaluation of precocious puberty starts by examining for secondary sex characteristics and documenting the Tanner stage of breast and pubic hair development using the **Sexual Maturation Index** (see Chapter 150). Plotting height and weight on a growth chart may assist in identifying accelerated growth velocity. Supportive laboratory findings include elevated serum luteinizing hormone levels, but the gold standard remains measurement of gonadotropin levels after stimulation with GnRH or a GnRH receptor agonist. Estradiol levels greater than 100 pg/mL can indicate either the presence of premature ovarian follicles or a peripheral tumor (e.g., ovarian germ cell tumor). A pelvic ultrasound should be used to evaluate for ovarian or adrenal pathology, as well as uterine maturation in response to estrogen. However, premature ovarian follicles typically produce estrogen for a very short period, in quantities just sufficient to stimulate growth and shedding of the endometrium. Follicular involution and return of estrogen to prepubertal levels may occur before an ultrasound can be obtained. An x-ray for bone maturity is simple and noninvasive. Other supportive radiologic findings include a brain MRI demonstrating a mass in the context of central precocious puberty. If indicated, central precocious puberty can be suppressed with GnRH agonist therapy. Peripheral tumors (i.e., ovarian germ cell tumors) are treated by surgical excision with staging and chemotherapy as indicated by oncologic protocols.

Differential diagnoses of vaginal bleeding attributed to premature estrogenization must also include exposure to **exogenous estrogens,** including hormonal contraceptives, certain foods (soy), beauty products (lavender, tea tree oil), and plastics with endocrine disruptors. Ingesting large quantities of Bisphenol A (BPA), a product that may leach into the contents of plastic cups and bottles, is known to convey an estrogenic effect, although the impact remains unknown. Treatment involves elimination of any problematic sources of estrogen from the patient's daily use.

Juvenile hypothyroidism (see Chapter 603) commonly causes pubertal delay, but severe cases may present with premature breast development, vaginal bleeding, and abdominal distention secondary to ovarian enlargement and ascites. The mechanism for this condition is unclear, but it has been proposed that elevated levels of thyroid-stimulating hormone cross-react with follicle-stimulating hormone receptors, resulting in follicle maturation and estradiol production. Treatment with thyroid hormone replacement (e.g., levothyroxine) results in improvement and ultimately reversal of symptoms.

Neoplasms of the vulva and vagina (see Chapter 590) are rare causes of bleeding in the pediatric patient. **Infantile hemangiomas** are the most common benign vascular neoplasm of infancy, affecting up to 5% of all infants. Most lesions initially proliferate before resolving spontaneously and seldom require intervention. However, on identifying a perineal hemangioma, a neurologic assessment should be performed due to an association with spinal dysraphism. If a persistent lesion is superficial, application of topical β blockers (e.g., Timolol 0.5%) 2-3 times daily for 6-12 months has demonstrated good response rates. Oral β blocker use and intralesional corticosteroids may be used as well. If conservative therapies fail, laser therapy and surgical excision may be beneficial. Vaginal polyps may result in bleeding, and vaginoscopy for evaluation of any upper vaginal or cervical etiologies for bleeding with expedient excision and pathologic evaluation is recommended.

Malignant gynecologic neoplasms (see Chapter 590) are a source of pediatric genital bleeding that requires scrupulous evaluation and timely management. **Rhabdomyosarcoma** is the most common soft tissue sarcoma of childhood; 3% arise from the uterus or vagina. The embryonal variant is responsible for uterine sarcomas, whereas the embryonal subvariant sarcoma botryoides is found in the vagina. Primary **endodermal sinus** (i.e., yolk sac) **tumors** of the vagina are exceedingly rare, but early diagnosis is imperative given the malignancy's aggressive nature and poor prognosis. Both sarcomatous and endodermal sinus tumors arise primarily in the first 3 years of life, presenting on examination with a cystic or polypoid mass, bloody discharge, and occasionally urinary retention. Treatment consists of a multimodal approach, including surgery, radiation, and chemotherapy per oncologic guidelines.

Vulvovaginal trauma is an especially concerning cause of pediatric genital bleeding. Most traumatic injuries are accidental, but physical and sexual abuse must be ruled out (see Chapter 17.1). **Straddle injuries** are commonly seen after falls at home, particularly after slipping on a wet surface in the bathroom; they may result in bruising, hematomas, or lacerations (Fig. 587.2). Accidental trauma usually spares the hymen and vagina, instead affecting the external impact-absorbing tissue of the mons and labia. *However, a physical finding consistent with external injuries does not exclude the need to rule out involvement of internal genital structures. If there are no eyewitnesses to the injury, if the history does not clarify or support the clinical findings, and especially if there is a hymenal laceration, abuse must be considered in the differential diagnosis and a forensic interview of the patient and family conducted.* If after initial inspection a penetrative injury is suspected, further examination and imaging are necessary to assess for potential damage to the urethra, bladder, anus, or intraabdominal structures. An examination under anesthesia may be needed to fully assess and repair extensive injuries, while minor lacerations in a cooperative child may potentially be repaired using local anesthesia and/or conscious sedation. If the patient can void spontaneously, nonexpanding hematomas can be observed and treated with ice, pressure, and pain medications. Large expanding hematomas may require drainage, ligation of bleeding vessels, and placement of a closed suction drain if the overlying skin is showing signs of necrosis. A Foley catheter should be placed in all children who are having difficulty with voiding secondary to the injury.

Vaginal bleeding in the infant or prepubertal female is distressing to the patient and their family and can result from a wide spectrum of pathologic conditions or traumatic incidents. A detailed history and thorough physical examination must be done to identify the source of bleeding and for a management plan to be established efficiently. Presentations suspicious for trauma or abuse should involve the appropriate healthcare staff and authorities from an early stage, with findings meticulously documented. If an intervention is indicated to manage bleeding, regardless of its source, the risks and benefits of any therapy should be reviewed carefully with the family before initiation.

Visit Elsevier eBooks+ at eBooks.Health.Elsevier.com for Bibliography.

Fig. 587.2 Vulvar hematoma in an adolescent female as a result of a straddle injury. *(From Mok-Lin EY, Laufer MR. Management of vulvar hematomas: Use of a Word catheter. J Pediatr Adolesc Gynecol. 2009; 22:e156-e158.)*

Chapter 588

Breast Health

Marcene R. McVay-Gillam and Amy D. DiVasta

Breast complaints in pediatric patients typically include concerns about breast appearance or development, pain, nipple discharge, or a lump/mass. Although the development of breast cancer is very rare during childhood and adolescence, this patient population should be evaluated by practitioners who have experience with the immature and developing breast to avoid overtreatment with unnecessary diagnostic or invasive procedures.

BREAST DEVELOPMENT

Prenatal breast development begins around the fifth week of gestation, when the ectoderm on the anterior body wall thickens into two **mammary ridges.** These ridges extend from the axilla to the region of the inguinal canal (Fig. 588.1). The ridge above and below the area of the pectoralis muscle recedes in utero, leaving the **mammary primordium**, which is the origin of the lactiferous ducts. The lactiferous ducts form between weeks 10 and 20 and become interspersed through the developing mesenchyme, which develops into the fibrous and fatty portions of the breast. The **breast bud**, under the stimulation of maternal estrogen, becomes palpable at week 34 of gestation. This breast bud regresses within the first month of life once estrogen stimulation is no longer present. The **areola** appears at 5 months of gestation, and the nipple is seen shortly after birth. It is initially depressed or inverted, and later becomes elevated.

Thelarche, the onset of pubertal breast development, is hormonally mediated. It occurs when the hypothalamus releases gonadotropin-releasing hormone (GnRH), which stimulates the pituitary gland to produce follicle-stimulating hormone (FSH) and luteinizing hormone (LH) (see Chapter 599). FSH and LH then stimulate the ovaries to produce estradiol, which leads to breast development. Thelarche typically occurs between ages 8 and 13 years. Age at thelarche is affected by familial predisposition and varies by ethnicity.

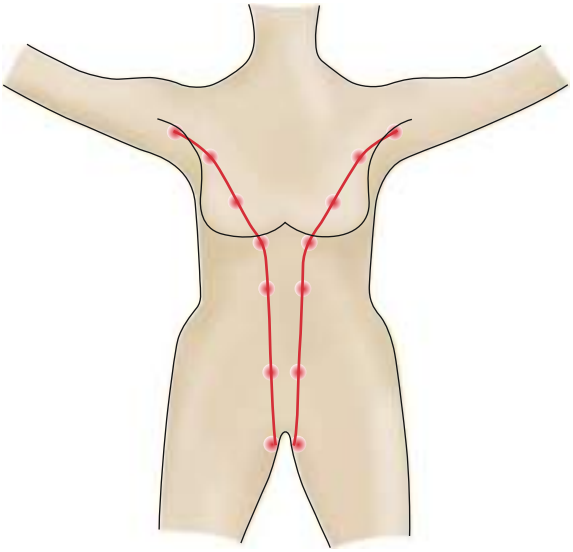

Fig. 588.1 Milk lines or mammary ridges. *(From Gao Y, Saksena MA, Brachtel EF, terMeulen DC, Rafferty EA. How to approach breast lesions in children and adolescents. Eur J Radiol. 2015;84:1350-1364; Fig. 1.)*

Breast development continues over a 2-4 year period after thelarche and is classified by the **Sexual Maturity Rating (SMR) system** (also known as **Tanner staging**) into five stages (see Chapter 150). Lack of breast development (**amastia**) by age 13 years is considered delayed and warrants evaluation. **Menarche** (onset of menses) usually occurs 2-3 years after thelarche.

BREAST EXAMINATION

Breast examination should be included in the routine healthcare maintenance examinations of all children and adolescents. Assessment of the newborn includes breast size, nipple position, presence of accessory nipples, and nipple discharge. Assessment of the prepubertal female includes inspection and palpation of the chest wall for masses, pain, nipple discharge, and signs of **premature thelarche.** Examination of the adolescent is performed with the patient in the supine position; the arm ipsilateral to the breast that is being examined should be placed next to the patient's head. The breast tissue is examined with the flat pads of the middle fingers, and the examiner should palpate all of the breast tissue in a uniform manner. The SMR should be noted and the axillary, supraclavicular, and infraclavicular nodes evaluated for lymphadenopathy. The areola should be gently compressed to assess for nipple discharge.

BREAST SELF-AWARENESS

Controversy exists as to the utility of breast self-examination in the adolescent population. Experts believe that it might be ill-advised to encourage breast self-examination in the adolescent because of a potential for unnecessary anxiety and possible unwarranted treatment in a population that is at low risk for malignant disease. The American College of Obstetricians and Gynecologists (ACOG) endorses breast self-awareness, which is defined as a female's awareness of the normal appearance and feel of their breasts. Breast self-awareness may increase an adolescent's understanding of their body, increase their comfort with exams, and provide opportunities for questions or discussion. Instruction in self-exam techniques should be considered for high-risk patients, such as those with a family history of conditions that may increase breast cancer risk or those at risk of secondary tumors. Adolescents should be educated to report any changes in their breasts or concerns to their healthcare providers.

Neonatal Breast Hypertrophy

Breast bud enlargement is a common condition in term newborns of either gender. It occurs as a result of elevated circulating maternal steroid hormones in late gestation. As maternal estrogen levels fall, prolactin levels can increase, and the breasts may produce a clear or cloudy (milk like) nipple discharge ("witch's milk") in male and female infants. Repeated manipulation of the breast can exacerbate the condition and should be discouraged.

ABNORMAL DEVELOPMENT

Premature Thelarche

Premature thelarche is defined as isolated unilateral or bilateral breast development in a female child under age 8 years without other signs of puberty; this is commonly seen in children under 3 years of age. Patient assessment includes a careful review of medications (including creams, ointments), home exposures to potential estrogens, review of growth charts, and x-ray for determination of bone age. Treatment consists of reassurance and follow-up to confirm that thelarche remains benign. Serial examinations, with particular emphasis on growth velocity, secondary sex characteristics such as pubic hair, pigmentation of the labia or areola, or vaginal bleeding, are imperative. Occasionally, patients with premature thelarche eventually develop true **central precocious puberty** (see Chapter 600.1). If puberty progresses, further workup should be performed to exclude central nervous system disorders or possible adrenal or gonadal neoplasm.

Amastia and Athelia

Complete absence of the breast, or **amastia,** is rare and is thought to occur from lack of formation of or obliteration of the mammary ridge. Amastia is usually unilateral and can be congenital or associated with systemic disorders (e.g., ectodermal dysplasia), endocrine disorders (e.g., congenital adrenal hyperplasia, gonadal dysgenesis, hypogonadotropic hypogonadism), or novel pathogenic gene variants. It can be associated with anomalies of the underlying mesoderm, such as the absence or hypoplasia of the pectoralis muscles seen in **Poland syndrome** (aplasia of the pectoralis muscles, rib deformities, webbed fingers, and radial nerve aplasia) (Fig. 588.2). Amastia or hypomastia can also be iatrogenic, resulting from injuries sustained during thoracotomy, chest tube placement, radiotherapy, severe burns, or incisional/excisional procedures on the breast bud. Surgical correction is individualized to the patient and the etiology. **Athelia**, the absence of a nipple either unilaterally or bilaterally, is rare and can be familial. It is also associated with exposure to endogenous androgens during pregnancy.

Fig. 588.2 Preoperative frontal view of a patient with left breast hypoplasia secondary to Poland syndrome. *(From Laberge LC, Bortoluzzi PA. Correction of breast asymmetry in teenagers. In: Hall-Findlay EJ, Evans GRD, eds. Aesthetic and Reconstructive Surgery of the Breast. London: Elsevier, 2010. Fig 39.14.)*

Fig. 588.3 Accessory nipple located inferior to the right breast. *(From Swartz MH. Textbook of Physical Diagnosis. Philadelphia: Elsevier, 2014; Fig 13-5.)*

Polymastia and Polythelia

Accessory breast tissue **(polymastia)** or accessory nipples **(polythelia)** occur in approximately 1–6% of the population (Fig. 588.3). The abnormally placed tissue can be seen anywhere along the mammary ridges ("milk lines") as a result of incomplete involution but is usually noted on the chest, axilla, or just inferior to the normally positioned breast. Polythelia has been reported in association with congenital malformations, particularly renal anomalies; it is therefore reasonable to perform a genitourinary ultrasound in an infant with supernumerary nipples. Surgical excision of the accessory breast or nipple is usually performed for pain (mastodynia), nipple discharge, or cosmesis.

Breast Hypoplasia and Asymmetry

Breast hypoplasia varies in degree from a near-total absence of breast tissue to well-formed breasts that are considered by the patient to be too small. Poor or absent breast development may simply be a delay in the development of normal secondary sex characteristics; the breasts develop slowly but are normal in all other respects. Family history may reveal other family members with a similar pattern. Other causes include ovarian dysfunction, hypothyroidism, eating disorders, chest wall irradiation, or surgery. Hypoplastic breast tissue can also be associated with a **tuberous breast** anomaly. Tuberous breasts are characterized by hypoplasia, a narrow breast base, and the appearance of herniation of the glandular tissue through enlarged areolae (Fig. 588.4).

More commonly, patients complain of *breast asymmetry*. Some degree of breast asymmetry is normal; it may be more pronounced during puberty while the breasts are developing. In asymmetry, the goals of evaluation are twofold. First, it is essential to exclude a neoplasm as the cause of the larger breast. Other etiologies may include a solitary large fibroadenoma, multiple fibroadenomas, or a parenchymal abscess. Alternatively, the possibility of tuberous breast development or Poland syndrome should be considered when evaluating the smaller side. Treatment depends on the underlying cause. Patients with mild asymmetry and no other associated pathology should be reassured. If a child has marked breast asymmetry, they may be initially offered cosmetic options, such as use of bra inserts or prostheses for the underdeveloped breast. Surgical correction may be pursued after breast development is complete. The American Society of Plastic Surgeons generally recommends that uncommon chest deformities or congenital breast asymmetry are the only cases in which a board-certified plastic surgeon should deem breast augmentation appropriate for a teenager. It is important that patients undergoing surgery have a realistic understanding of the potential results as well as the possible need for additional surgery. Saline-filled implants are the only type of implant approved by the U.S. Food and Drug Administration for females <22 years; saline-filled implants typically have a life span of about 10 years.

Macromastia

Adolescents may develop very large breasts **(macromastia)**, leading to both physical and psychologic symptoms. Common complaints include back pain, postural kyphosis, breast pain, intertrigo, limitation of physical activities, unwanted negative attention, diminished self-esteem, and eating disordered behaviors. Strong emotional support should be provided because macromastia can affect an adolescent's self-esteem at a vulnerable time in their psychologic development. The differential diagnosis for macromastia includes obesity, pregnancy, fibrocystic disease, end organ hormonal hypersensitivity, or lesions described in the previous paragraphs. Options for treatment of simple macromastia include surgical and nonsurgical interventions. Bras that provide maximal support can help correct symptoms. Alternatively, breast reduction mammoplasty may be desired. When adolescents are seeking breast surgery, ACOG first recommends education and reassurance regarding normal variations in anatomy, growth, and development for the patient and her family. Nonsurgical alternatives for comfort and appearance should be emphasized, and knowledge regarding indications and timing of surgical intervention and referral should be provided. Assessment of the adolescent's physical and emotional maturity level must be performed, as well as screening for **body dysmorphic disorder.**

Juvenile hypertrophy, or spontaneous massive growth of one or both breasts, is rare and should be distinguished from simple adolescent macromastia. This rapid growth of breast tissue may occur any time after thelarche but more commonly occurs abruptly over a several month period, after a preceding sustained period of normal breast development. Circulating estradiol levels are normal. Juvenile hypertrophy can cause extreme mastalgia, skin hyperemia or necrosis, and even damage to normal breast parenchyma due to compromised vascular supply. It can be unilateral or bilateral (Fig. 588.5). The etiology has not been elucidated; therefore treatment options include both pharmacologic and surgical interventions. The key to management is prompt recognition and intervention before the development of complications. Reduction mammoplasty is often the treatment of choice, with pharmacologic treatment (e.g., tamoxifen) or even mastectomy reserved for recurrence following surgery.

Infections

Mastitis is the most common infection of the breast and can occur any time from the neonatal period through adolescence and into adulthood. **Neonatal mastitis** is an infection that usually occurs in the first 2 months after delivery in term or near-term infants. Breast infections in adolescents occur most commonly with lactation. Adolescents can also develop **nonlactational mastitis** or a **breast abscess** as a result of irritation of the skin (e.g., acne lesions of the chest, shaving, or nipple stimulation), trauma, a foreign body (e.g., piercing), or ductal abnormality (such as ductal ectasia). *Staphylococcus aureus* is the cause of nearly all breast infections, but anaerobic bacilli *(Bacteroides)* may also be involved in the adolescent population. Methicillin-resistant *S. aureus* (MRSA) coverage should be considered in communities where the prevalence is high,

Fig. 588.5 Juvenile hypertrophy in a 12-year-old female. *(From Al-Saif AA, Al-Yahya GM, Al-Qattan MM. Juvenile mammary hypertrophy: is reduction mammaplasty always feasible? J Plast Reconstr Aesthet Surg. 2009;62:1470-1472; Fig. 1.)*

Fig. 588.4 Bilateral tuberous breast anomaly. *(Adapted from Pacifico MD, Kang NV. The tuberous breast revisited. J Plast Reconstr Aesthet Surg. 2007;60:455-464; Fig. 5.)*

especially for infants. Mastitis may be initially treated with warm compresses, analgesics, and oral antibiotics for 7-10 days. Antibiotic options include dicloxacillin, clindamycin, trimethoprim-sulfamethoxazole, or amoxicillin-clavulanic acid. If symptoms fail to resolve after a course of antibiotics, ultrasonography may reveal an abscess and can be used to guide needle aspiration. Incision and drainage should be reserved for failure of aspiration, and a periareolar incision is most cosmetic. Follow-up ultrasonography should be considered in adolescents to ensure that there is no remaining parenchymal lesion (e.g., cyst).

Trauma and Inflammation

Breast trauma is common in adolescent girls participating in contact sports. The trauma usually takes the form of contusion or **hematoma** and can resolve spontaneously or may be associated with late cystic changes in the breast, **fat necrosis** with calcium deposition over time, or fibrosis with retraction of the skin or the nipple over the injured area. When diagnosed with a hematoma, or when a palpable mass is present at the area of injury, serial follow-up by ultrasound is recommended until complete resolution. Persistent calcifications lasting more than 18 months after injury may require additional investigation by advanced imaging or biopsy.

Nipple Discharge

Nipple discharge must be carefully evaluated and characterized. Discharge may be milky and white **(galactorrhea)**, bloody, purulent, or serous (Table 588.1). A careful history and physical examination will help the practitioner determine the etiology. Examination of the discharge assists in diagnosis. Infection is usually associated with a purulent discharge; **ductal ectasia** (dilated subareolar ducts and periductal inflammation) may present with sticky, green or brown, or serosanguineous discharge. Discharge from the ducts of Montgomery (coming from the areola itself rather than through the nipple) may appear clear or brownish.

Galactorrhea is a specific type of nipple discharge that appears milky and is usually bilateral. Causes of galactorrhea are listed in Table 588.2. Cytologic evaluation of milky nipple discharge is not recommended. Laboratory evaluation should include a pregnancy test, prolactin, estradiol, and thyroid-stimulating hormone (TSH); these measures are obtained to rule out pregnancy, a pituitary prolactinoma, and/or the presence of a thyroid abnormality. If the prolactin level is elevated, visual field studies and a brain MRI might reveal the presence of a pituitary adenoma (see Chapter 598). Treatment is directed by results of the history, physical exam, and lab and imaging studies. Patients should be instructed to avoid nipple stimulation and stop any offending drugs, if appropriate to do so. Hypothyroidism should be treated and prolactin-releasing tumors managed with appropriate medical or surgical care. Medical treatment of galactorrhea consists primarily of dopamine agonists such as bromocriptine or cabergoline. Surgical intervention, usually transsphenoidal hypophysectomy, is rarely required.

Bloody discharge may be due to chronic nipple irritation (such as from **jogger's nipple**), ductal ectasia, phyllodes tumor, or intraductal papilloma (a rare, benign proliferative tumor). Unless the etiology of the bloody discharge is superficial (i.e., from obvious skin breakdown related to jogger's nipple), cytologic assessment of bloody discharge should be performed. Breast ultrasound may also be obtained to determine whether a mass or cyst is present.

Table 588.1 Common Causes of Nipple Discharge

DISCHARGE CHARACTERISTICS	POTENTIAL ETIOLOGY
Milky (galactorrhea)	Pregnancy or postpartum Medication use/drug use Herbal supplements Hypothyroidism Prolactinoma Chest wall trauma
Serous, serosanguineous	Ductal ectasia Intraductal papilloma
Sticky	Ductal ectasia Fibrocystic changes
Purulent	Mastitis Abscess
Bloody	Intraductal papilloma Phyllodes tumor Ductal ectasia Trauma ("jogger's nipple")
Episodic, clear to brown	Montgomery tubercles

Mastalgia

Mastalgia, or breast tenderness, is common in reproductive-age females. Mastalgia may be due to exercise, medications, early pregnancy, or benign breast changes **(fibrocystic changes)**. Physiologic swelling and tenderness can occur on a cyclic basis, most commonly during the premenstrual phase, and are secondary to hormonal stimulation and resulting proliferative changes. Hormonal imbalance can cause exaggerated responses in the breast tissue, especially in the upper and outer quadrants. Evaluation should include a pregnancy test and a breast examination. Nodularity,

Table 588.2 Etiologies of Hyperprolactinemia

PITUITARY DISEASE
Prolactinomas
Acromegaly
Empty sella syndrome
Lymphocytic hypophysitis
Cushing disease
HYPOTHALAMIC DISEASE
Craniopharyngiomas
Meningiomas
Dysgerminomas
Nonsecreting pituitary adenomas
Other tumors/metastatic disease
Sarcoidosis
Eosinophilic granuloma
Chiari-Frommel syndrome
Encephalitis
Pituitary stalk section or compression
MEDICATIONS
Anesthetics, including cocaine
Opiates
Selective serotonin reuptake inhibitors
Phenothiazines
Benzodiazepines
Protease inhibitors
Prostaglandins
Tricyclic antidepressants
Atypical antipsychotics
α-Methyldopa
Reserpine
Metoclopramide
Marijuana
Herbal supplements (fennel, anise, fenugreek)
NEUROGENIC DISORDERS
Chest wall lesions/surgery
Spinal cord lesions
Breast stimulation
OTHER CAUSES
Pregnancy, postpartum, and postabortion
Hypothyroidism
ROHHAD
Chronic renal failure
Cirrhosis
Stress
Idiopathic disorders

ROHHAD, rapid-onset obesity, hypothalamic dysregulation, hypoventilation, and autonomic dysregulation.
Modified from Chanson P, Maiter D. Prolactinoma. In Melmed S (ed). *The Pituitary*. 4th ed. Philadelphia: Elsevier, 2017; 467-514.

poorly localized tenderness, and soreness radiating to the axilla and arm are usual accompanying findings. Treatments for mastalgia include utilization of a firm, supportive sports-type bra, heat, and analgesics (oral or topical). Low-dose combined estrogen/progestin oral contraceptives often improve the breast pain. A course of NSAIDs is also typically effective. The effect of caffeine and chocolate on mastalgia is controversial, but if pain is worsened with increased intake, they should be avoided. Evening primrose oil, vitamin E, and chamomile extract are popular but unproven treatments.

BREAST MASSES

Peripubertal Masses

Initial breast development at the onset of thelarche can be unilateral and asymmetric, with the developing breast bud being mistaken for a "mass." Such asynchronous thelarche should be recognized to avoid unnecessary biopsy and potential injury to the maturing breast. If there is any question as to the etiology of the lump, ultrasound can be used to evaluate for a mass.

Adolescent Breast Masses

The differential diagnosis for breast masses in the adolescent patient is broad (Table 588.3). The patient should be questioned about variations associated with the menstrual cycle, associated symptoms such as nipple discharge, recent trauma to the breast, family history of breast masses or cancer, and personal history of chest radiation or malignancy. Physical examination should characterize the mass location, size, and firmness and determine whether tenderness, skin changes, nipple discharge, or lymphadenopathy is present. Because breast cancer in the adolescent is extremely rare (3.2 cases per million person-years for women <25 years), masses in this population can often be expectantly managed for extended periods of time.

Fibroadenomas are the most common solid mass found in the adolescent breast. Fibroadenomas are slow-growing, hormonal dependent masses most often located in the upper, outer quadrant of the breast. The average size at diagnosis is 2-3 cm; 10–25% of patients have multiple lesions. On examination, these lesions are well circumscribed, rubbery, mobile, and not tender. Given the slow-growing nature and lack of malignant potential, conservative management is recommended for most patients. If expectant management is chosen, serial exams and/or ultrasounds every 6-12 months may be done to prove lack of progression or rapid growth. Fibroadenomas have defined sonographic characteristics; biopsy is not required to make the diagnosis. A subset of fibroadenomas behave differently and can be distinguished from their routine counterparts by rapidity of growth and excisional biopsy alone. **Juvenile fibroadenomas** (or **giant fibroadenomas**) grow rapidly over 3-6 months to >5 cm and can replace the breast tissue or cause skin necrosis. The distinction between these and **phyllodes tumor** on core needle biopsy is difficult, so excisional biopsy is the recommended intervention. The only true histologic difference between juvenile and routine fibroadenomas is hypercellularity. Surgical excision of fibroadenomas is recommended when a mass has complex ultrasonographic signs, is >5 cm or rapidly growing, or causes anxiety to the patient or their family. The presence of five or more fibroadenomas in an adolescent should prompt a genetic evaluation for *PTEN* pathogenic variant.

Breast cysts are common, often arising from ductal ectasia, glands of Montgomery, or lymphatic malformations. Ultrasound is used for diagnosis and surveillance. Simple cysts are usually self-limited. If a simple cyst persists, it may be aspirated with a needle. Aspirated fluid that is clear may be discarded. Bloody fluid and other aspirated material should be sent for cytologic examination. Cysts that resolve with aspiration should be reevaluated in 3 months by ultrasound. If they recur, biopsy or excision should be considered.

Table 588.3	Breast Masses in the Adolescent Female
Developmental	Unilateral thelarche Macromastia, simple Juvenile hypertrophy or gigantomastia Intramammary lymph node
Infectious	Mastitis Abscess
Traumatic	Fat necrosis Hematoma
Cystic	Fibrocystic change Vascular malformation (hemangioma, lymphatic malformation) Galactocele
Benign tumors	Fibroadenoma (simple or juvenile/giant) Lipoma Hamartoma Intraductal papilloma Juvenile papillomatosis
Malignant tumors	Cystosarcoma phyllodes Breast carcinoma (secretory or ductal) Metastatic disease (lymphoma, neuroblastoma, sarcoma, rhabdomyosarcoma, acute leukemia)

Malignant Masses

Phyllodes tumors are classified as sarcomas and are the most common nonepithelial tumor of the breast. They are classified as benign, borderline, or malignant based on histopathology and are characterized by asymmetric breast enlargement in association with a firm, mobile, circumscribed mass. The tumor often grows rapidly and can become quite large, mimicking a giant or juvenile fibroadenoma. The majority of these tumors have a favorable prognosis, but malignant phyllodes can recur locally or with metastases. Excision with 1 cm margins is the preferred initial therapy in adolescent patients, regardless of the histologic classification of the lesion. Survival at 10 years approaches 90% after complete excision.

Juvenile papillomatosis is a rare proliferative tumor that often presents as a discrete mass. It is a marker for increased breast cancer risk in family members, and in patients with this condition, up to 15% may have a juvenile secretory carcinoma. Treatment of juvenile papillomatosis is total resection of the lesion with preservation of the breast. Family members of these patients should be screened.

Primary breast carcinoma is extremely rare in adolescents. Surveillance Epidemiology and End Results (SEER) data from 2015–2019 established an age-specific rate for female invasive breast cancer of 0.1/100,000 for ages <20 years. Although malignancy is rare, suspicion may be raised if a lesion is enlarging, hard, immobile, and poorly circumscribed. Biopsy of lesions with suspicious imaging findings (e.g., irregular shape or microlobulated/spiculated margins) or progressive growth is imperative. Contrary to adults with primary ductal carcinoma, 10-year survival is only slightly better than 50% in adolescents.

Rather than primary breast cancer, **secondary** cancers or **metastatic** tumors are more prevalent. Adolescents with previous *therapeutic radiation* to the chest or with malignancies with the potential to metastasize to the breast should be monitored more closely for breast masses. Rhabdomyosarcoma is the most common to metastasize to the breast. Other malignancies with risk of breast metastases include neuroblastoma, melanoma, renal cell carcinoma, and Ewing sarcoma. Breast tumors also may be the first manifestation of relapse (extramedullary) in acute lymphoblastic leukemia. Those with previous radiation therapy have increased risk of developing breast cancer at a young age and require careful ongoing surveillance.

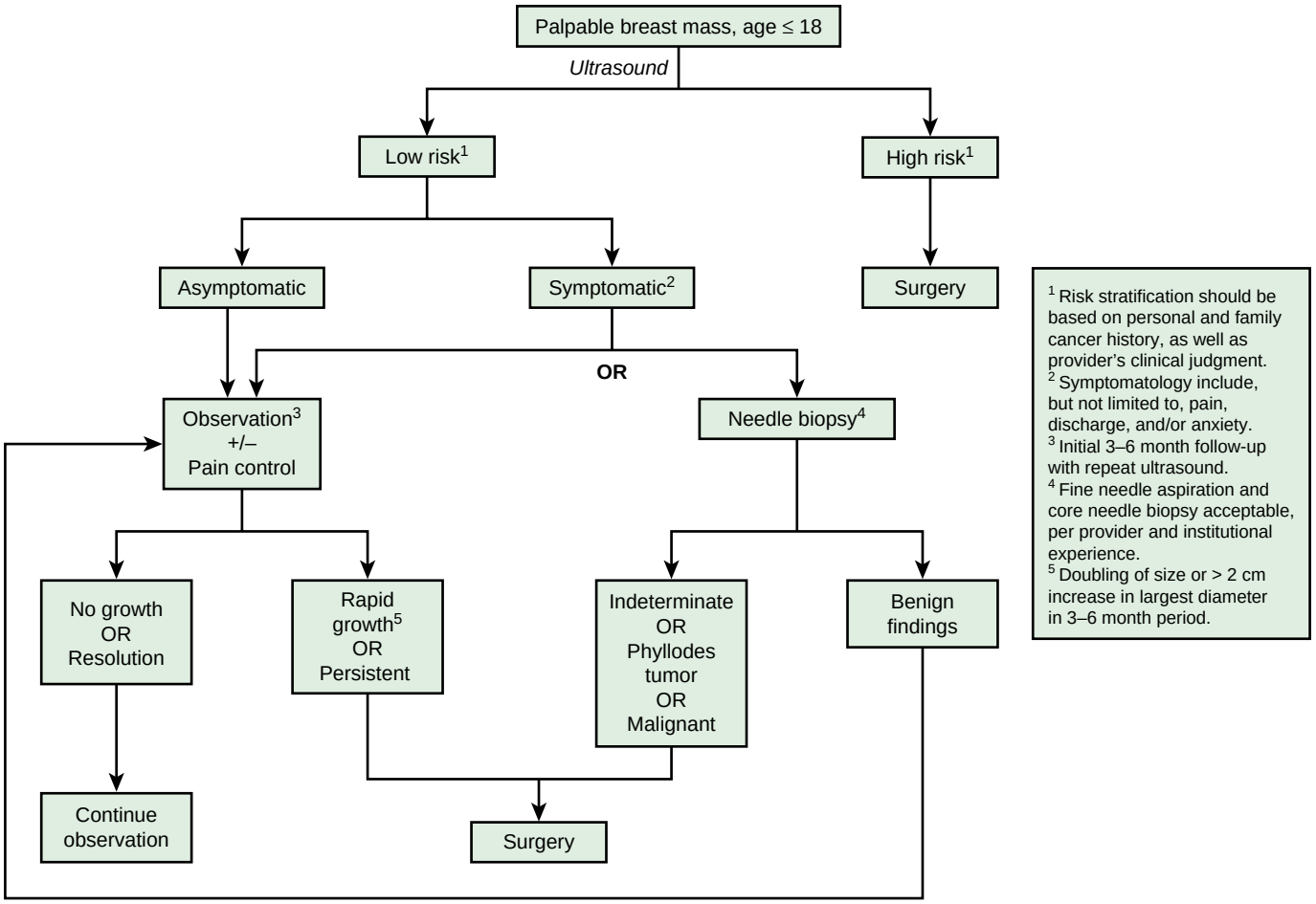

Fig. 588.6 Suggested clinical care algorithm for children presenting with a palpable breast mass. *(From McLaughlin CM, Gonzalez-Hernandez J, Bennett M, Piper HG. Pediatric breast masses: An argument for observation. J Surg Res. 2018;228:247-252; Fig 3.)*

Imaging of Breast Masses

Ultrasonography is the imaging modality of choice for palpable abnormalities in the pediatric and adolescent breast, given the diagnostic specificity and lack of ionizing radiation. MRI may be useful in select disease processes, but its use should be guided by a surgeon or oncologist. Because of the dense breast tissue in this patient population, there is no role for mammography.

MANAGEMENT OF BREAST MASSES

Figure 588.6 represents management algorithms for pediatric patients undergoing imaging for an identified breast mass. Core needle biopsy as a diagnostic tool is very sensitive but lacks specificity in distinguishing the hypercellular stroma of a juvenile fibroadenoma from a phyllodes tumor. Core needle biopsy should be recommended only for indeterminate masses, and based on co-decision-making between the patient, family, and clinician. Generally, observation and ultrasound surveillance should be the initial management for masses under 4 cm in size and excisional biopsy considered for those >4-5 cm.

Recommendations for Daughters of Women with Breast Cancer

Risk Reduction

There are a limited number of things that young people can do to lower their risk of breast cancer. The American Cancer Society recommends regular physical activity, limiting alcohol, eliminating cigarette smoking, and maintaining a healthy weight. Some studies have shown that breast-feeding for at least 1 year may slightly lower the breast cancer risk.

Screening Procedures

Screening mammography and/or ultrasound are not currently recommended in adolescents, regardless of family history. Routine testing of children and adolescents for the *BRCA1* and *BRCA2* pathogenic variants in families with a known history is also not typically recommended, because there are no guidelines for additional screening or treatment at this age, and *children* are very unlikely to develop a cancer related to an inherited *BRCA* variant.

Even in high-risk families, development of breast cancer below the age of 18 years is extremely rare. The American Cancer Society recommends a breast-screening regimen including mammography and MRI beginning at age 30 years for females with a known *BRCA* pathogenic variant or history of chest radiation between the ages of 10 and 30 years. Patients with an identified familial predisposition for malignancy should be referred for genetic evaluation to determine whether and/or when screening tests should occur. Any adolescent patient with a known primary breast malignancy should also be referred to a geneticist to be screened for pathogenic variants such as Li-Fraumeni (p53) or Cowden syndrome (*PTEN*).

Visit Elsevier eBooks+ at eBooks.Health.Elsevier.com for Bibliography.

Chapter 589

Polycystic Ovary Syndrome and Hirsutism

Heather G. Huddleston, Molly M. Quinn, and Mark Gibson

POLYCYSTIC OVARY SYNDROME

Etiology and Definition

Polycystic ovary syndrome (PCOS) is a common disorder of reproductive hormone function. The most widely accepted approach to the diagnosis of PCOS in adult females is the Rotterdam criteria, which require two out of three of the following features: **oligomenorrhea**, clinical or biochemical **hyperandrogenism**, and ovaries with a **polycystic morphology** on ultrasound examination (≥20 follicles in one ovary and/or ovarian volume >10 mm^3). Increased levels of antimüllarian hormone may be a marker of ovarian dysfunction and antral follicle count. Alternative criteria, such as the Androgen Excess Society and National Institutes of Health, place a greater emphasis on requiring hyperandrogenism be present (Table 589.1). The disorder, affecting 5–10% of females of reproductive age, depending on the diagnostic criteria used, typically emerges in adolescence when a normal menstrual pattern is not established and there is clinical evidence of androgen excess. Although not part of the *diagnostic* schemes, PCOS is often accompanied by cardiovascular disease risk factors, including insulin resistance, obesity, and dyslipidemia. Depression and anxiety have also been found to be more prevalent in females with PCOS.

Pathology, Pathogenesis, and Genetics

PCOS has a high concordance rate in twins, and in some studies either epigenetic or dominant inheritance patterns are observed. Nonetheless, a consistent hereditary pattern has not been identified.

Gonadotropic dysregulation with increased luteinizing hormone (LH) pulsatility and abnormally high ratios of circulating LH to follicle-stimulating hormone (FSH) are found in many patients with PCOS. Increased *ovarian* production of androgen in response to LH and impaired folliculogenesis owing to lower FSH are attributed to this gonadotropic pattern (Fig. 589.1). An increased ratio of circulating levels of LH:FSH is *not* a diagnostic criterion for PCOS.

Alterations in activities of steroidogenic enzymes that would explain *ovarian androgenic* hyperfunction are seen in PCOS subjects, but they are not consistently present in all patients, and it is unclear whether these alterations are a cause of PCOS or are a consequence of ovarian dysregulation. The size of ovarian stromal cells responsible for androgen production is increased; surgery that reduces this ovarian component (ovarian wedge resection or laparoscopic ablative procedures) reduces circulating androgen levels and often restores ovarian cyclicity. Patients with hyperandrogenic congenital or adult-onset adrenal hyperplasia exhibit PCOS-like ovarian dysfunction that can be reversed by reducing the *adrenal-derived* androgens with glucocorticoid therapy. A primary role for androgen excess in the pathophysiology of all instances of PCOS seems unlikely; many patients have minimal hyperandrogenism, and elimination of androgen excess (with gonadotropin-releasing hormone agonists) does not affect associated insulin resistance.

Measures of **insulin resistance** are greater and more prevalent among females with PCOS than controls even when accounting for body mass index (BMI). Insulin enhances ovarian androgen production directly and contributes to elevation of free testosterone levels through its suppression of hepatic production of sex steroid–binding globulin. Treatment with insulin sensitivity–enhancing agents that can reduce insulin levels is associated with modest reductions in measures of androgen excess and, in some patients, restoration of regular ovulation. The association of insulin resistance with weight might explain the appearance of features of PCOS among some females who gain weight, as well as the resolution of PCOS among affected females who lose weight.

Clinical Manifestations

PCOS, a lifelong disorder, commonly manifests as puberty progresses, but its onset can occur later, in young adulthood. Clinical hallmarks are menstrual abnormalities and manifestations of hyperandrogenism, but the severity of the disorder is variable (Table 589.2). Ovulation is typically irregular or absent, and menses are consequently irregular or absent. When menstrual bleeding does occur, it may be *anovulatory* bleeding, which is often heavy and/or protracted, resulting from an extended period of unopposed endometrial growth. Alternatively, bleeding can be relatively normal in character as a consequence of a preceding ovulation. Protracted spells of anovulation, with accompanying unopposed estrogen, are a risk factor for endometrial hyperplasia, and more severe premalignant and frankly malignant changes may eventuate. Hyperandrogenism is most commonly manifest as **hirsutism**, which is graded by the extent and locations of excessive male pattern hair growth (Fig. 589.2).

Obesity is common among individuals with PCOS. In some patients, the expression of features of PCOS is conditional on elevation of BMI and is reversible with weight loss. However, there is a subset of patients who present with a lean PCOS phenotype, and thus normal or low weight should not preclude consideration of the PCOS diagnosis. PCOS is associated with an increased prevalence of insulin resistance and type 2 diabetes independent of the tendency for many affected patients to have an elevated BMI. Additionally, PCOS confers a substantial and specific increase in risk for **metabolic syndrome** (hyperlipidemia, insulin resistance, type 2 diabetes) in adults as well as adolescent females after accounting for BMI.

Laboratory Findings, Diagnosis, and Differential Diagnosis

The diagnosis of PCOS requires exclusion of disorders that would otherwise account for hyperandrogenism and anovulation. Serum 17-hydroxyprogesterone should be measured when there is clear androgen excess to screen for adult-onset 21-hydroxylase deficiency (see Chapter 616). In the adolescent with amenorrhea but minimal hyperandrogenic findings, consideration should be given to functional hypothalamic suppression as a result of excessive exercise and/or dieting, and a careful history taken to rule out such behavioral patterns. All patients should be clinically evaluated for Cushing syndrome, and biochemical evaluation is indicated when clinical findings, including

Table 589.1 Diagnostic Criteria for Polycystic Ovary Syndrome in Adult Females*

NATIONAL INSTITUTES OF HEALTH CRITERIA	ROTTERDAM CRITERIA**	ANDROGEN EXCESS SOCIETY
Oligoovulation or anovulation *and* Clinical or biochemical hyperandrogenism	Two of three of the following: • Oligoovulation or anovulation • Polycystic ovaries on ultrasonography (20 or more follicles in a single ovary or ovarian volume of > 10 mm^3 in one ovary) • Clinical and/or biochemical hyperandrogenism	Clinical or biochemical hyperandrogenism and at least one of the following: • Polycystic ovaries *or* • Oligoovulation or anovulation

**In adolescents, diagnosis should be made when both hyperandrogenism and oligomenorrhea are present, with ultrasound criteria not required/recommended.

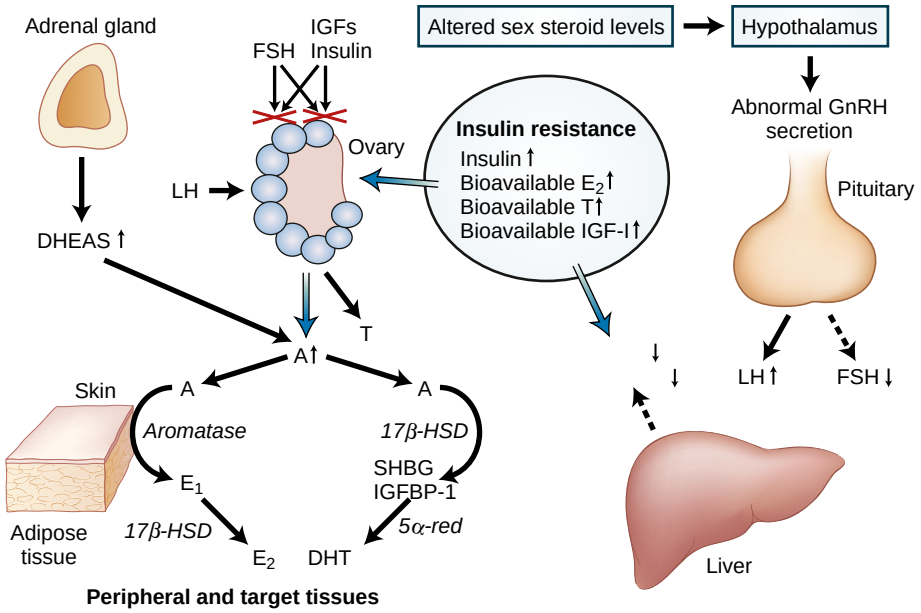

Fig. 589.1 Pathologic mechanisms in polycystic ovary syndrome (PCOS). A deficient in vivo response of the ovarian follicle to physiologic quantities of follicle-stimulating hormone (FSH), possibly because of an impaired interaction between signaling pathways associated with FSH and insulin-like growth factors (IGFs) or insulin, may be an important defect responsible for anovulation in PCOS. Insulin resistance associated with increased circulating and tissue levels of insulin and bioavailable estradiol (E_2), testosterone (T), and IGF-I gives rise to abnormal hormone production in a number of tissues. Oversecretion of luteinizing hormone (LH) and decreased output of FSH by the pituitary, decreased production of sex hormone–binding globulin (SHBG) and IGF-binding protein 1 (IGFBP-1) in the liver, increased adrenal secretion of dehydroepiandrosterone sulfate (DHEAS), and increased ovarian secretion of androstenedione (A) all contribute to the feed-forward cycle that maintains anovulation and androgen excess in PCOS. Excessive amounts of E_2 and T arise primarily from the conversion of A in peripheral and target tissues. T is converted to the potent steroids estradiol or DHT (dihydrotestosterone). Reductive 17β-hydroxysteroid dehydrogenase (17β-HSD) enzyme activity may be conferred by protein products of several genes with overlapping functions; 5α-reductase (5α-red) is encoded by at least two genes, and aromatase is encoded by a single gene. GnRH, Gonadotropin-releasing hormone. *(From Bulun SE. Physiology and pathology of the female reproductive axis. In Melmed S, Auchus RJ, Goldfine AB, eds. Williams Textbook of Endocrinology, 14th ed. Philadelphia: Elsevier, 2020. Fig 17-30.)*

Table 589.2 Phenotypes for Polycystic Ovary Syndrome Based on 2003 Rotterdam Criteria

SIGNS, RISKS, AND PREVALENCE	SEVERE PCOS	HYPERANDROGENISM AND CHRONIC ANOVULATION	OVULATORY PCOS	MILD PCOS
Periods	Irregular	Irregular	Normal	Irregular
Ovaries on ultrasonography	Polycystic	Normal	Polycystic	Polycystic
Androgen concentrations	High	High	High	Mildly raised
Insulin concentrations	Increased	Increased	Increased	Normal
Risks	Potential long term	Potential long term	Unknown	Unknown
Prevalence in affected females	61%	7%	16%	16%

PCOS, Polycystic ovary syndrome.
From Norman RJ, Dewailly D, Legro RS, Hickey TE. Polycystic ovary syndrome. *Lancet.* 2007;370(9588):685-697.

hypertension and/or characteristic exam features, are suggestive (see Chapter 619). The two disorders have in common a tendency for overweight and varying degrees of insulin resistance and androgen excess, but they differ in that Cushing syndrome demonstrates muscle wasting as a result of catabolism.

Evidence for androgen excess that is *rapid in onset and/or severe,* especially if masculinizing, warrants measurement of androgens (total testosterone, dehydroepiandrosterone [DHEAS]) to exclude the possibility of an androgen-secreting adrenal or ovarian tumor. The laboratory evaluation is completed with the exclusion of hyperprolactinemia, premature ovarian failure, and thyroid disease as causes of anovulation by measurement of prolactin, FSH, and thyroid-stimulating hormone, respectively.

The diagnosis of PCOS in reproductively mature females (at 8 years post menarche) is confirmed by the constellation of oligoovulation or anovulation, androgen excess (clinically or with biochemical confirmation), and typical ovarian morphology on ultrasound. Various experts weigh these three features differently and do not, as a rule, require the presence of all (see Table 589.1). Antimüllarian hormone levels are elevated in PCOS and may be a marker for ovarian dysfunction and cyst formation. Other recommendations have clarified that ultrasound features need not be assessed in adolescents, because normative values for ovarian anatomy have not been established. Indeed, young females often exhibit the multifollicular ovaries without any evidence of hyperandrogenism or oligomenorrhea, and not all patients with PCOS by the criteria of hyperandrogenism and ovulatory disruption exhibit ovarian changes typical of PCOS. *Therefore in the adolescent, diagnosis should only be made when both oligomenorrhea and hyperandrogenism are present and other causes of these symptoms have been ruled out.* Findings of anovulatory cycles and hyperandrogenism, particularly acne, may accompany the normal pubertal transition.

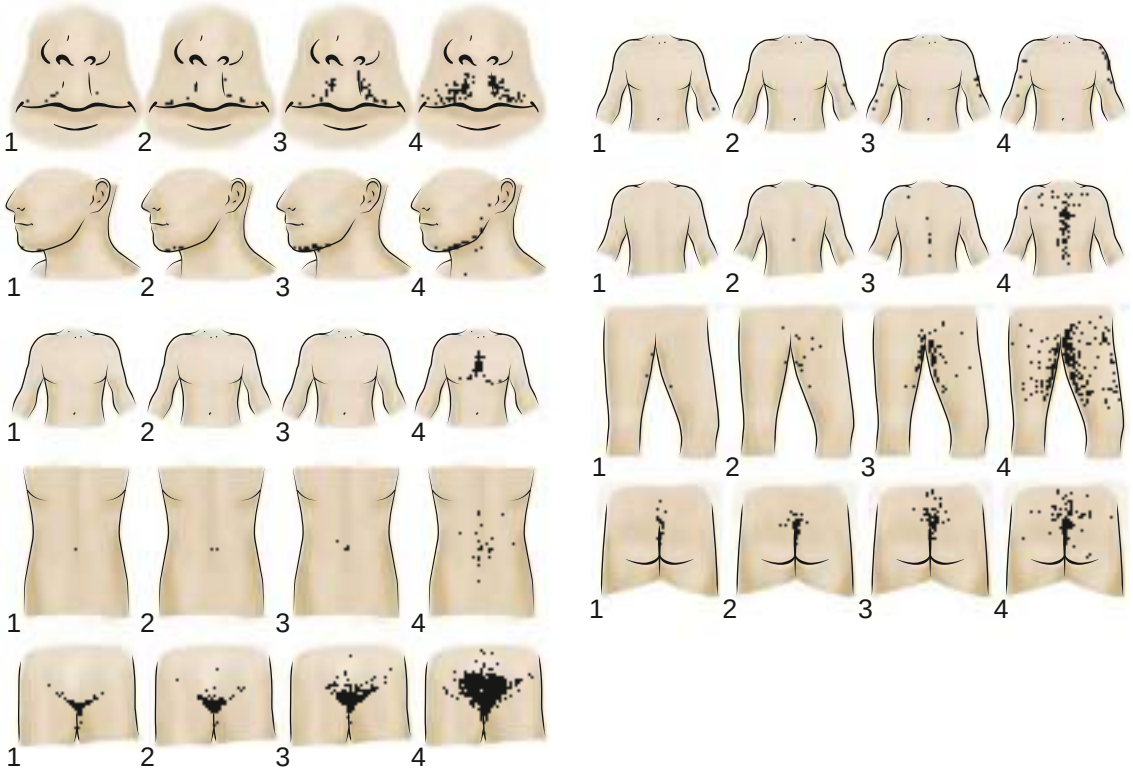

Fig. 589.2 Gender-neutral modified Ferriman-Gallwey (mFG) diagram. *(From Grimstad F, Moyer Q, Williams CR, Kremen J. A body-neutral and gender-neutral modified Ferriman-Gallwey diagram. J Pediatr Adolesc Gynecol. 2021;S1083-318800334-X. Fig 2.)*

For this reason, it is recommended that a formal PCOS diagnosis not be considered until at least 2 years post menarche. Adolescents with features of PCOS before this time can be considered "at risk" for PCOS, and a plan can be made for reevaluation in the future.

Insulin resistance is common among females with PCOS, and although not requisite for diagnosis, it should be considered when PCOS is identified. Adults, as well as adolescents, with hyperandrogenemia and anovulation should be evaluated for diabetes or impaired glucose tolerance with a 2-hour (75-g glucose load) glucose tolerance test.

Complications and Long-Term Outlook

Management of the features of hyperandrogenism, assistance with fertility, prevention of endometrial cancer, and reduction in the likelihood and severity of the common accompanying risk for the metabolic syndromes are long-term tasks for the PCOS patient and their healthcare providers (Table 589.3). Although there is a tendency for symptoms to ameliorate as menopause approaches, PCOS usually requires management throughout the reproductive years. Young patients should be counseled that modern fertility management allows most affected females to have children without great difficulty, and they should also know that the disorder does not confer reliable protection from unintended pregnancy. Endometrial cancer can develop as early as the third decade in females with PCOS who are not managed with progestins or ovulation induction; thus patients should understand the importance of long-term strategies for endometrial protection. Impaired glucose tolerance, type 2 diabetes, and metabolic syndrome are more common in females with PCOS compared to weight-matched controls. Metabolic disturbance can manifest as early as adolescence, and the prevalence increases over time. Weight control through diet and lifestyle measures, detection and management of impaired glucose tolerance and diabetes, and management of abnormal lipids are targets for long-term management.

Table 589.3 Lifelong Health Complications of Polycystic Ovary Syndrome

PRENATAL OR CHILDHOOD	ADOLESCENCE, REPRODUCTIVE YEARS	POST-MENOPAUSAL
REPRODUCTIVE		
Premature adrenarche Early menarche	Menstrual irregularity Hirsutism Acne Infertility Endometrial cancer Miscarriage Pregnancy complications	Delayed menopause
METABOLIC		
Abnormal fetal growth	Obesity Impaired glucose tolerance Insulin resistance Dyslipidemia Type 2 diabetes	Obesity Impaired glucose tolerance Insulin resistance Dyslipidemia Type 2 diabetes
OTHER		
	Sleep apnea Fatty liver Depression	Cardiovascular disease risk factors

From Norman RJ, Dewailly D, Legro RS, Hickey TE. Polycystic ovary syndrome. *Lancet.* 2007;370(9588):685-697.

Treatment

The management of PCOS is multifaceted and depends on the specific complaints of the patient. Primary goals include management of menstrual abnormalities, treatment of symptoms of androgen excess, and optimization of metabolic health. Weight loss through lifestyle

change, use of hormonal contraceptive agents for menstrual regulation as well as androgen suppression, antiandrogens as adjuncts for hirsutism treatment, and insulin-sensitizing agents are common components of treatment.

Lifestyle Changes

Comprehensive lifestyle programs for overweight and obese adults with PCOS aimed at fitness and weight loss can yield restoration of normal menstrual function in some patients. Lifestyle changes also lead to a reduction in the free androgen index, reduction in measures of insulin resistance, and improvement in serum lipids. Limited data show similar benefits from such interventions for obese adolescents with PCOS. Successful weight loss programs for adolescents with PCOS using both psychologic and nutritional counseling may result in improved menstrual function.

Hormonal Contraceptives

Combined (estrogen and progestin) hormonal contraceptive medications are considered first-line therapy for patients not desiring fertility (see Chapter 160). Avoidance of hyperplastic endometrial states resulting from unopposed estrogen and management of abnormal uterine bleeding in anovulatory episodes can be accomplished with the use of combined hormonal contraceptives. The progestational component inhibits endometrial proliferation, and the schedule of pill administration predictably regulates menstrual bleeding. The estrogenic component of the combined oral contraceptive elevates circulating sex hormone–binding globulin (SHBG), which reduces free and bioavailable testosterone levels. Both of the hormonal elements in oral contraceptives combine to suppress gonadotropic (particularly LH) stimulation of ovarian androgen production. DHEAS levels, often contributory to hyperandrogenemia in PCOS, are usually decreased by combined contraceptive use. Products with less androgenic progestational components (drospirenone, desogestrel) may provide better relief from androgenic symptoms.

Using hormonal contraception that is well tolerated in long-term use is more important than using a product with a particular progestational component. Products with reduced frequency and duration of pill-free intervals can provide superior androgen suppression and a welcome decrease in the frequency of bleeding episodes. Depot medroxyprogesterone acetate for contraception, endometrial protection, and androgen suppression may be a suitable alternative to combined hormonal contraceptives; it provides even more profound suppression of ovarian androgen production, but it does not elevate SHBG. Low-dose progestin-only regimens (oral minipills, implantable progestational contraceptives, and progestin-releasing intrauterine devices) also provide effective endometrial protection but would be expected to provide only partial and/or inconsistent androgen suppression and would not elevate SHBG.

Patients without the need for management of hyperandrogenic symptoms or contraception are often treated with periodic use of oral progestins to induce predictable menstrual bleeding and prevent endometrial hyperplasia and malignancy. Twelve-day courses of medroxyprogesterone acetate 10 mg daily or norethindrone acetate 5 mg daily are effective and safe for this purpose when taken every 1-2 months.

Oral contraceptives also provide the added benefit of contraception. Given the relative infrequency of ovulation, fertility in females with PCOS would be expected to be reduced relative to that of their peers, but they are still at risk for pregnancy and should be counseled accordingly.

Metformin

Metformin is a biguanide medication used to treat type 2 diabetes, which is its only FDA-approved indication. It has been used in a variety of settings and with differing objectives for patients with PCOS. Metformin exerts its principal effect by reducing hepatic production of glucose and limiting intestinal absorption of glucose. A subset of females with PCOS resume regular ovulation and menses when treated with metformin, obviating the need for progestational therapy to protect endometrial health or medications to induce ovulation. For some patients, the resulting normal reproductive function is appealing regardless of interest in fertility.

Metformin reduces insulin resistance and the levels of androgens. Its extended use can reduce the likelihood of development of impaired glucose tolerance or the progression of impaired glucose tolerance to type 2 diabetes; these effects are not yet proven for patients with PCOS. It should not be used in the presence of renal or hepatic impairment. Typical dosing is 1,500-2,000 mg/day, achieved through gradual increments because gastrointestinal intolerance is common. Long-acting preparations are helpful when gastrointestinal intolerance is a problem. The use of metformin in the treatment of PCOS depends on the patient's goals and preference. For the treatment of hyperandrogenic symptoms, metformin effects may be modest compared with other available agents. There are no empirical data supporting the theoretical benefits of long-term use of metformin in adolescents with PCOS and obesity compared with the outcomes achieved with weight loss and oral contraceptive medications. Use of metformin as a first-line agent is favored by some experts, in part for improvement in serum measures of intermediate outcomes, and in part because of evidence in other populations of reduced progression of insulin resistance. There is no evidence for a long-term benefit for clinical outcomes of adding metformin to treatment for patients managed primarily with oral contraceptives. For adolescents receiving metformin as a first-line medication, some element of progestational management (combined contraceptives or periodic progestins) will still be necessary for those not resuming ovulatory function, and oral contraceptives may still be an important adjunct for management of clinical hyperandrogenism and/or contraception. Metformin side effects include nausea, emesis, and diarrhea; more serious effects include lactic acidosis and vitamin B12 deficiency. Glucagon-like peptide receptor agonists are being studied as a possible add on therapy to metformin or as a single agent to treat PCOS.

Antiandrogens

Antiandrogenic medications may be added to other therapies or used alone for the treatment of hirsutism. These agents are usually used adjunctively with ovarian hormonal suppression, in part because of better reduction in hirsutism when antiandrogens are combined with ovarian suppression but also to reduce the risk of unintended embryonic or fetal exposure. The highly active androgen antagonist and progestin, cyproterone, is available in Europe and in Canada as a single agent for treatment of hirsutism or in combination with ethinyl estradiol as an oral contraceptive with enhanced antiandrogenic profile. In the United States, spironolactone is the most commonly used antiandrogen. Spironolactone antagonizes androgens at their receptor and also impairs androgen synthesis. Doses of 100-200 mg daily are commonly used. Other agents that have been studied are finasteride, a 5α-reductase inhibitor, and flutamide, a nonsteroidal and highly specific androgen receptor antagonist. These are rarely used because of lack of evidence of superior effectiveness, cost, and, in the case of flutamide, the potential for hepatotoxicity.

HIRSUTISM

Hirsutism is defined as abnormally increased terminal (mature, heavy, dark) hair growth in areas of the body where hair growth is normally androgen dependent (see Chapter 703). Its presence is a result of the combination of the extent of androgenic stimulation and familial regional follicle sensitivity to androgens, which varies considerably among ethnic groups. Patients' cosmetic concerns generally determine whether findings of hirsutism are a matter for clinical investigation and treatment. Hirsutism as an isolated finding is to be distinguished from **masculinization.** The latter includes alteration in muscle mass, clitoral enlargement, and voice change, generally manifesting as a rapid

Table 589.4 Treatment of Hirsutism

SYSTEMIC THERAPIES
Suppression of androgen production
Combined oral contraceptives (ethinyl estradiol + progestin with low androgenic activity)
Androgen blockers
Spironolactone
Finasteride
Flutamide
Cyproterone acetate (not available in the United States)
COSMETIC STRATEGIES
Temporary measures
Shaving, bleaching, chemical depilation
Permanent measures
Electrolysis
Laser therapy

evolution (over months). *Masculinization mandates a search for a neoplastic source of androgen.* Elevations of testosterone or DHEAS commonly indicate an ovarian or adrenal androgen source, respectively; specific imaging and occasionally selective catheterization studies are indicated (see Chapters 590 and 617).

Hirsutism without masculinization is common. The potential causes to consider are PCOS (when there is hyperandrogenism and anovulation), benign functional androgen excess (measurable hyperandrogenism without anovulation), idiopathic hirsutism (increased hair in androgen-dependent areas without measurable androgen excess), and adult-onset adrenal hyperplasia. Patients can be primarily distinguished by evidence of an ovulatory disorder by menstrual history, and for those with absent or irregular menses, a diagnosis of PCOS can be made. The remainder, for whom adult-onset adrenal hyperplasia and PCOS have been excluded, either have normal androgen levels with enhanced end-organ sensitivity owing to familial or ethnic predisposition or have a functional and benign overproduction of ovarian androgens. Measures of androgens (testosterone, DHEAS) may be normal or mildly elevated in the latter group. Testosterone suppresses circulating sex-steroid binding globulin, so states of testosterone overproduction might not be accompanied by elevated measures of total testosterone, although estimates of "free" or "bioavailable" testosterone reveal hyperandrogenism. Measures of unbound testosterone distinguish idiopathic hirsutism from mild benign hyperandrogenic states; making this distinction contributes little to patient management and adds cost. Idiopathic hirsutism (without evidence of androgen excess) usually responds to antiandrogen or androgen suppression therapy similarly to hirsutism associated with elevated androgens and anovulation (PCOS) and benign hyperandrogenism not associated with PCOS.

If hirsutism is present, and clinical evaluation excludes neoplasm, adult-onset adrenal hyperplasia, and Cushing syndrome, then management for symptoms of hyperandrogenism (regardless of whether measures of circulating androgens are elevated or not) can proceed as for patients with PCOS (Table 589.4). Estrogen and progestin suppression of ovarian function, with or without added antiandrogen treatment, is the mainstay of therapy for these patients. Androgen suppression and/or antagonism results in gradual regression of the size and productivity of follicles in androgen-sensitive areas of the face and body, and these changes will evolve over successive and months-long generations of hair growth and shedding. Patients should therefore be advised that the effects of medical therapy accrue slowly, over many months.

Visit Elsevier eBooks+ at eBooks.Health.Elsevier.com for Bibliography.

Chapter 590

Gynecologic Neoplasms and Prevention Methods for Human Papillomavirus Infections in Adolescents

Joan R. Tymon-Rosario, Levent Mutlu, and Alla Vash-Margita

OVERVIEW OF GYNECOLOGIC MALIGNANCIES IN CHILDREN AND ADOLESCENTS

Cancer is the second most common cause of death in children and adolescents, surpassed only by childhood injuries. The highest death rate is in the 5- to 14-year-old age group. Although rare, gynecologic malignancies can result in long-term sequelae such as infertility, depression, and a poor self-image, which may cause significant morbidity.

In children and adolescents younger than 18 years, ovarian cancer accounts for 87.5% of gynecologic malignancies, vaginal cancer for 4.5%, cervical cancer for 3.9%, uterine cancer for 2.5%, and vulvar cancer comprises 1.6% of all gynecologic cancers.

Ovarian cancers usually manifest as an abdominal or pelvic mass with acute or chronic lower abdominal pain and/or menstrual irregularities. The diagnostic workup includes a physical exam and laboratory tests such as a urine pregnancy test, hormone levels, and tumor markers. The preferred initial method of imaging is transabdominal pelvic ultrasonography. The differential diagnosis includes gynecologic tumors, other abdominal and pelvic organ-based tumors, and functional, physiologic, inflammatory/infectious, or pregnancy-related ovarian pathology. Although the majority of ovarian neoplasms are benign, approximately 9–33% of all pediatric or adolescent ovarian neoplasms are malignant. Ovarian neoplasms constitute 1.3% of all childhood malignancies but account for 60–70% of all gynecologic malignancies in this age group. Germ cell tumors are the most common type of neoplasm. Less often, the vagina or cervix is a site of malignant lesions in children, with a few specific tumors having their greatest incidence in this population. Vulvar and endometrial malignancies in children and adolescents are exceedingly rare.

IMPACT OF CANCER THERAPY ON FERTILITY

The treatment of gynecologic cancer, depending on the type and extent of disease, may include fertility-sparing cytoreductive surgery with adjuvant chemotherapy, definitive surgery including bilateral salpingo-oophorectomy, and comprehensive surgical staging, radiation, and/or secondary salvage surgery. Fertility-sparing surgery is defined as unilateral salpingo-oophorectomy, lymph node sampling, and omentectomy, whereas maximal cytoreduction includes hysterectomy and contralateral salpingo-oophorectomy. For malignant ovarian germ cell tumors, the most common adolescent gynecologic malignancy, the use of fertility-sparing surgery, is seen as the gold standard. This approach achieves a good prognosis, and the majority of patients achieve normal hormonal function and future pregnancies. Importantly, it does not seem to be associated with lower progression-free survival, overall survival, or mortality rates compared with radical surgery.

Platinum-based chemotherapeutic regimens are most often used for malignant ovarian tumors. The need for chemotherapy and radiation therapy is associated with acute ovarian failure, premature menopause, and infertility (Table 590.1). Risk factors include older age, abdominal or spinal radiation, and certain chemotherapeutic drugs, such as

Table 590.1 Effect of Cancer Treatment on the Development of Amenorrhea

TREATMENT	AGENT/MODALITY	IMPACT	TREATMENT FOR
Protocols containing nonalkylating agents or lower levels of alkylating agents	ABVD, CHOP, COP, multiagent therapies for leukemia	LOWER RISK <20% of women develop amenorrhea posttreatment	Non-Hodgkin lymphoma Leukemia
Protocols containing	Multiagent therapies using vincristine	VERY LOW/NO RISK No effect on menses	Leukemia Lymphomas
Protocols containing	Procarbazine MOPP and BEACOPP 3 cycles >6 cycles	HIGH RISK More than 80% develop amenorrhea posttreatment	Hodgkin lymphoma
Protocols containing	Temozolomide or BCNU + cranial radiation	HIGH RISK More than 80% develop amenorrhea posttreatment	Brain tumor
Abdominal or pelvic radiation	10-15 Gy in prepubertal females 5-10 Gy in postpubertal females	INTERMEDIATE RISK 30–70% of women develop amenorrhea posttreatment	Acute lymphoblastic leukemia Brain tumor Neuroblastoma Non-Hodgkin lymphoma Hodgkin lymphoma Spinal tumor Wilms tumor
Whole abdominal or pelvic radiation	>15 Gy in prepubertal females >10 Gy in postpubertal females >6 Gy in adult women	HIGH RISK More than 80% develop amenorrhea posttreatment	
Total cyclophosphamide	5 g/m^2 in women >30 yr 7.5 g/m^2 in women and females <20 yr	HIGH RISK More than 80% develop amenorrhea posttreatment	Non-Hodgkin lymphoma
Any alkylating agent + pelvic radiation	Busulfan, carmustine, cyclophosphamide, ifosfamide, lomustine, melphalan, procarbazine	HIGH RISK More than 80% develop amenorrhea posttreatment	Ovarian cancer Sarcoma
Any alkylating agent + total body irradiation	Busulfan, carmustine, cyclophosphamide, ifosfamide, lomustine, melphalan, procarbazine	HIGH RISK More than 80% develop amenorrhea posttreatment	Lymphomas Myelomas Choriocarcinoma Ewing sarcoma, neuroblastoma
Any cancer requiring bone marrow transplant/stem cell transplant		HIGH RISK More than 80% develop amenorrhea posttreatment	Hodgkin lymphoma Non-Hodgkin lymphoma Acute myeloid leukemia Chronic myeloid leukemia Myeloma Acute lymphoid lymphoma Chronic lymphoid lymphoma Some solid tumors (e.g., breast, ovarian, kidney, brain)

ABVD, Doxorubicin, bleomycin, vinblastine, dacarbazine; CHOP, cyclophosphamide, doxorubicin, vincristine, prednisolone; COP, cyclophosphamide, vincristine, prednisone; MOPP, mechlorethamine, vincristine, prednisone, procarbazine; BEACOPP, bleomycin, etoposide, doxorubicin, cyclophosphamide, vincristine, procarbazine, prednisone; BCNU, carmustine; Gy, gray.

Adapted from Female Fertility Preservation LIVESTRONG, a registered trademark of the LIVESTRONG Foundation. https://www.livestrong.org/we-can-help/just-diagnosed/female-fertility-preservation.

alkylating and platinum-based agents (cisplatin, cyclophosphamide, busulfan). Uterine irradiation is associated with infertility, spontaneous pregnancy loss, and intrauterine growth restriction. The vagina, bladder, ureters, urethra, and rectum can also be injured by radiation. Vaginal shortening, vaginal stenosis, urinary tract fistulas, and diarrhea are potential side effects of pelvic irradiation.

Advancements in oncologic treatments of gynecologic and systemic tumors have led to improvements in childhood cancer survival rates. Unfortunately, with these advances come an increase in short- and long-term adverse effects, which include gonadotoxicity and infertility. Approximately 15% of *all* childhood cancer survivors experience infertility, and pregnancy outcomes appear to be influenced by prior chemotherapy and radiation treatment (see Chapter 543). Cancer survivors have an increased rate of spontaneous abortion, premature delivery, and low birthweight infants compared with their healthy siblings. No data support an increased incidence of congenital malformations in offspring. Individualized risk of infertility should be discussed before gonadotoxic therapies and options for fertility preservation should be made available to all patients, with referrals to reproductive specialists and mental health professionals as appropriate. Multiple recommendations specifically address the pediatric population, stating that parents/guardians should be allowed to act for and consent in the interest of their minor children.

Mature oocyte and embryo cryopreservation are both standard of care preservation options available to postpubertal females with ample time before treatment to allow for ovarian stimulation (2-6 weeks). Ovarian tissue cryopreservation (OTC) is the only available option for prepubertal females. OTC is also an option for fertility preservation for postpubertal females with time-limiting treatment plans. The safety and feasibility of OTC and transplantation after nonsterilizing chemotherapy and in select leukemia survivors have been favorable, and there have been over 130 live births reported after orthotopic transplantation

of previously cryopreserved and thawed ovarian tissue as of 2017. Laparoscopic ovarian transposition can be used before radiation therapy where a high risk of ovarian radiation exposure in its anatomic position is expected. Hormone suppression with gonadotropin-releasing hormone (GnRH) analogs has been investigated as a means of fertility preservation, but evidence is lacking as to its efficacy.

Gonadotoxicity can also lead to primary ovarian insufficiency, which is associated with an increased risk for cardiovascular complications, osteoporosis, and difficulties with sexual function. Risks and benefits of hormone replacement therapy should be addressed as appropriate.

NEONATAL AND PEDIATRIC OVARIAN CYSTS

Normal follicles or physiologic ovarian cysts can be seen by ultrasound examination of the ovaries in healthy neonates, infants, and prepubertal females. The true incidence of neonatal cysts is unknown, but most are physiologic. Ovarian cysts are often detected during prenatal imaging and should be differentiated from masses originating from the urinary or gastrointestinal (GI) tract. Ovarian cysts that are less than 2 cm, sonolucent, and have a simple appearance on ultrasound are most likely physiologic. Simple neonatal ovarian cysts will resolve spontaneously and should be followed with observation. Larger cysts may be seen; in these cases, the interval to complete resolution is usually longer. Because of the risk of **ovarian torsion** and resultant autoamputation of the ovary, treatment modalities have been developed to prevent ovarian torsion, including ultrasound-guided aspiration, laparoscopic cystectomy, and detorsion, with the goal of ovarian preservation. Oophorectomy should be avoided. Treatment is usually reserved for the postnatal period unless the cyst is large enough to prevent embryonic development. Similarly, intervention might be necessary if the cyst is large enough to complicate delivery or if there is concern for compromise of the other organs because of the mass effect. If a conservative approach is chosen, serial ultrasonographic evaluation is reasonable until resolution in the prenatal and neonatal period. In the neonatal period, aspiration is an option for cysts that are larger than 6 cm and persistent over 4 months. Surgical exploration is generally reserved for complex, symptomatic, or enlarging cysts, with a great deal of effort exerted to preserve the surrounding normal ovary.

In **prepubertal** children, ovarian cysts are rare and, if present, usually asymptomatic and hormonally inactive. However, a careful exam is indicated because prepubertal ovarian cysts may be associated with peripheral precocious puberty. If symptomatic, cysts might present as an abdomino-pelvic mass resulting in pain, constipation, or urinary frequency. In **adolescents**, ovarian cysts are common and usually represent normal follicular development.

Cysts that are simple appearing, without septations or internal echogenicity, and less than 10 cm on transabdominal ultrasound are almost always benign, and observation is preferred (Fig. 590.1). Careful counseling and patient education should be provided for early recognition of complications related to ovarian cysts, such as cyst rupture and ovarian torsion. Unless associated with intractable symptoms or intraabdominal bleeding because of cyst rupture, cysts can be managed conservatively. Large ovarian cysts pose a risk of ovarian torsion. *Ovarian torsion* is a surgical emergency and can happen with ovarian cysts of any size, although the risk increases in adnexal masses larger than 5 cm. Rarely, torsion of the adnexa can occur without presence of an ovarian cyst, which is more common in prepubertal patients.

Functional Cysts

Over the course of several menstrual cycles, a **dominant follicle** forms and increases in size. After ovulation, the dominant follicle becomes a corpus luteum that, if it bleeds, is termed a **hemorrhagic corpus luteum**. These can become symptomatic owing to size or peritoneal irritation, and they have a characteristic complex appearance on ultrasound. Expectant and symptomatic management for a presumed functional or hemorrhagic cyst is appropriate. Physiologic cysts are usually ≤5 cm and resolve over the course of 6-8 weeks or several menstrual cycles without the need for any intervention. Monophasic oral contraceptives can be used to suppress future follicular development and prevent formation of additional cysts. When a cyst is found on ultrasound, a pregnancy test should be obtained because an adnexal mass on imaging could represent either a corpus luteum cyst that physiologically supports a normal pregnancy or an abnormal pregnancy state such as an ectopic pregnancy in the adnexa.

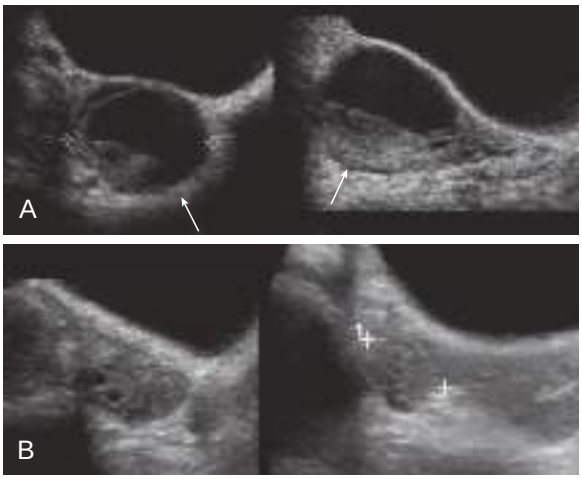

Fig. 590.1 Ovarian cyst. 14-yr-old female with pelvic pain. **A,** Transverse and sagittal images from a transabdominal pelvic ultrasound demonstrate a well-circumscribed cystic lesion in the right adnexa with a fluid–debris level *(arrows).* **B,** Follow-up imaging 6 weeks later demonstrates complete resolution of the cyst. *(From Walters MM, Robertson RL. Pediatric Radiology: The Requisites, 4th ed. Philadelphia: Elsevier, 2017:186; Fig. 6.70.)*

OVARIAN NEOPLASMS

Teratomas

Ovarian teratomas are the most common pediatric ovarian neoplasm and account for 25% of all pediatric teratomas. Aberrant migration and differentiation of primordial germ cells from the yolk sac to the gonadal ridge during embryogenesis is considered to be the embryologic origin of teratomas. Ovarian teratomas are usually asymptomatic but may become quite large and present with abdomino-pelvic pain and a palpable mass; ovarian torsion may be the initial presenting symptom. Ovarian teratomas are usually unilateral, but about 10% of cases are bilateral. **Mature cystic teratomas** (**dermoid cysts**) account for more than 95% of all teratomas. Depending on the germ layers, teratomas can be polydermal or monodermal and may contain mature tissue of ectodermal (skin, hair, sebaceous glands, neuroectodermal tissue), mesodermal (muscle, bone, cartilage, fat, teeth), and/or endodermal (thyroid, salivary, respiratory, GI) origin (Fig. 590.2). Mature teratomas are usually benign; malignant transformation is reported in less than 2% of the cases. Although any of the components of the mature teratoma can undergo malignant transformation, the most common secondary neoplasm arising from mature teratoma is squamous cell carcinoma. Teratomas have a characteristic sonographic appearance that includes findings such as fluid-fluid levels, Rokitansky nodules (a solid protuberance projecting from an ovarian cyst), echogenic sebaceous material, calcification, and hyperechoic regions. On abdominal radiograph, calcification is often a hallmark for teratomas. Ultrasound has a high sensitivity and specificity for diagnosing dermoid cysts with excellent diagnostic accuracy. Monodermal teratomas are rare and contain elements originating from a single germ cell layer. **Struma ovarii** is a monodermal teratoma that is composed of mature thyroid tissue that may result in clinically overt hyperthyroidism. **Ovarian carcinoid tumors** are another example of a monodermal teratoma. These rare tumors are generally associated with a mature teratoma but can be encountered in a pure form as a monodermal teratoma in a minority of cases. Approximately 30% of the time, clinical signs of carcinoid syndrome such as diarrhea, flushing, abdominal pain, and wheezing

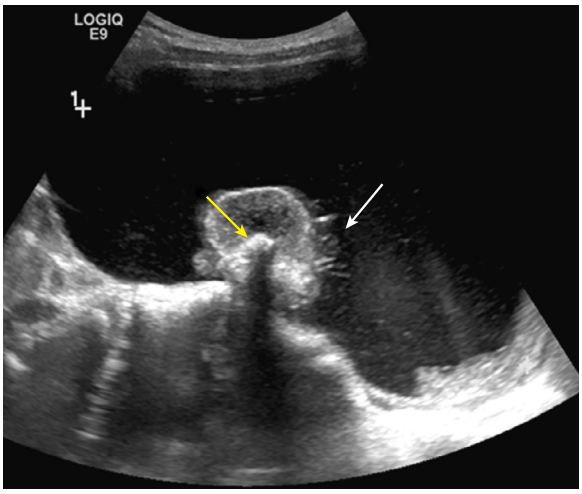

Fig. 590.2 Mature teratoma. 12-yr-old female with increasing abdominal girth. Transabdominal pelvic ultrasound image demonstrates a large pelvic mass with cystic and solid components. There is a rounded echogenic area in the center of the large, hypoechoic cystic portion. A central dense echogenic focus *(yellow arrow)* demonstrates posterior acoustic shadowing, consistent with calcification. Tiny linear echogenic foci *(white arrow)* are also associated with the central echogenic mass, representing hair. This constellation of findings is seen with a mature teratoma or dermoid cyst. *(From Walters MM, Robertson RL. Pediatric Radiology: The Requisites, 4th ed. Philadelphia: Elsevier, 2017: 187; Fig. 6.71.)*

may be present because of vasoactive amines secreted by the carcinoid tumors.

Benign teratomas can be observed if they are asymptomatic and small (<5 cm). However, when they are large or symptomatic, they should be surgically resected to prevent torsion or rupture, with preservation of the surrounding healthy ovarian parenchyma. Cystectomy is the treatment of choice, and minimally invasive techniques are increasingly used. Rupture of the cyst should be avoided as much as possible because of concerns for chemical peritonitis secondary to fatty acids of a teratoma and the rare risk of inadvertent upstaging of an occult carcinoma. During surgery, both ovaries should be evaluated for lesions. Intraoperative concern for a malignant lesion should prompt an evaluation of both the gross specimen and frozen section by pathology because malignant transformation of mature teratomas can occasionally occur.

An **immature teratoma (IT)** of the ovary is an uncommon tumor, accounting for <1% of ovarian teratomas. In contrast to the mature cystic teratoma, which is encountered most often during the reproductive years but occurs at all ages, IT has a specific age incidence, occurring most commonly in the first 2 decades of life. IT contain cells originating from three germ cell layers, but in contrast to mature teratomas, these elements have varying degrees of maturation. IT are histologically separated into three categories based on the proportion of the immature neural elements. Grade 3 IT have the highest percentage of immature neural elements, which correlates with the greatest risk of extraovarian spread. The presence of a yolk sac component also confers a higher risk of extraovarian spread. Clinically, IT present similarly to mature teratomas with pelvic pain or a mass. There is an association of dermoid tumors with neural elements and *anti–N-methyl-D-aspartase receptor (anti-NMDAR) encephalitis*. Patients may present with flu-like symptoms and progress to psychiatric and cognitive symptoms, autonomic instability, and seizure activity (see Chapter 638). The sonographic appearance of IT is nonspecific but is typically a heterogenous, partially solid mass with coarse calcifications.

Although the data are scant in the pediatric population, the stage and grade of the IT ultimately determines the treatment approach. Surgical staging for germ cell tumors in the pediatric population may differ from the adult population, and surgical staging in pediatric patients include collection of ascites and pelvic washings, examination of peritoneal surfaces with biopsy and excision of any nodules, examination of lymph nodes with sampling of any firm/enlarged lymph nodes, inspection/palpation of omentum with biopsy of any abnormal areas, and unilateral oophorectomy with preservation of the fallopian tube if uninvolved. It should be emphasized that grossly normal lymph nodes on palpation and normal appearing omentum may not need to be routinely removed. Stage I and grade 1 ITs can be managed with serial monitoring of associated tumor markers and pelvic imaging after initial fertility-sparing surgery. Grade 2-3 or stage II-IV IT are typically treated with systemic treatment in the form of the BEP chemotherapy regimen (bleomycin, etoposide, cisplatin).

Cystadenomas

Serous, mucinous, and mixed serous/endometrioid or mucinous/endometrioid cystadenomas are the second most common benign ovarian tumor in adolescents, representing 10–28% of adolescent tumors (Fig. 590.3). These tumors are usually thin walled, cystic, and may be associated with mild elevation of tumor markers such as carcinoembryonic antigen (CEA), CA-125, and CA 19-9, but high levels of these markers should raise suspicion for malignancy. These cystic lesions can become very large, yet, with care, these tumors can be resected, preserving normal ovarian tissue for future reproductive potential. Recurrence rates may be as high as 9%, and thus patients and providers may choose to continue surveillance postoperatively with pelvic ultrasound.

Endometriomas

Endometriosis is a syndrome defined by the presence of ectopic endometrial tissue usually located within the pelvis and abdomen but outside of the uterus. The principal clinical symptoms in adolescents consist of severe menstrual pain and pelvic pain but may also include abnormal uterine bleeding and GI, genitourinary, or constitutional symptoms. Diagnosis is often delayed, and a high clinical suspicion should be maintained. Although endometriosis has a variable presentation, it is associated with endometriomas in approximately 17–44% of adolescent cases; they may be unilateral or bilateral. **Endometriomas (chocolate cysts)** form when collections of old blood and hemosiderin deposit within an endometrium-lined cyst within or on the ovary. They have a typical homogeneous "ground glass" echogenic appearance on ultrasound and are more common in adults than in adolescents. Conservative management (suppressive therapy with ovulation suppression, nonsteroidal antiinflammatory drugs, combined oral contraceptives, or progestin therapy) is recommended for adolescents. An ovarian-sparing cystectomy should be performed if conservative care fails to control the symptoms or the size of the endometrioma is concerning for torsion. Recurrence of endometriosis occurs more commonly in adolescents than adults, and future fertility is associated with stage of disease. Early diagnosis and initiation of menstrual suppression with estrogen-progesterone, progesterone-only formulations, GnRH agonist, or GnRH antagonist may prevent progression of the disease.

Pelvic Inflammatory Disease and Tuboovarian Abscess

Pelvic inflammatory disease (PID) complicated by a tuboovarian abscess (TOA) should be considered in a sexually active adolescent with an adnexal mass and pain on examination (see Chapter 163). PID is a spectrum of upper genital tract inflammation and includes some combination of endometritis, salpingitis, and TOA. Rarely, TOA can occur in nonsexually active adolescents, particularly in association with obstructive Müllerian anomalies, ruptured appendicitis, obesity, and severe constipation. Patients with PID and TOA typically exhibit fever with leukocytosis, cervical motion, uterine or adnexal tenderness, vaginal discharge, nausea, peritoneal signs, and abnormal vaginal bleeding. TOAs are usually demonstrated on transvaginal ultrasound, but pelvic CT imaging may be used for uncertain cases. Treatment of PID with TOA consists of inpatient administration of intravenous (IV) antibiotics. After 48-72 hours of treatment with antibiotics

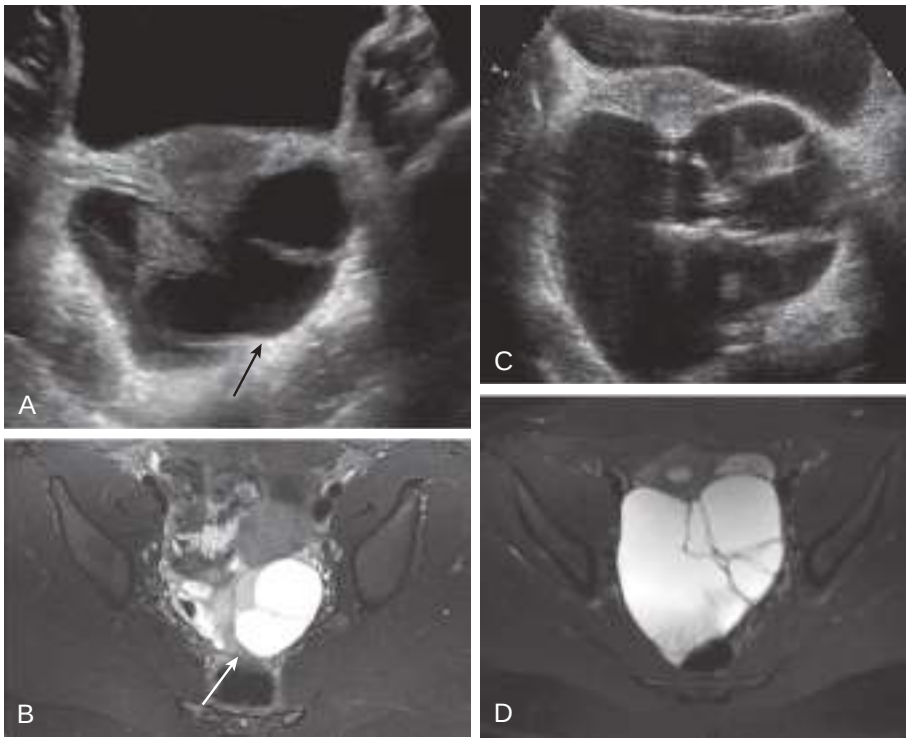

Fig. 590.3 Serous cystadenoma and mucinous cystadenoma. **A** and **B**, 20-yr-old female with pelvic pain. **A**, Transverse ultrasound and (**B**) axial T2 fat-saturated magnetic resonance images (MRIs) demonstrate a complex cystic mass with septations in the left adnexa *(arrows)*. This was removed and found to be a serous cystadenoma. **C** and **D**, 15-yr-old female with pelvic pain. **C**, Transverse ultrasound and (**D**) axial T2 fat-saturated MRIs demonstrate a cystic, septated mass posterior to the uterus. After surgical resection, pathology confirmed a mucinous cystadenoma. Note that the imaging appearances of serous and mucinous cystadenoma are similar. A specific diagnosis is difficult to discern based on imaging alone. *(From Walters MM, Robertson RL. Pediatric Radiology: The Requisites, 4th ed. Philadelphia: Elsevier, 2017; 188: Fig. 6.72.)*

alone, patients with TOAs who do not respond or who worsen should undergo imaging-guided abscess drainage. Conservative management with IV and then oral antibiotics and/or image-guided drainage is recommended as long as the patient continues to improve. TOAs that are large (>7-8 cm in the largest diameter) are associated with the need for surgical intervention and/or radiologically guided drainage. Clinical deterioration is an indication for surgical exploration, and a familiarity with bowel surgery is important with any attempt at resection of a pelvic abscess because of the challenges of encountering anatomic distortion, other organ involvement, and friable tissue planes.

Adnexal Torsion

Adnexal torsion of the ovary and/or fallopian tube is the fifth most common gynecologic emergency and occurs more often in children and adolescents than in adults. If ovarian torsion is suspected, timely surgical intervention is necessary to preserve ovarian function and future fertility. About 60% of ovarian torsions are on the right side; this is possibly because the right utero-ovarian ligament is longer than the left and/or due to the protective effect of the descending colon to the left adnexa. The most common presentation is *sudden*-onset abdominal pain, which is typically intermittent and nonradiating, with associated nausea and vomiting. Abdominal tenderness is common on physical exam and may be accompanied by peritoneal signs. Ultrasound with Doppler is the imaging modality of choice (Fig. 590.4). In adnexal torsion, ovarian venous flow is obstructed, and the fallopian tube and/or ovary become enlarged. Pelvic ultrasound findings include an edematous appearance of the ovary with subsequent hyperechogenicity, increase in size, "whirlpool" sign (twisted vascular pedicle of the ovary), and peripherally displaced follicles. Doppler studies in the evaluation of torsion are limited because of low sensitivity, and the presence of arterial flow does not rule out torsion. Therefore Doppler flow alone should not guide clinical decision-making. Prompt surgical intervention (i.e., diagnostic laparoscopy and laparoscopic ovarian detorsion) is essential to preserve ovarian function. Appearance of the ovary during surgery is not a reliable indicator for ovarian viability as even devascularized-appearing ovaries during laparoscopy have been reported to regain normal perfusion and function in several days. The goal of surgery should be to preserve the ovary regardless of the color and time from onset of symptoms to intervention. A torsed ovary should not be removed in adolescents unless it is severely necrotic and is disintegrating.

Although adnexal torsion may occur in individuals with normal ovaries, torsion occurs more commonly in adnexa enlarged by cystic changes or ovarian neoplasms. The rate of malignancy among premenarchal adolescents with ovarian torsion ranges from 0.4–5%. If an ovarian cyst is easily identified at the time of detorsion, it is reasonable to proceed with concomitant cystectomy; however, it should be noted that the concomitant cystectomy could be challenging because of the friable edematous ovary, which can result in ovarian damage and bleeding leading to oophorectomy. Given that most cysts are benign, drainage of the cyst's fluid is reasonable, and repeat ultrasound in 6-12 weeks usually demonstrates resolution of the cyst. Another approach may include detorsion and second-stage surgery at delayed interval for cystectomy. Oophoropexy is controversial, and the two most compelling reasons are the absence of a contralateral ovary and a history of recurrent ovarian torsion. Initiation of ovarian suppression is reasonable to prevent recurrent ovarian cysts.

OVARIAN MALIGNANCIES

Ovarian cancer is very uncommon in children; only 1.3% of all ovarian cancers are diagnosed in patients < 20 years old. Surveillance, Epidemiology, and End Results (SEER) age-adjusted incidence rates for 2016–2020 are 1.35/100,000 for females 15–19 years; mortality rates for this age group are 0.05/100,000.

Germ Cell Tumors

Germ cell tumors are the most common ovarian malignancy and originate from primordial germ cells that develop into a number of heterogeneous tumor types. **Dysgerminomas** are the most common malignant germ cell tumor of the ovary and have the best prognosis (Table 590.2). They may contain syncytiotrophoblastic cells that produce alpha-fetoprotein (AFP) and lactate dehydrogenase (LDH), making these serum proteins useful tumor markers for monitoring disease activity during surveillance (Table 590.3). Because of rapid growth and expansion, dysgerminomas may present as large abdomino-pelvic masses, and hemoperitoneum may result due to capsular rupture. Dysgerminomas are the most common bilateral ovarian germ cell tumor, occurring bilaterally in 10–15% of patients. **Yolk sac tumors**, also

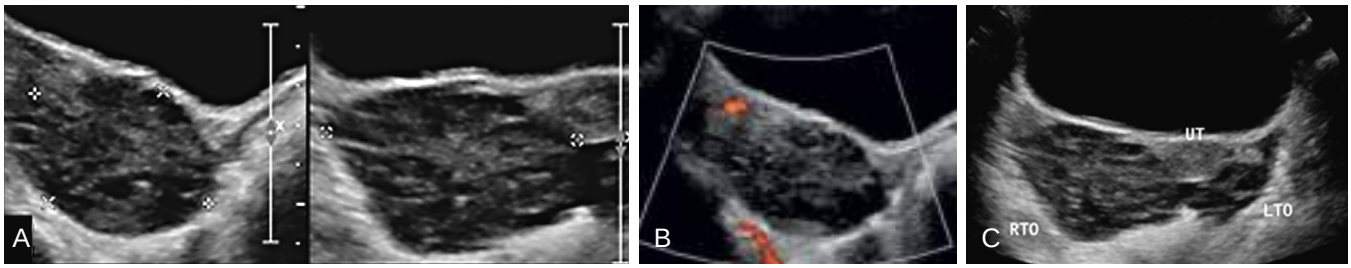

Fig. 590.4 Ovarian torsion. 15-yr-old female with acute-onset pelvic pain. **A,** Sagittal and transverse transabdominal pelvic ultrasound images demonstrate a rounded appearance of the right ovary, which is displaced medially and positioned posterior to the uterus. There is peripheralization of the ovarian follicles. **B,** Power Doppler imaging shows no demonstrable flow within the ovarian parenchyma. **C,** Transverse image of the pelvis shows marked asymmetric enlargement of the right ovary (RTO) in comparison with the normal left ovary (LTO). This patient went to surgery, and right ovarian torsion was confirmed. UT, Uterus. *(From Walters MM, Robertson RL. Pediatric Radiology: The Requisites, 4th ed. Philadelphia: Elsevier, 2017; 189: Fig. 6.74.)*

Table 590.2 Malignant Ovarian Tumors in Children and Adolescents

TUMOR	OVERALL 5-YR SURVIVAL	CLINICAL FEATURES
GERM CELL TUMORS		
Dysgerminoma	85%	10–20% bilateral Most common ovarian malignancy Gonadal dysgenesis/androgen insensitivity Sensitive to chemotherapy/radiation
Immature teratoma	97–100%	All three germ layers present
Endodermal sinus tumor	80%	Almost always large (>15cm) Schiller-Duval bodies
Choriocarcinoma	30%	Rare Can mimic ectopic pregnancy
Embryonal carcinoma	25%	Endocrinologic symptoms (precocious puberty) Highly malignant
Gonadoblastoma	100%	Primary amenorrhea Virilization 45,X or 45,X/46,XY mosaicism
SEX CORD STROMAL TUMORS		
Juvenile granulosa stroma cell tumor	92%	Produce estrogen Menstrual irregularities Isosexual precious pseudopuberty Call-Exner bodies rare
Sertoli-Leydig cell tumor	70–90%	Virilization in 40% Produce testosterone
Lipoid cell tumors	~80%	Rare heterogeneous group with lipid-filled parenchyma
Gynandroblastoma	90% or greater	Rare low-grade mixed tumors that produce either estrogen or androgen

referred to as **endodermal sinus tumors**, clinically present similarly to dysgerminomas with a rapidly enlarging pelvic mass and associated abdominal pain. Schiller Duval bodies are pathognomonic on pathology and contain a central blood vessel surrounded by cuboidal tumor cells. AFP is a useful marker for monitoring response to treatment and for surveillance. Immature teratomas and yolk sac tumors are more aggressive malignancies than dysgerminomas. Embryonal carcinomas are a relatively undifferentiated product of the primordial germ cells and are one of the most malignant germ cell tumors of the ovary. They may secrete β-hCG and AFP. **Gonadoblastomas** are almost always associated with chromosomal abnormalities; therefore chromosomal analysis is essential. Polyembryoma is a very aggressive ovarian malignancy and contains embryoid bodies. The treatment for stage Ia dysgerminomas and stage I immature teratomas is resection. For stage Ic and higher, treatment is surgical excision followed by postoperative chemotherapy. Radiotherapy may be administered for disease recurrence in dysgerminomas, but it is not included in routine treatment. For unresectable tumors or for patients who cannot undergo surgery, neoadjuvant chemotherapy is an option. Recurrences are treated with chemotherapy. Germ cell tumors may recur in up to 10% of cases, and thus yearly follow-up ultrasound is recommended.

Sex-Cord Stromal Tumors

Sex-cord stromal tumors (SCSTs) originate from the stromal component of the gonads and include benign **thecomas** and **fibromas,** as well as malignant **Sertoli-Leydig cell tumors** and **juvenile granulosa cell tumors**. Individuals with Peutz-Jeghers syndrome are at increased risk for developing SCSTs. SCSTs clinically present as an abdomino-pelvic mass, pain, and symptoms of excess sex steroid hormone production, such as hirsutism, virilization, and heterosexual or isosexual precocious puberty. When an SCST is suspected, serum levels of inhibin B, AFP, estradiol and testosterone should be obtained. SCSTs usually present as a unilateral solid mass on imaging, but some degree of necrosis could lead to a heterogenous appearance (Figs 590.5 and 590.6).

Most **juvenile granulosa** cell tumors have an intact capsule and therefore are associated with a good prognosis; however, in the case of capsular rupture or invasion, they potentially have an aggressive course. Juvenile granulosa cell tumors are usually associated with excess estrogen and precocious puberty in prepubertal females. Approximately 20% of the SCSTs in the pediatric population are **Sertoli-Leydig cell tumors,** which may be associated with clinical signs and symptoms of androgen excess. The *DICER1* pathogenic variant is associated with Sertoli-Leydig cell tumors, and the presence of the variant increases the risk of metachronous tumor in the contralateral ovary. Karyotype and referral to genetics is recommended for patients with SCSTs.

Epithelial Ovarian Cancers

Epithelial ovarian cancers are less common than germ cell tumors in the pediatric and adolescent population, comprising only 12.4% of ovarian malignancies in this group. Borderline ovarian tumors are similarly exceedingly rare in adolescents. Individuals with *BRCA1* and *BRCA2* pathogenic variants are at higher risk of developing epithelial ovarian cancer at younger ages compared with females without *BRCA* variants. Similarly, low-grade epithelial ovarian carcinomas tend to occur at younger ages compared with high-grade ovarian carcinomas. Common presenting symptoms include dysmenorrhea, abdominal pain, abdominal distention, nausea and vomiting, and vaginal

Table 590.3 Serum Tumor Markers

TUMOR	CA-125	AFP	β-HCG	LDH	E2	T	INHIBIN	MIS	VEGF	DHEA
Epithelial tumor	+									
Immature teratoma	+	+			+					+
Dysgerminoma			+	+	+					
Endodermal sinus tumor		+								
Embryonal carcinoma		+	+		+					
Choriocarcinoma			+							
Mixed germ cell		+	+	+						
Granulosa cell tumor	+				+		+	+		
Sertoli-Leydig						+	+			
Gonadoblastoma					+	+	+			+
Theca-fibroma									+	

AFP, α-Fetoprotein; CA-125, cancer antigen 125; DHEA, dehydroepiandrostenedione; E2, estradiol; β-hCG, human chorionic gonadotropin; LDH, lactate dehydrogenase; T, testosterone; MIS, Müllerian-inhibiting substance; VEGF, vascular endothelial growth factor.

Fig. 590.5 Complex 13.1 × 8.1 × 10.6 cm solid mass with smaller cystic foci, arising from the right ovary. Final pathology demonstrated juvenile granulosa cell tumor. *(Image courtesy Alla Vash-Margita, MD.)*

discharge; CA-125 is almost always elevated. Treatment involves surgical salpingo-oophorectomy, pelvic washings, and biopsies of suspicious omental, peritoneal, and lymph node lesions, with adjuvant chemotherapy for patients with Federation of Gynecology and Obstetrics (FIGO) stage II-IV disease. Given the young age of this population, although this is not the standard of care for adult patients, fertility-sparing surgery is recommended for stage I cancer to conserve the contralateral ovary and uterus if they appear normal. Data suggest that in patients with early-stage disease, such an approach with appropriate surgical staging results in optimal outcomes but is not recommended for stage II-IV disease due to the high rate of recurrence. The number of term pregnancies and use of oral combined hormonal contraceptive pills decrease the risk of invasive epithelial ovarian cancer. Young females with a family history of ovarian cancer should consider the use of long-term oral combined hormonal contraceptive pills for the preventive benefits when pregnancy is not being sought.

UTERINE MALIGNANCIES

Uterine malignancies account for 2.5% of all gynecologic malignancies of children and adolescents less than 18 years of age. The most common types are sarcomas (34%), followed by adenocarcinomas (34%) and squamous cell carcinomas (10%). **Rhabdomyosarcomas** are the most common type of soft tissue sarcoma occurring in patients <20 years of age (see Chapter 549). They can develop in any organ or tissue in the body except bone, and roughly 3% originate from the uterus or vagina. Of the various histologic subtypes, embryonal rhabdomyosarcomas in the female patient most often occur in the genital tract of infants or young children. They are rapidly growing entities that can cause the tumor to be expelled through the cervix, with subsequent complications such as uterine inversion or large cervical polyps. Irregular vaginal bleeding may be another presenting clinical symptom. They are defined histologically by the presence of mesenchymal cells of skeletal muscle in various stages of differentiation intermixed with myxoid stroma. A genetic link has been found between Li-Fraumeni cancer susceptibility syndrome, Beckwith-Wiedemann syndrome, pleuropulmonary blastoma, Costello syndrome, Noonan syndrome, and neurofibromatosis type I. Treatment recommendations are based on protocols coordinated by the Intergroup Rhabdomyosarcoma Study Group and consist of a multimodal approach including radiation therapy and chemotherapy. Vincristine, Adriamycin-D, and cyclophosphamide (VAC) with or without radiation therapy make up the first line of treatment. Intensity-modulated radiation therapy and proton beam radiotherapy are used to reduce the therapy burden and long-term toxicity. Resection rates are very low because of the risk of losing the form and function of local tissue; chemotherapy with restrictive surgery and adjunctive irradiation has enabled many patients to retain the uterus while achieving excellent long-term survival rates.

Leiomyosarcomas and **leiomyomas** are extremely rare, occurring in <2 in 10 million individuals in the pediatric and adolescent age-groups, although their numbers are increasing among pediatric patients with AIDS. They usually involve the spleen, lung, or GI tract, but they could also originate from uterine smooth muscle. Epstein-Barr virus pathogenesis has been shown in AIDS and solid-organ transplant patient populations (see Chapter 301). Despite treatment that demands complete surgical resection (and chemotherapy for the sarcomas), they tend to recur frequently.

Endometrial stromal sarcoma and **endometrial adenocarcinoma** of the uterine corpus are extremely rare in children and adolescents. A comprehensive review described 19 cases of endometrial cancer (EC) among adolescent females younger than 21 years in which five subjects (26.3%) had a genetic condition (Cowden syndrome and Turner syndrome). This emphasizes the consideration of genetic evaluation in very young patients with EC. In most cases, patients presented with abnormal uterine bleeding and had associated comorbidities such as obesity and polycystic ovary syndrome. Standard of care for treatment of EC consists of hysterectomy, removal of both ovaries and fallopian tubes and surgical staging, followed by adjunctive radiotherapy and/

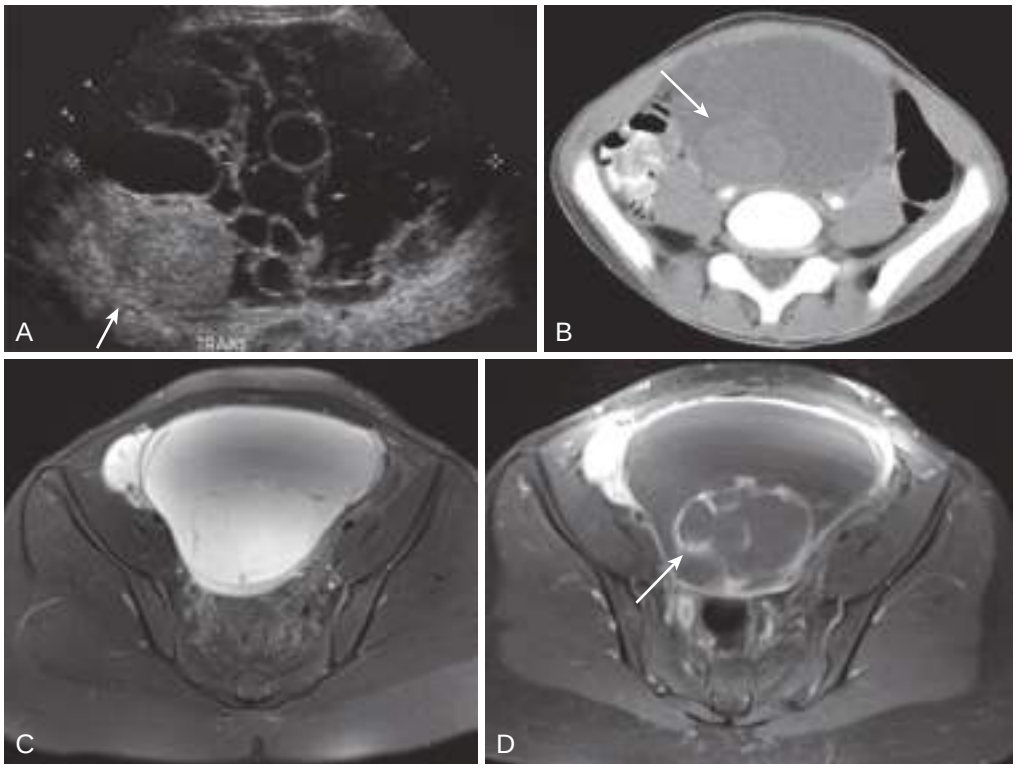

Fig. 590.6 Sertoli-Leydig cell tumor. 2-yr-old female with a palpable pelvic mass and secondary sex characteristics. **A,** Transabdominal pelvic ultrasound demonstrates a complex cystic, septated mass, with a solid component posteriorly *(arrow).* **B,** Contrast-enhanced computed tomography shows a predominantly cystic mass, with an enhancing mural nodule along the posterior margin *(arrow).* **C,** T2-weighted and **D,** contrast-enhanced magnetic resonance images in a different patient demonstrate a T2 hyperintense lesion in the pelvis, with enhancing internal solid components noted after contrast administration *(arrow). (From Walters MM, Robertson RL. Pediatric Radiology: The Requisites, 4th ed. Philadelphia: Elsevier, 2017; 188: Fig. 6.73.)*

or chemotherapy as indicated by final pathology and stage. In young patients who desire childbearing, fertility-sparing approaches with preservation of the uterus have been increasingly utilized. Per National Comprehensive Cancer Network (NCCN) guidelines, candidates for this approach are patients with grade 1 endometrioid adenocarcinoma on dilation and curettage, patients with disease confined to endometrium by MRI (preferred imaging modality) or ultrasound, absence of metastatic disease on imaging, and no contraindications to medical therapy or pregnancy. Patients should undergo counseling that fertility-sparing options are not standard of care for the treatment of endometrial carcinoma. Existing data on hormonal therapy come from observational studies and have variable rates of outcomes. Although there is no standard follow-up protocol, patients with EC treated with hormonal therapies should be reexamined with endometrial sampling every 3-6 months.

VAGINAL MALIGNANCIES

Vaginal tumors are rare with a variable clinical presentation that may include abdomino-pelvic pain, an abdominal mass, bloody vaginal discharge, genital ulceration, or tissue protruding from the vagina. **Embryonal rhabdomyosarcoma (RMS)** is the most common vaginal malignancy followed by germ cell tumor (GCT) and clear cell adenocarcinoma (CCA). The management of pediatric vaginal tumors consists of neoadjuvant chemotherapy followed by local control with surgery or radiotherapy.

Embryonal rhabdomyosarcoma (RMS) or **sarcoma botryoides** typically arises in the anterior wall of the vagina or within the wall of the bladder and presents as an edematous grapelike mass protruding from the vagina. Overall, RMS arising in the female genital tract accounts for less than 4% of all pediatric RMS. Approximately 90% of these sarcomas present before age 5 years. Embryonal RMS of the vagina is managed with multimodality treatment. A series of Intergroup Rhabdomyosarcoma Study Group (IRSG) reports demonstrated survival rates in excess of 85% employing the use of combination chemotherapy treatment with vincristine, actinomycin-D, and cyclophosphamide (VAC) and wide excision with or without adjuvant radiation treatment. This approach spares most patients from exenterative surgery. Because of the high rates of local recurrences in patients who did not receive radiation, the Soft Tissue Sarcoma committee of the Children's Oncology Group recommends local radiation treatment unless potential toxicity is considered unacceptable.

Endodermal sinus tumors or **yolk sac tumors** are the most common subtype of pediatric germ cell tumor of the vagina but are still quite rare. These tumors present almost exclusively in children under the age of 3 years with vaginal bleeding. Typically, patients have a markedly elevated serum AFP, which can be used to monitor treatment effect and disease recurrence. Management involves combination of surgery and chemotherapy (either carboplatin/etoposide/bleomycin, BEP regimen, or VAC regimen). Unfortunately, survival rates are low despite treatment.

There is an increased incidence of **clear cell adenocarcinoma** (CCA) of the vagina in young females related to in utero exposure to diethylstilbestrol (DES) during the first 16 weeks of pregnancy. The suggested mechanism of carcinogenesis involves the retention of nests of abnormal cells of Müllerian duct origin that, after stimulation by endogenous hormones during puberty, are promoted into adenocarcinomas. Most cases involve the anterior upper third of the vaginal wall. Treatment of CCA of the vagina includes a surgery and/or radiation treatment depending on the extent of disease. Fortunately, the incidence of CCA of the vagina has decreased since the practice of prescribing DES during pregnancy has been eliminated.

VULVAR MALIGNANCIES

Pediatric vulvar malignancies are rare. Patients typically present with an ulcerated or raised lesion and/or a mass. It is imperative that any concerning vulvar lesion be biopsied and submitted for pathologic evaluation. Vulvar malignancies that have been described in the literature include invasive squamous cell carcinomas, yolk sac tumors, Ewing sarcoma/primitive neuroectodermal tumors (ES/PNET), and melanomas. Each of these entities make up approximately 10% of reported cases. Cases of pediatric vulvar squamous cell carcinoma include those lesions that are **human papillomavirus (HPV)**-mediated and HPV-independent. Possible risk factors include HPV infection, immunosuppression, Fanconi anemia, and lichen sclerosis. Extragonadal germ cell tumors involving the vulva are very uncommon, and the leading hypothesis behind their pathogenesis is possible aberrant germ cell migration along the gubernaculum. These are aggressive tumors, and treatment options include various combinations of excisional

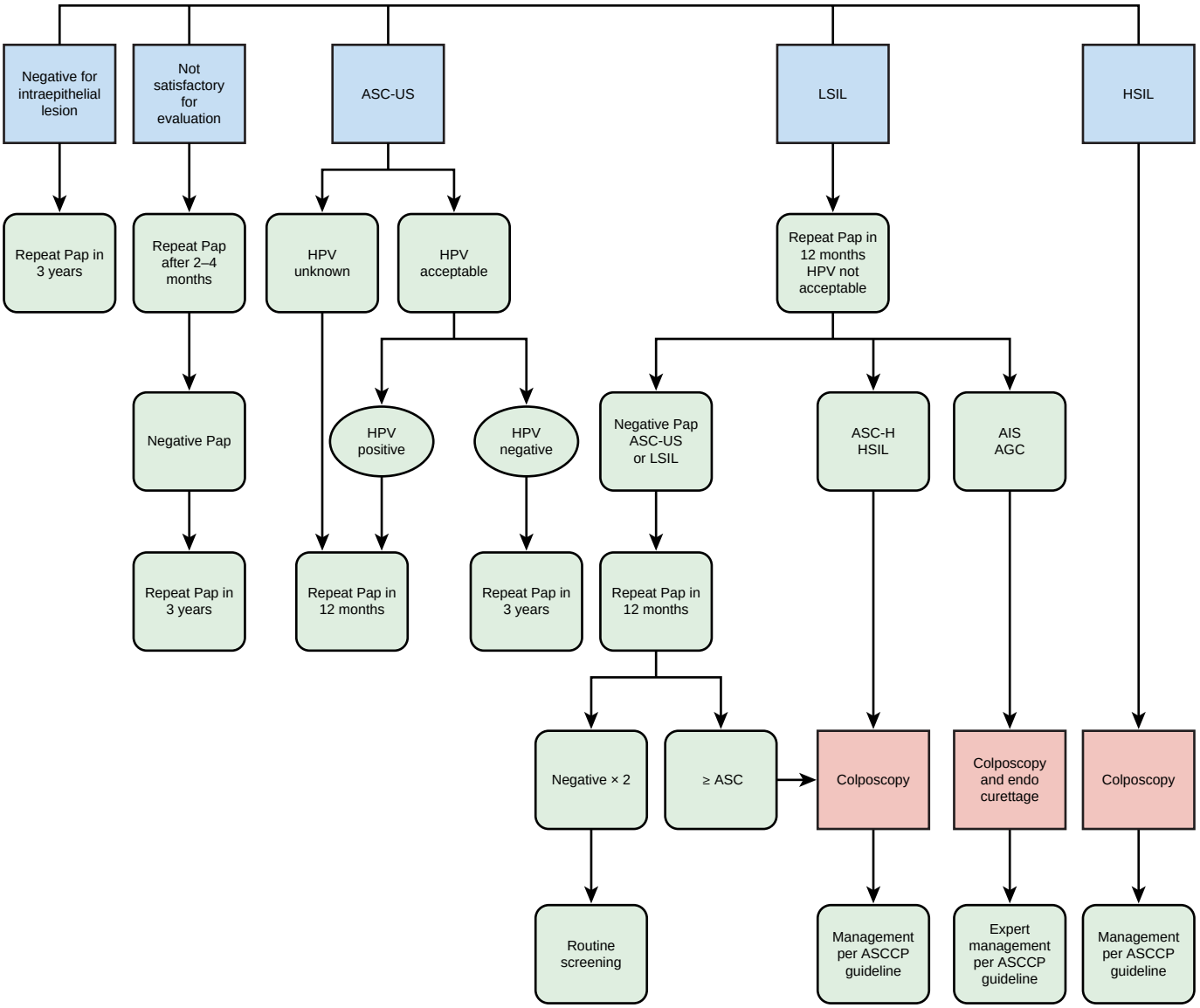

Fig. 590.7 Algorithm for the management of Pap smear results in women between age 21-24. AIS, adenocarcinoma in situ; AGC, atypical glandular cells; ASC, atypical squamous cells; ASCCP, American Society for Colposcopy and Cervical Pathology; ASC-H, atypical squamous cells that cannot exclude HSIL; ASC-US, atypical squamous cells of undetermined significance; LSIL, low-grade squamous intraepithelial lesion; HPV, human papilloma virus; HSIL, high-grade squamous intraepithelial lesion *(From Trotman GE, Vash-Margita A, Kahn JA, et al. Human papillomavirus infection and cervical cancer screening and prevention in adolescents. In: Emans SJ, Laufer MR, Di Vasta DP, eds. Pediatric and Adolescent Gynecology. Philadelphia: Lippincott Williams & Wilkins, 2020; 330–348: Fig 20.9.)*

procedures and neoadjuvant or adjuvant chemotherapy. **Malignant melanoma** of the vulva represents 2.4–10% of all vulvar malignancies, second to invasive squamous cell carcinomas in frequency. Early-stage melanoma treatment involves surgical excision followed by possible radiation treatment. Treatment of advanced stage melanoma involves systemic chemotherapy and/or targeted treatment agents such as checkpoint inhibitor immunotherapy. **Rhabdomyosarcomas** are the most common vulvar sarcomas reported in pediatric patients. The second most common sarcoma of the vulva in pediatric patients is ES/PNET. Management of both vulvar sarcomas includes surgical excision, multi-agent chemotherapy, and radiation treatment. ES/PNET cases often present in the advanced stage and have a poor prognosis.

Condyloma acuminata are common, raised, verrucous lesions of the vulva that result from squamous cell proliferation associated with HPV infection (most common genotypes HPV 6 and 11). Prevention of HPV infection and subsequent formation of condyloma acuminata has been achieved through HPV vaccination. *In young children with condyloma acuminata, sexual abuse must be ruled out.* These lesions are benign and can spontaneously regress. If lesions are bothersome, treatment modalities consist of topical podophyllin resin, imiquimod, trichloroacetic acid, local cryotherapy, electrocautery, excision, and laser ablation. Imiquimod is approved by the U.S. Food and Drug Administration (FDA) for individuals 12 years of age and above.

CERVICAL MALIGNANCIES AND THEIR PREVENTION

In 2020, cervical cancer accounted for an estimated 604,000 new cancer cases and 342,000 deaths worldwide, making it the fourth most common cancer in females of all ages. From 2016 to 2020, the United States age-adjusted incidence of cervical cancer in females under age 20 was <0.1 per 100,000. The adolescent population is at greatest risk of HPV infection, which predisposes them to development of cervical cancer because about half of HPV infections occur before the age of 24. Thus prevention of initial infection in the adolescent population is critical to decreasing cervical cancer rates.

Primary prevention of HPV infection includes vaccination before the onset of sexual activity with the HPV vaccine. The HPV vaccine is approved for males and females ages 9-26. The Centers for Disease Control and Prevention (CDC) recommends two doses of the HPV 9-valent vaccine for patients before age 15 years (typically between ages 11-12) given 6-12 months apart (see Chapter 215). For those initiating the vaccine series at 15 years of age or older, three doses of the HPV vaccine should be given at 0, 1-2, and 6 months. Three doses are also recommended for patients who are immunocompromised (i.e., solid organ transplant recipient, HIV infection). Children with a history of sexual abuse should start immunization at age 9. In 2018, the FDA approved the use of the HPV 9-valent vaccine to include adults age 27-45 years; while the vaccine is not routinely recommended in this group, it may be given after shared clinical decision-making between a patient and their healthcare provider. The HPV vaccine can be administered despite prior infection with HPV. Cervical cancer screening via Papanicolaou (Pap) testing and HPV co-testing are important secondary prevention strategies. ACOG recommends cervical cancer screening for females starting at age 21 years in immunocompetent females regardless of onset of penetrative vaginal intercourse or primary prevention with HPV vaccination. Separate guidelines describe cervical cancer screening recommendations for immunocompromised individuals. Briefly, sexually active immunocompromised adolescents (such as solid organ or hematopoietic stem cell transplant recipients, patients with inflammatory bowel disease on immunosuppressive therapy, and patients with systemic lupus erythematosus) should start screening 1 year after of onset of sexual activity and thereafter annually for 3 years. If consecutive screening is negative, patients may follow the guidelines for immunocompetent females. HIV positive patients should start screening at age 21 regardless of sexual activity. Additionally, condom use, limiting the number of sexual partners, and smoking cessation are recommended to lower the risk for cervical cancer.

Because of the high prevalence of HPV infection in the adolescent population and because HPV-associated lesions typically regress, HPV screening should be not done before age 21 years in immunocompetent patients. If an inadvertent HPV test is done in adolescents, the results should not be acted on. Guidelines on management of the abnormal results of cervical cancer screening (Pap smear) for females age 21-24 are shown in Figure 590.7. Overall, data shows that prevention strategies such as widespread implementation of HPV vaccine translates into reduced incidence of cervical cancer in the future. Pediatric providers should educate patients and caregivers about benefits of the HPV vaccine and offer it at the recommended age.

Visit Elsevier eBooks+ at eBooks.Health.Elsevier.com for Bibliography.

Chapter 591

Vulvovaginal and Müllerian Anomalies

Laura L. Hollenbach, Emanuele Pelosi, Miranda Margetts, and Alla Vash-Margita

EMBRYOLOGY

The formation of a normal reproductive system occurs in the developing embryo and early fetus and is regulated by several processes, including cellular differentiation, duct elongation, fusion, resorption, canalization, and programmed cell death. Numerous Müllerian and/or vulvovaginal anomalies can result from interruption of the intricate sequence or functions of any one of these processes during formation of the reproductive system (Table 591.1). Genetic, epigenetic, and environmental factors all have been described as playing some role in these processes (Table 591.2).

Table 591.1 Congenital Müllerian Anomalies

MÜLLERIAN ANOMALY	DESCRIPTION
Agenesis	Absence of uterus, cervix, and upper portion of vagina
Hypoplasia	Incomplete development of uterus, cervix, and upper portion of vagina
Unicornuate uterus	One cervix and one uterine horn, the result of failure of one Müllerian duct to descend
Septate uterus	Septum dividing the uterus, partially or completely
Didelphic uterus	Two cervices, each associated with one uterine horn
Bicornuate uterus	One cervix associated with two uterine horns
OHVIRA (obstructed hemivagina and ipsilateral renal anomaly)	Double uterus with unilateral obstructed hemivagina and ipsilateral renal agenesis
CONDITIONS ASSOCIATED WITH MÜLLERIAN ANOMALIES	**DESCRIPTION**
Hydrocolpos	Accumulation of mucus or nonsanguineous fluid in the vagina
Hematocolpos	Accumulation of blood in the vagina
Hematometra	Accumulation of blood in the uterus
Hydrosalpinx	Accumulation of serious fluid in the fallopian tube, often a result of pyosalpinx

Table 591.2 Genetic Conditions Associated with Müllerian Anomalies

MODE OF INHERITANCE	SYNDROME	ASSOCIATED MÜLLERIAN DEFECT
Autosomal dominant	Camptobrachydactyly	Longitudinal vaginal septum
	Hand-foot-genital	Incomplete Müllerian fusion
	Denys-Drash	Persistent Müllerian duct derivatives
Autosomal recessive	McKusick-Kaufman	Vaginal atresia, transverse vaginal septum
	Johanson-Blizzard	Longitudinal vaginal septum
	Renal-genital-middle ear anomalies	Vaginal atresia
	Fraser	Incomplete Müllerian fusion
	Persistent Müllerian duct	Persistent Müllerian duct derivatives
	Urioste syndrome	Persistent Müllerian duct derivatives
Polygenic/ multifactorial	Mayer-Rokitansky-Küster-Hauser	Müllerian aplasia
X-linked	Persistent Müllerian duct	Persistent Müllerian duct derivatives

Phenotypic sexual differentiation, especially during formation of the vulvovaginal and Müllerian systems, is determined from genetic, gonadal, and hormonal influences (see Chapter 622). Gonadal development determines the hormonal production regulating progression or regression of the genital ducts and subsequently the external genitalia.

In 46,XY embryos, the *SRY* (sex-determining region of Y-chromosome) gene is one of the first regulators driving the formation of a testis from a primitive gonad and triggering the expression of a cascade of additional factors responsible for testis development as well as spermatogenesis. The testis begins to develop between 6-7 weeks of gestation, first with Sertoli cells, which produce anti-Müllerian hormone (AMH), followed by Leydig cells, which produce testosterone starting at approximately 8 weeks of gestation. The genital tract in both male and female embryos initially includes both the Wolffian and the Müllerian (or paramesonephric) ducts and begins to differentiate later than the gonads. The differentiation of the Wolffian ducts, the primordia of the male reproductive tract, is regulated by testosterone, and the local action of testosterone activates development of the epididymis, vas deferens, and seminal vesicle. Concomitantly, the anti-Müllerian hormone (or Müllerian-inhibiting substance) will cause regression of the Müllerian ducts. Further male genital duct and external genital structures depend on the conversion of testosterone to dihydrotestosterone. Failure of Müllerian duct regression results in retention of Müllerian derivatives in males. One example is **persistent Müllerian duct syndrome (PMDS)**, which is characterized by the presence of Müllerian structures usually associated with undescended testes. The majority of PMDS cases are due to pathogenic variants in the *AMH* gene or its receptor *AMHR2*. Other conditions featuring the presence of Müllerian derivatives in males are **Denys-Drash syndrome** (characterized by gonadal dysgenesis), nephropathy, and Wilms tumor, each caused by pathogenic variants in the *WT1* gene, and Müllerian derivatives-lymphangiectasia-polydactyly syndrome **(Urioste syndrome)**, a condition of unknown etiology.

In a 46,XX embryo, female sexual differentiation occurs about 2 weeks later than gonadal differentiation in the male. The regression of the Wolffian ducts results from the lack of local gonadal testosterone production, and the persistence of the Müllerian ducts results from the absence of anti-Müllerian hormone production. The Müllerian ducts continue to differentiate into the fallopian tubes, uterus, and upper one-third of the vagina without interference from anti-Müllerian hormone. Because the ovaries develop separately from the Müllerian ducts, females with Müllerian ductal anomalies usually have normal ovaries and steroid hormone production. There are complex interactions among the Wolffian, Müllerian, and metanephric ducts (the latter giving rise to the urinary tract) early in embryonic development, and normal development of the Müllerian system depends on such interaction. If this process is interrupted, coexisting Müllerian and renal anomalies are often discovered in the female patient at the time of evaluation. Although most Müllerian defects seem sporadic, familial recurrence or clustering has been observed, which strongly supports the influence of genetic factors. The molecular processes underlying the developmental program of the female reproductive tract are extremely intricate and are regulated by numerous gene products, including *WNT4*, *WNT5*, *WNT7A*, *WNT9B*, *LIM1*, *HNF1B*, *EMX2*, *PAX8*, and *HOX*. The WNT family plays crucial roles in both the formation and differentiation of the Müllerian ducts, providing inductive signals for the correct patterning of the developing tract. Homeobox genes *LIM1* and *HNF1B* are expressed in duct epithelial cells and are necessary for the development of the entire urogenital tract. Similarly, *EMX2* and *PAX8* play fundamental roles in the initial steps of urogenital development by regulating the formation of the Wolffian and Müllerian ducts. The family of *HOXA* genes is one of the most well described and comprises regulatory molecules that encode highly conserved transcription factors regulating the developmental axis of the female reproductive tract. These genes display a characteristic expression pattern along the developing reproductive tract (Fig. 591.1). A role for environmental factors in Müllerian anomalies has also been proposed. During gestation, the Müllerian ducts develop in an estrogen-free environment because of the presence of α-fetoprotein peptides that sequester estrogen molecules. Therefore attention has been turned to **endocrine-disrupting chemicals (EDCs)**, especially compounds with estrogenic activity, for their potential teratogenic role in Müllerian anomalies. A striking example is provided by diethylstilbestrol (DES), an estrogen agonist once given to pregnant patients to prevent pregnancy-related complications, including miscarriage. However, DES was found to induce epigenetic modifications and cause reproductive malformations, including a T-shaped uterus ultimately associated with higher spontaneous abortion rates.

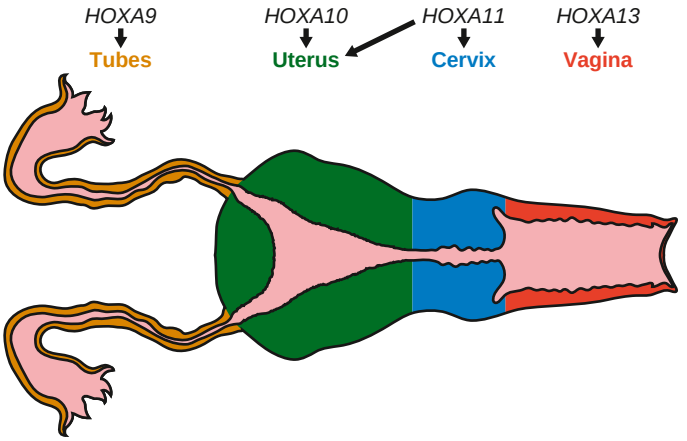

Fig. 591.1 Expression of *HOXA* genes in the developing Müllerian system. *(Adapted from Taylor HS. The role of HOX genes in the development and function of the female reproductive tract. Semin Reprod Med. 2000;18:81-89.)*

By 10 weeks of gestation, the caudal portions of the Müllerian ducts fuse together in the midline to form the uterus, cervix, and upper vagina, in a Y-shaped structure, with the open upper arms of the Y forming the primordial fallopian tubes. Initially, the Müllerian ducts are solid cords that gradually canalize as they grow along and cross the mesonephric ducts ventrally and fuse in the midline. The Müllerian ducts caudally open into the **urogenital sinus,** where proliferation of the cells at the point of contact form the Müllerian tubercle. Cells between the Müllerian tubercle and the urogenital sinus continue to proliferate, forming the vaginal plate. At the same time of the midline fusion of the Müllerian ducts, the medial walls—forming the septum—begin to degenerate, forming the central cavity of the uterovaginal canal. Uterine septal resorption is thought to occur in a caudal to rostral direction and to be complete at approximately 20 weeks of gestation. This theory has been scrutinized because some anomalies do not fit the standard classification system; it is possible that septal resorption starts at some point in the middle and proceeds in both directions. At approximately 16 weeks of gestation, the central cells of the vaginal plate desquamate, and resorption occurs, forming the vaginal lumen. The lumen of the vagina is initially separated from the urogenital sinus by a thin hymenal membrane. The hymenal membrane undergoes apoptosis and central resorption and is usually perforate before birth.

EPIDEMIOLOGY

Müllerian anomalies can include abnormalities in portions or all of the fallopian tubes, uterus, cervix, and vagina (Fig. 591.2). True estimates of prevalence are difficult because of the varied presentations and asymptomatic nature of some of the anomalies, use of different diagnostic procedures, subjectivity of the diagnostic criteria, and the inconsistent interpretation of the classification of Müllerian anomalies.

It is estimated that Müllerian anomalies are present in 6.7% of the general female population. The prevalence of Müllerian anomalies increases in females with a history of adverse pregnancy outcomes or infertility: 8% of females who are infertile, 15% of females with primary amenorrhea, 16.7% of females with recurrent pregnancy loss, and 24.5% of females with both miscarriage and infertility have Müllerian defects.

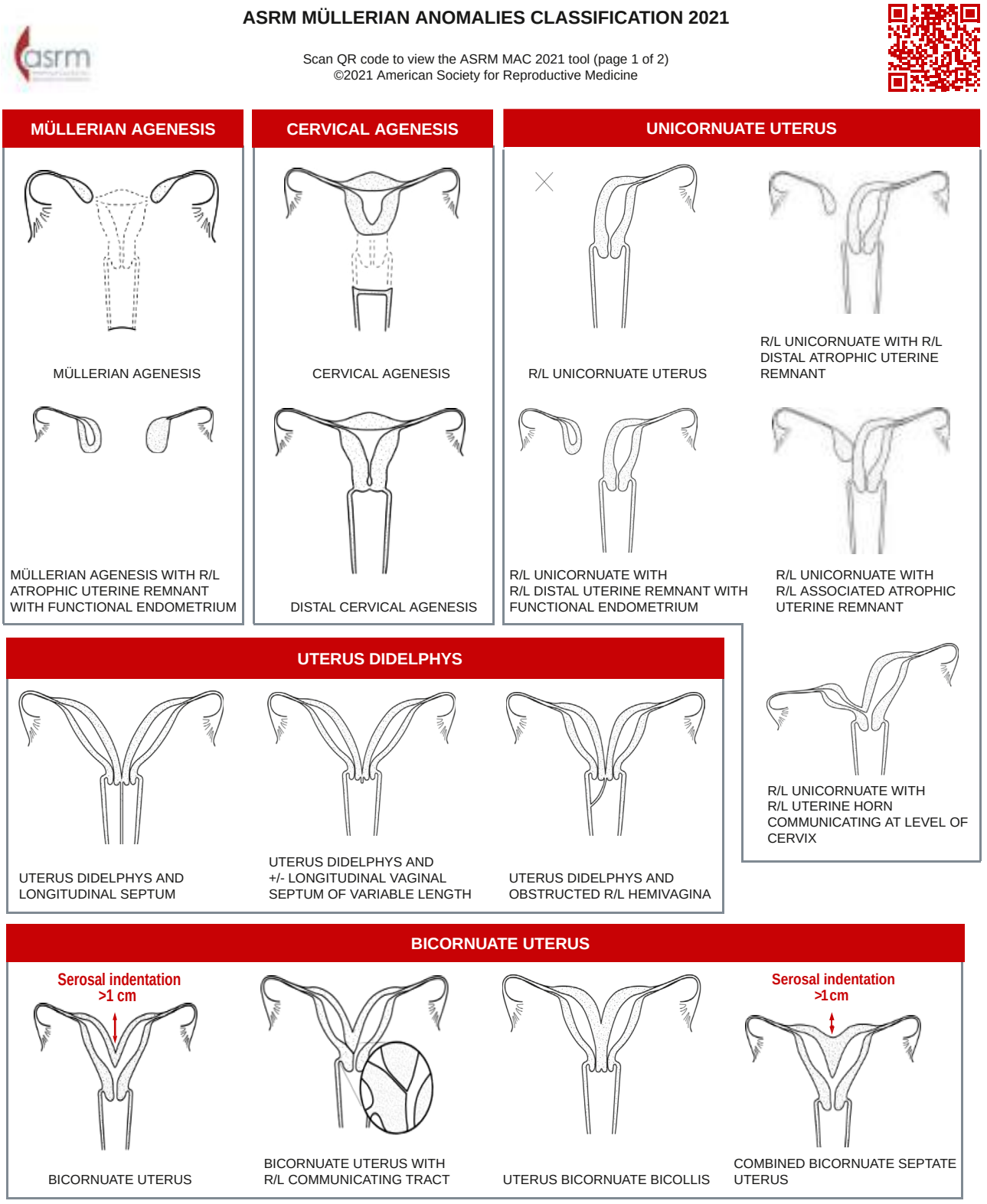

Fig. 591.2 Classification system of Müllerian duct anomalies developed by the American Society of Reproductive Medicine. *(From Pfeifer SM, Attaran M, Goldstein J, et al. ASRM Müllerian anomalies classification 2021. Fertil Steril. 2021;116:1238-1252; Fig 1.)*

SEPTATE UTERUS

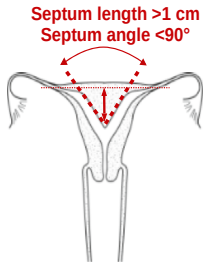

PARTIAL SEPTATE UTERUS

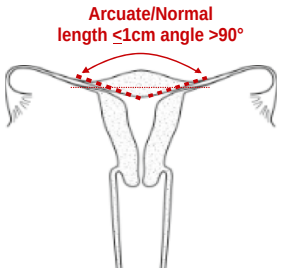

NORMAL/ARCUATE UTERUS

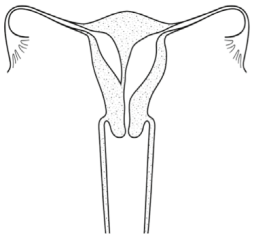

ROBERT'S UTERUS

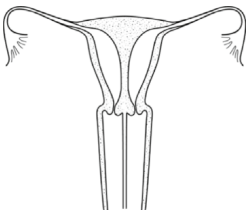

COMPLETE SEPTATE UTERUS WITH DUPLICATED CERVICES AND LONGITUDINAL VAGINAL SEPTUM

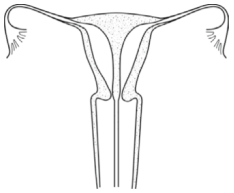

COMPLETE SEPTATE UTERUS WITH SEPTATE CERVIX AND LONGITUDINAL VAGINAL SEPTUM

COMPLETE SEPTATE UTERUS, DUPLICATED CERVICES, AND OBSTRUCTED R/L HEMIVAGINA

TRANSVERSE VAGINAL SEPTUM

MID VAGINAL SEPTUM

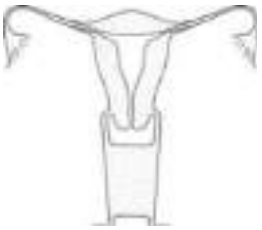

DISTAL VAGINAL AGENESIS

LONGITUDINAL VAGINAL SEPTUM

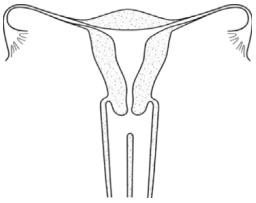

LONGITUDINAL VAGINAL SEPTUM OF VARIABLE LENGTH

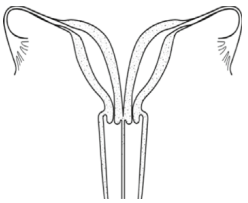

LONGITUDINAL VAGINAL SEPTUM OF VARIABLE LENGTH AND UTERUS DIDELPHYS

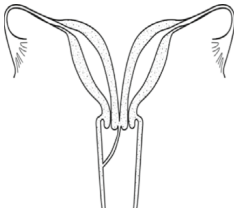

OBSTRUCTED R/L HEMIVAGINA AND UTERUS DIDELPHYS

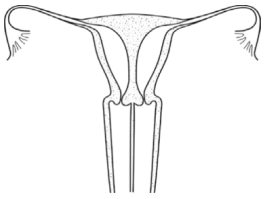

LONGITUDINAL VAGINAL SEPTUM OF VARIABLE LENGTH AND COMPLETE SEPTATE UTERUS WITH DUPLICATED CERVIX

OBSTRUCTED R/L HEMIVAGINA AND COMPLETE SEPTATE UTERUS WITH DUPLICATED CERVICES

COMPLEX ANOMALIES

BICORNUATE UTERUS WITH BILATERAL OBSTRUCTED ENDOMETRIAL CAVITIES



UTERUS DIDELPHYS WITH COMMUNICATING HEMIUTERI AND UNILATERAL R/L CERVICO-VAGINAL ATRESIA

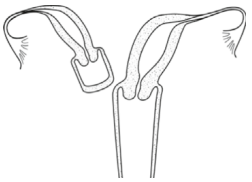

OBSTRUCTED R/L HEMIVAGINA, HEMIUTERUS AND SINGLE CERVIX WITH SEPARATE CONTRALATERAL R/L PATENT HEMIUTERUS, CERVIX AND VAGINA

BICORNUATE UTERUS WITH R/L COMMUNICATING TRACT AND TRANSVERSE VAGINAL SEPTUM

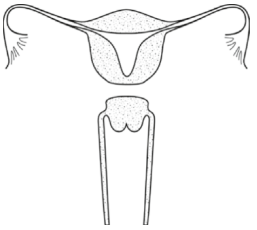

UTERUS ISTHMUS AGENESIS

Scan QR code to view the ASRM MAC 2021 tool (page 2 of 2)
©2021 American Society for Reproductive Medicine

Fig. 591.2 cont'd

Fig. 591.3 Sagittal MRI of pelvis showing large volume hematocolpos (*asterisk*). *B*, Bladder; *arrow*, hematometra.

Combinations of congenital anomalies in other organ systems are prevalent in females with Müllerian anomalies. Renal and musculoskeletal abnormalities are the most common. An estimated 29% of females with a renal anomaly will have an associated Müllerian abnormality. Concomitant congenital malformations are also prevalent in approximately 54.4% of females with **Mayer-Rokitansky-Kuster-Hauser (MRKH) syndrome**.

CLINICAL MANIFESTATIONS

Vulvovaginal and Müllerian anomalies can manifest at a variety of chronological time points during a female's life: from infancy, through childhood and adolescence, and during adulthood (see Table 591.1). The majority of external genitalia malformations manifest at birth, and often even subtle deviations from normal in either a male or female newborn warrant evaluation. Structural reproductive tract abnormalities can be seen at birth or can cluster at menarche or any time during a patient's reproductive life. Some Müllerian anomalies such as arcuate uterus are asymptomatic and have no implications clinically, whereas others can cause gynecologic, obstetric, or fertility issues.

Clinical manifestations and treatments depend on the specific type of Müllerian anomaly and are varied. There may be a pelvic mass, which may or may not be associated with symptoms. A mass bulging at the introitus or within the vagina indicates complete or partial **outflow tract obstruction.** A newborn can present with no evidence of a vaginal opening. An adolescent can present with cyclic pelvic pain either in association with **primary amenorrhea** or several months after the onset of menarche. Patients also may be asymptomatic until they present with miscarriage, pregnancy loss, or preterm delivery. When presentation is acutely symptomatic, emergency management may be required. Obstruction can result from a number of distinct anomalies, including an **imperforate hymen,** a **transverse vaginal septum,** a distal **vaginal agenesis,** or a **noncommunicating rudimentary horn.** As menstrual fluid accumulates proximal to the obstruction, the resulting **hematocolpos** (Fig. 591.3) and **hematometra** cause cyclic pain, pelvic mass and, occasionally, urinary dysfunction.

Prenatal or neonatal presentation of hydrometrocolpos from distal vaginal obstruction produces fluid accumulation in the vagina and uterus and presents as a lower abdominal mass with or without associated acute urinary tract obstruction. Hydrometrocolpos with polydactyly may be a result of two autosomal recessive disorders: **McKusick-Kaufman syndrome** (with associated congenital heart disease) and **Bardet-Biedl syndrome** (with associated obesity, learning disabilities, retinitis pigmentosa, and renal anomalies).

Adolescent patients can present with acute obstruction of the outflow tract because of a Müllerian anomaly, which requires emergency evaluation and surgical treatment. A small percentage of females can present with concomitant urinary retention caused by an altered urethral angle or pressure on the sacral plexus. Urinary hesitancy and incomplete emptying symptoms may be present before abdominopelvic pain increases from the obstruction in a patient of any age. Some menstruating adolescents may present with increasing cyclic abdominopelvic pain with their menses due to an obstructed hemivagina with uterine didelphys and ipsilateral renal agenesis (OHVIRA).

LABORATORY AND RADIOGRAPHIC FINDINGS

Laboratory evaluation in the setting of primary amenorrhea would include hormonal evaluation with assessment of the beta chorionic gonadotropin (beta-hCG) to rule out pregnancy, follicle-stimulating hormone (FSH), luteinizing hormone (LH), estradiol, and thyroid-stimulating hormone (TSH). Androgen evaluation may be done if virilization is seen on physical examination. The patient's karyotype may be obtained based on clinical presentation. Other hormonal testing might be indicated in specific cases. Several radiographic studies have been used, often in combination, to aid in diagnosis including ultrasound, hysterosalpingogram, sonohysterography (saline-infusion sonography), and MRI. The least invasive initial study for a young adolescent with cyclic pain, a pelvic mass, or amenorrhea is a transabdominal pelvic ultrasound; transvaginal pelvic ultrasound can be used in sexually active teens. MRI is considered the gold standard of care and best suited for complex anomalies because of its noninvasive, high-quality capabilities. MRI is the most sensitive and specific imaging technique used for evaluating Müllerian anomalies because it can image nearly all reproductive structures, blood flow, external contours, junctional zone resolution on T2-weighted images, and associated renal and other anomalies. MRI also has a high correlation with surgical findings because of its multiplanar capabilities and high spatial resolution. Three-dimensional ultrasound is another useful diagnostic tool and may be superior to traditional pelvic ultrasound and hysterosalpingogram but may not be easily accessible. Evaluation of the external contour of the uterus is important for differentiating types of uterine anomalies. This often requires a combination of radiologic modalities for the uterine cavity, external contour, and possible tubal patency. Diagnostic laparoscopy or hysteroscopy may be necessary depending on the presentation, but it is less common with advancement of MRI and other imaging modalities.

Diagnosis of Müllerian anomalies should include a complete history, including family history, with special attention to history of infertility for female relatives and renal and skeletal abnormalities. A complete physical exam including skeletal inspections for associated anomalies should be performed in addition to the radiology studies discussed above. Renal anomalies are noted in 30–40% and skeletal anomalies are associated in 10–15% of patients with Müllerian anomalies. Unilateral renal agenesis occurs in 15% of patients. The most common skeletal anomaly is scoliosis. Patients usually have a normal female karyotype (46, XX), and most malformations are sporadic, with a polygenic mechanism and multifactorial etiology (Table 591.2).

UTERINE ANOMALIES

Anomalous development of the uterus may be symmetric or asymmetric and/or obstructed or nonobstructed. Patients can present with primary amenorrhea or have either irregular or regular menstrual cycles. There may be an asymptomatic pelvic mass or dysmenorrhea. In adolescents and adults, pregnancy loss can cause the first suspicion of a uterine anomaly. Treatment is tailored to the specific anomaly.

Septate Uterus

Uterine septum (also known as a septate uterus) is the most common Müllerian anomaly, accounting for just over half of all abnormalities, and it is the most common structural uterine anomaly. After the two Müllerian ducts fuse in the midline, resorption must occur to unify the endometrial cavities; failure of this process results in some degree of uterine septum. It can vary in length from just below the fundus to beyond the cervix, depending on the amount of caudal resorption, but is generally defined as >1 cm. A septate uterus has a normal external uterine contour, which is what distinguishes it from a bicornuate or

didelphic uterus. An MRI can help delineate between a predominantly fibrous septum and a muscular or myometrial septum. There is insufficient evidence between an association of the uterine septum and infertility. Controversy still exists regarding whether a female should have such surgical removal of the septum as part of infertility treatment. A previous recommendation for surgical septum resection has been challenged by recent research, which demonstrated that septum resection did not improve live birth rates compared with expectant management. Limited data exist on the influence of the thickness and the length of the septum on the choice of treatment and reproductive outcomes. Differentiating precisely between bicornuate and septate uteri is extremely important to determine effective and safe treatment plans.

Bicornuate Uterus

Both Müllerian ducts develop and elongate in this anomaly, but they do not completely fuse in the midline. The vagina and external cervix are normal, but the extent of division of the two endometrial cavities can vary, depending on the extent of failed fusion between the cervix and the fundus. Bicornuate uteri are also associated with increased preterm labor and delivery, malpresentation, and miscarriage. This anomaly accounts for approximately 10–20% of Müllerian anomalies. Presently there is no pregnancy outcome data to provide evidence to support unification of a uterine duplication, and expectant management should be encouraged.

Unicornuate Uterus and Rudimentary Horns

A unicornuate uterus results from the normal creation of a fallopian tube, functional uterus, cervix, and vagina from one Müllerian duct. The other side fails to develop, resulting in either absence of the contralateral Müllerian duct or a rudimentary horn. There is a 30–40% association of renal anomalies. If a rudimentary horn is identified, it is important to determine whether functional endometrium is present (usually with T2-weighted MRI images). About two-thirds of rudimentary horns are noncommunicating, some with a fibrous band connecting the two structures. Rudimentary horns can also communicate with the contralateral uterus. A fertilized ovum can implant and develop within a rudimentary horn. Pregnancies within a rudimentary horn are incompatible with expectant management, and rupture of the horn could be life-threatening. Rupture tends to occur at a later gestation than with an ectopic pregnancy, and hemorrhage is severe. Patients with rudimentary horns with functioning endometrium can also present with pain caused by accumulating menses. Because the contralateral uterine horn has a normal outflow pathway, these patients present with cyclic pain and/or a mass, not primary amenorrhea. Pregnancies that arise in a unicornuate uterus are associated with increased preterm labor and delivery, malpresentation, and miscarriage. The patient should be counseled regarding these increased obstetric risks and be offered a preconception consult with a high-risk obstetric physician to best manage pregnancy.

Uterus Didelphys

A uterus didelphys is the result of a complete failure of fusion and represents 5% of Müllerian anomalies. There are two fallopian tubes, two separate uterine cavities, two cervices, and often two vaginal canals or two partial canals because of an associated longitudinal vaginal septum (75% of the time). At times, the longitudinal septum attaches to one sidewall and obstructs one side of the vagina (or hemivagina) (Fig. 591.4). Evaluation for renal anomalies should be pursued because they are common as well. The combination of uterine didelphys, obstructed hemivagina, and ipsilateral renal agenesis is a variant of the broad spectrum of Müllerian anomalies that is referred to as **obstructed hemivagina and ipsilateral renal anomaly (OHVIRA) syndrome** or **Herlyn-Werner-Wunderlich syndrome.** Adolescents with this disorder usually present with abdominal pain shortly after menarche. Although there still may be a risk of adverse pregnancy outcomes with a uterine didelphys (preterm labor, malpresentation), overall pregnancy outcomes are good and are associated with less risk than in other uterine anomalies, but preconception counseling and a consult with a high-risk obstetric physician should be offered.

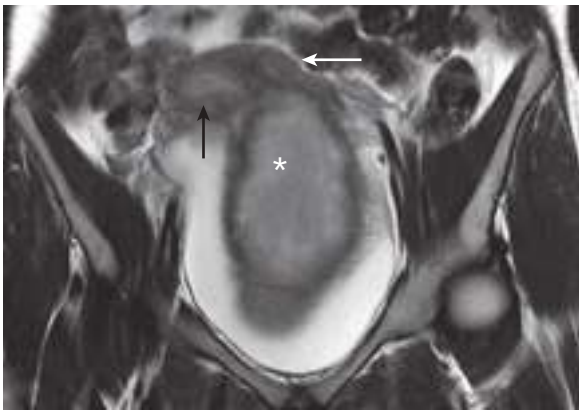

Fig. 591.4 Coronal MRI demonstrating large volume hematocolpos (*asterisk*) in a case of uterine didelphys with longitudinal vaginal septum. *Black arrow,* obstructed right uterus resulting in hematometra; white arrow, unobstructed left uterus.

Arcuate Uterus

An arcuate uterus is a uterine cavity that has a small midline septum from lack of a small amount of resorption (<1 cm), and sometimes a slight indentation of the uterine fundus. An arcuate uterus might represent a variant of normal rather than a Müllerian anomaly. Untoward pregnancy outcomes are rare, and *surgical correction is not warranted*.

Treatment

Treatment depends on the specific diagnosis and should be determined by a clinician with expertise in management of Müllerian anomalies. Most treatments focus on relief of obstruction and consider a patient's reproductive goals and history. Hysteroscopic surgical resection of the uterine septa was widely employed in the past, but a Cochrane systematic review shows no evidence to support surgical excision of the septum. Each individual case should be discussed with the patient, and a shared decision approach should be exercised based on the evidence of the benefit of such surgery.

A noncommunicating horn with functional endometrium should be resected to improve the quality of life or prevent future complications. Opinions vary as to whether resection of a communicating horn or one with no functional endometrium is warranted. Any surgical resection of a rudimentary horn requires careful surgical technique to protect the ipsilateral ovarian blood supply and the myometrium of the remaining unicornuate uterus.

Although metroplasty (also known as the Strassman unification method) had been employed with didelphic and bicornuate uteri in the past, currently most clinicians feel there is not enough evidence to support such a complicated procedure. Any obstruction to the outflow tract must be relieved; this can necessitate creation of a vaginal window or excision of the vaginal septum.

VAGINAL ANOMALIES

Abnormalities of the Hymen

An imperforate hymen is the most common obstructive anomaly, and familial occurrences have been reported (see Fig. 591.1). Its incidence is approximately 1 in 1,000. In the newborn period and early infancy, it may be diagnosed by a bulging membrane caused by a **mucocolpos** from maternal estrogen stimulation of the vaginal mucosa. This can eventually reabsorb if it is not too large or symptomatic. More often, it is diagnosed at the time of menarche when menstrual fluid accumulates **(hematocolpos)**. The clinical manifestations often are a bulging blue-black membrane, pain, and/or primary amenorrhea in a setting of normal secondary sex

characteristics. A mucocolpos or hematocolpos may obstruct urinary outflow. Depending on the circumstance, patients might have cyclic abdominal pain or a pelvic mass. Other hymenal variations can occur such as annular (most common) or crescentic configurations. In some cases, the hymenal membrane does not undergo complete resorption or perforation, resulting in a microperforate, cribriform, or septate-shaped hymen. Age of recognition varies, but hymenal variations are often discovered after menarche when it is difficult for an adolescent to place or remove a tampon.

Congenital Absence of the Vagina and Mayer-Rokitansky-Küster-Hauser Syndrome

Vaginal agenesis or atresia results when the vaginal plate fails to canalize. On physical exam, it appears as an extremely foreshortened vagina, sometimes referred to as a *vaginal dimple.* Isolated (partial) vaginal agenesis involves an area of aplasia between the distal vaginal portion and a normal upper vagina, cervix, and uterus. These patients present with cryptomenorrhea and eventually have cyclic pain caused by obstructed outflow. Each subsequent menses distends the upper vagina with menstrual blood. On initial presentation it may be confused with a low transverse septum or imperforate hymen, and therefore clear delineation of the anomaly with appropriate imaging is critical before attempting surgical repair. Surgical repair and reconstruction are complicated and best performed with consultation of specialists with expertise in managing these anomalies.

Uterine and **vaginal agenesis/aplasia** often occur together because of their close association during development, when Müllerian ductal development fails early in the process. The most common cause of uterovaginal agenesis/aplasia is **Mayer-Rokitansky-Küster-Hauser (MRKH) syndrome,** with an incidence reported at 1 in 5,000 female births. The etiology is believed to be multigenetic and multifactorial. This condition is present at birth but often not diagnosed until mid-adolescence. Females with MRKH syndrome have normal ovarian function and undergo normal secondary sexual development at puberty but do not have a menstrual cycle (primary amenorrhea). The range and severity of MRKH syndrome can vary greatly and the disorder may be type I (isolated uterovaginal anomaly) or type II, involving additional organ systems, including the renal, skeletal, auditory, or cardiac systems. Absence of the vagina and uterus has significant anatomic, physiologic, and psychologic implications for the patient and family, and counseling is recommended. Although most patients with Müllerian agenesis have small rudimentary Müllerian bulbs, approximately 2–7% of patients can have active endometrium within these uterine structures. These patients will often present with cyclic pelvic pain. MRI may be necessary to determine if any small uterine remnant is present (often located on the pelvic sidewall or near the ovaries) and to clearly delineate the anomaly. Laparoscopy is not necessary to diagnose Müllerian agenesis but may be useful in the treatment of rudimentary uterine horns, particularly when removal of obstructed uterine structures or associated endometriosis is indicated for pelvic pain. Any diagnosis of Müllerian agenesis must be differentiated from **androgen insensitivity**; karyotype, serum testosterone levels, and pubic hair distribution help distinguish between the two because testosterone levels and adrenarche will be normal in females with MRKH syndrome.

Abnormalities involving other organ systems occur in association with MRKH type II, or Müllerian duct aplasia, renal dysplasia, and cervical somite anomalies (MURCS) association. The most common are urinary tract anomalies (15–40%) primarily involving unilateral absence of a kidney; a horseshoe or pelvic kidney; and skeletal anomalies (5–10%), which primarily involve vertebral development but can also include cardiac anomalies and hearing impairment, and these should be evaluated at the time of diagnosis.

Longitudinal Vaginal Septum

Longitudinal vaginal septa represent failure of complete canalization of the vagina. These often occur in the presence of uterine anomalies. These septa can vary in length from the cervix or cervices caudally and at times extend fully to the introitus. Patients may report menstruation that overflows their tampon because they only have a single side of the vagina occluded.

Transverse Vaginal Septum (Vertical Fusion Defects)

Vertical fusion defects can result in a transverse septum, which may be imperforate and associated with hematocolpos or hematometra in adolescents or with mucocolpos in infants. These are uncommon anomalies, reportedly found in 1 in 80,000 females. Patients commonly present with primary amenorrhea and cyclical abdominal pain around the time of menarche. However, patients who have a small opening in the transverse septa might present with prolonged vaginal drainage and mucopurulent or sanguineous discharge. Transverse vaginal septa can vary in location (15–20% occur in the lower third, but the majority are in the middle or upper third of the vagina) and thickness (but are generally ≤1 cm). High locations, thicker septa (>1 cm), and narrow vaginal orifices present challenging surgical cases.

Transverse vaginal septa may be associated with other congenital anomalies, although this occurs less often than with Müllerian agenesis. These patients have a functional normal uterus, unlike females with MRKH syndrome. In the majority of cases with outflow obstruction, there is also an increased incidence of endometriosis secondary to retrograde menstruation.

Evaluation of transverse vaginal septa includes careful pelvic examination and pelvic imaging, usually with MRI and ultrasound, to delineate the anatomic abnormalities. MRI is especially helpful to determine the thickness of the septum and verify the presence of a cervix for surgical planning. Diagnosis and treatment plans should be made as soon as possible after menarche because significant accumulation of hematometra and/or hematosalpinx could affect future reproductive success by negatively affecting uterine and/or tubal function. Alternately, menstrual suppression is another option to provide adolescent patients time to mature psychologically and participate in the treatment phase of the resection of the transverse septum.

Treatment

An imperforate hymen requires resection to prevent or relieve the outflow tract obstruction. Many approach it with a horizontal, lunate, or cruciate incision; excision of excess tissue; and approximation of the mucosal edges. Repair should be done at time of diagnosis if the patient is symptomatic, although the lesion may be repaired any time during infancy, childhood, or adolescence. Elective surgery with general anesthesia is discouraged in the very young. Elective hymenal excision in the prepubertal child may have improved healing if topical estrogen is placed at the site postoperatively. Elective excision of an imperforate hymen can be performed after onset of thelarche but ideally before menses. Variants in the hymen with microperforations or hymenal septa may interfere with tampon use, and resection of this tissue is usually electively performed using local anesthesia or sedation according to patient preference.

Treatment of congenital absence of the vagina is usually delayed until the patient is mature enough to discuss and participate in the treatment. The nonsurgical approach using vaginal dilation is the most common first-line therapy because it is safer, patient-controlled, more cost effective than surgery, and successful in 90–96% of patients. If done correctly, it is possible to achieve a functional vaginal length (6-8 cm), width, and physiologic angle for intercourse in about 6-8 months of therapy. When the ultimate size that accommodates coitus is reached, the patient must use the dilator or have coitus with a frequency that maintains adequate length.

Surgical approaches require expertise and often some postoperative vaginal dilation to ensure a functional result. Controversy exists as to when creation of a neovagina should occur. Surgery is indicated at any age if there is a medical indication such as mucocolpos that causes urinary obstruction or any other surgical emergency.

However, literature reports better outcomes with delaying creation of the neovagina to when the patient is interested in sexual activity and can participate in the decision to have surgery and in their own postoperative recovery. There is no consensus as to the best surgical option. Surgery should be reserved for the rare patient for whom primary dilator therapy was unsuccessful or for those who request surgery after a thorough informed consent. Referral to centers with expertise should be offered.

Future options for having children should be addressed, including adoption and gestational surrogacy. Assisted reproductive techniques using ovum retrieval, fertilization, and implantation of embryos into gestational carriers (surrogates) have been successful. Female offspring usually have normal reproductive tracts. Uterine transplantation has resulted in live births, but this procedure remains rare. Opportunities for family building enable patients and their families to appreciate the potential for becoming parents and help cope with the diagnosis and its implications.

Surgical resection of transverse vaginal septa should be undertaken only by surgeons with expertise. Some surgeons advocate waiting for one or more menstrual cycles or using preoperative dilators from below to increase the depth and circumference of the distal vagina and to allow menstrual blood to accumulate and dilate the upper portion of the vagina. Complete resection of the septum, with primary anastomosis of the upper and lower mucosal segments, should be attempted. A vaginal stent is sometimes placed postoperatively in the vagina to maintain patency and allow squamous epithelialization of the upper vagina and cervix. Follow-up dilation may be necessary after the stent is removed. Careful preoperative assessment is important because surgeons who begin a case believing they are operating on an imperforate hymen can find themselves in entirely different and more complex surgical planes. Regardless of the approach, vaginoplasty is often best deferred until the patient is mature and physically and psychologically prepared to participate in the healing process and postoperative dilator treatments. It can be challenging to differentiate a low transverse septum from distal vaginal agenesis. If the distal vagina cannot be palpated close to the anal sphincter by rectal examination, the patient should be allowed to continue to menstruate to distend the upper vagina to within 3 cm of the anal sphincter. This enables the surgeon to dissect up to the lower vagina and perform a pull-through procedure, anastomosing the upper vagina to the introitus. Proper timing and surgical execution yield excellent outcomes.

Longitudinal vaginal septa themselves do not lead to adverse reproductive outcomes but may be symptomatic in a patient, causing dyspareunia, traumatic bleeding with intercourse, difficulties with tampon insertion, or impedance during vaginal birth. Such complaints can warrant a resection of the vaginal septa. A carefully planned incision and resection of the oblique septum to maintain patency of the upper tract is performed in cases of OHVIRA (Herlyn-Werner-Wunderlich syndrome).

CERVICAL ANOMALIES

Congenital atresia or complete agenesis of the uterine cervix is extremely rare and often manifests at puberty with amenorrhea and pelvic pain. It is associated with significant renal anomalies in 5–10% of patients. A pelvic MRI is often warranted to completely define the abnormality. Usually, pain and obstruction are significant, and a hysterectomy is necessary. Attempts to reconnect the uterus to the vagina are rarely successful and are associated with significant morbidity and reoperation rates. The ovaries usually have normal function, and future reproduction can still occur using in vitro fertilization and a gestational carrier.

VULVAR AND OTHER ANOMALIES

Complete Vulvar Duplication

Duplication of the vulva is a rare congenital anomaly that is seen in infancy and consists of two vulvas, two vaginas, and two bladders, a didelphic uterus, a single rectum and anus, and two renal systems. Treatment is individualized and requires a multidisciplinary approach with gynecology, urology, and plastic surgery.

Labial Asymmetry and Hypertrophy

With the onset of puberty, the labia minora enlarge and grow to an adult size. A female's labia can vary in size and shape. Asymmetry of the labia, where the right and left labia are different in size and appearance, is a normal variant. Some patients are uncomfortable with what they perceive to be their asymmetric or enlarged labia minora and complain about self-consciousness and discomfort while wearing tight clothing, exercising, or having sex. The mature labia minora can protrude beyond the labia majora, and this normal variant can be functionally or psychologically bothersome. Local irritation, problems of personal hygiene with bowel movements or menses, or interference with sexual intercourse or while sitting or exercising have resulted in requests for labial reduction. Patients may find online procedures advertised to reduce uneven or enlarged labia minora. Education and reassurance are very important for adolescents who have concerns about the appearance of their labia. Surgery is not recommended unless there is significant congenital malformation or persistent symptoms directly related to the labia. Surgical alteration of the labia that is not necessary to the health of the adolescent less than age 18 is considered a violation of federal law in the United States. Complications of labial surgery include loss of sensation, keloid formation, and dyspareunia.

Clitoral Abnormalities

Agenesis of the clitoris is rare. Clitoral duplication has been reported, often associated with cloacal and bladder exstrophy. Exposure to male hormones will result in clitoral enlargement and is often a sign of a difference of sex development, a testosterone-producing tumor, or use of exogenous steroids.

Cloacal Anomalies

Cloacal anomalies are rare lesions representing a common urogenital sinus into which the gastrointestinal, urinary, and vaginal canals all exit. Usually there is an abnormality in all or some of the processes of fusion of the Müllerian ducts, development of the sinovaginal bulbs, or development of the vaginal plate. The single opening (cloaca) requires surgical correction, which is often done very early in life, preferably by a multidisciplinary pediatric surgical team.

Ductal Remnants

Even though the opposite duct regresses in both sexes, there can sometimes be a small portion of either the Müllerian or Wolffian duct that remains in either the male or female, respectively. Such remnants can form cysts, which are what make them clinically visible during surgery, examination, or imaging. Most do not cause pain, although torsion of some has been reported, and small asymptomatic ones usually do not require resection. The most commonly reported are hydatid of Morgagni cysts (remnant of a Wolffian duct arising from the fallopian tube), cysts of the broad ligament, and Gartner's duct cysts, which can form an ectopic ureter or be found along the cervix or vaginal walls.

Visit Elsevier eBooks+ at eBooks.Health.Elsevier.com for Bibliography.

Chapter 592

Gynecologic Care for Adolescents with Special Needs

Elisabeth H. Quint and Melina L. Dendrinos

Adolescence presents challenges for all children and their families but particularly for teens with special needs and their families. The start of menstrual periods, the mood changes associated with puberty, the concerns about sexual activity with possible unplanned pregnancies, and worries about safety and abuse present teens with disabilities and their families with additional issues.

SEXUALITY AND SEXUAL EDUCATION

Adolescents with special needs can have physical and/or developmental disabilities. These young people are often seen as asexual by their families, care providers, and society and, therefore, sexual education might not have been provided or considered necessary, even though physically disabled teens report being sexually active. The care provider needs to assess the teen's knowledge of anatomy and sexuality, gender identity, social knowledge of relationships, ability to consent to sexual and intimate activities, and sexual orientation, as well as any previous sexual activity. Education regarding HIV and other sexually transmitted infections, disease prevention, and contraception, including emergency contraception, should be offered at a developmentally appropriate level.

ABUSE

The risk for sexual abuse in teens with disabilities is difficult to estimate. Teens with disabilities may be more at risk for isolation and depression during adolescence, leading to vulnerability.

Teens with disabilities are just as sexually active or even more so than their nondisabled counterparts, but more of their activity is nonvoluntary. Patients with cognitive impairment are often taught to be cooperative, which may make them more vulnerable to coercion. Abuse prevention education can include the No! Go! Tell! model. For teens with limited verbal capacity or developmental delay, abuse may be very hard to detect; thus screening for abuse is extremely important. The care provider needs to be vigilant in looking for signs on physical exam, such as unexplained bruises or scratches, or changes in behavior, such as regression, which may be indications of sexual abuse (see Chapters 17.1 and 162).

PELVIC EXAMINATION

An internal pelvic exam is rarely indicated in teens, as Papanicolaou smears are not recommended to start until age 21. An external genital exam can be performed if there are vulvovaginal issues such as discharge, irregular bleeding, suspicion for abuse, or foreign body. The frog-leg position is usually favored over the use of stirrups. If the vagina or cervix needs to be clearly visualized for a medical indication, an exam under anesthesia by a gynecologist can be considered. Testing for sexually transmitted infections can be accomplished by urine testing or vaginal swabs (see Chapter 163).

MENSTRUATION

Irregular menstruation is common in teenagers, especially during the first 5 years after menarche, because of immaturity of the hypothalamic-pituitary-ovarian axis and subsequent anovulation (see Chapter 159). Several conditions in teens with disabilities are associated with an even higher risk of irregular cycles. Thyroid disease is more common in teens with Down syndrome. There is a higher incidence of reproductive issues, including polycystic ovarian syndrome, in teens with epilepsy or those taking certain antiepileptic drugs. Antipsychotic medication can lead to hyperprolactinemia, which can affect menstruation.

For teens with disabilities, the main issue with menstrual cycles, whether they are regular, irregular, or heavy, is the impact of menstruation on the patient's life, health, and ability to perform their normal activities. The history should focus on this aspect, and menstrual calendars may be helpful to document the cycles, behavior, and impact of treatments. Most adolescents who self-toilet can learn to use menstrual hygiene products appropriately. Menstrual underwear have been very helpful for many teens. Premenarchal anticipatory guidance is recommended, but hormonal treatment before menarche should be avoided.

The medical evaluation for abnormal bleeding is the same as for all teens (see Chapter 159.2). Areas requiring particular attention for the teen with special needs are the consideration of menstrual suppression for hygiene or cyclical behavioral issues, like crying, tantrums, or withdrawal.

Treatment of Menstruation

If the impact of cycles, whether regular, irregular, or heavy, on the patient's well-being is significant (often documented through menstrual or behavioral charting for several months), the care provider, patient, and family may decide on menstrual intervention. Menstrual regulation or suppression is not much different from that in the nondisabled teenager in general, although there are some special considerations. Goals for treatment can be to decrease the heaviness of flow, regulate cycles to predictable bleeding, relieve pain or cyclical behavior symptoms, provide contraception, and/or obtain amenorrhea. Menstrual suppression leading to complete amenorrhea is usually difficult to obtain and infrequent scheduled bleeds may be easier to manage than unpredictable spotting, a common side effect of any suppressive treatment, for certain patients. After treatment has started, providers should continue to monitor outcomes, ideally with continued menstrual or behavioral calendars to assess efficacy and need for changes.

Nonhormonal Methods

If menorrhagia or dysmenorrhea (occasionally leading to cyclical behavior changes in nonverbal teens) is the main concern, the patient can be started on scheduled nonsteroidal anti-inflammatory drugs. These can decrease the flow by up to 20% in adequate doses and can be used alone or in combination with other treatments. Use of tranexamic acid during the first 5 days of menses can also be used to decrease heavy bleeding.

Estrogen-Containing Methods

All estrogen-containing medication can be used in a cyclical fashion with scheduled medication breaks to allow for monthly menses; in a more extended fashion, where the active hormonal method is used for 3 months with a scheduled break; or a more flexible schedule, where the hormones are used until bleeding starts, and a break for withdrawal bleeding can be done at that time.

Oral Contraceptives

Cyclical oral contraceptives usually lead to regular, lighter cycles with less cramping. Continuous daily use of active oral contraceptives can suppress cycles, with amenorrhea rates improving with time. Some unpredictable spotting is usually unavoidable, and often teens with special needs prefer to have predictable cycles several times a year. Chewable oral contraceptives are available for those with swallowing issues.

Contraceptive Ring

The contraceptive ring can be used in a pattern of 3 weeks in and 1 week out, but it can also be used (off-label) in a continuous 4-week pattern, which leads to less bleeding. However, the contraceptive ring may be difficult to use for a teen with dexterity problems, and help with placement has obvious privacy issues.

Contraceptive Patch

The weekly patch can also be used in a cyclic or extended fashion. Some teens with developmental disabilities and sensory issues may remove their patch erratically, and placement out of reach (e.g., on buttocks or shoulder) is advised.

Estrogen Use, Venous Thromboembolism, and Mobility Issues

Whether immobility and wheelchair use can lead to an increased risk of venous-thromboembolic events (VTEs) in association with estrogen-containing contraceptives remains controversial. The risk of thrombosis in young females is very low overall, but the use of combined hormonal contraceptives by adolescents who are immobile or who have limited mobility has not been studied. Immobility per se is not a contraindication to estrogen-containing contraceptives; however, it may increase the risk of VTE. There are limited data to support the concern that higher-dose oral estrogen and the third- and fourth-generation progestin preparations may have a higher risk for VTE. It is important to assess for other VTE risk factors in the patient's history before initiating estrogen therapy. Careful use of lower-dose (30 or 20 μg) ethinyl estradiol preparations after appropriate counseling may be advisable, and third-generation progestin combinations should only be used if second-generation medications have failed.

Progestin-Only Methods

Intramuscular Medroxyprogesterone Acetate

Intramuscular depot medroxyprogesterone acetate (DMPA) has long been used for menstrual suppression. Two issues are particularly relevant to teens with disabilities. Studies documenting a decrease in bone density associated with longer-term use of DMPA and a black box warning by the FDA have raised concerns about use of these products in young females, although research indicates that the bone density improves after the medication is stopped. For teens with mobility issues or those with very low body weight who are already at risk for low bone density, decreased bone density is a real concern, although the risk of fractures is unclear. Adequate calcium and vitamin D is recommended. The second issue for teens with mobility issues is weight gain associated with DMPA, especially among obese teens, which can lead to transfer and mobility issues. The potential health risks associated with the effects of DMPA on bone density and weight must be balanced against the need for menstrual suppression and the likelihood of unintended pregnancy. Weight should be monitored closely. Routine bone density scanning (DEXA) is not recommended in adolescents.

Oral Progestins

Continuous oral progestins can also be very effective in obtaining amenorrhea. The contraceptive progestin-only pill (norethindrone 0.35 mg) can cause significant irregular spotting, so if full suppression is the goal, then other progestins can be used daily, such as drospirenone 4 mg, norethindrone 2.5 or 5 mg, or micronized progesterone 200 mg.

Progesterone Intrauterine Device

The 8-year levonorgestrel-intrauterine device is used for many teenagers for contraception, as well as heavy menses and dysmenorrhea (off-label use). Teens with special needs might require anesthesia for insertion if the exam is difficult because of discomfort, contractures, or a narrow vagina. Checking for strings in a clinic setting may be challenging; however, the intrauterine device location can be confirmed by sonography. There may be a significant amount of irregular bleeding and spotting in the first several months, but there is 20% rate of amenorrhea after insertion and up to 50% rate of amenorrhea after 1 year of use. The bleeding profile of the smaller and lower dose 3-5 year levonorgestrel-intrauterine devices may not be as helpful for menstrual suppression; the amenorrhea rates from the initial studies by the manufacturer are 8–12% at 1 year, but more studies are needed.

Implants

Progestin subdermal implants have relatively low amenorrhea rates and higher rates of unscheduled bleeding; therefore they are often less desirable for menstrual suppression for teens with special needs. They also require significant patient cooperation for insertion.

Hormones and Antiepileptic Drugs

Certain enzyme-inducing seizure medications can interfere with estrogen-containing contraceptives, change their contraceptive effectiveness, and/or lead to intermittent bleeding. Higher estrogen dose or shorter injection intervals for DMPA may be considered. The only antiepileptic medication that is affected by combined oral contraceptives is lamotrigine; consequently, the dose of that medication may need to be adjusted if used in conjunction with hormones, so discussion with other providers is needed.

Surgical Methods

Surgical procedures, such as endometrial ablation, a procedure where the lining of the uterus is surgically removed, and hysterectomy, are available for treatment of abnormal and heavy bleeding in adults, but they should only rarely be used in extreme situations for teenagers where all other methods have failed, and the patient's health is severely compromised by their cycles. Endometrial ablation only leads to amenorrhea approximately 30% of the time, has a higher failure rate in females younger than 40 years of age, and is not recommended in the adolescent population. Ethical considerations around these methods leading to infertility and consent issues are complicated, and state law varies on this topic.

CONTRACEPTION

See also Chapter 160.

The menstrual management methods discussed above can also be used for contraception. A request for birth control, especially coming from a caregiver and not the teen, requires an evaluation of the teen's ability to consent to sexual activity and the safety of their environment. The method chosen should be the safest method for their situation with the highest protection rate. Therefore a long-acting reversible contraceptive method may be advisable. Sexually transmitted infections and condom use should be addressed with the teen and specific guidelines on how to obtain condoms and negotiate their use may be needed. A discussion about emergency contraception is recommended, as well as ways to help the teen obtain this if indicated.

Visit Elsevier eBooks+ at eBooks.Health.Elsevier.com for Bibliography.

Chapter 593

Female Genital Mutilation

Deborah Hodes and Sarah M. Creighton

Female genital mutilation (FGM) is a worldwide human rights issue that constitutes violence against women and children. It is defined by the World Health Organization (WHO) as procedures that involve partial or total removal of the external female genitalia, or other injury to the female genital organs for nonmedical reasons. In September 2015 the United Nations adopted the Sustainable Development Goals (SDGs), which includes the elimination of FGM by 2030. UNICEF (United Nations International Children's Emergency Fund) estimates that at least 200 million women and young females in 30 countries have undergone FGM. There has been a decline in the prevalence of FGM, but current trends suggest that actual numbers will rise because of population growth. FGM is commonly performed in Africa, the Middle East, and Asia, with data suggesting an estimated 40 million young females in Indonesia have undergone FGM. According to the UNICEF report 2020, the COVID-19 pandemic has caused disruption to the protection of young females from FGM leading to an estimated 2 million additional cases than would otherwise have occurred.

The migration of FGM-practicing communities means that FGM is a global problem, although there are scant data on the practice in high-income countries. Despite estimates, a British pediatric surveillance unit study found low numbers presenting to pediatricians; there were very few illegal cases and only one successful prosecution in the UK by 2021. FGM is almost always carried out on children, and pediatricians must be familiar with the identification of FGM, the impact on health, and ways to protect young females from this widespread form of child abuse.

FGM has no health benefits and can cause lifelong damage to physical and psychologic health. The WHO has classified FGM into four types, depending on the extent and type of genital tissue removed (Table 593.1). The traditional practitioner performs FGM without anesthetic or sterile conditions, and in some countries, it is done as part of a wider ritual related to early child marriage. The child is restrained whilst the external genitalia are removed or damaged using a knife, scalpel, or other sharp instrument. An increasing number of procedures are performed at a younger age, and the United Nations Population Fund (UNFPA) estimates that around one in five young females subjected to FGM were cut by a trained healthcare provider. Table 593.2 lists potential risks and protective factors for FGM.

COMPLICATIONS

Immediate complications of FGM include hemorrhage and infection. Deaths have been reported, although numbers are unknown. Infections include immediate wound infection, tetanus, and gangrene. FGM has been implicated in the transmission of blood-borne infections because of the use of shared and unsterile tools. Although procedure-related blood-borne infection is probable, there are no good studies to confirm this; infections such as hepatitis B and HIV are endemic in areas where FGM is prevalent. FGM leads to obstetric, gynecologic, and psychologic consequences in adult women. Gynecologic symptoms include painful and unsightly scarring, clitoral cysts, and recurrent urinary infections. Menstrual difficulties and infertility are reported, although the underlying mechanisms of these are unclear apart from type 3 FGM, where the vagina is narrowed. FGM damages sexual function by removing sensitive sexual tissue and narrowing the vagina. Mental health problems such as anxiety and depression have been linked to FGM. FGM also has a detrimental impact on obstetric outcomes for both the mother and baby, leading to increased risks of postpartum hemorrhage, perineal trauma, and perinatal death.

CLINICAL MANAGEMENT OF FGM

Most pediatricians will not see a child who is acutely unwell due to FGM. Management of FGM in the acute situation should include assessment for blood loss, sepsis, and urinary retention and treatment with antibiotics, analgesia, tetanus toxoid, and urinary catheterization. Pediatricians are more likely to see a child in whom FGM has been found during the investigation of other often vague symptoms as well as recurrent urinary tract infections and vulvovaginitis. FGM may also be alleged by the child or family member, or concerns may be raised by other health and social care professionals, particularly if the mother herself has undergone FGM and has little support from the husband (see Table 593.2). Pediatricians may be asked to confirm FGM on genital examination; it should be performed using a colposcope for magnification and video documentation, which can be used for peer review and in a court of law. The examination must be done in a sensitive and gentle manner by an appropriately trained clinician and in an age-appropriate setting. It is often assumed that FGM will be obvious. However, whilst type 3 FGM, in which the vagina is sealed, is usually easy to detect, other types of FGM can be more difficult to diagnose. This is particularly true for type 4 FGM, which may involve a prick or small scratch on or adjacent to the clitoris and may heal without a trace. General assessment of the child's health should include screening for blood-borne viruses.

If the child has type 3 FGM, then a deinfibulation procedure will be required at some point. Deinfibulation is a minor surgical procedure to divide any scar tissue that obscures the vaginal introitus. If the child is asymptomatic, this can be deferred until adolescence or before sexual activity. Deinfibulation procedures are usually performed under a local anesthetic in adult women, but in children a brief general anesthetic is more appropriate. The psychologic impact of FGM on a child may be severe, and flashbacks and nightmares have been reported. Input from a child psychologist or psychotherapist with experience in working with children with FGM and their families should be available. If a child is confirmed to have FGM, then other children in the family may be at risk, and local safeguarding pathways should be activated. Pediatricians must be advocates against FGM and contribute to training

Table 593.1 Summary of WHO Classification of FGM

Type 1: Clitoridectomy: Partial or total removal of the clitoris (a small sensitive and erectile part of the female genitals) and, in rare cases, only the prepuce (the fold of skin surrounding the clitoris).
Type 2: Excision: Partial or total removal of the clitoris and labia minora with or without removal of the labia majora (the labia are the "lips" that surround the vagina).
Type 3: Infibulation: Narrowing of the vaginal opening through the creation of a covering seal. The seal is formed by cutting and repositioning the labia minora or majora with or without removal of the clitoris.
Type 4: Other: All other harmful procedures to the genitalia for nonmedical reasons (e.g., pricking, piercing, incision, scraping, and cauterizing the genital area).

From the World Health Organization Female Genital Mutilation Fact Sheet. https://www.who.int/news-room/fact-sheets/detail/female-genital-mutilation

Table 593.2 Factors That Influence Whether or Not a Child May Have FGM

RISK FACTORS
Mother or sister cut
Isolated mother
Grandmother influential
Little information and discussion about FGM
PROTECTIVE FACTORS
Discussing with husband or friend
Knowing the law has been implemented
TV, global debate, media
Men's attitude and knowledge
Knowing an uncut person

healthcare workers who may treat patients. In developed countries, there are concerns that the emphasis on prosecution has stigmatized and alienated communities in the diaspora who have abandoned the practice; because of this, experts emphasize the need for a more community-centric approach to current and future FGM prevention efforts.

Visit Elsevier eBooks+ at eBooks.Health.Elsevier.com for Bibliography.

The Endocrine System

PART XXIV

Section 1

Disorders of the Hypothalamus and Pituitary Gland

Chapter 594

Hormones of the Hypothalamus and Pituitary

Eric I. Felner and Briana C. Patterson

The pituitary and hypothalamus are the major regulators of an elaborate hormonal system. The pituitary gland receives signals from the hypothalamus and responds by sending pituitary hormones to target glands. The target glands produce hormones that provide negative feedback at the level of the hypothalamus and pituitary (Figs. 594.1 and 594.2). This feedback mechanism enables the pituitary to regulate the amount of hormone released into the bloodstream by the target glands. The pituitary's central role in this hormonal system and its ability to interpret and respond to a variety of signals have led to its designation as the *master gland*. Table 594.1 lists the hypothalamic and pituitary hormones and their functions.

ANATOMY

The pituitary gland is located at the base of the skull in a saddle-shaped cavity of the sphenoid bone called the **sella turcica**. The bony structure protects and surrounds the pituitary bilaterally and inferiorly. The dura, a dense layer of connective tissue, forms the roof of the sella turcica. An external layer of the dura continues into the sella turcica to form its lining. As a result, the pituitary is extradural and is not normally in contact with cerebrospinal fluid. The pituitary gland is connected to the hypothalamus by the pituitary stalk. The pituitary gland is composed of an anterior (adenohypophysis) and a posterior (neurohypophysis) lobe. The anterior lobe constitutes approximately 80% of the gland.

EMBRYOLOGY

The anterior pituitary gland originates from Rathke's pouch as an invagination of the oral ectoderm. It then detaches from the oral epithelium and becomes an individual structure of rapidly proliferating cells. By 6 weeks of gestation, the connection between **Rathke's pouch** and oropharynx is completely obliterated. The pouch establishes a direct connection with the downward extension of the hypothalamus, which gives rise to the pituitary stalk. Persistent remnants of the craniopharyngeal duct, the original connection between Rathke's pouch and the oral cavity, can develop into adamantinous **craniopharyngiomas** (see Chapter 546).

VASCULAR SUPPLY

The arterial blood supply of the pituitary gland originates from the internal carotid via the inferior, middle, and superior **hypophyseal arteries**. This network of vessels forms a unique portal circulation connecting the hypothalamus and pituitary. The branches of the superior hypophyseal arteries penetrate the stalk and form a network of vessels that traverse the pituitary stalk and terminate in a network of capillaries within the anterior lobe. It is through this portal venous system that hypothalamic hormones are delivered to the anterior pituitary gland. Anterior pituitary hormones, in turn, are secreted into a secondary plexus of portal veins that drain into the dural venous sinuses.

ANTERIOR PITUITARY CELL TYPES

A series of sequentially expressed transcriptional activation factors directs the differentiation and proliferation of anterior pituitary cell types. These proteins are members of a large family of DNA-binding proteins resembling homeobox genes. The consequences of pathogenic variants in several of these genes are evident in human forms of multiple pituitary hormone deficiency. Five cell types in the anterior pituitary produce six peptide hormones. **Somatotropes** produce growth

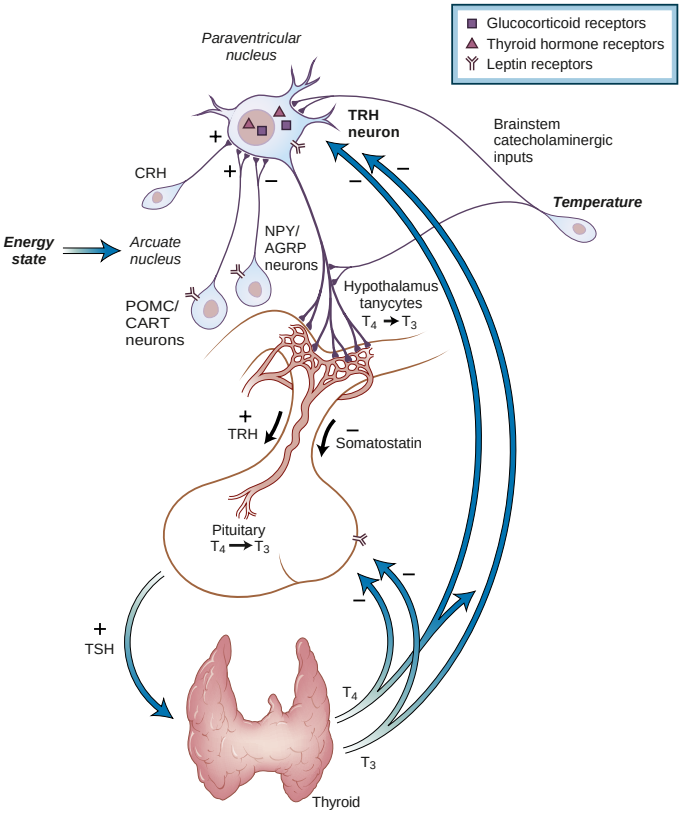

Fig. 594.1 Regulation of the hypothalamic-pituitary-thyroid axis. AGRP, Agouti-related peptide; CART, cocaine- and amphetamine-regulated transcript; CRH, corticotropin-releasing hormone; NPY, neuropeptide Y; POMC, proopiomelanocortin; T_3, triiodothyronine; T_4, thyroxine; TRH, thyrotropin-releasing hormone; TSH, thyrotropin. *(From Low MJ. Neuroendocrinology. In Melmed S, Polonsky KS, Larsen PR, Kronenberg HM, eds. Williams Textbook of Endocrinology, 13th ed. Philadelphia: Elsevier; 2016: Fig. 7.9.)*

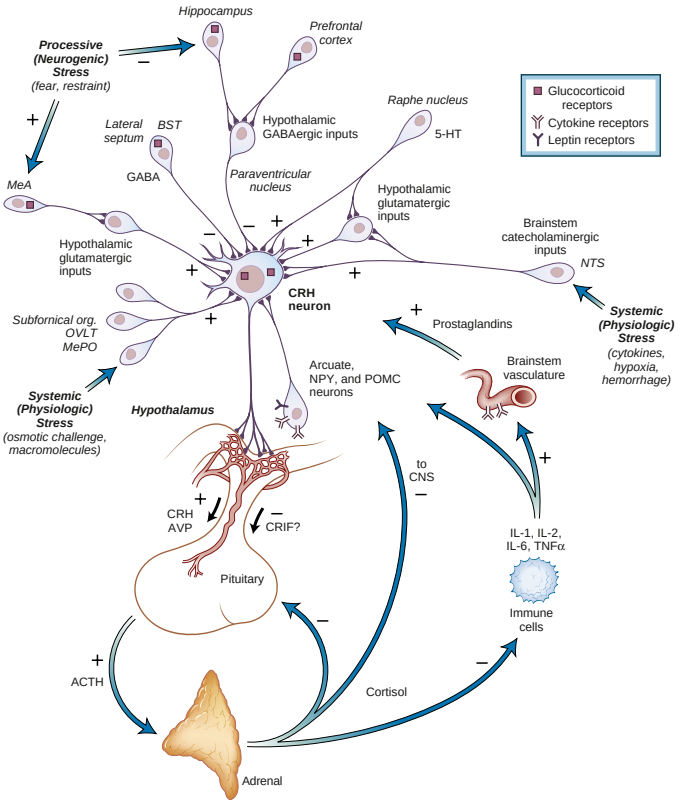

Fig. 594.2 Regulation of the hypothalamic-pituitary-adrenal axis. ACTH, Adrenocorticotropic hormone; AVP, arginine vasopressin; BST, bed nucleus of the stria terminalis; CNS, central nervous system; CRH, corticotropin-releasing hormone; CRIF, corticotropin release–inhibiting factor; GABA, γ-aminobutyric acid; 5-HT, 5-hydroxytryptamine; IL-1, interleukin 1; MeA, medial amygdala; MePO, medial preoptic nucleus; NPY, neuropeptide Y; NTS, nucleus of the tractus solitarius; OVLT, organum vasculosum of the lamina terminalis; POMC, proopiomelanocortin; TNF-α, tumor necrosis factor-α. *(From Low MJ. Neuroendocrinology. In Melmed S, Polonsky KS, Larsen PR, Kronenberg HM, eds. Williams Textbook of Endocrinology, 13th ed. Philadelphia: Elsevier; 2016: Fig. 7.18.)*

hormone (GH), **lactotropes** produce prolactin (PRL), **thyrotropes** make thyroid-stimulating hormone (TSH), **corticotropes** express proopiomelanocortin (POMC), the precursor of adrenocorticotropic hormone (ACTH), and **gonadotropes** express luteinizing hormone (LH) and follicle-stimulating hormone (FSH).

Growth Hormone

Human GH is a 191–amino acid, single-chain polypeptide that is synthesized, stored, and secreted by somatotropes in the pituitary. Its gene *(GH1)* is the first in a cluster of five closely related genes on the long arm of chromosome 17 (q22-24). The other four genes *(CS1, CS2, GH2,* and *CSP)* have >90% sequence identity with the *GH1* gene.

GH is secreted in a pulsatile fashion under the regulation of hypothalamic hormones. The alternating secretion of GH-releasing hormone (GHRH), which stimulates GH release, and somatostatin, which inhibits GH release, accounts for the rhythmic secretion of GH. Peaks of GH occur when peaks of GHRH coincide with troughs of somatostatin. **Ghrelin**, a peptide produced in the arcuate nucleus of the hypothalamus and in much greater quantities by the stomach, also stimulates GH secretion. In addition to these three hypothalamic hormones, physiologic factors play a role in stimulating and inhibiting GH. Sleep, exercise, physical stress, trauma, acute illness, puberty, fasting, and hypoglycemia stimulate the release of GH, whereas hyperglycemia, hypothyroidism, and glucocorticoids inhibit GH release (Fig. 594.3).

GH binds to receptor molecules on the surface of target cells. The GH receptor is a 620–amino acid, single-chain molecule with an extracellular domain, a single membrane-spanning domain, and a cytoplasmic domain. Proteolytically cleaved fragments of the extracellular domain circulate in plasma and act as a GH-binding protein. Similar to other members of the cytokine receptor family, the cytoplasmic domain of the GH receptor lacks intrinsic kinase activity; instead, GH binding induces receptor dimerization and activation of a receptor-associated Janus kinase (Jak2). Phosphorylation of the kinase and other protein substrates initiates a series of events that leads to alterations in nuclear gene transcription. The signal transducer and activator of transcription 5b (STAT5b) plays a critical role in linking receptor activation to changes in gene transcription.

The biologic effects of GH include increases in linear growth, bone thickness, soft tissue growth, protein synthesis, fatty acid release from adipose tissue, insulin resistance, and blood glucose. The mitogenic actions of GH are mediated through increases in the synthesis of **insulin-like growth factor** 1 (IGF-1), formerly named *somatomedin C*, a 70–amino acid single-chain peptide coded for by a gene on the long arm of chromosome 12 with considerable homology to insulin. Circulating IGF-1 is synthesized primarily in the liver and formed locally in mesodermal and ectodermal cells, particularly in the growth plates of children, where its effect is exerted by paracrine or autocrine mechanisms. Circulating levels of IGF-1 are bound to several different binding proteins and are related to blood levels of GH and nutritional status. The major binding protein is a 150-kDa complex (IGF-BP3) that is low in GH-deficient children. Human recombinant IGF-1 has been developed as a therapeutic in conditions characterized by primary IGF-1 deficiency, end-organ resistance to GH (e.g., **Laron syndrome**), and the development of antibodies for those individuals administered GH. **Insulin-like growth factor** 2 (IGF-2) is a 67–amino acid single-chain protein that is coded for by a gene on the short arm of chromosome 11 that is also homologous to insulin and IGF-1. Less is known about its physiologic role, but it appears to be an important mitogen in bone cells, where it occurs in a concentration many times higher than that of IGF-1.

Prolactin

PRL is a 199–amino acid peptide made in pituitary lactotropes. The regulation of PRL is unique because PRL is constitutively secreted by the pituitary unless it is actively inhibited by dopamine, a peptide produced by neurons in the hypothalamus. Disruption of the hypothalamus or pituitary stalk can result in elevated PRL levels. Dopamine antagonists, states of primary hypothyroidism, administration of thyrotropin-releasing hormone (TRH), hypothalamic injury secondary to radiation therapy, and pituitary tumors result in increased serum levels of PRL. Dopamine agonists and processes causing destruction of the anterior pituitary gland can reduce levels of PRL.

The primary physiologic role for PRL is the initiation and maintenance of lactation. PRL prepares the breasts for lactation and stimulates milk production postpartum. During pregnancy, PRL stimulates the development of the milk secretory apparatus, but lactation does not occur because of the high levels of estrogen and progesterone. After delivery, the estrogen and progesterone levels drop, and physiologic stimuli such as suckling and nipple stimulation signal PRL release and initiate lactation.

Thyroid-Stimulating Hormone

TSH consists of two glycoprotein chains (α, β) linked by hydrogen bonding: the α-subunit, which is composed of 89 amino acids and is identical to other glycoproteins (FSH, LH, and human chorionic gonadotropin), and the β-subunit, composed of 112 amino acids, that is specific for TSH.

TSH is stored in secretory granules and released into circulation primarily in response to TRH, which is produced by the hypothalamus. TRH is released from the hypothalamus into the hypothalamic-pituitary portal system and ultimately stimulates TSH release from

Table 594.1 Hormones of the Hypothalamus and Pituitary Gland

HORMONES	LOCATION	S/I	FUNCTION
ACTH	Anterior pituitary	S	Production and secretion of GCs, MCs, and androgens from adrenal gland
ADH	Posterior pituitary	S	Reabsorption of water into the bloodstream via renal collecting ducts
CRH	Hypothalamus	S	Secretion of ACTH
Dopamine	Hypothalamus	I	Secretion of PRL
FSH (females)	Anterior pituitary	S	Secretion of estrogen from ovary
FSH (males)	Anterior pituitary	S	Production of sperm from testis
GH	Anterior pituitary	S	Secretion of IGF-1
GHRH	Hypothalamus	S	Secretion of GH
Ghrelin	Hypothalamus	S	Secretion of GH
GnRH	Hypothalamus	S	Secretion of FSH and LH
LH (females)	Anterior pituitary	S	Ovulation and development of the corpus luteum
LH (males)	Anterior pituitary	S	Production and secretion of testosterone
Oxytocin	Posterior pituitary	S	Contractions of uterus at birth and release of milk from breast
PRL	Anterior pituitary	S	Promotion of milk synthesis
Somatostatin	Hypothalamus	I	Secretion of GH and TSH
TRH	Hypothalamus	S	Secretion of TSH and PRL
TSH	Anterior pituitary	S	Secretion of T_4 and T_3

ACTH, Adrenocorticotropic hormone; ADH, antidiuretic hormone; CRH, corticotropin-releasing hormone; FSH, follicle-stimulating hormone; GCs, glucocorticoids; GH, growth hormone; GHRH, growth hormone–releasing hormone; GnRH, gonadotropin-releasing hormone; IGF-1, insulin-derived growth factor 1; LH, luteinizing hormone; MCs, mineralocorticoids; PRL, prolactin; S/I, stimulate/inhibit; T_3, triiodothyronine; T_4, thyroxine; TRH, thyrotropin-releasing hormone; TSH, thyroid-stimulating hormone (thyrotropin).

pituitary thyrotropes. TSH stimulates release of thyroxine (T_4) and triiodothyronine (T_3) from the thyroid gland through the formation of cyclic adenosine monophosphate and the G protein second messenger system. In addition to the negative feedback inhibition by T_3, the release of TRH and TSH is inhibited by dopamine, somatostatin, and glucocorticoids.

Deficiency of TSH results in inactivity and atrophy of the thyroid gland, whereas excess TSH results in hypertrophy and hyperplasia of the thyroid gland.

Adrenocorticotropic Hormone

ACTH is a 39–amino acid single-chain peptide that is derived by proteolytic cleavage from POMC, which is a 240–amino acid precursor glycoprotein product of the pituitary gland. POMC also contains the sequences for the lipotropins, melanocyte-stimulating hormones (α, β, γ), and β-endorphin.

Secretion of ACTH is regulated by corticotropin-releasing hormone (CRH), a 41–amino acid peptide found predominantly in the median eminence but also in other areas in and outside of the brain. ACTH is secreted in a diurnal pattern. It acts on the adrenal cortex to stimulate cortisol synthesis and secretion. ACTH and cortisol levels are highest in the morning at the time of waking, are low in the late afternoon and evening, and reach their nadir within the first 2 hours after beginning sleep. Similar to TRH and TSH, CRH and ACTH function through the formation of cyclic adenosine monophosphate and the G protein second messenger system. Although CRH is the primary regulator of ACTH secretion, other hormones play a role. Arginine vasopressin, oxytocin, angiotensin II, and cholecystokinin stimulate release of CRH and ACTH, whereas atrial natriuretic peptide and opioids inhibit release of CRH and ACTH. Similar to the feedback inhibition T_3 has on TRH and TSH, cortisol also inhibits CRH and ACTH. Physiologic conditions, such as stress, fasting, and hypoglycemia, also stimulate release of CRH and ACTH.

Luteinizing Hormone and Follicle-Stimulating Hormone

Gonadotropic hormones include two glycoproteins: LH and FSH. They contain the same α subunit as TSH and human chorionic gonadotropin but distinct β subunits. Receptors for FSH on the ovarian granulosa cells and on testicular Sertoli cells mediate FSH stimulation of follicular development in the ovary and of gametogenesis in the testis. On binding to specific receptors on ovarian theca cells and testicular Leydig cells, LH promotes luteinization of the ovary and Leydig cell function of the testis (Fig. 594.4). The receptors for LH and FSH belong to a class of receptors with seven membrane-spanning protein domains. Receptor occupancy activates adenylyl cyclase through the mediation of G proteins.

LH-releasing hormone, a decapeptide, has been isolated, synthesized, and widely used in clinical studies. Because it leads to the release of LH and FSH from the same gonadotropic cells, it appears that it is the only gonadotropin-releasing hormone (GnRH).

Secretion of LH is inhibited by androgens and estrogens, and secretion of FSH is suppressed by gonadal production of inhibin, a 31-kDa glycoprotein produced by ovarian granulosa cells (females) and testicular Sertoli cells (males). Inhibin consists of α and β subunits joined by disulfide bonds. The β-β dimer activin also exists, and its actions generally oppose that of inhibin by stimulating FSH secretion. In addition to its endocrine effect, activin has paracrine effects in the testis. It facilitates LH-induced testosterone production, indicating a direct effect of Sertoli cells on Leydig cells.

POSTERIOR PITUITARY CELL TYPES

The posterior lobe of the pituitary is part of a functional unit, the neurohypophysis, that consists of the neurons of the supraoptic and paraventricular nuclei of the hypothalamus; neuronal axons, which form the pituitary stalk; and neuronal terminals in the median eminence or in the posterior lobe. Vasopressin (antidiuretic hormone

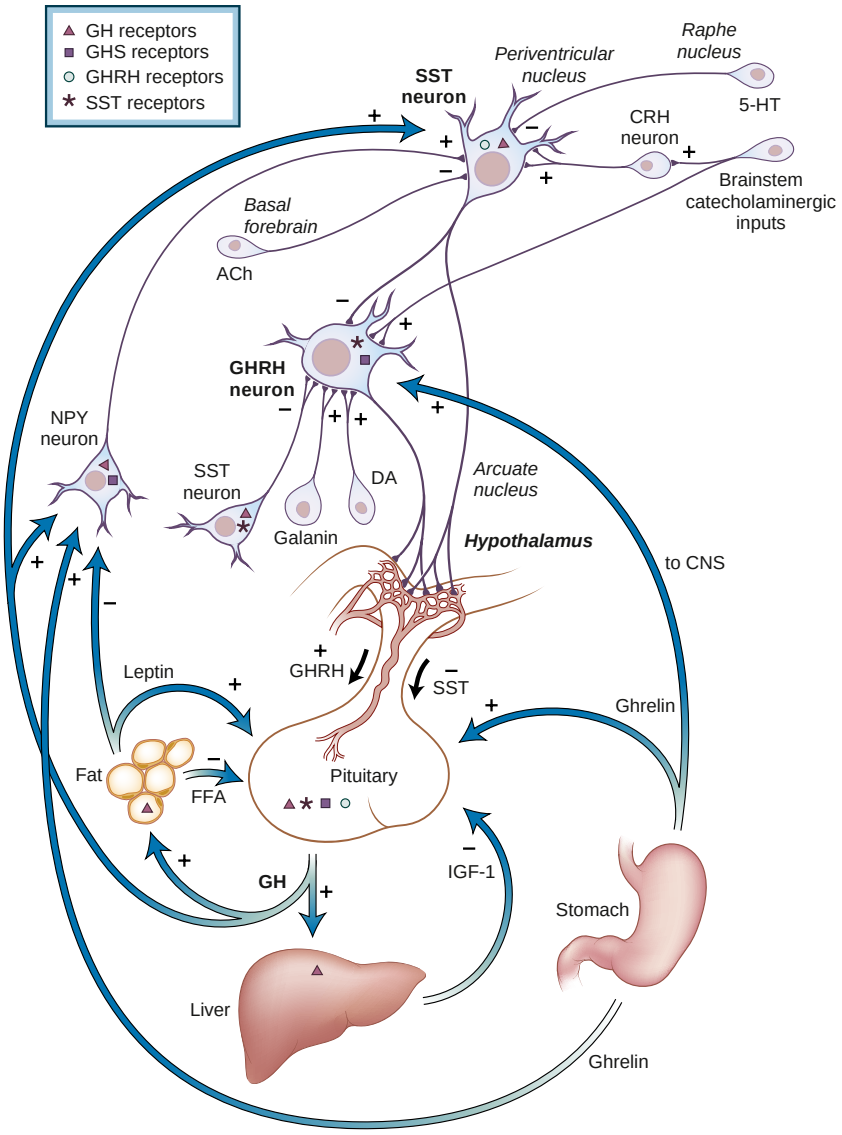

Fig. 594.3 Regulation of the hypothalamic-pituitary-growth hormone (GH) axis. GH secretion by the pituitary is stimulated by GH-releasing hormone (GHRH) and is inhibited by somatostatin (SST). Negative feedback control of GH secretion is exerted at the pituitary level by insulin-like growth factor 1 (IGF-1) and by free fatty acids (FFAs). GH itself exerts a short-loop negative feedback through activation of SST neurons in the hypothalamic periventricular nucleus. These SST neurons directly synapse on arcuate GHRH neurons and project axon collaterals to the median eminence. Neuropeptide Y (NPY) neurons in the arcuate nucleus also indirectly modulate GH secretion by integrating peripheral GH, leptin, and ghrelin signals and projecting to periventricular SST neurons. Ghrelin is secreted from the stomach and is a natural ligand for the GH secretagogue (GHS) receptor that stimulates GH secretion at both the hypothalamic and pituitary levels. On the basis of indirect pharmacologic data, it appears that release of GHRH is stimulated by galanin, γ-aminobutyric acid (GABA), and α_2-adrenergic and dopaminergic inputs and inhibited by SST. Secretion of SST is inhibited by muscarinic acetylcholine (ACh) and 5-HT-1D receptor ligands and increased by β_2-adrenergic stimuli and corticotropin-releasing hormone (CRH). CNS, Central nervous system; DA, dopamine; 5-HT, serotonin (5-hydroxytryptamine). *(From Low MJ. Neuroendocrinology. In Melmed S, Polonsky KS, Larsen PR, Kronenberg HM, eds. Williams Textbook of Endocrinology, 13th ed. Philadelphia: Elsevier; 2016: Fig. 7.22.)*

[ADH]) and oxytocin are the two hormones produced by neurosecretion in the hypothalamic nuclei and released from the posterior pituitary. They are octapeptides and differ by only two amino acids.

Vasopressin

Vasopressin (ADH) regulates water conservation at the level of the kidney by increasing the permeability of the renal collecting duct to water. It stimulates translocation of water channels through its interaction with vasopressin 2 (V2) receptors in the collecting duct, which act through G proteins to increase adenylyl cyclase activity and increase permeability to water. These V2 receptors also mediate von Willebrand factor and tissue plasminogen activator. At higher concentrations, ADH activates vasopressin 1 (V1) receptors in smooth muscle cells and hepatocytes and exerts pressor and glycogenolytic effects through mobilization of intracellular calcium stores. Separate vasopressin 3

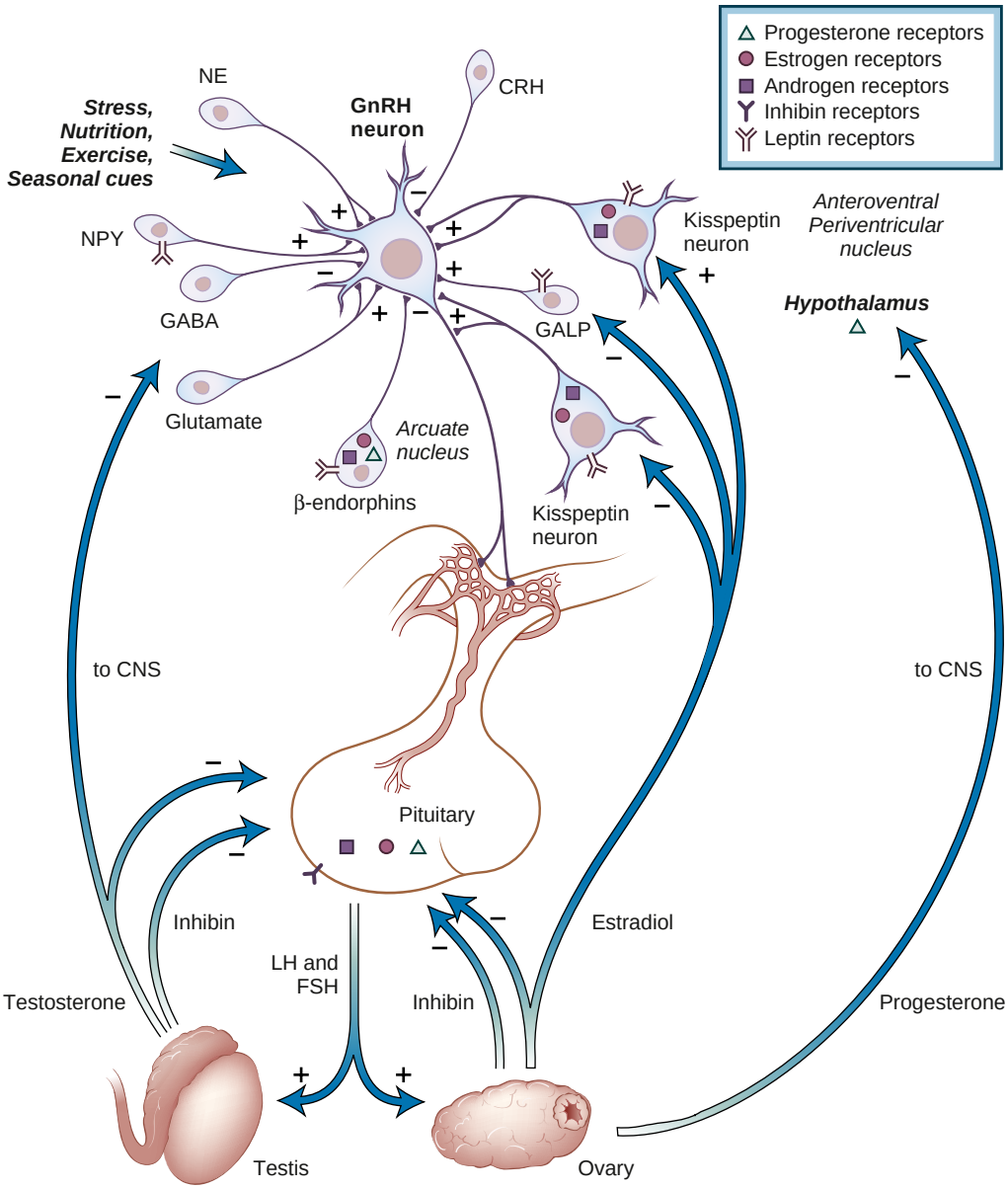

Fig. 594.4 Regulation of the hypothalamic-pituitary-gonadal axis. Schematic diagram of the hypothalamic-pituitary-gonadal axis showing neural systems that regulate gonadotropin-releasing hormone (GnRH) secretion and feedback of gonadal steroid hormones at the level of the hypothalamus and pituitary. CNS, Central nervous system; CRH, corticotropin-releasing hormone; FSH, follicle-stimulating hormone; GABA, γ-aminobutyric acid; GALP, galanin-like peptide; LH, luteinizing hormone; NE, norepinephrine; NPY, neuropeptide Y. *(From Low MJ. Neuroendocrinology. In Melmed S, Polonsky KS, Larsen PR, Kronenberg HM, eds. Williams Textbook of Endocrinology, 13th ed. Philadelphia: Elsevier; 2016: Fig. 7.30.)*

(V3) receptors mediate stimulation of ACTH secretion. These effects involve phosphatidylinositol hydrolysis rather than cyclic adenosine monophosphate production.

Vasopressin and its accompanying protein neurophysin II are encoded by the same gene. A single preprohormone is cleaved, and both are transported to neurosecretory vesicles in equimolar amounts in the posterior pituitary.

Vasopressin has a short half-life and responds quickly to changes in hydration. The stimuli for its release are increased plasma osmolality, perceived by osmoreceptors in the hypothalamus, and decreased blood volume, perceived by baroreceptors in the carotid sinus of the aortic arch.

Oxytocin

Oxytocin stimulates uterine contractions at the time of labor and delivery in response to distention of the reproductive tract and stimulates smooth muscle contraction in the breast during suckling, which results in milk letdown. Studies suggest that oxytocin also plays a role in orgasm, social recognition, pair bonding, anxiety, trust, love, and maternal behavior. Most recently, through the interaction with its G protein–coupled receptor in pancreatic and adipose tissue, oxytocin appears to play a significant role in appetite regulation and obesity by inducing anorexia.

Visit Elsevier eBooks+ at eBooks.Health.Elsevier.com for Bibliography.

Chapter 595

Hypopituitarism

Briana C. Patterson and Eric I. Felner

Hypopituitarism denotes underproduction of one or more pituitary hormones. Affected children have postnatal growth impairment and other endocrine deficiencies that are specifically corrected by hormone replacement. The incidence of *congenital* hypopituitarism is thought to be between 1 in 4,000 and 1 in 10,000 live births. An epidemiologic association between hypopituitarism and breech delivery has been reported, but the causal relationship is not understood. With expanding knowledge of the genes that direct pituitary development or hormone production, an increasing proportion of cases can be attributed to specific genetic alterations. Monogenic causes can only be identified in about 10% of persons with congenital hypopituitarism. The likelihood of finding a genetic alteration is increased by consanguinity and occurrence in siblings or across generations; however, in *most* cases of *isolated* **growth hormone deficiency (GHD)** and *sporadic* **multiple pituitary hormone deficiency (MPHD)**, no specific single-gene cause can be identified. It is likely that polygenic and/or environmental factors regularly play a role in the development of congenital hypopituitarism. The genes, hormonal phenotypes, associated abnormalities, and modes of transmission of several single-gene disorders causing congenital MPHD are shown in Table 595.1. Causes of *acquired* hypopituitarism, which usually has a later onset, has different causes (Table 595.2). Single-gene alterations causing disruption of the GH axis primarily are shown in Table 595.3.

MULTIPLE PITUITARY HORMONE DEFICIENCY

Genetic Forms (see Table 595.1)

Sequentially expressed transcriptional activation factors direct the differentiation and proliferation of anterior pituitary cell types. These proteins are members of a large family of DNA-binding proteins resembling homeobox genes. Alterations in different genes may produce different manifestations of MPHD. The *PROP1* and *POU1F1* genes are expressed later in pituitary development only in cells of the anterior pituitary and result in hypopituitarism without anomalies in other organ systems. The *HESX1, LHX3, LHX4, OTX2, SOX3,* and *PITX2* genes are expressed at earlier stages and are not restricted to the pituitary. Pathogenic alterations in these genes tend to produce phenotypes that extend beyond hypopituitarism to include abnormalities in other organs, and the degree of hypopituitarism is typically variable.

PROP1

PROP1 is found in the nuclei of somatotropes, lactotropes, and thyrotropes. Its roles include turning on *POU1F1* expression and downregulating *HESX1* expression. Although no genetic alteration can be identified in most patients with MPHD, pathogenic variants of *PROP1* are the most common explanation for recessive MPHD and are 10 times as common as the combined total of alterations in other pituitary transcription factor genes. Deletions of one or two base pairs in exon 2 are most common, followed by missense, nonsense, and splice-site pathogenic mutations. Anterior pituitary hormone deficiencies may not be evident in the neonatal period. The median age at diagnosis of GHD is around 6 years. Recognition of thyroid-stimulating hormone (TSH), luteinizing hormone (LH), follicle-stimulating hormone (FSH), and adrenocorticotropic hormone (ACTH) deficiencies is delayed relative to recognition of GHD. Anterior pituitary size is small in most patients, but in others there is progressive enlargement of the pituitary.

POU1F1 (PIT1)

POU1F1 (formerly *PIT1*) is a nuclear protein that binds to the GH and prolactin promoters. It is necessary for the emergence and mature function of somatotropes, lactotropes, and thyrotropes. Dominant and recessive pathogenic variants in *POU1F1* are responsible for complete deficiencies of growth hormone (GH) and prolactin and variable TSH deficiency. Affected patients exhibit nearly normal fetal growth but experience severe growth failure in the first year of life. With normal production of LH and FSH, puberty develops spontaneously, although at a later-than-normal age. These patients are not at risk for development of ACTH deficiency. Anterior pituitary size is normal to small.

HESX1

The *HESX1* gene is expressed in precursors of all five cell types of the anterior pituitary early in embryologic development. Pathogenic genetic variations in *HESX1* result in heterogeneous phenotypes with differences in development of the optic nerve and pituitary. The anterior pituitary may be hypoplastic or aplastic, and the posterior pituitary may be orthotopic or ectopic. Patients may have isolated GHD or MPHDs, with or without the **optic nerve hypoplasia syndrome**, historically called *septo-optic dysplasia* (incomplete development of the septum pellucidum with optic nerve hypoplasia and pituitary insufficiency). However, the majority of patients with optic nerve hypoplasia syndrome do not have *HESX1* gene alterations.

LHX3 and *LHX4*

The phenotype produced by recessive loss-of-function alterations of the *LHX3* gene resembles that produced by *PROP1* genetic variants. There are deficiencies of GH, prolactin, TSH, LH, and FSH but not ACTH. Some affected persons show enlargement of the anterior pituitary. The first patients to be described had the unusual findings of a short neck and a rigid cervical spine. Dominantly inherited pathogenic variations in the structurally similar *LHX4* gene consistently produce GH deficiency, with the variable presence of TSH and ACTH deficiencies. Additional findings can include a very small V-shaped pituitary fossa, **Chiari I malformation**, and an ectopic posterior pituitary.

Other Congenital Forms

Pituitary hypoplasia can occur as an isolated phenomenon or in association with more extensive developmental differences such as anencephaly or holoprosencephaly. Midline facial anomalies (cleft lip, palate; see Chapter 356) or the finding of a solitary maxillary central incisor may indicate a higher likelihood of GH or other anterior or posterior hormone deficiency (Fig. 595.1). At least 12 genes have been implicated in the complex genetic etiology of **holoprosencephaly**.

Hall-Pallister syndrome is caused by dominant loss-of-function alterations in the *GLI3* gene. Absence of the pituitary gland is accompanied by hypothalamic hamartoma, polydactyly, nail dysplasia, bifid epiglottis, imperforate anus, and anomalies of the heart, lungs, and kidneys. The combination of **anophthalmia** and **hypopituitarism** has been associated with pathogenic variants in the *SIX6, SOX2,* and *OTX2* genes.

Optic nerve hypoplasia syndrome may be detected as a result of clinical observation of nystagmus and visual impairment in infancy. Neuroimaging demonstrates optic nerve and brain abnormalities and is associated with anterior and/or posterior pituitary hormone deficiencies in up to 75% of cases (Fig. 595.2). Although these patients often show the triad of a small anterior pituitary gland, an attenuated pituitary stalk, and an ectopic posterior pituitary bright spot, the primary etiology of the hypopituitarism in this condition is thought to be hypothalamic dysfunction. GH deficiency is the commonly observed hormone deficiency, and other anterior pituitary hormone deficiencies are less common. Diabetes insipidus is reported in only about 5% of cases. The etiology is likely multifactorial and may involve interaction between genetic and environmental factors. In most cases, no single-gene alteration can be identified.

Severe, early-onset MPHD, including deficiency of ACTH, is often associated with the triad of anterior pituitary hypoplasia, absence or attenuation of the pituitary stalk, and an ectopic posterior pituitary bright spot seen on MRI. Most cases are sporadic, and there is a male predominance. Some are caused by pathogenic variants of the *SOX3* gene, located on the X chromosome.

Table 595.1 Etiologic Classification of Congenital and Genetic Forms of Multiple Pituitary Hormone Deficiency

GENE OR LOCATION	PHENOTYPE	INHERITANCE
GENETIC FORMS		
POU1F1 (PIT1)	GH, PRL deficiencies, variable TSH deficiency	AR, AD
PROP1	GH, TSH, PRL, LH, FSH deficiencies, variable ACTH deficiency, variable AP	AR
LHX3	GH, TSH, PRL, LH, FSH deficiencies, variable AP, ± short neck, limited neck rotation, sensorineural deafness	AR
LHX4	GH, TSH, ACTH deficiencies, small AP, EPP, variable Arnold-Chiari, cerebellar abnormalities	AD
TPIT	ACTH deficiency, severe neonatal form	AR
HESX1	GH deficiency, variable for others, small AP, EPP, optic nerve hypoplasia; septo-optic dysplasia	AR, AD
SOX2	LH, FSH deficiencies, variable GH deficiency, anophthalmia, microphthalmia, esophageal atresia, sensorineural hearing loss	AD
SOX3	Variable deficiencies, ± MR, EPP, small AP and stalk, developmental delay	XL
PITX2	Axenfeld-Rieger syndrome: hypogonadotropic hypogonadism, pituitary hypoplasia, anterior chamber abnormalities of the eye, dental hypoplasia	AD
GLI2	Hypopituitarism, holoprosencephaly, midline defects, polydactyly	AD
GLI3	Hall-Pallister syndrome, hypopituitarism	AD
SHH (Sonic Hedgehog)	GH deficiency with single central incisor	AD
OTX2	GH or combined deficiencies, anophthalmia or microphthalmia, coloboma, developmental delay	AD
TBX19	ACTH deficiency, neonatal hypoglycemia or cholestatic jaundice	AR
PC1	Hypogonadotropic hypogonadism, ACTH deficiency	AR
GIF, SHHT, SIX3	Pituitary stalk interruption syndrome: thin or absent pituitary stalk, hypoplasia of adenohypophysis, ectopic neurohypophysis, neonatal hypoglycemia, cholestasis, micropenis	Holoprosencephaly related gene group
FGF8	Hypopituitarism, holoprosencephaly	AD
FGFR1	Hypopituitarism, pituitary hypoplasia, agenesis of the corpus callosum, ocular defects	AD
PROKR2	GH, TSH and ACTH deficiencies, micropenis and neonatal hypoglycemia	AD, AR
UNKNOWN OR POLYGENETIC ETIOLOGY		
Congenital absence of pituitary gland		
Optic nerve hypoplasia syndrome/septo-optic dysplasia	Optic nerve hypoplasia, nystagmus, absent septum pellucidum, pituitary hypoplasia	

ACTH, Adrenocorticotropic hormone; AP, anterior pituitary; AD, autosomal dominant; EPP, ectopic posterior pituitary; FSH, follicle-stimulating hormone; GH, growth hormone; LH, luteinizing hormone; MR, mental retardation; PRL, prolactin; AR, autosomal recessive; TSH, thyroid-stimulating hormone; XL, X-linked.

Acquired Forms

Any lesion that damages the hypothalamus, pituitary stalk, or anterior pituitary can cause pituitary hormone deficiency (see Table 595.2). Because such lesions are not selective, multiple hormonal deficiencies are usually observed. Diabetes insipidus is more frequent in *acquired* than in congenital hypopituitarism. The most common structural lesion of the pituitary causing childhood-onset acquired MPHD is craniopharyngioma (see Chapter 546). Central nervous system germinoma, optic pathway or hypothalamic glioma, histiocytosis, tuberculosis, sarcoidosis, toxoplasmosis, meningitis, pituitary abscess, and aneurysms can also cause hypothalamic-hypophyseal damage and dysfunction. Additionally, children treated with radiation therapy for central nervous system or nasopharyngeal tumors are at increased risk for GHD and other pituitary hormone deficiencies to the extent that the radiation field includes the hypothalamus and/or pituitary, even if the tumor itself is anatomically remote from the pituitary and hypothalamus. The magnitude of the risk and the timing of the emergence of pituitary hormone deficiencies depend on the dose of radiation to the hypothalamic-pituitary axis and the duration of elapsed time after radiotherapy is complete. High doses of radiation (>50 Gy) are likely to produce GH deficiency sooner than 1 year after irradiation, whereas other anterior pituitary hormone deficiencies may not appear until later. GH production appears to be particularly vulnerable to the effects of irradiation, even at lower doses, whereas deficiencies of ACTH, gonadotropins, and thyrotropin-releasing hormone (TRH)/TSH occur with declining frequency and typically occur at higher doses of radiation. Irradiation alone does not typically result in diabetes insipidus. Traumatic brain injury, including abusive head trauma, motor vehicle accidents, and chronic repetitive head injury, is an increasingly recognized cause of pituitary dysfunction related to damage to the pituitary, its stalk, or the hypothalamus.

ISOLATED GROWTH HORMONE DEFICIENCY AND INSENSITIVITY

Genetic Forms of Growth Hormone Deficiency

Isolated GHD is caused by abnormalities of the GH-releasing hormone receptor, GH genes, and certain genes located on the X chromosome (see Table 595.3).

Growth Hormone–Releasing Hormone Receptor

Recessive loss-of-function alterations in the receptor for GH-releasing hormone interfere with proliferation of somatotropes during pituitary development and disrupt the most important signals for release of GH. The anterior pituitary is small, in keeping with the observation that

Table 595.2 Causes of Acquired Pituitary Insufficiency

TRAUMATIC
Surgical resection
Radiation damage
Traumatic brain injury
INFILTRATIVE/INFLAMMATORY
Primary hypophysitis
Lymphocytic
Granulomatous
Xanthomatous
Secondary hypophysitis
Sarcoidosis
Langerhans cell histiocytosis
Granulomatosis with polyangiitis
Takayasu disease
Hemochromatosis
INFECTIONS
Tuberculosis
Pneumocystis jirovecii infection
Fungal (histoplasmosis, aspergillosis)
Parasites (toxoplasmosis)
Viral (cytomegalovirus)
VASCULAR
Pregnancy related
Aneurysm
Apoplexy
Diabetes
Hypotension
Arteritis
Sickle cell disease
NEOPLASTIC
Pituitary adenoma
Parasellar mass
Rathke cyst
Dermoid cyst
Meningioma
Germinoma
Suprasellar/optic pathway glioma
Craniopharyngioma
Hypothalamic hamartoma
Pituitary metastatic deposits
Hematologic malignancy
Leukemia
Lymphoma
FUNCTIONAL
Nutritional
Caloric restriction
Malnutrition
Excessive exercise
Nonspecific illness
Acute critical illness
Chronic renal failure
Chronic liver failure
Hormonal
Hyperprolactinemia
Hypothyroidism
Drugs
Anabolic steroids
Glucocorticoid excess
GnRH agonists
Estrogen
Dopamine
Somatostatin analog
Immune check-point inhibitors

Modified from Kaiser U, Ho KKY. Pituitary physiology and diagnostic evaluation. In: Melmed S, Polonsky KS, Larsen PR, Kronenberg HM, eds. *Williams Textbook of Endocrinology,* 13th ed. Philadelphia: Elsevier; 2016: Table 8.5, p. 193.

somatotropes normally account for >50% of pituitary volume. There is some compromise of fetal growth followed by severe compromise of postnatal growth.

GH1

The *GH1* gene is one of a cluster of five genes on chromosome 17q22-24. This cluster arose through successive duplications of an ancestral GH gene. Unequal crossing over at meiosis has produced a variety of gene deletions. Small deletions (<10 kb) remove only the *GH1* gene, whereas large deletions (45 kb) remove one or more of the adjacent genes (*CSL, CS1, GH2,* and *CS2*). The growth phenotype is identical with deletion of *GH1* alone or *GH1* together with one or more of the adjacent genes. Loss of the *CS1, GH2,* and *CS2* genes without loss of *GH1* causes deficiency of chorionic somatomammotropin and placental GH in the maternal circulation, but it does not result in fetal or postnatal growth retardation. Most children with *GH1* gene deletions respond very well to recombinant GH treatment, but some develop *antibodies* to GH and cease growing despite treatment.

Recessively transmitted pathogenic variants in the *GH1* gene produce a similar phenotype. Missense, nonsense, and frameshift alterations have been described. Autosomal dominant isolated GHD is also caused by variants in *GH1*. These alterations usually involve splice-site errors in intron 3 and result in a variant protein that lacks the amino acids normally encoded by exon 3. Accumulation of this protein interferes with the processing, storage, and secretion of the normal GH protein and may result in additional deficiencies of TSH and/or ACTH. There are several reports of alterations in *GH1* that lead to variant proteins with reduced biologic activity.

X-Linked Isolated Growth Hormone Deficiency

Two loci on the X chromosome have been associated with hypopituitarism. The first lies at Xq21.3-q22 in the region of the *BTK* gene. Pathogenic variants in this region produce hypogammaglobulinemia and isolated GHD. The second locus maps farther out on the long arm, at Xq24-q27.1, a region containing the *SOX2* transcription factor gene. Abnormalities in this locus have been linked to isolated GHD with intellectual disability and to MPHD with the triad of pituitary hypoplasia, missing pituitary stalk, and ectopic posterior pituitary gland.

Acquired Forms

The GH axis is more susceptible to disruption by acquired conditions than are other hypothalamic-pituitary axes. Recognized causes of acquired GHD include the use of radiotherapy for malignancy, meningitis, histiocytosis, and trauma.

Children who receive radiotherapy for central nervous system tumors, leukemia, or total body irradiation before hematopoietic stem cell transplant are at risk for developing GHD. Spinal irradiation results in disproportionately poor growth of the axial skeleton relative to the appendicular skeleton; this problem is not remediable with GH treatment. Growth typically slows during radiation therapy or chemotherapy, may improve for 1-2 years after cancer treatment, and then declines with the development of GHD. The dose and frequency of radiotherapy are important determinants of hypopituitarism. GHD is almost universal 5 years after therapy with a total dose ≥35 Gy. More subtle defects are seen with doses around 20 Gy. Deficiency of GH is the most common defect, but deficiencies of TSH and ACTH can also occur. The evaluation of GHD is more complicated when radiation-associated precocious puberty is also present. The clinician is likely to encounter children in the 8- to 10-year age range who are growing at rates that are normal for chronological age but subnormal for stage of pubertal development.

GROWTH HORMONE INSENSITIVITY

Abnormalities of the Growth Hormone Receptor

GH insensitivity is caused by disruption of pathways distal to the production of GH (Table 595.4). **Laron syndrome** involves pathogenic genetic variations in the GH receptor. Children with this condition clinically resemble those with severe isolated GHD. Birth length tends to be about 1 standard deviation (SD) below the mean, and severe short stature with lengths >4 SD below the mean is present by 1 year of age. Resting and stimulated GH levels tend to be high, and insulin-like growth factor (IGF) 1 levels are low. The GH receptor has an extracellular GH-binding domain, a transmembrane domain, and an

Table 595.3 Established Genetic Defects of the GH-IGF Axis Resulting in Isolated GH Deficiency, GH Insensitivity, or IGF-1 Deficiency

GENE	INHERITANCE	PHENOTYPE
ISOLATED GROWTH HORMONE DEFICIENCY		
GHRHR	AR	Type IB form of isolated **GHD**; low levels of GH production, but less severe than type 1A isolated **GHD**; may also be caused by pathogenic variants in GH1
GHS-R	AD	**GHD** and ISS
GH1	AR	Type IA form of isolated **GHD**, in utero growth retardation; absent GH production caused by gene deletion, antibodies to GH develop over time during treatment
GH1	AR	Type IB form of isolated **GHD**; low levels of GH production, but less severe than type 1A isolated **GHD**; may also be caused by pathogenic variants in GHRHR
GH1	AD	Type II form of isolated **GHD**; dominant negative pathogenic variants in GH1, which decrease GH secretion
BTK	XL	Type III form of isolated **GHD**; hypogammaglobulinemia
GH1	AD	Bioinactive GH molecule; rare, dominant negative pathogenic variant in GH1 that interferes with GHR signaling
GROWTH HORMONE INSENSITIVITY		
GHR	AR, AD	IGF-I deficiency; high GH level; normal, decreased or increased GHBP (depending on which domain of the receptor is affected); unresponsive to GH treatment
IGF-1 DEFICIENCY		
IGF1	AR	IGF-1 deficiency; IUGR and postnatal growth failure, sensorineural deafness, insulin resistance, microcephaly
STAT5b	AR	IGF-1 deficiency, variable immune defect, hyperprolactinemia, chronic pulmonary infections, eczema
ALS	AR	IGF-1 deficiency; variable postnatal growth failure, delayed puberty

AD, Autosomal dominant; ALS, acid-labile subunit; AR, autosomal recessive; GH, growth hormone; GHBP, GH-binding protein; GHD, growth hormone deficiency; GHRHR, GH-releasing hormone receptor; IGF, insulin-like growth factor; ISS, idiopathic short stature; IUGR, intrauterine growth retardation; XL, X-linked.
Modified from Sperling MA. *Pediatric Endocrinology,* 4th ed. Philadelphia: Elsevier; 2014: Table 10.3, p. 333.

Fig. 595.1 Solitary median maxillary central incisor at age 16 mo. *(From Giannopoulou EZ, Rohrer T, Hoffmann P, et al. Solitary median maxillary central incisor. J Pediatr. 2015;167:770, Fig. 2.)*

Fig. 595.2 Septo-optic dysplasia with agenesis of the septum pellucidum. Sagittal T1 weighted MR image shows that fornices are inferiorly positioned *(long arrow)*. The optic apparatus is hypoplastic *(short arrow)*; there is no identifiable neurohypophysis. *(From Rollins N. Congenital brain malformations. In: Coley BD, ed. Caffey's Pediatric Diagnostic Imaging, 13th ed. Philadelphia: Elsevier; 2019: Fig. 31.13.)*

intracellular signaling domain. Pathogenic alterations in the extracellular domain interfere with binding of GH. Serum GH-binding protein activity, representing the circulating form of the membrane receptor for GH, is generally low. Variants in the transmembrane domain can interfere with anchoring of the receptor to the plasma membrane. In these cases, circulating GH-binding protein activity is normal or high. Alterations in the intracellular domain interfere with JAK/STAT signaling.

Post-Receptor Forms of Growth Hormone Insensitivity

Some children with severe growth failure, high GH and low IGF-1 levels, and normal GH-binding protein levels have abnormalities distal to the GH binding and activation of the GH receptor. Several have been found to have pathogenic variations in the gene-encoding signal transducer and activator of transcription 5b (STAT5b). Disruption of this key intermediate connecting receptor activation to gene transcription produces growth failure similar to that seen in Laron syndrome. These patients also suffer from *immunodeficiency* and chronic pulmonary

Table 595.4 Proposed Classification of Growth Hormone Insensitivity

PRIMARY GH INSENSITIVITY (HEREDITARY DEFECTS)
GH receptor defect (may be positive or negative for GH-binding protein)
• Extracellular alteration (e.g., Laron syndrome)
• Cytoplasmic alteration
• Intracellular alteration
GH signal transduction defects (distal to cytoplasmic domain of GH receptor)
• Stat5b pathogenic variants
Insulin-like growth factor-1 defects
• IGF-1 gene deletion
• IGF-1 transport defect (pathogenic variant in ALS)
• IGF-1 receptor defect
Bioinactive GH molecule (responds to exogenous GH)
SECONDARY GH INSENSITIVITY (ACQUIRED DEFECTS)
Circulating antibodies to GH that inhibit GH action
Antibodies to the GH receptor
GH insensitivity caused by malnutrition, liver disease, catabolic states, diabetes mellitus
Other conditions that cause GH insensitivity

ALS, Acid-labile subunit; GH, growth hormone; IGF, insulin-like growth factor.
From Sperling MA. *Pediatric Endocrinology,* 4th ed. Philadelphia: Elsevier; 2014: Box 10.4.

infections, consistent with important roles for STAT5b in interleukin cytokine signaling.

IGF-1 Gene Abnormalities

Pathogenic alterations of the *IGF-1* gene produce severe prenatal and postnatal growth impairment. Microcephaly, intellectual disability, and deafness are present in patients with exon deletion and a missense variant. These patients can be expected to respond to recombinant IGF-1 treatment.

Insulin-Like Growth Factor–Binding Protein Abnormalities

Pathogenic variants in the gene encoding the acid-labile subunit of the circulating 165-kDa IGF-1, IGF-BP3, acid-labile subunit complex has been associated with short stature. Total IGF-1 levels were very low. The index case, with homozygosity for an acid-labile subunit alteration, did not show an increase in IGF-1 levels or an increase in growth rate during GH treatment.

IGF-1 Receptor Gene Abnormalities

Pathogenic variants in the gene encoding the IGF-1 receptor also compromise prenatal and postnatal growth. The phenotype does not appear to be as severe as that seen with the absence of IGF-1. Adult heights are closer to the normal range, and affected patients do not have intellectual disability or deafness.

CLINICAL MANIFESTATIONS

Congenital Hypopituitarism

The child with congenital hypopituitarism is usually of normal size and weight at birth, although those with MPHD and those with pathogenic genetic variants in the *GH1* or *GHR* gene have birth lengths that average 1 SD below the mean. Children with severe deficits in GH production or action typically fall more than 4 SD below the mean for length by 1 year of age. Those with less severe deficiencies grow at rates below the 25th percentile for age and gradually diverge from normal height percentiles. Delayed closure of the epiphyses permits growth beyond the normal age when growth should be complete. Features of GH insensitivity, including Laron syndrome, are somewhat distinct from GHD and MPHD and are noted in Table 595.5.

Infants with congenital dysfunction of the pituitary or hypothalamus may present with neonatal emergencies such as apnea, cyanosis, or severe hypoglycemia with or without seizures. Prolonged neonatal cholestatic jaundice is common. It involves elevation of conjugated and unconjugated bilirubin and may be associated with giant cell neonatal hepatitis. Nystagmus can suggest optic nerve hypoplasia syndrome (see Chapter 671). Micropenis with or without testicular maldescent in males provides an additional diagnostic clue. Deficiency of GH may be accompanied by hypoadrenalism (see Chapter 615.2) and hypothyroidism (see Chapter 603), along with gonadotropin deficiency (see Chapters 623.2 and 626.2).

Table 595.5 Clinical Features of Growth Hormone Insensitivity, Including Classic Laron Syndrome

GROWTH AND DEVELOPMENT
Near-normal birthweight
Slightly decreased birthweight
Severe postnatal growth failure
Delayed bone age (may be advanced relative to height age)
Micropenis in childhood; normal for body size in adults
Puberty may be delayed 3-7 yr
Normal sexual function and fertility
OTHER PHYSICAL CHARACTERISTICS
Sparse hair (before age 7 yr)
Frontal bossing
Normal head circumference
Small facies (resulting in craniofacial disproportion)
Hypoplastic nasal bridge
Shallow orbits
Delayed dentition
Blue sclerae
High-pitched voice
Hip dysplasia
Limited extension in elbows
LATE FINDINGS/OTHER COMPLICATIONS
Hypoglycemia in infants and children (fasting symptoms in some adults)
Delayed walking and motor milestones
Avascular necrosis of femoral head
Thin, prematurely aged skin
Osteopenia

From Sperling MA. *Pediatric Endocrinology,* 4th ed. Philadelphia: Elsevier; 2014: Box 10.5.

Toddlers and school-age children tend to present with proportionate short stature. On physical examination, the head may be round and the face short and broad. The frontal bone may be prominent, and the bridge of the nose is often depressed and saddle shaped. The nose may be small, but the nasolabial folds are well developed. The mandible and the chin may be underdeveloped, and the teeth, which erupt late, are often crowded. The neck is short, and the larynx is small. The voice is high-pitched and remains high after puberty. The extremities are well proportioned, with small hands and feet. Weight for height is often normal, but there may be an imbalance of lean mass and adipose tissue. The genitals are usually small for age in males, and sexual maturation may be delayed or absent as the child ages.

In teens with undiagnosed congenital hypopituitarism, short stature is expected. Additionally, facial, axillary, and pubic hair may be decreased, and the scalp hair is fine. Intelligence is usually normal for age, unless there are other structural brain abnormalities, and the children may seem precocious compared with younger children of a similar size.

Acquired Hypopituitarism

The child is normal initially, and manifestations similar to those seen in idiopathic pituitary growth failure gradually appear and progress. When complete or almost complete destruction of the pituitary gland occurs, signs of pituitary insufficiency are present. Atrophy of the adrenal cortex, thyroid, and gonads results in loss of weight, asthenia, sensitivity to cold, mental torpor, and absence of sweating. Sexual maturation fails to take place or regresses if already present. There may be atrophy of the gonads and genital tract with amenorrhea and loss of pubic and axillary hair. There is a tendency to hypoglycemia. Growth slows dramatically. Diabetes insipidus (see Chapter 596) may be present but can by obscured by the development of yet untreated central adrenal insufficiency.

If the lesion is an **expanding tumor**, symptoms such as headache, vomiting, visual disturbances, pathologic sleep patterns, decreased school performance, seizures, polyuria, and growth failure can occur. Documented slowing of growth can antedate neurologic signs and symptoms, especially with craniopharyngioma, yet neurologic and ophthalmologic complaints are more often the presenting problems. In other cases, evidence of pituitary insufficiency may first appear after surgical intervention. In children with craniopharyngioma, visual field defects, optic atrophy, papilledema, obesity, and cranial nerve palsy are common. Skeletal age may be delayed in acquired MPHD but may be relatively normal if the pituitary dysfunction is of very recent onset.

LABORATORY FINDINGS

MPHD and/or GHD should be suspected in infants with hypoglycemia, micropenis, congenital nystagmus, and prolonged conjugated hyperbilirubinemia and in older children with severe postnatal growth failure (Table 595.6). Criteria for short stature include height below the first percentile for age and sex or height >2 SD below sex-adjusted mid-parent height. Acquired GHD can occur at any age, and when it is of acute onset, height may be within the normal range. In both congenital and acquired GH deficiency, height velocity will be low relative to sex- and bone age–matched peers. A strong clinical suspicion is important in establishing the diagnosis because laboratory measures of GH sufficiency lack specificity. Random GH levels are not helpful in the evaluation of toddlers and older children because of the pulsatile secretion of GH, *whereas measurement of GH may be useful in the first 2 weeks of life when levels are tonically increased.* Observation of low serum levels of IGF-1 and the GH-dependent IGF-BP3 can be helpful, but IGF-1 and IGF-BP3 levels should be matched to normal values for skeletal age and sexual maturity rating, rather than chronological age. Values in the upper part of the normal range for age effectively exclude GHD. IGF-1 values in the lower part of the normal range may occur in normally growing children, children with impaired nutrition, or those with hypopituitarism. The expected range for IGF-1 in normal and GH-deficient children overlaps somewhat during infancy and early childhood. IGF-1 levels in isolation should not be used to diagnose GH deficiency.

Table 595.6 Evaluation of Suspected Growth Hormone Deficiency

History	• Birthweight and length • Obstetric complications • Breech presentation • Neonatal hypoglycemia • Prolonged neonatal jaundice/cholestasis • Review of systems for systemic illness • Diet history
Physical exam	• Linear growth failure (may be the only clinical feature present) Proportionate short stature Low height velocity • Weight for length appropriate or increased • Micropenis with or without testicular maldescent in males • Small midface • Cleft palate • High-pitched voice • Delayed dental eruption • Optic nerve hypoplasia
Imaging	• Radiologic evaluation of bone age • Central nervous system imaging to evaluate the hypothalamus/pituitary and to exclude other conditions
Laboratory evaluation	• Measurements of IGF-1 and IGF-binding protein levels • Assess thyroid function • Exclude chronic medical illness CBC, metabolic profile, inflammatory markers, celiac testing, urinalysis • Determination of peak GH levels after stimulation test
Treatment considerations	• Replacement with rhGH • Dosage adjustment IGF-1 Height velocity Pubertal status Body weight • Predictors of improved response to treatment Early initiation of treatment Higher rhGH dose • Monitor during treatment Height velocity IGF-1 levels Glucose metabolism Skeletal age Thyroid function, adrenal function

GH, Growth hormone; IGF, insulin-like growth factor; rhGH, recombinant human growth hormone.

After infancy, a definitive diagnosis of GHD traditionally requires demonstration of absent or low levels of GH in response to stimulation, but provocative testing may be omitted if the patient has the expected auxologic findings, a documented hypothalamic or pituitary defect, and at least one other pituitary hormone deficiency. A variety of provocative tests have been devised that rapidly increase the level of GH in normal children. These include administration of insulin, arginine, clonidine, levodopa, or glucagon. Macimorelin is an oral ghrelin agonist approved in the United States for growth hormone stimulation testing in adults, but not in children. *Because thyroid hormone is a prerequisite for normal GH synthesis, it must always be assessed and replaced, if needed, before provocative GH testing.* In chronic GHD, the demonstration of subnormal linear growth, a delayed skeletal age, and low peak levels of GH (<10 ng/mL) in each of two provocative tests are compatible with the diagnosis. In acute GHD, a high clinical suspicion of GHD and low peak levels of GH (<10 ng/mL) in each of two provocative tests are compatible with the diagnosis. This rather arbitrary cutoff point is higher than the criteria used for diagnosis of adult GHD. There is no consensus regarding adoption of criteria that account for age, sex, and GH assay characteristics. Some studies indicate that many GH-sufficient prepubertal children fail to achieve GH values >10 ng/mL with two pharmacologic tests; pretest, short-term sex steroid priming has been proposed to increase the diagnostic specificity of this testing.

In addition to establishing the diagnosis of GHD, it is necessary to examine other pituitary functions. Levels of TSH, free thyroxine or total thyroxine with T_3 resin uptake, ACTH, cortisol, gonadotropins, and gonadal steroids might provide evidence of other pituitary hormonal deficiencies. Antidiuretic hormone deficiency may be established by appropriate studies (see Chapter 596). Infants with clear clinical and biochemical evidence of multiple pituitary hormone deficiencies and supportive anatomic variants demonstrated on MRI of the brain may not require provocative GH testing.

RADIOLOGIC FINDINGS

Neurologic imaging should be obtained when the cause of hypopituitarism is not known. CT is appropriate for recognizing suprasellar calcification associated with craniopharyngiomas and bony changes accompanying histiocytosis. However, MRI is usually used as the initial test to anatomically characterize the pituitary and hypothalamus, as MRI provides a much more detailed view of the relevant anatomy. Many cases of severe early-onset MPHD show the triad of a small anterior pituitary gland, a missing or attenuated pituitary stalk, and an ectopic posterior pituitary bright spot at the base of the hypothalamus (Fig. 595.3). Subnormal anterior pituitary height, implying a small anterior pituitary, is common in genetic and idiopathic causes of isolated GHD. Craniopharyngiomas are rare tumors in childhood, but common causes of acquired hypopituitarism, whereas pituitary adenomas rarely cause hypopituitarism in children. Both hypoplastic and

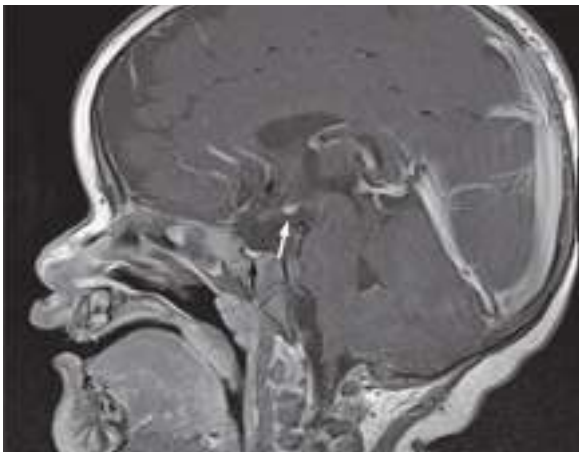

Fig. 595.3 Sagittal T1 weighted MRI shows an ectopic posterior pituitary *(white arrow)* and a small anterior pituitary *(black arrow). (From Giannopoulou EZ, Rohrer T, Hoffmann P, et al. Solitary median maxillary central incisor. J Pediatr. 2015;167:770, App Fig. 1.)*

markedly enlarged anterior pituitary glands are seen in patients with *PROP1* or *LHX3* gene alterations. Structural lesions causing isolated, acquired GHD are not common, but are important from a therapeutic perspective, such that MRI is usually recommended at the time of the diagnosis of GHD.

Skeletal maturation may be assessed with a plain film of the hand (bone age) and is delayed in patients with isolated GHD and may be even more delayed when there is combined GH and TSH deficiency. Importantly, in very recent or acute onset of hypopituitarism, initial assessment of skeletal age may not demonstrate the delay classically reported in congenital or long-standing hypopituitarism. Further, comorbid *central precocious puberty* may accelerate skeletal development when both precocious puberty and GHD are present, as may be seen in some patients with GHD after cranial irradiation. Dual-photon x-ray absorptiometry shows deficient bone mineralization, deficiencies in lean body mass, and a corresponding increase in adiposity, but it is not routinely recommended in the initial evaluation of pediatric GHD.

DIFFERENTIAL DIAGNOSIS

The causes of growth disorders are numerous. The differential diagnosis can be summarized broadly as follows: hormonal disorders, chronic illness, undernutrition, genetic conditions, nonsyndromic family trait, and constitutional delay of growth and development. Hormonal disorders include primary hypothyroidism and Cushing disease. Systemic conditions, such as inflammatory bowel disease, celiac disease, occult renal disease, and anemia, must be considered. Patients with systemic conditions often have a greater deficit of weight than length. Severe psychosocial deprivation may result in growth failure that mimics GH deficiency. Numerous **syndromic genetic** conditions include short stature as a manifestation, among other findings, whereas some specific genetic alterations may present with isolated short stature. These include Turner syndrome (see Chapter 99.4), pathogenic variants and deletions in *SHOX, ACAN, PTPN11,* and *IHH,* the skeletal dysplasias (see Chapter 735), and identifiable syndromes including Donohue *(INSR),* Kabuki *(KMT2D, KDM6A),* Noonan (RASopathy), Smith-Lemli Opitz *(DHCR7),* and Cornelia de Lange *(NIPBL, SMC1A, HDAC8, RAD21, SMC3).* Prenatal-onset short stature associated with being small for gestational age that persists during childhood may also be syndromic. Whole exome sequencing is helpful in identifying the specific syndrome.

Some otherwise normal children are short (i.e., >2.25 SD below the mean for age) and grow 5 cm/year or less but have normal levels of GH in response to provocative tests and normal spontaneous episodic secretion; this is often termed **idiopathic short stature**. Most of these children show increased rates of growth when treated with GH in doses comparable with those used to treat children with hypopituitarism. Plasma levels of IGF-1 in these patients may be normal or low. Several groups of treated children have achieved final or near-final adult heights. Different studies have found changes in adult height that range from −2.5 to +7.5 cm compared with pretreatment predictions. There are no methods that can reliably predict which of these children will become taller in adulthood as a result of GH treatment and which will have compromised adult height despite treatment.

Diagnostic strategies for distinguishing between permanent GH deficiency and other causes of impaired growth are imperfect. Children with a combination of genetic short stature and constitutional delay of growth have short stature, below-average growth rates, and delayed bone ages. Many of these children exhibit minimal GH secretory responses to provocative stimuli and may be treated with GH therapy. When children in whom idiopathic or acquired isolated GHD is diagnosed are treated with recombinant human GH and retested as adults, the majority have peak GH levels within the normal range.

Constitutional Growth Delay

Constitutional growth delay is one of the variants of normal growth commonly encountered by the pediatrician. Length and weight measurements of affected children are normal at birth, and growth is normal for the first 4-12 months of life. Height is sustained at a lower percentile during childhood. The pubertal growth spurt is delayed, so their growth rates persist at a lower prepubertal rate after their classmates have begun to accelerate. Detailed questioning often reveals other family members (often one or both parents) with histories of short stature in childhood, delayed puberty, and eventual normal stature. IGF-1 levels tend to be low for chronological age but within the normal range for bone age and sexual maturation rating. GH responses to provocative testing tend to be lower than in children with a more typical timing of puberty. The prognosis for these children to achieve normal adult height is guarded. Predictions based on height and bone age tend to overestimate eventual height to a greater extent in males than in females. Males with >2 years of pubertal delay can benefit from a short course of testosterone therapy to hasten puberty after 14 years of age. The cause of this variant of normal growth is thought to be persistence of the relative hypogonadotropic state of childhood.

TREATMENT

Although well-established treatments are available to replace the classical anterior pituitary hormone deficiencies, treatment must take into account patient age, pubertal maturation, and patient goals. Lifelong attention to correct administration of hormone replacement and monitoring for comorbidities are needed to optimize patient outcomes.

Recombinant human GH (rhGH) has been available by prescription since the 1980s. Multiple brands are marketed in the United States, which are therapeutically equivalent, with the major differences consisting of proprietary devices for subcutaneous injection and availability of solubilized liquid forms versus powders needing reconstitution before injection. Long-acting forms are under development and will need to demonstrate comparable efficacy, safety, and tolerability to the daily injections currently available.

The U.S. Food and Drug Administration (FDA) has approved eight pediatric indications for rhGH treatment to promote linear growth. They are GHD, Turner syndrome, chronic renal

failure before transplantation, idiopathic short stature, small-for-gestational-age short stature, Prader-Willi syndrome, *SHOX* gene abnormality, and Noonan syndrome. In the United States, FDA approval for a given indication does not ensure that a patient's insurance carrier will approve payment for the drug. Treatment should be started as soon as possible to narrow the gap in height between patients and their classmates during childhood and to have the greatest effect on mature height. For some infants with MPHD, initiation of rhGH treatment may be urgent to reduce the frequency and severity of episodes of hypoglycemia. The recommended initial dose of rhGH for treatment of GHD is 0.16-0.24 mg/kg/wk (22-35 μg/kg/day). Higher doses have been used during puberty and for non-GHD indications. Most currently available forms of rhGH are administered subcutaneously once daily, but a weekly preparation has been recently FDA approved for use in the United States.

Maximal response to rhGH occurs in the first year of treatment. Growth velocity during this first year is typically above the 95th percentile for age. With each successive year of treatment, the growth rate tends to decrease until it approximates a typical height velocity for skeletal age. If the growth rate drops below the 25th percentile, adherence should be evaluated before the dose is increased. IGF-1 may be measured as an objective assessment of adherence. GH therapy should be continued until near-final height is achieved. Criteria for stopping GH treatment include a decision by the adolescent that they are tall enough, a growth rate less than 1 inch per year, and a bone age greater than 14 years in females and greater than 16 years in males. Adolescents who have completed treatment for promotion of adult stature should be reevaluated for GHD based on adult criteria after treatment is complete. Some adolescents or young adults, particularly those with profound GHD and/or MPHD, may benefit from continuation of rhGH treatment as adults. The dose of rhGH is much lower in adults relative to growing teens. Children with hypopituitarism require coordinated transition to adult care and lifelong attention to their endocrine deficiencies.

Concurrent treatment with rhGH and a gonadotropin-releasing hormone agonist has been used in the hope that interruption of puberty will delay epiphyseal fusion and prolong growth. This strategy may increase adult height. Risks include increasing the discrepancy in physical maturity between GH-deficient children and their age peers, decreasing the upper to lower segment ratio, and impairing bone mineralization. There have also been attempts to forestall epiphyseal fusion in males by giving aromatase inhibitors, which inhibit the enzyme responsible for converting androgens to estrogens. These agents are not approved for this purpose in the United States, but some clinical trials have demonstrated an increase in predicted adult height with this approach.

Some patients develop either primary or central hypothyroidism while under treatment with GH. Similarly, there is a risk of developing adrenal insufficiency as an associated component of **hypopituitarism**. If unrecognized, this can be fatal. Periodic evaluation of thyroid and adrenal function is indicated for all patients diagnosed with GHD.

rhGH treatment may enhance the growth of non-GHD children as well. Intensive investigation is in progress to determine the full spectrum of short children who may benefit from treatment with GH. The FDA approval for use of GH in idiopathic short stature specifies a height below the 1.2 percentile (−2.25 SD) for age and sex, a predicted height below the 5th percentile, and open epiphyses. Studies of the effect of GH treatment on adult height suggest a median gain of 2-3 inches, depending on dose and duration of treatment.

In children with MPHD, replacement should also be directed at other hormonal deficiencies. In TSH-deficient patients, thyroid hormone replacement (levothyroxine) is given in full replacement doses. In ACTH-deficient patients, hydrocortisone should be prescribed in physiologic doses, about 8-12 mg/m^2/day. In patients deficient in both TSH and ACTH, initiation of adrenal replacement before thyroid hormone replacement is mandatory to reduce the risk of adrenal crisis. Individualized dose adjustment of hydrocortisone is needed to minimize the risk of side effects associated with excess glucocorticoid administration and prevent symptoms of adrenal insufficiency. *Increased doses of hydrocortisone are required to support vital functions and prevent adrenal crisis during illness or during and after surgical procedures (so-called "stress dosing.")*

In patients with a deficiency of gonadotropins, gonadal steroids are given at the appropriate time. Consideration of chronological age, height age, bone age, and psychosocial development may all play a role in determining the timing of initiation of low-dose sex steroid replacement in young adolescents. For infants with micropenis, one or two 3-month courses of monthly intramuscular injections of 25 mg of testosterone cypionate or testosterone enanthate can bring the penis to near-normal size without an inordinate effect on osseous maturation.

Recombinant IGF-1 (mecasermin) is approved for use in the United States for primary IGF-1 deficiency. It is given subcutaneously twice a day. Side effects are similar to rhGH, except that mecasermin can cause hypoglycemia. The risk of hypoglycemia is reduced by giving the injections concurrently with a meal or snack. In some situations, its use may be more efficacious than use of GH. These conditions include abnormalities of the GH receptor and *STAT5b* genes that alter GH signaling downstream. It may have utility for severe GHD in the rare patients who have developed clinically significant antibodies to administered rhGH. However, mecasermin is not an indicated treatment for most patients with GHD.

COMPLICATIONS AND ADVERSE EFFECTS OF GROWTH HORMONE TREATMENT

GH treatment influences glucose homeostasis. Fasting and postprandial insulin levels are characteristically low before treatment, and they normalize during GH replacement. GH treatment is associated with an increase in the risk for type 2 diabetes and no significant increase in the risk for type 1 diabetes.

Concerns have been raised about the safety of GH treatment in children who become deficient after treatment of brain tumors, leukemia, and other neoplasms. Long-term studies show no increase in risk of recurrence of craniopharyngioma, other brain tumors, or leukemia. Some studies indicate an increased risk of second neoplasms in cancer survivors treated with GH. However, other studies have found no increased risk for secondary brain tumors after adjustment for radiation therapy. Looking more broadly at young adults treated in childhood with GH for a variety of indications, the Safety and Appropriateness of Growth hormone treatments in Europe consortium (SAGhE) has reported an increase in cause-specific mortality due to circulatory and hematologic conditions, but no increase in all-cause mortality for youth treated with GH.

Other reported side effects include pseudotumor cerebri, slipped capital femoral epiphysis, gynecomastia, coarsening of features, and worsening of scoliosis. The risk of late development of Creutzfeldt-Jakob disease was limited to recipients of contaminated lots of extracted pituitary GH. No comparable risks have been seen with rhGH, which is the only pharmacologic form of hGH currently in clinical use.

Visit Elsevier eBooks+ at eBooks.Health.Elsevier.com for Bibliography.

Chapter 596

Diabetes Insipidus

Carmen L. Soto-Rivera, David T. Breault, and Joseph A. Majzoub

Diabetes insipidus (DI) manifests clinically with polyuria and polydipsia and can result from either vasopressin deficiency (central DI, also known as arginine vasopressin [AVP] deficiency) or vasopressin insensitivity at the level of the kidney (nephrogenic DI [NDI], also known as AVP resistance). Both central DI and NDI can arise from inherited defects of congenital or neonatal onset or can be secondary to a variety of causes (Table 596.1).

PHYSIOLOGY OF WATER BALANCE

The control of extracellular tonicity (osmolality) and volume within a narrow range is critical for normal cellular structure and function (see Chapter 73.2). Extracellular fluid tonicity is regulated almost exclusively by water intake and excretion, whereas extracellular volume is regulated by sodium intake and excretion. The control of plasma tonicity and intravascular volume involves a complex integration of endocrine, neural, behavioral, and paracrine systems (Fig. 596.1). Vasopressin, secreted from the posterior pituitary, is the principal regulator of tonicity, with its release largely stimulated by increases in plasma osmolality over 283 mOsm/kg H_2O. Volume homeostasis is largely regulated by the renin-angiotensin-aldosterone system, with contributions from both vasopressin and the natriuretic peptide family.

Vasopressin, a 9–amino acid peptide, has both antidiuretic and vascular pressor activity and is synthesized in the paraventricular and supraoptic nuclei of the hypothalamus. It is transported to the posterior pituitary via axonal projections, where it is stored awaiting release into the systemic circulation. The half-life of vasopressin in the circulation is 5-10 minutes, as it is rapidly degraded by a cysteine aminoterminal peptidase. The carboxyterminus of the vasopressin precursor, **copeptin**, is more stable than vasopressin, and blood concentrations of the two peptides are highly correlated when evaluating response to osmotic stimuli.

In addition to responding to osmotic stimuli, vasopressin is secreted in response to significant decreases in intravascular volume and pressure (minimum of 8% decrement) via afferent baroreceptor pathways arising from the aortic arch (carotid sinus) and volume receptor pathways in the cardiac atria and pulmonary veins. Osmotic and hemodynamic stimuli interact synergistically. Nausea is also a potent stimulus for vasopressin secretion.

The sensation of thirst and the release of vasopressin are regulated by cortical and hypothalamic neurons. The thirst threshold is approximately 10 mOsm/kg H_2O higher (i.e., 293 mOsm/kg H_2O) than the osmotic threshold for vasopressin release. Consequently, under conditions of hyperosmolality, vasopressin is released before thirst is initiated, allowing ingested water to be retained. Subsequently, anticipation of water ingestion by cortical and vasopressin-secreting neurons leads to a decrease in vasopressin release immediately before water ingestion, presumably to prevent subsequent hyponatremia. Chemoreceptors present in the oropharynx also downregulate vasopressin release after water ingestion. In addition, thirst drive decreases even before the ingested fluid lowers blood osmolality, presumably to prevent overdrinking leading to hyponatremia.

Vasopressin exerts its principal effect on the kidney via V2 (AVPR2) receptors located primarily in the collecting tubule, the thick ascending limb of the loop of Henle, and the periglomerular tubules. The human V2 receptor gene *(AVPR2)* is located on the long arm of the X chromosome (Xq28) at the locus associated with **congenital, X-linked, vasopressin-resistant DI**. Activation of the V2 receptor results in increases in intracellular cyclic adenosine monophosphate, which leads to the insertion of the aquaporin-2 water channel into the apical (luminal) membrane. This allows water movement along its osmotic gradient into the hypertonic inner medullary interstitium from the tubule lumen and excretion of concentrated urine. In contrast to aquaporin-2, aquaporin-3 and aquaporin-4 are expressed on the basolateral membrane of the collecting duct cells, and aquaporin-1 is expressed in the proximal tubule. These channels may also contribute to urinary concentrating ability.

Atrial natriuretic peptide, initially isolated from cardiac atrial muscle but also expressed in the brain, has several important effects on salt and water balance, including stimulation of natriuresis, inhibition of sodium resorption, inhibition of vasopressin secretion, and inhibition of vasopressin and aldosterone action in the renal tubules. Atrial natriuretic peptide is expressed in endothelial cells and vascular smooth muscle, where it appears to regulate relaxation of arterial smooth muscle. **Brain natriuretic peptide (BNP)**, synthesized and secreted by cardiac ventricular tissue, similarly induces natriuresis, whereas the physiologic role of C-type natriuretic peptide (CNP) has yet to be defined.

Table 596.1 Causes of Hypotonic Polyuria

CENTRAL (NEUROGENIC) DIABETES INSIPIDUS (DI)
Congenital (congenital malformations, autosomal dominant, arginine vasopressin [AVP] neurophysin pathogenic variants)
Drug or toxin induced (ethanol, diphenylhydantoin, snake venom)
Granulomatous (histiocytosis, sarcoidosis)
Neoplastic (craniopharyngioma, germinoma, lymphoma, leukemia, meningioma, pituitary tumor, metastases)
Infectious (meningitis, tuberculosis, encephalitis)
Inflammatory, autoimmune (lymphocytic infundibuloneurohypophysitis, immune check point inhibitors)
Trauma (neurosurgery, deceleration injury)
Vascular (cerebral hemorrhage or infarction, brain death)
Idiopathic
OSMORECEPTOR DYSFUNCTION
Granulomatous (histiocytosis, sarcoidosis)
Neoplastic (craniopharyngioma, pinealoma, meningioma, metastases)
Vascular (anterior communicating artery aneurysm or ligation, intrahypothalamic hemorrhage)
Other (hydrocephalus, ventricular or suprasellar cyst, trauma, degenerative diseases)
Idiopathic
INCREASED AVP METABOLISM
Pregnancy
NEPHROGENIC DIABETES INSIPIDUS
Congenital (X-linked recessive, AVP V2 receptor pathogenic variants, autosomal recessive or dominant, aquaporin-2 water channel pathogenic variants)
Drug induced (lithium, demeclocycline, cisplatin, methoxyflurane)
Hypercalcemia
Hypokalemia
Infiltrating lesions (sarcoidosis, amyloidosis)
Vascular (sickle cell anemia)
Mechanical (polycystic kidney disease, bilateral ureteral obstruction)
Solute diuresis (glucose, mannitol, sodium, radiocontrast dyes)
Idiopathic
PRIMARY POLYDIPSIA
Psychogenic (schizophrenia, obsessive-compulsive behaviors)
Dipsogenic (downward resetting of thirst threshold, idiopathic or similar lesions, as with central DI)

From Verbalis JG. Disorders of water balance. In Skorecki K, Chertow GM, Marsden PA, et al., eds. *Brenner & Rector's The Kidney,* 10th ed. Philadelphia: Elsevier; 2016: Table 16.2.

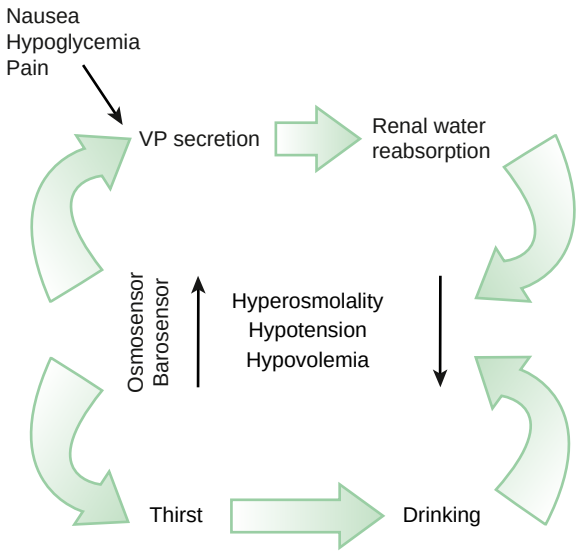

Fig. 596.1 Regulation of vasopressin secretion and serum osmolality. Hyperosmolality, hypovolemia, and hypotension are sensed by osmosensors, volume sensors, and barosensors, respectively. These stimulate both vasopressin secretion and thirst. Vasopressin, acting on the kidney, causes increased reabsorption of water (antidiuresis). Thirst causes increased water ingestion. The results of these dual negative feedback loops cause a reduction in hyperosmolality or in hypotension or hypovolemia. Additional stimuli for vasopressin secretion include nausea, hypoglycemia, and pain. *(From Srivasta A, Majzoub JA. Disorders of the posterior pituitary. In: Sperling MA, ed. Pediatric Endocrinology, 5th ed. Philadelphia: Elsevier; 2020: Fig. 12.6.)*

APPROACH TO THE PATIENT WITH POLYURIA, POLYDIPSIA, AND HYPERNATREMIA

The cause of pathologic polyuria or polydipsia (exceeding 2 L/m^2/24 hr) may be difficult to establish in children. Infants can present with irritability, failure to thrive, and intermittent fever. Patients with suspected DI should have a careful history taken, which should quantify the child's daily fluid intake and output and establish the voiding pattern, nocturia, and primary or secondary enuresis. A complete physical examination should establish the patient's hydration status, and the physician should search for evidence of visual and central nervous system dysfunction, as well as for other pituitary hormone deficiencies.

If pathologic polyuria or polydipsia is present, the following should be obtained: serum for osmolality, sodium, potassium, blood urea nitrogen, creatinine, glucose, hemoglobin A_{1c}, and calcium and urine for osmolality, specific gravity, and glucose determination. The diagnosis of DI is established if the serum osmolality is >300 mOsm/kg H_2O and the urine osmolality is <300 mOsm/kg. A baseline copeptin level above 20 pmol/L in this setting can confirm *nephrogenic* DI.

DI is unlikely if the serum osmolality is <270 mOsm/kg H_2O or the urine osmolality is >600 mOsm/kg. If the patient's serum osmolality is <300 mOsm/kg H_2O (but >270 mOsm/kg H_2O) and pathologic polyuria and polydipsia are present, a water deprivation test is indicated to establish the diagnosis of DI and to differentiate central from nephrogenic causes by assessing response to aqueous vasopressin at the end of the test.

Now that copeptin measurement is clinically available, test protocols aim to measure copeptin instead of AVP during water deprivation. Hypertonic saline infusion (3% saline) can also be given as an osmotic stimulus for copeptin secretion (instead of water deprivation tests), with a potentially higher diagnostic accuracy than water deprivation alone. In the inpatient postneurosurgical setting, central DI is likely if hyperosmolality (serum osmolality >300 mOsm/kg) is associated with urine osmolality less than serum osmolality. It is important to distinguish between polyuria resulting from postsurgical central DI and polyuria resulting from the normal diuresis of fluids received intraoperatively. Both cases may be associated with a large volume (>200 mL/m^2/hr) of dilute urine, although in patients with DI, the serum osmolality is high in comparison with patients undergoing postoperative diuresis.

CAUSES OF HYPERNATREMIA

Hypernatremia is discussed in Chapter 73.3.

Central Diabetes Insipidus

Central DI can result from multiple etiologies, including pathogenic variants in the vasopressin *(AVP)* gene; trauma (accidental or surgical) to vasopressin neurons; congenital malformations of the hypothalamus or pituitary; neoplasms; infiltrative, autoimmune, and infectious diseases affecting vasopressin neurons or fiber tracts; and increased metabolism of vasopressin. In approximately 10% of children with central DI, the etiology is idiopathic. Other pituitary hormone deficiencies may be present (see Chapter 595). *Over time, up to 35% of those with idiopathic central DI will develop other hormone deficiencies or have an underlying etiology identified.*

Autosomal dominant central DI usually occurs within the first 5 years of life and results from pathogenic variants in *AVP*. A number of these genetic variants can cause gene-processing defects in a subset of vasopressin-expressing neurons, which have been postulated to result in endoplasmic reticulum stress and cell death. **Wolfram syndrome**, which includes DI, diabetes mellitus, optic atrophy, and deafness, also results in vasopressin deficiency. Autosomal recessive pathogenic variants in the *WFS1* (most common) or *WFS2* (CISD2) genes, which give rise to endoplasmic reticulum proteins, are associated with this condition. Congenital brain abnormalities (see Chapter 631) such as **optic nerve hypoplasia syndrome** with agenesis of the corpus callosum, **Niikawa-Kuroki syndrome**, holoprosencephaly, and familial pituitary hypoplasia with absent stalk may be associated with central DI and defects in thirst perception (adipsia). Empty sella syndrome, possibly resulting from unrecognized pituitary infarction, can be associated with DI in children.

Trauma to the base of the brain and neurosurgical intervention in the region of the hypothalamus or pituitary are common causes of central DI. The **triphasic response** after surgery refers to an initial phase of transient DI, lasting 12-48 hours, followed by a second phase of syndrome of inappropriate antidiuresis (SIAD), lasting up to 10 days, which may be followed by permanent (or partial) DI. The initial phase may be the result of local edema interfering with normal vasopressin secretion; the second phase results from unregulated vasopressin release from dying neurons, whereas in the third phase, permanent DI results if more than 90% of the neurons have been destroyed.

Given the anatomic distribution of vasopressin neurons over a large area within the hypothalamus, **tumors** causing DI must either be very large and infiltrative or be strategically located near the base of the hypothalamus, where vasopressin axons converge before their entry into the posterior pituitary. Germinomas and pinealomas typically arise in this region and are among the most common primary brain tumors associated with DI. Germinomas can be very small and undetectable by MRI for several years after the onset of polyuria. Quantitative measurement of α-fetoprotein and β-human chorionic gonadotropin, often secreted by germinomas, should be performed in children with idiopathic or unexplained DI in addition to serial MRI scans. Craniopharyngiomas and optic gliomas can also cause central DI when they are very large, although this is more often a postoperative complication of the treatment for these tumors (see Chapter 546). Hematologic malignancies, such as acute myelocytic leukemia, can cause DI via infiltration of the pituitary stalk and sella.

Langerhans cell histiocytosis (see Chapter 556.2) and lymphocytic hypophysitis are common types of infiltrative disorders causing central DI, with **hypophysitis** as the cause in 50% of cases of "idiopathic" central DI. Infections involving the base of the brain (see Chapter 643), including meningitis (meningococcal, cryptococcal, listerial, toxoplasmal), congenital cytomegalovirus infection, and nonspecific

inflammatory diseases of the brain, may give rise to central DI that is often transient. Drugs associated with the inhibition of vasopressin release include ethanol, phenytoin, opiate antagonists, halothane, and α-adrenergic agents.

Nephrogenic Diabetes Insipidus

NDI can result from genetic or acquired causes. Genetic causes are less common but more severe than acquired forms of NDI. The polyuria and polydipsia associated with genetic NDI usually occur within the first several weeks of life but may become apparent only after weaning or with longer periods of nighttime sleep. Many infants initially present with fever, vomiting, and dehydration. Failure to thrive may be secondary to the ingestion of large amounts of water, resulting in caloric malnutrition. Long-standing ingestion and excretion of large volumes of water can lead to nonobstructive hydronephrosis, hydroureter, and megabladder.

Congenital X-linked NDI results from inactivating pathogenic variants of the vasopressin V2 receptor, *AVPR2*. **Congenital autosomal recessive NDI** results from defects in the aquaporin-2 gene, *AQP2*. An **autosomal dominant form of NDI** is associated with processing variants of the *AQP2* gene.

Acquired NDI can result from hypercalcemia or hypokalemia and is associated with lithium, demeclocycline, foscarnet, clozapine, amphotericin, methicillin, and rifampin. Impaired renal concentrating ability can also be seen with ureteral obstruction, chronic renal failure, polycystic kidney disease, medullary cystic disease, Sjögren syndrome, and sickle cell disease. Decreased protein or sodium intake or excessive water intake, as in primary polydipsia, can lead to diminished tonicity of the renal medullary interstitium, which impairs water reabsorption and thus the ability to concentrate the urine, leading to NDI.

TREATMENT OF CENTRAL DIABETES INSIPIDUS

Fluid Therapy

With an intact thirst mechanism and free access to oral fluids, a person with complete DI can maintain plasma osmolality and sodium in the high-normal range, although at great inconvenience. Neonates and young infants are often best treated solely with fluid therapy, given their requirement for large volumes (~3 L/m^2/24 hr) of nutritive fluid. The use of vasopressin analogs in patients with obligate high fluid intake is difficult given the risk of life-threatening hyponatremia. Although not FDA approved, the use of DDAVP (desmopressin) administered to infants with central DI, both as the diluted parenteral form given subcutaneously and as the diluted intranasal form given via the buccal mucosa, has been successful without causing severe hyponatremia. Patients with both central DI and NDI should ingest a diet without excessive solute (e.g., sodium chloride) to help decrease urine output when vasopressin action wanes.

Vasopressin Analogs

Treatment of central DI in older children is best accomplished with the use of DDAVP. DDAVP is available in an intranasal preparation (onset 5-10 minutes) and more commonly as tablets (onset 15-30 minutes). The intranasal preparation of DDAVP (10 μg/0.1 mL) can be administered by rhinal tube (allowing dose titration) or by nasal spray (10 μg/puff). Use of DDAVP oral tablets requires at least a 10-fold increase in the dosage compared with the intranasal preparation. Oral dosages of 25-300 micrograms every 8-12 hours are safe and effective in children. The appropriate dosage and route of administration are determined empirically based on the desired length of antidiuresis and patient preference. The use of oral DDAVP for the treatment of enuresis in older children should be regarded as a temporizing measure, given that it does not affect the underlying condition, and should be used with great caution given the risk of hyponatremia if water intake exceeds the capacity for renal clearance. To prevent water intoxication, patients should have at least 1 hour of urinary breakthrough between doses each day and be advised to drink only in response to thirst sensation, if present. The use of DDAVP nasal spray for childhood enuresis is no longer approved because of its risk of causing hyponatremia.

Aqueous Vasopressin

Central DI of acute onset after neurosurgery is best managed with continuous administration of synthetic aqueous vasopressin (Pitressin). Under most circumstances, total fluid intake must be limited to 1 L/m^2/24 hr during antidiuresis. A typical dosage for intravenous vasopressin therapy is 1.5 mU/kg/hr, which results in a blood vasopressin concentration of approximately 10 pg/mL. On occasion, after hypothalamic (but not transsphenoidal) surgery, higher initial concentrations of vasopressin may be required to treat acute DI, which has been attributed to the release of a vasopressin inhibitory substance. *Vasopressin concentrations >1,000 pg/mL should be avoided because they can cause cutaneous necrosis, rhabdomyolysis, cardiac rhythm disturbances, and hypertension*. Post-neurosurgical patients treated with vasopressin infusion should be switched from intravenous to oral fluids as soon as possible to allow thirst sensation, if intact, to help regulate osmolality.

Individuals with central DI caused by intracranial tumors that require chemotherapy often need hyperhydration with large amounts of intravenous fluids to prevent nephrotoxicity during treatment. Using a low-dose vasopressin continuous infusion to minimally concentrate urine above baseline can allow infusion of fluids over 1 L/m^2/day, while preventing the discomfort of full diuresis if done under careful monitoring of volume status and sodium levels.

TREATMENT OF NEPHROGENIC DIABETES INSIPIDUS

The treatment of acquired NDI focuses on eliminating, if possible, the underlying disorder, such as offending drugs, hypercalcemia, hypokalemia, or ureteral obstruction. Congenital NDI is often difficult to treat. The main goals are to ensure the intake of adequate calories for growth and to avoid severe dehydration. Foods with the highest ratio of caloric content to osmotic load (Na <1 mmol/kg/24 hr) should be ingested to maximize growth and to minimize the urine volume required to excrete the solute load. However, even with the early institution of therapy, growth failure and developmental disabilities are common.

Pharmacologic approaches to the treatment of NDI include the use of thiazide diuretics and are intended to decrease the overall urine output. Thiazides appear to induce a state of mild volume depletion by enhancing sodium excretion at the expense of water and by causing a decrease in the glomerular filtration rate, which results in proximal tubular sodium and water reabsorption. Indomethacin and amiloride may be used in combination with thiazides to further reduce polyuria. High-dose DDAVP therapy, in combination with indomethacin, has been used in some subjects with NDI. This treatment could prove useful in patients with genetic defects in the V2 receptor associated with a reduced binding affinity for vasopressin.

Visit Elsevier eBooks+ at eBooks.Health.Elsevier.com for Bibliography.

Chapter 597

Other Abnormalities of Arginine Vasopressin Metabolism and Action

Carmen L. Soto-Rivera, David T. Breault, and Joseph A. Majzoub

Hyponatremia (serum sodium <130 mEq/L) in children is usually associated with severe systemic disorders and is most often a result of intravascular volume depletion, excessive salt loss, or hypotonic fluid overload, especially in infants (see Chapter 73).

The initial approach to the patient with hyponatremia begins with determination of the volume status. A careful review of the patient's history, physical examination (including changes in weight), and vital signs helps to determine whether the patient is hypovolemic or hypervolemic. Supportive evidence includes laboratory data such as serum electrolytes, blood urea nitrogen, creatinine, uric acid, urine sodium, specific gravity, and osmolality (Tables 597.1 and 597.2; see Chapter 73).

CAUSES OF HYPONATREMIA

Systemic Dehydration

The initial manifestation of systemic dehydration is often hypernatremia and hyperosmolality, which subsequently lead to the activation of vasopressin secretion and a decrease in water excretion. As dehydration progresses, hypovolemia and/or hypotension become a major stimulus for vasopressin release, further decreasing free water clearance. Excessive free water intake (orally or intravenous infusion of hypotonic fluids) with ongoing salt loss can produce hyponatremia. Urinary sodium excretion is low (usually <20 mEq/L), owing to a low glomerular filtration rate and concomitant activation of the renin-angiotensin-aldosterone system unless primary renal disease or diuretic therapy is present.

Table 597.1 Differential Diagnosis of Hyponatremia

DISORDER	INTRAVASCULAR VOLUME STATUS	URINE SODIUM
Systemic dehydration	Low	Low
Decreased effective plasma volume	Low	Low
Primary salt loss (nonrenal)	Low	Low
Primary salt loss (renal)	Low	High
Adrenal insufficiency	Low	High
SIAD	High	High
Cerebral salt wasting	Low	Very high
Decreased free water clearance	Normal or high	Normal or high
Primary polydipsia	Normal or high	Normal
Runner's hyponatremia	Low	Low
NSIAD	High	High
Pseudohyponatremia	Normal	Normal
Factitious hyponatremia	Normal	Normal

NSIAD, Nephrogenic syndrome of inappropriate antidiuresis; SIAD, syndrome of inappropriate antidiuresis.

Runner's Hyponatremia

Excess hypotonic fluid ingestion during long-distance running (e.g., marathon running) can result in severe hyponatremia from hypovolemia-induced activation of arginine vasopressin secretion coupled with excessive water ingestion and is correlated with weight gain, long racing time, and extremes of body mass index.

Decreased Effective Plasma Volume

Hyponatremia can result from decreased effective plasma volume, as found in congestive heart failure, cirrhosis, nephrotic syndrome, positive pressure mechanical ventilation, severe burns, bronchopulmonary dysplasia in neonates, cystic fibrosis with obstruction, and severe asthma. The resulting decrease in cardiac output leads to reduced water and salt excretion, as with systemic dehydration, and an increase in vasopressin secretion. In patients with impaired cardiac output and elevated atrial volume (congestive heart failure, lung disease), atrial natriuretic peptide concentrations are elevated further, leading to hyponatremia by promoting natriuresis. However, owing to the marked elevation of aldosterone in these patients, their urine sodium remains low (<20 mEq/L) despite this. Unlike dehydrated patients, these patients also have excess *total body* sodium from activation of the renin-angiotensin-aldosterone system and can demonstrate peripheral edema as well.

Syndrome of Inappropriate Antidiuresis

The syndrome of inappropriate antidiuresis (SIAD) is characterized by hyponatremia, an inappropriately concentrated urine (often >800 mOsm/kg H_2O), normal or slightly elevated plasma volume, normal-to-high urine sodium, and low serum uric acid. SIAD is uncommon in children, and most cases result from excessive administration of vasopressin in the treatment of central diabetes insipidus (vasopressin deficiency). It can also occur with increased intracranial pressure, encephalitis, brain tumors, head trauma, psychiatric disease, prolonged nausea, pneumonia, tuberculous and bacterial meningitis, AIDS, and in the postictal phase after generalized seizures (Table 597.3). SIAD is the cause of the hyponatremic second phase of the triphasic response seen after hypothalamic-pituitary surgery. It is found in up to 35% of patients 1 week after surgery and can result from retrograde neuronal degeneration with cell death and vasopressin release. Common drugs that have been shown to increase vasopressin secretion or mimic vasopressin action, resulting in hyponatremia, include oxcarbazepine, carbamazepine, chlorpropamide, vinblastine, vincristine, and tricyclic antidepressants.

Nephrogenic Syndrome of Inappropriate Antidiuresis

Gain-of-function pathogenic variants in the V2 vasopressin receptor gene, *AVPR2,* on chromosome Xq28 have been described in male

Table 597.2 Clinical Parameters to Distinguish Among Syndrome of Inappropriate Antidiuresis (SIAD), Cerebral Salt Wasting, and Central Diabetes Insipidus (DI)

CLINICAL PARAMETER	SIAD	CEREBRAL SALT WASTING	CENTRAL DI
Serum sodium	Low	Low	High
Urine output	Normal or low	High	High
Urine sodium	High	Very high	Low
Intravascular volume status	Normal or high	Low	Low
Blood pressure	Normal	Decreased/ orthostatic hypotension	Decreased/ orthostatic hypotension
Vasopressin level	High	Low	Low
BUN	Low	High	High

Table 597.3 Disorders Associated with Syndrome of Inappropriate Antidiuresis

CANCER	PULMONARY DISORDERS	CENTRAL NERVOUS SYSTEM DISORDERS	OTHER DISORDERS
Thymoma Lymphoma Ewing sarcoma Oropharyngeal tumor	Viral pneumonia Bacterial pneumonia Pulmonary abscess Tuberculosis Aspergillosis Positive pressure ventilation Asthma Pneumothorax Cystic fibrosis	Encephalitis (viral or bacterial) Meningitis (viral, bacterial, tuberculous, fungal) Head trauma Brain abscess Guillain-Barré syndrome Subarachnoid hemorrhage or subdural hematoma Cerebellar and cerebral atrophy Cavernous sinus thrombosis Neonatal hypoxia Shy-Drager syndrome Rocky Mountain spotted fever Delirium tremens Cerebrovascular accident (cerebral thrombosis or hemorrhage) Acute psychosis Peripheral neuropathy Multiple sclerosis	AIDS Prolonged exercise Idiopathic (in older individuals) Nephrogenic Acute intermittent porphyria

Modified from Verbalis JG. Disorders of water balance. In Skorecki K, Chertow GM, Marsden PA, et al., eds, *Brenner & Rector's The Kidney,* 10th ed. Philadelphia: Elsevier; 2016: Table 16.6.

neonates with an SIAD-like clinical picture with undetectable vasopressin levels. Females are most often asymptomatic carriers. It is most commonly treated by fluid restriction, but oral urea has also been used to promote osmotic diuresis and increase water clearance. Germline activating pathogenic variants in *GNAS* have also been found in infants presenting with hyponatremia. Activating variants in the aquaporin-2 gene *(AQP2)* also give rise to the same syndrome.

Cerebral Salt Wasting

Cerebral salt wasting appears to be the result of hypersecretion of natriuretic peptides and is seen primarily with central nervous system disorders, including brain tumors, head trauma, hydrocephalus, neurosurgery, cerebrovascular accidents, and brain death. Hyponatremia is accompanied by elevated urinary sodium excretion (often >150 mEq/L), excessive urine output, hypovolemia, normal or high uric acid, and elevated atrial natriuretic peptide concentrations (>20 pmol/L). Thus it is distinguished from SIAD, in which normal or decreased urine output, normal or elevated blood volume, only modestly elevated urine sodium concentration, and an elevated vasopressin level occur. The distinction between cerebral salt wasting and SIAD is important because the treatment of the two disorders differs markedly. The existence of cerebral salt wasting has been controversial; however, current data support this entity as different from SIAD.

Primary Polydipsia (Increased Water Ingestion)

In patients with normal renal function, the kidney can excrete dilute urine with an osmolality as low as 50 mOsm/kg H_2O. To excrete a daily solute load of 500 mOsm/m^2 under these circumstances, the kidney must produce 10 L/m^2 of urine per day. Therefore to avoid hyponatremia, the maximum amount of water a person with normal renal function can consume daily is 10 L/m^2, or less if solute intake is lower. However, neonates cannot dilute their urine to this degree, putting them at risk for water intoxication if water intake exceeds 4 L/m^2/day (approximately 60 mL/hr in a newborn). Infants may develop transient hyponatremic seizures after being fed pure water without electrolytes rather than breast milk or formula.

Primary Salt Loss

Hyponatremia can result from the primary loss of sodium chloride, as seen in specific disorders of the kidney (congenital polycystic kidney disease, acute interstitial nephritis, chronic renal failure), gastrointestinal tract (gastroenteritis), and sweat glands (cystic fibrosis). The hyponatremia is not solely caused by salt loss, as it is often associated with hypovolemia, leading to an increase in vasopressin. Mineralocorticoid deficiency (hypoaldosteronism), pseudohypoaldosteronism (genetic or sometimes seen in children with urinary tract obstruction or infection), and diuretics can also result in loss of sodium chloride (Table 597.4). Low aldosterone states, such as primary adrenal insufficiency (Addison disease), are associated with salt wasting, hypovolemia, hyponatremia, hyperkalemia, and failure to thrive.

Decreased Free Water Clearance

Hyponatremia as a consequence of decreased renal free water clearance, even in the absence of an increase in vasopressin secretion, can result from adrenal insufficiency or thyroid deficiency or can be related to a direct effect of drugs on the kidney. Glucocorticoids are required for normal free water clearance in a vasopressin-independent manner. In patients with unexplained hyponatremia, adrenal and thyroid insufficiency should be considered. Patients with coexisting adrenal failure and diabetes insipidus might have no symptoms of the latter until glucocorticoid therapy unmasks the need for vasopressin replacement. Certain drugs can inhibit renal water excretion through direct effects on the nephron, thus causing hyponatremia; these drugs include high-dose cyclophosphamide, vinblastine, cisplatinum, carbamazepine, and oxcarbazepine.

Pseudohyponatremia and Other Causes of Hyponatremia

Pseudohyponatremia can result from hypertriglyceridemia (see Chapter 73.3). Elevated lipid levels result in a relative decrease in serum water content. As electrolytes are dissolved in the aqueous phase of the serum, they appear low when expressed as a fraction of the total serum volume. However, as a fraction of serum water, electrolyte content is normal. Modern laboratory methods that measure sodium concentration directly, independent of sample volume, do not cause this anomaly. Factitious hyponatremia can result from obtaining a blood sample downstream to the site of intravenous hypotonic fluid infusion.

Hyponatremia is also associated with hyperglycemia, which causes the influx of water into the intravascular space. Serum sodium decreases by ~1.6 mEq/L for every 100 mg/dL increment in blood glucose >100 mg/dL. Glucose is not ordinarily an osmotically active agent and does not stimulate vasopressin release, probably because it can equilibrate freely across plasma membranes. However, in the presence of insulin deficiency and hyperglycemia, glucose acts as an osmotic agent, presumably because its normal intracellular access to osmosensor sites is prevented. Under these circumstances, an osmotic gradient exists, stimulating vasopressin release.

TREATMENT

Patients with systemic dehydration and hypovolemia should be rehydrated with salt-containing fluids such as normal saline or lactated Ringer's solution. Because of activation of the renin-angiotensin-aldosterone system, the administered sodium is avidly conserved, and water diuresis quickly

Table 597.4 Pathogenic Gene Variants Associated with Hypoaldosteronism/ Pseudohypoaldosteronism (Type IV Renal Tubular Acidosis)

GENE CHROMOSOME OMIM	PATHOPHYSIOLOGY	PATHOGENIC VARIANT–CLINICAL MANIFESTATIONS–OMIM–INHERITANCE
PRIMARY HYPOALDOSTERONISM		
CYP21A2—cytochrome P450, subfamily XXIA, polypeptide 2 6p21.3 613815	P450c21—steroid 21-hydroxylase that converts 17 α-hydroxyprogesterone to 11-deoxycortisol and progesterone to 11-deoxycorticosterone in the adrenal zona fasciculata	Loss-of-function pathogenic variants decrease synthesis of cortisol and aldosterone, the latter resulting in the salt-losing form of classic congenital adrenal hyperplasia, AR–201910
CYP11B2—cytochrome P450, subfamily XIB, polypeptide 2 8q21 124080	P450c11B2—aldosterone synthase/corticosterone methyloxidase types I and II expressed only in the zona glomerulosa; hydroxylates deoxycorticosterone at carbon-11 and corticosterone at carbon-18 and oxidizes 18-hydroxycorticosterone to aldosterone	Loss-of-function pathogenic variants associated with severe salt loss and volume depletion but not with abnormalities of genital formation or glucocorticoid synthesis AR (CMOI 203400; CMOII 610600)
PSEUDOHYPOALDOSTERONISM TYPE I (PHA1)		
NR3C2—nuclear receptor subfamily 3, group C, member 2 (MR-mineralocorticoid receptor), 4q31.1 600983	Ligand-activated nuclear transcription factor that transmits aldosterone-mediated control of gene expression by binding to the mineralocorticoid response element in the promoter region of the target gene	Loss-of-function pathogenic variants in the MR lead to mineralocorticoid resistance and salt wasting, PHA1A, AD–177735
SCNN1A—sodium channel, non–voltage-gated, α-subunit 12p13.31 600228	Inactivating pathogenic variant of α-subunit of the epithelial sodium channel	Loss-of-function pathogenic variants in the epithelial sodium channel lead to mineralocorticoid resistance and salt wasting, PHA1B, AR–264350
SCNN1B—sodium channel, non–voltage-gated, β-subunit 16p12.2 600760	Inactivating mutation of β-subunit of the epithelial sodium channel	Loss-of-function pathogenic variants in the epithelial sodium channel lead to mineralocorticoid resistance and salt wasting, PHA1B, AR–264350
SCNN1G—sodium channel, non–voltage-gated, γ-subunit 16p12.2 600761	Inactivating mutation of γ-subunit of the epithelial sodium channel	Loss-of-function pathogenic variants in the epithelial sodium channel lead to mineralocorticoid resistance and salt wasting, PHA1B AR–264350
PSEUDOHYPOALDOSTERONISM TYPE II (PHA2) (GORDON SYNDROME)		
WNK4—protein kinase, lysine-deficient 4 17q21.31 601844	Multifunctional serine-threonine protein kinase whose substrate is SLC12A3, the thiazide-sensitive sodium/chloride co-transporter (NCCT)—OMIM 600968—that also regulates lysosomal degradation of NCCT and endocytosis of the KCNJ1 potassium channel	Gain-of-function pathogenic variants lead to hyperkalemia and hypertension, PHA2B, AD–614491
WNK1—protein kinase, lysine-deficient 1 12p13.33 605232	Serine-threonine protein kinase that inactivates WNK4 by phosphorylating its kinase domain	Gain-of-function pathogenic variants lead to hyperkalemia and hypertension, PHA2C, AD–614492
KLH3—Kelch-like 3 5q31.2 605775	Adaptor protein within the ubiquitination sequence that links WNK1 and WNK4 to CUL3	Gain-of-function pathogenic variants lead to hyperkalemia and hypertension, PHA2D, AD/AR–614495
CUL3—Cullin 3 2q36.2 603136	Scaffold protein that links to RING-box E3 ligase facilitating WNK4 ubiquitination and proteasomal destruction of WNK4	Gain-of-function pathogenic variants lead to hyperkalemia and hypertension, PHA2E, AD–614496

AD, Autosomal dominant; AR, autosomal recessive; CMO, corticosterone methyloxidase; OMIM, Online Mendelian Inheritance in Man.
From Root AW. Disorders of aldosterone synthesis, secretion, and cellular function. *Curr Opin Pediatr*. 2014;26:480–486, Table 1.

ensues as volume is restored and vasopressin concentrations decrease. Under these conditions, caution must be taken to prevent a too-rapid correction of hyponatremia (with a goal increase of <0.5 mEq/L/hr), which can result in central pontine myelinolysis characterized by discrete regions of axonal demyelination and the potential for irreversible brain damage.

Hyponatremia from a decrease in effective plasma volume caused by cardiac, hepatic, renal, or pulmonary dysfunction is more difficult to reverse. The most effective therapy is treatment of the underlying systemic disorder. Patients weaned from positive pressure ventilation undergo a prompt water diuresis and resolution of hyponatremia as cardiac output is restored and vasopressin concentrations decrease. Vaptans are a class of small-molecule arginine vasopressin V2 receptor antagonists (aquaretics) useful for the treatment of hypervolemic hyponatremia associated with severe congestive heart failure and chronic liver failure. Although these agents successfully increase plasma sodium, they also lead to increased thirst and plasma vasopressin levels, which can limit their effectiveness, can increase serum sodium more rapidly than is safe, and may cause hepatoxicity.

Patients with hyponatremia from primary salt loss require supplementation with sodium chloride and fluids. Initially, intravenous replacement with isotonic fluids containing sodium chloride (150 mEq/L) may be necessary. Hypertonic fluids (450 mEq/L sodium choride) should be reserved for treatment of acute neurologic deterioration caused by severe hyponatremia. Oral salt supplementation may be required subsequently. This treatment contrasts with that of SIAD, in which water restriction without sodium supplementation is the mainstay.

Emergency Treatment of Hyponatremia

The development of acute hyponatremia (onset <12 hr) or a serum sodium concentration <120 mEq/L may be associated with lethargy,

psychosis, coma, or generalized seizures, especially in younger children. Acute hyponatremia can cause cell swelling and lead to neuronal dysfunction or to cerebral herniation. *The emergency treatment of cerebral dysfunction resulting from acute hyponatremia includes water restriction and can require rapid correction with hypertonic 3% sodium chloride*. If hypertonic saline treatment is undertaken, the serum sodium should be raised only high enough to cause an improvement in mental status and, in no case, faster than 0.5 mEq/L/hr or 12 mEq/L/24 hr.

Treatment of Syndrome of Inappropriate Antidiuresis

Chronic SIAD is best treated by oral fluid restriction. With full antidiuresis (urine osmolality of 1,000 mOsm/kg H_2O), a normal daily obligate renal solute load of 500 mOsm/m^2 would be excreted in 500 mL/m^2 water. This, plus a daily nonrenal water loss of 500 mL/m^2, would require that oral fluid intake be limited to 1,000 mL/m^2/24 hr to avoid hyponatremia. In young children, this degree of fluid restriction might not provide adequate calories for growth. In this situation, a vaptan such as tolvaptan, although not FDA approved in children and may cause initial correction of hyponatremia too rapidly, may allow sufficient fluid intake for normal growth without concomitant hyponatremia. Urea has also been safely used to induce an osmotic diuresis in infants and children.

Treatment of Cerebral Salt Wasting

Treatment of patients with cerebral salt wasting consists of restoring intravascular volume with sodium chloride and water, as for the treatment of other causes of systemic dehydration. The underlying cause of the disorder, which is usually the result of acute brain injury, should also be treated if possible. Treatment involves the ongoing replacement of urine and sodium losses volume for volume.

Visit Elsevier eBooks+ at eBooks.Health.Elsevier.com for Bibliography.

Chapter 598

Hyperpituitarism

Omar Ali

Hyperpituitarism is defined as the excessive secretion or production of one or more of the hormones produced by the pituitary gland. The anterior pituitary normally produces prolactin, growth hormone (GH), thyroid-stimulating hormone (TSH), adrenocorticotropic hormone (ACTH), and the gonadotropin hormones (luteinizing hormone [LH] and follicle-stimulating hormone [FSH]); overproduction of any of these hormones is possible, though all are relatively rare. The posterior pituitary stores and releases antidiuretic hormone (ADH) and oxytocin, both produced by neurons in the hypothalamus. Although extremely rare cases of hypothalamic neurocytomas producing excess ADH have been reported (mostly in adults), these are vanishingly rare and will not be considered any further. *Hyperpituitarism refers to the overproduction of one or more of the anterior pituitary hormones.*

SECONDARY HYPERPITUITARISM

Several of the anterior pituitary hormones (all except GH and prolactin) act on other endocrine glands and regulate their secretion. They are regulated by negative feedback loops from their target glands, and their secretion increases if the end organ is not producing enough hormone. This can lead in extreme cases to severe hypertrophy of the relevant anterior pituitary cells and is a normal physiologic response to target hormone deficiencies resulting in decreased hormonal feedback, such as in hypogonadism, hypoadrenalism, or hypothyroidism. In these cases of *secondary hyperpituitarism,* chronic pituitary hypersecretion occurs in response to target hormone deficiencies that leads to pituitary hyperplasia; in extreme cases this can even enlarge and erode the sella and, on rare occasions, increase intracranial pressure. Such enlargements should not be confused with *primary* pituitary tumors; they disappear, and elevated pituitary hormone levels readily suppress to normal when the underlying hormone deficiency is treated by replacement of end-organ hormones.

Primary hypersecretion of pituitary hormones is uncommon in childhood. The most commonly diagnosed adenoma during childhood is prolactinoma, followed by corticotropinoma, and then somatotropinoma, which secrete prolactin, corticotropin, and GH, respectively. There are a handful of case reports of **thyrotropinoma** in children and adolescents. There are no pediatric reports of gonadotropinoma, but hypothalamic hamartomas that secrete excess gonadotropin-releasing hormone are one cause of precocious puberty. In very rare cases, pituitary hyperplasia can also occur in response to stimulation by ectopic production of releasing hormones such as that seen occasionally in patients with Cushing syndrome secondary to corticotropin-releasing hormone excess or in children with acromegaly secondary to growth hormone–releasing hormone (GHRH) produced by a variety of systemic tumors.

The monoclonal nature of most pituitary adenomas implies that most originate from a clonal event in a single cell. In some cases, the pituitary tumors result from stimulation with hypothalamic-releasing hormones and in other instances, as in **McCune-Albright syndrome** (MAS), the tumor is caused by activating pathogenic variants of the *GNAS1* gene that codes for the α subunit of $G_s\alpha$, a guanine nucleotide-binding protein. The clinical presentation typically depends on the pituitary hormone that is hypersecreted. In addition, disruptions of growth regulation and/or sexual maturation are common as a result of either hormone hypersecretion or local compression by the tumor. MAS also features polyostotic fibrous dysplasia of bone and café-au-lait spots in a distinct distribution.

EXCESS GROWTH HORMONE SECRETION AND PITUITARY GIGANTISM

In young persons with open epiphyses, overproduction of GH results in **gigantism**; in persons with closed epiphyses, the result is **acromegaly**. Often some acromegalic features are seen with gigantism, even in children and adolescents. After closure of the epiphyses, the acromegalic features become more prominent.

Gigantism is rare, with only several hundred reported cases worldwide to date. It must be emphasized that the vast majority of patients with tall stature will not have gigantism. The normal distribution of height predicts that 2.3% of the population will be taller than 2 standard deviations (SD) (97.7%) above the mean, and many cases of tall stature will therefore be normal-variant familial tall stature; if their growth is in line with their midparental height and no other concerning features are present, then no further investigation is needed. In cases where the tall stature is unexpected or extreme, other etiologies of rapid linear growth such as precocious puberty and hyperthyroidism should be carefully excluded. Coexisting findings (e.g., dysmorphic facial features, neurocognitive problems, hemihypertrophy) may suggest syndromic or chromosomal causes of tall stature, such as Sotos, Weaver, Klinefelter, or XYY syndrome.

The cardinal clinical feature of gigantism is longitudinal growth acceleration secondary to GH excess. The usual manifestations consist of coarse facial features and enlarging hands and feet. In young children, rapid growth of the head can precede linear growth. Some patients have behavioral and visual problems. In most recorded cases, the abnormal growth became evident at puberty, but the condition has been established as early as the newborn period. Giants have rarely been reported to grow to a height of over 8 feet. In some cases, the patient may present with local effects of the pituitary tumor (headache, visual field defects, and other pituitary hormone deficiencies) as the main complaint, and there is at least one report of a patient presenting with diabetic ketoacidosis induced by GH excess. The presentation of gigantism is usually dramatic, unlike the insidious onset of acromegaly in adults.

Pituitary adenomas secreting GH are more common in males, but females may present at an earlier age. Tumors with *AIP* pathogenic

psychosis, coma, or generalized seizures, especially in younger children. Acute hyponatremia can cause cell swelling and lead to neuronal dysfunction or to cerebral herniation. *The emergency treatment of cerebral dysfunction resulting from acute hyponatremia includes water restriction and can require rapid correction with hypertonic 3% sodium chloride*. If hypertonic saline treatment is undertaken, the serum sodium should be raised only high enough to cause an improvement in mental status and, in no case, faster than 0.5 mEq/L/hr or 12 mEq/L/24 hr.

Treatment of Syndrome of Inappropriate Antidiuresis

Chronic SIAD is best treated by oral fluid restriction. With full antidiuresis (urine osmolality of 1,000 mOsm/kg H_2O), a normal daily obligate renal solute load of 500 mOsm/m^2 would be excreted in 500 mL/m^2 water. This, plus a daily nonrenal water loss of 500 mL/m^2, would require that oral fluid intake be limited to 1,000 mL/m^2/24 hr to avoid hyponatremia. In young children, this degree of fluid restriction might not provide adequate calories for growth. In this situation, a vaptan such as tolvaptan, although not FDA approved in children and may cause initial correction of hyponatremia too rapidly, may allow sufficient fluid intake for normal growth without concomitant hyponatremia. Urea has also been safely used to induce an osmotic diuresis in infants and children.

Treatment of Cerebral Salt Wasting

Treatment of patients with cerebral salt wasting consists of restoring intravascular volume with sodium chloride and water, as for the treatment of other causes of systemic dehydration. The underlying cause of the disorder, which is usually the result of acute brain injury, should also be treated if possible. Treatment involves the ongoing replacement of urine and sodium losses volume for volume.

Visit Elsevier eBooks+ at eBooks.Health.Elsevier.com for Bibliography.

Chapter 598

Hyperpituitarism

Omar Ali

Hyperpituitarism is defined as the excessive secretion or production of one or more of the hormones produced by the pituitary gland. The anterior pituitary normally produces prolactin, growth hormone (GH), thyroid-stimulating hormone (TSH), adrenocorticotropic hormone (ACTH), and the gonadotropin hormones (luteinizing hormone [LH] and follicle-stimulating hormone [FSH]); overproduction of any of these hormones is possible, though all are relatively rare. The posterior pituitary stores and releases antidiuretic hormone (ADH) and oxytocin, both produced by neurons in the hypothalamus. Although extremely rare cases of hypothalamic neurocytomas producing excess ADH have been reported (mostly in adults), these are vanishingly rare and will not be considered any further. *Hyperpituitarism refers to the overproduction of one or more of the anterior pituitary hormones.*

SECONDARY HYPERPITUITARISM

Several of the anterior pituitary hormones (all except GH and prolactin) act on other endocrine glands and regulate their secretion. They are regulated by negative feedback loops from their target glands, and their secretion increases if the end organ is not producing enough hormone. This can lead in extreme cases to severe hypertrophy of the relevant anterior pituitary cells and is a normal physiologic response to target hormone deficiencies resulting in decreased hormonal feedback, such as in hypogonadism, hypoadrenalism, or hypothyroidism. In these cases of *secondary hyperpituitarism,* chronic pituitary hypersecretion occurs in response to target hormone deficiencies that leads to pituitary hyperplasia; in extreme cases this can even enlarge and erode the sella and, on rare occasions, increase intracranial pressure. Such enlargements should not be confused with *primary* pituitary tumors; they disappear, and elevated pituitary hormone levels readily suppress to normal when the underlying hormone deficiency is treated by replacement of end-organ hormones.

Primary hypersecretion of pituitary hormones is uncommon in childhood. The most commonly diagnosed adenoma during childhood is prolactinoma, followed by corticotropinoma, and then somatotropinoma, which secrete prolactin, corticotropin, and GH, respectively. There are a handful of case reports of **thyrotropinoma** in children and adolescents. There are no pediatric reports of gonadotropinoma, but hypothalamic hamartomas that secrete excess gonadotropin-releasing hormone are one cause of precocious puberty. In very rare cases, pituitary hyperplasia can also occur in response to stimulation by ectopic production of releasing hormones such as that seen occasionally in patients with Cushing syndrome secondary to corticotropin-releasing hormone excess or in children with acromegaly secondary to growth hormone–releasing hormone (GHRH) produced by a variety of systemic tumors.

The monoclonal nature of most pituitary adenomas implies that most originate from a clonal event in a single cell. In some cases, the pituitary tumors result from stimulation with hypothalamic-releasing hormones and in other instances, as in **McCune-Albright syndrome** (MAS), the tumor is caused by activating pathogenic variants of the *GNAS1* gene that codes for the α subunit of $G_s\alpha$, a guanine nucleotide-binding protein. The clinical presentation typically depends on the pituitary hormone that is hypersecreted. In addition, disruptions of growth regulation and/or sexual maturation are common as a result of either hormone hypersecretion or local compression by the tumor. MAS also features polyostotic fibrous dysplasia of bone and café-au-lait spots in a distinct distribution.

EXCESS GROWTH HORMONE SECRETION AND PITUITARY GIGANTISM

In young persons with open epiphyses, overproduction of GH results in **gigantism**; in persons with closed epiphyses, the result is **acromegaly**. Often some acromegalic features are seen with gigantism, even in children and adolescents. After closure of the epiphyses, the acromegalic features become more prominent.

Gigantism is rare, with only several hundred reported cases worldwide to date. It must be emphasized that the vast majority of patients with tall stature will not have gigantism. The normal distribution of height predicts that 2.3% of the population will be taller than 2 standard deviations (SD) (97.7%) above the mean, and many cases of tall stature will therefore be normal-variant familial tall stature; if their growth is in line with their midparental height and no other concerning features are present, then no further investigation is needed. In cases where the tall stature is unexpected or extreme, other etiologies of rapid linear growth such as precocious puberty and hyperthyroidism should be carefully excluded. Coexisting findings (e.g., dysmorphic facial features, neurocognitive problems, hemihypertrophy) may suggest syndromic or chromosomal causes of tall stature, such as Sotos, Weaver, Klinefelter, or XYY syndrome.

The cardinal clinical feature of gigantism is longitudinal growth acceleration secondary to GH excess. The usual manifestations consist of coarse facial features and enlarging hands and feet. In young children, rapid growth of the head can precede linear growth. Some patients have behavioral and visual problems. In most recorded cases, the abnormal growth became evident at puberty, but the condition has been established as early as the newborn period. Giants have rarely been reported to grow to a height of over 8 feet. In some cases, the patient may present with local effects of the pituitary tumor (headache, visual field defects, and other pituitary hormone deficiencies) as the main complaint, and there is at least one report of a patient presenting with diabetic ketoacidosis induced by GH excess. The presentation of gigantism is usually dramatic, unlike the insidious onset of acromegaly in adults.

Pituitary adenomas secreting GH are more common in males, but females may present at an earlier age. Tumors with *AIP* pathogenic

variants **(familial isolated pituitary adenoma)** are more common in males, are larger and invasive, and secrete GH or prolactin. **X-LAG syndrome (X-linked acrogigantism)** is a recognized cause of familial pituitary adenomas, and in these patients the rapid growth begins in infancy and is more frequent in females. Patients with MAS will usually exhibit other features, including polyostotic fibrous dysplasia, café-au-lait spots, and precocious puberty.

Pituitary tumors secrete extremely high levels of GH; approximately 50% of pituitary adenomas also exhibit hyperprolactinemia because they secrete both GH and prolactin. Adenomas can compromise other anterior pituitary function through growth or cystic degeneration. Secretion of gonadotropins, thyrotropin, or corticotropin may be impaired. Delayed sexual maturation or hypogonadism can occur. When GH hypersecretion is accompanied by gonadotropin deficiency, accelerated linear growth can persist for decades. In some cases, the tumor spreads outside the sella, invading the sphenoid bone, optic nerves, and brain. GH-secreting tumors in pediatric patients are more likely to be locally invasive or aggressive than are those in adults.

Acromegalic features consist chiefly of enlargement of the distal parts of the body, but manifestations of abnormal growth involve all portions. The circumference of the skull increases, the nose becomes broad, and the tongue is often enlarged, with coarsening of the facial features. The mandible grows excessively, and the teeth become separated. Visual field defects and neurologic abnormalities are common; signs of increased intracranial pressure appear later. The fingers and toes grow chiefly in thickness. There may be dorsal kyphosis. Fatigue and lassitude are early symptoms. GH levels are elevated and occasionally exceed 100 ng/mL. There is usually no suppression of GH levels by the hyperglycemia of a glucose tolerance test, and insulin-like growth factor 1 (IGF1) and insulin-like growth factor binding protein 3 (IGFBP-3) levels are consistently elevated in acromegaly and pituitary gigantism.

Diagnosis

GH hypersecretion should be screened for by testing IGF1 and IGFBP-3 levels. An elevated IGF1 level in a patient with appropriate clinical suspicion usually indicates GH excess. Potential confusion can arise in the evaluation of normal adolescents because significantly higher IGF1 levels occur during puberty than in adulthood; the IGF1 level must be age and gender matched. Serum IGFBP-3 levels are also sensitive markers of GH elevations and will be elevated in almost all cases. If IGF1 and/or IGFBP-3 levels are elevated, then the next step is to test for GH excess by doing an oral glucose-suppression test. The gold standard for the diagnosis of GH excess in adults is the failure to suppress serum GH levels to <1 ng/dL at any time during a 2-hour oral glucose tolerance test with 1.75 g/kg oral glucose challenge (maximum: 75 g). GH levels may not be suppressed to this level in normal adolescents, and a cutoff of 5 ng/mL may be more appropriate in this age-group. If laboratory findings suggest GH excess, the presence of a pituitary adenoma should be confirmed by MRI of the brain. In rare cases, a pituitary mass is not identified. This might be from an occult pituitary microadenoma or ectopic production of GHRH or GH. CT is acceptable when MRI is unavailable.

Genetic causes: Genetic pathogenic variants are recognized as being present in ~50% of cases, though many are sporadic. In a large series, detailed genetic testing revealed pathogenic variants in *AIP* in 29% of cases, X-LAG due to microdeletions at Xq26.3 in 10% of the cases, and MAS in 5% of the cases. No genetic abnormality was identified in 54% of the cases. Although GH-secreting adenomas eventually develop in up to 60% of patients with multiple endocrine neoplasia 1 (MEN1), most of these occur in adults and therefore cause acromegaly rather than gigantism. Increased GH secretion and GH-secreting adenomas may also be seen in neurofibromatosis; tuberous sclerosis; MEN4; Carney complex; and the paraganglioma, pheochromocytoma, and pituitary adenoma association known as *3PA*.

A genetics consultation and appropriate genetic testing is therefore indicated in all cases of pituitary gigantism.

Treatment

The goals of therapy are to remove or shrink the pituitary mass, to restore GH and secretory patterns to normal, to restore IGF1 and IGFBP-3 levels to normal, to retain the normal pituitary secretion of other hormones, and to prevent recurrence of disease.

For well-circumscribed pituitary adenomas, trans-sphenoidal surgery is the treatment of choice and may be curative. The tumor should be removed completely. The likelihood of surgical cure depends greatly on the surgeon's expertise and on the size and extension of the mass. Intraoperative GH measurements can improve the results of tumor resection. Trans-sphenoidal surgery to resect the tumors is as safe in children as in adults. At times, a transcranial approach might be necessary. The primary goal of treatment is to normalize GH and IGF1 levels. GH levels (<1 ng/mL within 2 hours after a glucose load) and serum IGF1 levels (age-adjusted normal range) are the best tests to define a biochemical cure.

If GH secretion and IGF1 levels are not normalized by surgery, the options include pituitary irradiation and medical therapy. Further growth of the tumor is prevented by irradiation in >99% of patients. The main disadvantage is the delayed efficacy in decreasing GH levels. GH is reduced by approximately 50% from the initial concentration by 2 years, by 75% by 5 years, and approaches 90% by 15 years. Multiple pituitary hormone deficiency is a predictable result of pituitary radiation, occurring in 40–50% of patients 10 years after irradiation.

Surgery fails to cure a significant number of patients, and radiotherapy may not work fast enough, so medical therapy has an important role in treating patients with GH excess. Treatment is effective and well tolerated with GH antagonists, long-acting somatostatin analogs, and in some cases, by dopamine agonists.

Pegvisomant is a GH-receptor antagonist that competes with endogenous GH for binding to the GH receptor. It effectively suppresses GH and IGF1 levels in patients with acromegaly caused by pituitary tumors and ectopic GHRH hypersecretion. Normalization of IGF1 levels occurs in up to 90% of patients treated daily with this drug for 3 months or longer. The adult dosage is 10-40 mg via subcutaneous injection once daily, although twice-weekly protocols have also been reported as highly successful. IGF1 levels and hepatic enzymes must be monitored. Combined therapy with somatostatin analogs and weekly pegvisomant injections also is effective. Pediatric experience is limited, but case reports indicate that it can successfully suppress IGF1 levels when used in doses of 10-30 mg/day.

The **somatostatin analogs** are frequently effective in the treatment of patients with GH excess. Octreotide suppresses GH to <2.5 ng/mL in 65% of patients with acromegaly and normalizes IGF1 levels in 70%. The effects of octreotide are well sustained over time. Tumor shrinkage also occurs with octreotide but is generally modest. Consistent GH suppression can be obtained with a continuous subcutaneous (SC) pump infusion of octreotide or with long-acting formulations, including long-acting octreotide and lanreotide. Octreotide injection in the pediatric population has been used at doses of 1-40 μg/kg/24 hr. In adults the long-acting form is used in a dose of 10-40 mg every month, but no pediatric dose range has been established.

For patients with both GH and prolactin oversecretion, **dopamine agonists, such as bromocriptine and cabergoline**, which bind to pituitary dopamine type 2 receptors and may also suppress GH secretion, can also be considered. Prolactin levels are often adequately suppressed, but GH levels and IGF1 levels are rarely normalized with this treatment modality alone. Tumor shrinkage occurs in a minority of patients. The effectiveness of these agents may be additive to that of octreotide. Cabergoline therapy at doses of 0.25-4.0 mg/wk (given 1-2 times per week) has been used in adults with acromegaly, and because of its less frequent dosing and lower incidence of side effects as compared to bromocriptine, this is now considered the dopamine agonist of choice in both adults and children. Side effects can include nausea, vomiting, abdominal pain, arrhythmias, nasal stuffiness, orthostatic hypotension, sleep disturbances, and fatigue.

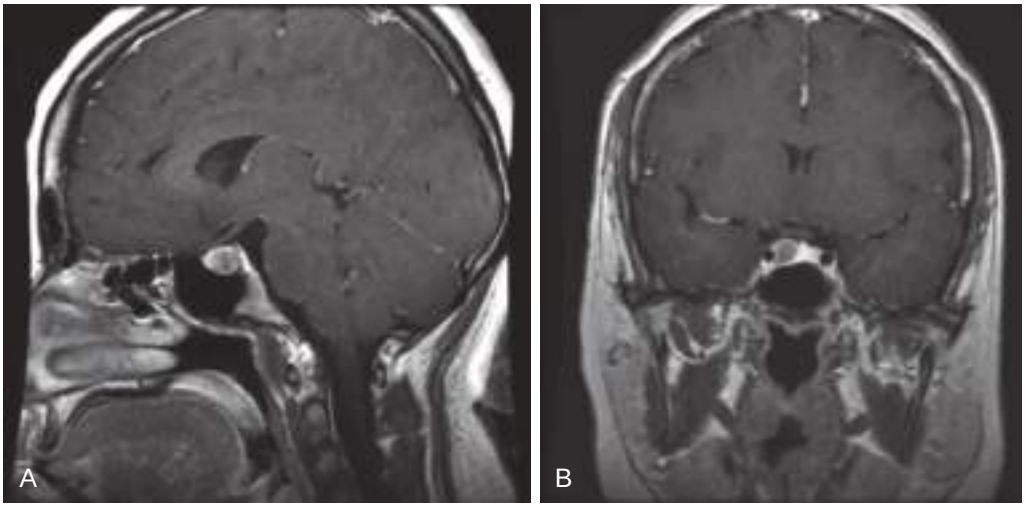

Fig. 598.1 Sagittal (A) and coronal (B) post-gadolinium T1-weighted MRI scans of a female with a microprolactinoma on the right side of the sella, who presented with amenorrhea and galactorrhea. Her serum prolactin was 89 ng/mL. *(From Wong A, Eloy JA, Couldwell WT, Liu JK. Update on prolactinomas. Part 1: clinical manifestations and diagnostic challenges. J Clin Neurosci. 2015;22:1562–1567, Fig. 1, p. 1563.)*

TREATMENT OF NORMAL-VARIANT TALL STATURE

Patients who have **familial tall stature** and no other underlying pathology usually require no treatment other than reassurance. The use of the bone age to predict adult height might provide some comfort for them, as will general supportive discussions on the social acceptability of this condition. Although treatment is possible for females and males with excessive growth, its use should be restricted to patients with predicted adult height >3-4 SD above the mean (79 inches or 200 cm in males, 73 inches or 185 cm in females) *and* evidence of significant psychosocial impairment.

Sex steroids have been used in the treatment of tall stature and are designed to accelerate puberty and to promote epiphyseal fusion; these are therefore of little benefit when given in late puberty. The lack of extensive experience with this form of therapy and the risks of estrogen or androgen treatment for tall stature should be carefully weighed and discussed with the family, and treatment should be discouraged except in the most extreme cases. Detailed discussion with the child at the child's level is also advisable, as up to 40% of those who underwent such treatments are dissatisfied as adults and feel they were not sufficiently consulted about this course of action. Therapy is initiated ideally before puberty or in early puberty (no later than bone age of 14). In the extremely rare instances where treatment is desired, testosterone enanthate is used at a dose of 250-500 mg intramuscularly every 2 weeks for 6 months in males. In females, oral estrogens in various doses have been used to reduce the predicted height, but average height reduction may be only 1.1-2.4 cm. Therapy must begin before the bone age has reached 12 years. In the rare case where treatment is advised, oral ethinyl estradiol has been used at a dose of 0.15-0.5 mg/day until cessation of growth occurs**.** Short-term side effects have included benign breast disease, cholelithiasis, hypertension, menstrual irregularities, weight gain, nausea, limb pain, galactorrhea, and thrombosis. Reduced fertility later in life may be a potential long-term complication. An alternative to sex-steroid therapy is the use of epiphysiodesis (destruction of the growth plates) around the knee to limit linear growth, but this intervention also remains controversial, and its long-term safety profile and psychologic risks and benefits remain unknown.

HYPERSECRETION OF OTHER PITUITARY HORMONES

Prolactinoma

Prolactin-secreting pituitary adenomas are the most common pituitary tumors in adolescents. With the use of MRI, more of these tumors, particularly microadenomas (<1 cm in diameter), are being detected (Fig. 598.1). The most common presenting manifestations are headache, primary or secondary amenorrhea, and galactorrhea. The disorder affects more than twice as many females as males; most patients have undergone normal puberty before becoming symptomatic. Only a few have delayed puberty. In some kindreds with **type I multiple endocrine neoplasia syndrome**, prolactinomas are the presenting feature during adolescence. Familial cases and sporadic cases with de novo pathogenic variants of the *AIP* gene and X-LAG are being recognized more often as genetic testing becomes more common.

Prolactin levels may be elevated mildly (40-50 ng/mL) or markedly (10,000-15,000 ng/mL), and there is a correlation between tumor size and prolactin levels. Most prolactinomas in children are large (macroadenomas), cause the sella to enlarge, and, in some cases, cause visual field defects. Approximately 30% of patients with macroadenomas develop other pituitary hormone deficiencies, particularly GH deficiency. Alternatively, prolactin-secreting adenomas might also stain for and secrete excess GH and/or TSH.

Prolactinomas should not be confused with the hyperprolactinemia and pituitary hyperplasia that can occur in patients with **primary hypothyroidism**, which is readily treated with thyroid hormone (see Chapter 603). Moderate elevations (<200 ng/mL) of prolactin are also associated with a variety of medications (antipsychotics, metoclopramide, phenothiazines, verapamil, opioids), with pituitary stalk dysfunction such as can occur with craniopharyngioma, with chronic renal failure, with chronic stress (rarely >40 ng/mL), and with nipple stimulation; hyperprolactinemia may also remain idiopathic in some cases (Table 598.1).

Drug-induced hyperprolactinemia is especially common, and in most cases the level is less than 100 ng/mL, though risperidone can cause elevations up to 300 ng/mL. No further investigation is needed if elevations in these ranges are seen in patients on antipsychotic medications who do not have any other suspicious features.

In extremely rare cases, prolactin may be produced by tumors outside the pituitary; in these cases there will be hyperprolactinemia with no sign of a pituitary tumor on imaging and no response to cabergoline treatment.

In some cases, extreme hyperprolactinemia is associated with a *hook effect* that leads to factitiously low values on blood tests. In cases where clinical features are compatible with hyperprolactinemia, serial dilution of the laboratory specimen should be done to rule out this kind of measurement error. On the other hand, patients may have factitiously elevated prolactin levels on immunoassay as a result of the presence of prolactin polymers and dimers **(macroprolactinemia)** that are not physiologically active. In cases where an elevated prolactin is detected in an asymptomatic patient, unnecessary diagnostic workup and treatment can be avoided by performing polyethylene glycol precipitation to exclude the presence of macroprolactinemia, which is clinically benign.

Table 598.1 Causes of Hyperprolactinemia

PHYSIOLOGIC
Pregnancy and lactation/nipple stimulation
Stress
Exercise
Sexual intercourse
PHARMACOLOGIC
Antipsychotics
Typical
Phenothiazines
Haloperidol
Atypical
Risperidone
Clozapine
Olanzapine
Antidepressants
Tricyclics
Monoamine oxidase inhibitors
Selective serotonin reuptake inhibitors
Antihypertensives
Verapamil
Reserpine
α-Methyldopa
Antiemetics
Metoclopramide
Domperidone
H2 blockers
Cimetidine
Ranitidine
Opiates
Morphine
Methadone
Others
Estrogens
Cocaine
Heroin
Alcohol
Anesthetics
Marijuana
PATHOLOGIC
Prolactinoma
Nonfunctioning pituitary adenoma causing stalk effect
Craniopharyngioma
Meningioma
Germinoma
Empty sella syndrome
Lymphocytic hypophysitis
Hypothalamic-pituitary disease
Infiltrative diseases
Sarcoidosis
Histiocytosis X
Tuberculosis
Metastasis
OTHER DISEASE STATES
ROHHAD
Primary hypothyroidism
Chronic renal failure
Cirrhosis, severe hepatic insufficiency
Ectopic secretion of prolactin
Chest-wall lesions (trauma, surgery, herpes zoster virus)

ROHHAD, rapid-onset obesity, hypothalamic dysfunction, hypoventilation, and autonomic dysregulation.
From Wong A, Eloy JA, Couldwell WT, Liu JK. Update on prolactinomas. Part 1: clinical manifestations and diagnostic challenges. *J Clin Neurosci.* 2015;22:1562–1567, Table 2.

It should be noted that there are occasional cases of galactorrhea where the prolactin level is completely normal (even after serial dilution to rule out the hook effect); the galactorrhea is usually mild in such cases and is not associated with any other clinical finding. No further treatment or investigation is indicated in these cases, and minimal galactorrhea can be left untreated. If the amount of milk discharge is bothersome, then low-dose cabergoline (0.25 mg once or twice weekly) may be effective even if elevated prolactin levels are not present.

In most patients where the hyperprolactinemia is secondary to an adenoma, it can be effectively treated with dopamine agonists. Treatment leads to lowering of prolactin levels and tumor shrinkage in the vast majority of patients and even large adenomas can usually be treated without surgical intervention. Because of its greater efficacy and lower incidence of side effects, cabergoline is considered the drug of choice for treatment of hyperprolactinemia. The usual protocol is to begin with 0.25 mg twice weekly and then increase as needed to 1 mg twice weekly. Even higher doses may be needed in some patients but should be carefully monitored; high doses of cabergoline used for long periods in older patients with parkinsonism are associated with cardiac valvular abnormalities, though this has not been reported with the doses used in pediatric hyperprolactinemia; monitoring of cardiac valves with echocardiography may be advisable if high doses are used for a prolonged period.

When dopamine agonist treatment has been unsuccessful in lowering the serum prolactin concentration or the size of the adenoma, and when symptoms or signs attributable to hyperprolactinemia or adenoma size persist during treatment, trans-sphenoidal surgery may be considered. Very rare cases of malignant prolactinomas may require chemotherapy with temozolomide, but a cure is difficult in such cases.

Corticotropinoma

Corticotropinoma is very rare in children, but unlike other types of pituitary adenomas, its incidence is higher in younger children and decreases with age. **Cushing disease** refers specifically to an ACTH-producing pituitary adenoma that stimulates excess cortisol production and secretion (see Chapter 619). It is more common than primary adrenal causes of Cushing syndrome, except in younger children (younger than 5 years of age), in whom adrenal carcinomas and adrenal activating variants of MAS are rare but dominant causes of the syndrome. Adenomas causing Cushing disease are almost always microadenomas with a diameter of <5 mm and are significantly smaller than all other types of adenomas at presentation. The most sensitive indicator of excess glucocorticoid secretion in children is growth failure, which generally precedes other manifestations. Patients develop weight gain that may be centripetal rather than generalized. Pubertal arrest, hypertension, large purplish striae, fatigue, and depression are also common. In prepubertal children, males are more frequently affected than females.

Midnight salivary cortisol measurements can be used as a screening test for cortisol excess, but confirmation requires at least one additional test (either 24-hour urinary free cortisol or an overnight dexamethasone suppression test). Location of the microadenoma is usually determined by MRI, and bilateral inferior petrosal sinus sampling may be needed in difficult cases. Trans-sphenoidal surgery is the treatment of choice for Cushing disease in children. Initial remission rates of 70–98% of patients and long-term success rates of 50–98% are reported. Residual transient hypoadrenalism is often observed after surgery, lasting as long as 30 months. Pituitary radiotherapy is used if cortisol levels remain elevated and/or ACTH levels continue to be detectable. Successful treatment may not correct the height deficit, and GH deficiency may be present after treatment and should be treated as required.

Thyrotropinomas are extremely rare, with only a few cases reported in the pediatric age-group. They present with symptoms of hyperthyroidism as well as local symptoms such as headaches and visual field defects. Laboratory testing reveals elevated thyroid hormone levels with inappropriately unsuppressed TSH levels. Treatment consists of trans-sphenoidal surgery in most cases, though radiation may be needed if surgery is unsuccessful.

598.1 Overgrowth Syndromes

Jennifer M. Kalish

OVERGROWTH IN THE FETUS AND NEONATE

Maternal diabetes is the most common cause of infants being large for gestational age. Even in the absence of clinical symptoms or a family history, the birth of a large-for-gestational-age infant should lead to evaluation for maternal (or gestational) diabetes.

Overgrowth syndromes: A group of disorders associated with excessive somatic growth and growth of specific organs has been described and is collectively referred to as *overgrowth syndromes.* These disorders are caused in many cases by excess production and availability of IGF2 encoded by the gene *IGF2.* The best described of these syndromes is **Beckwith-Wiedemann syndrome** (BWS), which is an overgrowth malformation syndrome that occurs with an incidence of 1:10,340 births, equal in males and females. It is caused by genetic or epigenetic abnormalities in the 11p15 chromosomal region, with most cases being the result of epigenetic abnormalities (loss or gain of DNA methylation) of two imprinting control regions, IC1 and IC2. Other causes include pathogenic variants, duplications, deletions, and loss of heterozygosity in this region. The imprinted genes involved in BWS and associated childhood tumors include, in addition to *IGF2,* the noncoding RNA *H19,* which is involved in *IGF2* suppression, cyclin-dependent kinase inhibitor 1C *(CDKN1C),* potassium channel voltage-gated KQT-like subfamily member 1 *(KCNQ1),* and *KCNQ1*-overlapping transcript 1 (*KCNQ1OT1*, or long QT intronic transcript 1, *LIT1*). Approximately 10% of cases are familial, whereas the rest appear to be sporadic. Cardinal clinical features of BWS include macroglossia, omphalocele, lateralized overgrowth (hemihypertrophy), bilateral Wilms tumor, hyperinsulinism, and pathologic findings (adrenal cytomegaly, pancreatic adenomatosis, and mesenchymal dysplasia). Suggestive features include macrosomia, mid-glabellar capillary malformation (nevus flammeus), earlobe creases and pits, umbilical hernia or diastasis recti, hepatomegaly, nephromegaly, transient hypoglycemia, and embryonal tumors (hepatoblastoma and unilateral Wilms tumor) (Fig. 598.2). The hyperinsulinemia is a result of pancreatic β-cell hyperplasia. These children are predisposed to embryonal tumors, including Wilms tumor, hepatoblastoma, neuroblastoma, and adrenocortical carcinoma. Management focuses on the omphalocele, airway issues (a result of macroglossia), neonatal hyperinsulinism/hypoglycemia, leg length differences, and tumor screening. Because of the cancer risk, screening is recommended until the seventh birthday. Screening includes complete abdominal ultrasound and measurement of α-fetoprotein every 3 months through the fourth birthday and renal ultrasounds every 3 months until the seventh birthday. Thereafter, renal ultrasound is recommended in cases of renal malformation such as medullary sponge kidney and nephrocalcinosis.

Pathogenic variants in *GPC3* and *GPC4,* glypican genes (which code for an IGF2–neutralizing membrane receptor), cause **Simpson-Golabi-Behmel** syndrome (Fig. 598.3). Other syndromic causes of fetal overgrowth include **Costello syndrome**, **Weaver syndrome**, **Sotos syndrome** (Fig. 598.4), and **Perlman syndrome** (Tables 598.2 and 598.3 and Fig. 598.5).

Overgrowth in Childhood or Adolescence

Normal-variant, familial, or constitutional tall stature is by far the most common cause of tall stature. Almost invariably, a family history of tall stature can be obtained, and no organic pathology is present. The child is often taller than the child's peers throughout childhood and has typical health. There are no abnormalities in the physical examination, and laboratory studies, if obtained, are negative.

Exogenous obesity is associated with rapid linear growth and relatively early onset of puberty (more so in girls). Bone age is accelerated, leading to relative tall stature in childhood but adult height is typically normal.

Klinefelter syndrome (XXY syndrome) is a relatively common (1 in 500-1,000 live male births) chromosomal abnormality associated with tall stature, learning disabilities (including requirement for speech therapy), gynecomastia, and decreased upper body:lower body segment ratio. Affected boys can have hypotonia, clinodactyly, and hypertelorism. The testes are invariably small, although androgen production by Leydig cells is often in the low-normal range. Spermatogenesis and Sertoli cell function are defective and lead to infertility. Other genital abnormalities include relatively small phallus and an increased incidence of hypospadias and cryptorchidism.

Fig. 598.2 Beckwith-Wiedemann syndrome in newborn infants. *(Courtesy Dr. Michael Cohen, Dalhousie University, Halifax, Nova Scotia. From Jones KL, Jones MC, Del Campo M. Smith's Recognizable Patterns of Human Malformation, 8th ed. Philadelphia: Elsevier; 2022, Fig. 1, p. 221.)*

Fig. 598.3 Simpson-Golabi-Behmel syndrome. Affected 16-yr-old male. Note the ocular hypertelorism, broad flat nose, 2-3 syndactyly, and nail hypoplasia. *(From Jones KL, Jones MC, Del Campo M. Smith's Recognizable Patterns of Human Malformation, 8th ed. Philadelphia: Elsevier, 2022. Fig. 1, p. 225.)*

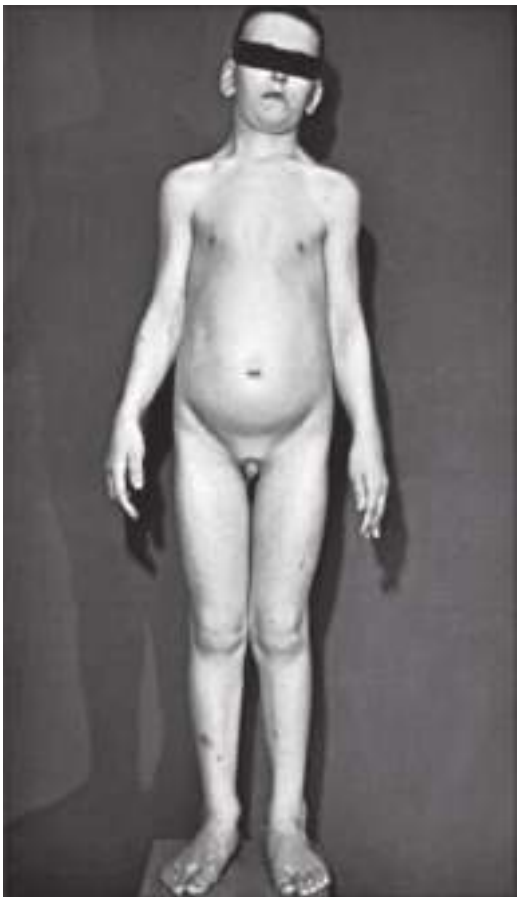

Fig. 598.4 Cerebral gigantism (Sotos syndrome) in an 8-yr-old male. The height age was 12 yr, and the bone age was 12 yr. IQ was 60. The electroencephalogram had abnormal findings. Note the prominence of the forehead and jaw and the large hands and feet. Sexual development was consistent with chronologic age. Hormone study results were normal. The adult height was 208 cm (6 ft 10 in); his sexual development was normal. He wears size 18 shoes.

Table 598.2 Differential Diagnosis of Tall Stature and Overgrowth Syndromes

FETAL OVERGROWTH
Maternal diabetes mellitus
Sotos syndrome *(NSD1)*
Weaver syndrome *(EZH2)*
Beckwith-Wiedemann syndrome (11p15 alterations)
Marshall-Smith syndrome *(NFIX)*
POSTNATAL OVERGROWTH LEADING TO CHILDHOOD OR ADULT TALL STATURE
Nonendocrine Causes
Familial (constitutional) tall stature
Exogenous obesity
Sotos syndrome *(NSD1)*
Weaver syndrome *(EZH2)*
Perlman syndrome *(DIS3L2)*
Simpson-Golabi-Behmel syndrome *(GPC3, GPC4)*
Marfan syndrome *(FBN1)*
Homocystinuria
Beckwith-Wiedemann syndrome (11p15 alterations)
Klinefelter syndrome (XXY)
Other syndromes with extra X or Y chromosomes
Overgrowth syndromes with intellectual disability *(DNMT3A, CHD8, HIST1H1E, EED)*
Endocrine Causes
Excess GH secretion caused by adenomas (pituitary gigantism)
X-linked acrogigantism (Xq26.3 duplication)
McCune-Albright syndrome or MEN associated with excess GH secretion
Aromatase deficiency and estrogen receptor defects
Precocious puberty (initial acceleration, ultimate short stature)
Hyperthyroidism (acceleration, but not adult tall stature)

GH, Growth hormone; MEN, multiple endocrine neoplasia.

XYY syndrome is associated with tall stature, severe acne in adolescence, increased incidence of learning disabilities, and behavioral problems, particularly impulsivity. Intelligence is usually in the normal range but may be 10-15 IQ points lower than their siblings. Other rare chromosomal abnormalities in which an excess number of X or Y chromosomes are present (e.g., XXX, XXXY, XYYY) are also associated with increased height.

Marfan syndrome is an autosomal dominant connective tissue disorder consisting of tall stature, arachnodactyly, thin extremities, increased arm span, and decreased upper body:lower body segment ratio (see Chapter 743). Additional abnormalities include ocular abnormalities (e.g., lens subluxation), hypotonia, kyphoscoliosis, cardiac valvular deformities, and aortic root dilation.

Homocystinuria is an autosomal recessive inborn error of amino acid metabolism caused by a deficiency of the enzyme cystathionine synthetase. It is characterized by intellectual disability when untreated, and many of its clinical features resemble Marfan syndrome, particularly ocular manifestations (see Chapter 105).

SOTOS SYNDROME

Children with Sotos syndrome (see Fig. 598.4) are typically above the 90th percentile for both length and weight at birth and may also have an increased head size. In other cases, macrocephaly becomes more apparent postnatally. Most cases of Sotos syndrome are caused by pathogenic variants in *NSD1*, but in the Japanese population most cases are attributable to microdeletions of the 5q35 region that includes this gene. Inheritance is autosomal dominant, but 95% of cases are a result of de novo (new) mutations. Incidence is estimated to be approximately 1 in 14,000 live births. The *NSD1* gene is thought to play a role in epigenetic regulation, but the exact mechanisms by which mutations lead to the features of Sotos syndrome are not yet understood.

Although it is characterized by rapid growth, there is no evidence that Sotos syndrome is caused by endocrine dysregulation. Growth is markedly rapid; by 1 year of age, affected infants are often taller than the 97th percentile in height. Accelerated growth continues for the first 4-5 years and then returns to a normal rate. Puberty usually occurs at the expected time but may occur slightly early. Adult height is usually in the upper-normal range.

Clinically the syndrome is characterized by a large (macrocephaly) dolichocephalic head, prominent forehead and jaw, hypertelorism, downslant of the palpebral fissures, high-arched palate, and large hands and feet with thickened subcutaneous tissue. Clumsiness and awkward gait are also noted, and affected children may have difficulty in sports, in learning to ride a bicycle, and in other tasks requiring coordination. Some degree of developmental disability affects most patients; in some affected children, perceptual deficiencies may predominate. Many different types of nonfebrile seizures have been reported, and up to 25% of patients with Sotos syndrome have seizures at some point in their life. Hyperinsulinism can also occur. Affected patients may be at somewhat increased risk for neoplasms, including neuroblastoma, hepatoblastoma, and leukemia, with a lifetime risk of between 2% and 4%. Osseous maturation is usually compatible with the patient's height, although

Table 598.3 Overgrowth Syndromes

SYNDROME	CLINICAL FEATURES	GENETIC ETIOLOGY	TUMOR SURVEILLANCE
Beckwith-Wiedemann syndrome (BWS)	Hypoglycemia, macroglossia, ear pits, omphalocele or umbilical hernia, lateralized overgrowth, organomegaly, high risk of embryonal tumors until age 7	Various genetic and epigenetic abnormalities in 11p15, most commonly in the IC2 region	Tumor surveillance until at least age 7 yr
Perlman syndrome	Macrosomia, unusual facies, nephroblastosis, severe hypotonia, very high risk of Wilms tumor	*DIS3L2* (DIS3 Like 3′-5′ exoribonuclease 2) (autosomal recessive)	Routine tumor surveillance recommended
Simpson-Golabi-Behmel syndrome	Coarse facial features, macroglossia, central groove lower lip, supernumerary nipples, cardiac and skeletal defects	*GPC3* (glypican 3) (X-linked recessive)	Tumor surveillance justified (per BWS protocol)
Sotos syndrome	Excessive growth in first 4 yr, dolichocephaly, macrocrania, typical facies, long limbs, seizures, hypotonia	*NSD1* deletion or variant (autosomal dominant) Rare familial cases *NFIX* (Nuclear Factor I X) may cause related Malan syndrome	Routine tumor screening not recommended
Tatton-Brown syndrome	Round face, heavy/horizontal eyebrows, narrow palpebral fissures, intellectual disability, and increased height	*DNMT3A* (DNA Methyltransferase 3 Alpha)	Routine tumor screening not recommended
Weaver syndrome	Broad forehead, hypertelorism, small chin, long philtrum, camptodactyly, redundant nuchal skin, heart and brain defects	*EZH2* (Enhancer of zeste homolog 2) gene in some cases	Routine tumor screening not recommended
PTEN-hamartoma syndromes (including Bannayan-Ruvalcaba-Riley)	Macrocephaly, hypotonia, pigmented skin, penile macules, lipomas, seizures	*PTEN* (phosphatase and TENsin homolog)(sporadic or autosomal dominant)	Tumor surveillance recommended
PIK3CA-related overgrowth spectrum	Brain overgrowth (megalencephaly), microgyria, cutaneous vascular malformations, syndactyly, seizures, developmental delay	Pathogenic variants in various PIK3 related genes, including *PIl3R2, AKT3, CCND2, PIK3CA,* etc.	Tumor surveillance is debated
Marfan syndrome	Facial gestalt, lens dislocation, arachnodactyly, scoliosis, pectus carinatum or excavatum, aortic root dilation	*FBN1* (Fibrillin 1) (autosomal dominant)	None
Loeys-Dietz syndrome	Marfan-like habitus, aortic root dilation, aortic dissection, vasculopathy (more aggressive than Marfan syndrome)	TGF-β pathway genes including *TGFBR1, TGFBR2, SMAD3,* and *TGFB2* (autosomal dominant)	None
Homocystinuria	Marfan-like habitus, developmental delay, lens dislocation	*CBS* gene (Cystathionine β-synthase) (autosomal recessive)	None
Lujan syndrome	Marfan-like habitus, intellectual disability, no eye or cardiovascular anomalies	*MED12* (Mediator Complex Subunit 12) gene (X-linked recessive)	None

advanced bone age has been reported. Scoliosis develops in up to 30% of cases, usually starting in school-age children. GH, IGF1, and other endocrine studies are usually normal; there is no distinctive laboratory or radiologic marker for the syndrome. Abnormal electroencephalograms are common; imaging studies often reveal an enlarged ventricular system, but intracranial pressure is normal. Genetic testing for *NSD1* pathogenic variants (or fluorescence in situ hybridization for 5q35 microdeletions in Japanese patients) is available and should be routinely used. Management is symptomatic and includes paying special attention to developmental and behavioral problems (which tend to improve with age), scoliosis, and seizure disorder. No specific treatment is needed for the overgrowth itself. There is no consensus on the need for cancer surveillance at this time.

Tatton-Brown Syndrome

Tatton-Brown syndrome is characterized by distinctive facial appearance (round face, heavy/horizontal eyebrows, and narrow palpebral fissures), intellectual disability, and increased height. It is caused by pathogenic variants in *DNMT3A*, a methyltransferase. Pathogenic variants in *DNMT3A* are also seen in hematologic malignances, which like *NSD1* and *EZH2*, show dual-gene functionality in overgrowth syndromes and myeloid neoplasms.

Hyperthyroidism in adolescents is associated with rapid growth but normal final adult height. It is almost always caused by Graves disease and is much more common in girls (see Chapter 606).

Visit Elsevier eBooks+ at eBooks.Health.Elsevier.com for Bibliography.

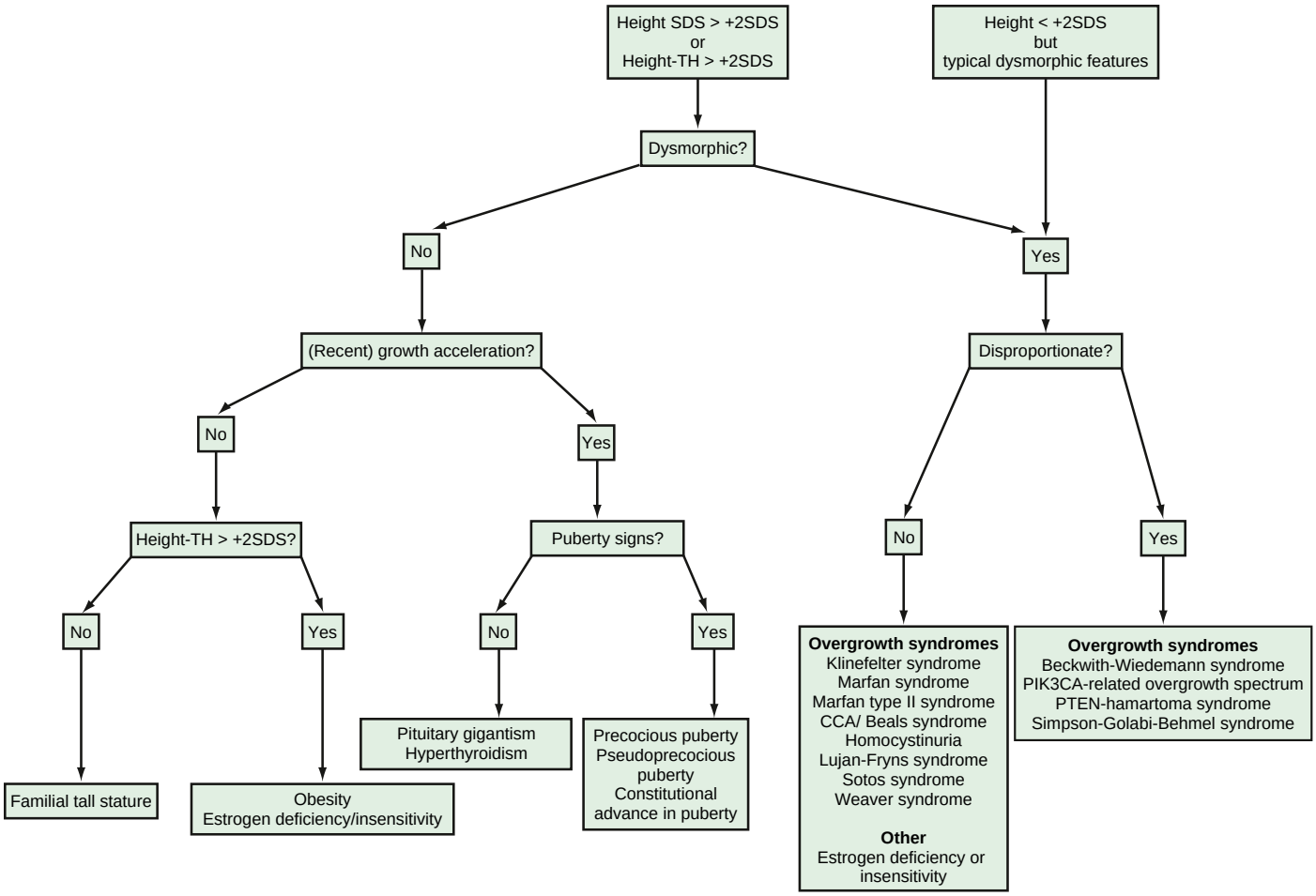

Fig. 598.5 Diagnostic algorithm for the differential diagnosis of tall stature and overgrowth syndromes. CCA, congenital contractural arachnodactyly; Height-TH, current height percentile >2 SDS from target height percentile, the latter based on midparental height calculation; *SDS*, standard deviation score. *(Adapted from Neylon OM, Werther GA, Sabin MA. Overgrowth syndromes. Curr Opin Pediatr. 2012;24:505–511, Fig. 1.)*

Chapter 599

Physiology of Puberty

Luigi R. Garibaldi and Wassim Chemaitilly

Between early childhood and approximately 8-9 years of age (prepubertal stage), the hypothalamic-pituitary-gonadal axis is dormant, as reflected by undetectable serum concentrations of luteinizing hormone (LH) and sex hormones (estradiol in females, testosterone in males). One to 3 years before the onset of clinically evident puberty, low serum levels of LH during sleep become demonstrable. This sleep-entrained LH secretion occurs in a pulsatile fashion and reflects endogenous episodic discharge of hypothalamic gonadotropin-releasing hormone (GnRH). Nocturnal pulses of LH continue to increase in amplitude and, to a lesser extent, in frequency as clinical puberty approaches. This pulsatile secretion of gonadotropins is responsible for enlargement and maturation of the gonads and the secretion of sex hormones. The appearance of the secondary sex characteristics in early puberty is the visible culmination of the sustained, active interaction occurring among the hypothalamus, pituitary, and gonads in the peripubertal period. By mid-puberty, LH pulses become evident even during the daytime and occur at about 90- to 120-minute intervals. A second critical event occurs in middle or late adolescence in females in whom cyclicity and ovulation occur. A positive feedback mechanism develops whereby increasing levels of estrogen in midcycle cause a distinct increase of LH.

The increasing secretion of hypothalamic GnRH in a pulsatile fashion thus underlies the onset of pubertal development. The *GnRH pulse generator* is regulated by multiple neuropeptides, including glutamic acid, kisspeptin, neurokinin-B (stimulatory); γ-aminobutyric acid, preproenkephalin, and dynorphin (inhibitory). Pathogenic variants of *KISS1R* (previously known as *GPR54*, a G protein–coupled receptor gene whose ligand is kisspeptin) are a rare cause of autosomal recessive hypogonadotropic hypogonadism (loss-of-function pathogenic variants) or precocious puberty (gain-of-function pathogenic variants). The imprinted paternally expressed gene makorin RING finger protein 3 *(MKRN3)* has been described as a *brake* for the onset of puberty. Loss-of-function pathogenic variants of this gene are responsible for paternally transmitted familial precocious puberty in both sexes.

The interpretation of the hormonal changes of puberty is complex. Challenges with interpreting LH and follicle-stimulating hormone (FSH) measurements include the presence of multiple gonadotropin isoforms, immunoassay-related variability, and problems inherent to their pulsatile secretion, which mandate serial sampling in plasma. In addition, important sex differences exist in the maturation of the hypothalamus and pituitary gland because serum LH concentrations tend to increase earlier in the course of the pubertal process in males than in females. Adrenocortical androgens also have a role in sexual maturation. Serum levels of dehydroepiandrosterone (DHEA) and its sulfate (DHEAS) begin to increase at approximately 6-8 years of age, before any increase in LH or sex hormones

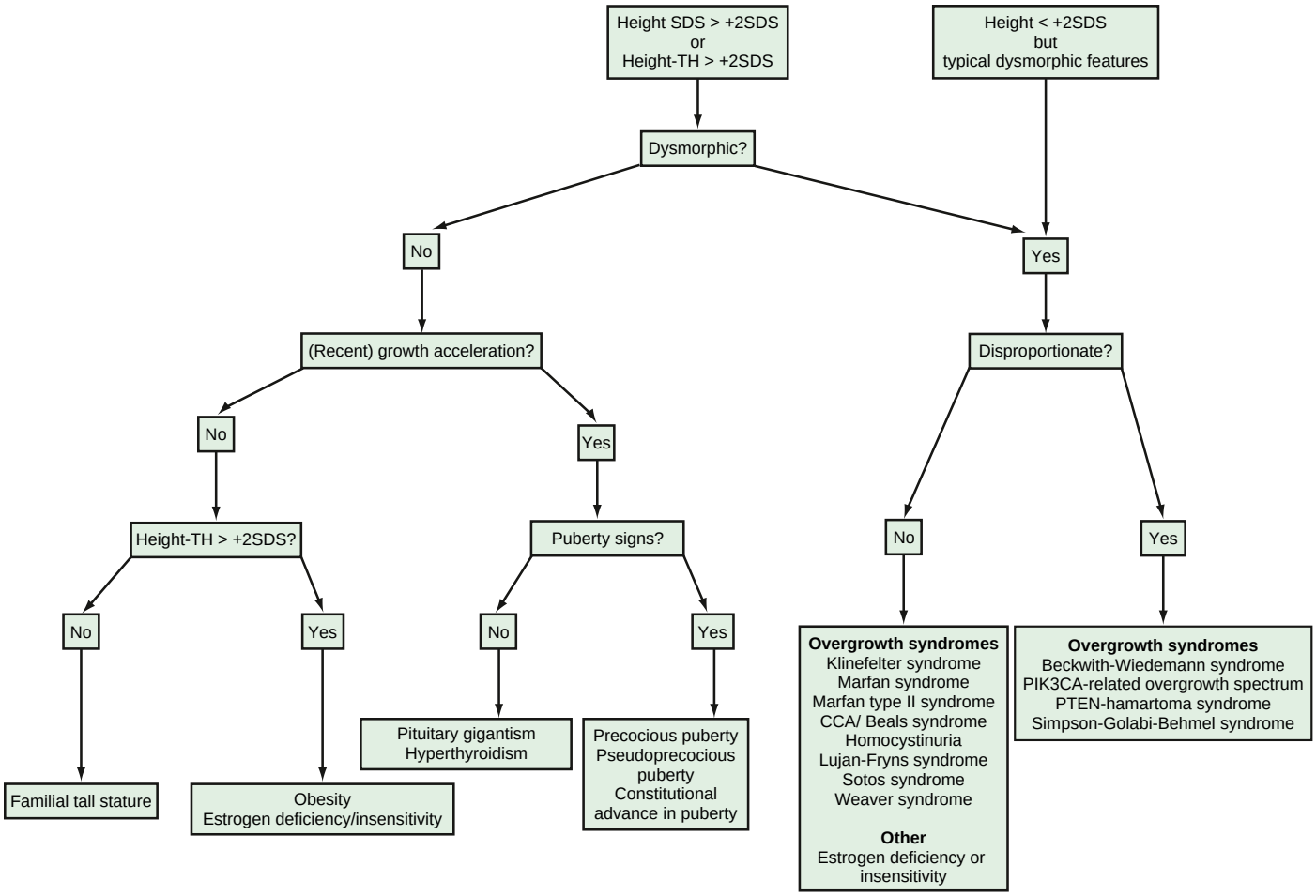

Fig. 598.5 Diagnostic algorithm for the differential diagnosis of tall stature and overgrowth syndromes. CCA, congenital contractural arachnodactyly; Height-TH, current height percentile >2 SDS from target height percentile, the latter based on midparental height calculation; *SDS*, standard deviation score. *(Adapted from Neylon OM, Werther GA, Sabin MA. Overgrowth syndromes. Curr Opin Pediatr. 2012;24:505–511, Fig. 1.)*

Chapter 599

Physiology of Puberty

Luigi R. Garibaldi and Wassim Chemaitilly

Between early childhood and approximately 8-9 years of age (prepubertal stage), the hypothalamic-pituitary-gonadal axis is dormant, as reflected by undetectable serum concentrations of luteinizing hormone (LH) and sex hormones (estradiol in females, testosterone in males). One to 3 years before the onset of clinically evident puberty, low serum levels of LH during sleep become demonstrable. This sleep-entrained LH secretion occurs in a pulsatile fashion and reflects endogenous episodic discharge of hypothalamic gonadotropin-releasing hormone (GnRH). Nocturnal pulses of LH continue to increase in amplitude and, to a lesser extent, in frequency as clinical puberty approaches. This pulsatile secretion of gonadotropins is responsible for enlargement and maturation of the gonads and the secretion of sex hormones. The appearance of the secondary sex characteristics in early puberty is the visible culmination of the sustained, active interaction occurring among the hypothalamus, pituitary, and gonads in the peripubertal period. By mid-puberty, LH pulses become evident even during the daytime and occur at about 90- to 120-minute intervals. A second critical event occurs in middle or late adolescence in females in whom cyclicity and ovulation occur. A positive feedback mechanism develops whereby increasing levels of estrogen in midcycle cause a distinct increase of LH.

The increasing secretion of hypothalamic GnRH in a pulsatile fashion thus underlies the onset of pubertal development. The *GnRH pulse generator* is regulated by multiple neuropeptides, including glutamic acid, kisspeptin, neurokinin-B (stimulatory); γ-aminobutyric acid, preproenkephalin, and dynorphin (inhibitory). Pathogenic variants of *KISS1R* (previously known as *GPR54*, a G protein–coupled receptor gene whose ligand is kisspeptin) are a rare cause of autosomal recessive hypogonadotropic hypogonadism (loss-of-function pathogenic variants) or precocious puberty (gain-of-function pathogenic variants). The imprinted paternally expressed gene makorin RING finger protein 3 *(MKRN3)* has been described as a *brake* for the onset of puberty. Loss-of-function pathogenic variants of this gene are responsible for paternally transmitted familial precocious puberty in both sexes.

The interpretation of the hormonal changes of puberty is complex. Challenges with interpreting LH and follicle-stimulating hormone (FSH) measurements include the presence of multiple gonadotropin isoforms, immunoassay-related variability, and problems inherent to their pulsatile secretion, which mandate serial sampling in plasma. In addition, important sex differences exist in the maturation of the hypothalamus and pituitary gland because serum LH concentrations tend to increase earlier in the course of the pubertal process in males than in females. Adrenocortical androgens also have a role in sexual maturation. Serum levels of dehydroepiandrosterone (DHEA) and its sulfate (DHEAS) begin to increase at approximately 6-8 years of age, before any increase in LH or sex hormones

and before the earliest physical changes of puberty are apparent; this process has been called *adrenarche*. DHEAS is the most abundant adrenal C-19 steroid in the blood, and its serum concentration remains fairly stable over 24 hours. A single measurement of this hormone is commonly used as a marker of adrenal androgen secretion. Although adrenarche typically precedes the onset of gonadal activity (gonadarche) by a few years, the two processes do not seem to be causally related, as evidenced by adrenarche and gonadarche being dissociated in conditions such as central precocious puberty and adrenocortical failure.

The effects of gonadal steroids (testosterone in males, estradiol in females) on bone growth and osseous maturation are critical. Both aromatase deficiency and estrogen receptor defects result in delayed epiphyseal fusion and tall stature in affected males. These observations suggest that estrogens, rather than androgens, are responsible for the process of bone maturation that ultimately leads to epiphyseal fusion and cessation of growth. Estrogens also mediate the increased production of growth hormone, which along with a direct effect of sex steroids on bone growth, is responsible for the pubertal growth spurt.

The age of onset of puberty varies and is more closely correlated with osseous maturation than with chronologic age (see Chapter 150). In females, the **breast bud** (thelarche) is usually the first sign of puberty (10-11 years), followed by the appearance of **pubic hair** (pubarche) 6-12 months later. The interval to the onset of **menstrual activity** (menarche) is usually 2-2.5 years but may be as long as 6 years. In the United States, at least one sign of puberty is present in approximately 95% of females by 12 years of age and in 99% of females by 13 years of age. Peak height velocity occurs early (at breast stage II-III, typically between 11 and 12 years of age) in females and always precedes menarche. The mean age of menarche is about 12.75 years. However, there are wide variations in the sequence of changes involving growth spurt, breast bud, pubic hair, and maturation of the internal and external genitalia.

In males, **growth of the testes** (≥4 mL in volume or 2.5 cm in longest diameter) and thinning of the scrotum are the first signs of puberty (11-12 years). These are followed by pigmentation of the scrotum and growth of the penis and by **pubarche**. Appearance of **axillary hair** usually occurs in mid-puberty. In males, unlike in females, acceleration of growth begins after puberty is well underway and is maximal at genital stage IV-V (typically between 13 and 14 years of age). In males, the growth spurt occurs approximately 2 years later than in females, and growth may continue beyond 18 years of age.

Genetic and environmental factors affect the timing for the onset of puberty. Population-based studies in the United States and Europe have suggested secular trends for earlier onset of puberty over the past few decades in females and, to a lesser degree, in males. African American, and to a lesser extent Hispanic, females *appear* to be more advanced in the development of secondary sex characteristics for age than White females. However, the timing of menarche has advanced only marginally (2.5-4 months) in White females and slightly more so (up to 6 months) in African American females. The Copenhagen Puberty Study showed that the earlier onset of breast development observed in females examined in 2006–2008 than those seen in 1991–1993 (means 10.9 years vs 9.9 years) *was not* associated with different levels of gonadotropins or estradiol when females of similar chronologic ages were compared between the two groups. Hence earlier breast development may not simply reflect earlier activation or maturation of the hypothalamic-pituitary-gonadal axis but could also stem from other factors such as increased adiposity or increased exposure to certain environmental agents. Positive correlations between the degree of adiposity and earlier pubertal development in females have been reported. Conversely, female athletes in whom leanness and strenuous physical activity have coexisted from early childhood frequently exhibit a marked delay in puberty or menarche, and they frequently have oligomenorrhea or amenorrhea as adults (see Chapter 732). Pubertal delay is also prevalent in males who are physically very active. Thus energy balance is closely related to the activity of the GnRH pulse generator and the mechanisms initiating and sustaining puberty, possibly via hormonal signals such as leptin; other adipokines; or by way of the central melanocortin-4 receptor (MC4R), which controls appetite, food intake, and energy expenditure.

Visit Elsevier eBooks+ at eBooks.Health.Elsevier.com for Bibliography.

Chapter 600

Disorders of Pubertal Development

Luigi R. Garibaldi and Wassim Chemaitilly

INTRODUCTION

Precocious puberty is defined by the onset of secondary sexual characteristics before the age of 8 years in females and 9 years in males. The variation in the age of the onset of puberty in normal children, particularly of different ethnicities, makes this definition somewhat arbitrary. It remains in use by most clinicians.

Depending on the primary source of the hormonal production, precocious puberty may be classified as **central** (also known as **gonadotropin dependent**, or **true**) or **peripheral** (also known as **gonadotropin independent**) (Table 600.1). **Central** precocious puberty (CPP) is always isosexual and stems from hypothalamic-pituitary-gonadal activation with ensuing sex hormone secretion and progressive sexual maturation. In **peripheral** precocious puberty, some of the secondary sex characteristics appear, but there is no activation of the normal hypothalamic-pituitary-gonadal interplay. In this latter group, the sex characteristics may be isosexual or heterosexual (see Chapters 622-628).

Peripheral precocious puberty can also induce maturation of the hypothalamic-pituitary-gonadal axis and trigger the onset of central puberty at a later time. This mixed type of precocious puberty occurs in congenital adrenal hyperplasia, particularly after adrenal androgens are suppressed by treatment; McCune-Albright syndrome; and familial male-limited precocious puberty, when the bone age reaches the pubertal range (10.5-12.5 years).

600.1 Central Precocious Puberty

Luigi R. Garibaldi and Wassim Chemaitilly

CPP is defined by the onset of pubertal development due to the early activation of the hypothalamic-pituitary-gonadal axis before the ages of 8 and 9 years in females and males, respectively. It occurs 5- to 10-fold more frequently in females than in males and is usually sporadic. Although at least 90% of females have an idiopathic form, a structural central nervous system (CNS) abnormality may occur in 25–75% of males with CPP. **Genetic forms of CPP**, such as the paternally transmitted types due to pathogenic variants of *MKRN3* gene or, more rarely *DLK1,* may account for 5–10% of all cases of CPP. A high prevalence of CPP has been reported in females adopted from developing countries, particularly if adopted several months or years after birth, possibly related to undefined nutritional or environmental factors.

CLINICAL MANIFESTATIONS

In females, CPP should be suspected when breast development is noted before the age of 8 years. In males who have not been exposed to gonadotoxic agents, CPP usually manifests first via increased testicular size (volume ≥4 mL) and scrotal thinning before the age of 9 years. Sexual development in affected individuals generally follows the sequence observed in normal puberty. In females, early menstrual cycles may be more irregular than they are with normal puberty. The initial cycles are usually anovulatory, but pregnancy has been reported as early as 5.5 years of age (Fig. 600.1). In males, testicular biopsies have shown stimulation of all elements of the testes, and spermatogenesis has been observed as early as 5-6 years of age. In affected females and males, height, weight, and height velocity are accelerated. The increased rate of bone maturation results in early closure of the epiphyses and compromised adult height, particularly

Table 600.1 Classification of Sexual Precocity

TRUE PRECOCIOUS PUBERTY OR COMPLETE ISOSEXUAL PRECOCITY (GNRH-Dependent Sexual Precocity or Premature Activation of the Hypothalamic GNRH Pulse Generator)
Idiopathic true precocious puberty CNS tumors Optic glioma associated with neurofibromatosis type 1 Hypothalamic astrocytoma Other CNS disorders Developmental abnormalities including hypothalamic hamartoma of the tuber cinereum Encephalitis Static encephalopathy Brain abscess Sarcoid or tubercular granuloma Head trauma Hydrocephalus Arachnoid cyst Myelomeningocele Vascular lesion Cranial irradiation True precocious puberty after late treatment of congenital virilizing adrenal hyperplasia or other previous chronic exposure to sex steroids True precocious puberty caused by pathogenic variants in the following genes: *KISS1R/GPR54* *KISS1* *MKRN3* *DLK1*
INCOMPLETE ISOSEXUAL PRECOCITY (HYPOTHALAMIC GNRH-INDEPENDENT) *Males* Gonadotropin-secreting tumors hCG-secreting CNS tumors (e.g., chorioepitheliomas, germinoma, teratoma) hCG-secreting tumors located outside the CNS (hepatoma, teratoma, choriocarcinoma) Increased androgen secretion by adrenal or testis Congenital adrenal hyperplasia (CYP21 and CYP11B1 deficiencies) Virilizing adrenal neoplasm Leydig cell adenoma Familial male-limited precocious puberty (FMPP, "testotoxicosis") (autosomal dominant gonadotropin-independent precocious Leydig cell and germ cell maturation) Cortisol resistance syndrome *Females* Ovarian cyst Estrogen-secreting ovarian or adrenal neoplasm Peutz-Jeghers syndrome with sex cord tumor with annular tubules (SCTAT) *Both Sexes* McCune-Albright syndrome Hypothyroidism Iatrogenic or exogenous sexual precocity (including inadvertent exposure to estrogens in food, drugs, or cosmetics)
VARIATIONS OF PUBERTAL DEVELOPMENT Premature thelarche Premature isolated menarche Premature adrenarche Adolescent gynecomastia in males Macroorchidism
HETEROSEXUAL PRECOCITY *Feminization in Males* Adrenal neoplasm Chorioepithelioma Testicular neoplasm (Peutz-Jeghers syndrome) Increased extraglandular conversion of circulating adrenal androgens to estrogen Iatrogenic (exposure to estrogens) *Virilization in Females* Congenital adrenal hyperplasia CYP21 deficiency CYP11B1 deficiency 3β-HSD deficiency Virilizing adrenal neoplasm (with or without Cushing syndrome) Virilizing ovarian neoplasm (e.g., arrhenoblastoma) Iatrogenic (exposure to androgens) Cortisol resistance syndrome Aromatase deficiency

CNS, Central nervous system; CYP11B1, 11-hydroxylase; CYP21, 21-hydroxylase; GnRH, gonadotropin-releasing hormone; hCG, human chorionic gonadotropin; 3β-HSD, 3β-hydroxysteroid dehydrogenase 4,5-isomerase; KISS1R/GPR54, kisspeptin receptor/G protein–coupled receptor 54.
Modified from Styne DM, Grumbach MM. Physiology and disorders of puberty. In Melmed S, Polonsky KS, Larsen PR, Kronenberg HM, eds. *Williams Textbook of Endocrinology,* 13th ed. Philadelphia: Elsevier; 2016: Table 25.25, p. 1163.

if puberty begins at a very early age. Historically, approximately 30% of females and an even larger percentage of males achieved a height below the fifth percentile as adults *without* treatment. Mental development is usually compatible with chronological age. Emotional behavior and mood swings are common, but serious psychologic problems are rare.

Although the clinical course is variable, three main patterns of pubertal progression can be identified. Most females (particularly those younger than 6 years of age at the onset) and a large majority of males have rapidly progressive puberty, characterized by rapid physical and osseous maturation, leading to a loss of height potential. An increasing percentage of females (older than 6 years of age at the onset with an idiopathic form) and, rarely, males have a slowly progressive variant, characterized by parallel advancement of osseous maturation and linear growth, with preserved height potential. Very rarely, central puberty may regress spontaneously (*unsustained* CPP). This variability in the natural course of sexual precocity underscores the need for longitudinal observation at the onset of sexual development before treatment is considered.

LABORATORY FINDINGS

Sex hormone concentrations are usually appropriate for the stage of puberty in both sexes (Table 600.2). Despite the availability of sensitive and specific assays for sex hormones, random serum estradiol concentrations are low or undetectable in the early phase of sexual precocity in females, as they are in normal puberty. In males, serum testosterone levels are usually detectable or elevated by the time the parents seek medical attention, provided that an early morning blood sample is obtained. With the use of highly sensitive assays, serum LH concentrations are undetectable in prepubertal children in random blood samples but become detectable in 50–75% of females and a higher percentage of males with CPP. Unfortunately, a number of hospitals use only moderately sensitive immunoenzymatic assays for LH and often insensitive assays for estradiol and testosterone, which decreases the diagnostic yield of these measurements. Measurement of LH in serial blood samples obtained during sleep has very

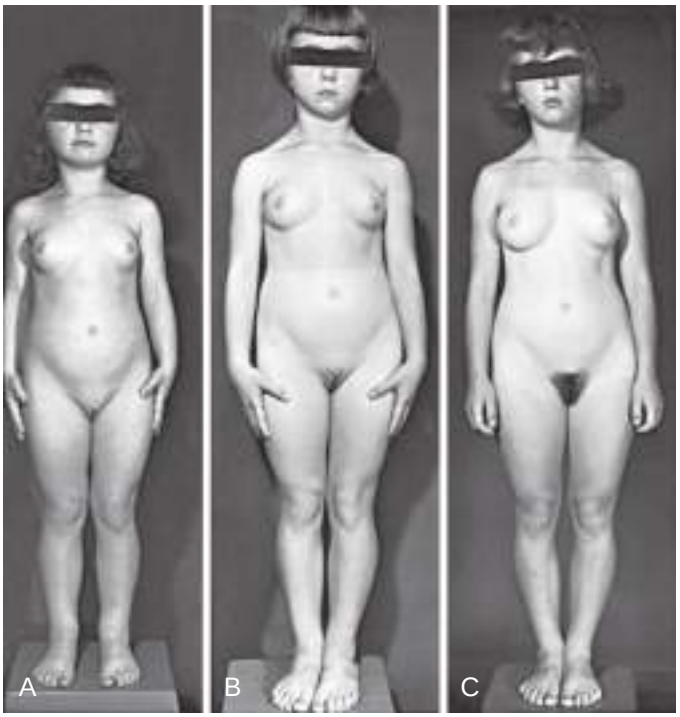

Fig. 600.1 Natural course of untreated idiopathic central precocious puberty. Patient (**A**) at 3 11/12, (**B**) at 5 8/12, and (**C**) at 8½ yr of age. Breast development and vaginal bleeding began at 2½ yr of age. Bone age was 7½ yr at 3 11/12 and 14 yr at 8 yr of age. Intelligence and dental age were normal for chronological age. Growth was completed at 10 yr; ultimate height was 142 cm (56 in). No effective therapy was available at the time this patient sought medical attention.

good diagnostic power and typically reveals a well-defined pulsatile secretion of LH in early puberty; it is, however, difficult to implement in a clinical setting. Dynamic tests using gonadotropin-releasing hormone (GnRH, intravenously; unavailable in the United States) or a GnRH agonist (leuprolide, subcutaneously) are helpful diagnostic tools, particularly for males, in whom a pubertal LH response (LH peak >5 IU/L) with predominance of LH over follicle-stimulating hormone (FSH) tends to occur early in the course of precocious puberty. In females with sexual precocity, however, the nocturnal LH secretion and the LH response to GnRH or GnRH agonist may be quite low at breast stages II to early III (LH peak, <5 IU/L), and the LH to FSH ratio may remain low until mid-advanced puberty. In such females with low LH response, the central nature of sexual precocity can be proven by detecting pubertal levels of estradiol (>50 pg/mL) 20-24 hours after stimulation with leuprolide.

Osseous maturation is variably advanced, often more than 2-3 standard deviations (SD). Pelvic ultrasonography in females reveals progressive enlargement of the ovaries, enlargement of the fundus, and then of the whole uterus to pubertal size. An MRI scan usually demonstrates physiologic enlargement of the pituitary gland, as seen in normal puberty; it may also reveal CNS pathology.

DIFFERENTIAL DIAGNOSIS

Organic CNS causes of central sexual precocity are more likely in males and in females who have rapid breast development, estradiol greater than 30 pg/mL, or are younger than 6 years of age. All children in these categories, and children with neurologic symptoms or signs, should undergo MRI scans of the brain and pituitary gland. Criteria for brain imaging in females older than 6 years are controversial, although some authorities recommend MRI scans for *all children* with CPP.

Gonadotropin-independent causes of isosexual precocious puberty must be considered in the differential diagnosis (see Tables 600.1 and 600.2). For females, these include tumors of the ovaries, autonomously functioning ovarian cysts, feminizing adrenal

Table 600.2 Differential Diagnosis of Sexual Precocity

DISORDER	PLASMA GONADOTROPINS	LH RESPONSE TO GNRH	SERUM SEX STEROID CONCENTRATION	GONADAL SIZE	MISCELLANEOUS
GONADOTROPIN DEPENDENT					
True (central) precocious puberty	Prominent LH pulses (premature reactivation of GnRH pulse generator), initially during sleep	Pubertal LH response	Pubertal values of testosterone or estradiol	Normal pubertal testicular enlargement or ovarian and uterine enlargement	MRI of brain to rule out CNS tumor or other abnormality
GONADOTROPIN INDEPENDENT					
Males					
Chorionic gonadotropin-secreting tumor in males	High hCG, low LH	Prepubertal LH response	Pubertal value of testosterone	Slight to moderate uniform enlargement of testes	Hepatomegaly suggests hepatoblastoma; MRI of brain if chorionic gonadotropin-secreting CNS tumor suspected
Leydig cell tumor in males	Suppressed	No LH response	High testosterone	Irregular, asymmetric enlargement of a testis	Testicular US
Familial, male-limited precocious puberty (FMPP, testotoxicosis)	Suppressed	No LH response	Pubertal values of testosterone	Testes symmetric and length >2.5 cm but smaller than expected for pubertal development; spermatogenesis occurs	Activating pathogenic variant of the LHCG receptor; autosomal dominant transmission
Virilizing congenital adrenal hyperplasia	Prepubertal	Prepubertal LH response	Elevated 17-OHP in CYP21 deficiency or elevated 11-deoxycortisol in CYP11B1 deficiency	Testes prepubertal	Autosomal recessive, variable severity/age of onset; may have salt loss in CYP21 deficiency or hypertension in CYP11B1 deficiency

Continued

Table 600.2 Differential Diagnosis of Sexual Precocity—cont'd

DISORDER	PLASMA GONADOTROPINS	LH RESPONSE TO GNRH	SERUM SEX STEROID CONCENTRATION	GONADAL SIZE	MISCELLANEOUS
Virilizing adrenal tumor	Prepubertal	Prepubertal LH response	High DHEAS, DHEA, and/or androstenedione values	Testes prepubertal	CT or MRI of abdomen
Females					
Granulosa cell tumor (follicular cysts may present similarly)	Suppressed	Prepubertal LH response	Very high estradiol	Ovarian enlargement on physical examination, CT, MRI, or US	Tumor often palpable on physical examination
Follicular cyst	Suppressed	Prepubertal LH response	Prepubertal to very high estradiol	Ovarian enlargement on physical examination, CT, MRI, or US	Single or recurrent episodes of menses and/or breast development; exclude McCune-Albright syndrome
Feminizing adrenal tumor	Suppressed	Prepubertal LH response	High estradiol, variable DHEAS increase	Ovaries prepubertal	Unilateral adrenal mass on CT or MRI
Nonclassical congenital adrenal hyperplasia	Prepubertal	Prepubertal LH response	Elevated 17-OHP in basal or in corticotropin-stimulated state	Ovaries prepubertal	Autosomal recessive
In Both Sexes					
McCune-Albright syndrome	Suppressed	Suppressed	Sex steroid pubertal; estradiol may be quite high in girls	Ovarian enlargement (asymmetrical) on US; slight (usually symmetrical) testicular enlargement	Skeletal survey/bone scan for polyostotic fibrous dysplasia and skin examination for café-au-lait macules
Primary hypothyroidism	LH prepubertal; FSH may be slightly elevated	Prepubertal; flat FSH, LH response	Estradiol often pubertal	Testicular enlargement; ovaries macrocystic	TSH very high, prolactin mildly elevated; T_4 low
INCOMPLETE PRECOCITY/VARIATIONS OF PUBERTY					
Premature thelarche	Prepubertal	Prepubertal LH	Prepubertal or early pubertal estradiol response	Ovaries prepubertal	Onset usually before 3 yr of age
Premature adrenarche (males)	Prepubertal	Prepubertal LH response	Prepubertal testosterone; DHEAS value appropriate for pubic hair stage	Testes prepubertal	Onset usually after 6 yr of age; more frequent in CNS-injured children
Premature adrenarche (females)	Prepubertal	Prepubertal LH response	Prepubertal estradiol; DHEAS value appropriate for pubic hair stage	Ovaries prepubertal	Onset usually after 6 yr of age; more frequent in brain-injured children

CNS, Central nervous system; CT, computed tomography; CYP, P450 cytochrome isoenzyme; DHEAS, dehydroepiandrosterone sulfate; FSH, follicle-stimulating hormone; GnRH, gonadotropin-releasing hormone; hCG, human chorionic gonadotropin; LH, luteinizing hormone; MRI, magnetic resonance imaging; 17-OHP, 17-hydroxyprogesterone; T_4, thyroxine; TSH, thyrotropin; US, ultrasonography.

Modified from Styne DM, Grumbach MM. Physiology and disorders of puberty. In: Melmed S, Polonsky KS, Larsen PR, Kronenberg HM, eds. *Williams Textbook of Endocrinology*, 13th ed. Philadelphia: Elsevier; 2016: Table 25.41, pp. 1196–1197.

tumors, McCune-Albright syndrome, and exogenous sources of estrogens. In males, congenital adrenal hyperplasia, adrenal tumors, Leydig cell tumors, human chorionic gonadotropin (hCG)–producing tumors, exposure to exogenous androgens, and familial male precocious puberty should be considered.

TREATMENT

Virtually all males and the large subgroup of females with *rapidly progressive precocious puberty,* including CPP beginning *before age 6 years,* are candidates for treatment. Females with slowly progressive idiopathic CPP do not seem to benefit in terms of height prognosis from GnRH agonist therapy. Former small-for-gestational-age infants may be at greater risk of short stature as adults and may require more aggressive treatment of precocious puberty, possibly in conjunction with human growth hormone (hGH) therapy. Certain patients require treatment predominantly for psychologic or social reasons, including children with special needs.

The observation that the pituitary gonadotropic cells require pulsatile, rather than continuous, stimulation by GnRH to maintain the ongoing release of gonadotropins provides the rationale for using GnRH agonists for treatment of CPP. By virtue of being more potent and having a longer duration of action than native GnRH, these GnRH agonists (after a brief period of stimulation) desensitize the gonadotropic cells of the pituitary to the stimulatory effect of endogenous GnRH and effectively halt the progression of central sexual precocity.

Long-acting formulations of GnRH agonists, which maintain fairly constant serum concentration of the drug for weeks or months, constitute the preparations of choice for treatment of CPP. In the United States, the available preparations include (1) **leuprolide acetate** (Lupron Depot Ped), in a dose of 0.2-0.3 mg/kg (7.5-15 mg) intramuscularly (IM) every 28 days; (2) longer-acting preparations of depot-leuprolide, including Lupron-Depot Ped 90-day, 11.25 or 30 mg IM every 3 months, or Fensolvi 45 mg subcutaneously every 24 weeks; (3) **histrelin** (Supprelin LA), a subcutaneous 50-mg implant with effects lasting at least 12 months; and (4) **triptorelin** (Triptodur), 22.5 mg IM every 24 weeks. Other preparations

are approved for treatment of precocious puberty in other countries. Recurrent sterile fluid collections at the sites of injections are an uncommon local side effect and occur in less than 1–3% of patients treated with IM depot-leuprolide. Breakage or malfunction of the histrelin implant is rare. Other available treatment options for children who cannot tolerate the products listed previously include subcutaneous injections of aqueous leuprolide, given once or twice daily (total dose 60 mcg/kg/24 hr), or intranasal administration of the GnRH agonist **nafarelin** (Synarel), 800 mcg bid. The potential for irregular compliance with daily administration, as well as the variable absorption of the intranasal route for nafarelin, may limit the efficacy and long-term benefit of the latter preparations. GnRH antagonists, including novel oral compounds, have not been investigated sufficiently in children and are not FDA approved.

Treatment results in decrease of the growth rate, generally to age-appropriate values, and an even greater decrease of the rate of osseous maturation. Some children, particularly those with greatly advanced (pubertal) bone age, may show marked deceleration of their growth rate and an arrest in the rate of osseous maturation. Treatment results in enhancement of the predicted height, more so in younger patients at diagnosis, male patients, and those children with more rapidly progressive CPP. In females, breast size may regress in those with Tanner stage II-III development but tends to remain unchanged in females with late stage III-V development or may even increase slightly because of progressive adipose tissue deposition. The amount of glandular tissue decreases. Pubic hair usually remains stable in females or may progress slowly during treatment, reflecting the gradual increase in adrenal androgens. Menses, if present, cease. Pelvic sonography demonstrates a decrease of the ovarian and uterine size. In males, there is a decrease of testicular size, variable regression of pubic hair, and decrease in the frequency of erections. Except for a reversible decrease in bone density (of uncertain clinical significance) and a reversible increase in body mass index (BMI) percentiles in some females, no serious adverse effects of GnRH analogs have been reported in children during or after treatment for sexual precocity. If treatment is effective, the serum sex hormone concentrations decrease to prepubertal levels (testosterone <10-20 ng/dL in males; estradiol <5-10 pg/mL in females). The serum LH and FSH concentrations, as measured by sensitive immunometric assays, decrease to less than 1 IU/L in most patients, although rarely does the LH return to truly prepubertal levels (<0.1 IU/L). Moreover, the incremental FSH and LH responses to GnRH stimulation decrease to less than 2-3 IU/L. Serum LH, FSH, and sex hormone levels are suppressed more completely and evenly by the histrelin implant than by GnRH agonist injections. Therapy is typically discontinued at a pubertal chronological age, after which puberty resumes promptly. In females, menarche generally appears at an average of 18 months (range 6-24 months) after cessation of IM therapy and somewhat earlier after removal of the histrelin implant. The addition of hGH to GnRH agonists has been used on an investigational basis in children with precocious puberty, markedly advanced bone age, and prediction of short stature. The available, albeit limited, data indicate that combined therapy may increase the adult height.

Visit Elsevier eBooks+ at eBooks.Health.Elsevier.com for Bibliography.

600.2 Precocious Puberty Resulting from Organic Brain Lesions

Wassim Chemaitilly and Luigi R. Garibaldi

Hypothalamic hamartoma is the most common brain lesion causing CPP (Fig. 600.2). This congenital malformation consists of ectopically located neural tissue, within which glial cells can produce transforming growth factor-α (TGF-α), which has the potential to activate the GnRH pulse generator. On MRI, it appears as a small pedunculated mass attached to the tuber cinereum or the floor of the third ventricle or, less often, as a sessile mass (Fig. 600.3) that remains static in size over years.

A wide variety of other CNS lesions or insults, usually involving the hypothalamus by scarring, invasion, or pressure, have been associated with CPP (see Table 600.1). These include postencephalitic scars, tuberculous meningitis, tuberous sclerosis, severe head trauma, and hydrocephalus, either isolated or associated with myelomeningocele. Gonadotropin-dependent precocious puberty occurs in 26–29% of children with tumors developing within or near the hypothalamus or optic pathways. Low-grade gliomas, the most common types of such neoplasms, are highly prevalent (15–20%) in children with neurofibromatosis type 1 (NF-1) and constitute the main etiologic factor for the central sexual precocity encountered in a small subset (approximately 3%) of children with NF-1.

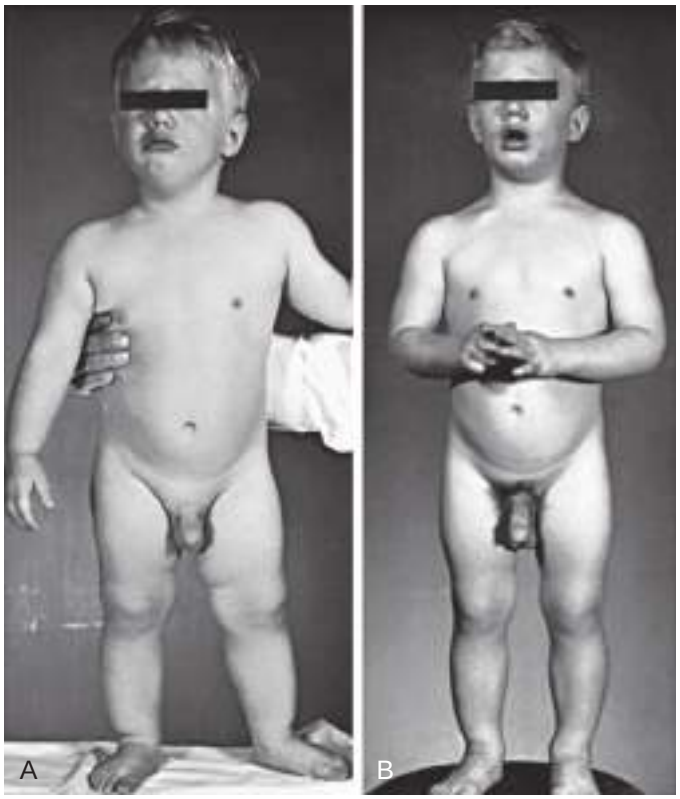

Fig. 600.2 Natural course of untreated precocious puberty with central nervous system lesion. Photographs at 1½ (A) and 2½ (B) yr of age. Accelerated growth, muscular development, osseous maturation, and testicular development were consistent with the degree of secondary sexual maturation. In early infancy, the patient began having frequent spells of rapid, purposeless motion; later in life, he had episodes of uncontrollable laughing with ocular movements. At 7 yr, he exhibited emotional lability, aggressive behavior, and destructive tendencies. Although a hypothalamic hamartoma had been suspected, it was not established until CT scanning became available when the patient was 23 yr of age. Epiphyses fused at 9 yr of age; final height was 142 cm (56 in). At 24 yr of age, he developed an embryonal cell carcinoma of the retroperitoneum.

About 50% of the tumors in the pineal region are germ cell tumors or astrocytomas; the remainder consists of a wide variety of histologically distinct tumor types. Pineal or hypothalamic germ cell tumors can cause CPP in males by secreting hCG, which stimulates the luteinizing hormone (LH) receptors in the Leydig cells of the testes (see Chapter 600.5).

CLINICAL MANIFESTATIONS

Hypothalamic hamartomas remain static in size or grow slowly and can be associated with gelastic or psychomotor seizures, but most often produce no signs other than precocious puberty. This is often rapidly progressive sexual precocity in very young children. For other lesions causing neurologic symptoms, the neuroendocrine manifestations may be present for 1-2 years before the tumor can be detected radiologically. Hypothalamic signs or symptoms such as diabetes insipidus, adipsia, hyperthermia, unnatural crying or laughing, obesity, and cachexia should suggest the possibility of an intracranial lesion. Visual signs (proptosis, decreased visual acuity, visual field defects) may be the first manifestation of an optic glioma.

The sexual precocity is always *isosexual,* and the endocrine patterns are generally those found in children without demonstrable organic

Fig. 600.3 MRI of a central nervous system lesion in a child with central precocious puberty. A 6-yr-old female was referred for stage IV breast development and growth acceleration. Serum luteinizing hormone and estradiol concentrations were in the adult range. The midsagittal T1-weighted image shows an isointense hypothalamic mass *(arrowheads)*, typical of a hamartoma. *(From Sharafuddin M, Luisiri A, Garibaldi LR, et al. MR imaging diagnosis of central precocious puberty: importance of changes in the shape and size of the pituitary gland. Am J Roentgenol. 1994;162:1167–1173.)*

lesions. In conditions other than hypothalamic hamartoma, growth hormone (GH) deficiency can occur and may be masked by the growth-promoting effect of the increased sex hormone levels. The pubertal staging of males treated with gonadotoxic modalities such as high-dose alkylating agents or testicular radiotherapy should not rely on testicular volume measurements because these are affected by treatment-induced germ cell and Sertoli depletion. Pubic hair development, scrotal thinning, and penile size may be better indicators, and providers should not hesitate to measure serum LH and testosterone levels when in doubt.

TREATMENT

GnRH agonists (depot forms or implant) are the treatment of choice of tumor-induced CPP. Neurosurgical treatment has been shown to have limited efficacy and to be associated with high complication rates in a subset of patients with hypothalamic hamartoma and associated intractable gelastic or psychomotor seizures. Stereotactic radiation therapy (gamma knife surgery) and, more recently, MRI-guided laser therapy, have been proposed as possible alternatives in these instances. For other neurologic lesions, therapy depends on the nature and location of the pathologic process. Combined GH therapy should be considered for patients with associated GH deficiency. The final height outcome will also depend on other factors such as the burden of disease from the primary tumor, side effects of cancer treatments, and associated chronic health conditions

Visit Elsevier eBooks+ at eBooks.Health.Elsevier.com for Bibliography.

600.3 Precocious Puberty After Irradiation of the Brain

Wassim Chemaitilly and Luigi R. Garibaldi

Children treated with cranial radiotherapy at a wide range of doses (18-50 Gy) are at an increased risk for gonadotropin-dependent precocious puberty. The prevalence of this condition in children treated with radiotherapy for tumors located outside of the hypothalamic pituitary or optic pathways region has been reported at 6.6%. Hydrocephalus, young age at exposure to radiation (<5 years), being female, and increased BMI are additional risk factors. This condition is often *associated with GH deficiency* and at times with other conditions (spinal irradiation, hypothyroidism) adversely affecting the adult height prognosis. Unless careful attention is paid to early signs of pubertal development in these children, the combination of GH deficiency and the growth-promoting effect of sex steroids often results in a normal growth rate at the expense of a rapidly advancing bone age and impaired adult height potential. The pubertal staging of males treated with gonadotoxic modalities such as high-dose alkylating agents or testicular radiotherapy should not rely on testicular volume measurements (see Chapter 600.2).

TREATMENT

GnRH analogs are effective in arresting pubertal progression, but concomitant GH (and/or thyroid hormone) deficiency should be diagnosed and treated promptly to improve the adult height prognosis.

Paradoxically, hypopituitarism with gonadotropin deficiency may subsequently develop as a late effect of high-dose CNS irradiation in patients with or without a history of precocious puberty, and it may require substitution therapy with sex steroids.

600.4 Syndrome of Precocious Puberty and Hypothyroidism

Wassim Chemaitilly and Luigi R. Garibaldi

The onset of puberty is usually delayed in children with mild forms of hypothyroidism. However, up to 50% of children with profound, untreated hypothyroidism of long duration may paradoxically develop precocious puberty (a condition known as **VanWyk-Grumbach syndrome**). **Hashimoto thyroiditis** is frequently the cause of such forms of hypothyroidism. Patients have the usual manifestations of hypothyroidism (see Chapter 603); the symptoms may be difficult to recognize in children with special needs. Children with precocious puberty caused by hypothyroidism have, contrary to other children with sexual precocity, decreased growth velocity and delayed bone age. Females may present with breast development and menstrual bleeding; the latter may occur even in females with minimal breast enlargement. Pelvic sonography may reveal large, multicystic ovaries. Males have testicular enlargement associated with modest or no penile enlargement. No pubic hair development occurs in either females or males. Enlargement of the sella, which is typical of long-standing primary hypothyroidism, may be demonstrated by skull film or MRI. Plasma levels of thyroid-stimulating hormone (TSH) are markedly elevated, often greater than 500 μU/mL, and those of prolactin and estradiol are mildly elevated. Although serum FSH is low and LH is undetectable, when measured by specific assays, the massively elevated concentrations of TSH appear to interact with the FSH receptor (specificity spillover), thus inducing FSH-like effects in the absence of LH effects on the gonads. The FSH-like effect suffices to induce estradiol secretion by the ovaries, whereas in males, testicular enlargement occurs without substantial testosterone secretion. Treatment of the hypothyroidism results in rapid return to normal of the biochemical and clinical manifestations. Possible progression to central puberty with rapid bone age advancement may occur in the months after the initiation of thyroid hormone replacement, a complication that would justify delaying puberty with GnRH analogs. Macroorchidism (testicular volume >30 mL) may persist in adult males despite adequate levothyroxine therapy. Children with a high risk of primary hypothyroidism, especially those with special needs such as patients with trisomy 21, should be screened at least annually via measurement of serum free T_4 and TSH levels.

Visit Elsevier eBooks+ at eBooks.Health.Elsevier.com for Bibliography.

600.5 Chorionic Gonadotropin-Secreting Tumors: Paraneoplastic Precocious Puberty

Wassim Chemaitilly and Luigi R. Garibaldi

hCG-secreting tumors are a rare cause of precocious puberty in males. Secretion of hCG activates luteinizing hormone/choriogonadotropin (LHCG) receptors in the Leydig cells causing testosterone production and virilization with minimal testicular enlargement. Testicular histology reveals interstitial cell hyperplasia with no spermatogenesis. Plasma levels of testosterone are elevated, whereas those of FSH and LH, as measured by specific assays, are low. Females with **hCG-secreting tumors** do not present with precocious puberty because the ovarian production of estradiol cannot occur in the absence of FSH stimulation.

HEPATIC TUMORS

All reported cases of hepatoblastoma causing isosexual precocious puberty have been in males, with the average age of onset of 2 years (range 4 months to 8 years). An enlarged liver or mass in the right upper quadrant should suggest the diagnosis. Plasma levels of hCG and α-fetoprotein (AFP) are usually markedly elevated and serve as useful markers for following the effects of therapy. As with other carcinomas of the liver, the prognosis for survival beyond 1-2 years from the time of diagnosis is poor.

INTRACRANIAL TUMORS

Nongerminomatous or mixed germ cell tumors, choriocarcinomas, teratomas, teratocarcinomas, and others account for <5% of intracranial tumors; are usually located in the neurohypophyseal area or the pineal area; and may cause precocious puberty in males if they secrete hCG—the mass effect can infrequently cause precocious puberty in females. Marked elevations of hCG and AFP often occur in the cerebrospinal fluid, although elevations in the blood may be modest. Treatment includes radiation, chemotherapy, and debulking surgery.

TUMORS IN OTHER LOCATIONS

Very rare locations include mediastinum, gonads, or even adrenal glands. Mediastinal germ cell tumors have been reported to cause precocious puberty in males with Klinefelter syndrome.

PERIPHERAL PRECOCIOUS PUBERTY

The adrenal causes of peripheral precocious puberty are discussed in Chapter 616, and the gonadal causes are discussed in Chapters 624 and 627.

Visit Elsevier eBooks+ at eBooks.Health.Elsevier.com for Bibliography.

600.6 McCune-Albright Syndrome

Luigi R. Garibaldi and Wassim Chemaitilly

McCune-Albright syndrome, or precocious puberty with *polyostotic fibrous dysplasia* and abnormal pigmentation, is a syndrome of endocrine dysfunction associated with patchy cutaneous pigmentation and fibrous dysplasia of the skeletal system. It is a rare condition with a prevalence between 1/100,000 and 1/1,000,000, characterized by autonomous hyperfunction of one or more glands (which may include pituitary, thyroid, and adrenal glands). An activating missense pathogenic variant in the *GNAS1* gene encoding the α-subunit of G_S, the G protein that stimulates cyclic adenosine monophosphate (cAMP) formation, results in activation of receptors (adrenocorticotropic hormone [ACTH], TSH, FSH, and LH receptors) that operate via a cAMP-dependent mechanism, as well as cell proliferation. Because the pathogenic variant is postzygotic rather than genomic, it is present variably in different tissues (somatic mosaicism) and hence results in variable clinical expression and limited diagnostic sensitivity of genetic testing from leukocyte DNA or unaffected tissues. The diagnostic sensitivity may improve with new techniques, however. Precocious puberty has been described predominantly in females (Fig. 600.4) and is characterized by recurrent ovarian cysts, bouts of estrogen secretion, and vaginal bleeding in the context of modest breast development. The age at onset in females is usually 3-6 years but has been reported as early as 4-6 months of age. Serum levels of LH and FSH are suppressed, with no response to GnRH stimulation. Estradiol levels fluctuate from low to markedly elevated (>300 pg/mL), are often cyclic, and may correlate with the size of the cysts. Precocious puberty is less commonly reported in males with McCune-Albright syndrome. Testicular enlargement is often symmetric and is followed by the appearance of phallic enlargement and pubic hair development, as in normal puberty. Testicular histology has shown foci or nodules (often sonographically detectable) of Leydig cell hyperplasia. In females and males, when the bone age reaches the usual pubertal age range, gonadotropin secretion begins and CPP ensues and overrides the antecedent (gonadotropin-independent) puberty. In females, menses become more regular, but often not completely so, and fertility has been documented.

Pubertal progression is variable in these patients. Functioning ovarian cysts often disappear spontaneously; aspiration or surgical excision of cysts is rarely indicated. For those females with persistent or recurrent estradiol secretion, **aromatase inhibitors** (which inhibit the final step of estrogen biosynthesis) such as **letrozole** (1.25-2.5 mg/day PO) have proven safe and effective in limiting the estrogen effects on pubertal and osseous maturation. The same compounds have also been used in males in combination with **antiandrogens**. These medications are not approved by the FDA for this indication. Associated therapy with **long-acting analogs of GnRH** is indicated only for young children whose puberty has shifted from a gonadotropin-independent to a predominantly gonadotropin-dependent mechanism. Ovarian torsion is a severe complication of large ovarian cysts.

EXTRAGONADAL MANIFESTATIONS

The hyperthyroidism that occurs in this condition is usually clinically mild or subclinical, unlike that observed in **Graves disease**. Mildly elevated triiodothyronine levels, suppressed TSH levels, and nodular abnormalities on ultrasound have been reported. Thyroidectomy is rarely necessary.

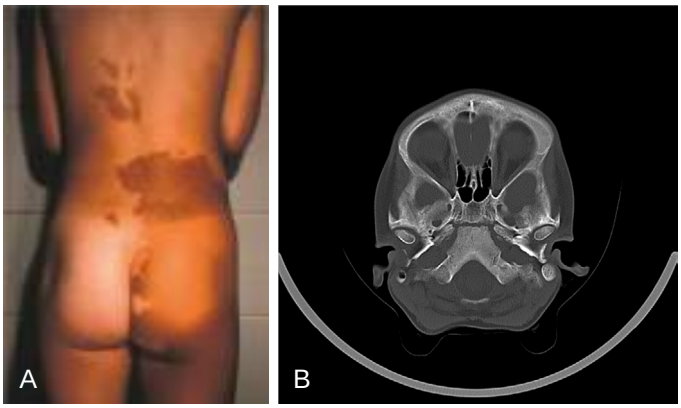

Fig. 600.4 Precocious puberty with McCune-Albright syndrome (MAS). **A,** A girl presented at 5 yr of age with early stage III breast development and vaginal bleeding. Note the extensive café-au-lait skin patches, some of which did not cross the midline. **B,** A girl presented with recurring episodes of mild breast enlargement and vaginal bleeding associated with ovarian cysts, starting at age 7 mo. She had no skin lesions and a negative skeletal survey and bone scan at age 4 yr. The diagnosis of MAS was established at 5 yr of age, when prominence of her left forehead and supraorbital ridge prompted a CT scan, which revealed unilateral thickening of the skull bones (**B**). Skull lesions are often hyperostotic, whereas long bone lesions usually have a lytic, "ground-glass" appearance.

Fig. 600.5 Polyostotic fibrous dysplasia in a 22-yr-old female. **A,** The femur is expanded and bowed with a "shepherd's crook" deformity. The femoral trabeculae are replaced by a "ground-glass" matrix. **B,** Diffuse sclerosis is seen in the hand and wrist with mild expansion and indistinct transition from the cortex to medullary space. *(From Thapa MM, Kaste SC, Meyer JS. Soft tissue bone tumors. In: Coley BD, ed. Caffey's Pediatric Diagnostic Imaging, 13th ed. Philadelphia: Elsevier; 2019: Fig. 138.31.)*

Cushing syndrome caused by bilateral nodular adrenocortical hyperplasia has occurred only in neonates or young infants. ACTH levels are low, and cortisol is elevated and not suppressible by dexamethasone. The condition may resolve spontaneously; if not, treatment is bilateral adrenalectomy.

Increased secretion of GH occurs uncommonly and is manifested clinically by **gigantism** or **acromegaly**. The growth rate is increased (even in the absence of precocious puberty); serum levels of GH are elevated, increase during sleep, and are poorly suppressed by oral glucose. Serum levels of prolactin are increased in most patients. Less than 50% of the patients have a demonstrable pituitary tumor. Treatment includes octreotide or lanreotide—long-acting somatostatin analogs—to lower the elevated GH levels or pegvisomant to antagonize the effect of GH at the receptor level.

Fibrous dysplasia of (usually) multiple bones (polyostotic) represents a major cause of morbidity in this syndrome (Fig. 600.5). The base of the skull and the proximal femurs are most commonly involved, but any bone can be affected. Even in the absence of deformities, a CT scan of the cranium is recommended by several investigators. The prognosis is favorable for longevity, but deformities, repeated fractures, pain, and occasional cranial nerve compression may result from the bony lesions. Bone pain often responds to IV pamidronate or other bisphosphonates. Extensive bony lesions may be associated with phosphaturia because of oversecretion of FGF23, leading to rickets or osteomalacia. Extraglandular manifestations of this syndrome are rare, but cardiovascular and hepatic involvement (severe neonatal cholestasis) may be life threatening.

Visit Elsevier eBooks+ at eBooks.Health.Elsevier.com for Bibliography.

600.7 Familial Male-Limited Gonadotropin-Independent Precocious Puberty

Wassim Chemaitilly and Luigi R. Garibaldi

This rare, autosomal dominant form of peripheral precocious puberty is transmitted from affected males and unaffected female carriers of the pathogenic variant to their male offspring. Signs of puberty appear by 2-3 years of age. The testes are only slightly enlarged. Testicular biopsies show Leydig cell maturation and, sometimes, marked hyperplasia. Maturation of seminiferous tubules may be present. Testosterone levels are variably elevated, often markedly so, even above the adult male range; however, baseline levels of LH are prepubertal, pulsatile secretion of LH is absent, and LH does not respond to stimulation with GnRH or a GnRH agonist. The cause for activation of Leydig cells independently of gonadotropin stimulation is a missense pathogenic variant of *LHCGR,* which encodes the LHCG receptor leading to constitutive activation of cAMP production. Osseous maturation may be markedly advanced; when it reaches the pubertal age range, hypothalamic maturation shifts the mechanism of pubertal development to a gonadotropin-dependent one. This sequence of events is similar to that occurring in children with McCune-Albright syndrome (see Chapter 600.6) or in those with congenital adrenal hyperplasia (see Chapter 616).

Gonadotropin-independent precocious puberty has been diagnosed in a few unrelated males with **type IA pseudohypoparathyroidism** with a specific pathogenic variant of *GNAS* that encodes the $G_s\alpha$ protein. This pathogenic variant is inactivating at normal body temperature and causes pseudohypoparathyroidism, but in the cooler temperature of the testes, it is constitutionally activating, resulting in adenyl cyclase stimulation and production of testosterone. Although this pathogenic variant differs from the constitutive LH receptor pathogenic variant, which usually causes familial male gonadotropin-independent precocious puberty, the end result is the same.

TREATMENT

Young males have been treated with ketoconazole (10-15 mg/kg/day in 8-hour divided doses), an antifungal drug that inhibits C-17,20-lyase and testosterone synthesis. Complications of ketoconazole include liver toxicity and tachyphylaxis. A combination of antiandrogens (such as spironolactone 50-100 mg bid, flutamide 125-250 mg daily or bid, or bicalutamide 25-50 mg daily) and **aromatase inhibitors** (letrozole 2.5 mg/day or anastrozole 1 mg/day) has been used—the latter compounds to suppress estrogens derived from androgens, which potently stimulate bone maturation. These medications are unable to revert the serum testosterone to normal (prepubertal) concentrations or completely offset the unfavorable effects of the elevated sex hormones. They slow down, but do not halt, the progression of puberty and may not improve the height prognosis. Males whose GnRH pulse generator has matured require combined therapy with GnRH agonists.

Visit Elsevier eBooks+ at eBooks.Health.Elsevier.com for Bibliography.

600.8 Incomplete (Partial) Precocious Development

Wassim Chemaitilly and Luigi R. Garibaldi

Isolated development of the breasts in females and growth of sexual hair in both sexes without other signs of puberty are the two most common forms of incomplete precocity and are not unusual in a pediatric practice.

PREMATURE THELARCHE

This term applies to a sporadic, transient condition of isolated breast development that most often appears in the first 2 years of life. In some females, breast development is present at birth and persists. It may be unilateral or asymmetric and often fluctuates in degree. Growth and osseous maturation are normal or slightly advanced. The genitalia show no evidence of estrogenic stimulation. Breast development may regress after 2 years, often persists for 3-5 years, and is rarely progressive. Menarche generally occurs at a normal age, and reproduction is also normal. Basal serum levels of FSH and the FSH response to GnRH stimulation may be greater than that seen in normal controls. Plasma levels of LH and estradiol are typically undetectable. Pelvic ultrasound reveals normal-sized ovaries, but a few small (<9 mm) cysts are not uncommon.

In some females, breast development may be associated with definite evidence of systemic estrogen effects, such as growth acceleration or bone age advancement. Pelvic sonography may reveal enlarged ovaries and/or uterus. This condition, referred to as **exaggerated or atypical thelarche**, differs from CPP because it spontaneously regresses. Leuprolide or GnRH stimulation elicits a robust FSH response, a low LH response, and (after leuprolide only) a moderate estradiol increment at 24 hours (average 60-90 pg/mL). The pathogenesis of typical and exaggerated forms of thelarche is unclear. Delayed inactivation of the hypothalamic-pituitary-ovarian axis, which is active during the prenatal and early postnatal period, increased peripheral sensitivity to estrogens, and other possibilities are unproven hypotheses. In addition to a detailed history, a bone age should be obtained if there are any unusual features. Random serum concentrations of FSH, LH, and estradiol are generally low and not diagnostic. Pelvic ultrasound examination or leuprolide stimulation testing is occasionally indicated. Continued observation is important because the condition cannot be readily distinguished from true precocious puberty. Regression and recurrence suggest functioning **follicular cysts**. Occurrence of thelarche in children older than 3 years of age most often is caused by a condition other than **benign premature thelarche**.

PREMATURE PUBARCHE (ADRENARCHE)

This term has traditionally applied to the appearance of sexual hair before the age of 8 years in females or 9 years in males without other evidence of maturation. It is much more frequent in females than in males. The higher prevalence of this condition in African American and, to a smaller extent, Latino females in comparison to White females may suggest that the cutoff age for the definition of *premature* should be adjusted for different ethnic groups on epidemiologic data. Hair appears on the mons and labia majora in females and perineal and scrotal area in males; axillary hair generally appears later. Adult-type axillary odor is common. Affected children are often slightly advanced in height and osseous maturation. **Premature adrenarche** is an early maturational event of adrenal androgen production. It coincides with precocious maturation of the zona reticularis, traditionally believed to be associated with a decrease in 3β-hydroxysteroid dehydrogenase activity and an increase in C-17,20-lyase activity. These enzymatic changes result in increased basal and ACTH-stimulated serum concentrations of the Δ^5-steroids (17-hydroxypregnenolone and dehydroepiandrosterone [DHEA]) and, to a lesser extent, of the Δ^4-steroids (particularly androstenedione) compared with age-matched control subjects. One class of androgens, the 11-oxygenated steroids, have been reported to play an important role in adrenal physiology and pathology, including adrenarche. **Idiopathic premature adrenarche** is a slowly progressive condition that requires no therapy. However, a subset of patients presents with **atypical premature adrenarche** characterized by one or more features of systemic androgen effects, such as marked growth acceleration, clitoral (females) or phallic (males) enlargement, cystic acne, and advanced bone age (2 SD greater than the mean for age). In this subgroup, an ACTH stimulation test with measurement of serum 17-hydroxyprogesterone concentration is indicated to rule out **nonclassical congenital adrenal hyperplasia** due to 21-hydroxylase deficiency. The prevalence of nonclassical 21-hydroxylase deficiency is approximately 3–6% of unselected children with precocious pubarche; other enzyme defects (i.e., 3β-hydroxysteroid dehydrogenase or 11β-hydroxylase deficiencies) are extremely rare. Although idiopathic premature adrenarche has been considered a benign condition, longitudinal observations suggest that approximately 50% of females with premature adrenarche are at high risk for hyperandrogenism and **polycystic ovary syndrome**, alone or more often in combination with other components of so-called metabolic syndrome (insulin resistance possibly progressing to type 2 diabetes mellitus, dyslipidemia, hypertension, increased visceral fat) as adults. Whether the unfavorable progression to pubertal hyperandrogenism can be prevented by insulin-sensitizing agents (metformin 850-2000 mg/day) or lifestyle interventions (diet, exercise) remains to be proven in large studies. An increased risk of premature adrenarche and **metabolic syndrome** has been documented in children born small for their gestational age. This appears to be associated with insulin resistance and decreased β-cell reserve, perhaps as a consequence of fetal undernutrition.

PREMATURE MENARCHE

This is a rare entity, much less frequent than premature thelarche or premature adrenarche, and is a diagnosis of exclusion. In females with isolated vaginal bleeding in the absence of other secondary sexual characteristics, more common causes, such as vulvovaginitis, a foreign body (typically associated with malodorous discharge), or sexual abuse, and uncommon causes, such as urethral prolapse and sarcoma botryoides, must be carefully excluded. Most females with idiopathic premature menarche have only one to three episodes of bleeding; puberty occurs at the usual time, and menstrual cycles are normal. Plasma levels of gonadotropins are low, but estradiol levels may be occasionally elevated, probably owing to episodic ovarian estrogen secretion associated with ovarian follicular cysts that can be sometimes detected on ultrasound.

Visit Elsevier eBooks+ at eBooks.Health.Elsevier.com for Bibliography.

600.9 Medicational Precocity

Luigi R. Garibaldi and Wassim Chemaitilly

Various medicaments can induce the appearance of secondary sexual characteristics (i.e., peripheral precocious puberty). Examples include the accidental ingestion of estrogens (including contraceptive pills) and the administration of anabolic steroids. Exogenous estrogens may produce a darkening of the areola that is not usually seen in central sexual precocity. The most common cause of medicational precocity is currently related to the widespread use of **testosterone gels or creams**, which are applied to the skin for treatment of male hypogonadism. Systemic absorption from the skin area of a male relative where the gel/cream was applied may result in elevated serum testosterone levels (50-100 mg/dL or higher), with ensuing virilization of exposed children and women. Intense application of diaper rash creams or ointments has recently been reported to cause mild pubarche, with an unclear mechanism.

Less commonly, estrogens in cosmetics, hair creams, and breast augmentation creams cause breast development in females and gynecomastia in males via percutaneous absorption. Lavender and tea tree oils have been associated with prepubertal gynecomastia in several reports. Genistein, a compound from soy, has estrogenic activity in mice, but data in humans are conflicting. The physical changes disappear after cessation of exposure to the hormones. A careful history focused on exploring the possibility of accidental exposure to, or ingestion of, sex hormones is important.

Visit Elsevier eBooks+ at eBooks.Health.Elsevier.com for Bibliography.

600.10 Delayed or Absent Puberty

Peter M. Wolfgram

For hypofunction of testis, see Chapter 623. For hypofunction of ovaries, see Chapter 626.

Delayed puberty is the failure of development of any pubertal feature by 13 years of age in females or by 14 years of age in males. A lower cutoff may be appropriate in a child with a strong familial pattern of early puberty.

DIFFERENTIAL DIAGNOSIS

Delay or absence of puberty is caused by:

- Constitutional delay: A variant of normal.
- Hypogonadotropic hypogonadism: Low gonadotropin levels as a result of a defect of the hypothalamus and/or pituitary gland (Tables 600.3, 600.4, and 600.5).
- Hypergonadotropic hypogonadism: High gonadotropin levels as a result of a lack of negative feedback because of a gonadal problem (see Tables 600.3, 600.4, and 600.5). Females may have evidence of adrenarche with absence of normal breast development.

Table 600.3 Classification of Delayed Puberty and Sexual Infantilism

IDIOPATHIC (CONSTITUTIONAL) DELAY IN GROWTH AND PUBERTY (DELAYED ACTIVATION OF HYPOTHALAMIC GNRH PULSE GENERATOR)

HYPOGONADOTROPIC HYPOGONADISM: SEXUAL INFANTILISM RELATED TO GONADOTROPIN DEFICIENCY

CNS Disorders

Tumors
- Craniopharyngiomas
- Germinomas
- Other germ cell tumors
- Hypothalamic and optic gliomas
- Astrocytomas
- Pituitary tumors (including MEN-1, prolactinoma)

Other Causes
- Langerhans histiocytosis
- Postinfectious lesions of the CNS
- Vascular abnormalities of the CNS
- Radiation therapy
- Congenital malformations especially associated with craniofacial anomalies
- Head trauma
- Lymphocytic hypophysitis

Isolated Gonadotropin Deficiency

Kallmann syndrome (with hyposmia or anosmia; without anosmia)
GnRH receptor pathogenic variant
Congenital adrenal hypoplasia (*DAX1* pathogenic variant)
Isolated LH deficiency
Isolated FSH deficiency
Prohormone convertase 1 deficiency (PCI)

Idiopathic and Genetic Forms of Multiple Pituitary Hormone Deficiencies Including PROP1 Pathogenic Variant

Miscellaneous Disorders

See Table 600.4 for syndromic etiologies
Functional gonadotropin deficiency
- Chronic systemic disease and malnutrition
- Sickle cell disease
- Cystic fibrosis
- Acquired immunodeficiency syndrome (AIDS)
- Chronic gastroenteric disease
- Chronic renal disease
- Malnutrition

Miscellaneous Disorders (continued)
- Anorexia nervosa
- Bulimia
- Psychogenic amenorrhea
- Impaired puberty and delayed menarche in female athletes and ballet dancers (exercise amenorrhea)
- Hypothyroidism
- Diabetes mellitus
- Cushing disease
- Hyperprolactinemia
- Marijuana use
- Gaucher disease

HYPERGONADOTROPIC HYPOGONADISM

Males

The syndrome of seminiferous tubular dysgenesis and its variants (Klinefelter syndrome)
Other forms of primary testicular failure
- Chemotherapy
- Radiation therapy
- Testicular steroid biosynthetic defects
- Sertoli-only syndrome
- LH receptor mutation
- Anorchia and cryptorchidism
- Trauma/surgery

Females

The syndrome of gonadal dysgenesis (Turner syndrome) and its variants
XX and XY gonadal dysgenesis
- Familial and sporadic XX gonadal dysgenesis and its variants
- Familial and sporadic XY gonadal dysgenesis and its variants

Aromatase deficiency
Other forms of primary ovarian failure
- Premature menopause
- Radiation therapy
- Chemotherapy
- Autoimmune oophoritis
- Galactosemia
- Glycoprotein syndrome type 1
- Resistant ovary
- FSH receptor pathogenic variant
- LH/hCG resistance
- Polycystic ovarian disease
- Trauma/surgery
- Noonan or pseudo-Turner syndrome
- Ovarian steroid biosynthetic defects

CNS, Central nervous system; FSH, follicle-stimulating hormone; hCG, human chorionic gonadotropin.
From Styne DM, Grumbach MM. Physiology and disorders of puberty. In Melmed S, Polonsky KS, Larsen PR, Kronenberg HM, eds. *Williams Textbook of Endocrinology*, 13th ed. Philadelphia: Elsevier; 2016: Table 25.15, p. 1129.

Table 600.4 Syndromes Associated with Pubertal Delay

	PHENOTYPE	GENETIC DEFECT
Prader-Willi syndrome	Cognitive impairment, morbid obesity, hypotonia	Deletions within paternally imprinted 15q 11.2-12 region
Bardet-Biedl syndrome	Cognitive impairment, obesity, retinitis pigmentosa, postaxial polydactyly	*BBS 1-11* (multiple loci) 20p12, 16q21, 15q22.3-23, 14q32.1
Biemond syndrome	Iris coloboma, polydactyly, short stature	
CHARGE anomaly	Coloboma, heart malformations, choanal atresia, growth retardation, genital anomalies and ear anomalies, HH, olfactory bulb aplasia, hypoplasia	*CHD7*
Adrenohypoplasia congenita	Primary adrenal deficiency	*NR0B1*
Septo-optic dysplasia	Small, dysplastic pale optic discs, pendular nystagmus, midline hypothalamic defect with diabetes insipidus, GH, ACTH, TSH, and LH/FSH deficiency, absent septum pellucidum	*HESX1*
Solitary median maxillary incisor syndrome	Prominent midpalatal ridge	*SHH 7q3*
Börjeson-Forssman-Lehmann syndrome	Cognitive impairment, gynecomastia, moderate short stature, truncal obesity	*PHF6*
Gordon Holmes syndrome	Cerebellar ataxia, dementia, chorioretinopathy, anterior hypopituitarism	*RNF216/OTUD4* *PNPLA6*

Modified from Howard SR, Dunkel L. Delayed puberty – phenotype diversity, molecular genetic mechanisms, and recent discoveries. *Endocrine Rev.* 2019;40:1285–1317, Table 3, p. 1301.

Table 600.5 Molecular Basis for Developmental Disorders Associated with Hypogonadotropic Hypogonadism

GENE	PHENOTYPE	COMPLEX PHENOTYPE
ISOLATED HYPOGONADOTROPIC HYPOGONADISM		
Kallmann Syndrome or Normosmic IHH (With the Same Pathogenic Gene Variant)		
KAL1 (Xp22.3)	X-linked Kallmann syndrome	Anosmia/hyposmia, renal agenesis, dyskinesia
FGFR1 (KAL2) (8p11.2)	Autosomal dominant Kallmann syndrome (± recessive)	Anosmia/hyposmia, cleft lip/palate
FGF8 (ligand for FGFR1) (10q25)		
NELF (9p34.3)	Autosomal dominant (?) Kallmann syndrome	
PROK2 (3p21.1)	Autosomal recessive Kallmann syndrome	
*PROKR2** (20p12.3)		
CHD7 (8p12.1)	Autosomal dominant (some)	CHARGE syndrome includes hyposmia
Normosmic Isolated Hypogonadotropic Hypogonadism		
GNRH1 (8p21-11.2)	Autosomal recessive	
*GNRHR** (4q13.2-3)	Autosomal recessive (± dominant)	
*GPR54** (19p13.3)	Autosomal recessive	
SNRPN		Prader-Willi syndrome
Lack of function of paternal 15q11-q13 region or maternal uniparental disomy		Obesity
LEP (7q31.3)	Autosomal recessive	Obesity
LEPR (1p31)	Autosomal recessive	Obesity
NR0B1 (DAX1) (X21.3-21.2)	X-linked recessive	Adrenal hypoplasia
TAC3 (12q13-12)	Autosomal recessive	
TACR3 (4q25)	Autosomal recessive	
Multiple Pituitary Hormone Deficiencies		
PROP1 (POU1F1)	Autosomal recessive GH, PRL, TSH, and LH/FSH (less commonly, later-onset ACTH deficiency)	
HESX1 (RPX)	Autosomal recessive; and heterozygous mutations Multiple pituitary deficiencies including diabetes insipidus, but LH/FSH uncommon	Septo-optic dysplasia
LHX3	Autosomal recessive GH, PRL, TSH, FSH/LH	Rigid cervical spine
PHF6	X-linked; GH, TSH, ACTH, LH/FSH	Börjeson-Lehmann syndrome: mental retardation; facies

*A G-protein–coupled receptor.
ACTH, Adrenocorticotropic hormone; CHD7, chromatin-remodeling factor; DAX1, dosage-sensitive sex reversal-adrenal hyperplasia congenita critical region on the X chromosome, gene 1; FGF, fibroblast growth factor; FSH, follicle-stimulating hormone; GH, growth hormone; GNRH, gonadotropin-releasing hormone; GPR54, kisspeptin G protein–coupled receptor 54; HESX1, homeobox gene expressed in ES cells; IHH, idiopathic hypogonadotropic hypogonadism; LEP, leptin; LH, luteinizing hormone; LHX3, lim homeobox gene 3; NELF, nasal embryonic luteinizing hormone–releasing factor; NR0B1, nuclear receptor family 0, group B, member 1; PHF6, plant homeodomain–like finger gene; PRL, prolactin; PROK2, prokineticin 2; PROP1, prophet of Pit-1; R, receptor; SNRPN, small nuclear ribonucleoprotein polypeptide SmN; TAC3, neurokinin 3; TSH, thyroid-stimulating hormone.
From Styne DM, Grumbach MM. Physiology and disorders of puberty. In: Melmed S, Polonsky KS, Larsen PR, Kronenberg HM, eds. *Williams Textbook of Endocrinology*, 13th ed. Philadelphia: Elsevier; 2016: Table 25.19, p. 1138.

Constitutional Delay of Growth and Puberty

This is the most common cause of delayed puberty and a normal variant of pubertal timing. It is predominately diagnosed in males, likely as a result of ascertainment bias from referral patterns. The cause is unknown, but approximately 50% of affected patients have a first-degree relative with delayed puberty and/or late growth. This tendency can occur in a child of the same gender as the affected parent or in a child of the opposite gender. An affected child typically presents in early adolescence, when peers are beginning to develop and having growth spurts but the patient is not. The patient's height is usually at or below the third percentile. In a classic patient, the affected child had a normal length at birth, followed by a slowdown in height velocity between 6 months and 2 years of age that resulted in a decreased height percentile, and then normal or near-normal height velocity thereafter along this decreased height percentile. The physical examination findings are unremarkable, except at the typical age of puberty the child will have delayed pubertal development and growth. The cardinal diagnostic finding is a bone age that is moderately delayed (or younger appearing) than the typical bone age for the patient's actual chronological age. There may also be a history of delayed dentition. Without intervention, final adult heights usually reach or approximate the genetic target height range. However, rarely, children with constitutional delay may have a blunted pubertal growth spurt in relation to their peers and therefore may not reach their target height range.

Hypogonadotropic Hypogonadism

A variety of CNS anomalies or injuries may disrupt production of gonadotropins. The GnRH pulse generator may be disrupted by an interfering substance, such as excess prolactin, chronic illness, malnutrition, or excessive physical activity. The hypothalamic arcuate nucleus may be damaged by trauma, radiation, infection, infiltration, increased intracranial pressure, or surgery. The most common mass lesions are craniopharyngiomas, gliomas, and cysts. Of note, congenital conditions or malformations may have allowed enough GnRH, LH, and FSH for infantile development but may not be enough later to begin and sustain puberty.

Kallmann Syndrome

This is the combination of a deficiency of gonadotropins with an impaired or absent sense of smell. Other features may include color blindness, atrial septal defects, and renal structural anomalies (unilateral renal agenesis). The X-linked form is caused by a pathogenic variant of *KAL*; there are autosomal recessive and autosomal dominant forms.

LH and FSH deficiencies may be isolated or accompanied by multiple pituitary hormone deficiencies. The deficiency may be a result of pituitary damage from trauma, radiation, infection, sickle cell disease, compression by infiltrate or tumor, or autoimmune processes. In differentiating primary pituitary deficiency from that secondary to hypothalamic deficiency, the clinician should remember that all pituitary hormones, except prolactin, are stimulated by hypothalamic-releasing hormones; however, prolactin is inhibited by hypothalamic prolactin inhibitory factor (dopamine). Therefore if all pituitary hormones, including prolactin, are deficient, the problem is in the pituitary gland. If prolactin levels are present or even elevated but the other pituitary hormones are deficient, the problem is above the pituitary gland, in the stalk or hypothalamus. In the case of isolated LH and FSH deficiencies, the primary abnormality may lie within the pituitary-hypothalamic neurons producing GnRH or farther upstream of the GnRH-secreting neurons. In particular, defects in molecules required for proper migration of GnRH neurons (including the *KAL* gene) or lack of necessary signaling to GnRH-producing neurons (defects in kisspeptin or neurokinin B and their receptors) can result in LH and FSH deficiency through inappropriate GnRH secretion.

Hypergonadotropic Hypogonadism: Males

If the testes are small, they may have been damaged by torsion, sickle cell disease, infection, autoimmune disease, chemotherapy, or radiation and may not be able to respond to LH and FSH stimulation. If the male is of pubertal age (bone age is greater than 10 years) and the hypothalamus has matured, the serum LH and FSH will be high because of lack of testicular response. Also, if there is a problem with testicular LH receptors, the LH can be high but the testosterone will not appropriately increase.

Klinefelter Syndrome

This occurs in 1:500 males and is often associated with a 47,XXY karyotype; common features include reduced intelligence, adolescent gynecomastia (often severe), and small, firm testes. The testes rarely exceed 5 mL in volume (approximately 25% of the average adult volume). Patients are often tall and thin with an eunuchoid habitus and may have delayed puberty with high FSH and LH. Virilization may be incomplete, the phallus is often smaller than average, and infertility approaches 100%.

Hypergonadotropic Hypogonadism: Females

In this condition, the ovary may be unable to synthesize estrogen (an inherited metabolic defect), the ovary may not be formed normally (dysgenesis), or the ovary may have been damaged by any of the factors listed for testicular damage and by galactosemia.

The ovary may be intact but may not be stimulated by gonadotropins—for example, FSH is present but there is an FSH receptor problem, so estradiol is not made appropriately.

Turner Syndrome

The two most common features of Turner syndrome are short stature (involving the limbs to a greater degree than the trunk) and ovarian insufficiency with high FSH. Lymphedema and a webbed neck are diagnostic features present in a neonate. Additional features include shield chest, increased carrying angle (cubitus valgus), short fourth metacarpal, hypoplastic nails, renal anomalies, and left-sided heart defects (coarctation of the aorta, bicuspid aortic valve). Approximately 50% of affected females have no stigmata except short stature and thus are typically identified later. About 20% may have spontaneous puberty with functioning ovaries for at least a short period, which is in large part dependent on the child's karyotype; the infertility rate is greater than 99%.

Females with Delayed or Absent Adrenarche

If a female has advanced breast development but no androgen signs, she may have a disorder of androgen activity as occurs in **androgen insensitivity syndrome** (testicular feminization). In females, the androgens come predominantly from the adrenal glands (adrenarche). If the bone age is less than 8 years, adrenarche may simply be delayed (delayed adrenarche). However, if the bone age is older, there may be an inherited problem in androgen synthesis from an enzyme deficiency, or the adrenal may be damaged secondary to autoimmune, infectious, or hypoxic injury. In these latter conditions of adrenal damage, other signs of adrenal insufficiency would be evident.

DIAGNOSTIC APPROACH TO DELAYED PUBERTY

A normal growth rate with delayed, but not absent, puberty and a family history of late puberty suggest the diagnosis of constitutional delay of growth and puberty, which is the most commonly encountered cause. A bone age that correlates with the patient's current pubertal status but is delayed for their chronological age confirms the clinical impression; no other testing is necessary.

Initial evaluation should include:

- Medical history: trauma, illness, medications (e.g., stimulants, chemotherapy), radiation, infection, malnutrition, autoimmune problems, sickle cell disease status, stresses, growth records, galactosemia
- Review of symptoms: vision problems, headache, vomiting, inability to detect odors (hyposmia or anosmia), age at onset of androgen signs, age at onset of estrogen signs, small genitalia at birth, signs of primary adrenal insufficiency such as hyperpigmentation, need for deodorant, need to wash hair more frequently
- Family history: timing of maternal and paternal growth and pubertal development; siblings and cousins with delayed development
- Physical examination: signs of chronic disease, temperature, blood pressure, height, weight, head circumference, dental age, hyperpigmentation, pubic and axillary hair, adult body odor, evidence of skin and hair oils, visual fields, optic discs, ability to detect odors, breast development, vaginal cornification/discharge, penis size, scrotal development, testicular volume, pubic hair stages, neurologic status, affect or mood, intellectual ability, dysmorphic features

Initial laboratory evaluation screens for chronic disease (complete blood cell count, chemistry profile, sedimentation rate), hypothyroidism (free thyroxine and TSH), and hyperprolactinemia (prolactin level) should be obtained. If growth is slow, the clinician should measure insulin-like growth factor-1 level (marker of basal GH activity) and consider GH testing. The clinician should measure testosterone levels in males and estradiol levels in females.

Measurements of random FSH and LH and results of a GnRH stimulation test may differentiate between hypogonadotropic hypogonadism and primary gonadal failure (Figs. 600.6 and 600.7). Elevated gonadotropin levels support a diagnosis of primary gonadal failure. A random LH or an LH after GnRH is not typically helpful in distinguishing between constitutional delay and hypogonadotropic hypogonadism because with both diagnoses the LH will be low. However, the child with constitutional delay eventually develops an appropriate pubertal development and LH values. If there are elevated gonadotropins, chromosomal karyotyping can be performed (Klinefelter syndrome in males and Turner syndrome in females).

If Kallmann syndrome is being considered, an MRI scan may show abnormalities in the olfactory region. If a 46,XX female has unexplained ovarian failure, antiovarian antibodies and müllerian-inhibiting substance can assess ovarian follicle reserve and potential fertility. In males, an hCG stimulation test to evaluate ability to produce testosterone and a serum level of müllerian-inhibiting substance (secreted by

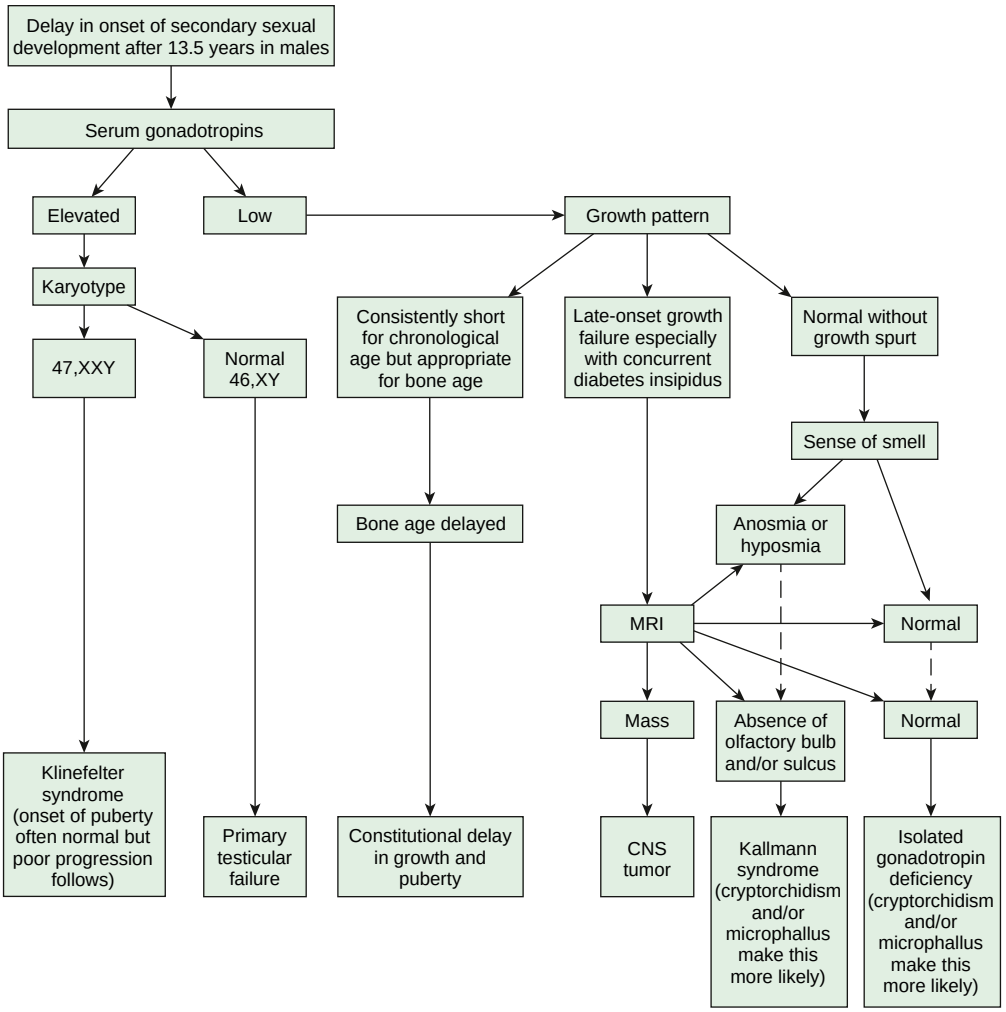

Fig. 600.6 Diagnostic algorithm for the evaluation of delayed puberty in males. CNS, Central nervous system; MRI, magnetic resonance imaging. *(From Styne DM, Grumbach MM. Physiology and disorders of puberty. In Melmed S, Polonsky KS, Larsen PR, Kronenberg HM, eds. Williams Textbook of Endocrinology, 13th ed. Philadelphia: Elsevier; 2016: Fig. 25.48.)*

Sertoli cells) are useful for determining whether functional testicular tissue is present.

TREATMENT OF DELAYED PUBERTY

If delayed puberty is a normal physiologic variant (constitutional delay of growth and puberty), sex steroid replacement is not medically necessary. Watchful waiting is usually the appropriate course of action. However, adolescent males with constitutional delay of growth and puberty who are short, underdeveloped, and psychologically compromised may benefit from a short course of testosterone therapy. This is usually given as long-acting intramuscular testosterone, at a dosage of 50-100 mg every 4 weeks for a course ranging between 6 and 12 months. Treatment is generally begun at about 14 years of age and, if possible, when the testes have enlarged to about 6-8 mL in volume. These doses stimulate height and weight gain, allow adequate virilization (increased pubic and axillary hair growth and penile enlargement), and do not typically suppress pituitary FSH and LH secretion, thereby allowing simultaneous endogenous pubertal progression (testicular enlargement). This narrows the physical gap between the patient and peers without causing undue advancement of bone age. Acne is the principal side effect, and the adult height is not altered. It is the hope that at the conclusion of treatment, the male will continue to grow and develop rapidly, with the testosterone treatment perceived as a jump starter of endogenous puberty. Additionally, a short course of a low-dose anabolic steroid, such as oxandrolone, can also be used in prepubertal and pubertal males, and low-dose estradiol has been used in prepubertal and pubertal females with constitutional delay.

Treatment of hypogonadism aims to mimic normal physiology with stepwise replacement of testosterone in males and estrogen and progesterone in females. For males with hypogonadism, low-dose parenteral testosterone is initiated at 50 mg every 4 weeks, with increases in 50-mg increments made over a 2- to 3-year period. Most adult males receive 200 mg every 2-4 weeks, which is based on the daily adult male testosterone production rate of 6 mg. Adult men can receive testosterone by patch, which is often associated with local irritation, or by gel, but, typically in growing adolescents, intramuscular testosterone is prescribed to allow more reliable control of testosterone activity.

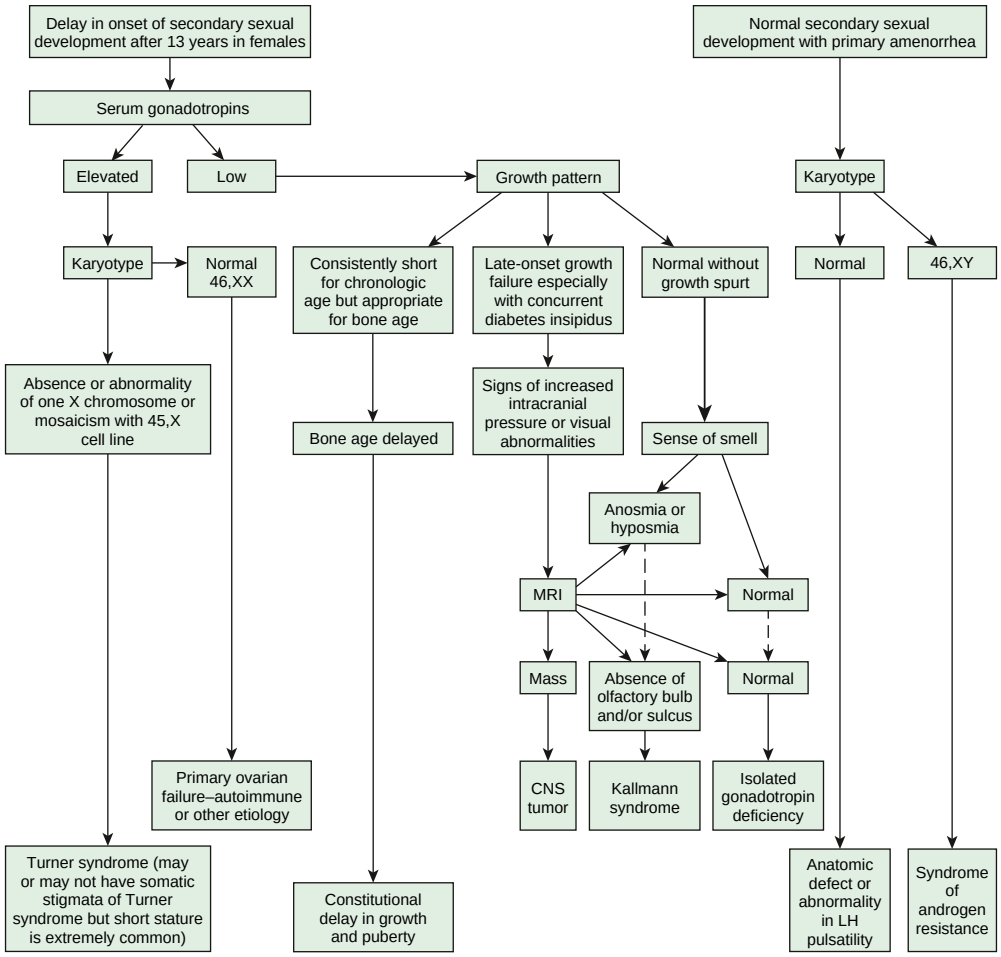

Fig. 600.7 Diagnostic algorithm for the evaluation of delayed puberty in females. CNS, Central nervous system; MRI, magnetic resonance imaging. *(From Styne DM, Grumbach MM. Physiology and disorders of puberty. In Melmed S, Polonsky KS, Larsen PR, Kronenberg HM, eds. Williams Textbook of Endocrinology, 13th ed. Philadelphia: Elsevier; 2016: Fig. 25.49, p. 1157.)*

For females with hypogonadism, daily estrogen therapy typically is provided through a transdermal 17β-estradiol patch 25 mcg/24 hr patch, which is more physiologic than oral preparations of the estrogens (conjugated estrogens [Premarin] or ethinyl estradiol) because transdermal therapy avoids initial first-pass hepatic metabolism. The transdermal or oral dose of estrogen (Premarin starts at 0.3 mg daily) is increased over the course of about 2 years. Two years of estrogen therapy without progesterone does not place the uterus at undue risk for hyperplasia and malignancy, but after 2 years (or sooner if spotting occurs prior), progesterone should be added. Options to consider when adding progesterone include continuing the 17β-estradiol patches or estrogen-only–containing pills (conjugated estrogens or ethinyl estradiol) in conjunction with oral medroxyprogesterone acetate (Provera), a progesterone eluting intrauterine device (IUD), or switching the patient to conventional oral contraceptives. If the patient is not put on a conventional oral contraceptive or a progesterone-eluting IUD, the estrogen (pill or patch) is prescribed on days 1-23 of the calendar month with the addition of medroxyprogesterone acetate on days 10-23. With this approach, withdrawal bleeding generally occurs between day 23 and the end of the month, although there can be some variability in the timing between patients.

Patients of either sex with hypogonadotropic hypogonadism are potentially fertile, but sex-steroid therapy alone is ordinarily not sufficient to initiate gametogenesis, although there are rare cases in males in which testosterone replacement alone has stimulated spermatogenesis. The general approach to fertility induction in either sex involves the addition of either cyclical gonadotropin therapy or pump-driven GnRH therapy at the age of desired conception. *When hypogonadotropic hypogonadism is present as one component of hypopituitarism, it is critical to adequately replace all deficient hormones* (see Chapter 595). In contrast, patients with primary hypogonadism have intrinsic gonadal damage and are normally infertile.

Visit Elsevier eBooks+ at eBooks.Health.Elsevier.com for Bibliography.

Section 2

Disorders of the Thyroid Gland

Chapter 601

Thyroid Development and Physiology

Ari J. Wassner and Jessica R. Smith

FETAL DEVELOPMENT

The fetal thyroid arises from an outpouching of the foregut at the base of the tongue (foramen cecum) and migrates to its normal location below the cricoid cartilage by 8-10 weeks of gestation. The thyroid's bilobed shape is apparent by 7 weeks of gestation, and thyroid follicular cells capable of forming colloid are present by 10 weeks. Thyroglobulin synthesis begins at 4 weeks, iodine trapping occurs by 8-10 weeks, and synthesis and secretion of thyroxine (T_4) and, to a lesser extent, triiodothyronine (T_3) occur from 12 weeks of gestation. Several transcription factors, including NKX2.1, FOXE1, and PAX8, are important in thyroid gland morphogenesis and differentiation and possibly also in its caudal migration. Thyrotropin (TSH) secretion is evident by 10-12 weeks of gestation. Maturation of the hypothalamic-pituitary-thyroid axis occurs during the second half of gestation, but normal hormonal feedback relationships are not mature until 1-3 months of postnatal life. Other transcription factors, including PROP1 and POU1F1, are important for the differentiation and growth of pituitary thyrotrophs, along with somatotrophs and lactotrophs.

THYROID PHYSIOLOGY

The primary function of the thyroid gland is to synthesize T_4 and T_3, of which iodine is a critical component. The only known physiologic role of iodine is in the synthesis of these hormones, and iodine deficiency results in hypothyroidism. The daily recommended dietary allowance of iodine is 110-130 μg for infants, 90-120 μg for children, and 150 μg for adolescents and adults (see Chapter 605.3).

Ingested iodine reaches the thyroid gland as its ionized form, iodide [I^-]. Thyroid tissue has a unique avidity for iodide and can take up and concentrate it in the follicular lumen to synthesize thyroid hormone. Transport of iodide from the circulation into the thyroid follicular cell is facilitated by the transmembrane sodium–iodide symporter (NIS). Once taken up, iodide diffuses across the cell and is transported across the apical membrane into the colloid by pendrin (and likely another unidentified transporter).

To form thyroid hormone, trapped inorganic iodide is organified onto tyrosine residues of thyroglobulin in the follicular lumen, a reaction catalyzed by thyroperoxidase (TPO). This reaction requires the H_2O_2 produced by the enzyme DUOX2, which is expressed in conjunction with dual oxidase maturation factor 2 (DUOXA2). Thyroglobulin is a large homodimeric glycoprotein that contains 138 tyrosine residues. Iodination of specific tyrosine residues forms monoiodotyrosines (MITs) and diiodotyrosines (DITs), which are further coupled by TPO to produce T_4 or T_3. Once formed, T_4 and T_3 remain stored as part of thyroglobulin in the thyroid colloid until they are secreted through a process of follicular cell endocytosis of colloid followed by endolysosomal degradation of thyroglobulin to release T_4 and T_3.

The thyroid secretes T_4 and T_3 in a ratio of about 12 to 1. Although T_3 circulates at about one-fiftieth the concentration of T_4, T_3 is the physiologically active thyroid hormone because it binds the thyroid hormone receptor with 10- to 15-fold greater affinity than T_4. Only 20% of circulating T_3 is secreted directly by the thyroid, and the remainder is produced by conversion from T_4 in extrathyroidal tissues by iodotyrosine deiodinases (types 1 and 2).

Thyroid hormones increase oxygen consumption, stimulate protein synthesis, influence growth and differentiation, and affect carbohydrate, lipid, and vitamin metabolism. Entry of T_4 and T_3 into cells is facilitated by specific thyroid hormone transporters, of which the most important is monocarboxylate transporter 8 (MCT8). Once inside the cell, T_4 is converted to T_3 by type 1 or 2 deiodinase. Intracellular T_3 enters the nucleus and binds to thyroid hormone receptors. Thyroid hormone receptors are members of the steroid hormone receptor superfamily, and three thyroid hormone receptor isoforms (α_1, β_1, and β_2) are expressed in different tissues. Binding of T_3 to a thyroid hormone receptor causes recruitment of co-activator molecules, transcription of messenger RNA, and protein synthesis. Deiodination, transmembrane transport, and thyroid hormone receptor expression provide multiple levels of tissue-specific modulation of thyroid hormone action in the face of a given level of circulating T_4.

Approximately 70% of circulating T_4 and 50% of T_3 are bound to thyroxine-binding globulin (TBG), and most of the remainder is bound to albumin and prealbumin (also called *transthyretin*). Only 0.03% of serum T_4 and 0.3% of T_3 are unbound (free T_4 and free T_3, respectively). Because the concentration or binding of TBG is altered in many clinical circumstances, its status must be considered when interpreting total T_4 or T_3 levels.

THYROID REGULATION

The thyroid is regulated by TSH, a glycoprotein hormone secreted by the anterior pituitary thyrotrophs. Binding of TSH to its receptor in the thyroid gland activates adenylate cyclase and stimulates all steps of thyroid hormone biosynthesis (see Fig. 594.1). TSH is a heterodimer composed of α and β subunits. The α subunit is common to luteinizing hormone, follicle-stimulating hormone, and chorionic gonadotropin, and the specificity of each hormone is conferred by its unique β subunit. TSH synthesis and release are stimulated by TRH, a tripeptide synthesized in the hypothalamus and secreted into the pituitary. In states of decreased thyroid hormone, TSH and TRH are increased, and increased thyroid hormone inhibits TSH and TRH production. TSH levels can be measured in serum, whereas circulating levels of TRH are not clinically measurable.

Further control of the level of circulating thyroid hormones occurs in the periphery. In many nonthyroidal illnesses, circulating T_3 levels fall because of decreased extrathyroidal production of T_3 by type 1 deiodinase and increased inactivation of T_4 (to reverse T_3) and T_3 (to T_2) by type 3 deiodinase. These changes may be induced by factors such as fasting, chronic malnutrition, acute illness, and certain drugs. Although levels of T_3 may be significantly decreased, levels of free T_4 and TSH may remain normal. The decreased levels of T_3 may be a physiologic adaptation, resulting in decreased rates of oxygen consumption, substrate use, and other catabolic processes.

Visit Elsevier eBooks+ at eBooks.Health.Elsevier.com for Bibliography.

601.1 Thyroid Hormone Studies

Ari J. Wassner and Jessica R. Smith

SERUM THYROID HORMONES

Methods are available to measure many thyroid hormones in serum, including T_4, free T_4, T_3, and free T_3. The metabolically inert reverse T_3 (rT_3) is present in serum, but measuring rT_3 is rarely useful clinically. Direct assays for free T_4 are widely available and are reliable in healthy patients, but these assays may be less reliable during acute illness or with severe abnormalities of thyroid hormone binding. Therefore in such situations it may be preferable to measure total T_4 as an index of TBG binding or to measure free T_4 by the gold standard technique of equilibrium dialysis. The clinical utility of many free T_3 assays is limited by their poor standardization. Because normal thyroid function changes over time, age-specific reference ranges should be used when interpreting thyroid hormone testing in children, particularly in neonates and infants.

Measuring serum levels of TSH and free T_4 can diagnose most clinical thyroid disorders. Serum TSH is the most sensitive test for primary thyroid dysfunction, and it is elevated in primary hypothyroidism and suppressed in primary thyrotoxicosis. In central (secondary) hypothyroidism, serum TSH is low or inappropriately in the normal range despite low serum T_4 and free T_4 levels. Biotin supplements may cause a false elevation of T_4 and T_3 and a false decrease of TSH.

Thyroglobulin is a glycoprotein secreted through the apical surface of the thyroid follicular cell into the colloid. Thyroglobulin is measurable in the serum, and levels of thyroglobulin increase with TSH stimulation and in proportion to functional thyroid mass. Athyreotic infants have markedly reduced levels of thyroglobulin. In contrast, thyroglobulin levels may be increased in neonates and in patients with Graves disease and other forms of autoimmune thyroid disease, differentiated thyroid carcinoma, or endemic goiter.

FETAL AND NEWBORN THYROID

Fetal serum T_4 and free T_4 increase from midgestation to approximately 9.5 μg/dL and 1.4 ng/dL, respectively, at term. Fetal levels of T_3 are low before 20 weeks and then gradually increase to approximately 60 ng/dL at term. Reverse T_3 levels, however, are high in the fetus (300 ng/dL at 30 weeks) and decrease to 200 ng/dL at term. Serum levels of TSH gradually increase to 6 mIU/L at term. Approximately one third of fetal T_4 at term is derived from the transplacental passage of maternal T_4. Maternal T_4 plays a key role in fetal development, especially that of the brain, beginning before fetal synthesis of thyroid hormone begins. Therefore a fetus with congenital hypothyroidism may be partially protected by maternal T_4 if the mother is euthyroid but may be at risk for neurodevelopmental injury if the mother is hypothyroid.

Immediately after birth there is an acute release of TSH, with peak serum concentrations reaching 70-100 mIU/L 30 minutes after delivery in full-term infants. TSH declines rapidly over the ensuing 24 hours and more gradually over the next 5 days to <10 mIU/L. After the first 1-3 months of life, normal levels of TSH are <5 mIU/L. The postnatal surge in TSH stimulates an increase in levels of T_4 to approximately 16 μg/dL and of T_3 to approximately 300 ng/dL in about 4 hours. T_4 levels gradually decrease during the first 2 weeks of life to 10-12 μg/dL. T_3 levels decline during the first week of life to below 200 ng/dL. Reverse T_3 levels remain high for 2 weeks (200 ng/dL) and decrease by 4 weeks to around 50 ng/dL. In preterm infants, changes in thyroid function after birth are qualitatively similar to but quantitatively smaller than in full-term infants. Serum T_4 and T_3 levels are decreased in proportion to gestational age and birthweight.

SERUM THYROXINE-BINDING GLOBULIN

The thyroid hormones are transported in plasma bound primarily to TBG, a glycoprotein synthesized in the liver. TBG binds approximately 70% of T_4 and 50% of T_3. Estimating TBG binding is occasionally necessary because changes caused by various clinical conditions can affect measured levels of total (but not free) T_4 and T_3. TBG levels increase in pregnancy; in the newborn period; with hepatitis; and with the administration of estrogens (oral contraceptives), selective estrogen receptor modulators, heroin or methadone, mitotane, and 5-fluorouracil. TBG levels decrease with androgens, anabolic steroids, glucocorticoids, nicotinic acid, and L-asparaginase. These effects are the result of altered hepatic synthesis of TBG. Severe TBG deficiency may be caused by genetic variants, decreased production with hepatocellular disease, or massive protein loss in the gut (protein-losing enteropathies) or the urine (congenital nephrotic syndrome) (see Chapter 602). Some medications, including furosemide, salicylates, nonsteroidal antiinflammatory drugs, heparin, and free fatty acids, can elevate levels of free T_4 by inhibiting binding to TBG.

THYROID ULTRASONOGRAPHY

The primary clinical uses of thyroid ultrasound are to assess thyroid morphology and to evaluate the characteristics of thyroid nodules. In infants with congenital hypothyroidism, evaluation of the size and location of the thyroid may clarify the diagnosis of thyroid dysgenesis; however, the sensitivity of ultrasound is user-dependent, and it will not reliably detect ectopic thyroid glands. Ultrasound is more accurate than physical examination for estimating thyroid gland size and assessing thyroid nodules. Certain characteristics of thyroid nodules, such as irregular margins, microcalcifications, hypoechogenicity, and taller-than-wide shape, increase the likelihood that a thyroid nodule is malignant and guide decisions about the need for fine-needle aspiration. In children with autoimmune thyroiditis or Graves disease, ultrasound may reveal heterogeneous echotexture or changes in vascularity. However, ultrasound generally is not clinically useful in these conditions unless a thyroid nodule is suspected. Ultrasound may also be useful to evaluate thyroglossal duct cysts.

RADIONUCLIDE STUDIES

The availability of highly sensitive tests of thyroid function has decreased the necessity for radioiodine uptake studies except in specific clinical situations. The ability of the thyroid to take up and organify iodine can be evaluated by measuring the uptake of radioactive isotope ^{123}I (half-life: 13 hours). Technetium (^{99m}Tc) is also a useful radioisotope for children because it is trapped but not organified by the thyroid and has a half-life of only 6 hours. Thyroid scintigraphy can demonstrate the anatomic distribution of tracer uptake by thyroid tissue and may be indicated to assess for possible thyroid dysgenesis or ectopic thyroid tissue or to evaluate possible autonomous (hot) thyroid nodules. ^{131}I may be used to treat hyperthyroidism or thyroid cancer, but its use generally should be avoided for thyroid uptake and scintigraphy because of its cytotoxic effect.

Visit Elsevier eBooks+ at eBooks.Health.Elsevier.com for Bibliography.

Chapter 602

Disorders of Thyroxine-Binding Globulin

Ari J. Wassner and Jessica R. Smith

Approximately 70% of circulating thyroxine (T_4) and 50% of triiodothyronine (T_3) are bound to thyroxine-binding globulin (TBG), and most of the remainder is bound to albumin and prealbumin (also called *transthyretin*). Only the unbound (free) fractions of these hormones, comprising 0.03% of serum T_4 and 0.3% of T_3, can exert biologic activity. Because regulation of the hypothalamic-pituitary-thyroid axis is mediated by the concentrations of free thyroid hormones, abnormalities of thyroid hormone binding tend to alter concentrations of total, but not free, thyroid hormones. *Therefore abnormalities in levels of TBG are not associated with clinical disease and do not require treatment.* They are usually discovered as an incidental finding of abnormally low or high levels of T_4 and may be a source of confusion in the diagnosis of hypothyroidism or hyperthyroidism.

Congenital TBG deficiency is an X-linked recessive trait that occurs in 1 in 1,700 male newborns. It is most often discovered through screening programs for neonatal hypothyroidism that measure levels of T_4 as the primary screening test. Affected males have low levels of total T_4 (usually <4 μg/dL) and elevated T_3 resin uptake, but levels of free T_4 and thyrotropin (TSH) are normal. The diagnosis is confirmed by the measurement of absent or low serum levels of TBG, although rare cases may have normal concentrations of TBG with reduced affinity for T_4. No treatment is required, but testing may be indicated in potentially affected family members to avoid the incorrect diagnosis of hypothyroidism in the future. More than 40 different pathogenic variants have been reported in the TBG gene. **Acquired** causes of TBG deficiency are listed in Table 602.1.

TBG excess is a benign X-linked dominant variant that occurs in approximately 1 in 25,000 individuals. It has been recognized primarily in adults, but newborn screening programs may uncover the condition in the neonate. The level of T_4 is elevated, T_3 is variably elevated, TSH and free T_4 are normal, and T_3 resin uptake is decreased. Elevated serum levels of TBG confirm the diagnosis. Affected neonates have been found to have levels of T_4 as high as 95 μg/dL, which decrease to 20-30 μg/dL after 2-3 weeks. Affected patients are euthyroid, but family studies may be indicated to alert other affected family members. Acquired causes of TBG excess are listed in Table 602.1.

Familial dysalbuminemic hyperthyroxinemia is an autosomal dominant variant caused by an abnormal albumin with a markedly increased affinity for T_4. This leads to increased serum concentrations of T_4 (and in some cases T_3) that can be mistaken for thyrotoxicosis. However, levels of free T_4, free T_3, and TSH are normal, and affected patients are euthyroid.

Visit Elsevier eBooks+ at eBooks.Health.Elsevier.com for Bibliography.

Table 602.1 Causes of Acquired Thyroxine-Binding Globulin (TBG) Deficiency and Excess

DECREASED TBG	INCREASED TBG
Androgens	Estrogens
Anabolic steroids	Selective estrogen receptor modulators
Glucocorticoids	Pregnancy
Hepatocellular disease	Hepatitis
Severe illness	Porphyria
Nephrotic syndrome	Heroin, methadone
Protein-losing enteropathy	Mitotane
Nicotinic acid	5-Fluorouracil
L-Asparaginase	Perphenazine

Chapter 603

Hypothyroidism

Ari J. Wassner and Jessica R. Smith

Hypothyroidism is a state of insufficient thyroid hormone action at the tissue level. Hypothyroidism most often results from deficient production of thyroid hormone caused either by a defect in the thyroid gland itself (primary hypothyroidism) or by reduced thyrotropin (TSH) stimulation (central or secondary hypothyroidism; Table 603.1). Hypothyroidism may be present from birth (congenital) or may be acquired, although some acquired cases are due to congenital defects in which the onset of hypothyroidism is delayed.

CONGENITAL HYPOTHYROIDISM

Most cases of congenital hypothyroidism are caused by abnormal formation of the thyroid gland **(thyroid dysgenesis)**, and ~30% of cases are due to inborn errors of thyroid hormone synthesis **(dyshormonogenesis)** or other causes. Most infants with congenital hypothyroidism are detected by newborn screening programs in the first week after birth, before significant clinical signs or symptoms develop. In regions without newborn screening, severely affected infants usually manifest features within the first week of life, but in infants with milder hypothyroidism, the clinical manifestations may not be evident for weeks or months.

Epidemiology

The incidence of congenital hypothyroidism was initially reported to be 1 in 4,000 infants based on the earliest established neonatal screening programs. The incidence of diagnosis has increased to about 1 in 2,000, primarily because more stringent screening algorithms have resulted in the detection of milder cases of hypothyroidism, mostly in patients with a eutopic thyroid gland.

Etiology

See Table 603.1.

Primary Hypothyroidism

Thyroid Dysgenesis. Thyroid dysgenesis is the most common cause of permanent congenital hypothyroidism, accounting for 80–85% of cases. In approximately one third of cases of dysgenesis, no thyroid tissue is present **(agenesis)**. In the other two thirds of infants, rudiments of thyroid tissue are present, either in the normal position **(hypoplasia)** or in an **ectopic** location along the embryologic path of descent of the thyroid from the base of the tongue (lingual thyroid) to the normal position. Thyroid dysgenesis occurs twice as common in females as in males.

The cause of thyroid dysgenesis is largely unknown. The condition is usually sporadic, but familial cases have been reported rarely. Thyroid developmental anomalies, such as thyroglossal duct cysts and thyroid hemiagenesis, are present in 8–10% of first-degree relatives of infants with thyroid dysgenesis. However, most thyroid dysgenesis is unlikely to be genetic given the high degree of discordance among monozygotic twins.

A small minority (2–5%) of thyroid dysgenesis is caused by genetic defects in one of several transcription factors essential for thyroid morphogenesis and differentiation, including NKX2.1 (formerly TTF1), FOXE1 (formerly TTF2), and PAX8. NKX2.1 is expressed in the thyroid, lung, and central nervous system, and recessive pathogenic variants in *NKX2-1* cause thyroid dysgenesis, respiratory distress, and neurologic problems (chorea and ataxia) **(brain-lung-thyroid syndrome)**. Recessive pathogenic variants in *FOXE1* cause thyroid dysgenesis, spiky or curly hair, cleft palate, and sometimes choanal atresia and bifid epiglottis **(Bamforth-Lazarus syndrome)**. PAX8 is expressed in the thyroid and kidney, and dominant *PAX8* variants are associated with thyroid dysgenesis and kidney and ureteral malformations.

Chapter 602

Disorders of Thyroxine-Binding Globulin

Ari J. Wassner and Jessica R. Smith

Approximately 70% of circulating thyroxine (T_4) and 50% of triiodothyronine (T_3) are bound to thyroxine-binding globulin (TBG), and most of the remainder is bound to albumin and prealbumin (also called *transthyretin*). Only the unbound (free) fractions of these hormones, comprising 0.03% of serum T_4 and 0.3% of T_3, can exert biologic activity. Because regulation of the hypothalamic-pituitary-thyroid axis is mediated by the concentrations of free thyroid hormones, abnormalities of thyroid hormone binding tend to alter concentrations of total, but not free, thyroid hormones. *Therefore abnormalities in levels of TBG are not associated with clinical disease and do not require treatment.* They are usually discovered as an incidental finding of abnormally low or high levels of T_4 and may be a source of confusion in the diagnosis of hypothyroidism or hyperthyroidism.

Congenital TBG deficiency is an X-linked recessive trait that occurs in 1 in 1,700 male newborns. It is most often discovered through screening programs for neonatal hypothyroidism that measure levels of T_4 as the primary screening test. Affected males have low levels of total T_4 (usually <4 μg/dL) and elevated T_3 resin uptake, but levels of free T_4 and thyrotropin (TSH) are normal. The diagnosis is confirmed by the measurement of absent or low serum levels of TBG, although rare cases may have normal concentrations of TBG with reduced affinity for T_4. No treatment is required, but testing may be indicated in potentially affected family members to avoid the incorrect diagnosis of hypothyroidism in the future. More than 40 different pathogenic variants have been reported in the TBG gene. **Acquired** causes of TBG deficiency are listed in Table 602.1.

TBG excess is a benign X-linked dominant variant that occurs in approximately 1 in 25,000 individuals. It has been recognized primarily in adults, but newborn screening programs may uncover the condition in the neonate. The level of T_4 is elevated, T_3 is variably elevated, TSH and free T_4 are normal, and T_3 resin uptake is decreased. Elevated serum levels of TBG confirm the diagnosis. Affected neonates have been found to have levels of T_4 as high as 95 μg/dL, which decrease to 20-30 μg/dL after 2-3 weeks. Affected patients are euthyroid, but family studies may be indicated to alert other affected family members. Acquired causes of TBG excess are listed in Table 602.1.

Familial dysalbuminemic hyperthyroxinemia is an autosomal dominant variant caused by an abnormal albumin with a markedly increased affinity for T_4. This leads to increased serum concentrations of T_4 (and in some cases T_3) that can be mistaken for thyrotoxicosis. However, levels of free T_4, free T_3, and TSH are normal, and affected patients are euthyroid.

Visit Elsevier eBooks+ at eBooks.Health.Elsevier.com for Bibliography.

Table 602.1 Causes of Acquired Thyroxine-Binding Globulin (TBG) Deficiency and Excess

DECREASED TBG	INCREASED TBG
Androgens	Estrogens
Anabolic steroids	Selective estrogen receptor modulators
Glucocorticoids	Pregnancy
Hepatocellular disease	Hepatitis
Severe illness	Porphyria
Nephrotic syndrome	Heroin, methadone
Protein-losing enteropathy	Mitotane
Nicotinic acid	5-Fluorouracil
L-Asparaginase	Perphenazine

Chapter 603

Hypothyroidism

Ari J. Wassner and Jessica R. Smith

Hypothyroidism is a state of insufficient thyroid hormone action at the tissue level. Hypothyroidism most often results from deficient production of thyroid hormone caused either by a defect in the thyroid gland itself (primary hypothyroidism) or by reduced thyrotropin (TSH) stimulation (central or secondary hypothyroidism; Table 603.1). Hypothyroidism may be present from birth (congenital) or may be acquired, although some acquired cases are due to congenital defects in which the onset of hypothyroidism is delayed.

CONGENITAL HYPOTHYROIDISM

Most cases of congenital hypothyroidism are caused by abnormal formation of the thyroid gland **(thyroid dysgenesis)**, and ~30% of cases are due to inborn errors of thyroid hormone synthesis **(dyshormonogenesis)** or other causes. Most infants with congenital hypothyroidism are detected by newborn screening programs in the first week after birth, before significant clinical signs or symptoms develop. In regions without newborn screening, severely affected infants usually manifest features within the first week of life, but in infants with milder hypothyroidism, the clinical manifestations may not be evident for weeks or months.

Epidemiology

The incidence of congenital hypothyroidism was initially reported to be 1 in 4,000 infants based on the earliest established neonatal screening programs. The incidence of diagnosis has increased to about 1 in 2,000, primarily because more stringent screening algorithms have resulted in the detection of milder cases of hypothyroidism, mostly in patients with a eutopic thyroid gland.

Etiology

See Table 603.1.

Primary Hypothyroidism

Thyroid Dysgenesis. Thyroid dysgenesis is the most common cause of permanent congenital hypothyroidism, accounting for 80–85% of cases. In approximately one third of cases of dysgenesis, no thyroid tissue is present **(agenesis)**. In the other two thirds of infants, rudiments of thyroid tissue are present, either in the normal position **(hypoplasia)** or in an **ectopic** location along the embryologic path of descent of the thyroid from the base of the tongue (lingual thyroid) to the normal position. Thyroid dysgenesis occurs twice as common in females as in males.

The cause of thyroid dysgenesis is largely unknown. The condition is usually sporadic, but familial cases have been reported rarely. Thyroid developmental anomalies, such as thyroglossal duct cysts and thyroid hemiagenesis, are present in 8–10% of first-degree relatives of infants with thyroid dysgenesis. However, most thyroid dysgenesis is unlikely to be genetic given the high degree of discordance among monozygotic twins.

A small minority (2–5%) of thyroid dysgenesis is caused by genetic defects in one of several transcription factors essential for thyroid morphogenesis and differentiation, including NKX2.1 (formerly TTF1), FOXE1 (formerly TTF2), and PAX8. NKX2.1 is expressed in the thyroid, lung, and central nervous system, and recessive pathogenic variants in *NKX2-1* cause thyroid dysgenesis, respiratory distress, and neurologic problems (chorea and ataxia) **(brain-lung-thyroid syndrome)**. Recessive pathogenic variants in *FOXE1* cause thyroid dysgenesis, spiky or curly hair, cleft palate, and sometimes choanal atresia and bifid epiglottis **(Bamforth-Lazarus syndrome)**. PAX8 is expressed in the thyroid and kidney, and dominant *PAX8* variants are associated with thyroid dysgenesis and kidney and ureteral malformations.

Table 603.1 Etiologic Classification of Congenital Hypothyroidism

PRIMARY HYPOTHYROIDISM
Defect of thyroid development (dysgenesis)
• Agenesis
• Hypoplasia
• Ectopia
Defects in thyrotropin (TSH) responsiveness
• TSH receptor–blocking antibodies
• Pathogenic variants in TSH receptor *(TSHR)*
• Defects in Gsα *(GNAS)*—pseudohypoparathyroidism
Defect in thyroid hormone synthesis (dyshormonogenesis)
• Defective iodide uptake into follicular cell: sodium–iodide symporter *(NIS)*
• Defective iodide transport from follicular cell into colloid: Pendred syndrome *(SLC26A4)*
• Iodide organification defects: thyroperoxidase *(TPO)*, dual oxidase 2 (*DUOX2)*, dual oxidase maturation factor 2 *(DUOXA2)*
• Thyroglobulin synthesis defect: thyroglobulin (TG)
• Deiodination defect: iodotyrosine deiodinase (IYD)
• Thyroid hormone transport defect: monocarboxylate transporter 8 *(SLC16A2)*—X-linked
Iodine deficiency (endemic goiter)
Iodine excess
Maternal medications
• Iodides, amiodarone
• Methimazole, propylthiouracil
• Radioactive iodine (^{131}I)
CENTRAL (SECONDARY) HYPOTHYROIDISM
Isolated TSH deficiency
• Pathogenic variant in TSH β-subunit (TSHβ)—depending on variant measured TSH level may be low, normal, or elevated
• Pathogenic variant in TRH receptor *(TRHR)*
• Pathogenic variant in *IGSF1*—X-linked central hypothyroidism and macroorchidism (prolactin deficiency and variable GH deficiency)
• Pathogenic variant in other genes: *TBL1X, IRS4*
Multiple pituitary hormone deficiencies
• Pathogenic variant in *POU1F1*—deficiency of TSH, GH, and prolactin
• Pathogenic variant in *PROP1*—deficiency of TSH, GH, LH, FSH, prolactin, and variably ACTH
• Pathogenic variant in *HESX1*—variable deficiencies of TSH, GH, LH, FSH, prolactin, and ACTH
• Pathogenic variants in other genes: *OTX2, LHX3, LHX4, SOX3, FGF8, FGFR1, GLI2, LEPR*

ACTH, Adrenocorticotropic hormone; FSH, follicle-stimulating hormone; GH, growth hormone; LH, luteinizing hormone; TRH, thyrotropin-releasing hormone.

Inactivating variants in the TSH receptor *(TSHR)* have been described in patients with congenital hypothyroidism, including thyroid dysgenesis or hypoplasia. *TSHR* variants may be homozygous or heterozygous with or without a concurrent change in another congenital hypothyroidism gene (such as *DUOX2* or *TG*). Infants with a severe TSHR defect have elevated TSH levels and are detected by newborn screening, whereas patients with a mild defect may remain euthyroid without treatment.

Congenital hypothyroidism can occur in infants with **pseudohypoparathyroidism** type 1a. These patients have somatic inactivating variants of the G-protein stimulatory α-subunit $G_s\alpha$ (GNAS), leading to impaired signaling of the TSH receptor (see Chapter 612).

Defects in Thyroid Hormone Synthesis (Dyshormonogenesis). A variety of defects in thyroid hormone biosynthesis account for 15% of cases of permanent congenital hypothyroidism detected by neonatal screening programs (1 in 30,000-50,000 live births). Because increased TSH stimulation has a trophic effect on thyroid follicular cells, a **goiter** is often present. When the synthetic defect is incomplete, the onset of hypothyroidism may be delayed for months or years.

Defective Iodide Transport. Rare defects in iodide uptake are caused by pathogenic variants in the sodium-iodide symporter (NIS) responsible for concentrating iodide in the thyroid gland. In contrast to other defects of thyroid hormone synthesis, uptake of radioiodine and pertechnetate is low, as in cases of thyroid dysgenesis. However, impaired iodide transport may be suggested by the absence of normal salivary gland iodine uptake on scintigraphy. A reduced saliva:serum ratio of ^{123}I supports the diagnosis, which can be confirmed by genetic testing of *NIS*. This condition may respond to large doses of potassium iodide, but treatment with levothyroxine is more reliable and preferable.

Pendred syndrome is a clinical syndrome consisting of sensorineural deafness and goiter. This syndrome is caused by a pathogenic variant in the chloride-iodide transport protein pendrin *(SLC26A4)* expressed in the thyroid gland and the cochlea. Pendrin allows the transport of iodide across the apical membrane of the thyroid follicular cell into the colloid, where it undergoes organification and incorporation into the tyrosine residues on thyroglobulin. Patients with a variant in *SLC26A4* have impaired iodide organification and a positive perchlorate discharge test. Pathogenic variants in pendrin are a relatively common genetic cause of sensorineural deafness, but some patients diagnosed based on their hearing disorder have no goiter or thyroid dysfunction. This finding has fueled speculation that pendrin is not the sole apical iodine transporter in the thyroid, but no other specific transporter has been confirmed to date.

Defects of Iodine Organification. Defects of iodine organification are the most common type of thyroid hormone synthetic defect. After the thyroid takes up iodide, it is rapidly oxidized and incorporated into tyrosine residues on thyroglobulin. These reactions are catalyzed by the key enzyme thyroperoxidase (TPO) and require H_2O_2 generated locally by the dual oxidase 2 system (DUOX2 and DUOXA2). Defects can occur in any of these components of organification, and there is considerable clinical and biochemical heterogeneity. In the Dutch neonatal screening program, a complete organification defect was present in 1 in 60,000 live births, but the prevalence in other areas is unknown. A characteristic finding of organification defects is a marked discharge of thyroid radioactivity when perchlorate or thiocyanate is administered 2 hours after a test dose of radioiodine (perchlorate discharge of 40–90% of radioiodine compared with <10% in normal individuals). Numerous pathogenic variants in *TPO* have been reported in children with congenital hypothyroidism.

Pathogenic variants in *DUOX2* can cause permanent or transient congenital hypothyroidism. Previously, it was thought that monoallelic *DUOX2* variants cause transient disease and biallelic variants cause permanent disease, but the reverse has been observed in some cases, and this relationship remains variable and unclear. *DUOX2* variants have been reported in 15–40% of patients with apparent dyshormonogenesis, with pathogenic variant rates as high as 50–60% in studies from China and South Korea. Dual oxidase maturation factor 2 (DUOXA2) is required to express DUOX2 enzymatic activity, and recessive variants in *DUOXA2* are a rare cause of congenital hypothyroidism.

Defects of Thyroglobulin Synthesis. Defects of thyroglobulin synthesis are characterized by congenital hypothyroidism with goiter and absent or low levels of circulating thyroglobulin. More than 40 different pathogenic variants in the thyroglobulin gene *(TG)* have been described.

Defects in Deiodination. Monoiodotyrosine and diiodotyrosine normally are released from thyroglobulin along with thyroxine (T_4) and triiodothyronine (T_3). The *IYD* gene (formerly *DEHAL1*) encodes the thyroidal enzyme iodotyrosine deiodinase, which deiodinates these intermediates so that the liberated iodide is recycled into thyroid hormone synthesis. In patients with rare variants in *IYD,* urinary excretion of monoiodotyrosine and diiodotyrosine rapidly causes severe iodine deficiency, leading to hypothyroidism and goiter that may present soon after birth or may be delayed.

Defects in Thyroid Hormone Transport. Passage of thyroid hormone into cells is facilitated by specific plasma membrane transporters. Pathogenic variants in the transporter MCT8 *(SLC16A2),* located on the X chromosome, impair the movement of T_4 and T_3 into cells. This leads to severe neurologic manifestations, including profound developmental delay, reduced muscle mass, dysarthria,

athetoid movements, and hypotonia that evolves to spastic paraplegia **(Allan-Herndon-Dudley syndrome)**. This syndrome is also characterized by low serum T_4 levels, normal or mildly elevated serum TSH levels, and elevated serum T_3 levels. Treatment with thyroid hormone analogs that do not require MCT8 for transmembrane transport can improve hypermetabolism in this disorder but has little effect on the neurologic phenotype.

Thyrotropin Receptor–Blocking Antibodies. Maternal TSHR–blocking antibodies (TRBAbs) cause about 2% of cases of congenital hypothyroidism detected by neonatal screening programs (1 in 50,000-100,000 infants). Transplacentally acquired maternal TRBAbs inhibit the binding of TSH to its receptor in the neonate. This condition should be suspected whenever there is a history of maternal autoimmune thyroid disease, including autoimmune thyroiditis or Graves disease, maternal hypothyroidism, or transient congenital hypothyroidism in previous siblings. However, TRBAbs can occur in the absence of any maternal history. When suspected, levels of TRBAb (measured as thyrotropin-binding inhibitory immunoglobulin [TBII]) should be measured in the mother during pregnancy or after birth in the neonate. Affected infants and their mothers also can have TSHR-stimulating antibodies and TPO antibodies. Ultrasonography typically demonstrates a normally positioned but small thyroid gland; however, thyroid tissue often will not be detected by scintigraphy because the blockade of TSHR function suppresses thyroidal iodine uptake. Serum thyroglobulin levels are low for the same reason. Treatment with levothyroxine is required initially, but remission of hypothyroidism occurs in approximately 3-6 months once the TRBAbs are cleared from the infant's circulation. Correct diagnosis of this cause of congenital hypothyroidism prevents unnecessarily protracted treatment and alerts the clinician to possible recurrences in future pregnancies. The prognosis is generally favorable, but developmental delay may occur in patients whose mothers had unsuspected (and untreated) hypothyroidism caused by TRBAbs during pregnancy.

Radioiodine Administration. Neonatal hypothyroidism can occur when radioiodine is administered to a mother during (a usually unrecognized) pregnancy as treatment for Graves disease or thyroid cancer. The fetal thyroid is capable of trapping iodide by 70-75 days of gestation. Therefore a pregnancy test must be performed in any individual capable of pregnancy before ^{131}I is given, regardless of menstrual history or reported history of contraception. Administration of radioactive iodine to lactating individuals is also contraindicated because it is excreted in breast milk.

Iodine Exposure. Congenital hypothyroidism can result from fetal exposure to excessive iodine. Perinatal exposure can occur from iodine-based antiseptic used to prepare the skin for cesarean section or to paint the cervix before delivery. In the neonate, especially in those of low birthweight (LBW), topical iodine-containing antiseptics used in nurseries or perioperatively can cause transient hypothyroidism, which newborn screening tests may detect. In older children, excess iodine may be present in proprietary preparations used to treat asthma or in amiodarone, an antiarrhythmic drug with high iodine content. In most of these instances, a goiter is present (see Chapter 605). Hypothyroidism has also been reported in breastfed infants born to mothers who consume large amounts of iodine daily (up to 12 mg) in nutritional supplements or large quantities of iodine-rich seaweed. Iodine-induced hypothyroidism is transient once the exposure is discontinued and therefore is important to distinguish from other forms of congenital hypothyroidism.

Iodine Deficiency (Endemic Goiter). See Chapter 605.3.

Iodine deficiency or endemic goiter is the most common cause of congenital hypothyroidism worldwide. The recommended iodine intake in adults is 150 μg daily, increasing to 220 μg daily during pregnancy to allow for fetal iodine requirements. Despite efforts at universal salt iodization, in many countries economic, political, and practical obstacles continue to prevent the realization of this goal. Although the U.S. population is generally iodine sufficient, approximately 15% of women of reproductive age are iodine deficient. Borderline iodine deficiency is more likely to cause problems in preterm infants, who depend on a maternal source of iodine for normal thyroid hormone production and often receive insufficient dietary iodine from standard preterm infant formulas or parenteral nutrition that is low in iodine.

Central (Secondary) Hypothyroidism

Thyrotropin (TSH) Deficiency. Central hypothyroidism caused by TSH deficiency can occur in any condition associated with developmental defects of the pituitary or hypothalamus (see Chapter 595). Central hypothyroidism occurs in 1 in 16,000-30,000 infants. However, neonatal screening does not detect many cases, mainly because many screening programs are designed to detect only primary hypothyroidism by measuring neonatal TSH. The majority (75%) of infants with central hypothyroidism have additional pituitary hormone deficiencies and may present with hypoglycemia, persistent jaundice, micropenis or cryptorchidism (in males), and midline defects such as midline cleft lip or palate or midface hypoplasia.

Congenital TSH deficiency may be caused by pathogenic variants in genes encoding transcription factors essential to pituitary development or thyrotroph cell differentiation. *POU1F1* variants cause deficiency of TSH, growth hormone, and prolactin. Patients with *PROP1* variants also have deficiency of TSH, growth hormone, prolactin, luteinizing hormone, follicle-stimulating hormone, and variable deficiency of adrenocorticotropic hormone. *HESX1* pathogenic variants are associated with TSH, growth hormone, prolactin, and adrenocorticotropic hormone deficiencies and are found in some patients with optic nerve hypoplasia (septo-optic dysplasia syndrome; see Chapter 631). Variants in multiple other genes involved in pituitary development can cause central hypothyroidism (Table 603.1).

Isolated congenital deficiency of TSH is rare. The most common genetic cause is a pathogenic variant in *IGSF1,* which results in an X-linked syndrome of congenital central hypothyroidism and macroorchidism. The mechanism remains unclear, but IGSF1 deficiency may impair TRH receptor signaling in pituitary thyrotrophs. Prolactin deficiency is usually present, and some patients also have growth hormone deficiency. Central hypothyroidism occurs in about 10% of female carriers of IGSF1 deficiency. Patients with pathogenic variants in the gene encoding the TSH β-subunit *(TSHB)* have central hypothyroidism with very low TSH levels, although in some cases, TSH levels are normal or even elevated. In other cases, levels of the TSH α-subunit are elevated. Variants in *TRHR,* which encodes the TRH receptor, are a rare cause of congenital central hypothyroidism. In this condition, both TSH and prolactin fail to respond to TRH stimulation.

Thyroid Function in Preterm and Low Birthweight Infants

Postnatal thyroid function in preterm and LBW infants is qualitatively similar but quantitatively reduced compared with term infants. The cord blood T_4 concentration is decreased in proportion to gestational age and birthweight. The postnatal TSH surge is reduced, and very premature or very LBW infants experience a decrease in serum T_4 in the first week of life, in contrast to term infants in whom T_4 increases during this time. Serum T_4 gradually increases to the range observed in term infants by about 6 weeks of life. However, serum free T_4 concentrations are less affected than total T_4, and free T_4 levels may be normal when measured by the gold standard technique of equilibrium dialysis. Preterm and LBW infants also have a higher incidence of delayed TSH elevation and apparent transient primary hypothyroidism. Mechanisms underlying these changes in thyroid function in preterm and LBW infants may include immaturity of the hypothalamic-pituitary-thyroid axis, loss of the maternal contribution of thyroid hormone normally present in the third trimester, severe illness and complications of prematurity, and exposure to medications that can affect thyroid function (e.g., dopamine and glucocorticoids).

Clinical Manifestations

Before neonatal screening programs, congenital hypothyroidism was rarely recognized in the newborn because most affected infants are asymptomatic at birth, even if there is complete agenesis of the thyroid gland. This is because of transplacental passage of maternal T_4, which provides fetal levels that are approximately one-third normal at

birth. Because symptoms are usually not present at birth, the clinician depends on neonatal screening tests to diagnose congenital hypothyroidism. However, some infants escape newborn screening, and laboratory errors occur, so pediatricians must be alert for symptoms and signs of hypothyroidism if they develop. Birth weight and length are normal, but head size may be slightly increased because of myxedema of the brain. The anterior and posterior fontanels are open widely, and the presence of this sign at birth may be a clue to early recognition of congenital hypothyroidism (only 3% of normal newborns have a posterior fontanel wider than 0.5 cm). Prolonged jaundice (indirect hyperbilirubinemia) may be present because of delayed maturation of hepatic glucuronide conjugation. Affected infants cry little, sleep much, have poor appetites, and are generally sluggish. Feeding difficulties, especially sluggishness, lack of interest, somnolence, and choking spells during nursing, may be present during the first month of life. Respiratory difficulties, partly caused by macroglossia, include apneic episodes, noisy respirations, and nasal obstruction. There may be constipation that does not respond to treatment. The abdomen is large, and an umbilical hernia is often present. The temperature may be subnormal (often <35°C/95°F), and the skin may be cold and mottled, particularly on the extremities. Edema of the genitals and extremities may be present. The pulse is slow, and heart murmurs, cardiomegaly, and asymptomatic pericardial effusion are common. Macrocytic anemia is often present. Because symptoms appear gradually and may be nonspecific, the clinical diagnosis of neonatal hypothyroidism is often delayed.

Approximately 10% of infants with congenital hypothyroidism have associated congenital anomalies. Cardiac anomalies are most common, but anomalies of the nervous system and eye have also been reported. Infants with congenital hypothyroidism may have associated hearing loss. Pathogenic variants in specific genes involved in thyroid gland development result in congenital hypothyroidism with other syndromic features (Table 603.2).

If congenital hypothyroidism goes undetected and untreated, the clinical manifestations progress. Delay of physical and mental development becomes more severe over time, and by 3-6 months of age, the clinical picture is fully developed (Fig. 603.1). When deficiency of thyroid hormone is only partial, the symptoms may be milder and their onset delayed. Although breast milk contains significant amounts of thyroid hormones, particularly T_3, this is inadequate to protect the breastfed infant from the effects of congenital hypothyroidism.

In the patient with untreated congenital hypothyroidism, growth is stunted, extremities are short, and head size is normal or increased. The anterior fontanel is large, and the posterior fontanel may remain open. The eyes appear far apart, and the bridge of the broad nose is depressed. The palpebral fissures are narrow, and the eyelids are swollen. The mouth is kept open, and the thick, broad tongue protrudes. Dentition is delayed. The neck is short and thick, and there may be fat deposits above the clavicles and between the neck and shoulders. The hands are broad, and the fingers are short. The skin is dry and scaly, and there is little perspiration. Myxedema occurs mainly in the skin of the eyelids, the back of the hands, and the external genitalia. The skin shows general pallor with a sallow complexion. Carotenemia can cause a yellow discoloration of the skin, but the sclerae remain white. The scalp is thickened, and the hair is coarse, brittle, and scanty. The hairline reaches far down on the forehead, which usually appears wrinkled, especially when the infant cries.

Development is usually delayed. Hypothyroid infants appear lethargic and are late in acquiring gross and fine motor skills. The voice is hoarse, and they do not learn to talk. The degree of physical and intellectual delay increases with age. Sexual maturation may be delayed or even absent. The muscles are usually hypotonic, but in rare instances, generalized muscular pseudohypertrophy occurs **(Kocher-Debré-Sémélaigne syndrome)**. Affected older children can have an athletic appearance because of pseudohypertrophy, particularly in the calf muscles. Its pathogenesis is unknown; nonspecific histochemical and ultrastructural changes seen on muscle biopsy return to normal with treatment.

Some infants with mild congenital hypothyroidism have normal thyroid function at birth and are not identified by newborn screening programs. In particular, some children with ectopic thyroid tissue produce adequate amounts of thyroid hormone for some time (even years) until the abnormal thyroid tissue fails. Affected children come to clinical attention because of a growing mass at the base of the tongue or in the midline of the neck, often at the level of the hyoid. Occasionally, thyroid ectopy is associated with **thyroglossal duct cysts**. Surgical removal of ectopic thyroid tissue from a euthyroid patient usually results in hypothyroidism because most such patients have no other thyroid tissue.

Laboratory Findings

In countries where newborn screening is performed, this is the most important method for identifying infants with congenital hypothyroidism. Blood obtained by heelprick between 1 and 5 days of life is placed on a filter paper card and sent to a central screening laboratory. Most

Table 603.2 Genes and Thyroid Development

GENE	THYROID PHENOTYPE	OTHER FEATURES
FOXE1	Athyreosis	Cleft palate, choanal atresia, kinky hair, bifid epiglottis
NKX2-1	Athyreosis to normal gland	Respiratory distress syndrome, developmental delays/hypotonia, ataxia/choreoathetosis
PAX8	Athyreosis to normal gland	Cysts within thyroid remnants, kidney and urinary tract malformations
GLIS3	Athyreosis to normal gland	Congenital glaucoma; deafness; liver/kidney and pancreatic abnormalities
TSHR	Athyreosis to normal gland	None
NKX2-5	Athyreosis, ectopy	Cardiac defects

From Kim G, Nandi-Munshi D, Diblasi CC. Disorders of the thyroid gland. In: Gleason CA, Juul SE, eds. *Avery's Diseases of the Newborn*, 10th ed. Philadelphia: Elsevier; 2018, Table 98.3, p. 1396.

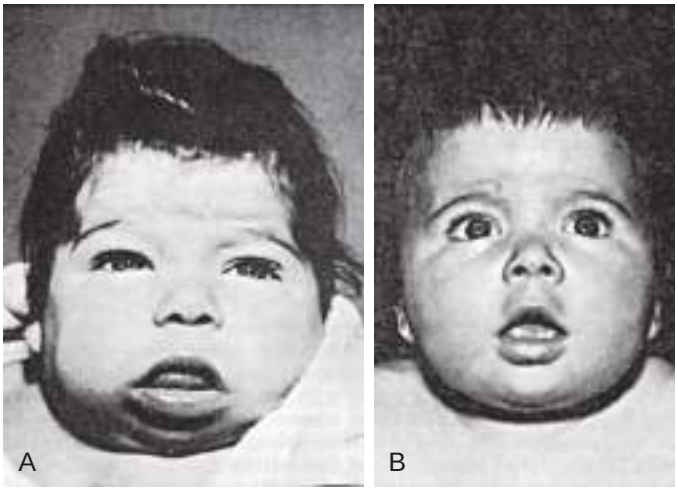

Fig. 603.1 Congenital hypothyroidism in an infant 6 mo of age. The infant ate poorly in the neonatal period and was constipated. She had persistent nasal discharge and a large tongue, was very lethargic, and had no social smile and no head control. **A,** Notice the puffy face, dull expression, and hirsute forehead. Tests revealed a negligible uptake of radioiodine. Osseous development was that of a newborn. **B,** Four months after treatment, note decreased face puffiness, decreased hirsutism of the forehead, and the alert appearance.

screening programs measure the level of TSH, which detects infants with primary hypothyroidism, including some with milder disease in whom TSH is elevated but T_4 is normal. However, this approach may not detect rarer disorders such as central hypothyroidism or primary congenital hypothyroidism with delayed TSH elevation. Some screening programs begin by measuring levels of T_4, followed by reflex measurement of TSH when the T_4 is low. This approach identifies infants with primary hypothyroidism, some with central hypothyroidism or delayed TSH elevation, and infants with thyroxine-binding globulin deficiency (a benign variant). All newborn screening results should be interpreted based on age-specific reference ranges, particularly in the first week of life (Table 603.3). Regardless of the approach used for screening, some infants escape detection because of technical or human errors, and clinicians must remain vigilant for clinical manifestations of hypothyroidism.

Several groups of patients deserve vigilance for congenital hypothyroidism. Infants with trisomy 21 or cardiac defects have an increased risk of congenital hypothyroidism. Monozygotic twins are usually *discordant* for congenital hypothyroidism. However, if twins are monochorionic, fetal hypothyroidism in the affected twin may be compensated by the normal twin through their shared fetal circulation. In such cases, the affected twin may go undetected on newborn screening in the first days of life and present later with untreated hypothyroidism. Preterm and LBW neonates have an increased incidence of congenital hypothyroidism and are more likely to have delayed TSH elevation that may be missed on initial screening. Therefore in all of these groups of infants, many newborn screening programs perform a routine second test 2-4 weeks after birth.

Patients with congenital hypothyroidism have low serum levels of T_4 and free T_4. Serum levels of T_3 are often normal and are not helpful for diagnosis. If primary hypothyroidism is present, levels of TSH are elevated, often to >100 mU/L in severe cases. Serum levels of thyroglobulin are usually low in infants with thyroid agenesis, defects of the TSH receptor (including *TSHR* pathogenic variants and TRBAb), or defects in the synthesis or secretion of thyroglobulin itself. In contrast, thyroglobulin levels are usually elevated in patients with thyroid ectopy and other defects of thyroid hormone synthesis, but there is a wide overlap of ranges.

Delay of osseous development can be shown radiographically at birth in approximately 60% of congenitally hypothyroid infants and indicates some deficiency of thyroid hormone during intrauterine life. The distal femoral and proximal tibial epiphyses, normally present at birth, are often absent (Fig. 603.2A). In untreated patients, the discrepancy between chronologic age and osseous development increases over time. The epiphyses often have multiple foci of ossification (epiphyseal dysgenesis; see Fig. 603.2B). Deformity (beaking) of the 12th thoracic or 1st or 2nd lumbar vertebra is common. X-rays of the skull show large fontanels and wide sutures, and intersutural (wormian) bones are common. The sella turcica may be enlarged and round, and in rare instances, there may be bony erosion and thinning. Formation and eruption of teeth can be delayed. Cardiac enlargement or pericardial effusion may be present.

Scintigraphy can help define the underlying cause in infants with congenital hypothyroidism, but treatment should not be delayed to obtain such imaging. ^{123}I–sodium iodide is superior to ^{99m}Tc–sodium pertechnetate for this purpose. Scintigraphy will demonstrate an ectopic thyroid gland, but the absence of uptake in disorders of the TSH receptor (including TRBAb) or NIS may be mistaken for thyroid agenesis. Ultrasound of the thyroid can document the presence or absence of an anatomically normal gland, but it can miss some ectopic glands that are detectable by scintigraphy. Demonstration of ectopic thyroid tissue or the absence of thyroid tissue in its normal location is diagnostic of thyroid dysgenesis and establishes the need for lifelong treatment. A normally located thyroid gland with normal or increased uptake indicates a defect in thyroid hormone synthesis. Although extensive evaluation can be performed to elucidate the precise nature of the synthetic defect, this rarely affects clinical management and is unnecessary in most cases. Similarly, genetic testing may reveal potentially relevant variants in 60% or more of patients with defects of thyroid hormone synthesis. However, such testing may be costly, is not always conclusive, and usually does not alter management.

Treatment

Levothyroxine (L-T_4) given orally is the treatment for congenital hypothyroidism. Although T_3 is the biologically active form of thyroid hormone, 80% of circulating T_3 is derived from deiodination of circulating T_4, and therefore treatment with L-T_4 alone restores normal serum levels of T_4 and T_3. The recommended initial dose of L-T_4 is 10-15 μg/kg/day (37.5-50 μg/day for most term infants), and within this range the starting dose can be adjusted based on the severity of hypothyroidism. Newborns with more severe hypothyroidism, as judged by a serum T_4 <5 μg/dL and/or imaging studies confirming aplasia, should be started at the higher end of the dosage range. Rapid normalization of thyroid function (ideally within 2 weeks) is essential in achieving optimal neurodevelopmental outcomes. Lower doses of L-T_4 (8-10 mcg/kg/day) may be considered for infants with mild hypothyroidism (mildly elevated TSH and normal free T_4).

L-T_4 should be prescribed in tablet form. A liquid L-T_4 preparation has been approved, but optimal dosing may differ slightly from the tablet form. Tablets should be crushed and mixed with a small volume (1-2 mL) of liquid. L-T_4 tablets should not be mixed with soy protein formulas, concentrated iron, or calcium because these can inhibit L-T_4 absorption. Although it is often recommended to administer L-T_4 on an empty stomach and avoid food for 30-60 minutes, this is not practical in an infant. As long as the method of administration is consistent, dosing can be adjusted based on serum thyroid test results to achieve the desired treatment goals. One trial has suggested that brand-name L-T_4 may be superior to generic formulations in children with severe congenital hypothyroidism.

The goals of treatment are to maintain serum TSH in the reference range for age and the serum free T_4 or total T_4 in the upper half of the reference range for age (see Table 603.3). Levels of serum T_4 or free T_4 and TSH should be monitored at recommended intervals (every 1-2 months in the first 6 months of life, and then every 2-4 months between 6 months and 3 years of age). Care should be taken to avoid undertreatment, which has been related to adverse neurodevelopmental outcomes, including decreased intelligence quotient (IQ).

About 35% of infants with congenital hypothyroidism and a normally located thyroid gland have transient disease and do not require lifelong therapy. In patients who might have transient disease, a trial of L-T_4 may be undertaken after 3 years of age for 4 weeks to assess whether the TSH rises significantly, indicating the presence of permanent hypothyroidism. Such a trial is unnecessary in infants with proven thyroid dysgenesis or in those who have previously manifested elevated levels of TSH after 6-12 months of therapy because of poor medication adherence or an inadequate dose of T_4.

Prognosis

Thyroid hormone is critical for normal neurodevelopment, particularly in the early postnatal months. Prompt diagnosis and initiation of adequate treatment of congenital hypothyroidism in the first 2 weeks of life are essential to prevent irreversible brain damage and normal growth and development. In most infants detected by newborn screening, verbal development, psychomotor development, and global IQ scores are similar to unaffected siblings. However, the most severely affected newborns—those with the lowest T_4 levels and most delayed skeletal maturation—may have reduced IQ and other neuropsychologic sequelae such as incoordination, hypotonia or hypertonia, or problems with attention or speech despite early diagnosis and adequate treatment. Psychometric testing can show problems with vocabulary and reading comprehension, arithmetic, and memory. Approximately 10% of children with congenital hypothyroidism have a neurosensory hearing deficit. Outcome studies in adults diagnosed and treated as neonates reveal delayed social development, lower self-esteem, and a lower health-related quality of life. The latter appears to be related to those individuals with lower neurocognitive outcomes and associated congenital malformations.

Delay in diagnosis or treatment, failure to rapidly correct the initial hypothyroidism, inadequate treatment, or poor adherence to treatment

Table 603.3 Thyroid Function Tests

AGE	U.S. REFERENCE VALUE	CONVERSION FACTOR	SI REFERENCE VALUE
THYROID THYROGLOBULIN, SERUM			
Cord blood	14.7-101.1 ng/mL	×1	14.7-101.1 μg/L
Birth to 35 mo	10.6-92.0 ng/mL	×1	10.6-92.0 μg/L
3-11 yr	5.6-41.9 ng/mL	×1	5.6-41.9 μg/L
12-17 yr	2.7-21.9 ng/mL	×1	2.7-21.9 μg/L
THYROID-STIMULATING HORMONE, SERUM			
Premature Infants (28-36 wk)			
First wk of life	0.7-27.0 mIU/L	×1	0.7-27.0 mIU/L
Term Infant			
Birth to 4 days	1.0-17.6 mIU/L	×1	1.0-17.6 mIU/L
2-20 wk	0.6-5.6 mIU/L	×1	0.6-5.6 mIU/L
5 mo-20 yr	0.5-5.5 mIU/L	×1	0.5-5.5 mIU/L
THYROXINE-BINDING GLOBULIN, SERUM			
Cord blood	1.4-9.4 mg/dL	×10	14-94 mg/L
1-4 wk	1.0-9.0 mg/dL	×10	10-90 mg/L
1-12 mo	2.0-7.6 mg/dL	×10	20-76 mg/L
1-5 yr	2.9-5.4 mg/dL	×10	29-54 mg/L
5-10 yr	2.5-5.0 mg/dL	×10	25-50 mg/L
10-15 yr	2.1-4.6 mg/dL	×10	21-46 mg/L
Adult	1.5-3.4 mg/dL	×10	15-34 mg/L
THYROXINE, TOTAL, SERUM			
Full-Term Infants			
1-3 days	8.2-19.9 μg/dL	×12.9	106-256 nmol/L
1 wk	6.0-15.9 μg/dL	×12.9	77-205 nmol/L
1-12 mo	6.1-14.9 μg/dL	×12.9	79-192 nmol/L
Prepubertal Children			
1-3 yr	6.8-13.5 μg/dL	×12.9	88-174 nmol/L
3-10 yr	5.5-12.8 μg/dL	×12.9	71-165 nmol/L
Pubertal Children and Adults			
>10 yr	4.2-13.0 μg/dL	×12.9	54-167 nmol/L
THYROXINE, FREE, SERUM			
Full term (3 days)	2.0-4.9 ng/dL	×12.9	26-63.1 pmol/L
Infants	0.9-2.6 ng/dL	×12.9	12-33 pmol/L
Prepubertal children	0.8-2.2 ng/dL	×12.9	10-28 pmol/L
Pubertal children and adults	0.8-2.3 ng/dL	×12.9	10-30 pmol/L
THYROXINE, TOTAL, WHOLE BLOOD			
Newborn screen (filter paper)	6.2-22 μg/dL	×12.9	80-283 nmol/L
TRIIODOTHYRONINE, FREE, SERUM			
Cord blood	20-240 pg/dL	×0.01536	0.3-0.7 pmol/L
1-3 days	180-760 pg/dL	×0.01536	2.8-11.7 pmol/L
1-5 yr	185-770 pg/dL	×0.01536	2.8-11.8 pmol/L
5-10 yr	215-700 pg/dL	×0.01536	3.3-10.7 pmol/L
10-15 yr	230-650 pg/dL	×0.01536	3.5-10.0 pmol/L
>15 yr	210-440 pg/dL	×0.01536	3.2-6.8 pmol/L
TRIIODOTHYRONINE RESIN UPTAKE TEST (RT_3U), SERUM			
Newborn	26–36%	×0.01	0.26-0.36 fractional uptake
Thereafter	26–35%	×0.01	0.26-0.35 fractional uptake

Continued

Table 603.3 Thyroid Function Tests—cont'd

AGE	U.S. REFERENCE VALUE	CONVERSION FACTOR	SI REFERENCE VALUE
TRIIODOTHYRONINE, TOTAL, SERUM			
Cord blood	30-70 ng/dL	×0.0154	0.46-1.08 nmol/L
1-3 days	75-260 ng/dL	×0.0154	1.16-4.00 nmol/L
1-5 yr	100-260 ng/dL	×0.0154	1.54-4.00 nmol/L
5-10 yr	90-240 ng/dL	×0.0154	1.39-3.70 nmol/L
10-15 yr	80-210 ng/dL	×0.0154	1.23-3.23 nmol/L
>15 yr	115-190 ng/dL	×0.0154	1.77-2.93 nmol/L

Adapted from Nicholson JF, Pesce MA. Reference ranges for laboratory tests and procedures. In: Behrman RE, Kliegman RM, Jenson HB, eds. *Nelson Textbook of Pediatrics*, 17th ed. Philadelphia: WB Saunders; 2004:2412–2413; TSH from Lem AJ, de Rijke YB, van toor H, et al. Serum thyroid hormone levels in healthy children from birth to adulthood and in short children born small for gestational age. *J Clin Endocrinol Metab*. 2012;97:3170–3178; Free T_3 from Elmlinger MW, Kuhnel W, Lambrecht H-G, et al. Reference intervals from birth to adulthood for serum thyroxine (T_4), triiodothyronine (T_3), free T_3, free T_4, thyroxine binding globulin (TBG), and thyrotropin (TSH). *Clin Chem Lab Med*. 2001;39:973–979.

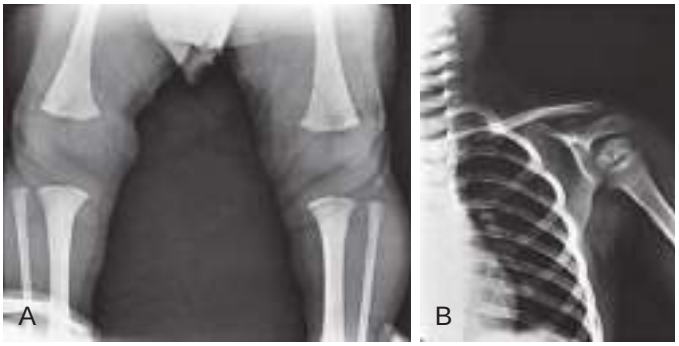

Fig. 603.2 Congenital hypothyroidism. **A,** Absence of distal femoral epiphyses in a 3-mo-old infant who was born at term. This is evidence for onset of the hypothyroid state during fetal life. **B,** Epiphyseal dysgenesis in the head of the humerus in a 9-yr-old girl who had been inadequately treated with thyroid hormone.

in the first 2-3 years of life may result in variable degrees of neurodevelopmental impairment. Without treatment, severely affected infants have profound intellectual disability and growth stunting. When hypothyroidism develops after 2 years of age, the outlook for neurodevelopment is much better even if diagnosis and treatment are delayed, which illustrates the critical dependence of brain development on thyroid hormone in the first year of life.

ACQUIRED HYPOTHYROIDISM

Epidemiology

Hypothyroidism occurs in approximately 0.3% (1 in 333) of school-age children. *Subclinical hypothyroidism* (defined as an elevated TSH with normal T_4 or free T_4) is more common, occurring in approximately 2% of adolescents. Autoimmune thyroiditis is the most common cause of acquired hypothyroidism: 6% of children age 12-19 years have evidence of autoimmune thyroiditis, and females are twice as likely to be affected as males. Although this condition typically arises in adolescence, it may present as early as the first year of life.

Etiology

The most common cause of acquired hypothyroidism (Table 603.4) is **autoimmune thyroiditis** (also called *Hashimoto* or *chronic lymphocytic thyroiditis*; see Chapter 604). Children with trisomy 21, Turner syndrome, Klinefelter syndrome, celiac disease, or type 1 diabetes mellitus are at higher risk for associated autoimmune thyroid disease (see Chapter 604), as are those with **autoimmune polyglandular syndromes** (**APSs**; see Chapter 608). APS type 1 (APS-1) is a rare autosomal recessive disorder caused by pathogenic variants in *AIRE*. It is classically characterized by the triad of mucocutaneous candidiasis, hypoparathyroidism, and primary adrenal insufficiency. Autoimmune

Table 603.4 Etiologic Classification of Acquired Hypothyroidism

Autoimmune
- Autoimmune thyroiditis (Hashimoto thyroiditis)
- Autoimmune polyglandular syndromes types 1 and 2 (APS-1, APS-2)
- IPEX
- Celiac disease

Drug-induced
- Excess iodide: amiodarone, nutritional supplements, expectorants
- Anticonvulsants: oxcarbazepine, phenytoin, phenobarbital, valproate
- Antithyroid drugs: methimazole, propylthiouracil
- Miscellaneous: lithium, rifampin, tyrosine kinase inhibitors, interferon-α, stavudine, thalidomide, aminoglutethimide, dopamine, amiodarone, tetracycline, ipilimumab, nivolumab

Iatrogenic
- Irradiation (e.g., cancer therapy, bone marrow transplant)
- Radioactive iodine (^{131}I)
- Thyroidectomy

Systemic infiltrative disease
- Cystinosis
- Langerhans cell histiocytosis

Consumptive: inactivation of thyroid hormone by large liver hemangiomas (type 3 deiodinase)

Decreased sensitivity to thyroid hormone (*MCT8, SEC16A2, THRA, THRB* pathogenic variants)

Hypothalamic-pituitary disease (often with multiple pituitary hormone deficiencies)
- Central nervous system tumors (e.g., craniopharyngioma)
- Meningoencephalitis
- Cranial irradiation
- Head trauma
- Langerhans cell histiocytosis

IPEX, Immunodysregulation polyendocrinopathy X-linked.

thyroiditis is a less common feature (~10%), as are type 1 diabetes mellitus, primary hypogonadism, pernicious anemia, vitiligo, alopecia, nephritis, hepatitis, and gastrointestinal dysfunction. APS type 2 (APS-2) is far more common than APS-1, and its pathogenesis remains an obscure combination of genetic and environmental factors. APS-2 may consist of any combination of autoimmune thyroiditis (~70%), type 1 diabetes mellitus, celiac disease, or less common manifestations such as primary adrenal insufficiency, primary hypogonadism, pernicious anemia, and vitiligo. Patients with any of these other autoimmune conditions are at increased risk of developing hypothyroidism. For example, about 20% of children with **type 1 diabetes mellitus** develop thyroid autoantibodies and about 5% become hypothyroid.

In children with **trisomy 21**, thyroid autoantibodies develop in approximately 30%, and subclinical or overt hypothyroidism occurs in approximately 15–20%. In females with **Turner syndrome**, thyroid autoantibodies

develop in approximately 40%, and subclinical or overt hypothyroidism occurs in approximately 15–30%, rising with increasing age. Additional autoimmune conditions with an increased risk of hypothyroidism include immune dysregulation–polyendocrinopathy–enteropathy–X-linked syndrome (IPEX) and IPEX-like disorders, immunoglobulin G_4–related diseases, Sjögren syndrome, and multiple sclerosis. **Williams syndrome** is associated with subclinical hypothyroidism, but this does not appear to be autoimmune, and thyroid autoantibodies are absent.

Medications can cause acquired hypothyroidism. Some medications containing iodine (e.g., expectorants or nutritional supplements) may cause hypothyroidism through the Wolff-Chaikoff effect (see Chapter 605). Amiodarone, a drug used for cardiac arrhythmias and consisting of 37% iodine by weight, causes hypothyroidism in approximately 20–30% of treated children. Children treated with amiodarone should have serial monitoring of thyroid function.

Anticonvulsants, including phenytoin, phenobarbital, and valproate, may cause thyroid dysfunction, usually in the form of subclinical hypothyroidism. In some cases, this is because of their effect of stimulating hepatic cytochrome P450 metabolism and excretion of T_4. The anticonvulsant oxcarbazepine can cause central (secondary) hypothyroidism. Hypothyroidism can be caused by overtreatment with antithyroid drugs (methimazole or propylthiouracil) for Graves disease. Additional drugs that can produce hypothyroidism include lithium, rifampin, tyrosine kinase inhibitors, interferon-α, stavudine, thalidomide, and aminoglutethimide.

Children who receive **therapeutic irradiation**, such as for Hodgkin disease or other head and neck malignancies or before bone marrow transplantation, are at risk for thyroid damage and hypothyroidism. Approximately 30% of such children acquire elevated TSH levels within a year after therapy, and another 15–20% progress to hypothyroidism within 5-7 years. **Radioactive iodine** ablative treatment or **thyroidectomy** for Graves disease or thyroid cancer results in iatrogenic hypothyroidism. Thyroid tissue in a thyroglossal duct cyst may constitute the only source of thyroid hormone, and in this case, excision of the cyst results in hypothyroidism. Ultrasonographic examination or a radionuclide scan before surgery is indicated in these patients.

Children with **nephropathic cystinosis,** a disorder characterized by intralysosomal storage of cystine in body tissues, acquire impaired thyroid function. Hypothyroidism is usually subclinical but may be overt, and periodic assessment of TSH levels is indicated. By 13 years of age, two thirds of these patients require L-T_4 replacement.

Histiocytic infiltration of the thyroid in children with **Langerhans cell histiocytosis** (see Chapter 556.1) can result in hypothyroidism. Children with chronic **hepatitis C infection** are at risk for subclinical hypothyroidism that does not appear to be autoimmune.

Consumptive hypothyroidism can occur in children with large hemangiomas of the liver. These tumors may express massive amounts of the enzyme type 3 deiodinase, which inactivates T_4 and T_3, respectively, to the inert metabolites reverse T_3 and diiodothyronine (T_2). Hypothyroidism occurs when increased thyroidal secretion of thyroid hormones is insufficient to compensate for their rapid inactivation.

Some patients with mild forms of congenital hypothyroidism (thyroid dysgenesis or genetic defects in thyroid hormone synthesis) do not develop clinical manifestations until childhood. Although these conditions are often detected by newborn screening, very mild defects can escape detection and present later with apparently acquired hypothyroidism.

Any **hypothalamic** or **pituitary** disease can cause acquired central hypothyroidism (see Chapter 595). TSH deficiency may result from a hypothalamic-pituitary tumor (craniopharyngioma is most common in children) or from treatment for a tumor. Central hypothyroidism may develop in up to 10% of children receiving craniospinal irradiation. Other causes include head trauma or infiltrative diseases affecting the pituitary gland, such as Langerhans cell histiocytosis.

Clinical Manifestations

Slowing of growth is usually the first clinical manifestation of acquired hypothyroidism, but this sign often goes unrecognized (Figs. 603.3 and 603.4). Goiter is a common presenting feature of primary hypothyroidism. In autoimmune thyroiditis, the thyroid is typically nontender

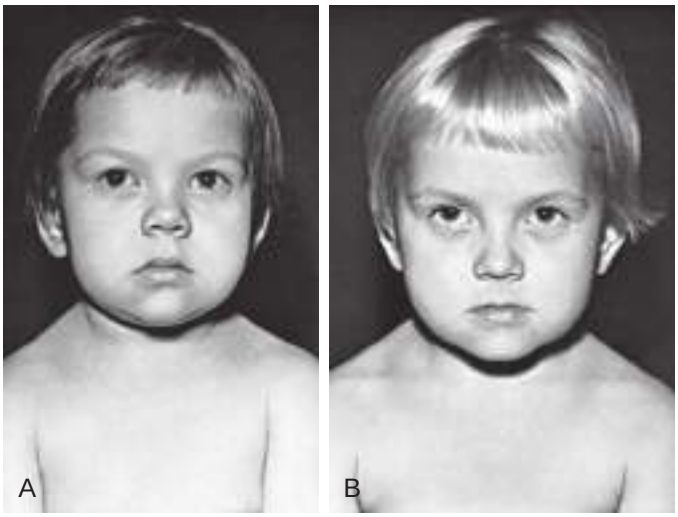

Fig. 603.3 **A,** Acquired hypothyroidism in a 6-yr-old female. She was treated with a wide variety of hematinics for refractory anemia for 3 years. She had almost complete cessation of growth, constipation, and sluggishness for 3 years. The height age was 3 years; the bone age was 4 years. She had a sallow complexion and immature facies with a poorly developed nasal bridge. Serum cholesterol, 501 mg/dL; radioiodine uptake, 7% at 24 hr; protein-bound iodine *(PBI),* 2.8 mg/dL. **B,** After therapy for 18 months, note the nasal development, increased luster and decreased pigmentation of hair, and maturation of the face. The height age was 5.5 years; the bone age was 7 years. There was a decided improvement in her general condition. Menarche occurred at 14 years. The ultimate height was 155 cm (61 in). She graduated from high school. The disorder was well controlled with daily L-thyroxine.

Fig. 603.4 **A,** This 12-yr-old male with hypothyroidism has short stature (108 cm, <3rd percentile), generalized myxedema, sleepy expression, protuberant abdomen, and coarse hair. Body proportions are immature for his age (1.25:1). **B,** Same boy 4 months after treatment. His height increased by 4 cm, and there is a marked change in body habitus owing to loss of myxedema, improved muscle tone, and bright facial expression. *(From LaFranchi SH. Hypothyroidism. Pediatr Clin North Am. 1979;26:33–51.)*

and firm, with a rubbery consistency and pebbly (bosselated) surface. Weight gain is mainly caused by fluid retention (myxedema), not true adiposity. Myxedematous changes of the skin, constipation, cold intolerance, decreased energy, and an increased need for sleep develop insidiously. School performance usually does not suffer, even in severely hypothyroid children. Additional features may include bradycardia, muscle weakness or cramps, nerve entrapment, and ataxia. Skeletal maturation is delayed, and the degree of delay reflects the duration of the hypothyroidism. Adolescents typically have delayed puberty. Older adolescent females may have menometrorrhagia, and some may develop galactorrhea because of increased TRH, which stimulates prolactin secretion. In fact, long-standing primary hypothyroidism can result in enlargement of the pituitary gland, sometimes leading to headaches and vision problems. This is believed to result from thyrotroph hyperplasia but may be mistaken for a pituitary tumor, particularly a prolactinoma if prolactin is elevated (see Chapter 595). Rarely, young children with profound hypothyroidism may develop secondary sex characteristics (pseudoprecocious puberty), including breast development or vaginal bleeding in females and testicular enlargement in males. It is hypothesized that this phenomenon results from abnormally high concentrations of TSH binding and stimulating the follicle-stimulating hormone receptor.

Laboratory abnormalities in hypothyroidism may include hyponatremia, macrocytic anemia, hypercholesterolemia, and elevated creatine phosphokinase. Table 603.5 lists complications of severe hypothyroidism, all of which normalize with adequate replacement of T_4.

Diagnostic Studies

Children with suspected hypothyroidism should undergo measurement of serum TSH and free T_4. Because the normal range for thyroid tests varies by age and is different in children than in adults, it is important to interpret results using age-specific reference ranges (see Table 603.3). Detection of autoantibodies to thyroglobulin or TPO is diagnostic of autoimmune thyroiditis. Measurement of urine iodine can confirm excess iodine exposure, if suspected. In cases of goiter resulting from autoimmune thyroiditis, ultrasonography typically shows diffuse enlargement and heterogeneous echotexture, but ultrasonography generally is not indicated unless the physical exam raises suspicion for a thyroid nodule. A bone age x-ray at diagnosis may suggest the duration and severity of hypothyroidism based on the degree of bone age delay.

Treatment and Prognosis

L-T_4 is the treatment for children with hypothyroidism. The dose on a weight basis gradually decreases with age. For children ages 1-3 years, the average daily L-T_4 dose is 4-6 μg/kg; for ages 3-10 years, 3-5 μg/kg; and for ages 10-16 years, 2-4 μg/kg. Treatment should be monitored by measuring serum TSH every 4-6 months and 4-6 weeks after any change in dosage, and TSH should be maintained in the age-specific reference range. In young children (under age 3 years), serum free T_4 should also be measured and ideally maintained in the upper half of the age-specific reference range. In older children with primary hypothyroidism, serum free T_4 need not be measured routinely but may be helpful in certain situations, such as to assess for poor medication adherence. In children with central hypothyroidism, in which TSH levels by definition do not reflect systemic thyroid status, serum free T_4 alone should be monitored and maintained in the upper half of the age-specific reference range.

During the first year of treatment, deterioration of schoolwork, poor sleeping habits, restlessness, short attention span, and behavioral problems may develop. However, these issues are transient and more easily managed if families are forewarned about them. Some practitioners feel that these symptoms may be partially ameliorated by starting at a lower dose of L-T_4 and advancing slowly. The development of persistent headaches or vision changes should prompt an evaluation for pseudotumor cerebri, a rare complication after initiation of L-T_4 treatment in older children (age 8-13 years).

In older children, after catch-up growth is complete, the growth rate provides a good index of the adequacy of therapy. In children with long-standing hypothyroidism, catch-up growth may be incomplete, and final adult height may be irremediably compromised (see Fig. 603.4).

Visit Elsevier eBooks+ at eBooks.Health.Elsevier.com for Bibliography.

Table 603.5 Clinical Presentation and Implications of Hypothyroidism

	PRESENTATION	SIGNS AND IMPLICATIONS
General metabolism	Weight gain, cold intolerance, fatigue	Increase in body mass index, low metabolic rate, myxedema,* hypothermia*
Cardiovascular	Fatigue on exertion, shortness of breath	Dyslipidemia, bradycardia, hypertension, endothelial dysfunction or increased intima–media thickness,* diastolic dysfunction,* pericardial effusion,* hyperhomocysteinemia,* electrocardiogram changes*
Neurosensory	Hoarseness of voice, decreased taste, vision, or hearing	Neuropathy, cochlear dysfunction, decreased olfactory and gustatory sensitivity
Neurologic and psychiatric	Impaired memory, paresthesia, mood impairment	Impaired cognitive function, delayed relaxation of tendon reflexes, depression,* dementia,* ataxia,* carpal tunnel syndrome, and other nerve entrapment syndromes,* myxedema coma*
Gastrointestinal	Constipation	Reduced esophageal motility, nonalcoholic fatty liver disease,* ascites (very rare)
Endocrinologic	Infertility and subfertility, menstrual disturbance, galactorrhea	Goiter, glucose metabolism dysregulation, infertility, sexual dysfunction, increased prolactin, pituitary hyperplasia*
Musculoskeletal	Muscle weakness, muscle cramps, arthralgia	Creatine phosphokinase elevation, Hoffman syndrome,* osteoporotic fracture* (most probably caused by overtreatment)
Hemostasis and hematologic	Bleeding, fatigue	Mild anemia, acquired von Willebrand disease,* decreased protein C and S,* increased red cell distribution width,* increased mean platelet volume*
Skin and hair	Dry skin, hair loss	Coarse skin, loss of lateral eyebrows,* yellow palms of the hand,* alopecia areata*
Electrolytes and kidney function	Deterioration of kidney function	Decreased estimated glomerular filtration rate, hyponatremia*

*Uncommon presentation.
From Chaker L, Bianco AC, Jonklaas J, et al. Hypothyroidism. *Lancet.* 2017;390:1550–1560, Table 1.

Chapter 604

Thyroiditis

Jessica R. Smith and Ari J. Wassner

Thyroiditis refers to inflammation of the thyroid gland. Thyroiditis can be acute or chronic and can be categorized by etiology, pathology, and/or clinical features. Painful thyroiditis is typically due to infection or trauma, whereas painless thyroiditis is often autoimmune-mediated or due to drug exposure.

Depending on the etiology and phase of illness, patients with thyroiditis may be euthyroid, hypothyroid, or thyrotoxic. The classic pattern of thyroid function changes in transient forms of thyroiditis is thyrotoxicosis followed by hypothyroidism and then restoration of euthyroidism. In some cases, hypothyroidism can persist after transient thyroiditis. The thyrotoxicosis caused by thyroiditis is not due to increased thyroid hormone synthesis (in contrast to Graves disease), but rather release of preformed thyroid hormone from the damaged gland, which can last up to 60 days.

Treatment for patients with thyroiditis is directed at alleviating symptoms of pain and symptoms of thyrotoxicosis such as tachycardia, palpations, and tremors. Nonsteroidal antiinflammatory drugs (NSAIDs) usually alleviate thyroid pain effectively, but a short course of steroids (prednisone) can be considered if pain is severe. Because the thyrotoxicosis is caused by the release of preformed thyroid hormone, antithyroid drugs (which block thyroid hormone synthesis) are ineffective. Instead, treatment with β blockers (atenolol or propranolol) may be used to control cardiovascular symptoms until thyrotoxicosis resolves. Thyroid function tests should be monitored every 6-8 weeks until they normalize. If hypothyroidism is prolonged or symptomatic, replacement with levothyroxine may be initiated.

THYROIDITIS WITH PAIN

Acute infectious (suppurative) thyroiditis is uncommon in children and typically is preceded by a respiratory infection or pharyngitis. The most common pathogenic organisms are α-hemolytic streptococci and *Staphylococcus aureus,* followed by gram-negative organisms and anaerobic bacteria. Other pathogens, including mycobacteria, fungi, and pneumocystis, cause more indolent infection and occur in immunocompromised patients. Abscess formation can occur, and the left thyroid lobe is more commonly affected than the right. Recurrent episodes or detection of mixed bacterial flora suggest that the infection arises from a **piriform sinus fistula** or, less commonly, from a **thyroglossal duct** remnant. Acute infectious thyroiditis is characterized by acute onset of neck pain, thyroid tenderness, swelling, erythema, dysphagia, and decreased range of motion of the neck. Fever, chills, sore throat, and leukocytosis are common. Thyroid function is usually normal, but thyrotoxicosis can occur. A suspected abscess can be assessed by thyroid ultrasound, and fine needle aspiration can help identify the responsible microorganism. Treatment of a thyroid abscess includes incision and drainage and administration of parenteral antibiotics. After the infection subsides, a CT scan with contrast may be obtained to identify a fistulous tract that may require surgical resection.

Subacute thyroiditis (de Quervain disease, subacute granulomatous thyroiditis) is believed to have a viral or postviral etiology and is usually transient. It typically presents with low-grade fever, minimal thyroid tenderness, and laboratory evidence of thyrotoxicosis (suppressed TSH and elevated T_4 and T_3). Mild symptoms of thyrotoxicosis may be present, but radioiodine uptake is depressed in the thyrotoxic phase. The erythrocyte sedimentation rate (ESR) is increased. The course is variable but usually follows the classic pattern of thyrotoxicosis, hypothyroidism, and finally resolution to euthyroidism, usually occurring over several months. There is a strong association with HLA-B35.

Radiation thyroiditis can occur after treatment with radioactive iodine or external beam radiation. Thyroid pain and tenderness develop after 2-5 days because of radiation-induced destruction of the thyroid follicular cells and subsequent release of preformed thyroid hormone. The neck pain is responsive to antiinflammatory therapies.

Palpation- or trauma-induced thyroiditis can result from direct trauma to the thyroid gland, typically from surgery, accidental trauma, biopsy, or rarely, vigorous palpation.

THYROIDITIS WITHOUT PAIN

Autoimmune Thyroiditis (Hashimoto Thyroiditis, Chronic Lymphocytic Thyroiditis)

Autoimmune thyroiditis is the most common cause of thyroid disease in children and adolescents and accounts for many of the formerly designated *adolescent* or *simple* goiters. It is also the most common cause of acquired hypothyroidism, with or without goiter. Between 1 and 2% of school-age children and 6–8% of adolescents have positive thyroid autoantibodies as evidence of autoimmune thyroid disease.

Etiology

This typical organ-specific autoimmune disease results from a combination of inherited susceptibility in genes involved in immunoregulation and from environmental triggers, both poorly characterized. Early in the disease, there may be thyroid hyperplasia only. This is followed by infiltration of lymphocytes and plasma cells into thyroid follicles and formation of lymphoid follicles with germinal centers. Chronic inflammation eventually leads to follicular fibrosis and atrophy. Certain human leukocyte antigen (HLA) haplotypes (HLA-DR4, HLA-DR5) are associated with an increased risk of goiter and thyroiditis, and others (HLA-DR3) are associated with the atrophic variant of thyroiditis.

A variety of different autoantibodies to thyroid antigens are also present. Circulating antibodies to thyroperoxidase (TPO-Abs) or thyroglobulin (Tg-Abs) are detectable in most children with autoimmune thyroiditis and many patients with Graves disease. TPO-Abs are involved in activation of the complement cascade and antibody-dependent, cell-mediated cytotoxicity. Tg-Abs do not appear to play a role in the autoimmune destruction of the gland. TSH receptor-blocking antibodies (TRBAbs) may cause thyroid atrophy and have been demonstrated in 18% of patients with severe hypothyroidism (TSH >20 mU/L) caused by autoimmune thyroiditis.

Clinical Manifestations

Autoimmune thyroiditis is 4-6 times more common in females than in males. It can occur during the first 3 years of life but becomes more common after 6 years of age and reaches its peak incidence during adolescence. The most common clinical manifestations are goiter and growth deceleration. Goiter is primarily caused by thyroid inflammation and fibrosis, and it can appear insidiously and may be variable in size. In most patients, the thyroid is diffusely enlarged, firm, and nontender. In some patients the gland may be asymmetric. Most affected children are euthyroid and asymptomatic. Children who develop hypothyroidism may be symptomatic, but others may have no symptoms despite laboratory evidence of overt hypothyroidism. In some cases, autoimmune thyroiditis can cause transient thyroiditis as a result of autoimmune thyroid destruction (so-called *Hashitoxicosis*). Such children may present with manifestations of thyrotoxicosis, such as tremulousness, irritability, increased sweating, and hyperactivity. Ophthalmopathy can occur in autoimmune thyroiditis even in the absence of Graves disease, although this is rare in childhood.

The clinical course of autoimmune thyroiditis is variable. Goiter may persist or regress spontaneously. Most children who are euthyroid at presentation remain euthyroid, but a subset of patients develop hypothyroidism within months or years. In children who have subclinical hypothyroidism at diagnosis (elevated TSH, normal free thyroxine [T_4]), approximately 35% revert to euthyroidism, 50% continue to have subclinical hypothyroidism, and approximately 15% develop overt hypothyroidism (elevated serum TSH, subnormal free T_4) within 5 years. There are few reliable predictors of progression to hypothyroidism, so periodic monitoring of TSH levels is indicated in children with autoimmune thyroiditis.

Familial clusters of autoimmune thyroiditis are common, and the incidence in siblings or parents of affected children may be as high as 25%. The concurrence within families of patients with autoimmune thyroiditis and Graves disease reflects a fundamental pathophysiologic relationship among these autoimmune thyroid disorders.

Autoimmune thyroiditis is associated with other autoimmune disorders. Autoimmune thyroiditis occurs in 10% of patients with **type 1 autoimmune polyglandular syndrome (APS-1),** characterized by autoimmune

polyendocrinopathy, candidiasis, and ectodermal dysplasia **(APECED)**, a rare autosomal recessive disorder caused by pathogenic variants in the autoimmune regulator *(AIRE)* gene (see Chapter 608). Autoimmune thyroiditis occurs in 70% of patients with **type 2 autoimmune polyglandular syndrome (APS-2)**, including type 1 diabetes mellitus, autoimmune primary adrenal insufficiency, pernicious anemia, vitiligo, and alopecia. TPO-Abs are found in approximately 20% of White and 4% of Black children with type 1 diabetes mellitus. The onset of APS-2 typically occurs in late childhood or early adulthood. Its cause is unknown but may be related to predisposing genetic factors shared among these autoimmune conditions (see Chapter 608). Autoimmune thyroiditis has also been described in children with **immunodysregulation polyendocrinopathy enteropathy X-linked (IPEX) syndrome**, including early-onset diabetes and colitis (see Chapter 608).

Autoimmune thyroiditis is common in patients with celiac disease or certain chromosomal disorders, particularly Turner syndrome (8–30%) and trisomy 21 (7–10%). Males with Klinefelter syndrome also appear to be at increased risk for autoimmune thyroid disease.

Table 604.1 compares the characteristics of autoimmune thyroiditis to other forms of thyroiditis.

Laboratory and Imaging Findings

Thyroid function tests are often normal. Elevation of serum TSH indicates hypothyroidism, which may be subclinical (normal free T_4) or overt (low free T_4). TPO-Abs are present in most children with autoimmune thyroiditis. Tg-Abs are present in many adolescents but are somewhat less sensitive in young children. Testing for both antibodies will detect about 95% of children with autoimmune thyroiditis. Antibody levels are lower in children than in adults, so repeated measurements of borderline levels may be indicated. Measurement of thyroid autoantibody levels is useful only for diagnosing autoimmune thyroiditis; antibody levels do not correlate with thyroid function and should not be monitored routinely after the initial diagnosis. In adolescent females with overt hypothyroidism, measurement of TSH receptor antibodies may identify patients at future risk of having babies with transient congenital hypothyroidism caused by transplacental passage of TRBAbs.

Thyroid scintigraphy and ultrasonography usually are not necessary for the diagnosis of autoimmune thyroiditis. If performed, thyroid scintigraphy reveals decreased radioisotope uptake that is patchy and irregular. Thyroid ultrasonography shows diffusely heterogeneous echogenicity and frequently an increased number of hyperplastic, benign-appearing cervical lymph nodes. Thyroid ultrasound is indicated for patients with a palpable thyroid nodule or significant thyroid asymmetry.

Treatment

If hypothyroidism is overt (elevated TSH with low free T_4) or symptomatic, treatment with levothyroxine is indicated at doses specific to size and age. Goiter may decrease in size but can persist for years. In a euthyroid patient, treatment with levothyroxine is unlikely to significantly decrease the goiter's size, and doses of levothyroxine sufficient to suppress TSH should be avoided because of potential adverse effects. Because autoimmune thyroiditis is self-limited in some instances, the need for continued therapy may be reevaluated periodically, particularly after growth and pubertal development are complete. Untreated euthyroid patients should have periodic monitoring for risk of progression to hypothyroidism. There is some controversy about the management of patients with subclinical hypothyroidism. Subclinical hypothyroidism has not been demonstrated to have clinically significant adverse effects, but studies are small and of limited quality. Therefore observation without treatment is acceptable, but some clinicians prefer to treat until growth and puberty are complete and then reevaluate their thyroid function.

OTHER CAUSES OF THYROIDITIS

Painless thyroiditis (silent thyroiditis) is characterized by transient thyrotoxicosis, followed sometimes by hypothyroidism, and then recovery. It accounts for 1–5% of cases of thyrotoxicosis. It can also occur in the postpartum period and in response to certain types of drugs.

Drug-induced thyroiditis can be caused by medications including lithium, amiodarone, interferon-α, interleukin-2, and tyrosine kinase inhibitors. Patients taking lithium are susceptible to both lithium-induced hypothyroidism and painless thyroiditis. The antiarrhythmic drug amiodarone contains a high concentration of iodine and can cause two types of thyrotoxicosis. Type 1 is caused by increased synthesis of thyroid hormone (hyperthyroidism), typically occurs in patients with underlying thyroid autoimmunity, and is amenable to treatment with antithyroid drugs (methimazole). Type 2 is a destructive thyroiditis causing excessive release of preformed thyroid hormone, which can be treated with glucocorticoids (prednisone).

Fibrous thyroiditis (invasive or Riedel thyroiditis) is quite rare in children and is characterized by extensive fibrosis and macrophage and eosinophil infiltration of the thyroid gland. The thyroid becomes enlarged, hard, and affixed to surrounding structures. Thyroid function tests are normal, and a biopsy is required to confirm the diagnosis. Glucocorticoids may alleviate symptoms.

Visit Elsevier eBooks+ at eBooks.Health.Elsevier.com for Bibliography.

Table 604.1 Characteristics of Thyroiditis Syndromes

CHARACTERISTIC	AUTOIMMUNE THYROIDITIS	PAINLESS THYROIDITIS	SUBACUTE THYROIDITIS	ACUTE INFECTIOUS THYROIDITIS	FIBROUS THYROIDITIS
Sex ratio (F:M)	4-6:1	2:1	5:1	1:1	3-4:1
Cause	Autoimmune	Autoimmune	Unknown (probably viral)	Infectious (bacterial)	Unknown
Pathologic findings	Lymphocytic infiltration, germinal centers, fibrosis	Lymphocytic infiltration	Giant cells, granulomas	Abscess formation	Dense fibrosis
Thyroid function	Usually euthyroidism; some hypothyroidism	Thyrotoxicosis, hypothyroidism, or both	Thyrotoxicosis, hypothyroidism, or both	Usually euthyroidism	Usually euthyroidism
TPO antibodies	Present, persistent	Present, persistent	Low titer, absent, or transient	Absent	Usually present
ESR	Normal	Normal	High	High	Normal
^{123}I uptake	Usually low	Low	Low	Normal	Low or normal

ESR, Erythrocyte sedimentation rate; ^{123}I, iodine 123; TPO, thyroid peroxidase.
Data from Farwell AP, Braverman LE. Inflammatory thyroid disorders. *Otolaryngol Clin North Am.* 1996;4:541–556.

Chapter 605

Goiter

Jessica R. Smith and Ari J. Wassner

A goiter is an enlargement of the thyroid gland. Average thyroid volume is approximately 1 mL at birth and increases with age and body mass index. For clinical assessment of thyroid size, the "rule of thumb" states that in older children (>5 years) each lobe of the thyroid gland is approximately the size of the distal phalanx of the child's thumb. Children with an enlarged thyroid can have normal thyroid function **(euthyroidism)**, underproduction of thyroid hormone **(hypothyroidism)**, or overproduction of thyroid hormone **(hyperthyroidism)**. Most goiters are discovered by the patient or a caregiver or on physical examination. Detection of a goiter should prompt an investigation of its cause and assessment of thyroid function.

Goiter may be congenital or acquired, endemic or sporadic. Goiter often results from increased pituitary secretion of thyroid-stimulating hormone (TSH) in response to decreased circulating levels of thyroid hormone. The most common causes of pediatric goiter are inflammation (autoimmune thyroiditis) and, in endemic areas, iodine deficiency (endemic goiter). Other causes include inborn errors in thyroid hormone synthesis (dyshormonogenesis), maternal ingestion of antithyroid drugs, goitrogens, abnormal activation of the TSH receptor by circulating antibodies (TRSAb) in Graves disease or by genetic gain-of-function pathogenic variants, or disorders of inappropriate TSH secretion. Thyroid enlargement can also result from thyroid nodules or infiltrative processes.

605.1 Congenital Goiter

Ari J. Wassner and Jessica R. Smith

Congenital goiter usually results from a defect in fetal thyroxine (T_4) synthesis that leads to neonatal hypothyroidism. This defect may be intrinsic to the fetal thyroid or may be caused by transplacental transfer from the mother of substances that decrease fetal thyroid hormone synthesis. Antithyroid drugs (methimazole or propylthiouracil) administered during pregnancy to treat maternal thyrotoxicosis cross the placenta and can interfere with fetal synthesis of thyroid hormone. The neonatal consequences are most severe when overtreatment with antithyroid drugs causes concomitant hypothyroidism in the mother, which reduces the supply of maternal thyroid hormone to the fetus. Fetal effects can occur even with low doses of antithyroid drugs; therefore infants born to women treated with such drugs in the third trimester should undergo serum thyroid studies at birth, even if they appear clinically euthyroid. Levothyroxine treatment may be indicated for severe hypothyroidism or to reduce the size of goiter that causes airway obstruction. Hypothyroidism caused by maternal antithyroid drugs is transient and resolves once the antithyroid drug has been excreted by the neonate, usually after 1-2 weeks. Like antithyroid drugs, other medications containing large amounts of iodine can cause congenital goiter, including amiodarone and some cough preparations.

In cases of congenital goiter and hypothyroidism in which no cause is identifiable from the maternal or medication history, an intrinsic defect in synthesis of thyroid hormone **(dyshormonogenesis)** should be suspected. Such disorders are caused by genetic defects in one of the proteins critical to thyroid hormone synthesis and are usually inherited in autosomal recessive fashion. Neonatal screening programs detect congenital hypothyroidism caused by such a defect in about 1 in 25,000 infants. Treatment with levothyroxine should be initiated immediately. If a specific defect is suspected, genetic testing to identify a mutation may be considered (see Chapter 603). Monitoring subsequent pregnancies with ultrasonography can be useful to detect fetal goiter (see Chapter 117).

Iodine deficiency is an important cause of congenital goiter that is rare in countries that have adopted universal salt iodization, but iodine deficiency persists in endemic areas (see Chapter 605.3). Severe maternal iodine deficiency early in pregnancy can cause neurologic damage during fetal development because maternal hypothyroidism reduces the transfer of maternal thyroid hormones that typically protect neurodevelopment in a fetus unable to synthesize its own thyroid hormone.

Goiter is almost always present in the infant with **neonatal Graves disease**. Thyroid enlargement results from transplacental passage of maternal TSH receptor-stimulating antibodies that promote thyroid hyperplasia (see Chapter 606.2). These goiters usually are not large, and the infant manifests clinical symptoms of hyperthyroidism. The diagnosis of maternal Graves disease is usually known but occasionally may be discovered by evaluating unexpected neonatal hyperthyroidism. Activating pathogenic variants of the TSH receptor are a rare cause of congenital goiter with hyperthyroidism.

A very large congenital goiter of any cause can lead to tracheal compression and respiratory distress that interferes with feeding and can even be fatal. Therefore intervening to reduce the size of a large fetal goiter may be necessary before delivery. Treatment should be directed at the underlying cause. Iodine deficiency should be treated if present. In pregnant women treated with antithyroid drugs, reducing the dose of maternal medication is appropriate. In severe cases, fetal goiter caused by fetal hypothyroidism (including dyshormonogenesis) may be reduced by intraamniotic injections of levothyroxine. If the fetal goiter is caused by fetal hyperthyroidism (e.g., fetal Graves disease), treatment with antithyroid drugs administered to the mother is indicated. Large obstructing fetal goiters are often managed with the ex utero intrapartum treatment (EXIT) procedure during elective delivery (see Chapter 117). When postnatal respiratory obstruction is severe, endotracheal intubation, hormone therapy, and occasionally partial thyroidectomy is indicated (Fig. 605.1).

When a palpable congenital goiter is lobulated, asymmetric, firm, or unusually large, a teratoma in or near the thyroid must be considered (see Chapter 607).

Visit Elsevier eBooks+ at eBooks.Health.Elsevier.com for Bibliography.

605.2 Intratracheal Goiter

Ari J. Wassner and Jessica R. Smith

One of the many potential ectopic locations of thyroid tissue is within the trachea. When present, intraluminal thyroid tissue lies beneath the tracheal mucosa and is often continuous with the normally located extratracheal thyroid gland. Both eutopic and ectopic thyroid tissue are susceptible to goitrous enlargement. Therefore when airway obstruction is associated with a goiter, it must be ascertained whether the obstruction is extratracheal or intratracheal. If obstructive manifestations are mild, administration of levothyroxine usually decreases the size of the goiter. When symptoms are severe, surgical removal of the intratracheal goiter is indicated.

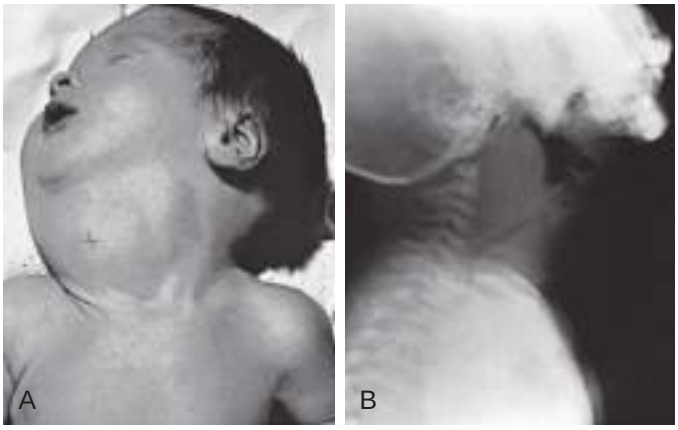

Fig. 605.1 Congenital goiter in infancy. **A,** Large congenital goiter in an infant born to a mother with thyrotoxicosis who had been treated with iodides and methimazole during pregnancy. **B,** A different infant, 6 wk old, with increasing respiratory distress and cervical mass since birth. Notice the anterior deviation and posterior compression of the trachea.

605.3 Endemic Goiter and Cretinism

Ari J. Wassner and Jessica R. Smith

ETIOLOGY

Goiter caused by iodine deficiency is termed *endemic goiter,* whereas *cretinism* refers to the clinical manifestations of severe hypothyroidism in early life. The association of dietary iodine deficiency with endemic goiter and cretinism is well established. The thyroid gland can overcome a moderate deficiency of iodine by increasing the efficiency of thyroid hormone synthesis. This increased activity is achieved by compensatory thyroid hypertrophy and hyperplasia (goiter). In cases of severe iodine deficiency, these compensatory mechanisms are insufficient, and hypothyroidism can result. The World Health Organization estimates that nearly 2 billion individuals have insufficient iodine intake, including one third of the world's school-age children. Thus despite significant progress in the global effort to reduce iodine deficiency, it remains a leading cause of preventable intellectual disability worldwide.

Because seawater is rich in iodine, endemic goiter is rare in coastal populations that consume much of their diet from the sea. In areas of iodine deficiency, iodized salt provides excellent prophylaxis, and endemic goiter has effectively disappeared in the United States and other countries that have introduced salt iodization programs. The U.S. recommended dietary allowance of iodine is:

- Infants under 6 months: 110 μg/day
- Infants 7-12 months: 130 μg/day
- Children 1-8 years: 90 μg/day
- Children 9-13 years: 120 μg/day
- Children 14 years and older: 150 μg/day
- Pregnant women: 220 μg/day
- Lactating women: 290 μg/day

Although the overall dietary iodine intake in the United States is considered adequate, recent data indicate that the median urinary iodine concentration among pregnant U.S. women has dropped to <150 μg/L (mild iodine deficiency). This highlights the re-emerging risk of iodine deficiency even in industrialized countries. These risks can be mitigated by the continued monitoring of iodine status, the adjustment of salt iodization levels, and the targeted supplementation of vulnerable subpopulations (e.g., promoting iodine-containing prenatal vitamins).

CLINICAL MANIFESTATIONS

In mild iodine deficiency, thyroid enlargement generally is not noticeable except when demand for thyroid hormone synthesis is increased, such as during rapid growth in adolescence and pregnancy. In regions of moderate iodine deficiency, goiter in school children can disappear with maturity and reappear during pregnancy or lactation. Iodine-deficient goiter is more common in girls than in boys. In areas of severe iodine deficiency, nearly half the population may have large goiters, and endemic cretinism is common (Fig. 605.2).

Serum T_4 levels are often low in individuals with endemic goiter, although clinical hypothyroidism is rare. Despite low serum T_4 levels, serum TSH concentrations are often normal or only mildly increased because of the elevated circulating levels of T_3 produced in response to iodine deficiency.

Endemic cretinism is the most severe consequence of iodine deficiency and occurs only in association with endemic goiter. The term *endemic cretinism* includes two distinct but overlapping syndromes (neurologic and myxedematous). The incidence of the two syndromes varies among different populations, but both syndromes are found in all endemic areas, and some individuals have intermediate or mixed features.

The **neurologic syndrome** is characterized by intellectual disability; deaf-mutism; disturbances in standing and gait; and pyramidal signs such as clonus of the foot, Babinski sign, and patellar hyperreflexia. Affected persons have a goiter but minimally impaired thyroid function and have normal pubertal development and adult stature. Persons with the **myxedematous syndrome** also have intellectual disability, deafness, and neurologic symptoms. In contrast to the neurologic type, they also have delayed growth and pubertal development and myxedema. Serum T_4 levels are low, TSH levels are markedly elevated, goiter is absent, and ultrasound demonstrates thyroid atrophy.

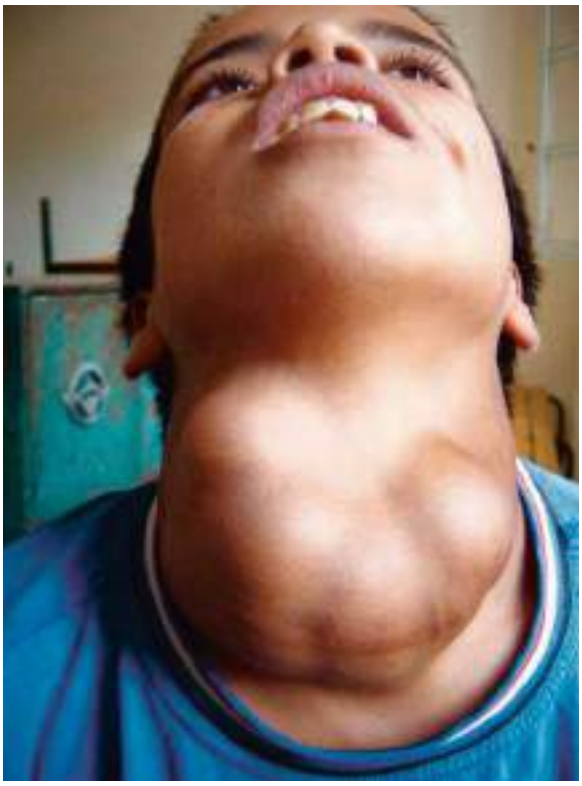

Fig. 605.2 A 14-yr-old male with a large nodular goiter was seen in 2004, in an area of severe iodine-deficiency disorders in northern Morocco. He had tracheal and esophageal compression and hoarseness, probably as a result of damage to the recurrent laryngeal nerves. *(From Zimmermann MB, Jooste PL, Pandav CS. Iodine-deficiency disorders. Lancet. 2008;372:1251–1262, Fig. 2.)*

PATHOGENESIS

The pathogenesis of the **neurologic syndrome** is attributed to maternal iodine deficiency and hypothyroidism during pregnancy, leading to fetal and postnatal hypothyroidism. Maternal thyroid hormone is critical for early fetal neurodevelopment. Thyroid hormone receptors are expressed in the fetal brain as early as 7 weeks of gestation. Although the fetal thyroid gland does not produce significant amounts of thyroid hormone until midgestation, as early as 6 weeks there is measurable T_4 in the coelomic fluid that is of maternal origin. In addition, there is transplacental passage of maternal thyroid hormone into the fetus throughout gestation, which ameliorates the neurologic effects of fetal hypothyroidism in the second half of pregnancy. Thus maternal iodine deficiency affects fetal neurodevelopment throughout pregnancy. However, iodine intake after birth is often sufficient for the infant to maintain (near-)normal thyroid function.

The pathogenesis of the **myxedematous syndrome** and its persistent postnatal hypothyroidism is not well understood. Multiple environmental factors have been implicated (Table 605.1), as have thyroid autoimmunity and TSH receptor-blocking antibodies, but studies are conflicting, and the pathogenesis remains obscure.

TREATMENT

The optimal treatment of endemic goiter is prevention by ensuring iodine sufficiency in women before pregnancy. A single intramuscular injection of iodinated poppy seed oil administered to women prevents iodine deficiency during future pregnancies for approximately 5 years. This therapy is also effective in children younger than 4 years with myxedematous cretinism. However, older children and adults respond poorly, indicating a progressive inability of the thyroid gland to synthesize hormone, and these patients require treatment with levothyroxine. Large-scale prevention efforts include universal salt iodization in many countries, as well as

Table 605.1 Goitrogens and Their Mechanisms

GOITROGEN	MECHANISM
FOODS	
Cassava, lima beans, linseed, sorghum, sweet potato	Contain cyanogenic glucosides that are metabolized to thiocyanates that compete with iodine for uptake by the thyroid
Cruciferous vegetables (cabbage, kale, cauliflower, broccoli, turnips)	Contain glucosinolates; metabolites compete with iodine for uptake by the thyroid
Soy, millet	Flavonoids impair thyroid peroxidase activity
INDUSTRIAL POLLUTANTS	
Perchlorate	Competitive inhibitor of the sodium-iodide symporter, decreasing iodide transport into the thyroid
Others (e.g., disulfides from coal processes)	Reduce thyroidal iodine uptake
Smoking	Smoking during breastfeeding is associated with reduced iodine concentrations in breast milk; high serum concentration of thiocyanate from smoking might compete with iodine for active transport into the secretory epithelium of the lactating breast
NUTRIENTS	
Selenium deficiency	Accumulated peroxides can damage the thyroid, and deiodinase deficiency impairs thyroid hormone activation
Iron deficiency	Reduces heme-dependent thyroperoxidase activity in the thyroid and may blunt the efficacy of iodine prophylaxis
Vitamin A deficiency	Increases TSH stimulation and goiter through decreased vitamin A–mediated suppression of the pituitary TSH-β gene

TSH, Thyroid-stimulating hormone.
From Zimmermann MB, Jooste PL, Pandav CS. Iodine-deficiency disorders. *Lancet.* 2008;372:1251–1262, Table 1.

iodination of irrigation water in some areas. Nevertheless, political, economic, and practical obstacles have limited iodization efforts in many parts of the world.

Visit Elsevier eBooks+ at eBooks.Health.Elsevier.com for Bibliography.

605.4 Acquired Goiter

Jessica R. Smith and Ari J. Wassner

Acquired goiter is usually sporadic and may develop from a variety of causes. The most common cause of acquired goiter is autoimmune thyroiditis (see Chapter 604). Other causes in children include painless sporadic thyroiditis and subacute thyroiditis (de Quervain disease; see Chapter 604). Ingestion of excess iodide or certain medications can cause goiter, as can congenital defects in thyroid hormone synthesis. The occurrence of goiter in siblings, onset in early life, and possible association with hypothyroidism are important clues to diagnosing congenital dyshormonogenesis.

IODIDE GOITER

Excessive iodine ingestion can result in a goiter. Large amounts of iodine are found in certain foods (such as seaweed) and some expectorants for chronic reactive airway disease or cystic fibrosis. Some children with iodine-induced goiter have underlying autoimmune thyroiditis or a subclinical congenital defect in thyroid hormone synthesis. In a normal thyroid gland, the acute intake of large doses of iodine inhibits thyroid hormone synthesis (Wolff-Chaikoff effect). However, this effect is short-lived and normally does not lead to hypothyroidism. If iodine administration continues, an autoregulatory mechanism limits iodide uptake by the thyroid, allowing thyroid hormone synthesis to resume. This "escape" from the Wolff-Chaikoff effect may not occur in individuals with underlying thyroid abnormalities (such as autoimmune thyroid disease or thyroid irradiation) or in neonates, potentially leading to hypothyroidism and iodine-induced goiter.

Iodine-Deficiency Goiter

Iodine deficiency is the most common cause of goiter worldwide, but salt iodization has nearly eradicated this entity in the United States and many other countries. A severely iodine-restricted diet can result in a goiter and hypothyroidism in children, adolescents, or neonates born to mothers with severe iodine deficiency (urine iodine concentration <50 mcg/L). Children with moderate or severe iodine deficiency and goiter have subclinical or mild hypothyroidism, but their serum T_3 concentrations may be normal or high because of preferential thyroidal T_3 secretion. Acquired iodine deficiency can be treated with either iodine or levothyroxine supplementation.

Goitrogens

Certain foods contain goitrogenic substances (see Table 605.1). When consumed alone, these substances are unlikely to cause goiter but can contribute to goiter formation when iodine intake is marginal.

Lithium carbonate can cause goiter and hypothyroidism in children. Lithium decreases T_4 and T_3 synthesis and release; the mechanism producing the goiter or hypothyroidism is similar to that described for iodide goiter. Lithium and iodide act synergistically to produce goiter, so their combined use should be avoided.

Amiodarone, a drug used to treat cardiac arrhythmias, can cause thyroid dysfunction with goiter because it is rich in iodine. Amiodarone can often cause hypothyroidism, particularly in patients with underlying autoimmune thyroid disease. In other patients, it can cause thyrotoxicosis through either transient thyroiditis or the Jod-Basedow effect.

SIMPLE GOITER (COLLOID GOITER)

Some children with euthyroid goiters have a simple goiter, a condition of unknown cause not associated with thyroid dysfunction and not caused by inflammation or neoplasia. Simple goiter is more common in girls, may be familial, and has its peak incidence during adolescence. Histologic examination of the thyroid either is normal or reveals variable follicular size, dense colloid, and flattened epithelium. The size of the goiter is variable. It can occasionally be firm, asymmetric, or nodular. Levels of TSH are normal, thyroid scintigraphy is normal, and thyroid antibodies are absent. Simple goiters usually decrease in size gradually over several years, without treatment. Patients should be reevaluated periodically because some have antibody-negative autoimmune thyroiditis and therefore are at risk for changes in thyroid function (see Chapter 604).

MULTINODULAR GOITER

Multinodular goiter is usually a firm goiter with a lobulated surface and one or more palpable nodules. Areas of cystic change, hemorrhage, and fibrosis may be present. The incidence of this condition has decreased markedly with the use of iodine-enriched salt. Ultrasonographic examination can reveal multiple nodules that are nonfunctioning on thyroid scintigraphy. Thyroid function is usually normal. Some children with autoimmune thyroiditis develop a multinodular goiter, and in such cases, thyroid antibodies may be present, and TSH may be elevated. If hypofunctioning nodules within a multinodular goiter grow to a significant size (≥1 cm) or have suspicious sonographic features, fine needle aspiration should be considered to rule out malignancy (see Chapter 607). Children with **McCune-Albright syndrome** or TSH receptor–activating mutations can develop a toxic multinodular goiter, characterized by suppressed TSH, hyperthyroidism, and multiple hyperfunctioning nodules.

TOXIC GOITER (HYPERTHYROIDISM)

See Chapter 606.

Visit Elsevier eBooks+ at eBooks.Health.Elsevier.com for Bibliography.

Chapter 606

Thyrotoxicosis

Jessica R. Smith and Ari J. Wassner

Although the terms *hyperthyroidism* and *thyrotoxicosis* are often interchanged in the literature, they are not synonymous. **Hyperthyroidism** specifically refers to the synthesis and secretion of excess thyroid hormone from the thyroid gland; in contrast, **thyrotoxicosis** refers to any state of excess circulating thyroid hormone (and its clinical manifestations) regardless of its source. This distinction is physiologically and clinically relevant because different therapies may be indicated depending on the mechanism of thyroid hormone excess.

Graves disease is the most common cause of hyperthyroidism in children (Table 606.1). It is an autoimmune disorder that results in the production of thyrotropin (TSH) receptor–stimulating antibodies (TRSAbs) that bind and activate the G protein–coupled TSH receptor (TSHR) to cause increased thyroid hormonogenesis and diffuse glandular growth. In infants born to mothers with Graves disease, hyperthyroidism can be caused by transplacental passage of TRSAbs, but this is transitory and resolves when TRSBAbs are cleared from the neonate's circulation. Etiologies of nonautoimmune hyperthyroidism include hyperfunctioning thyroid nodules and germline gain-of-function pathogenic variants in the TSHR (either autosomal dominant or sporadic). Hyperthyroidism can also occur in patients with **McCune-Albright syndrome** because of an activating pathogenic variant of the stimulatory α-subunit of the G protein. These patients can also develop a multinodular goiter. Other rare causes of hyperthyroidism include iodine-induced hyperthyroidism, TSH-secreting adenomas, toxic multinodular goiters, and hyperfunctioning thyroid carcinoma. Thyrotoxicosis not caused by hyperthyroidism (i.e., not the result of overproduction of thyroid hormone by the gland) can be caused by thyroiditis (see Chapter 604) or ingestion of exogenous thyroid hormone. Choriocarcinoma, hydatidiform mole, and struma ovarii can cause hyperthyroidism but are rarely diagnosed in children.

Laboratory evaluation of primary thyrotoxicosis reveals suppression of serum TSH and elevation of serum total thyroxine (T_4) and/or total triiodothyronine (T_3) levels. Elevated T_4 and T_3 with normal or elevated TSH suggests hyperthyroidism caused by inappropriate TSH secretion, which may be caused by a dominant-negative pathogenic variant in thyroid hormone receptor-β *(THRB)* resulting in **resistance to thyroid hormone (RTH)**. TSH-secreting pituitary tumors are extremely rare in the pediatric population. Elevated T_4 and/or T_3 levels with normal TSH may also be caused by abnormalities of thyroid hormone–binding proteins such as **thyroxine-binding globulin** excess or **familial dysalbuminemic hyperthyroxinemia**. In such cases, free T_4 levels are normal, and patients are euthyroid.

606.1 Graves Disease

Jessica R. Smith and Ari J. Wassner

EPIDEMIOLOGY

Graves disease occurs in approximately 0.02% of children (1:5,000) and is the most common cause of pediatric hyperthyroidism. It has a peak incidence in the 11- to 15-year-old age-group, and there is a 5:1 female:male ratio. Many children with Graves disease have a family history of autoimmune thyroid disease. Although rare in very young children, Graves disease has been reported between 6 weeks and 2 years of age in children born to mothers without a history of hyperthyroidism.

ETIOLOGY

Graves disease is a form of autoimmune thyroid disease characterized by infiltration of the thyroid gland by T-helper cells ($CD4^+$), cytotoxic T cells ($CD8^+$), and activated B lymphocytes. A postulated failure of T suppressor cells allows the expression of T helper cells sensitized to the TSH antigen to interact with B cells, which

Table 606.1 Pathogenic Mechanisms and Causes and Effects of Thyrotoxicosis

Thyrotoxicosis with hyperthyroidism (normal or high radioactive iodine uptake)	
EFFECT OF INCREASED THYROID STIMULATORS	
TSH-receptor antibody	Graves disease
Inappropriate TSH secretion	TSH-secreting pituitary adenoma; resistance to thyroid hormone β
Excess hCG secretion	Trophoblastic tumors (choriocarcinoma or hydatidiform mole); hyperemesis gravidarum
AUTONOMOUS THYROID FUNCTION	
Activating pathogenic variant in TSH receptor or $G_s\alpha$ protein	Solitary hyperfunctioning adenoma; multinodular goiter; familial nonautoimmune hyperthyroidism
Thyrotoxicosis without hyperthyroidism (low radioactive iodine uptake)	
INFLAMMATION AND RELEASE OF STORED HORMONE	
Autoimmune destruction of thyroid gland	Autoimmune thyroiditis; postpartum thyroiditis
Viral infection*	Subacute (painful) thyroiditis (de Quervain thyroiditis)
Toxic drug effects	Drug-induced thyroiditis (amiodarone, lithium, interferon-α)
Bacterial or fungal infection	Acute suppurative thyroiditis
Radiation	Radiation thyroiditis
EXTRATHYROIDAL SOURCE OF HORMONE	
Excess intake of thyroid hormone	Excess exogenous thyroid hormone (iatrogenic or factitious)
Ectopic hyperthyroidism (thyroid hormone produced outside the thyroid gland)	Struma ovarii; functional thyroid cancer
Ingestion of contaminated food	Hamburger thyrotoxicosis
EXPOSURE TO EXCESSIVE IODINE	
Jod-Basedow effect	Iodine-induced hyperthyroidism (radiocontrast agents or iodine in medications)

*Etiology is not definitive.
$G_s\alpha$, G protein alpha subunit; hCG, human chorionic gonadotropin; TSH, thyroid-stimulating hormone.
Modified from De Leo S, Lee SY, Braverman LE. Hyperthyroidism. *Lancet*. 2016;388:906–916, Table 1.

Table 606.2 Conditions Associated with Graves Disease

Type 1 diabetes mellitus
Celiac disease
Autoimmune adrenal insufficiency
Vitiligo
Psoriasis
Pernicious anemia
Alopecia areata
Myasthenia gravis
Rheumatoid arthritis
Trisomy 21
Turner syndrome

differentiate into plasma cells that produce TRSAbs. TRSAbs bind to and activate the TSHR, resulting in thyroid hyperplasia and unregulated thyroid hormone synthesis. Some patients with Graves disease also produce TSH receptor–blocking antibodies (TRBAbs) that bind to and block activation of the TSHR. In these cases, the clinical course of the disease correlates to the ratio between stimulating and blocking antibodies.

Ophthalmopathy may occur in Graves disease and appears to be caused primarily by autoimmunity to the TSHR, which is also expressed in orbital adipocytes and fibroblasts. TRSAb-mediated activation of these cells stimulates the synthesis of glycosaminoglycans and cytokines, resulting in retro-orbital inflammation and edema. Although 50–75% of children with Graves disease have some eye findings, the symptoms are much milder than in adults; significant ophthalmopathy is rare.

Graves disease is associated with specific human leukocyte antigen (HLA) haplotypes. It is also associated with other HLA-related disorders, such as autoimmune adrenal insufficiency, type 1 diabetes mellitus, myasthenia gravis, and celiac disease (Table 606.2). Systemic lupus erythematosus, rheumatoid arthritis, vitiligo, idiopathic thrombocytopenic purpura, and pernicious anemia have also been described in children with Graves disease. In family clusters, the condition associated most commonly with Graves disease is autoimmune thyroiditis. Polymorphisms in the *TSHR* gene and numerous immunomodulatory genes—including *FOXP3, IL2RA, CD40, CTLA4, PTPN22,* and *FCRL3*—have also been associated with increased susceptibility to Graves disease.

CLINICAL MANIFESTATIONS

The clinical course of Graves disease is variable, and children typically take longer to remit than adults. Because symptoms develop gradually, the interval between onset and diagnosis is typically 6-12 months and may be longer in prepubertal children than in adolescents.

Signs and symptoms of Graves disease in children are shown in Figure 606.1 and Table 606.3. Tremulousness, headaches, mood disturbances, behavioral swings, difficulties with sleep, decreased attention span, hyperactivity, and a decline in school performance are all common findings in childhood. Many hyperthyroid children are referred for evaluation of attention-deficit/hyperactivity disorder (ADHD). Children with hyperthyroidism may show acceleration in growth velocity and advanced skeletal maturation. The effect on growth may be more pronounced if hyperthyroidism presents earlier in childhood. The onset of puberty does not appear to be altered by hyperthyroidism, but postmenarchal females can develop secondary amenorrhea. There may also be an increase in appetite with either failure to gain weight or overt weight loss. Polyuria and more frequent defecation (although not usually frank diarrhea) contribute to changes in weight. Because of the increased risk

Fig. 606.1 A 15-yr-old female with classic Graves disease. Clinical features include a goiter and exophthalmos. She was treated with antithyroid drugs, to which she had a good response.

of comorbid autoimmune disorders, screening for type 1 diabetes, celiac disease, and inflammatory bowel disease should be considered in patients who present with these symptoms.

Most children with Graves disease have a diffuse goiter. The size of the thyroid is variable, but it is typically smooth and without nodules. A bruit can occasionally be auscultated over a markedly enlarged gland. Ocular manifestations can produce proptosis, pain, eyelid erythema, chemosis, decreased extraocular muscle function and decreased visual acuity (corneal or optic nerve involvement) (Table 606.4). In children with thyrotoxicosis and diffuse goiter, identifying these signs of ophthalmopathy on physical examination strongly suggests the diagnosis of Graves disease. However, stare and lid lag are eye findings caused by increased sympathetic activity and can be seen in thyrotoxicosis of any cause, not only Graves disease (Fig. 606.2). In general, ocular symptoms in children with Graves disease tend to be mild and improve with the restoration of euthyroidism.

Children with hyperthyroidism have an increase in cardiac output. Tachycardia, palpitations, increased systolic blood pressure, and a widened pulse pressure are common cardiac manifestations, whereas cardiac enlargement and insufficiency and atrial fibrillation are rare complications.

The skin is smooth and flushed, with excessive sweating. Occasionally, associated vitiligo or psoriasis can be present. Graves dermopathy, characterized by indurated, nonpitting edema often on the anterior shins (pretibial myxedema), is rare in children. Proximal muscular weakness may be present. Thyroid hormone stimulates bone resorption, leading to low bone density and increased fracture risk in patients with chronic hyperthyroidism. Bone density returns to normal with treatment.

Table 606.3 Clinical Manifestation of Thyrotoxicosis

	SYMPTOMS	SIGNS
Constitutional	Weight loss despite increased appetite; heat-related symptoms (heat intolerance, sweating, and polydipsia)	Weight loss
Neuromuscular	Tremor; nervousness; anxiety; fatigue; weakness; disturbed sleep; poor concentration	Tremor of the extremities; hyperactivity; hyperreflexia; pelvic and girdle muscle weakness
Cardiovascular	Palpitations	Tachycardia; systolic hypertension
Pulmonary	Dyspnea, shortness of breath	Tachypnea
Gastrointestinal	Hyperdefecation; nausea, vomiting	Abdominal tenderness
Skin	Increased perspiration	Warm and moist skin
Reproductive		Menstrual disturbances
Ocular (Graves disease)	Diplopia; sense of irritation in the eyes; eyelid swelling; retro-orbital pain or discomfort	Proptosis; eyelid retraction and lag; periorbital edema; conjunctival injection and chemosis; ophthalmoplegia

From De Leo S, Lee SY, Braverman LE. Hyperthyroidism. *Lancet*. 2016;388:906–916, Table 2.

Table 606.4 Clinical Assessment of the Patient with Graves Ophthalmopathy

ACTIVITY MEASURES*
- Spontaneous retrobulbar pain
- Pain on attempted up or down gaze
- Redness of the eyelids
- Redness of the conjunctivae
- Swelling of the eyelids
- Inflammation of the caruncle and/or plica
- Conjunctival edema

SEVERITY MEASURES
- Lid aperture (distance between the lid margins in millimeters with the patient looking in the primary position, sitting relaxed, and with distant fixation)
- Swelling of the eyelids (absent/equivocal, moderate, severe)
- Redness of the eyelids (absent/present)
- Redness of the conjunctivae (absent/present)
- Conjunctival edema (absent, present)
- Inflammation of the caruncle or plica (absent, present)
- Exophthalmos (measured in millimeters using the same Hertel exophthalmometer and the same intercanthal distance for an individual patient)
- Subjective diplopia score†
- Eye muscle involvement (ductions in degrees)
- Corneal involvement (absent/punctate keratopathy/ulcer)
- Optic nerve involvement (best corrected visual acuity, color vision, optic disc, relative afferent pupillary defect (absent/present), plus visual fields if optic nerve compression is suspected

*Based on the classic features of inflammation in Graves ophthalmopathy.
†Subjective diplopia score: 0, no diplopia; 1, intermittent (i.e., diplopia in primary position of gaze, when tired or when first awakening); 2, inconstant (i.e., diplopia at extremes of gaze); 3, constant (i.e., continuous diplopia in primary or reading position). The clinical activity score (CAS) is the sum (1 point each) of all items present; a CAS ≥3/7 indicates active ophthalmopathy.
From Davies TF, Laurberg P, Bahn RS. Hyperthyroid disorders. In: Melmed S, Polonsky KS, Larsen PR, Kronenberg HM, eds. *Williams Textbook of Endocrinology*, 13th ed. Philadelphia: Elsevier; 2016: Table 12.4.

Thyroid storm is an extreme form of hyperthyroidism characterized by severely elevated thyroid hormone levels, hyperthermia, tachycardia, heart failure, altered mental status, and GI symptoms (Table 606.5). If untreated, there may be rapid progression to delirium, coma, and death. Precipitating events include trauma, infection, radioactive iodine (RAI) treatment, or surgery.

Fig. 606.2 Retraction of upper eyelids in the primary gaze (Dalrymple sign). *(From Kanski JJ. Systemic Diseases and the Eye: Signs and Differential Diagnosis. London: Mosby; 2001.)*

LABORATORY FINDINGS

In Graves disease, serum TSH is suppressed and free T_4 and T_3 are elevated. Most patients with Graves disease have measurable TRSAbs at diagnosis. TRSAbs can be measured either by a functional assay (thyroid-stimulating immunoglobulin [TSI]) that assesses the presence of antibodies capable of stimulating TSHR-mediated cyclic adenosine monophosphate (cAMP) generation, or by a competitive binding assay (thyrotropin-binding inhibitory immunoglobulin [TBII]) that assesses the presence of antibodies that bind to the TSHR, regardless of their effect on receptor activity. In a patient with thyrotoxicosis, both assays are highly sensitive and specific for Graves disease.

When the diagnosis cannot be established by history, physical examination, and laboratory evaluation, RAI uptake can be measured, preferably using ^{123}I. RAI uptake is elevated in Graves disease, whereas it is low in other causes of thyrotoxicosis like thyroiditis or exogenous thyroid hormone ingestion. If scintigraphy is also performed, the increased RAI uptake in Graves disease is present diffusely throughout the gland, whereas focally increased uptake is observed in hyperfunctioning thyroid nodules.

DIFFERENTIAL DIAGNOSIS

Elevated serum levels of T_4 or free T_4 and T_3 in association with suppressed levels of TSH are diagnostic of thyrotoxicosis (see Table 606.1).

Table 606.5 Diagnostic Criteria for Thyroid Storm

	POINTS
TEMPERATURE °F (°C)	
99-99.9 (37.2-37.7)	5
100-100.9 (37.8-38.2)	10
101-101.9 (38.3-38.8)	15
102-102.9 (38.9-39.4)	20
103-103.9 (39.4-39.9)	25
≥104.0 (>40.0)	30
CENTRAL NERVOUS SYSTEM EFFECTS	
Absent	0
Mild (agitation)	10
Moderate (delirium, psychosis, extreme lethargy)	20
Severe (seizure, coma)	30
GASTROINTESTINAL-HEPATIC DYSFUNCTION	
Absent	0
Moderate (diarrhea, nausea/vomiting, abdominal pain)	10
Severe (unexplained jaundice)	20
CARDIOVASCULAR DYSFUNCTION	
Tachycardia	
90-109	5
110-119	10
120-129	15
130-139	20
≥140	25
Congestive Heart Failure	
Absent	0
Mild (pedal edema)	5
Moderate (bibasilar rales)	10
Severe (pulmonary edema)	15
Atrial Fibrillation	
Absent	0
Present	10
Precipitating History	
Absent	0
Present	10

In adults, a score ≥45 is highly suggestive of thyroid storm; a score of 25-44 is suggestive of impending thyroid storm; a score of <25 is unlikely to represent thyroid storm.
Data are from HB Burch, L Wartofsky. Life-threatening thyrotoxicosis. Thyroid storm. *Endocrinol Metab Clin North Am*. 1993;22:263–277. From De Leo S, Lee SY, Braverman LE. Hyperthyroidism. *Lancet*. 2016;388:906–916, Table 3.

The combination of diffuse goiter and prolonged thyrotoxicosis (>8 weeks) is most often caused by Graves disease; the presence of circulating TSHR antibodies or characteristic eye or skin changes is diagnostic.

If the etiology of thyrotoxicosis is unclear, ^{123}I radioiodine uptake can distinguish hyperthyroidism (increased uptake) from other causes of thyrotoxicosis, which will determine the appropriateness of antithyroid medication. If a discrete thyroid nodule is palpated, ^{123}I scintigraphy should be performed to assess for a hyperfunctioning nodule. Some children with toxic multinodular goiter may have a TSHR-activating pathogenic variant or McCune-Albright syndrome. If precocious puberty, polyostotic fibrous dysplasia, or café-au-lait macules are present, then McCune-Albright syndrome is likely.

Patients with thyroid hormone resistance have elevated levels of free T_4 and T_3, but levels of TSH are inappropriately elevated or normal. They must be differentiated from patients with TSH-secreting pituitary tumors who have elevated serum levels of the common α-subunit shared by TSH, luteinizing hormone (LH), follicle-stimulating hormone (FSH), and human chorionic gonadotropin (hCG). Most other causes of elevated serum T_4 are uncommon but can result in an erroneous diagnosis. Patients with elevated thyroxine-binding globulin levels or familial dysalbuminemic hyperthyroxinemia have high serum T_4 but normal levels of free T_4 and TSH and are clinically euthyroid. Rare patients with pathogenic variants in *SLC16A2* (encoding the MCT8 thyroid hormone transporter) or *THRA* (encoding thyroid hormone receptor α) can present with high serum T_3, inappropriately normal or high TSH, and low or low-normal serum T_4 concentrations.

When thyrotoxicosis is caused by exogenous thyroid hormone, free T_4 and TSH levels are the same as those seen in Graves disease, but in contrast to Graves disease, thyroid size is small, serum thyroglobulin is very low, and ^{123}I radioiodine uptake is suppressed.

TREATMENT

Antithyroid Drugs

In most cases, antithyroid drugs (ATDs) are the preferred initial therapy for Graves disease in children. Alternative treatments include radioiodine ablation (in children older than 10 years of age) and thyroidectomy. Each therapeutic option has advantages and disadvantages (Table 606.6). Methimazole is the first-line ATD for children with Graves disease and functions by blocking the organification of iodide necessary to synthesize thyroid hormone. Methimazole has a long serum half-life (6-8 hours) that allows once- or twice-daily dosing. Propylthiouracil is similar to methimazole, but its use is not recommended in children because of its potential to cause liver failure. However, in rare instances of severe hyperthyroidism in which methimazole cannot be used, a short course of propylthiouracil may be offered to restore euthyroidism before definitive therapy.

Adverse reactions can occur with ATDs and range from mild to life-threatening. Minor adverse effects occur in approximately 10–20% of patients, and severe adverse effects occur in 2–5%. Reactions most commonly occur during the first 3 months of therapy but can occur at any time. Transient urticaria is common and may be managed with antihistamines or by a short period off therapy followed by restarting ATD. Agranulocytosis is a severe adverse reaction that occurs in 0.1–0.5% of patients and can lead to a fatal infection. Therefore during any episode of significant fever, pharyngitis, or oral ulcers, patients should stop taking methimazole and have an absolute neutrophil count checked. On the other hand, transient, asymptomatic granulocytopenia (<2,000/mm^3) is common in Graves disease; it is not a harbinger of agranulocytosis and is not a reason to discontinue treatment. Other severe reactions include hepatitis (0.2–1.0%), a lupus-like polyarthritis syndrome, glomerulonephritis, and antineutrophilic cytoplasmic antibody–positive vasculitis. Severe liver disease, including liver failure requiring transplantation, has been reported with propylthiouracil. The most common liver disease associated with methimazole is cholestatic jaundice, which is reversible when the drug is discontinued. Patients with severe adverse effects should be treated with radioiodine or thyroidectomy. Importantly, methimazole and propylthiouracil have been associated with congenital malformations in infants exposed to these drugs in utero. Methimazole exposure may be associated with aplasia cutis, omphalocele, choanal atresia,

Table 606.6 Treatments for Graves Disease

TREATMENT	ADVANTAGE	DISADVANTAGE	COMMENT
Antithyroid drugs	Noninvasive Less initial cost No risk of permanent hypothyroidism Possible remission	Remission rate 30–50% (with long-term treatment) Adverse drug reactions Drug compliance required	First-line treatment in children and adolescents
Radioactive iodine (^{131}I)	Cure of hyperthyroidism	Permanent hypothyroidism Might worsen ophthalmopathy Pregnancy must be deferred for 6-12 mo, mother cannot breastfeed; small potential risk of exacerbation of hyperthyroidism	No evidence for infertility or birth defects with currently recommended doses
Surgery	Rapid, effective (especially in patients with large goiter)	Most invasive therapy Potential complications (recurrent laryngeal nerve damage, hypoparathyroidism) Permanent hypothyroidism Pain, surgical scar	Useful when coexisting suspicious nodule is present or thyromegaly is massive Option for patients who do not desire radioiodine

Modified from Cooper DS. Hyperthyroidism. *Lancet.* 2003;362:459–468.

Table 606.7 Management of Thyroid Storm in Adolescents

GOAL	TREATMENT
Inhibition of thyroid hormone formation and secretion	Propylthiouracil 400 mg q8h PO/IV/NGT Saturated solution of potassium iodide, 3 drops every 8 hr
Sympathetic blockade	Propranolol 20-40 mg q4-6h or 1 mg IV slowly (repeat doses until heart rate slows); not indicated in patients with asthma or heart failure that is not rate related
Glucocorticoid therapy	Prednisone 20 mg bid
Supportive therapy	Intravenous fluids (depending on indication: glucose, electrolytes, multivitamins) Temperature control (cooling blankets, acetaminophen; avoid salicylates) O_2 if required Digitalis for heart failure and to slow ventricular response; pentobarbital for sedation Treatment of precipitating event (e.g., infection)

From Goldman L, Ausiello D, eds. *Cecil Textbook of Medicine*, 22nd ed. Philadelphia: WB Saunders; 2004:1401.

and urinary system malformations, whereas propylthiouracil may be associated with malformations of the head, neck, and urinary system.

The initial dosage of methimazole is 0.5-1.0 mg/kg/24 hr (max 40 mg/day) administered once or twice daily. Smaller initial dosages should be used in early childhood or for mild disease. Careful surveillance is required after treatment is initiated. Low serum free T_4 or elevated serum TSH indicates overtreatment and warrants a dose reduction. The clinical response becomes apparent in 3-4 weeks, and adequate control is typically evident within 2-4 months. The dose is slowly decreased to the minimal level required to maintain a euthyroid state.

Most studies report a remission rate of approximately 25% after 2 years of ATD treatment in children. However, extended treatment appears to be associated with higher remission rates of 30–50% after 4-10 years of drug treatment. Among patients who remit, relapse may occur, often within 6-12 months after therapy has been discontinued. In cases of relapse, ATD therapy may be resumed, or definitive therapy with radioiodine or thyroidectomy can be pursued. Rituximab has been used as an adjuvant therapy for difficult-to-treat Graves disease.

Thyroid hormones potentiate the actions of catecholamines, leading to symptoms of tachycardia, tremor, excessive sweating, lid lag, and stare. *To ameliorate cardiovascular symptoms, a β-adrenergic blocking agent such as propranolol or atenolol is a useful initial supplement to ATDs.* However, these agents do not alter thyroid function or treat Graves ophthalmopathy. Table 606.7 lists additional therapies for **thyroid storm**.

Definitive Therapy

Radioiodine ablation or thyroidectomy is indicated when medical management is not possible because of patient nonadherence or severe side effects of ATDs, when an adequate trial of medical management has failed to result in remission, or if the patient prefers definitive therapy.

Radioiodine ablation with ^{131}I is an effective therapy for Graves disease in children. In patients with severe hyperthyroidism, euthyroidism should be restored with methimazole before radioiodine ablation to deplete the gland of preformed hormone and reduce the risk of a thyrotoxic flare from radiation thyroiditis. If a patient is taking methimazole, it should be stopped 3-5 days before radioiodine administration. The goal of radioiodine ablation is to administer a sufficient dose of radioiodine to ensure complete ablation of thyroid tissue. Some centers measure radioiodine uptake before treatment and use this to calculate an ^{131}I dose that delivers an absorbed thyroid dose of >150 μCi/g thyroid tissue (based on thyroid gland mass estimated by clinical examination or ultrasound). Alternatively, an empiric fixed dose of ^{131}I (usually 10-15 mCi) can be offered. The theoretical advantage of calculated doses is that they define the lowest administered dose for each patient who achieves the therapeutic target. This benefit is most important in small children because the absorbed radiation dose to the bone marrow and other normal tissues is inversely proportional to body size. Based on this concept and theoretical modeling of radiation exposure, ^{131}I therapy should be avoided in children younger than 5 years of age. It should be used in children between 5 and 10 years of age if the administered dose is <10 mCi. Radioiodine ablation has a low failure rate (5–20%), and

patients with persistent hyperthyroidism more than 6 months after their first ^{131}I therapy can be offered retreatment.

Thyroidectomy is a safe procedure when performed by an experienced surgeon. Thyroid surgery should be performed only after the patient has been rendered euthyroid with methimazole. A saturated solution of potassium iodide (SSKI; 1-3 drops, 2-3 times per day) may be added for 7-14 days before surgery to decrease the vascularity of the gland. Complications of surgical treatment include hypoparathyroidism (transient or permanent) and paralysis of the vocal cords. Total or near-total thyroidectomy should be performed rather than a less extensive subtotal resection. Patients become hypothyroid postoperatively, and recurrence of hyperthyroidism is rare. Referral to a surgeon with extensive experience in thyroidectomy and a low personal complication rate is paramount.

Graves **ophthalmopathy** usually remits gradually and independently of hyperthyroidism, but control of ophthalmopathy is facilitated by maintaining consistent euthyroidism. Severe ophthalmopathy can require treatment with high-dose glucocorticoids, orbital radiotherapy, or orbital decompression surgery. Teprotumumab, a human monoclonal antibody against the insulin-like growth factor 1 receptor (IGF-1R) is effective in adults with ophthalmopathy. Cigarette smoking is a risk factor for thyroid eye disease and should be avoided or discontinued to avoid progression of eye involvement.

Visit Elsevier eBooks+ at eBooks.Health.Elsevier.com for Bibliography.

606.2 Congenital Hyperthyroidism

Jessica R. Smith and Ari J. Wassner

Neonatal Graves disease is caused by transplacental passage of TRSAbs from mothers with a history of Graves disease. These mothers can have active Graves disease, Graves disease in remission, or a prior history of Graves disease treated with radioiodine ablation or thyroidectomy. Occasionally, there is a maternal history of autoimmune thyroiditis. High levels of TRSAb typically result in fetal and neonatal hyperthyroidism. However, if the mother has been treated with ATDs, the onset of hyperthyroidism may be delayed by 3-7 days postnatally until the ATD is metabolized by the neonate. If TRBAbs are also present, they may delay the onset of hyperthyroidism for several weeks or even cause neonatal hypothyroidism. Neonatal Graves disease typically remits spontaneously within 6-12 weeks but can persist longer, depending on the titer and rate of clearance of the TRSAbs (and TRBAbs, if present).

Neonatal hyperthyroidism occurs in approximately 2% of infants born to mothers with a history of Graves disease. Fetal tachycardia and goiter may suggest the diagnosis prenatally, and close ultrasound surveillance is recommended in mothers with uncontrolled hyperthyroidism, particularly in the third trimester. Elevated serum titers of TRSAb (more than 3 times the upper limit of normal) or a history of a prior child with neonatal thyroid dysfunction increases the likelihood of neonatal Graves disease.

CLINICAL MANIFESTATIONS

Many infants born with neonatal Graves disease are premature and have intrauterine growth restriction. Many infants also have a goiter, and tracheal compression can occur if the goiter is very large. Other signs and symptoms of neonatal Graves disease include stare, periorbital edema, retraction of the eyelids, hyperthermia, irritability, diarrhea, feeding difficulties, poor weight gain, tachycardia, heart failure, hypertension, hepatomegaly, splenomegaly, cholestasis, jaundice, thrombocytopenia, and hyperviscosity (Fig. 606.3). Laboratory evaluation shows suppressed serum TSH and elevated serum levels of T_4, free T_4, and T_3. TRSAbs are elevated at birth and typically resolve within 3 months of life. If symptoms and signs are not recognized and treated promptly, cardiac failure and death can occur. Permanent sequelae of neonatal hyperthyroidism can include craniosynostosis and developmental delay.

Fig. 606.3 Twins with neonatal hyperthyroidism confirmed by abnormal thyroid function tests. Clinical features include lack of subcutaneous tissue owing to a hypermetabolic state and a wide-eyed, anxious stare. They were given the diagnosis of neonatal Graves disease, but, in fact, their mother did not have Graves disease; they had persistent, not transient, hyperthyroidism. At age 8 years, they were treated with radioiodine. They are now believed to have had some other form of neonatal hyperthyroidism, such as a constitutive activation of the thyroid-stimulating hormone receptor.

TREATMENT

Treatment should be initiated at the onset of symptoms to avoid short-term and long-term complications. Therapy consists of methimazole (0.5-1.0 mg/kg/24 hr given every 12 hr) and oral or intravenous administration of a nonselective β-adrenergic blocker such as propranolol to decrease sympathetic hyperactivity. In refractory cases, Lugol solution or potassium iodide (1-2 drops per day) can be added. The first dose of iodide should be given at least 1 hour after the first dose of ATD to prevent the iodide from being used for further thyroid hormone synthesis. If severe hyperthyroidism induces heart failure, parenteral fluid therapy, corticosteroids, and digitalization may be indicated. Once serum thyroid hormone levels begin to decrease, ATDs should be gradually tapered to keep the infant euthyroid. Occasionally, a block-and-replace method with concurrent ATD and thyroid hormone replacement therapy may be required to ensure euthyroidism.

Most cases of neonatal Graves disease remit by 3 months of age, but occasionally neonatal hyperthyroidism persists into childhood. Typically, there is a family history of hyperthyroidism. **Neonatal hyperthyroidism** *without* evidence for autoimmune disease in mother or infant may be caused by a gain-of-function pathogenic variant in the *TSHR* gene that results in constitutive activation of the receptor. This can be transmitted in an autosomal dominant manner or can occur sporadically. Neonatal hyperthyroidism has also been reported in patients with McCune-Albright syndrome because of an activating pathogenic variant of the G protein stimulatory α-subunit. Under these circumstances, hyperthyroidism recurs when ATDs are discontinued, and these children eventually must be treated with radioiodine or surgery.

PROGNOSIS

Advanced osseous maturation, microcephaly, and cognitive impairment occur when treatment of neonatal hyperthyroidism is delayed. Intellectual development is normal in most treated infants with neonatal Graves disease, although some have neurocognitive problems likely caused by in utero hyperthyroidism. Therefore neurocognitive development should be monitored throughout childhood. After the resolution of neonatal hyperthyroidism, some infants develop transient or permanent central hypothyroidism that requires thyroid hormone replacement, likely resulting from poorly understood changes in hypothalamic-pituitary-thyroid feedback caused by in utero hyperthyroidism.

Resistance to Thyroid Hormone

The actions of thyroid hormones are mediated by two thyroid hormone receptors (α and β), each with a unique tissue distribution. Inactivating pathogenic variants in each of these receptors gives rise to a distinct syndrome of resistance to thyroid hormone. Resistance to thyroid hormone β (RTHβ) is an *autosomal dominant* disorder caused by pathogenic variants in the *THRB* gene. Because this receptor mediates the normal feedback of thyroid hormone on the hypothalamus and pituitary, patients have elevated serum levels of T_4 and T_3, but serum TSH levels are inappropriately normal or elevated. Goiter is almost always present, but symptoms of thyroid dysfunction are variable among individuals. There may be clinical features of hypothyroidism such as developmental delay, growth retardation, delayed skeletal maturation, and some features of hyperthyroidism like tachycardia and hyperreflexia. Affected children have an increased prevalence of learning disabilities and ADHD. The clinical symptoms, goiter, and elevated thyroid hormone levels may be mistaken for Graves disease, but RTHβ is confirmed by the presence of normal or elevated (not suppressed) TSH levels. This condition must also be differentiated from a pituitary TSH-secreting tumor, which is not familial and in which serum levels of the common α-subunit are elevated.

More than 100 distinct variants in *THRB* have been identified in patients with RTHβ, and genotype-phenotype correlation is poor even among affected members of the same family. Nearly all mutations have a dominant-negative effect in which the variant receptor interferes with normal receptor action, leading to disease even in heterozygotes. Individuals carrying two mutant alleles are severely affected. A very rare *autosomal recessive* form of this disorder has been reported in individuals homozygous for a deletion of the *THRB* gene.

Treatment usually is not required unless growth and skeletal stunting are present. Different therapies, including levothyroxine and triiodothyroacetic acid, have been successful in some patients. Intermittent administration of T_3 may be useful for reducing goiter size. Symptoms of hyperthyroidism can be treated with β blockers, but ATDs or radioiodine ablation are generally not used because they increase TSH levels and goiter size.

Pathogenic variants in the *THRA* gene, which encodes thyroid hormone receptor α, have also been reported. *THRA* variants are dominant negative and cause RTHα in heterozygous individuals. Clinical symptoms are those of untreated primary hypothyroidism, including skeletal dysplasia with short stature and macrocephaly, developmental delay, constipation, bradycardia, and macrocytic anemia. Serum thyroid function tests show subtle abnormalities of low or low-normal T_4, high or high-normal T_3 (with elevated T_3/T_4 ratio), and normal TSH, as well as the unique finding of markedly low reverse T_3. Treatment has not been clearly established for RTHα.

Visit Elsevier eBooks+ at eBooks.Health.Elsevier.com for Bibliography.

Chapter 607

Carcinoma of the Thyroid

Jessica R. Smith and Ari J. Wassner

Carcinoma of the thyroid is rare in childhood, with an annual incidence in children younger than 15 years of approximately 4-5 in 100,000 cases. The incidence of childhood thyroid cancer increases with age and peaks in adolescence. Females are more commonly affected than males. Compared to adults, childhood thyroid cancers are characterized by significantly higher rates of metastasis and recurrence. Despite often being metastatic at discovery, most pediatric thyroid cancers with adequate treatment have a favorable outcome.

PATHOGENESIS

The majority of differentiated thyroid cancers are of follicular cell origin; **papillary carcinoma** (85–90%) is the most common subtype. Although their histologic features are similar, papillary thyroid cancers of childhood are genetically distinct from their adult counterparts. About 70% of adults with papillary thyroid cancer exhibit pathogenic somatic variants in *BRAF* or *RAS*; pediatric papillary thyroid cancers are more commonly caused by somatic gene fusion events involving the oncogenic tyrosine kinases *RET* or *NTRK1/3*. **Follicular carcinoma** (8%) is the next most common type of childhood thyroid cancer and is also derived from thyroid follicular cells. **Medullary carcinoma** (4%), derived from thyroid C cells, and anaplastic thyroid cancers are relatively rare.

Up to 10% of cases of follicular cell–derived thyroid cancers may be familial. Genetic syndromes associated with an increased risk of thyroid neoplasia include ***PTEN* hamartoma tumor syndromes** (Cowden, Bannayan-Riley-Ruvalcaba, and Proteus syndromes) characterized by macrocephaly, mucocutaneous lesions (fibromas), and breast cancer and endometrial tumors; **familial adenomatous polyposis** (pathogenic variant in *APC*); and ***DICER1* syndrome**, which includes tumors of the lung, kidney, female reproductive tract, and other organs. The evaluation of a child with a thyroid nodule should include a medical and family history to assess for features of these syndromes. In addition, some families have a strong history of nonsyndromic nonmedullary thyroid cancer, but no specific genetic causes have been confirmed.

The thyroid gland of children is susceptible to radiation exposure, particularly in very young patients. Even a low dose (1 Gy) of radiation exposure results in a 7.7-fold increased relative risk of thyroid cancer. In past decades, irradiation of the cervical region for benign conditions (e.g., enlarged thymus or tonsils, adenitis) was a predominant cause of thyroid cancer in children. Currently, therapeutic irradiation for other regional neoplasms or bone marrow transplantation and the increased survival of these children have made this cause of thyroid cancer increasingly prevalent. Higher radiation dose, younger age at the time of treatment, and female sex are additional risk factors for the development of thyroid cancer. The relative risk of thyroid cancer is highest after radiation doses of 5-30 Gy, above which the excess risk declines but does not disappear. In studies of cancer survivors treated with radiation, ~10–30% develop benign thyroid nodules. There is an increased incidence of thyroid cancer beginning within 3-5 years after radiation treatment and peaking after 15-25 years.

Autoimmune thyroiditis and Graves disease may be associated with an increased risk of thyroid cancer, but data remain conflicting.

Therefore thyroid nodules detected in patients with these disorders should be evaluated for possible thyroid cancer. Thyroid cancer has been reported rarely in children with congenital goiter or ectopic thyroid tissue.

CLINICAL MANIFESTATIONS

Thyroid cancer usually presents as a *painless nodule* in the anterior neck. Rapid growth and large size, firmness, fixation to adjacent tissues, hoarseness, dysphagia, or neck lymphadenopathy should heighten the concern for thyroid cancer. Cervical lymph node metastasis is common, so any unexplained cervical lymphadenopathy warrants examination of the thyroid.

The lungs are the most common site of distant metastasis. Pulmonary metastases are usually asymptomatic, and pulmonary function testing may be normal even with widespread metastases. Radiologically, metastases may appear as diffuse miliary or nodular infiltrations, typically greatest in the posterior basal lung fields. Other sites of metastasis, including bones and brain, are rare in children. Almost all children with thyroid cancer are euthyroid, but rarely is the carcinoma functional and produces clinical and laboratory evidence of hyperthyroidism.

DIAGNOSIS

Patients usually present with a neck mass, and thyroid ultrasound demonstrates a thyroid nodule and/or diffuse infiltration of the thyroid. Although several imaging features (including calcifications, irregular margins, and the presence of abnormal lymph nodes) are significantly associated with thyroid cancer risk, the absence of these features does not exclude the possibility of thyroid cancer. The appropriate technique for evaluating sonographically suspicious nodules is fine needle aspiration (FNA), which can detect the characteristic nuclear abnormalities of papillary thyroid carcinoma, which is the most common form. In most cases, operative pathology is required to confirm the diagnosis of thyroid cancer and to determine the extent of disease.

TREATMENT

The primary therapy for thyroid cancer is surgical resection. Because intrathyroidal spread is common in papillary thyroid cancer, near-total thyroidectomy is recommended. Before surgery, neck ultrasonography should be performed to assess for abnormal lymph nodes, and suspicious lymph nodes may be biopsied preoperatively to determine the need for lymph node dissection. In patients with metastatic thyroid cancer, adjunctive therapy may be required with radioactive iodine (^{131}I) to ablate unresectable thyroid cancer and thyroid-stimulating hormone (TSH) suppression with supraphysiologic levothyroxine to reduce TSH-stimulated growth of residual cancer cells.

PROGNOSIS

Although regional and distant metastases are more common in the pediatric population than in adults, most children with thyroid cancer have an excellent prognosis. Long-term survival from pediatric thyroid cancer is >97%, although the disease may recur in up to 15–20%. Even in children with pulmonary metastasis at diagnosis, 30-year survival is 90%, and many patients who cannot achieve complete cure remain asymptomatic with stable or slowly progressive cancer burden over many years. For rare children with aggressive cancers that progress despite conventional therapy, targeted molecular therapies directed at the underlying genetic pathogenic variants are available and effective in many cases. Psychosocial supports, including access to social work and mental health professionals, are essential in caring for children with thyroid cancer.

Children with thyroid cancer require lifelong monitoring because of the risk of disease recurrence years or decades after initial treatment. For most patients, serum thyroglobulin is a sensitive and specific cancer marker. Circulating autoantibodies to thyroglobulin can confound the measurement of thyroglobulin levels and should be measured whenever serum thyroglobulin is assayed. Because most thyroid cancer recurrences occur in the thyroid bed or cervical lymph nodes, surveillance should include serial neck ultrasounds. Patients with a higher risk of recurrence or with distant metastases may require additional anatomic imaging (such as chest CT), whole-body radioactive iodine scanning (^{123}I), or combined anatomic and functional imaging (SPECT/CT).

MEDULLARY THYROID CARCINOMA

Medullary thyroid carcinoma (MTC) arises from the parafollicular cells (C cells) of the thyroid and accounts for approximately 4% of thyroid malignancies in children. In children, the majority of MTC cases are hereditary, as part of the syndrome of **multiple endocrine neoplasia type 2** (MEN2; see Chapter 609). Activating pathogenic variants in the *RET* proto-oncogene are responsible for most cases of MTC. These variants occur in the germline in patients with MEN2, but somatic *RET* changes are present in many sporadic cases of MTC.

The most common presentation of sporadic MTC is an asymptomatic thyroid nodule. When MTC occurs sporadically, it is usually unicentric, but in the familial form it may be multicentric. MTC begins as hyperplasia of the parafollicular cells (*C cell hyperplasia*), which is often present histologically in thyroid glands removed prophylactically from patients with MEN2. The diagnosis of MTC can also be made by cytology after FNA of a thyroid nodule. Because C cells produce calcitonin, a high calcitonin concentration in an FNA specimen or in a patient's serum can help confirm the diagnosis of MTC. The diagnosis warrants genetic testing for a germline *RET* variant, and in variant-positive patients, screening for pheochromocytoma and hyperparathyroidism should be obtained before anesthesia for thyroidectomy.

The most important treatment for MTC is surgical resection. Preoperative evaluation should include neck ultrasound to identify potential lymph node metastases. Baseline serum levels of calcitonin and carcinoembryonic antigen (CEA) should be measured preoperatively, and higher levels are correlated with a greater likelihood of metastatic disease. Surgical treatment includes total thyroidectomy and lymph node dissection of any involved lymph node compartments. Complete resection is often curative, but this can be difficult to achieve in patients with metastatic disease. Surveillance with neck ultrasound and serum levels of calcitonin and CEA can assess for the presence or progression of residual disease. Other treatment modalities for advanced or metastatic disease include specific *RET* inhibitors, external beam radiation, and radiofrequency ablation.

Visit Elsevier eBooks+ at eBooks.Health.Elsevier.com for Bibliography.

607.1 Thyroid Nodules

Jessica R. Smith and Ari J. Wassner

The frequency of thyroid nodules increases with age. Sonographically detectable thyroid nodules are present in 19–67% of adults but in only 1–2% of children. Although the risk of malignancy in a thyroid nodule is higher in children (20–25%) than in adults (5–15%), the majority of thyroid nodules in children are benign.

Benign disorders that can present as a thyroid mass include benign adenomatous or colloid nodules and various congenital cysts (Table 607.1). A thyroid mass that appears suddenly or enlarges rapidly can indicate hemorrhage into a cyst, a benign adenoma, or an infectious process.

Evaluation of a child with a thyroid nodule should begin by measuring serum TSH. A low serum TSH suggests a possible hyperfunctioning (autonomous) thyroid nodule, which should be evaluated by scintigraphy (^{123}I or ^{99m}Tc-pertechnetate). Autonomous nodules generally are not malignant and do not require biopsy. Patients with a normal or elevated TSH should undergo neck ultrasound, and any sonographically suspicious nodule(s) of significant size should be evaluated by ultrasound-guided FNA

Table 607.1 Etiologic Classification of Solitary Thyroid Nodules

Lymphoid follicle, as part of autoimmune thyroiditis
Thyroid developmental anomalies
Intrathyroidal thyroglossal duct cyst
Intrathyroidal ectopic thymus
Thyroid abscess (acute infectious thyroiditis)
Simple cyst
Neoplasms
Benign
Colloid (adenomatous) nodule
Follicular adenoma
Hyperfunctioning (toxic) adenoma
Lymphohemangioma
Malignant
Papillary carcinoma
Follicular carcinoma
Anaplastic carcinoma
Medullary carcinoma
Nonthyroidal
Lymphoma
Teratoma

(Fig. 607.1). Thyroid cytology is evaluated using a standardized system, most commonly the Bethesda System for Reporting Thyroid Cytopathology. Cytology may be interpreted as benign, positive for papillary thyroid cancer, indeterminate, or nondiagnostic. The predictive value of cytology for thyroid cancer varies by category and to some degree among institutions. In general, cytology positive for papillary thyroid cancer confers a >98% likelihood of cancer, and near-total thyroidectomy is appropriate. For a nodule of indeterminate cytology, lobectomy is commonly performed for definitive diagnosis; this may be followed by completion thyroidectomy if pathology shows a significant thyroid cancer. Molecular testing for oncogenic mutations may inform the management of certain indeterminate cytology. Patients with cytologically benign nodules have a low likelihood of malignancy and should be monitored with serial neck ultrasound. Surgical resection may be offered for benign nodules that cause symptoms, including dysphagia, globus sensation, or undesired appearance.

Visit Elsevier eBooks+ at eBooks.Health.Elsevier.com for Bibliography.

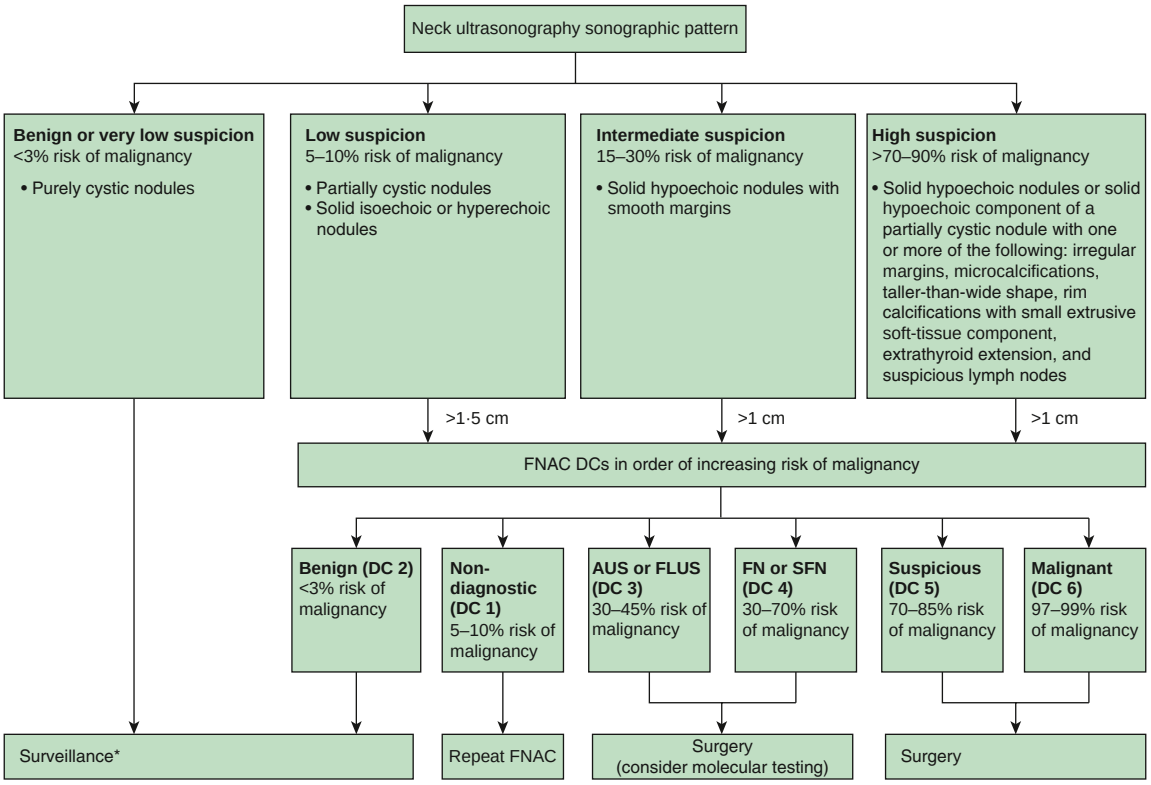

Fig. 607.1 Management algorithm for thyroid nodules based on sonographic patterns and cytology diagnostic categories of the Bethesda System. *Fine-needle aspiration can be considered (1) for nodules with a low-suspicion sonographic pattern and the largest diameter greater than 2 cm and (2) if there are suspicious clinical findings (e.g., firm mass, neck pain, cough, voice change, and a history of childhood neck irradiation or familial thyroid cancer), regardless of the sonographic appearances. AUS, Atypia of undetermined significance; DC, diagnostic category; FLUS, follicular lesion of undetermined significance; FN, follicular neoplasm; FNAC, fine needle aspiration cytology; SFN, suspicious for follicular neoplasm. *(From Cabanillas ME, McFadden DG, Durante C. Thyroid cancer. Lancet. 2016;388:2783–2794, Fig. 2.)*

Chapter 608

Autoimmune Polyglandular Syndromes

Christina M. Astley, Jessica R. Smith, and Ari J. Wassner

An **autoimmune polyglandular syndrome (APS)** occurs when autoimmunity is directed at multiple glands and/or nonendocrine organs, sometimes associated with **immune dysregulation**. Endocrine glands and other organs commonly affected by APS have unique autoantigens that increase these tissues' susceptibility to damage by an untamed immune response. Most autoimmune endocrinopathies are caused by cell-mediated immunity from autoreactive T cells. Antibodies to one or more autoantigens are commonly associated with specific autoimmune manifestations and are markers of immune dysregulation. These autoantibodies are directly pathogenic in some nonendocrine tissues, but this is rarely the case in autoimmune endocrine disease. A notable exception is the autoantibodies in Graves disease that cause primary hyperthyroidism by activating the thyroid-stimulating hormone receptor (TSHR).

APS caused by monogenic disorders of immune dysregulation (including APS type 1 [**APS-1**]) have heritable lesions in key aspects of immune tolerance (Table 608.1). Polygenic disorders associated with APS (APS type 2 [**APS-2**]) and some chromosomal abnormalities (e.g., trisomy 21) also result in an aberrant immune response that causes multiorgan autoimmunity. Nongenetic factors (e.g., immune **checkpoint inhibitors** for cancer therapy) may lead to autoimmune polyglandular disease. Although APS is uncommon, patients can experience significant morbidity, particularly if the syndrome is not identified early and managed appropriately. There may be 1-2 decades between the presentations of the first and subsequent endocrinopathy. *The presence of hypoparathyroidism, primary adrenal insufficiency, neonatal type 1 diabetes mellitus, chronic mucocutaneous candidiasis, immune dysregulation, or a family history should raise particular suspicion for APS.*

MONOGENIC AUTOIMMUNE POLYGLANDULAR SYNDROMES

The number of recognized monogenic defects of immune regulation leading to APS continues to grow (see Table 608.1). The best-characterized monogenic APSs are caused by pathogenic genetic variants that primarily affect central immune tolerance **(APS-1)** or the development of regulatory T cells (immune dysregulation polyendocrinopathy enteropathy X-linked, or **IPEX**). Other monogenic APSs (the so-called IPEX-like disorders) are caused by defects in regulatory T-cell suppression or signaling.

AUTOIMMUNE POLYGLANDULAR SYNDROME TYPE 1

APS-1 is an archetypal monogenic polyendocrinopathy syndrome. It is a rare, autosomal recessive disorder caused by loss-of-function variants in the autoimmune regulator gene *(AIRE)* on chromosome 21q22.3. *AIRE* plays a critical role in the presentation of self-antigens to developing T cells in the thymus, which normally leads to central immune tolerance by inducing apoptosis of T cells specific for these autoantigens (negative selection). *AIRE* also plays a role in the development of regulatory T cells (see Chapter 174). Therefore patients with APS-1 develop autoreactive T cells and autoantibodies directed at multiple tissues.

APS-1 is defined by the presence of at least two of three classic clinical features **(Whitaker triad)** of **chronic mucocutaneous candidiasis**, **hypoparathyroidism**, and primary **adrenal insufficiency**. These three manifestations tend to emerge over time—candidiasis before around 5 years of age, hypoparathyroidism around 10 years, and adrenal insufficiency around 15 years—but the precise order and age of onset of each component are variable. Most patients develop additional autoimmune manifestations over time, with skin and gastrointestinal disorders typically emerging before age 20 and other endocrine disorders after the second decade (see Table 608.1).

Nearly every endocrine gland may be affected by APS-1. The commonly affected glands include parathyroids and adrenals. Other glands affected, in decreasing order of frequency, are the ovaries, testes, thyroid, pancreatic β cells, and pituitary. A wide range of nonendocrine tissues can be affected, sometimes before the first endocrinopathy is detected. The commonly affected nonendocrine tissues are teeth and nails, and ectodermal dystrophy is present in most patients. For this reason, APS-1 has also been called **autoimmune polyendocrinopathy-candidiasis-ectodermal dystrophy (APECED)**. Other manifestations include gastrointestinal malabsorption, autoimmune hepatitis, pernicious anemia, vitiligo, and alopecia. APS-1 patients are at increased risk of infection, possibly related to a combination of cytokine autoantibodies, splenic dysfunction, and compromised gastrointestinal mucosal integrity. Mucocutaneous candidiasis is quite common and can lead to oral or esophageal cancer if not diagnosed and treated. Esophageal cancer, autoimmune hepatitis, adrenal crisis, and severe hypocalcemia are important causes of mortality in APS-1 patients. Therefore APS-1 patients require close clinical follow-up with a multidisciplinary team to manage disease manifestations. (Treatment of individual endocrinopathies and other manifestations are reviewed separately in the relevant chapters, including Chapters 280, 611, and 615).

The initial diagnosis of APS-1 generally is made clinically. Pathogenic *AIRE* variants can be detected in the majority of patients with clinical APS-1, and confirmation of the diagnosis by *AIRE* sequencing is indicated for any patient with known or suspected APS-1. APS-1 caused by pathogenic *AIRE* variants is more common in certain founder populations (e.g., Iranian Jews, Sardinians, Finns, and Norwegians reported a prevalence ranging from 1 in 9,000 to 1 in 90,000). Knowledge of the specific pathogenic variant facilitates clinical and genetic counseling, including testing of family members. *AIRE* variants with autosomal dominant inheritance and an atypical APS-2–like clinical presentation (especially with pernicious anemia or vitiligo) have been reported. APS-1 patients without identifiable *AIRE* variants may benefit from further evaluation (e.g., immune dysregulation gene panel, whole exome sequencing, imaging for thymoma).

The clinical presentation of APS-1 is variable, even within families with the same *AIRE* variant, making it difficult to predict the disease course for affected individuals. Therefore patients with APS-1 should have regular screening for the development of new clinical manifestations. The importance of screening is illustrated by unexplained deaths in APS-1 patients or their siblings, presumably the result of undiagnosed manifestations such as adrenal insufficiency.

Multiple autoantibodies may be detectable in patients with APS-1 (Table 608.2). Many of these autoantibodies are also present in the corresponding single-organ autoimmune disease, but autoantibodies to some antigens (e.g., NALP5, interleukin-17 family cytokine, and type 1 interferons) are unique to APS-1. Measuring organ-specific autoantibodies has variable utility for predicting the onset of endocrine gland failure or other APS-1 manifestations. Therefore clinical suspicion, laboratory screening, and education about symptoms of evolving endocrinopathies and/or other APS-1 manifestations are paramount regardless of autoantibody status.

IMMUNE DYSREGULATION-POLYENDOCRINOPATHY-ENTEROPATHY X-LINKED

IPEX is caused by loss-of-function variants in *FOXP3,* which is located on the X chromosome (Xp11.23) (see Chapter 174). The inactivation of *FOXP3* results in impaired peripheral immune tolerance caused by impaired development of regulatory T cells, leading to the emergence of autoreactive T cells. The endocrinopathies commonly associated with IPEX are early-onset type 1 diabetes mellitus and autoimmune thyroiditis. *Any diagnosis of type 1 diabetes mellitus*

Table 608.1 Autoimmune Polyglandular Syndrome (APS) due to Monogenic Disorders of Immune Dysregulation

	EPIDEMIOLOGY AND GENETICS				ENDOCRINOPATHIES				
APS	**GENETIC ABNORMALITY**	**INHERITANCE**	**ONSET**	**CLASSIC PHENOTYPE**	**ADRENAL INSUFFICIENCY**	**THYROID**	**TD1**	**HPT**	**GONADAL INSUFFICIENCY**
MONOGENIC APS									
APS-1	*AIRE*	AR (AD rare)	Infancy	Candidiasis, hypoparathyroidism, Addison disease, ectodermal dystrophy	●●●●	●●	●●	●●●●	●●
IPEX	*FOXP3*	XL	Infancy	Enteropathy, type 1 diabetes in infancy, eczematous dermatitis		●●●●	●●●●		
CTLA4	*CLTA4*	AD	Infancy	Enteropathy, cytopenia, lymphocytic aggregates, hypogammaglobulinemia		●●	●		
LRBA	*LRBA*	AR	Infancy	Enteropathy, respiratory tract disease, organomegaly, hypogammaglobulinemia		●	●		
STAT1	*STAT1*	AD	Infancy	Candidiasis, recurrent infections, multiple autoimmunity, cerebral aneurysm	●	●●	●		
STAT5b	*STAT5b*	AR	Infancy	Enteropathy, respiratory tract disease, recurrent infections, growth failure		●●			
CD25	*IL2RA*	AR	Infancy	Enteropathy, type 1 diabetes in infancy, recurrent infections		●●●●	●●●●		
OTHER APS AND APS-LIKE CONDITIONS									
APS-2	*HLA, MICA, PTPN22, CTLA4, NALP1*	Polygenic	Adulthood	Addison disease, autoimmune thyroid disease, type 1 diabetes	●●●●	●●●	●●		●
Turner syndrome	*46, X* (most)	N/A	Congenital	Short stature, ovarian insufficiency, webbed neck, coarctation of the aorta		●●	●		●●●●
Klinefelter syndrome	*47, XXY* (most)	N/A	Congenital	Tall stature, testicular insufficiency, gynecomastia	●	●	●		●●●●
Down syndrome	Trisomy 21	N/A (most)	Congenital	Hypotonia, epicanthal folds, Brushfield spots, single palmar crease, developmental delay		●●	●		

Inheritance
AR, Autosomal recessive; AD, autosomal dominant; XL, X-linked
●●●●, >75% (common); ●●●, 50–75%; ●●, 10–50%; ●, <10% (rare)
VZV, Varicella-zoster virus; EBV, Epstein-Barr virus; CMV, cytomegalovirus; IBD, inflammatory bowel disease; IRAE, immune-related adverse event; TD1, type 1 diabetes; HPT, hypoparathyroidism.

Table 608.1 Autoimmune Polyglandular Syndrome (APS) due to Monogenic Disorders of Immune Dysregulation—cont'd

	NONENDOCRINE MANIFESTATIONS							
OTHER ENDOCRINE	CANDIDA INFECTION	OTHER INFECTIONS	MALABSORP-TION, ENTEROPATHY	GI AUTOIM-MUNITY	AUTO-IMMUNE HEPATITIS	VITILIGO	ECZEMA, ALLERGIC DISEASE	OTHER
	●●●●	●●	●●	●●	●●	●●		Keratocon-junctivitis, periodic fever, asplenism
	●	●	●●●●		●		●●●●	Cytopenias, bacterial infections, nephritis
		●●●●	●●●●					Cytopenias, lung disease, psoriasis and skin disease
		●●●●	●●●	●		●	●	Respiratory infection, cytopenias, myasthenia gravis
	●●●●	●●●●	●●●●	●	●	●●	●●	Psoriasis, cytopenia, vascular, skin disease
GH resistance, hyperpro-lactinemia		●●●●	●●●●				●●●●	VZV infections, cytopenia
	●●●●	●●●●	●●●●				●●●●	EBV and CMV infections, cytopenia
			●	●●	●	●		
Short stature				●		●		Lymphedema, psoriasis, IBD
Tall stature, gynecomastia								Lupus, Sjogren syndrome, multiple sclerosis (rare)
Short stature				●				Congenital heart disease

Inheritance
AR, Autosomal recessive; AD, autosomal dominant; XL, X-linked
●●●●, >75% (common); ●●●, 50–75%; ●●, 10–50%; ●, <10% (rare)
VZV, Varicella-zoster virus; EBV, Epstein-Barr virus; CMV, cytomegalovirus; IBD, inflammatory bowel disease; IRAE, immune-related adverse event; TD1, type 1 diabetes; HPT, hypoparathyroidism.

Continued

Table 608.1 Autoimmune Polyglandular Syndrome (APS) due to Monogenic Disorders of Immune Dysregulation—cont'd

	EPIDEMIOLOGY AND GENETICS				ENDOCRINOPATHIES				
APS	GENETIC ABNORMALITY	INHERITANCE	ONSET	CLASSIC PHENOTYPE	ADRENAL INSUFFICIENCY	THYROID	TD1	HPT	GONADAL INSUFFICIENCY
DiGeorge syndrome	*22q11.2 del*	AD	Congenital	Absent thymus, congenital heart disease, hypocalcemia, developmental delay		●	●	●●	
ROHHAD	None identified	N/A	Early childhood	Rapid-onset obesity, hypothalamic dysfunction, autonomic dysregulation, neuroblastic tumor					
Checkpoint inhibitor IRAE		N/A	Post-treatment	Oncology treatment, possible pre-existing autoimmunity	●	●	●		

Inheritance
AR, Autosomal recessive; AD, autosomal dominant; XL, X-linked
●●●●, >75% (common); ●●●, 50–75%; ●●, 10–50%; ●, <10% (rare)
VZV, Varicella-zoster virus; EBV, Epstein-Barr virus; CMV, cytomegalovirus; IBD, inflammatory bowel disease; IRAE, immune-related adverse event; TD1, type 1 diabetes; HPT, hypoparathyroidism.

before 6-9 months of age should prompt consideration of a monogenic APS or a genetic cause of β-cell dysfunction. Patients with IPEX often have autoimmune enteropathy and eczematous dermatitis. They may also have other autoimmunity (e.g., liver, kidney, cytopenias) and allergic dysregulation (e.g., food allergy, peripheral eosinophilia). Therapy for IPEX consists of immune modulation with immunosuppressants (e.g., glucocorticoids, tacrolimus), novel therapeutics (e.g., abatacept), or stem cell transplantation.

OTHER MONOGENIC IMMUNE DYSREGULATION DISORDERS

Several other disorders involve failure of peripheral tolerance and emergence of autoimmunity, often with some degree of immune dysregulation. These disorders include loss-of-function genetic variants in *IL2RA* (CD25), *LRBA, CTLA4, STAT5b,* and gain-of-function variants in *STAT1* and *STAT3* that are pathophysiologically similar to IPEX. Broadly, patients with these **IPEX-like disorders** are at high risk of type 1 diabetes mellitus and autoimmune thyroiditis (see Table 608.1). They also have multiple nonendocrine diseases, especially autoimmunity and immunodeficiency affecting the skin, lungs, and gastrointestinal tract. *STAT5b* participates in the IL2/STAT5 signal transduction axis necessary for growth hormone signaling and may also affect prolactin secretion. Therefore patients with **STAT5b** defects may have nonautoimmune growth hormone insensitivity and hyperprolactinemia in addition to immune dysregulation, hypergammaglobulinemia, and multiple autoimmunity. ***STAT1*** gain-of-function variants inhibit the normal production of Th17 cytokines, which leads to chronic mucocutaneous candidiasis. These patients also have increased risk of infection, squamous cell cancer, enteropathy, and arterial aneurysms. Patients with **CD25** defects are also at increased risk of infection because interleukin (IL)-2 signaling plays a role in Th17 responses. Many IPEX-like patients develop nonautoimmune endocrinopathies, including iatrogenic adrenal insufficiency, dysglycemia, hypocalcemia, poor bone health from high-dose glucocorticoid therapy, chronic inflammation/infection, and/or malabsorption/malnutrition.

POLYGENIC AUTOIMMUNE POLYGLANDULAR SYNDROME

APS-2 is a clinical syndrome defined by the presence of two or more syndrome-specific endocrinopathies: autoimmune primary adrenal insufficiency (Addison disease), autoimmune thyroid disease (Hashimoto thyroiditis or Graves disease), and/or type 1 diabetes mellitus. Some classification systems subdivide APS-2 according to the particular glands affected (e.g., subtype 2, 3, and 4 if adrenal, thyroid, or neither gland, respectively) or other autoimmune manifestations present (e.g., subtype 3A, 3B, and 3C if additional endocrine, gastrointestinal, or systemic autoimmunity are present, respectively). However, because there is no clear pathophysiologic distinction between these subtypes, they can be considered collectively as APS-2. When describing the characteristics of APS-2, it is important to recognize some degree of overlap between patients with clinical APS-2 and those with a single autoimmune endocrinopathy who may later develop another and be classified as APS-2.

Unlike monogenic APSs, which are rare diseases with early-childhood onset and a mendelian inheritance pattern, APS-2 is a common polygenic disease that usually manifests after the second decade in a patient with a personal or family history of autoimmune disease. APS-2 is most common in middle-age females (prevalence near 1 in 20,000). Primary gonadal insufficiency, vitiligo, alopecia, and chronic atrophic gastritis (with or without pernicious anemia) can occur. Autoimmune hypoparathyroidism and candidiasis are not typical of APS-2 and should prompt consideration of APS-1.

Addison disease is uncommon in the general population (prevalence near 1 in 10,000). However, patients with this condition are at high risk of developing additional endocrine autoimmunity constituting APS-2. Two thirds will have evidence of additional subclinical or clinical autoimmunity. Patients with Addison disease should have close follow-up, screening, and education about other autoimmune manifestations. About half of patients with Addison disease have autoimmune thyroid disease (**Schmidt syndrome**), and about 10% have type 1 diabetes mellitus (**Carpenter syndrome**). Less frequent comorbid autoimmune manifestations include Graves disease, ovarian insufficiency, alopecia, vitiligo, pernicious anemia, or celiac disease.

APS-2 develops less frequently in patients with type 1 diabetes mellitus than in those with Addison disease. Nevertheless, many patients with type 1 diabetes develop additional autoimmunity, and comorbid autoimmune thyroid and gastrointestinal disease are much more common (each about 20%) than comorbid adrenal disease (<1%). Because thyroxine and cortisol affect insulin sensitivity, metabolism, and appetite, unexplained hypoglycemia or deterioration in glycemic control may be the first clinical sign of APS-2 in a patient with preexisting type 1 diabetes mellitus. Unexplained hypoglycemia may also signal the onset of celiac disease. Indeed, **celiac disease** often precedes the onset of autoimmune endocrinopathies, including type 1 diabetes mellitus, hypothyroidism, and Addison disease.

The development of APS-2 in individuals with autoimmune thyroid disease is relatively infrequent. Nevertheless, the clinician should consider the possibility of adrenal insufficiency before treating

Table 608.1 Autoimmune Polyglandular Syndrome (APS) due to Monogenic Disorders of Immune Dysregulation—cont'd

	NONENDOCRINE MANIFESTATIONS							
OTHER ENDOCRINE	**CANDIDA INFECTION**	**OTHER INFECTIONS**	**MALABSORPTION, ENTEROPATHY**	**GI AUTOIMMUNITY**	**AUTOIMMUNE HEPATITIS**	**VITILIGO**	**ECZEMA, ALLERGIC DISEASE**	**OTHER**
Short stature								Thymic dysplasia/aplasia, congenital heart disease, T-cell deficiency, cytopenias
Hypothalamic dysfunction, hyperprolactinemia								Autonomic dysregulation, central hypoventilation
								Multiple nonendocrine IRAE

Inheritance
AR, Autosomal recessive; AD, autosomal dominant; XL, X-linked
●●●●, >75% (common); ●●●, 50–75%; ●●, 10–50%; ●, <10% (rare)
VZV, Varicella-zoster virus; EBV, Epstein-Barr virus; CMV, cytomegalovirus; IBD, inflammatory bowel disease; IRAE, immune-related adverse event; TD1, type 1 diabetes; HPT, hypoparathyroidism.

Table 608.2 Autoantibodies Present in Autoimmune Polyglandular Syndromes and in Isolated Autoimmune Endocrinopathies

TISSUE OR GLAND	AUTOANTIGEN	DISEASE MANIFESTATION	NOTE
AUTOIMMUNE ENDOCRINOPATHIES			
Adrenal	CYP21A2, CYP11A1, CYP17A1	Primary adrenal insufficiency	Of the adrenal autoantibodies, CYP21A2 is most strongly associated with adrenal insufficiency. Higher risk of progression to adrenal insufficiency in children with positive adrenal autoantibodies (over 80%) compared with adults (near 20%). Adrenal autoantibodies detected in 50% of pediatric hypoparathyroidism and 1% of pediatric type 1 diabetes
Thyroid	TPO, Tg	Autoimmune thyroiditis (hypothyroidism)	Frequently positive without clinical thyroid disease
	TSHR	Graves disease (hyperthyroidism)	Only endocrine autoantibody that directly causes autoimmune endocrinopathy
Pancreatic β cell	IA-2, GAD65, insulin, ZnT8	Type 1 diabetes mellitus	Risk of type 1 diabetes increases with the number of positive autoantibodies; IA-2, but not GAD65, autoantibodies associated with time to type 1 diabetes diagnosis in APS-1
Parathyroid	NALP5, CaSR	Hypoparathyroidism	NALP5 antibodies are present only in hypoparathyroidism caused by APS-1
Gonad	CYP11A1, CYP17A1, NALP5 and TSGA10	Gonadal insufficiency	CYP11A1 antibodies associated with gonadal insufficiency in APS-1
Pituitary	TDRD6	Hypophysitis	Poorly predictive of clinical pituitary disease
NONENDOCRINE DISEASE			
Cytokines	IFN-ω, IFN-α, IL-22, IL-17F	APS-1	IFN-ω autoantibodies are 100% sensitive and 99% specific for APS-1; IL-22 autoantibodies associated with time to diagnosis and diagnosis of candidiasis in APS-1
Gastric	IF, H+/K+ ATPase	Pernicious anemia, autoimmune gastritis	IF autoantibodies associated with time to B_{12} deficiency in APS-1
Small intestine	TTG, gliadin	Celiac disease	
Gastrointestinal	TPH, GAD65	Intestinal dysfunction	TPH autoantibodies associated with time to intestinal dysfunction in APS-1. Both autoantibodies associated with diagnosis of intestinal dysfunction in APS-1

Continued

Table 608.2 Autoantibodies Present in Autoimmune Polyglandular Syndromes and in Isolated Autoimmune Endocrinopathies—cont'd

TISSUE OR GLAND	AUTOANTIGEN	DISEASE MANIFESTATION	NOTE
Liver	CYP1A2, TPH, AADC	Autoimmune hepatitis	TPH autoantibodies associated with diagnosis of autoimmune hepatitis in APS-1
Skin melanocytes	Tyrosinase, SOX9, SOX10, AADC	Vitiligo	
Hair follicle	Tyrosine hydroxylase	Alopecia	
Lung	KCNRG, BPIFB1	Interstitial lung disease	Both autoantibodies present in 90–100% of APS-1 patients with interstitial lung disease and are associated with time to diagnosis

AADC, Aromatic L-amino acid decarboxylase; BPIFB1, bactericidal/permeability-increasing fold-containing B1; CaSR, calcium sensing receptor; CYP11A1, side chain cleavage enzyme; CYP17A1, 17-α-hydroxylase; CYP1A2, cytochrome P450 1A2; CYP21A2, 21-hydroxylase; GAD65, glutamic acid decarboxylase; IA-2, islet antigen-2; IF, intrinsic factor; IFN, interferon; IL, interleukin; KCNRG, potassium channel-regulating protein; NALP5, NACHT leucine-rich-repeat protein 5; TDRD6, Tudor domain containing protein 6; Tg, thyroglobulin; TPH, tryptophan hydroxylase; TPO, thyroid peroxidase; TSGA10, testis-specific gene 10 protein; TSHR, thyroid-stimulating hormone receptor; TTG, tissue transglutaminase; ZnT8, zinc transporter 8.

hypothyroidism in a patient with features suggestive of APS-2 because thyroid hormone replacement may precipitate **adrenal crisis** in this setting. Autoantibodies to specific tissues may be detectable and may prompt functional screening before the onset of overt clinical disease (see Table 608.2); however, the predictive value of these autoantibodies for the development of clinical disease is variable.

Aberrant T-cell responses probably play a role in the pathogenesis of multiple gland destruction present in APS-2. The risk of autoimmunity directed against the adrenal glands, thyroid gland, and islet cells appears to be shared across certain human leukocyte antigen (HLA) haplotypes and other immune-related genetic loci. However, the magnitude of this risk varies substantially for each endocrinopathy. The prevalence of HLA-D3 and HLA-D4 alleles is increased in patients with APS-2, and they appear to confer an increased risk for the development of this disease. Particular alleles of the major histocompatibility complex class I chain-related genes A and B (*MICA* and *MICB*) also are associated with APS-2. Polymorphisms in other genes (e.g., *PTPN22*, *CTLA4*) have been associated with individual autoimmune endocrinopathies that constitute APS-2, but the contribution of these genes to the pathogenesis of APS-2 itself is uncertain. Although not well defined, there are likely environmental factors that promote the development of autoimmunity in genetically susceptible individuals, and many of the risk factors associated with endocrine and nonendocrine autoimmunity overlap (see individual chapters on these diseases for more detailed discussions of risk factors). Next-generation immune therapies combined with an understanding of autoimmunity pathways may lead to targeted treatments to prevent new endocrinopathies (e.g., type 1 diabetes mellitus) among those at high risk.

CHROMOSOMAL ABNORMALITIES ASSOCIATED WITH AUTOIMMUNE POLYGLANDULAR SYNDROME

Many genetic syndromes involving chromosomal deletions, duplications, and other copy number variations are associated with an increased risk of autoimmunity, particularly endocrine autoimmunity affecting the thyroid and pancreatic β cells (see Table 608.1). Clinical practice guidelines for many of these genetic syndromes recommend routine screening for autoimmune and endocrine manifestations. Males with **Klinefelter syndrome** and females with **Turner syndrome** have an increased risk of autoimmunity in multiple systems, including autoimmune endocrine disease. The mechanism of autoimmunity in **trisomy 21** remains unclear, although differences in *AIRE* gene expression, HLA susceptibility, and autoantibody profiles have been described. Thymic dysplasia is a typical feature of **DiGeorge syndrome** (22q11.2 deletion), and the resulting **immune dysregulation** may play a role in the increased risk of autoimmunity in this disorder. Patients with genetic syndromes and chromosomal abnormalities may have nonautoimmune endocrinopathies such as abnormal growth, primary gonadal failure, and hypoparathyroidism.

Mitochondrial diseases such as Kearns-Sayre syndrome (progressive external ophthalmoplegia, retinal pigmentation, cardiac conduction defects) and MELAS (mitochondrial encephalomyopathy, lactic acidosis, strokelike episodes) have been associated with polyendocrinopathy syndromes, with some rare cases reported to be associated with autoimmunity. Endocrine manifestations of mitochondrial disease include diabetes mellitus, hypogonadism, adrenal insufficiency, hypoparathyroidism, and hypothyroidism. These manifestations may develop before neurologic and other organ injury and could be an early clue of mitochondrial dysfunction.

NONGENETIC AUTOIMMUNE CAUSES OF MULTIPLE ENDOCRINOPATHY

Rapid-onset obesity with hypothalamic dysfunction, hypoventilation, and autonomic dysregulation **(ROHHAD)** is a rare pediatric syndrome diagnosed by its cardinal clinical features (see Chapter 468.3). Children with ROHHAD abruptly develop rapid weight gain and associated autonomic deficits (e.g., ophthalmologic findings, gastrointestinal dysmotility, thermal dysregulation, bradycardia), central hypoventilation, and/or hypothalamic dysfunction. Patients have progressive dysfunction of hypothalamic-pituitary axes such as central hypothyroidism, growth hormone deficiency, hyperprolactinemia, and vasopressin dysregulation (see Chapter 468.3). It is hypothesized that ROHHAD is an autoimmune paraneoplastic neurologic syndrome based on the presence of cerebrospinal fluid inflammatory markers, response to immunosuppressive therapy in some patients, and identification of neuroblastic tumors in about half. Antineural autoantibody profiling and genetic testing have not yet identified the underlying cause of ROHHAD.

Novel immune-modulating biologic compounds are used increasingly in the treatment of malignancies and immune disorders. Monoclonal antitumor drugs that *inhibit immune checkpoints* such as CLTA4, PD1, and PD-L1 are associated with immune-related adverse effects (IRAEs). Clinically important IRAEs include acute onset of multiple autoimmune endocrinopathies, including hypophysitis with hypopituitarism (especially with CTLA4-directed therapies), thyroiditis with hyperthyroidism or hypothyroidism, type 1 diabetes mellitus, and primary adrenal insufficiency. Anti-CD52 antibodies used to treat multiple sclerosis have been linked to the development of Graves disease and other antibody-mediated autoimmune diseases (e.g., immune thrombocytopenic purpura). Preexisting autoimmunity may be a risk factor for developing autoimmune disease after exposure to a wide range of immunomodulatory therapies.

Visit Elsevier eBooks+ at eBooks.Health.Elsevier.com for Bibliography.

Chapter 609

Multiple Endocrine Neoplasia Syndromes

Ari J. Wassner and Jessica R. Smith

Multiple endocrine neoplasia (MEN) syndromes are characterized by the development of tumors in two or more endocrine glands. These syndromes are divided clinically into two types based on the specific endocrine organs involved (Table 609.1). MEN type 1 is characterized by tumors of the parathyroid glands, anterior pituitary, and endocrine pancreas. In contrast, MEN type 2 is characterized by medullary thyroid cancer and pheochromocytoma. Both types of MEN are usually inherited in an autosomal dominant fashion, but sporadic cases can occur.

MULTIPLE ENDOCRINE NEOPLASIA TYPE 1

Multiple endocrine neoplasia type 1 (MEN1) most commonly presents in the fourth or fifth decade of life, but endocrine tumors can develop as early as 5 years of age. The endocrine tissues most frequently involved include the parathyroid glands, pituitary, and cells of the endocrine pancreas.

Primary hyperparathyroidism caused by a parathyroid adenoma or multigland hyperplasia is the most common manifestation of MEN1, with a lifetime cumulative incidence of 90–95%. In children with MEN1, hyperparathyroidism usually presents after 10 years of age and is often the first endocrine disorder to develop (in about 50% of cases). The diagnosis and management of hyperparathyroidism are discussed in Chapter 613. In patients with MEN1, bilateral surgical exploration is generally recommended over focused, minimally invasive approaches because of the tendency for multiple parathyroid glands to be hyperplastic. In such cases, subtotal (3- or 3.5-gland) parathyroidectomy may be required. MEN1 may be present in 15–70% of pediatric cases of primary hyperparathyroidism, and this syndrome should be considered in any child or adolescent with primary hyperparathyroidism, particularly if multigland hyperplasia is present.

Pituitary adenomas are the presenting feature of pediatric MEN1 in about 20% of cases and usually occur after age 10 years, although they have been reported in patients as young as 5 years. Although these adenomas most commonly secrete prolactin (60–70%), a few secrete growth hormone (5–10%) or adrenocorticotrophic hormone (5%), and the remainder are nonfunctioning (~25%). Diagnosis and management are similar to that of sporadic pituitary adenomas except that adenomas associated with MEN1 may be more locally aggressive and are more likely to cosecrete multiple pituitary hormones (see Chapter 598).

Patients with MEN1 can develop neoplasia of various **enteropancreatic endocrine** cells. Such tumors may occur in up to 70% of patients by adulthood but are found in only about 5–20% of affected children. Nonfunctioning pancreatic neuroendocrine tumors are the most common pancreatic lesions found in children with MEN1 and are usually detected by screening imaging. Insulinomas are the most common functional pancreatic tumor in children with MEN1, occurring in 3–10% of cases, and present with symptoms of hypoglycemia. These tumors may present before age 10 years but are more common in adolescence. Although gastrinomas represent over 50% of pancreatic tumors in adults with MEN1, they are rare in children (~2%) and occur after age 15 years. Rarer pancreatic tumors can secrete other hormones such as glucagon or vasoactive intestinal peptide (VIP).

MEN1 is also associated with several other rare tumors. Adrenocortical tumors in children with MEN1 may be benign or malignant, and they

Table 609.1 Clinical Manifestation of MEN Syndromes

SYNDROME	MEN 1	MEN 2		
		MEN 2A	MEN 2B	FAMILIAL MTC
Eponym	Wermer syndrome	Sipple syndrome	Gorlin syndrome	–
Gene	*MEN1* ~85%	*RET* ~100%	*RET* ~100%	*RET* ~100%
Prevalence	1/30,000	1/40,000	1/1,000,000	
Hyperparathyroidism	>90%	20–30%	–	–
Duodenopancreatic NETs: nonfunctioning 55%, gastrinoma 40%, insulinoma 10%, glucagonoma <1%, VIPoma <1%, somatostatinoma	30–80%	–	–	–
Pituitary adenoma	30–40%	–	–	–
Adrenal cortical tumor	20–40%	–	–	–
Pheochromocytoma	<1%	50%	50%	–
Medullary thyroid carcinoma (MTC)	–	100%	100%	100%
Thymic NET/bronchopulmonary NET/gastric NET	2%/5%/30%		–	
Angiofibroma/collagenoma/lipoma	85%/70%/30%	–	–	–
Other tumors: meningioma 8%, ependymoma, melanoma, thyroid 25%	0–25%	–	–	–
Marfanoid habitus	–	–	75%	–
Mucosal neuroma	–	–	~100%	–
Cutaneous lichen amyloidosis	–	Up to 36%	–	–

MEN, Multiple endocrine neoplasia; NET, neuroendocrine tumor.
Modified from Al-Salameh, A, Baudry C, Cohen R. Update on multiple endocrine neoplasia type 1 and 2. *La Presse Médicale*. 2018;47(9):722–731, Table 1.

may be nonfunctional or hypersecrete cortisol, androgens, or aldosterone. Pheochromocytomas have been reported rarely. Meningiomas, carcinoid tumors, and neuroendocrine tumors of the thymus, bronchopulmonary tree, or stomach can also occur, usually in older adolescents. Older patients with MEN1 frequently manifest cutaneous angiofibromas or collagenomas, which are benign but may be a useful diagnostic clue.

The diagnosis of MEN1 can be made clinically based on the presence of at least two of the classical endocrine tumor types (parathyroid, pituitary, pancreas) or the presence of one of these tumors in a first-degree relative of a patient with known MEN1. Genetic testing should be used to confirm a clinical diagnosis of MEN1 or to diagnose the condition preclinically in a relative of an affected individual. The *MEN1* gene on chromosome 11q13 encodes the tumor suppressor menin. A single germline inactivating pathogenic variant in *MEN1* is inherited but is not sufficient to cause tumorigenesis; a second *somatic* variant that inactivates the remaining normal allele then leads to tumor formation in a specific tissue. MEN1 is generally inherited in an autosomal dominant fashion, although sporadic variants account for about 10% of cases. Over 1,000 *MEN1* variants have been described, including deletions and changes in noncoding regions; therefore genetic testing should include analysis for deletions in patients in whom MEN1 sequencing does not reveal a pathogenic variant. Children diagnosed with MEN1 should undergo routine age-based clinical, laboratory, and imaging surveillance for disease manifestations.

MULTIPLE ENDOCRINE NEOPLASIA TYPE 2

Multiple endocrine neoplasia type 2 (MEN2) is a rare genetic disorder that occurs in about 1 in 2 million individuals and is characterized by the development of **medullary thyroid carcinoma (MTC)** and **pheochromocytoma**. MEN2 is an autosomal dominant disorder caused by activating pathogenic variants in the *RET* proto-oncogene, a tyrosine kinase encoded on chromosome 10q11.2. The clinical features of the syndrome are related to the specific *RET* mutation present, although disease manifestations can vary even among family members carrying the same mutation.

MULTIPLE ENDOCRINE NEOPLASIA TYPE 2A

Multiple endocrine neoplasia type 2A (MEN2A) is characterized by MTC, pheochromocytoma, and primary hyperparathyroidism. At least 50 different *RET* pathogenic variants have been described in patients with MEN2A, the majority occurring in exons 10 or 11 (codons 609, 611, 618, 620, or 634) in the *RET* extracellular domain. Almost all patients with MEN2A develop MTC, but the occurrence of other manifestations is more variable. MTC, or its precursor C cell hyperplasia, is usually the first manifestation to occur, but the age at which it develops is variable. Pheochromocytomas are often bilateral and may be multiple, and they usually develop in the third decade or later but may occur in childhood. Hyperparathyroidism is caused by hyperplasia that may involve one or more parathyroid glands. Hyperparathyroidism occurs at an average age of about 30 years but can occur in childhood or adolescence. Variants in *RET* codon 634 confer a relatively high risk of pheochromocytoma and hyperparathyroidism compared to variants at other sites.

Additional clinical conditions associated with MEN2A include cutaneous lichen amyloidosis and Hirschsprung disease. **Cutaneous lichen amyloidosis** is a dermatologic lesion consisting of pruritic hyperpigmented papules that are usually distributed in the interscapular region and on extensor surfaces. These skin lesions may develop before MTC and may provide an early clue to the diagnosis of MEN2A. Some patients with **Hirschsprung** disease have variants in *RET,* particularly in exon 10. Although the *RET* variants that cause Hirschsprung disease are generally loss-of-function variants, some of these can nevertheless cause MEN2A. Therefore individuals with Hirschsprung disease who carry such *RET* pathogenic variants should be evaluated for MEN2A.

MULTIPLE ENDOCRINE NEOPLASIA TYPE 2B

Multiple endocrine neoplasia type 2B (MEN2B) is characterized by MTC and pheochromocytoma, but *not* hyperparathyroidism. Rather, the distinguishing features of MEN2B are the presence of **multiple neuromas** and a characteristic phenotype that includes **Marfan-like habitus**. Nearly all patients with MEN2B have a specific missense pathogenic variant (M918T) in the tyrosine kinase catalytic domain of *RET*. Although MEN2B can be inherited, about 75% of cases are caused by de novo variants.

MTC in MEN2B can develop early in childhood, including in infancy, and metastasis of MTC to local and distant sites is often present at diagnosis. Pheochromocytomas occur in about half of patients. The neuromas of MEN2B can occur throughout the digestive tract, most commonly on the tongue, buccal mucosa, lips, and conjunctivae. Diffuse proliferation of nerves and ganglion cells is found in mucosal, submucosal, myenteric, and subserosal plexuses throughout the digestive tract and may be associated with gastrointestinal symptoms. Peripheral neurofibromas and café-au-lait patches may be present. Affected individuals may be tall, with arachnodactyly and a Marfan-like appearance, including scoliosis, pectus excavatum, pes cavus, and muscular hypotonia. The eyelids may be thickened and everted, lips thickened, and jaw prognathic. Feeding difficulties, poor sucking, diarrhea, constipation, and failure to thrive can begin in infancy or early childhood, sometimes years before the appearance of neuromas or endocrine symptoms.

FAMILIAL MEDULLARY THYROID CARCINOMA

The familial occurrence of MTC without other clinical manifestations of MEN2 has been termed *familial medullary thyroid carcinoma* (FMTC). *RET* variants are commonly present in individuals with FMTC, and although some families appear to have truly isolated MTC, in other kindreds, the pattern of apparent FMTC may represent MEN2A in which other manifestations have not yet occurred or have not been diagnosed. FMTC is frequently regarded as a form of MEN2A, and evaluation for other manifestations of MEN2A is warranted in patients with FMTC.

MANAGEMENT OF MULTIPLE ENDOCRINE NEOPLASIA TYPE 2

Genetic testing of affected family members often leads to the diagnosis of MEN2 in a child before the development of any disease manifestations. MTC is highly likely to develop in these individuals. Although thyroidectomy is curative if performed before the development of MTC or while it is still localized to the thyroid gland, the prognosis is poor once MTC has metastasized beyond the thyroid. Therefore prophylactic thyroidectomy is required in most individuals with MEN2. However, the timing of prophylactic thyroidectomy must be determined for each patient based on balancing the likelihood of developing metastatic MTC against the need to minimize the risks of surgery, which are higher in younger children.

Factors influencing the risk of MTC include the specific *RET* variants present, the history of MTC in the family, and serum levels of calcitonin. The first two factors are not entirely predictive, as MTC behavior can vary significantly even in family members with the same variant. Some *RET* variants are associated with earlier-onset MTC, and consensus guidelines categorize *RET* variants as highest risk (M918T, usually associated with MEN2B), high risk (codon 634 and 883 mutations), or moderate risk (other variants) for MTC. Patients at highest risk should undergo thyroidectomy within the first year of life. Those with high-risk variants should undergo thyroidectomy at 5 years of age or earlier if calcitonin levels begin to rise. Patients at moderate risk should be monitored by neck ultrasound and serum calcitonin levels beginning at age 5 years, and thyroidectomy should be performed if calcitonin levels rise. However, the timing of surgery may be influenced by other factors, including family history or desire to avoid prolonged monitoring by proceeding with thyroidectomy. For patients who do not wish to undergo prophylactic thyroidectomy, regular careful surveillance is mandatory. Thyroidectomy should be performed by an experienced thyroid surgeon, especially in the youngest patients, to minimize the risk of surgical complications. Prophylactic thyroidectomy reduces morbidity and mortality from MTC in patients with MEN2, many of whom are found to have C cell hyperplasia, or even MTC, at the time of prophylactic thyroidectomy. The management of MTC is described in detail in Chapter 607.

Screening for pheochromocytoma and hyperparathyroidism should be performed in children with MEN2. The age at which screening should commence depends on the specific RET variant (11 years for high and highest risk; 16 years for moderate risk). Management of pheochromocytoma (see Chapters 555.4 and 613) and hyperparathyroidism (see Chapter 621) are discussed elsewhere.

Visit Elsevier eBooks+ at eBooks.Health.Elsevier.com for Bibliography.

Section 3

Disorders of the Parathyroid Gland

Chapter 610

Hormones and Peptides of Calcium Homeostasis and Bone Metabolism

Evan G. Graber and Daniel A. Doyle

Parathyroid hormone (PTH) and vitamin D are the principal regulators of calcium homeostasis (see Chapters 69 and 746). Calcitonin and PTH-related peptide (PTHrP) are important primarily in the fetus.

PARATHYROID HORMONE

PTH is an 84–amino acid chain (95 kDa), but its biologic activity resides in the first 34 residues. In the parathyroid gland, a pre–pro-PTH (115–amino acid chain) and a pro-PTH (90 amino acids) are synthesized. Pre–pro-PTH is converted to pro-PTH and pro-PTH to PTH. PTH (consisting of amino acids 1-84) is the major secretory product of the gland, but it is rapidly cleaved in the liver and kidney into smaller COOH-terminal, midregion, and NH_2-terminal fragments.

The occurrence of these fragments in serum has led to the development of a variety of assays. The 1-34 aminoterminal (N-terminus) fragments possess biologic activity but are present in low amounts in the circulation; assay of these fragments is most useful for detecting acute secretory changes. The carboxyterminal (C-terminus) and midregion fragments, although biologically inert, are cleared more slowly from the circulation and represent 80% of plasma immunoreactive PTH; concentrations of the C-terminal fragment are 50-500 times the level of the active hormone. The C-terminal assays are effective in detecting hyperparathyroidism, but because C-terminal fragments are removed from the circulation by glomerular filtration, these assays are less useful for evaluating the secondary hyperparathyroidism characteristic of renal disease. Only certain sensitive radioimmunoassays for PTH can differentiate the subnormal concentrations that occur in hypoparathyroidism from normal levels.

When serum levels of calcium fall, the signal is transduced through the calcium-sensing receptor, and secretion of PTH increases (Fig. 610.1). PTH stimulates activity of 1α-hydroxylase in the kidney, enhancing production of 1,25-dihydroxycholecalciferol, also written as $1,25(OH)_2D_3$. The increased level of $1,25(OH)_2D_3$ induces synthesis of a calcium-binding protein (calbindin-D) in the intestinal mucosa, with resultant absorption of calcium. PTH also mobilizes calcium by directly enhancing bone resorption, an effect that requires $1,25(OH)_2D_3$. The effects of PTH on bone and kidney are mediated through binding to specific receptors on the membranes of target cells and through activation of a transduction pathway involving a G-protein coupled to the adenylate cyclase system (see Chapter 594).

The calcium-sensing receptor regulates the secretion of PTH and the reabsorption of calcium by the renal tubules in response to alterations in serum calcium concentrations. The gene for the receptor is located on chromosome 3q13.3-q21 and encodes a cell surface protein that is expressed in parathyroid glands and kidneys and belongs to the family of G-protein–coupled receptors. In the normally functioning calcium-sensing receptor, hypocalcemia induces increased secretion of PTH and hypercalcemia depresses PTH secretion. Loss-of-function pathogenic variants cause an increased set point with respect to serum calcium, resulting in hypercalcemia and in the conditions of familial hypocalciuric hypercalcemia and neonatal severe hyperparathyroidism. There is a close genotype/phenotype relationship that determines severity of illness. Acquired hypocalciuric hypercalcemia may be a result of autoantibodies to the calcium-sensing receptor and manifests with hypercalcemia and hyperparathyroidism. Gain-of-function variants result in depressed secretion of PTH in response to hypocalcemia, leading to the syndrome of familial hypocalcemia with hypercalciuria (see Fig. 610.1).

PARATHYROID HORMONE–RELATED PEPTIDE

PTHrP is homologous to PTH only in the first 13 amino acids of its amino terminus, 8 of which are identical to PTH. Its gene is on the short arm of chromosome 12 and that of PTH is on the short arm of chromosome 11.

PTHrP, like PTH, activates PTH receptors in kidney and bone cells and increases urinary cyclic adenosine monophosphate and renal production of $1,25(OH)_2D_3$. It is produced in almost every type of cell of the body, including every tissue of the embryo at some stage of development. PTHrP is critical for normal fetal development. Inactivating variants of the receptor for PTH/PTHrP results in a lethal bone disorder characterized by short limbs and markedly advanced bone maturation known as **Blomstrand chondrodysplasia** (see Fig. 610.1). PTHrP appears to have a paracrine or autocrine role because serum levels are low except in a few clinical situations. Cord blood contains levels of PTHrP that are threefold higher than in serum from adults; it is produced by the fetal parathyroid glands and appears to be the main agent stimulating maternal-fetal calcium transfer. PTHrP appears to be essential for normal skeletal maturation of the fetus, which requires 30 g of calcium during a normal gestation. During pregnancy, maternal absorption of calcium increases from about 150 mg daily to 400 mg during the second trimester.

PTHrP levels are increased during lactation and in patients with benign breast hypertrophy. Breast milk and pasteurized bovine milk have levels of PTHrP that are 10,000 times higher than those of normal plasma. Most instances of the hormonal **hypercalcemia syndrome of malignancy** are caused by elevated concentrations of PTHrP.

VITAMIN D

See Chapter 69.

CALCITONIN

Calcitonin is a 32–amino acid polypeptide. Its gene is on chromosome 11p and is tightly linked to that of PTH. The gene for calcitonin encodes three peptides: calcitonin, a 21–amino acid carboxyterminal flanking peptide (katacalcin), and a calcitonin gene–related peptide. Katacalcin and calcitonin are cosecreted in equimolar amounts by the parafollicular cells (C cells) of the thyroid gland. Calcitonin appears to be of little consequence in children and adults because very high levels in patients with medullary carcinoma of the thyroid (a tumor arising from the C cells) do not cause hypercalcemia. In the fetus, circulating levels are high and appear to augment bone metabolism and skeletal growth; these high levels are probably stimulated by the normally high fetal calcium levels. Unlike the high levels in cord blood and circulating concentrations in young children, levels in older children and adults are low. Infants and children with congenital hypothyroidism (and presumed deficiency of C cells) have lower levels of calcitonin than normal children.

Its action appears to be independent of PTH and vitamin D. Its main biologic effect appears to be the inhibition of bone resorption by decreasing the number and activity of bone-resorbing osteoclasts. This action of calcitonin is the rationale for its use in treatment of Paget disease. Calcitonin is synthesized in other organs, such as the gastrointestinal tract, pancreas, brain, and pituitary. In these organs, calcitonin is thought to behave as a neurotransmitter to impose a local inhibitory effect on cell function.

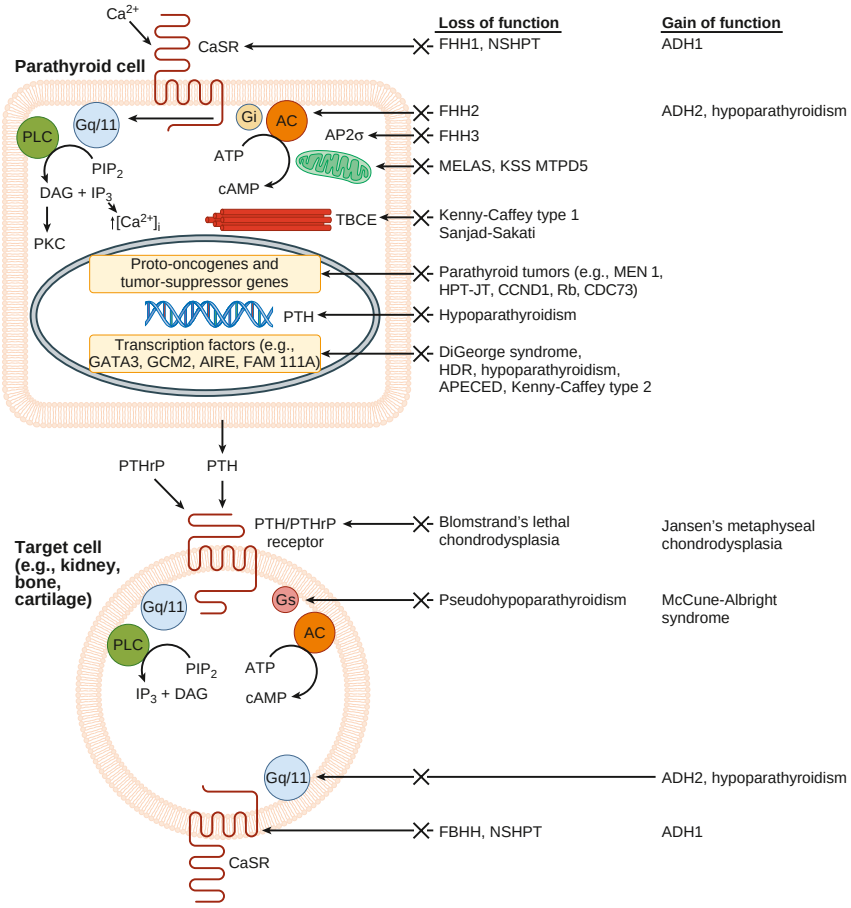

Fig. 610.1 Schematic representation of some of the components involved in calcium homeostasis. Alterations in extracellular calcium are detected by the calcium-sensing receptor *(CaSR)*, which is a 1078–amino acid, G protein–coupled receptor. The parathyroid hormone (PTH)/parathyroid hormone-related peptide (PTHrP) receptor, which mediates the actions of and PTHrP, is also a G protein–coupled receptor. Thus Ca^{2+}, PTH, and PTHrP involve G protein–coupled signaling pathways, and interaction with their specific receptors can lead to activation of Gs, Gi, and Gq, respectively. Gs stimulates adenylcyclase *(AC)*, which catalyzes the formation of cyclic adenosine monophosphate *(cAMP)* from adenosine triphosphate *(ATP)*. Gi inhibits AC activity. cAMP stimulates protein kinase A *(PKA)*, which phosphorylates cell-specific substrates. Activation of Gq stimulates phospholipase C *(PLC)*, which catalyzes the hydrolysis of the phosphoinositide *(PIP_2)* to inositol triphosphate *(IP_3)*, which then increases intracellular calcium, and diacylglycerol *(DAG)*, activating protein kinase C *(PKC)*. These proximal signals modulate downstream pathways, which results in specific physiologic effects. Loss of function in several genes, shown with their respective sites of action on the right, has been identified in specific disorders of calcium homeostasis. ADH, autosomal dominant hypocalcemia; APECED, autoimmune polyendocrinopathy candidiasis ectodermal dystrophy; FBHH, familial benign hypocalciuric hypercalcemia; FHH, familial hypocalciuric hypercalcemia; HDR, hypoparathyroidism, sensorineural deafness, and renal anomaly; HPT-JT, hyperparathyroidism-jaw tumor syndrome; KSS, Kearns-Sayre syndrome; MELAS, Mitochondrial encephalomyopathy, lactic acidosis, and stroke-like episodes; MEN, multiple endocrine neoplasia; MTPD, mitochondrial trifunctional protein deficiency; NSHPT, neonatal severe hyperparathyroidism. TBCE, tubulin-specific chaperone E. *(From Thakkerf RV. The parathyroid glands, hypercalcemia and hypocalcemia. In: Goldman L, Schafer AI, eds. Goldman-Cecil Medicine, 25th ed. Philadelphia: Elsevier; 2016: Fig. 245.2, p. 1651.)*

Visit Elsevier eBooks+ at eBooks.Health.Elsevier.com for Bibliography.

Chapter 611

Hypoparathyroidism

Patrick C. Hanley and Daniel A. Doyle

Hypocalcemia is common in neonates between 12 and 72 hours of life, especially in premature infants, in infants with asphyxia, and in infants of diabetic mothers (**early neonatal hypocalcemia**; see Chapter 121.4; Table 611.1 and Fig. 611.1). After the second to third day and during the first week of life, the type of feeding also is a determinant of the level of serum calcium **(late neonatal hypocalcemia)**. The role played by the parathyroid glands in these hypocalcemic infants is unclear, although functional immaturity of the parathyroid glands is invoked as one pathogenetic factor. In a group of infants with **transient idiopathic hypocalcemia** (1-8 weeks of age), serum levels of parathyroid hormone (PTH) are significantly lower than those in unaffected infants. It is possible that the functional immaturity is a manifestation of a delay in development of the enzymes that convert glandular PTH to secreted PTH; other mechanisms are possible.

APLASIA OR HYPOPLASIA OF THE PARATHYROID GLANDS

Aplasia or hypoplasia of the parathyroid glands is often associated with **DiGeorge/velocardiofacial syndrome**. This syndrome occurs in 1 in 4,000 newborns. In 90% of patients, the condition is caused by a deletion of chromosome 22q11.2 with involvement of the *TBX1* gene. Approximately 25% of these patients inherit the chromosomal abnormality from a parent. Neonatal hypocalcemia occurs in 60% of affected patients, but it is transitory in the majority; hypocalcemia may recur or can have its onset later in life. Associated abnormalities of the third and fourth pharyngeal pouches are common; these include conotruncal defects of the heart in 25%, velopharyngeal insufficiency in 32%, cleft palate in 9%, renal anomalies in 35%, and aplasia of the thymus with severe immunodeficiency in 1%. This syndrome has also been reported in a small number of patients with a deletion of chromosome 10p13 thought to affect the *NEBL* gene, in infants of diabetic mothers, and in infants born to mothers treated with retinoic acid for acne early in pregnancy. Loss-of-function pathogenic variants in the *GCM2* gene, which is a key regulator of parathyroid gland development, leads to isolated parathyroid aplasia and hypoparathyroidism.

Table 611.1 Causes of Hypocalcemia

I. NEONATAL
A. Maternal Disorders
1. Diabetes mellitus
2. Toxemia of pregnancy
3. Vitamin D deficiency
4. High intake of alkali or magnesium sulfate
5. Use of anticonvulsants
6. Hyperparathyroidism

B. Neonatal Disorders
1. Low birthweight: prematurity, intrauterine growth restriction
2. Peripartum asphyxia, sepsis, critical illness
3. Hyperbilirubinemia, phototherapy, exchange transfusion
4. Hypomagnesemia, hypermagnesemia
5. Acute/chronic renal failure
6. Nutrients/medications: high phosphate intake, fatty acids, phytates, bicarbonate infusion, citrated blood, anticonvulsants, aminoglycosides
7. Hypoparathyroidism
8. Vitamin D deficiency or resistance
9. Osteopetrosis type II

II. HYPOPARATHYROIDISM
A. Congenital
1. Transient neonatal
2. Congenital hypoparathyroidism
   a. Familial isolated hypoparathyroidism
      (i) Autosomal recessive hypoparathyroidism *(GMC2, PTH)*
      (ii) Autosomal dominant hypoparathyroidism *(CASR, GNA11)*
      (iii) X-linked hypoparathyroidism *(SOX3)*
   b. DiGeorge syndrome types 1 and 2 *(TBX1, NEBL)*
   c. Sanjad-Sakati syndrome (short stature, retardation, dysmorphism; HRD) *(TBCE)*
   d. Kenny-Caffey syndrome type 1 (short stature, medullary stenosis, retardation) *(TBCE)*
   e. Kenny-Caffey syndrome type 2 (short stature, medullary stenosis) *(FAM111A)*
   f. Barakat syndrome (sensorineural deafness, renal dysplasia; HDR) *(GATA3)*
   g. Lymphedema-Hypoparathyroidism syndrome (nephropathy, mitral valve prolapse and brachytelephalangy).
   h. Mitochondrial disorders (Kearns-Sayre, Pearson, MELAS, trifunctional protein deficiency)
3. Insensitivity to PTH
   a. Blomstrand chondrodysplasia *(PTHR1)*
   b. Pseudohypoparathyroidism type IA *(GNAS)*
      (i) Pseudohypoparathyroidism type IB *(STX16, GNAS-A1)*
      (ii) Pseudohypoparathyroidism type IC *(GNAS)*
      (iii) Pseudohypoparathyroidism type II
      (iv) Pseudopseudohypoparathyroidism
   c. Acrodysostosis with hormone resistance *(PRKAR1A)*
   d. Hypomagnesemia
4. CaSR-activating mutation
   a. Sporadic
   b. Autosomal dominant (G protein subunit α11 mutation)

II. HYPOPARATHYROIDISM—cont'd
B. Acquired
1. Autoimmune polyglandular syndrome type I (*AIRE* gene mutation)
2. Activating antibodies to the CaSR
3. Postsurgical, radiation destruction
4. Infiltrative—excessive iron (hemochromatosis, thalassemia) or copper (Wilson disease) deposition; granulomatous inflammation, neoplastic invasion; amyloidosis, sarcoidosis
5. Hypomagnesemia/hypermagnesemia

III. VITAMIN D DEFICIENCY

IV. OTHER CAUSES OF HYPOCALCEMIA
A. Calcium Deficiency
1. Nutritional deprivation
2. Hypercalciuria

B. Disorders of Magnesium Homeostasis
1. Congenital hypomagnesemia
2. Acquired
   a. Acute renal failure
   b. Chronic inflammatory bowel disease, intestinal resection
   c. Diuretics

C. Hyperphosphatemia
1. Renal failure
2. Phosphate administration (intravenous, oral, rectal)
3. Tumor cell lysis
4. Muscle injuries (crush, rhabdomyolysis)

D. Miscellaneous
1. Hypoproteinemia
2. Hyperventilation
3. Drugs: furosemide, aminoglycosides, bisphosphonates, calcitonin, anticonvulsants, ketoconazole, antineoplastic agents (plicamycin, asparaginase, cisplatinum, cytosine arabinoside, doxorubicin), citrated blood products
4. Hungry bone syndrome
5. Acute and critical illness: sepsis, acute pancreatitis, toxic shock
   a. Organic acidemia: propionic, methylmalonic, isovaleric

CaSR, Ca^2-sensing receptor; HDR, hypoparathyroidism, sensorineural deafness, and renal anomaly; HRD, hypoparathyroidism, retardation, dysmorphism; MELAS, mitochondrial encephalomyopathy with lactic acidosis and strokelike episode; PTH, parathyroid hormone.
Modified from Root AW, Diamond Jr FB. Disorders of mineral homeostasis in children and adolescents. In: Sperling MA. *Pediatric Endocrinology*, 4th ed. Philadelphia: Elsevier; 2014: Table 18.2A.

X-LINKED RECESSIVE HYPOPARATHYROIDISM

Familial clusters of hypoparathyroidism with various patterns of transmission have been described. In two large North American pedigrees, this disorder appears to be transmitted by an X-linked recessive gene located on Xq26-q27, which has a key role in the development of the parathyroid glands. In these families, the onset of afebrile hypocalcemic seizures characteristically occurs in infants from 2 weeks to 6 months of age. The absence of parathyroid tissue after detailed examination of a male with this condition suggests a defect in embryogenesis.

AUTOSOMAL RECESSIVE HYPOPARATHYROIDISM WITH DYSMORPHIC FEATURES

Autosomal recessive hypoparathyroidism with dysmorphic features has been described in Middle Eastern children. Parental consanguinity occurred for most of several dozen affected patients. Profound hypocalcemia occurs early in life, and dysmorphic features include microcephaly, deep-set eyes, beaked nose, micrognathia, and large floppy ears. Intrauterine and postnatal growth restriction are severe, and cognitive impairment is common. The putative gene *(TBCE)* is on chromosome 1q42-43. In a few patients with autosomal recessive inheritance of isolated hypoparathyroidism, pathologic variants of the *PTH* gene have been found.

HYPOPARATHYROIDISM, SENSORINEURAL DEAFNESS, AND RENAL ANOMALY SYNDROME

Hypoparathyroidism, sensorineural deafness, and renal anomaly (HDR) occur owing to pathologic variants of the *GATA3* gene. The protein encoded by this gene is essential in the development of the

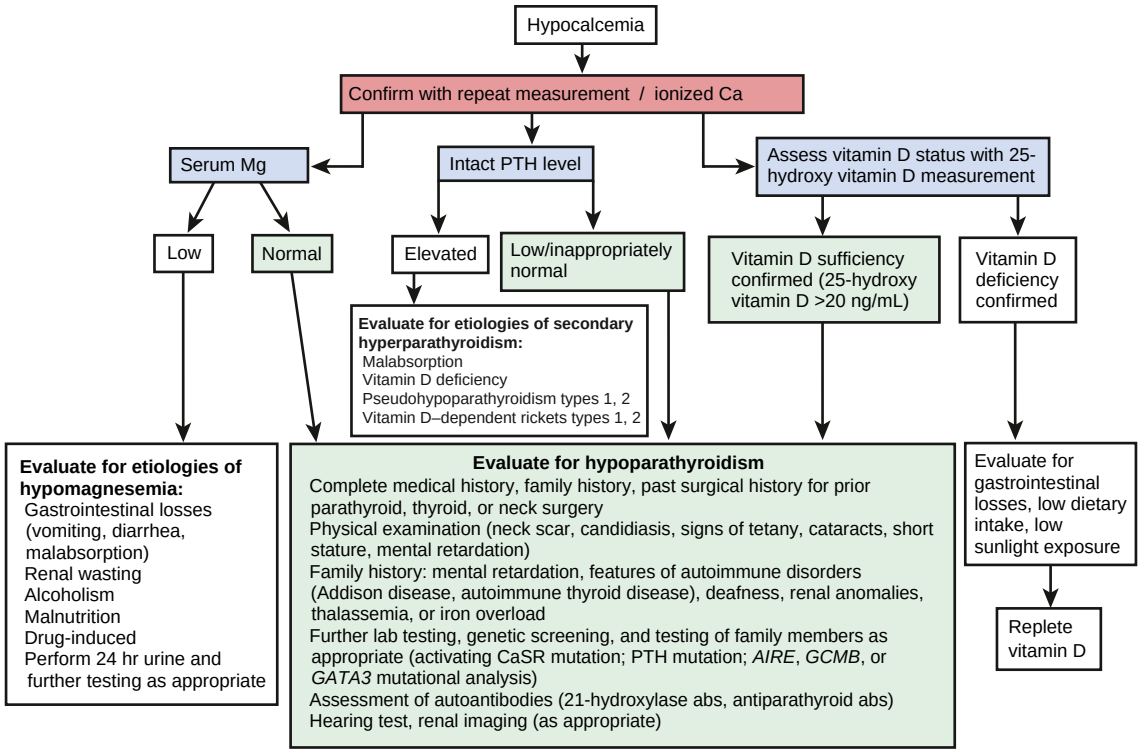

Fig. 611.1 Algorithm for the evaluation of hypocalcemia. Abs, autoantibodies; CaSR, Ca^2-sensing receptor; PTH, parathyroid hormone. *(From Bilezikian JP, Khan A, Potts Jr JT, et al. Hypoparathyroidism in the adult: epidemiology, diagnosis, pathophysiology, target-organ involvement, treatment, and challenges for future research. J Bone Miner Res. 2011;26:2317–2337, Fig. 1.)*

parathyroids, auditory system, and kidneys. The *GATA3* gene is located at chromosome 10p14 and is nonoverlapping with the DiGeorge critical region at 10p13 (see Fig. 610.1). Congenital ichthyosis and HDR have also been reported.

SUPPRESSION OF NEONATAL PARATHYROID HORMONE SECRETION BECAUSE OF MATERNAL HYPERPARATHYROIDISM OR MATERNAL FAMILIAL HYPOCALCIURIC HYPERCALCEMIA

Neonatal PTH secretion can be suppressed by maternal hyperparathyroidism, resulting in transient hypocalcemia in the newborn infant. It appears that neonatal hypocalcemia results from suppression of the fetal parathyroid glands by exposure to elevated levels of calcium in maternal and hence fetal serum. Tetany usually develops within 3 weeks but may be delayed by 1 month or more if the infant is breastfed. Seizures may occur within 1 week with familial hypocalciuric hypercalcemia (FHH1) because of maternal Ca^2-sensing receptor (CaSR) loss-of-function pathogenic variants. Hypocalcemia can persist for weeks or months. When the cause of hypocalcemia in an infant is unknown, measurements of calcium, phosphorus, and PTH should be obtained from the mother. Most affected mothers are asymptomatic, and the cause of their hyperparathyroidism is usually a parathyroid adenoma.

AUTOSOMAL DOMINANT HYPOPARATHYROIDISM

Patients with autosomal dominant hypoparathyroidism have an activating (gain-of-function) pathogenic variant of the Ca^{2+}-sensing receptor, forcing the receptor to an on state with subsequent depression of PTH secretion even during hypocalcemia. The patients have hypercalciuria. The hypocalcemia is usually mild and might not require treatment beyond childhood (see Fig. 610.1).

HYPOPARATHYROIDISM ASSOCIATED WITH MITOCHONDRIAL DISORDERS

Mitochondrial DNA pathogenic variants in Kearns-Sayre syndrome, MELAS (mitochondrial encephalomyopathy, lactic acidosis, and strokelike episodes) syndrome, and mitochondrial trifunctional protein–deficiency syndrome are associated with hypoparathyroidism. A diagnosis of mitochondrial cytopathy should be considered in patients with unexplained symptoms, such as ophthalmoplegia, sensorineural hearing loss, cardiac conduction disturbances, and tetany (see Fig. 610.1).

SURGICAL OR INFILTRATIVE HYPOPARATHYROIDISM

Removal or damage of the parathyroid glands can complicate thyroidectomy. Hypoparathyroidism has developed even when the parathyroid glands have been identified and left undisturbed at the time of operation. This may be the result of interference with the blood supply or of postoperative edema and fibrosis. Symptoms of tetany can occur abruptly postoperatively and may be temporary or permanent. In some instances, symptoms develop insidiously and go undetected until months after thyroidectomy. Occasionally, the first evidence of surgical hypoparathyroidism may be the development of cataract. The status of parathyroid function should be carefully monitored in all patients undergoing thyroidectomy.

Deposition of iron pigment or of copper in the parathyroid glands (thalassemia, Wilson disease) can also produce hypoparathyroidism.

AUTOIMMUNE HYPOPARATHYROIDISM

An autoimmune mechanism for hypoparathyroidism is strongly suggested by the finding of parathyroid antibodies and by its frequent association with other autoimmune disorders or organ-specific antibodies. Autoimmune hypoparathyroidism is often associated with Addison disease and chronic mucocutaneous candidiasis. The association of at least two of these three conditions has been classified as **autoimmune polyglandular disease type I** (see Chapter 608). It is also known as *autoimmune polyendocrinopathy, candidiasis, and ectodermal dystrophy* (APECED). This syndrome is inherited in an autosomal recessive fashion and is not related to any single human leukocyte antigen–associated haplotype. Approximately one third of pediatric patients with this syndrome have all three components; 66% have only two of three conditions. The candidiasis almost always precedes the other disorders (70% of cases

occur in children *younger* than 5 years of age); the hypoparathyroidism (90% of cases occur *after* 3 years of age) usually occurs before Addison disease (90% of cases occur *after* 6 years of age). A variety of other disorders, including alopecia areata or totalis, malabsorption disorder, asplenia, pernicious anemia, gonadal failure, autoimmune hepatitis, vitiligo, dental enamel hypoplasia, nail dystrophy, keratoconjunctivitis, and insulin-dependent diabetes, occur at various times. Some of these associations might not appear until adult life. Autoimmune thyroid disease is a rare concomitant finding in pediatric patients.

Affected siblings can have the same or different constellations of disorders (hypoparathyroidism, Addison disease). The disorder is exceptionally prevalent among Finns and Iranian Jews. The gene for this disorder is designated *AIRE* (autoimmune regulator); it is located on chromosome 21q22. It appears to be a transcription factor that plays an essential role in the development of immunologic tolerance. Patients with Addison disease as part of polyendocrinopathy syndrome type I have demonstrated adrenal-specific autoantibody reactivity directed against the side-chain cleavage enzyme.

IDIOPATHIC HYPOPARATHYROIDISM

The term *idiopathic hypoparathyroidism* should be reserved for the small residuum of children with hypoparathyroidism for whom no causative mechanism can be defined. Most children in whom onset of hypoparathyroidism occurs after the first few years of life have an **autoimmune condition**. Autoantibodies to the extracellular domain of the Ca^2-sensing receptor have been identified in some patients with acquired hypoparathyroidism. One should always consider incomplete forms of DiGeorge syndrome or an activating Ca^2-sensing receptor pathogenic variant in the differential diagnosis.

Clinical Manifestations

There is a spectrum of parathyroid deficiencies with clinical manifestations varying from no symptoms to those of complete and long-standing deficiency. Mild deficiency may be revealed only by appropriate laboratory studies. Muscular pain and cramps are early manifestations; they progress to numbness, stiffness, and tingling of the hands and feet. There may be only a positive Chvostek or Trousseau sign or laryngeal and carpopedal spasms. Seizures with or without loss of consciousness can occur at intervals of days, weeks, or months. These episodes can begin with abdominal pain, followed by tonic rigidity, retraction of the head, and cyanosis. Hypoparathyroidism is often mistaken for epilepsy. Headache, vomiting, increased intracranial pressure, and papilledema may be associated with seizures and might suggest a brain tumor.

In patients with long-standing hypocalcemia, the teeth erupt late and irregularly. Enamel formation is irregular, and the teeth may be unusually soft. The skin may be dry and scaly, and the nails might have horizontal lines. Mucocutaneous candidiasis, when present, antedates the development of hypoparathyroidism; the candidal infection most often involves the nails, the oral mucosa, the angles of the mouth, and less often, the skin; it is difficult to treat.

Cataracts in patients with long-standing untreated disease are a direct consequence of hypoparathyroidism; other autoimmune ocular disorders such as keratoconjunctivitis can also occur. Manifestations of Addison disease, lymphocytic thyroiditis, pernicious anemia, alopecia areata or totalis, hepatitis, and primary gonadal insufficiency may also be associated with those of hypoparathyroidism.

Permanent physical and mental deterioration occurs if initiation of treatment is long delayed.

Laboratory Findings

The serum calcium level is low (5-7 mg/dL), and the phosphorus level is elevated (7-12 mg/dL). Blood levels of ionized calcium (usually approximately 45% of the total) more nearly reflect physiologic adequacy but also are low. The serum level of alkaline phosphatase is normal or low, and the level of $1,25(OH)_2D_3$ is usually low, but high levels have been found in some children with severe hypocalcemia. The level of magnesium is normal but should always be checked in hypocalcemic patients. Levels of PTH are low relative to the calcium level when measured by immunometric assay. Radiographs of the bones occasionally reveal an increased density limited to the metaphyses, suggesting heavy metal poisoning, or an increased density of the lamina dura. Radiographs or CT scans of the skull can reveal calcifications in the basal ganglia. There is a prolongation of the QT interval on the electrocardiogram, which disappears when the hypocalcemia is corrected. The electroencephalogram usually reveals widespread slow activity; the tracing returns to normal after the serum calcium concentration has been within the normal range for a few weeks, unless irreversible brain damage has occurred or unless the parathyroid insufficiency is associated with epilepsy. When hypoparathyroidism occurs concurrently with Addison disease, the serum level of calcium may be normal, but hypocalcemia appears after effective treatment of the adrenal insufficiency.

Treatment

Emergency treatment of neonatal tetany consists of intravenous injections of 5-10 mL or 1-3 mg/kg of a 10% solution of calcium gluconate (elemental calcium 9.3 mg/mL) at the rate of 0.5-1.0 mL/min while the heart rate is monitored and a total dose not to exceed 20 mg of elemental calcium/kg. Additionally, 1,25-dihydroxycholecalciferol (calcitriol) should be given. The initial dosage is 0.25 μg/24 hr; the maintenance dosage ranges from 0.01-0.10 g/kg/24 hr to a maximum of 1-2 μg/24 hr. Calcitriol has a short half-life and should be given in two equally divided doses; it has the advantages of rapid onset of effect (1-4 days) and rapid reversal of hypercalcemia after discontinuation in the event of overdosage (calcium levels begin to fall in 3-4 days). Calcitriol is supplied as an oral solution.

An adequate intake of calcium should be ensured. Supplemental calcium can be given in the form of calcium gluconate or calcium glubionate to provide 800 mg of elemental calcium daily or 25-50 mg/kg day dosing of elemental calcium as needed. Foods with high phosphorus content such as milk, eggs, and cheese should be *reduced* in the diet. Other therapies used for some children with hypoparathyroidism in studies include hormone replacement with recombinant PTH 1-34 or recombinant PTH 1-84 given via a pump or subcutaneous injections in adult patients who do not respond to conventional therapy.

Clinical evaluation of the patient and frequent determinations of the serum calcium levels are indicated in the early stages of treatment to determine the requirement for calcitriol, calcium supplementation, or vitamin D_2. If hypercalcemia occurs, therapy should be discontinued and resumed at a lower dose after the serum calcium level has returned to normal. In long-standing cases of hypercalcemia, repair of cerebral and dental changes is not likely. Pigmentation, lowering of blood pressure, or weight loss can indicate adrenal insufficiency, which requires specific treatment. Patients with autosomal dominant hypocalcemic hypercalciuria can develop nephrocalcinosis and renal impairment if treated with vitamin D.

Differential Diagnosis

Magnesium deficiency must be considered in patients with unexplained hypocalcemia. Concentrations of serum magnesium <1.5 mg/dL (1.2 mEq/L) are usually abnormal (Table 611.2). Administration of calcium is ineffective, but administration of magnesium promptly corrects both calcium and magnesium levels. Oral supplements of magnesium are necessary to maintain levels of magnesium in the normal range.

Hypomagnesemia also occurs in malabsorption syndromes such as Crohn disease and cystic fibrosis. Patients with autoimmune polyglandular disease type I and hypoparathyroidism can also have concurrent

Table 611.2 Genetic Causes of Hypomagnesemia

CATEGORIES/NAMES OF DISORDERS*	GENE	INHERITANCE	DISTINCTIVE FINDINGS OTHER THAN HYPOMAGNESEMIA†
HYPERCALCIURIC HYPOMAGENESEMIAS			Hypercalciuria, nephrocalcinosis
FHHNC type 1	*CLDN16*	R	Polyuria/polydipsia, elevated serum iPTH, renal failure
FHHNC type 2	*CLDN19*	R	Same as FHHNC type 1, plus ocular abnormalities
ADHH Bartter syndrome type 5	*CASR*	D	Hypocalcemia with normal or low PTH
Bartter syndrome, type 3 (classical type)	*CLCNKB*	R	Gitelman-like phenotype possible, rarely nephrocalcinosis
GITELMAN-LIKE HYPOMAGNESEMIAS			Hypocalciuria, hypokalemia, metabolic alkalosis
Gitelman syndrome	*SLC12A3*	R	Chondrocalcinosis at older age
Bartter syndrome, type 4	*BSND*	R	Prenatal complications, renal failure early in life possible
EAST syndrome	*KCNJ10*	R	Sensorineural deafness, seizures, ataxia
IDH	*FXYD2*	D	
ADTKD/RCAD	*HNF1B*	D	Renal, genital, and pancreatic abnormalities and MODY5 in highly variable combination and presentation
HPABH4D/RCAD-like	*PCBD1*	R	MODY5-like
MITOCHONDRIAL HYPOMAGNESEMIAS			Variable
HHH	*MT-TI*	Mt	Hypertension and hypercholesterolemia
HUPRAS	*SARS2*	R	Hyperuricemia, pulmonary hypertension, renal failure, and alkalosis
KSS	Mitochondrial deletion	Mt	External ophthalmoplegia, retinopathy and cardiac conduction defects
OTHER HYPOMAGNESEMIAS			Variable
HSH	*TRPM6*	R	Neonatal presentation with severe hypomagnesemia
IRH	*EGF*	R	Intellectual disability
NISBD2	*EGFR*	R	Severe inflammation of skin and bowel from birth
HSMR	*CNNM2*	D/R	Intellectual disability, seizures
ADH/EA1	*KCNA1*	D	Episodic myokymia
KCS2	*FAM111A*	D	Impaired skeletal development and hypocalcemic hypoparathyroidism

*ADH, Autosomal dominant hypomagnesemia; ADHH, autosomal dominant hypocalcemia with hypocalciuria; ADTKD, autosomal dominant tubulointerstitial kidney disease; EA1, episodic ataxia type 1; EAST, epilepsy, ataxia, sensorineural deafness and tubulopathy; FHHNC, familial hypomagnesemia with hypocalcemia and nephrocalcinosis; HHH, hypertension, hypercholesterolemia and hypomagnesemia; HPABH4D, hyperphenylalaninemia BH4-deficient; HSH, hypomagnesemia with secondary hypocalcemia; HSMR, hypomagnesemia with seizures and mental retardation; HUPRAS, hyperuricemia, pulmonary hypertension, renal failure and alkalotic syndrome; IDH, isolated dominant hypomagnesemia; IRH, isolated recessive hypomagnesemia; KCS2, Kenny-Chaffey syndrome type 2; KSS, Kearns-Sayre syndrome; NISBD2, neonatal inflammatory skin and bowel disease type 2; RCAD, renal cysts and diabetes.

†iPTH, Intact parathyroid hormone; MODY5, maturity onset diabetes of the young type 5.

Modified from Viering DHHM, de Baaij JHF, Walsh SB. et al. Genetic causes of hypomagnesemia, a clinical overview. *Pediatr Nephrol*. 2017;32:1123–1135.

steatorrhea and low magnesium levels. Therapy with aminoglycosides causes hypomagnesemia by increasing urinary losses.

It is not clear how low levels of magnesium lead to hypocalcemia. Evidence suggests that hypomagnesemia impairs release of PTH and induces resistance to the effects of the hormone, but other mechanisms also may be operative.

Poisoning with inorganic phosphate leads to hypocalcemia and tetany. Infants administered large doses of inorganic phosphates, either as laxatives or as sodium phosphate enemas, have had sudden onset of tetany, with serum calcium levels <5 mg/dL and markedly elevated levels of phosphate. Symptoms are quickly relieved by intravenous administration of calcium. The mechanism of the hypocalcemia is not clear (see Chapter 73.6).

Hypocalcemia can occur early in treatment of acute lymphoblastic leukemia. Hypocalcemia is usually associated with hyperphosphatemia resulting from destruction of lymphoblasts.

Episodic symptomatic hypocalcemia occurs in **Kenny-Caffey syndrome**, which is characterized by medullary stenosis of the long bones, short stature, delayed closure of the fontanel, delayed bone age, and eye abnormalities. Idiopathic hypoparathyroidism and abnormal PTH levels have been found. Autosomal dominant and autosomal recessive modes of inheritance have been reported. Pathogenic variants of the *TBCE* gene (1q43-44) perturb microtubule organization in diseased cells in Kenny-Caffey syndrome type 1.

Visit Elsevier eBooks+ at eBooks.Health.Elsevier.com for Bibliography.

Chapter 612

Pseudohypoparathyroidism

Patrick C. Hanley and Daniel A. Doyle

In pseudohypoparathyroidism (PHP, also known as *Albright hereditary osteodystrophy*), the parathyroid glands are normal or hyperplastic, and they can synthesize and secrete parathyroid hormone (PTH). Serum levels of immunoreactive PTH are elevated even when the patient is hypocalcemic and may be elevated when the patient is normocalcemic. Neither endogenous nor administered PTH raises the serum levels of calcium or lowers the levels of phosphorus. The genetic defects in the **hormone receptor adenylate cyclase system** are classified into various types depending on the phenotypic and biochemical findings (Table 612.1).

TYPE Ia

Type Ia accounts for the majority of patients with PHP. Affected patients have a genetic defect of the α subunit of the stimulatory guanine nucleotide-binding protein ($G_s\alpha$). This coupling factor is required for PTH bound to cell surface receptors to activate cyclic adenosine monophosphate (cAMP). Heterogeneous pathogenic variants of the $G_s\alpha$ gene have been documented; the gene is located on chromosome 20q13.2. Deficiency of the $G_s\alpha$ subunit is a generalized cellular defect and accounts for the association of other endocrine disorders with type Ia PHP. The defect is inherited as an autosomal dominant trait, and the paucity of father-to-son transmissions is thought to be a result of decreased fertility in males.

Tetany is often the presenting sign. Affected children have a short, stocky build and a round face. Brachydactyly with dimpling of the dorsum of the hand is usually present. The second metacarpal is involved least often. As a result, the index finger occasionally is longer than the middle finger. Likewise, the second metatarsal is only rarely affected. There may be other skeletal abnormalities such as short and wide phalanges, bowing, exostoses, and thickening of the calvaria. These patients often have obesity, calcium deposits, and metaplastic bone formation subcutaneously. Moderate degrees of cognitive impairment, calcification of the basal ganglia, and lenticular cataracts are common in patients whose disease is diagnosed late.

Some members of affected kindreds may have the usual anatomic stigmata of PHP type Ia, but serum levels of calcium and phosphorus are normal despite reduced $G_s\alpha$ activity; however, PTH levels may be slightly elevated. Such patients have been labeled as having **pseudopseudohypoparathyroidism (PPHP)**. Affected patients with PPHP have pathologic variants in the *GNAS* gene inherited in an autosomal dominant pattern. PPHP patients have inactivating *GNAS* variants encoding the $G_s\alpha$ subunit that are paternally inherited. The signs and symptoms of PPHP are similar to those of patients with PHP type Ia, except patients with PPHP do not have the characteristic PTH resistance seen in PHP type Ia.

Patients with **PHP type Ic** also have the usual anatomic stigmata of PHP along with the laboratory abnormalities associated with PTH resistance, including elevated phosphorus and PTH in the setting of hypocalcemia. PHP type Ic is differentiated from PHP type Ia and PPHP in that patients do not have abnormal $G_s\alpha$ activity.

Transition from normocalcemia to hypocalcemia often occurs with increasing age of the patient. These phenotypically similar but metabolically dissimilar patients may be in the same family and have the same pathogenic variants of $G_s\alpha$ protein. It is not known what other factors cause clinically overt hypocalcemia in some

Table 612.1 Clinical, Biochemical, and Genetic Features of Hypoparathyroid and Pseudohypoparathyroid Disorders

		PSEUDOHYPOPARATHYROIDISM				
	HYPOPARATHYROIDISM	PHP 1a	PPHP	PHP 1b	PHP 1c	PHP 2
AHO manifestations	No	Yes	Yes	No	Yes	No
Serum calcium	↓	↓	N	↓	↓	↓
Serum PO_4	↑	↑	N	↑	↑	↑
Serum PTH	↓	↑	N	↑	↑	↑
Response to PTH:						
Urinary cAMP* (Chase-Auerbach test)	↑	↓	↑	↓	↓	↑
Urinary PO_4 (Ellsworth-Howard test)	↑	↓	↑	↓	↓	↓
$G_s\alpha$ activity	N	↓	↓	N	N	N
Inheritance	AD, AR, X	AD	AD	AD	AD	Sporadic
Molecular defect	PTH, CaSR, GATA3, Gcm2, others	GNAS1	GNAS1	GNAS1†	?Adenyl cyclase	?cAMP targets
Other hormonal resistance	No	Yes	No	No	Yes	No

*Plasma cyclic adenosine monophosphate (cAMP) responses are similar to those of urinary cAMP.
†Involves deletions that are located upstream of GNAS1.
↓, Decreased; ↑, increased; ?, presumed, but not proved; AD, autosomal dominant; AHO, Albright hereditary osteodystrophy; AR, autosomal recessive; N, normal; PHP, pseudoparathyroidism; PPHP, pseudopseudoparathyroidism; PTH, parathyroid hormone; X, X-linked.
From Thakker RV. The parathyroid glands, hypercalcemia and hypocalcemia. In: Goldman L, Schafer AI, eds. *Goldman-Cecil Medicine*, 25th ed. Philadelphia: Elsevier; 2016: Table 245-8.

affected patients and not in others. There is evidence that the $G_s\alpha$ variant is paternally transmitted in PPHP and maternally transmitted in patients with type Ia disease. The gene may be imprinted in a tissue-specific manner and have different methylation patterns.

In addition to resistance to PTH, resistance to other G protein–coupled receptors for thyroid-stimulating hormone (TSH), gonadotropins, growth hormone–releasing hormone (GHRH), calcitonin, and glucagon can result in various metabolic effects. Clinical hypothyroidism is uncommon, but basal levels of TSH are elevated and thyrotropin-releasing hormone–stimulated TSH responses are exaggerated. Moderately decreased levels of thyroxine and increased levels of TSH have been demonstrated by newborn thyroid-screening programs, leading to the detection of type Ia PHP in infancy. In adults, gonadal dysfunction is common, as manifested by sexual immaturity, amenorrhea, oligomenorrhea, and infertility. Each of these abnormalities can be related to deficient synthesis of cAMP secondary to a deficiency of $G_s\alpha$, but it is not clear why resistance to other G protein–dependent hormones (corticotropin, vasopressin) are much less affected.

Serum levels of calcium are low, and those of phosphorus and alkaline phosphatase are elevated. Clinical diagnosis can be confirmed by demonstration of a markedly attenuated response in urinary phosphate and cAMP after intravenous infusion of the synthetic 1-34 fragment of human PTH (teriparatide acetate). Definitive diagnosis is established by demonstration of the pathogenic variant in the G protein gene.

Type Ia with Precocious Puberty

Two males have been reported with both type Ia PHP and gonadotropin-independent precocious puberty (see Chapter 600.7). They were found to have a temperature-sensitive variant of the G_s protein. Thus at normal body temperature (37°C), the G_s is degraded, resulting in PHP, but in the cooler temperature of the testes (33°C) the G_s variant results in constitutive activation of the luteinizing hormone receptor and precocious puberty.

TYPE Ib

Affected patients have normal levels of G protein activity and a normal phenotypic appearance. These patients have tissue-specific resistance to PTH but not to other hormones. Serum levels of calcium, phosphorus, and immunoreactive PTH are the same as those in patients with type Ia PHP. These patients also show no rise in cAMP in response to exogenous administration of PTH. Bioactive PTH is not increased. The pathophysiology of the disorder in this group of patients is caused by paternal uniparental isodisomy of chromosome 20q and resulting *GNAS1* methylation. This, along with the loss of the maternal *GNAS1* gene, leads to PTH resistance in the proximal renal tubules, which leads to impaired mineral ion homeostasis. Pathologic genetic deletions in the *STX16* gene are also associated with PHP type Ib.

ACRODYSOSTOSIS WITH HORMONE RESISTANCE

Patients with acrodysostosis resemble those with PHP type Ia, but defects in the $G_s\alpha$ subunit are not present. Instead, in one subgroup of patients there is a defect in the gene encoding *PRKAR1A,* the cAMP-dependent regulatory subunit of protein kinase A that confers resistance to multiple hormones, including PTH. Another subgroup has a defect in a phosphodiesterase gene *Pde4d*. This subgroup also carries the phenotype of PHP type Ia but rarely exhibits the hormone resistance. **Acroscyphodysplasia** is a distinctive form of metaphyseal dysplasia characterized by the distal femoral and proximal tibial epiphyses embedded in cup-shaped, large metaphyses known as *metaphyseal scypho* or *cup deformity* and is a phenotypic variation of PHP and acrodysostosis.

Visit Elsevier eBooks+ at eBooks.Health.Elsevier.com for Bibliography.

Chapter 613

Hyperparathyroidism

Evan G. Graber and Daniel A. Doyle

Excessive production of parathyroid hormone (PTH) can result from a primary defect of the parathyroid glands such as an **adenoma** or hyperplasia **(primary hyperparathyroidism)**.

More often, the increased production of PTH is compensatory, usually aimed at correcting hypocalcemic states of diverse origins **(secondary hyperparathyroidism)**. In vitamin D–deficient rickets and the malabsorption syndromes, intestinal absorption of calcium is deficient, but hypocalcemia and tetany may be averted by increased activity of the parathyroid glands. In **pseudohypoparathyroidism**, PTH levels are elevated because a pathogenic variant in the $G_s\alpha$ protein interferes with response to PTH. Early in chronic renal disease, hyperphosphatemia results in a reciprocal fall in the calcium concentration with a consequent increase in PTH, but in advanced stages of renal failure, production of $1,25(OH)_2D_3$ is also decreased, leading to worsening hypocalcemia and further stimulation of PTH. In some instances, if stimulation of the parathyroid glands has been sufficiently intense and protracted, the glands continue to secrete increased levels of PTH for months or years after kidney transplantation, with resulting hypercalcemia.

ETIOLOGY

Childhood hyperparathyroidism is uncommon. Onset during childhood is usually the result of a single benign adenoma. It usually becomes manifested after 10 years of age. There have been some kindreds in which multiple members have hyperparathyroidism transmitted in an autosomal dominant fashion. Most of the affected family members are adults, but children have been involved in approximately 30% of the pedigrees. Some affected patients in these families are asymptomatic, and disease is detected only by careful study. In other kindreds, hyperparathyroidism occurs as part of the constellation known as the **multiple endocrine neoplasia** (MEN) syndromes (see Chapter 609) or of **hyperparathyroidism–jaw tumor syndrome**.

Neonatal severe hyperparathyroidism is rare. Symptoms develop shortly after birth and consist of anorexia, irritability, lethargy, constipation, and failure to thrive. Radiographs reveal subperiosteal bone resorption, osteoporosis, and pathologic fractures. Symptoms may be mild, resolving without treatment, or can have a rapidly fatal course if diagnosis and treatment are delayed. Histologically, the parathyroid glands show diffuse hyperplasia. Affected siblings have been observed in some kindreds, and parental consanguinity has been reported in several kindreds. Most cases have occurred in kindreds with the clinical and biochemical features of **familial hypocalciuric hypercalcemia**. Infants with neonatal severe hyperparathyroidism may be homozygous or heterozygous for the pathogenic variant in the Ca^{2+}-sensing receptor gene, whereas most persons with one copy of this variant exhibit autosomal dominant familial hypocalciuric hypercalcemia.

MEN type 1 (see Chapter 609) is an autosomal dominant disorder characterized by hyperplasia or neoplasia of the endocrine pancreas (which secretes gastrin, insulin, pancreatic polypeptide, and occasionally glucagon), the anterior pituitary (which usually secretes prolactin), and the parathyroid glands. In most kindreds, hyperparathyroidism is usually the presenting manifestation, with a prevalence approaching 100% by 50 years of age and occurring only rarely in children younger than 18 years of age. With genetic testing, it is possible to detect carriers of the gene with 99% accuracy at birth, avoiding unnecessary biochemical screening programs.

The gene for MEN type 1 is on chromosome 11q13; it appears to function as a tumor-suppressor gene and follows the two-hit hypothesis of tumor development. The first variant *(germinal)* is inherited and is recessive to the dominant allele; this does not result in tumor formation. A second variant *(somatic)* is required to eliminate the normal allele, which then leads to tumor formation.

Hyperparathyroidism–jaw tumor syndrome is an autosomal dominant (*CDC73*) disorder characterized by parathyroid adenomas and fibro-osseous jaw tumors. Affected patients can also have polycystic kidney disease, renal hamartomas, and Wilms tumor. Although the condition affects adults primarily, it has been diagnosed as early as age 10 years. **MEN type 2** may also be associated with hyperparathyroidism (see Chapter 609).

Transient neonatal hyperparathyroidism has occurred in a few infants born to mothers with hypoparathyroidism (idiopathic or surgical) or with pseudohypoparathyroidism. In each case, the maternal disorder had been undiagnosed or inadequately treated during pregnancy. The cause of the condition is chronic intrauterine exposure to hypocalcemia with resultant hyperplasia of the fetal parathyroid glands. In the newborn, manifestations involve the bones primarily, and healing occurs between 4 and 7 months of age.

CLINICAL MANIFESTATIONS

At all ages, the clinical manifestations of hypercalcemia of any cause include muscle weakness, fatigue, headache, hyporeflexia, anorexia, abdominal pain, nausea, vomiting, constipation, polydipsia and polyuria **(nephrogenic diabetes insipidus)**, weight loss, and fever. When hypercalcemia is of long duration, calcium may be deposited in the renal parenchyma (nephrocalcinosis), with progressively diminished renal function. Renal calculi can develop and can cause renal colic and hematuria. Osseous changes can produce pain in the back or extremities, disturbances of gait, genu valgum, fractures, and tumors. Height can decrease from compression of vertebrae; the patient can become bedridden. Detection of completely asymptomatic patients is increasing with the advent of automated panel assays that include serum calcium determinations.

Abdominal pain is occasionally prominent and may be associated with **acute pancreatitis**. Parathyroid crisis can occur, manifested by serum calcium levels >15 mg/dL and progressive oliguria, azotemia, stupor, and coma. In infants, failure to thrive, poor feeding, and hypotonia are common. Cognitive impairment, convulsions, and blindness can occur as sequelae of long-standing hypercalcemia. Psychiatric manifestations include depression, confusion, dementia, stupor, and psychosis.

LABORATORY FINDINGS

The serum calcium level is elevated; 39 of 45 children with adenomas had levels >12 mg/dL. The hypercalcemia is more severe in infants with parathyroid hyperplasia; concentrations ranging from 15 to 20 mg/dL are common, and values as high as 30 mg/dL have been reported. Even when the total serum calcium level is borderline or only slightly elevated, ionized calcium levels are often increased. The serum phosphorus level is reduced to approximately 3 mg/dL or less, and the level of serum magnesium is low. The urine can have a low and fixed specific gravity, and serum levels of nonprotein nitrogen and uric acid may be elevated. In patients with adenomas who have skeletal involvement, serum phosphatase levels are elevated, but in infants with hyperplasia, the levels of alkaline phosphatase may be normal even when there is extensive involvement of bone.

The ECG may demonstrate a prolonged PR interval, short QT interval, widened QRS complex and bradycardia.

Serum levels of intact PTH are elevated, especially in relation to the level of calcium. Calcitonin levels are normal. Acute hypercalcemia can stimulate calcitonin release, but with prolonged hypercalcemia, hypercalcitoninemia does not occur.

The most consistent and characteristic radiographic finding is resorption of subperiosteal bone, best seen along the margins of the phalanges of the hands. In the skull, there may be gross trabeculation or a granular appearance resulting from focal rarefaction; the lamina dura may be absent. In more advanced disease, there may be generalized rarefaction, cysts, tumors, fractures, and deformities. Approximately 10% of patients have radiographic signs of rickets. Radiographs of the abdomen can reveal renal calculi or nephrocalcinosis.

DIFFERENTIAL DIAGNOSIS

Other causes of hypercalcemia can result in a similar clinical pattern and must be differentiated from hyperparathyroidism (Table 613.1 and Fig. 613.1). A low serum phosphorus level with hypercalcemia is characteristic of primary hyperparathyroidism; elevated levels of PTH are also diagnostic. With hypercalcemia of any cause except hyperparathyroidism and familial hypocalciuric hypercalcemia, PTH levels are suppressed. Pharmacologic doses of corticosteroids lower the serum calcium level to normal in patients with hypercalcemia from other causes but generally do not affect the calcium level in patients with hyperparathyroidism.

TREATMENT

When hyperparathyroidism is clearly established, imaging and possibly surgical exploration are indicated. All glands should be carefully inspected and if an adenoma is discovered, it should be removed. Very few instances of carcinoma are known in children. Most neonates with severe hypercalcemia require total parathyroidectomy; less severe hypercalcemia remits spontaneously in others. Still others have been treated successfully with bisphosphonates and calcimimetics. The patient should be carefully observed postoperatively for the development of hypocalcemia and tetany; intravenous administration of calcium gluconate may be required for a few days. The serum calcium level then gradually returns to normal, and, under ordinary circumstances, a diet high in calcium and phosphorus must be maintained for only several months after operation.

CT, real-time ultrasonography, and subtraction scintigraphy using sestamibi/technetium-pertechnetate alone and in combination have proved effective in localizing a single adenoma versus diffuse hyperplasia in 50–90% of adults. Parathyroid surgeons often rely on intraoperative selective venous sampling with intraoperative assay of PTH for localizing and removing the source of increased PTH secretion.

PROGNOSIS

The prognosis is good if the disease is recognized early and there is appropriate surgical treatment. When extensive osseous lesions are present, deformities may be permanent. A search for other affected family members is indicated.

613.1 Other Causes of Hypercalcemia

Evan G. Graber and Daniel A. Doyle

FAMILIAL HYPOCALCIURIC HYPERCALCEMIA (FAMILIAL BENIGN HYPERCALCEMIA)

Patients with familial hypocalciuric hypercalcemia are usually asymptomatic, and the hypercalcemia is identified by chance during routine investigation for other conditions. Adults may have recurrent pancreatitis, chondrocalcinosis, or premature vascular calcification. The parathyroid glands are normal, PTH levels are inappropriately normal, and subtotal parathyroidectomy does not correct the hypercalcemia. Serum levels of magnesium are high-normal or mildly elevated. The ratio of calcium-to-creatinine clearance is usually decreased despite hypercalcemia.

The disorder is inherited in an autosomal dominant manner and is caused by a pathogenic variant *(CASR)* on chromosome 3q2 in ~65% of patients **(type 1)**. In **type 2**, there is a pathogenic variant in *GNA11,* and in **type 3**, the variant is on *AP2S1*. The disorder can be diagnosed early in childhood by serum and urinary calcium concentrations. Detection of other affected family members is important to avoid inappropriate parathyroid surgery. The defect in type 1 is an inactivating mutation in the Ca^{2+}-sensing receptor gene. This G-protein–coupled receptor senses the level of free Ca^{2+} in the blood and triggers the pathway to increase extracellular Ca^{2+} in the face of hypocalcemia. This receptor functions in the parathyroid and kidney to regulate calcium homeostasis; inactivating mutations lead to an increased set point with respect to serum Ca^{2+}, resulting in mild to moderate hypercalcemia in heterozygotes.

GRANULOMATOUS DISEASES

Hypercalcemia occurs in 30–50% of children with sarcoidosis and less often in patients with other granulomatous diseases such as tuberculosis. Levels of PTH are suppressed, and levels of $1,25(OH)_2D_3$ are elevated. The source of ectopic $1,25(OH)_2D_3$ is the activated macrophage, through stimulation by interferon-α from T lymphocytes, which are present in abundance in granulomatous lesions. Unlike renal tubular cells, the 1α-hydroxylase in macrophages is unresponsive to homeostatic regulation. Oral administration of prednisone lowers serum levels of $1,25(OH)_2D_3$ to normal and corrects the hypercalcemia.

Table 613.1 Causes of Hypercalcemia

I. NEONATE/INFANT
A. Maternal Disorders
1. Excessive vitamin D ingestion, hypoparathyroidism, pseudohypoparathyroidism
B. Neonate/Infant
1. Iatrogenic: excessive intake of calcium, vitamin D, vitamin A
2. Phosphate depletion
3. Subcutaneous fat necrosis
4. Williams syndrome (del7q11.23/WBSCR1)
5. Neonatal severe hyperparathyroidism *(CaSR)*
6. Metaphyseal chondrodysplasia, Murk-Jansen type *(PTH1R)*
7. Idiopathic infantile hypercalcemia *(CYP24A1)* (25-hydroxyvitamin D 24-hydroxylase)
8. Persistent parathyroid hormone–related protein
9. Lactase/disaccharidase deficiency *(LCT)*
10. Infantile hypophosphatasia *(TNSALP)*
11. Mucolipidosis type II *(GNPTAB)*
12. Blue diaper syndrome
13. Antenatal Bartter syndrome types 1 and 2 *(SLC12A1, KCNJ1)*
14. Distal renal tubular acidosis
15. IMAGe syndrome *(CDKN1C)*
16. Post bone marrow transplantation for osteopetrosis
17. Endocrinopathies: primary adrenal insufficiency, severe congenital hypothyroidism, hyperthyroidism

II. HYPERPARATHYROIDISM
A. Sporadic
1. Parathyroid hyperplasia, adenoma, carcinoma
B. Familial
1. Neonatal severe hyperparathyroidism *(CaSR)*
2. Multiple endocrine neoplasia, type 1 *(MEN1)*
3. Multiple endocrine neoplasia, type 2A *(RET)*
4. Multiple endocrine neoplasia, type 2B *(RET)*
5. Multiple endocrine neoplasia, type 4 *(CDKN1B)*
6. McCune-Albright syndrome *(GNAS)*
7. Familial isolated hyperparathyroidism 1 *(CDC73)*
8. Familial isolated hyperparathyroidism 2 (jaw tumor syndrome) *(CDC73)*
9. Familial isolated hyperparathyroidism 3
10. Jansen metaphyseal dysplasia *(PTH1R)*
C. Secondary/tertiary
1. Postrenal transplantation
2. Chronic hyperphosphatemia
D. Hypercalcemia of malignancy
1. Ectopic production of parathyroid hormone–related peptide
2. Metastatic dissolution of bone

III. FAMILIAL HYPOCALCIURIC HYPERCALCEMIA
A. Familial hypocalciuric hypercalcemia I (CaSR)
1. Loss-of-function mutations in *CaSR*
• Monoallelic: familial benign hypercalcemia
• Biallelic: neonatal severe hyperparathyroidism
B. Familial hypocalciuric hypercalcemia II (GNA11)
C. Familial hypocalciuric hypercalcemia III, Oklahoma variant (AP2S1)
D. CaSR-blocking autoantibodies

IV. EXCESSIVE CALCIUM OR VITAMIN D
A. Milk-alkali syndrome
B. Exogenous ingestion of calcium or vitamin D or topical application of vitamin D (calcitriol or analog)
C. Ectopic production of calcitriol associated with granulomatous diseases (sarcoidosis, cat scratch fever; tuberculosis, histoplasmosis, coccidioidomycosis, cryptococcosis, leprosy; human immunodeficiency virus; cytomegalovirus; chronic inflammatory bowel disease, Blau syndrome, granulomatosis with polyangiitis)
D. Neoplasia
1. Primary bone tumors
2. Metastatic tumors with osteolysis
3. Lymphoma, leukemia
4. Dysgerminoma
5. Pheochromocytoma
6. Langerhans cell histiocytosis
7. Tumors secreting parathyroid hormone–related peptide, growth factors, cytokines, prostaglandins, and osteoclast-activating factors
E. Williams-Beuren syndrome (del7q11.23)

V. IMMOBILIZATION
VI. OTHER CAUSES
A. Drugs: thiazides, lithium, vitamin A and analogs, calcium, alkali, antiestrogens, aminophylline, teriparatide, abaloparatide
B. Total parenteral nutrition
C. Endocrinopathies: hyperthyroidism, congenital hypothyroidism, Addison disease, pheochromocytoma
D. Vasoactive intestinal polypeptide–secreting tumor
E. Acute or chronic renal failure/administration of aluminum
F. Hypophosphatasia
G. Juvenile idiopathic arthritis: cytokine mediated
H. Late phase of rhabdomyolysis

IMAGe, intrauterine growth restriction, metaphyseal dysplasia, adrenal hypoplasia congenita, genital abnormalities; WBSCR1, Williams-Beuren syndrome chromosome region 1.
Adapted from Lietman SA, Germain-Lee EL, Levine MA. Hypercalcemia in children and adolescents. *Curr Opin Pediatr.* 2010;22:508–515; Benjamin RW, Moats-Staats BM, Calikoglu A, et al. Hypercalcemia in children. *Pediatr Endocrinol Rev.* 2008;5:778–784; Davies JH. A practical approach to the problems of hypercalcaemia. *Endocr Dev.* 2009;16:93–114.

HYPERCALCEMIA OF MALIGNANCY

Hypercalcemia often occurs in adults with a wide variety of solid tumors but is identified much less often in children. It has been reported in infants with malignant rhabdoid tumors of the kidney or congenital mesoblastic nephroma and in children with neuroblastoma, medulloblastoma, leukemia, Burkitt lymphoma, dysgerminoma, and rhabdomyosarcoma. Serum levels of PTH are rarely elevated. In most patients, the hypercalcemia associated with malignancy is caused by elevated levels of parathyroid hormone–related peptide and not PTH. Rarely, tumors produce $1,25(OH)_2D_3$ or PTH ectopically.

MISCELLANEOUS CAUSES OF HYPERCALCEMIA

Hypercalcemia can occur in infants with **subcutaneous fat necrosis**. Levels of PTH are normal. In one infant, the level of $1,25(OH)_2D_3$ was elevated, and biopsy of the skin lesion revealed granulomatous infiltration, suggesting that the mechanism of the hypercalcemia was akin to that seen in patients with other granulomatous disease. In another infant, although the level of $1,25(OH)_2D_3$ was normal, PTH was suppressed, suggesting the hypercalcemia was not related to PTH. Treatment with prednisone is effective. Bisphosphonate therapy has also been effective in severe cases.

Hypophosphatasia, especially the severe infantile form, is usually associated with mild to moderate hypercalcemia (see Chapter 747). Serum levels of phosphorus are normal, and those of alkaline phosphatase are subnormal. The bones exhibit rachitic-like lesions on radiographs. Urinary levels of phosphoethanolamine, inorganic pyrophosphate, and pyridoxal 5′-phosphate are elevated; each is a natural substrate to a tissue-nonspecific (liver, bone, kidney) alkaline phosphatase enzyme. Missense variants of the tissue-nonspecific alkaline phosphatase enzyme gene result in an inactive enzyme in this autosomal recessive disorder.

Idiopathic hypercalcemia of infancy is manifested by failure to thrive and hypercalcemia during the first year of life, followed by spontaneous remission. Serum levels of phosphorus and PTH are normal. The condition has been defined as resulting from increased absorption of calcium from decreased degradation of $1,25(OH)_2D_3$. Pathogenic variants in the *CYP24A1* gene that encodes 25-hydroxyvitamin D 24-hydroxylase, the key enzyme in $1,25(OH)_2D_3$ degradation, cause excessive levels of the active vitamin D metabolite, which, in turn, causes hypercalcemia in a subset of infants who receive supplemental vitamin D. An excessive rise in the level of $1,25(OH)_2D_3$ in response to PTH administration has been reported years after the hypercalcemic phase.

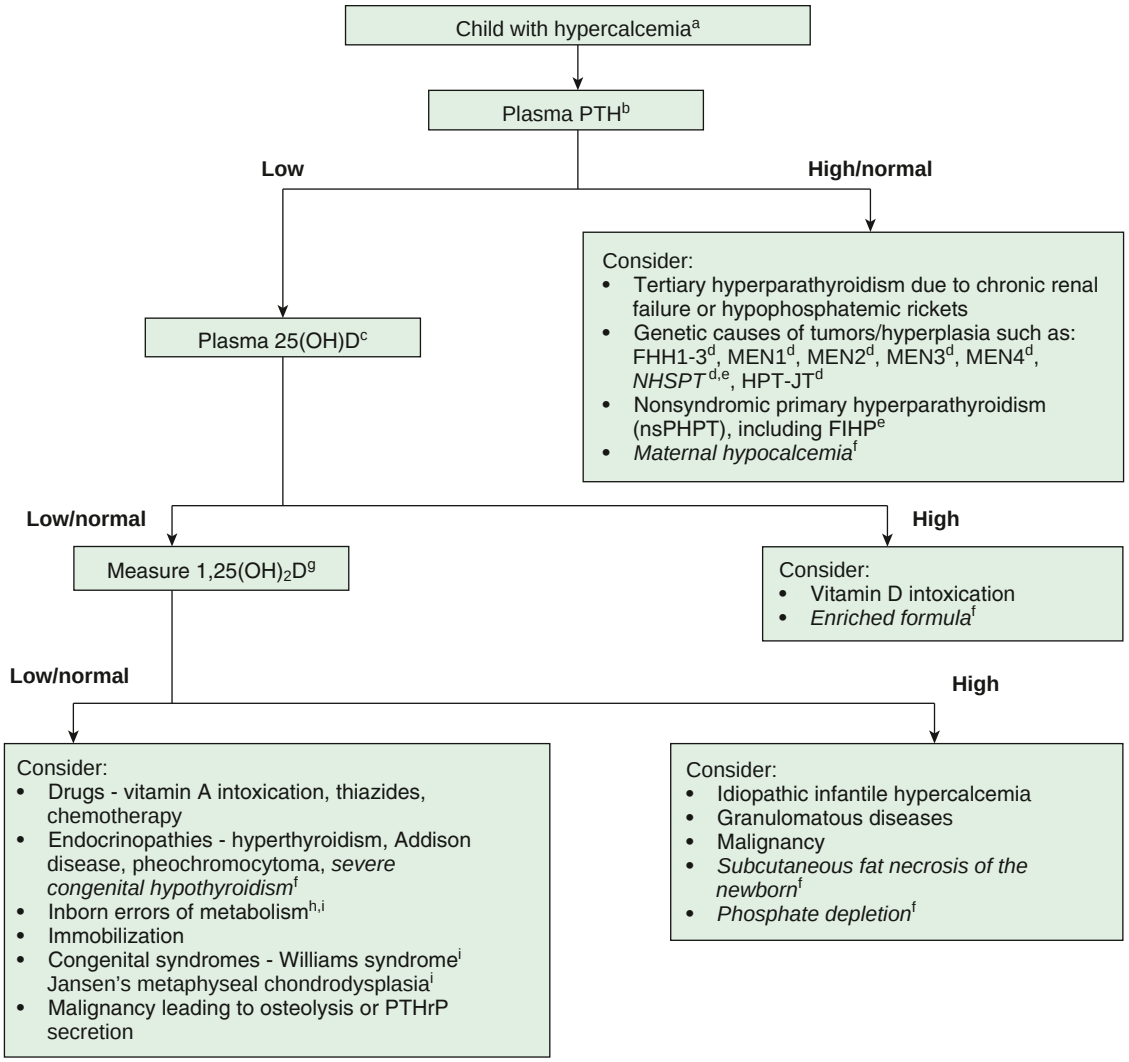

Fig. 613.1 Algorithm illustrating the clinical approach to investigation of causes of hypercalcemia in a child. [a]Confirm hypercalcemia, defined as plasma (or serum) adjusted calcium >10.5 mg/dL (2.60 mmol/L) or ionized calcium >5.25 mg/dL (1.32 mmol/L). [b]PTH, parathyroid hormone. [c]25(OH)D, 25-hydroxyvitamin D. [d]FHH1-3, familial hypocalciuric hypercalcemia types 1-3; MEN1, multiple endocrine neoplasia type 1; MEN2, multiple endocrine neoplasia type 2; MEN3, multiple endocrine neoplasia type 3; MEN4, multiple endocrine neoplasia type 4; NSHPT, neonatal severe primary hyperparathyroidism; HPT-JT, hyperparathyroid–jaw tumor syndrome. [e]FIHP, Familial isolated hyperparathyroidism. [f]Conditions affecting neonates (shown in italics). [g]$1,25(OH)_2D$, 1,25-dihydroxyvitamin D. [h]Inborn errors of metabolism, for example, hypophosphatasia, congenital lactase deficiency (CLD), and blue diaper syndrome. [i]These syndromes may be associated with dysmorphic features, for example, Williams syndrome, Jansen metaphyseal chondrodysplasia, and hypophosphatasia. PTHrP, parathyroid hormone-related peptide. *(From Stokes VJ, Nielsen MF, Hannan FM, Thaller RV. Hypercalcemic disorders in children. J Bone Miner Res. 2017;32:2157–2170, Fig. 2.)*

Approximately 15% of patients with **Williams syndrome** may exhibit hypercalcemia. Hypercalcemia is more common in patients <24 months of age. It is often transient and usually does not require treatment. The phenotype consists of feeding difficulties, slow growth, elfin facies (small mandible, prominent maxilla, upturned nose), renovascular disorders, and a gregarious "cocktail party" personality. Cardiac lesions include supravalvular aortic stenosis, peripheral pulmonic stenosis, aortic hypoplasia, coronary artery stenosis, and atrial or ventricular septal defects. **Nephrocalcinosis** can develop if hypercalcemia persists. The IQ score of 50-70 is curiously accompanied by enhanced quantity and quality of vocabulary, auditory memory, and social use of language. A contiguous gene deletion syndrome with a submicroscopic deletion at chromosome 7q11.23, which includes deletion of one elastin allele, occurs in 90% of patients and seems to account for the vascular problems. Definitive diagnosis can be established by specific fluorescence in situ hybridization. The hypercalcemia and central nervous system symptoms may be caused by deletion of adjacent genes. Hypercalcemia has been successfully controlled with either prednisone or calcitonin.

Hypervitaminosis D resulting in hypercalcemia from drinking milk that has been incorrectly fortified with excessive amounts of vitamin D has been reported. Not all patients with hypervitaminosis D develop hypercalcemia. Affected infants can manifest failure to thrive, nephrolithiasis, poor renal function, and osteosclerosis. Serum levels of 25(OH)D are a better indicator of hypervitaminosis D than levels of $1,25(OH)_2D_3$ because 25(OH)D has a longer half-life.

Prolonged immobilization can lead to hypercalcemia and occasionally to decreased renal function, hypertension, and encephalopathy. Children who have hypophosphatemic rickets and undergo surgery with subsequent long-term immobilization are at risk for hypercalcemia and should therefore have their vitamin D supplementation decreased or discontinued.

Jansen-type metaphyseal chondrodysplasia is a rare genetic disorder characterized by short-limbed dwarfism and severe but asymptomatic hypercalcemia (see Chapter 735). Circulating levels of PTH and parathyroid hormone–related peptide are undetectable. These patients have an activating PTH–parathyroid hormone–related peptide receptor mutation that results in aberrant calcium homeostasis and abnormalities of the growth plate.

Visit Elsevier eBooks+ at eBooks.Health.Elsevier.com for Bibliography.

Section 4

Disorders of the Adrenal Gland

Chapter 614

Physiology of the Adrenal Gland

614.1 Histology and Embryology

Perrin C. White

The adrenal gland is composed of two endocrine tissues: the medulla and the cortex. The chromaffin cells of the adrenal medulla are derived from neuroectoderm, whereas the cells of the adrenal cortex are derived from mesoderm. Mesodermal cells also contribute to the development of the gonads. The adrenal glands and gonads have certain common enzymes involved in steroid synthesis; an inborn error in steroidogenesis in one tissue can also be present in the other.

The adrenal cortex of the older child or adult consists of three zones: the **zona glomerulosa**, the outermost zone located immediately beneath the capsule; the **zona fasciculata**, the middle zone; and the **zona reticularis**, the innermost zone, lying next to the adrenal medulla. The zona fasciculata is the largest zone, constituting approximately 75% of the cortex; the zona glomerulosa constitutes approximately 15%; and the zona reticularis approximately 10%. Glomerulosa cells are small, with a lower cytoplasmic:nuclear ratio, an intermediate number of lipid inclusions, and smaller nuclei containing more condensed chromatin than the cells of the other two zones. The cells of the zona fasciculata are large, with a high cytoplasmic:nuclear ratio and many lipid inclusions that give the cytoplasm a foamy, vacuolated appearance. The cells are arranged in radial cords. The cells of the zona reticularis are arranged in irregular anastomosing cords. The cytoplasmic:nuclear ratio is intermediate, and the compact cytoplasm has relatively little lipid content.

The zona glomerulosa synthesizes **aldosterone**, the most potent natural **mineralocorticoid** in humans. The zona fasciculata produces **cortisol**, the most potent natural **glucocorticoid** in humans, and the zona fasciculata and zona reticularis synthesize the adrenal androgens.

The adrenal medulla consists mainly of neuroendocrine (chromaffin) cells and glial (sustentacular) cells with some connective tissue and vascular cells. Neuroendocrine cells are polyhedral, with abundant cytoplasm and small, pale-staining nuclei. Under the electron microscope, the cytoplasm contains many large secretory granules that contain catecholamines. Glial cells have less cytoplasm and more basophilic nuclei.

The adrenogonadal primordium differentiates from the coelomic mesothelium at 4 weeks of gestation at the urogenital ridge, just cephalad to the developing mesonephros. At 5-6 weeks, it develops into the steroidogenic cells of the gonads and adrenal cortex; the adrenal and gonadal cells separate, the adrenal cells migrate retroperitoneally, and the gonadal cells migrate caudad. At 6-8 weeks of gestation, the gland rapidly enlarges, the cells of the inner cortex differentiate to form the fetal zone, and the outer subcapsular rim remains as the definitive zone. The primordium of the adrenal cortex is invaded at this time by sympathetic neural elements of ectodermal origin that differentiate into the chromaffin cells capable of synthesizing and storing catecholamines. Catechol *O*-methyltransferase, which converts norepinephrine to epinephrine, is expressed later in gestation. By the end of the eighth week of gestation, the encapsulated adrenal gland is associated with the upper pole of the kidney. By 8-10 weeks of gestation, the cells of the fetal zone are capable of active steroidogenesis.

In the full-term infant, the combined weight of both adrenal glands is 7-9 g. At birth, the inner fetal zone of the cortex makes up approximately 80% of the gland and the outer definitive zone 20%. Within a few days the fetal cortex begins to involute, undergoing a 50% reduction by 1 month of age. Conversely, the adrenal medulla is relatively small at birth and undergoes a proportionate increase in size over the first 6 months after birth. By 1 year, the adrenal glands each weigh <1 g. Adrenal growth thereafter results in adult adrenal glands reaching a combined weight of 8 g. The zonae fasciculata and glomerulosa are fully differentiated by about 3 years of age. The zona reticularis is not fully developed until puberty.

Adrenocorticotropic hormone (ACTH) is essential for fetal adrenal growth and maturation; feedback regulation of ACTH by cortisol is apparently established by 8-10 weeks of gestation. Additional factors important in fetal growth and steroidogenesis include placental chorionic gonadotropins and a number of peptide growth factors produced by the placenta and fetus.

Many transcription factors are critical for the development of the adrenal glands. At least four, EMX2, LHX1 (also termed LIM1), WT1, and WNT4, are required for development of the adrenogonadal primordium. WT1 upregulates expression of steroidogenic factor-1 (SF-1, encoded by the *NR5A1* gene). NR5A1 is one of at least three transcription factors associated with **adrenal hypoplasia** in humans; the others are *NR0B1* (dosage-sensitive sex reversal, adrenal hypoplasia congenita, X chromosome; *DAX1*), and the *GLI3* oncogene. Disruption of *NR5A1,* encoded on chromosome 9q33, results in gonadal and often adrenal agenesis, absence of pituitary gonadotropes, and an underdeveloped ventral medial hypothalamus. In-frame deletions and frameshift and missense pathogenic variants of this gene are associated with **46,XX ovarian insufficiency** and **46,XY gonadal dysgenesis**. Pathogenic variants in the *NR0B1* gene, encoded on Xp21, result in **adrenal hypoplasia congenita** and **hypogonadotropic hypogonadism** (see Chapter 615.1). Pathogenic variants in *GLI3* on chromosome 7p13 cause **Pallister-Hall syndrome**, other features of which include hypothalamic hamartoblastoma, hypopituitarism, imperforate anus, and postaxial polydactyly.

The postnatal adrenal cortex is not static but is continually regenerated from a population of stem or progenitor cells under the adrenal capsule. These cells move radially inward (i.e., centripetally) and can differentiate into zona glomerulosa or fasciculata cells as needed in response to the appropriate trophic stimuli (see Chapter 614.3). Several signaling pathways, including sonic hedgehog (SHH) and WNT, regulate this process. SHH expression is restricted to the peripheral cortical cells that do not express high levels of steroidogenic genes but give rise to the underlying differentiated cells of the cortex. Wnt/β-catenin signaling maintains the undifferentiated state and adrenal fate of adrenocortical stem/progenitor cells, in part through induction of its target genes *DAX1* and inhibin-α, respectively. Adrenal tumors can result from constitutive activation of the WNT signaling pathway (see Chapter 617).

Visit Elsevier eBooks+ at eBooks.Health.Elsevier.com for Bibliography.

614.2 Adrenal Steroid Biosynthesis

Perrin C. White

Cholesterol is the starting substrate for all steroid biosynthesis (Fig. 614.1). Although adrenal cortex cells can synthesize cholesterol de novo from acetate, circulating plasma lipoproteins provide most of the cholesterol for adrenal cortex hormone formation. Receptors for both low-density lipoprotein and high-density lipoprotein cholesterol are expressed on the surface of adrenocortical cells; the receptor for high-density lipoprotein is termed *scavenger receptor class B, type I* (SR-BI). Patients with **homozygous familial hypercholesterolemia**

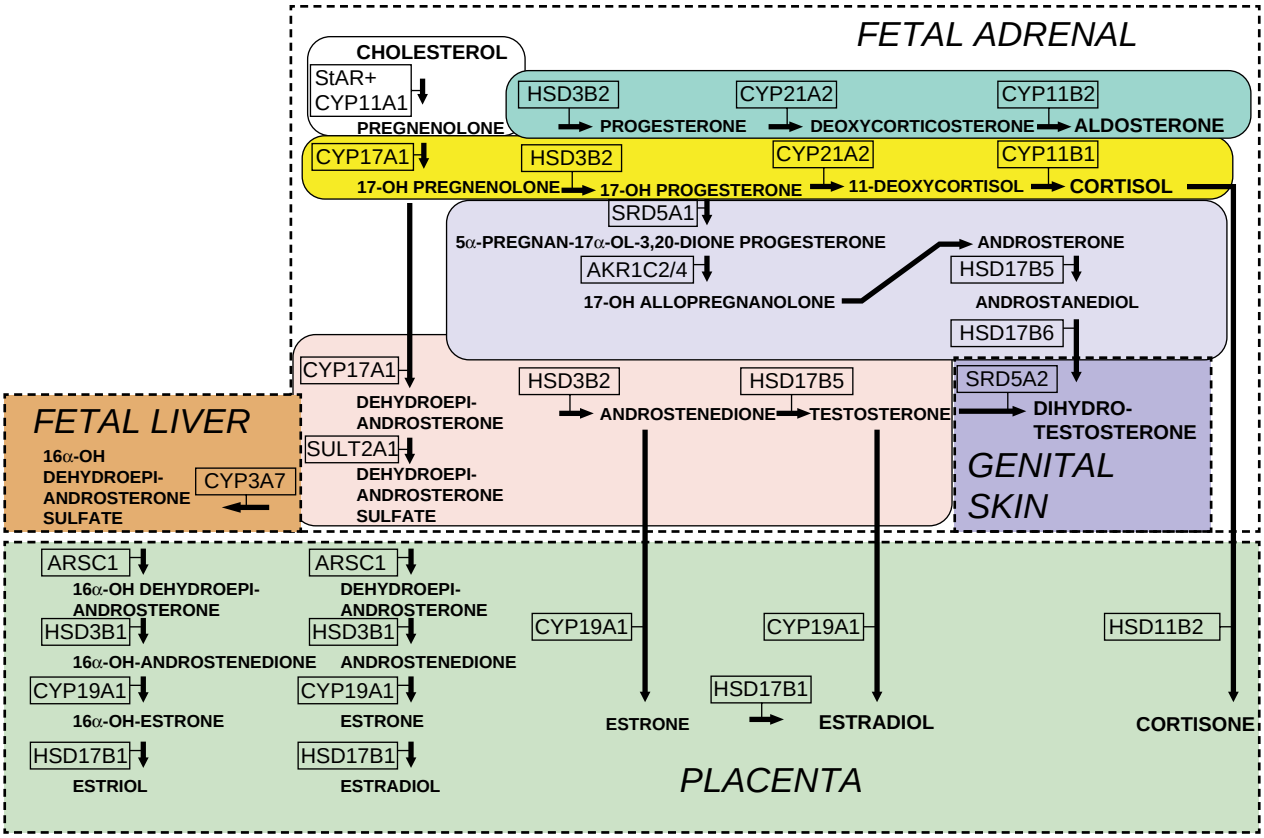

Fig. 614.1 Steroid biosynthesis and metabolism during gestation. Conversions within the fetal adrenal cortex, fetal liver *(brown rectangle)*, male (i.e., testosterone-exposed) genital skin *(purple rectangle)*, and placenta *(green rectangle)* are denoted by *arrows;* the enzyme mediating each conversion is also shown. Enzymatic conversions in the adrenal cortex are the same postnatally as prenatally, but cortisol and aldosterone biosynthesis (denoted by *yellow and turquoise boxes*, respectively) are more prominent, and normally little testosterone is synthesized *(pink rectangle)*. A "backdoor pathway" *(lavender rectangle)* to convert 17-hydroxyprogesterone to dihydrotestosterone is active in the fetal adrenal and may assume particular importance in congenital adrenal hyperplasia (see Chapter 616). Many of the involved enzymes are cytochromes P450 (CYPs). The first step in all steroid biosynthesis is importation of cholesterol into mitochondria *(white rectangle)* mediated by the steroidogenic acute regulatory (StAR) protein. Adrenal enzymes include CYP11A1, cholesterol side-chain cleavage enzyme (P450scc in older terminology); HSD3B2, 3β-hydroxysteroid dehydrogenase/Δ5,Δ4 isomerase type 2; CYP17A1, 17β-hydroxylase/17,20-lyase (P450c17); CYP21A2, 21-hydroxylase (P450c21); CYP11B1, 11β-hydroxylase (P450c11); CYP11B2, aldosterone synthase (P450aldo; this enzyme mediates successive 11β-hydroxylase, 18-hydroxylase, and 18-oxidase reactions in the zona glomerulosa for the conversion of deoxycorticosterone to aldosterone); and AKR1C2/4, aldo-ketoreductases 1C2 and 1C4. Other enzymes important in the fetoplacental unit include ARSC1, arylsulfatase; CYP19, aromatase (P450arom); HSD3B1, 3β-hydroxysteroid dehydrogenase/Δ5,Δ4 isomerase type 1; HSD11B2, 11β-hydroxysteroid dehydrogenase type 2; HSD17B1, HSD17B5, and HSD17B6 are three different 17-hydroxysteroid dehydrogenase enzymes; SRD5A1 and SRD5A2, steroid 5α-reductase types 1 and 2, respectively; and SULT2A1, steroid sulfotransferase.

who lack low-density lipoprotein receptors have only mildly impaired adrenal steroidogenesis, suggesting that high-density lipoprotein is the more important source of cholesterol. Cholesterol is stored as cholesteryl esters in vesicles and subsequently hydrolyzed by cholesteryl ester hydrolases to liberate free cholesterol for steroid hormone synthesis.

The rate-limiting step of adrenal steroidogenesis is importation of cholesterol across the mitochondrial outer and inner membrane. This requires several proteins, particularly the steroidogenic acute regulatory (StAR) protein. The StAR protein has a very short half-life, and its synthesis is rapidly induced by trophic factors (corticotropin); it is the main short-term (minutes to hours) regulator of steroid hormone biosynthesis.

At the mitochondrial inner membrane, the side chain of cholesterol is cleaved to yield pregnenolone. This is catalyzed by the cholesterol side-chain cleavage enzyme (cholesterol desmolase, side-chain cleavage enzyme, P450scc, CYP11A1—the last term is the current systematic nomenclature), a cytochrome P450 (CYP) enzyme. Like other CYP enzymes, this is a membrane-bound hemoprotein with a molecular mass of approximately 50 kDa. It accepts electrons from a reduced nicotinamide adenine dinucleotide phosphate–dependent mitochondrial electron transport system consisting of two accessory proteins: adrenodoxin reductase (also called *ferredoxin reductase*, a flavoprotein) and adrenodoxin (or ferredoxin; a small protein containing nonheme iron). CYP enzymes use electrons and O_2 to hydroxylate the substrate and form H_2O. In the case of cholesterol side-chain cleavage, three successive oxidative reactions are performed to cleave the C20,22 carbon bond. Pregnenolone then diffuses out of mitochondria and enters the endoplasmic reticulum. The subsequent reactions that occur depend on the zone of the adrenal cortex.

ZONA GLOMERULOSA

In the zona glomerulosa, pregnenolone is converted to progesterone by 3β-hydroxysteroid dehydrogenase type 2, an oxidized nicotinamide adenine dinucleotide–dependent enzyme of the short-chain dehydrogenase type. Progesterone is converted to 11-deoxycorticosterone by steroid 21-hydroxylase (CYP21A2, P450c21), which is another CYP enzyme. Like other such enzymes in the endoplasmic reticulum, it uses an electron transport system with only one accessory protein: P450 oxidoreductase.

Deoxycorticosterone then reenters mitochondria and is converted to aldosterone by aldosterone synthase (CYP11B2, P450aldo), a CYP enzyme structurally related to cholesterol side-chain cleavage enzyme. Aldosterone synthase also carries out three successive oxidations: 11β-hydroxylation, 18-hydroxylation, and further oxidation of the 18-methyl carbon to an aldehyde.

ZONA FASCICULATA

In the endoplasmic reticulum of the zona fasciculata, pregnenolone and progesterone are converted by 17α-hydroxylase (CYP17A1, P450c17) to 17-hydroxypregenolone and 17-hydroxyprogesterone, respectively. This enzyme is not expressed in the zona glomerulosa, which consequently cannot synthesize 17-hydroxylated steroids. 17-Hydroxypregnenolone is converted to 17-hydroxyprogesterone and 11-deoxycortisol by the same 3β-hydroxysteroid and 21-hydroxylase enzymes, respectively, as are active in the zona glomerulosa. Thus inherited disorders in these enzymes affect both aldosterone and cortisol synthesis (see Chapter 616). Finally, 11-deoxycortisol reenters mitochondria and is converted to cortisol by steroid 11β-hydroxylase CYP11B1 (P450c11). This enzyme is closely related to aldosterone synthase but has low 18-hydroxylase and nonexistent 18-oxidase activity. Thus under normal circumstances the zona fasciculata cannot synthesize aldosterone.

ZONA RETICULARIS

In the zona reticularis and to some extent in the zona fasciculata, the 17-hydroxylase (CYP17A1) enzyme has an additional activity: cleavage of the 17,20 carbon-carbon bond. This converts 17-hydroxypregnenolone to dehydroepiandrosterone (DHEA). DHEA is converted to androstenedione by HSD3B2. This may be further converted in other tissues to testosterone and estrogens.

The Alternative or "Backdoor" Pathway to Dihydrotestosterone

In addition to the classic pathway via DHEA, androstenedione, and testosterone, the most potent endogenous androgen, 5-dihydrotestosterone (DHT), can also be synthesized via an alternative or "backdoor" pathway, which is physiologically active during the major period of human sexual differentiation in the 6th to 10th week of human fetal development and into the second trimester. To enter the alternative pathway, progesterone or 17-hydroxyprogesterone is 5α-reduced by steroid 5α-reductase type 1 (SRD5A1) to yield 5α-dihydroprogesterone and 17α-hydroxydihydroprogesterone. These three ketosteroids are subsequently 3α-reduced to allopregnanolone and 17α-hydroxyallopregnanolone by isoforms of the AKR1C enzyme family. CYP17A1 converts allopregnanolone to 17α-hydroxyallopregnanolone and then to androsterone by its 17,20-lyase activity. Androsterone can then be activated to DHT by sequential 17β-reduction and 3α-oxidase reactions.

FETOPLACENTAL UNIT

Steroid synthesis in the fetal adrenal varies during gestation (see Figs. 614.1 and 614.2). Shortly after the fetal adrenal gland forms (weeks 8-10), it efficiently secretes cortisol, which is able to negatively feed back on the fetal pituitary and hypothalamus to suppress ACTH secretion. This is a critical time for differentiation of the external genitalia in both sexes (see Chapter 616.1); to prevent virilization, the female fetus must not be exposed to high levels of androgens of adrenal origin, and placental aromatase activity must remain low during this time to minimize conversion of testosterone to estradiol in male fetuses, which would interfere with masculinization. After week 12, HSD3B activity in the fetal adrenal gland decreases and steroid sulfokinase activity increases. Major steroid products of the midgestation fetal adrenal gland are DHEA and DHEA sulfate (DHEAS) and, by 16α-hydroxylation in the liver, 16α-hydroxy DHEAS. Aromatase activity increases in the placenta at the same time, and steroid sulfatase activity is high as well. The placenta uses DHEA and DHEAS as substrates for estrone and estradiol synthesis and 16α-OH DHEAS as a substrate for estriol synthesis. Cortisol activity is low during the second trimester, which might serve to prevent premature secretion of surfactant by the developing fetal lungs; surfactant levels can affect the timing of parturition. As term approaches, fetal cortisol concentration increases because of increased cortisol secretion and decreased conversion of cortisol to cortisone by 11β-hydroxysteroid dehydrogenase type 2 (HSD11B2). Low levels of aldosterone are produced in midgestation, but aldosterone secretory capacity increases near term.

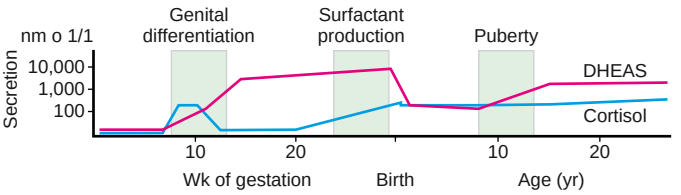

Fig. 614.2 Relative levels of cortisol and dehydroepiandrosterone sulfate (DHEAS) secretion by the fetal adrenal cortex during gestation and postnatally. Approximate times of several events are shown. Vertical axis is logarithmic, but values are approximate. Horizontal axis is not to scale.

Visit Elsevier eBooks+ at eBooks.Health.Elsevier.com for Bibliography.

614.3 Regulation of the Adrenal Cortex

Perrin C. White

REGULATION OF CORTISOL SECRETION

Glucocorticoid secretion is regulated mainly by ACTH (corticotropin), a 39–amino acid peptide that is produced in the anterior pituitary (see Fig. 594.2). It is synthesized as part of a larger-molecular-weight precursor peptide known as *pro-opiomelanocortin*. This precursor peptide is also the source of β-lipotropin. ACTH and β-lipotropin are cleaved further to yield α- and β-melanocyte–stimulating hormone, corticotropin-like intermediate lobe peptide, γ-lipotropin, β- and γ-endorphin, and enkephalin (see Chapter 594).

ACTH is released in secretory bursts of varying amplitude throughout the day and night. The normal diurnal rhythm of cortisol secretion is caused by the varying amplitudes of ACTH pulses. Pulses of ACTH and cortisol occur every 30-120 minutes, are highest at about the time of waking, are low in late afternoon and evening, and reach their lowest point 1 or 2 hours after sleep begins.

Corticotropin-releasing hormone (CRH), synthesized by neurons of the parvicellular division of the hypothalamic paraventricular nucleus, is the most important stimulator of ACTH secretion. Arginine vasopressin (AVP) augments CRH action. Neural stimuli from the brain cause the release of CRH and AVP (see Chapter 594). AVP and CRH are secreted in the hypophyseal-portal circulation in a pulsatile manner. This pulsatile secretion appears to be responsible for the pulsatile (ultradian) release of ACTH. The circadian rhythm of ACTH release is probably induced by the corresponding circadian rhythm of hypothalamic CRH secretion, regulated by the suprachiasmatic nucleus with input from other areas of the brain. Cortisol exerts a negative feedback effect on the synthesis and secretion of ACTH, CRH, and AVP. ACTH inhibits its own secretion, a feedback effect mediated at the level of the hypothalamus. Finally, the adrenal cortex has intrinsic rhythmicity in its responses to the ACTH. Thus the secretion of cortisol is a result of the interaction of the hypothalamus, pituitary, and adrenal glands and other neural stimuli.

ACTH acts through a specific G protein–coupled receptor (also termed *melanocortin receptor-2,* encoded by the *MCR2* gene) to activate adenylate cyclase and increase levels of cyclic adenosine monophosphate. Cyclic adenosine monophosphate has short-term (minutes to hours) effects on cholesterol transport into mitochondria by increasing expression of StAR protein. The long-term effects (hours to days) of ACTH stimulation are to increase the uptake of cholesterol and the expression of genes encoding the enzymes required to synthesize cortisol. These transcriptional effects occur at least in part through increased activity of protein kinase A, which phosphorylates several transcriptional regulatory factors. MC2R trafficking and signaling are dependent on the MC2R accessory protein (MRAP). Pathogenic variants in either MC2R or MRAP can cause **familial glucocorticoid deficiency** (see Chapter 615).

REGULATION OF ALDOSTERONE SECRETION

The rate of aldosterone synthesis, which is normally 100- to 1,000-fold less than that of cortisol synthesis, is regulated mainly by the renin-angiotensin system and by potassium levels, with ACTH having only a short-term effect. In response to decreased intravascular volume, renin is secreted by the juxtaglomerular apparatus of the kidney. Renin is a proteolytic enzyme that cleaves angiotensinogen (renin substrate), an α_2-globulin produced by the liver, to yield the inactive decapeptide angiotensin I. Angiotensin-converting enzyme in the lungs and other tissues rapidly cleaves angiotensin I to the biologically active octapeptide angiotensin II. Cleavage of angiotensin II produces the heptapeptide angiotensin III. Angiotensins II and III are potent stimulators of aldosterone secretion; angiotensin II is a more potent vasopressor agent. Angiotensins II and III occupy a G protein–coupled receptor activating phospholipase C. This protein hydrolyzes phosphatidylinositol bisphosphate to produce inositol triphosphate and diacylglycerol, which raise intracellular calcium levels and activate protein kinase C and calmodulin-activated kinases. Similarly, increased levels of extracellular potassium depolarize the cell membrane and increase calcium influx through voltage-gated L-type calcium channels. Phosphorylation of transcriptional regulatory factors by calmodulin-activated kinases increases transcription of the aldosterone synthase (CYP11B2) enzyme required for aldosterone synthesis.

REGULATION OF ADRENAL ANDROGEN SECRETION

The mechanisms by which the adrenal androgens DHEA and androstenedione are regulated are not completely understood. **Adrenarche** is a maturational process in the adrenal gland that results in increased adrenal androgen secretion between the ages of 5 and 20 years. The process begins before the earliest signs of puberty and continues throughout the years when puberty is occurring. Histologically, it is associated with the appearance of the zona reticularis. Whereas ACTH stimulates adrenal androgen production acutely and clearly is the primary stimulus for cortisol release, additional factors have been implicated in the stimulation of the adrenal androgens. These include a relative decrease in expression of HSD3B2 in the zona reticularis and possibly increases in 17,20-lyase activity owing to phosphorylation of CYP17 or increased cytochrome b5 expression.

Visit Elsevier eBooks+ at eBooks.Health.Elsevier.com for Bibliography.

614.4 Adrenal Steroid Hormone Actions

Perrin C. White

Steroid hormones act through several distinct receptors corresponding to the known biologic activities of the steroid hormones: glucocorticoid, mineralocorticoid, progestin, estrogen, and androgen. These receptors belong to a larger superfamily of nuclear transcription factors that include, among others, thyroid hormone and retinoic acid receptors. They have a common structure that includes a carboxyterminal ligand-binding domain and a midregion DNA-binding domain. The latter domain contains two zinc fingers, each of which consists of a loop of amino acids stabilized by four cysteine residues chelating a zinc ion.

Unliganded glucocorticoid and mineralocorticoid receptors are found mainly in the cytosol in complexes with other proteins. Hormone molecules diffuse through the cell membrane and bind receptors, changing their conformation and causing them to release their cytosolic binding proteins and translocate to the nucleus, where they bind DNA at specific hormone-response elements. Bound receptors can recruit other transcriptional coregulatory factors to DNA.

Whereas different steroids can share bioactivities because of their ability to bind to the same receptor, a given steroid can exert diverse biologic effects in different tissues. The diversity of hormonal responses is determined by the different genes that are regulated by each hormone in different tissues. Additionally, different combinations of coregulators are expressed in different tissues, allowing each steroid hormone to have many different effects. Moreover, enzymes can increase or decrease the affinity of steroids for their receptors and thus modulate their activity. 11β-Hydroxysteroid dehydrogenase type 1 (HSD11B1) converts cortisone, which is not a ligand for the glucocorticoid receptor, to cortisol, which is an active glucocorticoid. This increases local glucocorticoid concentrations in several tissues, especially the liver, where glucocorticoids maintain hepatic glucose output (see Chapter 615.4). Overexpression of this enzyme in adipose tissue can predispose to the development of obesity. Conversely, HSD11B2 oxidizes cortisol to cortisone, particularly in the kidney, preventing mineralocorticoid receptors from being occupied by high levels of cortisol (see Chapter 615.4).

Although corticosteroid receptors mainly act in the nucleus, some responses to both glucocorticoids and mineralocorticoids begin within minutes, an interval too short to be accounted for by increased gene transcription and protein synthesis. Such nongenomic effects can in some cases be mediated by cell membrane–associated isoforms of the classic glucocorticoid and mineralocorticoid receptors, which can couple to a variety of rapid intracellular signaling pathways such as G proteins. Direct interactions with other proteins, such as ion channels, have been documented as well, particularly in the nervous system.

ACTIONS OF GLUCOCORTICOIDS

Glucocorticoids are essential for survival. The term *glucocorticoid* refers to the glucose-regulating properties of these hormones. However, glucocorticoids have multiple effects on carbohydrate, lipid, and protein metabolism. They also regulate immune, circulatory, and renal function. They influence growth, development, bone metabolism, and central nervous system activity.

In stress situations, glucocorticoid secretion can increase up to 10-fold. This increase is believed to enhance survival through increased cardiac contractility, cardiac output, sensitivity to the pressor effects of catecholamines and other pressor hormones, work capacity of the skeletal muscles, and capacity to mobilize energy stores.

METABOLIC EFFECTS

The primary action of the glucocorticoids on carbohydrate metabolism is to increase glucose production by increasing hepatic gluconeogenesis. Glucocorticoids also increase cellular resistance to insulin, thereby decreasing entry of glucose into the cell. This inhibition of glucose uptake occurs in adipocytes, muscle cells, and fibroblasts. In addition to opposing insulin action, glucocorticoids can work in parallel with insulin to protect against long-term starvation by stimulating glycogen deposition and production in the liver. Both hormones stimulate glycogen synthetase activity and decrease glycogen breakdown. Glucocorticoid excess can cause hyperglycemia, and glucocorticoid deficiency can cause hypoglycemia.

Glucocorticoids increase free fatty acid levels by enhancing lipolysis, decreasing cellular glucose uptake, and decreasing glycerol production, which is necessary for reesterification of fatty acids. This increase in lipolysis is also stimulated through the permissive enhancement of lipolytic action of other factors such as epinephrine. This action affects adipocytes differently according to their anatomic locations. In the patient with glucocorticoid excess, fat is lost in the extremities, but it is increased in the trunk (centripetal obesity), neck, and face (moon facies). This may involve effects on adipocyte differentiation.

Glucocorticoids generally exert a catabolic or antianabolic effect on protein metabolism. Proteolysis in fat, skeletal muscle, bone, lymphoid, and connective tissue increases amino acid substrates that can be used in gluconeogenesis. Cardiac muscle and the diaphragm are almost entirely spared from this catabolic effect.

Circulatory and Renal Effects

Glucocorticoids have a positive inotropic influence on the heart, increasing the left ventricular work index. They have a permissive effect on the actions of epinephrine and norepinephrine on both the heart and the blood vessels. In the absence of glucocorticoids, decreased cardiac output and shock can develop; in states of glucocorticoid excess,

hypertension is often observed. This may be a result of activation of the mineralocorticoid receptor (see Chapter 615.4), which occurs when renal HSD11B2 is saturated by excessive levels of glucocorticoids.

Growth

In excess, glucocorticoids inhibit linear growth and skeletal maturation in children, apparently through direct effects on the epiphyses. However, glucocorticoids are also necessary for normal growth and development. In the fetus and neonate, they accelerate the differentiation and development of various tissues, including the hepatic and gastrointestinal systems, along with the production of surfactant in the fetal lung. Glucocorticoids are often given to pregnant women at risk for delivery of premature infants to accelerate these maturational processes.

Immunologic Effects

Glucocorticoids play a major role in immune regulation. They inhibit synthesis of glycolipids and prostaglandin precursors and the actions of bradykinin. They also block secretion and actions of histamine and proinflammatory cytokines (tumor necrosis factor-α, interleukin-1, and interleukin-6), thus diminishing inflammation. High doses of glucocorticoids deplete monocytes, eosinophils, and lymphocytes, especially T cells. They do so at least in part by inducing cell-cycle arrest in the G_1 phase and by activating apoptosis through glucocorticoid receptor–mediated effects. The effects on lymphocytes are primarily exerted on T-helper 1 cells and hence on cellular immunity, whereas the T-helper 2 cells are spared, leading to a predominantly humoral immune response. Pharmacologic doses of glucocorticoids can also decrease the size of immunologic tissues (spleen, thymus, and lymph nodes).

Glucocorticoids increase circulating polymorphonuclear cell counts, mostly by preventing their egress from the circulation. Glucocorticoids decrease diapedesis, chemotaxis, and phagocytosis of polymorphonuclear cells. Thus the mobility of these cells is altered such that they do not arrive at the site of inflammation to mount an appropriate immune response. High levels of glucocorticoids decrease inflammatory and cellular immune responses and increase susceptibility to certain bacterial, viral, fungal, and parasitic infections.

Effects on Skin, Bone, and Calcium

Glucocorticoids inhibit fibroblasts, leading to increased bruising and poor wound healing through cutaneous atrophy. This effect explains the thinning of the skin and striae that are seen in patients with Cushing syndrome.

Glucocorticoids have the overall effect of decreasing serum calcium and have been used in emergency therapy for certain types of hypercalcemia. This hypocalcemic effect probably results from a decrease in the intestinal absorption of calcium and a decrease in the renal reabsorption of calcium and phosphorus. Serum calcium levels, however, generally do not fall below normal because of a secondary increase in parathyroid hormone secretion.

The most significant effect of long-term glucocorticoid excess on calcium and bone metabolism is osteoporosis. Glucocorticoids inhibit osteoblastic activity by decreasing the number and activity of osteoblasts. Glucocorticoids also decrease osteoclastic activity but to a lesser extent, leading to low bone turnover with an overall negative balance. The tendency of glucocorticoids to lower serum calcium and phosphate levels causes secondary hyperparathyroidism. These actions decrease bone accretion and cause a net loss of bone mineral.

Central Nervous System Effects

Glucocorticoids readily penetrate the blood-brain barrier and have direct effects on brain metabolism. They decrease certain types of central nervous system edema and are often used to treat increased intracranial pressure. In large doses, they stimulate appetite and cause insomnia with a reduction in rapid eye movement sleep. There is an increase in irritability and emotional lability, with an impairment of memory and ability to concentrate. Mild to moderate glucocorticoid excess for a limited period often causes a feeling of euphoria or well-being, but glucocorticoid excess and deficiency can both be associated with clinical depression. *Glucocorticoid excess produces psychosis in some patients.*

Glucocorticoid effects in the brain are mediated largely through interactions with both the mineralocorticoid and glucocorticoid receptors (sometimes referred to in this context as *type I* and *type II corticosteroid receptors,* respectively). Activation of type II receptors increases sensitivity of hippocampal neurons to the neurotransmitter serotonin, which might help explain the euphoria associated with high doses of glucocorticoids. Glucocorticoids suppress release of CRH in the anterior hypothalamus, but they stimulate it in the central nucleus of the amygdala and lateral bed nucleus of the stria terminalis, where it can mediate fear and anxiety states. Glucocorticoids and other steroids might have nongenomic effects by modulating activities of both γ-aminobutyric acid and *N*-methyl-D-aspartate receptors.

ACTIONS OF MINERALOCORTICOIDS

The most important mineralocorticoids are aldosterone and, to a lesser degree, 11-deoxycorticosterone; corticosterone and cortisol are normally not important as mineralocorticoids unless secreted in excess. Mineralocorticoids have more limited actions than glucocorticoids. Their major function is to maintain intravascular volume by conserving sodium and eliminating potassium and hydrogen ions. They exert these actions in the kidney, gut, and salivary and sweat glands. Aldosterone can have distinct effects in other tissues. Mineralocorticoid receptors are found in the heart and vascular endothelium, and aldosterone increases myocardial fibrosis in heart failure.

Mineralocorticoids have their most important actions in the distal convoluted tubules and cortical collecting ducts of the kidney, where they induce reabsorption of sodium and secretion of potassium. In the medullary collecting duct, they act in a permissive fashion to allow vasopressin to increase osmotic water flux. Thus patients with mineralocorticoid deficiency can develop weight loss, hypotension, hyponatremia, and hyperkalemia, whereas patients with mineralocorticoid excess can develop hypertension, hypokalemia, and metabolic alkalosis (see Chapters 615, 616, and 620).

The mechanisms by which aldosterone affects sodium excretion are incompletely understood. Most effects of aldosterone are presumably the result of changes in gene expression mediated by the mineralocorticoid receptor, and indeed levels of subunits of both the Na^+, K^+-adenosine triphosphatase and the epithelial sodium channel increase in response to aldosterone. Additionally, aldosterone increases expression of the serum- and glucocorticoid-regulated kinase, which indirectly reduces turnover of epithelial sodium channel subunits and thus increases the number of open sodium channels.

The mineralocorticoid receptor has similar affinities in vitro for cortisol and aldosterone, yet cortisol is a weak mineralocorticoid in vivo. This discrepancy results from the action of HSD11B2, which converts cortisol to cortisone. Cortisone is not a ligand for the receptor, whereas aldosterone is not a substrate for the enzyme. Pharmacologic inhibition (as occurs with excessive consumption of licorice) or genetic deficiency of this enzyme allows cortisol to occupy renal mineralocorticoid receptors and produce sodium retention and hypertension; the genetic condition is termed **apparent mineralocorticoid excess syndrome**.

ACTIONS OF THE ADRENAL ANDROGENS

Many actions of adrenal androgens are exerted through their conversion to active androgens or estrogens such as testosterone, dihydrotestosterone, estrone, and estradiol. In males, <2% of the biologically important androgens are derived from adrenal production, whereas in females approximately 50% of androgens are of adrenal origin. The adrenal contribution to circulating estrogen levels is mainly important in pathologic conditions such as feminizing adrenal tumors. Adrenal androgens contribute to the physiologic development of pubic and axillary hair during normal puberty. They also play an important role in the pathophysiology of **congenital adrenal hyperplasia**, **premature**

adrenarche, **adrenal tumors,** and **Cushing syndrome** (see Chapters 616-619).

In humans, circulating levels of DHEA and DHEAS, the chief adrenal androgen precursors, reach a peak in early adulthood and then decline. This has led to speculation that some age-related physiologic changes might be reversed by DHEA administration, and beneficial effects have been suggested (but not proved) on insulin sensitivity, bone mineral density, muscle mass, cardiovascular risk, obesity, cancer risk, autoimmunity, and the central nervous system.

Synthetic Corticosteroids

Many synthetic analogs of cortisone and hydrocortisone are available. Prednisone and prednisolone are derivatives with an additional double bond in ring A. Similar to cortisone, prednisone is not an active steroid, but it is converted to prednisolone by HSD11B1 in the liver. Prednisone and prednisolone are 4-5 times as potent in antiinflammatory and carbohydrate activity but have slightly less effect on retention of water and sodium than cortisol. Halogenated derivatives have different effects. Betamethasone and dexamethasone have 25-40 times the glucocorticoid potency of cortisol but have little mineralocorticoid effect. These analogs are usually used in pharmacologic doses for their antiinflammatory or immunosuppressive properties. The antiinflammatory activity of fludrocortisone is about 15 times that of hydrocortisone, but fludrocortisone is more than 125 times as active a mineralocorticoid; it is used to treat aldosterone deficiency.

Visit Elsevier eBooks+ at eBooks.Health.Elsevier.com for Bibliography.

614.5 Adrenal Medulla

Perrin C. White

The principal hormones of the adrenal medulla are the physiologically active catecholamines: dopamine, norepinephrine, and epinephrine (Fig. 614.3). Catecholamine synthesis also occurs in the brain, in sympathetic nerve endings, and in chromaffin tissue outside the adrenal medulla. Metabolites of catecholamines are excreted in the urine, principally 3-methoxy-4-hydroxymandelic acid, metanephrine, and normetanephrine. Urinary metanephrines and catecholamines are measured to detect pheochromocytomas of the adrenal medulla and sympathetic nervous system (see Chapter 621).

The proportions of epinephrine and norepinephrine in the adrenal gland vary with age. In early fetal stages, there is practically no epinephrine; at birth, norepinephrine remains predominant. However, in adults, norepinephrine accounts for only 10–30% of the pressor amines in the medulla.

The effects of catecholamines are mediated through a series of G protein–coupled adrenergic receptors. Both epinephrine and norepinephrine raise the mean arterial blood pressure, but only epinephrine increases cardiac output. By increasing peripheral vascular resistance, norepinephrine increases systolic and diastolic blood pressures with only a slight reduction in the pulse rate. Epinephrine increases the pulse rate and, by decreasing the peripheral vascular resistance, decreases the diastolic pressure. The hyperglycemic and calorigenic effects of norepinephrine are much less pronounced than are those of epinephrine.

Visit Elsevier eBooks+ at eBooks.Health.Elsevier.com for Bibliography.

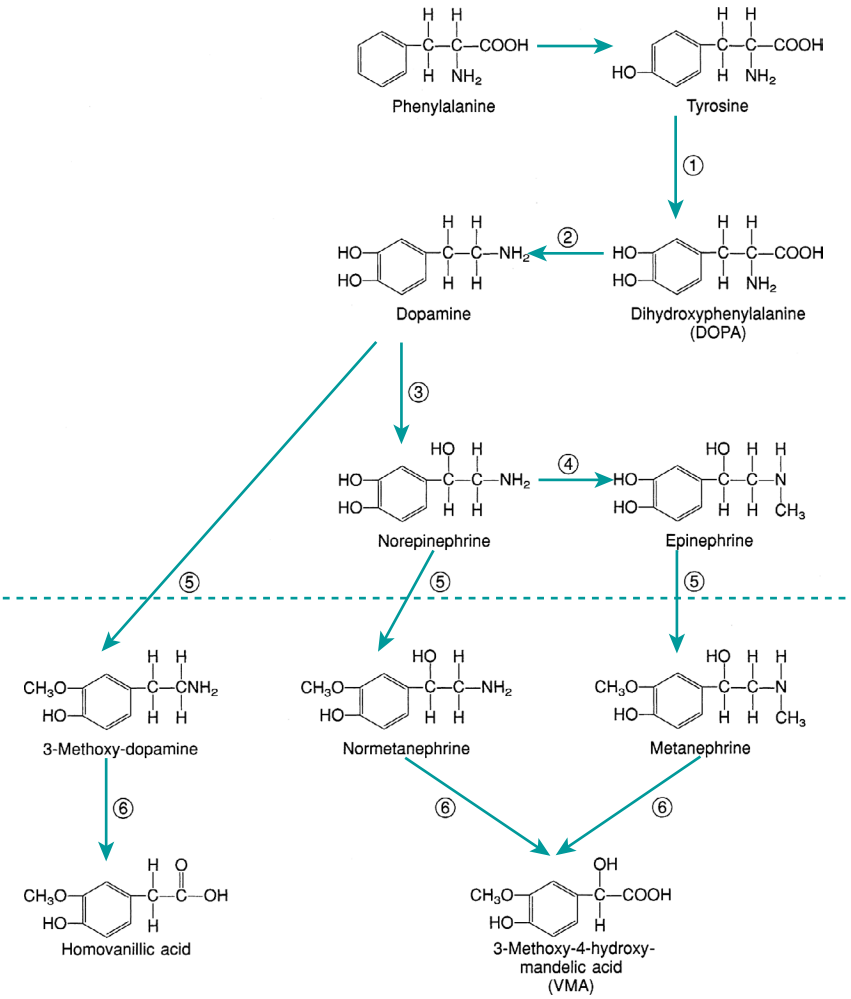

Fig. 614.3 Biosynthesis (above *dashed line*) and metabolism (below *dashed line*) of the catecholamines norepinephrine and epinephrine. Enzymes: *1*, tyrosine hydroxylase; *2*, dopa decarboxylase; *3*, dopamine β-oxidase; *4*, phenylethanolamine-*N*-methyltransferase; *5*, catechol *O*-methyltransferase; *6*, monoamine oxidase.

Chapter 615

Adrenocortical Insufficiency and Altered Sensitivity to Corticosteroids

Perrin C. White

In primary adrenal insufficiency, congenital or acquired lesions of the adrenal cortex prevent production of cortisol and often aldosterone (Table 615.1). Acquired primary adrenal insufficiency is termed **Addison disease**. Dysfunction of the anterior pituitary gland or hypothalamus can cause a deficiency of corticotropin (adrenocorticotropic hormone [ACTH]) and lead to hypofunction of the adrenal cortex, termed *secondary adrenal insufficiency;* the term *tertiary adrenal insufficiency* is sometimes used to denote cases arising from hypothalamic dysfunction (Tables 615.2 and 615.3).

615.1 Primary Adrenal Insufficiency

Perrin C. White

Primary adrenal insufficiency in children is most frequently caused by genetic conditions that are often, but not always, manifested in infancy and, less often, by acquired problems such as autoimmune conditions (Table 615.4) or syndromes (Table 615.5). Susceptibility to autoimmune conditions often has a genetic basis, and so these distinctions are not absolute.

INHERITED ETIOLOGIES

Inborn Defects of Steroidogenesis

The most common causes of adrenocortical insufficiency in *infancy* are the salt-losing forms of congenital adrenal hyperplasia (CAH, see Chapter 616). Approximately 75% of infants with 21-hydroxylase deficiency, almost all infants with lipoid adrenal hyperplasia, and most infants with a deficiency of 3β-hydroxysteroid dehydrogenase manifest salt-losing symptoms in the newborn period because they are unable to synthesize either cortisol or aldosterone. Relatively mild pathogenic variants in *STAR* (which controls cholesterol importation into mitochondria) or *CYP11A1* (which encodes the cholesterol side-chain cleavage enzyme) can cause adrenal insufficiency manifesting in childhood.

Aside from CAH and autoimmune adrenalitis, a genetic cause can be identified in >65% of patients with primary adrenal insufficiency presenting in *childhood*. These can be grouped into several categories: (1) ACTH unresponsiveness (familial glucocorticoid deficiency); (2) adrenal hypoplasia congenita caused by pathogenic variants in orphan nuclear hormone receptors that affect expression of other genes; (3) defects in lipid metabolism, particularly adrenoleukodystrophy; (4) syndromes associated with intrauterine growth restriction, adrenal hypoplasia, and disorders of sexual development, such as IMAGe and MIRAGE syndromes (activating variants of *CDKN1C* and *SAMD9,* respectively), and type 2 IMAGe syndrome (*POLE1* gene); and (5) deficiency of mitochondrial reactive oxygen species detoxification (*NNT* and *TXNRD2* genes).

Familial Glucocorticoid Deficiency

Familial glucocorticoid deficiency is a form of chronic adrenal insufficiency characterized by isolated deficiency of glucocorticoids, elevated levels of ACTH, and generally normal aldosterone production, although salt-losing manifestations present in most other forms of adrenal insufficiency occasionally occur. Patients may have hypoglycemia, seizures, and increased pigmentation during the first decade of life. The disorder affects both sexes equally and is inherited in an autosomal recessive manner. There is marked adrenocortical atrophy with relative sparing of the zona glomerulosa. Pathogenic variants in the gene for the ACTH receptor *(MCR2)* have been described in approximately 25% of these patients, most of which affect trafficking of receptor molecules from the endoplasmic reticulum to the cell surface. Another 10–20% of cases are caused by variants in *MRAP,* which encodes a melanocyte receptor accessory protein required for this trafficking.

Another syndrome of ACTH resistance occurs in association with achalasia and alacrima (**triple A** or **Allgrove syndrome**). These patients often have a progressive neurologic disorder that includes autonomic dysfunction, intellectual disability, motor neuropathy, and occasional deafness. This syndrome is autosomal recessive; the *AAAS* gene has been mapped to chromosome 12q13. The encoded protein, aladin, might help to regulate nucleocytoplasmic transport of other proteins.

Adrenal Hypoplasia Congenita

Adrenal hypoplasia congenita (AHC) is a relatively frequent cause of adrenal insufficiency in males, along with CAH, autoimmune disease, and adrenoleukodystrophy (ALD). AHC is predominantly a failure of development of the definitive zone of the adrenal cortex; the fetal zone may be relatively normal. Consequently, adrenal insufficiency generally becomes evident as the fetal zone involutes postnatally (see Chapter 614), with onset in infancy or in the first 2 years of life but occasionally in later childhood or even adulthood. In some cases, aldosterone deficiency becomes evident before cortisol deficiency.

The disorder is caused by pathogenic variants of *NR0B1 (DAX1)*, a member of the nuclear hormone receptor family, located on Xp21. Males with AHC often do not undergo puberty as a result of hypogonadotropic hypogonadism caused by the same variant of *NR0B1*. **Cryptorchidism**, sometimes noted in these males, is probably an early manifestation of hypogonadotropic hypogonadism, but often testicular function in infants is normal, with a typical or even an unusually prolonged testosterone surge in the first month of life.

AHC occasionally occurs as part of a *contiguous gene deletion* syndrome together with Duchenne muscular dystrophy, glycerol kinase deficiency, cognitive impairment, or a combination of these conditions.

The transcription factor NR5A1 (steroidogenic factor-1, SF-1) is required for adrenal and gonadal development (see Chapter 614). Males with heterozygous variants in *NR5A1* have impaired development of the testes despite the presence of a normal copy of the gene on the other chromosome and can appear to be female, similar to patients with lipoid adrenal hyperplasia (see Chapter 616). Rarely, such patients also have adrenal insufficiency.

Adrenal hypoplasia is also occasionally seen in patients with **Pallister-Hall syndrome** caused by pathogenic variants in *GLI3*.

Disorders of Lipid Metabolism

In **adrenal leukodystrophy (ALD)**, adrenocortical deficiency is associated with demyelination in the central nervous system (see Chapters 106.2 and 639.3). High levels of **very long-chain fatty acids** are found in tissues and body fluids, resulting from their impaired β-oxidation in the peroxisomes.

The most common form of ALD is an X-linked disorder with various presentations. The most common clinical picture is of a degenerative neurologic disorder appearing in childhood or adolescence and progressing to severe dementia and deterioration of vision, hearing, speech, and gait, with death occurring within a few years. Neurologic symptoms may be subtle at onset, sometimes consisting only of behavioral changes or deteriorating academic performance. Generalized but incomplete alopecia, resembling that of chemotherapy, is a characteristic but inconsistent finding. A milder form of X-linked ALD is **adrenomyeloneuropathy**, which begins in later adolescence or early adulthood. Patients may have evidence of adrenal insufficiency before, at the time of, or after neurologic symptoms develop, often with years

Table 615.1 Causes of Primary Adrenal Insufficiency

	GENE (OMIM*)	ASSOCIATED CLINICAL SIGNS AND SYMPTOMS
ADRENAL DESTRUCTION		
Autoimmunity		
Autoimmune primary adrenal insufficiency and autoimmune polyendocrine syndrome type 2	*HLA-DR3, DR4, CTLA4, BACH2, PTPN22, GATA3, CLEC16, MIC-A, MIC-B, NALP1,* and *AIRE*	Hypothyroidism, hyperthyroidism, premature ovarian insufficiency, vitiligo, type 1 diabetes, pernicious anemia, other organ-specific autoimmune features
Autoimmune polyendocrine syndrome type 1	*AIRE* (240300)	Hypoparathyroidism, chronic mucocutaneous candidiasis, other autoimmune disorders, lymphomas (rarely)
Immunodeficiency 31C	*STAT1* (614162)	Chronic mucocutaneous candidiasis, susceptibility to *Staphylococcus aureus* and other bacterial, viral, and fungal infections, polyendocrinopathy (including hypothyroidism and type 1 diabetes), cerebral aneurysms
Peroxisomal Defects		
X-linked adrenoleukodystrophy	*ABCD1* (300100)	Progressive neurodegeneration, behavioral changes, cognitive decline, loss of speech, hearing, and vision, dementia, spasticity, seizures
Refsum disease	*PEX7* (266500)	Least severe form of peroxisome biosynthesis defects
Neonatal adrenoleukodystrophy (autosomal recessive)	*PEX1* (601539)	Craniofacial abnormalities, liver dysfunction, absence of peroxisomes
Zellweger syndrome	*PEX1* (214100)	Craniofacial abnormalities, hepatomegaly, severe intellectual disability and growth failure, hypotonia, deafness, blindness, genitourinary abnormalities, stippled epiphyses
Mitochondrial Defects		
Kearns-Sayre syndrome	Mitochondrial DNA deletions (530000)	External ophthalmoplegia, retinal degeneration, cardiac conduction defects, other endocrinopathies
Hemorrhage	—	Bilateral adrenal hemorrhage of the newborn baby, primary antiphospholipid syndrome, anticoagulation
Trauma or Surgery	—	Bilateral adrenalectomy
Infection	—	Septic shock, meningococcal sepsis (Waterhouse-Friderichsen syndrome), tuberculosis, fungal infections (e.g., histoplasmosis, cryptococcosis, coccidioidomycosis, and blastomycosis), African trypanosomiasis, cytomegalovirus, HIV-1, syphilis
Infiltration	—	Metastatic cancers, primary adrenal lymphoma, amyloidosis, sarcoidosis (rare), hemochromatosis
DRUGS	—	Ketoconazole, rifampicin, phenytoin, phenobarbital, aminoglutethimide, mitotane, abiraterone acetate, etomidate, suramin, mifepristone, nivolumab, pembrolizumab
IMPAIRED STEROIDOGENESIS		
Impaired Cholesterol Transport		
Steroidogenic acute regulatory protein (congenital lipoid adrenal hyperplasia)	*StAR* (201710)	46,XY DSD, gonadal insufficiency
Steroidogenic Enzyme or Cofactor Deficiency Causing Congenital Adrenal Hyperplasia		
3β-hydroxysteroid dehydrogenase type 2	*HSD3B2* (201810)	46,XX and 46,XY DSD, gonadal insufficiency
21-hydroxylase	*CYP21A2* (201 910)	46,XX DSD, hyperandrogenism
11β-hydroxylase	*CYP11B1* (202 010)	46,XX DSD, arterial hypertension
CYP17A1 deficiency	*CYP17A1* (202 110)	46,XY DSD, arterial hypertension, gonadal insufficiency
P450 oxidoreductase	*POR* (201 750)	46,XX and 46,XY DSD, gonadal insufficiency, bone malformation, dysfunction of all endoplasmic CYP450 enzymes
Steroidogenic Enzyme Deficiency (Noncongenital Adrenal Hyperplasia)		
P450 side-chain cleavage enzyme	*CYP11A1* (118 485)	46,XY DSD, gonadal insufficiency
Aldosterone synthase	*CYP11B2* (124 080)	Isolated mineralocorticoid deficiency
Defects of Cholesterol Synthesis or Metabolism		
Wolman disease (lysosomal acid lipase deficiency, and cholesterol ester storage disease)	*LIPA* (278 000)	Diffuse punctate adrenal calcification, xanthomatous changes in multiple organs, hypercholesterolemia, steatorrhea, poor prognosis

Continued

Table 615.1 Causes of Primary Adrenal Insufficiency—cont'd

	GENE (OMIM*)	ASSOCIATED CLINICAL SIGNS AND SYMPTOMS
Smith-Lemli-Opitz disease	*DHCR7* (270 400)	Intellectual disability, craniofacial malformations, limb abnormalities, growth failure
Abetalipoproteinemia	*MTP* (200 100)	Ataxia, retinopathy, acanthocytosis, fat malabsorption
ADRENAL DYSGENESIS		
X-linked adrenal hypoplasia congenital	*NROB1* (300 200)	Combined primary and secondary hypogonadism, Duchenne muscular dystrophy in contiguous gene syndrome
Adrenal hypoplasia steroidogenic factor-1 deficiency	*NR5A1* (184757)	46,XY DSD, gonadal insufficiency
IMAGe syndrome	*CDKN1C* (300 290)	Intrauterine growth restriction, metaphyseal dysplasia, adrenal insufficiency, genital anomalies
MIRAGE syndrome	*SMAD9* (617 053)	Myelodysplasia, infection, adrenal hypoplasia, growth restriction, genital anomalies, enteropathy
Pallister-Hall syndrome	*GLI3* (165 240)	Hypothalamic hamartoblastoma, hypopituitarism, imperforate anus, postaxial polydactyly
Meckel syndrome	*MKS1* (249 000)	CNS malformation, polycystic kidneys with fibrotic liver changes, polydactyly
Pseudotrisomy 13	(264 480)	Holoprosencephaly, severe facial anomalies, postaxial polydactyly, various other congenital defects, and normal chromosomes
Hydrolethalus syndrome	*HYLS1* (236 680)	Severe prenatal-onset hydrocephalus, polydactyly
Galloway-Mowat syndrome	*WDR73* (251 300)	Early-onset severe encephalopathy, intractable epilepsy, nephrotic syndrome, microcephaly, hiatal hernia
ACTH RESISTANCE		
Familial glucocorticoid deficiency type 1	*MC2R* (202 200)	Tall stature, isolated deficiency of glucocorticoids, generally normal aldosterone production
Familial glucocorticoid deficiency type 2	*MRAP* (607398)	Isolated deficiency of glucocorticoids, generally normal aldosterone production
IMPAIRED REDOX HOMEOSTASIS		
Triple A syndrome (Allgrove syndrome)	*AAAS* (231550)	Alacrimia, achalasia, neurologic impairment, deafness, intellectual disability, hyperkeratosis
Mitochondrial deficiency of free radical detoxification	*NNT* (614736) and *TRXR2* (606448)	*NNT*: hypoglycemia, hyperpigmentation, low cortisol concentration, increased ACTH concentration, isolated deficiency of glucocorticoids; *TRXR2*: isolated deficiency of glucocorticoids
MISCELLANEOUS		
Defects in DNA repair	*MCM4* (609981)	Natural killer cell deficiency, growth failure, increased chromosomal breakage
Bioinactive ACTH	*POMC* (201400)	—
Sphingosine-1-phosphate lyase 1	*SGPL1* (617575)	Steroid-resistant nephrotic syndrome, ichthyosis, primary hypothyroidism, cryptorchidism, immunodeficiency, neurologic defects

*www.omim.org
ACTH, Adrenocorticotropic hormone; DSD, disorder of sex development; OMIM, Online Mendelian Inheritance in Man.
Modified from Husebye ES, Pearce SH, Krone NP, Kämpe O. Adrenal insufficiency. Lancet. 2021;397:613–629, Table 1.

separating their presentation. X-linked ALD is caused by pathogenic variants in *ABCD1* located on Xq28. The gene encodes a transmembrane transporter involved in the importation of very long-chain fatty acids into peroxisomes. Clinical phenotypes can vary even within families, perhaps owing to modifier genes or other unknown factors. There is no correlation between the degree of neurologic impairment and severity of adrenal insufficiency. Prenatal diagnosis by DNA analysis and family screening by very long-chain fatty acid assays and gene analysis are available. Females who are heterozygous carriers of the X-linked ALD gene can develop neurologic symptoms in midlife or later; adrenal insufficiency is rare. This condition is part of the newborn screening panel.

Neonatal ALD is a rare *autosomal recessive* disorder. Infants have neurologic deterioration and have or acquire evidence of adrenocortical dysfunction. Most patients have severe, progressive cognitive impairment and die before 5 years of age. This disorder is a subset of **Zellweger (cerebrohepatorenal) syndrome**, in which peroxisomes do not develop at all owing to pathogenic variants in any of several genes (*PEX5*, *PEX1*, *PEX10*, *PEX13*, and *PEX26*) controlling the development of peroxisomes.

Patients with disorders of cholesterol synthesis or metabolism, including abetalipoproteinemia with deficient lipoprotein B–containing lipoproteins (such as low-density lipoprotein), and homozygous **familial hypercholesterolemia**, with impaired or absent low-density lipoprotein receptors, have mildly impaired adrenocortical function. Heterozygous familial hypercholesterolemia patients have normal adrenocortical function, which is unaffected by treatment with statin (HMG-CoA reductase inhibitor) drugs. Adrenal insufficiency has been reported in patients with **Smith-Lemli-Opitz syndrome**, an autosomal recessive disorder manifesting with facial anomalies, microcephaly, limb anomalies, and developmental delay (see Chapter 106.3), caused by pathogenic variants in the gene coding for sterol Δ^7-reductase on chromosome 11q12-q13.

Table 615.2 Causes of Secondary Adrenal Insufficiency in the Form of Pituitary Disorders

	GENE (OMIM*)	ASSOCIATED CLINICAL SIGNS AND SYMPTOMS
ACQUIRED CAUSES		
Steroid withdrawal syndrome	*PDGFD*	Endogenous glucocorticoid hypersecretion caused by Cushing syndrome and exogenous glucocorticoid administration for more than 2 wk
Opioids	—	Hypogonadotropic hypogonadism
Tumor	—	Craniopharyngioma, glioma, meningioma, ependymoma, germinoma, intrasellar or suprasellar metastases, adenoma, carcinoma
Trauma	—	Pituitary stalk lesions, battered child syndrome, vehicular trauma
Pituitary apoplexy (Sheehan syndrome)	—	High blood loss or hypotension
CONGENITAL CAUSES		
Aplasia or Hypoplasia		
PROP1 deficiency	*PROP1* (262600)	Additional deficiency of growth hormone, prolactin, thyroid-stimulating hormone, and luteinizing hormone or follicle-stimulating hormone, or both
LHX4 deficiency	*LHX4* (262700)	Additional deficiency of growth hormone and thyroid-stimulating hormone
SOX3 deficiency	*SOX3* (312000)	Additional deficiencies of pituitary hormones
Isolated ACTH Deficiency		
TBX19 deficiency	*TBX19* (201400)	Severe neonatal-onset adrenal insufficiency
Proopiomelanocortin	*POMC* (609734)	Adrenal insufficiency, early-onset obesity, red hair pigmentation
Proprotein convertase 1	*PCSK1* (600955)	Hypoglycemia, malabsorption, hypogonadotropic hypogonadism

*www.omim.org.
ACTH, Adrenocorticotropic hormone; OMIM, Online Mendelian Inheritance in Man.
From Husebye ES, Pearce SH, Krone NP, Kämpe O. Adrenal insufficiency. Lancet. 2021;397:613–629, Table 2.

Table 615.3 Causes of Tertiary Adrenal Insufficiency

	GENE (OMIM*)	ASSOCIATED CLINICAL SIGNS AND SYMPTOMS
ACQUIRED CAUSES		
Steroid withdrawal syndrome	*PDGFD*	Endogenous glucocorticoid hypersecretion caused by Cushing syndrome and exogenous glucocorticoid administration for more than 2 wk
Opioids	—	Hypogonadotropic hypogonadism
Inflammatory disorders	—	Abscess, meningitis, encephalitis
Trauma	—	—
Radiation therapy	—	Craniospinal irradiation in leukemia and irradiation for tumors outside the hypothalamic-pituitary area
Surgery	—	—
Tumor	—	Craniopharyngioma, glioma, meningioma, ependymoma, germinoma, intrasellar or suprasellar metastases
Infiltrative diseases	—	Sarcoidosis, histiocytosis X, hemochromatosis
CONGENTIAL CAUSES		
Septo-optic dysplasia (de Morsier syndrome)	*HESX1* (182230)	Combined pituitary hormone deficiency, optic nerve hypoplasia, midline brain defects
Corticotropin-releasing hormone deficiency	—	—

*www.omim.org.
OMIM, Online Mendelian Inheritance in Man.
From Husebye ES, Pearce SH, Krone NP, Kämpe O. Adrenal insufficiency. Lancet. 2021;397:613–629, Table 3.

This impairs the final step in cholesterol synthesis with marked elevation of 7-dehydrocholesterol and abnormally low cholesterol. **Wolman disease** is a rare autosomal recessive disorder caused by pathogenic variants in the gene encoding human lysosomal acid lipase on chromosome 10q23.2-23.3. Cholesteryl esters accumulate in lysosomes in most organ systems, leading to organ failure. Infants during the first or second month of life have hepatosplenomegaly, steatorrhea, abdominal distention, and failure to thrive. Adrenal insufficiency and bilateral adrenal calcification are present, and death usually occurs in the first year of life.

Multisystem Syndromes Associated with Growth Restriction

Pathogenic variants in genes that affect DNA replication may be associated with primordial dwarfism, immune deficiency, and adrenal insufficiency. Minichromosome maintenance-deficient 4 homolog *(MCM4)* functions to integrate several protein kinase signals that regulate progression of DNA replication through the S phase. Homozygous deficiency of MCM4 causes a primary **immunodeficiency syndrome** characterized by severe intrauterine and extrauterine growth

Table 615.4 Frequencies of Etiologies of Primary Adrenal Insufficiency

ETIOLOGY	%	AGE AT DIAGNOSIS
Congenital adrenal hyperplasia	59	Infancy
Autoimmune	16	Childhood to adolescence
APECED (autoimmune polyendocrinopathy–candidiasis–ectodermal dystrophy)	6	Childhood to adolescence
Adrenoleukodystrophy	4	Childhood to adolescence
Other genetic causes	14*	
Hemorrhage	1	Infancy

*See Table 615.5.
Data from Perry R, Kecha O, Paquette J, et al. Primary adrenal insufficiency in children: twenty years' experience at the Sainte-Justine Hospital, Montreal. *J Clin Endocrinol Metab.* 2005;90:3243–3250; Hsieh S, White PC. Presentation of primary adrenal insufficiency in childhood. J Clin Endocrinol Metab. 2011;96:E925–E928.

Table 615.5 Other Genetic Etiologies for Primary Adrenal Insufficiency

GENE	FUNCTION	SYNDROME	FREQUENCY* %
MC2R	Melanocortin (ACTH) receptor	Familial glucocorticoid deficiency type 1	22
MRAP	Melanocortin receptor accessory protein	Familial glucocorticoid deficiency type 2	4
NROB1	DAX1 orphan nuclear receptor	X-linked adrenal hypoplasia congenita	6†
NR5A1	SF-1 orphan nuclear receptor	Gonadal dysgenesis	<1
STAR	Steroidogenic acute regulatory protein	Nonclassic lipoid adrenal hyperplasia	8
CYP11A1	Cholesterol side-chain cleavage enzyme	Nonclassic lipoid adrenal hyperplasia	8
NNT	Nicotinamide nucleotide transhydrogenase	Familial glucocorticoid deficiency type 4	8
AAAS	Aladin (nuclear transport protein)	Triple A syndrome	5
SAMD9	Factor inhibiting cell proliferation	MIRAGE syndrome	3
CDKN1C	Cyclin-dependent kinase inhibitor	IMAGE syndrome	1
POLE	Subunit of DNA polymerase	IMAGE syndrome type 2	rare

*Frequencies are from 95 Turkish and 155 United Kingdom patients in whom congenital adrenal hyperplasia, autoimmune etiologies, and metabolic disorders (e.g., adrenoleukodystrophy) had been excluded.
†Many cases of X-linked adrenal hypoplasia congenita had already been identified, so this frequency is an underestimate.

restriction, microcephaly, decreased numbers of natural killer (NK) cells, recurrent viral infections, and adrenal insufficiency. It is relatively frequent (1 in 2,506) in the Irish Traveller population.

MIRAGE syndrome is a form of syndromic adrenal hypoplasia, characterized by myelodysplasia, infections, restriction of growth, adrenal hypoplasia, genital abnormalities, and enteropathy. It is often fatal within the first decade of life, usually because of invasive infection. It is caused by pathogenic variants in *SAMD9* on chromosome 7q21, which encodes a protein that inhibits cell proliferation. Disease-causing variants are heterozygous and usually arise de novo. When expressed in cultured cells, the abnormal proteins strongly inhibit cell proliferation. There is a risk that affected cells will attempt to escape growth inhibition by selectively losing chromosome 7 carrying the variant causing haploinsufficiency of *SAMD9*. This can cause myelodysplastic syndrome.

IMAGE syndrome consists of intrauterine growth restriction, metaphyseal dysplasia, adrenal hypoplasia, and genital anomalies. Two forms have been identified: an autosomal dominant form caused by pathogenic variants in *CDKN1C* and an autosomal recessive form caused by variants in *POLE*. Adrenal insufficiency in cases associated with *CDKN1C* variants tends to present in early infancy, whereas in cases caused by *POLE* variants, it is manifested during early childhood. The recessive form is also associated with immunodeficiency and is therefore sometimes termed *IMAGEI syndrome.*

The *CDKN1C* gene product, also called *p57(KIP2),* binds G1 cyclin/CDK complexes and thus inhibits cell proliferation. It is located in the imprinted region of chromosome 11p15 and is preferentially expressed from the maternal allele. Inactivating variants in this gene cause some cases of Beckwith-Wiedemann syndrome (see Chapter 113), which is associated with macrosomia and tumor risk. Variants that interfere with binding of CDKN1C to DNA polymerase delta auxiliary protein enhance the growth inhibitory effect of CDKN1C (gain of function) and cause IMAGE syndrome when maternally inherited. Thus both genes involved in IMAGE syndrome have roles in DNA replication and repair.

Deficiency of Mitochondrial Reactive Oxygen Species Detoxification

Nicotinamide nucleotide transhydrogenase *(NNT)* is a mitochondrial protein that catalyzes transfer of a hydride ion between nicotinamide adenine dinucleotide, NAD(H), and oxidized nicotinamide dinucleotide phosphate, NADP(H). Its deficiency manifests generally in infancy or early childhood, and most patients have both mineralocorticoid and glucocorticoid deficiencies. A pathogenic variant in *TXNRD2* has been identified in a single kindred with glucocorticoid deficiency.

Type 1 Autoimmune Polyendocrinopathy Syndrome

Although autoimmune Addison disease most often occurs sporadically, it can occur as a component of two syndromes, each consisting of a constellation of autoimmune disorders (see Chapter 608). **Type 1 autoimmune polyendocrinopathy syndrome (APS-1)**, also known as *autoimmune polyendocrinopathy–candidiasis–ectodermal dystrophy* (APECED) syndrome, is inherited in a mendelian autosomal recessive manner, whereas APS-2 has complex inheritance. Patients with APS-1

may have autoantibodies to the adrenal cytochrome P450 enzymes CYP21A2, CYP17A1, and CYP11A1. The presence of such antibodies indicates a high likelihood of the development of Addison disease or, in female patients, ovarian failure. Adrenal failure can evolve rapidly in APS-1; death in patients with a previous diagnosis and unexplained deaths in siblings of patients with APS-1 have been reported, indicating the need to closely monitor patients with APS-1 (or any child with unexplained hypoparathyroidism) and to thoroughly evaluate apparently unaffected siblings of patients with this disorder.

Corticosteroid-Binding Globulin Deficiency and Decreased Cortisol-Binding Affinity

Corticosteroid-binding globulin deficiency (*SERPINA6* pathogenic variant) and decreased cortisol-binding affinity result in low levels of plasma cortisol but normal urinary free cortisol and normal plasma ACTH levels. A high prevalence of hypotension and fatigue has been reported in some adults with abnormalities of corticosteroid-binding globulin deficiency.

ACQUIRED ETIOLOGIES

Autoimmune Addison Disease

The most common cause of Addison disease is autoimmune destruction of the glands. The glands may be so small that they are not visible at autopsy, and only remnants of tissue are found in microscopic sections. Usually, the medulla is not destroyed, and there is marked lymphocytic infiltration in the area of the former cortex. In advanced disease, all adrenocortical function is lost, but early in the clinical course, isolated cortisol deficiency can occur. Most patients have **antiadrenal cytoplasmic antibodies** in their plasma; 21-hydroxylase (CYP21A2) is the most commonly occurring biochemically defined autoantigen.

Addison disease can occur as a component of two autoimmune polyendocrinopathy syndromes. Type 1 (APS-1) was discussed previously. **Type 2 autoimmune polyendocrinopathy (APS-2)** consists of Addison disease associated with autoimmune thyroid disease **(Schmidt syndrome)** or type 1 diabetes **(Carpenter syndrome)** (see Chapter 608). Frequencies of the human leukocyte antigen (HLA)-D3 and HLA-D4 alleles are increased in these patients and appear to confer an increased risk for development of this disease; particular alleles at the major histocompatibility complex class I chain–related genes A and B (*MICA* and *MICB*) also are associated with this disorder. Polymorphisms in genes involved in other autoimmune disorders have been inconsistently associated with primary adrenal insufficiency, and their contribution to its pathogenesis must be regarded as uncertain. These include the class II, major histocompatibility complex, transactivator *(CIITA),* C-type lectin domain family 16, member A (*CLEC16A*), and protein tyrosine phosphatase, nonreceptor type 22 *(PTPN22).* The disorder is most common in middle-age females and can occur in many generations of the same family. Antiadrenal antibodies, specifically antibodies to the CYP21A2, CYP17A1, and CYP11A1 enzymes, are also found in these patients. Autoimmune adrenal insufficiency may also be seen in patients with celiac disease and mitochondrial gene mutations.

Adrenal insufficiency remains a risk among patients previously treated with a prolonged course of steroids when stressed with an infection or trauma. Despite being "tapered or weaned" from the steroids, subclinical adrenal insufficiency may develop weeks to months later if stressed (see Chapter 615.2).

Infection

Tuberculosis was a common cause of adrenal destruction in the past but is currently much less prevalent. The most common infectious etiology for adrenal insufficiency is meningococcemia (see Chapter 237); adrenal crisis from this cause is referred to as **Waterhouse-Friderichsen syndrome**. Patients with AIDS can have a variety of subclinical abnormalities in the hypothalamic-pituitary-adrenal (HPA) axis, but frank adrenal insufficiency is rare. However, drugs used in the treatment of AIDS can affect adrenal hormone homeostasis.

Drugs

Ketoconazole, an antifungal drug, can cause adrenal insufficiency by inhibiting adrenal enzymes. Mitotane (o,p′-DDD), used in the treatment of adrenocortical carcinoma and refractory Cushing syndrome (see Chapters 617 and 619), is cytotoxic to the adrenal cortex and can also alter extraadrenal cortisol metabolism. Signs of adrenal insufficiency occur in a substantial percentage of patients treated with mitotane. **Etomidate**, used in the induction and maintenance of general anesthesia, inhibits 11β-hydroxylase (CYP11B1), and a single induction dose can block cortisol synthesis for 4-8 hours or longer. This may be problematic in severely stressed patients, particularly if repeated doses are used in a critical care setting. Abiraterone acetate, an androgen biosynthesis inhibitor that is used to treat metastatic prostate carcinoma, inhibits cortisol biosynthesis but leaves corticosterone biosynthesis unimpaired. This drug is not currently encountered in pediatric practice. **Immune checkpoint inhibitors** may rarely cause primary adrenal insufficiency. Although not themselves a cause of adrenal insufficiency, rifampicin and anticonvulsive drugs such as phenytoin and phenobarbital reduce the effectiveness and bioavailability of corticosteroid replacement therapy by inducing steroid-metabolizing enzymes in the liver.

Hemorrhage into Adrenal Glands

Hemorrhage into adrenal glands can occur in the neonatal period as a result of a difficult labor (especially breech presentation), or its etiology might not be apparent (Fig. 615.1). An incidence rate of 3 in 100,000 live births has been suggested. The hemorrhage may be sufficiently extensive to result in death from exsanguination or hypoadrenalism. An abdominal mass, anemia, unexplained jaundice, or scrotal hematoma may be the presenting sign. Often, the hemorrhage is asymptomatic initially and is identified later by calcification of the adrenal gland. Fetal adrenal hemorrhage has also been reported. Postnatally, adrenal hemorrhage most often occurs in patients being treated with anticoagulants. It can also occur as a result of child abuse.

CLINICAL MANIFESTATIONS

Primary adrenal insufficiency leads to cortisol and often aldosterone deficiencies. The signs and symptoms of adrenal insufficiency are most easily understood in the context of the normal actions of these hormones (see Chapter 614; Table 615.6).

Fig. 615.1 Contrast-enhanced coronal CT confirming intraadrenal localization of a round hyperdense lesion compatible with a large calcification. *(From Llano JP, Beaufils E, Nicolino M. Uncommon cause of large paravertebral calcification in a child. J Pediatr. 2013;162:881, Fig. 2.)*

Table 615.6 Clinical Manifestations and Biochemical Findings in Adrenal Insufficiency

	PATHOPHYSIOLOGIC MECHANISM	PREVALENCE (%)*
SYMPTOMS		
Fatigue	Glucocorticoid deficiency	90
Anorexia, weight loss	Glucocorticoid deficiency	90
Nausea, vomiting	Glucocorticoid deficiency, mineralocorticoid deficiency	90
Salt craving (primary adrenal insufficiency only)	Mineralocorticoid deficiency	20
Myalgia or joint pain	Glucocorticoid deficiency	
SIGNS		
Low blood pressure, orthostatic hypotension	Mineralocorticoid deficiency, glucocorticoid deficiency	70-100
Skin or mucosal hyperpigmentation (primary adrenal insufficiency only)	Excess of proopiomelanocortin-derived peptides	70
LABORATORY FINDINGS		
Hyponatremia	Mineralocorticoid deficiency, glucocorticoid deficiency (leading to decreased free water excretion)	90
Hyperkalemia (primary adrenal insufficiency only)	Mineralocorticoid deficiency	50
Hypoglycemia	Glucocorticoid deficiency	30
Ketosis	Glucocorticoid deficiency	30
Low random cortisol level	Glucocorticoid deficiency	80
Eosinophilia, lymphocytosis	Glucocorticoid deficiency	
High ACTH level (primary adrenal insufficiency only)	Glucocorticoid deficiency	100
High plasma renin activity (primary adrenal insufficiency only)	Mineralocorticoid deficiency	100

*Prevalence data are for primary insufficiency only. Blanks indicate that no pediatric prevalence data are available.
Data from Hsieh S, White PC. Presentation of primary adrenal insufficiency in childhood J Clin Endocrinol Metab. 2011;96:E925–E928.

Cortisol deficiency decreases cardiac output and vascular tone; moreover, catecholamines such as epinephrine have decreased inotropic and pressor effects in the absence of cortisol. These problems are initially manifested as orthostatic hypotension in older children and can progress to frank shock in patients of any age. They are exacerbated by aldosterone deficiency, which causes hypovolemia owing to decreased resorption of sodium in the distal nephron.

Hypotension and decreased cardiac output decrease glomerular filtration and thus decrease the ability of the kidney to excrete free water. Vasopressin (AVP) is secreted by the posterior pituitary in response to hypotension and as a direct consequence of lack of inhibition by cortisol. These factors decrease plasma osmolality and lead to hyponatremia. Hyponatremia is also caused by aldosterone deficiency and may be much worse when both cortisol and aldosterone are deficient.

In addition to hypovolemia and hyponatremia, aldosterone deficiency causes hyperkalemia by decreasing potassium excretion in the distal nephron. Cortisol deficiency alone does not cause hyperkalemia.

Cortisol deficiency decreases negative feedback on the hypothalamus and pituitary, leading to increased secretion of ACTH. Hyperpigmentation is caused by ACTH and other peptide hormones (γ-melanocyte–stimulating hormone) arising from the ACTH precursor, proopiomelanocortin. In patients with a fair complexion, the skin can have a bronze cast. Pigmentation may be more prominent in skin creases, mucosa, and scars. In dark-skinned patients, it may be most readily appreciated in the gingival and buccal mucosa.

Hypoglycemia is a feature of adrenal insufficiency. It is often accompanied by ketosis as the body attempts to use fatty acids as an alternative energy source. Ketosis may cause or be aggravated by anorexia, nausea, and vomiting, all of which occur frequently.

The clinical presentation of adrenal insufficiency depends on the age of the patient, whether both cortisol and aldosterone secretion are affected, and to some extent on the underlying etiology. The most common causes in early infancy are inborn errors of steroid biosynthesis, sepsis, AHC, and adrenal hemorrhage. Infants have a relatively greater requirement for aldosterone than do older children, possibly owing to immaturity of the kidney and to the low sodium content of human breast milk and infant formula. Hyperkalemia, hyponatremia, and hypoglycemia are prominent presenting signs of adrenal insufficiency in infants. Ketosis is not consistently present because infants generate ketones less well than do older children. Hyperpigmentation is not usually seen because this takes weeks or months to develop, and orthostatic hypotension is obviously difficult to demonstrate in infants.

Infants can become ill very quickly. There may be only a few days of decreased activity, anorexia, and vomiting before critical electrolyte abnormalities develop.

In older children with Addison disease, symptoms include muscle weakness, malaise, anorexia, vomiting, weight loss, and orthostatic hypotension. These may be of insidious onset. It is not unusual to elicit, in retrospect, an episodic history spanning years with symptoms being noticeable only during intercurrent illnesses. Such patients can present with acute decompensation **(adrenal crisis)** during relatively minor infectious illnesses. *Some of these patients have been initially misdiagnosed with chronic fatigue syndrome, postmononucleosis syndrome, chronic Lyme disease, or psychiatric disorders (depression or anorexia nervosa).*

Hyperpigmentation is often, but not necessarily, present. **Hyponatremia** is present at diagnosis in almost 90% of patients. **Hyperkalemia** tends to occur later in the course of the disease in older children than in infants and is present in only half of patients at diagnosis. *Normal potassium levels must never be presumed to rule out primary adrenal insufficiency.*

Hypoglycemia and ketosis are common. The clinical presentation can be easily confused with gastroenteritis or other acute infections. Chronicity of symptoms can alert the clinician to the possibility of Addison disease, but this diagnosis should be considered in any child with

orthostatic hypotension, hyponatremia, hypoglycemia, and ketosis. Salt craving is seen in primary adrenal insufficiency with mineralocorticoid deficiency. Fatigue, myalgias, fever, eosinophilia, lymphocytosis, hypercalcemia, and anemia may be noted with glucocorticoid deficiency.

LABORATORY FINDINGS

Hypoglycemia, ketosis, hyponatremia, and hyperkalemia have been discussed. An electrocardiogram is useful for quickly detecting hyperkalemia in a critically ill child. Acidosis is often present, and the blood urea nitrogen level is elevated if the patient is dehydrated.

Cortisol levels are sometimes at the low end of the normal range but are invariably low when the patient's degree of illness is considered. ACTH levels are high in primary adrenal insufficiency but can take time to be reported by the laboratory. Similarly, aldosterone levels may be within the normal range but inappropriately low considering the patient's hyponatremia, hyperkalemia, and hypovolemia. Plasma renin activity is elevated. Blood eosinophils may be increased in number, but this is rarely useful diagnostically.

Urinary excretion of sodium and chloride is increased and urinary potassium is decreased, but these are difficult to assess in random urine samples. Accurate interpretation of urinary electrolytes requires more prolonged (24 hours) urine collections and knowledge of the patient's sodium and potassium intake.

The most definitive test for adrenal insufficiency is measurement of serum levels of cortisol before and after administration of ACTH; resting levels are low and do not increase normally after administration of ACTH. Occasionally, normal resting levels that do not increase after administration of ACTH indicate an absence of adrenocortical reserve. A low initial level followed by a significant response to ACTH can indicate secondary adrenal insufficiency. Traditionally, this test has been performed by measuring cortisol levels before and 30 or 60 minutes after giving 0.250 mg of cosyntropin (ACTH 1-24) by rapid intravenous infusion. Aldosterone will transiently increase in response to this dose of ACTH and may also be measured. A low-dose test (1 μg ACTH 1-24/1.73 m^2) is a more sensitive test of pituitary-adrenal reserve but has somewhat lower specificity (more false-positive tests).

DIFFERENTIAL DIAGNOSIS

Upon presentation, Addison disease often needs to be distinguished from more acute illnesses such as gastroenteritis with dehydration or sepsis. Additional testing is directed at identifying the specific cause for adrenal insufficiency. When CAH is suspected, serum levels of cortisol precursors (17-hydroxyprogesterone) should be measured along with cortisol in an ACTH stimulation test (see Chapter 616) (Fig. 615.2). Elevated levels of very long-chain fatty acids are diagnostic of ALD (see Chapter 639.3). Many genetic etiologies for primary adrenal insufficiency may be identified by direct genetic testing, but it can take weeks for results to become available. The presence of antiadrenal antibodies suggests an autoimmune pathogenesis. Patients with autoimmune Addison disease must be closely observed for the development of other autoimmune disorders. In children, hypoparathyroidism is a commonly associated disorder, and it is suspected if hypocalcemia and elevated phosphate levels are present.

Ultrasonography, CT, or MRI can help to define the size of the adrenal glands, but this is not usually necessary.

TREATMENT

Treatment of acute adrenal insufficiency must be immediate and vigorous. If the diagnosis of adrenal insufficiency has not been established, a blood sample should be obtained before therapy to determine electrolytes, glucose, ACTH, cortisol, aldosterone, and plasma renin activity. If the patient's condition permits, an ACTH stimulation test can be performed while initial fluid resuscitation is underway. An intravenous solution of 5% glucose in 0.9% saline should be administered to correct hypoglycemia, hypovolemia, and hyponatremia. Hypotonic fluids (e.g., 5% glucose in water or 0.2% saline) must be avoided because they can precipitate or exacerbate hyponatremia. If hyperkalemia is severe, it can require treatment with intravenous calcium and/or bicarbonate, intrarectal potassium-binding resin (sodium polystyrene sulfonate, Kayexalate), or intravenous infusion of glucose and insulin. A water-soluble form of hydrocortisone, such as hydrocortisone sodium succinate, should be given intravenously. As much as 10 mg for infants, 25 mg for toddlers, 50 mg for older children, and 100 mg for adolescents should be administered as a bolus and a similar total amount then given in divided doses at 6-hour intervals for the first 24 hours. These doses may be reduced during the next 24 hours if progress is satisfactory. Adequate fluid and sodium repletion is achieved by intravenous saline administration, aided by the mineralocorticoid effect of high doses of hydrocortisone.

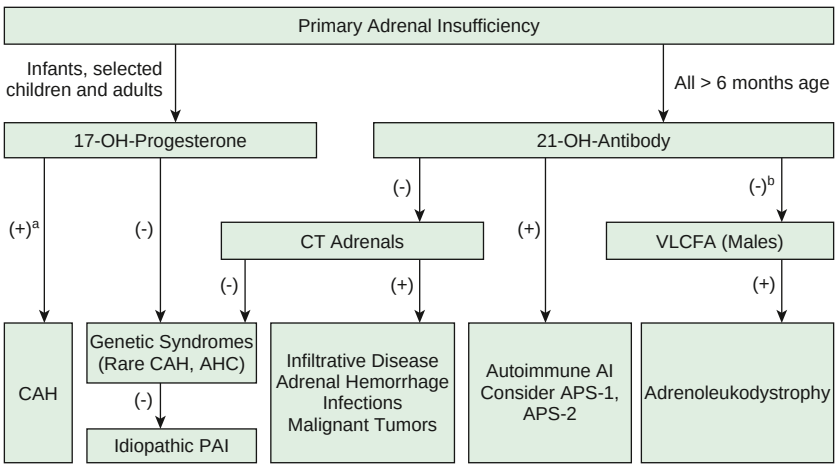

Fig. 615.2 Algorithm for the diagnostic approach to the patient with primary adrenal insufficiency (PAI). The most common causes of PAI are autoimmune destruction of the adrenal cortex in adults and congenital adrenal hyperplasia (CAH) in children. These etiologies can be screened for using 21-hydroxylase antibodies and a baseline serum 17-hydroxyprogesterone level, respectively. Males with negative 21-hydroxylase antibodies should be tested for adrenoleukodystrophy with plasma VLCFAs. If these diagnoses are excluded, a CT scan of the adrenals may reveal evidence of adrenal infiltrative processes or metastases, but this is of low yield in children and adolescents. The individual's clinical picture and family history may render some steps in the algorithm redundant or suggest specific genetic syndromes. The latter includes subtypes of autoimmune polyglandular syndromes or specific rare genetic disorders where adrenal failure is part of a broader phenotype. AHC, Adrenal hypoplasia congenita; AI, adrenal insufficiency; APS-1, type 1 autoimmune polyendocrinopathy syndrome; VLCFA, very long-chain fatty acid. [a]17-OH-progesterone >1,000 ng/dL is diagnostic for 21-OH deficiency. [b]VLCFA should be measured in the initial evaluation of preadolescent boys. *(Adapted from Husebye ES, Allolio B, Arlt W, et al. Consensus statement on the diagnosis, treatment, and follow-up of patients with primary adrenal insufficiency. J Intern Med. 2014;275:104–115.)*

Caution should be exercised in the rare patient with concomitant adrenal insufficiency and hypothyroidism, because thyroxine can increase cortisol clearance. Thus an adrenal crisis may be precipitated if hypothyroidism is treated without first ensuring adequate glucocorticoid replacement.

After the acute manifestations are under control, most patients require chronic replacement therapy for their cortisol and aldosterone deficiencies. Hydrocortisone (cortisol) may be given orally in daily doses of 10 mg/m^2/24 hr in three divided doses; some patients require 15 mg/m^2/24 hr to minimize fatigue, especially in the morning. Dividing the hydrocortisone into four doses daily may yield more physiologic drug profiles, but adherence to such frequent dosing may be problematic. Timed-release preparations of hydrocortisone are available in Europe and are undergoing clinical trials in the United States as of 2021. Subcutaneous infusion of hydrocortisone with a pump has also been examined in clinical trials; although this has the advantage that it can very closely mimic normal diurnal variation in cortisol secretion, it is expensive and has not yet entered routine clinical practice. Equivalent doses (20–25% of the hydrocortisone dose) of prednisone or prednisolone may be divided and given twice daily. ACTH levels may be used to monitor adequacy of glucocorticoid replacement in primary adrenal insufficiency; in CAH, levels of precursor hormones are used instead. Blood samples for monitoring should be obtained at a consistent time of day and in a consistent relation to (i.e., before or after) the hydrocortisone dose. Normalizing ACTH levels is unnecessary and can require excessive doses of hydrocortisone; in general, morning ACTH levels high in the normal range to 3-4 times normal are satisfactory. Because untreated or severely undertreated patients can acutely decompensate during relatively minor illnesses, assessment of symptoms (or lack thereof) should not be used as a substitute for biochemical monitoring. During situations of stress, such as periods of infection or minor operative procedures, the dose of hydrocortisone should be increased twofold to threefold. Major surgery under general inhalation anesthesia requires high intravenous doses of hydrocortisone similar to those used for acute adrenal insufficiency.

If aldosterone deficiency is present, fludrocortisone, a synthetic mineralocorticoid, is given orally in doses of 0.05-0.2 mg daily. Measurements of plasma renin activity are useful in monitoring the adequacy of mineralocorticoid replacement. Chronic overdosage with glucocorticoids leads to obesity, short stature, and osteoporosis, whereas overdosage with fludrocortisone results in hypertension and occasionally hypokalemia.

Replacement of dehydroepiandrosterone (DHEA) in adults remains controversial; prepubertal children do not normally secrete large amounts of DHEA. Many adults with Addison disease complain of having decreased energy, and replacing DHEA can improve this problem, particularly in women in whom adrenal androgens represent approximately 50% of total androgen secretion.

Additional therapy might need to be directed at the underlying cause of the adrenal insufficiency regarding infections and certain metabolic defects. Previous therapeutic approaches to ALD included administration of glycerol trioleate and glycerol trierucate (Lorenzo's oil), bone marrow transplantation, and lovastatin (see Chapter 639.3). Introducing a normal *ABCD1* gene into autologous stem cells with a lentiviral vector (officially termed *elivaldogene autotemcel*) has shown excellent results in preventing neurologic progression, but it remains investigational as of 2021.

Visit Elsevier eBooks+ at eBooks.Health.Elsevier.com for Bibliography.

615.2 Secondary and Tertiary Adrenal Insufficiency

Perrin C. White

ABRUPT CESSATION OF ADMINISTRATION OF CORTICOSTEROIDS

Secondary adrenal insufficiency most commonly occurs when the HPA axis is suppressed by prolonged administration of high doses of a potent glucocorticoid and that agent is suddenly withdrawn or the dose is tapered too quickly. Patients at risk for this problem include those with leukemia, asthma (particularly when patients are transitioned from oral to inhaled corticosteroids), and collagen vascular disease or other autoimmune conditions and those who have undergone tissue transplants or neurosurgical procedures. The maximal duration and dosage of glucocorticoid that can be administered before encountering this problem is not known, but it is assumed that high-dose glucocorticoids (the equivalent of >10 times physiologic cortisol secretion) can be administered for less than 1 week without requiring a subsequent taper of dose. On the other hand, when high doses of dexamethasone are given to children with leukemia, it can take 6 months or longer after therapy is stopped before tests of adrenal function return to normal. Signs and symptoms of adrenal insufficiency are most likely in patients who are subsequently subjected to stresses such as severe infections or additional surgical procedures.

Corticotropin (Adrenocorticotropic Hormone) Deficiency

Pituitary or hypothalamic dysfunction can cause corticotropin deficiency (see Chapter 595), usually associated with deficiencies of other pituitary hormones such as growth hormone and thyrotropin. Destructive lesions in the area of the pituitary, such as craniopharyngioma and germinoma, are the most common causes of corticotropin deficiency. In many cases the pituitary or hypothalamus is further damaged during surgical removal or radiotherapy of tumors in the midline of the brain. Traumatic brain injury (see Chapter 750) frequently causes pituitary dysfunction, especially in the first days after the injury. However, corticotropin deficiency is difficult to detect in that period owing to frequent use of high doses of dexamethasone to minimize brain swelling, and permanent corticotropin deficiency is unusual after traumatic brain injury. In rare instances, autoimmune hypophysitis is the cause of corticotropin deficiency.

Congenital lesions of the pituitary also occur. The pituitary alone may be affected, or additional midline structures may be involved, such as the optic nerves or septum pellucidum. The latter type of abnormality is termed **septo-optic dysplasia**, or de Morsier syndrome (see Chapter 631.9). More severe developmental anomalies of the brain, such as anencephaly and holoprosencephaly, can also affect the pituitary. These disorders are usually sporadic, although a few cases of autosomal recessive inheritance have occurred. Isolated deficiency of corticotropin has been reported, including in several sets of siblings. Patients with multiple pituitary hormone deficiencies caused by pathogenic variants in the *PROP1* gene may develop progressive ACTH/cortisol deficiency. Isolated deficiency of corticotropin-releasing hormone has been documented in an Arab kindred as an autosomal recessive trait.

Up to 60% of children with **Prader-Willi syndrome** (see Chapter 99.8) have some degree of secondary adrenal insufficiency as assessed by provocative testing with metyrapone, although diurnal cortisol levels are normal. The clinical significance of this finding is uncertain, but it might contribute to the relatively high incidence of sudden death with infectious illness that occurs in this population. Although it is not yet a standard of care, some endocrinologists advocate treating patients who have Prader-Willi syndrome with hydrocortisone during febrile illness.

CLINICAL PRESENTATION

Aldosterone secretion is unaffected in secondary adrenal insufficiency because the adrenal gland is, by definition, intact and the renin-angiotensin system is not involved. Thus signs and symptoms are those of cortisol deficiency. Newborns often have hypoglycemia. Older children can have orthostatic hypotension or weakness. Hyponatremia may be present.

When secondary adrenal insufficiency is the consequence of an inborn or acquired anatomic defect involving the pituitary, there may be signs of associated deficiencies of other pituitary hormones. The penis may be small in male infants if gonadotropins are also deficient. Infants with secondary hypothyroidism are often jaundiced. Children with associated growth hormone deficiency grow poorly after the first year of life.

Some children with pituitary abnormalities have hypoplasia of the midface. Children with optic nerve hypoplasia can have obvious visual impairment. They usually have a characteristic wandering nystagmus, but this is often not apparent until several months of age.

LABORATORY FINDINGS

Because the adrenal glands themselves are not directly affected, the diagnosis of secondary adrenal insufficiency is sometimes challenging. The most commonly used test to diagnose secondary adrenal insufficiency is **low-dose ACTH stimulation testing** (1 μg/1.73 m^2 of cosyntropin given intravenously), the rationale being that there will be some degree of atrophy of the adrenal cortex if normal physiologic ACTH stimulation is lacking. Thus this test may be falsely negative in cases of acute compromise of the pituitary (e.g., injury or surgery). Such circumstances rarely pose a diagnostic dilemma; in general, this test provides excellent sensitivity and specificity. Although assays vary somewhat, a threshold cortisol level of 18-20 μg/dL 30 minutes after cosyntropin administration may be used to dichotomize normal and abnormal responses.

There seems to be little reason to use stimulation with corticotropin-releasing hormone instead of ACTH; although the corticotropin-releasing hormone test has the theoretical advantage of testing the ability of the anterior pituitary to respond to this stimulus by secreting ACTH (thus distinguishing secondary and tertiary adrenal insufficiency), in practice it does not provide improved sensitivity and specificity, and the agent is not as widely available.

TREATMENT

Iatrogenic secondary adrenal insufficiency (caused by chronic glucocorticoid administration) is best avoided by use of the smallest effective doses of systemic glucocorticoids for the shortest period. When a patient is thought to be at risk, tapering the dose rapidly to a level equivalent to or slightly less than the physiologic replacement (~10 mg/m^2/24 hr of hydrocortisone) and further tapering over several weeks can allow the adrenal cortex to recover without the patient developing signs of adrenal insufficiency. Patients with anatomic lesions of the pituitary should be treated indefinitely with glucocorticoids. Mineralocorticoid replacement is not required. In patients with panhypopituitarism, treating cortisol deficiency can increase free water excretion, thus unmasking central diabetes insipidus. Electrolytes must be monitored carefully when initiating cortisol therapy in panhypopituitary patients.

Visit Elsevier eBooks+ at eBooks.Health.Elsevier.com for Bibliography.

615.3 Adrenal Insufficiency in the Critical Care Setting

Perrin C. White

Critical illness–related corticosteroid insufficiency (CIRCI) is encountered in up to 20–50% of critically ill pediatric patients, often as a transient condition. In many cases, it is considered functional or relative in nature, meaning that cortisol levels are within normal limits but cannot increase sufficiently to meet the demands of critical illness. The causes are heterogeneous (see Chapter 615.1). They include adrenal hypoperfusion from shock, particularly septic shock, as is often seen in meningococcemia. Inflammatory mediators during septic shock, particularly interleukin-6, can suppress ACTH secretion, directly suppress cortisol secretion, or both. Etomidate, used as sedation for intubation, inhibits steroid 11β-hydroxylase and thus blocks cortisol biosynthesis. Neurosurgical patients with closed head trauma or with tumors that involve the hypothalamus or pituitary might have ACTH deficiency in the context of panhypopituitarism. Some children have been previously treated with systemic corticosteroids (e.g., children with leukemia) and have suppression of the HPA axis for that reason. In the intensive care nursery, premature infants have not yet developed normal cortisol biosynthetic capacity and thus may not be able to secrete adequate amounts of this hormone when ill.

Additionally, plasma clearance of cortisol is markedly reduced during critical illness, owing to decreased activity of cortisol-metabolizing enzymes in the liver and kidney. Although this may help defend plasma levels of cortisol in the context of decreased cortisol secretion, the inflammation associated with sepsis may increase glucocorticoid resistance through activation of mitogen-activated protein kinases (MAPKs) and decreased activity of their regulators, dual-specific phosphatases (DUSPs).

CLINICAL MANIFESTATIONS

Cortisol is required for catecholamines to have their normal pressor effects on the cardiovascular system (see Chapters 614.4 and 614.5). Accordingly, adrenal insufficiency is often suspected in hypotensive patients who do not respond to intravenous pressor agents. Patients may be at increased risk for hypoglycemia or a presentation resembling the syndrome of inappropriate antidiuretic hormone secretion, but these conditions commonly occur in the context of sepsis, and the contribution of adrenal insufficiency may be difficult to distinguish.

LABORATORY FINDINGS

Although low random cortisol levels in severely stressed patients are certainly abnormal, very high levels are also associated with a poor outcome in such patients; the latter situation presumably reflects a maximally stimulated adrenal cortex with diminished reserve. ACTH (cosyntropin) stimulation testing is generally considered the best way to diagnose adrenal insufficiency in this setting (see Chapter 615.1); evidence suggests that the low-dose (1 μg/1.73 m^2) test may be superior to the 250-μg standard dose test, although this remains controversial. In general, a peak cortisol level <18 μg/dL or an increment of <9 μg/dL from baseline is considered suggestive for adrenal insufficiency in this context. In evaluating cortisol levels, cortisol in the circulation is mostly bound to cortisol-binding globulin; in hypoproteinemic states, total cortisol levels may be decreased, whereas free cortisol levels might be normal. It may be prudent to measure free cortisol before initiating treatment when total cortisol is low and albumin is <2.5 g/dL, but such measurements are not readily available in all institutions.

TREATMENT

It is likely that stress doses of hydrocortisone (e.g., 100 mg/m^2/day) improve responses to pressor agents in patients with shock *and* documented adrenal insufficiency (Waterhouse-Friderichsen syndrome). In adults with sepsis, corticosteroids probably reduce intensive care unit (ICU) and hospital length of stay and 28-day and hospital mortality, but there are limited data regarding treatment efficacy in critically ill children. The Surviving Sepsis Guidelines suggest using IV hydrocortisone (or not using it) to treat pediatric septic shock only if fluids and vasopressor therapy are unable to restore hemodynamic stability. This is a weak recommendation with low-quality evidence.

Visit Elsevier eBooks+ at eBooks.Health.Elsevier.com for Bibliography.

615.4 Altered End-Organ Sensitivity to Corticosteroids

Perrin C. White

Diseases can result from altered actions of hormones at their physiologic targets. These may be caused by abnormal metabolism of hormones, mutations in hormone receptors, or defects in cellular effectors (such as ion channels) that are targets of hormone action.

GENERALIZED GLUCOCORTICOID RESISTANCE

Patients with generalized glucocorticoid resistance have target-tissue insensitivity to glucocorticoids. The condition is usually inherited in an autosomal dominant manner, but sporadic cases occur. Impairment of normal negative feedback of cortisol at the levels of the hypothalamus and pituitary activates the HPA axis, with consequent increases in ACTH and cortisol concentrations. Generalized glucocorticoid resistance is caused by pathogenic variants in the glucocorticoid receptor *(NR3C1)*. Most variants are heterozygous; glucocorticoid receptors usually bind DNA as dimers, and three out of four dimers will contain at least one abnormal receptor molecule when a heterozygous variant is present.

Clinical Manifestations

The excess ACTH secretion causes adrenal hyperplasia with increased production of adrenal steroids with mineralocorticoid activity, including cortisol, deoxycorticosterone, and corticosterone, and also androgens and precursors, including androstenedione, DHEA, and DHEA sulfate. The high cortisol concentrations do not cause Cushing syndrome (see Chapter 619) because of the insensitivity to glucocorticoids; conversely, most signs and symptoms of adrenal insufficiency are absent except for the frequent occurrence of chronic fatigue and occasional anxiety (neonatal hypoglycemia was reported in one very unusual patient with a homozygous null variant). The mineralocorticoid and androgen receptors are normally sensitive to their ligands. Signs of **mineralocorticoid excess**, such as hypertension and hypokalemic alkalosis, are frequently noted. The increased concentrations of adrenal androgens may cause ambiguous genitalia in females and gonadotropin-independent precocious puberty in children of either gender; acne, hirsutism, and infertility in both sexes; menstrual irregularities in females; and oligospermia in males. Testicular adrenal rest tumors and ACTH-secreting pituitary adenomas occasionally occur.

Laboratory Findings

The diagnosis of generalized glucocorticoid resistance is suggested by elevated serum cortisol concentrations and increased 24-hour urinary free cortisol excretion in the absence of Cushing syndrome. Levels of other adrenal steroids are also increased. Plasma concentrations of ACTH may be normal or high. The circadian pattern of ACTH and cortisol secretion is preserved, although at higher-than-normal concentrations, and there is resistance of the HPA axis to dexamethasone suppression. Sequencing of the *NR3C1* gene can confirm the diagnosis.

Differential Diagnosis

Generalized glucocorticoid resistance should be distinguished from relatively mild cases of Cushing syndrome (whether caused by a pituitary adenoma or adrenal tumor, see Chapter 619); the latter is more likely to be associated with excessive weight gain or poor linear growth. Adrenocortical tumors may secrete mineralocorticoids such as deoxycorticosterone and also androgens, but ACTH levels are often suppressed and, of course, the tumor can usually be visualized with appropriate imaging techniques. CAH (see Chapter 616), particularly 11β-hydroxylase deficiency, may present with hypertension and signs of androgen excess, but in that condition cortisol levels are low and levels of cortisol precursors (17-hydroxyprogesterone, 11-deoxycortisol) are elevated. Obese patients may be hypertensive and have hyperandrogenism, but cortisol secretion should be readily suppressed by dexamethasone.

Treatment

The goal of treatment is to suppress the excess secretion of ACTH, thereby suppressing the increased production of adrenal steroids with mineralocorticoid and androgenic activity. This requires administration of high doses of a pure glucocorticoid agonist such as dexamethasone (typically ~20-40 μg/kg/day) with careful titration to suppress endogenous corticosteroid secretion without causing signs of glucocorticoid excess such as excessive weight gain or suppression of linear growth.

CORTISONE REDUCTASE DEFICIENCY

Levels of active glucocorticoids in target tissues are modulated by two isozymes of 11β-hydroxysteroid dehydrogenase. The HSD11B2 isozyme converts cortisol to an inactive metabolite, cortisone; the two steroids differ in the presence of an 11β-hydroxyl versus an 11-oxo group, respectively. Pathogenic variants in this enzyme cause the syndrome of **apparent mineralocorticoid excess**. Conversely, the HSD11B1 isozyme converts cortisone to cortisol, and so it is sometimes referred to as *cortisone reductase*. This isozyme is expressed at high levels in glucocorticoid target tissues, particularly the liver, where it ensures adequate levels of active glucocorticoids (cortisol and corticosterone) to meet metabolic demands without requiring excessive adrenal cortisol secretion.

The HSD11B1 isozyme is located in the endoplasmic reticulum (i.e., it is a microsomal enzyme) and functions as a dimer. It accepts electrons from reduced nicotine–adenine dinucleotide phosphate, which is generated within the endoplasmic reticulum by hexose-6-phosphate dehydrogenase, an enzyme distinct from cytoplasmic glucose-6-phosphate dehydrogenase.

Apparent cortisone reductase deficiency is caused by homozygous pathogenic variants in hexose-6-phosphate dehydrogenase that prevent generation of reduced nicotine–adenine dinucleotide phosphate within the endoplasmic reticulum and thus starve HSD11B1 of its essential cofactor for the reductase reaction. Very rare patients have been reported to have heterozygous variants in *HSD11B1* itself and thus have "true" cortisone reductase deficiency; because the enzyme functions as a homodimer, heterozygous variants are able to impair three fourths of all dimers.

Clinical Manifestations

Because circulating cortisone is not converted to cortisol, the circulating half-life of cortisol is decreased, and the adrenal cortex must secrete additional cortisol to compensate. This leads to adrenocortical overactivity analogous to, but generally much milder than, that seen in generalized glucocorticoid resistance. This is usually not severe enough to cause hypertension, presenting instead with mild to moderate signs of androgen excess such as hirsutism, oligomenorrhea or amenorrhea, and infertility in females and precocious pseudopuberty (axillary and pubic hair and penile enlargement, but not testicular enlargement) in males.

Laboratory Findings

The ratio of cortisol to cortisone in blood is lower than usual. The same is true of urinary metabolites, typically measured as a ratio of the sum of the tetrahydrocortisol and allotetrahydrocortisol excretion to that of tetrahydrocortisone. These determinations are best accomplished by gas chromatography followed by mass spectrometry and are available in specialized reference laboratories. Absolute levels of cortisol and ACTH are within normal limits.

Differential Diagnosis

Cortisone reductase deficiency should be distinguished from and is much less common than other causes of androgen excess such as polycystic ovarian syndrome and nonclassical CAH as a result of 21-hydroxylase deficiency.

Treatment

Treatment is aimed at decreasing adrenal overactivity and thus reducing secretion of androgens. This can be accomplished by administration of hydrocortisone.

ALTERED END-ORGAN SENSITIVITY TO MINERALOCORTICOIDS

Pseudohypoaldosteronism

Pseudohypoaldosteronism type 1 (PHA1) is a monogenic disease in which aldosterone action is deficient and patients are thus unable

to resorb urinary sodium or excrete potassium properly. There are two forms. A relatively mild autosomal dominant form is caused by pathogenic variants in *NR3C2* encoding the human mineralocorticoid receptor. A heterozygous variant is sufficient to cause disease because the mineralocorticoid receptor interacts with DNA as a dimer, and three fourths of the dimers are defective in individuals carrying heterozygous variants (assuming mutant protein is synthesized). A more severe autosomal recessive form is usually the result of homozygous pathogenic variants in the α *(SCNN1A)*, β *(SCNN1B)*, or γ *(SCNN1G)* subunits of the epithelial Na^+ channel; one reported case of severe autosomal recessive disease was caused by homozygous variants in *NR3C2*.

PHA1 should not be confused with **pseudohypoaldosteronism type 2**, a rare mendelian syndrome characterized by hyperkalemia and, in contrast to PHA1, by hypertension from excessive renal sodium reabsorption. This disorder is caused by variants in the renal regulatory kinases WNK1 and WNK4 or components of an E3 ubiquitin ligase complex, Kelch-like 3 (KLHL3) and Cullin 3 (CUL3).

Transient or "secondary" (nongenetic) pseudohypoaldosteronism can occur in infants, mainly male, with urinary tract malformations and/or urinary tract infections.

Clinical Manifestations

Infants with PHA1 present with hyperkalemia, hyponatremia, hypovolemia, hypotension, and failure to thrive. In more severe (usually autosomal recessive) cases, salt loss is not confined to the kidney, but instead occurs from most epithelia. Mothers may report that the skin of their affected infants tastes salty. Some infants suffer from *cystic fibrosis–like pulmonary symptoms*. It is often difficult to control electrolyte abnormalities in patients with the autosomal recessive form, leading to frequent hospitalizations and a need for close clinical monitoring.

It is noteworthy that signs and symptoms of aldosterone deficiency tend to remit as the patients get older, particularly in the autosomal dominant form. This is similar to what is seen in actual aldosterone deficiency, as occurs in the salt-losing forms of CAH or aldosterone synthase deficiency. The kidney matures after early infancy to become more efficient at excreting potassium, and although breast milk and infant formula are low in sodium, the normal adult Western diet is relatively high in sodium, thus compensating for the renal salt wasting.

Laboratory Findings

Infants have marked hyperkalemia and hyponatremia. Both plasma renin and aldosterone are markedly elevated. Levels of cortisol and ACTH are normal. If hypovolemia is severe, patients may develop prerenal azotemia. With severe hyperkalemia, the electrocardiogram may include tall-peaked T waves or ventricular tachycardia.

Differential Diagnosis

PHA in infants should be distinguished from other causes of hyperkalemia and hyponatremia. These include renal failure of any cause, CAH, aldosterone synthase deficiency, and other causes of adrenocortical insufficiency such as AHC. Patients with renal failure will have elevated blood urea nitrogen and creatinine, but these may also be seen in severely dehydrated patients with PHA or adrenal insufficiency. Patients with any form of adrenal insufficiency in this clinical context will have low or low-normal aldosterone levels (with elevated plasma renin), in contrast to the elevated aldosterone levels seen in PHA. Patients with CAH have elevated levels of steroid precursors such as 17-hydroxyprogesterone (in patients with 21-hydroxylase deficiency), and patients with most forms of adrenal insufficiency have elevated ACTH levels.

Treatment

Infants must be given sodium supplementation (initially IV and then oral or enteral), typically approximately 8 mEq/kg/day. Potassium levels in the infant formula often need to be reduced, which may be accomplished by mixing the formula with polystyrene resin (Kayexalate) and then decanting the formula before feeding. Fludrocortisone, a synthetic mineralocorticoid, may be efficacious in milder autosomal dominant cases if administered in high doses (titrating up to ~0.5 mg daily). Significant electrolyte abnormalities require treatment with IV normal saline and rectal polystyrene resin. Severe hyperkalemia may require glucose and insulin infusions to keep it under control.

Secondary PHA owing to urinary tract infections or malformations generally resolves when the underlying condition is treated.

ACTIVATING PATHOGENIC VARIANTS IN THE MINERALOCORTICOID RECEPTOR

In contrast to PHA1, the S810L (serine-810 to leucine) variant of *NR3C2* causes autosomal dominant, severe, early-onset hypertension. This variant alters the ligand specificity of the mineralocorticoid receptor so that it is activated by cortisone and so HSD11B2 cannot protect it. It is also activated by progesterone, and consequently the hypertension is *exacerbated by pregnancy*. Conversely, the glucocorticoid and progesterone receptor antagonist mifepristone (RU-486) antagonizes the mutant receptor and might be useful therapeutically in nonpregnant individuals.

APPARENT MINERALOCORTICOID EXCESS

The syndrome of apparent mineralocorticoid excess is an autosomal recessive disorder caused by pathogenic variants in *HSD11B2* encoding the type 2 isozyme of 11β-hydroxysteroid dehydrogenase. The mineralocorticoid receptor has nearly identical affinities for aldosterone (the main mineralocorticoid hormone) and cortisol, yet cortisol is normally only a weak mineralocorticoid in vivo. This is because HSD11B2 is expressed along with the mineralocorticoid receptor in most target tissues such as the renal cortical collecting duct epithelium. It converts cortisol to cortisone, which is not an active steroid, thus preventing it from occupying the mineralocorticoid receptor. In contrast, aldosterone is not a substrate for the enzyme because its 11β-hydroxyl group forms a hemiketal with the 18-aldehyde group of the steroid and is thus not accessible to the enzyme. Thus in the absence of HSD11B2, cortisol efficiently occupies the mineralocorticoid receptor, and because cortisol concentrations are normally far higher than those of aldosterone, this results in signs and symptoms of mineralocorticoid excess.

A similar clinical picture occurs with excessive consumption of licorice or licorice-flavored chewing tobacco; licorice contains compounds, including glycyrrhetinic and glycyrrhizic acids, that inhibit HSD11B2. Carbenoxolone, an antihypertensive drug that is not marketed in the United States, has similar effects.

Clinical Manifestations

Affected infants often have some degree of intrauterine growth restriction, with birthweights of 2 kg typical for term infants. Infants and children often fail to thrive. Severe hypertension (to ~200/120 mm Hg) is almost always present. In some patients, the hypertension tends to be labile or paroxysmal with severe emotional stress as a precipitating factor. Complications of hypertension have included cerebrovascular accidents. Several patients have died during infancy or adolescence, either from electrolyte imbalances leading to cardiac arrhythmias or from vascular sequelae of hypertension. Hypokalemic alkalosis can eventually cause nephrocalcinosis (often visible on renal ultrasound) and nephrogenic diabetes insipidus leading to polyuria and polydipsia. Deleterious effects on muscle range from elevations in serum creatine phosphokinase to rhabdomyolysis. Electrocardiograms show left ventricular hypertrophy.

Laboratory Findings

Hypokalemia and alkalosis are common but not consistently present. Sodium levels are generally in the upper part of the reference range. Aldosterone and renin levels are very low because the

hypertension and hypervolemia are independent of aldosterone concentrations. Serum cortisol and ACTH levels are generally within normal limits. The serum half-life of cortisol is increased, but the test for this requires a radioactive tracer and is not clinically available. Total urinary excretion of cortisol metabolites is markedly decreased. The urinary ratio of free cortisol to free cortisone is elevated, as is the ratio of urinary tetrahydrocortisol plus allotetrahydrocortisol to tetrahydrocortisone.

Differential Diagnosis

The differential diagnosis includes other forms of severe childhood hypertension such as renal artery anomalies, but relatively few conditions present with suppressed renin and aldosterone levels. **Liddle syndrome** has a similar presentation but no abnormalities in the steroid profile, typically has an autosomal dominant mode of inheritance, and does not respond to treatment with mineralocorticoid receptor antagonists. Hypertensive forms of CAH (see Chapter 616) also have suppressed renin and aldosterone levels, but they present with signs of androgen excess (11β-hydroxylase deficiency) or androgen deficiency (17α-hydroxylase deficiency); the latter can be difficult to appreciate in young children. The steroid profiles in CAH differ from those seen in apparent mineralocorticoid excess syndrome.

Patients with severe Cushing syndrome may have high enough cortisol levels to overwhelm renal HSD11B2, leading to severe hypertension with alterations in urinary cortisol-to-cortisone ratios. This occurs most often in patients with ectopic ACTH syndrome. This generally does not present a diagnostic dilemma because other signs of Cushing syndrome are present, including high cortisol levels.

Treatment

Treatment includes a low-salt diet, potassium supplementation, and mineralocorticoid receptor blockade with spironolactone or eplerenone; a sodium channel blocker, such as amiloride or triamterene, may work at least as well. In principle, suppression of cortisol secretion with dexamethasone (which does not bind the mineralocorticoid receptor) should work, but in practice it is much less effective than mineralocorticoid receptor blockade.

LIDDLE SYNDROME

Liddle syndrome is a form of hypertension and hypokalemia that is clinically similar to the syndrome of apparent mineralocorticoid excess, but it is inherited in an autosomal dominant manner. It is caused by an activating pathogenic variant in the β *(SCNN1B)* or γ *(SCNN1G)* subunits of the epithelial sodium channel. Most of these mutations prevent the channel subunits from being ligated to ubiquitin and targeted to the proteasome for degradation, a process that is normally regulated indirectly by aldosterone. The net effect is to increase the number of open channels at the apical surface of epithelial cells of the renal collecting duct, thus facilitating sodium resorption and potassium excretion.

Clinical Manifestations, Laboratory Findings, and Differential Diagnosis

Liddle syndrome is characterized by severe early-onset hypertension and by hypokalemia, which may not be persistent. Aldosterone and renin levels are suppressed, but all steroid hormone levels are normal.

The differential diagnosis is the same as that for apparent mineralocorticoid excess.

Treatment

The mainstays of treatment are a low-salt diet, potassium supplementation, and a sodium channel blocker such as amiloride or triamterene. Mineralocorticoid receptor antagonists such as spironolactone are ineffective.

Visit Elsevier eBooks+ at eBooks.Health.Elsevier.com for Bibliography.

Chapter 616

Congenital Adrenal Hyperplasia and Related Disorders

Perrin C. White and Ming Yang

Congenital adrenal hyperplasia (CAH) is a family of autosomal recessive disorders of cortisol biosynthesis (normal adrenal steroidogenesis is discussed in Chapter 614). Cortisol deficiency increases secretion of corticotropin (adrenocorticotropic hormone [ACTH]), which, in turn, leads to adrenocortical hyperplasia and overproduction of intermediate metabolites. Depending on the enzymatic step that is deficient, there may be signs, symptoms, and laboratory findings of mineralocorticoid deficiency or excess; incomplete virilization or precocious puberty in affected males; and virilization or sexual infantilism in affected females (Figs. 616.1 and 616.2, Table 616.1).

616.1 Congenital Adrenal Hyperplasia Caused by 21-Hydroxylase Deficiency

Perrin C. White and Ming Yang

More than 90% of CAH cases are caused by 21-hydroxylase deficiency. This P450 enzyme (CYP21A2, P450c21) hydroxylates progesterone and 17-hydroxyprogesterone to yield 11-deoxycorticosterone and 11-deoxycortisol, respectively (see Fig. 614.1 in Chapter 614). These conversions are required for synthesis of aldosterone and cortisol, respectively. Both hormones are deficient in the most severe,

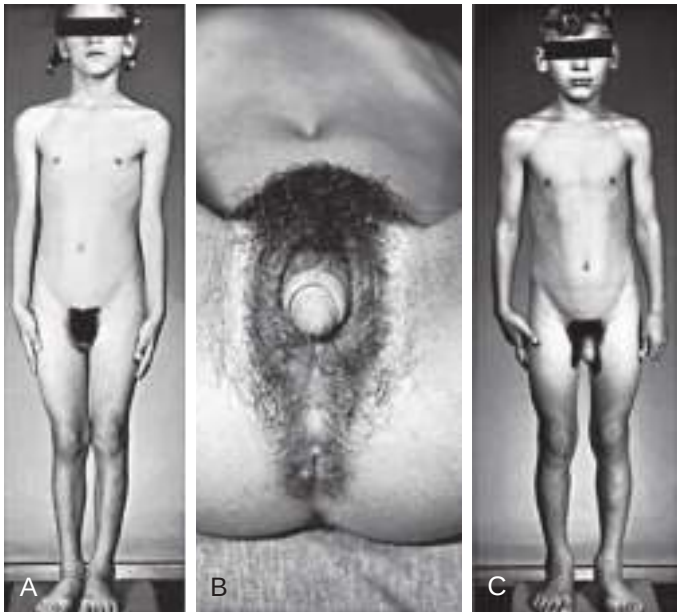

Fig. 616.1 **A,** A 6-yr-old female with congenital virilizing adrenal hyperplasia. The height age was 8.5 yr, and the bone age was 13 yr. **B,** Notice the clitoral enlargement and labial fusion. **C,** Her 5-yr-old brother was not considered to be abnormal by the parents. The height age was 8 yr, and the bone age was 12.5 yr.

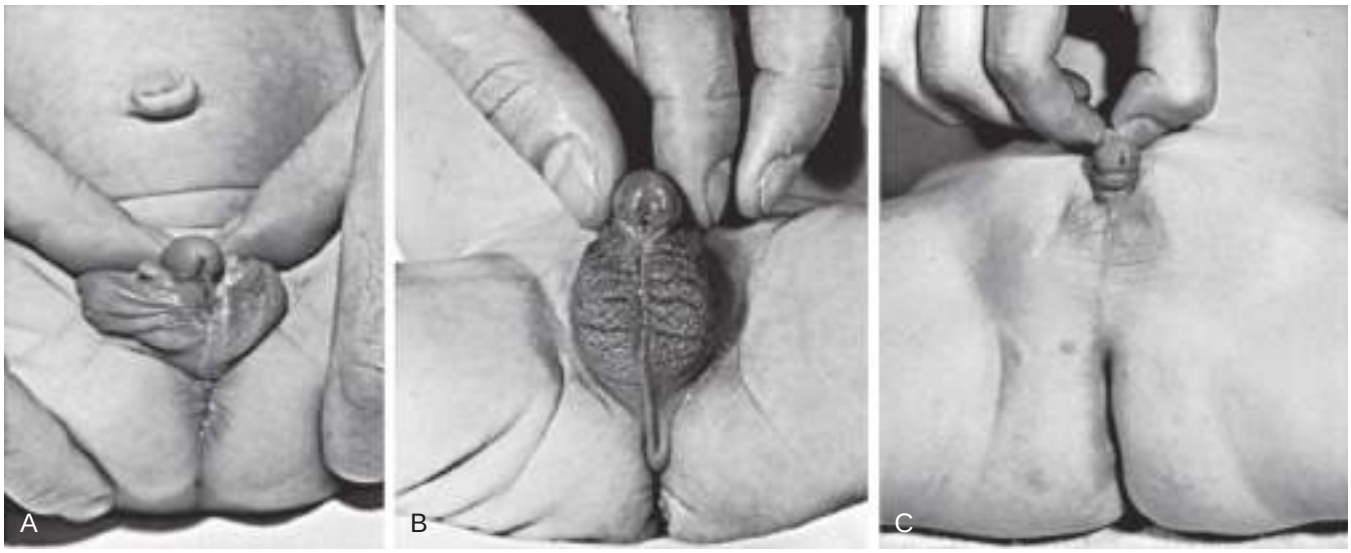

Fig. 616.2 Three virilized females with untreated congenital adrenal hyperplasia. All were erroneously assigned male sex at birth, and each had a normal female sex-chromosome complement. Infants **A** and **B** had the salt-wasting form and received the diagnosis early in infancy. Infant **C** was referred at 1 yr of age because of bilateral cryptorchidism. Notice the completely penile urethra; such complete masculinization in females with adrenal hyperplasia is rare; most of these infants have the salt-wasting form.

salt-wasting form of the disease. Slightly less severely affected patients are able to synthesize adequate amounts of aldosterone but have elevated levels of androgens of adrenal origin; this is termed **simple virilizing disease**. These two forms are collectively termed **classic 21-hydroxylase deficiency**. Patients with **nonclassic** disease have relatively mildly elevated levels of androgens and may be asymptomatic or have signs of androgen excess at any time after birth. Clinical presentation is dependent, in part, on the genotype (Table 616.2).

EPIDEMIOLOGY

Classic 21-hydroxylase deficiency occurs in approximately 1 in 14,000-18,000 births in most populations. Approximately 70% of affected infants have the salt-losing form, whereas 30% have the simple virilizing form of the disorder. In the United States, CAH is less common in African Americans compared with White children (1:42,000 vs 1:15,500). Nonclassic disease has a prevalence of approximately 1 in 1,000 in the general population but occurs more frequently in specific ethnic groups such as Ashkenazi Jews and Hispanics.

GENETICS

There are two steroid 21-hydroxylase genes—*CYP21P (CYP21A1P, CYP21A)* and *CYP21 (CYP21A2, CYP21B)*—which alternate in tandem with two genes for the fourth component of complement (C4A and C4B) in the human leukocyte antigen (HLA) major histocompatibility complex on chromosome 6p21.3 between the HLA-B and HLA-DR loci. Many other genes are in this cluster. *CYP21* is the active gene; *CYP21P* is 98% identical in DNA sequence to *CYP21* but is a pseudogene because of at least 10 different pathogenic variants. Although almost 300 variants have been reported, more than 90% of abnormal alleles causing 21-hydroxylase deficiency are the result of recombinations between *CYP21* and *CYP21P.* Approximately 20% are deletions generated by unequal meiotic crossing-over between *CYP21* and *CYP21P,* whereas the remainder are nonreciprocal transfers of deleterious variants from *CYP21P* to *CYP21,* a phenomenon termed *gene conversion.*

The deleterious variants in *CYP21P* have different effects on enzymatic activity when transferred to *CYP21.* Several variants completely prevent synthesis of a functional protein, whereas others are missense variants that yield enzymes with 1–50% of normal activity. Disease severity correlates well with the variants carried by an affected individual; patients with salt-wasting disease usually carry variants on both alleles that result in no enzymatic activity. Patients are frequently compound heterozygotes for different types of variants (i.e., one allele is less severely affected than the other), in which case the severity of disease expression is largely determined by the activity of the less severely affected of the two alleles.

Closely adjacent to, but on the opposite DNA strand from, *CYP21* is the tenascin-X *(TNX)* gene, which encodes a connective tissue protein. Rarely, deletions of *CYP21* extend into *TNX*. Such patients may have a contiguous gene syndrome (see Chapter 99.1) consisting of CAH and **Ehlers-Danlos syndrome** (see Chapter 744).

PATHOGENESIS AND CLINICAL MANIFESTATIONS

Aldosterone and Cortisol Deficiency

Because both cortisol and aldosterone require 21-hydroxylation for their synthesis, both hormones are deficient in the most severe, salt-wasting form of the disease. This form constitutes approximately 70% of cases of classic 21-hydroxylase deficiency. The signs and symptoms of cortisol and aldosterone deficiency, and the pathophysiology underlying them, are essentially those described in adrenal insufficiency (see Chapter 615). These include progressive weight loss, anorexia, vomiting, dehydration, weakness, hypotension, hypoglycemia, hyponatremia, and hyperkalemia. These problems typically first develop in affected infants at approximately 10-14 days of age. Without treatment, shock, cardiac arrhythmias, and death may occur within days or weeks.

CAH differs from other causes of primary adrenal insufficiency in that precursor steroids accumulate proximal to the blocked enzymatic conversion. Because cortisol is not synthesized efficiently, ACTH levels are high, leading to hyperplasia of the adrenal cortex and levels of precursor steroids that may be hundreds of times normal. In the case of 21-hydroxylase deficiency, these precursors include 17-hydroxyprogesterone and progesterone. Progesterone and perhaps other metabolites act as antagonists of the mineralocorticoid receptor and thus may exacerbate the effects of aldosterone deficiency in untreated patients.

It is not unusual for children with classic CAH to require hospitalization for intercurrent illnesses during childhood. This is most likely to occur in the first 2 years of life and to be precipitated by gastroenteritis, because such illnesses may cause fluid and electrolyte losses, and vomiting may interfere with medication dosing. Children requiring high fludrocortisone doses are most likely to be hospitalized, presumably because those patients have the greatest propensity to salt wasting.

Prenatal Androgen Excess

The most important problem caused by accumulation of steroid precursors is that 17-hydroxyprogesterone is shunted into the pathway for androgen biosynthesis, leading to high levels of androstenedione that

Table 616.1 Diagnosis and Treatment of Congenital Adrenal Hyperplasia

DISORDER	AFFECTED GENE AND CHROMOSOME	SIGNS AND SYMPTOMS	LABORATORY FINDINGS	THERAPEUTIC MEASURES
21-Hydroxylase deficiency, classic form	*CYP21* 6p21.3	Glucocorticoid deficiency	↓ Cortisol, ↑ACTH ↑↑ Baseline and ACTH-stimulated 17-hydroxy-progesterone	Glucocorticoid (hydrocortisone) replacement
		Mineralocorticoid deficiency (salt-wasting crisis)	Hyponatremia, hyperkalemia ↑ Plasma renin	Mineralocorticoid (fludrocortisone) replacement; sodium chloride supplementation
		Ambiguous genitalia in females	↑ Serum androgens	Vaginoplasty and clitoral recession
		Postnatal virilization in males and females	↑ Serum androgens	Suppression with glucocorticoids
21-Hydroxylase deficiency, nonclassic form	*CYP21* 6p21.3	May be asymptomatic; precocious adrenarche, hirsutism, acne, menstrual irregularity, infertility	↑ Baseline and ACTH-stimulated 17-hydroxyprogesterone ↑ Serum androgens	Suppression with glucocorticoids
11β-Hydroxylase deficiency	*CYP11B1* 8q24.3	Glucocorticoid deficiency	↓ Cortisol, ↑ ACTH ↑↑ Baseline and ACTH-stimulated 11-deoxycortisol and deoxycorticosterone	Glucocorticoid (hydrocortisone) replacement
		Ambiguous genitalia in females	↑ Serum androgens	Vaginoplasty and clitoral recession
		Postnatal virilization in males and females	↑ Serum androgens	Suppression with glucocorticoids
		Hypertension	↓ Plasma renin, hypokalemia	Suppression with glucocorticoids
3β-Hydroxysteroid dehydrogenase deficiency, classic form	*HSD3B2* 1p13.1	Glucocorticoid deficiency	↓ Cortisol, ↑ ACTH ↑↑ Baseline and ACTH-stimulated Δ5 steroids (pregnenolone, 17-hydroxy-pregnenolone, DHEA)	Glucocorticoid (hydrocortisone) replacement
		Mineralocorticoid deficiency (salt-wasting crisis)	Hyponatremia, hyperkalemia ↑ Plasma renin	Mineralocorticoid (fludrocortisone) replacement; sodium chloride supplementation
		Ambiguous genitalia in females and males	↑ DHEA, ↓ androstenedione, testosterone, and estradiol	Surgical correction of genitals and sex hormone replacement as necessary, consonant with sex of rearing
		Precocious adrenarche, disordered puberty	↑ DHEA, ↓ androstenedione, testosterone, and estradiol	Suppression with glucocorticoids
17α-Hydroxylase/17,20-lyase deficiency	*CYP17* 10q24.3	Cortisol deficiency (corticosterone is an adequate glucocorticoid)	↓ Cortisol, ↑ ACTH ↑ DOC, corticosterone Low 17α-hydroxylated steroids; poor response to ACTH	Glucocorticoid (hydrocortisone) administration
		Ambiguous genitalia in males	↓ Serum androgens; poor response to hCG	Orchidopexy or removal of intraabdominal testes; sex hormone replacement consonant with sex of rearing
		Sexual infantilism	↓ Serum androgens or estrogens	Sex hormone replacement consonant with sex of rearing
		Hypertension	↓ Plasma renin; hypokalemia	Suppression with glucocorticoids

Table 616.1 Diagnosis and Treatment of Congenital Adrenal Hyperplasia—cont'd

DISORDER	AFFECTED GENE AND CHROMOSOME	SIGNS AND SYMPTOMS	LABORATORY FINDINGS	THERAPEUTIC MEASURES
Congenital lipoid adrenal hyperplasia	*STAR* 8p11.2	Glucocorticoid deficiency	↑ ACTH Low levels of all steroid hormones, with decreased or absent response to ACTH	Glucocorticoid (hydrocortisone) replacement
		Mineralocorticoid deficiency (salt-wasting crisis)	Hyponatremia, hyperkalemia ↓ Aldosterone, ↑ plasma renin	Mineralocorticoid (fludrocortisone) replacement; sodium chloride supplementation
		Ambiguous genitalia in males	Decreased or absent response to hCG in males	Orchidopexy or removal of intraabdominal testes; sex hormone replacement consonant with sex of rearing
		Poor pubertal development or premature ovarian failure in females	↑ FSH, ↑ LH, ↓ estradiol (after puberty)	Estrogen replacement
P450 oxidoreductase deficiency	*POR* 7q11.3	Glucocorticoid deficiency	↓ Cortisol, ↑ ACTH ↑ Pregnenolone, ↑ progesterone	Glucocorticoid (hydrocortisone) replacement
		Ambiguous genitalia in males and females	↑ Serum androgens prenatally, ↓ androgens and estrogens at puberty	Surgical correction of genitals and sex hormone replacement as necessary, consonant with sex of rearing
		Maternal virilization Antley-Bixler syndrome	Decreased ratio of estrogens to androgens	

↓, Decreased; ↑, increased; ↑↑, markedly increased; ACTH, adrenocorticotropic hormone; DHEA, dehydroepiandrosterone; DOC, 11-deoxycorticosterone; FSH, follicle-stimulating hormone; hCG, human chorionic gonadotropin; LH, luteinizing hormone.

Table 616.2 Genotype-Phenotype Correlations in Congenital Adrenal Hyperplasia Owing to 21-Hydroxylase Deficiency

VARIANT GROUP	A	B	C
Enzymatic activity, % normal	Nil	1–2%	20–50%
CYP21 variants (phenotype generally corresponds to the least affected allele)	Gene deletion Exon 3 del 8 bp Exon 6 cluster Q318X R356W Intron 2 splice*	I172N	P30L V281L P453S
Severity	Salt wasting	Simple virilizing	Nonclassic
Aldosterone synthesis	Low	Normal	Normal
Age at diagnosis (without newborn screening)	Infancy	Infancy (females) Childhood (males)	Childhood to adulthood, or asymptomatic
Virilization	Severe	Moderate to severe	None to mild
Incidence	1/20,000	1/50,000	1/500

*This variant is associated with both salt-wasting and simple virilizing disease.

are converted outside the adrenal gland to testosterone. This problem begins in affected fetuses by 8-10 weeks of gestation and leads to abnormal genital development in females (see Figs. 616.1 and 616.2).

The external genitalia of males and females normally appear identical early in gestation (see Chapter 622). Affected females who are exposed in utero to high levels of androgens of adrenal origin have masculinized external genitalia (see Figs. 616.1 and 616.2). This is manifested by enlargement of the clitoris and by partial or complete labial fusion. The vagina usually has a common opening with the urethra (urogenital sinus). The clitoris may be so enlarged that it resembles a penis; because the urethra opens below this organ, some affected females may be mistakenly presumed to be males with hypospadias and cryptorchidism. The severity of virilization is usually greatest in females with the salt-losing form of 21-hydroxylase deficiency (see Table 616.2). The internal genital organs are normal because affected females have normal ovaries and not testes and thus do not secrete antimüllerian hormone.

Prenatal exposure of the brain to high levels of androgens may influence subsequent sexually dimorphic behaviors in affected females. Females may demonstrate aggressive play behavior, tend to be interested in masculine toys such as cars and trucks, and often show decreased interest in playing with dolls. Women may have decreased interest in maternal roles. There is an increased frequency of homosexuality in affected females. Nonetheless, most function heterosexually and do not have gender identity confusion or dysphoria. It is unusual

for affected females to assign themselves a male role except in some with the severest degree of virilization.

Male infants appear normal at birth. The diagnosis may not be made in males until signs of adrenal insufficiency develop. Because patients with this condition can deteriorate quickly, infant males are more likely to die than infant females. For this reason, all 50 American states and many countries have instituted newborn screening for this condition (see Chapter 616.2).

Postnatal Androgen Excess

Untreated or inadequately treated children of both sexes develop additional signs of androgen excess after birth. Males with the simple virilizing form of 21-hydroxylase deficiency often have a delayed diagnosis because they appear normal and rarely develop adrenal insufficiency.

Signs of androgen excess include **rapid somatic growth** and **accelerated skeletal maturation**. Affected patients are tall in childhood, but premature closure of the epiphyses causes growth to stop relatively early, and adult stature is stunted (see Fig. 616.1). Muscular development may be excessive. Pubic and axillary hair may appear, and acne and a deep voice may develop. The penis, scrotum, and prostate may become enlarged in affected males; however, the testes are usually prepubertal in size so that they appear small relative to the enlarged penis. Occasionally, ectopic adrenocortical cells in the testes of patients become hyperplastic similarly to the adrenal glands, producing **testicular adrenal rest tumors** (see Chapter 624). The clitoris may become further enlarged in affected females (see Fig. 616.1). Although the internal genital structures are female, breast development and menstruation may not occur unless the excessive production of androgens is suppressed by adequate treatment.

Similar but usually milder signs of androgen excess may occur in **nonclassic 21-hydroxylase deficiency** (see Table 616.2). In this attenuated form, cortisol and aldosterone levels are normal and affected females have normal genitals at birth. Males and females may present with precocious pubarche and early development of pubic and axillary hair. Hirsutism, acne, menstrual disorders, and infertility may develop later in life, but many females and males are completely asymptomatic.

Adrenomedullary Dysfunction

Development of the adrenal medulla requires exposure to the extremely high cortisol levels normally present within the adrenal gland. Thus patients with classic CAH have abnormal adrenomedullary function, as evidenced by blunted epinephrine responses, decreased blood glucose, and lower heart rates with exercise. Ability to exercise is unimpaired, and the clinical significance of these findings is uncertain. Adrenomedullary dysfunction may exacerbate the cardiovascular effects of cortisol deficiency in untreated or undertreated patients.

LABORATORY FINDINGS

See Table 616.1.

Patients with salt-losing disease have typical laboratory findings associated with cortisol and aldosterone deficiency, including hyponatremia, hyperkalemia, metabolic acidosis, and, often, hypoglycemia, but these abnormalities can take 10-14 days or longer to develop after birth. Blood levels of 17-hydroxyprogesterone are markedly elevated. However, levels of this hormone are high during the first 2-3 days of life even in unaffected infants and especially if they are ill or premature. After infancy, once the circadian rhythm of cortisol is established, 17-hydroxyprogesterone levels vary in the same circadian pattern, being highest in the morning and lowest at night. Blood levels of cortisol are usually low in patients with the salt-losing type of disease. They are often normal in patients with simple virilizing disease but inappropriately low in relation to the ACTH and 17-hydroxyprogesterone levels. In addition to 17-hydroxyprogesterone, levels of androstenedione and testosterone are elevated in affected females; testosterone is not elevated in affected males because normal infant males have high testosterone levels compared with those seen later in childhood. Levels of urinary 17-ketosteroids and pregnanetriol are elevated but are now rarely used clinically because blood samples are easier to obtain than 24-hour urine collections. ACTH levels are elevated but have no diagnostic utility over 17-hydroxyprogesterone levels. Plasma levels of renin are elevated, and serum aldosterone is inappropriately low for the renin level. However, renin levels are high in normal infants in the first few weeks of life.

Diagnosis of 21-hydroxylase deficiency is most reliably established by measuring 17-hydroxyprogesterone before and 30 or 60 minutes after an intravenous bolus of 0.125-0.25 mg of cosyntropin (ACTH 1-24). Nomograms exist that readily distinguish between unaffected individuals and patients with nonclassic and classic 21-hydroxylase deficiency. Heterozygous carriers of this autosomal recessive disorder tend to have higher ACTH-stimulated 17-hydroxyprogesterone levels than genetically unaffected individuals, but there is significant overlap between subjects in these two categories. However, in infants with frank electrolyte abnormalities or circulatory instability, it may not be possible or necessary to delay treatment to perform this test, as levels of precursors will be sufficiently elevated on a random blood sample to make the diagnosis.

Genotyping is clinically available and may help to confirm the diagnosis. Because the gene conversions that generate most pathogenic alleles may transfer more than one variant, at least one parent should also be genotyped to determine which variants are on each allele.

DIFFERENTIAL DIAGNOSIS

Disorders of sexual development are discussed more generally in Chapter 628. The initial step in evaluating an infant with ambiguous genitalia is a thorough physical examination to define the anatomy of the genitals, locate the urethral meatus, palpate the scrotum or labia and the inguinal regions for testes (palpable gonads usually indicate the presence of testicular tissue and that the infant is a genetic male), and look for any other anatomic abnormalities. Ultrasonography is helpful in demonstrating the presence or absence of a uterus and can often locate the gonads. A rapid karyotype (such as fluorescence in situ hybridization of interphase nuclei for X and Y chromosomes) can quickly determine the genetic sex of the infant. These results are all likely to be available before the results of hormonal testing and together allow the clinical team to advise the parents as to the genetic sex of the infant and the anatomy of internal reproductive structures. Injection of contrast medium into the urogenital sinus of a virilized female demonstrates a vagina and uterus; surgeons use this information to formulate a plan for surgical management.

PRENATAL DIAGNOSIS

Prenatal diagnosis of 21-hydroxylase is possible late in the first trimester by analysis of DNA obtained by chorionic villus sampling or during the second trimester by amniocentesis. This is usually done because the parents already have an affected child. Most often, the *CYP21A2* gene is analyzed for frequently occurring pathogenic variants; less common variants may be detected by DNA sequencing. Cell-free fetal DNA may be an adjunctive noninvasive testing method to help guide decision-making for possible prenatal treatment with dexamethasone, given that prenatal sex typing can be performed as early as 6-9 weeks. As of 2021, cell-free fetal DNA testing for this disorder is not yet available as part of routine clinical care.

NEWBORN SCREENING

Because 21-hydroxylase deficiency is often undiagnosed in affected males until they have severe adrenal insufficiency, all states in the United States and many other countries have instituted newborn screening programs. These programs analyze 17-hydroxyprogesterone levels in dried blood obtained by heelstick and absorbed on filter paper cards; the same cards are screened in parallel for other congenital conditions, such as hypothyroidism and phenylketonuria. Potentially affected infants are typically quickly recalled for additional testing (electrolytes and repeat 17-hydroxyprogesterone determination) at approximately 2 weeks of age. Infants with salt-wasting disease often have abnormal electrolytes by this age but are usually not severely ill. Screening programs are effective in preventing many cases of adrenal crisis in affected males. The nonclassic form of the disease is not

reliably detected by newborn screening, but this is of little clinical significance because adrenal insufficiency does not occur in this type of 21-hydroxylase deficiency.

The main difficulty with current newborn screening programs is that to reliably detect all affected infants, the cutoff 17-hydroxyprogesterone levels for first-tier screening are set so low that there is a very high frequency of false-positive results (i.e., the test has a low positive predictive value of as little as 1%). This problem is worst in premature infants. Positive predictive value can be improved by using cutoff levels based on gestational age and by using more specific second-tier screening methods such as liquid chromatography followed by tandem mass spectrometry.

TREATMENT

Glucocorticoid Replacement

Cortisol deficiency is treated with glucocorticoids. Treatment also suppresses excessive production of androgens by the adrenal cortex and thus minimizes problems such as excessive growth and skeletal maturation and virilization. This often requires larger glucocorticoid doses than are needed in other forms of adrenal insufficiency, typically 12-15 $mg/m^2/24$ hr of hydrocortisone daily administered orally in 3 divided doses. Affected infants usually require dosing at the high end of this range. Double or triple doses are indicated during periods of stress, such as infection or surgery. Glucocorticoid treatment must be continued indefinitely in all patients with classic 21-hydroxylase deficiency but may not be necessary in patients with nonclassic disease unless signs of androgen excess are present. Therapy must be individualized. It is desirable to maintain linear growth along percentile lines; crossing to higher height percentiles may suggest undertreatment, whereas loss of height percentiles often indicates overtreatment with glucocorticoids. Overtreatment is also suggested by excessive weight gain. Pubertal development should be monitored by periodic examination, and skeletal maturation is evaluated by serial radiographs of the hand and wrist for bone age. Hormone levels, particularly 17-hydroxyprogesterone and androstenedione, should be measured early in the morning, before taking the morning medications, or at a consistent time in relation to medication dosing. Desirable 17-hydroxyprogesterone levels are in the high-normal range or several times normal; low-normal levels can usually be achieved only with excessive glucocorticoid doses. Hydrocortisone is the preferred glucocorticoid in growing children because its shorter half-life minimizes adverse side effects such as growth suppression, which is seen with longer half-life glucocorticoids. It is available as tablets, immediate-release granules, and a custom-compounded suspension. Use of continuous subcutaneous pump infusion devices to deliver hydrocortisone in a pattern more closely approximating the normal diurnal rhythm variation in cortisol secretion has been studied but has not entered clinical practice. Clinical trials for delayed-release hydrocortisone tablets are currently underway in the pediatric population.

Menarche occurs at the appropriate age in most females in whom good control has been achieved; it may be delayed in females with suboptimal control. Children with simple virilizing disease, particularly males, are frequently not diagnosed until 3-7 years of age, at which time skeletal maturation may be 5 years or more in advance of chronological age. In some children, especially if the bone age is 12 years or more, spontaneous central (i.e., gonadotropin-dependent) puberty may occur when treatment is instituted, because therapy with hydrocortisone suppresses production of adrenal androgens and thus stimulates release of pituitary gonadotropins if the appropriate level of hypothalamic maturation is present. This form of superimposed true precocious puberty may be treated with a gonadotropin hormone–releasing hormone analog such as leuprolide (see Chapter 600.1).

Males with 21-hydroxylase deficiency who have had inadequate corticosteroid therapy may develop **testicular adrenal rest tumors**, which may regress with increased steroid dosage. Testicular MRI, ultrasonography, and color flow Doppler examination help to define the character and extent of disease. Testis-sparing surgery to resect steroid-unresponsive tumors may be required in adult men to preserve fertility.

Mineralocorticoid Replacement

Patients with salt-wasting disease (i.e., aldosterone deficiency) require mineralocorticoid replacement with fludrocortisone. Infants may have very high mineralocorticoid requirements in the first few months of life, usually 0.1-0.3 mg daily in 2 divided doses, but occasionally up to 0.4 mg daily, and often require sodium supplementation (sodium chloride 8 mmol/kg) in addition to the mineralocorticoid. Older infants and children are usually maintained with 0.05-0.1 mg daily of fludrocortisone. In some patients, simple virilizing disease may be easier to control with a low dose of fludrocortisone in addition to hydrocortisone even when these patients have normal aldosterone levels in the absence of mineralocorticoid replacement. Therapy is evaluated by monitoring of vital signs; tachycardia and hypertension are signs of overtreatment with mineralocorticoids. Serum electrolytes should be measured frequently in early infancy as therapy is adjusted. Plasma renin activity is a useful way to determine adequacy of therapy; it should be maintained in or near the normal range but not suppressed.

Additional approaches to improve outcome have been proposed but have not yet become the standard of care. These include an antiandrogen such as flutamide to block the effects of excessive androgen levels and/or an aromatase inhibitor such as anastrozole or letrozole, which blocks conversion of androgens to estrogen and thus retards skeletal maturation, a process that is sensitive to estrogens in both males and females. Aromatase inhibitors generally should not be used in pubertal females, except in combination with a gonadotropin-releasing hormone agonist because this will expose the ovaries to excessive levels of gonadotropins. Growth hormone, with or without gonadotropin–releasing hormone agonists, has been suggested to improve adult height. Corticotropin-releasing hormone receptor antagonists such as crinecerfont and tildacerfont are in phase 2-3 studies as of 2021; they may reduce ACTH secretion, thus suppressing secretion of abnormal steroids at lower glucocorticoid doses than otherwise necessary. This strategy may reduce the adverse effects of high glucocorticoid doses. Abiraterone acetate, a CYP17A1 inhibitor that suppresses secretion of androgens and estrogens and is used for treatment of prostate cancer, may also permit reductions in glucocorticoid dosing and is in early-phase trials for CAH as of 2021.

Surgical Management of Ambiguous Genitals

Significantly virilized females usually undergo surgery between 2 and 6 months of age. If there is severe clitoromegaly, the clitoris is reduced in size, with partial excision of the corporal bodies and preservation of the neurovascular bundle; however, moderate clitoromegaly may become much less noticeable without surgery as the patient grows. Vaginoplasty and correction of the urogenital sinus usually are performed at the time of clitoral surgery; revision in adolescence is often necessary.

Risks and benefits of surgery should be fully discussed with parents of affected females. There is limited long-term follow-up of functional outcomes in patients who have undergone modern surgical procedures. It appears that female sexual dysfunction increases in frequency and severity in those with the most significant degrees of genital virilization and with the degree of enzymatic impairment (prenatal androgen exposure) caused by each patient's pathogenic variant (see Table 616.2). Sex assignment of infants with disorders of sexual differentiation (including CAH) is usually based on expected sexual functioning and fertility in adulthood, with early surgical correction of the external genitalia to conform with the sex assignment. The majority of females with CAH identify as female gender and are heterosexual. Gender dysphoria is not common with CAH; it occurs mostly in females with the salt-wasting form of the disease and the greatest degree of virilization.

Lay and medical opponents of genital surgery for other disorders of sexual differentiation raise the concern that it ignores any prenatally influenced gender role effects from androgen exposure and precludes the patient from having any decision as to the patient's own preferred sexual identity and what surgical correction of the genitals should be performed. They advocate that treatment should be aimed primarily at educating the patient, family, and others about the medical condition

and its treatment. They propose that surgery should be delayed until the patient decides on what, if any, surgery should be performed. There have not been any studies comparing early with late surgery. Not all lay groups support delaying surgery, and many agree with appropriate surgery during infancy. Severely virilized genotypic (XX) females raised as males have generally functioned well in the male gender as adults.

In adolescent and adult females with poorly controlled 21-hydroxylase deficiency (hirsutism, obesity, amenorrhea), bilateral laparoscopic adrenalectomy (with hormone replacement) may be an alternative to standard medical hormone replacement therapy, but because the adrenal glands have been removed, patients treated in this way may be more susceptible to acute adrenal insufficiency if treatment is interrupted. Moreover, they may exhibit signs of elevated ACTH levels such as abnormal pigmentation. There have also been reports of development of adrenal rest tumors in women after adrenalectomy, which defeats the purpose of adrenalectomy and allows the recurrence of androgen excess.

Prenatal Treatment

Besides genetic counseling, the main goal of prenatal diagnosis is to facilitate prenatal treatment of affected females. Mothers with pregnancies at risk may be given dexamethasone, a steroid that readily crosses the placenta, in an amount of 20 μg/kg pre-pregnancy maternal weight daily in 2 or 3 divided doses. This suppresses secretion of steroids by the fetal adrenal, including secretion of adrenal androgens. If started by 6 weeks of gestation, it ameliorates virilization of the external genitals in affected females. Chorionic villus biopsy is then performed to determine the sex and genotype of the fetus; therapy is continued only if the fetus is an affected female. DNA analysis of fetal cells isolated from maternal plasma for sex determination and *CYP21* gene analysis may permit earlier identification of the affected female fetus. Treatment should be considered only in affected female fetuses. Children exposed to this therapy have slightly lower birthweights. Reports of failure to thrive, stroke-like events, and midline defects have been observed in treated cases. Effects on personality or cognition, such as increased shyness, have been suggested but not consistently observed. At present there is insufficient information to determine whether the long-term risks are acceptable, particularly in the males and unaffected females who derive no direct benefit from the treatment. Maternal side effects of prenatal treatment have included edema, excessive weight gain, hypertension, glucose intolerance, cushingoid facial features, and severe striae. Consensus statements from professional societies recommend that prenatal treatment be carried out only under institutional protocols, but it is sometimes offered as an option outside the research setting by some high-risk obstetricians.

Visit Elsevier eBooks+ at eBooks.Health.Elsevier.com for Bibliography.

616.2 Congenital Adrenal Hyperplasia Caused by 11β-Hydroxylase Deficiency

Perrin C. White and Ming Yang

Deficiency of 11β-hydroxylase is caused by a pathologic variant in the *CYP11B1* gene located on chromosome 8q21-q22. *CYP11B1* mediates 11-hydroxylation of 11-deoxycortisol to cortisol. Because 11-deoxycortisol is not converted to cortisol, levels of corticotropin are high. In consequence, precursors—particularly 11-deoxycortisol and deoxycorticosterone—accumulate and are shunted into androgen biosynthesis in the same manner as occurs in 21-hydroxylase deficiency. The adjacent *CYP11B2* gene encoding aldosterone synthase is generally unaffected in this disorder, so patients are able to synthesize aldosterone normally.

EPIDEMIOLOGY

11β-Hydroxylase deficiency accounts for approximately 5% of cases of adrenal hyperplasia; its incidence in the general population has been estimated as 1 in 250,000 to 1 in 100,000. The disorder occurs relatively frequently in Israeli Jews of North African origin (1 in 5,000-7,000 live births). In this ethnic group, almost all alleles carry an Arg448 to His (R448H) variant in *CYP11B1,* but many other variants have been identified. This disorder presents in a classic, severe form and very rarely in a nonclassic, milder form.

CLINICAL MANIFESTATIONS

Although cortisol is not synthesized efficiently, aldosterone synthetic capacity is normal, and some corticosterone is synthesized from progesterone by the intact aldosterone synthase enzyme. Thus it is unusual for patients to manifest signs of adrenal insufficiency such as hypotension or hypoglycemia. On the contrary, approximately 65% of patients become *hypertensive,* although this can take several years to develop. Hypertension is probably a consequence of elevated levels of deoxycorticosterone, which has mineralocorticoid activity. Infants may transiently develop signs of mineralocorticoid deficiency after treatment with hydrocortisone is instituted. This is presumably from sudden suppression of deoxycorticosterone secretion in a patient with atrophy of the zona glomerulosa caused by chronic suppression of renin activity.

All signs and symptoms of androgen excess that are found in 21-hydroxylase deficiency may also occur in 11β-hydroxylase deficiency.

LABORATORY FINDINGS

Plasma levels of 11-deoxycortisol and deoxycorticosterone are elevated. Because deoxycorticosterone and some metabolites have mineralocorticoid activity, plasma renin activity is suppressed. Consequently, aldosterone levels are low even though the ability to synthesize aldosterone is intact. *Hypokalemic alkalosis occasionally occurs.*

TREATMENT

Patients are treated with hydrocortisone in doses similar to those used for 21-hydroxylase deficiency. Mineralocorticoid replacement is sometimes transiently required in infancy but is rarely necessary otherwise. Hypertension often resolves with glucocorticoid treatment but may require additional therapy if it is of long standing. Calcium channel blockers may be beneficial under these circumstances.

Visit Elsevier eBooks+ at eBooks.Health.Elsevier.com for Bibliography.

616.3 Congenital Adrenal Hyperplasia Caused by 3β-Hydroxysteroid Dehydrogenase Deficiency

Perrin C. White and Ming Yang

Deficiency of 3β-hydroxysteroid dehydrogenase (3β-HSD) occurs in less than 2% of patients with adrenal hyperplasia. This enzyme is required for conversion of Δ5 steroids (pregnenolone, 17-hydroxypregnenolone, dehydroepiandrosterone [DHEA]) to Δ4 steroids (progesterone, 17-hydroxyprogesterone, and androstenedione). Thus deficiency of the enzyme results in decreased synthesis of cortisol, aldosterone, and androstenedione but increased secretion of DHEA (see Fig. 614.1 in Chapter 614). The 3β-HSD isozyme expressed in the adrenal cortex and gonad is encoded by the *HSD3B2* gene located on chromosome 1p13.1. More than 30 pathogenic variants in *HSD3B2* have been described in patients with 3β-HSD deficiency.

CLINICAL MANIFESTATIONS

Because cortisol and aldosterone are not synthesized in patients with the classic form of the disease, infants are prone to **salt-wasting crises**. Because androstenedione and testosterone are not synthesized, *males*

are incompletely virilized; varying degrees of hypospadias may occur, with or without bifid scrotum or cryptorchidism. Because DHEA levels are elevated and this hormone is a weak androgen, females are mildly virilized, with slight to moderate clitoral enlargement. Postnatally, continued excessive DHEA secretion can cause precocious adrenarche. During adolescence and adulthood, hirsutism, irregular menses, and polycystic ovarian disease occur in females. Males manifest variable degrees of hypogonadism, although appropriate male secondary sexual development may occur. However, a persistent defect of testicular 3β-HSD is demonstrated by the high Δ5:Δ4 steroid ratio in testicular effluent.

LABORATORY FINDINGS

The hallmark of this disorder is the marked elevation of the Δ5 steroids (such as 17-hydroxypregnenolone and DHEA) preceding the enzymatic block. Patients may also have elevated levels of 17-hydroxyprogesterone because of the extraadrenal 3β-HSD activity that occurs in peripheral tissues; these patients may be mistaken for patients with 21-hydroxylase deficiency. The ratio of 17-hydrox ypregnenolone:17-hydroxyprogesterone is markedly elevated in 3β-HSD deficiency, in contrast to the decreased ratio in 21-hydroxylase deficiency. Plasma renin activity is elevated in the salt-wasting form.

DIFFERENTIAL DIAGNOSIS

It is not unusual for children with premature adrenarche, or females with signs of androgen excess, to have mild to moderate elevations in DHEA levels. It has been suggested that such individuals have *nonclassic 3β-HSD deficiency*. Variants in *HSD3B2* are usually not found in such individuals, and a nonclassic form of this deficiency may be quite rare. The activity of 3β-HSD in the adrenal zonae fasciculata and reticularis, relative to CYP17A1 (17-hydroxylase/17,20-lyase) activity, normally decreases during adrenarche to facilitate DHEA synthesis, and so modest elevations in DHEA in preteenage children or women usually represent a normal variant.

TREATMENT

Patients require glucocorticoid and mineralocorticoid replacement with hydrocortisone and fludrocortisone, respectively, as in 21-hydroxylase deficiency. Incompletely virilized genetic males in whom a male sex of rearing is contemplated may benefit from several injections of 25 mg of a depot form of testosterone every 4 weeks early in infancy to increase the size of the phallus. They may also require testosterone replacement at puberty.

Visit Elsevier eBooks+ at eBooks.Health.Elsevier.com for Bibliography.

616.4 Congenital Adrenal Hyperplasia Caused by 17-Hydroxylase Deficiency

Perrin C. White and Ming Yang

Less than 1% of CAH cases are caused by 17-hydroxylase deficiency, but the condition is apparently more common in Brazil and China. A single polypeptide, CYP17A1, catalyzes two distinct reactions: 17-hydroxylation of pregnenolone and progesterone to 17-hydroxypregnenolone and 17-hydroxyprogesterone, respectively, and the 17,20-lyase reaction–mediating conversion of 17-hydroxypregnenolone to DHEA and, to a lesser extent, 17-hydroxyprogesterone to Δ4-androstenedione. DHEA and androstenedione are steroid precursors of testosterone and estrogen (see Fig. 614.1 in Chapter 614). The enzyme is expressed in both the adrenal cortex and the gonads and is encoded by a gene on chromosome 10q24.3. Most pathogenic variants affect both the hydroxylase and lyase activities, but rare variants can affect either activity alone.

Pathogenic variants in genes other than *CYP17A1* can have the same phenotype as 17,20-lyase deficiency (i.e., deficient androgen synthesis with normal cortisol synthesis). These include an accessory electron transfer protein, cytochrome-b_5, (CYB5) and variants in two aldo-keto reductases AKR1C2 and AKR1C4. These AKR1C isozymes normally catalyze 3α-HSD activity, which allows synthesis of the potent androgen dihydrotestosterone through an alternative backdoor biosynthetic pathway that does not include testosterone as an intermediate (see Chapter 614).

CLINICAL MANIFESTATIONS AND LABORATORY FINDINGS

Patients with 17-hydroxylase deficiency cannot synthesize cortisol, but their ability to synthesize corticosterone is intact. Because corticosterone is an active glucocorticoid, patients do not develop adrenal insufficiency. Deoxycorticosterone, the immediate precursor of corticosterone, is synthesized in excess. This can cause **hypertension**, **hypokalemia**, and suppression of renin and aldosterone secretion, as occurs in 11β-hydroxylase deficiency. However, in contrast to 11β-hydroxylase deficiency, patients with 17-hydroxylase deficiency are unable to synthesize sex hormones. *Affected males are incompletely virilized* and present as phenotypic females (but the gonads are usually palpable in the inguinal region or the labia) or with sexual ambiguity. Affected females usually present with *failure of sexual development* at the expected time of puberty. 17-Hydroxylase deficiency in females must be considered in the differential diagnosis of primary hypogonadism (see Chapter 626). Levels of deoxycorticosterone are elevated, and renin and aldosterone are consequently suppressed. Cortisol and sex steroids are unresponsive to stimulation with ACTH and human chorionic gonadotropin, respectively.

Patients with isolated 17,20-lyase deficiency have deficient androgen synthesis with normal cortisol synthesis and therefore do not become hypertensive.

TREATMENT

Patients with 17-hydroxylase deficiency require glucocorticoid replacement with hydrocortisone to suppress secretion of deoxycorticosterone and thus control hypertension. Additional antihypertensive medication may be required. Females require estrogen replacement at puberty. Genetic males may require either estrogen or androgen supplementation depending on the sex of rearing. Because of the possibility of malignant transformation of abdominal testes, genetic males with severe 17-hydroxylase deficiency being reared as females require gonadectomy at or before adolescence.

Visit Elsevier eBooks+ at eBooks.Health.Elsevier.com for Bibliography.

616.5 Lipoid Adrenal Hyperplasia

Perrin C. White and Ming Yang

Lipoid adrenal hyperplasia is a rare disorder, most frequently found in Japanese persons. Patients with this disorder exhibit marked accumulation of cholesterol and lipids in the adrenal cortex and gonads associated with severe impairment of all steroidogenesis. Lipoid adrenal hyperplasia is usually caused by pathogenic variants in the gene for steroidogenic acute regulatory protein (StAR), a mitochondrial protein that promotes the movement of cholesterol from the outer to the inner mitochondrial membrane. However, pathogenic variants in *CYP11A1* (which encodes the cholesterol side-chain cleavage enzyme) have been reported in more than 30 patients. A milder, nonclassic form of StAR deficiency has been reported.

Some cholesterol is able to enter mitochondria even in the absence of StAR, so it might be supposed that this disorder would not completely impair steroid biosynthesis. However, the accumulation of cholesterol in the cytoplasm is cytotoxic, eventually leading to death of all steroidogenic cells in which StAR is normally expressed. This occurs prenatally in the adrenals and testes. The ovaries do not

normally synthesize steroids until puberty, so cholesterol does not accumulate, and the ovaries can retain the capacity to synthesize estrogens until adolescence.

Although estrogens synthesized by the placenta are required to maintain pregnancy, the placenta does not require StAR for steroid biosynthesis. Variants of StAR are not prenatally lethal.

CLINICAL MANIFESTATIONS

Patients with lipoid adrenal hyperplasia are usually unable to synthesize any adrenal steroids. Thus affected infants are likely to be confused with those with adrenal hypoplasia congenita. Salt-losing manifestations are typical, and many infants die in early infancy. Genetic males are unable to synthesize androgens and thus are **phenotypically female** but with gonads palpable in the labia majora or inguinal areas. Genetic females appear normal at birth and may undergo feminization at puberty with menstrual bleeding. They, too, progress to hypergonadotropic hypogonadism when accumulated cholesterol damages granulosa (i.e., steroid synthesizing) cells in the ovary.

LABORATORY FINDINGS

Adrenal and gonadal steroid hormone levels are low in lipoid adrenal hyperplasia, with a decreased or absent response to stimulation (ACTH, human chorionic gonadotropin). Plasma renin levels are increased.

Imaging studies of the adrenal gland demonstrating massive adrenal enlargement in the newborn help to establish the diagnosis of lipoid adrenal hyperplasia.

TREATMENT

Patients require glucocorticoid and mineralocorticoid replacement. Genetic males are usually assigned a female sex of rearing; thus both genetic males and females require estrogen replacement at the expected age of puberty.

Visit Elsevier eBooks+ at eBooks.Health.Elsevier.com for Bibliography.

616.6 Deficiency of P450 Oxidoreductase (Antley-Bixler Syndrome)

Perrin C. White and Ming Yang

P450 oxidoreductase (*POR*; gene located on chromosome 7q11.3) is required for the activity of all microsomal cytochrome P450 enzymes (see Chapter 614), including the adrenal enzymes CYP17 and CYP21. Complete *POR* deficiency abolishes all microsomal P450 activity. This is embryonically lethal in mice and presumably also in humans. Patients with pathogenic variants that decrease but do not abolish *POR* activity have partial deficiencies of 17-hydroxylase and 21-hydroxylase activities in the adrenals. A single recurrent variant A287P (alanine-287 to proline) is found on approximately 40% of alleles.

Deficiency of 17-hydroxylase leads to incomplete masculinization in males; 21-hydroxylase deficiency may lead to virilization in females. In addition, aromatase *(CYP19)* activity in the placenta is decreased, leading to unopposed action of androgens produced by the fetal adrenal. This exacerbates virilization of female fetuses and may **virilize the mother** of an affected fetus as well. Although it is puzzling that affected females could be virilized despite a partial deficiency in *CYP17* (which is required for androgen biosynthesis), an alternative (backdoor) biosynthetic pathway is used in which 17-hydroxyprogesterone is converted to 5α-pregnane-3α,17α-diol-20-one, a metabolite that is a much better substrate for the 17,20-lyase activity of *CYP17* than the usual substrate, 17-hydroxypregnenolone (see Chapter 614). The metabolite is then converted in several enzymatic steps to dihydrotestosterone, a potent androgen.

Because many other P450 enzymes are affected, patients may have other congenital anomalies collectively referred to as **Antley-Bixler syndrome**. These include craniosynostosis; brachycephaly; frontal bossing; severe midface hypoplasia with proptosis and choanal stenosis or atresia; humeroradial synostosis; medial bowing of ulnas; long, slender fingers with camptodactyly; narrow iliac wings; anterior bowing of femurs; and malformations of the heart and kidneys.

EPIDEMIOLOGY

More than 130 cases of *POR* deficiency have been reported. Although the prevalence is not known with certainty, it might be the second most common cause of CAH in some populations such as Korea and Japan.

LABORATORY FINDINGS

Serum steroids that are not 17- or 21-hydroxylated are most increased, including pregnenolone and progesterone. 17-Hydroxy and 21-deoxysteroids are also increased, including 17-hydroxypregnenolone, 17-hydroxyprogesterone, and 21-deoxycortisol. Urinary steroid metabolites may be determined by quantitative mass spectrometry. Metabolites excreted at increased levels include pregnanediol, pregnanetriol, pregnanetriolone, and corticosterone metabolites. Urinary cortisol metabolites are decreased. Genetic analysis demonstrates pathogenic variants in *POR*.

DIFFERENTIAL DIAGNOSIS

This disorder must be distinguished from other forms of CAH, particularly 21-hydroxylase deficiency in females, which is far more common and has similar laboratory findings. Suspicion for *POR* deficiency may be raised if the mother is virilized or if the associated abnormalities of Antley-Bixler syndrome are present. Conversely, virilization of both the mother and her daughter can result from a luteoma of pregnancy, but in this case postnatal abnormalities of corticosteroid biosynthesis should not be observed. Antley-Bixler syndrome may also occur without abnormalities of steroid hormone biosynthesis, resulting from pathogenic variants in the fibroblast growth factor receptor FGFR2.

Visit Elsevier eBooks+ at eBooks.Health.Elsevier.com for Bibliography.

616.7 Aldosterone Synthase Deficiency

Perrin C. White and Ming Yang

This is an autosomal recessive disorder in which conversion of corticosterone to aldosterone is impaired; a group of Iranian Jewish patients has been the most thoroughly studied. Most cases result from pathogenic variants in *CYP11B2* coding for aldosterone synthase; however, linkage to *CYP11B2* has been excluded in other kindreds. When not caused by *CYP11B2* variants, the disorder has been termed **familial hyperreninemic hypoaldosteronism type 2**; the causative gene or genes have not yet been identified.

Aldosterone synthase mediates the three final steps in the synthesis of aldosterone from deoxycorticosterone (11β-hydroxylation, 18-hydroxylation, and 18-oxidation). Although 11β-hydroxylation is required to convert deoxycorticosterone to corticosterone, this conversion can also be catalyzed by the related enzyme, CYP11B1, located in the fasciculata, which is unaffected in this disorder. For the same reason, these patients have normal cortisol biosynthesis.

The disease has been classified into two types, termed **corticosterone methyloxidase deficiency types I and II**. They differ only in levels of the immediate precursor of aldosterone, 18-hydroxycorticosterone; levels are low in type I deficiency and elevated in type II deficiency.

CLINICAL MANIFESTATIONS

Infants with aldosterone synthase deficiency may have severe electrolyte abnormalities with **hyponatremia**, **hyperkalemia**, and

metabolic acidosis. Because cortisol synthesis is unaffected, infants rarely become as ill as untreated infants with salt-losing forms of CAH such as 21-hydroxylase deficiency. Thus some infants escape diagnosis. Later in infancy or in early childhood they may exhibit failure to thrive and poor growth. Adults often are asymptomatic, although they may develop electrolyte abnormalities when depleted of sodium through procedures such as bowel preparation for a barium enema.

LABORATORY FINDINGS

Infants have elevated plasma renin activity. Aldosterone levels are decreased; they may be at the lower end of the normal range but are always inappropriately low for the degree of hyperkalemia or hyperreninemia. Corticosterone levels are often elevated.

Some, but not all, patients have marked elevation of 18-hydroxycorticosterone; however, low levels of this steroid do not exclude the diagnosis. In those kindreds in which 18-hydroxycorticosterone levels are elevated in affected individuals, this biochemical abnormality persists in adults even when they have no electrolyte abnormalities.

DIFFERENTIAL DIAGNOSIS

It is important to distinguish aldosterone synthase deficiency from primary adrenal insufficiency in which both cortisol and aldosterone are affected (including salt-wasting forms of CAH), because the latter condition is usually associated with a much greater risk of shock and hyponatremia. This becomes apparent after the appropriate laboratory studies. **Adrenal hypoplasia congenita** may initially present with aldosterone deficiency; all male infants with apparently isolated aldosterone deficiency should be carefully monitored for subsequent development of cortisol deficiency. **Pseudohypoaldosteronism** (see Chapter 615.4) may have similar electrolyte abnormalities and hyperreninemia, but aldosterone levels are high, and this condition usually does not respond to fludrocortisone treatment.

TREATMENT

Treatment consists of giving enough fludrocortisone (0.05-0.2 mg daily) or sodium chloride, or both, to return plasma renin levels to normal. With increasing age, salt-losing signs usually improve, and drug therapy can often be discontinued.

Visit Elsevier eBooks+ at eBooks.Health.Elsevier.com for Bibliography.

616.8 Glucocorticoid-Remediable Aldosteronism

Perrin C. White

Glucocorticoid-remediable aldosteronism (glucocorticoid-suppressible hyperaldosteronism, familial hyperaldosteronism type I) is an autosomal dominant form of *low-renin hypertension* in which hyperaldosteronism is rapidly suppressed by glucocorticoid administration. This unusual effect of glucocorticoids suggests that aldosterone secretion in this disorder is regulated by ACTH instead of by the renin-angiotensin system. In addition to abnormally regulated secretion of aldosterone, there is marked overproduction of 18-hydroxycortisol and 18-oxocortisol. The synthesis of these steroids requires both 17-hydroxylase (CYP17A1) activity, which is expressed only in the zona fasciculata, and aldosterone synthase (CYP11B2) activity, which is normally expressed only in the zona glomerulosa. These features imply that aldosterone synthase is being expressed in a manner similar to the closely related enzyme steroid 11-hydroxylase *(CYP11B1)*. The disorder is caused by unequal meiotic crossing-over events between the *CYP11B1* and *CYP11B2* genes, which are closely linked on chromosome 8q24. An additional "chimeric" gene is produced, having regulatory sequences of *CYP11B1* juxtaposed with coding sequences of *CYP11B2*. This results in the inappropriate expression of a *CYP11B2*-like enzyme with aldosterone synthase activity in the adrenal fasciculata.

CLINICAL MANIFESTATIONS

Some affected children have no symptoms, the diagnosis being established after incidental discovery of moderate hypertension, typically approximately 30 mm Hg higher than unaffected family members of the same age. Others have more symptomatic hypertension with headache, dizziness, and visual disturbances. A strong family history of early-onset hypertension or early strokes may alert the clinician to the diagnosis. Some patients have chronic hypokalemia, but this is not a consistent finding and is usually mild.

LABORATORY FINDINGS

Patients have elevated plasma and urine levels of aldosterone and suppressed plasma renin activity. *Hypokalemia is not consistently present.* Urinary and plasma levels of 18-oxocortisol and 18-hydroxycortisol are markedly increased. The hybrid *CYP11B1/CYP11B2* gene can be readily detected by molecular genetic methods.

DIFFERENTIAL DIAGNOSIS

This condition should be distinguished from primary aldosteronism based on bilateral hyperplasia or an aldosterone-producing adenoma (see Chapter 620). Most cases of primary aldosteronism are sporadic, although several affected kindreds have been reported. Patients with primary aldosteronism may also have elevated levels of 18-hydroxycortisol and 18-oxocortisol, and these biochemical tests should be used cautiously when attempting to distinguish primary and glucocorticoid-suppressible aldosteronism. By definition, a therapeutic trial of dexamethasone should suppress aldosterone secretion only in glucocorticoid-remediable aldosteronism, and genetic testing should identify the hybrid gene if it is present.

TREATMENT

Glucocorticoid-remediable aldosteronism is managed by daily administration of a glucocorticoid, usually dexamethasone 25 μg/kg/day in divided doses. If necessary, effects of aldosterone can be blocked with a potassium-sparing diuretic such as spironolactone, eplerenone, or amiloride. Hypertension resolves in patients in whom the hypertension is not severe or of long standing. If hypertension is long standing, additional antihypertensive medication may be required, such as a calcium channel blocker.

GENETIC COUNSELING

Because of the autosomal dominant mode of inheritance, at-risk family members should be investigated for this easily treated cause of hypertension.

Visit Elsevier eBooks+ at eBooks.Health.Elsevier.com for Bibliography.

Chapter 617

Adrenocortical Tumors and Masses

Perrin C. White

Adrenocortical tumors are rare in childhood, with an incidence of 0.3-0.5 cases per 1 million child-years. They occur in all age-groups but most commonly in children younger than 6 years of age and are slightly more frequent (1.6-fold) in females. In 2–10% of cases, the tumors are bilateral. Almost half of childhood adrenocortical tumors are carcinomas. Pathogenic variants in many genes can influence the risk of developing adrenal tumors (Table 617.1).

Tumors may be associated with hemihypertrophy, usually occurring during the first few years of life. They are also associated with other congenital defects, particularly genitourinary tract and central nervous system abnormalities and hamartomatous defects.

Many adrenocortical tumors secrete sex hormones, cortisol, or aldosterone; these are discussed in Chapters 618, 619, and 620, respectively.

617.1 Adrenocortical Carcinoma

Perrin C. White

ETIOLOGY

The incidence of adrenocortical carcinoma is increased in several familial cancer syndromes resulting from abnormalities in genes that encode transcription factors implicated in cell proliferation, differentiation, senescence, apoptosis, and genomic instability. These include tumor protein 53 *(TP53)*, menin (the *MEN1* gene involved in multiple endocrine neoplasia type 1; 1–2% of MEN1 patients develop adrenocortical carcinoma), the *APC* gene involved in familial adenomatous polyposis coli, and the *PRKAR1A* gene encoding a cyclic adenosine monophosphate–dependent protein kinase regulatory subunit (also see Chapter 619).

Germline pathogenic variants in *TP53* (on chromosome 17p13.1) occur in 50–80% of children with adrenocortical carcinoma. They have been found in patients with isolated adrenal carcinoma and in patients with familial clustering of unusual malignancies (choroid plexus tumors, sarcomas, early-onset breast cancers, brain cancers, and leukemias); this latter condition is termed **Li-Fraumeni syndrome**. A 15-fold increased incidence of childhood adrenocortical tumors is found in southern Brazil, associated with an R337H variant in *TP53*.

Overexpression of insulin-like growth factor (IGF) 2 (encoded by *IGF2,* on chromosome 11p15.5) occurs in 80% of sporadic childhood adrenocortical tumors and in those associated with **Beckwith-Wiedemann syndrome**, in which there is loss of the normal imprinting of genes in this chromosomal region, including *H19, CDKN1C, KCNQ1,* and *KCNQ1OT1*. However, whereas 5–10% of patients with Beckwith-Wiedemann syndrome develop tumors, <1% develop an adrenocortical carcinoma. Further implicating IGFs in pathogenesis, many pediatric adrenocortical tumors overexpress the IGF receptor, IGF1R.

Pathogenic variants in the *MENIN* gene on chromosome 11q13 cause **multiple endocrine neoplasia type 1**. Approximately 10% of MEN1 patients have adrenocortical tumors, of which ~14% are malignant. Adrenocortical carcinomas also occur in patients with **Lynch syndrome**, a hereditary cancer syndrome (mainly colorectal and endometrial cancer) caused by pathogenic variants in genes involved in DNA mismatch repair, including *MLH1, MSH2, MSH6,* and *PMS2,* or loss of expression of *MSH2* caused by deletion in the *EPCAM* gene. Occasional adrenocortical carcinomas occur in patients with familial adenomatous polyposis, neurofibromatosis type 1, Werner syndrome, and Carney complex.

In adult adrenocortical carcinoma samples, *somatic* pathogenic variants are detected in nine genes (*ZNRF3, CTNNB1, TP53, CDKN2A, RB1, MEN1, DAXX, MED12,* and *TERT*), most frequently (21%) in *ZNRF3*. This gene encodes a cell surface transmembrane E3 ubiquitin ligase that acts as a negative feedback regulator of Wnt/β-catenin signaling. There are also tumor-specific differences in DNA methylation and in micro-RNA (miRNA) expression that have prognostic significance in adults, but there are no corresponding data in children.

CLINICAL MANIFESTATIONS

Symptoms of endocrine hyperfunction are present in 80–90% of children with adrenal tumors. Tumors that secrete cortisol and aldosterone are discussed in Chapters 619 and 621. Other tumors are detected because of symptoms related to local tumor growth, such as abdominal pain, or as incidental findings on abdominal imaging.

Tumors can usually be detected by ultrasonography, CT, or MRI. Preoperatively, the presence of metastatic disease should be determined by MRI or CT of the chest, abdomen, and pelvis. Because these tumors are metabolically active, ^{18}F-fluorodeoxyglucose positron emission tomography (PET)/CT has very good sensitivity and specificity in distinguishing benign from malignant lesions, but it cannot distinguish adrenocortical carcinomas from other metabolically active tumors such as metastases, lymphoma, or pheochromocytoma. Radiochemical imaging of these tumors by PET may be improved with ^{11}C-metomidate or single photon emission CT or MRI with ^{123}I-iodometomidate.

PATHOLOGIC FINDINGS

Most pediatric adrenocortical tumors would be classified as malignant by the criteria used to classify adult tumors. Size is a useful prognostic factor, with tumors weighing less than 200 g, 200-400 g, and >400 g being classified, respectively, as low, intermediate, and high risk (>10 cm diameter has also been suggested as a high-risk category). Incomplete resection and gross local invasion or metastasis are also associated with a poor prognosis. However, most tumors occurring in children younger than 4 years of age have a favorable prognosis. Tumors associated with Cushing syndrome may have a poor prognosis, whereas the presence of germline *TP53* variants may be more favorable.

DIFFERENTIAL DIAGNOSIS

For functioning tumors, the differential diagnoses are those of the main presenting signs and symptoms. The differential diagnosis for Cushing syndrome is discussed in Chapter 619. For virilizing signs, the differential includes virilizing forms of adrenal hyperplasia (see Chapter 616) and factitious exposure to androgens, such as topical testosterone preparations. The differential diagnosis for hormonally

Table 617.1 Genes Involved in Adrenal Neoplasia

SYNDROME	ADRENAL NEOPLASIA TYPE	GENE	OTHER PHENOTYPE
Li-Fraumeni syndrome	Adrenocortical carcinoma	*TP53*	Sarcoma, choroid plexus tumor, brain cancer, early breast cancer, leukemia, lymphoma
Multiple endocrine neoplasia type 1	Diffuse hyperplasia, nodular hyperplasia, adrenal adenoma, adrenocortical carcinoma	*MENIN*	Foregut neuroendocrine tumors, pituitary tumors, parathyroid hyperplasia or tumors, collagenoma, angiofibroma
Lynch syndrome	Adrenocortical carcinoma	*MSH2, MSH6, MLH1, PMS2*	Colorectal cancer, endometrial cancer, sebaceous neoplasms, ovarian cancer, pancreatic cancer, brain cancer
Beckwith-Wiedemann syndrome	Adrenal adenoma, adrenocortical carcinoma	*IGF2, CDKN1C, H19* methylation changes on 11p15	Macrosomia, hemihypertrophy, macroglossia, omphalocele, ear pits; Wilms tumor, hepatoblastoma
Familial adenomatous polyposis coli	Bilateral macronodular adrenal hyperplasia, aldosterone-producing adenoma, adrenocortical carcinoma	*APC*	Intestinal polyps, colon cancer, duodenal carcinoma, thyroid cancer, desmoid tumor, supernumerary teeth, congenital hypertrophy of the retina, osteoma, epidermoid cysts
Neurofibromatosis type 1	Adrenocortical carcinoma, pheochromocytoma	*NF1*	Malignant peripheral nerve sheet tumor, café-au-lait spots, neurofibroma, optic glioma, Lisch nodule, skeletal abnormalities
ADRENAL ADENOMA AND CARCINOMA			
Carney complex	Primary pigmented nodular adrenal disease, adrenocortical carcinoma	*PRKAR1A*	Large-cell calcifying Sertoli cell tumors, thyroid adenoma, myxoma, somatotroph pituitary adenoma, lentigines
	Primary pigmented nodular adrenal disease	*PDE8B* or *PDE11A*	
Overexpression of steroidogenic factor-1	Adrenal adenoma, adrenocortical carcinoma	Somatic amplification of *NR5A1*	
McCune-Albright syndrome	Nodular hyperplasia, cortisol-secreting adenoma	Activating somatic mosaic variant of *GNAS*	Hyperfunction of bone (producing fibrous dysplasia), gonads, thyroid, and pituitary
	Cortisol-secreting adenomas	Activating somatic variant in *PRKACA*	
Somatic pathogenic variants	Adrenocortical carcinoma	*CDKN2A, CTNNB1, DAXX, MED12, MEN1, RB1,TERT, or TP53*	
PRIMARY ALDOSTERONISM			
Genetic causes of excess cortisol and aldosterone secretion	Hypertrophy of zona glomerulosa, aldosterone-producing adenoma	Germline or somatic activating variant in *KCNJ5*	
	Aldosterone-producing adenoma	Germline variants in *CYP11B2, CLCN2, or CACNA1H*	
	Aldosterone-producing adenoma	Germline and somatic activating variants in *CACNA1D*	
	Aldosterone-producing adenoma	Somatic variants in *ATP1A1, ATP2B3, CTNNB1, or APC*	
Pheochromocytoma			
von Hippel-Landau syndrome	Pheochromocytoma	*VHL*	Retinal and central nervous system hemangioblastomas, renal clear cell carcinomas
Multiple endocrine neoplasia syndromes *MEN2A* and *MEN2B*	Pheochromocytoma	*RET*	Medullary thyroid carcinoma and parathyroid tumors; type 2B also may include multiple mucosal neuromas and intestinal ganglioneuromas, a marfanoid habitus, and other skeletal abnormalities
	Pheochromocytoma, often malignant	*SDHB, SDHD, SDHC, SDHA, SDHAF2, MAX, TMEM127*	Paragangliomas, sometimes associated with gastrointestinal stromal tumors and/or pulmonary chondromas (Carney-Stratakis dyad or triad)

inactive adrenocortical adenomas includes pheochromocytomas (see Chapter 621), adrenocortical carcinoma, and metastasis from an extraadrenal primary carcinoma (very rare in children). Careful history, physical examination, and endocrine evaluation must be performed to seek evidence of autonomous cortisol, androgen, mineralocorticoid, or catecholamine secretion. Not infrequently, a low level of autonomous cortisol secretion is detected that does not cause clinically apparent symptoms; this condition is sometimes referred to as *subclinical Cushing syndrome.*

TREATMENT

Functioning adrenocortical tumors should be removed surgically. There are no data on which to base a recommendation regarding nonfunctioning childhood incidentalomas; in adults, such tumors may be closely observed with imaging and repeat biochemical studies if smaller than 4 cm in diameter, but it is not certain that this is prudent in children. Adrenalectomy should be performed transperitoneally to minimize the risk of surgical rupture of the capsule and consequent dissemination of malignant cells. Some adrenocortical neoplasms are highly malignant and metastasize widely, but less malignant, encapsulated tumors (stage I-II) are often curable if they can be resected without tumor spillage. Postoperatively, patients should be closely monitored biochemically, with frequent determinations of adrenal androgen levels and imaging studies. Recurrent symptoms or biochemical abnormalities should prompt a careful search for metastatic disease. Metastases primarily involve liver, lung, and regional lymph nodes. Most metastatic recurrences appear within 1 year of tumor resection. Repeat surgical resection of metastatic lesions should be performed if possible and adjuvant therapy instituted. Radiation therapy has not been generally helpful. Antineoplastic agents such as cisplatin, doxorubicin and etoposide, ifosfamide and carboplatin, and 5-fluorouracil and leucovorin have had limited use in children, toxicity is high, and in adults with metastatic disease, progression-free survival is only a few months. Therapy with o,p′-DDD (mitotane), an adrenolytic agent, may relieve the symptoms of hypercortisolism or virilization in recurrent disease. In adults, treatment with mitotane plus local or regional treatment (surgery or radiotherapy) is associated with improved survival. Other agents that interfere with adrenal steroid synthesis, such as ketoconazole, aminoglutethimide, and metyrapone, may also relieve symptoms of steroid excess but do not improve survival.

A neoplasm of one adrenal gland may produce atrophy of the other because excessive production of cortisol by the tumor suppresses adrenocorticotropic hormone stimulation of the normal gland. Consequently, **adrenal insufficiency** may follow surgical removal of the tumor. This situation can be avoided by giving 10-25 mg of hydrocortisone every 6 hours, starting on the day of operation and gradually decreased postoperatively. Adequate quantities of water, sodium chloride, and glucose also must be provided.

617.2 Adrenal Incidentaloma

Perrin C. White

Adrenal masses are discovered with increasing frequency in patients undergoing abdominal imaging for reasons unrelated to the adrenal gland. There are no published data on the frequency of the occurrence of such tumors in childhood. They are likely to be infrequent, being found in approximately 7% of autopsies of persons older than age 70 years but in <1% of those younger than age 30 years. They are detected in 1–4% of abdominal CT examinations in adults.

The unexpected discovery of such a mass presents the clinician with a dilemma in terms of diagnostic steps to undertake and treatment interventions to recommend. The differential diagnosis of adrenal incidentaloma includes benign lesions such as cysts, hemorrhagic cysts, hematomas, and myelolipomas. These lesions can usually be identified on CT or MRI. If the nature of the lesion is not readily apparent, additional evaluation is required. Included in the differential diagnosis of lesions requiring additional evaluation are benign adenomas, pheochromocytomas, adrenocortical carcinoma, and metastasis from an extraadrenal primary carcinoma. Benign, hormonally inactive adrenocortical adenomas make up the majority of incidentalomas. Careful history, physical examination, and endocrine evaluation must be performed to seek evidence of autonomous cortisol, androgen, mineralocorticoid, or catecholamine secretion. Functional tumors require removal. If the adrenal mass is nonfunctional but is larger than 4-6 cm, recommendations are to proceed with surgical resection of the mass. Lesions of 3 cm or less should be followed clinically with periodic reimaging. Treatment must be individualized; nonsecreting adrenal incidentalomas may enlarge and become hyperfunctioning. Nuclear scan, and occasionally fine-needle aspiration, may be helpful in defining the mass.

617.3 Adrenal Calcification

Perrin C. White

Calcification within the adrenal glands may occur in a wide variety of situations, some serious and others of no obvious consequence. Adrenal calcifications are often detected as incidental findings in radiographic studies of the abdomen in infants and children. The physician may elicit a history of anoxia or trauma at birth. Hemorrhage into the adrenal gland at or immediately after birth is probably the most common factor that leads to subsequent calcification (see Fig. 615.1). Although it is advisable to assess the adrenocortical reserve of such patients, there is rarely any functional disorder.

Neuroblastomas, ganglioneuromas, adrenocortical carcinomas, pheochromocytomas, and cysts of the adrenal gland may be responsible for calcifications, particularly if hemorrhage has occurred within the tumor. Calcification in such lesions is almost always unilateral.

In the past, tuberculosis was a common cause of both calcification within the adrenals and Addison disease. Calcifications may also develop in the adrenal glands of children who recover from Waterhouse-Friderichsen syndrome; such patients are usually asymptomatic. Infants with Wolman disease, a rare lipid disorder caused by a deficiency of lysosomal acid lipase, have extensive bilateral calcifications of the adrenal glands (see Chapter 106.4).

Visit Elsevier eBooks+ at eBooks.Health.Elsevier.com for Bibliography.

Chapter 618

Virilizing and Feminizing Adrenal Tumors

Perrin C. White

Virilization is the most common presenting symptom in children with adrenocortical tumors (see Chapter 617), occurring in 50–80%. In males, the clinical picture is similar to that of simple virilizing congenital adrenal hyperplasia: accelerated growth velocity and muscle development, acne, penile enlargement, and the precocious development of pubic and axillary hair. In females, virilizing tumors of the adrenal gland cause masculinization of a previously normal female with clitoral enlargement, growth acceleration, acne, deepening of the voice, and premature pubic and axillary hair development.

Conversely, adrenal tumors can occasionally (<10%) secrete high levels of estrogens because of overexpression of CYP19 (aromatase). Gynecomastia in males or premature thelarche in females is often the initial manifestation. Growth and development may be otherwise normal, or concomitant virilization may occur.

In addition to virilization, 15–40% of children with adrenocortical tumors also have Cushing syndrome (see Chapter 619). Whereas isolated virilization occurs relatively frequently, children with adrenal tumors usually do not have Cushing syndrome alone.

LABORATORY FINDINGS

Serum levels of dehydroepiandrosterone, dehydroepiandrosterone sulfate, and androstenedione are usually elevated, often markedly. Serum levels of testosterone are often increased, usually because of peripheral conversion of androstenedione, but infants with predominantly testosterone-secreting adenomas have been reported. Levels of estrone and estradiol are elevated in tumors from patients with feminizing signs. Urinary 17-ketosteroids (sex steroid metabolites) are also increased but are no longer routinely measured. Many adrenocortical tumors have a relative deficiency of 11β-hydroxylase activity and secrete increased amounts of deoxycorticosterone; these patients are hypertensive, and their tumors are often malignant.

DIFFERENTIAL DIAGNOSIS

For virilizing signs, the differential includes virilizing forms of adrenal hyperplasia (see Chapter 616) and factitious exposure to androgens, such as topical testosterone preparations. The differential diagnosis for adrenal tumors is discussed in Chapter 617.

TREATMENT

Functioning adrenocortical tumors should be removed surgically (see Chapter 617).

Visit Elsevier eBooks+ at eBooks.Health.Elsevier.com for Bibliography.

Chapter 619

Cushing Syndrome

Perrin C. White

Cushing syndrome is the result of abnormally high blood levels of cortisol or other glucocorticoids. This can be iatrogenic or the result of endogenous cortisol secretion, a result of either an adrenal tumor or of hypersecretion of corticotropin (adrenocorticotropic hormone [ACTH]) by the pituitary (Cushing disease), or by a tumor (Table 619.1).

Table 619.1 Etiologic Classification of Adrenocortical Hyperfunction

EXCESS ANDROGEN
Congenital adrenal hyperplasia
21-Hydroxylase (CYP21A2) deficiency
11β-Hydroxylase (CYP11B1) deficiency
3β-Hydroxysteroid dehydrogenase (HSD3B2) defect (deficiency or dysregulation)
Tumor
EXCESS CORTISOL (CUSHING SYNDROME)
Bilateral adrenal hyperplasia
Adenoma
Hypersecretion of corticotropin (Cushing disease)
Ectopic secretion of corticotropin
Exogenous corticotropin
Adrenocortical nodular dysplasia
Pigmented nodular adrenocortical disease (Carney complex)
Tumor
McCune-Albright syndrome
EXCESS MINERALOCORTICOID
Primary hyperaldosteronism
Aldosterone-secreting adenoma
Bilateral micronodular adrenocortical hyperplasia
Glucocorticoid-suppressible aldosteronism
Tumor
Deoxycorticosterone excess
Congenital adrenal hyperplasia
• 11β-Hydroxylase (CYP11B1)
• 17α-Hydroxylase (CYP17A1)
Tumor
Apparent mineralocorticoid excess (deficiency of 11β-hydroxysteroid dehydrogenase type 2 [HSD11B2])
EXCESS ESTROGEN
Tumor

ETIOLOGY

The most common cause of Cushing syndrome is prolonged exogenous administration of glucocorticoid hormones, especially at the high doses used to treat lymphoproliferative disorders. This rarely represents a diagnostic challenge, but management of hyperglycemia, hypertension, weight gain, linear growth retardation, and osteoporosis often complicates therapy with corticosteroids.

Endogenous Cushing syndrome is most often caused in infants by a functioning adrenocortical tumor (see Chapter 617). Patients with these tumors often exhibit signs of hypercortisolism along with signs of hypersecretion of other steroids such as androgens, estrogens, and aldosterone.

Although extremely rare in infants, the most common etiology of endogenous Cushing syndrome in children older than 7 years of age is **Cushing disease**, in which excessive ACTH secreted by a **pituitary adenoma** causes bilateral adrenal hyperplasia. Such adenomas are often too small to detect by imaging techniques and are termed **microadenomas**. They consist principally of chromophobe cells and frequently show positive immunostaining for ACTH and its precursor, proopiomelanocortin. Although most such tumors are sporadic, a small number occur in kindreds with **familial isolated pituitary adenoma syndrome**. This syndrome, which is caused by pathogenic variants in the *AIP* gene, accounts for perhaps 2% of pituitary adenomas; more commonly tumors with *AIP* variants secrete growth hormone or prolactin, and only rarely do they secrete ACTH. Similarly, multiple endocrine neoplasia type 1 (MEN1) patients who have pathogenic variants in the *MEN1* gene may develop pituitary tumors, but these are typically prolactinomas. Other genes have also been implicated (Fig. 619.1).

ACTH-dependent Cushing syndrome may also result from ectopic production of ACTH, although this is uncommon in children. Ectopic ACTH secretion in children is associated with islet cell carcinoma of the pancreas, neuroblastoma or ganglioneuroblastoma, hemangiopericytoma, Wilms tumor, and thymic carcinoid. Hypertension is more

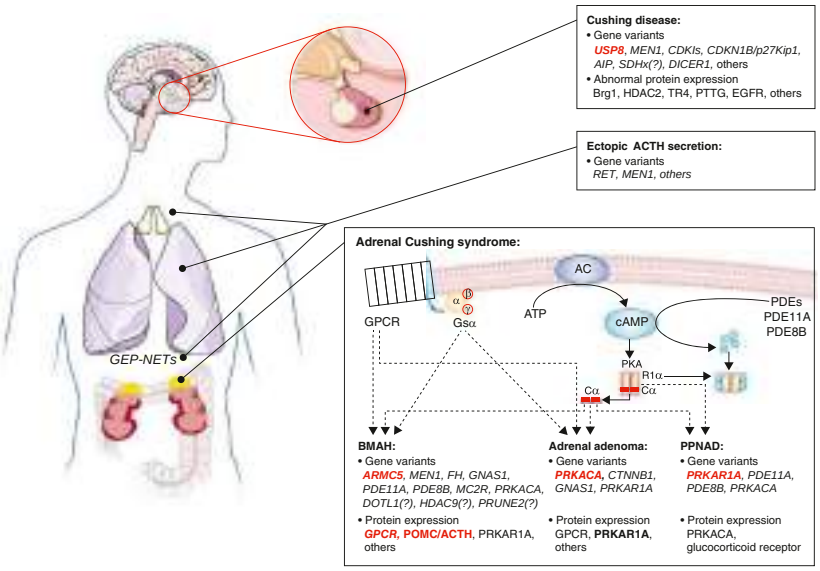

Fig. 619.1 Summary of genetic and molecular mechanisms implicated in Cushing syndrome. For each cause, the various pathogenic variants or abnormal protein expression believed to play a part in the pathophysiology is shown. The most frequent mechanisms are highlighted in red; the well-characterized mechanisms are highlighted in bold characters, and other potential mechanisms are in normal characters; a question mark shows an unconfirmed association or genetic predisposition. Please refer to the text for explanation of the various genetic defects under each diagnostic category. AC, Adenylate cyclase; ACTH, adrenocorticotropic hormone; BMAH, bilateral macronodular adrenal hyperplasia; Cα, catalytic subunit of PKA; GEP-NETs, gastroenteropancreatic neuroendocrine tumors; GPCR, G protein–coupled receptor; PDEs, phosphodiesterases; PKA, protein kinase A; PPNAD, primary pigmented nodular adrenocortical disease; R1α, type 1α regulatory subunit of PKA. *(From Lacroix A, Feelders RA, Stratakis CA, et al. Cushing's syndrome. Lancet. 2015;386:913–927. Fig. 1.)*

common in ectopic ACTH syndrome than in other forms of Cushing syndrome, because very high cortisol levels may overwhelm type 2 11β-hydroxysteroid dehydrogenase in the kidney (see Chapter 615) and thus have an enhanced mineralocorticoid (salt-retaining) effect.

Several syndromes are associated with the development of multiple autonomously hyperfunctioning nodules of adrenocortical tissue, rather than single adenomas or carcinomas (see Chapter 617). In many cases they are caused by pathogenic variants in genes in the cyclic adenosine monophosphate (cAMP)–mediated signaling pathway by which ACTH normally regulates cortisol secretion. **Primary pigmented nodular adrenocortical disease (PPNAD)** is a distinctive form of ACTH-independent Cushing syndrome. It may occur as an isolated event or, more commonly, as a familial disorder with other manifestations. The adrenal glands are small and have characteristic multiple small (<4 mm in diameter), pigmented (black) nodules containing large cells with cytoplasm and lipofuscin; there is cortical atrophy between the nodules. This adrenal disorder occurs as a component of **Carney complex**, an autosomal dominant disorder also consisting of centrofacial lentigines and blue nevi; cardiac and cutaneous myxomas; pituitary, thyroid, and testicular tumors; and pigmented melanotic schwannomas. Carney complex is inherited in an autosomal dominant manner, although sporadic cases occur. Genetic loci for Carney complex have been mapped to the gene for the type 1α regulatory subunit of protein kinase A *(PRKAR1A)* on chromosome 17q22-24 and less frequently to chromosome 2p16. Patients with Carney complex and *PRKAR1A* variants generally develop PPNAD as adults, and those with the disorder mapping to chromosome 2 (and most sporadic cases) develop PPNAD less frequently and later. Conversely, children presenting with PPNAD as an isolated finding rarely have pathogenic variants in *PRKAR1A,* or subsequently develop other manifestations of Carney complex. Some patients with isolated PPNAD have pathogenic variants in *PDE8B* or *PDE11A* encoding different phosphodiesterase isozymes. In contrast, activating *somatic* variants have been documented in the PRKACA catalytic subunit of protein kinase A in cortisol-secreting adenomas.

ACTH-independent Cushing syndrome with nodular hyperplasia and adenoma formation occurs rarely in cases of **McCune-Albright syndrome**, with symptoms beginning in infancy or childhood. McCune-Albright syndrome is caused by *somatic* variants of *GNAS* encoding the G protein, $G_s\alpha$, through which the ACTH receptor (MCR2) normally signals. When the variant is present in adrenal tissue, cortisol and cell division are stimulated independently of ACTH. Other tissues in which activating mutations may occur are bone (producing fibrous dysplasia), gonads, thyroid, and pituitary. Clinical manifestations depend on which tissues are affected.

The genes causing nodular adrenocortical hyperplasia that have been identified mainly produce overactivity of the ACTH signaling pathway either by constitutively activating $G_s\alpha$ (McCune-Albright syndrome), by reducing the breakdown of cAMP and thus increasing its intracellular levels (variants of *PDE8B* or *PDE11A*), by disrupting the regulation of the cAMP-dependent enzyme protein kinase A (PRKAR1A mutations), or via microduplications encompassing *PRKACA*. Additionally, *ARMC5,* a tumor-suppressor gene, is abnormal in approximately 40% of cases of primary bilateral macronodular adrenocortical hyperplasia. Adrenocortical lesions, including diffuse hyperplasia, nodular hyperplasia, adenoma, and rarely carcinoma, may occur as part of MEN1 syndrome (see Chapter 617), an autosomal dominant disorder in which there is homozygous inactivation of the menin (MEN1) tumor-suppressor gene on chromosome 11q13.

CLINICAL MANIFESTATIONS

Signs of Cushing syndrome have been recognized in infants younger than 1 year of age. The disorder appears to be more severe and the clinical findings more dramatic in infants than in older children. The face is rounded, with prominent cheeks and a flushed appearance (moon facies). Generalized obesity is common in younger children. In children with adrenal tumors, signs of abnormal masculinization occur frequently; accordingly, there may be hirsutism on the face and trunk, pubic hair, acne, deepening of the voice, and enlargement of the clitoris in females. Growth is impaired, with length falling below the third percentile, except when significant virilization produces normal or even accelerated growth. Hypertension is common and may occasionally lead to heart failure. An increased susceptibility to infection may also lead to sepsis.

In older children, in addition to obesity, short stature is a common presenting feature (Table 619.2). Gradual onset of obesity and deceleration or cessation of growth may be the only early manifestations. Older children most often have more severe obesity of the face and trunk compared with the extremities. However, obesity of the neck and upper back ("buffalo hump") is a nonspecific finding to which excessive importance should not be attached. Purplish striae on the hips, abdomen, and thighs are common. Pubertal development may be delayed, or amenorrhea may occur in females past menarche. Weakness, headache, and emotional lability may be prominent. Hypertension and hyperglycemia usually occur; hyperglycemia may progress to frank diabetes. Osteoporosis is common and may cause pathologic fractures.

Table 619.2	Presenting Signs and Symptoms of Cushing Syndrome in Children
Dermatologic	Facial plethora, acne, acanthosis nigricans, easy bruising, supratemporal and supraclavicular fat pads, moon facies, fungal infection, hirsutism, fine downy hair, violaceous striae (unusual in children <7 yr age)
Neurologic	Headaches
Cardiovascular	Hypertension, coagulopathy
Growth	Growth deceleration with concomitant weight gain, central obesity
Gonadal	Amenorrhea, virilization, gynecomastia
Other	Nephrolithiasis, bone fractures, impaired glucose tolerance, type 2 diabetes
Psychologic	Depression, anxiety, mood swings, irritability, fatigue

From Lodish MB, Keil MF, Stratakis CA. Cushing's syndrome in pediatrics: an update. *Endocrinol Metab Clin N Am*. 2018;47:451–462. Table 1.

LABORATORY FINDINGS

Cortisol levels in blood are normally highest at 8 AM and decrease to less than 50% of peak levels by midnight, except in infants and young children, in whom a diurnal rhythm is not always established. In patients with Cushing syndrome, this circadian rhythm is lost; *midnight cortisol levels >4.4 μg/dL strongly suggest the diagnosis*. It is difficult to obtain diurnal blood samples as part of an outpatient evaluation, but cortisol can be measured in *saliva samples*, which can be obtained at home at the appropriate times of day. Elevated nighttime salivary cortisol levels raise suspicion for Cushing syndrome.

Urinary excretion of free cortisol is increased. This is best measured in a 24-hour urine sample and is expressed as a ratio of micrograms of cortisol excreted per gram of creatinine. This ratio is independent of body size and completeness of the urine collection.

A single-dose dexamethasone suppression test is often helpful; a dose of 25-30 μg/kg (maximum: 2 mg) given at 11 PM results in a plasma cortisol level of less than 5 μg/dL at 8 AM the next morning in normal individuals but not in patients with Cushing syndrome. It is prudent to measure the dexamethasone level in the same blood sample to ensure the adequacy of dosing.

A glucose tolerance test is often abnormal but is of no diagnostic utility. Levels of serum electrolytes are usually normal, but potassium may be decreased, especially in patients with tumors that secrete ACTH ectopically.

After the diagnosis of Cushing syndrome has been established, it is necessary to determine whether it is caused by a pituitary adenoma, an ectopic ACTH-secreting tumor, or a cortisol-secreting adrenal tumor (Fig. 619.2). ACTH concentrations are usually suppressed in patients with cortisol-secreting tumors and are very high in patients with ectopic ACTH-secreting tumors, but may be normal in patients with ACTH-secreting pituitary adenomas. After an intravenous bolus of corticotropin-releasing hormone, patients with ACTH-dependent Cushing syndrome have an exaggerated ACTH and cortisol response, whereas those with adrenal tumors show no increase in ACTH and cortisol. The two-step dexamethasone suppression test consists of administration of dexamethasone, 30 and 120 μg/kg/24 hr in four divided doses, on consecutive days. In children with pituitary Cushing syndrome, the larger dose, but not the smaller dose, suppresses serum levels of cortisol. Typically, patients with ACTH-independent Cushing syndrome do not show suppressed cortisol levels with dexamethasone.

CT detects virtually all adrenal tumors larger than 1.5 cm in diameter. MRI may detect ACTH-secreting pituitary adenomas, but many are too small to be seen; the addition of gadolinium contrast increases the sensitivity of detection. Bilateral inferior petrosal blood sampling to measure concentrations of ACTH before and after corticotropin-releasing hormone administration may be required to localize the tumor when a pituitary adenoma is not visualized; this is not routinely available in many centers, and moreover may be of decreased specificity in children.

DIFFERENTIAL DIAGNOSIS

Cushing syndrome is frequently suspected in children with obesity, particularly when striae and hypertension are present. Children with simple obesity are usually tall, whereas those with Cushing syndrome are short or have a decelerating growth rate. Although urinary excretion of cortisol is often elevated in simple obesity, salivary nighttime levels of cortisol are usually normal, and cortisol secretion is normally suppressed by oral administration of low doses of dexamethasone.

Elevated levels of cortisol and ACTH without clinical evidence of Cushing syndrome occur in patients with generalized glucocorticoid resistance (see Chapter 615.4). Affected patients may be asymptomatic or exhibit hypertension, hypokalemia, and precocious pseudopuberty; these manifestations are caused by increased mineralocorticoid and adrenal androgen secretion in response to elevated ACTH levels. Mutations in the glucocorticoid receptor have been identified.

TREATMENT

Transsphenoidal pituitary microsurgery is the treatment of choice in *pituitary* Cushing disease in children. The overall success rate with follow-up of less than 10 years is 60–80%. Low postoperative serum or urinary cortisol concentrations predict long-term remission in most cases. Relapses are treated with reoperation or pituitary irradiation.

Cyproheptadine, a centrally acting serotonin antagonist that blocks ACTH release, has been used to treat Cushing disease in adults; remissions are usually not sustained after discontinuation of therapy. This agent is rarely used in children. Inhibitors of adrenal steroidogenesis (metyrapone, ketoconazole, aminoglutethimide, etomidate) have been used preoperatively to normalize circulating cortisol levels and reduce perioperative morbidity and mortality. Mifepristone, a glucocorticoid receptor antagonist, has been used in a limited number of cases. Pasireotide, a somatostatin analog, can inhibit ACTH secretion and is approved for use in adults with persistent disease after surgery or in whom surgery is contraindicated.

If a pituitary adenoma does not respond to treatment or if ACTH is secreted by an ectopic metastatic tumor, the adrenal glands may need to be removed. This can often be accomplished laparoscopically. Adrenalectomy may lead to increased ACTH secretion by an unresected pituitary adenoma, evidenced mainly by marked hyperpigmentation; this condition is termed **Nelson syndrome**, which occurs in ~25% of adults who have undergone adrenalectomy for Cushing syndrome.

Several drugs that inhibit adrenocortical function may be an alternative to adrenalectomy. FDA-approved agents include mitotane (which is toxic to adrenocortical cells) and osilodrostat (a cortisol synthesis inhibitor); levoketoconazole, a stereoisomer of ketoconazole, inhibits several steroidogenic enzymes and is in an advanced stage of development.

Management of patients undergoing adrenalectomy requires adequate preoperative and postoperative replacement therapy with a corticosteroid. Tumors that produce corticosteroids usually lead to atrophy of the normal adrenal tissue, and replacement with cortisol (10 mg/m^2/24 hr in three divided doses after the immediate postoperative period) is required until there is recovery of the hypothalamic-pituitary-adrenal axis. Postoperative complications may include sepsis, pancreatitis, thrombosis, poor wound healing, and sudden collapse, particularly in infants with Cushing syndrome. Substantial catch-up growth, pubertal progress, and increased bone density occur, but bone density remains abnormal and adult height is often compromised. The management of adrenocortical tumors is discussed in Chapter 617.

Visit Elsevier eBooks+ at eBooks.Health.Elsevier.com for Bibliography.

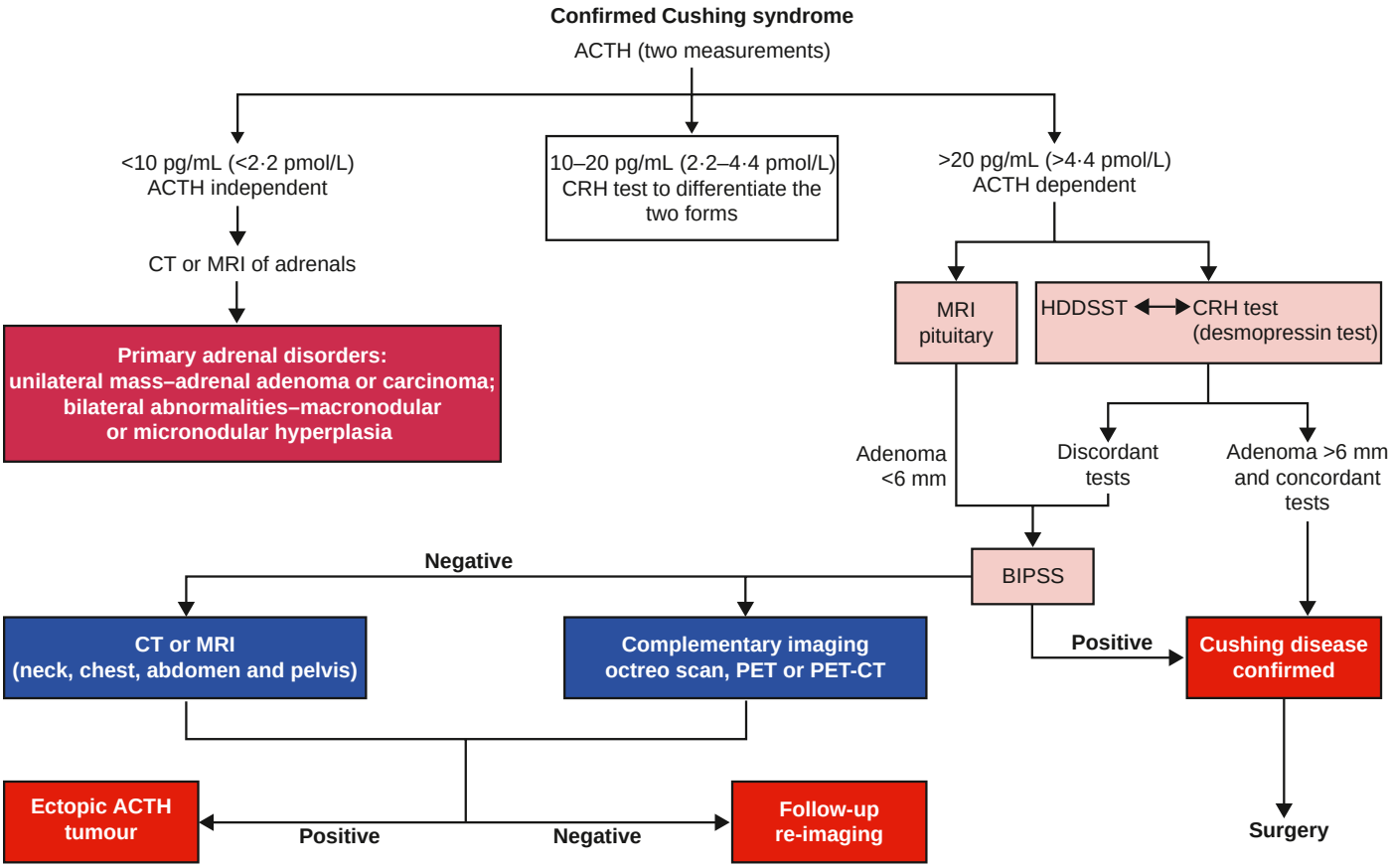

Fig. 619.2 Clinical decision-making algorithm for the differential diagnosis of confirmed Cushing syndrome of different causes. ACTH, Adrenocorticotropic hormone; BIPSS, bilateral inferior petrosal sinus sampling; CRH, corticotropin-releasing hormone; HDDSST, high-dose dexamethasone suppression test. *(From Lacroix A, Feelders RA, Stratakis CA, et al. Cushing's syndrome. Lancet. 2015;386:913–927. Fig. 3.)*

Chapter 620

Primary Aldosteronism

Perrin C. White

Primary aldosteronism encompasses disorders caused by excessive aldosterone secretion independent of the renin-angiotensin system. These disorders are characterized by hypertension, hypokalemia, and suppression of the renin-angiotensin system.

Aldosterone-secreting adenomas are unilateral and have been reported in children as young as 3.5 years of age. They are rarely malignant. Bilateral micronodular adrenocortical hyperplasia tends to occur in older ages. Primary aldosteronism caused by unilateral adrenal hyperplasia may also occur. Glucocorticoid-suppressible hyperaldosteronism is discussed in Chapter 616.8.

EPIDEMIOLOGY

These conditions are thought to be rare in children, but they may account for 5–10% of cases of hypertension in adults. Although usually sporadic, kindreds with several affected members have been reported. Genetic linkage to chromosome 7p22 was reported in some kindreds, but the involved gene has not yet been identified. Pathogenic variants in *KCNJ5* on chromosome 11q24 (encoding G protein–gated inward rectifier potassium channel 4) have been identified in several kindreds; these variants (*G151R* and *G151E*) altered channel selectivity, producing increased Na^+ conductance and membrane depolarization, which increase aldosterone production and proliferation of adrenal glomerulosa cells. Such variants have been identified in a subset of sporadic aldosterone-producing adenomas. Germline variants have also been reported in *CYP11B2* (encoding aldosterone synthase), *CLCN2* (encoding voltage-gated chloride channel ClC-2), and *CACNA1H* (encoding a subunit of the T-type voltage-gated calcium channel CaV3.2). Germline and somatic variants have also been reported in *CACNA1D* encoding a voltage-sensitive calcium channel and *somatic* variants in *ATP1A1* and *ATP2B3,* respectively, encoding sodium-potassium and calcium ATPases. Most aldosterone-producing adenomas have pathogenic variants that activate the Wnt/β-catenin signaling pathway, either in β-catenin *(CTNNB1)* itself, or in *APC,* which regulates this pathway.

CLINICAL MANIFESTATIONS

Some affected children have no symptoms, the diagnosis being established after incidental discovery of moderate hypertension. Others have severe hypertension (up to 240/150 mm Hg), with headache, dizziness, and visual disturbances. If present, chronic hypokalemia may lead to polyuria, nocturia, enuresis, and polydipsia. Muscle weakness and discomfort, tetany, intermittent paralysis, fatigue, and growth failure affect children with severe hypokalemia.

LABORATORY FINDINGS

Hypokalemia occurs frequently. Serum pH and carbon dioxide and sodium concentrations may be elevated and serum chloride and magnesium levels decreased. Serum levels of calcium are normal, even in children who manifest tetany. The urine is neutral or alkaline, and urinary potassium excretion is high. Plasma levels of aldosterone may be normal or elevated. Aldosterone concentrations in 24-hour urine collections are always increased. Plasma levels of renin are persistently low.

The diagnostic test of choice for primary aldosteronism is controversial. Both renin and aldosterone levels may vary by time of day, posture, and sodium intake, making it difficult to establish consistent reference ranges. It is desirable to establish a consistent sampling protocol, for example, at midmorning after the patient has been sitting for 15 minutes. If possible, antihypertensive drugs or other medications that can affect aldosterone or renin secretion should be avoided for several weeks before testing, including diuretics, β blockers, angiotensin-converting enzyme inhibitors, angiotensin receptor blockers, clonidine, and nonsteroidal anti-inflammatory agents. Patients taking these agents may need to be changed to α-adrenergic blockers or calcium channel blockers that have smaller effects on the biochemical measurements. The ratio of plasma aldosterone concentration to renin activity is always high, and this represents a cost-effective screening test for primary aldosteronism. Aldosterone does not decrease with administration of saline solution or fludrocortisone, and renin does not respond to salt and fluid restriction. Urinary and plasma levels of 18-oxocortisol and 18-hydroxycortisol may be increased but not to the extent seen in glucocorticoid-suppressible hyperaldosteronism.

DIFFERENTIAL DIAGNOSIS

Primary aldosteronism should be distinguished from glucocorticoid-remediable aldosteronism (also termed **glucocorticoid-suppressible hyperaldosteronism**, see Chapter 616.8), which is specifically treated with glucocorticoids. An autosomal dominant pattern of inheritance should raise suspicion for the latter disorder. **Glucocorticoid-remediable aldosteronism** is diagnosed by dexamethasone suppression tests or by specific genetic testing.

Patients with primary aldosteronism should be evaluated by computed tomography (CT). It does not reliably distinguish aldosterone-producing adenomas, which tend to be small, from bilateral hyperplasia, but it can exclude the presence of large tumors that might otherwise raise concern for adrenocortical carcinomas. Adrenal venous sampling can accurately determine if excess aldosterone secretion is originating in one gland or both, but it is invasive and may not be available in all centers. Positron emission tomography with ^{11}C-metomidate is a noninvasive alternative.

TREATMENT

The treatment of an aldosterone-producing adenoma is laparoscopic adrenalectomy; successful enucleation of aldosterone-producing adenomas has also been reported. Hyperaldosteronism caused by bilateral adrenal hyperplasia is treated with the mineralocorticoid antagonist spironolactone (1-3 mg/kg/day to a maximum of 100 mg/day) or eplerenone (25-100 mg/day in 2 divided doses), often normalizing blood pressure and serum potassium levels. There is greater experience with spironolactone, but this agent has antiandrogenic properties that may be unacceptable in pubertal males. Eplerenone is a more specific antimineralocorticoid that is safe in children, but there is little specific experience with primary aldosteronism in the pediatric age-group. As an alternative, an epithelial sodium channel blocker, such as amiloride, may be used, with other antihypertensive agents added as necessary. In patients whose condition cannot be controlled medically, unilateral adrenalectomy may be considered.

Visit Elsevier eBooks+ at eBooks.Health.Elsevier.com for Bibliography.

Chapter 621
Pheochromocytoma

Perrin C. White

See also Chapter 555.4.

Pheochromocytomas are catecholamine-secreting tumors arising from chromaffin cells. The most common site of origin (approximately 90%) is the adrenal medulla; however, tumors may develop anywhere along the abdominal sympathetic chain and are likely to be located near the aorta at the level of the inferior mesenteric artery or at its bifurcation. They also appear in the periadrenal area, urinary bladder or ureteral walls, thoracic cavity, and cervical region. Ten percent occur in children, presenting most frequently between 6 and 14 years of age. Tumors vary from 1 to 10 cm in diameter; they are found more often on the right side than on the left. In more than 20% of affected children, the adrenal tumors are bilateral; in 30–40% of children, tumors are found in both adrenal and extraadrenal areas or only in an extraadrenal area.

Most pheochromocytomas are associated with germline pathogenic variants (see Table 555.2 in Chapter 555.4). They may be associated with genetic syndromes such as **von Hippel-Lindau disease, multiple endocrine neoplasia** (MEN) syndromes MEN2A and MEN2B, and less often, in association with **neurofibromatosis (type 1)** or **tuberous sclerosis**. The classic features of von Hippel-Landau syndrome, which occurs in 1 in 36,000 individuals, include retinal and central nervous system hemangioblastomas, renal clear cell carcinomas, and pheochromocytomas, but kindreds differ in their propensity to develop pheochromocytoma; in some kindreds, pheochromocytoma is the only tumor to develop. Germline variants in the *VHL* tumor-suppressor gene on chromosome 3p25-26 have been identified in patients with this syndrome. Variants of the *RET* protooncogene on chromosome 10q11.2 have been found in families with MEN2A and MEN2B. Patients with MEN2 are at risk of developing medullary thyroid carcinoma and parathyroid tumors; approximately 50% develop pheochromocytoma, with patients carrying variants at codon 634 of the *RET* gene being at particularly high risk. Variants are present in the *NF1* gene on chromosome 17q11.2 in neurofibromatosis type 1 patients (see Table 555.2 in Chapter 555.4).

Pheochromocytomas may occur in kindreds along with paragangliomas, particularly at sites in the head and neck. Such families typically carry pathogenic variants in *SDHB, SDHD,* and rarely the *SDHC* encoding subunits of the mitochondrial enzyme succinate dehydrogenase. Approximately 50% of tumors with *SDHB* variants are malignant. The *VHL* and the various *SDH* gene products participate in the *pseudohypoxia* signaling pathway (pseudohypoxia is a decrease in the ratio of the cytosolic oxidized to reduced forms of nicotinamide adenine dinucleotide [NAD (+)/NADH]) and thus represent a common pathogenetic pathway. In rare cases, individuals with germline variants in SDH genes develop pheochromocytomas and/or paragangliomas along with pituitary adenomas, which is termed the **3P association (3Pas)**.

Pheochromocytomas and paragangliomas can occur in association with **gastrointestinal stromal tumors** (GISTs; the association is termed the *Carney-Stratakis dyad*) and/or pulmonary chondromas (Carney-Stratakis triad) and adrenocortical tumors. These associations have heterogenous genetic etiologies but often involve variants in SDH genes.

CLINICAL MANIFESTATIONS

Pheochromocytomas detected by surveillance of patients who are known carriers of variants in tumor-suppressor genes may be asymptomatic. Particularly in adults, some are diagnosed on abdominal CT or MRI performed for another purpose (see Chapter 617). Otherwise, patients are detected owing to hypertension, which results from excessive secretion of metanephrines, epinephrine and norepinephrine. All

patients have hypertension at some point. Paroxysmal hypertension should particularly suggest pheochromocytoma as a diagnostic possibility, but in contrast to adults, the hypertension in children is more often sustained rather than paroxysmal. When there are paroxysms of hypertension, the attacks are usually infrequent at first, but become more frequent and eventually give way to a continuous hypertensive state. Between attacks of hypertension, the patient may be free of symptoms. During attacks, the patient complains of headache, palpitations, abdominal pain, and dizziness; pallor, vomiting, and sweating also occur. Seizures and other manifestations of hypertensive encephalopathy may occur. In severe cases, precordial pains radiate into the arms; pulmonary edema and cardiac and hepatic enlargement may develop. Symptoms may be exacerbated by exercise or with the use of nonprescription medications containing stimulants such as pseudoephedrine. Patients have a good appetite but because of the hypermetabolic state may not gain weight, and severe cachexia may develop. Polyuria and polydipsia can be sufficiently severe to suggest diabetes insipidus. Growth failure may be striking. The blood pressure may range from 180 to 260 mm Hg systolic and from 120 to 210 mm Hg diastolic, and the heart may be enlarged. Ophthalmoscopic examination may reveal papilledema, hemorrhages, exudate, and arterial constriction. The differential diagnosis is noted in Table 555.3.

LABORATORY FINDINGS

The urine may contain protein, a few casts, and occasionally glucose. Gross hematuria suggests that the tumor is in the bladder wall. Polycythemia is occasionally observed.

Pheochromocytomas produce norepinephrine and epinephrine. Normally, norepinephrine in plasma is derived from both the adrenal gland and adrenergic nerve endings, whereas epinephrine is derived primarily from the adrenal gland. In contrast to adults with pheochromocytoma in whom both norepinephrine and epinephrine are elevated, children with pheochromocytoma predominantly excrete norepinephrine in the urine (see Fig. 614.3 in Chapter 614). Daily urinary excretion of these compounds by unaffected children increases with age. Although urinary excretion of vanillylmandelic acid (3-methoxy-4-hydroxymandelic acid), the major metabolite of epinephrine and norepinephrine, is increased, vanilla-containing foods and fruits can produce falsely elevated levels of this compound, which therefore is no longer routinely measured.

Elevated levels of free catecholamines and metanephrines can also be detected in plasma. The consensus is to measure plasma free metanephrines and urinary fractionated metanephrines. The patient should be instructed to abstain from caffeinated drinks and to avoid acetaminophen, which can interfere with plasma normetanephrine immunoassays. If possible, the blood sample should be obtained from an indwelling intravenous catheter to avoid acute stress associated with venipuncture.

Most tumors in the area of the adrenal gland are readily localized by CT or MRI (Fig. 621.1), but extraadrenal tumors may be difficult to detect. ^{123}I or ^{131}I-metaiodobenzylguanidine (MIBG) is taken up by chromaffin tissue anywhere in the body and is useful for localizing small tumors. PET-CT with ^{18}F-fluorodeoxyglucose or ^{68}Ga-DOTA(0)-Tyr(3)-octreotate (a somatostatin receptor ligand) is highly sensitive and a more favored imaging approach (Fig. 621.2 and Fig. 555.2) for difficult-to-localize tumors. Venous catheterization with sampling of blood at different levels for catecholamine determinations is now only rarely necessary for localizing the tumor.

DIFFERENTIAL DIAGNOSIS

Various causes of hypertension in children must be considered, such as renal or renovascular disease; coarctation of the aorta; hyperthyroidism; Cushing syndrome; deficiencies of 11β-hydroxylase, 17α-hydroxylase, or 11β-hydroxysteroid dehydrogenase (type 2 isozyme); primary aldosteronism; adrenocortical tumors; and, rarely, essential hypertension (see Chapter 494). A nonfunctioning kidney may result from compression of a ureter or of a renal artery by a pheochromocytoma. Paroxysmal hypertension may be associated with porphyria or familial dysautonomia. Cerebral disorders and hyperthyroidism must also be considered in the differential diagnosis. Hypertension in patients with neurofibromatosis may be caused by renal vascular involvement or by concurrent pheochromocytoma.

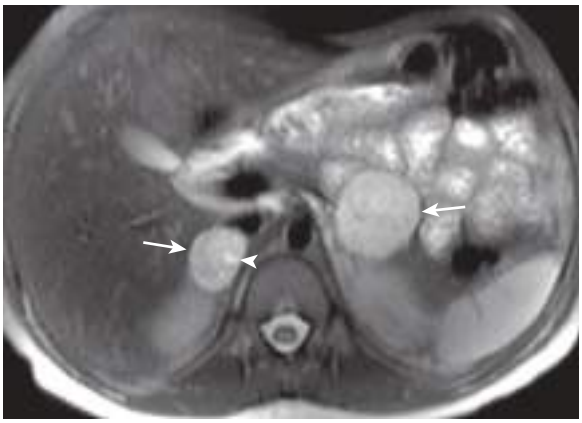

Fig. 621.1 Bilateral pheochromocytoma in an 11-yr-old child with von Hippel-Lindau disease and arterial hypertension. An axial fat-suppressed T2 weighted magnetic resonance image shows bilateral adrenal masses *(arrows)*, larger on the left. The masses are hyperintense with small cystic change on the right medially. *(From Navarro OM, Daneman A. Acquired conditions. In: Coley B, ed. Caffey's Pediatric Diagnostic Imaging, 12th ed. Philadelphia: Elsevier; 2013: Fig. 123.9.)*

Neuroblastoma, ganglioneuroblastoma, and ganglioneuroma frequently produce catecholamines, but urinary levels of most catecholamines are higher in patients with pheochromocytoma, although levels of dopamine and homovanillic acid are usually higher in neuroblastoma. Secreting neuroendocrine tumors often produce hypertension, excessive sweating, flushing, pallor, rash, polyuria, and polydipsia. Chronic secretory diarrhea may be associated with these tumors, particularly with ganglioneuroma.

TREATMENT

These tumors must be removed surgically, but careful preoperative, intraoperative, and postoperative management is essential. Manipulation and excision of these tumors result in marked increases in catecholamine secretion that increase blood pressure and heart rate. Therefore preoperative α- *and β-adrenergic blockade* are required. Whereas phenoxybenzamine has been most often used, it may not be covered by insurance, and selective α_1-blockers, such as doxazosin, as well as calcium channel blockers like amlodipine, have also been used. Because these tumors are often multiple in children, a thorough transabdominal exploration of all the usual sites offers the best opportunity to find them all. Appropriate choice of anesthesia and *expansion of blood volume with appropriate fluids before and during surgery* are critical to avoid a precipitous drop in blood pressure during operation or within 48 hours postoperatively. Surveillance must continue postoperatively.

Because bilateral and recurrent pheochromocytomas occur frequently, some have advocated for adrenal cortex–sparing surgery to reduce the probability of causing Addison disease. However, this approach increases the risk of tumor recurrence.

Although these tumors often appear malignant histologically, the only accurate indicators of malignancy are the presence of metastatic disease or local invasiveness that precludes complete resection, or both. Approximately 10% of all adrenal pheochromocytomas are malignant. Such tumors are rare in childhood; pediatric malignant pheochromocytomas occur more frequently in extraadrenal sites and are often associated with pathogenic variants in *SDHB* encoding a subunit of succinate dehydrogenase. Prolonged follow-up is indicated, particularly in patients with germline mutations in risk loci, because functioning tumors at other sites may be manifested many years after the initial operation. Examination of relatives of affected patients may reveal other individuals harboring unsuspected tumors that may be asymptomatic.

Visit Elsevier eBooks+ at eBooks.Health.Elsevier.com for Bibliography.

Fig. 621.2 Paraganglioma in a 30-yr-old woman who presented with refractory hypertension. **A,** Axial T2-weighted MRI shows homogeneously T2-hyperintense left periaortic mass just above the level of the aortic bifurcation (Zuckerkandl organ), illustrating the "light bulb" T2-bright appearance of pheochromocytomas and paragangliomas. **B,** Axial contrast-enhanced T1-weighted MRI demonstrates heterogeneous enhancement within the mass. **C,** ^{123}I-MIBG fused SPECT/CT axial image shows diffuse uptake within the tumor, compatible with paraganglioma. *(From Ho LM. Adrenal glands. In: Haaga JR, Boll DT, eds. CT and MRI of the Whole Body, 6th ed. Philadelphia: Elsevier; 2017: Fig. 53-18.)*

Section 5

Disorders of the Gonads

Chapter 622

Development and Function of the Gonads

Patricia A. Donohoue

GENETIC CONTROL OF EMBRYONIC GONADAL DIFFERENTIATION

Gonadal differentiation is a complex, multistep process that requires the sequential action and interaction of multiple gene products. Early in the first trimester, the undifferentiated, bipotential fetal gonad begins as a thickening of the urogenital ridge, near the developing kidney and adrenal cortex. At 6 weeks of gestation, the gonad contains germ cells, stromal cells that will become Leydig cells in the testes or theca, interstitial, or hilar cells in the ovaries, and supporting cells that will develop into Sertoli cells in the testes or granulosa cells in the ovaries. In males, the *SRY* gene (**s**ex-determining **r**egion on the **Y** chromosome) is transiently expressed, followed by a sequential upregulation of a number of testis-specific genes. In the absence of *SRY,* the bipotential gonad will be able to develop into an ovary. Ovarian development is also characterized by expression of ovary-specific genes during the same period. One such gene is *R-spondin1*. During the gestation period of 6-9 weeks, a number of genes are upregulated to the same degree in both the testis and the ovary, including *WNT4* and *CTNNB1*.

A chromosome complement of 46,XX is necessary for the development of normal ovaries. Both the long and short arms of the X chromosome contain genes for normal ovarian development. The DSS (**d**osage **s**ensitive/**s**ex reversal) locus associated with the *DAX1* (**D**SS **a**drenal hypoplasia on the **X** chromosome) gene, which is defective in 46,XY patients with X-linked congenital adrenal hypoplasia and hypogonadotropic hypogonadism, is a member of the nuclear receptor superfamily and acts as a repressor of male gene expression. The *DAX1* gene product acts by binding to a related nuclear receptor SF-1 (**s**teroidogenic **f**actor-1, also known as *NR5A1*). In vitro, the signaling gene *WNT4* stimulates expression of *DAX1,* resulting in the suppression of androgen synthesis in XX females. The WNTs are ligands that activate receptor-mediated signal transduction pathways and are involved in modulating gene expression as well as cell behavior, adhesion, and polarity. Once developed, the ovary requires FAX12 to preserve its differentiation and stability. A key to its role in humans was elucidated by a loss-of-function pathogenic variant of *WNT4* that was found in an 18-year-old 46,XX woman. She had an absence of müllerian-derived structures (uterus and fallopian tubes), unilateral renal agenesis, and clinical signs of androgen excess.

Pathogenic variants of the Wilms tumor 1 *(WT1)* gene may also affect sex differentiation. *WT1* pathogenic variants are associated with **Denys-Drash syndrome** (early-onset renal failure, abnormal external genitalia in genetic males, and Wilms tumor). Haploinsufficiency of a three–amino acid (KTS) form of *WT1* has been implicated in the gonadal dysgenesis of patients with **Fraser syndrome** (late-onset progressive glomerulopathy and 46,XY gonadal dysgenesis). Variants in the *FOXL2* and *SF-1* genes are associated with ovarian failure. Pathogenic variants of the *R-spondin1* gene has been described in individuals with 46,XX disorder of sex development (DSD). Other autosomal genes also play a role in normal ovarian organogenesis and testicular development. Several conditions of gonadal dysgenesis are associated with gross abnormalities of both autosomes and sex chromosomes. A deletion affecting the short arm of the X chromosome produces the typical somatic anomalies of Turner syndrome.

Development of the testis requires the short arm of the Y chromosome; this contains the *SRY* gene, which is required for testicular differentiation. During male meiosis, the Y chromosome must segregate from the X chromosome so that both X and Y chromosomes do not occur in the same spermatozoa. The major portion of the Y chromosome is composed of Y-specific sequences that do not pair with the X chromosome. However, a minor portion of the Y chromosome shares sequences with the X chromosome, and pairing does occur in this region. The genes and sequences in this area recombine between the sex chromosomes, behaving like autosomal genes. Therefore the term *pseudoautosomal region* is used to describe this portion of the chromosome, and the term indicates genetic behavior of these genes relative to pairing and recombinational events. The *SRY* gene is localized to the 35-kb portion proximal to the pseudoautosomal region of the Y chromosome. It contains a high-mobility group (HMG) nonhistone protein (HMG box), supporting SRY's role as a transcriptional regulator of other genes involved in sex differentiation. The gonadal ridge forms at around 33 days of gestation. SRY is detected at 41 days, peaks at 44 days when testis cords are first visible, and persists into adulthood.

Other genes that are found on autosomes are important in this process. *SOX9,* an *SRY*-related gene containing a region homologous with the HMG box 9 of *SRY,* is located on chromosome 17. Pathogenic variants of this gene result in **XY sex reversal** and **campomelic dysplasia**. *SF-1 (NR5A1)* on chromosome 9q33 is important

in adrenal and gonadal development, as well as the development of gonadotropin-releasing hormone–secreting neurons in the hypothalamus. *WTI,* especially the KST isoform on chromosome 11p13, is needed for early gonadal, adrenal, and renal development. Fibroblast growth factor-9, GATA-4, XH-2, and SOY9 are also important.

When genetic recombination events on sex chromosomes extend beyond the pseudoautosomal region, X- and Y-specific DNA may be transferred between the chromosomes. Such aberrant recombinations result in X chromosomes carrying *SRY,* resulting in **XX males**, or Y chromosomes that have lost *SRY,* resulting in **XY females**. SRY acts as a transcriptional regulator to increase cellular proliferation, attract interstitial cells from adjacent mesonephros into the genital ridge, and stimulate testicular Sertoli cell differentiation. Sertoli cells act as an organizer of steroidogenic and germ cell lines and produce **antimüllerian hormone** (AMH) that causes the female duct system to regress. Table 622.1 lists additional genes involved in sex development that, if abnormal, result in DSD.

Table 622.1 Pathogenic Genes in Disorders of Sex Development

GENE	PROTEIN	OMIM #	LOCUS	INHERITANCE	GONAD	MÜLLERIAN STRUCTURES	EXTERNAL GENITALIA	ASSOCIATED FEATURES/VARIANT PHENOTYPES
46,XY DSD								
DISORDERS OF GONADAL (TESTICULAR) DEVELOPMENT: SINGLE-GENE DISORDERS								
WT1	TF	607102	11p13	AD	Dysgenetic testis	±	Female or ambiguous	Wilms tumor, renal abnormalities, gonadal tumors (WAGR, Denys-Drash, and Frasier syndromes)
SF1 (NR5A1)	Nuclear receptor TF	184757	9q33	AD/AR	Dysgenetic testis; ovotestis	±	Female or ambiguous	More severe phenotypes include primary adrenal failure; milder phenotypes have isolated partial gonadal dysgenesis; mothers who carry SF-1 mutation have premature ovarian insufficiency
SRY	TF	480000	Yp11.3	Y	Dysgenetic testis or ovotestis	±	Female or ambiguous	
SOX9	TF	608160	17q24-25	AD	Dysgenetic testis or ovotestis	±	Female or ambiguous	Camptomelic dysplasia (17q24 rearrangements milder phenotype than point mutations)
DHH	Signaling molecule	605423	12q13.1	AR	Dysgenetic testis	±	Female	The severe phenotype of one patient included minifascicular neuropathy; other patients have isolated gonadal dysgenesis
ATRX	Helicase (?chromatin remodeling)	300032	Xq13.3	X	Dysgenetic testis	–	Female, ambiguous or male	α-Thalassemia, intellectual disability
ARX	TF	3003382	Xp22.13	X	Dysgenetic testis	–	Ambiguous	X-linked lissencephaly, epilepsy, temperature instability
Gata4	TF	615542	8p23.1	AD in XY subjects	Dysgenetic testes	_	Ambiguous	Congenital heart disease
DISORDERS OF GONADAL (TESTICULAR) DEVELOPMENT: CHROMOSOMAL CHANGES INVOLVING KEY CANDIDATE GENES								
DMRT1	TF	602424	9p24.3	Monosomic deletion	Dysgenetic testis	±	Female or ambiguous	Intellectual disability
DAX1 (NR0B1)	Nuclear receptor TF	300018	Xp21.3	dupXp21	Dysgenetic testis or ovary	±	Female or ambiguous	
WNT4	Signaling molecule	603490	1p35	dup1p35	Dysgenetic testis	+	Ambiguous	Intellectual disability

Table 622.1 Pathogenic Genes in Disorders of Sex Development—cont'd

GENE	PROTEIN	OMIM #	LOCUS	INHERITANCE	GONAD	MÜLLERIAN STRUCTURES	EXTERNAL GENITALIA	ASSOCIATED FEATURES/VARIANT PHENOTYPES
DISORDERS IN HORMONE SYNTHESIS OR ACTION								
LHGCR	G-protein receptor	152790	2p21	AR	Testis	–	Female, ambiguous or micropenis	Leydig cell hypoplasia
DHCR7	Enzyme	602858	11q12-13	AR	Testis	–	Variable	Smith-Lemli-Opitz syndrome: coarse facies, 2nd-3rd toe syndactyly, failure to thrive, developmental delay, cardiac and visceral abnormalities
StAR	Mitochondrial membrane protein	600617	8p11.2	AR	Testis	–	Female	Congenital lipoid adrenal hyperplasia (primary adrenal failure), pubertal failure
CYP11A1	Enzyme	118485	15q23-24	AR	Testis	–	Female or ambiguous	Congenital adrenal hyperplasia (primary adrenal failure), pubertal failure
HSD3B2	Enzyme	201810	1p13.1	AR	Testis	–	Ambiguous	CAH, primary adrenal failure, partial androgenization caused by ↑ DHEA
CYP17	Enzyme	202110	10q24.3	AR	Testis	–	Female ambiguous or micropenis	CAH, hypertension caused by ↑ corticosterone and 11-deoxycorticosterone (except in isolated 17,20-lyase deficiency)
POR (P450 oxido-reductase)	CYP enzyme electron donor	124015	7q11.2	AR	Testis	–	Male or ambiguous	Mixed features of 21-hydroxylase deficiency, 17α-hydroxylase/17,20-lyase deficiency, and aromatase deficiency; sometimes associated with Antley-Bixler skeletal dysplasia
HSD17B3	Enzyme	605573	9q22	AR	Testis	–	Female or ambiguous	Partial androgenization at puberty, ↑ androstenedione: testosterone ratio
SRD5A2	Enzyme	607306	2p23	AR	Testis	–	Ambiguous or micropenis	Partial androgenization at puberty, ↑ testosterone:DHT ratio
AKR1C4	Enzyme	600451	10p15.1	Unclear	Testis	–	Ambiguous or micropenis	DHT deficiency in patients once thought to have 17,20 lyase deficiency; dose effect with *AKR1C2* variant is possible
AKR1C2	Enzyme	600450	10p15.1	Unclear	Testis	–	Ambiguous or micropenis	DHT deficiency in patients once thought to have 17,20 lyase deficiency; dose effect with *AKR1C2* variant is possible
AMH	Signaling molecule	600957	19p13.3-13.2	AR	Testis	+	Normal male	Persistent müllerian duct syndrome (PMDS); male
AHM receptor	Serine-threonine kinase transmembrane receptor	600956	12q13	AR	Testis	–	Normal male	External genitalia, bilateral cryptorchidism

Continued

Table 622.1 Pathogenic Genes in Disorders of Sex Development—cont'd

GENE	PROTEIN	OMIM #	LOCUS	INHERITANCE	GONAD	MÜLLERIAN STRUCTURES	EXTERNAL GENITALIA	ASSOCIATED FEATURES/VARIANT PHENOTYPES
Androgen receptor	Nuclear receptor TF	3130700	Xq11-12	X	Testis	–	Female, ambiguous, micropenis, or normal male	Phenotypic spectrum from complete androgen insensitivity syndrome (female external genitalia) and partial androgen insensitivity (ambiguous) to normal male genitalia/infertility
46,XX DSD								
DISORDERS OF GONADAL (OVARIAN) DEVELOPMENT								
SRY	TF	480000	Yp11.3	Translocation	Testis or ovotestis	–	Male or ambiguous	
SOX9	TF	608160	17q24	dup17q24	ND	–	Male or ambiguous	
R-spondin1	TF	610644	1p34.3	AR	Ovotestis	±	Male or ambiguous	Palmoplantar hyperkeratosis and certain malignancies
ANDROGEN EXCESS								
HSD3B2	Enzyme	201810	1p13	AR	Ovary	+	Clitoromegaly	CAH, primary adrenal failure, partial androgenization caused by ↑ DHEA
CYP21A2	Enzyme	201910	6p21-23	AR	Ovary	+	Ambiguous	CAH, phenotypic spectrum from severe salt-losing forms associated with adrenal failure to simple virilizing forms with compensated adrenal function, ↑ 17-hydroxyprogesterone
CYP11B1	Enzyme	20210	8q21-22	AR	Ovary	+	Ambiguous	CAH, hypertension caused by ↑ 11-deoxycortisol and 11-deoxycorticosterone
POR (P450 oxidoreductase)	CYP enzyme electron donor	124015	7q11.2	AR	Ovary	+	Ambiguous	Mixed features of 21-hydroxylase deficiency, 17α-hydroxylase/17,20-lyase deficiency, and aromatase deficiency; associated with Antley-Bixler skeletal dysplasia
CYP19	Enzyme	107910	15q21	AR	Ovary	+	Ambiguous	Maternal virilization during pregnancy, absent breast development at puberty, except in partial cases
Glucocorticoid receptor	Nuclear receptor TF	138040	5q31	AR	Ovary	+	Ambiguous	↑ ACTH, 17-hydroxyprogesterone and cortisol; failure of dexamethasone suppression (patient heterozygous for a variant in *CYP21*)

ACTH, Adrenocorticotropin; AD, autosomal dominant (often de novo mutation); AR, autosomal recessive; CAH, congenital adrenal hyperplasia; ND, not determined; *OMIM #*, Online Mendelian Inheritance in Man number; TF, transcription factor; WAGR, Wilms, aniridia, genital anomalies, and retardation; X, X-chromosomal; Y, Y-chromosomal. Chromosomal rearrangements likely to include key genes are included.

From Lee PA, Houk CP, Ahmed SF, et al. International Consensus Conference on Intersex organized by the Lawson Wilkins Pediatric Endocrine Society and the European Society for Paediatric Endocrinology. Consensus statement on management of intersex disorders. International Consensus Conference on Intersex. Pediatrics. 2006;118:e488–e500; with additional data from Baxter RM, Arboleda VA, Lee H, et al. Exome sequencing for the diagnosis of 46,XY disorders of sex development. J Clin Endocrinol Metab. 2015;100:e333–e344; and Lourenco D, Brauner R, Rybczynska M, et al. Loss-of-function mutation in *GATA4* causes anomalies of human testicular development. PNAS. 2011;108:1597–1602.

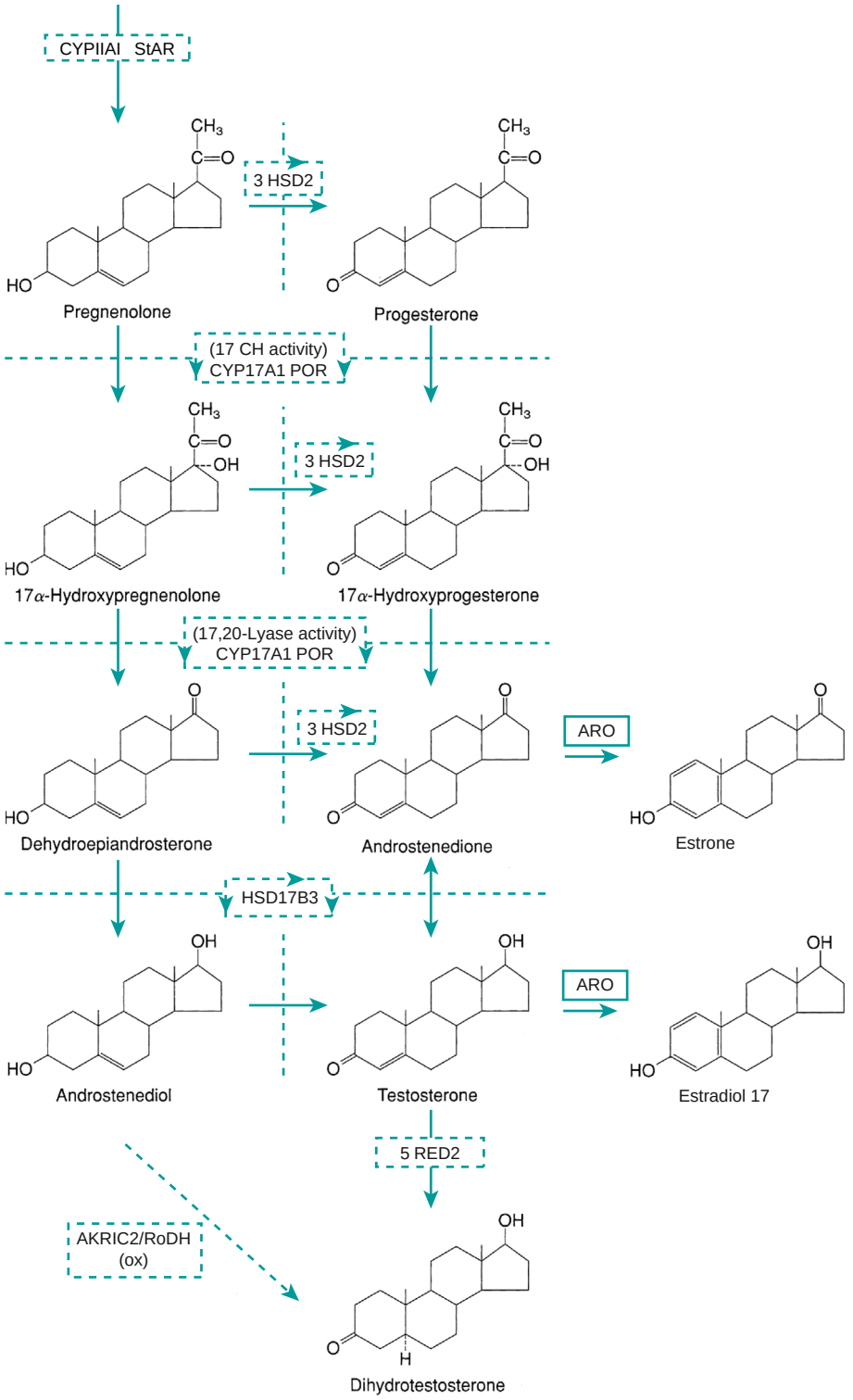

Fig. 622.1 Biosynthesis of sex steroids. *Dashed lines* indicate enzymatic defects associated with 46,XY disorders of sex development. 3β-HSD2, 3β-hydroxysteroid dehydrogenase type 2; 5RED2, 5α-reductase type 2; AKR1C2/RoDH (Ox), one of the enzymes in the alternative androgen biosynthetic pathway; ARO, aromatase; CYP17A1, the enzyme that catalyzes both 17α-hydroxylase (17-OH) and 17,20-lyase activities; HSD17B3, the enzyme that catalyzes the 17-ketoreductase reaction; POR, P450 oxidoreductase; StAR, steroidogenic acute regulatory protein.

Development of the ovary was once thought to be a passive process in the absence of SRY. Although the morphologic changes in the developing ovary are less marked than in the testis, sequentially expressed genes and pathways are required for complete ovarian development along with maintenance of ovarian integrity postnatally. One of these genes is *R-spondin1,* which if abnormal can result in testicular or ovotesticular development in 46,XX individuals. Some peptides in the Wnt-signaling pathway may antagonize testicular development, thus allowing for ovarian differentiation. This effect may be mediated by β-catenin signaling, which is required for suppressing testicular features. Once developed, the ovary requires FAX12 to preserve its differentiation and stability.

FUNCTION OF THE TESTES

Levels of placental chorionic gonadotropin peak at 8-12 weeks of gestation and stimulate the fetal Leydig cells to secrete testosterone, the main hormonal product of the testis (Fig. 622.1). By way of two different biosynthetic pathways, the more potent metabolite of testosterone, dihydrotestosterone (DHT), is produced. In the originally described

pathway, testosterone is converted by the enzyme 5α-reductase to DHT. In another pathway, DHT is produced from androstanediol. The early fetal period of DHT production and action is critical for normal and complete virilization of the XY fetus. Defects in this process lead to different forms of atypical male development (see Chapter 628.2). After virilization occurs, fetal levels of testosterone decrease but are maintained at lower levels in the latter half of pregnancy by luteinizing hormone (LH) secreted by the fetal pituitary; this LH-mediated testosterone secretion is required for continued penile growth and to some degree also for testicular descent.

As part of the normal transition from intrauterine to extrauterine life, perhaps related to the sudden withdrawal of maternal and placental hormones, newborns and young infants experience a transient surge of gonadotropins and sex steroids. This is the so-called **minipuberty**.

In males, LH and testosterone peak at 1-2 months of age and then decline to reach prepubertal levels by 4-6 months of age. Follicle-stimulating hormone (FSH), along with inhibin B, peak at 3 months and decline to prepubertal levels by 9 and 15 months, respectively. The LH rise is more dominant than that of FSH.

The neonatal surge may be important for postnatal maturation of the gonads, stabilization of male external genitalia, and perhaps also for gender identity and sexual behaviors. The postnatal surge in LH and testosterone is absent or blunted in infants with hypopituitarism, cryptorchidism, and complete androgen insensitivity syndrome. The development of nocturnal pulsatile secretion of LH marks the beginning of puberty.

Within specific target cells, 6–8% of testosterone is converted by 5α-reductase to DHT, the more potent androgen (see Fig. 622.1), and approximately 0.3% is acted on by aromatase to produce estradiol. Approximately half of circulating testosterone is bound to sex hormone–binding globulin and half to albumin; only 2% circulates in the free form. Plasma levels of sex hormone–binding globulin are low at birth, rise rapidly during the first 10 days of life, and then remain stable until the onset of puberty. Thyroid hormone may play a role in this physiologic increase because neonates with athyreosis (absence of the thyroid gland) have very low levels of sex hormone–binding globulin.

AMH (previously referred to as *müllerian inhibitory substance*), **inhibin**, and **activin** are members of the transforming growth factor-β (TGF-β) superfamily of growth factors. This group, which has more than 45 members, also includes bone morphogenetic proteins. Members of the TGF-β superfamily are involved in the regulation of developmental processes and multiple diverse human disease states, including chondrodysplasias and cancer.

AMH, a homodimeric glycoprotein hormone encoded by a gene on chromosome 19, is the earliest secreted product of the Sertoli cells of the fetal testis. Produced as a prohormone, its carboxyterminal fragment is cleaved to make it active. *AMH* transcription is initiated by *SOX9* acting through the HMG box, and its expression is upregulated by SF-1 binding to its promoter and further interacting with *SOX9, WT1,* and *GATA4*. AMH binds to two distinct serine/threonine receptors, each having a single transmembrane domain. The activated type 1 receptor signals to the SMAD family of intracellular mediators.

The gene for the AMH receptor (on chromosome 12) is expressed in Sertoli cells. In the female, it is expressed in fetal müllerian duct cells and in fetal and postnatal granulosa cells. During sex differentiation in males, AMH causes involution of the müllerian (paramesonephric) ducts, which are embryologic precursors of the cervix and uterus. It works in concert with SF-1 to cause involution of the fallopian tubes.

AMH is secreted in males by Sertoli cells during both fetal and postnatal life. In females, it is secreted by granulosa cells from 36 weeks of gestation to menopause but at lower levels. The serum concentration of AMH in males is highest at birth, whereas in females it is highest at puberty. After puberty, both sexes have similar serum concentrations of AMH. Its role in postnatal life is not yet fully characterized.

Inhibin is another glycoprotein hormone secreted by the Sertoli cells of the testes and granulosa and theca cells of the ovary. Inhibin A consists of an α-subunit disulfide linked to the β-A subunit, whereas inhibin B consists of the same α subunit linked to the β-B subunit. Activins are dimers of the B subunits, either homodimers (BA/BA, BB/BB) or heterodimers (BA/BB). Inhibins selectively inhibit, whereas activins stimulate pituitary FSH secretion. By means of immunoassays specific for inhibin A or B, it has been shown that inhibin A is absent in males and is present mostly in the luteal phase in women. Inhibin B is the principal form of inhibin in males and in females during the follicular phase. Inhibin B may be used as a marker of Sertoli cell function in males. FSH stimulates inhibin B secretion in females and males, but only in males is there also evidence for gonadotropin-independent regulation. Levels of inhibin B are potentially informative in children with various forms of gonadal and pubertal disorders. In males with delayed puberty, inhibin B may be a useful screening test to differentiate between constitutional delay of puberty and hypogonadotropic hypogonadism. In hypogonadotropic hypogonadism, the serum inhibin B level is very low to undetectable.

Like inhibin and activin, follistatin (a single-chain glycosylated protein) is produced by gonads and other tissues such as the hypothalamus, kidney, adrenal gland, and placenta. Follistatin inhibits FSH secretion principally by binding activins, thereby blocking the effects of activins at the level of both ovary and pituitary.

Many additional peptides act as mediators of the development and function of the testis. They include neurohormones such as growth hormone–releasing hormone, gonadotropin-releasing hormone, corticotropin-releasing hormone, oxytocin, arginine vasopressin, somatostatin, substance P, and neuropeptide Y; growth factors such as insulin-like growth factors (IGFs) and IGF-binding proteins, TGF-β, and fibroblast, platelet-derived, and nerve growth factors; vasoactive peptides; and immune-derived cytokines such as tumor necrosis factor and interleukins 1, 2, 4, and 6.

Clinical patterns of pubertal changes vary widely (see Chapter 599). In 95% of males, enlargement of the genitals begins between 9.5 and 13.5 years of age, reaching maturity at 13-17 years of age. In a minority of normal males, puberty begins after 15 years of age. In some males, pubertal development is completed in less than 2 years, but in others it may take longer than 4.5 years. Pubertal development and the adolescent growth spurt occur at an older age in males than in females by approximately 2 years.

The median age of sperm production (spermarche) is 14 years. This event occurs in midpuberty as judged by pubic hair, testis size, evidence of growth spurt, and testosterone levels. Nighttime levels of FSH are in the adult male range at the time of spermarche; the first conscious ejaculation occurs at about the same time.

FUNCTION OF THE OVARIES

In the normal female, the undifferentiated gonad can be identified histologically as an ovary by 10-11 weeks of gestation, after the upregulation of *R-spondin1*. Oocytes are present from the fourth month of gestation and reach a peak of 7 million by 5 months of gestation. For normal maintenance, oocytes need granulosa cells to form primordial follicles. Functional FSH (but not LH) receptors are present in oocytes of primary follicles during follicular development. Two normal X chromosomes are needed for maintenance of oocytes. In contrast to somatic cells, in which only one X chromosome is active, both X chromosomes are active in germ cells. At birth, the ovaries contain approximately 1 million active follicles, which decrease to 0.5 million by menarche. Thereafter, they decrease at a rate of 1,000/month and at an even higher rate after the age of 35 years.

The hormones of the fetal ovary are provided for the most part by the fetoplacental unit. As in males, peak gonadotropin secretion occurs in fetal life and then again at 2-3 months of life, with the lowest levels at about 6 years of age. In contrast to males, the FSH surge predominates over LH in females. FSH peaks around 3-6 months of age and declines by 12 months, but remains detectable for 24 months. Under LH influence, estradiol peaks at 2-6 months of age. The inhibin B response is variable, peaking between 2 and 12 months and remaining above prepubertal levels until 24 months.

In both infancy and childhood, gonadotropin levels are higher in females than in males.

The most important estrogens produced by the ovary are estradiol-17β (E_2) and estrone (E_1); estriol is a metabolic product of these two, and all three estrogens may be found in the urine of mature females. Estrogens also arise from androgens produced by the adrenal gland and both the female and male gonads (see Fig. 622.1). This conversion explains why in certain types of DSD in males, feminization occurs at puberty. In 17-ketosteroid reductase deficiency, for example, the enzymatic block results in markedly increased secretion of androstenedione, which is converted in the peripheral tissues to estradiol and estrone. These estrogens, in addition to those directly secreted by the testis, result in gynecomastia. Estradiol produced from testosterone in complete androgen insensitivity syndrome causes complete feminization in these XY individuals.

Estrogen regulates a host of functionally different activities in multiple tissues. There are at least two distinct estrogen receptors with different expression patterns. The ovary also synthesizes progesterone, the main progestational steroid; the adrenal cortex and testis also synthesize progesterone, where it is a precursor for other adrenal and testicular hormones.

A host of other hormones with autocrine, paracrine, and intracrine effects have been identified in the ovary. They include inhibins, activins, relaxin, and the growth factors IGF-1, TGF-α and TGF-β, and cytokines.

Plasma levels of estradiol increase slowly but steadily with advancing sexual maturation and correlate well with clinical evaluation of pubertal development, skeletal age, and rising levels of FSH. Levels of LH do not rise until secondary sexual characteristics are well developed. Estrogens, like androgens, inhibit secretion of both LH and FSH (negative feedback). In females, estrogens also provoke the surge of LH secretion that occurs in the midmenstrual cycle and stimulates ovulation. The capacity for this positive feedback is another maturational milestone of puberty.

The average age at menarche in American females is approximately 12.5-13 years, but the range of normal is wide, and 1–2% of normal females have not menstruated by 16 years of age. The age at onset of pubertal signs varies, with studies suggesting earlier ages than previously thought, especially in the US Black population (see Chapter 599). Menarche generally correlates closely with skeletal age. Maturation and closure of the epiphyses is estrogen-dependent, as demonstrated by a very tall 28-year-old, normally masculinized male with continued growth as a result of incomplete closure of the epiphyses, who had complete estrogen insensitivity caused by an estrogen receptor defect.

DIAGNOSTIC TESTING

In male infants, measurements of LH, FSH, and testosterone can detect pituitary and testicular defects. Leydig cell integrity in childhood can be determined by the testosterone response after human chorionic gonadotropin administration. One protocol is to inject 5,000 IU IM daily for 3 days; other protocols are available. The integrity and maturity of the hypothalamic-pituitary-gonadal axis in males and females can be assessed by measuring serial sex steroid, LH, and FSH levels after the subcutaneous administration of the gonadotropin-releasing hormone analog leuprolide. An ultrasensitive LH assay has been shown to differentiate between males with delayed puberty and those with complete, but not partial, hypogonadotropic hypogonadism.

The normal range for inhibin B levels has been established in infant males. Inhibin B may be a marker of spermatogenesis and also of tumors such as granulosa cell tumors. Inhibins may be involved in tumor suppression. Estrogen receptor assays may be clinically useful in the management of various ovarian cancers. AMH measurements are useful in the evaluation of children with nonpalpable gonads and DSD.

Visit Elsevier eBooks+ at eBooks.Health.Elsevier.com for Bibliography.

Chapter 623

Hypofunction of the Testes

Omar Ali and Patricia A. Donohoue

Testicular hypofunction during fetal life can be a component of some types of **disorders of sex development** (see Chapter 628.2) and may lead to varying degrees of ambiguous genitalia. After birth, neonates undergo *minipuberty* with relatively high levels of gonadotropins and sex steroids, but this phenomenon is transient, and its absence does not appear to lead to any obvious clinical findings. Because prepubertal children normally do not produce significant amounts of testosterone and are not yet producing sperm, there are no discernible effects of testicular hypofunction in this age-group. Testicular hypofunction from the age of puberty onward may lead to testosterone deficiency, infertility, or both. Such hypofunction may be primary in the testes **(primary hypogonadism)** or secondary to deficiency of pituitary gonadotropic hormones **(secondary hypogonadism)**. Insults to the testes (primary hypogonadism) tend to affect sperm counts more than testosterone secretion, as the seminiferous tubules take up much more of the testicular volume than Leydig cells do, so sperm production is usually affected more than testosterone production. On the other hand, hypogonadotropic hypogonadism tends to affect both testosterone and sperm production.

Both types of hypogonadism may be caused by inherited genetic defects or acquired causes, and in some cases the etiology may be unclear, but the level of the lesion (primary or secondary) is usually well defined; patients with primary hypogonadism have elevated levels of gonadotropins (hypergonadotropic); those with secondary hypogonadism have inappropriately low or absent levels (hypogonadotropic). Table 623.1 details the etiologic classification of male hypogonadism (see also Fig. 600.6).

623.1 Hypergonadotropic Hypogonadism in the Male (Primary Hypogonadism)

Omar Ali and Patricia A. Donohoue

Complete absence or severe dysfunction of the testes in the first trimester will lead to a lack of male sex differentiation and the fetus will have a female phenotype or pronounced ambiguous genitalia (see Chapter 628). If testicular function is present, sex differentiation is normally complete by the 14th week of intrauterine life. *Testicular dysfunction after this stage will lead to hypergonadotropic hypogonadism, and this can occur for a variety of reasons;* genetic or chromosomal anomalies may lead to testicular hypofunction that does not become apparent until the time of puberty, when these males may have delayed or incomplete pubertal development. In other cases, normally developed testes may be damaged by infarction, trauma, radiation, chemotherapy, infections, infiltration, or other causes after sexual differentiation has occurred. In some cases, genetic defects may predispose to atrophy or maldescent; torsion or infarction may lead to progressive testicular damage and atrophy after a period of normal development. If testicular compromise is global, both testosterone secretion and fertility (sperm production) are likely to be affected. Even when the primary defect is in testosterone production, low levels of intratesticular testosterone will frequently lead to infertility. The reverse is not necessarily true. Defects in sperm production and in the storage and transit of sperm may not be associated with low testosterone levels; infertility may thus be seen in patients with normal testosterone levels, normal libido, and normal secondary sexual characteristics.

Table 623.1 Etiologic Classification of Male Hypogonadism

HYPERGONADOTROPIC HYPOGONADISM (PRIMARY HYPOGONADISM; TESTES)
Congenital
Follicle-stimulating hormone (FSH) and luteinizing hormone (LH) resistance
Pathogenic variants in steroid synthetic pathways
Gonadal dysgenesis
Klinefelter syndrome (47,XXY)
Noonan syndrome (RASopathy genes)
Cystic fibrosis (infertility)
Acquired
Cryptorchidism (some cases)
Vanishing testes
Chemotherapy
Testicular radiation
Infection (e.g., mumps)
Infarction (testicular torsion)
Trauma
HYPOGONADOTROPIC HYPOGONADISM (SECONDARY HYPOGONADISM; HYPOTHALAMIC-PITUITARY)
Congenital
Genetic defects causing Kallmann syndrome and/or normosmic hypogonadotropic hypogonadism (HH)
Other genetic disorders associated with HH: leptin gene, leptin receptor, DAX1 (dosage-sensitive/sex-reversal adrenal hypoplasia on the X chromosome), SF-1 (steroidogenic factor-1)
Inherited syndromes: Prader-Willi, Bardet-Biedl, Laurence-Moon-Biedl, Alström
Isolated HH at pituitary level (gonadotropin-releasing hormone receptor, FSH and LH β-subunit)
Multiple pituitary hormone deficiencies: septo-optic dysplasia (*HESX-1* in some cases) and other disorders of pituitary organogenesis (e.g., *PROP1, LHX3, LHX4, SOX-3*)
Idiopathic
Acquired
Anorexia nervosa
Drug use
Malnutrition
Chronic illness, especially Crohn disease
Hyperprolactinemia
Pituitary tumors
Pituitary infarction
Infiltrative disorders (e.g., histiocytosis, sarcoidosis)
Hemosiderosis and hemochromatosis
Cranial radiation

Various degrees of primary hypogonadism occur in a significant percentage of patients with chromosomal aberrations, as in **Klinefelter syndrome**, **males with more than one X chromosome**, and **XX males**. These chromosomal anomalies are also associated with other characteristic findings. Noonan syndrome is also associated with cryptorchidism and infertility, but other (nongonadal) features dominate its clinical picture (see Chapters 100 and 101).

CONGENITAL ANORCHIA OR TESTICULAR REGRESSION SYNDROME

Males in whom the external genitalia have developed normally (or nearly normally) and paramesonephric (müllerian) duct derivatives (uterus, fallopian tubes) are absent have had testicular function for at least some part of gestation. If their testes cannot be palpated at birth, they are said to have **cryptorchidism**. In most such cases, the testes are undescended or retractile, but in some cases no testes are found in any location, even after extensive investigation. This syndrome of absence of testes in a phenotypic male with a normal 46,XY karyotype (indicating that there was some period of testicular function in intrauterine life) is known as *vanishing testes, congenital anorchia,* or testicular regression syndrome.

Testicular regression syndrome is not uncommon. Cryptorchidism occurs in 1.5–9% of male births; in 10–20% of these cases, the testes are impalpable. Of children with impalpable testes, up to 50% may have no detectable testes after extensive investigation. Most cases appear to be sporadic and are thought to be the result of torsion or vascular accidents. The incompletely descended testis may be more prone to torsion, and this may be one of the causes of vanishing testes. Most cases are sporadic, but in a subset of patients, testicular regression syndrome occurs in monozygotic twins or in families with other affected individuals, suggesting a genetic etiology. Some cases are associated with micropenis, and in these cases the testicular loss probably occurred after the 14th week but well before the time of birth, or this may indicate a preexisting dysfunction of male hormonal development. Low levels of testosterone (<10 ng/dL) and markedly elevated levels of luteinizing hormone (LH) and follicle-stimulating hormone (FSH) are found in the early postnatal months; thereafter levels of gonadotropins tend to decrease even in agonadal children, rising to very high levels again as the pubertal years approach. Stimulation with human chorionic gonadotropin (hCG) fails to evoke an increase in the level of testosterone. *Serum levels of antimüllerian hormone (AMH) are undetectable or low.* All patients with undetectable testes should be tested for AMH and should undergo an hCG stimulation test. If the results indicate that no testicular tissue is present (absent AMH and no rise in testosterone after hCG stimulation), then the diagnosis of testicular regression syndrome is confirmed. If testosterone secretion is demonstrated, then imaging with abdominal magnetic resonance imaging (MRI) and/or surgical exploration is indicated. A small fibrotic nodule may be found at the end of the spermatic cord in many cases of testicular regression syndrome. There is no possibility of normal fertility in these patients.

Treatment of male hypogonadism (primary or secondary) is discussed in Chapter 623.2.

Chemotherapy and Radiation-Induced Hypogonadism

Testicular damage is a frequent consequence of chemotherapy and radiotherapy for cancer. The frequency and extent of damage depend on the agent used, total dose, duration of therapy, and posttherapy interval of observation. Another important variable is age at therapy; it has been suggested that prepubertal testes are less prone to damage than pubertal testes, though the evidence is not conclusive. Chemotherapy is most damaging if more than one agent is used, and alkylating agents and platinum-containing agents are the ones most likely to lead to testicular damage. Although many chemotherapeutic agents produce azoospermia and infertility, Leydig cell damage (leading to low testosterone levels) is less common. In many cases the damage is transient and sperm counts recover after 12-24 months. The use of alkylating agents such as cyclophosphamide in prepubertal children may not impair pubertal development, even though there may be biopsy evidence of germ cell damage. Cisplatin causes transient azoospermia or oligospermia at lower doses, whereas higher doses (400-600 mg/m^2) can cause permanent infertility. Interleukin 2 can depress Leydig cell function, whereas interferon-α does not seem to affect gonadal function. Both chemotherapy and radiotherapy are associated with an increase in the percentage of abnormal gametes, but data concerning the outcomes of pregnancies after such therapy have *not* shown any increase in genetically mediated birth defects, possibly because of selection bias against abnormal sperm.

Radiation damage is dose dependent. Temporary oligospermia can be seen with doses as low as 0.1 Gy, with permanent azoospermia seen with doses greater than 2 Gy. Recovery of spermatogenesis can be seen 5 years (or more) after irradiation, with higher doses leading to slower recovery. Leydig cells are more resistant to irradiation. Mild damage as determined by elevated LH levels can be seen with up to 6 Gy; doses greater than 30 Gy cause hypogonadism in most patients. Whenever possible, testes should be shielded from irradiation. Testicular function should be carefully evaluated in adolescents after multimodal treatment for cancer in childhood. Replacement therapy with testosterone and counseling concerning fertility may be indicated. The storage of sperm before chemotherapy or radiation treatment in pubertal

and postpubertal males is an option. Even in those cases where sperm counts are abnormal, recovery is possible, though the chances of recovery decline with increasing dose of radiation. If sperm counts remain low, fertility is still possible in some cases with testicular sperm extraction and intracytoplasmic sperm injection.

Sertoli Cell–Only Syndrome

Small testes and azoospermia are seen in patients with the extremely rare Sertoli cell–only syndrome (**SCO**, **germ cell aplasia**, or **Del Castillo syndrome**). These patients have no germ cells in the testes but usually have normal testosterone production and present as adults with infertility. Typically, patients have small testes and elevated FSH levels with normal LH and testosterone. They may have gynecomastia because of FSH stimulation of aromatase activity. Inhibin B levels may be decreased when compared with individuals with normal spermatogenesis. Most cases are sporadic and idiopathic, but large deletions involving the azoospermia factor (AZF) region of the Y chromosome (Yq11) may be found in some cases. Y chromosome microdeletions are also occasionally identified as a cause of SCO syndrome.

Other Causes of Testicular Hypofunction

Atrophy of the testes may follow damage to the vascular supply because of manipulation of the testes during surgical procedures for correction of cryptorchidism or because of bilateral torsion of the testes. **Cryptorchidism** is a common condition (found in 3% of male children at birth, decreasing to 1% by age 6 months), and guidelines stress the importance of treatment before age 12 months (or even earlier) to maximize future fertility. But a small percentage of cases will develop fertility issues even when surgical treatment is successful and is completed within the first year of life. These cases may represent intrauterine damage, surgical damage, or genetic defects in testicular development and are therefore included among the causes of testicular hypofunction.

Acute orchitis is common in pubertal or adult males with mumps and may lead to subfertility in ~10% of cases, though infertility is rare. Testosterone secretion usually remains normal. The incidence of mumps orchitis in postpubertal males has increased in some areas because of a decrease in measles, mumps, and rubella vaccination uptake. **Autoimmune polyendocrinopathy** may be associated with primary hypogonadism (associated with anti-P450scc antibodies), but this appears to be more common in females.

Testicular Dysgenesis Syndrome

The incidence of testicular cancer has increased in many developed societies, and the incidence of cryptorchidism, hypospadias, low sperm counts, and sperm abnormalities also appears to have increased in some, but not all, studies. It has been proposed that all these trends are linked by prenatal testicular dysgenesis. The hypothesis is that some degree of testicular dysgenesis develops in intrauterine life from genetic and environmental factors and is associated with an increased risk of cryptorchidism, hypospadias, hypofertility, and testicular cancer. The environmental influences that have been implicated in this syndrome include environmental chemicals that act as endocrine disruptors, such as bisphenol A and phthalates (components of many types of plastics), several pesticides, phytoestrogens or mycoestrogens, and other chemicals. The fact that these lesions can be reproduced in some animal models by environmental chemicals has led to efforts to remove these chemicals from products used by infants and pregnant mothers and from the environment in general. Nonetheless the evidence is only suggestive and not conclusive.

CLINICAL MANIFESTATIONS

Primary hypogonadism may be suspected at birth if the testes and penis are abnormally small. Normative data are available for different populations. The condition is often not noticed until puberty, when secondary sex characteristics fail to develop. Facial, pubic, and axillary hair are scant or absent; there is neither acne nor regression of scalp hair; and the voice remains high pitched. The penis and scrotum remain infantile and may be almost obscured by pubic fat; the testes are small or not palpable. Fat accumulates in the region of the hips and buttocks and sometimes in the breasts and on the abdomen. The epiphyses close later than normal; therefore the extremities are long. The span may be several inches longer than the height, and the distance from the symphysis pubis to the soles of the feet (lower segment) is much greater than that from the symphysis to the vertex (upper segment). The proportions of the body are described as **eunuchoid**. The ratio of the upper to lower segment is considerably less than 0.9. Many individuals with milder degrees of hypogonadism may be detected only by appropriate studies of the pituitary-gonadal axis. Examination of the testes should be performed routinely by the pediatrician; testicular volumes as determined by comparison with standard orchidometers or by measurement of linear dimensions should be recorded.

DIAGNOSIS

Levels of serum FSH and, to a lesser extent, of LH are elevated to greater than age-specific normal values in early infancy (when minipuberty normally occurs and the gonadotropins are normally disinhibited). This is followed by a time when even agonadal children may not exhibit significant elevation in gonadotropins, indicating that the gonadotropins are also suppressed at this stage by some mechanism independent of feedback inhibition by gonadal hormones. In the latter half of childhood and several years before the onset of puberty, this inhibition is released and gonadotropin levels again rise above age-based normal levels in subjects with primary hypogonadism. These elevated levels indicate that even in the prepubertal child there is an active hypothalamic-gonadal feedback relationship. After the age of 11 years, FSH and LH levels rise significantly, reaching the agonadal range. Measurements of random plasma testosterone levels in prepubertal males are not helpful because they are low in normal prepubertal children, rising during puberty to attain adult levels. During puberty, these levels, when measured in an early morning blood sample, correlate better with testicular size, stage of sexual maturity, and bone age than with chronological age. In patients with primary hypogonadism, testosterone levels remain low at all ages. There is an attenuated rise or no rise at all after administration of hCG, in contrast to normal males in whom hCG produces a significant rise in plasma testosterone at any stage of development.

AMH is secreted by the Sertoli cells, and this secretion is suppressed by testosterone. AMH levels are elevated in prepubertal males and suppressed at the onset of puberty. Males with primary hypogonadism continue to have elevated AMH levels in puberty. Detection of AMH may be used in the prepubertal years as an indicator of the presence of testicular tissue (e.g., in patients with bilateral cryptorchidism). Inhibin B is also secreted by the Sertoli cells, is present throughout childhood, and rises at the onset of puberty (more in males than in females). It may be used as another marker of the presence of testicular tissue in bilateral cryptorchidism and as a marker of spermatogenesis (e.g., in delayed puberty, cancer survivors, and patients with Noonan syndrome). Bone age x-rays are useful to document delayed bone age in patients with constitutional growth delay as well as primary hypogonadism.

NOONAN SYNDROME

The term *Noonan syndrome* has been applied to males and females with normal karyotypes who have certain phenotypic features that occur also in females with Turner syndrome (although the genetic causes are completely distinct) (see Chapter 101). Males with this syndrome frequently have cryptorchidism and small testes. Testosterone secretion may be low or normal, but spermatogenesis may be affected even in those with normal testosterone (and normal secondary sexual characteristics). Serum inhibin-B is a useful marker of Sertoli cell function in these patients. Puberty is delayed, and adult height is achieved by the end of the second decade; the syndrome is discussed in detail in Chapter 101. Patients with significant hypogonadism will need treatment as discussed in Chapter 623.2.

KLINEFELTER SYNDROME

See also Chapter 99.4.

Klinefelter syndrome is the most common sex chromosomal aneuploidy in males, with an incidence of 0.1–0.2% in the general population

(1 in 500-1,000) and rising to 4% among infertile males and 10–11% in those with oligospermia or azoospermia. Approximately 80% of them have a 47,XXY chromosome complement, whereas mosaics and higher degrees of poly-X are seen in the remaining 20%. Even with as many as four X chromosomes, the Y chromosome determines a male phenotype. The chromosomal aberration most often results from meiotic nondisjunction of an X chromosome during parental gametogenesis; the extra X chromosome is maternal in origin in 54% and paternal in origin in 46% of patients. A national study in Denmark revealed a prenatal prevalence of 213 per 100,000 male fetuses, but in adult men the prevalence was only 40 per 100,000, suggesting that 25% of adult males with Klinefelter syndrome were diagnosed. The incidence of Klinefelter syndrome increases with maternal age and possibly also with paternal age.

Clinical Manifestations

In patients who do not have a prenatal diagnosis, the diagnosis is rarely made before puberty because of the paucity or subtlety of clinical manifestations in childhood. Behavioral or psychiatric disorders may be apparent long before defects in sexual development. These children tend to have learning disabilities and deficits in executive function (concept formation, problem solving, task switching, and planning), and the condition should be considered in males with psychosocial, learning, or school adjustment problems. Affected children may be anxious, immature, or excessively shy and tend to have difficulty in social interactions throughout life. In a prospective study, a group of children with 47,XXY karyotypes identified at birth exhibited relatively mild deviations from normal during the first 5 years of life. None had major physical, intellectual, or emotional disabilities; some were inactive, with poorly organized motor function and mild delay in language acquisition. Problems often first become apparent after the child begins school. Full-scale IQ scores may be normal, with verbal IQ being somewhat decreased. Verbal cognitive defects and underachievement in reading, spelling, and mathematics are common. By late adolescence, many males with Klinefelter syndrome have generalized learning disabilities, most of which are language based. Despite these difficulties, most complete high school.

The patients tend to be tall and slim and have a specific tendency to have long legs (disproportionate to the arms and longer than those seen with other causes of hypogonadism), but body habitus can vary markedly. The testes tend to be small for age, but this sign may become apparent only after puberty, when normal testicular growth fails to occur. The phallus tends to be smaller than average, and cryptorchidism is more common than in the general population. Bone mineral density may be low in adults with Klinefelter syndrome, and this correlates with lower testosterone levels.

Pubertal development may be delayed, although some children undergo apparently normal or nearly normal virilization. Despite normal testosterone levels, serum LH and FSH concentrations and their responses to gonadotropin-releasing hormone (GnRH) stimulation are elevated starting at around 13 years of age. Approximately 50–80% of adults have **gynecomastia**; they have sparser facial hair. The most common testicular lesions are spermatogenic arrest and Sertoli cell predominance. The sperm have a high incidence of sex chromosomal aneuploidy. Azoospermia and infertility are usual, although rare instances of fertility are known. It is now clear that germ cell numbers and sperm counts are higher in early puberty and decline with age. Testicular sperm extraction followed by intracytoplasmic sperm injection can result in the birth of healthy infants, with success rates declining with increasing age. In nonmosaic Klinefelter patients, most testicular sperm (94%) have a normal pattern of sex chromosome segregation, indicating that meiotic checkpoints can remove most aneuploid cells. Antisperm antibodies have been detected in 25% of tested specimens.

There is an increased incidence in adulthood of central adiposity, metabolic syndrome, pulmonary disease, varicose veins, and cancer of the breast. Among 93 unselected **male breast cancer** patients, 7.5% were found to have Klinefelter syndrome. Mediastinal germ cell tumors have been reported; some of these tumors produce hCG and cause precocious puberty in young males. They may also be associated with leukemia, lymphoma, and other types of hematologic neoplasia. The highest cancer risk (relative risk: 2.7) occurs in the 15- to 30-year age-group. A large cohort study in Britain demonstrated an overall significantly increased standardized mortality ratio, with increases in deaths from diabetes, epilepsy, peripheral and intestinal vascular sufficiency, pulmonary embolism, and renal disease. Mortality from ischemic heart disease was decreased. In adults, structural brain abnormalities correlate with cognitive deficits.

Patients with Klinefelter syndrome also have an increased risk of *autoimmune disorders*. It seems that the presence of one or more X chromosomes changes the risk of autoimmune disorders, which are similar to those seen in XX females. These patients have an increased incidence of rheumatoid arthritis, Sjogren syndrome, systemic lupus erythematosus (SLE), and other autoimmune disorders.

In adults with XY/XXY mosaicism, the features of Klinefelter syndrome are decreased in severity and frequency. Children with mosaicism have a better prognosis for virilization, fertility, and psychosocial adjustment.

Klinefelter Variants and Other Poly-X Syndromes

When the number of X chromosomes exceeds two, the clinical manifestations, including intellectual disability and impairment of virilization, are more severe. Height decreases with increasing number of X chromosomes. The **XXYY** variant is the most common variant (1 in 18,000-40,000 male births). In most, intellectual disability occurs with IQ scores between 60 and 80, but 10% have IQs greater than 110. The XXYY male phenotype is not distinctively different from that of the XXY patient except that XXYY adults tend to be taller than the average XXY patient. The **49,XXXXY** variant is sufficiently distinctive to be detected in childhood. Its incidence is estimated to be 1 in 80,000-100,000 male births. The disorder arises from sequential nondisjunction in meiosis. Affected patients are severely cognitively impaired and have short necks and typical coarse facies. The eyes are wide set, with a mild upward slant of the fissures as well as epicanthus and strabismus; the nose is upturned, wide, and flat; also noted is a large open mouth and large malformed ears. The testes are small and may be undescended, the scrotum is hypoplastic, and the penis is very small. Defects suggestive of Down syndrome (short, incurved terminal fifth phalanges, single palmar creases, and hypotonia) and other skeletal abnormalities (including defects in the carrying angle of the elbows and restricted supination) are common. The most frequent radiographic abnormalities are radioulnar synostosis or dislocation, elongated radius, pseudoepiphyses, scoliosis or kyphosis, coxa valga, and retarded bone age. Most patients with such extensive changes have a 49,XXXXY chromosome karyotype; several mosaic patterns have also been observed: 48,XXXY/49,XXXXY; 48,XXXY/49,XXXXY/50,XXXXXY; and 48,XXXY/49,XXXXY/50,XXXXYY. Prenatal diagnosis of a 49,XXXXY infant has been reported. The fetus had intrauterine growth restriction, edema, and cystic hygroma colli.

The **48,XXXY** variant is relatively rare. The characteristic features are generally less severe than those of patients with 49,XXXXY and more severe than those of 47,XXY patients. Mild intellectual disability, delayed speech and motor development, and immature but passive and pleasant behavior are associated with this condition.

Very few patients have been described with 48,XYYY and 49,XXYYY karyotypes. Dysmorphic features and cognitive impairment are common to both.

Laboratory Findings

Most males with Klinefelter syndrome go through life undiagnosed. The chromosomes should be examined in all patients suspected of having Klinefelter syndrome, particularly those attending child guidance, psychiatric, and cognitive disability clinics. In infancy, inhibin B and AMH levels are normal but testosterone levels are lower than in controls. Before 10 years of age, males with 47,XXY Klinefelter syndrome have normal basal plasma levels of FSH and LH. Responses to gonadotropin-stimulating hormone and to hCG are normal. The testes show normal growth early in puberty, but by midpuberty the testicular growth stops, gonadotropins become elevated, and testosterone levels

are slightly low. Inhibin B levels are normal in early puberty, decrease in late puberty, and are low in adults with the syndrome. Elevated levels of estradiol, resulting in a high ratio of estradiol to testosterone, account for the development of gynecomastia during puberty. Sex hormone–binding globulin levels are elevated, further decreasing free testosterone levels. A long androgen receptor polyglutamine (CAG) repeat length is associated with the more severe phenotype, including gynecomastia, small testes, and short penile length.

Testicular biopsy before puberty may reveal only deficiency or absence of germinal cells. After puberty, the seminiferous tubular membranes are hyalinized and there is adenomatous clumping of Leydig cells. Sertoli cells predominate. Azoospermia is characteristic, and infertility is the rule.

Management

Males known to have Klinefelter syndrome should be monitored closely for speech, learning, and behavioral problems; they should be referred for early evaluation and treatment as needed. Testosterone, LH, and FSH levels should be checked at 11-12 years of age; replacement therapy with testosterone is recommended once FSH and LH begin to rise above normal. Fasting glucose, lipids, and hemoglobin A_{1C} should also be obtained, as these children are at risk for central adiposity and metabolic syndrome. A baseline dual-energy x-ray absorptiometry scan to assess bone density is also recommended by some authorities. Although testosterone treatment will normalize testosterone levels, stimulate the development of secondary sexual characteristics, increase bone and muscle mass, and improve body composition, it will *not* improve fertility (and will, in fact, suppress spermatogenesis). There is some evidence that it also improves mood and may have a positive effect on cognition and social functioning, but the findings are not conclusive at this time. Either long-acting testosterone injections or a daily application of testosterone gel may be used (testosterone patches have a high incidence of skin rash and are not frequently used in pediatrics). Testosterone enanthate or cypionate ester may be used in a starting dose of 25-50 mg injected intramuscularly or subcutaneously every 3-4 weeks, with 50-mg increments every 6-12 months until a maintenance dose for adults (200-250 mg every 3-4 weeks) is achieved. At that time, testosterone patches or testosterone gel may be substituted for the injections. Depending on patient and physician preference, transdermal testosterone may also be used as initial treatment instead of injections. For older males, larger initial doses and increments can achieve more rapid virilization. The various transdermal preparations differ somewhat, and standard references should be consulted for recommendations regarding dosage and mode of application.

Gynecomastia may be treated with aromatase inhibitors (which will also increase endogenous testosterone levels), but medical treatment is not always successful and plastic surgery may be needed. Fertility is usually not an issue in the pediatric age-group, but adults can father children using testicular sperm extraction followed by intracytoplasmic sperm injection. Because sperm counts decrease rapidly after the onset of puberty in children with Klinefelter syndrome, sperm banking during early puberty is an option that can be discussed with a fertility specialist. Sperm counts can be stimulated using hCG treatment before testicular sperm extraction. Therapy, counseling, and psychiatric services should be provided as needed for learning difficulties and psychosocial disabilities.

XX MALES

This disorder is thought to occur in 1 in 20,000 newborn males. Affected individuals have a male phenotype, small testes, a small phallus, and no evidence of ovarian or müllerian duct tissue. They therefore appear to be *distinct from* those with the **ovotesticular disorder of sexual development**. Undescended testes and hypospadias occur in a minority of patients. Infertility occurs in practically all cases, and the histologic features of the testes are essentially the same as in Klinefelter syndrome. Patients with the condition usually come to medical attention in adult life because of hypogonadism, gynecomastia, or infertility. Hypergonadotropic hypogonadism occurs secondary to testicular failure. A few cases have been diagnosed perinatally as a result of discrepancies between prenatal ultrasonography and karyotype findings.

In 90% of XX males with normal male external genitalia, one of the X chromosomes carries the *SRY* (sex-determining region on the Y chromosome) gene. The exchange from the Y to the X chromosome occurs during paternal meiosis, when the short arms of the Y and X chromosomes pair. XX males inherit one maternal X chromosome and one paternal X chromosome containing the translocated male-determining gene. A few cases of 46,XX males with 9P translocations have also been identified. Most XX males who are identified before puberty have hypospadias or a micropenis; this group of patients may lack Y-specific sequences, suggesting other mechanisms for virilization. Fluorescent in situ hybridization and primed in situ labeling have been used to identify small *SRY* DNA segments. Yp fragment abnormalities may result in sexually ambiguous phenotypes.

45,X MALES

In a few male patients recognized with a 45,X karyotype, Yp sequences are translocated to an autosomal chromosome. In one instance, the terminal short arm of the Y chromosome was translocated onto an X chromosome. In another, *SRY/autosomal* translocation was postulated. A male with the 45,X karyotype and Leri-Weill dyschondrosteosis, *SHOX* gene loss, and an SRY to Xp translocation has also been described.

47,XXX MALES

A Japanese male with poor pubic hair development, hypoplastic scrotal testes (4 mL), normal penis and normal height, gynecomastia, and severe cognitive impairment had 47,XXX karyotype caused by an abnormal X-Y interchange during paternal meiosis and X-X nondisjunction during maternal meiosis.

Visit Elsevier eBooks+ at eBooks.Health.Elsevier.com for Bibliography.

623.2 Hypogonadotropic Hypogonadism in the Male (Secondary Hypogonadism)

Omar Ali and Patricia A. Donohoue

In hypogonadotropic hypogonadism (HH), lack of gonadal function is secondary to deficiency of one or both gonadotropins: FSH or LH. The primary defect may lie either in the anterior pituitary or in the hypothalamus. Hypothalamic etiologies result in deficiency of GnRH. The testes are normal but remain in the prepubertal state because stimulation by gonadotropins is lacking. The disorder may be recognized in infancy but is much more commonly recognized because of marked pubertal delay. Rarely, patients with a milder inherited form of HH may go through puberty and may present with hypogonadism as adults.

HH may be genetic or acquired (Table 623.2). Several different genes can cause inherited forms of HH; the affected genes may be upstream of GnRH, at the level of GnRH receptors, or at the level of gonadotropin production. In addition, various genetic defects in transcription factors—such as POUF-1, LHX-3, LHX-4, and HESX-1—lead to defects in pituitary development and multiple pituitary hormone deficiencies, including deficiency of gonadotropins. Acquired pituitary gonadotropin deficiency may develop from various lesions in the hypothalamic-pituitary region (e.g., tumors, infiltrative disease, autoimmune disease, trauma, stroke).

ISOLATED GONADOTROPIN DEFICIENCY

Isolated gonadotropin deficiency in which other pituitary hormone levels are normal is more likely to be from defects in the secretion of GnRH from the hypothalamus rather than defects in gonadotropin synthesis in the pituitary. It affects approximately 1 in 10,000 males and 1 in 50,000 females and encompasses a heterogeneous group of entities. Many cases are associated with anosmia, and this combination of anosmia and HH defines **Kallmann syndrome**.

Table 623.2 Forms of Congenital Hypogonadotropic Hypogonadism and Differential Diagnosis

FORMS OF CHH
GnRH Deficiency and Defective Sense of Smell
Kallmann syndrome
Isolated GnRH Deficiency (Normal Sense of Smell)
Normosmic CHH
Complex Syndromes Including CHH or KS
Combined pituitary hormone deficiency
Septo-optic dysplasia
CHARGE syndrome
Adrenal hypoplasia congenita with HH
Waardenburg syndrome
Bardet-Biedl syndrome
Gordon Holmes syndrome
Others
DIFFERENTIAL DIAGNOSIS
Functional Causes
Malnutrition and/or malabsorption
Any chronic disease (e.g., IBD or asthma)
Celiac disease
Eating disorders
Excessive exercise
Systemic Causes
Hemochromatosis
Sarcoidosis
Histiocytosis
Thalassemia
Acquired Causes
Hyperprolactinemia
Pituitary adenomas and/or brain tumors
Rathke cleft cyst
Pituitary apoplexy
Radiation (brain or pituitary)
Medication induced (such as by steroids, opiates, or chemotherapy)

CHARGE, Coloboma, heart defects, atresia of choanae, retardation of growth and/or development, genital and/or urinary defects, ear anomalies or deafness; CHH, congenital hypogonadotropic hypogonadism; GnRH, gonadotropin-releasing hormone; HH, hypogonadotropic hypogonadism; IBD, inflammatory bowel disease; KS, Kallmann syndrome.

From Boehm U, Bouloux PM, Dattani MT, et al. European consensus statement on congenital hypogonadotropic hypogonadism—pathogenesis, diagnosis and treatment. Nat Rev. 2015;11:547–564. Box 2.

Kallmann syndrome is the most common form of HH and is genetically heterogeneous, with autosomal recessive, X-linked, and autosomal dominant forms of inheritance. Clinically it is characterized by its association with anosmia or hyposmia; 85% of cases appear to be autosomal and 15% are X-linked, but a specific genetic defect may not be identified in more than half of the cases of HH. There is a wide spectrum of severity and associated features in patients with Kallmann syndrome, and the same genetic pathogenic variants may be associated with different phenotypes, even within the same family. Some kindreds contain anosmic individuals *with or without* hypogonadism; others contain hypogonadal individuals who are anosmic. Cleft lip and palate, hypotelorism, median facial clefts, sensorineural hearing loss, unilateral renal aplasia, neurologic deficits, and other findings occur in some affected patients.

The **X-linked** form (*ANOS1*, formerly known as *KAL1*) is caused by variants of *ANOS1* at Xp22.3. This leads to failure of olfactory axons and GnRH-expressing neurons to migrate from their common origin in the olfactory placode to the brain. The *ANOS1* gene product anosmin-1, an extracellular 95-kDa matrix glycoprotein, facilitates neuronal growth and migration. The *ANOS1* gene is also expressed in various parts of the brain, facial mesenchyme, and mesonephros and metanephros, thus explaining some of the associated findings in patients with Kallmann syndrome, such as synkinesia (mirror movements), hearing loss, midfacial defects, and renal agenesis.

When Kallmann syndrome is caused by terminal or interstitial deletions of the Xp22.3 region, it may be associated with other contiguous gene syndromes, such as steroid sulfatase deficiency, chondrodysplasia punctata, X-linked ichthyosis, or ocular albinism.

The **autosomal dominant** form of Kallmann syndrome (sometimes referred to as *KAL2*) occurs in up to 10% of patients and is caused by a loss-of-function pathogenic variant in the fibroblast growth factor receptor 1 *(FGFR1)* gene. Cleft lip and palate are associated with this form, but not with the X-linked form. Oligodontia and hearing loss may occur with both KAL1 and KAL2.

A variety of other genes—including *SOX10, FGF8, PROK2/PROKR2, NELF, CHD7* (responsible for CHARGE [coloboma of the eye, heart anomaly, choanal atresia, retardation, and genital and ear anomalies] syndrome, which includes hypogonadism in its phenotype), *HS6ST1, WDR11,* and *SEMA3A*—are associated with defects in neuronal migration that can result in Kallmann syndrome.

Hypogonadotropic Hypogonadism Without Anosmia

A specific genetic defect is not found in most cases of *normosmic idiopathic hypogonadotropic hypogonadism (IHH)*, but the list of genes associated with this disorder is growing; pathogenic variants in *KISS1/KISS1R, TAC3/TACR3,* and *GNRH1/GNRHR* lead to abnormalities in the secretion and action of GnRH and are seen exclusively in patients with normosmic IHH. Variants in *FGFR1, FGF8, PROKR2, CHD7,* and *WDR11* more commonly present with anosmia/hyposmia (Kallmann syndrome) but are also associated with normosmic IHH in some cases. It appears that kisspeptin (the gene product of the *KISS1* gene) and its G protein–coupled receptor (GPCR54) play an important role in triggering puberty in humans and act downstream of the leptin receptor in this pathway. Rare cases of leptin deficiency and leptin receptor defects are also associated with HH. In addition, starvation and anorexia are associated with hypogonadism, most likely acting via the leptin pathway.

There are no known human variants of the *GnRH* gene, but several families with variants in the GnRH *receptor* have been described. These variants account for 2–14% of IHH without anosmia. The severity of the defect is variable, and many patients will respond to high-dose GnRH with increased gonadotropin secretion, indicating that the receptor defect is partial.

Variants in gonadotropin genes are extremely rare. Variants in the common α-subunit are not known in humans. Variants in the LH-β subunit have been described in a few individuals and may lead to low, absent, or elevated LH levels, depending on the variant. This leads to testosterone deficiency (diminished Leydig cell function), but because intratesticular testosterone is critical for spermatogenesis, this also leads to diminished sperm counts. Defects in the FSH-β subunit may be the cause of azoospermia in a few rare cases. Interestingly these patients may also have testosterone deficiency, indicating that Sertoli cells also play a role in supporting normal Leydig cell function.

Children with **X-linked adrenal hypoplasia congenita (AHC)** have associated HH because of impaired GnRH secretion. In these patients, there is a pathogenic variant of *DAX1* at Xp21.2-21.3. This region of the X chromosome includes genes for glycerol kinase, Duchenne muscular dystrophy, and ornithine transcarbamoyltransferase (OTC); these genes may be affected as part of a contiguous gene deletion syndrome that includes AHC, glycerol kinase deficiency, Duchenne muscular dystrophy, and OTC deficiency. Most males with *DAX1* variants develop HH in adolescence, although a patient with adult-onset adrenal insufficiency and partial HH and two females with HH and delayed puberty have also been described, the latter as part of extended families including males with classic HH. The *DAX1* gene defect is, however, rare in patients with delayed puberty or HH without at least a family history of adrenal failure (see Chapter 616).

It should be noted that genotype-phenotype correlations in IHH appear to be complex, and pedigrees with digenic or oligogenic inheritance have been described. The same genetic defect may be associated with Kallmann syndrome, normosmic IHH, additional birth defects,

delayed normal puberty, or an apparently normal phenotype. This variability has been observed more frequently in kindreds with pathogenic variants in *FGF8/FGFR1* and in *PROK2/PROKR2* ligand-receptor pairs and may result from other interacting genes, epigenetic effects, or environmental factors.

OTHER DISORDERS WITH HYPOGONADOTROPIC HYPOGONADISM

HH has been observed in a few patients with **polyglandular autoimmune syndrome**, in some with elevated melatonin levels, and in those with a variety of other syndromes, such as **Bardet-Biedl, Prader-Willi, multiple lentigines, and several ataxia syndromes**. In rare cases, HH is associated with complex chromosomal abnormalities.

HYPOGONADOTROPIC HYPOGONADISM ASSOCIATED WITH OTHER PITUITARY HORMONE DEFICIENCIES

Defects in pituitary transcription factors such as PROP-1, HESX-1, LHX-4, SOX-3, and LHX-3 lead to multiple pituitary deficiencies including HH. Most of these present with multiple pituitary hormone deficiency in infancy, but some cases (especially with *PROP-1* pathogenic variants) may present with hypogonadism or hypoadrenalism in adult life. Growth hormone is almost always affected in multiple pituitary hormone deficiency, but thyroid-stimulating hormone and adrenocorticotropic hormone may be spared in some cases. In patients with organic lesions in or near the pituitary, the gonadotropin deficiency is usually pituitary in origin.

DIAGNOSIS

Levels of gonadotropins and gonadal steroids are normally elevated for up to 6 months after birth (minipuberty); if the diagnosis of HH is suspected in early infancy, these levels will be found to be inappropriately low. By the second half of the first year of life, these normally decline to nearly undetectable levels and remain suppressed until late childhood. Routine laboratory tests cannot distinguish HH from normal suppression of gonadotropins in this age-group. At the normal age of puberty, these patients fail to show clinical signs of puberty or a normal increase in LH and FSH levels. *Children with constitutional delay of growth and puberty will have the same clinical picture and similar laboratory findings (these cases are far more common than true HH, especially in males), and their differentiation from patients with HH is extremely difficult.* Dynamic testing with GnRH or hCG may *not* be able to distinguish these groups in a reliable manner. A testosterone level greater than 50 ng/dL (1.7 nmol/L) generally indicates that normal puberty is likely, but a lower level does not reliably distinguish these groups. At least one study showed that an inhibin B level of <35 pg/mL in Tanner stage 1 and <65 pg/mL in Tanner stage 2 may be able to distinguish IHH from constitutional delay in males, but no single test will reliably distinguish these conditions in all patients.

Insulin-like growth factor-1, thyroid-stimulating hormone, free thyroxine, and morning cortisol levels should be checked to assess the status of other anterior pituitary hormones; dynamic testing for growth hormone deficiency and adrenal insufficiency may be necessary if these are abnormal or equivocal. HH is very likely if the patient has evidence of another pituitary deficiency, such as a deficiency of growth hormone, particularly if it is associated with adrenocorticotropic hormone deficiency. **Hyperprolactinemia** is a known cause of delayed puberty and should be excluded by determination of serum prolactin levels in all patients. The presence of *anosmia* usually indicates permanent gonadotropin deficiency, but occasional instances of markedly delayed puberty (18-20 years of age) have been observed in anosmic individuals. Although anosmia may be present in the family or in the patient from early childhood, its existence is rarely volunteered, and direct questioning is necessary in all patients with delayed puberty. Formal olfactometry, such as the University of Pennsylvania Smell Identification Test, is advisable to determine if partial degrees of hyposmia are present, because IHH patients display a broad spectrum of olfactory function.

In the absence of family history, it may not be possible to make the diagnosis of HH with certainty, but the diagnosis will become more and more likely as puberty is delayed further beyond the normal age. If pubertal delay persists beyond age 18 years with low 8 AM testosterone levels and inappropriately low gonadotropins (normal values are inappropriately low in this setting), then the patient can be presumptively diagnosed with HH. *An MRI of the brain is indicated* to look for tumors and other anomalies in the hypothalamic-pituitary region. Genetic testing for pituitary transcription factors and several of the genes involved in isolated HH is also available and should be performed when possible. A renal ultrasound is recommended in patients with Kallmann syndrome because of its association with unilateral renal agenesis. Some authorities also recommend obtaining a baseline bone-density evaluation.

TREATMENT

Constitutional delay of puberty should be ruled out before a diagnosis of HH is established and treatment is initiated. Testicular volume of less than 4 mL by 14 years of age occurs in approximately 3% of males, but most of these are cases of constitutional delay of puberty, and true HH is a rare condition. Although constitutional delay is a benign condition that will (by definition) resolve spontaneously, even relatively moderate delays in sexual development and growth may result in significant psychologic distress and require attention. Initially an explanation of the variations characteristics of puberty and reassurance suffice for the majority of males. If by 15 years of age no clinical evidence of puberty is apparent and the testosterone level is <50 ng/dL, a brief course of testosterone may be recommended. Various regimens are used, including testosterone enanthate or cypionate 100 mg intramuscularly once monthly for 4-6 months or 150 mg once monthly for 3 months. Some practitioners use oral oxandrolone in a dose of 1.25-2.5 mg daily for 6-12 months, which has the theoretical advantage that it is not aromatized and may have less effect on bone age advancement (though definitive evidence of advantage is lacking). Oral oxandrolone may cause hepatic dysfunction, and liver function tests should be monitored if it is used. Treatment is not necessary in all cases of constitutional delay, but if used it is usually followed by normal progression through puberty, and this may differentiate constitutional delay in puberty from isolated gonadotropin deficiency. The age of initiation of this treatment must be individualized.

If puberty fails to progress spontaneously after a short course of testosterone has been attempted, then HH becomes the likely diagnosis and necessitates continuous use of testosterone for normal pubertal development. At this point the patient should undergo an MRI scan and genetic testing to try to make a specific diagnosis. Once a diagnosis of HH has been made, treatment with testosterone will induce secondary sexual characteristics but will *not* stimulate testicular growth or spermatogenesis. Treatment with gonadotropins (either as a combination of hCG and human menopausal gonadotropins or as GnRH pulse therapy) will lead to testicular development, including spermatogenesis, but it is much more complex to manage, so in most cases testosterone treatment is still the best option. Either long-acting testosterone injections or a daily application of testosterone gel may be used (testosterone patches have a high incidence of skin rash and are infrequently used in pediatrics). Testosterone enanthate or cypionate ester may be used in a starting dose of 25-50 mg injected intramuscularly or subcutaneously every 3-4 weeks, with 50-mg increments every 6-9 months until a maintenance dose for adults (200-250 mg every 3-4 weeks) is achieved. At that time, testosterone patches or testosterone gel may be substituted for the injections. Depending on patient and physician preference, transdermal testosterone may also be used as initial treatment instead of injections. For older males, larger initial doses and increments can achieve more rapid virilization.

Treatment with gonadotropins is more physiologic but is expensive and complex, so it is less commonly used in adolescence. This treatment may be attempted in adult life when fertility is desired. The treatment schedule varies from 1,250 to 5,000 IU hCG in combination with 12.5-150 IU human menopausal gonadotropins 3 times per week intramuscularly. It may require up to 2 years of treatment to achieve

adequate spermatogenesis in adults. Recombinantly produced gonadotropins (LH and FSH) are also able to stimulate gonadal growth and function but are much more expensive. Treatment with GnRH (when available) is the most physiologically appropriate, but it requires the use of a subcutaneous infusion pump to deliver appropriately pulsed therapy because continuous exposure to GnRH will suppress gonadotropins rather than stimulate them. In some cases, patients with GnRH defects also have pituitary or testicular dysfunction (a dual defect) and may fail to respond adequately to GnRH or gonadotropin treatment. The rare patient with isolated LH deficiency can be treated effectively using hCG injections.

It has been found that up to 10% of patients diagnosed with HH (with or without anosmia) may exhibit spontaneous reversal of hypogonadism with sustained normal gonadal function after treatment has been discontinued; this may even occur in patients with known genetic variants in various genes, including *FGFR1, PROK2, GNRH, CHD7,* and *TAC/TACR3*. Such recovery is more likely in patients who show an increase in testicular volume during treatment or when treatment has been discontinued. A brief trial of interruption of treatment is justified in patients with idiopathic HH. However, the recovery of gonadal function may not be lifelong.

Visit Elsevier eBooks+ at eBooks.Health.Elsevier.com for Bibliography.

Chapter 624

Pseudoprecocity Resulting from Tumors of the Testes

Omar Ali and Patricia A. Donohoue

Testicular tumors are relatively rare tumors in childhood, accounting for only 2–4% of all childhood cancers. 35% of prepubertal tumors are malignant, but in pubertal children most tumors are malignant (98% of painless testicular masses in pubertal males are malignant). Testicular tumors are discussed further in Chapter 552. Tumors that cause masculinization or feminization are rare and are derived from Leydig cells (producing androgens) or Sertoli cells (producing feminization). In addition, *enlargement* of the testes can be seen in congenital adrenal hyperplasia (CAH, caused by adrenal rests), in fragile X syndrome, and in cases where one testis is lost and the other hypertrophies to compensate.

Leydig cell tumors of the testes are rare causes of precocious pseudopuberty (gonadotropin-independent puberty) and cause asymmetric enlargement of the testes. Leydig cells are sparse before puberty, and tumors derived from them are more common in the adult. However, rare cases do occur in children; the youngest reported case was in a 1-year-old male. Although up to 10% of adult tumors may be malignant, metastasizing malignant tumors have not been reported in children, and pediatric Leydig cell tumors are usually unilateral and benign. Some tumors may be the result of somatic activating pathogenic variants of the luteinizing hormone receptor.

The clinical manifestations are those of puberty in the male; onset usually occurs at 5-9 years of age. Unilateral pubarche caused by local hormone action has been described. Gynecomastia may occur. The tumor of the testis can usually be readily felt; the contralateral unaffected testis is normal in size for the age of the patient.

Plasma levels of testosterone are markedly elevated, and follicle-stimulating hormone and luteinizing hormone levels are suppressed. Ultrasonography may aid in the detection of small nonpalpable tumors. Fine-needle aspiration biopsy may help define the diagnosis.

Treatment consists of surgical removal of the affected testis. These tumors are generally resistant to chemotherapy. Progression of virilization ceases after removal of the tumor, and partial reversal of the signs of precocity may occur.

Testicular adrenal rests may develop into tumors that mimic Leydig cell tumors. **Testicular adrenal rest tumors (TARTs)** are usually bilateral and occur in children with inadequately controlled CAH, usually of the salt-losing variety, during adolescence or young adult life. The stimulus for the growth of the adrenal rests is inadequate corticosteroid suppressive therapy causing excess adrenocorticotropic hormone secretion; treatment with adequate doses may result in their regression if they have not become quite large. These tumors are histologically similar to primary Leydig cell tumors, but definite evidence of their origin may be achieved by demonstrating their 21-hydroxylase activity. Misdiagnosis of these tumors as primary Leydig cell tumors may lead to unnecessary orchiectomy and should be avoided. Treatment is frequently unsatisfactory; improving the control of CAH will lower adrenocorticotropic hormone (ACTH) levels and prevent further growth of TARTs but may not shrink existing masses. Surgical removal can relieve pain (and is indicated if severe pain is present) but will not necessarily restore fertility. Sperm banking is recommended in adults with TARTs because these treatment modalities may not reverse their effect on fertility.

Fragile X syndrome (see Chapter 59) is caused by the amplification of a polymorphic CGG repeat in the 5′ untranslated region of *FMRI* at Xp17.3. The gene encodes an RNA-binding protein that is highly expressed in the brain and the testis. In otherwise normal individuals, 6-50 CGG repeats are present in the gene; the presence of 50-200 repeats is associated with mild intellectual disability and other abnormalities, and the presence of more than 200 repeats (fragile X pathogenic variant) is associated with the classic fragile X syndrome. 50 to 200 repeats are present in 1 in 1,000 White males, and pathogenic variants are found in 1 in 4,000-8,000. A cardinal characteristic of the condition is testicular enlargement *(macroorchidism)*, reaching 40-50 mL after puberty. Although the condition has been recognized in a child as young as 5 months of age, affected males younger than 6 years of age rarely have testicular enlargement; by 8-10 years of age, most have testicular volumes greater than 3 mL. The testes are enlarged bilaterally, are not nodular, and are histologically normal. Results of hormonal studies are normal. Direct DNA analysis searching for CGG repeat sequences permits definitive diagnosis.

Large-cell calcifying Sertoli cell tumors of the testes (usually associated with **Carney complex**) and **sex cord tumors with annular tubules** (frequently associated with **Peutz-Jeghers syndrome**) are extremely rare Sertoli cell tumors that may be a cause of breast development in young males. These tumors often occur bilaterally, are multifocal, and are detectible by ultrasonography. Excessive production of aromatase (P450arom), the enzyme that converts testosterone to estradiol, causes feminization of these males. Because these tumors are usually benign, they may be left in place if they are not causing pain; the gynecomastia can be treated with aromatase inhibitors.

Other causes of testicular enlargement are also present. In males with unilateral cryptorchidism, the contralateral testis is approximately 25% larger than normal for age. Testicular enlargement has also been noted in males with Henoch-Schönlein purpura and lymphangiectasia. Epidermoid and dermoid cysts of the testes have been reported but are rare.

Visit Elsevier eBooks+ at eBooks.Health.Elsevier.com for Bibliography.

Chapter 625

Gynecomastia

Omar Ali and Patricia A. Donohoue

Gynecomastia, the proliferation of mammary glandular tissue in the male, is a common condition. True gynecomastia (the presence of glandular breast tissue) must be distinguished from pseudogynecomastia, which is the result of accumulation of adipose tissue in the area of the breast that is commonly seen in overweight males. True gynecomastia is characterized by the presence of a palpable fibroglandular mass at least 0.5 cm in diameter that is located concentrically beneath the nipple and areolar region.

PHYSIOLOGIC FORMS OF GYNECOMASTIA

Gynecomastia occurs in many newborn males as a result of normal stimulation by maternal estrogen; the effect usually disappears in a few weeks. It is then extremely rare in prepubertal males, in whom it should always be investigated to identify the cause, but it again becomes common during normal puberty.

Neonatal Gynecomastia

Transient gynecomastia occurs in 60–90% of male newborns secondary to exposure to estrogens during pregnancy. Breast development may be asymmetric, and galactorrhea is seen in approximately 5%. Most cases resolve within 4-8 weeks of birth, but a few can last as long as 12 months. No treatment is necessary.

Pubertal Gynecomastia

During early to mid-puberty, up to 70% of males develop various degrees of subareolar hyperplasia of the breasts. Incidence peaks at the same time as peak height velocity, which is around 14 years of age, at Tanner stage 3-4 and at a testicular volume of 5-10 mL. Physiologic pubertal gynecomastia may involve only one breast, and it is not unusual for both breasts to enlarge at disproportionate rates or at different times. Tenderness of the breast is common but transient. Spontaneous regression may occur within a few months; it rarely persists longer than 2 years. Significant psychosocial distress may be present, especially in obese males with relatively large breasts.

The cause is thought to be an imbalance between estrogen and androgen action at the level of breast tissue. Testing usually fails to reveal any significant difference in circulating estrogen and androgen levels between affected and unaffected males, but minor degrees of imbalance in free hormone levels may still be present. Other hormones, including leptin, insulin-like growth factor 1 (IGF-1), and luteinizing hormone, may directly stimulate breast development and may play a role in pubertal gynecomastia. Some cases may be caused by an increased sensitivity to estrogens and/or relative androgen resistance in the affected tissue. As androgen levels continue to rise in later puberty, *most cases resolve and no specific treatment is needed.*

Pathologic Gynecomastia

Monogenic forms of gynecomastia are extremely rare. Familial gynecomastia has occurred in several kindreds as an X-linked or autosomal dominant sex-limited trait. Some of these cases were found to be caused by constitutive activation of the P450 aromatase enzyme *(CYP19A1),* leading to increased peripheral conversion of C-19 steroids to estrogens (increased aromatization). A report of this syndrome in a father and his son and daughter suggests autosomal dominant inheritance.

Exogenous sources of estrogens are an important cause of gynecomastia in prepubertal children. Very small amounts of estrogens can cause gynecomastia in male children, and accidental exposure may occur by inhalation, percutaneous absorption, or ingestion. Common sources of estrogens include oral contraceptive pills and oral and transdermal estrogen preparations. Gynecomastia has been reported in workers involved in the manufacture of estrogens and even in the children of such workers. Gynecomastia can also occur secondary to exposure to medications that decrease the level of androgens (especially free androgens), increase estradiol, or displace androgens from breast androgen receptors. Spironolactone, alkylating agents, anabolic steroids, human chorionic gonadotropin, ketoconazole, cimetidine, and androgen inhibitors such as flutamide are all associated with the occurrence of gynecomastia. Antipsychotic medications may also cause gynecomastia by inducing hyperprolactinemia and hypogonadism. Weaker associations are seen with a large number of other medications and drugs, including opiates, alcohol, and marijuana, although the association with marijuana may not be as strong as previously thought. Lavender, tea tree oils, and excessive consumption of soy are also implicated as possible causes of prepubertal gynecomastia. An increased incidence of gynecomastia has also been reported in cancer survivors, in whom the mechanisms include the antiandrogenic or hypogonadotropic effects of cytotoxic drugs and radiotherapy.

Klinefelter syndrome and other causes of *male hypogonadism* are strongly associated with gynecomastia. Significant gynecomastia is seen in 50% of adolescents with Klinefelter syndrome; it is also seen in other conditions characterized by male undervirilization, including partial androgen insensitivity syndrome and 17-ketosteroid reductase deficiency. Gynecomastia has also been observed in children with congenital virilizing adrenal hyperplasia caused by 11β-hydroxylase deficiency and with Leydig and Sertoli cell tumors of the testis or with feminizing tumors of the adrenal gland. Patients with Klinefelter syndrome may also develop gynecomastia because of estrogen-secreting germ cell tumors of the mediastinum. The finding of such a tumor should prompt a karyotype; conversely, the finding of elevated β-human chorionic gonadotropin (HCG) in a patient with Klinefelter syndrome should lead to imaging of the mediastinum to look for a possible germ cell tumor there. The testes may not be enlarged in patients with Sertoli or Leydig cell tumors, and the tumor is frequently multifocal and bilateral. Excessive aromatase production and/or excessive estrogen production accounts for the gynecomastia. Feminizing Sertoli cell tumors are also a feature of Peutz-Jeghers syndrome and Carney complex. When gynecomastia is associated with galactorrhea, a prolactinoma should be considered. Hyperprolactinemia can also cause gynecomastia indirectly by inducing hypogonadism. Hyperthyroidism alters the ratio of androgen to estrogen by increasing bound androgen and decreasing the free testosterone; this may result in gynecomastia in up to 40% of cases. Gynecomastia is also seen in malnourished patients after restoration of normal nutrition (refeeding syndrome), in whom it may result from hepatic dysfunction or abnormal activation of the gonadotropin axis.

EVALUATION OF GYNECOMASTIA

In pubertal cases a detailed history and physical examination may be all that is needed to exclude rare pathologic causes. Historical evaluation should include family history of male relatives with gynecomastia, history of liver or renal disease, use of medications or drugs of abuse, and exposure to herbal and cosmetic products that may contain phytoestrogens. Physical examination should include special attention to the breasts (looking for overlying skin changes, fixation, local lymphadenopathy, and nipple discharge) as well as a testicular exam. No laboratory evaluation is indicated in routine cases with no other associated abnormality; however, all prepubertal cases and pubertal cases with suspicious features should be investigated. *Suspicious features include diameter >4 cm, rapid progression, persistence for more than 2 years, and persistence after age 17.*

Initial laboratory evaluation should include thyroid function tests (to rule out hyperthyroidism), testosterone, estradiol, HCG, luteinizing hormone, follicle-stimulating hormone, and prolactin levels. Because of circadian variation, these hormone levels should ideally be obtained in the morning. Liver and kidney function should also be evaluated. Most cases of hyperprolactinemia are associated with galactorrhea, but hyperprolactinemia can also cause gynecomastia without associated galactorrhea by suppressing gonadotropins and

inducing some degree of hypogonadism. A karyotype should be checked in all cases where history, examination, or laboratory tests suggest the possibility of Klinefelter syndrome. Gonadotropin levels can be a useful screen for Klinefelter syndrome and will be elevated in pubertal males with this condition. If they are elevated, a karyotype should be performed.

TREATMENT

Treatment in cases of benign pubertal gynecomastia usually consists of reassuring the boy and his family of the physiologic and transient nature of the phenomenon. When the enlargement is striking and persistent and causes serious emotional disturbance to the patient, specific treatment may be justified. Unfortunately, medical treatment is generally ineffective in long-standing cases. Early cases respond better to medical treatment, but it is then harder to justify, as most cases will resolve spontaneously. Agents that have been used for medical treatment include androgens, aromatase inhibitors, and estrogen antagonists. The effectiveness of synthetic androgens is variable and side effects are a concern, so these are rarely used in pediatrics. Aromatase inhibitors have a physiologic rationale, but placebo-controlled trials have been disappointing. Estrogen antagonists like tamoxifen and raloxifene are more effective, with raloxifene being the superior agent in at least one well-designed trial. If medical treatment is attempted, it should be in early cases (<12 months standing) using raloxifene (in a dose of 60 mg/day) or tamoxifen (10-20 mg/day) for 3-9 months, with the understanding that success rates are generally low in severe cases and that mild cases will likely resolve on their own without treatment.

In those cases where breast development is excessive (Tanner stages 3-5), causes significant psychologic distress, or fails to regress in 18-24 months, surgical removal of the enlarged breast tissue may be indicated, particularly in males who have completed or nearly completed pubertal development. Careful examination and laboratory testing to exclude nonphysiologic causes are advisable before proceeding to surgery.

Visit Elsevier eBooks+ at eBooks.Health.Elsevier.com for Bibliography.

Chapter 626

Hypofunction of the Ovaries

Alvina R. Kansra and Patricia A. Donohoue

Hypofunction of the ovaries can be either primary or central in etiology. It may be caused by congenital failure of development, postnatal injury (primary or hypergonadotropic hypogonadism), or lack of central stimulation by the pituitary and/or hypothalamus (secondary or tertiary hypogonadotropic hypogonadism). **Primary ovarian insufficiency** (hypergonadotropic hypogonadism), also termed *premature ovarian failure* (POF), is characterized by the arrest of normal ovarian function before 40 years of age. Certain genetic pathogenic variants have been identified that can result in primary ovarian insufficiency. Hypofunction of the ovaries because of a lack of central stimulation (hypogonadotropic hypogonadism) can be associated with other processes, such as multiple pituitary hormone deficiencies and some chronic diseases. Table 626.1 details the etiologic classification of ovarian hypofunction (see also Fig. 600.7).

626.1 Hypergonadotropic Hypogonadism in the Female (Primary Hypogonadism)

Alvina R. Kansra and Patricia A. Donohoue

A diagnosis of hypergonadotropic hypogonadism before puberty is difficult. Except in the case of Turner syndrome, most affected patients have no prepubertal clinical manifestations.

TURNER SYNDROME

The term *Ullrich-Turner syndrome* is frequently used in Europe but is infrequently used in the United States, where the condition is called just *Turner syndrome* (see Chapter 99.4). The syndrome is defined as the combination of the characteristic phenotypic features accompanied by a complete or partial absence of the second X chromosome with or without mosaicism.

Pathogenesis

Half the patients with Turner syndrome have a 45,X chromosomal complement. Approximately 15% of patients are mosaics for 45,X and a normal cell line (45,X/46,XX). Other mosaics with isochromosomes, 45,X/46,X,i(Xq); with rings, 45,X/46,X,r(X); or with fragments, 45,X/46fra, occur less often. Mosaicism is commonly detected when more than one tissue is examined. The single X chromosome is of maternal origin in nearly 80% of 45,X patients. The mechanism of chromosome loss is unknown, and the risk for the syndrome does not increase with maternal age. The genes involved in the Turner phenotype are X-linked genes that escape inactivation. A major locus involved in the control of linear growth has been mapped within the pseudoautosomal region of the X chromosome (PAR1). *SHOX,* a homeobox-containing gene of 170 kb of DNA within the PAR1, is thought to be important for controlling growth in children with Turner syndrome, with Leri-Weill syndrome, and, rarely, patients with idiopathic short stature. Genes for the control of normal ovarian function are postulated to be on Xp and perhaps two supergenes on Xq.

Turner syndrome occurs in approximately 1 in 1,500-2,500 liveborn females. The frequency of the 45,X karyotype at *conception* is approximately 3%. However, 99% of these are spontaneously aborted, accounting for 5–10% of all abortuses. Mosaicism (45,X/46,XX) occurs in a proportion higher than that seen with any other aneuploid state, but the mosaic Turner constitution is rare among the abortuses; these findings indicate preferential survival for mosaic forms.

The normal fetal ovary contains approximately 7 million oocytes, but these begin to disappear rapidly after the fifth month of gestation. At birth, there are only 2 million (1 million active follicles); by menarche, there are 400,000-500,000; and at menopause, 10,000 remain. In the absence of one X chromosome, this process is accelerated, and nearly all oocytes are gone by 2 years of age. In aborted 45,X fetuses, the number of primordial germ cells in the gonadal ridge appears to be normal, suggesting that the normal process of oocyte loss is accelerated in patients with Turner syndrome. Eventually, the ovaries are described as streaks and consist only of connective tissue, with very few germ cells present.

Clinical Manifestations

Many patients with Turner syndrome are recognizable at birth because of a characteristic edema of the dorsa of the hands and feet and loose skinfolds at the nape of the neck. Low birthweight and decreased birth length are common (see Chapter 99.4). Clinical manifestations in childhood include webbing of the neck, a low posterior hairline, small mandible, prominent ears, epicanthal folds, high arched palate, a broad chest presenting the illusion of widely spaced nipples, cubitus valgus, and hyperconvex fingernails. The diagnosis is often first suspected at puberty when breast development fails to occur.

Short stature, the cardinal finding in virtually all females with Turner syndrome, may be present with few other clinical manifestations. The linear growth deceleration begins in infancy and early childhood, gets progressively more pronounced in later childhood and adolescence,

Table 626.1 Etiologic Classification of Ovarian Hypofunction

HYPOGONADOTROPIC HYPOGONADISM
Hypothalamic
Genetic defects
• Kallmann syndrome: *KAL1, FGFR1, FGF8, PROK2, PROKR2, CHD7, WDR11, NELF, SEMA3A*
• Other gene defects: leptin, leptin receptor, KISS-1 (deficiency of kisspeptin), *DAX-1, TAC3* (deficiency of neurokinin B), *TACR3, SEMA7A*
• Inherited syndromes: Prader-Willi, Bardet-Biedl, and others
• Marked constitutional growth delay
Acquired defects (reversible)
• Anorexia nervosa
• Drug use
• Malnutrition
• Chronic illness, especially Crohn disease
• Hyperprolactinemia
Pituitary
Genetic defects
• Isolated gonadotropin deficiency (GnRH receptor, FSH, and LH β-subunit)
• Septo-optic dysplasia (*HESX-1* defect in some cases)
• Disorders of pituitary organogenesis (*PROP1, LHX3, LHX4, SOX-3*)
Acquired defects
• Hyperprolactinemia
• Pituitary tumors
• Pituitary infarction
• Infiltrative disorders (histiocytosis, sarcoidosis)
• Hemosiderosis and hemochromatosis
• Radiation
HYPERGONADOTROPIC HYPOGONADISM
Genetic
• Follicle-stimulating hormone and luteinizing hormone resistance
• Pathogenic variants in steroidogenic pathways
• 46,XX gonadal dysgenesis
• Turner syndrome and its variants
• Noonan syndrome (RASopathy genes)
• *SF-1* pathogenic variants
• Galactosemia
• Fragile X–associated disorders
• Bloom syndrome
• Werner syndrome
• Ataxia-telangiectasia
• Fanconi anemia
Acquired
• Chemotherapy
• Radiation
• Autoimmune ovarian failure from autoimmune polyendocrine syndromes 1 and 2

Fig. 626.1 Turner syndrome in a 15-yr-old female exhibiting failure of sexual maturation, short stature, cubitus valgus, and a goiter. There is no webbing of the neck. Karyotyping revealed 45,X/46,XX chromosome complement.

and results in significant adult short stature. Sexual maturation (breast development) fails to occur at the expected age; however, signs of adrenarche (pubic hair) are normally present. Among untreated patients with Turner syndrome, the mean adult height is 143-144 cm in the United States and most of Northern Europe, but 140 cm in Argentina and 147 cm in Scandinavia (Fig. 626.1). The height is well correlated with the midparental height (average of the parents' heights adjusted for child's sex). Specific growth curves for height have been developed for females with Turner syndrome.

Associated **cardiac defects** are common. In females with Turner syndrome, life-threatening consequences of X chromosome haploinsufficiency involve the cardiovascular system. There is a four- to fivefold increase in the rate of premature mortality secondary to congenital heart disease and premature coronary heart disease in adults with Turner syndrome. Clinically silent cardiac defects, mainly bicuspid aortic valve, are present in patients with Turner syndrome. Regardless of age, all patients with Turner syndrome need comprehensive cardiovascular evaluation by a cardiologist specializing in congenital heart disease at the time of diagnosis. Complete cardiologic evaluation, including echocardiography, reveals isolated nonstenotic bicuspid aortic valves in one third to half of the patients. In later life, bicuspid aortic valve disease can progress to dilation of the aortic root or aortic dissection. Less frequent defects include aortic coarctation (20%), aortic stenosis, mitral valve prolapse, and anomalous pulmonary venous drainage. In one study, 38% of patients with 45,X chromosomes had cardiovascular malformations compared with 11% of those with mosaic monosomy X; the most common were aortic valve abnormalities and aortic coarctation. Webbed neck in patients with or without recognized chromosome syndromes is associated with both flow-related and non–flow-related heart defects. Among patients with Turner syndrome, those with webbed necks have a much greater chance of having coarctation of the aorta than do those without webbed necks. Transthoracic echocardiogram in young females is adequate if cardiac anatomy is clearly seen; otherwise, magnetic resonance angiographic screening studies should be considered in asymptomatic individuals with Turner syndrome. During adolescence, and certainly before pregnancy (when possible) is contemplated, repeat cardiac evaluation should be considered even in those without prior findings of cardiac abnormalities. Blood pressure should be routinely monitored even in the absence of cardiac or renal lesions, especially in those with suggestions of aortic root dilation. Cardiac MRI is a valuable tool to detect and monitor aortic root dilation.

Renal ultrasound should be performed in all females with Turner syndrome at diagnosis. One fourth to one third of patients have **renal malformations** on ultrasonographic examination (50% of those with 45,X karyotypes). The more serious defects include pelvic kidney, horseshoe kidney, double collecting system, the complete absence of one kidney, and ureteropelvic junction obstruction. Some of the malformations may increase the risk of hypertension and urinary tract

infection. Idiopathic hypertension is also common. Females with Turner syndrome who had normal baseline renal ultrasound findings did not develop the renal disease during a follow-up period averaging 6 years.

When the ovaries are examined by ultrasonography, there are no age-related differences in detecting ovarian tissue; 27–46% of patients have detectable ovaries at various ages; 76% of those with X mosaicism and 26% of those with 45,X karyotypes have detectable ovaries.

Sexual maturation usually fails to occur, but 10–20% of females have spontaneous breast development, and a small percentage may have menstrual periods. Primary gonadal failure is associated with early onset of adrenarche (elevation in dehydroepiandrosterone sulfate) but delayed pubarche (pubic hair development). Spontaneous pregnancies have been reported in menstruating patients with Turner syndrome. Premature menopause, increased risk of miscarriage, and offspring with increased risk of trisomy 21 have been reported. A woman with a 45,X/46,X,r(X) karyotype treated with hormone replacement therapy had three pregnancies, resulting in a normal 46,XY male infant, a spontaneous abortion, and a healthy term female with Turner syndrome 45,X/46,Xr(X).

Antithyroid antibodies (thyroid peroxidase and/or thyroglobulin antibodies) occur in 30–50% of patients. The prevalence increases with advancing age. **Autoimmune thyroid disease**, with or without a goiter, occurs in 10–30% of patients. Age-dependent abnormalities in carbohydrate metabolism characterized by abnormal glucose tolerance and insulin resistance and, only rarely, frank type 2 diabetes occur in older patients with Turner syndrome. Impaired insulin secretion has been described in 45,X women. Cholesterol levels are elevated in adolescence, regardless of body mass index or karyotype.

Inflammatory bowel disease (both Crohn disease and ulcerative colitis), gastrointestinal bleeding because of abnormal mesenteric vasculature, and delayed gastric emptying time have all been reported. Screening for celiac disease is recommended because the risk of celiac disease is increased in Turner syndrome, with 4–6% of individuals affected. Although autoimmune diseases have been associated with Turner syndrome, the prevalence of type 1 diabetes with Turner syndrome is not very high.

Chronic liver disease may develop in adults with Turner syndrome. Its pathogenesis is poorly defined.

Sternal malformations can be detected by lateral chest radiography. An increased carrying angle at the elbow is usually not clinically significant. Scoliosis occurs in approximately 10% of adolescent females. Congenital hip dysplasia occurs more commonly than in the general population. Reported eye findings include anterior segment dysgenesis and keratoconus. Pigmented nevi become more prominent with age; melanocytic nevi are common. Essential hyperhidrosis, torus mandibularis, and alopecia areata occur rarely.

Recurrent bilateral otitis media develops in approximately 75% of patients. Sensorineural hearing deficits are common, and the frequency increases with age. Problems with gross and fine motor sensory integration, failure to walk before 15 months of age, and early language dysfunction often raise questions about developmental delay, but intelligence is normal in most patients. However, cognitive impairment does occur in patients with 45,X/46,X,r(X); the ring chromosome is unable to undergo inactivation and leads to two functional X chromosomes.

Special attention should be given to psychosocial development in females with Turner syndrome. In general, behavior is normal in females with Turner syndrome, but they are at an increased risk for social isolation, immaturity, and anxiety. Other conditions, such as dyslexia, nonverbal learning disability, and attention-deficit disorder, have been reported in females with Turner syndrome. In adults, deficits in perceptual spatial skills are more common than they are in the general population. Some unconfirmed data suggest the existence of an imprinted X-linked locus that affects cognitive function such as verbal and higher-order executive function skills. These functions are apparently better when the X is paternal in origin.

The prevalence of mosaicism depends in large part on the techniques used for studying chromosomal patterns. The use of fluorescent in situ hybridization and reverse transcription–polymerase chain reaction (PCR) has increased the reported prevalence of mosaic patterns to as high as 60–74%.

Mosaicism involving the Y chromosome occurs in 5%. A population study using PCR with five different primer sets found Y chromosome material in 12.2%. **Gonadoblastoma** among Y-positive patients occurred in 7–10%. Therefore the recommendation is that prophylactic gonadectomy be performed even in the absence of MRI or CT evidence of tumors. The recommended timing of this procedure is at the time of diagnosis, but this may need to be reevaluated in the future. The gonadoblastoma locus on the Y chromosome (GBY) maps close to the Y centromere. The presence of only the SRY (sex-determining region on the Y chromosome) locus is not sufficient to confer increased susceptibility for the development of gonadoblastoma. Routine PCR for Y chromosome detection for the purpose of assigning gonadoblastoma risk is not indicated. High-throughput quantitative genotyping may provide an effective and inexpensive method for the identification of X chromosome abnormalities and Y chromosome material identification.

In patients with 45,X/46,XX mosaicism, the clinical abnormalities are attenuated and fewer; short stature is as frequent as it is in the 45,X patient and may be the only manifestation of the condition other than ovarian failure (see Fig. 626.1).

Laboratory Findings

Chromosomal analysis must be considered routinely in females who have unexpected short stature based on parental heights. Turner syndrome is detected in ~5% of females referred to an endocrinology service because of short stature. Patients with a marker chromosome in some or all cells should be tested for DNA sequences at or near the centromere of the Y chromosome for GBY.

Ultrasonography of the heart, kidneys, and ovaries is indicated after the diagnosis is established. The most common skeletal abnormalities are shortening of the fourth metatarsal and metacarpal bones, epiphyseal dysgenesis in the joints of the knees and elbows, Madelung deformity, scoliosis, and, in older patients, inadequate osseous mineralization.

Plasma levels of gonadotropins, particularly follicle-stimulating hormone (FSH), are markedly elevated to greater than those of age-matched controls during infancy; at 2-3 years of age, a progressive decrease in levels occurs until they reach a nadir at 6-8 years of age, and by 10-11 years of age, they rise to adult agonadal levels.

Thyroid peroxidase antibodies should be checked to detect autoimmune thyroiditis if the thyroid-stimulating hormone (TSH) level is abnormal. Annual or biannual TSH levels are recommended. Females with Turner syndrome should be screened for celiac disease by measuring tissue transglutaminase immunoglobulin A antibodies. Initial testing should be done around age 4 years and repeated every 2-5 years. Extensive studies have failed to establish that growth hormone deficiency plays a primary role in the pathogenesis of the growth disorder. Defects in normal secretory patterns of growth hormone are seen in adolescents because of a lack of gonadal steroids, but not in younger females with Turner syndrome.

Treatment

Treatment with recombinant human growth hormone increases height velocity and ultimate stature in most, but not all, children with Turner syndrome. Many females achieve heights of greater than 150 cm with early initiation of treatment. In one clinical trial, 99 patients with Turner syndrome who started receiving growth hormone at a mean age of 10.9 years at doses between 0.27 and 0.36 mg/kg/wk achieved a mean height of 149 cm, with nearly one third reaching heights greater than 152.4 cm (60 in). In the Netherlands, higher doses of growth hormone (up to 0.63 mg/kg/wk in the third year of treatment) resulted in 85% of the subjects reaching adult heights in the normal range for the Dutch reference population. Growth hormone treatment should be initiated in early childhood and/or when there is evidence of height velocity attenuation on specific Turner syndrome growth curves. Growth hormone therapy does not significantly aggravate carbohydrate tolerance and does not result in marked adverse events in patients with Turner syndrome. Serum levels of insulin-like growth factor 1 should be monitored if the patient is receiving high doses of growth hormone. If the insulin-like growth

factor 1 levels are significantly elevated, the dose of growth hormone may need to be reduced. Treatment with growth hormone can cause excessive growth of the hands and feet in some females with Turner syndrome.

Oxandrolone has also been used to treat the short stature associated with Turner syndrome, either alone or in combination with growth hormone. This nonaromatizable synthetic anabolic steroid has weak androgenic effects, and patients should be monitored for signs of pubarche and hepatotoxicity. The latter is rare.

Replacement therapy with estrogens is indicated, but there is variation among pediatric endocrinologists about the optimal age at which to initiate treatment. The psychologic preparedness of the patient to accept therapy must be considered. The improved growth achieved by females treated with growth hormone in childhood permits initiation of estrogen replacement at 12-13 years. Delaying estrogen therapy to optimize height potential until 15 years of age, as previously recommended, seems unwarranted. This change to starting earlier estrogen therapy was considered because of the psychologic importance of age-appropriate pubertal maturation. In addition, delaying estrogen therapy could be deleterious for bone health and potentially other aspects of the child's health. Low-dose estrogen replacement at 12 years of age permits a normal pace of puberty without interfering with the positive effect of growth hormone on the final adult height. Estrogen therapy improves verbal and nonverbal memory in females with Turner syndrome. In young women with age-appropriate pubertal development who achieve normal height, health-related quality-of-life questionnaires have yielded normal results.

Many forms of estrogen are available. Oral estrogens had been mostly used in the past. Transdermal patches are increasing in popularity. This is because transdermal patches bypass the first-pass hepatic metabolism, requiring only a small amount of estrogen to attain adequate function. Many treatment protocols have been developed, and several are as follows. For oral preparations, a conjugated estrogen (Premarin), 0.15-0.625 mg daily, or micronized estradiol (Estrace), 0.5 mg given daily for 3-6 months, is usually effective in inducing puberty. The recommendations for transdermal patch therapy are 6.25 μg daily, gradually increased over 2 years to the adult dose of 100-200 μg daily. The estrogen may be cycled (taken on days 1-23) or not. A progestin (Provera) is added (taken on days 10-23) in a dose of 5-10 mg daily. In the week after the progestin, withdrawal bleeding usually occurs. Combination oral contraceptive pills may also be used for hormone replacement therapy.

Prenatal chromosome analysis for advanced maternal age has revealed a frequency of 45,X/46,XX that is 10 times higher than when diagnosed postnatally. Most of these patients have no clinical manifestations of Turner syndrome, and levels of gonadotropins are normal. Awareness of this mild phenotype is important in counseling patients.

Psychosocial support for these females is an integral component of treatment. A comprehensive psychologic education evaluation is recommended either at the time of Turner syndrome diagnosis, depending on the patient's age, when any of the components of behavior or cognition become obvious, or immediately preceding school entry. In addition to the healthcare team, the Turner Syndrome Society, which has local chapters in the United States and similar groups in Canada and other countries, provides a valuable support system for these patients and their families.

Successful pregnancies have been carried to term using ovum donation and in vitro fertilization. Adolescents with few signs of spontaneous puberty may have ovaries with follicles. There remains a future possibility of using cryopreserved ovarian tissue with immature oocytes before the regression of the ovaries for future pregnancies. In adult women with Turner syndrome, there seems to be a high prevalence of undiagnosed bone mineral density, lipid, and thyroid abnormalities. Glucose intolerance diminished first-phase insulin response, elevated blood pressure, and lowered fat-free mass are common. Glucose tolerance worsens, but fat-free mass and blood pressure and general physical fitness improve with sex hormone replacement. The neurocognitive profile of adult women is unaffected by estrogen status.

XX GONADAL DYSGENESIS

Some phenotypically and genetically normal females have gonadal lesions identical to those in 45,X patients but without somatic features of Turner syndrome; their condition is termed **pure gonadal dysgenesis** or pure **ovarian dysgenesis**.

The disorder is rarely recognized in prepubertal children because the external genitals are normal, no other abnormalities are visible, and growth is normal. At pubertal age, sexual maturation fails to take place. Plasma gonadotropin levels are elevated. Delay of epiphyseal fusion may result in a *eunuchoid* habitus. Pelvic ultrasonography reveals streak ovaries.

Affected siblings, parental consanguinity, and failure to uncover mosaicism suggest female-limited autosomal recessive inheritance. The disorder appears to be especially frequent in Finland (1 in 8,300 liveborn females). In this population, several pathogenic variants in the FSH receptor gene (on chromosome 2p) are demonstrated as the cause of the condition. In contrast, FSH receptor gene variants are not detected in Mexican women with 46,XX gonadal dysgenesis. In some patients, XX gonadal dysgenesis has been associated with sensorineural deafness (**Perrault syndrome**). A patient with this condition and concomitant growth hormone deficiency and virilization has also been reported. There may be distinct genetic forms of this disorder. **Müllerian agenesis**, or **Mayer-Rokitansky-Küster-Hauser** syndrome, which is second to gonadal dysgenesis as the most common cause of primary amenorrhea, occurring in 1 in 4,000-5,000 females, has been reported in association with 46,XX gonadal dysgenesis in a 17-year-old adolescent with primary amenorrhea and lack of breast development. One case of dysgerminoma with syncytiotrophoblastic giant cells was reported. An 18-year-old woman with primary amenorrhea and an absence of müllerian-derived structures, unilateral renal agenesis, and clinical signs of androgen excess—a phenotype resembling Mayer-Rokitansky-Küster-Hauser syndrome—was found to have a loss-of-function variant in *WNT4*. Treatment consists of estrogen replacement therapy.

45,X/46,XY GONADAL DYSGENESIS

45,X/46,XY gonadal dysgenesis, also called **mixed gonadal dysgenesis**, has extreme postnatal phenotypic variability that may extend from a Turner-like syndrome to a male phenotype with a penile urethra; it is possible to delineate three major clinical phenotypes. Short stature is a major finding in all affected children. Ninety percent of prenatally diagnosed cases have a normal male phenotype.

Some patients have no evidence of virilization; they have a female phenotype and often have the somatic signs of Turner syndrome. The condition is discovered prepubertally when chromosomal studies are made in short females or later when chromosomal studies are made because of failure of sexual maturation. Fallopian tubes and uterus are present. The gonads consist of intraabdominal undifferentiated streaks; chromosomal study of the streak often reveals an XY cell line. The streak gonad differs somewhat from that in females with Turner syndrome; in addition to wavy connective tissue, there are often tubular or cordlike structures, occasional clumps of granulosa cells, and, frequently, mesonephric or hilar cells.

Some children have mild virilization manifested only by prepubertal clitoromegaly. Normal müllerian structures are present, but at puberty virilization occurs. These patients usually have an intraabdominal testis, a contralateral streak gonad, and bilateral fallopian tubes.

Many 45,X/46,XY children present with frank ambiguity of the genitals in infancy (Fig. 626.2). A testis and vas deferens are found on one side in the labioscrotal fold, and a streak gonad is identified on the contralateral side. Despite the presence of a testis, fallopian tubes are often present bilaterally. An infantile or rudimentary uterus is often present.

Other genotypes and phenotypes have been described in mixed gonadal dysgenesis. Approximately 25% of 200 analyzed patients have a dicentric Y chromosome (45,X/46,X,dic Y). In some patients the Y chromosome may be represented by only a fragment (45,X/45,X +fra); application of Y-specific probes can establish the origin of the fragment. It is unclear why the same genotype (45,X/46,XY) can result in

Fig. 626.2 A 45,X/46XY neonate with sex chromosome disorder of sex development was noted at birth to have male-appearing external genitalia with a phallus measured at 2.5 × 1.2 cm and penoscrotal hypospadias. The left gonad was palpable in an incompletely fused scrotum, whereas the right gonad was not palpable. Gonadal biopsy revealed a testis on the left side and streak gonad on the right. The diagnosis was mixed gonadal dysgenesis. *(From Remeithi SA, Wherret DK. Disorders of sexual development. In: Martin RJ, Fanaroff AA, Walsh MC, eds. Fanaroff and Martin's Neonatal-Perinatal Medicine, 10th ed. Philadelphia: Elsevier; 2015: Fig. 98–13)*

diverse phenotypes. Pathogenic variants in *SRY* have been described in some patients.

Children with a female phenotype present no problem in gender of rearing. Patients who are only slightly virilized are usually assigned a female gender of rearing before a diagnosis is established. Patients with ambiguity of the genitals are often clinically indistinguishable from patients with various types of 46,XY disorders of sex development (46,XY DSD). In some instances, there may need to be careful consideration regarding gender of rearing. Factors that may influence this decision include short stature, the need for surgical genital reconstruction, the presence of müllerian structures, and the need for gonadectomy because of predisposition of the gonad to the development of malignancy. In some patients followed to adulthood, the putative normal testis proves to be dysgenetic with eventual loss of Leydig and Sertoli cell function (see Chapter 623). In an analysis of 22 patients with mixed gonadal dysgenesis, no significant associations or correlations were found between internal and external phenotypes or endocrine function and gonadal morphologic features. The appearance of the external genitalia determined the gender of rearing. In 11 patients, basal and human chorionic gonadotropin–stimulated testosterone levels were lower than in control subjects.

Gonadal tumors, usually **gonadoblastomas**, occur in approximately 25% of these children. A gonadoblastoma locus has been localized to a region near the centromere of the Y chromosome (GBY). These germ cell tumors are preceded by the changes of carcinoma in situ. Accordingly, both gonads should be removed in all patients reared as females, and the undifferentiated gonad should be removed in the patients reared as males.

There is no correlation among the proportion of 45,X/46,XY cell lines in either blood or fibroblasts with the phenotype. In the past, all patients came to clinical attention because of their abnormal phenotypes. However, 45,X/46,XY mosaicism is found in approximately 7% of fetuses, with true chromosome mosaicism encountered prenatally. Of 76 infants with 45,X/46,XY mosaicism diagnosed prenatally, 72 had a normal male phenotype, 1 had a female phenotype, and only 3 males had hypospadias. Of 12 males whose gonads were examined, only 3 were abnormal. These data must be considered when counseling a family in which a 45,X/46,XY infant is discovered prenatally.

XXX, XXXX, AND XXXXX FEMALES

XXX Females

The 47,XXX (trisomy) chromosomal constitution is the most frequent extra X chromosome abnormality in females, occurring in almost 1 in 1,000 liveborn females. In 68%, this condition is caused by maternal meiotic nondisjunction, but paternal sex chromosome errors cause most 45,X and half of 47,XXY constitutions. The phenotype is that of a normal female; affected infants and children are not recognized based on the genital appearance.

Sexual development and menarche are normal. Most pregnancies have resulted in normal infants. By 2 years of age, delays in speech and language become evident, and some see a lack of coordination, poor academic performance, and immature behavior. These females tend to be tall, manifest behavior disorders, and often require special education classes. Using high-resolution MRI, 47,XXX subjects have lower amygdala volumes than euploid controls; 47,XXY subjects had even lower amygdala volumes. In a review of 155 females, 62% were physically normal. There is marked variability within the syndrome, and a small proportion of affected females are well coordinated, socially outgoing, and academically superior.

XXXX and XXXXX Females

The great majority of females with these rare karyotypes have intellectual disabilities. Commonly associated defects are epicanthal folds, hypertelorism, clinodactyly, transverse palmar creases, radioulnar synostosis, and congenital heart disease. Sexual maturation is often incomplete and may not occur at all. Nevertheless, three women with tetra-X syndrome gave birth, but no pregnancies were reported in 49,XXXXX women. Most 48,XXXX women tend to be tall, with an average height of 169 cm, whereas short stature is a common feature of the 49,XXXXX phenotype.

NOONAN SYNDROME

Females with Noonan syndrome show certain anomalies also seen in females with 45,X Turner syndrome, but they have normal 46,XX chromosomes (see Chapter 101.1). The most common abnormalities are the same as those described for males with Noonan syndrome (see Chapter 623). Short stature is one of the cardinal signs of this syndrome. The phenotype differs from Turner syndrome in several respects. Cognitive impairment is often present, the cardiac defect is most often pulmonary valvular stenosis or an atrial septal defect rather than an aortic defect, normal sexual maturation usually occurs but is delayed by 2 years on average, and POF has been reported. The FDA approves growth hormone therapy for use in Noonan syndrome patients with short stature.

OTHER OVARIAN DEFECTS

Some young women with no chromosomal abnormalities are found to have streak gonads that may contain only occasional or no germ cells. Gonadotropins are increased. Cytotoxic drugs, especially alkylating agents such as cyclophosphamide and busulfan, procarbazine, etoposide, and exposure of the ovaries to irradiation for the treatment of malignancy are frequent causes of ovarian failure. Young women with Hodgkin disease demonstrate that combination chemotherapy and pelvic irradiation may be more deleterious than either therapy alone. Teenagers are more likely than older women to retain or recover ovarian function after irradiation or combined chemotherapy; normal pregnancies have occurred after such treatment. Treatment regimens may result in some ovarian damage in most females treated for cancer. The median lethal dose for the human oocyte is estimated to be approximately 4 Gy; doses as low as 6 Gy have produced primary amenorrhea. Ovarian transposition before abdominal and pelvic irradiation

in childhood can preserve ovarian function by decreasing the ovarian exposure to less than 4-7 Gy.

Autoimmune ovarian failure occurs in 60% of children older than 13 years of age with type I autoimmune polyendocrinopathy (Addison disease, hypoparathyroidism, mucocutaneous candidiasis). This condition, also known as *polyglandular autoimmune disease type 1,* is rare worldwide but not in Finland, where, as a result of a founder gene effect, it occurs in 1 in 25,000 people. Affected females may not develop sexually; secondary amenorrhea may occur in young women. The ovaries may have lymphocytic infiltration or appear simply as streaks. Most affected patients have circulating steroid cell antibodies and autoantibodies to 21-hydroxylase. Among patients with polyglandular autoimmune syndromes, 5% have hypogonadism.

The condition also occurs in young women as an isolated event or in association with other autoimmune disorders, leading to secondary amenorrhea (POF). It occurs in 0.2–0.9% of women younger than 40 years of age. POF is a heterogeneous disorder with many causes: chromosomal, genetic, enzymatic, infectious, and iatrogenic. When associated with autoimmune adrenal disease, steroid cell autoantibodies are usually present. These antibodies react with P450scc, 17α-OH, or 21-OH enzymes. Steroid cell autoantibodies are rarely found when associated with an entire host of endocrine and nonendocrine autoimmune diseases and not adrenal autoimmunity. A second autoimmune disorder, often subclinical, is found in 10–39% of adult patients with POF, including autoimmune thyroid disease, type 1 diabetes, systemic lupus erythematosus (SLE), inflammatory bowel disease, immune thrombocytopenia or hemolytic anemia, celiac disease, myasthenia gravis, and rheumatoid arthritis. One 17-year-old with idiopathic thrombocytopenic purpura and 47,XXX chromosomes had autoimmune POF. Patients with POF do not have the neurocognitive defects found in Turner syndrome patients.

Galactosemia, particularly the classical form of the disease, usually results in ovarian damage, beginning during intrauterine life. Levels of FSH and luteinizing hormone (LH) are elevated early in life. Ovarian damage may be caused by deficient uridine diphosphate-galactose (see Chapter 107.2). **Denys-Drash syndrome** caused by a *WT1* pathogenic variant can result in ovarian dysgenesis.

Ataxia-telangiectasia may be associated with ovarian hypoplasia and elevated gonadotropins; the cause is unknown. Gonadoblastomas and dysgerminomas have occurred in a few females.

Hypergonadotropic hypogonadism occurs as a result of resistance of the ovary to both endogenous and exogenous gonadotropins **(Savage syndrome)**. This condition also occurs in women with POF. Antiovarian antibodies or FSH receptor abnormalities may cause this condition. The FSH receptor gene variants have been reported as an autosomal recessive condition (see Chapter 622). A few females with 46,XX chromosomes presenting in primary amenorrhea with elevated gonadotropin levels were found to have inactivating variants of the LH receptor gene. This suggests that LH action is needed for normal follicular development and ovulation. Other genetic defects associated with ovarian failure include pathogenic variants in *SF-1, FOXL2, GNAS, CYP17,* and *CYP19.*

Visit Elsevier eBooks+ at eBooks.Health.Elsevier.com for Bibliography.

626.2 Hypogonadotropic Hypogonadism in the Female (Secondary Hypogonadism)

Alvina R. Kansra and Patricia A. Donohoue

Hypofunction of the ovaries can result from failure to secrete normal pulses of the gonadotropins LH and FSH. Hypogonadotropic hypogonadism (HH) may occur if the hypothalamic-pituitary-gonadal axis is interrupted either at the hypothalamic or pituitary level. The mechanisms that result in HH include failure of the hypothalamic LH–releasing hormone (also known as *gonadotropin-releasing hormone*) pulse generator or inability of the pituitary to respond with secretion of LH and FSH. It is often difficult to distinguish between marked constitutional delay and HH.

HYPOPITUITARISM

Hypogonadotropic hypogonadism is most commonly seen with multiple pituitary hormone deficiencies resulting from malformations (e.g., septo-optic dysplasia, other midline defects), pituitary transcription factor defects such as in PROP-1, or lesions of the pituitary that are acquired postnatally. Familial isolated gonadotropin deficiency associated with anosmia (Kallmann syndrome) may occur in females. Many other genetic causes for HH have been identified. A gene important in LH-releasing hormone secretion is named *KISS* (encoding the protein kisspeptin), which is suggested to play a significant role in the development of the LH-releasing hormone–secreting cells. Another set of genes implicated in HH are the genes for neurokinin B *(TAC3)* and its receptor *(TAC3R)*.

In children with idiopathic hypopituitarism, the defect is usually found in the hypothalamus. In these patients, administration of gonadotropin-releasing hormone results in increased plasma levels of FSH and LH, establishing the integrity of the pituitary gland.

Hypogonadotropic hypogonadism is less common than hypergonadotropic hypogonadism. Ovarian function may be abnormal when associated with LH excess, a condition known as *polycystic ovarian syndrome* (polycystic ovary syndrome; see Chapter 589).

Isolated Deficiency of Gonadotropins

This heterogeneous group of disorders is evaluated more fully with the use of the gonadotropin-releasing hormone analog stimulation test rather than a single measurement of gonadotropin levels. In most children the pituitary gland is normal, and the defect causing gonadotropin deficiency resides in the hypothalamus. Patients with **hyperprolactinemia**, most often caused by a pituitary prolactin-secreting adenoma, often have suppression of gonadotropin secretion. If breast development has occurred, then galactorrhea and amenorrhea are frequently seen.

Several sporadic instances of anosmia with hypogonadotropic hypogonadism have been reported. **Anosmic** hypogonadal females have also been reported in kindreds with Kallmann syndrome, but hypogonadism more frequently affects the males in these families. Pathogenic variants in the gene for the β-subunit of FSH and LH have been reported.

Some autosomal recessive disorders, such as Laurence-Moon-Biedl, multiple lentigines, and Carpenter syndromes, appear in some instances to include gonadotropic hormone deficiency. Patients with Prader-Willi syndrome usually have some degree of HH. Females with severe thalassemia may have gonadotropin deficiency from pituitary damage caused by chronic iron overload secondary to multiple transfusions. Anorexia nervosa frequently results in HH. The rare patients described with leptin deficiency or leptin receptor defects have failure of pubertal maturation because of gonadotropin deficiency.

DIAGNOSIS

The diagnosis may be apparent in patients with other deficiencies of pituitary tropic hormones, but, as in males, it is difficult to differentiate isolated hypogonadotropic hypogonadism from physiologic delay of puberty. Repeated measurements of FSH and LH, particularly during sleep, may reveal the rising levels that herald the onset of puberty. Stimulation testing with gonadotropin-releasing hormone analog may help to establish the diagnosis. Morbidity for both men and women with hypogonadism includes infertility and an increased risk of osteoporosis.

Visit Elsevier eBooks+ at eBooks.Health.Elsevier.com for Bibliography.

Chapter 627

Pseudoprecocity Resulting from Lesions of the Ovary

Alvina R. Kansra and Patricia A. Donohoue

Females with signs of early puberty may, in rare circumstances, have ovarian tumors or cysts that secrete estrogenic, androgenic, or both types of hormones. In these patients, the sex steroid production is not mediated by pituitary gonadotropin secretion; they produce pseudoprecocity.

Ovarian tumors are rare in the pediatric population, occurring at a rate of fewer than 3 in 100,000. Most ovarian masses are benign, but 10–30% may be malignant. If they occur before 8 years of age, they may cause signs of puberty. Ovarian malignancies, the most common genital neoplasms in adolescence, account for only 1% of childhood cancers. More than 60% are germ cell tumors, which are dysgerminomas that can secrete tumor markers and sex hormones (see Chapter 552). Five to 10% of germ cell tumors occur in phenotypic females, with abnormal gonads associated with the presence of a Y chromosome. The next most common are epithelial cell tumors (20%), and nearly 10% are sex cord/stromal tumors (granulosa, Sertoli cell, and mesenchymal tumors). Multiple tumor markers can be seen in ovarian tumors, including α-fetoprotein, human chorionic gonadotropin, carcinoembryonic antigen, oncoproteins, p105, p53, *KRAS* pathogenic variants, cyclin D_1, epidermal growth factor–related proteins and receptors, cathepsin B, and others. Variable levels of inhibin-activin subunit gene expression have been detected in ovarian tumors.

Functioning lesions of the ovary consist of benign cysts or malignant tumors. The majority synthesize estrogens; a few synthesize androgens. The most common estrogen-producing ovarian tumor causing precocious puberty is the granulosa cell tumor. Other tumors that can cause precocious puberty are thecomas, luteomas, mixed types, theca-lutein, follicular cysts, and other ovarian tumors (i.e., teratoma, choriocarcinoma, and dysgerminoma).

ESTROGENIC LESIONS OF THE OVARY

These lesions cause **isosexual** precocious sexual development but account for only a small percentage of all cases of precocity. Benign ovarian follicular cysts are the most common tumors associated with isosexual precocious puberty in females; they may rarely be gonadotropin dependent. Gonadotropin-independent follicular cysts that produce estrogen are often associated with **McCune-Albright syndrome**.

Juvenile Granulosa Cell Tumor

In childhood, the most common neoplasm of the ovary with estrogenic manifestations is the granulosa cell tumor, although it makes up only 1–10% of all ovarian tumors. These tumors have distinctive histologic features that differ from those encountered in older females (adult granulosa cell tumor). The cells have high mitotic activity, follicles are often irregular, Call-Exner bodies are rare, and luteinization is frequent. The tumor may be solid or cystic or both. It usually is benign. This tumor has been associated with multiple enchondromas **(Ollier disease)** and with multiple subcutaneous hemangiomas **(Maffucci syndrome)**.

Clinical Manifestations and Diagnosis

The juvenile granulosa cell tumor has been observed in newborns and may manifest with sexual precocity at 2 years of age or younger; about half these tumors occurred before 10 years of age. The mean age at diagnosis is 7.5 years. The tumors are almost always unilateral. The breasts become enlarged, rounded, and firm, and the nipples prominent. The external genitals resemble those of a normal girl at puberty, and the uterus is enlarged. A white vaginal discharge is followed by irregular or cyclic menstruation. However, ovulation does not occur. The presenting manifestation may be abdominal pain or swelling. Pubic hair is usually absent unless there is mild virilization.

A mass is readily palpable in the lower portion of the abdomen in most children by the time sexual precocity is evident. However, the tumor may be small and escape detection even on careful rectal and abdominal examination; ultrasonography may detect the tumors, but CT or MRI scans are most sensitive. Most tumors are diagnosed at very early stages of malignancy.

Plasma estradiol levels are markedly elevated. Plasma levels of gonadotropins are suppressed and do not respond to gonadotropin-releasing hormone analog stimulation. Levels of antimüllerian hormone, inhibin B, and α-fetoprotein may be elevated. Activating pathogenic variants of $G_S\alpha$ are seen in 30%, and GATA-4 expression is retained in the more aggressive tumors, whereas antimüllerian hormone levels are inversely proportional to tumor size. Bone age is moderately advanced. Several case reports showing the association of 45,X/46,XY karyotype and ambiguous genitalia with ovarian granulosa tumor have been published.

Treatment and Prognosis

The tumor should be removed as soon as the diagnosis is established. Prognosis is excellent because less than 5% of these tumors in children are malignant. However, advanced-stage tumors behave aggressively and require difficult decisions regarding surgical approaches and the use of irradiation and chemotherapy. In adults with granulosa cell tumors, p53 expression is associated with unfavorable prognosis. Vaginal bleeding immediately after removal of the tumor is common. Signs of precocious puberty abate and may disappear within a few months after the operation. The secretion of estrogens returns to normal.

Sex cord tumor with annular tubules is a distinctive tumor, thought to arise from granulosa cells, that occurs primarily in patients with **Peutz-Jeghers syndrome**. These tumors are multifocal, bilateral, and usually benign. The presence of calcifications aids ultrasonographic detection. Increased aromatase production by these tumors results in gonadotropin-independent precocious puberty. Inhibin A and B levels are elevated and decrease after tumor removal. In one study, 9 of 13 sex cord/stromal tumors exhibited follicle-stimulating hormone receptor pathogenic variants, suggesting a role for such mutation in the development of these tumors.

Chorioepithelioma has been reported only rarely. This highly malignant tumor is thought to arise from a preexisting teratoma. The usually unilateral tumor produces large amounts of human chorionic gonadotropin, which stimulates the contralateral ovary to secrete estrogen. Elevated levels of human chorionic gonadotropin are diagnostic.

Follicular Cyst

Small ovarian cysts (<0.7 cm in diameter) are common in prepubertal children. At puberty and in females with true isosexual precocious puberty, larger cysts (1-6 cm) are often seen; these are secondary to stimulation by gonadotropins. Similar larger cysts occur occasionally in young females with precocious puberty in the absence of luteinizing hormone and follicle-stimulating hormone. Surgical removal or spontaneous involution of these cysts results in regression of pubertal changes. The mechanism of production of these autonomously functioning cysts is unknown. Such cysts may form only once, or they may disappear and recur, resulting in waxing and waning of the signs of precocious puberty. They may be unilateral or bilateral. The sexual precocity that occurs in young females

with **McCune-Albright syndrome** is usually associated with autonomous follicular cysts caused by somatic-activating pathogenic variants of the $G_S\alpha$-protein occurring early in development (see Chapter 600.6). Gonadotropins are suppressed, and estradiol levels are often markedly elevated, but they may fluctuate widely and even temporarily may return to normal. Gonadotropin-releasing hormone analog stimulation fails to evoke an increase in gonadotropins. Ultrasonography is the method of choice for the detection and monitoring of such cysts. Aromatase inhibitors are shown to be the mainstay of therapy in females with McCune-Albright syndrome and persistent estradiol elevation. Estrogen receptor blockers have also been used. A short period of observation to ascertain the lack of spontaneous resolution is advisable before cyst aspiration or cystectomy is considered. Cystic neoplasms must be considered in the differential diagnosis.

ANDROGENIC LESIONS OF THE OVARY

Virilizing ovarian tumors are rare at all ages but particularly so in prepubertal females. **Arrhenoblastoma** has been reported as early as 14 days of age, but few cases have been reported in females younger than 16 years of age.

The **gonadoblastoma** occurs exclusively in dysgenetic gonads, particularly in phenotypic females who have a Y chromosome or a Y fragment in their genotype (46,XY; 45,X/46,XY; 45,X/46,X-fra). There is a gonadoblastoma locus on the Y chromosome (GBY). The tumors may be bilateral. Virilization occurs with some, but not all, tumors. The clinical features are the same as those seen in patients with virilizing adrenal tumors and include accelerated growth, acne, clitoral enlargement, and growth of sexual hair. A palpable, abdominal mass is found in about 50% of patients. Plasma levels of testosterone and androstenedione are elevated, and gonadotropins are suppressed. Ultrasonography, CT, and MRI usually localize the lesion. The dysgenetic gonad of phenotypic females with a Y chromosome or fragment of Y chromosome containing GBY should be removed prophylactically. *When a unilateral tumor is removed, the contralateral dysgenetic gonad should also be removed.* Association of gonadoblastoma and WAGR (Wilms tumor, aniridia, genitourinary anomalies, mental retardation) syndrome is also reported. In an immunohistochemical study of two gonadoblastomas, expressions of *WT1, p53,* and *MIS*, as well as inhibin, were all demonstrated.

Virilizing manifestations occur occasionally in females with **juvenile granulosa cell tumors**. Adrenal rests and hilum cell tumors rarely lead to virilization. Activating pathogenic variants of G protein genes have been described in ovarian (and testicular) tumors. $G_S\alpha$ variants, usually seen in gonadal tumors associated with **McCune-Albright syndrome**, were also noted in four of six Leydig cell tumors (three ovarian, one testicular). Two granulosa cell tumors and 1 thecoma of 10 ovarian tumors studied were found to have *GIP-2* variants.

Sertoli-Leydig cell tumors, rare sex cord/stromal neoplasms, constitute less than 1% of ovarian tumors. The average age at diagnosis is 25 years; less than 5% of these tumors occur before puberty. α-Fetoprotein levels may be mildly elevated. In one 12-month-old with Sertoli-Leydig cell tumor presenting with isosexual precocity, the only detectable tumor marker was the serum inhibin level, with elevations in both A and B subunits. Five-year survival rates are 70–90%.

Of 102 consecutive patients who underwent surgery because of ovarian masses over a 15-year period, the presenting symptoms were acute abdominal pain in 56% and abdominal or pelvic mass in 22%. Of nine children whose cause for surgery was presumed malignancy, three had dysgerminomas, two had teratomas, two had juvenile granulosa cell tumors, one had a Sertoli-Leydig cell tumor, and one had a yolk sac tumor.

Visit Elsevier eBooks+ at eBooks.Health.Elsevier.com for Bibliography.

Chapter 628

Disorders of Sex Development

Patricia A. Donohoue

SEX DIFFERENTIATION

See also Chapter 622.

Differentiation and development of the gonads and genitalia are largely complete in the first half of gestation. In normal differentiation, the final form of all sexual structures is consistent with normal sex chromosomes (either XX or XY). A 46,XX complement of chromosomes, as well a genetic factors such as DAX1 (dosage-sensitive/sex-reversal adrenal hypoplasia on the X chromosome), the signaling molecule WNT-4, and R-Spondin1, are among the many needed for the development of normal ovaries. Development of the male phenotype is potentially more complex. It requires a Y chromosome and, specifically, an intact *SRY* (sex-determining region on the Y chromosome) gene, which, in association with genes such as *SOX9, SF-1* (steroidogenic factor-1), *WT1* (Wilms tumor 1), and others (see Chapter 622), directs the undifferentiated gonad to become a testis. Aberrant recombinations may result in X chromosomes carrying *SRY,* resulting in XX males, or Y chromosomes that have lost *SRY,* resulting in XY females.

Antimüllerian hormone (AMH) causes the müllerian (paramesonephric) ducts to regress; in its absence, they persist as the uterus, fallopian tubes, cervix, and upper vagina. AMH activation in the testes probably requires the *SF-1* gene. By about 8 weeks of gestation, the Leydig cells of the testis begin to produce testosterone. During this critical period of male differentiation, testosterone secretion is stimulated by placental human chorionic gonadotropin (hCG), which peaks at 8-12 weeks. In the latter half of pregnancy, lower levels of testosterone are maintained by luteinizing hormone (LH) secreted by the fetal pituitary. Testosterone produced locally initiates development of the ipsilateral wolffian (mesonephric) duct into the epididymis, vas deferens, and seminal vesicle. Complete development of the external genitalia also requires dihydrotestosterone (DHT), the more active metabolite of testosterone. DHT is produced largely from circulating testosterone and is necessary to fuse the genital folds to form the penis and scrotum. DHT is produced from testosterone via the action of the enzyme 5α-reductase. DHT is also produced through an alternative biosynthetic pathway from androstanediol, and this pathway must be intact for normal and complete prenatal virilization to occur. Figure 628.1 illustrates the production of steroid hormones in various glands and the integrated pathways to the synthesis of DHT. A functional androgen receptor, produced by an X-linked gene, is required for testosterone and DHT to induce these androgen effects.

In the XX fetus with normal long and short arms of the X chromosome, the bipotential gonad develops into an ovary by about the 10th to 11th week. This occurs only in the absence of SRY, testosterone, and AMH and requires a normal gene in the dosage-sensitive/sex-reversal locus *DAX1,* the WNT-4 molecule, and R-Spondin1. A female external phenotype develops in the absence of fetal gonads. However, the male phenotype development requires androgen production and action. Estrogen is unnecessary for normal prenatal sexual differentiation, as demonstrated by 46,XX patients with aromatase deficiency.

Chromosomal aberrations may result in ambiguity of the external genitalia. Conditions of aberrant sex differentiation may also occur with the XX or XY genotype. The appropriate term for what was previously called *intersex* is **disorders of sex development (DSD)**. This term defines a condition "in which development of chromosomal, gonadal, or anatomic sex is atypical." It is increasingly preferable to use the term *atypical genitalia* rather than *ambiguous genitalia.* Tables 628.1 and 628.2 compare previous

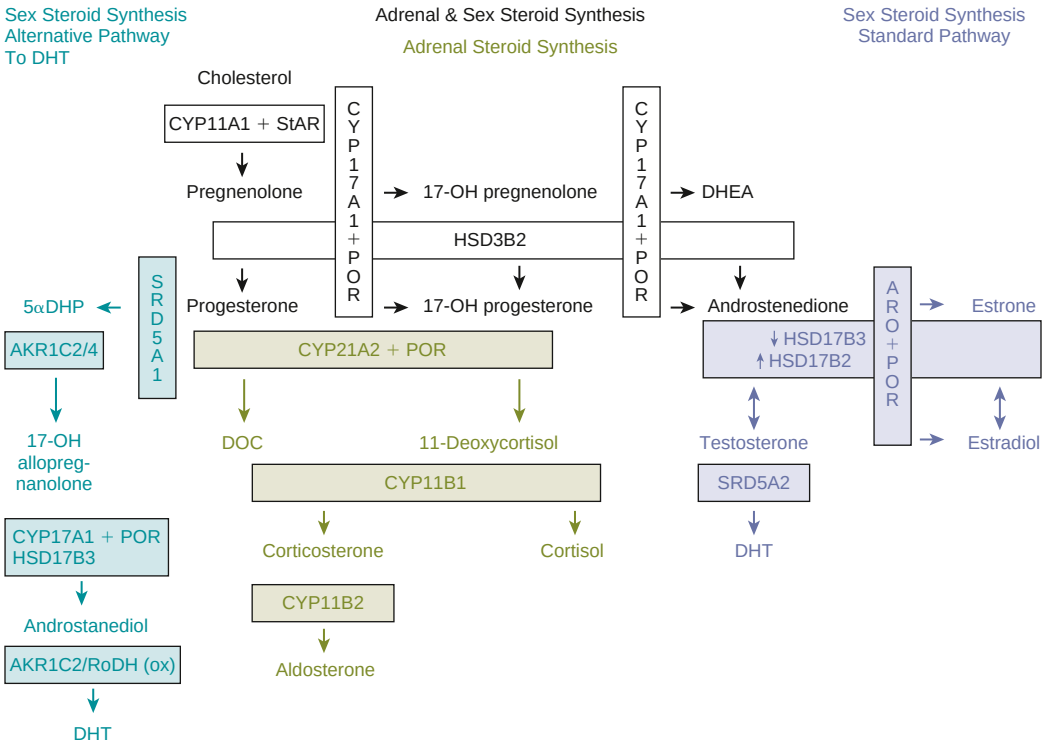

Fig. 628.1 Steroidogenic pathways enzyme names and activities. CYP11A1: cholesterol side-chain cleavage. Enzyme activities include 20-hydroxylase, 22-hydroxylase, and 20,22-lyase. CYP17A1: activities include 17α-hydroxylase and 17,20-lyase. 3βHSD2 (HSD3B2): activities include 3β-hydroxysteroid dehydrogenase (type 2) and D5D4-isomerase. CYP21A2: activity is 21-hydroxylase. CYP11B1: activity is 11β-hydroxylase. CYP11B2: activities include 18-hydroxylase (CMOI) and 18-dehydrogenase (CMOII). SRD5A1: activity is 5α-reductase type 1. SRD5A2: activity is 5α-reductase type 2. HSD17B2: activity is 17β-hydroxysteroid dehydrogenase type 2. HSD17B3: activity is 17β-hydroxysteroid dehydrogenase type 3. AKR1C2/4: activities are 3α-reductase types 1 and 3. AKR1C2/RoDH (ox): activities are 3α-reductase and 3-hydroxyepimerase. ARO, aromatase; CMOI, corticosterone methyl oxidase type 1; CMOII, corticosterone methyl oxidase type 2; DHEA, dehydroepiandrosterone; DHT, dihydrotestosterone; 5αDH*P*, 5α dihydroprogesterone. *(Adapted from Kim MS, Donohoue PA. Adrenal disorders. In Kappy MS, Allen DB, Geffner ME, eds. Pediatric Practice Endocrinology, 2nd ed. New York: McGraw Hill, 2014; and Flück CE, Meyer-Böni M, Pandey AV, et al. Why boys will be boys: two pathways of fetal testicular androgen biosynthesis are needed for male sexual differentiation. Am J Hum Genet. 2011;89:201–218.)*

Table 628.1 Revised Nomenclature

PREVIOUS	CURRENTLY ACCEPTED
Intersex	Disorders of sex development (DSDs)
Male pseudohermaphrodite	46,XY DSD
Undervirilization of an XY male	46,XY DSD
Undermasculinization of an XY male	46,XY DSD
46,XY intersex	46,XY DSD
Female pseudohermaphrodite	46,XX DSD
Overvirilization of an XX female	46,XX DSD
Masculinization of an XX female	46,XX DSD
46,XX intersex	46,XX DSD
True hermaphrodite	Ovotesticular DSD
Gonadal intersex	Ovotesticular DSD
XX male or XX sex reversal	46,XX testicular DSD
XY sex reversal	46,XY complete gonadal dysgenesis

From Lee PA, Houk CP, Ahmed SF, et al. Consensus statement on management of intersex disorders. *Pediatrics*. 2006;118:e488–e500. Table 1.

terms with their revised etiologic classification nomenclature. Table 622.1 in Chapter 622 lists some of the many genes that may be abnormal in various forms of DSD. Gender fluidity (nonconformity) has become a socially and, in New York State, legally accepted concept and is often expressed by self-identified people as intersex. New York State has an intersex category on its birth certificate. Partial androgen insensitivity, 5α-reductase deficiency, and mixed gonadal dysgenesis are often associated with gender dissatisfaction, and an intersex designation may help with future self-identification once the child is mature.

The definition of atypical or ambiguous genitalia, in a broad sense, is any case in which the external genitalia do not appear completely male or completely female. Although there are standards for genital size dimensions, variations in size of these structures do not always constitute ambiguity.

Development of the external genitalia begins with the potential to be either male or female (Fig. 628.2). Virilization of a female, the most common form of DSD, results in varying phenotypes (Fig. 628.3) that develop from the basic bipotential genital appearances of the embryo (see Fig. 628.2).

DIAGNOSTIC APPROACH TO THE PATIENT WITH ATYPICAL OR AMBIGUOUS GENITALIA

The appearance of the external genitalia is rarely diagnostic of a particular disorder and thus does not often allow distinction among the various forms of DSD. The most common forms of 46,XX DSD are *virilizing forms of congenital adrenal hyperplasia*. It is important to note that in 46,XY DSD, the specific diagnosis is not found in up to 50% of cases; partial androgen insensitivity syndrome (PAIS) and

Table 628.2 Etiologic Classification of Disorders of Sex Development

46,XX DSD
Androgen Exposure
Fetal/fetoplacental source
21-Hydroxylase (P450c21 or CYP21) deficiency
11β-Hydroxylase (P450c11 or CYP11B1) deficiency
3β-Hydroxysteroid dehydrogenase II (3β-HSD II) deficiency
Cytochrome P450 oxidoreductase (POR deficiency)
Aromatase (P450arom or CYP19) deficiency
Glucocorticoid receptor gene pathogenic variant
Maternal source
Virilizing ovarian tumor
Virilizing adrenal tumor
Androgenic drugs
Disorder of Ovarian Development
XX gonadal dysgenesis
Testicular DSD (SRY+, SOX9 duplication)
Undetermined Origin
Associated with genitourinary and gastrointestinal tract defects
46,XY DSD
Defects in Testicular Development
Denys-Drash syndrome (pathogenic variant in *WT1*)
WAGR syndrome (Wilms tumor, aniridia, genitourinary malformation, retardation)
Deletion of 11p13
Campomelic syndrome (autosomal gene at 17q24.3-q25.1) and SOX9 pathogenic variant
XY pure gonadal dysgenesis (Swyer syndrome)
Pathogenic variant in SRY
XY gonadal agenesis
Unknown cause
Deficiency of Testicular Hormones
Leydig cell aplasia
Pathogenic variant in LH receptor
Lipoid adrenal hyperplasia (P450scc or CYP11A1) deficiency; pathogenic variant in StAR (steroidogenic acute regulatory protein)
3β-HSD II deficiency
17-Hydroxylase/17,20-lyase (P450c17 or CYP17) deficiency
Persistent müllerian duct syndrome because of antimüllerian hormone gene variants or receptor defects for antimüllerian hormone
Defect in Androgen Action
Dihydrotestosterone deficiency because of 5α-reductase II pathogenic variants or AKR1C2/AKR1C4 variants
Androgen receptor defects:
Complete androgen insensitivity syndrome
Partial androgen insensitivity syndrome (Reifenstein and other syndromes)
Smith-Lemli-Opitz syndrome (defect in conversion of 7-dehydrocholesterol to cholesterol, DHCR7)
OVOTESTICULAR DSD
XX
XY
XX/XY chimeras
SEX CHROMOSOME DSD
45,X (Turner syndrome and variants)
47,XXY (Klinefelter syndrome and variants)
45,X/46,XY (mixed gonadal dysgenesis, sometimes a cause of ovotesticular DSD)
46,XX/46,XY (chimeric, sometimes a cause of ovotesticular DSD)

DSD, Disorders of sex development.
Data from Lee PA, Houk CP, Ahmed SF, et al. Consensus statement on management of intersex disorders. *Pediatrics*. 2006;118:e488–e500.

pure gonadal dysgenesis are common identifiable etiologies in XY DSD. At one center with a large experience, the etiologies of DSD in 250 patients older than 25 years were compiled. The six most common diagnoses accounted for 50% of the cases. These included virilizing congenital adrenal hyperplasia (14%), androgen insensitivity syndrome (AIS; 10%), mixed gonadal dysgenesis (8%), clitoral/labial anomalies (7%), hypogonadotropic hypogonadism (6%), and 46,XY small-for-gestational-age males with hypospadias (6%). Potential diagnostic clues are noted in Tables 628.3 and 628.4.

The potential of not finding a diagnosis in patients with DSD and the resulting lack of specific management emphasizes the need for thorough diagnostic evaluations. These include biochemical characterization of possible steroidogenic enzymatic defects in each patient with genital ambiguity. The parents need counseling about the potentially complex nature of the baby's condition and guidance as to how to deal with their well-meaning but curious friends and family members. The evaluation and management should be carried out by a multidisciplinary team of experts that includes pediatric endocrinology, pediatric surgery/urology, pediatric radiology, newborn medicine, genetics, and psychology. Once the sex of rearing has been agreed on by the family and team, treatment can be organized. Genetic counseling should be offered when the specific diagnosis is established.

After a complete history and physical exam, the common diagnostic approach includes multiple steps, described in the following outline. These steps are usually performed simultaneously rather than waiting for results of one test before performing another, because of the sensitive and sometimes urgent nature of the condition. Careful attention to the presence of physical features other than the genitalia is crucial to determine if a diagnosis of a particular multisystem syndrome is possible (see Chapters 628.1, 628.2, and 628.3). Table 628.5 summarizes many of the features of commonly encountered causes of DSD. Exome sequencing or molecular testing using specific DSD DNA panels are quite useful in the diagnostic evaluation, especially in 46,XY DSD, and may become first-line diagnostic tests.

Diagnostic tests include the following:

1. Blood karyotype, with rapid determination of sex chromosomes (in many centers this is available within 24-48 hours)
2. Other blood tests
   a. Screen for congenital adrenal hyperplasia: cortisol biosynthetic precursors and adrenal androgens (particularly 17-hydroxyprogesterone and androstenedione for 21-hydroxylase deficiency, the most common form). In the United States, all 50 states have a newborn screen for 21-hydroxylase deficiency.
   b. Screen for androgen biosynthetic defects with serum levels of androgens and their precursors.
   c. Assess for gonadal response to gonadotropin stimulation to screen for the presence and function of testicular gonadal tissue: obtain serum levels of testosterone and DHT before and after IM injections of hCG.
   d. Molecular genetic analyses for SRY, other Y-specific loci, and when needed, other single-gene defects associated with DSD.
   e. Gonadotropin (LH and follicle-stimulating hormone [FSH]) levels.
3. The internal anatomy of patients with ambiguous genitalia can be defined with one or more of the following studies:
   a. Voiding cystourethrogram
   b. Endoscopic examination of the genitourinary tract
   c. Pelvic ultrasound; renal and adrenal ultrasound
   d. Pelvic MRI
   e. Exploratory laparoscopy to locate and characterize/biopsy the gonads

Visit Elsevier eBooks+ at eBooks.Health.Elsevier.com for Bibliography.

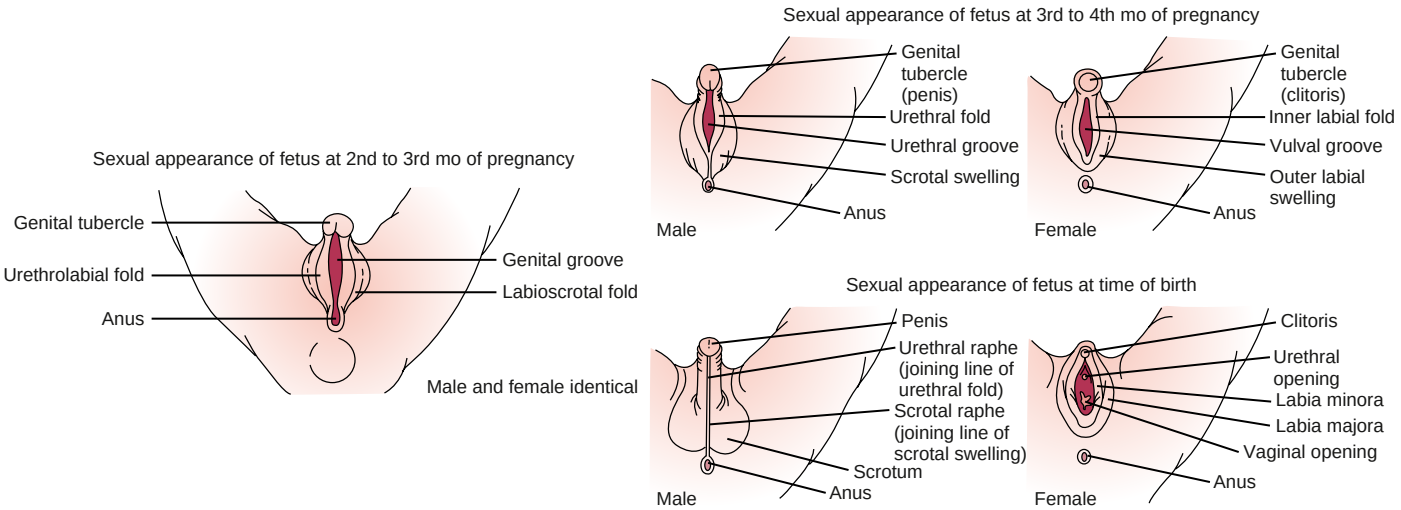

Fig. 628.2 Schematic demonstration of differentiation of normal male and female genitalia during embryogenesis. *(From Zitelli BJ, Davis HW. Atlas of Pediatric Physical Diagnosis, 4th ed. St. Louis: Mosby, 2002: p. 328.)*

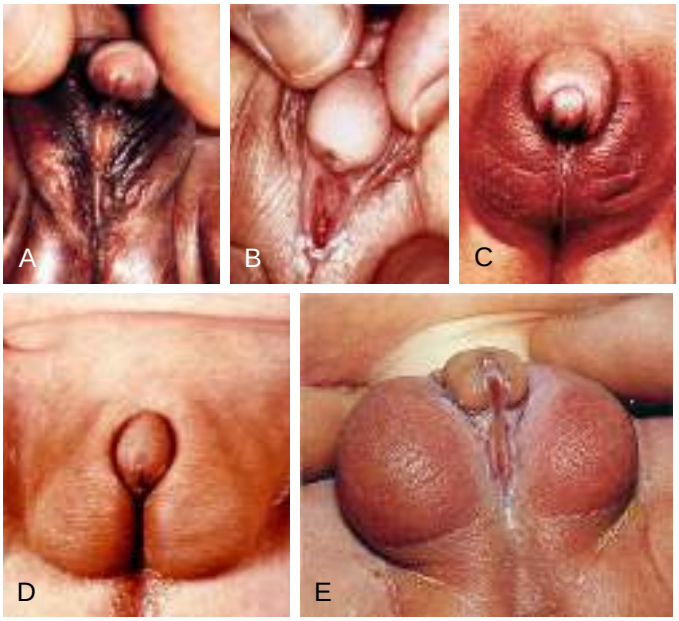

Fig. 628.3 Examples of atypical genitalia. These cases include ovotesticular disorder of sexual development (**A**) and congenital virilizing adrenal hyperplasia (**B-E**). (**B-D**, *Courtesy D. Becker, MD, Pittsburgh. From Zitelli BJ, Davis HW. Atlas of Pediatric Physical Diagnosis, 4th ed. St. Louis: Mosby, 2002: p. 329.)*

628.1 46,XX DSD

Patricia A. Donohoue

The genotype is XX and the gonads are ovaries, but the external genitalia are virilized. There is no significant prenatal AMH production because the gonads are ovaries. Thus the uterus, fallopian tubes, and cervix develop. The varieties and causes of this condition are relatively few. Most instances result from exposure of the female fetus to excessive *exogenous* or *endogenous* androgens during intrauterine life. The changes consist principally of virilization of the external genitalia (clitoral hypertrophy and labioscrotal fusion).

CONGENITAL ADRENAL HYPERPLASIA

See Chapter 616.1.

Table 628.3 Associations of Genital Abnormalities

ABNORMAL CHARACTERISTICS	EXAMPLES OF ASSOCIATED DISORDERS
MALE-APPEARING GENITALIA	
Micropenis	Growth hormone or luteinizing hormone deficiency Testosterone deficiency (in second and third trimesters) Partial androgen insensitivity Syndrome: idiopathic
Hypospadias (more severe)	Disorders of gonadal development 46,XX DSD Ovotesticular DSD 46,XX or 46,XY DSD Syndrome: idiopathic
Impalpable gonads	Anorchia Persistent müllerian duct syndrome 46,XX DSD with 21- or 11β-hydroxylase deficiency Cryptorchidism
Small gonads	47,XXY, 46,XX DSD Dysgenetic or rudimentary testes
Inguinal mass (uterus or tube)	Persistent müllerian duct syndrome, dysgenetic testes
FEMALE-APPEARING GENITALIA	
Clitoromegaly	XX with 21- or 11β-hydroxylase or 3β-hydroxy dehydrogenase deficiency Other 46,XX DSD Gonadal dysgenesis, dysgenetic testes, ovotesticular DSD 46,XY DSD Tumor infiltration of clitoris Syndrome: idiopathic
Posterior labial fusion	As for clitoromegaly
Palpable gonad(s)	Gonadal dysgenesis, dysgenetic testes, ovotesticular DSD 46,XY DSD
Inguinal hernia or mass	As for palpable gonad(s)

DSD, Disorders of sex development.
From Al Remeithi S, Wherrett DK. Disorders of sex development. In: Martin RJ, Fanaroff AA, Walsh MC, eds. *Fanaroff and Martin's Neonatal-Perinatal Medicine*, 10th ed. Philadelphia: Elsevier; 2015: Table 98.3.

Table 628.4 Key Points in Evaluation of Infants with Disorders of Sexual Development

Identification of syndromic features in physical exam	• Craniosynostosis and other synostosis in POR deficiency • Cleft palate and second to third toe syndactyly in Smith-Lemli-Opitz (SLO) syndrome • Pierre Robin sequence or campomelia for *SOX9* pathogenic variants • Kidney abnormalities or dysfunction in *WTI* or *WNT4* pathogenic variants • Cardiac abnormalities in Turner syndrome, mixed gonadal dysgenesis or *GATA4* pathogenic variants • Adrenal insufficiency in cases of *SLO*, *NR5A1 (SF-1)* pathogenic variants • POR deficiency or congenital adrenal hyperplasia or hypoplasia forms • Polyneuropathy in *DHH* pathogenic variants • Chondrodysplasia in *HHAT* pathogenic variants • Blepharophimosis/ptosis in *FOXL2* pathogenic variants
Evaluation of internal genitalia to conclude about exposure to AMH using pelvic ultrasound or MRI	*Normal Uterus In:* 46,XY complete gonadal dysgenesis (CGD) 46,XX CGD 46,XX with androgen exposure (i.e., virilizing forms of CAH) Turner syndrome *Abnormal Uterus In:* 46,XY PGD (partial gonadal dysgenesis) Mixed gonadal dysgenesis *Absent Uterus In:* 46,XY DSD with androgen synthesis defects and androgen action defects 46,XX testicular DSD

POR, P450 oxidoreductase; AMH, anti-Mullerian hormone; CAH, congenital adrenal hyperplasia.
Modified from Rodriguez-Buritica D. Overview of genetics of disorders of sexual development. Curr Opin Pediatr. 2015;27:675–684. Table 1.

This is the most common cause of atypical genitalia and of 46,XX DSD. Females with the 21-hydroxylase and 11-hydroxylase defects are the most highly virilized, although minimal virilization also occurs with the type II 3β-hydroxysteroid dehydrogenase defect (see Fig. 628.3). Female patients with salt-losing congenital adrenal hyperplasia (CAH) caused by 21-hydroxylase deficiency tend to have more virilization than do patients with the non–salt-losing form. Masculinization may be so complete that a penile urethra results, and the patient may appear to be a male with bilateral cryptorchidism.

AROMATASE DEFICIENCY

In 46,XX females, the rare condition of aromatase deficiency during fetal life leads to 46,XX DSD and results in hypergonadotropic hypogonadism at puberty because of ovarian failure to synthesize estrogen.

Examples of this condition include two 46,XX infants who had enlargement of the clitoris and posterior labial fusion at birth. In one instance, maternal serum and urinary levels of estrogen were very low and serum levels of androgens were high. Cord serum levels of estrogen were also extremely low, and levels of androgen were elevated. The second patient also had virilization of unknown cause since birth, but the aromatase deficiency was not diagnosed until 14 years of age, when she had further virilization and failed to go into puberty. At that time, she had elevated levels of gonadotropins and androgens but low estrogen levels, and ultrasonography revealed large ovarian cysts bilaterally. These patients demonstrate the important role of aromatase in the conversion of androgens to estrogens. Additional female and male patients with aromatase deficiency as a consequence of pathogenic variants in the *aromatase gene (CYP19)* are known. Two siblings with this gene defect were described, both of whom had tall stature because of a lack of estrogen-mediated epiphyseal fusion. The 28-year-old XX proband was 177.6 cm tall (+2.5 SD) after having received hormonal replacement therapy. Her 24-year-old brother was 204 cm tall (+3.7 SD) and had a bone age of 14 years. Low-dose estradiol replacement, carefully adjusted to maintain normal age-appropriate levels, may be indicated for affected females, even prepubertally.

CORTISOL RESISTANCE CAUSED BY A GLUCOCORTICOID RECEPTOR GENE PATHOGENIC VARIANT

A 9-year-old female with 46,XX DSD, thought to be caused by 21-hydroxylase deficiency (CAH) since the age of 5 years, had elevated cortisol levels both at baseline and after dexamethasone, hypertension, and hypokalemia, suggestive of the diagnosis of generalized glucocorticoid resistance. A novel homozygous variant in exon 5 of the glucocorticoid receptor was demonstrated. In this Brazilian family, the condition was autosomal recessive. Virilization occurs because of excess adrenocorticotropic hormone (ACTH) stimulation of adrenal steroid production because the glucocorticoid receptor defect is also present in the pituitary gland, which senses inadequate cortisol effect to provide negative feedback.

P450 Oxidoreductase Deficiency

Cytochrome P450 oxidoreductase (POR), encoded by a gene on 7q11.2, is a cofactor required for normal enzymatic activity of the microsomal 21- and 17-hydroxylases. POR deficiency thus causes partial combined P450C17 and P450C21 steroidogenic defects. Females are born with ambiguous genitalia, but as opposed to classic CAH, the virilization does not progress postnatally and androgen levels are normal or low. Males may be born undervirilized. Both may exhibit bony abnormalities seen in **Antley-Bixler syndrome**. Conversely, in a series of Antley-Bixler syndrome patients, those with ambiguous genitalia and disordered steroidogenesis had cytochrome POR deficiency. Those without genital ambiguity with normal steroidogenesis had *FGFR2* pathogenic variants. The cardinal features of Antley-Bixler syndrome include craniosynostosis, severe midface hypoplasia, proptosis, choanal atresia/stenosis, frontal bossing, dysplastic ears, depressed nasal bridge, radiohumeral synostosis, long bone fractures and femoral bowing, and urogenital abnormalities.

VIRILIZING MATERNAL TUMORS

Rarely, the female fetus has been virilized by a *maternal* androgen-producing tumor. In a few cases, the lesion was a benign adrenal adenoma, but all others were ovarian tumors, particularly androblastomas, luteomas, and Krukenberg tumors (Table 628.6). **Maternal virilization** may be manifested by enlargement of her clitoris, acne, deepening of the voice, decreased lactation, hirsutism, and elevated levels of androgens. In the infant, there is enlargement of the clitoris of varying degrees, often with labial fusion. Mothers of children with unexplained 46,XX DSDs should undergo physical examination and measurements of their own levels of plasma testosterone, dehydroepiandrosterone (DHEA) sulfate, and androstenedione.

EXPOSURE TO ANDROGENIC DRUGS BY WOMEN DURING PREGNANCY

Testosterone and 17-methyltestosterone have been reported to cause 46,XX DSDs in some instances (see Table 628.6). The greatest number of cases has resulted from the use of certain progestational compounds

Table 628.5 Atypical Genitalia: Steps in Establishing the Diagnosis

	21-OH DEFICIENCY	GONADAL DYSGENESIS WITH Y CHROMOSOME	OVOTESTICULAR DSD	PARTIAL ANDROGEN INSENSITIVITY	BLOCK IN TESTOSTERONE SYNTHESIS
CLINICAL FEATURE					
Palpable gonad(s)	–	±	±	+	+
Uterus present*	+	+	Usually	–	–
Increased skin pigmentation	±	–	–	–	–
Sick baby	±	–	–	–	±
Dysmorphic features	–	±	–	–	–
DIAGNOSTIC CONSIDERATIONS					
Serum 17-OHP	Elevated	Normal	Normal	Normal	Normal
Electrolytes	Possibly abnormal	Normal	Normal	Normal	Possibly abnormal
Karyotype	46,XX	45,X/46,XY or others	46,XX most common	46,XY	46,XY
Testosterone response to hCG	NA	Positive	Normal or reduced	Positive response	Reduced or absent
Gonadal biopsy	NA	Dysgenetic gonad	Ovotestis	Normal testis with ± Leydig cell hyperplasia	Normal testis
Other testing				Genital skin fibroblast culture AR assay, OR blood DNA screening for AR gene variants	Measure testosterone precursors

*As determined by ultrasound, MRI, or rectal examination.
AR, Androgen receptor; DSD, disorder of sex development; hCG, human chorionic gonadotropin; 21-OH, 21-hydroxylase; 17-OHP, 17-hydroxyprogesterone; NA, not applicable.
Adapted from Donohoue PA, Saenger PH. Ambiguous genitalia. In Finberg L, Kleinman RE, eds. Saunders Manual of Pediatric Practice, Philadelphia: WB Saunders, 2002: p. 874.

Table 628.6 Sources of Maternal-Derived Androgens

ENDOGENOUS
Benign
Luteoma of pregnancy
Adrenal adenoma
Hyperreactio luteinalis
Thecoma/fibroma
Stromal hyperthecosis
Brenner tumor
Serous cystadenoma
Mature cystic teratoma (dermoid cyst)
Malignant
Metastatic carcinomas (Krukenberg tumor)
Sex-cord stromal tumors—granulosa cell and Sertoli-Leydig tumors
Adrenal cortical carcinoma
Cystadenocarcinoma
Hilar cell tumor
EXOGENOUS
Synthetic Androgens
Danazol
Progestins (medroxyprogesterone acetate)
Potassium-sparing diuretics

From Auchus RJ, Chang AY. 46,XX DSD: the masculinised female. *Best Pract Res Clin Endocrinol Metab*. 2010;24:219–242. Table 2.

for the treatment of threatened abortion. These progestins have since been replaced by nonvirilizing ones.

Infants with virilization and 46,XX chromosomes and caudal anomalies have been reported for whom no virilizing agent could be identified. In such instances, the disorder is usually associated with other congenital defects, particularly of the urinary and gastrointestinal tracts. Y-specific DNA sequences, including *SRY*, are absent. In one case, a scrotal raphe and elevated testosterone levels were found, but the cause remains unknown.

SF-1 Pathogenic Variants

In a worldwide study of patients with **46,XX ovotesticular DSD**, a specific variant in *SF-1* was identified: p.Arg92Trp. Functional studies showed that the variant probably interfered with inhibition of testicular development. In one family with a maternally transmitted variant, the mother had early menopause. Multiple other *SF-1* variants have been reported to cause isolated ovarian insufficiency, some associated with 46,XY DSDs in their offspring.

46,XX Testicular DSD

In this condition, also known as **XX male**, the gonads are testicular and virilization is typically incomplete. Infertility and/or gonadal failure may develop after childhood. Many cases are caused by translocation of *SRY* sequences onto one of the X chromosomes, often paired with duplication of *SOX-9*. The appropriate sex of rearing may be difficult to determine.

46,XX Gonadal Dysgenesis

These females typically present at puberty with normal female genitalia and lack of breast development and hypergonadotropic hypogonadism. Normal müllerian structures are present, but ovaries are absent or streaked.

Undetermined/Unknown

Rarely, 46,XX DSDs can be associated with other congenital anomalies, especially those of the GU or GI tract, and are thus multifactorial in

origin. These include cloacal exstrophy and **MURCS association** (müllerian hypoplasia, renal agenesis, and cervicothoracic somite abnormalities). Isolated deficiency of müllerian development is known as **Meyer-Rokitansky-Küster-Hauser syndrome**.

Visit Elsevier eBooks+ at eBooks.Health.Elsevier.com for Bibliography.

628.2 46,XY DSD

Patricia A. Donohoue

In this condition the genotype is XY but the external genitalia are either not completely virilized, are ambiguous (atypical), or are completely female. When gonads can be found, they typically contain *testicular* elements; their development ranges from rudimentary to normal. Because the process of normal virilization in the fetus is so complex, it is not surprising that there are many varieties and causes of 46,XY DSD. The etiology is not identified in up to 50% of cases.

DEFECTS IN TESTICULAR DIFFERENTIATION

The first step in male differentiation is conversion of the bipotential gonad into a testis. In the XY fetus, if there is a deletion of the short arm of the Y chromosome or of the *SRY* gene, male differentiation does not occur. The phenotype is female; müllerian (paramesonephric) ducts are well developed because of the absence of AMH, and gonads consist of undifferentiated streaks. By contrast, even extreme deletions of the long arm of the Y chromosome (Yq−) have been found in normally developed males, most of whom are azoospermic and have short stature. This indicates that the long arm of the Y chromosome normally has genes that prevent these manifestations. In many syndromes in which the testes fail to differentiate, Y chromosomes are morphologically normal on karyotyping.

Wilms Tumor-Suppressor Gene Pathogenic Variants: Denys-Drash, Frasier, and WAGR Syndromes

Denys-Drash syndrome: The constellation of nephropathy with atypical (ambiguous) genitalia and bilateral Wilms tumor is the major phenotype of this syndrome. Most reported cases have been 46,XY. Müllerian ducts are often present, indicating a global deficiency of fetal testicular function. Patients with a 46,XX karyotype have normal external genitalia. The onset of proteinuria in infancy progresses to nephrotic syndrome and end-stage renal failure by 3 years of age, with focal or diffuse mesangial sclerosis being the most consistent histopathologic finding. Wilms tumor usually develops in children younger than 2 years of age and is frequently bilateral. Gonadoblastomas have also been reported.

Several pathogenic variants in *WT1,* located on chromosome 11p13, have been found. *WT1* functions as a tumor suppressor gene and a transcription factor and is expressed in the genital ridge and fetal gonads. Nearly all reported variants are near or within the zinc finger–coding region. One report found a zinc finger domain variant in the *WT1* alleles of a patient with no GU abnormalities, suggesting that some cases of sporadic Wilms tumor may carry the *WT1* pathogenic variant.

Frasier syndrome: Different pathogenic variants in *WT1,* constitutional heterozygote variants at intron 9, have been described in Frasier syndrome, a condition of nonspecific focal and segmental glomerulosclerosis, 46,XY gonadal dysgenesis, and frequent gonadoblastoma, but *without* Wilms tumor.

WAGR syndrome: This acronym refers to a contiguous gene syndrome consisting of Wilms tumor, aniridia, GU malformations, and retardation (WAGR). These children have a deletion of one copy of chromosome 11p13, which may be visible on karyotype analysis. The deleted region encompasses the aniridia gene *(PAX6)* and the Wilms tumor suppressor gene *(WT1).* Only the 46,XY patients have genital abnormalities, ranging from cryptorchidism to severe deficiency of virilization. Gonadoblastomas have developed in the dysgenetic gonads. Wilms tumor usually occurs by 2 years of age. Some cases also had unexplained obesity, raising the question of an obesity-associated gene in this region of chromosome 11 and naming the syndrome *WAGRO.*

Campomelic Syndrome

See Chapter 735.

This form of **short-limbed skeletal dysplasia** is characterized by anterior bowing of the femur and tibia, small, bladeless scapulae, small thoracic cavities, and 11 pairs of ribs, along with malformations of other organs. It is usually lethal in early infancy. Approximately 75% of reported 46,XY patients exhibit a completely **female phenotype**; the external and internal genitalia are female. Some 46,XY patients have ambiguous genitalia. The gonads appear to be ovaries but histologically may contain elements of both ovaries and testes.

The gene responsible for the condition is *SOX9* and is on 17q24-q25. This gene is structurally related to *SRY* and directly regulates development of the type II collagen gene *(COL2A1)*. The same variants may result in different gonadal phenotypes. Gonadoblastoma was reported in a patient with this condition. The inheritance is autosomal dominant.

SF-1 (Also Known as *Ad4BP* and *NR5A1*) Defects and 46,XY DSD

Adrenal insufficiency and 46,XY gonadal dysgenesis have been described in patients with pathogenic variants in *SF-1*. In some of these patients, if the mother shares the *SF-1* variant, she has premature ovarian insufficiency. *SF-1*–related 46,XY DSD may also occur in the absence of adrenal insufficiency and may resemble PAIS.

46,XY sex reversal has also been described in patients with deletions of parts of autosomal loci on chromosomes 2q, 9p, and 10q.

XY Pure Gonadal Dysgenesis (Swyer Syndrome)

The designation *pure* distinguishes this condition from forms of gonadal dysgenesis that are of chromosomal origin and associated with somatic anomalies. Affected patients have normal stature and a female phenotype, including vagina, uterus, and fallopian tubes, but at pubertal age, breast development and menarche fail to occur. None of the other phenotypic features associated with 45,X (Turner syndrome) are present. Patients present at puberty with hypergonadotropic primary amenorrhea. Familial cases suggest an X-linked or a sex-limited dominant autosomal transmission. Most of the patients examined have had pathogenic variants in *SRY*. The gonads consist of almost totally undifferentiated streaks despite the presence of a cytogenetically normal Y chromosome. The primitive gonad cannot accomplish any testicular function, including suppression of müllerian (paramesonephric) ducts. There may be hilar cells in the gonad capable of producing some androgens; accordingly, some virilization, such as clitoral enlargement, may occur at the age of puberty. The streak gonads may undergo neoplastic changes, such as gonadoblastomas and dysgerminomas, and should be removed as soon as the diagnosis is established, regardless of the age of the patient.

Pure gonadal dysgenesis also occurs in XX individuals.

XY Gonadal Agenesis Syndrome (Embryonic Testicular Regression Syndrome)

In this rare syndrome, the external genitalia are slightly ambiguous but more nearly female. Hypoplasia of the labia; some degree of labioscrotal fusion; a small, clitoris-like phallus; and a perineal urethral opening are present. No uterus, no gonadal tissue, and usually no vagina can be found. At the age of puberty, no sexual development occurs and gonadotropin levels are elevated. Most children have been reared as females. In several patients with XY gonadal agenesis in whom no gonads could be found on exploration, significant rises in testosterone followed stimulation with hCG, indicating

Leydig cell function somewhere. Siblings with the disorder are known.

It is presumed that testicular tissue was active long enough during fetal life for AMH to inhibit development of müllerian ducts but not long enough for testosterone production to result in virilization. In one patient, no deletion of the Y chromosome was found by means of Y-specific DNA probes. Testicular degeneration seems to occur between the 8th and 12th fetal week. Regression of the testis before the 8th week of gestation results in Swyer syndrome; between the 14th and 20th weeks of gestation, it results in the rudimentary testis syndrome; and after the 20th week, it results in anorchia.

In **bilateral anorchia**, sometimes referred to as *vanishing testes syndrome,* testes are absent, but the male phenotype is complete; it is presumed that tissue with fetal testicular function was active during the critical period of genital differentiation but that sometime later it was damaged. Bilateral anorchia in identical twins and unilateral anorchia in identical twins and in siblings suggest a genetic predisposition. Coexistence of anorchia and gonadal agenesis syndrome in a sibship is evidence for a relationship between the disorders. A retrospective review of urologic explorations revealed absent testes in 21% of 691 testes. Of those, 73% had blind-ending cord structures with the suggested site of the vanishing testes being the inguinal canal (59%), abdomen (21%), superficial inguinal ring (18%), and scrotum (2%). It was suggested that the presence of cord structures on laparoscopy should prompt inguinal exploration because viable testicular tissue was found in four of these children.

DEFICIENCY OF TESTICULAR HORMONE PRODUCTION

Several genetic defects have been delineated in the enzymatic synthesis of testosterone by the fetal testis, and a defect in Leydig cell differentiation has been described. These defects produce 46,XY males with inadequate masculinization. Because levels of testosterone are normally low before puberty, an hCG stimulation test may be needed in children to assess the ability of the testes to synthesize testosterone.

Leydig Cell Aplasia

Patients with aplasia or hypoplasia of the Leydig cells usually have female phenotypes, but there may be mild virilization. Testes, epididymis, and vas deferens are present; the uterus and fallopian tubes are absent because of normal production of AMH. There is no breast development at puberty, but pubic hair development may be normal because of the production of adrenal androgens. Plasma levels of testosterone are low and do not respond to hCG; LH levels are elevated. The Leydig cells of the testes are absent or markedly deficient. The defect may involve a lack of functional receptors for LH. In children, hCG stimulation is necessary to differentiate the condition from the AISs. There is male-limited autosomal recessive inheritance. The human LH/chorionic gonadotropin (CG) receptor is a member of the G-protein–coupled superfamily of receptors that contains seven transmembrane domains. Several inactivating pathogenic variants of the LH/CG receptor have been described in males with hypogonadism suspected of having Leydig cell hypoplasia or aplasia.

High serum LH and low FSH were noted in one male with hypogonadism owing to a pathogenic variant in the gene for the β-subunit of FSH (see Table 622.1).

Lipoid Adrenal Hyperplasia

See Chapter 616.

This is the most severe form of CAH; enlarged adrenal glands result from accumulation of cholesterol and cholesterol esters. The rate-limiting process in steroidogenesis is the transport of free cholesterol through the cytosol to the inner mitochondrial membrane, where the P450 side-chain cleavage enzyme (P450scc; CYP11A1) acts. Cholesterol transport into mitochondria is mediated by the steroidogenic acute regulatory protein (StAR). StAR is a 30-kDa protein essential for steroidogenesis and is encoded by a gene on chromosome 8p11.2. The mitochondrial content of StAR increases between 1 and 5 hours after ACTH stimulation, long after the acute ACTH-induced increase in steroidogenesis. This has led some to suggest that extramitochondrial StAR might also be involved in the acute response to ACTH. Most patients with lipoid CAH have pathogenic variants in the gene encoding *StAR,* and a few have variants in *CYP11A1*.

All serum steroid levels are low or undetectable, whereas ACTH and plasma renin levels are quite elevated. The phenotype is female in both genetic females and males. Genetic males have no müllerian structures because the testes can produce normal AMH but no steroid hormones. These children present with acute adrenal crisis and salt wasting in infancy. Most patients are 46,XY. In a few patients, ovarian steroidogenesis is present at puberty.

The regulatory role of StAR-independent steroidogenesis is illustrated by 46,XX 4-month-old twins with lipoid adrenal hyperplasia. One died at 15 months because of cardiac complications related to coarctation of the aorta. The adrenal glands had characteristic lipid deposits. The surviving twin had spontaneous puberty with feminization at 11.5 years and menarche at 13.8 years. When restudied at the age of 15 years, a homozygous frameshift-inactivating variant in *StAR* was discovered. This supports the hypothesis that StAR-independent steroidogenesis was able to proceed until enough intracellular lipid accumulated to damage steroidogenic activity. Partial defects in only partially virilized males and delayed onset of salt wasting have been described. Complete *CYP11A1* defects may be incompatible with life because only this enzyme can convert cholesterol to pregnenolone, which then becomes progesterone, a hormone essential for the maintenance of normal mammalian pregnancy. Heterozygous variants in *CYP11A1* were described in a 4-year-old with 46,XY sex reversal and late-onset form of lipoid adrenal hyperplasia. At 6-7 weeks of gestation, when maternal corpus luteum progesterone synthesis stops, the placenta, which does not express StAR, produces progesterone by StAR-independent steroidogenesis using the CYP11A1 enzyme system.

3β-Hydroxysteroid Dehydrogenase Deficiency

Males with this form of CAH (see Chapter 616) have various degrees of hypospadias, with or without bifid scrotum and cryptorchidism, and, rarely, a complete female phenotype. Affected infants usually develop salt-losing manifestations shortly after birth. Incomplete defects, occasionally seen in males with premature pubarche, as well as late-onset nonclassic forms, have been reported. These children have pathogenic variants of the gene for type II 3β-hydroxysteroid enzyme, resulting in impairment of steroidogenesis in the adrenals and gonads; the impairment may be unequal between adrenals and gonads. Normal pubertal changes in some males could be explained by the normally present type I 3β-hydroxysteroid dehydrogenase present in many peripheral tissues. Infertility is frequent. There is no correlation between degree of salt wasting and degree of phenotypic abnormality.

Deficiency of 17-Hydroxylase/17,20-Lyase

A single enzyme (CYP17A1) encoded by a single gene on chromosome 10q24.3 has both 17-hydroxylase and 17,20-lyase activities in adrenal and gonadal tissues (see Chapter 616). Many different pathogenic gene variants have been reported. Genetic males usually have a complete female phenotype or, less often, various degrees of undervirilization, from labioscrotal fusion to perineal hypospadias and cryptorchidism. Pubertal development fails to occur in both genetic sexes.

In the classical disorder, there is decreased synthesis of cortisol by the adrenals and of sex steroids by the adrenals and gonads. Levels of the steroid precursor with mineralocorticoid activity, deoxycorticosterone and corticosterone, are markedly increased and lead to the hypertension and hypokalemia characteristic of this form of 46,XY

DSD. Although levels of cortisol are low, the elevated ACTH and corticosterone levels prevent symptomatic cortisol deficiency. The renin-aldosterone axis is suppressed because of the strong mineralocorticoid effect of elevated deoxycorticosterone. Virilization does not occur at puberty; levels of testosterone are low and those of gonadotropins are increased. Because fetal production of AMH is normal, no müllerian duct remnants are present. In XY phenotypic females, gonadectomy and replacement therapy with hydrocortisone and sex steroids are indicated.

The defect follows autosomal recessive inheritance. Affected XX females are usually not detected until young adult life, when they fail to experience normal pubertal changes and are found to have hypertension and hypokalemia. This condition should be suspected in patients presenting with primary amenorrhea and hypertension whose chromosomal complement is either 46,XX or 46,XY.

Some patients originally described as having isolated 17,20 lyase deficiency were subsequently shown to have a defect in the production of DHT because of deficiency of enzymes in the alternative pathway of DHT synthesis.

Deficiency of 17-Ketosteroid Reductase

This enzyme, also called *17β-hydroxysteroid dehydrogenase,* catalyzes the final step in testosterone biosynthesis. It is necessary to convert androstenedione to testosterone, DHEA to androstenediol, and estrone to estradiol. Deficiency of 17-ketosteroid reductase in the fetal testis causes the male fetus to have complete or near-complete female phenotype. Müllerian ducts are absent, and a shallow vagina is present. The diagnosis is based on the ratio of androstenedione to testosterone. In prepubertal children, stimulation with hCG may be necessary to make the diagnosis.

The defect is inherited in an autosomal recessive fashion. At least four different types of 17β-hydroxysteroid dehydrogenase are recognized, each coded by genes on different chromosomes. Type III is the enzyme responsible for testicular production of testosterone. This defect is more common in a highly inbred Arab population in Gaza than it is in other populations. The gene for the disorder is at 9q22 and is expressed only in the testes, where it converts androstenedione to testosterone. Most patients are diagnosed at puberty because of virilization and the failure to menstruate. Testosterone levels at puberty may approach normal, presumably as a result of peripheral conversion of androstenedione to testosterone; at this time, some patients may spontaneously adopt a male gender role.

Type I 17β-hydroxysteroid dehydrogenase, encoded by a gene on chromosome 17q21, converts estrone to estradiol and is found in the placenta, ovary, testis, liver, prostate, adipose tissue, and endometrium. Type II, whose gene is on chromosome 16q24, reverses the reactions of types I and III (converting testosterone to androstenedione and estrone to estradiol, respectively). Type IV is similar in action to type II. A late-onset form of 17-ketosteroid reductase deficiency presents as gynecomastia in young adult males.

Persistent Müllerian Duct Syndrome

In this disorder, there is persistence of müllerian (paramesonephric) duct derivatives in otherwise completely virilized males. Cases have been reported in siblings and identical twins. Cryptorchidism is present in 80% of affected males, and during surgery for this or inguinal hernia, the condition is discovered when a fallopian tube and uterus are found. The degree of müllerian development is variable and may be asymmetric. Testicular function is normal in most, but testicular degeneration has been reported. Some affected males acquire testicular tumors after puberty. In a study of 38 families, 16 families had defects in the AMH gene, located on the short arm of chromosome 19. Affected patients had low AMH levels. In 16 families with high AMH levels, the defect was in the AMH type II receptor gene, with 10 of 16 having identical 27-bp deletions on exon 10 in at least one allele.

Fig. 628.4 5α-Reductase deficiency. *(From Wales JKH, Wit JM, Rogol AD. Pediatric Endocrinology and Growth, 2nd ed. Philadelphia: Saunders, 2003: p. 165.)*

Treatment consists of removal of as many of the müllerian structures as possible without causing damage to the testis, epididymis, or vas deferens.

DEFECTS IN ANDROGEN ACTION

Dihydrotestosterone Deficiency

Decreased production of DHT in utero results in marked ambiguity of external genitalia of affected males. Biosynthesis and peripheral action of testosterone are normal.

The phenotype commonly associated with this condition results in males who have a small phallus, bifid scrotum, urogenital sinus with perineal hypospadias, and a blind vaginal pouch (Fig. 628.4). Testes are in the inguinal canals or labioscrotal folds and are normal histologically. There are no müllerian structures. Wolffian (mesonephric) structures—the vas deferens, epididymis, and seminal vesicles—are present. Most affected patients have been identified initially as females but at puberty, *virilization occurs;* the phallus enlarges, the testes descend and grow normally, and spermatogenesis occurs. There is no gynecomastia. Beard growth is scanty, acne is absent, the prostate is small, and recession of the temporal hairline fails to occur. Virilization of the wolffian duct is caused by the action of testosterone itself, although masculinization of the urogenital sinus and external genitals depends on the action of DHT during the critical period of fetal masculinization. Growth of facial hair and of the prostate also appears to be DHT dependent.

The adult height reached is close to that of the father and other male siblings. There is significant phenotypic heterogeneity. This has led to a classification of such patients into five types of **steroid 5α-reductase deficiency (SRD)**.

Several different gene defects of *SRD5A2* (the 5α-reductase type 2 gene leading to SRD) have been identified, located on the short arm of chromosome 2, in patients from throughout the world. Familial clusters have been reported from the Dominican Republic, Turkey, Papua New Guinea, Brazil, Mexico, and the Middle East. There is no reliable correlation between genotype and phenotype.

The disorder is inherited as an autosomal recessive trait but is limited to males; normal homozygous females with normal fertility indicate that in females DHT has no clinically significant role in sexual differentiation or in ovarian function later in life. The clinical diagnosis

should be made as early as possible in infancy. It is important to distinguish this from PAIS because patients with PAIS are far less sensitive to androgen than are patients with SRD. The biochemical diagnosis of SRD is based on finding normal serum testosterone levels, normal or low DHT levels with markedly increased basal and especially hCG-stimulated testosterone:DHT ratios (>17), and high ratios of urinary etiocholanolone to androsterone. Children with androgen insensitivity have normal hepatic 5α reduction and thus a normal ratio of tetrahydrocortisol to 5α-tetrahydrocortisol, as opposed to those with SRD.

It is important to note that many, but not all, children with SRD reared as females in childhood have changed to a male role around the time of puberty. It appears that exposures to testosterone in utero, neonatally, and at puberty have variable contributions to the formation of male gender identity. Infants with this condition should be reared as males whenever practical. Treatment of male infants with DHT results in phallic enlargement.

Another cause of DHT deficiency is a block in an alternative pathway of DHT synthesis. Patients previously thought to have 46,XY DSD because of isolated 17,20-lyase deficiency have subsequently been characterized as having pathogenic variants in *AKR1C2* (3α-reductase type 3) or both *AKR1C2* and *AKR1C4* (3α-reductase type 4) (see Fig. 628.1). These findings showed that both the classical and alternative pathways to DHT must be intact for normal prenatal virilization.

Androgen Insensitivity Syndromes

The AISs are the most common forms of male DSDs, occurring with an estimated frequency of 1/20,000 genetic males. This group of heterogeneous X-linked recessive disorders is caused by more than 150 different pathogenic variants in the androgen receptor gene, located on Xq11-12: single point variants result in amino acid substitutions or premature stop codons, frameshift and premature terminations, gene deletions, and splice-site variants.

Clinical Manifestations

The clinical spectrum of patients with AISs, all of whom have a 46,XY chromosomal complement, range from phenotypic females (in *complete* AIS), to males with various forms of ambiguous genitalia and undervirilization (*partial* AIS, or clinical syndromes such as **Reifenstein syndrome**), to phenotypically normal-appearing males with infertility. In addition to normal 46,XY chromosomes, the presence of testes and normal or elevated testosterone and LH levels are common to all such children (Figs. 628.5 and 628.6).

In **complete androgen insensitivity syndrome (CAIS)**, an extreme form of failure of virilization, genetic males appear female at birth and are invariably reared accordingly. The external genitalia are female. The vagina ends blindly in a pouch, and the uterus is absent because of the normal production and effect of AMH by the testes. In ~30% of patients, unilateral or bilateral fallopian tube remnants are found. The testes are usually intraabdominal but may descend into the inguinal canal; they consist largely of seminiferous tubules. At puberty, there is normal development of breasts and the habitus is female, but menstruation does not occur and sexual hair is absent. Adult heights are commensurate with those of normal males despite profound congenital deficiency of androgenic effects.

The testes of affected adult patients produce normal male levels of testosterone, which are converted to normal levels of DHT. Failure of normal male differentiation during fetal life reflects a defective response to androgens at that time. The absence of androgenic effects is caused by a striking resistance to the action of endogenous or exogenous testosterone at the cellular level.

Prepubertal phenotypic females with this disorder are often detected when inguinal masses prove to be testes or when a testis is unexpectedly found during herniorrhaphy. Approximately 1–2% of females with an inguinal hernia prove to have this disorder. In infants, elevated LH levels should suggest the diagnosis. In older children and adults, amenorrhea is the usual presenting symptom. In prepubertal children, the condition must be differentiated from other types of XY undervirilized males in which there is complete feminization. These include XY gonadal dysgenesis **(Swyer syndrome)**, true agonadism, Leydig cell aplasia including LH receptor defects, and 17-ketosteroid reductase deficiency. All these conditions, unlike CAIS, are characterized by low

Fig. 628.5 **A,** Partial androgen insensitivity with descended testes in bifid labioscrotal folds. **B,** Less severe partial androgen insensitivity with severe hypospadias and maldescent of testes. *(From Wales JKH, Wit JM, Rogol AD. Pediatric Endocrinology and Growth, 2nd ed. Philadelphia: Saunders, 2003: p. 165.)*

Fig. 628.6 Partial androgen insensitivity syndrome at adolescence, male sex of rearing. Note gynecomastia from peripheral aromatase conversion of testosterone to estrogen. Abundant pubic hair implies only partial resistance. *(From Wales JKH, Wit JM, Rogol AD. Pediatric Endocrinology and Growth, 2nd ed. Philadelphia: Saunders, 2003: p. 165.)*

Table 628.7 Causes of a Partial Androgen Insensitivity Syndrome–Like Phenotype

DEFECTS IN ANDROGEN PRODUCTION
Partial gonadal dysgenesis
Pathogenic variants in *SRY, NR5A1, WT1*
Pathogenic variants of the luteinizing hormone receptor
Biosynthetic enzyme deficiencies
17,20-Lyase deficiency
P450 oxidoreductase deficiency
17β-hydroxysteroid dehydrogenase deficiency type 3
5α-Reductase deficiency type 2
GENETIC
Klinefelter syndrome
Smith-Lemli-Opitz syndrome
Denys-Drash syndrome
Frasier syndrome
PAIS
Pathogenic variants of the androgen receptor gene
Normal androgen receptor gene with fetal growth restriction

NR5A1, Nuclear receptor subfamily 5 A1; PAIS, partial androgen insensitivity syndrome; SRY, sex-determining region Y; WT1, Wilms tumor 1.
From Hughes IA, Davies JD, Bunch TI, et al. Androgen insensitivity syndrome. *Lancet.* 2012;380:1419–1428. Panel 1.

levels of testosterone as neonates and during adult life and by failure to respond to hCG during the prepubertal years.

Although patients with CAIS have unambiguously female external genitals at birth, those with **PAIS** have a wide variety of phenotypic presentations, ranging from **perineoscrotal hypospadias**, bifid scrotum, and cryptorchidism to extreme undervirilization appearing as clitoromegaly and labial fusion. Some forms of PAIS are known as specific syndromes. Patients with **Reifenstein syndrome** have incomplete virilization characterized by hypogonadism, severe hypospadias, and gynecomastia (see Fig. 628.6). **Gilbert-Dreyfus** and **Lubs syndromes** are also classified as PAISs. In all cases, abnormalities in the androgen receptor gene have been identified. Table 628.7 lists other causes of a PAIS-like syndrome.

Diagnosis

The diagnosis of patients with PAIS may be particularly difficult in infancy. The postnatal surge in testosterone and LH is diminished in those with CAIS but not in those with PAIS. In some, especially those sufficiently virilized in infancy, the diagnosis is not suspected until puberty, when there is inadequate virilization with lack of facial hair or voice change and the appearance of gynecomastia. Azoospermia and infertility are common. Androgen receptor defects are recognized in adults who have a small phallus and testes and infertility. A single–amino acid substitution in the androgen receptor was reported in a large Chinese family in whom some affected members were fertile whereas others had gynecomastia and/or hypospadias.

Treatment and Prognosis

In patients with CAIS whose sexual orientation is unambiguously female, the testes should be removed because they have malignant potential. Historically, they were removed as soon as they were discovered. However, there is a trend to allow the testes to remain because they are the source of estradiol (through conversion from testosterone), and this results in normally timed puberty with the individual's endogenous hormones. Careful monitoring for testicular masses should be performed, and removal of the testes is advised in early adulthood. Laparoscopic removal of Y chromosome–bearing gonads has been performed in patients with AIS and in those with gonadal dysgenesis. In ~30% of patients, malignant tumors, usually seminomas, develop by 50 years of age. Several teenage females developed seminomas. Replacement therapy with estrogens is indicated at the age of puberty in those whose testes were removed in childhood.

Normal breasts develop in affected females who have not had their testes removed by the age of puberty. The absence of androgenic activity in addition to the production of estradiol contributes to the feminization of these women.

The psychosexual and surgical management of patients with PAIS is extremely complex and depends in large part on the presenting phenotype. Osteopenia is recognized as a late feature of AIS.

Molecular analyses have suggested that phenotype may depend in part on somatic mosaicism of the androgen receptor gene. The presence of mosaicism shifts the phenotype to a higher degree of virilization than expected from the genotype of the mutant allele alone.

Genetic counseling is difficult in families with androgen receptor gene variants. In addition to lack of genotype-phenotype correlations, there is a high rate (27%) of de novo pathogenic variants in families.

Sex hormone–binding globulin reduction after exogenous androgen administration (stanozolol) correlates with the severity of the receptor defect and may become a useful clinical tool. Successful therapy with supplemental androgens has been reported in patients with PAIS and various variants of the androgen receptor in the DNA-binding domain and the ligand-binding domain.

Pathogenic variants in androgen receptors are also reported in patients with **spinal and bulbar muscular atrophy** in whom clinical manifestations including testicular atrophy, infertility, gynecomastia, and elevated LH, FSH, and estradiol levels usually manifest between the third and fifth decades of life.

UNDETERMINED CAUSES

Other XY undervirilized males display great variability of the external and internal genitalia and various degrees of phallic and müllerian development. The testes may be histologically normal or rudimentary, or there may only be one. No recognized cause is identified in up to 50% of children with 46,XY DSDs. Some ambiguity of the genitalia is associated with a wide variety of chromosomal aberrations, which must always be considered in the differential diagnosis, the most common being 45,X/46,XY syndrome (see Chapter 626.1). It may be necessary to karyotype several tissues to establish mosaicism. Other complex genetic syndromes, many resulting from single-gene variants, are associated with varying degrees of ambiguity of the genitalia, particularly in the male. These entities must be identified by the associated extragenital malformations.

Smith-Lemli-Opitz syndrome is an autosomal recessive disorder caused by pathogenic variants in the sterol Δ7-reductase gene located on chromosome 11q12-q13. It is characterized by prenatal and postnatal growth restriction, microcephaly, ptosis, anteverted nares, broad alveolar ridges, syndactyly of the second to third toes, and severe cognitive impairment (see Chapter 106.3). Its incidence is 1 in 20,000-30,000 live births in populations of Northern and Central European origin; 70% are male. Genotypic males usually have genital ambiguity and, occasionally, partial sex reversal with female genital ambiguity or complete sex reversal with female external genitalia. Müllerian duct derivatives are usually absent. Affected 46,XX patients have normal genitalia. Two types of Smith-Lemli-Opitz syndrome have been recognized: the **classical form (type I)** described earlier and the acrodysgenital syndrome, which is usually lethal within 1 year and is associated with severe malformations, postaxial polydactyly, and extremely abnormal external genitalia **(type II)**. Pyloric stenosis is associated with Smith-Lemli-Opitz syndrome type I and Hirschsprung disease with type II. Cleft palate, skeletal abnormalities, and one case of a lipoma of the pituitary gland have been seen in **type II** cases. Some authors believe in a spectrum of disease severity rather than in the previous classification. Low plasma cholesterol with elevated 7-dehydrocholesterol, its precursor, are found in types I and II, and the levels do not correlate with severity. Maternal apolipoprotein E values do seem to correlate with severity. The most common prenatal expression of Smith-Lemli-Opitz syndrome is intrauterine growth retardation (see Chapter 106.3 for treatment).

46,XY DSD subjects also have been described in siblings with α-thalassemia/mental retardation syndrome.

Visit Elsevier eBooks+ at eBooks.Health.Elsevier.com for Bibliography.

628.3 Ovotesticular DSD

Patricia A. Donohoue

In ovotesticular DSD, both ovarian and testicular tissues are present, either in the same or in opposite gonads. Affected patients have ambiguous genitalia, varying from normal female genitalia with only slight enlargement of the clitoris to almost normal male external genitalia (see Fig. 628.3A).

Approximately 70% of all patients have a 46,XX karyotype. Ninety-seven percent of affected patients of African descent are 46,XX. Less than 10% of persons with ovotesticular DSD are 46,XY. Approximately 20% have 46,XX/46,XY mosaicism. Half of these are derived from more than one zygote and are chimeras (chi 46,XX/46,XY). The presence of paternal and both maternal alleles for some blood groups is demonstrated. An ovotesticular DSD chimera, 46,XX/46,XY, was reported as resulting from embryo amalgamation after in vitro fertilization. Each embryo was derived from an independent, separately fertilized ovum.

Examination of 46,XX ovotesticular DSD patients with Y-specific probes has detected less than 10% with a portion of the Y chromosome, including the *SRY* gene. Ovotesticular DSD is usually sporadic, but several siblings have been reported. The cause of many cases of ovotesticular DSD is unknown.

The most frequently encountered gonad in ovotesticular DSD is an ovotestis, which may be bilateral. If unilateral, the contralateral gonad is usually an ovary but may be a testis. The ovarian tissue is normal, but the testicular tissue is dysgenetic. The presence and function of testicular tissue can be determined by measuring basal and hCG-stimulated testosterone levels along with AMH levels. Patients who are highly virilized and have had adequate testicular function with no uterus are usually reared as males. If a uterus exists, virilization is often mild and testicular function minimal; assignment of female sex may be indicated. Selective removal of gonadal tissue inconsistent with sex of rearing may be indicated. In a few families, 46,XY ovotesticular DSD subjects and 46,XX males have been described in the same sibship.

Defects in R-Spondin1, encoded by the *RSPO1* gene, have been described in 46,XX ovotesticular DSD. Defects in SF-1 have been described in both XX and XY ovotesticular DSD.

Pregnancies with living offspring have been reported in 46,XX ovotesticular DSD individuals reared as females, but very few males with ovotesticular DSD have fathered children. Approximately 5% of patients will develop gonadoblastomas, dysgerminomas, or seminomas.

DIAGNOSIS AND MANAGEMENT OF DISORDERS OF SEX DEVELOPMENT

In the neonate, ambiguity of the genitals requires immediate attention to decide on the sex of rearing as early in life as possible. The family of the infant needs to be informed of the child's condition as early, completely, compassionately, and honestly as possible. Caution must be used to avoid feelings of guilt, shame, and discomfort. Guidance needs to be provided to alleviate both short-term and long-term concerns and to allow the child to grow up in a completely supportive environment. The initial care is best provided by a team of professionals that includes neonatologists and pediatric specialists, endocrinologists, radiologists, surgeons/urologists, psychologists, and geneticists, all of whom remain focused foremost on the needs of the child. Management of the potential psychologic upheaval that these disorders can generate in the child or the family is of paramount importance and requires physicians and other healthcare professionals with sensitivity, training, and experience in this field.

While awaiting the results of chromosomal analysis, pelvic ultrasonography is indicated to determine the presence of a uterus and ovaries. Presence of a uterus and absence of palpable gonads usually suggest a virilized XX female; however, as described previously, these structures may also be found in 46,XY DSD. A search for the source of virilization should be undertaken; this includes studies of adrenal hormones to rule out varieties of congenital adrenal hyperplasia, and studies of androgens and estrogens occasionally may be necessary to rule out aromatase deficiency. Virilized XX females are generally (but not always) reared as females even when highly virilized.

The absence of a uterus, with or without palpable gonads, often indicates an undervirilized male and an XY karyotype. Measurements of levels of gonadotropins, testosterone, AMH, and DHT are necessary to determine whether testicular production of androgen is present and is normal. Undervirilized males who are totally feminized may be reared as females. Certain significantly feminized infants, such as those with 5α-reductase deficiency, may be reared as males because these children virilize normally at puberty. Sixty percent of individuals with 5α-reductase deficiency assigned as female in infancy live as males as adults. An infant with a comparable degree of feminization resulting from an androgen receptor defect, such as CAIS, may be successfully reared as a female.

When receptor disorders are suspected in the XY male with a small phallus (micropenis), a course of three monthly IM injections of testosterone enanthate (25-50 mg) may assist in the differential diagnosis of androgen insensitivity and in the treatment of the small phallus.

In some mammals, the female exposed to androgens prenatally or in early postnatal life exhibits nontraditional sexual behavior in adult life. Most, but not all, females who have undergone fetal masculinization from CAH or from maternal progestin therapy have female sexual identity, although during childhood they may appear to prefer male playmates and activities over female playmates and feminine play with dolls in mothering roles.

In the past it was thought that surgical treatment of ambiguous genitalia to create a female appearance, particularly when a vagina is present, was more successful than construction of male genitalia. Considerable controversy exists regarding these decisions. Sexual functioning is to a large extent more dependent on neurohormonal and behavioral factors than the physical appearance and functionality of the genitalia. Similarly, controversy exists regarding the timing of the performance of invasive and definitive procedures, such as surgery. Whenever possible without endangering the physical or psychologic health of the child, an expert multidisciplinary team should consider deferring elective surgical repairs and gonadectomies until the child can participate in the informed consent for the procedure. One study of children (59 males and 18 females) with gender dysphoria but without documentation of genomic or enzymologic abnormalities indicated that most of these children no longer have gender dysphoria after completion of puberty. Among those who do, homosexuality and bisexuality are the most frequent diagnoses.

For patients with DSD who have Y-chromosome material and intraabdominal gonads, gonadectomy is generally recommended because of the risk of gonadal tumors, many of which are malignant.

The pediatrician, pediatric endocrinologist, and psychologist, along with the appropriate additional specialists, should provide ongoing compassionate, supportive care to the patient and the patient's family throughout childhood, adolescence, and adulthood. Support groups are available for families and patients with many of the conditions discussed.

Visit Elsevier eBooks+ at eBooks.Health.Elsevier.com for Bibliography.

Section 6

Diabetes Mellitus in Children

Chapter 629

Diabetes Mellitus

629.1 Classification of Diabetes Mellitus

David R. Weber

Diabetes mellitus (DM) is a common chronic metabolic disease characterized by hyperglycemia as a cardinal biochemical feature. The major forms of diabetes are differentiated by insulin deficiency versus insulin resistance: **type 1 diabetes mellitus (T1DM)** results from deficiency of insulin secretion because of pancreatic β-cell damage; **type 2 diabetes mellitus (T2DM)** is a consequence of insulin resistance occurring at the level of skeletal muscle, liver, and adipose tissue, with various degrees of β-cell impairment. T1DM is the most common endocrine metabolic disorder of childhood and adolescence, with important consequences for physical and emotional development. Individuals with T1DM confront serious lifestyle alterations, including an absolute daily requirement for exogenous insulin, the need to monitor their own glucose level, and the need to pay attention to dietary intake. Morbidity and mortality stem from a constant potential for acute metabolic derangements and from long-term complications. Potential acute complications include the development of hypoglycemia related to insulin excess or hyperglycemic ketoacidosis from insulin deficiency. Long-term complications typically manifest in adulthood and are related to the adverse effects of chronic hyperglycemia and associated metabolic abnormalities on tissues and organ systems. This can result in microvascular diseases such as retinopathy, nephropathy, and neuropathy and macrovascular complications such as ischemic heart disease and arterial obstruction with gangrene of the extremities.

DM is not a single entity, but rather a heterogeneous group of disorders in which there are distinct genetic patterns and other etiologic and pathophysiologic mechanisms that lead to impairment of glucose tolerance through deficient insulin production or action. The American Diabetes Association (ADA) has proposed a diabetes classification system that includes four categories: type 1 diabetes, type 2 diabetes, other specific types, and gestational diabetes. An expanded list of diabetes etiologies is provided in Table 629.1. The current criteria for the diagnosis of diabetes are provided in Table 629.2. A thorough clinical history and physical exam are often sufficient to determine the etiology; however, in some cases additional testing may be required.

TYPE 1 DIABETES MELLITUS

Formerly called *insulin-dependent diabetes mellitus* (IDDM) or *juvenile diabetes,* T1DM is characterized by low or absent levels of endogenously produced insulin and by dependence on exogenous insulin to prevent development of ketoacidosis, an acute life-threatening complication of T1DM. The natural history includes four distinct stages: (1) preclinical β-cell autoimmunity with progressive defect of insulin secretion, (2) onset of clinical diabetes, (3) transient remission honeymoon period, and (4) established diabetes during which there may occur acute and/or chronic complications and decreased life expectancy. The onset occurs predominantly in childhood, with a median age of 7-15 years, but it may present at any age. The incidence of T1DM varies markedly across the world but has increased in nearly all parts of the world over recent decades (Fig. 629.1). Both genetic susceptibility and environmental factors contribute to the pathogenesis. Susceptibility to T1DM is genetically controlled by alleles of the major histocompatibility complex (MHC) class II genes expressing human leukocyte antigens (HLAs). Autoantibodies to β-cell antigens, including islet cell cytoplasm (ICA), insulin autoantibody (IAA), glutamic acid decarboxylase (GAD), islet antigen 2 (IA-2A, formerly ICA512), and zinc transporter 8 (ZnT8A), are detected in serum from affected subjects. These can be detected months to years before the clinical onset of T1DM. In some children and adolescents with apparent T1DM, the β-cell destruction is not immune mediated. This subtype of diabetes occurs in patients of African or Asian origin and is distinct from known causes of β-cell destruction such as drugs or chemicals, viruses, mitochondrial gene defects, pancreatectomy, and ionizing radiation. These individuals may have ketoacidosis, but they have extensive periods of remission with variable insulin deficiency, similar to patients with T2DM. Patients with T1DM require lifelong treatment with insulin.

TYPE 2 DIABETES MELLITUS

Formerly known as *adult-onset diabetes mellitus* or *non–insulin-dependent diabetes mellitus,* T2DM develops because of insulin resistance and progressive non-autoimmune β-cell failure. There is a strong heritable component to T2DM, although the genetic basis remains poorly understood. Population-based studies have linked T2DM risk with polymorphisms in a large number of genes related to insulin secretion, insulin action, energy expenditure, and birthweight; however, the collective contribution of these variants to overall T2DM risk remains low at <20%. Although T2DM has long been the most prevalent form of diabetes in adults, the rise in childhood obesity over the past few decades has led to a markedly increased incidence of this disease in children and adolescents. Pediatric T2DM accounts for most of the new cases of diabetes in high-risk populations such as obese adolescents of Black or Hispanic population ancestry (see Chapter 65). *Childhood-onset T2DM differs from adult disease in that it is associated with a more rapid decline in β-cell function and the earlier development of T2DM-related complications.*

The presentation of T2DM is typically more insidious than that with T1DM. In contrast to patients with T1DM, who are usually ill at the time of diagnosis and whose presentation rarely spans more than a few weeks, children with T2DM often seek medical care because of excessive weight gain and fatigue as a result of insulin resistance and/or the incidental finding of glycosuria during routine physical examination. A history of polyuria and polydipsia is not always a cardinal clinical feature in these patients. **Acanthosis nigricans** (dark pigmentation of skin creases in the nape of the neck especially), a sign of insulin resistance, is present in the majority of patients with T2DM and is accompanied by a relative hyperinsulinemia at the time of the diagnosis. However, as the disease progresses, β-cell function becomes increasingly impaired such that children with advanced T2DM often present in diabetic ketoacidosis (DKA).

Healthy lifestyle interventions and treatment with metformin remain the cornerstones of T2DM treatment in children and adolescents. Liraglutide (a glucagon-like peptide-1 receptor agonist) is approved in children ≥10 years and may have an additional benefit of slowing weight gain. Insulin therapy is required for patients who present with severe hyperglycemia and for those patients in whom hyperglycemia worsens in spite of lifestyle modification and noninsulin pharmacologic management.

OTHER SPECIFIC TYPES OF DIABETES

Monogenic Diabetes

The term *monogenic diabetes* is used to refer to a heterogeneous group of single-gene disorders resulting in impaired insulin secretion. This category encompasses **maturity-onset diabetes of the young (MODY)** and **transient and permanent neonatal diabetes (TND or PND)**. Characteristics of monogenic diabetes can include age of onset before 6 months (for TND or PND), development of hyperglycemia before 25 years of age, and strong family history of diabetes. Monogenic etiologies are estimated to comprise anywhere from 1% to 10% of all diabetes cases, with the uncertainty related to the clinical difficulty in differentiating these cases from T1DM and T2DM. Monogenic forms of diabetes may present with hyperglycemia, and consequent polyuria and polydipsia, or may be diagnosed simply by routine screening. Extrapancreatic manifestations vary by genetic defect (see Table 629.1 and Chapter 629.4) and can include hepatic, renal, and central nervous system (CNS) manifestations. Treatment is guided by genetic diagnosis and clinical course, with

Table 629.1 Etiologic Classifications of Diabetes Mellitus

I. TYPE 1 DIABETES (B-CELL DESTRUCTION ULTIMATELY LEADING TO COMPLETE INSULIN DEFICIENCY)
- *A. Immune Mediated*
- *B. Idiopathic*

II. TYPE 2 DIABETES (VARIABLE COMBINATIONS OF INSULIN RESISTANCE AND INSULIN DEFICIENCY)
- *A. Typical*
- *B. Atypical*

III. OTHER SPECIFIC TYPES
- *A. Genetic Defects Of β-Cell Function (Monogenic Diabetes)*
  1. Neonatal diabetes
     - a. Pathogenic variants leading to transient neonatal diabetes (*KCNJ11, ABCC8, 6q24 overexpression, INS, ZFP57, SLC2A2 HNF1β*)
     - b. Pathogenic variants leading to permanent neonatal diabetes (*KCNJ11, ABCC8, INS, GATA6, EIF2AK3, GCK, PTF1A, FOXP3, GLIS3, PDX1, SLC2A2, SLC19A2, GATA4, NEUROD1, NEUROG3, NKX2-2, RFX5, IER3IP1, MNX1*)
  2. MODY (maturity-onset diabetes of the young) syndromes
     - a. MODY 1 chromosome 20, *HNF4α*
     - b. MODY 2 chromosome 7, *GCK*
     - c. MODY 3 chromosome 12q24.2, *HNF1α, TCF-1*
     - d. MODY 4 chromosome 13q12.1, *IPF-1 (PDX1)*
     - e. MODY 5 chromosome 17, *HNF1β, TCF-2*
     - f. MODY 6 chromosome 2q32, *NEUROD1*
     - g. MODY 7 chromosome 2p25, *KLF11*
     - h. MODY 8 chromosome 9q34, *CEL*
     - i. MODY 9 chromosome 7q32, *PAX4*
     - j. MODY 10 chromosome 11p15.5, *INS*
     - k. MODY 11 chromosome 8p23, *BLK*
     - l. MODY 12 chromosome 11p15, *ABCC8*
     - m. MODY 13 chromosome 11p15, *KCNJ11*
     - n. MODY 14 chromosome 3p14, *APPL1*
  3. Mitochondrial DNA pathogenic variants (includes one form of Wolfram syndrome, Pearson syndrome, Kearns-Sayre, and maternally inherited diabetes and deafness)
  4. Wolfram syndrome—DIDMOAD (diabetes insipidus, diabetes mellitus, optic atrophy, deafness):
     - a. WFS1-Wolframin—chromosome 4p
     - b. Wolfram locus 2—chromosome 4q22-24
     - c. Wolfram mitochondrial
  5. Thiamine-responsive megaloblastic anemia and diabetes
- *B. Genetic Defects of Insulin Action*
  1. Type A insulin resistance
  2. Donohue syndrome
  3. Rabson-Mendenhall syndrome
  4. Lipoatrophic diabetes syndromes
- *C. Other Genetic Syndromes Associated With Diabetes (Insulin Resistance Or Deficiency)*
  1. Down syndrome
  2. Turner syndrome
  3. Klinefelter syndrome
  4. Prader-Willi syndrome
  5. Bardet-Biedl syndrome
  6. Alström syndrome
  7. Werner syndrome
  8. Friedreich ataxia
- *D. Other Autoimmune Syndromes Associated With Diabetes*
  1. IPEX (immunodysfunction, polyendocrinopathy, enteropathy, X-linked)
  2. Autoimmune polyendocrinopathy syndromes (APS)
     - a. APS-1 (APCED)
     - b. APS-2
  3. Stiff person syndrome
  4. Anti-insulin receptor antibodies
- *E. Drug Or Chemical Induced*
  1. Antirejection—cyclosporine, sirolimus
  2. Glucocorticoids (with impaired insulin secretion; e.g., cystic fibrosis)
  3. l-Asparaginase
  4. β-Adrenergic blockers
  5. Vacor (rodenticide)
  6. Phenytoin (Dilantin)
  7. α-Interferon
  8. Diazoxide
  9. Nicotinic acid
  10. Pentamidine
  11. Immune checkpoint inhibitors (immune mediated)
- *F. Diseases of Exocrine Pancreas*
  1. Cystic fibrosis
  2. Trauma/pancreatectomy
  3. Pancreatitis/ionizing radiation
  4. Hemochromatosis
  5. Fibrocalculous pancreatopathy
- *G. Infections*
  1. Congenital rubella
  2. Cytomegalovirus
  3. Hemolytic-uremic syndrome
- *H. Endocrinopathies Associated With Diabetes*
  1. Cushing (hypercortisolism)
  2. Acromegaly (growth hormone excess)
  3. Pheochromocytoma
  4. Glucagonoma
  5. Somatostatinoma
  6. Aldosteronoma

IV. GESTATIONAL DIABETES

Modified from Sperling MA, Tamborlane WV, Battelino T, et al. Diabetes mellitus. In: Sperling MA. *Pediatric Endocrinology*, 4th ed. Philadelphia: Elsevier; 2014: Box 19-1.

some forms being responsive to oral sulfonylureas and others requiring insulin replacement. *Children diagnosed with diabetes before 6 months of age should have genetic testing for TND/PND, and older individuals with diabetes not characteristic of T1DM or T2DM in the setting of a family history of diabetes should have genetic testing for monogenic forms of diabetes.* A comparison of the four types of diabetes is noted in Table 629.3.

OTHER ETIOLOGIES OF DIABETES

Examples include diabetes secondary to exocrine pancreatic diseases (cystic fibrosis), other endocrine diseases (Cushing syndrome), infection, and ingestion of certain drugs or poisons (the rodenticide Vacor). In organ transplantation survivors, there is a linkage between cyclosporine and tacrolimus and post-transplantation DM, ascribed to a number of mechanisms. Certain genetic syndromes, including those with abnormalities of the insulin receptor or the immune system, are also included in this category.

PREDIABETES

The term *prediabetes* is used to identify individuals with abnormalities in blood glucose homeostasis who are at increased risk for the development of diabetes (see Table 629.2). Prediabetes is defined by **impaired fasting glucose** (IFG, fasting glucose 100-125 mg/dL

Table 629.2 Diagnostic Criteria for Dysglycemia and Diabetes Mellitus

DYSGLYCEMIA	DIABETES MELLITUS
IMPAIRED FASTING GLUCOSE	
Fasting (at least 8 hr) plasma glucose 100-125 mg/dL (5.6-7.0 mmol/L)	Fasting (at least 8 hr) plasma glucose ≥126 mg/dL (7.0 mmol/L) *Or*
IMPAIRED GLUCOSE TOLERANCE	
2-hr plasma glucose during OGTT ≥140 mg/dL (7.8 mmol/L), but <200 mg/dL (11.1 mmol/L)	2-hr plasma glucose during OGTT ≥200 mg/dL (11.1 mmol/L) *Or*
PREDIABETES	
Hemoglobin A_{1c} 5.7–6.4% (39-47 mmol/mol)	Hemoglobin A_{1c} ≥6.5% (48 mmol/mol) *Or* Symptoms* of diabetes mellitus plus random or casual plasma glucose ≥200 mg/dL (11.1 mmol/L)†

*Symptoms include polyuria, polydipsia, and unexplained weight loss with glucosuria and ketonuria.
†Results should be confirmed by repeat testing if in absence of unequivocal hyperglycemia.
OGTT, Oral glucose tolerance test.
Adapted from the Report of the Expert Committee on the Diagnosis and Classification of Diabetes Mellitus. Diabetes Care. 1999;20(Suppl 1):S5; with data from American Diabetes Association. Standards in Medical Care of Diabetes – 2017. *Diabetes Care.* 2017;40(Suppl 1):S11–S24.

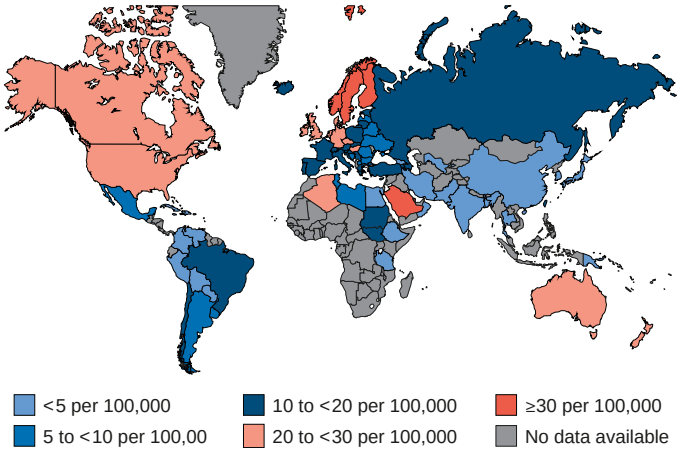

Fig. 629.1 Map of age-sex standardized incidence rates (per 100,000) from publications of type 1 diabetes in children age under 15 yr. *(From Patterson CC, Karuranga S, Salpea P, et al. Worldwide estimates of incidence, prevalence and mortality of type 1 diabetes in children and adolescents: results from the International Diabetes Federation Diabetes Atlas, 9th edition. Diabetes Res Clin Pract. 2019;157:107842. Fig 1.)*

[5.6-6.9 mmol/L]), **impaired glucose tolerance** (IGT, 2 hours postprandial glucose 140-199 mg/dL [7.8-11 mmol/L]), or hemoglobin A_{1c} (HbA_{1c}) values of 5.7–6.4% (39-47 mmol/mol). A fasting glucose concentration of 99 mg/dL (5.5 mmol/L) is the upper limit of normal. This choice is near the level above which acute-phase insulin secretion is lost in response to intravenous administration of glucose and is associated with a progressively greater risk of the development of microvascular and macrovascular complications. Many individuals with IFG are euglycemic in their daily lives and may have normal or nearly normal HbA_{1c} levels. Individuals with IFG often manifest hyperglycemia only when challenged with the oral glucose load used in the standardized oral glucose tolerance test (OGTT).

Prediabetes is not a clinical entity, but rather a risk factor for future diabetes and cardiovascular disease. This may be observed as an intermediate stage in any of the disease processes listed in Table 629.1. Prediabetes is often associated with **insulin resistance syndrome** (also known as **metabolic syndrome**), which consists of insulin resistance, compensatory hyperinsulinemia to maintain glucose homeostasis, obesity (especially abdominal or visceral obesity), dyslipidemia of the high-triglyceride or low- or high-density lipoprotein type, or both in addition to hypertension. Insulin resistance is directly involved in the pathogenesis of T2DM.

629.2 Type 1 Diabetes Mellitus (Immune Mediated)

David R. Weber

EPIDEMIOLOGY

T1DM accounts for approximately 10% of all cases of diabetes in all ages, affecting up to 2 million people in the United States and more than 15 million people in the world; approximately 15,000 youths are diagnosed with T1DM each year. Although T1DM accounts for most cases of diabetes in childhood, it is not limited to this age-group; new cases continue to present in adult life, and up to 50% of individuals with T1DM present as adults. The incidence of T1DM is highly variable among different racial and ethnic groups (see Fig. 629.1). The overall age-adjusted incidence of T1DM varies from <5 in 100,000 per year in parts of Asia, Africa, and South America to more than 30 in 100,000 per year in Northern Europe. The incidence of T1DM is increasing in most (but not all) populations, and this increase appears to be most marked in populations where the incidence of autoimmune diseases was historically low. Data from Western European diabetes centers suggest that the annual rate of increase in T1DM incidence is 2–5%, whereas some Central and Eastern European countries demonstrate an even more rapid increase—up to 9%. Data from the United States have shown that the incidence of T1DM in children increased by 1.9% per year from 2002 to 2015 from 19.5/100,000 to 22.3/100,000. Steeper increases in annual incidence were seen in people of Asian/Pacific Islander (4.4%), Hispanic (4%), and Black (2.7%) versus those of White (0.7%) racial/ethnic background.

Females and males are almost equally affected, with a modest male preponderance in some populations (Western European/United States and a female preponderance in others (Japanese); there is no apparent correlation with socioeconomic status. Peaks of presentation occur in two age-groups: at 5-7 years of age and at the time of puberty. The first peak may correspond to the time of increased exposure to infectious agents coincident with the beginning of school; the second peak may correspond to the pubertal growth spurt induced by gonadal steroids and the increased pubertal growth hormone secretion (which antagonizes insulin). The understanding of the cause of diabetes or of its increased incidence remains elusive. A growing number of cases are presenting between 1 and 2 years of age, especially in high-risk groups; the average age of presentation is older in low-risk populations. Low-risk groups that migrate to a high-risk country seem to acquire the increased risk of that country. There can be marked differences in incidence rates in various ethnic groups within the same country; incidence rates (per 100,000) in the 10- to 14-year-old age-group in the United States range from a low of 7.1 in Native Americans to 17.6 in Hispanics, 19.2 in Black Americans, and 32.9 in Whites.

GENETICS

There is a clear familial clustering of T1DM, with prevalence in siblings approaching 8%, whereas the prevalence in the general population in the United States is only 0.4%. Risk of T1DM is also increased when a parent has T1DM, and this risk differs between the two parents; the risk is 3–4% if the mother is affected but 5–6% when the father is affected. In monozygotic twins, the concordance rate ranges from 30% to 65%, whereas dizygotic twins have a concordance rate of 6–10%.

Table 629.3 Key Features of Diabetes in Pediatric Patients

	TYPE 1 DIABETES	TYPE 2 DIABETES	MONOGENIC DIABETES (MATURITY-ONSET DIABETES IN THE YOUNG)	NEONATAL DIABETES
Age at diagnosis	6 mo-18 yr	Puberty; rarely younger than 10 yr	Younger than 25 yr	Younger than 6 mo
Causes and genetic factors	Autoimmune; genetic predisposition (HLA and other genes)	Obesity; genetic and ethnic predisposition	Autosomal dominant; *HNF1A, HNF4A, GCK, HNF1B* (see Table 629.1)	*KCNJ11, ABCC8, INS* (see Table 629.1)
Associated features	Lean or mildly overweight at diagnosis, often with weight loss; thyroid autoimmunity; celiac disease	Obesity; acanthosis nigricans; polycystic ovarian syndrome; hypertension; hyperlipidemia; fatty liver disease; family history	Lean or weight loss at diagnosis; *GCK* variants are asymptomatic	Failure to thrive
Diabetic ketoacidosis at presentation	Yes; about 25%	Yes; 5–20%	No	Yes; frequency not described
Treatment	Insulin	Lifestyle modification; metformin; liraglutide; insulin; bariatric surgery	Sulfonylurea; no treatment for *GCK* variants	Sulfonylurea for *KCJN11* and *ABCC8* variants; insulin for other variants

Adapted from Cameron FJ, Wherrett DK. Care of diabetes in children and adolescents: controversies, changes, and consensus. Lancet. 2015;385:2096–2104. Table 1.

Because the concordance rate of dizygotic twins is higher than the sibling risk, factors other than the shared genotypes (e.g., the shared intrauterine environment) may play a role in increasing the risk in dizygotic twins. Furthermore, the genetic susceptibility for T1DM in the parents of an affected child is estimated at 3%. It should be kept in mind that although there is a large genetic component in T1DM, 85% of newly diagnosed patients with T1DM do not have an affected family member.

Monogenic Type 1 Diabetes Mellitus

Classic single-gene defects are an extremely rare cause of autoimmune-mediated T1DM. **IPEX (immune dysfunction, polyendocrinopathy, enteropathy, X-linked) syndrome** is caused by pathogenic variants in *FOXP3* and other genes. The *FOXP3* is a gene involved in immune system responses. A member of the FOX protein family, *FOXP3* appears to function as the master regulator in the development and function of regulatory T cells. These variants lead to the lack of a major population of regulatory T lymphocytes, with resulting overwhelming autoimmunity and development of diabetes (as early as 2 days of age) in approximately 80% of the children with this disorder.

Wolfram syndrome (DIDMOD: diabetes insipidus, diabetes mellitus, optic atrophy, deafness) is an autosomal recessive disease caused predominantly by pathogenic variants in *WFS1* and is a progressive neurodegenerative disease. Case definition requires the presence of T1DM and optic atrophy. This syndrome may be present in ~5% of patients with T1DM.

Autoimmune polyendocrinopathy syndrome type 1 (APS-1) is caused by pathogenic variants in *AIRE* leading to abnormalities in expression of peripheral antigens within the thymus and/or abnormalities of negative selection in the thymus. This results in widespread autoimmunity. Approximately 18% of children with this syndrome develop T1DM.

Genes Altering the Risk of Autoimmune Type 1 Diabetes Mellitus

The risk of developing T1DM is modified by the influence of several risk loci. The genomic region with by far the greatest contribution to the risk of T1DM is the MHC on chromosome 6p21. Outside of the MHC, genome-wide association studies have identified T1DM to be associated with at least 100 different single-nucleotide polymorphisms, from which about 50 genes have emerged as potentially causal. Notable high-risk loci include *INS*, *PTPN22*, *IL2RA*, *CTLA4*, *IFIH1*, *ERBB3*, and *BAD*. The contribution of each non-MHC locus to T1DM risk is small, making individual variants less useful for predicting the genetic risk of T1DM in a patient. The known functions of these genes suggest the primary etiologic pathways of diabetes, namely, HLA class II and class I molecules binding, T- and β-cell activation, innate pathogen viral responses, chemokine and cytokine signaling, and T-regulatory and antigen-presenting cell functions.

Major Histocompatibility Complex/Human Leukocyte Antigen–Encoded Susceptibility to Type 1 Diabetes Mellitus

The MHC is a large genomic region that contains a number of genes related to immune system function in humans. These genes are further divided into HLA classes I, II, III, and IV. Class II genes are the ones most strongly associated with risk of T1DM, but some of the risk associated with various HLA types is a result of variation in genes in HLA classes other than class II. Overall, genetic variation in the HLA region can explain 40–50% of the genetic risk of T1DM.

Some of the known associations include the HLA DR3/4-DQ2/8 genotype; compared to a population prevalence of T1DM of approximately 1 in 300, DR3/4-DQ2/8 newborns from the general population have a 1 in 20 genetic risk. This risk of development of T1DM is even higher when the high-risk HLA haplotypes are shared with a sibling or parent with T1DM. If one sibling has T1DM and shares the same high-risk DR3/4-DQ2/8 haplotype with another sibling, the risk of autoimmunity in the other sibling is 50%. Moreover, this risk approaches 80% when siblings share both HLA haplotypes identical by descent. This is known as the *relative paradox* and points to the existence of other shared genetic risk factors (most likely in the extended HLA haplotype).

With advances in genotyping, further discrimination is possible and we can identify more specific risk ratios for specific haplotypes. For example, the DRB1*0401-DQA1*0301g-DQB1*0302 haplotype has an odds ratio (OR) of 8.39, whereas the DRB1*0401-DQA1*0301g-DQB1*0301 haplotype has an OR of 0.35, implicating the DQB1*0302 allele as a critical susceptibility allele. There are some dramatically protective DR-DQ haplotypes (e.g., DRB1*1501-DQA1*0102-DQB1*0602 [OR = 0.03], DRB1*1401-DQA1*0101-DQB1*0503 [OR = 0.02], and DRB1*0701-DQA1*0201-DQB1*0303 [OR = 0.02]). The DR2 haplotype (DRB1*1501-DQA1*0102-DQB1*0602) is dominantly protective and is present in 20% of the general population but is seen in only 1% of patients with T1DM.

Role of Aspartate at Position 57 in DQB1

DQB1*0302 (high risk for diabetes) differs from DQB1*0301 (protective against diabetes) only at position 57, where it lacks an aspartic acid

residue. The DQB1*0201 allele (increased risk for diabetes) also lacks aspartic acid at position 57, and it has been proposed that the presence of aspartate at this position alters the protein-recognition and protein-binding characteristics of this molecule. Although the absence of aspartate at this position appears to be important in most studies on White individuals, it does not have the same role in Korean and Japanese populations. Moreover, certain low-risk DQB1 genotypes also lack aspartic acid at position 57, including DQB1*0302/DQB1*0201 (DR7) and DQB1*0201 (DR3)/DQB1*0201 (DR7). Thus the presence of aspartate at this position is usually, but not always, protective in White populations but not necessarily in other populations.

Role of Human Leukocyte Antigen Class I

Although the alleles of class II HLA genes appear to have the strongest associations with diabetes, recent genotyping studies and analyses of pooled data have identified associations with other elements in the HLA complex, especially HLA-A and HLA-B. The most significant association is with HLA-B39, which confers high risk for T1DM in three different populations, makes up the majority of the signal from HLA-B, and is associated with a lower age of onset of the disease.

Non-MHC/HLA Genes Associated with T1DM Risk

The second locus found to be associated with risk of T1DM was localized to a region upstream of the *INS*. Susceptibility in this region has been primarily mapped to a variable number of tandem repeats approximately 500 base pairs (bp) upstream of the insulin gene. This highly polymorphic region consists of anywhere from 30 to several hundred repeats of a 14- to 15-bp unit sequence (ACAGGGGTCTGGGG). The high-risk allele has been found to be associated with lower insulin and messenger RNA (mRNA) production in the thymus, suggesting a possible mechanism for decreased immune tolerance to insulin. A number of candidate genes linked to T1DM susceptibility have also been associated with increased risk of *other* autoimmune disease. These include the genes *PTPN22, IL2RA, CTLA4,* and *IFIH1,* which are involved in immune system regulation. Others, such as *ERBB3* and *BAD,* are thought to be associated with cell apoptosis.

ENVIRONMENTAL FACTORS

That ~45–70% of monozygotic twins are discordant for T1DM, the variation seen in urban and rural areas populated by the same ethnic group, the change in incidence that occurs with migration, the increase in incidence that has been seen in almost all populations in the last few decades, and the occurrence of seasonality all provide evidence that environmental factors also play a significant role in the causation of T1DM.

Viral Infections

It is possible that various viruses play a role in the pathogenesis of T1DM, but no single virus, and no single pathogenic mechanism, stands out in the environmental etiology of T1DM. Instead, a variety of viruses and mechanisms may contribute to the development of diabetes in genetically susceptible hosts. Invoked mechanisms involve direct infection of β cells by viruses resulting in lysis and release of self-antigens, direct viral infection of antigen-presenting cells causing increased expression of cytokines, and molecular mimicry, which is the notion that viral antigens exhibit homology to self-epitopes.

The clearest evidence of a role for viral infection in human T1DM is seen in congenital rubella syndrome. Prenatal infection with rubella is associated with β-cell autoimmunity in up to 70%, with development of T1DM in up to 40% of infected children. The time lag between infection and development of diabetes may be as large as 20 years. T1DM after congenital rubella is more likely in patients who carry the higher-risk genotypes. Interestingly, there appears to be no increase in risk of diabetes when rubella infection develops after birth or when live-virus rubella immunization is used.

Studies have shown an increase in evidence of enteroviral infection in patients with T1DM and an increased prevalence of enteroviral RNA in prenatal blood samples from children who subsequently develop T1DM. It has been reported that mumps infection leads to the development of β-cell autoimmunity with high frequency and to T1DM in some cases. Although mumps may play a role in some cases, the fact that T1DM incidence has increased steadily in several countries after universal mumps vaccination was introduced and that the incidence is extremely low in several populations where mumps is still prevalent indicates that mumps alone is not a major causal factor in diabetes.

The Hygiene Hypothesis: Possible Protective Role of Infections

Although some viral infections may increase the risk of T1DM, infectious agents may also play a protective role against diabetes. The hygiene hypothesis states that T1DM risk is increased in industrialized countries, where the observation that there are fewer infections implies that the immune system is less well trained for its main task, namely host defense. Some call this theory the *microbial deprivation hypothesis*. The hygiene hypothesis states that lack of exposure to childhood infections may increase an individual's chances of developing autoimmune diseases, including T1DM. Rates of T1DM and other autoimmune disorders are generally lower in underdeveloped nations with a high prevalence of childhood infections and tend to increase as these countries become more developed. The incidence of T1DM differs almost sixfold between Russian Karelia and Finland, even though both are populated by genetically related populations and are adjacent to each other and at the same latitude. The incidence of autoimmunity in the two populations varies inversely with immunoglobulin (Ig) E antibody levels, and IgE is involved in the response to parasitic infestation. All these observations suggest that decreased exposure to certain parasites and other microbes in early childhood may lead to an increased risk of autoimmunity in later life, including autoimmune diabetes. Nonetheless, retrospective case-control studies have been equivocal at best, and direct evidence of protection by childhood infections is still lacking.

Gastrointestinal Microbiome

There is emerging evidence that the intestinal microbiome is altered in T1DM; however, a cause-and-effect relationship has yet to be established. Human studies have found that the intestinal microbiome in T1DM has decreased diversity of microbial species and contains fewer butyrate-producing organisms compared to healthy controls. Butyrate is a short-chain fatty acid that is thought to be antiinflammatory and may have a role in protecting the intestinal epithelium, either directly or indirectly, through an effect to increase mucin production. Theoretically, a disruption in epithelial integrity (the so-called *leaky gut*) could trigger inflammation and an enhanced autoimmune response because of increased entry of pathogenic or dietary antigens into the bloodstream. Early, small-scale prospective studies in infants and children at high risk for T1DM have shown an imbalance favoring species including *Bacteroides dorei* and *Bacteroides vulgatus* among individuals who went on to develop T1DM autoantibodies or disease compared with those who did not. A larger study across six different study sites in The Environmental Determinants of Diabetes in the Young (TEDDY) study identified significant geographic differences in fecal microbiome composition, highlighting the challenges in this field of study.

Diet

Dietary exposure may modify T1DM risk; a definitive link between any single dietary exposure and T1DM development has not been found. The majority of interventional studies have not shown an effect of delayed gluten exposure or the use of hydrolyzed formula to reduce the risk for development of T1DM autoantibodies of disease. A meta-analysis of both interventional and observational studies concluded that there was no association between early exposure of gluten or milk protein and risk of T1DM. Some, but not all, studies have suggested that breastfeeding lowers the risk of T1DM. The potential mechanism for a protective effect of breast milk is not well understood but could be related to a beneficial effect of breast milk on the infant immune system or an indirect effect such as reduced exposure to other dietary antigens early in life. Timing of solid food introduction may modify T1DM risk, as seen in a report from the Diabetes Autoimmunity Study in the

Young (DAISY), which found that both early (before 4 months of age) and late (after 6 months of age) introduction of solid foods predicted development of T1DM.

Other dietary factors that have been suggested at various times as playing a role in T1DM risk include omega-3 fatty acids, vitamin D, ascorbic acid, zinc, and vitamin E. Vitamin D is biologically plausible (it has a role in immune regulation), and deficiency is more common in northern countries like Finland where T1DM incidence is highest; however, most observational studies have failed to find associations between vitamin D level or supplementation and T1DM risk. Interventional studies to assess the effect of vitamin D supplementation on T1DM risk are lacking.

PATHOGENESIS AND NATURAL HISTORY OF TYPE 1 DIABETES MELLITUS

In T1DM, a genetically susceptible host develops autoimmunity against the host's own β cells. What triggers this autoimmune response is complex and multifactorial. In some (but not all) patients, this immune-mediated process results in progressive destruction of β cells until a critical mass of β cells is lost and insulin deficiency develops. Insulin deficiency, in turn, leads to the onset of clinical signs and symptoms of T1DM. At the time of diagnosis, if viable β cells are still present and produce some insulin, there may be a partial remission of the disease (**honeymoon period**), but over time, more β-cell mass is destroyed, despite any regeneration and/or persistence of β cells, and the patient becomes totally dependent on exogenous insulin for survival (Fig. 629.2). Over time, some of these patients develop secondary complications of diabetes that appear, in part, to be related to how well-controlled the diabetes has been. The natural history of T1DM involves some or all of the following stages, with two distinct identifiable stages before onset of symptoms:

1. Persistence of one or more islet autoantibodies with normoglycemia and presymptomatic; can last years to decades (onset of autoimmune islet disease AID])
2. β-cell autoimmunity with dysglycemia and presymptomatic; shorter
3. Onset of symptomatic disease; usually quite brief, weeks, rarely months
4. Transient remission, usually within weeks of onset, may last 6-12 months ("honeymoon")
5. Established disease, lifelong
6. Development of complications, quite variable

Initiation of Autoimmunity

Genetic susceptibility to T1DM is determined by several genes, with the largest contribution coming from variants in the HLA system. Nonetheless even with the highest-risk haplotypes, most carriers will not develop T1DM. In monozygotic twins, the concordance of the development of T1DM is reported to be 30–65%. The observed rise in incidence of T1DM, and particularly so in younger children with an essentially genetically stable patient population, implies that something has accordingly changed in the environment. A number of factors, including maternal and intrauterine environmental influences, route of neonatal delivery, foods and diet in infancy, viral infections, lack of exposure to certain infections and antibiotic use, host microbiome, and even psychologic stress, are implicated in the pathogenesis of T1DM, but their exact role and the mechanism by which they trigger or aggravate autoimmunity remain uncertain. What is clear is that markers of autoimmunity are much more prevalent than clinical T1DM, indicating that initiation of autoimmunity is a necessary, but not a sufficient, condition for T1DM. Although no conclusive triggering factor has been identified, it seems that in most cases of T1DM that are diagnosed in childhood, the onset of autoimmunity occurs very early in life. In most children diagnosed before age 10 years, the first signs of autoimmunity appear before age 2 years. Development of autoimmunity is associated with the appearance of several autoantibodies. IAAs are usually the first to appear in young children, followed by GAD, and later by IA-2 and ZnT8 antibodies. The earliest antibodies are predominantly of the IgG_1 subclass. Not only is there spreading of autoimmunity to more antigens (IAA, GAD, IA-2A, ZnT8) but there is also epitope spreading within one antigen. Initial GAD antibodies tend to be against the middle region or the carboxyl-terminal region, whereas amino terminal antibodies usually appear later and are less common in children.

Preclinical Autoimmunity with Progressive Loss of β-Cell Function

In nearly all patients, the appearance of autoimmunity is followed by progressive or eventual destruction of β cells (Figs. 629.3 and 629.4).

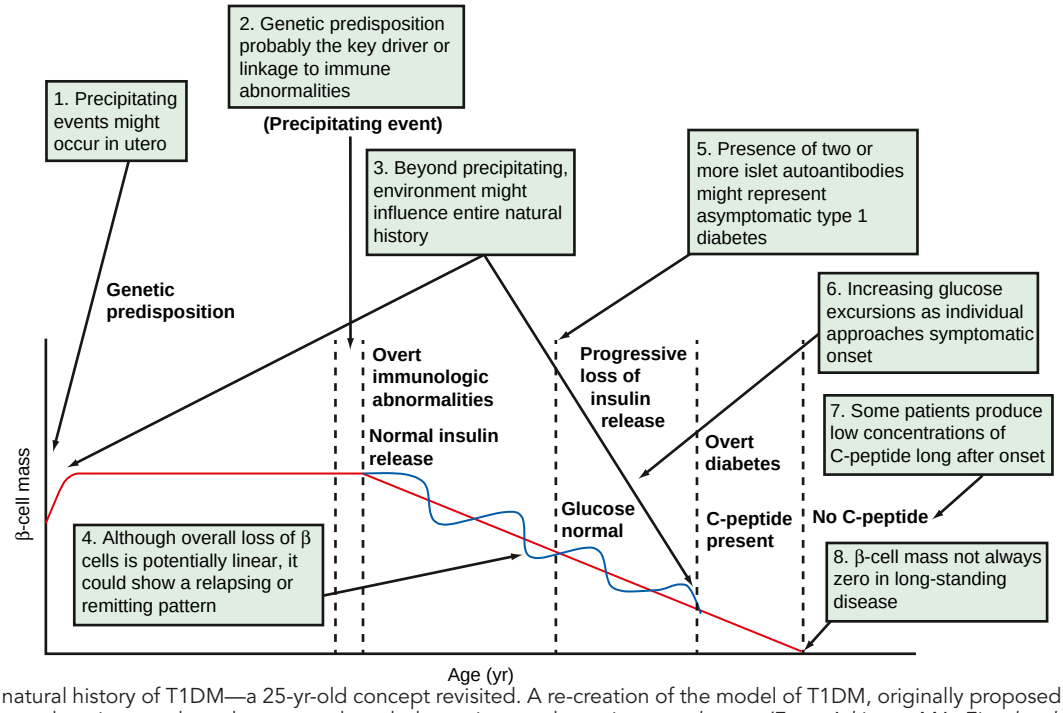

Fig. 629.2 The natural history of T1DM—a 25-yr-old concept revisited. A re-creation of the model of T1DM, originally proposed in 1986, is shown in *black*. Additions and conjectures based on recent knowledge gains are shown in *green boxes*. *(From Atkinson MA, Eisenbarth GS, Michels AW. Type 1 diabetes. Lancet. 2014;383:69–78. Fig. 4.)*

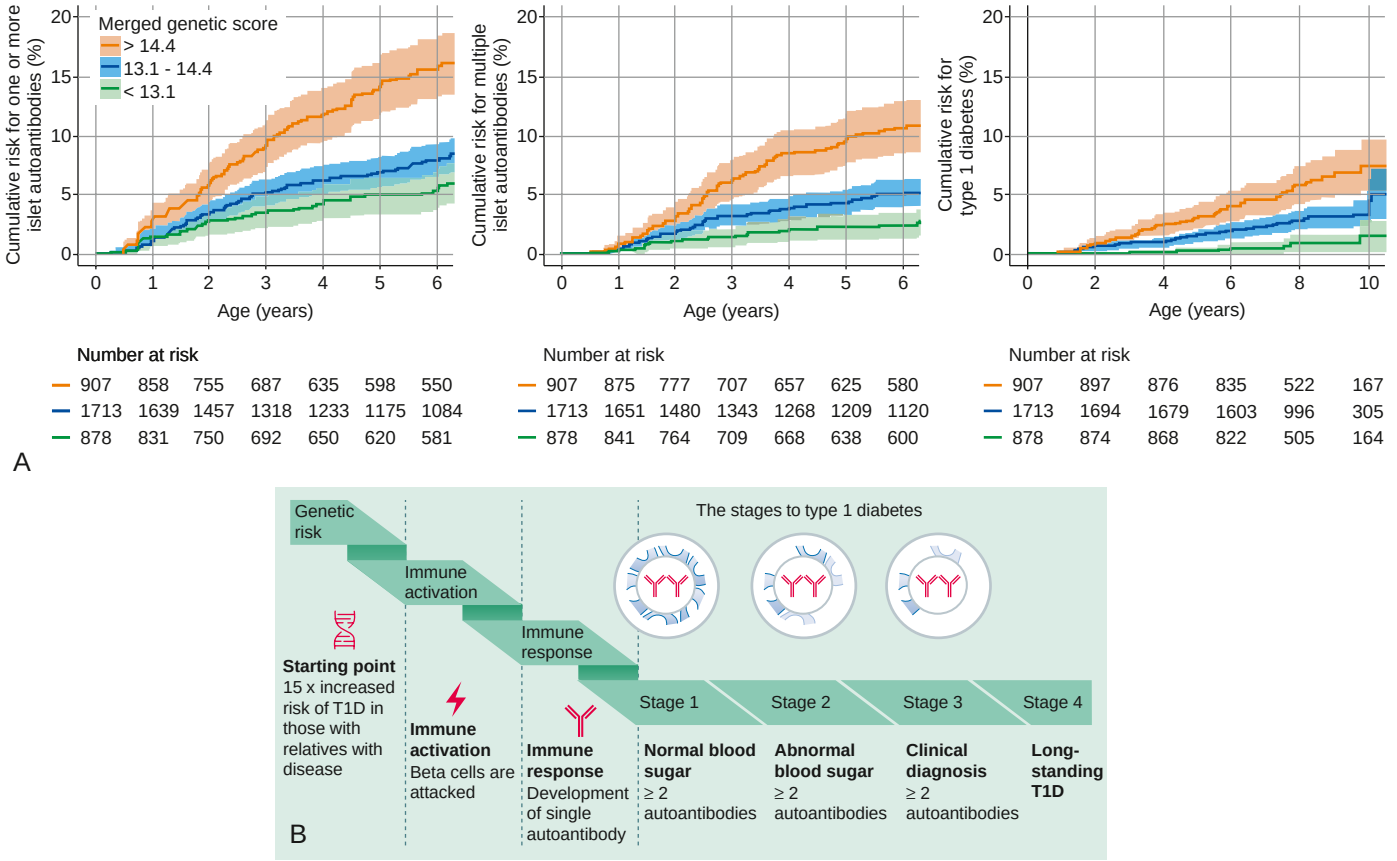

Fig. 629.3 Contributing factors and disease progression in type 1 diabetes. **A,** Cumulative risks of one or more islet autoantibodies, multiple islet autoantibodies, and type 1 diabetes development in TEDDY children with the HLA DR3/DR4-DQ8 or DR4-DQ8/DR4-DQ8 genotype stratified by their merged score. The cumulative risk of developing one or more islet autoantibodies *(left graph)*, multiple islet autoantibodies *(middle graph)*, and type 1 diabetes (*right graph, y* axis) is shown relative to age in yr (*x* axis) and was calculated using the Kaplan ± Meier method. Curves are shown for children with genetic scores in the upper *(orange line)*, lower *(green line)*, and two middle *(blue line)* quartiles. The shaded areas represent the 95% confidence interval of the cumulative risk. The numbers at risk indicate the number of children included in the analysis at each age. **B,** Type 1 diabetes progression and stages of type 1 diabetes. Stage 1 is the start of type 1 diabetes, marked by individuals having two or more diabetes-related autoantibodies and normal blood sugar concentrations. In stage 2, individuals have dysglycemia without symptoms. Stage 3 is the time of clinical diagnosis. T1D, type 1 diabetes. *(**A** from Bonifacio E, Beyerlein A, Hippich M, et al. Genetic scores to stratify risk of developing multiple islet autoantibodies and type 1 diabetes: A prospective study in children. PLoS Med. 2018;15:e1002548. Fig. 4; **B** from Greenbaum CJ, Speake C, Krischer J, et al. Strength in numbers: opportunities for enhancing the development of effective treatments for type 1 diabetes—the TrialNet experience. Diabetes. 2018;67:1216–1225.)*

Antibodies are a marker for the presence of autoimmunity, but the actual damage to the β cells is primarily T-cell mediated (see Fig. 629.4). Histologic analysis of the pancreas from patients with recent-onset T1DM reveals insulitis, with an infiltration of the islets of Langerhans by mononuclear cells, including T and B lymphocytes, monocytes/macrophages, and natural killer cells. The process in human T1DM is not necessarily linear, and there may be an undulating downhill course, with remissions and relapses, in the development of T1DM.

Role of Autoantibodies

Even though T1DM does not occur as a direct consequence of autoantibody formation, the risk of developing clinical disease increases dramatically with an increase in the number of antibodies; only 15% of children with one antibody will progress to diabetes in 10 years, but this risk increases to 70% when two antibodies are present and 90% when three are present. The risk of progression also varies with the intensity of the antibody response, and those with higher antibody titers are more likely to progress to clinical disease. Another factor that appears to influence progression of β-cell damage is the age at which autoimmunity develops; children in whom IAAs appeared within the first 2 years of life rapidly developed anti–islet cell antibodies and progressed to diabetes more frequently than children in whom the first antibodies appeared between ages 5 and 8 years.

Role of Genetics in Disease Progression

In a large study of *healthy* children, the appearance of single antibodies is relatively common and usually transient and does not correlate with the presence of high-risk HLA alleles; those carrying high-risk HLA alleles are more likely to develop multiple antibodies and progress to disease. Similarly, the appearance of antibodies is more likely to predict diabetes in those with a family history of diabetes versus those with no family history of T1DM. Environmental factors may induce transient autoimmunity in many children, but those with genetic susceptibility are more likely to see progression of autoimmunity and eventual development of diabetes.

Role of Environmental Factors

Environmental factors may also act as accelerators of T1DM after the initial appearance of autoimmunity. This is evident from the fact that the incidence of T1DM can vary several-fold between populations that have the same prevalence of autoimmunity. The incidence of T1DM in Finland is almost fourfold higher than in Lithuania, but the incidence of autoimmunity is similar in both countries.

The fact that all children with evidence of autoimmunity and of autoreactive T cells do not progress to diabetes indicates that there are checkpoints at which the autoimmune process can be halted or reversed before it progresses to full-blown diabetes.

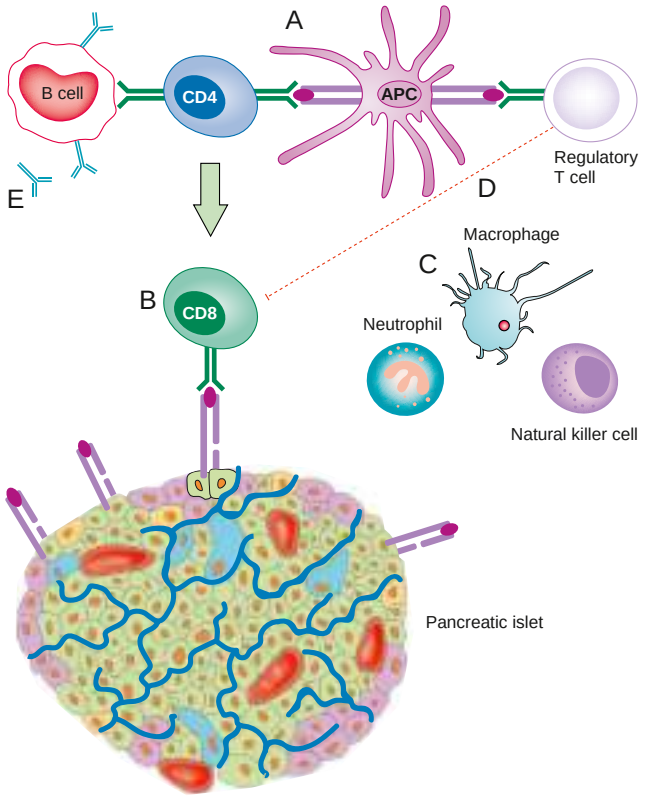

Fig. 629.4 The immunopathogenesis of type 1 diabetes. The development of type 1 diabetes is thought to be initiated by the presentation of β-cell peptides by antigen-presenting cells *(APCs)*. APCs bearing these autoantigens migrate to the pancreatic lymph nodes, where they interact with autoreactive CD4+ T lymphocytes, which in turn mediate the activation of autoreactive CD8+ T cells *(A)*. These activated CD8+ T cells return to the islet and lyse β cells expressing immunogenic self-antigens on major histocompatibility complex class I surface molecules *(B)*. β-Cell destruction is further exacerbated by the release of proinflammatory cytokines and reactive oxygen species from innate immune cells (macrophages, natural killer cells, and neutrophils) *(C)*. This entire process is amplified by defects in regulatory T lymphocytes, which do not effectively suppress autoimmunity *(D)*. Activated T cells within the pancreatic lymph node also stimulate B lymphocytes to produce autoantibodies against β-cell proteins. These autoantibodies can be measured in circulation and are considered a defining biomarker of type 1 diabetes *(E)*. *(From DiMeglio LA, Evans-Molina C, Oram RA. Type 1 diabetes. Lancet. 2018;391:2449–2458. Fig. 3.)*

Onset of Clinical Disease

Patients with progressive β-cell destruction will eventually present with clinical T1DM. It was thought that 90% of the total β-cell mass is destroyed by the time clinical disease develops, but other studies have revealed that this is not always the case. It appears that β-cell destruction is more rapid and more complete in younger children, whereas in older children and adults, the proportion of surviving β cells is greater (10–20% in autopsy specimens), and some β cells (about 1% of the normal mass) survive up to 30 years after the onset of diabetes. Because autopsies are usually done only on patients who died of DKA, these figures may underestimate the actual β-cell mass present at diagnosis. Functional studies indicate that up to 40% of the insulin secretory capacity may be preserved in adults at the time of presentation of T1DM. Ultrasensitive assays indicate that C-peptide production is measurable decades after the onset of T1DM. The fact that newly diagnosed diabetic individuals may still have a significant surviving β-cell mass is important because it raises the possibility of *secondary* prevention of T1DM. Similarly, the existence of viable β cells years or decades after initial presentation indicates that even patients with long-standing diabetes may be able to exhibit some recovery of β-cell function if the autoimmune destructive process could be halted and if islet cell regeneration could occur.

PREDICTION

Autoimmunity precedes clinical T1DM, and indicators of autoimmune responses may be useful markers for disease prediction. Individuals at risk for T1DM can be identified by a combination of genetic, immunologic, and metabolic markers. The most informative genetic locus, HLA class II, confers about half of the total genetic risk but has a low positive predictive value (PPV) when used in the general population. Autoantibodies provide a practical readout of β-cell autoimmunity, are easily sampled in venous blood, and have become the mainstay of T1DM prediction efforts. By comparison, and even though T lymphocytes mediate β-cell destruction, T cells are rare in blood, and assays of their function have been difficult to standardize and validate. In the first-degree relatives of patients with T1DM, the number of positive autoantibodies can help estimate the risk of developing T1DM: low risk (single autoantibodies: PPV of 2–6%), moderate risk (2 autoantibodies: PPV of 21–40%), and high risk (>2 autoantibodies: PPV of 59–80%) over a 5-year period. In children carrying the T1DM highest-risk genotype (HLA-DQB1*0201-DQA1*05/DQB1*0302-DQA1*03), insulitis is almost 10 times more frequent (PPV 21%) than in children with other genotypes (PPV 2.2%). But although autoantibodies are useful for the prediction of T1DM in the relatives of patients with T1DM, outside of that obvious population, the screening of the general population would be required to identify healthy subjects at risk of T1DM. Indeed, ~90% of individuals with new-onset T1DM have no family background of T1DM. Screening the general population is difficult to justify, in part, because the observed autoantibody prevalence greatly exceeds the low disease prevalence in nonrelatives, leading to high false-positive rates.

PREVENTION

Strategies for the prevention of T1DM are focused primarily on slowing progression of β-cell loss after the onset of autoimmune islet disease through targeted immunosuppression of autoreactive regulatory T cells. Numerous compounds are under investigation for this purpose, including agents that could modulate regulatory T cells via stimulating interleukin (IL)-2, tumor necrosis factor (TNF)-α signaling, or CTLA signaling and by inhibiting IL-17 or T-cell receptor (TCR) signaling. Teplizumab, a humanized anti-CD3 monoclonal antibody that inhibits TCR signaling, has been shown to delay the onset of clinical diabetes in high-risk children and young adults. It is approved for use in the United States for patients 8 years and older with stage 2 T1DM, defined by at least two positive pancreatic islet cell autoantibodies and dysglycemia without hyperglycemia.

PATHOPHYSIOLOGY OF T1DM

Insulin performs a critical role in the storage and retrieval of cellular fuel. Its secretion in response to feeding is exquisitely modulated by the interplay of neural, hormonal, and substrate-related mechanisms to permit controlled disposition of ingested foodstuff as energy for immediate or future use. Insulin levels must be lowered to then mobilize stored energy during the fasted state. Thus in normal metabolism, there are regular swings between the postprandial, high-insulin anabolic state and the fasted, low-insulin catabolic state that affect liver, muscle, and adipose tissue (Table 629.4). T1DM is a progressive low-insulin catabolic state in which feeding does not reverse, but rather exaggerates, these catabolic processes. With moderate insulinopenia, glucose use by muscle and fat decreases and postprandial hyperglycemia appears. At even lower insulin levels, the liver produces excessive glucose via glycogenolysis and gluconeogenesis, and fasting hyperglycemia begins. Hyperglycemia produces an osmotic diuresis (glycosuria) when the renal threshold is exceeded (180 mg/dL; 10 mmol/L). The resulting loss of calories and electrolytes, as well as the worsening dehydration, produces a physiologic stress with hypersecretion of stress hormones (epinephrine, cortisol, growth hormone, and glucagon). These hormones, in turn, contribute to the metabolic decompensation by further impairing insulin secretion (epinephrine), by antagonizing its action (epinephrine, cortisol, growth hormone), and by promoting

Table 629.4 Influence of Feeding (High Insulin) or of Fasting (Low Insulin) on Some Metabolic Processes in Liver, Muscle, and Adipose Tissue*

	HIGH PLASMA INSULIN (POSTPRANDIAL STATE)	LOW PLASMA INSULIN (FASTED STATE)
Liver	Glucose uptake	Glucose production
	Glycogen synthesis	Glycogenolysis
	Absence of gluconeogenesis	Gluconeogenesis
	Lipogenesis	Absence of lipogenesis
	Absence of ketogenesis	Ketogenesis
Muscle	Glucose uptake	Absence of glucose uptake
	Glucose oxidation	Fatty acid and ketone oxidation
	Glycogen synthesis	Glycogenolysis
	Protein synthesis	Proteolysis and amino acid release
Adipose tissue	Glucose uptake	Absence of glucose uptake
	Lipid synthesis	Lipolysis and fatty acid release
	Triglyceride uptake	Absence of triglyceride uptake

*Insulin is considered to be the major factor governing these metabolic processes. Diabetes mellitus may be viewed as a permanent low-insulin state that, if untreated, results in exaggerated fasting.

glycogenolysis, gluconeogenesis, lipolysis, and ketogenesis (glucagon, epinephrine, growth hormone, and cortisol) while decreasing glucose use and glucose clearance (epinephrine, growth hormone, cortisol).

The combination of insulin deficiency and elevated plasma values of the counterregulatory hormones is also responsible for accelerated lipolysis and impaired lipid synthesis, with resulting increased plasma concentrations of total lipids, cholesterol, triglycerides, and free fatty acids. The hormonal interplay of insulin deficiency and glucagon excess shunts the free fatty acids into ketone body formation; the supranormal rate of formation of these ketone bodies, principally β-hydroxybutyrate and acetoacetate, exceeds the capacity for peripheral use and renal excretion. Accumulation of these keto acids results in metabolic acidosis (DKA) and compensatory rapid, deep, nondyspneic breathing to excrete excess CO_2 (Kussmaul respiration). Acetone, formed by nonenzymatic conversion of acetoacetate, is responsible for the characteristic fruity odor of the breath. Ketones are excreted in the urine in association with cations and thus further increase losses of water and electrolyte and bicarbonate regenerating ability. With progressive dehydration, acidosis, hyperosmolality, and diminished cerebral oxygen use, consciousness becomes impaired, and the patient ultimately becomes comatose.

CLINICAL MANIFESTATIONS

The classic clinical manifestations of new-onset diabetes in children reflect the hyperglycemic and catabolic physiologic state and include polyuria, polydipsia, polyphagia, and weight loss. Other common symptoms include fatigue, weakness, and a general feeling of malaise. Patients presenting with more advanced disease will exhibit signs of **DKA**, including dehydration, nausea, vomiting, lethargy, altered mental status, and in extreme cases, coma. If the diagnosis is not recognized, the progression of symptoms follows a predictable course from early intermittent polyuria, to sustained polyuria and weight loss, followed by development of DKA. In most cases, this initial progression occurs over a period of weeks rather than months.

Initially, when only insulin reserve is limited, occasional asymptomatic postprandial hyperglycemia occurs. When insulin secretory capacity declines, blood glucose levels begin to rise. When the blood glucose increases above the renal threshold, intermittent polyuria and/or nocturia begins. With further β-cell loss, chronic hyperglycemia causes a more persistent diuresis, which often includes nocturnal enuresis in younger children. Female patients may develop vulvovaginal candidiasis from the chronic glycosuria. Eventually, daily losses of water and glucose may be as high as 5 L and 250 g, respectively, representing 1,000 calories, or 50%, of the average daily caloric intake. These losses trigger compensatory polydipsia and polyphagia; however, progressive dehydration and weight loss will inevitably ensue unless treatment is initiated.

When the disease continues to progress, ketoacids begin to accumulate. At this stage in the disease, rapid clinical deterioration is possible. Ketoacids produce abdominal pain, anorexia, nausea, and emesis and thereby impede the patient's ability to maintain sufficient oral replacement of urinary water losses. Dehydration accelerates, as manifested by weakness, orthostasis, and further weight loss. As in any hyperosmotic state, the degree of dehydration may be clinically underestimated because intravascular volume is conserved at the expense of intracellular volume. Signs and symptoms of advanced ketoacidosis include Kussmaul respirations (deep, heavy, nonlabored, rapid breathing), fruity breath odor (acetone), prolonged corrected Q-T interval, diminished neurocognitive function, and coma. Approximately 20–40% of children with new-onset diabetes progress to DKA before diagnosis; data from the United States suggest that the prevalence of DKA at onset of T1DM is increasing.

Clinical progression typically happens more quickly in younger children, owing to either more aggressive autoimmune destruction of β-cells and/or to lower β-cell mass. Disease onset in infancy is associated with a greater likelihood of DKA at presentation. Weight loss in younger children and individuals with more rapidly progressive disease will be composed mostly of acute fluid loss, whereas weight loss in adolescents and individuals with slowly progressive disease will also include significant fat and lean mass deficits as a result of prolonged starvation. In any child, the progression of symptoms may be accelerated by the stress of an intercurrent illness or trauma, when counterregulatory (stress) hormones counter the limited insulin secretory capacity.

DIAGNOSIS

The diagnosis of T1DM is usually straightforward (see Table 629.2). Although most symptoms are nonspecific, the most important clue is an inappropriate polyuria in any child with signs of dehydration and poor weight gain. Hyperglycemia can be identified quickly from capillary blood by use of a glucometer; glycosuria and ketonuria can readily be determined by urine dipstick. Nonfasting blood glucose greater than 200 mg/dL (11.1 mmol/L) with typical symptoms is diagnostic with or without ketonuria. In the obese child, T2DM must be considered (see Chapter 629.3). Once hyperglycemia is confirmed, it is prudent to determine whether DKA is present (especially if ketonuria is found) by checking a venous blood sample for bicarbonate and pH and also to evaluate for electrolyte abnormalities—even if signs of dehydration are minimal. A baseline HbA_{1c} will be confirmatory and allows an estimate of the duration of hyperglycemia and provides an initial value by which to compare the effectiveness of subsequent therapy. Falsely low HbA_{1c} levels are noted in hemolytic anemias (sickle cell anemia, others), pure red cell aplasia, blood transfusions, and anemias associated with hemorrhage, cirrhosis, myelodysplasias, or renal disease treated with erythropoietin.

Testing for autoimmunity (T1DM autoantibodies) (see Chapter 629.1) should be considered in cases where the differentiation between T1DM and T2DM is not apparent and in cases where there is a strong family history suggestive of monogenic and syndromic diabetes. The presence of other autoimmune diseases associated with T1DM should be sought at or shortly after diagnosis, including celiac disease (by tissue transglutaminase immunoglobulin A [IgA] and total IgA) and autoimmune hypothyroidism (by thyroid-stimulating hormone [TSH] and free or total thyroxine). Because significant physiologic perturbations can affect thyroid and celiac screening tests, individuals with

only mild abnormalities should have tests repeated *after* several weeks before instituting therapy. In addition, because there is an increased risk of cardiovascular disease associated with diabetes, it is also recommended to obtain a fasting lipid profile in children ≥10 years of age once glucose control has been established.

Rarely, a child has transient hyperglycemia with glycosuria while under substantial physical stress or illness. This usually resolves permanently during recovery from the stressors. **Stress-produced hyperglycemia** can reflect a limited insulin reserve temporarily revealed by elevated counterregulatory hormones. A child with temporary hyperglycemia should therefore be monitored for the development of symptoms of persistent hyperglycemia and be tested with an HbA_{1c} if such symptoms occur. Formal testing in a child who remains clinically asymptomatic is not necessary.

Routine screening procedures, such as postprandial determinations of blood glucose or screening OGTTs, have yielded low detection rates in healthy, asymptomatic children, even among those considered at risk, such as siblings of diabetic children. Accordingly, such screening procedures are not recommended in children.

TREATMENT

Therapy is tailored to the degree of insulinopenia at presentation. Most children with new-onset T1DM have mild to moderate symptoms, have minimal dehydration with no history of emesis, and have not progressed to ketoacidosis. They can be started on subcutaneous insulin therapy directly. About 20–40% of children with new-onset diabetes present in DKA, which can be arbitrarily classified as mild, moderate, or severe (Table 629.5), and the range of symptoms depends on the degree of ketoacidosis. Cardinal biochemical abnormalities include elevations in blood and urine ketones, an increased anion gap, a decreased serum bicarbonate (or total CO_2) and pH, and an elevated effective serum osmolality. Hyponatremia is commonly present with hyperglycemia and is the result of an osmotic dilution as water shifts into the extracellular fluid. Potassium and phosphate depletion is common after prolonged polyuria but may be masked by acidosis, which leads to extracellular shifting of these ions.

Treatment of Diabetic Ketoacidosis

Severe insulinopenia (or lack of effective insulin action) results in a physiologic cascade of events in three general pathways:

1. Excessive glucose production coupled with reduced glucose use raises serum glucose. This triggers an osmotic diuresis, with urinary loss of fluid and electrolytes, dehydration, and activation of the renin-angiotensin-aldosterone axis with accelerated potassium loss. When glucose elevation and dehydration are severe and persist for several hours, the risk of cerebral edema increases.
2. Increased catabolic processes result in cellular losses of sodium, potassium, and phosphate.
3. Increased release of free fatty acids from peripheral fat stores supplies substrate for hepatic ketoacid production. When ketoacids accumulate, buffer systems are depleted, and a metabolic acidosis ensues.

Therapy must address both the initiating event in this cascade (insulinopenia) and the subsequent physiologic disruptions.

Reversal of DKA is associated with inherent risks that include hypoglycemia, hypokalemia, and cerebral edema. Any protocol must be used with caution and close monitoring of the patient. Adjustments based on sound medical judgment may be necessary for any given level of DKA (Figs. 629.5 and 629.6).

Dehydration and Hyperglycemia

Judicious fluid resuscitation is the first step in the medical management of DKA. Correction of fluid deficits must be tempered by the potential risk of cerebral edema. It is prudent to approach any child in any hyperosmotic state with cautious rehydration. The effective serum osmolality ($E_{osm} = 2 \times [Na_{uncorrected}] + [glucose]$) is an accurate index of tonicity of the body fluids, reflecting intracellular and extracellular hydration better than measured plasma osmolality. It is calculated with sodium and glucose in mmol/L. This value is usually elevated at the beginning of therapy and should steadily normalize. A rapid decline, or a slow decline to a subnormal range, may indicate an excess of free water entering the vascular space and an increasing risk of cerebral edema. Therefore patients should not be allowed oral fluids until rehydration is well underway and significant electrolyte shifts are no longer likely. Limited ice chips may be given as a minimal oral intake. All fluid intake and output should be closely monitored.

Calculation of fluid deficits using clinical signs is difficult in children with DKA because intravascular volume is better maintained in the hypertonic state. For any degree of tachycardia, delayed capillary refill, decreased skin temperature, or orthostatic blood pressure change, the child with DKA will be more dehydrated than the child with a normotonic fluid deficit. Typically, an initial intravenous bolus of 10-20 mL/kg of glucose-free isotonic sodium salt solution such as Ringer lactate or 0.9% sodium chloride is given over 1 to 2 hours. Further fluid boluses should be given only for hemodynamically unstable patients. This bolus is given as isotonic saline because the patient is inevitably hypertonic, keeping most of the initial infusion in the intravascular space. Subsequent fluid replacement then consists of 0.45% or 0.9% sodium chloride infused at a rate calculated to replace the fluid deficit (after subtracting initial fluid bolus) over 24-48 hours plus maintenance. The fluid deficit can be calculated empirically if a recent weight is available, estimated at 5–10% of body weight based upon clinical severity, or by assuming a standard water deficit (85 mL/kg). Practically, this is generally equivalent to a rate of ~1.5 times maintenance, which can be substituted for simplicity in most situations.

The optimal fluid protocol to prevent CNS complications (cerebral edema) of DKA remains uncertain. When children with DKA were randomly assigned to one of four treatment arms consisting of fast or slow fluid deficit repletion of 0.9% or 0.45% sodium chloride, there were no differences in short- or long-term neurocognitive outcomes among any of the treatment arms. In general, after reestablishing the intravascular volume and avoiding rapid declines of blood glucose levels and hyponatremia, fluid replacement rates or fluid composition may subsequently be administered per protocol (see Fig. 629.5). *It is possible that cerebral injury preceded therapy and is the result of DKA and not rates or composition of IV fluids.*

Insulin must be given to promote movement of glucose into cells, to subdue hepatic glucose production, and to halt the movement of fatty acids from the periphery to the liver. An initial IV insulin bolus does not speed recovery and may increase the risk of hypokalemia and hypoglycemia. *Therefore insulin infusion is typically begun without an insulin bolus at*

Table 629.5 Classification of Diabetic Ketoacidosis

	NORMAL	MILD	MODERATE	SEVERE*
HCO_2 (mEq/L, venous)†	20-28	16-20	10-15	<10
pH (venous)†	7.35-7.45	7.25-7.35	7.15-7.25	<7.15
Clinical	No change	Oriented, alert but fatigued	Kussmaul respirations; oriented but sleepy; arousable	Kussmaul or depressed respirations; sleepy to depressed sensorium to coma

*Severe hypernatremia (corrected Na >150 mEq/L) would also be classified as severe diabetic ketoacidosis.
†HCO_2 and pH measurement are method dependent; normal ranges may vary.

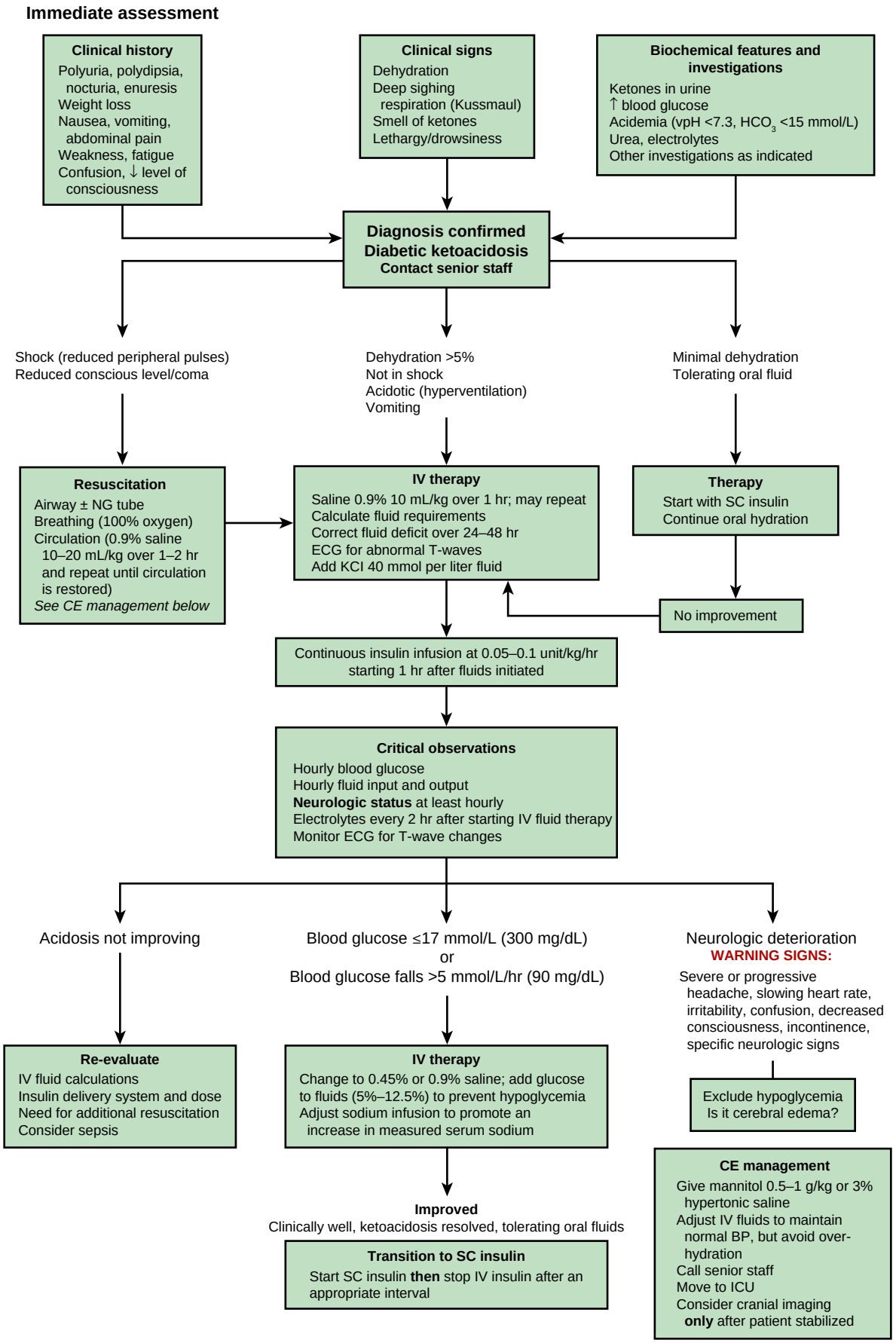

Fig. 629.5 Algorithm for the management of diabetic ketoacidosis. CE, cerebral edema; ECG, electrocardiogram; KCl, potassium chloride; SC, subcutaneous. *(Adapted from Pinhas-Hamiel O, Sperling M. Diabetic ketoacidosis. In: Hochberg Z, ed. Practical Algorithms in Pediatric Endocrinology. 3rd ed. Basel, Switzerland: Karger; 2017:112–113.)*

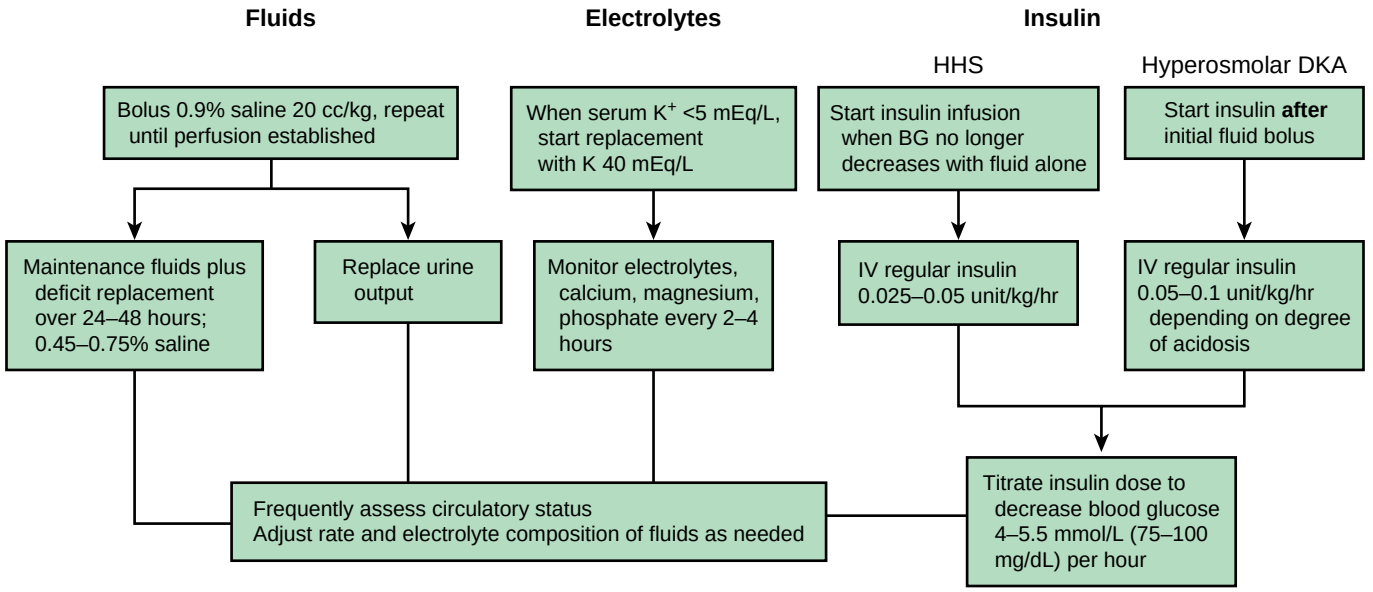

Fig. 629.6 Algorithm for the treatment of hyperglycemic hyperosmolar syndromes (HHS). BG, blood glucose. *(From Zeitler P, Haqq A, Rosenbloom A, Glaser N. Hyperglycemic hyperosmolar syndrome in children: pathophysiological considerations and suggested guidelines for treatment. J Pediatr. 2011;158(1):9–14, 14.e1–2.)*

a rate of 0.05 to 0.1 units/kg/hr after initial fluid resuscitation is complete. This approximates maximal insulin output in normal subjects during an OGTT. Rehydration alone also lowers glucose levels by improving renal perfusion and enhancing renal excretion. The combination of these therapies usually causes a rapid initial decline in serum glucose levels. Persistent decreases in serum glucose of >100 mg/dL/hr may increase the risk of cerebral edema; therefore careful monitoring of serum glucose and adjustment of the dextrose concentration of the IV fluids is essential. The dextrose concentration of the IV fluids should be 5% (D5) once serum glucose falls below ~300 mg/dL and 10% once glucose is below 200 mg/dL. The use of a two-bag system is the preferred approach for managing the dextrose concentrations of the infused IV fluid during DKA. A two-bag system consists of two IV bags of identical electrolyte concentrations, where one bag contains 0% dextrose and the other contains 10% dextrose. The fluids are administered via a Y-site and can be easily titrated to infuse fluids ranging from 0% to 10% dextrose.

Once the blood glucose level decreases below ~180 mg/dL (10 mmol/L), the osmotic diuresis stops and rehydration accelerates without further increase in the infusion rate. Repair of hyperglycemia occurs well before correction of acidosis. Therefore insulin is still needed to control fatty acid release and ketosis after normal glucose levels are reached. If serum glucose levels fall below 100 mg/dL despite an infusion of D10-containing IV fluids, the glucose infusion rate can be increased by increasing dextrose to 12.5% or by increasing the infusion rate. Alternatively, the IV insulin rate can be decreased if ketosis continues to improve.

The initial serum sodium is usually normal or low because of the osmolar dilution caused by hyperglycemia and the effect of an elevated sodium-free lipid fraction. An estimate of the reconstituted, or "true," serum sodium for any given glucose level above 100 mg/dL (5.6 mmol/L) is calculated as follows:

$$\left[Na^{+}\right] + \left(\begin{array}{l}1.6\,\text{mEq / L Na}^{+}\text{ for every 100 mg / dL glucose in}\\ \text{excess of 100}\end{array}\right)$$

or

$$\left[Na^{+}\right] + \left(\frac{\dfrac{1.6\,\text{mEq}}{\text{LNa}^{+}\text{ for every 5.6 mmol}}}{\text{L glucose}}\text{ in excess of 5.6}\right)$$

The sodium should *increase* by approximately 1.6 mmol/L for each 100 mg/dL *decline* in the glucose. The corrected sodium is usually normal or slightly elevated and indicates moderate hypernatremic dehydration. If the corrected value is greater than 150 mmol/L, severe hypernatremic dehydration may be present and may require *slower* fluid replacement. The sodium should steadily increase with therapy. *Declining sodium may indicate excessive free water accumulation and increased risk of cerebral edema.*

Both the metabolic shift to a catabolic predominance and the acidosis move potassium and phosphate from the cell to the serum. The osmotic diuresis, the kaliuretic effect of the hyperaldosteronism, and the ketonuria then accelerate renal losses of potassium and phosphate. Sodium is also lost with the diuresis, but free water losses are greater than isotonic losses. With prolonged illness and severe DKA, total body losses can approach 10-13 mEq/kg of sodium, 5-6 mEq/kg of potassium, and 4-5 mEq/kg of phosphate. These losses continue for several hours during therapy until the catabolic state is reversed and the diuresis is controlled. For example, 50% of infused sodium may be lost in the urine during IV therapy. Even though the sodium deficit may be repaired within 24 hours, intracellular potassium and phosphate may not be completely restored for several days.

Although patients with DKA have a total body potassium deficit, the initial serum level is often normal or elevated. This is caused by the movement of potassium from the intracellular space to the serum, both as part of the ketoacid buffering process and as part of the catabolic shift. These effects are reversed with therapy, and potassium returns to the cell. Improved hydration increases renal blood flow, allowing for increased excretion of potassium in the elevated aldosterone state. The net effect is often a dramatic decline in serum potassium levels, especially in severe DKA. This can precipitate changes in cardiac conductivity, flattening of T waves, and prolongation of the QRS complex and can cause skeletal muscle weakness or ileus. The risk of myocardial dysfunction is increased with shock and acidosis. Potassium levels must be closely followed and electrocardiographic monitoring continued until DKA is substantially resolved. Potassium should be added to the IV fluids once serum potassium declines below 5.5 mEq/L and titrated. A 1:1 mixture of potassium chloride (or acetate) and potassium phosphate is typically used. Rarely, the IV insulin must be temporarily held if serum potassium levels drop below 3 mEq/L. It is unclear whether phosphate deficits contribute to symptoms of DKA such as generalized muscle weakness. In pediatric patients, a deficit has not been shown to compromise oxygen delivery via a deficiency of 2,3-diphosphoglycerate. In most cases, the inclusion of potassium phosphate as outlined earlier will be sufficient; however, additional IV supplementation with potassium phosphate can be used if needed.

Pancreatitis (usually mild) is occasionally seen with DKA, especially if prolonged abdominal distress is present; serum amylase and lipase may be elevated. If the serum lipase is not elevated, the amylase is likely nonspecific or salivary in origin. Serum creatinine adjusted for age may be falsely elevated owing to interference by ketones in the autoanalyzer methodology. An initial elevated value rarely indicates renal failure and should be rechecked when the child is less ketonemic. Blood urea nitrogen may be elevated with prerenal azotemia and should be rechecked as the child is rehydrated. Mildly elevated creatinine or blood urea nitrogen is not a reason to withhold potassium therapy if good urinary output is present.

Ketoacid Accumulation

Low insulin infusion rates (0.02-0.05 units/kg/hr) are usually sufficient to stop peripheral release of fatty acids, thereby eliminating the flow of substrate for ketogenesis. Ketogenesis continues until fatty acid substrates already in the liver are depleted, but this production declines much more quickly without new substrate inflow. Bicarbonate buffers, regenerated by the distal renal tubule and by metabolism of ketone bodies, steadily repair the acidosis once ketoacid production is controlled. *Bicarbonate therapy may increase the risk of hypokalemia and cerebral edema; it should be considered only in rare situations with severe acidosis unresponsive to standard DKA management.*

There should be a steady increase in pH and serum bicarbonate as therapy progresses. Kussmaul respirations should abate and abdominal pain resolve. Persistent acidosis may indicate inadequate insulin or fluid therapy, infection, or rarely lactic acidosis. Urine ketones may be positive after ketoacidosis has resolved because the nitroprusside reaction routinely used to measure urine ketones by dipstick measures only acetoacetate. During DKA, most excess ketones are β-hydroxybutyrate, which increases the normal ratio to acetoacetate from 3:1 to as high as 8:1. With resolution of the acidosis, β-hydroxybutyrate converts to acetoacetate, which is excreted into the urine and detected by the dipstick test. Therefore persistent ketonuria may not accurately reflect the degree of clinical improvement and should not be relied on as an indicator of therapeutic failure. β-Hydroxybutyrate can be measured from serum and even by bedside capillary ketometer and is used in some protocols to monitor the resolution of DKA and help determine when to transition from IV to subcutaneous insulin administration.

All patients with known diabetes presenting in DKA should be checked for precipitating events (infection, poor compliance, trauma) that may have triggered the metabolic decompensation.

Diabetic Ketoacidosis Protocol

See Figure 629.5.

Even though DKA can be of variable severity, a common approach to all cases simplifies the therapeutic regimen and can be safely used for most children. Fluids are best calculated based on weight, not body surface area (m^2), because heights are rarely available for the acutely critically ill child. Children with milder DKA recover in 10-20 hours (and need less total IV fluid before switching to oral intake), whereas those with more severe DKA may require up to 36 hours with this protocol. Any child can be transitioned to oral intake and subcutaneous insulin when DKA has resolved (total CO_2 >15 mEq/L; pH >7.30; sodium is stable between 135 and 145 mEq/L; anion gap closed; no emesis). A dose of long-acting insulin is given (or continuous subcutaneous infusion is started via pump) and the insulin drip is discontinued approximately 30 minutes later. Typically, transition is timed to occur around mealtime so that short-acting insulin can be given as well. Frequent (every 2-3 hours) short-acting insulin bolusing may need to be given until ketosis resolves.

A flow sheet is mandatory for accurate monitoring of changes in acidosis, electrolytes, fluid balance, and clinical status, especially if the patient is transferred from the emergency department to an inpatient setting with new caretakers. This flow sheet is best implemented by a central computer system, which allows for rapid update and wide availability of results, as well as rule-driven highlighting of critical values. A paper flow sheet suffices if it stays with the patient, is kept current, and is reviewed frequently by the physician. Any flow sheet should include columns for serial electrolytes, pH, glucose, and fluid balance. Blood glucose should be tested every hour and electrolytes should be tested every 1-2 hours for children with severe DKA and every 3-4 hours for those with mild to moderate DKA.

Cerebral Edema

Cerebral edema is an important cause of morbidity and mortality in children and adolescents with T1DM. Despite the clinical significance of this complication, its etiology remains incompletely understood. A case control study of DKA suggested that baseline acidosis and abnormalities of sodium, potassium, and blood urea nitrogen concentrations were important predictors of risk of cerebral edema. Early bolus administration of insulin and high volumes of fluid were also identified as risk factors. The incidence of cerebral edema in children with DKA has not changed over the past 15-20 years, despite the widespread introduction of gradual rehydration protocols during this interval. Radiographic imaging is frequently unhelpful in making the diagnosis of cerebral edema. Consequently, each patient must be closely monitored (see Fig. 629.5). For all but the mildest cases, this includes frequent neurologic checks for any signs of increasing intracranial pressure, such as a change of consciousness, depressed respiration, worsening headache, bradycardia, apnea, pupillary changes, papilledema, ptosis, posturing, and seizures. In the event of the development of cerebral edema, immediate interventions should include elevation of the head of the bed, reduction in IV fluid rate, and administration of mannitol (typically 1 g/kg infused intravenously over 20 minutes). Children with moderate to severe DKA have a higher overall risk of cerebral edema and should be treated in a hospital environment where appropriate monitoring can occur.

Nonketotic Hyperosmolar Coma

This syndrome is characterized by severe hyperglycemia (blood glucose >800 mg/dL; 44 mmol/L), absence of or only slight ketosis, nonketotic acidosis, severe dehydration, depressed sensorium or frank coma, and various neurologic signs that may include grand mal seizures, hyperthermia, hemiparesis, and positive Babinski signs. Respirations are usually shallow, but coexistent metabolic (lactic) acidosis may be manifested by Kussmaul breathing. Serum osmolarity is commonly 350 mOsm/kg or greater. This condition is uncommon in children, although it may be increasing in frequency with the rise in the incidence of T2DM. Among adults, mortality rates are high, possibly in part because of delays in recognition and institution of appropriate therapy. In children, there has been a high incidence of preexisting neurologic injury. Profound hyperglycemia may develop over a period of days, and initially, the obligatory osmotic polyuria and dehydration may be partially compensated for by increasing fluid intake. In some cases, consumption of excessive sugar-sweetened beverages may further exacerbate hyperglycemia. With progression of disease, thirst becomes impaired, possibly because of alteration of the hypothalamic thirst center by hyperosmolarity and, in some instances, because of a preexisting defect in the hypothalamic osmoregulating mechanism.

The low production of ketones is attributed mainly to the hyperosmolarity, which in vitro blunts the lipolytic effect of epinephrine and the antilipolytic effect of residual insulin; blunting of lipolysis by the therapeutic use of β-adrenergic blockers may contribute to the syndrome. Depression of consciousness is closely correlated with the degree of hyperosmolarity in this condition and in DKA. Hemoconcentration may also predispose to cerebral arterial and venous thromboses before therapy is initiated.

Treatment of nonketotic hyperosmolar coma is directed at rapid repletion of the vascular volume deficit with normal saline and very slow correction of the hyperosmolar state (see Fig. 629.6). The fluid deficit should be estimated at 12–15% of body weight. Additional normal saline boluses may be required to reduce tachycardia and poor perfusion. One-half isotonic saline (0.45% NaCl; may use normal saline) is administered at a rate estimated to replace 50% of the volume deficit in the first 12 hours, and the remainder is administered during the ensuing 24 hours. The rate of infusion and the saline concentration are titrated to result in a slow decline of serum osmolality. When

the blood glucose concentration approaches 300 mg/dL, the hydrating fluid should be changed to 5% dextrose in 0.45% NaCl. Approximately 20 mEq/L of potassium chloride should be added to each of these fluids to prevent hypokalemia. Serum potassium and plasma glucose concentrations should be monitored at 2-hour intervals for the first 12 hours and at 4-hour intervals for the next 24 hours to permit appropriate adjustments of administered potassium and insulin.

Insulin can be given by continuous intravenous infusion only after serum glucose levels no longer decline with fluid administration. The IV insulin should be initiated at a low dose of 0.025-0.05 units/kg/hr and titrated to achieve a slow decline in serum glucose of 50-75 mg/dL/hr (2.8-4.2 mmol/L/hr). The presence of ketosis or more severe acidosis may necessitate earlier insulin initiation.

INITIATION OF SUBCUTANEOUS INSULIN THERAPY

Excellent diabetes control involves many goals: to maintain blood glucose and HbA_{1c} levels as close to normal without causing hypoglycemia, to eliminate polyuria and nocturia, to prevent ketoacidosis, to permit normal growth and development, and to avoid development of diabetes-related complications—all while minimizing the impact on lifestyle. The specific components of therapy include initiation and adjustment of insulin, extensive teaching of the child and caretakers, and reestablishment of the life routines. Each aspect should be addressed early in the overall care.

Insulin Therapy

Insulin therapy is initiated at the time of diagnosis for all patients with T1DM. The starting dose may range from 0.4 to 1.2 units/kg/day and is calculated based on a number of factors, including age, pubertal stage, and presence or absence of DKA. Typically, prepubertal children presenting without DKA can be started on a dose of 0.4-0.6 units/kg/day. Overweight pubertal adolescents presenting with DKA may need up to 1-1.2 units/kg/day. Insulin requirements in infancy vary tremendously, from <0.2 units/kg/day to >1 unit/kg day. Table 629.6 shows typical starting ranges for total daily insulin dose (units/kg/day) in children.

The precise optimal insulin dose can only be determined empirically, after beginning with the previously mentioned starting doses, with frequent self-monitored blood glucose levels and insulin adjustment by the diabetes team. Many children with new-onset diabetes have some residual β-cell function (the honeymoon period), which is associated with reduced exogenous insulin needs shortly after starting treatment. Residual β-cell function usually fades within a few months and is reflected as a steady increase in insulin requirements and wider glucose excursions.

The initial insulin schedule should be directed toward the optimal degree of glucose control in an attempt to duplicate the activity of the β cell. There are inherent limits to our ability to mimic the β cell. Exogenous insulin does not have a first pass to the liver, whereas 50% of pancreatic portal insulin is taken up by the liver, a key organ for the disposal of glucose. Absorption of an exogenous dose continues despite hypoglycemia, whereas endogenous insulin secretion ceases and serum levels quickly lower with a normally rapid clearance. The absorption rate from an injection varies by injection site and patient activity level, whereas endogenous insulin is secreted directly into the portal circulation. Despite these fundamental physiologic differences, acceptable glucose control can be obtained with insulin analogs used in a **basal-bolus regimen**. Basal-bolus regimens can be accomplished with multiple daily injections (MDIs), where a slow-onset, long-duration background insulin is given once or twice daily for between-meal glucose control (basal) and a rapid-onset insulin is given with meals to provide carbohydrate coverage and correct hyperglycemia. Alternatively, an **insulin pump** can be used, where a rapid-onset insulin is used to provide both basal (via continuous infusion) and bolus (at mealtimes and as needed for hyperglycemia) coverage. The doses of short-acting insulin include two components: **carbohydrate ratio** (typically expressed as 1 unit of insulin for a set number of grams of carbohydrates) and **insulin sensitivity factor** (ISF), also referred to as the *correction factor,* and typically expressed as 1 unit of insulin will decrease blood sugar by a set number of mg/dL to achieve a target blood glucose level). Target blood glucose levels should be individualized according to factors including age, duration of diabetes, history of hypoglycemia, time of day, and physical activity, but will generally range between 90 and 180 mg/dL. Formulas for calculating the basal dose, carbohydrate ratio, and ISF from the total daily insulin dose are provided in Table 629.6

Table 629.6 Approach to Calculating Initial Subcutaneous Insulin Doses at Diagnosis of Type 1 Diabetes (or Type 2 Diabetes Requiring Intensive Insulin Therapy) for Patients Starting on a Basal-Bolus Regimen

CALCULATE *TOTAL DAILY DOSE* (TDD) OF INSULIN*	
Minimum starting dose:	0.2 units/kg/day
Add to the minimum dose as follows:	
- Initial blood glucose >200 mg/dL	+ 0.2 units/kg/day
- Ketosis at presentation	+ 0.2 units/kg/day
- Acidosis (by pH or serum bicarbonate)	+ 0.2 units/kg/day
- Puberty (Tanner stage 2 or greater)†	+ 0.2 units/kg/day
CALCULATE DOSES OF *BASAL* AND *BOLUS* INSULIN‡	
Basal dose (long-acting insulin)	x = 50% of TDD (x = daily dose of basal insulin, typically given as one dose before bedtime)
Carbohydrate coverage (short-acting insulin)	y = 450 / TDD (1 unit of insulin for every "y" grams of carbohydrates consumed at snacks/meals)
Insulin sensitivity factor (short-acting insulin)	z = 1800 / TDD (1 unit of insulin will lower blood glucose by "z" mg/dL)

*Patients with obesity or severe insulin resistance may require an additional 0.2 units/kg/day (or more) of insulin.
†For example, a prepubertal child presenting with hyperglycemia only with a blood glucose of 325 mg/dL would be started on a TDD of insulin of 0.4 units/kg/day, whereas a pubertal adolescent presenting in DKA would be started on 1 units/kg/day.
‡Other equations for calculating basal and bolus insulin doses have been proposed and can be found in the literature. All equations provide only an estimate of insulin requirements. All patients need frequent monitoring of blood glucose after initiation of insulin, and most will require dose adjustments.

All preanalog insulins form hexamers, which must dissociate into monomers subcutaneously before being absorbed into the circulation. Thus a detectable effect for **regular insulin** is delayed by 30-60 minutes after injection. This, in turn, requires delaying the meal 30-60 minutes after the injection for optimal effect—a delay rarely attained in a busy child's life. Regular insulin has a wide peak and a long tail for bolus insulin. This profile limits postprandial glucose control, produces prolonged peaks with excessive hypoglycemic effects between meals, and increases the risk of nighttime hypoglycemia. **Neutral protamine Hagedorn** (**NPH**, also known as *insulin isophane*) is an intermediate-acting insulin with inherent limitations as a basal insulin because it does not achieve a peakless background insulin level. This produces a significant hypoglycemic effect during the midrange of the duration. Thus it is often difficult to predict its interaction with fast-acting insulins. When regular insulin is combined with NPH, the composite insulin profile poorly mimics normal endogenous insulin secretion. Lente and ultralente insulins were other intermediate-acting insulins that have since been discontinued.

Lispro, **aspart**, and **glulisine insulin** are rapid-onset analogs that are absorbed much more quickly because they do not form hexamers. They provide discrete pulses, with onset of action in as little as 10 minutes, with little, if any, overlap and short tail effect. This allows better control of postmeal glucose increase and reduces between-meal or nighttime hypoglycemia. Other ultra-fast-acting insulin analogs are being developed that promise even faster onset of action, a feature that

may make these insulins especially useful in insulin pumps and closed-loop systems.

The **long-acting analogs glargine**, **detemir**, and **degludec** are designed to provide longer duration of action, ranging from ~20 hours (glargine) to ~40 hours (degludec). Glargine forms a precipitate after subcutaneous injection, detemir binds to circulating albumin, and degludec forms dihexamers—all of which lead to stabilization of the hexameric structure, slower disassociation into insulin monomers, and prolonged duration of action. The result is a flatter 24-hour profile, making it easier to predict the combined effect of a rapid bolus (lispro, aspart, or glulisine) on top of the basal insulin and thereby create a more physiologic pattern of insulin effect. Postprandial glucose elevations are better controlled, and between-meal and nighttime hypoglycemia are reduced. An illustration of the insulin effect profiles of the currently available short- and long-acting insulins is provided in Figures 629.7 and 629.8.

At diagnosis, the basal dose of long-acting insulin is typically calculated to provide around 50% of the total daily dose, with the remainder provided with bolus doses of short-acting insulin at mealtimes (calculations used to determine insulin doses are provided in Table 629.6). Over time the ratio of basal to bolus will typically shift downward and will be affected by the magnitude of carbohydrate intake (especially during adolescence). Some infants and toddlers may do well with a higher percentage of their daily insulin provided as basal. There is considerable individual variability in the duration of action of long-acting insulins, and some younger children and obese adolescents will require twice-daily dosing of glargine. Both long- and short-acting insulins are available for administration via multidose insulin pens, which are generally easier to use compared with a traditional syringe and vial approach.

Some families may be unable to administer four daily injections. In these cases, a compromise may be needed. A three-injection regimen combining NPH with a rapid analog bolus at breakfast, a rapid-acting analog bolus at supper, and glargine at bedtime may provide fair glucose control and eliminate the need for an injection at school. Further compromise to a two-injection regimen may occasionally be needed and frequently involves use of premixed insulin preparations that include both rapid- and intermediate-acting insulins (e.g., 70/30). For this regimen, 70% of the total daily dose (TDD) is typically provided with breakfast and 30% of TDD with dinner. An illustration of commonly used insulin regimens is shown in Figure 629.8.

Insulin Pump Therapy

Continuous subcutaneous insulin infusion (CSII) via battery-powered pumps provides a closer approximation of normal plasma insulin profiles and increased flexibility regarding timing of meals and snacks compared with conventional insulin injection regimens. Insulin pump models can be programmed with a patient's personal insulin dose algorithms, including the ISF and carbohydrate ratios for premeal glucose levels. At mealtimes, the patient enters the blood glucose level (or it is automatically transmitted from a linked glucometer) and the carbohydrate content of the meal, and the pump computer will calculate the proper insulin bolus dose. Although CSII frequently improves metabolic control, this may not always be the case. The degree of glycemic control is mainly dependent on how closely patients adhere to the principles of diabetes self-care, regardless of the type of intensive insulin regimen. One benefit of pump therapy may be a reduction in severe hypoglycemia and associated seizures. Randomized trials comparing multiple daily insulin regimens using glargine insulin and CSII in children with T1DM demonstrate similar metabolic control and frequency of hypoglycemic events. Most patients will initiate therapy with insulin pens; timing of transition to an insulin pump can be individualized per patient preference as soon as 6-12 months after diagnosis.

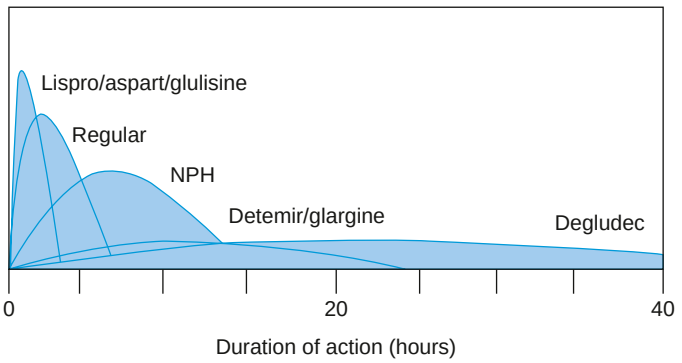

Fig. 629.7 Approximate insulin effect profiles. The following relative peak effect and duration units are used: lispro/aspart/glulisine, peak 20 for 4 hr; regular, peak 15 for 7 hr; neutral protamine Hagedorn *(NPH)* peak 12 for 12 hr; detemir/glargine, peak 5 for 20-24 hr; degludec peak 5 for 42 hr.

Continuous Glucose Monitoring Systems

Continuous glucose monitoring systems (CGMs) consist of a subcutaneous glucose sensor that continuously measures interstitial fluid glucose levels and a receiver to collect and display glucose data. CGMs reduce, but do not eliminate, the need for finger stick blood glucose checking, as calibrations with capillary blood glucose readings are required at least every 12 hours. CGMs report blood glucose levels to the patient/caregiver in real time and can be integrated with smartphones/watches for remote monitoring. To avoid hypoglycemia, the CGM system sounds an alarm once a critical low blood sugar threshold is reached. Additional alerts can be set to notify users of hyperglycemia or rapid rates of change in glucose levels. Short-term studies indicate clinical benefits of these devices as compared to conventional methods of blood glucose monitoring when used by motivated and well-informed patients. CGMs also allow for the determination of **time in range**, where the amount of time in and out of the target glycemic range *(defined by international consensus as glucose between 70 and 180 mg/dL)* can be determined and tracked. Glycemic control has been traditionally monitored by HbA_{1c}, which provides an estimate of average blood glucose over the prior 2 to 3 months. Time in range allows for a more granular assessment of glucose excursions within and between days and may prove to be a more clinically significant metric of diabetes control. A limitation of CGM-only systems is that they require the user to respond to the alert, interpret the data, and intervene to prevent hypoglycemic or hyperglycemic episodes. This limitation is mitigated when the CGM is combined with an insulin pump in a closed-loop system.

Closed-Loop Systems

A closed-loop system allows for direct communication between the continuous glucose sensor and insulin pump for automatic adjustment of insulin infusion rates in response to glucose levels (Fig. 629.9). A fully closed-loop system would be completely independent of the user and theoretically could improve glycemic control through the early identification and response to glucose perturbation and by minimizing the opportunity for human error in insulin dosing. Both single-hormone (insulin only) and bihormone (insulin and glucagon) systems are undergoing clinical investigation.

Several hybrid closed-loop systems with integrated insulin pumps and continuous glucose sensors have gained regulatory approval and entered clinical practice. There is emerging evidence from short-term clinical trials that the use of hybrid closed-loop systems can improve time in range and reduce hyperglycemia and hypoglycemia compared to sensor-augmented systems. Current issues hampering full implementation of this technology include limitations in the accuracy and precision of interstitial fluid glucose sensing, the need for short-acting insulins with more rapid onset of action, and complexity of day-to-day use.

Adjunct Pharmacotherapy

Pramlintide acetate, a synthetic injectable analog of amylin, may be of therapeutic value combined with insulin therapy. However, it has not

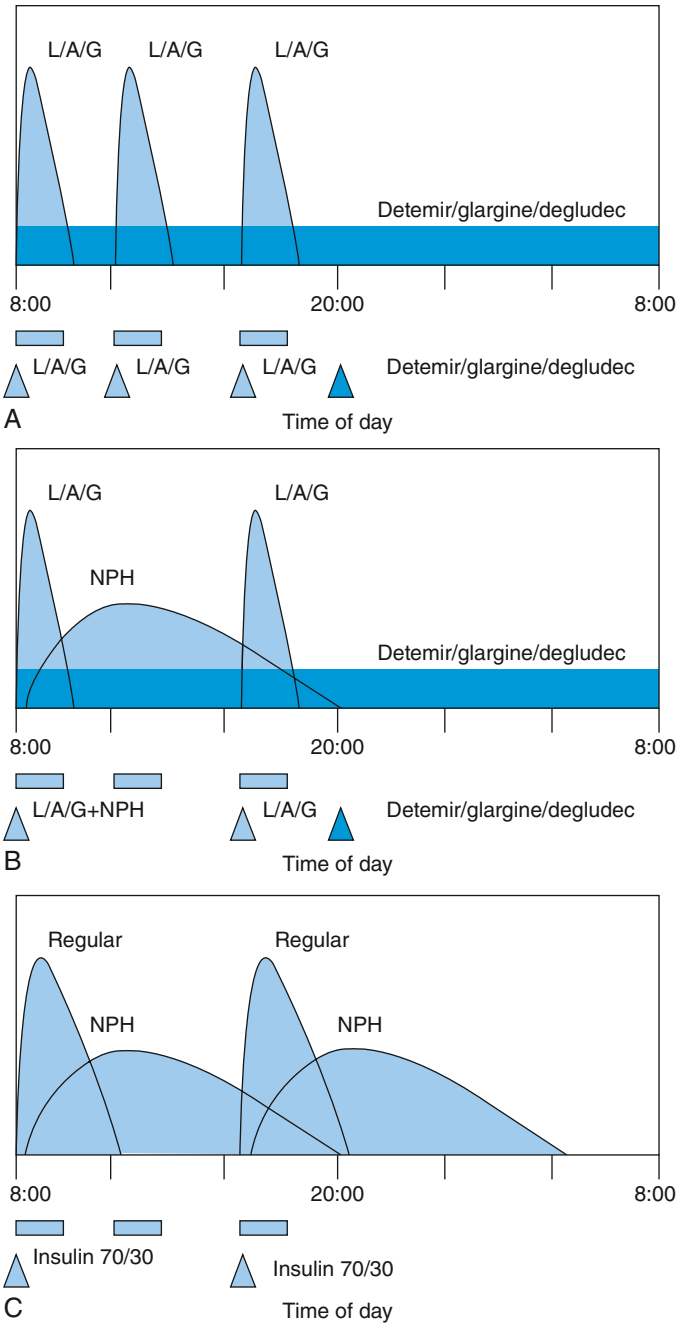

Fig. 629.8 Approximate composite insulin effect profiles of various insulin dosing strategies. Meals are shown as *rectangles* below the time axis. Injections are shown as labeled *triangles;* L/A/G, lispro, aspart, glulisine. All profiles are idealized using average absorption and clearance rates. In typical clinical situations, these profiles vary among patients. A given patient has varying rates of absorption depending on the injection site, physical activity, and other variables. **A,** Basal-bolus regimen: A short-acting insulin (Lantus/aspart/glulisine) is injected before meals, and a long-acting basal insulin (glargine/detemir/degludec) is injected at bedtime. Additional short-acting insulin is given to cover between-meal snacks as needed (not shown). For patients on insulin pumps, the composite insulin profile is similar; however, the basal insulin coverage is provided by a continuous infusion of short-acting insulin. **B,** Thrice-daily injection regimen: A short-acting insulin (Lantus/aspart/glulisine) and neutral protamine Hagedorn *(NPH)* are injected with breakfast (the two types of insulin can be drawn up into one syringe for administration with a single injection), a short-acting insulin is injected with dinner, and a long-acting basal insulin (glargine/detemir/degludec) is injected at bedtime. Because NPH is not a peakless insulin, this regimen is associated with greater risk of hypoglycemia compared with the basal-bolus regimen show in Figure 629.6A but does offer the advantage of eliminating the need for an injection at lunchtime. **C,** Twice-daily injection regimen: The use of a premixed insulin containing a short- and an intermediate-acting insulin that is given twice daily is sometimes necessary for families who are unable to manage more complex dosing regimens. Insulin 70/30 is one such product that combines regular and NPH insulins. This produces the least physiologic profile, with large excesses before lunch and during the early night, combined with poor coverage before supper and breakfast.

gained widespread use. Metformin, an oral antihyperglycemic commonly used to treat T2DM, is sometimes used clinically as an adjunct therapy in T1DM patients with evidence of significant insulin resistance (i.e., obesity, insulin requirements >1.2 units/kg/day, acanthosis nigricans on exam). A clinical trial investigating the addition of metformin in overweight adolescents with T1DM did not find a sustained effect of metformin to lower HbA_{1c} but did show a reduction in daily insulin dose and body mass index (BMI). Reports from observational studies are likewise mixed. These agents would typically not be started at diagnosis of T1DM.

Basic and Advanced Diabetes Education

Therapy consists not only of initiation and adjustment of insulin dose but also of education of the patient and family. Teaching is most efficiently provided by experienced diabetes educators and dietitians. In the acute phase, the family must learn the basics, which includes monitoring the child's blood glucose and urine and/or blood ketones, preparing and injecting the correct insulin dose subcutaneously at the proper time, recognizing and treating low blood glucose reactions, and having a basic meal plan. Most families are trying to adjust psychologically to the new diagnosis of diabetes in their child and thus have a limited ability to retain new information. Written materials covering these basic topics help the family during the first few days.

Children and their families are also required to complete advanced self-management classes to facilitate implementation of flexible insulin management. These educational classes will help patients and their families acquire skills for managing diabetes during athletic activities and sick days. Likewise, further patient and caregiver education with a diabetes educator familiar with diabetes technology is imperative when adding a CGM or transitioning to an insulin pump.

Nutritional Management

Nutrition plays an essential role in the management of patients with T1DM. This is of critical importance during childhood and adolescence, when appropriate energy intake is required to meet the needs for energy expenditure, growth, and pubertal development. There are no special nutritional requirements for the diabetic child other than those for optimal growth and development. Nutritional requirements for the child are outlined on the basis of age, sex, weight, activity, and food preferences. Cultural ethnic considerations must also be integrated into the nutrition plan.

Total recommended caloric intake is based on size or surface area and can be obtained from standard tables (Tables 629.7 and 629.8). The caloric mixture should comprise approximately 55% carbohydrate, 30% fat, and 15% protein, but must be individualized to meet specific patient needs. Approximately 70% of the carbohydrate content should be derived from complex carbohydrates such as starch; intake of sucrose and highly refined sugars should be limited. Complex carbohydrates require prolonged digestion and absorption and thereby raise plasma glucose levels slowly, whereas glucose from refined sugars, including carbonated beverages, is rapidly absorbed and may cause wide swings in the metabolic pattern. The consumption of sugar-sweetened beverages, including soda and juice, should be discouraged. Priority should be given to total calories and total carbohydrates consumed rather than the source. Carbohydrate counting has become a mainstay in the nutrition education and management of patients with T1DM. Patients and their families are provided with information regarding the carbohydrate contents of different foods and food label reading. This allows patients to adjust their insulin dosage to their mealtime carbohydrate

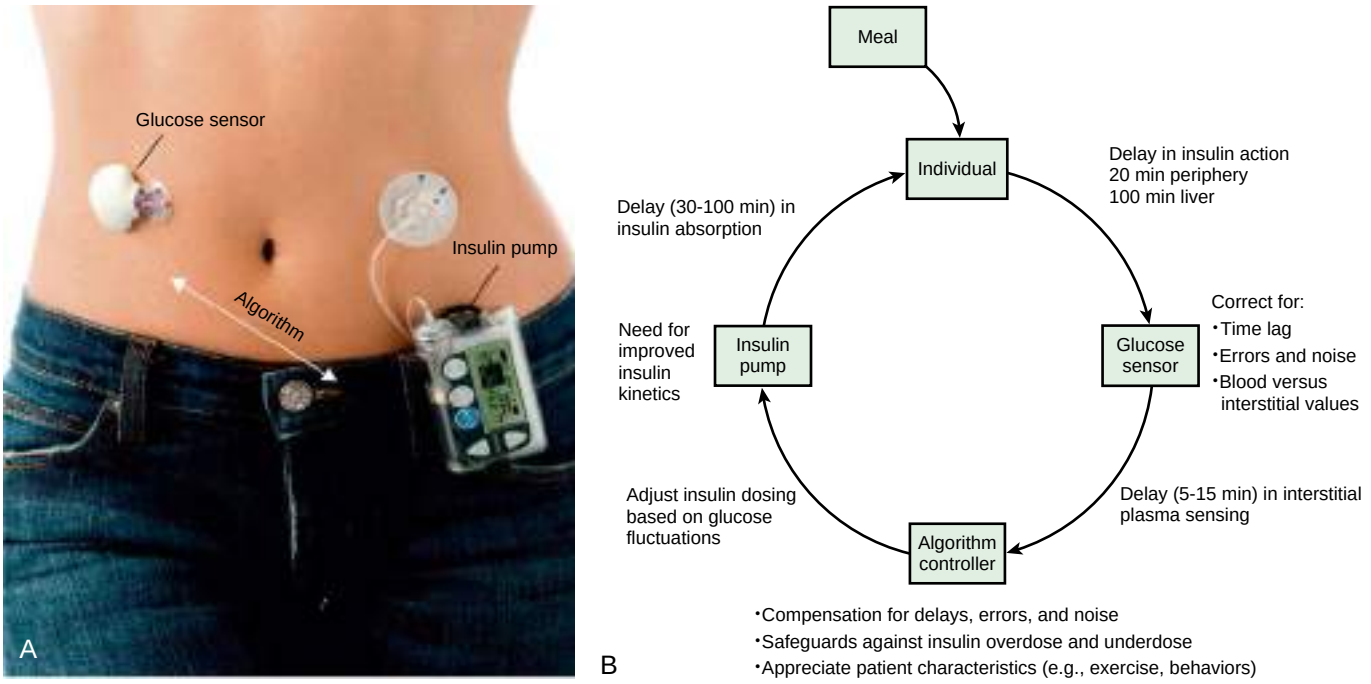

Fig. 629.9 Closed-loop system for T1DM (artificial pancreas). **A,** Prototype of a closed-loop system. **B,** Components of a closed-loop system. Three potential delays in the system include glucose sensing in interstitial fluid, insulin absorption (depends on use of rapid vs regular insulin), and insulin action in peripheral tissues and liver. *(From Atkinson MA, Eisenbarth GS, Michels AW. Type 1 diabetes. Lancet. 2014;383:69–78. Fig. 5.)*

Table 629.7 Calorie Needs for Children and Young Adults

AGE	KCAL REQUIRED/KG BODY WEIGHT*
CHILDREN	
0-12 mo	120
1-10 yr	100-75
YOUNG WOMEN	
11-15 yr	35
≥16 yr	30
YOUNG MEN	
11-15 yr	80-55 (65)
16-20 yr	
Average activity	40
Very physically active	50
Sedentary	30

*Gradual decline in calories per unit weight as age increases.
Numbers in parentheses are means.
From *Nutrition Guide for Professionals. Diabetes education and meal planning.* Alexandria, VA, and Chicago, IL: The American Diabetes Association and The American Dietetic Association, 1988.

intake. The use of carbohydrate counting and insulin-to-carbohydrate ratios as a part of an MDI regimen allows for less rigid meal planning. Flexibility in the use of insulin in relation to carbohydrate content of food improves the quality of life.

Diets with high fiber content are useful in improving control of blood glucose. Daily recommended fiber intake can be determined using the equation:

$$\text{Age in years} + 5 = \text{grams of fiber per day}$$

Moderate amounts of sucrose consumed with fiber-rich foods such as whole-grain bread may have no more glycemic effect than their low-fiber, sugar-free equivalents. Saturated fat intake may increase in patients with T1DM who reduce carbohydrate consumption to avoid taking insulin doses by ingesting carbohydrate-free foods. Total energy from fat should not exceed 35%, and education should be provided such that <10% of total energy should come from saturated and trans fats. Dietary fats derived from animal sources should be reduced and replaced by polyunsaturated fats from vegetable sources. Substituting vegetable oil for animal oils or butter in cooking and lean cuts of meat, poultry, and fish for fatty meats can help to achieve these goals. The intake of cholesterol is also reduced by these measures. These simple measures may reduce serum low-density lipoprotein cholesterol, a predisposing factor to atherosclerotic disease. Table 629.8 summarizes typical nutritional guidelines for T1DM.

Each child and family can and should select a diet based on personal taste with the help of the physician or dietitian (or both). Emphasis should be placed on lifestyle changes to promote adherence to a healthy, balanced diet on a daily basis. Occasional excesses (treats) are permissible but should be limited just as for any child without diabetes. Adjustments in meal planning must constantly be made to meet the needs and the desires of each child. A consistent eating pattern with appropriate supplements for exercise, the pubertal growth spurt, and pregnancy in an adolescent with diabetes is important for metabolic control.

Monitoring

Success in the daily management of the child with diabetes can be measured by the competence acquired by the family, and subsequently by the child, in assuming responsibility for daily self-care. Their initial and ongoing instruction in conjunction with their supervised experience can lead to a sense of confidence in adjusting an insulin dosage for dietary deviations, for unusual physical activity, and for some intercurrent illnesses. Such acceptance of responsibility should make them relatively independent of the physician for their ordinary care. The physician must maintain ongoing interested supervision and shared responsibility with the family and the child.

Self-monitoring of blood glucose is an essential component of managing diabetes. Effective monitoring often also includes other factors that influence blood glucose such as insulin dose, physical activity,

Table 629.8 Summary of Nutrition Guidelines for Children and/or Adolescents with Type 1 Diabetes Mellitus

NUTRITION CARE PLAN		
Promotes optimal compliance.		
Incorporates goals of management: normal growth and development, control of blood glucose, maintenance of optimal nutritional status, and prevention of complications. Uses staged approach.		
NUTRIENT RECOMMENDATIONS AND DISTRIBUTION		
NUTRIENT	% OF CALORIES	RECOMMENDED DAILY INTAKE
Carbohydrate	Will vary	High fiber, especially soluble fiber; optimal amount unknown
Fiber		>20 g/day
Protein	12–20	
Fat	<30	
Saturated	<10	
Polyunsaturated	6–8	
Monounsaturated	Remainder of fat allowance	
Cholesterol		300 mg
Sodium		Avoid excessive; limit to 3,000-4,000 mg if hypertensive
ADDITIONAL RECOMMENDATIONS		
Energy: If using measured diet, reevaluate prescribed energy level at least every 3 mo.		
Protein: High-protein intakes may contribute to diabetic nephropathy. Low intakes may reverse preclinical nephropathy. Therefore 12–20% of energy is recommended; lower end of range is preferred. In guiding toward the end of the range, a staged approach is useful.		
Alcohol: Safe use of moderate alcohol consumption should be taught as routine anticipatory guidance as early as junior high school.		
Snacks: Snacks vary according to individual needs (generally three snacks per day for children; midafternoon and bedtime snacks for junior high children or teens).		
Alternative sweeteners: Use of a variety of sweeteners is suggested.		
Educational techniques: No single technique is superior. Choice of educational method used should be based on patient needs. Knowledge of variety of techniques is important. Follow-up education and support are required.		
Eating disorders: Best treatment is prevention. Unexplained poor control or severe hypoglycemia may indicate a potential eating disorder.		
Exercise: Education is vital to prevent delayed or immediate hypoglycemia and to prevent worsened hyperglycemia and ketosis.		

From Connell JE, Thomas-Doberson D. Nutritional management of children and adolescents with insulin-dependent diabetes mellitus: a review by the Diabetes Care and Education Dietetic Practice Group. J Am Diet Assoc. 1991;91:1556.

dietary changes, hypoglycemia, and illness. A record of these items may be valuable in interpreting the self-monitoring of blood glucose, prescribing appropriate adjustments in insulin doses, and teaching the family. If there are discrepancies in the self-monitoring of blood glucose and other measures of glycemic control (such as the HbA_{1c}), the clinician should attempt to clarify the situation in a manner that does not undermine their mutual confidence.

Daily blood glucose monitoring is accomplished using blood test strips or a CGM. Test strips are impregnated with glucose oxidase that permit blood glucose measurement from a drop of blood. A portable calibrated reflectance meter can approximate the blood glucose concentration accurately. Glucometers contain a memory chip enabling recall of each measurement and the ability to calculate measurement average over a given interval and display the pattern on a computer screen. Such information is a useful educational tool for verifying degree of control and modifying recommended regimens. A small, spring-loaded device that automates capillary bloodletting (lancing device) in a relatively painless fashion is commercially available. Parents and patients should be taught to use these devices and measure blood glucose at least 4 times daily—before breakfast, lunch, and supper and at bedtime. When insulin therapy is initiated and when adjustments are made that may affect the overnight glucose levels, self-monitoring of blood glucose should also be performed at midnight and 3 AM to detect nocturnal hypoglycemia. Standard blood glucose targets are 90-130 mg/dL before meals and 90-150 mg/dL before bedtime; however, glycemic goals must be individualized to the patient based on age, hypoglycemia risk, and other factors.

Glucose measurements that are consistently at or outside these limits, in the absence of an identifiable cause such as exercise or dietary indiscretion, are an indication for a change in the insulin dose. If the fasting blood glucose is high, the evening dose of long-acting insulin (or the early morning/overnight basal rate for insulin pump users) is increased by 10–20% and/or additional fast-acting insulin coverage for a bedtime snack may be considered. If the noon glucose level exceeds set limits, the morning fast-acting insulin-to-carbohydrate ratio is increased by 10–20%. If the presupper glucose is high, the noon fast-acting insulin-to-carbohydrate ratio is increased by 10–20%. If the prebedtime glucose is high, the presupper fast-acting insulin-to-carbohydrate ratio is increased by 10–15%. The ISF can be increased by 10–20% if it is found that insulin corrections given for hyperglycemia do not normalize glucose levels as expected. Similarly, reductions in the insulin type and dose should be made if the corresponding blood glucose measurements are consistently below desirable limits.

A minimum of four daily blood glucose measurements (or CGM use) should be performed. However, some children and adolescents may need to have more frequent blood glucose monitoring based on their level of physical activity and history of frequent hypoglycemic reactions. Families should be encouraged to become sufficiently knowledgeable about managing diabetes.

The FDA has approved the use of CGMs to replace finger stick blood glucose checking for the monitoring and treatment of diabetes in children 2 years of age and older. CGMs are minimally invasive and entail the placement of a small, subcutaneous catheter that can be easily worn by adults and children. The system provides information that allows the patient and healthcare team to adjust the insulin regimen and the nutrition plan to improve glycemic control. CGMs can be helpful in detecting asymptomatic nocturnal hypoglycemia and in lowering HbA_{1c} values without increasing the risk for severe hypoglycemia. Although there are potential pitfalls in CGM use, including suboptimal compliance, human error, incorrect technique, and sensor

failure, the implementation of CGMs in ambulatory diabetes practice allows the clinician to diagnose abnormal glycemic patterns in a more precise manner. In many cases, CGMs are now factory calibrated and nearly eliminate the need for finger sticks. For these reasons, CGMs are increasingly replacing finger stick blood testing as the primary means of glucose monitoring in many patients with T1DM.

Glycosylated Hemoglobin (HbA_{1c})

A reliable index of long-term glycemic control is provided by measurement of glycosylated hemoglobin. HbA_{1c} represents the fraction of hemoglobin to which glucose has been nonenzymatically attached in the bloodstream. The formation of glycosylated hemoglobin is a slow reaction that is dependent on the prevailing concentration of blood glucose; it continues irreversibly throughout the red blood cell's life span of approximately 120 days. The higher the blood glucose concentration and the longer the red blood cell's exposure to it, the higher the fraction of glycosylated hemoglobin, which is expressed as a percentage of total hemoglobin. Because a blood sample at any given time contains a mixture of red blood cells of varying ages, exposed for varying times to varying blood glucose concentrations, an HbA_{1c} measurement reflects the average blood glucose concentration from the preceding 2-3 months. For some patients, it may be helpful to translate HbA_{1c} into estimated average glucose (eAG) using the following equation:

$$eAG = 28.7 * HbA_{1c} - 46.7$$

When measured by standardized methods to remove labile forms, HbA_{1c} is not influenced by an isolated episode of hyperglycemia.

HbA_{1c} measurements should be obtained three to four times a year to obtain a profile of long-term glycemic control. The lower the HbA_{1c} level, the more likely it is that microvascular complications such as retinopathy and nephropathy will be less severe, delayed in appearance, or even avoided altogether. Depending on the method used for determination, HbA_{1c} values may be spuriously elevated in thalassemia (or other conditions with elevated hemoglobin F) and spuriously lower in sickle cell disease (or other conditions with high red blood cell turnover). Fructosamine can be used instead of HbA_{1c} in these patients. Although values of HbA_{1c} may vary according to the method used for measurement, in individuals without diabetes, the HbA_{1c} is usually less than 6%. The HbA_{1c} target should be individualized, but the general recommendation of the ADA and the International Society for Pediatric and Adolescent Diabetes is that children, adolescents, and young adults with T1DM should aim to achieve an HbA_{1c} of <7%.

Exercise

Regular, daily exercise with the goal of 60 minutes of moderate- to vigorous-intensity aerobic activity daily, with vigorous muscle-strengthening and bone-strengthening activities at least 3 days per week is recommended for all children with T1D. A potential complication of exercise in patients with diabetes is the development of hypoglycemia during or within the hours after exercise. Patients and families should be educated on the risk of hypoglycemia and taught strategies to ameliorate this risk, including frequent glucose monitoring before, during, and after exercise; modifying diet and insulin doses around times of exercise; and ensuring access to fast-acting carbohydrates during exercise to treat hypoglycemia should it develop. Regular exercise also improves glucoregulation by increasing glucose use by muscles and increasing the insulin receptor number. In patients who are in poor metabolic control, vigorous exercise may precipitate ketoacidosis because of the exercise-induced increase in the counterregulatory hormones.

Benefits of Improved Glycemic Control

The Diabetes Control and Complications Trial (DCCT) established conclusively the association between higher glucose levels and long-term microvascular complications. Intensive management produced dramatic reductions of retinopathy, nephropathy, and neuropathy by 47–76%. The data from the adolescent cohort demonstrated the same degree of improvement and the same relationship between the outcome measures of microvascular complications.

The beneficial effect of intensified treatment was determined by the degree of blood glucose normalization independently of the type of intensified treatment used. Frequent blood glucose monitoring was considered an important factor in achieving better glycemic control for the intensively treated adolescents and adults. Patients who were intensively treated had individualized glucose targets, frequent adjustments based on ongoing capillary blood glucose monitoring, and a team approach that focused on the person with diabetes as the prime initiator of ambulatory care. Care was constantly adjusted toward reaching normal or near-normal glycemic goals while avoiding or minimizing severe episodes of hypoglycemia. Teaching emphasized a preventive approach to blood glucose fluctuations with constant readjustment to counterbalance any high or low blood glucose readings. Target blood glucose goals were adjusted upward if hypoglycemia could not be prevented.

Total duration of diabetes contributes to development and severity of complications. Nonetheless, many professionals have concerns about applying the results of the DCCT to preschool-age children, who often have hypoglycemia unawareness with unique safety issues, and to prepubertal school-age children, who were not included in the DCCT. The follow-up study to the DCCT, called Epidemiology of Diabetes Interventions and Complications (EDIC), assessed the incidence and predictors of cardiovascular disease events such as heart attack, stroke, or needed heart surgery, as well as diabetic complications related to the eye, kidney, and nerves. The EDIC demonstrated that intensive blood glucose control reduced the risk of any cardiovascular disease event by 42%. In addition, intensive therapy reduced the risk of nonfatal heart attack, stroke, or death from cardiovascular causes by 57%.

Hypoglycemic Reactions

Hypoglycemia is the major limitation to tight control of glucose levels. Once injected, insulin absorption and action are independent of the glucose level, thus creating a unique risk of hypoglycemia from an unbalanced insulin effect. Insulin analogs may help reduce, but cannot eliminate, this risk. Most children with T1DM can expect mild hypoglycemia each week, moderate hypoglycemia a few times each year, and severe hypoglycemia every few years. These episodes are usually not predictable, although exercise, delayed meals or snacks, and wide swings in glucose levels increase the risk. Infants and toddlers are at higher risk for hypoglycemia because they have more variable meals and activity levels, are unable to recognize early signs of hypoglycemia, and are limited in their ability to seek a source of oral glucose to reverse the hypoglycemia. The very young have an increased risk of permanently reduced cognitive function as a long-term sequela of severe hypoglycemia. For these reasons, a more relaxed degree of glucose control may be tolerated in infants and young children.

Hypoglycemia can occur at any time of the day or night. Early symptoms and signs (mild hypoglycemia) may occur with a sudden decrease in blood glucose to levels that do not meet standard criteria for hypoglycemia in children without diabetes. The child may show pallor, sweating, apprehension or fussiness, hunger, tremor, and tachycardia, all as a result of the surge in catecholamines as the body attempts to counter the excessive insulin effect. Behavioral changes such as tearfulness, irritability, and aggression are more prevalent in children. As glucose levels decline further, cerebral glucopenia occurs with drowsiness, personality changes, mental confusion, and impaired judgment (moderate hypoglycemia), progressing to inability to seek help and seizures or coma (severe hypoglycemia). Prolonged severe hypoglycemia can result in a depressed sensorium or strokelike focal motor deficits that persist after the hypoglycemia has resolved. Although permanent sequelae are rare, severe hypoglycemia is frightening for the child and family and can result in significant reluctance to attempt even moderate glycemic control afterward.

Important counterregulatory hormones in children include growth hormone, cortisol, epinephrine, and glucagon. The latter two seem more critical in the older child. Many older patients with long-standing T1DM lose their ability to secrete glucagon in response to hypoglycemia. In the young adult, epinephrine deficiency may also develop as part of a general autonomic neuropathy. This substantially increases the

risk of hypoglycemia because the early warning signals of a declining glucose level are as a result of catecholamine release. Recurrent hypoglycemic episodes associated with tight metabolic control may aggravate partial counterregulatory deficiencies, producing a syndrome of hypoglycemia unawareness and reduced ability to restore euglycemia (hypoglycemia-associated autonomic failure). Avoidance of hypoglycemia allows some recovery from this unawareness syndrome.

The most important factors in the management of hypoglycemia are an understanding by the patient and family of the symptoms and signs of the reaction and an anticipation of known precipitating factors such as gym or sports activities. Tighter glucose control increases the risk. Families should be taught to look for typical hypoglycemic scenarios or patterns in the home blood glucose log, so that they may adjust the insulin dose and avert predictable episodes. A source of emergency glucose should be available at all times and places, including at school and during visits to friends. If possible, it is important to document the hypoglycemia before treating, because some symptoms may not always be from hypoglycemia. Any child suspected of having a moderate to severe hypoglycemic episode should be treated before testing. It is important not to give too much glucose in response to hypoglycemia; 15 g should be given as juice or a sugar-containing beverage or candy, and the blood glucose checked 15-20 minutes later.

Patients, parents, and teachers should also be instructed in the administration of **glucagon** when the child cannot take glucose orally. Glucagon is available for intramuscular or subcutaneous injection and as a nasal powder. A glucagon kit should be kept at home and school. The intramuscular dose of glucagon is 0.5 mg if the child weighs less than 20 kg and 1.0 mg if more than 20 kg; the subcutaneous dose (via prefilled device) is 0.5 mg if less than 45 kg and 1.0 mg if more than 45 kg; the intranasal dose is 3 mg. Glucagon produces a brief release of glucose from the liver. Glucagon often causes emesis, which precludes giving oral supplementation if the blood glucose declines after the glucagon effects have waned. Caretakers must then be prepared to take the child to the hospital for IV glucose administration, if necessary. Mini-dose glucagon (10 μg/yr of age up to a maximum of 150 μg subcutaneously) is effective in treating hypoglycemia in children with blood glucose less than 60 mg/dL who fail to respond to oral glucose and remain symptomatic. Glucagon is reconstituted as per standard instructions, then drawn up for subcutaneous injection using a standard insulin syringe, whereby 1 unit is the equivalent of 10 mcg of glucagon.

Dawn Phenomenon and Somogyi Phenomenon

There are several reasons that blood glucose levels increase in the early morning hours before breakfast. The most common is a simple decline in insulin levels. This usually results in routinely elevated morning glucose. The **dawn phenomenon** is thought to be mainly caused by overnight growth hormone secretion and increased insulin clearance. It is a normal physiologic process seen in most adolescents without diabetes, who compensate with more insulin output. A child with T1DM cannot compensate. The dawn phenomenon is usually recurrent and modestly elevates most morning glucose levels. Rarely, high morning glucose is caused by the **Somogyi phenomenon**, a theoretical rebound from late-night or early-morning hypoglycemia thought to be from an exaggerated counterregulatory response. It is unlikely to be a common cause, in that most children remain hypoglycemic (do not rebound) once nighttime glucose levels decline. CGMs may help clarify a child's ambiguously elevated morning glucose levels.

Behavioral/Psychologic Aspects and Eating Disorders

Diabetes in a child affects the lifestyle and interpersonal relationships of the entire family. Feelings of anxiety and guilt are common in parents. Similar feelings, coupled with denial and rejection, are equally common in children, particularly during the rebellious teenage years. Family conflict has been associated with poor treatment adherence and poor metabolic control among youths with T1DM. On the other hand, it has been shown that shared responsibility is consistently associated with better psychologic health, good self-care behavior, and good metabolic control, whereas responsibility assumed by either the child or parent alone does not have outcomes that are equally successful. In some cases, links of shared responsibility to health outcomes were stronger among older adolescents. However, no specific personality disorder or psychopathology is characteristic of diabetes; similar feelings are observed in families with children who have other chronic diseases.

COGNITIVE FUNCTION

There is evidence that children with T1DM are at higher risk of developing small differences in cognitive abilities compared to healthy age-matched peers. Evidence suggests that early-onset diabetes (younger than 7 years) is associated with cognitive difficulties compared to late-onset diabetes and healthy controls. The cognitive difficulties observed were primarily learning and memory skills (both verbal and visual) and attention/executive function skills. It is likely that the impact of diabetes on pediatric cognition appears shortly after diagnosis. Indeed, it has been observed that early-onset diabetes and longer duration of diabetes in some children with diabetes adversely affect their school performance and educational achievements.

COPING STYLES

Children and adolescents with T1DM are faced with a complex set of developmental changes and shifting burdens of the disease. Adjustment problems might affect psychologic well-being and the course of the disease by affecting self-management and leading to poor metabolic control. Coping styles refer to typical habitual preferences for ways of approaching problems and might be regarded as strategies that people generally use to cope across a wide range of stressors. Problem-focused coping refers to efforts directed toward rational management of a problem, and it is aimed at changing the situation causing distress. On the other hand, emotion-focused coping implies efforts to reduce emotional distress caused by the stressful event and to manage or regulate emotions that might accompany or result from the stressor. In adolescents with diabetes, avoidance coping and venting emotions have been found to predict poor illness-specific self-care behavior and poor metabolic control. Patients who use more mature defenses and exhibit greater adaptive capacity are more likely to adhere to their regimen. Coping strategies seem to be age dependent, with adolescents using more avoidance coping than younger children with diabetes.

NONADHERENCE

Family conflict, anger, sadness, or denial and feelings of anxiety or loss of control find expression in nonadherence to instructions regarding nutritional and insulin therapy and in noncompliance with self-monitoring. When adolescents externalize behavior problems, such behaviors interfere with adherence and may result in deterioration of glycemic control. Such externalizing behaviors are common, whereas repeated omission of insulin resulting in ketoacidosis in the same individual is less common, and episodes of deliberate overdosage with insulin resulting in hypoglycemia are even less prevalent. They may, however, be pleas for psychologic help or be manipulative attempts to escape an environment perceived as undesirable or intolerable; occasionally, they may be manifestations of suicidal intent. Frequent admissions to the hospital for ketoacidosis or hypoglycemia should arouse suspicion of an underlying emotional conflict. Overprotectiveness on the part of parents is common and often is not in the best interest of the adolescent patient. Feelings of being different or of being alone, or both, are common and must be acknowledged. Tailoring the insulin administration and the timing of meals and blood sugar tests may support individual lifestyle choices. Aggregating what they know about diabetes, families and patients worry about the risk of complications from diabetes and about the decreased life span. Unfortunately, misinformation abounds about the risks of the development of diabetes in siblings or offspring and of pregnancy in young diabetic women. Even appropriate information may cause further anxiety.

All of these issues must be spoken about at the outset, and many of these problems can be averted through continued empathic counseling based on correct information, focusing on normality and on planning to be a productive member of society. Recognizing the potential

impact of these problems and that feelings of isolation and frustration tend to be lessened by the sharing of common problems, peer discussion groups have been organized in many locales. Summer camps for diabetic children afford an excellent opportunity for learning and sharing under expert supervision. Education about the pathophysiology of diabetes, insulin dose, technique of administration, nutrition, exercise, and hypoglycemic reactions can be reinforced by medical and paramedical personnel. The presence of numerous peers with similar problems offers new insights to the diabetic child. Residential treatment for children and adolescents with difficult-to-manage T1DM is rarely available.

ANXIETY AND DEPRESSION

It has been shown that there are significant correlations between poor metabolic control and depressive symptoms, a high level of anxiety, or a previous psychiatric diagnosis. In a similar way, poor metabolic control is related to higher levels of personal, social, school maladjustment, or family environment dissatisfaction. It is estimated that 20–26% of adolescent patients may develop major depressive disorder. The prevalence of depression is twofold greater than controls in children with diabetes and threefold greater in adolescents. Additionally, the prevalence of psychopathology is greater in people with diabetes. The course characteristics of depression in young diabetic subjects and psychiatric control subjects appear to be similar. However, eventual propensity of diabetic youths for more protracted depressions is greater. There is also a higher risk of recurrence among young diabetic females. On balance, anxiety and depression play an important and complex role in T1DM; their relationship to metabolic control does not yet appear clear. Therefore the healthcare providers managing a child or adolescent with diabetes should be aware of their pivotal role as counselor and advisor and should closely monitor the mental health of patients with diabetes. Accordingly, the recommendation is screening for anxiety and/or depression in subjects exhibiting symptoms, using a validated screening tool, followed by the appropriate referral to mental health providers when warranted.

FEAR OF SELF-INJECTING AND SELF-TESTING

Extreme fear of self-injecting insulin *(injection phobia)* is likely to compromise glycemic control and emotional well-being. Likewise, fear of finger pricks of CGM and pump site insertions can be a source of distress and may seriously hamper self-management. Children and adolescents may either omit insulin dosing or refuse to rotate their injection sites because repeated injection in the same site is associated with less pain sensation. Failure to rotate injection sites results in subcutaneous scar formation **(lipohypertrophy)**. Insulin injection into the lipohypertrophic skin is usually associated with poor insulin absorption, consequent frustration with lack of expected glucose control, and/or insulin leakage with resultant suboptimal glycemic control. Children and adolescents with injection phobia and fear of self-testing can be counseled by a trained behavioral therapist and benefit from such techniques as desensitization and biofeedback to attenuate pain sensation and psychologic distress associated with these procedures.

EATING DISORDERS

Treatment of T1DM involves constant monitoring of food intake. In addition, improved glycemic control is sometimes associated with increased weight gain. These factors, along with individual, familial, and socioeconomic factors, can lead to an increased incidence of both nonspecific and specific eating disorders, which can disrupt glycemic control and increase the risk of long-term complications. Eating disorders and subthreshold eating disorders are almost twice as common in adolescent females with T1DM as in their nondiabetic peers. There is less information regarding the prevalence of eating disorders among male adolescents with T1DM. The prevalence of eating disorders identified in females with T1DM has ranged from 9% to 32% in different studies. Other studies have found that approximately 11% of T1DM adolescent females take less insulin than prescribed to lose weight. Among adolescent females with T1DM and an eating disorder, the misuse of insulin to lose weight is not uncommon.

When behavioral/psychologic problems and/or eating disorders are assumed to be responsible for poor adherence with the medical regimen, referral for psychologic evaluation and management is indicated. Behavioral therapists and psychologists usually form part of the pediatric diabetes team in most centers and can help assess and manage emotional and behavioral disorders in diabetic children. Evaluation of nurse-delivered motivational enhancement with and without cognitive-behavioral therapy in adults revealed that combined therapy resulted in modest improvement in glycemic control. However, motivational enhancement therapy alone did not improve glycemic control. Whereas in some studies the effect of therapist-delivered motivational enhancement therapy on glycemic control in adolescents with T1DM lasted only as long as intensive individualized counseling continued, in other studies, motivational interviewing was shown to be an effective method of facilitating changes in a teenager's behavior with T1DM, with corresponding improvement in glycemic control.

Management During Infections

Although infections are no more common in diabetic children than in nondiabetic ones, they can disrupt glucose control and may precipitate DKA. In addition, the child with diabetes is at increased risk of dehydration if hyperglycemia causes an osmotic diuresis or if ketosis causes emesis. Counterregulatory hormones associated with stress blunt insulin action and elevate glucose levels. If anorexia occurs from ketosis, lack of caloric intake increases the risk of hypoglycemia. Although children younger than 3 years of age tend to become hypoglycemic and older children tend toward hyperglycemia, the overall effect is unpredictable. Therefore frequent blood glucose monitoring, monitoring of urine and/or blood ketones, and adjustment of insulin doses are essential elements of **sick day guidelines** (Table 629.9).

The overall goals are to maintain hydration, control glucose levels, and avoid ketoacidosis. This can usually be done at home if proper sick day guidelines are followed and with telephone contact with healthcare providers. The development of ketones in a patient on insulin pump therapy may be a sign of infusion failure and the infusion set should be changed. The family should seek advice if home treatment does not

Table 629.9 Guidelines for Sick Day Management

	GLUCOSE TESTING AND EXTRA RAPID-ACTING INSULIN		
URINE KETONE STATUS	**INSULIN**	**CORRECTION DOSES***	**COMMENT**
Negative or small†	q2h	q2h for glucose >250 mg/dL	Check ketones every other void
Moderate to large‡	q1h	q1h for glucose >250 mg/dL	Check ketones each void; go to hospital if emesis occurs

*Give insulin based on individualized dosing schedule. Also give usual dose for carbohydrate intake if glucose >150 mg/dL.
†For home serum ketones <1.5 mmol/L per commercial kit.
‡For home serum ketones >1.5 mmol/L.
Basal insulin: glargine or detemir basal insulin should be given at the usual dose and time. NPH and lente should be reduced by half if blood glucose <150 mg/dL and the oral intake is limited.
Oral fluids: sugar-free if blood glucose >250 mg/dL (14 mmol/L); sugar-containing if blood glucose <250 mg/dL.
Call physician or nurse if blood glucose remains elevated after three extra doses, if blood glucose remains <70 mg/dL and child cannot take oral supplement, if dehydration occurs.

control ketosis, hyperglycemia, or hypoglycemia or if the child shows signs of dehydration or has persistent vomiting. A child with significant ketosis and emesis should be seen in the emergency department for a general examination, to evaluate hydration, and to determine whether ketoacidosis is present by checking serum electrolytes, glucose, pH, and total CO_2. A child whose blood glucose declines to less than 50-60 mg/dL (2.8-3.3 mmol/L) and who cannot maintain oral intake may need IV glucose, especially if further insulin is needed to control ketosis.

Management During Surgery

Surgery can disrupt glucose control in the same way as intercurrent infections can. Stress hormones associated with the underlying condition and with the surgery itself cause insulin resistance. This increases glucose levels, exacerbates fluid losses, and may initiate DKA. On the other hand, caloric intake is usually restricted, which decreases glucose levels. The net effect is as difficult to predict as during an infection. Vigilant monitoring and frequent insulin adjustments are required to maintain euglycemia and avoid ketosis.

For most elective and other smaller surgical procedures, patients can simply be continued on their typical home basal regimens. This includes injection of the usual dose of long-acting insulin at the usual time for patients on shots. Patients on pumps can simply wear the pump during the surgery, if approved by hospital policy. Blood sugar should be monitored hourly during the procedure and perioperatively; hyperglycemia can be corrected using the standard home ISF, and IV dextrose can be provided as needed for hypoglycemia. For major procedures, trauma, or situations where a prolonged period of decreased oral intake is expected postoperatively, it is advisable to manage insulin requirements with an IV insulin drip (Table 629.10). IV insulin is typically started at a dose of 0.03 units/kg/hr for patients who are euglycemic at the time of surgery. Serum glucose levels should be followed every hour operatively and perioperatively, and the insulin dose and/or the dextrose concentration of the IV fluids can be adjusted as needed. In patients who are found to be hyperglycemic preoperatively (serum glucose >250 mg/dL), it is advisable to check for ketones before starting surgery. If significant ketosis is identified, surgery should be delayed (if possible) until the ketosis can be treated and resolved. Postoperatively, the patient should not be discharged until blood glucose levels are stable and oral intake is tolerated.

LONG-TERM COMPLICATIONS: RELATION TO GLYCEMIC CONTROL

Complications of DM include microvascular complications, such as retinopathy and nephropathy; macrovascular complications, including coronary artery disease, cerebrovascular disease, and peripheral vascular disease; peripheral and autonomic neuropathies; and diabetic osteopathy manifesting as increased risk for osteoporosis and fracture.

Diabetic Retinopathy

Diabetic retinopathy is the leading cause of blindness in the United States in adults age 20-65 years. The risk of diabetic retinopathy after 15 years' duration of diabetes is 98% for individuals with T1DM and 78% for those with T2DM. Rates for diabetic retinopathy range from close to 15% to up to 30%. Lens opacities (caused by glycation of tissue proteins and activation of the polyol pathway) are present in at least 5% of those younger than age 19 years. Metabolic control has an impact on the development of this complication, as prevalence rates are substantially higher with increased duration of diabetes and higher HbA_{1c}, hypertension, and high cholesterol levels. Independent of duration, the prevalence of diabetic retinopathy is higher in T1DM. Genetic factors may have a role, because only 50% of patients develop proliferative retinopathy. The earliest clinically apparent manifestations of diabetic retinopathy are classified as nonproliferative or background diabetic retinopathy—microaneurysms, dot and blot hemorrhages, hard and soft exudates, venous dilation and beading, and intraretinal microvascular abnormalities. These changes do not impair vision. The more severe form is proliferative diabetic retinopathy, which manifests by neovascularization, fibrous proliferation, and preretinal and vitreous hemorrhages. Proliferative retinopathy, if not treated, is relentlessly progressive and impairs vision, leading to blindness. The mainstay of treatment is panretinal laser photocoagulation. In advanced diabetic eye disease—manifested by severe vitreous hemorrhage or fibrosis, often with retinal detachment—vitrectomy is an important therapeutic modality. Eventually, the eye disease becomes quiescent, a stage termed *involutional retinopathy.* A separate subtype of retinopathy is diabetic maculopathy, which is manifested by severe macular edema impairing central vision. Focal laser photocoagulation may be effective in treating diabetic maculopathy.

Diabetic patients should have an initial dilated and comprehensive examination by an ophthalmologist shortly after the diagnosis of diabetes is made in patients with T2DM and within 3-5 years after the onset of T1DM (but not before age 10 years). Any patients with visual symptoms or abnormalities should be referred for ophthalmologic evaluation. Subsequent evaluations for both T1DM and T2DM patients should be repeated every 1-2 years as recommended by an eye care professional experienced in the diagnosis and management of diabetic retinopathy (Table 629.11).

Diabetic Nephropathy

Diabetic nephropathy is the leading known cause of end-stage renal disease (ESRD) in the United States. Most ESRD from diabetic nephropathy is preventable. Diabetic nephropathy affects 20–30% of patients with T1DM and 15–20% of T2DM patients 20 years after onset. The mean 5-year life expectancy for patients with diabetes-related ESRD is less than 20%. The increased mortality risk in long-term T1DM may be the result of nephropathy, which may account for approximately 50% of deaths. The risk of nephropathy increases with the duration of diabetes (up until 25-30 years' duration, after which this complication rarely begins), degree of metabolic control, and genetic predisposition to essential hypertension. Only 30–40% of patients affected by T1DM eventually experience ESRD. The glycation of tissue proteins results in glomerular basement membrane thickening. The course of diabetic nephropathy is slow. An increased urinary albumin excretion rate of 30-300 mg/24 hr (20-200 μg/min)—**microalbuminuria**—can be detected and constitutes an early stage of nephropathy from intermittent to persistent (incipient), which is commonly associated with glomerular hyperfiltration and blood pressure elevation. As nephropathy evolves to an early overt stage with proteinuria (albumin excretion rate >300 mg/24 hr or >200 μg/min), it is accompanied by hypertension. Advanced-stage nephropathy is defined by a progressive decline in renal function (declining glomerular filtration rate and elevation of serum blood urea and creatinine), progressive proteinuria, and hypertension. Progression to ESRD is recognized by the appearance of uremia, nephrotic syndrome, and the need for renal replacement (transplantation or dialysis).

Screening for diabetic nephropathy is a routine aspect of diabetes care. The ADA recommends yearly screening for individuals with T2DM and yearly screening for those with T1DM after 5 years' duration of disease with a random spot urine sample for albumin-to-creatinine ratio. Abnormal results should be confirmed by two

Table 629.10 Guidelines for Intravenous Insulin Coverage During Surgery

BLOOD GLUCOSE LEVEL (mg/dL)	INSULIN INFUSION (units/kg/hr)	BLOOD GLUCOSE MONITORING
<120	0.00	1 hr
121-200	0.03	2 hr
200-300	0.06	2 hr
300-400	0.08	1 hr*
400	0.10	1 hr*

*Check urine ketones.
An infusion of 5% glucose and 0.45% saline solution with 20 mEq/L of potassium acetate is given at 1.5 times the maintenance rate.

Table 629.11 Screening Guidelines

	INITIAL TESTING	FREQUENCY	TEST
Thyroid disease	At diagnosis	Every 1-2 yr or sooner if symptoms	TSH, thyroid antibodies
Celiac	At diagnosis	Within 2 yr and again at 5 yr or sooner if symptoms	IgA and TTG
Hypertension	At diagnosis	Each visit	Elevated BP based on ≥90th% for age, sex, height on three separate occasions
Dyslipidemia	≥10 yr of age at diagnosis once glucose control established	If abnormal annually; every 5 yr if initially normal	Goal LDL-C <100 mg/dL
Nephropathy	At puberty or age ≥10 yr whichever comes first, if T1DM ≥5 yr	Annually	Albuminuria; urine albumin-to-creatinine ratio
Retinopathy	T1DM ≥3-5 yr when ≥10 yr or puberty, whichever comes first	Annually	Dilated eye exam
Neuropathy	At puberty or ≥10 year, whichever earlier if T1DM >5 yr	Annually	Foot exam

BP, Blood pressure; IgA, immunoglobulin A; LDL, low density lipoprotein; TSH, thyroid-stimulating hormone; TTG, tissue transglutaminase.
Data from American Diabetes Association. Children and adolescents: standards of medical care in diabetes—2018. Diabetes Care. 2018;41(Suppl 1):S126–S136.

additional specimens on separate days because of the high variability of albumin excretion in patients with diabetes. Short-term hyperglycemia, strenuous exercise, urinary tract infections, marked hypertension, heart failure, and acute febrile illness can cause transient elevation in urinary albumin excretion. There is marked day-to-day variability in albumin excretion, so at least two of three collections done in a 3- to 6-month period should show elevated levels before microalbuminuria is diagnosed and treatment is started. Once albuminuria is diagnosed, a number of factors attenuate the effect of hyperfiltration on kidneys: (1) meticulous control of hyperglycemia, (2) aggressive control of systemic blood pressure, (3) selective control of arteriolar dilation by use of angiotensin-converting enzyme inhibitors (thus decreasing transglomerular capillary pressure), and (4) dietary protein restriction (because high protein intake increases the renal perfusion rate). Tight glycemic control will delay the progression of microalbuminuria and slow the progression of diabetic nephropathy.

DIABETIC NEUROPATHY

Both the peripheral and autonomic nervous systems can be involved; diabetic neuropathy can develop in both children and adolescents. The etiology of diabetic neuropathy remains incompletely understood, and the impact of hyperglycemia on its development remains uncertain. Observational studies done in the years before the era of intensive insulin therapy for T1DM reported a higher incidence of neuropathy compared with more recent studies. However, several studies have found that the development of preclinical and symptomatic peripheral diabetic neuropathy in childhood is not strongly associated with either glycemic control or duration of disease. The polyol pathway, nonenzymatic glycation, and/or disturbances of myoinositol metabolism, affecting one or more cell types in the multicellular constituents of the peripheral nerve, have been hypothesized to have an inciting role. Other factors, such as possible direct neurotrophic effects of insulin, insulin-related growth factors, nitric oxide, and stress proteins, may also contribute to the development of neuropathy. Using quantitative sensory testing, abnormal cutaneous thermal perception is a common finding in both upper and lower limbs in neurologically asymptomatic young diabetic patients. Heat-induced pain threshold in the hand is correlated with the duration of the diabetes. There is no correlation between quantitative sensory testing scores and metabolic control. Subclinical motor nerve impairment as manifested by reduced sensory nerve conduction velocity and sensory nerve action potential amplitude have been detected in as many as 10–58% of children with diabetes. An early sign of autonomic neuropathy, such as decreased heart rate variability, may present in adolescents with a history of long-standing disease and poor metabolic control. A number of therapeutic strategies have been attempted with variable results. These treatment modalities include (1) improvement in metabolic control, (2) use of aldose reductase inhibitors to reduce by-products of the polyol pathway, (3) use of α-lipoic acid (an antioxidant) that enhances tissue nitric oxide and its metabolites, (4) use of anticonvulsants (e.g., lorazepam, valproate, gabapentin, carbamazepine, pregabalin, phenytoin, tiagabine, and topiramate) for treatment of neuropathic pain, and (5) use of antidepressants (amitriptyline, imipramine, and selective serotonin reuptake inhibitors). Additional medications include antiarrhythmics such as lidocaine, topical analgesics, and nonsteroidal antiinflammatory drugs.

Skeletal Effects of Type 1 Diabetes Mellitus

The skeleton is adversely affected by diabetes, with T1DM patients at greater risk for skeletal complications than those with T2DM. T1DM is associated with an increased risk of fracture that first becomes evident in childhood and persists across the entire life span. This includes a dramatically increased hip fracture risk in adults, ranging from two- to sevenfold higher than patients without diabetes, depending on the population studied. Most, but not all, studies have shown T1DM to be associated with low bone mineral density. This differs from T2DM, where bone density is normal or even above average because of increased mechanical loading in association with obesity. The deficits in bone density do not appear to be sufficient to explain the degree of increased fracture risk, leading to the hypothesis that bone quality may be impaired as well. The mechanism(s) underlying diabetic-related osteopathy is poorly understood and presumed to be multifactorial. Most, but not all, studies show an association between poor glycemic control and adverse skeletal outcomes, suggesting a role for hyperglycemia and/or insulin deficiency. Chronic exposure to hyperglycemia may weaken bone strength through the accumulation of advanced glycation end products (AGEs) in bone. Other factors hypothesized to impair bone health in diabetes include chronic inflammation, abnormalities in the growth hormone-insulin-like growth factor 1 (IGF-1) axis, and abnormalities in bone mineral metabolism including excess urinary calcium loss. There are no standard guidelines for bone health screening in children. Assessment of bone density by dual-energy x-ray absorptiometry (DXA) and markers of bone mineral metabolism is recommended in adults with fracture history and other risk factors for osteoporosis. Dietary education should reinforce the importance of meeting the recommended daily allowance (RDA) for calcium and vitamin D intake from diet and supplements.

Other Complications

Mauriac syndrome is a rare complication related to chronic underinsulinization that is characterized by growth failure and hepatomegaly

caused by excess glycogen accumulation in the liver. It has become much less common since longer-acting insulins have become available. Clinical features of Mauriac syndrome include moon face, protuberant abdomen, proximal muscle wasting, and enlarged liver from fat and glycogen infiltration.

The syndrome of **limited joint mobility** is frequently associated with the early development of diabetic microvascular complications, such as retinopathy and nephropathy, which may appear before 18 years of age. The prevalence of limited joint mobility has significantly decreased, which is attributed to the improved overall metabolic control of children and adolescents with T1DM.

PROGNOSIS

T1DM is a serious, chronic disease. It has been estimated that the average life span of individuals with diabetes is approximately 10 years shorter than that of people without diabetes, but with improved care, that figure is lessening consistently. Although most children with T1DM eventually attain a height within the normal adult range, puberty may be delayed, and the final height may be less than the genetic potential. From studies in identical twins, it is apparent that despite seemingly satisfactory control, the affected twin manifests delayed puberty and a substantial reduction in height when the onset of disease occurs before puberty. These observations indicate that, in the past, conventional criteria for judging control were inadequate and that adequate control of T1DM was almost never achieved by routine means.

The changing pattern of metabolic control is having a profound influence on reducing the incidence and the severity of certain complications. For example, after 20 years of diabetes, there was a decline in the incidence of nephropathy in T1DM in Sweden among children whose disease was diagnosed in 1971–1775 compared with in the preceding decade. In addition, in most patients with microalbuminuria in whom it was possible to obtain good glycemic control, microalbuminuria disappeared. This improved prognosis is directly related to metabolic control.

PANCREAS AND ISLET TRANSPLANTATION AND REGENERATION

In an attempt to cure T1DM, transplantation of a segment of the pancreas or of isolated islets has been performed in adults. These procedures are both technically demanding and associated with the risks of disease recurrence and complications of rejection or its treatment by immunosuppression. Long-term complications of immunosuppression include the development of malignancy. Some antirejection drugs, notably cyclosporine and tacrolimus, are toxic to the islets of Langerhans, impairing insulin secretion and even causing diabetes. Hence, segmental pancreas transplantation is generally only performed in association with transplantation of a kidney for a patient with ESRD caused by diabetic nephropathy in which the immunosuppressive regimen is indicated for the renal transplantation. Several thousand such transplants have been performed in adults. With experience and better immunosuppressive agents, functional survival of the pancreatic graft may be achieved for up to several years, during which time patients may be in metabolic control with no or minimal exogenous insulin and reversal of some of the microvascular complications. However, because children and adolescents with DM are not likely to have ESRD from their diabetes, pancreas transplantation as a primary treatment in children cannot be recommended.

Islet cell transplantation is challenging because of limited survival of the transplanted cells and because of rejection. An islet transplantation strategy (Edmonton protocol) infused isolated pancreatic islets into the portal vein of adults with T1DM, along with immunosuppressive medications that had lower side effect profiles than other drugs. Although lasting insulin independence was initially low, engraftment and insulin independence have improved over the last decade, and over a thousand patients have undergone the procedure. There has been improved islet engraftment using improved induction and maintenance immunosuppression. Still, in 5-year follow-up studies, only ~10% maintain insulin independence, with an average duration of insulin independence of ~15 months. Long-term challenges remain the toxicity of immunosuppression, the limited procurement of viable tissue, and funding and limitations of engraftment itself.

629.3 Type 2 Diabetes Mellitus

David R. Weber

Formerly known as *non–insulin-dependent diabetes* or *adult-onset diabetes,* T2DM is a heterogeneous disorder, characterized by peripheral insulin resistance and failure of the β cell to keep up with increasing insulin demand. Patients with T2DM have relative rather than absolute insulin deficiency. Generally, they are not ketosis prone, but ketoacidosis is the initial presentation in 5–10% of affected subjects (Table 629.12).

NATURAL HISTORY

T2DM is a heterogenous, polygenic disease aggravated by environmental factors, including low physical activity and excessive caloric intake. Most patients are obese, although the disease can occasionally be seen in normal-weight individuals. People of Asian ancestry appear to be at risk for T2DM at lower degrees of total adiposity. Obesity, in particular central obesity, is associated with the development of insulin resistance (Fig. 629.10). In addition, patients who are at risk for developing T2DM exhibit decreased glucose-induced insulin secretion. Obesity does not lead to the same degree of insulin resistance in all individuals, and even those who develop insulin resistance do not necessarily exhibit impaired β-cell function. Thus many obese individuals have some degree of insulin resistance but compensate for it by increasing insulin secretion.

Those individuals who are unable to adequately compensate for insulin resistance by increasing insulin secretion develop IGT and IFG, usually, although not always, in that order. Hepatic insulin resistance leads to excessive hepatic glucose output (failure of insulin to suppress hepatic glucose output), and skeletal muscle insulin resistance leads to decreased glucose uptake in a major site of glucose disposal. Over time hyperglycemia worsens, a phenomenon that has been attributed to the deleterious effect of chronic hyperglycemia (glucotoxicity) or chronic hyperlipidemia (lipotoxicity) on β-cell function and is often accompanied by increased triglyceride content and decreased insulin gene expression.

At some point, blood glucose elevation meets the criteria for a diagnosis of T2DM (see Table 629.2), but most patients with T2DM remain asymptomatic for months to years after this point because hyperglycemia is moderate and symptoms are not as dramatic as the polyuria and weight loss at presentation of T1DM. Weight gain may even continue. The prolonged hyperglycemia may be accompanied by the development of microvascular and macrovascular complications. Among the differences between T2DM in children and adults is a faster decline in β-cell function and insulin secretion, as well as faster development of diabetes complications in children.

In T2DM, insulin deficiency is rarely absolute, so patients usually do not need insulin to survive, at least early in the disease course. However, in some cases, the degree of hyperglycemia is such that exogenous insulin therapy is needed. DKA is uncommon in patients with T2DM but does occur and appears to be more common in children than in adults. Although it is generally believed that autoimmune destruction of pancreatic β-cells does not occur in T2DM, autoimmune markers of T1DM—namely, GAD, ICA512, and IAA—may be positive in ~30% of the cases of adolescent T2DM. The presence of these autoimmune markers does not rule out T2DM in children and adolescents. At the same time, because of the general increase in obesity, the presence of obesity does not preclude the diagnosis of T1DM. Although most newly diagnosed children and adolescents can be confidently assigned a diagnosis of T1DM or T2DM, a few exhibit features of both types and are difficult to classify.

EPIDEMIOLOGY

The prevalence of T2DM in children (10-19 years) has risen dramatically from 34 cases per 100,000 youth in 2001 to 67 cases per 100,000

Table 629.12 Characteristics at Presentation for Type 1, Type 2, and Monogenic Diabetes

	TYPE 1 DIABETES	TYPE 2 DIABETES	MATURITY-ONSET DIABETES OF THE YOUNG
Age of onset during childhood and adolescence	Any	Rarely before puberty	Any
Weight status	Any	Rarely with normal weight	Any
Symptomatic (polyuria, polydipsia, weight loss)	Nearly universal	Two thirds	Common
Duration of symptoms before presentation	<1 mo	Frequently >1 mo	Any
Diabetic ketoacidosis at presentation	Common	Rare (6–11%)	—
Family history of diabetes before age 40	Uncommon	Strong family history for type 2 diabetes	Very strong family history, classically in three generations
Acanthosis nigricans	Rare	Common (86%)	—
Ethnicity	Any	Predominantly Black or minority ethnicity	Any
Diabetes-associated antibodies (IA2, glutamate decarboxylase, insulin)	Positive in majority	Negative (<10%)	Negative (<1%)
Pathogenic variants in *HNF1A, GCK,* or *HNF4A*	Negative	Negative	Nearly universal
Complications at presentation	Very rare	Common	Rare

IA2, Tyrosine phosphatase-related islet antigen 2.
From Viner R, White B, Christie D. Type 2 diabetes in adolescents: a severe phenotype posing major clinical challenges and public health burden. Lancet. 2017;389:2252–2260.

in 2017. Certain ethnic groups appear to be at higher risk; for example, Native Americans, Hispanic Americans, and Black Americans (in that order) have higher incidence rates than White Americans (Fig. 629.11). Although most children presenting with diabetes have T1DM, the percentage of children presenting with T2DM is increasing and represents up to 50% of the newly diagnosed children in some centers.

GENETICS

T2DM has a strong genetic component; concordance rates among identical twins are in the 40–80% range, but there is not a simple mendelian pattern. Twinning itself increases the risk of T2DM (because of intrauterine growth restriction), and this may distort estimates of genetic risk. Monozygotic twins have a lifetime concordance of T2DM of around 70%, indicating that shared environmental factors (including the prenatal environment) may have a role in the development of T2DM; dizygotic twins have a lifetime concordance of around 20–30%. The genetic basis for T2DM is complex and incompletely defined; no single identified defect predominates. Genome-wide association studies have identified certain genetic polymorphisms that are associated with increased T2DM risk in most populations studied; the most consistently identified are variants of *TCF7L2,* which may have a role in β-cell function. Other identified risk alleles include variants in *PPARG* and *KCNJ11-ABCC8*. These variants only explain a small portion (probably less than 20%) of the population risk of diabetes, and in many cases the mechanism by which these polymorphisms confer risk of T2DM is not clear.

EPIGENETICS AND FETAL PROGRAMMING

Low birthweight and intrauterine growth restriction are associated with increased risk of T2DM. This risk appears to be higher in low-birthweight infants who gain weight more rapidly in the first few years of life. These findings have led to the formulation of the *thrifty phenotype hypothesis,* which postulates that poor fetal nutrition programs these children to maximize storage of nutrients and makes them more prone to future weight gain and development of diabetes. Epigenetic modifications may play a role in this phenomenon, given that so few of the known T2DM genes are associated with low birthweight.

ENVIRONMENTAL AND LIFESTYLE-RELATED RISK FACTORS

Obesity is the most important lifestyle factor associated with development of T2DM. This, in turn, is associated with the intake of high-energy foods, physical inactivity, excess screen time, and low socioeconomic status. Maternal smoking also increases the risk of diabetes and obesity in the offspring. Increasingly, exposure to land pollutants and air pollutants is demonstrated to contribute to insulin resistance. The lipophilic nature of these organic pollutants and their consequent storage in adipose tissue may promote obesity and insulin resistance. In addition, sleep deprivation and psychosocial stress are associated with increased risk of obesity in childhood and with IGT in adults, possibly via overactivation of the hypothalamic-pituitary-adrenal axis. Many antipsychotics (especially the atypical antipsychotics like olanzapine and quetiapine) and antidepressants (both tricyclic antidepressants and newer antidepressants like fluoxetine and paroxetine) induce weight gain. In addition to the risk conferred by increased obesity, some of these medications may also have a direct role in causing insulin resistance, β-cell dysfunction, leptin resistance, and activation of inflammatory pathways.

CLINICAL FEATURES

In the United States, T2DM in children is more likely to be diagnosed in Native American, Hispanic American, and Black American youth, with the highest incidence being reported in Pima Indian youth. Although cases may be seen as young as 4 years of age, most are diagnosed in adolescence; the incidence increases with increasing age. Family history of T2DM is present in most cases. Patients are obese and present with mild symptoms of polyuria and polydipsia or are asymptomatic and T2DM is detected on screening tests. Presentation with DKA occurs in ~10% of cases. Physical examination frequently reveals the presence of acanthosis nigricans, most commonly on the neck and in other flexural areas. Other findings may include striae and an increased waist-to-hip ratio. Laboratory testing reveals elevated HbA_{1c} levels. Hyperlipidemia characterized by elevated triglycerides and low-density lipoprotein cholesterol levels is commonly seen in patients with T2DM at diagnosis. Lipid screening is indicated in all new cases of T2DM. The current recommendation is that blood pressure measurement, random urine

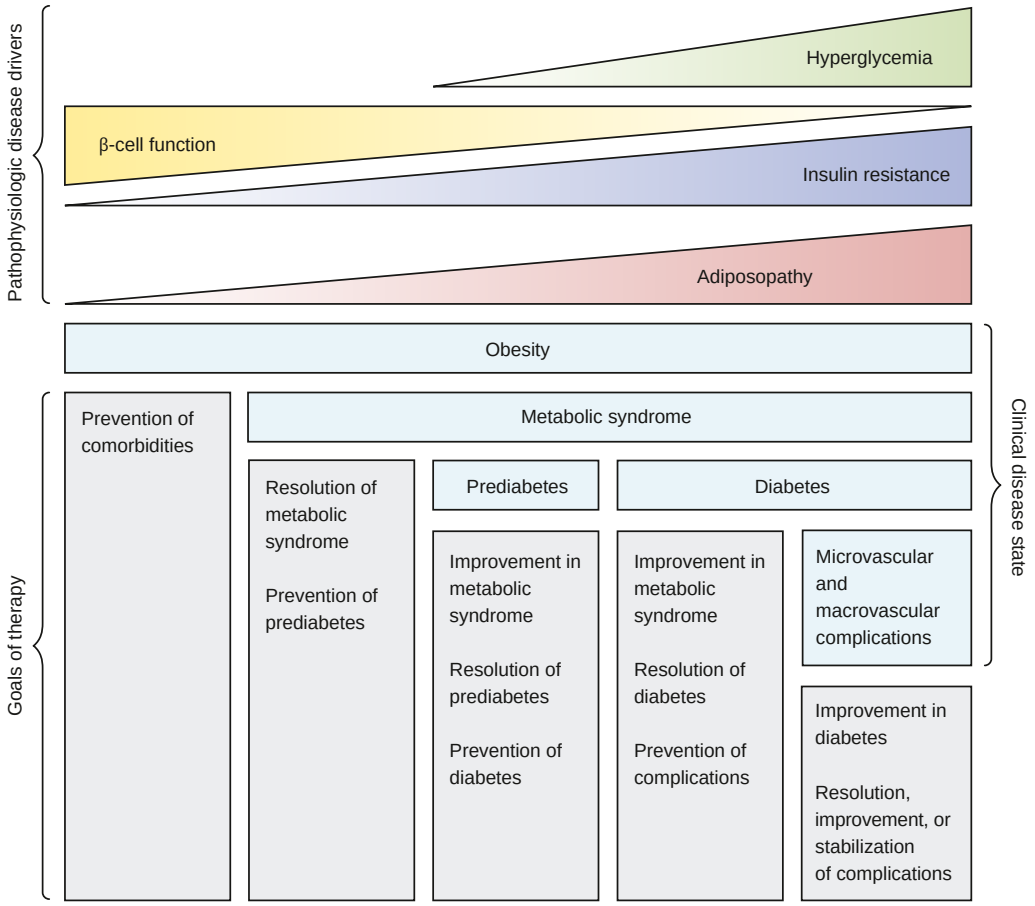

Fig. 629.10 The disease continuum for weight-related type 2 diabetes. *(From Lingvay I, Sumithran P, Cohen RV, le Roux CW. Obesity management as a primary treatment goal for type 2 diabetes: time to reframe the conversation. Lancet. 2022;399:394–404.)*

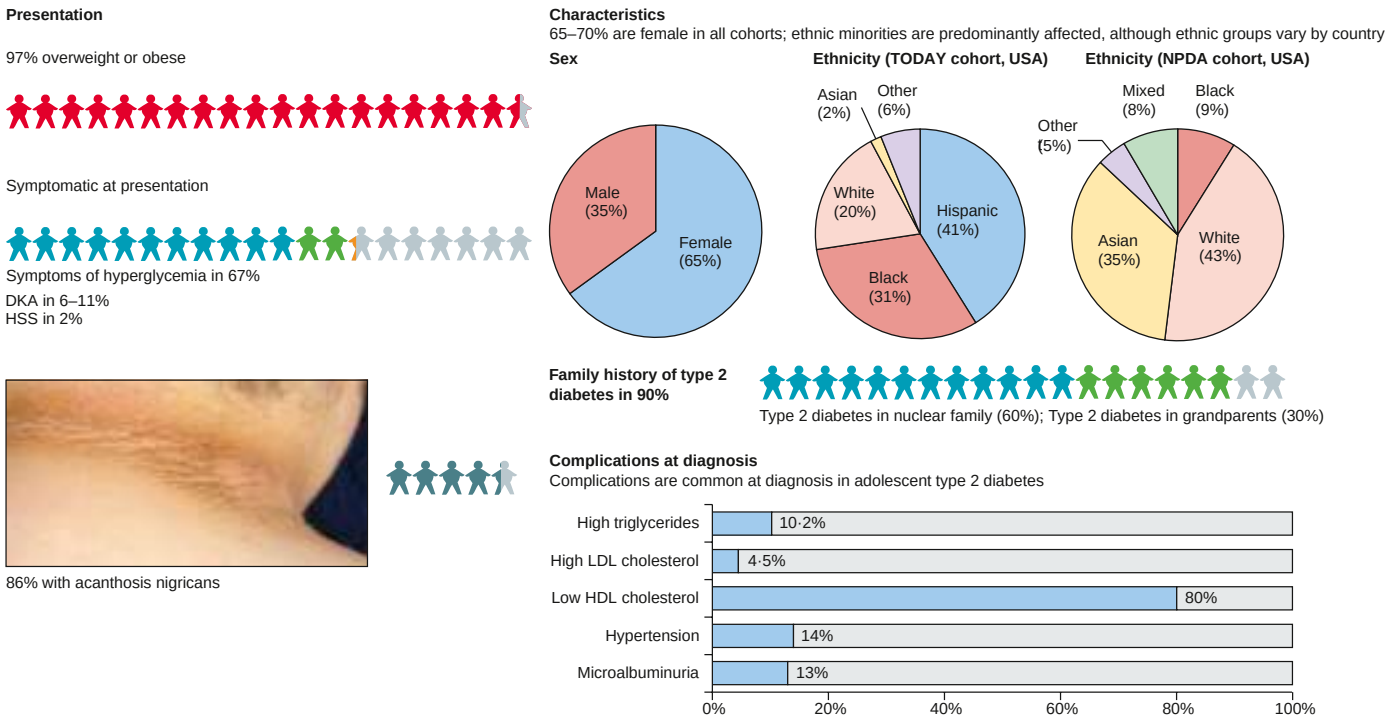

Fig. 629.11 Features of adolescent type 2 diabetes at diagnosis. DKA, diabetic ketoacidosis. HHS, hyperglycemic hyperosmolar syndrome; NPDA, National Diabetes Pediatric Audit; TODAY, Treatment Options for Type 2 Diabetes in Adolescents and Youth. *(From Viner R, White B, Christie D. Type 2 diabetes in adolescents: a severe phenotype posing major clinical challenges and public health burden. Lancet. 2017;389:2252–2260.)*

albumin-to-creatinine ratio, and a dilated eye examination should be performed at diagnosis.

Because hyperglycemia develops slowly and patients may be asymptomatic for months or years after they develop T2DM, screening is recommended in high-risk children (Table 629.13). All youth who are overweight and have at least one other risk factor should be tested for T2DM beginning at age 10 years or at the onset of puberty. Risk factors include family history of T2DM in first- or second-degree relatives, history of gestational diabetes in the mother, belonging to a high-risk racial or ethnic group (i.e., Native American, Black American, Hispanic, or Asian/Pacific Islander groups), and having signs of insulin resistance (e.g., acanthosis nigricans, hypertension, dyslipidemia, or polycystic ovary syndrome). The current recommendation is to use the HbA_{1c} the screening tool; fasting plasma glucose is also acceptable. In borderline or asymptomatic cases, the diagnosis may be confirmed using a standard OGTT, but this test is not required if typical symptoms are present or fasting plasma glucose or HbA_{1c} is clearly elevated.

TREATMENT

T2DM is a progressive syndrome that gradually leads to complete insulin deficiency during the patient's life. A systematic approach for the treatment of T2DM should be implemented according to the natural course of the disease, including adding insulin when hyperglycemia cannot be controlled by lifestyle and noninsulin pharmacotherapy. Lifestyle modification (diet and exercise) is an essential part of the treatment regimen, and consultation with a dietitian is usually necessary (see Fig. 629.10). An oral agent monotherapy may not maintain lasting glucose control in close to half of those with T2DM.

Recommendations are to implement a comprehensive lifestyle modification plan designed to induce weight loss of 7–10%. There is no specific dietary or exercise regimen that has been conclusively shown to be superior, and practitioners recommend a low-calorie, low-fat diet and 30-60 minutes of physical activity at least 5 times a week. Screen time should be limited to 1-2 hours a day. Education is provided to diminish unhealthy habits such as skipping meals, heavy snacking, and excessive screen time. Adolescents may engage in non–appetite-based eating (i.e., emotional eating, television-cued eating, boredom) and cyclic dieting ("yo-yo" dieting). Treatment in these cases is frequently challenging and may not be successful unless the entire family buys into the need to change their unhealthy lifestyle.

Pharmacologic therapy should be initiated at diagnosis of T2DM. Noninsulin pharmacotherapies used in the treatment of T2DM are shown in Table 629.14; most of these are not approved for use in patients under the age of 18 years. Metformin is the first line of pharmacotherapy and should be started in all patients. Renal insufficiency and liver disease are contraindications to metformin use and may increase the risk of lactic acidosis. Patients with markedly elevated liver transaminases should undergo evaluation by a gastroenterologist/hepatologist before initiating therapy. The starting dose is 500-1000 mg/day, which should be increased over a few weeks to the full therapeutic dose of 2,000 mg daily. Patients who present with significant (HbA_{1c} >8.5%) or symptomatic (e.g., polyuria, polydipsia) hyperglycemia should be started on basal insulin with a long-acting insulin analog, typically at a dose of 0.5 units/kg/day. Those presenting in DKA will require initial treatment with insulin using protocols similar to those used for treating T1DM. Once blood glucose levels are under control, many cases can be managed with hypoglycemic agents and lifestyle interventions, but some patients will continue to require insulin therapy.

Ongoing care should include periodic review of weight and BMI, diet, and physical activity; blood glucose monitoring; and monitoring of HbA_{1c} at 3-month intervals. Frequency of home glucose monitoring can range from 3-4 times daily for those on multiple daily insulin injections to twice daily for those on a stable long-acting insulin regimen or metformin. Alternatively, blood glucose monitoring can be done by CGM. Patients who fail to achieve glycemic targets (typically HbA_{1c} <7%) with lifestyle modification and metformin alone will require escalation of therapy with the addition of basal insulin or liraglutide. Liraglutide is an injectable glucagon-like peptide-1 (GLP-1) analog approved by the FDA for use in children ≥10 years. A potential benefit of liraglutide over basal insulin is that it may promote weight loss. The typical starting dose is 0.6 mg/daily, increased as tolerated by 0.6 mg/day per week until a maximum dose of 1.8 mg is achieved. Gastrointestinal symptoms are the most common side effect. Liraglutide is contraindicated in patients with a personal or family history of medullary thyroid cancer or multiple endocrine neoplasia type 2 (MEN 2), based on animal data showing a dose- and duration-dependent effect to promote thyroid C-cell tumors in rodents.

Other agents such as thiazolidinediones, sulfonylureas, other GLP-1 analogs, dipeptidyl peptidase-4 inhibitors (DPP-4 inhibitors), pramlintide, and sodium-glucose transport protein inhibitors (SGLT2 inhibitors) are used with variable frequency in adults but are infrequently used in children. Sulfonylureas cause insulin release by closing the potassium channel (K_{ATP}) on β cells. They are occasionally used when metformin monotherapy is unsuccessful or contraindicated for some reason (use in certain forms of neonatal diabetes is discussed in the relevant section). Thiazolidinediones increase insulin sensitivity via activation of the peroxisome proliferator-activated receptor pathway, but use is limited because of concerns about adverse cardiac effects. Pramlintide is an analog of islet amyloid polypeptide (IAPP), which delays gastric emptying, suppresses glucagon, and possibly suppresses food intake. It is not approved for pediatric use and increases the risk of hypoglycemia when used with insulin or other hypoglycemic agents.

Incretins are gut-derived peptides like GLP-1, GLP-2, and GIP (glucose-dependent insulinotropic peptide, previously known as *gastric inhibitory protein*) that are secreted in response to meals and act to enhance insulin secretion and action, suppress glucagon production, and delay gastric emptying (among other actions). Other daily and weekly forms of GLP-1 agonists beyond liraglutide are commonly used in adults. DPP-4 inhibitors are oral agents that prolong the action of GLP-1 and are currently being studied for use in children. The SGLT-2 inhibitors act by blocking glucose reabsorption in the proximal renal tubule and are commonly used as second- or third-line agents in adults, with specific benefits in improving cardiorenal outcomes in patients with heart failure or declining renal function. SGLT-2 inhibitors are currently under evaluation for potential use in children. Adults with T2DM have been treated with *double incretion* therapy (tirzepatide) with the combination of a GLP-1 agonist and GIP.

Further rises in HbA_{1c} despite the addition of basal insulin and/or liraglutide will necessitate addition of short-acting insulin at mealtimes. Bariatric surgery is also used in adolescents with moderate to severe obesity and frequently leads to complete remission of T2DM. Guidelines for the routine use of bariatric surgery in adolescents continue to emerge, but expert opinion suggests that adolescents with BMI ≥35 or 120% of the 95th percentile for age and gender with a clinically significant complication (including T2DM) are potential candidates, provided there is access to a quality multidisciplinary center with pediatric experience.

Table 629.13 | Testing for Type 2 Diabetes in Children

- **Criteria***

Overweight (body mass index >85th percentile for age and sex
Plus
One or more of the following risk factors:
  Family history of type 2 diabetes in first- or second-degree relative or gestational diabetes in the mother
  High risk racial/ethnic background (Native American, Black American, Hispanic, Asian/Pacific Islander)
  Signs of insulin resistance or conditions associated with insulin resistance (acanthosis nigricans, hypertension, dyslipidemia, polycystic ovary syndrome)

- **Age of initiation**: age 10 yr or at onset of puberty if puberty occurs at a younger age
- **Frequency:** every 1-2 yr, based upon clinical suspicion
- **Test:** fasting glucose, HbA_{1c}, or oral glucose tolerance teat

*Clinical judgment should be used to test for diabetes in high-risk patients who do not meet these criteria.

Table 629.14 Noninsulin Pharmacotherapies Used to Treat T2DM

MEDICATIONS	CLASS	MECHANISM OF ACTION	ROUTE	FDA-APPROVED AGE
Pramlintide	Amylin analogue	Increases satiety, slows gastric emptying, and suppresses postprandial glucagon secretion, resulting in decreased postmeal glucose excursions	Subcutaneous injection	>18 yr
Metformin	Biguanide	Improves hepatic insulin sensitivity. Increases GLP-1 and PYY	Oral	>10 yr
Alogliptin Linagliptin Saxagliptin Sitagliptin	DPP-4 inhibitors	Inhibits DPP-4 from degrading GLP-1 and GIP	Oral	>18 yr
Albiglutide Dulaglutide Exenatide Liraglutide Lixisenatide Semaglutide	Glucagon-like peptide agonists	Increase release of GLP-1, which stimulates release of insulin	Subcutaneous injection	>8 yr, with exception of liraglutide, which is >10 yr
Nateglinide Repaglinide	Meglitinides	Causes rapid secretion of insulin by acting on the ATP sensitive potassium channel of pancreatic beta cells	Oral	>18 yr
Canagliflozin Dapagliflozin Empagliflozin Ertugliflozin	Sodium-glucose co-transporter 2 inhibitors	Promotes renal excretion of glucose at the level of the proximal tubule causing an osmotic diuresis	Oral	>18 yr
Gliclazide Glimepiride Glipizide Glyburide	Sulfonylureas	Increase insulin section via interaction with the K-ATP channel in β cells	Oral	>18 yr
Pioglitazone Rosiglitazone	Thiazolidinediones	Increase insulin sensitivity at adipose and muscle tissue	Oral	>18 yr

DPP-4, Dipeptidyl peptidase 4; GIP, glucose-dependent insulinotropic peptide; GLP-1, glucagon-like peptide 1 agonist; PYY, peptide YY.

COMPLICATIONS

In one study of diabetes in youth, 92% of the patients with T2DM had two or more elements of **metabolic syndrome** (hypertension, hypertriglyceridemia, decreased high-density lipoprotein, increased waist circumference), including 70% with hypertension. In addition, the incidence of microalbuminuria and diabetic retinopathy appears to be higher in T2DM than it is in T1DM. In long-term follow-up from another study, the participants at a mean of age 26 years reported a cumulative incidence of hypertension of 68%, dyslipidemia 52%, diabetic kidney disease 55%, and nerve disease 32%.

Given the extremely high risk of diabetes-related comorbidities, routine screening for microalbuminuria, dyslipidemia, hypertension, and retinopathy should commence shortly after diagnosis. Sleep apnea and fatty liver disease are being diagnosed with increasing frequency and may necessitate referral to the appropriate specialists. Complications associated with all forms of diabetes and recommendations for screening are noted in Table 629.12; Table 629.15 lists conditions particularly associated with T2DM.

PREVENTION

The difficulties in achieving good glucose control and preventing diabetes complications make prevention a compelling strategy. This is particularly true for T2DM, which is linked to modifiable risk factors (obesity, a sedentary lifestyle). The Diabetes Prevention Program demonstrated that intensified lifestyle or drug intervention in individuals with IGT prevented or delayed the onset of T2DM. Lifestyle intervention reduced the diabetes incidence by 58%; metformin reduced the incidence by 31% compared with placebo. Lifestyle interventions are believed to have similar beneficial effects in obese adolescents with IGT.

629.4 Other Specific Types of Diabetes

David R. Weber

Most cases of diabetes in children and adults fall into the two broad categories of T1DM and T2DM, but between 1% and 10% of cases are caused by single-gene disorders. These disorders include hereditary defects of β-cell function and insulin action, as well as rare forms of mitochondrial diabetes.

GENETIC DEFECTS OF β-CELL FUNCTION

Transient Neonatal Diabetes Mellitus

Neonatal diabetes is transient in approximately 50% of cases, but after an interim period of normal glucose tolerance, 50–60% of these patients develop permanent diabetes (at an average age of 14 years). It remains to be determined whether this association of transient diabetes in the newborn followed much later in life by classic T1DM is a chance occurrence or causally related (Fig. 629.12).

The syndrome of **transient DM** in the newborn infant has its onset in the first week of life and persists several weeks to months before spontaneous resolution. Median duration is 12 weeks. It occurs most often in infants who are small for gestational age and is characterized by hyperglycemia and pronounced glycosuria, resulting in severe dehydration and, at times, metabolic acidosis, but with only minimal or no ketonemia or ketonuria. There may also be findings such as umbilical hernia or large tongue. Insulin responses to glucose or tolbutamide are low to absent; basal plasma insulin concentrations are normal. After spontaneous recovery, the insulin responses to these same stimuli are brisk and normal, implying a possible functional delay in β-cell maturation with spontaneous resolution. Occurrence of the syndrome in

Table 629.15 Monitoring for Complications and Comorbidities in T2DM

CONDITION	SCREENING TEST	COMMENT
Hypertension	Blood pressure	
Fatty liver	Aspartate aminotransferase, alanine aminotransferase, possibly liver ultrasound	
Polycystic ovary syndrome	Menstrual history, assessment for androgen excess with free/total testosterone, dehydroepiandrosterone sulfate	
Microalbuminuria	Urine albumin concentration and albumin-to-creatinine ratios	
Dyslipidemia	Fasting lipid profile (total, low-density lipoprotein, high-density lipoprotein cholesterol, triglycerides)	Obtain at diagnosis and every 2 yr
Sleep apnea	Polysomnography: Sleep study to assess overnight oxygen saturation, airflow, heart rate, electromyography, and eye movements	

consecutive siblings has been reported. About 70% of cases are the result of abnormalities of an imprinted locus on chromosome 6q24, resulting in overexpression of paternally expressed genes such as *PLAGL1/ZAC* and *HYMAI*. Most of the remaining cases are caused by pathogenic variants in K_{ATP} channels. Variants in K_{ATP} channels also cause many cases of permanent neonatal diabetes, but there is practically no overlap between the variants that lead to transient neonatal DM and those causing permanent neonatal DM. This syndrome of transient neonatal DM should be distinguished from the severe hyperglycemia that may occur in hypertonic dehydration that usually occurs in infants beyond the newborn period and responds promptly to rehydration with minimal or no requirement for insulin.

Administration of insulin is mandatory during the active phase of DM in the newborn. Rehydration and IV insulin are usually required initially; transition to subcutaneous insulin can occur once clinically stable. A variety of regimens, including intermediate- or long-acting insulin given in one to two daily doses or continuous insulin therapy with an insulin pump, have been used successfully. The starting dose is typically 1-2 units/kg/day but will need to be adjusted based upon blood glucose levels. Attempts at gradually reducing the dose of insulin may be made as soon as recurrent hypoglycemia becomes manifested or after 2 months of age.

Permanent Neonatal Diabetes Mellitus

Permanent DM in the newborn period is caused, in approximately 50% of the cases, by pathogenic variants in the *KCNJ11* and *ABCC8* genes (see Figs. 629.12 and 629.13). These genes code for the Kir6.2 and SUR1 subunits of the adenosine triphosphate–sensitive potassium channel, which is involved in an essential step in insulin secretion by the β cell. Some cases are caused by pancreatic agenesis because of homozygous pathogenic variants in *IPF-1* (where heterozygous variants cause MODY4); homozygous variants in the glucokinase gene (where heterozygous variants cause MODY2); and variants in the insulin gene (see Tables 629.1 and 629.12). Almost all these infants are small at birth because of the role of insulin as an intrauterine growth factor. Instances of affected twins and families with more than one affected infant have been reported. Infants with permanent neonatal DM may be initially euglycemic and typically present between birth and 6 months of life (mean age of presentation is 5 weeks), but rarely can present up to 1 year of age. There is a spectrum of severity, and up to 20% have neurologic features. The most severely affected patients have the syndrome of *d*evelopmental delay, *e*pilepsy, and *n*eonatal *d*iabetes (**DEND syndrome**).

Activating pathogenic variants in the *KCNJ11* gene (encoding the adenosine triphosphate–sensitive potassium channel subunit Kir6.2) are associated with both TND and PND, with variants associated with each phenotype. More than 90% of these patients respond to sulfonylureas (at higher doses than those used in T2DM), but patients with severe neurologic disease may be less responsive. Pathogenic variants in *ABCC8* (encoding the SUR1 subunit of this potassium channel) were thought to be less likely to respond to sulfonylureas (because this is the subunit that binds sulfonylurea drugs), but some of these variants are reported to respond; patients have been successfully switched from insulin to oral therapy. Several protocols for switching the patient from insulin to glyburide are available, and patients are usually stabilized on doses ranging from 1 to 2.5 mg/kg/day. Because approximately 50% of neonatal diabetics have potassium-channel variants that can be switched to sulfonylurea therapy, with dramatic improvement in glycemic control, neurologic outcomes, and quality of life, all patients with diabetes diagnosed before 6 months of age (and perhaps even those diagnosed before 12 months of age) in whom insulin dependence persists beyond 7-10 days should have genetic testing (Fig. 629.14).

Maturity-Onset Diabetes of Youth

Several forms of diabetes are associated with **monogenic defects in β-cell function**. Before these genetic defects were identified, this subset was diagnosed on clinical grounds and described by the term *MODY*. This subtype of DM consists of a group of heterogeneous clinical entities that are characterized by onset before 25 years, autosomal dominant inheritance, and a primary defect in insulin secretion. Strict criteria for the diagnosis of MODY include diabetes in at least three generations with autosomal dominant transmission and diagnosis before age 25 years in at least one affected subject. Pathogenic variants have been found in at least 14 different genes, accounting for the dominantly inherited monogenic defects of insulin secretion, for which the term MODY is used (Table 629.16). The ADA groups these disorders together under the broader category of *genetic defects of β-cell function*. Just three of them (MODY2, MODY3, and MODY5) account for 90% of the cases in this category in European populations, but the distribution may be different in other ethnic groups. Except for MODY2 (which is caused by variants in the enzyme glucokinase), all other forms are caused by genetic defects in various transcription factors (see Table 629.16).

MODY2

This is the second most common form of MODY and accounts for approximately 15–30% of all patients diagnosed. Glucokinase plays an essential role in β-cell glucose sensing, and heterozygous pathogenic variants in this gene lead to mild reductions in pancreatic β-cell response to glucose. Homozygotes with the same variants are completely unable to secrete insulin in response to glucose and develop a form of PND. Patients with heterozygous variants have a higher threshold for insulin release but are able to secrete insulin adequately at higher blood glucose levels (typically 125 mg/dL [7 mmol/L] or higher). This results in a relatively mild form of diabetes (HbA_{1c} is usually less than 7%), with mild fasting hyperglycemia and IGT in most patients. MODY2 may be misdiagnosed as T1DM in children, gestational diabetes in pregnant women, or well-controlled T2DM in adults (see Table 629.12). An accurate diagnosis is important because most cases are not progressive, and except for gestational diabetes, may not require treatment. When needed, they can usually be treated with small doses of exogenously administered insulin. Treatment with oral agents (sulfonylureas and related drugs) can be successful and may be more acceptable to many patients.

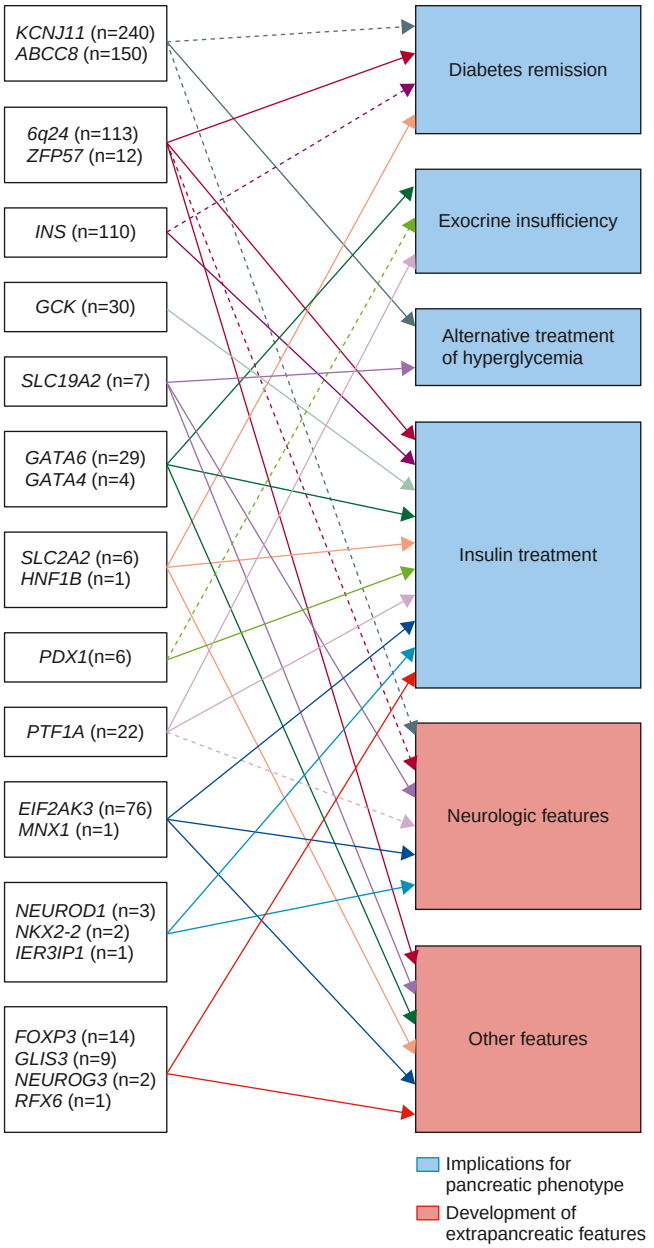

Fig. 629.12 A genetic diagnosis guides clinical management. Schematic representation of genetic causes of neonatal diabetes and the implications of this genetic diagnosis. *n* indicates the number of patients identified with pathogenic variants in each of the genes in the 1,020 neonatal diabetes patient cohort. *Solid arrows* indicate implications for most pathogenic variants in the genes. *Dashed arrows* indicate the implications for specific variants. *(From De Franco E, Flanagan SE, Houghton JAL, et al. The effect of early, comprehensive genomic testing on clinical care in neonatal diabetes: an international cohort study. Lancet. 2015;386:957–963. Fig. 3.)*

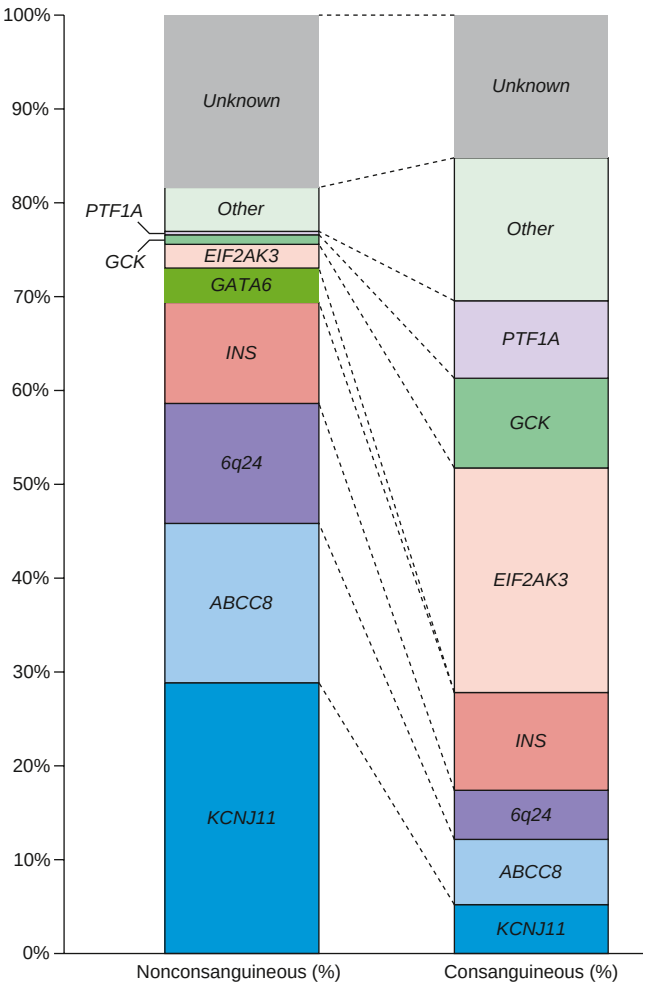

Fig. 629.13 Different genetic causes of neonatal diabetes in patients born to nonconsanguineous and consanguineous parents. Comparison of genetic causes of neonatal diabetes in nonconsanguineous (*n* = 790) and consanguineous groups (*n* = 230). Consanguinity is defined by parents being second cousins or more closely related or by the presence of 1.56% or higher total homozygosity. Genes involved in less than 2.5% of patients in both cohorts were grouped in the other category. *(From De Franco E, Flanagan SE, Houghton JAL, et al. The effect of early, comprehensive genomic testing on clinical care in neonatal diabetes: an international cohort study. Lancet. 2015;386:957–963. Fig. 2.)*

MODY3

Patients affected with pathogenic variants in the transcription factor hepatocyte nuclear factor-1α show abnormalities of carbohydrate metabolism varying from IGT to severe diabetes and often progressing from a mild to a severe form over time. They are also prone to the development of vascular complications. This is the most common MODY subtype and accounts for 30–60% of all cases of MODY. These patients are very sensitive to the action of sulfonylureas and can usually be treated with relatively low doses of these oral agents, at least in the early stages of the disease. In children, this form of MODY is sometimes misclassified as T1DM and treated with insulin. Evaluation of autoimmune markers helps to rule out T1DM; genetic testing for MODY is available and is indicated in patients with relatively mild diabetes and a family history suggestive of autosomal dominant inheritance. Accurate diagnosis can lead to avoidance of unnecessary insulin treatment and specific genetic counseling (see Fig. 629.14).

Less Common Forms of Monogenic Diabetes

Hepatocyte nuclear factor-4α (MODY1), insulin promoter factor (IPF)-1, also known as (PDX-1) (MODY4), hepatocyte nuclear factor 1β/TCF2 (MODY5), and NeuroD1 (MODY6) are all transcription factors that are involved in β-cell development and function, and mutations in these lead to various rare forms of MODY. In addition to diabetes, they can also have specific findings unrelated to hyperglycemia; for example, MODY1 is associated with low triglyceride and lipoprotein levels, and MODY5 is associated with renal cysts and renal dysfunction. In terms of treatment, MODY1 and MODY4 may respond to oral sulfonylureas, but MODY5 does not respond to oral agents and requires treatment with insulin. NeuroD1 defects are extremely rare and not much is known about their natural history.

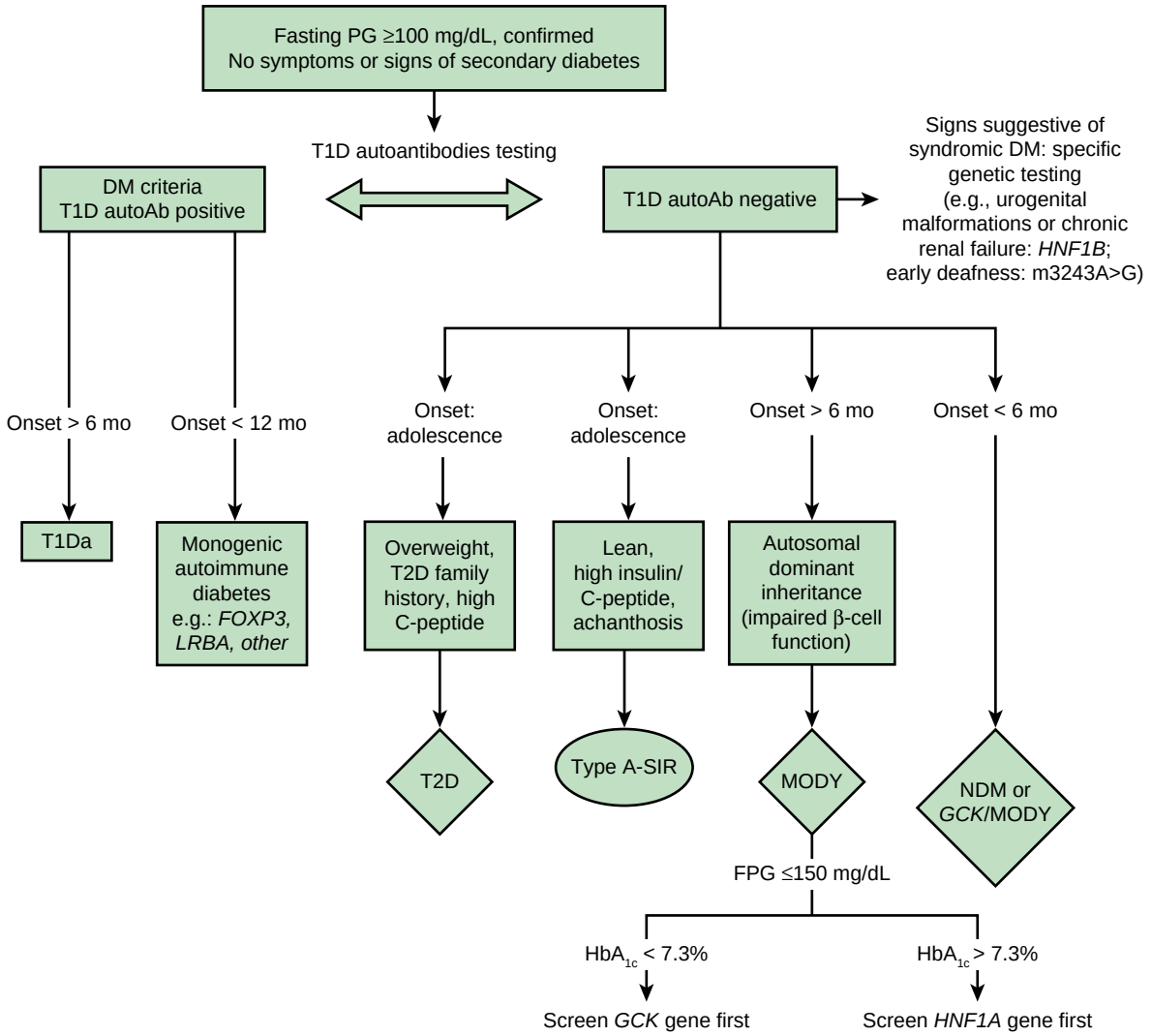

Fig. 629.14 Diagnostic algorithm of monogenic forms of diabetes. Negativity of genetic testing of two common subtypes of MODY in children and adolescents implies that further testing is mandatory if the clinical diagnosis is robust. FPG, fasting plasma glucose; MODY, maturity onset diabetes of the young; NDM, neonatal diabetes mellius; SIR, severe insulin resistance. *(From Barbetti F, D'Annunzio G. Genetic causes and treatment of neonatal diabetes and early childhood diabetes. Best Pract Res Clin Endocrinol Metab. 2018;32[4]:575-591. Fig. 1.)*

Primary or secondary defects in the glucose transporter-2, which is an insulin-independent glucose transporter, may also be associated with diabetes. Diabetes may also be a manifestation of a polymorphism in the glycogen synthase gene. This enzyme is crucially important for storage of glucose as glycogen in muscle. Patients with this defect are notable for marked insulin resistance and hypertension, as well as a strong family history of diabetes.

Another form of IDDM is **Wolfram syndrome** (Table 629.17). Wolfram syndrome 1 is characterized by diabetes insipidus, DM, optic atrophy, and deafness—thus the acronym **DIDMOAD**. Some patients with diabetes appear to have severe insulinopenia, whereas others have significant insulin secretion as judged by C-peptide. The overall prevalence is estimated at 1 in 770,000 live births. The sequence of appearance of the stigmata is as follows: non-autoimmune IDDM in the first decade, central diabetes insipidus and sensorineural deafness in ~65–75% of the patients in the second decade, renal tract anomalies in ~50% of the patients in the third decade, and neurologic complications such as cerebellar ataxia and myoclonus in half to two thirds of the patients in the fourth decade. Other features include primary gonadal atrophy in most males and a progressive neurodegenerative course with neurorespiratory death at a median age of 30 years. Some cases are caused by pathogenic variants in *WFS-1*. Wolfram syndrome 2 has early-onset optic atrophy, DM, deafness, and a shortened life span but no diabetes insipidus; the associated gene is *CISD2*. Other forms of Wolfram syndrome may be caused by variants in mitochondrial DNA. Other syndromes associated with diabetes are noted in Table 629.17.

Mitochondrial Gene Defects

Pathogenic variants in mitochondrial DNA are associated with **maternally inherited DM and deafness**. The most common mitochondrial DNA variant in these cases is the variant m.3243A>G in the transfer RNA leucine gene. This variant is identical to the variant in MELAS (myopathy, encephalopathy, lactic acidosis, and strokelike syndrome), but MELAS syndrome is not associated with diabetes; the phenotypic expression of the same defect varies. Diabetes in most of these cases presents insidiously, but approximately 20% of patients have an acute presentation resembling T1DM. The mean age of diagnosis of diabetes is 37 years, but cases have been reported as young as 11 years; not all patients have deafness. This variant has been estimated to be present in 1.5% of Japanese people with diabetes, which may be higher than the prevalence in other ethnic groups. Metformin should be avoided in these patients because of the theoretical risk of severe lactic acidosis in the presence of mitochondrial dysfunction. Some children with mitochondrial DNA mutations affecting complex I and/or complex IV may also develop diabetes.

Table 629.16 Clinical Characteristics of Maturity-Onset Diabetes of the Young (MODY) Genetic Subtypes

MODY TYPE	GENE NAME (LOCUS)	PREVALENCE (%)	OTHER FEATURES	TREATMENT
MODY 1	*HNF4A* (20ql2)	5–10	Neonatal hyperinsulinemia and hypoglycemia with associated macrosomia, low serum levels of cholesterol	Sensitive to sulfonylureas
MODY 2	*GCK* (7pl3)	30–60	Mild fasting hyperglycemia throughout life, often asymptomatic, gestational diabetes, low birthweight (with unaffected mother)	No treatment outside of pregnancy
MODY 3	*HNF1A* (12q24.2)	30–60	Glycosuria	Sensitive to sulfonylureas
MODY 4	*PDX1* (13ql2.1)	<1	Homozygote: pancreatic agenesis	Diet, OAD, or insulin
MODY 5	*HNFIB* (17q21)	5–10	Diabetes in association with renal and genitourinary abnormalities	Insulin
MODY 6	*NEUROD I* (2q31.3)	<1	Obesity and insulin resistance	OAD or insulin
MODY 7	*KLF11* (2p25)	<1	Impaired glucose tolerance to overt diabetes	OAD or insulin
MODY 8	*CEL* (9p34)	<1	Diabetes and pancreatic exocrine deficiency	OAD or insulin
MODY 9	*PAX4* (7q32)	<1	Ketosis-prone diabetes	Diet, OAD, or insulin
MODY 10	*INS* (llpl5.5)	<1	May result in neonatal diabetes, antibody-negative diabetes, and MODY	OAD or insulin
MODY 11	*BLK* (8p23)	<1	Obesity common	Diet, OAD, or insulin
MODY 12	*ABCC8* (11pl5.1)	<1	Usually associated with neonatal diabetes, rare cause of MODY	Sensitive to sulfonylureas
MODY 13	*KCNJ11* (11p 15.13)	<1	Usually associated with neonatal diabetes, rare cause of MODY	Sensitive to sulfonylureas
MODY 14	*APPL1* (3pl4.3)	<1	Adult-onset diabetes	Diet, OAD, or insulin

ABCC8, ATP-binding cassette, subfamily C (CFTR/MRP), member 8; APPL1, adaptor protein, phosphotyrosine interacting with PH domain and leucine zipper 1; BLK, B-lymphocyte kinase; CEL, carboxyl ester lipase enzyme; GCK, glucokinase; HNF1A, hepatocyte nuclear factor-lα; HNF1B, hepatocyte nuclear factor-lβ; INS, preproinsulin; KCNJ11, potassium channel, inwardly rectifying subfamily J, member 11; KLF11, Kruppel-like factor 11; NEUROD 1, neurogenic differentiation factor 1; OAD, oral antidiabetic; PAX4, paired box gene 4; PDX1, pancreas/duodenum homeobox protein 1.

Modified from Sanyoura M, Philipson LH, Naylor R. Monogenic diabetes in children and adolescents: recognition and treatment options. Curr Diab Rep. 2018;18:58. Table 1.

Abnormalities of the Insulin Gene

Diabetes of variable degrees may also result from pathogenic variants in the insulin gene that impair the effectiveness of insulin at the receptor level. Insulin gene defects are exceedingly rare and may be associated with relatively mild diabetes or even normal glucose tolerance. Diabetes may also develop in patients with faulty processing of proinsulin to insulin (an autosomal dominant defect). These defects are notable for the high concentration of insulin as measured by radioimmunoassay, whereas MODY and glucose transporter-2 defects are characterized by relative or absolute deficiency of insulin secretion for the prevailing glucose concentrations.

GENETIC DEFECTS OF INSULIN ACTION

Various genetic variants in the insulin receptor can impair the action of insulin at the insulin receptor or impair postreceptor signaling, leading to insulin resistance. The mildest form of the syndrome with variants in the insulin receptor was previously known as **type A insulin resistance**. This condition is associated with hirsutism, hyperandrogenism, and cystic ovaries in females, without obesity. Acanthosis nigricans may be present, and life expectancy is not significantly impaired. More severe forms of insulin resistance are seen in two variants in the insulin receptor gene that cause the pediatric syndromes of **Donohue syndrome** (formerly called *leprechaunism*) and **Rabson-Mendenhall syndrome**.

Donohue Syndrome

This is a syndrome characterized by intrauterine growth restriction, fasting hypoglycemia, and postprandial hyperglycemia in association with profound resistance to insulin; severe hyperinsulinemia is seen during an OGTT. Various defects of the insulin receptor have been described, thereby attesting to the important role of insulin and its receptor in fetal growth and possibly in morphogenesis. Many of these patients die in the first year of life. Potential treatments include high-dose insulin, metformin, and continuous IGF-1 via insulin pump.

Rabson-Mendenhall Syndrome

This entity is defined by clinical manifestations that appear to be intermediate between those of acanthosis nigricans with insulin resistance type A and Donohue syndrome. The features include extreme insulin resistance, acanthosis nigricans, abnormalities of the teeth and nails, and pineal hyperplasia. It is not clear whether this syndrome is entirely distinct from Donohue syndrome; however, by comparison, patients with Rabson-Mendenhall tend to live significantly longer. Therapies with modest benefit have included IGF-1 and leptin.

Lipoatrophic Diabetes

Various forms of lipodystrophy are associated with insulin resistance and diabetes (Table 629.18). **Familial partial lipoatrophy**, or **lipodystrophy**, is associated with pathogenic variants in *LMNA*, encoding nuclear envelope proteins lamin A and C. **Severe congenital generalized lipoatrophy** is associated with variants in the seipin and *AGPAT2* genes, but the mechanism by which these variants lead to insulin resistance and diabetes is not known.

Stiff-Person Syndrome

This is an extremely rare autoimmune CNS disorder that is characterized by progressive stiffness and painful spasms of the axial muscles

Table 629.17 Syndromic Forms of Diabetes that May Present in Childhood or Early Childhood

SYNDROME	GENE (LOCUS)	INHERITANCE	TYPE OF DIABETES	CLINICAL FEATURES
Diabetes and deafness	Mitochondria tRNA	Maternal	Insulin deficient	Adult-onset diabetes, sensorineural deafness
Wolfram syndrome 1	*WFS1*(4p16)	AR/AD	Insulin deficient	Childhood-onset diabetes, optic atrophy, deafness, diabetes insipidus
Wolfram syndrome 2	*CISD2*(4q24)	AR	Insulin deficient	Childhood-onset, diabetes, optic atrophy, deafness, and defective platelet aggregation
Thiamine-responsive megaloblastic anemia syndrome	*SLC19A2*(1q23)	AR	Vitamin dependent	Childhood-onset diabetes, megaloblastic or sideroblastic anemia, sensorineural deafness
Mitchell-Riley syndrome	*RFX6*(6q22)	AR	Insulin deficient	Rare cases with childhood-onset, pancreatic hypoplasia, intestinal atresia, and gallbladder aplasia or hypoplasia
Alström syndrome	*ALMS1*(2p13)	AR	Insulin resistant	Childhood to early adulthood, pigmentary retinopathy, deafness, obesity, dilated cardiomyopathy
Bardet-Biedl syndrome	*BBS1–BBS21*	AR/DR	Insulin resistant	Childhood to early adulthood, developmental delay, pigmentary retinopathy, polydactyly, obesity, hypogonadism
Insulin resistance syndrome type A	*INSR*(19p13)	AD/AR	Insulin resistant	Childhood to early adulthood, obesity, diabetes, and acanthosis nigricans

ALMS1, Alström syndrome 1; AD, autosomal dominant; AR, autosomal recessive; BBS, Bardet-Biedl; CISD2, CDGSH iron sulfur domain 2; DR, digenic recessive; INSR, insulin receptor; RFX6, regulatory factor X6; SLC19A2, solute carrier family 19 member 2; tRNA, transfer RNA; WFS1, wolframin.
Modified from Sanyoura M, Philipson LH, Naylor R. Monogenic diabetes in children and adolescents: recognition and treatment options. Curr Diab Rep. 18:58, 2018. Table 2.

Table 629.18 Clinical and Biochemical Features of Inherited Lipodystrophies

	CONGENITAL GENERALIZED LIPODYSTROPHY		FAMILIAL PARTIAL LIPODYSTROPHY	
SUBTYPE	***BSCL1***	***BSCL2***	***FPLD2***	***FPLD3***
DEFECTIVE GENE	***AGPAT2***	***BSCL2***	***LMNA***	***PPARG***
Clinical onset	Soon after birth	Soon after birth	Puberty	Usually puberty, but may present in younger children
Fat distribution	Generalized absence	Generalized absence	Loss of limb and gluteal fat; typically excess facial and nuchal fat; trunk fat often lost	Loss of limb and gluteal fat; preserved facial and trunk fat
Cutaneous features	Acanthosis nigricans and skin tags; hirsutism common in women	Acanthosis nigricans and skin tags; hirsutism common in women	Acanthosis nigricans and skin tags; hirsutism common in women	Acanthosis nigricans and skin tags; hirsutism common in women
Musculoskeletal	Acromegaloid features common	Acromegaloid features common	Frequent muscle hypertrophy; some have overlap features of muscular dystrophy	Muscle hypertrophy
Nonalcoholic fatty liver disease	Severe	Severe	Yes	Yes
Dyslipidemia	Severe; associated with pancreatitis	Severe; associated with pancreatitis	Yes, may be severe	Yes, may be severe
Insulin resistance	Severe; early onset	Severe; early onset	Severe	Severe; early onset in some
Diabetes onset	<20 yr	<20 yr	Variable; generally later in men than women	Variable; generally later in men than women
Hypertension	Common	Common	Common	Very common
Other		Mild mental retardation possible		

From Semple RK, Savage DB, Halsall DJ, O'Rahilly S. Syndromes of severe insulin resistance and/or lipodystrophy. In Weiss RE, Refetoff S, eds. *Genetic Diagnosis of Endocrine Disorders*. Philadelphia: Elsevier; 2010: Table 4.2.

and very high titers of glutamic acid decarboxylase antibodies. About one third of patients also develop T1DM.

Systemic Lupus Erythematosus

In rare cases, patients with systemic lupus erythematosus may develop autoantibodies to the insulin receptor, leading to insulin resistance and diabetes.

CYSTIC FIBROSIS–RELATED DIABETES

See Chapter 454.

As patients with cystic fibrosis (CF) live longer, an increasing number are being diagnosed with **cystic fibrosis–related diabetes (CFRD)**; up to 20% of children and 50% of adults are affected with CFRD. There is an association with pancreatic insufficiency, and there may be a higher risk in patients with class I and class II CF transmembrane conductance regulator variants. Cross-sectional studies indicate that the prevalence of IGT may be significantly higher than this, and up to 65% of children with CF have diminished first-phase insulin secretion, even when they have normal glucose tolerance. In Denmark, oral glucose tolerance screening of the entire CF population demonstrated no diabetes in patients younger than 10 years, diabetes in 12% of patients age 10-19 years, and diabetes in 48% of adults age 20 years and older.

Patients with CFRD have features of both T1DM and T2DM. In the pancreas, exocrine tissue is replaced by fibrosis and fat; many of the pancreatic islets are destroyed. The remaining islets demonstrate diminished numbers of β-, α-, and pancreatic polypeptide-secreting cells. Secretion of the islet hormones insulin, glucagon, and pancreatic polypeptide is impaired in patients with CF in response to a variety of secretagogues. This pancreatic damage leads to slowly progressive insulin deficiency, of which the earliest manifestation is an impaired first-phase insulin response. When patients age, this response becomes progressively delayed and less robust than normal. At the same time, these patients develop insulin resistance because of chronic inflammation and the intermittent use of corticosteroids. Insulin deficiency and insulin resistance lead to a gradual onset of IGT that eventually evolves into diabetes. In some cases, diabetes may wax and wane with disease exacerbations and the use of corticosteroids. The clinical presentation is similar to that of T2DM in that the onset of the disease is insidious and the occurrence of ketoacidosis is rare. Islet antibody titers are negative. Microvascular complications do develop but may do so at a slower rate than in typical T1DM or T2DM. Macrovascular complications do not appear to be of concern in CFRD. Several factors unique to CF influence the onset and the course of diabetes: (1) frequent infections are associated with waxing and waning of insulin resistance; (2) energy needs are increased because of infection and pulmonary disease; (3) malabsorption is common, despite enzyme supplementation; (4) nutrient absorption is altered by abnormal intestinal transit time; (5) liver disease is frequently present; (6) anorexia and nausea are common; (7) there is a wide variation in daily food intake based on the patient's acute health status; and (8) both insulin and glucagon secretion are impaired (in contrast to autoimmune diabetes, in which only insulin secretion is affected).

IGT and CFRD are associated with poor weight gain, and there is evidence that treatment with insulin improves weight gain and slows the rate of pulmonary deterioration. Because of these observations, guidelines recommend that routine diabetes screening of all children with CF begin at age 10 years. Despite debate over the ideal screening modality, the recommendation is the 2-hour OGTT, although growing evidence suggests a role for mid-OGTT hyperglycemia at the 1-hour mark as a clinically relevant finding. When hyperglycemia develops, the accompanying metabolic derangements are usually mild, and relatively low doses of insulin usually suffice for adequate management. Basal insulin may be started initially, but basal-bolus therapy similar to that used in T1DM will eventually be needed. Dietary restrictions are minimal, as increased energy needs are present and weight gain is usually desired. Ketoacidosis is uncommon but may occur with progressive deterioration of islet cell function. IGT is not necessarily an indication for treatment, but patients who have poor growth and inadequate weight gain may benefit from the addition of basal insulin even if they do not meet the criteria for a diagnosis of diabetes.

Friedreich Ataxia

Friedreich ataxia (FRDA) is a multisystem neurodegenerative disorder resulting from alterations in *FXN*. Approximately 20% of patients with FRDA will develop diabetes. Individuals with early-onset diabetes during childhood display a phenotype similar to T1DM characterized by insufficient pancreatic insulin secretion, hyperglycemia, and ketosis. Insulin therapy is typically required from diagnosis. By contrast, adults with FRDA who develop diabetes have a phenotype more similar to T2DM, where insulin resistance appears to play a role in the pathogenesis.

DRUGS

High-dose oral or parenteral steroid therapy usually results in significant insulin resistance leading to glucose intolerance and overt diabetes. The immunosuppressive agents cyclosporine and tacrolimus are toxic to β cells, causing IDDM in a significant proportion of patients treated with these agents. Their toxicity to pancreatic β cells was one of the factors that limited their usefulness in arresting ongoing autoimmune destruction of β cells. Streptozotocin and the rodenticide Vacor are also toxic to β cells, causing diabetes.

There are no consensus guidelines regarding treatment of *steroid-induced hyperglycemia* in children. Many patients on high-dose steroids have elevated blood glucose during the day and evening but become normoglycemic late at night and early in the morning. In general, significant hyperglycemia in an inpatient setting is treated with short-acting insulin on an as-needed basis. Basal insulin may be added when fasting hyperglycemia is significant. Outpatient treatment can be more difficult, but when treatment is needed, protocols similar to the basal-bolus regimens used in T1DM are used.

Immune checkpoint inhibitors used to treat malignancies by blocking inhibitory immune receptors have been associated with the rare development of DM and other autoimmune diseases. DM may develop after one to two cycles of therapy and present with DKA. Some are GAD antibody positive; all require insulin therapy.

GENETIC SYNDROMES ASSOCIATED WITH DIABETES MELLITUS

A number of rare genetic syndromes associated with IDDM or carbohydrate intolerance have been described (see Tables 629.1 and 629.17). These syndromes represent a broad spectrum of diseases, ranging from premature cellular aging, as in **Werner** and **Cockayne** syndromes (see Chapter 109), to excessive obesity associated with hyperinsulinism, resistance to insulin action, and carbohydrate intolerance, as in **Prader-Willi syndrome** (see Chapters 97 and 98). Some of these syndromes are characterized by primary disturbances in the insulin receptor or in antibodies to the insulin receptor without any impairment in insulin secretion. Although rare, these syndromes provide unique models to understand the multiple causes of disturbed carbohydrate metabolism from defective insulin secretion or from defective insulin action at the cell receptor or postreceptor level.

AUTOIMMUNE DISEASES ASSOCIATED WITH T1DM

IPEX Syndrome

IPEX (immunodysregulation, polyendocrinopathy, and enteropathy, X-linked) is a genetic syndrome leading to autoimmune disease. In most patients with IPEX, pathogenic variants in *FOXP3,* a specific marker of natural and adaptive regulatory T cells, leads to severe immune dysregulation and rampant autoimmunity. Autoimmune diabetes develops in >90% of cases, usually within the first year of life, and is accompanied by enteropathy, failure to thrive, and other autoimmune disorders.

Autoimmune Polyendocrine Syndromes

Autoimmune polyendocrine syndrome type 1 (APS-1, also known as *APCED*) is a syndrome of multiple endocrinopathy related to pathogenic variants in *AIRE*. It typically first manifests in infancy with

recurrent mucocutaneous candidiasis, followed variably by hypocalcemia (autoimmune hypoparathyroidism), adrenal insufficiency (Addison disease), T1DM, hypothyroidism (Hashimoto disease), celiac disease, and other autoimmune conditions. It is clear that any patient with an autoimmune disease is at increased risk for the development of T1DM (and any patient with T1DM is at increased risk of other autoimmune diseases) and should be counseled regarding the signs and symptoms of new-onset diabetes. See Table 629.11 for recommendations regarding screening tests to look for other autoimmune diseases in patients with T1DM.

Chronic lymphocytic thyroiditis (Hashimoto thyroiditis) is frequently associated with T1DM in children (see Chapter 604). About 20% of patients with insulin-dependent diabetes have thyroid antibodies in their serum; the prevalence is 2-20 times greater than in control populations. Only a small proportion of these patients acquire clinical hypothyroidism; the interval between diagnosis of diabetes and thyroid disease averages about 5 years.

Celiac disease, which is caused by hypersensitivity to dietary gluten, is another autoimmune disorder that occurs with significant frequency in children with T1DM (see Chapter 384). It is estimated that approximately 7–15% of children with T1DM develop celiac disease within the first 6 years of diagnosis, and the incidence of celiac disease is significantly higher in children younger than 4 years of age and in females. Young children with T1DM and celiac disease can present with gastrointestinal symptoms (abdominal cramping, diarrhea, constipation, gastroesophageal reflux), growth failure as a consequence of suboptimal weight gain, unexplained hypoglycemic reactions because of nutrient malabsorption, and less commonly hypocalcemia caused by severe vitamin D malabsorption; in some cases the disease can be asymptomatic.

When diabetes and thyroid disease coexist, the possibility of autoimmune adrenal insufficiency should be considered. It may be heralded by decreasing insulin requirements, increasing pigmentation of the skin and buccal mucosa, salt craving, weakness, asthenia and postural hypotension, or even frank adrenal crisis. This syndrome is unusual in the first decade of life, but it may become apparent in the second decade or later.

Circulating antibodies to gastric parietal cells and to intrinsic factor are 2-3 times more common in patients with T1DM than in control subjects. The presence of antibodies to gastric parietal cells is correlated with atrophic gastritis, and antibodies to intrinsic factor are associated with malabsorption of vitamin B_{12}. However, megaloblastic anemia is rare in children with T1DM.

Visit Elsevier eBooks+ at eBooks.Health.Elsevier.com for Bibliography.

The Nervous System

PART XXV

Chapter 630

Neurologic Evaluation

Yolanda F. Holler-Managan

HISTORY

A detailed history is the cornerstone of neurologic assessment. Although parents may be the primary informants, most children older than 3-4 years can contribute to their history and should be questioned. The history should begin with the chief complaint and its significance in the context of normal development (see Chapters 21-28). The latter step is critical because a 13-month-old who cannot walk may be normal, whereas a 4-year-old who cannot walk might have a serious neurologic condition.

Next, the history of the present illness should provide a chronological outline of the patient's symptoms, with attention paid to location, quality, intensity, duration, associated features, and alleviating or exacerbating factors. It is essential to perform a review of systems because abnormalities of the central nervous system (CNS) often manifest with vague, nonfocal symptoms that may be misattributed to other organ systems (e.g., vomiting, constipation, urinary incontinence). A detailed history might suggest that vomiting is a result of increased intracranial pressure (ICP) rather than gastritis or that constipation and urinary incontinence are caused by a spinal cord tumor rather than behavioral stool withholding. In addition, a systemic illness may produce CNS manifestations, as do lupus erythematosus (seizures, psychosis, demyelination), mitochondrial disorders (developmental delay, strokes, hypotonia), or celiac disease (headaches, seizures, peripheral neuropathy).

After obtaining the chief complaint and history of the present illness, the physician should obtain a complete birth history, particularly if a congenital or perinatal disorder is suspected. The birth history should begin with a review of the pregnancy, including specific questions about common complications, such as pregnancy-induced hypertension, preeclampsia, gestational diabetes, vaginal bleeding, infections, and falls. It is important to quantify any cigarette, alcohol, or drug (prescription, herbal, illicit) use. Inquiring about fetal movement might provide clues to an underlying diagnosis, because decreased or absent fetal activity can be associated with chromosomal anomalies and CNS or neuromuscular disorders. Finally, any abnormal ultrasound or amniocentesis results should be noted.

The mother's labor history should address the gestational age at birth and mode of delivery (spontaneous vaginal, vacuum- or forceps-assisted, cesarean section) and should comment on the presence or absence of fetal distress. If delivery was by cesarean section, it is essential to record the indication for surgery.

The birthweight, length, and head circumference provide useful information about the duration of a given problem, as well as insights into the uterine environment. Parents can usually provide a reliable history of their child's postnatal course; however, if the patient was resuscitated or had a complicated hospital stay, it is often helpful to obtain the hospital records. The physician should inquire about the infant's general well-being, feeding and sleeping patterns, activity level, and the nature of the infant's cry. If the infant had jaundice, it is important to determine both the degree of jaundice and how it was managed. Features of neurologic dysfunction at full term include inability to breathe spontaneously; poor, uncoordinated suck; or the need for an inordinate amount of time to feed or a requirement for gavage feeding. Again, it is important to consider the developmental context because all of these issues would be expected in premature infants, particularly those with a very low birthweight. Double-checking the newborn screening results may provide a clue to abnormal neurologic manifestations in an infant.

A major component of the neurologic history is the **developmental assessment** (see Chapters 21-28). Careful evaluation of a child's social, cognitive, language, fine motor skills, and gross motor skills is required to distinguish normal development from either an isolated or a global (i.e., in two or more domains) developmental delay. A static abnormality in development from birth suggests a congenital, intrauterine, or perinatal cause, but a loss of skills **(regression)** over time strongly suggests an underlying degenerative disease of the CNS, such as an inborn error of metabolism or genetic disorder. The ability of parents to recall the precise timing of their child's developmental milestones is extremely variable. It is often helpful to request old photographs of the child or to review the baby book, where the milestones may have been dutifully recorded. In general, parents are aware when their child has a developmental problem, and the physician should show appropriate concern. Table 630.1 outlines the upper limits of normal for attaining specific developmental milestones. Chapter 28 includes a comprehensive review of developmental screening tests and their interpretation.

Next, the family history must be reviewed. Most parents are cooperative in securing medical information about family members, particularly if it might have relevance for their child. The history should document the age and history of neurologic disease, including developmental delay, epilepsy, migraine, stroke, and inherited disorders, for all first- and second-degree relatives. It is important to inquire directly about miscarriages or fetal deaths and to document the sex of the relevant embryo or fetus, as well as the gestational age at the time of demise. When available, the results of postmortem examinations should be obtained, because they can have a direct bearing on the patient's condition. The parents should be questioned about their ethnic backgrounds because some genetic disorders occur more commonly within specific populations (e.g., Tay-Sachs disease in the Ashkenazi Jewish population). They should also be asked if there is any chance that they could be related to each other, because the incidence of metabolic and degenerative disorders of the CNS is increased significantly in children of *consanguineous* marriages.

The social history should detail the child's current living environment and the child's relationship with other family members. It is important to inquire about recent stressors, such as divorce, remarriage, birth of a sibling, or death of a loved one, because they can affect the child's behavior. If the child is in daycare or school, one should document the child's academic and social performance, paying particular attention to any abrupt changes. Academic performance can be assessed by asking about the child's latest report card, and peer relationships can be evaluated by having the child name his or her best friends. Any child who is unable to name at least two or three playmates might have abnormal social development. In some cases, discussions with the daycare worker or teacher provide useful ancillary data.

NEUROLOGIC EXAMINATION

The neurologic examination begins during the interview. Indirect observation of the child's appearance and movements can yield valuable information about the presence of an underlying disorder. For instance, it may be obvious that the child has dysmorphic facies, an unusual posture, or an abnormality of motor function manifested by a hemiparesis or gait disturbance. The child's behavior while playing and interacting with his or her parents may also be telling. A normal child usually plays independently early in the visit but then engages in the interview process. A child with attention-deficit/hyperactivity disorder

Table 630.1 Screening Scheme for Developmental Delay: Upper Range

AGE (MO)	GROSS MOTOR	FINE MOTOR	SOCIAL SKILLS	LANGUAGE
3	Supports weight on forearms	Opens hands spontaneously	Smiles appropriately	Coos, laughs
6	Sits momentarily	Transfers objects	Shows likes and dislikes	Babbles
9	Pulls to stand	Pincer grasp	Plays pat-a-cake, peek-a-boo	Imitates sounds
12	Walks with one hand held	Releases an object on command	Comes when called	One to two meaningful words
18	Walks upstairs with assistance	Feeds self from a spoon	Mimics actions of others	At least six words
24	Runs	Builds a tower of six blocks	Plays with others	Two- to three-word sentences

might display impulsive behavior in the examining room, and a child with neurologic impairment might exhibit complete lack of awareness of the environment. Finally, note should be made of any unusual odors about the patient, because some metabolic disorders produce characteristic scents (e.g., the musty smell of phenylketonuria or the sweaty feet smell of isovaleric acidemia; see Chapter 104). If such an odor is present, it is important to determine whether it is persistent or transient, occurring only with illnesses.

The examination should be conducted in a nonthreatening, child-friendly setting. The child should be allowed to sit where the child is most comfortable, whether it be on a parent's lap or on the floor of the examination room. The physician should approach the child slowly, reserving any invasive, painful, or discomforting tests for the end of the examination (e.g., measurement of head circumference, gag reflex). In the end, the more that the examination seems like a game, the more the child will cooperate. Because the neurologic examination of an infant requires a somewhat modified approach from that of an older child, these two groups are considered separately (see Chapters 21-23 and 115 vs Chapters 24-27).

Mental State

Age aside, the neurologic examination should include an assessment of the patient's mental state in terms of both the level of arousal and the interaction with the environment. Premature infants born at <28 weeks of gestation do not have consistent periods of alertness, whereas slightly older infants arouse from sleep with gentle physical stimulation. Sleep–wake patterns are well developed at term. Because the level of alertness of a neonate depends on many factors, including the time of the last feeding, room temperature, and gestational age, serial examinations are critical when evaluating for changes in neurologic function. An older child's mental state can be assessed by watching the child play. Having the child tell a story, draw a picture, or complete a puzzle can also be helpful in assessing cognitive function. Memory can be evaluated informally as patients recount their personal information, as well as more formally by asking them to register and recall three objects or perform a digit span.

Head

Correct measurement of the **head circumference** is important. It should be performed at every visit for patients younger than 3 years and should be recorded on a suitable head growth chart. To measure, a nondistensible plastic measuring tape is placed over the mid-forehead and extended circumferentially to include the most prominent portion of the occiput. If the patient's head circumference is abnormal, it is important to document the head circumferences of the parents and siblings. Errors in the measurement of a newborn skull are common because of scalp edema, overriding sutures, and the presence of cephalohematomas. The average rate of head growth in a healthy premature infant is 0.5 cm in the first 2 weeks, 0.75 cm in the third week, and 1.0 cm in the fourth week and every week thereafter until the fortieth week of development. The head circumference of an average term infant measures 34-35 cm at birth, 44 cm at 6 months, and 47 cm at 1 year of age (see Chapters 21 and 22).

If the brain is not growing, the skull will not grow; therefore a small head frequently reflects a small brain, or **microcephaly**. Microcephaly

Fig. 630.1 Congenital hydrocephalus. Note the enlarged cranium and prominent scalp veins.

may develop in utero or postnatally and may, for example, be related to intrauterine infection or drug exposure or to perinatal or postnatal injury. Conversely, a large head may be associated with a large brain, or **macrocephaly**, which is most commonly familial but may be from a disturbance of growth (Sotos syndrome), neurocutaneous disorder (e.g., neurofibromatosis), chromosomal defect (e.g., Klinefelter syndrome), or lysosomal storage disorder. Alternatively, the head size may be increased secondary to hydrocephalus (Fig. 630.1) or chronic subdural hemorrhages. In the latter case, the skull tends to assume a square or boxlike shape, because the long-standing presence of fluid in the subdural space causes enlargement of the middle fossa.

The shape of the head should be documented carefully. Plagiocephaly, or flattening of the skull, can be seen in normal infants but may be particularly prominent in hypotonic or weak infants, who are less mobile. A variety of abnormal head shapes can be seen when cranial sutures fuse prematurely, as in the various forms of inherited **craniosynostosis** (see Chapter 631.10).

An infant has two **fontanels** at birth: a diamond-shaped anterior fontanel at the junction of the frontal and parietal bones that is open at birth, and a triangular posterior fontanel at the junction of the parietal and occipital bones that can admit the tip of a finger or may be closed at birth. If the posterior fontanel is open at birth, it should close over the ensuing 6-8 weeks; its persistence suggests underlying hydrocephalus or congenital hypothyroidism. The anterior fontanel varies greatly in size, but it usually measures approximately 2 × 2 cm. The average time of closure is 18 months, but the fontanel can close normally as early as 9 months. A very small or absent anterior fontanel at birth might indicate craniosynostosis or microcephaly, whereas a very large fontanel can signify a variety of problems. The fontanel is normally slightly depressed and pulsatile and is best evaluated by holding the infant upright while the infant is asleep or feeding. A bulging fontanel is a potential indicator of increased ICP, but vigorous crying can cause a protuberant fontanel in a normal infant.

Inspection of the head should include observation of the venous pattern, because increased ICP and thrombosis of the superior sagittal sinus can produce marked venous distention. Dysmorphic facial features can indicate a neurodevelopmental aberration. Likewise, cutaneous abnormalities, such as cutis aplasia or abnormal hair whorls, can suggest an underlying brain malformation or genetic disorder.

Palpation of a newborn's skull characteristically reveals **molding** of the skull accompanied by **overriding sutures**—a result of the pressures exerted on the skull during its descent through the pelvis. Marked overriding of the sutures beyond the early neonatal period is cause for alarm, because it suggests an underlying brain abnormality. Palpation additionally might reveal bony bridges between sutures **(craniosynostosis)**, cranial defects, or, in premature infants, softening of the parietal bones **(craniotabes)**.

Auscultation of the skull is an important adjunct to the neurologic examination. **Cranial bruits** may be noted over the anterior fontanel, temporal region, or orbits and are best heard using the diaphragm of the stethoscope. Soft symmetric bruits may be discovered in normal children younger than 4 years of age or in association with a febrile illness. Demonstration of a loud or localized bruit is usually significant and warrants further investigation because it may be associated with severe anemia, increased ICP, or arteriovenous malformations of the middle cerebral artery or vein of Galen. It is important to exclude murmurs arising from the heart or great vessels, because they may be transmitted to the cranium.

Cranial Nerves

Olfactory Nerve (Cranial Nerve I)

Anosmia, or loss of smell, most commonly occurs as a transient abnormality in association with an upper respiratory tract infection or allergies. Permanent causes of anosmia include head trauma with damage to the ethmoid bone or shearing of the olfactory nerve fibers as they cross the cribriform plate, tumors of the frontal lobe, intranasal drug use, and exposure to toxins (acrylates, methacrylates, cadmium). Occasionally, a child who recovers from purulent meningitis or develops hydrocephalus has a diminished sense of smell. Rarely, anosmia is congenital, in which case it can occur as an isolated deficit or as part of **Kallmann syndrome**, a familial disorder characterized by hypogonadotropic hypogonadism and congenital anosmia. Although not a routine component of the examination, smell can be tested reliably as early as the 32nd week of gestation by presenting a stimulus and observing for an alerting response or withdrawal, or both. Care should be taken to use appropriate stimuli, such as coffee or peppermint, as opposed to strongly aromatic substances (e.g., ammonia inhalants) that stimulate the trigeminal nerve. Each nostril should be tested individually by pinching shut the opposite side.

Optic Nerve (Cranial Nerve II; see also Part XXVII)

Assessment of the optic disc and retina (see Chapters 659, 670, and 671) is a critical component of the neurologic examination. Although the retina is best visualized by dilating the pupil, most physicians do not have ready access to mydriatic agents at the bedside; therefore it may be necessary to consult an ophthalmologist in some cases. Mydriatics should not be administered to patients whose pupillary responses are being followed as a marker for impending cerebral herniation or to patients with glaucoma or cataracts. When mydriatics are used, both eyes should be dilated, because unilateral papillary fixation and dilation can cause confusion and worry in later examiners unaware of the pharmacologic intervention. Examination of an infant's retina may be facilitated by providing a nipple or soother and by turning the head to one side. The physician gently strokes the patient to maintain arousal while examining the closer eye. An older child should be placed in the parent's lap and should be distracted by bright objects or toys. The color of the optic nerve is salmon-pink in a child but may be gray-white in a newborn, particularly if the newborn has fair coloring. This normal finding can cause confusion and can lead to the improper diagnosis of optic atrophy.

Disc edema refers to swelling of the optic disc, and **papilledema** specifically refers to swelling that is secondary to increased ICP. Papilledema rarely occurs in infancy because the skull sutures can separate to accommodate the expanding brain. In older children, papilledema may be graded according to the Frisen scale (Fig. 630.2). Disc edema must be differentiated from **papillitis**, or inflammation of the optic nerve.

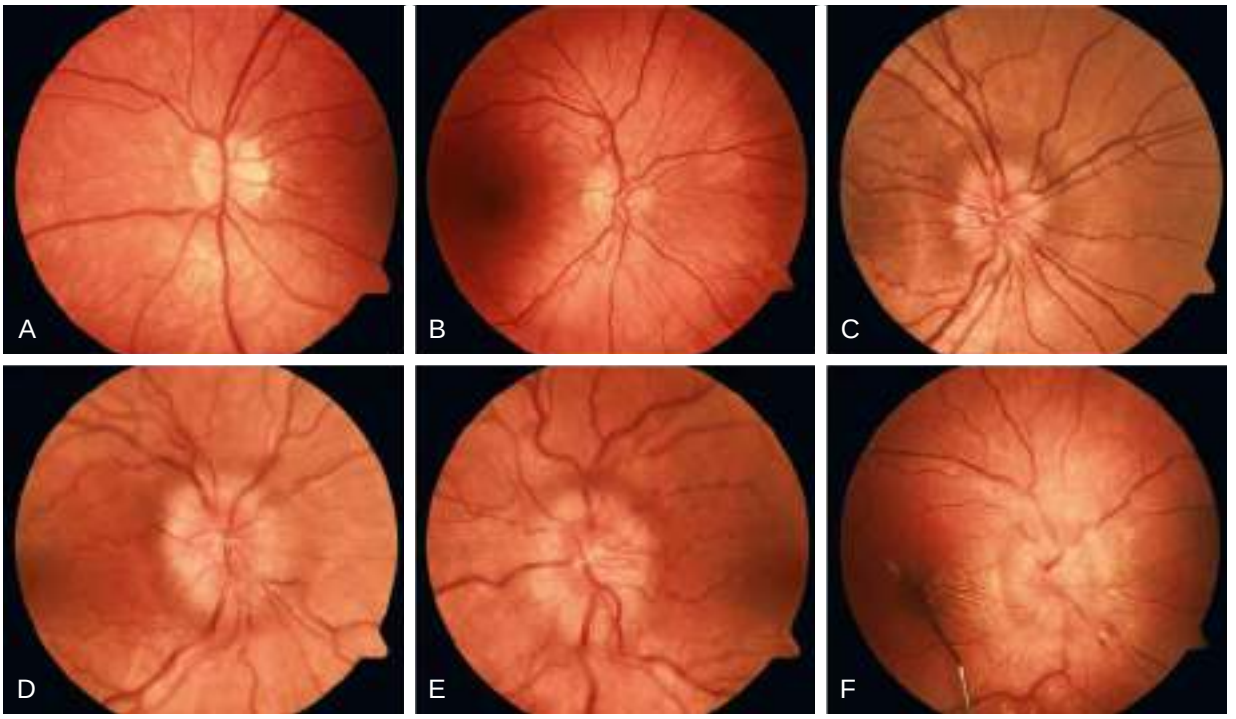

Fig. 630.2 Stages of papilledema (Frisen scale). **A**, Stage 0: Normal optic disc. **B**, Stage 1: Very early papilledema with obscuration of the nasal border of the disc only, without elevation of the disc borders. **C**, Stage 2: Early papilledema showing obscuration of all borders, elevation of the nasal border, and a complete peripapillary halo. **D**, Stage 3: Moderate papilledema with elevation of all borders, increased diameter of the optic nerve head, obscuration of vessels at the disc margin, and a peripapillary halo with finger-like extensions. **E**, Stage 4: Marked papilledema characterized by elevation of the entire nerve head and total obscuration of a segment of a major blood vessel on the disc. **F**, Stage 5: Severe papilledema with obscuration of all vessels and obliteration of the optic cup. Note also the nerve fiber layer hemorrhages and macular exudate. *(**A-C** courtesy Dr. Deborah Friedman; **D-F** courtesy Flaum Eye Institute, University of Rochester.)*

Both conditions manifest with enlargement of the blind spot, but visual acuity and color vision tend to be spared in early papilledema in contrast to what occurs in optic neuritis.

Retinal hemorrhages occur in 30–40% of all full-term newborn infants. The hemorrhages are more common after vaginal delivery than after cesarean section and are not associated with birth injury or with neurologic complications. They disappear spontaneously by 1-2 weeks of age. The presence of retinal hemorrhages beyond the early neonatal period should raise a concern for nonaccidental trauma.

Vision

A full description of the age-appropriate evaluation of vision can be found in Chapter 659. Evaluation of vision in the premature infant presents unique challenges. At 28 weeks of corrected gestational age, a premature infant blinks in response to a bright light, and at 32 weeks, the infant maintains eye closure until the light source is removed. The pupil reacts to light by 29-32 weeks of corrected gestational age; however, the pupillary response is often difficult to evaluate, because premature infants resist eye opening and have poorly pigmented irises. A normal 37-week infant turns the head and eyes toward a soft light, and a term infant is able to fix on and follow a target, such as the examiner's face.

Oculomotor (Cranial Nerve III), Trochlear (Cranial Nerve IV), and Abducens (Cranial Nerve VI) Nerves

The globe is moved by six extraocular muscles, which are innervated by the oculomotor, trochlear, and abducens nerves. These muscles and nerves can be assessed by having the patient follow an interesting toy or the examiner's finger in the six cardinal directions of gaze. The physician observes the range and nature (conjugate vs dysconjugate, smooth vs choppy or saccadic) of the eye movements, particularly noting the presence and direction of any abnormal eye movements. Premature infants older than 25 weeks of gestational age and comatose patients can be evaluated using the oculocephalic (doll's eye) maneuver, in which the patient's head is quickly rotated to evoke reflex eye movements. If the brainstem is intact, rotating the patient's head to the right causes the eyes to move to the left and vice versa. Similarly, rapid flexion and extension of the head elicits vertical eye movement.

Dysconjugate gaze can result from extraocular muscle weakness; cranial nerve (CN) III, IV, or VI palsies; or brainstem lesions that disrupt the medial longitudinal fasciculus. Infants who are younger than 2 months can have a slightly dysconjugate gaze at rest, with one eye horizontally displaced from the other by 1 or 2 mm **(strabismus)**. Vertical displacement of the eyes requires investigation because it can indicate trochlear nerve (CN IV) palsy or **skew deviation** (supranuclear ocular malalignment that is often associated with lesions of the posterior fossa). Strabismus is discussed further in Chapter 663.

The oculomotor nerve innervates the superior, inferior, and medial recti, as well as the inferior oblique and levator palpebrae superioris muscles. Complete paralysis of the oculomotor nerve causes ptosis, dilation of the pupil, displacement of the eye outward and downward, and impairment of adduction and elevation. The trochlear nerve supplies the superior oblique muscle, which depresses and internally rotates the globe during activities such as reading and walking down stairs. Patients with an isolated paralysis of the trochlear nerve often have a compensatory head tilt away from the affected side, which helps to alleviate their diplopia. The abducens nerve innervates the lateral rectus muscle; its paralysis causes medial deviation of the eye with an inability to abduct beyond the midline. Patients with increased ICP often respond positively when questioned about double vision **(diplopia)** and exhibit incomplete abduction of the eyes on lateral gaze as a result of partial palsies of nerve VI. This false-localizing sign occurs because CN VI has a long intracranial course, making it particularly susceptible to being stretched. **Internuclear ophthalmoplegia**, caused by a lesion in the medial longitudinal fasciculus of the brainstem which functionally serves the conjugate gaze by connecting CN VI on one side to CN III on the other, results in paralysis of the medial rectus function in the adducting eye and nystagmus in the abducting eye.

When there is a subtle eye movement abnormality, the **red glass test** may be helpful in localizing the lesion. To perform this test, a red glass is placed over one of the patient's eyes and the patient is instructed to follow a white light in all directions of gaze. The child sees one red/white light in the direction of normal muscle function but notes a separation of the red and white images that is greatest in the plane of action of the affected muscle.

In addition to gaze palsies, the examiner might encounter a variety of adventitious movements. **Nystagmus** is an involuntary, rapid movement of the eye that may be subclassified as being **pendular**, in which the two phases have equal amplitude and velocity, or **jerk**, in which there is a fast and a slow phase. Jerk nystagmus can be further characterized by the direction of its fast phase, which may be left-, right-, up-, or downbeating; rotatory; or mixed. Many patients have a few beats of nystagmus with extreme lateral gaze **(end-gaze nystagmus)**, which is of no consequence. Pathologic horizontal nystagmus is most often congenital, drug-induced (e.g., alcohol, anticonvulsants), or a result of vestibular system dysfunction. By contrast, vertical nystagmus is often associated with structural abnormalities of the brainstem and cerebellum. **Ocular bobbing** is characterized by a downward jerk followed by a slow drift back to primary position and is associated with pontine lesions. **Opsoclonus** describes involuntary, chaotic, conjugate oscillations of the eyes, which are often seen in the setting of neuroblastoma or viral infection.

Trigeminal Nerve (Cranial Nerve V)

The three divisions of the trigeminal nerve—ophthalmic, maxillary, and mandibular—convey information about facial protopathic (pain, temperature) and epicritic (vibration, proprioception) sensation. Each modality should be tested and compared with the contralateral side. In patients who are uncooperative or comatose, the integrity of the trigeminal nerve can be assessed by the corneal reflex, elicited by touching the cornea with a small pledget of cotton and observing for symmetric eye closure, and nasal tickle, obtained by stimulating the nasal passage with a cotton swab and observing for symmetric grimace. An absent reflex may be because of a sensory defect (trigeminal nerve) or a motor deficit (facial nerve). The motor division of the trigeminal nerve can be tested by examining the masseter, pterygoid, and temporalis muscles during mastication and by evaluation of the jaw jerk.

Facial Nerve (Cranial Nerve VII)

The facial nerve is a predominantly motor nerve that innervates the muscles of facial expression—the buccinator, platysma, stapedius, and stylohyoid muscles—and the posterior belly of the digastric muscle. It also has a separate division, called the *chorda tympani,* that contains sensory, special sensory (taste), and parasympathetic fibers. Because the portion of the facial nucleus that innervates the upper face receives bilateral cortical input, lesions of the motor cortex or corticobulbar tract have little effect on upper face strength. Rather, such lesions manifest with flattening of the contralateral nasolabial fold or drooping of the corner of the mouth. Conversely, lower motor neuron or facial nerve lesions tend to involve upper and lower facial muscles equally. Facial strength can be evaluated by observing the patient's spontaneous movements and by asking the patient to mimic a series of facial movements (e.g., smiling, raising the eyebrows, inflating the cheeks). A facial nerve palsy may be congenital; idiopathic **(Bell palsy)**; or secondary to trauma, demyelination (Guillain-Barré syndrome), infection (Lyme disease, herpes simplex virus, HIV), granulomatous disease, neoplasm, or meningeal inflammation or infiltration. Facial nerve lesions that are proximal to the junction with the chorda tympani will result in an inability to taste substances with the anterior two thirds of the tongue. If necessary, taste can be tested by placing a solution of saline or glucose on one side of the extended tongue. Normal children can identify the test substance in <10 seconds. Other findings that may be associated with facial nerve palsy include hyperacusis, resulting from stapedius muscle involvement, and impaired tearing.

Vestibulocochlear Nerve (Cranial Nerve VIII)

The vestibulocochlear nerve has two components within a single trunk: the vestibular nerve, which innervates the semicircular canals of the inner ear and is involved with equilibrium, coordination, and

orientation in space, and the cochlear nerve, which innervates the cochlea and carries auditory sensory information.

Dysfunction of the vestibular system results in **vertigo**, the sensation of environmental motion. On examination, patients with vestibular nerve dysfunction typically have nystagmus, in which the fast component is directed away from the affected nerve. With their arms outstretched and eyes closed, their limbs tend to drift toward the injured side. Likewise, if they march in place, they slowly pivot toward the lesion **(Fukuda stepping test)**. On Romberg and tandem gait testing, they tend to fall toward the abnormal ear. Vestibular function can be further evaluated with **caloric testing**. Before testing, the tympanic membrane should be visualized to ensure that it is intact and unobstructed. In an obtunded or comatose patient, 30-50 mL of ice water is then delivered by syringe into the external auditory canal with the patient's head elevated 30 degrees. If the brainstem is intact, the eyes deviate toward the irrigated side. A much smaller quantity of ice water (2 mL) is used in awake, alert patients to avoid inducing nausea. In normal subjects, introduction of ice water produces eye deviation toward the stimulated labyrinth followed by nystagmus, with the fast component away from the stimulated labyrinth.

Because hearing is integral to normal language development, the physician should inquire directly about hearing problems. The parents' concern is often a reliable indicator of hearing impairment and warrants a formal audiologic assessment with either audiometry or brainstem auditory evoked potential testing (see Chapter 677). Even in the absence of parents' concern, formal testing is recommended in all newborns with the goal for all infants to be tested within the first month of life. Children at risk for hearing problems include those with a family history of early-life or syndromic deafness or a personal history of prematurity, severe asphyxia, exposure to ototoxic drugs, hyperbilirubinemia, congenital anomalies of the head or neck, bacterial meningitis, and congenital TORCH (toxoplasmosis, other infections, rubella, cytomegalovirus, herpes simplex virus) infections. For all other infants and children, a simple bedside assessment of hearing is usually sufficient. Newborns might have subtle responses to auditory stimuli, such as changes in breathing, cessation of movement, or opening of the eyes and/or mouth. If the same stimulus is presented repeatedly, normal neonates cease to respond, a phenomenon known as *habituation*. By 3-4 months of age, infants begin to orient to the source of sound. Hearing-impaired toddlers are visually alert and appropriately responsive to physical stimuli but might have more frequent temper tantrums and abnormal speech and language development.

Glossopharyngeal Nerve (Cranial Nerve IX)

The glossopharyngeal nerve conveys motor fibers to the stylopharyngeus muscle; general sensory fibers from the posterior third of the tongue, pharynx, tonsil, internal surface of the tympanic membrane, and skin of the external ear; special sensory (taste) fibers from the posterior third of the tongue; parasympathetic fibers to the parotid gland; and general visceral sensory fibers from the carotid bodies. The nerve is tested by stimulating one side of the lateral oropharynx or soft palate with a tongue blade and observing for symmetric elevation of the palate **(gag reflex)**. An isolated lesion of CN IX is rare because it runs in close proximity to CN X. Potential causes of injury and/or dysfunction include birth trauma, ischemia, mass lesions, motor neuron disease, retropharyngeal abscess, and Guillain-Barré syndrome.

Vagus Nerve (Cranial Nerve X)

The vagus nerve has 10 terminal branches: meningeal, auricular, pharyngeal, carotid body, superior laryngeal, recurrent laryngeal, cardiac, pulmonary, esophageal, and gastrointestinal. The pharyngeal, superior laryngeal, and recurrent laryngeal branches contain motor fibers that innervate all of the muscles of the pharynx and larynx, with the exception of the stylopharyngeus (CN IX) and tensor veli palatini (CN V) muscles. Thus unilateral injury of the vagus nerve results in weakness of the ipsilateral soft palate and a hoarse voice; bilateral lesions can produce respiratory distress as a result of vocal cord paralysis, as well as nasal regurgitation of fluids, pooling of secretions, and an immobile, low-lying soft palate. Isolated lesions to the vagus nerve may be a complication of thoracotomies or may be seen in neonates with type II Chiari malformations. If such a lesion is suspected, it is important to visualize the vocal cords. In addition to motor information, the vagus nerve carries somatic afferents from the pharynx, larynx, ear canal, external surface of the tympanic membrane, and meninges of the posterior fossa; visceral afferents; taste fibers from the posterior pharynx; and preganglionic parasympathetics.

Accessory Nerve (Cranial Nerve XI)

The accessory nerve innervates the sternocleidomastoid (SCM) and trapezius muscles. The left SCM acts to turn the head to the right side and vice versa; acting together, the SCMs flex the neck. The trapezius acts to elevate the shoulder. Lesions to the accessory nerve result in atrophy and paralysis of the ipsilateral SCM and trapezius muscles, with resultant depression of the shoulder. Because several cervical muscles are involved in head rotation, unilateral SCM paresis might not be evident unless the patient is asked to rotate the head against resistance. Skull base fractures or lesions, motor neuron disease, myotonic dystrophy, and myasthenia gravis commonly produce atrophy and weakness of these muscles; congenital torticollis is associated with SCM hypertrophy.

Hypoglossal Nerve (Cranial Nerve XII)

The hypoglossal nerve innervates the tongue. Examination of the tongue includes assessment of its bulk and strength, as well as observation for adventitious movements. Malfunction of the hypoglossal nucleus or nerve produces atrophy, weakness, and fasciculations of the tongue. If the injury is unilateral, the tongue deviates toward the side of the injury; if it is bilateral, tongue protrusion is not possible, and the patient can have difficulty swallowing **(dysphagia)**. Werdnig-Hoffmann disease (infantile spinal muscular atrophy, or spinal muscular atrophy type 1) and congenital anomalies in the region of the foramen magnum are the principal causes of hypoglossal nerve dysfunction.

Motor Examination

The motor examination includes assessment of muscle bulk, tone, and strength, as well as observation for involuntary movements that might indicate central or peripheral nervous system pathology.

Bulk

Decreased muscle bulk **(atrophy)** may be secondary to disuse or to diseases of the lower motor neuron, nerve root, peripheral nerve, or muscle. In most cases, neurogenic atrophy is more severe than myogenic atrophy. Increased muscle bulk **(hypertrophy)** is usually physiologic (e.g., body builders). **Pseudohypertrophy** refers to muscle tissue that has been replaced by fat and connective tissue, giving it a bulky appearance with a paradoxical reduction in strength, as in Duchenne muscular dystrophy.

Tone

Muscle tone, which is generated by an unconscious, continuous, partial contraction of muscle, creates resistance to passive movement of a joint. Tone varies greatly based on a patient's age and state. At 28 weeks of gestation, all four extremities are extended and there is little resistance to passive movement. Flexor tone is visible in the lower extremities at 32 weeks and is palpable in the upper extremities at 36 weeks. A normal term infant's posture is characterized by flexion of all four extremities.

There are three key tests for assessing postural tone in neonates: the traction response, vertical suspension, and horizontal suspension (Fig. 630.3; see Chapters 115 and 122). To evaluate the **traction response**, the physician grasps the infant's hands and gently pulls the infant to a sitting position. Normally, the infant's head lags slightly behind the infant's body and then falls forward upon reaching the sitting position. To test **vertical suspension**, the physician holds the infant by the axillae without gripping the thorax. The infant should remain suspended with the infant's lower extremities held in flexion; a hypotonic infant will slip through the physician's hands. With **horizontal suspension**, the physician holds the infant prone by placing a hand under the

Fig. 630.3 Normal tone in a full-term neonate. A, Flexed resting posture. B, Traction response. C, Vertical suspension. D, Horizontal suspension.

infant's abdomen. The head should rise and the limbs should flex, but a hypotonic infant will drape over the physician's hand, forming a U shape. Assessing tone in the extremities is accomplished by observing the infant's resting position and passively manipulating the infant's limbs. When the upper extremity of a normal term infant is pulled gently across the chest, the elbow does not quite reach the mid-sternum **(scarf sign)**, whereas the elbow of a hypotonic infant extends beyond the midline with ease. Measurement of the **popliteal angle** is a useful method for documenting tone in the lower extremities. The examiner flexes the hip and extends the knee. Normal term infants allow extension of the knee to approximately 80 degrees. Similarly, tone can be evaluated by flexing the hip and knee to 90 degrees and then internally rotating the leg, in which case the heel should not pass the umbilicus.

Abnormalities of tone include spasticity, rigidity, and hypotonia. **Spasticity** is characterized by an initial resistance to passive movement, followed by a sudden release, referred to as the **clasp-knife** phenomenon. Because spasticity results from upper motor neuron dysfunction, it disproportionately affects the upper-extremity flexors and lower-extremity extensors and tends to occur in conjunction with disuse atrophy, hyperactive deep tendon reflexes, and extensor plantar reflexes **(Babinski sign)**. In infants, spasticity of the lower extremities results in scissoring of the legs upon vertical suspension. Older children can present with prolonged commando crawling or toe-walking. **Rigidity**, seen with lesions of the basal ganglia, is characterized by resistance to passive movement that is equal in the flexors and extensors regardless of the velocity of movement **(lead pipe)**. Patients with either spasticity or rigidity might exhibit **opisthotonos**, defined as severe hyperextension of the spine caused by hypertonia of the paraspinal muscles (Fig. 630.4), although similar posturing can be seen in patients with Sandifer syndrome (gastroesophageal reflux or hiatal hernia associated with torsional dystonia). **Hypotonia** refers to abnormally diminished tone and is the most common abnormality of tone in neurologically compromised neonates. A hypotonic infant is floppy and often assumes a frog-leg posture at rest. Hypotonia can reflect pathology of the cerebral hemispheres, cerebellum, spinal cord, anterior horn cell, peripheral nerve, neuromuscular junction, or muscle.

Strength

Older children are usually able to cooperate with formal strength testing, in which case muscle power is graded on a scale of 0-5 as follows: 0 = no contraction; 1 = flicker or trace of contraction; 2 = active movement with gravity eliminated; 3 = active movement against gravity; 4 = active movement against gravity and resistance; and 5 = normal power. An examination of muscle power should include all muscle groups, including the neck flexors and extensors and the muscles of respiration. It is important not only to assess individual muscle groups but also to determine the pattern of weakness (i.e., proximal vs distal; segmental vs regional). Testing for **pronator drift** can be helpful in localizing the lesion in a patient with weakness. This test is accomplished by having the patient extend his or her arms away from the body with the palms facing upward and the eyes closed. *Together, pronation and downward drift of an arm indicate a lesion of the contralateral corticospinal tract.*

Because infants and young children are not able to participate in formal strength testing, they are best assessed with functional measures. Proximal and distal strength of the upper extremities can be tested by having the child reach overhead for a toy and by watching the child manipulate small objects. In infants younger than 2 months, the physician can also take advantage of the palmar grasp reflex in assessing distal power and the Moro reflex in assessing proximal power. Infants with decreased strength in the lower extremities tend to have diminished spontaneous activity in their legs and are unable to support their body weight when held upright. Older children may have difficulty climbing or descending steps, jumping, or hopping. They might also use their hands to climb up their legs when asked to rise from a prone position, a maneuver called **Gowers sign** (Fig. 630.5).

Fig. 630.4 Opisthotonos in a brain-injured infant.

Involuntary Movements

Patients with lower motor neuron or peripheral nervous system lesions might have **fasciculations**, which are small, involuntary muscle contractions that result from the spontaneous discharge of a single motor unit and create the illusion of a bag of worms under the skin. Because most infants have abundant body fat, muscle fasciculations are best observed in the tongue in this age-group.

Most other involuntary movements, including tics, dystonia, chorea, and athetosis, stem from disorders of the basal ganglia. Tremor seems to be an exception, as it is thought to be mediated by cerebellothalamocortical pathways. Further detail on the individual movement disorders is provided in Chapter 637.

Sensory Examination

The sensory examination is difficult to perform on an infant or uncooperative child and has a relatively low yield in terms of the information that it provides. A gross assessment of sensory function can be achieved by distracting the patient with an interesting toy and then touching the patient with a cotton swab in different locations. Normal infants and children indicate an awareness of the stimulus by crying, withdrawing the extremity, or pausing briefly; however, with repeated testing, they lose interest in the stimulus and begin to ignore the examiner. It is therefore critical that any areas of concern are tested efficiently and, if necessary, reexamined at an appropriate time.

Fortunately, isolated disorders of the sensory system are less common in the very young pediatric population than in the adult population, so

Fig. 630.5 A-D, Gowers sign in a child with hip girdle weakness because of Duchenne muscular dystrophy. When asked to rise from a prone position, the patient uses his hands to walk up his legs to compensate for proximal lower extremity weakness.

Table 630.2 Timing of Selected Primitive Reflexes

REFLEX	ONSET	FULLY DEVELOPED	DURATION
Palmar grasp	28 wk gestation	32 wk gestation	2-3 mo postnatal
Rooting	32 wk gestation	36 wk gestation	4-6 mo postnatal
Moro	28-32 wk gestation	37 wk gestation	5-6 mo postnatal
Tonic neck	35 wk gestation	1 mo postnatal	6-7 mo postnatal
Parachute	7-8 mo postnatal	10-11 mo postnatal	Remains throughout life

detailed sensory testing is rarely warranted. Furthermore, most patients who are old enough to voice a sensory complaint are also old enough to cooperate with formal testing of light touch, pain, temperature, vibration, proprioception, and cortical sensation (e.g., stereognosis, two-point discrimination, extinction to double simultaneous stimulation). A notable exception is when the physician suspects a spinal cord lesion in an infant or young child and needs to identify a sensory level. In such situations, observation might suggest a difference in color, temperature, or perspiration, with the skin cool and dry below the level of injury. Lightly touching the skin above the level can evoke a squirming movement or physical withdrawal. Other signs of spinal cord injury include decreased anal sphincter tone and strength and absence of the superficial abdominal, anal wink, and cremasteric reflexes.

Reflexes

Deep Tendon Reflexes and the Plantar Response

Deep tendon reflexes are readily elicited in most infants and children. In infants, it is important to position the head in the midline when assessing reflexes, because turning the head to one side can alter reflex tone. Reflexes are graded from 0 (absent) to 4+ (markedly hyperactive), with 2+ being normal. Reflexes that are 1+ or 3+ can be normal as long as they are symmetric. Sustained clonus is always pathologic, but infants younger than 3 months old can have 5-10 beats of clonus, and older children can have 1-2 beats of clonus, provided that it is symmetric.

The ankle jerk is hardest to elicit, but it can usually be obtained by passively dorsiflexing the foot and then tapping on either the Achilles tendon or the ball of the foot. The knee jerk is evoked by tapping the patellar tendon. If this reflex is exaggerated, extension of the knee may be accompanied by contraction of the contralateral adductors **(crossed adductor response)**. Hypoactive reflexes generally reflect lower motor neuron or cerebellar dysfunction, whereas hyperactive reflexes are consistent with upper motor neuron disease, although acute upper motor neuron injury can result in hypoactive or absent deep tendon reflexes. The plantar response is obtained by stimulation of the lateral aspect of the sole of the foot, beginning at the heel and extending to the base of the toes. The **Babinski sign**, indicating an upper motor neuron lesion, is characterized by extension of the great toe and fanning of the remaining toes. Too vigorous stimulation may produce withdrawal, which may be misinterpreted as a Babinski sign. Plantar responses have limited diagnostic utility in neonates because they are mediated by several competing reflexes and can be either flexor or extensor, depending on how the foot is positioned. Asymmetry of the reflexes or plantar response is a useful lateralizing sign in infants and children.

Primitive Reflexes

Primitive reflexes appear and disappear at specific times during development (Table 630.2), and their absence or persistence beyond those times signifies CNS dysfunction. Although many primitive reflexes have been described, the Moro, grasp, tonic neck, and parachute reflexes are the most clinically relevant. The **Moro reflex** is elicited by supporting the infant in a semierect position and then allowing the infant's head to fall backward onto the examiner's hand. A normal response consists of symmetric extension and abduction of the fingers and upper extremities, followed by flexion of the upper extremities and an audible cry. An asymmetric response can signify a fractured clavicle, brachial plexus injury, or hemiparesis. Absence of the Moro reflex in a term newborn is ominous, suggesting significant dysfunction of the CNS. The **grasp response** is elicited by placing a finger in the open palm of each hand; by 37 weeks of gestation, the reflex is strong enough that the examiner

can lift the infant from the bed with gentle traction. The **tonic neck reflex** is produced by manually rotating the infant's head to one side and observing for the characteristic fencing posture (extension of the arm on the side to which the face is rotated and flexion of the contralateral arm). An obligatory tonic neck response, in which the infant becomes stuck in the fencing posture, is always abnormal and implies a CNS disorder. The **parachute reflex**, which occurs in slightly older infants, can be evoked by holding the infant's trunk and then suddenly lowering the infant as if he or she were falling. The arms will spontaneously extend to break the infant's fall, making this reflex a prerequisite to walking (Fig. 630.6).

Coordination

Ataxia refers to a disturbance in the smooth performance of voluntary motor acts and is usually the result of cerebellar dysfunction. Lesions to the cerebellar vermis result in unsteadiness while sitting or standing **(truncal ataxia)**. Affected patients might have a wide-based gait or may be unable to perform tandem gait testing. Lesions of the cerebellar hemispheres cause appendicular ataxia, which may be apparent as the patient reaches for objects and performs finger-to-nose and heel-to-shin movements. Other features of cerebellar dysfunction include errors in judging distance **(dysmetria)**, inability to inhibit a muscular action **(rebound)**, impaired performance of rapid alternating movements **(dysdiadochokinesia)**, intention tremor, nystagmus, scanning dysarthria, hypotonia, and decreased deep tendon reflexes. Acute ataxia suggests an infectious or postinfectious, endocrinologic, toxic, traumatic, vascular, or psychogenic process, and chronic symptoms suggest a metabolic, neoplastic, or degenerative process.

Station and Gait

Observation of a child's station and gait is an important aspect of the neurologic examination. Normal children can stand with their feet close together without swaying; however, children who are unsteady may sway or even fall. On gait testing, the heels should strike either side of an imaginary line, but children with poor balance tend to walk with their legs farther apart to create a more stable base. Tandem gait testing forces patients to have a narrow base, which highlights subtle balance difficulties.

There are a variety of abnormal gaits, many of which are associated with a specific underlying etiology. Patients with a **spastic gait** appear stiff-legged like a soldier. They may walk on tiptoe as a result of tightness or contractures of the Achilles tendons, and their legs may scissor as they walk. A **hemiparetic gait** is associated with spasticity and circumduction of the leg, as well as decreased arm swing on the affected side. **Cerebellar ataxia** results in a wide-based, reeling gait like that of a drunk person, whereas **sensory ataxia** results in a wide-based **steppage gait**, in which the patient lifts the legs up higher than usual in the swing phase and then slaps the foot down. A **myopathic**, or waddling, **gait** is associated with hip girdle weakness. Affected children often develop a compensatory lordosis and have other signs of proximal muscle weakness, such as difficulty climbing stairs. During gait testing, the examiner might also note hypotonia or weakness of the lower extremities; extrapyramidal movements, such as dystonia or chorea; or orthopedic deformities, such as pelvic tilt, genu recurvatum, varus or valgus deformities of the knee, pes cavus (high arches) or pes planus (flat feet), and scoliosis.

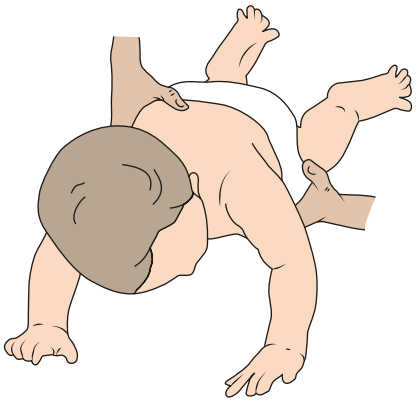

Fig. 630.6 Infant in the parachute reflex position. This primitive reflex develops later in infancy (around 6 mo), and its absence can signal delayed walking. It is elicited by holding the infant face down and rapidly lowering the infant, causing the infant to extend out the arms.

GENERAL EXAMINATION

Examination of other organ systems is essential because myriad systemic diseases affect the nervous system. Dysmorphic features can indicate a genetic syndrome (see Chapter 95). Heart murmurs may be associated with rheumatic fever (Sydenham chorea), cardiac rhabdomyoma (tuberous sclerosis), cyanotic heart disease (cerebral abscess or thrombosis), and endocarditis (cerebral vascular occlusion). Hepatosplenomegaly can suggest an inborn error of metabolism, storage disease, HIV infection, or malignancy. Cutaneous lesions may be a feature of a neurocutaneous syndrome (see Chapter 636).

SPECIAL DIAGNOSTIC PROCEDURES

Lumbar Puncture and Cerebrospinal Fluid Examination

Examination of the cerebrospinal fluid (CSF) and measurement of the pressure it creates in the subarachnoid space is essential in confirming the diagnosis of meningitis, encephalitis (autoimmune, infectious), and idiopathic intracranial hypertension (previously referred to as *pseudotumor cerebri*), and it is often helpful in assessing subarachnoid hemorrhage; demyelinating, degenerative, and collagen vascular diseases; and intracranial neoplasms. Having an experienced assistant who can position, restrain, and comfort the patient is critical to the success of the procedure.

The patient should be situated in a lateral decubitus or seated position with the neck and legs flexed to enlarge the intervertebral spaces. As a rule, sick neonates should be maintained in a seated position to prevent problems with ventilation and perfusion. Regardless of the position chosen, it is important to make sure that the patient's shoulders and hips are straight to prevent rotating the spine.

Once the patient is situated, the physician identifies the appropriate interspace by drawing an imaginary line from the iliac crest downward perpendicular to the vertebral column. In adults, lumbar punctures are usually performed in the L3-L4 or L4-L5 interspaces. Next, the physician dons a mask, gown, and sterile gloves. The skin is thoroughly prepared with a cleansing agent, and sterile drapes are applied. The skin and underlying tissues are anesthetized by injecting a local anesthetic (e.g., 1% lidocaine) at the time of the procedure or by applying a eutectic mixture of lidocaine and prilocaine (EMLA) to the skin 30 minutes before the procedure. A 22-gauge, 1.5- to 3.0-inch, sharp, beveled spinal needle with a properly fitting stylet is introduced in the midsagittal plane and directed slightly cephalad. The physician should pause frequently, remove the stylet, and assess for CSF flow. Although a pop can occur as the needle penetrates the dura, it is more common to experience a subtle change in resistance.

Once CSF has been detected, a manometer and three-way stopcock can be attached to the spinal needle to obtain an opening pressure. If the patient was seated as the spinal needle was introduced, the patient should be moved carefully to a **lateral decubitus position** with the head and legs extended before the manometer is attached. In children between 1 and 18 years of age, the reference range parameter for abnormally elevated opening pressure, determined as the 90th percentile for all patients in the reference population, is 28 cm of water. The threshold for an abnormally reduced pressure in the 10th percentile is 11.5 cm of water. The most common cause of an elevated opening pressure is an agitated patient. Sedation and a high body mass index can also increase the opening pressure (see Chapter 645).

Contraindications to performing a lumbar puncture include suspected mass lesion of the brain, especially in the posterior fossa or

above the tentorium and causing shift of the midline; suspected mass lesion of the spinal cord; symptoms and signs of impending cerebral herniation in a child with probable meningitis; critical illness (on rare occasions); skin infection at the site of the lumbar puncture; and thrombocytopenia with a platelet count of $<20 \times 10^9$/L. If optic disc edema or focal findings suggest a mass lesion, a rapid CT scan of the head should be obtained before proceeding with lumbar puncture to prevent uncal or cerebellar herniation as the CSF is removed. In the absence of these findings, routine head imaging is not warranted. The physician should also be alert to clinical signs of impending herniation, including alterations in the respiratory pattern (e.g., hyperventilation, Cheyne-Stokes respirations, ataxic respirations, respiratory arrest), abnormalities of pupil size and reactivity, loss of brainstem reflexes, and decorticate or decerebrate posturing. If any of these signs are present or the child is so ill that the lumbar puncture might induce cardiorespiratory arrest, blood cultures should be drawn and supportive care, including antibiotics, should be initiated. Once the patient has stabilized, it may be possible to perform a lumbar puncture safely.

Normal CSF contains up to 5/mm^3 white blood cells, and a newborn can have as many as 15/mm^3. Polymorphonuclear cells are always abnormal in a child, but 1-2/mm^3 may be present in a normal neonate. An elevated polymorphonuclear count suggests bacterial meningitis or the early phase of aseptic meningitis (see Chapter 643). CSF lymphocytosis can be seen in aseptic, tuberculous, or fungal meningitis; demyelinating diseases; brain or spinal cord tumor; immunologic disorders, including collagen vascular diseases; and chemical irritation (after myelogram, intrathecal methotrexate).

Normal CSF contains no red blood cells; thus their presence indicates a traumatic tap or a subarachnoid hemorrhage. Progressive clearing of the blood between the first and last samples indicates a traumatic tap. Bloody CSF should be centrifuged immediately. A clear supernatant is consistent with a bloody tap, whereas **xanthochromia** (yellow color that results from the degradation of hemoglobin) suggests a subarachnoid hemorrhage. Xanthochromia may be absent in bleeds <12 hours old, particularly when laboratories rely on visual inspection rather than spectroscopy. Xanthochromia can also occur in the setting of hyperbilirubinemia, carotenemia, and markedly elevated CSF protein.

The normal CSF protein is 10-40 mg/dL in a child and as high as 120 mg/dL in a neonate. The CSF protein falls to the normal childhood range by 3 months of age. The CSF protein may be elevated in many processes, including infectious, immunologic, vascular, and degenerative diseases; blockage of CSF flow; as well as tumors of the brain (primary CNS tumors, systemic tumors metastatic to the CNS, infiltrative acute lymphoblastic leukemia) and spinal cord. With a traumatic tap, the CSF protein is increased by approximately 1 mg/dL for every 1,000 red blood cells/mm^3. Elevation of CSF immunoglobulin G, which normally represents approximately 10% of the total protein, is observed in subacute sclerosing panencephalitis, in postinfectious encephalomyelitis, and in some cases of multiple sclerosis. If the diagnosis of multiple sclerosis is suspected, the CSF should be tested for the presence of oligoclonal bands.

The CSF glucose content is approximately 60% of the blood glucose in a healthy child. To prevent a spuriously elevated blood:CSF glucose ratio in a case of suspected meningitis, it is advisable to collect the blood glucose before the lumbar puncture when the child is relatively calm. Hypoglycorrhachia is found in association with diffuse meningeal disease, particularly bacterial and tubercular meningitis. Widespread neoplastic involvement of the meninges, subarachnoid hemorrhage, disorders involving the glucose transporter protein type 1 (e.g., GLUT1 deficiency), fungal meningitis, and, occasionally, aseptic meningitis can produce low CSF glucose as well.

A Gram stain of the CSF is essential if there is a suspicion for bacterial meningitis; an acid-fast stain and India ink preparation can be used to assess for tuberculous and fungal meningitis, respectively. CSF is then plated on different culture media depending on the suspected pathogen. When indicated by the clinical presentation, it can also be helpful to assess for the presence of specific antigens or polymerase chain reaction studies (e.g., *Neisseria meningitidis, Haemophilus influenzae* type b, or *Streptococcus pneumoniae*) or to obtain antibody or polymerase chain reaction studies (e.g., herpes simplex virus 1 and 2, West Nile virus, Zika, enteroviruses). In noninfectious cases, levels of CSF metabolites, such as lactate, amino acids, and autoimmune encephalitis panel, can provide clues to the underlying metabolic disease.

Neuroradiologic Procedures

Skull x-rays have limited diagnostic utility. They can demonstrate fractures, bony defects, intracranial calcifications, or indirect evidence of increased ICP. Acutely increased ICP causes separation of the sutures, whereas chronically increased ICP is associated with erosion of the posterior clinoid processes, enlargement of the sella turcica, and increased convolutional markings.

Cranial ultrasonography is the imaging method of choice for detecting intracranial hemorrhage, periventricular leukomalacia, and hydrocephalus in infants younger than 6 months with patent anterior fontanels. Ultrasound is less sensitive than either cranial CT scanning or MRI for detecting hypoxic-ischemic injury, but the use of color Doppler or power Doppler sonography, both of which show changes in regional cerebral blood flow velocity, improve its sensitivity. In general, ultrasound is not a useful technique in older children, although it can be helpful intraoperatively when placing shunts, locating small tumors, and performing needle biopsies.

Cranial CT is a valuable diagnostic tool in the evaluation of many neurologic emergencies and in some nonemergent conditions. It is a noninvasive, rapid procedure that can usually be performed without sedation. CT scans use conventional x-ray techniques, meaning that they produce ionizing radiation. Because children younger than 10 years of age are several times more sensitive to radiation than adults, it is important to consider whether imaging is actually indicated and, if it is, whether an ultrasound or MRI might be the more appropriate study. In the emergency setting, a noncontrast CT scan can demonstrate skull fractures, pneumocephalus, intracranial hemorrhages, hydrocephalus, and impending herniation. If the noncontrast scan reveals an abnormality and an MRI cannot be performed in a timely fashion, nonionic contrast should be used to highlight areas of breakdown in the blood-brain barrier (e.g., abscesses, tumors) and/or collections of abnormal blood vessels (e.g., arteriovenous malformations). CT is less useful for diagnosing acute infarcts in children because radiographic changes might not be apparent for up to 24 hours. Some subtle signs of early (<24 hours) infarction include sulcal effacement, blurring of the gray-white junction, and the hyperdense middle cerebral artery sign (increased attenuation in the middle cerebral artery that is often associated with thrombosis). In the routine setting, CT imaging can be used to demonstrate intracranial calcifications or, with the addition of three-dimensional reformatting, to evaluate patients with craniofacial abnormalities or craniosynostosis. Although other pathologic processes may be visible on CT scan, *MR is generally preferred because it provides a more detailed view of the anatomy without exposing the patient to ionizing radiation* (Table 630.3).

Cranial CT angiography is a useful tool for visualizing vascular structures and is accomplished by administering a tight bolus of iodinated contrast through a large-bore intravenous catheter and then acquiring CT images as the contrast passes through the arteries.

Brain MRI is a noninvasive procedure that is well suited for detecting a variety of abnormalities, including those of the posterior fossa and spinal cord. MR scans are highly susceptible to patient motion artifact; consequently, many children younger than age 8 years require sedation to ensure an adequate study. The need for sedation has decreased in some centers as MRI technology improves and allows for faster performance of studies and as visual distraction techniques are better designed to be used by a child while in the MRI scanner. Because the American Academy of Pediatrics recommends that infants be kept nothing by mouth (NPO) for 4 hours or longer and older children for 6 hours or longer before deep sedation, it is often difficult to obtain an MRI on an infant or young child in the acute

Table 630.3 Preferred Imaging Procedures in Neurologic Diseases

ISCHEMIC INFARCTION OR TRANSIENT ISCHEMIC ATTACK	
CT/CTA (head and neck) ± CT perfusion for patients who are unstable or are potential candidates for tissue plasminogen activator or other acute interventions	
Otherwise, MRI/MRA (head and neck) with and without gadolinium and with diffusion-weighted images	
If the examination findings localize to the anterior circulation, carotid ultrasound should be performed rather than neck CTA or MRA	
Obtain an MRV if the infarct does not follow an arterial distribution	
CT or MRI can detect infarcts more than 24 hours old, although MRI is generally preferred to avoid exposure to ionizing radiation	
INTRAPARENCHYMAL HEMORRHAGE	
CT if <24 hr; MRI if >24 hr	
MRI and MRA to assess for underlying vascular malformation, tumor, and so on	
Catheter angiography if MRA is nondiagnostic	
ARTERIOVENOUS MALFORMATION	
CT for acute hemorrhage; MRI and MRA with and without gadolinium as early as possible	
Catheter angiography if noninvasive imaging is nondiagnostic	
CEREBRAL ANEURYSM	
CT without contrast for acute subarachnoid hemorrhage	
MRA or CTA to identify the aneurysm	
Catheter angiography may be necessary in some cases	
TCD to detect vasospasm	
HYPOXIC-ISCHEMIC BRAIN INJURY	
Ultrasound in infants	
If ultrasound is negative or there is a discrepancy between the clinical course and the sonogram, obtain an MRI	
In older children, CT if unstable; otherwise, MRI	
MRS can show a lactate peak even in the absence of structural abnormalities and can be useful for prognostication purposes	
METABOLIC DISORDERS	
MRI, particularly T2-weighted and FLAIR images	
Diffusion-weighted images may be useful in distinguishing acute and chronic changes	
MRS, SPECT, and PET may be useful in certain disorders	
HYDROCEPHALUS	
Ultrasound (in infants), CT with and without contrast, or MR with and without gadolinium for diagnosis of communicating hydrocephalus	
MR with and without gadolinium for diagnosis of noncommunicating hydrocephalus	
Ultrasound (in infants) or CT to follow ventricular size in response to treatment	
HEADACHE	
CT with and without contrast or MRI with and without gadolinium if a structural disorder is suspected (MRI is preferred in nonemergent situations because it does not involve ionizing radiation and provides a better view of the parenchyma)	
HEAD TRAUMA	
CT without contrast initially	
MRI after initial assessment and treatment if clinically indicated; diffusion tensor imaging and/or diffusion kurtosis sequences may be useful to detect subtle white matter abnormalities	
EPILEPSY	
MRI with and without gadolinium; thin slices through the mesial temporal lobes may be helpful if a temporal focus is suspected	
PET	
Interictal SPECT	
BRAIN TUMOR	
MRI with and without gadolinium	
MRS	
PET	
MULTIPLE SCLEROSIS	
MRI with and without gadolinium	
Obtain sagittal FLAIR images	
MENINGITIS OR ENCEPHALITIS	
CT without and with contrast before lumbar puncture if there are signs of increased ICP on examination	
MRI with and without gadolinium after initial assessment and treatment for patients with complicated meningitis or encephalitis	
BRAIN ABSCESS	
MRI with and without gadolinium	
Diffusion-weighted images and MRS can help to differentiate abscess from necrotic tumor	
If the patient is unstable, CT with and without contrast followed by MRI with and without contrast when feasible	
MOVEMENT DISORDERS	
MRI with and without gadolinium	
PET	
DaTscan (SPECT scan using ioflupane iodine-123 as the contrast agent for detecting dopamine transporters in suspected parkinsonian syndromes)	

CTA, computed tomographic angiography; FLAIR, fluid-attenuated inversion recovery; ICP, intracranial pressure; MRA, magnetic resonance angiography; MRS, magnetic resonance spectroscopy; MRV, magnetic resonance venography; PET, positron emission tomography; SPECT, single-photon emission computed tomography; TCD, transcranial Doppler ultrasonography.

setting. MRI can be used to evaluate for congenital or acquired brain lesions, migrational defects, dysmyelination or demyelination, posttraumatic gliosis, neoplasms, cerebral edema, and acute stroke (see Table 630.3). Paramagnetic MR contrast agents (e.g., gadolinium-diethylenetriaminepentaacetic acid [DTPA]) are efficacious in identifying areas of disruption in the blood-brain barrier, such as those occurring in primary and metastatic brain tumors, meningitis, cerebritis, abscesses, and active demyelination. **MR angiography** and **MR venography** provide detailed images of major intracranial vasculature structures and assist in the diagnosis of conditions such as stroke, vascular malformations, and cerebral venous sinus thrombosis. MR angiography is the procedure of choice for infants and young children because of the lack of ionizing radiation and contrast; however, CT angiography may be preferable in older children because it is faster and can eliminate the need for sedation; it is particularly useful for looking at blood vessels in the neck, where there is less interference from bone artifact than in the skull-encased brain.

Functional MRI is a noninvasive technique used to map neuronal activity during specific cognitive states and/or sensorimotor functions. Data are usually based on blood oxygenation, although they can also be based on local cerebral blood volume or flow. Functional MRI is useful for presurgical localization of critical brain functions and has several advantages over other functional imaging techniques. Specifically, functional MRI produces high-resolution images without exposure to ionizing radiation or contrast, and it allows coregistration of functional and structural images.

Proton MR spectroscopy (MRS) is a molecular imaging technique in which the unique neurochemical profile of a preselected brain region is displayed in the form of a spectrum. Many metabolites can be detected, the most common of which are *N*-acetylaspartate, creatine and phosphocreatine, choline, myoinositol, and lactate. Changes in the spectral pattern of a given area can yield clues to the underlying pathology, making MRS useful in the diagnosis of inborn errors of metabolism, as well as the preoperative and posttherapeutic

assessment of intracranial tumors. MRS can also detect areas of cortical dysplasia in patients with epilepsy because these patients have low *N*-acetylaspartate:creatine ratios. Finally, MRS may be useful in detecting hypoxic-ischemic injury in newborns in the first day of life because the lactate peak enlarges and the *N*-acetylaspartate peak diminishes before MRI sequences become abnormal.

Catheter angiography is the gold standard for diagnosing vascular disorders of the CNS, such as arteriovenous malformations, aneurysms, arterial occlusions, and vasculitis. A four-vessel study is accomplished by introducing a catheter into the femoral artery and then injecting contrast media into each of the internal carotid and vertebral arteries. Because catheter angiography is invasive and requires general anesthesia, it is typically reserved for treatment planning of endovascular or open procedures and for cases in which noninvasive imaging results are not diagnostic.

Positron emission tomography (PET) provides unique information on brain metabolism and perfusion by measuring blood flow, oxygen uptake, and/or glucose consumption. PET is an expensive technique that is most often used in the context of epilepsy surgery programs. **Single-photon emission CT** using ^{99m}Tc hexamethylpropyleneamine oxime is a sensitive and inexpensive technique to study regional cerebral blood flow. Single-photon emission CT is particularly useful in assessing for vasculitis, herpes encephalitis, dysplastic cortex, and recurrent brain tumors. PET-MRI is only available in a few pediatric centers in the United States; it provides better resolution and tissue definition than single-photon emission CT. This emerging clinical modality is of particular use in epilepsy surgery evaluation and neuro-oncology.

Electroencephalography

An electroencephalogram (EEG) provides a continuous recording of electrical activity between reference electrodes placed on the scalp. Although the genesis of the electrical activity is not certain, it likely originates from postsynaptic potentials in the dendrites of cortical neurons. Even with amplification of the electrical activity, not all potentials are recorded because there is a buffering effect of the scalp, muscles, bone, vessels, and subarachnoid fluid. EEG waves are classified according to their frequency as delta (1-3 Hz), theta (4-7 Hz), alpha (8-12 Hz), and beta (13-20 Hz). These waves are altered by many factors, including age, level of alertness, eye closure, drugs, and disease states.

The normal waking EEG is characterized by the posterior dominant rhythm—a sinusoidal, 8- to 12-Hz rhythm that is most prominent over the occipital region in a state of relaxed wakefulness with the eyes closed. This rhythm first becomes apparent at 3-4 months of age, and most children have achieved the adult frequency of 8-12 Hz by age 8 years.

Normal sleep is divided into three stages of non–rapid eye movement sleep—designated N1, N2, and N3—and rapid eye movement sleep. N1 corresponds to drowsiness, and N3 represents deep, restorative, slow-wave sleep. Rapid eye movement sleep is rarely captured during a routine EEG but may be seen on an overnight recording. The American Electroencephalography Society Guideline and Technical Standards states that "sleep recordings should be obtained whenever possible"; however, it appears that sleep deprivation—not sleep during the EEG—is what increases the yield of the study, particularly in children with one or more clinically diagnosed seizures and in children older than 3 years of age.

EEG abnormalities can be divided into two general categories: epileptiform discharges and slowing. Epileptiform discharges are paroxysmal spikes or sharp waves, often followed by slow waves, which interrupt the background activity. They may be focal, multifocal, or generalized. Focal discharges are often associated with cerebral dysgenesis or irritative lesions, such as cysts, slow-growing tumors, or glial scar tissue; generalized discharges typically occur in children with structurally normal brains. Generalized discharges can occur as an epilepsy trait in children who have never had a seizure and, by themselves, are not an indication for treatment. Epileptiform activity may be enhanced by activation procedures, including hyperventilation and photic stimulation.

As with epileptiform discharges, slowing can be either focal or diffuse. Focal slowing should raise a concern for an underlying functional or structural abnormality, such as an infarct, hematoma, or tumor. Diffuse slowing is the hallmark of encephalopathy and is usually secondary to a widespread disease process or toxic-metabolic insult.

Long-term video EEG monitoring provides a precise characterization of seizure types, which allows specific medical or surgical management. It facilitates more accurate differentiation of epileptic seizures from paroxysmal events that mimic epilepsy, including recurrent psychogenic seizure-like attacks. Long-term EEG monitoring can also be useful during medication adjustments.

Evoked Potentials

An evoked potential is an electrical signal recorded from the CNS after the presentation of a specific visual, auditory, or sensory stimulus. Stimulation of the visual system by a flash or patterned stimulus, such as a black-and-white checkerboard, produces **visual evoked potentials** (VEPs), which are recorded over the occiput and averaged in a computer. Abnormal VEPs can result from lesions to the visual pathway anywhere from the retina to the visual cortex. Many demyelinating disorders and neurodegenerative diseases, such as Tay-Sachs, Krabbe, or Pelizaeus-Merzbacher disease, or neuronal ceroid lipofuscinoses show characteristic VEP abnormalities. Flash VEPs can also be helpful in evaluating infants who have sustained an anoxic injury; however, detection of an evoked potential does not necessarily mean that the infant will have functional vision.

Brainstem auditory evoked responses (BAERs) provide an objective measure of hearing and are particularly useful in neonates and in children who have failed, or are uncooperative with, audiometric testing. BAERs are abnormal in many neurodegenerative diseases of childhood and are an important tool in evaluating patients with suspected tumors of the cerebellopontine angle. BAERs can be helpful in assessing brainstem function in comatose patients because the waveforms are unaffected by drugs or by the level of consciousness; however, they are not accurate in predicting neurologic recovery and outcome.

Somatosensory evoked potentials (SSEPs) are obtained by stimulating a peripheral nerve (peroneal, median) and then recording the electrical response over the cervical region and contralateral parietal somatosensory cortex. SSEPs determine the functional integrity of the dorsal column-medial lemniscal system and are useful in monitoring spinal cord function during operative procedures for scoliosis, aortic coarctation, and myelomeningocele repair. SSEPs are abnormal in many neurodegenerative disorders and are the most accurate evoked potential in the assessment of neurologic outcome after a severe CNS insult.

Specific and General Genetic and Metabolic Testing

Children with intellectual disability or developmental delay are often evaluated with metabolic and/or genetic testing. Newborn screening study results should be rechecked before new studies are done. Specific accompanying features of the child's history and physical examination may point to a particular disorder or group of disorders, allowing for specific genetic or metabolic testing or for chromosomal studies to be fruitful. Whole exome sequencing is often used in situations in which these studies are negative or there are no distinguishing features of the child's history or physical examination that point to a particular subgroup of diagnoses.

Visit Elsevier eBooks+ at eBooks.Health.Elsevier.com for Bibliography.

Chapter 631

Congenital Anomalies of the Central Nervous System

Sara K. Trowbridge, Edward Yang, and Christopher J. Yuskaitis

631.1 Neural Tube Defects

Sara K. Trowbridge, Edward Yang, and Christopher J. Yuskaitis

Neural tube defects (NTDs) account for the largest proportion of congenital anomalies of the CNS and result from failure of the neural tube to close properly during development. The etiology of NTDs appears to be multifactorial and remains incompletely understood. There is evidence for various environmental risk factors, including hyperthermia, teratogens (e.g., valproic acid, dolutegravir), maternal malnutrition, suboptimal folate levels, and maternal obesity or diabetes. Genetic determinants also play a role; studies have revealed relatively few monogenic causes and suggest a polygenic mode of inheritance. Genes associated with NTDs are also linked to known environmental risk factors (maternal obesity/diabetes and folate metabolism). NTDs vary widely in type and severity, depending on when and how the developmental process is disrupted.

The human nervous system originates from the primitive ectoderm, which, along with the endoderm and mesoderm, form the three primary germ layers (Fig. 631.1). During primary neurulation (3-4 weeks postgestation), the dorsal neural ectoderm differentiates into the neural plate. The neural plate then begins to invaginate as the edges fold upward, forming the neural tube, the structure that will ultimately give rise to the brain and spinal cord. Initial closure of the neural tube is accomplished in the area corresponding to the future junction of the spinal cord and medulla and moves rapidly both caudally and rostrally. As the neural tube is closing, a conglomerate of cells from the dorsal tube differentiates into the neural crest, which forms the peripheral nervous system, leptomeninges, and Schwann cells. The surrounding mesoderm gives rise to the dura and vertebrae. Defects in primary neurulation lead to open NTDs, in which neural tissue is exposed. Failure of the neural tube to close allows excretion of fetal substances (e.g., α-fetoprotein [AFP], acetylcholinesterase) into the amniotic fluid. *Fetal ultrasonography has a higher sensitivity to detect NTDs and has largely replaced prenatal screening of maternal serum for AFP in the 16th to 18th wk of gestation; both can be used to identify pregnancies at risk for fetuses with NTDs in utero.* The type of open NTD depends on the location of the defect. Anterior NTDs affect the brain (anencephaly, encephalocele), whereas posterior lesions affect the spinal cord (myelomeningocele).

Secondary neurulation occurs after completion of primary neurulation during weeks 5-6 of gestation and refers to the formation of the caudal neural tube. Defects in secondary neurulation are thought to underlie closed NTDs (occult spinal dysraphism), in which the neural tissue is covered by skin and not exposed. Relative to the severity of open NTDs, closed NTDs usually present with relatively mild, if any, neurologic deficits.

Visit Elsevier eBooks+ at eBooks.Health.Elsevier.com for Bibliography.

631.2 Myelomeningocele

Sara K. Trowbridge, Edward Yang, and Christopher J. Yuskaitis

Myelomeningocele is the most common NTD and results from incomplete closure of the posterior neural tube, leading to protrusion of neural tissue through a defect in the vertebra. This is also known as an *open* NTD because the neural tissue is exposed to the environment.

ETIOLOGY

The etiology of myelomeningocele remains incompletely understood, but as with all neural tube closure defects, a genetic predisposition exists. The risk of recurrence after one affected child is 3–4% and increases to 10% with two prior affected children. Both epidemiologic evidence and the familial aggregation studies indicate polygenic risk factors contribute to the etiology of NTDs.

Nutritional and environmental factors have a role in the etiology of myelomeningocele as well. In particular, folate is intricately involved in the prevention and etiology of NTDs. Folate coenzymes are involved in DNA synthesis, purine synthesis, and amino acid interconversion—specifically, the conversion of homocysteine to methionine. Pathogenic variants in the genes encoding the enzymes involved in homocysteine metabolism may play a role in the pathogenesis of meningomyelocele. These enzymes include 5,10-methylenetetrahydrofolate reductase (encoded by *MTHFR*), cystathionine β-synthase, and methionine synthase. An association between a thermolabile variant of *MTHFR* and mothers of children with NTDs might account for up to 15% of preventable NTDs.

PREVENTION

See also Chapter 67.6.

Maternal periconceptional use of folic acid supplementation reduces the incidence of NTDs in pregnancies at risk by at least 50%. The US Public Health Service recommends that all women of childbearing age who can become pregnant take 0.4-0.8 mg of folic acid daily. To be effective, folic acid supplementation should be initiated before conception and continued until at least the 12th week of gestation, when neurulation is complete. If a pregnancy is planned in high-risk women (previously affected child), supplementation should be started with 4 mg of folic acid daily, beginning 1 month before the time of the planned conception.

The modern diet provides about half the daily requirement of folic acid. To increase folic acid intake, fortification of flour, pasta, rice, and cornmeal with 0.15 mg folic acid per 100 g was mandated in the United States and Canada in 1998. Although this decreased the incidence of NTDs, the added folic acid is insufficient to maximize the prevention of preventable NTDs, and it is believed that many women may still have suboptimal folate levels, estimated as a red blood cell folate level less than 900-1,000 nmol/L. Therefore informative educational programs and folic acid vitamin supplementation remain essential for women planning a pregnancy and possibly for all women of childbearing age. In addition, certain drugs, including drugs that antagonize folic acid, such as trimethoprim and some anticonvulsants (valproic acid, carbamazepine, phenytoin, phenobarbital, and primidone), increase the risk of myelomeningocele. The anticonvulsant valproic acid causes NTDs in approximately 1–2% of pregnancies when administered during pregnancy, prompting some epilepsy clinicians to recommend that all female patients of childbearing potential who take anticonvulsant medications also receive folic acid supplements.

Diagnosis is usually made prenatally by fetal ultrasonography (see Chapter 117.7). Measurement of maternal serum AFP is an alternative screening test, although it has been shown to have a lower sensitivity than second-trimester ultrasonography. Early diagnosis allows time for prenatal counseling, further testing, and early treatment options, including fetal surgery. When a prenatal diagnosis is made, it is helpful to look for other associated anomalies. Genetic testing, particularly

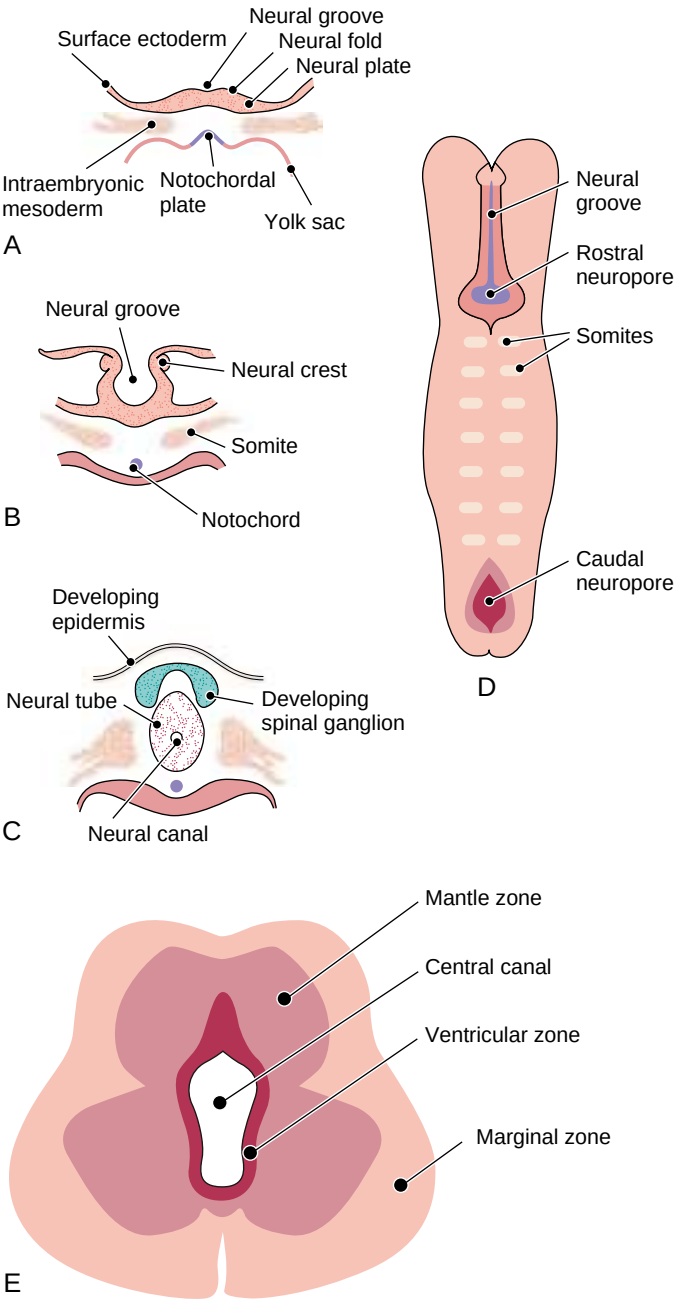

Fig. 631.1 Diagrammatic illustration of the developing nervous system. **A,** Transverse sections of the neural plate during the third wk. **B,** Formation of the neural groove and the neural crest. **C,** The neural tube is developed. **D,** Longitudinal drawing showing the initial closure of the neural tube in the central region. **E,** Cross-sectional drawing of the embryonic neural tube (primitive spinal cord).

chromosomal microarray, can be considered because chromosomal abnormalities are found at higher rates in fetuses with NTDs, particularly in the setting of other associated anomalies. Current cell-free fetal DNA prenatal tests only detect trisomies and sex aneuploidies as screening tests and are not diagnostic and do not detect NTDs.

CLINICAL MANIFESTATIONS

Neurologic deficits are hypothesized to be caused in part by neurodegeneration of the exposed area of the spinal cord secondary to contact with amniotic fluid in utero. The extent and degree of the neurologic deficit depend largely on the location of the myelomeningocele and any associated intracranial abnormalities.

Although a myelomeningocele may be located anywhere along the neuraxis, the lumbosacral region accounts for ~75% of the cases. The majority of patients with myelomeningocele have bowel and bladder incontinence. Ambulation and motor control over the lower extremities depend greatly on the level of the lesion. Generally, patients with a lesion in the low sacral region are ambulatory, in contrast to patients with lesions above L2, who are usually nonambulatory; those with intermediate lesions may walk with assistive devices (crutches, braces). Cervical myelomeningoceles are rare and differ in their anatomy from other myelomeningoceles because the spinal cord structure is usually close to normal and the neural tissue itself is covered by skin (i.e., a closed NTD). Therefore patients with these lesions generally have a more favorable prognosis, although they can have bowel/bladder dysfunction.

On exam, the myelomeningocele is generally readily apparent as a saclike cystic structure covered by a thin layer of partially epithelialized tissue or an exposed flat neural placode without overlying tissues (Fig. 631.2C). When a cyst or membrane is present, remnants of neural tissue are visible beneath the membrane, which occasionally ruptures and leaks CSF.

Examination of the infant generally shows a flaccid paralysis of the lower extremities, an absence of deep tendon reflexes, a lack of response to touch and pain, and a high incidence of lower-extremity deformities (clubfeet, ankle and/or knee contractures, and subluxation of the hips). Some children have constant urinary dribbling and a relaxed anal sphincter. Other children do not leak urine and in fact have a high-pressure bladder and sphincter dyssynergy. Myelomeningocele above the midlumbar region tends to produce lower motor neuron signs because of abnormalities and disruption of the conus medullaris and higher spinal cord structures.

Most children with a myelomeningocele also have displacement of the cerebellum and brainstem down through the foramen magnum, which is termed a **Chiari II malformation** (see Fig. 631.2A). Because this malformation can lead to obstruction of CSF outflow, hydrocephalus is a common complication, particularly if surgical repair is not pursued early. Therefore there should be a low threshold for consideration of hydrocephalus, which can present with classic signs of increased intracranial pressure (ICP), including a bulging anterior fontanel, dilated scalp veins, setting-sun appearance of the eyes, irritability, and vomiting in association with an increased head circumference. Older children may also have headache, emesis, and lethargy. Additionally, approximately 15% of infants with hydrocephalus and Chiari II malformation develop symptoms of hindbrain (brainstem) dysfunction, including difficulty feeding, choking, stridor, apnea, vocal cord paralysis, pooling of secretions, and spasticity of the upper extremities, which, if untreated, can lead to death. This **Chiari crisis** is caused by downward herniation of the medulla and cerebellar tonsils through the foramen magnum, as well as endogenous malformations in the cerebellum and brainstem.

Other CNS anomalies are associated with myelomeningocele, including cortical dysplasias, polymicrogyria, callosal abnormalities, and cerebellar abnormalities. Long-term complications include tethered cord, usually secondary to scar tissue at the surgical repair site, and hydromyelia, which is CSF buildup in the central canal of the spinal cord caused by worsening hydrocephalus.

TREATMENT (SEE ALSO CHAPTER 754)

Management and supervision of a child and family with a myelomeningocele require a multidisciplinary team approach, including surgeons, other physicians, and therapists, with one individual (often a pediatrician) acting as the advocate and coordinator of the treatment program.

Surgery to close the lesion is usually performed prenatally or within the first 72 hours of life (see Chapters 117 and 118). After repair of a myelomeningocele (especially postnatal repair), most infants require a shunting procedure for hydrocephalus. If symptoms or signs of hindbrain dysfunction appear, early surgical decompression of the posterior fossa is indicated. Clubfeet can require taping or casting. The

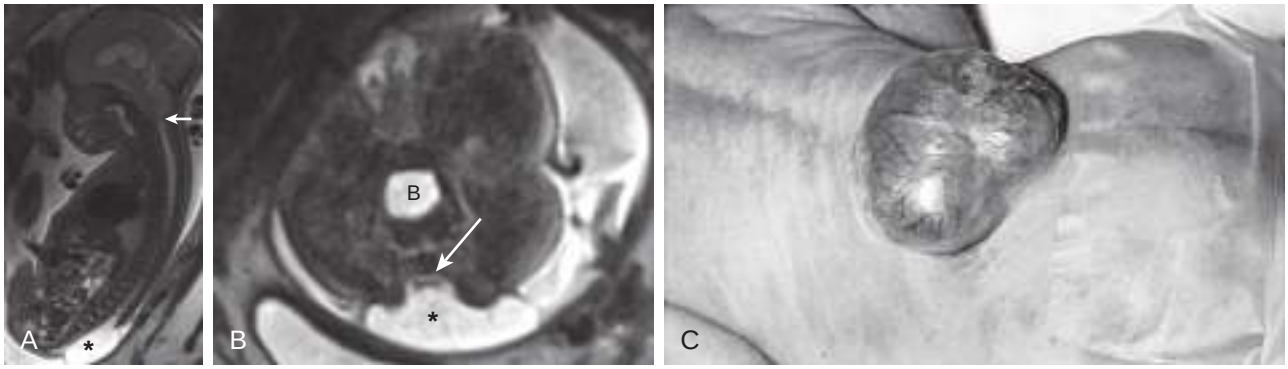

Fig. 631.2 Typical MRI imaging and physical exam findings of a lumbosacral myelomeningocele. **A,** Single-shot sagittal T2-weighted image of a fetus at 28 wk gestation demonstrates a lumbosacral spinal defect with protruding myelomeningocele sac *(asterisk)* and herniation of the brainstem/cerebellum into the upper spinal canal, a Chiari II malformation *(arrow)*. **B,** Single-shot axial T2-weighted images of the same fetus at the level of the myelomeningocele demonstrates a neural placode *(arrow)* at the base of the myelomeningocele sac *(asterisk)*. Urinary bladder marked with B. **C,** A lumbar myelomeningocele is covered by a thin layer of skin.

Management of Myelomeningocele Study (MoMS) has demonstrated the success of in utero surgical closure (see Chapters 117.7 and 118) with a lower incidence of hindbrain abnormalities and hydrocephalus (fewer shunts). Long-term follow-up of prenatal treatment into the school-age years demonstrates improved motor outcomes, although there are no differences in cognitive functioning. This suggests that some deficits may be progressive in utero and that prenatal closure might prevent the development of further loss of function.

Careful evaluation and reassessment of the genitourinary system is an important component of management. Teaching the parents and, ultimately, the patient, to regularly catheterize a neurogenic bladder is a crucial step in maintaining a low residual volume and bladder pressure that prevents urinary tract infections and reflux, which can lead to pyelonephritis, hydronephrosis, and bladder damage. *Latex-free catheters and gloves must be used to prevent development of latex allergy*. Periodic urine cultures and assessment of renal function, including serum electrolytes and creatinine as well as renal scans, vesiculourethrograms, renal ultrasonograms, and cystometrograms, are obtained according to the risk status and progress of the patient and the results of the physical examination. This approach to urinary tract management has greatly reduced the need for urologic diversionary procedures and has decreased the morbidity and mortality associated with progressive renal disease in these patients. Some children can become continent with bladder augmentation at a later age.

Incontinence of fecal matter is common and distressing to patients and families; occasionally, fecal impaction and/or megacolon may develop. Many children can be bowel-trained with a regimen of timed enemas or suppositories that allows evacuation at a predetermined time once or twice a day. Special attention to low anorectal tone and enema administration and retention is often required. Appendicostomy for antegrade enemas may also be helpful.

Functional ambulation may be possible, depending on the level of the lesion and on intact function of the iliopsoas muscles (see Chapter 754). Most children with a sacral or lumbosacral lesion obtain functional ambulation; approximately half the children with higher defects ambulate with the use of braces, other orthotic devices, and canes. Ambulation is often more difficult as adolescence approaches and when body mass increases. *Deterioration of ambulatory function, particularly during earlier years, should prompt referral for evaluation of tethered spinal cord, shunt malfunction, hydromyelia, and other neurosurgical issues.*

PROGNOSIS

For a child who is born with a myelomeningocele and who is treated aggressively, the mortality rate is 10–15%, and most deaths occur before age 4 years, often the result of hydrocephalus, infections, and cardiac/respiratory complications. However, life-threatening complications occur at all ages, and renal dysfunction is one of the most important determinants of mortality. At least 70% of individuals (nonsyndromic, no associated anomalies) have no intellectual disability, but learning problems and seizure disorders are more common than in the general population. Previous episodes of meningitis (shunt infections) or ventriculitis may adversely affect intellectual and cognitive function. Because myelomeningocele is a chronic disabling condition, periodic and consistent multidisciplinary follow-up is required for life.

Visit Elsevier eBooks+ at eBooks.Health.Elsevier.com for Bibliography.

631.3 Occult Spinal Dysraphism

Sara K. Trowbridge, Edward Yang, and Christopher J. Yuskaitis

Occult spinal dysraphisms, often called *spina bifida occulta,* are a closed NTD that consist of a midline defect of the vertebral bodies without protrusion of the spinal cord or meninges. The most common type only affects the vertebra, which are often asymptomatic and lack neurologic signs. Other clinically more significant forms of closed spinal cord malformations can be associated with developmental abnormalities of the spinal cord, including syringomyelia, diastematomyelia, lipoma, fatty filum, dermal sinus, and/or a tethered cord. In most of these cases, there are overlying cutaneous manifestations such as a hemangioma, discoloration of the skin, pit, lump, dermal sinus, or hairy patch (Figs. 631.3 and 631.4). A spine x-ray in simple spina bifida occulta shows a defect in closure of the posterior vertebral arches and laminae, typically involving L5 and S1; there is no abnormality of the meninges, spinal cord, or nerve roots. However, a spine x-ray in cases with spinal cord involvement might show bone defects or may be normal. *All cases of occult spinal dysraphism are best investigated with MRI* (Fig. 631.5 and see Fig. 631.4). Initial *screening* in the neonate may include ultrasonography, but MRI is more accurate at any age.

A **meningocele** is formed when the meninges herniate through a defect in the posterior vertebral arches or the anterior sacrum. The spinal cord is usually normal and assumes a normal position in the spinal canal; therefore neurologic outcome is often normal. However, there may be tethering of the cord, syringomyelia, or diastematomyelia, so careful neurologic examination and follow-up are necessary. Orthopedic and urologic examination should also be considered. In asymptomatic children with normal neurologic findings and full-thickness skin covering the meningocele, surgery may be delayed. Given the high rate of association between meningocele and tethered cord syndrome, exploration of the spinal canal is necessary to potentially release the associated tethered cord.

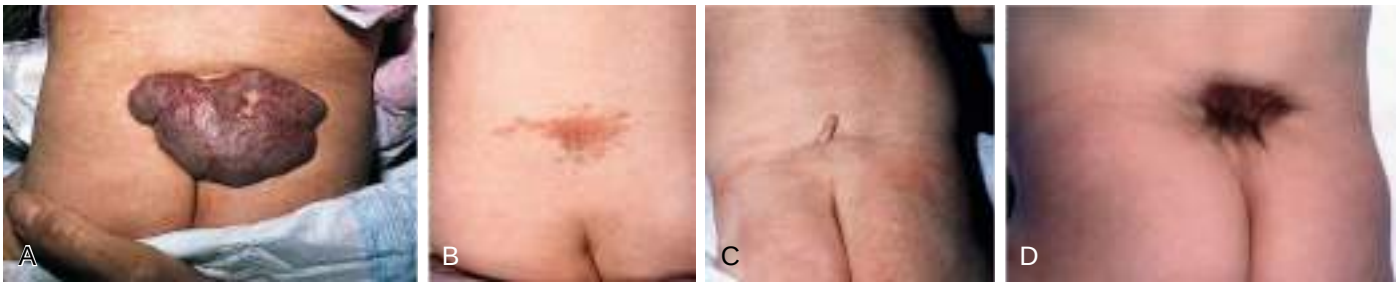

Fig. 631.3 Clinical aspects of congenital median lumbosacral cutaneous lesions. **A,** Midline sacral hemangioma in a patient with an occult lipomyelomeningocele. **B,** Capillary malformation with a subtle patch of hypertrichosis in a patient with a dermal sinus. **C,** Human tail with underlying lipoma in an infant with lipomyelomeningocele. **D,** Midline area of hypertrichosis (faun tail) overlying a patch of hyperpigmentation. *(**A-C** from Kos L, Drolet BA. Developmental abnormalities. In: Eichenfield LF, Frieden IJ, Esterly NB, eds. Neonatal Dermatology, 2nd ed. Philadelphia: WB Saunders; 2008; **D** from Tay VS, Kornberg A, Cook M. Spine and spinal cord: developmental disorders. In: Schapira AH, ed. Neurology and Clinical Neuroscience. Philadelphia: Mosby; 2007, Fig. 38-11C.)*

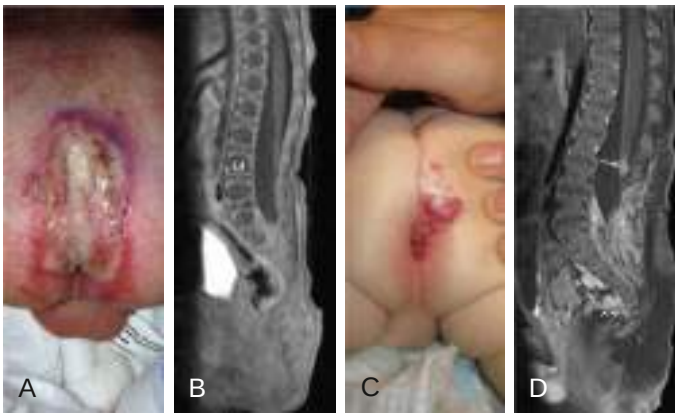

Fig. 631.4 **A,** Lumbosacral ulcerative plaque with surrounding red vascular rim was noted on initial examination. **B,** Midline sagittal contrast-enhanced, T1-weighted, fat-saturated image of the lumbosacral spine at presentation reveals low-lying conus at the L4 vertebral level suggestive of tethered cord. **C,** Recurrence of lumbosacral hemangioma after discontinuation of oral propranolol. **D,** Midline sagittal contrast-enhanced, T1-weighted, fat-saturated image of the lumbosacral spine at 6 mo of age shows new nodular enhancing lesion at the lower end of the conus *(arrow)* compatible with intrathecal hemangioma. In addition, there is a large hemangioma in the epidural space in the sacral spinal canal *(asterisks)* with presacral extension *(arrowheads). (From Yu J, Maheshwari M, Foy AB, et al. Neonatal lumbosacral ulceration masking lumbosacral and intraspinal hemangiomas associated with occult spinal dysraphism. J Pediat. 2016;175:211–215.)*

A **congenital dermal sinus** is a tract between the skin and the spinal cord, sometimes indicated at the skin surface by protruding hairs, a hairy patch, or a vascular nevus. Dermal sinuses occur in the midline at the sites where meningoceles or encephaloceles can occur: the lumbosacral region or occiput, respectively, and occasionally in the cervical or thoracic area. Dermal sinus tracts can pass through the dura, acting as a conduit for the spread of infection. Recurrent meningitis of occult origin should prompt careful examination for a small sinus tract in the posterior midline region, including the back of the head. Lumbosacral sinuses are usually *above* the gluteal fold and are *directed* cephalad. Tethered spinal cord syndrome may also be an associated problem.

Diastematomyelia is when the spinal cord is split, or bifid, and commonly has bony abnormalities that require surgical intervention along with untethering of the spinal cord.

An approach to imaging of the spine in patients with cutaneous lesions is noted in Table 631.1.

Visit Elsevier eBooks+ at eBooks.Health.Elsevier.com for Bibliography.

631.4 Encephalocele

Sara K. Trowbridge, Edward Yang, and Christopher J. Yuskaitis

Two major forms of dysraphism affect the skull, resulting in protrusion of tissue through a bony midline defect, called **cranium bifidum**. A cranial *meningocele* consists of a CSF-filled meningeal sac only. Cranial *encephalocele* contains the sac plus cerebral cortex, cerebellum, or portions of the brainstem (Fig. 631.6). These abnormalities are one tenth as common as neural tube closure defects involving the spine. Microscopic examination of the neural tissue within an encephalocele often reveals abnormalities, but not always, which has led to speculation that the primary problem is not abnormal neurulation, but rather abnormal mesodermal development leading to skull anomalies. The cranial defect occurs most commonly in the occipital region at or below the inion. However, in certain parts of the world, frontal or nasofrontal encephaloceles (transethmoidal, sphenoethmoidal, sphenomaxillary, sphenoorbital, transsphenoidal) are more common. Some frontal lesions are associated with a cleft lip and palate.

Cranial encephalocele is often part of a larger syndrome. One of the more commonly associated genetic syndromes is **Meckel-Gruber syndrome**, a rare autosomal recessive condition caused by pathogenic variants in multiple genes involved in cilia function. This syndrome is characterized by an occipital encephalocele, cleft lip or palate, microcephaly, microphthalmia, abnormal genitalia, polycystic kidneys, and polydactyly. Other associated syndromes include muscular dystrophy–dystroglycanopathy type A1 (Walker-Warburg syndrome, due to pathogenic variants in *POMT*) and Knobloch syndrome (due to pathogenic variants in *COL18A*).

Determination of maternal serum AFP levels and ultrasound measurement of the biparietal diameter, as well as identification of the encephalocele itself, can diagnose encephaloceles in utero. Fetal MRI can help define the extent of associated CNS anomalies and the degree of brain herniated into the encephalocele.

Infants with a cranial encephalocele are at increased risk for developing hydrocephalus because of **aqueductal stenosis**, **Chiari malformation**, or **Dandy-Walker syndrome**. Examination might show a small sac with a pedunculated stalk or a large cystlike structure that can exceed the size of the cranium. The lesion may be completely covered with skin, but areas of denuded lesion can occur and require urgent surgical management. Transillumination of the sac can indicate the presence of neural tissue. A plain x-ray of the skull and cervical spine is indicated to define the anatomy of the cranium and vertebrae. Ultrasonography is most helpful in determining the contents of the sac. MRI or CT further helps define the spectrum of the lesion. Children with a cranial meningocele generally have a good prognosis, whereas patients with an encephalocele are at risk for vision problems, microcephaly, intellectual disability, and seizures. Generally, children with neural

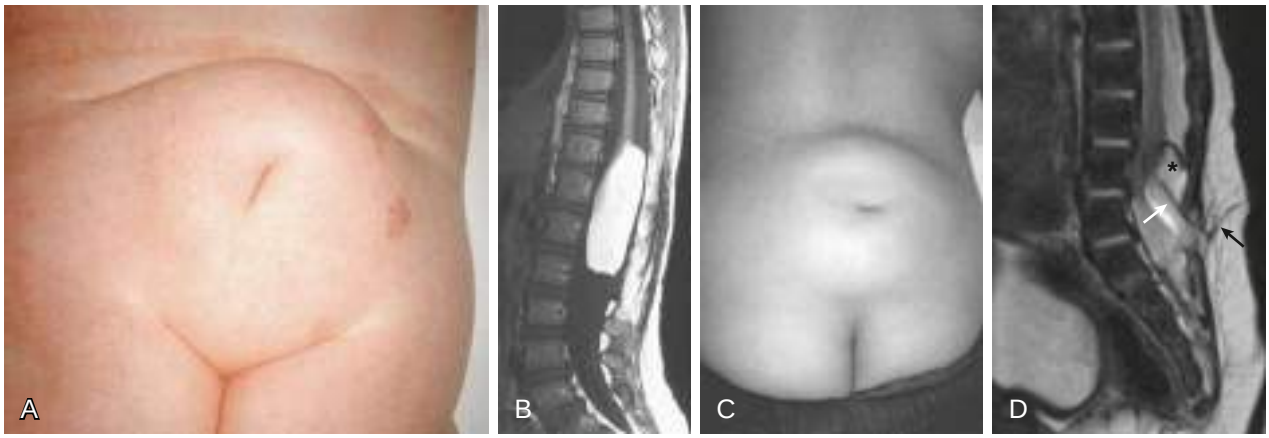

Fig. 631.5 Clinical features and imaging findings associated with occult spinal dysraphism. **A,** Lumbosacral lipoma. The subcutaneous lipoma is in continuity with the spinal cord via a defect in the underlying muscles, bone, and dura. **B,** Sagittal T1-weighted image shows a huge intradural lipoma merging with the conus medullaris superiorly. **C,** Lipoma and central dermal sinus. **D,** A sagittal T2-weighted MRI of the lumbar spine demonstrates a dermal sinus *(black arrow)* looping underneath the lowest lamina before ascending to the low-lying conus medullaris, which it tethers. The intradural portion of the sinus tract *(white arrow)* is encircled by intradural lipoma *(asterisk). (**A** from Thompson DNP. Spinal dysraphic anomalies: classification, presentation and management. Paed Child Health. 2014;24:431–438. Fig. 4; **B** from Rossi A, Biancheri R, Cama A, et al. Imaging in spine and spinal cord malformations. Eur J Radiol. 2004;50[2]:177–200, Fig. 9a; **C,** From Jaiswal AK, Garg A, Mahapatra AK. Spinal ossifying lipoma. J Clin Neurosci. 2005;12:714–717, Fig. 1.)*

Table 631.1	Cutaneous Lesions Associated with Occult Spinal Dysraphism
IMAGING INDICATED	
Subcutaneous mass or lipoma	
Hairy patch	
Dermal sinus or cyst	
Atypical dimples (deep, >5 mm, >25 mm from anal verge)	
Vascular lesion (e.g., hemangioma or telangiectasia)	
Skin appendages or polypoid lesions (e.g., skin tags, tail-like appendages)	
Scarlike lesions (aplasia cutis)	
IMAGING UNCERTAIN	
Hyperpigmented patches	
Deviation of the gluteal fold	
IMAGING NOT REQUIRED	
Simple dimples (<5 mm, <25 mm from anal verge)	
Coccygeal pits	

From Williams H. Spinal sinuses, dimples, pits and patches: what lies beneath? *Arch Dis Child Educ Pract Ed.* 2006;91:ep75–80.

tissue within the sac and associated hydrocephalus have the least favorable prognosis.

Visit Elsevier eBooks+ at eBooks.Health.Elsevier.com for Bibliography.

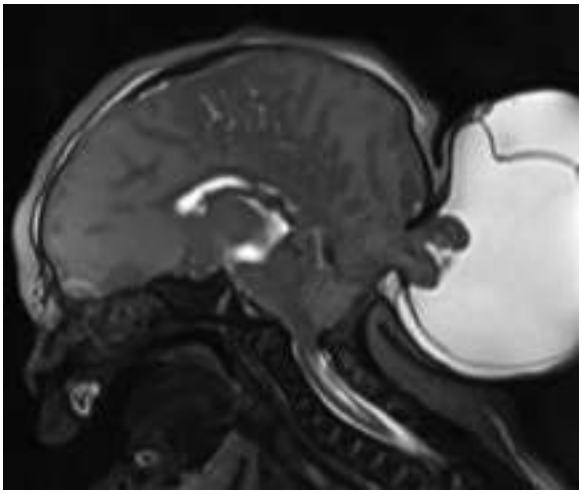

Fig. 631.6 Occipital encephalocele. Sagittal T2-weighted MRI of a newborn with prenatally diagnosed cephalocele demonstrates encephalomalacic brain protruding through an occipital skull defect with entrapped CSF in the cephalocele sac representing a mixture of subarachnoid (deep) and subdural (superficial) fluid. Note that the intracranial subarachnoid spaces (e.g., basal cistern) are contracted because of the large extracranial CSF reservoir.

631.5 Anencephaly

Sara K. Trowbridge, Edward Yang, and Christopher J. Yuskaitis

An anencephalic infant presents with a large defect of the calvarium, meninges, and scalp associated with a rudimentary brain. Anencephaly is a result of failure of closure of the rostral neuropore, the opening of the anterior neural tube. The opened neural tube leads to failure of the development of the skull vault. The embryologic precursor stages of anencephaly start with acrania (absence of the skull), followed by exencephaly (cerebral tissue protruding without an overlying skull), and ultimately the cerebral tissue degenerates because of prolonged exposure to the amniotic fluid.

In anencephaly, the cerebral hemispheres and cerebellum are usually absent, and only a residue of the brainstem can be identified (Fig. 631.7). The pituitary gland is hypoplastic, and the spinal cord pyramidal tracts are missing because of the absence of the cerebral cortex. Additional anomalies, including folding of the ears, cleft palate, and congenital heart defects, occur in 10–20% of cases. Most anencephalic infants are stillborn or die within several days of birth.

The incidence of anencephaly in the United States has been decreasing since the 1990s and approximates 0.2-0.3 in 1,000 live births; this varies across the world. As with myelomeningoceles, the recurrence risk is approximately 4% and increases to 10% if a couple has had two previously affected pregnancies. Environmental factors in addition to genetics are implicated as a cause of anencephaly, including low socioeconomic status, nutritional and vitamin deficiencies, as well as certain exposures. It is very likely that several noxious stimuli interact on a genetically susceptible host to produce anencephaly. Approximately 50% of cases of anencephaly have associated polyhydramnios. Couples who have had an anencephalic infant should have successive

Fig. 631.7 Anencephaly. On this sagittal MR image of an 18-wk-gestational-age fetus, there is abrupt truncation of the neuraxis above the brainstem *(arrow)*, no cerebral tissue, and an open skull defect exposed to amniotic fluid consistent with anencephaly.

pregnancies monitored, including with amniocentesis, determination of AFP levels, and ultrasound examination, between the 14th and 16th weeks of gestation. Prenatal folic acid supplementation decreases the risk of this condition.

Visit Elsevier eBooks+ at eBooks.Health.Elsevier.com for Bibliography.

631.6 Malformations of Cortical Development

Sara K. Trowbridge, Edward Yang, and Christopher J. Yuskaitis

Disorders of neuronal proliferation, migration, and organization can cause a spectrum of abnormalities of CNS structure and/or function. Often these present with developmental delays/intellectual disability and/or epilepsy; less severe cases may be detected as incidental findings on a brain MRI.

The major period for neuronal proliferation in the developing human brain occurs between 8 and 15 weeks of gestation. Neural progenitor cells and radial glial cells (which generate both neurons and glial cells) proliferate in the ventricular and subventricular zones. The radial glial cells then play a critical role in the control of neuronal migration, as they form the radial glial fiber system that guides cortical projection neurons to their proper sites. Migrating neurons attach to the radial glial fiber and disembark at predetermined sites to form the precisely designed six-layered cerebral cortex by 28 weeks of gestation. Another important mechanism is the tangential migration of progenitor neurons destined to become cortical interneurons. The severity and the extent of a disorder of neuronal proliferation, migration, and/or organization depend on numerous factors, including the timing of a particular insult and a host of environmental and genetic contributors.

Disorders of neuronal *proliferation* generally present with abnormal brain size (microcephaly, megalencephaly). Disorders of neuronal *migration* and *organization* may also present with associated abnormalities in brain size, but this is not always present. *These disorders often present clinically with either seizures and/or developmental delays and are best diagnosed by identification of the specific cortical malformation by brain MRI.* Although many brain malformations can be apparent from early in life (even on fetal MRI), some more subtle malformations (e.g., focal cortical dysplasias) may not be clearly visible until myelination is largely completed (around 2 years of age). *Genetic testing is indicated given the increasing number of identifiable genetic causes of brain malformations* (Table 631.2). *Somatic variants* have been found to cause some disorders of migration/organization. Somatic variants are genetic changes that *occur after* conception and do not affect the germ cells. Mosaicism from somatic variants is often not detected by standard clinical genetic testing.

MICROCEPHALY

Microcephaly is defined as a head circumference that measures more than 2-3 standard deviations (SD) below the mean for age and sex. Microcephaly may be subdivided into two main groups: primary (genetic) microcephaly, thought to be caused by defects in neuronal proliferation, and secondary (nongenetic) microcephaly, generally associated with destructive events after initial neuronal proliferation (e.g., hypoxic-ischemic injury, infection). A precise diagnosis is important for genetic counseling and for prediction of future pregnancies.

ETIOLOGY

Primary microcephaly refers to a group of conditions that follow a mendelian pattern of inheritance or are associated with a specific genetic syndrome and is generally thought to be secondary to a disruption in neuronal proliferation. Affected infants are usually identified prenatally or at birth because of a small head circumference. **Microcephaly vera** refers to a group of autosomal recessive disorders characterized by isolated microcephaly, with 16 genetic loci implicated to date. Many of the causative genes at those loci have been identified, including several involved in normal mitosis (e.g., *CDK5RAP2*, *ASPM*, *CENPJ*). The genetic causes of microcephaly also include autosomal dominant and X-linked recessive disorders, as well as a series of chromosomal syndromes (Table 631.3); some of these are associated with other malformations of cortical development. **Secondary microcephaly** can result from a number of noxious agents that affect early neurodevelopment; these include irradiation, maternal alcohol or cocaine use, maternal hyperphenylalaninemia, and infections (rubella, cytomegalovirus, HIV, Zika virus).

Acquired microcephaly, which develops postnatally, can be seen as a result of parenchymal injury (e.g., hypoxic ischemic injury), as well as various genetic conditions, including Rett, Seckel, and Angelman syndromes and developmental epileptic encephalopathy syndromes.

CLINICAL MANIFESTATIONS AND DIAGNOSIS

A thorough family history should be taken, seeking additional cases of microcephaly or disorders affecting the nervous system. It is important to measure a patient's head circumference at birth to diagnose microcephaly as early as possible. A very small head circumference implies a process that began early in embryonic or fetal development. An insult to the brain that occurs later in life, particularly beyond the age of 2 years, is less likely to produce severe microcephaly. Serial head circumference measurements are more meaningful than a single measurement, particularly when the measurement is borderline or if the microcephaly is progressive. The head circumference of each parent and any siblings should be recorded. The timing and progression of microcephaly, along with familial measurements, may help narrow the differential diagnosis.

Laboratory investigation of a microcephalic child is determined by the history and physical examination. If the cause of the microcephaly is unknown, the mother's serum phenylalanine level should be determined. High phenylalanine serum levels in an asymptomatic mother can produce marked brain damage in an otherwise normal nonphenylketonuric infant. Newborn screening in the United States will detect most of these cases. *Array comparative genomic hybridization*

Table 631.2 Malformations of Cortical Development

CLASSIFICATION	CLINICAL FINDING	GENETIC/METABOLIC ETIOLOGY
Disorders primarily of neuronal proliferation	Microcephaly	Primary microcephaly (MCPH 1-18)*: *MCPH1, WDR62, CDK5RAP2, CASC5, ASPM, CENPJ, STIL, CEP135, CEP152, ZNF335, PHC1, CDK6, CENPE, SASS6, MFSD2A, ANKLE2, CIT, WDFY3*
		Syndromic microcephaly
		Acquired microcephaly
	Macrocephaly†	Metabolic: • Organic acid disorders (e.g., glutaric aciduria – *GCDH*) • Lysosomal storage disorders (e.g., Tay-Sachs disease – *HEXA*) • Leukoencephalopathies (e.g., Alexander disease – *GFAP*)
		Somatic overgrowth: *NSD1, GPC3, GPC4, FMR1, EZH2, PTEN*
		Neurocutaneous: *NF1, NF2, TSC1, TSC2*
		More than 300 listed conditions in OMIM
Disorders primarily of neuronal migration	Lissencephaly-pachygyria spectrum	Isolated: *PAFAH1B1 (LIS1)* Miller-Dieker syndrome: 17p13.3 deletion *(PAFAH1B1, YWHAE)*
		Subcortical band heterotopia: *DCX* (female)
		X-linked: *DCX* (male), *ARX*
		Tubulinopathies: *TUBA1A, TUBB2A, TUBB2B*
		Cobblestone: *POMT1, POMT2, POMGNT1, FKTN, FKRP, LARGE*
		More than 50 listed conditions in OMIM (e.g., *RELN, VDLR*)
	Neuronal heterotopias	Isolated periventricular nodular heterotopias: *FLNA* (female)
		Also seen in association with other malformations, more than 10 listed conditions in OMIM
Disorders primarily of neuronal organization	Polymicrogyria	Over 200 listed conditions in OMIM (also see Table 631.4)
	Schizencephaly	In utero injury/infection
		For most cases, unclear genetic etiology; few cases associated with *COL4A1, SHH, SIX3*
Mixed disorders	Hemimegalencephaly	*AKT1, AKT3, DEPDC5, MTOR, PIK3CA, PIK3R2, PTEN, TSC1, TSC2*
	Focal cortical dysplasia	*DEPDC5, MTOR, NPRL2, NPRL3, PIK3CA, TSC1, TSC2*

*See Jayaraman D, Bae BI, Walsh CA. The genetics of primary microcephaly. *Annu Rev Genomics Hum Genet*. 2018;19:177–200 for comprehensive review.
†See Winden KD, Yuskaitis CJ, Poduri A. Megalencephaly and macrocephaly. *Semin Neurol*. 2015;35(3):277–287 for comprehensive review.

(chromosome microarray) study and/or karyotype is obtained if a chromosomal syndrome is suspected or if the child has abnormal facies, short stature, or any additional congenital anomalies. Whole exome sequencing or gene panel testing should also be considered, as pathogenic genetic variants can also cause primary microcephaly and syndromic microcephaly. MRI is useful in identifying any associated structural abnormalities of the brain, such as lissencephaly, pachygyria, and polymicrogyria. CT scanning is useful to detect intracerebral calcification. Additional studies include a fasting plasma and urine amino acid and organic acid analysis; serum ammonia determination; *t*oxoplasmosis, *r*ubella, *c*ytomegalovirus, and *h*erpes simplex (TORCH) titers; HIV testing of the mother and child; and a urine sample for the culture of cytomegalovirus. Zika virus–specific testing is also indicated when the infant is born in a high-risk environment or if a parent has a history of travel to endemic areas.

MACROCEPHALY AND MEGALENCEPHALY

Megalencephaly is an anatomic disorder of brain growth defined as a brain weight:volume ratio of more than the 98th percentile for age (or ≥2 SD above the mean) that is usually accompanied by macrocephaly (an occipitofrontal circumference >98th percentile). Macrocephaly can also be secondary to enlarged skull bones, hydrocephalus/ventriculomegaly, and enlarged extraaxial spaces.

Megalencephaly can be categorized as anatomic or metabolic. Although metabolic diseases can present with microcephaly as well, there are certain syndromes (e.g., Alexander disease, Canavan disease, megalencephalic leukoencephalopathy with subcortical cysts) that classically present with macrocephaly and should be considered in the differential diagnosis.

The most common cause of anatomic megalencephaly is **benign familial macrocephaly**. This condition is easily diagnosed by a careful family history and measurement of the parents' head circumferences (occipitofrontal circumferences). Other common megalencephaly-associated macrocephaly syndromes include syndromes with prenatal and/or postnatal somatic overgrowth, such as Sotos *(NSD1)*, Simpson-Golabi-Behmel (*GPC3* and *GPC4*), fragile X *(FMR1)*, Weaver *(EZH2)*, and macrocephaly–cutis marmorata telangiectatica congenita syndromes. Multiple somatic overgrowth syndromes are associated with macrocephaly and pathogenic variants in *PTEN*, including Bannayan-Ruvalcaba-Riley, Cowden, and Proteus-like syndromes. *PTEN* has also been commonly implicated in patients with autism spectrum disorder and macrocephaly.

Additionally, many of the neurocutaneous syndromes, including neurofibromatosis (*NF1* and *NF2*), Sturge-Weber syndrome, and tuberous sclerosis, can present with macrocephaly. Tuberous sclerosis results from pathogenic variants in *TSC1* or *TSC2*, encoding the proteins hamartin and tuberin, which act in the mammalian target of rapamycin (mTOR) signaling pathway, a pathway known to be critical to regulating cell growth and proliferation. Indeed, variants in many genes in the mTOR signaling pathway have emerged as important causes of cortical malformations (Fig. 631.8) (see Hemimegalencephaly and Focal Cortical Dysplasia).

Table 631.3 Causes of Microcephaly

PRIMARY MICROCEPHALY	
Isolated microcephaly	Microcephaly vera (autosomal recessive microcephaly) Autosomal dominant microcephaly X-linked microcephaly
Syndromic microcephaly	Chromosomal abnormalities • Trisomy 13 • Trisomy 18 • Trisomy 21
	Chromosomal deletions • 4p deletion (Wolf-Hirschhorn syndrome) • 5p deletion (Cri-du-chat syndrome) • 7q11.23 deletion (Williams syndrome) • 17p13.3 deletion (Miller-Dieker syndrome)
	Over 1000 other syndromes listed in OMIM, including: • Feingold syndrome *(MYCN, MIR17HG)* • Cornelia de Lange syndrome *(NIPBL, SMC1A, SMC3, RAD21, HDAC8)* • Smith-Lemli-Opitz syndrome *(DHCR7)* • Rubinstein-Taybi syndrome *(CREBBP, EP300)*
ACQUIRED MICROCEPHALY	
Genetic acquired microcephaly	Rett syndrome *(MECP2)* Angelman syndrome *(UBE3A)* Developmental epileptic encephalopathies
Intrauterine infection	Toxoplasmosis Cytomegalovirus Rubella Zika virus
Teratogens	Alcohol Hydantoin Radiation
Other exposures/injury	Maternal hyperphenylalaninemia Maternal diabetes mellitus Hypoxic-ischemic injury

Adapted from Abuelo D. Microcephaly syndromes. *Semin Pediatr Neurol*. 2007;14(3):118–127.

HEMIMEGALENCEPAHLY

Hemimegalencephaly, or unilateral macrocephaly, appears to result from a more focal aberrancy in neuronal proliferation during development, which also results in abnormal neuronal migration and organization (see Fig. 631.8). These patients generally present with early-onset refractory epilepsy and developmental delays. Various syndromes are associated with hemimegalencephaly, including epidermal nevus syndrome, Proteus syndrome, and hypomelanosis of Ito. As with other malformations of cortical development (see Macrocephaly and Megalencephaly and Focal Cortical Dysplasias), the mTOR signaling pathway appears to play a critical role in the pathogenesis of hemimegalencephaly, with many cases resulting from variants in genes involved in this pathway, including *AKT1* in Proteus syndrome.

FOCAL CORTICAL DYSPLASIAS

Focal cortical dysplasias consist of abnormal cortical lamination in a discrete area of cortex and are thought to be disorders of neuronal proliferation, migration, and organization. These can be difficult to detect, particularly in younger children with immature myelination. Therefore high-resolution, thin-section MRI can be useful, particularly in patients with refractory epilepsy undergoing consideration for surgery (see Fig. 631.8). Increasingly, germline and somatic pathogenic variants in genes involved in the mTOR pathway (*DEPDC5, NPRL2, NPRL3, AKT3,* others) have been implicated in the pathogenesis of focal cortical dysplasias.

LISSENCEPHALY-PACHYGYRIA

Lissencephaly, or agyria, is a rare disorder that is characterized by the absence of cerebral convolutions and a poorly formed sylvian fissure, giving the appearance of a 3- to 4-month-old fetal brain. The condition is probably a result of faulty neuronal migration during early embryonic life. The cortical layering of a lissencephalic brain is disrupted and results in a two- to four-layered cortex, rather than the usual six-layered one. A unique form of lissencephaly is subcortical band heterotopia, or double-cortex syndrome, in which a thick band of gray matter is located deep to the cortex, which may appear normal. **Pachygyria** is on the milder end of the lissencephaly spectrum, with some gyri present, although these are abnormal and markedly reduced in number.

Infants with lissencephaly-pachygyria present with failure to thrive, progressive microcephaly, marked developmental delay, and

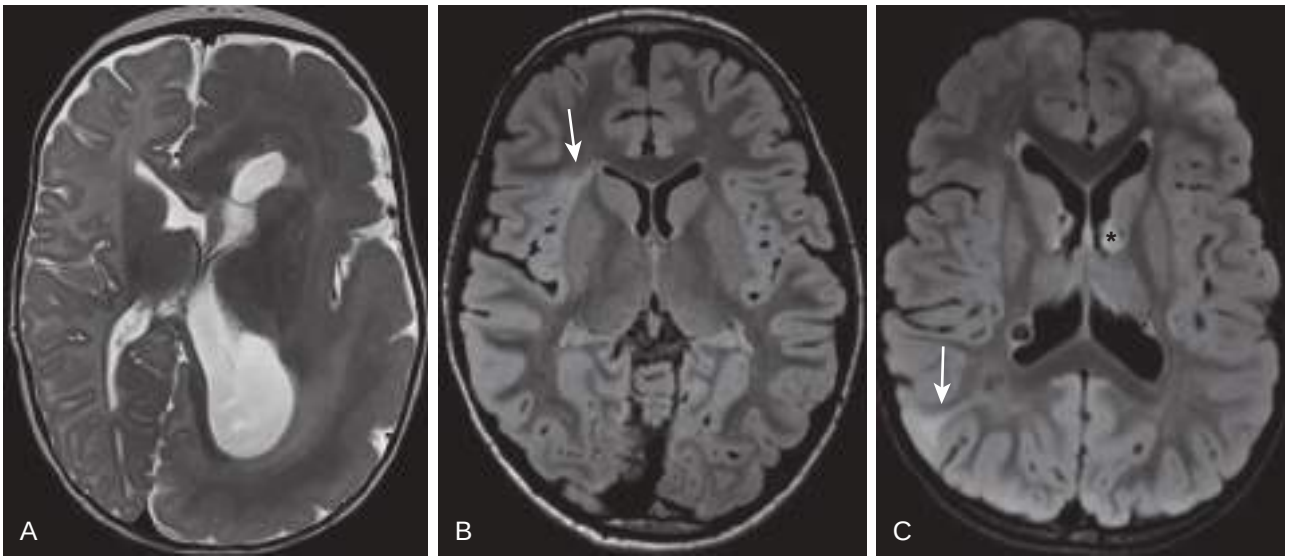

Fig. 631.8 Spectrum of *mTOR*-related cortical malformations on brain MRI. **A,** An axial T2-weighted image of a 4-mo-old female with hemimegalencephaly caused by a somatic *mTOR* variant demonstrates diffuse enlargement of the left hemisphere, cortical thickening, and white matter T2 hypointensity consistent with some combination of accelerated myelination and heterotopic neurons. **B,** Axial FLAIR imaging of a 6-yr-old female with intractable epilepsy demonstrates a transmantle region of signal abnormality *(arrow)*, which fans out as it extends centrifugally from the periventricular white matter to the cortex, a typical appearance of focal cortical dysplasia type IIB. **C,** By comparison, an axial FLAIR image of a 4-yr-old male with tuberous sclerosis demonstrates a multiplicity of transmantle signs consistent with tubers (largest right occipital focus denoted by an *arrow*) as well as subependymal nodules lining the lateral ventricles and a subependymal giant cell tumor at the left caudothalamic groove *(asterisk)*.

often refractory epilepsy. Various genetic causes of lissencephaly have been identified, including pathogenic variants in *PAFAH1B1 (LIS1)* on chromosome 17p13.3 (Fig. 631.9); larger deletions at this locus (encompassing the *YWHAE* gene in addition to the *PAFAH1B1* gene) are linked to **Miller-Dieker syndrome**, characterized by lissencephaly and other features, including distinctive facies (a prominent forehead, bitemporal hollowing, anteverted nostrils, a prominent upper lip, and micrognathia), and cardiac and genital anomalies. *DCX* is on the X chromosome, with genetic disruption leading to lissencephaly in males and subcortical band heterotopia in females (see Fig. 631.9). Pathogenic variants in *ARX* are a rarer cause of X-linked lissencephaly in males. The tubulinopathies (related to variants in *TUBA1A, TUBB2A, TUBB2B,* and others) are another important cause of lissencephaly. Certain disorders (e.g., Walker-Warburg syndrome, Fukuyama congenial muscular dystrophy, and muscle-eye-brain disease) present with a cobblestone lissencephaly, an overmigration disorder, with a bumpy cortical surface composed of groups of heterotopic neurons and altered myelination (see Fig. 631.9).

NEURONAL HETEROTOPIAS

Subtypes of neuronal heterotopias include **periventricular nodular heterotopias**, **subcortical heterotopia** (including band type), and marginal glioneuronal heterotopias. Intractable seizures are a common feature. Several genes have been identified that are a cause of these conditions, including most commonly the X-linked *FLNA* gene, which causes bilateral periventricular nodular heterotopia in affected females (Fig. 631.10).

POLYMICROGYRIA AND SCHIZENCEPHALY

Polymicrogyria is characterized by an augmentation of small convolutions separated by shallow enlarged sulci (Fig. 631.11). Polymicrogyria is commonly seen in the temporal lobes in the perisylvian region. Pathogenic variants in numerous genes have been associated with polymicrogyria, as noted in Table 631.4. Epilepsy, including drug-resistant forms, and oromotor discoordination are common features.

Schizencephaly is the presence of unilateral or bilateral *clefts* within the cerebral hemispheres caused by an abnormality of morphogenesis (see Fig. 631.11). The cleft may be fused or unfused and, if unilateral and large, may be confused with a porencephalic cyst. Not infrequently, the borders of the cleft are surrounded by abnormal brain, particularly polymicrogyria.

When the clefts are bilateral, many patients are severely intellectually challenged, with seizures that are difficult to control and microcephaly with spastic quadriparesis. Some cases of bilateral schizencephaly are associated with **septo-optic dysplasia** and endocrinologic disorders. Unilateral schizencephaly is a common cause of *congenital hemiparesis*. Schizencephaly is associated with fetal cytomegalovirus infection. It can also be secondary to in utero vascular injury, sometimes in the setting of pathogenic variants in *COL4A1,* a gene associated with increased risk of intracranial hemorrhage. Some reports have suggested the involvement of the sonic hedgehog signaling pathway, but most cases remain without a clearly defined genetic etiology.

Visit Elsevier eBooks+ at eBooks.Health.Elsevier.com for Bibliography.

631.7 Disorders with Midline Defects

Sara K. Trowbridge, Edward Yang, and Christopher J. Yuskaitis

HOLOPROSENCEPHALY

Holoprosencephaly encompasses a group of developmental disorders that result from defective prosencephalic cleavage. These disorders span a spectrum of severity and are classified into three groups, alobar, semilobar, and lobar, depending on the degree of the cleavage abnormality (Fig. 631.12). **Alobar holoprosencephaly** is the most severe form, with complete fusion of the cerebral hemispheres and deep nuclei and complete absence of the corpus callosum and olfactory bulbs and tracts. **Semilobar holoprosencephaly** presents with fusion of the anterior cerebral hemispheres and absence of the anterior corpus callosum. **Lobar holoprosencephaly**, the least severe form, generally presents with full separation between the cerebral hemispheres, partial or full separation between the deeper nuclei, and full development of the posterior corpus callosum, with some underdevelopment of the anterior corpus callosum. A fourth type, the middle interhemispheric variant, or **syntelencephaly**, involves a segmental area of nonseparation of the posterior frontal and parietal lobes. Facial abnormalities, including cyclopia, synophthalmia, cebocephaly, single nostril, choanal atresia, solitary

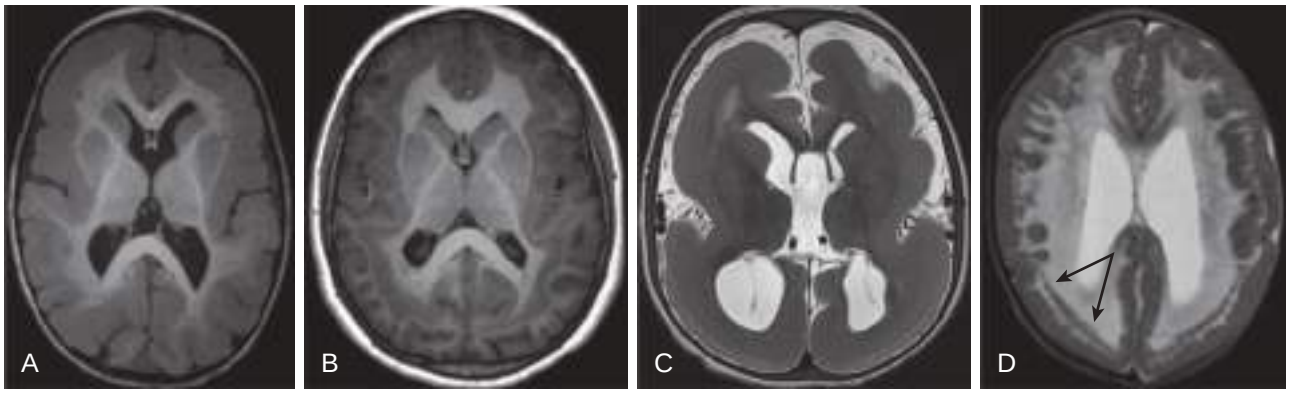

Fig. 631.9 Pachygyria and subcortical band heterotopia spectrum on brain MRI. **A,** An axial T1-weighted image of an 18-mo-old male demonstrates thickening of the cortex and attenuation of gyration, hallmarks of pachygyria. In this patient with a pathogenic *DCX* variant, there is greater severity of the pachygyria anteriorly, which is typically the case for pachygyria caused by mutations in this gene. **B,** By contrast, an axial T1-weighted sequence of a 10-yr-old female demonstrates a normal-thickness cortical ribbon with a subjacent layer of gray matter signal, consistent with subcortical band heterotopia. This patient also has a pathogenic *DCX* variant but has an attenuated phenotype because of X-linked inactivation and mosaic expression of the disease-causing variant. **C,** An axial T2-weighted image of a 4-yr-old female demonstrates marked cortical thickening and severe posterior predominant agyria (lissencephaly), the latter being a classic manifestation of the patient's *LIS1* variant. **D,** An axial T2-weighted image of cobblestone malformation (previously called *type II lissencephaly*) from a 3-mo-old female with infantile spasms, occipital cephalocele, developmental delay, and elevated creatine kinase levels. Note the centrifugal streaks of gray matter extending to a smooth thickened cortex. Although superficially reminiscent of lissencephaly like that in the prior case, a key distinguishing feature is the nodularity of the gray-white matter interface and the centrifugal islands of gray matter (e.g., *arrowed* right occipital foci). The islands of gray matter represent migration of neurons through the pial limiting membrane into the subarachnoid space, a typical feature of cobblestone malformation.

Fig. 631.10 Periventricular nodular heterotopia. An axial T1-weighted brain MR image of a 16-yr-old female with valvular heart disease and joint laxity demonstrates confluent subependymal nodules of gray matter signal consistent with periventricular nodular heterotopia (marked with *dashed oval*). The patient was ultimately found to have a pathogenic *FLNA* variant.

central incisor tooth, and premaxillary agenesis, are common in severe cases, because the prechordal mesoderm that induces the ventral prosencephalon is also responsible for induction of the median facial structures. Milder facial abnormalities, such as ocular hypotelorism, can be seen in milder forms.

Affected children with the severe alobar type have a high mortality rate within the first year of life, but some can live for years. Mortality and morbidity with milder types are more variable, with neurologic symptoms generally correlating with the severity of the underlying abnormality. In addition to neurologic symptoms, patients with impaired hypothalamic cleavage can also have various endocrinopathies. The incidence of holoprosencephaly is 1 in 10,000 live births. A prenatal diagnosis can be confirmed by ultrasonography after the 10th week of gestation for more severe types, but fetal MRI at later gestational ages gives far greater anatomic, and therefore diagnostic, precision.

Genetic and environmental factors both play a role in the development of holoprosencephaly. Chromosomal abnormalities account for approximately 60% of all cases, of which trisomy 13 is the most common. Other associated chromosomal abnormalities include trisomy 18 and deletions or trisomies of chromosomes 2, 3, 7, and 21. Diagnosis with a chromosomal abnormality in the setting of holoprosencephaly is a negative prognostic factor, with most patients not surviving past the first year of life. Monogenic syndromic causes include CHARGE syndrome *(CHD)*, Pallister-Hall *(GLI3)*, Rubenstein-Taybi *(CREB-BP)*, and Smith-Lemli-Opitz *(DHCR7)* syndromes. Genetic variants, particularly in the sonic hedgehog signaling pathway *(SHH, SIX3)*, have also been implicated in nonsyndromic holoprosencephaly. Environmental factors, particularly maternal diabetes, are risk factors for holoprosencephaly.

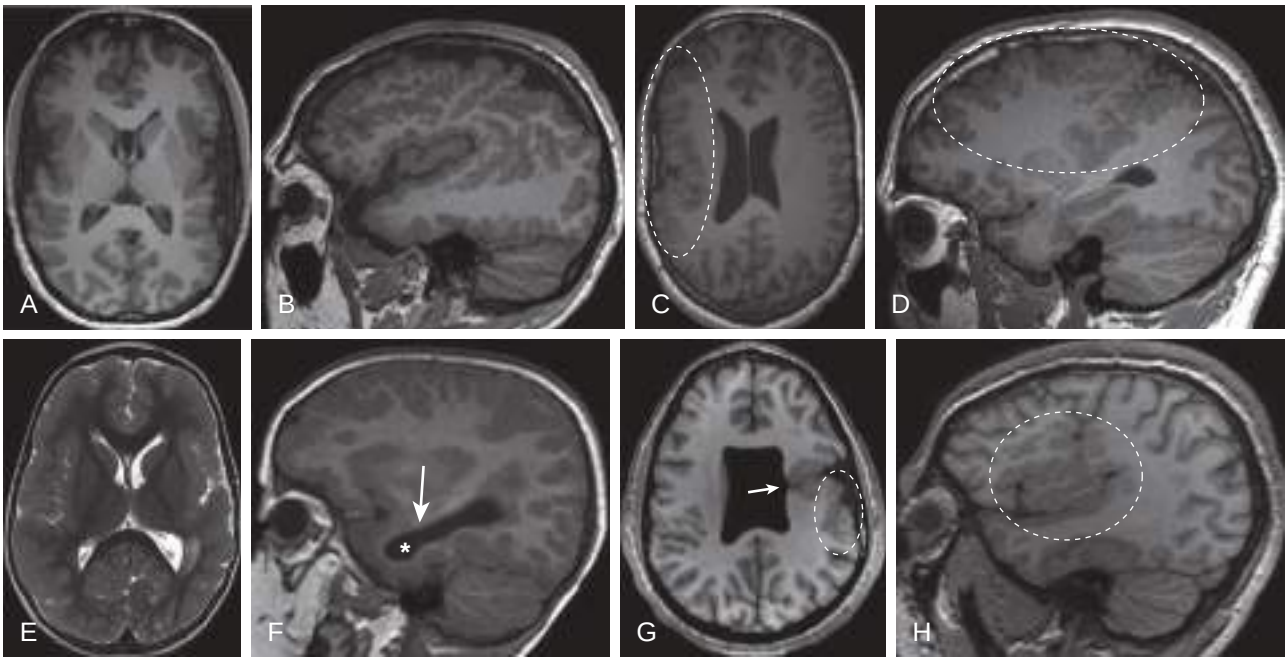

Fig. 631.11 Polymicrogyria spectrum by brain MRI. Axial (**A**) and sagittal (**B**) T1-weighted images of a 17-yr-old male with 22q11 deletion syndrome demonstrate diffusely increased gyral frequency and a bumpy surface contour of the cerebral cortex consistent with polymicrogyria, with some sparing of the frontal poles and occipital lobes. Axial (**C**) and sagittal (**D**) T1-weighted images of a 23-yr-old male demonstrate a unilateral area of right perisylvian polymicrogyria *(dashed ovals)* with reduced underlying white matter volume. Axial T2-weighted (**E**) and sagittal T1-weighted (**F**) sequences demonstrate diffuse polymicrogyria in a 28-mo-old with hearing loss, developmental delay, and congenital cytomegalovirus (CMV) exposure. Although the calcifications associated with TORCH infections are frequently not evident on MRI, clues to CMV as the etiology for polymicrogyria include microcephaly on clinical evaluation and subependymal cysts, the latter evident in this patient at the classic temporal horn location *(asterisk)* where it is separated from the remaining ventricular system by a thin membrane (*arrow*, **F**). Axial (**G**) and sagittal (**H**) T1-weighted images of a 17-yr-old male demonstrate an absent septum pellucidum and an apposed gray matter lined cleft through the left frontal lobe consistent with closed-lip schizencephaly (*arrow*, **G**). As is invariably the case in schizencephaly, the schizencephalic cleft is marginated by polymicrogyria (*ovals*, **G** and **H**).

Table 631.4 Genes Associated with Polymicrogyria

PATHWAY/ PATHOLOGY	GENE[1]	HEAD SIZE[2]			BRAIN FINDINGS	DISORDER NAME	MOI
		MAC	MIC	N/MS			
mTORopathies	*AKT3*	x			Bilateral perisylvian PMG	MPPH syndrome	AD
	CCND2	x					
	MTOR	x				Smith-Kingsmore syndrome	AD
	DEPDC5	x			Diffuse, focal, or multifocal PMG (less common than FCD)		AD
	PI4KA			x	Perisylvian PMG		AR
	PIK3CA	x			Bilateral perisylvian PMG	MCAP syndrome	See footnote 4
	PIK3R2	x				MPPH syndrome	AD
	PTEN	x			Diffuse, focal, or multifocal PMG		AD
Tubulinopathies	*DYNC1H1*		x	x	Frontal or diffuse PMG		AD
	KIF5C			x	Perisylvian PMG		AD
	TUBA1A		x	x	Diffuse, focal, or multifocal PMG; bilateral, asymmetric, perisylvian PMG	Lissencephaly 3	AD
	TUBB		x		PMG		AD
	TUBB2A		x		Bilateral, asymmetric, anterior predominant PMG		AD
	TUBB2B		x	x			
	TUBB3		x	x	Frontoparietal PMG		AD
Cobblestone dysplasia – alpha dystroglycan-opathies	*FKTN*			x	Diffuse (cerebral and cerebellar) PMG		AR
	POMGNT1			x	PMG		AR
	POMT2			x	PMG		AR
Cobblestone dysplasia – other (laminopathies and congenital disorders of glycosylation)	*ADGRG1 (GPR56)*			x	Bilateral frontoparietal PMG		AR
	COL3A1	x		x	Diffuse cobblestone cortex; PMG A > P		AR
	ATP6V0A2		x	x	Frontoparietal PMG	Autosomal recessive cutis laxa type 2A	AR
	LAMA2			x	Occipital PMG; white-matter signal abnormalities	Muscular dystrophy, congenital merosin-deficient, 1A	AR
	LAMB1	x		x	Porencephaly; cobblestone lissencephaly P > A	Lissencephaly 5	AR
	LAMC3			x	Occipital PMG		AR
	SNAP29		x		Perisylvian or diffuse PMG		AR
	SRD5A3			x	Frontal PMG	SRD5A3-CDG *(CDG-Iq)*	AR

Continued

Table 631.4 Genes Associated with Polymicrogyria—cont'd

PATHWAY/ PATHOLOGY	GENE[1]	HEAD SIZE[2] MAC	MIC	N/MS	BRAIN FINDINGS	DISORDER NAME	MOI
Other	*BICD2*			x	Perisylvian PMG		AD
	COL18A1			x	Frontal PMG	Knobloch syndrome 1	AR
	DDX3X		x	x	Frontoparietal or diffuse PMG	*DDX3X*-related neurodevelopmental disorder	XL
	EML1	x			Ribbon-like heterotopia with overlying PMG; ACC		AR
	EOMES (TBR2)		x		Bilateral perisylvian or diffuse PMG		AR
	EZH2	x			Bilateral perisylvian PMG	Weaver syndrome	AD
	FIG4		x	x	Bilateral or temporo-occipital PMG		AR
	GPSM2	x			Parasagittal PMG; ACC	Chudley-McCollough syndrome	AR
	GRIN1		x		Extensive bilateral PMG		AD
	GRIN2B		x	x	Diffuse PMG		AD
	KIFBP (KIAA1279)		x		Diffuse PMG	Goldberg-Shprintzen syndrome	AR
	MAP1B				Perisylvian PMG; PNH		AD
	NDE1		x		Diffuse PMG		AR
	NEDD4L			x	Bilateral perisylvian PMG; PNH		AD
	OCLN		x		Bandlike calcifications with diffuse PMG	Pseudo-TORCH syndrome 1	AR
	OFD1	x			Frontal and parietal PMG	Joubert syndrome (XLR); orofaciodigital syndrome 1 (XLD)	XL
	PAX6		x		Variable temporal PMG		AR
	RAB18		x	x	Diffuse or frontal PMG	RAB18 deficiency[3]	AR
	RAB3GAP1		x	x			
	RAB3GAP2		x	x			
	RTTN		x		Variable diffuse, asymmetric PMG		AR
	TBC1D20			x	Diffuse or bilateral frontal PMG	RAB18 deficiency[3]	AR
	TCTN1			x	Frontal PMG	Joubert syndrome	AR
	TMEM216			x	Variable PMG	Meckel-Gruber syndrome, Joubert syndrome	AR
	WDR62		x		± Diffuse or asymmetric PMG		AR
Metabolic disorders	*FH*		x		Variable PMG	Fumeric aciduria	AR
	PEX genes		x	x	Perisylvian PMG	Zellweger spectrum disorders	AR

[1]Genes are in alphabetic order.
[2]Head size:
N/MS = normal/mildly small (i.e., head circumference >3 SD and <97%)
MIC = severe microcephaly (i.e., birth head circumference <3 SD or earliest HC <4 SD)
MAC = macrocephaly (i.e., head circumference >97%)
[3]RAB18 deficiency is a spectrum that includes Warburg microsyndrome (at the severe end) and Martsolf syndrome (at the mild end). Additional findings are eye involvement (bilateral congenital cataracts, microphthalmia, and microcornea); severe-to-profound intellectual disability; and hypogonadism.
[4]De novo germline pathogenic variants in PIK3CA are reported; however, most affected individuals with MCAP reported had somatic mosaicism for pathogenic variants in PIK3CA, suggesting that the mutation occurred post fertilization in one cell of the multicellular embryo.https://www.ncbi.nlm.nih.gov/books/n/gene/glossary/def-item/de-novo/
A, Anterior; ACC, absence of the corpus callosum; AD, autosomal dominant; AR, autosomal recessive; CDG, congenital disorder of glycosylation; FCD, focal cortical dysplasia; MCAP, megalencephaly-capillary malformation-PMG; MOI, mode of inheritance; MPPH, megalencephaly-polymicrogyria-polydactyly-hydrocephalus; P, posterior; PNH, periventricular nodular heterotopia; XL, X-linked; XLD, X-linked dominant; XLR, X-linked recessive
Adapted from Stutterd CA, Dobyns WB, Jansen A, et al. Polymicrogyria overview. In: Adam MP, Ardinger HH, Pagon RA, et al., eds. *GeneReviews*. Seattle, WA: University of Washington; 2005.

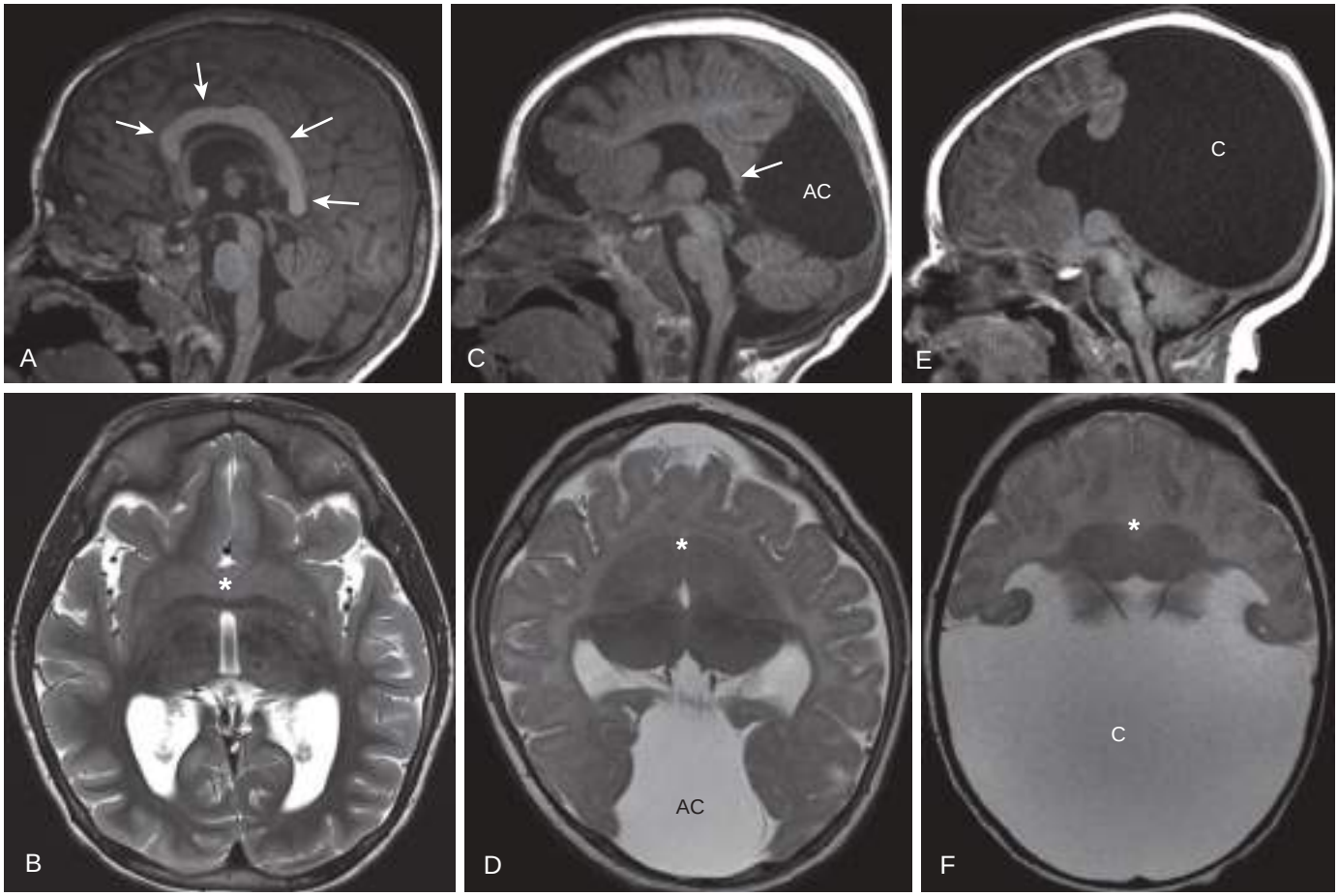

Fig. 631.12 Gradations of severity in holoprosencephaly. Holoprosencephaly results from incomplete cleavage of the cerebral hemispheres early in embryogenesis. As illustrated in these pairs of brain MRI sagittal T1-weighted (**A, C, and E**) and axial T2-weighted images (**B, D, and F**), severity ranges from mildly affected patients with lobar holoprosencephaly (**A, B**), to more severely affected patients with semilobar holoprosencephaly (**C, D**), to the most severely affected patients with alobar holoprosencephaly (**E, F**). More mildly affected holoprosencephaly patients have greater separation of the cerebral hemispheres, particularly anteriorly and ventrally (e.g., less deep gray matter structure fusion marked with *asterisks* in **B, D, and F**). Milder holoprosencephaly also demonstrates greater formation of the corpus callosum (*arrows* in **A, C**) which is absent in alobar holoprosencephaly (**E**). Unlike alobar holoprosencephaly, which typically demonstrates a monoventricle with or without a dorsal cyst (C in **E, F**), semilobar and lobar holoprosencephaly demonstrate partial to complete formation of the lateral ventricles (e.g., frontal/temporal horns). The shown case of semilobar holoprosencephaly (**C, D**) has an arachnoid cyst (AC), but it is not in communication with the ventricular system.

AGENESIS OF THE CORPUS CALLOSUM

Agenesis of the corpus callosum consists of a heterogeneous group of disorders that result from defective midline prosencephalic development. These disorders vary in clinical presentation from patients with severe intellectual deficits and neurologic abnormalities to the asymptomatic and normally intelligent patient (Fig. 631.13). In addition, patients may experience hypethermia or hypothermia and hyperhidrosis (Shapiro syndrome).

When agenesis of the corpus callosum is an *isolated* phenomenon, the patient may be asymptomatic. When it is accompanied by associated brain anomalies, such as heterotopias, polymicrogyria, and pachygyria (broad, wide gyri), and/or other syndromic or genetic disorders, patients often have significant neurologic abnormalities, including intellectual disability, microcephaly, hemiparesis or diplegia, and seizures.

The anatomic features of agenesis of the corpus callosum are best depicted on MRI and include widely separated frontal horns with an abnormally high position of the third ventricle between the lateral ventricles. MRI precisely outlines the extent of the corpus callosum defect. **Colpocephaly** refers to an abnormal enlargement of the occipital horns of the ventricular system and can be identified as early as the fetal period. It is often associated with agenesis of the corpus callosum, but it can occur in isolation. There are numerous genetic causes of agenesis of the corpus callosum, including chromosomal abnormalities, syndromic genetic disorders, and nonsyndromic monogenetic disorders (Table 631.5).

Aicardi syndrome is one syndrome that presents with partial or complete agenesis of the corpus callosum, as well as other brain abnormalities (e.g., cortical dysplasias, periventricular nodular heterotopias, intracranial cysts) and distinctive chorioretinal lacunae. Patients are almost all female, suggesting that the genetic abnormality is X-linked dominant. Seizures, including infantile spasms, are common and are typically resistant to anticonvulsants. An electroencephalogram shows independent activity recorded from both hemispheres as a result of the absent corpus callosum and often shows hemihypsarrhythmia. All patients have severe intellectual disability and can have abnormal vertebrae that may be fused or only partially developed (hemivertebra).

ABSENCE OF THE SEPTUM PELLUCIDUM

Absence of the septum pellucidum is another developmental midline defect that is almost always associated with other brain anomalies, particularly schizencephaly, although it can also be seen with holoprosencephaly, agenesis of the corpus callosum, and septo-optic dysplasia. It can also result through destruction of the septum pellucidum, secondary to hydrocephalus or ischemic injury. Therefore the clinical presentation of patients with absence of the septum pellucidum largely depends on the etiology, associated brain anomalies, and any underlying chromosomal and/or genetic diagnosis. Cavum septum pellucidum refers to the cavity between the two septal leaflets; although this is normal in the fetal brain, the septal leaflets generally fuse during development. A persistent cavum septum pellucidum is generally considered to be a normal variant (Fig. 631.14).

Visit Elsevier eBooks+ at eBooks.Health.Elsevier.com for Bibliography.

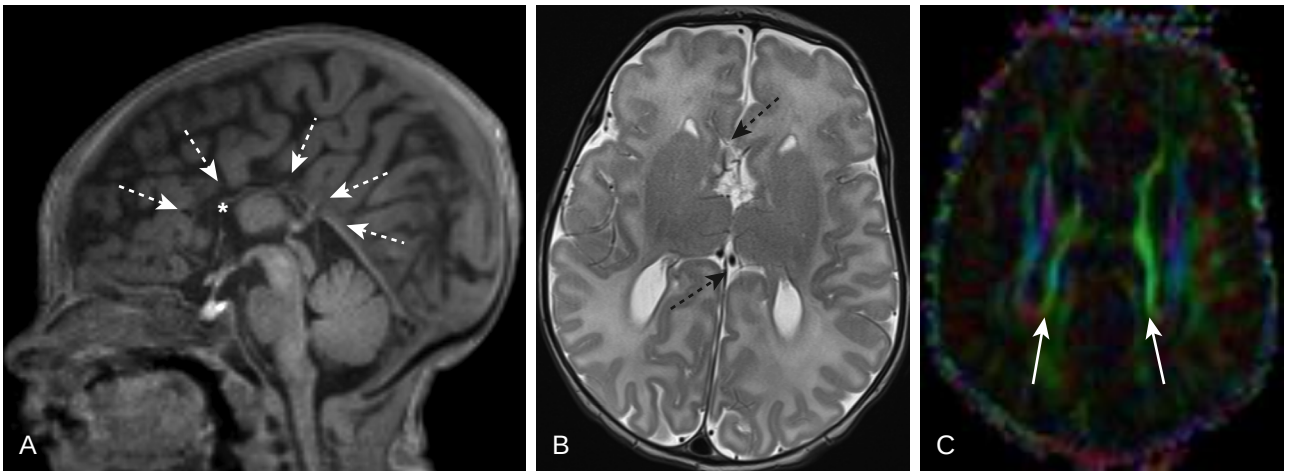

Fig. 631.13 Complete corpus callosum (callosal) agenesis by brain MRI. **A,** Sagittal T1-weighted sequence of a newborn with callosal agenesis demonstrates lack of a normal corpus callosum (*dashed arrows* along expected course) with multiple sulci radiating without interruption from the third ventricle *(asterisk).* **B,** An axial T2-weighted image of this patient demonstrates a parallel rather than curved course of the lateral ventricles (missing callosal genu and rostrum denoted by *dashed arrows*). **C,** Redirection of white matter tracts (Probst bundles) can be directly visualized in callosal agenesis using colored fractional anisotropy maps, where green denotes anteroposterior fiber tracts running parallel to the lateral ventricles rather than crossing the midline.

Table 631.5 Disorders Associated with Agenesis of the Corpus Callosum*

DISORDER	SALIENT FEATURES
WITH IDENTIFIED GENES†	
Andermann syndrome *(KCC3)*	ACC, progressive neuropathy, and dementia
Donnai-Barrow syndrome *(LRP2)*	Diaphragmatic hernia, exomphalos, ACC, deafness
Frontonasal dysplasia *(ALX1)*	ACC, bilateral extreme microphthalmia, bilateral oblique facial cleft
XLAG *(ARX)*	Lissencephaly, ACC, intractable epilepsy
Microcephaly *(TBR2)*	ACC, polymicrogyria
Microcephaly with simplified gyral pattern and ACC *(WDR62)*	ACC, other brain malformations
Mowat-Wilson syndrome *(ZFHX1B)*	Hirschsprung disease, ACC
Pyridoxine-dependent epilepsy *(ALDH7A1)*	ACC, seizures, other brain malformations
Pyruvate dehydrogenase deficiency *(PDHA1, PDHB, PDHX)*	ACC with other brain changes
ACC with fatal lactic acidosis *(MRPS16)*	Complexes I and IV deficiency, ACC, brain malformations
HSAS/MASA syndromes *(L1CAM)*	Hydrocephalus, adducted thumbs, ACC, MR
ACC SEEN CONSISTENTLY (NO GENE YET IDENTIFIED)	
Acrocallosal syndrome	ACC, polydactyly, craniofacial changes, MR
Aicardi syndrome	ACC, chorioretinal lacunae, infantile spasms, MR
Chudley-McCullough syndrome	Hearing loss, hydrocephalus, ACC, colpocephaly
FG syndrome	MR, ACC, craniofacial changes, macrocephaly
Genitopatellar syndrome	Absent patellae, urogenital malformations, ACC
Temtamy syndrome	ACC, optic coloboma, craniofacial changes, MR
Toriello-Carey syndrome	ACC, craniofacial changes, cardiac defects, MR
Vici syndrome	ACC, albinism, recurrent infections, MR
ACC SEEN OCCASIONALLY (PARTIAL LIST)‡	
ACC with spastic paraparesis *(SPG11, SPG15)*	Progressive spasticity and neuropathy, thin corpus callosum
Craniofrontonasal syndrome	Coronal craniosynostosis, facial asymmetry, bifid nose
Fryns syndrome	CDH, pulmonary hypoplasia, craniofacial changes
Marden-Walker syndrome	Blepharophimosis, micrognathia, contractures, ACC
Meckel-Gruber syndrome	Encephalocele, polydactyly, polycystic kidneys

Table 631.5 Disorders Associated with Agenesis of the Corpus Callosum —cont'd

DISORDER	SALIENT FEATURES
Nonketotic hyperglycinemia *(GLDC, GCST, GCSH)*	ACC, cerebral and cerebellar atrophy, myoclonus, progressive encephalopathy
Microphthalmia with linear skin defects	Microphthalmia, linear skin markings, seizures
Opitz G syndrome	Pharyngeal cleft, craniofacial changes, ACC, MR
Orofaciodigital syndrome	Tongue hamartoma, microretrognathia, clinodactyly
Pyruvate decarboxylase deficiency	Lactic acidosis, seizures, severe MR and spasticity
Rubinstein-Taybi syndrome	Broad thumbs and great toes, MR, microcephaly
Septooptic dysplasia (de Morsier syndrome)	Hypoplasia of septum pellucidum and optic chiasm
Sotos syndrome	Physical overgrowth, MR, craniofacial changes
Warburg micro syndrome	Microcephaly, microphthalmia, microgenitalia, MR
Wolf-Hirschhorn syndrome	Microcephaly, seizures, cardiac defects, 4p−

*Reliable incidence data are unavailable for these very rare syndromes.
†Gene symbols in parentheses.
‡Many of these also may consistently have a thin dysplastic corpus callosum, such as Sotos syndrome or agenesis of the corpus callosum (ACC) with spastic paraparesis (SPG11). The overlap between ACC and these conditions is still under investigation. Other gene symbols are omitted from this section.
4p−, Deletion of the terminal region of the short arm of chromosome 4, defines the genotype for Wolf-Hirschhorn patients; ACC, agenesis of the corpus callosum; ARX, Aristaless-related homeobox gene; CDH, congenital diaphragmatic hernia; HSAS/MASA, X-linked hydrocephalus/mental retardation, aphasia, shuffling gait, and adducted thumbs; KCC3, KCl co-transporter 3; L1CAM, L1 cell adhesion molecule; MR, mental retardation; MRPS16, mitochondrial ribosomal protein S16; SPG11, spastic paraplegia 11; XLAG, X-linked lissencephaly with absent corpus callosum and ambiguous genitalia; ZFHX1B, zinc finger homeobox 1b.
From Sherr EH, Hahn JS. Disorders of forebrain development. In: Swaiman KF, Ashwal S, Ferriero DM, Schor NF, eds. *Swaiman's Pediatric Neurology*, 5th ed. Philadelphia: WB Saunders; 2012: Table 23-2.

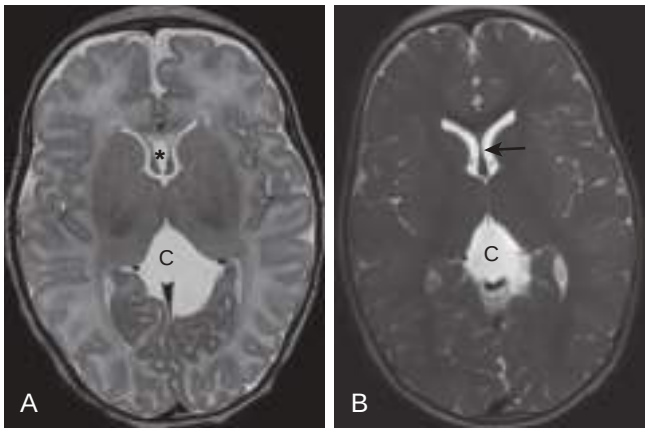

Fig. 631.14 Age-expected evolution of the septum pellucidum. Throughout fetal life, the septum pellucidum exists as paired leaflets enclosing a midline CSF space. This configuration is known as a *cavum septum pellucidum* and undergoes fusion into a single membrane during the first months of postnatal life. **A,** A brain MRI axial T2-weighted image of a 42-day-old female followed for a cistern of the velum interpositum cyst (C) demonstrates normal separation of the septal leaflets with an intervening CSF pocket, the cavum septum pellucidum *(asterisk)*. **B,** An axial single-shot T2-weighted brain MR image at 13 mo in the same patient demonstrates expected fusion of the leaflets into a single membrane *(arrow)*.

631.8 Dysgenesis of the Cranial Nerves and the Posterior Fossa

Sara K. Trowbridge, Edward Yang, and Christopher J. Yuskaitis

The classification of disorders of development of the cranial nerve, brainstem, and cerebellum remains anatomic, but future classification systems will likely be based on the molecular biology of brain development based on the genes involved and the roles they play in orchestrating brain architecture.

CONGENITAL CRANIAL DYSINNERVATION DISORDERS

Congenital cranial dysinnervation disorders (CCDDs) are congenital nonprogressive disorders that affect the cranial nerves, primarily presenting with abnormal eye and/or facial movements. These disorders include Möbius syndrome, Duane syndrome, and congenital fibrosis of the external ocular muscles (CFEOM). Increasingly, genetic causes for these disorders have been identified.

Möbius syndrome is generally characterized by bilateral facial weakness (seventh cranial nerve) and sixth nerve palsies (limited eye abduction). Injury or abnormal development at any level (i.e., cranial nerve nuclei, roots, nerves, or muscles) can lead to Möbius syndrome, but most patients have pathology at the level of the cranial nerve nuclei. The genetics of Möbius syndrome remain incompletely understood. Genetic linkage mapped inheritance to chromosome 13q12.2-q13, with identification of de novo pathogenic variants in *PLXND1* and *REV3L* in some patients. Environmental factors may also play a role. Affected infants present in the newborn period with facial weakness, causing feeding difficulties owing to a poor suck. Möbius syndrome can also be associated with other congenital anomalies, including talipes equinovarus (clubfoot), arthrogryposis, and syndactyly. Over 30% of patients with Möbius syndrome are reported to have autism spectrum disorder and/or intellectual disability.

Duane retraction syndrome is characterized by congenital limitation of horizontal globe movement and globe retraction and palpebral fissure narrowing on attempted adduction. This is caused by underdevelopment or absence of the abducens nuclei and nerves, as well as aberrant innervation of the lateral rectus muscle by the oculomotor nerve. Duane syndrome often occurs in families with an autosomal dominant pattern of inheritance, with three genes (*CHN1, MAFB,* and *SALL4*) identified thus far as well as associations with chromosome 8q13, 20q12, and 2q21.1.

Congenital fibrosis of the extraocular muscles (CFEOM) is characterized by severe restriction of eye movements and ptosis from abnormal oculomotor and trochlear nerve development and/or from abnormalities of extraocular muscle innervation. The most common form is caused by pathogenic autosomal dominant variants in *KIF21A,* which encodes a kinesin motor protein. Variants in *KIF21A* therefore lead to abnormal axonal transport. Other autosomal dominant causes

of CFEOM include pathogenic variants in the tubulin genes *TUBA1A, TUBB2B,* and *TUBB3*. Malformations of cortical development can also be associated with these and other tubulinopathy genes. Autosomal recessive forms of CFEOM are associated with variants in *PHOX2A* and *COL25A1*.

BRAINSTEM AND CEREBELLAR DISORDERS

Disorders of the posterior fossa structures include abnormalities not only of the brainstem and cerebellum but also of the CSF spaces.

Chiari malformation, the most common malformation of the posterior fossa and hindbrain, consists of downward displacement of the cerebellum and sometimes the brainstem through the foramen magnum. Often, there is an associated developmental abnormality of the bones of the skull base leading to a small posterior fossa. Chiari malformations are divided into three groups (type I, II, and III). In **Chiari type I**, the cerebellar tonsils are downwardly displaced (Fig. 631.15). Chiari type I malformations can be asymptomatic. When symptoms develop, they often do not do so until late childhood. Symptoms include headaches that are worse with straining and other Valsalva maneuvers that increase ICP. Symptoms of brainstem compression such as diplopia, oropharyngeal dysfunction, spasticity, tinnitus, sleep apnea, and vertigo can also occur. Type I malformations are not associated with hydrocephalus. Syrinx of the spinal cord, especially in the cervical region, should be looked for on MRI imaging. This can result in neck pain, urinary frequency, and progressive lower extremity spasticity. Although the pathogenesis is unknown, a prevailing theory suggests that obstruction of the caudal portion of the fourth ventricle during fetal development is responsible. Chiari type I malformations may be associated with Ehlers-Danlos syndrome.

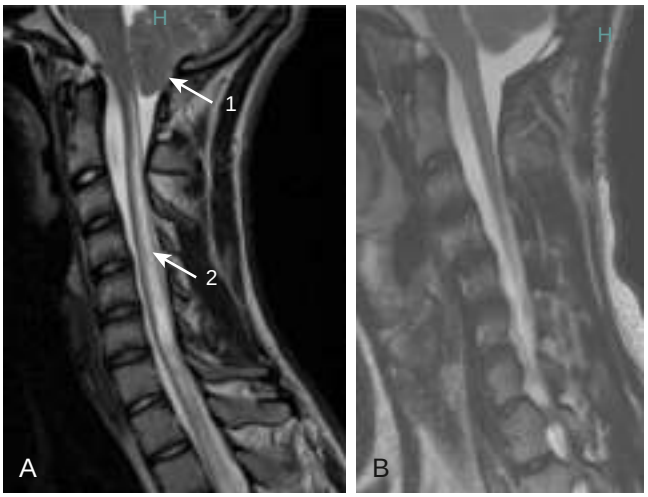

Fig. 631.15 **A,** A 16-yr-old male with Chiari malformation type 1 *(arrow 1)* and syringomyelia *(arrow 2)*. **B,** Postoperative MRI reveals decompression of the Chiari malformation and resolution of the syrinx. *(From Albert GW. Chiari malformation in children. Pediatr Clin N Am. 2021;68:783–792, Fig. 1, p. 786.)*

With **Chiari type II**, the inferior cerebellar vermis, cerebellar tonsils, and medulla are displaced through the foramen magnum. Most patients with myelomeningocele have a Chiari type II malformation (also see Neural Tube Defects). **Chiari type III**, the rarest form, also consists of downward displacement of the medulla, as well as a high cervical or occipital encephalocele. Chiari type II is usually identified early in life because of the association with myelomeningocele and, as with Chiari type I, can cause symptoms from brainstem compression. Complications for all the Chiari malformations include obstructive hydrocephalus and/or syringomyelia. Patients with Chiari type III are more severely affected, with high mortality and neurologic morbidity.

Dandy-Walker malformation consists of cystic dilation of the fourth ventricle, hypoplasia or agenesis of the cerebellar vermis, and an enlarged posterior fossa with elevation of the lateral venous sinuses and the tentorium (Fig. 631.16). Various associated brain malformations can also be seen, including agenesis of the corpus callosum and malformations secondary to abnormal neuronal migration. Most patients will develop hydrocephalus in infancy, and variable degrees of neurologic impairment are usually present. The etiology of Dandy-Walker malformation is heterogeneous and includes chromosomal abnormalities, single gene disorders, and exposure to teratogens. It is important to distinguish Dandy-Walker malformation from other causes of posterior fossa CSF collections (see Fig. 631.16). These include the **Blake pouch cyst**, a benign variant that consists of enlargement of the fourth ventricle, caused by persistence of the developmental Blake pouch structure. Isolated **mega cisterna magna**, another benign normal variant, refers to an enlarged cisterna magna with otherwise normal cerebellar architecture and size. Finally, posterior fossa **arachnoid cysts** can lead to hydrocephalus caused by obstruction of CSF flow but often remain asymptomatic.

Joubert syndrome and related disorders are a group of autosomal recessive disorders in which there is cerebellar vermis hypoplasia and the pontomesencephalic **molar tooth sign** (a deepening of the interpeduncular fossa with thick and straight superior cerebellar peduncles) (Fig. 631.17). It is associated with hypotonia, ataxia, characteristic breathing abnormalities including episodic apnea and hyperpnea (which improves with age), global developmental delay, nystagmus, strabismus, ptosis, and oculomotor apraxia. Joubert syndrome is

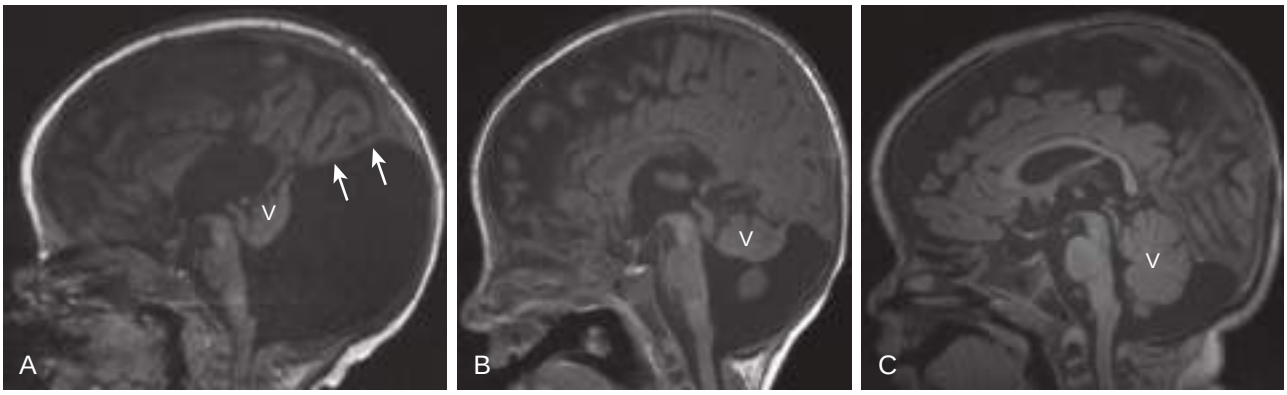

Fig. 631.16 Dandy-Walker spectrum posterior fossa abnormalities. Abnormal fenestration of embryologic outlets of the fourth ventricle and associated hypoplasia of the vermis (V in **A-C**) result in so-called Dandy-Walker spectrum. As illustrated by these sagittal T1-weighted brain MRI sequences, the most severe end of the spectrum consists of the classic Dandy-Walker malformation (**A**) where there is severe vermian hypoplasia and a remodeling of an enlarged posterior fossa CSF space (e.g., elevation of the tentorium and torcula above the confluence of the lambdoid sutures, *arrows*). At the least severe end of the spectrum, the vermis is fully formed but there is a prominent retrocerebellar and cisterna magna CSF space without expansion of the posterior fossa: a mega cisterna magna (**C**). In between these extremes, one may encounter vermian hypoplasia and posterior fossa CSF space prominence without overt expansion of the posterior fossa (e.g., vermian hypoplasia with rotation in **B**).

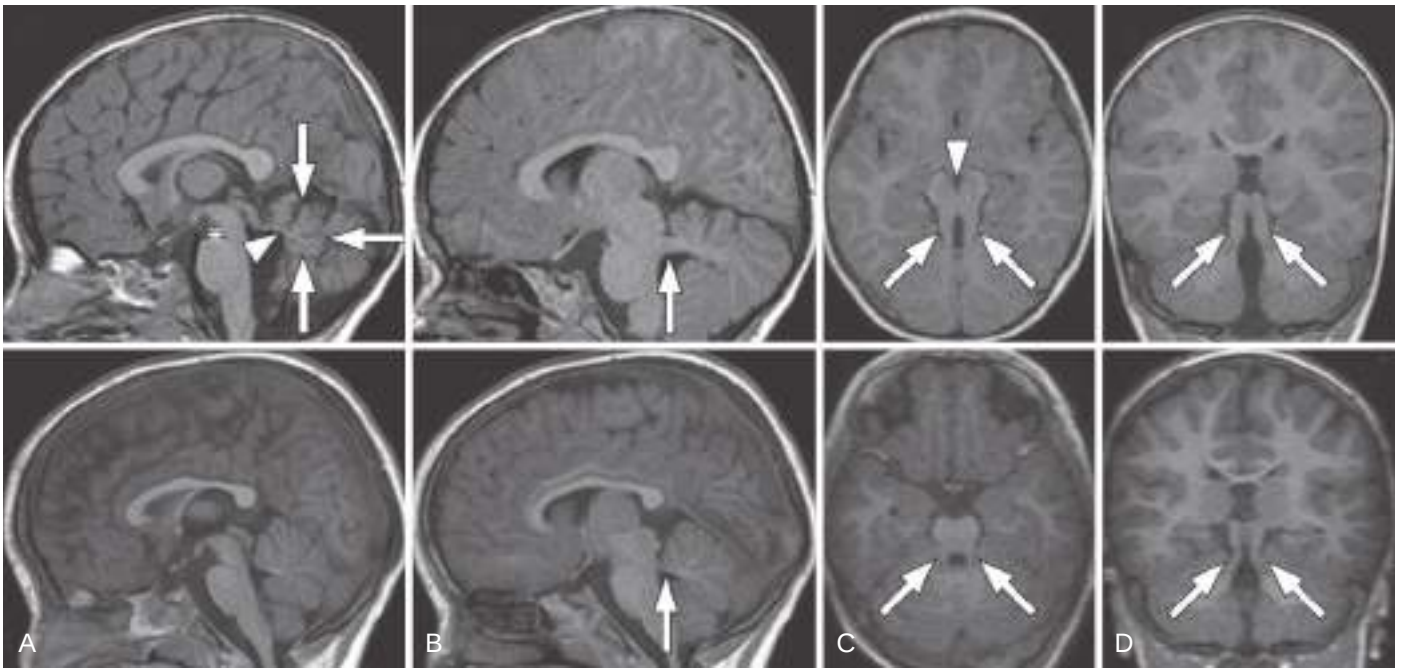

Fig. 631.17 Neuroimaging findings in a 2-yr-old child with pure Joubert syndrome *(upper panels)* compared with a healthy control *(lower panels)*. **A,** Parasagittal T1-weighted image shows the thickened, elongated, and horizontally oriented superior cerebellar peduncles *(white arrow)*. **B,** Midsagittal T1-weighted image demonstrates a moderate hypoplasia and dysplasia of the cerebellar vermis *(white arrows)* with secondary distortion and enlargement of the fourth ventricle, with rostral shifting of the fastigium *(white arrowhead)*. A deepened interpeduncular fossa is also noted. **C,** Axial T1-weighted image at the level of the pontomesencephalic junction shows the molar tooth sign with a deepened interpeduncular fossa *(white arrowhead)* and elongated, thickened, and horizontally oriented superior cerebellar peduncles *(white arrows)*. Additionally, the cerebellar vermis appears to be hypoplastic and its remnants dysplastic. **D,** Coronal T1-weighted image reveals the thickened superior cerebellar peduncles *(white arrows)*. *(From Romani M, Micalizzi A, Valente EM. Joubert syndrome: congenital cerebellar ataxia with the molar tooth. Lancet Neurol. 2013;12:894–905, Fig. 1.)*

considered a ciliopathy, as many of the 35 genes implicated encode for proteins important in cilia function (e.g., *AHI1, CC2D2A, CEP290*). There can also be associated systemic features, including progressive retinal dysplasia (Leber congenital amaurosis), coloboma, congenital heart disease, microcystic kidney disease, liver fibrosis, polydactyly, tongue protrusion, and soft tissue tumors of the tongue (Fig. 631.18).

Rhombencephalosynapsis consists of an absent or small vermis associated with a nonseparation or fusion of the deep midline cerebellar structures. Ventriculomegaly or hydrocephalus is often seen. There is a variable clinical presentation from normal function to cognitive and language impairments, epilepsy, and spasticity.

The **pontocerebellar hypoplasias** (PCHs) are a group of autosomal recessive disorders characterized by impairment of cerebellar and pontine development. Ten types have been defined to date, with increasing identification of underlying genetic causes (e.g., *TSEN2, TSEN34, RARS2*). Patients tend to be severely affected, with hypotonia, feeding difficulties, developmental delay, breathing difficulties, and seizures. Other disorders can also present with some PCH, most commonly including Walker-Warburg syndrome, muscle-eye-brain disease, congenital disorders of glycosylation type 1A, and mitochondrial cytopathies.

Visit Elsevier eBooks+ at eBooks.Health.Elsevier.com for Bibliography.

631.9 Hydrocephalus

Sara K. Trowbridge, Edward Yang, and Christopher J. Yuskaitis

Hydrocephalus is not a specific disease; it represents a diverse group of conditions that result from impaired circulation and/or absorption of CSF or, in rare circumstances, from increased production of CSF by a choroid plexus papilloma (Tables 631.6 and 631.7).

PHYSIOLOGY

The CSF is formed primarily in the ventricular system by the choroid plexus, which is situated in the lateral, third, and fourth ventricles. Although most CSF is produced in the lateral ventricles, approximately 25% originate from extrachoroidal sources, including the capillary endothelium within the brain parenchyma. There is active neurogenic control of CSF formation because adrenergic and cholinergic nerves innervate the choroid plexus. Stimulation of the adrenergic system diminishes CSF production, whereas excitation of the cholinergic nerves may double the normal CSF production rate. In a normal child, approximately 20 mL/hr of CSF is produced. The total volume of CSF approximates 50 mL in an infant and 150 mL in an adult. Most of the CSF is extraventricular. The choroid plexus forms CSF in several stages; through a series of intricate steps, a plasma ultrafiltrate is ultimately processed into a secretion, the CSF.

CSF flow results from the pressure gradient that exists between the ventricular system and venous channels. Intraventricular pressure may be as high as 180 mmH_2O in the normal state, whereas the pressure in the superior sagittal sinus is in the range of 90 mmH_2O. Normally, CSF flows from the lateral ventricles through the foramina of Monro into the third ventricle. It then traverses the narrow aqueduct of Sylvius, which is approximately 3 mm long and 2 mm in diameter in a child, to enter the fourth ventricle. The CSF exits the fourth ventricle through the paired lateral foramina of Luschka and the midline foramen of Magendie into the cisterns at the base of the brain. Hydrocephalus resulting from obstruction within the ventricular system is called *obstructive* or *noncommunicating hydrocephalus*. The CSF then circulates from the basal cisterns posteriorly through the cistern system and over the convexities of the cerebral hemispheres. CSF is absorbed primarily by the arachnoid villi through tight junctions of their endothelium by the pressure forces that were noted earlier. CSF is absorbed to a much lesser

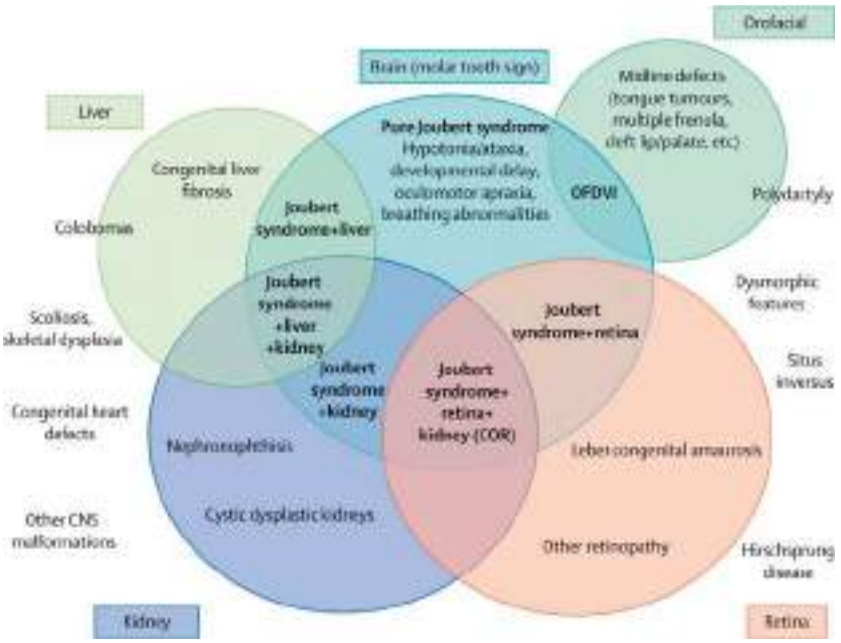

Fig. 631.18 Spectrum of organ involvement in Joubert syndrome and classification in clinical subgroups *(in bold)*. Chorioretinal colobomas are more frequently found in the subgroup of Joubert syndrome with liver involvement but can be present also in other subgroups. Similarly, polydactyly (especially if preaxial or mesoaxial) is invariably present in the orofaciodigital type VI subgroup, but postaxial polydactyly is frequently observed also in association with other Joubert syndrome phenotypes. Other clinical features outside the circles occur more rarely, without a specific association to a clinical subgroup. CNS, Central nervous system; COR, cerebellooculorenal; OFDVI, orofaciodigital type VI syndrome. *(From Romani M, Micalizzi A, Valente EM. Joubert syndrome: congenital cerebellar ataxia with the molar tooth. Lancet Neurol. 2013;12:894–905, Fig. 3.)*

Table 631.6 Causes of Pediatric Hydrocephalus

	CAUSE	PROPOSED MECHANISM
ACQUIRED HYDROCEPHALUS		
Inflammatory		
Subarachnoid hemorrhage or infection	Arachnoid scar	Dysfunctional subarachnoid space
Intraventricular hemorrhage or infection	Ependymal scar	Ventricular obstruction
Neoplasm		
Parenchymal brain tumor	Mass effect	Ventricular obstruction
Spinal cord tumor	Altered CSF composition	Dysfunctional subarachnoid space
Disseminated tumor	Tumors with meningeal infiltration (e.g., primitive neuroectodermal tumor)	Dysfunctional subarachnoid space
Choroid plexus tumor	Altered CSF composition	Dysfunctional subarachnoid space
Choroid plexus tumor	Mass effect	Ventricular obstruction
Choroid plexus tumor or hyperplasia	Altered choroid plexus function	CSF overproduction or hyperdynamic intraventricular pulsations
Vascular		
Vascular malformation	Ventricular obstruction (e.g., vein of Galen malformation); venous hypertension (e.g., arteriovenous malformation)	Ventricular obstruction; decreased venous compliance or decreased CSF absorption
Disordered cerebral venous function	Extrinsic venous obstruction (e.g., skeletal dysplasias); intrinsic venous obstruction (e.g., venous sinus thrombosis); idiopathic venous dysfunction (e.g., congenital idiopathic hydrocephalus)	Decreased venous compliance or decreased CSF absorption
CONGENITAL OR DEVELOPMENTAL HYDROCEPHALUS		
Congenital aqueduct stenosis	Third ventricle outlet obstruction	Ventricular obstruction
Neural tube defects (e.g., myelomeningocele and Chiari II malformation)	Third or fourth ventricle outlet obstruction; altered venous compliance; arachnoid or ependymal scar	Variable
Posterior fossa malformations	Fourth ventricle outlet obstruction (e.g., Dandy-Walker complex); Chiari I malformation	Ventricular obstruction
Developmental cysts	Mass effect	Ventricular obstruction
Congenital foramen of Monro atresia	Lateral ventricle outlet obstruction	Ventricular obstruction

From Kahle KT, Kulkarni AV, Limbick DD Jr, et al. Hydrocephalus in children. *Lancet*. 2016;387:788–798, Table 1.

extent by the lymphatic channels directed to the paranasal sinuses, along nerve root sleeves, and by the choroid plexus itself. Hydrocephalus resulting from obliteration of the subarachnoid cisterns or malfunction of the arachnoid villi is called *nonobstructive* or *communicating hydrocephalus*.

Table 631.7 Genetic Abnormalities Associated with Pediatric Hydrocephalus

	PUTATIVE GENETIC LINK
X-linked hydrocephalus with aqueduct stenosis (307000)	*L1CAM*
Nonsyndromic autosomal recessive hydrocephalus (HYC; 236600 [HYC1]; 615219 [HYC2])	*CCDC88C; MPDZ*
Fried-type syndromic mental retardation (304340)	*AP1S2*
Walker-Warburg syndrome (multiple subtypes)	*POMT1, POMT2, POMGNT1,* and others
Neural tube defects (folate-sensitive [601634] and insensitive [182940] forms)	Multiple susceptibility genes involved in planar-cell polarity (e.g., *FUZ, VANGL1/2, CCL2,* and others); folate-sensitive neural tube defects associated with genes in folate synthesis pathway (*MTR, MTRR, MTHFR, MTHFD*)
Primary ciliary dyskinesias and other ciliopathies (including the many heterogeneous subtypes of Meckel-Gruber syndrome and Joubert syndrome)	Multiple genes involved in cilia structure, function, and regulation (e.g., *CC2D2A, TMEM67, MKS1,* and others)
RAS-opathies (e.g., neurofibromatosis type 1, Noonan syndrome, Costello syndrome, cardiofaciocutaneous syndrome)	*NF1*; Ras-Raf-MEK-ERK pathway genes) e.g., *KRAS, BRAF, PTPN11,* and others)
VACTERL-H (association of vertebral, anal, cardiac, tracheoesophageal, renal, and limb anomalies plus hydrocephalus; 276950)	*PTEN*
X-linked VACTERL-H (300515)	*FANCB*

Numbers given are Online Mendelian Inheritance in Man (OMIM) identifiers.
From Kahle KT, Kulkarni AV, Limbick DD Jr, et al. Hydrocephalus in children. *Lancet.* 2016;387:788–798, Table 2.

PATHOPHYSIOLOGY AND ETIOLOGY

Obstructive or noncommunicating hydrocephalus develops most commonly in children because of an abnormality of the aqueduct of Sylvius or a lesion in the fourth ventricle. Aqueductal stenosis results from an abnormally narrow aqueduct of Sylvius that is often associated with branching or forking (Fig. 631.19). In a small percentage of cases, aqueductal stenosis is inherited as a sex-linked recessive trait. These patients occasionally have minor neural tube closure defects, including spina bifida occulta. Rarely, aqueductal stenosis is associated with neurofibromatosis. Aqueductal gliosis can also give rise to hydrocephalus. As a result of neonatal meningitis or a subarachnoid hemorrhage in a premature infant, the ependymal lining of the aqueduct is interrupted, and a brisk glial response results in complete obstruction. Intrauterine viral infections can also produce aqueductal stenosis followed by hydrocephalus. A vein of Galen malformation can expand and, because of its midline position, obstruct the flow of CSF. Lesions or malformations of the posterior fossa are prominent causes of hydrocephalus, including posterior fossa brain tumors, Chiari malformation, and Dandy-Walker syndrome, as previously discussed.

Nonobstructive or communicating hydrocephalus most commonly follows a subarachnoid hemorrhage, which is usually a result of intraventricular hemorrhage in a premature infant. Blood in the subarachnoid spaces can disrupt CSF flow through the cisterns or damage the arachnoid villi resulting in obstruction of CSF flow. Pneumococcal and tuberculous meningitis have a propensity to produce a thick, tenacious exudate that obstructs the basal cisterns, and intrauterine infections can also destroy the CSF pathways. Leukemic infiltrates can seed the subarachnoid space and produce communicating hydrocephalus. Tumors or arteriovenous malformations in the spinal cord or cauda equina are uncommon etiologies of communicating hydrocephalus.

CLINICAL MANIFESTATIONS

The clinical presentation of hydrocephalus is variable and depends on many factors, including the age at onset, the nature of the lesion causing the obstruction, and the duration and rate of increase of the ICP. In an infant, an accelerated rate of enlargement of the head is the most prominent sign. In addition, the anterior fontanel is wide open and bulging, and scalp veins can be dilated. The forehead is broad, and the eyes might deviate downward (i.e., setting-sun eye sign) because of impingement of the dilated suprapineal recess on the brainstem tectum. Long-tract signs, including brisk tendon reflexes, spasticity, clonus (particularly in the lower extremities), and Babinski sign, are common because of stretching and disruption of the corticospinal fibers originating from the leg region of the motor cortex. In an older child, the cranial sutures are less accommodating, so that the signs of hydrocephalus may be subtler. Irritability, lethargy, poor appetite, and vomiting are common to both age-groups, and headache is a prominent symptom in older patients. A gradual

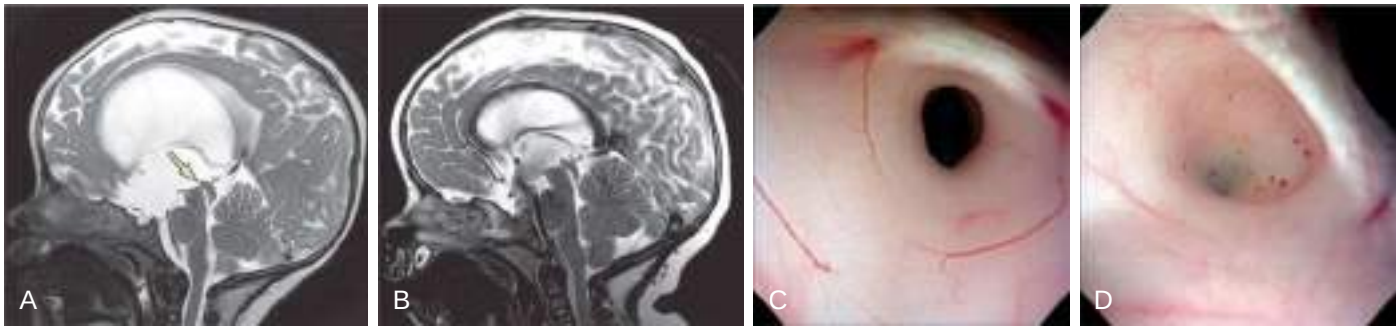

Fig. 631.19 Aqueduct stenosis. **A,** Sagittal brain T2-weighted MRI of infant with hydrocephalus secondary to congenital aqueduct stenosis. *Arrow* indicates point of obstruction. **B,** Same patient after endoscopic third ventriculostomy; note dark flow void indicating flow across endoscopic third ventriculostomy. **C,** Endoscopic view of healthy patent aqueduct. **D,** Endoscopic view of obstructed aqueduct in aqueduct stenosis; note posterior commissure at dorsal margin of the aqueduct ostium in both **A** and **B**. *(From Kahle KT, Kulkarni AV, Limbick Jr DD, et al. Hydrocephalus in children. Lancet. 2016;387:788–798, Fig. 1.)*

change in personality and deterioration in academic productivity suggest a slowly progressive form of hydrocephalus. Percussion of the skull might produce a cracked pot sound or Macewen sign, indicating separation of the sutures. Serial head circumference measurements, with special attention to the velocity of growth, are important measurements when identifying hydrocephalus and tracking resolution. A foreshortened occiput suggests Chiari malformation, and a prominent occiput suggests Dandy-Walker malformation. Papilledema, abducens nerve palsies, and pyramidal tract signs, which are most evident in the lower extremities, are apparent in many cases.

Type II Chiari malformations can manifest with progressive hydrocephalus. Approximately 10% of type II malformations produce symptoms during infancy, consisting of stridor, weak cry, and apnea, which may be relieved by shunting or by decompression of the posterior fossa. A more indolent form consists of abnormalities of gait, spasticity, and increasing incoordination (including the arms and hands) during childhood. Plain skull radiographs show a small posterior fossa and a widened cervical canal. CT scanning with contrast and MRI display the cerebellar tonsils protruding downward into the cervical canal and the hindbrain abnormalities. The anomaly is treated by surgical decompression, but asymptomatic or mildly symptomatic patients may be managed conservatively.

Approximately 90% of patients with Dandy-Walker malformation have hydrocephalus, and a significant number of children have associated anomalies, including agenesis of the posterior cerebellar vermis and corpus callosum. Infants present with a rapid increase in head size and a prominent occiput. Most children have evidence of long-tract signs, cerebellar ataxia, and delayed motor and cognitive milestones, probably because of the associated structural anomalies. Dandy-Walker malformation is managed by shunting the cystic cavity (and on occasion the ventricles as well) in the presence of hydrocephalus.

DIAGNOSIS AND DIFFERENTIAL DIAGNOSIS

Investigation of a child with hydrocephalus begins with the history. Familial cases suggest X-linked or autosomal hydrocephalus secondary to aqueduct stenosis. A history of prematurity with intracranial hemorrhage, meningitis, or mumps encephalitis is important to ascertain. Multiple café-au-lait spots and other clinical features of neurofibromatosis point to aqueductal stenosis as the cause of hydrocephalus.

Examination includes careful inspection, palpation, and auscultation of the skull and spine. The occipitofrontal head circumference is recorded and compared with previous measurements. The size and configuration of the anterior fontanel are noted, and the back is inspected for abnormal midline skin lesions, including tufts of hair, lipoma, or angioma, that might suggest spinal dysraphism. The presence of a prominent forehead or abnormalities in the shape of the occiput can suggest the pathogenesis of the hydrocephalus. A cranial bruit is audible in association with many cases of vein of Galen arteriovenous malformation (Fig. 631.20). Transillumination of the skull is positive with massive dilation of the ventricular system or in Dandy-Walker syndrome. A fundoscopic exam is mandatory because the finding of chorioretinitis suggests an intrauterine infection, such as toxoplasmosis, as a cause of the hydrocephalus. Papilledema is observed in older children but is rarely present in infants because the cranial sutures separate in the setting of the increased pressure.

An ultrasound is a quick and easy study to perform on infants with an open fontanelle to identify and monitor the trajectory of hydrocephalus. Brain MRI has the capability to perform specific sequences to evaluate CSF flow dynamics as well as evaluating for etiology and additional abnormalities that may be present. In many centers, CT scans are often limited to evaluating for acute symptomatic hydrocephalus and skull abnormalities to avoid radiation exposure. Although rarely used, plain skull films can show separation of the sutures, erosion of the posterior clinoids in an older child, and an increase in convolutional markings (beaten-silver appearance) on the inside of the skull with long-standing increased ICP.

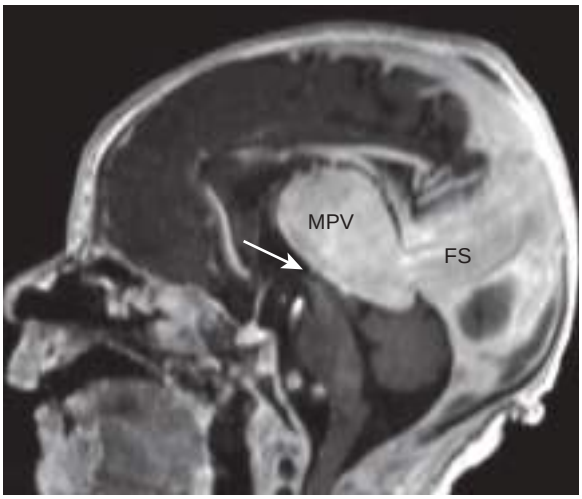

Fig. 631.20 Vein of Galen malformation. A vein of Galen malformation is an arteriovenous fistula between intracranial arteries and the embryologic median prosencephalic vein. As seen in this postcontrast sagittal T1-weighted brain MR image of a newborn with a prenatally diagnosed vein of Galen malformation, this vascular malformation is characterized by marked distension of the median prosencephalic vein (MPV) and distension of downstream dural sinuses, commonly through a persistent embryologic falcine sinus (FS). The ensuing high-velocity arteriovenous shunting can cause venous hypertension, communicating hydrocephalus, and high-output cardiac failure. Although large median prosencephalic veins can compress the cerebral aqueduct *(arrow)*, the primary treatment modality is still endovascular intervention (embolization) rather than CSF diversion.

Rapid head growth raises suspicion of hydrocephalus; however, other etiologies must be considered. Accelerated skull growth from a thickened cranium can result from chronic anemia, rickets, osteogenesis imperfecta, and epiphyseal dysplasia. Chronic subdural collections can produce bilateral parietal bone prominence. Benign external hydrocephalus is often associated with macrocephaly with notable increase in volume of the subarachnoid spaces on brain imaging. No intervention is required for this self-limited hydrocephalus, which is hypothesized to be the result of a delayed maturation of the arachnoid villi. Various metabolic and degenerative disorders of the CNS produce megalencephaly as a result of abnormal storage of substances within the brain parenchyma. These disorders include lysosomal diseases (Tay-Sachs disease, gangliosidosis, and the mucopolysaccharidoses), the aminoacidurias (maple syrup urine disease), and the leukodystrophies (metachromatic leukodystrophy, Alexander disease, Canavan disease). In addition, cerebral gigantism (Sotos syndrome), other overgrowth syndromes, and neurofibromatosis are characterized by increased brain mass. Familial megalencephaly is inherited as an autosomal dominant trait and is characterized by delayed motor milestones and hypotonia but normal or near-normal intelligence. Measurement of the parents' head circumferences is necessary to establish the diagnosis.

Ventriculomegaly can exist without increased ICP (normal-pressure hydrocephaly) or in patients with loss of white or gray matter secondary to prior injury (cerebral atrophy with ventricular dilation ex vacuo). It can be difficult to distinguish between ventriculomegaly and true hydrocephalus by static neuroimaging alone unless CSF flow assessment is included in the MRI. Additional clinical information (e.g., clinical context, fundoscopic exam, lumbar puncture with pressure measurements) may also be required. This is an important clinical distinction to make, as the management of ventriculomegaly secondary to hydrocephalus is quite different from the management of ventriculomegaly secondary to brain volume loss.

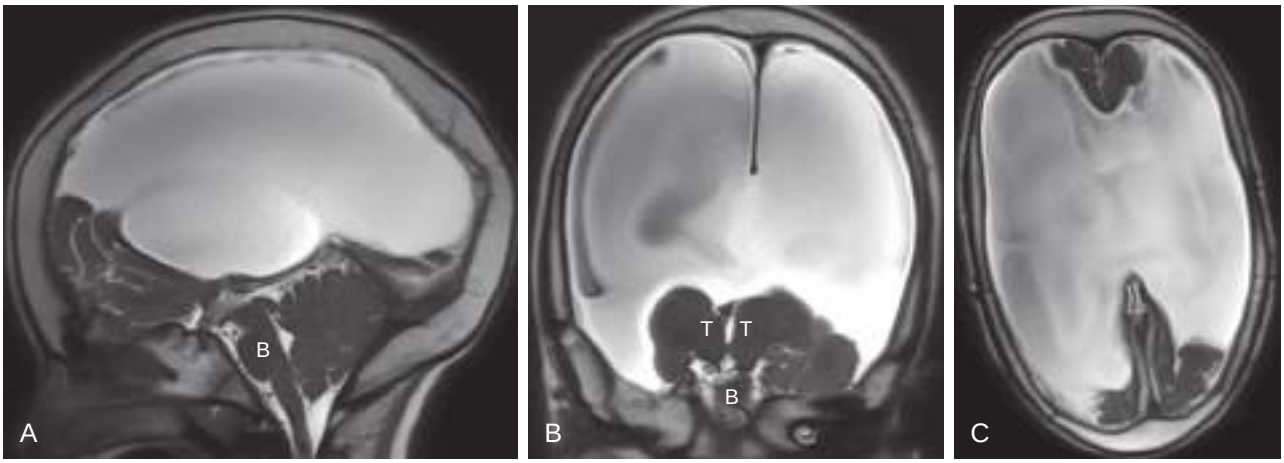

Fig. 631.21 Hydranencephaly. Brain MRI sagittal (**A**), coronal (**B**), and axial (**C**) single-shot T2-weighted images of a 13-yr-old female with severe neurologic impairment demonstrates lysis of the cerebral hemispheres apart from small remnants of the frontal/occipital poles and left temporal pole. There is preservation of the thalami (T) and brainstem (B). This congenital lysis of the cerebrum is dubbed *hydranencephaly* and believed to reflect anterior circulation vascular insufficiency in utero.

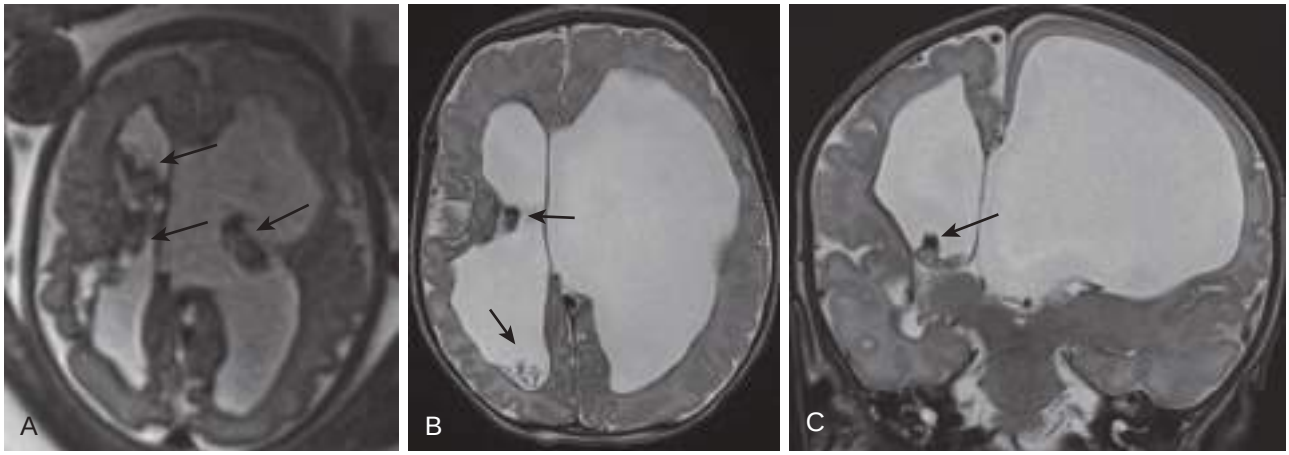

Fig. 631.22 Porencephaly from in utero encephaloclastic/hemorrhagic injury. High-grade in utero germinal matrix hemorrhage results in venous infarction and hemorrhagic injury to the brain parenchyma. As a result, there is focal lysis and thinning of the brain parenchyma, resulting in a hemispheric cavity in communication with the ventricular system called *porencephaly*. **A,** Axial single-shot brain MR T2-weighted imaging of a fetus at 32 wk demonstrates severe ventriculomegaly with a clot in the ventricular system *(arrows)* and hemosiderin-stained (hypointense) tissue lysis in the surrounding cerebral hemispheres. Axial (**B**) and coronal (**C**) T2-weighted imaging of the same patient during the first day of life better depicts the areas of hemosiderin staining and parenchymal thinning/lysis as well as residual clot in the ventricular system *(arrows)*.

HYDRANENCEPHALY

Hydranencephaly may be confused with hydrocephalus. The cerebral hemispheres are absent or represented by membranous sacs with remnants of frontal, temporal, or occipital cortex dispersed over the membrane. The midbrain and brainstem are relatively intact (Fig. 631.21). The cause of hydranencephaly is unknown, but bilateral occlusion of the internal carotid arteries during early fetal development would explain most of the pathologic abnormalities. Affected infants can have a normal circumference at birth that grows at an excessive rate postnatally because of excessive CSF production and absorption. Transillumination shows an absence of the cerebral hemispheres. The child is irritable, feeds poorly, develops seizures and spastic quadriparesis, and has little or no cognitive development. A ventriculoperitoneal shunt prevents massive enlargement of the cranium.

PORENCEPHALY

Porencephaly is the presence of cysts or cavities within the brain that result from developmental defects or acquired lesions, including infarction of tissue. True porencephalic cysts are most commonly located in the region of the sylvian fissure and typically communicate with the subarachnoid space or the ventricular system, or both. They represent developmental abnormalities of cell migration and are often associated with other malformations of the brain, including microcephaly, abnormal patterns of adjacent gyri, and encephalocele. Affected infants tend to have many problems, including intellectual disability, spastic hemiparesis or quadriparesis, optic atrophy, and seizures.

Several risk factors for porencephalic cyst formation have been identified, including hemorrhagic venous infarctions, various thrombophilias such as protein C deficiency and factor V Leiden variants, perinatal alloimmune thrombocytopenia, von Willebrand disease, maternal warfarin use, maternal cocaine use, congenital infections, trauma such as amniocentesis, and maternal abdominal trauma. Pathogenic variants in the *COL4A1* and *COL4A2* genes have been described in cases of familial porencephaly (Fig. 631.22).

TREATMENT

Therapy for hydrocephalus depends on the cause. Medical management, including the use of acetazolamide and furosemide, can provide temporary relief by reducing the rate of CSF production, but long-term results have been disappointing. Most cases of hydrocephalus require extracranial shunts, particularly a ventriculoperitoneal shunt. Endoscopic third ventriculostomy is a viable approach, and criteria have been developed for its use, but the procedure might need to be repeated to be effective. Endoscopic fenestration of the floor of the third ventricle with drainage into the subarachnoid space (prepontine cistern) is attempted in patients over 6 months of age with noncommunicating hydrocephalus. It often requires cauterization of the choroid plexus as an additional procedure (see Fig. 631.19). Ventricular shunting may be avoided with this approach. The major complications of shunting are occlusion (characterized by headache, papilledema, emesis, and mental status changes) and bacterial infection (fever, headache, meningismus), usually caused by *Staphylococcus epidermidis*. With meticulous preparation, the shunt infection rate can be reduced to <5%. The results of intrauterine surgical management of fetal hydrocephalus have been poor (possibly because of the high rate of associated cerebral malformations in addition to the hydrocephalus) except for some promise in cases of hydrocephalus associated with fetal meningomyelocele.

PROGNOSIS

The prognosis depends on the cause of the dilated ventricles and not on the size of the cortical mantle at the time of operative intervention, except in cases in which the cortical mantle has been severely compressed and stretched. Children with hydrocephalus are at increased risk for various developmental disabilities. The mean intelligence quotient is reduced compared with the general population, particularly for performance tasks as compared with verbal abilities. Many children have abnormalities in memory function. Vision problems are common, including strabismus, visuospatial abnormalities, visual field defects, and optic atrophy with decreased acuity secondary to increased ICP. The visual evoked potential latencies are delayed and take some time to recover after correction of the hydrocephalus. Accelerated pubertal development in patients with shunted hydrocephalus or myelomeningocele is relatively common, possibly because of increased gonadotropin secretion in response to increased ICP. It is imperative that children with hydrocephalus receive long-term follow-up in a multidisciplinary setting.

Visit Elsevier eBooks+ at eBooks.Health.Elsevier.com for Bibliography.

631.10 Craniosynostosis

Irene M.J. Mathijssen

See also Chapter 101.4.

Craniosynostosis is defined as premature closure of the cranial sutures and is classified as primary or secondary. It is associated with varying types of abnormal skull shape (see Fig. 101.5). Primary craniosynostosis refers to closure of one or more sutures owing to abnormalities of skull development, whereas secondary craniosynostosis results from failure of brain growth and expansion (e.g., microcephaly or after insertion of a ventriculoperitoneal shunt), specific medication during pregnancy (e.g., valproate), or metabolic disorders. The incidence of primary craniosynostosis approximates 1 in 2,000 live births. The cause is unknown in the majority of children; however, genetic syndromes account for 10–20% of cases (see Table 101.5). The distinction between craniosynostosis and deformational forces is important in occipital and frontal plagiocephaly to allow successful intervention to be offered in the form of physical therapy for torticollis and other positional asymmetries that lead to plagiocephaly.

Table 631.8 Commonly Used Clinical Genetic Classifications of Craniosynostoses

DISORDER	CAUSE
ISOLATED CRANIOSYNOSTOSIS	
Unicoronal synostosis	Unknown, consider *TWIST1, FGFR1, FGFR2, FGFR3, TCF12, IL11RA*, ERF pathogenic variants
Metopic and sagittal synostosis	SMAD6
SYNDROMIC CRANIOSYNOSTOSIS	
Antley-Bixler syndrome	*FGFR2, POR*
Apert syndrome	Usually one of two pathogenic variants in *FGFR2*
Beare-Stevenson syndrome	*FGFR2*
Baller-Gerold syndrome	*RECQL4*
Carpenter syndrome	*RAB23* in most; *MEGF8* in some
Craniofrontonasal syndrome	*EFNB1*
Crouzon syndrome (and Pfeiffer syndrome)	Numerous different pathogenic variants at *FGFR2; rarely FGFR1*
Crouzon acanthosis nigricans syndrome	Ala391Glu pathogenic variants in *FGFR3*
Muenke syndrome	Pro250Arg pathogenic variants in *FGFR3*
Saethre-Chotzen syndrome	Pathogenic variants or deletion in *TWIST1*
TCF-12 related craniosynostosis	Pathogenic variants or deletion of *TCF12*
IL11RA-related craniosynostosis	*IL11RA*
ERF-related craniosynostosis	*ERF*
Shprintzen-Goldberg syndrome	Pathogenic variants in *FBN1 or SKI*

DEVELOPMENT AND ETIOLOGY

The bones of the cranium are well developed by the fifth month of gestation (frontal, parietal, temporal, and occipital) and are separated by sutures and fontanels. The brain grows rapidly in the first several years of life and is normally not impeded because of equivalent growth along the suture lines. The cause of craniosynostosis is largely unknown. Genetic factors have been identified for some isolated and for many syndromic causes of craniosynostosis (Table 631.8; see Table 101.5).

CLINICAL MANIFESTATIONS AND TREATMENT

Most cases of craniosynostosis are evident at birth and are characterized by a progressive skull deformity that is a direct result of premature suture fusion. Fusion of metopic and sagittal suture reveals a palpable prominent bony ridge, and fusion of the suture may be confirmed by plain skull roentgenograms, ultrasound, 3D-CT scan, or black bone MRI (Table 631.9).

Scaphocephaly is the result of premature closure of the sagittal suture and produces a long and narrow skull, the most common form of craniosynostosis. Scaphocephaly is associated with a prominent occiput, a broad forehead, and a triangular-shaped anterior fontanel. The condition is sporadic, is more common in males, and can cause difficulties during labor because of cephalopelvic disproportion resulting from a head circumference of ≥2 SD. Scaphocephaly is associated with increased ICP in about 10% of patients

Table 631.9 Epidemiology and Clinical Characteristics of the Common Craniosynostoses

TYPE	EPIDEMIOLOGY	SKULL DEFORMITY	CLINICAL PRESENTATION
Sagittal	Most common CSO affecting a single suture, 80% male	Dolichocephaly or scaphocephaly (boat-shaped)	Frontal bossing, prominent occiput, palpable keel ridge; OFC increased and reduced biparietal diameter
Coronal	More common in girls Associated with various syndromes	Unilateral: plagiocephaly Bilateral: brachycephaly	Unilateral: flattened forehead and elevated orbit on affected side, nose deviation; higher supraorbital margin Bilateral: broad, flattened forehead.
Lambdoid	Rare	Unilateral: Lambdoid/occipital plagiocephaly Bilateral: pachycephaly	Unilateral: flattening of ipsilateral occiput, bulging of ipsilateral forehead, ipsilateral ear and mastoid is inferiorly displaced, curvature in face Bilateral: brachycephaly with bilateral inferiorly displaced ears and mastoids
Metopic	SMAD 6 mutation; genetic overlap with developmental delay disorders	Trigonocephaly	Pointed forehead and midline ridge, hypotelorism
Multiple	Often syndromic	Depending on which sutures are involved	

CSO, Craniosynostosis; OFC, occipital–frontal circumference.

at the age of 12 months if left untreated and thus requires surgical treatment.

Trigonocephaly is the next most common form of craniosynostosis, caused by premature fusion of the metopic suture. These children have a keel-shaped forehead and hypotelorism and are at risk for associated cognitive impairment, behavioral problems and visual disturbances. The phenotype also includes milder presentations, which are usually self-limiting over time. Metopic ridging occurs with closure of the suture around the time of birth and is a physiologic process. The risk on increased ICP is limited, even in the more severe presentation.

Frontal plagiocephaly is characterized by unilateral flattening of the forehead, elevation of the orbit and eyebrow, and a caudal displacement of the ear on the corresponding side, with contralateral bossing of the forehead. The condition is more common in females and is the result of premature fusion of one of the coronal sutures. These children can present with raised ICP in up to 16% at 1 year of age and have a high risk of visual disturbances. Therefore skull surgery is indicated in addition to close monitoring by the optometrist. Unicoronal synostosis can be a presentation of a syndrome, and genetic analysis is always indicated (see Table 101.5).

Occipital plagiocephaly is most often a result of positioning during infancy and is more common in an immobile child or a child with a disability, but fusion of the lambdoid suture can cause unilateral occipital flattening and caudal displacement of the ipsilateral ear and mastoid and of the contralateral parietal bone. Surgery is indicated to prevent the development of distinct asymmetry of the face.

GENETIC DISORDERS

The most prevalent genetic disorders associated with craniosynostosis include Crouzon, Apert, Saethre-Chotzen, and Muenke syndromes.

Crouzon syndrome (including Pfeiffer syndrome) is characterized by premature craniosynostosis and is inherited as an autosomal dominant trait. The shape of the head depends on the timing and order of suture fusion but often is a compressed back-to-front diameter or **brachycephaly** resulting from bilateral closure of the coronal sutures. Pansynostosis is also common, in which all sutures close and the skull shape appears to be normal initially. The orbits are underdeveloped, and ocular proptosis is prominent. Hypoplasia of the maxilla and orbital hypertelorism are typical facial features. Crouzon syndrome can be associated with the skin condition acanthosis nigricans.

Apert syndrome has many features in common with Crouzon syndrome. Apert syndrome is usually a sporadic condition and linked to increased paternal age, although autosomal dominant inheritance can occur. It is associated with premature fusion of multiple sutures, especially the two coronal sutures. Apert syndrome is characterized by symmetric complex syndactyly of the hands and feet. Severe acne often develops during puberty, and most patients have a developmental delay.

Saethre-Chotzen syndrome is characterized by unicoronal or bicoronal synostosis. The condition is inherited as an autosomal dominant trait. It is associated with ptosis of one or both eyelids, short fingers, and soft tissue syndactyly of the second and third fingers and/or toes.

Muenke syndrome is the most prevalent of the genetic syndromes and usually presents with bicoronal synostosis. It is associated with sensorineural hearing loss and behavioral issues.

Pathogenic variants of the fibroblast growth factor receptor (FGFR) gene family have been shown to be associated with specific types of craniosynostosis. Crouzon syndrome is mainly caused by variants in *FGFR2* and incidentally of *FGFR1* and *FGFR3*. Apert syndrome is mainly caused by two specific types of *FGFR2* variants. Saethre-Chotzen syndrome results from variants or deletions in *TWIST1,* and Muenke syndrome is solely caused by the Pro250Arg variant in *FGFR3*.

Each of the genetic syndromes poses a risk of additional anomalies, including hydrocephalus, increased ICP, optic atrophy, respiratory problems secondary to upper airway anomalies, and disorders of speech and hearing. Vault expansion is mandatory for management of increased ICP, treatment to reduce the respiratory difficulties such as midface advancement, and a multidisciplinary craniofacial team is essential for the long-term follow-up of affected children until adulthood. Craniosynostosis may be surgically corrected with good outcomes and relatively low morbidity and mortality, especially for nonsyndromic infants.

Visit Elsevier eBooks+ at eBooks.Health.Elsevier.com for Bibliography.

Chapter 632

Deformational Plagiocephaly

Megan L. Dietze-Fiedler and John A. Girotto

Deformational plagiocephaly (DP), also known as positional plagiocephaly, is the development of cranial flattening and asymmetry in the infant as a result of extrinsic molding forces placed on the skull, such as consistently sleeping on the same area of the head. Since the suggestion was made to place sleeping infants on their backs for the prevention of sudden infant death syndrome, the incidence of DP has risen dramatically, up to 46.6% and peaking between 7 weeks and 4 months of age.

EPIDEMIOLOGY AND ETIOLOGY

Risk Factors

Infants cannot reposition their heads in the first few postnatal weeks and are unable to hold their heads up until about 4 months of age. It is for this reason that DP is most severe around 4 months of age. It is also during this time that an infant's head circumference increases rapidly: about 2 cm/month in the first 3 months, 1 cm/month from 4 to 6 months of age, and 0.5 cm/month after 6 months of age. By ~6 months of age, infants have developed head control, and this ability to actively reposition their head allows for the gradual improvement of the cranial shape because of pressure offloading and continued brain growth.

Congenital torticollis, positional preference when sleeping, and lower levels of activity are especially prominent in patients with DP. Table 632.1 lists other risk factors. Many of these risk factors cannot be prevented, but sleeping supine with the head always turned to the same side is associated with DP independent of the other factors, and this factor *can* be prevented. There may be an association between developmental delay and DP. Although not causal, studies have identified significant differences in gross motor development (e.g., sitting up, crawling, and rolling back to side) between babies with and without DP. Family demographics, such as lower maternal education, primiparity, more prenatal education, and siblings with cranial asymmetries, may also be associated with the development of DP. The increased prevalence of DP in infants of mothers receiving more prenatal education is considered related to the emphasis placed on sudden infant death syndrome and the Back to Sleep campaign.

Causes

Prenatal causes of DP include uterine compression and intrauterine constraint, such as occurs with oligohydramnios or multifetus pregnancy. Postnatal causes of DP include infant sleeping position and congenital muscular torticollis.

Table 632.1 Factors that Increase the Risk for Deformational Plagiocephaly

- Male
- First-born child
- Prematurity
- Multiple pregnancy (twins, triplets)
- Limited passive neck rotation at birth (e.g., congenital torticollis)
- Developmental delay
- Sleep position is supine at birth and at 6 wk
- Bottle feeding only
- Tummy time <3 times/day
- Lower activity level, slower milestone achievement
- Sleeping with head to same side, positional preference

Muscular torticollis is a condition that is present in as many as one in six newborns and causes continuous tightening of muscles in the neck, preventing passive rotation (see Chapter 721.1). It is thought that this condition precedes the development of cranial deformity. However, head position preference may result from cervical asymmetry that leads to torticollis and later flattening of a side of the skull from acquired positional preference. Muscular and positional issues lead to nonsynostotic plagiocephaly rather than the opposite. Given that DP results from more time spent on one side of the head and that torticollis (and other neck muscle imbalances) are likely to lead to this disproportional partitioning of time, they are most likely causes, not effects, of DP.

Sleeping position plays a major role in the incidence of DP. When an infant continuously sleeps with the same part of the skull resting on a flat surface, a continuous force is placed in this area. During this time of rapid skull development, the growth is inhibited at the area where it rests on a hard surface, causing a flat spot. Because of this inhibition, growth is increased in opposite directions, causing a deformation that can be distinguished from other types of plagiocephaly.

EXAMINATION AND DIFFERENTIATING BETWEEN DEFORMATIONAL PLAGIOCEPHALY AND CRANIOSYNOSTOSIS

An abnormal head shape in an infant is distressing for parents. DP is a clinical diagnosis. Management also requires accurate counseling about its cause and treatment. It is especially important to be able to rule out **craniosynostosis** as a primary cause for cranial asymmetry in infants because management of this condition is quite different from that of DP and requires immediate referral to a craniofacial surgeon for evaluation (see Chapter 631.10). Craniosynostosis occurs in approximately 1 in 2,000 live births and results in plagiocephaly as a consequence of the early closure of skull sutures. Craniosynostosis must be distinguished from DP because the management is different. Lambdoidal craniosynostosis, although extremely rare (1 in 300,000 live births), presents with features most similar to those of DP. It can be distinguished from DP by a variety of historical and physical findings. Bilateral coronal synostosis also presents similarly to posterior DP.

History and Physical Examination

Tables 632.2 and 632.3 outline the key components of the history and physical examination.

Observation of cranial shape and ear displacement are the first steps. It is critical to observe the child anteriorly, laterally, and from a vertex view. When cranial shape is viewed from above, DP typically looks like a **parallelogram**, and the ear on the same side of the flat or bald spot is **displaced anteriorly**. In lambdoidal craniosynostosis, the head has a trapezoid shape and the ear on the same side as the flat spot is posteriorly displaced (Fig. 632.1). It is important to note that the ear position, though more likely to be anterior in DP and posterior in lambdoidal craniosynostosis, may present anteriorly in both conditions.

Palpation will help to differentiate these two conditions. Craniosynostosis presents with palpable ridges along the suture, whereas DP does not. Additionally, patients with craniosynostosis will not have mobile calvarial bones. This can be tested by applying gentle pressure on two adjacent skull bones separated by a suspected synostotic suture. If the plates do not move relative to each other, then the suspicion for craniosynostosis is raised.

Verifying neck muscle tone and range of motion is a key part of the examination because it helps in evaluating motor development and in diagnosing congenital torticollis. Resistance to passive motion raises the concern for torticollis. Decreased tone should prompt further evaluation of motor development. Infants do not gain the muscle control to turn or lift their heads until approximately 4 months of age, and delays in motor development could increase the infant's risk of DP at later

Table 632.2 Important Factors to Evaluate in the History and Physical Examination of the Patient with Plagiocephaly

	DEFORMATIONAL	SYNOSTOTIC
Birth history	Intrauterine compression First-born child	Typically no complications
Head shape at birth	Typically normal	Can be irregular
Age at which shape irregularity first noticed	Usually in first few months of life	Can be at birth
How patient prefers to sleep	Same side, same position Same even during naps	Variable
Bald spot	Yes	No
Motor development for age	If age is atypical for deformational plagiocephaly, motor development is typically slow for age Torticollis present History of limited activity or mobility	Varies depending on presence of concomitant syndrome
Tummy time	Decreased	Suggested time
Signs or symptoms of increasing intracranial pressure	No	Possible

Table 632.3 Key Differences Between Synostotic (Craniosynostosis) and Deformational Plagiocephaly

	DEFORMATIONAL PLAGIOCEPHALY	CRANIOSYNOSTOSIS
Causes	External forces applied to the skull Prenatal: uterine compression, intrauterine constrained Postnatal: congenital torticollis, sleeping position	Premature fusion of one or more cranial sutures
Common types	Lateral Posterior	Bilateral coronal Sagittal Metopic
Common distinguishing features	Normal round head shape at birth Parallelogram shape to head Ipsilateral ear anteriorly displaced No palpable bony ridges or open fontanels	Can have abnormal head shape at birth Trapezoid shape to head Ipsilateral ear posteriorly displaced Palpable bony ridges
Management	Repositioning Physical therapy Helmet in some cases	Surgery Helmet in some cases

Adapted from Nield LS, Brunner MD, Kamat D. The infant with a misshapen head. *Clin Pediatr (Phila).* 2007;46:292–298, Tables 1 and 2.

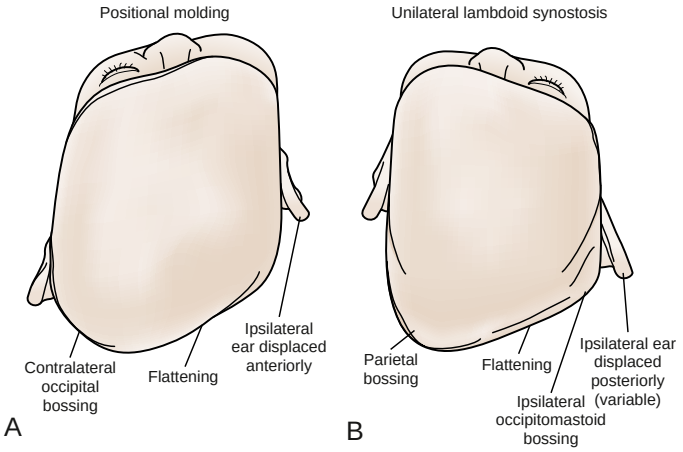

Fig. 632.1 Differentiating physical findings between deformational plagiocephaly and craniosynostosis. Vertex views. **A,** Right-sided deformational plagiocephaly exhibiting a parallelogram head shape. **B,** Right-sided lambdoid craniosynostosis exhibiting a trapezoid-like head shape. *(From Lin AY, Losee JE. Pediatric plastic surgery. In: Zitelli BJ, McIntire SC, Norwalk AJ, eds. Zitelli and Davis' Atlas of Pediatric Physical Diagnosis, 6th ed. Philadelphia: Elsevier; 2012: Fig. 22-5.)*

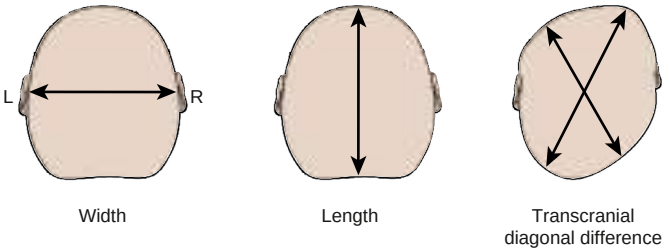

Fig. 632.2 Cranial measurements. *(Modified from Looman WS, Flannery AB. Evidence-based care of the child with deformational plagiocephaly, part I: assessment and diagnosis. J Pediatr Health Care. 2012;26:242–250, Table 1.)*

ages than those at which it usually occurs. Decreased range of motion can also be seen in cervical spine abnormalities, although this is rare. Early recognition of these conditions is critical in treatment, management, and outcome.

Accurate and consistent measurements will help to distinguish etiologies and manage infants presenting with an abnormally shaped skull. Along with the usual head circumference measurements, the clinician should also measure cranial width, length, and transcranial diagonal diameter (Fig. 632.2), which is best performed with calipers. These

Table 632.4 Diagnostic Guide for Determining Type and Severity of Lateral and Posterior Deformational Plagiocephaly

	LATERAL DEFORMATIONAL PLAGIOCEPHALY	POSTERIOR DEFORMATIONAL PLAGIOCEPHALY (BRACHYCEPHALY)			
DETERMINING TYPE BASED ON CLINICAL FINDINGS					
Occiput (vertex view)	Ipsilateral occipital flattening; contralateral occipital bossing	Uniform occipital flattening			
Ear position (vertex view)	Ipsilateral ear may be anteriorly displaced	Normal			
Face, forehead (anterior, lateral, and vertex views)	May be normal; more severe cases may present with the following: mandibular asymmetry, ipsilateral frontal bossing, contralateral forehead flattening, ipsilateral cheek anteriorly displaced	Temporal bossing, increase in vertical height in severe cases			
Other	Torticollis, head position preference	Large size, history of limited activity or limited mobility			
DETERMINING SEVERITY					
Mild	TDD 3-10 mm	Type I	Flattening restricted to back of the skull	CI: 0.82-0.9	Central posterior deformity (ping-pong ball depression)
Moderate	TDD 10-12 mm	Type II Type III	Malposition of ear Forehead deformity	CI: 0.9-1.0	Central posterior deformity and widening of posterior skull
Severe	TDD > 12 mm	Type IV Type V	Malar deformity Vertical or temporal skull growth	CI: >1.0	Vertical head, head growth, or temporal bossing

CI, Cephalic index (cranial index); TDD, transcranial diagonal diameter difference.

measurements allow the clinician to diagnose, determine severity, and monitor the plagiocephaly:

- *Cranial length:* Distance from the most prominent point between the eyebrows to the most prominent point of the occiput.
- *Width:* Maximum transverse diameter, horizontal.
- *Cephalic index* (cranial index): Ratio of the cranial width to the cranial length.
- *Occipital-frontal transcranial diameter:* Find the points on either side of the head where the deformation is the worst (two on the right, two on the left), then measure the diagonal distances between these points.
- *Transdiagonal difference* (transcranial diagonal difference): The difference between two transcranial diagonal diameters.
- *Cranial vault asymmetry:* Ratio of oblique measurements. This is difficult to implement because different physicians and authors propose varying points to use for these measurements.

One technology for the evaluation of the severity and improvement over time of DP is the three-dimensional photographic system. Advantages of this system include an easy and comfortable ability to image in an unbiased manner. Similarly, the use of laser scanners for the prefabrication scans for helmets is frequently employed by orthotists.

After observations and measurements, the clinician can determine the type and severity of the DP (Table 632.4 and Fig. 632.3). For *lateral DP,* bossing of the occiput occurs opposite the flattened deformity and the ear on the same side as the flat area can be anteriorly displaced. This type of DP is typically associated with infants who have torticollis or a head position preference to one side. Transdiagonal diameter is typically abnormal in this type of plagiocephaly, and this measurement is the gold standard for determining severity.

In *posterior DP,* the occiput is uniformly flattened, temporal bossing can occur, and the ears are normal. It is usually associated with large head size and a history of limited activity or mobility. The cephalic index is increased with posterior DP.

Time and accurate exam records can help in management. If deformation is worsening when DP typically begins to demonstrate improving head shape, craniosynostosis should be suspected.

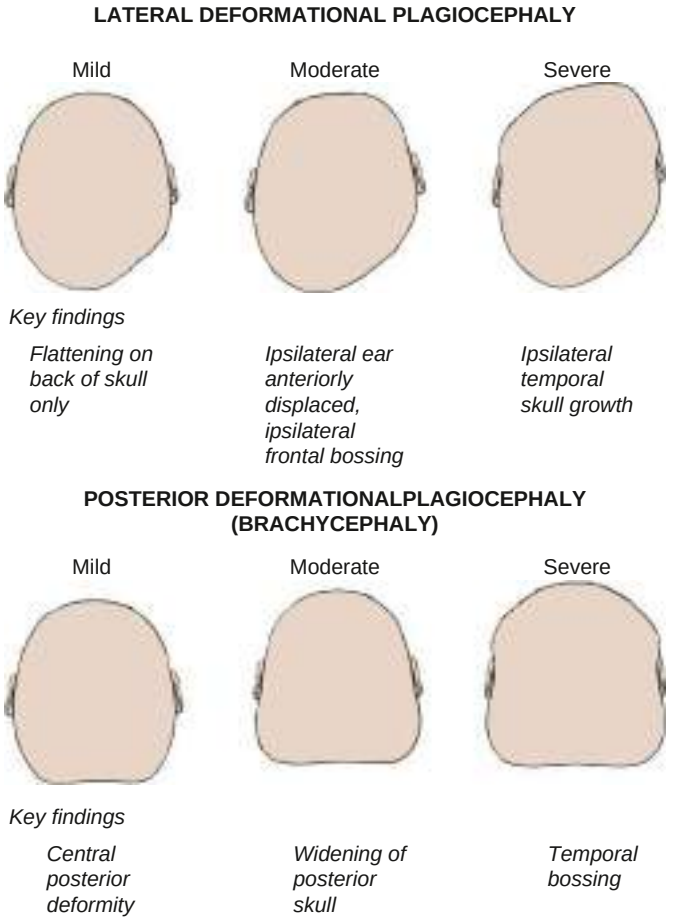

Fig. 632.3 Types of deformational plagiocephaly. *(From Looman WS, Flannery AB. Evidence-based care of the child with deformational plagiocephaly, part I: assessment and diagnosis. J Pediatr Health Care. 2012;26:242–250, Fig. 1.)*

TREATMENT

Prevention

The sleep position should be monitored and varied. Alternating the infant's head to face the head and foot of the crib on alternate nights will allow the infant to sleep facing into the room without always lying on the same side of the head. Consistently alternating the sleeping position early on allows the infant to have equal time on both sides of the occiput, and the infant will become used to this pattern. Infants who have an obvious positional preference for a particular side will take more time and make more effort to purposefully reposition themselves counter to their preference. Parents must be counseled in the benefit of this strategy in preventing bald spots or flat spots that can progress to cranial deformity.

Tummy time is the term used to describe the infant's awake time spent lying on the stomach. The suggested amount of tummy time is 10-15 minutes at least 3 times a day. Reassure parents that sleep is the only time during which the prone position should be avoided, and educate the parents as to the benefits for the infant of awake prone positioning to help progression of motor development.

Treatment Options

Cranial asymmetry from DP does not usually spontaneously improve, nor do the more severe manifestations of facial and ear asymmetry disappear. Once a flat spot develops, it is unlikely that the infant will be able to overcome the pull to lie on the same spot in time to allow for reversal of the asymmetry.

Watch-and-wait management is not recommended in infants with DP. Evidence suggests that, at a minimum, repositioning and physiotherapy (RPPT) should be initiated as soon as asymmetry is observed.

RPPT includes the counseling and teaching of parents about positional changes and tummy time for their child, as well as the referral to physical therapy in the case of congenital torticollis. RPPT is the optimal treatment choice for patients younger than 4 months of age who have mild or moderately severe DP. The earliest types of behavioral modifications can be as simple as increasing tummy time or repositioning the infant's crib such that everything interesting in the room is on the side opposite the DP.

Molding therapy (helmet therapy) is the use of an orthotic helmet to promote the resolution of cranial asymmetry while the infant's head is still rapidly growing. Orthotic helmets do not actively mold the skull; rather, they protect the areas that are flat and allow the child to grow into the flat spot. Helmet therapy achieves correction 3 times faster and better than repositioning alone. This therapy is still debated because of its expense, time requirements, coverage, and side effects (irritation, rashes, and pressure sores). Combined treatment with helmet therapy and RPPT is the most beneficial management of infants older than 4 months with severe DP or with worsening of mild or moderate DP trialed on RPPT. Infants with severe DP should be considered for helmet therapy at any age.

Studies suggest helmet therapy should be started for significant DP between 4 and 8 months and continued for 7-8 months. Parents should be counseled on the commitment involved in this treatment because helmets need to be worn up to 23 hours per day. Noncompliance has been documented in 80% of study patient populations in as little as 4 months.

Risk factors are associated with failure of RRPT and helmet therapy. Table 632.5 provides a list of these risk factors by treatment modality. These are important to consider when prescribing treatment regimens to families in order to give the patient the best chance at a successful outcome.

Table 632.5 Risk Factors for Failure of Conservative and Helmet Therapy in the Treatment of Deformational Plagiocephaly

CONSERVATIVE THERAPY	HELMET THERAPY
Poor compliance Advanced age* Presence of torticollis Presence of developmental delay Increases severity of cranial deformity at time of therapy (via cranial ratio and diagonal difference)	Advanced age* Poor compliance

*Advanced age is defined as older than 6 mo.

Patients with **craniosynostosis** require surgery. Sometimes, a molding helmet can be used as an adjunctive therapy after surgery but never as monotherapy.

OUTCOMES

Outcomes may be better when helmet therapy is started before 6 months of age; infants starting therapy later than that do not achieve the same degree of normal head measurements as those whose helmet therapy is started before 6 months of age. Significant improvements in asymmetry are usually obvious at 4-11 weeks after starting helmet therapy. An 8-year single-center review analyzing 4,378 patients found complete correction in 77.1% of patients undergoing conservative (RRPT) therapy and 94.4% of patients treated with helmet therapy.

Studies in patients with a median follow-up age of 9 years found that 75% of cases had what both parents and patients considered to be a normal head appearance. Nine percent of patients and 4% of parents noted residual asymmetry that they considered significant. Though some literature hints at more satisfaction and less anxiety in parents of helmeted children, there is evidence to suggest that the treatment modality and outcome make no difference regarding parents' long-term satisfaction.

There is a small but growing body of literature that suggests conservative therapy (RRPT) may be as effective as helmet therapy for correcting certain cases of DP. Generalization of these findings to larger populations is not currently possible.

Cognitive and academic outcomes may be different depending on the side of deformity. Poorer academic performance and greater speech abnormalities were found in patients with left-sided deformities than in those with right-sided deformities. This manifested as double the number of patients with expressive speech abnormalities and triple the number of special education needs. It is unclear what the underlying mechanism is; treatment differences were apparently not a factor. In general, children with DP and without comorbid conditions are usually developmentally normal, healthy children. This development contrasts with craniosynostosis, in which increases in intracranial pressure may have deleterious effects on central nervous system function.

Visit Elsevier eBooks+ at eBooks.Health.Elsevier.com for Bibliography.

Chapter 633

Seizures in Childhood

Mohamad A. Mikati, Dmitry Tchapyjnikov, and Kevin M. Rathke

An epileptic seizure is a sudden transient occurrence of signs and/or symptoms resulting from abnormal excessive or synchronous neuronal activity in the brain. The International League Against Epilepsy (ILAE) operational classification of seizure types divides epileptic seizures into four categories based on the presumed mode of seizure onset: focal, generalized, unknown onset, and unclassified (Figs. 633.1 and 633.2). In **focal** (formerly known as *partial*) **seizures**, the first clinical and electroencephalographic (EEG) changes suggest initial activation of a system of neurons limited to part of one cerebral hemisphere. Focal seizures can be described as motor or nonmotor and are further characterized by preserved or impaired consciousness, which is used synonymously with the term **awareness**. Simple partial seizure is an outdated term that refers to a focal seizure with no alteration in consciousness or awareness; the current term is **focal aware seizure**. Complex partial seizure is also an outdated term that denotes focal seizures with altered consciousness or awareness of the surroundings; they are currently referred to as **focal seizures with impaired awareness**. In **generalized seizures**, the first clinical and EEG changes indicate synchronous involvement of both hemispheres. A seizure may be labeled as being of **unknown onset** if there is not enough clinical information available to determine if the seizure is focal or generalized. If the clinical characteristics of a seizure are unusual and a determination of onset cannot be made despite an adequate evaluation, the seizure may be labeled as **unclassified**. Approximately 30% of patients who have a first afebrile seizure later develop epilepsy; the risk is approximately 20% if the neurologic exam, EEG, and neuroimaging are normal.

Febrile seizures are a separate category (see Chapter 633.1). **Acute symptomatic** or **provoked seizures** occur secondary to an acute problem affecting brain excitability, such as an electrolyte imbalance; most children with these types of seizures do well. However, sometimes these seizures signify major structural, inflammatory, or metabolic disorders of the brain, such as meningitis, encephalitis, acute stroke, or brain tumor. Consequently, the prognosis depends on the underlying disorder, including its reversibility or treatability and the likelihood of developing epilepsy from it. An **unprovoked seizure** is one that is not an acute symptomatic seizure. A **remote symptomatic seizure** is one secondary to a distant brain injury, such as an old stroke.

Reflex seizures are a type of seizure precipitated by a sensory stimulus. These types of seizures can be caused by a variety of stimuli, including visual (flickering lights, patterns, reading), auditory (music), somatosensory, or proprioceptive stimuli; praxis; eating; bathing in hot water; or being startled (see Chapter 631.9).

Epilepsy is a disorder of the brain characterized by an enduring predisposition to generate seizures and by the neurobiologic, cognitive, psychologic, and social consequences of this condition (see Fig. 633.2). The clinical diagnosis of epilepsy usually requires the occurrence of at least one unprovoked epileptic seizure with either a second such seizure or enough EEG and clinical information to convincingly establish an enduring predisposition to develop recurrences. For epidemiologic and, commonly, for clinical purposes, epilepsy is considered present when two or more unprovoked seizures occur in a time frame of longer than 24 hours in between them. Approximately 4–10% of children experience at least one seizure (febrile or afebrile) in the first 16 years of life. The cumulative lifetime incidence of epilepsy is 3%, and more than half of the disorders start in childhood. The annual prevalence is 0.5–1.0%. Thus the occurrence of a single seizure or of febrile seizures does not necessarily imply the diagnosis of epilepsy. **Seizure disorder** is a general term that is usually used to include any one of several disorders, including epilepsy, febrile seizures, and, possibly, single seizures and symptomatic seizures secondary to metabolic, infectious, or other etiologies (e.g., hypocalcemia, meningitis).

An **epileptic syndrome** is a disorder that manifests as one or more specific seizure types and has a specific age of onset and a specific prognosis. Several types of epileptic syndromes can be distinguished (Tables 633.1-633.6; Fig. 633.3). This category must be distinguished from the category of epileptic seizures that refers to single events rather than to clinical syndromes. In general, the seizure type is the primary determinant of the medications to which the patient is likely to respond, and the epilepsy syndrome determines the prognosis one could expect. An **epileptic encephalopathy** is an epilepsy syndrome in which there is a severe EEG abnormality that is thought to result in cognitive and other impairments. **Developmental encephalopathy** denotes a disorder in which the underlying etiology (e.g., a specific gene variant) contributes to a developmental delay independently of the patient's seizure burden and/or EEG abnormalities. The terms *epileptic* and *developmental encephalopathy* can be combined (i.e., **developmental epileptic encephalopathy**) in specific situations where both the EEG abnormalities and the underlying etiology contribute to the patient's developmental delay.

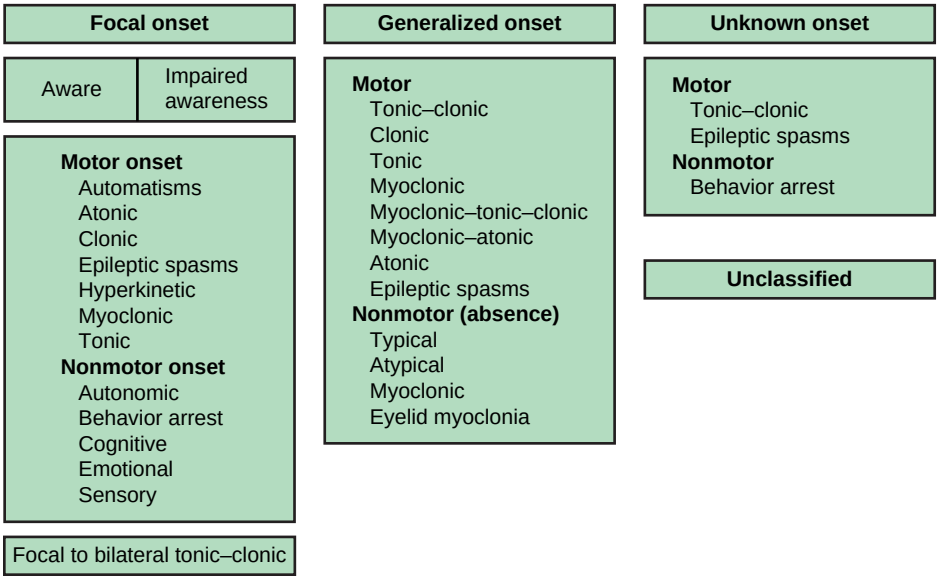

Fig. 633.1 International League Against Epilepsy classification of seizures. *(Modified from Katyayan A, Diaz-Medina G. Epilepsy: epileptic syndromes and treatment. Neurol Clin. 2021;39:779–794, Fig. 1, p. 780.)*

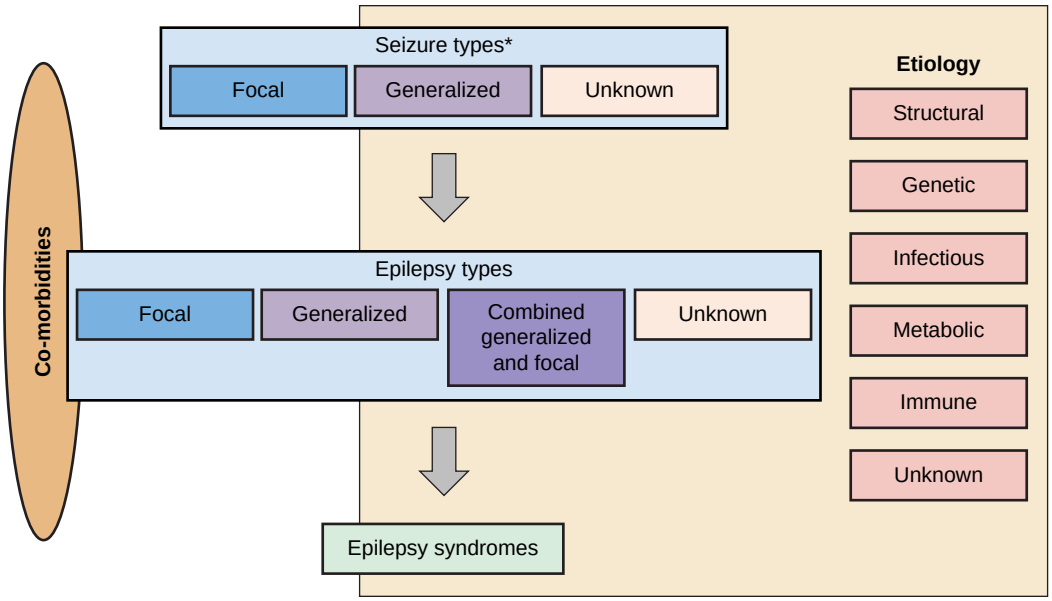

Fig. 633.2 ILAE classification of epilepsies. *Denotes onset of seizure. *(From Katyayan A, Diaz-Medina G. Epilepsy: epileptic syndromes and treatment. Neurol Clon. 2021;39:779–794, Fig. 2, p. 781.)*

The ILAE Task Force on Classification has proposed a multilevel framework for categorizing epilepsies (Table 633.7). This framework should help guide therapeutic decisions and assist with prognostication. At the most basic level **(level 1)**, a patient's epilepsy can be classified by seizure type (focal, generalized, focal and generalized, or unknown). At the next level **(level 2)**, based on available clinical data and known seizure types, an epilepsy type can be assigned (focal, generalized, focal and generalized, or unknown). At the next level **(level 3)**, if further clinical data are available and based on supporting studies (e.g., EEG and/or MRI), the diagnosis of a specific epilepsy syndrome can be made (e.g., juvenile myoclonic epilepsy). Concurrent to this classification paradigm, the associated comorbidities and the underlying cause for the epilepsy must also be considered. If categorized by etiology, epilepsies are grouped into genetic, structural, metabolic, immune, infectious, or unknown categories. It is important to note that these categories are not mutually exclusive, and a patient's epilepsy may have multiple concurrent etiologies (e.g., genetic and structural). At the final level **(level 4)** of categorizing and diagnosing the epilepsy, the epilepsy syndrome, the underlying etiology, and associated comorbidities are considered.

Genetic epilepsy (previously also referred to as *idiopathic epilepsy*) implies that the epilepsy syndrome is the direct result of a known or presumed genetic defect(s) that is not causative of a brain structural or metabolic disorder other than the epilepsy. This category encompasses *genetic generalized epilepsies* (previously called *idiopathic generalized epilepsies*), such as childhood absence epilepsy, as well as epilepsies caused by a known gene defect (see Tables 633.1-633.6).

Structural epilepsy (previously called *symptomatic epilepsy*) refers to an epilepsy syndrome caused by an underlying structural brain disorder that may or may not be genetic. This includes etiologies such as old stroke or hypoxic-ischemic injury, as well as epilepsy secondary to tuberous sclerosis (which is also genetic). **Immune-mediated epilepsy** is an important category that describes epilepsies occurring secondary to immune-mediated central nervous system (CNS) inflammation. This group of disorders warrants special attention because immunotherapies such as steroids and intravenous immunoglobulin (IVIG) may be the first-line treatments. **Autoimmune encephalitides** such as anti–*N*-methyl-D-aspartate (NMDA) receptor encephalitis and anti-LG1 limbic encephalitis are examples of immune-mediated epilepsies. **Infectious epilepsy** describes epilepsies secondary to chronic infectious conditions such as tuberculosis and HIV rather than acute infections such as bacterial meningitis or herpes simplex virus (HSV) encephalitis.

The older terms *cryptogenic epilepsy* and *presumed symptomatic epilepsy* refer to an epilepsy syndrome in which there is a presumed underlying brain disorder causing the epilepsy and affecting neurologic function, but the underlying disorder is not known; the disorder is now referred to as **unknown epilepsy**, designating that the underlying cause of the epilepsy is still unknown.

EVALUATION OF THE FIRST SEIZURE

The initial evaluation of an infant or a child during or shortly after a suspected seizure should include an assessment of the adequacy of the airway, ventilation, and cardiac function, as well as measurement of temperature, blood pressure, and glucose concentration. For acute evaluation of the first seizure, the physician should search for potentially life-threatening causes of seizures, such as meningitis, systemic sepsis, unintentional or intentional head trauma, and ingestion of drugs or medications or other toxins. The history should aim to determine if the event was a seizure or not and to define factors that might have promoted the convulsion and to provide a detailed description of the seizure and the child's postictal state.

The subsequent step in an evaluation is to determine whether the seizure has a focal onset or is generalized. **Focal seizures** could include forceful turning of the head and eyes to one side, unilateral clonic movements beginning in the face or extremities, or a sensory disturbance, such as paresthesia or pain localized to a specific area. Focal seizures in an adolescent or adult usually indicate a localized lesion, whereas these seizures during childhood are often either secondary to a lesion or the result of a genetic, formerly known as *idiopathic,* epilepsy. Focal seizures in a neonate may be seen because of focal lesions such as perinatal stroke or because of a metabolic abnormality such as hypocalcemia that results in focal seizures that may not generalize because of immaturity of the brain connections. Focal and generalized motor seizures may be tonic-clonic, tonic, clonic, myoclonic, or atonic. **Tonic seizures** are characterized by increased tone or rigidity (usually lasting 2 seconds up to several minutes), and **atonic seizures** are characterized by flaccidity and lack of movement. **Clonic seizures** consist of rhythmic, fast muscle contractions and slightly longer relaxations; **myoclonus** is a shocklike contraction of a muscle of <50 milliseconds that is often repeated. The duration of

Table 633.1 Classification of Epilepsy Syndromes with an Indication of Age of Onset, Duration of Active Epilepsy, Prognosis, and Therapeutic Options

SPECIFIC SYNDROMES	AGE RANGE AT ONSET	AGE AT REMISSION	PROGNOSIS	MONOTHERAPY OR ADD-ON*	POSSIBLE ADD-ON†	SURGERY†
NEONATAL						
Benign neonatal seizures	Newborn	Newborn	Good	LEV, TPM, PB	—	No
Early myoclonic encephalopathy and Ohtahara syndrome	Newborn infant	Poor, Ohtahara syndrome evolves into West syndrome	Ominous	PB, steroids, VGB	BZD, ZON, TPM, LEV, ketogenic diet	No
Benign familial neonatal convulsions	Newborn to young infant	Newborn to young infant	Good	LEV, TPM, PB	—	No
INFANCY						
Benign infantile seizures (nonfamilial)	Infant	Infant	Good	LEV, TPM, PB	—	No
Benign familial infantile convulsions	Infant	Infant	Good	LEV, TPM, OXC, CBZ, PB	—	No
Epilepsy of infancy with migrating focal seizures	Infant	No remission	Ominous	LEV, PB, OXC, CBZ, PHT, TPM, QND	BZD, bromides, LAC, VPA, ZON	No
West syndrome	Infant	Variable	Variable	ACTH, steroids, VGB	BZD, FBM, IVIG, TPM, ZON, ketogenic diet	Lesionectomy ± cortical resection
Dravet syndrome (severe myoclonic epilepsy in infancy)	Infant	No remission	Severe	CLB, stiripentol, VPA (only after age 2 yr)	BZD, TPM, LEV, ZON, ketogenic diet	No
Benign myoclonic epilepsy in infancy	3 mo-3 yr	3-5 yr	Variable	LEV, TPM, BZD	VPA, ZON	No
CHILDHOOD						
Benign childhood epilepsy with centrotemporal spikes	3-13 yr	16 yr	Good	OXC, CBZ, LEV, VPA	LAC, PER	No
Early and late-onset idiopathic occipital epilepsy	2-8 yr; 6-17 yr	12 yr or younger; 18 yr	Good	OXC, CBZ, LEV, VPA	LAC, PER	No
Autosomal dominant nocturnal frontal lobe epilepsy	Childhood		Variable	OXC, CBZ, LEV	CLB, PB, PHT, LAC, PER, GBP, TPM	No
Familial lateral temporal lobe epilepsy	Childhood to adolescence		Variable	OXC, CBZ, LEV	CLB, PB, PHT, GBP, TPM, VPA, LAC, PER	No, except in rare cases
Generalized epilepsies with febrile seizures plus	Childhood to adolescence		Variable	ESM, LTG, LEV, VPA (depending on seizure type)	CLB, TPM, PER	No
Mesial temporal lobe epilepsy with hippocampal sclerosis	School-age or earlier	Long- lasting	Variable	OXC, CBZ, LEV	CLB, GBP, LAC, PB, PER, PHT, ZON, TPM, VPA	Temporal resection
Rasmussen syndrome	6-12 yr	Progressive	Ominous	LEV, OXC, CBZ, plasmapheresis, immunoglobulins	LAC, PB, PER, PHT, TPM	Functional hemispherectomy
Hemiconvulsion-hemiplegia syndrome	1-5 yr	Chronic	Severe	OXC, CBZ, LEV	CLB, GBP, LAC, PB, PER, PHT, ZON, TPM, VPA	Functional hemispherectomy
Epilepsy with myoclonic astatic seizures	3-5 yr	Variable	Variable	ESM, TPM, VPA, LEV, ZON	BZD, ketogenic diet, LTG, PER, steroids	No
Childhood absence epilepsy	5-6 yr	10-12 yr	Good	ESM, LTG, VPA	Acetazolamide, CZP, ketogenic diet, ZON	No
Epilepsy with myoclonic absences	1-12 yr	Variable	Guarded	ESM, VPA, CZP	ZON, LTG	No

Table 633.1 Classification of Epilepsy Syndromes with an Indication of Age of Onset, Duration of Active Epilepsy, Prognosis, and Therapeutic Options—cont'd

SPECIFIC SYNDROMES	AGE RANGE AT ONSET	AGE AT REMISSION	PROGNOSIS	MONOTHERAPY OR ADD-ON*	POSSIBLE ADD-ON†	SURGERY†
Lennox-Gastaut syndrome	3-10 yr	No remission	Severe	CLB, LTG, RFD, TPM, VPA	BZD, FBM, IVIG, PER, steroids, ZON, ketogenic diet	Callosotomy
Landau-Kleffner syndrome	3-6 yr	8-12 yr	Guarded	Nocturnal DZP, steroids, VPA, LEV	CLB, ESM, IVIG, LTG, ketogenic diet	Multiple subpial transections, rarely lesionectomy
Epilepsy with continuous spike waves during slow-wave sleep	4-7 yr	8-12 yr	Guarded	Nocturnal DZP, steroids, VPA, LEV	CLB, ESM, IVIG, LTG, ketogenic diet	No
Other visual-sensitive epilepsies	2-5 yr	Unclear	Variable	VPA	BZD, LEV, LTG, ZON	No
Febrile seizures	3-5 yr	3-6 yr	Good	BZD (only as needed for febrile periods if frequent febrile seizures)	—	No
JUVENILE ONSET						
Juvenile absence epilepsy	10-12 yr	Usually lifelong	Good	ESM, LTG, VPA	Same as in childhood absence epilepsy	No
Juvenile myoclonic epilepsy	12-18 yr	Usually lifelong	Good	LEV, TPM, VPA	BZD, LTG, PB, PER, PRM, ZON	No
Epilepsy with generalized tonic-clonic seizures only	12-18 yr	Usually lifelong	Good	LEV, LTG, TPM, VPA	BZD, CBZ, PER, ZON	No
Idiopathic photosensitive occipital lobe epilepsy	10-12 yr	Unclear	Variable	VPA, LEV	BZD, LTG, ZON	No
Progressive myoclonic epilepsies (e.g., Unverricht-Lundborg, Lafora, ceroid lipofuscinoses)	Late infant to adolescent	Progressive	Ominous	TPM, VPA, ZON, LEV	BZD, PB, CLB, PER, ketogenic diet	No
VARIABLE AGE OF ONSET						
Mesial temporal lobe epilepsy defined by location and cause	Variable	Long-lasting	Variable	LEV, OXC, CBZ, TPM, VPA	PHT, PB, CLB, GBP, LAC, PER, ZON	Lesionectomy ± cortical resection
Mesial temporal lobe epilepsy defined by specific causes	Variable	Long-lasting	Variable	LEV, OXC, CBZ, TPM, VPA	CLB, GBP, LAC, PB, PER, PHT, ZON	Temporal resection
Startle epilepsy	Variable	Long-lasting	Guarded	OXC, CBZ, LEV, TPM, VPA	CLB, LEV, PB, PHT, ZON, GBP	Lesionectomy ± cortical resection in some
Reflex seizures	Variable	n/a		LEV, VPA	LTG, ZON	No
Drug or other chemically induced seizures	Variable	n/a		Withdraw offending agent	—	No
Immediate and early posttraumatic seizures	Variable	n/a		LEV, PHT	—	No

*Reflects current trends in practice, which may be off-label and may not be FDA-approved for that indication. Order of listing does not necessarily imply preference of use in that order. See Table 633.13 for FDA indications.

†May apply to selected cases only. Vagus nerve stimulation has been used for all types of refractory seizures and epilepsy types but has been FDA-approved as an adjunct therapy in patients 4 yr or older with medically refractory partial-onset seizures.

ACTH, Adrenocorticotropic hormone; BZD, benzodiazepine; CBZ, carbamazepine; CLB, clobazam; DZP, diazepam; ESM, ethosuximide; FBM, felbamate; GBP, gabapentin; IVIG, intravenous immunoglobulin; LAC, lacosamide; LEV, levetiracetam; LTG, lamotrigine; n/a, not applicable; OXC, oxcarbazepine; PB, phenobarbital; PER, perampanel; PHT, phenytoin; PRM, primidone; QND, quinidine; RFD, rufinamide; TPM, topiramate; VGB, vigabatrin; VPA, valproic acid; ZON, zonisamide.

Modified from Guerrini R. Epilepsy in children. *Lancet*. 2006;367:499–524; and Parisi P, Verrotti A, Paolino MC, et al. "Electro-clinical syndromes" with onset in the pediatric age group: the highlights of the clinical-EEG, genetic, and therapeutic advances. *Ital J Pediatr*. 2011;37:58.

Table 633.2 Ion Channel Pathogenic Gene Variants and Associated Epilepsy Syndromes/Seizure Types

ION CHANNEL	GENE	EPILEPSY SYNDROMES/SEIZURE TYPES	SEIZURE ONSET
SODIUM			
α Subunit	*SCN1A*	DS, GEFS+, GTCs	Infancy, childhood
	SCN2A	Benign familial neonatal-infantile epilepsy, sporadic infantile spasm, sporadic neonatal epileptic encephalopathy	Neonatal, infancy
	SCN3A	Cryptogenic focal epilepsy, focal unaware to bilateral GTC, GTC, myoclonic	Neonatal, infancy, childhood
	SCN8A	GTC, tonic, myoclonic	Neonatal, infancy
β Subunit	*SCN9A*	Febrile seizures, focal unaware, GTC	Childhood
	SCN1B	GEFS+	Childhood, adolescence, adulthood
POTASSIUM			
Voltage dependent	*KCNA2*	GTC, focal unaware, alternating hemiclonic seizures, absence, juvenile myoclonic epilepsy	Infancy, childhood
	KCNB1	GTC, focal unaware, infantile spasm, West syndrome, Lennox-Gastaut	Infancy, childhood
	KCND2	GTC, focal unaware	Infancy, adolescence
	KCNQ2	Benign familial neonatal seizures, tonic	Neonatal, infancy
	KCNQ5	Focal unaware, infantile spasm	Infancy, childhood
	KCNH1	Temple-Baraitser syndrome, GTC, focal unaware, myoclonic, tonic, clonic	Neonatal, infancy
	KCNH5	GTC, hemiclonic	Infancy
	KCNMA1	GTC	Childhood
Non–voltage dependent	*KCNT1*	MMFSI, ADNFLE	Infancy, childhood
	KCNJ10	EAST syndrome, idiopathic generalized epilepsies, childhood absence epilepsy	Infancy, childhood
CHLORIDE			
K^+/Cl^-co-transporter	*CLCN1*	Idiopathic generalized epilepsies	Infancy
	CLCN2	Idiopathic generalized epilepsies, childhood absence, juvenile absence, GTC, tonic	Infancy, childhood
	SLC12A5	Epileptic encephalopathy with focal migrating seizures, idiopathic generalized epilepsy, GTC, myoclonic, absence	Infancy
CALCIUM			
α Subunit	*CACNA1H*	Idiopathic generalized epilepsies	Infancy, childhood
	CACNA1A	Epileptic encephalopathy, absence	Infancy
β Subunit	*CNCNB4*	Myoclonic epilepsy, tonic, idiopathic generalized epilepsies	Infancy, childhood

ADNFLE, Autosomal dominant nocturnal frontal lobe epilepsy; EAST, epilepsy, ataxia, sensorineural deafness, and tubulopathy; GEFS+, genetic epilepsy with febrile seizures plus; GTCs, generalized tonic-clonic seizures; MMFSI, malignant migrating focal seizures of infancy.
Modified from Martinez LA, Lai YV, Holder JL Jr, Anderson AE. Genetics in epilepsy. *Neurol Clin*. 2021;39:743–777, Table 1, p. 745–747.

Table 633.3 Defects in Neurotransmitter Receptors and Associated Epilepsy Syndromes/Seizure Types

RECEPTOR	GENE	EPILEPSY SYNDROMES/SEIZURE TYPES	SEIZURE ONSET
GABA	*GABRA1*	Absence, idiopathic generalized epilepsy, epileptic encephalopathy, juvenile myoclonic epilepsy	Infancy, childhood, adolescence
	GABRB3	Childhood absence, epileptic encephalopathy	Neonatal, infancy, childhood
	GABRG2	Childhood absence, GEFS+, idiopathic generalized epilepsy, epileptic encephalopathies	Neonatal, infancy
	GABRE	Infantile spasm, focal unaware, focal unaware to bilateral GTC, GTC	Infancy
Nicotinic acetylcholine	*CHRNA4*	ADSHE	Childhood, adolescence
	CHRNB2	ADSHE	Childhood, adolescence
	CHRNA2	Benign infantile familial seizures	Infancy
Glutamate	*GRIN1*	Infantile spasm, tonic, atonic, hypermotor, focal dyscognitive, GTC	Neonatal, infancy, childhood
	GRIN2A	Childhood focal epilepsy, rolandic epilepsy, epileptic encephalopathy, absence, tonic, myoclonic	Infancy, childhood
	GRIN2B	West syndrome, childhood-onset focal epilepsy, epileptic encephalopathy	Infancy, childhood
	GRIN2D	Infantile spasm, focal unaware to bilateral GTC, GTC, myoclonic, atypical absence	Neonatal, infancy, childhood

ADSHE, Autosomal dominant sleep-related hypermotor epilepsy; GEFS+, genetic epilepsy with febrile seizures plus; GTC, generalized tonic-clonic seizure.
Modified from Martinez LA, Lai YV, Holder Jr. JL, Anderson AE. Genetics in epilepsy. *Neurol Clin*. 2021;39:743–777. Table 2, p. 748.

Table 633.4 Pathogenic Gene Variants of Synaptic Complexes and Associated Epilepsy Syndromes/Seizure Types

LOCATION	GENE	EPILEPSY SYNDROMES/SEIZURE TYPES	SEIZURE ONSET
Presynaptic	*DNM-1*	Infantile spasms, absence with eyelid myoclonia, atonic, myoclonic, tonic, focal, GTCs	Neonatal, infancy
	NRXN1	Absence, GTCs, myoclonic	Childhood
	SNAP25	Infantile spasms, GTCs, focal, absence, myoclonic, tonic	Neonatal, infancy, childhood
	STX1B	GTC, partial, absence, tonic, atonic, Ohtahara syndrome, West syndrome	Infancy, childhood, adolescence
	SV2A	Myoclonic, tonic	Infancy
	TBC1D24	Myoclonic, GTC, partial, absence, infantile spasms	Neonatal, infancy, childhood
Postsynaptic	*CNTNAP2*	Focal, tonic	Infancy, childhood
	IQSEC2	Atypical absence, GTCs	Infancy, childhood
	PCDH19	GTC, tonic, absence, atonic, partial, myoclonic	Infancy
	SHANK3	GTC, partial, absence, tonic, myoclonic, atonic	Infancy, childhood
	SYNGAP1	GTC, atonic, absence with eyelid myoclonia, myoclonic	Childhood
	STXBP1	Infantile spasms, myoclonic, GTC, atonic, absence, partial	Neonatal, infancy

GTCs, Generalized tonic-clonic seizures.
Modified from Martinez LA, Lai YV, Holder JL Jr, Anderson AE. Genetics in epilepsy. *Neurol Clin*. 2021;39:743–777, Table 3, p. 749.

Table 633.5 Defects in Intracellular Pathways/Organelles and Associated Epilepsy Syndromes/Seizure Types

	GENE	EPILEPSY SYNDROMES/SEIZURE TYPES	SEIZURE ONSET
mTOR pathway	*TSC1, TSC2*	Tuberous sclerosis	Infancy, childhood, adolescence, adulthood
	MTOR	Focal cortical dysplasia	Variable age of onset
	RHEB	Focal cortical dysplasia	Variable age of onset
	DEPDC5	Focal cortical dysplasia	Neonatal, infancy, childhood
	NPRL2, NPRL3	Nocturnal frontal lobe epilepsy, frontal lobe epilepsy, temporal lobe epilepsy	Infancy, childhood
	AKT3	Infantile spasm	Infancy
Mitochondria	*POLG*	Alpers-Huttenlocher syndrome	Childhood
	MT-TK	Myoclonic epilepsy with red, ragged fibers	Childhood, adolescence, adulthood
	PDHA1	Infantile spasm, myoclonic absence, atypical absence, West syndrome, Lennox-Gastaut	Neonatal, infancy
	PDHB	Infantile spasm, myoclonic absence, atypical absence, West syndrome, Lennox-Gastaut	Neonatal, infancy
Lysosome	*SCARB2*	AMRF	Adolescence, adulthood
	CLN1–CLN8, CLN10–CLN14	Myoclonic epilepsy, atypical absence	Variable age of onset depending on specific *CLN* gene defect
	NEU1	Progressive myoclonic epilepsy, GTC	Adolescence, adulthood

AMRF, Action myoclonus–renal failure, progressive myoclonic epilepsy; mTOR, mechanistic target of rapamycin; PDHB, pyruvate dehydrogenase complex E1-beta.
Modified from Martinez LA, Lai YV, Holder JL Jr, Anderson AE. Genetics in epilepsy. *Neurol Clin*. 2021;39:743–777, Table 4, p. 750.

Table 633.6 Metabolic Defects and Associated Epilepsy Syndromes/Seizure Types

	GENE	EPILEPSY SYNDROMES/SEIZURE TYPES	SEIZURE ONSET
Pyridoxine	*ALDH7A1*	Focal, GTC, infantile spasm, myoclonic	Neonatal, infancy, childhood
	PNPO	GTC, tonic, clonic, myoclonic, focal	Neonatal
Biotin	*BTD*	GTC, myoclonic, infantile spasm, Ohtahara syndrome	Neonatal, infancy
Folic acid	*FOLR1*	Myoclonic-astatic, myoclonic, GTC	Childhood
Glycine	*GLDC*	Nonketotic hyperglycinemia	Neonatal
	AMT	Nonketotic hyperglycinemia	Neonatal
Glutamate	*SLC2A1*	Focal, absence, myoclonic-astatic	Infancy
Uridine	*CAD*	GTC, focal	Infancy

GTC, Generalized tonic-clonic seizures.
Modified from Martinez LA, Lai YV, Holder JL Jr, Anderson AE. Genetics in epilepsy. *Neurol Clin*. 2021;39:743–777, Table 5, p. 751.

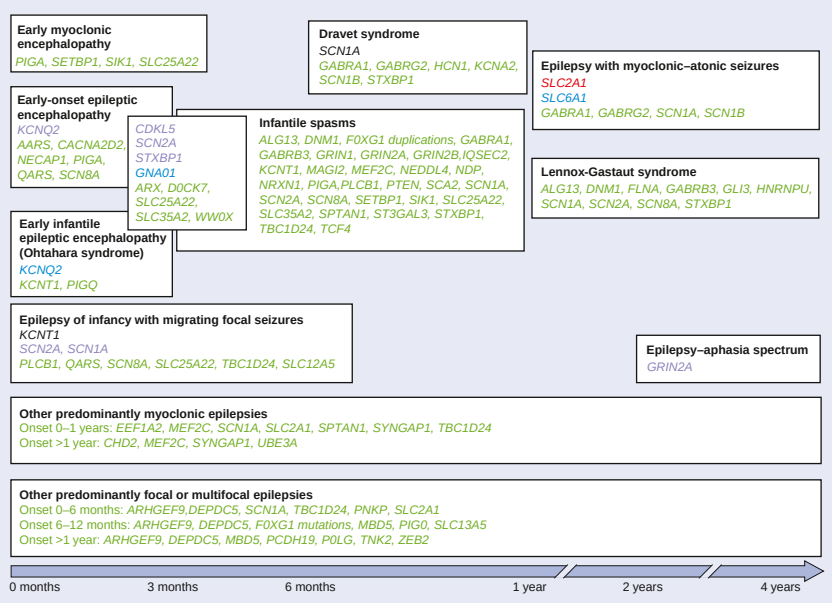

Fig. 633.3 Genetic causes, and proportion of cases caused by each gene, including only nonchromosomal, nonmalformative, and nonmetabolic disorders. Only genes with more than one case reported are included. *Black font* denotes genes that account for at least 50% of cases, *purple font* 10–50% of cases, and *red font* 5–10% of cases. *Blue font* denotes genes that account for less than 5% of cases, and *green font* denotes genes that account for an unknown percentage of cases. *(From McTague A, Howell KB, Cross JH, et al. The genetic landscape of the epileptic encephalopathies of infancy and childhood. Lancet. 2016;15:304–316.)*

Table 633.7 Diagnostic and Classification Scheme of Epilepsies

Level 1: Determine if the event was an epileptic seizure and, if so, characterize the seizure type or types based on available clinical information as focal, generalized, or unknown. (Refer to Fig. 633.1 for more detailed characterizations.)
Level 2: Determine the type of epilepsy the patient has (focal, generalized, focal and generalized, or unknown).
Level 3: Determine if the epilepsy fits into a particular epilepsy syndrome (refer to Table 633.2).
Level 4: Establish a unifying diagnosis that takes into account the epilepsy syndrome, underlying etiologies, and associated comorbidities.
The etiology for the epileptic seizures should be considered at **all** levels of an epilepsy diagnosis as listed earlier; etiologic categories include:
Genetic
Structural
Metabolic
Immune
Infectious
Unknown
Comorbidities should be considered at **all** levels of an epilepsy diagnosis. These can include developmental delay, psychiatric symptoms, behavioral issues, academic difficulties, movement abnormalities, and many others.

Modified from Scheffer IE, Berkovic S, Capovilla G, et al. ILAE classification of the epilepsies: position paper of the ILAE Commission for Classification and Terminology. *Epilepsia*. 2017;58(4):512–521.

the seizure and state of consciousness (retained or impaired) should be documented. The history should determine whether an **aura** preceded the convulsion and the behavior the child was exhibiting immediately preceding the seizure. Auras can take the form of a number of sensations, including visual (e.g., flashing lights or seeing colors or complex visual hallucinations), somatosensory (tingling), olfactory, auditory, vestibular, or experiential (e.g., déjà vu, déjà vécu feelings) sensations, depending on the precise localization of the origin of the seizures. The most common aura experienced by children consists of epigastric discomfort or pain and a feeling of fear. The posture of the patient, presence or absence and distribution of cyanosis, vocalizations, loss of sphincter control (more commonly of the urinary bladder), and postictal state (including sleep, headache, and hemiparesis) should be noted. The provider taking the history should ask specifically about each of these symptoms as appropriate because caretakers may not spontaneously report them. Determination of focal versus generalized onset is sometimes difficult historically. A seizure may start focally and secondarily generalize too quickly to manifest observable early focal symptoms. In addition, a caregiver witnessing the seizure later in its evolution may describe only the more generalized-appearing signs.

In addition to clarifying the seizure semiology, a detailed history is crucial in identifying an underlying cause for the seizure. Reported personality changes or symptoms of increased intracranial pressure can suggest an intracranial tumor. Similarly, a history of cognitive regression can suggest a degenerative or metabolic disease. A history of prenatal or perinatal distress or of developmental delay can suggest etiologic congenital or perinatal brain dysfunction. Acute to subacute personality changes, psychiatric symptoms, and/or associated movement abnormalities may suggest an autoimmune etiology.

The examination of a child with a seizure disorder should also be geared toward the search for an organic cause. The child's head circumference, length, and weight are plotted on a growth chart and compared with previous measurements. A careful general and neurologic examination should be performed. A funduscopic exam should be performed to evaluate for the presence of papilledema, optic neuritis, retinal hemorrhages, uveitis, chorioretinitis, coloboma, or macular changes, as well as retinal phakoma. The finding of unusual facial features or of associated physical findings such as hepatosplenomegaly may point to storage disease or inborn error of metabolism as the cause of the neurologic disorder. The presence of a **neurocutaneous disorder** may be indicated by the presence of vitiliginous ash leaf–type lesions usually better seen using an ultraviolet light (Wood lamp); of adenoma sebaceum, shagreen patches, or retinal phakomas (tuberous sclerosis); of multiple café-au-lait spots (neurofibromatosis); or of V1- or V2-distribution nevus flammeus (Sturge-Weber syndrome) (see Chapter 636).

Localizing neurologic signs, such as a subtle **hemiparesis** with hyperreflexia, an equivocal or positive Babinski sign, and pronator drifting of an extended arm with eyes closed, might suggest a contralateral hemispheric structural lesion, such as a slow-growing glioma, as the cause of the seizure disorder. Unilateral growth arrest of the thumbnail, hand, or extremity in a child with a focal seizure disorder suggests a chronic condition, such as a porencephalic cyst, arteriovenous malformation, or cortical atrophy of the opposite hemisphere.

In an acute setting such as the emergency department, the decision to pursue further laboratory testing, including serum electrolytes, a

complete blood count, and/or urine toxicology tests, should be made on a case-by-case basis that considers the patient's clinical history and examination. ECG to rule out long QT or other cardiac dysrhythmias and other tests directed at disorders that could mimic seizures may be needed (see Chapter 634). A lumbar puncture is usually of limited value in an acute workup of a *nonfebrile* seizure unless the history or examination is concerning for an infectious or inflammatory process or if there is clinical concern for intracranial bleeding despite normal brain imaging. *A routine EEG should be performed in all cases of a first unprovoked nonfebrile seizure to help predict the risk of seizure recurrence.* If the patient's neurologic status has returned to baseline, the EEG can often be done on an outpatient basis even though the yield may be slightly lower because the EEG has been delayed beyond the first 12 hours. Emergent brain imaging with a head CT or brain MRI is usually performed if the seizure was focal, if there are postictal focal deficits on neurologic exam, or if the patient's status is not returning to baseline; in patients with trauma preceding the seizure; and in patients with a high-risk medical history. In other situations, the yield of emergent imaging identifying an abnormality that warrants emergent intervention is less than 1%. *Brain MRI is preferred over a CT scan, and performing it on a nonemergent basis should be considered in most patients.* CT is useful if a rapid study is needed to look for trauma, a mass, or signs of increased intracranial pressure. In select situations, such as when the clinical and EEG manifestations are consistent with a genetic generalized epilepsy such as childhood absence epilepsy, a brain MRI may not be necessary. Gadolinium (contrast) does not need to be routinely used when performing the brain MRI unless there is clinical suspicion of a neoplasm, vascular malformation, abscess, or another infectious or inflammatory process. Further details regarding the approach to a first seizure are included in Chapter 633.2. The 2021 guidelines from the American College of Radiology provide recommendations in different clinical scenarios (variants) for pediatric patients presenting with seizures while taking into consideration the patient's age, precipitating events, clinical findings, EEG, and neurodevelopmental status. These address neonatal seizures, simple and complex febrile seizures, posttraumatic seizures, focal seizures, and primary generalized seizures (Table 633.8).

Table 633. 8 American College of Radiology Panel Summary of Recommendations for Imaging After a Seizure

Variant 1: MRI head without IV contrast is usually appropriate for the initial imaging of neonatal seizures.
Variant 2: Imaging is usually not appropriate for the assessment of simple febrile seizures in children 6 months to 5 years of age.
Variant 3: MRI head without IV contrast may be appropriate for the initial imaging of children 6 months to 5 years of age with complex febrile seizures.
Variant 4: CT head without IV contrast or MRI head without IV contrast is usually appropriate for the initial imaging of children with posttraumatic seizures (not including abusive head trauma). These procedures are equivalent alternatives (i.e., only one procedure will be ordered to provide the clinical information to effectively manage the patient's care).
Variant 5: MRI head without IV contrast is usually appropriate for the initial imaging of a child with focal seizures (not including abusive head trauma). The panel did not agree on recommending MRI head without and with IV contrast for this clinical scenario. There is insufficient medical literature to conclude whether or not these patients would benefit from this procedure in this clinical setting. Imaging in this patient population is controversial but may be appropriate.
Variant 6: MRI head without IV contrast may be appropriate for the initial imaging of children with primary generalized seizure (neurologically normal).
Variant 7: MRI head without IV contrast is usually appropriate for the initial imaging of children with generalized seizure (neurologically abnormal).
Variant 8: MRI head without IV contrast is usually appropriate for children with intractable seizures or refractory epilepsy. The panel did not agree on recommending MRI head without and with IV contrast for children with intractable seizures or refractory epilepsy. There is insufficient medical literature to conclude whether or not these patients would benefit from administration of IV gadolinium contrast in this clinical setting.

Modified from Expert Panel on Pediatric Imaging, Trofimova A, Milla SS, Ryan ME, et al. ACR appropriateness criteria seizures-child. *J Am Coll Radiol.* 2021;18(55):S199–S210 (Summary of Expectations, p. S208-S209).

633.1 Febrile Seizures

Mohamad A. Mikati, Dmitry Tchapyjnikov, and Kevin M. Rathke

Febrile seizures are seizures that occur between the ages of 6 and 60 months of life (peak 12-18 months old) with a temperature of 38°C (100.4°F) or higher, that are not the result of CNS infection or any metabolic imbalance, and that occur in the absence of a history of prior afebrile seizures. A **simple febrile seizure** is a primary generalized, usually tonic-clonic, attack associated with fever, lasting for a maximum of 15 minutes, and not recurrent within a 24-hour period. A **complex febrile seizure** is more prolonged (>15 minutes), and/or is focal, and/or recurs within 24 hours. **Febrile status epilepticus** is a febrile seizure lasting longer than 30 minutes. Most patients with simple febrile seizures have a very short postictal state and usually return to their baseline normal behavior and consciousness within minutes of the seizure. **Febrile infection–related** (or **refractory**) **epilepsy syndrome (FIRES)** is a very different disorder seen predominantly in older (>5 years of age) usually male children and associated with an encephalitis-like illness but without an identifiable infectious agent. Children with FIRES were previously normal but subsequently develop difficult-to-treat epilepsy.

Between 2% and 5% of neurologically healthy infants and children experience at least one, usually simple, febrile seizure. Simple febrile seizures do not have an increased risk of mortality even though they are concerning to the parents. Complex febrile seizures may have an approximately twofold long-term increase in mortality rates as compared with the general population over the subsequent 2 years, probably secondary to a coexisting pathology. There are no long-term adverse effects of having one or more *simple* febrile seizures. Compared with age-matched controls, patients with febrile seizures do not have any increase in the incidence of abnormalities of behavior, scholastic performance, neurocognitive function, or attention. Children who develop later epilepsy, however, might experience such difficulties. Febrile seizures recur in approximately 30% of those experiencing a first episode, in 50% after two or more episodes, and in 50% of infants younger than 1 year of age at febrile seizure onset. Several factors affect the recurrence risk (Table 633.9). Although approximately 15% of children with epilepsy have had febrile seizures, only 5% (range 1–33%, dependent on risk factors) of children who experience febrile seizures proceed to develop epilepsy later in life. There are several predictors of epilepsy after febrile seizures (Table 633.10).

GENETIC AND OTHER FACTORS LEADING TO FEBRILE SEIZURES

The genetic contribution to the incidence of febrile seizures is manifested by a positive family history for febrile seizures in many patients. In some families, the disorder is inherited as an autosomal dominant trait, and multiple single genes that cause the disorder have been identified in such families. However, in most cases the disorder appears to be polygenic, and many genes predisposing to it remain to be identified. Genes associated with febrile seizures include *SCN1A, SCN1B, SCN9A,* and *CPA6.* In terms of other etiologies, a dysregulation between the proinflammatory interleukin (IL)-1β, IL-6, and IL-8 cytokines and antiinflammatory ILR-1A cytokines has been associated with **febrile status epilepticus**. A decreased ILR-1A/IL-8 ratio (suggestive of an overall proinflammatory state) is predictive of hippocampal abnormalities on MRI done after febrile status epilepticus. The ILR-1A/IL-8 ratio may thus prove to be a potential biomarker for identifying febrile seizure patients who may be at higher risk for developing mesial temporal lobe epilepsy later in life.

Table 633.9 Risk Factors for Recurrence of Febrile Seizures*

MAJOR
Age <1 yr
Duration of fever <24 hr
Fever 38–39°C (100.4–102.2°F)
MINOR
Family history of febrile seizures
Family history of epilepsy
Complex febrile seizure
Daycare
Male gender
Lower serum sodium at time of presentation

*Having no risk factors carries a recurrence risk of approximately 12%; one risk factor, 25–50%; two risk factors, 50–59%; three or more risk factors, 73–100%.

Table 633.10 Risk Factors for Occurrence of Subsequent Epilepsy After a Febrile Seizure*

RISK FACTOR	RISK FOR SUBSEQUENT EPILEPSY
Simple febrile seizure	1%
Recurrent febrile seizures	4%
Complex febrile seizures (>15 min in duration or recurrent within 24 hr)	6%
Fever <1 hr before febrile seizure	11%
Family history of epilepsy	18%
Complex febrile seizures (focal)	29%
Neurodevelopmental abnormalities	33%

*Having more than one risk factor is at least in part additive.

Almost any type of epilepsy can be preceded by febrile seizures. A few epilepsy syndromes typically start with febrile seizures; these are **generalized epilepsy with febrile seizures plus** (GEFS+), **severe myoclonic epilepsy of infancy** (SMEI or **Dravet syndrome**), and, in many patients, temporal lobe epilepsy secondary to mesial temporal sclerosis. **GEFS+** is an autosomal dominant syndrome with a highly variable phenotype. Onset is usually in early childhood, and remission is usually in mid-childhood. It is characterized by multiple febrile seizures and by several subsequent types of afebrile generalized seizures, including generalized tonic-clonic, absence, myoclonic, atonic, or myoclonic astatic seizures with variable degrees of severity. A focal febrile seizure plus epilepsy variant, in which the seizures are focal rather than generalized, has also been described.

Dravet syndrome is the most severe of the phenotypic spectrum of *febrile seizure–associated epilepsies*. It constitutes a distinct entity, the onset of which is in infancy. It is initially characterized by febrile and afebrile unilateral clonic seizures that recur every 1 or 2 months. These early seizures are typically induced by fever, but they differ from the usual febrile convulsions in that they are more prolonged, more frequent, and focal and recur in clusters. Seizures subsequently start to occur with lower fevers and then without fever. During the second year of life, myoclonus, atypical absences, and focal seizures occur frequently, and developmental delay usually follows (Fig. 633.4). This syndrome is usually caused by a de novo pathogenic variant, although rarely it is inherited in an autosomal dominant manner or may be inherited from a nonaffected carrier parent. Variants in the *SCN1A* gene are the most common cause of Dravet syndrome (causing ~80% of all cases). The same gene is affected in the GEFS+ spectrum; however, in Dravet syndrome the variant leads to loss of function and

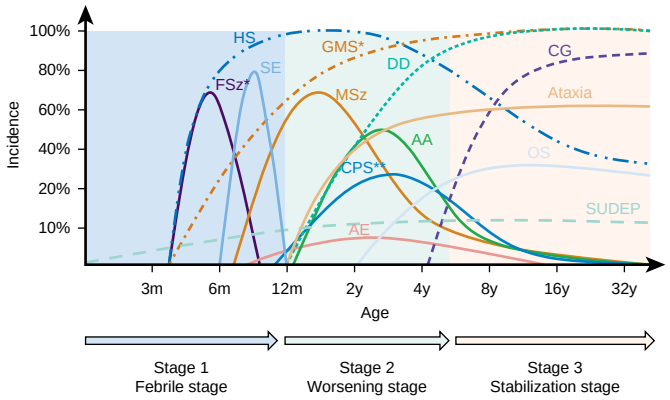

Fig. 633.4 Schematic representation of the varied clinical manifestations of Dravet syndrome and their relative incidence according to age. AA, Atypical absences; AE, acute encephalopathy; CG, crouching gait; CPS, complex partial seizures; DD, developmental delay; FSz, complex febrile seizures; GMS, generalized motor seizures; HS, hyperthermia sensitivity; MSz, myoclonic seizures; OS, obtundation status; SE, convulsive status epilepticus; Ataxia; SUDEP, sudden unexpected death in epilepsy. *Moderate fever for 60%; mostly clonic generalized and unilateral motor seizures. **Difficult distinction between atypical absences and complex partial seizures without ictal EEG recording, so their precise incidence is unknown; including generalized tonic-clonic and unilateral seizures. However, unilateral seizures are less frequent after the age of 7 yr, whereas sleep seizures increase after 6-7 yr and become predominant after age of 9-10 yr. *(From Gataullina S, Dulac O. From genotype to phenotype in Dravet disease. Seizure. 2017;44:58–64, Fig. 1, p. 59.)*

thus to a more severe phenotype. There are several *milder variants* of Dravet syndrome that manifest some, but not all, of the previous features and that are referred to as **Dravet syndrome spectrum** or SMEI-Borderland. Rarely the *GABRG2, SCN1B,* and *SCN2A* genes may cause Dravet syndrome; however, in 10–20% of the cases a specific gene variant is not identified.

The majority of patients who had prolonged febrile seizures and encephalopathy after vaccination and who had been presumed to have suffered from vaccine encephalopathy (seizures and psychomotor regression occurring after vaccination and presumed to be caused by it) turn out to have Dravet syndrome pathogenic gene variants, indicating that their disease is caused by the variant and not secondary to the vaccine. This has raised doubts about the very existence of the entity termed *vaccine encephalopathy.*

EVALUATION

Figure 633.5 delineates the general approach to the patient with febrile seizures. Each child who presents with a febrile seizure requires a detailed history and a thorough general and neurologic examination. Febrile seizures often occur in the context of otitis media; roseola and human herpesvirus (HHV) 6 infections; and infections with norovirus, parechovirus, enteroviruses, *Shigella,* or similar agents, making the evaluation more demanding. In patients with febrile status epilepticus, HHV-6B (more frequently) and HHV-7 infections may account for 30% of the cases.

Lumbar Puncture

Meningitis should be considered in the differential diagnosis, and lumbar puncture should be performed for all infants younger than 6 months of age who present with fever and seizure, if the child is ill-appearing, or at any age if there are clinical signs or symptoms of concern. A lumbar puncture is an option in a child 6-12 months of age who is deficient in *Haemophilus influenzae* type b and *Streptococcus pneumoniae* immunizations or for whom the immunization status is unknown. A lumbar puncture is an option in children who have been pretreated with antibiotics. In uninfected patients presenting with febrile status epilepticus, a nontraumatic lumbar puncture rarely shows cerebrospinal fluid (CSF) pleocytosis (96% have <3 nucleated cells in

the CSF) with a concurrently normal CSF protein and glucose. Pleocytosis suggests bacterial or viral infection.

Electroencephalogram

If the child is presenting with the first simple febrile seizure and is otherwise neurologically healthy, an EEG need not be performed as part of the evaluation. An EEG would not predict the future recurrence of febrile seizures or epilepsy even if the result is abnormal. Spikes during drowsiness are often seen in children with febrile seizures, particularly those older than age 4 years, and these do not predict later epilepsy. EEGs performed within 2 weeks of a febrile seizure often have nonspecific slowing, usually posteriorly. Thus in many cases, if an EEG is indicated, it is delayed until or repeated after more than 2 weeks have passed. An EEG should therefore generally be restricted to special cases in which epilepsy is highly suspected (see Table 633.10), and, generally, it should be used to delineate the type of epilepsy rather than to predict its occurrence. If an EEG is done, it should be performed for at least 20 minutes in wakefulness and in sleep according to international guidelines to avoid misinterpretation and drawing of erroneous conclusions. At times, if the patient does not recover immediately from a seizure, an EEG can help distinguish between ongoing seizure activity and a prolonged postictal state. After febrile status epilepticus, focal EEG slowing over the temporal lobe increases the chance that the patient may have medial temporal sclerosis on follow-up.

Blood Studies

Blood studies (serum electrolytes, calcium, phosphorus, magnesium, and a complete blood count) are not routinely recommended in the workup of a child with a first simple febrile seizure. Blood glucose should be measured initially and with prolonged postictal obtundation or with poor oral intake (prolonged fasting). Serum electrolyte values may be abnormal in children after a febrile seizure, but this should be suggested by precipitating or predisposing conditions elicited in the history and reflected in the physical examination. If clinically indicated (e.g., dehydration), these tests should be performed. A low sodium level is associated with a higher risk of recurrence of the febrile seizure within the following 24 hours.

Neuroimaging

A CT or MRI is not recommended in evaluating the child after a first simple febrile seizure. The workup of children with complex febrile seizures needs to be individualized. This can include an EEG and neuroimaging, particularly if the child is neurologically abnormal. Approximately 10% of children with febrile status epilepticus are reported to have unilateral or, less frequently, bilateral swelling of their hippocampus acutely; subsequent long-term hippocampal atrophy is evident in about 71% of those who had the acute findings. Whether these patients will ultimately develop temporal lobe epilepsy remains to be determined.

TREATMENT

In general, antiepileptic therapy, continuous or intermittent, is not recommended for children with one or more simple febrile seizures. Parents should be counseled about the relative risks of recurrence of febrile seizures and recurrence of epilepsy, educated on how to handle a seizure acutely, and given emotional support. If the seizure lasts for longer than 5 minutes, acute treatment with lorazepam, midazolam, or diazepam is needed (see Chapter 633.8 for acute management of seizures and status epilepticus). Rectal diazepam is often prescribed to families to be used at home as a rescue medication if a febrile seizure lasts longer than 5 minutes (see Table 633.14 for dosing). Alternatively, buccal or intranasal midazolam or diazepam may be used. In cases of frequently recurring febrile seizures, intermittent oral clonazepam (0.01 mg/kg every 8-12 hours up to a maximum dose of 1.5 mg/day) or oral diazepam (0.33 mg/kg every 8 hours) can be given during febrile illnesses. Such therapies help reduce, but do not eliminate, the risks of recurrence of febrile seizures. Historically, continuous therapy with the antiepileptic drugs (AEDs) phenobarbital or valproic acid was occasionally used to prevent febrile seizures. However, in the vast majority of cases, use of continuous therapy is not justified because of the risk of side effects and lack of demonstrated long-term benefits, even if the recurrence rate of febrile seizures is expected to be decreased by these drugs.

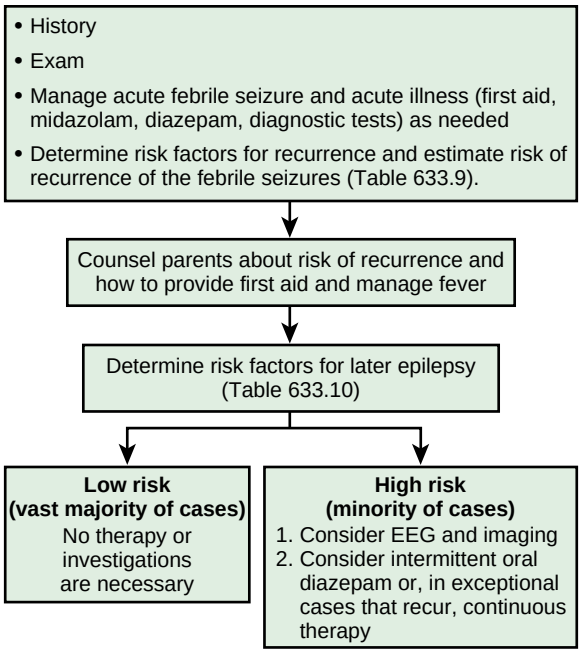

Fig. 633.5 Treatment algorithm for the management of febrile seizures. *(Modified from Mikati MA, Rahi A. Febrile seizures: from molecular biology to clinical practice. Neurosciences [Riyadh]. 2004;10:14–22.)*

Antipyretics can decrease the discomfort of the child but do not reduce the risk of having a recurrent febrile seizure. Chronic antiepileptic therapy may be considered for children with a high risk for later epilepsy. The possibility of future epilepsy does not change with or without antiepileptic therapy. Iron deficiency is associated with an increased risk of febrile seizures, and thus screening for that problem and treating it appear appropriate. A recent Delphi-type European study generated specific recommendations for providers to deliver to caretakers after a febrile seizure (reference provided later). These included the definition of febrile seizures, basis of this clinical diagnosis, acknowledging parental stress, risk of recurrence, and long-term care of the child, which also should include that the parents should avoid cosleeping, which is dangerous for their child and does not prevent febrile seizures.

Visit Elsevier eBooks+ at eBooks.Health.Elsevier.com for Bibliography.

633.2 Unprovoked Seizures

Mohamad A. Mikati, Dmitry Tchapyjnikov, and Kevin M. Rathke

HISTORY AND EXAMINATION

Evaluation of a first-time seizure was discussed earlier in this chapter. It entails stabilization of the patient if the child presents during or shortly after the seizure. A careful history and examination are done to accurately characterize the seizure, exclude acute intervenable causes, and attempt to determine the underlying etiology of the seizure.

DIFFERENTIAL DIAGNOSIS

This involves consideration of nonepileptic paroxysmal events (see Chapter 634), determination of the seizure type as classified by the ILAE system (see Fig. 633.1), and consideration of potential underlying etiologies. Some seizures might begin with **auras**, which are sensory experiences reported by the patient and are not observed externally.

Motor seizures can be **tonic**, **clonic**, **myoclonic**, **atonic**, or **astatic**. **Astatic** seizures often follow myoclonic seizures and cause a momentary loss of tone with a sudden fall. **Atonic** seizures, on the other hand, are usually longer, and the loss of tone often develops more slowly. Sometimes it is difficult to distinguish among tonic, myoclonic, atonic, or astatic seizures based on the history alone when the family reports only that the patient falls; in such cases, the seizure may be described as a **drop attack**. Loss of tone or myoclonus in only the neck muscles results in a milder seizure referred to as a **head drop**. Tonic, clonic, tonic-clonic, myoclonic, and atonic seizures can be focal (including one limb or one side only), focal with secondary generalization, or primary generalized. Epileptic spasms, or **axial spasms** (these terms being preferred over infantile spasms because the spasms can occur beyond infancy), consist of flexion or extension of the truncal and extremity musculature that is sustained for 1-2 seconds, shorter than the duration seen in tonic seizures, which last longer than 2 seconds. Focal motor clonic and/or myoclonic seizures that persist for days, months, or even longer are termed **epilepsia partialis continua**.

Absence seizures are generalized seizures consisting of staring, unresponsiveness, and eye flutter lasting usually for a few seconds. **Typical absences** are associated with 3-Hz spike–and–slow-wave discharges and with childhood absence epilepsy, which has a good prognosis. **Atypical absences** are associated with 1- to 2-Hz spike–and–slow-wave discharges and with head atonia and myoclonus during the seizures. They occur in **Lennox-Gastaut syndrome** and similar syndromes, which have a poor prognosis. **Juvenile absences** are similar to typical absences but are associated with 4- to 5-Hz spike–and–slow-wave discharges and often occur in juvenile myoclonic epilepsy. Seizure type and other EEG and clinical manifestations determine the type of **epilepsy syndrome** with which a particular patient is afflicted (see Tables 633.1-633.6; see also Chapters 633.3 and 633.4).

A family history of certain forms of epilepsy, such as benign familial neonatal seizures, can suggest the specific epilepsy syndrome. More often, however, different members of a family with a positive history of epilepsy have different types of epilepsy. Specific findings on physical exam may point to an underlying disorder causing the seizure, such as tuberous sclerosis, Sturge-Weber syndrome, neurofibromatosis, or other brain malformations.

LONG-TERM APPROACH TO THE PATIENT AND ADDITIONAL TESTING

The approach to the patient with epilepsy is based on the diagnostic scheme proposed by the ILAE Task Force on Classification and Terminology and presented in Table 633.7. Most epilepsy syndromes are potentially caused by any one of multiple underlying or still undetermined etiologies. However, in addition, there are many epilepsy syndromes that are associated with specific gene mutations (see Tables 633.1-633.6 and Fig. 633.3). Different pathogenic variants of the same gene can result in different epilepsy syndromes, whereas variants of different genes can cause the same epilepsy syndrome phenotype. The clinical use of gene testing in the diagnosis and management of childhood epilepsy is indicated in patients manifesting specific underlying malformational, metabolic, or degenerative disorders; patients with severe epilepsy syndromes (such as West and Dravet syndromes and progressive myoclonic epilepsies); and patients with syndromes of mendelian inheritance (see Tables 633.1 and 633.6). Gene testing is indicated in epilepsy encephalopathy syndromes and in patients with other organ involvement (hepatic, muscle, cardiac, intestinal) and in atypical phenotypes.

In patients with drug-resistant epilepsy or in infants with new-onset epilepsy in whom the initial testing did not reveal an underlying etiology, a full metabolic workup, including amino acids, organic acids, biotinidase, and CSF studies, is needed. Additional testing can include, depending on the case, some or most of the following:

1. Measurement of serum lactate, pyruvate, acyl carnitine profile, creatine, very long-chain fatty acids, ammonia, and guanidino-acetic acid.
2. Blood and serum sometimes need to be tested for white blood cell lysosomal enzymes, serum coenzyme Q levels, and serum copper and ceruloplasmin levels (for Menkes syndrome).
3. Serum immune isoelectric focusing (or gene panels) is performed for carbohydrate-deficient transferrin in disorders of glycosylation.

CSF glucose testing looks for glucose transporter deficiency, and the CSF can be examined for cells and proteins (for parainfectious and postinfectious syndromes and for Aicardi-Goutières syndrome, which also shows cerebral calcifications and has a specific gene defect test available).

4. Other laboratory studies include CSF immunoglobulin (Ig) G index, NMDA receptor, and other autoimmune encephalitis–associated antibodies, as well as measles titers in serum and CSF.
5. CSF tests can also confirm, with the appropriate clinical setup, the diagnosis of cerebral folate deficiency, pyridoxine dependency, pyridoxal-5-phosphate dependency, mitochondrial disorders, nonketotic hyperglycinemia, neopterin/biopterin metabolism disorders, adenylosuccinate lyase deficiency, and neurotransmitter deficiencies.

In infants who do not respond immediately to antiepileptic therapy, vitamin B_6 (100 mg intravenously) is given as a therapeutic trial to help diagnose pyridoxine-responsive seizures, with precautions to guard against possible apnea. The trial is best done with continuous EEG monitoring, including a preadministration baseline recording period. Before the vitamin B_6 trial, a pipecolic acid level and serum, urine, or CSF α-aminoadipic acid semialdehyde levels should be drawn because they are often elevated in this rare syndrome and the therapeutic trial result may not be definitive. Some patients are pyridoxal phosphate, rather than pyridoxine, dependent. Patients with cerebral folate deficiency can also have intractable seizures. Thus trials of pyridoxal phosphate given orally (up to 50 mg/kg/day given every 6 hours) and folinic acid (2.5-5 mg twice a day, if needed; can titrate up to a maximum dose of 8 mg/kg/day) over several weeks can help diagnose these rare disorders while one is waiting for the definitive diagnosis from CSF or genetic testing. Certain EEG changes such as continuous spike–and–slow-wave seizure activity and burst-suppression patterns may also suggest these vitamin-responsive syndromes.

6. Urine may also need to be tested for urinary sulfites indicating molybdenum cofactor deficiency and for oligosaccharides and mucopolysaccharides. MR spectroscopy can be performed for lactate and creatine peaks to rule out mitochondrial disease and creatine transporter deficiency.
7. Gene testing looks for specific disorders that can manifest with seizures, including *SCN1A* pathogenic variants in Dravet syndrome; *ARX* gene for West syndrome in males; *MECP2, CDKL5,* and protocadherin 19 for Rett syndrome and similar presentations; syntaxin-binding protein for Ohtahara syndrome; and polymerase G for West syndrome and other seizures in infants. Gene testing can also be performed for other dysmorphic or metabolic syndromes.
8. Muscle biopsy can be performed for mitochondrial DNA and oxidative enzymes as well as coenzyme Q10 levels, and skin biopsy for inclusion bodies seen in neuronal ceroid lipofuscinosis and Lafora body disease.
9. Genetic panels are available that include multiple genes that can cause epilepsy at specific ages; whole exome or genome sequencing is also available. The availability of gene panels, particularly ones that can test for amenably treatable conditions such as vitamin B_6–dependent epilepsy, and the rapid turnaround time have replaced the need for many of the tests listed in points 1-9.
10. MRI should also be performed to identify congenital disorders (cortical dysplasias, lissencephaly, schizencephaly), calcifications, focal lesions (basal ganglia), and myelinization disorders (acute disseminated encephalomyelitis [ADEM], leukodystrophies). MRI may identify specific disorders such as posterior reversible encephalopathy syndrome (PRES), stroke (mitochondrial encephalopathy, lactic acidosis, and strokelike episodes [MELAS]), Rasmussen encephalitis, tumors, cerebral edema, hemorrhage, or venous thrombosis (see Table 633.8). It should also be noted that seizures alone may cause nonspecific-nondiagnostic transient MRI abnormalities; these may include transient gray matter and subcortical white matter signals or transient hippocampal and temporal lobe abnormalities.

Most patients do not require an extensive evaluation. The pace and extent of the workup must depend on the clinical epileptic and non-epileptic features, the family and antecedent personal history of the patient, the medication responsiveness of the seizures, the likelihood of identifying a treatable condition, and the wishes and need of the family to assign a specific diagnosis to the child's illness.

Visit Elsevier eBooks+ at eBooks.Health.Elsevier.com for Bibliography.

633.3 Focal Seizures and Related Epilepsy Syndromes

Mohamad A. Mikati and Dmitry Tchapyjnikov

Focal seizures account for approximately 40% of seizures in children and can be divided into **focal seizures with preserved awareness**, in which consciousness is not impaired, and **focal seizures with impaired awareness**, in which consciousness is affected.

Focal seizures with preserved or impaired awareness can each occur in isolation, one can temporally lead to the other (usually from preserved to impaired awareness), and/or each can progress into secondary generalized seizures, called **focal to bilateral tonic-clonic seizures**, although less commonly, the secondary generalized seizure may also be tonic, clonic, or atonic.

FOCAL SEIZURES WITH PRESERVED AWARENESS

These can take the form of sensory seizures (auras, called *focal aware seizures*) or brief motor seizures, the specific nature of which gives clues as to the location of the seizure focus. Brief motor seizures are the most common and include focal tonic, clonic, or atonic seizures. Often there is a motor (Jacksonian) march from face to arm to leg, adversive head and eye movements to the contralateral side, or postictal **(Todd) paralysis** that can last minutes or hours, and sometimes longer. Unlike tics, motor seizures are not under partial voluntary control; seizures are more often stereotyped and are less likely than tics to manifest different types in a given patient.

FOCAL SEIZURES WITH IMPAIRED AWARENESS

These seizures usually last 1-2 minutes and are often preceded by an **aura**, such as a rising abdominal feeling, déjà vu or déjà vécu, a sense of fear, complex visual hallucinations, micropsia or macropsia (temporal lobe), generalized difficult-to-characterize sensations (frontal lobe), focal sensations (parietal lobe), or simple visual experiences (occipital lobe). Children younger than 7 years old are less likely than older children to report auras, but parents might observe unusual preictal behaviors that suggest the experiencing of auras. Subsequent manifestations consist of decreased responsiveness, staring, looking around seemingly purposelessly, and automatisms. **Automatisms** are automatic semipurposeful movements of the mouth (oral, alimentary such as chewing) or of the extremities (manual, such as manipulating the sheets; leg automatisms such as shuffling, walking, or bicycling movements). Often there is salivation, dilation of the pupils, and flushing or color change. The patient might appear to react to some of the stimulation around him or her but does not later recall the epileptic event. At times, walking and/or marked limb flailing and agitation occur, particularly in patients with frontal lobe seizures. Frontal lobe seizures often occur at night and can be very numerous and brief, but other complex partial seizures from other areas in the brain can also occur at night. There is often contralateral dystonic posturing of the arm and, in some cases, unilateral or bilateral tonic arm stiffening. Some seizures have these manifestations with minimal or no automatisms. Others consist of altered consciousness with contralateral motor, usually clonic, manifestations. After the seizure, the patient can have postictal automatisms, sleepiness, and/or other transient focal deficits such as weakness (Todd paralysis) or aphasia.

FOCAL TO BILATERAL TONIC-CLONIC SEIZURES

These can either start with generalized clinical phenomena (from rapid spread of the discharge from the initial focus) or as focal seizures with subsequent clinical generalization. There is often adversive eye and head deviation to the side contralateral to the side of the seizure focus, followed by generalized tonic, clonic, or tonic-clonic activity. Tongue biting, urinary and stool incontinence, vomiting with risk of aspiration, and cyanosis are common. Fractures of the vertebrae or humerus are rare complications. Most such seizures last 1-2 minutes. Focal tonic or focal to bilateral tonic-clonic seizures often manifest as adversive head deviation to the contralateral side, fencing, hemi- or full figure-of-four arm, and/or Statue of Liberty postures. These postures usually suggest a frontal origin and, when awareness is preserved during them, favor that the seizure originated from the medial frontal supplementary motor area.

EEG in patients with focal/partial seizures usually shows focal spikes or sharp waves in the lobe where the seizure originates. A *sleep-deprived* EEG with recording during sleep increases the diagnostic yield and is advisable in all patients (Fig. 633.6). Despite that, approximately 15% of children with epilepsy initially have normal EEGs because the discharges are relatively infrequent or the focus is deep. If repeating the test does not detect paroxysmal findings, longer recordings in the laboratory or using ambulatory EEG or even inpatient 24-hour video EEG monitoring may be helpful. The latter is particularly helpful if the seizures are frequent enough because it then can allow visualization of the clinical events and the corresponding EEG tracing.

Brain imaging is critical in patients with focal seizures. MRI is preferable to CT, which misses subtle but, occasionally, potentially clinically significant lesions. MRI can show pathologies such as changes as a result of previous strokes or hypoxic injury, malformations, medial temporal sclerosis, arteriovenous malformations, inflammatory pathologies, or tumors (Fig. 633.7). Of note is that patients with focal seizures and epilepsies can have focal corresponding neuropsychologic deficits but also have patterns of network-related deficits such as impaired social cognition, deficits that are shared with generalized epilepsies.

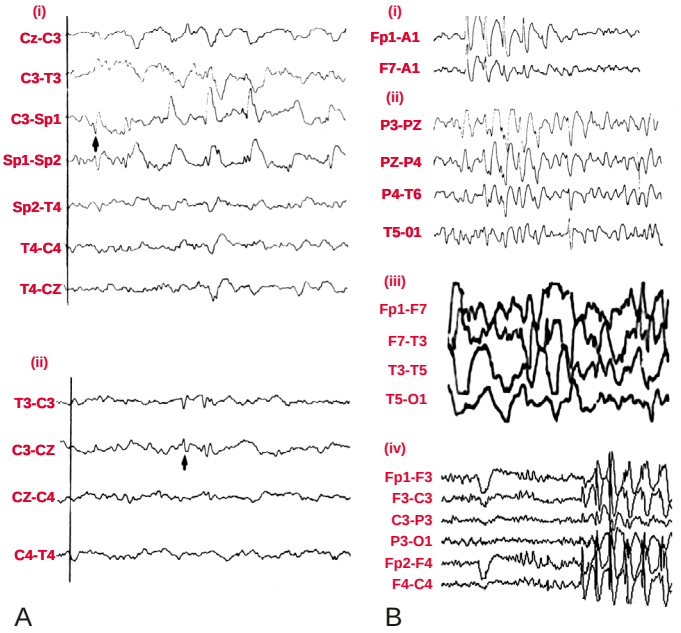

Fig. 633.6 A, Representative EEG associated with partial seizures: (i) Spike discharges from the left temporal lobe *(arrow)* in a patient with complex partial seizures caused by mesial temporal sclerosis; (ii) left central-parietal spikes *(arrow)* characteristic of benign partial epilepsy with centrotemporal spikes. B, Representative EEGs associated with generalized seizures: (i) 3/sec spike-and-wave discharge of absence seizures with normal background activity; (ii) 1-2/sec interictal slow spike waves in a patient with Lennox-Gastaut syndrome; (iii) hypsarrhythmia with irregular multifocal high-voltage spike-and-wave activity with a chaotic high-voltage slow background; (iv) juvenile myoclonic epilepsy EEG showing 4-6/sec spike and waves enhanced by photic stimulation.

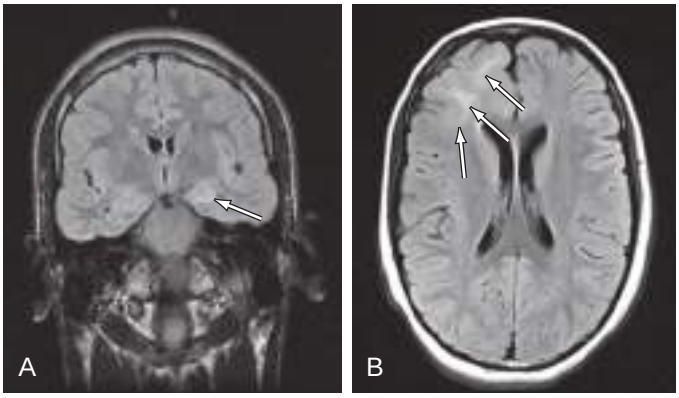

Fig. 633.7 **A,** Coronal fluid-attenuated inversion-recovery (FLAIR) MRI scan of a 13-yr-old with intractable seizures and mesial temporal sclerosis (MTS). The *arrow* points at the hippocampus with the high-intensity signal characteristic of MTS. **B,** Axial FLAIR MRI of a 7-yr-old with intractable seizures and right frontal cortical dysplasia. The *arrows* point at the high-intensity signal corresponding to the dysplasia. *(**A** from Lee JYK, Adelson PD. Neurosurgical management of pediatric epilepsy. Pediatr Clin North Am. 2004;51:441–456.)*

These observations support current thinking that not only generalized but also focal epilepsy involves network-related pathophysiology.

BENIGN EPILEPSY SYNDROMES WITH FOCAL SEIZURES

The most common such syndrome is **benign childhood epilepsy with centrotemporal spikes (BECTS)**, which typically starts during childhood (ages 3-10 years) and is outgrown by adolescence. The child typically wakes up at night because of a focal seizure with preserved awareness causing buccal and throat tingling and tonic or clonic contractions of one side of the face, with drooling and inability to speak but with preserved consciousness and comprehension. Focal seizures with impaired awareness and secondary generalized seizures can also occur. EEG shows typical wide-based centrotemporal spikes that are markedly increased in frequency during drowsiness and sleep. MRI is normal. Patients respond very well to AEDs such as oxcarbazepine and carbamazepine. In some patients who only have rare and mild seizures, treatment might not be needed. Traditionally patients with BECTS are considered to have normal neurocognitive development, but some studies have documented problems in memory and in other neuropsychologic functions and in attention. **Atypical BECTS** is a less common variant of the disorder characterized by often a younger age of onset, multiple seizure types including drop attacks, atypical EEG patterns including secondary bilateral synchrony, and/or other comorbidities such as developmental delay.

Benign epilepsy with occipital spikes can occur in early childhood **(Panayiotopoulos type)** and manifests with focal seizures with impaired awareness and with ictal vomiting; they may also first appear in later childhood **(Gastaut type)** as focal seizures with impaired awareness, visual auras, and migraine headaches that occur independently or postictally (epilepsy-migraine sequence). Both are typically outgrown in a few years.

In infants, several less common **benign infantile familial convulsion syndromes** have been reported. For some of these, the corresponding gene variant and its function are known (see Table 633.1), including **benign familial neonatal seizures** *(KCNQ2, KCNQ3)*, **benign familial neonatal infantile seizures** *(SCN2A)*, and **early familial neonatal infantile seizures** (*SCN2A*).

A number of **benign infantile nonfamilial syndromes** have been reported, including focal seizures with impaired awareness with temporal foci, focal to bilateral tonic-clonic seizures with variable foci, tonic seizures with midline foci, and focal seizures in association with mild gastroenteritis. All of these have a good prognosis and respond to treatment promptly; often, only short-term therapy (e.g., 6 months), if any therapy, is needed. **Nocturnal autosomal dominant frontal lobe epilepsy** has been linked to acetylcholine-receptor and to *KCNT1* pathogenic variants. It manifests with nocturnal seizures with dystonic posturing, agitation, screaming, and kicking that respond promptly to carbamazepine. Several other less frequent familial benign epilepsy syndromes with different localizations have also been described, some of which occur exclusively or predominantly in adults.

SEVERE EPILEPSY SYNDROMES WITH FOCAL SEIZURES

Symptomatic structural/metabolic epilepsy secondary to focal brain lesions has a higher chance of being severe and refractory to therapy than genetic (idiopathic) epilepsy. Many patients with focal lesions, for example, old strokes or brain tumors, either never have seizures or have well-controlled epilepsy. In infants, *drug-resistant epilepsy* with focal seizures is often caused by severe metabolic problems, hypoxic-ischemic injury, or congenital malformations. In addition, in this age-group, a syndrome of multifocal severe partial seizures with progressive mental regression and cerebral atrophy called **epilepsy of infancy with migrating focal seizures** (EIMFS; previously called *malignant migrating partial seizures of infancy*) has been described. Some cases of EIMFS are secondary to pathogenic variants in the calcium-sensitive potassium channel *KCNT1*. Brain malformations causing focal epilepsy include focal cortical dysplasia, hemimegalencephaly, Sturge-Weber cutaneous lesion, tuberous sclerosis, and congenital tumors such as ganglioglioma and dysembryoplastic neuroepithelial tumors and others. The intractable seizures can be focal seizures with or without impaired awareness, focal to bilateral tonic-clonic seizures, or combinations thereof. If secondary generalized seizures predominate and take the form of absence-like seizures and drop attacks, the clinical picture can mimic the generalized epilepsy syndrome of Lennox-Gastaut syndrome and has been termed by some as **pseudo–Lennox-Gastaut syndrome**.

Temporal lobe epilepsy can be caused by any temporal lobe lesion. A common cause is **mesial** (also termed **medial**) **temporal sclerosis**, a condition often preceded by febrile seizures. They are rarely genetic in origin. Pathologically, these patients have atrophy, gliosis, or cortical dysplasia of the hippocampus and, in some these conditions, of the amygdala. Some patients with mesial temporal sclerosis have pathogenic variants in *SUCO*. Medial temporal lobe epilepsy is the most common cause of surgically remediable partial epilepsy in adolescents and adults. Occasionally, in patients with other structural or genetic focal or generalized epilepsies, the focal discharges are so continuous that they cause an epileptic encephalopathy. Activation of temporal discharges in sleep can lead to loss of speech and verbal auditory agnosia **(Landau-Kleffner epileptic aphasia syndrome)**. Activation of secondary generalized and at times focal discharges in sleep leads to more global delay secondary to the **syndrome of continuous spike waves in slow-wave sleep** (>85% of the slow-wave sleep recording is dominated by discharges).

The syndrome of **Rasmussen encephalitis** is a form of chronic encephalitis that manifests with *unilateral* intractable partial seizures, epilepsia partialis continua, and progressive hemiparesis of the affected side, with progressive atrophy of the involved hemisphere. The etiology is usually unknown, although autoimmune etiologies have been hypothesized.

Visit Elsevier eBooks+ at eBooks.Health.Elsevier.com for Bibliography.

633.4 Generalized Seizures and Related Epilepsy Syndromes

Mohamad A. Mikati and Dmitry Tchapyjnikov

ABSENCE SEIZURES

Typical absence seizures usually start at 5-8 years of age and are often, because of their brevity, overlooked by parents for many months even though they can occur up to hundreds of times per day. Unlike focal seizures with impaired awareness, they *do not* have an aura, usually last

for only a few seconds, and are sometimes accompanied by eyelid flutter or upward rolling of the eyes but typically not by the usually more florid automatisms seen in focal seizures with impaired awareness (absence seizures can have simple automatisms such as lip smacking or picking at clothing, and the head can very minimally fall forward). Absence seizures do not have a postictal period and are characterized by immediate resumption of what the patient was doing before the seizure. Hyperventilation for 3-5 minutes can precipitate the seizures and the accompanying 3-Hz spike–and–slow-wave discharges. The presence of eye closure eyelid myoclonia **(Jeavons syndrome)** and periorbital, perioral, or limb myoclonic jerks (the latter called **myoclonic absences**) with the typical absence seizures usually predicts difficulty in controlling the seizures with medications. Early-onset absence seizures (<4 years of age) or drug resistance should trigger evaluation for a glucose transporter defect, which is often associated with low CSF glucose levels and an abnormal sequencing test of the *SLC2A1* transporter gene.

Atypical absence seizures have associated myoclonic components and tone changes of the head (head drop) and body, usually last longer than typical absence seizures, and are also usually more difficult to treat. They are precipitated by drowsiness and are usually accompanied by 1- to 2-Hz spike–and–slow-wave discharges.

Juvenile absence seizures are similar to typical absences but occur at a later age and are accompanied by 4- to 6-Hz spike–and–slow-wave and polyspike–and–slow-wave discharges. These are usually associated with juvenile myoclonic epilepsy (see "Benign Generalized Epilepsies").

GENERALIZED MOTOR SEIZURES

The most common generalized motor seizures are generalized tonic-clonic seizures that can be either primarily generalized (bilateral) or focal to bilateral tonic-clonic (as described in Chapter 633.3) from a unilateral focus. If there is no partial component, the seizure usually starts with loss of consciousness and, at times, with a sudden cry, upward rolling of the eyes, and a generalized tonic contraction with falling, apnea, and cyanosis. In some, a clonic or myoclonic component precedes the tonic stiffening. The tonic phase is followed by a clonic phase that, as the seizure progresses, shows slowing of the rhythmic contractions until the seizure stops, usually 1-2 minutes later. Incontinence and a postictal period often follow. The latter usually lasts for a few minutes up to several hours with semicoma or obtundation and postictal sleepiness, weakness, ataxia, hyperreflexia or hyporeflexia, and headaches. There is a risk of aspiration and injury. First aid measures include positioning the patient on his or her side, clearing the mouth if it is open, loosening tight clothes or jewelry, and gently extending the head and, if necessary, insertion of an airway by a trained professional. The mouth should not be forced open with a foreign object (this could dislodge teeth, causing aspiration) or with a finger in the mouth (this could result in serious injury to the examiner's finger). Many patients have single **genetic generalized tonic-clonic seizures** that may be associated with a concurrent illness or with a cause that cannot be ascertained (see Chapter 633.2). Generalized tonic, atonic, and astatic seizures often occur in severe generalized pediatric epilepsies. Generalized myoclonic seizures can occur in either benign or difficult-to-control generalized epilepsies (see "Benign Generalized Epilepsies" and "Severe Generalized Epilepsies").

BENIGN GENERALIZED EPILEPSIES

Childhood absence epilepsy typically starts in mid-childhood, and most patients outgrow it before adulthood. Approximately 25% of patients also develop generalized tonic-clonic seizures, half before and half after the onset of absences. **Benign myoclonic epilepsy of infancy** consists of the onset of myoclonic and other seizures during the first year of life, with generalized 3-Hz spike–and–slow-wave discharges. Often, it is initially difficult to distinguish this type from more severe syndromes, but follow-up clarifies the diagnosis. **GEFS+** manifests as febrile seizures and multiple types of generalized seizures in multiple family members, and at times different individuals within the same family manifest different generalized and febrile seizure types (see Chapter 633.1).

Juvenile myoclonic epilepsy (Janz syndrome) is the most common generalized epilepsy in young adults, accounting for 5% of all epilepsies. It has been linked to pathogenic variants in many genes, including *CACNB4; CLNC2; EJM2, 3, 4, 5, 6, 7, 9; GABRA1; GABRD;* and *myoclonin1/EFHC1*. Typically, it starts in early adolescence with one or more of the following manifestations: myoclonic jerks in the morning, often causing the patient to drop things; generalized tonic-clonic or clonic-tonic-clonic seizures upon awakening; and juvenile absences. Sleep deprivation, alcohol (in older patients), and photic stimulation or, rarely, certain cognitive activities can act as precipitants. The EEG usually shows generalized 4- to 5-Hz polyspike–and–slow-wave discharges.

There are other forms of generalized epilepsies such as **photoparoxysmal epilepsy**, in which generalized tonic-clonic, absence, or myoclonic generalized seizures are precipitated by photic stimuli such as strobe lights, flipping through TV channels, and viewing video games. Other forms of **reflex** (i.e., **stimulus-provoked**) **epilepsy** can occur; associated seizures are usually generalized, although some may be focal (see Chapter 633.9).

SEVERE GENERALIZED EPILEPSIES

Severe generalized epilepsies are associated with intractable seizures *and* developmental delay. **Early myoclonic encephalopathy (EME)** starts during the first 2 months of life with severe myoclonic seizures and a burst suppression pattern on EEG. It is usually caused by inborn errors of metabolism such as nonketotic hyperglycinemia. **Early infantile epileptic encephalopathy (Ohtahara syndrome)** has a similar age of onset and EEG but manifests as tonic seizures and is usually caused by brain malformations or various epileptogenic gene mutations. The term *early infantile epileptic encephalopathy* (EIEE) has also been applied to the increasing number (~36) of other genetic epileptic encephalopathies and developmental epileptic encephalopathies that are associated with an increasing number of specific genes with pathogenic variants (Table 633.11); these may or may not manifest as Ohtahara syndrome, but all share the characteristic of early-onset epileptic encephalopathy. For example, EIEE type 4 is Ohtahara syndrome caused by syntaxin-binding protein 1 pathogenic variants. **Severe myoclonic epilepsy of infancy (Dravet syndrome)**, most often caused by pathogenic variants in *SCN1A,* starts as focal febrile status epilepticus or focal febrile seizures and later manifests as myoclonic and other seizure types (see Chapter 633.1).

West syndrome starts between the ages of 2 and 12 months and consists of a triad of infantile epileptic spasms that usually occur in clusters (particularly in drowsiness or upon arousal), developmental regression, and a typical EEG picture called **hypsarrhythmia** (see Fig. 633.6). Hypsarrhythmia is a high-voltage, slow, chaotic background with multifocal spikes. Patients with *cryptogenic/idiopathic* (referred to as *unknown etiology*) West syndrome have normal development before onset, whereas patients with *symptomatic* West syndrome have preceding developmental delay owing to perinatal encephalopathies, malformations, underlying metabolic disorders, infections like with congenital Zika virus, or other etiologies (see Chapter 633.2). In males, West syndrome can also be caused by *ARX* gene variants (often associated with ambiguous genitalia and cortical migration abnormalities). West syndrome, especially in cases where the etiology is unknown (i.e., cases that are not explained by the presence of a gene variant or a structural brain anomaly), is a medical emergency because a delay in diagnosis of 3 weeks or longer can affect the long-term prognosis. The spasms are often overlooked by parents and by physicians, being mistaken for startles caused by colic or other benign paroxysmal syndromes (see Chapter 634).

Lennox-Gastaut syndrome typically starts between the ages of 2 and 10 years and consists of a triad of developmental delay, multiple seizure types that as a rule include atypical absences, and myoclonic, astatic, and tonic seizures, as well as specific EEG abnormalities. The tonic and/or atonic seizures occur either in wakefulness (causing falls and injuries, broadly termed **drop attacks**) or also, typically, in sleep. The third component is the EEG findings (see Fig. 633.6): 1- to 2-Hz spike and slow waves, polyspike bursts in sleep (also *called generalized*

Table 633.11 Early Infantile Epileptic Encephalopathy (EIEE)

GENE	PROTEIN
ARX (EIEE1)	Aristaless-related homeobox
CDKL5 (EIEE2)	Cyclin-dependent kinase-like 5
SLC25A22 (EIEE3)	Mitochondrial glutamate carrier 1
STXBP1 (EIEE4)	Syntaxin-binding protein 1
SPTAN1 (EIEE5)	α_2-Spectrin
SCN1A (EIEE6)	Sodium-channel protein type 1α
KCNQ2 (EIEE7)	Potassium voltage-gated channel
ARHGEF9 (EIEE8)	Rho guanine nucleotide exchange factor 9
PDCH19 (EIEE9)	Protocadherin-19
PNKP (EIEE10)	Bifunctional polynucleotide phosphatase/kinase
SCN2A (EIEE11)	Sodium-channel protein type 2α
PLCβ1 (EIEE12)	Phospholipase C β1
SCN8A (EIEE13)	Sodium-channel, voltage-gated, type VIII, alpha subunit
KCNT1 (EIEE14)	Potassium-channel subfamily T, member 1
ST3GAL3 (EIEE15)	ST3 beta-galactoside alpha-2,3-sialyltransferase 3
TBC1D24 (EIEE16)	TBC1 domain family, member 24
GNAO1 (EIEE17)	Guanine nucleotide-binding protein G(o) subunit alpha
SZT2 (EIEE18)	Seizure threshold 2 homolog
GABRA1 (EIEE19)	Gamma-aminobutyric acid receptor subunit alpha-1
PIGA (EIEE20)	Phosphatidylinositol N-acetylglucosaminyltransferase subunit A
NECAP1 (EIEE21)	Adaptin ear-binding coat-associated protein 2
SLC35A2 (EIEE22)	UDP-galactose translocator
DOCK7 (EIEE23)	Dedicator of cytokinesis 7
HCN1 (EIEE24)	Potassium/sodium hyperpolarization–activated cyclic nucleotide-gated channel 1
SLC13A5 (EIEE25)	Solute carrier family 13 (sodium-dependent citrate transporter), member 5
KCNB1 (EIEE26)	Potassium voltage-gated channel, Shab-related subfamily, member 1
GRIN2B (EIEE27)	NMDA receptor subtype 2B
WWOX (EIEE28)	WW domain–containing oxidoreductase
AARS (EIEE29)	Alanyl-tRNA synthetase
SIK1 (EIEE30)	Salt inducible kinase 1
DNM1 (EIEE31)	Dynamin-1
KCNA2 (EIEE32)	Potassium voltage-gated channel subfamily A member 2
EEF1A2 (EIEE33)	Elongation factor 1-alpha 2
SLC12A5 (EIEE34)	Potassium–chloride transporter member 5
ITPA (EIEE35)	Inosine triphosphate pyrophosphatase
ALG13 (EIEE36)	Asparagine-linked glycosylation 13 homolog

paroxysmal fast activity or GPFA), and a slow background in wakefulness. Most patients are left with long-term cognitive impairment and intractable seizures despite multiple therapies. Some patients start with Ohtahara syndrome, develop West syndrome, and then progress to Lennox-Gastaut syndrome. **Myoclonic astatic epilepsy (Doose syndrome)** is a syndrome similar to, but milder than, Lennox-Gastaut syndrome and is characterized by seizures consisting of myoclonic jerking rapidly followed by an atonic (astatic) drop attack. Patients with Doose syndrome usually do not have tonic seizures or polyspike bursts in sleep. The prognosis is more favorable than that for Lennox-Gastaut syndrome. Another syndrome characterized by atonic seizures causing head nodding as well as tonic, clonic, and stimulus-sensitive seizures is **nodding syndrome**, which is seen in some African countries and is often associated with encephalopathy, stunted growth, and variable degrees of cognitive deficits. The underlying etiology is a likely autoimmune reaction to the parasitic worm *Onchocerca volvulus.* The head nodding is associated with generalized slow waves and electrodecrement, likely representing generalized ictal activity, but is commonly resistant to drug therapy.

Progressive myoclonic epilepsies (EPM) are a group of epilepsies characterized by progressive dementia and worsening myoclonic and other seizures. **Type I**, or **Unverricht-Lundborg disease**, is caused by pathogenic variants in the *CSTB* gene, is more slowly progressive than the other types, and usually starts in adolescence. **Type II**, or **Lafora body disease**, can have an early childhood onset but usually starts in adolescence, is more quickly progressive, and is usually fatal within the second or third decade of life. It can be associated with photosensitivity, manifests periodic acid–Schiff–positive Lafora inclusions on muscle or skin biopsy (in eccrine sweat gland cells), and has been shown to be caused by laforin *(EPM2A)* or malin *(EPM2B)* gene variants and possibly *PRDM8* in 90% of patients. Other causes of progressive myoclonic epilepsy include **myoclonic epilepsy with ragged red fibers** (**MERRF**, caused by various pathogenic variants in mitochondrial DNA), **sialidosis type I** (caused by variants in *NEU1*), **neuronal ceroid lipofuscinoses** (lysosomal storage disorders caused by variants in *CLN1-CLN14*), **type 3 neuronopathic Gaucher disease** (caused by lysosomal glucocerebrosidase deficiency), **dentatorubral-pallidoluysian atrophy** (caused by unstable expansion of trinucleotide repeats on the *ATN1* gene), **action myoclonus–renal failure syndrome** (aka *EPM4,* caused by variants in *SCARB2*), **progressive myoclonus epilepsy–ataxia syndrome** (aka *EPM5,* caused by variants in *PRICKLE1*), and **North Sea progressive myoclonic epilepsy** (aka *EPM6,* caused by variants in *GOSR2*).

Myoclonic encephalopathy in nonprogressive disorders is an epileptic encephalopathy that occurs in some congenital disorders affecting the brain, such as Angelman syndrome, and consists of almost continuous and difficult-to-treat myoclonic and, at times, other seizures.

Landau-Kleffner syndrome is a rare condition of presumed autoimmune but sometimes also of genetic (*GRIN2A* variants) etiology. It is characterized by loss of language skills and by verbal auditory agnosia in a previously normal child; ~70% have associated clinical seizures. The seizures, when they occur, are of several types, including focal with preserved awareness, focal to bilateral tonic-clonic, atypical absence, focal with impaired awareness, and occasionally myoclonic seizures. High-amplitude spike-and-wave discharges predominate and tend to be bitemporal. In the later evolutionary stages of the condition, the EEG findings may be normal. The spike discharges are always more apparent during non–rapid eye movement sleep; a child in whom Landau-Kleffner syndrome is suspected should have an EEG during sleep. CT and MRI studies typically yield normal results. In the related but clinically distinct epilepsy syndrome called **epileptic encephalopathy with continuous spike waves in slow-wave sleep (CSWS)**, the discharges occur in >85% of the slow-wave sleep, a finding termed **electrical status epilepticus in sleep (ESES)**. ESES can also occur in Landau-Kleffner syndrome, but in CSWS the discharges are usually frontal or generalized and the delays usually global. The approach to and therapy for the two syndromes are similar. Although valproic acid and benzodiazepines are often used first, the evidence favors that they address the seizures and that steroids and possibly nocturnal diazepam are the more effective agents for the aphasia. Some children respond to the combination of valproic acid and clobazam or to levetiracetam. Nocturnal diazepam (0.2-0.5 mg/kg orally at bedtime for several months) is often used as first- or second-line therapy, as are steroids used either

orally (more commonly studied) or intravenously. Oral prednisone is started at 2 mg/kg/day for 1-2 months, then weaned over a period of 1-3 months. Alternatively, monthly infusions of high-dose intravenous methylprednisolone have been used instead of oral steroids. Long-term therapy is often needed irrespective of which drug(s) elicit a patient response. If the seizures and aphasia persist after diazepam and steroid trials, then a course of IVIGs should be considered because many patients can respond to that. It is imperative to initiate speech therapy and maintain it for several years, because improvement in language function occurs over a prolonged period.

Amenably treatable metabolic epilepsies are well recognized (see Table 633.6). **Pyridoxine-dependent epilepsy** typically presents with a neonatal or infantile (and rarely childhood) onset of encephalopathy with, at times, reports of increased fetal movements (seizures) in utero. There are recurrent focal motor seizures, generalized tonic seizures, and myoclonus. Seizures progress to status epilepticus if no pyridoxine is used. Diagnosis is confirmed by the presence of elevated plasma, urine, and CSF α-aminoadipic semialdehyde and elevated plasma and CSF pipecolic acid levels. The presence of either homozygous or compound heterozygous pathogenic variants in *ALDH7A1* (which encode the protein antiquitin) confirms the diagnosis. The use of pyridoxine 100 mg daily orally (higher doses, up to 500-600 mg/day, have been used) or intravenously helps stop the seizures. Variants of *PROSC* can also cause pyridoxine-dependent epilepsy. **Pyridoxal phosphate–responsive neonatal epileptic encephalopathy** (pyridox[am]ine 5′-phosphate oxidase [PNPO] deficiency) may present similarly in the absence of gastrointestinal symptoms sometimes seen with pyridoxine-dependent epilepsy. Diagnostically, there are reduced pyridoxal phosphate levels in the CSF with increased levels of CSF levodopa and 3-methoxytyrosine, along with decreased CSF homovanillic acid and 5-hydroxyindoleacetic acid. The EEG may show a burst suppression pattern. Treatment is by enteral administration of pyridoxal phosphate (up to 50 mg/kg/day every 6 hours). **Folinic acid–responsive seizures** may also present with neonatal or infantile epileptic encephalopathy and intractable seizures. Some of these patients have a diagnostic profile similar to that of pyridoxine-dependent epilepsy patients, and their disorder is caused by the same gene variants but responds to folinic acid supplementation in addition to pyridoxine. **Cerebral folate deficiency**, which also responds to high doses of folinic acid (1-3 mg/kg/day), may manifest with epilepsy, intellectual disability, developmental regression, dyskinesias, and autism. CSF 5-methyltetrahydrofolate levels are decreased, with normal plasma and red blood cell folate levels. There are usually pathogenic variants in the folate receptor *(FOLR1)* gene or blocking autoantibodies against membrane-associated folate receptors of the choroid plexus. **Tetrahydrobiopterin deficiencies** with or without hyperphenylalaninemia may present with epilepsies and symptoms resulting from deficiencies of dopamine (parkinsonism, dystonia), noradrenaline (axial hypotonia), serotonin (depression, insomnia, temperature changes), and folate (myelin formation, basal ganglia calcifications, and seizures). Treatment is by substitution therapy with tetrahydrobiopterin and neurotransmitter precursors started as early as possible. **Creatine deficiency syndromes** present typically with developmental delay, seizures, autistic features, and movement disorders and are diagnosed by gene sequencing and abnormal levels of urine creatine and guanidinoacetic acid and/or, particularly in the case of creatine transporter deficiency, an absent creatine peak on MR spectroscopy of the brain. Use of creatine monohydrate and dietary restrictions is helpful. **Biotinidase deficiency** presenting as developmental delay, seizures, ataxia, alopecia, and skin rash and often associated with intermittent metabolic acidosis and an organic acid profile of lactic and propionic acidemia, responds to the use of biotin. Serine biosynthesis defects with low serine levels in plasma or CSF amino acids often present with congenital microcephaly, intractable seizures, and psychomotor retardation and respond to supplemental serine and glycine. **Developmental delay**, **epilepsy**, and **neonatal diabetes** are caused by activating pathogenic variants in the adenosine triphosphate–sensitive potassium channels. Sulfonylurea drugs that block the potassium channel treat the neonatal diabetes and probably also favorably affect the CNS symptoms and affect seizures. **Hyperinsulinism-hyperammonemia syndrome** is caused by activating variants of the glutamate dehydrogenase encoded by *GLUD1*. Patients present with hypoglycemic seizures after a protein-rich meal with hyperammonemia (ammonia levels 80-150 μmol/L). They are managed with a combination of protein restriction, AEDs, and diazoxide (a potassium channel agonist that inhibits insulin release). **GLUT-1 deficiency syndrome** (caused by pathogenic variants in *SLC2A1,* which encodes for a glucose transporter) classically presents with infantile-onset epilepsy, developmental delay, acquired microcephaly, and complex movement disorders. It causes impaired glucose transport to the brain that is typically diagnosed by genetic testing or a finding of low CSF lactate and CSF glucose or low CSF–to–serum glucose ratios (<0.4). The manifestations of the disease are usually responsive to the ketogenic diet. **Thiamine transporter variants with acute basal ganglia disease** often presents with accompanying seizures and is responsive to biotin and thiamine supplementation. **Riboflavin transporter deficiency** can also manifest as a seizure in addition to the usual symptoms of neuromuscular (polyneuropathy) weakness; it is treated with high-dose riboflavin supplementation.

Visit Elsevier eBooks+ at eBooks.Health.Elsevier.com for Bibliography.

633.5 Mechanisms of Seizures

Mohamad A. Mikati, Muhammad S. Zafar, and Dmitry Tchapyjnikov

There are four distinct, often sequential, mechanistic processes in the pathophysiology of epilepsy. First is the **underlying etiology**, which is any pathology or pathologic process that can disrupt neuronal function and connectivity, leading to the second process **(epileptogenesis)**, which makes the brain epileptic. Sometimes the underlying etiology can directly increase excitability even without the contribution of the downstream effects of epileptogenesis.

In some **genetic epilepsies**, a disorder in ion channel function and/or structure is the underlying etiology that leads to aberrant signal transduction, which can cause seizures (see Tables 633.2-633.4). These variants can involve voltage-gated channels (Na^+, K^+, Ca^{2+}, Cl^-, and HCN [hydrogen cyanide]), ligand-gated channels (nicotinic acetylcholine and γ-aminobutyric acid A receptors [$GABA_A$]), or other proteins. For example, in Dravet syndrome, the loss-of-function pathogenic variant in *SCN1A* encodes a voltage-gated sodium channel and causes decreased excitability in inhibitory GABAergic interneurons, leading to increased excitability and epilepsy. In human cortical dysplasia, the expression of the NR2B subunit of the NMDA receptor is increased, leading to excessive depolarizing currents. Gene variants can also affect neurotransmitter function through other mechanisms (see Table 633.3). For example, *ARX* variants can lead to dysfunction in GABAergic neurons and can cause X-linked West syndrome, among other epilepsies. In fragile X syndrome, it is hypothesized that variants in *FMR* cause enhanced glutamatergic signaling via the mGluR5 receptor. In Rett syndrome, variants in *MECP2* lead to increased NMDA receptor expression, which can cause epilepsy and other symptoms associated with the disorder.

In infantile spasms, animal models suggest that increases in the stress-related corticotropin-releasing hormone, sodium channel blockade, and NMDA receptor stimulation are contributing mechanisms.

Autoimmune etiologies for epilepsy are also recognized. Autoantibodies, sometimes generated because of cross-reactivity from a recent infection or secondary to a malignancy, can bind to extracellular receptors or other proteins expressed in neurons. This, in turn, leads to an inflammatory response and, in some cases, seizures. NMDA-receptor antibody encephalitis is probably the best-characterized autoimmune cause of epilepsy. Other epilepsy syndromes have been associated with autoantibodies targeting the voltage-gated potassium channel complex (anti-LGI2 and anti-CASPR2), GABA receptors (GABA-A and GABA-B), glycine receptors, and glutamic acid decarboxylase (GAD).

Abnormalities in the **structure** of the brain can be the underlying etiology for epilepsy. The structural abnormalities can be scarring from

previous injuries (hypoxic ischemic encephalopathy [HIE], stroke, cerebral hemorrhage), brain tumors, vascular malformations (cavernomas or arteriovenous malformations), and Sturge-Weber syndrome. In some cases where no identifying underlying etiology is found, epilepsy may be from the self-resolving maturational process of developing brains like BECTS and childhood occipital epilepsy syndromes (Gastaut and Panayiotopoulos types).

Second, **epileptogenesis** is the mechanism through which the brain, or part of it, turns epileptic. The role of large-scale molecular cell signaling pathways in epileptogenesis has been implicated in the mechanisms leading to epilepsy, namely, the mammalian target of rapamycin (mTOR), the Ras/ERK, and repressor element 1 (RE1)–silencing transcription factor (REST) pathways. The mTOR pathway is seen in tuberous sclerosis, hemimegalencephaly, and cortical dysplasia–related epilepsies; the Ras/ERK pathway in a number of syndromes; and the REST pathway in epileptogenesis after acute neuronal injury. Repeat seizures lead through the earlier and other mechanisms to rewiring of the brain and to long-term epilepsy.

The third process is the resultant **epileptic state of increased excitability** present in all patients irrespective of the underlying etiology or mechanism of epileptogenesis. A dysregulation of glutamatergic excitation versus GABAergic inhibition occurs in epileptogenic neurons, which creates a seizure focus or network.

The fourth process is **seizure-related neuronal injury**, as often is demonstrated by MRI in patients after prolonged status epilepticus or those with long-term drug-resistant epilepsy. Many patients show acute swelling in the hippocampus or other regions after status epilepticus and long-term hippocampal atrophy with sclerosis on MRI. There is evidence from surgically resected epileptic tissue that apoptotic pathways are activated in foci of drug-resistant epilepsy. There is evidence that the pathophysiology of epileptic seizures, whether focal or generalized, and of the coexisting comorbidities involves disruption of neural networks of the brain resulting not only in increased excitability but the often-associated abnormal neurologic dysfunction.

Visit Elsevier eBooks+ at eBooks.Health.Elsevier.com for Bibliography.

633.6 Treatment of Seizures and Epilepsy

Mohamad A. Mikati, Muhammad S. Zafar, and Dmitry Tchapyjnikov

DECIDING ON LONG-TERM THERAPY

After a first seizure, if the risk of recurrence is low, such as when the patient has a normal neurodevelopmental status, EEG, and MRI (risk ~20%), treatment is usually not started. If the patient has an abnormal EEG, MRI, developmental status, and/or neurologic exam and/or has a positive family history of epilepsy, the risk is higher, and often treatment is started. Other considerations are also important, such as motor vehicle driving status and type of employment in older patients or the parents' ability to manage recurrences or AED therapy in children. The decision is individualized and should be discussed with the family. Figure 633.8 presents an overview of the approach to the treatment of seizures and epilepsy.

COUNSELING

An important part of the management of a patient with epilepsy is educating the family and the child about the disease, its management, and the limitations it might impose and how to live with them. Restrictions on driving (in adolescents), swimming, and certain sports are usually necessary (Table 633.12). In most states, the physician is not required to report the epileptic patient to the motor vehicle registry; this is the patient's responsibility. The physician is then requested to complete a specific form for patients who are being cleared to drive. In addition, in most states, a seizure-free period of 6 months, and in some states longer, is required before driving is allowed. Often swimming in rivers, lakes, or the sea and underwater diving are prohibited, but swimming in pools may be allowable. When swimming, even patients with epilepsy under excellent control should be under the continuous supervision of an observer who is aware of the condition and capable of lifeguard-level rescue.

The physician, parents, and child should jointly evaluate the risk of involvement in athletic activities. To participate in athletics, proper medical management, good seizure control, and proper supervision are crucial to avoid significant risks. The ILAE Task Force on Sports and Epilepsy recommendations group sports into categories based on the potential risk of injury or death to the patient and to bystanders. **Group 1 sports** are associated with no significant additional risk to patients with epilepsy and include most athletics (excluding pole vaulting), bowling, most collective contact sports such as judo and wrestling, most ground-based collective sports (e.g., baseball, basketball, cricket, field hockey, football, rugby), cross country skiing, curling, dancing, golf, and racquet sports, including tennis and table tennis. **Group 2 sports** are associated with moderate risk to patients with epilepsy but not to bystanders; they include alpine skiing, archery, pole vaulting, biathlon/triathlon/modern pentathlon, canoeing, collective sports that can potentially lead to serious injury (e.g., boxing, karate, kickboxing), cycling, fencing, gymnastics, horse riding, ice hockey, shooting, skateboarding, roller and ice skating, skiing and snowboarding, swimming, water skiing, and weightlifting. **Group 3 sports** are considered high risk for the patient and for bystanders; they include aviation, climbing, platform and springboard diving, horse racing, motorsports, parachuting and other forms of skydiving, rodeo, scuba diving, ski jumping, solitary sailing, and surfing and windsurfing (see Table 633.12). In general, there has been a shift toward encouraging safe sports participation in patients with epilepsy rather than indiscriminately restricting their participation; however, the decision has to be individualized to the patient and his or her family. Staying physically active has been shown to reduce the chance for neuropsychologic impairments that often are associated with epilepsy.

Counseling is helpful to support the family and to educate them about the resources available in the community. Educational and, in some cases, a psychologic evaluation may be necessary to evaluate for possible learning disabilities or abnormal behavioral patterns that might coexist with epilepsy. Epilepsy does carry a risk of increased mortality rates (2 or more times the standardized mortality rates of the general population) and of sudden unexpected death. This is mostly related to the conditions associated with or underlying epilepsy (e.g., tumor, metabolic diseases), to poor seizure control (e.g., in patients with severe epileptic encephalopathies or drug-resistant seizures), and to poor compliance with prescribed therapies. Thus it is recommended that family members be informed about this increased risk without inappropriately increasing their anxiety. Many family members feel they need to observe the patient continuously in wakefulness and sleep and have the patient sleep in the parents' room to detect seizures. There are advertised seizure-detection devices that use motion sensors placed under the mattress or worn on the wrist to detect seizures. Some are disappointing and ineffective in detecting seizures, whereas data from other equipment are encouraging. They are useful in detecting a majority of generalized tonic-clonic seizures during sleep; most have not been rigorously studied. Whether such measures can reduce the risk of **sudden unexpected death in epilepsy (SUDEP)** remains to be seen. The parents need to guard against being overprotective to avoid adversely affecting the child's psychology. Education about what to do in case of seizures, the choices of treatment or no treatment and medications and their side effects, and the potential complications of epilepsy should be provided to the parents and, if the child is old enough, to the child.

PRINCIPLE OF DRUG THERAPY

The clinical pharmacology of an AED consists of three important facets: pharmacokinetics, pharmacodynamics, and pharmacogenomics.

Pharmacokinetics describes how the body affects antiepileptics after administration through the mechanisms of absorption and distribution, as well as the metabolic changes of the substance in the body. The steps involved in pharmacokinetics are liberation (the process of release of a drug from the pharmaceutical formulation), absorption

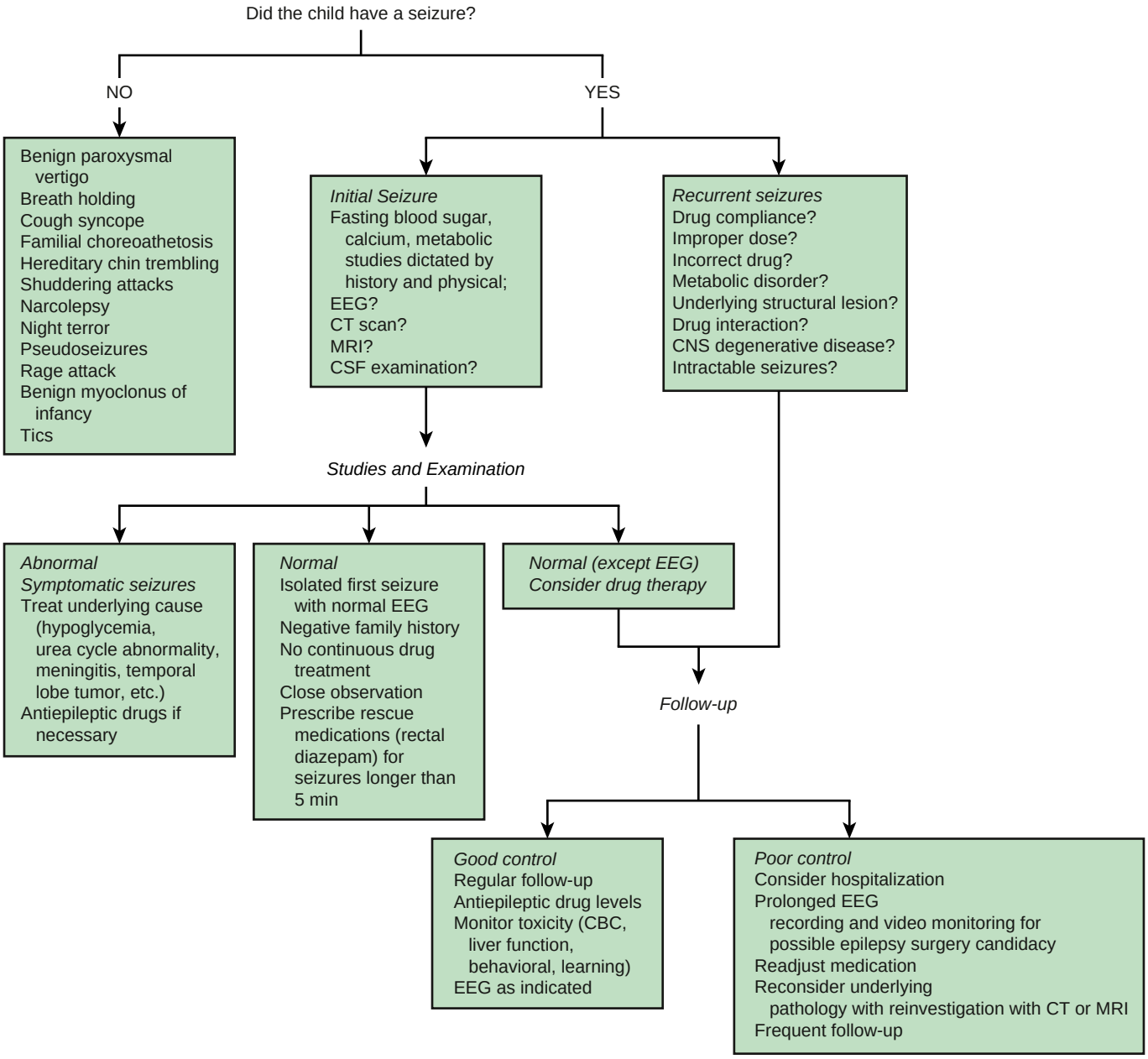

Fig. 633.8 Algorithm for the approach to the child with a suspected convulsive disorder.

Table 633.12 Sports and Special Considerations for the Child with Epilepsy*

CLINICAL SITUATION	GROUP 1	GROUP 2	GROUP 3
Acute symptomatic seizures (one or more)	Permitted	Neurologist's discretion	Neurologist's discretion
One unprovoked seizure	Permitted	Permitted if >12 mo of seizure freedom	Permitted if >12 mo of seizure freedom
Seizure freedom for >12 mo	Permitted	Permitted	Permitted
Sleep-related seizures	Permitted	Neurologist's discretion	Neurologist's discretion
Seizures without impaired awareness	Permitted	Neurologist's discretion	Not recommended
Seizures with impaired awareness	Neurologist's discretion	Neurologist's discretion	Not recommended
Resolved epilepsy with no seizures >10 yr and off AEDs >5 yr	Permitted	Permitted	Permitted
Medication withdrawal	Neurologist's discretion	Neurologist's discretion	Neurologist's discretion

*Specific advice should be individualized, depending on the patient's clinical condition. Group 1: low-risk sports; Group 2: moderate-risk sports; Group 3: high-risk sports. Refer to Chapter 633.6 for further details about the definition of each group.

Modified from Capovilla G, Kaufman KR, Perucca E, et al. Epilepsy, seizures, physical exercise, and sports: a report from the ILAE Task Force on Sports and Epilepsy. *Epilepsia*. 2016;57:6–12.

(the process of a substance entering the blood circulation), distribution (the dispersion or dissemination of substances throughout the fluids and tissues of the body), metabolism (the irreversible transformation of parent compounds into daughter metabolites), and excretion (the removal of the substances from the body).

Pharmacodynamics describes the biochemical and physiologic effect of AED dose or concentration. The response may be desirable *(effectiveness)* or untoward *(toxicity)*. **Pharmacogenomics** is the study of how variant forms of human genes contribute to interindividual variability in drug response.

MECHANISMS OF ACTION OF ANTIEPILEPTIC DRUGS

AEDs reduce excitability by interfering with sodium, potassium, or calcium ion channels by reducing excitatory neurotransmitter release or function or enhancing GABAergic inhibition (Fig. 633.9). Most medications have multiple mechanisms of action, and the exact mechanism responsible for their activity in human epilepsy is usually not fully understood. Often, medications acting on sodium channels are effective against partial seizures, and medications acting on T-type calcium channels are effective against absence seizures. Voltage-gated sodium channels are blocked by felbamate, valproate, topiramate, carbamazepine, oxcarbazepine, lamotrigine, phenytoin, rufinamide, lacosamide, and zonisamide. T-type calcium channels found in the thalamus area are blocked by valproate, zonisamide, and ethosuximide. Voltage-gated calcium channels are inhibited by gabapentin, pregabalin, lamotrigine, and felbamate. N-type calcium channels are inhibited by levetiracetam.

$GABA_A$ receptors are activated by phenobarbital, benzodiazepines, topiramate, felbamate, and levetiracetam. Tiagabine, by virtue of its binding to GABA transporters 1 (GAT-1) and 3 (GAT-3), is a GABA reuptake inhibitor. GABA levels are increased by vigabatrin via its irreversible inhibition of GABA transaminases. Valproate inhibits GABA transaminases, acts on $GABA_B$ presynaptic receptors (also done by gabapentin), and activates glutamic acid decarboxylase (the enzyme that forms GABA).

Glutaminergic transmission is decreased by felbamate that blocks NMDA and AMPA (α-amino-3-hydroxy-5-methyl-4-isoxazole-propionic acid)/kainate receptors. Topiramate also blocks AMPA/kainate receptors. Levetiracetam and brivaracetam bind to the presynaptic vesicle protein SV2A found in all neurotransmitter vesicles and possibly result in inhibition of presynaptic neurotransmitter release in a use-dependent manner. Perampanel blocks glutamate AMPA receptors.

The precise mechanisms by which cannabidiol (CBD) exerts its anticonvulsant effect in humans are unknown. CBD does not appear to exert its anticonvulsant effects through interaction with cannabinoid receptors. Fenfluramine increases extracellular levels of serotonin through interaction with serotonin transporter proteins and exhibits agonist activity at serotonin 5HT-2 receptors. Everolimus is

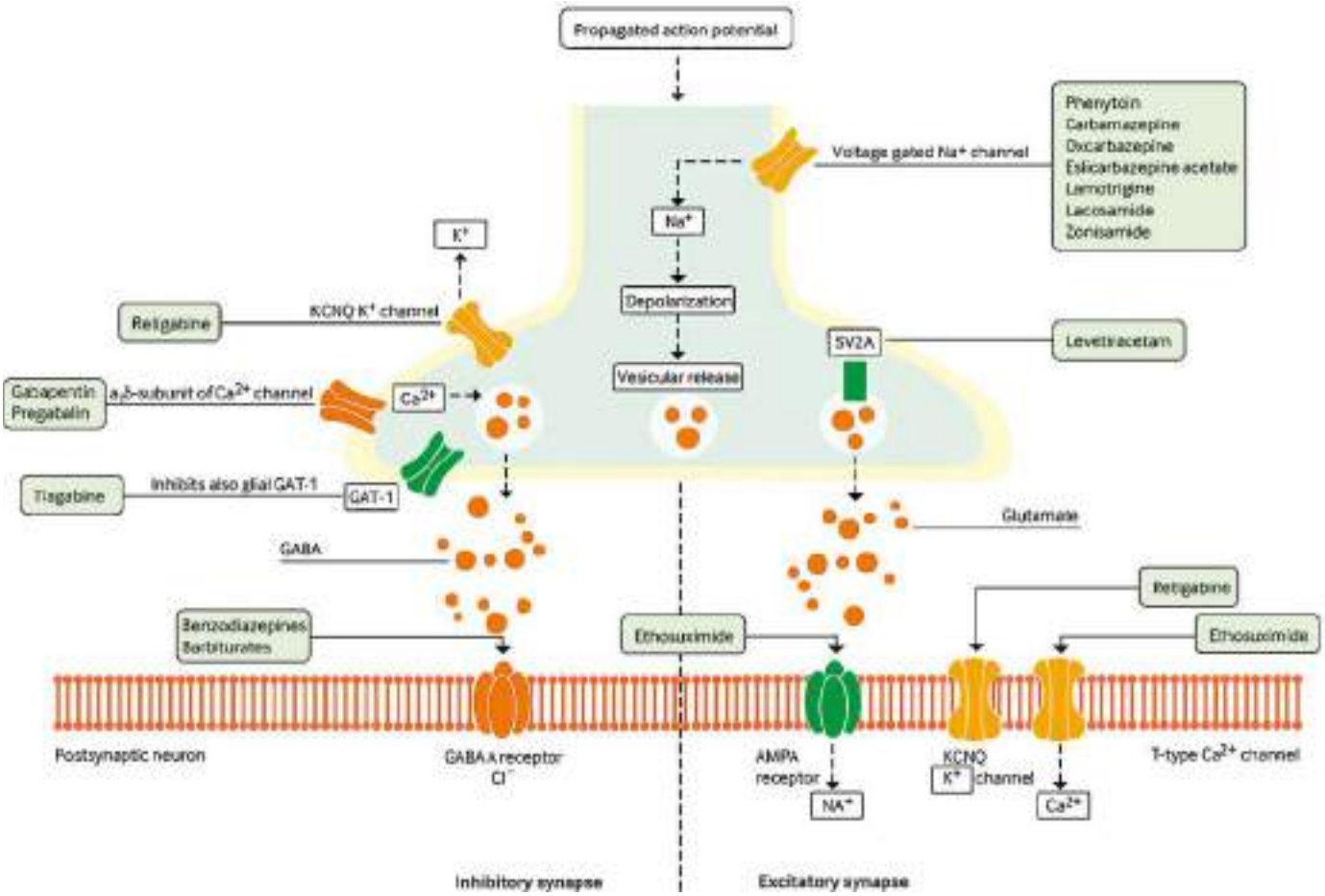

Fig. 633.9 Mechanisms of action of AEDs, which are diverse, mainly involving modulation of voltage-activated ion channels, potentiation of GABA, and inhibition of glutamate. Approved AEDs have effects on inhibitory *(left-hand side)* and excitatory *(right-hand side)* nerve terminals. The antiepileptic efficacy in trials of most of these drugs as initial add-ons does not differ greatly, indicating that seemingly similar antiseizure activity can be obtained by mechanisms aimed at diverse targets. However, putative mechanisms of action were determined only after discovering the antiseizure effects; mechanism-driven drug discovery has played only a minor role. AMPA, α-Amino-3-hydroxy-5-methyl-4-isoxazole propionic acid; GABA, γ-aminobutyric acid; GAT-1, sodium-dependent and chloride-dependent GABA transporter 1; SV2A, synaptic vesicle glycoprotein 2A. *(From Schmidt D, Schachter SC. Drug treatment of epilepsy in adults. BMJ. 2014;348:g254.)*

an inhibitor of mTOR, a serine-threonine kinase, downstream of the PI3K/AKT pathway. The mTOR pathway is dysregulated (too active) in tuberous sclerosis. Ganaxolone is a positive allosteric modulator of synaptic and extrasynaptic $GABA_A$ receptors. It is being studied for long-term use in certain types of epilepsy and in acute treatment of status epilepticus.

There is also a role for immune modulation in treating epilepsy, as depicted by the use of adrenocorticotropic hormone (ACTH), IVIG, oral prednisone, and intravenous methylprednisolone.

CHOICE OF DRUG ACCORDING TO SEIZURE TYPE AND EPILEPSY SYNDROME

Drug therapy should be based on the type of seizure and the epilepsy syndrome and on other individual factors. In general, the **drugs of first choice** for focal seizures and epilepsies are oxcarbazepine and levetiracetam; for absence seizures, ethosuximide; for juvenile myoclonic epilepsy, valproate (less so in women because of its hormonal and fetal side effects); other choices include levetiracetam (which is often the first drug to use in other primary generalized seizures), lamotrigine, zonisamide, topiramate, and perampanel. There is significant controversy about these choices, and therapy should always be individualized (see "Choice of Drug: Other Considerations").

West syndrome is best treated with hormonal therapy in the form of either ACTH injections or, possibly, oral steroids. There are several protocols that range in dose from high to intermediate to low. The recommended regimen of ACTH (80 mg/mL) is a daily dose of 150 units/m^2 (divided into twice-daily intramuscular injections of 75 units/m^2) administered over a 2-week period with a subsequent gradual taper over a 2-week period (30 units/m^2 in the morning for 3 days; 15 units/m^2 in the morning for 3 days; 10 units/m^2 in the morning for 3 days; and 10 units/m^2 every other morning for 6 days; then stop). Response is usually observed within the first 7 days. During the tapering period of any regimen, spasm relapse can occur. Remediation entails increasing the dose to the previously effective dose for 2 weeks and then beginning the taper again. Synthetic ACTH (tetracosactide/cosyntropin) can also be used as long as the long-acting (depot) preparation is chosen. Oral high-dose prednisolone is a lower-cost alternative to ACTH and does not necessitate families learning how to administer intramuscular injections; however, it may be inferior in efficacy to ACTH, particularly in those with cryptogenic (of unknown etiology) West syndrome.

Awake and asleep EEGs are often done 1, 2, and 4 weeks after the initiation of hormonal therapy to monitor the patient's response, with the aim of clearing the EEG from hypsarrhythmia and of stopping the seizures. Side effects, more common with the higher doses, include hypertension, electrolyte imbalance, infections, hyperglycemia and/or glycosuria, and gastric ulcers. Prophylactic therapy for ulcers with an H_2 blocker or protein pump inhibitor is desirable while the patient is receiving hormonal therapy. Also, live vaccines are contraindicated, and other vaccines are not effective during ACTH and steroid therapy because of the immune-suppressive effects of these hormonal agents. Thus all vaccines are not given during hormonal therapy and in the period after it (usually ≤3 months after the last dose).

Vigabatrin can be used as a first-line agent to treat **infantile spasms** in patients with tuberous sclerosis and is the second-line choice if hormonal therapy was unsuccessful in other cases of infantile spasms. Its principal side effect is retinal toxicity, seen in approximately 30% of patients, most often if the drug is used for longer than 6 months, with resultant visual field defects that persist despite the withdrawal of the drug. Because of this toxicity, vigabatrin is available only through a restricted distribution Risk Evaluation and Mitigation Strategy (REMS) program. The level of evidence for its efficacy is weaker than that for ACTH but stronger than that of other alternative medications. Emerging evidence suggests that dual treatment with vigabatrin and hormonal therapy at the onset of spasms may be superior to hormonal therapy alone but may predispose to the CNS neurotoxicity of vigabatrin associated with increased T2 signal in the basal ganglia. The ketogenic diet is probably the third-line therapy. Subsequent alternative treatment options for spasms include valproate, benzodiazepines such as nitrazepam and clonazepam, topiramate, lamotrigine, zonisamide, pyridoxine, and IVIG. None of these alternative drugs offers uniformly satisfactory results. However, they are useful for decreasing the frequency and severity of seizures in patients with symptomatic infantile spasms and as adjunctive therapy in patients with idiopathic infantile spasms who do not respond completely to ACTH or vigabatrin.

Lennox-Gastaut syndrome is another difficult-to-treat epilepsy syndrome. Treatment of seizures in the syndrome varies according to the preponderant seizure type. For drop attacks (tonic, atonic, or myoclonic-astatic seizures), clobazam, valproate, lamotrigine, topiramate, felbamate, and rufinamide are considered effective. The FDA also approved CBD and fenfluramine to be used in Lennox-Gastaut syndrome. Fenfluramine is available only through a restricted distribution REMS program because of the risk of valvular heart disease and pulmonary arterial hypertension.

Felbamate is used as a last-resort medication because of its potential toxicity. These drugs might control other types of seizures (partial, generalized tonic-clonic, atypical absence, other tonic, myoclonic). For patients who have a preponderance of atypical absence seizures, valproate, lamotrigine, or ethosuximide are often suitable drugs to try because they are relatively less toxic than many alternative drugs. Clonazepam is often helpful but produces significant sedation, hyperactivity, and drooling and often tolerance to its antiepileptic effects develops in a few months. Consequently, in Lennox-Gastaut or other drug-resistant epilepsy syndromes, clonazepam is often used as a rescue medication for clusters of seizures (disintegrating tablet preparation) or as a bridge over a few days until dose changes of background medications take effect. In resistant cases of Lennox-Gastaut syndrome and related epilepsies, ketogenic diet, zonisamide, levetiracetam, acetazolamide, methsuximide, corticosteroids, or IVIG can be used.

Dravet syndrome is usually treated with benzodiazepines such as clobazam and with valproate. The ketogenic diet can also be useful in patients with this syndrome, including cases with refractory status. Stiripentol, which is available in some countries, is useful, particularly if used in combination with valproate and clobazam; doses need to be adjusted because stiripentol can increase clobazam levels, and valproate can increase stiripentol levels. Other medications include zonisamide and topiramate. Lamotrigine, carbamazepine, oxcarbazepine, and phenytoin are reported to exacerbate seizures in Dravet syndrome. Barbiturate use during status epilepticus in this syndrome is suspected to be associated with adverse outcomes; consequently, alternative acute therapies in such cases need to be considered.

The FDA has approved CBD and fenfluramine for the treatment of seizures associated with Lennox-Gastaut syndrome or Dravet syndrome in patients ≥2 years. The starting dose is 2.5 mg/kg taken twice daily (5 mg/kg/day). After 1 week, the dose is usually increased to a maintenance dosage of 5 mg/kg twice daily (10 mg/kg/day). If it is tolerated and needed, the dose may be increased up to 10 mg/kg twice daily (20 mg/kg/day). It comes as an oral solution (100 mg/mL). Checking the package insert of all these medications before initiating their use is essential because of the frequent interactions with concurrent antiseizure and other medications.

Absence seizures are most often initially treated with ethosuximide, which is as effective as, but less toxic than, valproate; both are more effective than lamotrigine (which has fewer side effects than valproate). Alternative drugs of first choice are lamotrigine and valproate, especially if generalized tonic-clonic seizures coexist with absence seizures. These two medications are effective against the latter seizures, whereas ethosuximide is not. Patients resistant to ethosuximide might still respond to valproate or to lamotrigine. In absence seizures, the EEG is usually helpful in monitoring the response to therapy and is often more sensitive than the parents' observations in detecting these seizures. The EEG often normalizes when complete seizure control is achieved. This is usually not true for partial epilepsies. Other medications that could be used for absence seizures include acetazolamide, zonisamide, or clonazepam.

Benign myoclonic epilepsies are often best treated with valproate, particularly when patients have associated generalized tonic-clonic and absence seizures. Zonisamide, clonazepam, lamotrigine, and topiramate are alternatives.

Severe myoclonic epilepsies are treated with medications effective for Lennox-Gastaut syndromes, such as topiramate, clobazam, valproate, and zonisamide. Levetiracetam may also have efficacy in myoclonic epilepsies.

Focal and focal to bilateral tonic-clonic seizures can be treated with oxcarbazepine, levetiracetam, carbamazepine, phenobarbital, topiramate, lacosamide, zonisamide, valproic acid, lamotrigine, clobazam, perampanel, or clonazepam (see Table 633.1). Oxcarbazepine and levetiracetam are often used first.

Vigabatrin is the preferred treatment for infantile spasms due to **tuberous sclerosis**. The FDA also approved CBD and everolimus to treat a seizure in tuberous sclerosis in patients older than 2 years of age.

For children with ESES and SWS, nighttime benzodiazepine and daily or pulsed-dose steroids are preferentially used. Alternatively, other AEDs like valproate, clobazam, levetiracetam, and acetazolamide and ketogenic therapy have been used.

CHOICE OF DRUG: OTHER CONSIDERATIONS

Because there are many options for each patient, the choice of which drug to use is always an individualized decision based on comparative effectiveness data from randomized controlled trials and on several other considerations delineated next:

- **Comparative effectiveness** (Tables 633.13 and 633.14 list dosages) and the **potential for paradoxical seizure aggravation** by some AEDs (e.g., precipitation of myoclonic seizures by lamotrigine in Dravet syndrome and exacerbation of absence seizures by carbamazepine and tiagabine) must be considered. Although many antiseizure medications have not been studied in the pediatric population, off-label use of these medications in children is common, and there are studies that have shown that, in general, their efficacy in adults is predictive of their efficacy in children with the same seizure types.
- **Comparative tolerability** (Table 633.15): Adverse effects can vary according to the profile of the patient. The most prominent example is the increased risk of liver toxicity for valproate therapy in children who are younger than 2 years of age, taking polytherapy, and/or have metabolic disorders. Thus if metabolic disorders are suspected, other drugs should be considered first, and valproate should not be started until the metabolic disorders are ruled out by normal amino acids, organic acids, acylcarnitine profile, lactate, pyruvate, liver function tests, and perhaps gene testing for mitochondrial disorders (see the paragraph on the presence of comorbid conditions later). The choice of an AED can also be influenced by the likelihood of occurrence of nuisance side effects, such as weight gain (valproate, carbamazepine), gingival hyperplasia (phenytoin), alopecia (valproate), hyperactivity (benzodiazepines, barbiturates, levetiracetam, valproate, gabapentin), or irritability/anger (levetiracetam and perampanel). Children with behavior problems and/or with attention-deficit disorder can become particularly hyperactive with the GABAergic drugs mentioned earlier. This often affects the choice of medications. In general, newer-generation antiepileptic medications provide a better side effect profile than older medications.
- **Cost and availability**: The cost of the newer AEDs often precludes their use, particularly in developing countries. Many drugs are not available in all countries (1) because they are too expensive; (2) because, paradoxically, they are too inexpensive (lower profit margin); or (3) because of regulatory restrictions. AEDs have a narrow therapeutic range, and thus switching from brand name to generic formulations or from one generic to another can result in changes in levels that could result in breakthrough seizures or side effects.
- **Ease of initiation** of the AED: Medications started very gradually, such as lamotrigine and topiramate, should not be chosen in situations when there is a need to quickly achieve a therapeutic level. In such situations, medications that have intravenous preparations or

Table 633.13 Comparison of Recommendations for the Treatment of Pediatric Epilepsy

SEIZURE TYPE OR EPILEPSY SYNDROME	FDA APPROVED†	ILAE (2013)* †
Focal-onset	CBZ, ezogabine, lacosamide, LEV, LTG, OXC, PB, PER, PHT, TPM, VGB	A: OXC B: None C: CBZ, PB, PHT, TPM, VGB, VPA D: CLB, CZP, LTG, ZNS
BCECT	None	A, B: None C: CBZ, VPA D: GBP, LEV, OXC, STM
Childhood absence epilepsy	ESM, VPA	A: ESM, VPA B: None C: LTG D: None
Juvenile myoclonic epilepsy	LEV, LTG, TPM	A, B, C: None D: TPM, VPA
Lennox-Gastaut syndrome	CLB, FLB, LTG, rufinamide (atonic), TPM	Not reviewed
Infantile spasms	ACTH, VGB	Not reviewed
Primary generalized tonic-clonic seizures	LEV, LTG, TPM, PER	A: None B: None C: CBZ, PB, PHT, TPM, VPA D: OXC

*ILAE recommendations are listed according to levels of evidence supporting the efficacy of the options. Level A: one or more class I randomized controlled trials (RCTs) or two or more class II RCTs; Level B: one class II RCT or two or more class III RCTs; Level C: two or more class III RCTs; Level D: one class III double-blind or open-label study *or* one class IV clinical study *or* data from expert committee reports, opinions from experienced clinicians.

†More recent data are available after FDA approval and ILAE review, and the implications of these data have been incorporated as much as possible into Table 633.13. Together, these two tables aim to provide as complete a picture as possible of the state of the art and the approved indications for the therapy of pediatric epilepsy.

ACTH, Adrenocorticotropic hormone; BCECT, benign childhood epilepsy with centrotemporal spikes; CBZ, carbamazepine; CLB, clobazam; CZP, clonazepam; ESM, ethosuximide; FDA, Food and Drug Administration; FLB, felbamate; GBP, gabapentin; ILAE, International League Against Epilepsy; LEV, levetiracetam; LTG, lamotrigine; OXC, oxcarbazepine; PB, phenobarbital; PER, perampanel; PHT, phenytoin; STM, sulthiame; TPM, topiramate; VGB, vigabatrin; VPA, valproic acid; ZNS, zonisamide.

Modified and updated from Perucca E, Tomson T. ILAE Subcommission on AED Guidelines: updated ILAE evidence review of antiepileptic drug efficacy and effectiveness as initial monotherapy for epileptic seizures and syndromes. *Epilepsia*. 2013;54(3):551–563.

Table 633.14 Dosages of Selected Antiepileptic Drugs

MEDICATION	FDA APPROVAL (AGE APPROVED)	MAINTENANCE ORAL DOSAGE (mg/kg/day) UNLESS OTHERWISE SPECIFIED	USUAL DOSING	THERAPEUTIC LEVELS	PREPARATIONS
Acetazolamide	Absence seizures (adults)	1-12 mo: 10 >1 yr: 20-30	bid or tid	10-15 mg/L	125, 250, 500 mg tabs
Brivaracetam	Focal sz (age >16 yr)	50-200 mg/day	bid		10, 25, 50, 75, 100 mg tabs; 10 mg/mL oral and IV solns
Bromide		50-100	bid or qd	10-15 mEq/L, other references 75-352 mg/dL	Supplied as triple bromide soln (240 mg/mL or 500 mg/mL of bromide salt)
Carbamazepine*	Focal and GTC (all ages)	10-20	tid or qid SR usually bid	3-12 mg/L	150, 300 mg ER caps; 100, 200, 400 mg ER tabs 100 mg chewable tabs; 200 mg tabs; 100 mg/5 mL susp
Cenobamate	Focal in adults ≥18 yr	200-400 mg/day final dose	Once per day	—	12.5, 25, 50, 100, 150, 200 and 400 mg tabs
Clobazam†	LGS (all ages above 2 yr)	10-40 mg/day	bid	60-200 μg/L	10 mg, 20 mg tabs; 2.5 mg/mL soln
Clonazepam†	Absence sz, LGS, myoclonic sz (all ages)	0.05	bid or tid	25-85 μg/L	0.5, 1, 2 mg tabs; 0.125, 0.25, 0.5 mg orally disintegrating tabs
Diazepam	Focal sz (all ages >6 mo)	0.25-1.5 0.01-0.25 IV 0.2-0.5 mg/kg rectal (according to age)	bid or tid	100-700 μg/L	2, 5, 10 mg tabs 5 mg/mL, 5 mg/5 mL soln; rectal gel that can be dialed to dispense 2.5, 5, 7.5, 10, 12.5, 15, 17.5, 20 mg
Eslicarbazepine	Focal sz (adult)	800-1600 mg/day	qd		200, 400, 600, 800 mg tabs
Ethosuximide	Absence sz (>3 yr)	20-30	bid or tid	40-100 mg/L	250 mg caps; 250 mg/5 mL soln
Felbamate	LGS (>2 yr) Focal sz (>14 yr)	15-45	bid or tid	50-110 mg/L	400, 600 mg tabs; 600 mg/5 mL susp
Gabapentin‡	Focal sz (>3 yr)	30-60	tid	2-20 mg/L	100, 300, 400 mg caps; 300, 600, 800 mg tabs; 250 mg/5 mL soln; 25 mg/mL susp
Lacosamide	Focal sz (>17 yr)	4-12	bid	≤15 μg/L	50, 100, 150, 200 mg tabs 10 mg/mL oral soln
Lamotrigine	LGS, focal and tonic-clonic sz (age >2 yr)	5-15§ 1-5¶	tid bid	1-15 mg/L	25, 100, 150, 200 mg tabs 5, 25 mg chewable dispersible tabs 25, 50, 100, 200 mg ODTs 25, 50, 100, 200, 250, 300 mg ER tabs
Levetiracetam†	Focal-onset (age ≥1 mo), tonic-clonic sz (age ≥6 yr), myoclonic (age ≥12 yr)	20-60	bid or tid	6-40 mg/L	250, 500, 750 mg tabs 100 mg/mL soln 500, 750 mg SR (ER) tabs
Lorazepam	Status epilepticus (all ages)	0.05-0.1	bid or tid	20-30 μg/L	0.5, 1, 2 mg tabs 2 mg/mL soln

Continued

Table 633.14 Dosages of Selected Antiepileptic Drugs—cont'd

MEDICATION	FDA APPROVAL (AGE APPROVED)	MAINTENANCE ORAL DOSAGE (mg/kg/day) UNLESS OTHERWISE SPECIFIED	USUAL DOSING	THERAPEUTIC LEVELS	PREPARATIONS
Methsuximide	Absence sz (children and older)	10-30	bid or tid	10-50 mg/L	150, 300 mg caps
Nitrazepam	—	0.25-1	bid or tid	<200 µg/L	5 mg tabs
Oxcarbazepine*	Focal sz (>2 yr)	20-60	bid	13-35 mg/L	150, 300, 600 mg tabs 300 mg/5 mL susp
Perampanel	Focal sz (>12 yr)	2-12 mg per day (>12 yr)	qhs	20-800 ng/mL	2, 4, 6, 8, 10, 12 mg tabs; 0.5 mg/mL soln
Phenobarbital	Myoclonic, focal and tonic-clonic sz and status (all ages)	<5 yr, 3-5 >5 yr, 2-3	bid or qd	10-40 mg/L	15, 30, 60, 90, 100 mg tabs 4 mg/mL soln
Phenytoin	Focal, tonic-clonic sz and status (all ages)	<3 yr, 8-10 >3 yr, 4-7	tabs, susp: tid caps: qd	5-20 mg/L	50 mg tabs 30,100 mg caps 125 mg/5 mL susp
Pregabalin	Focal sz (adults)	2-14	bid	Up to 10 µg/mL	25, 50, 75, 100, 150, 200, 225, 300 mg caps 20 mg/mL soln
Primidone	Focal and tonic-clonic sz (all ages)	10-20	bid or tid	4-13 mg/L	50, 250 mg tabs, susp
Rufinamide†	LGS (age >4 yr)	30-45	bid	<60 µg/mL	200, 400 mg tabs
Sulthiame**		5-15	bid or tid	1.5-20 µg/mL	50, 200 mg caps
Tiagabine	Focal sz (age >2 yr)	0.5-2	bid, tid, qid	80-450 µg/L	2, 4, 12, 16 mg tabs
Topiramate†	LGS, focal and tonic-clonic sz (all ages)	3-9, slow titration	bid or tid	2-25 mg/L	25, 100, 200 mg tabs 15, 25 mg sprinkle caps
Valproate	Absence, myoclonic, focal and tonic-clonic sz (age >2 yr)	15-40; higher doses are used if patient is on enzyme inducers (≤60 mg/kg/day)	Sprinkle caps: bid Soln: tid	50-100 mg/L	250 mg caps 125 mg sprinkle caps 125, 250, 500 mg tabs 250 mg/5 mL soln
Vigabatrin	Infantile spasms and focal sz (age >1 mo)	50-150	bid	20-160 µg/mL (following levels is not useful for this drug)	500 mg tabs 500 mg powder for soln
Zonisamide	Focal sz (age >16 yr)	4-8	bid or qd	10-40 mg/L	100 mg caps

*Usually start with one-fourth maintenance dose and increase by one-fourth every 2-3 days to full dose.
†Usually start with one-fourth maintenance dose and increase by one-fourth every 7 days to full dose.
‡Usually start with one-fourth maintenance dose and increase by one-fourth every day to full dose.
§Child receiving enzyme inducers.
**Available in some European countries.
¶Child receiving valproate.
Unless specified otherwise earlier, one would usually target the lower range of the therapeutic dose and then adjust it as needed, depending on the response, side effects, and/or levels. The dosing schedule (e.g., bid or tid) can depend on if a sustained-release preparation is available and if the patient is taking enzyme inducers (e.g., carbamazepine) or inhibitors (e.g., valproic acid) that could affect the drug (as indicated in the dosing schedule in the table and in the text).
cap, Capsule; ER, extended release; GTC, generalized tonic-clonic; LGS, Lennox-Gastaut syndrome; ODT, orally disintegrating tablet; soln, solution; SR, sustained release; susp, suspension; sz, seizure(s); tab, tablet.

Table 633.15 Some Adverse Effects of Antiepileptic Drugs*

ANTIEPILEPTIC DRUG	SIDE EFFECTS
Acetazolamide	Nuisance: dizziness, polyuria, electrolyte imbalance Serious: Stevens-Johnson syndrome, renal calculi
Benzodiazepines	Nuisance: dose-related neurotoxicity (drowsiness, sedation, ataxia), hyperactivity, drooling, increased secretions Serious: apnea
Brivaracetam	Dizziness, nausea/vomiting, fatigue, depressed mood
Bromide	Nuisance: irritability, spurious hyperchloremia (falsely high chloride due to bromide) Serious: psychosis, rash, toxicity developing slowly owing to the very long half-life
Carbamazepine	Nuisance: tics, transient leukopenia; hyponatremia, weight gain, nausea; dizziness Serious: Stevens-Johnson syndrome, agranulocytosis, aplastic anemia, liver toxicity
Cenobamate	Drug reaction with eosinophilia and systemic symptoms (DRESS), short QT, sedation, H/A Contraindicated in familial short QT syndrome
Clobazam	Nuisance: drowsiness, sedation, drooling Serious: Stevens-Johnson syndrome, toxic epidermal necrolysis
Eslicarbazepine	Dizziness, ataxia, nausea/vomiting, diplopia, tremor, somnolence, headache, fatigue
Felbamate	Nuisance: anorexia, vomiting, insomnia, hyperactivity, dizziness Serious: major risks for liver and hematologic toxicity requiring close monitoring (1 in 500 in children >2 yr with complex neurologic disorders)
Gabapentin	In children: acute onset of aggression, hyperactivity In adults: euphoria and behavioral disinhibition, weight gain
Lacosamide	Nuisance: diplopia, headache, dizziness, nausea Serious: possibly cardiac arrhythmias (if predisposed)
Lamotrigine	Nuisance: CNS side effects: headache, ataxia, dizziness, tremor, but usually less than other AEDs Serious: Stevens-Johnson syndrome, ECG abnormalities (both have FDA warning about them), rarely liver toxicity
Levetiracetam	CNS adverse events: somnolence, asthenia, dizziness, but usually less than other AEDs In children: anger, irritability, other behavioral symptoms In adults: depressive mood
Oxcarbazepine	Somnolence, headache, dizziness, nausea, apathy, rash, hypertrichosis, gingival hypertrophy, hyponatremia
Perampanel	Aggression, homicidal ideation, suicidal thoughts/behavior
Phenobarbital and other barbiturates	Nuisance: neurotoxicity, insomnia, hyperactivity, signs of distractibility, fluctuation of mood, aggressive outbursts Serious: liver toxicity, Stevens-Johnson syndrome
Phenytoin and other hydantoins	Nuisance: gingival hyperplasia, coarsening of the facies, hirsutism, cerebellovestibular symptoms (nystagmus and ataxia) Serious: Stevens-Johnson syndrome, liver toxicity
Pregabalin	Nuisance: dizziness, peripheral edema, blurred vision, weight gain, thrombocytopenia Serious: hypersensitivity reactions
Primidone	Nuisance: CNS toxicity (dizziness, slurred speech, giddiness, drowsiness, depression) Serious: liver toxicity, Stevens-Johnson syndrome
Rufinamide	Nuisance: somnolence, vomiting Serious: contraindicated in familial short QT interval
Succinimides	Nuisance: nausea, abdominal discomfort, anorexia, hiccups Serious: Stevens-Johnson syndrome, drug-induced lupus
Tiagabine	Nuisance: dizziness, somnolence, asthenia, headache and tremor, precipitation of absence or myoclonic seizures Serious: precipitation of nonconvulsive status epilepticus
Topiramate	Nuisance: cognitive dysfunction, weight loss, hypohidrosis, fever Serious: precipitation of glaucoma, renal calculi
Valproic acid	Nuisance: weight gain, hyperammonemia, tremor, alopecia, menstrual irregularities Serious: hepatic and pancreatic toxicity
Vigabatrin	Nuisance: hyperactivity Serious: irreversible visual field deficits, retinopathy that requires frequent ophthalmologic evaluations and follow-up
Zonisamide	Fatigue, dizziness, anorexia, psychomotor slowing, ataxia, rarely hallucinations, hypohidrosis and fever, renal calculi

*Essentially all AEDs can cause CNS toxicity and potentially rashes and serious allergic reactions. For a full list of side effects, please review the drug's FDA-approved packet insert.
AED, Antiepileptic drug; CNS, central nervous system.

that can be started and titrated more quickly, such as levetiracetam, phenytoin, lacosamide, or valproate, should be considered instead.

- **Drug interactions** and the presence of background medications: An example is the potential interference of enzyme-inducing drugs with many chemotherapeutic agents. In those cases, medications such as gabapentin or levetiracetam are used. Also, valproate inhibits the metabolism and increases the levels of lamotrigine, phenobarbital, and felbamate; it also displaces protein-bound phenytoin from protein-binding sites, increasing the free fraction; and thus the free and not the total level needs to be checked when both medications are used together. Enzyme inducers such as phenobarbital, carbamazepine, phenytoin, and primidone reduce levels of lamotrigine, valproate, and, to a lesser extent, topiramate, zonisamide, and perampanel. Medications exclusively excreted by the kidney, such as levetiracetam and gabapentin, are not subject to such interactions.
- **The presence of comorbid conditions**: The presence of migraine in a patient with epilepsy can lead to the choice of a medication that is effective against both conditions, such as valproate, topiramate, or zonisamide. In an obese patient, a medication such as valproate might be avoided, and a medication that decreases the appetite, such as topiramate or zonisamide, might be used instead. In adolescent females of child-bearing potential, enzyme-inducing AEDs are often avoided because they can interfere with birth control pills; other AEDs, particularly valproate, can increase risks for fetal malformations. Valproic acid may unmask or exacerbate certain underlying metabolic disorders; these include nonketotic hyperglycinemia, DNA polymerase γ pathogenic variant *(POLG)* with mitochondrial DNA depletion (also known as **Alpers-Huttenlocher syndrome**), other mitochondrial disorders (Leigh syndrome; **MELAS**; myoclonic epilepsy with ragged red fibers; myoclonic epilepsy–myopathy–sensory ataxia syndrome), and hyperammonemic encephalopathies. Manifestations may include hepatotoxicity or encephalopathy. Attention-deficit/hyperactivity disorder (ADHD) is a common comorbid condition in children with epilepsy. The presence of epilepsy should not necessarily discourage treatment with stimulants if indicated.
- **Coexisting seizures**: In a patient with both absence and generalized tonic-clonic seizures, a drug that has a broad spectrum of antiseizure effects, such as lamotrigine or valproate, could be used rather than medications that have a narrow spectrum of efficacy, such as phenytoin and ethosuximide.
- **History of prior response** to specific AEDs: For example, if a patient or a family member with the same problem had previously responded to levetiracetam, levetiracetam could be a desirable choice.
- **Mechanism of drug actions**: At present, in most patients the current understanding of the pathophysiology of epilepsy does not allow a specific choice of AEDs based on the assumed pathophysiology of the epilepsy. However, it is believed that it is better to avoid combining medications that have similar mechanisms of action, such as phenytoin and carbamazepine (both work on sodium channels). A number of medications, such as lamotrigine and valproate or topiramate and lamotrigine, are reported to have synergistic effects, possibly because they have different mechanisms of action.
- **Ease of use**: Medications given once or twice a day are easier to use than medications given 3 or 4 times a day. Availability of a pediatric liquid preparation, particularly if palatable, also plays a role. Some drugs are also available as sprinkles and biofilm formulation for use in children.
- **Ability to monitor the medication** and adjust the dose: Some medications are difficult to adjust and to follow, requiring frequent blood levels. The prototype of such medications is phenytoin, but many of the older medications, such as valproate and phenobarbital, also require blood level monitoring for optimal titration. Monitoring can represent a practical or patient satisfaction disadvantage for the older drugs compared with the newer AEDs, which generally require less blood level monitoring most often to check for compliance.
- **Patient's and family's preferences**: The choice between two or more acceptable alternative AEDs might also depend on the patient's or family's preferences. For example, some patients might want to avoid gingival hyperplasia and hirsutism as side effects but might tolerate weight loss or vice versa.
- **Genetics** and genetic testing: A genetic predisposition to developing AED-induced side effects is another factor that may be a consideration. There is a strong association between the human leukocyte antigen HLA-B*1502 allele and severe cutaneous reactions induced by carbamazepine, oxcarbazepine, phenytoin, or lamotrigine in Chinese Han patients and, to a lesser extent, Southeast Asian populations; hence, these AEDs should be avoided in genetically susceptible persons after testing for the allele. Pathogenic variants of the *SCN1A* sodium channel gene indicating Dravet syndrome could also lead to avoiding lamotrigine, carbamazepine, oxcarbazepine, and phenytoin and to the use of the more appropriate valproate, clobazam, or stiripentol.
- **Teratogenic profiles**: Based on available evidence, levetiracetam and lamotrigine are FDA pregnancy category C drugs and probably the safest AEDs to use during pregnancy. Valproate is a category X drug that is associated with neural tube defects, hypospadias, and cardiovascular malformations. *The use of valproate should thus be avoided during pregnancy if possible.* Topiramate, phenobarbital, and phenytoin are category D drugs with birth defects associated with their use reported in humans. The decision to transition to a less teratogenic AED rather than continuing with an existing regimen must be made on a case-by-case basis and consider the risk of seizures during pregnancy versus the risk of teratogenicity.
- **Underlying etiology**: The cause for the patient's epilepsy must be considered and can lead to more specific therapy choices, such as the use of immune-modulating therapy for autoimmune encephalopathy or personalized and precision therapies for specific epileptic channelopathies or vitamin-responsive epilepsies.

INITIATING AND MONITORING THERAPY

In nonemergency situations or when loading is not necessary, the **maintenance dose** of the chosen AED is started (see Table 633.14). With some medications (e.g., oxcarbazepine, carbamazepine, topiramate, and perampanel), even smaller doses are initially started and then **gradually increased** up to the maintenance dose to build a tolerance to adverse effects such as sedation. The starting dose of oxcarbazepine is usually 8-10 mg/kg/day. Increments of 5 mg/kg/day can be added every 3 days until a therapeutic level is achieved and therapeutic response is established or until unacceptable adverse effects occur. With other medications such as zonisamide, phenobarbital, phenytoin, or valproate, starting at the maintenance dose is usually tolerated. With some, such as levetiracetam and gabapentin, either approach can be used. Patients should be counseled about potential adverse effects, and these should be monitored during follow-up visits (see Table 633.15).

Titration

Levels of many AEDs should usually be determined after initiation to ensure compliance and therapeutic concentrations. Monitoring is most helpful for the older AEDs, such as phenytoin, carbamazepine, valproate, phenobarbital, and ethosuximide. After starting the maintenance dosage or after any change in the dosage, a steady state is not reached until 5 half-lives have elapsed, which, for most AEDs, is 2-7 days (half-life: 6-24 hours). For phenobarbital, it is 2-4 weeks (mean half-life: 69 hours). For zonisamide, it is 14 days during monotherapy and less than that during polytherapy with enzyme inducers (half-life: 63 hours in monotherapy and 27-38 hours during combination therapy with enzyme inducers). If a therapeutic level has to be achieved faster, a loading dose may be used for some drugs, usually with a single dose that is twice the average maintenance dose per half-life. For valproate, it is 20 mg/kg; for phenytoin, it is 20 mg/kg; and for phenobarbital, it is 10-20 mg/kg. A lower loading dosage of phenobarbital is sometimes given in older children (5 mg/kg, which may be repeated once or more in 24 hours) to avoid excessive sedation.

Only one drug should be used initially, and the dose increased until complete control is achieved or until side effects prohibit further increases. Then, and only then, may another drug be added and

the initial drug subsequently tapered. Control with one drug **(monotherapy)** should be the goal, although some patients eventually need to take multiple drugs. When appropriate, levels should also be checked upon addition (or discontinuation) of a second drug because of potential drug interactions. During follow-up, repeating the EEG every few months may be helpful to evaluate changes in the predisposition to seizures. This is especially true in situations where tapering off of medication is contemplated in any seizure type and during follow-up to assess the response for absence seizures because the EEG mirrors the response in such patients.

Monitoring

For the older AEDs, before starting treatment, baseline laboratory studies, including complete blood count, platelets, liver enzymes, and possibly kidney function tests and urinalysis, are often obtained and repeated periodically. Laboratory monitoring is more relevant early on because idiosyncratic adverse effects such as allergic hepatitis and agranulocytosis are more likely to occur in the first 3-6 months of therapy. These laboratory studies are usually initially checked once or twice during the first month, then every 3-4 months after that. Significant concerns have been raised about the usefulness of routine monitoring in the absence of clinical signs because the yield of significant adverse effects is low. There are currently many advocates of less frequent routine monitoring.

In approximately 10% of patients, a reversible dose-related leukopenia may occur in patients taking carbamazepine or phenytoin. This adverse effect responds to decreasing the dose or stopping the medication and is distinguished from the much less common idiosyncratic aplastic anemia or agranulocytosis. One exception requiring frequent (even weekly) monitoring of liver function and blood counts throughout the therapy is felbamate, owing to the high incidence of liver and hematologic toxicity (1 in 500 children under 2 years of age with complex neurologic disorders who are taking the drug). The gum hyperplasia that is seen with phenytoin necessitates good oral hygiene (brushing teeth at least twice per day and rinsing the mouth after taking the phenytoin); in a few cases, it may be severe enough to warrant surgical reduction and/or a change of medication. An allergic rash can occur with any medication but is probably most common with lamotrigine, carbamazepine, and phenytoin.

Because of the risk of valvular heart disease and pulmonary arterial hypertension with fenfluramine and irreversible peripheral vision loss with vigabatrin, these drugs are available only through a restricted distribution REMS program. In addition, the FDA has circulated a warning about factoring in the possibility of cardiac arrhythmias when deciding on lamotrigine use, particularly in cardiac patients and the need to monitor ECG during its use.

SIDE EFFECTS

Occasionally, a Stevens-Johnson–like syndrome develops, probably most commonly with lamotrigine but also with other medications like clobazam; it also has been found to be particularly common in Chinese patients who have the allele HLA-B*1502 and are taking oxcarbazepine, carbamazepine, and/or lamotrigine.

Other potential side effects are rickets from phenytoin, phenobarbital, primidone, and carbamazepine (enzyme inducers that reduce the 25-hyrdroxy-vitamin D level by inducing its metabolism) and hyperammonemia from valproate. Skeletal monitoring is warranted in patients taking chronic AED therapy because it is often associated with osteopenia independent of or secondary to vitamin D deficiency (low bone density, rickets, and hypocalcemia), particularly in patients taking enzyme-inducing medications. Thus counseling the patient about sun exposure and vitamin D intake, monitoring vitamin D levels, and, in most cases, giving vitamin D supplementation are recommended. There is currently no consensus on the dose to be used for supplementation or prophylaxis, but starting doses of 2,000 IU/day with follow-up of the levels are reasonable.

Irreversible hepatic injury and death are particularly feared in young children (<2 years old) who are receiving valproate in combination with other AEDs, particularly those who might have inborn errors of metabolism such as aminoacidopathies and mitochondrial disease. Virtually all AEDs can produce sleepiness, ataxia, nystagmus, and slurred speech with toxic levels.

The FDA has determined that the use of AEDs may be associated with an increased risk of suicidal ideation and action and has recommended counseling about this side effect before starting these medications.

When adding a new AED, the doses used are often affected by the background medications. If the patient is receiving enzyme inducers, the doses needed of valproate, lamotrigine, topiramate, zonisamide, and perampanel are often higher, sometimes 1.5-2 times, than the usual maintenance doses. On the other hand, if the patient is taking valproate (an enzyme-inhibiting AED), the doses of phenobarbital or lamotrigine are approximately half of what is usually needed. Changes in the dosing of the background medication are often done as the interacting medication is being started or stopped. Genetic variability in enzymes that metabolize AEDs and in the presence of inducible multidrug-resistance genes (pharmacogenomics) might account for some of the variation among individuals in responding to certain AEDs and for the variability in the drug dose necessary for seizure control.

ADDITIONAL TREATMENTS

The principles of monotherapy indicate that a second medication needs to be considered after the first either is pushed as high as tolerated and still does not control the seizures or results in intolerable adverse effects. In those cases, a second drug is started and the first is tapered and then discontinued. The second drug is then again pushed to the dose that controls the seizure or that results in intolerable side effects. If the second drug fails, monotherapy with a third drug and **dual (combination) therapy** are considered.

Patients with **drug-resistant** (previously referred to as *intractable* or *refractory*) **epilepsy** (those who have failed at least two trials of appropriate medications) warrant a careful diagnostic reevaluation to look for degenerative, metabolic, or inflammatory underlying disorders (e.g., mitochondrial disease, Rasmussen encephalitis; see Chapter 633.2) and to investigate drug-resistant patients for candidacy for epilepsy surgery. Treatable metabolic disorders that can manifest as drug-resistant epilepsy include pyridoxine-dependent and pyridoxal-responsive epilepsy; cerebral folate deficiency; other vitamin-responsive conditions (such as biotin/thiamine-responsive basal ganglia disease and riboflavin-responsive epilepsy); neurotransmitter disorders; biotinidase deficiency; glucose transporter 1 deficiency (responds to the ketogenic diet); serine synthesis defects; creatine deficiency syndromes; untreated phenylketonuria; developmental delay, epilepsy, and neonatal diabetes; and hyperinsulinemia-hyperammonemia. Often patients who do not respond to AEDs are candidates for steroids, IVIG, or the ketogenic diet.

Steroids may be the first-line treatment in certain cases (e.g., ACTH use in West syndrome) but may also be used for other drug-resistant epilepsy syndromes such as Lennox-Gastaut, myoclonic-astatic, continuous spike waves in slow-wave sleep, and Landau-Kleffner syndromes. In these situations, steroid therapy is typically given as a monthly intravenous infusion (pulse steroids) or as daily oral prednisone 2 mg/kg/day (or equivalent). This dose is maintained for 1-2 months, then tapered off over 1-3 months. Pulse steroids are usually better tolerated than a daily steroid regimen, which can cause more weight gain, hyperglycemia, hypertension, immunosuppression, and other side effects. Because relapses occur commonly during tapering and in such syndromes as Landau-Kleffner and continuous spike waves in slow-wave sleep, therapy for longer than 1 year is often needed.

IVIG has also been reported to be similarly effective in nonimmunodeficient patients with West, Lennox-Gastaut, Landau-Kleffner, and continuous spike waves in slow-wave sleep syndromes and may also have efficacy in partial seizures. One should check the IgA levels before starting the infusions (to assess the risk for allergic reactions because these are increased in patients with complete IgA deficiency) and guard against allergic reactions during the infusion that can occur even in the absence of IgA deficiency. Low IgA, low IgG_2, and male sex are reported to predict a possibly favorable response. The usual regimen is 2 g/kg divided over 2-4 consecutive days followed by 1 g/kg once a month for 6 months.

The mechanisms of action of steroids and IVIG are not known but are presumed to be antiinflammatory because it has been demonstrated that seizures increase cytokines and that these, in turn, increase neuronal excitability by several mechanisms, including activation of glutamate receptors. Steroids and ACTH might also stimulate brain neurosteroid receptors that enhance GABA activity and might reduce corticotrophin-releasing hormone, which is known to be epileptogenic.

The ketogenic diet is considered effective in glucose transporter protein 1 deficiency (GLUT-1), pyruvate dehydrogenase deficiency, myoclonic-astatic epilepsy, tuberous sclerosis complex, Rett syndrome, severe myoclonic epilepsy of infancy (Dravet syndrome), and infantile spasms. There is also a suggestion of possible efficacy in selected mitochondrial disorders—glycogenosis type V, Landau-Kleffner syndrome, Lafora body disease, and subacute sclerosing panencephalitis. The diet is absolutely contraindicated in carnitine deficiency (primary), carnitine palmitoyltransferase I or II deficiency, carnitine translocase deficiency, β-oxidation defects, medium-chain acyl dehydrogenase deficiency, long-chain acyl dehydrogenase deficiency, short-chain acyl dehydrogenase deficiency, long-chain 3-hydroxyacyl-coenzyme A deficiency, medium-chain 3-hydroxyacyl–coenzyme A deficiency, pyruvate carboxylase deficiency, and porphyrias. Thus an appropriate metabolic workup, depending on the clinical picture, usually needs to be performed before starting the diet (e.g., acyl carnitine profile, total and free carnitine levels). The diet has been used for refractory seizures of various types (partial or generalized) and consists of an initial period of fasting followed by a diet with a 3:1 or 4:1 fat:nonfat calorie ratio, with fats consisting of animal fat, vegetable oils, or medium-chain triglycerides. Many patients do not tolerate it, owing to diarrhea, vomiting, hypoglycemia, dehydration, or lack of palatability. Diets such as the low-glycemic-index diet and the modified Atkins diet are easier to institute, do not require hospitalization, and may also be effective in treating epilepsy.

CBD is a nonpsychoactive extract of the cannabis plant that has gained prominence as a possible adjunct (add-on) therapy for drug-resistant epilepsies such as Dravet and Lennox-Gastaut syndromes.

Precision genetic-based therapy is defined as a patient-specific, or more accurately physiology-specific, selection of therapy as determined by the available information regarding the underlying pathophysiology based on the primary specific genetic, metabolic, and/or other cause of epilepsy in that patient. The use of precision therapies (Table 633.16) has expanded as more epileptogenic gene pathogenic variants are identified as part of routine genetic screening for drug-resistant epilepsies. This has allowed for targeted therapy based on the specific gene variant (see Table 633.16). Examples include the use of quinidine for gain-of-function *KCNT1* variants and retigabine for loss-of-function *KCNQ2* variants. Gain-of-function *KCNQ2* variants do not respond to retigabine, a fact that emphasizes the need for careful gene analysis that accounts for the functional outcome of each particular gene. The same applies to pathogenic variants of sodium channels; patients with epilepsy caused by **gain-of-function** variants show good response to sodium channel–blocking agents, a response not shared by patients with epilepsy caused by *loss-of-function* variants in the sodium channel gene.

Vitamin-responsive epilepsies also warrant special attention because if they are diagnosed early and precision therapy is given for them, the therapy can significantly affect seizure control and neurodevelopmental outcomes. Examples include the use of pyridoxine for antiquitin deficiency–associated epilepsies, biotin for biotinidase deficiency, folate for cerebral folate deficiency, and biotin/thiamine for **biotin thiamine–responsive basal ganglia disease**, which can have coexisting epilepsy and is caused by defects in a cerebral thiamine transporter.

Table 633.16 Precision Therapy: Treatment Considerations for Genetic Epilepsies and Other Syndromes with a High Prevalence of Epilepsy

GENE MUTATION	EPILEPTIC DISORDER	TREATMENT CONSIDERATIONS
ALDH7A1	Pyridoxine-dependent epilepsy	Pyridoxine
BTD	Biotinidase deficiency–associated epilepsy	Biotin
FOLR1	Cerebral folate deficiency	Folinic acid
GRIN2A	GRIN2A-related epilepsy	Memantine and dextromethorphan for gain-of-function variant
KCNQ2	Benign familial neonatal or infantile seizures; KCNQ2-related epileptic encephalopathy	Retigabine for loss-of-function variants*
KCNT1	Migrating focal seizures of infancy	Quinidine for gain-of-function variants
PNPO	Pyridoxal 5′-phosphate dependent epilepsy	Pyridoxal 5′-phosphate
PRRT2	Benign familial infantile epilepsy; paroxysmal dyskinesias; hemiplegic migraine; episodic ataxia	Oxcarbazepine and carbamazepine
SCN1A	Dravet syndrome; GEFS+; other SCN1A-related epilepsies	Avoid using sodium channel blockers (carbamazepine, oxcarbazepine, lamotrigine, lacosamide, phenytoin) and vigabatrin
SCN2A	Benign neonatal or infantile seizures; Dravet syndrome; GEFS+; infantile spasms; other early infantile epileptic encephalopathies	Phenytoin and carbamazepine
SCN8A	Early infantile epileptic encephalopathies; benign infantile seizures; movement disorders	High-dose phenytoin
SLC2A1	Glucose transporter–deficiency syndrome	Ketogenic diet
SLC19A3	Biotin thiamine–responsive basal ganglia disease	Biotin and thiamine
TSC1; TSC2	Tuberous sclerosis complex	Vigabatrin for infantile spasms; possibly everolimus for drug-resistant seizures

*Withdrawn from market.

Data from Hani A, Mikati MA. Current and emerging therapies of severe epileptic encephalopathies. *Semin Pediatr Neurol*. 2016;23(2):180–186; Mudigoudar B, Weatherspoon S, Wheeless JW. Emerging antiepileptic drugs for severe pediatric epilepsies. *Semin Pediatr Neurol*. 2016;23(2):167–179; and Smith LA, Ullman JFP, Olson HE, et al. A model program for translational medicine in epilepsy genetics. *J Child Neurol*. 2017;32(4):429–436.

APPROACH TO EPILEPSY SURGERY

If a patient has failed three drugs, the chance of achieving seizure freedom using AEDs is <10%. Therefore proper evaluation for surgery is necessary when a patient fails two or three AEDs, usually within 2 years of the onset of epilepsy and often sooner than 2 years. Performing epilepsy surgery in children at an earlier stage (e.g., <5 years of age) allows the transfer of function in the developing brain. Candidacy for epilepsy surgery requires proof of resistance to AEDs used at maximum, tolerably nontoxic doses; absence of expected unacceptable adverse consequences of surgery; and a properly defined **epileptogenic zone** (the area that needs to be resected to achieve seizure freedom). The epileptogenic zone is identified by careful analysis of the following parameters: seizure semiology, video-EEG long-term monitoring, neuropsychologic profile, and brain MRI. 7-Tesla MRI may, in some cases, have some advantage over 3-Tesla MRI. Other techniques, such as high-density EEG (HD-EEG), invasive EEG (depth electrodes, subdural grid or strips, intraoperative electrocorticography), single-photon emission CT (SPECT), magnetoencephalography (MEG), and positron emission tomography (PET), are also needed if the epileptogenic zone is difficult to localize or when it is close to the eloquent cortex. **Stereo-EEG** is a method of invasive EEG monitoring used to localize epileptic areas of the cortex. It involves the stereotactic implantation of depth electrodes through multiple burr holes in the skull using robot-assisted implantations and computer-based 3D localization. Several procedures can be used to avoid resection of eloquent cortex, including the **Wada test**, **functional MRI**, MEG, transcranial magnetic stimulation, and cortical stimulation with subdural and depth electrodes. Developmental delay or psychiatric diseases must be considered in assessing the potential impact of surgery on the patient. The usual minimal presurgical evaluation includes video-EEG monitoring, brain imaging, and age-specific neuropsychologic assessment.

Epilepsy surgery is often used to treat drug-resistant epilepsy of a number of etiologies, including cortical dysplasia, tuberous sclerosis, polymicrogyria, hypothalamic hamartoma, encephalomalacia from prior cerebrovascular insult, mesial temporal sclerosis, Landau-Kleffner syndrome, and hemispheric syndromes such as Sturge-Weber syndrome, hemimegalencephaly, and Rasmussen encephalitis. Patients with drug-resistant epilepsy resulting from metabolic or degenerative problems *are not* candidates for resective epilepsy surgery. **Focal resection** of the epileptogenic zone is the most common procedure. **Hemispherectomy** is used for diffuse hemispheric lesions in cases such as Rasmussen encephalitis, hemimegalencephaly, large perinatal stroke, Sturge-Weber syndrome; **multiple subpial transections**, a surgical technique in which the horizontal connections of the epileptic focus are partially cut without resecting it, is sometimes used for unresectable foci located in the eloquent cortex, as in Landau-Kleffner syndrome. In Lennox-Gastaut syndrome, **corpus callosotomy** is used as a palliative procedure for drop attacks.

Laser interstitial thermal therapy (LITT) is a less invasive surgical technique that uses a laser to ablate relatively small (<3 × 3 cm) epileptic areas in the cortex; it has been used to treat mesial temporal sclerosis, tuberous sclerosis, and hypothalamic hamartomas and for corpus callosotomies. Other minimally invasive techniques include gamma knife stereotactic radiosurgery that uses gamma radiation. Focal resection and hemispherectomy result in a high rate (50–80%) of seizure freedom. Corpus callosotomy and vagal nerve stimulation result in lower rates of seizure freedom (5–10% for vagus nerve stimulation [VNS] and lower for callosotomy); however, these procedures do result in significant reductions in the frequency and severity of seizures, decreases in medication requirements, and meaningful improvements in the patient's quality of life in approximately half or more of eligible patients.

VNS is often used for drug-resistant epilepsies of various types (partial, generalized, Lennox-Gastaut) and for seizures of diffuse focal or multifocal anatomic origin that do not yield themselves to resective surgery (Fig. 633.10). VNS is approved for age 4 years and above but has also been used in even younger ages. This technique is considered palliative rather than curative because it most often leads to seizure

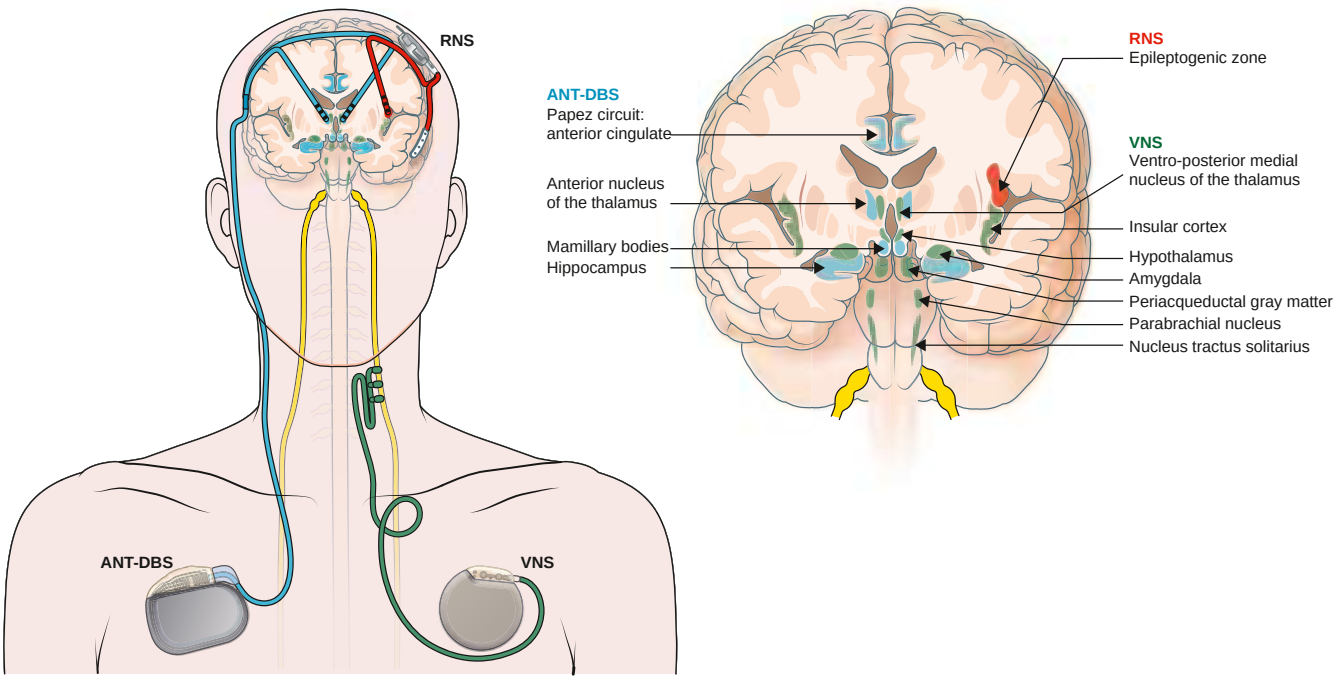

Fig. 633.10 Approved neuromodulation therapies in epilepsy. The brain targets for each neuromodulation approach according to sites of stimulation and known primary anatomic pathways. This illustration is not meant to be comprehensive. VNS is expected to activate the nucleus tractus solitarius, with downstream effects on its brainstem, subcortical, and cortical efferences; ANT-DBS stimulation is expected to modulate the activity of the anterior nucleus of the thalamus and the associated Papez circuit, and RNS stimulation is expected to inhibit the suspected cortical epileptogenic zone. ANT-DBS, Deep brain stimulation of the anterior nucleus of the thalamus; RNS, responsive neurostimulation; VNS, vagus nerve stimulation. *(From Ryvlin P, Rheims S, Hirsch LJ, et al. Neuromodulation in epilepsy: state-of-the art approved therapies. Lancet Neurol. 2021;20[12]:1038–1047, Fig. 1, p. 1039.)*

frequency *reduction* rather than seizure cessation. By producing low-amplitude current stimulations, usually once every 5 minutes, this device results in a reduction of seizures. Also, caretakers can activate the device by swiping a magnet over it at the time of the seizure, which can shorten seizure duration. Vagus nerve stimulators also have integrated heart rate monitoring that detects tachycardia patterns typically associated with seizures and then activates the stimulator during these times. **Responsive neurostimulation (RNS)** is a technique that has been used in adults with epilepsy; it requires the implantation of subdural or depth electrodes to directly monitor seizure activity on a long-term basis to detect and abort the seizures. Once a seizure is detected, electrical stimulation is delivered to that area of the brain to stop the seizure. **Deep brain stimulation (DBS)** is approved for refractory partial epilepsy in adults. In DBS, the electrical stimulation is provided by two stereotactically placed electrodes in bilateral thalamic nuclei (anterior nuclei for focal epilepsy and centromedian nuclei, as being studied, in generalized epilepsies).

DISCONTINUATION OF THERAPY

Discontinuation of AEDs is usually indicated when otherwise well children are free of seizures for at least 2 years. In more severe syndromes, such as temporal lobe epilepsy secondary to mesial temporal sclerosis, Lennox-Gastaut syndrome, or severe myoclonic epilepsy, a prolonged period of seizure freedom with treatment is often warranted before AEDs are withdrawn, if withdrawal is attempted at all. In self-limited (benign) epilepsy syndromes, the duration of therapy can often be as short as 6 months.

Many factors should be considered before discontinuing medications, including the likelihood of remaining seizure-free after drug withdrawal based on the type of epilepsy syndrome and etiology; the risk of injury in case of seizure recurrence (e.g., if the patient drives); and the adverse effects of AED therapy. Most children who have not had a seizure for 2 years or longer and who have a normal EEG when AED withdrawal is initiated remain free of seizures after discontinuing medication, and most relapses occur within the first 6 months.

Certain risk factors can help clinicians predict the prognosis after AED withdrawal. The most important risk factor for seizure relapse is an abnormal EEG before medication is discontinued. Children who have remote structural (symptomatic) epilepsy are less likely to be able to stop AEDs than are children who have a benign (idiopathic) epilepsy. In patients with absences or in patients treated with valproate or other medications for primary generalized epilepsy, the risk of relapse might be high despite a normal EEG because valproate (and less so other AEDs for primary generalized epilepsy) can normalize EEGs with generalized spike-wave abnormalities. Thus in these patients, repeating the EEG during drug tapering may help identify a recurrence of the EEG abnormality and associated seizure risk before clinical seizures recur. Older age of epilepsy onset, longer duration of epilepsy, presence of multiple seizure types, and need to use more than one AED are all factors associated with a higher risk of seizure relapse after AED withdrawal.

AED therapy should be discontinued gradually, often over a period of 3-6 months, but many advocate for shorter periods down to 6 weeks. Abrupt discontinuation can result in withdrawal seizures or in status epilepticus. Withdrawal seizures are especially common with phenobarbital and benzodiazepines; consequently, special attention must be given to a prolonged tapering schedule during the withdrawal of these AEDs. Seizures that occur more than 2-3 months after AEDs are completely discontinued indicate a relapse, and resumption of treatment is usually warranted. Seizures that occur before that, such as during or shortly after a medication taper, may be withdrawal seizures or may indicate a relapse.

The decision to attempt AED withdrawal must be assessed mutually by the clinician, the parents, and the child depending on the child's age. The American Academy of Neurology in collaboration with the American Epilepsy Society has developed guidelines regarding such withdrawals. In addition, there is an online risk calculator tool that has been generated based on clinical nomograms from an independent participant data meta-analysis. This tool can be used, with caution, as an aid to estimate risk of recurrence, but individualized decision based on each case's particulars and on the discussions with the caretakers should be the final guide in planning the course of care. The patient and family should be counseled fully on what to expect, what precautions to take (e.g., cessation of driving for a period), and what to do in case of relapse. A prescription for rectal diazepam or intranasal midazolam to be given at the time of seizures that might occur during and after tapering is usually warranted (see Table 633.23 for dosing).

Table 633.17 Measures in Clinical Practice to Reduce the Risk of SUDEP

Counseling: Explaining SUDEP and risk factors is imperative, even if the discussion may be uncomfortable. Emphasize modifiable risk factors, such as compliance with taking medication.
Reduction of tonic-clonic seizures: Optimum treatment, good drug compliance, lifestyle advice (e.g., alcohol intake, sleep deprivation).
Treatment changes: Change in a gradually staged manner; when switching drugs, introduce the new drug before withdrawing the old drug; the patient should have access to immediate advice in the event of worsening seizures during periods of change.
Supervision at night for patients at high risk: Attendance, use of alarms (balancing the benefits of independent living and the penalties of intrusive monitoring).
Choice of drugs: Caution with AEDs with potential cardiorespiratory adverse effects.
Act on ictal warning signs: Tonic-clonic seizures that are prolonged, associated with marked cyanosis, severe bradycardia or apnea, and postictal EEG suppression; complex partial seizures with marked atonia (drop attacks); seizure in those with preexisting cardiac or respiratory impairment.
Supervision after a tonic-clonic seizure: Continuous attendance until full consciousness is restored; call emergency services for high-risk seizures.

EEG, Electroencephalogram; SUDEP, sudden unexpected death in epilepsy.
From Shorvan S, Tomson T. Sudden unexpected death in epilepsy. *Lancet.* 2011;378:2028–2036.

SUDDEN UNEXPECTED DEATH IN EPILEPSY

SUDEP is the most common epilepsy-related cause of mortality and is responsible for up to 17% of deaths in patients with epilepsy. Risk factors include polytherapy with more than three AEDs, male gender, young age at epilepsy onset, developmental delay, poor AED compliance, nocturnal seizures, poorly controlled convulsive seizures (especially if >3 per year), high frequency of seizures (especially if >50 per year), and having epilepsy for >30 years in adults. Patients are usually found dead in their bed in a prone position, with evidence suggesting a recent seizure.

Respiratory, cardiogenic, and mixed respiratory/cardiogenic mechanisms have been hypothesized to cause SUDEP. Respiratory models include seizure-induced central hypoventilation, neurogenic pulmonary edema, and disturbances in the brainstem serotonergic system leading to respiratory arrest. Cardiogenic models include seizure-induced cardiac arrhythmia as well as **cardiocerebral channelopathies** in which ion channels are expressed in both the brain and heart, causing cardiac dysfunction concurrent with the seizures. *SCN1A, SNC8A, ATP1A3,* and *KCNQ1* are examples of genes that encode for cardiocerebral ion channels known to cause epilepsy and that have also been associated with SUDEP. Mixed respiratory/cardiogenic models include seizure-induced dysautonomia, high adenosine levels during seizure causing cardiorespiratory collapse, and spreading depression in the brainstem causing dysautonomia. More data are needed to determine if safety pillows, seizure detection devices, or selective serotonin reuptake inhibitors may be of benefit in preventing SUDEP. *It is currently recommended to counsel the patients and family regarding SUDEP, even if the topic is not comfortable to talk about.* In addition to providing them with important information, such counseling may also encourage families to address modifiable risk factors such as AED compliance. Table 633.17 lists other possible preventive measures.

Visit Elsevier eBooks+ at eBooks.Health.Elsevier.com for Bibliography.

633.7 Neonatal Seizures

Mohamad A. Mikati and Monica E. Lemmon

Seizures are possibly the most important and common indicator of significant neurologic dysfunction in the neonatal period. Seizure incidence is higher during this period than in any other period of life: seizures occur in 57.5 per 1,000 in infants with birthweights <1,500 g and 2.8 per 1,000 in infants weighing between 2,500 and 3,999 g. The etiology of neonatal seizures depends on postnatal age of onset (Fig. 633.11, Table 633.18) as well as EEG and clinical features (Fig. 633.12, Table 633.18 and Table 633.19).

PATHOPHYSIOLOGY

The immature brain has many differences from the mature brain that render it more excitable and more likely to develop seizures. Based predominantly on animal studies, these include a delay in Na^+, K^+-adenosine triphosphatase maturation and increased NMDA and AMPA receptor density. In addition, the specific types of these receptors that are increased are those that are permeable to calcium (GLUR2 AMPA receptors). This contributes to increased excitability and to the long-term consequences associated with seizures, particularly those resulting from perinatal hypoxia. Medications that block AMPA receptors, such as topiramate, may thus prove useful in this clinical scenario.

Another difference is delay in the development of inhibitory GABAergic transmission. In fact, GABA in the immature brain has an excitatory function because the chloride gradient is reversed relative to the mature brain, with higher concentrations of chloride being present intracellularly than extracellularly. Thus opening of the chloride channels in the immature brain results in depolarizing the cell and not in hyperpolarizing it. How applicable this is to human neonates and, if so, at what conceptional ages, is not clear yet. This phenomenon, however, appears to be more prominent in male neonates, perhaps explaining their greater predisposition to seizures.

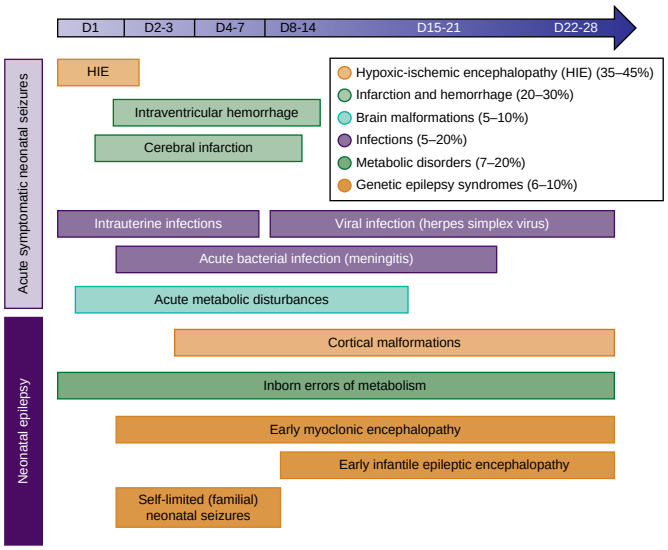

Fig. 633.11 Etiologies of neonatal seizures according to seizure onset timing. The most common causes of seizures occurring within the first 24 hr of life are hypoxic-ischemic encephalopathy or vascular etiologies, followed by acute metabolic disturbances such as hypoglycemia or inborn errors of metabolism such as pyridoxine dependency. Within the next 24-72 hr, the main etiologies include infection, cortical malformations, cerebral infarction, inborn errors of metabolism such as glycine encephalopathy, urea cycle disturbances, pyridoxine dependency, and benign familial neonatal seizures. Over the next 72 hr to a week, causes include cortical malformations, cerebral infarction or hemorrhage, or inborn errors of metabolism, such as urea cycle disturbances. In the next 1-4 wk, the differential includes cortical malformations, viral infections such as herpes simplex, or genetic epilepsy syndromes. *(From Kim EH, Shin J, Lee BK. Neonatal seizures: diagnostic updates based on new definition and classification. Clin Exp Pediatr. 2022;65[8]:387–397, Fig. 1, p. 389.)*

TYPES OF NEONATAL SEIZURES

There are two main neonatal seizure types: electroclinical and electrographic only. Electroclinical seizures can be categorized as motor, nonmotor, and sequential. Motor seizures include automatisms, clonic seizures, epileptic spasms, myoclonic seizures, and tonic seizures. Nonmotor seizures include autonomic seizures and behavioral arrest (see Fig. 633.12 and Table 633.19). Differentiating seizure types based on

Table 633.18 Causes of Neonatal Seizures According to Common Age of Presentation

AGES 1-4 DAYS
Hypoxic-ischemic encephalopathy
Drug withdrawal, maternal drug use of opiate or barbiturates
Drug toxicity: lidocaine, penicillin
Intraventricular hemorrhage
Sepsis
Acute metabolic disorders
• Hypocalcemia
• Maternal hyperthyroidism, or hypoparathyroidism
• Hypoglycemia
• Maternal diabetes
• Hyperinsulinemic hypoglycemia
• Hypomagnesemia
• Hyponatremia or hypernatremia
• Iatrogenic or inappropriate antidiuretic hormone secretion
Inborn errors of metabolism
• Galactosemia
• Hyperglycinemia
• Urea cycle disorders
Pyridoxine dependency and pyridoxal-5-phosphate dependency (must be considered at any age)
AGES 4-14 DAYS
Infection
• Meningitis (bacterial)
• Encephalitis (enteroviral, herpes simplex)
Metabolic disorders
• Hypocalcemia related to diet, milk formula
• Hypoglycemia, persistent
• Inherited disorders of metabolism
• Galactosemia
• Fructosemia
• Leucine sensitivity
• Hyperinsulinemic hypoglycemia, hyperinsulinism, hyperammonemia syndrome
• Anterior pituitary hypoplasia, pancreatic islet cell tumor
• Beckwith syndrome
Drug withdrawal, maternal drug use of narcotics or barbiturates
Benign neonatal convulsions, familial and nonfamilial
Kernicterus, hyperbilirubinemia
Developmental delay, epilepsy, neonatal diabetes syndrome
AGES 2-8 WK
Infection
• Herpes simplex or enteroviral encephalitis
• Bacterial meningitis
Head injury
• Subdural hematoma
• Child abuse
Inherited disorders of metabolism
• Aminoacidurias
• Urea cycle defects
• Organic acidurias
• Neonatal adrenoleukodystrophy
Malformations of cortical development
• Lissencephaly
• Focal cortical dysplasia
Tuberous sclerosis
Sturge-Weber syndrome

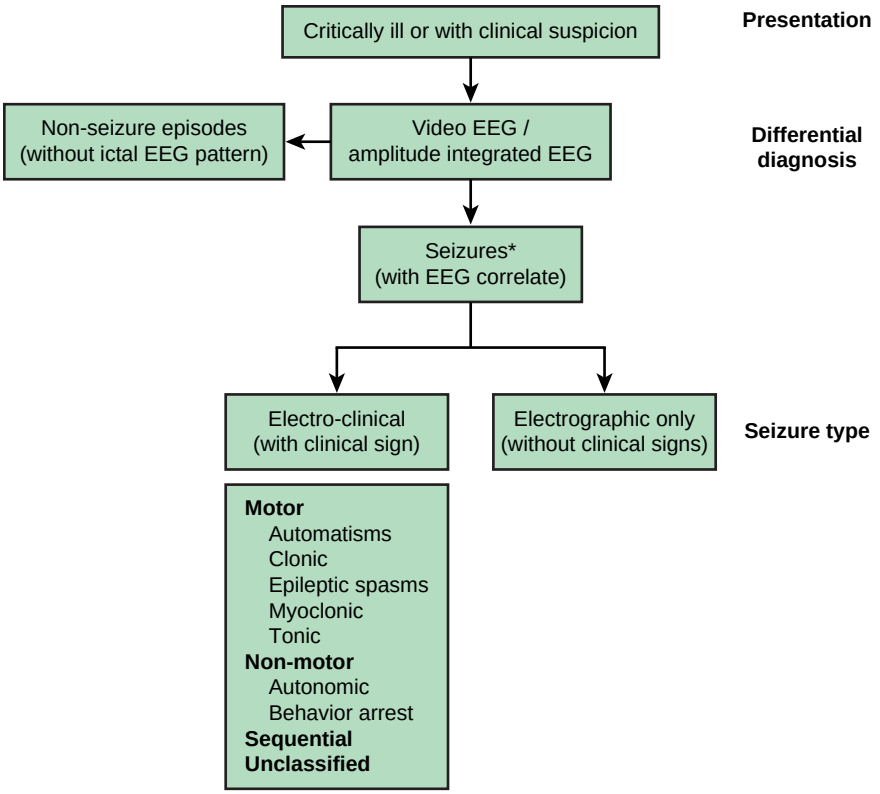

Fig. 633.12 Diagnostic framework of seizures in the neonatal period, including classification of seizures. Adapted from 2017 ILAE seizure classification. Neonates present with discrete events suspected to be epileptic seizures or are critically ill (often ventilated, sedated, and treated with muscle relaxants in intensive care). *If no EEG is available, refer to global alignment of immunization safety assessment in pregnancy levels of diagnostic certainty. *(From Pressler RM, Cilio MR, Mizrahi EM, et al, The ILAE classification of seizures and the epilepsies: modification for seizures in the neonate. Position paper by the ILAE Task Force on Neonatal Seizures. Epilepsia. 2021;62[3]:615–628, Fig. 2.)*

Table 633.19 Clinical Characteristics, Classification, and Presumed Pathophysiology of Neonatal Seizures

CLASSIFICATION	CHARACTERIZATION
Focal clonic	Repetitive, rhythmic contractions of muscle groups of the limbs, face, or trunk May be unifocal or multifocal May occur synchronously or asynchronously in muscle groups on one side of the body May occur simultaneously but asynchronously on both sides Cannot be suppressed by restraint Pathophysiology: epileptic
Focal tonic	Sustained posturing of single limbs Sustained asymmetric posturing of the trunk Sustained eye deviation Cannot be provoked by stimulation or suppressed by restraint Pathophysiology: epileptic
Generalized tonic	Sustained symmetric posturing of limbs, trunk, and neck May be flexor, extensor, or mixed extensor/flexor May be provoked or intensified by stimulation May be suppressed by restraint or repositioning Presumed pathophysiology: nonepileptic
Myoclonic	Random, single, rapid contractions of muscle groups of the limbs, face, or trunk: asymmetric or symmetric Typically not repetitive or may recur at a slow rate May be generalized, focal, multifocal, or fragmentary May be provoked by stimulation Presumed pathophysiology: may be epileptic or nonepileptic
Spasms	May be flexor, extensor, or mixed extensor/flexor Unilateral or bilateral May occur in clusters Asymmetric or symmetric Cannot be provoked by stimulation or suppressed by restraint Pathophysiology: epileptic
MOTOR AUTOMATISMS (UNILATERAL, BILATERAL, ASYMMETRIC OR SYMMETRIC)	
Ocular signs	Random and roving eye movements or nystagmus (distinct from tonic eye deviation) May be provoked or intensified by tactile stimulation Presumed pathophysiology: nonepileptic
Oral-buccal-lingual movements	Sucking, chewing, tongue protrusions May be provoked or intensified by stimulation Presumed pathophysiology: nonepileptic
Progression movements	Rowing or swimming movements Pedaling or bicycling movements of the legs May be provoked or intensified by stimulation May be suppressed by restraint or repositioning Presumed pathophysiology: nonepileptic
Complex purposeless movements	Sudden arousal with transient increased random activity of limbs May be provoked or intensified by stimulation Presumed pathophysiology: nonepileptic

From Mizrahi EM, Kellaway P. *Diagnosis and Management of Neonatal Seizures.* Philadelphia: Lippincott-Raven, 1998: Table 4, p. 21.

clinical appearance alone is challenging. Thus in many cases, specifically in sick neonates with a history of suspected neurologic injury, continuous bedside EEG is necessary to make this distinction.

Motor Seizures

Automatisms

Automatisms include transient eye deviations, nystagmus, blinking, mouthing, and abnormal extremity movements (rowing, swimming, bicycling, pedaling, and stepping). Automatisms occur more commonly in premature than in full-term infants.

Clonic Seizures

Clonic seizures can be focal or multifocal. Multifocal clonic seizures incorporate several body parts and are migratory in nature. The migration follows a non-Jacksonian trend; for example, jerking of the left arm can be associated with jerking of the right leg. Generalized clonic seizures that are bilateral, symmetric, and synchronous are uncommon in the neonatal period, presumably because of decreased connectivity associated with incomplete myelination at this age.

Epileptic Spasms

Epileptic spasms are sudden generalized jerks lasting 1-2 seconds that are distinguished from generalized tonic spells by their shorter duration and by the fact that spasms are usually associated with a single, very brief, generalized discharge.

Myoclonic Seizures

Myoclonic seizures are divided into focal, multifocal, and generalized types. Myoclonic seizures can be distinguished from clonic seizures by the rapidity of the jerks (<50 milliseconds) and by their lack of rhythmicity. Focal myoclonic seizures characteristically affect the flexor muscles of the upper extremities and are sometimes associated with seizure activity on EEG. Multifocal myoclonic movements involve asynchronous twitching of several parts of the body and are not commonly associated with seizure discharges on EEG. Generalized myoclonic seizures involve bilateral jerking associated with flexion of the upper and occasionally lower extremities. The latter type of myoclonic jerks is more commonly correlated with EEG abnormalities than the other types.

Tonic Seizures

Tonic seizures can be focal or generalized (generalized are more common). Focal tonic seizures include persistent posturing of a limb or posturing of the trunk or neck in an asymmetric way, often with persistent horizontal eye deviation. Generalized tonic seizures are bilateral tonic limb extensions or tonic flexions of the upper extremities often associated with tonic extension of the lower extremities and trunk.

Nonmotor Seizures

Autonomic

Autonomic seizures involve fluctuations in autonomic system function, including alterations in the cardiovascular, vasomotor, pupillary, and thermoregulatory function. These seizures may include heart rate changes, hypertension episodes, and apnea. Autonomic seizures typically accompany additional seizure types and are rarely seen in isolation.

Behavioral Arrest

Behavioral arrest seizures include cessation of activity or immobilization. This seizure type is rarely seen in isolation and can be seen as a component of sequential seizures.

Sequential

Sequential seizures have been defined by the ILAE as a seizure type for "events with a sequent of signs, symptoms, and EEG changes at different times." An example would be a sequence of tonic, then clonic, then automatisms, and autonomic manifestations with varying lateralization during one seizure. In these seizures, it can be challenging to define the predominant semiology, and features present in a sequence. These are most commonly associated with genetic epilepsies, including KCNQ2 encephalopathy.

Seizures Versus Jitteriness

Jitteriness can be defined as rapid motor activities, such as a tremor or shake, that can be ended by flexion or holding the limb. Seizures generally do not end with tactile or motor suppression. Jitteriness, unlike most seizures, is usually induced by a stimulus. Unlike jitteriness, seizures often involve eye deviation and autonomic changes.

ETIOLOGY

Table 633.18 and Table 633.20 and Figure 633.11 list causes of neonatal seizures.

Hypoxic-Ischemic Encephalopathy

This is the most common cause of neonatal seizures, accounting for 50–60% of patients. Seizures secondary to this encephalopathy occur within 24 hours of birth. Abnormal EEG background, including excessive discontinuity, burst suppression, and extremely low voltage patterns, are strongly associated with the development of seizures.

Vascular Events

These include intracranial bleeds and ischemic strokes and account for 10–20% of patients. Three types of hemorrhage can be distinguished: primary subarachnoid hemorrhage, germinal matrix–intraventricular hemorrhage, and subdural hemorrhage. Patients with arterial strokes or venous sinus thrombosis can present with seizure, and these can be diagnosed by neuroimaging. Venous sinus thrombosis could be missed unless MR or CT venography studies are requested.

Intracranial Infections

Bacterial and nonbacterial infections account for 5–10% of the cases of neonatal seizures and include bacterial meningitis, TORCH (*t*oxoplasmosis, *o*ther infections, *r*ubella, *c*ytomegalovirus, *h*erpes simplex virus) infections, and, particularly, herpes simplex encephalitis.

Brain Malformations

Brain malformations account for 5–10% of neonatal seizure cases. An example is **Aicardi syndrome**, which affects girls only and consists of retinal lacunae, agenesis of the corpus callosum, and severe seizures, including subsequent infantile spasms with hypsarrhythmia that is sometimes initially unilateral on EEG.

Metabolic Disturbances

Metabolic disturbances include disturbances in glucose, calcium, magnesium, other electrolytes, amino acids, or organic acids and pyridoxine dependency (Table 633.21).

Hypoglycemia can cause neurologic disturbances and is common in small neonates and neonates whose mothers are diabetic or prediabetic. The duration of hypoglycemia is very critical in determining the incidence of neurologic symptoms.

Hypocalcemia occurs with two peaks. The first peak corresponds to low birthweight infants and is evident in the first 2-3 days of life. The second peak occurs later in neonatal life and often involves large, full-term babies who consume milk that has an unfavorable ratio of phosphorus to calcium and phosphorus to magnesium. **Hypomagnesemia** is often associated with hypocalcemia. **Hyponatremia** can cause seizures and is often secondary to inappropriate antidiuretic hormone secretion or water intoxication.

Local anesthetic intoxication seizures can result from neonatal intoxication with local anesthetics that are inadvertently administered into the infant's scalp.

Neonatal seizures can also result from disturbances in **amino acid or organic acid** metabolism. These are usually associated with acidosis and/or hyperammonemia. However, even in the absence of these findings, if a cause of the seizures is not immediately evident, then ruling out metabolic causes requires a full metabolic workup (see Chapter 633.2), including examination of serum amino acids, acyl carnitine profile, lactate, pyruvate, ammonia, very long-chain fatty acids (for neonatal adrenoleukodystrophy and Zellweger syndrome), examination of urine

Table 633.20 Clinical Characteristics and Genetic Variants of Neonatal Epilepsy Syndromes

SYNDROME	SEIZURE ONSET	TYPES OF SEIZURE	ETIOLOGY	EEG FEATURES	PROGNOSIS
Self-limited familial neonatal seizures	Days 2-3	Focal tonic seizures, often with apnea, vocalization, or autonomic change, frequent brief seizures	Autosomal dominant variants in *KCNQ2, KCNQ3, SCN2A*	Background: usually normal Interictal: a theta pointu alternant pattern or focal or multifocal epileptiform abnormalities	Favorable outcome, typically resolved seizures by 6 mo of age
Self-limited neonatal seizures	Days 4-6	Unilateral or bilateral clonic seizures, frequent seizure clusters	Most unknown, rare *KCNQ2* variant	Ictal: focal rhythmic spike or slow waves	Favorable outcome, usually decreased seizure within 48 hr
Early-infantile epileptic encephalopathy	First 2 wk, up to 3 mo	Tonic seizures, epileptic spasms	Structural brain malformations, genetic variants in *ARX, CDKL5, SLC25A22, STXBP1, KCNQ2, SPTAN1, SCN2A*, metabolic disorders	Background/interictal: suppression-burst patten: same asleep and awake Ictal: diffuse attenuation with emergency of low-voltage, high-frequency activity, or focal ictal rhythms	Frequent early-life mortality, severe developmental disabilities
Early myoclonic encephalopathy	Hours to months	Multifocal erratic myoclonus	Metabolic disorders, genetic variants in *STXBP1, TBC1D24, GABRA1*	Background/interictal: suppression-burst patten, enhanced by sleep Ictal: no ictal pattern but followed by bursts, or focal ictal rhythms	
Epilepsy of infancy with migrating focal seizures	Days to months	Nearly continuous focal clonic and/or tonic, autonomic, migrating seizures	Pathogenic variants in *KCNT1, SCN2A, SCN1A, SLC25A22, PLCB1, QARS*	Background: normal or diffuse slowing Interictal: multifocal discharges Ictal: rhythmic alpha or theta activities that evolve simultaneously from different brain regions and migrate to contiguous or contralateral regions	Generally poor with refractory seizures and severe developmental disabilities

From Kim EH, Shin J, Lee BK. Neonatal seizures: diagnostic updates based on new definition and classification. *Clin Exp Pediatr*. 2022;65(8):387–397. Table 1, p. 390.

for organic acids, α-aminoadipic acid semialdehyde, and sulfocysteine, as well as examination of CSF for glucose, protein, cells, amino acids, lactate, pyruvate, α-aminoadipic acid semialdehyde, pyridoxal phosphate, 5-methyltetrahydrofolate (5-MTHF), succinyladenosine, and CSF neurotransmitter metabolites. This is because many inborn errors of metabolism, such as nonketotic hyperglycinemia, can manifest with neonatal seizures (often mistaken initially for hiccups, which these patients also have) and can be detected only by performing these tests. Definitive diagnosis of **nonketotic hyperglycinemia**, for example, requires measuring the ratio of CSF glycine to plasma glycine.

Pyridoxine- and **pyridoxal-dependency disorders** can cause severe seizures. These seizures, which are often multifocal clonic, usually start during the first few hours of life. Cognitive impairment is often associated if therapy is delayed (see Chapter 633.4).

Drug Withdrawal

Seizures can rarely be caused by the neonate's passive addiction and then drug withdrawal after birth. Such drugs include narcotic analgesics, sedative-hypnotics, and others. The associated seizures appear during the first 3 days of life.

Neonatal Seizure Genetic Syndromes

Seizure syndromes include **benign neonatal convulsions (fifth-day fits)**, which are usually apneic, and focal motor seizures that start around the fifth day of life (see Table 633.20). Interictal EEG shows a distinctive pattern called *theta pointu alternant* (runs of sharp 4- to 7-Hz activity), and ictal EEG shows multifocal electrographic seizures. Patients have a good response to medications and a good prognosis. Autosomal dominant **benign familial neonatal seizures** have an onset at 2-4 days of age and usually remit at 2-15 weeks of age. The seizures consist of ocular deviation, tonic posturing, clonic jerks, and, at times, motor automatisms. Interictal EEG is usually normal. These are caused by pathogenic variants in *KCNQ2* and *KCNQ3*. Approximately 16% of patients develop later epilepsy. **Early myoclonic encephalopathy** and **early infantile epileptic encephalopathy (Ohtahara syndrome)** are discussed in Chapter 633.4.

Miscellaneous Conditions

Miscellaneous conditions include benign neonatal sleep myoclonus and hyperekplexia, which are nonepileptic conditions (see Chapter 634).

DIAGNOSIS

Some cases can be correctly diagnosed by simply taking the prenatal and postnatal history and performing an adequate physical examination; however, the *American Clinical Neurophysiology Society Guidelines for Neonatal EEG Monitoring recommend EEG monitoring in cases where there is a clinical concern for seizure and/or when*

Table 633.21 Overview of Diagnostic Findings in Inborn Errors of Metabolism Presenting with Isolated Neonatal Seizures

DISORDER	MRI AND MRS FINDINGS	CSF FINDINGS	FURTHER DIAGNOSTIC TESTING
Pyridoxine-dependent seizures	Normal or hypoplasia of corpus callosum and cerebellum	Increased levels of α-AASA, pipecolic acid, and neurotransmitter markers	Urinary and serum α-AASA or pipecolic acid, *ALDH7A1* gene testing
Pyridoxal-phosphate–dependent seizures	Generalized atrophy	May be normal or nonspecific changes	Pyridoxamine-5-phosphate oxidase gene testing
Defects of serine biogenesis	Initially normal, progressing to profound hypomyelination	Low levels of serine; may also have low levels of glycine or 5-MTHF	Skin biopsy for 3-phosphoglycerate dehydrogenase activity
GLUT-1 deficiency	Normal or generalized atrophy	CSF glucose <40 mg/dL or <half of serum glucose	FDG-PET; 3-OMG uptake in red blood cells; gene testing for *SLC2A1*
Nonketotic hyperglycinemia	Normal, or agenesis or thinning of the corpus callosum	Increased levels of glycine, and increased CSF/plasma glycine ratio	Liver glycine cleavage complex enzyme activity; gene testing for nonketotic hyperglycinemia
Sulfite oxidase/molybdenum cofactor deficiency	MRI findings can mimic those of hypoxic-ischemic injury; MRS reveals increased levels of lactate, myoinositol, and choline, with decreased levels of NAA	Normal or nonspecific changes in amino acid profile	Plasma homocysteine and uric acid; urine sulfites, sulfocysteine, and thiosulfates; sulfite oxidase enzyme activity in skin or liver biopsy
Congenital neuronal ceroid-lipofuscinosis	Generalized cerebral hypoplasia	Normal	Cathepsin D gene testing
γ-Aminobutyric acid transferase deficiency	MRI indicates leukodystrophy and agenesis of the corpus callosum; MRS indicates elevated levels of γ-aminobutyric acid in the basal ganglia	Increased levels of homocarnosine	Enzyme activity in lymphocytes
Dihydropyrimidine dehydrogenase deficiency	Diffuse atrophy	Increased levels of uracil and thymine	Dihydropyrimidine dehydrogenase gene testing
Creatine deficiency syndromes	MRI indicates delayed myelination MRS reveals absent creatine peak	Normal	Serum creatine and guanidinoacetate; urinary creatine, creatinine, and guanidinoacetate; fibroblast enzyme activity; specific genetic testing

For current information on the best locations to perform biochemical and genetic testing, see genereviews.org.
3-OMG, 3-O-methyl-D-glucose; 5-MTHF, 5-methyltetrahydrofolate; α-AASA, α-aminoadipic emialdehyde; CSF, cerebrospinal fluid; FDG-PET, fluorodeoxyglucose–positron emission tomography; MRI, magnetic resonance imaging; MRS, magnetic resonance spectroscopy; NAA, N-acetylaspartate.
From Ficicioglu C, Bearden D. Isolated neonatal seizures: when to suspect inborn errors of metabolism. *Pediatric Neurol.* 2011;45:283–291. Table 2.

an infant has a condition that predisposes the infant to seizures. EEG monitoring can show epileptiform activity (e.g., sharp waves) between the seizures (suggesting an increased risk for seizures) and confirm electrographic seizure activity if a clinical seizure is recorded. Additionally, EEG monitoring is often necessary because electrographic seizures can occur without observed clinical signs **(electroclinical dissociation)**. This is presumed to be caused by the immaturity of cortical connections, resulting, in many cases, in no or minimal clinical manifestations.

Continuous bedside EEG monitoring in the neonatal intensive care unit is the preferred clinical practice for neonates at risk for neonatal seizures and brain injury. Amplitude-integrated EEG (aEEG) monitoring is also used as an *adjunct* to conventional EEG monitoring and provides a bedside graphic representation of a neonate's electrocerebral activity, which may aid in earlier seizure identification. Appropriately trained nurses and providers can identify possible seizure activity using aEEG and can then contact the neurophysiologist to confirm the presence or absence of seizures. Examples of situations in which continuous EEG monitoring should be used include cases of **hypoxic-ischemic injury** (particularly if an infant is undergoing therapeutic hypothermia), intracranial infarct or hemorrhage, or CNS infection; for seizure screening in infants receiving paralytics; in infants with congenital cerebral malformations; and/or in infants in whom clinical events suspected to be seizures need to be characterized.

Careful neurologic examination of the infant might uncover the cause of the seizure disorder. Examination of the retina might show the presence of chorioretinitis, suggesting a congenital TORCH infection, in which case titers of mother and infant are indicated. **Aicardi syndrome** is associated with coloboma of the iris and retinal lacunae. Inspection of the skin might show hypopigmented lesions characteristic of tuberous sclerosis (seen best on ultraviolet light examination) or the typical crusted vesicular lesions of incontinentia pigmenti; both neurocutaneous syndromes are often associated with generalized myoclonic seizures beginning early in life. An unusual body or urine odor suggests an inborn error of metabolism.

Blood should be obtained for determinations of glucose, calcium, magnesium, electrolytes, and blood urea nitrogen. If hypoglycemia is a possibility, bedside serum glucose testing is indicated so that treatment can be initiated immediately. Hypocalcemia can occur in isolation or in association with hypomagnesemia. A lowered serum calcium level is often associated with birth trauma or a CNS insult in the perinatal period. Additional causes include maternal diabetes, prematurity,

DiGeorge syndrome, and high-phosphate feedings. Hypomagnesemia (<1.5 mg/dL) is often associated with hypocalcemia and occurs particularly in infants of malnourished mothers. In this situation, the seizures are resistant to calcium therapy but respond to intramuscular magnesium 0.2 mL/kg of a 50% solution of $MgSO_4$. Serum electrolyte measurement can indicate significant hyponatremia (serum sodium <115 mEq/L) or hypernatremia (serum sodium >160 mEq/L) as a cause of the seizure disorder.

A **lumbar puncture** may be indicated in neonates with seizures, unless the cause is obviously related to a metabolic disorder (such as hypoglycemia or hypocalcemia) or attributable to a structural etiology such as hypoxic-ischemic injury or intracranial hemorrhage. The CSF findings can indicate a bacterial meningitis or aseptic encephalitis. Prompt diagnosis and appropriate therapy improve the outcome for these infants. Bloody CSF indicates a traumatic tap or a subarachnoid or intraventricular bleed. Immediate centrifugation of the specimen can assist in differentiating the two disorders. A clear supernatant suggests a traumatic tap, and a xanthochromic color suggests a subarachnoid bleed. Mildly jaundiced normal infants can have a yellowish discoloration of the CSF that makes inspection of the supernatant less reliable in the newborn period.

Many **inborn errors of metabolism** cause generalized convulsions in the newborn period. Because these conditions are often inherited in an autosomal recessive or X-linked recessive fashion, it is imperative that a careful family history be obtained to determine if there is consanguinity or whether siblings or close relatives developed seizures or died at an early age. Serum ammonia determination is useful for screening for the hypoglycemic hyperammonemia syndrome and for suspected urea cycle abnormalities. In addition to having generalized clonic seizures, these latter infants present during the first few days of life with increasing lethargy progressing to coma, anorexia and vomiting, and a bulging fontanel. If the blood gases show an anion gap and a metabolic acidosis with the hyperammonemia, urine organic acids should be immediately determined to investigate the possibility of an **organic acidemia** such as methylmalonic or propionic acidemia.

Maple syrup urine disease should be suspected when a metabolic acidosis occurs in association with generalized clonic seizures, vomiting, a bulging fontanel, and muscle rigidity during the first week of life. The result of a rapid screening test using 2,4-dinitrophenylhydrazine that identifies keto derivatives in the urine is positive in maple syrup urine disease.

Additional metabolic causes of neonatal seizures include **nonketotic hyperglycinemia**, an intractable condition characterized by markedly elevated plasma and CSF glycine levels, prominent hiccups, persistent generalized seizures, and lethargy rapidly leading to coma; ketotic hyperglycinemia in which seizures are associated with vomiting, fluid and electrolyte disturbances, and a metabolic acidosis; and Leigh disease, suggested by elevated levels of serum and CSF lactate or an increased lactate:pyruvate ratio. **Biotinidase deficiency** should also be considered. A comprehensive description of the diagnosis and management of these metabolic diseases is discussed in Part IX, Metabolic Disorders.

Unintentional **injection of a local anesthetic** into a fetus during labor can produce intense tonic seizures. These infants are often thought to have had a traumatic delivery because they are flaccid at birth, have abnormal brainstem reflexes, and show signs of respiratory depression that sometimes require ventilation. Examination may show a needle puncture of the skin or a perforation or laceration of the scalp. An elevated serum anesthetic level confirms the diagnosis. The treatment consists of supportive measures and promotion of urine output by administering intravenous fluids with appropriate monitoring to prevent fluid overload.

Benign familial neonatal seizures, an autosomal dominant condition, begins on the second to third day of life, with a seizure frequency of 10-20/day. Patients are normal between seizures, which stop in 1-6 months. These are caused by pathogenic variants in the voltage-sensitive potassium channel genes *Kv7.2* and *Kv7.3* (*KCNQ2* and *KCNQ3*). Other variants in *Kv7.2* cause severe neonatal epileptic encephalopathy. **Fifth-day fits** occur on day 5 of life (4-6 days) in normal-appearing neonates. The seizures are multifocal and are often present for <24 hours. The diagnosis requires exclusion of other causes of seizures and sequencing of the previously mentioned genes. The prognosis is good for the benign form.

Pyridoxine dependency, a rare disorder, must be considered when seizures begin shortly after birth with signs of fetal distress in utero and are resistant to conventional anticonvulsants such as phenobarbital or phenytoin even if there is an initial treatment response. The history may suggest that similar seizures occurred in utero. When pyridoxine-dependent seizures are suspected, 100 mg of pyridoxine should be administered intravenously during the EEG, which should be promptly performed once the diagnosis is considered. The seizures abruptly cease, and the EEG often normalizes in the next few hours or longer. Not all cases of pyridoxine dependency respond dramatically to the initial bolus of intravenous pyridoxine. Therefore a 6-week trial of oral pyridoxine (100-200 mg/day) or, preferably, pyridoxal phosphate (because pyridoxine does not help infants with the related but distinct syndrome of pyridoxal dependency) is recommended for infants in whom a high index of suspicion continues after a negative response to intravenous pyridoxine. Measurement of serum pipecolic acid and α-aminoadipic acid semialdehyde (elevated) and CSF pyridoxal-5-phosphate (decreased) needs to be performed before initiation of the trials without delay. These children require lifelong supplementation of oral pyridoxine (100 mg/day at times with folinic acid) or pyridoxal phosphate (up to 50 mg/kg/day given every 6 hours). **Cerebral folate deficiency** should also be ruled out by a medication trial (folinic acid 1-3 mg/kg/day) and by CSF levels of 5-methyltetrahydrofolate assay. Gene sequencing can confirm the diagnosis (see Chapter 633.4). The earlier the therapy is initiated in these vitamin-responsive disorders, the more favorable the outcome.

Drug withdrawal seizures can occur in the newborn nursery but can take several weeks to develop because of prolonged excretion of the drug by the neonate. Drugs include barbiturates, benzodiazepines, heroin, buprenorphine, fentanyl, and methadone. The infant may be jittery, irritable, and lethargic and can have myoclonus or frank clonic seizures. The mother might deny the use of drugs; a serum or urine drug screen might identify the responsible agent.

Infants with focal seizures, suspected stroke or intracranial hemorrhage, and severe **cytoarchitectural abnormalities** of the brain (including lissencephaly and schizencephaly) who clinically may appear normal or microcephalic should undergo MRI or CT scan. Indeed, it is appropriate to recommend imaging of all neonates with seizures unexplained by serum glucose, calcium, or electrolyte disorders.

PROGNOSIS

The prognosis of neonatal seizures has improved owing to advancements in obstetric and intensive neonatal care but depends on the etiology and other organ system injury. Prematurity and high seizure burden have been shown to be associated with early death. The correlation between EEG findings and prognosis is clear. An abnormal EEG background is a powerful predictor of a less favorable later outcome. In addition, prolonged electrographic seizures (>10 min/hr), multifocal periodic electrographic discharges, and spread of the electrographic seizures to the contralateral hemisphere are also correlated with a poorer outcome. Patients with seizures secondary to severe hypoxic-ischemic encephalopathy have a 50% chance of typical development, whereas those with seizures caused by primary subarachnoid hemorrhage or hypocalcemia have a much better prognosis.

TREATMENT

A mainstay in the therapy of neonatal seizures is the diagnosis and treatment of the underlying etiology (e.g., HIE, hypoglycemia, hypocalcemia, meningitis, drug withdrawal, trauma) whenever one can be identified. There are conflicting approaches regarding the control of neonatal seizures. Most experts advocate complete control of electroclinical and electrographic seizures. An important consideration before starting anticonvulsants is deciding, based on the severity, duration, and frequency of the seizures, if the patient needs to receive intravenous therapy and loading with an initial bolus or can simply

be started on maintenance doses of a long-acting drug. Patients may require assisted ventilation after receiving intravenous or oral loading doses of AEDs, and thus precautions for observations and for needed interventions are necessary.

Lorazepam and Other Benzodiazepines

Lorazepam is often used in the acute treatment of neonatal seizures; it is distributed to the brain very quickly and exerts its anticonvulsant effect in less than 5 minutes. It is not very lipophilic and does not clear out from the brain very rapidly. Its action can last 6-24 hours. Usually, it does not cause hypotension or respiratory depression. The dose is 0.1 mg/kg when used for acute treatment of seizures, and 0.05 mg/kg (range: 0.02-0.10 mg/kg) every 4-8 hours when used as a scheduled medication. Diazepam has also been used, and midazolam is often started as a continuous infusion for refractory cases of neonatal seizures. Midazolam doses used have been in the range of 0.05-0.15 mg/kg as an initial intravenous bolus, with a continuous infusion of 0.5-1 μg/kg/min intravenously that can then be gradually titrated upward, if tolerated, every 5 minutes or longer, to a maximum of approximately 33 μg/kg/min (2 mg/kg/hr).

Phenobarbital

Consensus guidelines and existing data support the use of phenobarbital as the first-choice treatment of neonatal seizures. The usual loading dose is 20 mg/kg. If this dosage is not effective, then additional doses of 10-20 mg/kg can be given until a cumulative dose of 40 mg/kg is reached. Respiratory support may be needed after phenobarbital loading. Twenty-four hours after starting the loading dose, maintenance dosing can be started at 3-6 mg/kg/day, usually administered in two separate doses. Phenobarbital is metabolized in the liver and is excreted through the kidneys. Thus any abnormality in the function of these organs alters the drug's metabolism and can result in toxicity. In infants with acidosis or critical illness that might alter the serum protein content, free (i.e., not protein bound) levels of the drug should be followed carefully. The use of phenobarbital can be associated with electroclinical dissociation, where electrographic seizures persist despite the resolution of clinical seizures, after the drug is given. Subsequent EEG monitoring is therefore imperative to rule out subclinical seizure activity.

Phenytoin and Fosphenytoin

Consensus guidelines support the use of fosphenytoin as a second line anti-seizure medication in neonatal seizures. The only randomized controlled trial to compare the efficacy of phenobarbital versus phenytoin did not find that one drug was superior to the other for the treatment of neonatal seizures. Because of its reduced solubility, potentially severe local cutaneous reactions, interactions with other drugs, and possible cardiac toxicity, intravenous phenytoin is not widely used, and fosphenytoin is the preferred agent. Phenytoin is given at a loading dose of 20 mg/kg at a rate not to exceed 0.5-1.0 mg/kg/min, so as to prevent cardiac problems; the medication should be used with caution or avoided in patients with significant heart disease. The heart rate should be monitored while the drug is administered. It is not possible to mix phenytoin or fosphenytoin with dextrose solutions. Additionally, phenytoin and fosphenytoin should not be used in conjunction with intravenous lidocaine owing to the concern that both drugs can increase the risk of cardiac arrhythmias and hypotension.

As stated earlier, fosphenytoin, which is a phosphate ester prodrug, is preferable to phenytoin. It is highly soluble in water and can be administered safely intravenously and intramuscularly, without causing injury to tissues. Fosphenytoin is administered in phenytoin equivalents (PE). The usual loading dose of fosphenytoin is 15-20 PE/kg administered over 30 minutes. Maintenance doses of 4-8 PE/kg/day can be given. As is the case for phenobarbital, free levels of the drug should be monitored in neonates whose serum pH or protein content might not be normal.

Other Medications

Approximately 45% of neonates respond to the first drug used if it is phenobarbital or phenytoin, and an additional 15% respond to the second agent. **Levetiracetam** (which can be given intravenously with a later convenient conversion to oral solution) is commonly used as a second- or third-line agent. In a randomized controlled trial of levetiracetam (40-60 mg/kg) versus phenobarbital (20-40 mg/kg) for neonatal seizures, 28% of infants responded to levetiracetam as a first-line agent, as compared with 80% of infants who received phenobarbital. The maintenance dosages used are 40-60 mg/kg/day of levetiracetam, dosed 3 times daily. Topiramate, a possible third line agent, can be given at a dose of 5-10 mg/kg/day (sometimes higher). There is growing evidence that lidocaine is an effective second- or third-line agent, and some studies suggest it may be superior to benzodiazepines in treating neonatal seizures. A bolus dose of 2 mg/kg is given, followed by an infusion at a rate of 4-6 mg/kg/hr. Cardiac arrhythmias and hypotension were not reported at this dosing range but are potential side effects at higher doses. Lidocaine should not be used in conjunction with phenytoin or fosphenytoin owing to concern for cardiac side effects. A randomized controlled trial suggested that bumetanide provided added reduction in seizure burden when used as an adjunct agent without an increased risk of adverse events. Studies of the efficacy and safety of lacosamide for neonatal seizures are ongoing. Primidone, carbamazepine, lamotrigine, or valproate use, although reported in some studies, is rarely warranted. Valproate, for example, is more likely to be toxic in children younger than 2 years of age than in older children.

Duration of Therapy

The duration of therapy is related to the risk of epilepsy developing later in infants suffering from neonatal seizures, a risk that ranges from 10% to 30% and depends on the individual neurologic examination and the etiology of the seizures. Existing data and consensus guidelines support the discontinuation of anticonvulsant medications before hospital discharge in neonates with acute symptomatic seizures.

ADDRESSING FAMILY NEEDS

Over half of parents of newborns with seizures experience symptoms of anxiety, one third experience symptoms of depression. Existing data suggest that parents of newborns with seizures experience consistent challenges, including prognostic uncertainty, concern about adapting their family life, and the physical and emotional toll of caring for a critically ill infant. Clinicians can help address these needs by attending to parent psychosocial needs, connecting parents to peer support, and communicating effectively.

Visit Elsevier eBooks+ at eBooks.Health.Elsevier.com for Bibliography.

633.8 Status Epilepticus

Mohamad A. Mikati and Dmitry Tchapyjnikov

Status epilepticus (SE) is a medical emergency that should be anticipated in any patient who presents with an acute seizure. The ILAE has refined the definition of SE to reflect the time at which treatment should be initiated (t_1) and time at which continuous seizure activity leads to long-term sequelae (t_2) such as neuronal injury, depending on the type of SE. For generalized tonic-clonic seizures, SE is defined as continuous convulsive activity or recurrent generalized convulsive seizure activity without regaining consciousness (t_1 = 5 minutes, t_2 ≥30 minutes). The definition differs for SE consisting of focal seizures with impaired awareness (t_1 = 10 minutes, t_2 = 30 minutes) and absence SE (t_1 = 10-15 minutes, t_2 = unknown). The most common type of SE is **convulsive status epilepticus** (generalized tonic, clonic, or tonic-clonic), but other types do occur, including **nonconvulsive status** (focal with impaired awareness, absence), myoclonic status, epilepsia partialis continua, and neonatal SE. The incidence of SE ranges between 10 and 60 per 100,000 population in various studies. SE is most common in children younger than 5 years of age, with an incidence in this age-group of ~100 per 100,000 children.

Approximately 30% of patients presenting with SE are having their first seizure, and approximately 40% of these later develop epilepsy.

Febrile status epilepticus is the most common type of SE in children. Currently, with the recognition of SE as a medical emergency, the mortality rate is 4–5%, most of it secondary to the underlying etiology rather than to the seizures. SE carries an approximately 14% risk of new neurologic deficits, most of them (12.5%) secondary to the underlying pathology.

Nonconvulsive status epilepticus (NCSE) can manifest as a confusional state, dementia, fluctuating mental status, hallucinations, paranoia, aggressiveness, catatonia, and/or psychotic symptoms. It should be considered in all children who present to the hospital in an encephalopathic state or in the intensive care unit when a child's mental status fails to improve. **Epilepsia partialis continua** has been defined previously and can be caused by tumor, vascular etiologies, mitochondrial disease (MELAS), and Rasmussen encephalitis.

Refractory status epilepticus is SE in which a child's seizures fail to resolve despite therapy with both a benzodiazepine and a non-benzodiazepine medication. **Superrefractory status epilepticus** is SE that has failed to resolve, or recurs, within 24 hours or more despite therapy that includes a continuous infusion such as midazolam and/or pentobarbital.

New-onset refractory status epilepticus (NORSE) is defined as SE without a clear etiology after initial investigations (typically brain imaging as well as blood and CSF analysis) have ruled out common causes for SE, including stroke, infection, and toxic/metabolic derangements. Children presenting with NORSE may sometimes have a prodromal flulike illness before developing seizures but are otherwise often previously healthy with no history of seizures. A clear etiology is ultimately determined only 50% of the time and includes inflammatory and autoimmune causes (such as anti–NMDA receptor encephalitis), rare infectious disorders, or genetic causes that predispose the child to having prolonged seizures (such as pathogenic variants in *PCDH19*). Children with NORSE almost always develop superrefractory status epilepticus, and the prognosis is often poor with >10% mortality and up to two thirds developing long-term neurologic disability. **Febrile infection-related epilepsy syndrome (FIRES)** is a subtype of NORSE in which the child also has a febrile illness 1-14 days preceding seizure onset (Table 633.22 and Fig. 633.13). A fever does not have to be present at the time of seizure onset as long as a fever was present in the preceding period. FIRES was thought to be a condition mostly affecting children; however, it is recognized that NORSE and FIRES can occur in both adults and children. An international group of pediatric epileptologists, pediatric neurointensivists, rheumatologists, and basic scientists with interest and expertise in FIRES published recommendations regarding the approach to and management of FIRES (Figs. 633.14 and 633.15). FIRES should be considered in all previously healthy patients older than 2 years of age who present with sudden-onset refractory SE within 2 weeks of a prior febrile illness (see Table 633.22). They also recommended early use of the ketogenic diet and the IL-1 receptor

Table 633.22 Clinical Features of Febrile Infection–Related Epilepsy Syndrome (FIRES)

Age of onset: 2-17 (median 8) yr
Medical history: febrile seizures in rare cases, no epilepsy or other chronic disease, normal psychomotor development
Family history: uninformative (e.g., no allergies and especially no other family member with FIRES)
Prodromal phase:
- Different types of febrile infections, often flulike
- Frequently followed by an afebrile and asymptomatic interval of 1-2 days resulting in a consistent neurologic syndrome

Neurologic syndrome:
- Peracute/explosive onset of multifocal or generalized seizures of different types directly evolving into superrefractory status epilepticus
- Without other neurologic features (pure seizure phenotype)

EEG: global slowing or multifocal discharges with bilateral frontotemporal predominance, or both
CSF: normal or pleocytosis, normal protein concentration, no oligoclonal bands
MRI (during the acute phase of status epilepticus):
- No or nonextensive bitemporal or diffuse abnormalities
- Sporadic involvement of the basal ganglia, diffuse cortical edema, and/or hydrocephalus

Cause: extensive infectiologic (e.g., brain biopsies), metabolic (e.g., muscle biopsy), and genetic investigations (e.g., *POLG, SCN1A, PCDH19* genes, CNVs, exome sequencing) without causative findings
Coexisting autoimmunities: some patients with autoantibodies (e.g., TPO or GluR antibodies)
Treatment: resistance to nearly all drugs and even anesthetics
Outcome:
- Almost always chronic epilepsy without silent period
- Often global brain atrophy after a few weeks with mild to severe neuropsychologic impairments

CNVs, Copy number variants; GluR, glutamate receptor; TPO, thyroid peroxidase.
From van Baalen A, Vezzani A, Hausker M, et al. Febrile infection-related epilepsy syndrome: clinical review and hypotheses of epileptogenesis. *Neuropediatrics.* 2017;48:5–18, Table 1, p.6.

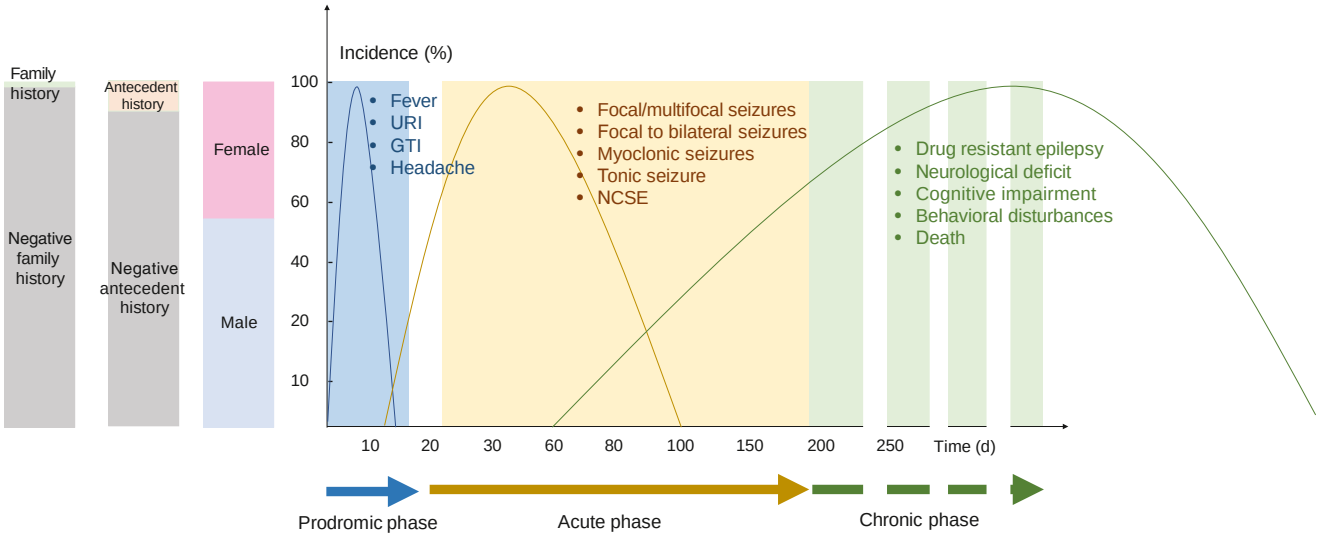

Fig. 633.13 Clinical findings in FIRES and NORSE, including family history, antecedents, and sex predominance. The graph shows the symptoms during the prodromic phase, type of seizures in the acute phase, and clinical findings during the chronic phase. GTI, Gastrointestinal tract infections; NCSE, nonconvulsive status epilepticus; URI, upper respiratory infection. *(From Specchio N, Pietrafusa N. New-onset refractory status epilepticus and febrile infection-related epilepsy syndrome. Dev Med Child Neurol. 2020;62:897–905, Fig. 1, p. 899.)*

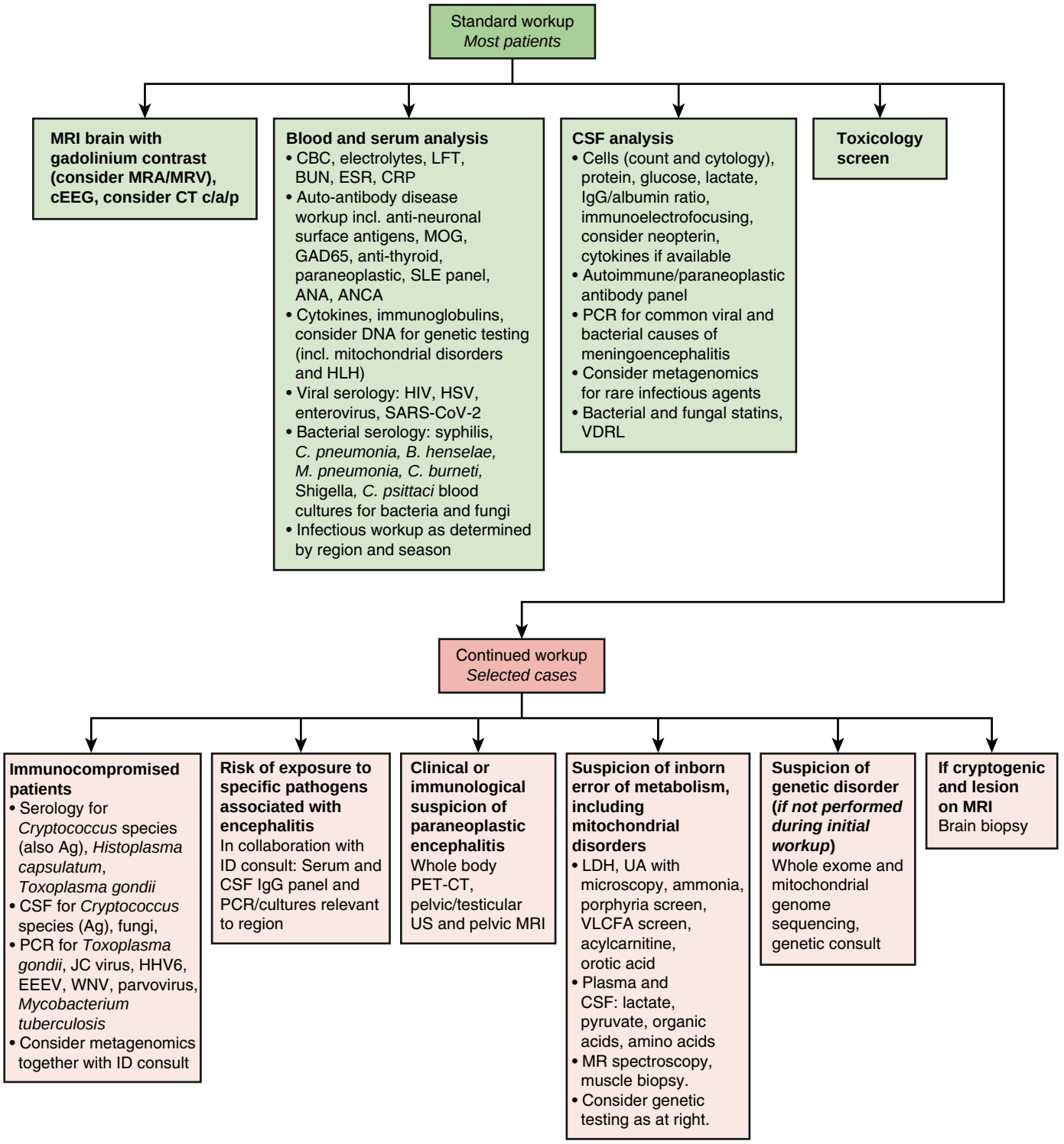

Fig. 633.14 Algorithm for diagnostic workup in NORSE, including FIRES. Ag, Antigen; ANA, anti-nuclear antibodies, ANCA, anti-neutrophil cytoplasmic antibodies; *B. henselae*, *Bartonella henselae*; BUN, blood urea nitrogen; *C. burnetii*, *Coxiella burnetii*; *C. pneumoniae*, *Chlamydia pneumoniae*; *C. psittaci*, *Chlamydia psittaci*; CBC, complete blood count; cEEG, continuous EEG; CRP, C-reactive protein; CSF, cerebrospinal fluid; DNA, deoxyribonucleic acid; EEEV, eastern equine encephalitis virus; EEG, electroencephalography; ESR, erythrocyte sedimentation rate; GAD, glutamic acid decarboxylase; HHV, human herpesvirus; HIV, human immunodeficiency virus; HLH, hemophagocytic lymphohistiocytosis; HSV, herpes simplex virus; ID, infectious disease; IgG, immunoglobulin G; JC, John Cunningham; LDH, lactate dehydrogenase; LFT, liver function test; *M. pneumoniae*, *Mycoplasma pneumoniae*; MOG, myelin oligodendrocyte glycoprotein; MRA, magnetic resonance angiography; MRI, magnetic resonance imaging; MRV, magnetic resonance venography; PCR, polymerase chain reaction; PET-CT, positron emission tomography–computed tomography; SARS-CoV2, severe acute respiratory syndrome coronavirus 2; SLE, systemic lupus erythematosus; UA, urine analysis; US; ultrasound; VLCFA, very long-chain fatty acid; VDRL, Venereal Disease Research Laboratory; VZV, varicella-zoster virus; WNV, West Nile virus. *(Adapted from NORSE Institute website norseinstitute.org; and from Sculier C, Gaspard N. New onset refractory status epilepticus [NORSE]. Seizure. 2019;68:72–78, Fig. 1.)*

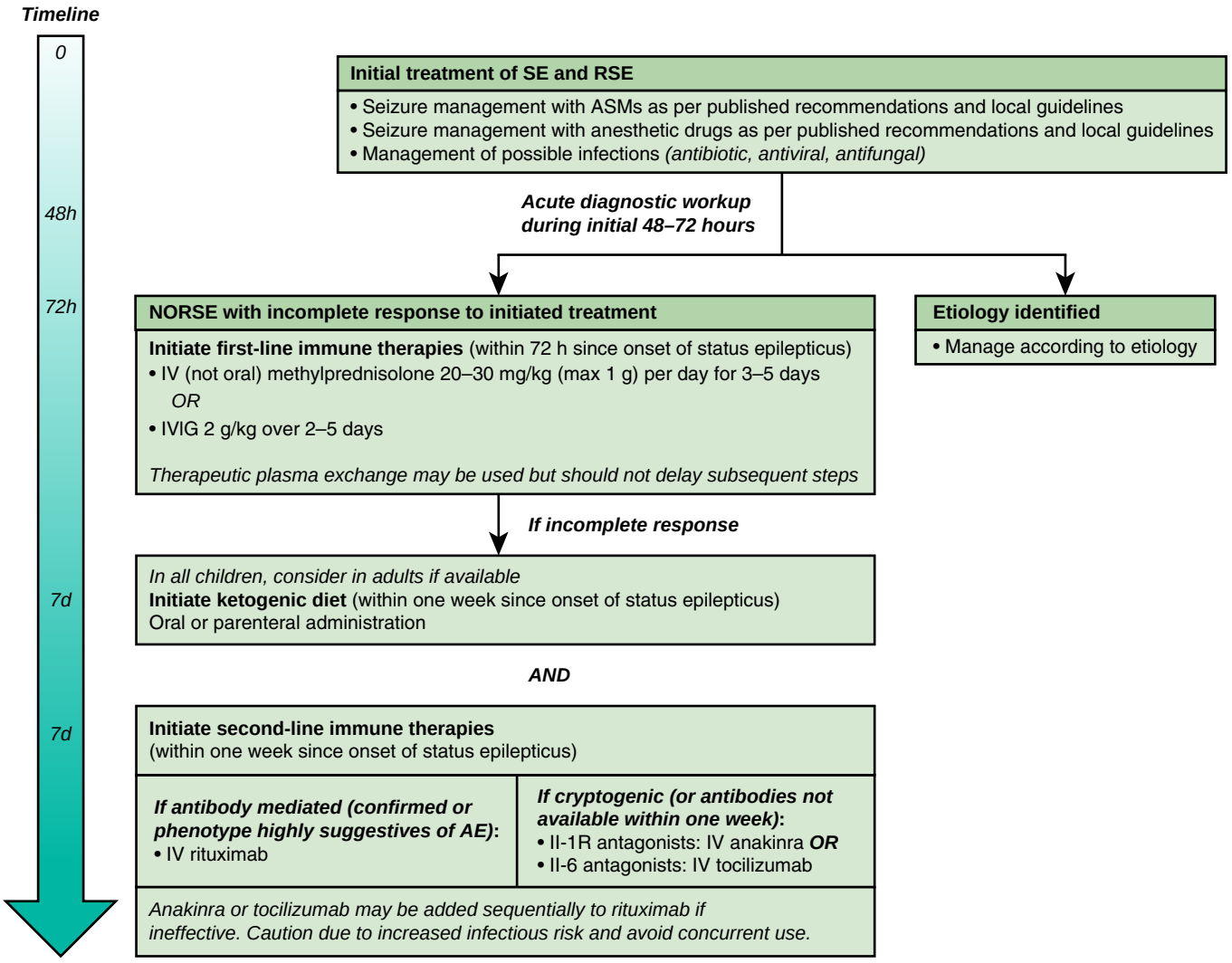

Fig. 633.15 Suggested treatment algorithm for NORSE, including FIRES (expert opinion). AE, Autoimmune encephalitis; ASM, antiseizure medication; IV, intravenous; IVIG, intravenous immunoglobulins; RSE, refractory status epilepticus; SE, status epilepticus. *(From Wickström R, Taraschenko O, Dilena R, et al. International consensus recommendations for management of new onset refractory status epilepticus [NORSE] including febrile infection-related epilepsy syndrome [FIRES]: summary and clinical tools. Epilepsia. 2022;63:2827–2839, Fig. 2, p. 2836.)*

antagonist that blocks IL-1β activity, anakinra, in FIRES patients (see Fig. 633.15).

ETIOLOGY

Etiologies of SE include new-onset epilepsy of any type; drug intoxication (e.g., tricyclic antidepressants) in children and drug and alcohol misuse in adolescents; drug withdrawal or overdose in patients taking AEDs; hypoglycemia; hypocalcemia; hyponatremia; hypomagnesemia; acute head trauma; encephalitis; meningitis; autoimmune encephalitis (anti–NMDA receptor; steroid-responsive encephalopathy associated with autoimmune thyroiditis [SREAT], and anti–voltage-gated potassium channel complex antibody syndromes); ischemic (arterial or venous) stroke; intracranial hemorrhage; folinic acid and pyridoxine- and pyridoxal-phosphate dependency (these usually present in infancy, but childhood onset is also possible); inborn errors of metabolism (see Chapter 633.2) such as nonketotic hyperglycinemia in neonates and MELAS in infants, children, and adolescents; ion channel–related epilepsies (e.g., sodium and potassium channel mutations reviewed in the sections earlier); hypoxic-ischemic injury (e.g., after cardiac arrest); systemic conditions (such as hypertensive encephalopathy, posterior reversible encephalopathy, renal or hepatic encephalopathy); brain tumors; and any other disorder that can cause epilepsy (such as brain malformations, neurodegenerative disorders, different types of progressive myoclonic epilepsy, and storage diseases).

A rare condition called **hemiconvulsion-hemiplegia-epilepsy syndrome** consists of prolonged febrile SE presumably caused by focal acute encephalitis with resultant atrophy in the involved hemisphere, contralateral hemiplegia, and chronic epilepsy. It should be suspected early on to attempt to control the seizures as early as possible. This and the somewhat similar condition FIRES are likely to have a parainfectious-autoimmune etiology. In addition, hemophagocytic lymphocytic histiocytosis has been reported to cause FIRES. **Rasmussen encephalitis** often causes epilepsia partialis continua (see Chapter 633.3) and sometimes convulsive SE. Several types of infections are more likely to cause encephalitis with SE, such as herpes simplex (complex partial and convulsive status), *Bartonella* (particularly nonconvulsive status), Epstein-Barr virus, and mycoplasma (postinfectious encephalomyelitis with any type of status epilepticus). Postinfectious encephalitis and acute disseminated encephalomyelitis are common causes of SE, including refractory SE. HHV-6 can cause a distinct epileptic syndrome with limbic SE in immunosuppressed patients.

MECHANISMS

The mechanisms leading to the establishment of sustained seizure activity seen in SE appear to involve (1) failure of desensitization of AMPA glutamate receptors, thus causing the persistence of increased excitability, and (2) reduction of GABA-mediated inhibition as a result of intracellular internalization of $GABA_A$ receptors. This explains the clinical observation that SE is often less likely to stop in the next specific period the longer the seizure has lasted and why benzodiazepines appear to be decreasingly effective the longer seizure activity lasts. During SE, there is an increased cerebral metabolic rate and a compensatory increase in cerebral blood flow that, after approximately 30 minutes, is not able to keep up with the increases in cerebral metabolic rate. This leads to a transition from adequate to inadequate cerebral oxygen tensions and, together with other factors, contributes to neuronal injury resulting from SE.

THERAPY

SE is a medical emergency that requires initial and continuous attention to securing the airway, breathing, and circulation (with continuous monitoring of vital signs including ECG) and determination and management of the underlying etiology (e.g., hypoglycemia). Laboratory studies, including glucose, sodium, calcium, magnesium, complete blood count, basic metabolic panel, CT scan, and continuous EEG, are needed for all patients. Blood and spinal fluid cultures, toxic drug screens, and tests for inborn errors of metabolism are often needed. AED levels need to be determined in all patients known already to be taking these drugs. EEG is helpful in ruling out **pseudo–status epilepticus** (psychologic functional neurologic disorder mimicking SE) or other movement disorders (chorea, tics), rigors, clonus with stimulation, and decerebrate/decorticate posturing. The EEG can also be helpful in identifying the type of SE (generalized vs focal), which can guide further testing for the underlying etiology and further therapy. EEG can also help distinguish between postictal depression and later stages of SE in which the clinical manifestations are subtle (e.g., minimal myoclonic jerks) or absent (electroclinical dissociation) and can help in monitoring the therapy, particularly in patients who are paralyzed and intubated. Neuroimaging must be considered after the child has been stabilized, especially if it is indicated by the clinical manifestations, by an asymmetric or focal nature of the EEG abnormalities, or by lack of knowledge of the underlying etiology.

The initial emergent therapy should be started for convulsive seizures lasting longer than 5 minutes and involves the use of a benzodiazepine medication (Fig. 633.16). The American Epilepsy Society SE

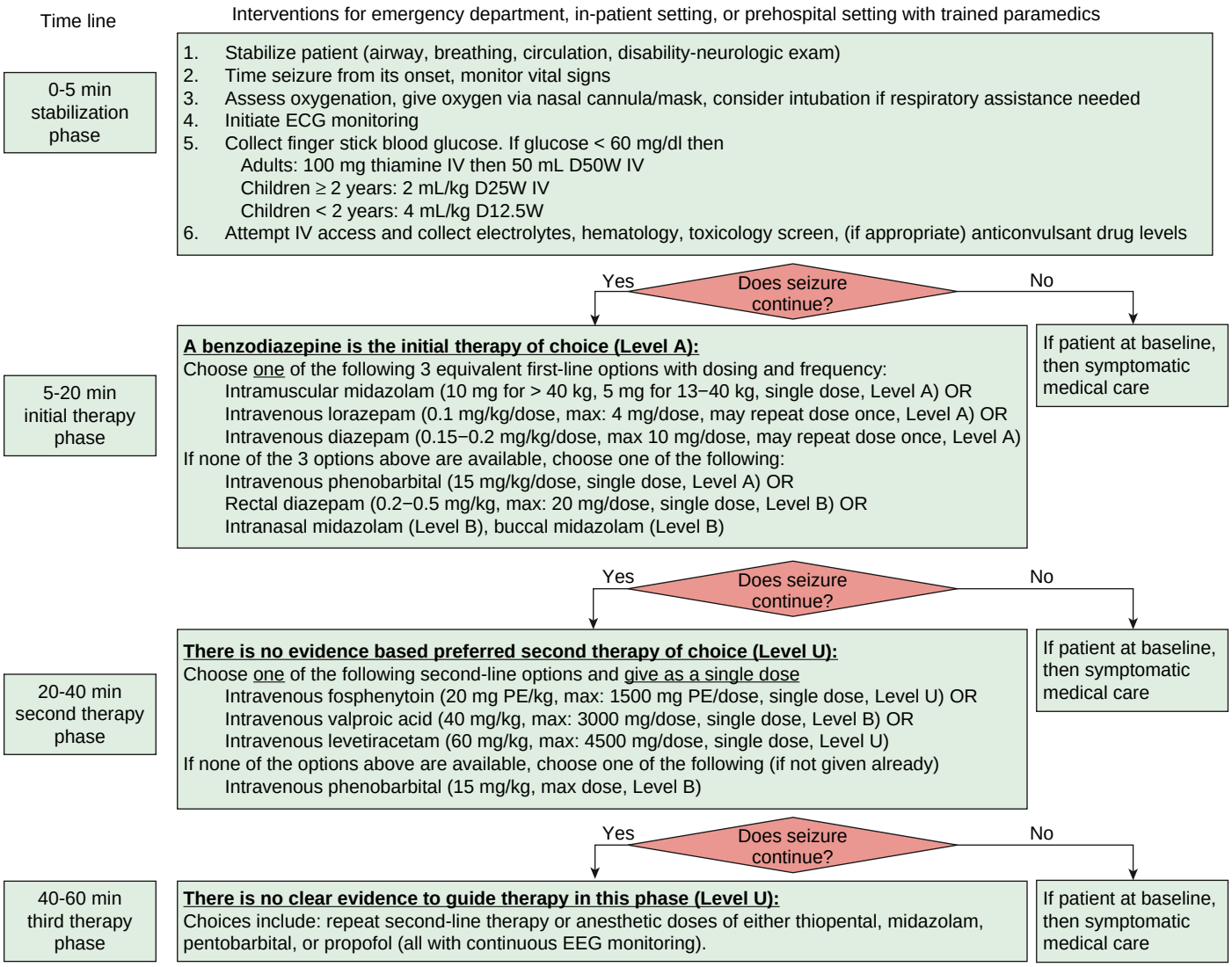

Fig. 633.16 Proposed treatment algorithm for status epilepticus. Disclaimer: This clinical algorithm/guideline is designed to assist clinicians by providing an analytic framework for evaluating and treating patients with status epilepticus. It is not intended to establish a community standard of care, replace a clinician's medical judgment, or establish a protocol for all patients. The clinical conditions contemplated by this algorithm/guideline will not fit or work with all patients. Approaches not covered in this algorithm/guideline may be appropriate. *(From Glauser T, Shinnar S, Gloss D, et al. Evidence-based guideline: treatment of convulsive status epilepticus in children and adults: report of the guideline committee of the American Epilepsy Society. Epilepsy Curr. 2016;16[1]:48–61, Fig.1.)*

Table 633.23 Doses of Commonly Used Antiepileptic Drugs in Status Epilepticus

DRUG*	ROUTE	DOSAGE
Lorazepam	Intravenous Intranasal	0.1 mg/kg up to maximum of 4 mg, may repeat in 5-10 min 0.1 mg/kg up to maximum of 5 mg
Midazolam	Intravenous	0.2 mg/kg up to 10 mg total dose, may repeat in 5-10 min Continuous infusion maintenance: 0.05-2 mg/kg/hr
	Intramuscular	0.2 mg/kg
	Intranasal	0.2 mg/kg
	Buccal	0.5 mg/kg
Diazepam	Intravenous	0.15 mg/kg up to a maximum total dose of 10 mg; may repeat in 5-10 min
	Rectal	2-5 yr: 0.5 mg/kg 6-11 yr: 0.3 mg/kg ≥12 yr: 0.2 mg/kg
Fosphenytoin	Intravenous	Loading: 20 mg/kg PE, infusion rate maximum 50 mg PE/min Maintenance: 4-8 mg/kg/24 hr divided tid
Ketamine	Intravenous	Loading: 1 mg/kg Maintenance: 0.5-2 mg/kg/hr
Phenobarbital	Intravenous	Loading: 15-20 mg/kg (maximum 1,000 mg) Maintenance: 3-5 mg/kg/24 hr divided bid
Pentobarbital coma	Intravenous	Loading: 5-15 mg/kg Maintenance: 1-5 mg/kg/hr
Propofol	Intravenous	Loading: 1-2 mg/kg Maintenance infusion: 1.2 -3.9 mg/kg/hr
Thiopental	Intravenous	Loading: 2-7 mg/kg, infusion rate maximum 50 mg/min Maintenance infusion: 0.5-5 mg/kg/hr
Valproate	Intravenous	Loading: 20-40 mg/kg Maintenance: 30-60 mg/kg/24 hr divided bid
Lacosamide†	Intravenous	Loading: 4-8 mg/kg (maximum 400 mg) Maintenance: 4-12 mg/kg/day divided bid (maximum 400 mg/day)
Levetiracetam	Intravenous	Loading: 30-60 mg/kg (maximum 4,500 mg) Maintenance: 30-60 mg/kg/24 hr divided bid (maximum 3,000 mg/day)
Topiramate	Enterally	Loading: 5-10 mg/kg Maintenance: 5-12 mg/kg/day divided bid (maximum 400 mg/day)

*Reflects current trends in use that may not be FDA approved. For FDA indications, see Table 633.13.
†May cause PR prolongation.
PE, Phenytoin sodium equivalents.

Guidelines recommend using either intravenous lorazepam, intravenous diazepam, or intramuscular midazolam as a first-line agent. The Neurocritical Care Society SE Guidelines recommend intravenous lorazepam as a first-line agent and, if the patient does not have intravenous access, using intramuscular midazolam. Table 633.23 outlines the drugs and dosages typically used in SE. If intravenous access is not available, other options besides intramuscular midazolam include buccal or intranasal midazolam, intranasal lorazepam, or rectal diazepam. With all options, respiratory depression is a potential side effect for which the patient should be monitored and managed as needed. If seizures persist 5 minutes after the initial benzodiazepine dose, a second dose of the drug should be given. Less evidence supports the use of phenytoin/fosphenytoin, phenobarbital, valproate, or levetiracetam as alternative first-line agents. Additionally, in some infants, a trial of pyridoxine may be warranted.

If the emergency therapy with a benzodiazepine is unsuccessful (persistent seizures 5 minutes after the second benzodiazepine dose), fosphenytoin, valproate, or levetiracetam is the recommended option for urgent therapy. Fosphenytoin is given at a loading dose of 20 mg/kg, and a level is usually taken 2 hours later to ensure achievement of a therapeutic concentration. Depending on the level and response, a maintenance dose can be started right away or, more commonly, 6 hours after the initial bolus. Valproate is given at a loading dose of 40 mg/kg, but its use should be avoided in patients younger than 2 years of age and in those with hepatic dysfunction or mitochondrial disease. Levetiracetam is given at loading doses of 60 mg/kg and is well tolerated. Several prospective studies have compared the efficacy of these second-line agents in treating SE that failed to respond to benzodiazepines. One demonstrated the noninferiority of levetiracetam, fosphenytoin, and valproate. Others demonstrated the noninferiority of levetiracetam to phenytoin. In all of these studies, roughly half the patients have seizure resolution with a second-line agent.

Intravenous phenobarbital is an alternative option if valproate, fosphenytoin, or levetiracetam is not available but is not recommended as a first-line urgent therapy because of its side effects. The phenobarbital dose used in neonates is usually 20 mg/kg as a loading dose, but in infants and children the dose is often lower to avoid respiratory depression, with the dose repeated if there is not an adequate response. If seizures persist after administration of the urgent therapy medication, a decision must be made regarding redosing with another second-line agent or proceeding to a continuous infusion. This decision is case-dependent. The Neurocritical Care Society Guidelines on SE suggest that definitive seizure control should be achieved within 60 minutes of seizure onset, which may prompt opting for the more aggressive therapy (i.e., proceeding to continuous infusion and intubation) in a

patient who has already had convulsive seizures for more than 30-60 minutes.

After the second or third medication is given, and sometimes before that, the patient might need to be intubated. All patients with SE, even the ones who respond, need to be admitted to the intensive care unit for completion of therapy and monitoring. Ideally, emergent and urgent therapies should have been received within less than 30 minutes so as to initiate the subsequent therapy soon, thus reducing the chances of sequelae. For **refractory status epilepticus treatment**, an intravenous bolus followed by continuous infusion of midazolam, propofol, pentobarbital, or thiopental is used. Subsequent boluses and adjustment of the rate of the infusion are usually made, depending on clinical and EEG responses. Because most of these patients need to be intubated and paralyzed, the EEG becomes the method of choice by which to monitor response to therapy. The goal is to stop electrographic seizure activity before reducing the therapy. Usually this implies achievement of complete flattening of the EEG, a pattern called **burst suppression**. Some consider that achieving a burst suppression pattern may be enough, and the periods of flattening in such a case need to be 8-20 seconds to ensure interruption of electrographic seizure activity. Evidence suggests that patients who receive higher doses of intravenous anesthetic therapy earlier and achieve EEG voltage suppression sooner are more likely to have fewer complications and shorter duration for need for mechanical ventilation.

Patients receiving these therapies require careful attention to blood pressure and to systemic complications, and some develop multiorgan failure. It is not unusual for patients put into pentobarbital coma to have to be given multiple vasopressors to maintain their blood pressure during therapy.

The choice among these options to treat refractory and superrefractory SE often depends on the experience of the specific center. Midazolam probably has fewer side effects but is less effective, and barbiturate coma is more effective but carries a higher risk of side effects. Some patients taking propofol develop propofol infusion syndrome with lactic acidosis, hemodynamic instability, and rhabdomyolysis with higher infusion rates (>67 μg/kg/min). This limits the use of propofol in the pediatric population. Electrolytes, creatine phosphokinase, and organ function studies need to be monitored if a patient is being given propofol infusion therapy. Often, barbiturate coma and similar therapies are maintained for one or more days before it is possible to gradually taper the therapy, usually over a few days. However, in some cases, including cases of NORSE, such therapies need to be maintained for several weeks or even months. Even though the prognosis in NORSE (and FIRES) cases is often poor and many patients do not survive, meaningful recovery despite a prolonged course is still possible.

Patients with **superrefractory status epilepticus (SRSE)** have persistent seizure activity or seizure recurrence despite 24 hours of general anesthesia with medications such as midazolam, pentobarbital, and/or propofol. In addition to these continuous infusions, polytherapy with other AEDs is usually initiated, although data are lacking regarding the optimal treatment strategy. The most commonly used drugs are fosphenytoin, valproate, phenobarbital, levetiracetam, topiramate, and lacosamide.

Ketamine infusion is a recognized treatment option for SRSE. It is an NMDA receptor antagonist and may be of particular benefit because NMDA receptors are upregulated in SE. The **ketogenic diet** has also been found to be effective in children, although the response may take up to a week after diet initiation and ketosis may be more difficult to achieve if the patient is receiving pentobarbital, which has a carbohydrate-rich carrier fluid. Immunotherapy with intravenous steroids, immunoglobulins, and/or plasma exchange is often used in cases of SRSE of unclear etiology. In specific situations such as **anti–NMDA receptor encephalitis** or **CNS vasculitis**, immunotherapy may be the first-line therapy. Because it can take some time to definitively diagnose autoimmune encephalitides, immunotherapy is often initiated empirically if the clinical history is consistent with the diagnosis. **Inhaled anesthetics** such as isoflurane have been used for SRSE but are associated with a number of adverse reactions and require the presence of an anesthesiologist at bedside, which limits their use. **Induced hypothermia** has also been used, but further studies are needed to assess its safety and efficacy. In select cases of lesional SRSE, emergent neurosurgery may be an option. Such cases include performing hemispherectomy for **Rasmussen encephalitis** or focal resection if the seizures are secondary to an area of cortical dysplasia. The use of VNS, electroconvulsive therapy, and transcranial magnetic stimulation (for epilepsia partialis continua) has also been reported. Allopregnanolone, a neurosteroid, has shown promise in the treatment of pediatric and adult SRSE, and clinical trials are currently underway to better determine its efficacy.

For **nonconvulsive status epilepticus** and **epilepsia partialis continua**, therapy needs to be tailored according to the clinical manifestations and often consists of trials of sequential oral or sometimes parenteral AEDs without resorting to barbiturate coma or overmedication that could result in respiratory compromise. The approach to focal SE with impaired awareness is sometimes similar to the approach to generalized convulsive SE and sometimes intermediate between the approach for epilepsia partialis and that for convulsive status, depending on severity.

Visit Elsevier eBooks+ at eBooks.Health.Elsevier.com for Bibliography.

633.9 Reflex Seizures (Stimulus-Precipitated Seizures)

Mohamad A. Mikati, Dmitry Tchapyjnikov, and Kevin M. Rathke

Many patients with epilepsy can identify precipitating or provoking events that predispose them to having a seizure. Common precipitants in these patients include stress, lack of sleep, fever, or fatigue.

However, there is another group of patients who have seizures in response to a specifically identifiable sensory stimulus or activity and are considered to have reflex seizures. Because no known reflex may be involved, more appropriate terms may be *sensory-precipitated* or *stimulus-sensitive seizures.* Stimuli may be external (light, patterns, music, brushing teeth) or internal (math, reading, thinking, self-induced). Reflex seizures may be generalized, focal, nonconvulsive, absence, or myoclonic. One pattern is photosensitive seizures in which repetitive **photic stimulation** induces photoparoxysmal epileptogenic discharges on EEG and sometimes seizures.

Photosensitive seizures are a well-recognized disorder stimulated by bright or flashing lights (TV, video games, discotheques, concert light shows) or by patterns (TV, video games, lines on the road while traveling). Visual sensitivity may occur in 0.3–3% of the population, whereas photosensitive or pattern-induced seizures may occur in 1 in 4,000 people in the at-risk age-group of 5-25 years. When Japanese children were exposed to a Pokémon cartoon that induced seizures in many, only 24% of those had a history of prior spontaneous seizures. Some children with photosensitive epilepsies stimulate seizures purposefully by rapidly blinking or waving a hand in front of their face (sunflower syndrome). Patients tend to outgrow photosensitive or pattern-induced seizures in their 30s. Photoparoxysmal responses, with an abnormal EEG response to photic stimulation, are more common than photic-induced seizures.

For patients with isolated photosensitive or pattern-induced seizures, avoidance or modification of stimuli is the initial approach. Such activities may include wearing blue or polarized sunglasses, avoiding high-contrast flashing-light video games, avoiding discotheques, watching television in a well-lit room at a distance of >8 feet, and covering one eye when in a provocative situation. A number of genes have been associated with certain patients with reflex epilepsy such as *CHD2* with photosensitive or self-induced seizures caused by fixation-off sensitivity, *LGI1* or *SCN1A* with musicogenic seizures, *MECP2* with eating seizures in Rett syndrome, and *SYN1, GPR56,* or *SYNGAP1* with hot water or bathing epilepsy. Not all patients with these reflex seizures have these pathogenic variants, nor do all patients with variants in these genes have reflex seizures.

Visit Elsevier eBooks+ at eBooks.Health.Elsevier.com for Bibliography.

633.10 Nodding Syndrome

Michael J. Boivin and Itziar Familiar-Lopez

Nodding syndrome (NS) is form of epilepsy that mainly affects children between 3 and 18 years of age who live in distinct regions of Uganda, Liberia, Tanzania, the Democratic Republic of Congo, and southern Sudan. The prevalence is approximately 6.8 per 1,000 children. The first clinical symptom is usually an involuntary nodding of the head in a previously healthy child. These nodding episodes are characterized by at least daily rapid, paroxysmal, forward head-bobbing spells lasting several minutes; some patients are unresponsive, whereas others may respond to commands or continue what they were doing before the episode. Nodding episodes may be triggered during meals while eating hot foods or drinking cold liquids; cold environmental temperatures may also trigger a nodding episode. Head nodding has been determined to be a type of atonic seizure, although other types of seizures, including generalized tonic-clonic or *absence* seizures, may develop. Given the extent of the brain pathogenesis in NS, it is not surprising that it is accompanied by lifelong profound cognitive neurodisability, severe behavior and psychiatric difficulties, growth stunting, delayed puberty, and high mortality rates (Table 633.24 lists case definitions).

Although the diagnosis remains largely based on clinical presentation, the EEG demonstrates a disorganized slow background and interictal generalized 2.5- to 3.0-Hz spike–and–slow waves, with generalized electrodecrement and paraspinal electromyography dropout suggestive of an atonic seizure. NS is characterized by stunted brain growth, which includes significant brain atrophy near the hippocampal and glial matter of the brain and significant cerebellar involvement. Routine CSF analyses are usually negative, but brain MRI shows cerebral and cerebellar atrophy. An MRI study of Tanzanian nodding disease patients revealed that the most frequent abnormality was generalized atrophy, followed by intraparenchymal pathologies such as changes in the hippocampus, gliotic lesions, and subcortical signal abnormalities.

Treatment of seizures is indicated, and choice of AED should be based on the type of seizure presented. Sodium valproate is indicated for atonic seizures and may be a good option to simultaneously treat behavioral difficulties like aggression and impulsive behavior. The suggested starting dose is 10 mg/kg/day in two divided doses and increase the dose by 5 mg/kg/day until seizure control is achieved or the maximum dose is reached (40 mg/kg/day). Other antiepileptic medications used for NS include phenytoin and phenobarbitone, either individually or combined. Management of behavioral and psychiatric difficulties, nursing care, nutritional, and subsequently, physical and cognitive rehabilitation should also be considered.

Despite extensive investigations, the etiology of NS remains unknown. A systematic review using the Bradford Hill criteria for causality identified *Onchocerca volvulus* as the most likely trigger of NS and other forms of onchocerciasis-associated epilepsy. *O. volvulus* is a nematode carried by the blackfly, the bites of which can cause onchocerciasis, a highly prevalent type of blindness caused by infection. High prevalence of NS overlaps with onchocerciasis-endemic areas with high rates of *O. volvulus* transmission and low or no coverage of community-directed treatment with ivermectin. However, the pathophysiologic mechanism through which *O. volvulus* could directly cause the neurologic damage observed in NS patients remains unknown, as microfilariae are not known to invade the brain.

Studies in Uganda support the hypothesis that NS may be an autoimmune epileptic disorder caused by molecular mimicry with *O. volvulus* antigens. Histologic postmortem examination of brains has revealed polarizable material in the majority of specimens, but it has proved difficult to characterize or identify. There is evidence of autoantibodies to leiomodin-1 in both the sera and CSF of Ugandan patients with nodding syndrome. Because leiomodin-1 antibodies cross react with *O. volvulus* proteins, nodding syndrome may be an autoimmune epilepsy initiated by the infection caused by this parasite. Therefore it may be preventable by treatment with antiparasitic strategies, such as the drug ivermectin. It may also perhaps be treatable in its early stages with immunomodulatory therapies.

Onchocerciasis tends to have the highest prevalence in rural east and central African areas with poorly developed healthcare and social service infrastructures. Because of this, families with children affected by nodding disease, often existing on the margins of their resources in impoverished areas, have little in the way of caregiving resources needed to cope with the profound disability that results from this disease. This further diminishes the prognosis for these children because of further risk to their health from accidental injury (e.g., burns from cooking fires), malnutrition because of difficulty in feeding, and/or neglect.

Visit Elsevier eBooks+ at eBooks.Health.Elsevier.com for Bibliography.

Table 633.24 Consensus Case Definition and Modified Consensus Case Definition for Nodding Syndrome, Uganda, 2012–2013*

TYPE OF CASE	CONSENSUS CASE DEFINITION	MODIFIED CONSENSUS CASE DEFINITION
Suspected case	Reported head nodding (repetitive involuntary drops of the head toward the chest on two or more occasions) in a previously normal person	Reported head nodding (repetitive involuntary drops of the head toward the chest on two or more occasions) in a previously normal person
Probable case	Suspected case of head nodding, with both major criteria: Age of onset of nodding ranging from 3 to 18 yr Frequency of nodding 5-20 per min Plus at least one of the following minor criteria: Other neurologic abnormalities (cognitive decline, school dropout because of cognitive or behavioral problems, other seizures or neurologic abnormalities) Clustering in space or time with similar cases Triggering by food or cold weather Stunting or wasting Delayed physical development/absence of development of secondary sexual characteristics Psychiatric symptoms	Suspected case of head nodding, with one major criterion: Age of onset of nodding ranging from 3 to 18 yr Plus at least one of the following minor criteria: Other neurologic abnormalities (cognitive decline, school dropout because of cognitive or behavioral problems, other seizures or neurologic abnormalities) Clustering in space or time with similar cases Triggering by food or cold weather Stunting or wasting Psychiatric symptoms
Confirmed case	Probable case, with documented nodding episode Observed and recorded by a trained healthcare worker, *or* Videotaped nodding episode, *or* Video/EEG/EMG documenting head nodding as atonic seizures	Probable case, with documented nodding episode Observed and recorded by a trained healthcare worker, *or* Videotaped nodding episode, *or* Video/EEG/EMG documenting head nodding as atonic seizures

*The consensus case definition was drafted at the first International Scientific Meeting on Nodding Syndrome, held July 30 to August 1, 2012, in Kampala, Uganda. Meeting report available at http://www.who.int/neglected_diseases/diseases/Nodding_syndrom_Kampala_Report_2012.pdf. The modified consensus case definition was developed during the March 2013 single-stage cluster survey conducted by the Centers for Disease Control and Prevention (CDC) and the Ugandan Ministry of Health to assess the prevalence of nodding syndrome in Uganda.

EEG, Electroencephalographic; EMG, electromyographic.

From Iyengar PJ, Wamala J, Ratto J, et al. Prevalence of nodding syndrome–Uganda, 2012-2013. *MMWR Morb Mortal Wkly Rep*. 2014;63:603–606, Table 1.

Chapter 634

Conditions That Mimic Seizures

Mohamad A. Mikati and Makram M. Obeid

The misdiagnosis of epilepsy is estimated to be as high as 5–40%. Often all that is needed to differentiate nonepileptic paroxysmal disorders from epilepsy is a careful and detailed history in addition to a thorough clinical examination, but sometimes an electroencephalogram (EEG) or more advanced testing may be necessary. The ready availability of video recording on mobile phones can provide invaluable information. Nonepileptic paroxysmal disorders can be classified according to the age at presentation and the clinical manifestations: (1) syncope and other generalized paroxysms, (2) movement disorders and other paroxysmal movements and postures, (3) oculomotor and visual abnormalities and visual hallucinations, and (4) sleep-related disorders (Table 634.1 and Fig. 634.1).

SYNCOPE AND OTHER GENERALIZED PAROXYSMS

Apnea

Apneic episodes (cessation of breathing >20 seconds) in neonates and apnea caused by brainstem compression are usually associated with bradycardia. In contrast, apnea associated with seizures is usually accompanied by tachycardia. Exceptions are seen because bradycardia can occur during some epileptic seizures, and severe apnea of any cause can be followed by anoxic seizures. The term **brief resolved unexplained event (BRUE)** is defined as an event in an infant reported as a sudden, brief, self-resolving episode consisting of one or more of the following: (1) cyanosis or pallor; (2) absent, decreased, or irregular breathing; (3) a marked change in tone (hyper- or hypotonia); and (4) an altered level of responsiveness (see Chapter 424). A BRUE, which usually lasts less than 1 minute, is diagnosed only when no explanation is evident after an appropriate history and physical examination have been conducted. **Apnea** can either be obstructive or central, most commonly in premature neonates. Central apnea also occurs in the context of certain neurogenetic syndromes, the prototype of which is congenital central hypoventilation syndrome secondary to pathogenic variants in *PHOX2B*. **Ondine's curse** (idiopathic congenital central alveolar hypoventilation syndrome) consists of an inadequate respiratory drive in sleep with periods of prolonged apnea requiring tracheostomy and mechanical ventilation (see Chapter 468.2). Apnea can also be secondary to near cerebral herniation and intermittent brainstem compression in the context of increased intracranial pressure or Chiari malformations.

Breath-Holding Spells

The term *breath-holding spells* is actually a misnomer, because they are not necessarily self-induced but result from the immaturity of the autonomic system and occur in two different forms. The first type is the **pallid breath-holding spell**, which is caused by reflex vagal-cardiac bradycardia and asystole. The second type is the **cyanotic**, or **blue**, **breath-holding spell**, which does not occur during inspiration but results from prolonged expiratory

Table 634.1 Conditions that Mimic Seizures According to Age of Presentation

AGE	SYNCOPE AND OTHER GENERALIZED PAROXYSMS	MOVEMENT DISORDERS AND OTHER ABNORMAL MOVEMENTS	OCULOMOTOR AND VISUAL ABNORMALITIES	SLEEP DISORDERS
Neonate	Apnea Paroxysmal extreme pain disorder	Jitteriness, tremor, increased startle reflex, hiccups Hyperekplexia, paroxysmal dystonic choreoathetosis	Paroxysmal tonic upgaze Alternating hemiplegia of childhood, staring, daydreaming, and time-out "unresponsiveness"	Benign neonatal sleep myoclonus Sleep transition disorders, REM
Infants	Reflex anoxic seizures Breath-holding spells Benign paroxysmal vertigo Paroxysmal extreme pain disorder	Jitteriness Sandifer syndrome Paroxysmal dystonic choreoathetosis Benign myoclonus of early infancy Pathologic startle Shuddering attacks, infantile head atonic attacks Benign paroxysmal torticollis Psychologic disorders Alternating hemiplegia of childhood Jactatio capitis (head banging) Drug reactions	Paroxysmal tonic upgaze Oculomotor apraxia Spasmus nutans Opsoclonus-myoclonus syndrome, staring, daydreaming, and time-out "unresponsiveness"	Non-REM partial arousal disorders REM sleep disorders Narcolepsy Sleep transition disorders (somnambulism, somniloquy)
Children and adolescents	Benign paroxysmal vertigo Compulsive Valsalva-like maneuver Familial hemiplegic migraine Syncope (long QT, vasovagal, orthostatic, migraine-induced) Psychogenic seizures Transient global amnesia Hyperventilation spells, factitious disorder	Tics Tremor Pathologic startle Paroxysmal dyskinesias Alternating hemiplegia of childhood Benign paroxysmal torticollis Episodic ataxia Psychologic disorders, including factitious disorder imposed on another, malingering Masturbation Psychogenic seizures Cataplexy Jactatio capitis (head banging) Episodic rage, drug reactions, factitious disorder	Staring, daydreaming, and time-out "unresponsiveness" Drug reactions, hallucinations, visual snow Conversion reactions, factitious disorder	Non-REM partial arousal disorders REM sleep disorders Narcolepsy Sleep transition disorders (somnambulism, somniloquy) Sleep myoclonus Restless legs syndrome, conversion reactions, factitious disorder

REM, Rapid eye movement.
From Obeid M, Mikati MA. Expanding spectrum of paroxysmal events in children: potential mimickers of epilepsy. *Pediatr Neurol*. 2007;37(5):309–316.

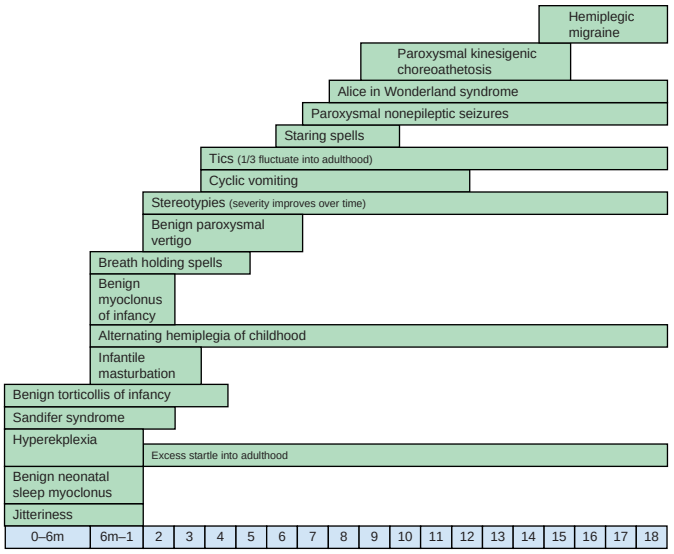

Fig. 634.1 Age ranges (months and years) of seizure mimics, typical onset, and resolution. *(From Stainman RS, Kossoff EH. Seizure mimics in children: an age-based approach. Curr Probl Pediatr Adolesc Health Care. 2020;50:100894, Fig. 1.)*

apnea and intrapulmonary shunting (see Chapter 43). Episodes usually start with a cry (often, in the case of the pallid type, a silent cry with marked pallor) and progress to apnea and cyanosis. Spells usually begin between 6 and 18 months of age. Syncope, tonic posturing, and even reflex anoxic seizures may follow the more severe episodes, particularly in breath-holding spells of the pallid type. Injury (such as even a minor bump on the head), pain, and frustration, particularly with surprise, are common triggers. There usually is a family history of vasovagal syncope or breath-holding spells. Education and reassurance of the parents are usually all that is needed because these episodes are, as a rule, self-limited and are outgrown within a few years. However, screening for anemia and for electrical cardiac disturbances with an electrocardiogram is recommended because the spells are worsened by iron-deficiency anemia and can rarely be the presenting sign of long QT (LQT) syndromes. Anticholinergic drugs, for the selected cases of pallid breath-holding spells (e.g., atropine sulfate 0.03 mg/kg/day in two to three divided doses with a maximum daily dose of 1.2 mg) or antiseizure drug therapy for coexisting anoxic seizures that are recurrent, prolonged, and not responding to other measures may rarely be needed. If antiseizure medications are needed, it is ill-advised to use medications that may increase irritability, such as levetiracetam. It is important also to educate parents on how to handle more severe spells with first aid measures or even basic cardiopulmonary resuscitation when needed. Extremely severe episodes resulting in marked bradycardia and asystole have been reported to respond to a cardiac pacemaker. All parents should be taught not to provide secondary gain when the episodes occur, because this can reinforce them. Also, preparation for unpleasant experiences (such as receiving a shot) rather than surprising the child with them can help limit the number of spells.

Compulsive Valsalva-Like Maneuver

In children with intellectual disability, including Rett syndrome, syncopal convulsions may be self-induced by maneuvers such as the Valsalva maneuver. In this case, true breath holding occurs, and it usually lasts for approximately 10 seconds during inspiration. Some clinicians advocate the use of naloxone in such cases. In the authors' experience, a compulsive Valsalva-like maneuver can rarely be a feature of a panic attack or conversion disorder. When clinically stereotyped, a prolonged EEG and a careful workup by a pediatric epileptologist are needed in order to rule out epileptic seizures.

Neurally Mediated Syncope

Syncope can present with drop attacks and can also lead to generalized convulsions, termed *anoxic seizures*. These convulsions, triggered by a sudden reduction of oxygen to the brain, are clinically similar to, and can be misdiagnosed as, generalized epileptic seizures. **Vasovagal (neurocardiogenic) syncope** is usually triggered by dehydration, heat, standing for a long time without movement, hot showers, the sight of blood, pain, swallowing, vomiting, sudden exposure to cold as with cold water immersion, and a sudden episode of stress (see Chapter 84). The history is usually the clue to distinguishing syncope from epileptic seizures: there is initially pallor and sweating followed by blurring of vision, dizziness, and nausea and then a gradual collapse with loss of consciousness. Of importance is the fact that such prodromal features have an insidious onset and build up gradually, often arising from a state of malaise when they precede syncope. However, in epilepsy, when auras with similar features precede an epileptic seizure, such features are usually sudden, short in duration, and followed by other manifestations of complex partial seizures such as stereotyped automatisms. Abdominal pain, a common aura in temporal lobe epilepsy, occurs in vasovagal syncope and can be a trigger or a consequence of that process (intestinal vagal hyperactivity). Urinary incontinence and a brief period of convulsive jerks are not uncommon in vasovagal syncope. These occur with a frequency of 10% and 50%, respectively. Postictal confusion only rarely occurs, and the rule is the occurrence of only brief postictal tiredness with a subsequent remarkable ability to resume planned activities. Most children with vasovagal syncope have an affected first-degree relative; reports demonstrate autosomal dominant inheritance at least in some families. The EEG is normal, and the tilt test has been used for diagnostic purposes in selected cases. In most cases with a typical history, this test is not needed. In addition, **exercise-induced anaphylaxis** has rarely been reported. In **stretch syncope**, which occurs mostly in adolescents while stretching the neck and the trunk backward and the arms outward or during flexion of the neck, the presumed mechanism is mechanical disruption of brain perfusion caused by compression of the vertebral arteries. In some other cases, this may be associated with an abnormally prolonged stylomastoid process compressing the carotids. If the latter condition is suspected, neuroimaging with cranial CT or MRI is required for proper diagnosis of the stylomastoid anomaly. **Migraine** can also induce vasovagal syncope. Other causes of syncope include primary autonomic failure, which is rare in children, and familial dysautonomia is the only relatively common form. **Familial dysautonomia**, a disease found in Ashkenazi Jews, is characterized by absence of overflow emotional tears, depressed patellar reflexes, and lack of a flare reaction after intradermal histamine. **Dopamine β-hydroxylase deficiency** is a rare cause of primary autonomic failure and is characterized by a complicated perinatal course (hypotension, hypotonia, hypothermia), ptosis, highly arched palate, hyperflexible joints, nocturia, and later impaired ejaculation.

Postural Tachycardia Syndrome

See Chapter 84.1.

Cardiac Syncope

See Chapters 84 and 485.

LQT syndromes can cause life-threatening pallid syncope. Accompanying this are ventricular arrhythmias and, usually, torsades de pointes or even ventricular fibrillation. When accompanied by congenital deafness, it is part of the autosomal recessive Jervell and **Lange-Nielsen syndrome** (type 1, LQT 1, associated with the *KvLQT1* potassium channel pathogenic variant). **Romano-Ward syndrome** is an autosomal dominant syndrome with incomplete penetrance (LQT 2 associated with an *HERG* potassium channel variant). LQT 3 is associated with an *SCN1A* sodium channel variant, LQT 4 with an ankyrin protein mutation, LQT 5 (milder form) with *KCNE1* variants, LQT 6 with *KCNE2* potassium channel gene variants, LQT 9 with caveolin sodium channel–related protein variants, and LQT 10 with *SCN4B* sodium channel variants. LQT 7 and LQT 8 have associated clinical and neurologic manifestations. LQT 7 **(Andersen-Tawil)** syndrome is associated with periodic paralysis, skeletal developmental abnormalities, clinodactyly, low-set ears, and micrognathia (variants in *KCNJ2*). LQT 8, or **Timothy syndrome** (variants in the calcium channel gene *CACNA1C*), manifests with congenital heart disease, autism, syndactyly, and immune deficiency. All family members of an affected child should be investigated. Affected individuals

need insertion of cardiac defibrillators, and their families should be taught cardiopulmonary resuscitation. Children with a new-onset seizure disorder of unclear etiology should get an electrocardiogram to rule out LQT syndrome masquerading as a seizure disorder. Cardiac syncope is usually sudden, without the gradual onset and symptoms that accompany vagal syncope. Aortic stenosis can cause sudden syncope at the height of exercise (usually hypertrophic) or directly at the end (usually valvular) and, if suspected, warrants an echocardiogram.

Migraine and Migraine Variants

Familial hemiplegic migraine (FHM) is a rare type of autosomal dominant migraine with the prominent feature of transient motor weakness. Attacks begin as early as 5-7 years of age. In a genetically susceptible child, attacks may be precipitated by head trauma, exertion, or emotional stress. The three genes commonly identified are *CACNA1*A in FHM1 (neuronal calcium channel subunit), *ATP1A2* in FHM2 (sodium potassium adenosine triphosphatase subunit), and *SCN1A* in FHM3 (neuronal sodium channel subunit). Pathogenic variants of other genes such as *PRRT2* may also cause FHM. However, at least a quarter of the affected families and most of the sporadic patients do not carry a pathogenic variant in these genes. Headaches occur in all attacks in most patients. The presence of negative phenomena (e.g., numbness, visual scotomas) in addition to positive phenomena (pins and needles, flickering lights) and the progressive and successive occurrence of visual, sensory, motor, aphasic, and basilar signs and symptoms, in that order, help differentiate these attacks from epileptic seizures. Persistent cerebellar deficits (e.g., nystagmus, ataxia) may be present. Verapamil, acetazolamide, and lamotrigine have been successfully used to prevent attacks, and verapamil and ketamine have been used for the acute episode; ergot derivatives, nimodipine, Midrin (isometheptene mucate, dichloralphenazone, and paracetamol), and probably triptans and propranolol are to be avoided because of concerns of exacerbating the attacks. Interestingly, the co-occurrence of epileptic seizures has been reported in a minority of patients with hemiplegic migraine. It is important also to note that recurrent attacks akin to hemiplegic migraine can be symptomatic of Sturge-Weber syndrome or various metabolic diseases (e.g., mitochondrial encephalopathy with lactic acidosis and strokelike episodes, as well as alternating hemiplegia of childhood).

Benign paroxysmal vertigo of childhood is a common migraine equivalent that consists of brief seconds-to-minutes episodes of vertigo that are often accompanied by postural imbalance and nystagmus. It is important to note that vertigo does not always refer to a spinning motion; it can also refer to a backward or forward motion (vertigo titubans) where children sometimes report that objects seem to be moving toward them. The child appears frightened during the episode. Diaphoresis, nausea, vomiting, and, rarely, tinnitus may be present. Episodes usually remit by 6 years of age. MRIs and EEGs are normal, but caloric testing, if done, can show abnormal vestibular function. Diphenhydramine 5 mg/kg/day (maximum of 300 mg/day) may be used for a cluster of attacks. Preventive therapy with cyproheptadine may rarely be needed for frequent attacks.

Cyclic vomiting syndrome (CVS) is another related periodic migraine variant that can respond to antimigraine or antiepileptic drugs. Recurrent vomiting can also be caused by neuromyelitis optica, juvenile Alexander disease, brainstem pathology, inborn errors of metabolism with intermittent presentations, and seizures, usually from the nondominant temporal lobe. With the latter, there is, as a rule, impaired consciousness. Prophylaxis for CVS has included medications such as amitriptyline, propranolol, cyproheptadine, sumatriptan, erythromycin, coenzyme Q, fluoxetine, or antiepileptics. Acute therapy usually consists of 10% dextrose intravenously with ondansetron and an antihistamine or benzodiazepine.

Alice in Wonderland syndrome (see "Visual Hallucinations," later), confusional migraine, and abdominal migraine are also migraine variants. One should note that many patients with migraine or migraine variants (including FHM) have coexisting epilepsy, and children with epilepsy have a higher incidence of migraine headaches compared with the general population, so providers should be aware that such patients may have symptoms attributable to either.

Nonepileptic Seizures (Formerly, Functional Disorders)

Nonepileptic seizures are a form of functional neurologic disorder that can be diagnosed clinically based on the characteristics of the spells (Tables 634.2 and 634.3). A video of the event is usually possible because most of the events are witnessed and tend to be more prolonged than epileptic seizures. If needed, a diagnosis can be confirmed by video-EEG with capture of an episode to eliminate any residual doubts about its nature because these functional paroxysms can often occur in patients who also have epileptic seizures. A social history is very important because psychogenic nonepileptic seizures (PNESs) are often a reaction to physical or sexual abuse or to the inability to cope with psychosocial tasks. They are best managed acutely by reassurance about their relatively benign nature and by a supportive attitude while at the same time avoiding positive reinforcement of the episodes; an early accurate diagnosis and timely management result in more favorable outcomes. The use of terms such as *nonepileptic stress seizures* facilitates communication with families, given the often-perceived negative connotation of the term *psychogenic.* Psychiatric evaluation and follow-up are needed to uncover an underlying psychopathology and to establish continued support because psychogenic seizures can persist over long periods. Malingering and factitious disorder imposed on another (formerly called *Munchausen syndrome by proxy*) are often difficult to diagnose, but an approach similar to that for psychogenic seizures, including video-EEG monitoring, is often helpful. Sad cases of loss of consciousness related to suffocation by caregivers in infants and toddlers have also been reported.

Paroxysmal Extreme Pain Disorder

Paroxysmal extreme pain disorder, previously called *familial rectal pain syndrome,* is caused by an autosomal dominant gain-of-function variant in a sodium channel (Nav1.7) encoded by the *SCN9A* gene. Paroxysmal extreme pain disorder usually starts in infancy and persists throughout life. Autonomic manifestations predominate initially, with skin flushing in all cases and harlequin color change and tonic attacks in most. Dramatic syncope with bradycardia and sometimes asystole occurs. Later, the disorder is characterized by attacks of excruciating, deep burning pain often in the rectal, ocular, or jaw areas, but also diffusely in some. Attacks are triggered by defecation, cold, wind, eating, and emotion. Carbamazepine is used, but the response is often incomplete. Neurologically impaired children can often have irritability without clear etiology even after investigations, and this has been reported to respond to gabapentin (for neurologic irritability).

Autonomic Storms

Autonomic storms are also referred to as diencephalic seizures, paroxysmal sympathetic hyperactivity, sympathetic storms, paroxysmal autonomic instability with dystonia, dysautonomia, and central autonomic dysfunction. Spells of hyperhidrosis and changes in blood pressure, temperature, and autonomic instability occur in patients with severe diffuse brain injury or localized hypothalamic injury and have been termed autonomic storms. The term diencephalic seizures is discouraged because the episodes are not truly seizures. Therapy is difficult and has included, with mixed results, clonidine, propranolol, baclofen (oral or intrathecal), benzodiazepines (particularly clonazepam), bromocriptine, chlorpromazine, hydralazine, methadone, cyproheptadine, morphine, and sympathectomy.

Serotonin syndrome caused by antidepressants, stimulants, opioids, certain herbs such as St. John's wort, and some other medications can produce similar symptoms, and if not recognized, can at times be fatal, as can the similar **neuroleptic malignant syndrome** caused by antipsychotic medications.

Table 634.2 Comparison of Generalized Seizures and Some Disorders That Can Mimic Them

CONDITION	PRECIPITANTS (MAY NOT APPLY TO ALL PATIENTS)	PRODROME	ICTAL SYMPTOMS	POSTICTAL SYMPTOMS
Generalized seizures	Sleep deprivation, television, video games, visual patterns, and photic stimulation	Rarely irritability or nonspecific behavioral changes	Usually 2-3 min Consciousness might be preserved if atonic or, in some, tonic seizures Synchronous bilateral movements Tongue biting	Delayed recovery with postictal depression, incontinence (may be ictal also)
Syncope: vasovagal	Fatigue, emotional stress, dehydration, vomiting, choking, swallowing	Blurring of vision, tinnitus, dizziness, nausea, sweating Crying in breath-holding spells	Loss of consciousness for seconds, pallor, and rarely reflex anoxic seizures	Rapid recovery with no postictal depression
Syncope with reflex anoxic seizures	Minor bump to head, upsetting surprises			
Syncope: trigeminal vagal	Cold water on face			
Syncope: orthostatic	Standing up, bathing, awakening			
Hyperekplexia	Auditory and tactile stimuli	None	Tonic stiffening, cyanosis if severe, nonfatigable nose-tap–induced startles	Depending on severity, may have postictal depression
Cardiac	Exercise	None	Loss of consciousness, often only for a few seconds, pallor	Rarely
Nonepileptic seizures (formerly, functional disorders)	Suggestion, stress	None; some have headache, nausea, palpitations, poor concentration, panic-like attack	Eyes closed, with active opposition to attempts to open them Asynchronous (nonrhythmic) flailing or tremulous limb movements that vary between attacks Motor activity stops and starts during a spell Weeping and crying No injury May respond to suggestion during "loss of consciousness" Usually longer than 5 min, decrease in intensity when provider places hand on patient's shoulder	No postictal depression

Adapted from Obeid M, Mikati MA. Expanding spectrum of paroxysmal events in children: potential mimickers of epilepsy. *Pediatr Neurol*. 2007;37(5):309–316.

Table 634. 3 Positive Diagnostic Features and Biomarkers of Nonepileptic Seizures and Functional Movement Disorder

	ESTABLISHED DIAGNOSTIC FEATURES	NEW DIAGNOSTIC FEATURES*
NONEPILEPTIC SEIZURES		
Seizures	Eyes closed; prolonged attacks; hyperventilation; awareness during generalized shaking; ictal or postictal weeping	Suggestive seizure induction; qualitative conversation analysis; use of smartphone video; wrist-worn accelerometers; postictal plasma proteins
FUNCTIONAL MOVEMENT DISORDER		
Tremor	Tremor entrainment or cessation to externally cued rhythm; variability of frequency and amplitude of tremors	"Whack-a-mole" sign: holding down a tremulous body part induces tremor in another body part; coherence between antagonist muscles measured with standard coherence or wavelets
Dystonia	Fixed inverted or plantar flexed ankle; fixed clenched fist	Dystonia of the face: downward lip pulling, orbicularis oculi spasm, platysma spasm; sustained facial movement to evoke a spasm; functional hemifacial spasm lacks the "other Babinski sign" (i.e., raising of eyebrow on affected side)
Gait and balance	Variability of gait performance; gait performance shows excellent balance; "walking-on-ice" gait, dragging monoplegic gait, or knee-buckling gait	Classification of gait types into seven types: ataxic, spastic, weak gait, antalgic, parkinsonian, hemiparetic, and dystonic; "huffing and puffing" sign: huffing, grunting, grimacing, and breath holding after small amounts of exercise; posturographic improvement with distraction (guessing numbers written on back or cognitive task)
Jerks or myoclonus	Truncal jerking, especially with facial movement†; positive bereitschaftspotential before movement using back averaging	Increased startle; event-related desynchronization using back averaging
Limb weakness and generic motor dysfunction	Hoover sign; hip abductor sign; drift without pronation	Absence of amplitude suppression of median nerve somatosensory evoked potential; decreased prepulse inhibition of the blink reflex by stimulation of the index finger; absence of contingent negative variation in reaction time task

*Described in the past 10 years.
†The diagnosis of functional jerks can be difficult, but 104 (58%) of 179 patients with truncal myoclonus had functional neurologic disorder in one series.
From Hallett M, Aybek S, Dworetzky BA, et al. Functional neurological disorder: new subtypes and shared mechanisms. *Lancet Neurol*. 2022;21:537–550, p. 539.

MOVEMENT DISORDERS AND OTHER PAROXYSMAL MOVEMENTS AND POSTURES

Neonatal Jitteriness and Clonus

Jitteriness consists of recurrent tremors. These movements manifest as equal backward-and-forward movements of the limbs, either occurring spontaneously or triggered by touch or loud sounds. Movement suppression by stimulus removal or by relaxing the affected limbs, the lack of autonomic symptoms, and the clear difference from the two-phased (fast contraction, slow relaxation) clonic activity and the very quick myoclonic jerks point to a nonepileptic event. Hypocalcemia, hypoglycemia, drug withdrawal, and hypoxic-ischemic encephalopathy are possible etiologies, but jitteriness is also often seen in normal neonates. Clonus as a result of corticospinal tract injury usually occurs in later infancy and childhood and can be stopped by a change in position. Two to three beats of clonus can be within normal in some neonates.

Hyperekplexia (Stiff Baby Syndrome) and Pathologic Startles

Hyperekplexia is a rare, sporadic, or dominantly inherited (less often recessive or X-linked) disorder with neonatal onset of life-threatening episodes of tonic stiffening that precipitate apnea and convulsive hypoxic seizures. It is characterized by a triad of generalized stiffness, nocturnal myoclonus, and later a pathologic startle reflex. Stiffness may result in difficulty in swallowing, choking spells, hip dislocations, umbilical or inguinal hernias, and delayed motor development. Stiffness in the neonatal form improves by 1 year of age and may disappear during sleep. The genetic cause is a defect in the α or β subunits of the strychnine-sensitive glycine receptors. However, other less common pathogenic variants that disrupt the glycine receptor signaling complex have also been described. Pathogenic variants in *GLRA1* or *SLC6A5* are the most common genes followed by *GLRB, GPHM,* and *ARHGEF9* (X-linked). A specific diagnostic sign can be elicited by tapping the nose, which produces a nonfatigable startle reflex with head retraction. Bathing, sudden awakening, and auditory or tactile stimuli can induce attacks. The differential diagnosis includes congenital stiff person syndrome, startle epilepsy, myoclonic seizures, neonatal tetany, phenothiazine toxicity, and Schwartz-Jampel syndrome. Making a prompt diagnosis is extremely important so that treatment with clonazepam can be initiated, because hypoxic brain injury can result from a prolonged episode. Other antiepileptics have also been effective. Repeatedly flexing the baby at the neck and hips (the Vigevano maneuver) can abort the episodes. Rare challenging cases of children with hyperekplexia and concomitant epileptic seizures (including myoclonic seizures) have been reported. In other children after brain injury, and in many patients with cerebral palsy, an **exaggerated startle reflex** can occur; this is more common than hyperekplexia. In Tay-Sachs disease and similar gangliosidoses, an exaggerated startle to sound occurs and has been inappropriately interpreted as hyperacusis. **Hiccups** can occur normally in newborns but can be a feature of nonketotic hyperglycinemia, citrullinemia, and neuromyelitis optica syndromes, with the latter presenting during later childhood and adolescence rather than in neonates. In addition, in children with neurologic diseases, a related limited repertoire of movements and behaviors, startle, arousal, or signs of distress may be clinically expressed with stereotyped movements that can mimic epileptic seizures.

Benign Paroxysmal Torticollis of Infancy

This condition typically presents as morning episodes of painless retrocollis and, later, torticollis, often triggered by changes in posture. Attacks may start with abnormal ocular movements and progress to stillness in an abnormal posture. Vomiting, malaise, irritability, and ataxia may be present during the spells that usually last minutes (paroxysmal) or, more commonly, hours and, at times, days (periodic). Neurologic exam between attacks, EEG, and neuroimaging studies are normal. The condition affects girls more than boys (3:1), often begins in infancy, and spontaneously remits before the age of 5 years. However, some children, particularly those with migrainous features during attacks, develop migraine later in life. Indeed, this condition is considered to be a migraine equivalent and cosegregates with migraine in families. Medical therapy is supportive during the attacks, especially when vomiting is a prominent feature.

Sandifer Syndrome and Rumination

Gastroesophageal reflux in infants may cause paroxysmal episodes of generalized stiffening and opisthotonic posturing that may be accompanied by apnea, staring, and minimal jerking of the extremities. Episodes often occur 30 minutes after a feed. In older children, this syndrome manifests with episodic dystonic or dyskinetic movements consisting of laterocollis, retrocollis, or torticollis, the exact pathophysiology of which remains elusive. Reflux can also present with rumination consisting of contraction of abdominal muscles followed by mouthing and swallowing movements and at times vomiting.

Alternating Hemiplegia of Childhood

This is a rare, often severe, disorder that consists of attacks of flaccid hemiplegia affecting one or both sides lasting minutes to days, starting in the first 18 months of life. Earlier manifestations include paroxysmal nystagmus, which is often monocular and ipsilateral to the hemiplegia or dystonia. Dystonic spells are the rule also. Patients can have episodes of reduced consciousness and confusion that are not epileptic. Most affected children also have ataxia and developmental delay, and many have choreoathetosis and behavioral problems. Most of the patients are initially misdiagnosed as having refractory focal epilepsy with Todd paralysis. About half of them also have epileptic seizures, which makes the differential diagnosis even more difficult. Flunarizine 2.5-20 mg/day reduces the frequency and severity of the attacks. This condition is most commonly caused by variants in *ATP1A3,* but it can also result from variants in *ATP1A2* or the glucose transporter 1 *(GLUT-1/SLC2AI)*, variants that are notoriously associated with diagnostically challenging protean manifestations ranging from epilepsy, usually in early life, to movement disorders thereafter. The *ATP1A3* gene has also been reported in a syndrome of **relapsing encephalopathy with cerebellar ataxia (RECA)** during febrile illnesses. Another syndrome is benign nocturnal alternating hemiplegia, which manifests during sleep and is generally outgrown and has been linked to *PRRT2* variants.

Paroxysmal Dyskinesias and Other Movement Disorders

These disorders are characterized by sudden attacks that consist of choreic, dystonic, ballistic, or mixed movements (Table 633.4 and see Table 634.3). Despite their historical classification into distinct entities, emerging insight into their clinical features and their underlying genetic causes is revealing a significant overlap with phenotypic pleiotropy whereby a pathogenic variant in a single gene may be associated with multiple types of dyskinesias and paroxysms, including epileptic seizures even in the same child. A sensation of fatigue or weakness confined to one side may herald an attack. Consciousness is preserved and patients may be able to perform a motor activity, such as walking, despite the attack. The variability in the pattern of severity and localization between different attacks may also help in differentiating them from seizures. The frequency of attacks increases in adolescence and steadily decreases in the third decade. Neurologic examination between attacks, laboratory investigations, and imaging studies are usually normal. Because the co-occurrence of movement disorders and epileptic seizures is not uncommon, the nature of each type of paroxysmal event has to be characterized as epileptic or not, often with a cautiously analyzed video-EEG, as movement-related artifact may be misread as epileptiform. **Chorea** consists of involuntary rapid fast movements that are slower than myoclonus and not rhythmic. Common causes are poststreptococcal Sydenham chorea, antiphospholipid antibody syndrome, and systemic lupus erythematosus. Action

Table 634.4 Differential Diagnoses of Various Types of Paroxysmal Dyskinesia

FEATURES	PKD	PNKD		PED	PHD (EPILEPSY WITH DYSTONIC EPILEPTIC SEIZURES)
		PNKD1 (MR1+ VE)	PNKD2 (MR1- VE)		
Nomenclature	PKC	PDC, FPC	PDC, FPC	PEDt	ADNFLE
Inheritance	AD–16q	AD–2q35	AD–2q13	AD/AR	AD–20q13, 15q24, 1q21, 8p21
Gene	*PRRT2* (most common), *SCN8A*, *DEPDC5*	*MR1* (now called *PNKD*)	Not well characterized *KCNMA1*, *ATP1A3*	*SLC2A1*	*CHRNA4*, *CHRNB2*, *KCNT1*
Age at onset (yr)	1-20	<1-12	1-23	Usually childhood	Usually childhood
Triggers	Sudden whole-body movement	Coffee, alcohol, stress	Exercise	After 10-15 min of exercise	Sleep
Clinical features	Chorea, athetosis, ballismus, dystonia	Chorea, athetosis, dystonia, ballismus	Chorea, athetosis, dystonia, ballismus	Mainly leg dystonia	Wakes up with dystonic posture
Usual duration	<1-5 min	10 min to 1 hr	10 min to 2-3 hr	10-15 min	<1 min
Frequency	1-20/day	1/wk	1/wk	Daily, weekly, or monthly	Several/night
Associations	Infantile seizures (ICCA), migraine, writer's cramp, essential tremor	Migraine	Epilepsy	RE-PED-WC	
Medication	Carbamazepine Phenytoin Oxcarbazepine	Benzodiazepines, mainly clonazepam	Benzodiazepines, mainly clonazepam	Acetazolamide L-DOPA Antiepileptics Trihexyphenidyl Ketogenic diet in *SLC2A1* mutation cases	Carbamazepine Oxcarbazepine
Prognosis	Excellent	Excellent, worse than PKD	Minimally worse than PNKD MR1+	Poor medication response	Excellent

AD, Autosomal dominant; ADNFLE, autosomal dominant nocturnal frontal lobe epilepsy; AR, autosomal recessive; FPC, familial paroxysmal choreoathetosis; ICCA, infantile convulsions choreoathetosis syndrome; MR1+, myofibrillogenesis regulator 1–positive; MR1−, myofibrillogenesis regulator 1–negative; PDC, paroxysmal dystonic choreoathetosis; PED, paroxysmal exercise-induced dyskinesia; PEDt, paroxysmal exercise-induced dystonia; PHD, paroxysmal hypnogenic dyskinesia; PKC, paroxysmal kinesigenic choreoathetosis; PKD, paroxysmal kinesigenic dyskinesia; PNKD, paroxysmal nonkinesigenic dyskinesia; RE-PED-WC, rolandic epilepsy–paroxysmal exercise-induced dystonia–writer's cramp.
From Friedman NR, Ghosh D, Moodley M. Syncope and paroxysmal disorders other than epilepsy. In: Swaiman KF, Ashwal S, Ferriero DM, et al, eds. *Swaiman's Pediatric Neurology*, 5th ed. Philadelphia: WB Saunders; 2012: Table 65-1.

myoclonus and paroxysmal lower body action dystonia occur in children with myoclonus dystonia—a syndrome caused by pathogenic variants in *SGCE* or *RELN*. **Drug reactions** can result in abnormal movements; they include **oculogyric crisis** with many antiemetics and lamotrigine toxicity, choreoathetosis with phenytoin, dystonia and facial dyskinesias with antidopaminergic drugs, and tics with carbamazepine. Strokes, focal brain lesions, connective tissue disorders (e.g., systemic lupus erythematosus), vasculitis, or metabolic and genetic disorders can also cause movement disorders. Indeed, paroxysmal dyskinesia may be secondary to basal ganglia lesions, and various forms of nonepileptic paroxysms, including dystonic posturing, bicycling, and rhythmic boxing, may occur in children with decompensated maple syrup urine disease.

Episodic Ataxias

Episodic ataxias form a clinically and genetically heterogeneous group of diseases that manifest with recurrent truncal ataxia and incoordination. Of the nine syndromes described so far, only two (types 1 and 2) have been reported in a large number of families from different ethnic groups. **Type 1** is caused by pathogenic variants in *KCNA1* that encodes the voltage-gated potassium channel Kv1.1. It consists of brief episodes (seconds to minutes) of cerebellar ataxia and occasional seizures with interictal myokymia as a main diagnostic feature. **Type 2** is characterized by longer attacks (minutes to hours) and interictal cerebellar signs. It is caused by variants in the voltage-gated calcium channel gene *CACNA1A*. This type is more responsive than type 1 to acetazolamide; the drug can reduce the frequency and severity of attacks but not the interictal signs and symptoms. The other types of episodic ataxia are not well-characterized, but types 5, 6, and 9 have been associated with variants in *CACNB4*, *SLC1A3*, and *FGF14*, respectively. Spells of episodic ataxia may also occur in children with paroxysmal dyskinesia secondary to variants in *CACNA1A* or *PRRT2*, in line with the previously discussed phenotypic pleiotropy of these conditions. Although epileptic seizures have been primarily described in episodic ataxia type 1, they have also been reported with the other types, specifically types 2 and 6. Glucose transporter deficiency can at times present as episodic ataxia.

Motor Tics

These are movements that are under partial control and are associated with an urge to do them and with subsequent relief. They are usually exacerbated by emotions and often change in character over time. **Simple tics**, which occur at some time in about one in five children, involve one or two muscle groups; **complex tics** involve multiple tics or muscle groups; and **Tourette syndrome** consists of multiple motor tics and vocal tics for more than a year. In patients with tics who have Tourette syndrome, there is often a family history of tics and/or obsessive-compulsive disorder or personality traits. Some rare cases appear to occur after preceding streptococcal infections and have been termed **PANDAS** (pediatric autoimmune neuropsychiatric disorder associated with streptococcal infections). **PANS**, on the other hand, refers to an acute onset of obsessive-compulsive symptoms

with other behavioral problems and often with tics but without the association of streptococcal infections (acute-onset neuropsychiatric syndrome).

Benign Motoric Paroxysms in Infancy

Benign myoclonus of infancy consists of myoclonic jerks of the extremities in wakefulness and sometimes also in sleep with no concurrent epileptic EEG changes in a neurologically normal child. **Shuddering attacks** are characterized by rapid tremors of the head, shoulder, and trunk lasting a few seconds, often associated with eating, and recurring many times a day. Others have considered shuddering as an early manifestation of essential tremor because a family history of essential tremor is often present. **Infantile head atonic attacks** consist of repeated head drops, hundreds to thousands per day, usually appearing at 3-6 months of life and spontaneously subsiding by the first year of life, without concurrent EEG epileptic activity. Spontaneous remission occurs in all three syndromes, usually within a few months. Video-EEG is normal ictally and interictally in these syndromes but should be performed to differentiate them from infantile spasms and epileptic myoclonus. **Hereditary chin trembling** at a frequency faster than 3 Hz starting shortly after birth and precipitated by stress has been described in several families.

Brainstem Dysfunction

Decorticate or decerebrate posturing that mimics epileptic tonic seizures may be secondary to decompensated hydrocephalus, intracranial hemorrhage, brainstem tumors, Chiari malformation, or other causes of sudden rises in intracranial pressure that lead to brainstem dysfunction. The term *cerebellar fits* has been used to describe drop attacks, extensor posturing with varying degrees of altered consciousness and respiratory compromise secondary to crowding of the posterior fossa, and near herniation in decompensated cerebellar tumors and certain cases of Chiari malformation.

Behavioral Conditions

Many behavioral disorders can be mistaken for epileptic seizures. Pleasurable behaviors similar to masturbation may occur from infancy onward and may consist of rhythmic rocking movements in the sitting or lying position or rhythmic hip flexion and adduction. **Infantile gratification** (masturbation), which is more common in females, usually occurs at 2-3 years of age and is often associated with perspiration, irregular breathing, and grunting but no loss of consciousness. Occasionally this is associated with child abuse or with other psychopathology. **Stereotypies**, or repetitive movements that are more complex than tics and do not change and wax and wane as do tics (e.g., head banging, head rolling, body rocking, and hand flapping), usually occur in neurologically impaired children. A **mannerism** is a pattern of socially acceptable, situational behavior that is seen in particular situations such as gesturing when talking. Mannerisms should not be confused with stereotypies, which are generally pervasive over almost every other activity, such as head shaking or hand flapping in multiple situations. Stereotypies, unlike mannerisms, increase with stress. Unlike tics and mannerisms, stereotypies usually start before the age of 3 years, involve more body parts, are more rhythmic, and most importantly occur when a child is engrossed with an object or activity of interest; children rarely try to suppress stereotypies. **Panic and anxiety attacks** have been described in children; at times, these may be clinically indistinguishable from actual epileptic seizures and therefore may necessitate video-EEG monitoring. **Rage attacks** usually occur in patients with a personality disorder and are usually not seizures, although rare cases of partial seizures can manifest as rage attacks. **Hyperventilation spells** can be precipitated by anxiety and are associated with dizziness, tingling, and, at times, carpopedal spasm. **Transient global amnesia** consists of isolated short-term memory loss for minutes to hours that occurs mostly in adults but has been reported in children. The etiology can be emotional stress, an epileptic disorder, migraine, a vascular disorder, or a drug-related reaction.

OCULOMOTOR AND VISUAL ABNORMALITIES

Paroxysmal Tonic Upgaze of Childhood

This usually starts before 3 months of age and consists of protracted attacks (hours to days) of continuous or episodic upward gaze deviation, during which horizontal eye movements are preserved. A downbeating nystagmus occurs on downward gaze. Symptoms are reduced or relieved by sleep, exacerbated by fatigue and infections, and spontaneously remit after a few years. Up to 50% of patients may have psychomotor and language delay. Although imaging and laboratory tests were nonrevealing in the seminal cases, white matter lesions have been later reported in some patients. An association with *CACNA1A* gene variants in a few patients who also suffered from ataxia has been reported, pointing to etiologic and clinical heterogeneity. The differential diagnosis includes drug reactions, tics, Chediak-Higashi disease, Rett syndrome, and Wilson disease. Most of those, however, occur at a later age. Therapy with carbonic anhydrase inhibitors or low-dose levodopa/carbidopa may be helpful in severe cases. Concomitant absence epilepsy has been reported in few cases.

Oculomotor Apraxia and Saccadic Intrusions

In oculomotor apraxia, saccadic eye movements are impaired. Sudden head turns compensating for lateral gaze impairment mimic seizures. This disorder may be idiopathic (Cogan congenital oculomotor apraxia) or may occur in the context of Joubert syndrome, ataxia telangiectasia, spinocerebellar ataxias, or lysosomal storage diseases. A selective loss of Purkinje cells required to suppress omnipause neurons and initiate saccadic eye movement is believed to occur in some of the disorders. Saccadic intrusions are involuntary, sudden, conjugate eye movements away from the desired eye position. These are not necessarily pathologic.

Spasmus Nutans

This disorder presents with a triad of nystagmus, head tilt, and head nodding. If diurnal fluctuation occurs, symptoms may look like those of epileptic seizures. A brain MRI should be performed because the triad has been associated with masses in the optic chiasm and third ventricle. Retinal disease should also be ruled out. In the absence of these associations, remission occurs before 5 years of age.

Opsoclonus-Myoclonus Syndrome

In opsoclonus-myoclonus syndrome, the term *dancing eyes* refers to continuous, random, irregular, and conjugate eye movements that may fluctuate in intensity. The finding usually accompanies myoclonus and ataxia (dancing feet). Neuroblastoma (more commonly), encephalitis, and a presumed postinfectious etiology are possible causes. In addition to treating the underlying etiology, adrenocorticotropic hormone (ACTH), corticosteroids, rituximab, and clonazepam are often needed. Recurrences are not infrequent, and developmental delay is common. The opsoclonus and myoclonus may recur after treatment. The long-term neurologic prognosis remains poor, yet the presence of this syndrome is associated with a favorable treatment response of a coexisting neuroblastoma. Opsoclonus with epileptic myoclonus has also been described in a child with GLUT-1 deficiency.

Daydreaming and Behavioral Staring

Staring may be a manifestation of absence seizures, which should be differentiated from daydreaming and from behavioral staring because of fatigue and inattention. This is common in children with **attention-deficit disorder** because these patients are often referred to rule out absence seizures. Hyperventilation in the office precipitates absences and is a useful clinical test. Episodes of staring only in certain settings

(e.g., school) are unlikely to be seizures. In addition, responsiveness to stimulation such as touch and lack of interruption of playing activity characterize nonepileptic staring. **Daydreaming** occurs often in children, and **time-out staring** occurs in children when they are overwhelmed with external stimuli or with demands and shut down, ignoring their surroundings and staring.

Visual Hallucinations

Temporal lobe seizures can be associated with complex visual auras, such as seeing people and places, often with subsequent focal seizure manifestations. **Occipital lobe seizures** usually cause simple visual hallucinations and may occur as isolated auras or may be accompanied by headache and nausea (**Gastaut type** of benign occipital epilepsy), making them difficult to differentiate from **migraine**. Hallucinations in occipital seizures are characterized by colorful shapes, circles, and spots seen for seconds and confined to one hemifield, whereas migrainous auras usually last minutes and consist of black-and-white lines, scotomas, and/or fortification spectra that start in the center of the vision. **Visual snow** is a phenomenon that can be confused with occipital seizures and a migraine aura. It consists of dynamic continuous tiny dots in all of the visual field lasting >3 months with at least two to four additional specific visual symptoms (afterimages [i.e., palinopsia], enhanced visual phenomena [i.e., entotopic phenomena such as excessive floaters and photopsias], photophobia, and impaired night vision [i.e., nyctalopia]). Although it can occur in patients with migraine or with psychologic stress, the underlying pathology is not clear. Unlike migraine, it is associated with increased, rather than decreased, metabolism on PET scans of the lingual gyrus, which is the visual memory area, and patients usually do not respond to antimigraine therapies. **Alice in Wonderland syndrome** consists of the visual distortion of one's body or surroundings (bigger, smaller, closer, or more distant) and has been associated with migraine, epilepsy, acute infection such as Epstein-Barr virus, or fever. Hallucinations can also be **secondary to other causes**: drug exposure, midbrain lesions, and psychiatric illnesses. In addition, retinal-associated hallucinations can occur in the form of flashes of light in the context of inflammatory etiologies, trauma, or optic nerve edema. **Charles Bonnet syndrome** is the occurrence of visual hallucinations caused by ocular-origin visual loss or, at times, intracranial pathology.

SLEEP-RELATED DISORDERS (SEE ALSO CHAPTER 31)

Paroxysmal nonepileptic sleep events are more common in epileptic patients than in the general population, which makes their diagnosis difficult. The EEG pattern of frontal lobe epileptic seizures may be similar to the one seen in normal arousals, making their diagnosis challenging, especially because they have nonspecific hypermotor manifestations such as thrashing, body rocking, kicking, boxing, pedaling, bending, running, and various vocalizations. The diagnosis of such epileptic seizures is made on the basis of highly stereotyped, usually brief (<1 minute) events arising several times a night from non–rapid eye movement sleep.

Benign Sleep Myoclonus and Neonatal Sleep Myoclonus

Physiologic sleep myoclonus consists of repetitive, usually bilateral, rhythmic jerks involving the upper and lower limbs during non–rapid eye movement (REM) sleep, sometimes mimicking clonic seizures. Although the rule is that it is not stimulus sensitive, a slow (1-Hz) rocking of the infant in a head-to-toe direction is a specific diagnostic test that may sometimes reproduce the neonatal sleep myoclonus. The lack of autonomic changes, occurrence only in sleep, and suppression by awakenings may help in differentiating these events from epileptic seizures. Remission is spontaneous, usually at 2-3 months of age. In older children and adults, sleep myoclonus consists of random myoclonic jerks of the limbs.

Non–Rapid Eye Movement Partial Arousal Disorders

Brief **nocturnal confusional arousals** occur during slow-wave sleep and are normal in children. Such episodes can vary from chewing, sitting up, and mumbling to agitated sleepwalking and usually last for 10-15 minutes. With **somnambulism**, there is often a positive family history, and it usually occurs 1-3 hours after sleep onset. **Night terrors** similarly occur in deep sleep, most often at 2-7 years of age and more so in males. Stress increases the risk of both. In night terrors, the child screams; appears terrified; has dilated pupils, tachycardia, tachypnea, unresponsiveness, agitation, and thrashing that increase with attempts to be consoled; is difficult to arouse; and may have little or no vocalization. In older children with persistent night terrors, an underlying psychologic etiology may be present. The diagnosis is based on the history. However, rarely, video-EEG monitoring may be needed, especially if stereotyped motoric features are suggested by the history. At times, the use of bedtime diazepam (0.2-0.3 mg/kg) or clonazepam (0.125-0.5 mg) may help control the problem while psychologic factors are being investigated. **Restless legs syndrome** can cause painful leg dysesthesias that cause nocturnal arousals and insomnia. It can be either genetic or associated with iron deficiency, systemic illness, or some drugs such as antidepressants. Therapy depends on treating the underlying cause and, if needed, on dopaminergic drugs, such as levodopa/carbidopa, or antiepileptics, such as gabapentin.

Rapid Eye Movement Sleep Disorders

Unlike night terrors, **nightmares** tend to occur later during the night and the child has a memory of the event. **REM sleep behavior disorder** consists of loss of atonia during REM sleep, enabling patients to act out their dreams and thus mimicking nocturnal frontal or temporal lobe seizures. It is more common in adults. Children with autism and developmental delay are more likely to have it than other children.

Sleep Transition Disorders

Nocturnal head banging **(jactatio capitis nocturna)**, rolling, repetitive limb movements, or body rocking often occur in infants and toddlers as they are trying to fall asleep and can be mistaken for seizures or spasms. They usually remit spontaneously by 5 years of age. No specific therapy is needed, but in exceptional cases, clonazepam at bedtime may be used.

Narcolepsy-Cataplexy Syndrome

Narcolepsy is characterized by excessive daytime sleepiness, cataplexy, sleep paralysis, hypnogogic hallucinations, and disturbed nighttime sleep (see Chapter 31). The persistence of REM sleep atonia upon awakening or its intrusion during wakefulness leads to sleep paralysis or cataplexy, respectively. Loss of tone in cataplexy occurs in response to strong emotions and spreads from the face downward, leading to a fall in a series of stages rather than a sudden one. Consciousness is maintained in cataplexy. A selective loss of hypocretin-secreting neurons in the hypothalamus is at the origin of this disorder. The fact that DQB1*0602 is a predisposing human leukocyte antigen (HLA) allele identified in 85–95% of patients with narcolepsy-cataplexy suggests an autoimmune-mediated neuronal loss. Secondary narcolepsy has also been described in children with brain lesions affecting the brainstem or hypothalamic regions subserving wakefulness. The diagnosis is based on the multiple sleep latency test. Therapy relies on scheduled naps; medications such as amphetamines, methylphenidate, tricyclic antidepressants, modafinil, or sodium oxybate; and counseling about precautions in work and driving.

Visit Elsevier eBooks+ at eBooks.Health.Elsevier.com for Bibliography.

Chapter 635

Headaches

Andrew D. Hershey, Marielle Kabbouche, and Joanne Kacperski

Headache is a common complaint in children and adolescents. Headaches can be a *primary* problem or occur as a symptom of another disorder (a *secondary* headache). Recognizing this difference is essential for choosing the appropriate evaluation and treatment to ensure successful management of the headache. Primary headaches should be thought of as a disease themselves and are most often present as recurrent, episodic headaches, and for most children are sporadic in their presentation. This oftentimes creates confusion when patients and providers focus on the events (i.e., the headache, calling it a "migraine") rather than the disease itself.

The most common forms of *primary headache* in childhood are migraine and tension-type headache (Table 635.1). Other forms of primary headache, including the trigeminal autonomic cephalalgias and cluster headaches, occur much less commonly. Primary headache disorders can progress to very frequent or even daily headaches, with chronic migraine and chronic tension-type headache being recognized as a problem for children and adolescents. These more frequent headaches can have an enormous impact on the life of the child and adolescent, as reflected in school absences and decreased school performance, social withdrawal, and changes in family interactions. To reduce this impact, a treatment strategy that incorporates acute treatments, preventive treatments, and biobehavioral therapies must be implemented.

Secondary headache is a headache that is a symptom of an underlying illness (see Table 635.1). The underlying illness should be clearly present as a direct cause of the headaches with close association of timing and symptomatology. This is often difficult when two or more common conditions occur in close temporal association. This frequently leads to the misdiagnosis of a primary headache as a secondary headache. This is the case when the headaches caused by migraine are misdiagnosed as sinus headaches. The key components of a secondary headache are the likely direct cause-and-effect relationship between the headache and the precipitating condition. In this regard, when the presumed cause of the secondary headache has been treated (antibiotics) or given adequate time to recover (posttraumatic headache), the headache symptoms should resolve. If this does not occur, either the diagnosis must be reevaluated or the effectiveness of the treatment reassessed.

In all instances of primary headaches, the neurologic examination should be normal. If it is not normal or a secondary headache is suspected, this raises a red flag. *The presence of an abnormal neurologic examination (including fundoscopic) or unusual neurologic symptoms is a key clue that additional investigation is warranted.*

635.1 Migraine

Andrew D. Hershey, Marielle Kabbouche, and Joanne Kacperski

Migraine is a disease that has a genetic basis (Table 635.2) and represents the most frequent reason recurrent headaches are brought to the attention of parents and primary care providers, but it remains underrecognized and undertreated, particularly in children and adolescents. Migraine is characterized by episodic attacks. These attacks are typically thought of as headaches, but in children there are also periodic syndromes that may represent attacks of migraine. The headaches may be moderate to severe in intensity, be focal in location, have a throbbing quality, and be associated with nausea, vomiting, light sensitivity, and/or sound sensitivity. Compared with migraine in adults, migraine in children and adolescents may be shorter in duration and has a bilateral, often bifrontal, location. The headaches can also be associated with an aura that may be typical (visual, sensory, or dysphasic) or atypical (hemiplegic, Alice in Wonderland syndrome) (Tables 635.3-635.7). Migraine may present with a number of variants in children, including abdominally related symptoms without headache and components of the periodic syndromes of childhood—also called *episodic disorders associated with migraine* (see Table 635.1). Treatment of migraine requires the incorporation of an acute treatment plan, a preventive treatment plan if the migraine occurs frequently or is disabling or long lasting, and a biobehavioral plan to help cope with both the acute attacks and frequent or persistent attacks if present.

EPIDEMIOLOGY

Up to 75% of children report having a significant headache by the time they are 15 years of age. Recurrent headaches are less common but remain highly frequent. Migraine has been reported to occur in up to 10.6% of children between the ages of 5 and 15 years and up to 28% of older adolescents. When headaches are occurring more than 15 days per month, they are termed *chronic migraine* and may occur in up to 1% of children and adolescents. The risk of conversion to a daily headache becomes more likely as the frequency increases or ineffective acute treatments are used. This explains the necessity to treat the headaches aggressively or prevent the headaches altogether, trying to block transformation to chronic migraine.

Migraine can affect a patient's life through school absences, limitation of home activities, and restriction of social activities. This can be assessed through simple tools such as PedMIDAS (pediatric migraine disability assessment tool). When headaches become more frequent, their negative impact increases in magnitude. This can lead to further complications, including anxiety and school avoidance, requiring a more extensive treatment plan.

CLASSIFICATION AND CLINICAL MANIFESTATIONS

Criteria have been established to guide the clinical and scientific study of headaches; these are summarized in *The International Classification of Headache Disorders*, 3rd edition (ICHD-3). Table 635.1 contrasts the different clinical types of migraine; Tables 635.3-635.7 list the specific criteria for migraine types.

Migraine Without Aura

Migraine without aura is the most common form of migraine in both children and adults. The ICHD-3 (see Table 635.3) requires this to be recurrent (at least five headaches that meet the criteria, typically over the past year, but no firm period is required). The recurrent episodic nature helps differentiate this from a secondary headache and separates migraine from tension-type headache. Because headaches may first start in young childhood, this may limit the diagnosis in children as they are just beginning to develop headaches.

The duration of the headache is defined as 4-72 hours for adults. It has been recognized that children may have shorter-duration headaches, so an allowance has been made to reduce this duration to 2-72 hours in children and adolescents under the age of 18 years. Note that this duration is for the untreated or unsuccessfully treated headache. Furthermore, if the child falls asleep with the headache, the entire sleep period is considered part of the duration. These duration limits help differentiate migraine from both short-duration headaches, including the trigeminal autonomic cephalalgias, and prolonged headaches, such as those caused by idiopathic intracranial hypertension (pseudotumor cerebri). Some prolonged headaches may still be migraine, but a migraine that persists beyond 72 hours is classified as a variant termed **status migrainosus**.

The quality of migraine pain is often, but not always, throbbing or pounding. This may be difficult to elicit in young children, and drawings or demonstrations may help confirm the throbbing quality.

The location of the pain has classically been described as **unilateral (hemicrania)**; in young children it is more commonly bilateral. A more appropriate way to think of the location would therefore be focal to differentiate it from the diffuse pain of tension-type headaches.

Table 635.1 Classification of Headaches (ICHD-3 Code Diagnosis)

MIGRAINE
Migraine with or without aura
Migraine with typical aura (with or without headache)
Migraine with brainstem aura
Hemiplegic migraine (sporadic or familial types 1, 2, 3 or other genetic loci)
Retinal migraine
Chronic migraine

Complications of Migraine
Status migrainosus
Persistent aura without infarction
Migrainous infarction
Migraine aura–triggered seizure

Episodic Syndromes that May Be Associated with Migraine
Recurrent gastrointestinal disturbance
Cyclical vomiting syndrome
Abdominal migraine
Benign paroxysmal vertigo
Benign paroxysmal torticollis
Episodic colic

TENSION-TYPE HEADACHE (TTH)
Infrequent episodic TTH associated with or without pericranial tenderness
Frequent episodic TTH associated with or without pericranial tenderness
Chronic TTH associated with or without pericranial tenderness
Probable TTHs

TRIGEMINAL AUTONOMIC CEPHALALGIAS (TACS)
Cluster headache (episodic or cluster)
Paroxysmal hemicrania (episodic or cluster)
Short-lasting unilateral neuralgiform headache attacks with or without conjunctival injection and tearing (SUNCT)
Episodic SUNCT
Chronic SUNCT
Short-lasting unilateral neuralgiform headache attacks with or without cranial autonomic symptoms (SUNA)
Episodic SUNA
Chronic SUNA
Hemicrania continua
Probable trigeminal autonomic cephalalgias

OTHER PRIMARY HEADACHE DISORDERS
Primary cough headache
Primary exercise headache
Primary headache associated with sexual activity
Primary thunderclap headache
Cold-stimulus headache (external application, ingestion, or inhalation)
External-pressure headache
External-compression headache
External-traction headache
Primary stabbing headache
Nummular headache
Hypnic headache
New daily persistent headache (NDPH)

HEADACHE ATTRIBUTED TO TRAUMA OR INJURY TO THE HEAD AND/OR NECK
Acute headache attributed to traumatic (mild, moderate, or severe) injury to the head
Persistent headache attributed to traumatic (mild, moderate, or severe) injury to the head
Acute or persistent headache attributed to whiplash
Acute or persistent headache attributed to craniotomy

HEADACHE ATTRIBUTED TO CRANIAL OR CERVICAL VASCULAR DISORDER
Headache attributed to ischemic stroke or transient ischemic attack
Headache attributed to nontraumatic intracerebral hemorrhage
Headache attributed to nontraumatic subarachnoid hemorrhage
Headache attributed to nontraumatic acute subdural hemorrhage
Headache attributed to unruptured vascular malformation
Headache attributed to unruptured saccular aneurysm
Headache attributed to arteriovenous malformation
Headache attributed to dural arteriovenous fistula
Headache attributed to cavernous angioma
Headache attributed to encephalotrigeminal or leptomeningeal angiomatosis (Sturge-Weber syndrome)
Headache attributed to arteritis
Headache attributed to giant cell arteritis
Headache attributed to primary angiitis of the central nervous system
Headache attributed to secondary angiitis of the central nervous system
Headache attributed to cervical carotid or vertebral artery disorder
Headache or facial or neck pain attributed to cervical carotid or vertebral artery dissection
Postendarterectomy headache
Headache attributed to carotid or vertebral angioplasty
Headache attributed to cerebral venous thrombosis
Headache attributed to other acute intracranial arterial disorder
Headache attributed to an intracranial endovascular procedure
Angiography headache
Headache attributed to reversible cerebral vasoconstriction syndrome
Headache attributed to intracranial arterial dissection
Headache attributed to genetic vasculopathy
Cerebral autosomal dominant arteriopathy with subcortical infarcts and leukoencephalopathy (CADASIL)
Mitochondrial encephalopathy, lactic acidosis, and strokelike episodes (MELAS)
Headache attributed to another genetic vasculopathy
Headache attributed to pituitary apoplexy

HEADACHE ATTRIBUTED TO NONVASCULAR INTRACRANIAL DISORDER
Headache attributed to increased cerebrospinal fluid pressure
Headache attributed to idiopathic intracranial hypertension
Headache attributed to intracranial hypertension secondary to metabolic, toxic, or hormonal causes
Headache attributed to intracranial hypertension secondary to hydrocephalus
Headache attributed to low cerebrospinal fluid pressure
Post–dural puncture headache
Cerebrospinal fluid fistula headache
Headache attributed to spontaneous intracranial hypotension
Headache attributed to noninfectious inflammatory disease
Headache attributed to neurosarcoidosis
Headache attributed to aseptic (noninfectious) meningitis
Headache attributed to other noninfectious inflammatory disease
Headache attributed to lymphocytic hypophysitis
Syndrome of transient headache and neurologic deficits with cerebrospinal fluid lymphocytosis (HaNDL)
Headache attributed to intracranial neoplasm
Headache attributed to colloid cyst of the third ventricle
Headache attributed to carcinomatous meningitis
Headache attributed to hypothalamic or pituitary hypersecretion or hyposecretion
Headache attributed to intrathecal injection
Headache attributed to epileptic seizure
Hemicrania epileptica
Postictal headache
Headache attributed to Chiari malformation type I
Headache attributed to other nonvascular intracranial disorder

Table 635.1 Classification of Headaches (ICHD-3 Code Diagnosis)—cont'd

HEADACHE ATTRIBUTED TO A SUBSTANCE OR ITS WITHDRAWAL
- Headache attributed to use of or exposure to a substance
- Nitric oxide donor–induced headache
- Phosphodiesterase inhibitor–induced headache
- Carbon monoxide–induced headache
- Alcohol-induced headache
- Monosodium glutamate–induced headache
- Cocaine-induced headache
- Histamine-induced headache
- Calcitonin gene-related peptide–induced headache
- Headache attributed to exogenous acute pressor agent
- Headache attributed to occasional or long-term use of non–headache medication
- Headache attributed to exogenous hormone

Medication-Overuse Headache (MOH)
- Ergotamine-overuse headache
- Triptan-overuse headache
- Simple analgesic–overuse headache
- Paracetamol (acetaminophen)-overuse headache
- Acetylsalicylic acid–overuse headache
- Other nonsteroidal antiinflammatory drug–overuse headache
- Opioid-overuse headache
- Combination analgesic–overuse headache

Headache Attributed to Substance Withdrawal
- Caffeine-withdrawal headache
- Opioid-withdrawal headache
- Estrogen-withdrawal headache

HEADACHE ATTRIBUTED TO INFECTION
- Acute or chronic headache attributed to bacterial meningitis or meningoencephalitis
- Persistent headache attributed to past bacterial meningitis or meningoencephalitis
- Acute or chronic headache attributed to intracranial fungal or other parasitic infection
- Headache attributed to brain abscess
- Headache attributed to subdural empyema
- Headache attributed to systemic infection (acute or chronic)

HEADACHE ATTRIBUTED TO DISORDER OF HOMEOSTASIS
- Headache attributed to hypoxia and/or hypercapnia
- High-altitude headache
- Headache attributed to airplane travel
- Diving headache
- Sleep apnea headache
- Dialysis headache
- Headache attributed to arterial hypertension
- Headache attributed to pheochromocytoma
- Headache attributed to hypertensive crisis with or without hypertensive encephalopathy
- Headache attributed to preeclampsia or eclampsia
- Headache attributed to autonomic dysreflexia
- Headache attributed to hypothyroidism
- Headache attributed to fasting
- Cardiac cephalalgia
- Headache attributed to other disorder of homoeostasis

HEADACHE OR FACIAL PAIN ATTRIBUTED TO DISORDER OF THE CRANIUM, NECK, EYES, EARS, NOSE, SINUSES, TEETH, MOUTH, OR OTHER FACIAL OR CERVICAL STRUCTURE
- Headache attributed to disorder of cranial bone
- Headache attributed to retropharyngeal tendonitis
- Headache attributed to craniocervical dystonia
- Headache attributed to acute glaucoma
- Headache attributed to refractive error
- Headache attributed to heterophoria or heterotropia (latent or persistent squint)
- Headache attributed to ocular inflammatory disorder
- Headache attributed to tracheitis
- Headache attributed to disorder of the ears
- Headache attributed to acute or chronic or recurring rhinosinusitis
- Headache attributed to temporomandibular disorder
- Head or facial pain attributed to inflammation of the stylohyoid ligament
- Headache or facial pain attributed to other disorder of the cranium, neck, eyes, ears, nose, sinuses, teeth, mouth, or other facial or cervical structure

HEADACHE ATTRIBUTED TO PSYCHIATRIC DISORDER
- Headache attributed to somatization disorder
- Headache attributed to psychotic disorder

PAINFUL CRANIAL NEUROPATHIES AND OTHER FACIAL PAINS
- Classical trigeminal neuralgia
- Classical trigeminal neuralgia, purely paroxysmal or with concomitant persistent facial pain
- Painful trigeminal neuropathy
- Painful trigeminal neuropathy attributed to acute herpes zoster
- Postherpetic trigeminal neuropathy
- Painful posttraumatic trigeminal neuropathy
- Painful trigeminal neuropathy attributed to multiple sclerosis (MS) plaque
- Painful trigeminal neuropathy attributed to space-occupying lesion
- Painful trigeminal neuropathy attributed to other disorder
- Glossopharyngeal neuralgia
- Classical nervus intermedius (facial nerve) neuralgia
- Nervus intermedius neuropathy attributed to herpes zoster
- Occipital neuralgia
- Optic neuritis
- Headache attributed to ischemic ocular motor nerve palsy
- Tolosa-Hunt syndrome
- Paratrigeminal oculosympathetic (Raeder) syndrome
- Recurrent painful ophthalmoplegic neuropathy
- Burning mouth syndrome (BMS)
- Persistent idiopathic facial pain (PIFP)
- Central neuropathic pain
- Central neuropathic pain attributed to multiple sclerosis
- Central post-stroke pain (CPSP)

From Headache Classification Committee of the International Headache Society (IHS). *The International Classification of Headache Disorders,* 3rd ed. Cephalalgia. 2018;38(1):1–211.

Of particular concern is the exclusively occipital headache because although these can be migraines, they are more frequently secondary to another more proximate etiology such as posterior fossa abnormalities.

The headaches of migraine, when allowed to fully develop, often worsen with activity. Worsening of the pain occurs classically in adults when going up or down stairs. This history is often not elicited in children. A change in the child's activity pattern can be easily observed as a reduction in play or physical activity. Older children may limit or restrict their sports activity or exercise during a headache attack.

The attacks may have a variety of associated symptoms. In younger children, nausea and vomiting may be the most obvious symptoms and often outweigh the headache itself. This often leads to the overlap with several of the gastrointestinal periodic diseases, including recurrent abdominal pain, recurrent vomiting, cyclic vomiting, and abdominal migraine. The common feature among all of these related conditions is an increased propensity among children with them for the later development of a typical description of a headache caused by migraine. Early childhood recurrent vomiting may in fact be migraine, but the child is not asked about or is unable to describe headache pain. This may occur as early as infancy because babies with colic have a higher incidence of migraine once they are able to express their symptoms. Once a clear head pain becomes evident, the earlier diagnosis of a gastrointestinal disorder is no longer appropriate.

Table 635.2 Genetics in Migraine

KEY FACTS
- Based on studies with twins, the heritability of migraine has been estimated as 42%
- A genome-wide association meta-analysis identified 38 genomic loci that affect migraine risk
- The relative risk of migraine without aura is 1.9 in first-degree relatives of probands with migraine without aura
- The relative risk of migraine with aura is 3.8 in first-degree relatives of probands with migraine with aura

GENETIC BIOMARKERS FOR MONOGENIC SUBTYPES OF MIGRAINE OR MIGRAINE-RELATED SYNDROMES
- Familial hemiplegic migraine
  - Type 1 (*CACNA1A* gene)
  - Type 2 (*ATP1A2* gene)
  - Type 3 (*SCN1A* gene)
  - Possible association with *PRRT2* gene
- Cerebral autosomal dominant arteriopathy with subcortical infarcts and leukoencephalopathy (*NOTCH3* gene)
- Retinal vasculopathy with cerebral leukoencephalopathy and systemic manifestations (*TREX1* gene)
- Familial advanced sleep phase syndrome (*CSNK1D* gene)

Modified from Ashina M, Terwindt GM, Al-Mahdi Al-Karagholi M, et al. Migraine: disease characterization, biomarkers, and precision medicine. *Lancet*. 2021;397:1496–1504, Panel 2, p. 1498.

Table 635.3 Migraine Without Aura

A. At least five attacks fulfilling criteria B-D
B. Headache attacks lasting 4-72 hr (untreated or unsuccessfully treated)
C. Headache has at least two of the following four characteristics:
   1. Unilateral location
   2. Pulsating quality
   3. Moderate or severe pain intensity
   4. Aggravation by or causing avoidance of routine physical activity (e.g., walking or climbing stairs)
D. During headache at least one of the following:
   1. Nausea and/or vomiting
   2. Photophobia and phonophobia
E. Not better accounted for by another ICHD-3 diagnosis

From Headache Classification Committee of the International Headache Society (IHS). *The International Classification of Headache Disorders*, 3rd ed. Cephalalgia. 2018;38(1):1–211, Table 4.

Table 635.4 Migraine with Typical Aura

A. At least two attacks fulfilling criteria B and C
B. One or more of the following fully reversible aura symptoms:
   1. Visual
   2. Sensory
   3. Speech/language symptoms
   4. Motor
   5. Brainstem
   6. Retinal
C. At least three of the following six characteristics:
   1. At least one aura symptom spreads gradually over 5 or more minutes
   2. Two or more symptoms occur in succession
   3. Each individual aura symptom lasts 5-60 min
   4. At least one aura symptom is unilateral
   5. At least one aura symptom is positive
   6. The aura is accompanied, or followed within 60 minutes, by headache
D. Not better accounted for by another ICHD-3 diagnosis, and transient ischemic attack has been excluded

From Headache Classification Committee of the International Headache Society (IHS). *The International Classification of Headache Disorders*, 3rd ed. Cephalalgia. 2018;38(1):1–211, Table 6.

Table 635.5 Migraine with Brainstem Aura

A. At least two attacks fulfilling criteria for migraine with aura and criterion B
B. Aura with both of the following
   1. At least two of the following brainstem symptoms:
      a. Dysarthria
      b. Vertigo
      c. Tinnitus
      d. Hyperacusis
      e. Diplopia
      f. Ataxia
      g. Decreased level of consciousness
   2. No motor or retinal symptoms

From Headache Classification Committee of the International Headache Society (IHS). *The International Classification of Headache Disorders*, 3rd ed. Cephalalgia. 2018;38(1):1–211, Table 7.

Table 635.6 Vestibular Migraine with Vertigo

A. At least five episodes fulfilling criteria C and D
B. A current or past history of *migraine without aura* or *migraine with aura*
C. Vestibular symptoms of moderate or severe intensity, lasting between 5 min and 72 hr
D. At least 50% of episodes are associated with at least one of the following three migrainous features:
   1. Headache with at least two of the following four characteristics:
      a. Unilateral location
      b. Pulsating quality
      c. Moderate or severe intensity
      d. Aggravation by routine physical activity
   2. Photophobia and phonophobia
   3. Visual aura
E. Not better accounted for by another ICHD-3 diagnosis or by another vestibular disorder

From Headache Classification Committee of the International Headache Society (HIS). *The International Classification of Headache Disorders*, 3rd ed. Cephalalgia. 2018;38(1):1–211, Table 8.

Table 635.7 Chronic Migraine

A. Headache (tension-type–like and/or migraine-like) on 15 or more days/mo for more than 3 mo and fulfilling criteria B and C
B. Occurring in a patient who has had at least five attacks fulfilling criteria B-D for *migraine without aura* and/or criteria B and C for *migraine with aura*
C. On 8 or more days/mo for more than 3 mo, fulfilling any of the following:
   1. Criteria C and D for *migraine without aura*
   2. Criteria B and C for *migraine with aura*
   3. Believed by the patient to be migraine at onset and relieved by a triptan or ergot derivative
D. Not better accounted for by another ICHD-3 diagnosis

From Headache Classification Committee of the International Headache Society (IHS). *The International Classification of Headache Disorders*, 3rd ed. Cephalalgia. 2018;38(1):1–211, Table 9.

When headache is present, vomiting raises the concern of a secondary headache, particularly related to increased intracranial pressure. *One of the red flags for this is the daily or near-daily early morning vomiting or headaches waking the child up from sleep or with the Valsalva maneuver.* When the headaches associated with vomiting episodes are sporadic and not worsening, it is more likely that the diagnosis is migraine. Vomiting and headache caused by increased intracranial pressure are frequently present on first awakening and remit with maintenance of upright posture. In contrast, if a migraine is present on

first awakening *(a relatively infrequent occurrence in children)*, getting up and going about normal, upright activities usually makes the headache and vomiting worse.

When the child matures, light and sound sensitivity (**photophobia** and **phonophobia**) may become more apparent. This is either by direct report of the patient or the interpretation by the parents of the child's activity because the parent may become aware of this symptom before the child. These symptoms are likely a component of the hypersensitivity that develops during an acute migraine attack and may also include smell sensitivity **(osmophobia)** and touch sensitivity **(cutaneous allodynia)**. Although only the photophobia and phonophobia are components of the ICHD-3 criteria, these other symptoms are helpful in confirming the diagnosis and may be helpful in understanding the underlying pathophysiology and determining the response to treatment. The final ICHD-3 requirement is the exclusion of causes of secondary headaches, and this should be an integral component of the headache history.

Migraine typically runs in families, with reports of up to 90% of children having a first- or second-degree relative with recurrent headaches. Given the underdiagnoses and misdiagnosis in adults, this is often not recognized by the family, and a headache family history is required. When a family history is not identified, this may be the result of either a lack of awareness of migraine within the family or an underlying secondary headache in the child. *Any child whose family, upon close and both direct and indirect questioning, does not include individuals with migraine or related syndromes (e.g., motion sickness, cyclic vomiting, menstrual headache) should have an imaging procedure performed to look for anatomic etiologies for headache.*

In addition to the classifying features, there may be additional markers of a migraine disorder. These include such things as **triggers** (skipping meals, inadequate or irregular sleep, dehydration, and weather changes are the most common), **pattern recognition** (associated with menstrual periods in adolescents or Monday-morning headaches resulting from changes in sleep patterns over the weekend and nonphysiologic early waking on Monday mornings for school), and **prodromal symptoms** (a feeling of irritability, tiredness, and food cravings before the start of the headache) (Fig. 635.1). Although these additional features may not be consistent, they do raise the index of suspicion for migraine and provide a potential mechanism of intervention. In the past, food triggers were considered widely common, but the majority have either been discredited with scientific study or represent such a small number of patients that they only need to be addressed when consistently triggering the headache.

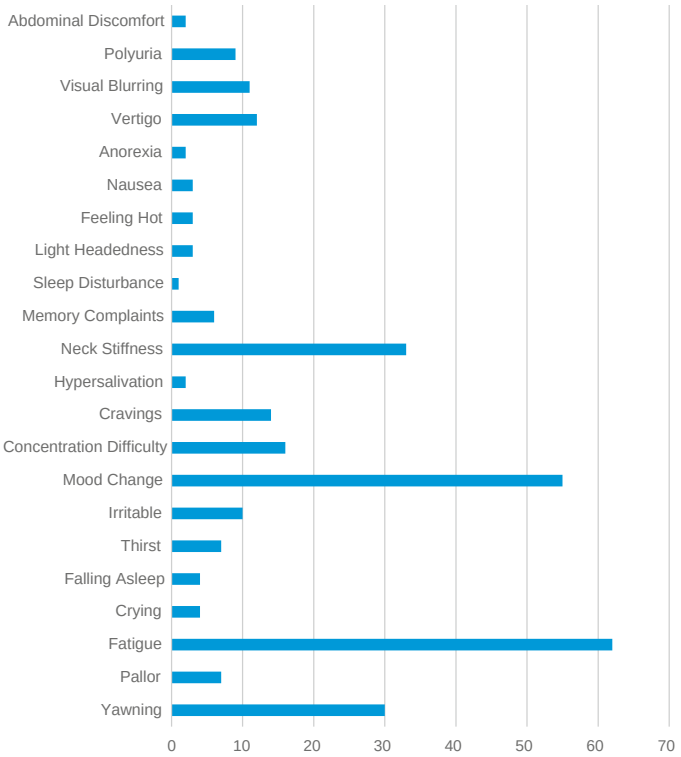

Fig. 635.1 Frequency of different premonitory symptoms reported. *(From Karsan N, Prabhakar P, Goadsby PJ. Characterizing the premonitory stage of migraine in children: a clinic-based study of 100 patients in a specialist headache service. J Head Pain. 2016;17:94, Fig. 1.)*

Migraine with Aura

The aura associated with migraine is a neurologic warning that a migraine is going to occur. In the common forms, this can be the start of a typical headache without migraine, or it may even occur in isolation. For a typical aura, the aura needs to be visual, sensory, or dysphasic, lasting longer than 5 minutes and less than 60 minutes, with the headache starting within 60 minutes (see Table 635.4). The importance of the aura lasting longer than 5 minutes is to differentiate the migraine aura from a seizure with a postictal headache, whereas the 60-minute maximal duration is to separate migraine aura from the possibility of a more prolonged neurologic event such as a transient ischemic attack. The ICHD-3 criteria have also added the requirements that for a diagnosis of aura, there needs to be a positive symptom and not just a loss of function (i.e., flashing lights, tingling, not just blurring of vision).

The most common type of visual aura in children and adolescents is **photopsia** (flashes of light or light bulbs going off everywhere). These photopsias are often multicolored, and when gone, the child may report not being able to see where the flash occurred. Less likely in children are the typical adult auras, including *fortification spectra* (brilliant white zigzag lines resembling a starred pattern castle) or *shimmering scotoma* (sometimes described as a shining spot that grows or a sequined curtain closing). In adults, the auras typically involve only half the visual field, whereas in children they may be randomly dispersed. Blurred vision is often confused as an aura but is difficult to separate from photophobia or difficulty concentrating during the pain of the headache.

Sensory auras are less common. They typically occur unilaterally. Many children describe this sensation as insects or worms crawling from their hand, up their arm, to their face with a numbness following this sensation. Once the numbness occurs, the child may have difficulty using the arm because they have lost sensory input, and a misdiagnosis of hemiplegic migraine may be made.

Dysphasic auras are the least common type of typical aura and have been described as an inability or difficulty to respond verbally. The patient afterward will describe an ability to understand what is being asked but cannot answer back. This may be the basis of what in the past has been referred to as *confusional migraine,* and special attention needs to be paid to asking the child about this possibility and their degree of understanding during the initial phases of the attack. Most of the time, these episodes are described as a motor aphasia, and they are often associated with sensory or motor symptoms.

Much less commonly, *rarer forms of aura can occur,* including hemiplegia (true weakness, not numbness, and may be familial), vertigo or lower cranial nerve symptoms–brainstem aura (formerly called *basilar-type* and once thought to be caused by basilar artery dysfunction, now thought to be a more brainstem-based migraine with brainstem aura) (see Table 635.4), and distortion (Alice in Wonderland syndrome). Whenever these rarer forms of aura are present, further investigation is warranted. Not all motor auras can be classified as hemiplegic migraine spectrum, and they should be differentiated from those specific migrainous events, because the diagnosis of hemiplegic migraine has genetic, pathophysiologic, and therapeutic implications.

Hemiplegic migraine is one of the better-known forms of rare auras. This transient unilateral weakness usually lasts only a few hours but may persist for days. Both familial and sporadic forms have been described. The familial hemiplegic migraine is an autosomal dominant disorder with pathogenic variants in three separate genes: *CACNA1A, ATP1A2,* and *SCN1A* (see Table 635.2). Some patients with familial hemiplegic migraine have other yet-to-be-identified genetic variants. Multiple polymorphisms have been described for these genes. Hemiplegic migraines may be triggered by minor head

trauma, exertion, or emotional stress. The motor weakness is usually associated with another aura symptom and may progress slowly over 20-30 minutes, first with a visual aura and then, in sequence, with sensory, motor, aphasic, and basilar auras. Headache is present in more than 95% of patients and usually begins during the aura; headache may be unilateral or bilateral and may have no relationship to the motor weakness. Some patients may develop attacks of coma with encephalopathy, cerebrospinal fluid (CSF) pleocytosis, and cerebral edema. Long-term complications may include seizures, repetitive daily episodes of blindness, cerebellar signs with the development of cerebellar atrophy, and mental disabilities.

Migraine with brainstem aura (basilar-type migraine) was formerly considered a disease of the basilar artery because many of the unique symptoms were attributed to dysfunction in this area of the brainstem. Some of the symptoms described include vertigo, tinnitus, diplopia, blurred vision, scotoma, ataxia, and an occipital headache. The pupils may be dilated, and ptosis may be evident.

Syndrome of transient headache and neurologic deficits with CSF lymphocytosis (HaNDL) describes transient migraine-like headaches associated with neurologic deficits (motor, sensory, language impairments) and CSF showing pleocytosis. It is considered a self-limited migraine-like syndrome of unknown etiology and is rarely reported in the pediatric population.

Childhood periodic syndromes are a group of potentially related symptoms that occur with increased frequency in children with migraine. The hallmark of these symptoms is the recurrent episodic nature of the events. Some of these have included gastrointestinal-related symptoms (colic, motion sickness, recurrent abdominal pain, recurrent vomiting including cyclic vomiting, and abdominal migraine), sleep disorders (sleepwalking, sleep talking, and night terrors), unexplained recurrent fevers, and even seizures.

The **gastrointestinal symptoms** span the spectrum from the relatively mild (motion sickness on occasional long car rides) to severe episodes of uncontrollable vomiting that may lead to dehydration and the need for hospital admission to receive fluids. These latter episodes may occur on a predictable time schedule and are called **cyclic vomiting**. During these attacks, the child may appear pale and frightened but does not lose consciousness. After a period of deep sleep, the child awakens and resumes normal play and eating habits as if the vomiting had not occurred. Many children with cyclic vomiting have a positive family history of migraine and as they grow older have a higher-than-average likelihood of developing migraine. Cyclic vomiting may be responsive to migraine-specific therapies; careful attention is needed for fluid replacement if the vomiting is excessive. **Cyclic vomiting of migraine** must be differentiated from gastrointestinal disorders, including intestinal obstruction (malrotation, intermittent volvulus, duodenal web, duplication cysts, superior mesenteric artery compression, and internal hernias), peptic ulcer, gastritis, giardiasis, chronic pancreatitis, and Crohn disease. Abnormal gastrointestinal motility and pelviureteric junction obstruction can also cause cyclic vomiting. Metabolic causes include disorders of amino acid metabolism (heterozygote ornithine transcarbamylase deficiency), organic acidurias (propionic acidemia, methylmalonic acidemia), fatty acid oxidation defects (medium-chain acyl-coenzyme A dehydrogenase deficiency), disorders of carbohydrate metabolism (hereditary fructose intolerance), acute intermittent porphyria, and structural central nervous system lesions (posterior fossa brain tumors, subdural hematomas, or effusions). The diagnosis is a diagnosis of exclusion, and children will need a full workup to be labeled as having cyclic vomiting syndrome. Cyclic vomiting syndrome is more frequent in younger children and will gradually transform into a typical migraine attack by puberty (see Chapter 390).

The diagnosis of **abdominal migraine** can be confusing but can be thought of as a migraine without the headache. Like a migraine, it is an episodic disorder characterized by midabdominal pain with pain-free periods between attacks. At times this pain is associated with nausea and vomiting (thus crossing into the recurrent abdominal pain or cyclic vomiting spectrum). The pain is usually described as dull and may be moderate to severe. The pain may persist from 1 to 72 hours, and although it is usually in the midline, it may be periumbilical or poorly localized by the child. To meet the criteria of abdominal migraine, the child must complain at the time of the abdominal pain of at least two of the following: anorexia, nausea, vomiting, or pallor. Similar to cyclic vomiting, a thorough history and physical examination with appropriate laboratory studies must be completed to rule out an underlying gastrointestinal disorder as a cause of the abdominal pain. Careful questioning about the presence of headache or head pain needs to be addressed directly to the child because many times, this is truly a migraine but in the child's mind (and the parents' observation), the abdominal symptoms are paramount.

DIAGNOSIS AND DIFFERENTIAL DIAGNOSIS

A thorough history and physical examination, including a neurologic examination with special focus on headache, has been shown to be the most sensitive indicator of an underlying etiology. The history needs to include a thorough evaluation of the prodromal symptoms, any potential triggering events or timing of the headaches, associated neurologic symptoms, and a detailed characterization of the headache attacks, including frequency, severity, duration, associated symptoms, use of medication, and disability. The disability assessment should include the impact on school, home, and social activities and can easily be assessed with tools such as PedMIDAS. A family history of headaches and any other neurologic, psychiatric, and general health conditions is also important both for identification of migraine within the family and the identification of possible secondary headache disorders. The familial penetrance of migraine is so robust that the absence of a family history of migraine or its equivalent phenomena should raise the concern that the diagnosis may not be migraine and warrants further history taking, referral to a headache specialist, or investigation. The lack of a family history may be the result of a lack of awareness of the family of the migraine ("doesn't everybody get headaches?"). When headaches are refractory, a history of potential comorbid conditions, which includes mood disorders and illicit substance use, especially in teenagers, that may influence adherence and acceptability of the treatment plan, may also need to be addressed. Patients with difficult-to-treat chronic migraines may have raised intracranial pressure; a lumbar puncture with lowering of the pressure may resolve the migraine. These patients may not have papilledema. In addition, disorders such as cerebral autosomal dominant arteriopathy with subcortical infarcts and leukoencephalopathy (CADASIL), Moyamoya disease, reversible cerebral vasoconstriction syndrome, and strokelike migraine attacks after radiation therapy (SMART) may initially present with migraines (Table 635.8).

Neuroimaging is warranted when the neurologic examination is abnormal or unusual neurologic features occur during the migraine; when the child has headaches that awaken the child from sleep or that are present on first awakening and remit with upright posture; when the child has brief headaches that only occur with cough or bending over; when the headache is mostly in the occipital area; and when the child has migrainous headache with an absolutely negative family history of migraine or its equivalent (e.g., motion sickness, cyclic vomiting; Table 635.9). In this case, an MRI is the imaging method of choice because it provides the highest sensitivity for detecting posterior fossa lesions and does not expose the child to radiation.

In the child with a headache that is instantaneously at its worst at onset, a CT scan looking for blood is the best initial test; if it is negative, a lumbar puncture should be done looking especially for xanthochromia of the CSF. There is no evidence that laboratory studies or an electroencephalogram is beneficial in a typical migraine without aura or migraine with aura.

TREATMENT

Table 635.10 outlines the drugs used to manage migraine headaches in children. The American Academy of Neurology established useful practice guidelines for the management of migraine as follows:

- Reduction of headache frequency, severity, duration, and disability
- Reduction of reliance on poorly tolerated, ineffective, or unwanted acute pharmacotherapies
- Improvement in quality of life
- Avoidance of acute headache medication escalation

Table 635.8 Migraine Mimics and Secondary Migraine

Trigeminal autonomic cephalgias (TACs)
Cluster headache
Hemicrania continua
Short-lasting unilateral neuralgiform headache attacks with or without conjunctival tearing (injection) (SUNCT/SUNA)
Ophthalmoplegic (CN III, IV, VI) migraine
Arterial dissection
Vasculitis/vasculopathies
- Giant cell arteritis
- Moyamoya
- Cerebral autosomal dominant arteriopathy with subcortical infarcts and leukoencephalopathy (CADASIL) *(NOTCH 3)*
- Cerebral autosomal recessive arteriopathy with subcortical infarcts and leukoencephalopathy (CARASIL) *(HTRA1)*
- SLE
- Granulomatosis with polyangiitis
- Primary CNS vasculitis
- Reversible cerebral vasoconstriction syndrome (RCVS)
- Antiphospholipid antibody syndrome

MELAS
Idiopathic intracranial hypertension (pseudotumor cerebri)
Occipital epilepsy
Sudden vision loss
Transient ischemic attack
Acute glaucoma
Sinusitis with intracranial extension
Epilepsy with aura
Transient headache and neurologic deficits with CSF lymphocytosis (HaNDL)
Alternating hemiplegia of childhood *(ATP1A3)*
Fabry disease
SMART syndrome

CN, Cranial nerve; CNS, central nervous system; CSF, cerebrospinal fluid; MELAS, mitochondrial encephalopathy, lactic acidosis, and strokelike episodes; SMART, strokelike migraine attack after radiation therapy.
Modified from Lauck SM, Gage S. Headaches. In: Kliegman RM, Toth H, Bordini BJ, et al., eds. *Nelson Pediatric Symptom-Based Diagnosis*, 2nd ed. Philadelphia: Elsevier; 2023: Table 34.17, p. 560.

Table 635.9 Indications for Neuroimaging in a Child with Headaches

Abnormal neurologic examination
Abnormal or focal neurologic signs or symptoms
- Focal neurologic symptoms or signs developing during a headache (i.e., complicated migraine)
- Focal neurologic symptoms or signs (except classic visual symptoms of migraine) develop during the aura, with fixed laterality; focal signs of the aura persisting or recurring in the headache phase

Seizures or very brief auras (<5 min)
Unusual headaches in children
- Atypical auras, including basilar-type, hemiplegic
- Trigeminal autonomic cephalalgia, including cluster headaches in child or adolescent
- An acute secondary headache (i.e., headache with known underlying illness or insult)

Headache in children younger than 6 yr old or any child who cannot adequately describe his or her headache
Brief cough headache in a child or adolescent
Headache worst on first awakening or that awakens the child from sleep
Migrainous headache in the child with no family history of migraine or its equivalent

- Education and enabling of patients to manage their disease to enhance personal control of their migraine
- Reduction of headache-related distress and psychologic symptoms

To accomplish these goals, three components need to be incorporated into the treatment plan: (1) an acute treatment strategy should be developed for stopping a headache attack on a consistent basis with return to function as soon as possible, with the goal being 2 hours maximum; (2) a preventive treatment strategy should be considered when the headaches are frequent (one or more per week) and disabling; and (3) biobehavioral therapy should be started, including a discussion of adherence, elimination of barriers to treatment, and healthy habit management.

Acute Treatment

Management of an acute attack is designed to provide headache freedom as quickly as possible with return to normal function. This mainly includes two groups of medicines: nonsteroidal antiinflammatory drugs (NSAIDs) and triptans. Small-molecule calcitonin gene–related peptide modulator (CGRP receptor antagonists) therapies are approved for patients 18 and older for acute headache treatment, but they are still under investigation for efficacy and tolerability in children and adolescents. Most headaches caused by migraine in children will respond to appropriate doses of NSAIDs when they are administered at the *onset* of the headache attack. Ibuprofen has been well documented to be effective at a dose of 7.5-10.0 mg/kg and is often preferred; however, acetaminophen (15 mg/kg) can be effective in those with a contraindication to NSAIDs. Special concern for the use of ibuprofen or other NSAIDs includes ensuring that the children can recognize and respond to onset of the headache. This means discussing with the child the importance of telling the teacher when the headache starts at school and ensuring that proper dosing guidelines and permission have been provided to the school. In addition, medication overuse needs to be avoided, limiting NSAIDs and other pain medications for headache (or any combination of nonprescription analgesics) to not more than 2-3 times per week. The limitation of any analgesic to not more than three headaches per week is necessary to prevent the transformation of the migraines into **medication-overuse headaches (MOHs)**. If a patient has maximized the weekly allowance of analgesics, the patient's next step is to only use hydrating fluids for the rest of the week as an abortive approach. If ibuprofen is not effective, naproxen sodium also may be tried in similar doses. Aspirin is also a reasonable option but is usually reserved for older children (>16 years). Use of other NSAIDs has yet to be studied in pediatric migraine. The goal of the acute medication should be relief of headache and associated symptoms within 1 hour, with return to function in 10 of 10 headaches.

When an attack of migraine is especially severe, NSAIDs alone may not be sufficient. In this case, a triptan may be considered. Multiple studies have demonstrated their effectiveness and tolerability. There are currently three triptans that are approved by the U.S. Food and Drug Administration (FDA) for the treatment of episodic migraine in the pediatric population. Almotriptan is approved for the treatment of acute migraine in adolescents (ages 12-17 years). Rizatriptan is approved for the treatment of migraine in children as young as age 6 years. The intranasal formulation of zolmitriptan is also approved by the FDA in the United States for use in children ages 12 and over. Several studies have shown it to provide rapid and effective relief, and it has been demonstrated to be well tolerated for treatment of acute migraine in patients 12 years and older. Zolmitriptan nasal spray may be of particular benefit to those with nausea and in patients who have difficulty swallowing tablets.

The combination of naproxen sodium and sumatriptan has been studied and may be effective in children. Controlled clinical trials demonstrate that intranasal sumatriptan is safe and effective in children older than age 8 years with moderate to severe migraine. At present, pediatric studies showing the effectiveness of oral sumatriptan are lacking, and there is insufficient evidence to support the use of subcutaneous sumatriptan in children. For most adolescents, dosing is the same as for adults; a reduction in dose is made for children weighing less than 40 kg. The triptans vary by rapidity of onset and biologic half-life. This is related to both their variable lipophilicity and dose. Clinically, 60–70% of patients respond to the first triptan tried, with 60–70% of

Table 635.10 Drugs Used in the Management of Migraine Headaches in Children

DRUG	DOSE	MECHANISM	SIDE EFFECTS	COMMENTS
ACUTE MIGRAINE				
Analgesics				
Acetaminophen	15 mg/kg/dose	Analgesic effects	Overdose, fatal hepatic necrosis	Effectiveness limited in migraine
Ibuprofen	7.5-10 mg/kg/dose	Antiinflammatory and analgesic	GI bleeding, stomach upset, kidney injury	Avoid overuse (2-3 times per wk)
Triptans				
Almotriptan* (ages 12-17 yr)	12.5 mg	5-$HT_{1b/1d}$ agonist	Vascular constriction, serotonin symptoms such as flushing, paresthesias, somnolence, GI discomfort	Avoid overuse (>4-6 times per mo)
Eletriptan	40 mg	Same	Same	Avoid overuse (>4-6 times per mo)
Frovatriptan	2.5 mg	Same	Same	May be effective for menstrual migraine prevention Avoid overuse (>4-6 times per mo)
Naratriptan	2.5 mg	Same	Same	May be effective for menstrual migraine prevention Avoid overuse (>4-6 times per mo)
Rizatriptan* (ages 6-17 yr)	5 mg for child weighing <40 kg, 10 mg	Same	Same	Available in tablets and melts Avoid overuse (>4-6 times per mo)
Sumatriptan	Oral: 25, 50, 100 mg Nasal: 10 mg SC: 6 mg	Same	Same	Avoid overuse (>4-6 times per mo)
Zolmitriptan (NS ages 12+)	Oral: 2.5, 5 mg Nasal: 5 mg*	Same	Same	Available in tablets and melts Avoid overuse (>4-6 times per mo)
PROPHYLAXIS (NONE APPROVED BY FDA FOR CHILDREN)				
Calcium Channel Blockers				
Flunarizine†	5 mg hs	Calcium channel blocking agent	Headache, lethargy, dizziness	May ↑ to 10 mg hs
Anticonvulsants				
Valproic acid	20 mg/kg/24 hr (begin 5 mg/kg/24 hr)	↑ Brain GABA	Nausea, pancreatitis, fatal hepatotoxicity	↑ 5 mg/kg every 2 wk
Topiramate* (12-17 yr)	100-200 mg divided bid	↑ Activity of GABA	Fatigue, nervousness	Increase slowly over 12-16 wk
Levetiracetam	20-60 mg/kg divided bid	Unknown	Irritability, fatigue	Increase every 2 wk starting at 20 mg/kg divided bid
Gabapentin	900-1800 mg divided bid	Unknown	Somnolence, fatigue, aggression, weight gain	Begin 300 mg, ↑ 300 mg/wk
Antidepressants				
Amitriptyline	1 mg/kg/day	↑ CNS serotonin and norepinephrine	Cardiac conduction, abnormalities and dry mouth, constipation, drowsiness, confusion	Increase by 0.25 mg/kg every 2 wk Morning sleepiness reduced by administration at dinnertime
Antihistamines				
Cyproheptadine	0.2-0.4 mg/kg divided bid; max: 0.5 mg/kg/24 hr	H_1-receptor and serotonin agonist	Drowsiness, thick bronchial secretions	Preferred in children who cannot swallow pills; not well tolerated in adolescents
Antihypertensive				
Propranolol	10-20 mg tid	Nonselective β-adrenergic blocking agent	Dizziness, lethargy	Begin 10 mg/24 hr ↑ 10 mg/wk (contraindicated in asthma and depression)
Others				
Coenzyme Q10	1-3 mg/kg/day	Increases fatty acid oxidation in mitochondria	No adverse effects reported	Fat soluble; ensure brand contains small amount of vitamin E to help absorption
Riboflavin	50-400 mg daily	Cofactor in energy metabolism	Bright yellow urine, polyuria and diarrhea	

Table 635.10 Drugs Used in the Management of Migraine Headaches in Children—cont'd

DRUG	DOSE	MECHANISM	SIDE EFFECTS	COMMENTS
Magnesium	9 mg/kg divided tid	Cofactor in energy metabolism	Diarrhea or soft stool	
Butterbur	50-150 mg daily	May act similar to a calcium channel blocker	Burping	
OnabotulinumtoxinA	100 units (age 11-17 yr)	Inhibits acetylcholine release from nerve endings	Ptosis, blurred vision, hematoma at injection site	Used off-label in children
SEVERE INTRACTABLE				
Prochlorperazine	0.15 mg/kg/IV; max dose 10 mg	Dopamine antagonist	Agitation, drowsiness, muscle stiffness, akinesia and akathisia	May have increased effectiveness when combined with ketorolac and fluid hydration
Metoclopramide	0.2 mg/kg IV; 10 mg max dose	Dopamine antagonist	Drowsiness, urticaria, agitation, akinesia and akathisia	Caution in asthma patients
Ketorolac	0.5 mg/kg IV; 15 mg max dose	Antiinflammatory and analgesic	GI upset, bleeding	
Valproate sodium injection	15 mg/kg IV: 1,000 mg max dose	↑ Brain GABA	Nausea, vomiting, somnolence, thrombocytopenia	Would avoid in hepatic disease
Dihydroergotamine IV	0.5 mg/dose every 8 hr (<40 kg) 1.0 mg/dose every 8 hr (>40 kg)		Nausea, vomiting, vascular constriction, phlebitis	Dose may need to be adjusted for side effects (decrease) or limited effectiveness (increase)
Nasal spray	0.5-1.0 mg/dose 0.5 mg/spray			

*FDA approved in the pediatric population.
†Available in Europe.
↑, Increase; CNS, central nervous system; GABA, γ-aminobutyric acid; GI, gastrointestinal; hs, at night; SC, subcutaneous.

the patients who did not respond to the first triptan responding to the next triptan. Therefore in the patient who does not respond to the first triptan in the desired way (rapid reproducible response without relapse or side effects), it is worthwhile to try a different triptan. The most common side effects of the triptans are caused by their mechanism of action—tightness in the jaw, chest, and fingers as a result of vascular constriction and a subsequent feeling of grogginess and fatigue from the central serotonin effect. The vascular constriction symptoms can be alleviated through adequate fluid hydration during an attack.

The most effective way to administer acute treatment is with the recognition that NSAIDs and triptans have different mechanisms of action. NSAIDs are used for all headaches, mild to severe, with their use being restricted to fewer than two to three attacks per week; the triptans are added for moderate to severe headaches, with their use being restricted to not more than six to eight attacks per month. For an acute attack, the NSAIDs can be repeated once in 3-4 hours, if needed for that specific attack, and the triptans can be repeated once in 2 hours if needed. It is important to consider the various formulations available, and these options should be discussed with pediatric patients and their parents, especially if a child is unable to swallow pills or take an oral dose because of nausea and/or vomiting.

Because vascular dilation is a common feature of migraine that may be responsible for some of the facial flushing, followed by paleness and the lightheaded feeling accompanying the attacks, fluid hydration should be integrated into the acute treatment plan. For oral hydration, this can include the sports drinks that combine electrolytes and sugar to provide the intravascular rehydration.

Antiemetics are used for acute treatment of the nausea and vomiting. Further study has identified that their unique mechanism of effectiveness in headache treatment is related to their antagonism of dopaminergic neurotransmission. Therefore the antiemetics with the most robust dopamine antagonism (i.e., prochlorperazine and metoclopramide) have the best efficacy. These can be very effective for status migrainosus or a migraine that is unresponsive to NSAIDs and triptans. They require intravenous administration because other forms of administration of these drugs are less effective than the NSAIDs or triptans. When combined with ketorolac and intravenous fluids in the emergency department or an acute infusion center, intravenous antiemetics can be highly effective. When they are not effective, further inpatient treatment may be required using dihydroergotamine (DHE), which will mean an admission to an inpatient unit for more aggressive therapy of an intractable attack.

There are also a growing number of devices that appear to be effective for the acute treatment of headache attacks caused by migraine. Currently both a remote electrical neuromodulation (REN) device and a vagal nerve stimulator are approved for the acute treatment of attacks down to age 12. These devices have the benefit of improving the adolescent's locus of control, as they can modulate the degree and duration of treatment, without the need to swallow a pill.

Emergency Department Treatments for Intractable Headaches

When an acute migraine attack does not respond to the recommended outpatient regimen and the headache is disabling, more aggressive therapeutic approaches are available and may be necessary to prevent further increase in the duration and frequency of headaches. These migraines fall into the classification of status migrainosus (migraine attack lasting more than 72 hours), and patients may need to be referred to an infusion center, the emergency room, or an inpatient unit.

Available specific treatments for migraine headache in an emergency room setting include the following: antidopaminergic medications such as prochlorperazine and metoclopramide, NSAIDs such as ketorolac, vasoconstrictor medications such as DHE, and antiepileptic drugs such as sodium valproate.

Antidopaminergic Drugs: Prochlorperazine and Metoclopramide

The use of antidopaminergic medications is not limited to controlling the nausea and vomiting often present during a migraine headache. Their potential pharmacologic effect may be a result of their antidopamine property and the underlying pathologic process involving the dopaminergic system during a migraine attack. Prochlorperazine is highly effective in aborting an attack in the emergency room when given intravenously with a bolus of intravenous fluid. Results show a 75% improvement with 50% headache freedom at 1 hour and 95% improvement with 60% headache freedom at 3 hours. Prochlorperazine may be more effective than metoclopramide. The average dose of metoclopramide is 0.13-0.15 mg/kg, with a maximum dose of 10 mg given intravenously over 15 minutes. The average dose of prochlorperazine is 0.15 mg/kg, with a maximum dose of 10 mg. These medications are usually well-tolerated, but *extrapyramidal reactions* are more frequent in children than in older persons. An acute extrapyramidal reaction can be controlled in the emergency room with 25-50 mg of diphenhydramine given intravenously. There is no need for premedication with diphenhydramine to prevent side effects. Diphenhydramine should only be used if needed when side effects are present.

Nonsteroidal Antiinflammatory Drugs: Ketorolac

It is known that an aseptic inflammation occurs in the central nervous system as a result of the effect of multiple reactive peptides in patients with migraines, including the CGRP molecules. Ketorolac is often used in the emergency department as monotherapy for a migraine attack or in combination with other drugs. In monotherapy, the response to ketorolac is 55.2% improvement. When ketorolac is combined with prochlorperazine, the response rate jumps to 93%.

Antiepileptic Drugs: Sodium Valproate

Antiepileptic drugs have been used as prophylactic treatment for migraine headache for years with adequate double-blinded, controlled studies on their efficacy in adults. The mechanism by which sodium valproate acutely aborts migraine headaches is not well understood. Sodium valproate is given as a bolus of 15-20 mg/kg push (over 10 minutes). This intravenous load is followed by an oral dose (15-20 mg/day) in the 4 hours after the injection. Patients may benefit from a short-term preventive treatment with an extended-release form after discharge from the emergency room for 2 weeks to keep the level in the therapeutic range. Sodium valproate is usually well tolerated. Patients should receive a fluid load during the procedure to prevent a possible hypotensive episode.

Triptans

Subcutaneous sumatriptan (0.06 mg/kg) has an overall efficacy of 72% at 30 minutes and 78% at 2 hours, with a recurrence rate of 6%. Because children tend to have a shorter duration of headache, a recurrence rate of 6% would seem appropriate for this population. DHE, if recommended for the recurrences, should not be given in the 8 hours after triptan use. Triptans are contraindicated in patients treated with ergotamine within 24 hours and within 2 weeks of treatment with monoamine oxidase inhibitors. Triptans may rarely produce serotonin syndrome in patients taking a serotonin receptor reuptake inhibitor. *Both triptans and ergotamine are contraindicated in hemiplegic migraines.*

Dihydroergotamine

DHE is a medication used as a vasoconstrictor to abort the vascular phase of migraine headache. The effectiveness is discussed in detail in the section "Inpatient Management of Intractable Migraine and Status Migrainosus," next. One dose of DHE can be effective for abortive treatment in the emergency department. Emergency room treatment of migraine shows a recurrence rate of 29% at 48-72 hours, with 6% of patients needing even more aggressive therapy in an inpatient unit.

Inpatient Management of Intractable Migraine and Status Migrainosus

About 6–7% of patients fail acute treatment in the emergency department. These patients are usually admitted for 3-5 days to an inpatient unit and receive extensive parenteral treatment. Admission is reserved for patients who are disabled by their acute migraine attack and those who did not experience relief from all other abortive approaches as discussed earlier: (1) for acute status migrainosus, (2) for exacerbation of an underlying chronic migraine when the episode fits the criteria for a status migrainosus occurring on top of their continuous baseline headache, and (3) for severe analgesic overuse headache that did not respond to any other recommended abortive therapy. The goal of inpatient treatment is to control a headache that has been unresponsive to other outpatient abortive therapies and is disabling to the child. Treatment protocols include the use of DHE, antiemetics, sodium valproate, and other drugs.

Dihydroergotamine

Ergots are one of the oldest treatments for migraine headache. DHE is a parenteral form used for acute exacerbations. Its effect stems from the $5HT_{1A\text{-}1B\text{-}1D\text{-}1F}$ receptor agonist affinity and central vasoconstriction. DHE has greater α-adrenergic antagonist activity and is less vasoconstrictive peripherally. Before initiation of an intravenous ergot protocol, a full history should be obtained and a neurologic examination performed to rule out any possibility of secondary headache before the initiation of the treatment, keeping in mind that patients with migraine can still develop a secondary headache. Females of childbearing age should be evaluated for pregnancy before ergots are administered.

The DHE protocol consists of the following: Patients are premedicated with 0.13-0.15 mg/kg of prochlorperazine 30 minutes before the DHE dose (maximum of three prochlorperazine doses to prevent extrapyramidal syndrome; after three doses of prochlorperazine, a non–dopamine antagonist antiemetic should be used, such as ondansetron). A dose of 0.5-1.0 mg of DHE is used (depending on age and tolerability) every 8 hours until headache freedom is achieved or headache returns back to baseline for those with a continuous headache. The first dose should be divided into two half-doses separated by 30 minutes if the patient is naïve to treatment with DHE. When the headache ceases, an extra dose of DHE is given in an attempt to prevent recurrence after discharge. The response to this protocol is a 97% improvement and 77% headache freedom. The response is noticeable by the fifth dose; the drug can reach its maximum effects after the tenth dose. Common side effects of DHE include nausea, vomiting, abdominal discomfort, a flushed face, muscle cramping, and increased blood pressure. The maximum dose used in this protocol is 15 mg total of DHE.

Sodium Valproate

Sodium valproate is used when DHE is contraindicated or has been ineffective. One adult study recommends the use of valproate sodium as follows: bolus with 15 mg/kg (maximum of 1,000 mg), followed by 5 mg/kg every 8 hours until headache freedom or up to a maximum of 10 doses. An extra dose is recommended after the headache ceases to prevent recurrence. This protocol was studied in adults with chronic daily headaches and showed an 80% improvement. It is well tolerated and is useful in children when DHE is ineffective, contraindicated, or not tolerated.

Other Inpatient Therapies

During an inpatient admission for status migrainosus, other services such as behavioral medicine and holistic medicine should be involved if they are available. The behavioral medicine staff can play a major role in talking to patients about their specific triggers and can also evaluate school, as well as home and social stressors. The staff would also initiate some coping skills training during the admission and evaluate the necessity for further outpatient follow-up for cognitive-behavioral therapy, biofeedback, or treatment for other comorbidities. The holistic medicine staff, when consulted, can offer holistic approaches to pain control, including relaxation techniques, medical massage, and craniosacral therapy.

Preventive Therapy

When the headaches are frequent (more than one headache per week) or disabling (causing the patient to miss school, home, or social activities or with a PedMIDAS score >20), preventive or **prophylactic**

therapy may be warranted. The goal of this therapy should be to reduce the frequency to one headache or fewer per week and level of disability (PedMIDAS score <10). Prophylactic agents should be given for at least 4-6 months at an adequate dose and then weaned over several weeks. Evidence in adult studies has begun to demonstrate that persistent frequent headaches foreshadow an increased risk of progression with decreased responsiveness and increased risk of refractoriness in the future. It is unclear whether this also occurs in children and/or adolescents and whether early treatment of headache in childhood prevents development of refractory headache in adulthood.

Multiple preventive medications have been used for migraine prophylaxis in children. When analyzed as part of a practice parameter, one medication, **flunarizine** (a calcium channel blocking agent), demonstrated a level of effectiveness viewed as substantial; it is not available in the United States. Flunarizine is typically given at 5 mg orally daily and increased after 1 month to 10 mg orally daily, with a month off the drug every 4-6 months.

A commonly used preventive therapy for headache and migraine is amitriptyline. Typically, a dose of 1 mg/kg daily at dinner or in the evening is effective. However, this dose needs to be reached slowly (i.e., over weeks, with an increase every 2 weeks until the goal is reached) to minimize side effects and improve tolerability. Side effects include sleepiness and those related to amitriptyline's anticholinergic activity. Weight gain has been observed in adults using amitriptyline but is a less frequent occurrence in children. Amitriptyline does have the potential to exacerbate prolonged QT syndrome, so it should be avoided in patients with this diagnosis and looked for in patients taking the drug who complain of a rapid or irregular heart rate.

Antiepileptic medications are also used for migraine prophylaxis, with topiramate, valproic acid, and levetiracetam having been demonstrated to be effective in adults. There are limited studies in children for migraine prevention, but all of these medications have been assessed for safety and tolerability in children with epilepsy.

Topiramate has become widely used for migraine prophylaxis in adults. Topiramate was also demonstrated to be effective in an adolescent study. This study demonstrated that a 25-mg dose twice a day was equivalent to placebo, whereas a 50-mg dose twice a day was superior. Thus it appears that the adult dosing schedule is also effective in adolescents with an effective dosage range of 50 mg twice a day to 100 mg twice a day. This dose needs to be reached slowly to minimize the cognitive slowing associated with topiramate use. Side effects include weight loss, paresthesias, kidney stones, lowered bicarbonate levels, decreased sweating, and rarely glaucoma and changes in serum transaminases. In addition, in adolescent females taking birth control pills, the lowering of the effectiveness of the birth control by topiramate needs to be discussed.

A comparative effectiveness study in children (8-17 years) of the two most common treatments (amitriptyline and topiramate) compared with placebo (the CHAMP study) demonstrated that all three treatments were effective, but there was not statistical superiority for amitriptyline or topiramate over placebo.

Valproic acid has long been used for epilepsy in children and has been demonstrated to be effective in migraine prophylaxis in adults. The effective dose in children appears to be 10 mg/kg orally twice a day. Side effects of weight gain, ovarian cysts, and changes in serum transaminases and platelet counts need to be monitored. Other antiepileptics, including lamotrigine, levetiracetam, zonisamide, gabapentin, and pregabalin, are also used for migraine prevention.

β Blockers have long been used for migraine prevention. The studies on β blockers have a mixed response pattern with variability both between β blockers and between patients with a given β blocker. Propranolol is the best studied for pediatric migraine prevention with unequivocally positive results. The contraindication for the use of propranolol in children with asthma or allergic disorders or diabetes and the increased incidence of depression in adolescents using propranolol limit its use somewhat. It may be effective for a mixed subtype of migraine (basilar-type migraine with postural orthostatic tachycardia syndrome). This syndrome has been reported to be responsive to propranolol. α-Blockers and calcium channel blockers, aside from flunarizine, also have been used in pediatric migraine; their effectiveness, however, remains unclear.

In very young children, cyproheptadine may be effective in the prevention of migraine or the periodic syndromes of childhood. Young children tend to tolerate the increased appetite induced by the cyproheptadine and tend not to be subject to the lethargy seen in older children and adults; the weight gain is limiting once children start to enter puberty. Typical dosing is 0.1-0.2 mg/kg orally twice a day.

Nutraceuticals are popular choices, especially among families who prefer a more natural approach to headache treatment. Despite studies showing success of these therapies in adults, few studies have shown effectiveness in pediatric headaches. Riboflavin (vitamin B_2), at doses ranging from 25 to 400 mg, is the most widely studied with good results. Side effects are minimal and include bright yellow urine, diarrhea, and polyuria. Coenzyme Q10 supplementation may be effective in reducing migraine frequency at doses of 1-2 mg/kg/day. Butterbur is also effective in reducing headaches, with minimal side effects, including burping. Use in children has been limited to avoid the potential toxicity of butterbur-containing pyrrolizidine alkaloids, which are naturally contained and are a known carcinogen and toxic to the liver.

OnabotulinumtoxinA is the first medication FDA-approved for chronic migraine in adults. There are studies in children indicating its effectiveness; use in children is considered off-label. The limited available studies revealed the following: The average dose used was 188.5 units ± 32 units with a minimum dose of 75 units and maximum of 200 units. The average age of patients receiving the treatment was 16.8 ± 2.0 years (minimum 11 years; maximum 21 years). OnabotulinumtoxinA injections improved disability scores (PedMIDAS) and headache frequency in pediatric chronic daily headache patients and chronic migraine in this age-group. OnabotulinumtoxinA not only had a positive effect on the disability scoring for these young patients with headache but was also able to transform the headaches from chronic daily to intermittent headaches in more than 50% of the patients.

Eptinezumab, erenumab, galcanezumab, and fremanezumab—humanized monoclonal antibodies against the CGRP or its receptor—have demonstrated safety and efficacy in adult patients with migraine. The FDA has approved these agents for use in adults with migraine, including chronic migraine. There are no completed studies in children and adolescents.

Biobehavioral Therapy

Biobehavioral evaluation and therapy are essential for effective migraine management. This includes identification of behavioral barriers to treatment, such as a child's shyness or limitation in notifying a teacher of the start of a migraine or a teacher's unwillingness to accept the need for treatment. Additional barriers include a lack of recognition of the significance of the headache problem and reverting to bad habits once the headaches have responded to treatment. Adherence is equally important for acute and preventive treatment. The need to have a sustained response long enough to prevent relapse (to stay on preventive medication) is often difficult when the child starts to feel better. Establishing a defined treatment goal (one or two or fewer headaches per month for 4-6 months) helps with acceptance.

Because many of the potential triggers for attacks of migraine (skipping meals, dehydration, decreased or altered sleep) are related to a child's daily routine, a discussion of healthy habits is a component of biobehavioral therapy. This should include adequate fluid intake without caffeine, regular exercise, not skipping meals and making healthy food choices, and adequate (8-9 hours) sleep on a regular basis. Sleep is often difficult in adolescents because middle and high schools often have very early start times, and the adolescent's sleep architecture features a shift to later sleep onset and waking. This has been one of the explanations for worsening headaches during the school year in general and at the beginning of the school year and week.

Biofeedback-assisted relaxation and cognitive-behavioral therapy (usually in combination with amitriptyline) are effective for both acute and preventive therapy and may be incorporated into this multiple treatment strategy. This provides the child with a degree of self-control over the headaches and may further help the child cope with frequent headaches.

Young Adults and the Transition of Headache Care from a Pediatric to an Adult Provider

Migraine is a chronic condition that may first present in childhood. Males are diagnosed at a younger age than females; however, during development, the prevalence becomes highest among women, starting at puberty. Some adolescents and women report migraine associated with menses; the pain symptoms are described as lasting longer and having a higher intensity. The role of oral contraceptive pills (OCPs) is often a topic of discussion among female adolescents and young women. Studies have shown improvement of menstrual migraine in adult patients taking oral estrogens and progesterone; similar studies have not been done in adolescents. OCPs are not approved by the FDA for treatment of menstrual migraine; they have been associated with an increased risk of stroke among women with migraine aura. Therefore their use in adolescents as a prophylactic agent is not advised.

Comorbid conditions such as anxiety and depression are seen with a high prevalence among adults with migraine; however, the prevalence among adolescent patients remains unclear. Diagnostic tools capable of differentiating mood disorders from pain symptoms in the pediatric population are limited, which makes identifying those at risk challenging. However, it is important to keep in mind the potential of mood disorders, especially in young adults.

Remission of migraine is seen in up to 34% of adolescents, and almost 50% continue to have migraine persisting into adulthood. Successful transition of care from a pediatric to an adult provider has been shown to improve outcomes in patients with chronic disease.

Early diagnosis and treatment of migraine can help minimize the progression of the disease in adults. This, together with careful screening for comorbid conditions, may help identify those at risk for refractory migraine, minimize disability, and improve overall headache outcomes.

Visit Elsevier eBooks+ at eBooks.Health.Elsevier.com for Bibliography.

635.2 Secondary Headaches

Andrew D. Hershey, Marielle Kabbouche, and Joanne Kacperski

Headaches can be a common symptom of other underlying illnesses. In recognition of this, the ICHD-3 has classified potential secondary headaches (see Table 635.1). The key to the diagnosis of a secondary headache is to recognize the underlying cause and demonstrate a direct cause and effect. Until this has been done, the diagnosis is speculative. This is especially true when the suspected etiology is common.

Headache is a common occurrence after concussion or mild traumatic brain injury (mTBI), reported in as many as 86% of high school and college athletes who have suffered from head trauma (see Chapter 729). Although there are no strict criteria for determining who will develop persistent headache after concussion, it is important to gather information to rule out other secondary headaches and significant primary headache disorders and to identify those who may be at risk for persistent headache after concussion.

Chronic or persistent headaches are headaches that last for more than 3 months after head trauma. This definition is consistent with the classification of persistent posttraumatic headaches in the ICHD-3. Although concussion and posttraumatic headache are rapidly evolving areas of study, there is an unfortunate lack of definitive scientific evidence at this time on these topics in pediatrics. The ICHD-3 classifies posttraumatic headaches as acute if they last less than 3 months and persistent if they last more than 3 months after injury. This period is consistent with ICHD-II diagnostic criteria, although the term *persistent* has been adopted in place of *chronic*. Although the ICHD-3 criteria state that posttraumatic headaches begin within 7 days after injury to the head or after regaining consciousness, this 7-day cutoff is arbitrary, and some experts believe that headaches may develop after a longer interval. Some studies have shown that ~50% of children with posttraumatic headache 3 months after concussion had a history of preexisting headaches, and 31% had a history of migraine or probable migraine before the injury. Furthermore, 56% of patients with headaches at 3 months after injury had a family history of migraine. Based on clinical experiences of patients with prolonged postconcussion symptoms, those with *prior* concussion and *persistent* posttraumatic headaches, preexisting anxiety and/or depression, and maladaptive coping styles may also be at higher risk for persistent posttraumatic headache.

Despite being classified as a secondary headache, a posttraumatic headache generally presents with clinical features that are observed in primary headache disorders, including tension-type, migraine, and cervicogenic headaches. The few reports that have thus far assessed the characteristics of posttraumatic headache in the pediatric population have also reported various proportions of migraine or tension-type characteristics, with the reported prevalence of each varying among individual studies.

Although headache is reported to be the most common symptom after concussion, there is a paucity of studies regarding the safety and efficacy of headache treatments for persistent posttraumatic headaches. Posttraumatic headaches may be difficult to treat. There are currently no established guidelines for their treatment, especially when persistent, and practices can vary widely. Most treatment algorithms proposed have been extrapolated from the primary headache literature and small noncontrolled trials of posttraumatic headache regimens. When posttraumatic headaches become problematic or persistent, a multidimensional management approach, including pharmacologic intervention, physical rehabilitation, and cognitive-behavioral therapies, are often used. Management should therefore be relevant to the type of headache and focused on the clinical needs of the child.

Like primary headache disorders, these headaches can have a substantial effect on the child's life, leading to lost school days and withdrawal from social interactions. Referral for biobehavioral therapy and coping strategies may be necessary. Adherence should be promoted and can be optimized by educating both the patient and the family about the proper use of acute and prophylactic medications, establishing realistic expectations (including expectations for recovery), and emphasizing compliance at the initiation of treatment.

Children with persistent posttraumatic headaches may require frequent analgesics. Rebound headaches are common and can complicate treatment. The excessive use of symptomatic headache medicines, most commonly simple analgesics, can cause MOHs in susceptible patients and has been well-described in patients with primary headache disorders. Medication overuse can be a contributing factor in headache chronicity in 20–30% of children and adolescents, with chronic daily headache unrelated to concussion. Because analgesics are commonly recommended for the treatment of acute headaches after concussion, some susceptible patients with concussion are at risk for developing a medication-overuse pattern that causes a chronic headache syndrome.

There is no clear evidence to help guide the clinician on the timing of initiation of preventive therapy in children to decrease the likelihood of developing persistent posttraumatic headaches. Although many medications are being used to manage persistent posttraumatic headaches, most have supporting data for the management of migraine or chronic migraine, and few have been studied for the treatment of persistent posttraumatic headaches in a systematic manner.

Sinus headache is the most overdiagnosed form of recurrent headache. Although no studies have evaluated the frequency of misdiagnosis of an underlying migraine as a sinus headache in children, in adults, it has been found that up to 90% of adults diagnosed as having a sinus headache either by themselves or their physician appear to have migraine. When headaches are recurrent and respond within hours to analgesics, migraine should be considered first. In the absence of purulent nasal discharge, fever, or chronic cough, the diagnosis of sinus headache should not be made.

MOHs frequently complicate primary and secondary headaches. An MOH is defined as a headache present for more than 15 days/month for longer than 3 months and intake of a simple analgesic on

Table 635.11 History-Related Red Flags for Secondary Headache

QUALITY
"Thunderclap" rapid-onset headache or the "worst headache of my life"
Recent worsening in severity or frequency
Change in quality
New-onset symptoms consistent with cluster headache
LOCATION
Unilateral without alteration of sides
Chronic or recurrent occipital headache
TIMING
Awakens from sleep
Occurs in morning or causes morning vomiting
Acute or chronic progressive pattern
POSITIONAL OR ACTIVITY-RELATED VARIATIONS
Worsened in the recumbent position or when bending over
Headache experienced or worsened with cough or the Valsalva maneuver
ASSOCIATED NEUROLOGIC HISTORY
Neurologic dysfunction other than typical aura
Altered sensorium during headache
Sensory deficits or changes in vision, gait, or coordination
Other focal neurologic deficits
Seizures or syncope
Decreased visual acuity
Mental status changes (e.g., confusion or disorientation)
Regression in fine or gross motor developmental skills
Decline in cognition or school performance
Change in mood, behavior, or personality
ASSOCIATED GENERAL HISTORY
Vomiting without nausea and morning/fasting nausea or vomiting
Polyuria or polydipsia
Preschool or younger age
History of head trauma
Neck pain
Medical comorbidities
History of ventriculoperitoneal shunt
Certain medications
Signs of systemic or localized head/neck infection
Negative family history of primary headache disorders

From Lauck SM, Gage S. Headaches. In: Kliegman RM, Toth H, Bordini BJ, et al., eds. *Nelson Pediatric Symptom-Based Diagnosis*, 2nd ed. Philadelphia: Elsevier; 2023: Table 34.5, p. 553.

Table 635.12 Physical Examination Red Flags for Secondary Headaches

ABNORMAL VITAL SIGNS
Hypertension
Growth failure
Increased head circumference or bulging fontanel
Fever
Meningeal signs with or without fever
Evidence of cranial trauma
Cranial bruit
Frontal bony tenderness
Macrocephaly
ABNORMAL OPHTHALMOLOGIC FINDINGS
Papilledema
Abnormal ocular movements
Squinting
Pathologic pupillary response
Visual field defects
ABNORMAL NEUROLOGIC FINDINGS
Impaired mental status
Cranial nerve palsy
Ataxia
Abnormal gait
Abnormal coordination
Abnormal reflexes
Asymmetric motor or sensory examination
Hemiparesis
Developmental regression
Precocious, delayed, or arrested puberty
SKIN FINDINGS
Café-au-lait or ash leaf macules
Petechiae or purpura
Facial hemangioma
Malar rash

From Lauck SM, Gage S. Headaches. In: Kliegman RM, Toth H, Bordini BJ, et al., eds. *Nelson Pediatric Symptom-Based Diagnosis*, 2nd ed. Philadelphia: Elsevier; 2023: Table 34.6, p. 553.

more than 15 days/month and/or prescription medications, including triptans or combination medications, on more than 10 days/month. Some of the signs that should raise suspicion of medication overuse are the increasing use of analgesics (nonprescription or prescription) with either decreased effectiveness or frequent wearing off (i.e., analgesic rebound). An MOH can be worsened by ineffective medications or misdiagnosis of the headache. Patients should be cautioned against the frequent use of antimigraine medications, including combination analgesics or triptans.

Serious causes of secondary headaches are likely to be related to **increased intracranial pressure**. This can be caused by a mass (tumor, vascular malformation, cystic structure) or an intrinsic increase in pressure (idiopathic intracranial hypertension, also known as *pseudotumor cerebri*). In the former case, the headache is caused by the mass effect and local pressure on the dura; in the latter case, the headache is caused by diffuse pressure on the dura. The etiology of idiopathic intracranial hypertension may be the intake of excessive amounts of fat-soluble compounds (e.g., vitamin A, retinoic acid, and minocycline), hormonal changes (increased incidence in females), or blockage of venous drainage (as with inflammation of the transverse venous sinus from mastoiditis). When increased pressure is suspected, either by historical suspicion or the presence of papilledema, an MRI with magnetic resonance angiography and magnetic resonance venography should be performed, followed by a lumbar puncture if no mass or vascular anomaly is noted. The lumbar puncture can be diagnostic and therapeutic of idiopathic intracranial hypertension but must be performed with the patient in a relaxed recumbent position with legs extended, because abdominal pressure can artificially raise intracranial pressure. If headache persists or there are visual field changes, pharmaceutical treatment with a carbonic anhydrase inhibitor, optic nerve fenestration, or a shunt needs to be considered.

Additional causes of secondary headaches in children that may not be associated with increased intracranial pressure include arteriovenous malformations, berry aneurysm, collagen vascular diseases affecting the central nervous system, hypertensive encephalopathy, infectious or autoimmune etiologies, acute subarachnoid hemorrhage, and stroke. The management of secondary headache depends on the cause. Helpful laboratory tests and neuroradiologic procedures depend on the clues provided by the history (Table 635.11) and physical (Table 635.12) examination. By definition, a secondary headache has a specific cause and should resolve once this cause is treated. If the headache persists, the diagnosis and treatment should be questioned because either the diagnosis, which may include a primary headache, or the treatment, or both, may be incorrect.

Visit Elsevier eBooks+ at eBooks.Health.Elsevier.com for Bibliography.

635.3 Tension-Type Headaches

Andrew D. Hershey, Marielle Kabbouche, and Joanne Kacperski

Tension-type headaches (TTHs) may be common in children and adolescents, with a prevalence in some studies as high as 48%, with those having a combination of migraine and TTH around 20%. Because of their mild to moderate nature, relative lack of associated symptoms, and lower degree of associated disability, they are often ignored or have minimal impact. The ICHD-3 subclassifies TTHs as infrequent (<12 headaches/year) (Table 635.13), frequent (1-15 headaches/month), and chronic (>15 headaches/month). They can further be separated into headaches with or without pericranial muscle tenderness. The classification of TTH can be likened to the opposite of migraine. Whereas migraines are typically moderate to severe, are focal in location, are worsened by physical activity or limit physical activity, and have a throbbing quality, TTHs are mild to moderate in severity, are diffuse in location, are not affected by activity (although the patient may not feel like being active), and are nonthrobbing (often described as a constant pressure). TTH is much less frequently associated with nausea, photophobia, or phonophobia and is never associated with more than one of these at a time or with vomiting. TTH must be recurrent, but at least 10 headaches are required, and the duration can be 30 minutes to 7 days. Secondary headaches with other underlying etiologies must be ruled out.

Evaluation of patients with suspected TTHs requires a detailed headache history and complete general and neurologic examination. This is to establish the diagnosis and ensure exclusion of secondary etiologies. When secondary headaches are suspected, further directed evaluation is indicated.

Treatment of TTHs can require acute therapy to stop attacks, preventive therapy when frequent or chronic, and behavioral therapy. It is often suspected that there may be underlying psychologic stressors (hence, the misnomer as a stress headache), but this is often difficult to identify in children, and although it may be suspected by the parents, it cannot be confirmed in the child. Studies of and conclusive evidence to guide the treatment of TTH in children are lacking, but the same general principles and medications used in migraine can be applied to children with TTHs (see Chapter 635.1). Oftentimes, simple analgesics (ibuprofen or acetaminophen) can be effective for acute treatment. Flupirtine is a nonopioid analgesic that has been approved in Europe for the treatment of TTH in children as young as age 6 years but is not available in the United States. Amitriptyline has the most evidence of effective prevention of TTH; biobehavioral intervention, including biofeedback-assisted relaxation training and coping skills, can be useful as well.

Visit Elsevier eBooks+ at eBooks.Health.Elsevier.com for Bibliography.

Table 635.13 Infrequent Episodic Tension-Type Headache

A. At least 10 episodes of headache occurring on <1 day/mo on average (<12 days/yr) and fulfilling criteria B-D
B. Lasting from 30 min to 7 days
C. At least two of the following four characteristics:
   1. Bilateral location
   2. Pressing or tightening (nonpulsating) quality
   3. Mild or moderate intensity
   4. Not aggravated by routine physical activity, such as walking or climbing stairs
D. Both of the following:
   1. No nausea or vomiting
   2. No more than one of photophobia or phonophobia
E. Not better accounted for by another ICHD-3 diagnosis

From Headache Classification Committee of the International Headache Society (HIS). *The International Classification of Headache Disorders*, 3rd ed. Cephalalgia. 2018;38(1):1–211, Table 10.

Chapter 636

Neurocutaneous Syndromes

Mustafa Sahin, Nicole Ullrich, Siddharth Srivastava, and Anna L. Pinto

The neurocutaneous syndromes include a heterogeneous group of disorders characterized by abnormalities of both the integument and central nervous system (CNS) of variable severity (Table 636.1). Many of the disorders are hereditary and believed to arise from a defect in differentiation of the primitive ectoderm (nervous system, eyeball, retina, and skin). Disorders classified as neurocutaneous syndromes include neurofibromatosis type 1 (NF1), neurofibromatosis type 2 (NF2), tuberous sclerosis complex (TSC), Sturge-Weber syndrome (SWS), von Hippel-Lindau disease (VHL), PHACE (posterior fossa malformations, hemangiomas, arterial anomalies, coarctation of the aorta, cardiac defects, eye abnormalities) syndrome, ataxia-telangiectasia (AT), linear nevus syndrome, hypomelanosis of Ito, and incontinentia pigmenti.

636.1 Neurofibromatosis

Nicole Ullrich

NF refers to a group of autosomal dominant genetic conditions that cause tumors to grown on nerves throughout the body. The types of NF include neurofibromatosis type 1 (NF1) and all types of schwannomatosis (SWN), including NF2-related schwannomatosis (NF2-SWN, formerly called neurofibromatosis type 2, or NF2).

CLINICAL MANIFESTATIONS AND DIAGNOSIS

NF1 has an incidence of 1 in 2,500 live births and is caused by autosomal dominant loss-of-function pathogenic variants in the *NF1* gene. Approximately 50% are inherited from an affected parent, and the other 50% result from a sporadic gene variant. The diagnostic criteria for NF1 were updated in 2021 by an international expert panel. The disease is clinically diagnosed when any two of the following manifestations are present: **(1)** Six or more café-au-lait macules (CALMs) >5 mm in greatest diameter in prepubertal individuals and >15 mm in greatest diameter in postpubertal individuals (Fig. 636.1). CALMs are the hallmark of neurofibromatosis and are present in almost 100% of patients. They are present at birth but increase in size, number, and pigmentation, especially during the first few years of life. The CALMs are scattered over the body surface, with predilection for the trunk and extremities. CALMs are not specific for NF1 and may be observed in other disorders (Table 636.2). **(2)** Axillary or inguinal freckling consisting of multiple hyperpigmented areas 2-3 mm in diameter; at least one of the two pigmentary findings (café-au-lait macules or freckling) must be bilateral (Fig. 636.2). Skinfold freckling usually appears between 3 and 5 years of age. The frequency of axillary and inguinal freckling is reported to be >80% by 6 years of age. **(3)** Two or more iris Lisch nodules, which are hamartomas located within the iris and are best identified by a slit-lamp examination, or two or more choroidal abnormalities (Fig. 636.3). They are present in more than 74% of patients with NF1. The prevalence of Lisch nodules increases with age, from only 5% of children younger than 3 years of age, to 42% among children 3-4 years of age, and virtually 100% of adults older than 21 years of age. **(4)** Two or more neurofibromas or one plexiform neurofibroma. Neurofibromas are most visible on the skin, but they may occur on any peripheral nerve in the body, including along peripheral nerves and blood vessels and within viscera, including the gastrointestinal

Table 636.1 Genetic and Clinical Features Associated with Neurocutaneous Syndromes

SYNDROME	GENE(S)	INHERITANCE	CLINICAL FEATURES
Tuberous sclerosis complex	*TSC1 (tuberous sclerosis 1; hamartin)* *TSC2 (tuberous sclerosis 2; tuberin)*	Autosomal dominant	Angiofibromas, hypomelanotic macules, shagreen patches, ungual fibromas, cortical dysplasias, subependymal giant cell astrocytomas, subependymal nodules, intellectual disability, epilepsy including infantile spasms, autism spectrum disorder, retinal hamartomas, cardiac rhabdomyomas, lymphangioleiomyomatosis, renal angiomyolipomas
Neurofibromatosis type 1	*NF1* (neurofibromin)	Autosomal dominant	
Schwannomatosis		Autosomal dominant	
NF2-related schwannomatosis	*NF2*		Vestibular schwannoma, meningioma, ependymoma, schwannoma, juvenile subcapsular or cortical cataract, retinal hamartoma, epiretinal membrane, affected parent, *NF2* pathogenic variant in at least two distinct tumors (formerly called NF2)
Non-NF2-related schwannomatosis			Two or more schwannomas or hybrid nerve sheath tumors AND pathogenic variant identified; no vestibular schwannomas identified
SMARCB1-related schwannomatosis	*SMARCB1*		
LZTR1-related schwannomatosis	*LZTR1*		
22q-related schwannomatosis	LOH of chromosome 22		
Schwannomatosis NOS (not otherwise specified): For those who have not had genetic testing			
Schwannomatosis NEC (not elsewhere classified): For those in whom genetic testing of blood/saliva and tumors failed to detect a pathogenic variant			
Von Hippel-Lindau	*VHL (von Hippel-Lindau tumor suppressor)*	Autosomal dominant	Cerebellar hemangioblastomas, retinal angiomas, endolymphatic sac tumors, pancreatic neuroendocrine tumors, renal cysts, renal cell carcinomas, pheochromocytomas
Linear nevus sebaceous	*HRAS (HRas proto-oncogene, GTPase)* *KRAS (KRAS proto-oncogene, GTPase)* *NRAS (neuroblastoma RAS viral oncogene homolog)*	Somatic mosaicism	Linear sebaceous nevus, hemimegalencephaly, ventriculomegaly, intellectual disability, epilepsy, ocular defects (e.g., strabismus), cardiac defects (e.g., coarctation of the aorta), urogenital defects (e.g., horseshoe kidney), skeletal defects (e.g., fibrous dysplasia)
PHACE	Unknown		Posterior fossa malformations, hemangiomas, arterial lesions (e.g., dysplasia of cerebral arteries), cardiac defects (e.g., coarctation of the aorta), ocular defects (e.g., microphthalmia), ventral defects (e.g., sternal clefting)
Incontinentia pigmenti	*IKBKG (inhibitor of kappa B kinase gamma)*	X-linked dominant	Distinctive skin lesion appearing in four stages (bullous, verrucous, pigmentary, atretic), alopecia, dental anomalies (e.g., hypodontia), intellectual disability, epilepsy, ocular defects (e.g., retinal neovascularization), nail defects (e.g., dystrophic nails)

tract. These lesions appear characteristically during adolescence or pregnancy, suggesting a hormonal influence. They are usually small, rubbery lesions with a slight purplish discoloration of the overlying skin. Plexiform neurofibromas are typically congenital and result from diffuse thickening of nerve trunks and surrounding soft tissues. The skin overlying a plexiform neurofibroma may be coarse and associated with hyperpigmentation. Plexiform neurofibromas may produce overgrowth of an extremity and a deformity of the corresponding bone. **(5)** A distinctive osseous lesion such as sphenoid dysplasia (which may cause pulsating exophthalmos), anterolateral bowing of tibia (tibial dysplasia), or pseudarthrosis of a long bone. **(6)** Optic pathway gliomas are present in approximately 15–20% of individuals with NF1;

Fig. 636.1 Neurofibromatosis type 1 (NF1). The presence of six or more café-au-lait (CAL) spots larger than 0.5 cm in diameter in children and 1.5 cm in adolescents suggests the possibility of NF1, although having CAL spots alone does not allow for definitive diagnosis. *(From Paller AS, Mancini AJ. Hurwitz Clinical Pediatric Dermatology, 5th ed. Philadelphia: Elsevier; 2016, Fig. 11-44.)*

however, only ~30% of these are clinically symptomatic and require tumor-directed therapy. They are the most frequently observed CNS tumor in NF1. Because of visual acuity compromise, it is recommended that all children with NF1 undergo at least annual ophthalmologic examinations, or more frequent ones if there is a concern. The most common time to develop symptoms is between the ages of 2 and 6 years; they manifest as a change in visual acuity, a change in the visual fields, or pallor of the optic nerve. Extension into the hypothalamus can lead to precocious puberty. The brain MRI findings of an optic glioma include diffuse thickening, localized enlargement, or a distinct focal mass originating from the optic nerve or chiasm (Fig. 636.4). **(7)** A parent with NF1 whose diagnosis was based on the aforementioned criteria. **(8)** A pathogenic *NF1* gene variant. It is important to note that genetic testing is not required to make a diagnosis of NF1, but it may allow for an earlier diagnosis. In addition, presence of a genetic variant *alone* is not sufficient to diagnose NF1; a second diagnostic feature is required.

Children with NF1 are susceptible to **neurologic complications**. MRI studies of selected children have shown abnormal hyperintense T2-weighted signals in the optic tracts, brainstem, globus pallidus, thalamus, internal capsule, and cerebellum (Fig. 636.5). These signals, **unidentified bright objects** or focal areas of signal abnormality (FASI), tend to disappear with age; most have disappeared by 30 years of age. It is unclear what the unidentified bright objects represent pathologically, and there is disagreement as to the relationship between the presence and number of unidentified bright objects and the occurrence of learning disabilities, attention-deficit disorders, behavioral and psychosocial problems, and abnormalities of speech among affected children. Therefore imaging studies such as brain MRIs should be reserved for patients with clinical symptoms only.

One of the most common complications is a learning disability affecting more than half of individuals with NF1. Seizures are observed in approximately 8% of NF1 patients. The cerebral vessels may develop aneurysms or stenosis consistent with moyamoya syndrome (see Chapter 641). Neurologic sequelae of these vascular abnormalities include transient cerebrovascular ischemic attacks, hemiparesis, and cognitive defects. Precocious puberty may become evident in the presence or absence of lesions of the optic pathway tumors. Malignant peripheral nerve sheath tumors are in the family of aggressive sarcomas and occur either de novo or as the result of malignant degeneration of an existing plexiform neurofibroma. The lifetime risk is 8–13%. Additionally, the incidence of pheochromocytoma, rhabdomyosarcoma, leukemia, and Wilms tumor is higher than in the general population. Scoliosis is a common complication found in approximately 10% of the patients. Patients with NF1 are at risk for hypertension, which may be present in isolation or result from renal vascular stenosis or a pheochromocytoma.

Table 636.2 Diseases Associated with Multiple Café-Au-Lait Macules

DISEASE	MAJOR FEATURES
Ataxia telangiectasia	Progressive ataxia, lymphoreticular malignancy
Bannayan-Riley-Ruvalcaba syndrome	Macrosomia, megalencephaly, lipomas, intestinal polyps
Basal cell nevus syndrome	Multiple basal cell epitheliomas, jaw cysts, skeletal anomalies
Bloom syndrome	Short stature, photosensitivity, chromosome breaks, malignancy
Fanconi anemia	Limb anomalies, renal anomalies, pancytopenia
Gaucher disease	Jewish predilection, ataxia, mental retardation
Hunter syndrome	Thickened skin, coarse facies, skin papules, joint contractures
Jaffe-Campanacci syndrome	Fibromas of long bones, hypogonadism, mental retardation, ocular/cardiac anomalies
Legius syndrome	Axillary freckling, macrocephaly, a Noonan-like facial dysmorphism, lipomas
Maffucci syndrome	Venous malformations, enchondromas
McCune-Albright syndrome	Polyostotic fibrous dysplasia, precocious puberty
Multiple lentigines syndrome	Multiple lentigines, hypertelorism, pulmonic stenosis
Multiple mucosal neuroma syndrome	Mucosal neuromas, thyroid carcinoma, pheochromocytoma, parathyroid adenoma, dysautonomia
Neurofibromatosis type 1	Neurofibromas, optic pathway glioma, central nervous system tumors, iris hamartomas, axillary freckles, skeletal anomalies, learning disabilities
Neurofibromatosis type 2-related schwannomatosis	Vestibular schwannoma, meningioma, subcapsular cataracts, skin plexiform schwannomas, ependymoma
Schwannomatosis	Multiple schwannomas or hybrid nerve sheath tumors; subtypes distinguished by the molecular phenotype of the tumor. No vestibular schwannomas present.
Russell-Silver syndrome	Short stature, asymmetry, limb anomalies
Tuberous sclerosis	White macules, multiple hamartomas, central nervous system anomalies
Watson syndrome	Pulmonic stenosis, axillary freckles, low intelligence

From Marcoux DA, Duran-McKinster C, Baselga E, et al. Pigmentary abnormalities. In: Schachner LA, Hansen RC, eds. *Pediatric Dermatology,* 4th ed. Philadelphia: Mosby; 2011: Table 10-2.

Mosaic NF1 (also called *segmental NF1*) results from a pathogenic variant that occurs after conception, leading to a mixture of cells with and without the gene variant. The manifestations are therefore limited to one or more body segments secondary to somatic (or gonadal) variants expressed in those locations. Lesions may be unilateral or bilateral, asymmetric or symmetric, and confined to a narrow band or a single quadrant. Neurologic manifestations are rare but have been reported.

Fig. 636.2 Neurofibromatosis. Axillary freckling (Crowe's sign) is a pathognomonic sign. *(From Habif TP, ed. Clinical Dermatology, 4th ed. Philadelphia: Mosby; 2004: Fig. 26-11.)*

Fig. 636.3 Neurofibromatosis type 1 (NF1). Pigmented hamartomas of the iris (Lisch nodules). *(From Zitelli BJ, McIntire S, Nowalk AJ, eds. Zitelli and Davis' Atlas of Pediatric Physical Diagnosis, 6th ed. Philadelphia: Mosby; 2012: Fig. 15-9.)*

Fig. 636.4 Optic glioma. Sagittal T1-weighted MRI scan of a patient with NF1 shows thickening of the optic nerve *(arrow)*.

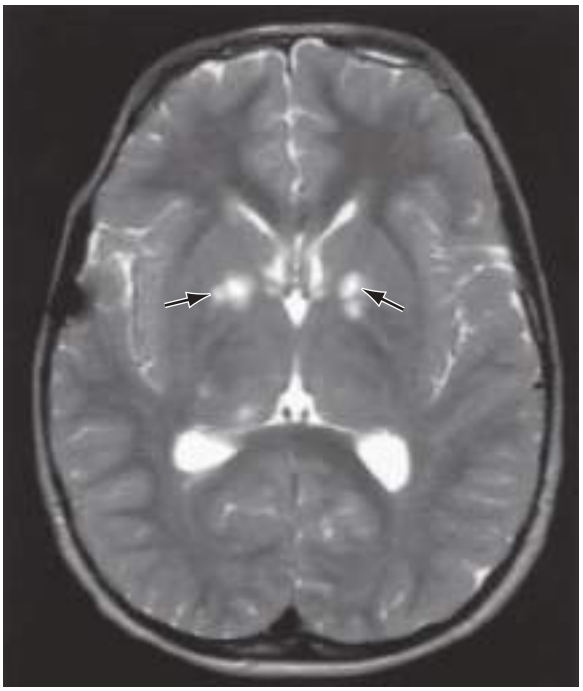

Fig. 636.5 T2-weighted MRI scan of a patient with NF1. Note the high-signal areas (unidentified bright objects or focal areas of signal abnormality [FASI]) in the basal ganglia *(arrows)*.

MANAGEMENT

Because of the diverse and unpredictable complications associated with NF1, close multidisciplinary follow-up is necessary. Patients with NF1 should have regular clinical assessments at least yearly, focusing the history and examination on the potential problems for which they are at increased risk. These assessments include yearly ophthalmologic examination, neurologic assessment, blood pressure monitoring, and scoliosis evaluation. Neuropsychologic and educational testing should be considered as needed. The National Institutes of Health (NIH) Consensus Development Conference has advised against routine imaging studies of the brain and optic tracts because treatment in these *asymptomatic* NF1 children is rarely required. However, all symptomatic cases (i.e., those with changes in visual acuity, optic pallor, proptosis, precocious puberty) should undergo MR imaging. Selumetinib, an oral inhibitor of mitogen-activated protein kinase kinase (MEK) 1 and 2, has been demonstrated in children (≥2 years of age) with NF1-related inoperable plexiform neurofibromas to be effective in inducing partial responses and reducing tumor progression.

GENETIC COUNSELING

Although NF1 is an autosomal dominant disorder, more than half the cases are sporadic, representing de novo pathogenic variants. The *NF1* gene on chromosome region 17q11.2 encodes for a protein also known as *neurofibromin*. Neurofibromin acts as an inhibitor of the oncogene Ras (Fig. 636.6). The diagnosis of NF1 is based on the clinical features; molecular testing for the *NF1* gene variants is available and now is included as one of the diagnostic criteria. Some scenarios in which genetic testing is particularly helpful include patients who meet only one of the criteria for clinical diagnosis, those with unusually severe disease, and those seeking prenatal/preimplantation diagnosis.

An international consensus group of NF experts updated the diagnostic criteria for neurofibromatosis type 2 and **schwannomatosis** (SWN). SWN is the umbrella term used to describe the group of overlapping conditions in which a patient has multiple schwannomas. The criteria also address the discovery of the genes involved, assists in distinguishing the types of neurofibromatosis and SWN using classification according to

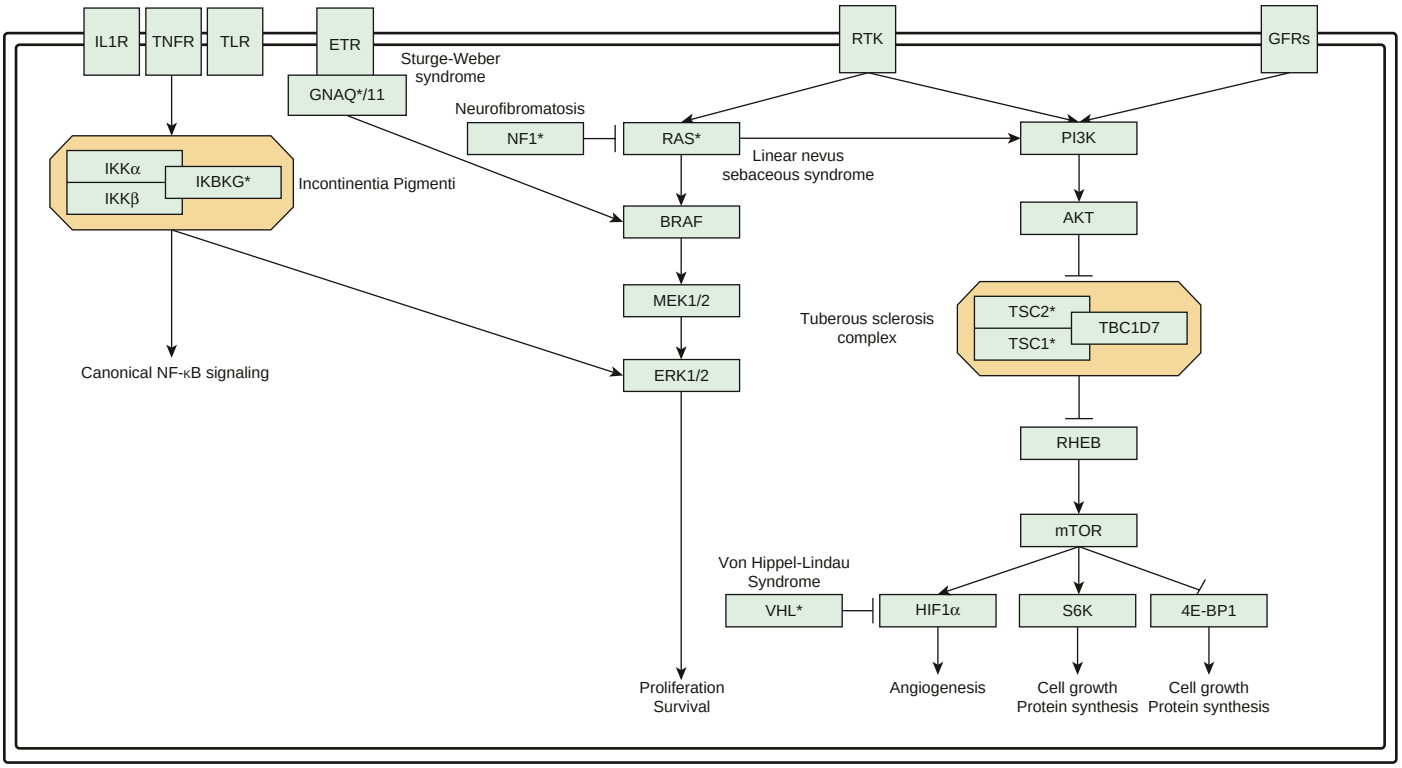

Fig. 636.6 Schematic representation of the cellular pathways affected by pathogenic variants in the genes associated with neurocutaneous disorders, such as NF1, TSC, and SWS. The *asterisks* denote genes with associated syndromes discussed in the chapter.

the pathogenic variant identified, and minimizes the misdiagnosis with NF1. Genetic testing for the variants involved in all subtypes of SWN is available and should be completed whenever possible for a patient suspected of having this diagnosis. This can be performed on a blood or saliva sample, but often requires tumor tissue. There are several key updates to the former NF2 diagnostic criteria: *NF2* pathologic variant added; clarification of first-degree relative with "other than sibling"; cataract clarified as juvenile cataract; retinal hamartoma added as a criterion; glioma and neurofibroma removed; and ependymoma added (Table 636.3).

Genetic testing identifies pathogenic variants in the *NF2* gene in 66-90% of individuals with *NF2*-schwannomatosis (*NF2*-SWN), which has an incidence of 1:25,000 worldwide. The *NF2* gene (which codes for a protein known as merlin or schwannomin) is located on chromosome 22q1.11. Table 636.4 notes the frequency of lesions in *NF2*. Testing is *not* required for the diagnosis and it remains possible to diagnose *NF2*-SWN based on clinical criteria. Genetic testing *is* required for the diagnosis of a specific type of schwannomatosis (except *NF2*-related or NOS). Excluding *NF2*-SWN, the other types of SWN affect 1:70,000 individuals. Genetic testing alone is not sufficient to make a diagnosis and there must also be a clinical feature. In most cases, tissue from schwannoma or hybrid nerve sheath tumor is required to diagnose the type of SWN and to distinguish between *LZTR1*-related SWN, *SMARCB1*-related SWN, *22q*-related SWN and SWN NOS/NEC.

Individuals with *NF2*-SWN may present with tinnitus, hearing loss, facial weakness, headache, and gait instability. Although this may present in childhood, VS are more likely to appear in the second and third decades of life. In the pediatric age group, café au lait macules and cutaneous plexiform schwannomas are the most common presentation and can be confused with the skin findings in NF1.

Workup should include ophthalmologic evaluation (assessing for subcapsular or cortical cataracts), MRI of the brain and spine, and audiology evaluation. These are all important components of ongoing surveillance and management of individuals with suspected or confirmed *NF2*-related SWN. The goal is to preserve hearing related to VS. Other forms of SWN should be suspected when an individual has two or more schwannomas in the absence

Table 636.3 Diagnostic Criteria for *NF2*-Related Schwannomatosis (Formerly Called Neurofibromatosis Type 2 [NF2])

A diagnosis of *NF2*-related schwannomatosis can be made when a patient has **one of the following:**

- Bilateral vestibular schwannomas (VS)
- An identical *NF2* pathogenic variant in at least two anatomically distinct *NF2*-related tumors (schwannoma, meningioma, and/or ependymoma)

Either **two major** OR **one major and two minor** criteria are present as follows:

MAJOR CRITERIA

- Unilateral vestibular schwannoma
- First-degree relative other than a sibling with *NF2*-related schwannomatosis
- Two or more meningiomas
- *NF2* pathogenic variant in an unaffected tissue, such as blood

MINOR CRITERIA

Can count more than one of a type (e.g. two schwannomas = two minor criteria)

- Ependymoma
- Schwannoma (note that if the major criterion is a unilateral VS, at least one schwannoma must be dermal in location)

Can count only once

- Juvenile subcapsular or cortical cataract
- Retinal hamartoma
- Epiretinal membrane in a person aged less than 40 years
- Single meningioma (meningioma cannot be used as both a major and a minor criteria)

Table 636.4 Frequency of Lesions Associated with Neurofibromatosis Type 2-Related Schwannomatosis*

	FREQUENCY OF ASSOCIATION WITH NF2-RELATED SCHWANNOMATOSIS
NEUROLOGIC LESIONS	
Bilateral vestibular schwannomas	90–95%
Other cranial nerve schwannomas	24–51%
Meningioma	45–58%
Spinal schwannomas	63–90%
Spinal ependymoma	20%
Peripheral neuropathy	Up to 66%
OPHTHALMOLOGIC LESIONS	
Juvenile subcapsular or cortical cataract	60–81%
Epiretinal membranes (age less than 40 years)	12–40%
Retinal hamartomas	6–22%
CUTANEOUS LESIONS	
Cutaneous schwannomas	59–68%
Subcutaneous tumors	43–48%
Intradermal tumors	Rare

*Formerly known as NF2.
Modified from Asthagiri AR, Parry DM, Butman JA, et al. Neurofibromatosis type 2. *Lancet*. 2009;373:1974–1984, Table 1.

of bilateral vestibular schwannomas. Evaluation also includes imaging of the brain and spine to exclude VS and to distinguish from *NF2*-related SWN.

Legius syndrome (caused by *SPRED1* pathogenic variants) is an autosomal dominant disorder with skin findings that resemble and may be hard to distinguish from NF1 in younger individuals. Persons with Legius syndrome present with multiple CALMs and macrocephaly, with and without skinfold freckling. However, other typical features of NF1, such as Lisch nodules, neurofibromas, optic nerve gliomas, long bone dysplasia, plexiform neurofibromas, and malignant peripheral nerve sheath tumors, are not seen in individuals with *SPRED1* variants.

Visit Elsevier eBooks+ at eBooks.Health.Elsevier.com for Bibliography.

636.2 Tuberous Sclerosis

Siddharth Srivastava and Mustafa Sahin

Tuberous sclerosis complex (TSC) is a multisystem disease characterized by an autosomal dominant mode of inheritance, variable expressivity, and a prevalence of 1 in 6,000-10,000 newborns. Spontaneous pathogenic variants occur in 65% of the cases. Molecular genetic studies have identified two foci for TSC: the *TSC1* gene (located on chromosome 9q34) and the *TSC2* gene (located on chromosome 16p13). The *TSC1* gene encodes a protein called *hamartin,* and the *TSC2* gene encodes a protein called *tuberin*. Within a cell, these two molecules form a complex along with a third protein, TBC1D7 (Tre2-Bub2-Cdc16 1 domain family, member 7). Consequently, a pathogenic variant in either the *TSC1* gene or the *TSC2* gene results in a similar disease in patients, though individuals with *TSC2* variants tend to be more severely affected.

Tuberin and hamartin are involved in a key pathway in the cell that regulates protein synthesis and cell size (see Fig. 636.6). One of the ways cells regulate their growth is by controlling the rate of protein synthesis. A protein called *mechanistic target of rapamycin* (mTOR) is one of the master regulators of cell growth (mTOR has additional roles in the CNS, where it helps regulate neuronal development and synaptic plasticity). mTOR, in turn, is controlled by Ras homolog enriched in brain (RHEB), a small cytoplasmic guanosine triphosphatase. When RHEB is activated, the protein synthesis machinery is turned on, most likely via mTOR signaling, and the cell grows. Under normal conditions, the tuberin/hamartin complex keeps RHEB in an inactive state. However, in TSC, there is disinhibition of RHEB and subsequent overactivation of the mTOR pathway. Accordingly, the *TSC1* and *TSC2* genes can be considered tumor-suppressor genes. The loss of either tuberin or hamartin protein results in the formation of numerous benign tumors (hamartomas).

TSC is an extremely heterogeneous disease with a wide clinical spectrum varying from severe intellectual disability and intractable epilepsy to normal intelligence and a lack of seizures. This variation is often seen within the same family, that is, with individuals within a family carrying the same variant. The disease affects many organ systems other than the skin and brain, including the heart, kidney, eyes, lungs, and bone (Fig. 636.7).

CLINICAL MANIFESTATIONS AND DIAGNOSIS

Definite TSC is diagnosed when at least two major or one major plus two minor features are present (Tables 636.5 and 636.6 list the major and minor features). In addition, carrying a pathogenic variant in *TSC1* or *TSC2* is sufficient for the diagnosis of TSC.

The hallmark of TSC is the involvement of the CNS. The characteristic brain lesion is a cortical tuber (Fig. 636.8). Brain MRI is the best way of identifying cortical tubers, which can form before birth.

Subependymal nodules are lesions found along the wall of the lateral ventricles, where they undergo calcification and project into the ventricular cavity, producing a candle-dripping appearance. These lesions do not cause any problems; however, in 5–10% of cases, these benign lesions can grow into **subependymal giant cell astrocytomas (SEGAs)**. These tumors can grow and block the circulation of cerebrospinal fluid around the brain and cause hydrocephalus, which requires immediate neurosurgical intervention. Thus it is recommended that all asymptomatic TSC patients undergo brain MRI every 1-3 years to monitor for new occurrences of SEGA. Patients with large or growing SEGAs, or with SEGAs causing ventricular enlargement without other manifestations, should undergo MRI scans more frequently, and the patients and their families should be educated regarding the potential of new symptoms caused by increased intracranial pressure. Surgical resection should be performed for acutely symptomatic SEGA. For growing but otherwise asymptomatic SEGAs, either surgical resection or medical treatment with an mTOR inhibitor (sirolimus, everolimus) may be used. Treatment with everolimus can be effective in slowing the growth or even reducing the size of SEGAs. Everolimus is also effective in treating renal angiomyolipomas. Sirolimus is also effective in treating lymphangioleiomyomatosis, renal angiomyolipomas, and cardiac rhabdomyomas.

The most common neurologic manifestations of TSC are epilepsy, intellectual disability, and autism spectrum disorder. TSC may present during infancy with infantile spasms and a hypsarrhythmic electroencephalogram pattern. However, it is important to remember that TSC patients can have infantile spasms without hypsarrhythmia. The seizures may be difficult to control, and at a later age, they may develop into other seizure types such as focal-onset seizures or generalized myoclonic seizures (see Chapter 633). Vigabatrin is the first-line therapy for infantile spasms. Adrenocorticotropic hormone (ACTH) or prednisolone can be used if treatment with vigabatrin fails. Anticonvulsant therapy for other seizure types in TSC should generally follow that of other epilepsies, and epilepsy surgery can be considered for medically refractory TSC patients. Everolimus (adjunctive) has received U.S. Food and Drug Administration (FDA) approval for treatment-refractory focal seizures in TSC. Studies on prevention of epilepsy with preemptive treatment with vigabatrin have yielded mixed results so far. However, it is recommended that infants with TSC should undergo baseline EEG to enable early detection and treatment

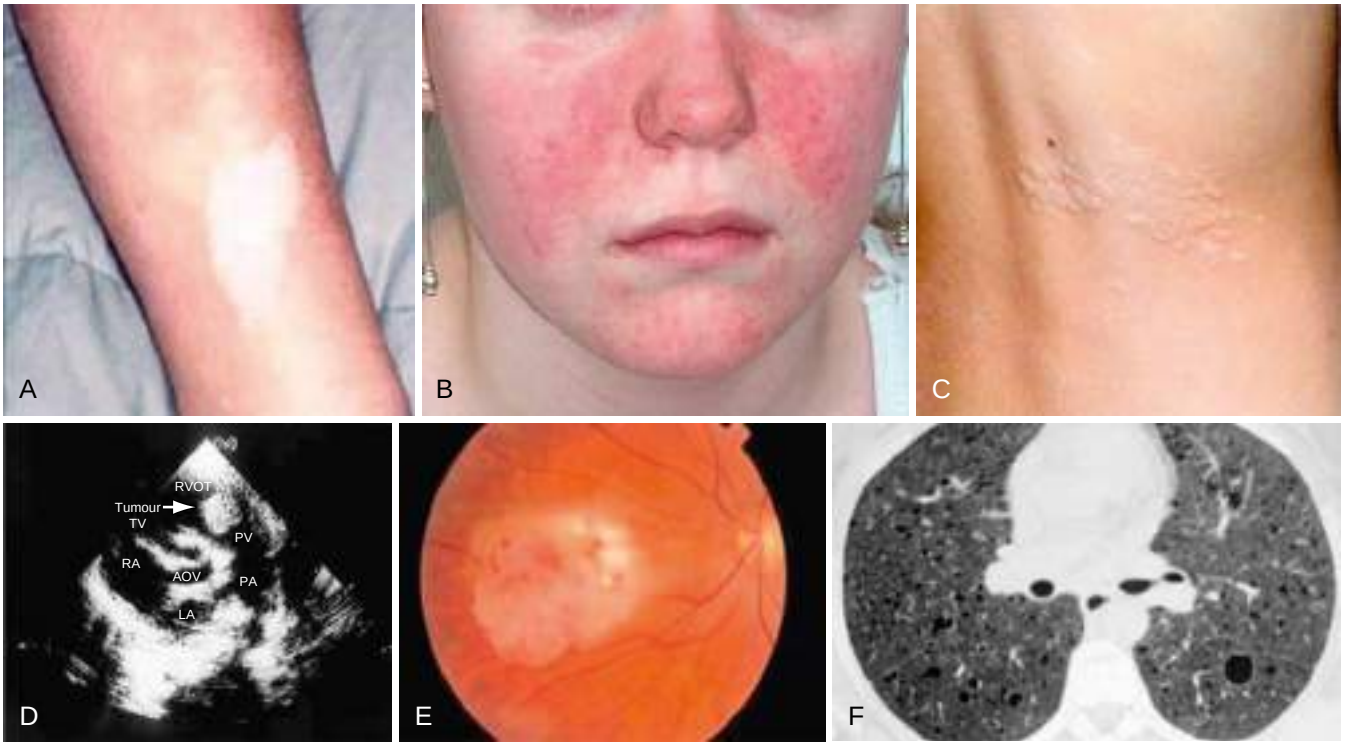

Fig. 636.7 Dermatologic, cardiac, and pulmonary manifestations of tuberous sclerosis. **A,** Hypomelanotic macules. **B,** Facial angiofibromas. **C,** Shagreen patch. **D,** Hyperechoic rhabdomyoma detected by echocardiography. **E,** Retinal hamartoma. **F,** Lymphangioleiomyomatosis. *(From Curatolo P, Bombardieri R, Jozwiak S. Tuberous sclerosis. Lancet. 2008;372:657–668, Fig. 7.)*

Table 636.5	Major Features of Tuberous Sclerosis Complex
Cortical dysplasias (including tubers and cerebral white matter migration lines)	
Subependymal nodules	
Subependymal giant cell astrocytoma	
Facial angiofibromas (≥3) or forehead plaque	
Ungual fibromas (≥2)	
Hypomelanotic macules (≥3, ≥5 mm in diameter)	
Shagreen patch	
Multiple retinal nodular hamartomas	
Cardiac rhabdomyoma	
Renal angiomyolipoma	
Pulmonary lymphangioleiomyomatosis	

Table 636.6	Minor Features of Tuberous Sclerosis Complex
Dental enamel pits (>3)	
Intraoral fibromas (≥2)	
Retinal achromic patch	
Confetti skin lesions	
Nonrenal hamartomas	
Multiple renal cysts	

of seizures, and this should be repeated every 6 weeks until 12 months of age. In addition to epilepsy, about 90% of individuals with TSC have a spectrum of cognitive, behavioral, psychiatric, and academic impairments termed *tuberous sclerosis–associated neuropsychiatric disorders (TANDs),* which include intellectual disability, autism spectrum disorder, attention-deficit/hyperactivity disorder, anxiety, and depression. About 45% of individuals with TSC have intellectual disability, and up to 25-50% have autism spectrum disorder.

Skin Lesions

More than 90% of patients show the typical hypomelanotic macules that have been likened to an ash leaf on the trunk and extremities.

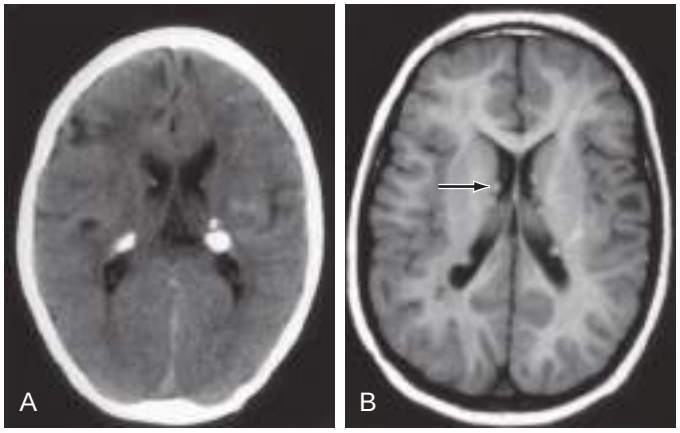

Fig. 636.8 Tuberous sclerosis. **A,** CT scan with subependymal calcifications characteristic of tuberous sclerosis. **B,** The MRI demonstrates multiple subependymal nodules in the same patient *(arrow)*. Parenchymal tubers are also visible on both the CT and the MRI scan as low-density areas in the brain parenchyma.

Visualization of the hypomelanotic macule is enhanced by using a Wood ultraviolet lamp (see Chapter 694). To count as a major feature, at least three hypomelanotic macules must be present (see Fig. 636.7). Facial angiofibromas develop between 4 and 6 years of age; they appear as tiny red nodules over the nose and cheeks and are sometimes confused with acne (see Fig. 636.7). Later, they enlarge, coalesce, and assume a fleshy appearance. Topical rapamycin is approved for treatment of facial angiofibromas. A shagreen patch is also characteristic of TSC and consists of a roughened, raised lesion with an orange-peel consistency located primarily in the lumbosacral region (see Fig. 636.7). Forehead fibrous plaques usually occur on one side of the forehead. They are characteristically raised, yellow-brown or flesh-colored, and soft to hard in consistency. Forehead plaques are histologically similar to facial angiofibromas, though the former can appear at any point. During adolescence or later, small fibromas or nodules of skin may form around fingernails or toenails (ungual fibromas) in 15–20% of TSC patients (Fig. 636.9).

Fig. 636.9 Periungual fibroma in a patient with tuberous sclerosis complex (TSC).

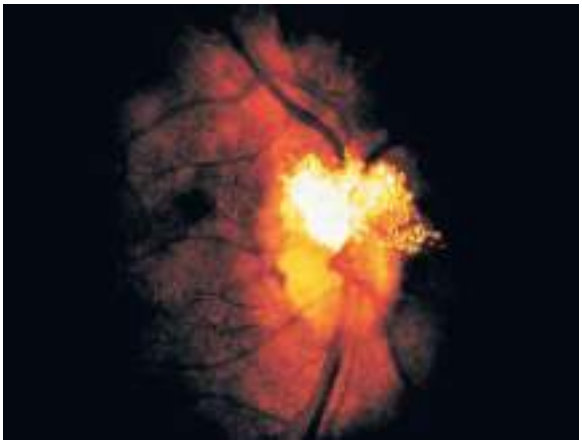

Fig. 636.10 A mulberry lesion involving the superior part of the optic nerve in a patient with tuberous sclerosis. *(From Yanoff M, Sassani JW. Ocular Pathology, 7th ed. Philadelphia: WB Saunders; 2015: Fig. 2-7.)*

Other Organ Involvement

Retinal lesions consist of two types: hamartomas (elevated mulberry lesions or plaquelike lesions (Fig. 636.10) and white depigmented patches (similar to the hypopigmented skin lesions). Approximately 50% of children with TSC have cardiac rhabdomyomas, which may be detected in the fetus by an echocardiogram, usually by 20-30 weeks of gestation. The rhabdomyomas may be numerous and located throughout the ventricular myocardium, and although they can cause congestive heart failure and arrhythmias in a minority of patients, they tend to slowly resolve spontaneously. In 75–80% of patients older than 10 years of age, the kidneys display angiomyolipomas that are usually benign tumors. Angiomyolipomas begin in childhood in many individuals with TSC, but they may not be problematic until young adulthood. By the third decade of life, they may cause lumbar pain and hematuria from slow bleeding, and rarely they may result in sudden retroperitoneal bleeding. Embolization followed by corticosteroids to alleviate postembolization syndrome is first-line therapy for angiomyolipoma presenting with acute hemorrhage. Nephrectomy should be avoided as a way of maintaining renal function, because lesions can be numerous and bilateral. For asymptomatic, growing angiomyolipomas measuring larger than 3 cm in diameter, an mTOR inhibitor, everolimus, is approved for treatment by the FDA. Selective embolization or kidney-sparing resection is an alternative therapy for asymptomatic angiomyolipoma. Single or multiple renal cysts are also commonly present in TSC; renal cell carcinoma, on the other hand, is rare. Lymphangioleiomyomatosis is the classic pulmonary lesion in TSC and only affects women, beginning in late adolescence (≥15 years). Sirolimus is approved by the FDA for lymphangioleiomyomatosis. Topical rapamycin should be considered for treatment of facial angiofibromas.

Diagnosis of TSC relies on a high index of suspicion, especially when assessing a child with infantile spasms. A careful evaluation for the typical skin and retinal lesions should be completed in all patients with a seizure disorder or autism spectrum disorder. Brain MRI can confirm the clinical diagnosis in many cases. Genetic testing for pathogenic *TSC1* and *TSC2* variants is available and should be considered when the individual patient does not meet all the clinical criteria, or in order to provide molecular confirmation of a clinical diagnosis. Prenatal testing may be offered when a known pathogenic *TSC1/TSC2* variant exists in that family.

MANAGEMENT

The following are recommended for routine follow-up of individuals with TSC in addition to physical examination: brain MRI every 1-3 years, abdominal MRI to evaluate the kidneys every 1-3 years; echocardiogram every 1-3 years in patients with cardiac rhabdomyomas until there is regression of the rhabdomyomas; electrocardiogram every 3-5 years; high-resolution chest CT every 5-10 years in females older than 18 years; dental examination twice a year; skin examinations once a year; detailed ophthalmic examination once a year in patients with vision concerns or retinal lesions (sooner if they are receiving treatment with vigabatrin); neurodevelopmental testing at the beginning of first grade or sooner based on concerns; and screening for TAND at each clinic visit. Based on the complications of the disease, additional follow-up testing may be required for each individual. Symptoms and signs of increased intracranial pressure suggest obstruction of the foramen of Monro by a SEGA and warrant immediate investigation and surgical intervention.

Visit Elsevier eBooks+ at eBooks.Health.Elsevier.com for Bibliography.

636.3 Sturge-Weber Syndrome

Anna L. Pinto

Sturge-Weber syndrome (SWS) is a segmental vascular neurocutaneous disorder with a constellation of symptoms and signs characterized by capillary malformation in the face (port-wine birthmark [PWB]) and brain (leptomeninges), as well as abnormal blood vessels of the eye leading to glaucoma. Low flow of the leptomeningeal capillary malformation appears to result in a chronic hypoxic state leading to cortical atrophy and calcifications. Patients present with seizures, hemiparesis, strokelike episodes, headaches, and developmental delay. Approximately 1 in 20,000-50,000 live births are affected with SWS.

ETIOLOGY

The nonsyndromic PWBs and SWS are caused by a pathologic somatic single-nucleotide variant (c.548G→A, p.Arg183Gln) in the *GNAQ* gene (see Fig. 636.6). Brain tissue from SWS patients also demonstrates the same change in the *GNAQ* gene. These results strongly suggest that SWS occurs as a result of a *mosaic pathologic genetic variant* in *GNAQ*.

The *GNAQ* p.R183Q variant is enriched in endothelial cells in SWS brain lesions, thereby revealing endothelial cells as a source of aberrant Gαq signaling. The timing of the somatic variant in *GNAQ* during development likely affects the clinical phenotype. Mosaic-activating *GNA11* and *GNB2* gene variants have been described in atypical SWS cases. The aberrant G-protein signaling provides a molecular basis to explain SWS lesions.

CLINICAL MANIFESTATIONS

Facial PWBs are present at birth, but not all are associated with SWS (Table 636.7). In fact, the overall incidence of SWS has been reported to be 20–40% in those with a PWB involving the forehead and upper eyelid. High-risk PWB for SWS includes hemifacial, median, and forehead phenotypes (Fig. 636.11), along with large segmental PWB. The PWB tends to be unilateral and ipsilateral to the brain involvement (Fig. 636.12). The capillary malformation may also be evident over the lower face and trunk and in the mucosa of the mouth and pharynx. Buphthalmos and glaucoma of the ipsilateral eye are common

Table 636.7 Port-Wine Birthmark–Associated Syndromes

Sturge-Weber syndrome
Klippel-Trénaunay syndrome
Parkes Weber syndrome
Phakomatosis pigmentovascularis
Proteus syndrome
CLOVES syndrome
Macrocephaly–capillary malformation (M-CM) syndrome
Capillary malformation–arteriovenous malformation (CM-AVM) syndrome
Cobb syndrome
Bannayan-Riley-Ruvalcaba syndrome
Beckwith-Wiedemann syndrome
Von Hippel-Lindau disease
Rubinstein-Taybi syndrome
Wyburn-Mason syndrome
Roberts syndrome
Coat disease
Nonsyndromic, idiopathic, neurologically asymptomatic

CLOVES, Congenital lipomatous overgrowth, vascular malformations, epidermal nevi, and scoliosis/skeletal and spinal anomalies.
From Paller AS, Mancini AJ. *Hurwitz Clinical Pediatric Dermatology,* 5th ed. Philadelphia: Elsevier; 2016: Box 12-2.

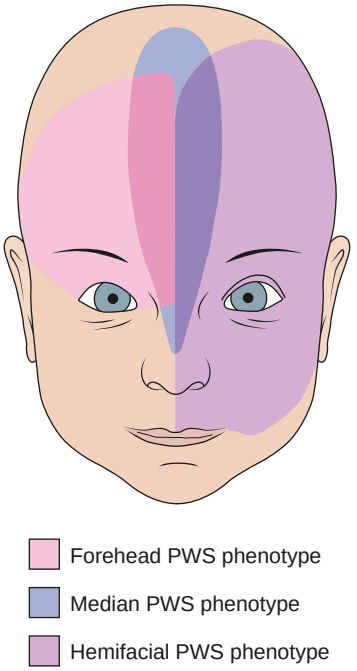

Fig. 636.11 Port-wine stain (birthmark) phenotypes associated with highest risk of Sturge-Weber syndrome. *(From Zallmann M, Mackay MT, Leventer RJ, et al. Retrospective review of screening for Sturge-Weber syndrome with brain magnetic resonance imaging and electroencephalography in infants with high-risk port-wine stains. Pediatr Dermatol. 2018;35:575–581, Fig.1, p. 576.)*

complications. Seizures occur in 75–80% of all SWS patients and in over 90% of those with bilateral brain involvement. Early onset of seizures will likely occur during the first year of life but rarely during the first month of life, and they are typically focal clonic and contralateral to the side of the facial PWB. They may become refractory to anticonvulsants, and status epilepticus is often associated. One third of children with intractable epilepsy associated with SWS experience episodes of *prolonged postictal deficits,* which would last from 1 day to a few years, until recovering back to baseline. Some patients also develop slowly progressive hemiparesis. Transient strokelike episodes or visual field defects persisting for several days and unrelated to seizure activity are common and probably result from thrombosis of cortical veins in the affected region. Although neurodevelopment appears to be normal in the first year of life, intellectual disability

Fig. 636.12 Port-wine birthmark involving both the V1 and V2 dermatomes. *(Courtesy Dr. Anne W. Lucky, Cincinnati Children's Hospital.)*

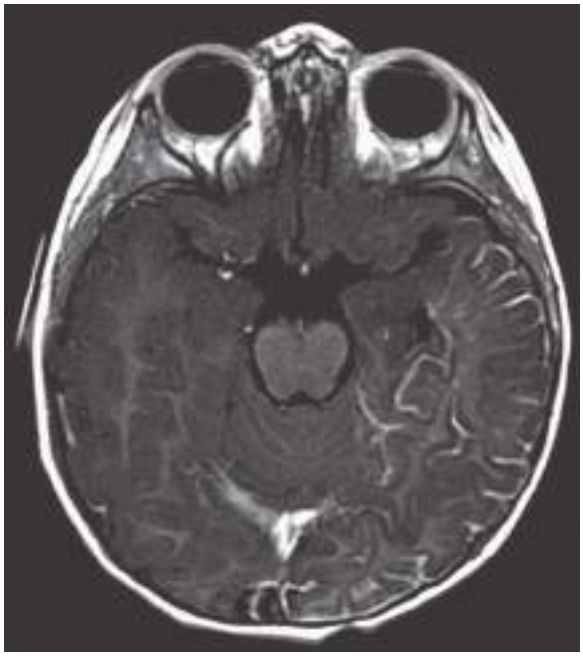

Fig. 636.13 Gadolinium-enhanced axial T1 fluid-attenuated inversion recovery (FLAIR) images of a 15-mo-old with Sturge-Weber syndrome show leptomeningeal enhancement in the left hemisphere.

or severe learning disabilities are present in at least 50% of patients in later childhood, probably the result of intractable epilepsy and increasing cerebral atrophy. The degree of visual field defect, hemiparesis, seizure frequency, and cognitive function (based on age-group: infant/preschooler, child, and adult) can be rated using a validated SWS neurologic rating system.

DIAGNOSIS

Brain MRI with contrast is the imaging modality of choice for demonstrating the extension of pial capillary malformation in SWS (Fig. 636.13). White matter abnormalities are common and are thought to be a result of chronic hypoxia. Often, atrophy is noted ipsilateral to the leptomeningeal capillary malformation. Calcifications can be seen best with a head CT (Fig. 636.14). The choroid plexus is frequently enlarged, and the degree of plexal enlargement shows a positive correlation with the extent of the leptomeningeal capillary malformation. Positron emission tomography using 18 F-deoxyglucose has been used to study cerebral metabolism in patients with SWS, and it has been useful for the surgical planning and prognosis. Ophthalmologic evaluation examining for glaucoma is also necessary and is a lifelong concern because ocular complications can occur at any moment during a lifetime. Based on the involvement of the brain and the face, there are three types of SWS in the Roach Scale:

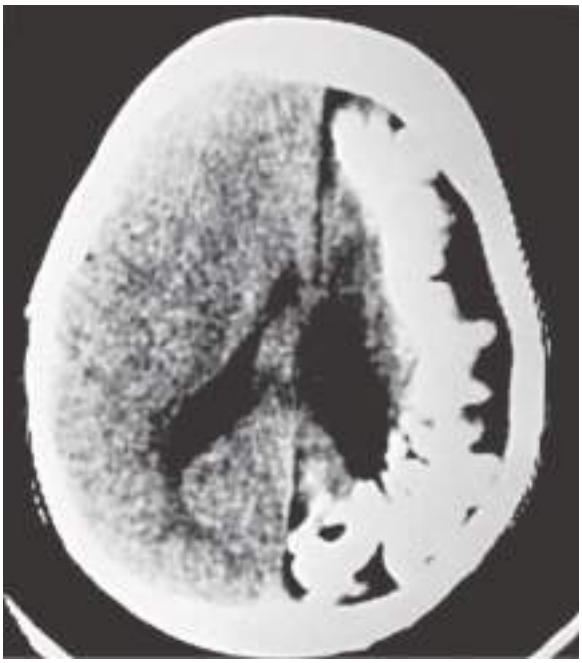

Fig. 636.14 CT scan of a patient with Sturge-Weber syndrome showing unilateral calcification and underlying atrophy of a cerebral hemisphere.

Type I: Classic facial and leptomeningeal capillary malformation present; often with glaucoma.
Type II: Facial capillary malformation alone (no CNS involvement); may have glaucoma.
Type III: Isolated leptomeningeal capillary malformation; usually no glaucoma.

In addition, there is an overlap syndrome between SWS and **Klippel-Trénaunay syndrome** (mixed capillary, venous, or lymphatic malformations involving bone and muscle in one limb).

MANAGEMENT

The management of SWS is primarily symptomatic and multidisciplinary but not well studied by prospective studies. Treatment is aimed at seizure control, relief of headaches, and prevention of strokelike episodes, as well as monitoring of glaucoma and laser therapy for the cutaneous capillary malformations. Most infants with SWS brain involvement have seizure onset by 2 years of age. Presymptomatic treatment in high-risk babies may prevent or delay seizure onset. For patients with well-controlled seizures and normal or near-normal development, management consists of anticonvulsants and surveillance for complications, including glaucoma and behavioral abnormalities. If the seizures are refractory to anticonvulsant therapy, especially in infancy and the first 1-2 years and arise from primarily one hemisphere, most medical centers advise a hemispherectomy or, if well indicated, focal disconnections. The use of low-dose aspirin is controversial. The medication is not used routinely, but patients with strokelike events and frequent refractory seizures may benefit from this form of treatment. Because of the risk of glaucoma, regular measurement of intraocular pressure is indicated. The facial PWB is often a target of ridicule by classmates, leading to psychologic trauma. Pulsed-dye laser therapy often provides excellent clearing of the PWB, particularly if it is located on the forehead.

Visit Elsevier eBooks+ at eBooks.Health.Elsevier.com for Bibliography.

636.4 Von Hippel-Lindau Disease

Siddharth Srivastava and Mustafa Sahin

von Hippel-Lindau disease affects many organs, including the cerebellum, spinal cord, retina, endolymphatic sac of the inner ear, kidney, pancreas, adrenal glands, epididymis, and broad ligament of the uterus. Its incidence is around 1 in 36,000 newborns. It results from an autosomal dominant pathogenic variant affecting a tumor suppressor gene, *VHL*. Approximately 80% of affected individuals have an inherited variant, and approximately 20% have a de novo variant. Molecular testing is available and detects pathogenic variants in most probands.

The major neurologic feature of the condition is CNS hemangioblastomas, including brain hemangioblastomas and spinal hemangioblastomas. In affected individuals, brain hemangioblastomas commonly affect the cerebellum. Patients with cerebellar hemangioblastoma can present in early adult life with symptoms and signs of increased intracranial pressure. A brain CT or MRI scan typically shows a cystic cerebellar lesion with a vascular mural nodule. A smaller number of patients have hemangioblastoma of the spinal cord, producing pain as well as sensory and motor changes. Syringomyelia often accompanies symptomatic spinal hemangioblastomas in von Hippel-Lindau disease. Surgical intervention for symptomatic CNS hemangioblastomas and syringomyelia is often warranted.

Approximately 70% of individuals with von Hippel-Lindau disease have retinal angiomas (also known as *retinal hemangioblastomas*), which have identical histology as CNS hemangioblastomas. Retinal angiomas, which can present in childhood, are characterized by small masses of thin-walled capillaries that are fed by large and tortuous arterioles and venules. They are usually located in the peripheral retina so that vision is unaffected. Exudation in the region of the angiomas may lead to retinal detachment and visual loss. Retinal angiomas are treated with photocoagulation and cryocoagulation, though outcomes can vary depending on the characteristics of the lesions, and complications such as retinal edema can occur.

Cysts (affecting the kidneys, pancreas, and liver), as well as tumors/malignancies (including endolymphatic sac tumors, pheochromocytoma, paragangliomas, neuroendocrine tumors of the pancreas, renal cell carcinomas, epididymis cystadenomas, and broad ligament cystadenomas) are associated with von Hippel-Lindau disease. Renal carcinoma and CNS hemangioblastomas can be causes of death in affected individuals. Regular follow-up and appropriate imaging studies are necessary to identify lesions that may be treated at an early stage. In affected individuals ≥1 year, there should be yearly ophthalmology evaluation for retinal angiomas. Beginning in the first decade of life, there should be yearly clinical assessment for neurological concerns, vision concerns, and hearing concerns, as well as measurement of blood pressure. At age 5 years, laboratory screening for pheochromocytoma should begin. Beginning at age 11 years, there should be brain and complete spine MRI every 2 years to evaluate for CNS lesions, with particular focus on the inner/petrous temporal bone and posterior fossa. Beginning at age 11 years, there should also be formal audiology assessment every 2-3 years to screen for endolymphatic sac tumors. Formal audiological assessment should occur sooner and more frequently if symptoms such as hearing loss, tinnitus, and vertigo are present. Beginning at age 15 years, there should be MRI of the abdomen (including kidney, pancreas, and adrenal glands) every 2 years to evaluate for visceral lesions. At age 15-20 years in asymptomatic individuals, there should be an MRI of internal auditory canals to screen for endolymphatic sac tumor.

Visit Elsevier eBooks+ at eBooks.Health.Elsevier.com for Bibliography.

636.5 Linear Nevus Sebaceous Syndrome

Siddharth Srivastava and Mustafa Sahin

This sporadic condition is characterized by a large facial nevus, neurodevelopmental abnormalities, and systemic defects. The nevus is usually located on the forehead and nose and tends to be midline in its distribution, although it may affect other locations, such as the scalp and neck. It may be quite faint during infancy but later becomes hyperkeratotic, with a yellow-brown appearance.

The most common associated CNS finding is unilateral hemimegalencephaly (enlargement of one cerebral hemisphere), which affects

about half of patients. Other structural brain abnormalities include enlargement of the lateral ventricles, white matter hyperintensity on T2-weighted imaging, cortical dysplasia, pachygyria, agyria, agenesis of the corpus callosum, and Dandy-Walker malformation. The incidence of epilepsy and intellectual disability is as high as 75% and 60%, respectively. Focal neurologic signs, including hemiparesis and homonymous hemianopia, may occur.

Other organ systems may be involved, including the eyes (strabismus, retinal abnormalities, coloboma, cataracts, corneal revascularization, ocular hemangiomas, and lipodermoid scleral tumors); heart (aortic coarctation, ventricular septal defect); kidneys (horseshoe kidney); and skeleton (fibrous dysplasia, skeletal hypoplasia, scoliosis/kyphoscoliosis, and vitamin D-resistant hypophosphatemic rickets).

The syndrome is associated with somatic variants in members of the Ras family of oncogenes, including *HRAS* (HRas proto-oncogene, GTPase), *KRAS* (KRAS proto-oncogene, GTPase), and *NRAS* (neuroblastoma RAS viral oncogene homolog) (see Fig. 636.6).

Visit Elsevier eBooks+ at eBooks.Health.Elsevier.com for Bibliography.

636.6 PHACE Syndrome

Siddharth Srivastava and Mustafa Sahin

See also Chapter 691.

The syndrome denotes *p*osterior fossa malformations, *h*emangiomas, *a*rterial anomalies, *c*oarctation of the aorta and other cardiac defects, and *e*ye abnormalities (see Chapter 691). It is also referred to as *PHACES syndrome* when ventral developmental defects, including *s*ternal clefting and/or a *s*upraumbilical raphe, are present. The hallmark of the disorder is infantile hemangiomas affecting the face, neck, and/or scalp. The underlying pathogenesis of PHACE syndrome remains unknown, though evidence that infantile hemangiomas may result from abnormal growth and differentiation of hemogenic endothelium highlights some avenues for further investigation. Overall, there is a female predominance, but the reasons for this association are unclear.

Other organ systems besides the skin are commonly affected in PHACE syndrome. Posterior fossa anomalies affect up to 80% of patients and encompass Dandy-Walker malformation and cerebellar hypoplasia/dysplasia. Less common structural brain anomalies include neuronal migration defects (polymicrogyria, heterotopia, cortical dysplasia), dysgenesis of the corpus callosum or septum pellucidum, and pituitary defects. Congenital heart disease affects up to two thirds of patients, and common defects are aortic anomalies (coarctation of aorta, dysplasia of aortic arch) and aberrant left subclavian artery. The facial hemangioma is typically ipsilateral to the aortic arch anomalies. Arterial anomalies include hypoplasia/dysplasia/altered anatomic course of cervical, cerebral, and brachiocephalic arteries. Cerebrovascular anomalies can result in progressive arterial stenosis and acute ischemic stroke. Ophthalmologic findings include persistent fetal vasculature (also known as *persistent hyperplastic primary vitreous*), retinal vascular anomalies, morning glory disc anomaly, optic nerve hypoplasia, peripapillary staphyloma, coloboma, cataracts, and microphthalmia. Endocrinopathies (such as hypopituitarism, hypogonadism, hypothyroidism, ectopic thyroid gland, growth hormone deficiency, and diabetes insipidus) can occur. Midline defects of the chest and abdomen encompass sternal defect, sternal pit, sternal cleft, and supraumbilical raphe. Dental abnormalities, specifically enamel hypoplasia, can be associated with PHACE syndrome.

There can be an assortment of neurologic symptoms, the most common of which is headaches, specifically migraines. Other reported neurologic symptoms are seizures, cyclical vomiting, developmental delay (language, gross motor, fine motor), hypotonia, tremor, dysphagia, opisthotonus, hearing loss (conductive, sensorineural, or mixed), and cranial nerve deficits. New onset of headaches in an individual with PHACE syndrome should prompt further evaluation for vessel disease and cerebral ischemia. Development can be affected: according to a case series of 29 children with PHACE syndrome, 69% had abnormal neurodevelopment, including 44% with language delay, 36% with gross motor delay, and 8% with fine motor delay. Certain medical comorbidities like posterior fossa malformations and oropharyngeal hemangiomas increase the risk for dysphagia. Sensorineural hearing loss may be caused by involvement of the cranial nerve VIII that is on the same side as the infantile hemangioma; similarly, conductive hearing loss may be caused by compression of the eustachian tube that is on the same side as the infantile hemangioma.

There are clinical diagnostic criteria for PHACE syndrome that delineate definite PHACE syndrome and possible PHACE syndrome. Definite PHACE syndrome is defined by either of the following: (1) infantile hemangioma (>5 cm in diameter) affecting the head/scalp in combination with one major or two minor criteria or (2) segmental infantile hemangioma of the neck, upper trunk, or trunk/proximal arm in combination with two major criteria. Possible PHACE syndrome is defined by one of the following: (1) infantile hemangioma (>5 cm in diameter) affecting the head/scalp in combination with one minor criteria; (2) segmental infantile hemangioma of the neck, upper trunk, or trunk/proximal arm in combination with one major or two minor criteria; and (3) absence of hemangioma but presence of two major criteria. Major and minor criteria pertain to arterial, structural brain, cardiovascular, ocular, and ventral/midline features of the syndrome.

Children newly diagnosed with PHACE syndrome should undergo a complete physical examination, screening echocardiogram, ophthalmologic examination, hearing screening, and MRI with and without gadolinium of the brain/neck as well as MRA of the brain/neck/aortic arch. Results of these baseline evaluations steer further management. The presence of a severe midline defect would prompt evaluation with pediatric surgery. Abnormalities on echocardiogram would require expertise from pediatric cardiology. Anomalies on ophthalmologic exam would likely require ongoing care. Hearing loss can be a risk factor for language delay, so affected children should have hearing screening if not already performed. If there are structural brain abnormalities identified on MRI, evaluation by pediatric neurology and neurosurgery (in the case of Dandy-Walker malformation or hydrocephalus) would be necessary. Pituitary defects would require endocrinologic evaluation. Results from MRA of cervical and cerebral arteries would classify patients into one of three risk tiers for cerebrovascular changes and stroke (low risk, intermediate risk, high risk), each with varying levels of need for follow-up neuroimaging and ongoing neurologic care.

Treatments in PHACE syndrome are symptom targeted. The β blocker propranolol can be used for infantile hemangiomas associated with PHACE syndrome, though there must be careful consideration in the presence of cerebrovascular abnormalities predisposing to stroke. Treatment of headaches is per standard clinical care, but certain vasoconstrictive medications, like triptans and ergotamine derivatives, should be avoided if there are arterial abnormalities. Dysphagia would require referral for feeding evaluation. Developmental delays should prompt neurodevelopmental assessment and developmental therapies such as physical therapy and speech-language therapy.

LUMBAR syndrome (*l*ower-segment hemangioma, *u*rogenital defects, *m*yelopathy of spinal cord, *b*ony deformities, *a*rterial and anorectal defects, *r*enal anomalies), also called **SACRAL syndrome** (*s*pinal dysraphism, *a*nogenital anomalies, *c*utaneous anomalies, *r*enal-urologic anomalies, *a*ngioma of *l*umbosacral localization), is a possible variant of PHACES syndrome in the lumbosacral region.

Visit Elsevier eBooks+ at eBooks.Health.Elsevier.com for Bibliography.

636.7 Incontinentia Pigmenti

Siddharth Srivastava and Mustafa Sahin

Incontinentia pigmenti (IP) is a rare, heritable, multisystem ectodermal disorder that features dermatologic, dental, ocular, and CNS abnormalities. The phenotype is produced by defects in the X-linked

dominant gene *IKBKG (*previously *NEMO)*, which plays a role in activating the antiapoptotic signaling molecule NF-kappaB (NF-κB). In the majority of males, IP causes embryonic lethality, so affected males who survive have *somatic mosaicism* for a pathogenic *IKBKG* variant or a 47,XXY karyotype. With respect to a male with IP, some of his daughters may inherit a pathogenic *IKBKG* variant and hence be affected, but all of his sons would be unaffected. Among affected females, an abnormal gene product causes apoptosis in cells; therefore highly skewed X-inactivation can be a result. With respect to a female with IP, one third of her offspring are expected to be unaffected females, one third are expected to be affected females, and one third are expected to be unaffected males; this ratio accounts for the high rate of miscarriages in pregnancies with a male conceptus carrying a pathogenic variant in *IKBKG*.

CLINICAL MANIFESTATIONS AND DIAGNOSIS

This disease has four stages, not all of which may occur in a given patient. The **first (bullous) stage** is evident at birth or in the first few weeks of life and consists of erythematous linear streaks and plaques of vesicles (Fig. 636.15) that are most pronounced on the limbs and circumferentially on the trunk. The lesions may be confused with those of herpes simplex, bullous impetigo, or mastocytosis, but the linear configuration is unique. Histopathologically, epidermal edema and eosinophil-filled intraepidermal vesicles are present. Eosinophils also infiltrate the adjacent epidermis and dermis. Blood eosinophilia as high as 65% of the white blood cell count is common. The **first stage** generally resolves by 4 months of age, but mild, short-lived recurrences of blisters may develop during febrile illnesses. In the **second (verrucous) stage**, as blisters on the distal limbs resolve, they become dry and hyperkeratotic, forming verrucous plaques. The verrucous plaques rarely affect the trunk or face and generally involute within 6 months. Epidermal hyperplasia, hyperkeratosis, dyskeratosis, and papillomatosis are characteristic. The **third (pigmentary) stage** is the hallmark of IP. It generally develops over weeks to months and may overlap the earlier phases or, more commonly, begin to appear in the first few months of life. Hyperpigmentation is more often apparent on the trunk than the limbs and is distributed in macular whorls, reticulated patches, flecks, and linear streaks that follow Blaschko lines. The axillae and groin are characteristically affected. The sites of involvement are not necessarily those of the preceding vesicular and warty lesions. The pigmented lesions, once present, persist throughout childhood. They generally begin to fade by early adolescence and often disappear by age 16 years. Occasionally, the pigmentation remains permanently, particularly in the groin. Histopathologically, the lesion shows vacuolar degeneration of the epidermal basal cells and melanin in melanophages of the upper dermis as a result of incontinence of pigment. In the **fourth (atretic) stage**, hairless, anhidrotic, hypopigmented patches or streaks occur as a late manifestation of IP; they may develop, however, before the hyperpigmentation of stage 3 has resolved. The lesions develop mainly on the flexor aspect of the lower legs and less often on the arms and trunk. On histology, there are decreased rete ridges (epidermal protrusions) and sweat gland secretory coils during this stage.

Fig. 636.15 Whorled vesicular phase of incontinentia pigmenti.

A large percentage of affected children have other dermal/dental defects. Alopecia, which may be scarring and patchy or diffuse, is most common on the vertex and occurs in up to 40% of patients. Hair may be coarse and wooly or sparse and brittle. Fingernails and toenails may demonstrate pigmentary or dystrophic changes (ridging, pitting), as well as painful subungual and periungual keratotic tumors. Dental anomalies consist of late dentition, hypodontia, conical teeth, malocclusion, and impaction.

CNS manifestations are found in up to 30% of affected children and include seizures, intellectual disability, learning disabilities, microcephaly, hemiplegia/hemiparesis (in the setting of stroke), spasticity, and cerebellar ataxia. Brain MRI in patients can be notable for periventricular and subcortical white matter changes, ischemic/hemorrhagic infarcts, hemorrhagic necrosis, dysgenesis of the corpus callosum, cerebral atrophy, cerebellar hypoplasia, cystic changes, and ventricular enlargement.

Ocular anomalies, such as retinal neovascularization, microphthalmos, strabismus, optic nerve atrophy, cataracts, and retrolenticular masses, occur in up to 77% of affected individuals. Nonetheless, >90% of patients have normal vision. Notably, retinal neovascularization could herald abnormalities in the CNS vasculature that predispose the patient to ischemic or hemorrhagic stroke.

Other medical issues have been reported in IP. Leukocytosis with eosinophilia can occur. Primary pulmonary hypertension is seen in some affected individuals.

Diagnosis of IP is made on clinical grounds, although major and minor criteria have been established to aid in the diagnosis. Satisfaction of the sole major criteria (pertaining to the characteristic skin lesions in the varying stages) is needed for a clinical diagnosis; lack of fulfillment of any of the minor criteria may direct the clinician toward the possibility of another diagnosis. Wood lamp examination may be useful in older children and adolescents to highlight pigmentary abnormalities. Clinical molecular testing is available, and around 65% of affected females and 16% of affected males have a recurrent pathogenic variant, an 11.7-kb deletion of exons 4-10 of *IKBKG*. Skin biopsy may be helpful if the patient has unclear clinical findings and negative genetic testing. For male patients with negative genetic testing from blood, a variant may be detectable in skin cells from an affected region, increasing the utility of a skin biopsy. The differential diagnosis includes hypomelanosis of Ito, which presents with similar skin manifestations and is often associated with chromosomal mosaicism.

MANAGEMENT

The choice of investigative studies and the plan of management depend on the occurrence of particular noncutaneous abnormalities. Medical genetics and genetic counseling can help establish a molecular diagnosis in addition to providing family counseling. Dermatology may be involved to characterize the nature of skin lesions and to manage skin manifestations that are extensive. Dentistry can provide teeth implants along with routine care. If dental issues affect speech or feeding, then input from speech pathologists and nutritionists may be necessary. Ophthalmology is important for delineating the presence and extent of retinal neovascularization (which can be treated with cryotherapy and laser photocoagulation) and other ocular abnormalities. Cardiology may be necessary if there is pulmonary hypertension. Neurology can help evaluate and treat relevant concerns such as microcephaly, seizures, and motor abnormalities. A brain MRI is useful if there are focal neurologic deficits or retinal neovascularization. Finally, developmental medicine can formulate recommendations regarding developmental and behavioral concerns. Surveillance includes regular ophthalmologic assessment (monthly until age 4 months, then every 3 months until age 1 year, then every 6 months until age 3 years, then annually thereafter). Regular evaluation with dentistry and neurologic/neurodevelopmental assessments are appropriate.

Visit Elsevier eBooks+ at eBooks.Health.Elsevier.com for Bibliography.

Chapter 637

Movement Disorders

Jonathan W. Mink

INTRODUCTION

Movement disorders are characterized by impaired voluntary movements or excessive involuntary movements that may result in abnormalities in posture, tone, balance, or fine motor control. Most movement disorders in children are characterized by involuntary movements. These involuntary movements can represent the sole disease manifestation, or they may be one of many signs and symptoms.

Evaluation of movement disorders begins with a comprehensive history and careful neurologic examination. It is often difficult for children and caregivers to describe abnormal movements, which makes observation of the movements by the clinician an essential component of the evaluation. If the movements are not apparent at the time of the examination, video examples from home or school can be invaluable.

There is no specific diagnostic test to differentiate among movement disorders. The category of movement assists in localizing the pathologic process, whereas the onset of the disorder, age of the patient, and degree of abnormal motor activity and associated neurologic findings help organize the investigation.

When considering the type of movement disorder, the following questions concerning the history and examination of the movement are helpful:

- What is the distribution of the movements across body parts?
- Are the movements symmetric?
- What is the speed of the involuntary movements? Are they rapid and fast or slow and sustained?
- When do the movements occur? Are they present at rest? Are they present with maintained posture or with voluntary actions?
- Are the movements seen in relation to certain postures or body positions?
- Do the abnormal movements occur only with specific tasks?
- Can the child voluntarily suppress the movements, even for a short time?
- Are the movements stereotyped?
- Are the movements rhythmic?
- What is the temporal pattern of the movements? Are they continuous or intermittent? Do they occur in discrete episodes?
- Are the involuntary movements preceded by an urge to make the movement?
- Do the movements persist during sleep?
- Are the movements associated with impairment of motor function?
- What factors aggravate or alleviate the movements?

The first decision to be made is whether the movement disorder is **hyperkinetic** (characterized by excessive and involuntary movements) or **hypokinetic** (characterized by slow voluntary movements and a general paucity of movement). Hyperkinetic movement disorders are much more common than hypokinetic disorders in children. Once the category of movement disorder is recognized, the etiology can be considered. The clinical history, including the birth history, medication/toxin exposure, trauma, infections, family history, progression of the involuntary movements, developmental progress, and behavior, should be explored as the underlying cause is established. Table 637.1 lists the types and clinical characteristics of selected hyperkinetic movement disorders. A diagnostic approach to paroxysmal movement disorders is noted in Figure 637.1; age-related presentations of paroxysmal movement disorders are noted in Figure 637.2.

Visit Elsevier eBooks+ at eBooks.Health.Elsevier.com for Bibliography.

637.1 Ataxias

Peter E. Morrison and Jonathan W. Mink

Ataxia is the inability to make smooth, accurate, and coordinated movements. It occurs because of a dysfunction of the cerebellum, its inputs or outputs, its sensory pathways in the posterior columns of the spinal cord, or a combination of these. Ataxias may be generalized but can also primarily affect the gait, the hands and arms, or the trunk; they may be acute or chronic, or acquired or genetic (Tables 637.2-637.8).

Signs and symptoms of ataxia include clumsiness, difficulty walking or sitting, falling to one side, slurred speech, low muscle tone, intention tremor, dizziness, delayed motor development, or a combination of these. Genetic or chronic causes of cerebellar ataxia are often characterized by a long duration of symptoms, a positive family history, muscle weakness and abnormal gait, abnormal tone and strength, abnormal deep tendon reflexes, pes cavus, and sensory defects. Distinguishing ataxia from vestibular dysfunction may be difficult; however, labyrinth disorders are often characterized by severe vertigo, nausea and vomiting, position-induced vertigo, and a severe sense of unsteadiness.

Congenital anomalies of the posterior fossa, including Dandy-Walker malformation, Chiari malformation, and encephalocele, are prominently associated with ataxia because of their destruction or abnormal development of the cerebellum (see Chapter 631.8). *MRI*

Table 637.1 Selected Types of Involuntary Movement in Childhood

TYPE	CHARACTERISTICS
Stereotypies (see Chapter 37)	Involuntary, patterned, coordinated, repetitive, rhythmic movements that occur in the same fashion with each repetition
Tics (see Chapter 37)	Involuntary, sudden, rapid, abrupt, repetitive, nonrhythmic, simple or complex motor movements or vocalizations (phonic productions). Tics are usually preceded by an urge that is relieved by carrying out the movement.
Tremor (see Chapter 637.2)	Oscillating, rhythmic movements about a fixed point, axis, or plane
Dystonia (see Chapter 637.4)	Intermittent and sustained involuntary muscle contractions that produce abnormal postures and movements of different parts of the body, often with a twisting quality
Chorea (see Chapter 637.2)	Involuntary, continual, irregular movements or movement fragments with variable rate and direction that occur unpredictably and randomly
Ballism	Involuntary, high-amplitude, flinging movements typically occurring proximally. Ballism is essentially a large-amplitude chorea
Athetosis (see Chapter 637.2)	Slow, writhing, continuous, involuntary movements
Myoclonus (see Chapter 637.3)	Sudden, quick, involuntary muscle jerks

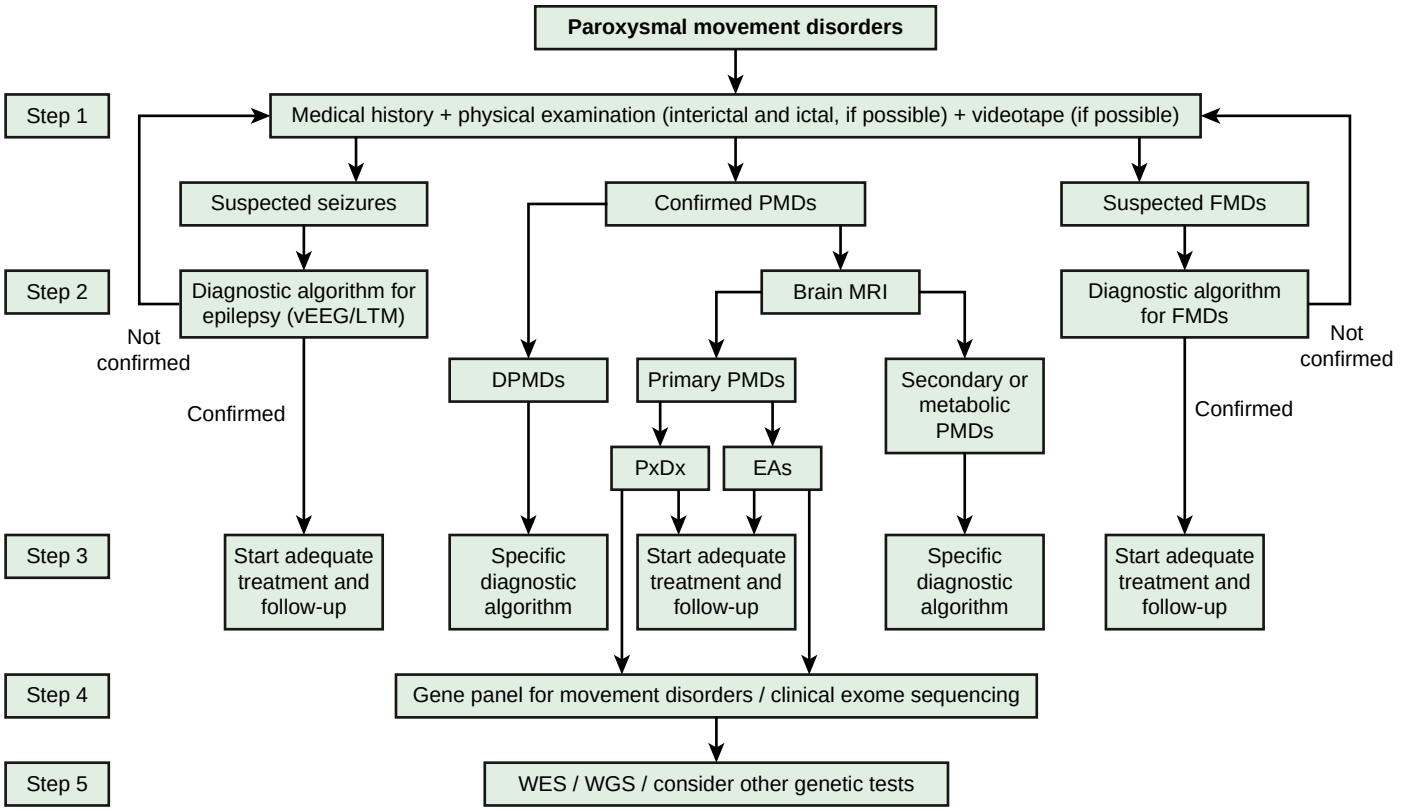

Fig. 637.1 Operative algorithm for pediatric-onset PMDs. DPMDs, developmental PMDs; EAs, episodic ataxias; FMDs, functional movement disorders; LTM, long-term EEG monitoring; PxDx, paroxysmal dyskinesias; vEEG, video electroencephalogram; WES, whole exome sequencing; WGS, whole genome sequencing. *(Modified from Garone G, Capuano A, Travaglini L, et al. Clinical and genetic overview of paroxysmal moment disorders and episodic ataxias. Inter J Mol Sci. 2020;21:3603, Fig. 5.)*

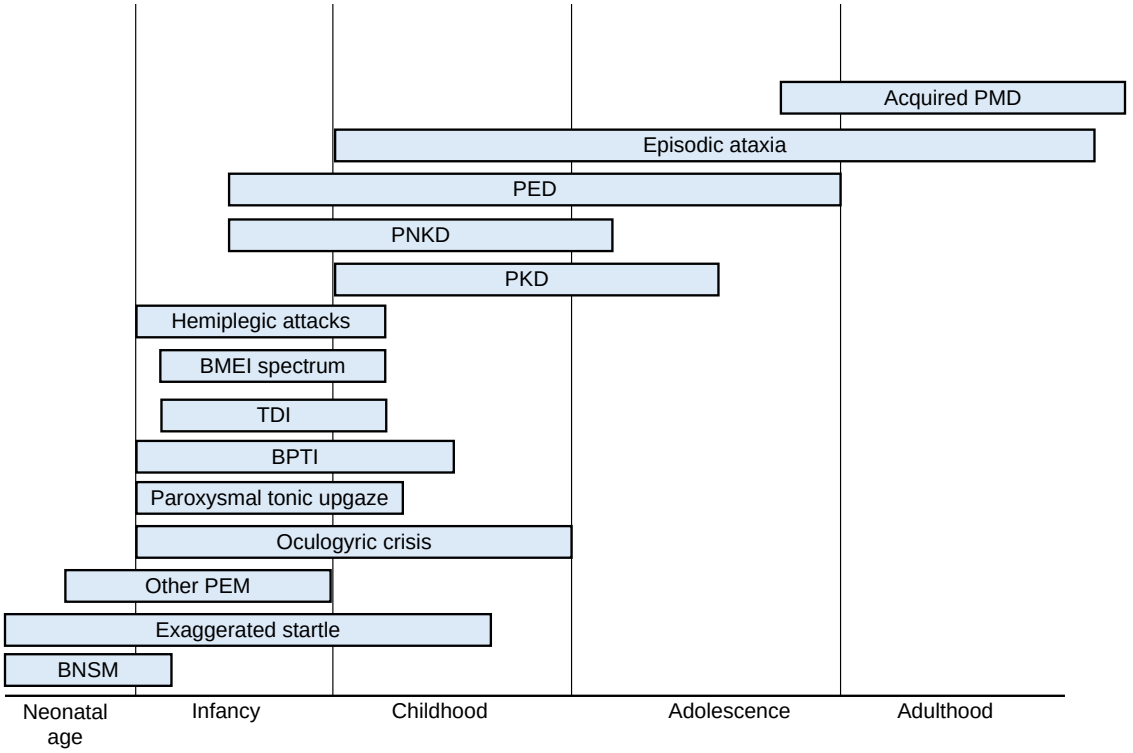

Fig. 637.2 Onset of different paroxysmal movement disorders (PMDs) according to age. BNSM, benign neonatal sleep myoclonus; BMEI, benign myoclonus of early infancy; BPTI, benign paroxysmal torticollis of infancy; PEM, paroxysmal eye movements; PED, paroxysmal exercise-induced dyskinesia; PKD, paroxysmal kinesigenic dyskinesia; PNKD, paroxysmal nonkinesigenic dyskinesia. *(From Garone G, Capuano A, Travaglini L, et al. Clinical and genetic overview of paroxysmal moment disorders and episodic ataxias. Inter J Mol Sci. 2020;21:3603, Fig. 1.)*

Table 637.2 Selected Causes of Ataxia in Childhood

CONGENITAL CAUSES
Agenesis of vermis of the cerebellum
Aplasia or dysplasia of the cerebellum
Basilar impression
Cerebellar dysplasia with microgyria, macrogyria, or agyria
Cervical spinal bifida with herniation of the cerebellum (Chiari malformation type 3)
Chiari malformation
Dandy-Walker syndrome
Encephalocele
Hydrocephalus (progressive)
Hypoplasia of the cerebellum

DEGENERATIVE AND/OR GENETIC CAUSES
Acute intermittent cerebellar ataxia
Ataxia, retinitis pigmentosa, deafness, vestibular abnormality, and intellectual deterioration
Ataxia-telangiectasia
Biemond posterior column ataxia
Cerebellar ataxia with deafness, anosmia, absent caloric responses, nonreactive pupils, and hyporeflexia
Cockayne syndrome
Dentate cerebellar ataxia (dyssynergia cerebellaris progressiva)
Familial ataxia with macular degeneration
Friedreich ataxia
Hereditary cerebellar ataxia, intellectual retardation, choreoathetosis, and eunuchoidism
Hereditary cerebellar ataxia with myotonia and cataracts
Hypertrophic interstitial neuritis
Marie ataxia
Marinesco-Sjögren syndrome
Multiple system atrophy
Pelizaeus-Merzbacher disease
Periodic attacks of vertigo, diplopia, and ataxia: autosomal dominant inheritance
Posterior and lateral column difficulties, nystagmus, and muscle atrophy
Progressive cerebellar ataxia and epilepsy
Ramsay Hunt syndrome (myoclonic seizures and ataxia)
Roussy-Lévy disease
Spinocerebellar ataxia (SCA); olivopontocerebellar ataxias
Vanishing white matter syndrome

ENDOCRINOLOGIC CAUSES
Hypothyroidism (acquired or congenital)

INFECTIOUS, POSTINFECTIOUS, AND IMMUNE INFLAMMATORY CAUSES
Acute cerebellar ataxia
Acute disseminated encephalomyelitis
Autoimmune (anti–glutamic acid decarboxylase, anti–γ-aminobutyric acid-B receptor antibodies, idiopathic, gluten ataxia, Miller-Fisher syndrome, Hashimoto encephalopathy, lupus)
Cerebellar abscess
Cerebellitis
Coxsackievirus
Diphtheria
Echovirus
Fisher syndrome
Infectious mononucleosis (Epstein-Barr virus infection)
Infectious polyneuropathy
Japanese B encephalitis
Multiple sclerosis
Mumps encephalitis
Mycoplasma pneumonia
Paraneoplastic (opsoclonus-myoclonus-ataxia syndrome)
Pertussis
Polio
Postbacterial meningitis
Rubeola
Tuberculosis
Typhoid
Varicella

METABOLIC CAUSES
Abetalipoproteinemia
Argininosuccinic aciduria
Ataxia with vitamin E deficiency (AVED)
Congenital disorders of glycosylation
GM_2 gangliosidosis (late)
Hartnup disease
Hyperalaninemia
Hyperammonemia I and II (urea cycle defects)
Hypoglycemia
Kearns-Sayre syndrome
Leigh disease
Maple syrup urine disease (intermittent)
Myoclonic epilepsy with ragged red fibers (MERRF)
Metachromatic leukodystrophy
Mitochondrial complex defects (I, III, IV)
Multiple carboxylase deficiency (biotinidase deficiency)
Neuronal ceroid-lipofuscinosis
Neuropathy, ataxia, retinitis pigmentosa (NARP)
Niemann-Pick disease (late infantile)
5-Oxoprolinuria
Pyruvate decarboxylase deficiency
Refsum disease
Sialidosis
Triose-phosphate isomerase deficiency
Tryptophanuria
Wernicke encephalopathy

NEOPLASTIC CAUSES
Frontal lobe tumors
Hemispheric cerebellar tumors
Midline cerebellar tumors
Neuroblastoma
Pontine tumors (primarily gliomas)
Spinal cord tumors

PRIMARY PSYCHOGENIC CAUSES
Functional disorder

TOXIC CAUSES
Alcohol
Benzodiazepines
Carbamazepine
Clonazepam
Dextromethorphan
Lead encephalopathy
Neuroblastoma
Phenobarbital
Phenytoin
Primidone
Tic paralysis poisoning

TRAUMATIC CAUSES
Acute cerebellar edema
Acute frontal lobe edema

VASCULAR CAUSES
Angioblastoma of the cerebellum
Basilar migraine
Cerebellar embolism
Cerebellar hemorrhage
Cerebellar thrombosis
Posterior cerebellar artery disease
Vasculitis
von Hippel-Lindau disease

Modified from Jafar-Nejad P, Maricich SM, Zoghbi HY. The cerebellum and the hereditary ataxias. In: Swaiman KF, Ashwal S, Ferriero DM, et al., eds. *Swaiman's Pediatric Neurology*, 5th ed. Philadelphia: WB Saunders; 2012: Box 67-1.

Table 637.3 Treatable Causes of Inherited Ataxia

DISORDER	METABOLIC ABNORMALITY	DISTINGUISHING CLINICAL FEATURES	TREATMENT
Acute disseminated encephalomyelitis	Demyelination	Positive MRI findings	Steroids, IVIG, rituximab
Ataxia with vitamin E deficiency	Pathogenic variants in α-tocopherol transfer protein	Ataxia, areflexia, retinopathy	Vitamin E
Bassen-Kornzweig syndrome	Abetalipoproteinemia	Acanthocytosis, retinitis pigmentosa, fat malabsorption	Vitamin E
Hartnup disease	Tryptophan malabsorption	Pellagra rash, intermittent ataxia	Niacin
Familial episodic ataxia type 1 and type 2	Pathogenic variants in potassium channel (KCNA1) and α_{1A} voltage-gated calcium channel, respectively	Episodic attacks, worse with pregnancy or birth control pills	Acetazolamide
Multiple carboxylase deficiency	Biotinidase deficiency	Alopecia, recurrent infections, variable organic aciduria	Biotin
Mitochondrial complex defects	Complexes I, III, IV	Encephalomyelopathy	Possibly riboflavin, CoQ10, dichloroacetate
Opsoclonus-myoclonus-ataxia syndrome	Paraneoplastic or spontaneous autoimmune	Underlying neuroblastoma or autoantibodies	Steroids, IVIG, rituximab
Primary CoQ10 deficiency (multiple types)	Mitochondrial dysfunction	Seizures, sensorineural hearing loss, lactic acidosis, cardiomyopathies	Possibly CoQ10
Pyruvate dehydrogenase deficiency	Block in E-M and Krebs cycle interface	Lactic acidosis, ataxia	Ketogenic diet, possibly dichloroacetate
Refsum disease	Phytanic acid, α-hydroxylase	Retinitis pigmentosa, cardiomyopathy, hypertrophic neuropathy, ichthyosis	Dietary restriction of phytanic acid
Urea cycle defects	Urea cycle enzymes	Hyperammonemia	Protein restriction, arginine, benzoate, α-ketoacids

CoQ10, Coenzyme Q10; E-M, mitochondrial electron transport; IVIG, intravenous immunoglobulin.
Modified from Stumpf DA. The inherited ataxias. *Pediatr Neurol*. 1985;1:129–133, Table 1; and from Jafar-Nejad P, Maricich SM, Zoghbi HY. The cerebellum and the hereditary ataxias. In: Swaiman KF, Ashwal S, Ferriero DM, et al., eds. *Swaiman's Pediatric Neurology*, 5th ed. Philadelphia: WB Saunders; 2012: Table 67-1.

Table 637.4 Hereditary Ataxias Caused by Nucleotide Repeat Expansions: Clinical Findings

GENE*	DISORDER	MOI	DISTINGUISHING NONATAXIC CLINICAL FEATURES	COMMENT
MOST COMMONLY INVOLVED GENES				
ATN1	DRPLA	AD	Chorea, dementia, myoclonus, seizures; mimics Huntington disease	• Anticipation is prominent • More common in Japan
ATXN1	SCA1	AD	Peripheral neuropathy, pyramidal signs; early bulbar features; occasional cognitive decline	• Anticipation is more likely with paternal transmission.
ATXN2	SCA2	AD	↓ DTRs, dementia, peripheral neuropathy, slow saccadic eye movements	• Anticipation is more likely with paternal transmission • Large Cuban founder population
ATXN3	SCA3	AD	Amyotrophy, fasciculations, sensory loss; lid retraction, nystagmus, and ↓ saccade velocity; pyramidal and extrapyramidal signs; shortened life span	• Anticipation may be more likely with paternal transmission • Large Portuguese founder population • Also known as Machado-Joseph disease
ATXN7	SCA7	AD	Visual loss with retinopathy; often rapidly progressive; shortened life span	Anticipation is prominent with more marked repeat expansions with paternal transmission
ATXN8 *ATXN8OS*	SCA8	AD	Slowly progressive, sometimes brisk DTRs, ↓ vibration sense; rarely, cognitive impairment in persons with earlier onset	Anticipation is more likely with maternal transmission

Continued

Table 637.4 Hereditary Ataxias Caused by Nucleotide Repeat Expansions: Clinical Findings—cont'd

GENE*	DISORDER	MOI	DISTINGUISHING NONATAXIC CLINICAL FEATURES	COMMENT
ATXN10	SCA10	AD	Seizures in certain families	• Anticipation can occur with paternal transmission • Large Mexican founder population
CACNA1A	SCA6	AD	May begin with episodic ataxia, very slow progression; onset often after age 50 yr; normal life span	• Anticipation is not seen • See Table 637.6 for ataxia caused by missense variants
FXN	Friedreich ataxia	AR	Generally childhood onset with slowly progressive ataxia, absent tendon reflexes, Babinski responses, posterior column sensory loss, cardiomyopathy, scoliosis, pes cavus, and diabetes; in some: onset ≥25 yr, slower progression, and retained reflexes	Anticipation is not seen
RFC1	RFC1 CANVAS/ spectrum disorder	AR	Spectrum ranges from typical cerebellar ataxia, neuropathy, and vestibular areflexia syndrome (CANVAS), to cerebellar, sensory, and vestibular impairment, to more limited phenotypes involving predominantly or exclusively one of the systems involved in balance control	Anticipation is not seen
TBP	SCA17	AD	Mental deterioration; occasional chorea, dystonia, myoclonus, epilepsy	Anticipation is infrequently observed
LESS COMMONLY INVOLVED GENES				
BEAN1	SCA31 (OMIM 117210)	AD	Normal sensation	Common in Japan
FMR1	Fragile X-associated tremor/ataxia syndrome (FXTAS)	XL		• Anticipation occurs almost exclusively with maternal transmission • Most common X-linked ataxia; occurs in male and female premutation carriers
NOP56	SCA36	AD	Hyperreflexia, muscle fasciculations, tongue atrophy	Insufficient evidence for anticipation
PPP2R2B	SCA12 (OMIM 604326)	AD	Action tremor in the fourth decade, cognitive/psychiatric disorders, including dementia, hyperreflexia, slowly progressive ataxia, subtle parkinsonism possible	Insufficient evidence for anticipation

*Genes are listed in alphabetic order within prevalence categories.
DRPLA, Dentatorubral-pallidoluysian atrophy; DTR, deep tendon reflex; SCA, spinocerebellar ataxia.
From Perlman S. Hereditary ataxia overview. 1998 Oct 28 [Updated 2022 Jun 16]. In: Adam MP, Mirzaa GM, Pagon RA, et al., eds. GeneReviews® [Internet]. Seattle (WA): University of Washington, Seattle; 1993-2023, Table 1.

Table 637.5 Hereditary Ataxias Caused by Nucleotide Repeat Expansions: Molecular Genetics

GENE[1]	PATHOGENIC VARIANTS (%)	NUCLEOTIDE REPEAT (AMINO ACID)	REPEAT LOCATION	NORMAL REPEAT NUMBER	FULL-PENETRANCE PATHOGENIC REPEAT NUMBER	COMMENT
ATN1	100	CAG (Gln)	Exon 5	6-35	≥48	
ATXN1	100	CAG (Gln)	Exon 8	6-35	≥39	
ATXN2	100	CAG (Gln)	Exon 1	≤31	≥33	
ATXN3	100	CAG (Gln)	Exon 8	12-44	60-87	
ATXN7	100	CAG (Gln)	Exon 1	4-19	≥36	
ATXN8	100	CAG (Gln)	Exon 1	~80	Unknown	
ATXN8OS	100	CTG	3′ UTR	15-50 CTA/CTG	≥71-1300 CTA/CTG[2]	Penetrance is <100%[2]
ATXN10	100	ATTCT	Intron 9	10-32	≥800	Repeat interruptions are associated with presence of seizures

Table 637.5 Hereditary Ataxias Caused by Nucleotide Repeat Expansions: Molecular Genetics—cont'd

GENE[1]	PATHOGENIC VARIANTS (%)	NUCLEOTIDE REPEAT (AMINO ACID)	REPEAT LOCATION	NORMAL REPEAT NUMBER	FULL-PENETRANCE PATHOGENIC REPEAT NUMBER	COMMENT
BEAN1	100	TGGAA	Intron 6	0	2.5- to 3.8-kb insertion	
CACNA1A[3]	>99	CAG (Gln)	Exon 7	≤18	20-33	See Table 637.6 for phenotype associated with variants that are not nucleotide repeat disorders
FMR1	>99	CGG	5′ UTR	5-44	≥200	Premutation alleles: 55-200 CGG repeats
FXN	~98	GAA	Intron 1	5-33	≥66	In about 5% of affected persons one FXN allele is an expanded GAA repeat and one is a pathogenic missense variant
NOP56	100	GGCCTG	Intron 1	3-14	≥650	
PPP2R2B	100	CAG	Promoter	7-31	51-78	
RFC1	100	AAGGG[4]	Intron 2	Unknown	~400 to ~2000	ACAGG repeat expansion has been reported in three persons from Asian and Asian Pacific populations[4]
TBP	100	CAG or CAA (Gln)	Exon 3	25-40	≥49	

Based on Resources for Genetics Professionals — Genetic Disorders Caused by Nucleotide Repeat Expansions and Contractions
[1]Genes are listed in alphabetic order.
[2]Although penetrance less than 100% has been reported at all repeat sizes, higher penetrance is reported for CTA/CTG repeat sizes of 80-250.
[3]The majority of *CACNA1A* pathogenic variants are CAG repeat expansions associated with spinocerebellar ataxia type 6. Heterozygous *CACNA1A* missense, nonsense, splice site, frameshift, and exon/multiexon deletions have been reported in individuals with episodic ataxia type 2 and progressive cerebellar ataxia.
[4]*RFC1* intron 2 contains a microsatellite region with variable benign AAAAG repeats (range: 11-200 repeats) and/or benign AAAGG repeats (range: 40-1000 repeats). Interruption of the benign AAAAG/AAAGG repeated units with biallelic pathogenic AAGGG expansions has been identified in individuals with *RFC1* CANVAS/spectrum disorder.
From Perlman S. Hereditary Ataxia overview. 1998 Oct 28 [Updated 2022 Jun 16]. In: Adam MP, Mirzaa GM, Pagon RA, et al., eds. GeneReviews® [Internet]. Seattle (WA): University of Washington, Seattle; 1993-2023, Table 2.

Table 637.6 Most Common Hereditary Ataxias (Excluding Nucleotide Repeat Disorders)

GENE[1]	MOI	PHENOTYPE		OTHER PHENOTYPIC FEATURES/COMMENTS	DESIGNATION/*GENEREVIEW*/OMIM
		ATAXIA	SPASTICITY		
AFG3L2	AD	+	+	Ophthalmoparesis, slow saccades, ptosis[3]	SCA28 (OMIM 610246)
	AR				SCAR5 (OMIM 614487)
ANO10	AR	+	+	Downbeat nystagmus, fasciculations	SCAR10 (OMIM 613728)
APTX	AR	+		Early-onset ataxia, oculomotor apraxia, extrapyramidal features, sensorimotor neuropathy, hypoalbuminemia; secondary coenzyme Q10 deficiency (see primary coenzyme Q10 deficiency)	Ataxia with oculomotor apraxia type 1
ATM	AR	+		Early-onset ataxia, oculomotor apraxia, extrapyramidal features, immunodeficiency, cancer risk, ↑ alpha-fetoprotein	Ataxia-telangiectasia
CACNA1A[2]	AD	+			Episodic ataxia type 2 (OMIM 108500)

Continued

Table 637.6 Most Common Hereditary Ataxias (Excluding Nucleotide Repeat Disorders)—cont'd

GENE[1]	MOI	PHENOTYPE		OTHER PHENOTYPIC FEATURES/COMMENTS	DESIGNATION/*GENEREVIEW*/OMIM
		ATAXIA	SPASTICITY		
ITPR1	AD	+		Adult onset, slowly progressive	SCA15/16 (OMIM 606658)
	AD[3]	+		Congenital, nonprogressive	SCA29 (OMIM 117360)
KCNC3	AD[3]	+		Adult onset, slowly progressive	SCA13
				Congenital, nonprogressive	
KCND3[4]	AD	+			SCA19/22 (OMIM 605411)
PRKCG	AD	+			SCA14
SACS	AR	+	+	Early-onset ataxia with spastic paraparesis and axonal-demyelinating sensorimotor neuropathy; hypointense pontine stripes on T2-weighted MRI[5]	ARSACS (SPAX6)
SETX[6]	AR	+	+	Early-onset ataxia, oculomotor apraxia with ↑ alpha-fetoprotein[5]	Ataxia with oculomotor apraxia type 2 (SCAR1)
SPG7	AR	+	+	Variable spasticity and cerebellar ataxia[5]	Spastic paraplegia 7
SPTBN2	AD	+			SCA5 (OMIM 600224)
	AR				SCAR14 (OMIM 615386)
SYNE1[7]	AR	+	+	Cerebellar ataxia, variable spasticity, and further multisystemic neurologic damage[5]	ARCA1 (SCAR8) (see SYNE1 deficiency)

Based on Synofzik & Schüle [2017] and Galatolo et al. [2018].
[1]Genes are listed in alphabetic order.
[2]Allelic disorders include familial hemiplegic migraine and spinocerebellar ataxia type 6.
[3]The disorder may occur as the result of a de novo pathogenic variant.
[4]Allelic disorder: Brugada syndrome.
[5]Synofzik and Schüle [2017].
[6]Allelic disorder: amyotrophic lateral sclerosis.
[7]Allelic phenotype: arthrogryposis multiplex congenita (see SYNE1 deficiency).
AD, Autosomal dominant; AR, autosomal recessive; ARCA, autosomal recessive cerebellar ataxia; MOI, mode of inheritance; OMIM, Online Mendelian Inheritance in Man; SCA, spinocerebellar ataxia; SCAR, spinocerebellar ataxia, autosomal recessive.
From Perlman S. Hereditary Ataxia overview. 1998 Oct 28 [Updated 2022 Jun 16]. In: Adam MP, Mirzaa GM, Pagon RA, et al., eds. GeneReviews [Internet]. Seattle (WA): University of Washington, Seattle; 1993-2023, Table 3.

Table 637.7 The Hereditary Spastic Ataxias

SPASTIC ATAXIA (MIM#)	GENE	MODE OF INHERITANCE	AGE OF ONSET (YR)	FEATURES
SPAX1 (108600)	*VAMP1*		10-20 yr	Progressive leg spasticity, dysarthria, ocular movement abnormalities
SPAX2 (611302)	*KIF1C*		1-16 yr	Frequent falls, ataxia, head tremor, hyperreflexia, fasciculations
SPAX3/ARSAL (611390)	*MARS2*	AR	2-59 yr; mean 15 yr	Ataxia and spasticity
SPAX4 (613672)	*MTPAP*	AR	Early childhood	Ataxia, spastic paraparesis, dysarthria, optic atrophy, upper limb hypertonia
SPAX5 (614487)	*AFG3L2*	AR	Childhood	Spasticity, ataxia, oculomotor apraxia, dystonia, myoclonic epilepsy
SPAX6/SACS/ARCSACS (270660)	*SACS*	AR	Childhood	Spasticity and ataxia, very slow course, stops progressing after age 20
SPAX7	Unknown	AD	Infancy to 20 yr	Symmetric ataxia, dysarthria, pyramidal signs, optic atrophy
SPAR (607565)	Unknown	—	15-35 yr	Later onset: spastic paraplegia Early onset + ataxia, mental retardation

From Jafar-Nejad P, Maricich SM, Zoghbi H. The cerebellum and the hereditary ataxias. In: Swaiman KF, Ashwal S, Ferriero DM, et al., eds. *Swaiman's Pediatric Neurology*, 6th ed. Philadelphia: WB Saunders; 2018: Table 91-5.

Table 637.8 Genetic and Metabolic Disorders that Can Cause a Spastic-Ataxic Syndrome

	AGE AT ONSET	TREATMENT AVAILABLE	DIAGNOSTIC TESTS, IN ADDITION TO METABOLIC TESTS	MODE OF INHERITANCE	GENES
Abetalipoproteinemia (MIM #200100)	C	Yes	Blood lipid profile, vitamin E	AR	*MTP*
Adrenomyeloneuropathy (MIM #300100)	A	Yes	MRI spinal cord, blood VLCFA	X-linked	*ABCD1*
Ataxia with (primary) vitamin E deficiency (MIM #277460)	C	Yes	Blood vitamin E	AR	*TTPA*
CAMOS (also SCAR5; MIM #606937)*	C	No	—	AR	*ZNF592*
CARASIL (MIM #600142)	A	No	MRI	AR	*HTRA1*
Cerebral amyloid angiopathy: presenile dementia with spastic ataxia (MIM #176500)*	A	No	MRI	AD	*ITM2B*
Cerebral folate deficiency (MIM #613068)	C	Yes	CSF folates	AR	*FOLR1*
Childhood-onset spastic ataxia with optic atrophy and mental retardation (MIM %270500)*	C	No	—	AR	Unknown
Coenzyme Q10 deficiency (MIM #607426)	C	Yes	—	AR	>3 different genes
Female carriers of EIEE1 (MIM #308350)*	A	No	—	X-linked	*ARX*
Gaucher disease type III (MIM #231000)	C-A	Yes	—	AR	*GBA*
Glutaric acidemia II (MIM #231680)	C	Yes	MRI	AR	*ETFA, ETFB, ETFDH*
GM2 gangliosidosis (MIM #272800)	A	No	MRI	AR	*HEXA, HEXB, GM2A*
Hereditary spastic ataxia with congenital miosis (MIM%108650) (SPAX7)*	C	No	—	AD	Unknown
Krabbe disease (MIM #245200)	C-A	No	MRI	AR	*GALC*
LBSL (MIM #611105)*	C-A	No	MRI	AR	*DARS2*
Megalencephalic leukoencephalopathy with subcortical cysts (MIM #604004)*	C	No	MRI	AR	*MLC1*
Metachromatic leukodystrophy (MIM #250100)	C-A	Yes	MRI	AR	*ARSA*
Nonketotic hyperglycinemia (MIM #605899)	C-A	Yes	CSF amino acids	AR	>3 different genes
Optic atrophy ± deafness, ophthalmoplegia, myopathy, ataxia, neuropathy (MIM #605290)*	C	No	—	AD	*OPA1*
PHARC (MIM #612674)*	C	No	—	AR	*ABHD12*
Triple H syndrome (MIM #238970)*	C-A	Yes	Blood ammonia, amino acids	AR	*SLC25A15*
Type III 3-methylglutaconic aciduria (MIM #258501)*	C	No	Urine organic acids	AR	*OPA3*
Vanishing white matter leukodystrophy (#603896)*	C	No	MRI	AR	>3 different genes

*OMIM (Online Mendelian Inheritance in Man).

A, Adult onset; C, childhood onset; C-A, all ages possible, predominantly onset in adolescence; CAMOS, cerebellar ataxia with mental retardation, optic atrophy, and skin abnormalities; CARASIL, cerebral arteriopathy with subcortical infarcts and leukoencephalopathy; EIEE1, early infantile epileptic encephalopathy 1; LBSL, leukoencephalopathy with brainstem and spinal cord involvement and lactate elevation; MIM%, phenotype description or locus, molecular basis unknown; MIM#, phenotype description, molecular basis known; MRI, brain MRI unless otherwise stated; when MRI is indicated, a typical or pathognomonic pattern can be recognized; PHARC, polyneuropathy, hearing loss, ataxia, retinitis pigmentosa, and cataract; triple H, hyperornithinemia-hyperammonemia-homocitrullinuria; VLCFA, very long-chain fatty acids.

Modified from deBot ST, Willemsen MAAP, Vermeer S, et al. Reviewing the genetic causes of spastic-ataxias. *Neurology*. 2012;79:1507–1514, Table 2.

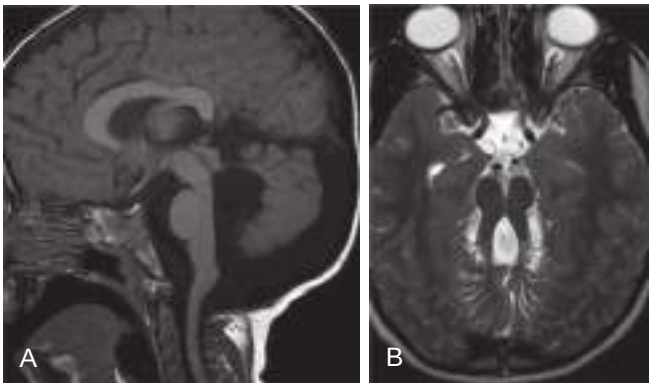

Fig. 637.3 Molar tooth syndrome. **A,** Sagittal T1-weighted MR image shows hypoplasia of the superior cerebellar vermis with upward bowing of the roof of the fourth ventricle. **B,** Axial T2-weighted image shows the molar tooth at the level of the midbrain, the hallmark of Joubert syndrome and related disorders (JSRD). *(From Rollins N. Congenital brain malformations. In: Coley BD, ed. Caffey's Pediatric Diagnostic Imaging, 13th ed. Philadelphia: Elsevier; 2019, Fig. 31.29AB, p. 286.)*

Fig. 637.4 Conjunctival telangiectasia in a patient with ataxia-telangiectasia. *(From Daroff RB, Jankovic J, Mazziotta JC, et al., eds. Bradley's Neurology in Clinical Practice, 7th ed. Philadelphia: Elsevier; 2016, Fig. 97.6, p. 1468.)*

is the method of choice for investigating congenital abnormalities of the cerebellum, vermis, and related structures. **Agenesis of the cerebellar vermis** presents in infancy with generalized hypotonia and decreased deep tendon reflexes. Delayed motor milestones and truncal ataxia are typical. **Joubert syndrome and related disorders** are autosomal recessive disorders marked by developmental delay, hypotonia, abnormal eye movements, abnormal respirations, and a distinctive malformation of the cerebellum and brainstem that manifests as the "molar tooth sign" on axial MRI (Fig. 637.3). Pathogenic variants in more than 21 different genes are associated with Joubert syndrome, but only approximately 50% of patients have demonstrated a pathogenic variant.

The major **infectious or postinfectious causes of ataxia** include acute cerebellar ataxia, infectious cerebellitis, immune-mediated cerebellitis, and acute labyrinthitis. **Acute cerebellar ataxia** occurs primarily in children 1-3 years of age and is a diagnosis of exclusion. The condition often follows a viral illness, such as varicella virus, coxsackievirus, or echovirus infection, by 2-3 weeks. It is thought to represent an autoimmune response to the viral agent affecting the cerebellum (see Chapter 643). The onset is typically sudden, and the truncal ataxia can be so severe that the child is unable to stand or sit. Vomiting may occur initially, but fever and nuchal rigidity are absent because of the lack of meningeal involvement. Horizontal nystagmus is evident in ~50% of cases; if the child is able to speak, dysarthria may be impressive. Examination of the cerebrospinal fluid is typically normal at the onset of ataxia, but a mild lymphocytic pleocytosis (10-30/mm^3) is not unusual. Later in the course, the cerebrospinal fluid protein undergoes a moderate elevation. The ataxia begins to improve in a few weeks but may persist for as long as 3 months, and rarely longer than that. The incidence of acute cerebellar ataxia appears to have declined with increased rates of vaccination against varicella. The prognosis for complete recovery is excellent. A small number of patients have long-term sequelae, including behavioral and speech disorders, as well as ataxia and incoordination. **Acute cerebellitis**, in contrast, is a more severe form of cerebellar ataxia characterized by abnormalities on MRI scans, more severe symptoms, and a worse long-term prognosis. Infectious agents include Epstein-Barr virus, mycoplasma, mumps, and influenza virus. An inflammatory process such as hemophagocytic lymphohistiocytosis may involve the cerebellum. Cerebellar abscesses can also occur with bacterial infections. In many, the etiology is unknown, but autoimmune cerebellitis may represent some of these unknown cases. Clinically, patients may present with ataxia, increased intracranial pressure from obstructive hydrocephalus, headache, and fever. **Acute labyrinthitis** may be difficult to differentiate from acute cerebellar ataxia in a toddler. The condition is associated with middle ear infections and presents with intense vertigo, vomiting, and abnormalities in labyrinthine function.

Toxic causes of ataxia include alcohol, thallium (which is used occasionally in homes as a pesticide), dextromethorphan, and anticonvulsants, particularly phenytoin and carbamazepine, when serum levels exceed the usual therapeutic range.

Brain tumors (see Chapter 546), including tumors of the cerebellum and frontal lobe, may present with ataxia. Cerebellar tumors cause ataxia because of direct disruption of cerebellar function or indirectly because of increased intracranial pressure from compression of the fourth ventricle. Frontal lobe tumors may cause ataxia as a consequence of destruction or interruption of the associated fibers connecting the frontal lobe with the cerebellum or because of increased intracranial pressure. Neuroblastoma (see Chapter 547) may be associated with a paraneoplastic encephalopathy characterized by progressive ataxia, myoclonic jerks, and opsoclonus (nonrhythmic, conjugate horizontal and vertical oscillations of the eyes).

Several **metabolic disorders** are characterized by ataxia, including abetalipoproteinemia, arginosuccinic aciduria, and Hartnup disease (see Table 637.2). **Abetalipoproteinemia** (Bassen-Kornzweig disease) is an autosomal recessive disorder caused by a pathogenic variant in the microsomal triglyceride transfer protein (MTP). This disorder begins in childhood with steatorrhea and failure to thrive. A blood smear shows acanthocytosis, which consists of spiculated red blood cells. Serum chemistries reveal decreased levels of cholesterol and triglycerides and absent serum β-lipoproteins. Neurologic signs become evident by late childhood and consist of ataxia, retinitis pigmentosa, peripheral neuritis, abnormalities of position and vibration sense, muscle weakness, and intellectual disability. Vitamin E is undetectable in the serum of patients with neurologic symptoms. In addition, ataxia may be one manifestation of a **mitochondrial disorder**; these include myoclonic epilepsy with ragged red fibers (MERFF), Kearns-Sayre syndrome, *POLG1* pathogenic variants, and Charlevoix-Saguenay syndrome.

Degenerative diseases of the central nervous system represent an important group of ataxic disorders of childhood because of the genetic consequences and poor prognosis. **Ataxia-telangiectasia**, an autosomal recessive condition, is the most common of the degenerative ataxias and is heralded by ataxia beginning at approximately age 2 and progressing to loss of ambulation by adolescence. Ataxia-telangiectasia is caused by pathogenic variants in *ATM*. ATM is a phosphatidylinositol-3 kinase that phosphorylates proteins involved in DNA repair and cell-cycle control. Oculomotor apraxia of horizontal gaze, defined as difficulty shifting the gaze from one object to another and overshooting the target with lateral movement of the head, followed by refixating the eyes, is a frequent finding. In addition, strabismus, hypometric saccade pursuit abnormalities, and nystagmus are often seen. Ataxia-telangiectasia may also present with chorea (see Chapter 637.2) rather than ataxia. The telangiectasia becomes evident by mid-childhood and is found on the bulbar conjunctiva, over the bridge of the nose, and on the ears and exposed surfaces of the extremities (Fig. 637.4). Examination of the skin shows a loss of elasticity. Abnormalities of

immunologic function that lead to frequent sinopulmonary infections include decreased serum and secretory immunoglobulin (Ig) A, as well as diminished IgG2, IgG4, and IgE levels in more than 50% of patients. Children with ataxia-telangiectasia have a 50- to 100-fold increased risk of developing lymphoreticular tumors (lymphoma, leukemia, and Hodgkin disease) and brain tumors. Additional laboratory abnormalities include an increased incidence of chromosome breaks, particularly of chromosome 14, and elevated levels of α-fetoprotein. Death typically results from infection or tumor dissemination.

Friedreich ataxia is inherited as an autosomal recessive disorder involving the spinocerebellar tracts, dorsal columns in the spinal cord, pyramidal tracts, and cerebellum and medulla. Most patients are homozygous for a GAA trinucleotide repeat expansion in the noncoding region of the gene coding for the mitochondrial protein frataxin. Pathogenic variants cause oxidative injury associated with excessive iron deposits in mitochondria. The onset of ataxia is somewhat later than in ataxia-telangiectasia but usually occurs before the age of 10. The ataxia is slowly progressive and involves the lower extremities to a greater degree than the upper extremities. Examination will demonstrate a positive Romberg test and absent deep tendon reflexes (particularly at the ankle); the plantar response is typically extensor (Babinski sign). Patients develop a characteristic explosive, dysarthric speech; nystagmus is present in most children. Although patients may appear apathetic, their intelligence is preserved. They may have significant weakness of the distal musculature of the hands and feet. Marked loss of vibration and joint position sense is common and is caused by degeneration of the posterior columns. Friedreich ataxia is also characterized by skeletal abnormalities, including high-arched feet (pes cavus) and hammer toes, as well as progressive kyphoscoliosis. Results of electrophysiologic studies, including visual, auditory brainstem, and somatosensory-evoked potentials, are often abnormal. Hypertrophic cardiomyopathy with progression to intractable congestive heart failure is the cause of death for most patients.

In addition to ataxia-telangiectasia and Friedreich ataxia, there are more than 40 other known inherited causes of either autosomal dominant or recessive forms of ataxia (Fig. 637.5; see Tables 637.4-637.8). More specifically, there are more than 20 dominantly inherited spinocerebellar ataxias (SCAs), some of which are also repeat expansion disorders and can present in childhood. These include those associated with CAG (polyglutamine) trinucleotide repeats and noncoding microsatellite expansions. There is also a separate group of dominantly inherited episodic ataxias (EAs) caused by potassium or calcium channel dysfunction. These disorders present as episodes of ataxia and muscle weakness and at times may respond to acetazolamide. The dominantly inherited **olivopontocerebellar atrophies** include ataxia, cranial nerve palsies, and abnormal sensory findings in the second or third decade, but can present in children with rapidly progressive ataxia, nystagmus, dysarthria, and seizures. **Roussy-Levy disease** has, in addition to ataxia, atrophy of the muscles of the lower extremity with a pattern of wasting similar to that observed in Charcot-Marie-Tooth disease. **Ramsay Hunt syndrome** has an associated myoclonic epilepsy.

Additional degenerative ataxias include **Pelizaeus-Merzbacher disease**, **neuronal ceroid lipofuscinoses**, and late-onset **GM_2 gangliosidosis** (see Chapter 639). Rare forms of progressive cerebellar ataxia have been described in association with **vitamin E deficiency**.

Visit Elsevier eBooks+ at eBooks.Health.Elsevier.com for Bibliography.

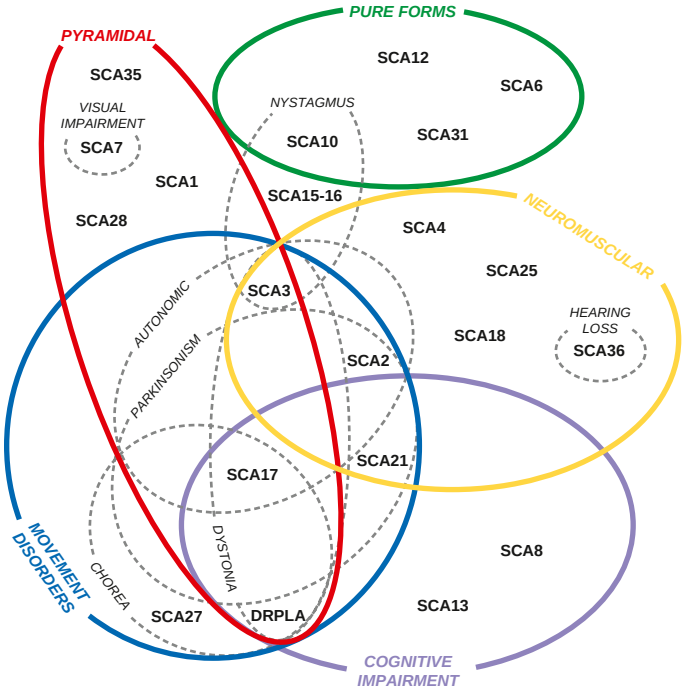

Fig. 637.5 Organization of spinocerebellar ataxias (SCA) according to main clinical features. *(From Rossi M, Perez-Lloret S, Doldan L, et al. Autosomal dominant cerebellar ataxias: a systematic review of clinical features. Eur J Neurol. 2014;21:607–615, Fig. 2.)*

637.2 Chorea, Athetosis, and Tremor

Jennifer A. Vermilion and Jonathan W. Mink

Chorea, meaning "dance-like" in Greek, refers to rapid, chaotic movements that seem to flow unpredictably from one body part to another. Affected individuals often appear restless, and movements exhibit randomness. They often demonstrate motor impersistence on neurologic examination, showing classic signs such as "darting tongue" (difficulty maintaining tongue protrusion) or "milkmaid grip" (difficulty maintaining grip). Chorea tends to occur both at rest and with action, although certain actions or postures can exacerbate chorea. Patients often attempt to incorporate the involuntary movements into more purposeful-seeming movements, making them appear fidgety. *Chorea increases with stress and disappears in sleep.* Chorea has traditionally been divided into primary and secondary forms; however, this classification scheme in movement disorders can cause confusion given the recent explosion of genetic discoveries in the field. Rather, it may be more helpful to classify chorea causes by etiology: acquired or inherited (Tables 637.9 and 637.10).

Sydenham chorea (St. Vitus dance; rheumatic chorea) is the most common acquired chorea of childhood, although the prevalence varies worldwide. It occurs in 10–20% of patients with **acute rheumatic fever**, typically weeks to months after a group A β-hemolytic streptococcal infection (see Chapter 194). Peak incidence is at age 8-9 years, with a female predominance of 2:1. There is evidence that group A β-hemolytic streptococci promote the generation of cross-reactive or polyreactive antibodies through molecular mimicry between streptococcal and host antigens. Specifically, antibodies against the *N*-acetyl-β-d-glucosamine epitope (GlcNAc) of streptococcal group A carbohydrate appear to target intracellular β-tubulin and extracellular lysoganglioside GM_1 in human caudate-putamen preparations. These antibodies are also capable of causing calcium/calmodulin–dependent protein kinase II activation, which may cause the neurologic manifestations of Sydenham chorea by increasing dopamine release into the synapse.

The clinical hallmarks of Sydenham chorea are chorea, hypotonia, and emotional lability. Onset of the chorea is typically over hours to days, but it may be more abrupt. Chorea is typically generalized, although often asymmetric; up to 20% have hemichorea. Parents may describe the child as seeming clumsy and dropping items while awake with cessation of adventitious movements during sleep. Hypotonia manifests with the *pronator sign* (arms and palms turn outward when held overhead) and the *choreic hand* (spooning of the extended hand by flexion of the wrist and extension of the fingers). When chorea and hypotonia are severe, the child may be incapable of feeding, dressing, or walking without assistance. Speech is often involved, sometimes to the point of being unintelligible. Periods of uncontrollable crying and extreme mood

Table 637.9 Acquired Causes of Chorea

STRUCTURAL-BASAL GANGLIA LESIONS	
Stroke	
Moyamoya disease	
Vascular malformations	
Hemorrhage	
Choreoathetoid cerebral palsy (dyskinetic cerebral palsy)	
Postcardiac transplant (postpump chorea)	
Mass lesions (CNS lymphoma, metastatic brain tumors)	
Multiple sclerosis plaque	
Extrapontine myelinolysis	
Trauma	
PARAINFECTIOUS AND AUTOIMMUNE DISORDERS	
Poststreptococcal Sydenham chorea	
Chorea secondary to systemic lupus erythematosus	
Chorea secondary to antiphospholipid antibody syndrome	
Acute disseminated encephalomyelitis	
Anti-NMDA receptor encephalitis	
Rasmussen encephalitis	
Chorea gravidarum	
Postinfectious or postvaccinal encephalitis	
Paraneoplastic choreas	
Celiac disease	
INFECTIOUS DISORDERS	
HIV encephalopathy	
Toxoplasmosis	
Cysticercosis	
Diphtheria	
Bacterial endocarditis	
Neurosyphilis	
Scarlet fever	
Viral encephalitis (mumps, measles, varicella)	
METABOLIC OR TOXIC DISORDERS	
Acute intermittent porphyria	
Hyponatremia/hypernatremia	
Hypocalcemia	
Hyperthyroidism	
Hypoparathyroidism	
Hepatic/renal failure	
Carbon monoxide poisoning	
Methyl alcohol	
Toluene	
Manganese poisoning	
Mercury poisoning	
Organophosphate poisoning	
Pheochromocytoma	
PSYCHOGENIC DISORDERS	
DRUG-INDUCED DISORDERS	
Dopamine-blocking agents (upon withdrawal or as a tardive syndrome)	Phenothiazines Butyrophenones Benzamides
Antiparkinsonian drugs	L-DOPA Dopamine agonists Anticholinergics
Antiepileptic drugs	Phenytoin Carbamazepine Valproic acid
Psychostimulants	Amphetamines Methylphenidate Cocaine
Calcium channel blockers	Cinnarizine Flunarizine Verapamil
Others	Lithium Baclofen Digoxin Tricyclic antidepressants Cyclosporine Steroids/oral contraceptives Theophylline Propofol

swings are characteristic and may precede the onset of the movement disorder. Patients may also demonstrate inattention, anxiety, obsessive-compulsive symptoms, paranoia, and a reluctance to speak. It is not clear if these psychiatric symptoms represent an increased susceptibility to developing Sydenham chorea or if they are part of the disorder.

Sydenham chorea is a clinical diagnosis; a combination of acute *and* convalescent serum antistreptolysin O titers may help to confirm an acute streptococcal infection. Negative titers do not exclude the diagnosis. All patients with Sydenham chorea should be evaluated for carditis and treated with long-term antibiotic prophylaxis to decrease the risk of rheumatic heart disease with recurrence (see Chapter 487). This prophylaxis should be continued until the patient is 21 years old. For patients with chorea that is impairing, treatment options include valproate, carbamazepine, and dopamine receptor antagonists. There have been conflicting data regarding the efficacy of prednisone, intravenous immunoglobulin (IVIG), and other immunomodulatory agents in Sydenham chorea, making it difficult to recommend their routine use. One study compared high-dose prednisone (2 mg/kg/day, max: 60 mg) for 4 weeks to placebo and found that steroids reduced the time to remission. Another trial of IVIG, plasma exchange, and low-dose prednisone demonstrated an overall decreased severity of chorea in the IVIG and plasma exchange groups at 1-month follow-up. There is no evidence that prednisone, IVIG, or plasma exchange *alters the recurrence rate or long-term outcome*. Given the lack of impact on long-term outcome and the potential for side effects, immunomodulatory treatments are optional.

Sydenham chorea usually resolves spontaneously within 1 year, but symptoms may recur in about 20% of patients despite penicillin prophylaxis. Remote recurrence of chorea is rare, but may be provoked by streptococcal infections, pregnancy **(chorea gravidarum)**, or oral contraceptive use.

Although less common than Sydenham chorea, **systemic lupus erythematosus (SLE) and antiphospholipid antibody syndrome (APS)** (see Chapter 199) are known causes of chorea in children. In some cases, chorea may be the presenting sign of these disorders and clinically may be indistinguishable from Sydenham chorea.

Anti *N*-methyl-D-aspartic acid (anti-NMDA) receptor encephalitis is an immune-mediated encephalitis with movement disorder as a prominent feature. Abnormal movements, including chorea, may be the presenting feature in some cases. Other commonly reported abnormal movements include dystonia, stereotypies (limb and oral), and motor perseveration. In addition to abnormal movements, psychiatric symptoms, seizures, and autonomic instability commonly occur. Treatment includes removal of the tumor, if present, and immune therapies such as steroids, IVIG, plasma exchange, and rituximab.

Additional causes of acquired chorea include metabolic (hyperthyroidism, hypoparathyroidism), infectious (Lyme disease), vascular (stroke, moyamoya disease, postpump chorea), heredodegenerative disorders (Wilson disease), and drugs (see Table 637.9). Although chorea is a hallmark of Huntington disease in adults, children who develop Huntington disease tend to present with rigidity and bradykinesia **(Westphal variant)** or dystonia rather than chorea.

Various genetic diseases may manifest with chorea; some present with predominantly chorea, but most have a combination of neurologic, psychiatric, and systemic manifestations that accompany the movement disorder (see Table 637.10). **Benign hereditary chorea** is a relatively rare cause of chorea in childhood. It typically presents before age 5 years; the chorea is either stable or slowly progressive. Chorea tends to improve in the late teen to young adult years and often remits by mid-adulthood. It is most commonly secondary to a pathogenic variant in *NKX2-1*, which encodes for the protein thyroid transcription factor-1 (TTF1). The majority of patients (80%) also have hypothyroidism or neonatal respiratory distress syndrome **(brain-lung-thyroid syndrome)**. Variants in *NKX2-1* confer increased risk of lung cancer or emphysema in adulthood. Although children are considered cognitively normal, there are reports of an increased incidence of learning disabilities and attention-deficit/hyperactivity disorder (ADHD) in this population.

In ***ADCY5*-related dyskinesia**, chorea is a core feature. There is a phenotypic variability to this disorder, but some patients present with a form of familial benign chorea with onset of paroxysmal movements starting

Table 637.10 Inherited Causes of Childhood-Onset Chorea

DISEASE NAME	INHERITANCE	ASSOCIATED GENE	AGE OF ONSET	NEUROLOGIC OR PSYCHIATRIC MANIFESTATIONS	SYSTEMIC SYMPTOMS
CHOREA PROMINENT FEATURE					
Ataxia-telangiectasia	AR	*ATM*	18 mo to 3 yr	Chorea often initial symptom; also have oculomotor apraxia, ataxia, and dystonia	Telangiectasias, increased sinopulmonary infections, increased incidence of cancer
Ataxia with oculomotor apraxia 1 and 2 (especially type 1)	AR	*APTX*	Onset later than ataxia-telangiectasia	Chorea, dystonia, oculomotor apraxia, ataxia, distal sensory axonal neuropathy	
Friedreich ataxia	AR	GAAn in *FRDA*	Over 2 yr, usually teenagers	Gait ataxia, axonal neuropathy, areflexia, extensor plantar response. Can have various movements (tremor, dystonia, chorea, myoclonus). Cases of chorea without cerebellar signs described.	Cardiomyopathy, diabetes
GNAO1-related dyskinesias	AR	*GNAO1*	Infancy	Ballismus, chorea, orofacial dyskinesias; can alternatively cause Ohtahara syndrome	
FOXG1-related dyskinesias	AD	*FOXG1*	Infancy	Chorea, dystonia, athetosis, hand-mouthing stereotypies, postnatal microcephaly, epilepsy, severe developmental delay	
Benign hereditary chorea	AD	*NKX2-1*	Before age 5 yr	Chorea; can have myoclonus, learning disability	Thyroid disease, lung disease
ADCY5-associated dyskinesias	AD	ADCY5	Infancy to late adolescence	Chorea, choreic facial twitches (previously called myokymia); can have myoclonus or dystonia	Some reports of congestive heart failure
PDE10A-associated dyskinesias	AD or AR	*PDE10A*	AD: childhood AR: infancy	Chorea, MRI striatal changes in AD form	
Paroxysmal nonkinesigenic dyskinesias	AD	*PNKD*	Infancy to 10 yr	Dystonia, chorea, or a combination	
3-methylglutaconic aciduria type III (Costeff syndrome)	AR	*OPA3*	Infancy	Bilateral optic atrophy and chorea early; spasticity, ataxia, and dementia later	
Congenital cataracts, facial dysmorphism, and neuropathy	AR	*CTDP1*	Infancy or childhood	Progressive neuropathy, delayed psychomotor development, mild chorea, hypomyelination, hearing loss	Skeletal abnormalities, dysmorphic face, congenital cataracts, microcornea, hypogonadism
Dentatorubral-pallidoluysian atrophy	AD	CAGn in *atrophin-1*	Mostly adults but seen in a few children	Neurodegeneration, chorea, tics, dementia, seizures, ataxia, psychiatric symptoms	
Huntington chorea/disease	AD	CAGn in *HTT*	Adolescence to 40s	Younger onset *without* chorea and with parkinsonism, but later, teenagers can manifest chorea, emotional disturbances similar to adult form	
Huntington disease-like-3 (HDL3)	AR	Linked to chromosome 4p15.3	Childhood	Neurodegeneration, chorea, dystonia, ataxia, dementia, seizures	
Idiopathic basal ganglia calcification (IBGC), childhood onset (bilateral striopallidodentate calcinosis)	AR or AD	*SLC20A2* or *PDGFRB*	Infancy to second decade of life	Tetraplegia, chorea, severe cognitive impairment, microcephaly, basal ganglia calcifications	Early death

Continued

Table 637.10 Inherited Causes of Childhood-Onset Chorea—cont'd

DISEASE NAME	INHERITANCE	ASSOCIATED GENE	AGE OF ONSET	NEUROLOGIC OR PSYCHIATRIC MANIFESTATIONS	SYSTEMIC SYMPTOMS
Choreoacanthocytosis	AR	*VPS13A*	Mean age 20 yr but described in childhood	Psychiatric symptoms (e.g., obsessive-compulsive disorder) can precede neurologic symptoms. Neurodegeneration, progressive hyperkinetic movements (limb chorea, orofacial dyskinesias, tics, dystonia), dementia, seizures, cognitive decline, sensorimotor polyneuropathy.	Acanthocytosis, increased CK and/or liver transaminases
Spinocerebellar ataxia 1	AD	CAGn in *ATXN1*	Childhood	Neurodegeneration, progressive ataxia, mild cognitive impairment, dysarthria, ophthalmoplegia, optic atrophy, spasticity, dystonia or chorea	
Spinocerebellar ataxia 17	AD	CAGn or CAAn in *TBP*	Mostly early adulthood but some teenagers reported	Neurodegeneration, psychiatric symptoms (depression, hallucinations), frontal release signs, chorea, dystonia, and parkinsonism; may have ocular movement abnormalities	
Leigh syndrome	X-linked	*PDHA1*	Infancy or childhood	Neurodegeneration, psychomotor delay, hypotonia and chorea and other hyperkinetic movements can be prominent, progresses to feeding and swallowing defects, nystagmus, ophthalmoplegia, optic atrophy, seizures Lesions in basal ganglia, cerebrum, cerebellum, spinal cord	Lactic acidemia, respiratory failure
Nonketotic hyperglycemia (glycine encephalopathy)	AR	*GLDC, GCST,* or *GCSH*	Neonates/ infancy	Hypotonia, severe myoclonic epilepsy, profound cognitive impairment, restlessness	Hyperglycemia
Infantile bilateral striatal necrosis	AR	*NUP62*	Infancy	Developmental regression, intellectual disability, pendular nystagmus, optic atrophy, dysphagia, dystonia, choreoathetosis, spasticity, and severe bilateral striatal atrophy	
CHOREA SOMETIMES PRESENT					
Spinocerebellar ataxia 7	AD	CAGn in *ATXN7*	Childhood	Neurodegenerative mitochondrial disorder, progressive ataxia, dysarthria, dysphagia, optic atrophy, ophthalmoplegia, spasticity, dystonia or chorea may occur	Retinal degeneration
Wilson disease	AR	*ATP7B*	12 yr to early 20s	Dysarthria, drooling, pharyngeal dysmotility, clumsiness, tremor ("wing-beating"), psychiatric symptoms (decline in school, anxiety, depression, psychosis); chorea and dystonia variable	Hepatic dysfunction (asymmetric hepatomegaly, acute transient or fulminant hepatitis), Kayser-Fleischer rings of cornea
Lesch-Nyhan disease	X-linked	*HPRT*	Early childhood	Self-injurious behaviors, intellectual disability, motor disability, pyramidal signs, dystonia superimposed on hypotonia, may have chorea or ballismus, abnormal ocular motility	Hyperuricemia, nephrolithiasis, gout
Pantothenate kinase–associated neurodegeneration (PKAN), classic form	AR	*PANK2*	Before 6 yr old (in classic onset)	Progressive motor difficulties, personality changes, cognitive decline, dysarthria, spasticity; later onset of movements (dystonia most common, chorea or tremor may also be present); "eye of the tiger" sign on MRI of brain	Pigmentary retinal degeneration, acanthocytosis

Table 637.10 Inherited Causes of Childhood-Onset Chorea—cont'd

DISEASE NAME	INHERITANCE	ASSOCIATED GENE	AGE OF ONSET	NEUROLOGIC OR PSYCHIATRIC MANIFESTATIONS	SYSTEMIC SYMPTOMS
Paroxysmal kinesigenic dyskinesia (PKD)	AD	*PRRT2*	1-20 yr	Short episodes triggered by sudden movement; dystonia is most common movement but can have chorea	
Biopterin-dependent hyperphenylalaninemia (group of disorders)	Usually AR	Multiple genetic causes	Neonate	Initially hypotonic with poor suck, decreased movements, and microcephaly; months later, oculogyric crises, swallowing difficulties, variable hypokinetic and hyperkinetic movements, seizures, cognitive impairment	Elevated phenylalanine level at birth; autonomic symptoms start several months later
Glutaric aciduria	AR	*GCDH*	First 6 mo	Hypotonia and jitteriness at birth; at 6-18 mo, progressive hyperkinetic movements (dystonia, choreoathetosis); may have seizures	
Alternating hemiplegia of childhood	AR	*ATP1A-3*	Neonate to <18 mo	Transient episodes of alternating hemiplegia/hemiparesis, dystonic attacks, paroxysmal abnormal ocular movements, seizures, episodes of autonomic dysfunction; between attacks, may have ataxia, dystonia, and/or choreoathetosis; most have intellectual disability	
Succinate semialdehyde dehydrogenase deficiency	AR	*ALDH5A*	Infancy to early childhood	Intellectual disability, pronounced language dysfunction, autistic traits, hypotonia, aggression, ataxia, anxiety, hallucinations, can have choreoathetosis	

anywhere from infancy to late adolescence. Although chorea is the most commonly described movement, there are reports of myoclonic or dystonic movements as well. Movements are more common in the arms and face and less common in the legs. *ADCY5*-related dyskinesia has commonly been associated with choreic facial twitches that were previously considered facial myokymia (known as **familial dyskinesia with facial myokymia**). Interestingly, movements in this form can persist in sleep. Symptoms can fluctuate such that chorea may be paroxysmal; they tend to be worsened by specific actions and anxiety. These patients also tend to have a stable or very slowly progressive course that tends to stabilize and even improve in middle age. *ADCY5*-related dyskinesia can have a more severe presentation with infantile onset of axial hypotonia and developmental delay. *ADCY5*-related dyskinesia has not been associated with thyroid or lung disease; however, heart failure has been reported in five patients. Although these conditions are called benign, these movements can be disabling and progressive in some patients. Therefore some patients may warrant symptomatic treatment. Although there is no proven symptomatic treatment for these conditions, there have been reports of benefit with dopamine receptor–blocking or –depleting agents. In a few cases, low-dose levodopa has provided benefit.

A pure, benign, and nonprogressive childhood-onset chorea has been described in a few patients with pathogenic variants in *PDE10A*, which encodes for a phosphodiesterase. Children with de novo dominant variants characteristically have symmetric T2 hyperintensities in the bilateral striatum on brain MRI. Children with recessive homozygous variants have been described with an earlier age of onset and a more severe clinical course.

Paroxysmal dyskinesias can present with chorea or dystonia, or both; chorea is most commonly associated with **paroxysmal nonkinesigenic dyskinesia (PNKD)**. This disorder presents in the first decade of life, with ~30% of patients manifesting symptoms in the first year of life. Patients often have both chorea and dystonia, although some patients manifest only dystonia. Episodes can last minutes to hours, and children are normal between episodes. The episodes are not triggered by sudden movement but can be precipitated by alcohol, caffeine, or emotional stress. About half of patients report a premonitory sensation or a sense of anxiety before an episode. Although various genes have been implicated in this disorder, *PNKD* (formerly known as *MR-1*) is most commonly associated with PNKD. Patients with a *PNKD* pathogenic variant often respond to benzodiazepines; avoidance of triggers is also important. Symptoms typically improve with age. Variants in *KCNMA1* can also cause a PNKD phenotype, although these children often have other neurologic abnormalities.

Some inherited disorders classified as ataxia syndromes also manifest with significant chorea. **Ataxia-telangiectasia** typically presents as a mixed movement disorder with ataxia, dystonia, and chorea in early childhood (18 months to 3 years). These symptoms present before the appearance of telangiectasias. Over time, children have progression of limb and gait involvement and typically become nonambulatory in childhood. Children also present with oculomotor apraxia (difficulty in initiating horizontal and vertical saccades). Ataxia-telangiectasia is an autosomal recessive disorder secondary to pathogenic variants in *ATM*. Because this gene encodes for a protein involved in DNA repair mechanisms, affected children are at increased risk of sinopulmonary infectious and lymphoreticular neoplasms. When this disease is suspected, the initial workup involves testing the alpha-fetoprotein (AFP) level, which is abnormally increased in this population. **Ataxia with oculomotor apraxia type 1 (AOA1)** is also associated with a mixed movement disorder and is caused by variants in *APTX*, which encodes for the aprataxin protein. Up to 80% of children have chorea and dystonia as their initial symptoms. Other neurologic symptoms include oculomotor apraxia, ataxia, and a distal sensory axonal neuropathy. The movement disorder tends to be most severe early in the disease and improves as the disease progresses. Unlike ataxia-telangiectasia, this disorder is not associated with skin findings or an increased incidence of cancer.

Chorea can also be a major manifestation in children with inherited conditions that have a progressive, severe course. **Pontocerebellar hypoplasia type 2A (PCH-2A)** is associated with chorea present from a young age. The majority of patients have chorea within the first 6 months of life. PCH-2A is associated with an acquired microcephaly, extrapyramidal dyskinesias, and spasticity. These children have significant psychomotor delay with early death. Although various genes have

been implicated in the different forms of pontocerebellar hypoplasia, PCH-2A is associated with pathogenic variants in *TSEN54,* which encodes for a protein involved in transfer RNA (tRNA) splicing. Variants in *GNAO1,* which encodes for the alpha subunit of G proteins, have been described as causing a particular movement disorder in affected children. This gene has previously been described as a cause of early infantile epileptic encephalopathy **(Ohtahara syndrome)**. However, affected children may instead manifest with hypotonia, developmental delay without epilepsy, and a movement disorder characterized by chorea and ballismus in the first decade of life. Chorea tends to start acutely during an illness. Some children with *GNAO1* variants have a severe movement disorder without seizures. Orofacial dyskinesias are common. Children often have periods of movement exacerbations that can be accompanied by autonomic changes. These movements can be refractory to treatment and led to death in two of the children in a study. Deep brain stimulation has been proposed as a potential treatment for these medically refractory children. *FOXG1* variants are associated with postnatal microcephaly, an early epileptic encephalopathy, and abnormal movements. Chorea is commonly reported and may involve the upper extremities and orolingual muscles. Dystonia, athetosis, and stereotypies are also reported.

Athetosis is characterized by slow, continuous, writhing movements that repeatedly involve the same body part(s), usually the distal extremities, face, neck, or trunk. Like chorea, athetosis may occur at rest and is often worsened by voluntary movement. Because athetosis tends to occur with other movement disorders, such as chorea **(choreoathetosis)** and dystonia, it is often difficult to distinguish as a discrete entity. Choreoathetosis is common in dyskinetic cerebral palsy, which can result from hypoxic ischemic encephalopathy, kernicterus, or other basal ganglia injuries. Cerebral palsy is a static disturbance in the developing brain that results in motor impairment. Dyskinetic cerebral palsy, the second most common form after spastic cerebral palsy, typically presents with dystonia and choreoathetosis. The choreoathetosis is typically more common in the upper body. Choreoathetosis is often seen in conjunction with **rigidity**—increased muscle tone that is equal in the flexors and extensors in all directions of passive movement regardless of the velocity of the movement. This is to be differentiated from **spasticity**, a velocity-dependent (clasp-knife) form of hypertonia that is seen with upper motor neuron dysfunction. Case reports in dyskinetic cerebral palsy report chorea improvement with levetiracetam. In addition, a small study of risperidone in children with dyskinetic cerebral palsy reported improvement in abnormal movements and behavior.

Tremor is a rhythmic, oscillatory movement around a central point or plane that results from the action of antagonist muscles. Tremor can affect the extremities, head, trunk, or voice and can be classified by both its frequency (slow [4 Hz], intermediate [4-7 Hz], and fast [>7 Hz]) and by the context in which it is most pronounced. **Rest tremor** is maximal when the affected body part is inactive and supported against gravity, whereas **postural tremor** is most notable when the patient sustains a position against gravity. **Action tremor** occurs with performance of a voluntary activity and can be subclassified into **simple kinetic tremor**, which occurs with limb movement, and **intention tremor**, which occurs as the patient's limb approaches a target and is a feature of cerebellar disease.

Essential tremor (ET) is the most common movement disorder in adults, and 50% of persons diagnosed with ET report an onset in childhood; thus ET may be the most common tremor disorder in children as well. Clinical experience in a pediatric movement disorders clinic suggests that ET is more common in the pediatric population than the literature would suggest. ET is an autosomal dominant condition with variable expressivity but complete penetrance by the age of 60 years. Although the genetics of ET are not fully understood, at least five genes (*EMT1, EMT2, EMT3, EMT4,* and *EMT5*) are linked to this condition. In addition, polymorphisms in the gene *LINGO1* (also known as *LRRN6A*) have been associated with ET.

ET is characterized by a slowly progressive, bilateral, 4- to 9-Hz postural tremor that involves the upper extremities and occurs in the absence of other known causes of tremor. Face, neck, and voice tremors are less common but can occur. Mild asymmetry in the upper extremities is common, but ET is rarely unilateral. ET may be worsened by actions, such as trying to pour water from cup to cup. Affected adults may report a history of ethanol responsiveness. In the adult literature, there is a consensus on diagnostic criteria; there are no specific criteria in children. Unlike adults, children do not require a 5-year duration of symptoms to make the diagnosis of ET. Most young children come to medical attention once a parent, teacher, or therapist notices the tremor, rather than because the tremor causes impairment. Most children with ET do not require pharmacologic intervention. If they are having difficulty with their handwriting or self-feeding, an occupational therapy evaluation and/or assistive devices, such as wrist weights and weighted silverware, may be helpful. Teenagers tend to report more impairment from ET. Teenagers who do warrant pharmacotherapy usually respond to the same medications that are used in adults—propranolol and primidone. Propranolol, which is generally considered the first-line treatment, can be started at 10-40 mg daily and titrated to effect, with most patients responding to doses of 60-80 mg/day. Propranolol should not be used in patients with reactive airway disease. Primidone can be started at 12.5-25 mg at bedtime and increased gradually in a twice-daily schedule. Most patients respond to doses of 50-200 mg/day. Other treatment options for ET reported in the adult literature include atenolol, gabapentin, pregabalin, topiramate, and alprazolam. Surgical treatments, which include deep brain stimulation of the thalamus and unilateral thalamotomy, are generally reserved for adults with medically refractory disabling tremor.

Enhanced physiologic tremor is one of the most common etiologies of tremor in adolescents. This tremor occurs in healthy people and is characterized by a symmetric hand tremor that is often of faster frequency and lower amplitude than an ET. Triggers include increased emotions, fatigue, fever, hunger, and waking from sleep. Substances such as caffeine may enhance a tremor. Weighted objects may decrease tremor frequency.

In children 3-7 years old, coordination difficulties due to developmental delay can present with nonprogressive tremor. Many children with motor delays will have a hand and possibly truncal tremor that is most apparent with fine motor tasks, such as drawing, using scissors, or playing with small toys. The history often shows that these children are behind typically developing children in terms of fine and/or gross motor skills and speech articulation. Examination shows that the movement tends to be a small-amplitude, regular or irregular postural or intention tremor. Walking and running may be clumsy. Evidence-based treatment has not been established for tremor related to developmental delay; however, referral to occupational therapy may help to identify strategies to improve coordination in these children.

Infantile tremor syndrome is a disorder of unknown etiology that presents at age 6-18 months with regression or plateaued development, coarse tremor, and anemia. Potential etiologies include deficiencies in vitamin B_{12}, iron, zinc, or magnesium.

There are numerous secondary etiologies of tremor in children (Table 637.11). **Holmes tremor**, previously referred to as *midbrain* or *"rubral" tremor,* is characterized by a slow-frequency, high-amplitude tremor that is present at rest and with intention. It is a symptomatic tremor, which usually results from lesions of the brainstem, cerebellum, or thalamus. **Functional (psychogenic) tremor** is distinguished by its variable appearance, abrupt onset and remission, nonprogressive course, and association with selective but not task-specific disabilities.

In some cases, tremor may even occur as a manifestation of another movement disorder, as is seen with position- or task-specific tremor (e.g., writing tremor), dystonic tremor, and myoclonic tremor.

When evaluating a child with tremor, it is important to screen for common metabolic disturbances, including electrolyte abnormalities and thyroid disease, assess the child's caffeine intake, and review the child's medication list for known tremor-inducing agents. It is also critical to exclude Wilson disease in teenagers with characteristic "wing-beating" tremor (low-frequency/high-amplitude posture initiated with horizontal position and abduction of arms, flexed elbows, and downward-facing palms with resultant shoulder and hand tremors) because this is a treatable condition.

Visit Elsevier eBooks+ at eBooks.Health.Elsevier.com for Bibliography.

Table 637.11 Selected Causes of Tremor in Children
BENIGN TREMORS
Enhanced physiologic tremor
Developmental delay
Shuddering attacks
Jitteriness
Spasmus nutans
STATIC INJURY/STRUCTURAL TREMORS
Cerebellar malformation
Stroke (particularly in the midbrain or cerebellum)
Multiple sclerosis
HEREDITARY/DEGENERATIVE TREMORS
Familial essential tremor
Fragile X premutation
Wilson disease
Huntington disease
Juvenile parkinsonism (tremor is rare)
Pallidonigral degeneration
METABOLIC TREMORS
Hyperthyroidism
Hyperadrenergic state (including pheochromocytoma and neuroblastoma)
Hypomagnesemia
Hypocalcemia
Hypoglycemia
Hepatic encephalopathy
Vitamin B12 deficiency
Inborn errors of metabolism
Mitochondrial disorders
DRUGS/TOXINS
Valproate, phenytoin, carbamazepine, lamotrigine, gabapentin, lithium, tricyclic antidepressants, stimulants (cocaine, amphetamine, caffeine, thyroxine, beta agonist, bronchodilators), neuroleptics, cyclosporine, toluene, mercury, thallium, amiodarone, nicotine, lead, manganese, arsenic, cyanide, naphthalene, ethanol, lindane, serotonin reuptake inhibitors
PERIPHERAL NEUROPATHIES
FUNCTIONAL (PSYCHOGENIC) TREMORS

637.3 Myoclonus

Jonathan W. Mink

Myoclonus refers to brief, abrupt, involuntary, nonsuppressible, jerky contractions (or interruption of contractions) involving a single muscle or muscle group. The rapidity of these movements is often described as *shocklike*. In some cases, myoclonus can be elicited by a sensory stimulus (reflex myoclonus; the most common example is the acoustic startle response in infancy) or volitional movement (action myoclonus). It is present in normal and pathologic situations, both epileptic and nonepileptic. Epileptic myoclonus is discussed in Chapter 633. Etiologic classification of myoclonus is summarized in Table 637.12.

Physiologic myoclonus occurs in healthy individuals in specific settings. It includes such entities as hiccups, sleep starts, and sleep myoclonus. Sleep starts, also known as *hypnic or hypnagogic myoclonus,* occur with sleep initiation. They are often accompanied by a sense of falling. Sleep starts are normal physiologic phenomena, and no treatment is required. Sleep myoclonus (nocturnal myoclonus) is also a part of normal sleep physiology. It typically occurs during rapid eye movement (REM) sleep owing to transient failure of brainstem inhibition. Sleep myoclonus tends to persist throughout life. No treatment is required.

Benign myoclonus may occur in association with specific developmental stages. Benign neonatal sleep myoclonus is characterized by repetitive myoclonic jerks occurring during sleep. The myoclonus is typically more distal than proximal and is more prominent in the upper than the lower extremities. The myoclonus can be focal, multifocal, unilateral, or bilateral. Typically, the movements occur in clusters of jerks at 1-5 Hz over a period of several seconds. Benign neonatal sleep myoclonus begins during the first week of life, diminishes in the second month, and is usually gone before 6 months of age. The movements are most likely to occur during quiet (non-REM) sleep but have been described in all sleep stages. Waking the baby causes the movements to abruptly cease. Neurologic examination and outcome are normal.

Myoclonus also can occur with fever in otherwise normal children. The myoclonic jerks may be quite frequent, but they are self-limited, ceasing when the fever resolves. Febrile myoclonus may be more common in younger children. No treatment is required.

Opsoclonus myoclonus (ataxia) syndrome (OMS/OMAS) is characterized by a combination of rapid, chaotic involuntary eye movements (opsoclonus), multifocal myoclonus, and ataxia. Irritability is a common feature. It typically begins abruptly in early childhood, most often before age 5 years. A common misdiagnosis is acute cerebellar ataxia (ACA) because both ACA and OMAS have subacute, progressive disturbances in gait, truncal instability, and behavioral irritability. Irritable toddlers are difficult to examine thoroughly, adding to the challenge of discerning the presence of multifocal mini-myoclonus and action myoclonus plus ataxia in a toddler with OMAS versus titubation, gait, and limb ataxia in ACA. At its peak, OMAS can cause marked disability for the child.

OMAS is an autoimmune condition in which there is abnormal B-cell trafficking in the central nervous system. It may follow a viral infection in many cases. A large proportion of children (40% by one estimate) with OMAS have a neuroblastoma, a potentially fatal neural crest tumor (see Chapter 547). Conversely, only a small proportion of children with neuroblastoma (probably <5%) have OMAS. The subacute onset of OMAS and the association with neural crest tumors support an autoimmune paraneoplastic etiology. Intensive research into multiple circulating autoantibodies, including antibodies to Purkinje cell targets, has not, to date, identified any unique, consistently present, disease-associated antibody.

OMAS is a clinical diagnosis. In the presence of subacute irritability, tremor, and ataxia, a diagnosis of OMAS must be considered, and children diagnosed with ACA should continue to be monitored for the emergence of symptoms characteristic of OMAS. The presence of opsoclonus has a high positive predictive value for OMAS, but its absence does not have a high negative predictive value. That is because opsoclonus can be subtle, intermittent, or late, so clinicians and parents need to continue to watch for it. Brain MRI should be normal, and cerebrospinal fluid unremarkable. No immune studies are clinically established for this diagnosis. The search for a neuroblastoma should be thorough and persistent in this clinical setting. MRI with gadolinium or CT with contrast of the chest and abdomen has the highest yield. Nuclear medicine ^{131}I-MIBG (metaiodobenzylguanidine) or ^{111}In-penetreotide (somatostatin receptor ligand) PET scans and urine collection for elevated 24-hour urine catecholamines and serum neuron-specific enolase may be considered but have a lower yield.

Multimodal treatment is required for OMAS. If related to neuroblastoma, the child will likely need immune-modulating treatments even if a tumor is identified and resected. Adrenocorticotrophin (ACTH) protocols are recommended based on expert consensus and clinical experience. In addition to ACTH, combination treatment with IVIG, plasmapheresis, rituximab, or other immune-modulating therapies may be needed. Symptomatic pharmacologic and behavioral therapy for myoclonus, behavioral problems, aggression, and insomnia may also be beneficial. Physical therapy, occupational therapy, and speech therapy may be beneficial. Suboptimal cognitive outcomes occur in most cases.

Causes of other types of myoclonus are listed in Table 637.12. Differentiating myoclonus and other movement disorders from a functional neurologic disorder may be difficult. Clues to a functional disorder are noted in Table 637.13.

Treatment of myoclonus is symptomatic and may be ineffective in many cases. Cortical myoclonus may respond to benzodiazepines and is commonly treated with clonazepam (although sleep myoclonus may worsen). Valproic acid is sometimes helpful, but it must be used with caution because of its ability to cause tremor as a side effect, with consequent confusion of symptoms. Other epilepsy medications, including levetiracetam and zonisamide, may be effective in some forms of myoclonus. Carbamazepine can worsen myoclonus.

Visit Elsevier eBooks+ at eBooks.Health.Elsevier.com for Bibliography.

Table 637.12 Etiologic Classification of Myoclonus

I. **Physiologic myoclonus (normal subjects)**
- A. Sleep jerks (hypnic jerks)
- B. Anxiety-induced
- C. Exercise-induced
- D. Hiccup (singultus)
- E. Benign infantile myoclonus with feeding

II. **Essential myoclonus (no known cause other than genetic and no other gross neurologic deficit)**
- A. Hereditary (autosomal dominant and most are likely myoclonus dystonia)
- B. Sporadic

III. **Epileptic myoclonus (seizures dominate and no encephalopathy, at least initially)**
- A. Fragments of epilepsy
  - Isolated epileptic myoclonic jerks
  - Photosensitive myoclonus
  - Myoclonic absences in petit mal
  - Epilepsia partialis continua
- B. Childhood myoclonic epilepsies
  - Infantile spasms
  - Myoclonic astatic epilepsy (Lennox-Gastaut)
  - Cryptogenic myoclonus epilepsy (Aicardi)
  - Juvenile myoclonus epilepsy of Janz
- C. Benign familial myoclonic epilepsy (Rabot)
- D. Progressive myoclonus epilepsy (Unverricht-Lundborg)

IV. **Symptomatic myoclonus (progressive or static encephalopathy dominates)**
- A. Storage disease
  - Lafora body disease
  - Lipidoses (e.g., GM1 and GM2 gangliosidosis, Krabbe)
  - Ceroid-lipofuscinosis (Batten)
  - Sialidosis ("cherry-red spot")
- B. Spinocerebellar degeneration
  - Unverricht-Lundborg disease
  - Ataxia telangiectasia
  - Adult-onset cerebellar ataxias
  - Some spinocerebellar ataxias (SCAs)
  - Multiple system atrophy type C
- C. Basal ganglia degenerations
  - Wilson disease
  - Dystonia
  - Pantothenate kinase–associated neurodegeneration
  - Progressive supranuclear palsy
  - Multiple system atrophy type P
  - Huntington disease
  - Corticobasal ganglionic degeneration
  - Dentatorubro-pallidoluysian atrophy
  - Parkinson disease
- D. Dementias
  - Creutzfeldt-Jakob disease
  - Alzheimer disease
- E. Viral encephalopathies
  - Subacute sclerosing panencephalitis (SSPE)
  - Encephalitis lethargica
  - Arbor virus encephalitis
  - Herpes simplex encephalitis
  - Postinfectious encephalitis
  - Whipple disease
  - AIDS
  - SARS-CoV-2
- F. Autoimmune
  - Opsoclonus-myoclonus syndrome
  - Celiac disease
- G. Metabolic
  - Hepatic failure
  - Renal failure
  - Dialysis syndrome
  - Hyponatremia
  - Hypoglycemia
  - Infantile myoclonic encephalopathy
  - Nonketotic hyperglycemia
  - Mitochondrial encephalomyopathy
  - Multiple carboxylase deficiency
  - Biotin deficiency
- H. Toxic encephalopathies
  - Bismuth
  - Heavy metal poisons
  - Methyl bromide, DDT
  - Drugs, including levodopa
  - Serotonin syndrome (e.g., SSRIs)
- I. Physical encephalopathies
  - Posthypoxic (Lance-Adams)
  - Posttraumatic
  - Heat stroke
  - Electric shock
  - Decompression injury
- J. Focal central nervous system damage
  - Poststroke
  - Postthalamotomy
  - Tumor
  - Trauma
  - Dentato-olivary lesions (palatal myoclonus/tremor)
- K. Functional

From Jankovic J, Hallett M, Okun MS, et al., eds. *Principles and Practice of Movement Disorders,* 3rd ed. Philadelphia: Elsevier; 2022: Table 18.2, p. 498.

637.4 Dystonia

Shannon L. Dean and Erika F. Augustine

Dystonia is a disorder of movement characterized by sustained muscle contractions, frequently causing twisting and repetitive movements or abnormal postures (Table 637.14). Major causes of dystonia include primary generalized dystonia, medications, metabolic disorders, and perinatal asphyxia (Tables 637.15 and 637.16).

INHERITED PRIMARY DYSTONIAS

Primary generalized dystonia, also referred to as *primary torsion dystonia* or *dystonia musculorum deformans,* is caused by a group of genetic disorders with onset in childhood (Fig. 637.6). Many of these disorders are autosomal dominant with incomplete penetrance, but genetic dystonias may also appear sporadically or be inherited in an autosomal recessive, X-linked, or mitochondrial pattern. Children are more likely to manifest with or progress to generalized dystonia, whereas segmental or focal dystonia is more common in adolescents and adults.

One form, which occurs more commonly in the Ashkenazi Jewish population, is caused by a dominant change in *DYT1* coding for the adenosine triphosphate (ATP)–binding protein torsinA. The initial manifestation of ***DYT1* dystonia** is often intermittent unilateral posturing of a lower extremity, which assumes an extended and rotated position. Ultimately, all four extremities and the axial musculature can be affected, but the dystonia may also remain localized to one limb. Cranial involvement can occur in *DYT1* dystonia, but it is uncommon compared with non-*DYT1* dystonias. There is a wide clinical spectrum, varying even within families. If a family history of dystonia is absent, the diagnosis should still be considered, given the intrafamilial variability in clinical expression.

More than two dozen loci for genes for **torsion dystonia** have been identified *(DYT1-DYT31).* More sophisticated genetic testing and genotype-phenotype correlation have eliminated some of these designations, and others have been linked to specific chromosomal regions but not yet to a specific gene. In this text we review only those linked definitively to a specific gene.

One is the autosomal dominant disorder **dopa-responsive dystonia (DRD, *DYT5a*)**, also called *Segawa syndrome.* The gene for DRD codes

for guanosine triphosphate cyclohydrolase 1, the rate-limiting enzyme for tetrahydrobiopterin synthesis, which is a cofactor for synthesis of the neurotransmitters dopamine and serotonin. Thus the genetic alteration results in dopamine deficiency. The hallmark of the disorder, particularly in adolescents and adults, is diurnal variation: symptoms worsen as the day progresses and may transiently improve with sleep. Early-onset patients, who tend to present with delayed or abnormal gait from dystonia of a lower extremity, can easily be confused with patients with dystonic cerebral palsy. It should be noted that in the presence of a progressive dystonia, diurnal fluctuation, or loss of previously achieved motor skills, a prior diagnosis of cerebral palsy should be reexamined. **DRD responds dramatically to small daily doses of levodopa**. The responsiveness to levodopa is a sustained benefit, even if the diagnosis is delayed several years, as long as contractures have not developed. More rarely, an autosomal recessive form of this disorder is caused by alterations in the *TH* gene.

Table 637.13 Clues Relating to the Signs and Symptoms That Suggest a Functional Movement Disorder

1. Abrupt onset
2. Inconsistent movements (changing characteristics over time; pattern, body distribution, rapidly varying severity)
3. Incongruous movements and postures (movements that do not fit with recognized patterns or with normal physiologic patterns)
4. Presence of certain types of abnormal movements that are fairly common among individuals with functional movement disorders, such as:
   - Rhythmical shaking
   - Bizarre gait
   - Deliberate slowness carrying out requested voluntary movement
   - Bursts of verbal gibberish
   - Excessive startle (bizarre movements in response to sudden, unexpected noise or threatening movement)
5. Presence of additional types of abnormal movements that are not known to be part of the primary or principal movement pattern that the patient manifests
6. Manifesting exhaustion, excessive fatigue
7. Delayed, often excessive, startle response to a stimulus
8. Spontaneous remissions
9. Decrease or disappearance of movements with distraction
10. Disappearance of tremors when handling treasured objects
11. Entrainment of the tremor to the rate of the requested rapid successive movement the patient is asked to perform
12. Response to placebo, suggestion, or psychotherapy
13. Dystonia beginning as a fixed posture
14. Twisting facial movements that move the mouth to one side or the other (note that organic dystonia of the facial muscles usually does not move the mouth sideways)

From Jankovic J, Hallett M, Okun MS, et al., eds. *Principles and Practice of Movement Disorders*, 3rd ed. Philadelphia: Elsevier; 2022: Table 27.2, p. 598.

Myoclonus dystonia (DYT11), caused by alterations in the *SCGE* gene, is characterized by dystonia involving the upper extremities, head, and/or neck, as well as myoclonic movements in these regions. Although a combination of myoclonus and dystonia typically occurs, each manifestation can present in isolation. When repetitive, the myoclonus may take on a tremor-like appearance, termed *dystonic tremor.* Improvement in symptoms after alcohol ingestion, reported by affected adult family members, may be a helpful clue to this diagnosis.

Common to the inherited dystonias, there is considerable intrafamilial variability in clinical manifestations, distribution, and severity of dystonia. In primary dystonias, although the main clinical features are motor, there may be an increased risk for major depression. Anxiety, obsessive-compulsive disorder, and depression have all been reported in myoclonus-dystonia syndrome. Screening for psychiatric comorbidities should not be overlooked in this population.

DRUG-INDUCED DYSTONIAS

A number of medications are capable of inducing involuntary movements or drug-induced movement disorders in children and adults. Dopamine-blocking agents, including antipsychotics (e.g., haloperidol) and antiemetics (e.g., metoclopramide, prochlorperazine), as well as atypical antipsychotics (e.g., risperidone, aripiprazole) can produce acute dystonic reactions or delayed (tardive) drug-induced movement disorders. **Acute dystonic reactions**, occurring in the first days of exposure, typically involve the face and neck and manifest as torticollis, retrocollis, oculogyric crisis, or tongue protrusion. Life-threatening presentations with laryngospasm and airway compromise can also occur, requiring prompt recognition and treatment of this entity. Intravenous diphenhydramine 1-2 mg/kg/dose (maximum dose 50 mg) may rapidly reverse the drug-related dystonia. The degree of potency of the dopamine blocker, young age, and prior dystonic reactions may be predisposing factors. Acute dystonic reactions have also been described with cetirizine.

Severe rigidity combined with high fever, autonomic symptoms (tachycardia, diaphoresis), delirium, and dystonia are signs of **neuroleptic malignant syndrome**, which typically occurs a few days after starting or increasing the dose of a neuroleptic drug or in the setting of withdrawal from a dopaminergic agent. In contrast to acute dystonic reactions, which take place within days, neuroleptic malignant syndrome typically occurs within a month of medication initiation or dose increase.

Delayed-onset involuntary movements, **tardive dyskinesias**, develop in the setting of chronic neuroleptic use, usually longer than 3 months. Involvement of the face, particularly the mouth, lips, and/or jaw with chewing or tongue thrusting, is characteristic. The risk of tardive dyskinesia, which is much less frequent in children compared with adults, increases as the medication dose, duration of treatment, and polypharmacy increase. There are data to suggest that children

Table 637.14 Classification of Dystonias by Affected Body Part

TYPE OF DYSTONIA	NO. OF BODY PARTS AFFECTED	DETAIL
Focal*	1	• Eyelids (blepharospasm) • Mouth (oromandibular dystonia, musician's cramp) • Larynx (dystonic adductor dysphonia, "whispering dysphonia") • Neck (cervical dystonia, previously known as spasmodic torticollis) • Hand and arm (writer's cramp)
Segmental	≥2 contiguous body parts	• Axial (neck and trunk) • Brachial (1 arm and trunk; both arms ± neck ± trunk) • Crural (1 leg and trunk; both legs ± trunk)
Multifocal	≥2 noncontiguous body parts	Faciobrachial (blepharospasm and writer's cramp)
Hemidystonia	≥2	Ipsilateral arm and leg
Generalized	≥3	Trunk and ≥2 other sites ± leg involvement

*Some localized dystonias may spread and eventually generalize.
From Klein C, Lohmann K, Marras C, et al. Hereditary dystonia overview. 2003 Oct 28 [Updated 2017 Jun 22]. In: Adam MP, Mirzaa GM, Pagon RA, et al., eds. GeneReviews [Internet]. Seattle (WA): University of Washington, Seattle; 1993-2023, Table 1.

Table 637.15 Causes of Dystonia in Childhood

STATIC INJURY/STRUCTURAL DISORDERS	METABOLIC DISEASE
Cerebral palsy	Glutaric aciduria types 1 and 2
Hypoxic-ischemic injury	Acyl-coenzyme A (CoA) dehydrogenase deficiencies
Kernicterus	Dopa-responsive dystonia
Head trauma	Aromatic l-amino acid decarboxylase deficiency
Encephalitis	Aminolevulinic acid dehydrase
Tumors	Biotin-responsive basal ganglia disease
Stroke in the basal ganglia (which may be a result of vascular abnormalities or varicella)	Mitochondrial disorders
Congenital malformations	Wilson disease
	Vitamin E deficiency
HEREDITARY/DEGENERATIVE DISORDERS	Homocystinuria
DYT1 (early-onset primary torsion dystonia, *TOR1A*)	Methylmalonic aciduria
DYT2 (early-onset dystonia with craniocervical involvement, autosomal recessive)	Tyrosinemia
DYT3 (adult-onset dystonia-parkinsonism, X-linked *TAF1*)	**DRUGS/TOXINS**
DYT4 (adult-onset spasmodic dysphonia, *TUBB4A*)	Neuroleptic and antiemetic medications (haloperidol, chlorpromazine, olanzapine, risperidone, prochlorperazine)
DYT5 (dopa-responsive dystonia, *GCH1*)	Calcium channel blockers
DYT6 (adult-onset torsion dystonia with craniocervical and laryngeal involvement, *THAP1*)	Stimulants (amphetamine, cocaine, ergot alkaloids)
DYT7 (adult-onset cervical dystonia)	Anticonvulsants (carbamazepine, phenytoin)
DYT8 (paroxysmal nonkinesigenic dyskinesia, *MR1*)	Thallium
DYT10 (paroxysmal kinesigenic dyskinesia, *PRRT2*)	Manganese
DYT11 (myoclonus dystonia, *SGCE*)	Carbon monoxide
DYT12 (rapid-onset dystonia-parkinsonism, *ATP1A3*)	Ethylene glycol
DYT16 (early-onset dystonia-parkinsonism, autosomal recessive, PRKRA)	Cyanide
DYT18 (paroxysmal exercise-induced dyskinesia, *SLC2A1*)	Methanol
DYT23 (adult-onset cervical dystonia and myoclonus, CACNA1B/CIZ1)	Wasp sting
DYT24 (craniocervical dystonia with limb tremor, *ANO3*)	**PAROXYSMAL DISORDERS**
DYT26 (early-onset myoclonic dystonia, KCTD17)	Paroxysmal kinesigenic choreoathetosis (PKD)
DYT27 (early-onset segmental dystonia, autosomal recessive, COL6A30	Paroxysmal nonkinesigenic choreoathetosis (PNKD)
DYT 28 (early-onset generalized dystonia, KMT2B)	Paroxysmal exercise-induced dystonia (PED)
DYT29 (early-onset dystonia with optic atrophy and basal ganglia abnormalities, MECR)	Complex migraine
DYT30 (progressive early-onset dystonia, VPS16)	Alternating hemiplegia of childhood (AHC)
DYT31 (early-onset multifocal or generalized dystonia, autosomal recessive, AOPEP)	Paroxysmal torticollis of infancy
Fahr disease (often caused by hypoparathyroid disease)	**DISORDERS THAT MIMIC DYSTONIA**
Neurodegeneration with brain iron accumulation	Tonic seizures (including paroxysmal nocturnal dystonia caused by nocturnal frontal lobe seizures)
Huntington disease (particularly the Westphal variant, IT15-4p16.3)	Arnold-Chiari malformation type II
Spinocerebellar ataxias (SCAs, including SCA3/Machado-Joseph disease)	Atlantoaxial subluxation
Neuronal ceroid-lipofuscinoses (NCLs)	Syringomyelia
Rett syndrome	Posterior fossa mass
Striatal necrosis	Cervical spine malformation (including Klippel-Feil syndrome)
Leigh disease	Skew deviation with vertical diplopia causing neck twisting
Leber hereditary ocular neuropathy (LHON)	Juvenile rheumatoid arthritis
Neuroacanthocytosis	Sandifer syndrome (associated with hiatal hernia in infants)
HARP syndrome (hypoprebetalipoproteinemia, acanthocytosis, retinitis pigmentosa, and pallidal degeneration)	Spasmus nutans
Ataxia-telangiectasia	Tics
POLG1 gene alterations	Infant masturbation
Tay-Sachs disease	Spasticity
Sandhoff disease	Myotonia
Niemann-Pick type C	Rigidity
GM_1 gangliosidosis	Stiff-person syndrome
Mitochondrial membrane protein–associated neurodegeneration (MPAN)	Isaac syndrome (neuromyotonia)
Metachromatic leukodystrophy (MLD)	Startle disease (hyperekplexia)
Lesch-Nyhan disease	Neuroleptic malignant syndrome
Pantothenate kinase–associated neurodegeneration (PKAN)	Central herniation with posturing
	Psychogenic dystonia

From Sanger TD, Mink JW. Movement disorders. In: Swaiman KF, Ashwal S, Ferriero DM, et al., eds. *Swaiman's Pediatric Neurology*, 5th ed. Philadelphia: Saunders; 2012: Box 68-2.

with autism spectrum disorders may also be at increased risk for this drug-induced movement disorder. Unlike acute dystonic reactions and neuroleptic malignant syndrome, discontinuation of the offending agent may not result in clinical improvement. In these patients, use of dopamine-depletors, such as reserpine, tetrabenazine, or valbenazine, may prove helpful.

Therapeutic doses of phenytoin, carbamazepine, or valproate rarely cause progressive dystonia in children with epilepsy, particularly in those who have an underlying structural abnormality of the brain.

During evaluation of new-onset dystonia, a careful history of prescriptions and potential medication exposures is critical

Table 637.16 Examples of Primary and Secondary Dystonia in Childhood

DIAGNOSIS	ADDITIONAL CLINICAL FEATURES
Aicardi-Goutières syndrome	Encephalopathy, developmental regression Acquired microcephaly Sterile pyrexias Lesions on the digits, ears (chilblain) Epilepsy CT: calcification of the basal ganglia
Alternating hemiplegia of childhood	Episodic hemiplegia/quadriplegia Abnormal ocular movements Autonomic symptoms Epilepsy Global developmental impairment Environmental triggers for spells
Aromatic amino acid decarboxylase deficiency (AADC)	Developmental delay Oculogyric crises Autonomic dysfunction Hypotonia
ARX gene alteration (X-linked)	Male Cognitive impairment Infantile spasms, epilepsy Brain malformation
Benign paroxysmal torticollis of infancy	Episodic Cervical dystonia only Family history of migraine
Complex regional pain syndrome	Lower limb involvement Prominent pain
Dopa-responsive dystonia (DRD)	Diurnal variation
Drug-induced dystonia	
Dystonia-deafness optic neuropathy syndrome	Sensorineural hearing loss in early childhood Psychosis Optic atrophy in adolescence
DYT1 dystonia	Lower limb onset followed by generalization
Glutaric aciduria type 1	Macrocephaly Encephalopathic crises MRI: striatal necrosis
GM_1 gangliosidosis type 3	Short stature, skeletal dysplasia Orofacial dystonia Speech/swallowing disturbance Parkinsonism MRI: putaminal hyperintensity
Huntington disease	Parkinsonism Epilepsy Family history of Huntington disease
Kernicterus	Jaundice in infancy Hearing loss Impaired upgaze Enamel dysplasia MRI: hyperintense lesions in the globus pallidus
Leigh syndrome	Motor delays, weakness, hypotonia Ataxia, tremor Elevated lactate MRI: bilateral symmetric hyperintense lesions in the basal ganglia or thalamus
Lesch-Nyhan syndrome (X-linked)	Male Self-injurious behavior Hypotonia Oromandibular dystonia, inspiratory stridor Oculomotor apraxia Cognitive impairment Elevated uric acid
Myoclonus dystonia	Myoclonus Head, upper limb involvement
Niemann-Pick type C	Hepatosplenomegaly Hypotonia Supranuclear gaze palsy Ataxia, dysarthria Epilepsy Psychiatric symptoms
Neuroacanthocytosis	Oromandibular and lingual dystonia
Neurodegeneration with brain iron accumulation	Cognitive impairment Retinal pigmentary degeneration, optic atrophy
Rapid-onset dystonia parkinsonism (DYT12)	Acute onset Distribution face > arm > leg Prominent bulbar signs
Rett syndrome	Female Developmental regression after a period of normal development Stereotypic hand movements Acquired microcephaly Epilepsy
Spinocerebellar ataxia 17 (SCA17)	Ataxia Dementia, psychiatric symptoms Parkinsonism
Tics	Stereotyped movements Premonitory urge, suppressible
Tyrosine hydroxylase deficiency	Infantile encephalopathy, hypotonia Oculogyric crises, ptosis Autonomic symptoms Less diurnal fluctuation than DRD

CEREBRAL PALSY

See Chapter 638.1.

METABOLIC DISORDERS

Disorders of monoamine neurotransmitter metabolism, of which dopa-responsive dystonia is one, present in infancy and early childhood with dystonia, hypotonia, oculogyric crises, and/or autonomic symptoms. Common comorbidities such as epilepsy, developmental delay, and microcephaly, which are also found in cerebral palsy and other more common disorders, likely contribute to underdiagnosis of this group of rare diseases. The more common disorders in this group include DRD, tyrosine hydroxylase deficiency, and aromatic amino acid decarboxylase deficiency. With the exception of aromatic amino acid decarboxylase deficiency, most do respond at least partially to

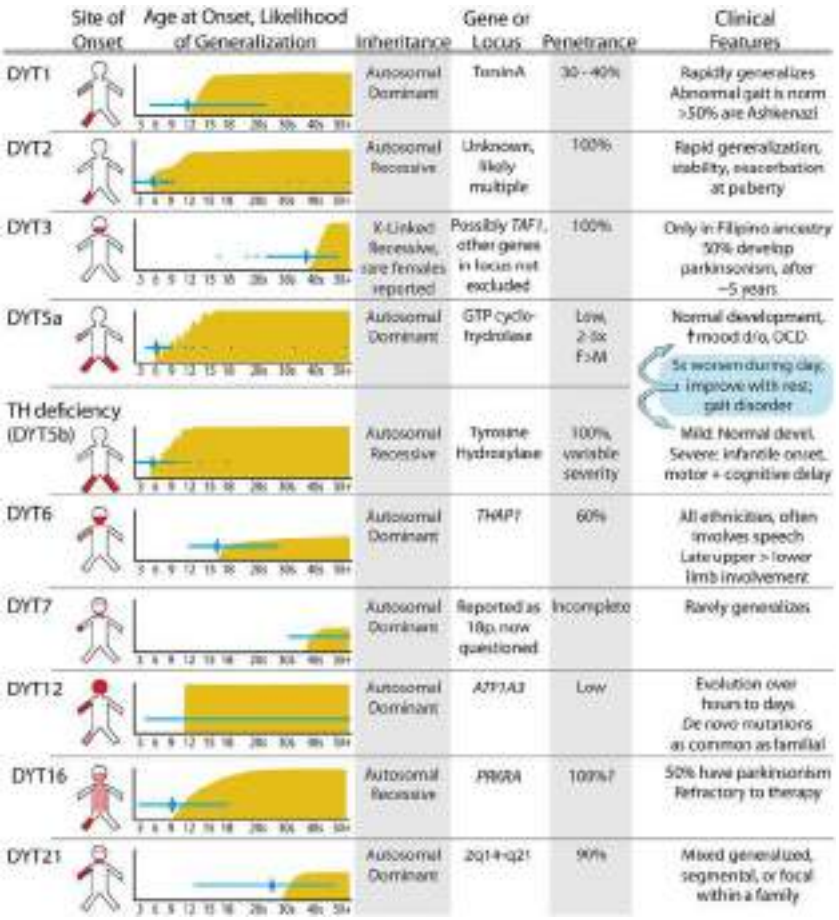

Fig. 637.6 Syndromes with dystonia as the presenting or a predominant feature; primary dystonias or dystonia-plus syndromes that commonly begin with dystonia are listed. The most common sites of dystonia onset are indicated on the homunculus in *red*, with less common sites of onset in *pink*. The distribution in age of onset is indicated by a *blue bar*, with the mean age indicated by a *blue diamond*, and rare but reported outliers indicated by *extralinear blue dashes*. Typical rates of progression and the likelihood of generalization are indicated by *yellow plots*. Note that homunculi and plots represent the most common clinical presentations, but variations on these axes are not uncommon. *(From Waugh JL, Sharma N. Clinical neurogenetics: dystonia from phenotype to genotype. Neurol Clin. 2013;31:969–986, Fig. 1.)*

levodopa. Abnormalities of the dopamine transporter (DAT) can also present in infancy with dystonia.

Wilson disease is an autosomal recessive inborn error of copper transport characterized by cirrhosis of the liver and degenerative changes in the central nervous system, particularly the basal ganglia (see Chapter 405.2). It has been determined that there are multiple alterations in the Wilson disease gene *(WND)*, accounting for the variability in presentation of the condition. The neurologic manifestations of Wilson disease rarely appear before age 10 years, and the initial sign is often progressive dystonia. Tremors of the extremities develop, unilaterally at first, but they eventually become coarse, generalized, and incapacitating. Other neurologic signs of Wilson disease relate to a progressive basal ganglia disease, such as parkinsonism, dysarthria, dysphonia, and choreoathetosis. Less frequent are ataxia and pyramidal signs. The MRI or CT scan shows ventricular dilation in advanced cases, with atrophy of the cerebrum, cerebellum, and/or brainstem, along with signal intensity change in the basal ganglia, thalamus, and/or brainstem, particularly the midbrain.

Pantothenate kinase–associated neurodegeneration is a rare autosomal recessive neurodegenerative disorder. Many patients have alterations in pantothenate kinase 2 *(PANK2)* localized to mitochondria in neurons. The condition usually begins before 6 years of age and is characterized by rapidly progressive dystonia, rigidity, and choreoathetosis. Spasticity, extensor plantar responses, dysarthria, and intellectual deterioration become evident during adolescence, and death usually occurs by early adulthood. MRI shows lesions of the globus pallidus, including low signal intensity in T2-weighted images (corresponding to iron pigments) and an anteromedial area of high signal intensity (tissue necrosis and edema), or *eye-of-the-tiger* sign (Fig. 637.7). Neuropathologic examination indicates excessive accumulation of iron-containing pigments in the globus pallidus and substantia nigra. Similar disorders of high brain iron content without *PANK2* gene alterations, including phospholipase A2–associated neurodegeneration (PLAN), mitochondrial membrane protein–associated neurodegeneration (MPAN), beta-propeller protein–associated neurodegeneration (BPAN), neuroferritinopathy, aceruloplasminemia, and others, have been grouped as disorders of **neurodegeneration with brain iron accumulation** (Table 637.17). Patterns of iron deposition visualized by brain MRI have shown utility in differentiating these disorders.

Biotin-responsive basal ganglia disease manifests with episodes of acute dystonia, external ophthalmoplegia, and encephalopathy. *SLC19A3* is the responsible mutated gene. MRI demonstrates involvement of the basal ganglia, with vasogenic edema and the *bat-wing* sign (Fig. 637.8). **Treatment with biotin and thiamine results in improvement in 2-4 days** (Table 637.18).

Although dystonia may present in isolation as the first sign of a metabolic or neurodegenerative disorder, this group of diseases should be considered mainly in those who demonstrate signs of systemic disease (e.g., organomegaly, short stature, hearing loss, vision impairment, epilepsy) and those with episodes of severe illness, evidence of regression, or cognitive impairment. Table 637.16 outlines additional features suggestive of specific disorders.

OTHER DISORDERS

Although uncommon, movement disorders, including dystonia, may be part of the presenting symptoms of **complex regional pain syndrome**. Onset of involuntary movements within 1 year of the traumatic event, an affected lower limb, pain disproportionate to the inciting event, and changes in the overlying skin and blood flow to the affected area suggest complex regional pain syndrome. Although sustained dystonia can produce pain or discomfort, complex regional pain syndrome should be considered in those who have a prominent component of pain and a recent history of trauma to the affected limb.

Paroxysmal dyskinesias can cause a combination of dystonic posturing and choreoathetoid movements (Table 637.19). By far the most

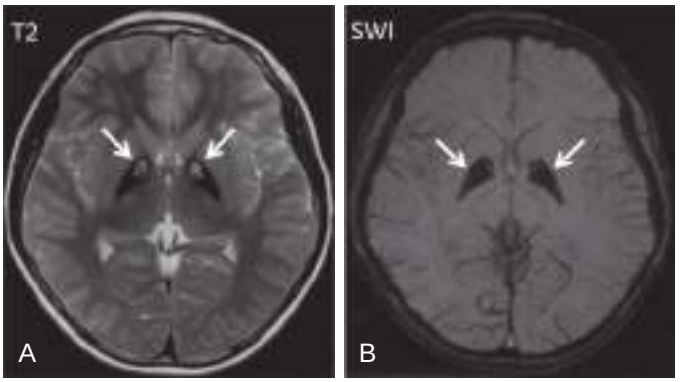

Fig. 637.7 Pantothenate kinase–associated neurodegeneration (PKAN). **A,** Axial T2-weighted image showing symmetric hypointensity in the bilateral globi pallidi with central hyperintensity (eye-of-the-tiger sign, *arrows*). **B,** Axial susceptibility-weighted image (SWI) image showing hypointensity in the globi pallidi representing increased iron accumulation *(arrows). (From Bosemani T, Meoded A, Poretti A. Susceptibility-weighted imaging in pantothenate kinase-associated neurodegeneration. J Pediatr. 2014;164:212.)*

common is **paroxysmal kinesigenic dyskinesia** (PKD), which most commonly presents around the age of 10 years with attacks of chorea or dystonic posturing lasting seconds to minutes. The movements are most commonly precipitated by voluntary movements and are often easily controlled by low doses of carbamazepine or other antiepileptic medications. Many patients have a gene alteration in *PRRT2,* a transmembrane protein that interacts with SNAP 25. **Paroxysmal nonkinesigenic dyskinesia** (PNKD) is characterized by prolonged attacks precipitated by emotional stress or alcohol rather than voluntary movement. The attacks are less frequent, perhaps a few times per year or less, but they may last hours. PNKD is less responsive to treatment than PKD. The rarest form of paroxysmal dyskinesia is **exercise-induced dystonia**. Dystonia in this disorder occurs after periods of prolonged exercise and tends to last between 10 and 30 minutes. Patients may also suffer from migraines and epilepsy. This disorder is caused by gene alteration in *SLC2A1,* which encodes the glucose transporter type 1 protein and is part of GLUT-1 deficiency syndrome. Dystonia may be present in classic GLUT-1 deficiency, although it is generally not the presenting sign. Case reports indicate some patients may have improvement in dystonia with the ketogenic diet.

There are disorders unique to childhood that warrant exploration in this section as well. **Benign paroxysmal torticollis of infancy** is

Table 637.17 Overview of NBIA Conditions and Genes (If Known)

CONDITION (ACRONYM)	SYNONYM	GENE	CHROMOSOMAL POSITION	AREAS OF HIGHEST IRON DENSITY	PATHOLOGIC MANIFESTATIONS
PKAN	NBIA1	*PANK2*	20p13	GP, eye of the tiger sign (central hyperintensity within a surrounding area of hypointensity).	GP with variable involvement of adjacent structures (putamen and internal capsule). Spheroid bodies. Only occasional peripheral manifestation.
PLAN	NBIA2, PARK14	*PLA2G6*	22q12	GP. Additional SN involvement in some.	Widespread cortical alpha-synuclein-positive Lewy body pathology. Presence of tau. Degeneration of the cerebellum, optic pathway and of brainstem and spinal cord long tracts.
FAHN	SPG35	*FA2H*	16q23	GP. Often white matter changes.	No human brain data. In animal models, cerebellar abnormalities, demyelination, and profound axonal loss in the CNS.
MPAN	—	C19orf12	19q12	GP and SN.	GP and SN iron-containing deposits, axonal spheroids, Lewy body-like inclusions, and tau-positive inclusions.
Kufor-Rakeb disease	PARK9	*ATP13A2*	1p36	Putamen and caudate.	No human brain data. On peripheral nerve biopsy cytoplasmic inclusion bodies resembling irregular primary lysosomes.
Aceruloplasminemia	—	*CP*	3q23	Basal ganglia, thalamus, dentate nuclei, and cerebral and cerebellar cortices. Liver, pancreas.	Basal ganglia and dentate nuclei, extending to the cerebral cortex.
Neuroferritinopathy	—	*FTL*	19q13	Caudate, GP, putamen, SN, and red nuclei.	Ferritin-positive spherical inclusions in iron-rich areas, mainly in the posterior putamen and cerebellum. Spheroids immunoreactive to ubiquitin and tau. Hepatic iron deposits may be present.
SENDA syndrome	—	n.k.	n.k.	GP and SN. White matter changes.	n.k.
Idiopathic late-onset cases	—	Probably heterogeneous	Probably heterogeneous	Heterogeneous.	n.k.

CP, Ceruloplasmin; FA2H, fatty acid 2-hydroxylase; FTL, ferritin light chain; GP, globus pallidus; MPAN, mitochondrial-associated neurodegeneration; NBIA, neurodegeneration with brain iron accumulation; PANK2, pantothenate kinase 2; PKAN, pantothenate kinase-associated neurodegeneration; PLA2G6, phospholipase A2; PLAN, phospholipase A2–associated neurodegeneration; SENDA, static encephalopathy of childhood with neurodegeneration in adulthood; SN, substantia nigra; SPG, spastic paraplegia; n.k., not known.
From Schneider SA, Bhatia KP. Syndromes of neurodegeneration with brain iron accumulation. *Sem Pediatr Neurol*. 2012;19:57–66, Table 1, p. 58.

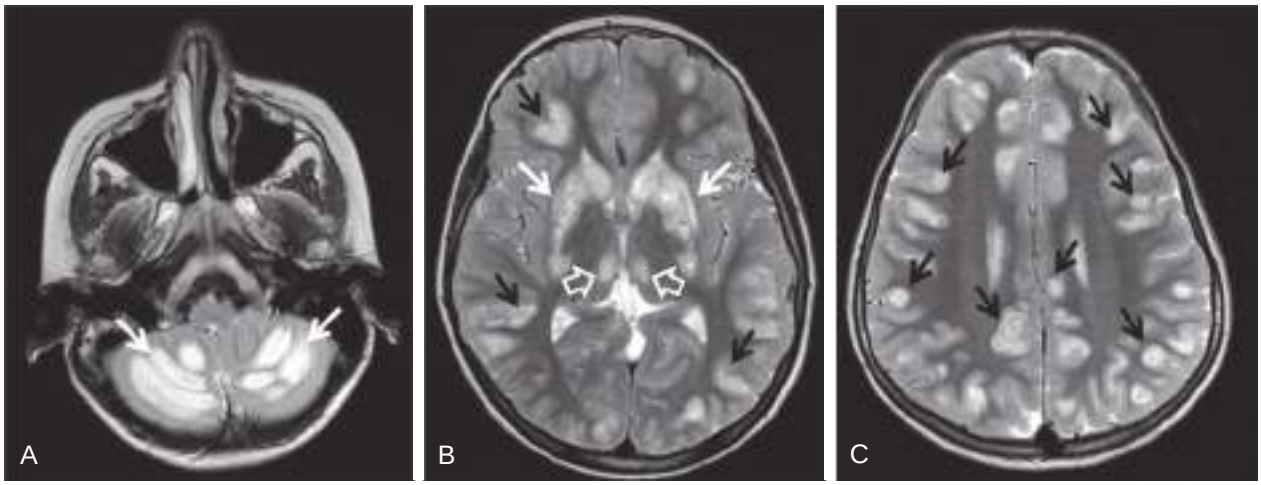

Fig. 637.8 Biotin-responsive basal ganglia disease. An initial brain MRI showed high signal intensity alterations on T2-weighted images bilaterally involving the (**A**) cerebellum *(arrows)*, (**B**) basal ganglia *(white arrows)*, and medial nucleus of the thalamus *(open arrows)* and (**B, C**) cerebral cortex *(black arrows)*. *(Modified from Tabarki B, Al-Sheikh F, Al-Shahwan S, Zuccoli G. Bilateral external ophthalmoplegia in biotin-responsive basal ganglia disease. J Pediatr. 2013;162:1291–1292.)*

Table 637.18 Dystonia Treatment

Nonspecific dystonia management	Trial of carbidopa/levodopa Botulinum toxin injection Also consider: neuroleptics, dopamine depletors Surgical options: baclofen pump, deep brain stimulation
Neurotransmitter disorders, including Segawa syndrome	Carbidopa/levodopa (except aromatic L-amino acid decarboxylase deficiency, which may worsen), dopamine agonists
Acute drug-induced dystonic reaction	Diphenhydramine, removal of offending agent
Tardive dyskinesia	Dopamine depletors, removal of offending agent
Paroxysmal dyskinesias	Carbamazepine, other AEDs (especially paroxysmal kinesogenic dyskinesia), acetazolamide (paroxysmal nonkinesogenic dyskinesia), ketogenic diet (exercise-induced dyskinesia)
Biotin-responsive basal ganglia disease	Biotin and thiamine
Complex regional pain syndrome and functional movement disorders	Physical therapy, occupational therapy, cognitive behavioral therapy

characterized by recurrent episodes of cervical dystonia beginning in the first few months of life. The torticollis may alternate sides from one episode to the next and may also persist during sleep. Associated signs and symptoms include irritability, pallor, vomiting, vertigo, ataxia, and occasionally limb dystonia. The family history is often notable for migraine and/or motion sickness in first-degree relatives. Despite the high frequency of spells, imaging studies are normal, and the outcome is uniformly benign with resolution by 3 years of age.

In **alternating hemiplegia of childhood (AHC)**, episodic hemiplegia affecting either side of the body is the hallmark of the disorder. However, patients are also affected by episodes of dystonia, ranging from minutes to days in duration. On average, both features of the disorder commence at approximately 6 months of age. Episodic abnormal eye movements are observed in a large proportion of patients (93%) with onset as early as the first week of life. AHC is associated with pathogenic variants in *ATP1A2* and *ATP1A3*. The disorder can be triggered by fluctuations in temperature, certain foods, or water exposure. Over time, epilepsy and cognitive impairment emerge, and the involuntary movements change from episodic to constant. Infantile onset and the paroxysmal nature of symptoms early in the disease course are key features to this diagnosis. Another disorder linked to variants in *ATP1A3*, **rapid-onset dystonia parkinsonism (RODP)**, often presents in adolescents with acute to subacute progressive dystonia and bradykinesia, often after a stressor such as recent illness. Although the classic forms of these two disorders, AHC and RODP, are generally caused by nonoverlapping gene alterations, molecular genetics has allowed the identification of patients with intermediate phenotypes.

Although it is a diagnosis of exclusion, the presence of odd movements or selective disability may indicate a functional dystonia in older children. There is considerable overlap in features of organic and **functional movement disorders**, making the diagnosis difficult to establish. Both organic and psychogenic movement disorders have the potential to worsen in the setting of stress and may dissipate with relaxation or sleep. The history should include a review of recent stressors, psychiatric symptoms, and exposure to others with similar disorders. On examination, a changing movement disorder, inconsistent motor or sensory exam, or response to suggestion is supportive of a possible psychogenic movement disorder. Early recognition of this disorder may lessen morbidity caused by unnecessary diagnostic and interventional procedures (see Table 637.13).

Practice guidance had once involved targeted, single-gene testing; currently the most appropriate approach to a child with dystonia not explained by a clear mechanism of injury will be a dystonia gene sequencing panel, followed by a microarray and then whole exome or genome sequencing if the panel was unrevealing. This includes children previously diagnosed with cerebral palsy but without severe perinatal distress and/or with injury solely confined to the basal ganglia on brain imaging. In families with a known history of a specific genetic dystonia, single-gene testing is the most appropriate initial approach. Because dystonia panels may vary in which genes they include, a knowledge of phenotypic features expected in various disorders can ensure that the dystonia panel selected is appropriate to a given patient. An approach to diagnostic testing is noted in Table 637.20 and Figure 637.9.

TREATMENT

Acute Treatment

Status dystonicus, or "dystonic storm," is a rare but potentially life-threatening emergency that often requires management in an intensive care setting. It is characterized by severe frequent dystonic posturing leading to vital sign instability, exhaustion, and/or muscle breakdown. It is likely underrecognized. About half of patients have

Table 637.19 Classification of Primary and Epilepsy Paroxysmal Dyskinesias

	PKD	PNKD	PED	PHD*
Inheritance	AD	AD	AD	Usually sporadic
Gender M:F	4:1	2:1	2:3	7:3
Age at onset, yr	<1-20	<1-20s	2-30	4-20s
Phenomenology of abnormal movements	Dystonia with or without chorea/ballism, unilateral or bilateral	Dystonia with or without choreoathetosis, unilateral or bilateral, rarely spasticity	Dystonia, sometimes in combination with choreoathetosis, unilateral or bilateral	Dystonia, chorea, ballism
Triggers	Sudden movement, change in direction, acceleration, startle	Alcohol, caffeine, emotions, fatigue	Prolonged exercise, muscle vibration	Sleep
Duration of paroxysms	Seconds up to 5 min	2 min to 4 hr	5 min to 2 hr	30 min up to 50 min
Frequency of paroxysms	1 per month to 100 per day	Few per week to few in a lifetime	Few per month	Few per year to few per night
Genetics	1. EKD1: 16p11.2-q12.1 (DYT10) with *PRRT2* gene within this region 2. EKD2: 16q13-q22.1 (DYT19) 3. EKD3: no variant on chromosome 16	1. *PNKD*: 2q35 (DYT8) 2. *SCL2A1*: chromosome 1 (DYT9) 3. *KCNMA1*: 10q22 4. Locus on 2q31 (DYT20)	1. *SCL2A1*: 1p35-p31.3 (DYT18)	1. *CHRNA4*: 20q13.2-q13.3 2. *CHRNB2*: chromosome 1q21 3. Locus on chromosome 15q24 4. Locus on chromosome 8p21
Treatment	Anticonvulsants (carbamazepine, phenytoin, others)	Avoiding triggers, benzodiazepines (clonazepam)	Avoiding triggers, ketogenic diet (in GLUT-1 deficiency)	Anticonvulsants

*Also known as autosomal dominant nocturnal frontal lobe epilepsy.
AD, Autosomal dominant; PED, paroxysmal exercise-induced dyskinesia; PHD, paroxysmal hypogenic dyskinesia (a seizure disorder); PKD, paroxysmal kinesigenic dyskinesia; PNKD, paroxysmal nonkinesigenic dyskinesia.
From Joseph SA. Movement disorders in childhood. In: Kliegman RM, Toth H, Bordini BJ, et al., eds. *Nelson Pediatric Symptom-Based Diagnosis*, 2nd ed. Philadelphia: Elsevier; 2023: Table 40.2, p. 719.

Table 637.20 Genetic Testing

All patients with early-onset dystonia without a clear family history or clear mechanism of injury, including those with "cerebral palsy" in the setting of only mild perinatal insults: comprehensive dystonia panel, consider microarray and whole exome sequencing if unrevealing

If the following features are present, ensure the appropriate gene is included in panel testing:

Limb-onset dystonia in early adolescence: torsinA (DYT1), especially with Ashkenazi ancestry

Cervical/cranial onset in mid-adolescence: THAP1 (DYT6), especially with strained speech (spasmodic dysphonia)

Normal gait in the morning, disabled by the evening: give levodopa; if symptoms improve, check guanosine triphosphate (GTP) cyclohydrolase 1 (DYT5a); tyrosine hydroxylase (DYT5b)

Mixed myoclonus and dystonia with onset throughout childhood: ε-sarcoglycan (DYT11), especially if symptoms are alcohol responsive in family members

Onset of dystonia ± parkinsonism over hours to days: ATP1A3 (DYT12), especially if symptoms progress in a rostral to caudal fashion

Paroxysmal dystonia ± chorea triggered by:

- Sudden movement: PRRT2 (DYT10), especially if there is a family history of complex migraines or benign seizures/chorea in infancy
- Caffeine or alcohol: PNKD (DYT8), especially if symptoms are rare but last many minutes to hours
- Exertion or if the ratio of cerebrospinal fluid/serum glucose is less than 0.5, SLC2A1 (DYT18), especially in families with unexplained cognitive delay or seizure disorder

Modified from Waugh JL, Sharma N. Clinical neurogenetics: dystonia from phenotype to genotype. *Neurol Clin*. 2013;31:969–986, Box, p. 975.

an underlying known cause of dystonia, such as cerebral palsy. Infections and changes in medications are frequently cited triggers. In addition, dystonic storm can also present in children with no prior history of movement disorders secondary to neurologic insults such as encephalitis or stroke. There are no consensus guidelines on treatment, but in general aggressive management with antidystonic agents such as anticholinergics, trihexyphenidyl, benzodiazepines, and baclofen is recommended. Midazolam infusion is generally chosen when sedation is needed because of its muscle relaxing properties. Intubation and other critical care supportive measures are commonly needed during treatment.

Chronic Treatment

Treatment strategy is summarized in Table 637.18. Children with Segawa syndrome and other neurotransmitter disorders generally have a robust response to low-dose carbidopa-levodopa. The evidence for efficacy in other causes of dystonia such as cerebral palsy is mixed. However, because neurotransmitter disorders are underdiagnosed and low-dose carbidopa-levodopa is generally well tolerated, a treatment trial is recommended unless there is a clear family history of a non–dopa-responsive dystonia.

Children with generalized dystonia, including those with involvement of the muscles of swallowing, may respond to the anticholinergic agent trihexyphenidyl. Titration occurs slowly over the course of months in an effort to limit untoward side effects, such as urinary retention, mental confusion, or blurred vision. Oral baclofen may also be used, although sedation may be a problem at higher doses. Dopamine depletors may be considered in treatment-refractory cases. Additional drugs that may be effective include benzodiazepines, neuroleptics, and antiepileptic drugs such as carbamazepine.

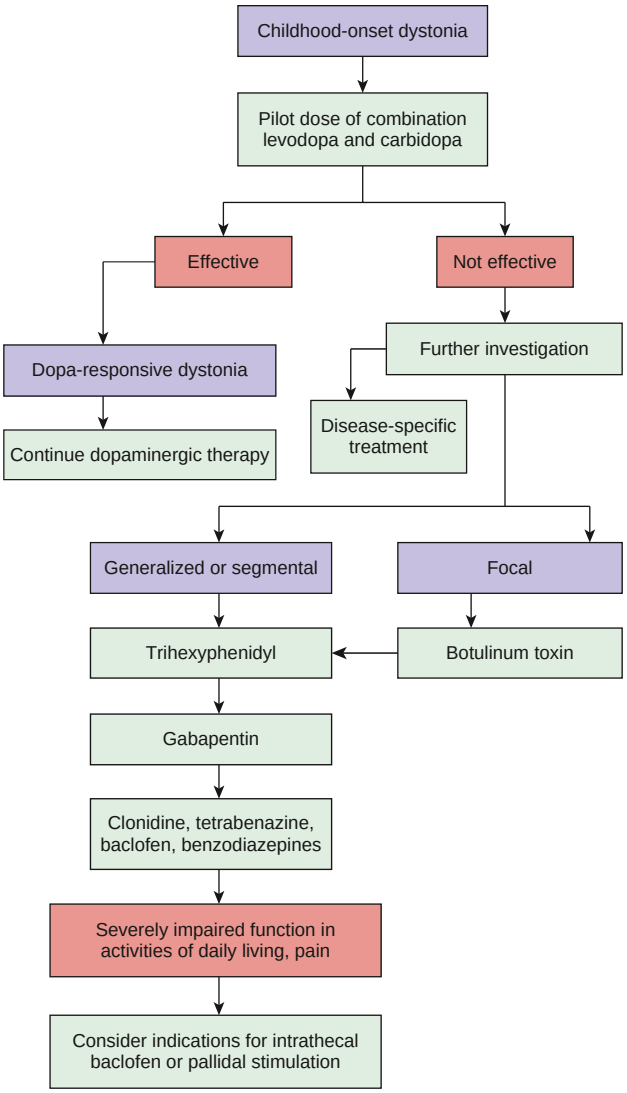

Fig. 637.9 Algorithm showing therapeutic approaches to the management of childhood-onset dystonia. Pharmacologic agents should be used sparingly where possible. High doses and polypharmacy inevitably arise when dystonia is severe enough to cause pain and interferes with daily cares, sitting comfort, and sleep. As with intractable epilepsy, consideration for functional neurosurgery should be considered when two or more drugs have failed to control dystonia. *(From Lin JP. Advances in pharmacotherapies for movement disorders in children: current limitations and future progress. Curr Opin Pediatr. 2017;29:652–664, Fig. 6.)*

Oral medications are not the only options for treatment. Segmental dystonia, such as torticollis, often responds well to botulinum toxin injections. Safe dosage restrictions limit the use of botulinum toxin in generalized dystonia, but it may be used as a supplemental treatment if symptoms in particular muscle groups are the most bothersome or functionally impairing.

Intrathecal baclofen delivered through an implantable constant-infusion pump may be helpful in some patients. It is often more effective in the lower extremities than the upper extremities.

Deep brain stimulation with leads implanted in the globus pallidus is most helpful for children with severe primary generalized dystonia. Deep brain stimulation may also be of benefit in children with secondary dystonias, such as cerebral palsy, although the effect is not as robust. A combination of factors are thought to reduce the efficacy in cerebral palsy, including a lack of normal neural substrate, reduced opportunity for motor learning during critical developmental windows, and the frequent presence of other neurologic impairments such as spasticity and weakness. It should only be considered if a trial of two to three oral agents has been unsuccessful.

DRUG-INDUCED DYSTONIAS

In the case of drug-induced dystonias, removal of the offending agent and treatment with intravenous diphenhydramine typically suffice. For neuroleptic malignant syndrome, dantrolene may be indicated. As tardive symptoms may not always respond to removal of the offending agent, dopamine depletors may be necessary

Visit Elsevier Ebooks+ at eBooks.Health.Elsevier.com for Bibliography.

Chapter 638
Encephalopathies

Elizabeth Barkoudah

Encephalopathy is a generalized disorder of cerebral function that may be acute or chronic, progressive or static. The etiologies of the encephalopathies in children include infectious, toxic (carbon monoxide, drugs, lead), metabolic, genetic, and ischemic causes. Hypoxic-ischemic encephalopathy is discussed in Chapter 122.4.

638.1 Cerebral Palsy

Elizabeth Barkoudah

See also Chapters 56 and 637.4.

Cerebral palsy (CP) is a complex and heterogeneous disorder denoting a group of permanent motor conditions that cause physical disability in human development, chiefly in the various areas of body movement. It can be defined as a central motor dysfunction affecting muscle tone, posture, and movement that is attributed to *nonprogressive* disturbances in the developing fetal or infant brain. Despite being described as a nonprogressive disorder (historically referred to as *static encephalopathy* by some), the clinical expression of brain injury or insult changes over time. Therefore the condition should be viewed as a dynamic disorder that evolves because of factors such as growth, nervous system maturation, and aging.

Several classification systems are used to describe CP, which reflects the complexity underlying the heterogeneity of cause, distribution, type of motor involvement, and severity. Consideration of associated manifestations such as cognitive deficits, seizures, communication difficulties, visual impairment, and so on, as well as addressing the medical, surgical, and psychosocial needs requires a multidisciplinary approach.

EPIDEMIOLOGY AND ETIOLOGY

Cerebral palsy is the most common neuromotor disorder in childhood, with an overall incidence of 2.6-2.9 cases per 1,000 live births in the United States. Within developed countries, both cross-sectional and cohort-based studies estimate prevalence of CP as nearly 1-4 per 1,000 live births. In developing countries, available estimates of prevalence are similar. The estimated lifetime cost to care for someone with CP in 2003, according to the Centers for Disease Control and Prevention (CDC), was $1 million. Adjusting for inflation, this is now $1.2 million per individual and will continue to increase over time.

CP is caused by a broad group of developmental, genetic, metabolic, ischemic, infectious, and other etiologies that produce a common group of neurologic phenotypes. Thus CP should be based on phenotype rather than etiology. The prevalence of CP is higher for children born preterm or at a low birthweight, though this is influenced by sex, ethnicity, and socioeconomic status. There is a 30–40% greater prevalence in males. Prevalence is higher in low- and middle- versus

high-income communities. Rates of CP have only recently begun to decrease in developed countries, though direct interpretation of trends is complicated by changing patterns of neonatal care and survivorhood. Although overall prevalence has fluctuated, the specific etiologies and injury patterns have shifted over time given advances in perinatal and neonatal management.

In addition to prematurity and birthweight, numerous other prenatal and perinatal risk factors have been reported, though for many of these, a causal relationship has not been established. These risk factors include antenatal infection (chorioamnionitis, urinary tract infection), multiple pregnancy, and neonatal infection. Infertility treatments are also associated with a higher rate of CP, probably because these treatments are often associated with multiple pregnancies. CP is most often multifactorial, and multiple risk factors coexist.

The cerebral disruption associated with CP can occur prenatally, perinatally, or postnatally in the first 2 years of life given that brain development is ongoing during this critical period. Congenital CP (due to cerebral injury/maldevelopment before or during birth) accounts for 85–90% of total cases, whereas acquired CP (due to cerebral injury after 1 month of life) is responsible for the remaining cases.

One can also consider different etiologies based on premature versus term births. The major lesions that contribute to CP in preterm infants are **intracerebral hemorrhage** and **periventricular leukomalacia** (PVL). Although the incidence of intracerebral hemorrhage has declined significantly, PVL remains a major problem. The incidence of cystic PVL caused by a more diffuse injury pattern is being replaced by focal necrosis. PVL reflects the enhanced vulnerability of immature oligodendroglia in premature infants to oxidative stress caused by ischemia or infectious/inflammatory insults. White matter abnormalities (loss of volume of periventricular white matter, extent of cystic changes, ventricular dilation, thinning of the corpus callosum) present on MRI at 40 weeks of gestational age in former preterm infants are a predictor of later CP. MRI with diffusion tensor imaging is being used to map white matter tracts more precisely in patients with spastic diplegia, and this technique has shown that thalamocortical sensory pathways are often injured as severely as motor corticospinal pathways (Fig. 638.1).

In term births, causes historically have primarily been thought to be by events during labor and delivery causing hypoxia. The mechanisms are predominately the result of cerebral ischemia and excitotoxicity. The cause can be obvious (i.e., placental abruption, meconium aspiration), though at other times the etiology can be difficult to pinpoint. Risk factors can include eclampsia, hypercoagulability, and placental pathology. For some, no predisposing clinical factors are identified. **Hypoxic-ischemic encephalopathy (HIE)** may be decreasing as an apparent cause of CP in developed countries. Therapeutic hypothermia may reduce the risk of CP in term patients with HIE.

There are several causes of acquired CP. The most common cause in this category is perinatal stroke, which can be ischemic, hemorrhagic, or thromboembolic in nature. The second most common cause is meningitis or encephalitis during infancy. Kernicterus is a rare cause of CP in developed countries, though cases (particularly in very preterm infants) persist.

Cryptogenic CP traditionally refers to an individual in which no clear perinatal etiology has been identified and accounts for ~30% of cases. Chromosomal copy number variants and single gene disorders have been identified in ~30% of patients with CP. Monogenic genetic variants have been identified in ~30% of cases who met diagnostic criteria for CP. A wide range of genes have been implicated in CP phenotypes, though a few are relatively more frequently seen including *TUBA1A, TUBB4A, COL4A1, SPAST, CTNNB1, GNAO1, STXBP1,* and *KIF1A*. Factors associated with exome sequencing–identified gene variants include patients without a perinatal risk factor, those with a positive family history, and patients with intellectual disability, epilepsy, or autism spectrum disorders.

CLINICAL MANIFESTATIONS

There are several classification systems to describe CP, a reflection of the complexity underlying the heterogeneity of cause, distribution, type of motor involvement, and severity (Table 638.1). Classification aids in understanding cause, coordinating care, monitoring comorbidities, treatment offerings and their prognosis, and long-term outcomes. One such classification system starts by determining the type of motor involvement: spastic or extrapyramidal. **Spastic** CP can then be

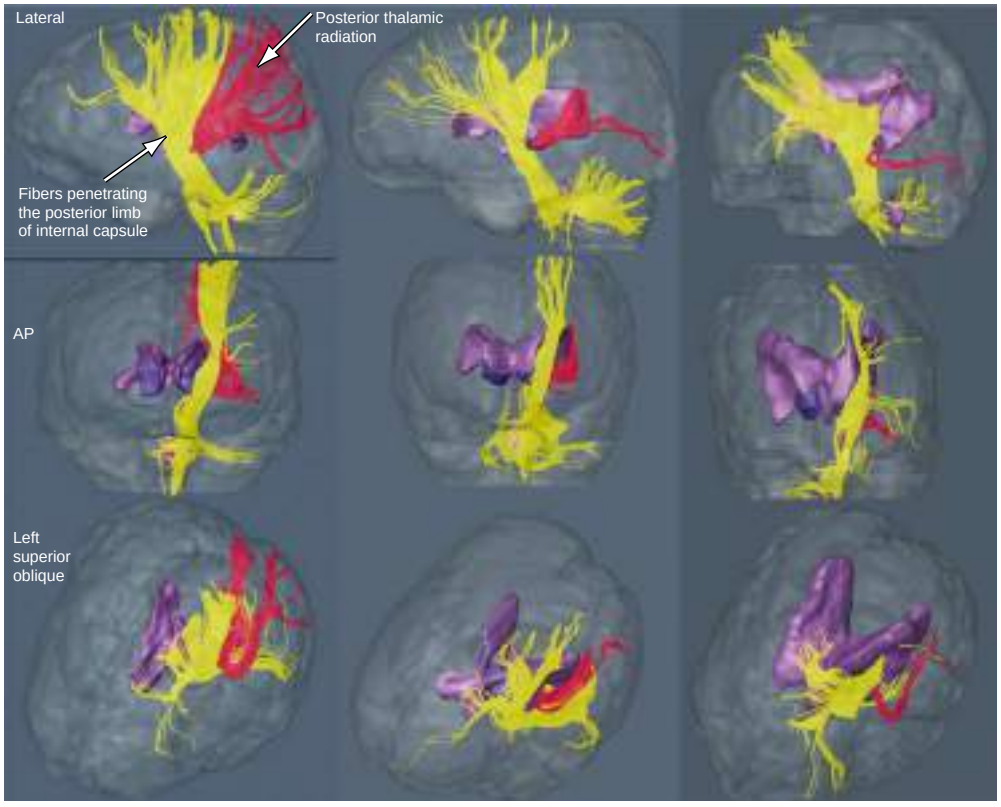

Fig. 638.1 Diffusion tensor image of white matter pathways in the brains of two patients with spastic diplegia on the right compared with a normal child on the far left. Yellow fibers are corticospinal pathways projected from the motor cerebral cortex at the top downward into the brainstem, whereas red fibers are thalamocortical sensory fibers projected from the thalamus upward to the cortex. In children with spastic diplegia, both the corticospinal and thalamocortical pathways are reduced in size but the ascending thalamocortical pathways are more affected. *(From Nagae LM, Hoon AH Jr, Stashinko E, et al. Diffusion tensor imaging in children with periventricular leukomalacia: variability of injuries to white matter tracts. AJNR Am J Neuroradiol. 2007;28:1213–1222.)*

Table 638.1 Classification of Cerebral Palsy and Major Causes

MOTOR SYNDROME (APPROX % OF CP)	NEUROPATHOLOGY/MRI	MAJOR CAUSES
Spastic diplegia (35%)	Periventricular leukomalacia Periventricular cysts or scars in white matter, enlargement of ventricles, squared-off posterior ventricles	Prematurity Ischemia Infection Endocrine/metabolic (e.g., thyroid)
Spastic quadriplegia (20%)	Periventricular leukomalacia	Ischemia, infection
	Multicystic encephalomalacia Cortical malformations	Endocrine/metabolic, genetic/developmental
Hemiplegia (25%)	Stroke: in utero or neonatal Focal infarct or cortical, subcortical damage Cortical malformations	Thrombophilic disorders Infection Genetic/developmental Periventricular hemorrhagic infarction
Extrapyramidal (athetoid, dyskinetic) (15%)	Asphyxia: symmetric scars in putamen and thalamus Kernicterus: scars in globus pallidus, hippocampus Mitochondrial: scarring of globus pallidus, caudate, putamen, brainstem No lesions: ? dopa-responsive dystonia	Hypoxia Kernicterus Mitochondrial Genetic/metabolic

further truncated topographically (Fig. 638.2), whereas extrapyramidal is further categorized based on the type of involuntary movement seen. In **extrapyramidal** CP, the brain injury or insult spares the pyramidal tracts that cause spasticity resulting in disorders of movement, coordination, and balance. Clinically, these patients exhibit dystonia and/or choreoathetosis (collectively referred to as *dyskinetic*) or ataxia associated with lesions in the cerebellum or its connections. Spastic CP accounts for 80% of cases, whereas extrapyramidal makes up 20% of cases (15% dyskinetic and 5% ataxic).

Historically, CP has been classified as mild, moderate, and severe without specified criteria for each group and primarily used for diagnostic purposes. The Gross Motor Function Classification System (GMFCS) was developed to categorize CP based on abilities and limitations in motor functioning. Goals included improved communication for treatment decisions, research into treatment outcomes, improved understanding and communication of the development of a child with CP, and anticipated future ambulatory needs. The emphasis is on *usual* rather than *best* motor performance in a variety of settings: home, school, and community.

Spastic hemiplegia has decreased spontaneous movements on the affected side and shows hand (handedness) preference at a very early age. The arm is often more involved than the leg, and difficulty in hand manipulation is evident by 1 year of age. Walking is usually delayed until 18-24 months, and a circumductive gait is apparent. Examination of the extremities may show growth arrest leading to shortened limbs and decreased muscle bulk on the affected side. Spasticity refers to the quality of increased muscle tone, which increases with the speed of passive muscle stretching and is greatest in antigravity muscles. It is apparent in the affected extremities, particularly at the ankle, causing an equinovarus deformity of the foot. An affected child often walks on tiptoe (toe-walking) because of the increased tone in the antigravity gastrocnemius muscles and tight contracted Achilles tendon; the affected upper extremity assumes a flexed posture when the child runs. Ankle clonus and a Babinski sign may be present, the deep tendon reflexes are increased, and weakness of the hand and foot dorsiflexors is evident. Difficulty in selective motor control is also present.

Spastic monoplegia is when only one limb is affected and may not be as obvious as other types of CP. Depending on which limb is affected, the child's motor disability ranges from challenges with either fine or gross motor skills. A monoplegia that affects the arm may result in challenges with bimanual tasks, whereas when the legs are involved, toe walking may be seen.

Spastic diplegia is bilateral spasticity of the legs that is greater than in the arms. Spastic diplegia is strongly associated with injury to the immature white matter during the vulnerable period of immature oligodendroglia between 20 and 34 weeks of gestation, hence seen in those born prematurely. The first clinical indication of spastic diplegia is often noted when an affected infant begins to crawl. The child uses the arms in a normal reciprocal fashion but tends to drag the legs behind more as a rudder (commando crawl) rather than using the normal four-limbed crawling movement. If the spasticity is severe, application of a diaper is difficult because of the excessive adduction of the hips. Examination of the child reveals symmetric spasticity in the legs with brisk reflexes, ankle clonus, and a bilateral Babinski sign. When the child is suspended by the axillae, an extended scissoring posture of the lower extremities is maintained. Walking can be significantly delayed, the feet are held in a position of equinovarus, and the child walks on tiptoes. Severe spastic diplegia is characterized by disuse atrophy, impaired growth of the lower extremities, and disproportionate growth with normal development of the upper torso.

Spastic quadriplegia is the most severe form of CP because of marked motor impairment of all extremities and the high association with other comorbidities, including intellectual disabilities, seizure disorders, communication and visual impairment, and feeding difficulties. Swallowing difficulties are common as a result of supranuclear bulbar palsies, often leading to aspiration pneumonia and growth failure. Neurologic examination shows increased tone and spasticity in all extremities, decreased spontaneous movements, brisk reflexes, and plantar extensor responses. Flexion contractures of the knees, elbows, and wrists are often present by late childhood. Children with spastic quadriparesis can also have extrapyramidal findings given the diffuse involvement of the brain injury.

Extrapyramidal CP can be divided into the two main types of involuntary movement seen: ataxia and dyskinesias. In this type of CP, injury is typically to the subcortical areas, which are centers for coordination in movement and balance. Injury may not produce weakness, but rather the inability to voluntarily control movements. This type is less common than spastic CP and makes up approximately 15–20% of patients with CP.

Ataxic CP is the rarest form whose clinical picture is variable ranging from hypotonia to mild spasticity in addition to incoordination depending on the other systems involved. Walking gait is often very wide and sometimes irregular. Control of eye movements and depth perception can be impaired. Often, fine motor skills requiring coordination of the eyes and hands, such as writing, are difficult. Other causes of ataxia in infancy and childhood, including hydrocephalus, neoplasms, and degenerative disorders, should be ruled out before CP is diagnosed (see Chapter 637.1).

Dyskinetic CP is further divided into two groups: athetoid and dystonic. **Athetoid** CP includes cases with involuntary movement,

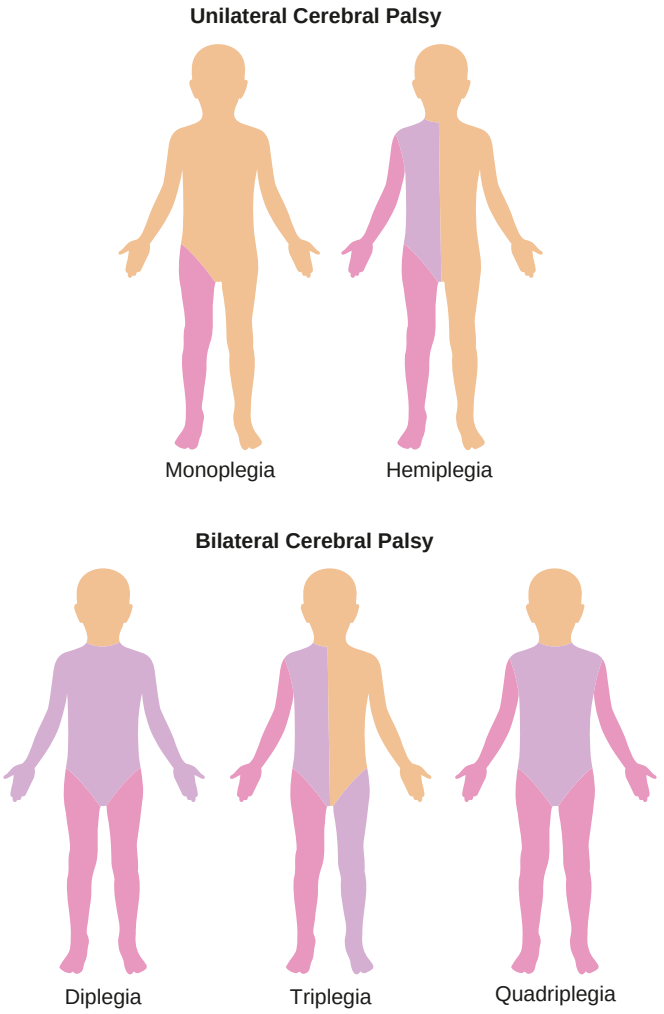

Fig 638.2 Topographical description in spastic cerebral palsy. Spastic cerebral palsy accounts for 70–80% of cases and is caused by an injury of the pyramidal tracts affecting voluntary movement. Monoplegia and hemiplegia affect one side of the body; in monoplegia one limb is affected, whereas in hemiplegia both the arm and leg on one side are affected. Hemiplegia can be asymmetric, affecting the arm or leg greater than the other extremity. Diplegia, triplegia, and quadriplegia affect both sides of the body. In diplegia, the predominant picture is involvement of the lower extremities. However, the arms can be affected though not to the same degree. In triplegia, both lower extremities and one arm are affected. A common picture is diplegia from periventricular leukomalacia and hemiplegia from an interventricular hemorrhage. This results in one lower extremity being more severely affected because of a dual mechanism of injury. In quadriplegia, all extremities are involved. *(From Graham HK, Rosenbaum P, Paneth N, et al. Cerebral palsy. Nat Rev Dis Primers. 2016;2:15082, Fig. 2.)*

especially in the arms, legs, and hands. With the current management of Rh and ABO incompatibility, the incidence of CP characterized by athetosis has markedly decreased (see Chapter 637). Athetoid CP is often caused by **kernicterus** secondary to high levels of bilirubin, and in this case the MRI scan shows lesions in the globus pallidus bilaterally, or it may be normal. Cases are still seen as a result of HIE as well. The affected infant is initially hypotonic, but a tendency toward arching and opisthotonus (dystonia) is noted, and obligatory tonic neck reflexes are present. These primitive motor patterns preclude orderly motor development such as reaching, rolling, and sitting. **Dystonic CP** encompasses cases that affect the trunk muscles more than the limbs and results in a fixed, twisted posture. Toward the end of the first year, repetitive, involuntary movements become more consistent with the full-blown picture of dystonic CP. Dystonia in CP presents as hypertonia, involuntary postures and movements, or a combination.

Nearly all individuals with CP will have one or more medical, neurologic, or psychiatric comorbidities. Neuropsychiatric comorbidities that occur at higher rates with CP include intellectual disability, anxiety, depression, and attention-deficit/hyperactivity disorder (ADHD) compared with the general population. Other associated comorbidities are common and include chronic pain, sleep difficulties, urinary dysfunction, decreased bone health, sialorrhea, respiratory disorders, feeding and growth challenges, gastrointestinal disorders including constipation and dysmotility, speech/communication difficulties, visual impairment, and hearing loss.

DIAGNOSIS

CP is a clinical diagnosis that considers elements from the history, physical examination, and ancillary testing including neuroimaging. The history should focus on whether there was perinatal or postnatal injury to the brain, what factors led to this injury, and contributory pregnancy factors. Another important factor is the developmental trajectory. It is important to quantify rates of development in the various domains and whether that trajectory has been one of continued acquisition of skills, plateauing, or regression. This—especially no loss of acquired milestones (regression)—helps preclude a **progressive disorder** of the central nervous system (CNS), including degenerative diseases, metabolic disorders, spinal cord tumor, or muscular dystrophy.

Multiple components to the physical examination are necessary to characterize abnormalities of tone, reflexes, movements, posture, and balance that may be consistent with the diagnosis of CP. The physical examination should focus on the following features: presence of any limb deformities, curvature of the spine, range of motion of joints, muscle tone, muscle strength, reflexes, presence of any movement disorders, and gait.

An MRI scan of the brain is indicated to determine the location and extent of structural lesions or associated congenital malformations; an MRI scan of the spinal cord is indicated if there is any question about spinal cord pathology. An MRI with abnormalities consistent with CP supports the diagnosis and increases the level of certainty, but the diagnosis remains a clinical one. An early diagnosis of CP is desirable to initiate appropriate services and therapies and to provide a definitive diagnosis for families.

Additional studies may include tests of hearing and visual function. Genetic evaluation should be considered in patients with congenital malformations, evidence of metabolic disorders (e.g., amino acids, organic acids, MR spectroscopy), clinical features atypical of CP, or when there are no perinatal risk factors especially in term infants (Fig. 638.3, Tables 638.2 and 638.3).

The differential diagnosis must include disorders that may **mimic** the various types of CP (see Fig. 638.3). These may include the hereditary spastic diplegias (Table 638.4), monoamine transmitter disorders such as dihydroxyphenylalanine (DOPA)-responsive dystonia **(Segawa disease)** (Table 638.5 and Fig. 638.4), and many treatable inborn errors of metabolism, including disorders of amino acids, creatine, fatty acid oxidation, lysosomes, mitochondria, organic acids, and vitamin cofactors.

TREATMENT

The treatment strategy for CP is best developed in a multidisciplinary patient-centered setting, where medical interventions are embedded in a rehabilitation context considering the patient's individual goals (see Chapter 752). The overarching goal for patients with CP is to maximize functioning by improved biomechanics resulting from abnormal tone, musculoskeletal deformities, and muscle weakness. Other goals outside of those related to the neuromotor component can be equally important when they pertain to quality of life, comfort, and social stigmatization. Clear communication and coordination among the multidisciplinary team (physiatry, orthopedic, neurology/neurodevelopmentalists, neurosurgery) as well as physical and occupational therapy, speech pathology, social work, primary care physicians, developmental pediatricians, and educators maximize the chances of success.

Parents should be taught how to work with their child in daily activities such as feeding, carrying, dressing, bathing, and playing in ways that reduce the effects of abnormal muscle tone. Families and children also need to be instructed in the performance of a series of exercises designed to promote developmental progress, prevent long-term complications such as the development of contractures, preserve range of motion,

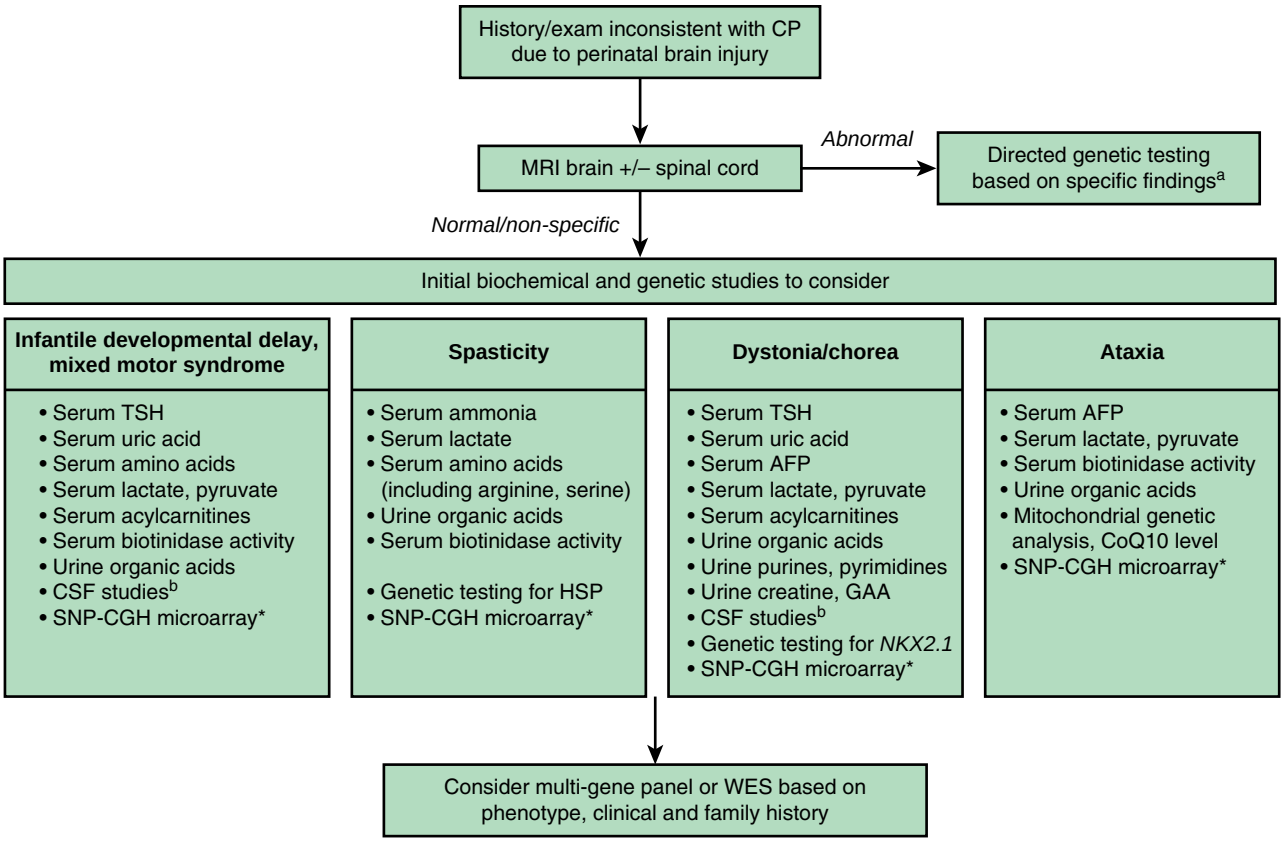

Fig. 638.3 Genetic mimics of cerebral palsy. Algorithm showing the general diagnostic approach to the patient with an infantile-onset, apparently nonprogressive motor disorder. Studies are grouped by predominant clinical presentation; it may be appropriate to consider investigations from more than one group depending on the specific clinical context. *In many situations WES has replaced microarray testing. [a]See examples in Tables 638.2 and 638.3 [b]CSF studies: glucose (+ serum glucose), lactate, pyruvate, neurotransmitter metabolites (biogenic amines + GABA), pterins, 5-methyltetrahydrofolate; HSP, hereditary spastic paraplegia. *(From Pearson TS, Pons R, Ghaoui R, Sue CM. Genetic mimics of cerebral palsy. Mov Disord. 2019;34:625–636, Fig. 1, p. 627.)*

Table 638.2 Clinical Features That Should Prompt Evaluation for Genetic and Metabolic Conditions in a Patient Presenting with Symptoms of CP

Absent history of any perinatal risk factor for brain injury
Family history of sibling with similar neurologic symptoms
Motor symptom onset after an initial period of normal development
Developmental regression
Progressive neurologic symptoms
Paroxysmal motor symptoms or marked fluctuation of motor symptoms
Clinical exacerbation in the setting of a catabolic state (e.g., febrile illness)
Isolated generalized hypotonia
Prominent ataxia
Signs of peripheral neuromuscular disease (reduced or absent reflexes, sensory loss)
Eye movement abnormalities (e.g., oculogyria, oculomotor apraxia, or paroxysmal saccadic eye-head movements)

From Pearson TS, Pons R, Ghaoui R, et al. Genetic mimics of cerebral palsy. *Mov Disord.* 2019;34:625–636, Table. 1, p. 628.

Table 638.3 Brain MRI Findings Suggestive of Selected Genetic CP Mimics

FINDING	SELECTED CONDITIONS
Hypomyelination	*PLP1*-related dysmyelinating disorders H-ABC (*TUBB4A* variant) AGS (may also have basal ganglia and WM calcification) GM1 gangliosidosis
Demyelination	Krabbe disease Metachromatic leukodystrophy
Thin corpus callosum	HSP (i.e., SPG4, SPG11, SPG15, and others)
Globus pallidus lesions	T_2-hypointense: NBIA (SN also involved in BPAN, MPAN), fucosidosis T_2-hyperintense: MMA, PDH deficiency, creatine deficiency syndromes
Focal atrophy or hypoplasia	Glutaric aciduria type 1 (frontotemporal) H-ABC (cerebellum ± putamen) Joubert syndrome (cerebellum)

AGS, Aicardi-Goutières syndrome; BPAN, beta-propeller protein–associated neurodegeneration; H-ABC, hypomyelination with atrophy of the basal ganglia and cerebellum; HSP, hereditary spastic paraplegia; MMA, methylmalonic aciduria; MPAN, mitochondrial membrane protein-associated neurodegeneration; NBIA, neurodegeneration with brain iron accumulation; PDH, pyruvate dehydrogenase; WM, white matter.

From Pearson TS, Pons R, Ghaoui R, et al. Genetic mimics of cerebral palsy. *Mov Disord.* 2019;34:625–636, Table 2, p. 628.

and strengthen weak muscles. Therapists help children to achieve their full potential and often recommend further evaluations and adaptive equipment.

Rehabilitative strategies include orthotics, casting, and physiotherapy (see Chapter 752). Adaptive equipment can help individuals with CP achieve a greater level of independence and autonomy. Equipment such as braces, wheelchairs, and walkers can significantly improve mobility and increase self-confidence. Orthotics are devices that are used to help prevent foot and ankle deformities, improve stability during walking, and

Table 638.4 Clinical and Neuroimaging Findings in Hereditary Spastic Paraplegias (HSP) with Pediatric Onset*

HSP FORM	HSP TYPE	INHERITANCE	GENE	CHILDHOOD ONSET	DISEASE CHARACTERISTICS†	NEUROIMAGING FINDINGS (BRAIN)
Pure	SPG3A	AD	*ATL1*	+++	None	Normal
Pure	SPG4	AD	*SPAST*	++	None	Leukoencephalopathy, thin corpus callosum
Pure	SPG6	AD	*NIPA1*	+	None	Normal
Pure	SPG10	AD	*KIF5A*	+++	Neuropathy	Normal
Pure	SPG12	AD	*RTN2*	+++	None	Normal
Pure	SPG31	AD	*REEP1*	++	None	Normal
Complicated	SPG1	X-linked	*L1CAM*	++	Intellectual disability, adducted thumb	Thin corpus callosum
Complicated	SPG2	X-linked	*PLP1*	+++	Intellectual disability, epilepsy	Normal
Complicated	SPG7	AR	*SPG7*	+	Optic atrophy, neuropathy, cerebellar ataxia	Cerebellar atrophy
Complicated	SPG11	AR	*KIAA1840*	+++	Intellectual disability, neuropathy	Leukoencephalopathy, thin corpus callosum
Complicated	SPG15	AR	*ZFYVE26*	+++	Intellectual disability, retinopathy, cerebellar ataxia	Leukoencephalopathy, thin corpus callosum
Complicated	SPG17	AR	*BSCL2*	+	Neuropathy	Normal

*Onset before 18 yr of age.
†Other than the classic HSP symptoms, including spastic paraparesis, atrophy of the distal lower extremities, and neurogenic bladder dysfunction.
AD, autosomal dominant; AR., autosomal recessive; +, occasional; ++, common; +++, characteristic.
From Lee RW, Poretti A, Cohen JS, et al. A diagnostic approach for cerebral palsy in the genomic era. *Neurol Med.* 2014;16:821–844, Table 5, p. 832.

Table 638.5 Clinical Features of the Monoamine Neurotransmitter Disorders

ENZYME DEFICIENCY	AGE AT PRESENTATION	MOTOR AND COGNITIVE DELAY	EXTRAPYRAMIDAL HYPERKINETIC FEATURES	EXTRAPYRAMIDAL HYPOKINETIC FEATURES	PYRAMIDAL TRACT FEATURES	EPILEPSY	AUTONOMIC FEATURES	NEUROPSYCHIATRIC FEATURES
AD GTPCH-D	Childhood (but can occur at any age)	Not common	Yes	Yes	No	No	No	Yes
SR-D	Infancy	In most	Yes	Yes	Yes	Yes	Yes	Yes
AR GTPCH-D	Infancy	Yes	Yes	Yes	Yes	Yes	Yes	Yes
PTPS-D	Infancy to childhood	In most	Yes	Yes	Yes	Yes	Yes	Yes
DHPR-D	Infancy to childhood	Yes	Yes	Yes	Yes	Yes	Yes	Yes
PCD-D	Infancy	No	No	No	No	No	No	No
TH-D	Infancy to early childhood	In most	Yes	Yes	Yes	Yes	Yes	No
AADC-D	Mainly infancy (but can occur at any age)	Yes	Yes	Yes	Yes	Yes	Yes	Yes
PLP-DE	Infancy to early childhood	In most	Yes	Yes	Yes	Yes	Yes	Yes
DTDS	Infancy	Yes	Yes	Yes	Yes, in older children	No	Yes	No

AD GTPCH-D, autosomal dominant GTP cyclohydrolase deficiency; SR-D, D-Serine; AR GTPCH-D, autosomal recessive GTP cyclohydrolase deficiency; PTPS-D, 6-pyruvoyl tetrahydropterin synthase deficiency; DHPR-D, dihydropteridine reductase deficiency; PCD-D, pterin-4α carbinolamine dehydrase deficiency; TH-D, tyrosine hydroxylase deficiency; AADC-D, aromatic l-amino acid decarboxylase deficiency; PLP-DE, pyridoxal 5 phosphate dependent enzymes; DTDS, dopamine transporter deficiency syndrome.
From Kurian MA, Gissen P, Smith M, et al. The monoamine neurotransmitter disorders: an expanding range of neurological syndromes. *Lancet Neurol.* 2011;10:721–731, Table, p. 722.

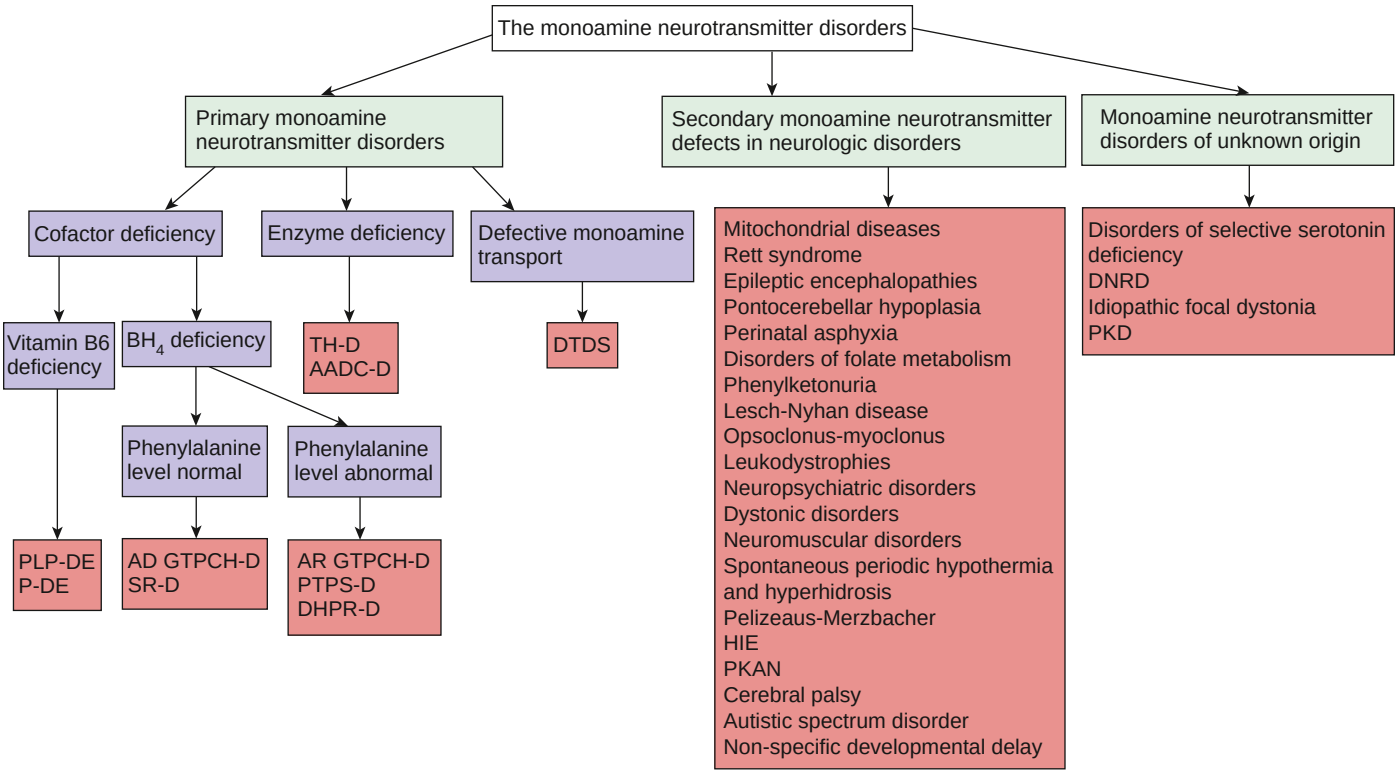

Fig. 638.4 Classification of the monoamine neurotransmitter disorders. BH_4, Tetrahydrobiopterin; TH-D, tyrosine hydroxylase deficiency; AADC-D, aromatic L-amino acid decarboxylase deficiency; DTDS, dopamine transporter deficiency syndrome; PLP-DE, pyridoxal-phosphate–dependent epilepsy; P-DE, pyridoxine-dependent epilepsy; AD GTPCH-D, autosomal dominant GTP cyclohydrolase 1 deficiency; SR-D, sepiapterin reductase deficiency; AR GTPCH-D, autosomal recessive GTP cyclohydrolase 1 deficiency; PTPS-D, 6-pyruvoyltetrahydropterin synthase deficiency; DHPR-D, dihydropteridine reductase deficiency; HIE, hypoxic-ischemic encephalopathy; PKAN, pantothenate kinase associated neurodegeneration; DNRD, dopa-nonresponsive dystonia; PKD, paroxysmal kinesigenic dyskinesia. *(From Kurian MA, Gissen P, Smith M, et al. The monoamine neurotransmitter disorders: an expanding range of neurological syndromes. Lancet Neurol. 2011;10:721–731, Fig. 1.)*

sometimes relieve pain. Additional equipment needs address activities of daily living such as bathing and hygiene, communication, and driving.

Pharmacotherapy is often the first-line approach used to manage the various tone abnormalities seen in CP and includes both enteral options and targeted injections. Systemic medications are often chosen for more widespread management of spasticity and dyskinesias. Although baclofen is routinely favored, other antispasticity medications such as tizanidine, dantrolene, and benzodiazepines are also available. Second-line medications such as clonidine or gabapentin may provide dual benefit for both tone management and other neurologic associations, including sleep disruption, dysautonomia, pain, and neuroirritability. Medications used to treat dystonia include enteral baclofen, benzodiazepines, trihexyphenidyl, clonidine, dantrolene, levodopamine, and gabapentin, but practice varies widely. Tetrabenazine can be useful for hyperkinetic movement disorders, including athetosis or chorea.

The management of focal/segmental spasticity or dystonia includes chemodenervation agents that target these specific locations. Targeted injections are often used in combination with systemic medications to augment tone management in specific areas that are more problematic. Examples include **botulinum toxin A** (BoNT-A), phenol, and ethyl alcohol. Targeted injections combined with rehabilitative therapies can allow for improved motor functioning and delay or avoid orthopedic surgery; these injections require repeat administration. Typically repeat injections are performed every 4-6 months, primarily to avoid the development of resistance; 3 months may be necessary. Injections into salivary glands may also help reduce the severity of drooling if it is not adequately treated with anticholinergic agents.

Neurosurgical options include intrathecal baclofen (ITB), selective dorsal rhizotomy (SDR), and deep brain stimulation (DBS). **ITB** can be considered in patients whose spasticity is not adequately treated with enteral baclofen or who are experiencing side effects such as sedation, weakness, or gastrointestinal (GI) symptoms. Baclofen is delivered with an implanted pump in children with severe spasticity; it is useful because it delivers the drug directly around the spinal cord, where it reduces neurotransmission of afferent nerve fibers. Direct delivery to the spinal cord overcomes the problem of CNS side effects caused by the large oral doses needed to penetrate the blood-brain barrier. ITB may reduce dystonia with evidence for benefit with higher catheter placement.

The main goal of **SDR** is to improve the gait or functioning in those that function at GMFCS I-III with good selective motor control and minimal weakness. However, SDR is being looked at for management of tone, minimizing pain, and ease of caregiving in patients functioning on a GMFCS IV-V level. Because SDR is an irreversible treatment for spasticity, optimal selection of ideal candidates from a multidisciplinary approach is necessary to avoid short- and long-term complications. SDR's spasticity benefits are caused by a partial sensory deafferentation of the spinal cord. This is achieved by resection of dorsal nerve rootlets based on abnormal motor responses to electrical stimulation (Fig. 638.5). The total number of nerve rootlets resected ranges from 25% to 40%, though in some institutions it exceeds >40%. Combining both ventral and dorsal rhizotomies can help manage both spasticity and dystonia. SDR manages lower extremity tone equally as the ITB pump, may provide more upper-extremity tone control compared with the ITB pump, and improves bladder function.

DBS can be considered if there is severe hypertonia with combined spasticity and dystonia. DBS is a neurosurgical procedure that evolved from the recognition that pallidotomies and thalamotomies could help patients with medically refractory dystonia. It involves the introduction of stimulating electrodes in areas of the brain such as the globus pallidus and the subthalamic nucleus, which are connected to an extracranial pulse generator (see Chapter 637). After the surgical procedure, the beneficial effects are not immediately

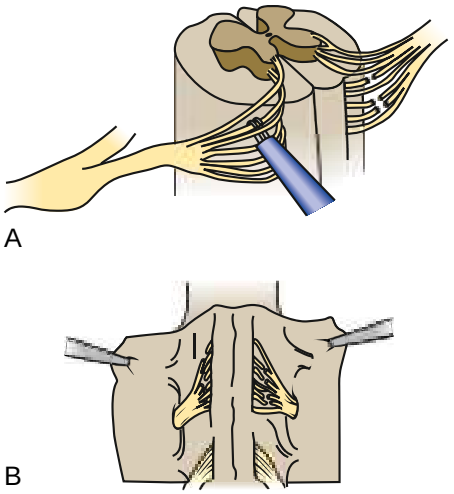

Fig. 638.5 Schematic of the technique of selective dorsal rhizotomy. **A,** After laminectomy, the dura is opened and the dorsal spinal rootlets are exposed. The rootlets are stimulated so that abnormal rootlet activity can be identified. **B,** A proportion of rootlets is transected. *(From Koman LA, Smith BP, Shilt JS. Cerebral palsy. Lancet. 004;363:1619–1631. Reproduced with permission from Wake Forest University Orthopaedic Press.)*

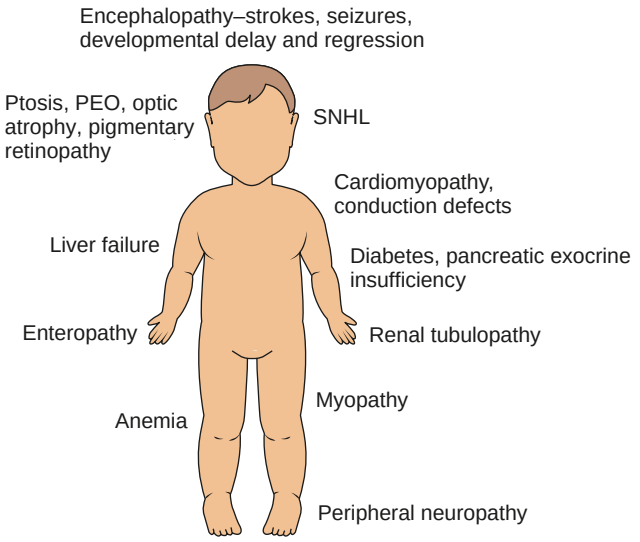

Fig. 638.6 Clinical features of mitochondrial encephalomyopathies. PEO, progressive external ophthalmoplegia; SNHL, sensorineural hearing loss. *(Adapted from Rahman S. Mitochondrial disease in children. J Intern Med. 2020;287[6]:609–633.)*

visible, often taking several months. The procedure is associated with perioperative risks as well as infection and hardware complications. Therefore patient selection and consideration of the appropriate target for stimulation for DBS are key. Most agree that the presence of spasticity, contractures/deformities, and myelopathy are poor predictors of response and that neurosurgical expertise, anatomic factors, and severity/time of dystonic symptoms may influence response.

Orthopedic interventions address musculoskeletal pathology, including fixed muscle contractures, torsion of long bones, hip displacement, and spine deformities. Several surgical methods exist for lengthening the muscle-tendon units for contraction management, though these are rarely necessary before 6 years of age. Before this, prevention of contracture development is key and often is a combination of tone management, bracing, and stretching exercises. Femoral and tibial torsion occur, respectively, because of failure of remodeling fetal anteversion and mostly as a response to abnormal biomechanical forces during walking. Derotational osteotomies are ideally performed between 6 and 12 years of age. With increasing GMFCS level comes increased risk of developing hip displacement and neuromuscular scoliosis. Monitoring and prevention strategies are paramount, as both hip displacement and scoliosis may progress with age. Conservative treatment and surgical approaches can be challenging when balancing the complexity of these surgical interventions and outcome goals defined presurgically.

Visit Elsevier eBooks+ at eBooks.Health.Elsevier.com for Bibliography.

638.2 Mitochondrial Encephalomyopathies

Shamima Rahman

Mitochondrial encephalomyopathies are complex neurologic disorders caused by disturbed mitochondrial function. Mitochondria are dynamic cellular organelles with multitudinous roles, most notably energy generation via oxidative phosphorylation (OXPHOS), but other mitochondrial functions include intermediary metabolism (the Krebs cycle, fatty acid beta oxidation, and part of the urea cycle are housed in the mitochondrion), calcium homeostasis, intracellular signaling, apoptosis, and biosynthesis of coenzyme Q_{10}, heme, iron-sulfur clusters, and lipoic acid. Aberrant mitochondrial function most commonly involves disturbed energy generation via the OXPHOS system, but other mechanisms include oxidative stress mediated by increased production of reactive oxygen species (ROS), alterations of other metabolic processes within the mitochondria (such as pyruvate dehydrogenase, the Krebs cycle, vitamin metabolism and transport, and cofactor biosynthesis) and of the mitochondrial lipid membranes, protein quality control, import system, and organelle dynamics (disturbed fission and fusion).

Mitochondria are unique among cellular organelles in that they contain their own genome: the maternally inherited circular mitochondrial DNA (mtDNA) molecule comprising 16,569 base pairs in humans encoding 37 genes: 13 protein-coding genes, 22 transfer RNAs (tRNAs), and 2 ribosomal RNAs (rRNAs). The mitochondrial genome is present in multiple copies within each mitochondrion, and there are hundreds to thousands of mtDNA molecules per cell. mtDNA gene variants may be heteroplasmic (only a percentage of the mtDNA is mutated) or homoplasmic (100% of the mtDNA is mutated). Primary mitochondrial disease may be caused by maternally inherited or sporadic variants affecting the mtDNA or by recessive, dominant, X-linked, or de novo variants in nearly 400 nuclear genes involved in mitochondrial function and structure.

Mitochondrial disorders, especially those presenting in childhood, have a predilection for high-energy-consuming organs: the brain, skeletal muscle, eyes, ears, heart, kidneys, and liver. Neurologic features of primary mitochondrial disease in childhood include hypotonia, dystonia, spasticity, ptosis, progressive external ophthalmoplegia (PEO), seizures, and ataxia. Multisystem features that may be observed in children with mitochondrial disease are illustrated in Figure 638.6. Some mitochondrial syndromes with characteristic constellations of symptoms and signs were recognized many decades before their genetic basis was understood; several of these syndromes are summarized in Table 638.6.

Mitochondrial encephalomyopathies can be considered according to age at onset of symptoms. In early **infancy** the most frequent presentations include Leigh syndrome, the mtDNA depletion syndromes (MDDS), disorders of coenzyme Q_{10} (CoQ_{10}) biosynthesis, and reversible infantile respiratory chain disease (RIRCD). Clinical syndromes observed later in **childhood** include Kearns-Sayre syndrome (KSS), mitochondrial encephalomyopathy with lactic acidosis and stroke-like episodes (MELAS), myoclonic epilepsy with ragged red fibers (MERRF), and neurogenic muscle weakness, ataxia, and retinitis pigmentosa (NARP). However, many children presenting with mitochondrial disease have overlapping features not specific to an individual

Table 638.6 Clinical Manifestations of Syndromic Mitochondrial Encephalomyopathies

TISSUE	SYMPTOMS/SIGNS	LSS	KSS	MELAS	MERRF	NARP	LHON
CNS	Regression	+	+	+	+		
	Seizures	±		+	+		
	Ataxia	±	+	+	+	+	
	Cortical blindness	±		+			
	Deafness	±		+		+	
	Migraine			+			
	Hemiparesis			+			
	Myoclonus			+	+		
	Movement disorder	+		+	+		±
Nerve	Peripheral neuropathy	±	+	+	+	+	
Muscle	Ophthalmoplegia	±	+				
	Weakness	+	+	+	+	+	
	RRF on muscle biopsy	±	+	+	+		
	Ptosis	±	+				
Eye	Pigmentary retinopathy	±	+			+	
	Optic atrophy	+	+				+
Heart	Conduction block		+				±
	Cardiomyopathy	±	+				
	Lactic acidosis	+	+	+	+	+	
Endocrine	Diabetes mellitus		+	+			
	Short stature	+	+	+	+		
Kidney	Tubulopathy	±	+	+	+		

KSS, Kearns-Sayre syndrome; LHON, Leber hereditary optic neuropathy; MELAS, mitochondrial myopathy, encephalopathy, lactic acidosis, and strokelike episodes; MERRF, myoclonic epilepsy with ragged red fibers; NARP, neuropathy, ataxia, and retinitis pigmentosa; RRF, ragged red fibers.
Courtesy Prof. Shamima Rahman, Great Ormond Street Institute of Child Health, London, United Kingdom.

syndrome, whereas others may present with a single clinical feature, such as an epileptic encephalopathy, leukoencephalopathy, myopathy, or isolated optic atrophy.

LEIGH SYNDROME

Leigh syndrome, or subacute necrotizing encephalomyelopathy, is a clinical syndrome of neurodevelopmental delay and/or regression and variable other neurologic features, including dystonia, hypotonia, spasticity, ataxia, and seizures, with characteristic MRI brain appearances and biochemical evidence of mitochondrial dysfunction. Peak onset is usually in the first 2 years of life (mean 7 months), although longer surviving cases and adult onset are both recognized. Initial symptoms may be nonneurologic, including feeding difficulties, vomiting, and poor weight gain in infancy. Eye involvement is a frequent finding, including nystagmus, ptosis, PEO, optic atrophy, and retinitis pigmentosa. MRI reveals bilateral, usually symmetric T2-weighted hyperintense lesions variably affecting the basal ganglia, thalamus, midbrain, and brainstem structures (Fig. 638.7). These imaging lesions reflect the neuropathology, which consists of spongiform lesions with cavitation, neuronal loss, demyelination, and capillary proliferation.

Biochemical features are variable in Leigh syndrome and include elevated lactate in blood and/or cerebrospinal fluid (CSF) and isolated or combined deficiency of one or more OXPHOS enzymes. Normal biochemical findings do not exclude the diagnosis. Leigh syndrome is genetically heterogeneous, and more than 100 monogenic causes have been identified, including variants in both mtDNA-encoded genes (responsible for 25–30% of cases) and nuclear genes. Modes of inheritance include maternal (for mtDNA variants), autosomal recessive, X-linked, and de novo dominant. **MEGDEL** (3-**me**thyl**g**lutaconic aciduria with **d**eafness and **e**ncephalopathy, **L**eigh-like) syndrome is a subtype of Leigh syndrome caused by biallelic variants in *SERAC1* encoding a protein involved in remodeling mitochondrial membrane lipids. Affected infants typically fail the newborn hearing screen and have problems with hypoglycemia and hyperammonemia related to hepatic dysfunction. Some infants succumb to liver failure, but hepatic function improves in most affected individuals, who later progress to a neurodegenerative course with prominent dystonia and loss of skills.

A few causes of Leigh syndrome are potentially treatable. These include deficiencies of biotinidase (an enzyme required for biotin recycling within the cell), the thiamine transporter SLC19A3 (also associated with biotin-thiamine–responsive basal ganglia disease), and proteins required for biosynthesis of CoQ_{10}, a mobile electron carrier in the mitochondrial respiratory chain. All other forms of Leigh syndrome have no curative treatments and are associated with a progressive neurodegenerative course with early death, usually caused by respiratory failure secondary to brainstem lesions affecting the respiratory center. Median age at death was reported as 2.4 years in one cohort, but this is variable and related to the underlying genetic cause. Longer survival has been reported in some forms of Leigh syndrome, including MEGDEL and deficiencies of SURF1 (an assembly factor for OXPHOS complex IV) and SUCLA2 (a subunit of the Krebs cycle enzyme succinyl-CoA ligase).

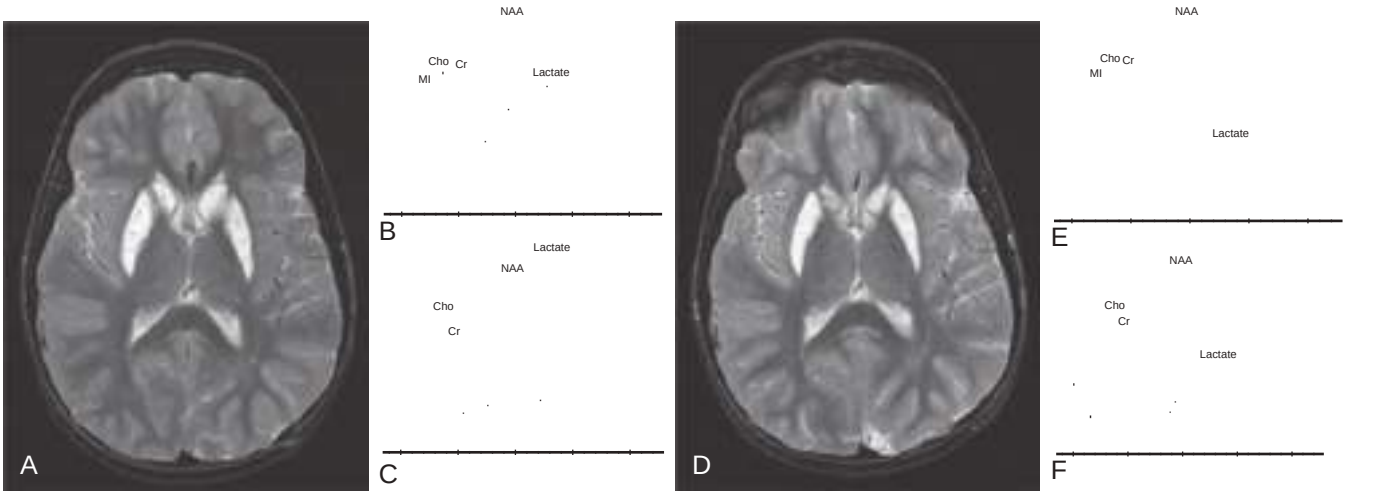

Fig. 638.7 Complex I deficiency in an 8-yr-old child with magnetic resonance examinations acquired approximately 3 mo apart. Axial T2-weighted (**A**), short echo magnetic resonance spectroscopy (MRS) (**B**), and long echo MRS (**C**) images were obtained. The imaging reveals a pattern characteristic of Leigh syndrome with an abnormal hyperintense signal bilaterally within the caudate and globus pallidus. The MRS image acquired in the left basal ganglia at a period of clinical exacerbation caused by febrile illness demonstrates a dramatic elevation of lactate compared with her routinely observed levels as shown in axial T2-weighted (**D**), short echo MRS (**E**), and long echo MRS (**F**) images. The spectra acquired 3 mo later demonstrate a significant reduction in lactate. A comparison of the imaging data is unremarkable between the examinations. The dramatic elevation of lactate revealed on MRS in (**B**) and (**C**) corresponds to worsening clinical symptoms (seizures and leg stiffening). The lactate levels observed in (**E**) and (**F**) are typical and consistent with this mitochondrial defect. *(From Cecil KM. MR spectroscopy of metabolic disorders. Neuroimaging Clin N Am. 2006;16:87–116.)*

Table 638.7 Mitochondrial DNA Depletion Syndromes

GENE*	FUNCTION	CLINICAL FEATURES	mtDNA DEPLETION	MULTIPLE DELETIONS
POLG	mtDNA replication	Alpers, juvenile epilepsy syndromes, ataxia, PEO	+	+
TWNK	mtDNA replication	Hepatocerebral disease, IOSCA, juvenile epilepsy syndromes, PEO	+	+
TFAM	mtDNA replication	Hepatocerebral disease	+	
MGME1	mtDNA replication	Encephalomyopathic	+	+
SLC25A4	Nucleoside metabolism	Encephalomyopathic, cardiac	+	+
DGUOK	Nucleoside metabolism	Hepatocerebral disease	+	+
TK2	Nucleoside metabolism	Progressive myopathy	+	+
MPV17	Nucleoside metabolism	Hepatocerebral disease	+	+
RRM2B	Nucleoside metabolism	Encephalomyopathic, SNHL, renal tubulopathy	+	+
SUCLA2	Nucleoside metabolism	Encephalomyopathic (LSS), SNHL	+	
SUCLG1	Nucleoside metabolism	Encephalomyopathic, hepatocerebral disease	+	
TYMP	Nucleoside metabolism	MNGIE	+	+

*All are recessive disorders, but, in addition, de novo dominant variants of *SLC25A4* may also present as MDDS.
IOSCA, Infantile-onset spinocerebellar ataxia; LSS, Leigh syndrome spectrum; MNGIE, mitochondrial neurogastrointestinal encephalopathy; PEO, progressive external ophthalmoplegia.
Courtesy Prof. Shamima Rahman, Great Ormond Street Institute of Child Health, London, United Kingdom.

MITOCHONDRIAL DNA DEPLETION SYNDROMES

The most prevalent MDDS is **Alpers-Huttenlocher syndrome** (progressive neuronal degeneration of childhood with epilepsy, PNDE) caused by recessively inherited gene variants in *POLG* encoding the catalytic subunit of DNA polymerase γ, the polymerase responsible for replicating the mtDNA. Affected individuals frequently present with intractable epilepsy, particularly epilepsia partialis continua, around 12 months of age. A characteristic EEG finding in the early stages of the disease is rhythmic high amplitude with delta spikes (RHADS). Repeated episodes of status epilepticus frequently lead to a median age of death of around 16 months (there is typically a median of 4 months between presentation with seizures and death). Sodium valproate is absolutely contraindicated in Alpers-Huttenlocher syndrome and other presentations of *POLG* disease because exposure to valproate may trigger fatal hepatic failure.

Recessive pathologic variants of at least 12 genes have been linked to infantile- and childhood-onset MDDS (Table 638.7). There is often a period of normal development lasting weeks to months before clinical

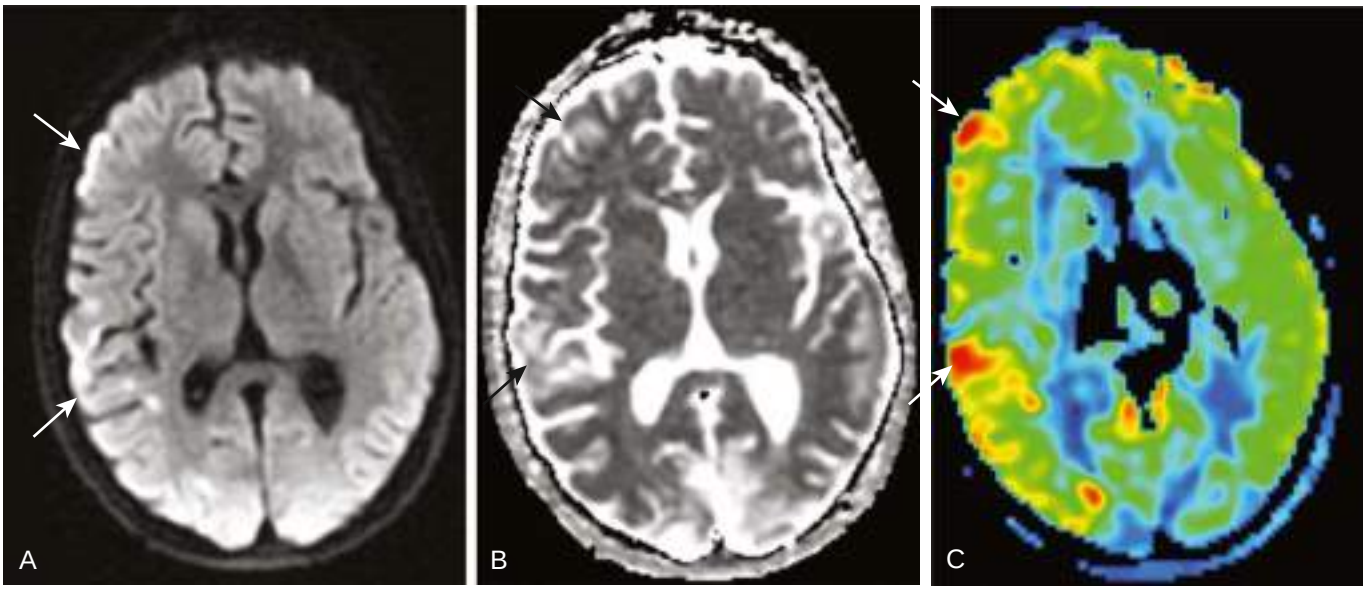

Fig. 638.8 Mitochondrial encephalomyopathy, lactic acidosis, and strokelike symptoms (MELAS) in a 13-yr-old male. Axial diffusion-weighted imaging (**A**), axial apparent diffusion coefficient (ADC) map (**B**), and an axial arterial spin labeling color map (**C**) are shown. Scattered foci of vasogenic edema denoted by *arrows* corresponding to increased perfusion are identified in the acute phase of the disease in the right cerebral hemisphere. *(From Zuccoli G, Cecil KM. Inherited metabolic and neurogenerative disorders. In: Coley BD, ed. Caffey's Pediatric Diagnostic Imaging, 13th ed. Philadelphia: Elsevier; 2019: Fig. 33.8, p. 312.)*

manifestations become apparent. Associated organ involvement may provide a clue to the underlying genetic diagnosis: sensorineural hearing loss (SNHL) and methylmalonic aciduria occur in *SUCLA2* defects, SNHL and renal tubular involvement in *RRM2B* defects, and hepatic involvement is associated with *DGUOK*, *MPV17*, *POLG*, *TWNK*, *TFAM*, and *SUCLG1* gene variants. **Thymidine kinase 2 (TK2) deficiency** appears to be a special case because this disorder leads to a pure myopathic presentation in most affected cases. Clinical response to nucleoside supplementation has been reported for TK2 deficiency but not for any other form of MDDS.

DISORDERS OF COENZYME Q_{10} BIOSYNTHESIS

CoQ_{10} functions as a mobile electron carrier and antioxidant in the mitochondrial inner membrane. CoQ_{10} is synthesized by a complex biosynthetic pathway, 10 defects of which have been linked to human disease. Clinical presentations of these recessive disorders include an infantile encephalomyopathy with prominent seizures and dystonia variably associated with multisystem features: SNHL, optic atrophy, pigmentary retinopathy, cardiomyopathy, and renal disease. Other presentations include ataxia, myopathy, and steroid-resistant nephrotic syndrome. Affected patients should be treated with high-dose CoQ_{10} supplementation, although clinical response is variable.

REVERSIBLE INFANTILE RESPIRATORY CHAIN DEFICIENCY

RIRCD, also known as *benign reversible mitochondrial myopathy,* typically presents after a period of normal development lasting 3-6 weeks with profound lactic acidosis and progressive muscle weakness, often leading to a need for enteral tube feeding and, in some cases where the respiratory muscles are severely affected, artificial ventilation. A ventilatory requirement may persist for up to 18 months. Muscle biopsy reveals ragged red and cytochrome *c* oxidase negative fibers with multiple OXPHOS enzyme deficiencies on spectrophotometric assay. This condition is linked to two homoplasmic variants at the same nucleotide in mtDNA: m.14674T>G and m.14674T>C. Although all maternally related individuals are homoplasmic for the variant, only a small proportion are clinically affected. Studies have also identified potential modifying variants in several nuclear-encoded genes involved in mitochondrial translation, particularly *EARS2*. Spontaneous recovery of muscle strength is associated with excellent neurodevelopmental outcomes. Because it is not possible to distinguish RIRCD from fatal infantile mitochondrial myopathies, rapid testing for the m.14674T>G/C variants is recommended in all infants presenting with severe muscle weakness and lactic acidosis, so that ventilatory support can be provided to affected infants if needed.

Another form of RIRCD is a reversible hepatopathy caused by recessive variants in the *TRMU* gene encoding a protein required to modify mitochondrial tRNAs. Affected infants present with acute liver failure, variably associated with encephalomyopathic features.

KEARNS-SAYRE SYNDROME

KSS is defined by a *clinical triad* of PEO, pigmentary retinopathy, and heart block, with age of onset <20 years. Other neurologic features include cerebellar ataxia, elevated CSF protein levels, progressive myopathy, and cognitive decline. A peculiar feature of KSS is white matter disease associated with cerebral folate deficiency. Low levels of CSF 5-methyltetrahydrofolate (5-MTHF) and clinical response to folinic acid supplementation have been documented in some patients. Variable associated multisystem disease features include SNHL, renal tubulopathy, endocrine dysfunction (diabetes mellitus, hypoparathyroidism, and short stature with growth hormone deficiency in some cases), and cardiomyopathy. KSS is usually a sporadic condition caused by single large-scale mtDNA deletions (SLSMDs); many individuals have a common 4.9kb mtDNA deletion. SLSMDs are associated with a continuous clinical spectrum ranging from infantile-onset Pearson syndrome to adult-onset isolated PEO without systemic features.

MITOCHONDRIAL ENCEPHALOMYOPATHY WITH LACTIC ACIDOSIS AND STROKELIKE EPISODES

MELAS is a maternally inherited disorder that typically presents toward the end of the first decade with migraine headache, vomiting, and seizures, which may lead to a strokelike episode. MRI of the brain reveals focal lesions with a parieto-occipital predilection not confined to a vascular territory (Fig. 638.8). Other clinical features include hemianopia during the strokelike episodes, ptosis, optic atrophy, pigmentary retinopathy, SNHL, exercise intolerance, cognitive decline, GI dysmotility, cardiomyopathy, renal impairment, and diabetes mellitus. Eighty percent of cases have a common maternally inherited mtDNA gene variant m.3243A>G in the *MT-TL1* gene encoding a tRNA for leucine. This gene variant is present in 1 in 400 of the general population, yet MELAS is a rare disorder. Most individuals harboring the

m.3243A>G variant are asymptomatic or oligosymptomatic or have non-MELAS presentations, including **maternally inherited diabetes and deafness (MIDD)**, cardiomyopathy, sudden unexpected death, or isolated renal involvement (focal segmental glomerulosclerosis). Other causes of MELAS include other mtDNA variants, particularly in the *MT-TL1* gene or in mtDNA-encoded subunits of complex I (especially ND5), and occasionally *POLG* disease can mimic MELAS.

MYOCLONIC EPILEPSY WITH RAGGED RED FIBERS

MERRF is a maternally inherited syndrome characterized by progressive myoclonic epilepsy and cerebellar ataxia with nystagmus and dysarthria. Onset may be in late childhood or adult life, and the disorder may be rapidly progressive or have a more indolent course. Other neurologic features include other seizure types, spasticity, peripheral neuropathy, SNHL, ptosis, PEO, optic atrophy, cognitive decline, and psychiatric manifestations. MERRF can also mimic MELAS, including strokelike episodes. MERRF is typically a multisystemic disorder; extraneurologic features include multiple symmetric lipomatosis, endocrine disturbance (growth hormone deficiency, hypothyroidism, adrenal insufficiency), and cardiomyopathy. A common mtDNA pathologic variant, m.8344A>G in the *MT-TK* gene encoding the tRNA for lysine, accounts for 80% of cases of MERRF. Patients with a very high percentage of this variant (typically >90%) present with **Leigh syndrome** in infancy. The remaining patients with MERRF have other mtDNA tRNA gene variants; occasionally *POLG* disease may mimic MERRF.

NEUROGENIC MUSCLE WEAKNESS, ATAXIA, AND RETINITIS PIGMENTOSA

NARP is a maternally inherited disorder caused by a relatively common mtDNA gene variant, m.8993T>G, in the *MT-ATP6* gene encoding the ATP6 subunit of ATP synthase (OXPHOS complex V). Patients usually have a gene variant load of ~70%, but those with a higher variant load (typically >90%) of the same variant present with maternally inherited Leigh syndrome. Clinical presentation of NARP is usually in late childhood or early adult life with numbness and paresthesias caused by the sensory neuropathy associated with muscle weakness and ataxia. Retinitis pigmentosa initially causes poor night vision and progresses slowly to severe visual loss. Other clinical features include developmental delay, learning disability, dementia, seizures, SNHL, diabetes mellitus, and cardiac conduction defects. *MT-ATP6* variants have also been reported to cause axonal **Charcot-Marie-Tooth disease** without CNS or other features.

MITOCHONDRIAL NEUROGASTROINTESTINAL ENCEPHALOMYOPATHY

Mitochondrial neurogastrointestinal encephalomyopathy (MNGIE) is a late-onset MDDS characterized by widespread demyelinating polyneuropathy leading to predominant GI symptoms and peripheral neuropathy with a relatively asymptomatic leukoencephalopathy. Onset of symptoms is usually toward the end of the second decade, but presentation in early childhood may occur. Major symptoms relate to GI dysmotility and pseudo-obstruction (nausea, vomiting, early satiety, abdominal pain, diarrhea) leading to severe weight loss and cachexia. Other clinical features include ptosis, PEO, SNHL, painful paresthesias, and foot drop. The disorder is caused by recessive variants in the *TYMP* gene encoding thymidine phosphorylase, a cytosolic enzyme whose function is essential to the maintenance of intramitochondrial nucleotide pools. Allogeneic hematopoietic stem cell or liver transplantation may be beneficial if performed early in the disease course.

JUVENILE *POLG* SYNDROMES

POLG variants may also present in later childhood or adult life with a range of clinical presentations, including PEO, proximal or distal myopathy, and juvenile and adult-onset epilepsy syndromes. Myoclonic epilepsy, myopathy, and sensory ataxia (MEMSA), incorporating an entity previously known as *spinocerebellar ataxia with epilepsy (SCAE),* typically presents with cerebellar ataxia in adolescence or young adult life, with later development of epilepsy. The seizures are focal initially, often affecting the right hand. Later they become generalized, including epilepsia partialis continua (EPC), and are refractory to therapy. The ataxia neuropathy spectrum (ANS) is characterized by ataxia and neuropathy and includes the previous acronyms MIRAS (mitochondrial recessive ataxia syndrome) and SANDO (sensory ataxia, neuropathy, dysarthria, ophthalmoplegia). ANS also frequently leads to an encephalopathy with seizures, so there is some overlap between MEMSA and ANS. *POLG* disease may also mimic MELAS, MERRF, and MNGIE. Variants in the *MT-ATP6* gene have also been linked to this condition.

MITOCHONDRIAL LEUKOENCEPHALOPATHIES

Several recessive mitochondrial disorders cause *cavitating* leukoencephalopathies (Table 638.8) that typically present in infancy or early childhood with acute- or subacute-onset of motor regression. Other clinical features include epileptic encephalopathy, hemiparesis, spastic paraparesis, bulbar problems, and visual loss (optic atrophy). Mitochondrial leukoencephalopathies may also present later in childhood or in adult life. Some of the mitochondrial tRNA aminoacyl synthetase deficiencies appear to cause specific white matter changes. Other genetic causes of mitochondrial leukoencephalopathy include variants in subunits of complexes I and II and defects of iron-sulfur cluster biosynthesis (see Table 638.8).

LEBER HEREDITARY OPTIC NEUROPATHY AND AUTOSOMAL DOMINANT OPTIC ATROPHY

Leber hereditary optic neuropathy (LHON) and autosomal dominant optic atrophy (ADOA) are two mitochondrial optic neuropathies that may occasionally present with additional encephalomyopathic features. **LHON** is maternally inherited and typically presents in the second or third decade of life (mean onset ~20 years, but childhood presentation is well-recognized) with subacute or acute visual loss sequentially affecting *both* eyes. Three common mtDNA variants in genes encoding complex I subunits (m.3460G>A in *MT-ND1*, m.11778G>A in *MT-ND4*, and m.14484T>C in *MT-ND6*) account for 90% of cases. Penetrance is incomplete, and there is an extreme male preponderance, which may be explained by a protective effect of estrogen in females with LHON variants. In most cases LHON presents as an isolated optic neuropathy, but other clinical manifestations in occasional cases include dystonia (with bilateral striatal necrosis), peripheral neuropathy, or cardiac conduction defects.

ADOA, also known as *Kjer disease,* is the most frequent genetic optic neuropathy and is caused by dominant variants of *OPA1,* encoding a protein needed for mitochondrial fusion. Usually this is an isolated optic neuropathy but may be associated with SNHL. In some patients there are biallelic variants of *OPA1* leading to multiple mtDNA deletions and additional manifestations, including PEO, RRF myopathy and white matter lesions, and cerebellar atrophy associated with ataxia, pyramidal signs, spasticity, and learning disability.

NONSYNDROMIC MITOCHONDRIAL DISORDERS

In childhood, many patients affected by mitochondrial disease present with complex multisystem features that do not align closely with any of the specific known mitochondrial syndromes or with nonsyndromic features, such as isolated epilepsy, leukoencephalopathy, or myopathy. These patients may lack biochemical features of mitochondrial disease such as lactic acidosis and are identified by exome and genome sequencing as a first-line diagnostic strategy in children with encephalomyopathies.

APPROACH TO DIAGNOSIS

When a mitochondrial disease is suspected, it is important to take a thorough personal and family history, including enquiring about early deaths within the extended family, and to screen for multisystemic involvement. This may include formal ophthalmologic, audiologic, and cardiac evaluation. There is no single diagnostic test that can detect all mitochondrial diseases. There are some characteristic MRI appearances, such as bilateral symmetric involvement of the basal ganglia and/or brainstem in Leigh syndrome, strokelike lesions

Table 638.8 Mitochondrial Leukoencephalopathies

GENE DEFECT(S)	CLASS OF MITOCHONDRIAL DISORDER	TYPE OF LEUKOENCEPHALOPATHY
NDUFV1	Complex I deficiency	Cystic leukoencephalopathy
NDUFA2	Complex I deficiency	Cystic leukoencephalopathy with tigroid-like changes
NUBPL	Complex I deficiency	Complex leukoencephalopathy involving deep cerebral white matter, basal ganglia, thalami and corpus callosum, with progressive cerebellar atrophy
SDHA, SDHB, SDHAF1	Complex II deficiency	Cystic leukoencephalopathy with succinate peak on MRS
LYRM7	Complex III deficiency	Cystic leukoencephalopathy
COA7	Complex IV deficiency	Cystic leukoencephalopathy with spinal cord hypotrophy
COA8	Complex IV deficiency	Cystic leukoencephalopathy with posterior predominance
TYMP	Disorder of mtDNA maintenance	Demyelinating leukoencephalopathy
mtDNA deletion	Disorder of mitochondrial translation	T2-hyperintense abnormalities of subcortical cerebral white matter, globus pallidus and substantia nigra (Kearns-Sayre syndrome)
DARS2	Disorder of mitochondrial translation	Leukoencephalopathy with Brainstem and Spinal cord involvement and Lactate elevation on proton MRS (LBSL)
EARS2	Disorder of mitochondrial translation	Leukoencephalopathy (sparing periventricular rim) with Thalamus and Brainstem involvement and Lactate elevation on proton MRS (LTBL)
IBA57, ISCA2, NFU1	Iron-sulfur cluster biosynthesis defect	Cystic leukoencephalopathy

Courtesy Prof. Shamima Rahman, Great Ormond Street Institute of Child Health, London, United Kingdom.

in MELAS, and the specific leukoencephalopathies outlined in Tables 638.6 and 638.8. However, brain MRI rarely leads to a specific genetic diagnosis other than in these distinctive leukoencephalopathies. Metabolic investigations that may provide diagnostic clues include blood lactate, plasma amino acids and acylcarnitines, urine organic acids, and CSF lactate, amino acids, neurotransmitters, and 5-MTHF. The traditional approach to diagnose a mitochondrial disease included a muscle biopsy, which was subject to histologic, histochemical, and electron microscopic analysis, as well as spectrophotometric or polarographic assay of the individual OXPHOS enzyme complexes. However, in most centers muscle biopsy has been replaced by first-line genetic approaches that utilize next-generation sequencing to sequence the mtDNA, a large panel of nuclear genes, the exome or the whole genome. Muscle biopsy still retains a place in the investigation of critically unwell children with suspected mitochondrial disease and to provide functional validation of variants of unknown significance identified by genetic testing.

MANAGEMENT

There are no curative therapies for most mitochondrial encephalomyopathies, but there are a few notable exceptions. Leigh syndrome caused by deficiency of the SLC19A3 thiamine transporter may respond to a combination of biotin and thiamine, and some patients with disorders of CoQ_{10} biosynthesis may improve with high-dose CoQ_{10} supplementation. High-dose CoQ_{10} supplementation appears to be particularly effective in preventing (but not reversing) the renal manifestations of CoQ_{10} deficiency but has proved ineffective in treating the CNS manifestations of this disorder in prenatal/neonatal-onset CoQ_{10} biosynthesis disorders associated with *COQ4* and *COQ9* variants.

Symptomatic therapies are the mainstay of management for children with mitochondrial encephalomyopathies. Supportive measures may include antiepileptic drugs, hearing aids, cochlear implantation, ptosis surgery, enteral feeding, pancreatic enzyme supplements, hormone replacement (thyroxine, cortisol, growth hormone, insulin, estrogen), cardiac pacing (which can be lifesaving in heart block caused by KSS), and medical management of heart failure.

Emerging therapies under investigation for mitochondrial encephalomyopathies can be divided broadly into pharmacologic and genetic approaches. Pharmacologic therapies under development include redox modulation and strategies to replenish reduced nicotinamide adenine dinucleotide (NAD) boost mitochondrial biogenesis, and stabilize cardiolipin, the membrane lipid unique to mitochondria. A successful trial of adeno-associated virus (AAV) gene replacement has been published for LHON caused by *MT-ND4* variants, and gene therapy has been reported for mouse models of several nuclear-encoded mitochondrial diseases but has yet to be translated to the clinic.

Visit Elsevier eBooks+ at eBooks.Health.Elsevier.com for Bibliography.

638.3 Other Encephalopathies

Michael Perry and Cheryl Hemingway

POSTERIOR REVERSIBLE ENCEPHALOPATHY SYNDROME

Posterior reversible encephalopathy syndrome (PRES) is a rare clinical syndrome of acute neurologic dysfunction in the presence of vasogenic subcortical brain edema.

The pathophysiologic mechanisms underlying PRES are poorly understood. Endothelial injury, however, with subsequent blood-brain barrier breakdown and vasogenic edema, appears to be a critical factor. Sudden increases in blood pressure exceeding capacity for cerebral blood flow autoregulation, direct cytokine effects, and cytotoxic drugs are all plausible mediators of the endothelial dysfunction. The posterior circulation may be more vulnerable to increased blood pressure because of a relative lack of sympathetic innervation. Children taking immunosuppressant or cytotoxic drugs (e.g., calcineurin inhibitors,

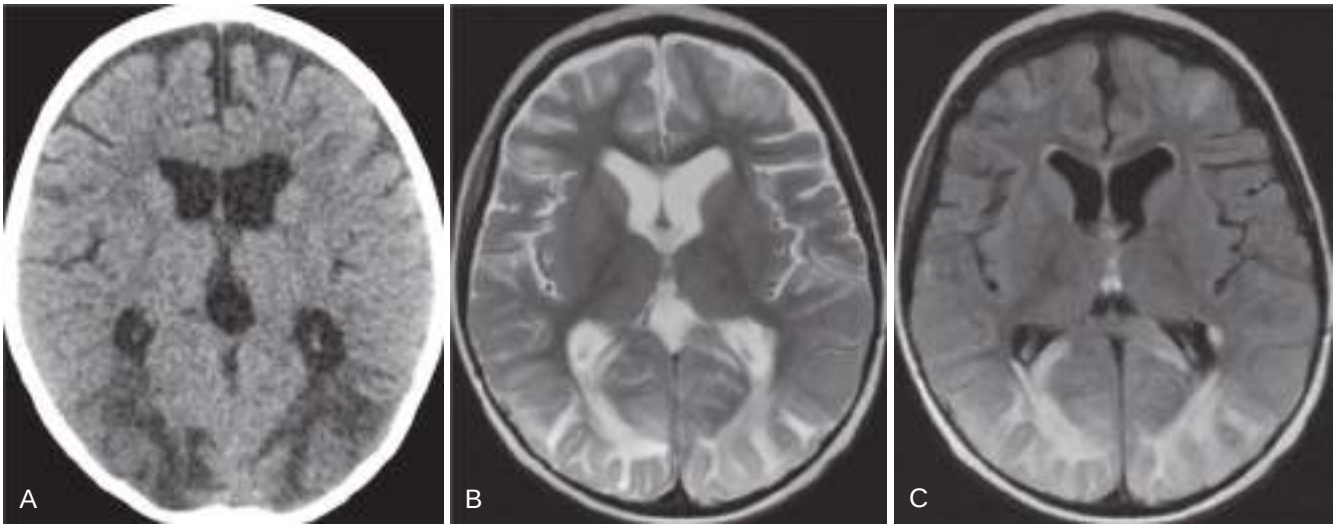

Fig. 638.9 Posterior reversible encephalopathy syndrome (PRES). **A,** Emergent head CT was performed for acute hypertension in this 2-yr-old female with a history of severe aplastic anemia undergoing bone marrow transplantation. A symmetric pattern of posterior-predominant vasogenic edema was evident. Also noteworthy is the moderate parenchymal volume loss, likely related to the patient's other underlying medical conditions. Subsequently obtained T2-weighted **(B)** and FLAIR **(C)** MRIs showed a symmetric abnormally high signal in the posterior cerebral white matter. *(From Nazarian JP, Wolansky L, Gupta A, Coffey M. Demyelinating disease and leukoencephalopathies. In: Haaga JR, Boll DT, eds. CT and MRI of the Whole Body, 6th ed. Philadelphia: Elsevier; 2017: Fig. 19.18, p. 580.)*

cyclosporine, tacrolimus) in the context of organ transplantation, cancer, and autoimmune disease are at highest risk of developing PRES; renal disease (e.g., glomerulonephritis, IgA vasculitis) is also a risk factor.

Neurologic symptoms in PRES (i.e., seizures, encephalopathy, headache, and visual disturbances) develop over hours to days. Seizures occur almost universally; a focal onset with subsequent generalization is common, and status epilepticus may occur. Encephalopathy can range from mild alteration of mental state to coma. Focal deficits (e.g., hemiparesis) are seen in a small minority of patients.

MRI characteristically shows asymmetric T2/FLAIR high-signal intensities corresponding to vasogenic edema predominantly in the parieto-occipital regions (Fig. 638.9). The basal ganglia, cerebellar hemispheres, and brainstem may also be involved. The changes are almost always seen bilaterally and invariably involve the subcortical white matter with or without hemorrhage (intraparenchymal, petechial, or subarachnoid), restricted diffusion, or contrast enhancement (leptomeningeal, cortical, or nodular). Radiologic resolution typically occurs in days to weeks.

There are no PRES-specific treatments. Care is therefore supportive and should be directed at restoration of a normotensive state, control of seizures with appropriate anticonvulsants, and discontinuation of any offending agent (e.g., cytotoxic drugs). Continuous infusions of antihypertensives may be useful to prevent dramatic fluctuations of blood pressure.

Contrary to what its name suggests, PRES is not always reversible (nor does it always occur posteriorly). Despite this, the prognosis is generally favorable with complete recovery seen in up to 85% of children. Clinical and radiologic improvement becomes evident days to weeks after symptom onset. Hemorrhage is most often responsible for permanent disability.

ACUTE NECROTIZING ENCEPHALOPATHY

Acute necrotizing encephalopathy (ANE) is a rare severe encephalopathy characterized by a rapid and fulminant course. It is seen most often in children under 2 years old in East Asian countries, particularly Japan and Taiwan. Most cases are monophasic and sporadic. However, a familial and recurrent form has been reported in White children in North America and Europe. Approximately half of these cases are associated with pathogenic variants in the mitochondria-related RAN-binding protein 2 *(RANBP2)* gene; this variant is termed *ANE1*. The pathogenesis is not well understood but may be driven by hyper-cytokinemia (e.g., interleukin [IL]-6) triggered by a preceding viral infection (e.g., influenza, rotavirus, respiratory syncytial virus [RSV], parainfluenza virus, enterovirus, human herpesvirus [HHV]-6, SARS-CoV-2) in a genetically susceptible host.

ANE presents with a dramatic encephalopathy after a febrile, "viral" prodrome. Neurologic deficits are profound with rapid progression to coma. Seizures are normally present, and progression of systemic inflammatory dysregulation such as shock, organ failure, and disseminated intravascular coagulation is common. Elevated hepatic enzymes without hyperammonemia are a unique feature. MRI is characterized by bilateral symmetric thalamic lesions with or without lesions in the tegmentum, cerebellar medulla, internal capsule, or periventricular white matter (Fig. 638.10). Table 638.9 lists the diagnostic criteria.

Table 638.9 Diagnostic Criteria for Acute Necrotizing Encephalopathy of Childhood

1. Acute encephalopathy after (1-3 days) a febrile disease. Rapid deterioration in the level of consciousness. Seizures.
2. No cerebrospinal fluid pleocytosis. Increase in cerebrospinal fluid protein.
3. CT or MRI evidence of symmetric, multifocal brain lesions. Involvement of the bilateral thalami. Lesions also common in the cerebral periventricular white matter, internal capsule, putamen, upper brainstem tegmentum, and cerebellar medulla. No involvement of other central nervous system regions.
4. Elevation of serum aminotransferases of variable degrees. No increase in blood ammonia.
5. Exclusion of mimics.
   A. Differential diagnosis from clinical viewpoints.
      Overwhelming bacterial and viral infections, and fulminant hepatitis; toxic shock, hemolytic-uremic syndrome, and other toxin-induced diseases; Reye syndrome, hemorrhagic shock and encephalopathy syndrome, and heat stroke
   B. Differential diagnosis from radiologic viewpoints.
      Leigh encephalopathy and related mitochondrial cytopathies; glutaric acidemia, methylmalonic acidemia, and infantile bilateral striatal necrosis; Wernicke encephalopathy and carbon monoxide poisoning; acute disseminated encephalomyelitis, acute hemorrhagic leukoencephalitis, other types of encephalitis, and vasculitis; arterial or venous infection, and the effects of severe hypoxia or head trauma

Modified from Hoshino A, Saitoh M, Oka A, et al. Epidemiology of acute encephalopathy in Japan, with emphasis on the association of viruses and syndromes. *Brain Dev.* 2012;34:337–343, Table 1.

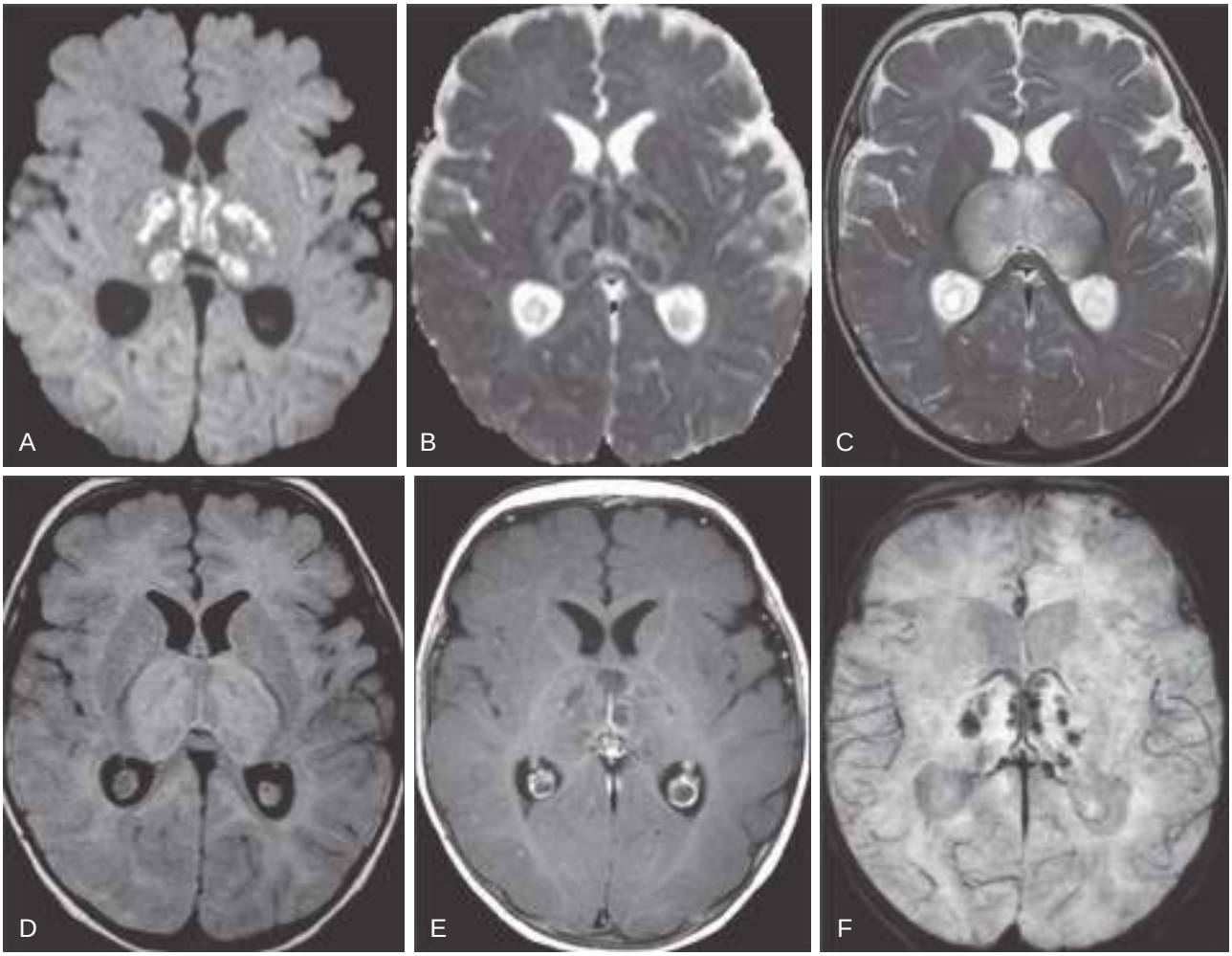

Fig. 638.10 Acute necrotizing encephalopathy. MRI at presentation. **A,** Axial diffusion-weighted image. **B,** Axial apparent diffusion coefficient (ADC) map. **C,** Axial T2-weighted image. **D,** Axial fluid-attenuated inversion recovery (FLAIR) image. **E,** Contrast-enhanced axial T1-weighted image. **F,** Axial susceptibility weighted image. Diffusion-weighted images (**A**) and corresponding ADC map (**B**) clearly show multiple areas of restricted diffusion against a background of increased diffusion involving both thalami, which are swollen. On T2-weighted (**C**) and FLAIR (**D**) images, the thalami are markedly swollen and hyperintense. On T1-weighted images obtained after intravenous gadolinium chelate injection (**E**), multiple necrotic portions are well delineated by peripheral faint, linear enhancement. Incidental choroid plexus cysts are detected. Susceptibility weighted image (**F**) shows multiple hypointense spots, consistent with petechial hemorrhage. *(From Bergamino L, Capra V, Biancheri R, et al. Immunomodulatory therapy in recurrent acute necrotizing encephalopathy ANE1: is it useful? Brain Dev. 2012;34:384–391, Fig. 1.)*

There are no formal treatment guidelines. There is limited evidence from small case series demonstrating some response to early (<24 hours from symptom onset) and aggressive high-dose pulsed IV methylprednisolone. Intravenous immunoglobulin (IVIG) may also be of some benefit. Treatment is otherwise supportive, usually in an intensive care setting. Prognosis in ANE is poor, particularly in children with brainstem involvement. Mortality rates approach 40%, and severe neurologic sequelae are typical in surviving children.

Visit Elsevier eBooks+ at eBooks.Health.Elsevier.com for Bibliography.

638.4 Autoimmune Encephalitis

Thaís Armangué and Josep Dalmau

Autoimmune encephalitis comprises an expanding group of clinical syndromes that can occur at all ages (<1 year to adult) but preferentially affect children and younger adults. Some of these disorders are associated with antibodies against neuronal cell surface proteins and synaptic receptors involved in synaptic transmission, plasticity, or neuronal excitability. The syndromes vary according to the associated antibody, with phenotypes that resemble those in which the function of the target antigen is pharmacologically or genetically modified.

Most of these disorders are severe and potentially fatal, but patients frequently respond to immunotherapy with good outcomes. Moreover, because of the broad spectrum of symptoms—including alterations of behavior, psychosis, catatonia, insomnia, memory deficits, seizures, abnormal movements, and autonomic dysregulation—patients usually require a multidisciplinary treatment approach.

The identification of autoimmune mechanisms has provided a definitive diagnosis to many cases of encephalitis previously considered idiopathic, infectious, or postinfectious even though no causative agents were found. More than half of cases previously defined as encephalitis lethargica or choreoathetosis post–herpes simplex encephalitis are currently known to be anti–*N*-methyl-D-aspartate receptor **(NMDAR) encephalitis**.

The mechanisms that trigger the production of the antibodies are unknown. In a small subgroup of adolescent or young adult patients, the presence of a tumor that expresses the target neuronal antigen likely contributes to the triggering of the immune response. In addition, the high prevalence of prodromal viral-like symptoms has suggested that nonspecific viral infections may contribute to altering the

immune tolerance for neuronal proteins and increasing the permeability of the blood-brain barrier to antibodies. Nonetheless, in many of these diseases the blood-brain barrier appears intact, and there is evidence that the autoantibodies are synthesized within the CNS by plasma cells that form part of the local brain and meningeal inflammatory infiltrates.

GENERAL DIAGNOSTIC APPROACH TO AUTOIMMUNE ENCEPHALITIS

Most autoimmune encephalitides have a rapid presentation of multiple symptoms, usually in less than 3 months, including neurologic and/or psychiatric alterations frequently associated with seizures or abnormal EEG, and CSF or MRI evidence of inflammatory changes.

Depending on the combination of clinical features and presence of neuronal-specific antibodies, three diagnostic categories have been established: possible autoimmune encephalitis, probable antibody-negative autoimmune encephalitis, and definite antibody-positive autoimmune encephalitis (Table 638.10).

In the pediatric population, the number of autoimmune encephalitis cases associated with well-defined antibodies is substantially lower than that affecting the adult population (Table 638.11).

ANTI-*N*-METHYL-D-ASPARTATE RECEPTOR ENCEPHALITIS

In this disease, the immunoglobulin G antibodies target the GluN1 subunit of the NMDA receptor. The estimated annual incidence of this disorder is 1.2-1.5 cases per million persons, and it is considered the second most common cause of autoimmune encephalitis after acute disseminated encephalomyelitis (ADEM) in children and adolescents. Overall, the disease predominates in females (80%); in patients younger than 12 years, the frequency of males is >40%. The resulting syndrome is highly predictable and usually evolves in stages. In teenagers and young adults, the disorder usually presents with *prominent psychiatric manifestations* that may include rapidly progressive anxiety, agitation, delusional thoughts, bizarre behavior, labile affect, mood disturbances (mania), catatonic features, memory deficit, language disintegration, aggression, and insomnia or other sleep disturbances. In many cases, these symptoms had been preceded by a few days of prodromal headache, fever, or viral infection–like symptoms. Patients are often misdiagnosed with new-onset psychosis or a primary psychiatric disorder. However, in a few days or weeks, additional symptoms occur, including a decreased level of consciousness, seizures (including status epilepticus), limb or oral dyskinesias, choreoathetoid movements, and *autonomic instability* that usually includes tachycardia, bradycardia, fluctuation of blood pressure, hypoventilation, hyperthermia, and sialorrhea. In rare instances, bradycardia and cardiac pauses occur, at times requiring the transient use of a pacemaker. The disorder also occurs in toddlers and infants (the youngest patient identified to date was 2 months old), and although the evolution of the syndrome is similar to that of adults, young patients more frequently present with seizures and movement disorders. Because of the age of patients, the psychiatric-behavioral features may be missed. In this young age-group, behavior changes include irritability, new-onset temper tantrums, agitation, aggression, reduced speech, mutism, and autistic-like regression. Moreover, compared with adults, some children also develop cerebellar ataxia and hemiparesis; in contrast, autonomic dysfunction is usually milder and less severe in children.

Brain MRI studies are abnormal in approximately 35% of patients, usually showing nonspecific cortical and subcortical T2–fluid-attenuated inversion recovery (FLAIR) signal abnormalities, sometimes with transient cortical or meningeal enhancement; nonspecific white matter abnormalities can occur. However, if white matter changes are predominant, an overlapping syndrome with a demyelinating disease should be suspected (Fig. 638.11A). The CSF is initially abnormal in approximately 80% of patients, showing moderate lymphocytic pleocytosis and, less frequently, increased protein synthesis and oligoclonal bands. The EEG is abnormal in *virtually all* patients; it usually shows focal or diffuse slow activity in the delta and theta ranges, which does not correlate with abnormal movements. In addition, many patients develop epileptic activity, requiring video monitoring for adequate clinical management. A distinctive EEG pattern called *extreme delta brush,* characterized by beta-delta complexes, occurs in 30% of adults and less frequently in children (Fig. 638.12).

The diagnosis of the disorder is established by demonstrating NMDAR antibodies in CSF. The sensitivity is higher in CSF compared with serum (100% vs 85%), and the levels of antibodies in CSF appear to correlate better with the outcome. Antibodies may remain detectable, albeit at lower titers, after patients recover.

The presence of an underlying tumor, usually a teratoma, is age and sex dependent. Whereas 40% of females older than 12 years have an underlying teratoma of the ovary, the presence of a tumor is unusual in young males and females or young adult male patients. In children, an MRI of the abdomen and pelvis and abdominal and testicular ultrasound are the preferred tumor screening tests.

In a small number of patients, anti-NMDAR encephalitis occurs simultaneously with or after infections with a variety of pathogens, including *Mycoplasma pneumoniae,* herpes simplex virus (HSV), human herpesvirus 6, enterovirus, COVID-19, and influenza virus. With the exception of HSV1, a pathogenic link with most of these infections has not been established. There is evidence that about 50% of patients with HSV encephalitis develop antibodies against the GluN1 subunit of the NMDAR and other neuronal cell surface proteins and receptors, and of these about half the patients develop new or relapsing neurologic symptoms 2-12 weeks after completing treatment for HSV encephalitis. In children younger than 4 years, this type of autoimmune encephalitis usually manifests with choreoathetosis and dyskinesias (known as *choreoathetosis post-HSV encephalitis;* see **Videos 638.1, 638.2, and 638.3**). In contrast, older children and adults more often develop predominantly behavioral symptoms. A similar complication has been reported in patients with Japanese encephalitis, who develop autoimmune encephalitis (usually with NMDAR antibodies) after the viral encephalitis has subsided.

There is evidence that tumor removal, when appropriate, and prompt immunotherapy improve the outcome. Most children receive first-line immunotherapies, including corticosteroids, IVIG, or plasma exchange. However, because these treatments fail in ~50% of patients, and with multiple reports showing that rituximab is effective, this treatment is increasingly being used in combination with IVIG and steroids or after first-line immunotherapies fail. Cyclophosphamide can be effective when there has been no response to these treatments.

Approximately 80% of patients recover substantially or fully; mortality is estimated to be ~5%, usually as a result of infections or autonomic dysregulation during the acute phase of the disease. Recovery is usually slow and can take as long as 2 years after symptom onset. The last symptoms to improve are problems in social interactions and language and executive functions. **Relapses** occur in approximately 15% of patients; they can develop as partial syndromes, are usually milder than the initial episode, and respond equally well to immunotherapy. Initial comprehensive immunotherapy and rituximab appear to prevent or reduce the number of relapses. The efficacy of chronic immunosuppression with drugs such as azathioprine or mycophenolate mofetil in preventing relapses is unknown. Young children with autoimmune encephalitis, post-HSV encephalitis, and NMDAR antibodies have a poorer prognosis than patients with classical anti-NMDAR encephalitis (see Fig. 638.11B).

The differential diagnosis of anti-NMDAR encephalitis is extensive and varies according to the stage of the disease (Table 638.12). The most frequently considered disorders are viral encephalitis, neuroleptic malignant syndrome, acute psychosis, and drug misuse.

OTHER TYPES OF ENCEPHALITIS ASSOCIATED WITH ANTIBODIES AGAINST NEURONAL CELL SURFACE ANTIGENS

Encephalitis with antibodies against the γ-aminobutyric acid A receptor ($GABA_AR$) is a rare autoimmune encephalitis that can affect

Table 638.10 Classification Criteria for Possible and Definite Antibody-Positive Autoimmune Encephalitis and Probable Antibody-Negative Pediatric Autoimmune Encephalitis

CATEGORICAL FEATURES OF AUTOIMMUNE ENCEPHALITIS	SPECIFIC DIAGNOSTIC FEATURES	DIAGNOSTIC CATEGORIES		
		POSSIBLE AE	PROBABLE ANTIBODY-NEGATIVE AE	DEFINITE ANTIBODY-POSITIVE AE
1. Evidence of acute or subacute symptom onset	Onset of neurologic and/or psychiatric symptoms over ≤3 mo in a previously healthy child	Yes	Yes	Yes
2. Clinical evidence of neurologic dysfunction	Features include:	≥2 features present	≥2 features present	≥2 features present
	Altered mental status/level of consciousness or EEG with slowing or epileptiform activity (focal or generalized)			
	Focal neurologic deficits			
	Cognitive difficulties[a]			
	Acute developmental regression			
	Movement disorder (except tics)			
	Psychiatric symptoms			
	Seizures not explained by a previously known seizure disorder or other condition			
3. Paraclinical evidence of neuroinflammation	Features include:	Not available*	≥1 feature present	≥1[b] feature present
	CSF inflammatory changes (leukocytosis >5 cells/mm^3 and/or oligoclonal banding)			
	MRI features of encephalitis			
	Brain biopsy showing inflammatory infiltrates and excluding other disorders			
4. Autoimmune encephalitis serology	Presence in serum and/or CSF of well-characterized autoantibodies associated with autoimmune encephalitis[b]	Not available	No	Yes
5. Exclusion of other etiologies	Reasonable exclusion of alternative causes, including other causes of CNS inflammation	Yes	Yes	Yes

[a]Severe cognitive dysfunction that is not attributable to a primary psychiatric syndrome as documented by a qualified clinician (e.g., neurologist, psychiatrist, and neuropsychologist) or a significant drop in IQ (>20 points).

[b]When antibodies against *N*-methyl-D-aspartate receptor (NMDAR), gamma-aminobutyric acid A receptor ($GABA_AR$), or glutamic acid decarboxylase 65 (GAD65) are present in the CSF, further paraclinical biomarkers of neuroinflammation are not required to diagnose definite autoimmune encephalitis. When only serum antibodies are present, one or more paraclinical marker(s) of neuroinflammation is required.

*If clinical criteria of possible AE are met, the authors recommend proceeding with paraclinical and antibody testing and consider initiating immune therapy if the paraclinical tests are abnormal.

AE, Autoimmune encephalitis.

Adapted from Cellucci T, Van Matter H, Graus F, et al. Clinical approach to the diagnosis of autoimmune encephalitis in the pediatric patient. *Neurol Neuroimmunol Neuroinflamm*. 2020;7:e663.

Table 638.11 Autoimmune Encephalitis in Children

DISEASE	ANTIBODIES AND/OR MECHANISMS	SYNDROME	ANCILLARY TEST	TREATMENT/PROGNOSIS
Anti-NMDAR encephalitis	Antibodies against the GluN1 subunit of the NMDAR. In children, most cases are idiopathic. In a subgroup of patients, the disease is triggered by the presence of a tumor. In another subgroup, the disease is triggered by HSV encephalitis.	Psychiatric symptoms, decreased verbal output, sleep disorder (mainly insomnia), seizures, dyskinesias (orofacial, limbs), dystonia, rigidity and other abnormal movements, autonomic dysfunction, hypoventilation	EEG: almost always abnormal (epileptic and/or slow activity). In some patients it shows the pattern of extreme delta brush. Brain MRI: nonspecific abnormal findings in ~35% CSF: pleocytosis and/or increased proteins in ~80%	80% substantial or complete recovery after immunotherapy and tumor removal (if appropriate). About 50% of patients need second-line immunotherapies.* Relapses in ~15% of patients. Worse outcome when post-HSV encephalitis
Encephalitis associated with $GABA_AR$ antibodies	Antibodies against α1, β3, or γ2 subunits of the $GABA_AR$. ~40% of adults have an underlying tumor (thymoma). Children usually do not have tumor association.	Refractory seizures, epilepsia partialis continua. Patients may develop limb or orofacial dyskinesias.	EEG: almost always abnormal; frequent epileptic activity MRI: multifocal corticosubcortical FLAIR/T2 hyperintensities in 77% of patients CSF: pleocytosis and/or increased proteins	80% show moderate or good recovery after immunotherapy.
Encephalitis with mGluR5 antibodies** (Ophelia syndrome)	Antibodies against mGluR5 Frequent association with Hodgkin lymphoma	Abnormal behavior, seizures, memory deficits	EEG: frequently abnormal with nonspecific findings MRI: normal or nonspecific findings CSF: frequent pleocytosis and/or increased proteins	Good recovery after tumor treatment and immunotherapy
Other autoimmune encephalitis** (very infrequent in children)	Antibodies against neuronal cell surface ($GABA_BR$, DPPX, GlyR, mGluR2, LGI1, Caspr2, GluK2) or intraneuronal antigens (Hu, Ma2, GAD65 amphiphysin) All these antibodies rarely associate with tumors in children.	The syndrome varies depending on the autoantibody, and the phenotypes are often different from those reported in adults. $GABA_BR$: encephalitis, seizures, cerebellar ataxia DPPX: CNS hyperexcitability, PERM GlyR: PERM, stiff person syndrome*** mGluR2: paraneoplastic cerebellar ataxia LGI1: similar syndrome as that of the adults but without FBDS and hyponatremia. Caspr2: similar syndrome as that of the adults and hypertensive encephalopathy, hormonal dysfunction, palmoplantar erythema Gluk2: cerebellitis and/or autoimmune encephalitis with prominent ataxia Hu: brainstem or limbic encephalitis GAD65****: encephalitis with epilepsy	MRI: variable changes depending on the syndrome. CSF: frequent pleocytosis and/or increased proteins	Disorders with antibodies against cell surface antigens are substantially more responsive to immunotherapy than those with antibodies against intracellular antigens.
Encephalitis associated with MOG antibodies	In children the most common clinical manifestation is ADEM	Seizures, motor deficits, ataxia, or visual dysfunction accompanied by encephalopathy	MRI with T2/FLAIR large, hazy abnormalities, with or without involvement of the deep gray matter Some patients develop encephalitis with predominant cortical involvement CSF: frequent pleocytosis and/or increased proteins	In ~70-80% of patients, the disease is monophasic and shows good response to steroids. Some patients develop relapsing disease (with prolonged detection of serum MOG antibodies).

Continued

Table 638.11 Autoimmune Encephalitis in Children—cont'd

DISEASE	ANTIBODIES AND/OR MECHANISMS	SYNDROME	ANCILLARY TEST	TREATMENT/PROGNOSIS
NMOSD	Patients can have AQP4 or MOG antibodies; some patients are seronegative.	Typical involvement of optic nerves and spinal cord Encephalopathy in the context of diencephalic or area postrema syndromes	Characteristic involvement of brain areas rich in AQP4 (periaqueductal gray matter, hypothalamus, optic nerve and central involvement of the spinal cord)	High risk of relapses and long-term disability. Requires chronic immunotherapy. Patients with MOG antibodies have better long-term outcome than those with AQP4 antibodies or seronegative cases.
Acute cerebellar ataxia and acute cerebellitis	Frequently triggered by infections. Most patients do not have detectable autoantibodies (a few patients have GluK2 antibodies).	Ataxia and dysmetria. Some patients present with headache, vomiting, and decreased level of consciousness caused by intracranial hypertension	MRI: normal in acute cerebellar ataxia; several MRI patterns in acute cerebellitis: diffuse (more frequent) or focal bihemispheric acute cerebellitis with T2/FLAIR hyperintensities in the cerebellar parenchyma; hemicerebellitis (only one hemisphere involved).	Usually self-limiting and benign course in acute cerebellar ataxia; Immunotherapy is usually effective in acute cerebellitis, but some patients may need urgent decompressive craniectomy, and residual neurologic symptoms are frequent.
Opsoclonus-myoclonus and other cerebellar-brainstem encephalitis	Most patients do not have detectable autoantibodies (a few patients with neuroblastoma have Hu antibodies). Neuroblastoma occurs in 50% of children <2yr old; teratoma in teenagers and young adults.	Opsoclonus often accompanied by irritability, ataxia, falling, myoclonus, tremor, and drooling	MRI: usually normal; it may show cerebellar atrophy over time. EEG: Normal. CSF: may be normal or show abnormalities suggesting B-cell activation.	Neuroblastoma treatment (if it applies). Partial neurologic response to immunotherapy in many young children regardless of presence or absence of neuroblastoma. (Better outcomes if aggressive immunotherapy is used.) Good response to treatment in teenagers with teratoma-associated opsoclonus.
Bickerstaff encephalitis	GQ1b antibodies (~65%, nonspecific for this disorder)	Ophthalmoplegia, ataxia, and decreased level of consciousness. Frequent hyperreflexia. Patients may develop hyporeflexia and overlap with Miller-Fisher syndrome.	MRI: abnormal in ~30% (T2-signal abnormalities in the brainstem, thalamus, and cerebellum) Nerve conduction studies: abnormal in ~45% (predominant axonal degeneration, and less often demyelination)	Good response to steroids, IVIG, or plasma exchange
Steroid responsive encephalopathy with autoimmune thyroiditis (SREAT) (Hashimoto encephalitis)	TPO antibodies† (nonspecific for this disorder)	Strokelike symptoms, tremor, myoclonus, aphasia, seizures, ataxia, sleep and behavioral problems	48% hypothyroidism (usually subclinical), MRI often normal EEG: slow activity CSF: elevated protein	Steroid-responsive. Partial responses are frequent.
Rasmussen encephalitis	Most likely immune mediated (unclear mechanism)	Progressive refractory partial seizures, cognitive decline, focal deficits, and brain hemiatrophy	MRI: progressive unilateral hemispheric atrophy	Limited response to immunotherapy. The most effective treatment is functional hemispherectomy.
Basal ganglia encephalitis	Infrequent antibodies against D2R	Lethargy, abnormal movements, behavioral change, agitation, psychosis	MRI: Basal ganglia T2/FLAIR abnormalities, but may be normal in up to 50% CSF: frequently, elevated protein	Mostly monophasic, variable outcome; 40% complete recovery with immunotherapy.
CLIPPERS	No specific autoantibody association Probably represents different diseases. Important differential diagnosis with lymphoma	Episodic diplopia or facial paresthesias with subsequent development of symptoms of brainstem and occasionally spinal cord dysfunction	MRI: symmetric curvilinear gadolinium enhancement peppering the pons and extending variably into the medulla, brachium pontis, cerebellum, midbrain, and, occasionally, spinal cord	Steroid-responsive but patients may require chronic steroid or other immunosuppressive therapy.

Table 638.11	Autoimmune Encephalitis in Children—cont'd			
DISEASE	**ANTIBODIES AND/OR MECHANISMS**	**SYNDROME**	**ANCILLARY TEST**	**TREATMENT/PROGNOSIS**
ROHHAD	Postulated autoimmune or genetic; some patients have antibodies against ZSCAN1. Frequently associated with neural crest tumors	Rapid-onset obesity, hyperphagia, abnormal behavior, autonomic dysfunction, and central hypoventilation	Brain MRI, usually normal	Symptomatic treatment. In some patients, limited response to immunotherapy.

*Includes rituximab and cyclophosphamide.
**Commercial testing panels do not include GluK2, D2R, or mGluR antibodies. Therefore when one of these conditions is suspected, the samples should be investigated in a research laboratory.
***Low titers of GlyR ab have been reported in the serum of multiple different disorders, and their clinical significance is unclear; demonstration of antibodies in CSF has higher disease-specificity and is found usually associated with PERM.
****Lower titers of GAD65 antibodies in serum are found in patients with diabetes mellitus (~100-fold lower titers than those associated with GAD-antibody–associated neurologic disorders), other non-neurologic autoimmune conditions, and healthy persons.
†Diagnosis of exclusion, after ruling out relevant autoantibodies (e.g., NMDAR, AMPAR, among others).
AQP4, Aquaporin 4; CLIPPERS, chronic lymphocytic inflammation with pontine perivascular enhancement responsive to steroids; Caspr2, contactin-associated protein-like 2; CSF, cerebrospinal fluid; D2R, dopamine 2 receptor; DPPX, dipeptidyl-peptidase-like protein-6; EEG, electroencephalography; FBDS, faciobrachial dystonic seizures; FLAIR, fluid-attenuated inversion recovery; $GABA_AR$, γ-aminobutyric acid-A receptor; $GABA_BR$, γ-aminobutyric acid-B receptor; GAD65, glutamic acid decarboxylase 65; GluK2, glutamate kainate receptor 2; HSV, herpes simplex virus; IVIG, intravenous immunoglobulin; LGI1, leucine-rich glioma-inactivated 1; mGluR, metabotropic glutamate receptor; MOG, myelin oligodendrocyte glycoprotein; MRI, magnetic resonance imaging; NMDAR, *N*-methyl-D-aspartate receptor; NMOSD, neuromyelitis optica spectrum disorder; PERM, progressive encephalomyelitis with rigidity and myoclonus; ROHHAD, rapid-onset obesity with hypothalamic dysfunction, hypoventilation, and autonomic dysregulation; TPO, thyroid peroxidase; ZSCAN1, Zinc finger and SCAN domain-containing protein 1.

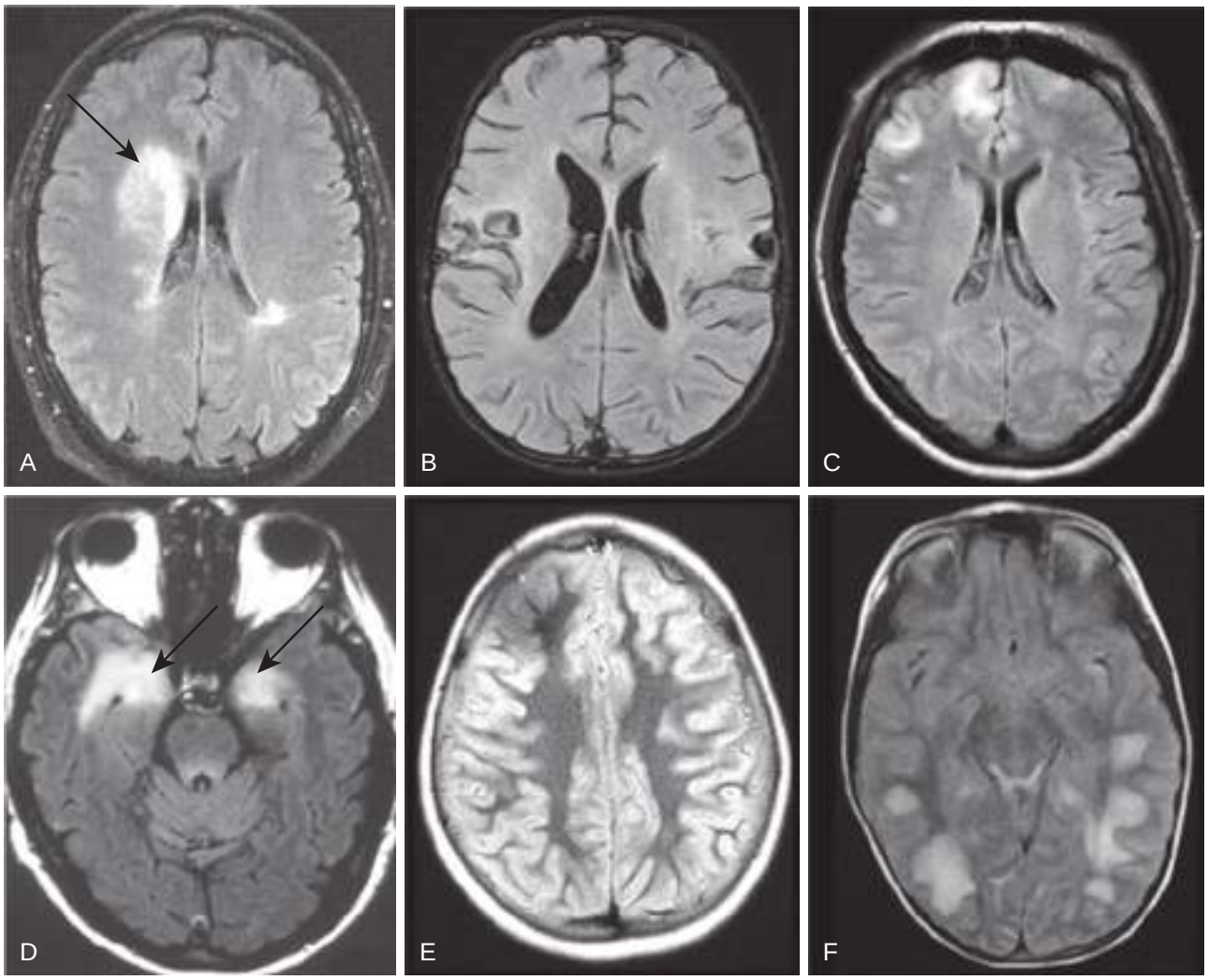

Fig 638.11 Brain MRI patterns in autoimmune encephalitis. **A,** FLAIR MRI image of a patient with anti-NMDAR encephalitis and concurrent MOG antibodies; it shows a prominent right frontal abnormality compatible with demyelination. **B,** T1-weighted MRI image of a 2-yr-old male with anti-NMDAR encephalitis after herpes simplex encephalitis. There are extensive necrotic areas in temporal regions that are residual from the viral encephalitis, without new MRI lesions produced by the autoimmune encephalitis. **C,** FLAIR MRI image from a patient with anti-$GABA_AR$ encephalitis; it shows multiple cortical-subcortical bilateral right frontal predominant hyperintensities. **D,** FLAIR MRI image showing typical features of limbic encephalitis with bilateral medial temporal lobe abnormalities; this adult patient with autopsy-proven limbic encephalitis did not have serum or CSF antineuronal antibodies. **E,** FLAIR MRI image showing extensive cortical involvement in a 9-yr-old with fatal encephalitis associated with MOG antibodies and severe intracranial hypertension. **F,** Typical FLAIR MRI findings in a 4-yr-old female with acute disseminated encephalomyelitis associated with MOG antibodies; it shows bilateral large abnormalities in the white matter. Left side of images = right side of brain. *(**A** and **D** from Graus F, Titulaer MJ, Balu R, et al. A clinical approach to diagnosis of autoimmune encephalitis. Lancet Neurol. 2016;15:391–404. Fig. 2.; **C** courtesy Dr. Mateus Mistieri Simabukuro; **B**, **E**, and **F** courtesy Drs. Thaís Armangué and Josep O. Dalmau.)*

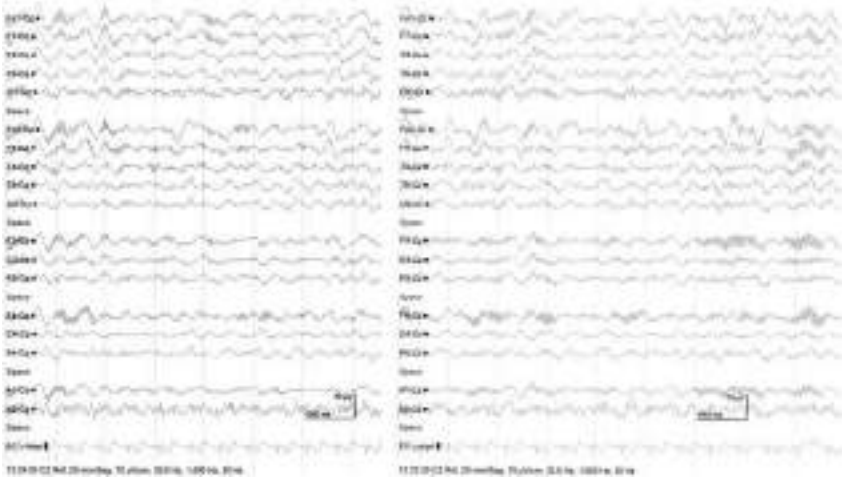

Fig. 638.12 Electroencephalogram showing a pattern called extreme delta brush in a 14-yr-old female with anti–*N*-methyl-D-aspartate receptor (NMDAR) encephalitis. This pattern has been found to be characteristic of anti-NMDAR encephalitis. It consists of a nearly continuous combination of delta activity with superimposed fast activity, usually in the beta range, symmetrically involving all regions, with a frontal preference in patients who are not under sedation or anesthesia. *(From Armangue T, Titulaer MJ, Málaga I, et al. Pediatric anti-N-methyl-D-aspartate receptor encephalitis: clinical analysis and novel findings in a series of 20 patients. J Pediatr. 2012;162:850–856, Fig. 2.)*

children (40% of patients are <18 years) and develops with status epilepticus, refractory seizures, or epilepsia partialis continua in association with antibodies against the α1, β3, or γ2 subunits of the $GABA_AR$. Young children can develop abnormal movements suggestive of anti-NMDAR encephalitis but with studies negative for NMDAR antibodies. Unlike other types of autoimmune encephalitis in which the brain MRI is usually normal or shows nonspecific findings, pediatric and adult patients with this disorder frequently develop multifocal hyperintense cortical-subcortical FLAIR/T2 abnormalities (see Fig. 638.11C). In adults, this encephalitis may occur with thymoma, but children rarely have an underlying tumor.

Ophelia syndrome is a form of encephalitis that occurs in association with Hodgkin lymphoma and predominantly affects young adults, teenagers, or children. Some patients develop antibodies against mGluR5, a receptor involved in learning and memory. Neurologic symptoms are highly responsive to treatment of the tumor and immunotherapy.

Autoimmune limbic encephalitis refers to an inflammatory process of the limbic system, including the medial temporal lobes, amygdala, and cingulate gyri (see Fig. 638.11D). In adults, the most frequent immune-mediated limbic encephalitis occurs in association with antibodies against proteins that were once thought to be voltage-gated potassium channels (VGKCs) but which, in fact, target a secreted neuronal protein called *leucine-rich glioma-inactivated 1* (LGI1) and a protein called *Caspr2* expressed in the brain and the juxtaparanodal regions of myelinated nerves. Adult patients with LGI1 antibody–associated limbic encephalitis often develop *hyponatremia;* in some patients, the disorder is preceded by dystonic or myoclonic-like movements, described as *faciobrachial dystonic seizures.* Adult patients with Caspr2 antibodies can develop limbic encephalitis, neuromyotonia, or **Morvan syndrome**, which includes encephalopathy, seizures, a sleep disorder, autonomic dysfunction, and neuromyotonia. In children, encephalitis with LGI1 or Caspr2 antibodies is extremely rare. Children with LGI1 antibodies do not develop hyponatremia or faciobrachial dystonic seizures. Younger children with Caspr2 antibodies often have similar symptoms to those of the adults, which can also be accompanied by generalized weakness, flaccid paresis, hypertensive encephalopathy, hormonal dysfunction, and palmoplantar erythema or eczema that has been attributed to sweating and itching. Children with Caspr2 antibodies do not have associated tumors.

VGKC-complex antibodies have very limited clinical utility unless they are specifically characterized as antibodies against LGI1 or Caspr2 proteins. Thus a positive test for VGKC-complex antibodies without further information on LGI1 or Caspr2 specificity should be interpreted with caution because it does not necessarily indicate autoimmune encephalitis.

Excluding patients with anti-NMDAR– or GABAAR antibody–associated encephalitis, an exceptionally low number of children with limbic and other types of neuronal antibody-associated encephalitis have been reported in the English literature, some of them with antibodies against neuronal cell surface proteins ($GABA_BR$, DPPX, GlyR) or intracellular proteins (Hu, Ma2, GAD65, amphiphysin). In some patients, an underlying malignancy was identified, including leukemia, ganglioneuroblastoma, neuroblastoma, or small cell carcinoma of the ovary.

Determination of the type of autoantibodies and location of the target antigens is important because an encephalitis in which the antigens are on the cell surface (e.g., NMDAR or GABAAR) responds better to immunotherapy than one in which the antigens are intracellular (e.g., GAD65).

ACQUIRED DEMYELINATING SYNDROMES WITH ENCEPHALOPATHY

ADEM is the most frequent autoimmune encephalitis in children (see Chapter 640.1). Symptoms may include seizures, motor deficits, ataxia, and visual dysfunction, among others. The brain MRI typically shows multifocal demyelinating lesions that can also involve the basal ganglia, brainstem, or cerebellum, with variable contrast enhancement (see Fig. 638.11F). Antibodies against myelin oligodendrocyte glycoprotein (MOG) occur in 50–60% of patients with ADEM and have a negative predictive value for evolution to multiple sclerosis in children with a first demyelinating event (see Chapter 640.1). Some children with MOG antibodies develop a clinical picture resembling autoimmune encephalitis with MRI FLAIR/T2 increased signal involving cortical regions, with variable contrast enhancement, or presenting as nondemyelinating focal or diffuse lesions (see Fig. 638.11E). MOG antibodies may also coexist with NMDAR antibodies; these patients usually develop overlapping syndromes related to these autoimmunities.

Neuromyelitis optica spectrum disorder (NMOSD) can present as an encephalopathy with predominant involvement of diencephalic and area postrema regions. These patients often harbor aquaporin 4 (AQP4) antibodies or MOG antibodies. Determination of these antibodies should be considered in patients with encephalopathy and MRI findings showing involvement of AQP4-rich regions, such as the periaqueductal gray matter, hypothalamus, optic nerves, and central region of the spinal cord (see Chapter 640.2).

HASHIMOTO ENCEPHALOPATHY

Hashimoto encephalopathy, also known as **steroid-responsive encephalopathy with autoimmune thyroiditis (SREAT)**, is a controversial disorder defined by the detection of thyroid peroxidase (TPO) antibodies in patients with acute or subacute encephalitis that responds to corticosteroids. Clinical features are not specific and may include strokelike episodes, tremor, myoclonus, transient aphasia, sleep and behavior abnormalities, hallucinations, seizures, and ataxia. The CSF, MRI, and EEG findings are not specific. The diagnosis of this disorder should be based on the exclusion of other inflammatory and autoimmune diseases. Pretreatment criteria of Hashimoto encephalopathy do

Table 638.12 Differential Diagnosis of Anti-NMDAR and Other Types of Autoimmune Encephalitis in Children

DISORDER	COMMENTS
Viral encephalitis	Viral encephalitis is often suggested by the acute onset of symptoms, CSF pleocytosis, and hyperthermia. Most viral encephalitides (except rabies) occur with higher levels of CSF pleocytosis and protein concentration. Psychosis and dyskinesias are significantly less frequent in viral encephalitis than in anti-NMDAR encephalitis.
New neurological symptoms post-HSV encephalitis	Occurs ~2-12 wk after successful treatment of HSV encephalitis. This may represent a true viral relapse of encephalitis (CSF PCR-positive, progression of necrotic MRI changes, response to acyclovir) or an autoimmune disorder (CSF PCR-negative, no new necrotic lesions on MRI, lack of response to acyclovir). In a proportion of the latter patients, the disorder is anti-NMDAR encephalitis.
New-onset psychosis	Because most patients with anti-NMDAR encephalitis present with psychosis, a psychiatric disorder is frequently considered. When the disease evolves, the development of neurologic symptoms usually reveals the diagnosis.
Drugs/toxins	The acute development of personality and behavioral changes and symptoms suggesting involvement of dopaminergic pathways (rigidity, dystonia, orofacial movements) usually leads to a suspicion of drug use (e.g., ketamine, phencyclidine, synthetic cannabinoids, among others).
Neuroleptic malignant syndrome (NMS)	The occurrence of an altered level of consciousness, episodes of rigidity, hyperthermia, and autonomic instability often suggest NMS. In addition, some patients with anti-NMDAR encephalitis have elevated serum creatine kinase and rhabdomyolysis (in the absence of antipsychotic medication). The frequent use of neuroleptics to control the abnormal behavior adds further confusion between both syndromes. The presence of dyskinesias and catatonia suggest anti-NMDAR encephalitis.
Limbic encephalitis (LE)	Criteria of LE are well defined. Patients with LE do not have dyskinesias or central hypoventilation; the MRI usually shows abnormalities restricted to the medial temporal lobes, and the EEG findings (epileptic or slow activity) are largely restricted to the temporal lobes.
Encephalitis lethargica	This is an ill-defined entity, likely representing multiple disorders. Criteria include acute or subacute encephalitis with at least three of the following: signs of basal ganglia involvement; oculogyric crises; ophthalmoplegia; obsessive-compulsive behavior; akinetic mutism; central respiratory irregularities; and somnolence and/or sleep inversion. Many patients categorized as encephalitis lethargica hyperkinetica have anti-NMDAR encephalitis.
Childhood disintegrative disorder/late-onset autism	Children with anti-NMDAR encephalitis often show cognitive regression, rapid loss of language function, autistic features, and seizures, suggesting a childhood disintegrative disorder. Although the prognosis of CDD is poor, most patients with anti-NMDAR encephalitis respond to immunotherapy and have a substantial clinical recovery.
Kleine-Levin syndrome	Symptoms of hypersomnia, compulsive hyperphagia, hypersexuality, apathy, and childlike behavior, which are typical components of Kleine-Levin syndrome, may occur transiently during the process of recovery of anti-NMDAR encephalitis or as permanent sequelae. However, different from the Kleine-Levin syndrome, the symptoms in anti-NMDAR encephalitis are not relapsing-remitting
Inborn errors of metabolism	Glutaric aciduria type I can present in previously asymptomatic patients as episodes of encephalopathy with dystonia, coinciding with an infection or febrile process. Several inborn errors of metabolism can also occur with acute or subacute encephalopathy with extrapyramidal signs, including 3-methylglutaconic aciduria, creatine transport deficiency, mitochondrial disorders (Leigh syndrome), Wilson syndrome, and Lesch-Nyhan syndrome. Pantothenate kinase–associated neurodegeneration, porphyria, and urea cycle defects should also be considered.
Genetic disorders that can manifest as autoimmune encephalitis	HLH (often initial presentation as primary CNS with later 1-2 yr onset of systemic features) RANBP2 variants, interferonopathies, autoinflammatory syndromes including cryopyrin-associated periodic syndromes, Aicardi-Goutières syndrome, and CTLA4 deficiency can present with clinical features mimicking ADEM or autoimmune or infectious encephalitis. MRI often shows hyperintense T2/FLAIR abnormalities involving white matter with contrast enhancement in HLH and CTLA4 deficiency; both thalami in *RANBP2* variants; and may show striatal necrosis with or without associated hypomyelination in ADAR1 interferonopathy. CSF is abnormal in most patients. Some patients develop systemic symptoms (e.g., fever, arthralgias or rash in autoinflammatory syndromes, or autoimmune cytopenias or hypogammaglobulinemia in CTLA4 deficiency) that can help to make the diagnosis, which is confirmed by genetic testing.
Monoamine neurotransmitter disorders	Deficiency of dopamine or serotonin, or both, can result in encephalopathy, epilepsy, and pyramidal and extrapyramidal symptoms. The diagnosis is established by examining the CSF for levels of these neurotransmitters.
Acquired demyelinating disorders	ADEM and NMOSD are immune-mediated inflammatory and demyelinating disorders of the central nervous system. These disorders should be considered in the differential diagnosis of multifocal neurologic abnormalities and encephalopathy in children. As with anti-NMDAR encephalitis, these disorders may be preceded by an infection and can show pleocytosis. The diagnosis is suggested by the MRI findings. In NMOSD, the presence of AQP4 antibodies in serum or CSF is associated with relapses and poor prognosis. MOG antibodies occur in ~50% of children with ADEM and some patients with NMOSD.

Continued

Table 638.12 Differential Diagnosis of Anti-NMDAR and Other Types of Autoimmune Encephalitis in Children—cont'd

DISORDER	COMMENTS
CNS vasculitis	CNS vasculitis (including RVCLS: *TREX1*) results in neurologic deficits and psychiatric manifestations. The diagnosis is established by angiography in large-vessel angiitis and brain biopsy in small vessel angiitis. In the latter, serum inflammatory markers (erythrocyte sedimentation rate, C-reactive protein, Complement 3, von Willebrand factor antigen) are usually elevated, and the MRI shows FLAIR/T2 abnormalities in the white and/or gray matter suggesting ischemia and microhemorrhages, but are not restricted to vascular territories and frequent leptomeningeal and/or local enhancement.
Systemic rheumatic disorders	Systemic lupus erythematosus and other rheumatic disorders can result in encephalopathy and multifocal neurologic and psychiatric manifestations. These disorders are usually suggested by the presence of signs and symptoms of involvement of systemic organs: skin, joints, kidneys, blood-forming cells, and blood vessels.

ADEM, Acute disseminated encephalomyelitis; CDD, childhood disintegrative disorder; CNS, central nervous system; CSF, cerebrospinal fluid; HSV, herpes simplex virus; EEG, electroencephalography; FLAIR, fluid-attenuated inversion recovery; HLH, hemophagocytic lymphohistiocytosis; LE, limbic encephalitis; MOG, myelin oligodendrocyte glycoprotein; MRI, magnetic resonance imaging; NMDAR, *N*-methyl-D-aspartate receptor; NMOSD, neuromyelitis optica spectrum disorders; NMS, neuroleptic malignant syndrome; PCR, polymerase chain reaction; RANBP2, Ras-related nuclear protein-binding protein 2; RVCLS, retinovasculopathy and cerebral leukodystrophy with systemic features, CTLA4, cytotoxic T-lymphocyte–associated protein 4; ADAR1, adenosine deaminase acting on RNA 1.

not predict steroid responsiveness. Because TPO antibodies occur in approximately 10% of asymptomatic children (i.e., nonencephalopathic and, in most cases, euthyroid) and can also be found in some patients who have more relevant antibody-associated diseases, the detection of TPO antibodies should be viewed as a marker of autoimmunity rather than a disease-specific or pathogenic antibody. Therefore detection of TPO antibodies should not prevent testing for more relevant antibodies, such as NMDAR antibodies.

Acute cerebellar ataxia and acute cerebellitis are the most frequent causes of cerebellar dysfunction in children. Ataxia and dysmetria are usually the main presenting symptoms, but some patients present with headache, vomiting, and decreased level of consciousness caused by intracranial hypertension. Brain MRI is normal in patients with acute cerebellar ataxia, but in cases of cerebellitis it shows T2/FLAIR hyperintensities in the white and gray matter of the cerebellum along with edema that may cause obstruction of the fourth ventricle and hydrocephalus. Treatment with steroids is usually effective, but some patients may need decompressive craniectomy. Whereas acute cerebellar ataxia with normal MRI is often self-limiting and has a benign course, cerebellitis with MRI abnormalities associates with a less favorable prognosis and almost half of them have residual neurologic deficits. The most frequent cause of acute cerebellar ataxia and cerebellitis is a viral infection; much less frequently, they may occur after bacterial infections or vaccines. A few cases with antibodies against the glutamate kainate 2 (GluK2) receptor have been reported.

OPSOCLONUS-MYOCLONUS AND OTHER TYPES OF RARE BRAINSTEM-CEREBELLAR ENCEPHALITIS

Opsoclonus-myoclonus occurs in infants, teenagers, and adults, although it probably represents different diseases and pathogenic mechanisms. In infants, the syndrome usually develops in the first 2 years of life (mean: 20 months), and at least 50% of patients have an underlying neuroblastoma. The child often presents with irritability, ataxia, falling, myoclonus, tremor, and drooling. Additional symptoms may include a refusal to walk or sit, speech problems, hypotonia, and the typical features of opsoclonus characterized by rapid, chaotic, multidirectional eye movements without saccadic intervals. Because opsoclonus may be absent at symptom presentation, patients may initially be diagnosed with acute cerebellitis. Typically, CSF abnormalities suggest B-cell activation, and the presence of antibodies against neuronal proteins has been demonstrated in rare instances, but the identification of a specific autoantigen has been elusive.

Immunotherapy, including corticosteroids and IVIG, often improves the abnormal eye movements, but residual behavioral, language, and cognitive problems persist in the majority of patients. In addition, insomnia and an abnormal response to pain are common. Relapses occur in 50% of patients, usually as a result of an intercurrent infection or drug tapering. Patients treated with more aggressive immunosuppression (often including rituximab) have better outcomes compared with historic control series or patients who did not receive these treatments. Delay in treatment appears to be associated with a poorer neurologic outcome; therefore in cases with neuroblastoma, removal of the tumor should not delay the start of immunotherapy.

In teenagers and young adults, opsoclonus-myoclonus and brainstem-cerebellar encephalitis without opsoclonus are often considered idiopathic or postinfectious; however, there is evidence that some of these patients have an underlying **teratoma**, usually in the ovaries. These patients do not harbor NMDAR antibodies, and compared with those with anti-NMDAR encephalitis, they are less likely to present with psychiatric symptoms or dyskinesias. Although these patients do not appear to have neuronal antibodies, the CSF often shows pleocytosis and an elevated protein concentration. Treatment with immunotherapy (corticosteroids, IVIG, and/or plasma exchange) and removal of the ovarian teratoma frequently associate with full recovery. The prognosis of opsoclonus-myoclonus in teenagers and young adults seems better than that of young children (with or without neuroblastoma) or of the paraneoplastic opsoclonus of older patients, usually related to breast, ovarian, or lung cancer.

BICKERSTAFF ENCEPHALITIS

This term is used to describe patients with rapid progression (<4 weeks) of bilateral external ophthalmoplegia, ataxia, and decreased level of consciousness. Although this entity has been described more frequently in adults, children as young as 3 years old have been identified. Most patients are treated with steroids, IVIG, or plasma exchange; they often have a good outcome. Serum GQ1b immunoglobulin G antibodies are found in 66% of patients. Brain MRI abnormalities occur in 30% of patients and usually include increased T2-signal abnormalities in the brainstem, thalamus, and cerebellum and sometimes in the cerebral white matter. Some patients develop hyporeflexia and limb weakness, with predominant axonal involvement, overlapping with symptoms of Miller-Fisher syndrome and the axonal subtype of Guillain-Barré syndrome.

CHRONIC LYMPHOCYTIC INFLAMMATION WITH PONTINE PERIVASCULAR ENHANCEMENT RESPONSIVE TO STEROIDS

This is a clinically and radiologically distinct pontine-predominant encephalomyelitis. Patients usually present with episodic diplopia or facial paresthesias with subsequent development of symptoms of

brainstem, cerebellum, and, occasionally, spinal cord dysfunction. A brain MRI shows symmetric curvilinear gadolinium enhancement peppering the pons and extending variably into the medulla, brachium pontis, cerebellum, and midbrain and occasionally into the spinal cord. The clinical and radiologic findings usually respond to high-dose steroids but may worsen after steroid tapering, requiring chronic steroid or other immunosuppressive therapy. The differential diagnosis is extensive and includes infections, acquired demyelinating syndromes, granulomatous disease, lymphoma, or vasculitis. Biopsy studies may be needed to exclude these and other conditions.

AUTOIMMUNE ENCEPHALOPATHIES ASSOCIATED WITH EPILEPSY AND STATUS EPILEPTICUS

Rasmussen encephalitis is an inflammatory encephalopathy characterized by progressive refractory focal seizures, cognitive deterioration, and focal neurologic deficits that occur with gradual atrophy of one brain hemisphere. The disorder frequently presents in children 6-8 years old, although adolescents and adults can be affected. The etiology is unknown, and therefore multiple theories are proposed, including the presence of neuronal antibodies and T-cell–mediated mechanisms triggered by a viral infection. None of these mechanisms satisfactorily explain the unilateral brain involvement characteristic of the disorder. Treatment with high-dose steroids, plasma exchange, or IVIG can ameliorate symptoms in early stages of the disease. Multiple different approaches with immunotherapy, including rituximab, tacrolimus, azathioprine, adalimumab, mycophenolate mofetil, natalizumab, or anakinra have not substantially changed the poor outcome of most patients. The most effective treatment for control of the seizures is functional hemispherectomy, which consists of surgical disconnection of the affected hemisphere.

OTHER SUSPECTED TYPES OF AUTOIMMUNE ENCEPHALITIS

Vasculitis of the CNS and rheumatic diseases associated with autoimmune mechanisms that can result in encephalitis are discussed in Chapter 642.

Rapid-onset obesity with hypothalamic dysfunction, hypoventilation, and autonomic dysregulation (ROHHAD) is discussed in Chapter 468.3.

The term **basal ganglia encephalitis** is used to describe patients with predominant or isolated involvement of the basal ganglia. These patients typically have abnormal movements such as dystonia, chorea, or parkinsonism and neuropsychiatric disease. Although these clinical manifestations may have multiple etiologies, including metabolic, toxic, genetic, and infectious processes, an immune-mediated etiology has been postulated in some patients. There have been no clinical trials, but case reports and small noncontrolled case series describe the potential benefit of immunotherapy. Antibodies against the dopamine-2 receptor have been infrequently identified in these patients.

Pseudomigraine syndrome with CSF pleocytosis (PMP) or **headache with neurologic deficits and CSF lymphocytosis (HaNDL)** is an ill-defined entity that predominantly affects young male adults with a family history of migraine, although adolescents can be affected. This syndrome is characterized by repeat episodes of severe headache with transient neurologic deficits, accompanied by aseptic CSF lymphocytosis and a normal brain MRI. Patients frequently show a high CSF opening pressure, an elevated CSF protein concentration, and focal EEG slowing, which normalize after the episodes of headache. Because of the inflammatory characteristics of the CSF and the high prevalence of prodromal viral-like symptoms, an infectious–immune-mediated mechanism has been proposed. Other theories include spreading cortical depression and trigeminal-vascular activation.

Visit Elsevier eBooks+ at eBooks.Health.Elsevier.com for Bibliography.

Chapter 639

Neurodegenerative Disorders of Childhood

Kristin A. Seaborg and Jennifer M. Kwon

Neurodegenerative disorders of childhood encompass a large, heterogeneous group of diseases caused by specific genetic and biochemical defects. Although many children with neurodegenerative disorders first present with developmental delay or seizures, the hallmark of a neurodegenerative disease is **regression and progressive deterioration** of neurologic function with loss of speech, vision, hearing, locomotion, feeding difficulties, and cognitive decline. The age of onset, rate of progression, and principal neurologic findings determine whether the disease affects primarily the white or the gray matter. Upper motor neuron signs and progressive spasticity are the hallmarks of white matter disorders; convulsions and intellectual and visual impairments that occur early in the disease course are the hallmarks of gray matter disorders. A precise history confirms regression or delay of developmental milestones, and the neurologic examination localizes the process within the nervous system. At that point, modern neuroimaging techniques and specific biochemical and molecular diagnostic tests are used to arrive at a diagnosis. Although available therapies are often limited, it is important to make the correct diagnosis so that genetic counseling may be offered and prevention strategies can be implemented. Bone marrow transplantation, enzyme replacement therapies, cell-based gene therapy, immune modulation, and dietary restrictions may prevent the progression of disease in certain individuals who are either presymptomatic or very early in their disease course. For all conditions in which the specific genetic defect is known, prevention by prenatal diagnosis through chorionic villus sampling or amniocentesis is possible, as is carrier detection. Table 639.1 summarizes selected inherited neurodegenerative and metabolic disorders by their usual age of onset.

639.1 Sphingolipidoses

Kristin A. Seaborg and Jennifer M. Kwon

The sphingolipidoses are characterized by intracellular storage of lipid substrates resulting from defective catabolism of the sphingolipids comprising cellular membranes (Fig. 639.1). Poorly degraded sphingolipids accumulate in neuronal lysosomes leading to cellular dysfunction and death. There are multiple sphingolipidoses, including Niemann-Pick disease, Gaucher disease, GM_1 gangliosidosis, GM_2 gangliosidosis, Krabbe disease (KD), and metachromatic leukodystrophy. Niemann-Pick disease and Gaucher disease are discussed in Chapter 106.4.

GANGLIOSIDOSES

See also Chapter 106.4.

Gangliosides are sphingolipids consisting of an oligosaccharide chain attached to a hydroxyl group of ceramide and sialic acid bound to galactose. The gangliosides are catabolized by sequential cleavage of the sugar molecules by specific exoglycosidases. Abnormalities in catabolism result in an accumulation of the ganglioside within the cell, resulting in disease. Defects in ganglioside degradation include GM_1 gangliosidosis and the GM_2 gangliosidoses.

GM_1 Gangliosidosis

GM_1 gangliosidosis is an autosomal recessive condition caused by deficiency of acid β-galactosidase from pathogenic variants in *GLB1*. It is further classified by age at presentation: infantile (type I), juvenile (type II), and adult (type III), where the age of onset and severity

Table 639.1 Selected Metabolic Conditions Associated with Developmental Regression

AGE AT ONSET (YR)	CONDITIONS	COMMENTS
<2, often with hepatomegaly or hepatic effects	Fructose intolerance	Vomiting, hypoglycemia, poor feeding, failure to thrive (when given fructose)
	Galactosemia	Lethargy, hypotonia, icterus, cataract, hypoglycemia (when given lactose)
	Glycogenosis (glycogen storage disease) types I-IV	Hypoglycemia, cardiomegaly (type II)
	Mucopolysaccharidosis types I and II	Coarse facies, stiff joints
	GM_1 gangliosidosis	Coarse facies, macroglossia, cherry- red spot in macula
	Niemann-Pick disease, infantile type	Gray matter disease, failure to thrive
	Zellweger syndrome	Hypotonia, high forehead, flat facies
	Gaucher disease (neuronopathic form)	Extensor posturing, irritability
	Carbohydrate-deficient glycoprotein syndromes	Dysmyelination, cerebellar hypoplasia
<2, without hepatomegaly	Krabbe disease	Irritability, extensor posturing, optic atrophy, and blindness
	Rett syndrome	Girls with deceleration of head growth, loss of hand skills, hand wringing, impaired language skills, gait apraxia
	Maple syrup urine disease	Poor feeding, tremors, myoclonus, opisthotonos
	Phenylketonuria	Light pigmentation, microcephaly
	Menkes kinky hair disease	Hypertonia, irritability, seizures, abnormal hair
	Tay-Sachs disease, GM_2 gangliosidoses	Seizures, cherry-red spot of macula, increased startle response
	Subacute necrotizing encephalopathy or Leigh disease	White matter disease, basal ganglia, brainstem lesions
	Canavan disease	White matter disease, macrocephaly
	Neurodegeneration with brain iron accumulation disease (see Table 639.4)	Cerebellar atrophy, optic atrophy, iron accumulation in basal ganglia, movement disorder
2-5	Niemann-Pick disease types III and IV	Hepatosplenomegaly, gait difficulty
	Wilson disease	Liver disease, Kayser-Fleischer ring; deterioration of cognition is late
	Neuronal ceroid lipofuscinosis	Gray matter disease
	Mitochondrial encephalopathies (e.g., myoclonic epilepsy with ragged red fibers [MERRF])	Gray matter disease
	Ataxia-telangiectasia	Basal ganglia disease
	Neurodegeneration with brain iron accumulation syndrome	Basal ganglia disease
	Metachromatic leukodystrophy	White matter disease
	Adrenoleukodystrophy	White matter disease, behavior problems, deteriorating school performance, vision loss
5-15	Adrenoleukodystrophy	Same as for adrenoleukodystrophy in 2- to 5-yr-olds
	Neuronal ceroid lipofuscinosis, juvenile and adult forms	Gray matter disease
	Refsum disease	Peripheral neuropathy, ataxia, retinitis pigmentosa
	Sialidosis II, juvenile form	Cherry-red macula, myoclonus, ataxia, coarse facies

Adapted from Kliegman RM, Greenbaum LA, Lye PS, eds. *Practical Strategies in Pediatric Diagnosis and Therapy,* 2nd ed. Philadelphia: Elsevier; 2004:542.

depends on the degree of β-galactosidase deficiency. Diagnosis can be made by enzyme assay or by identification of biallelic pathogenic variants in *GLB1* by molecular genetic testing. Prenatal diagnosis is possible by enzyme or direct molecular testing of cultured amniotic cells.

Infantile GM_1 gangliosidosis presents during the neonatal period with poor sucking and inadequate weight gain. Development is delayed, and generalized seizures are prominent. The phenotype is characterized by coarse facial features, prominent forehead, depressed nasal bridge, large tongue (macroglossia), and gum hypertrophy. There is early hepatosplenomegaly from intracellular accumulation of foamy histiocytes and kyphoscoliosis from anterior beaking of the vertebral bodies. The neurologic examination is notable for progressive blindness, deafness,

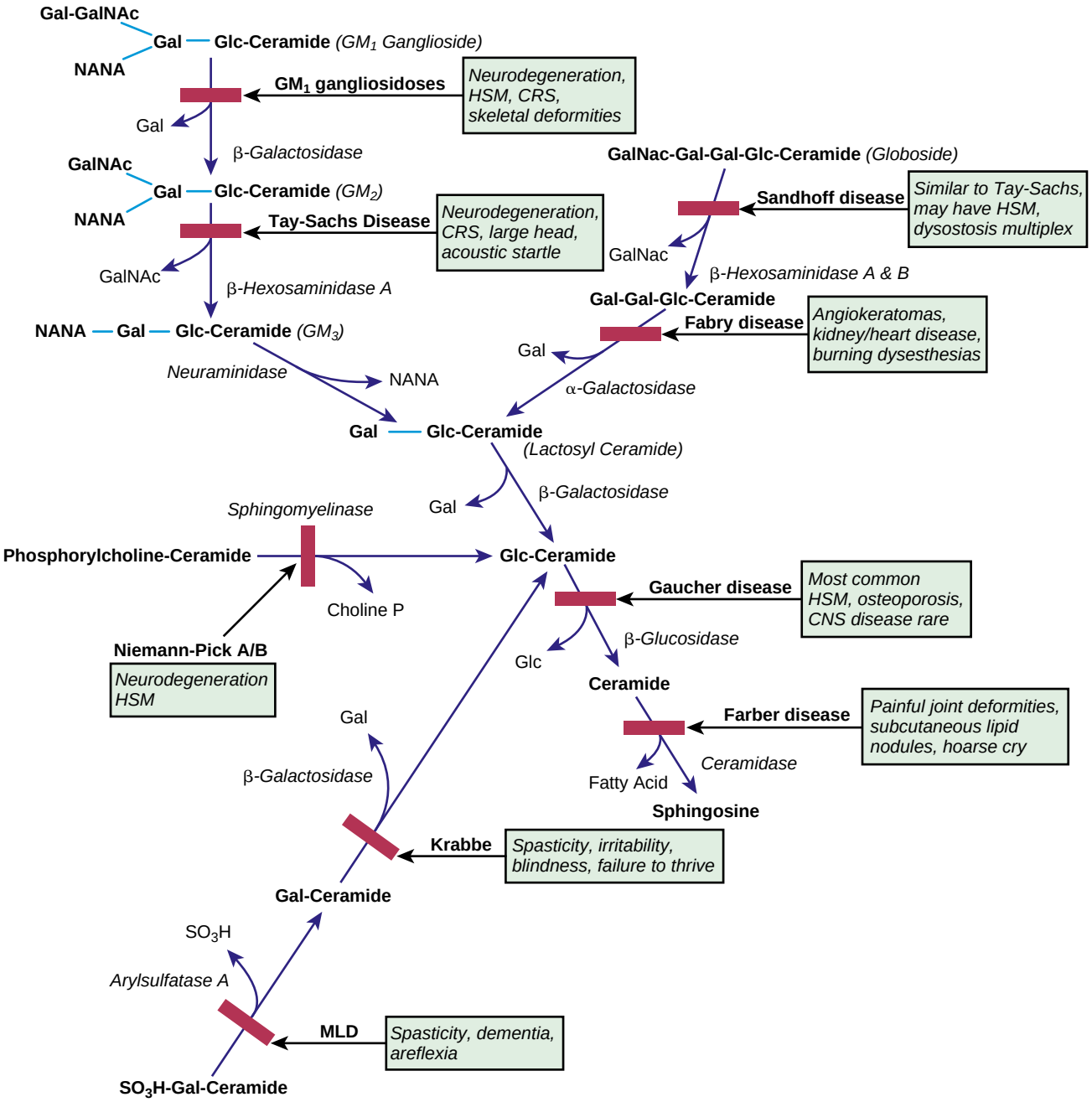

Fig. 639.1 Sphingolipid degradation pathway showing the sites of enzyme deficiencies and their associated disorders. Sphingolipids are composed of a ceramide backbone with oligosaccharide side chains. CRS, cherry-red spot (retinal); Gal-, galactosyl-; GalNAc, N-acetyl-galactose; Glc-, glucosyl-; HSM, hepatosplenomegaly; MLD, metachromatic leukodystrophy; NANA, N-acetyl-neuraminic acid.

spastic quadriplegia, and decerebrate rigidity. A cherry-red spot in the macula is visualized in approximately 50% of cases (Fig. 639.2). Treatment is supportive, and children rarely survive beyond age 2-3 years. Death is often from aspiration pneumonia.

Type II GM_1 gangliosidosis presents later in infancy, before 3 years. Initial symptoms consist of weakness, ataxia, and regression of language. Thereafter, convulsions, spasticity, decerebrate rigidity, and blindness are the major findings. Unlike type I, coarse facial features and hepatosplenomegaly are not usually seen. Lumbar vertebrae may show minor beaking. Children rarely survive beyond 10 years of age. **Adult GM_1 gangliosidosis** is a slowly progressive disease with onset between ages 3 and 30 years consisting of spasticity, ataxia, dysarthria, cardiomyopathy, and a gradual loss of cognitive function.

GM_2 Gangliosidoses

The GM_2 gangliosidoses are a heterogeneous group of autosomal recessive disorders caused by abnormal catabolism of the GM_2 ganglioside, which accumulates in neuronal lysosomes. GM_2 catabolism requires functional isoenzymes β-hexosaminidase and GM_2 activator protein. Tay-Sachs disease (TSD), Sandhoff disease, juvenile GM_2 gangliosidosis, and adult GM_2 gangliosidosis are caused by genetic variants in the genes that encode the alpha and beta subunits of β-hexosaminidase and lead to decreased or absent β-hexosaminidase activity with subsequent accumulation of GM_2.

TSD is most prevalent in the Ashkenazi Jewish population, with an approximate carrier rate of 1 in 30 Jews in the United States. TSD is caused by pathogenic variants in *HEXA* on chromosome 15q23, which

Fig. 639.2 A cherry-red spot in a patient with GM_1 gangliosidosis. Note the whitish ring of sphingolipid-laden ganglion cells surrounding the fovea. *(From Leavitt JA, Kotagal S. The "cherry red" spot. Pediatr Neurol. 2007;37:74–75, Fig. 1.)*

encodes the α subunit of β-hexosaminidase. Affected infants often have a *marked startle reaction* to noise that is evident soon after birth but otherwise have normal development until ~6 months of age. They then begin to lag in developmental milestones and gradually lose the ability to stand, sit, and vocalize by age 1. Children with TSD have earlier onset of dysphagia than children with other GM_2 gangliosidoses. Early hypotonia develops into progressive spasticity and relentless deterioration follows, with convulsions, blindness, deafness, and cherry-red spots in almost all patients (see Fig. 639.2). Macrocephaly becomes apparent by 1 year of age and results from the 200- to 300-fold normal content of GM_2 ganglioside deposited in the brain. Few children live beyond 3-4 years of age, and death is usually associated with aspiration or bronchopneumonia.

To diagnose TSD or any of the GM_2 gangliosidoses, a deficiency of the isoenzyme β-hexosaminidase is found in blood, serum, or fibroblasts. In addition, molecular genetic testing may be done to evaluate for variants in the *HEXA* or *HEXB* gene to confirm the diagnosis.

Sandhoff disease occurs secondary to a variant *HEXB* gene located on chromosome 5q13. Affected infants present very similar to TSD, including progressive loss of motor and language milestones beginning at 6 months of age. Unlike children with TSD, children with Sandhoff disease may also have visceromegaly. The visual evoked potentials (VEPs) are normal early in the course of Sandhoff disease and TSD but become abnormal or absent as the disease progresses. The auditory brainstem responses show prolonged latencies. The diagnosis of Sandhoff disease is established by finding deficient levels of hexosaminidases A and B in serum and leukocytes. Children usually die by 3 years of age.

Juvenile GM_2 gangliosidosis develops in mid-childhood, initially with clumsiness followed by ataxia. Signs of spasticity, athetosis, loss of language, and seizures gradually develop. Progressive visual loss is associated with optic atrophy, but cherry-red spots rarely occur in juvenile GM_2 gangliosidosis. A deficiency of hexosaminidase is variable (total deficiency to near normal) in these patients. Death occurs around 15 years of age.

Although the genetic etiologies of the gangliosidoses are well-established, there is currently no known treatment for these disorders other than supportive management and palliative care. An adeno-associated virus-HEXA/HEXB–directed gene therapy proof-of-concept trial has been performed in two children with TSD.

KRABBE DISEASE (GLOBOID CELL LEUKODYSTROPHY)

Krabbe disease (KD) is a rare autosomal recessive neurodegenerative disorder characterized by severe myelin loss and the presence of globoid bodies in the white matter. The gene for KD *(GALC)* is located on chromosome 14q24.3-q32.1. The disease results from a marked deficiency of the lysosomal enzyme galactocerebroside β-galactosidase (GALC). KD is a disorder of myelin destruction rather than abnormal myelin formation. Normally, myelination begins in the third trimester, corresponding with a rapid increase of GALC activity in the brain. In patients with KD, galactocerebroside cannot be metabolized during the normal turnover of myelin because of deficiency of GALC. Nonmetabolized galactocerebroside stimulates the formation of globoid cells, which can be cytotoxic to oligodendrocytes. Because oligodendroglial cells are responsible for the elaboration of myelin, their loss results in myelin breakdown, thus producing additional galactocerebroside and causing a vicious circle of myelin destruction.

Myelin exists in both the central and peripheral nervous system and allows for rapid conduction along axons. With GALC deficiency and associated rapid and severe demyelination, the symptoms of KD become evident in the first few months of life and include excessive irritability and crying, poor head control, episodes of hyperpyrexia, vomiting, and difficulty feeding. In the initial stage of KD, children are often treated for colic or milk allergy with frequent formula changes. Generalized seizures may appear early in the course of the disease. Alterations in body tone with rigidity and opisthotonos as well as visual inattentiveness caused by optic atrophy become apparent as the disease progresses. In the later stages of the illness, blindness, deafness, absent deep tendon reflexes, autonomic instability, and decerebrate rigidity constitute the major physical findings. Most patients die by 2 years of age. MRI and magnetic resonance spectroscopy are useful for evaluating the extent of demyelination in KD. Umbilical cord blood (stem cell) transplantation from unrelated donors in asymptomatic babies may favorably alter the natural history but will not help patients who already have neurologic symptoms. Recombinant GALC triggers an immune reaction, and the large protein does not efficiently cross the blood-brain barrier.

Late-onset KD has been described beginning in childhood or adolescence. Patients present with pes cavus, sensorimotor demyelinating neuropathy, optic atrophy, and cortical blindness; their condition may be confused with adrenoleukodystrophy. Slowly progressive gait disturbances, including spasticity and ataxia, are prominent. Globoid cells are abundant in the white matter, and leukocytes are deficient in GALC. MRI may reveal white matter lesions. An examination of the cerebrospinal fluid shows an elevated protein content, and the nerve conduction velocities are markedly delayed as a result of segmental demyelination of the peripheral nerves.

METACHROMATIC LEUKODYSTROPHY

This disorder of myelin metabolism is inherited as an autosomal recessive trait and is characterized by a deficiency of arylsulfatase A activity. The *ARSA* gene is located on chromosome 22q13.33. The absence or deficiency of arylsulfatase A leads to accumulation of cerebroside sulfate within the myelin in both the central and peripheral nervous systems, and the excessive cerebroside sulfate is thought to cause myelin breakdown. Prenatal diagnosis of metachromatic leukodystrophy (MLD) is made by assaying arylsulfatase A activity in chorionic villi or cultured amniotic fluid cells. Those affected with MLD are generally classified according to age of onset: late infantile, juvenile, and adult.

Late infantile MLD begins with insidious onset of gait disturbances between 1 and 2 years of age. The child initially appears awkward and frequently falls, but locomotion is gradually impaired significantly and support is required to walk. The extremities are hypotonic, and the deep tendon reflexes are absent or diminished. Within the next several months, the child can no longer stand, and deterioration in intellectual function becomes apparent. The speech is slurred and dysarthric, and the child appears dull and apathetic. Visual fixation is diminished, nystagmus is present, and examination of the retina shows optic atrophy. Within 1 year from the onset of the disease, the child is unable to sit unsupported, and progressive decorticate postures develop. Feeding and swallowing are impaired because of pseudobulbar palsies. Affected children develop seizures and painful muscle spasms and generalized irritability. Patients ultimately become stuporous and die of aspiration or bronchopneumonia by age 5-6 years. Neurophysiologic evaluation shows slowing of peripheral nerve conduction velocities caused by

peripheral myelin damage and progressive changes in the VEPs, auditory brainstem responses, and somatosensory evoked potentials. CT and MRI images of the brain indicate diffuse symmetric attenuation of the cerebellar and cerebral white matter, and examination of the cerebrospinal fluid shows an elevated protein content.

Late infantile MLD is characterized by little to no functional arylsulfatase A, resulting in rapid accumulation of sulfatides and disease progression. Bone marrow transplant or lentiviral autologous hematopoietic stem cell gene (ARSA-cDNA) therapy is a promising experimental therapy for the management of late infantile MLD patients identified very early in the course of their disease.

Juvenile MLD has many features in common with late infantile MLD, but the onset of symptoms is delayed to 5-10 years of age. Deterioration in school performance and alterations in personality may herald the onset of the disease. This is followed by incoordination of gait, urinary incontinence, and dysarthria. Muscle tone becomes increased, and ataxia, dystonia, tremor, or diminished deep tendon reflexes may be present. In the terminal stages, generalized tonic-clonic convulsions are prominent and are difficult to control. Patients rarely live beyond mid-adolescence. Patients with juvenile MLD usually have one functional copy of *ARSA* with some residual enzyme activity.

Visit Elsevier eBooks+ at eBooks.Health.Elsevier.com for Bibliography.

639.2 Neuronal Ceroid Lipofuscinoses

Kristin A. Seaborg and Jennifer M. Kwon

The neuronal ceroid lipofuscinoses (NCLs) are a group of inherited, neurodegenerative, **lysosomal storage disorders** characterized by visual loss, progressive dementia, seizures, motor deterioration, and early death. The NCLs are named because of the intracellular accumulation of fluorescent lipopigments ceroid and lipofuscin. They comprise a genetically and phenotypically heterogeneous group of disorders (currently there are at least 14 NCL types) that have traditionally been subclassified by age of onset, among other clinical features. With the exception of CLN4 (Parry disease), which is transmitted as an autosomal dominant trait, all other types of NCL are autosomal recessive. They differ from one another in the associated ultrastructural patterns of the inclusions as seen by electron microscopy. With the advent of enzymatic and molecular testing methods, clinicians can make specific NCL diagnoses using genetic and biochemical testing (Table 639.2).

Table 639.2 NCL of Childhood Onset: Clinical Classification and Major Diagnostic Procedure

CLINICAL FORM	AGE OF ONSET	DISEASE	GENE	DIAGNOSIS	MAJOR SYMPTOMS AT ONSET
Congenital	Birth	CLN10	*CLN10/CTSD*	NGS Enzymatic assay	Microcephaly, dysmorphic features, seizures, hyperkinetic movements
Infantile	6-18 mo	CLN1	*CLN1/PPT1*	NGS enzymatic assay	Decreased head growth, neurodevelopmental regression, seizures
		CLN10	*CLN10/CTSD*	NGS enzymatic assay	Decreased head growth, neurodevelopmental regression
		CLN14	*CLN14/KCDT7*	NGS	Decreased head growth, seizures (myoclonus)
LATE INFANTILE Classical	2-4 yr	CLN2	*TPP1*	NGS enzymatic assay	Seizures, ataxia, visual loss, delayed language development
Variant	2-5 yr	CLN1	*CLN1/PPT1*	NGS enzymatic assay	Seizures, neurodevelopmental regression, behavioral disturbances
		CLN5	*CLN5*	NGS	Impaired learning and cognition
		CLN6	*CLN6*	NGS	Seizures, ataxia, delayed language development
		CLN7	*CLN7/MFSD8*	NGS	Seizures, visual loss, motor and cognitive regression
		CLN8	*CLN8*	NGS	Seizures, visual loss, motor and cognitive regression
JUVENILE Classical	3-5 yr	CLN3	*CLN3*	NGS	Visual loss, behavioral problems, cognitive decline
	5-7 yr	CLN5	*CLN5*	NGS	Motor and cognitive regression, behavioral problems
	5-7 yr	CLN1	*CLN1/PPT1*	NGS enzymatic assay	Visual loss, cognitive decline
Late	8-12 yr	CLN6 CLN10	*CLN6* *CLN10/CTSD*	NGS NGS enzymatic assay	Myoclonic seizures, cognitive decline; ataxia, cognitive decline, visual loss
	13-16 yr	CLN12	*ATP13A2*	NGS	Rigidity, hypokinesia

NSG, Next-generation sequencing.
From Simonati A, Williams RE. Neuronal ceroid lipofuscinosis: the multifaceted approach to the clinical issues, an overview. *Frontiers Neurol*. 2022;13:Article 811686, Table 1.

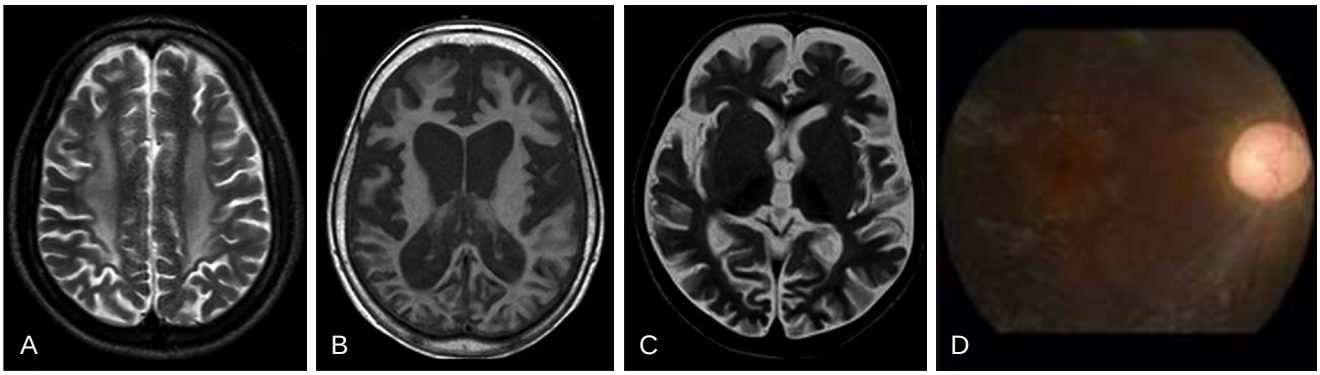

Fig. 639.3 A, T2-weighted (axial) image showing leukoencephalopathy in a child with late infantile neuronal ceroid lipofuscinoses (NCL). B, T1-weighted (axial) sequence revealing diffuse atrophy in a child with late infantile NCL. C, A child with late infantile NCL with cerebellar atrophy in T2-weighted axial section of the brain. D, Fundus photograph showing atypical retinitis pigmentosa with optic atrophy in a child with juvenile NCL. *(Modified from Jadav RH, Sinha S, Yasha TC, et al. Clinical, electrophysiological, imaging, and ultrastructural description in 68 patients with neuronal ceroid lipofuscinoses and its subtypes. Pediatr Neurol. 2014;50:85–95, Fig. 1, p. 88.)*

Infantile-type neuronal ceroid lipofuscinosis (ICLN, Santavuori disease) begins in the first year of life with developmental delay, myoclonic seizures, intellectual deterioration, and blindness. Optic atrophy and brownish discoloration of the macula are evident on examination of the retina, and cerebellar ataxia is prominent. The infantile form is caused by recessive pathogenic variants of the gene for the lysosomal enzyme palmitoyl-protein thioesterase-1 (PPT1) on chromosome 1p32. A number of cell types in INCL patients show characteristic intracellular fine granular osmiophilic deposits discernible by electron microscopy.

Although death typically occurs during early childhood, a subset of children with PPT1 enzyme deficiency has a much less severe course with clinical features resembling those of the juvenile-onset NCL patients. Clinically, these variant INCL patients have a course that is often quite distinct from the typical, classic, rapidly degenerating infantile form, yet they have PPT1 deficiency and granular osmiophilic deposits on pathology. There is no clear *CLN1* genotype that predicts severity of phenotype.

Late infantile-type neuronal ceroid lipofuscinosis (LINCL, Jansky-Bielschowsky) is the second most common type of NCL and generally presents with myoclonic seizures beginning between 2 and 4 years of age in a previously normal child. Dementia and ataxia are combined with a progressive loss of visual acuity and microcephaly. Examination of the retina shows marked attenuation of vessels, optic atrophy, and a subtle brown pigment in the macular region, with associated visual changes early in the course of disease (Fig. 639.3). The autofluorescent material is deposited in neurons, fibroblasts, and secretory cells.

LINCL can be caused by autosomal recessive variants of several different genes: *CLN2* gene, which codes for a tripeptidyl peptidase-1 (TPP1) that is essential for the degradation of cholecystokinin-8, as well as the *CLN5, CLN6,* CLN8, and *CLN14* genes, which code for membrane proteins that have not been completely characterized. *CLN8* is also known as *locus of northern epilepsy syndrome,* which is often called *progressive epilepsy with cognitive impairment.*

At this time, there is only one clinically approved treatment for all types of NCL. *CLN2* can be treated with *intraventricular* cerliponase alfa, a recombinant human proenzyme of TPP1. Treatment with cerliponase alfa can attenuate motor and language decline but does not alter visual symptoms. Stem cell therapy, gene therapy, and immunomodulatory therapy to repair genetic variants or alter adaptive immunoresponses are all in preclinical studies for adjunctive treatment of NCL.

Juvenile-type neuronal ceroid lipofuscinosis (JNCL, Spielmeyer-Vogt or Batten disease) is the most common form of NCL disease and is generally caused by autosomal recessive variants in *CLN3*. Children affected with JNCL tend to develop normally for the first 5 years of life. Their initial symptom is usually progressive visual loss, and their retinal pigmentary changes often result in an initial diagnosis of retinitis pigmentosa. The funduscopic changes are similar to those for LINCL. After disease onset, there may be a rapid decline with changes in cognition and personality, motor incoordination, and seizures. Myoclonic seizures are not as prominent as in LINCL, but parkinsonism can develop and impair ambulation. Patients die in their late 20s to early 30s. In JNCL caused by *CLN3,* the electron microscopy of tissues shows deposits called *fingerprint profiles,* and routine light microscopy of a peripheral blood smear may show lymphocyte vacuoles.

A possible mimic of JNCL is **Lafora disease (LD)** caused by pathogenic variants in *EPM2A* and *EPM2B*. LD also has skin (eccrine) inclusion bodies in addition to seizures, myoclonus, ataxia, dysarthria, progressive loss of milestones, and death within 10 years of onset. The diseases can be distinguished by specific gene sequencing.

Visit Elsevier eBooks+ at eBooks.Health.Elsevier.com for Bibliography.

639.3 Adrenoleukodystrophy

See Chapter 106.2.

639.4 Sialidosis

Kristin A. Seaborg and Jennifer M. Kwon

Sialidosis is the result of lysosomal sialidase deficiency secondary to an autosomal recessive pathogenic variant in the sialidase (α-neuraminidase, *NEU1*) gene on chromosome 6p21.3. Up to 40 pathologic variants of *NEU1* have been identified. The accumulation of sialic acid–oligosaccharides with markedly increased urinary excretion of sialic acid–containing oligosaccharides is associated with clinical presentations that range from the milder sialidosis type I to the more severe sialidosis type II.

Sialidosis type I, **cherry-red spot myoclonus syndrome**, usually presents in the second decade of life, when a patient complains of visual deterioration. Inspection of the retina shows a cherry-red spot, but, unlike patients with TSD, visual acuity declines slowly in individuals with cherry-red spot myoclonus syndrome. Myoclonus of the extremities is gradually progressive and eventually renders patients nonambulatory. The myoclonus is triggered by voluntary movement, touch, and sound and is not controlled with anticonvulsants. Generalized convulsions responsive to antiseizure medications occur in most patients.

Sialidosis type II patients present at a younger age and have cherry-red spots and myoclonus, as well as somatic involvement, including coarse facial features, hepatosplenomegaly, corneal clouding (rarely), and dysostosis multiplex, producing anterior beaking of the lumbar vertebrae. Type II patients may be further subclassified into congenital and infantile (childhood) and juvenile forms, depending on the age of onset and severity. Examination of lymphocytes shows vacuoles in the cytoplasm, biopsy of the liver demonstrates cytoplasmic vacuoles in Kupffer cells, and membrane-bound vacuoles are found in Schwann cell cytoplasm, all attesting to the multiorgan nature of sialidosis type II. Identification of genetic variants in the *NEU1* gene can confirm the diagnosis.

Some cases of what appears to be sialidosis type II are the result of combined deficiencies of β-galactosidase and α-neuraminidase resulting from deficiency of protective protein/cathepsin A that prevents premature intracellular degradation of these two enzymes. These patients have galactosialidosis, and they are clinically indistinguishable from those with sialidosis type II. Consequently, patients who have features of sialidosis type II with marked urinary excretion of oligosaccharides should be tested for protective protein/cathepsin A deficiency as well as sialidase deficiency.

Visit Elsevier eBooks+ at eBooks.Health.Elsevier.com for Bibliography.

639.5 Miscellaneous Neurodegenerative Disorders

Kristin A. Seaborg and Jennifer M. Kwon

PELIZAEUS-MERZBACHER DISEASE

Pelizaeus-Merzbacher disease (PMD) is an X-linked recessive disorder characterized by nystagmus and abnormalities of myelin. PMD is caused by gene variants in the *PLP1* gene on chromosome Xq22, which is essential for CNS myelin formation and oligodendrocyte differentiation. Different variants in the same gene can cause a spectrum of disorders, ranging from the milder **familial spastic paraparesis** (progressive spastic paraparesis type 2, SPG2) to the more severe connatal form associated with rapid neurologic decline from an early age and death in the first decade of life. *PLP1* variants causing disease include point changes, deletions, gene duplications, and other gene dosage variants.

Classic PMD is the most common type, clinically recognized by nystagmus and roving eye movements along with head nodding during infancy. Developmental milestones are delayed; ataxia, choreoathetosis, and spasticity ultimately develop. Optic atrophy and dysarthria are associated findings, and death occurs in the second or third decade. The major pathologic finding is a loss of myelin with intact axons, suggesting a defect in the function of oligodendroglia. An MRI scan shows a symmetric pattern of delayed myelination. The final diagnosis can be made through genetic testing for variants in the *PLP1* gene.

Other PMD-like, hypomyelinating leukodystrophies continue to be identified and should be considered in the differential diagnosis of PMD. These include Allan-Herndon-Dudley syndrome, TUBB4A-related disorders, and hypomyelinating leukodystrophy 7 or 8.

ALEXANDER DISEASE

This is a rare disorder that causes progressive macrocephaly and leukodystrophy. Alexander disease is caused by dominant pathogenic variants in the *GFAP* gene on chromosome 17q21; cases are usually sporadic. Pathologic examination of the brain discloses deposition of eosinophilic hyaline bodies called *Rosenthal fibers* in astrocyte processes. In the classic infantile form of Alexander disease **(type I)**, degeneration of white matter is most prominent frontally. The diagnosis may be suggested by MRI (Fig. 639.4) and MR spectroscopy demonstrating abnormal metabolic substrates. Affected children develop progressive loss of intellect, spasticity, and treatment-resistant seizures causing death by 5 years of age. Patients with **type II** Alexander disease present later in life and may not have the characteristic frontal predominance or megalencephaly. Most patients with type II Alexander disease develop ataxia, and approximately 50% develop difficulty with speech or swallowing.

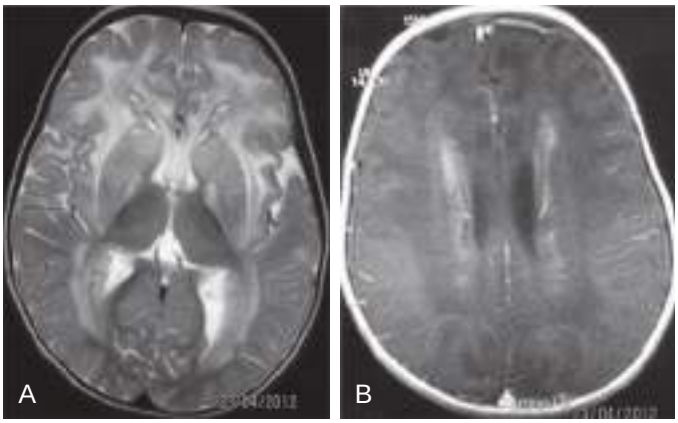

Fig. 639.4 Alexander disease. MRI of the index patient at the age of 15 mo. **A,** Axial T2-weighted sequences (TR/TE: 4000/99) at the basal ganglia and thalamus level demonstrating diffuse bilateral, symmetric increased signal predominantly of the frontal periventricular but also of the subcortical, white matter and the basal ganglia. **B,** Significant periventricular rim after intravenous gadolinium infusion (T1-weighted sequences; TR/TE: 400/88). *(From Zafeiriou DI, Dragoumi P, Vargiami E. Alexander disease. J Pediatr. 2013;162:648.)*

CANAVAN SPONGY DEGENERATION

See Chapter 105.15.

OTHER LEUKODYSTROPHIES

Metabolic and degenerative disorders can present with significant cerebral white matter changes, such as some mitochondrial disorders (see Chapters 106.1 and 108) and glutaric aciduria type 1. In addition, the broader use of brain MRI has brought to light new leukodystrophies.

One example is vanishing white matter disease or childhood ataxia with central nervous system (CNS) hypomyelination characterized by ataxia and spasticity (Fig. 639.5). Some patients also have optic

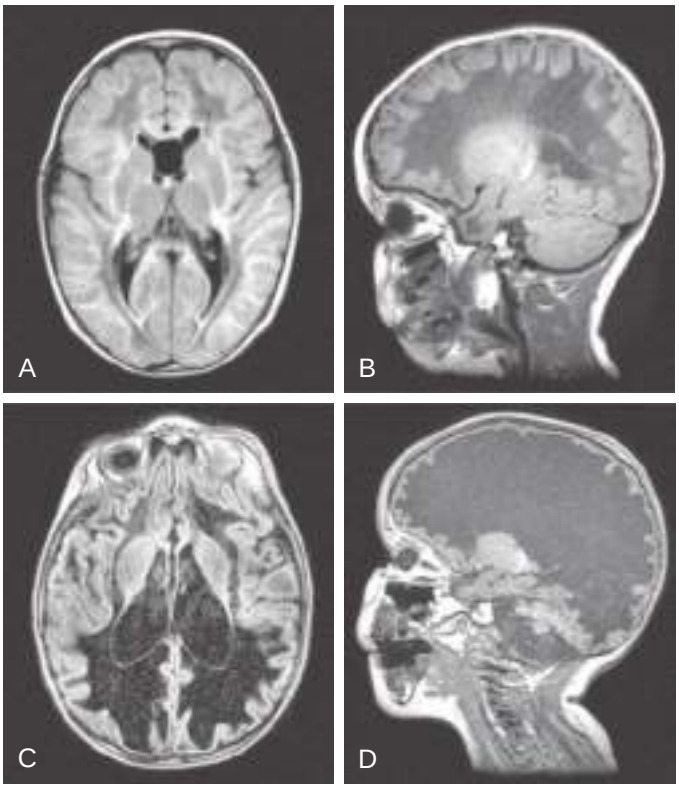

Fig. 639.5 T1-weighted and FLAIR images of a patient with vanishing white matter disease. Axial FLAIR (**A, C**) and sagittal T1-weighted (**B, D**) images of a patient at ages 1½ and 2½ yr. The first MRI (**A, B**) was obtained soon after the onset of symptoms. The initial FLAIR image (**A**) shows diffuse abnormality and partial cystic degeneration of the cerebral white matter, whereas the follow-up FLAIR image (**C**) shows that all of the cerebral white matter has been replaced by fluid. The initial T1-weighted sagittal image (**B**) shows the typical stripelike pattern within the abnormal white matter, whereas the follow-up image (**D**) shows that all of the cerebral white matter has disappeared and that only the cerebral cortex and ependymal lining are preserved. The cerebellum has become highly atrophic. *(A, C from Van der Knaap MS, Valk J. Magnetic Resonance of Myelination and Myelin Disorders, 3rd ed. Heidelberg: Springer; 2005, Fig 65.3; B, D from van der Knaap MS, Pronk JC, Scheper GC. Vanishing white matter disease. Lancet Neurol. 2006;5:413-423. Fig. 3.)*

atrophy, seizures, and cognitive deterioration. Symptoms worsen rapidly after episodes of fever, head trauma, or external stressors. The age of presentation and the rapidity of decline in leukodystrophies can be quite variable. In the early-onset forms, decline is usually rapid and followed quickly by death; in the later-onset forms, mental decline is usually slower and milder. Interestingly, acute demyelination in these disorders can be triggered by fever or fright. The diagnosis of vanishing white matter disease or childhood ataxia with CNS hypomyelination is based on clinical findings, characteristic abnormalities on cranial MRI, and autosomal recessive gene variants in one of five causative genes (*EIF2B1*, *EIF2B2*, *EIF2B3*, *EIF2B4*, and *EIF2B5*) encoding the five subunits of the eukaryotic translation initiation factor, eIF2B, which regulates cellular protein synthesis. An approach to leukodystrophies based on MRI findings is noted in Figure 639.6 and associated clinical features in Figure 639.7, and the diagnostic evaluation is noted in Table 639.3.

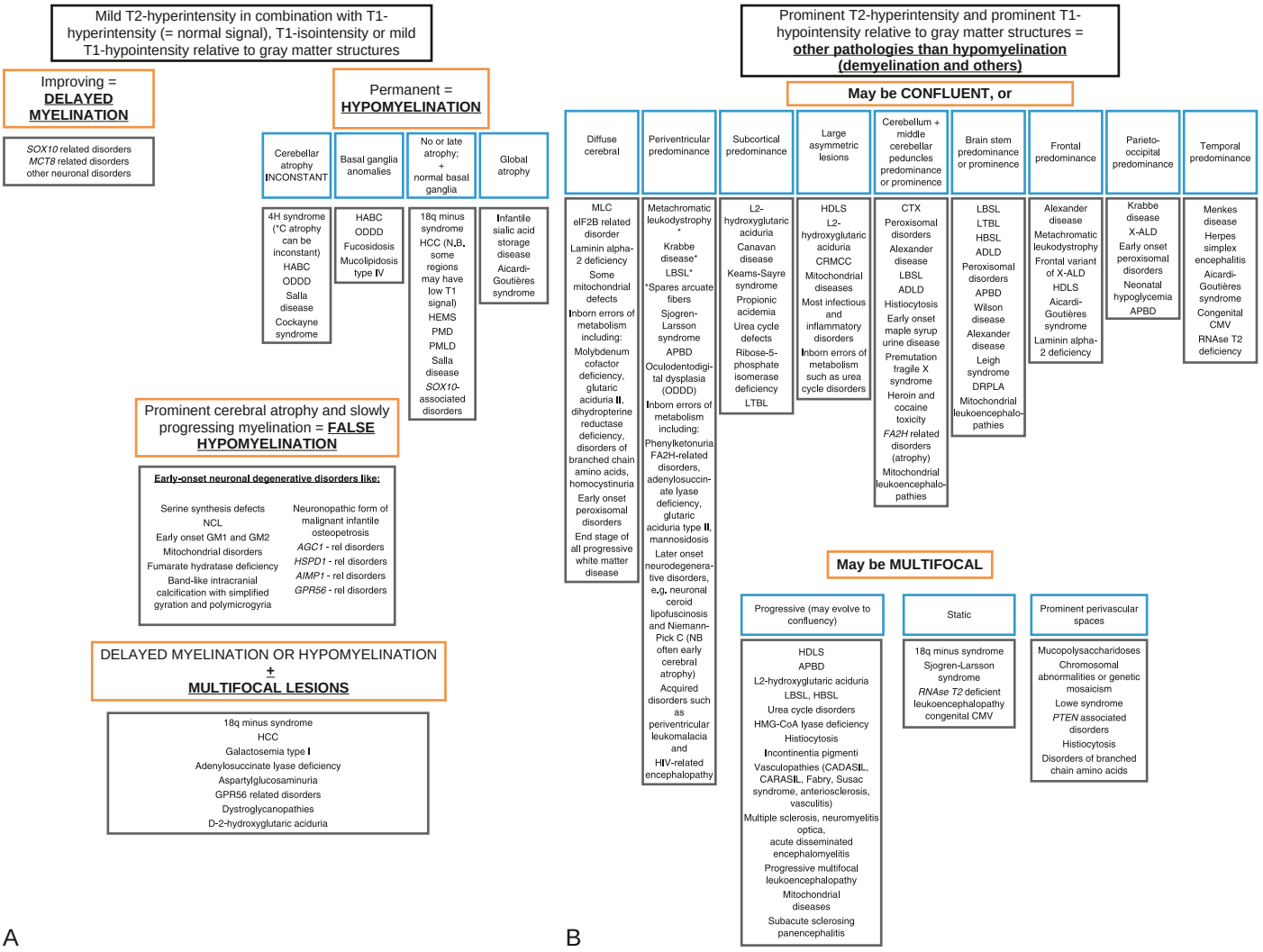

Fig. 639.6 MRI pattern recognition in the leukodystrophies and genetic leukoencephalopathies (gLEs). Three major MRI characteristics help to discriminate between the different types of leukodystrophy and gLE. The first discriminator is the presence or absence of *hypomyelination* (**A**). Within this subset, the presence of improvement of myelination or atrophy directs the clinician toward a series of gLEs. Within the true hypomyelinating leukodystrophies, the presence of basal ganglia and cerebellar involvement further helps refine the diagnosis. If the pattern is not one of hypomyelination, then the second discriminator is whether the white matter abnormalities are *confluent or isolated and multifocal* (**B**). If the white matter abnormalities are confluent, then the third discriminator is the *predominant localization of the abnormalities* (**B**). 4H, Hypomyelination, hypodontia, and hypogonadotropic hypogonadism; HACB, hypomyelination with atrophy of the basal ganglia and cerebellum; HEMS, hypomyelination of early myelinating structures; ODDD, oculodentodigital dysplasia; HCC, hypomyelination with congenital cataract; PMD, Pelizaeus-Merzbacher disease; PMLD, Pelizaeus-Merzbacher–like disease; NCL, neuronal ceroid lipofuscinosis; APBD, adult polyglucosan body disease; ADLD, autosomal dominant leukodystrophy with autonomic symptoms; CRMCC, cerebroretinal microangiopathy with calcifications and cysts; CTX, cerebrotendinous xanthomatosis; DRPLA, dentatorubral pallidoluysian atrophy); HDLS, hereditary diffuse leukoencephalopathy with spheroids/neuroaxonal leukodystrophy with spheroids; HBSL, hypomyelination with brainstem and spinal cord and leg involvement; LTBL, leukoencephalopathy with thalamic and brainstem involvement and high lactate; LBSL, leukoencephalopathy with brainstem and spinal cord involvement and lactate elevation; MLC, megalencephalic leukodystrophy with subcortical cysts; X-ALD, X-linked adrenoleukodystrophy. *(Pattern recognition reprinted with permission from GeneReviews; from Parikh S, Bernard G, Leventer RJ, et al. A clinical approach to the diagnosis of patients with leukodystrophies and genetic leukoencephalopathies. Mol Gen Metab. 2018;114:501–515, Fig. 2, pp. 508–509.)*

Leukodystrophies: "special" clinical features

Peripheral neuropathy	Ophthalmologic	Hearing loss	Endocrine	Skin	Dental	Skeletal	Other
MLD Krabbe PMDL PMD (mutations leading to loss of both PLP1 and DM20) HCC LCC *SOX10*-related disorder APBD CTX ALD and variants MNGIE	Early-onset VWM (cataracts) HCC (cataracts) 4H leukodystrophy (severe myopia) Aicardi-Goutières (glaucoma) Cockayne (retinitis pigmentosa) HSMD (retinitis pigmentosa) CTX (cataracts) SLS (macular degeneration, retinitis pigmentosa, white glistening spots) Coats plus (retinal telangiectasia and exudates) *SOX10*-related disorder (iris heterochromia) AMACR deficiency (retinitis pigmentosa) Early-onset peroxisomal disorders (retinitis pigmentosa) Mitochondrial LDs (cataracts, retinitis pigmentosa) Late stage of many LDs (optic atrophy)	*SOX10*-related disorder Cockayne 18q minus Early-onset peroxisomal disorders Fabry Mitochondrial LDs	VWM (premature ovarian failure) *AARS2*-related LD (premature ovarian failure) ALD and variants (adrenal failure, testicular failure) 4H leukodystrophy (delayed puberty, growth hormone deficiency) Cockayne (hypothyreosis) 18q minus (growth hormone deficiency) KSS (growth hormone deficiency, diabetes, hypo-parathyroidism)	Generalized pigmentation (ALD and variants) Aicardi-Goutières (chilblains) Cockayne (photo-sensitivity) Trichothiodys-trophy (photosensitivity) CTX (tendon xanthomas) SLS (ichthyosis) Fabry (angiokeratoma) Fucosidosis (angiokeratoma) Hyperpigmentation (Addison in ALD and variants) Linear pigment alterations (chromosomal mosaicism)	4H leukodystrophy (delayed dentition, hypodontia, abnormal tooth shape, caries) ODDD (hypodontia, abnormal tooth shape, caries) Cockayne (caries) Early-onset peroxisomal disorders (enamel hypoplasia) Periodontal Ehlers Danlos (premature loss of teeth)	HSMD (spondylo-metaphyseal dysplasia) 4H leukodystrophy (osteosclerosis) Fucosidosis (dysostosis multiplex) ODDD (syndactyly of 4th and 5th fingers) Coats plus (osteopenia with poor bone healing) Early-onset peroxisomal disorders (skeletal dysplasia)	MLD (gallbladder) Early-onset VWM (liver, pancreas, kidneys) Salla (hepatospleno-megaly) Fucosidosis (hepatospleno-megaly) Early-onset peroxisomal disorders (liver, kidney) CTX (neonatal cholestasis, diarrhea) Congenital muscular dystrophies 18q minus (congenital heart defects) Coats plus (gastrointestinal bleeding and portal hypertension) *SOX10*-related disorder (Hirschsprung disease; white lock of hair) MNGIE (intestinal pseudo-obstruction) *NRF2*-related LD (immune deficiency) *PUS3*-related LD (nephropathy)

Fig. 639.7 Leukodystrophies: "Special" clinical features. MLD, Metachromatic leukodystrophy; PMDL, Pelizaeus-Merzbacher–like disease; PMD, Pelizaeus-Merzbacher disease; HCC, hypomyelination with congenital cataracts; LCC, leukodystrophy with calcifications and cysts; APBD, adult polyglucosan body disease; CTX, cerebrotendinous xanthomatosis; ALD, adrenoleukodystrophy; MNGIE, myoneurogastrointestinal encephalopathy; VWM, vanishing white matter; HSMD, X-linked hypomyelination with spondylometaphyseal dysplasia; SLS, Sjögren-Larsson syndrome; AMACR, alpha-methylacyl-CoA racemase; KSS, Kearns-Sayre syndrome; ODDD, oculodentodigital dysplasia; LD, leukodystrophy. *(From van der Knaap MS, Schiffmann R, Mochel F, Wolf NI. Diagnosis, prognosis, and treatment of leukodystrophies. Lancet Neurol. 2019;18:962–972, Appendix Fig. 2.)*

MENKES DISEASE

Menkes disease (kinky hair disease) is a progressive neurodegenerative condition inherited as an X-linked recessive trait. The Menkes gene, *ATP7A*, on Xq21.1, codes for a copper-transporting, P-type adenosine triphosphatase, and mutations in the protein are associated with low serum copper and ceruloplasmin levels, as well as a defect in intestinal copper absorption and transport. The clinical symptoms of Menkes disease depend on the activity of different enzymes that use copper as a cofactor, such as superoxide dismutase, cytochrome *c* oxidase, and dopamine β hydroxylase, among others. Symptoms begin in the first few months of life and include hypothermia, hypotonia, and generalized myoclonic seizures. The facies are distinctive, with chubby, sagging, rosy cheeks and kinky, colorless, friable hair. Microscopic examination of the hair shows several abnormalities, including **trichorrhexis nodosa** (fractures along the hair shaft) and **pili torti** (twisted hair). Feeding difficulties are prominent and lead to failure to thrive. Severe cognitive impairment, vascular tortuosity, and optic atrophy are constant features of the disease. Neuropathologic changes include tortuous degeneration of the gray matter and marked changes in the cerebellum with loss of the internal granule cell layer and necrosis of the Purkinje cells. Death can occur by 3 years of age in untreated patients. Very rarely does Menkes disease manifest in females, and when it does, symptoms are milder.

Copper histidine therapy may be effective in preventing neurologic deterioration in some patients with Menkes disease, particularly when treatment is begun in the neonatal period or, preferably, with the fetus. These presymptomatic children are identified because of a family history of an affected brother and confirmed by target analysis for variants in the *ATP7A* gene. Infants diagnosed presymptomatically in the first 10 days of life can be started on an experimental protocol of daily

Table 639.3 Clinical and Laboratory Tests that Aid in the Diagnosis of Leukodystrophies and Genetic Leukoencephalopathies

CLINICAL/LABORATORY TEST*	DIAGNOSTIC TARGET
Brain and spinal MRI (± gadolinium, ± MRS)	Establish white matter disease; ± evidence of leaky blood-brain barrier and metabolite accumulation (mitochondrial disorders, Canavan disease, Sjögren-Larson syndrome, peroxisomal biogenesis disorders)
Ophthalmologic exam	Document ophthalmologic signs in several leukodystrophies
Head CT	Assess for calcifications
Plasma very long-chain fatty acids	X-linked adrenoleukodystrophy and adrenomyeloneuropathy and peroxisomal biogenesis disorders
Lysosomal enzymes (leukocytes)	Metachromatic leukodystrophy, Krabbe disease, multiple sulfatase deficiency, galactosialidosis, sialidosis
Blood lactate, pyruvate, amino acids	Mitochondrial disorders
Lumbar puncture (cell count, protein, ± CSF neopterin, ± interferon-alpha)	Nonspecific marker of demyelination; ± pleocytosis and markers for Aicardi-Goutières syndrome
Urine sulfatides	Metachromatic leukodystrophy, multiple sulfatase deficiency
Urine organic acids	L-2-hydroxyglutarate; N-acetyl aspartic acid for Canavan disease; Krebs cycle intermediates (mitochondrial disorders)
Neurophysiologic studies (BAER EMG/NCV, VEP, SSEP)	Characterize involvement of cranial and peripheral nerves, optic tracts, and spinal tracts
Genetic analyses	As indicated for each leukodystrophy or genetic leukoencephalopathy

*Additional tests may be indicated for patients with certain distinctive clinical presentations or extraneurologic features suggestive of one or more specific leukodystrophies.

BAER, Brainstem auditory evoked response test; CSF, cerebrospinal fluid; CT, computed tomography; EMG, electromyogram; MRI, magnetic resonance imaging; MRS, magnetic resonance spectroscopy; NCV, nerve conduction velocity test; SSEP, somatosensory evoked potential test; VEP, visual evoked potential test.

From Parikh S, Bernard G, Leventer RJ, et al. A clinical approach to the diagnosis of patients with leukodystrophies and genetic leukoencephalopathies. *Mol Gen Metab.* 2018;114:501–515, Table 6.

copper-histidine subcutaneous injections. Optimal response to treatment appears to occur only in patients who are identified in the newborn period and whose mutations permit residual copper transport activity.

RETT SYNDROME

This syndrome is characterized as a disorder of early brain development marked by a period of developmental regression and deceleration of brain growth after a relatively normal neonatal course. It is an X-linked disease that occurs predominantly in females and is one of the most common causes of cognitive disability in females. The frequency is approximately 1 in 10,000-15,000 live births. Rett syndrome is caused by pathogenic variants in *MeCP2* on Xq28, which codes for a transcription factor that binds to methylated CpG islands and silences transcription.

Clinically, development may proceed normally until 1 year of age, when regression of language and motor milestones and acquired microcephaly become apparent. Some atypical forms of Rett syndrome are congenital and can be associated with early-onset seizures and developmental impairment within the first months of life. An ataxic gait or fine tremor of hand movements is an early neurologic finding. Most children develop peculiar sighing respirations with intermittent periods of apnea that may be associated with cyanosis. The hallmark of Rett syndrome is repetitive hand-wringing movements and a loss of purposeful and spontaneous use of the hands; these features may not appear until 2-3 years of age. Autistic behavior is a typical finding in all patients. Generalized tonic-clonic convulsions occur in the majority but may be well controlled by anticonvulsants. Feeding disorders and poor weight gain are common. After the initial period of neurologic regression, the disease process appears to plateau, with persistence of the autistic behavior. Cardiac arrhythmias may result in sudden, unexpected death at a rate that is higher than the general population. Females usually survive into adulthood.

Although very few males survive with the classic Rett syndrome phenotype, genotyping of males without the classic Rett syndrome phenotype but with intellectual disability and other atypical neurologic features has detected patients with variants in *MeCP2.* Gene variants in *MeCP2* have been demonstrated in normal female carriers, females with Angelman syndrome, and males with fatal encephalopathy, Klinefelter (47,XXY) syndrome, and familial X-linked cognitive impairment. Males may present with a Rett-like syndrome if they have an *MECP2* duplication.

Classic Rett syndrome has been treated with trofinetide, an analog of the amino-terminal tripeptide of insulin-like growth factor 1. Its potential antiinflammatory and trophic properties may be the mechanisms that produce a positive clinical effect. It is approved for patients ≥2 years of age.

Some females have an atypical Rett phenotype associated with severe myoclonic seizures in infancy, slowing of head growth, and developmental arrest and have variants in another X-linked gene encoding for cyclin-dependent kinase–like 5 (CDKL5), which may interact with MeCP2 and other proteins regulating gene expression.

NEURODEGENERATION WITH BRAIN IRON ACCUMULATION

Neurodegeneration with brain iron accumulation represents multiple age-of-onset–dependent disorders characterized by extrapyramidal symptoms and intellectual deterioration and regression, with iron deposition in the basal ganglia. There is significant phenotypic variability of these disorders; however, a characteristic finding on MRI demonstrates symmetric T2-signal homogeneous *hypointensity.* Common neurodegeneration with brain iron accumulation disorders are distinguished in Table 639.4, and an approach to their diagnosis is noted in Figure 639.8. Clinical features, which are highly variable, may include dystonia, parkinsonism, ataxia, spasticity, psychiatric symptoms, and intellectual impairment. Treatment should focus on the specific disorder and is usually symptomatic relief rather than curative. Iron chelation has been attempted without major long-term benefit.

Visit Elsevier eBooks+ at eBooks.Health.Elsevier.com for Bibliography.

Table 639.4 Overview of Neurodegeneration with Brain Iron Accumulation Conditions and Genes (If Known)

					CHILDHOOD-ONSET VARIANT		LATE-ONSET VARIANT	
CONDITION (ACRONYM)	**SYNONYM**	**GENE**	**CHROMOSOMAL POSITION**	**LB PATHOLOGY**	**AGE OF ONSET**	**CLINICAL PRESENTATION**	**AGE OF ONSET**	**CLINICAL PRESENTATION**
PKAN	NBIA1	*PANK2*	20p13	No	Early childhood, around age 3	Typical PKAN	Teens or early adulthood	Atypical PKAN
PLAN	NBIA2, PARK14	*PLA2G6*	22q12	√	Infancy	Infantile neuroaxonal dystrophy	Teens or early adulthood	Dystonia parkinsonism
FAHN	SPG35	*FA2H*	16q23	Not known	Childhood	Leukodystrophy, hereditary spastic paraplegia	Adulthood (age range up to 30 yr)	May resemble idiopathic Parkinson disease
MPAN	—	*C19orf12*	19q12	√	—	Pyramidal extrapyramidal syndrome		
Kufor-Rakeb disease	PARK9	*ATP13A2*	1p36	√	Childhood- teens	Parkinsonism, pyramidal tract signs, eye movement disorder		
BPAN	SENDA syndrome	*WDR45*	Xp11.23	Not known	Childhood	Encephalopathy with psychomotor regression, then static	Then: 20s to 30s	Sudden-onset progressive dystonia parkinsonism
Aceruloplasminemia	—	*CP*	3q23	No	—	—	50s (range: 16-70)	Extrapyramidal, diabetes, dementia
Neuroferritinopathy	—	*FTL*	19q13	No	—	—	40s	Chorea, dystonia, dementia
Idiopathic late-onset cases	—	Probably heterogeneous	Probably heterogeneous	Heterogeneous	—	—	Heterogeneous	Parkinsonism; it may resemble idiopathic Parkinson disease

√, Present; BPAN, beta-propeller–associated neurodegeneration; CP, ceruloplasmin; FA2H, fatty acid 2-hydroxylase; FAHN, fatty acid 2-hydroxylase–associated neurodegeneration; FTL, ferritin light chain; LB, Lewy body; MPAN, mitochondrial membrane–associated neurodegeneration; NBIA, neurodegeneration with brain iron accumulation; PANK2, pantothenate kinase 2; PKAN, pantothenate kinase–associated neurodegeneration; PLA2G6, phospholipase A2; PLAN, PLA2G6-associated neurodegeneration; SENDA, static encephalopathy of childhood with neurodegeneration in adulthood; SPG, spastic paraplegia.

From Schneider SA, Zorzi G, Nardocci N. Pathophysiology and treatment of neurodegeneration with brain iron accumulation in the pediatric population. *Curr Treat Option Neurol.* 2013;15:652–667, Table 1.

Downloaded for mohamed ahmed (dr.mms2020@gmail.com) at University of Southern California from ClinicalKey.com by Elsevier on April 22, 2024. For personal use only. No other uses without permission. Copyright ©2024. Elsevier Inc. All rights reserved.

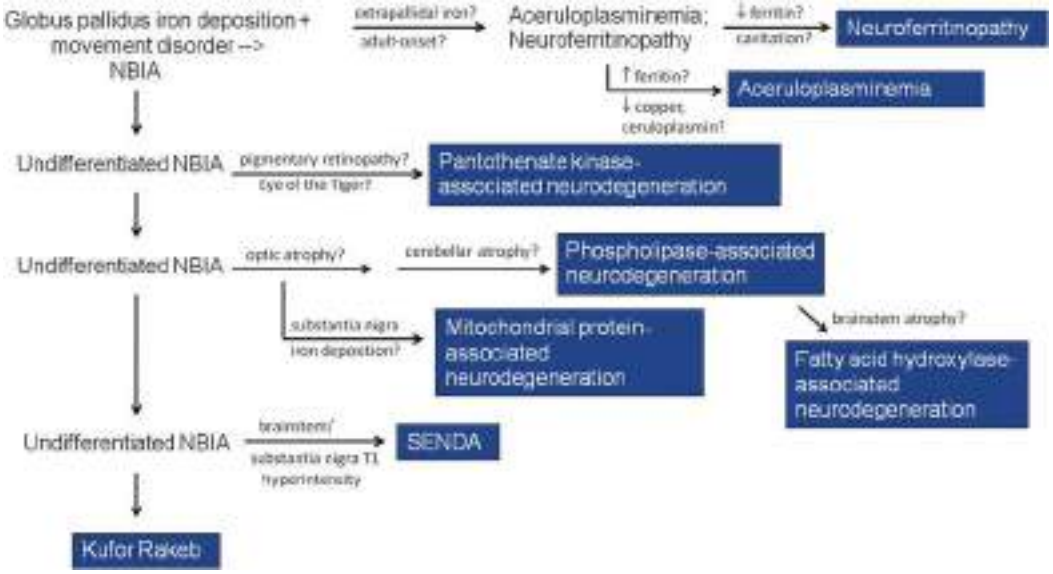

Fig. 639.8 Algorithm showing the clinical and radiographic approach to neurodegeneration with brain iron accumulation. NBIA, neurodegeneration with brain iron accumulation; SENDA, static encephalopathy of childhood with neurodegeneration in adulthood. *(From Kruer MC, Boddaert N. Neurodegeneration with brain iron accumulation: a diagnostic algorithm. Semin Pediatr Neurol. 2012;19:67–74, Fig. 1.)*

Chapter 640

Demyelinating Disorders of the Central Nervous System

Michael Perry and Cheryl Hemingway

Acquired demyelinating syndromes (ADSs) of the central nervous system (CNS) are rare disorders, occurring with an approximate annual incidence of 9.8 per million children per year. They present with neurologic dysfunction caused by immune-mediated injury to the myelin sheath of the brain, optic nerves, and spinal cord. In contrast to genetically determined **leukodystrophies** (sometimes called *dysmyelinating disorders*) that *produce* disrupted white matter, acquired demyelinating disorders target normally formed white matter. They can be monophasic or relapsing.

The pathogenesis often involves demyelination together with B cells and CNS antibodies. Two immunoglobulin G (IgG) antibodies recognized as playing an important part in demyelination are aquaporin 4-antibody (AQP4-Ab) and myelin oligodendrocyte glycoprotein antibody (MOG-Ab). The aquaporins are plasma membrane water-transporting proteins expressed in astrocytes and are primarily involved in water movement, cell migration, and neuroexcitation. Myelin oligodendrocyte glycoprotein (MOG) is exclusively expressed in the CNS. Although MOG comprises only a minor component of the myelin sheath, its location on the outermost lamellae and on the cell surface of oligodendrocytes makes it available for antibody binding. Increasing knowledge of the importance of these antibodies in disease, together with available disease-modifying treatments (DMTs) has made accurate diagnosis in demyelinating disorders crucial. Pediatric demyelinating syndromes may be clinically characterized by:

1. Localization of neurologic deficits: monofocal vs polyfocal
2. Presence or absence of encephalopathy
3. Disease course: monophasic vs polyphasic
4. Presence or absence of specific antibodies

MRI of the brain and spine is essential to characterize both symptomatic and *clinically silent* demyelinating lesions, aid in the diagnosis of the specific demyelinating syndrome, predict likelihood of recurrence, and rule out other etiologies. Serial MRIs may be needed to confirm the diagnosis and can also be used to monitor the treatment response and guide DMT use. The presence of **oligoclonal bands (OCBs)** in cerebrospinal fluid (CSF) analysis is useful to help confirm the diagnosis of multiple sclerosis (MS) (Table 640.1); their absence may suggest an alternative diagnosis. OCBs, matched or unmatched (to blood OCB), may also be seen in other CNS inflammatory diseases. Additional laboratory studies, including an autoimmune profile, antibody testing, metabolic testing, genetic testing, catheter angiography, and less often, brain biopsy, may be required to evaluate for mimics of demyelination. These mimics may include conditions such as migraine, systemic rheumatologic disorders, mitochondrial disorders, primary CNS angiitis, infection, neoplasm, and genetic conditions such as the inherited white matter disorders (e.g., leukodystrophies) and primary CNS hemophagocytic lymphohistiocytosis (HLH) (Tables 640.2 and 640.3).

Most children presenting with a first episode of demyelination will experience a monophasic course and do not relapse. Monophasic demyelinating disorders of childhood may include acute disseminated encephalomyelitis (ADEM), optic neuritis (ON), and transverse myelitis (TM); relapsing forms of demyelination include MS, MOG, multiphasic disseminated encephalomyelitis (MDEM), relapsing ON, and AQP4-Ab–associated demyelination and neuromyelitis optica spectrum disorder (NMOSD). Relapsing disease is often characterized by gradual accrual of physical disability and cognitive impairment.

Visit Elsevier eBooks+ at eBooks.Health.Elsevier.com for Bibliography.

Table 640.1 Acute Demyelinating Disorders of the Central Nervous System

DISORDER	DEFINITION
Acute disseminated encephalomyelitis (ADEM)	A first polyfocal CNS event with presumed inflammatory cause Encephalopathy present that cannot be explained by fever MRI often showing bilateral diffuse, poorly demarcated T2 lesions No new symptoms, signs, or MRI findings after initial 3 mo
Multiphasic ADEM	New event of ADEM 3 mo or more after the initial event that can be associated with new or reemerging clinical and MRI findings Frequently associated with the presence of MOG-Ab
Clinically isolated syndrome (CIS)	A first monofocal or multifocal CNS demyelinating event Encephalopathy is absent, unless caused by fever
Multiple sclerosis (MS)	MS can be diagnosed in those for whom there is **no better explanation** if both dissemination in time (DIT) and dissemination in space (DIS) can be demonstrated. DIS Demonstrated by one or more T2 lesions affecting at least two of the following CNS sites: • Periventricular • Juxtacortical or cortical • Infratentorial • Spinal cord DIT Demonstrated by one of the following: • Simultaneous presence on MRI of one or more gadolinium-enhancing lesions AND one or more nonenhancing lesions • CSF oligoclonal bands • Follow-up MRI (>30 days from previous scan) with one or more new enhanced OR nonenhanced lesions • Two or more acute episodes typical of MS each lasting >24 hr and at least 30 days apart
Primary progressive MS (PPMS)	PPMS is exceedingly rare in childhood, and therefore in cases of suspected PPMS, or diagnostic uncertainty, specialist advice should be obtained. Biopsy and/or further genetic investigation may be appropriate to rule out mimics.
MOG-Ab–associated demyelination	MDEM: recurrent ADEM (see earlier) ADEM-ON: ADEM or MDEM followed by optic neuritis (ON) NMOSD: ON and acute transverse myelitis (ATM), either sequentially or simultaneously Relapsing inflammatory ON (RION) Brainstem demyelination: recurrent episodes of demyelination often involving the posterior fossa and brainstem
Neuromyelitis optica spectrum disorder (NMOSD)	If AQP4–positive, one of the following core criteria is required: • Optic neuritis • Acute myelitis • Area postrema syndrome (nausea, vomiting, hiccups) • Acute brainstem syndrome • Narcolepsy, acute diencephalic syndrome with MRI lesions • Symptomatic cerebral syndrome with MRI lesions If AQP4-negative or unavailable, two core criteria and all the following: 1. At least one core criteria must be optic neuritis, longitudinally extensive TM, or area postrema syndrome 2. Dissemination in space (≥2 different core criteria) 3. Exclusion of alternative diagnoses If Mog-Ab–positive with both ON and TM, then MOG + NMOSD may be diagnosed

640.1 Acute Disseminated Encephalomyelitis

Michael Perry and Cheryl Hemingway

Acute disseminated encephalomyelitis is an inflammatory, demyelinating event of early childhood presenting with acute-onset *polyfocal* neurologic deficits, accompanied by *encephalopathy* and MRI changes consistent with demyelination (see Table 640.1).

EPIDEMIOLOGY

Although ADEM can occur at any age, most studies report a mean age between 5 and 8 years with a slight male predominance and an incidence of 0.1-0.6 per 100,000 children per year. ADEM is usually *monophasic*, but recurrence can occur; this is termed **multiphasic disseminated encephalomyelitis (MDEM)** if the recurrence is 3 months or longer after the incident episode. Approximately 50% of ADEM cases are associated with serum MOG-Ab positivity (MOGAD) (see Chapter 640.5). MDEM patients are almost exclusively MOG-Ab positive. An episode of ADEM can also be followed by non-ADEM demyelination in a new location. If ADEM is followed by a relapse in a specific location, such as the optic nerve, then **ADEM-ON** is diagnosed. If the optic nerve and spinal cord are involved, then **NMOSD** (see Table 640.1) is diagnosed. Both ADEM-ON and NMOSD are associated with MOG-Ab positivity.

PATHOGENESIS

Molecular mimicry induced by infectious exposure has long been thought to trigger the production of CNS autoantigens, though causality has never been proven. Many patients experience a transient febrile

illness in the month before ADEM onset. Preceding infections associated with ADEM include influenza, Epstein-Barr virus (EBV), cytomegalovirus, varicella, enterovirus, measles, mumps, rubella, herpes simplex, *Mycoplasma pneumoniae,* and COVID-19.

Table 640.2 Differential Diagnosis of Demyelinating Disorders

Multifocal white matter lesions	Demyelination (e.g., ADEM, MS, CIS, NMOSD, AHL) Autoantibody (e.g., NMDAR-Ab, Hashimoto encephalopathy) Migraine Prior insult and residual gliosis (e.g., congenital infections or hypoxic damage) Primary and secondary vasculitides (e.g., primary angiitis of the CNS, neurosarcoidosis, SLE, Behçet syndrome, scleroderma) Mitochondrial (e.g., Leber hereditary optic neuropathy [LHON], POLG) Leukoencephalopathy (e.g., DARS) X-linked Charcot-Marie-Tooth disease
Bilateral or diffuse white matter lesions	Leukodystrophy (e.g., X-linked adrenoleukodystrophy, Alexander disease, metachromatic LD, Krabbe disease) Leukoencephalopathy (e.g., Aicardi-Goutières syndrome) Mitochondrial (e.g., LHON, Leigh disease, MELAS, MERFF) Infection Tumor (e.g., gliomatosis cerebri, astrocytoma, lymphoma) Hemophagocytic lymphohistiocytosis (HLH)
Deep gray, thalamic, and striatal lesions	Infection (e.g., mycoplasma, Epstein-Barr virus, West Nile virus, Japanese B encephalitis, enterovirus) Biotin-responsive basal ganglia disease (e.g., *SLC19A3*) Acute necrotizing encephalopathy (ANE) and *RANBP2* pathogenic variant

CLINICAL MANIFESTATIONS

Initial symptoms of ADEM may include lethargy, fever, headache, vomiting, meningeal signs, and seizures, including status epilepticus. Encephalopathy is the hallmark of ADEM. It can range from behavioral change and persistent irritability to coma. Common neurologic signs include visual loss, ataxia, motor and sensory deficits, and cranial neuropathies. In cases with concurrent spinal cord involvement, bladder/bowel dysfunction may be seen. Focal neurologic deficits, however, can be difficult to ascertain in the obtunded or very young child. The clinical course is usually rapidly progressive over days, and intensive care may be required, particularly for patients with brainstem dysfunction or raised intracranial pressure.

NEUROIMAGING

Brain MRI typically shows large (sometimes confluent), bilateral, multifocal, edematous, masslike T2 lesions of the cerebral hemispheres, cerebellum, and brainstem. Deep gray matter structures (e.g., thalami, basal ganglia) are often involved (Figs. 640.1 and 640.2). Contrast enhancement is variable. The spinal cord may have an abnormal T2 signal or enhancement, with or without clinical signs of myelitis. ADEM lesions will typically appear to be of similar age on MRI, but their evolution often lags the clinical presentation. Serial MRI imaging 3-12 months after ADEM frequently demonstrates near-complete resolution of T2 abnormalities, though residual gliosis may remain.

Severe involvement may progress to an **acute hemorrhagic leukoencephalopathy** (Weston-Hurst disease). This leukodystrophy-like picture is characterized by large lesions, edema with mass affect, and a polymorphonucleated cell pleocytosis; this contrasts with the CSF lymphocytic pleocytosis typically noted in ADEM.

LABORATORY FINDINGS

There is no biologic marker for ADEM, and laboratory findings can vary widely. CSF studies are often normal or can exhibit pleocytosis with lymphocytic or monocytic predominance. CSF protein can be elevated, especially on repeat studies. Elevated CSF immunoglobulin production can be present, but true OCB positivity is rare. Electroencephalograms often show generalized slowing, consistent with encephalopathy. Polyregional demyelination of ADEM can also cause focal slowing or epileptiform discharges.

Table 640.3 MR Imaging Red Flags for the Diagnosis of Children with Acquired Demyelinating Syndromes

LEPTOMENINGEAL ENHANCEMENT	SVcPACNS Infection Tumor HLH	Leptomeningeal enhancement is not a feature of MS in adults; it has emerged as a red flag for vasculitic or malignant processes in the pediatric cohort.
LESION EXPANSION	Tumor Lymphoma PML Sarcoidosis	Increased size of T2 lesions on serial imaging is well recognized in MS, although this should always prompt consideration of malignancy. Increasing size of a white matter–predominant lesion without lesion enhancement in a patient treated with immunosuppressant therapy (or a patient with known HIV) should prompt consideration of PML. PML is a risk for MS patients exposed to more intense immunosuppressive therapies.
HEMORRHAGE	ANE Stroke Cerebellitis AHLE Large-vessel CNS vasculitis SVcPACNS	Although susceptibility-weighted imaging reveals tiny microfoci of hemosiderin in MS patients, hemorrhage large enough to be visible on conventional MRI sequences is not a feature of ADS or MS and should prompt consideration of disorders in which the cerebral vasculature is specifically involved.

ADS, Acquired demyelinating syndrome; AHLE, acute hemorrhagic leukoencephalitis; CNS, central nervous system; HIV, human immunodeficiency virus; HLH, hemophagocytic lymphohistiocytosis; MS, multiple sclerosis; PML, progressive multifocal leukoencephalopathy; SVcPACNS, small-vessel childhood primary angiitis of the central nervous system.
From O'Mahony J, Shroff M, Banwell B. Mimics and rare presentations of pediatric demyelination. *Neuroimaging Clin North Am.* 2013;23:321–336, Table 2.

DIFFERENTIAL DIAGNOSIS

ADEM is a clinical diagnosis supported by MRI, CSF, and serum findings. The differential diagnoses for ADEM are broad; empirical antibiotic and antiviral treatment should be considered while infectious evaluations are pending. Follow-up MRI examinations 3-12 months after typical ADEM should show improvement; new or enlarging T2 lesions should prompt reevaluation for other etiologies such as MS, antibody-associated disorders, leukodystrophies, tumor, vasculitis, mitochondrial, metabolic, or rheumatologic disorders (Table 640.4 and see Tables 640.1-640.3).

TREATMENT

High-dose intravenous steroids are often prescribed (most commonly methylprednisolone 20-30 mg/kg/day for 5 days with a maximum dose of 1,000 mg/day) followed by an oral prednisolone taper of 1-2 mg/kg/day (maximum 40-60 mg/day) over 4-6 weeks. In *refractory* or *severe* cases, additional treatment options include intravenous immunoglobulin (2 g/kg administered over 2-5 days) or plasmapheresis (5-7 exchanges administered every other day). There is no consensus about the timing of these treatments for ADEM.

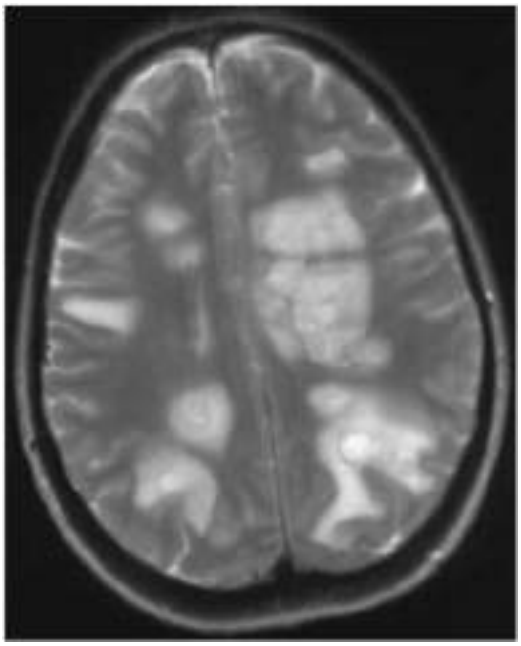

Fig. 640.1 6-year-old patient diagnosed with ADEM presenting with encephalopathy, ataxia, and motor deficits after mild viral infection. Axial T2-weighted MRI shows bilateral, diffuse, poorly demarcated lesions. Gray matter involvement, including the thalamus and basal ganglia, is commonly seen.

PROGNOSIS

Most children experience full motor recovery after ADEM, but residual deficits can be seen. Cognitive impairment or behavioral changes are not uncommon. Recovery starts within days to weeks, but symptoms can fluctuate throughout the course.

Visit Elsevier eBooks+ at eBooks.Health.Elsevier.com for Bibliography.

640.2 Optic Neuritis

Michael Perry and Cheryl Hemingway

Optic neuritis (ON) is inflammation of one or both optic nerves. It presents with visual dysfunction. ON can occur in three phenotypes: (1) as a clinically isolated monophasic syndrome; (2) recurrently in isolation; or (3) as part of other multifocal systemic or CNS-specific inflammatory conditions such as ADEM, MS, or antibody-associated demyelination (e.g., AQP-4-Ab NMOSD or MOGAD).

EPIDEMIOLOGY AND CLINICAL PRESENTATION

ON is one of the most common of the acquired demyelinating syndromes, accounting for ~25% of all demyelinating presentations in childhood. The typical presentation is unilateral or bilateral visual loss over hours to days with abnormal color vision (typically red-green desaturation), visual field loss, and sometimes a relative afferent pupillary defect. The visual loss is often severe, with most children at 20/200 visual acuity (VA) or worse. Periocular pain and painful eye movements (often reported as headache in young children) are common. Bilateral ON is more common in younger children and frequently associated with MOG-Ab disease. Unilateral ON is more common in older children and more likely to be associated with MS. Funduscopic examination in over half of children reveals acute optic nerve head swelling (papillitis). However, when the inflammation occurs in the retrobulbar optic nerve portion, the appearance of the optic nerve may be normal. Optic nerve pallor is more often noted in the chronic stage after an initial episode or in those with relapsing ON. Bilateral ON, longitudinally extensive (>50% of the optic nerve), perineural optic sheath enhancement (perineuritis), and optic disc edema are features suggestive of ON caused by MOG-Ab disease. ON without papillitis and that involves the optic chiasm or tract is more typical of AQP4-Ab (NMOSD) disease.

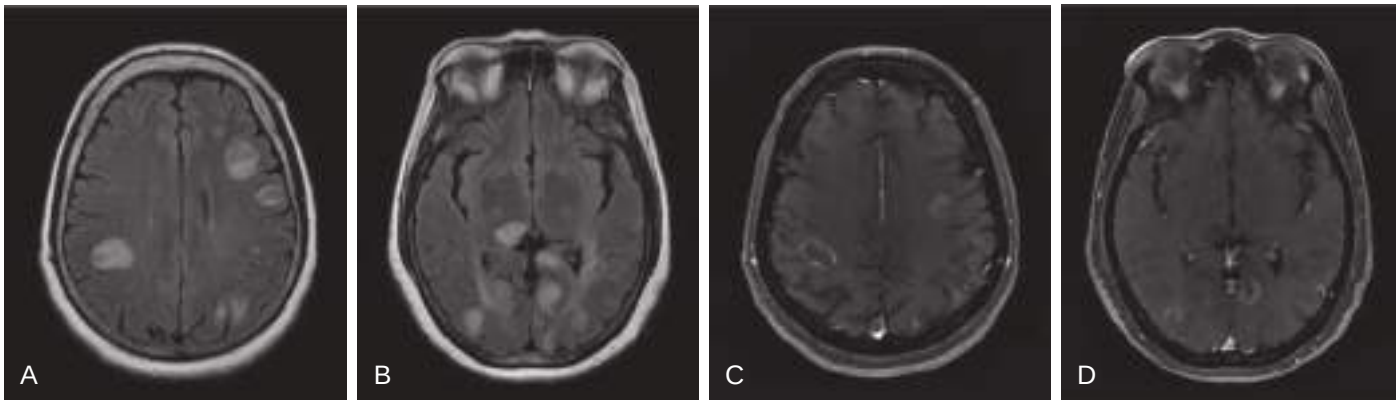

Fig. 640.2 Acute disseminated encephalomyelitis (ADEM). **A** and **B**, T2-weighted FLAIR images show numerous asymmetric, rounded, hyperintense, predominantly subcortical white matter lesions. Some lesions involve the cortex. A right pulvinar lesion is also seen. **C** and **D**, Postcontrast T1-weighted image demonstrates incomplete ring enhancement associated with these lesions. All the lesions show similar imaging features. Marked improvement was seen after steroid therapy. *(From Lerner A, Rajamohan A, Shiroishi MS, et al. Cerebral infections and inflammation. In: Haaga JR, Boll DT, eds. CT and MRI of the Whole Body, 6th ed. Philadelphia: Elsevier; 2017: Fig. 10-15, p. 280.)*

Table 640.4 Features that May Distinguish ADEM from a First Attack of MS

	ADEM WITH OR WITHOUT MOG-AB	MS
Age and sex	<10 yr Males and females equal	>10 yr Female preponderance
Seizures	+	–
Encephalopathy	+ /+/– for MOG-Ab	–
Fever/vomiting	+	–
Family history	No	20%
Optic neuritis	Bilateral	Unilateral
Manifestations	Polysymptomatic	Monosymptomatic
CSF	Pleocytosis (lymphocytosis) OCBs negative	Acellular OCBs positive
MRI	Large, fluffy, poorly demarcated T2 lesions involving white and gray matter	Ovoid T2 lesions involving juxtacortical, periventricular, or infratentorial areas or spinal lesions; T1 hypointense lesions
MRI follow-up after 30 days	No new lesions	New lesions seen

+, More likely to be present; –, less likely to be present; ADEM, acute disseminated encephalomyelitis; CSF, cerebrospinal fluid; MS, multiple sclerosis; MOG-Ab, myelin oligodendrocyte glycoprotein antibody; OCBs, oligoclonal bands.

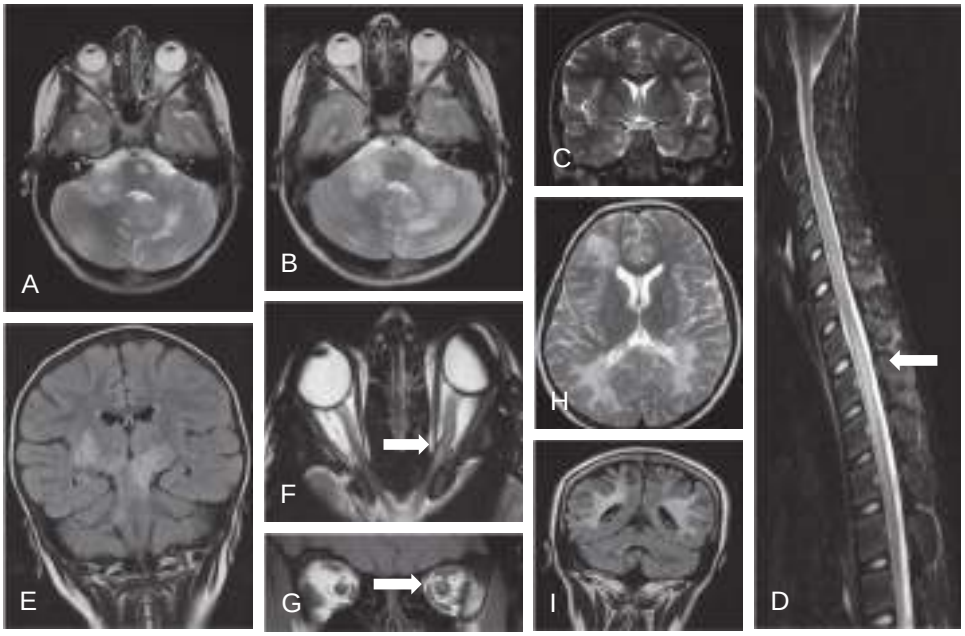

Fig. 640.3 MRI images highlighting the spectrum of possible phenotypes in relapsing myelin oligodendrocyte glycoprotein (MOG) antibody–associated disorders. **A,** Axial T2-weighted FLAIR MRI of brain from a 6-yr-old female with bilateral ON, ataxia, and lethargy, initially diagnosed with ADEM until her relapse (**B**) with further multiple brainstem lesions associated with MOG-Ab positivity. **C,** Coronal T2-weighted MRI with longitudinally extensive ON with both pre- and post-chiasm involvement and (**D**) sagittal MRI of spine with longitudinally extensive TM from a 9-yr-old female diagnosed with MOG-Ab–associated NMOSD after simultaneous presentation of bilateral visual impairment and paraparesis requiring ventilatory support. **E,** T2-weighted FLAIR MRI of brain demonstrating asymmetric, bilateral, poorly defined lesion involving the brainstem and extending into the middle cerebellar peduncle. **F** and **G,** Orbital MRI shows a thickened left optic nerve in a 13-yr-old female with recurrent left ON associated with positive MOG-Ab. **H,** Axial T2-weighted image shows diffuse, bilateral, asymmetric leukodystrophy-like phenotype associated with MOG-Ab. **I,** Coronal T2-weighted FLAIR MRI of brain similarly showing the leukodystrophy-like appearance seen over time in those with young-onset relapsing MOG-Ab–associated demyelination.

DIAGNOSTIC EVALUATION

MRI, optical coherence tomography (OCT), and visual evoked potentials (VEPs) are useful for evaluating and quantifying the functional and structural integrity of the optic nerve of a child with suspected ON.

Orbital MRI is useful but not required for a diagnosis of ON. Though sometimes normal, it will usually show optic nerve thickening on T1-weighted images with T2 hyperintensities and contrast enhancement. (Fig. 640.3F, G). Longitudinally extensive ON involving the chiasm is thought to be more commonly associated with antibody-mediated demyelination (see Fig. 640.3C). **Optical coherence tomography** can detect structural neuronal and retinal change, such as retinal nerve fiber layer (RNFL) thinning and may be helpful in monitoring the young child experiencing recurrent disease. In acute ON, VEPs may detect prolonged latency. VEPs in children may also detect clinically silent episodes of ON in the seemingly unaffected contralateral eye.

CSF OCB analysis is not always indicated; however, in the context of a normal MRI brain scan, negative OCBs predict a very low risk of subsequent MS development.

Many conditions can both mimic and be associated with ON. Therefore although a detailed ophthalmologic review is essential, other investigations must be carefully considered to exclude systemic rheumatologic disorders (e.g., systemic lupus erythematosus [SLE], sarcoidosis, celiac disease, Behçet disease), infectious diseases (viral disease, Lyme disease, syphilis, tuberculosis), mitochondrial disorders (e.g., Leber hereditary optic neuropathy), vascular events, toxic (methanol, ethylene, glycol, chloroquine, hydroxychloroquine), nutritional (folate, vitamin B12, copper deficiencies), or metabolic disorders, and optic nerve sheath meningioma or optic nerve glioma. Antibody testing in serum with live cell-based assays (CBAs) for both AQP4-Ab and MOG-Ab is recommended to ensure that prophylactic treatment can be provided if indicated (e.g., AQP4-Ab positive) or to provide counseling on the risk of recurrence (MOG-Ab positivity).

TREATMENT

The standard of care is based on expert clinical opinion and adult trials and typically includes high-dose intravenous steroids (e.g., methylprednisolone 20-30 mg/kg/day for 3-5 days, maximum 1000 mg/day). In adults, steroid administration leads to faster recovery, but with no difference in long-term visual outcome. As with other severe episodes of demyelination, further treatment options include intravenous immunoglobulin (usually 2 g/kg administered over 2-5 days) or plasmapheresis (typically 5-7 exchanges administered every other day); there is neither definitive trial evidence of their benefit nor consensus about when to use them in isolated ON. Trials in adults have concentrated on neuroprotection; phenytoin has a beneficial effect on RNFL thinning in acute ON.

The initiation of chronic immunotherapy is dependent on etiology, the presence or absence of glial antibodies (e.g., MOG-Ab), and risk of relapse (i.e., ON caused by AQP4 +NMOSD) and is best considered by a multidisciplinary team experienced in the treatment of pediatric neuroinflammatory disorders.

PROGNOSIS

Although it is reassuring that full recovery of high-contrast visual acuity (HCVA) does usually occur in children, irreversible damage is often detected in the structural integrity of affected optic nerves. This may be evidenced by RNFL thinning on OCT, defective color vision, and impairments in low-contrast visual acuity (LCVA). Pediatric patients with AQP4-antibody–associated optic nerve demyelination are more commonly left with long-term visual disability than patients with other causes of ON.

Visit Elsevier eBooks+ at eBooks.Health.Elsevier.com for Bibliography.

640.3 Transverse Myelitis

Michael Perry and Cheryl Hemingway

Transverse myelitis (TM) is a condition characterized by the rapid development of both motor and sensory deficits of the spinal cord. It presents acutely as either partial or complete cord involvement at any level with bilateral neurologic signs; in adults and older children, there will usually be a clear sensory level. TM has multiple causes (Tables 640.5 and 640.6). It can be secondary to an immune-mediated condition (postinfectious or antibody-driven), a result of direct infection (e.g., infectious myelitis), or idiopathic. In TM, evidence of spinal cord inflammation can be demonstrated by an enhancing lesion on MRI, CSF pleocytosis (>10 cells), or an increased IgG index. The progression is rapid. Time to maximal disability typically occurs 5-6 days after symptom onset.

EPIDEMIOLOGY

TM is more common in adults but is estimated to affect ~2 children/million per year. A bimodal age distribution is observed in those younger than 5 years and older than 10 years. Children less than 5 years of age develop spinal cord dysfunction over hours to a few days. They often have a history of an infectious disease (e.g., viral or mycoplasma) in the weeks preceding development of neurologic symptoms. The motor dysfunction is often severe, approaching a complete loss of function. Recovery is slow (weeks to months) and usually incomplete, most commonly with residual bowel and bladder dysfunction (15–50%). Pathologic findings of perivascular infiltration with mononuclear cells suggest an infectious or inflammatory basis. Overt necrosis of the spinal cord may occur.

The syndrome may differ in older children, and outcomes vary by etiology. Although the onset is also rapid, recovery is faster and more

Table 640.5 Reported Cases of Transverse Myelitis

1. Acquired demyelinating disorders
   a. Multiple sclerosis
   b. NMO
   c. ADEM
   d. MOGAD
2. Systemic inflammatory autoimmune disorders
   a. SLE
   b. SS
   c. Antiphospholipid syndrome
   d. Behçet disease
   e. Vogt-Koyanagi-Harada disease
   f. Ankylosing spondylitis
   g. Mixed connective tissue disease
   h. Others: systemic sclerosis, anti-Jo-1 antibody, urticarial vasculitis, psoriatic arthritis, perinuclear ANCA systemic vasculitis, graft-versus-host disease, common variable immunodeficiency, celiac disease
3. Neurosarcoidosis
4. Parainfectious TM
   a. Viral: hepatitis A, hepatitis B, hepatitis C, hepatitis E, measles, mumps, rubella, varicella zoster, Epstein-Barr, cytomegalovirus, herpes simplex, influenza A/B, lymphocytic choriomeningitis virus, chikungunya, hantavirus, HIV, human T-cell lymphotropic virus, human herpes virus 6, Japanese encephalitis, Murray Valley encephalitis, St. Louis encephalitis, tickborne encephalitis, vaccinia, Rocky Mountain spotted fever, dengue virus, enterovirus 71, coxsackievirus A and B, West Nile virus, parvovirus B19, human corona virus, and echovirus
   b. Bacterial: *Mycoplasma pneumoniae, Campylobacter jejuni, Borrelia burgdorferi, Acinetobacter baumannii, Coxiella burnetii, Bartonella henselae, Chlamydia psittaci, Leptospira, Chlamydia pneumoniae*, Legionella pneumonia, *Orientia tsutsugamushi* (scrub typhus), *Salmonella* paratyphi B, *Mycobacterium tuberculosis, Treponema pallidum, Brucellosis melitensis*, and groups A and B streptococci
   c. Fungal: *Actinomyces, Blastomyces, Coccidioides, Aspergillus, Cryptococcus*, and *Cladophialophora bantiana*
   d. Parasitic: *Toxocara* species, *Schistosoma* species, *Gnathostoma spinigerum, Echinococcus granulosus, Taenia solium, Toxoplasma gondii, Acanthamoeba* species, *Paragonimus westermani*, and *Trypanosoma brucei*
5. Paraneoplastic syndromes
   a. Anti-Ri (ANNA-2) antibody
   b. CRMP-5-IgG antibody
   c. Anti-amphiphysin IgG antibody
   d. Anti-GAD65 antibody
   e. NMDAR antibody
6. Atopic myelitis
7. Drugs and toxins
   a. Tumor necrosis factor-alpha inhibitors
   b. Sulfasalazine
   c. Epidural anesthesia
   d. Chemotherapeutic agents: gemcitabine, cytarabine, cisplatin
   e. Heroin
   f. Benzene
   g. Brown recluse spider toxin
8. Idiopathic TM

MOGAD, MOG antibody disease.
From Beh SC, Greenberg BM, Frohman T, et al. Transverse myelitis. *Neurol Clin.* 2013;31:79–138, Box 5, p. 88–89.

Table 640.6 Mimics of Transverse Myelitis

ETIOLOGY	DESCRIPTION
Vitamin B_{12} deficiency	May present as an isolated myelopathy or in combination with neuropathy, encephalopathy, and/or behavioral changes. Dorsal column impairment is the most common manifestation, followed by pyramidal dysfunction (the classic subacute combined degeneration of the cord). Hematologic manifestations may be absent in up to 30% of patients with neurologic manifestations. MRI reveals T2-hyperintense signal in the posterior columns (the "inverted V" or "inverted rabbit ear" sign on axial views). In severe cases, MRI shows the "anchor" sign (because of involvement of the posterior, anterior, and pyramidal tracts).
Vitamin E deficiency	May cause a predominantly dorsal column syndrome associated with a peripheral neuropathy because of axonal degeneration. Preferentially affects the cervical cord. Clinically and radiologically similar to B_{12} deficiency.
Copper deficiency	May cause both myelopathy and optic neuropathy. Causes of acquired copper deficiency include malnutrition, zinc toxicity, Menke disease, bariatric surgery, gastrectomy, malabsorption syndromes, and use of copper chelating agents. Clinically and radiologically indistinguishable from B_{12} deficiency.
Nitrous oxide (N_2O) toxicity	Analgesic gas commonly abused because of euphoric effects. N_2O inactivates vitamin B_{12} by irreversible oxidation of the cobalt center of methylcobalamin, thereby inhibiting the methionine synthesis pathway. In healthy subjects, this does not cause clinical manifestations. In subclinically B_{12}-deficient individuals, N_2O exhausts residual stocks of vitamin B_{12}, leading to neurologic manifestations.
Neurolathyrism and neurocassivism	Neurolathyrism is caused by consumption of grass pea. Neurocassivism (konzo) is caused by bitter cassava root consumption. Both are found in malnourished populations and are characterized by subacute paraparesis with prominent UMN features.
Intramedullary primary spinal cord tumors	May be ependymomas, astrocytomas, or hemangioblastomas. Typically cause an insidious, progressive myelopathy. Hemorrhage or infarction of the tumor may result in an acute presentation and radiologic appearance mimicking TM.
Primary CNS lymphoma	May give rise to a clinical and radiologic picture mimicking TM compounded by its corticosteroid responsiveness. Congenital or acquired immunodeficiency is the only established risk factor. More common in middle-age and older men. Insidious onset of myelopathy with back pain and constitutional symptoms. Serum lactate dehydrogenase may be elevated. CSF: lymphocytic pleocytosis, markedly elevated protein, and hypoglycorrhachia. OCBs and IgG index are absent. Cytologic analysis may demonstrate malignant cells (large-volume CSF examination can increase the diagnostic yield). MRI: T2 hyperintensity, gadolinium enhancement, cord swelling, conus medullaris involvement, and concomitant brain lesions.
Intravascular lymphoma	Predominantly affects vessels in the skin and neurologic system. May mimic TM and even LETM. CSF: lymphocytic pleocytosis and increased protein, but no malignant cells. MRI: affects the conus medullaris (unlike TM).
Radiation myelitis	Early radiation myelopathy: begins 10-16 wk after starting radiotherapy with predominantly sensory phenomena (including Lhermitte sign) and typically resolves spontaneously. Delayed radiation myelopathy: begins months or years after radiation exposure and manifests as a subacute or insidious myelopathy. Concurrent use of chemotherapeutic agents may cause widespread white matter necrosis owing to synergistic toxicity. Preexisting myelopathy from any cause may be risk factors for radiation myelitis. MRI: cord swelling on T1-weighted images, intramedullary T2 hyperintensity, ringlike gadolinium enhancement.

CNS, Central nervous system; CSF, cerebrospinal fluid; Ig, immunoglobulin; LETM, longitudinally extensive transverse myelitis; MRI, magnetic resonance imaging; OCB, oligoclonal bands; TM, transverse myelitis; UMN, upper motor neuron.
Modified from Beh SC, Greenberg BM, Frohman T, et al. Transverse myelitis. *Neurol Clin*. 2013;31:79–138, Table 10, p. 102–103.

likely to be complete. Necrosis and irreversible injury may occur in a small but important number of cases. Potentially associated underlying etiologies include systemic vasculitic entities (e.g., SLE), antibody-mediated CNS disorders (e.g., AQP4-Ab– or MOG-Ab–associated NMOSD), infectious etiologies (e.g., mycoplasma, enterovirus), or idiopathic disease. Pathology and imaging studies show acute inflammation with demyelination in some cases.

Acute Flaccid Myelitis

Acute flaccid myelitis (AFM) is an idiopathic neurologic disorder presenting with acute weakness and/or paralysis in previously healthy children. It is predominantly of infectious etiology. Although many viruses have been implicated, the recent biennial outbreaks since 2014 are likely to have been caused by enterovirus-D68. Abnormalities are often seen in the lower motor neurons of the anterior horn gray matter

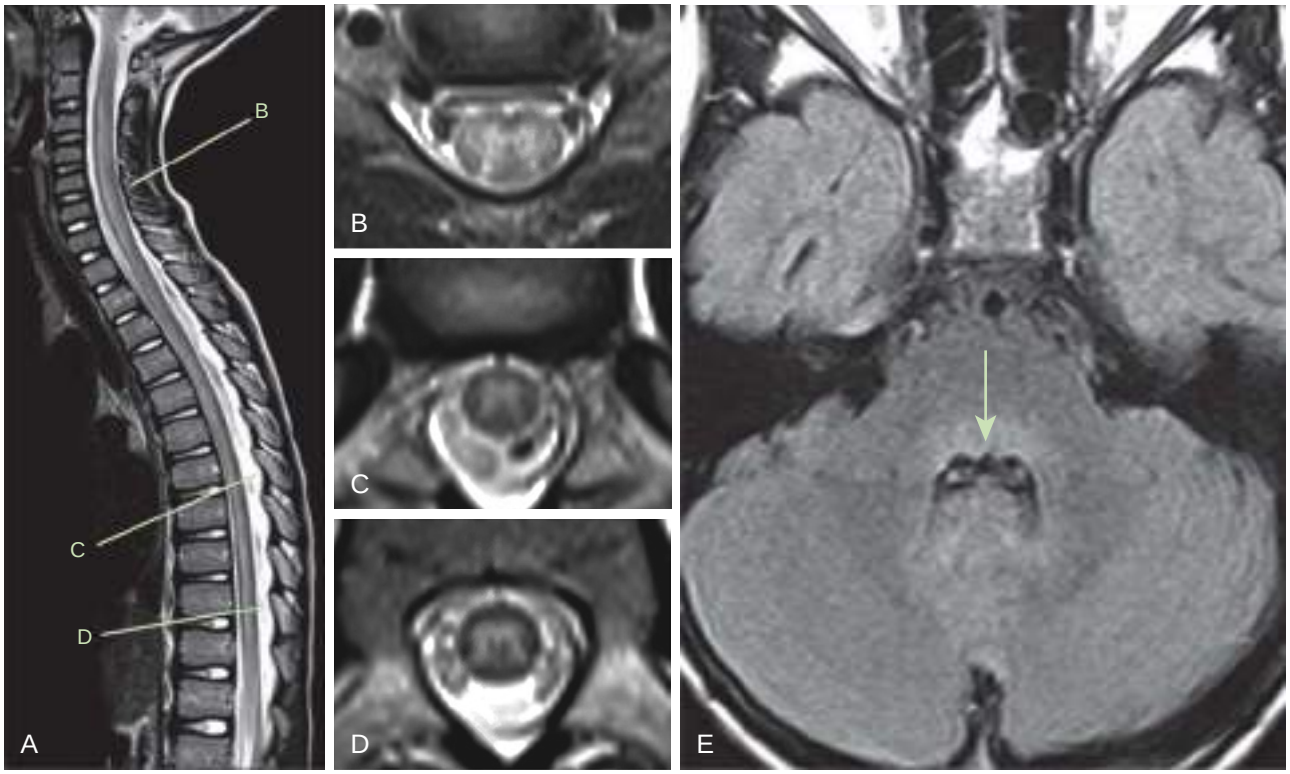

Fig. 640.4 Typical MRI findings in the acute phase of AFM. Spinal MRIs are shown of an 8-yr-old child with AFM, acquired 24 hr after onset of neurologic symptoms. **A,** Sagittal T2-weighted image showing an ill-defined, longitudinally extensive central/anterior spinal cord lesion. **B,** Axial T2-weighted image from C5–C6 shows hyperintensity of the entire gray matter of the spinal cord, with associated edema and some surrounding white matter hyperintensity. **C,** Axial T2-weighted image from T7 shows asymmetric hyperintensity of the gray matter (right more than left). **D,** Axial T2-weighted image from T10 shows hyperintensity of the entire gray matter. **E,** Axial FLAIR image at the level of the middle cerebellar peduncle demonstrates hyperintensity of the dorsal pons *(arrow).* AFM, acute flaccid myelitis. *(From Murphy OC, Messacar K, Benson L, et al. Acute flaccid myelitis: cause, diagnosis, and management. Lancet. 2021;397:334–344, Fig. 1, p. 338.)*

(Fig. 640.4). Symptoms can progress rapidly; paralysis is often asymmetric and is not usually accompanied by a sensory deficit; cranial nerve involvement may include facial weakness, dysarthria, and dysphagia (Table 640.7).

In the United States, AFP is considered a generalized "umbrella" term for multiple clinical entities, including paralytic poliomyelitis, transverse myelitis, AFM, Guillain-Barré syndrome, toxic neuropathy, and muscle disorders. Essentially, this grouping helps with case ascertainment of AFM, but the individual diagnoses still remain important because each has its own differential diagnoses to consider.

A pragmatic case definition of AFP is "a clinical syndrome with rapid onset of weakness that frequently involves the respiratory and bulbar muscles." Whenever these criteria are met and poliomyelitis is a possibility, thorough investigation and reporting of potential poliomyelitis is required. Two diagnostic stool samples more than 24 hours apart should be collected within 14 days of onset of paralysis and then processed in a World Health Organization–approved laboratory. If poliomyelitis is confirmed, it may be caused by *wild poliovirus* (serotypes 1-3) or *vaccine-associated paralytic poliomyelitis*, and it will need full epidemiologic investigation. In the individual patient, disease progression with paralysis (with sensory preservation) is rapid, asymmetrical, and involves proximal more than distal muscles.

Other potential viral causes of AFP include coxsackie and echoviruses, Japanese B encephalitis, Murray Valley encephalitis, St. Louis encephalitis, and Russian spring encephalitis, tickborne viruses, and herpes virus. These causes vary by geography with, for example, EV-A71 being the cause in parts of Southeast Asia and West Nile virus being a cause in the United States. Therefore consider the following investigations for possible viral causes of AFP, as well as other conditions in the differential diagnosis:

- Imaging with MRI of the spine (and possibly brain)
- CSF sampling for differential cell counts, glucose, and protein; microbiology and diagnostic polymerase chain reaction (PCR) testing for enteroviruses and other infectious diseases; and for autoantibodies such as anti–myelin oligodendrocyte glycoprotein (anti-MOG, see later)
- Respiratory/nasopharyngeal secretion samples for viral PCR testing (e.g., enterovirus)
- Peripheral neurophysiology with nerve conduction studies (NCS) if differentiation from GBS is needed or botulism is suspected
- Studies for identification of possible metabolic disease (e.g., acute hypokalemic periodic paralysis, thyrotoxic periodic paralysis, acute intermittent porphyria) and/or toxin exposures (e.g., sporadic hypokalemic paralysis secondary to licorice, barium, or cottonseed oil exposure)
- Investigations to exclude paralytic syndromes that mimic or are misdiagnosed as AFP, such as vitamin B_{12} deficiency, which may be exacerbated by chronic cycad poisoning from evergreens, cyanide toxicity from cassava ingestion, and lathyrism.

CLINICAL MANIFESTATIONS OF TM

TM is often preceded within the previous 1-3 weeks by a mild nonspecific illness or minimal trauma. Discomfort or overt pain in the neck or back is common. Depending on its severity, the condition progresses to numbness, anesthesia, ataxia, areflexia, and motor weakness in the truncal and appendicular musculature at or distal to the lesion. Paralysis begins as flaccidity (paraparesis, tetraparesis). Spasticity then develops over weeks, accompanied by hyperreflexia and clonus. Weakness may rarely be unilateral, but usually such a finding suggests a hemicord lesion, which is most often associated with MS (particularly in adolescence). Urinary retention is a common early symptom; incontinence occurs later in the course. Early sensory findings may be isolated to the posterior column, necessitating evaluation of vibratory sensation. Progressive sensory loss may manifest as anesthesia, paresthesia, or

Table 640.7 Diagnostic Criteria for AFM

Diagnostic items	Definite	Probable	Possible	Uncertain
H1: Acute onset of limb(s) weakness (period from onset to nadir: hours to 10 days)	P	P	P*	P
H2: Prodromal fever or illness†	P/A	P/A	P/A	P
E1: Weakness involving one or more limbs, neck, face, or cranial nerves	P	P	P*	P
E2: Decreased muscle tone in at least one weak limb	P	P	P/A	P
E3: Decreased or absent deep tendon reflexes in at least one weak limb‡	P	P	P/A	P
MRI: Spinal cord lesion with predominant gray matter involvement, with or without nerve root enhancement§	P	P	P	ND
CSF: Pleocytosis (white cell count >5 cells/L)¶	P	A or ND	P/A or ND	P/A or ND

Factors that might suggest an alternative diagnosis

1. Encephalopathy that cannot be explained by fever, illness, respiratory distress, metabolic abnormalities, or medications
2. Presence of sensory deficits on examination‖
3. Presence of lesions in supratentorial white matter or cortex, which should prompt consideration of ADEM, MOG-antibody associated disease, neuromyelitis optica spectrum disorder, encephalomyelitis, and others
4. Absence of CSF pleocytosis, which should prompt consideration of Guillain-Barré syndrome, botulism, ischemic cord lesions, and others
5. Positive serum aquaporin-4 (AQP-4) antibody, which would exclude AFM
6. Positive serum MOG antibody, which would suggest MOG-antibody associated disease‖

From Murphy OC, Messacar K, Benson L, et al. Acute flaccid myelitis: cause, diagnosis, and management. *Lancet.* 2021;397:334–344, Fig. 2, p. 339.

allodynia. Other potential findings include priapism, respiratory compromise, and spinal shock with subsequent autonomic dysreflexia. Rarely an overlap syndrome of TM with features of Guillain-Barré syndrome may occur.

DIAGNOSTIC EVALUATION

TM is a diagnosis of exclusion, and a thorough evaluation should be completed in all cases. The differential diagnoses include, among others, Guillain-Barré syndrome, demyelinating disorders, systemic rheumatologic conditions, meningitis, infectious myelitis, spinal cord infarction, arteriovenous malformations, trauma, mass lesions, bony and intervertebral disk distortion, abscess, and tumors of the spine and spinal cord (see Tables 640.5 and 640.6).

MRI with and without contrast enhancement is essential to rule out a mass lesion. T1-weighted images of the spine at the anatomic level of involvement may be normal or show spinal cord distension. In the infantile form, T2-weighted images show high signal intensity over multiple spinal segments. In the adolescent form, the high signal is often centrally located and involves both gray and white matter. It may be limited to one or two segments but is frequently more extensive. A limited degree of gadolinium contrast enhancement is expected (especially in the infantile form) and is indicative of an inflammatory condition. Cervical and cervicothoracic lesions represent most acute TM lesions. Axial cuts of the spinal cord are invaluable and can help to establish potential etiologies. Hemicord involvement may indicate MS. Holocord involvement with typical brain and optic nerve involvement suggests NMOSD. If gray matter involvement predominates, consider a vasculitic or infectious process (e.g., SLE or enterovirus). Nerve root enhancement is occasionally seen and should raise suspicion for a mixed picture (central and peripheral demyelination) or anterior horn cell involvement (Fig. 640.5). Up to 6% of cases do not show spinal cord lesions on MRI. Repeat imaging at 7 days may reveal atrophy in these cases. *MRI of the brain is also indicated.* Evidence of other foci of demyelination is seen in at least 40% of patients; lesion localization should guide further consideration for MS, ADEM, NMOSD, SLE, and enterovirus-associated acute flaccid myelitis. In any child with *encephalopathy,* ADEM must be considered.

Lumbar puncture is indicated after exclusion of a mass on MRI and should be analyzed for cells, protein, immunoglobulin index, OCBs, and infectious pathogens. Mononuclear cells are usually elevated in TM. Protein may be elevated or normal. The presence of CSF inflammatory cells is essential for the diagnosis of TM.

Because one of the most important possibilities for this condition is NMOSD, the serum and CSF of all patients should be analyzed for both AQP-4 and MOG antibodies. Older children should also have serum studies sent for other autoimmune disorders, particularly SLE.

TREATMENT

Treatment of childhood TM has not been standardized. Available evidence suggests immune response modulation may be effective in reducing the severity and duration of disease. High-dose steroids (i.e., methylprednisolone) are used acutely in TM. In cases of poor response to high-dose steroids, other acute therapeutic approaches include

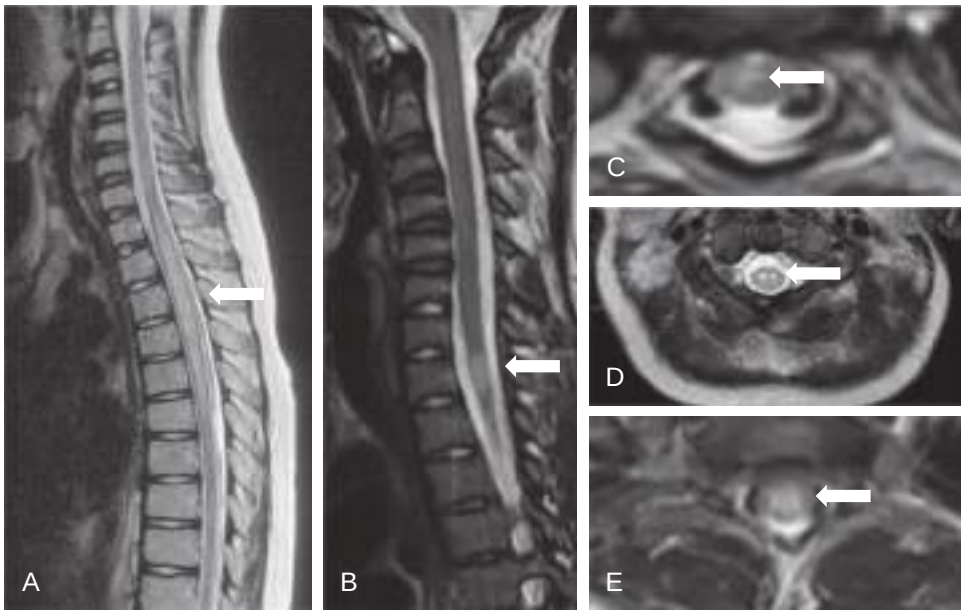

Fig. 640.5 Transverse myelitis. **A,** Sagittal T2-weighted image demonstrates a longitudinal hyperintense spinal cord lesion in a 12-yr-old female with first presentation of AQP4-Ab–positive NMOSD *(arrow)*. **B,** Sagittal T1-weighted image shows a short segment at T1-weighted *(arrow)* in a 14-yr-old female with ON and MS. Axial T2-weighted images of the spine with different etiologies showing typical hemicord appearance in MS (**C**), anterior horn cell involvement in polio (**D**), and holocord involvement in NMOSD (**E**). *(C- E courtesy Dr. Felice D'Arco, Great Ormond Street Hospital, London.)*

intravenous immunoglobulin (IVIG) and plasma exchange (PLEX). Rituximab may be considered if an antibody-driven TM is suspected. Long-term prophylactic therapy is recommended for children with either relapsing disease or biomarkers indicating a risk for recurrence.

PROGNOSIS

Older children with acute TM have a better outcome than adults, with nearly 50% making a good recovery by 2 years. This may reflect the higher likelihood of MOG-Ab–associated disorders in the older child. The most common sequelae in the remaining 50% are sensory problems and bladder dysfunction. Outcomes in younger children with TM are comparatively poor. Recovery is slow and usually incomplete; the likelihood of independent ambulation is approximately 40%.

Visit Elsevier eBooks+ at eBooks.Health.Elsevier.com for Bibliography.

640.4 Multiple Sclerosis

Michael Perry and Cheryl Hemingway

Multiple sclerosis (MS) is a chronic demyelinating autoimmune disorder of the brain, spinal cord, and optic nerves. It exhibits a relapsing-remitting course of neurologic events *without* encephalopathy separated in time (i.e., more than one episode of at least 24 hours at least 30 days apart) and space (i.e., in more than one CNS region). When occurring in those under 18 years, it is known as **pediatric-onset MS (POMS)**. Recurrent events lead to a characteristic accumulation of physical disability, cognitive impairment, and brain atrophy.

EPIDEMIOLOGY AND RISK FACTORS

MS is rare in childhood. In northern countries such as the United Kingdom and Canada, the annual incidence is estimated at 2 children per million. Interestingly, 5% of adult MS patients report in retrospect that they first experienced symptoms before age 18. POMS affects prepubescent males and females equally, but after puberty there is a 2:1 female predominance. Childhood MS is almost invariably relapsing-remitting in nature; features suggestive of primary progressive MS should prompt careful specialist evaluation for alternative conditions (Table 640.8).

In adults, a complex interplay of environmental (e.g., low sunlight exposure, low vitamin D, obesity, toxins), infectious (e.g., EBV exposure), and genetic/epigenetic factors (e.g., HLADRB1*15:01 homozygosity) are thought to synergistically influence MS susceptibility. Studies in pediatric MS have so far confirmed the role of some of the earlier factors; however, the rarity of MS, the modest effects of a multitude of candidate risk factors, and the near ubiquity of EBV in the general population have made identification of causality and quantification of risk challenging. A landmark study of U.S. military service members, however, has provided the best evidence yet that EBV infection, long postulated as a putative cause of MS, precedes the onset of disease and confers a 32-fold increase in the risk of disease development. B cells, then, a reservoir of latent EBV infection, may help to explain the effectiveness of anti-CD20 DMTs in MS and provide a target for future therapeutics or vaccines.

PATHOGENESIS

Dysregulation of both the innate and adaptive immune systems is at the heart of MS pathogenesis. The precise sequence of events leading to aberrant production of autoreactive immune cells is not well understood. Restriction of inflammation to the CNS suggests the presence of a CNS autoantigen. How and where an immune response (i.e., B- and T-cell activation) to a purported autoantigen is initiated is unclear; it is possible that CNS antigens migrate into the peripheral lymph nodes (via antigen-presenting cells) where autoreactive T and B cells become activated or that the triggering antigen is derived from the periphery itself (e.g., systemic infection). Clonal cells targeting the brain and spinal cord initiate a self-perpetuating deleterious cycle of inflammation, axonal demyelination, and astrocytic gliosis, and eventual axonal degeneration occurs in both white and gray matter. It is this axonal degeneration that directly contributes to permanent disability. DMTs target inflammatory infiltrates within actively demyelinating lesions of relapsing-remitting MS in an attempt to attenuate this cycle before axonal loss.

CLINICAL MANIFESTATIONS

Presenting symptoms are polyregional in more than half of patients. These include focal sensory loss or other paresthesia (39–63%); cerebellar symptoms such as ataxia or dysarthria (50%); unilateral (and sometimes bilateral) painful eye movement and reduced visual acuity (ON) (37%); brainstem symptoms in 30%; and motor deficits in up to 50%. Such motor dysfunction can manifest as focal deficits, hemiparesis, paraparesis, and bowel/bladder dysfunction (from TM or other spinal lesions). Except in cases of significant brainstem involvement, encephalopathy is not a feature.

Table 640.8 Differential Diagnosis of Multiple Sclerosis: Selected Disorders with a Progressive Course

	CLINICAL FEATURES	MRI FINDINGS	CSF FINDINGS	OTHER INVESTIGATIONS
HTLV1-associated myelopathy	Progressive myelopathy; residence or travel to an endemic area (especially West Indies or Japan)	Spinal cord atrophy (thoracic more than cervical); T2-hyperintense brain lesions in some patients	OCBs sometimes present	CSF HTLV1 antibody testing
Tumor	Progressive, variable features; headache, nonlocalizing symptoms of raised intracranial pressure; encephalopathy, vomiting, seizures, motor and/or sensory disturbances	Progressive enhancing and nonenhancing T2 lesions on serial imaging	OCBs absent	MRI; biopsy ± genetic investigations
Nutritional myelopathy (vitamin B_{12} or copper deficiency)	Subacute progressive myelopathy or myeloneuropathy; optic atrophy (severe vitamin B_{12} deficiency); anemia or pancytopenia	T2 hyperintensity of upper cervical cord classically affecting posterior columns; brain MRI normal	OCBs absent	Serum B_{12}, methylmalonic acid; serum copper levels, ceruloplasmin
Leukodystrophies: adrenomyeloneuropathy; Krabbe disease; Alexander disease; hereditary diffuse leukoencephalopathy with axonal spheroids	Progressive myelopathy (adrenomyeloneuropathy, Krabbe disease); bulbar symptoms, ataxia (Alexander disease); early cognitive impairment (hereditary diffuse leukoencephalopathy with axonal spheroids)	Highly variable; diffuse, symmetric T2 hyperintensity sparing subcortical U-fibers; with posterior hemispheric predominance (adrenomyeloneuropathy); spinal cord MRI normal or showing atrophy	OCBs absent	Very long-chain fatty acids (adrenomyeloneuropathy); genetic testing available for some leukodystrophies
Hereditary spastic paraplegia (especially *SPG5*)	Slowly progressive myelopathy (spasticity greater than weakness) with or without other neurologic symptoms and family history	Spinal cord atrophy; supratentorial and infratentorial white matter lesions (*SPG5*); atrophy of corpus callosum	OCBs absent	Genetic testing
Spinocerebellar ataxias	Progressive cerebellar ataxia, with or without other neurologic symptoms and family history	Early, prominent cerebellar findings, with or without spinal cord atrophy	OCBs absent	Genetic testing

CSF, Cerebrospinal fluid; HTLV1, human T-lymphotropic virus type 1; OCB, oligoclonal band.
From Brownlee WJ, Hardy TA, Fazekas F, et al. Multiple sclerosis 1: diagnosis of multiple sclerosis: progress and challenges. *Lancet*. 2017;389:1336–1346, Table 2, p. 1341.

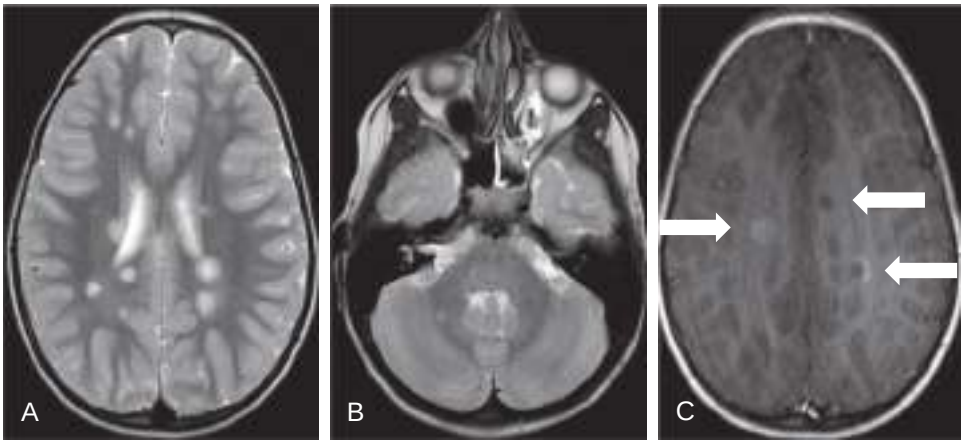

Fig. 640.6 5-year-old patient diagnosed on imaging with MS after presentation with left-sided weakness. **A,** Axial T2-weighted MRI of brain shows multiple discrete, ovoid white matter lesions in the periventricular region and cortical, juxtacortical, and infratentorial lesions (**B**). **C,** Axial T1-weighted area of hypointensity and two contrast-enhancing lesions *(arrows)*.

IMAGING AND LABORATORY FINDINGS

Brain MRI exhibits typically discrete, ovoid, asymmetric T2 lesions in cerebral white matter, particularly periventricular, juxtacortical, cortical, brainstem and cerebellar. Less commonly, lesions are noted in the deep gray matter (Fig. 640.6). When involved, spine MRI typically reveals partial-width cord lesions restricted to one to two spinal segments. Longitudinally extensive lesions are more likely to occur in NMOSD (associated with MOG-Ab and AQP4-Ab) than in MS. CSF may be normal or exhibit mild lymphocytosis. OCBs are positive in CSF but not in serum (type 2 pattern) in more than 90% of pediatric

MS patients. In NMOSD, OCBs are usually either negative (type 1 pattern) or present in both CSF and serum (type 4 pattern). Evoked potential studies can localize disruptions in visual, auditory, or somatosensory pathways.

DIAGNOSIS AND DIFFERENTIAL DIAGNOSIS

Pediatric MS can usually be diagnosed after two demyelinating episodes *without* encephalopathy. Episodes must localize to one of four distinct CNS regions, last longer than 24 hours, and be separated by more than 30 days. Importantly in pediatric MS, there must exist no other plausible explanation for the symptoms. MRI may serve as a surrogate for recurrent demyelination, thereby enabling MS diagnosis after the first clinical event so long as it demonstrates dissemination in space (at least two T2 lesions involving juxtacortical, periventricular, infratentorial, or spine regions) and time (presence of gadolinium-enhancing lesion and nonenhancing T2 lesion in the same scan). A 10-year longitudinal study demonstrated that 96% of children diagnosed with POMS met 2017 McDonald criteria at presentation. Alternatively, MS can be diagnosed with a follow-up MRI at any time interval that exhibits accumulation of T2 or gadolinium-enhancing lesions in the brain or spine. The 2017 McDonald diagnostic criteria allow the presence of intrathecal OCBs to substitute for dissemination in time (see Table 640.1). Challenges may arise in distinguishing a first attack of pediatric MS from other acquired demyelinating syndromes, particularly those associated with antibodies (e.g., AQP4-Ab, MOG-Ab) or ADEM (Table 640.9 and see Table 640.4). Although irritability and lethargy may be present (particularly with brainstem lesions), encephalopathy is a highly atypical feature of MS, and one should be extremely cautious in making this diagnosis in a child with such symptoms. Indeed, the 2017 McDonald criteria's positive predictive value (PPV) was shown to be reduced because of the relative predominance of ADEM compared with MS in the under-12-years cohort. The absence of encephalopathy is therefore required to make a diagnosis of MS in this age-group.

TREATMENT

Relapses causing functional disability may be treated with intravenous methylprednisolone 20-30 mg/kg/day (maximum 1000 mg/day) for 3-5 days, with or without prednisolone taper. It should be noted that a study in adults demonstrated noninferiority of oral vs intravenous methylprednisolone in acute relapses in MS.

DMTs reduce both relapse frequency and T2 lesion load by targeting elements of the inflammatory response that predominates during the relapsing-remitting phase of MS. There is an increasing number of immunomodulatory and immunosuppressive treatment options available. They include injectables, oral medications, and infusions. The choice and sequencing of medications are becoming increasingly highly specialized (Table 640.10). Nearly all DMT use in pediatrics is currently off-label, though several randomized controlled trials are in progress. The only medication with FDA approval at the present time is fingolimod. One trial comparing oral fingolimod with intramuscular interferon-beta-1α demonstrated that fingolimod reduced the annualized relapse rate by 82% when compared with interferon-beta-1α in children between 10 and 18 years of age. This efficacy is greater than that seen in adults, possibly because of the greater inflammatory burden in POMS. This is but one of the reasons that prompt initiation of treatment is recommended for all those diagnosed with POMS.

An ongoing debate about DMT use concerns escalation vs induction—that is, whether to start with safer, less efficacious first-line agents and only escalate if treatment fails or whether remission should first be induced with the more aggressive and effective treatments before then maintaining on safer medications. Adult trials to answer this question are underway, and currently, the more efficacious treatments are generally reserved only for those with highly active MS. However, the increased inflammatory activity, higher relapse rate, and young age at which disability occurs in POMS have inspired research to investigate the theorized benefits of high-efficacy early treatment (HEET). One effectiveness study of DMTs in pediatric MS provided evidence in favor of HEET, having demonstrated marked superiority of high-efficacy medications in preventing both relapses and new brain lesions.

PROGNOSIS

Reliable prognostication in POMS remains a challenge for several reasons. The first is the long time over which the disease progresses. The second is the disconnect between inflammatory activity (e.g., lesion accumulation, relapse rate) and neuronal/axonal degeneration, which more directly corresponds to disability. Pediatric MS studies before widespread DMT use suggested a higher relapse rate but slower rate of disability accumulation compared with adults. Despite this longer interval to irreversible disability (20-30 years), pediatric MS patients acquire disability at a younger age than adults owing to the earlier age of onset of disease. Indeed, emerging evidence suggests the plasticity of the young brain likely accounts for the relative delays in disability accumulation and cognitive impairment. Nonetheless, like adults with MS, pediatric MS patients can acquire fixed neurologic deficits affecting the visual and other cranial nerves, motor and sensory function, balance, and bowel/bladder function. Children with MS have also been shown to have an overall smaller head size and brain volume that can be attributed to gray matter degeneration. Despite the marked reduction in annualized relapse rate (ARR), lesion load, and overall inflammatory burden compared with interferon-beta-1α, children treated with fingolimod still lost brain volume and failed to achieve age-expected brain volume increase. This underscores the difficulty in addressing cognitive impairment, which is increasingly recognized and present in up to 50% of young people with POMS, more than that seen in adult-onset MS.

Fatigue is also a major symptom in pediatric MS that can lead to a poor quality of life. It is important to address this in a multidisciplinary setting together with other factors, such as mood, sleep quality, and sleep hygiene. Pharmacologic management of fatigue is challenging, but psychology-based therapy with cognitive-behavioral therapy and pacing has been shown to be effective.

Visit Elsevier eBooks+ at eBooks.Health.Elsevier.com for Bibliography.

640.5 Myelin Oligodendrocyte Glycoprotein–Associated Disorders

Michael Perry and Cheryl Hemingway

Myelin oligodendrocyte glycoprotein antibody–associated disease (MOGAD) encompasses a group of demyelinating disorders characterized by IgG autoantibodies to the MOG glycoprotein expressed in the outer layer of the myelin sheath. MOG antibodies are present in about 40% of all children with acquired demyelinating syndromes at first presentation. This increases to half of children with ADEM and nearly all those with relapsing ADEM (MDEM).

There is considerable *phenotypic* overlap between MOGAD, MS, and AQP4-Ab–positive NMOSD. Children with MOG-Ab seropositivity have often been classified as early MS or NMOSD; emerging evidence is drawing lines of demarcation between these entities. This paradigm is owed primarily to improved MOG-Ab assay techniques and specific clinical phenotypic description; differences in symptomatology, epidemiology, disease course, treatment response, prognosis, and histopathology between MOGAD, MS, and AQP4-Ab–positive NMOSD have been described. MOGAD may be either monophasic or relapsing; both MS and AQP4-NMOSD are characterized by a relapsing course. MOGAD has also demonstrated age-dependent variation of phenotype not seen in either MS or AQP4-NMOSD. Indeed, a minority of children with MOG antibodies may fit strict clinical and imaging criteria for a diagnosis of NMOSD with MOG (see Chapter 640.6). Most MOG-positive children (~60%) previously classified as NMOSD would no longer fit this criterion and thus represent a cohort distinct from NMOSD.

CLINICAL PRESENTATION

There are four main clinical phenotypes of MOGAD: (1) ADEM, (2) ON, (3) TM (NMOSD: ON and TM sequentially or simultaneously), and (4) cortical encephalitis. These may be monophasic or relapsing in nature, such as is seen with relapsing inflammatory optic neuritis (RION) or ADEM followed by

Table 640.9 Differential Diagnosis of Multiple Sclerosis: Clinical, MRI, and Serologic Findings of the Main Disorders that Can Resemble Relapsing-Remitting Disease

	NEUROLOGIC FEATURES	MRI FEATURES	BLOOD TEST AND CSF FINDINGS
Acute disseminated encephalomyelitis (most typically found in in pediatric cohorts)	Similar to MS symptoms but encephalopathy is typical; frequently multifocal symptoms	Large spectrum from small punctate lesions to tumefactive lesions with mass effect, in the supratentorial or infratentorial white matter, bilateral, and asymmetric; involvement of cerebral cortex, deep gray matter, brainstem, and spinal cord; enhancement	CSF pleocytosis; serum antibody to MOG
Antibody-associated disease (e.g., AQP-4 NMOSD, MOG-Ab ON)	ON or TM (often concomitant and/or severe in NMOSD); nausea and vomiting	Variable depending on etiology; longitudinally extensive spinal cord lesion (>3 vertebral segments) (NMOSD); longitudinally extensive optic nerve lesions (MOG); posterior optic nerve or chiasmal involvement (NMOSD); spinal lesions with prominent gray matter involvement (H-sign) (MOG); pencil-thin ependymal enhancement and cloudlike enhancement	Serum antibody to AQP4 or MOG; possible mild pleocytosis; CSF OCBs infrequent
Neurosarcoidosis	Cranial nerve involvement (primarily facial and optic nerve); headache; raised intracranial pressure; meningitis; seizures; myelopathy	Meningeal enhancement with pituitary, hypothalamic, and cranial nerve involvement; brain white matter lesions; simultaneous enhancement of all lesions	Raised serum and CSF ACE (not sensitive or specific for sarcoidosis); CSF OCBs sometimes present
CNS vasculitis	Confusion, headache, personality change; seizures; strokelike symptoms	Ischemic, multiple lesions; predominance of lesions at cortico-subcortical junction; intracranial hemorrhage; meningeal enhancement; simultaneous enhancement of all lesions; microbleeds	Serum antineutrophil cytoplasmic antibodies; CSF OCBs sometimes present
Susac syndrome	Visual loss; sensorineural hearing loss; encephalopathy; headache; memory loss; behavioral disturbances	Focal and small lesions in supratentorial and infratentorial regions (both white matter and gray matter); involvement of corpus callosum (snowball lesions); leptomeningeal enhancement	CSF OCBs usually absent
Hypoxic-ischemic vasculopathies (particularly small-vessel disorder)	Stroke events; cognitive decline; focal neurologic signs; gait disturbance	Punctate and peripheral white matter lesions, sparing U-fibers; symmetric and confluent periventricular lesions; lacunar infarcts; involvement of central transverse fibers in pons; microbleeds	Serum testing for vascular risk factors (diabetes, hypercholesterolemia); CSF OCBs absent
Cerebral autosomal dominant arteriopathy with subcortical infarcts and leukoencephalopathy (CADASIL)	Migraine; stroke events; psychiatric problems and dementia	Temporal pole lesions; external capsule and U-fiber lesions; microbleeds	CSF OCBs absent; testing for *NOTCH3* gene variant
Connective tissue disorders (SLE, Sjögren syndrome, antiphospholipid antibodies syndrome)	Optic nerve, brain, and spinal cord involvement; neuropsychiatric symptoms; seizures; ischemic episodes	Brain infarcts and hemorrhage; basal ganglia lesions; punctate (subcortical) lesions; spinal cord lesions; cerebral venous sinus thrombosis; parotid gland involvement in Sjögren syndrome	Serum antinuclear antibody; extractable nuclear antigens (in particular, anti SS-A(Ro) and SS-B(La) antibodies for Sjögren syndrome, and anti-Sm for SLE); CSF OCBs usually absent
Neuro-Behçet disease	Brainstem syndrome; myelopathy; meningoencephalitis	Large brainstem lesions; basal ganglia, subcortical white matter, and spinal cord lesions; gadolinium enhancement; cerebral venous sinus thrombosis	HLA-B5; CSF pleocytosis; CSF OCBs usually absent
Chronic lymphocytic inflammation with pontine perivascular enhancement responsive to steroids (CLIPPERS)	Cranial nerve dysfunction and long-tract signs; symptoms referable to brainstem or cerebellar dysfunction; spinal cord syndrome; cognitive dysfunction	Multiple punctate, patchy, and linear regions of gadolinium enhancement relatively confined to pons; lesions also involving cerebellum, basal ganglia, supratentorial white matter, brainstem, and spinal cord	CSF OCBs sometimes present; consider testing for primary CNS hemophagocytic lymphohistiocytosis even if meeting criteria for CLIPPERS (see later)

Table 640.9 Differential Diagnosis of Multiple Sclerosis: Clinical, MRI, and Serologic Findings of the Main Disorders that Can Resemble Relapsing-Remitting Disease—cont'd

	NEUROLOGIC FEATURES	MRI FEATURES	BLOOD TEST AND CSF FINDINGS
Primary CNS hemophagocytic lymphohistiocytosis (HLH)	Mimic of CLIPPERS, MDEM, and small vessel CNS vasculitis with a treatment-resistant and steroid-dependent disease pattern; symptoms include seizures, encephalopathy, weakness, ataxia, nystagmus, vomiting	Multifocal cerebral and cerebellar matter lesions with variable T2 hyperintensities; homogeneous enhancing nodules and curvilinear and punctate lesions of pons like that seen in CLIPPERS; diffuse cerebellar cortical edema	Genetic testing (e.g., *PRF1, UNC13D*); natural killer (NK)–cell function; CSF proteinosis or pleocytosis; neopterin may be a useful biomarker of disease activity
Fabry disease	Stroke events; vertigo	Posterior infarcts; multiple white matter lesions with pulvinar involvement (T1 hypointense lesions)	Reduced activity of GLA enzyme; analysis of *GLA* gene
Leber hereditary optic neuropathy	Bilateral sequential optic neuropathies with poor visual recovery; more common in men than women	Normal or might show white matter lesions (Harding disease)	OCBs absent; mitochondrial DNA (mtDNA) genetic testing for three most common (~90%) variants in first instance: MTND1m.3460G>A, MTND4m.11778G>A, MTND6m.14484T>C); full mtDNA sequencing indicated if targeted sequencing negative and clinical suspicion remains high

Infectious diseases are not included in this table but should be considered, especially in cases of atypical demyelinating lesions.
CSF, Cerebrospinal fluid; ACE, angiotensin-converting enzyme; GLA, α galactosidase A; OCB, oligoclonal band.
Modified from Thompson AJ, Baranzini SE, Geurts J, et al. Multiple sclerosis. *Lancet*. 2018;391:1622–1636, Table 3, pp. 1628–1629.

Table 640.10 Overview of Available and Emerging Therapies Used in Pediatric Multiple Sclerosis and Other Relapsing Demyelinating Disorders

MEDICATION AND ROUTE OF ADMINISTRATION	MEDICATION CLASS	MECHANISM IN MS	COMMONLY REPORTED OR SERIOUS SIDE EFFECTS	EFFICACY
FIRST-LINE THERAPIES APPROVED FOR MS IN ADULTS				
Interferon-β-1a and β-1b (subcutaneous or intramuscular injection on alternate days, 3 times weekly, weekly or bimonthly depending on preparation)	Immunomodulator	Modulates T cells and cytokine production	Injection site reaction; flulike symptoms; headache, muscle aches, transaminitis; leukopenia; tissue necrosis at injection site (rare)	~33% decrease in ARR and slows progression of disability
Glatiramer acetate (daily or 3 times weekly, subcutaneous injection)	Immunomodulator	Stimulation of Th-2 regulatory T-cells	Injection site reactions; transient flushing, chest tightness and shortness of breath. Lipodystrophy at injection sites	~33% decrease in ARR and slows progression of disability
Dimethyl fumarate (DMF) (oral medication 12 hourly with food, i.e., twice a day)	Immunomodulator	Unclear mechanism; likely antiinflammatory promotion via modulation of nuclear factor κB; modulates cytokine production and reduces lymphocyte count. neuroprotectant; antioxidant	Flushing; viral URTI; dysmenorrhea; GI upset; headache; proteinuria, leukopenia. Rare reports of PML in those with severe prolonged lymphopenia	Reduces number of relapses by ~ 50% compared with placebo in adults; this has recently been shown to remain stable over 10 yr of treatment (ENDORSE). Small single-arm pediatric phase 2 + extension study (FOCUS + CONNECTED) demonstrates favorable safety and efficacy profile. Phase 3 pediatric RCT (CONNECT) ongoing
SECOND-LINE THERAPIES APPROVED FOR MS IN ADULTS				
Teriflunomide	Immunomodulator	Pyrimidine synthesis impairment via dihydroorotate dehydrogenase inhibition; reduction of T and B cells proliferation	Infections (respiratory tract); pancreatitis; headaches; diarrhea; liver inflammation or injury; alopecia; nail and skin disorders; teratogenicity	43% reduction in combined risk of clinical relapse or high MRI activity vs placebo; 55% reduction in new or enlarged T2 lesions vs placebo (TERIKIDS trial)

Continued

Table 640.10 Overview of Available and Emerging Therapies Used in Pediatric Multiple Sclerosis and Other Relapsing Demyelinating Disorders—cont'd

MEDICATION AND ROUTE OF ADMINISTRATION	MEDICATION CLASS	MECHANISM IN MS	COMMONLY REPORTED OR SERIOUS SIDE EFFECTS	EFFICACY
Natalizumab (infusion over 2-3 hr every 4 wk; alternatively subcutaneous injection every 4 wk)	Monoclonal antibody	Targets α_4-integrin on vascular endothelium, preventing T- and B-cell migration into CNS	Infusion reactions with headache, dizziness, rash; rare anaphylaxis. May affect liver function. Risk of PML able to be stratified by JC virus status, length of treatment, and previous treatments. Immune reconstitution syndrome after discontinuation; melanoma	Reduces number of relapses by ~70% in adults
Fingolimod (daily oral medication: first dose, cardiac monitoring required and need to ensure good compliance because of risks of first-dose bradycardia and heart block)*	Immunomodulator	Modulates sphingosine-1-phosphate receptors; causes T-cell sequestration in lymphoid compartments	First-dose bradycardia; cardiac arrhythmia; systemic viral infection; persistent lymphopenia with risk of severe herpetic and varicella infection; macular edema; transaminitis; basal cell carcinoma. Rare cases of PML	FDA approved for pediatrics May 2018 after first prospective RCT in children with POMS (PARADIGMS) showing 82% decrease in ARR compared with interferon β
Alemtuzumab (infusions 2 courses: first for 5 consecutive days; second 12 mo later for 3 consecutive days)†	Monoclonal antibody	Anti-CD52 antibody target; depletes mature B and T cells	Vascular disorders (see footnotes re: FDA black box warning: ischemic stroke, arterial dissection); Infusion reactions within first 2-3 hr; opportunistic infection, secondary autoimmune disorders, including thyroiditis (50% risk), hemophagocytic lymphohistiocytosis (HLH), autoimmune hepatitis, immune thrombocytopenia (1%); glomerular nephropathies including anti–glomerular basement membrane disease (Goodpasture syndrome). Monthly blood tests required for 4 yr after last course	Highly effective in adults; ~ 55% decrease in ARR compared with interferons. Pediatric single-arm, before and after switch study (LemKids) ongoing.
Cladribine (oral tablets two courses: first for 4-5 consecutive days during mo 1 and 2; second as before 12 mo later)	Immunomodulator	Selective activity against CD4 and CD8 T cells and CD19 B cells via adenosine deaminase activity	Neutropenia, lymphopenia, infection, oral herpes, GI disorders, and rash	Reduced relapses by ~58% vs placebo in adults and delay in disability progression. No pediatric trials conducted to date
Rituximab (infusions given 2 wk apart ~every 6 mo)	Monoclonal antibody	Targets CD20, a marker of immature B cells; depletes B-cell populations	Infusion-related side effects; hepatitis, PML (rate undefined)	Used off-label for adult MS; no efficacy assessments available in pediatric MS
Ocrelizumab (infusions given 2 wk apart ~every 6 mo)	Monoclonal antibody	Targets CD20, a marker of immature B cells; depletes B-cell populations	Headache; infusion-related side effects; theoretic risk of PML (undefined) and, possibly, malignancy	In adult MS showed 50% reduction in ARR compared with interferons; a phase 3 pediatric trial (OPERETTA 2) is ongoing
OTHER MEDICATIONS USED FOR DEMYELINATING DISORDERS				
Azathioprine (intravenous infusion or oral tablets daily)	Chemotherapeutic	Disrupts purine metabolism; effects include cytotoxic immune cell depletion	GI side effects, alopecia, bone marrow suppression, and blood dyscrasias, transaminitis, infections, secondary malignancy, alopecia. Increased side effects with low TPMT enzyme activity	No efficacy assessments available in pediatric MS; small retrospective studies for NMOSD

Table 640.10 Overview of Available and Emerging Therapies Used in Pediatric Multiple Sclerosis and Other Relapsing Demyelinating Disorders—cont'd

MEDICATION AND ROUTE OF ADMINISTRATION	MEDICATION CLASS	MECHANISM IN MS	COMMONLY REPORTED OR SERIOUS SIDE EFFECTS	EFFICACY
Intravenous immunoglobulin (IVIG)	Immunotherapy	Inhibits complement binding; promotes antiinflammatory interleukin secretion; promotes regulatory T cells	Generally better tolerated than PLEX; headache; rash; allergic reaction	Limited class C evidence (small pediatric case series) suggests improved outcomes in severe and/or relapsing cases of ADS
Mycophenolate mofetil (MMF) (intravenous infusion or oral tablets twice daily)	Immunosuppressant	Disrupts purine synthesis and impairs B- and T-lymphocyte proliferation	GI side effects, alopecia, bone marrow suppression and blood dyscrasias, transaminitis, infections, secondary malignancy, alopecia. Teratogenic.	
Plasma exchange (PLEX)	Extracorporeal immunotherapy	Removal of pathogenic autoantibodies and proinflammatory macromolecules	Electrolyte abnormalities (particularly hypocalcemia); infection; hypotension; allergic reaction; anemia	Limited pediatric case series and adult studies available support use as rescue and/or second-line therapy
Vitamin D	Vitamin/hormone	Modulates immune cell expression	Hypercalcemia and kidney stones at serum 25(OH) vitamin D level > 100 ng/mL	Prospective trials in pediatric and adult MS are currently underway

*Additional S1P inhibitors with more specific receptor selectivities (i.e., less cardiac cross reactivity) are coming to market; pediatric trials are currently ongoing.
†U.S. FDA black box warning regarding rare but serious vascular side effects including ischemic and hemorrhagic stroke and cervicocephalic dissection. To be used with caution only in specialist centers.
CNS, Central nervous system; ARR, annualized relapse rate; MS, multiple sclerosis; JC virus, John Cunningham virus; PML, progressive multifocal leukoencephalopathy; TPMT, thiopurine methyltransferase; GI, gastrointestinal.

optic neuritis (ADEM-ON) (see Table 640.1). Tumefactive lesions, cerebellar demyelination, cranial neuropathies, monofocal or polyfocal cerebral motor deficits, and occasionally a widespread progressive leukodystrophy-like pattern may also be seen. Children with cortical encephalitis may present with seizures, headache, fever, and cortical symptoms with cortical hyperintensities on T2-weighted MRI sequences. Symptoms may be preceded by a viral prodrome, but no pathogens have been causally linked.

The diagnostic guideline of the International MOGAD Panel requires fulfillment of three criteria (Table 640.11):

1. Presence of one of six core clinical demyelinating events: optic neuritis, myelitis, ADEM, cerebral monodical or polyfocal deficits, brainstem or cerebellar deficits, or cerebral cortical encephalitis
2. Serum MOG-Ab positivity
3. Exclusion of MS and other demyelinating syndromes

IMAGING AND LABORATORY FINDINGS

MRI findings are atypical for MS (Fig. 640.7 and see Fig. 640.3). Brain MRI may show widespread involvement of the supratentorial and infratentorial white matter that can over time develop into a leukodystrophy-like pattern. This may extend into the pons, middle cerebellar peduncle, medulla, or deep gray matter. Spinal imaging suspicious for MOG-Ab disease may show longitudinally extensive myelitis, a characteristic H-sign of the central cord, or a lesion of the conus medullaris. Accrual of MRI lesions in the absence of relapse (i.e., clinically silent), a hallmark of MS, is not a typical feature of MOGAD. MRI of the optic nerves can be particularly useful in discrimination of phenotype and may show specific findings that together may indicate MOG-Ab disease. These include perineural sheath enhancement, papilledema, bilateral ON, and longitudinal nerve involvement. Previously attributed to those with POMS, these findings are now recognized as hallmarks of MOG-Ab–associated disease.

Suspected cases should have serum tested for MOG antibodies via live CBA for the IgG Fc or IgG1 secondary antibodies; importantly, laboratories should ideally report both quantitative (i.e., titers) and qualitative results (i.e., low-positive or high-positive) (Fig. 640.8). Despite variation in assay protocols across laboratories globally, high positivity is reliably predictive of true MOG-Ab positivity. Low-positive or borderline results less reliably differentiate MOG-Ab disease from other entities and should prompt reconsideration of other diagnoses, particularly MS. Fixed CBAs may be used with some caution if live CBA is not available, but enzyme-linked immunosorbent assay (ELISA) should be avoided. Although useful for diagnostic purposes, MOG-Ab titer *levels* are unhelpful in predicting risk of relapse.

Intrathecal OCBs are not normally present. However, OCB positivity should not preclude a diagnosis of MOG in the presence of supportive clinical features (particularly TM) and high MOG-IgG antibodies. Elevated CSF white blood cells with pleocytosis is often present.

TREATMENT

Treatment of acute attacks is similar to other demyelinating disorders: high-dose methylprednisolone, PLEX, and IVIG. Most children with MOGAD will experience a monophasic course and thus should not be offered DMT after a first event.

There is currently no clarity about DMTs that may be helpful over the long term and in relapsing disease. A complicating factor is the potential for long intervals between relapses. This makes it exceedingly difficult to determine the true efficacy of DMTs and guide early decisions about initiating treatment. Some studies have even demonstrated an exacerbation of MOG-Ab disorders treated with traditional MS medications, highlighting again the importance of an accurate clinical diagnosis.

The decision to use long-term immunosuppressive agents after induction therapy can be difficult. Unlike MS and AQP4-NMOSD, MOGAD may be monophasic or relapsing. At present, reliable predictors for risk of relapse do not exist. Therefore children with MOGAD are assessed holistically to determine the appropriateness of chronic therapy based on the risk:benefit ratio of each individual patient. This may include the severity of initial presentation, response to acute treatment, recovery from index attack, and likelihood of relapse. In children assessed as likely to benefit from DMTs, medications such as mycophenolate mofetil and azathioprine are frequently

Table 640.11 Proposed Diagnostic Criteria for MOGAD*

(A) Core clinical demyelinating event	• Optic neuritis • Myelitis • ADEM • Cerebral monofocal or polyfocal deficits • Brainstem or cerebellar deficits • Cerebral cortical encephalitis often with seizures		
(B) Positive MOG-IgG test	Cell-based assay: serum	Clear positive	No additional supporting features required
		Low positive Positive without reported titer Negative but CSF positive	AQP4-IgG seronegative *AND* ≥1 supporting clinical or MRI feature
Supporting clinical or MRI features	Optic neuritis	• Bilateral simultaneous clinical involvement • Longitudinal optic nerve involvement (> 50% length of the optic nerve) • Perineural optic sheath enhancement • Optic disc edema	
	Myelitis	• Longitudinally extensive myelitis • Central cord lesion or H-sign • Conus lesion	
	Brain, brainstem, or cerebral syndrome	• Multiple ill-defined T2 hyperintense lesions in supratentorial and often infratentorial white matter • Deep gray matter involvement • Ill-defined T2-hyperintensity involving pons, middle cerebellar peduncle, or medulla • Cortical lesion with or without lesional and overlying meningeal enhancement	
(C) Exclusion of better diagnoses including multiple sclerosis			

*Requires fulfillment of A, B, and C.
Modified from Banwell B, Bennett JL, Marignier R et al. Diagnosis of myelin oligodendrocyte glycoprotein antibody-associated disease: International MOGAD Panel proposed criteria. *Lancet Neurol.* 2023;22(3):268-282.

offered. This can be done with or without steroids. Rituximab has been used with some reports of benefit. However, there have also been concerning cases of severe exacerbations despite B-cell depletion, particularly in those with relapsing brainstem demyelination. It is important to remember that although both AQP4 and MOG disorders are antibody-driven, the former is an astrocytopathy, whereas the latter is an oligodendrocytopathy. Therefore extrapolation of treatment effects from one condition to the other is not necessarily possible. Monthly IVIG is the only treatment to date to consistently have shown benefit in high-risk individuals. However, there is great promise in new treatments such as satralizumab, an anti-IL-6 antibody, and anti-neonatal Fc receptor antibodies, which aim to reduce levels of pathogenic autoantibody by blocking IgG recycling.

PROGNOSIS

MOGAD is generally associated with a more benign course and favorable recovery compared with AQP4-Ab demyelination. Dramatic resolution is often seen in as little as 30 days on follow-up MRIs. MOGAD is particularly heterogenous, however, and certain phenotypes such as brainstem demyelination can have a very high relapse rate. Progression of disability is directly related with relapse rate, and therefore predictors of relapse rate is a focus of intense research. Approximately one third of MOG-positive children will relapse within 8 years of the first presentation. This risk is slightly higher in MOG-related ON and lower in isolated TM. Relapses can also occur many years after the first event, with intervals of more than 10 years having been reported. Cognitive deficits are seen frequently in those with young onset and frequent relapses.

Visit Elsevier eBooks+ at eBooks.Health.Elsevier.com for Bibliography.

640.6 Neuromyelitis Optica Spectrum Disorders

Michael Perry and Cheryl Hemingway

The neuromyelitis optica spectrum disorders (NMOSDs) are severe autoimmune inflammatory diseases classically characterized by episodes of ON and/or longitudinally extensive TM. The discovery of pathogenic antibodies to the astrocyte water channel protein aquaporin-4 (AQP4) and the incorporation of these antibodies into the 2015 revised diagnostic criteria for NMOSDs have helped to distinguish AQP4-Ab–related disorders from other demyelinating conditions; it has also widened the spectrum of the group of disorders to include brainstem syndromes (e.g., area postrema syndrome) and recurrent forms of ON and TM (see Table 640.1). MOG-Ab has also been identified in many cases that were initially thought to have been AQP4-antibody–negative presentations. Reports of both antibodies being simultaneously present in a single individual are exceedingly rare; in these circumstances, a diagnosis of AQP4-Ab–positive NMOSD should take precedence and guide management.

EPIDEMIOLOGY

AQP4-Ab–positive NMOSD typically presents in older adults, whereas MOG-Ab NMOSD is much more common in children and young people. Both, however, can occur across a wide age spectrum. Population studies vary significantly but suggest a pediatric incidence for NMOSDs of 0.5–4.5% of all ADS presentations. AQP4-Ab–driven NMOSD is significantly more common in females than in males. NMOSD appears to have a higher mortality rate in Black people. Most cases of NMOSD are idiopathic; only occasionally have familial cases have been reported. Several genetic risk factors have been described, including the HLA-DRB1*0301 allele and a single-nucleotide polymorphism in CD58.

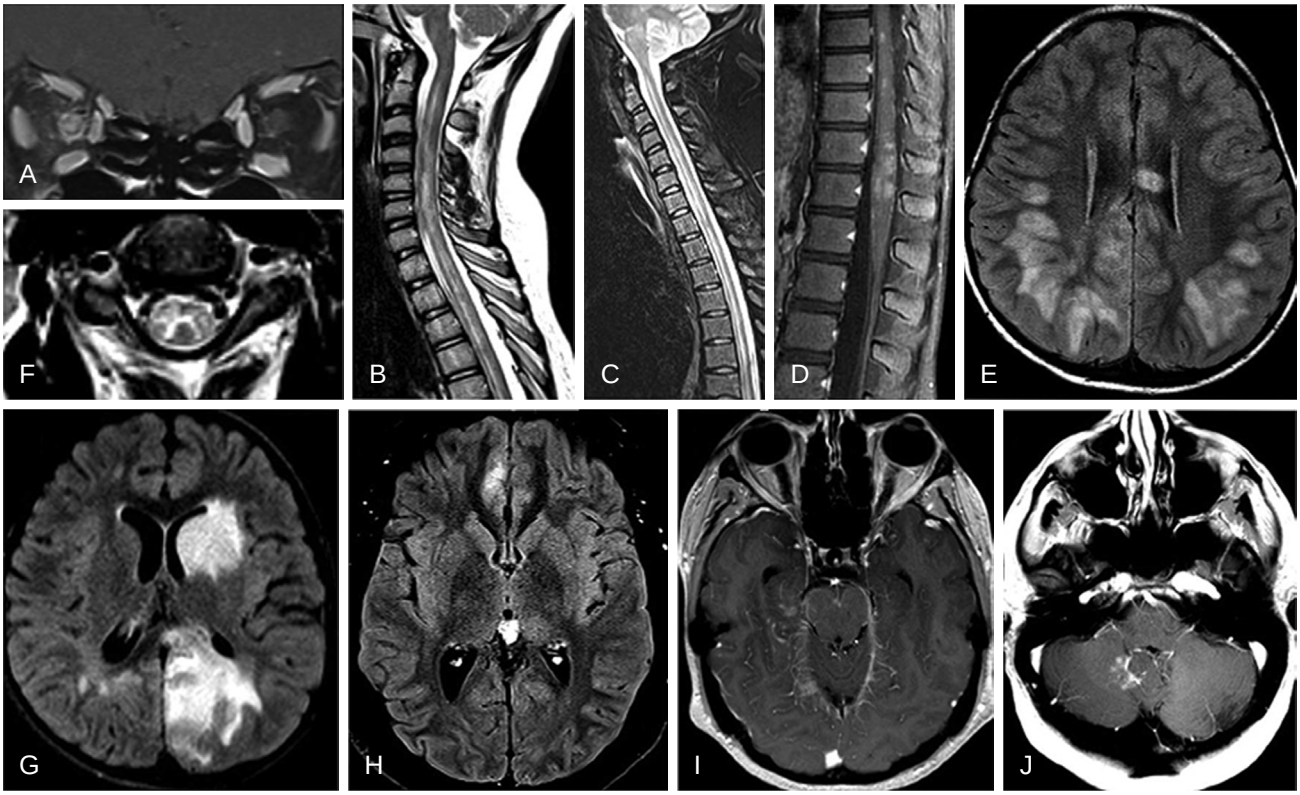

Fig. 640.7 Spectrum of anti-MOG–associated diseases. **A**, Coronal T1-weighted MRI of brain post-gadolinium contrast showing contrast enhancement of bilateral optic nerves and right optic nerve sheath consistent with perioptic neuritis. **B**, Sagittal STIR MRI of spine showing longitudinal extensive patchy lesion spanning from cervical to thoracic cord. **C**, Sagittal T2-weighted MRI of spine showing hyperintense, longitudinally extensive "pseudo-dilation" of central canal. **D**, Sagittal T1-weighted MRI of spine post-gadolinium contrast showing patchy enhancement of the conus medullaris. **E**, Axial FLAIR MRI of brain showing large subcortical and septal white matter lesions in a pediatric patient presenting with ADEM. **F**, Axial T2-weighted MRI of brain with hyperintense "H" sign outlining the central gray matter of the upper cervical cord in a teenager with myelitis. **G**, Axial T2-weighted MRI of brain with "fluffy" hyperintense lesion of gray and white matter of the left caudate and left occipital parietal regions in a pediatric patient who presented with ADEM. **H**, Axial T2-weighted MRI of brain showing unilateral FLAIR hyperintensity and edema of the right mesial frontal cortex in a patient with FLAMES syndrome. **I**, Axial T1-weighted MRI of brain post-gadolinium contrast showing leptomeningeal enhancement of the midbrain and right mesial temporal lobe. **J**, Axial T1-weighted MRI of brain post-gadolinium contrast showing a lesion adjacent to the cerebellar vermis and dorsal medulla in a patient with brainstem syndrome and no other lesions. *(From Parrotta E, Kister I. The expanding clinical spectrum of myelin oligodendrocyte glycoprotein [MOG] antibody associated diseases in children and adults. Front Neurol. 2020;11:Article 960, Fig. 1.)*

PATHOGENESIS

The water channels against which the AQP4-IgG antibody is directed are most abundant on the astrocyte foot processes within the periventricular regions, brainstem, optic nerves, and spinal cord; thus strictly speaking, NMOSD can be characterized as an autoimmune *astrocytopathy* with secondary demyelination. Antibody (primarily IgG1 subtype) binding occurs at the extracellular loops of the AQP4 protein. This activates the classical complement pathway with C5b-C9 component, stimulating leukocyte migration and degranulation, ultimately resulting in astrocytic death. Chemokine secretion from the dying astrocytes and activated leukocytes further attract additional macrophages, leading to oligodendrocyte and neuronal death. Subsequent necrosis or cavitation may occur.

CLINICAL MANIFESTATIONS

AQP4-positive NMOSD presents most commonly with ON, TM, or area postrema syndrome (i.e., hiccups, nausea, and/or intractable vomiting); vomiting is highly unusual in MOG-Ab NMOSD. The symptoms and signs of TM depend on the spinal level and completeness of the inflammatory changes. ON or TM may occur simultaneously or may be separated in time by weeks or even years. Some patients, particularly in MOG-Ab NMOSD, present with seizures and encephalopathy mimicking ADEM. Others exhibit endocrinopathies such as the syndrome of inappropriate antidiuretic hormone secretion (SIADH), diabetes insipidus (DI), hyperinsulinemia, disrupted puberty, or obesity. NMOSD may also be associated with other autoimmune conditions, such as SLE, Sjögren syndrome, diabetes mellitus (DM), and thyroiditis.

IMAGING AND LABORATORY FINDINGS

Neuroimaging studies must include the entire spine, optic nerves if visual symptoms are present, and brain. Although often manifesting with large, hazy, ill-defined white matter lesions and/or gray matter involvement, such as thalamic lesions, brain imaging may have only subtle white matter changes, or even be normal. Brain lesions most frequently localize to areas of high AQP4-Ab expression such as the periaqueductal gray matter, dorsal brainstem, and diencephalon (Fig. 640.9). Spinal imaging may reveal short or longitudinally extensive TM; longitudinally extensive ON involving the chiasm is more common in MOG-Ab disease. Imaging does not reliably differentiate AQP4-Ab and MOG-Ab. Both, however, are readily distinguished from MS by the absence of discrete, well-defined oval lesions in the periventricular white matter.

Although AQP4-Ab and MOG-Ab can be found in both the serum and CSF, their relative increased prevalence in the serum suggests extrathecal production of antibody. There are several different methods of varying sensitivity for antibody testing; the gold standard is the live CBA. Repeat testing is advised in cases of high clinical suspicion of an antibody-driven

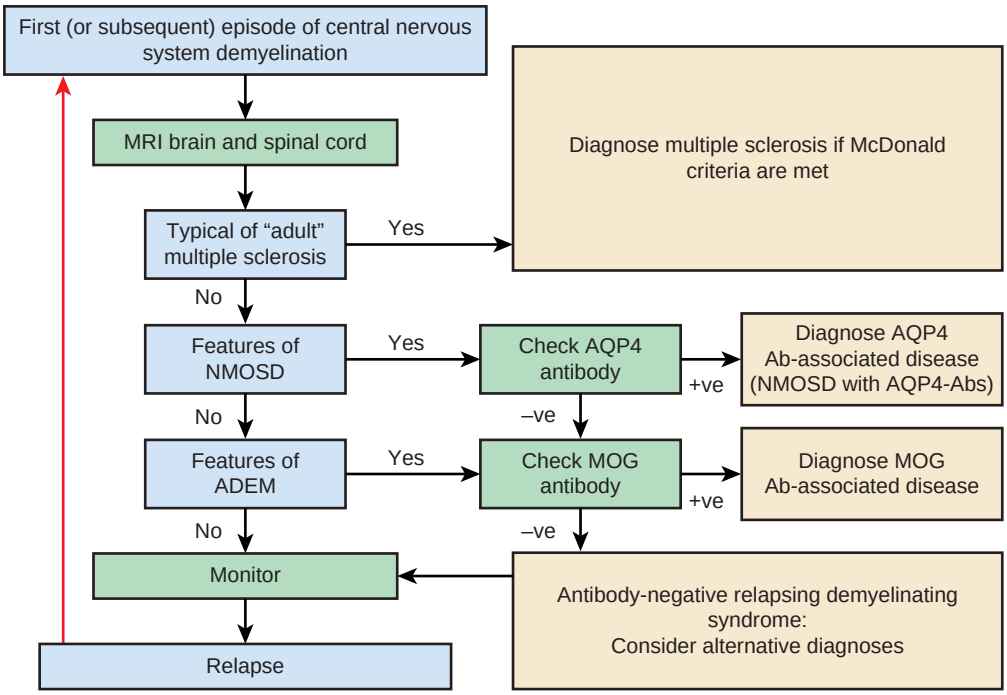

Fig. 640.8 Diagnostic algorithm that can be applied to any episode of CNS demyelination in children. The first recommended diagnostic test is brain and spinal cord MRI. If MRI findings are considered to be typical or suggestive of adult MS, then the McDonald diagnostic criteria should be applied. In children whose MRI is not typical or suggestive of MS but who have clinical and radiologic features suggestive of NMOSD, AQP4-Ab testing is recommended. In particular, this test is advised in children presenting with an area postrema syndrome, MRI abnormalities localized to the brainstem and hypothalamus, and destructive lesions. If AQP4-Ab is negative, then MOG-Ab should be tested. In children whose MRI is not typical of MS or NMOSD but the clinical and radiologic presentation has features of ADEM, MOG-Ab testing is recommended. Supporting features for MOG-Ab–associated disease include lesions in the cerebellar peduncle and leukodystrophy-like MRI pattern in the very young. Alternative diagnoses should be considered in the remaining Ab-negative patients. *(From Hacohen Y, Mankad K, Chong WK, et al. Diagnostic algorithm for relapsing acquired demyelinating syndromes in children. Neurology. 2017;89:269–287, Fig. 2.)*

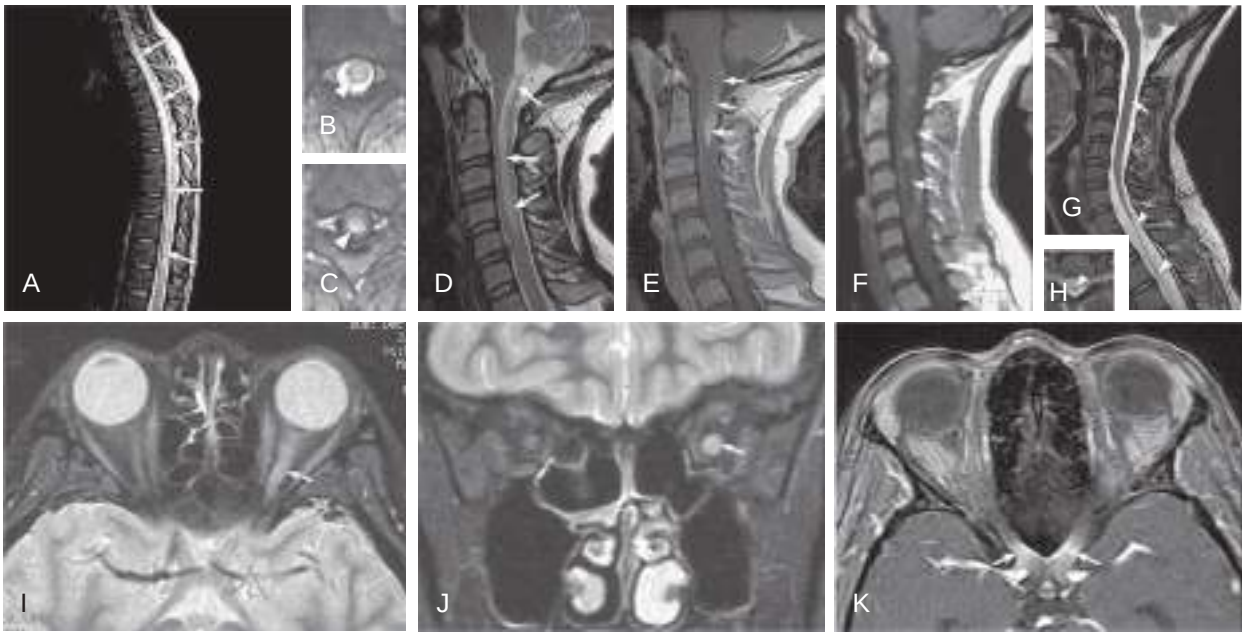

Fig. 640.9 Spinal cord and optic nerve MRI patterns in NMOSD. Spinal cord imaging in the context of acute myelitis in NMOSDs usually reveals a longitudinally extensive transverse myelitis (LETM) lesion extending over three or more vertebral segments. **A,** Sagittal T2-weighted MRI of the thoracic spinal cord demonstrates a typical LETM lesion involving most of the thoracic spinal cord *(arrows).* LETM lesions have a predilection for the central cord, as shown by axial T2-weighted (**B**; *arrowhead*) and T1-weighted MRIs with gadolinium (**C**; *arrowhead*). Cervical LETM may extend into the medulla, a characteristic NMOSD pattern demonstrated in **D** (*arrows;* sagittal T2-weighted MRI) and **E** (*arrows;* sagittal T1-weighted MRI with gadolinium). Acute LETM lesions can be associated with intralesional hypointensity, as shown by sagittal T1-weighted MRI (**F**; *arrow*); in this example, a rim of gadolinium enhancement surrounds the hypointense region. Chronic sequelae of LETM may include longitudinally extensive segments of spinal cord atrophy, as shown by T2-weighted MRI using the sagittal plane (**G**; the two *arrowheads* indicate the atrophic segment, and the top *arrow* indicates the normal diameter of unaffected cervical spinal cord) and axial plane (**H**; *arrowhead* shows an atrophic spinal cord). Fast spin echo fat-suppressed T2-weighted MRI in the axial (**I**) and coronal (**J**) planes shows increased signal throughout most of the length of the left optic nerve, especially its posterior portion *(arrows).* **K,** Axial T1-weighted MRI with gadolinium shows enhancement of the optic chiasm (*arrows*). These images are from two different patients experiencing acute ON in the setting of NMOSD. *(From Wingerchuk DM, Banwell B, Bennett JL, et al. International consensus diagnostic criteria for neuromyelitis optica spectrum disorders. Neurology. 2015;85:177–189, Fig. 1.)*

disorder despite a negative test. CSF typically reveals elevated white blood cells (WBCs) and, unlike in MS, is usually negative for OCBs.

DIAGNOSIS AND DIFFERENTIAL DIAGNOSIS

The International Panel for NMO Diagnosis (IPND) published new criteria for NMOSD in 2015. Emphasis is now placed on the presence or absence of AQP4 antibody (see Table 640.1). In seropositive patients (after exclusion of alternative diagnoses), only one core clinical criterion is required from the following six: (1) ON, (2) TM, (3) area postrema syndrome, (4) acute brainstem syndrome, (5) narcolepsy *or* diencephalic syndrome with compatible MRI lesions, and (6) symptomatic cerebral syndrome with typical brain lesions. If AQP4-Ab negative, the diagnosis is more stringent and two core clinical criteria are required, one of which must be ON, longitudinally extensive transverse myelitis (LETM), or area postrema syndrome. The heterogenous nature of this seronegative cohort suggests that further antibodies are yet to be discovered and likely represent multiple subgroups.

The differential diagnoses include other demyelinating disorders, such as MS or ADEM; vasculitis and rheumatologic disorders, including SLE, Behçet disease, and neurosarcoidosis (usually accompanied by other nonneurologic manifestations); idiopathic TM, tropical spastic paraparesis, and viral encephalomyelitis (none of which have NMO antibodies in the serum or CSF); genetic disorders such as familial HLH or pathogenic variants in *DARS*; metabolic causes such as biotinidase deficiency and riboflavin-responsive conditions; idiopathic causes of isolated ON; or other acute forms of monocular or binocular visual loss (Table 640.12; see also Chapter 671). Additional considerations include lymphoma, Langerhans cell histiocytosis, tuberculosis, and vitamins B_{12} and E deficiencies.

TREATMENT

In principle, treatment of NMOSD involves acute treatment with early aggressive antiinflammatory therapy (e.g., steroids) and removal of the antibody (PLEX or monoclonal) and longer-term relapse prevention with DMTs.

Initial episodes and relapses may be treated acutely with methylprednisolone 20-30 mg/kg/day (maximum 1,000 mg/day) usually for 5 days; this can be extended for severe attacks. An oral taper (though there is no consensus regarding length) is recommended, particularly if antibody results are not available at the time of discharge. In certain circumstances, treatment escalation in the acute phase may be indicated: for example, when minimal or no improvement is seen with steroids, or even initially in patients deemed to be high-risk (i.e., brainstem symptoms or ON in a child with preexisting deficit in the contralateral eye). In these cases, PLEX either before or after IVIG (2 g/kg over 2-5 days) with a repeat course of steroids may be considered. Rituximab can be used both acutely and to prevent further relapses.

In adults, AQP4-Ab–positive NMOSD has historically been treated with a range of DMTs, including azathioprine, mycophenolate mofetil (MMF), and rituximab. A study of satralizumab (interleukin [IL]-6 reuptake inhibitor of T- and B-cell activation, Th17 differentiation, and plasmablast survival) in NMOSD demonstrated clear benefit in pediatric patients, particularly those who were AQP4-Ab–positive, and it is licensed for use in children in the United States and Canada. Preliminary evidence in adults suggests that eculizumab, a monoclonal antibody against the C5 complement protein, reduces recurrence and may improve disability in patients with severe NMOSD. A pilot study of tocilizumab, an anti–IL-6 monoclonal antibody, demonstrated efficacy in AQP4-NMOSD in adults. Inebilizumab, an anti-CD19 antibody, has been shown to effectively ameliorate multiple NMOSD endpoints (time to relapse, disability scores, new MRI lesions) in adults and is now in pediatric clinical trials. Importantly, medications used for the treatment of MS are ineffective and can even exacerbate relapses, again highlighting the criticality of accurate diagnosis.

PROGNOSIS

The relapsing and aggressive nature of AQP4-positive NMOSD in pediatric patients very often results in poor recovery and a progressive accrual of disability. MOG-Ab–positive NMOSD is more likely to be monophasic. In relapsing phenotypes (either AQP4-Ab or MOG-Ab), the relapse rate is higher in those with AQP4-Ab, with emerging consensus for a better recovery and long-term prognosis for MOG-Ab–associated disorders. Like adults with NMOSD, pediatric patients are often (>50%) left with fixed neurologic deficits affecting VA, visual fields, color vision, motor and sensory function, balance, and bowel/bladder function, and the best outcomes are achieved with prompt treatment by a multidisciplinary team experienced in pediatric neuroinflammatory care.

Table 640.12 Red Flags: Findings Atypical for NMOSD and TM*

RED FLAGS (CLINICAL AND LABORATORY)
1. Clinical features and laboratory findings
Progressive overall clinical course (neurologic deterioration unrelated to attacks; consider MS)
Atypical time to attack nadir: less than 4 hr (consider cord ischemia/infarction); continual worsening for more than 4 wk from attack onset (consider sarcoidosis or neoplasm)
Partial TM, especially when not associated with LETM MRI lesion (consider MS)
Presence of CSF OCBs (OCBs occur in <20% of NMO cases vs >80% of MS cases)
2. Comorbidities associated with neurologic syndromes that mimic NMOSD
Sarcoidosis, established or suggestive clinical, radiologic, or laboratory findings thereof (e.g., mediastinal adenopathy, fever and night sweats, elevated serum angiotensin-converting enzyme or interleukin-2 receptor levels)
Cancer, established or with suggestive clinical, radiologic, or laboratory findings thereof; consider lymphoma or paraneoplastic disease (e.g., collapsin response mediator protein-5–associated optic neuropathy and myelopathy or anti-Ma–associated diencephalic syndrome)
Chronic infection, established or with suggestive clinical, radiologic, or laboratory findings thereof (e.g., HIV, syphilis)
RED FLAGS AND MIMICS (CONVENTIONAL NEUROIMAGING)
1. Brain
a. Imaging features (T2-weighted MRI) suggestive of MS (MS typical)
Lesions with orientation perpendicular to a lateral ventricular surface (Dawson fingers)
Lesions adjacent to lateral ventricle in the inferior temporal lobe
Juxtacortical lesions involving subcortical U-fibers
Cortical lesions
b. Imaging characteristics suggestive of diseases other than MS and NMOSD
Lesions with persistent (>3 mo) gadolinium enhancement
2. Spinal cord
a. Spinal nerve root inflammation (e.g., Guillain-Barré syndrome)
b. Tumor (e.g., neuroblastoma, Wilms tumor, Ewing sarcoma)
c. Destructive lesions (e.g., tuberculosis, lymphoma, Langerhans cell histiocytosis)
d. Vascular disorders (e.g., arteriovenous infarct, arteriovenous malformation, cavernomas, Cobb syndrome, spinal cord infarction)
e. Vasculitis (e.g., SLE, Behçet disease)
f. Characteristics more suggestive of MS than TM/NMOSD:
Lesions in <3 complete vertebral segments on sagittal T2-weighted sequences
Lesions located predominantly (>70%) in the peripheral cord on axial T2-weighted sequences
Diffuse, indistinct signal change on T2-weighted sequences (as sometimes seen with long-standing or progressive MS)

*These are some common or key findings that should prompt a thorough investigation for competing differential diagnoses before making a diagnosis of NMOSD or isolated TM.

LETM, Longitudinally extensive transverse myelitis lesions; TM, transverse myelitis; MS, multiple sclerosis; NMO, neuromyelitis optica; NMOSD, neuromyelitis optica spectrum disorders.

Modified from Wingerchuk DM, Banwell B, Bennett JL, et al. International consensus diagnostic criteria for neuromyelitis optica spectrum disorders. *Neurology*. 2015;85:177–189, Table 2, p. 180 and 182; with data from Thomas T, Branson HM. Childhood transverse myelitis and its mimics. *Neuroimaging Clin North Am*. 2013;23:267–278, Box 1.

Visit Elsevier eBooks+ at eBooks.Health.Elsevier.com for Bibliography.

Chapter 641

Pediatric Stroke

Nomazulu Dlamini and Gabrielle A. deVeber

Stroke is an important cause of acquired brain injury in newborns, children, and adolescents. The ischemic varieties of arterial ischemic stroke (AIS) and cerebral sinovenous thrombosis (CSVT) are, together, more common than brain malignancy (incidence ~5 in 100,000 children per year). Perinatal ischemic stroke is especially common (1 in 2,500-4,000 live births) and is the leading cause of hemiparetic cerebral palsy. Beyond ischemic stroke, a similar number of children have hemorrhagic stroke (HS) and other forms of cerebrovascular disease. Acute stroke is a neurologic emergency; unfortunately, delays in recognition are common, and delayed treatment worsens outcomes. In comparison with stroke in adults, there is a more diverse group of disorders producing stroke in neonates and children.

641.1 Arterial Ischemic Stroke

Nomazulu Dlamini and Gabrielle A. deVeber

Arterial blood reaches the brain via the anterior (internal carotid) and posterior (vertebrobasilar) circulations, converging at the circle of Willis. Strokes most often involve the middle cerebral artery territory but can occur in any cerebral artery of any size. AIS is the focal brain infarction that results from occlusion of these arteries.

The diagnosis of stroke in children is frequently delayed. This is a consequence of subtle and nonspecific clinical presentations, poor awareness by primary care physicians, a complicated differential diagnosis for hemiparesis (see Chapter 641.5), and a high frequency (>50%) of negative initial brain CT scans in true AIS. *The acute onset of a focal neurologic deficit in a child is stroke until proven otherwise.* The most common focal presentation is hemiparesis, but acute visual, speech, sensory, or balance deficits also occur. Importantly, new-onset seizures, especially focal motor seizures, frequently herald stroke, especially in infants and younger children. Children with these presentations require urgent neuroimaging and consultation with a child neurologist because emergency interventions may be indicated. AIS is a clinical and radiographic diagnosis. Although CT imaging can demonstrate mature AIS and exclude hemorrhage, cerebral MRI is required to identify early and small infarcts and disorders of the cerebral arteries. **Diffusion-weighted MRI** demonstrates AIS from minutes to 7 days after the onset; MR angiography can confirm vascular occlusion and suggest possible arteriopathy (Fig. 641.1). Diffusion-weighted MRI can also demonstrate Wallerian degeneration in the descending corticospinal tract, which correlates with chronic hemiparesis.

Many possible risk factors for childhood AIS are recognized (Tables 641.1-641.3), although their specific pathophysiologic mechanisms remain poorly understood. Half of children with AIS are healthy before stroke onset. Three main categories of etiology should be considered: **arteriopathy**, **cardiac disease**, and **hematologic disease** (see Table 641.1). Hence, in addition to a careful history taking and physician examination, a full investigation (including vascular imaging,

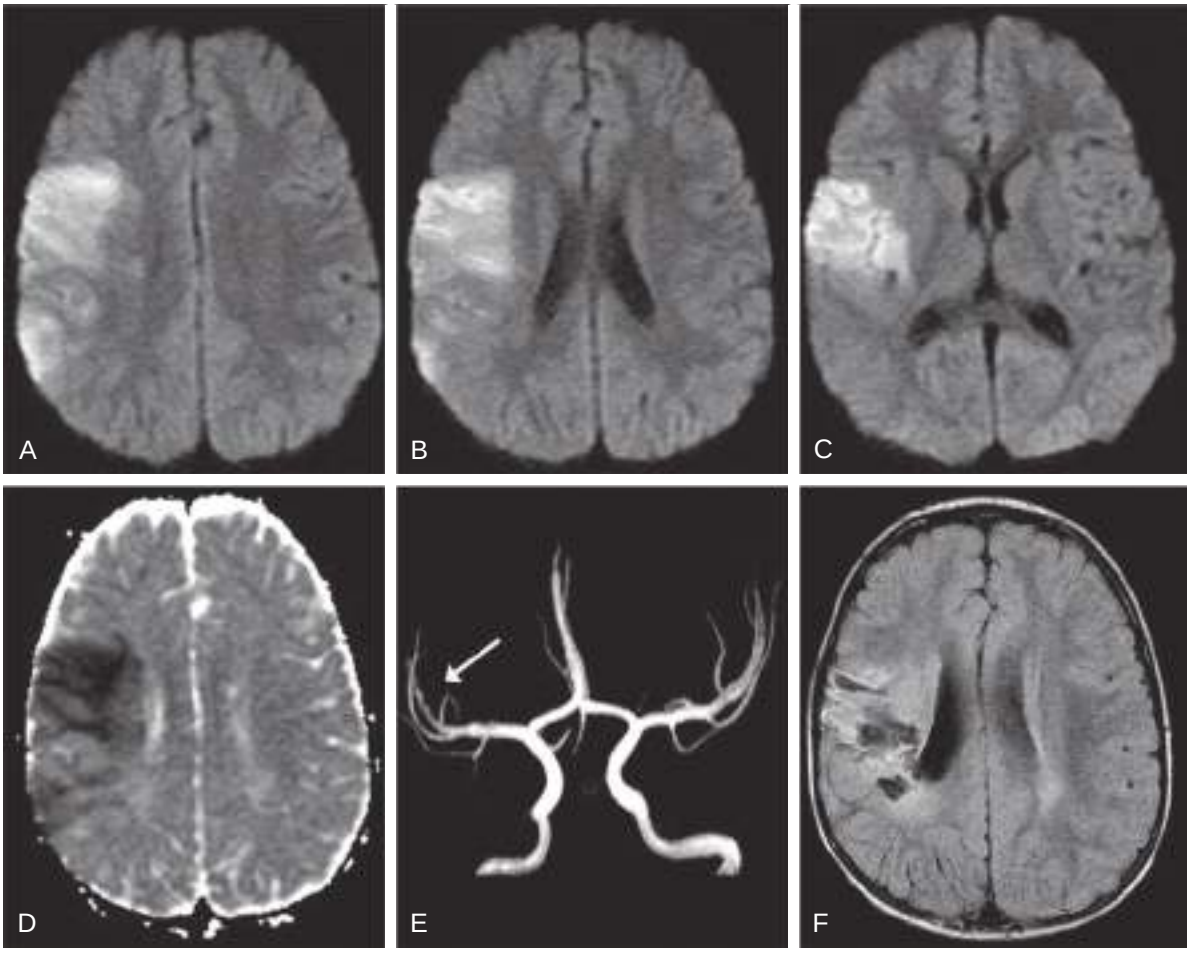

Fig. 641.1 Arterial ischemic stroke. A healthy 3-yr-old male had sudden onset of left-sided weakness. Examination also demonstrated left-sided hemisensory loss and neglect. **A-C,** Diffusion-weighted MRI shows focal increased signal in the right temporal-parietal region in the territory of the middle cerebral artery (MCA). **D,** Apparent diffusion coefficient map confirms restricted diffusion consistent with infarction (ischemic stroke). **E,** MR angiogram shows decreased flow in the corresponding branch of the MCA. **F,** Follow-up MRI at 3 mo shows atrophy and gliosis in the same region.

Table 641.1 Risk Factors and Causes of Stroke in Children

ARTERIOPATHIES
Focal or transient cerebral arteriopathy
Craniocervical arterial dissection
Fibromuscular dysplasia
Moyamoya disease or syndrome
Sickle cell arteriopathy
Primary CNS angiitis
HANAC syndrome
Genetic variants (see text and Table 641.2)
CARDIOVASCULAR DISEASE
Congenital
Aortic stenosis
Mitral stenosis
Ventricular septal defects
Patent ductus arteriosus
Patent foramen ovale
PHACE syndrome
Cyanotic congenital heart disease
Acquired
Endocarditis
Kawasaki disease
Cardiomyopathy
Atrial myxoma
Arrhythmia
Rheumatic heart disease
Prosthetic heart valve
Catheterization/surgery
ECMO
HEMATOLOGIC ABNORMALITIES
Hemoglobinopathies
Polycythemia
Leukemia/lymphoma
Thrombocytopenia including TTP
Disorders of coagulation
• Protein C deficiency
• Protein S deficiency
• Antithrombin III deficiency
• Factor V (Leiden) resistance to activated protein C
• Lupus anticoagulant
• Oral hormonal contraception
• Pregnancy and the postpartum state
• Disseminated intravascular coagulation
• Paroxysmal nocturnal hemoglobinuria
• Inflammatory bowel disease
• Protein-losing enteropathy
• Nephrotic syndrome
• L-Asparaginase
• Prothrombin G20210A variant
• MTHFR deficiency
• Lipoprotein(a) elevation
• Antiphospholipid antibody syndrome
• PNH
SYSTEMIC DISORDERS
Meningitis
• Viral
• Bacterial
• Tuberculous
Systemic infection
• Viremia
• Bacteremia
• Local head and neck infections, including Lemierre syndrome
• Postinfectious (including varicella and other viruses)
Drug-induced inflammation and vasoconstriction
• Amphetamine
• Cocaine
• Ergot alkaloids
Autoimmune disease
• Systemic lupus erythematosus
• Juvenile idiopathic arthritis
• Takayasu arteritis
• Mixed connective tissue disease
• Polyarteritis nodosa
• Primary CNS vasculitis
Trisomy 21
METABOLIC DISEASES
Hyperhomocysteinemia/homocystinuria/elevated homocysteine levels
Fabry disease
Pseudoxanthoma elasticum
Sulfite oxidase deficiency (see Table 641.2)
MITOCHONDRIAL DISORDERS
MELAS
Leigh syndrome
INTRACEREBRAL VASCULAR PROCESSES
Ruptured aneurysm
Arteriovenous malformation
Migraine headache
Post–subarachnoid hemorrhage vasospasm
Hereditary hemorrhagic telangiectasia
Sturge-Weber syndrome
Carotid or vertebral artery dissection
Neurofibromatosis type 1
CADASIL
CARASIL
TRAUMA AND OTHER EXTERNAL CAUSES
Nonaccidental trauma
Head and neck trauma
Oral trauma
Placental embolism
Neck hyperextension (carotid dissection)
Lollipop stroke (pharyngeal trauma)

CADASIL, Cerebral autosomal dominant arteriopathy with subcortical infarcts and leukoencephalopathy; CARASIL, cerebral autosomal recessive arteriopathy with subcortical infarcts and leukoencephalopathy; CNS, central nervous system; ECMO, extracorporeal membrane oxygenation; HANAC, hereditary angiopathy with nephropathy aneurysms, muscle cramps; MELAS, mitochondrial encephalomyopathy, lactic acidosis, strokelike episodes; MTHFR, methylenetetrahydrofolate reductase; PHACE, posterior fossa brain malformations, hemangiomas of the face, neck, and scalp, arterial anomalies, coarctation of the aorta and cardiac anomalies, and eye defects; PNH, paroxysmal nocturnal hemoglobinuria; TTP, thrombotic thrombocytopenic purpura.

Modified from Farias-Moeller R. Stroke. In: Kliegman RM, Toth H, Bordini BJ, et al., eds. *Nelson Pediatric Symptom-Based Diagnosis,* 2nd ed. Philadelphia: Elsevier; 2023: Table 37.15, p. 652.

echocardiography, and blood tests for inflammatory, infectious, and prothrombotic disorders) are important because these tests often reveal multiple predispositions and triggering risk factors.

Arteriopathy, a disorder of the cerebral arteries, is a leading cause of childhood AIS, present in more than 50% of children. One common arteriopathy that affects healthy school-age children features unilateral irregular stenosis of the proximal middle cerebral artery and neighboring arteries with associated basal ganglia infarction. **Transient cerebral arteriopathy** is monophasic, nearly always self-limited, and may be the result of focal inflammation. This entity has been published under multiple names—**transient cerebral arteriopathy**, post–varicella angiopathy (Fig. 641.2), and nonprogressive childhood primary angiitis of the central nervous system (CNS). The term *focal cerebral arteriopathy (FCA)* is now used, reflecting uncertainty

Table 641.2 Genetic Associations with Thrombotic, Hemorrhagic, or Vascular Stroke

LIPID AND OTHER DISORDERS WITH ATHEROSCLEROSIS
Hereditary dyslipoproteinemias
Familial hypercholesterolemia
Familial hypertriglyceridemia
Hyperlipoproteinemia (types III and IV)
Familial hypoalphalipoproteinemia
Tangier disease
Progeria (de Lange, Seckel, Bloom, Cockayne syndromes)
ARTERIOPATHY, ANGIOPATHY, VASCULITIS
Ehlers-Danlos (type IV) syndrome
Pseudoxanthoma elasticum
Menkes syndrome
Marfan syndrome
Rendu-Osler-Weber syndrome (hereditary hemorrhagic telangiectasia)
Sturge-Weber syndrome
Neurofibromatosis 1
Tuberous sclerosis complex
Polycystic kidney disease (autosomal dominant type 1, 2)
Fibromuscular dysplasia von Hippel-Lindau syndrome
Bannayan-Zonana syndrome
Moyamoya disease (*GUCY1A3*, *RNF213*, unknown)
Fabry disease
CARASIL *(HTRA1)*
CADASIL *(NOTCH3)*
RVCL *(TREX-1)*
DADA2 *(CECR1)*
COL4A1/A2 angiopathies, including:
• Hereditary angiopathy nephropathy and cramps (HANAC)
• Autosomal dominant porencephaly with infantile hemiplegia (POREN1)
FOXC1/PITX2: Digenetic inheritance
CARASAL (*CTSA*)
HCHWA – Dutch type
HCHWA – Icelandic type
FAP
ADA2 deficiency
ACTA2 gene variant
HEMATOLOGIC DISORDERS
Antithrombin deficiency
Protein C and S deficiency
Thrombomodulin deficiency
Activated protein C resistance
Factor V Leiden variant
Prothrombin G20210A variant
Sickle cell disease
Factor V, VII, VIII, IX, X, XI, XII, XIII deficiency
Hemoglobinopathies (hemoglobin C or S disorders)
Prekallikrein deficiency
C2 deficiency
β-thalassemia
Disorders of fibrinogen
• Afibrinogenemia
• Hypofibrinogenemia
• Dysfibrinogenemia
Elevated thrombin-activatable fibrinolysis inhibitor
Elevated factor VIII
Elevated factor IX
Elevated factor XI
Disorders of the fibrinolytic system
• Hypoplasminogenemia
• Tissue plasminogen activator defects
MTHFR gene variant
Heparin cofactor II deficiency
Hereditary platelet defects
CARDIAC DISORDERS
Familial atrial myxomas
Rhabdomyomas (tuberous sclerosis)
Mitral valve prolapse
Cardiac papillary fibroelastoma
Hereditary cardiac conduction disorders
Hereditary cardiomyopathies
INBORN ERRORS OF METABOLISM
Mitochondrial abnormalities
• MELAS
• Leigh disease
• MERRF
Organic acidemia
• Methylmalonic acidemia
• Propionic acidemia
• Isovaleric acidemia
Homocystinuria
Glutaric aciduria type II
Sulfite oxidase deficiency
11β-hydroxylase deficiency, 11β-ketoreductase deficiency, 17α-hydroxylase deficiency
3-Methylcrotonyl-CoA carboxylase 3-hydroxy-3-methylglutaryl-CoA lyase deficiency
OTHER DISORDERS
CCM1 *(KRIT1)*
CCM2 *(CCM2)*
CCM3 *(PDCD10)*

CADASIL, Cerebral autosomal dominant arteriopathy with subcortical infarcts and leukoencephalopathy; CARASAL, cathepsin A–related arteriopathy with strokes and leukoencephalopathy; CARASIL, cerebral autosomal recessive arteriopathy with subcortical infarcts and leukoencephalopathy; CCM, cerebral cavernous malformation; DADA2, deficiency of adenosine deaminase 2; FAP, familial amyloid polyneuropathy; HCHWA, hereditary cerebral hemorrhage with amyloidosis; MELAS, mitochondrial encephalopathy, lactic acidosis, and strokelike episodes; MERRF, mitochondrial encephalopathy with ragged red fibers; RVCL, retinal vasculopathy with deficiency of adenosine deaminase 2.
Modified from Farias-Moeller R. Stroke. In: Kliegman RM, Toth H, Bordini BJ, et al., eds. *Nelson Pediatric Symptom-Based Diagnosis,* 2nd ed. Philadelphia: Elsevier; 2023: Table 37.17, p. 655.

regarding AIS pathogenesis at the time of presentation because it may be indistinguishable from intracranial dissection or early moyamoya disease. FCA can be subclassified as FCA inflammation type, FCA dissection type, and undetermined FCA.

Arterial dissection can be spontaneous or posttraumatic and involves extracranial (carotid, vertebral) arteries more frequently than intracranial arteries. **Moyamoya** demonstrates progressive occlusion of the distal internal carotid arteries. It may be idiopathic **(moyamoya disease)** or associated with other conditions **(moyamoya syndrome)** such as sickle cell anemia, neurofibromatosis type 1, trisomy 21, William syndrome, Alagille syndrome, chromosomal microdeletions/microduplications, and disorders after irradiation (Fig. 641.3). Diffuse, bilateral, progressive **vasculitis** is rare and can represent progressive childhood primary angiitis of the CNS or occur in association with systemic vasculitides (Table 641.4; see also Chapter 642). Cranial infections (e.g., bacterial or tuberculous meningitis) also produce **infectious arteritis** and thrombophlebitis of surface vessels. **Congenital/genetic disorders** of craniocervical arteries include PHACES (posterior fossa abnormalities, hemangioma, and arterial, cardiac, eye, and sternal abnormalities) syndrome, fibromuscular dysplasia, or CADASIL (cerebral autosomal dominant arteriopathy, subcortical infarcts, and leukoencephalopathy). *ACTA2, COL4A1,* and *ADA2* gene variants may be associated with AIS, and new genetic arteriopathic conditions are steadily being added to this list. Hence, targeted genetic testing and whole exome sequencing are recommended (see Table 641.2). Vasospasm, as occurs in migraine, subarachnoid hemorrhage, or reversible

Table 641.3 Risk Factors for Perinatal Arterial Ischemic Stroke (AIS)

TYPE OF RISK FACTOR	RISK FACTORS
TERM INFANTS WITH NEONATAL AIS	
Maternal	Thrombophilia Infertility Prolonged rupture of membranes Preeclampsia or gestational hypertension Smoking Intrauterine growth restriction Infection Maternal fever during delivery Smoking
Fetal	Thrombophilia (MTHFR variant, FVL, prothrombin gene variant, protein C/S deficiency) Congenital heart disease Arteriopathy Twin-twin transfusion syndrome Hypoglycemia Perinatal asphyxia Infection (sepsis/meningitis) Need for resuscitation Apgar score of <7 at 5 min
Placental	Chorioamnionitis Placental infarcts Distal villous immaturity Placenta weighing <10th percentile
PRETERM INFANTS WITH NEONATAL AIS	
Maternal	Infection Gestational bleeding
Fetal	Maternal smoking Maternal drug use Twin-twin transfusion syndrome Twin demise Abnormal fetal heart rate Hypoglycemia Thrombophilia (MTHFR variant, FVL)
PRESUMED PERINATAL AIS	
Maternal	Preeclampsia Infection
Fetal	Gestational bleeding Gestational diabetes Thrombophilia Congenital heart disease

MTHFR, Methylenetetrahydrofolate reductase deficiency; FVL, factor V Leiden deficiency.
Modified from Lehman LL, Rivkin MJ. Perinatal arterial ischemic stroke: presentation, risk factors, evaluation, and outcome. *Pediatr Neurol*. 2014;51:760–768.

cerebral vasoconstriction syndrome (sometimes called *Call-Fleming syndrome*), can cause AIS. Metabolic strokes are seen in organic acidemia, methylmalonic acidemia, propionic acidemia, isovaleric acidemia, glutaric aciduria type II, mitochondrial encephalomyopathies, MELAS (mitochondrial encephalopathy, lactic acidosis, and stroke-like episodes), MERRF (mitochondrial encephalopathy with ragged red fibers), MERRF/MELAS overlap syndrome, and Kearns-Sayre syndrome.

Cardioembolic stroke makes up approximately 25% of childhood AIS cases, with the maximal embolic risk concurrent with interventional catheterization, surgical repair, or ventricular assist device use. AIS complicates approximately 0.5% of pediatric cardiac surgeries, and reoperation increases the risk. Although **complex congenital heart diseases** are most frequently associated with AIS, acquired conditions, including arrhythmia, cardiomyopathy, and infective endocarditis, should also be considered. A **patent foramen ovale**

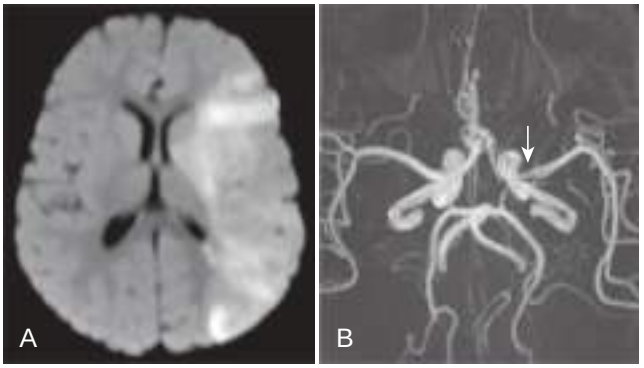

Fig. 641.2 A, Axial diffusion-weighted magnetic resonance imaging demonstrating hyperintense signal in the left middle cerebral artery distribution consistent with acute infarct. B, Magnetic resonance angiography axial maximum intensity projection images demonstrating narrowing of the left middle cerebral artery M1 segment *(arrow). (From Vora SB, Amlie-Lefond C, Perez FA, et al. Varicella-associated stroke. J Pediatr. 2018;199:281, p. 281.)*

provides a possible conduit for paradoxical venous thromboembolism to the brain. All children with suspected AIS require a thorough cardiovascular examination, an electrocardiogram, and an echocardiogram. Prothrombotic coagulation disorders and infection identified at the time of the index cardiogenic stroke increase the stroke recurrence risk.

Hematologic disorders associated with AIS include **sickle cell anemia**, in which the stroke risk is increased 400-fold, although effective screening (using transcranial Doppler) and transfusion therapy have reduced the incidence. Iron-deficiency anemia also increases the risk and is easily treatable. **Coagulation disorders** are associated with childhood AIS. They include hereditary (e.g., factor V Leiden) and acquired (e.g., antiphospholipid antibodies, lipoprotein-a elevation) **prothrombotic states** and **prothrombotic medications**, including oral contraceptives and asparaginase chemotherapy. Additional AIS risk factors include migraine, acute childhood illnesses, chronic systemic illnesses, illicit drugs and toxins, and rare inborn errors of metabolism.

Treatment of childhood AIS is multifaceted, and multiple consensus-based guidelines are available. The safety and efficacy of thrombolysis and/or thrombectomy in children with AIS has only been reported anecdotally. Nonetheless, some pediatric stroke centers offer thrombolysis with or without thrombectomy for pediatric patients with AIS. Most candidates are preteen or adolescent patients with AIS; younger children may also be candidates for thrombolysis but often have mimics of stroke and must be evaluated carefully for other diagnoses. In adults, treatment with both thrombolysis (~4.5 hours) and endovascular thrombectomy (~16-24 hours) results in improved functional outcome. Pending additional data, for younger children (e.g., <5 years age who often have comorbidities, e,g., congential heart disease), thrombectomy treatment should probably be avoided.

Early initiation of antithrombotic strategies is paramount to prevent early reinfarction. Depending on the suspected cause, this includes anticoagulation with heparin or antiplatelet strategies, usually aspirin. Hyperacute neuroprotective strategies are essential to initiate within minutes in suspected stroke because they prevent progressive ischemic brain injury. These include control of blood glucose (avoid hypoglycemia and hyperglycemia) and temperature (avoid hyperthermia, maintain normal temperature) and maintenance of adequate cerebral perfusion (avoid hypotension and hypertension) and oxygenation. Urgent treatment of seizures is an important neuroprotective strategy, including possible monitoring with continuous electroencephalography (EEG). Early malignant infarct edema is life-threatening, more common in children, and predictable, and emergency surgical decompression can be lifesaving. Disease-specific treatments include transfusion therapy in sickle cell disease, immunosuppression in vasculitis, and revascularization surgery in moyamoya. Long-term

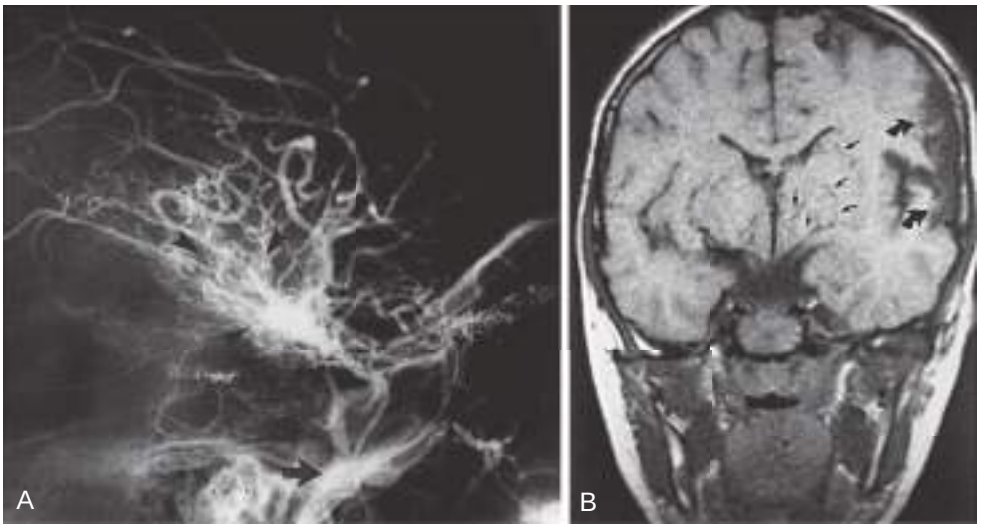

Fig. 641.3 Sudden onset of right hemiparesis in a 6-yr-old male. **A,** Cerebral angiogram shows the left internal carotid artery *(arrow)* leading to a highly arborized, telangiectatic network of vessels *(arrowheads)* characteristic for moyamoya disease. The typical middle cerebral artery vascular tree is absent. **B,** Cranial coronal MRI scan shows region of low signal in the middle cerebral artery territory and denotes infarction *(curved arrows)*. Flow voids in the basal ganglia *(straight arrows)* are radiographic manifestations of the basilar collateral circulation typical of this vascular anomaly. *(From Farias-Moeller R. Stroke. In Kliegman RM, Toth H, Bordini BJ, Basel D, eds. Nelson Pediatric Symptom-Based Diagnosis, 2nd ed. Philadelphia: Elsevier; 2023, Fig. 37.17, p. 653.)*

Table 641.4 Classification of Cerebral Vasculitis

INFECTIOUS VASCULITIS BACTERIAL, FUNGAL, PARASITIC Spirochetal (syphilis, Lyme disease, leptospirosis) Viral, rickettsial, mycobacterial, free-living amebae, cysticercosis, other helminths
NECROTIZING VASCULITIDES CLASSIC POLYARTERITIS NODOSA Granulomatosis with polyangiitis Eosinophilic granulomatosis with polyangiitis Necrotizing systemic vasculitis overlap syndrome Lymphomatoid granulomatosis
VASCULITIS ASSOCIATED WITH COLLAGEN VASCULAR DISEASE Systemic lupus erythematosus Rheumatoid arthritis Scleroderma Sjögren syndrome
VASCULITIS ASSOCIATED WITH OTHER SYSTEMIC DISEASES Behçet disease Ulcerative colitis Sarcoidosis Relapsing polychondritis Kohlmeier-Degos disease Takayasu arteritis
HYPERSENSITIVITY VASCULITIDES IgA vasculitis Drug-induced vasculitides
CHEMICAL VASCULITIDES MISCELLANEOUS VASCULITIDES VASCULITIS ASSOCIATED WITH NEOPLASIA Vasculitis associated with radiation Cogan syndrome Dermatomyositis–polymyositis X-linked lymphoproliferative syndrome Kawasaki disease Primary central nervous system vasculitis

From Biller J, Mathews KD, Love BB. *Stroke in Children and Young Adults.* Boston: Butterworth-Heinemann; 1994.

treatment goals include **secondary stroke prevention**, for example with antiplatelet therapy in arteriopathy and anticoagulation in cardiogenic causes. Multimodal, family-centered rehabilitation programs are required for most survivors, targeting motor deficits, language and intellectual impairments, behavioral and social disabilities, and epilepsy. Long-term attention to arterial health lifestyle factors is also important. Outcomes after childhood AIS include recurrent stroke in 10–50%, depending on the cause and preventive treatment, death in 2–6%; neurologic deficits in 60–70% (usually mild); and seizure disorders long-term in 30%.

Adolescents and young adults with idiopathic (cryptogenic) AIS and a patent foramen ovale (PFO) may benefit from percutaneous PFO closure to prevent a recurrent stroke.

PERINATAL ARTERIAL ISCHEMIC STROKE

Perinatal stroke is common. It differs from childhood stroke, and it has two distinct clinical presentations. Acute symptomatic neonatal AIS presents with focal seizures within 24-28 hours of birth (Fig. 641.4 and see Table 641.3). Cranial ultrasound frequently misses the diagnosis of AIS. MRI diffusion abnormalities in an arterial territory confirm recent infarction. Alternatively, some affected neonates are asymptomatic at birth and present in later infancy with signs of early hand preference and congenital hemiparesis. Hand dominance within the first year of life is abnormal and may be the result of perinatal stroke. Imaging reveals focal encephalomalacia in an arterial territory, typically porencephaly in the middle cerebral artery territory.

In acute neonatal AIS, seizure control is important, but antithrombotic agents are rarely required because recurrent stroke is rare; the exceptions are neonates with congenital heart disease and cardiac embolism, prothrombotic disorders, and, perhaps, those with congenital arterial anomalies (stenosis, hypoplasia). The pathophysiology is complex and poorly understood. Most are idiopathic, although established causes include congenital heart disease, thrombotic placentopathy, and meningitis. The role of prothrombotic conditions in noncardiac neonatal AIS is controversial, but they likely play an additive role alongside other risk factors. Many other maternal, prenatal, perinatal, obstetric, and neonatal factors have been investigated with several strong associations found (e.g., chorioamnionitis, infertility, primiparity, monozygotic twins). Outcomes include normal or mild deficit in ~50% of children; however, ~25% of children have significant long-term disabilities. Perinatal stroke accounts for most cases of hemiparetic cerebral palsy (congenital hemiplegia, see Chapter 638.1). Additional morbidity, seen in ~25%, includes disorders of language, learning, cognition, and behavior and longer-term epilepsy. Stroke recurrence rates in subsequent pregnancies are extremely low in the absence of a familial prothrombotic disorder.

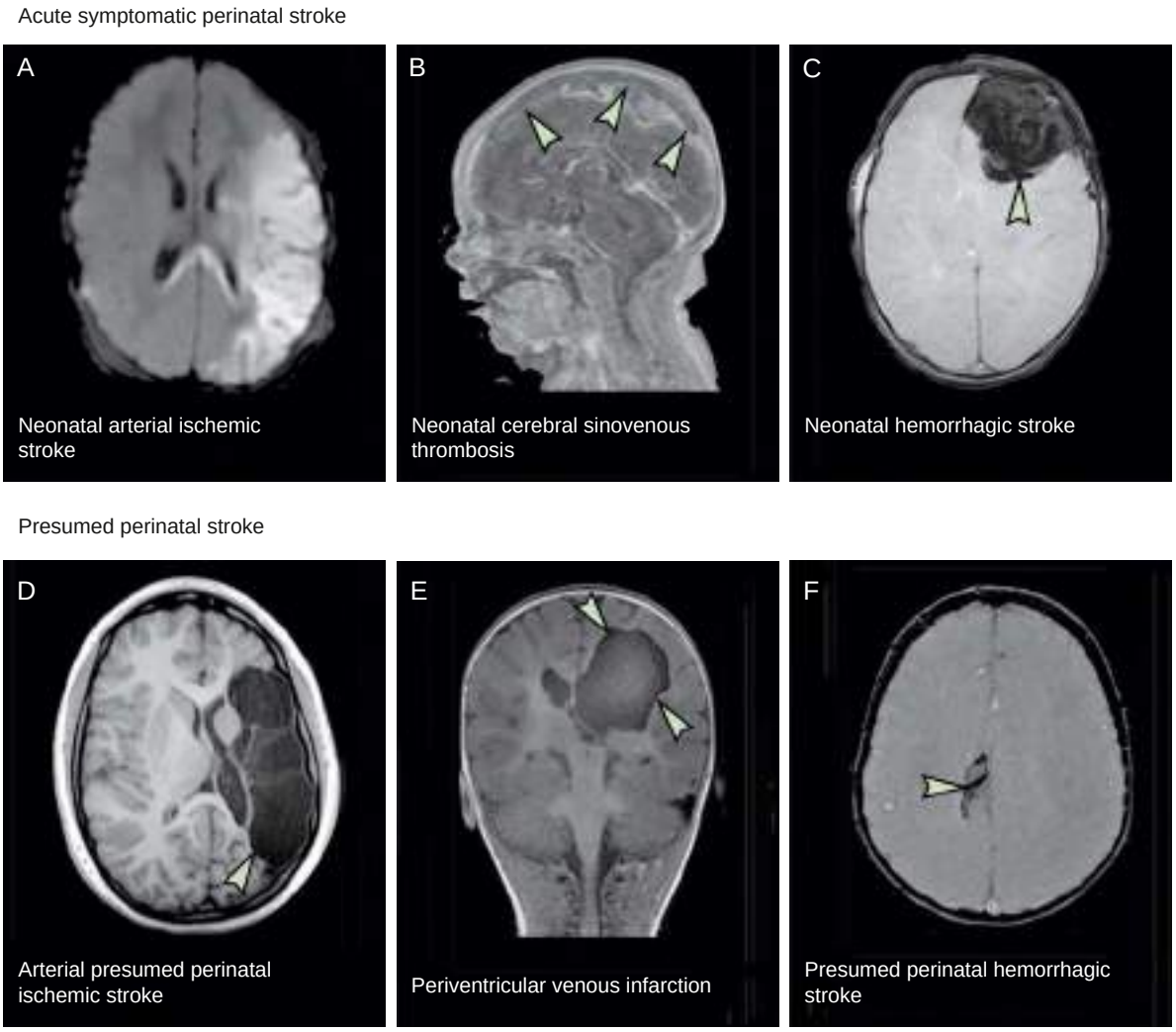

Fig. 641.4 Perinatal stroke diseases by MRI. **A,** Neonatal arterial ischemic stroke features acute restriction on axial diffusion-weighted MRI in an arterial territory; diaschisis of the splenium of the corpus callosum is also evident. **B,** Neonatal cerebral sinovenous thrombosis is evident as a filling defect on sagittal MR venogram (shown), in this case, in the superior sagittal sinus *(arrows).* **C,** Neonatal hemorrhagic stroke detectable on gradient echo or susceptibility-weighted MRI *(arrow).* **D,** Arterial presumed perinatal ischemic stroke in a child with hemiparesis is diagnosed by focal encephalomalacia on CT or MRI (axial T1-weighted MRI shown) in an arterial territory *(arrow).* **E,** Periventricular venous infarction presents with congenital hemiparesis with a focal lesion affecting the periventricular white matter with sparing of the cortex and basal ganglia, shown on coronal T1-weighted MRI (porencephaly indicated with *arrows*). **F,** Presumed perinatal hemorrhagic stroke with a focal area of remote parenchymal injury showing hemorrhage (gradient echo, *arrow*). *(From Dunbar M, Kirton A. Perinatal stroke: mechanisms, management, and outcomes of early cerebrovascular brain injury. Lancet. 2018;2:666–676, Fig. 2, p. 668.)*

Visit Elsevier eBooks+ at eBooks.Health.Elsevier.com for Bibliography.

641.2 Cerebral Sinovenous Thrombosis

Nomazulu Dlamini and Gabrielle A. deVeber

Cerebral venous drainage occurs via the cerebral sinovenous system. The superficial system (i.e., cortical veins, superior sagittal sinus) and deep system (i.e., internal cerebral veins, straight sinus) converge at the torcula to exit the cranial vault via the paired transverse and sigmoid sinuses and jugular veins. In cerebral sinovenous thrombosis (CSVT), thrombotic occlusion of these venous structures can create regional or diffuse increased intracranial pressure, cerebral edema, and, in 50% of cases, venous infarction or hemorrhage (venous stroke). CSVT is more common in children than in adults, and risk is greatest in the neonatal period (Table 641.5).

Clinical presentations are typically gradual, variable, and nonspecific compared with AIS. Neonates often present with encephalopathy and seizures. Children may present with symptoms mimicking idiopathic intracranial hypertension, including progressive headache, papilledema, diplopia secondary to sixth cranial nerve palsy, or acute focal deficits. Seizures, lethargy, and confusion are common. Diagnosis requires a high clinical suspicion and specifically requested imaging of the cerebral venous system. Nonenhanced CT is insensitive in detecting CSVT, and so either contrast **CT venography** or MR venography is necessary to demonstrate filling defects in the cerebral venous system (Fig. 641.5). MRI offers superior parenchymal imaging compared with CT.

Table 641.5 lists the risk factors for CSVT. **Prothrombotic states** associated with childhood CSVT include inherited conditions (e.g., prothrombin gene mutation of 20210A) and acquired conditions (e.g., antiphospholipid antibodies), prothrombotic medications (e.g., asparaginase, oral contraceptives), and common childhood illnesses (e.g., otitis media, iron-deficiency anemia, and dehydration). **Systemic diseases** associated with increased risk of CSVT include leukemia, inflammatory bowel disease, and nephrotic syndrome.

Head and neck disorders can directly involve cerebral veins and sinuses thereby causing CSVT. Common infections, including

Table 641.5 Causes of Cerebral Venous Thrombosis

IDIOPATHIC PROTHROMBOTIC STATE	**INFECTIONS**
Protein C or S deficiency	Herpes zoster virus
Antithrombin deficiency	Myeloidosis
Factor V Leiden variant	Mucormycosis
Activated protein C resistance	Aspergillosis
Prothrombin G20210A variant	Pneumococcal meningitis
Variants in thrombomodulin	Syphilis
Platelet glycoprotein IIIa (β_3) variant	HIV
Heparin cofactor II deficiency	Otitis media
Variants in plasminogen gene	Mastoiditis
MTHFR C677 variant	Sinusitis
Dysfibrinogenemia	Peritonsillar abscess
Elevated plasminogen activator inhibitor	Endotoxemia
Tissue plasminogen activator deficiency	Trichinosis
Increased factors VIII, IX, X; von Willebrand factor	Sepsis
Variants in tissue factor pathway inhibitor	**VASCULITIDES**
Sickle cell disease and trait	Behçet disease
Reactive thrombocytosis and essential thrombocythemia	Sarcoidosis
Pregnancy and puerperium	Polyangiitis with granulomatosis
POSTOPERATIVE STATE	Systemic lupus erythematosus
Antiphospholipid antibody syndrome	Polyarteritis nodosa
Hyperhomocysteinemia	**TRAUMA**
Homocystinuria	Head trauma
Cancer	Neurosurgical procedures
Inflammatory bowel diseases	Strangulation
Dehydration	Intravenous catheters
Congestive heart failure	Cardiac pacemakers
Paroxysmal nocturnal hemoglobinuria	**OTHERS**
Marasmus	Osteopetrosis
Iron-deficiency anemia	Malignant atrophic papulosis (Kohlmeier-Degos disease)
Nephrotic syndrome	Chronic lung disease
Thrombocytopenia	Diabetes mellitus
Essential thrombocythemia	Budd-Chiari syndrome
Disseminated intravascular coagulation	Arteriovenous malformation
Thrombotic microangiopathies	Sturge-Weber syndrome
Polycythemia vera and secondary polycythemia	Cerebral arterial occlusions
Hyperlipidemia	Neoplasm (meningioma, metastasis, glomus tumors)
Familial histidine-rich glycoprotein deficiency	
DRUGS	
Asparaginase	
Estrogen and oral contraceptives	
Androgen	
ε-Aminocaproic acid	
Cisplatin and etoposide	
Medroxyprogesterone	
Heparin (heparin-induced thrombocytopenia)	
Immunoglobulin G (intravenous immunoglobulin)	

From Biller J. *Stroke in Children and Young Adults*. 2nd ed. Philadelphia: Saunders; 2009: Table 12-3, p. 237.

meningitis, otitis media, and mastoiditis, can cause **septic thrombophlebitis** of venous channels. CSVT can complicate head trauma especially in veins/venous sinuses adjacent to skull fractures. Neurosurgical procedures in proximity to cerebral venous structures may also lead to injury and CSVT. Finally, obstruction of the jugular veins and proximal stasis may result in CSVT. In neonates, because the cranial sutures are unfused, mechanical distortion of the underlying venous sinuses may occur and predispose to CSVT either during labor and delivery or with supine lying because of occipital bone compression of the posterior sagittal sinus.

Anticoagulation therapy plays an important role in childhood CSVT treatment. Substantial indirect evidence has led to a consensus recommendation for anticoagulation with unfractionated or low molecular weight heparins in most children. The presence of hemorrhagic venous infarcts is not an absolute contraindication. Treatment is usually planned for 6 months, although if reimaging at 3 months confirms recanalization, treatment is usually discontinued. However, anticoagulation of neonates is more controversial, and guidelines differ. Evidence suggests that 30% of untreated neonates and children will extend their thrombosis in the first week after diagnosis, and additional venous infarction can result. Therefore if anticoagulation is withheld, early (e.g., 5-7 days) repeat venous imaging is paramount. Protocols supporting initial anticoagulation recommend shorter treatment durations (i.e., 6 weeks to 3 months) in neonates. Children with persistent risk factors may require prophylactic long-term anticoagulation. At initial diagnosis, supportive interventions include management of infection, detection and treatment of seizures, and neuroprotective measures (e.g., normothermia, normotension, normovolemia, normoglycemia). **Compressive optic neuropathy** secondary to prolonged increased intracranial pressure after CSVT is an important complication that can lead to permanent visual loss. Regular funduscopic examination by an ophthalmologist and treatment directed at reducing intracranial pressure (e.g., acetazolamide, serial lumbar puncture) may be required. Most neurologic morbidity is suffered by those incurring venous infarction. Consistent with other forms of childhood stroke, a comprehensive neurorehabilitation program is required.

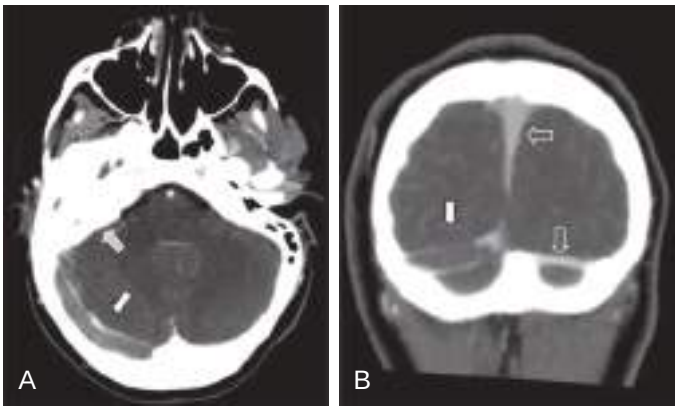

Fig. 641.5 Cerebral sinovenous thrombosis. A 9-yr-old female presented with fever and progressive right-sided headache. She complained of double vision and had papilledema on examination. Axial (**A**) and coronal (**B**) CT venography demonstrates a large thrombus in the right transverse sinus that fails to opacify with contrast *(solid arrows)*. Note normal filling in superior sagittal sinus and smaller left transverse sinuses *(open arrows, right)* and opacification of the mastoid air cells *(hatched arrow, left)*. The cause was otitis media/mastoiditis with septic thrombophlebitis of transverse sinus.

Visit Elsevier eBooks+ at eBooks.Health.Elsevier.com for Bibliography.

641.3 Spinal Cord Lesions Associated with Vascular Processes

Nomazulu Dlamini and Gabrielle A. deVeber

Most cases of **transverse myelitis** (TM) in childhood are postinfectious or, if recurrent, are associated with underlying demyelinating processes, such as multiple sclerosis (see Chapter 640.4) or neuromyelitis optica (see Chapter 640.2). However, in a small proportion of children presenting with acute spinal cord symptoms, infarction and necrosis may occur. This pathology may be associated with disease of the vessels, such as systemic lupus erythematosus (SLE)–associated **vasculitis** (see Chapter 199) or other vascular events such as **embolism** (including nucleus propulsus embolism–fibrocartilaginous embolism). Rarely, **arteriovenous malformations** of the spinal cord may exist and may cause myelopathy and infarction with hemorrhage in the spinal cord. An acute onset and a peak of symptoms over minutes to hours suggest a vascular process.

VASCULITIC PROCESSES: SYSTEMIC LUPUS ERYTHEMATOSUS

Most cases of SLE-associated *myelitis* are longitudinally extensive, and although reports in pediatric populations are rare, the disorder can occur. In 23–60% of cases, myelitis may be the first clinical manifestation of lupus and in many cases occurs at times of low systemic SLE disease activity. Poor recovery is frequent in these cases, with only 14% of patients experiencing complete recovery. In children, other vasculitic etiologies of cord disease, such as Bechet disease, exist.

SPINAL CORD EMBOLISM

Other rare etiologies of an acute increased T2 signal on a spinal cord MRI presenting clinically as TM include cord infarction caused by thromboembolism, either the result of fibrocartilaginous embolism or originating from a lower segment vertebral artery dissection or aortic dissection at the artery of Adamkiewicz. Ischemic myelopathy caused by a **vertebral artery dissection** occurs in the cervical spine; however, fibrocartilaginous embolism may occur anywhere in the spinal cord. A hyperacute onset and lesion appearance (wedge-shaped distribution) together with MRI diffusion-weighted imaging showing diffusion restriction may be helpful in distinguishing ischemic thromboembolic abnormalities from inflammatory TM.

Clinical Manifestations

Similar to *inflammatory* TM, patients present with acute onset of motor weakness accompanied by sensory abnormalities. The weakness progresses over minutes to hours. Pain or discomfort localized to the back or neck, depending on lesion localization, is frequent, with rapid progression of motor weakness and early areflexia reflecting **spinal shock**. Spasticity, hyperreflexia, and clonus occur in the ensuing weeks. A sensory level and motor weakness are present distal to the lesion, with urinary symptoms, including urinary retention, a frequent occurrence.

Investigations

MRI of the spinal cord, including T1- and T2-weighted axial as well as sagittal cuts with gadolinium, are necessary to evaluate for the presence of a focal spinal cord lesion. Given the frequency of longitudinally extensive lesions in myelopathy in pediatric populations, both cervical and thoracic spine imaging should be included in all patients presenting with acute TM. Inclusion of imaging sequences sensitive for hemorrhage (gradient echo sequences) may help, as will diffusion sequences. The inclusion of brain MRI scans, including associated vascular imaging of head and neck vessels, are useful to evaluate the possibility of large-vessel disease. In the event of a cervical spine lesion combined with ischemic brain lesions in the distribution of the posterior circulation, vertebral artery dissection should be investigated.

Lumbar puncture can be performed once MRI evaluation has ruled out a severe cord expansion or mass leading to complete spinal column block. Although inflammatory TM may be associated with elevations in the CSF white blood cells (WBCs) and protein, ischemic myelopathy caused by embolism does not show an acute pleocytosis. However, in a vasculitic event such as myelopathy associated with SLE, increased CSF protein and WBCs may be present.

Serum testing for the presence of underlying rheumatologic disorders should be performed in patients presenting with TM. A workup for hypercoagulable states should also be performed in cases with a high suspicion for ischemic myelopathy.

TREATMENT

In addition to supportive care, treatment is directed at the suspected underlying disease process. Given the low likelihood of complete recovery in ischemic lesions of the spinal cord and the significant disability associated with spinal cord injury, when underlying etiologies such as SLE are found, prophylactic treatment is recommended. Supportive care, including pain control for neuropathic pain, spasticity management, and management of urinary symptoms, is frequently required in this population. When vascular abnormalities are identified or if ischemic myelitis is the suspected cause, low-dose aspirin (2-4 mg/kg/day) for prevention of recurrence may be indicated.

Visit Elsevier eBooks+ at eBooks.Health.Elsevier.com for Bibliography.

641.4 Hemorrhagic Stroke

Nomazulu Dlamini and Gabrielle A. deVeber

HS includes nontraumatic intracranial hemorrhage and is classified by the intracranial compartment containing the hemorrhage. Intraparenchymal bleeds may occur in any location within the brain's substance. Intraventricular hemorrhage may be isolated within ventricles or an extension of intraparenchymal hemorrhage. Bleeding outside the brain may occur in the subarachnoid, subdural, or epidural spaces.

Clinical presentations vary according to location, cause, and rate of bleeding. Acute hemorrhages may feature instantaneous or **thunderclap headache**, loss of consciousness, and nuchal rigidity in addition to focal neurologic deficits and seizures. HS can be rapidly fatal. In bleeds associated with vascular malformations, pulsatile tinnitus,

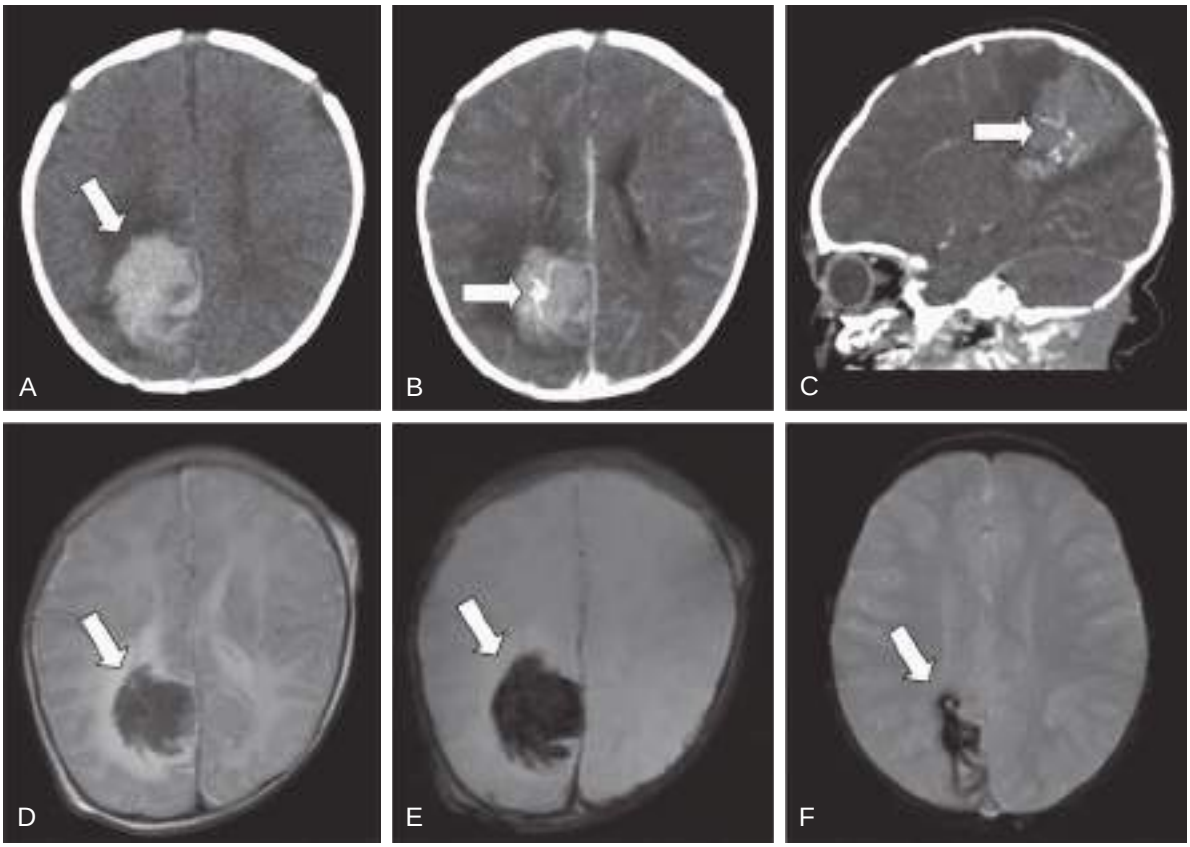

Fig. 641.6 Hemorrhagic stroke. A healthy 1-mo-old presented with sudden-onset irritability followed by focal left body seizures. Plain CT scan of head demonstrates a large hyperdense lesion in the right parietal region with surrounding edema, consistent with acute hemorrhage (**A**). Axial (**B**) and sagittal (**C**) contrast CT scans suggest an abnormal cluster of vessels in the center of the hemorrhage, consistent with an arteriovenous malformation. T2-weighted MRI differentiates the acute hemorrhage from surrounding edema (**D**). Gradient echo MRI, both acutely (**E**) and at 3 mo (**F**), demonstrates the presence of blood product.

cranial bruit, macrocephaly, and high-output heart failure may be present. The diagnosis relies on imaging, and CT scanning is highly sensitive to acute HS. However, lumbar puncture may be required to exclude subarachnoid hemorrhage. MRI is highly sensitive to even small amounts of both acute and chronic hemorrhage and offers improved diagnostic accuracy (Fig. 641.6). Angiography by CT, MR, or conventional catheterization means is often required to exclude underlying vascular abnormalities (e.g., vascular malformations, aneurysms).

Abusive head trauma with intracranial bleeding in children may present as primary subdural or parenchymal hemorrhage with no apparent history of trauma. Clinicians should search for the following: subtle scalp, suborbital, or ear bruising; retinal hemorrhages in multiple layers; and chronic failure to thrive. In infants with subdural bleeds, x-rays should be performed to rule out fractures. Epidural hematoma is nearly always caused by trauma, including middle meningeal artery injury typically associated with skull fracture. Subdural hematoma can occur spontaneously or with trivial trauma in children with brain atrophy because of stretching of bridging veins.

Causes of and risk factors for HS (Table 641.6) include vascular malformations and systemic disorders. **Arteriovenous malformations** are the most common cause of childhood subarachnoid and intraparenchymal HS and may occur anywhere. Neonates with vein of Galen malformations may present with heart failure, progressive macrocephaly, or, rarely, hemorrhage. In older children with arteriovenous malformations, the risk of bleeding is approximately 2–4% per year throughout life. Somatic gene variants in *KRAS* have been noted in some patients with arteriovenous malformations of the brain. Other vascular malformations leading to HS include cavernous angiomas **(cavernomas)**, dural arteriovenous fistulas, and vein of Galen malformations (Fig. 641.7). Cerebral cavernous malformations may be sporadic or familial (autosomal dominant) and associated with gene variants in the *CCM1, CCM2,* or *CCM3* genes. Cerebral aneurysms are a less common cause of subarachnoid hemorrhage in children and may suggest an underlying disorder (e.g., polycystic kidney disease, infective endocarditis) (Fig. 641.8 and Table 641.7). A common cause for HS is bleeding from a preexisting brain tumor. Arterial diseases that usually cause ischemic stroke, including fibromuscular dysplasia, vasculitis, intracranial dissection, and moyamoya, can also predispose to HS. Additional causes of parenchymal HS include hypertensive hemorrhage and hematologic disorders such as thrombocytopenic purpura, hemophilia, acquired coagulopathies (e.g., disseminated intravascular coagulopathy, liver failure), anticoagulant therapy (e.g., warfarin), or illicit drug use. Ischemic infarcts may undergo hemorrhagic transformation, particularly in CSVT, and may be difficult to differentiate from primary HS.

Management of acute childhood HS requires emergency neurosurgical intervention for a large or rapidly expanding hemorrhage. The same principles of neuroprotection for vulnerable brain suggested in the AIS sections also apply to HS. Reversal of anticoagulant therapy (with, for example, vitamin K, fresh-frozen plasma) may be required. The recurrence risk for those with structural lesions is significant, and serial imaging may be required. Definitive repair or removal of the vascular malformation may require a combined approach with interventional endovascular methods and neurosurgery. Outcomes from childhood HS are not well studied but likely depend on lesion size,

Table 641.6 Causes of Spontaneous Intracerebral Hemorrhage in Young Adults

VASCULAR MALFORMATIONS AVMs Capillary telangiectasias (HTT) Cavernous malformations Developmental venous anomalies	**ICELANDIC FORM OF CAA** **ARTERITIS/ARTERIOPATHIES** Infectious vasculitides Multisystem vasculitides Isolated CNS angiitis Moyamoya disease HANAC syndrome
ANEURYSMS Saccular Infective Traumatic Neoplastic	**DRUG RELATED** Amphetamines Cocaine Phenylpropanolamine Pentazocine (Talwin)– tripelennamine (Pyribenzamine) Phencyclidine Heroin Monoamine oxidase inhibitor Other drugs
ARTERIAL HYPERTENSION Secondary Primary	**INTRACRANIAL TUMORS** Primary malignant or benign Metastatic
BLEEDING DIATHESES Leukemia Thrombocytopenia Disseminated intravascular coagulation Polycythemia Hyperviscosity syndromes Hemophilia Hypoprothrombinemia Afibrinogenemia Selective factor deficiencies von Willebrand disease Sickle cell anemia Antiplatelet therapy Anticoagulant therapy Thrombolytic therapy Vitamin K deficiency	**CEREBRAL VENOUS OCCLUSIVE DISEASE** **MISCELLANEOUS** Post–carotid endarterectomy Post–selective neurosurgical procedures Post–spinal anesthesia Postmyelography Cold related Post–painful dental procedures Protracted migraine Methanol intoxication

AVM, Arteriovenous malformation; CAA, cerebral amyloid angiopathy; CNS, central nervous system; HANAC, hereditary angiopathy with nephropathy, aneurysms, muscle cramps; HHT, hereditary hemorrhagic telangiectasia.

From Farias-Moeller R. Stroke. In: Kliegman RM, Toth H, Bordini BJ, et al., eds. *Nelson Pediatric Symptom-Based Diagnosis,* 2nd ed. Philadelphia: Elsevier; 2023: Table 37.2, p. 633.

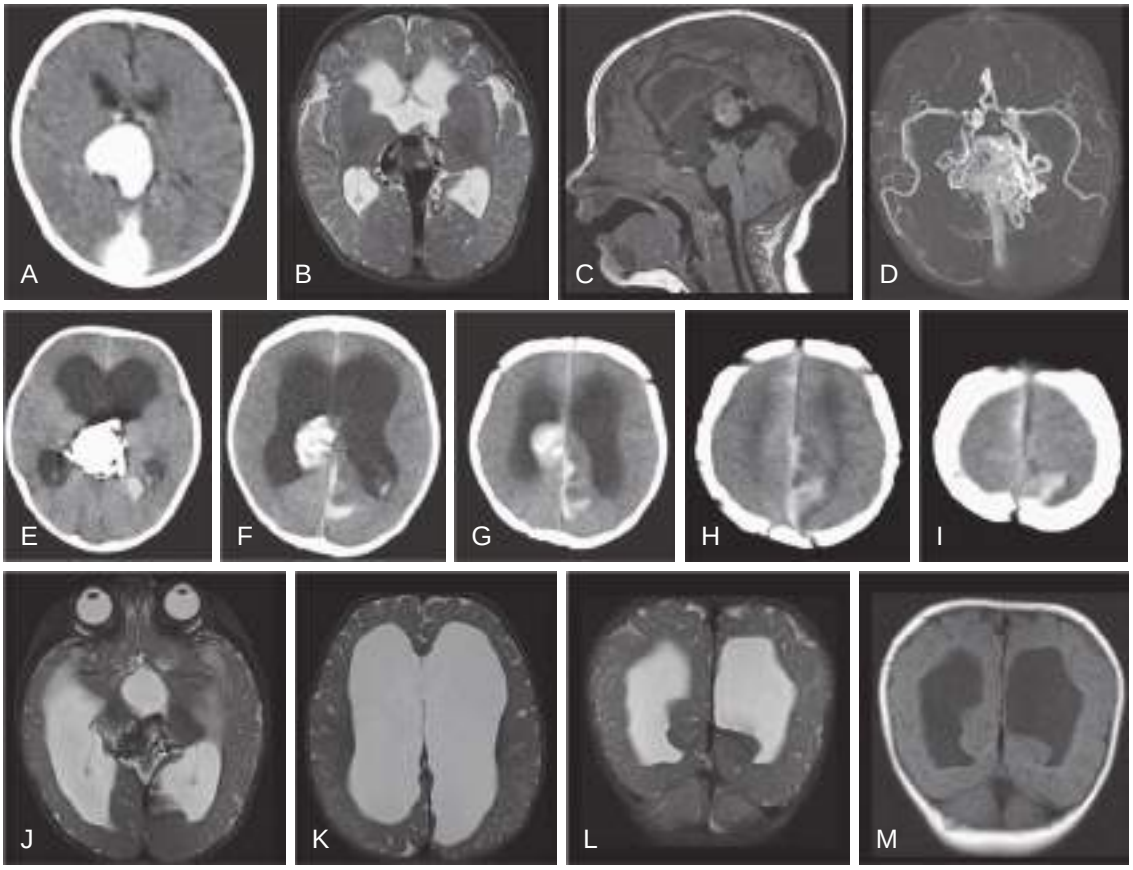

Fig. 641.7 Neonatal vein of Galen malformation and intraventricular hemorrhage. A 5-day-old female born at 38 weeks was noted to be drowsy with poor feeding. She had signs of cardiac failure. A CT scan (**A**) demonstrates vein of Galen aneurysmal malformation, which was partly treated by transarterial glue embolization without complication but with significant residual arteriovenous shunting (**B-D**). After a second embolization procedure, there was acute clinical deterioration with signs of raised intracranial pressure (**E-I**). CT shows acute intraventricular hemorrhage and hydrocephalus and a left parieto-occipital lobe low-density lesion (**E-G**) with adjacent subarachnoid and subdural hematoma (**H** and **I**). Some linear hyperdensity was believed to be the result of thrombus within the persistent falcine sinus (**H** and **I**). Follow-up imaging shows maturation of the focal left parieto-occipital lesion in keeping with an infarct (**J-M**), which is probably venous in origin. *(From Gunny RS, Lin D. Imaging of pediatric stroke. Magn Reson Imaging Clin North Am. 2012;20:1–33, Fig. 18.)*

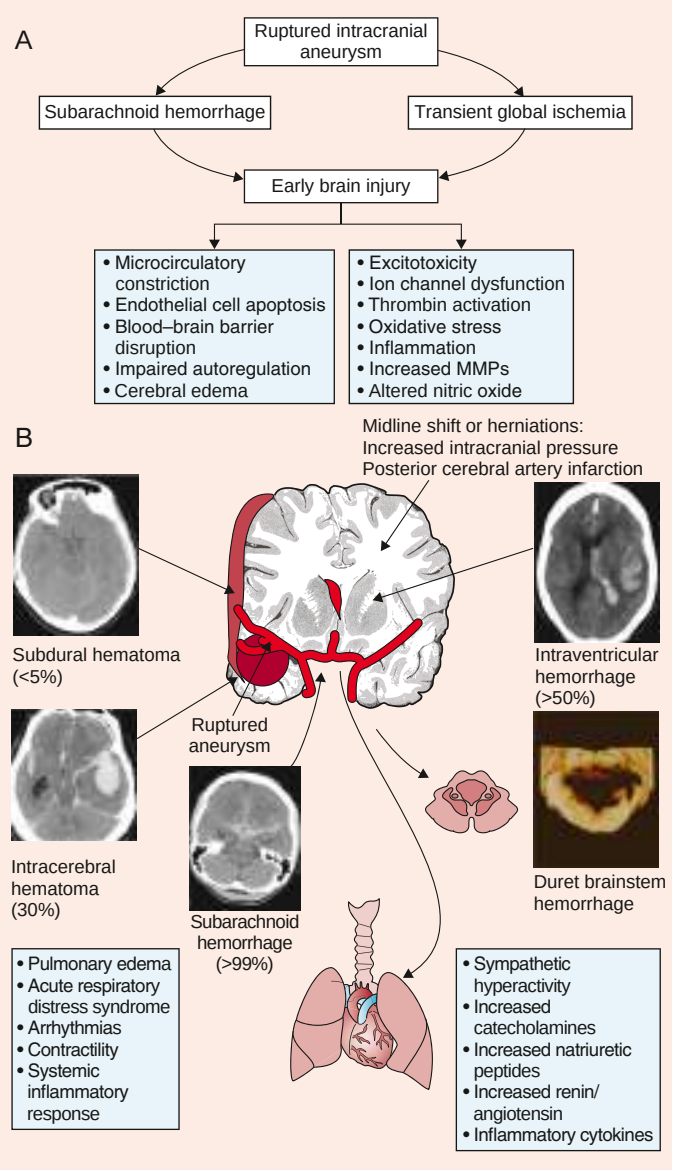

Fig. 641.8 Pathophysiology of subarachnoid hemorrhage. Hemorrhage into various compartments (subarachnoid, intraventricular, intracerebral, subdural) can cause brain shift, increased intracranial pressure, herniation, Duret brainstem hemorrhages, and death. Systemic effects of subarachnoid hemorrhage include cardiac and pulmonary complications. Brain injury from this condition initially is the result of transient global ischemia and effects of the hemorrhage. Delayed neurologic complications can ensue. MMPs, Matrix metalloproteinases. *(From Macdonald RL, Schweizer TA. Spontaneous subarachnoid haemorrhage. Lancet. 2017;389:655–666, Fig. 2.)*

location, and etiology. Compared with AIS, the HS mortality rate is higher, but long-term deficits are less common.

Neonatal HS has unique features. Cranial ultrasound can detect many neonatal parenchymal bleeds, especially in the preterm infant, where bleeds are located centrally within the cranium including germinal matrix bleeding and intraventricular hemorrhage, and in the cerebellum (see Chapter 122.3). Germinal matrix injury or bleeding may also occur in utero, resulting in periventricular venous infarction that presents in later infancy as chronic hemiparesis. Subarachnoid and subdural blood are common postpartum in normal-term newborns and may be detected by imaging in up to 25%. Term newborn HS is poorly studied and includes the etiologies listed earlier, although HS may be idiopathic in more than 50% of cases. Term intraventricular bleeding is often secondary to deep CSVT with specific management implications.

Visit Elsevier eBooks+ at eBooks.Health.Elsevier.com for Bibliography.

Table 641.7 Causes of Spontaneous Subarachnoid Hemorrhage in Young Adults

Cerebral aneurysm rupture
Perimesencephalic hemorrhage
Vascular malformation rupture (arteriovenous malformation, arteriovenous fistula, cavernous malformations)
Other
Congenital disorders
Coarctation of the aorta
Pseudoxanthoma elasticum
Menkes kinky hair syndrome
Sturge-Weber syndrome
Tuberous sclerosis complex
Neurofibromatosis 1 (von Recklinghausen disease)
Hereditary hemorrhagic telangiectasia (Rendu-Osler disease)
Ehlers-Danlos syndrome
Klinefelter syndrome
Autosomal dominant polycystic kidney disease
Systemic vascular disease
Hypertension
Cerebral embolism
Moyamoya disease
Cerebral venous occlusive disease
Eclampsia
Hematologic disorders
Hemophilia
Aplastic anemia
Sickle cell anemia
Leukemias
Thrombocytopenic purpura
Anticoagulant therapy
Thrombolytic therapy
Infectious diseases
Infective endocarditis
Tuberculous meningitis
Luetic meningoencephalitis
Fungal central nervous system infections
Infectious mononucleosis
Tickborne relapsing fever
Autoimmune disorders
Systemic lupus erythematosus
Polyarteritis nodosa
Henoch-Schönlein purpura
Poststreptococcal glomerulonephritis
Kawasaki disease
Other systemic diseases
Heat stroke
Conn syndrome
Thyrotoxicosis
Wolman disease
Spinal endometriosis
Neoplasms
Gliomas
Meningiomas
Acoustic neuromas
Choroid plexus papillomas
Pituitary adenomas
Pineocytomas
Chordomas
Subependymomas
Metastatic carcinoma
Intraspinal neoplasms
Drugs
Amphetamines
Cocaine
Ephedrine
Monoamine oxidase inhibitors
Oral contraceptive pills
Phencyclidine
Alcohol
Miscellaneous
α-Galactosidase deficiency
α_1-Antitrypsin deficiency
Cystic fibrosis
Klippel-Trénaunay-Weber syndrome
Parry-Romberg syndrome
3-M syndrome

From Biller J. Stroke in Children and Young Adults. 2nd ed. Philadelphia: Saunders, 2009. Table 15-1. p. 290.

641.5 Differential Diagnosis of Strokelike Events

Nomazulu Dlamini and Gabrielle A. deVeber

The diagnosis of stroke in childhood requires a high index of suspicion balanced with awareness of the differential diagnosis for strokelike events (Table 641.8). An acute onset of a focal neurologic deficit should be considered a stroke until proven otherwise and assessed with urgent neuroimaging. However, pediatric stroke must also be differentiated from other strokelike disorders that may require their own urgent specific treatment.

MIGRAINE

A careful history and examination can often suggest migraine as the cause of acute focal deficits (see Chapter 635.1). Neurologic deficits associated with migraine typically evolve slowly compared with stroke, with sensory disturbance or weakness marching across body areas over minutes. Migraine auras should last between 5 and 60 minutes and resolve completely. Although evolution into a headache is expected in migraine, headache may also accompany true AIS. Furthermore, a group of uncommon "acephalic" migraine subtypes can occur without headache and can more closely mimic stroke in children. These entities include familial hemiplegic migraine, basilar migraine, and migraine aura without headache. Migraine can also (rarely) cause a stroke, referred to as *migrainous infarction*.

Reversible cerebral vasoconstriction syndrome (RCVS) presents in patients with a history of migraine, pregnancy, or exposure to drugs (sympathomimetic agents, SSRIs, migraine abortive agents). There is both multifocal arterial constriction and dilation producing intense (thunderclap) headache, migraine-like symptoms, seizures, or focal

Table 641.8 Distinguishing Clinical and Imaging Features of Stroke Mimics

DISORDER	CLINICAL DISTINCTION FROM STROKE	IMAGING DISTINCTION FROM STROKE
Migraine	Evolving or "marching" symptoms, short duration, complete resolution, headache, personal or family history of migraine	Typically normal Migrainous infarction is extremely rare
Seizure*	Positive symptoms, Todd paralysis is postseizure and time limited	Normal or may identify source of seizures (e.g., malformation, old injury)
Infection	Fever, encephalopathy, gradual onset, meningismus	Normal or signs of encephalitis/cerebritis, which are typically diffuse and bilateral. Arterial ischemic stroke and cerebral sinovenous thrombosis can occur in bacterial meningitis.
Demyelination	Gradual onset, multifocal symptoms, encephalopathy Accompanying optic neuritis or transverse myelitis	Multifocal lesions, characteristic appearance (e.g., patchy in acute disseminated encephalomyelitis, ovoid in multiple sclerosis), typical locations (e.g., pericallosal in multiple sclerosis), less likely to show restricted diffusion
Hypoglycemia	Risk factor (e.g., insulin therapy), related to meals, additional systemic symptoms	Bilateral, symmetric May see restricted diffusion Posterior dominant pattern
Hypertensive encephalopathy (posterior reversible leukoencephalopathy syndrome)	Documented hypertension, bilateral visual symptoms, encephalopathy	Posterior dominant, bilateral, patchy lesions involving gray and white matter; usually no restricted diffusion
Inborn errors of metabolism	Preexisting delays/regression, multisystem disease, abnormal biochemical profiles	May have restricted diffusion lesions but bilateral, symmetric, not conforming to established vascular territories. Magnetic resonance spectroscopy changes (e.g., high lactate in mitochondrial myopathy, encephalopathy, lactic acidosis, and strokelike episodes).
Vestibulopathy	Symptoms limited to vertigo, imbalance (i.e., no weakness); gradual onset	Normal
Acute cerebellar ataxia	Sudden-onset bilaterally symmetric ataxia; postviral	Normal
Channelopathy	Syndromic cluster of symptoms not localizing to single lesion; gradual onset, progressive evolution	Normal
Alternating hemiplegia	History of contralateral events Choreoathetosis/dystonia	Normal
Functional neurologic disorders	Recent psychosocial stressors Failure of signs and symptoms to localize to a specific lesion within the neural axis Presence of inconsistent examination findings Positive Hoover sign (when being evaluated for supposed lower extremity weakness, the patient with a functional disorder will exert downward pressure at the heel of the unaffected limb if the examiner holds the heel while asking the patient to raise the affected leg off the bed)	Normal

*Seizures, however, can also herald the onset of true stroke.

From Farias-Moeller R. Stroke. In: Kliegman RM, Toth H, Bordini BJ, et al., eds. *Nelson Pediatric Symptom-Based Diagnosis*, 2nd ed. Philadelphia: Elsevier; 2023: Table 37.5, p. 636.

neurologic deficits (stroke). MRI is useful in differentiating RCVS from other disorders, especially primary angiitis of the central nervous system.

SEIZURE

Prolonged focal motor seizure activity is typified by stiffening or jerking movements, termed *positive* symptoms frequently followed by a period of focal neurologic deficit (so-called **Todd paresis**), which typically resolves rapidly over hours after the seizure (see Chapter 633). Very rarely, focal seizures can manifest with only "negative" symptoms producing only hemiparesis or other acute-onset focal neurologic deficits. A known history of seizures and epileptiform EEG findings may be helpful. Urgent brain imaging should be considered in new cases of prolonged or recurrent focal seizure with persisting Todd paresis because stroke in children is often associated with seizures at onset.

INFECTION

Life-threatening and treatable brain infections, including abscess, bacterial meningitis, and herpes encephalitis, can be mistaken for stroke (see Chapter 643). However, symptom onset in primary CNS infection is typically more gradual and less focal with fever as a consistent feature. Children with bacterial meningitis are at risk for both venous and arterial stroke.

DEMYELINATION

Acute disseminated encephalomyelitis, clinically isolated syndrome, multiple sclerosis, and other demyelinating conditions can present with acute focal neurologic deficits (see Chapter 640). The symptom onset and initial progression are, however, more gradual compared with stroke onset (i.e., typically hours or days versus minutes). Multifocal deficits, or concurrent encephalopathy in the case of acute disseminated encephalomyelitis, decreases the probability of stroke.

HYPOGLYCEMIA

Acute lowering of blood glucose levels can produce focal deficits mimicking stroke. New-onset hypoglycemia in otherwise healthy children is rare, but predisposing conditions include insulin-dependent diabetes, adrenal insufficiency, steroid withdrawal, and ketogenic diet.

GLOBAL HYPOXIC-ISCHEMIC ENCEPHALOPATHY

Generalized reduction in cerebral perfusion can produce focal areas of watershed brain infarction, which, when asymmetric, can mimic vasoocclusive forms of stroke. Watershed ischemic injury should be accompanied by recognized hypotension or conditions predisposing to low cerebral perfusion, such as sepsis, dehydration, or cardiac dysfunction. Clinical presentations tend to be generalized and include bilateral cerebral dysfunction compared with stroke, and the anatomic location of the infarct on MRI or CT scanning is in typical bilateral watershed zones rather than conforming to an established arterial territory.

HYPERTENSIVE ENCEPHALOPATHY

Posterior reversible leukoencephalopathy syndrome is seen in children with hypertension, often in the context of an acute rise in blood pressure. The posterior regions are selectively involved, possibly resulting in symptoms of bilateral cortical visual dysfunction in addition to encephalopathy and seizures.

INBORN ERRORS OF METABOLISM

Mitochondrial myopathy, encephalopathy, lactic acidosis, and strokelike episodes (MELAS; see Chapter 638.2) is the classic example of a metabolic strokelike condition, though other mitochondrial diseases can mimic stroke. Features favoring MELAS include a history of developmental regression, deafness, posterior (and often bilateral) lesions not respecting vascular territories on MRI, and elevated serum or CSF lactate on MR spectroscopy. In contrast to these types of metabolic infarctions, children with Fabry disease (see Chapter 653.6), hyperhomocysteinemia, and homocystinuria (see Chapter 105.4) are at risk of true ischemic stroke.

VESTIBULOPATHY AND ATAXIA

Acute-onset vertigo and/or ataxia can be confused with brainstem or cerebellar stroke. Simple bedside tests of vestibular function with otherwise intact brainstem functions are reassuring. This differential diagnosis includes acute vestibular neuronopathy, viral labyrinthitis, and the benign paroxysmal vertigos, as well as acute postviral cerebellar ataxia and episodic ataxias.

CHANNELOPATHIES

An increasing number of nervous system ion channel mutations are described that feature sudden focal neurologic deficits, thereby mimicking stroke. These include the migraine syndromes, as well as a growing list of episodic ataxias. A strong family history raises suspicion, but most require additional investigation.

ALTERNATING HEMIPLEGIA OF CHILDHOOD

Alternating hemiplegia of childhood typically presents in late infancy with acute intermittent episodes of hemiplegia that alternate from one side of the body to the other. The hemiplegia persists for minutes to weeks and then resolves spontaneously. Choreoathetosis and dystonic movements are commonly observed in the hemiparetic extremity. Signs spontaneously regress with sleep but recur with awakening. Affected children may also experience sudden attacks of redness and warmth (i.e., flushing) or unusual paleness (i.e., pallor) of the skin occurring during or separately from episodes of hemiplegia. Almost all affected individuals have some level of developmental delay and intellectual disability that typically progresses over time. Neuroimaging, including MRA, should be completed to exclude moyamoya disease. Alternating hemiplegia of childhood is linked to variants in the *ATP1A3* gene.

Chapter 642

Central Nervous System Vasculitis

Sona Narula

Autoimmune-mediated inflammatory brain diseases include primary central nervous system (CNS) vasculitis, secondary CNS vasculitis, and autoimmune encephalitis (Fig. 642.1; see Chapter 638.4).

Primary vasculitis or angiitis of the CNS (PACNS) is recognized as an underlying etiology of a broad spectrum of neurologic and psychiatric symptoms in children. Criteria characteristic of primary angiitis of the CNS in childhood (cPACNS) include (1) newly acquired focal and/or diffuse neurologic deficits and/or psychiatric symptoms in a child 18 years of age or younger, **plus** (2) angiographic and/or histologic evidence of vasculitis **in the absence of** (3) a systemic underlying condition known to cause or mimic the findings. Two broad categories of cPACNS are recognized based on the predominant vessel size affected: large/medium-vessel cPACNS and small-vessel cPACNS. Large/medium-vessel cPACNS is diagnosed by angiography demonstrating features of vessel wall inflammation, such as wall thickening and resulting luminal stenosis. Based on the clinical course and the corresponding distribution of vessel stenosis within the vascular tree of the CNS, children with large/medium-vessel cPACNS are classified as having a monophasic, nonprogressive subtype (NPcPACNS) or a progressive subtype (PcPACNS). The latter is characterized by chronic, progressive vessel wall inflammation affecting both proximal and distal vessel segments in one or both hemispheres. In contrast, NPcPACNS is a monophasic illness; vessel inflammation occurs in a characteristic distribution and is limited to

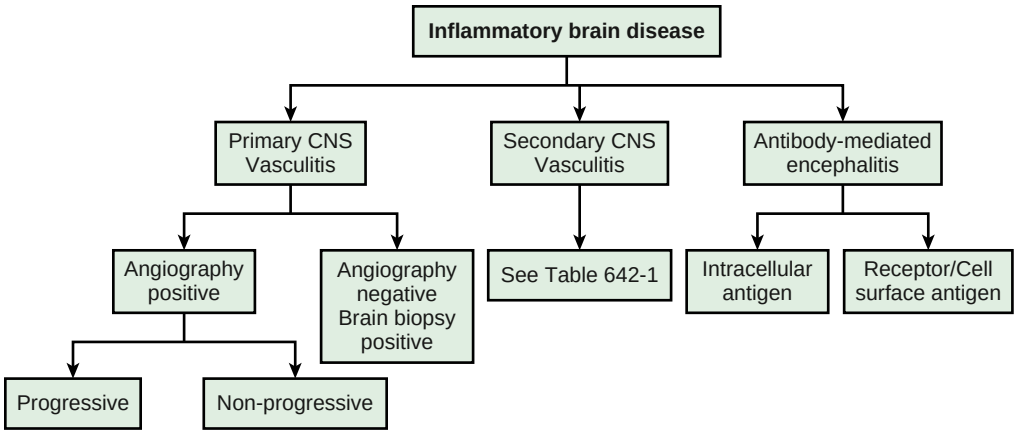

Fig. 642.1 Classification algorithm for CNS vasculitis within the spectrum of immune-mediated inflammatory brain diseases.

the proximal vessel segments of the anterior and/or middle cerebral artery and/or distal internal carotid artery of one hemisphere. Small-vessel cPACNS (SVcPACNS) is considered a progressive illness; the diagnosis is confirmed by brain biopsy, as angiography is typically normal.

Secondary childhood CNS vasculitis can affect all cerebral vessel segments and can occur in the context of infections, or rheumatic or other inflammatory conditions, or as a result of systemic or local vascular irritation (Table 642.1). The neuropsychiatric manifestations of secondary CNS vasculitis are the same as those of primary CNS vasculitis. Secondary CNS vasculitis is distinguished from primary CNS vasculitis largely by the non-CNS manifestations of the underlying systemic vasculitic disease.

EPIDEMIOLOGY

The incidence and prevalence of primary CNS vasculitis are undetermined. Increased physician awareness, improved diagnostic markers, sensitive neuroimaging techniques, and utilization of brain biopsies have led to dramatically increased recognition and decreased mortality rates. The disease has many names, including *isolated angiitis of the CNS, transient cerebral angiitis, postvaricella angiopathy,* and *focal cerebral arteriopathy*. Furthermore, children are frequently diagnosed with their presenting clinical phenotype, such as stroke, movement disorder, psychosis, or cognitive decline. Within clinical phenotypes such as arterial ischemic stroke or status epilepticus in children without preexisting epilepsy, cPACNS should be considered an important etiology.

CLINICAL MANIFESTATIONS

Recognition of childhood CNS vasculitis requires a very high level of suspicion because any neurologic or psychiatric presentation can be the result of an underlying CNS vasculitis. The clinical phenotype may provide clues to the size of the primarily affected vessel segments and resulting cPACNS subtype: the majority of children with large/medium cPACNS present with arterial ischemic stroke. Focal neurologic deficits, such as hemiparesis, facial droop, aphasia, or any other distinct gross or fine motor deficits, may be the result of large-vessel inflammation causing stenosis and a decreased blood supply to the specific functional areas of the brain. Initially, these focal deficits wax and wane; they may even briefly resolve without therapeutic intervention and can therefore be easily overlooked. Headaches can be a symptom of vascular disease and are commonly reported in cPACNS. New-onset headaches in children without any family history of migraine can serve as a diagnostic clue. Cognitive dysfunction in cPACNS often includes loss of higher executive function, concentration difficulties, learning and memory problems, atypical behavior or personality changes, and loss of social and emotional control. Seizures are a hallmark of SVcPACNS, as more than 80% of children with SVcPACNS present with seizures. In many centers, refractory status epilepticus is increasingly recognized as the presenting phenotype of SVcPACNS. Optic neuritis and spinal cord disease can also occur in the setting of SVcPACNS.

Constitutional features of fever or fatigue may point toward an underlying systemic illness causing a secondary CNS vasculitis. All children with suspected or confirmed CNS vasculitis require a careful assessment for a systemic illness.

Table 642.1 Causes of Secondary CNS Vasculitis

VIRAL INFECTIONS
Varicella-zoster virus, HIV, hepatitis C virus, cytomegalovirus, parvovirus B19
BACTERIAL INFECTIONS
Treponema pallidum, Borrelia burgdorferi, Mycobacterium tuberculosis, Mycoplasma pneumoniae, Bartonella henselae, Rickettsia spp.
FUNGAL INFECTIONS
Aspergillosis, mucormycosis, coccidioidomycosis, candidiasis
PARASITIC INFECTIONS
Cysticercosis
SYSTEMIC VASCULITIDES
Granulomatosis with polyangiitis, eosinophilic granulomatosis with polyangiitis, Behçet disease, polyarteritis nodosa, IgA vasculitis, Kawasaki disease, giant-cell arteritis, Takayasu arteritis, Degos disease, *ADA2* deficiency, *TREX1*-associated diseases
CONNECTIVE TISSUE DISEASES
Systemic lupus erythematosus, rheumatoid arthritis, Sjögren syndrome, dermatomyositis, mixed connective tissue disease
MISCELLANEOUS
Antiphospholipid antibodies syndrome, Hodgkin and non-Hodgkin lymphomas, neurosarcoidosis, inflammatory bowel disease, graft-versus-host disease, bacterial endocarditis, acute bacterial meningitis, **drug-induced CNS vasculitis** (cocaine, amphetamine, ephedrine, phenylpropanolamine, immune checkpoint inhibitors), hemophagocytic lymphohistiocytosis, reversible vasoconstriction syndrome, Fabry disease, migrainous infarction, primary (*RNF213*) and secondary moyamoya disease, *NOTCH3* and *HTRA1* vasculopathies, genetic structural disorders (*COL4A1, ACTA2, MOPD2*).

From Salvarani C, Brown RD Jr, Hunder GG. Adult primary central nervous system vasculitis. *Lancet*. 2012;380:767–776.

DIAGNOSIS

The first step is considering vasculitis as a possible underlying etiology of newly acquired neurologic deficits and/or psychiatric symptoms (Table 642.2). The likelihood of CNS vasculitis in general and a specific

Table 642.2 Proposed Diagnostic Evaluation of Suspected Childhood Primary CNS Vasculitis

1. Clinical evaluation: Newly acquired symptom or deficit in a previously healthy child
   - Focal neurologic deficit: hemiparesis, hemisensory loss, aphasia, ataxia, movement abnormality, paresthesia, facial droop, ataxia, vision loss, spinal cord symptoms, others
   - Seizures or status epilepticus
   - Diffuse neurologic deficit, including cognitive decline with loss of higher executive function, concentration difficulties, learning or memory problems, behavior or personality changes, loss of social skills or emotional/impulse control, others
   - Headaches
   - Meningitis symptoms, abnormal level of consciousness
   - Psychiatric symptoms, including hallucinations

   Differential diagnosis approach:
   - Underlying illness known to cause, be associated or mimic CNS vasculitis: check all potential clinical features
2. Laboratory tests
   - Blood inflammatory markers: C-reactive protein, erythrocyte sedimentation rate and complete blood counts
   - Endothelial markers: von Willebrand factor (vWF) antigen
   - Cerebrospinal fluid (CSF) inflammatory markers: opening pressure, cell count, protein, oligoclonal bands

   Differential diagnosis approach:
   - Infections/postinfectious inflammation: cultures, serologies, Gram stain
   - Autoimmune encephalitis: check neuronal antibodies in CSF and blood
   - Systemic inflammation/rheumatic disease: characteristic laboratory markers such as complement, autoantibodies
   - Thromboembolic conditions: procoagulatory profile
3. Neuroimaging
   - Parenchymal imaging on MRI
   - Inflammatory lesions: T2/fluid attenuated inversion recovery sequences plus gadolinium
   - Ischemic lesions: diffusion-weighted images/apparent diffusion coefficient mapping
   - Vessel imaging
4. Brain biopsy

subtype of CNS vasculitis in particular depends on the demographic characteristics of the patient, the CNS and non-CNS features of the clinical presentation, the preceding symptoms, and the mode of onset of the disease. SVcPACNS is more commonly seen in females, whereas large/medium cPACNS has a clear male predominance. Seizures are a hallmark of SVcPACNS, whereas strokes often reflect large/medium-vessel inflammation. Laboratory markers of vasculitis typically include C-reactive protein, erythrocyte sedimentation rate, and complete blood counts. *However, inflammatory markers lack sensitivity and specificity in cPACNS, particularly when the CNS is involved in isolation.* More than 50% of children with large/medium-vessel cPACNS have normal inflammatory markers at diagnosis. In contrast, the majority of children with SVcPACNS present with mild to moderately raised markers. Von Willebrand factor antigen, an endothelial cell–derived protein, is a proposed biomarker of vasculitis correlating closely with disease activity in cPACNS. It may be of particular importance for distinguishing SVcPACNS from demyelinating disorders. Cerebrospinal fluid (CSF) analysis is abnormal in up to 90% of SVcPACNS patients and less than half of large/medium-vessel cPACNS patients. Within the latter group, children with the progressive subtype have a higher likelihood of presenting with abnormal CSF findings, including elevated opening pressure, raised CSF cell count (typically with lymphocyte predominance), and raised CSF protein. Oligoclonal bands are positive in 20% of children with SVcPACNS. They are rarely seen in other subtypes. Autoimmune encephalitis (see Chapter 638.4) and anti–myelin oligodendrocyte glycoprotein (MOG)–associated encephalitis are two of the key neuroinflammatory differential diagnoses of SVcPACNS.

Neuroimaging is a valuable diagnostic modality for cPACNS. Parenchymal lesions may be inflammatory or ischemic in nature and are best viewed on MRI, including T2/fluid-attenuated inversion recovery (FLAIR) sequences and diffusion-weighted images (DWIs) (Fig. 642.2). CNS lesions in children with large/medium-vessel cPACNS are predominantly ischemic in nature and restricted to large vascular territories. In contrast, MRI lesions in children with SVcPACNS are not restricted to major vascular territories; lesions are primarily inflammatory and may enhance with contrast. In this subtype, focal or generalized meningeal enhancement is commonly seen if children are imaged before initiation of immunosuppressive therapy.

Evidence of vessel stenosis confirms the diagnosis in large/medium-vessel cPACNS subtypes; brain biopsies are not required. Important information about the disease activity can be obtained from post–gadolinium contrast studies of the vascular wall. The vessel wall of an inflamed cerebral vessel in active large/medium-vessel cPACNS subtypes is thickened and enhances contrast. Vessel wall enhancement may also be useful for the assessment of ongoing disease activity. Conventional angiography, when compared with MR angiography, has a higher sensitivity in detecting vessel stenosis in the distal vessel segments, the posterior circulation, and in very young children. Vessel wall imaging is often normal in children with SVcPACNS, often mandating a brain biopsy to definitively confirm the diagnosis. Studies of regional blood flow or therapeutic trials of antiinflammatory or immunosuppressive agents are nonsurgical alternatives that do not afford specific diagnostic information.

If a biopsy is pursued, a targeted lesional biopsy is preferred if an accessible lesion is identified on imaging. Biopsies should target low-risk, nonfunctional areas identified on MRI. In the appropriate clinical context, nonlesional biopsies can also be done to confirm the diagnosis of SVcPACNS and are typically taken from the nondominant frontal lobe. Diagnostic yield is improved if the biopsy is full thickness and includes the meninges and gray and white matter and if it is done before initiation of immunosuppression. In adults, one study reported the diagnostic yield of biopsies for PACNS to be 11%, with an identified alternative diagnosis reported in about 30% of cases. In this study, smaller biopsies and closed procedures were less likely to be diagnostic, and biopsy-related complications occurred in 16% of patients.

Characteristic findings on biopsy in SVcPACNS include an intramural and/or perivascular lymphocytic infiltrate, evidence of endothelial activation, and reactive astrocyte activation. Gliosis and perivascular demyelination are hallmarks of long-standing disease. Hemorrhagic lesions have also been reported. Findings typically seen in adult PACNS, including granulomas or vessel wall necrosis, are less commonly seen in children with SVcPACNS. Disorders that may be seen in adolescents and young adults that produce the reversible vasoconstriction syndrome must also be considered. These include migraine, drug-induced vasospasm, and postpartum angiopathy. Differentiating vasculitis from these other etiologies is important for therapy and prognosis (Table 642.3).

TREATMENT

Corticosteroids are the mainstay of acute immunosuppressive management of cPACNS. Usually pulse therapy is initially given. Antithrombotic therapy is equally important, particularly in large/medium-vessel cPACNS subtypes, because children are at high risk for recurrent ischemic events. For the distinct cPACNS subtypes, different treatment regimens should be considered. Nonprogressive cPACNS is a monophasic inflammatory illness with the highest risk of poor neurologic outcome. Vessel wall inflammation causes severe proximal stenosis and a high risk of stroke recurrence. High-dose corticosteroid pulses are commonly given,

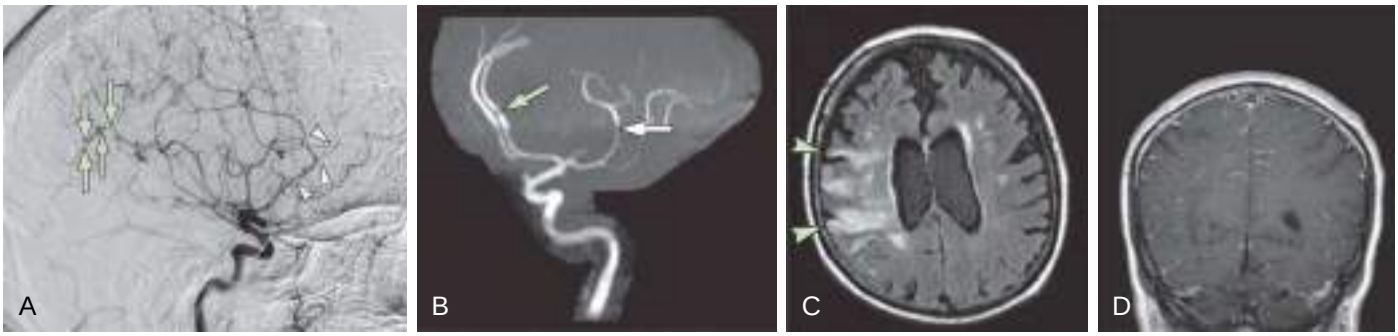

Fig. 642.2 Imaging of patients with primary CNS vasculitis. **A,** Cerebral angiogram shows alternating stenosis and dilation of the distal middle cerebral artery *(arrows)* and the anterior cerebral artery *(arrowheads).* **B,** MR angiography of the brain shows a short-segment stenosis of the anterior cerebral artery *(green arrow)* and stenosis of the distal middle cerebral artery *(white arrow).* **C,** Fluid attenuation inversion recovery–weighted MRI shows a large abnormality within the right cerebral hemisphere consistent with ischemia *(arrowheads).* **D,** MRI shows diffuse, asymmetric, nodular, and linear leptomeningeal enhancement, with the dura only slightly affected. *(From Salvarani C, Brown RD Jr, Hunder GG. Adult primary central nervous system vasculitis. Lancet. 2012;380:767–776, Fig. 2.)*

Table 642.3 Characteristics of Primary CNS Vasculitis and Reversible Cerebral Vasoconstriction Syndrome

	PCNSV	RCVS
Precipitating factor	None	Postpartum onset or onset after exposure to vasoactive substances
Onset	More insidious, progressive course	Acute onset followed by a monophasic course
Headaches	Chronic and progressive	Acute, thunderclap type
CSF findings	Abnormal (leukocytosis and high total protein concentration)	Normal to near normal
MRI	Abnormal in almost all patients	Initially may be normal or demonstrate vasogenic edema, vasospasm, or sequelae of vasospasm
Angiography	Possibly normal; otherwise, diffuse abnormalities are often indistinguishable from RCVS; irregular and asymmetric arterial stenoses or multiple occlusions are more suggestive of PCNSV; abnormalities might be irreversible	Always abnormal, strings-of-beads appearance of cerebral arteries; abnormalities reversible within 6-12 wk
Cerebral biopsy	Vasculitis	No vasculitic changes
Drug treatment	Prednisone with or without cytotoxic agents	Nimodipine

CSF, Cerebrospinal fluid; PCNSV, primary CNS vasculitis; RCVS, reversible cerebral vasoconstriction syndrome.
From Salvarani C, Brown RD Jr, Hunder GG. Adult primary central nervous system vasculitis. *Lancet.* 2012;380:767–776, Table 2.

followed by a 6- to 12-week course of oral steroids at tapering doses. Second-line immunosuppressive agents are uncommonly used. All children require antithrombotic therapy, though no unifying regimen exists. Many centers initially use low molecular weight heparin followed by long-term antiplatelet therapy. When reimaged at 3 months, children should have stable or improved vessel disease, no newly affected vessel segments, and no evidence of vessel wall enhancement. At this point, the immunosuppressive therapy is commonly discontinued, and children are only kept on antiplatelet therapy.

Progressive cPACNS and SVcPACNS are considered chronic progressive vasculitis subtypes requiring a prolonged course of combination immunosuppression. High-dose corticosteroids are initially used, followed by long-term oral corticosteroids with a slow taper. Many centers use an induction-maintenance protocol, adding cyclophosphamide to corticosteroids (for 6 months), followed by mycophenolate mofetil or other oral second-line agents during maintenance therapy (usually 18 months). Symptomatic therapy is essential, including anticonvulsants or psychotropic medication if required. Supportive therapy includes bone protection with calcium and vitamin D, prophylaxis against *Pneumocystis* pneumonia, and gastric mucosal protection as required.

PROGNOSIS

The mortality rate of cPACNS has significantly improved. In large-vessel cPACNS, the risk of stroke recurrence is thought to be high in patients who are found to have progression on vascular imaging at 12 months (especially if there was simultaneous progression and improvement occurring across multiple vessels).

Some treatment protocols for SVcPACNS report a good outcome, defined as no functional neurologic deficits, in two thirds of children. Children presenting with status epilepticus and SVcPACNS have the poorest cognitive outcome. Multidisciplinary care involving neurology, rheumatology, hematology, and rehabilitation is ideal and may improve outcomes.

Visit Elsevier eBooks+ at eBooks.Health.Elsevier.com for Bibliography.

Chapter 643

Central Nervous System Infections

Andrew B. Janowski and David A. Hunstad

Infection of the central nervous system (CNS) is a significant cause of morbidity and mortality in children. Identification of CNS infections can be problematic for clinicians because symptoms can be nonspecific in younger infants, and delayed or missed diagnosis can amplify the morbidity and mortality rates associated with these diseases. Implementation of multiple conjugate vaccines has greatly reduced the incidence of bacterial infections of the CNS. Nonetheless, bacterial and viral infections remain a significant cause of CNS disease, with atypical bacterial, fungal, and parasitic pathogens also causing a smaller number of cases.

Independent of etiology, many patients with CNS infection have similar clinical manifestations. **Common symptoms** include headache, nausea, vomiting, anorexia, photophobia, restlessness, altered state of consciousness, and irritability. **Common signs** of CNS infection include fever, neck pain, nuchal rigidity, focal neurologic deficits, seizures, obtundation, and coma. The severity and constellation of signs are determined by host-pathogen interactions and the affected region of the CNS. **Meningitis** describes primary involvement of the meninges, and **encephalitis** indicates brain parenchymal involvement. However, these anatomic boundaries may be indistinct during infection, and many patients have clinical or imaging evidence of both meningeal and parenchymal involvement. Terms such as *meningoencephalitis* may better describe diffuse infections of the CNS by pathogens such as viruses. Brain abscess is the most common example of a focal infection of the CNS (see Chapter 644).

The diagnosis of CNS infection depends on a combination of imaging of the brain, testing the cerebrospinal fluid (CSF) by culture, polymerase chain reaction (PCR), and serologic methods and, in rare situations, biopsy of brain tissue. Pending many of these tests, standard CSF studies provide initial data to help guide selection of empiric antimicrobials. Table 643.1 provides an overview of the typical CSF abnormalities with various CNS disorders.

643.1 Acute Bacterial Meningitis Beyond the Neonatal Period

Andrew B. Janowski and David A. Hunstad

Bacterial meningitis is one of the most serious pediatric infections because it is associated with a high rate of acute complications and a risk of long-term morbidity and mortality. However, the use of antibiotics and vaccines against the most common causes of bacterial meningitis has significantly altered the spectrum of disease. In the 1980s, the most common causes of bacterial meningitis in children older than 1 month of age in the United States were *Haemophilus influenzae* type b, *Streptococcus pneumoniae,* and *Neisseria meningitidis.* The incidence of meningitis caused by all three organisms has been significantly reduced in countries that have introduced universal immunization against these pathogens. *S. pneumoniae* is now the most common cause of bacterial meningitis in the United States. Demonstrating the impact of vaccination in the United States, invasive *H. influenzae* disease occurred in 67-129 cases per 100,000 children under 5 years of age in the 1980s. By 2019, *H. influenzae* type b–associated diseases were exceptionally rare; there were only 18 invasive cases in the United States, with a calculated national rate of 0.08 cases per 100,000 children under 5 in the year 2017. Nonetheless, other serotypes of *H. influenzae* (particularly type a and, rarely, other serotypes have emerged as a cause of meningitis).

EPIDEMIOLOGY

A major risk factor for bacterial meningitis is the lack of preexisting immunity to specific pathogens and serotypes, reflected in a higher incidence of meningitis in young infants. Additional risk factors include recent colonization with pathogenic bacteria, close contact (household, daycare centers, college dormitories, military barracks) with individuals having invasive disease caused by *N. meningitidis* or *H. influenzae* type b, crowding, poverty, and male sex. The mode of transmission of these pathogens is through contact with respiratory tract secretions or droplets. The risk of meningitis is increased among infants and young children with occult bacteremia; the odds ratio is greater for meningococcus (85 times) and *H. influenzae* type b (12 times) relative to that for pneumococcus.

Indigenous Nation and Eskimo populations exhibit a higher incidence of bacterial meningitis because these populations have altered immunoglobulin production in response to encapsulated pathogens. Defects of the complement system (C5-C8) are associated with recurrent meningococcal infection, and defects of the properdin system are associated with a significant risk of lethal meningococcal disease. Splenic dysfunction (e.g., in sickle cell anemia) or asplenia (caused by trauma or a congenital defect) is associated with an increased risk of pneumococcal, *H. influenzae* type b, and meningococcal sepsis and meningitis. T-lymphocyte defects (congenital or acquired by chemotherapy, AIDS, or malignancy) are associated with an increased risk of *Listeria monocytogenes* infections of the CNS.

The risk of pneumococcal meningitis is increased in children with congenital or acquired CSF leak across a mucocutaneous barrier, such as a lumbar dural sinus, cranial or midline facial defects (cribriform plate), fistulas of the middle ear (stapedial foot plate) or inner ear (oval window, internal auditory canal, cochlear aqueduct), or CSF leakage as a result of basilar or other skull fracture. The risk of pneumococcal bacterial meningitis was historically increased by more than 30-fold in children with cochlear implants, though advances in implant design have reduced this risk. Lumbosacral dermal sinus and myelomeningocele are associated with staphylococcal, anaerobic, and gram-negative enteric bacterial meningitis. CSF shunt infections increase the risk of meningitis caused by *Pseudomonas aeruginosa, Staphylococcus* spp. (*S. aureus* and coagulase-negative species), *Cutibacterium* spp. (formerly *Propionibacterium* spp.), and other lower-virulence bacteria that typically colonize the skin.

Streptococcus pneumoniae

See also Chapter 228.

Although the incidence of pneumococcal meningitis has been reduced, *S. pneumoniae* remains the most frequently identified pathogen from cases of bacterial meningitis in the United States and in other countries that have adopted similar vaccination strategies. The seven-valent pneumococcal conjugate vaccine (PCV7) was included in the routine U.S. vaccination schedule in 2000 and contained serotypes 4, 6B, 9V, 14, 18C, 19F, and 23F, responsible for ~85% of invasive pneumococcal infections in the country. A dramatic decrease in the rate of pneumococcal meningitis followed, from 8.2 cases per 100,000 in 1998-1999 to 0.59 cases per 100,000 in 2004–2005. Similar reductions were also identified in other nations that introduced this vaccine. However, this was followed by an increased incidence of invasive disease caused by serotypes not contained in the original vaccine, known as *serotype replacement*. In response, a 13-valent pneumococcal conjugate vaccine (PCV13) was licensed in the United States in 2010, containing the serotypes in PCV7 plus serotypes 1, 3, 5, 6A, 7F, and 19A. Postmarketing surveillance data suggest the rate of invasive pneumococcal infections has decreased further, though there are conflicting data as to whether the rate of pneumococcal meningitis has decreased. Based on data from the Centers for Disease Control and Prevention (CDC) Active Bacterial Surveillance system, the incidence of invasive pneumococcal infections has fallen from 142.9 per 100,000 children under age 1 in 1977 to 13.3 per 100,000 children under age 1 in 2018. Children with anatomic or functional asplenia secondary to sickle cell disease and those infected with HIV have infection rates that are 20- to 100-fold higher than those of healthy children in the first 5 years of

Table 643.1 Cerebrospinal Fluid Findings in Central Nervous System Disorders

CONDITION	PRESSURE (cm H_2O)	LEUKOCYTES (mm^3)	PROTEIN (mg/dL)	GLUCOSE (mg/dL)	COMMENTS
Normal	<28	<5, ≥75% Lymphocytes in neonates: <20	20-45	>50 (or 75% serum glucose)	
COMMON FORMS OF MENINGITIS					
Acute bacterial meningitis	Usually elevated	100-10,000 or more; usually 300-2,000; PMNs predominate	Usually 100-500	Decreased, usually <40 (or <50% of serum glucose)	Organisms usually seen on Gram stain and isolated by culture or identified by PCR
Partially treated bacterial meningitis	Normal or elevated	5-10,000; PMNs usual, but mononuclear cells may predominate if pretreated for extended period	Usually 100-500	Normal or decreased	Organisms may be seen on Gram stain. Pretreatment may render CSF sterile. PCR-based assays may detect bacterial DNA.
Viral meningitis or meningoencephalitis	Normal or slightly elevated	Rarely >1,000 cells. Eastern equine encephalitis and lymphocytic choriomeningitis may have cell counts of several thousand. PMNs early, but mononuclear cells predominate through most of the course,	Usually 50-200	Generally normal; may be decreased to <40 in some viral diseases, particularly mumps (15–20% of cases)	HSV encephalitis is suggested by focal seizures or by focal findings on MRI or CT scans or EEG. Most arboviruses detected by PCR of CSF or urine and serology.
UNCOMMON FORMS OF MENINGITIS					
Tuberculous meningitis	Usually elevated	10-500; PMNs early, but lymphocytes predominate through most of the course	100-3,000; may be higher in presence of obstruction	<50 in most cases; decreases with time if treatment is not provided	Acid-fast organisms rarely seen on smear. Large volumes of CSF required for recovery of organisms. *Mycobacterium tuberculosis* can be detected by PCR of CSF.
Fungal meningitis	Usually elevated	5-500; PMNs early, but mononuclear cells predominate for most of the course. Cryptococcal meningitis may lack pleocytosis. Coccidioidal meningitis may have eosinophilia	25-500	<50; decreases with time if treatment is not provided	Budding yeast may be seen. Organisms may be recovered by culture. Cryptococcal antigen (CSF and serum) may be positive in cryptococcal infection.
Syphilis (acute), Lyme disease, and leptospirosis	Usually elevated	50-500; lymphocytes predominate	50-200	Usually normal	Positive CSF serology. Spirochetes not demonstrable by smear or culture; dark-field examination may be positive. Positive Lyme serology.
Amebic *(Naegleria)* meningoencephalitis	Elevated	1,000-10,000 or more; PMNs predominate	50-500	Normal or slightly decreased	Mobile amoebas may be seen by wet-mount microscopy of CSF
BRAIN ABSCESSES AND PARAMENINGEAL FOCUS					
Brain abscess	Usually elevated	5-200; CSF rarely acellular; lymphocytes predominate; if abscess ruptures into ventricle, PMNs predominate and cell count may reach >100,000	75-500	Normal unless abscess ruptures into ventricular system	CSF cultures are only positive in 24% of cases unless abscess ruptures into ventricular system

Continued

Table 643.1 Cerebrospinal Fluid Findings in Central Nervous System Disorders—cont'd

CONDITION	PRESSURE (cm H_2O)	LEUKOCYTES (mm^3)	PROTEIN (mg/dL)	GLUCOSE (mg/dL)	COMMENTS
Subdural empyema	Usually elevated	100-5,000; PMNs predominate	100-500	Normal	No organisms on smear or culture of CSF unless meningitis also present; organisms found on tap of subdural fluid
Cerebral epidural abscess	Normal to slightly elevated	10-500; lymphocytes predominate	50-200	Normal	No organisms on smear or culture of CSF
Spinal epidural abscess	Usually low, with spinal block	10-100; lymphocytes predominate	50-400	Normal	No organisms on smear or culture of CSF
Chemical (drugs, dermoid cysts, myelography dye)	Usually elevated	100-1,000 or more; PMNs predominate	50-100	Normal or slightly decreased	Epithelial cells may be seen within CSF by use of polarized light in some children with ruptured dermoids
NONINFECTIOUS CAUSES					
Sarcoidosis	Normal to elevated slightly	0-100; mononuclear	40-100	Normal	No specific findings
Systemic lupus erythematosus with CNS involvement	Slightly elevated	0-500; PMNs usually predominate; lymphocytes may be present	100	Normal or slightly decreased	No organisms on smear or culture. Positive neuronal and ribosomal P protein antibodies in CSF.
Tumor, leukemia	Slightly elevated to very high	0-100 or more; mononuclear or blast cells	50-1,000	Normal to decreased (20-40)	Cytology may be positive
Acute disseminated encephalomyelitis	Normal or elevated	~100 lymphocytes	Normal to elevated	Normal	MRI adds to diagnosis
Autoimmune encephalitis	Normal	~100 lymphocytes	Normal to elevated	Normal	Anti-NMDAR or other autoimmune antibody–positive (CSF is often more sensitive than serum)

CSF, Cerebrospinal fluid; EEG, electroencephalogram; HSV, herpes simplex virus; NMDAR, *N*-methyl-D-aspartate receptor; PCR, polymerase chain reaction; PMN, polymorphonuclear neutrophils.

life. Additional risk factors for contracting pneumococcal meningitis include endocarditis, otitis media, mastoiditis, sinusitis, pneumonia, CSF otorrhea or rhinorrhea, the presence of a cochlear implant, and immunosuppression.

Neisseria meningitidis

See also Chapter 237.

Six serogroups of meningococcus (A, B, C, X, Y, and W-135) are responsible for invasive disease in humans. Meningococcal meningitis may be sporadic or may occur in major epidemics, particularly in the African meningitis belt, where serogroup A accounts for 80–85% of outbreaks. In the United States, serogroup B is the most common cause of meningitis in infants and is also a cause of outbreaks on college campuses. Meningococcal cases are more common in the winter and spring, likely because of associations with viral infections, including influenza. Nasopharyngeal carriage of *N. meningitidis* occurs in up to 15% of adults. Most infections in children are acquired from a contact in a daycare facility, a colonized adult family member, or an ill patient with meningococcal disease. Colonization may last weeks to months; recent colonization places nonimmune younger children at greatest risk for meningitis. The incidence of disease occurring in association with an index case in the family is 1%, a 1,000-fold increase in risk in comparison to the general population. The risk of secondary cases occurring in contacts at daycare centers is approximately 1 in 1,000. Children under 5 years of age have the highest rates of meningococcal infection, and a second peak in incidence occurs in persons between 15 and 24 years of age. First-year college students living in dormitories have an increased incidence of infection compared with non–college-attending, age-matched controls.

Haemophilus influenzae Type b

See also Chapter 240.

Before universal *H. influenzae* type b vaccination in the United States, approximately 70% of cases of bacterial meningitis occurring in the first 5 years of life were caused by this pathogen. Invasive infections occurred primarily in infants 2 months to 2 years of age, the peak incidence was at 6-9 months of age, and 50% of cases occurred in the first year of life. The risk to children was markedly increased among household or daycare contacts of patients with *H. influenzae* type b disease. Global vaccination efforts have also led to remarkable declines in the incidence of this disease. Incompletely vaccinated individuals, those in underdeveloped countries who are not vaccinated, and those with immune-compromising conditions remain at risk for *H. influenzae* type b meningitis. Other serotypes of *H. influenzae* (a, f) have been associated with meningitis.

PATHOLOGY AND PATHOPHYSIOLOGY

A purulent exudate of varying thickness may be distributed around the cerebral veins, venous sinuses, convexity of the brain, and cerebellum and in the sulci, sylvian fissures, basal cisterns, and spinal cord. Ventriculitis with bacteria and inflammatory cells in ventricular fluid may be present (more often in neonates) in addition to subdural effusions

and empyema. Perivascular inflammatory infiltrates may also be evident, and the ependymal membrane may be disrupted. Vascular and parenchymal cerebral changes have been described at autopsy, including polymorphonuclear infiltrates extending to the subintimal region of small arteries and veins, vasculitis, thrombosis of small cortical veins, occlusion of major venous sinuses, necrotizing arteritis producing subarachnoid hemorrhage, and cerebral cortical necrosis in the absence of identifiable thrombosis. Cerebral infarction is a frequent sequela that is caused by vascular occlusion from inflammation, vasospasm, or thrombosis. The extent of an infarct may range from microscopic to an entire hemisphere.

Inflammation of spinal nerves and roots produces meningeal signs, and inflammation of the cranial nerves produces cranial neuropathies of optic, oculomotor, facial, and auditory nerves. Increased intracranial pressure (ICP) also produces oculomotor nerve palsy because of temporal lobe compression of the nerve during tentorial herniation. Abducens nerve palsy may be an early nonlocalizing sign of elevated ICP.

Increased ICP is a result of cell death (cytotoxic cerebral edema), cytokine-induced increased capillary vascular permeability (vasogenic cerebral edema), and increased hydrostatic pressure (interstitial cerebral edema) after obstructed reabsorption of CSF in the arachnoid villus or obstruction of the flow of fluid from the ventricles. ICP may exceed 30 cm H_2O and cerebral perfusion may be further compromised if the cerebral perfusion pressure (mean arterial pressure minus mean ICP) falls below 50 mm Hg as a result of systemic hypotension. The syndrome of inappropriate antidiuretic hormone secretion (SIADH) may produce excessive water retention and potentially increase the risk of elevated ICP (see Chapter 597). Hypotonicity of brain extracellular spaces may cause cytotoxic edema with cell swelling and lysis. Tentorial, falcine, or cerebellar herniation does not usually occur, because the increased ICP is transmitted to the entire subarachnoid space and there is little structural displacement. Furthermore, if the fontanels are still patent, increased ICP is not always dissipated.

Hydrocephalus can occur as an acute complication of bacterial meningitis because it is often caused by adhesive thickening of the arachnoid villi around the cisterns at the base of the brain. Thus this thickening leads to interference with the normal resorption of CSF and development of hydrocephalus. Less often, obstructive hydrocephalus develops after fibrosis and gliosis of the cerebral aqueduct or the foramina of Magendie and Luschka.

Elevated CSF protein levels are partly a result of increased vascular permeability of the blood-brain barrier (BBB) and the loss of albumin-rich fluid from the capillaries and veins traversing the subdural space. Continued transudation may result in subdural effusions, usually observed in the later phase of acute bacterial meningitis. **Hypoglycorrhachia** (reduced CSF glucose level) is attributable to altered glucose transport by the cerebral tissue.

Damage to the cerebral cortex may be a result of the focal or diffuse effects of vascular occlusion (infarction, necrosis, lactic acidosis), hypoxia, bacterial invasion (cerebritis), toxic encephalopathy (bacterial toxins), elevated ICP, ventriculitis, and/or transudation (subdural effusions). These pathologic factors result in the clinical manifestations of impaired consciousness, seizures, cranial nerve deficits, motor and sensory deficits, and later, psychomotor retardation.

PATHOGENESIS

Bacterial meningitis outside the neonatal period is typically the result of bacterial colonization of the nasopharynx with subsequent invasion into the bloodstream, causing bacteremia. Circulating bacteria then breach the BBB to cause CNS infection and inflammation.

Meningitic pathogens frequently colonize the nasopharynx of asymptomatic children, but rapid invasion after recent colonization may also occur. Bacterial proteins termed *adhesins* act to enhance colonization by enabling *N. meningitidis* and *H. influenzae* type b to attach to mucosal epithelial cell receptors. The microbiome of the nasopharynx is a complex community of bacteria that may enhance or inhibit colonization by other bacteria. *S. pneumoniae* can synthesize hydrogen peroxide, which can inhibit growth of *H. influenzae* type b; conversely, *H. influenzae* type b can invoke a specific immune response that targets clearance of *S. pneumoniae*. Other bacteria may alter the microbiome of the nasopharynx, and studies after implementation of PCVs have identified alterations to the composition of nasopharyngeal bacterial populations. Viruses can also enhance bacterial adherence by a combination of expression of viral factors that interact with host adhesion proteins.

After attachment to epithelial cells, bacteria may breach the mucosa and enter the bloodstream. Various models of invasion have been developed; *N. meningitidis* can be transported across the mucosal surface within a phagocytic vacuole after ingestion by the epithelial cell. Expression of the polysaccharide capsule in relevant bacteria also appears to be tightly regulated, as it can enhance or inhibit the efficiency of bacterial translocation across the mucosal barrier. Viral infection can disrupt the mucosal barrier, thereby facilitating bacterial invasion; specifically, there is a significant association between recent influenza infection and development of meningococcemia. Once bacteria reach the bloodstream, the capsule is a critical component for survival because it interferes with opsonic phagocytosis. Host-related immune defects in bacterial opsonic phagocytosis can also allow bacteremia. In nonimmune hosts, the defect may be from an absence of preformed IgM or IgG anticapsular antibodies (as in an unimmunized toddler), whereas deficiencies in components of the complement or properdin system may preclude effective opsonic phagocytosis. Asplenia may also hamper opsonic phagocytosis by the reticuloendothelial system.

There is a positive correlation between the bloodstream bacterial titer and the accompanying risk of developing meningitis, suggesting that a critical threshold may be necessary for breaching the BBB. Bacterial factors, including the capsule, play a role in crossing the BBB through transcellular, paracellular, or Trojan horse (within infected phagocytes) mechanisms. Bacteria gain entry to the CSF through the choroid plexus of the lateral ventricles and the meninges and then circulate to the extracerebral CSF and subarachnoid space. Bacteria multiply rapidly because CSF concentrations of complement and antibodies are inadequate to contain bacterial proliferation. Chemotactic factors then incite a local inflammatory response characterized by polymorphonuclear cell (neutrophil) infiltration. The presence of lipopolysaccharide (endotoxin) from gram-negative bacteria (*H. influenzae* type b, *N. meningitidis*) or of pneumococcal cell wall components (teichoic acid, peptidoglycan) stimulates a marked inflammatory response, with local production of tumor necrosis factor, interleukin-1, prostaglandin E, and other inflammatory mediators. The subsequent inflammatory response is characterized by neutrophilic infiltration, increased vascular permeability, further compromise of the BBB, and vascular thrombosis. Meningitis-associated brain injury is not simply caused by bacterial-derived factors but also occurs as a consequence of the host inflammatory cascade triggered by bacterial components.

Uncommonly, meningitis may follow bacterial invasion from a contiguous focus of infection such as paranasal sinusitis, otitis media, mastoiditis, orbital cellulitis, or cranial or vertebral osteomyelitis; or it may occur after introduction of bacteria via penetrating cranial trauma, dermal sinus tracts, or myelomeningocele.

CLINICAL MANIFESTATIONS

The onset of acute meningitis has two predominant patterns. Most often, meningitis is preceded by several days of fever accompanied by upper respiratory tract or, less often, gastrointestinal symptoms, followed by nonspecific signs of CNS infection, such as lethargy and irritability. Fortunately, the more dramatic presentation is less common and features sudden and progressive shock, purpura, disseminated intravascular coagulation, and reduced levels of consciousness, often resulting in progression to coma or death within 24 hours.

The signs and symptoms of meningitis reflect the nonspecific findings associated with any systemic infection and the manifestations of meningeal irritation. Nonspecific findings include fever, anorexia or poor feeding, headache, upper respiratory symptoms, myalgias, arthralgias, tachycardia, hypotension, and various cutaneous signs, such as petechiae, purpura, or an erythematous macular rash. The rash of meningococcemia is typified by an initial petechial rash that evolves into ecchymotic and purpuric lesions. Meningeal irritation is manifested as nuchal rigidity, back pain, **Kernig sign** (flexion of

the hip 90 degrees with subsequent pain upon extension of the leg), and **Brudzinski sign** (involuntary flexion of the knees and hips after passive flexion of the neck while supine). In children, particularly in those younger than 12-18 months, Kernig and Brudzinski signs are not consistently present. In adults, fever, headache, and nuchal rigidity are present in only 40% of cases of bacterial meningitis. Increased ICP is suggested by headache, emesis, bulging fontanelle or diastasis (widening) of the sutures, oculomotor (anisocoria, ptosis) or abducens nerve paralysis, hypertension with bradycardia, apnea, or hyperventilation, decorticate or decerebrate posturing, stupor, coma, or signs of herniation. Papilledema is more common in complicated meningitis and is suggestive of a chronic process, such as the presence of an intracranial abscess, subdural empyema, or occlusion of a dural venous sinus. Focal neurologic signs usually are a result of vascular occlusion. Cranial neuropathies of the ocular, oculomotor, abducens, facial, and auditory nerves may also be the result of focal inflammation. Overall, 10–20% of children with bacterial meningitis have focal neurologic signs.

Seizures (focal or generalized) related to cerebritis, infarction, or electrolyte disturbances occur in 20–30% of patients with meningitis. Seizures that occur on presentation or within the first 4 days of onset usually are of little prognostic significance. Poorer prognosis is suggested when seizures persist after the fourth day of illness, as these can be refractory to treatment.

Alteration in mental status is common among patients with meningitis and may be the consequence of increased ICP, cerebritis, or hypotension; manifestations include irritability, lethargy, stupor, obtundation, and coma. Comatose patients have a poor prognosis. Additional manifestations of meningitis include photophobia and tache cérébrale, which is elicited by stroking the skin with a blunt object and observing a raised red streak within 30-60 seconds.

DIAGNOSIS

Lumbar puncture (LP), to obtain CSF for Gram stain and culture, is the most important step in the diagnosis of meningitis. Testing of the CSF for neutrophilic pleocytosis, elevated protein, and/or reduced glucose concentrations can yield results within a few hours and can indicate bacterial meningitis (see Table 643.1). **Contraindications** to immediate LP include (1) evidence of increased ICP (other than a bulging fontanel), such as third or sixth cranial nerve palsy with a depressed level of consciousness, or the Cushing reflex (hypertension and bradycardia associated with respiratory abnormalities; see Chapter 630); (2) severe cardiopulmonary compromise requiring prompt resuscitative measures for shock or in patients in whom positioning for the LP would further compromise cardiopulmonary function; or (3) infection of the skin overlying the site of the LP. Thrombocytopenia is a relative contraindication for LP. **If LP is delayed, empiric antibiotic therapy should be initiated.**

Some clinicians obtain a head CT scan before LP to evaluate for evidence of increased ICP because an LP in the setting of elevated ICP may promote brain herniation. However, a head CT scan may delay diagnosis of meningitis and initiation of antimicrobials, and it does not always rule out increased ICP. Therefore **head CT scans before LP are not routinely recommended** unless the patient has clinical signs or is at risk for elevated ICP, including papilledema, focal neurologic findings, coma, history of hydrocephalus, or prior neurosurgical procedures including shunt placement. However, if a CT scan is to be obtained before LP, antimicrobial therapy should not be delayed. LP can safely be performed after increased ICP (if present) has been appropriately treated.

Blood cultures should be performed in all patients with suspected meningitis. Blood cultures reveal the responsible bacteria in up to 80–90% of cases of meningitis. Elevations of C-reactive protein, erythrocyte sedimentation rate, and procalcitonin can be seen in both bacterial and viral meningitis, but some clinical prediction tools include these tests to determine risk for bacterial meningitis.

Lumbar Puncture

See also Chapter 630.

The CSF leukocyte count in bacterial meningitis often is elevated to >1,000/mm^3 and, typically, there is a neutrophilic predominance (75–95%). Turbid CSF is observed when the leukocyte count exceeds 200-400/mm^3. Healthy neonates may have as many as 20 leukocytes/mm^3, but older children without viral or bacterial meningitis have <8 leukocytes/mm^3 in the CSF, and these should be nearly all lymphocytes or monocytes.

The CSF leukocyte count is <250/mm^3 in as many as 20% of patients with acute bacterial meningitis. Pleocytosis may be absent in patients with severe overwhelming sepsis associated with meningitis; this is a poor prognostic sign. Of note, neutrophilic pleocytosis may be present in the early stages of acute viral meningitis. The shift to lymphocytic-monocytic predominance in viral meningitis invariably occurs within 8-24 hours of an initial LP. In the absence of CNS infection or inflammatory disease, children with seizures (including febrile seizures) *do not* exhibit CSF pleocytosis.

A diagnostic conundrum in the evaluation of children with suspected bacterial meningitis is the analysis of CSF obtained from children who have already received antibiotic therapy. This is a common clinical scenario, as 25–50% of children undergoing evaluation for bacterial meningitis have received antibiotics before a CSF sample is obtained. CSF from children with bacterial meningitis can be negative on Gram stain and culture as early as 2-4 hours after administration of antibiotics, especially in situations of *N. meningitidis* and sensitive *S. pneumoniae* meningitis. However, pleocytosis with a predominance of neutrophils, an elevated protein level, and a reduced concentration of CSF glucose will usually persist for several days after initiation of appropriate parenteral antibiotics. Therefore despite negative cultures, the presumptive diagnosis of bacterial meningitis can be made on the basis of an abnormal CSF cell count, protein, and glucose. A multiplex PCR test for common CNS bacterial and viral pathogens is available for testing on CSF samples, with turnaround times of only a few hours. This test is often used as an adjunct (and rapid) diagnostic test, as its current sensitivity and specificity have not supplanted the use of routine bacterial cultures; in particular, its highest false-positive rate is for *S. pneumoniae*. PCR of bacterial 16S ribosomal RNA sequences may be useful in diagnosing the cause of culture-negative meningitis caused by prior antibiotic therapy or for the detection of nonculturable or fastidious pathogens.

A traumatic LP may also complicate the interpretation of CSF tests, as CSF leukocyte count and protein concentration are significantly affected by blood in the sample. However, the Gram stain, culture, and glucose level are unlikely to be influenced by blood in a CSF sample. Repeat LP at a higher interspace may produce fluid that is less hemorrhagic, but this fluid usually still contains red blood cells. Although methods for correcting for the presence of red blood cells have been proposed for red blood cell counts <10,000 cells/mm^3, these corrections can be imprecise and unreliable, so empiric treatment with antibiotics pending any bacterial culture result might be indicated.

DIFFERENTIAL DIAGNOSIS

Most bacterial meningitis is caused by *S. pneumoniae* and *N. meningitidis,* whereas *H. influenzae* type b is relatively rare in nations with high immunization rates. However, other pathogens less frequently identified in meningitis can cause similar clinical manifestations. These organisms include other bacteria, including non–type-b *H. influenzae, Mycobacterium tuberculosis, Nocardia* spp., *Treponema pallidum* (syphilis), and *Borrelia burgdorferi* (Lyme disease); fungi, such as those endemic to specific geographic areas (*Coccidioides, Histoplasma,* and *Blastomyces*) and those responsible for infections in compromised hosts (*Candida, Cryptococcus,* and *Aspergillus*); parasites, such as *Toxoplasma gondii* and *Taenia solium;* and most frequently, viruses (Tables 643.2 and 643.3 and see Chapter 643.2). Focal infections of the CNS, including brain abscess and parameningeal abscess (subdural empyema, cranial and spinal epidural abscess), may also be confused with meningitis. In addition, noninfectious illnesses can cause generalized inflammation of the CNS; relative to infections, these disorders are very uncommon and include malignancy (lymphoma), immunologic diseases (CNS vasculitis, sarcoidosis, autoimmune encephalitis), and exposure to toxins (see Table 643.3).

Table 643.2 Causes of Aseptic Meningitis and Encephalitis Including Differential Diagnosis at Different Ages

AGE	INFECTIOUS	INFLAMMATION	AUTOIMMUNE	MIMICS
0-24 mo	Enteroviruses Parechovirus HSV Congenital infections Arboviruses HIV	Cryopyrin disorders Interferonopathies Complement disorders (HUS/TTP) Aicardi-Goutieres syndrome	Paraneoplastic rare under 12 mo	• Bacterial meningitis • Urea cycle disorders, maple syrup urine disease, MCAD deficiency, CPT2, mitochondrial disorders (Leigh) • Brain malformations • Intoxication • Epilepsy • Dravet (*SCNA1*) and other epilepsy encephalopathy syndromes • Acute adrenal crisis • Hydrocephalus • HLH • Glioma
2-5 yr	Enteroviruses HSV Influenza Arboviruses Adenovirus *Bartonella* *Ehrlichia* and *Borrelia* spp. Rabies	Complement disorders (HUS/TTP)	ADEM NMOSD VZV AFP TM	• Bacterial meningitis • Intoxication • MCAD deficiency • Epilepsy • Dravet (*SCNA1*) and other epilepsy encephalopathy syndromes • Infectious HUS • HLH • Mitochondrial disorders (MELAS) • Glioma; CNS lymphoma
5-18 yr	Enteroviruses HSV Influenza Arboviruses Adenovirus *Bartonella* *Ehrlichia* and *Borrelia* spp. Rabies		ADEM NMDAR NMOSD VZV AFP SLE TM	• Bacterial meningitis • Epilepsy • Intoxication • Psychosis • Wilson disease • Pseudotumor cerebri • Multiple sclerosis • Dravet (*SCNA1*) and other epilepsy encephalopathy syndromes • HLH • Mitochondrial disorders (MELAS) • Vasculitis (primary, rickettsia, VZV) • Tumors: Glioma; CNS lymphoma; Metastatic
Young adult	Enteroviruses HSV Influenza Arboviruses *Ehrlichia* and *Borrelia* spp. HIV Rabies		ADEM NMDAR NMOSD SLE Paraneoplastic AFP TM	• Bacterial meningitis • Intoxication • Psychosis • Wilson disease • HLH • Periarteritis nodosa, Takayasu, giant cell, ANCA + arteritis • Acute intermittent porphyria • Multiple sclerosis • Vasculitis (primary, rickettsia, VZV) • Tumors: Glioma; CNS lymphoma; metastatic
Older adult	Enteroviruses HSV Influenza Arboviruses *Ehrlichia* and *Borrelia* spp. HIV Rabies		Limbic encephalitis SLE AFP NMOSD NMDAR	• Bacterial meningitis • Intoxication • TTP • Neurodegeneration • Tumor metastases • HLH • Periarteritis nodosa, Takayasu, giant cell, ANCA + arteritis • Multiple sclerosis • Mitochondrial disorders (MELAS) • Vasculitis (primary, rickettsia, VZV) • Tumors: Glioma; CNS lymphoma; metastatic

ADEM, Acute disseminated encephalomyelitis; AFP, acute flaccid paralysis; ANCA, antineutrophil cytoplasmic antibody; CNS, central nervous system; CPT2, carnitine palmitoyltransferase-2; HLH, hemophagocytic lymphohistiocytosis; HSV, herpes simplex virus; HUS, hemolytic uremic syndrome; MCAD, medium-chain acylcarnitine deficiency; MELAS, mitochondrial encephalopathy lactic acidosis syndrome; NMDAR, N-methyl-D-aspartate receptor encephalitis; NMOSD, neuromyelitis optica spectrum disorder; SCNA1, sodium voltage-gated channel alpha subunit 1; SLE, systemic lupus erythematosus; SMA, spinal muscular atrophy; TM, transverse myelitis; TTP, thrombotic thrombocytopenic purpura; VZV, varicella-zoster virus

Modified from Kliegman RM. Encephalitis. In: Kliegman RM, Toth H, Bordini BJ, et al, eds. *Nelson Pediatric Symptom-Based Diagnosis*, 2nd ed. Philadelphia: Elsevier, 2023: Table 42.2, p. 768.

Table 643.3 Exposures Associated with Agents Causing Aseptic Meningitis, Encephalitis, and Encephalitis-Like Syndrome

EXPOSURE	AGENT	RISK FACTORS AND EPIDEMIOLOGY
ARTHROPODS Mosquitoes		
	Togaviridae	
	Chikungunya virus	Humans and other vertebrates serve as reservoirs. Vertical transmission has been reported.
	Eastern equine encephalitis virus	Like Western equine encephalitis, birds are the primary reservoir, exposure to horses is not a risk factor. High frequency of symptomatic infections in children and elderly.
	Semliki Forest virus	Cases are rare; one reported death attributed as part of a possible laboratory accident
	Venezuelan equine encephalitis virus	Equids and small mammals are the primary reservoir. Children are at higher risk for development of long-term neurological sequelae.
	Western equine encephalitis (WEE) virus	Birds are the primary reservoir. Viremia is too low in humans or horses to infect mosquitoes, so horse exposure is not a true risk factor for disease.
	Flaviviridae	
	Dengue virus	The primary reservoir is humans and other primates. Vertical transmission has been reported, as well through organ transplant and blood transfusion
	Japanese encephalitis virus	Primary reservoir is birds and pigs. Bats may also contribute to circulation of the virus.
	Murray Valley encephalitis virus	Waterfowl are the primary reservoir
	St. Louis encephalitis virus	Birds are the primary reservoir
	West Nile virus	Birds are the primary reservoir. Transmission has also been reported through organ transplantation or blood transfusions.
	Zika virus	Humans and non-human primates are the like primary reservoir. Transmission has also been reported through sexual contact and vertical transmission.
	Reoviridae	
	Banna virus	Unknown reservoir
	Bunyavirales	
	Jamestown Canyon virus	The primary reservoir is deer and other ungulates (moose and bison)
	La Crosse encephalitis virus	Small mammals (chipmunks and squirrels) serve as the primary reservoir. Peak incidence in school-age children
	Rift Valley fever virus	Mosquitos are the vector and reservoir. Further viral amplification occurs in livestock and other domestic ruminants. Small mammals and bats may also contribute to persistence. Transmission may also occur from handling infected animal tissue or drinking unpasteurized milk.
Ticks		
	Anaplasma phagocytophilum	White-footed mouse is hypothesized the primary reservoir, with other sources including various mammals including deer. Rare reports of transmission through blood transfusion.
	Borrelia burgdorferi	White-footed mouse and other small mammals are the primary reservoir. Deer serve to support the tick population but not Borrelia.
	Ehrlichia chaffeensis	Primary reservoir is white-tailed deer. Transmission also reported through blood transfusion or solid organ transplantation.
	Ehrlichia ewingii	Dogs and deer are hypothesized to be the primary reservoirs.
	Powassan virus	Small mammals are the primary reservoir.
	Rickettsia rickettsii	Transmission may occur with very short tick attachment times. Ticks serve as both the vector and reservoir. Rare reports of transmission through blood transfusion.
	Kyasanur Forest disease virus	Transmission may also occur from contact with an infected animal. While it can infect livestock, there are no reports of transmission through unpasteurized milk
	Tickborne encephalitis virus	Reservoirs include ticks, birds, and small mammals. Transmission may also occur via direct contact, consuming unpasteurized dairy products, blood transfusion, organ transplantation, and breastfeeding.
Sandflies	*Bartonella bacilliformis*	Reservoir is unknown. Most infections occur at sunrise or sundown as the flies are most active during these time periods.

Table 643.3 Exposures Associated with Agents Causing Aseptic Meningitis, Encephalitis, and Encephalitis-Like Syndrome—cont'd

EXPOSURE	AGENT	RISK FACTORS AND EPIDEMIOLOGY
	Chandipura vesiculovirus	Mosquitos may also play a role in transmission. No other vertebrate has been identified as a potential reservoir. Cases described from India and West Africa.
	Toscana virus	Reservoir is presumed to be sandflies; very little data exist as to whether other mammals could serve as a source of the virus.
Tsetse flies	*Trypanosoma brucei gambiense*	Humans are the primary reservoir although it can also be identified in primates and ungulates. Vertical transmission has been reported.
	Trypanosoma brucei rhodesiense	Livestock such as cattle and other large mammals are considered to be the primary reservoir
WILD OR DOMESTIC ANIMALS		
Bats	Australian bat lyssavirus	It is assumed that any bat in Australia could carry this virus.
	Histoplasma capsulatum	Guano promotes fungal growth. Bats can develop chronic and disseminated infection with *Histoplasma*, but risk of transmission is likely highest through guano exposure.
	Nipah virus	Reports of transmission via direct contact with bats or coming into contact with bat bodily fluids on food. Human to human transmission has been reported.
	Rabies virus	Some bat bites are too small to be detected, often post-exposure prophylaxis is offered to anyone with direct contact with bats or if contact cannot be ruled out (e.g., an individual waking up to a bat flying in the same room). Transmission has been reported via solid organ transplant
Cattle	*Brucella abortus*	Many large mammals can be infected. Nearly eradicated from cattle in the US, Canada, Europe, Australia, New Zealand, and some Asian countries including Japan and Israel.
Dogs	Rabies virus	Many countries have been declared rabies-free in dogs, including Europe, Japan, the US, Australia, and New Zealand. Other countries remain at high risk for transmission from dogs.
	Toxocara canis	Dogs (especially puppies) shed eggs in feces, and organism survives in soil for prolonged period
Cats	*Bartonella henselae*	Typically follows scratch or bite from cat or kitten; highest incidence in children, in the fall, and around holidays (when cats are given as gifts)
	Rabies virus	In the US, more rabid cats are detected than dogs. In other countries, cats are second to dogs in prevalence.
	Toxoplasma gondii	Cats and other felines are reservoir hosts; they shed oocytes in feces, and the soil becomes contaminated. Sheep, goats, swine, cattle serve as intermediate hosts. Transmission may also occur vertically or through blood transfusion or solid organ transplantation. Worldwide distribution
	Toxocara cati	Cats, (specially kittens) shed eggs in feces, and organism survives in soil for prolonged period
Rodents	*Leptospira* spp.	Rodents (and many other animals) excrete organism in urine, and the organism remains viable in soil or water for weeks to months
	Lymphocytic choriomeningitis virus	Peak incidence in fall and winter; chronic infection in mice, hamsters, and guinea pigs; humans infected by inhalation or ingestion of dust or food contaminated by urine, feces, blood, nasopharyngeal secretions of infected rodents. Transmission has also occurred by vertical transmission and solid organ transplant,
Raccoons	*Baylisascaris procyonis*	Young children at risk due to pica, particularly near raccoon latrines. Other animal handlers, including hunters, at risk.
	Rabies virus	"Raccoon strain" extends along Eastern seaboard of the USA and has reached northward into Canada
Sheep, goats	*Brucella melitensis*	Direct contact with infected animals or their secretions. Present world-wide but has been eradicated in some countries including Northern and Central Europe, US, Canada, Australia, New Zealand, and Japan. Transmission has also occurred from sexual intercourse, vertical transmission, solid organ transplantation and transfusions.
	Coxiella burnetii	Inhalation; either direct exposure to animal or exposure to contaminated materials particularly dust or during birth. Rare reports of vertical transmission, through blood transfusions, or sexual intercourse
Birds	*Chlamydophila psittaci*	Birds can harbor and transmit organism to humans; usually acquired via inhalation of fecal dust/sections of birds. Rare cases have been reported in exposures to other non-avian livestock.

Continued

Table 643.3 Exposures Associated with Agents Causing Aseptic Meningitis, Encephalitis, and Encephalitis-Like Syndrome—cont'd

EXPOSURE	AGENT	RISK FACTORS AND EPIDEMIOLOGY
	Cryptococcus neoformans	Primarily in immunocompromised individuals. Some association with exposure to soil contaminated with bird droppings, particularly pigeons
Old World monkeys	B virus	Bite of Old World macaques. Present in both wild and captive settings.
Horses	Hendra virus	Endemic in Australia; associated with excretions/tissues from horses
Swine	Nipah virus	Close contact with pigs was the primary cause of an outbreak in Malaysia
	Brucella suis	Prevalent in many locations in the world, some countries have achieved eradication including Europe, Canada, US, and Australia.
Skunks	Rabies virus	Skunk populations are the primary reservoir in the central US and California
Squirrels	Variegated squirrel bornavirus 1	Detected in Germany, particularly in captive squirrels originating from Latin America or Asia. Unclear if this virus originates in Europe or was imported.
INGESTION OR INHALATION		
Fresh water	*Leptospira* spp.	Organisms from animal urine or placental tissue can remain viable for weeks to months in soil or water; recreational exposure associated with wading or swimming in contaminated water (particularly after floods or hurricanes)
	Naegleria fowleri	Swimming in warm, natural bodies of water (rarely poorly chlorinated pools reported). Not found in salt water. Cases also linked to nasal rinses or neti pot usage.
Soil	Acanthamoeba spp.	Found in soil and water. Transmission through inhalation or inoculation; cases of keratitis associated with contact lens usage
	Balamuthia mandrillaris	Soil living organism, transmission presumably occurs through inhalation or inoculation into cuts or wounds. Transmission has also been reported via solid organ transplantation.
	Baylisascaris procyonis	Widespread in the US; export of raccoons has led to spread to Europe and Asia.
	Blastomyces dermatitidis	Present in the eastern half of the US (particularly along the Mississippi, Ohio, and St. Lawrence Rivers), Canada, Africa, and India.
	Coccidioides spp.	Also known as valley fever. Infection is seasonal and is acquired by inhalation of soil or dust. Transmission has occurred from solid organ transplantation.
	Histoplasma capsulatum	Inhalation of airborne spores from soil. Outbreaks have occurred in endemic areas with exposure to bird, chicken, or bat droppings or recently contaminated soil. Globally distributed, with as many as 80% of children have been infected.
	Toxocara canis/Toxocara cati	Eggs in sandboxes and playgrounds; organisms survive long periods in soil
Spelunking	*Histoplasma capsulatum*	Reports of infections due to indirect exposure near the entrance of bat caves
	Rabies virus	Aerosol transmission has been implicated in very rare cases after exploring caves with large bat populations
Undercooked pork, lamb, or beef	*Toxoplasma gondii*	Cook meats to a minimum of 145-160°F. Meat color is an insufficient marker to kill tissue cysts
Undercooked freshwater fish, birds, reptiles, or amphibians	*Gnathostoma* spp.	Marinating in lime juice (ceviche) does not kill the parasite.
Freshwater crayfish or crabs	*Paragonimus westermani*	Mostly in Asia. Related species present in Africa, North and South America.
Raw or undercooked meat	*Trichinella* spp.	Mostly associated with pigs but has been found in other wild game meat. Worldwide distribution
Raw or undercooked snails, slugs, freshwater prawns, crabs, or frogs,	*Angiostrongylus cantonensis*	Worldwide distribution. Snails and slugs can be accidentally chopped up with vegetables and consumed, leading to infection.

Table 643.3 Exposures Associated with Agents Causing Aseptic Meningitis, Encephalitis, and Encephalitis-Like Syndrome—cont'd

EXPOSURE	AGENT	RISK FACTORS AND EPIDEMIOLOGY
Unpasteurized milk	Tickborne encephalitis virus	Unpasteurized milk or cheeses from cows, sheep, or goats have been implicated
	Coxiella burnetii	Highly prevalent in many types of raw milk, pasteurization reduces risk
	Listeria monocytogenes	Also found in various raw dairy, vegetable, and meat products
	Toxoplasma gondii	Consumption of raw goat, sheep, or camel milk
SEASONAL		
	Arthropod-borne pathogens	Prevalence mirrors insect populations, infections nadir during the winter in temperate regions.
	Common viral infections (influenza, coronaviruses, adenoviruses, astroviruses, and other respiratory or gastrointestinal viruses); mycoplasma	Many viral and atypical bacterial infections predominant in the winter in temperate regions. Unclear if SARS-CoV-2 will follow the same seasonality.
	Enteroviruses and parechoviruses	Peak incidence in late summer and early fall in temperate regions. In tropical regions, enteroviruses circulate year round. Hypothesized that humidity may stabilize viral particles in the environment.
	Enterovirus D68	Reemergence in 2014 in causing acute flaccid paralysis. Outbreaks occurred every two years until 2020.
	Naegleria fowleri	Thrives in warmer water temperatures, leading to increased incidence of disease during the summer and early fall.
SEXUAL ACTIVITY		
	Herpes simplex virus 1/2	Primary HSV-2 infection can cause meningitis particularly in young females.
	HIV	Highest risk with unprotected sex with viremic subjects. Undetectable viral load equals untransmittable.
	Treponema pallidum	Resurgence in cases over the past decade particularly in the US
	Zika virus	Reports of sexual transmission. Virus is present in saliva, semen, vaginal fluids, urine, and breast milk. Virus may persist longer in semen than other bodily fluids.
FOREIGN TRAVEL		
Global	Chikungunya virus	Spread to the Africa, Americas, Asia, and Europe. Large outbreak in Latin America in the mid 2010's.
	Dengue virus	Cases occur on most continents. In the US, occasional local transmission reported in Florida, Texas, Arizona, Hawaii, and US territories
	Rabies virus	Prevalent worldwide but most cases occur in Asia and Africa. Dog bites are the most common mode of acquisition in developing countries
	West Nile virus	Outbreaks have been reported on all continents except Antarctica. In the US, most cases now occur west of the Mississippi River. A few thousand cases are diagnosed each year in the US.
	Zika virus	Worldwide distribution including North/South America, Africa, Asia
	Measles	Most cases now occur in South America, Africa, and Asia, including the Malay Archipelago and the Philippines. Secondary spread has led to outbreaks in many other countries.
	Mumps	Remains prevalent worldwide and a frequent cause of viral meningitis
	Rubella	Endemic in the Eastern Hemisphere, particularly in Asia and Africa.
	Gnathostoma spp	Worldwide distribution of different species. Most cases have occurred in Asia and Latin America.
	Plasmodium spp.	Tropical and subtropical areas in most continents
	Taenia spp.	Endemic to most countries. Most cases are travel associated when they occur in the US, Canada, and Australia.
Africa	Poliovirus	Africa was declared polio free in 2020, but in 2023, transmission of poliovirus type 1 was detected in Mozambique
	Rift Valley fever virus	Most prevalent in southern and eastern Africa, most countries report cases or isolation of virus
	Toscana virus	Reported in Morocco, Tunisia, and Algeria

Continued

Table 643.3 Exposures Associated with Agents Causing Aseptic Meningitis, Encephalitis, and Encephalitis-Like Syndrome—cont'd

EXPOSURE	AGENT	RISK FACTORS AND EPIDEMIOLOGY
	Blastomyces dermatitidis	Rare cases described throughout Africa. Other related *Blastomyces* spp. present in Africa.
	Trypanosoma brucei gambiense	West and central Sub-Saharan Africa
	Trypanosoma brucei rhodesiense	East Africa, predominantly Uganda, Kenya, Tanzania, Zambia, Malawi, Zimbabwe, and Mozambique
Asia	Banna virus	Detected in mosquitoes in China, Vietnam, Indonesia
	Japanese encephalitis virus	Mostly southern and eastern Asia, Malay archipelago, and Australia
	Kyasanur Forest disease virus	Detected so far only in India
	Nipah virus	Southeast Asia, particularly Malaysia
	Poliovirus	Wild type continues to circulate in Pakistan and Afghanistan.
	Tickborne encephalitis virus	Central Europe to eastern Asia, includes Japan
	Borrelia burgdorferi	Temperate forested regions throughout northern Asia
Australia	Australian bat lyssavirus	Exclusive to Australia, spread by bats. Closely related to rabies virus.
	Hendra virus	Exposure to body fluids and excretions of infected horses is the primary risk for transmission. Most cases reported in Queensland
	Japanese encephalitis virus	Cases reported in northern and eastern regions
	Murray Valley encephalitis virus	Cases throughout Australia, many have occurred in the Northern Territory. Also in New Guinea
Europe	Tickborne encephalitis virus	Central Europe to Japan
	Toscana virus	Endemic in most Mediterranean countries
	Anaplasma phagocytophilum	Temperate zones, particularly western and central Europe
	Borrelia burgdorferi	Temperate forested regions, particularly eastern and central Europe
North America	California/La Crosse virus	Most cases in Ohio, West Virginia, Tennessee, and North Carolina, but many other cases reported in the Midwest and South. From 2003-2022, a total of 1,431 cases have been reported to the CDC.
	Eastern equine encephalitis	A total of 189 cases reported to the CDC from 2003-2022. Most cases east of the Mississippi River, particularly Michigan, Florida, New Hampshire, and Massachusetts.
	Jamestown canyon virus	Majority of cases in Wisconsin and Minnesota, with other Midwest and Eastern states reporting cases. A total of 282 cases reported in the past decade to the CDC.
	Powassan virus	Wisconsin Minnesota, northeastern US, Canada. A total of 290 cases have been reported to the CDC between 2004-2002.
	St. Louis encephalitis virus	Most cases in Arizona, California and Texas, but many other states have sporadic cases. A total of 284 cases reported to the CDC in the past two decades
	Venezuelan equine encephalitis virus	Sporadic cases in Florida and along the Mexican border
	Western equine encephalitis virus	Most cases occurred west of the Mississippi River extending into Latin America. Cases are now rare; no infections reported to the CDC in over a decade.
	Anaplasma phagocytophilum	Majority of cases in Wisconsin, Minnesota and northeastern US. Cases also occur in mid-Atlantic, Midwest, West coast
	Borrelia burgdorferi	Eastern USA as far south as Ohio, West Virginia, Virginia, and North Carolina. Also includes Wisconsin and Minnesota, with cases occurring less commonly in California, Oregon, and Washington state. Nearly 500,000 Americans are diagnosed with Lyme disease each year.
	Ehrlichia chaffeensis	Southern and central USA and Mid-Atlantic and coastal states
	Rickettsia rickettsii	Majority of cases in a central band of the US including Kansas, Missouri, Arkansas, Kentucky, Tennessee, Mississippi, Alabama, Virginia and North Carolina. Other cases identified throughout the US.
	Blastomyces dermatitidis	Predominates along the Mississippi, Ohio, and St Lawrence Rivers, but many cases reported throughout the eastern US and Canada. Estimated ~2 cases per 100,000 each year in the US.

Table 643.3 Exposures Associated with Agents Causing Aseptic Meningitis, Encephalitis, and Encephalitis-Like Syndrome—cont'd

EXPOSURE	AGENT	RISK FACTORS AND EPIDEMIOLOGY
	Coccidioides spp.	Semiarid regions of southwestern US (California, Nevada, Utah, Arizona, New Mexico, Texas, and southern portions of Colorado and Oklahoma. Extends south into much of Mexico and central America. Around 20,000 cases diagnosed each year in the US.
South America	St. Louis encephalitis virus	Sporadic cases in Argentina, Brazil, and Peru, but far more prevalent in the US.
	Venezuelan equine encephalitis virus	Tropical latitudes, particularly Colombia, Venezuela, Peru, and Ecuador. Sporadic cases reported in Brazil, Bolivia, and Argentina.
	Western equine encephalitis virus	Rare cases in Brazil and Colombia.
	Rickettsia rickettsii	Cases reported in Colombia, Brazil, and Argentina.
	Coccidioides spp.	Many countries in Latin America, including Brazil, Argentina, Colombia, Venezuela, and Paraguay
	Bartonella bacilliformis	Predominantly occurs in the Andes at elevations of 3,000 to 10,000 feet above sea level. Most cases in Peru, but has been reported in Colombia and Ecuador.

Modified from Kliegman RM. Encephalitis. In: Kliegman RM, Toth H, Bordini BJ, et al., eds. *Nelson Pediatric Symptom-Based Diagnosis*, 2nd ed. Philadelphia: Elsevier, 2023: Table 42.3, p. 770-775.

Determining the specific cause of CNS infection is facilitated by careful examination of the CSF with specific stains (e.g., Kinyoun carbol fuchsin for mycobacteria, India ink for fungi), cytology, antigen detection *(Cryptococcus)*, CSF serology (syphilis, West Nile virus [WNV], arboviruses), and PCR (bacteria and viruses). Other potentially valuable diagnostic tests include blood cultures, CT or MRI of the brain, serum serologic tests, and, rarely, meningeal or brain biopsy.

Acute viral meningoencephalitis is the most likely infection to be confused with bacterial meningitis (see Table 643.2 and Table 643.3). Although children with viral meningoencephalitis typically appear less ill than those with bacterial meningitis, both types of infection have a spectrum of severity. Some children with bacterial meningitis may have relatively mild signs and symptoms, whereas some with viral meningoencephalitis may be critically ill. Although classic CSF profiles associated with bacterial versus viral infection tend to be distinct (see Table 643.1), these cases can overlap in the number of CSF leukocytes and glucose and protein levels. Quite often, children are empirically treated with antibiotics for >48 hours to await CSF culture and PCR results to distinguish these two groups of pathogens.

TREATMENT

Essential to improving clinical outcomes in patients with bacterial meningitis is prompt recognition, diagnostic testing, and initiation of appropriate antimicrobial therapy. Several studies have demonstrated that delays in initiating antimicrobial therapy, even a few hours, are significantly associated with adverse clinical outcomes and death. If focal neurologic findings, papilledema, or increased ICP is present, antibiotics should be given before obtaining a head CT scan (and subsequent LP), and the increased ICP should be treated simultaneously (see Chapter 82). Some patients with meningitis will develop multisystem organ failure, shock (see Chapter 85), and acute respiratory distress syndrome (see Chapter 86), requiring further management in an intensive care unit.

Initial Antibiotic Therapy

The initial (empiric) choice of antibiotic therapy for meningitis in immunocompetent infants and children should achieve bactericidal levels in the CSF and have excellent activity against the typical bacterial causes of meningitis (Table 643.4). Although there is substantial geographic variation in the frequency of resistance of *S. pneumoniae* to β-lactam antibiotics, rates are increasing throughout the world. In the United States, 25–50% of meningitic strains of *S. pneumoniae* have some level of resistance to penicillin; relative resistance (minimal inhibitory concentration = 0.1-1.0 μg/mL) is more common than high-level resistance (minimal inhibitory concentration = 2.0 μg/mL). Resistance to ceftriaxone and cefepime is globally variable, but in some studies can be as high as 25%. Resistance to cephalosporins declined in the United States after the introduction of PCV13 because of the reduction in disease caused by serotype 19A, which is commonly associated with resistance. However, current surveillance suggests rising rates of cephalosporin resistance in non-PCV13 serotypes. In contrast, most strains of *N. meningitidis* are sensitive to penicillin and cephalosporins, although rare resistant isolates have been reported. Approximately 30–40% of isolates of *H. influenzae* type b and 10% of *H. influenzae* type a produce β-lactamases and therefore are resistant to ampicillin. These β-lactamase–producing strains remain sensitive to third- and fourth-generation cephalosporins.

The recommended empiric antibiotic regimen in suspected bacterial meningitis beyond the neonatal period is a third-generation cephalosporin (ceftriaxone) plus vancomycin. Because of the efficacy of third-generation cephalosporins in the therapy of meningitis caused by sensitive *S. pneumoniae, N. meningitidis,* and *H. influenzae* type b, ceftriaxone (50 mg/kg/dose given every 12 hours) should be part of initial therapy. Based on the current incidence of cephalosporin-resistant strains of *S. pneumoniae,* vancomycin is also recommended as part of empiric therapy. Vancomycin dosing guidelines have shifted from trough-based dosing to area under the curve/minimum inhibitory concentration (AUC/MIC; see Chapter 225). Although current clinical data are limited, vancomycin dosing for meningitis should attain a target AUC/MIC of 400-600 mg*h/L (previous vancomycin trough goals were 15-20 mg/L). Patients allergic to penicillin and cephalosporin antibiotics can be treated with meropenem (40 mg/kg/dose every 8 hours); other alternatives include fluoroquinolones or chloramphenicol, if available. Alternatively, allergic patients can be desensitized to the preferred antibiotic (see Chapter 193).

If *L. monocytogenes* infection is suspected, as in young infants or those with a T-lymphocyte deficiency, ampicillin (300 mg/kg/day, divided every 6 hours) also should be given because cephalosporins are inactive against *L. monocytogenes.* Intravenous trimethoprim-sulfamethoxazole is an alternative treatment for *L. monocytogenes* and has documented clinical efficacy.

If a patient is immunocompromised and gram-negative bacterial meningitis is suspected, initial therapy might include cefepime or meropenem.

Duration of Antibiotic Therapy

The duration of antibiotic therapy for meningitis had been based on experience and expert opinion rather than randomized clinical trials.

Table 643.4 Antibiotics Used for the Treatment of Bacterial Meningitis*

DRUGS	NEONATES (TERM) 0-7 DAYS	NEONATES (TERM) 8-28 DAYS	INFANTS AND CHILDREN
Amikacin†‡	15 divided q24h	18 divided q24h	15-22.5 divided q8h, q12h, or q24h
Ampicillin	300 divided q8h	300 divided q6h	300-400 divided q4h, max 12 g/day
Cefepime	100 divided q12h	100 divided q12h	150 divided q8h, max 6 g/day
Ceftriaxone§	—	—	100 divided q12h or q24h. max 4 g/day
Ceftazidime	100 divided q12h	150 divided q8h	150-200 divided q8h, max 6 g/day
Gentamicin†‡	4 divided q24h	5 divided q24h	7.5 divided q8h
Meropenem	60 divided q8h	90 divided q8h for days 14-28	120 divided q8h, max 6 g/day
Nafcillin	75 divided q8h	100 divided q6h	200 divided q4h-q6h, max 12 g/day
Penicillin G	450,000 divided q8h	500,000 divided q6h	300,000-400,000 divided q4h, max 24 million U/day
Rifampin	—	10 q24h	15-20 divided q12h or q24h, max 600 mg/day
Tobramycin†‡	4 divided q24h	5 divided q24h	7.5 divided q8h
Vancomycin†‡#	40 divided q12h	60 divided q8h	age 3 mo-12: 60-80 divided q6h age >12 yr: 60-70 divided q6h-q8h

*Dosages in mg/kg (units/kg for penicillin G) per day.
†Smaller doses and longer dosing intervals, especially of aminoglycosides and vancomycin for very low-birthweight neonates, may be advisable.
‡Monitoring of serum levels is recommended to ensure safe and therapeutic values.
§Use in neonates is not routinely recommended because of inadequate experience in neonatal meningitis and concerns of displacement of bilirubin from albumin, leading to worsening of hyperbilirubinemia. Some centers use ceftriaxone in term neonates older than 7 days of age who are not receiving calcium-containing solutions or total parenteral nutrition and have normal albumin level and total serum bilirubin <5 mg/dL.
#Goal vancomycin AUC/MIC of 400-600 mg*hr/L or trough of 15-20 mg/L.
Adapted from Tunkel AR, Hartman BJ, Kaplan SL, et al. Practice guidelines for the management of bacterial meningitis. *Clin Infect Dis.* 2004;39:1267–1284. Table 6; with updated data from Kimberlin DW, Barnett ED, Lynfield R, et al. Red Book (2021): Report of the Committee on Infectious Diseases, 32nd ed. Itasca, IL: American Academy of Pediatrics; 2021.

In the past, the standard of care for the treatment of meningitis included repeating an LP before the end of antimicrobial therapy. The total length of therapy would be determined according to whether the CSF parameters (white blood cell count, protein, and glucose) had normalized or not. However, further studies showed that abnormal CSF parameters did not predict which patients would develop relapsed infection after stopping antibiotics. Therefore repeat LP before discontinuation of antibiotics for typical bacterial meningitis is not recommended.

Currently, the recommended treatment duration for uncomplicated *S. pneumoniae* meningitis is 10-14 days with a third-generation cephalosporin, or intravenous penicillin (300,000-400,000 units/kg/day, divided every 4 hours) for penicillin-sensitive isolates, or vancomycin if the isolate is resistant to penicillins and cephalosporins. For *N. meningitidis* meningitis, the recommended treatment duration is 5-7 days with intravenous penicillin for strains with an MIC of penicillin <0.1 μg/mL, or ceftriaxone for strains with an MIC of 0.1-1 μg/mL. Uncomplicated *H. influenzae* type b meningitis should be treated for 7-10 days with ampicillin for β-lactamase–negative strains or with a third-generation cephalosporin for β-lactamase–positive isolates. Patients who receive intravenous or oral antibiotics before LP and do not have an identifiable pathogen from cultures but do have evidence of bacterial meningitis based on their CSF profile and PCR should receive therapy with ceftriaxone for 7-10 days. Shorter durations of antibiotics for meningitis might be effective; one double-blinded, randomized study of children with meningitis demonstrated equivalent outcomes when treating with ceftriaxone for 5 versus 10 days. In addition, during epidemics of meningococcal meningitis in Africa, single intramuscular dosages of ceftriaxone or chloramphenicol can be used.

Meningitis caused by *Escherichia coli* or *P. aeruginosa* may require therapy with a third- or fourth-generation cephalosporin or carbapenem active against the isolate in vitro. Many isolates of *E. coli* are sensitive to ceftriaxone, and isolates of *P. aeruginosa* are often sensitive to ceftazidime. Repeat examination of CSF should be considered in some neonates and in patients with meningitis from gram-negative bacilli or β-lactam–resistant *S. pneumoniae.* The CSF in most cases will be sterile within 24-48 hours of initiation of appropriate antibiotic therapy. Gram-negative bacillary meningitis should be treated for 3 weeks, or at least 2 weeks after CSF sterilization, if documented.

Side effects of antibiotic therapy for meningitis include phlebitis, drug fever, rashes, emesis, oral or vaginal candidiasis, and diarrhea. Ceftriaxone may cause reversible gallbladder pseudolithiasis, detectable by abdominal ultrasonography. This is usually asymptomatic but may be associated with emesis and upper right quadrant pain.

Corticosteroids

Rapid killing of bacteria in the CSF by the host's immune response and antibiotics leads to release of inflammatory agents (e.g., endotoxin) that precipitate a cytokine-mediated inflammatory cascade. The resultant edema and neutrophilic infiltration may aggravate neurologic injury with worsening of CNS signs and symptoms. Therefore agents that restrain production of inflammatory mediators could be of benefit in bacterial meningitis.

In a Cochrane review of corticosteroid use in meningitis, steroids reduced hearing loss in children with meningitis caused by *H. influenzae* type b but not by other pathogens. The use of adjunctive steroids in children did not reduce mortality; however, steroids did improve survival rates in adults with pneumococcal meningitis. These data support

the use of intravenous dexamethasone 0.15 mg/kg/dose given every 6 hours for 2 days in the treatment of *H. influenzae* type b meningitis in children over 6 weeks of age. Corticosteroids appear to have maximum benefit if given 1-2 hours before antibiotics are initiated, which is difficult to operationalize; steroids may also be effective if given concurrently with or soon after the first dose of antibiotics. Pediatric data regarding benefits, if any, of corticosteroids in the treatment of meningitis caused by other bacteria remain inconclusive.

COMPLICATIONS

Treatment of meningitis can be accompanied by acute CNS complications, including seizures, increased ICP, cranial nerve palsies, stroke, cerebral or cerebellar herniation, SIADH, and thrombosis of dural venous sinuses.

Collections of fluid in the subdural space develop in 10–30% of patients with meningitis and are asymptomatic in 85–90% of patients. Subdural effusions are especially common in infants. Symptomatic subdural effusions may result in a bulging fontanel, diastasis of sutures, enlarging head circumference, emesis, seizures, fever, or abnormal results of cranial transillumination. CT or MRI scanning can confirm the presence of subdural effusion. In the presence of increased ICP or depressed level of consciousness, symptomatic subdural effusion should be treated by aspiration through the open fontanel (see Chapters 82 and 630). Fever alone is not an indication for aspiration.

SIADH occurs in some patients with meningitis, resulting in hyponatremia and reduced serum osmolality. This may exacerbate cerebral edema or result in hyponatremic seizures (see Chapter 82).

Fever associated with bacterial meningitis usually resolves within 5-7 days of the onset of therapy. Prolonged fever (>10 days) is noted in approximately 10% of patients. Prolonged fever is usually related to intercurrent viral infection, nosocomial or secondary bacterial infection, thrombophlebitis, or drug reaction. In meningitis caused by *N. meningitidis,* pericarditis or arthritis may occur during treatment (sometimes accompanied by recrudescent fever) and is caused by either bacterial dissemination or immune complex deposition. In general, infectious pericarditis or arthritis occurs earlier in the course of treatment than immune-mediated disease.

Thrombocytosis, eosinophilia, and anemia may develop during therapy for meningitis. Anemia may be a result of hemolysis or bone marrow suppression. Disseminated intravascular coagulation is most often associated with the rapidly progressive pattern of presentation and is observed most commonly in patients with shock and purpura. The combination of endotoxemia and severe hypotension initiates the coagulation cascade; coexistence of ongoing thrombosis may produce symmetric peripheral gangrene.

PROGNOSIS

Appropriate antibiotic therapy and supportive care have reduced the mortality rate of bacterial meningitis beyond the neonatal period to under 10%. The highest mortality rates are observed with pneumococcal meningitis. Severe neurodevelopmental sequelae may occur in 10–20% of patients recovering from bacterial meningitis, and as many as 50% have some neurologic sequelae. The prognosis is poorer among infants under 6 months of age and in those with high CSF bacterial burden. Those with seizures occurring later than 4 days into therapy or with coma or focal neurologic signs on presentation also have increased risk of long-term sequelae. There does not appear to be a correlation between the duration of symptoms before a diagnosis of meningitis and the subsequent outcome.

The most common neurologic sequelae of meningitis include hearing loss, cognitive impairment, recurrent seizures, delay in acquisition of language, visual impairment, and behavioral problems. Sensorineural hearing loss is most frequently detected and is often already present at the time of initial presentation. It results from cochlear or auditory nerve inflammation and occurs in as many as 30% of patients with pneumococcal meningitis, 10% with meningococcal meningitis, and 5–20% of those with *H. influenzae* type b meningitis. All patients with bacterial meningitis should undergo careful audiologic assessment before or soon after discharge from the hospital. Frequent reassessment in the outpatient setting is indicated for patients who develop a hearing deficit.

PREVENTION

Vaccination and antibiotic prophylaxis of susceptible at-risk contacts represent two opportunities to reduce the transmission and development of secondary cases of bacterial meningitis.

Neisseria meningitidis

See also Chapter 237.

Chemoprophylaxis is recommended for all close contacts of patients with meningococcal meningitis, regardless of age or immunization status. Close contacts >1 month of age should be treated with rifampin 15-20 mg/kg/dose every 12 hours (maximum dose 600 mg) for 2 days as soon as possible after identification of a case of suspected meningococcal meningitis or sepsis. Alternative options include intramuscular ceftriaxone (125 mg once for children under age 15 years, or 250 mg once for persons older than 15 years) or ciprofloxacin 20 mg/kg as a single oral dose (maximum 500 mg). Close contacts include household, daycare, and nursery school contacts and healthcare workers who have direct exposure to oral secretions (mouth-to-mouth resuscitation, suctioning, intubation). If there is a high suspicion of meningococcemia in the index patient, exposed contacts should be prophylaxed immediately. In addition, all contacts should be educated about the early signs of meningococcal disease and the need to seek prompt medical attention if these signs develop.

Many countries have included quadrivalent conjugate meningococcal vaccine (types A, C, Y, and W-135) as part of routine immunization schedules. The Advisory Committee on Immunization Practices (ACIP) of the U.S. CDC recommends a two-dose vaccine series for all children, with the first dose administered at the age of 11-12 years and a second dose at age 16-18 years. Vaccination is also recommended for persons 2 months to 18 years of age who are at increased risk for meningococcal disease, including those with anatomic or functional asplenia or complement deficiencies or who are receiving a terminal complement inhibitor (e.g., eculizumab). Two meningococcal vaccines against serogroup B have been developed. In the United Kingdom, the vaccine is administered to all infants at 2, 4, and 12 months of age. This differs from the United States, where currently meningococcal B vaccine is recommended for children 10 years and older at increased risk for invasive disease and is optional for persons 16-23 years of age.

Haemophilus influenzae Type b

See also Chapter 240.

Rifampin prophylaxis should be given to all household contacts of patients with invasive disease caused by *H. influenzae* type b *if* any close family member younger than 48 months has not been fully immunized or if an immunocompromised child of any age resides in the household. A household contact is one who lives in the residence of the index case or who has spent a minimum of 4 hours with the index case for at least 5 of the 7 days preceding the patient's hospitalization. Family members should receive rifampin prophylaxis immediately after the diagnosis is suspected in the index case, because over 50% of secondary cases occur in the first week after the index patient is hospitalized. The dose of rifampin is 20 mg/kg/day (maximum dose 600 mg) given once daily for 4 days.

Three conjugate monovalent vaccines for *H. influenzae* type b are licensed in the United States along with two other multivalent vaccines that include *H. influenzae* type b components. Although each vaccine elicits different profiles of antibody response in infants immunized at 2-6 months of age, all result in protective levels of antibody with a 93% efficacy rate against invasive infections after the primary series. Thus all children should be immunized with *H. influenzae* type b conjugate vaccine beginning at 2 months of age. Efficacy is not as consistent in Indigenous Nation populations, a group recognized as having a higher incidence of *H. influenzae* disease.

Streptococcus pneumoniae

See also Chapter 228.

Antibiotic prophylaxis should not be administered to contacts of children diagnosed with pneumococcal meningitis. Routine administration of pneumococcal conjugate vaccine is recommended for children under 5 years of age. The initial dose of the series is given at 2 months of age. Children who are at high risk for invasive pneumococcal infection, including those with functional or anatomic asplenia (including sickle cell disease), cochlear implants, CSF leaks, chronic illnesses (chronic heart disease, chronic lung disease, or diabetes mellitus), and underlying immunodeficiency (such as infection with HIV, primary immunodeficiency, and those receiving immunosuppressive therapy) should receive pneumococcal conjugate vaccine and the 23-valent pneumococcal polysaccharide vaccine (PPSV23).

Visit Elsevier eBooks+ at eBooks.Health.Elsevier.com for Bibliography.

643.2 Viral Meningoencephalitis

Andrew B. Janowski and David A. Hunstad

Viral meningoencephalitis is an acute inflammatory process involving the meninges and/or brain parenchymal tissue. These infections are caused by a number of different pathogens, and quite often, no pathogen can be identified from the CSF or brain tissue specimens after routine clinical testing. The CSF is characterized by pleocytosis and the absence of microorganisms on Gram stain and routine bacterial culture. Outcomes are quite variable because cases of meningoencephalitis caused by some pathogens are self-limited, whereas others cause significant long-term neurologic sequelae.

ETIOLOGY

Among the most common causes of viral meningoencephalitis are viruses of the family Picornaviridae, including the **enteroviruses** (poliovirus, coxsackievirus, enterovirus, and echovirus) and **parechoviruses** (see Chapters 296 and 297) (see Tables 643.2 and 643.3). Meningoencephalitis caused by these viruses is often self-limited but can be severe in neonates or chronic in immunocompromised hosts (particularly X-linked agammaglobulinemia; see Chapter 166). Human coxsackievirus A7 and enteroviruses D68 and 71 have been associated with neurologic symptoms, including acute flaccid paralysis. Parechoviruses are an important cause of meningoencephalitis in infants and rarely cause disease in older children. Clinical manifestations in infants are generally similar to those of enteroviral infection, but infants with parechovirus infection may also exhibit abdominal signs or a sepsis-like syndrome. In addition, parechovirus infection is associated with more severe MRI lesions of the cerebral cortex, and CSF pleocytosis may be minimal or absent.

The term **arbovirus** refers to a broad range of viruses from multiple viral families that are transmitted by arthropod vectors, typically mosquitoes or ticks (see Chapters 314 and 315). Most of these viral infections are considered zoonotic, as their primary reservoir is in birds or small animals. Humans often represent dead-end hosts because sufficient viremia does not develop to enable transmission back to arthropod vectors. However, humans are the primary reservoir for viruses such as Zika, chikungunya, and dengue. The arboviruses that most often cause meningoencephalitis include WNV, Japanese encephalitis virus, and La Crosse virus; other arboviruses are described in Table 643.3. WNV made its appearance in the Western Hemisphere in 1999 and is now the most common arbovirus causing meningoencephalitis in the United States. WNV may also be transmitted by blood transfusion, organ transplantation, or vertically across the placenta. Most children with WNV are either asymptomatic or have nonspecific viral-like illness. Approximately 1% of infected humans develop CNS disease; adults are more severely affected than children.

Several members of the viral family Herpesviridae can cause meningoencephalitis (see Chapters 299-304). Herpes simplex virus (HSV) type 1 is an important cause of severe, sporadic encephalitis in children and adults, with progression to coma and death in 70% of cases without antiviral therapy. In neonates, severe encephalitis with diffuse brain involvement can be caused by HSV type 2, transmitted vertically at delivery. A mild transient (and sometimes recurrent) form of meningoencephalitis with HSV-2 may accompany genital herpes infection in sexually active adolescents and adults. Varicella-zoster virus (VZV) may cause CNS infection in a close temporal relationship with clinical manifestations of chickenpox. The most common manifestation of CNS involvement by VZV is cerebellar ataxia, whereas the most severe form is acute encephalitis. After primary infection, VZV establishes latency in spinal and cranial nerve roots and ganglia, and reactivation is evidenced by herpes zoster that can be accompanied by mild meningoencephalitis. Epstein-Barr virus is associated with various CNS syndromes (see Chapter 301). Cytomegalovirus (CMV) infection of the CNS can occur with congenital infection or disseminated disease in immunocompromised hosts, but it is an exceptionally rare cause of meningoencephalitis in immunocompetent infants and children (see Chapter 302). Human herpesvirus 6 is associated with encephalitis, but detection of the virus can also be reflective of latency in lymphocytes with reactivation caused by inflammation (see Chapter 303).

Mumps can cause meningoencephalitis and has a higher incidence in regions where the mumps vaccine is not implemented (see Chapter 295). Mumps meningoencephalitis is typically mild, but deafness from damage of the eighth cranial nerve can occur. Meningoencephalitis is also associated with acute infection with measles, rubella, respiratory viruses (adenovirus, coronaviruses, influenza virus, parainfluenza virus, respiratory syncytial virus), rotavirus, astroviruses, lymphocytic choriomeningitis virus, or rabies. HIV is associated with acute meningoencephalitis and can cause chronic encephalopathy leading to neurocognitive decline (see Chapter 322). In exceptionally rare situations, meningoencephalitis may follow live virus vaccination against polio, measles, mumps, rubella, or varicella.

EPIDEMIOLOGY

Meningoencephalitis has a seasonal pattern, with a peak incidence in the summer and late fall caused by a spike in circulation of enteroviruses and arboviruses. In 2018, the most common identifiable arbovirus responsible for meningoencephalitis in the United States was WNV, with a total of 2,647 cases; fewer than 200 combined cases were caused by the La Crosse, Jamestown Canyon, Powassan, St. Louis, and eastern equine encephalitis viruses (see Chapter 314). In 2019, an outbreak of 39 cases of eastern equine encephalitis occurred across the eastern United States, and 15 cases of St. Louis encephalitis were present in the western and central United States. In Asia, the most common cause is Japanese encephalitis virus, with an estimated >60,000 cases per year. Epidemiologic considerations in aseptic meningitis caused by agents other than enteroviruses also include the season, location of residence, recent travel, animal exposures, mosquito or tick bites, and additional factors related to specific pathogens.

Several studies have attempted to describe the causative pathogens associated with meningoencephalitis, including the California Encephalitis Project. Despite extensive testing, however, no pathogen can be identified in up to 63% of cases. Newer assays such as next-generation sequencing have the potential to identify novel or previously unrecognized pathogens in causing meningoencephalitis. Occult meningoencephalitis cases caused by pathogens such as *Leptospira,* astroviruses, and *Cutibacterium* (formerly *Propionibacterium*) *acnes* have been identified through this methodology. In addition to infectious agents, autoimmune encephalitis is a common cause of encephalitis-like illness (see Chapter 638.4).

PATHOGENESIS AND PATHOLOGY

Neurologic damage is caused by direct invasion and destruction of neural cells and tissues by actively multiplying viruses and by the host reaction to viral antigens. Tissue sections of the brain generally are characterized by meningeal congestion and mononuclear infiltration, perivascular cuffs of lymphocytes and plasma cells, some perivascular tissue necrosis with myelin breakdown, and neuronal disruption in various stages, including, ultimately, neuronophagia and endothelial proliferation or necrosis. A marked degree of demyelination with preservation of neurons and their axons is considered to represent

predominantly "postinfectious" or autoimmune encephalitis. In HSV encephalitis, the cerebral cortex (classically the temporal lobes in HSV-1 infection) is often severely affected. Arboviruses tend to affect the entire brain, whereas rabies has a predilection for the basal structures. The involvement of the spinal cord, nerve roots, and peripheral nerves can be variable with these viruses.

CLINICAL MANIFESTATIONS

The progression and severity of disease are related to the relative degree of meningeal and parenchymal involvement, which, in part, is determined by the specific etiology. The clinical course of infection varies from case to case, even with the same causative pathogen. Some children may have mild symptoms at onset, only to lapse into a coma and rapidly die. In others, the illness may be ushered in by high fever, violent convulsions interspersed with bizarre movements, and hallucinations, followed by complete recovery.

The onset of meningoencephalitis is generally acute, although CNS signs and symptoms are often preceded by a nonspecific febrile illness of a few days' duration. The presenting manifestations in older children include headache and hyperesthesia and, in infants, irritability and lethargy. Headache is most often frontal or generalized; adolescents frequently complain of retrobulbar pain. Fever, nausea and vomiting, photophobia, and pain in the neck, back, and legs are common. With high fevers, patients may develop altered mental status that progresses to encephalopathy in combination with uncontrolled body movements and seizures. Focal neurologic signs may be persistent, fluctuating, or migratory. WNV and nonpolio enteroviruses, including enterovirus D68, may cause anterior horn cell injury and acute flaccid paralysis. Encephalitis is more common than aseptic meningitis in WNV infection, whereas acute flaccid paralysis may be noted in approximately 5% of patients. Loss of bowel and bladder control and unprovoked emotional outbursts may also occur. Nonetheless, many patients have a nonspecific febrile illness caused by WNV infection and may never seek medical attention. Specific conditions associated with CNS viral infection include Guillain-Barré syndrome, transverse myelitis, hemiplegia, and cerebellar ataxia.

Exanthems can precede or accompany CNS signs, especially with enteroviruses, VZV, measles, rubella, and WNV.

During the pandemic caused by SARS-CoV-2, neurologic diseases were uncommonly associated with this infection in children, including encephalitis, Guillain-Barré syndrome, and stroke. In addition, in the multisystem inflammatory syndrome of children (MIS-C), encephalopathy is often observed, with some case series describing neurologic symptoms in over 50% of patients with MIS-C. Similar neurologic conditions have been observed in adults with SARS-CoV-2 infection, and persistent symptoms and impairments can be observed months after acute infection. It is unclear if the constellation of symptoms are the result of direct infection of the CNS by SARS-CoV-2 or if the inflammatory response to viral infection also contributes to the development of acute and chronic neurologic symptoms.

A syndrome of **mild encephalopathy with a reversible splenial lesion** (of the corpus callosum) has been associated with various pathogens, including rotavirus, respiratory syncytial virus (RSV), salmonella, CMV, adenovirus, and influenza virus.

DIAGNOSIS

CSF findings in viral meningoencephalitis are characterized by a pleocytosis of leukocytes with counts typically <1,000/mm^3 (see Table 643.1). In the initial hours of disease, the cells may be polymorphonuclear, whereas mononuclear cells predominate for the remainder of the illness. CSF protein concentration tends to be elevated, especially if brain destruction is extensive, as with HSV encephalitis. The glucose level is typically normal, although hypoglycorrhachia can occur with certain viruses (e.g., mumps). With parechoviruses, the CSF glucose, protein, and cell counts may be normal.

Identification of an infectious cause relies on analysis of the CSF for the presence of pathogens by PCR and serology and, in rare situations, identification of pathogens in brain biopsy material. CSF metagenomic sequencing is available in limited centers. A commercial multiplex PCR assay combines testing for common bacterial and viral pathogens in CNS infections. However, this assay does exhibit false-positive and false-negative results, so many clinicians still order individual PCR tests for common viral pathogens. In WNV meningoencephalitis, by the time patients present for medical care, viral nucleic acid may be absent in the CSF. Therefore the test of choice for detection of WNV and other arboviruses is serologic (on both blood and CSF). If initial CSF PCRs and serology are not diagnostic, serologic testing should be repeated 2-3 weeks later. A fourfold increase in titers for a specific virus or other pathogen would suggest the etiology of the patient's presentation.

Viruses detected in blood, nasopharyngeal, stool, and urine specimens can be used to suggest a potential viral etiology. However, caution must be practiced when viruses are detected in locations outside the CSF, because detection of these viruses may be incidental and not explain the patient's CNS symptoms. Other tests of potential value in the evaluation of patients with suspected viral meningoencephalitis include an electroencephalogram (EEG) and MRI. EEG typically shows diffuse slow-wave activity, although focal changes in temporal regions can be observed in HSV meningoencephalitis. MRI of the brain may demonstrate focal brain lesions that correlate with clinical disease, including temporal lobe involvement to suggest HSV-1 disease. Hyperdense lesions may also be identified on T2 and FLAIR imaging (Fig. 643.1).

A diagnostic approach is noted in Table 643.5.

DIFFERENTIAL DIAGNOSIS

Meningoencephalitis is not exclusively caused by viruses, as other pathogens are also associated with this condition (see Table 643.3). The most important diagnosis to differentiate from meningoencephalitis is bacterial meningitis, given the consequences if that disease is untreated. Most children with acute bacterial meningitis are more critically ill than those with CNS viral infection (with HSV as an exception). Parameningeal bacterial infections, such as brain abscess or subdural or epidural empyema, may have features similar to viral CNS infections. Infections caused by *M. tuberculosis* (see Chapter 261), *T. pallidum* (syphilis, see Chapter 264), and *B. burgdorferi* (Lyme disease, see Chapter 268) may exhibit more indolent clinical courses. *Bartonella henselae* is associated with cat exposure, a papule at the site of inoculation, regional lymphadenopathy, and new-onset seizures (see Chapter 255). *Mycoplasma pneumoniae* has been suggested as a causative pathogen in meningoencephalitis, either as a direct pathogen or a trigger of postinfectious symptoms (see Chapter 269). However, serologic testing for *Mycoplasma* can be nonspecific, and IgM titers can be elevated for several months after infection, leading to incorrect interpretation of a positive result.

Infections caused by fungi, rickettsiae, protozoa, and other parasites may also need to be included in the differential diagnosis. Consideration of these agents usually arises as a result of exposure history, accompanying symptoms, local geographic epidemiology, and host immune factors.

Nonetheless, a significant proportion of patients will have a presentation and clinical testing that is consistent with a diagnosis of encephalitis, but despite exhaustive testing for pathogens, including metagenomic sequencing, no etiology will be identified. In this situation, many clinicians would agree that an infectious cause is less likely but still cannot be fully ruled out. Various noninfectious disorders may be associated with CNS inflammation and have manifestations overlapping with those associated with viral meningoencephalitis. Some of these disorders include malignancy, autoimmune diseases, intracranial hemorrhage, and exposure to certain drugs or toxins. Attention to the history and other organ involvement usually allows elimination of these diagnostic possibilities. Autoimmune encephalitis caused by anti–*N*-methyl-D-aspartate (anti-NMDA) receptor antibodies is an important cause of noninfectious encephalitis in adolescents and young adults (see Chapter 638.4). Detection of these antibodies in the serum and CSF confirms this diagnosis. Anti-NMDA receptor encephalitis has also been associated with recent HSV encephalitis, but a mechanism explaining this posited association is unknown. Acute

disseminated encephalomyelitis (ADEM) may also initially be confused with encephalitis (see Chapter 640).

TREATMENT

For most causes of viral meningoencephalitis, no effective antiviral agents exist; therefore treatment is primarily supportive care. Intravenous fluids are typically administered because of poor oral intake. NSAIDs are often used for symptomatic relief of headache. It is important to monitor patients with severe encephalitis closely for seizures, cerebral edema, disturbed fluid and electrolyte balance, aspiration, respiratory failure, and cardiac arrest.

Members of the herpesvirus family can be treated with antivirals, with acyclovir, ganciclovir, cidofovir, and foscarnet having variable activities against these viruses (see Chapters 299-304). Parenteral acyclovir has been specifically shown to dramatically reduce morbidity and mortality rates in HSV-associated meningoencephalitis. When no pathogens are identified and a postinfectious or autoimmune etiology is suspected, patients are in some cases treated with a combination of steroids, intravenous immunoglobulin, and plasmapheresis (see Chapters 638 and 640).

PROGNOSIS

Supportive and rehabilitative efforts are very important after patients recover from the acute phase of illness. Motor incoordination, seizures, total or partial deafness, and behavioral disturbances may follow viral meningoencephalitis. Visual disturbances from chorioretinopathy and perceptual amblyopia may also occur. Some sequelae of infection may be subtle; therefore neurologic, developmental, and audiologic evaluations should be part of the routine follow-up of children who have recovered from viral meningoencephalitis.

Recovery from viral infections of the CNS depends on the severity of the clinical illness, the specific causative agent, and the age of

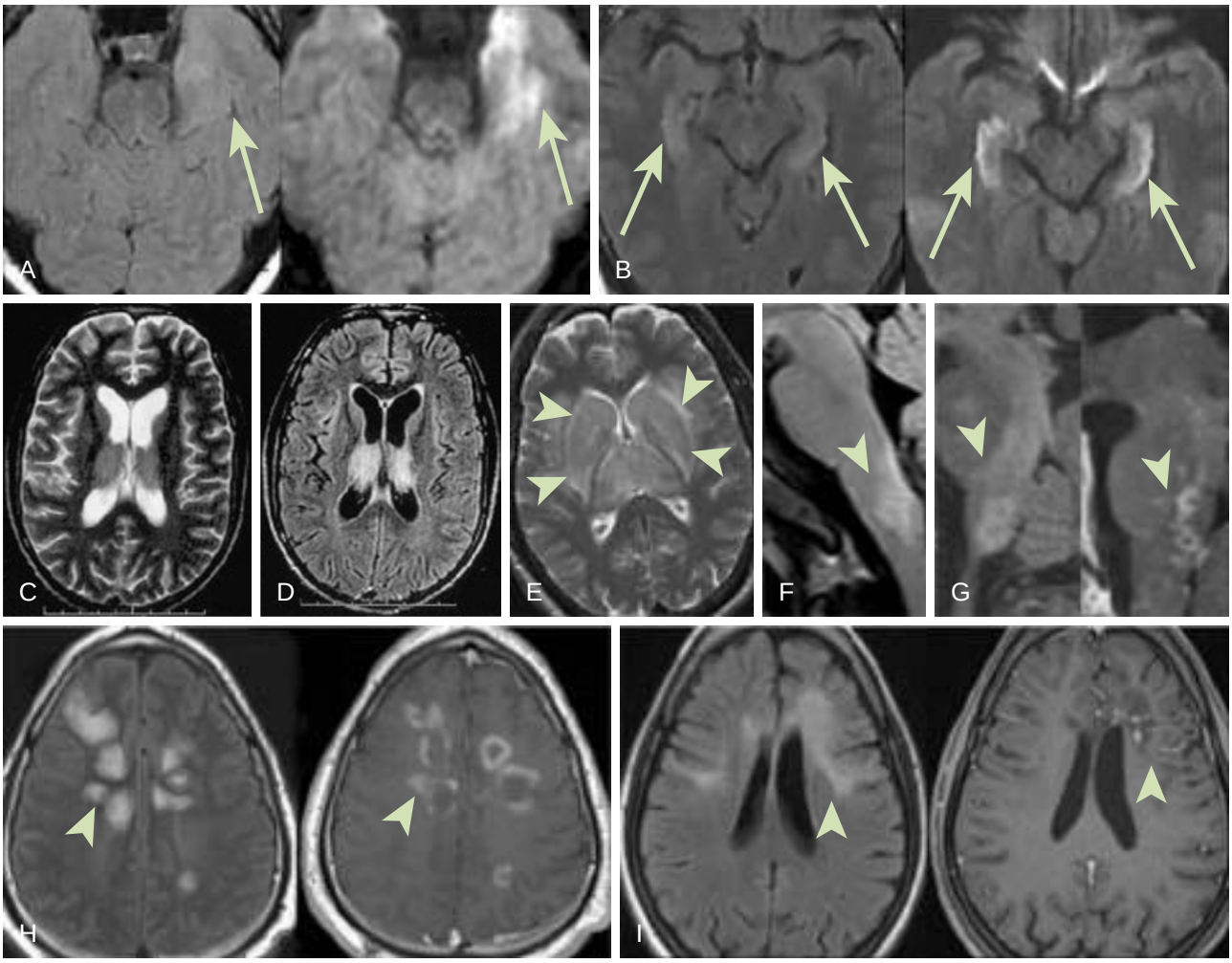

Fig. 643.1 MRI findings in acute encephalitis. Representative images from infectious and autoimmune encephalitides are shown. **A,** Early herpes simplex encephalitis; left temporal lobe abnormalities are more clearly seen on diffusion-weighted imaging (DWI) *(right)* than fluid-attenuated inversion recovery (FLAIR) *(left)*. **B,** Autoimmune limbic encephalitis; bilateral mesial temporal lobe abnormalities seen on both DWI *(right)* and FLAIR *(left)*—note the symmetric nature of the lesions. **C-E,** Arboviral encephalitis; T2-weighted image of a patient with Japanese encephalitis shows hyperintensities in bilateral thalamus (**C**). The hyperintensities are better visualized in FLAIR image (**D**). T2-weighted image of patient with (**E**) Eastern equine encephalitis shows increased signal intensity and swelling in the deep gray matter. **F,** Neuromyelitis optica; FLAIR image of a patient who presented with brainstem encephalitis and found to have antibodies to aquaporin-4. **G,** *Listeria* brainstem encephalitis; FLAIR *(left)* and post-gadolinium *(right)* images show T2 abnormalities similar to neuromyelitis optica (NMO) but also multiple rim-enhancing brainstem lesions typical of *Listeria*. **H,** In acute disseminated encephalomyelitis, multifocal areas of T2 hyperintensity are seen on FLAIR *(left)* with characteristic incomplete rims of enhancement after gadolinium administration *(right)*. **I,** In myelin oligodendrocyte glycoprotein encephalomyelitis, multifocal and confluent lesions can be seen on FLAIR imaging *(left)*, and post-gadolinium imaging *(right)* shows patchy areas of enhancement. *(**A, B,** and **F-H,** Modified from Venkatesan A, Michael BD, Probasco JC, et al. Acute encephalitis in immunocompromised adults. Lancet. 2019;393:702–716, Fig. 1, p. 709; **C** and **D,** Modified from Misra UK, Kalita J, Phadke RV, et al. Usefulness of various MRI sequences in the diagnosis of viral encephalitis. Acta Trop. 2010;116[3]:206–211, Fig 1ab; **E,** From Harvala H, Bremner J, Kealey S, et al. Case report: Eastern equine encephalitis virus imported to the UK. J Med Virol. 2009;81[2]:305–308; **I,** Courtesy Dr Michael Levy, Harvard Medical School.)*

Table 643.5 Laboratory Testing and Neuroimaging Characteristics of Selected Pathogens

	LABORATORY TESTING	CHARACTERISTIC BRAIN MRI FINDINGS
VIRUSES		
HSV	CSF PCR (false negative can occur in first 72 hours). PCR of skin lesions may also be helpful if they occur in conjunction with neurological disease. Blood PCR in neonates. In neonatal CNS disease, CSF PCR is completed near the end of therapy to guide final treatment duration.	For HSV-1: Asymmetric abnormalities in mesiotemporal lobes, orbitofrontal lobes, and insular cortex with edema, possible restricted diffusion or hemorrhage (late stage) HSV-2 in neonates can appear like HSV-1. In adults, HSV-2 meningitis has variable findings (including no abnormalities) or may mimic HSV-1 encephalitis.
Varicella-zoster virus	CSF PCR; skin lesion PCR, biopsy, or DFA for VZV	Could affect temporal lobes, similar to HSV-1; lesions can occur in cerebellum and brainstem; ischemic or hemorrhagic lesions in white matter or gray-white matter junction suggest vasculopathy
Enteroviruses	CSF PCR; Blood PCR; nasopharyngeal swabs can be difficult to interpret as asymptomatic rhino/enterovirus infections are frequently detected. Stool testing only recommended for epidemiological tracing, including for poliovirus or enterovirus D68.	Wide range of findings from normal to diffuse white matter changes. EV 71 causes lesions in the dorsal brainstem, dentate nuclei of cerebellum, and anterior horns of spinal cord. EV D68 often causes lesions of the brainstem, spinal cord with involvement of the central gray matter, and of anterior horn cells.
Parechoviruses	CSF PCR; blood PCR	Variable findings from normal to restricted diffusion of thalami, corpus callosum, subcortical, and periventricular white matter, predominating in the frontal and parietal regions.
Measles*	Serum IgG and IgM; PCR of nasopharyngeal, throat, or urine samples in early infection	Cerebral edema, multifocal lesions, can resemble ADEM in acute setting
Mumps*	CSF and serum IgM and IgG; PCR from throat swab	Lesions in brainstem, hippocampus, and splenium of corpus callosum
Influenza virus	PCR or antigen testing of respiratory secretions; CSF PCR is infrequently positive	Neuroimaging is often normal, although abnormalities can include reversible splenial lesions, deep gray T2 abnormalities, diffuse edema, and hemorrhagic and necrotizing lesions of thalami, brainstem, and cerebellum
Arboviruses (many including alphaviruses such as eastern equine encephalitis, and flaviviruses, such as Japanese encephalitis or West Nile)	CSF and serum IgM and IgG (some viruses will have serological cross-reactivity with related viruses and further confirmation is needed through plaque reduction neutralization testing); CSF PCR (low sensitivity because viral nucleic acid is often absent by the time the patient presents for medical care. Can be useful in immunocompromised individuals); serum PCR (Zika); urine PCR (Zika, West Nile virus)	Up to half will have normal brain MRI; abnormalities might involve deep gray matter (i.e., thalamus, basal ganglia) and brainstem
Rabies virus*	PCR from saliva; PCR and immunofluorescent staining from nuchal skin biopsy or brain tissue; serum and CSF rabies virus neutralizing antibodies	Multifocal abnormalities in temporal cortex, hippocampi, deep gray nuclei, substantia nigra, brainstem, cerebral white matter, gray matter >> white matter
BACTERIA		
Borrelia spp.	Serology (serial EIA and Western blot); VlsE C6 ELISA; CSF antibody index; and CSF PCR (low sensitivity and specificity)	Multifocal lesions in subcortical white matter, potentially mimicking multiple sclerosis
Brucella spp.	Serum and CSF IgG and IgM; CSF culture	Variably enhancing lesions with marked surrounding edema
Listeria monocytogenes	Blood and CSF culture	In rhombencephalitis, multiple small rim-enhancing lesions with variable restriction of diffusion
*Mycobacterium tuberculosis**	CSF AFB smear, culture, and PCR; sputum and blood AFB smear, culture, and PCR (in young children gastric aspirates are obtained instead of sputum). Often testing needs to be repeated (≥3) from the same site to enhance sensitivity; Tuberculin skin test or interferon-gamma release assay	Basilar meningeal enhancement, hydrocephalus, rim-enhancing lesions, and strokes in deep gray matter or internal capsule
Rickettsia and related diseases (*i.e.*, *Anaplasma* spp., *Coxiella burnetti*, *Ehrlichia* spp., and *Rickettsia* spp.)	Serum IgG and IgM; whole blood PCR (useful for *Ehrlichia* and *Anaplasma*); if rash, PCR or immunohistochemical staining of skin biopsy	Reversible splenial lesions; punctate areas of restricted diffusion
Treponema pallidum	Diagnosed via combination of serum and CSF treponemal (e.g., FTA-ABS) and non-treponemal (e.g., serum RPR, CSF VDRL) antibodies, CSF white count, protein	Variable mesial temporal lobe involvement has been described

Continued

Table 643.5 Laboratory Testing and Neuroimaging Characteristics of Selected Pathogens—cont'd

	LABORATORY TESTING	CHARACTERISTIC BRAIN MRI FINDINGS
FUNGI		
Cryptococcus spp.	CSF and serum cryptococcal antigen, CSF culture and PCR. Opening pressure from the lumbar puncture may also be significantly elevated.	Basilar meningeal enhancement and hydrocephalus; cryptococcomas are T1 hypointense and 12 hyperintense lesions in basal ganglia and midbrain
Others (*Coccidioides* spp., *Histoplasma* spp., and *Blastomyces* spp.)	CSF and serum serology; large volume CSF culture; serum and urine antigen	Basilar meningeal enhancement, hydrocephalus, and rim-enhancing lesions
PARASITES AND FREE-LIVING AMEBAE*		
Acanthoemeba *spp.*	Brain histopathology; CSF and brain tissue PCR and culture; serology	Hemorrhagic and necrotic rim-enhancing lesions
Balamuthia mandrillaris	Brain histopathology; CSF and brain tissue PCR; serology	Multifocal T2-weighted hyperintensities with rim enhancement, surrounding edema, and leptomeningeal extension
Baylisascaris procyonis	CSF and serum antibodies; peripheral or CSF eosinophilia	Multifocal or confluent white matter abnormalities and nodular enhancement
Naegleria fowleri	Wet mount preparation of warm CSF; brain histopathology; CSF and brain PCR and culture	Necrotic and hemorrhagic lesions often in CSF and brain PCR frontal lobes

*Coordinate testing with local, state, and national health departments.
When serum IgM/IgG testing is performed, acute and convalescent titers are typically obtained 1-4 weeks apart. Seroconversion and fourfold or greater rise in titer using paired sera are supportive of infection.
ADEM, Acute disseminated encephalomyelitis; AFB, acid-fast bacillus; CSF, cerebrospinal fluid; DFA, direct fluorescent antibody; EIA, enzyme immunoassay, EV, enterovirus; FTA-ABS, fluorescent treponemal antibody absorption; HSV, herpes simplex virus; RPR, rapid plasma reagin; VDRL, venereal disease research laboratory; VZV, varicella-zoster virus.
Adapted From Venkatesan A, Michael BD, Probasco JC, et al. Acute encephalitis in immunocompromised adults. *Lancet*. 2019-393-702-716, Table 3, p. 708.

the child. If the clinical illness is severe and substantial parenchymal involvement is evident, the prognosis is poor, with potential deficits being intellectual, motor, psychiatric, epileptic, visual, or auditory in nature. Severe sequelae should also be anticipated in those with infection caused by HSV if it was not diagnosed and treated early in the disease. Overall, several studies have found that most children will have persistent symptoms years after the diagnosis of meningoencephalitis. These poor outcomes are likely reflective of a combination of suboptimal diagnostics for identifying pathogens that cause meningoencephalitis and a lack of specific therapies for most viral pathogens.

PREVENTION

For some viruses that cause meningoencephalitis, vaccines are available for prevention. Widespread use of effective viral vaccines for polio, measles, mumps, rubella, and varicella has almost eliminated CNS complications from these diseases in the United States. Vaccination against Japanese encephalitis virus is also available, but because of high costs, this vaccine has not been widely distributed in Asia. The availability of domestic animal vaccine programs against rabies has reduced the frequency of rabies encephalitis.

Control of encephalitis caused by arboviruses has been less successful because specific vaccines are only in various stages of development for clinical trials. The primary method for reducing arbovirus infections is vector control, through methods that include insecticides and eradicating insect breeding sites. Furthermore, minimizing mosquito and tick bites through the application of *N,N*-diethyl-3-methylbenzamide (DEET)–containing insect repellents on exposed skin and wearing long-sleeved shirts, long pants, and socks when outdoors, especially at dawn and dusk, reduces risk for arboviral infection.

Visit Elsevier eBooks+ at eBooks.Health.Elsevier.com for Bibliography.

643.3 Eosinophilic Meningitis

Andrew B. Janowski and David A. Hunstad

Eosinophilic meningitis is defined as >10 eosinophils/mm^3 of CSF or a finding that at least 10% of leukocytes in the CSF are eosinophils. The most common cause worldwide of eosinophilic CSF pleocytosis is CNS infection with helminthic parasites. Nonetheless, the differential diagnosis of CSF eosinophilic pleocytosis is broad, especially in countries where helminthic infestation is uncommon, such as the United States (Table 643.6).

ETIOLOGY

Although any tissue-migrating helminth may cause eosinophilic meningitis, the most common worldwide cause is human infection with the rat lungworm, *Angiostrongylus cantonensis* (see Chapter 343). Other parasites that can cause eosinophilic meningitis include *Gnathostoma spinigerum* (dog and cat roundworm; see Chapter 343), *Baylisascaris procyonis* (raccoon roundworm), *Ascaris lumbricoides* (human roundworm, see Chapter 337), *Toxocara canis* (see Chapter 344), *Trichinella spiralis* (see Chapter 345), *Toxoplasma gondii* (see Chapter 336), *Paragonimus westermani, Paragonimus kellicotti, Echinococcus granulosus* (see Chapter 350), *Schistosoma japonicum* (see Chapter 346), *Onchocerca volvulus,* and *Taenia solium* (see Chapter 349). Eosinophilic meningitis may also occur as an unusual manifestation of more common viral, bacterial, or fungal infections of the CNS; for example, coccidioidomycosis has been particularly associated with eosinophilic meningitis. Noninfectious causes of eosinophilic meningitis include multiple sclerosis, malignancy, hypereosinophilic syndrome, or a reaction to medications or ventriculoperitoneal shunt materials.

EPIDEMIOLOGY

A. cantonensis is found in Southeast Asia, the South Pacific, Japan, Taiwan, Egypt, the Ivory Coast, and Cuba. Infection is acquired by eating raw or undercooked freshwater snails, slugs, prawns, or crabs containing infectious third-stage larvae. *Gnathostoma* infections are found in Japan, China, India, Bangladesh, and Southeast Asia. Gnathostomiasis is acquired by eating undercooked or raw fish, frog, bird, or snake meat. *B. procyonis* is endemic in the United States and is acquired by children playing outdoors where raccoons may deposit the organisms (raccoon latrines).

CLINICAL MANIFESTATIONS

Patients with eosinophilic meningitis from helminthic infestation typically become ill 1-3 weeks after exposure, as this reflects the transit time for parasites to migrate from the gastrointestinal tract to the CNS. Concomitant findings include fever, vomiting, abdominal pain, creeping skin eruptions, pleurisy, or peripheral eosinophilia. Neurologic symptoms may include headache, meningismus, ataxia, cranial nerve

Table 643.6 Common Infectious Etiologies of Eosinophilic Meningitis

DISEASE	ETIOLOGIC AGENT	SOURCE	LOCATION	SYMPTOMS	DIAGNOSIS	TREATMENT	PROGNOSIS
Angiostrongyliasis (rat lung worm)	*Angiostrongylus cantonensis* *Angiostrongylus costaricensis*	Definitive host: rats Intermediate hosts: mollusks (snails, slugs) Paratenic hosts: crustaceans, frogs, vegetables	Thailand, China, South America, Caribbean Islands, United States (Hawaii, Louisiana), Australia, Egypt, Nigeria, Côte d'Ivoire	Severe headache Neck stiffness Nausea, vomiting Low-grade fever Hyperesthesia, paresthesia Rarely have focal neurologic deficits Children: more systemic symptoms (fever, abdominal pain)	CSF: eosinophilia, normal glucose, elevated protein, elevated opening pressure, symptomatic relief after lumbar puncture Peripheral blood eosinophilia ELISA (epitopes 29 kDa and 31 kDa) CT head: normal MRI brain: leptomeningeal enhancement, micronodular enhancement	Supportive interventions (repeat lumbar puncture, analgesics) Prednisolone 60 mg/day divided three times a day for 2 weeks Albendazole 15 mg/kg/day orally in two divided doses for 2 weeks	Self-limiting within 3–6 weeks Severe disease can cause coma, respiratory failure, and death (case fatality 5%) Children and elderly may have more severe disease
Gnathostomiasis (neurognathostomiasis)	*Gnathostoma spinigerum*	Definitive host: dogs, cats, pigs, fish-eating mammals Intermediate hosts: freshwater crustaceans Secondary intermediate hosts: freshwater fish, frogs Paratenic hosts: birds, reptiles, mammals	Southeast Asia (Thailand), China, India, Zambia, Botswana, Mexico, Central America, South America	Prodrome: abdominal pain, nausea, vomiting, diarrhea, cutaneous larvae migrans, fever Severe headache Neck stiffness Radicular pain Paresis Paralysis Cranial nerve deficits Seizures	CSF: eosinophilia, xanthochromia, elevated protein, normal glucose Peripheral blood eosinophilia ELISA (24 kDa epitope, immunoglobulin subclasses) CT head: nodular lesions, hemorrhage MRI brain: diffuse or segmental hyperintense micronodules, hemorrhagic tracts, intracerebral hemorrhage, subarachnoid hemorrhage, subdural hemorrhage	Supportive (repeat lumbar punctures, analgesics) Use of anthelmintics is controversial Steroids may help CNS inflammation Monitor closely for intracranial hemorrhage	Long-term neurologic disability 23–46% of survivors, including paraplegia, paresis, radicular pain, cranial nerve Case fatality rate 7-25%
	Baylisascaris procyonis	Definitive host: raccoons, domesticated dogs, kinkajou Paratenic hosts: small mammals (rabbits, rodents), birds	North America	Lethargy Seizures Sensory loss Ataxia Paralysis Spasticity Cranial nerve deficits Paresis Concurrent ocular involvement Rarely have fever More common in young children	CSF: eosinophilia, variable protein, normal glucose Variable peripheral blood eosinophilia ELISA (epitopes 33 kDa, 45 kDa, BpRAG1 protein) CT head and MRI brain: parenchyma inflammation, cerebral atrophy	Exposure: albendazole (2550 mg/kg per day orally for 1020 days) Treatment: albendazole (2550 mg/kg per day orally for 14 weeks) Corticosteroids	Fulminant eosinophilic meningoencephalitis Severe neurologic impairment Case fatality rate 38%

Continued

Downloaded for mohamed ahmed (dr.mms2020@gmail.com) at University of Southern California from ClinicalKey.com by Elsevier on April 22, 2024. For personal use only. No other uses without permission. Copyright ©2024. Elsevier Inc. All rights reserved.

Table 643.6 Common Infectious Etiologies of Eosinophilic Meningitis—cont'd

DISEASE	ETIOLOGIC AGENT	SOURCE	LOCATION	SYMPTOMS	DIAGNOSIS	TREATMENT	PROGNOSIS
CNS coccidioidomycosis (valley fever)	*Coccidioides immitis*, *Coccidioides posadasii*	Colonized soil in southwestern United States, Mexico, South America	Southwestern United States, Mexico, South America	Additional organ system involvement (lungs, skin, bone, soft tissue) Prodrome: febrile respiratory infection Gradual neurologic symptom onset Headache Vomiting Lethargy Fever	CSF: pleocytosis, elevated protein, decreased glucose, elevated opening pressure, culture CSF complement fixation antibodies	Lifelong fluconazole Ventriculoperitoneal shunt placement	Long-term neurologic sequelae (hydrocephalus, fatal without treatment)

CSF, Cerebrospinal fluid; *CT*, computed tomography; *ELISA*, enzyme-linked immunosorbent assay; *MRI*, magnetic resonance imaging.
From Weatherhead J, Mejia R. Eosinophilic meningitis. In Cherry J, Demmler-Harrison GJ, Kaplan SL, Steinbach W, Hotez PJ, eds. *Feigin and Cherry's Textbook of Pediatric Infectious Diseases*. 8th ed, vol 1, Philadelphia: Elsevier; 2019, Table 34.1. pp 350-351.

Downloaded for mohamed ahmed (dr.mms2020@gmail.com) at University of Southern California from ClinicalKey.com by Elsevier on April 22, 2024. For personal use only. No other uses without permission. Copyright ©2024. Elsevier Inc. All rights reserved.

palsies, and paresthesias. Paraparesis or incontinence can result from radiculitis or myelitis.

DIAGNOSIS

The presumptive diagnosis of helminth-induced eosinophilic meningitis is most often based on travel and exposure history in the presence of typical clinical and laboratory findings. Direct visualization of helminths in CSF is difficult because there typically is a low burden of organisms. Serologic assays for helminthic infections are also of limited utility because they are not readily available commercially and there is substantial cross-reactivity among different helminth species.

TREATMENT

Treatment is supportive, but anthelmintic drugs with or without steroids may be indicated (see Table 643.6). Anthelmintic drugs may provoke an inflammatory response because dying organisms can exacerbate symptoms. However, **treatment of *B. procyonis* should be initiated with albendazole and corticosteroids**. Steroids may decrease the duration of headaches in adults with eosinophilic meningitis. Analgesics should be given for headache and radiculitis, and CSF removal or shunting should be performed to relieve hydrocephalus, if present.

PROGNOSIS

Overall, up to 70% of patients improve significantly within 4 weeks after the onset of symptoms. The mortality rate associated with eosinophilic meningitis is <5%; untreated *Baylisascaris* infection may be fatal or associated with severe sequelae.

Visit Elsevier eBooks+ at eBooks.Health.Elsevier.com for Bibliography.

Chapter 644

Brain Abscess

Andrew B. Janowski and David A. Hunstad

Annually, approximately 0.3-1.3 cases of brain abscess per 100,000 people are diagnosed. Development of brain abscess is most often associated with an underlying etiology, including contiguous spread from an associated infection (meningitis, otitis media, mastoiditis, sinusitis, soft tissue infection of the face or scalp, orbital cellulitis, or dental infections); direct compromise of the blood-brain barrier due to penetrating head injuries or surgical procedures; embolic phenomena (endocarditis); right-to-left shunts (congenital heart disease or pulmonary arteriovenous malformation); immunodeficiency; or infection of foreign material inserted into the central nervous system (CNS), including ventriculoperitoneal shunts (Table 644.1).

PATHOLOGY

Cerebral abscesses occur in both hemispheres in children, but in adults, left-sided abscesses are more common, likely because of penetrating injuries from right-handed assailants. Nearly 80% of abscesses occur in the frontal, parietal, and temporal lobes, whereas abscesses in the occipital lobe, cerebellum, and brainstem account for the remainder of cases. In 18% of cases, multiple brain abscesses are present, and in nearly 20% of cases, no predisposing risk factor can be identified. Abscesses in the frontal lobe are often caused by extension from sinusitis or orbital cellulitis, whereas abscesses located in the temporal lobe or cerebellum are frequently associated with otitis media and mastoiditis.

Table 644.1 Predisposing Conditions and Microbiology of Brain Abscess

PREDISPOSING CONDITION	USUAL MICROBIAL ISOLATES
Otitis media or mastoiditis	Streptococci, *Bacteroides* spp., *Haemophilus* spp., Enterobacteriales, *Pseudomonas aeruginosa*
Sinusitis (frontoethmoid or sphenoid)	Streptococci, *Bacteroides* spp., Enterobacterales, *Staphylococcus aureus*, *Haemophilus* spp., *Fusobacterium* spp.
Dental infection	Streptococci, *Fusobacterium* spp., *Prevotella* spp., *Actinomyces* spp., *Bacteroides* spp., *Haemophilus* spp.
Penetrating trauma or postneurosurgical	*Staphylococcus* spp., streptococci, *Enterobacteriaceae*, *Clostridium* spp., *Cutibacterium* spp.
Lung abscess, empyema, bronchiectasis	Streptococci, *Fusobacterium* spp., *Actinomyces* spp., *Nocardia* spp.
Bacterial endocarditis	*Staphylococcus* spp., streptococci
Congenital heart disease	Streptococci, *Haemophilus* spp.
Neonates	*Streptococcus agalactiae* and other streptococci, Enterobacterales including *Citrobacter koserii*, *Cronobacter sakazakii*, *Serratia marcescens*, *Proteus mirabilis*, *Listeria monocytogenes*, *Candida* spp.
Neutropenia or after hematopoietic cell transplant	Streptococci, Enterobacterales, *Aspergillus* spp., Mucorales, *Candida* spp., *Nocardia* spp., *Cryptococcus neoformans*, *Coccidioides immitis*, *Blastomyces dermatitidis*, dematiaceous fungi and other mycoses, *Toxoplasma gondii*, *Mycobacterium tuberculosis*
Solid organ transplantation	Streptococci, Enterobacterales, *Aspergillus* spp., Mucorales, *Candida* spp., *Cryptococcus neoformans*, *Coccidioides immitis*, *Blastomyces dermatitidis*, dematiaceous fungi and other mycoses, *Nocardia* spp., *Toxoplasma gondii*, *Mycobacterium tuberculosis*, *Listeria monocytogenes*
HIV infection	*Toxoplasma gondii*, *Nocardia* spp., *Mycobacterium* spp., *Listeria monocytogenes*, *Cryptococcus neoformans*, *Coccidioides immitis*, *Blastomyces dermatitidis*

Adapted from Gea-Banacloche JC, Tunkel AR. Brain abscess. In: Bennett JE, Dolin R, Blaser MJ, eds. *Mandell, Douglas, and Bennett's Principles and Practice of Infectious Diseases*, 9th ed. Philadelphia: Elsevier; 2020: Table 90.1, p. 1249.

ETIOLOGY

The predominant organisms that cause brain abscesses are streptococci, which account for one third of all cases in children, with members of the *Streptococcus anginosus* group (*S. anginosus*, *Streptococcus constellatus*, and *Streptococcus intermedius*) being the most common streptococci. Other important streptococci include *Streptococcus pneumoniae*, *Enterococcus* spp., and other viridans streptococci. *Staphylococcus aureus* is the second most common organism in pediatric brain abscesses, accounting for 11% of cases, and is most often associated with penetrating injuries. Other bacteria isolated from brain abscesses include gram-negative bacilli (*Haemophilus* spp., *Escherichia coli*, *Klebsiella pneumoniae*, *Proteus* spp., and other Enterobacterales) and anaerobic bacteria (gram-positive organisms, *Bacteroides* spp., *Fusobacterium* spp., *Prevotella* spp., and *Actinomyces* spp.). In neonates with meningitis, abscess

formation is a complication in 13% of cases, with *Citrobacter koseri, Cronobacter sakazakii, Serratia marcescens,* and *Proteus mirabilis* being special considerations in this age group. In up to 27% of all cases, more than one organism is isolated on routine bacterial cultures. Metagenomics sequencing has revealed that this percentage is likely a significant underestimate, as DNA from additional uncultured species has been detected from purulent abscess fluid, including rare case reports of detection of archaea. Abscesses associated with mucosal infections (sinusitis or dental infections) are more frequently polymicrobial and include anaerobic pathogens. Atypical bacteria, including *Nocardia, Mycobacterium,* and *Listeria* spp., and fungi *(Aspergillus, Candida, Cryptococcus)* are more common in children with impaired host defenses.

CLINICAL MANIFESTATIONS

Often the early stages of cerebritis and abscess formation are asymptomatic or are associated with nonspecific symptoms, including low-grade fever, headache, and lethargy. As the inflammatory process proceeds, vomiting, severe headache, seizures, papilledema, focal neurologic signs (hemiparesis), and coma may develop. The classic triad of headache, fever, and a focal deficit is noted in <50% of patients. A cerebellar abscess is characterized by nystagmus, ipsilateral ataxia and dysmetria, vomiting, and headache. If an abscess ruptures into the ventricular cavity, overwhelming shock and death may occur.

DIAGNOSIS

The key to diagnosis of brain abscesses is prompt imaging of the CNS. Brain MRI with contrast is the diagnostic test of choice because it can aid in differentiating abscesses from cysts and necrotic tumors (Fig. 644.1). As an alternative, cranial CT can provide more rapid imaging results but cannot provide the fine parenchymal detail offered by MRI (Fig. 644.2). Both MRI and CT scans with contrast can demonstrate a ring-enhancing abscess cavity. CT findings of cerebritis are characterized by a parenchymal low-density lesion, whereas T2-weighted MRI images feature increased signal intensity. Other abnormalities in common laboratory tests can be observed in children with brain abscesses. The peripheral white blood cell count is elevated in 60% of cases, and blood cultures are positive in 28% of cases. Lumbar puncture is not routinely recommended in cases of brain abscess, because the procedure could cause brain herniation from elevated intracranial pressure. When tested, the cerebrospinal fluid (CSF) is normal in 16% of cases, 71% of cases exhibit CSF pleocytosis, and 58% will have an elevated CSF protein level. CSF cultures are positive in only 24% of cases; therefore a culture obtained from the abscess fluid is essential for identifying bacterial pathogens. In some cases, culture of the abscess fluid can be sterile, and alternative testing, including 16S ribosomal RNA sequencing, may be used to identify organisms. An electroencephalogram (EEG) may identify corresponding focal slowing.

TREATMENT

The initial management of brain abscess includes prompt diagnosis and initiation of an antibiotic regimen that is based on the most likely pathogens (Table 644.2). Empiric therapy consists of a combination of a third-generation cephalosporin and metronidazole; often, vancomycin is added to provide coverage of methicillin-resistant *S. aureus* and resistant *S. pneumoniae.* Pharmacokinetics and penetration of the blood-brain barrier are essential considerations when using alternative agents. If resistant gram-negative organisms are suspected, as in cases of infected ventriculoperitoneal shunts, cefepime or meropenem may be used as the β-lactam in the initial regimen. *Listeria monocytogenes* may cause brain abscess in the neonate, and if this etiology is suspected, penicillin G or ampicillin with gentamicin is recommended. In immunocompromised patients, broad-spectrum antibiotic coverage is used, and amphotericin B or azole therapy should be considered for coverage of potential fungi.

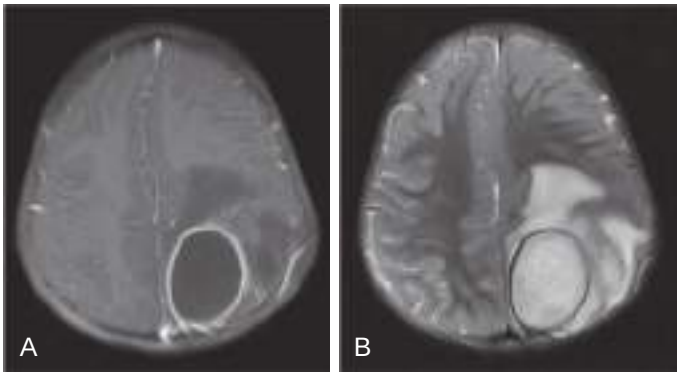

Fig. 644.1 Brain MRI in a 2-yr-old child with an atrial septal defect and brain abscess caused by MRSA. **A,** T1 fl2D postcontrast axial image demonstrating enhancement of the rim of the abscess. **B,** T2 TSE axial image showing a large fluid-filled lesion with surrounding edema.

Fig. 644.2 Brain abscess shown on CT with contrast. Note the large, wall-enhancing abscess in the left frontal lobe causing a rightward parenchymal shift. The patient had no neurologic signs until just before the CT scan, likely because the frontal lobe is a relatively "silent" area of the brain.

Neurosurgical procedures for brain abscess have been greatly enhanced by stereotactic MRI or CT systems, allowing for optimized approaches to minimize morbidity. Aspiration of the abscess is recommended for diagnostic cultures and decompression unless contraindicated based on its location or the patient's condition. There are limited data regarding injection of antibiotics into the abscess cavity, and this technique is not routinely recommended. Small abscesses (under 2.5 cm in diameter) or multiple abscesses may be treated initially with antibiotics and without surgical drainage, with follow-up neuroimaging studies to ensure a decrease in abscess size. Surgical excision of an abscess is rarely required, because such a procedure may be

Table 644.2 Antimicrobial Therapy for Brain Abscess

ORGANISM	STANDARD THERAPY	ALTERNATIVE THERAPIES
BACTERIA[1,2]		
Actinomyces spp.	Penicillin G	Ampicillin, ceftriaxone
Bacteroides fragilis	Metronidazole	Meropenem
Enterobacterales	Ceftriaxone or ceftazidime	Cefepime, meropenem, fluoroquinolones
Fusobacterium spp.	Metronidazole	Meropenem
Haemophilus spp.	Ampicillin or ceftriaxone/ceftazidime	Cefepime, meropenem
Listeria monocytogenes	Ampicillin or penicillin G + gentamicin	Trimethoprim-sulfamethoxazole, fluoroquinolones
Mycobacterium tuberculosis	Isoniazid + rifampin + pyrazinamide + ethionamide or streptomycin	Consultation with an expert at TB Centers of Excellence is recommended for drug-resistant TB
Nocardia spp.	Trimethoprim-sulfamethoxazole + imipenem + amikacin (if involvement outside of the brain)	Minocycline, doxycycline, clarithromycin, ceftriaxone, linezolid
Prevotella melaninogenica	Metronidazole	Meropenem
Pseudomonas aeruginosa	Ceftazidime or cefepime	Meropenem, ciprofloxacin, aztreonam
Staphylococcus aureus		
Methicillin-sensitive	Nafcillin or oxacillin	Vancomycin, linezolid
Methicillin-resistant[3]	Vancomycin	Linezolid, trimethoprim-sulfamethoxazole
Streptococcus anginosus (milleri) group, other Penicillin G streptococci	Penicillin G or ceftriaxone	Vancomycin
SELECTED FUNGI		
Aspergillus spp.	Voriconazole	Liposomal amphotericin B, amphotericin B lipid complex, amphotericin B deoxycholate, or salvage therapy[4]
Candida spp.	Liposomal amphotericin B, amphotericin B lipid complex, amphotericin B deoxycholate (recommended in neonates) + flucytosine (in non-neonates)	Fluconazole, voriconazole
Cryptococcus neoformans	Liposomal amphotericin B, amphotericin B lipid complex, amphotericin B deoxycholate + flucytosine	Fluconazole
Mucorales	Liposomal amphotericin B, amphotericin B lipid complex, amphotericin B deoxycholate	Salvage therapy[4]
PROTOZOA		
Toxoplasma gondii	Pyrimethamine + sulfadiazine with folinic acid	Pyrimethamine + clindamycin;other options: trimethoprim- sulfamethoxazole; atovaquone

[1]Choice of specific antimicrobial agents for standard therapy, or consideration of alternative therapies, should be based on in vitro susceptibility testing for pathogens for which testing can be performed.
[2]Depending on the pathogenesis of bacterial brain abscess (see text), these bacteria may be isolated as part of a mixed infection.
[3]Other antibiotics with activity against methicillin-resistant *Staphylococcus* spp., daptomycin and ceftaroline, have limited data regarding penetration into the central nervous system. These drugs have been used in cases of salvage therapy.
[4]There is limited evidence for use of alternative anti-fungals for the central nervous system (CNS). Isavuconazole may have good CNS penetration but is understudied. Posaconazole and itraconazole have poor penetration, but successful usage has been reported. Echinocandins, in general, do not penetrate into the CNS.
Adapted from Gea-Banacloche JC, Tunkel AR. Brain abscess. In: Bennett JE, Dolin R, Blaser MJ, eds. Mandell, Douglas, and Bennett's Principles and Practice of Infectious Diseases, 9th ed. Philadelphia: Elsevier; 2020: Table 90.4, p. 1257

associated with greater morbidity compared with aspiration of a cavity. Administration of glucocorticoids can reduce edema, though evidence for improved outcomes with steroids is lacking.

The antibiotic regimen may be narrowed or made more specific once abscess culture data are available; importantly, most abscesses are polymicrobial, and not all organisms present may be isolated in culture. The duration of parenteral antibiotic therapy depends on the causative organism(s) and response to treatment (clinically and by imaging) but is typically 6 weeks. There has been interest in shorter regimens or use of oral antibiotics as an alternative to parenteral antibiotics, but clinical data are currently insufficient to support these alternative approaches.

PROGNOSIS

Mortality rates with contemporary use of CT and MRI, improved microbiologic techniques, and prompt antibiotic and surgical management are <10%. Factors associated with high mortality rate at the time of admission include delayed administration of antimicrobials, age <1 year, multiple abscesses, and coma. Long-term sequelae occur in about one third of patients and include hemiparesis, seizures, hydrocephalus, cranial nerve abnormalities, and behavioral and learning difficulties.

Visit Elsevier eBooks+ at eBooks.Health.Elsevier.com for Bibliography.

Chapter 645

Idiopathic Intracranial Hypertension (Pseudotumor Cerebri)

Alasdair P.J. Parker and Pooja D. Harijan

Idiopathic intracranial hypertension (IIH), or pseudotumor cerebri, is frequently considered a potential cause of headache *with* papilledema in children with normal findings on standard brain MRI. A false-positive diagnosis is common, and strategies are needed to avoid this. The pathophysiology remains poorly understood, particularly in children.

IIH is rare, affecting 1 in 100,000-150,000 children, but accurate diagnosis is essential because of the risk of loss of vision. Previously, normal levels of intracranial pressure (ICP) were unclear, leading to overdiagnosis of IIH. Studies in children with ICP monitoring show an upper limit of normal as 10 mm Hg (13.5 cm H_2O) between the ages of 2 and 5 years, with the adult level of cerebrospinal fluid (CSF) pressure being reached by 8 years of age. Currently, the 90th percentile of CSF pressure on lumbar puncture (LP) has been reported to be 28 cm CSF (22 mm Hg) in children age 5 to 18 years, without a significant age effect. Other normal parameters include CSF cell count, protein content, and ventricular size (although this could be slightly decreased on brain MRI). Papilledema may be overdiagnosed. With the advent of orbital coherence tomography (OCT), *B*-ultrasound, and MRI/venography, identification has improved (Figs. 645.1-645.3). Great care should be taken before the diagnosis of IIH, as there is a high rate of misdiagnosis (Fig. 645.4) and management is challenging.

ETIOLOGY

IIH, by definition, will not have an identifiable cause, despite typical findings. A large proportion of children referred to the pediatrician with possible/probable IIH after a thorough history, examination, and careful investigation will have *secondary IH* with an underlying cause identified. Table 645.1 lists some of the many disorders that cause IH with no obstructive lesion on MRI. Research in adults suggests abnormal CSF androgen profiles/endocrine dysfunction leading to abnormal CSF pressure; glucagon-like peptide-1 and 11β-hydroxysteroid dehydrogenase type 1 have been implicated.

Fig. 645.1 Optic nerve ultrasonography. *Left*, A sagittal schematic view of gel applied on top of the closed right eyelid with the orientation of the operator hand and ultrasonography probe to the orbit. *Right*, An ultrasonography machine screen showing a coronal section of the orbit and optic nerve sheath. The distance between the stars represents the diameter of the optic nerve sheath. *(From Koziarz A, Sne N, Kegel F, et al. Bedside optic verve ultrasonography for diagnosing increased intracranial pressure. Ann Intern Med. 2019;171[12]:896–905, Fig. 1, p. 897.)*

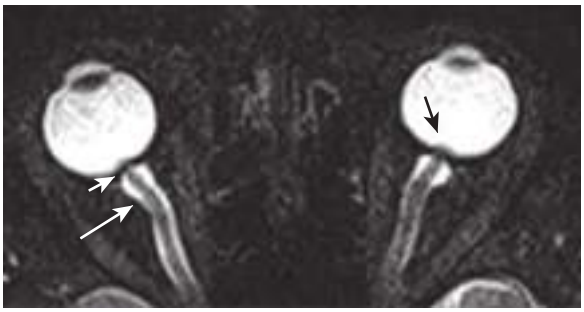

Fig. 645.2 Papilledema. Axial T2-weighted image with fat saturation of the orbits shows enlargement of the optic nerve sheaths *(long white arrow)*, flattening of the posterior sclera *(short white arrow)*, and protrusion of the optic disc head into the globe *(black arrow)*. *(Modified from Guarnizo A, Albreiki D, Cruz JP, et al. Papilledema: a review of the pathophysiology, imaging findings, and mimics. Can Assoc Radiol J. 2022;73[3]:557–567, Fig. 3a, p.561.)*

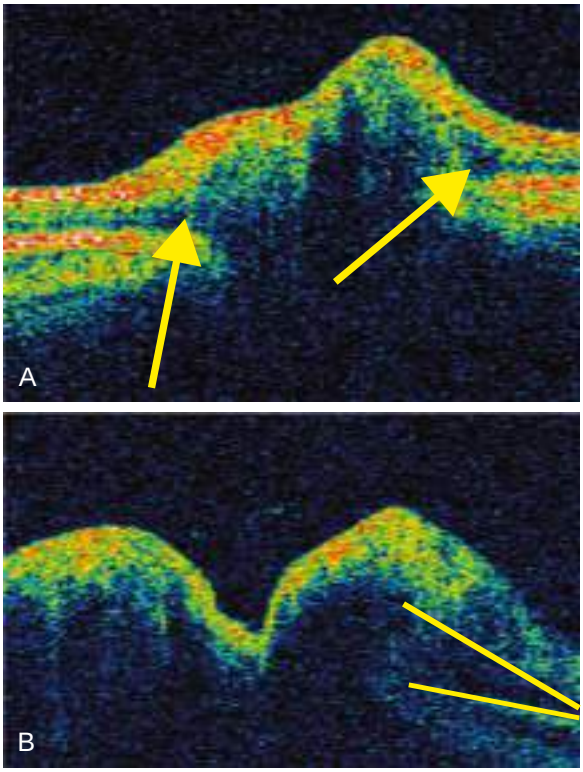

Fig. 645.3 **A**, Optical coherence tomogram (cross-sectional image) through an optic disc with drusen showing the typically irregular tissue underlying the elevated surface of the disc with no extension of the subretinal hyporeflective layer *(arrows)* beyond the optic nerve head. **B**, Optical coherence tomogram (cross-sectional image) of a papilledematous optic disc showing a smoothly elevated disc with underlying hyporeflective fluid extending beyond the disc into the subretinal space in a lazy-V pattern (illustrated by *yellow lines*). *(Courtesy Louise Allen, MD, FRCOphth, Cambridge, United Kingdom.)*

CLINICAL MANIFESTATIONS

IIH is rare under the age of 10 years. In postpubertal children, there is a female sex preponderance, and for reasons that are poorly understood, patients are much more likely to be obese. However, most obese children with headache do not have IH and are at risk of false-positive

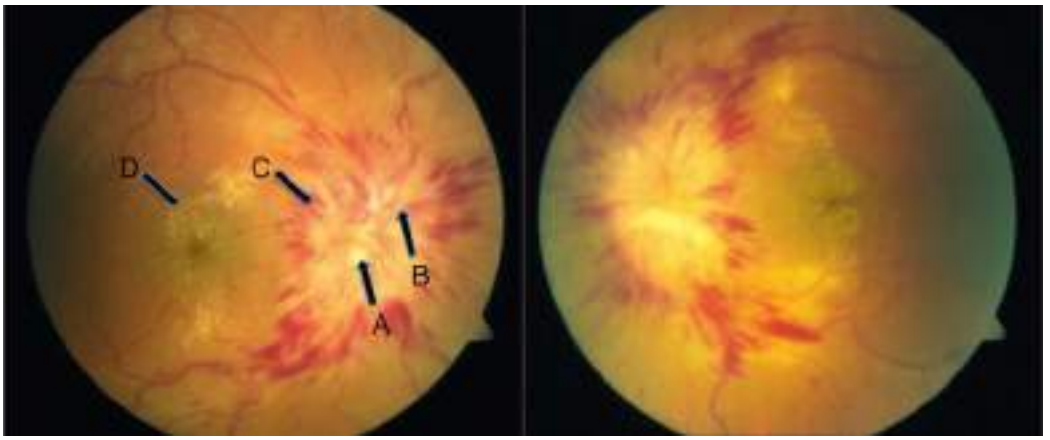

Fig. 645.4 Optic nerve photos of the right and left eyes, respectively, demonstrating grade 5 optic nerve head edema with characteristics, including *(A)* total obscuration of the optic cup, *(B)* total obscuration of a segment of a major blood vessel, *(C)* total obscuration of the disc margin, and *(D)* macular star. *(From Vickers AL, El-Dairi MA. Subacute vision loss in young, obese female. J Pediatr. 2013;163:1518–1519, Fig. 1.)*

Table 645.1 Secondary Intracranial Hypertension Without an Obstructive Lesion on MRI

HEMATOLOGIC DISORDERS Wiskott-Aldrich syndrome Iron-deficiency anemia Aplastic anemia Sickle cell disease Polycythemia Bone marrow transplantation and associated treatments Prothrombotic states Fanconi anemia Hemolytic anemia	**NUTRITIONAL DISORDERS** Hypovitaminosis A Vitamin A intoxication Hyperalimentation in malnourished patient Refeeding syndrome Vitamin D–dependent rickets
INFECTIONS Acute sinusitis Otitis media (lateral sinus thrombosis) Mastoiditis Tonsillitis Measles Roseola Varicella, recurrent varicella-zoster virus infection Lyme disease HIV or associated treatment complications	**CONNECTIVE TISSUE DISORDERS** Antiphospholipid antibody syndrome Systemic lupus erythematosus Behçet disease
DRUG-RELATED CONDITIONS Tetracyclines Sulfonamides Nalidixic acid Fluoroquinolones Corticosteroid therapy and withdrawal Nitrofurantoin Cytarabine Cyclosporine Phenytoin Mesalamine Isotretinoin Amiodarone Oral contraceptive pills/implants Valproic acid	**ENDOCRINE DISORDERS** Polycystic ovarian syndrome Hypothyroidism Hypoparathyroidism/hyperparathyroidism Pseudohypoparathyroidism Congenital adrenal hyperplasia Addison disease Recombinant growth hormone Menarche
RENAL DISORDERS Nephrotic syndrome Chronic renal insufficiency Post–renal transplantation Peritoneal dialysis	**OTHER CONDITIONS** Dural sinus thrombosis Transverse sinus stenosis Obesity (in pubertal patients) Superior vena cava syndrome Sleep apnea Guillain-Barré syndrome Crohn disease Ulcerative colitis Turner syndrome Galactosemia Atrial septal defect repair Moebius syndrome Sarcoidosis Hypophosphatasia Pregnancy

misdiagnosis. The most frequent symptom is chronic (weeks to months), progressive, frontal headache that may worsen with postural changes or a Valsalva maneuver. The headache phenotype attributed to IIH may mimic and/or coexist with chronic migraine and chronic tension-type headache. Calcitonin gene–related peptide has been implicated in the headache attributed to IIH (and in migraine). Although vomiting may occur, it is rarely as persistent and insidious as that associated with a posterior fossa tumor. **Transient visual obscuration (TVO)** lasting seconds and diplopia (secondary to dysfunction of the abducens nerve) may also occur, as may pulsatile tinnitus. TVO is a transient graying out or vision loss often associated with postural changes or Valsalva maneuvers. Children are alert and lack constitutional symptoms. **Papilledema** with an enlarged blind spot is the most consistent sign. It is frequently misdiagnosed. Optic nerve head drusen and/or optic neuritis may be mistaken for papilledema, and failure/delay on treating the latter can lead to irreversible visual

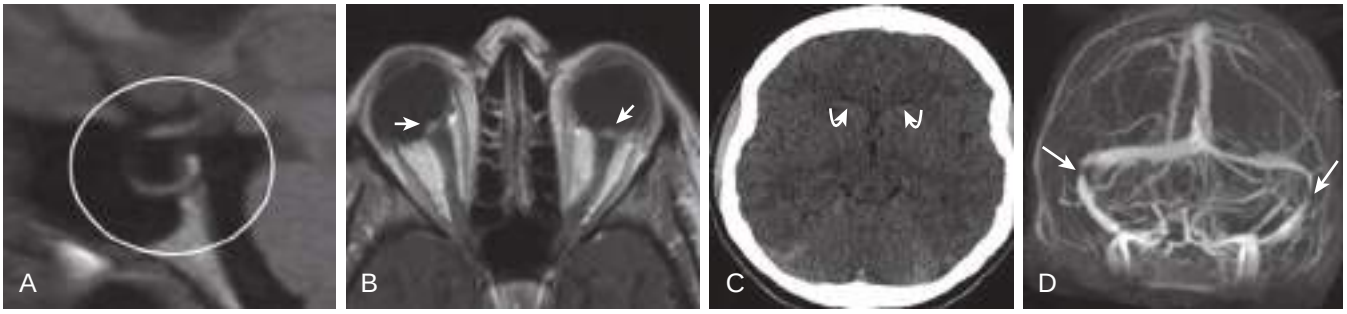

Fig. 645.5 Female with idiopathic intracranial hypertension. **A,** Sagittal T1-weighted image shows a partially empty sella. The pituitary gland is flattened against the floor of the sella, and the rest of the sella is filled with CSF *(circle)*. **B,** Axial T1-weighted postgadolinium image of the orbits demonstrates protrusion of the optic disc heads into the vitreous, with associated enhancement *(arrows)*. **C,** Axial head CT (shows slitlike appearance of the lateral ventricles *(arrows)*. **D,** Coronal CE-MRV MIP image shows focal stenosis at the junction of the transverse and sigmoid venous sinuses *(arrows)*. *(From Guarnizo A, Albreiki D, Cruz JP, et al. Papilledema: a review of the pathophysiology, imaging findings, and mimics. Can Assoc Radiol J. 2022;73:557–567, Fig. 2, p. 560.)*

impairment. OCT (see Fig. 645.3), *B*-ultrasound, and autofluorescence studies are strongly advised in all cases, as these will identify drusen and image the swelling. Inferior nasal or peripheral visual field defects may be detected. The presence of other focal neurologic signs prompts investigations to uncover a process other than IIH. All children should undergo cranial MRI, which may show any of the following: empty sella (in postpubertal children), posterior pituitary stalk displacement, meningoceles, posterior globe flattening, optic nerve head protrusion, optic nerve enhancement, optic nerve sheath distension, optic nerve tortuosity, slitlike ventricles, tight subarachnoid spaces, and inferior position of cerebellar tonsils (Fig. 645.5 and see Fig. 645.2). Absence of these findings does not rule out the diagnosis.

MR venography is essential, both to exclude venous thromboses/stenoses and to identify the tapering of the transverse sinuses that is commonly seen in intracranial hypertension (see Fig. 645.5). All children require measurement of their CSF pressure. Standard opening pressures in cm H_2O using a manometer can be falsely raised when the child is distressed or overflexed. More accurate recording will be achieved using an electronic transducer (similar equipment routinely attaches onto an arterial line), which will give a computer-aided recording with waveform analysis, both on opening and in steady state for 20 minutes (when the child is relaxed, happy, in the lateral decubitus position, and not held tightly or in an overflexed position). Cooperation of the child is required and is helped by the presence of a play specialist or use of nitrous oxide during needle insertion, thereby minimizing factors that may artificially alter ICP such as pain, crying, Valsalva maneuver, or abnormal respiration.

When LP opening pressure is measured under general anesthesia, it is important to record a normal end-tidal partial pressure of carbon dioxide (ET-PCo_2). Because secondary IH is more common, renal, liver, thyroid, hematologic, inflammatory, and autoimmune profiles should be obtained on venous blood testing. CSF infusion studies can also be helpful, particularly in borderline cases. Sterile fluid is infused via the spinal needle, and the resultant pressure-volume data can be analyzed to give the CSF dynamics and variables such as the pulse amplitude of ICP, the compensatory reserve, and the magnitude of slow waves of CSF pressure. Typically in IIH, the CSF pressure is elevated, the resistance to CSF outflow is low, and there is a depleted compensatory reserve. A summary of diagnostic criteria is noted in Table 645.2.

Table 645.2 Diagnostic Criteria for Idiopathic Intracranial Hypertension (IIH)

DIAGNOSIS OF IIH	DIAGNOSIS OF IIH WITHOUT PAPILLEDEMA
Diagnosis of IIH is definite if the patient fulfils A-E: A. Papilledema B. Normal neurologic examination except for sixth cranial nerve abnormalities C. Neuroimaging: Normal brain parenchyma without evidence of hydrocephalus, mass, or structural lesion and no abnormal meningeal enhancement on MRI, venous thrombosis excluded in all (best done on MRV) D. Normal CSF composition E. Elevated lumbar puncture opening pressure (≥250 mm CSF in adults; ≥280 in children or obese adults) in an appropriately performed lumbar puncture	In the absence of papilledema, a diagnosis of IIH can be made if B-E are satisfied and in addition the patient has unilateral or bilateral abducens nerve palsy In the absence of papilledema or sixth nerve palsy, a diagnosis of IIH can be suggested, but not made, if B-E are satisfied and in addition at least three of the following are present on neuroimaging: 1. Empty sella 2. Flattening of the posterior aspect of the globe 3. Distention of the perioptic subarachnoid space ± a tortuous optic nerve 4. Transverse venous sinus stenosis

From Mollan SP, Davies B, Silver NC, et al. Idiopathic intracranial hypertension: consensus guidelines on management. *J Neurol Neurosurg Psychiatry*. 2018;89(10):1088–1100.

TREATMENT

Any causes of secondary IH should be treated (e.g., withdrawal of a drug). There are no randomized clinical trials (RCTs) to guide the treatment of IIH. The initial diagnostic LP may be therapeutic. The spinal needle produces a small hole in the dura that allows CSF to escape the subarachnoid space, thus reducing ICP. An additional LP and the removal of sufficient CSF to reduce the opening pressure by 50% occasionally lead to resolution of the process. Obese children with IIH need a weight-loss regimen, but the success rate is low. Medical management may include acetazolamide and topiramate. Acetazolamide (10-30 mg/kg/24 hours) has been found effective in adult RCT studies: some authors have recommended using topiramate, which has the added benefits of possible migraine prophylaxis and, in obese children, of being an appetite suppressant. Corticosteroids are not routinely administered because there is no benefit. When the symptoms such as headache and, in particular, visual deterioration, do not improve with an LP and acetazolamide or topiramate, then consideration of surgical management is necessary. In children first-line surgical management is currently CSF diversion (e.g., ventriculoperitoneal [VP] shunt, LP shunt); risks include obstruction and infection. There is a potential role for endovascular management of dural sinus stenosis (the technique of inserting a catheter to direct a self-expanding stent over a guide wire across a venous sinus stenosis)—this is increasingly first-line surgical treatment in adults; pediatric experience is limited. Repeated LP is likely to be traumatic for the child and unlikely to produce a longer-term solution. The value of optic nerve sheath fenestration (a decompressive procedure) is debated and is rarely performed; risks include ischemia and hemorrhage.

Any child whose ICP proves to be refractory to treatment warrants repeat full investigation. Serial monitoring of visual function (i.e., visual acuity, color vision, and visual fields) is required in children old enough to participate but remains a challenge in younger children. Serial optic nerve examination is also essential. OCT is useful to serially follow changes in papilledema. Serial visual-evoked potentials are useful if the visual acuity cannot be reliably documented.

Multidisciplinary management, including a pediatrician, pediatric neurologist, ophthalmologist, orthoptist, radiologist, specialist nurses, and, as needed, dietician, psychologist, interventional radiologist, and neurosurgeon, is helpful both in diagnosis and ongoing management.

The majority of adults with IIH continue to have headache after normalization of ICP and hence require continued headache management. Permanent visual function loss in IIH is rare; data from small studies suggest reduced visual acuity in up to 10% and permanent visual field defects in less than 17% of children.

Visit Elsevier eBooks+ at eBooks.Health.Elsevier.com for Bibliography.

Chapter 646

Spinal Cord Disorders

Katie P. Fehnel and Mark R. Proctor

646.1 Tethered Cord

Katie P. Fehnel and Mark R. Proctor

Normally, as the spine flexes and extends, the spinal cord is free to move up and down within the spinal canal. If the spinal cord is fixed at any point, its movement is restricted, and the spinal cord and nerve roots can become stretched. This fixing of the spinal cord, regardless of the underlying cause, is called a *tethered cord*. When pain, neurologic deterioration, or bladder and bowel dysfunction occurs in response to the fixation, it is called **tethered cord syndrome**.

By full gestational age, the spinal cord ends, on average, at the lumbar L1-2 disk space, although there is a normal bell-shaped distribution from thoracic T12-L3. Spinal cord tethering cannot be determined by position of the conus medullaris alone, but a position below L3 is concerning for tethering, especially when associated with an abnormality that connects the cord to the bones or soft tissues around the spine. Similarly, the spinal cord can be tethered even if it terminates in a normal position if a tethering lesion is present. This can occur from a variety of causes.

In its simplest form, tethered cord syndrome results from a thickened filum terminale, which normally extends as a thin, very mobile structure from the tip of the conus to the sacrococcygeal region, where it attaches. When this structure is thickened and/or shortened, the cord can become tethered. This stretching between two points can cause symptoms later in life. Fatty infiltration is often seen in the thickened filum (Fig. 646.1).

Other conditions that are well-established as causes of symptomatic tethering include various forms of occult dysraphism, such as lipomyelomeningocele, myelocystocele, and diastematomyelia. These conditions can be associated with cutaneous manifestations such as midline lipomas, asymmetry of the gluteal fold (Fig. 646.2), dimples, and hairy patches called *hypertrichosis* (Fig. 646.3). Probably the most commonly known type of symptomatic tethered cord involves patients who had previously undergone closure of an open myelomeningocele and later become symptomatic with pain or neurologic deterioration. Tethered cord syndrome can also be iatrogenic and associated with scarring of the spinal cord in patients who have undergone surgical procedures that disrupt the pial surface of the spinal cord.

CLINICAL MANIFESTATIONS

Patients at risk for the subsequent development of tethered cord syndrome can often be identified at birth by the presence of an open myelomeningocele or by cutaneous manifestations of dysraphism (see Chapter 631). It is important to examine the back of the newborn for cutaneous midline lesions (lipoma, dermal sinus, tail, or hairy patch) that may signal an underlying form of occult dysraphism. Dermal sinuses are almost always located *above* the gluteal fold, and dimples in the gluteal cleft directly overlying the coccyx are generally benign fibrous tracts called *coccygeal pits* that are not associated with spinal tethering. However, cutaneous abnormalities may be absent in patients

Fig. 646.1 Sagittal T1-weighted MRI showing thickening and fatty infiltration of the filum terminale *(arrow)* in a patient with a symptomatic tethered spinal cord.

Fig. 646.2 Child with a lipomyelomeningocele demonstrating an extraspinal mass and an asymmetry of the gluteal fold indicative of underlying occult dysraphism. *(Used with permission from Barrow Neurological Institute.)*

Fig. 646.3 Hairy patch or hypertrichosis usually associated with diastematomyelia. *(Used with permission from Barrow Neurological Institute.)*

with tethered spinal cord, and these patients present later in life with clinical manifestations.

Patients who become symptomatic later in life generally present with one of four clinical manifestations, including neurologic, orthopedic, bowel/bladder, and/or pain symptoms. One orthopedic presentation is asymmetry of the feet, with a smaller, high-arched foot with clawing of the toes (Fig. 646.4), sometimes referred to as **neuroorthopedic syndrome**. Characteristically, there is no ankle jerk on the involved side and the calf is atrophied. Scoliosis can also be a presenting sign. Another clinical presentation is increasing urinary urgency, which may progress to incontinence. Constipation progressing to incontinence can affect the gastrointestinal system as well. Finally, severe generalized back pain, often radiating into the lower extremities, can occur, particularly in older adolescents and adults.

DIAGNOSTIC EVALUATION

When patients present with symptoms related to tethered cord syndrome, a thorough motor and sensory examination of the patient must be documented. Assessment of bladder function with an ultrasound of the bladder and urodynamic studies is useful in analyzing bladder innervation. Magnetic resonance imaging (MRI) is the diagnostic study of choice for the anatomy of the tethering lesion and to provide information about the risks of surgical intervention.

TREATMENT

There are no nonsurgical options for the management of tethered cord syndrome. Because the presence of asymptomatic tethering is most likely to be at least suspected in the newborn, prophylactic surgery to prevent late deterioration has been advocated by some neurosurgeons. This strategy remains controversial and depends to some extent on a careful assessment of the risks compared with the benefits. If surgical intervention is chosen, microsurgical dissection with release of the spinal cord attachment to the overlying dura and soft tissues is the goal of treatment.

OUTCOME

The outcome of surgery depends on the complexity of the underlying lesion and the presenting condition of the child because existing deficits are generally not reversed. Releasing a thickened filum terminale or detethering of patients with diastematomyelia generally yields a good outcome, and the chance of recurrent symptoms is quite low. Patients with symptomatic tethered cord who undergo repair of a myelomeningocele or a lipomyelomeningocele have a significant possibility of recurrent tethering and recurrent symptoms. In this cohort, the

Fig. 646.4 Example of neuropathic changes to the right foot as a result of spinal cord tethering, with a smaller high-arched foot and absent ankle jerk on exam. *(Used with permission from Barrow Neurological Institute.)*

potential need for reoperation and sometimes even multiple reoperations is high. Given the technical challenges and increased neurologic risk in a patient multiply reoperated on for tethered cord, in adolescent patients for whom axial growth has completed, spinal column shortening procedures have been proposed as an alternative treatment modality. As opposed to surgery at the site of tethering, the tension is released by actual shortening of the vertebral column.

Visit Elsevier eBooks+ at eBooks.Health.Elsevier.com for Bibliography.

646.2 Diastematomyelia (Split-Cord Malformation)

Katie P. Fehnel and Mark R. Proctor

Diastematomyelia is a relatively rare form of occult dysraphism in which the spinal cord is divided into two halves and can present as tethered spinal cord. In **type 1** split-cord malformation, there are two spinal cords, each in its own dural tube and separated by a spicule of bone and cartilage (Fig. 646.5). In a **type 2** split-cord malformation, the two spinal cords are enclosed in a single dural sac with a fibrous septum between the two spinal segments (Fig. 646.6). In both cases, the anatomy of the outer half of the spinal cord is essentially normal but the medial half is extremely underdeveloped. Undeveloped nerve roots and dentate ligaments terminate medially into the medial dural tube in type 1 cases and terminate in the membranous septum in type 2 cases. Both types have an associated defect in the bony spinal segment. In the case of type 2 lesions, this defect can be quite subtle.

CLINICAL MANIFESTATIONS

Patients with both type 1 and type 2 split-cord malformations will have presentations similar to other types of spinal tethering lesions. This may include subtle signs of neurologic involvement, such as unilateral calf atrophy and a high arch in one or both feet early in life, but they are more likely to be neurologically normal. These patients are tethered by the adherence of the spinal cord, so they may develop progressive loss of bowel and bladder function and sensory and motor difficulties in the lower extremities. Back pain is a common symptom in adolescents and adults with split-cord malformation but is uncommon in small children.

Cutaneous manifestations of dysraphism are present in 90% of patients with split-cord malformations. Large, hairy, midline patches called *hypertrichosis,* the most common cutaneous manifestations, are present in approximately 60% of the cases.

DIAGNOSTIC EVALUATION

MRI, the study of choice, shows the two spinal cords. The frequent association of bony abnormalities in this condition may require further evaluation with computed tomography (CT).

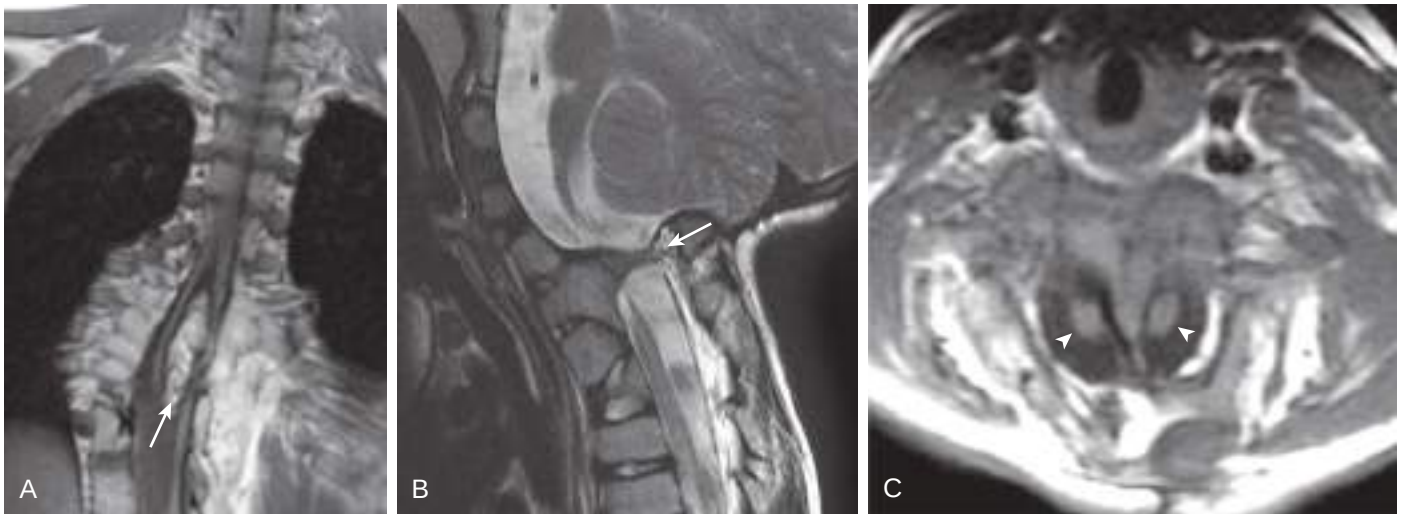

Fig. 646.5 Diastematomyelia type 1. **A,** Coronal T1-weighted MRI in a patient with type 1 DSM shows a large ossified spur *(arrow)* that splits the thoracic spinal cord. Numerous vertebral segmentation anomalies with posterior rib fusions are present. Sagittal T2-weighted (**B**) and axial T1-weighted (**C**) MRI of a different patient shows a type 1 cervical DSM with ossified spur (*arrow* in **B**) and two hemicords (*arrowheads* in **C**). *(From Moore KR. Congenital abnormalities of the spine. In: Coley BD, ed. Caffey's Pediatric Diagnostic Imaging, 13th ed. Philadelphia: Elsevier; 2019: Fig. 43-12.)*

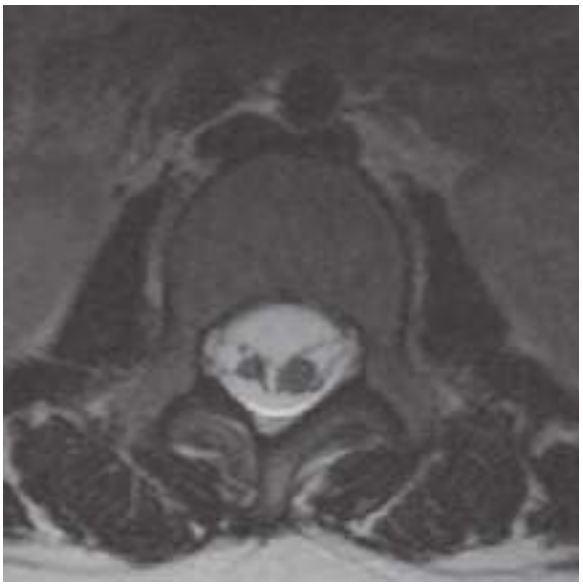

Fig. 646.6 Diastematomyelia type 2. Axial T2-weighted MRI in a patient with type 2 DSM shows the spinal cord split into two hemicords within a single dural tube. No fibrous or osseous septum was identified. *(From Moore KR. Congenital abnormalities of the spine. In: Coley BD, ed. Caffey's Pediatric Diagnostic Imaging, 13th ed. Philadelphia: Elsevier; 2019: Fig. 43-13.)*

TREATMENT

The treatment of split-cord malformation is surgical. This abnormality is a form of tethered cord syndrome, and its treatment is to release the spinal cord to move freely with movement of the spine. In type 1 split-cord malformations, the two half-cords are in separate dural sacs with medial attachment to the dura and bony septum. In this case, the dura needs to be opened, the bony septum removed, the medial attachments to the dura lysed, and a single dural tube created. For type 2 lesions, the membranous septum should be lysed. An attachment of this membrane to the anterior dura should be explored and lysed as well. Retethering of this type is rare, as there is no reason to disrupt the pial layer of the spinal cord.

Visit Elsevier eBooks+ at eBooks.Health.Elsevier.com for Bibliography.

646.3 Syringomyelia

Katie P. Fehnel and Mark R. Proctor

Syringomyelia is a cystic distention of the spinal cord caused by obstruction of the flow of spinal fluid from within the spinal cord to its point of absorption. There are three recognized forms of syringomyelia, depending on the underlying cause. Communicating syringomyelia implies that cerebrospinal fluid (CSF) from within the ventricles communicates with the fluid within the spinal cord and is assumed to be the source of the CSF that distends the spinal cord. Noncommunicating syringomyelia implies that ventricular CSF does not communicate with the fluid within the spinal cord. It primarily occurs in the context of intramedullary tumors and obstructive lesions. In the final form of syringomyelia, that is, posttraumatic syringomyelia, spinal cord injury results in damage and subsequent softening of the spinal cord. This softening, combined with the scarring of the surrounding spinal cord tissue, results in progressive distention of the cyst. Syringomyelia is highly associated with Chiari malformation and can also be seen after infection or trauma, but many cases seen on imaging are normal anatomic variants unassociated with syndromes or any symptoms. It is also associated with connective tissue disorders (Ehlers-Danlos syndrome).

CLINICAL MANIFESTATIONS

Signs and symptoms of syringomyelia develop insidiously over years or decades. The classic presentation is **central cord syndrome**. Syringomyelia affects the spinal cord beginning from the central region, where the cervical and thoracic nerve fibers are located, so it less commonly affects the lumbar and sacral fibers, which are more laterally located in the spinal cord. Therefore in syringomyelia the patient develops numbness beginning in the shoulder in a capelike distribution followed by the development of atrophy and weakness in the upper extremities. Trophic ulcers of the hands are characteristic of advanced cases.

Other forms of presentation include scoliosis that may be rapidly progressive and often can be presumed from the absence of superficial abdominal reflexes. Urgency and bladder dysfunction as well as lower extremity spasticity also may be part of the presentation.

In patients with syringomyelia related to significant prior spinal cord injury, the presentation is usually severe pain in the area of the spinal cord distention above the level of the initial injury. There is also an ascending level of motor and sensory dysfunction.

DIAGNOSTIC EVALUATION

MRI is the radiologic study of choice (Figs. 646.7 and 646.8). The study should include the entire spine, and gadolinium-enhanced sequences should be a part of it if there is a suspicion for tumor. Specific attention should be paid to the craniovertebral junction because of the frequent association of syringomyelia with Chiari malformations. Obstruction to the flow of CSF from the fourth ventricle can cause syringomyelia; therefore most patients also should undergo imaging of the brain if a Chiari malformation is seen on the cervical imaging.

TREATMENT

The treatment of syringomyelia should be tailored to the underlying cause, and rarely is the syringomyelia addressed directly. If that cause can be removed or ameliorated, the syrinx should improve. Direct surgery on the syrinx is associated with a much higher surgical risk profile.

Communicating syringomyelia is most frequently seen in the context of abnormalities at the craniovertebral junction, often associated with Chiari malformations (see Fig. 646.7). In such cases, decompression of the craniovertebral junction is usually effective in the management of the syringomyelia. In the context of Chiari II malformation associated with spina bifida, syringomyelia usually results from an insidious failure of the shunt used to treat the hydrocephalus. This distention of the spinal cord results in a rapid development of scoliosis and occasionally spasticity in the lower extremities. Repair of the shunt is often effective treatment, and only rarely is surgical decompression at the craniovertebral junction necessary. Other conditions that can cause obstruction at the craniocervical junction include inflammatory conditions such as chronic meningitis, as seen in tuberculosis or meningeal carcinomatosis.

Noncommunicating syringomyelia results from blocking the flow of spinal cord extracellular fluid or CSF within the central canal by an intramedullary spinal cord tumor or severe external compression of the spinal cord. In such cases, management should be directed to tumor resection or to decompression of constricting elements.

Traumatic syrinxes result from hematomyelia in the substance of the spinal cord coupled with severe arachnoidal scarring around the circumference of the spinal cord. When progressive, this form of syringomyelia is treated by exploration and lysis of the adhesions that fix the spinal cord to the overlying dura. Microscopic lysis of the scar surrounding the spinal cord at the point of injury allows the spinal cord to collapse and prevents it from being distorted by a hydrostatic column of spinal fluid pulsations.

In rare cases, direct drainage procedures must be employed and can result in symptomatic and radiographic improvement. Syrinx-to-subarachnoid or pleural shunting with a small piece of silicone tubing is the treatment option. These procedures often have short-lived success because the tubing tends to become obstructed, so they should be reserved for cases with obstructive symptoms.

In the current era, where many children are undergoing spinal MRI, some children who demonstrate no neurologic deficits are being referred to pediatric neurosurgeons with the diagnosis of syringomyelia. Many of these children were scanned because of back pain or as part of a screening for scoliosis. They are found on MRI to have a **persistent central canal**, and the diagnosis of syringomyelia is made. These syrinxes are 1-3 mm in diameter and may extend over several segments (see Fig. 646.8). There is no distortion of the spinal cord in the region and no change in signal of the surrounding spinal cord. These syrinxes have been called "idiopathic" syrinxes. Follow-up of significant numbers of such children has shown them to be benign in nature and probably represent a normal variant. There does not seem to be a need for routine follow-up imaging without new symptoms. They need no treatment and do not require limitations of activity.

Visit Elsevier eBooks+ at eBooks.Health.Elsevier.com for Bibliography.

Fig. 646.7 Sagittal MRI of patient with a Chiari I malformation and a holocord syrinx. *(Used with permission from Barrow Neurological Institute.)*

Fig. 646.8 T2-weighted MRI scan of the cervical and thoracic spinal cord showing dilation of the central canal (C5-T1) in the absence of a Chiari malformation or other pathology.

646.4 Spinal Cord Tumors

Katie P. Fehnel and Mark R. Proctor

Tumors of the spine and spinal cord are rare in children. Different types of tumors have different relationships with the spinal cord, meninges, and bony elements of the spine (Fig. 646.9). Intramedullary spinal cord tumors arise within the substance of the spinal cord itself (Fig. 646.10). They represent between 5% and 15% of primary central nervous system tumors. This percentage may well reflect the relative volume of spinal cord compared with brain. Approximately 10% of intramedullary spinal cord tumors are malignant astrocytic tumors, but most are World Health Organization grade I or II tumors of glial or ependymal origin. In children, low-grade astrocytomas and gangliogliomas represent the most common tumor types, with ependymomas being less common than in adults.

Except in the context of neurofibromatosis (NF-1 and NF-2; see Chapter 636.1), intradural extramedullary tumors are extremely rare in children. Most are nerve sheath tumors, either schwannomas or neurofibromas. Intraspinal meningiomas in children are essentially found only in patients with NF-2 or those who have undergone prior irradiation for some reason. The intradural extramedullary compartment is also a site for metastatic tumors from primary cancers such as leukemia or primitive neuroectodermal tumors. Myxopapillary ependymoma, a benign subtype found in the filum terminale, is another extramedullary tumor seen in children.

Extradural spinal tumors characteristically begin in the bones of the spine. Primary tumors in this location include aneurysmal bone cysts, Langerhans cell histiocytosis (formerly called *eosinophilic granuloma*), osteoid osteoma, and giant cell tumors. In infants, the extradural space is often the site of neuroblastomas or ganglioneuroblastomas, which tend to extend from a paraspinal location into the epidural space through the intervertebral foramen. In older patients, the bones of the spine may be the site of multiple myeloma and metastases from common malignant tumors, such as chordoma and sarcomas.

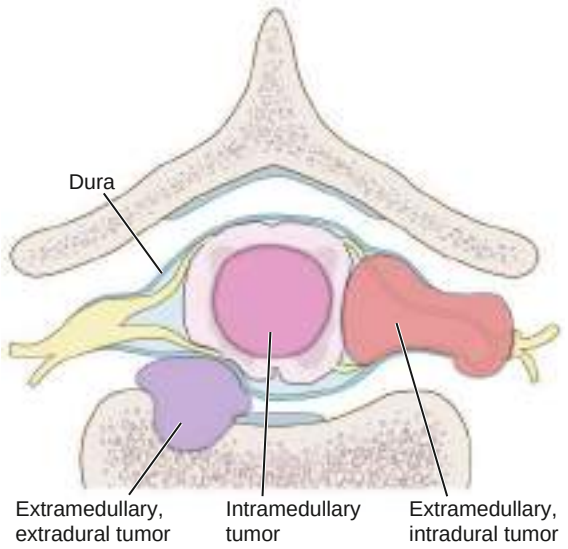

Fig. 646.9 Diagram of the relationship of various tumors to the spine, nerve roots, and spinal cord. *(Used with permission from Barrow Neurological Institute.)*

Fig. 646.10 T1 weighted MRI scan of a spinal cord tumor *(arrow)*. The fusiform expansion of the cervical cord enhances after intravenous gadolinium injection.

CLINICAL MANIFESTATIONS

With the exception of the uncommon malignant glial tumors of the spinal cord, which tend to present precipitously, intramedullary spinal cord tumors present in a very insidious manner. Back pain related to the level of the tumor is a common presenting complaint. It is likely that this pain will awaken the child from sleep and improve as the day progresses. Before the use of MRI became routine, the time from the first onset of symptoms to diagnosis of the tumor could be very prolonged, extending years. Weakness, gait disturbance, and sensory deficits are usually subtle but detectable on formal neurologic examination. Scoliosis, limb asymmetry, and bowel or bladder disturbance may be the presenting complaints associated with intramedullary spinal cord tumors.

Nerve sheath tumors primarily arise from the sensory rootlet of the exiting spinal nerve. They are very slow-growing tumors and present with symptoms and signs relative to the nerve root involved. Pain in a bandlike distribution around the chest or into an extremity is the most common presenting complaint. Tumor growth eventually leads to spinal cord compression and involvement of adjacent nerve roots, but pain is the more likely presenting symptom.

Extramedullary extradural tumors have a tendency to present more acutely owing to rapid growth within a confined space. Such children may present with acute paresis and urinary retention. They can also present abruptly with severe pain and neurologic deficit at the time of pathologic fracture of the vertebral body. Benign tumors such as giant cell tumors and aneurysmal bone cysts present more insidiously as the tumor slowly grows and begins to compress neural structures. Osteoid osteomas present with severe pain relieved by nonsteroidal antiinflammatory drugs.

DIAGNOSTIC EVALUATION

MRI with and without gadolinium enhancement of the spinal cord is the diagnostic study of choice and is essential in the diagnosis of spinal cord tumors, especially intramedullary spinal cord tumors. Most astrocytic tumors of the spinal cord and most ependymomas show diffuse enhancement and will distend the spinal cord focally. These tumors may involve the entire length of the spinal cord (holocord astrocytomas), although much of the change might be due to the associated syrinx. Nerve sheath tumors characteristically enhance and are focal. They may exit through the neural foramen and distend the canal, as can be seen on MRI. They also may be visualized on plain radiographs of the affected area of the spine because of their chronic effect on the bones.

Plain radiographs of the spine are helpful in defining the relationship of extradural tumors to the bony spine and in documenting evidence of instability in the case of pathologic compression fractures. When a pathologic fracture occurs, CT is essential to determine the effect of the tumor on the bone. Because many of these tumors occur as metastatic lesions, a general staging of the extent of disease is essential. In the

case of Langerhans cell histiocytosis, a thorough bone survey should be conducted to look for other lesions. Radionucleotide bone scanning, rapid STIR MRI, or PET MRI scans are useful in determining the extent of the disease.

TREATMENT

The primary treatment of both intramedullary and extramedullary intradural tumors is surgical removal. For both low-grade astrocytomas and ependymomas, microsurgical removal with the intent of total removal is the treatment of choice. This goal should be attainable in most patients with ependymomas and gangliogliomas and in many patients with low-grade astrocytomas. Though the majority of intramedullary spinal cord tumors are benign, the extent of resection may be limited in tumors that are diffusely infiltrating midline gliomas because of tumor invasion and infiltration of gray and white matter tracts. The invasive nature of these tumors is a leading cause of the poor prognosis for many of these patients, resulting in symptom progression and ultimately loss of neurologic function with profound implications on both quality and extent of life and is one of the most significant problems in spinal neurooncology. With the advent of routine molecular genetic testing, targetable pathogenic variants have been identified in some intramedullary spinal cord tumors, which will potentially expand nonsurgical and chemotherapeutic treatment options in as of now unresectable spinal cord tumors. Adjunctive treatment is often unnecessary in patients treated with adequate surgical resection. Likewise, schwannomas should be resectable. Occasionally, however, the nerve root must be resected. Doing so may be of no consequence in the thoracic spinal cord, but an attempt to remove the tumor while salvaging the motor root in the cervical and lumbosacral region is critical to preserve movement. Malignant astrocytic tumors cannot be resected without major morbidity and, in any case, carry an extremely poor prognosis. In the case of grades III and IV astrocytomas of the spinal cord, decompression and biopsy followed by radiation therapy and possibly chemotherapy are used.

The diagnosis and treatment of extramedullary spinal cord tumors must be individualized. Patients with bony involvement may be at risk of instability, and treatment will therefore involve both tumor resection and stabilization of the spine. For extramedullary tumors with soft tissue components such as neuroblastomas, treatment is determined by the nature of the tumor and degree of spinal cord compression and may require needle biopsy of the lesion to direct treatment. In the absence of significant neurologic compression, surgical intervention may not be indicated if adjuvant therapies might be effective.

OUTCOME

The prognosis for patients with benign intramedullary spinal cord tumors depends, to some extent, on the patient's condition at the time of surgical intervention. It is very unlikely that nonambulatory patients will improve after surgery, and most patients will have at least transient worsening with surgery. If, however, patients are ambulatory at the time of surgery, they are likely to recover at least to their preoperative level of function. The majority of intramedullary tumors in children are benign and behave like tumors with the same histologic findings in the brain. The evidence would point to the fact that intramedullary ependymomas act in a more benign fashion than they do in the fourth ventricle. Gross total removal without adjuvant treatment is the preferred method of treatment and carries not only a much longer progression-free survival time but an improved quality of life as well.

Malignant spinal cord tumors are usually lethal, with death resulting from diffuse metastases via the CSF pathways. Successful resection of nerve sheath tumors should be curative. In the context of neurofibromatosis, however, many more tumors can be found at other levels or can be expected to develop later in life. Surgical intervention in the context of neurofibromatoses should be performed only for clearly symptomatic lesions.

The outcome of treatment of extramedullary tumors depends on the cell type and, in most cases, on the efficacy of nonsurgical, adjunctive therapies. For aneurysmal bone cysts and giant cell tumors, resection of the tumor and fusion of the spine are the treatments of choice.

Fig. 646.11 T2 weighted MRI showing an extensive thoracic spinal arteriovenous malformation.

Visit Elsevier eBooks+ at eBooks.Health.Elsevier.com for Bibliography.

646.5 Spinal Arteriovenous Malformations

Katie P. Fehnel and Mark R. Proctor

Arteriovenous malformations of the spinal cord are rare lesions in children. Only about 60 patients younger than age 18 years are treated in the United States each year. These lesions are complex, and despite their rarity there are multiple subtypes, which require different treatment strategies. Patients commonly present with back or neck pain, depending on the segments of the spinal cord involved, and they may experience the insidious onset of motor and sensory disturbances. Sudden onset of paraplegia secondary to hemorrhage has been reported. Occasionally, patients present with subarachnoid hemorrhage without overt neurologic deficits, similar to the presentation associated with cerebral aneurysms. In some cases, bruits are audible upon auscultation over the bony spine.

DIAGNOSTIC EVALUATION

When a spinal arteriovenous malformation is suspected, MRI of the spinal cord is first needed to make the diagnosis and to obtain a general idea of the location of the lesion (Fig. 646.11). MR angiography or CT angiography may provide further information, but formal catheter angiography of the spinal cord is needed to obtain an adequate understanding of the complex anatomy of the lesion and to plan the intervention.

TREATMENT

Open microsurgery had been the mainstay of treatment for spinal cord arteriovenous fistulas and arteriovenous malformations. With the rapid development of interventional techniques, the percentage of patients undergoing microsurgery has decreased from 70% to approximately 30%. Stereotactic radiosurgery may be used adjunctively. Treatment of these complex lesions requires the commitment of an organized neurovascular treatment program.

Visit Elsevier eBooks+ at eBooks.Health.Elsevier.com for Bibliography.

Neuromuscular Disorders

PART XXVI

Chapter 647

Evaluation and Investigation of Neuromuscular Disorders

*Adnan Y. Manzur**

The term *neuromuscular disease* defines disorders of the motor unit and excludes influences on muscular function from the brain, such as spasticity. The motor unit has four components: a motor neuron in the brainstem or ventral horn of the spinal cord; its axon, which together with other axons forms the peripheral nerve; the neuromuscular junction; and all muscle fibers innervated by a single motor neuron. The size of the motor unit varies among different muscles and with the precision of muscular function required. In large muscles, such as the glutei and quadriceps femoris, hundreds of muscle fibers are innervated by a single motor neuron; in small, finely tuned muscles, such as the stapedius or the extraocular muscles, a 1:1 ratio can prevail. The motor unit is influenced by suprasegmental or upper motor neuron control that alters properties of muscle tone, precision of movement, reciprocal inhibition of antagonistic muscles during movement, and sequencing of muscle contractions to achieve smooth, coordinated movements. Suprasegmental impulses also augment or inhibit the monosynaptic stretch reflex; the corticospinal tract is inhibitory upon this reflex.

Diseases of the motor unit are common in children. These neuromuscular diseases may be genetically determined, congenital or acquired, acute or chronic, and progressive or static. Because specific therapy is available for many diseases and because of genetic and prognostic implications, a precise diagnosis is important; laboratory confirmation is required for most diseases because of overlapping clinical manifestations. Precise genetic diagnosis, to the point of characterization of the specific pathogenic gene variant, is crucial for the genetically based neuromuscular disorders because of increasing availability of specific genetic-based treatments; examples include nonsense variants and exon-specific treatments in Duchenne muscular dystrophy, and gene therapy chromosome 5q linked spinal muscular atrophy.

GENETIC TESTING

Many chromosomal loci are identified with specific neuromuscular diseases as a result of genetic linkage studies and the isolation and cloning of specific genes. In some cases, such as Duchenne muscular dystrophy, the genetic variant is a deletion, duplication, or point variant of nucleotide sequences and is associated with a defective protein product, dystrophin. In other cases, such as myotonic muscular dystrophy, the genetic variant is an expansion or repetition, rather than a deletion, in a codon (a set of three consecutive nucleotide repeats that encodes for a single amino acid), with many copies of a particular codon (in this example they are also associated with abnormal messenger RNA). Some diseases manifest as autosomal dominant and autosomal recessive traits in different pedigrees; these distinct mendelian genotypes can result from different genetic variants on different chromosomes (nemaline myopathy) or from small differences in the same gene at the same chromosomal locus (myotonia congenita), despite many common phenotypic features and shared histopathologic findings in a muscle biopsy specimen. Among the several clinically defined mitochondrial myopathies, specific mitochondrial DNA deletions and transfer RNA point variants are recognized. The inheritance patterns and chromosomal and mitochondrial loci of common neuromuscular diseases affecting infants and children are summarized in Table 648.2 in Chapter 648.

Genotype:phenotype correlations are not always as precise as one would like for diagnosis; many genetic variants, even on different chromosomes, cause the same phenotype, and the converse is also true in that the same pathogenic genetic variant may yield many clinical phenotypes in different patients. Even a disease as stereotyped and predictable as Duchenne muscular dystrophy is known to be associated with dozens of different genotype variations, in and out-of-frame deletions and point variants of the large dystrophin gene. This explains why specific therapies might be beneficial for some patients and not alter the natural course of the disease in others.

CLINICAL MANIFESTATIONS

Examination of the neuromuscular system includes an assessment of muscle bulk, tone, and strength. Tone and strength should not be confused: **passive tone** is range of motion around a joint, and a**ctive tone** is physiologic resistance to movement. Head lag when an infant is pulled to a sitting position from supine is a sign of weakness, not of low tone. Hypotonia may be associated with normal strength or with weakness; enlarged muscles may be weak or strong; and thin, wasted muscles may be weak or have unexpectedly normal strength. The distribution of these components is of diagnostic importance. In general, myopathies follow a proximal distribution of weakness and muscle wasting (with the notable exception of myotonic muscular dystrophy). Neuropathies are generally distal in distribution, with the notable exception of chromosome 5q spinal muscular atrophy (SMA 0,1,2,3; Table 647.1). Involvement of the face, tongue, palate, and extraocular muscles provides an important distinction in the differential diagnosis. **Tendon stretch reflexes** are generally lost in neuropathies and in motor neuron diseases and are diminished but preserved in myopathies (see Table 647.1). A few specific clinical features are important in the diagnosis of some neuromuscular diseases. **Fasciculations** of muscle, which are often best seen in the tongue, are a sign of denervation. Sensory abnormalities indicate neuropathy. Fatigable weakness is characteristic of neuromuscular junctional disorders. Myotonia is specific for myotonic dystrophy and non-dystrophic myotonias also described as skeletal muscle channelopathies.

Some features do not distinguish myopathy from neuropathy. Muscle pain or **myalgias** are associated with acute disease of either myopathic or neurogenic origin. Acute dermatomyositis and acute polyneuropathy (Guillain-Barré syndrome) are characterized by myalgias. Muscle pain is unusual in most muscular dystrophies and spinal muscular atrophies at presentation, but myalgia and cramps on exercise are a characteristic feature of Becker muscular dystrophy. Myalgias also occur in several metabolic diseases of muscle and in ischemic myopathy, including vascular diseases such as dermatomyositis. Myalgias denote the acuity, rather than the nature, of the process, so that progressive but chronic diseases, such as muscular dystrophy and spinal muscular atrophy, are not painful, but acute stages of inflammatory myopathies and acute denervation of muscle often do present with muscular pain and tenderness to palpation. **Contractures** of muscles, whether present at birth or developing later in the course of an illness, occur in both myopathic and neurogenic diseases.

* The editors are grateful to Dr. Harvey B. Sarnat, much of whose work on previous editions of this chapter is retained here.

Table 647.1 Localization of Symptoms on Neural Axis

	UPPER MOTOR UNIT		LOWER MOTOR UNIT			
	BRAIN	SPINAL CORD	ANTERIOR HORN CELL / ALPHA MOTOR NEURONS	PERIPHERAL NERVE	NEUROMUSCULAR JUNCTION	MUSCLE
Level of consciousness	↓	Normal	Normal	Normal	Normal	Normal
Strength	Mild to moderate ↓	Mild to moderate ↓	Marked ↓	Marked ↓	Marked ↓	Marked ↓
Tone	Spastic (hypotonia at onset possible)	↓ Acutely; ↑	↓, flaccid	↓	↓	↓
Deep tendon reflexes	Normal to ↑	↓ Acutely; ↑	↓ to absent	↓ to absent (lost early)	Normal	Normal to ↓ to absent
Babinski	Present	Present usually	Absent	Absent	Absent	Absent
Fasciculations	Absent	Absent	Present	Rarely	Absent	Absent
Atrophy	Mild to moderate	Mild to moderate	Present	Present	Absent	Present Pseudohypertrophy
Sensation	Normal	Absent below level of lesion	Normal	Abnormal in defined peripheral nerve distribution or glove/stocking	Normal	Normal
Creatine kinase level	Normal	Normal	Normal to moderately elevated (several 1,000s IU/L)	Normal or mildly elevated (100s IU/L)	Normal	Normal to severely elevated
Overall pattern	Hemibody deficits	Spinal level present	Proximal weakness in SMA; asymmetric weakness in other diseases	Distal, length-dependent usually, defined nerve territory	Symmetric, painless weakness of tonically active muscles	Proximal > distal weakness
Other	Seizures Developmental delay Regression Cortical signs (e.g., language)	Radicular back pain, bowel/bladder dysfunction			Fluctuating diurnal variation Fatigability	Myalgia, Gower sign

SMA, Spinal muscular atrophy.
From Konersman C. Hypotonia and weakness. In: Kliegman RM, Toth H, Bordini BJ, et al., eds. *Nelson Pediatric Symptom-Based Diagnosis*, 2nd ed. Philadelphia: Elsevier; 2023: Table 35.3, p. 572.

Infant males who are weak in late fetal life and in the neonatal period often have **undescended testes.** The testes are actively pulled into the scrotum from the anterior abdominal wall by a pair of cords that consist of smooth and striated muscle called the gubernacula. The gubernacula are weakened in many congenital neuromuscular diseases, including spinal muscular atrophy, myotonic muscular dystrophy, and many congenital myopathies.

The thorax of infants with congenital neuromuscular disease often has a funnel shape, and the ribs are thin and radiolucent as a result of intercostal muscle weakness during intrauterine growth. This phenomenon is characteristically found in infantile spinal muscular atrophy but also occurs in myotubular myopathy, neonatal myotonic dystrophy, and other disorders (Fig. 647.1). Because of the small muscle mass, the birthweight may be low for gestational age.

Generalized hypotonia and motor developmental delay are the most common presenting manifestations of neuromuscular disease in infants and young children (Table 647.2 and Figs. 647.2-647.4). These features can also be expressions of neurologic disease, endocrine and systemic metabolic diseases, and Down syndrome, or they may be nonspecific neuromuscular expressions of malnutrition or chronic systemic illness (Table 647.3). A prenatal history of decreased fetal movements and intrauterine growth retardation is often found in patients who are symptomatic at birth. Developmental disorders tend to be of slow onset and are progressive. Acute flaccid paralysis in older infants

and children has a different differential diagnosis (Tables 647.4 and 647.5; see Fig. 647.3).

LABORATORY FINDINGS

Serum Enzymes

Several lysosomal enzymes are released by damaged or degenerating muscle fibers and may be measured in serum. The most useful of these enzymes is **creatine kinase (CK),** which is mainly found in three organs and may be separated into corresponding isozymes: MM for skeletal muscle, MB for cardiac muscle, and BB for brain. Serum CK determination is not a universal screening test for neuromuscular disease because many diseases of the motor unit are not associated with elevated enzymes. The CK level is characteristically elevated in certain diseases, such as Duchenne muscular dystrophy, and the magnitude of increase is characteristic for particular diseases. CK may also be elevated in certain nonneuromuscular disorders (Table 647.6).

Rhabdomyolysis is often a dramatic event associated with high plasma CK levels, myoglobinuria, and muscle pain or tenderness. It may be acquired (Table 647.7; see Fig. 647.4), due to metabolic diseases (Table 647.8), or occur spontaneously or secondary to various triggers (Fig. 647.5).

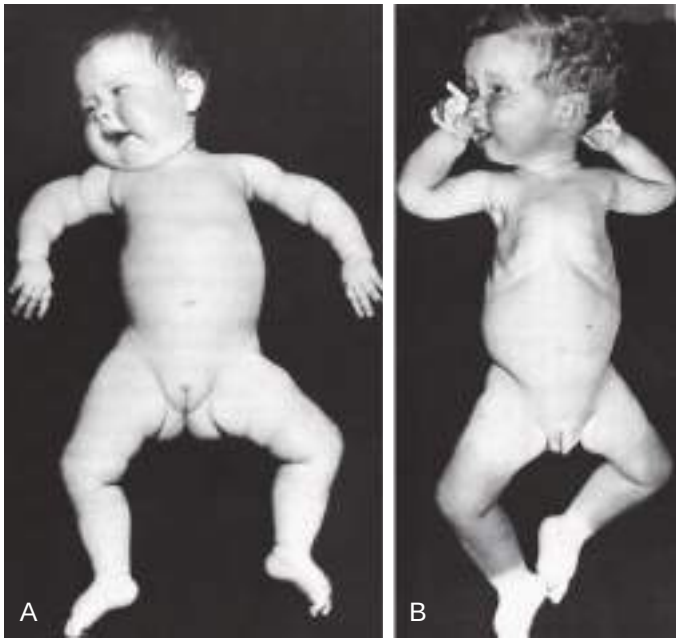

Fig. 647.1 Type 1 spinal muscular atrophy (Werdnig-Hoffmann disease). Characteristic postures in 6-wk-old (A) and 1-yr-old (B) infants with severe weakness and hypotonia from birth. Note the frog-leg posture of the lower limbs and internal rotation ("jug handle") (A) or external rotation (B) at the shoulders. Note also intercostal recession, especially evident in B, and normal facial expressions. *(From Volpe J. Neurology of the Newborn, 4th ed. Philadelphia: Saunders; 2001: p 645.)*

Molecular Genetic Markers

Many DNA markers of hereditary neuromuscular diseases, including the common muscular dystrophies, and neuropathies are available from specific gene panels or whole exome or genome sequencing. If the clinical manifestations for a positive family history suggest a particular disease, these genetic tests can provide a definitive diagnosis and not subject the child to more invasive procedures, such as muscle biopsy. Other molecular markers are available only in muscle biopsy tissue.

Nerve Conduction Velocity

Motor and sensory nerve conduction velocity may be measured electrophysiologically by using surface electrodes. Neuropathies of various types are detected by decreased conduction. The site of a traumatic nerve injury may also be localized. The nerve conduction value at birth is about half of the mature value achieved by the age of 2 years. Tables are available for normal values at various ages in infancy, including for preterm infants. Because the nerve conduction velocity study measures only the fastest conducting fibers in a nerve, 80% of the total nerve fibers must be involved before slowing in conduction is detected.

Electromyography

Electromyography (EMG) requires insertion of a needle into the belly of a muscle and recording of the electrical potentials in various states of contraction. It is less useful in pediatrics than in adult medicine, in part because of technical difficulties in recording these potentials in young children and in part because the best results require the patient's cooperation for full relaxation and maximal voluntary contraction of a muscle. Many children are too frightened to provide such cooperation. Characteristic EMG patterns distinguish denervation from myopathic involvement. The specific type of myopathy is not usually definitively diagnosed, but certain specialized myopathic conditions, such as myotonia, may be demonstrated. An EMG can transiently raise the serum CK level.

EMG combined with repetitive electrical stimulation of a motor nerve supplying a muscle to produce tetany is useful in demonstrating myasthenic decremental responses. Small muscles, such as the

Table 647.2 Pattern of Weakness and Localization in the Hypotonic Infant

ANATOMIC REGION OF HYPOTONIA	CORRESPONDING DISORDERS	PATTERN OF WEAKNESS AND INVOLVEMENT
Central nervous system	Chromosomal disorders Inborn errors of metabolism Cerebral dysgenesis Cerebral, spinal cord trauma	Central hypotonia Axial hypotonia more prominent Hyperactive reflexes
Motor neuron	Spinal muscular atrophy	Generalized weakness; often spares the diaphragm, facial muscles, pelvis, and sphincters
Nerve	Peripheral neuropathies	Distal muscle groups involved Weakness with wasting
Neuromuscular junction	Myasthenia syndromes Infantile botulism	Bulbar, oculomotor muscles exhibit greater degree of involvement
Muscle	Congenital myopathies Metabolic myopathies Congenital muscular dystrophy Congenital myotonic dystrophy	Weakness is prominent Proximal musculature Hypoactive reflexes Joint contractures

From Prasad AN, Prasad C. The floppy infant: contribution of genetic and metabolic disorders. *Brain Dev.* 2003;27:457–476.

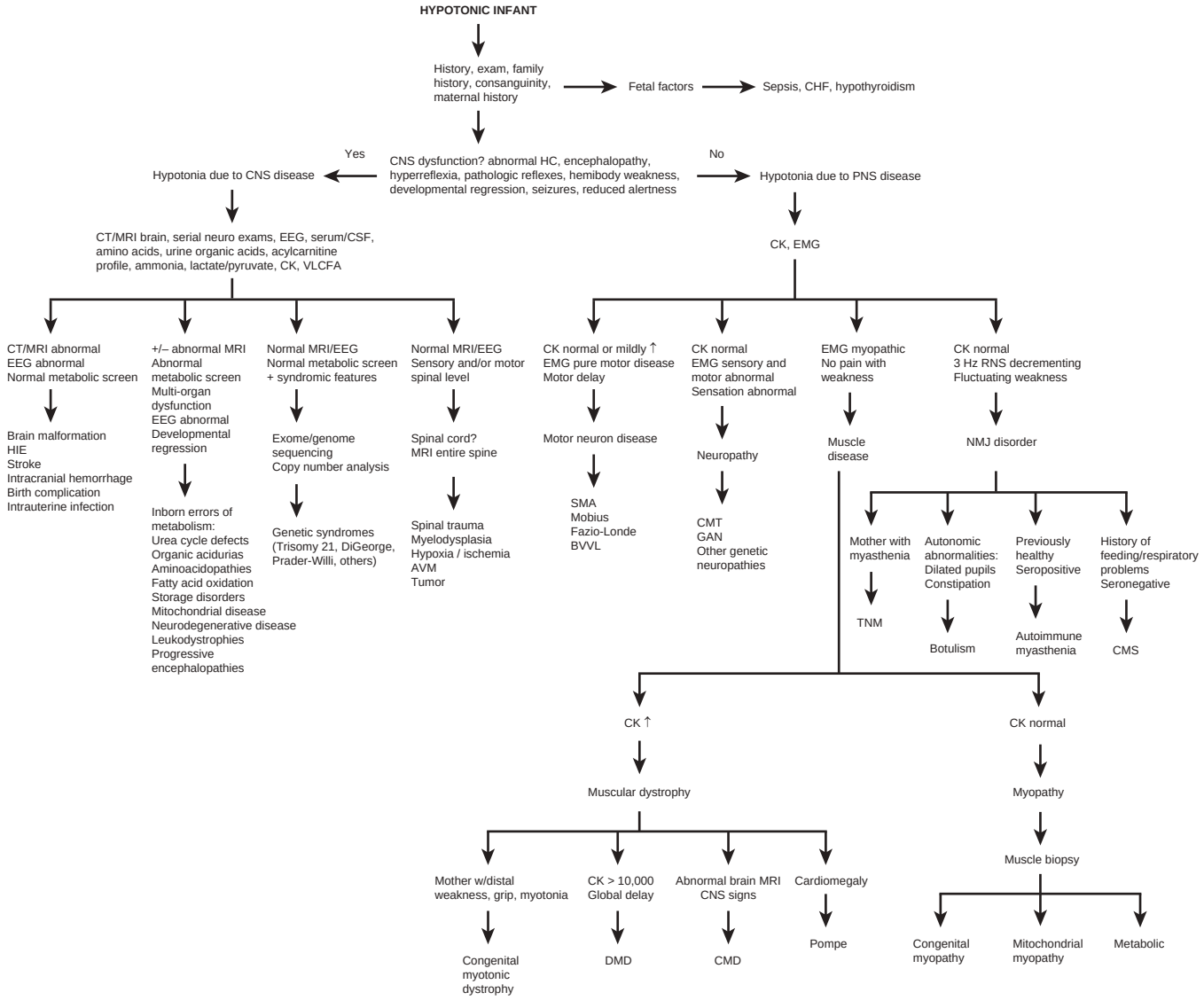

Fig. 647.2 Algorithm showing the diagnostic approach to the hypotonic infant. AVM, Arteriovenous malformation; BVVL, Brown-Vialetto-Van Laere syndrome; CHF, congestive heart failure; CK, creatine kinase; CMD, congenital muscular dystrophy; CMS, congenital myasthenic syndrome; CMT, Charcot-Marie-Tooth disease; CNS, central nervous system; CSF, cerebrospinal fluid; DMD, Duchenne muscular dystrophy; EMG, electromyography with nerve conduction; GAN, giant axonal neuropathy; HC, head circumference; HIE, hypoxic-ischemic encephalopathy; NMJ, neuromuscular junction; PNS, peripheral nervous system; RNS, repetitive nerve stimulation; SMA, spinal muscular atrophy; TNM, transient neonatal myasthenia; VLCFA, very long-chain fatty acids. *(From Konersman C. Hypotonia and weakness. In: Kliegman RM, Toth H, Bordini BJ, Basel D, eds. Nelson Pediatric Symptom-Based Diagnosis, 2nd ed. Philadelphia: Elsevier; 2023: Fig. 35.1, p. 569.)*

abductor digiti quinti of the hypothenar eminence, are used for such studies. Additional specialized tests, such as single myofiber EMG, may provide supplementary evidence in selected cases, but are performed only in large neuromuscular centers.

IMAGING OF MUSCLES AND THE CENTRAL NERVOUS SYSTEM

Ultrasonography, computed tomography (CT) scans, and, more often and most helpful, magnetic resonance imaging (MRI) are used to image muscle in many neuromuscular diseases. Although these methods are not always definitively diagnostic, in experienced hands, they provide a supplementary means of following the progression of disease over time. MRI is quite useful in identifying inflammatory myopathies of immune (dermatomyositis) or infectious (viral, bacterial, parasitic) origin. MRI is the study of choice to image the spinal cord, if a tumor or other structural lesion of the spinal cord is suspected as the cause of muscular dysfunction, and the nerve roots and plexus (e.g., brachial plexus). Brain MRI is indicated in some myopathies, such as the congenital muscular dystrophies, in which cerebral malformations often accompany the myopathy because the mutated gene responsible is expressed in both muscle and the developing brain.

MUSCLE BIOPSY

The muscle biopsy is traditionally the most important and specific diagnostic study of most neuromuscular disorders. Molecular genetic diagnosis supersedes the muscle biopsy or renders it as secondary in diagnostic importance, to be used if a definitive diagnosis of a hereditary disease is not provided by molecular genetic testing in blood. Thus the muscle biopsy is no longer essential for spinal muscular atrophy, most muscular dystrophies, and most congenital myopathies. Muscle

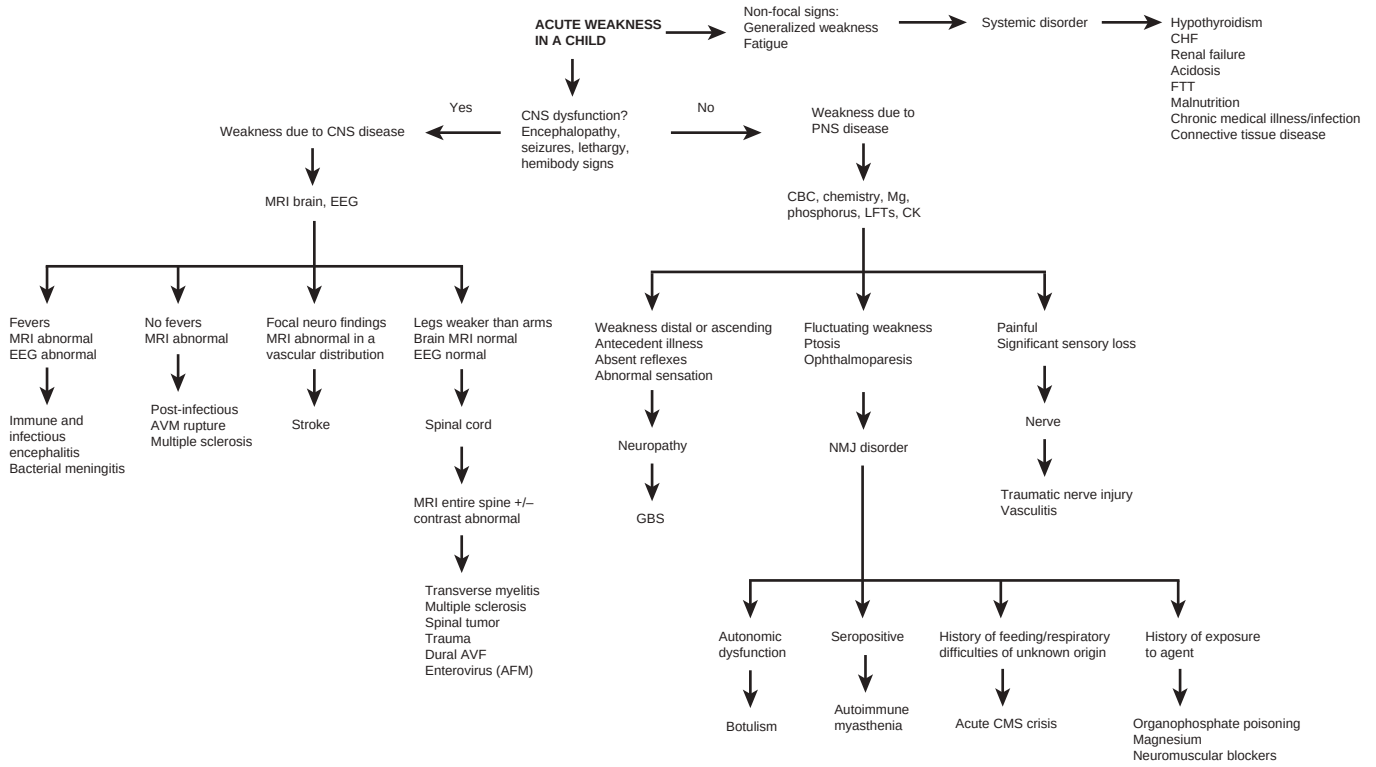

Fig. 647.3 Algorithm showing the diagnostic approach to the child with acute weakness. AFM, acute flaccid myelitis; AVF, arteriovenous fistula; AVM, arteriovenous malformation; CHF, congestive heart failure; CK, creatine kinase; CMS, congenital myasthenic syndrome; CNS, central nervous system; FTT, failure to thrive; GBS, Guillain-Barré syndrome; LFTs, liver function tests; NMJ, neuromuscular junction; PNS, peripheral nervous system. *(From Konersman C. Hypotonia and weakness. In: Kliegman RM, Toth H, Bordini BJ, Basel D, eds. Nelson Pediatric Symptom-Based Diagnosis, 2nd ed. Philadelphia: Elsevier; 2023: Fig. 35.9, p. 579.)*

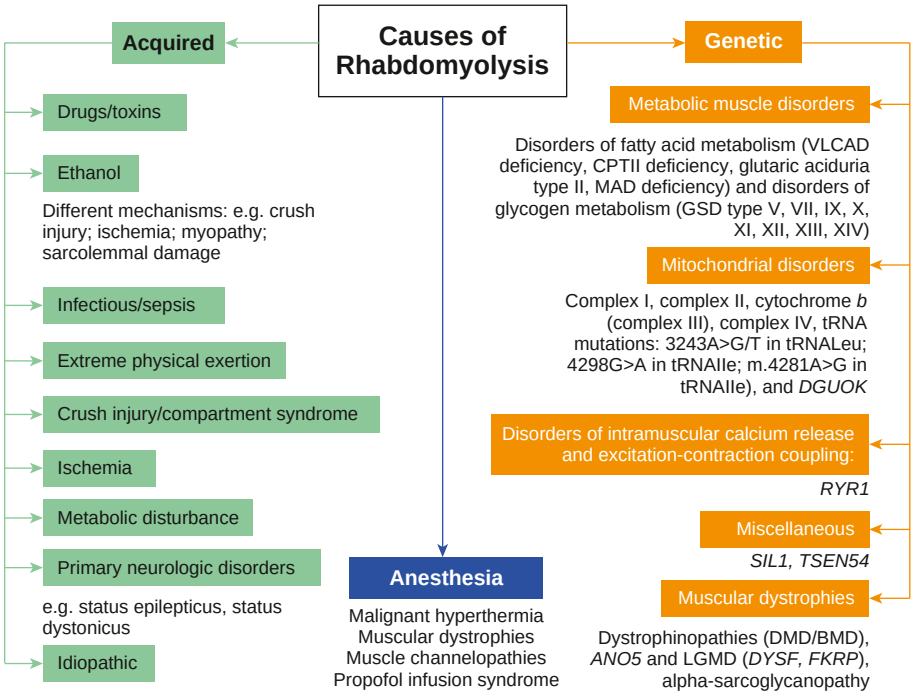

Fig. 647.4 Examples of conditions associated with rhabdomyolysis. In individual cases, both genetic and environmental factors may combine to trigger a rhabdomyolysis event; anesthesia-induced rhabdomyolysis is the best-characterized example. VLCAD, Very-long-chain acyl-CoA dehydrogenase; CPTII, carnitine palmitoyl-transferase-II; MAD, multiple acyl-CoA dehydrogenase; GSD, glycogen storage disease; tRNA, transfer ribonucleic acid; *DGUOK*, deoxyguanosine kinase gene; *RYR1*, ryanodine receptor 1 gene; *SIL1*, *Saccharomyces cerevisiae*, homolog of; *TSEN54:* tRNA splicing endonuclease 54 gene, *S. cerevisiae*, homolog of; DMD, Duchenne muscular dystrophy; BMD, Becker muscular dystrophy; *ANO5*, anoctamin 5 gene; LGMD, limb-girdle muscular dystrophy; *DYSF*, dysferlin gene; *FKRP*, fukutin-related protein gene. *(From Scalco RS, Gardiner AR, Pitceathly RDS, et al. Rhabdomyolysis: a genetic perspective. Orphanet J Rare Dis. 2015;10:51. Fig. 1.)*

Table 647.3 Differentiating the Causes of Infantile Hypotonia

LOCALIZATION	CAUSE	HISTORY AND EXAM FINDINGS	INVESTIGATION TO AID IN DIAGNOSIS
Brain	HIE Intracerebral hemorrhage	Prematurity, difficult delivery	Brain MRI
	Brain malformations	Cranial nerve abnormalities, Babinski sign, gradual development of hypertonia (especially axial), respiratory or feeding difficulties, global delay, micro-macrocephaly	Cerebral ultrasound, brain MRI
	Intrauterine infection	Fever, altered mental status	Microbial cultures/evaluations, CSF evaluation
	Postnatal birth injury	Seizures, focal neurologic deficits	Brain MRI, EEG
	Progressive encephalopathies (leukodystrophies, progressive myoclonic epilepsies, Lennox-Gastaut syndrome, infantile spasms)	Seizures, developmental regression, ataxia, focal neurologic deficits, visual loss	Brain MRI, EEG, EMG/NCS (useful in adrenoleukodystrophy, Krabbe disease, and metachromatic leukodystrophy), specific genetic testing
	Mitochondrial disease	Seizures, focal neurologic deficits, global delay, visual loss, hyper- or hyporeflexia	Brain MRI, lactate, pyruvate, creatine kinase, GDF-15, muscle biopsy, mitochondrial DNA sequencing and deletion/duplication analysis on muscle or affected tissue, EMG/NCS
Brainstem	Joubert syndrome Pontocerebellar hypoplasia Cobblestone malformations	Multiple cranial nerve abnormalities, breathing and feeding difficulties, possible intellectual delay, nystagmus, possible hyperreflexia, ataxia	Brain MRI (molar tooth sign in Joubert syndrome), genetic panels for specific disorders
Spinal cord	Myelodysplasia Spinal cord tumor Syringomyelia Hypoxia-ischemia Trauma AVM	Spinal level on exam, weakness below a defined spinal level, absent reflexes (acutely) or hyperreflexia (chronically) below the level, may have Babinski sign, history of trauma	Brain MRI, complete spinal MRI
Motor neuron	Spinal muscular atrophy	Absence of antigravity movements, tongue fasciculations, absent reflexes to hyporeflexia, normal cognition, breathing/feeding difficulties; weakness in legs more than arms in SMA types II-III	*SMN1* genetic analysis
	Poliomyelitis	Neck stiffness, muscle spasms, areflexia, asymmetric flaccid paralysis of a limb, respiratory distress, muscle atrophy, normal sensation	Isolation of poliovirus from stool, confirmation using RT-PCR, acute and convalescent serology showing fourfold increase in titer, EMG/NCS showing pure motor neuronopathy
	Incontinentia pigmenti	Skin blistering, verrucous skin lesions, hyperpigmented streaks, pale/hairless atrophic linear streaks that respect Blaschko lines, dental abnormalities, intellectual delay	DNA analysis, EMG/NCS showing pure motor neuronopathy
	Fazio-Londe disease Brown-Vialetto-Van Laere syndrome (BVVL)	Optic atrophy, nystagmus, bulbar palsy, facial weakness, hearing loss (BVVL only), tongue fasciculations, ptosis, respiratory compromise, muscle weakness	DNA analysis
Nerve	Guillain-Barré syndrome (GBS) Chronic inflammatory demyelinating polyneuropathy (CIDP)	Sensory ataxia with walking difficulties, rapidly (GBS) or slowly (CIDP) progressive weakness, absent reflexes or hyporeflexia, autonomic dysfunction, antecedent gastrointestinal or respiratory illness in GBS	EMG/NCS with absent or prolonged F waves, prolonged distal latencies, conduction block, demyelinating nerve conduction velocities, CSF showing cytoalbuminologic dissociation, MRI with edematous enhancing nerve roots
	Toxic neuropathies	History and temporal correlation with exposure to a neurotoxic drug, distal then proximal muscle weakness, absent reflexes or hyporeflexia, sensory ataxia with walking difficulties	EMG/NCS showing mixed axonal/demyelinating features, plasma drug levels
	Charcot-Marie-Tooth disease	Family history of similar disease, pes cavus and hammer toe foot deformities, ataxic gait, foot drop, absent reflexes or hyporeflexia	EMG/NCS to determine whether axonal or demyelinating subtypes, DNA analysis
	Hereditary sensory and autonomic neuropathies	Sensory loss in a stocking/glove distribution, chronic skin ulceration and poor wound healing, distal muscle weakness with foot deformity, absent reflexes or hyporeflexia, variable anhidrosis	EMG/NCS showing normal or mildly abnormal motor responses and abnormal sensory responses, nerve biopsy showing reduced myelinated and unmyelinated fibers, DNA analysis

Table 647.3 Differentiating the Causes of Infantile Hypotonia—cont'd

LOCALIZATION	CAUSE	HISTORY AND EXAM FINDINGS	INVESTIGATION TO AID IN DIAGNOSIS
	Refsum disease	Autosomal recessive inheritance, stocking/glove distribution of sensory and motor weakness, anosmia, hearing loss, ataxia, ichthyosis, short metacarpals and metatarsals, cardiac arrhythmia, and cardiomyopathy	Elevated plasma phytanic acid concentration, DNA analysis
	Giant axonal neuropathy	Stocking/glove distribution of sensory loss and motor weakness, cerebellar ataxia, absent reflexes or hyporeflexia, kinky hair (tightly curled), nystagmus, dysarthria, pyramidal tract signs, optic neuropathy, seizures	Brain MRI with white matter abnormalities, axonal sensorimotor polyneuropathy on EMG/NCS, nerve biopsy showing giant axons (axonal swelling) and disorganized neurofilaments, DNA analysis
	Metachromatic leukodystrophy Krabbe disease Adrenoleukodystrophy	Developmental regression, absent reflexes or hyporeflexia, Babinski signs	EMG/NCS showing demyelinating neuropathy, brain MRI showing white matter disease, DNA analysis
Neuromuscular junction	Botulism	Sudden poor feeding, constipation, weak cry, gradual muscle weakness, dilated poorly reactive pupils, exposure to soil/dust with bacterium or honey consumption	Presence of toxin in stool/serum, culture bacterium from stool, EMG/NCS showing low-amplitude motor responses or decrement on repetitive nerve stimulation in a weak muscle
	Transient acquired neonatal myasthenia	Ptosis, feeding and respiratory difficulties, aspiration, mother with signs or symptoms of autoimmune myasthenia	Maternal history of myasthenia, EMG/NCS showing decrement on repetitive nerve stimulation in a weak muscle, good response to acetylcholinesterase inhibitors
	Infantile (autoimmune) myasthenia	Ptosis, episodic weakness, recurrent feeding and respiratory difficulties, easy fatigability	EMG/NCS showing decrement on repetitive nerve stimulation in a weak muscle, good response to acetylcholinesterase inhibitors, anti-acetylcholine receptor antibody serology
	Congenital myasthenic syndrome	Ptosis, episodic weakness, recurrent feeding and respiratory difficulties, easy fatigability	EMG/NCS showing decrement on repetitive nerve stimulation in a weak muscle, DNA analysis, negative anti-acetylcholine receptor antibody serology
Muscle	Duchenne/Becker muscular dystrophy	X-linked pattern of inheritance, enlarged calves, proximal muscle weakness with a Gower maneuver	Markedly elevated CK, DNA analysis
	Congenital myotonic dystrophy	Autosomal dominant pattern of inheritance, frog-leg position, open down-turned mouth, minimal antigravity movements in infants, distal > proximal weakness in children, impaired relaxation of grip, dysarthria, myopathic facies with temporal wasting	Test mother (then father) for clinical myotonia or electrical myotonic discharges, EMG/NCS with myopathy in newborn period and myotonic discharges in older children, normal to mildly elevated CK, *DPMK* gene CTG repeat analysis
	Pompe disease	Absence of antigravity movements, severe cardiomegaly, feeding/respiratory difficulties, hepatomegaly	GAA enzyme activity in dried blood spot, lymphocytes or fibroblasts, *GAA* gene analysis
	Congenital muscular dystrophy	Family history, proximal > distal muscle weakness, feeding and respiratory difficulties, early-onset contractures in specific subtypes, keloids/hyperkeratosis pilaris in specific subtypes, CNS dysfunction in specific subtypes	Brain MRI, mild to markedly elevated CK, muscle biopsy showing dystrophic changes, muscle MRI, EMG/NCS to assess for demyelinating neuropathy component and myopathy, DNA analysis
	Congenital myopathies	Family history, proximal > distal muscle weakness, feeding and respiratory difficulties, ptosis and ophthalmoparesis in specific subtypes	Normal to mildly elevated CK, muscle biopsy showing specific changes (nemaline rods, cores, centrally placed nuclei), DNA analysis
	Metabolic myopathies	Family history, proximal muscle weakness, history of rhabdomyolysis or myoglobinuria, second-wind phenomenon in some subtypes	Normal to markedly elevated CK, EMG/NCS usually myopathic, metabolic evaluation (lactate, pyruvate, acylcarnitine profile, plasma amino acids, urine organic acids), muscle biopsy, DNA analysis
	Mitochondrial myopathies	Maternal inheritance pattern, proximal > distal weakness, ptosis, ophthalmoparesis, short stature, variable cardiac and CNS involvement, recurrent rhabdomyolysis	Normal to moderately elevated CK, abnormal GDF-15, EMG/NCS showing myopathy and variable neuropathy, muscle biopsy with ragged red fibers, mitochondrial DNA analysis

AVM, Arteriovenous malformation; CK, creatine kinase; CNS, central nervous system; CSF, cerebrospinal fluid; CTG, cytosine-thymine-guanine; EMG/NCS, electromyography/nerve conduction study; GAA, acid α-glucosidase; GDF-15, growth differentiation factor-15; HIE, hypoxic-ischemic encephalopathy; RT-PCR, reverse transcription-polymerase chain reaction; SMA, spinal motor atrophy.

Modified from Sparks SE. Neonatal hypotonia. *Clin Perinatol*. 2015;42:363–371.

biopsy remains useful in select cases, however, to provide morphologic details and metabolic profiles not revealed by genetic testing alone or as a primary diagnostic procedure if the genetics are equivocal or negative. Not only are neurogenic and myopathic processes distinguished by muscle biopsy, but the type of myopathy and specific enzymatic deficiencies also may be determined. *In addition, there are conditions that may have associated identifiable disease-causing genes in most but not all patients.*

The vastus lateralis (quadriceps femoris) is most frequently sampled. The deltoid should be avoided in most cases because it normally exhibits a 60–80% predominance of type I fibers, so that the distribution patterns of fiber types are difficult to recognize. Muscle biopsy is a simple outpatient procedure that may be performed under local anesthesia with or without femoral nerve block. Needle biopsies are preferred in some centers but are not percutaneous and require an incision in the skin similar to open biopsy; numerous samples must be taken to conduct an adequate examination of the tissue, and they provide inferior specimens. The volume of tissue from a needle biopsy is usually not adequate for all required studies, including supplementary biochemical studies, such as mitochondrial respiratory chain enzymes; a small, clean, open biopsy is therefore advantageous.

Histochemical studies of frozen sections of the muscle are obligatory in all pediatric muscle biopsies because many congenital and metabolic myopathies cannot be diagnosed from paraffin sections using conventional histologic stains. Immunohistochemistry is a useful supplement in some cases, such as for demonstrating dystrophin in suspected Duchenne muscular dystrophy or merosin in congenital muscular dystrophy. A portion of the biopsy specimen should be fixed for potential electron microscopy, but the ultrastructure has additional diagnostic value only in selected cases. Interpretation of muscle biopsy samples is complex and should be performed by an experienced pathologist. A portion of frozen muscle tissue should also be routinely saved for possible biochemical analysis (mitochondrial cytopathies, carnitine palmitoyltransferase, acid maltase).

Immunocytochemical reactivities can be applied to formalin-fixed, paraffin-embedded sections and do not require frozen sections. Some reactivities, such as slow and fast myosin, can distinguish fiber types and hence substitute for myofibrillar adenosine triphosphatase histochemical stains in frozen sections. An increasing number of sarcolemmal regional proteins can be demonstrated that are specific for each of the various muscular dystrophies and include the dystrophins, merosin, sarcoglycans, and dystroglycans. Ryanodine receptors, important in myasthenia gravis and in malignant hyperthermia, also can be demonstrated. In addition, immunocytochemical reactivities can distinguish the various types of inflammatory cells in autoimmune myopathies, including T and B lymphocytes and macrophages.

Table 647.4 Differential Diagnosis of Acute Flaccid Paralysis

- Brainstem stroke
- Brainstem encephalitis
- Acute anterior poliomyelitis
  - Caused by poliovirus
  - Caused by other neurotropic viruses
  - Unknown cause of acute flaccid myelitis
- Acute myelopathy
  - Space-occupying lesions
  - Acute transverse myelitis
- Peripheral neuropathy
  - Guillain-Barré syndrome
  - Post–rabies vaccine neuropathy
  - Diphtheritic neuropathy
  - Heavy metals, biologic toxins, or drug intoxication
  - Acute intermittent porphyria
  - Vasculitic neuropathy
  - Critical illness neuropathy
  - Lymphomatous neuropathy
- Disorders of neuromuscular transmission
  - Myasthenia gravis
  - Biologic or industrial toxins
  - Tic paralysis
- Disorders of muscle
  - Hypokalemia
  - Hypophosphatemia
  - Inflammatory myopathy
  - Acute rhabdomyolysis
  - Trichinosis
  - Familial periodic paralyses (normokalemic, hypokalemic, hyperkalemic)

From Hughes RAC, Camblath DR. Guillain-Barré syndrome. *Lancet*. 2005;366:1653–1666.

NERVE BIOPSY

Nerve biopsy is applied less frequently because of the precision diagnosis of many hereditary peripheral neuropathies by less invasive and more specific genetic diagnosis. In some cases not definitively diagnosed by genetic testing, the nerve biopsy still provides valuable diagnostic information. The most commonly sampled nerve is the sural nerve, a pure sensory nerve that supplies a small area of skin on the lateral surface of the foot. Whole or fascicular biopsy specimens of this nerve may be taken. When the sural nerve

Table 647.5 Differentiating Acute Flaccid Myelitis from Clinical Mimics

	ACUTE FLACCID MYELITIS	GUILLAIN-BARRÉ SYNDROME	ACUTE TRANSVERSE MYELITIS (DEMYELINATING OR IDIOPATHIC)	SPONTANEOUS SPINAL CORD INFARCTION
Prodromal illness	+++	+++	+/−	−
Temporal evolution	Hours to days	Days to weeks	Days to weeks	Minutes to hours
Pattern of weakness	Asymmetric, arms > legs	Symmetric, ascending	Variable	Symmetric, severe
Facial/bulbar weakness	++	++	+/−	+/−
Respiratory failure	++	++	+/−	+/−
Numbness/paresthesia	+/−	+++ (except AMAN)	+++	+
Sensory level	−	−	++	++
Optic neuritis	−	−	Variable	−
Encephalopathy	−	−	+/− (e.g., ADEM)	−
Bowel/bladder dysfunction	+/−	+/−	++	+++

From Murphy OC, Messacar K, Benson L, et al. Acute flaccid myelitis: cause, diagnosis, and management. Lancet. 2021;397:334-344. Table 2, p. 337.

Table 647.5 Differentiating Acute Flaccid Myelitis from Clinical Mimics—cont'd

	ACUTE FLACCID MYELITIS	GUILLAIN-BARRÉ SYNDROME	ACUTE TRANSVERSE MYELITIS (DEMYELINATING OR IDIOPATHIC)	SPONTANEOUS SPINAL CORD INFARCTION
Possible associated symptoms or syndromes	Headache, neck pain/stiffness, neuropathic pain	Neuropathic pain	Optic neuritis, encephalitis, seizures	Severe back/limb pain at onset
MRI spinal cord	Ill-defined gray matter–predominant lesion, +/− nerve root enhancement	Normal cord, +/− nerve root enhancement	Variable, but usually a well-defined enhancing white > gray matter lesion	No-enhancing anterior cord or gray matter lesion
CSF	Mild-moderate pleocytosis	Elevated protein	Mild-moderate pleocytosis	Sometimes elevated protein or mild pleocytosis
Microbiologic tests	Nasopharyngeal, rectal swabs and CSF for enteroviruses including polio and live polio vaccine virus if indicated. West Nile virus titers	Stool sample: bacterial culture, viral RT-PCR panel; respiratory sample: viral RT-PCR panel; serum: *Campylobacter jejuni* and *Mycoplasma pneumoniae* IgM/IgG; other organisms according to region and season	If indicated based on clinical presentation	Not usually indicated
Other useful tests	+/− EMG/NCS	EMG/NCS; serum: anti-ganglioside antibodies	Serum: MOG-IgG, aquaporin-4-IgG; CSF: oligoclonal bands	Angiography

AMAN, Acute motor axonal neuropathy subtype; ADEM, acute disseminated encephalomyelitis; CSF, cerebrospinal fluid; EMG/NCS, electromyography and nerve conduction studies; MOG, myelin oligodendrocyte glycoprotein; RT-PCR, reverse transcription-polymerase chain reaction.
Modified from Murphy OC, Messacar K, Benson L, et al. Acute flaccid myelitis: cause, diagnosis, and management. *Lancet*. 2021;397:334–344. Table 2, p. 337.

Table 647.6 Nonneuromuscular Disorders That Can Cause Elevated Creatine Kinase Levels

ENDOCRINE DISORDERS Hyperthyroidism (rare) Hypothyroidism Hyperparathyroidism Acromegaly Cushing syndrome	MEDICATIONS Statins Fibrates Antiretrovirals β Blockers Clozapine Angiotensin II receptor blockers Hydroxychloroquine Isotretinoin Colchicine
METABOLIC DISTURBANCES Hyponatremia Hypokalemia Hypophosphatemia	
MUSCLE TRAUMA Strenuous exercise Intramuscular injections Needle electromyography Seizures	OTHERS Celiac disease Malignancy Macro creatine kinase Surgery Pregnancy Cardiac disease Acute kidney disease Viral illness Predisposition to malignant hyperthermia

From Moghadam-Kia S, Oddis CV, Aggarwal R. Approach to asymptomatic creatine kinase elevation. *Cleve Clin J Med*. 2016;83(1):37–42. Table 1.

is severed behind the lateral malleolus of the ankle, regeneration of the nerve occurs in more than 90% of cases, so that permanent sensory loss is not experienced. The sural nerve is often involved in many neuropathies in which the clinical manifestations are predominantly motor.

Electron microscopy is performed on most nerve biopsy specimens because many morphologic alterations cannot be appreciated at the resolution of a light microscope. Teased fiber preparations are sometimes useful in demonstrating segmental demyelination, axonal swellings, and other specific abnormalities, but these time-consuming procedures are not done routinely. Special stains may be applied to ordinary frozen or paraffin sections of nerve biopsy material to demonstrate myelin, axoplasm, and metabolic products.

CARDIAC ASSESSMENT

Cardiac evaluation is important if myopathy is suspected because of involvement of the heart in muscular dystrophies and in inflammatory and metabolic myopathies (Table 647.9). Electrocardiography often detects early cardiomyopathy or conduction defects that are clinically asymptomatic. At times, a more complete cardiac workup, including echocardiography and consultation with a pediatric cardiologist, is indicated. Serial pulmonary function tests also should be performed in muscular dystrophies and in other chronic or progressive diseases of the motor unit.

Visit Elsevier eBooks+ at eBooks.Health.Elsevier.com for Bibliography.

Table 647.7 Causes of Rhabdomyolysis

NONTRAUMATIC CAUSES *Nonexertional Causes* Alcohol/drug use: Ethanol, methanol, ethylene glycol, heroin, methadone, barbiturates, cocaine, caffeine, amphetamine, lysergic acid diethylamide, 3,4-methylene dioxymethamphetamine (MDMA, ecstasy), phencyclidine, benzodiazepines, toluene (from glue sniffing), gasoline/paint sniffing
Medication: Salicylates, fibric acid derivatives (bezafibrate, clofibrate, fenofibrate, gemfibrozil), neuroleptics, antipsychotics (haloperidol, fluphenazine, perphenazine, chlorpromazine), quinine, corticosteroids, statins (atorvastatin, fluvastatin, lovastatin, pravastatin, rosuvastatin, simvastatin, cerivastatin), theophylline, cyclic antidepressants, selective serotonin reuptake inhibitors, antibiotics (fluoroquinolones, pyrazinamide, trimethoprim/sulfonamide, amphotericin B, itraconazole, levofloxacin), zidovudine, benzodiazepines, antihistamines, aminocaproic acid, phenylpropanolamine
Toxic agents: Carbon monoxide (CO), hemlock herbs from quail, snake bites, spider venom, massive honey bee envenomations, *Tricholoma equestre* (mushroom), buffalo fish
Anesthetics and neuromuscular blocking agents: Barbiturates, benzodiazepines, propofol, succinylcholine in patients with Duchenne/Becker muscular dystrophy
Infections: *Viral:* influenza A and B, HIV, enterovirus, adenovirus, coxsackievirus, Epstein-Barr virus, echovirus, cytomegalovirus, herpes simplex virus, varicella-zoster virus, West Nile virus. *Bacterial: Legionella* species, *Salmonella* species, *Francisella* species, *Streptococcus pneumoniae, Staphylococcus aureus, Enterococcus, Pseudomonas aeruginosa, Neisseria meningitidis, Haemophilus influenzae, Coxiella burnetii, Leptospira* species, *Mycoplasma* species, *Escherichia coli*, fungal and malarial infections
Electrolyte disturbances: Hyponatremia, hypernatremia, hypokalemia, hypophosphatemia, hypocalcinemia, hyperosmotic conditions
Endocrine disorders: Hypothyroidism, hyperthyroidism, diabetic ketoacidosis, nonketotic hyperosmolar diabetic coma, hyperaldosteronism
Idiopathic inflammatory myopathies: Polymyositis, dermatomyositis, necrotizing myositis
Temperature extremes: Heatstroke, malignant hyperthermia, exposure to cold
Muscle ischemia: Thrombosis, embolism
NEUROLEPTIC MALIGNANT SYNDROME *Exertional Causes* Extreme physical exertion, sickle cell disease (crisis), status epilepticus, hyperkinetic syndrome, severe dystonia, status asthmaticus
TRAUMATIC CAUSES *Multiple Injury* Crush injury: Bombings, earthquakes, building collapse, mine accidents, train or motor vehicle accidents
High-voltage electrical injury
Extensive third-degree burns
Vascular/orthopedic surgery: Intraoperative use of tourniquets, tight dressings or casts, prolonged application of air splints or pneumatic antishock garments, and clamping of vessels during surgery
Prolonged immobility: Immobilization after trauma, anesthesia, coma, drug- or alcohol-induced unconsciousness

Modified from Zutt R, van der Kooi AJ, Linthorst GE, et al. Rhabdomyolysis: review of the literature. *Neuromuscul Disord.* 2014;24:651–659. Table 2.

Table 647.8 Inherited Neuromuscular Disorders Associated with Episodes of Rhabdomyolysis*

GENE	DISEASE NAME	BASELINE CREATINE KINASE LEVELS	PATTERN OF INHERITANCE	TRIGGER FOR RHABDOMYOLYSIS
DISORDERS OF GLYCOGEN METABOLISM				
PYGM	Glycogen storage disease type V, McArdle disease	High	AR	Aerobic and anaerobic exercise, symptom onset within minutes
PFKM	Glycogen storage disease type VII, Tarui disease	High	AR	Aerobic and anaerobic exercise, symptom onset within minutes
ALDOA	Glycogen storage disease type XII	Normal Mild elevation, high	AR	Febrile illness, infection
ENO3	Glycogen storage disease type XIII	Normal High	AR	Aerobic and anaerobic exercise, symptom onset within minutes
PGAM2	Glycogen storage disease type X	High	AR	Aerobic and anaerobic exercise, symptom onset within minutes
PGK1	Phosphoglycerate kinase 1 deficiency	Normal High	X-linked	Aerobic and anaerobic exercise, symptom onset within minutes
PGM1	Glycogen storage disease type XIV	High	AR	Aerobic and anaerobic exercise, symptom onset within minutes, general anesthesia
PHKA1 *PHKB*	Glycogen storage disease type IX	?	X-linked AR	Aerobic and anaerobic exercise, symptom onset within minutes
DISORDERS OF FATTY ACID METABOLISM:				
ACADVL	Deficiency of very-long-chain acyl-CoA dehydrogenase	Normal High	AR	Fasting, prolonged exercise, cold, infections, fever
CPT2	Carnitine palmitoyl-transferase deficiency	Normal	AR	Prolonged exercise, fasting, fever, infection, high fat intake, cold exposure, heat, emotional stress, drugs
ETFA *ETFB* *ETFDH*	Glutaric aciduria type II Multiple acyl-coenzyme A dehydrogenase deficiency	Normal Mildly to moderately elevated	AR	Physical exercise, fasting, irregular diet or infection
MITOCHONDRIAL DISORDERS				
COI (MTCO1)	Mitochondrial disorder	Normal	Maternal inheritance	Prolonged or repetitive exercise
COII (MTCO2)	Mitochondrial disorder	Normal	Maternal inheritance	Exercise
COIII (MTCO3)	Mitochondrial disorder	Normal	Maternal inheritance	Prolonged exercise, viral illness, unknown cause

Continued

Table 647.8 Inherited Neuromuscular Disorders Associated with Episodes of Rhabdomyolysis*—cont'd

GENE	DISEASE NAME	BASELINE CREATINE KINASE LEVELS	PATTERN OF INHERITANCE	TRIGGER FOR RHABDOMYOLYSIS
DGUOK	Mitochondrial disorder	?	AR	Viral illness
FDX1L	Mitochondrial disorder	Normal High	AR	?After exercise
HADHA *HADHB*	Mitochondrial trifunctional protein deficiency	Normal	AR	Strenuous physical activity
ISCU	Iron–sulfur cluster deficiency myopathy (mitochondrial disorder)	?	AR	Exercise
MTCYB	Mitochondrial disorder	Normal	Sporadic variants	Exercise
POLG1	One case report of rhabdomyolysis in association with propofol infusion syndrome		AD, AR	Propofol infusion syndrome
DISORDERS OF INTRAMUSCULAR CALCIUM RELEASE AND EXCITATION—CONTRACTION COUPLING				
RYR1	Malignant hyperthermia susceptibility, exertional rhabdomyolysis, congenital myopathy	Normal or mildly to moderately elevated (usually <1,000 IU/L)	AD, AR	Heat, infection, alcohol, drugs, anesthetic (malignant hyperthermia susceptibility), and exercise
MUSCULAR DYSTROPHIES				
ANO5	Anoctaminopathy-5	High	AR	Unprovoked; no trigger has been identified
DMD	Duchenne muscular dystrophy, Becker muscular dystrophy	High	X-linked	Exercise, anesthetic drugs
DYSF	Limb-girdle muscular dystrophy 2B, Miyoshi myopathy	High	AR	Exercise
FKTN	Fukuyama congenital muscular dystrophy	High	AR	One case following the use of halothane and succinylcholine
FKRP	Limb-girdle muscular dystrophy 2I	High	AR	Exercise
MISCELLANEOUS				
LPIN1	Phosphatidic acid phosphatase deficiency	Normal, high	AR	Febrile illness, anesthesia, and fasting
SIL1	Marinesco-Sjögren syndrome	Normal, high	AR	Febrile infection
TSEN54	Pontocerebellar hypoplasia type 2	Normal, high	AR	Hyperthermia
TANGO2	Encephalocardiomyopathy	High	AR	Encephalocardiomyopathy crisis

*The table summarizes genes, disease names, baseline serum CK levels (between acute episodes of rhabdomyolysis), patterns of inheritance, and triggers for rhabdomyolysis. Genes commonly associated with rhabdomyolysis episodes are in **bold**.
AD, Autosomal dominant; AR, autosomal recessive.
From Scalco RS, Gardiner AR, Pitceathly RDS, et al. Rhabdomyolysis: a genetic perspective. *Orphanet J Rare Dis.* 2015;10:51. Table 1.

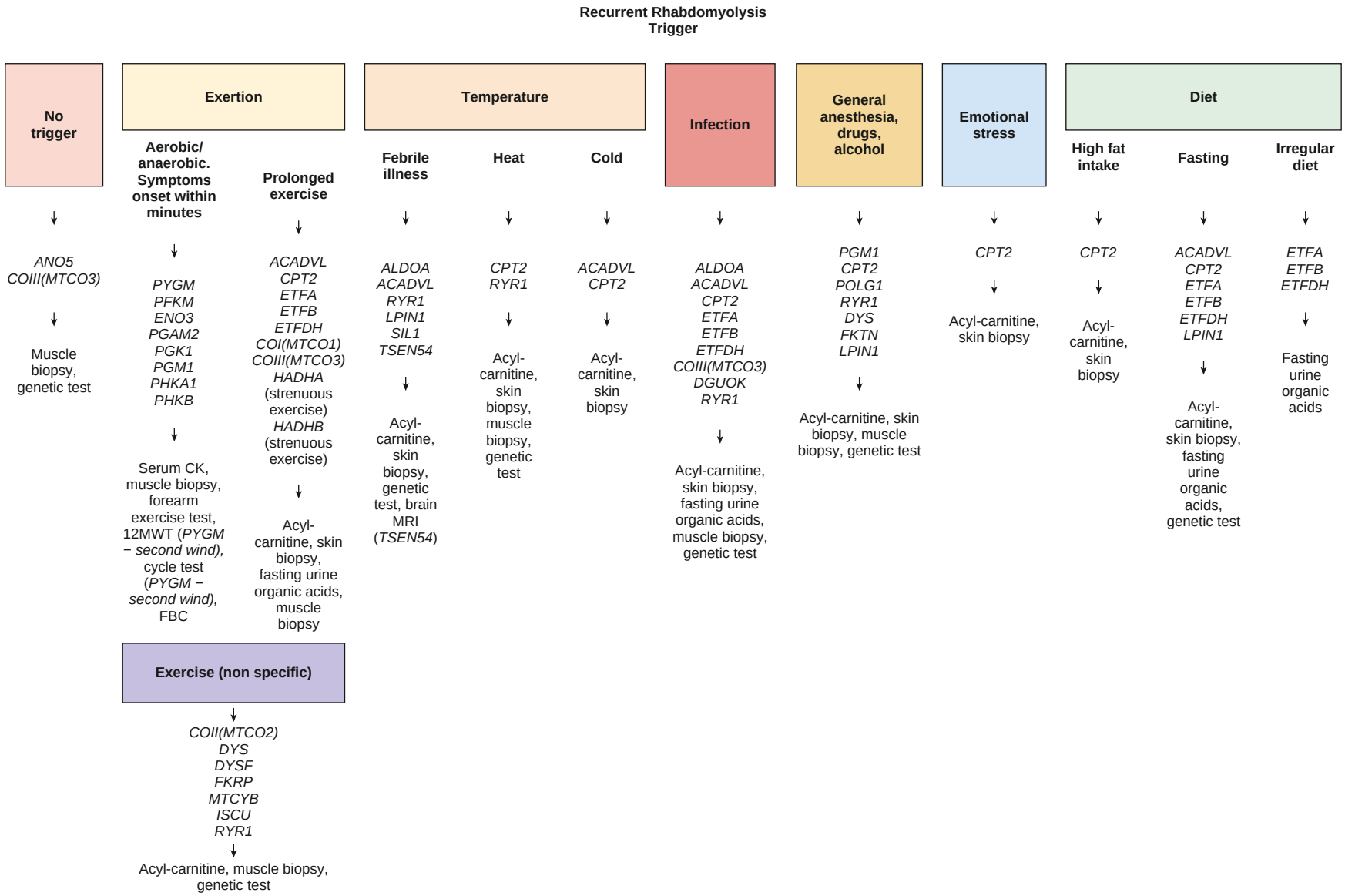

Fig. 647.5 Examples of different triggers of rhabdomyolysis. The identification of triggers may help in guiding genetic testing and may also aid in the interpretation of variants of uncertain significance identified on next-generation sequencing in patients presenting with rhabdomyolysis. CK, Creatine kinase; 12MWT, 12-minute walk test; FBC, full blood count. *(From Scalco RS, Gardiner AR, Pitceathly RDS, et al. Rhabdomyolysis: a genetic perspective. Orphanet J Rare Dis. 2015;10:51. Fig. 2.)*

Downloaded for mohamed ahmed (dr.mms2020@gmail.com) at University of Southern California from ClinicalKey.com by Elsevier on April 22, 2024. For personal use only. No other uses without permission. Copyright ©2024. Elsevier Inc. All rights reserved.

Table 647.9 Gene Variants and Cardiac Manifestations of the Neuromuscular Disorders

NEUROMUSCULAR DISORDER	GENE	CARDIOMYOPATHY	ECG	ARRHYTHMIA
Duchenne muscular dystrophy	Dystrophin	Dilated	Short PR interval, prolonged QT interval, increased QT:PT ratio, right ventricular hypertrophy, deep Q waves II, III, aVF, %, v6	Increased baseline HR, decreased rate variability, premature ventricular beats (58% of patients by 24 yr of age)
Duchenne muscular dystrophy, female carrier	Dystrophin	Dilated	None	Uncommon
Becker muscular dystrophy	Dystrophin	Dilated	Conduction system disease	Similar to DMD
Emery-Dreifuss autosomal dominant or proximal dominant limb-girdle muscular dystrophy IB	Lamin A/C	Dilated	Conduction abnormalities: prolonged PR interval and sinus bradycardia	Atrial fibrillation or flutter and atrial standstill. Ventricular dysrhythmias
Limb-girdle muscular dystrophy	α, β, γ, δ sarcoglycans	Dilated	Incomplete right bundle branch block, tall R waves in VI and V2 or left anterior hemiblock	Uncommon
Congenital muscular dystrophy	Laminin alpha 2	Dilated	None	None
Limb-girdle muscular dystrophy 21	Fukutin	Dilated	AV node and bundle branch block, age at onset late teens and early 20s	Atrial arrhythmias and/or ventricular arrhythmias
Emery-Dreifuss X-linked	Emerin	Rare	Conduction abnormalities: prolonged PR interval and sinus bradycardia	Atrial fibrillation or flutter and atrial standstill
Friedreich ataxia	Frataxin gene	Hypertrophic	T-wave inversion, left axis deviation and repolarization abnormalities	Ventricular arrhythmias
Myotonic dystrophy type 1, infantile	Myotonic dystrophy protein kinase gene	Hypertrophic	Conduction disease, prolonged PR interval, widening of the QRS complex	Atrial fibrillation and flutter, complete heart block
Myotonic dystrophy type 1	Myotonic dystrophy protein kinase gene	LV noncompaction	Conduction disease, prolonged PR interval, widening of the QRS complex	Atrial fibrillation and flutter, complete heart block

HR, Heart rate; DMD, Duchenne muscular dystrophy; AV, atrioventricular; LV, left ventricular.
From Hsu DT. Cardiac manifestations of neuromuscular disorders in children. *Paediatr Respir Rev*. 2010;11:35–38. Table 1.

Chapter 648

Developmental Disorders of Muscle

*Adnan Y. Manzur**

A heterogeneous group of congenital neuromuscular disorders is known as **congenital myopathies** (see Tables 649.1-649.7 in Chapter 649; Tables 648.1 and 648.2). Most of these disorders have subcellular abnormalities that can be demonstrated only by muscle biopsy, by means of histochemistry, immunocytochemistry, and electron microscopy. In others, the muscle biopsy abnormality is not a subcellular anatomic defect but an aberration in the ratio and sizes of specific myofiber types. A genetic etiology is demonstrated in most of the congenital myopathies, and molecular genetic testing from blood samples may confirm the diagnosis without muscle biopsy in several of the congenital myopathies, muscular dystrophies, and spinal muscular atrophy (SMA).

Most congenital myopathies are *nonprogressive conditions,* but some patients show slow clinical deterioration accompanied by additional changes in their muscle histology. In some congenital myopathies, such as severe neonatal nemaline myopathy, the clinical expression can be life-threatening because of dysphagia and respiratory and/or cardiac insufficiency. Cardiomyopathy develops in some patients with congenital myopathies (Table 648.3). Most of the diseases in the category of congenital myopathies are hereditary, some as classical mendelian traits and others as sporadic or novel point variants. Though clinical features (Table 648.4), including phenotype, can raise a strong suspicion of a congenital myopathy, the definitive diagnosis is determined by the histopathologic findings in the muscle biopsy specimen or by genetic testing in lymphocytes, most commonly by testing for panels of genes with next-generation sequencing (NGS). The morphologic and histochemical abnormalities differ considerably from those of the muscular dystrophies, spinal muscular atrophies, and neuropathies, but there may be coexpression, exemplified by congenital muscle fiber–type disproportion (CMFTD) in infantile myotonic dystrophy. Many are reminiscent of the embryologic development of muscle, thus suggesting possible defects in the genetic regulation of muscle development.

Congenital myopathies often show closer genetic relationships than previously appreciated between entities that have quite distinct pathologic phenotypes in the muscle biopsy and distinctiveness in clinical expression with a degree of overlap. Pathogenic variants of the *TPM3* gene are one of the well-documented etiologies of nemaline myopathy, but identical genetic variants of this gene are also shown to be capable of causing isolated congenital fiber–type disproportion without nemaline rods, cap myopathy, centronuclear ("myotubular") myopathy, and central core/minicore disease.

MYOGENIC REGULATORY GENES AND GENETIC LOCI OF INHERITED DISEASES OF MUSCLE

A family of four myogenic regulatory genes shares encoding transcription factors of basic helix-loop-helix proteins associated with common DNA nucleotide sequences. These genes direct the differentiation of striated muscle from any undifferentiated mesodermal cell. The earliest basic helix-loop-helix gene to program the differentiation of myoblasts is myogenic factor 5 *(MYF5).* The second gene, *myogenin,* promotes fusion of myoblasts to form myotubes. *Herculin* (also known as *MYF6*) and *MYOD1* are the other two myogenic genes. *Myf5* cannot support myogenic differentiation without *myogenin, MyoD,* and *MYF6.* Each of these four genes can activate the expression of at least one other and, under certain circumstances, can autoactivate as well. Another gene known as myomaker also facilitates myoblast fusion. The expression of *MYF5* and of *herculin* is transient in early ontogenesis but returns later in fetal life and persists into adult life.

The human locus of the *MYOD1* gene is on chromosome 11, very near to the domain associated with embryonal rhabdomyosarcoma. The genes *Myf5* and *herculin* are on chromosome 12, and *myogenin* is on chromosome 1.

The myogenic genes are activated during muscle regeneration, recapitulating the developmental process; *MyoD* in particular is required for myogenic stem cell (progenitor satellite cell) activation in adult muscle. The *PAX3, PAX7,* and *WNT3a* genes also play important roles in myogenesis and interact with each of the four basic genes mentioned earlier. Another gene, *myostatin,* is a negative regulator of muscle development by preventing myocytes from differentiating.

The myogenic genes are important not only for fetal myogenesis but also for regeneration of muscle at any age, particularly in degenerative diseases such as muscular dystrophies and autoimmune inflammatory myopathies and in injuries of muscle secondary to trauma or to toxins. Satellite cells in mature muscle that mediate regeneration have the same somitic origin as embryonic muscle progenitor cells, but the genes that regulate them differ. *Pax3* and *Pax7* mediate the migration of primitive myoblast progenitors from the myotomes of the somites to their peripheral muscle sites in the embryo, but only one of two *Pax7* genes continues to act postnatally for satellite cell survival. Then it, too, no longer is required after the juvenile period for muscle satellite (i.e., stem) cells to become activated for muscle regeneration.

Table 648.1 Diagnosis of Myopathy Based on Age of Onset

MYOPATHIES PRESENTING AT BIRTH
Central core disease
Centronuclear (myotubular) myopathy
Congenital fiber-type disproportion
Congenital muscular dystrophy
Congenital myotonic dystrophy
Glycogen storage diseases (acid maltase and phosphorylase deficiencies)
Lipid storage diseases (carnitine deficiency)
Nemaline (rod) myopathy
MYOPATHIES PRESENTING IN CHILDHOOD
Congenital myopathies: nemaline myopathy, centronuclear myopathy, central core
Endocrine-metabolic disorders: hypokalemia, hypocalcemia, hypercalcemia
Glycogen storage disease (acid maltase deficiency)
Inflammatory myopathies: dermatomyositis, polymyositis (rarely)
Lipid storage disease (carnitine deficiency)
Mitochondrial myopathies
Muscular dystrophies: congenital, Duchenne, Becker, Emery-Dreifuss, facioscapulohumeral, limb-girdle
MYOPATHIES PRESENTING IN ADULTHOOD
Centronuclear myopathy
Distal myopathies
Endocrine myopathies: thyroid, parathyroid, adrenal, pituitary disorders
Inflammatory myopathies: polymyositis, dermatomyositis, inclusion body myositis, viral (human immunodeficiency virus)
Metabolic myopathies: acid maltase deficiency, lipid storage diseases, debrancher deficiency, phosphorylase b kinase deficiency
Mitochondrial myopathies
Muscular dystrophies: limb-girdle, facioscapulohumeral, Becker, Emery-Dreifuss
Myotonic dystrophy
Nemaline myopathy
Toxic myopathies: alcohol, corticosteroids, local injections of narcotics, colchicine, chloroquine

From Barohn RJ, Dimachkie MM, Jackson CR. A pattern recognition approach to the patient with a suspected myopathy. *Neurol Clin.* 2014;32(1):569–593. Box 7.

* The editors are grateful to Dr. Harvey B. Sarnat and Dr. Goknur Haliloglu, much of whose work on previous editions of this chapter is retained here.

Table 648.2 The Genetics of Congenital Myopathies

GENE	SUBTYPE	INHERITANCE PATTERN	PROTEIN	PRIMARY SUBCELLULAR INVOLVEMENT	POSSIBLE PATHOGENESIS
ACTA 1	Nemaline myopathy (NM)	AD, AR	Actin, alpha skeletal muscle	Thin filament involvement	Abnormal thin filament structure
	Cap disease (NM variant)	AD			
	Zebra body myopathy (NM variant)	AD			
	Congenital fiber type disproportion	AD			
TPM3	Nemaline myopathy (NM variant)	AD, AR	Tropomyosin-3		
	Cap disease (NM variant)	AD			
	Congenital fiber-type disproportion	AD			
TPM2	Nemalin myopathy (NM)	AD	Tropomyosin-2 (beta)		
	Cap disease (NM variant)	AD			
TNNTI	Nemalin myopathy (NM)	AR	Troponin T type 1 (skeletal, slow)		
NEB	Nemaline myopathy (NM) Core–rod myopathy	AR	Nebulin		Thin filament remodeling ± stability
LMOD3	Nemalin myopathy (NM)	AR	Leiomodin-3		
KBTBD13	Nemalin myopathy (NM)	AD	Kelch repeat and BTB (POZ) domain containing protein 13		
CFL2	Nemalin myopathy (NM)	AR	Cofilin 2 (muscle)		
KLHL40	Nemalin myopathy (NM)	AR	Kelchlike family member 40		
KLHL41	Nemalin myopathy (NM)	AR	Kelchlike family member 41		
MYO18B	Nemalin myopathy	AR	Myosin 18B	Unknown	Unknown
RYR1	Central core myopathy	AD, AR	Ryanodine receptor I	Triad involvement	Abnormal EC coupling
	Multiminicore myopathy	AR			
	Core–rod myopathy	AD, AR			
	Nemalin myopathy	AR			
	Congenital fiber type disproportion	AR			
	Centronuclear myopathy	AR			
	Congenital neuromuscular disease with uniform type 1 fiber	AD			
CACNASI	Congenital fiber type disproportion	AR	DHPR		
STAC3	Native American myopathy	AR	SH3 and cysteine-rich domain containing protein 3		
ORA11	Tubular aggregate myopathy	AD	Transmembrane protein 142A		Abnormal SOCE
ST1M1	Tubular aggregate myopathy	AD	Stromal interaction molecule 1		
SEPN1	Multiminicore myopathy	AR	Selenoprotein N1		Oxidative defects
	Congenital fiber type disproportion	AR			
CCDC78	Centronuclear myopathy	AD	Coiled coil domain containing protein 78		Abnormal EC coupling?
BIN 1	Centronuclear myopathy	AR, AD	Amphiphysin		Membrane remodeling ± stability
DNM2	Centronuclear myopathy	AD	Dynamin 2		
MTM1	Myotubular myopathy	XR	Myotubularin 1		

Table 648.2 The Genetics of Congenital Myopathies—cont'd

GENE	SUBTYPE	INHERITANCE PATTERN	PROTEIN	PRIMARY SUBCELLULAR INVOLVEMENT	POSSIBLE PATHOGENESIS
MTMR14[a]	Centronuclear myopathy		Myotubularin-related protein 14		
SPEG	Centronuclear myopathy with dilated cardiomyopathy	AR	SPEG complex locus		
PTPLA (=HCDA1)	Congenital myopathy related to PTPLA	AR	Protein tyrosine phosphatase-like (3-hydroxyacyl-CoA dehydratase)		
TTN	Centronuclear myopathy	AR	Titin		
	Congenital myopathy with fatal cardiomyopathy	AR			
MYH7	Myosin storage myopathy	AD	Myosin, heavy chain 7, cardiac muscleb		Abnormal ATPase and actin-binding properties
	Myosin storage myopathy with cardiomyopathy	AR			Structural abnormalities
	Congenital fiber type disproportion	AD			
MYH2	Myosin IIa myopathy	AD, AR	Myosin, heavy-chain 2, skeletal muscle	Heavy-chain neuromuscular junction (NJ)	Abnormal ATPase and actin-binding properties
CNTN1	Compton-North congenital myopathy	AR	Contactin-1		Structural abnormalities Aberrant NJ adhesion?
MEGF10	Early-onset myopathy, areflexia respiratory distress, and dysphagia	AR	Multiple EGF-like domains 10	Satellite cells	Abnormal regulation of satellite cells
	Minicores	AR			
ZAK	Congenital fiber type disproportion	AR	Sterile alpha motif and leucine zipper containing kinase AZK	Unknown	Mitogen-activated protein kinase (MAPK) signaling pathway

[a]Until now *MTMR14* has been proven to produce a myopathy only in animal models.
AD, Autosomal-dominant; AR, autosomal-recessive; AZK, sterile alpha motif and leucine zipper containing kinase; BTB, broad-complex, tramtrack and bric a brac; DHPR, dihydropyridine receptor; EC, excitation–contraction; EGF, epidermal growth factor; POZ, Pox virus and zinc finger; SOCE, store-operated calcium entry; XR, X-linked recessive.
From Castro D, Henriquez A. Treatment and management of spinal muscular atrophy and congenital myopathies. In: Bertorini TE, ed. *Neuromuscular Disorders Treatment and Management*, 2nd ed. Philadelphia: Elsevier; 2022: Table 13.2, p. 265.

Table 648.3 Myopathies Developing Ventricular Arrhythmias or Sudden Cardiac Death

MYOPATHIES	ARRHYTHMIAS	SUDDEN CARDIAC DEATH
DMD, XL-EDMD, MD1, MD2, mitochondrial MP, FAODs, VLCAD, Danon disease	VTs	r
BMD	Reentry VT	r
Laminopathy	VT, ventricular fibrillation	r
FSH, hypokalemic periodic paralysis	VTs	nr
MFM	Nonsustained VT	r
Desminopathy, MELAS	Sustained VT	r
NARP, PEO	Nonsustained VTs	nr
KSS	Torsade de pointes	r
CPT-II deficiency	Cardiac arrest	r
Barth syndrome	Ventricular arrhythmia	r

BMD, Becker muscular dystrophy; CPT, carnitine palmityl transferase; DMD, Duchenne muscular dystrophy; FAODs, fatty acid oxidation disorders; FSH, facioscapulohumeral muscular dystrophy; KSS, Kearns-Sayre syndrome; MD1 MD2, myotonic dystrophy; MELAS, mitochondrial encephalomyelopathy with lactic acidosis and stroke; MFM, myofibrillar myopathy; MP, myopathy; NARP, neuropathy, ataxia, and retinitis pigmentosa; nr, not reported; PEO, progressive external ophthalmoplegia; r, reported; VLCAD, very long chain acyl-CoA dehydrogenase deficiency; VT, ventricular tachycardia; XL-EDMD, Emery-Dreifuss muscular dystrophy.
Modified from Finsterer J, Stollberger C, Keller H. Arrhythmia-related workup in hereditary myopathies. *J Electrocardiol*. 2012;45:376–384. Table 5.

Table 648.4 Functional Assessment of Muscle Weakness

LOCATION	SIGNS OR SYMPTOMS OF WEAKNESS
Facial	Inability to bury eyelashes, horizontal smile, inability to whistle
Ocular	Double vision, ptosis, disconjugate eye movements
Bulbar	Nasal speech, weak cry, nasal regurgitation of liquids, poor suck, difficulty swallowing, recurrent aspiration pneumonia, cough during meals
Neck	Poor head control
Trunk	Scoliosis, lumbar lordosis, protuberant abdomen, difficulty sitting up
Shoulder girdle	Difficulty lifting objects overhead, scapular winging
Forearm/hand	Inability to make a tight fist, finger or wrist drop, inability to prevent escape from hand grip
Pelvic girdle	Difficulty climbing stairs, waddling gait, Gower sign
Leg/foot	Foot drop, inability to walk on heels or toes
Respiratory	Use of accessory muscles

From Barohn RJ, Dimachkie MM, Jackson CR. A pattern recognition approach to the patient with a suspected myopathy. *Neurol Clin.* 2014;32(1):569–593. Box 12, p. 578.

TREATMENT OF CONGENITAL MYOPATHIES

Treatment remains largely supportive care for respiratory insufficiency and feeding and swallowing difficulties in particular, but genetic approaches specific for identified mutations are being investigated and may eventually reverse some of the most disabling clinical deficits. Administration of steroids, as well as other antiinflammatory agents, which is useful in many patients with Duchenne muscular dystrophy, is not effective for the congenital myopathies. There is optimism for efficacy of adenoviral vector-based gene therapy for some of the congenital myopathies, and X-linked *MTM1* gene–related myotubular myopathy is a good example where efficacy and safety is being evaluated in human clinical trials. Long-term outcomes for some congenital myopathies are noted in Figures 648.1 and 648.2.

Visit Elsevier eBooks+ at eBooks.Health.Elsevier.com for Bibliography.

648.1 Myotubular Myopathy (Centronuclear Myopathy)

Adnan Y. Manzur

The term **myotubular myopathy** is a misnomer because it implies maturational arrest of fetal muscle during the myotubular stage of development at 8-15 weeks of gestation. It was based on the morphologic appearance of myofibers as a row of central nuclei and mitochondria within a core of cytoplasm, with contractile myofibrils forming a cylinder around this core. These morphologically abnormal myofibers are not true fetal myotubes; hence, the more neutral and descriptive term ***centronuclear myopathy*** (CNM) is preferred.

PATHOGENESIS

The common pathogenesis involves loss of myotubularin protein, leading to structural and functional abnormalities in the organization of T-tubules and sarcoplasmic reticulum and defective excitation-contraction coupling. In true fetal myotubes, the peripheral migration of central nuclei and the core of internuclear mitochondria is initiated

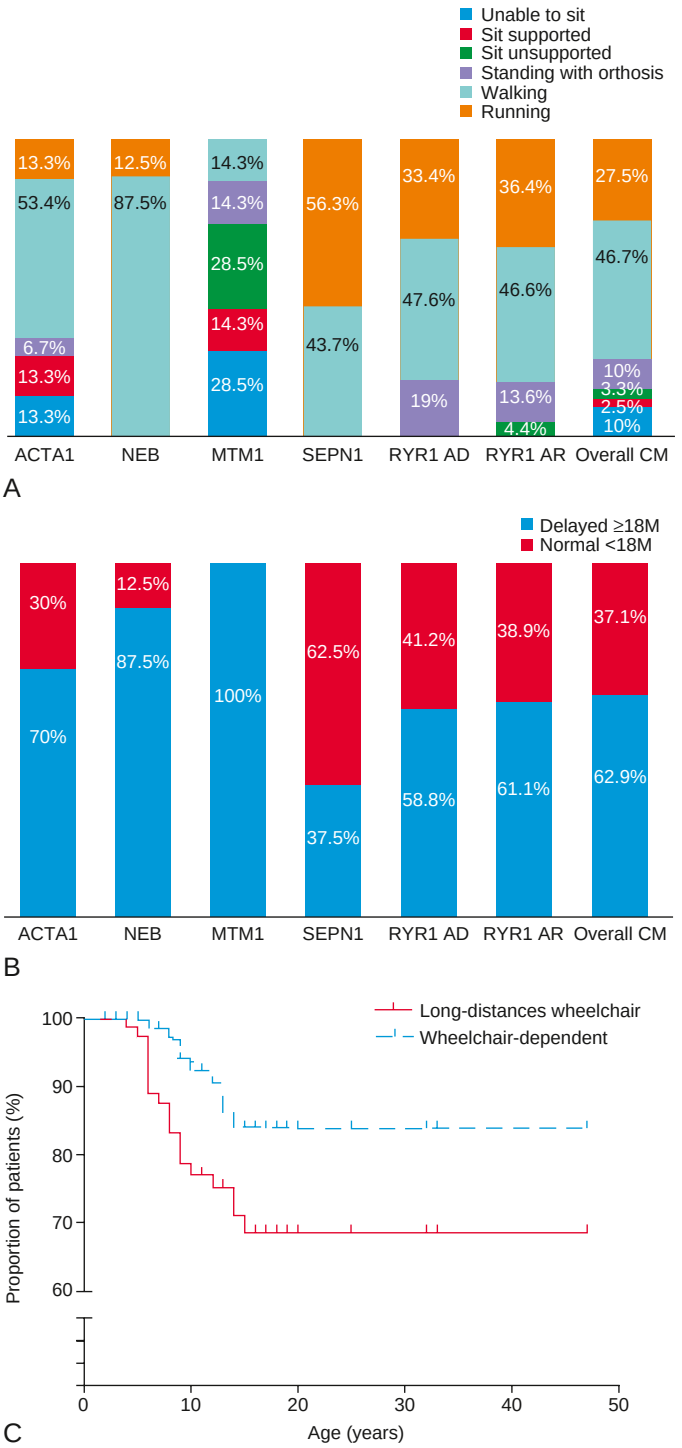

Fig. 648.1 Motor abilities. **A,** Maximal motor ability: all patients with *SEPN1* and *NEB* pathogenic variants walked independently, whereas motor ability was more variable with other genetic backgrounds. **B,** Walking age. The majority of ambulant patients walked late (39.3%) or at the upper limit of normal at 18 mo (23.6%). At last follow-up, 3.2% were younger than 18 mo. **C,** Kaplan-Meier curve showing wheelchair use in patients who achieved independent ambulation: 20 of 89 (22.5%) started with a manual wheelchair for long distances, whereas a further deterioration of motor performance was observed in 8 of 20, who became wheelchair-bound. *ACTA1*, Skeletal muscle α-actin; AD, autosomal dominant; AR, autosomal recessive; CM, congenital myopathy; *MTM1*, myotubularin; *NEB*, nebulin; *RYR1*, ryanodine receptor type 1; *SEPN1*, selenoprotein N. *(From Colombo I, Scoto M, Manzur AY, et al. Congenital myopathies. Neurology. 2015;84:28–35. Fig. 3.)*

by the regression of fetal vimentin intermediate filaments at 15-20 weeks of gestation that hold these structures in the center of the myotube, but this is not the mechanism of centronuclear myopathies, except perhaps in *neonatal myotonic dystrophy,* which does involve maturational arrest of some myofibers.

CLINICAL MANIFESTATIONS

Fetal movements can decrease in late gestation. Polyhydramnios is a common complication because of pharyngeal weakness of the fetus and inability to swallow amniotic fluid.

At birth, affected infants have a thin muscle mass involving axial, limb girdle, and distal muscles; severe generalized hypotonia; and diffuse weakness. Respiratory efforts may be ineffective, requiring ventilatory support. Gavage feeding may be required because of weakness of the muscles of sucking and deglutition. The testes are often undescended. Facial muscles may be weak, but infants *do not* have the characteristic facies of myotonic dystrophy. Ptosis may be a prominent feature. Ophthalmoplegia is observed in a few cases. The palate may be high. The tongue is thin, but fasciculations *are not* seen. Tendon stretch reflexes are weak or absent.

Myotubular myopathy is not associated with cardiomyopathy (mature cardiac muscle fibers normally have central nuclei), but one report describes complete atrioventricular block without cardiomyopathy in a patient with confirmed X-linked myotubular myopathy. Congenital anomalies of the central nervous system (CNS) or of other systems are not associated. A single patient with progressive dementia was reported that had a variant removing the start signal of exon 2. Patients with much milder symptoms or a much later age of onset with variants in the same gene are also known. Some of these are *manifesting* carriers.

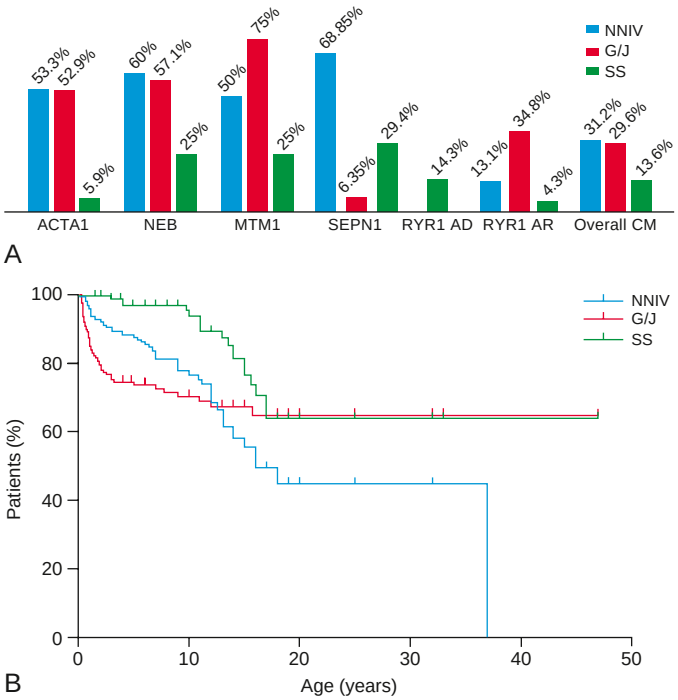

Fig. 648.2 Respiratory, feeding, and orthopedic procedures. **A,** Prevalence of NNIV, gastrostomy/jejunostomy (G/J), and scoliosis surgery (SS) according to genetic background: overall about one third of cases required NNIV and G/J insertion. Only a minority of cases required scoliosis surgery. **B,** Kaplan-Meier curves showing ventilation, G/J, and SS-free patients: NNIV was started at a mean age of 8.53 yr, whereas G/J was placed earlier, at a mean age of 2.74 yr, usually within the first year. SS was performed at a mean age of 12.0 yr. AD, Autosomal dominant; AR, autosomal recessive; CM, congenital myopathy. *(From Colombo I, Scoto M, Manzur AY, et al. Congenital myopathies. Neurology. 2015;84:28–35. Fig. 4.)*

LABORATORY FINDINGS

Serum levels of creatine kinase (CK) are normal. Electromyography does not show evidence of denervation; results are usually normal or show minimal nonspecific myopathic features in early infancy. Nerve conduction velocity may be slow but is usually normal. The electrocardiogram appears normal. Chest radiographs show no cardiomegaly; the ribs may be thin.

DIAGNOSIS

If the diagnosis is strongly suspected from the clinical presentation, especially if this diagnosis was confirmed in a sibling, genetic tests can be performed in the neonatal period. In most cases the diagnosis is not so evident, but the muscle biopsy findings are diagnostic at birth, even in premature infants. More than 90% of muscle fibers are small and have centrally placed, large vesicular nuclei in a single row. Spaces between nuclei are filled with sarcoplasm containing mitochondria. Histochemical stains for oxidative enzymatic activity and glycogen reveal a central distribution as in fetal myotubes. The cylinder of myofibrils shows mature histochemical differentiation with adenosine triphosphatase stains. The connective tissue of muscle spindles, blood vessels, intramuscular nerves, and motor end plates is mature. Ultrastructural features other than those that define the disease are also mature. Electron microscopy shows disorganized triads and focal loss of myofilaments. Vimentin and desmin show strong immunoreactivity in muscle fibers in congenital CNM and no demonstrable activity in normal-term neonatal muscle. Several myotubularins are present in circulating platelets and may prove to be a simple noninvasive screening test in patients suspected of having this disease. The molecular genetic marker in blood is available also for early prenatal diagnosis if suspicion is strong because of a family history. Prenatal diagnosis by amniocentesis is feasible in strongly suspected involved fetuses. Table 648.5 distinguishes CNM from other congenital myopathies.

GENETICS

At least five genes are involved in this disorder and account for approximately 80% of patients. These include variants in myotubularin (*MTM1* gene) with X-linked severe manifestations; dynamin 2

Table 648.5 Specific Congenital Myopathies: Distinguishing Clinical Features

MYOPATHY	NEONATAL HYPOTONIA AND WEAKNESS	SEVERE FORM WITH NEONATAL DEATH	FACIAL WEAKNESS	PTOSIS	EXTRAOCULAR MUSCULAR WEAKNESS
Central core disease	+	0	±	0	0
Nemaline myopathy	+	+	+	0	0
Myotubular myopathy (centronuclear myopathy)	+	+	+	+	+
Congenital fiber-type disproportion	+	±	±	0	+

+, Often a prominent feature; ±, variably a prominent feature; 0, not a prominent feature.
From Volpe JJ. *Neurology of the Newborn*, 5th ed. Philadelphia: Saunders; 2008: p 820.

(DNM2) with autosomal dominant or sporadic occurrence; amphiphysin 2 *(BIN1)* and titin *(TTN)* variants with autosomal recessive inheritance and ryanodine receptor 1 *(RYR1),* with autosomal recessive or sporadic occurrence.

X-linked recessive inheritance is the most common trait in this disease affecting males. The mothers of affected infants are clinically asymptomatic, but their muscle biopsy specimens show minor alterations. Genetic linkage on the X chromosome has been localized to the Xq28 site, a locus different from the Xp21 gene of Duchenne and Becker muscular dystrophies. A deletion in the responsible *MTM1* gene has been identified. It encodes a protein called myotubularin. This gene belongs to a family of similar genes encoding enzymatically active and inactive forms of phosphatidylinositol-3-phosphatases that form dimers. *MTM1*, dynamin-2, and amphiphysin all are localized to the T-tubule wall in triads. This crucial region is where the action potential releases a signal to the ryanodine receptor to release calcium. The pathogenesis is in the regulation of enzymatic activity and binding to other proteins induced by dimer interactions. Although only a single *MTM1* gene is involved, five distinct point variants and many different alleles, as well as large duplications, can produce the same clinical disease. Variants in the dynamin-2 protein result in an autosomal dominant form of CNM and may account for up to half of all patients with CNM, but these cases usually are mild and might not manifest clinically until adult life as diffuse, slowly progressive weakness and generalized muscular pseudohypertrophy.

Other rarer centronuclear myopathies are also known; some are autosomal recessive and affect both sexes and others are sporadic and of unknown genetic origin. The recessive forms are sometimes divided into an early-onset form with or without ophthalmoplegia and a late-onset form without ophthalmoplegia.

TREATMENT

Only supportive and palliative treatment is presently available. Progressive scoliosis may be treated by long posterior fusion. Genetic and neuropathologic studies of X-linked centronuclear (myotubular) myopathy have led to effective gene therapy in mice and in dogs, so that the animals are more ambulatory and have improved weakness; the therapy results in long-term expression of the myotubularin transgene with normal muscular performance and neurologic function in the absence of muscle pathology. Human trials of gene therapy for X-linked CNM are in progress.

PROGNOSIS

Approximately 75% of severely affected neonates with the X-linked disease die within the first few weeks or months of life. Survivors experience a slowly progressive course and have major physical handicaps, rarely walk, remain severely hypotonic and weak, and mostly ventilator dependent. Late-onset and especially autosomal dominant forms have a much better prognosis, often with mild static weakness. Treatment by gene therapy may dramatically change this prognosis.

Visit Elsevier eBooks+ at eBooks.Health.Elsevier.com for Bibliography.

648.2 Congenital Muscle Fiber–Type Disproportion

Adnan Y. Manzur

Congenital muscle fiber–type disproportion (CMFTD) occurs as an isolated congenital myopathy but also develops in association with various unrelated disorders, which include nemaline rod disease and Krabbe disease (globoid cell leukodystrophy), early in the course before the expression of the neuropathy; congenital muscular dystrophy (CMD) with merosin deficiency (occasionally); cerebellar hypoplasia and certain other brain malformations; fetal alcohol syndrome; some glycogenoses; multiple sulfatase deficiency; Lowe syndrome; rigid spine myopathy; and some infantile cases of myotonic muscular dystrophy. *CMFTD is, therefore, a syndrome.* Several specific genetic variants are confirmed causing the CMFTD histologic appearance and these include *TPM2, TPM3, MYH7, RYR1,* skeletal muscle α-actin gene *(ACTA1),* and *LMNA.*

PATHOGENESIS

The association of CMFTD with *cerebellar hypoplasia* suggests that the pathogenesis may be an abnormal suprasegmental influence on the developing motor unit during the stage of histochemical differentiation of muscle between 20 and 28 weeks of gestation. Muscle fiber types and growth are determined by innervation and are mutable even in adults. Although CMFTD does not actually correspond with any normal stage of development, it appears to be an embryologic disturbance of fiber-type differentiation and growth.

CLINICAL MANIFESTATIONS

As an isolated condition not associated with other diseases, CMFTD is usually a *nonprogressive* disorder present at birth. Patients have generalized hypotonia and weakness, but the weakness is usually not severe. *Contractures* are present at birth in 25% of patients. Poor head control and developmental delay for gross motor skills are common in infancy. Walking is usually delayed until 18-24 months but is eventually achieved. Because of the hypotonia, subluxation of the hips can occur. Muscle bulk is reduced. The muscle wasting and hypotonia are proportionately greater than the weakness, and the child may be stronger than expected during examination. Cardiomyopathy is a rare complication. Respiratory weakness usually is mild but can be demonstrated in 30% of neonates and young infants. Dysphagia is infrequent except if CMFTD is secondary to myotonic dystrophy, nemaline myopathy, or a systemic metabolic disease with additional encephalopathy.

The facies of children with CMFTD often raise suspicion, especially if the child is referred for assessment of developmental delay and hypotonia. The head is dolichocephalic, and facial weakness is present. The palate is usually high arched. Thin muscles of the trunk and extremities give a thin, wasted appearance. The phenotype is very similar to that of nemaline myopathy, which also includes CMFTD as part of the pathologic phenotype. Patients do not complain of myalgias. The clinical course generally is nonprogressive or only slowly progressive unless it is associated with other congenital myopathies.

LABORATORY FINDINGS

The serum CK, electrocardiogram, electromyography studies, and nerve conduction velocity results are normal in isolated CMFTD. If other diseases are associated, laboratory investigation of those conditions discloses the specific features. Specific genetic studies are indicated if there is a family history.

DIAGNOSIS

CMFTD is diagnosed by muscle biopsy that shows a disproportion in the size and relative ratios of the histochemical fiber types: type I fibers are uniformly small, and type II fibers are hypertrophic; type I fibers are more numerous than type II fibers. Degeneration of myofibers and other primary myopathic features are absent. The biopsy is diagnostic at birth. Table 648.5 lists the features that distinguish CMFTD from other congenital myopathies. Selective atrophy or even hypoplasia of type II myofibers is not CMFTD, though it has sometimes been labeled as *reverse CMFTD.*

GENETICS

Many cases of simple CMFTD are sporadic, although an autosomal recessive inheritance is well documented in some families and an autosomal dominant trait is suspected in others. The genetic basis is heterogeneous in hereditary forms; a pathogenic variant in the insulin receptor gene at 19p13.2 is reported. Translocation t(10;17) was seen in one family. X-linked transmission with linkage to Xp23.12-p11.4 and Xq13.1-q22.1 is also described. *LMNA* gene variants produce familial CMFTD, clearly a germline genetic variant with mendelian autosomal transmission. In three unrelated families with CMFTD, a heterozygous missense variant of the skeletal muscle α-actin gene *(ACTA1)* was demonstrated, but this genetic defect represents a minority; variants in

TPM3 or *TPM2* are the more common genetic findings. Large duplications in the *TPM3* gene can cause CMFTD. *MYH7* de novo gene variants lead to exon skipping. CMFTD may occur in RYR1 disease without obvious cores on muscle biopsy. In CMFTD associated with cerebellar hypoplasia, the epigenetic effect is on cerebellar development and the muscular expression is secondary.

TREATMENT

No drug therapy is available. Physiotherapy may be helpful for some patients in strengthening muscles that do not receive sufficient exercise in daily activities. Mild congenital contractures often respond well to gentle range-of-motion exercises and rarely require plaster casting or surgery. The relative rarity of early-onset congenital myopathies such as CMFTD and the diversity of the genotype make focused gene therapies difficult, but the identification of specific molecular mechanisms and novel gene editing strategies are a basis for future therapy.

Visit Elsevier eBooks+ at eBooks.Health.Elsevier.com for Bibliography.

648.3 Nemaline Rod Myopathy

Adnan Y. Manzur

Nemaline rods are rod-shaped, inclusion-like abnormal structures within muscle fibers. They are difficult to demonstrate histologically with conventional hematoxylin and eosin stain but are easily seen with special stains. They are not foreign inclusion bodies but rather consist of excessive Z-band material with a similar ultrastructure (Fig. 648.3). Chemically, the rods are composed of actin, α-actinin, tropomyosin-3, and the protein nebulin. Nemaline rod formation may be an unusual reaction of muscle fibers to injury because these rod structures have rarely been found in other diseases. They are most abundant in the congenital myopathy known as *nemaline rod disease.* Most rods are within the myofibrils, but intranuclear rods are occasionally demonstrated by electron microscopy. Intranuclear rods occur mainly in neonates with severe weakness. Fourteen causative genes have been identified, and *ACTA1* pathologic variants account for more than half of the severe cases. Nemaline myopathy caused by an *ACTA1* gene variant is one of a spectrum of *actinopathies*.

Pathologic variants in *TPM2* can cause a congenital myopathy *related* to nemaline rod myopathy, designated cap myopathy, in which accumulations of distorted myofilaments are focally present on the periphery of fibers. They may coexist with myofibrillar nemaline rods. Somatic mosaicism is demonstrated in *TPM2*-related nemaline myopathy with cap structures.

Gene variants in muscle-specific Kelch BTB genes *(KBTBD13, KLHL40, KLHL41)* cause nemaline myopathy with potential pathologic signatures on muscle biopsy. Autosomal dominant *KBTBD13* gene variants are identified in families with nemaline myopathy and cores. Autosomal recessive *KLHL40* and *KLHL41* variants are described in severe early onset nemaline myopathy with fetal akinesia phenotypes and congenital fractures (see Chapter 648.10).

CLINICAL MANIFESTATIONS

Prenatal, neonatal, infantile, juvenile, and adult-onset forms of the disease are known. There is a highly variable degree of muscle weakness, ranging from presentations within the *fetal akinesia* spectrum to only mildly affected adults. All defining features of congenital myopathies can occur in different contexts; although there is not a clear genotype-phenotype correlation, there may be clinical clues for specific gene variants. Prenatal and neonatal forms are severe and usually fatal because of respiratory failure since birth. In the infantile form, generalized hypotonia and weakness, which can include bulbar-innervated and respiratory muscles, and a very thin muscle mass are characteristic (Fig. 648.4). The head is dolichocephalic, and the palate high arched or even cleft. Muscles of the jaw may be too weak to hold it closed (Fig. 648.5). Decreased fetal movements are reported by the mother, and neonates suffer from hypoxia and dysphagia; arthrogryposis may be present (see Chapter 648.10). Infants with severe neonatal and infantile nemaline myopathy have facies and a phenotype that are nearly indistinguishable from those of *neonatal myotonic dystrophy,* but their mothers have normal facies.

In *NEB*-related nemaline myopathy, which is the most common form, patients usually present in infancy or childhood, and there is a disproportional axial and bulbar involvement compared with limb weakness. In spite of preserved ambulation, scoliosis and respiratory involvement are universal. Distal muscle involvement may be a presenting feature in some patients. *ACTA1*-related nemaline myopathy is typically severe, and additional phenotypes include (1) progressive scapuloperoneal and distal weakness in a large single family with autosomal dominant inheritance, demonstrating muscle atrophy without nemaline rods; (2) a severe congenital presentation with myofibrillar features on muscle biopsy; (3) limb-girdle muscular dystrophy (LGMD) phenotype; (4) autosomal recessive CMD with a rigid spine;



Fig. 648.3 Nemaline rods. Electron micrograph of the muscle from a patient shown in Figure 648.5. Nemaline rods (nr) are seen within many myofibrils. They are identical in composition to the normal Z bands (z) (×6,000).

Fig. 648.4 Back of a 13-yr-old female with the juvenile form of nemaline rod disease. The paraspinal muscles are very thin, and winging of the scapulae is evident. The muscle mass of the extremities is also greatly reduced proximally and distally.

Fig. 648.5 Infantile form of nemaline rod disease in a 6-yr-old male. Facial weakness and generalized muscle wasting are severe. The head is dolichocephalic. The mouth is usually open because the masseters are too weak to lift the mandible against gravity for more than a few seconds.

and (5) zebra body myopathy. Cardiomyopathy is not a feature of *NEB*-related nemaline myopathy; however, it has been rarely reported in patients with *ACTA1* gene variants.

The *juvenile form* is the mildest and is not associated with respiratory failure, but the phenotype, including facial involvement, is similar. *Adult-onset* presentations are in the form of slowly progressive proximal weakness with axial involvement, and although not symptomatic in childhood and adolescence, these patients retrospectively report difficulties with sportive activities in childhood.

LABORATORY FINDINGS

The serum CK level is normal or mildly elevated. The muscle biopsy is diagnostic. In addition to the characteristic nemaline rods, it also shows CMFTD or, at least, fiber-type I predominance. In some patients, uniform type I fibers are seen with few or no type II fibers. Focal myofibrillar degeneration and an increase in lysosomal enzymes have been found in a few severe cases associated with progressive symptoms. Intranuclear nemaline rods, demonstrated by electron microscopy, are correlated with the most severe neonatal manifestations. Potential pathologic hallmarks of *KLHL40* gene variants are miliary bodies and *LMOD3* gene variants; the latter are a fringe of thin filaments radiating from the nemaline bodies and paired nemaline bodies interconnected by thin filaments. Because nemaline bodies can occur in other myopathies, their presence in the muscle biopsy is **not** pathognomonic in the absence of the supportive clinical manifestations. **Sporadic late-onset nemaline myopathy (SLONM)** may be associated with monoclonal gammopathy, HIV infection, and various autoimmune disorders, and should be differentiated from genetic causes because it is a potentially treatable condition.

GENETICS

Autosomal dominant, autosomal recessive, and X-linked dominant forms in females can occur. Nemaline myopathy can be caused by gene variants in at least 10 genes, including *ACTA1* (skeletal muscle α-actin), *NEB* (nebulin), *TPM3* (slow muscle αα-tropomyosin), *TPM2* (ββ-tropomyosin), *CFL2* (skeletal muscle cofilin), *TNNT1* (slow muscle troponin-T), *LMOD3* (leiomodin 3), *KBTBD13* (Kelch-repeat and BTB domain containing 13), *KLHL40,* and *KLHL41* (Kelch-like 40 and 41). All of the genes implicated in nemaline myopathy encode proteins constituting the thin filaments of myofibrils or regulate thin-filament organization and stability. Overall, recessive gene variants in *NEB* and de novo dominant gene variants in *ACTA1* are most common, and represent approximately 50% and 25% of cases, respectively. *TNNT1* nemaline myopathy known to be specific for Old Order Amish populations is also identified in other populations. Gene variants in muscle specific Kelch proteins are increasingly recognized. *KBTBD13* nemaline myopathy is characterized by autosomal dominant inheritance and phenotypic variability. *KLHL40* and *KLHL41* nemaline myopathies represent the severest end of the spectrum, with in utero presentations, fetal akinesia, arthrogryposis, congenital fractures, and specific signatures on muscle biopsy samples (see Chapter 648.10). Kelch-BTB proteins act as E3-ubiquitin ligases and mediate protein turnover. In animal and cell culture studies, *KLHL40* was shown to stabilize leiomodin-3 (Lmod3) and the absence of KLHL40 was shown to reduce Lmod3 and Neb, which was further confirmed in muscle biopsy samples of some patients with *KLHL40*. This led to identification of pathologic variants in the gene encoding *leiomodin-3*, a protein especially present at the pointed end of muscle thin filaments. *LMOD3* nemaline myopathy is characterized by a severe phenotype with, again, potential hallmarks on muscle biopsy.

TREATMENT AND PROGNOSIS

There is no cure, and management is mainly supportive and symptomatic. Survivors are usually wheelchair dependent and unable to overcome gravity. Both proximal and distal muscles are involved. Congenital *arthrogryposis* and *fractures* can occur and predict a poor prognosis. Gastrostomy may be needed for chronic dysphagia. Special attention to respiratory function in patients presenting with scoliosis and axial involvement is important to recognize early signs and symptoms of **nocturnal hypoventilation syndrome.** In the juvenile form, patients are ambulatory and are able to perform most tasks of daily living. Weakness is not usually progressive, but some patients have more difficulty over time or enter a phase of progressive weakness. Cardiomyopathy is an uncommon complication. Death usually results from respiratory insufficiency, with or without superimposed pneumonia.

Based on preclinical data in experimental models of *ACTA1*-related nemaline myopathy, a variety of pharmacologic compounds and supplements, including L-tyrosine, have been tested in five patients with nemaline myopathy; a beneficial effect has been suggested, with reduced fatigue and improvement of drooling. Treatments targeting the neuromuscular junction are another option; a single patient with *KLHL40*-related nemaline myopathy had a sustained beneficial response to the acetylcholinesterase inhibitor pyridostigmine, a result that corresponds to experiences in other congenital myopathies, mainly centronuclear myopathies. Drugs targeting thin filaments and their interactions, myostatin inhibitors to promote muscle growth, and cardiac α-actin upregulation in *ACTA1*-related nemaline myopathy are being investigated in animal models.

Despite advances in our understanding of pathophysiologic concepts and efforts for therapy, genetic counseling and prenatal diagnosis should be considered in families with an index patient and a precise genetic diagnosis.

Visit Elsevier eBooks+ at eBooks.Health.Elsevier.com for Bibliography.

648.4 Core Myopathies

Adnan Y. Manzur

The core myopathies are the most common form of congenital myopathy, consisting of *central core diseases* (CCDs), *multiminicore disease* (MmD), and *atypical cores.* Cores are regions within muscle fibers in which only amorphous, granular cytoplasm is found, with an absence of myofibrils and organelles. Cores are devoid of mitochondria that contain disordered sarcomeric proteins. Histochemical stains show a lack of enzymatic activities of all types within these cores, as well as an absence of contractile proteins (actin and myosin) that form the thin

and thick myofilaments. Longitudinally extensive areas in the central area of myofiber devoid of oxidative enzyme activity represent central cores, and multiple smaller areas of reduced activity affecting shorter segments of the myofiber are characteristic of multicores and minicores. On electron microscopy, cores are characterized by an abnormal sarcomeric structure, including Z-band streaming, complete myofibrillary disorganization, and accumulation of Z-band material. Although variants of central cores, called minicores and multicores, are described in some families, they are believed to represent the same basic disease process. Pathologic features may evolve, with changes and abnormalities becoming more evident over time.

CLINICAL MANIFESTATIONS

The phenotypical spectrum of core myopathies ranges from mild to severe. Hypotonia, joint laxity, motor developmental delay, hip girdle or axial muscle weakness, orthopedic complications such as recurrent shoulder or patellar dislocations, congenital hip dislocation or dysplasia, or foot deformities may be presenting features. In older children, CCD is an important differential diagnosis of progressive thoracolumbar scoliosis. There is also an intrafamilial variability, with some individuals presenting only with muscle stiffness, exertional myalgia, or rhabdomyolysis.

Genetic resolution of core myopathies has led to gene variant-specific clinical presentations and phenotype-genotype correlations.

Central Core Disease

Central core disease (CCD) is most commonly associated with *RYR1* gene variants, which are described as the predominant genetic causes of nondystrophic neuromuscular disorders. These disorders range from dominantly inherited CCD, subgroups of recessively inherited MmD, and CNM (see Chapter 648.1), and CFTD (see Chapter 648.2) to **malignant hyperthermia susceptibility (MHS)** trait. MHS is a dominantly inherited allelic trait, described as a pharmacogenetic predisposition to a severe and potentially life-threatening reaction in response to halogenated anesthetic agents and depolarizing muscle relaxants. MHS is suspected in an individual with congenital myopathy when (1) there is a positive family history of MHS, (2) there have been previous difficulties with anesthesia, and (3) the patient has a documented *RYR1* gene variant.

Dominantly inherited *RYR1*-related CCD is characterized by mild to moderate muscle weakness presenting from infancy to childhood (Fig. 648.6). The clinical spectrum ranges from fetal akinesia deformation sequence to milder adult forms. The distribution of weakness is typically proximal, with prominent hip girdle and axial muscle involvement. Congenital hip dislocation, scoliosis, and generalized joint laxity are common. In contrast to the recessive forms with a more severe clinical phenotype, there is no extraocular muscle involvement. Bulbar, respiratory, and cardiac involvement is uncommon. Myalgia may be prominent. Except for patients with a severe neonatal onset, most patients with CCD achieve independent ambulation. CCD tends to be stable over long periods, with a possible slowly progressive course in adulthood. *RYR1*-related MHS is allelic to CCD, and some patients with CCD may also be malignant hyperthermia susceptible. Figure 648.7 shows a family with a recessive *RYR1* gene variant in the index patient and his asymptomatic father who is carrying a dominant *RYR1*-MHS gene. Characteristics and phenotypes due to *RYR1* gene variants are summarized in Table 648.6.

Fig. 648.6 Central core disease. Photograph of twins, one of whom has the disease. Note the weakness of the proximal upper extremities. *(From Cohen ME, Duffner PK, Heffner R. Central core disease in one of identical twins. J Neurol Neurosurg Psychiatry. 1978;41:659–663.)*

MHS-related *RYR1* gene variants have also been described as a common cause of induced and episodic phenotypes such as *exertional rhabdomyolysis,* which account for up to 30% of presentations in otherwise healthy individuals throughout life (see Chapter 647). Late-onset presentations in adulthood highlight the relevance of the congenital myopathies for adult neuromuscular practice. A predisposing genetic background should be considered if episodes are familial, recurrent, out of context to the exercise performed, or preceded by other symptoms, such as cramps, myalgia, and weakness. *RYR1*-related rhabdomyolysis may occur up to 72 hours after exercise and may mimic viral myositis; in contrast to other metabolic myopathies, fasting *does not* appear to be a triggering factor.

Due to expression of ryanodine receptors other than striated skeletal muscle, *nonskeletal muscle presentations of RYR1-related myopathies* are recognized. *Mild bleeding abnormalities* are described in patients with malignant hyperthermia carrying gain-of-function *RYR1* gene variants by altering vascular smooth muscle cell function. A bleeding defect in the animal model and one patient was reversed by treatment with the RyR1 antagonist dantrolene, suggesting a therapeutic role for *RYR1*-related bleeding disorders and, potentially, other bleeding disorders, as well. Another observed phenotype is severe CNS involvement in an adolescent suffering a malignant hyperthermia episode. Striking similarities in terms of cerebellar involvement seen in this patient and *heat stroke victims* indicated a potential link between *RYR1*-related exertional rhabdomyolysis and neuroleptic malignant syndrome. Some of the psychopharmacologic drugs, such as olanzapine, should be considered as triggering agents in patients with *RYR1* gene variants and exertional rhabdomyolysis. An emerging question is *cardiac involvement* in *RYR1*-related myopathies. Sudden unexplained death, dilated cardiomyopathy presumed to be due to a viral infection, bicuspid aortic valve, and sinus bradycardia are described; cardiologic assessment should be considered to define a cardiac phenotype associated with *RYR1*-related myopathies.

Multiminicore Disease

MmD is typically recessively inherited, and the clinical phenotype depends on the underlying genetic background. Presentations may vary and overlap between the most common and recognizable classic form, a severe neonatal form, a form with external ophthalmoplegia, and a moderate form with hand involvement. The *classic phenotype* due to recessive *SEPN1* gene variants can be summarized as axial weakness, early spinal rigidity, scoliosis, and respiratory impairment (Fig. 648.8). The onset is early, with predominant involvement of the neck muscles. Infants unable to hold up their heads, despite being able to walk independently, can present as having an *isolated neck myopathy* or *dropped-head syndrome.* A myopathic face, high-arched or cleft palate, high-pitched voice, feeding difficulties, and failure to thrive can be accompanying features. These patients may look very similar to each other, with an asthenic and atrophic muscle phenotype and growth retardation, and are mainly investigated and referred with a preliminary diagnosis of celiac disease. The proximal shoulder girdle muscles and inner thigh are affected more. Axial weakness is replaced with contractures of the spinal extensor muscles in time, leading to a *rigid spine deformity.* Usually by the second decade, there is a progressive scoliosis, lateral deviation of the trunk, and respiratory impairment that is overall in disproportion to the skeletal muscle weakness. MmD should be considered in the differential diagnosis of diseases presenting with

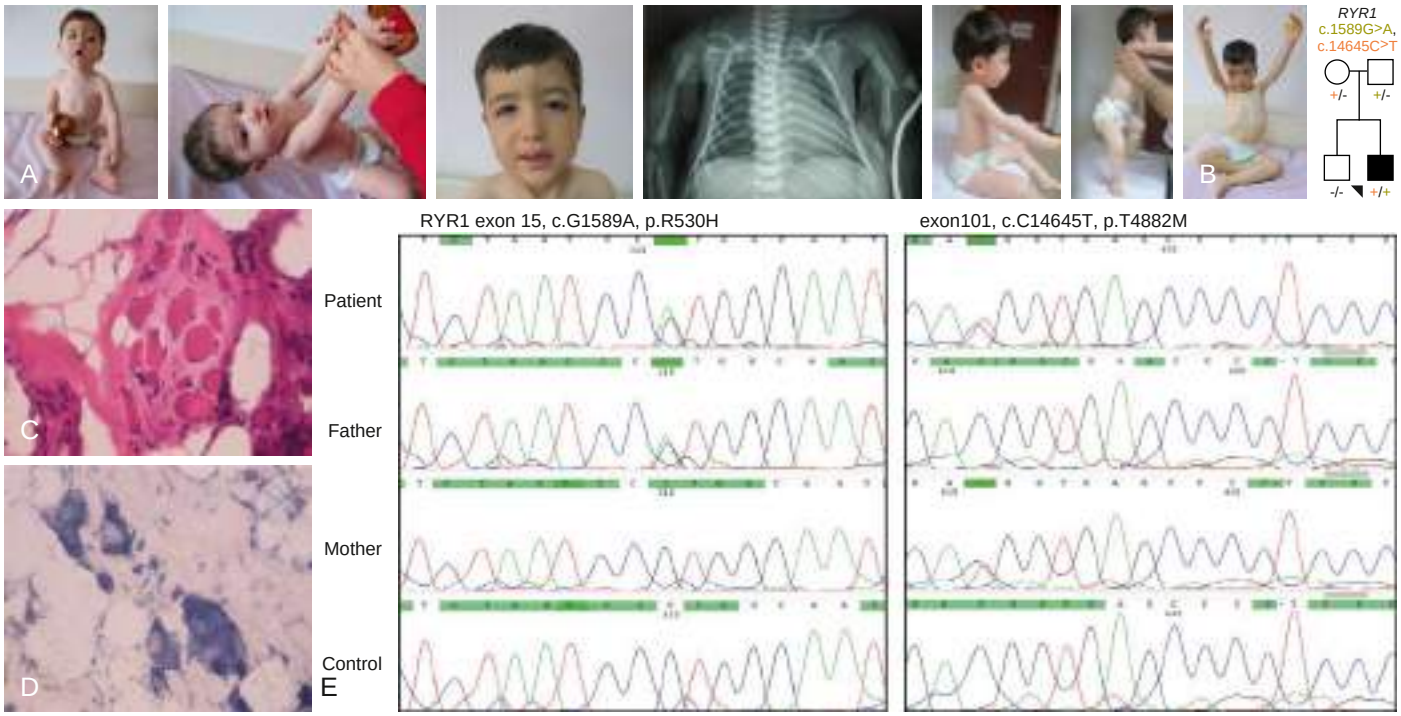

Fig. 648.7 Index patient presenting with developmental delay and hypotonia at the age of 19 mo. Note the bilateral humerus fractures at birth. He had a previous diagnosis of osteogenesis imperfecta. He has facial weakness, a myopathic face, and involvement of the neck flexor muscles with head-lag; his maximum motor capacity is to sit without support. **A,** He is unable to stand on his feet. **B,** At 4 yr of age, the patient is unable to walk. Muscle biopsy at the age of 19 mo demonstrating myopathic changes with increased fatty and fibrous tissue infiltration (HE) **(C)** and central cores (NADH) **(D).** The index patient is carrying a recessive *RYR1* gene variant, and his father is carrying a dominant *RYR1*-malignant hyperthermia susceptibility variant **(E).**

Table 648.6 Characteristics and Clinical Phenotypes Related to Ryanodine 1 *(RYR1)* Gene Variant–Related Central Core Disease

EARLY-ONSET *RYR1*-RELATED PHENOTYPES	LATE-ONSET *RYR1*-RELATED PHENOTYPES
Dominant gene variants typically present with congenital hypotonia, weakness, and hip dislocation at birth. Motor milestones are delayed; independent ambulation is eventually achieved. Weakness tends to involve hip girdle and quadriceps with sparing of facial and extraocular muscles.	Malignant hyperthermia susceptibility (MHS)
Recessive gene variants have a tendency of earlier and more severe presentation compared with most patients with dominant gene variants; however, they are also associated with a wide range of clinical phenotypes and pathologic features.	King-Denborough syndrome
Recessive phenotypes can be further grouped as clinical groups with and without ophthalmoparesis.	Exertional rhabdomyolysis
Dominant and recessive gene variants with a severe neonatal presentation leading to death are described.	Periodic paralysis
RYR1-related centronuclear myopathy (CNM) presents with a variable degree of external ophthalmoparesis, frequently associated with facial weakness.	Late-onset axial myopathy
Histopathologic features may resemble congenital fiber-type disproportion (CFTD) congenital muscular dystrophy (CMD).	

early neuromuscular chronic respiratory failure (i.e., chronic-onset respiratory muscle weakness while the patient is still ambulant). Respiratory involvement may lead to secondary cardiac failure. Ophthalmoplegia is not a feature of this classic form, but it has exceptionally been recognized in the last stages of disease in patients with a severe course.

MmD phenotypes due to *recessive RYR1 pathologic variants* are characterized by a milder respiratory but prominent bulbar impairment compared with those with the classic form. External ophthalmoplegia, recurrent episodes of periodic paralysis, distal weakness and wasting mainly affecting the hands, arthrogryposis, cryptorchidism, and dysmorphic features have also been described in the *RYR1*-related MmD spectrum. Hypertrophic cardiomyopathy associated with short-chain acyl-coenzyme A dehydrogenase deficiency, and primary cardiomyopathies due to gene variants in myosin heavy chain 7 *(MYH7)* or titin *(TTN)* genes, have been described in MmD. Although not reported in *SEPN1*-related MmD, there is a potential risk for MHS in *RYR1*-related MmD.

LABORATORY FINDINGS

The diagnosis of core myopathies may be challenging and requires a combination of a detailed clinical (phenotype recognition) and laboratory (histopathologic, muscle imaging, genetic) evaluation and interpretation. The serum CK value is normal, except during crises of malignant hyperthermia, which can result in rhabdomyolysis or

Fig. 648.8 Patients with a typical *SEPN1*-related multiminicore disease (MmD) phenotype at the ages of 10 yr (**A**), 12 yr (**B**), 7 yr (**C**), and 8 yr (**D**). Note asthenic, atrophic phenotype, with rigid spine syndrome, weakness in neck flexor muscles, and varying degrees of scoliosis.

extensive acute myofiber necrosis (see Chapter 651.2). Muscle imaging (ultrasonography and MRI) may serve as a noninvasive tool to describe characteristic selective muscle involvement. Recognition of these patterns may help to distinguish typical dominantly inherited CCD forms and *SEPN1*-related MmD from a variety of neuromuscular diseases. The diagnosis of a core myopathy based on pathologic findings may be straightforward; however, the typical picture may evolve over time, with early muscle biopsies showing almost no or minimal changes. Core formation is a nonspecific finding and may be observed in the denervation process, tenotomy, metabolic conditions, or even healthy probands after eccentric exercise. *Moth-eaten fibers* described in muscular dystrophies may resemble minicores in MmD. The presence of cores without associated weakness, as reported in some MHS individuals, is not sufficient to give a diagnosis of core myopathy. Cores and other structural abnormalities specific for other structural myopathies, such as nemaline rods or centralized nuclei, can coexist. Muscular dystrophies due to lamin A/C *(LMNA)* gene variants, collagen VI–related myopathies, metabolic myopathies (Pompe disease), myofibrillary myopathies in patients with cardiomyopathy, and congenital myasthenic syndromes may mimic core myopathies based on clinical and/or pathologic features and should be considered in the differential diagnosis.

Due to the extreme clinical and pathologic overlaps among the early-onset muscle diseases, there has been a shift in the traditional diagnostic pathways. Taking all of these issues into account, the diagnosis of core myopathies, like other congenital myopathies, requires a combined effort on the part of the clinician, pathologist, and molecular geneticist.

GENETICS

Central core myopathies are transmitted as either an autosomal dominant or autosomal recessive trait, or de novo dominant gene variants. They are caused by the same abnormal gene at the 19q13.1 locus. This gene programs the ryanodine receptor *(RYR1),* a tetrameric receptor that contains a non–voltage-gated calcium channel; it is prevalent in the sarcoplasmic reticulum and especially at the junction of the T-tubule with the cisternae of the sarcoplasmic reticulum. It contains the channel by which calcium is released among the myofilaments. Gene variants in the *RYR1* gene are also the cause of **malignant hyperthermia (MH).** In CNMs, autosomal recessive gene variants of *RYR1* are known to be a frequent cause, and a patient with a dominant de novo gene variant of *RYR1* was also described (see Chapter 651.2). Patients presenting with congenital myopathy, ptosis, external ophthalmoplegia, and prominent internal nuclei in addition to other structural findings are highly likely candidates for *RYR1* gene variants. Recessive core disease may be associated with tissue-specific silencing of the normal allele, an epigenetic phenomenon. Certain missense gene variants can be associated with autosomal dominant MH, and management of the asymptomatic carrier of the MHS allele should be treated accordingly.

Gene variants in the slow β-myosin gene *(MYH7),* autosomal recessive titin *(TTN)* gene variants, and recessive gene variants of the satellite cell gene *(MEGF10)* are other identified causes of core myopathy. The latter is characterized by *early-onset myopathy, areflexia, respiratory distress, and dysphagia* (**EMARRD**). A single patient has been described who presented with severe congenital myopathy and ophthalmoplegia and recessive variants in the gene encoding the alpha-1 subunit of the dihydropyridine receptor *(CACNA1S),* a gene in which dominant gene variants are known to be associated with **hypokalemic periodic paralysis** and **MH.** Functional studies are required to link *CACNA1S* gene variants to congenital myopathies.

MmD is caused mainly by recessive gene variants in *SEPN1* and *RYR1*. Selenoprotein N is an integral membrane protein localized in the endoplasmic reticulum, which is expressed in several tissues, including the skeletal muscle, heart, lung, and placenta. It is also highly expressed in the diaphragm; this could explain the finding of early restrictive respiratory insufficiency in patients. *SEPN1* gene variants also cause CFTD (see Chapter 648.2) and rigid spine muscular dystrophy (see Chapter 649).

TREATMENT AND PROGNOSIS

The treatment for core myopathies is symptomatic and should be, in general, parallel to consensus standard care guidelines in congenital myopathies. Orthopedic complications, rehabilitation, and feeding problems should be managed accordingly. Scoliosis and other skeletal deformities require special attention because they may develop quickly and progress in severity disproportionately to the limb weakness. Compared with other congenital myopathies, there are a higher number of treatment failures in congenital hip dislocation and dysplasia in CCD.

CCD is consistently associated with **MH,** which can precede the diagnosis of CCD. All patients and asymptomatic carriers should be counseled in terms of a potentially fatal adverse reaction to volatile anesthetics and muscle relaxants. Preoperative **anesthetic consultation** in patients known to be subject to general anesthesia should be considered. **Wearing a medical alert bracelet** should be advised in terms of any emergency. Treatment of MH requires dantrolene and additional supportive care measures. Prophylactic dantrolene is not recommended before anesthesia even in cases where MHS has been established.

There may be an insidious onset of respiratory muscle involvement, particularly in patients with MmD and *SEPN1* gene variants. Patients may be symptomatic after an intercurrent illness or anesthesia or even sedation at the time of a muscle biopsy procedure. Multidisciplinary care requires input from pulmonologists. Signs and symptoms of **sleep-disordered breathing, such as nocturnal hypoventilation syndrome,** should be questioned. Respiratory function tests in sitting and supine positions and polysomnography are necessary to introduce noninvasive positive-pressure ventilation in a timely manner. Patients with severe early-onset disease may require invasive mechanical ventilation. Cardiac complications are uncommon in CCD, but baseline electrocardiography and echocardiography studies are appropriate in most cases. Secondary right ventricular dysfunction and cardiac failure may complicate the situation in patients with respiratory impairment.

A subjective improvement in muscle strength and functional test results has been reported in patients with CCD who are taking β_2-agonists (salbutamol, albuterol). Current and future therapeutic approaches include (1) modification of *RYR1* function, (2) correction of associated oxidative abnormalities, (3) use of pharmacologic compounds enhancing muscle contractility and/or neuromuscular transmission, and (4) correction of a specific gene defect. N-acetylcysteine (NAC), as an antioxidant, may serve as a potential treatment option for *RYR1*- and *SEPN1*-related myopathies, and the first clinical trials in humans are currently under way.

Visit Elsevier eBooks+ at eBooks.Health.Elsevier.com for Bibliography.

648.5 Myofibrillar Myopathies

Adnan Y. Manzur

Myofibrillar myopathies (MFMs) are rare, inherited or sporadic, *progressive* neuromuscular disorders, diagnosed based on distinct morphologic features. There is a wide range of clinical and genetic heterogeneity within MFMs, which are also subgrouped as **protein aggregate myopathies**. A variety of phenotypic presentations are described due to cardiac, skeletal, and smooth muscle involvement. Core histopathologic findings can be defined as focal disintegration of myofibrils predominantly at the Z-disc level, accumulation of myofibrillar degradation products, and ectopic expression of a large number of proteins. Myofibril dissolution begins at the Z-disc, and some sarcomeres of myofibers have disorganization or dissolution of myofibrils adjacent to other areas of normal sarcomeres within the same fiber. Abnormal protein aggregations, intense congophilia of many hyaline structures, internalized nuclei, fiber splitting, vacuoles, *corelike* lesions, a mild to severe increase in endomysial collagen, and increased fiber size variability ranging from very hypotrophic to hypertrophic fibers are among the common features. These zones are associated with streaming of the Z-discs, and there is an expression of a large number of proteins in the aggregates, including dystrophin, sarcoglycans, ubiquitin, desmin intermediate filaments, αB-crystallin, and several Z-disc proteins such as myotilin and filamin-C. *Mitochondrial dysfunction* in the form of abnormal mitochondrial distribution is a frequent finding. Although a detailed immunocytochemical and ultrastructural study of the muscle biopsy tissue is required for the diagnosis and can provide clues about the underlying causative gene, the final diagnosis of the MFM subtype depends on molecular genetic testing. Overexpression or upregulation of normal proteins, such as desmin or αB-crystallin in myofibers, may be an additional feature in many other neuromuscular conditions, so MFM should be used when these accumulations are due to a gene variant in the respective protein. The MFM subtypes are classified according to the affected protein, such as **desminopathy**, **αB-crystallinopathy**, or **Bag3opathy**.

CLINICAL MANIFESTATIONS AND MFM SUBTYPES ACCORDING TO GENETIC BACKGROUND

Most MFMs are not symptomatic in childhood, but occasionally older children and adolescents show early symptoms of nonspecific proximal and distal weakness. MFMs usually present in mid-adulthood, with a slowly progressive weakness involving proximal and distal muscles. The distal presentation is usually more pronounced than the proximal weakness. Sensory symptoms, muscle stiffness, aching, and cramps may be additional symptoms. Affected individuals may show signs of *peripheral neuropathy* and overt *cardiomyopathy.* Autosomal recessive forms present with an early and more severe course compared with autosomal dominant forms. There is also a large interfamilial and intrafamilial variability in the clinical expression of the disease. The degree of involvement and pattern of progression vary between affected individuals.

MFM subtypes with main clinical features are summarized in Table 648.7. Cardiac involvement can sometimes be the initial and only symptom, especially in desminopathies. Syncopal episodes, conduction defects (complete atrioventricular block, right bundle branch block, left anterior hemiblock), rhythm problems (ventricular arrhythmia), cardiomyopathy (dilated, restrictive, hypertrophic), persistent ductus arteriosus, and congestive heart failure are among the cardiac presentations. Facial, axial, and neck muscle involvement, bulbar signs, swallowing and feeding difficulties, rigid spine deformity, early respiratory insufficiency, and early-onset cataracts can be additional clues for the diagnosis. Smooth muscle involvement can present in the form of intestinal malabsorption and pseudoobstruction.

Some MFM subtypes may be associated with early-infantile onset. An example is a unique autosomal recessive myopathy in *Cree native infants* characterized by severe generalized muscular hypertonia that is not relieved by neuromuscular blockade; hence, it is myopathic in origin. Most die in infancy of respiratory insufficiency because of diaphragmatic involvement. The muscle biopsy shows similar findings to many other MFMs (Fig. 648.9); a novel αB-crystallin gene variant is the cause. An early disease onset may also be seen in desminopathy, Bag3opathy, autosomal recessive epidermolysis bullosa simplex with muscular dystrophy (EBS-MD) within the group of *plectinopathies,* hereditary myopathy with early respiratory failure (HMERF) within the group of *titinopathies,* actin-related MFM, and PYROXD1-myopathy.

MFM disease genes encode proteins that are structural and functional components of the sarcomere, extrasarcomeric cytoskeleton, or protein quality control systems. PYROXD1 is classified as a class I pyridine nucleotide-disulfide oxidoreductase, which belongs to an ancient family of enzymes that regulate the redox state of other proteins. An early-onset PYROXD1-myopathy is described, characterized histologically by multiple internalized nuclei, large zones of sarcomeric disorganization, accumulation of thin filaments, thickened Z bands, and desmin-positive inclusions. There is a distinctive histopathology that combines features of central and minicore disease and the centronuclear, myofibrillar, and nemaline myopathies in patients described so far, which clearly indicates the overlap between congenital myopathies and MFMs.

In about half of the affected individuals with MFMs, the genetic defect remains unknown.

LABORATORY FINDINGS

The diagnosis of MFMs rests on common morphologic features observed in muscle histologic studies. Immunocytochemical studies and electron microscopy of muscle can provide clues about the causative gene. Peripheral nerve and myocardial pathologic findings have been described briefly in a small number of patients with MFMs; testing is not routinely performed on clinical grounds. The serum CK level can be normal or mildly elevated. Electromyography reveals myopathic

Table 648.7 Subtypes of Myofibrillar Myopathies

GENE/PROTEIN	DISEASE	INHERITANCE PATTERN	AGE OF ONSET	MAIN CLINICAL FEATURES
DES/desmin	Desminopathy	Dominant, de novo	Early/middle adulthood	Distal > proximal weakness, cardiopathy, respiratory insufficiency
	Desminopathy	Recessive	Infancy/childhood	
CRYAB/αB-crystallin	αB-crystallinopathy	Dominant	Middle adulthood	Distal > proximal weakness, cardiopathy, respiratory insufficiency, cataracts
	αB-crystallinopathy	Recessive	Infancy	Limb and axial stiffness and weakness, respiratory failure
MYOT/myotilin	Myotilinopathy	Dominant	Middle/late adulthood	Distal and proximal weakness, cardiopathy, and respiratory insufficiency in a minority of patients
	Myotilinopathy	Recessive	Early/middle adulthood	Distal and proximal weakness, arrhythmia
ZASP/ZASP	ZASPopathy	Dominant	Middle/late adulthood	Distal > proximal weakness, cardiopathy, and neuropathy in a minority of patients
FLNC/filamin C	MFM-filaminopathy	Dominant	Middle adulthood	Proximal > distal weakness, respiratory failure, and cardiopathy in a subset of patients
BAG3/BAG3	BAG3 myopathy	De novo	Childhood	Proximal and distal weakness, respiratory insufficiency, hypertrophic cardiomyopathy, peripheral neuropathy
FHL1/FHL1	Reducing body myopathy, FHL1 myopathy	X-linked	Infancy/childhood, adulthood (rare)	Delayed motor milestones, proximal > distal weakness, scoliosis, contractures, rapid loss of ambulation, respiratory insufficiency; milder course in adult-onset patients
TTN/titin	Hereditary myopathy with early respiratory failure (HMERF)	Dominant	Early/late adulthood	Distal, proximal, and neck weakness, early respiratory insufficiency
PLEC/plectin	Epidermolysis bullosa simplex with muscular dystrophy (EBS-MD)	Recessive	Skin blistering since birth, myopathy in infancy/childhood, adulthood	Proximal and distal weakness, cardiomyopathy, cataracts, epidermolysis, nail and tooth abnormalities, brain abnormalities
ACTA1/α-actin	MFM-actinopathy	De novo	Infancy	Upper limb > lower limb weakness, respiratory insufficiency, contractures
HSPB8/HSPB8	HSPB8 myopathy	Dominant	Early/middle adulthood	Distal > proximal weakness, peripheral motor neuropathy
DNAJB6/DNAJB6	Limb-girdle muscular dystrophy 1D	Dominant	Middle adulthood	Distal and proximal weakness
PYROXD1/PYROXD1*	PYROXD1 myopathy	Recessive	Infancy/early childhood	Slowly progressive symmetric proximal and distal weakness, generalized reduction in muscle bulk, neck weakness, scapular winging, mild to moderate facial weakness, mild ptosis, high-arched palate, nasal speech, swallowing difficulties, mild restrictive lung disease, mild length-dependent axonal neuropathy and evidence of cardiac involvement in the third decade

*PYROXD1 is a nuclear-cytoplasmic oxidoreductase localized to the nucleus and to the striated sarcomeric components.
MFM, Myofibrillar myopathy.
Adapted from Kley RA, Olive M, Schroder R. New aspects of myofibrillar myopathies. *Curr Opin Neurol*. 2016;29:628–634.

or both myopathic and neuropathic features, abnormal nerve conduction studies, and electrical irritability (fibrillation potentials, positive sharp waves, complex repetitive discharges, and myotonic discharges). Muscle MRI can demonstrate different patterns of involvement according to MFM subtypes. The final diagnosis is based on the combination of clinical features, muscle biopsy features, and molecular genetic test results.

Proteomic analysis of protein aggregates yields to identification of diagnostic biomarkers in different MFM subtypes. The ratio of filamin C to myotilin in aggregates is described as a highly sensitive and specific diagnostic marker for myotilinopathy. The combination of immunofluorescence studies with proteomic findings will further facilitate identification of several proteins involved in protein quality control and degradation, which may also act as therapeutic targets.

The differential diagnosis includes congenital myopathies, myotonic dystrophy, mitochondrial diseases, and peripheral neuropathies in childhood.

TREATMENT

There is no curative treatment available for MFMs. Treatment is supportive and symptomatic. Cardiac screening (electrocardiography, echocardiography, and 24-hr Holter monitoring) should be performed

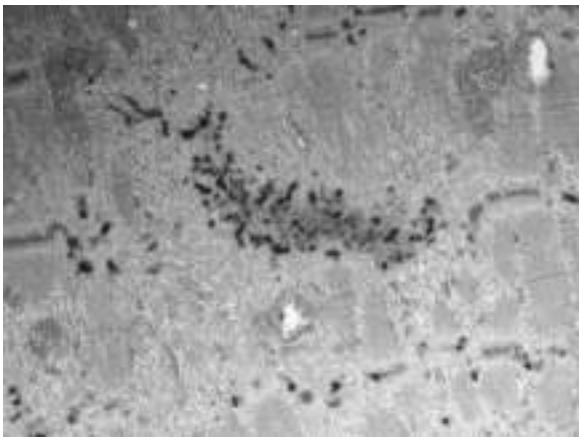

Fig. 648.9 Electron micrograph of quadriceps femoris muscle biopsy of a 1-mo-old Indigenous infant with Cree myofibrillar myopathy. Within the same myofiber, some sarcomeres are well formed and others exhibit disarray of the thick and thin myofilaments and fragmentation of Z bands. Mitochondria appear normal (×21,400).

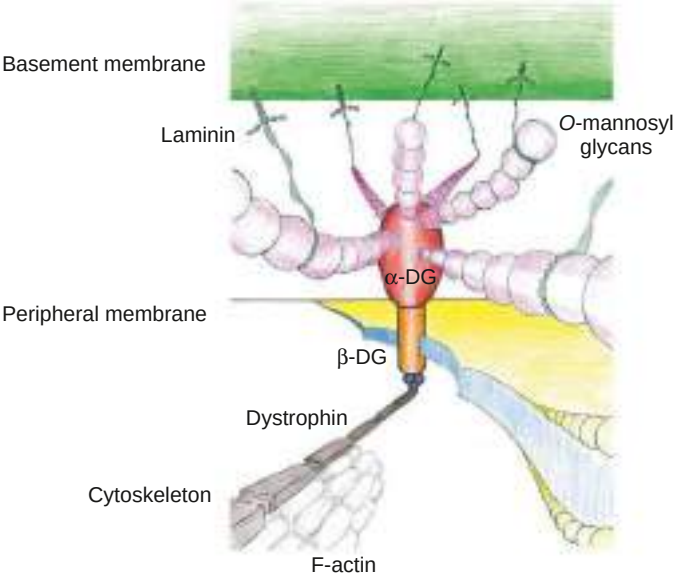

Fig. 648.10 Schematic drawing of dystrophin-glycoprotein complex (DGC) and glycosylated α-dystroglycan (DG). α-DG links extracellular components such as laminin, and links β-DG, a transmembrane glycoprotein. Via dystrophin it binds to actin cytoskeleton. α-DG is heavily glycosylated, and its glycans play a role in binding to laminin. *(From Taniguchi-Ikeda M, Morioka I, Iijima K, et al. Mechanistic aspects of the formation of α-dystroglycan and therapeutic research for the treatment of α-dystroglycanopathy: A review. Mol Aspects Med. 2016;51:115–124.)*

at least once a year. In the case of cardiac abnormalities or in patients with desminopathies, pediatric cardiology follow-up is recommended twice a year. A pacemaker and an implantable cardioverter defibrillator (ICD), cardiac transplantation, respiratory support, range-of-motion physical therapy, and assisted devices can be introduced accordingly. Slit-lamp examination for the detection of lens opacities should be considered. There is no known increased risk for MH; however, the possibility cannot yet be completely excluded. Genetic counseling and prenatal diagnosis should be offered according to the inheritance pattern and underlying gene defect.

The generation of patient-mimicking cell and animal models provides a basis for preclinical and clinical evaluation of novel therapeutic strategies. Initial animal studies are based on avoiding strenuous exercise, treatment with an antioxidant-N-acetyl-L-cysteine, modulation of autophagic activity, and use of antiaggregation drugs such as doxycycline and 4-phenylbutyrate (a chemical chaperone approved for urea cycle disorders).

Visit Elsevier eBooks+ at eBooks.Health.Elsevier.com for Bibliography.

648.6 Brain Malformations and Muscle Development

Adnan Y. Manzur

Infants with cerebellar **hypoplasia** are hypotonic and developmentally delayed, especially in gross motor skills. Muscle biopsy is sometimes performed to exclude a congenital myopathy. A biopsy specimen can show delayed maturation of muscle, fiber-type predominance, or CMFTD. Other malformations of the brain may also be associated with abnormal histochemical patterns, but supratentorial lesions are less likely than brainstem or cerebellar lesions to alter muscle development. Abnormal descending impulses along bulbospinal pathways probably alter discharge patterns of lower motor neurons that determine the histochemical differentiation of muscle at 20-28 weeks of gestation. The corticospinal tract does not participate because it is not yet functional during this period of fetal life.

There are a variety of **muscular dystrophies** associated with cerebral and ocular phenotypes, suggesting common mechanisms affecting development of the muscle, the brain, and the eye. It is clear that in at least some of these cases, the abnormal protein implicated in pathogenesis is expressed in the muscle, brain, and eye, and is important for the stabilization of muscle, migration of central neurons, and normal tissue development in the eye.

Alpha dystroglycan–related dystrophies (αDG-RD) are a group of muscle diseases with a broad phenotypic and genetic spectrum, including several congenital muscular dystrophies (see Chapter 649.6), with severe brain involvement in the form of cobblestone lissencephaly (Walker-Warburg syndrome, Fukuyama disease, and muscle-eye-brain disease of Santavuori) to the LGMD spectrum (see Chapter 649.4).

The dystrophin-glycoprotein complex forms a critical link between the extracellular matrix and cytoskeleton, and in the muscle tissue, stabilizes the muscle membrane. Dystroglycans simply interact with proteins in the extracellular matrix and cytoskeleton via dystrophin (Fig. 648.10). αDG is a transmembrane glycoprotein, and extensive post-translational glycosylation (*O*-linked mannosylation) is required for its proper function, to mediate binding to basement membrane proteins (laminin alpha-2 chain, perlecan, agrin), neurexin in the brain, pikachurin in the eye, and Slit (by interaction with laminin globular [G] domains).

Defects of *O*-glycosylation of αDG are considered to be central to the pathogenesis of αDG-RD. Deletion of dystroglycan or its glycosyltransferases results in migration defects in the form of type II cobblestone lissencephaly and a variety of eye malformations affecting both the retina and anterior chamber, such as glaucoma and cataracts.

Dystroglycan is required not only for the integrity of basement membranes along which developing axonal pathways extend, but also because it directly binds to the laminin G domain of Slit, organizing Slit distribution in vivo. It maintains a growth environment and functions as an extracellular scaffold that controls axon guidance events by organizing the availability of axonal growth and guidance cues at critical intermediate targets. Misregulation of Slit-Robo signaling involved in axonal guidance and neuronal connectivity is reflected to patients with αDG-RD.

Clinical classification is difficult because there are patients with milder abnormalities, such as microcephaly, cerebellar hypoplasia with or without cysts, learning disabilities with normal neuroimaging features and CMD or LGMD phenotype, and with normal cognitive function. Neuroimaging signatures on brain MRI can be summarized as cobblestone complex (type II cobblestone lissencephaly to focal pachygyria or polymicrogyria), midbrain hypoplasia, relatively thick tectum, fused colliculi, ventral pontine cleft, pontomesencephalic kink, abnormalities of cerebellar foliation, cerebellar cysts, hydrocephalus, occipital encephalocele, and patchy and confluent involvement of white matter

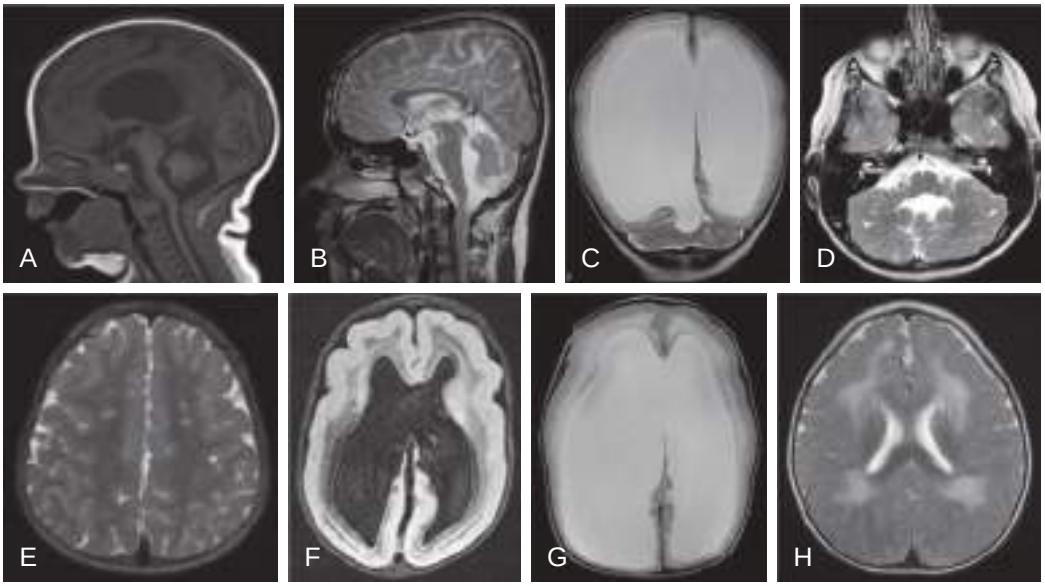

Fig. 648.11 A, Sagittal T1-weighted image shows hypoplastic and "kinked" brainstem, and cerebellar hypoplasia *(POMGnt1)*. B, Sagittal T2-weighted image reveals dorsal pontine flattening *(POMK)*. C, Coronal T2-weighted image demonstrates huge ventriculomegaly, cerebellar hypoplasia, and cortical cobblestone lissencephaly *(ISPD)*. D, Axial T2-weighted image showing cerebellar microcysts *(FKRP)*. E, Axial T2-weighted image reveals bilateral frontal polymicrogyria. F, Axial FLAIR image shows lissencephaly *(POMGnt1)*. G, Axial T2-weighted image reveals cobblestone lissencephaly. H, Axial T2-weighted image shows cerebral periventricular white matter lesions.

with a high signal intensity on T2 weighted and fluid-attenuated inversion recovery (FLAIR) images (Fig. 648.11). A **high serum CK level** in the presence of the previously mentioned imaging features simply differentiates a muscle disorder from other genetic causes of cortical malformations of development. A reduction or absence of immunolabeling with antibodies, which recognize glycosylated epitopes of αDG in muscle biopsy, is a pathologic signature for αDG-RD.

There is an ever-expanding list of genes involved in αDG-RD. Gene variants in up to 19 glycosyltransferases and accessory proteins have been found to be involved in the glycosylation of αDG *(DAG1, POMT1, POMT2, POMGnT1, POMGnT2, LARGE, FKRP, FKTN, ISPD, GTDC2, B3GNT1, B3GALNT2, GMPPB, TMEM5, SGK196, DPM1, DPM2, DPM3, DOLK);* the availability of targeted gene panels and NGS techniques increases the diagnostic yield in this spectrum.

Congenital disorders of glycosylation, involving both *N*- and *O*-glycosylation (gene variants in *DPM1, DPM2,* and *DPM3*), overlap with αDG-RD, and may present with high serum CK levels, cognitive impairment, microcephaly, feeding difficulties, myoclonic epilepsy, and cerebellar hypoplasia.

Another example is a **CMD form overlapping with Marinesco-Sjögren syndrome (MSS) and dystroglycanopathy** due to *INPP5K* gene variants, in patients with short stature, intellectual disability, and cataracts, described as a continuum of αDG-RD. *INPP5K* encodes inositol polyphosphate-5-phosphatase K, which has been shown to regulate myoblast differentiation and protein processing through its interaction with the endoplasmic reticulum chaperones.

Genes identified so far, functioning in the endoplasmic reticulum and/or Golgi apparatus, point to a common mechanism involving an interaction between the cells and the surrounding extracellular matrix in terms of brain malformations and muscle development.

Visit Elsevier eBooks+ at eBooks.Health.Elsevier.com for complete Bibliography.

648.7 Amyoplasia

Adnan Y. Manzur

Congenital absence of individual muscles is common and is often asymmetric. A common aplasia is the *palmaris longus muscle* of the ventral forearm, which is absent in 30% of normal subjects and is fully compensated for by other flexors of the wrist. Unilateral absence of a *sternocleidomastoid muscle* is one cause of congenital torticollis. Absence of one *pectoralis major muscle* is part of the **Poland anomalad.**

When innervation does not develop, as in the lower limbs in severe cases of *myelomeningocele,* muscles can fail to develop. In sacral *agenesis,* the abnormal somites that fail to form bony vertebrae can also fail to form muscles from the same defective mesodermal plate, a disorder of induction resulting in segmental amyoplasia. Skeletal muscles of the extremities fail to differentiate from embryonic myomeres if the long bones do not form. The absence of one long bone, such as the radius, is associated with variable aplasia or hypoplasia of associated muscles, such as the flexor carpi radialis. End-stage *neurogenic atrophy* of muscle is sometimes called **amyoplasia,** but this use is semantically incorrect.

Generalized amyoplasia usually results in fetal death, and live-born neonates rarely survive. A pathogenic variant in one of the myogenic genes is the suspected etiology because of genetic knockout studies in mice, but it has not been proven in humans. An estimated 400 discrete diagnoses can lead to congenital arthrogryposis. The two largest categories are amyoplasia and distal arthrogryposis, which combined make up 50–65% of all diagnoses within the arthrogryposis subset. Amyoplasia, the most common, is not clearly an inherited genetic syndrome of characteristic upper and lower limb contractures. Distal arthrogryposes, by contrast, have an underlying genetic abnormality, which in many cases seems to target the fast-twitch muscles of the developing fetus.

Visit Elsevier eBooks+ at eBooks.Health.Elsevier.com for Bibliography.

648.8 Muscular Dysgenesis (Proteus Syndrome Myopathy)

Adnan Y. Manzur

Proteus syndrome is a disturbance of cellular growth involving ectodermal and mesodermal tissues, representing a cellular mosaicism. The genetic defect is a variant in the *AKT1* gene, of the same genetic family as *AKT3,* which causes hemimegalencephaly; indeed, many children with Proteus syndrome also have hemimegalencephaly as another tissue overgrowth, not a separate association. These genes participate in

the mammalian target of rapamycin (mTOR) pathway. Proteus syndrome also manifests as asymmetric overgrowth of the extremities, verrucous cutaneous lesions, angiomas of various types, thickening of bones, and excessive growth of muscles without weakness. Severe seizures, beginning in neonates, are uncommon. Histologically, the muscle demonstrates a unique *muscular dysgenesis.* Abnormal zones are adjacent to zones of normal muscle formation and do not follow anatomic boundaries.

Proteus syndrome is recognized as a phenotypical variety of the *epidermal nevus syndrome,* together with linear sebaceous nevus of Jadassohn, CLOVES syndrome, and others, as a postzygotic somatic mosaicism.

Visit Elsevier eBooks+ at eBooks.Health.Elsevier.com for Bibliography.

648.9 Benign Congenital Hypotonia

Adnan Y. Manzur

Benign congenital hypotonia is not a disease, but it is a descriptive term for infants or children with nonprogressive hypotonia of unknown origin. The hypotonia is not usually associated with weakness or developmental delay, although some children acquire gross motor skills more slowly than normal. Tendon stretch reflexes are normal or hypoactive. There are no cranial nerve abnormalities, and intelligence is normal.

The **diagnosis** is one of exclusion (see Table 647.2 in Chapter 647) after results of laboratory studies, including muscle biopsy and imaging of the brain with special attention to the cerebellum, are normal. Muscle biopsy is deferred in some mild cases to follow the clinical evolution over time, but the diagnosis in these infants is more provisional. No known molecular genetic basis for this syndrome has been identified in the majority, but a rare form with an *RYR1* variant and MH is recognized. Table 647.3 in Chapter 647 lists the differential diagnoses.

The prognosis is generally good; no specific therapy is required. Contractures do not develop. Physical therapy might help achieve motor milestones (walking) sooner than expected. Hypotonia persists into adult life. The disorder is not always as *benign* as its name implies because a common complication is recurrent dislocation of joints, especially the shoulders. Excessive motility of the spine can result in stretch injury, compression, or vascular compromise of nerve roots or of the spinal cord. These are particular hazards for patients who perform gymnastics or who become circus performers because of agility of joints without weakness or pain.

Visit Elsevier eBooks+ at eBooks.Health.Elsevier.com for Bibliography.

648.10 Arthrogryposis

Adnan Y. Manzur

See also Chapter 723.

Arthrogryposis (*arthro,* joint; *gryp,* curved), arthrogryposis multiplex congenita (*multiplex,* multiple; *congenita,* present at birth), and multiple congenital contractures are descriptive terms, used interchangeably to define contractures in two or more different body parts (Table 648.8). Arthrogryposis is a sign rather than a diagnosis; anything that interferes or limits normal fetal movement can lead to congenital contractures. The contractures usually (1) involve the limbs, but also may include the jaw, neck, and spine; (2) are nonprogressive in nature; and (3) improve over time with early physiotherapy and orthopedic interventions.

Although each specific type is rare, the incidence of arthrogryposis is described as 1 in 3,000-5,000 live births, according to population-based studies.

FETAL MOVEMENT AND THE LINK TO ARTHROGRYPOSIS

The main background factor in all forms of arthrogryposis is decreased or lack of fetal movement *(fetal akinesia/hypokinesia),* and the clinical severity is directly correlated with the onset. An early onset and long duration of decreased movements lead to a more severe phenotype at birth. The first trimester is a critical period in terms of progressive motor development. There is an evolution of the movement pattern; early fetal activity is believed to be generated by central pattern networks in the spinal cord and mediated by feedback from the immature muscle fibers of myotomes, shifting to a more specific pattern due to the development of the supraspinal parts of the brain. The development of joints, joint spaces, and movements start at 5½, 7, and 8 embryonic weeks, respectively. Therefore decreased fetal movement beyond 10 weeks is a sign of maldevelopment and/or dysfunction of the early fetal central or peripheral nervous system. General movements with relatively simple and stereotypical sideways bending of the head and trunk can be noticed as early as 7 weeks of gestation (embryonal, 5 weeks). They develop in a craniocaudal and proximal-to-distal direction, with a propagation from the shoulders and hips first, to the upper and, then, lower limbs (7-9 weeks). At this time point, jaw opening also begins. Isolated arm and leg movements can be visible from 8-9 weeks to 10 weeks, respectively. By 11 weeks of gestation, a full range of limb movements (extension, flexion, rotation, abduction, and adduction of each limb) develops. Developmentally, fetal sucking and swallowing are described in the early second trimester. Fetal breathing movements begin around 12-14 weeks, and by 20 weeks they become more regular. Facial movements are recognized in the late second trimester, and between 24 and 35 weeks show a developmental progression from unrelated facial movements toward fetal facial gestalts.

Table 648.8 Consensus-Based Definitions

TERM	DESCRIPTION/DEFINITION
Arthrogryposis multiplex congenita (AMC)	AMC is a term used to describe a group of congenital conditions characterized by joint contractures in two or more body areas.
Amyoplasia (classical arthrogryposis)	Amyoplasia is characterized by multiple congenital contractures presenting in a very specific pattern. It is typically symmetric, involving all four limbs, with internally rotated shoulders, fully extended and fixed elbows, the wrists fixed in flexion, partially flexed fingers, hips fixed in flexion or extension, adducted or abducted, and sometimes dislocated. The knees may be fixed in extension or flexion, and the feet are usually in severe equinovarus position. The jaw and trunk are relatively spared. Normal limb muscle tissue is replaced by fatty, fibrous tissue.
Distal arthrogryposis (DA)	DA is a group of rare arthrogryposis syndromes characterized by congenital contractures of two or more areas of the body, primarily involving the hands and feet, while the proximal joints are largely spared, in the absence of primary neurologic and/or muscle disease affecting limb function. Diagnostic features include camptodactyly or pseudocamptodactyly, hypoplastic or absent flexion creases, overriding fingers, ulnar deviation at the wrist, talipes equinovarus, calcaneovalgus deformities, vertical talus, and/or metatarsus varus.

From Hermansen MV, Wekre LL, Lidal IB. The range of publications on arthrogryposis multiplex congenita from 1995 to 2022—a scoping review. *Am J Med Genet.* 2023;1–11. Table 1.

Contracting musculature is the main role player in maintaining joint progenitor cells committed to their fate, and for correct joint cavitation and formation. A key modulator of joint formation, beta-catenin, is activated in a contraction-dependent manner. Further, a reduced muscle phenotype also has a differential effect on ossification centers, with significant decreases in bone formation. Muscle development, early spontaneous contraction, innervation, and joint and bone formation seem to be complex interdependent developmental processes that finally allow normal limb movement and maintenance. Although not investigated in detail, normal fetal breathing and/or swallowing and lung and gastrointestinal maturation may be affected through the same developmental processes.

Decreased movement is associated with a compensatory connective tissue response, *collagenosis* (an increase of connective tissue around the joints), which limits the joint movements and increases contractures. Any effort to mobilize the joints may lead to minor fractures of abnormal joint surfaces. Diaphragmatic and intercostal muscle dysfunction further results in loss of rhythmic thoracic movements and leads to a small thoracic cage and failure of maturation of the alveoli and surfactant, leading to pulmonary hypoplasia. By 15 weeks of gestation, development of the lung is arrested at the canalicular phase, which is also a critical point for joint development. Lack of muscle pull at sites of normal attachment may lead to craniofacial abnormalities, with facial weakness leading to a tented upper lip appearance.

Pathologic changes with an onset during intrauterine development are confined to primary alterations in anterior horn cells, roots, peripheral nerves, motor end plates, or muscles. Spinal cord involvement, with abnormal histology and unequal distribution of alpha motor neurons in anterior horn cells, is described in infants with the neurogenic forms of arthrogryposis.

BASIC CATEGORIES, ETIOLOGIES, AND CLASSIFICATIONS

Decreased or lack of in utero movements are all reflected in the clinical features of the **lethal forms of lower motor neuron diseases** and the **fetal akinesia/hypokinesia deformation sequence (FADS), Pena-Shokeir phenotype,** which represents the severe end of the arthrogryposis spectrum. This phenotype can be described as intrauterine growth restriction, multiple joint contractures, shortened limbs, craniofacial changes (micrognathia, cleft palate, high nasal root, ocular hypertelorism), pulmonary hypoplasia, polyhydramnios, decreased gut motility, a shortened gut, a short umbilical cord, skin changes, and short limbs. Iatrogenic fractures due to osteoporosis of long bones in the prenatal period can be an additional feature. They may be isolated or associated with additional organ system abnormalities.

Lower motor neuron diseases, characterized by degeneration of anterior horn cells of the spinal cord and descending tracts, may overlap with arthrogryposis and FADS. The prototype in childhood is **SMA** (see Chapters 652.2 and 652.3).

Lethal congenital contracture syndrome (LCCS) and **lethal arthrogryposis with anterior horn cell disease (LAAHD)** are two independent neurogenic arthrogryposis subtypes, with a remarkable phenotypic overlap and ever-expanding heterogeneity at the phenotypic and molecular genetic levels.

Amyoplasia and **distal arthrogryposis (DA)** are the two most common categories of conditions, accounting for up to 50–65% of the patients presenting with arthrogryposis.

The most common type is Amyoplasia (*A,* no; *myo,* muscle; and *plasia,* growth); it is also called classic arthrogryposis. Amyoplasia is a sporadic condition in which limb muscle tissue is replaced by fatty tissue. Despite extensive genetic studies, no chromosomal or single gene etiology has been identified to date. Amyoplasia (with a capital A), is a diagnosis of exclusion, so it should be distinguished from other genetic forms of arthrogryposis presenting with decreased or absent muscle mass. The natural course, management, and genetic counseling depend on a correct diagnosis. The incidence of Amyoplasia is 1/10,000 live births. Discordant monozygotic twinning is described, that is, at least 6.6% of the affected individuals are described to have an unaffected monozygotic twin.

Fig. 648.12 Typical appearance of a patient with amyoplasia with internal rotation of the shoulders, fixed extension of the elbows, clenched wrist (**A**), hip dysplasia, and equinovarus deformity (**B**).

The diagnosis should be considered in the presence of symmetric congenital, rigid contractures with a characteristic position of limbs in the newborn period (internal rotation of the shoulders, fixed extension of the elbows, pronation of the forearm, flexion of the wrist, camptodactyly, and severe equinovarus deformity of the feet; Fig. 648.12), accompanied by shortness of the affected limbs; a marked decrease in limb muscle mass; lack of flexion creases on limbs, fingers, and hands; mild intrauterine growth retardation; dimples overlying affected joints; spared trunk; nevus flammeus over the craniofacial midline; bone fractures; osteoporosis of the long bones; normal CNS function; and a negative family history. There may be spinal involvement. Muscle defects in the abdominal wall, inguinal hernias, bowel atresia, absence of trunk muscles, digit compromise, or constriction bands of the limbs or digits can accompany the clinical picture due to vascular compromise. There is a range of severity, from very mild to severe involvement, with almost 15% of patients presenting with a pure, isolated upper extremity or lower extremity involvement. The diagnosis of these forms requires experience and evaluation of a differential diagnostic list. Contractures usually improve over time with early physiotherapy and orthopedic care (see Chapter 723), with almost 85% of affected individuals being ambulatory by age 5 years and two thirds being able to live independent lives.

Distal arthrogryposis (DA) is a heterogeneous group with a wide phenotypic variability, primarily involving the hands and feet, with sparing of the proximal joints. The prevalence is not known. It is often associated with abnormal facies and autosomal dominant inheritance, but autosomal recessive and sporadic patients are also described. Patients usually present in an orthopedic environment. There is an expanded classification with 11 different syndromes (see Chapter 723, Table 723.2). Abnormalities of fast-twitch muscles are identified in a majority of patients with DA. Gene variants in sarcomeric muscle proteins (troponin, tropomyosin, and myosin) can cause DA or congenital myopathies. Other than this clinical overlap due to a particular gene variant, a particular phenotype may be associated with variants in different genes. Some of the DA forms prove that embryonic expression of some of the genes during fetal life, such as *MYH3,* affects sarcomeric proteins and the force generation in muscle cells. Dominant and recessive gene variants related to mechanotransduction are identified in the DA group.

Among over 400 conditions described within this complex category (including syndromes, gene variants, chromosomal abnormalities, deletions, and duplications), over 320 genes have been implicated, and a responsible gene has been identified in more than 150 of the conditions (Fig. 648.13). Considering this extreme clinical and genetic heterogeneity, it is suggested that classifications can be done at different levels, depending on the *area of involvement, overall cause of fetal*

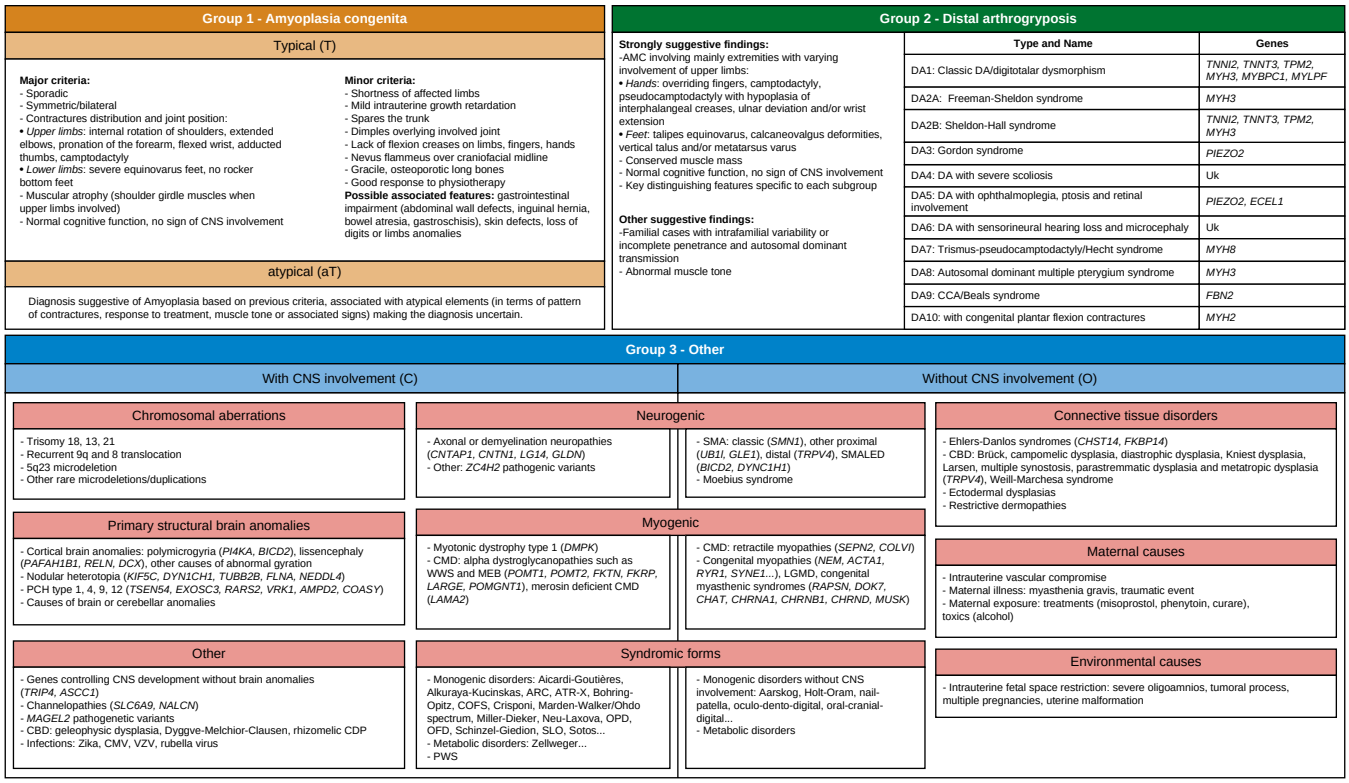

Fig. 648.13 Clinical classification of AMC. Clinical classification routinely used at the University Hospital Grenoble Alpes. It aims at distinguishing straight away the two main causes of AMC: Amyoplasia (Group 1) and DA (Group 2). Details on clinical criteria used to classify these patients into these groups are provided. Patients that cannot be classified into one of the previous groups are classified in Group 3 in which we distinguish cases with (C) or without (O) CNS involvement. Nine etiologic subgroups are defined in this Group 3. ARC, Arthrogryposis renal dysfunction and cholestasis; ATR-X, alpha-thalassemia/mental retardation syndrome; CBD, congenital bone disorder; CCA, congenital contractures arachnodactyly; CDP, chondrodysplasia; CMD, congenital muscular dystrophies; COFS, cerebro-facio-oculo-skeletal syndrome; LGMD, limb-girdle muscular dystrophies; MEB, muscle eye brain; OFD, oro-facio-digital syndrome; OPD, oto-palato-digital syndrome; PCH, pontocerebellar hypoplasia; PWS, Prader Willi syndrome; SLO, Smith-Lemli-Opitz syndrome; SMA, spinal muscular atrophy; SMALED, spinal muscular atrophy lower extremities predominant autosomal dominant; Uk, unknown; WWS, Walker Warburg syndrome. *(From Le Tanno P, Latypova X, Rendu J, et al. Diagnostic workup in children with arthrogryposis: description of practices from a single reference centre, comparison with literature and suggestion of recommendations. J Med Genet. 2023;60:13–24. Fig. 2.)*

akinesia/hypokinesia, and *etiologic process underlying the developmental dysfunction,* or taking into consideration the *cardinal features,* as in the case of amyoplasia and DA (Table 648.9). With the utility of NGS technologies, the field of arthrogryposis is moving to *gene-based classification* systems and grouping conditions according to affected or associated gene products and involved developmental pathways.

The etiology can be based on abnormalities of the CNS, nerve, muscle, and connective tissue; lack of space; maternal illness; environmental agents; or vascular compromise. They may result in decreased intrauterine movements. As an alternative approach, genetic, sporadic (amyoplasia), and environmental backgrounds or neurogenic, myopathic, syndromic, and metabolic categories can be used to review possible etiologies.

For practical purposes, the clinical classification is often based on the presence and absence of additional organ system abnormalities or malformations and the presence or absence of CNS involvement, including intellectual disability, and lethality. Of the children with arthrogryposis, ~30% will primarily have limb involvement, ~30% will have affected limbs plus other body areas but normal cognitive function, and ~30% will have CNS dysfunction.

DIAGNOSTIC APPROACH AND LABORATORY EVALUATION

In such a diverse group of disorders with extreme heterogeneity at the etiologic, phenotypic, and molecular genetic levels, establishing a specific diagnosis is important. The natural history, evolution, prognosis, therapeutic interventions, and genetic counseling/prenatal diagnosis depend on a precise diagnosis.

The first step in the diagnostic approach is detailed history taking, including information about the pregnancy, delivery, and family history, with at least a three-generation pedigree analysis (Table 648.10). The maternal perception of intrauterine movements, any difference compared with previous pregnancies, polyhydramnios, oligohydramnios, intrauterine infections, toxic exposures, maternal illness, maternal and paternal age, breech presentation, type of delivery, and any event complicating the delivery should be reviewed. Newborns with arthrogryposis are prone to hypoxic-ischemic insults.

There is not a standard set of laboratory investigations that can serve as a diagnostic tool (Table 648.11). Radiologic tests (brain and muscle MRIs), electrophysiologic tests (electromyography, nerve conduction velocities), muscle biopsy, chromosomal microarray analysis (array comparative genomic hybridization [CGH]), and molecular genetic tests must be individualized for each patient. Input from a clinical geneticist and experienced multidisciplinary team is invaluable. Documentation of the range of motion, distribution of contractures, muscle tone and strength, and facial involvement with serial photographs and/or videos should be a part of follow-up visits. There is no laboratory test that can substitute for experience in making the clinical judgment.

In the case of a recognized phenotype, molecular tests can be directed toward the working diagnosis. Depending on the availability of NGS technologies, the traditional diagnostic trend has shifted to a diagnosis by genetic sequencing. Disease-specific targeted gene panels can serve a diagnostic purpose, because other than a variety of early-onset muscle diseases, mitochondrial and metabolic diseases are covered, as well. In a large cohort of patients presenting with fetal akinesia/hypokinesia, arthrogryposis, or severe congenital myopathies,

Table 648.9 Major Causes of Arthrogryposis Multiplex Congenita

SITE OF MAJOR PATHOLOGIC FINDINGS	DISORDER
Cerebrum-brainstem	Microcephaly; migrational disorders: lissencephaly-pachygyria (e.g., Zellweger syndrome), schizencephaly, polymicrogyria, agenesis of corpus callosum; fetal alcohol syndrome; cytomegalovirus infection; pontocerebellar hypoplasia (type I); dentato-olivary dysplasia; leptomeningeal angiomatosis; encephaloclastic processes: neuronal destruction, porencephalies, hydranencephaly, multicystic encephalomalacia; hydrocephalus
Anterior horn cell	Developmental agenesis-hypoplasia-dysgenesis (amyoplasia congenita); destructive disorders (apparent intrauterine ischemic events); degenerative disorders (severe Werdnig-Hoffmann disease [SMA type 0 or IA], lethal congenital contracture syndrome, spinal muscular atrophy with pontocerebellar hypoplasia, spinal muscular atrophy with respiratory distress, X-linked infantile spinal muscular atrophy, early-onset non-5q spinal muscular atrophy); Möbius syndrome; cervical spinal atrophy; lumbar spinal atrophy; lumbosacral meningomyelocele; sacral agenesis; other
Peripheral nerve or root	Hypomyelinative polyneuropathy; axonal polyneuropathy; neurofibromatosis
Neuromuscular junction	Infant of myasthenic mother; congenital myasthenic syndromes; multiple pterygium syndrome (Escobar type); infant of mother with multiple sclerosis (?)
Muscle	Congenital muscular dystrophy (merosin-positive and merosin-negative); congenital myotonic dystrophy; myotubular myopathy; central core disease; nemaline myopathy; congenital myopathy due to sodium channel gene variant; congenital polymyositis; congenital fiber-type disproportion; glycogen storage myopathy (muscle phosphorylase deficiency, phosphofructokinase deficiency); mitochondrial myopathy; Freeman-Sheldon syndrome
Primary disorder of joint or connective tissue	Marfan syndrome; contractural arachnodactyly; other disorders of connective tissue; intrauterine periarticular inflammation
Intrauterine mechanical obstruction	Uterine abnormality; amniotic bands; oligohydramnios; twin pregnancy; extrauterine pregnancy

SMA, Spinal muscular atrophy.
From Ghosh PS, Volpe JJ. Arthrogryposis multiplex congenita. In: Volpe JJ, Inder TE, Darras BT, et al., eds. *Volpe's Neurology of the Newborn*, 6th ed. Philadelphia: Elsevier; 2018: Table 31-3.

Table 648.10 Clinical Evaluation of Arthrogryposis: Clues for a Detailed History

PREGNANCY
- Maternal illness, acute or chronic (diabetes, myasthenia gravis, myotonic dystrophy, etc.)
- Infections (rubella, rubeola, zika virus, coxsackievirus, enterovirus, Akabane virus, etc.)
- Fever (>39°C, determine timing in gestation)
- Nausea (viral encephalitis, position of baby, etc.)
- Drugs (curare, Robaxin, alcohol, phenytoin, addictive drugs, misoprostol, etc.)
- Fetal movement (polyhydramnios, fetal kicking in one place, rolling decreased)
- Oligohydramnios, chronic leakage of amniotic fluid
- Polyhydramnios, hydrops
- Trauma during pregnancy (blow to the abdomen, attempted termination, car accident, etc.)
- Other complications during pregnancy, such as bleeding, abnormal lie, threatened abortion
- Prenatal diagnosis (early amniocentesis, ultrasound studies, etc.)

DELIVERY HISTORY
- Presentation (breech, transverse, etc.)
- Length of gestation
- Traumatic delivery (limb, CNS, fracture, etc.)
- Intrauterine mass (twin, fibroid, etc.)
- Abnormal uterine structure or shape
- Abnormal placenta, membranes, or cord length or position
- Time of year, geographic location

FAMILY HISTORY
- Marked variability within family
- Change with time (degeneration vs improvement)
- Increased incidence of congenital contractures in second- and third-degree relatives
- Hyperextensibility or hypotonia present in family member
- Rule out myotonic dystrophy, myasthenia gravis in parents (particularly mother)
- Consanguinity
- Advanced parental (mother or father) age
- Increased stillbirths or miscarriages
- If more than one consecutively affected child, consider maternal antibodies to fetal neurotransmitter

Continued

Table 648.10 Clinical Evaluation of Arthrogryposis: Clues for a Detailed History—cont'd

NEWBORN EVALUATION

Description of contractures
- Which limbs and joints
- Proximal vs distal
- Flexion vs extension
- Amount of limitation (fixed vs passive vs active movement)
- Characteristic position at rest
- Severity
- Complete fusion or ankylosis vs soft tissue contracture

Other anomalies (contractures are most obvious, look for other anomalies)
Deformities
Genitalia (cryptorchid, lack of labia, microphallus, etc.)
Limbs (pterygium, shortening, webs, cord wrapping, absent patella, dislocated radial heads, dimples, etc.)
Jaw (micrognathia, trismus, etc.)
Facies (asymmetry, flat bridge of nose, hemangioma, movement, etc.)
Scoliosis and kyphosis (fixed or flexible)
Dimple (over specific joints or bones)
Skin (hemangioma, defects, hirsutism)
Dermatoglyphics
Hernias, inguinal and umbilical, abdominal wall defect
Other features of fetal akinesia sequence
- Intrauterine growth restriction
- Pulmonary hypoplasia
- Craniofacial anomalies (hypertelorism, cleft palate, depressed tip of nose, high-bridged nose)
- Functional short gut with feeding problem
- Short umbilical cord

MALFORMATIONS
- Eyes (small, corneal opacities, malformed, ptosis, strabismus, etc.)
- CNS (structural malformation, seizures, ID, etc.)
- Palate (high, cleft, submucous, etc.)
- Limb (deletion anomalies, radioulnar synostosis, etc.)
- GU (structural anomalies of kidneys, ureters, and bladder)
- Skull (craniosynostosis, asymmetry, microcephaly, etc.)
- Heart (congenital structural anomalies vs cardiomyopathy)
- Lungs (hypoplasia vs weak muscles or hypoplastic diaphragm)
- Tracheal and laryngeal clefts and stenosis
- Changes in vasculature (hemangiomas, cutis marmoratus, blue cold distal limbs, etc.)
- Other visceral anomalies

OTHER FEATURES

Neurologic examination (detailed)
- Vigorous vs lethargic
- Deep tendon reflexes (present vs absent, slow vs fast)
- Sensory intact or not

Muscle
- Mass (normal or decreased)
- Texture (soft vs firm)
- Fibrous bands
- Normal tendon attachments or not
- Changes with time

COURSE

Changes with time
Developmental landmarks (motor vs social and language)
Growth of affected limbs
Progression of contractures
Lethal vs CNS damage vs stable vs improvement
Asymmetry
Trunk vs limb changes
Intellectual abilities
Socialization
Feeding problems
Response to therapy
Spontaneous improvement
Response to physical therapy
Response to casting
Which surgery at which time
Development of motor strength proportionate to limb size
Abnormal reaction to drugs

CNS, Central nervous system; ID, intellectual disability; GU, genitourinary.
From Hall JG. Arthrogryposis (multiple congenital contractures): diagnostic approach to etiology, classification, genetics, and general principles. *Eur J Med Genet*. 2014;57:464–472.

Table 648.11 Laboratory Evaluation

Documentation of range of motion and position with photographs
Radiographs if • Bony anomalies (gracile, fusions, extra or missing carpals and tarsals, etc.) • Disproportionate • Scoliosis • Ankylosis • Dislocation (hips, radial head, patella, etc.)
MRI to evaluate CNS (brain and spinal cord) and muscle mass obscured by contractures
Ultrasonographic evaluation of CNS (brain and spinal cord) or other anomalies, and to establish potential muscle tissue
Chromosome studies/CGH array if • Multiple system involvement • CNS abnormality (eye, microcephaly, ID, lethargy, degenerative course) • Streaky or segmental involvement • Consider fibroblast studies if lymphocytes were normal and patient has ID with no diagnosis • DNA gene testing if condition fits a known disorder for which gene testing is available • Consider next-generation sequencing technologies (targeted gene panels, whole-exome sequencing, whole-genome sequencing) if family available
Video of movement, including facial, range of movement, strength-repeat at regular intervals
Viral culture as appropriate and specific antibodies or IgM levels in newborn
Muscle biopsy in normal and affected areas at time of surgery to distinguish myopathic forms from neuropathic forms (do special histopathology and electron microscopic studies). If elevated creatine kinase or unusual muscle response, consider muscle biopsy earlier, examine mitochondria
EMG in normal and affected area
Nerve conduction in normal and affected area
Creatine kinase if • Generalized weakness • Doughy or decreased muscle mass • Progressive course
Eye examination (opacities, retinal degeneration, etc.)
Maternal antibodies to neurotransmitters, if myasthenia gravis or recurrent affected pregnancies without diagnosis
Spinal muscular atrophy (SMA) DNA testing according to clinical features
Mitochondrial DNA analysis
Metabolic screening

CGH, Comparative genomic hybridization; CNS, central nervous system; EMG, electromyography; ID, intellectual disability; IgM, immunoglobulin M.
From Hall JG. Arthrogryposis (multiple congenital contractures): diagnostic approach to etiology, classification, genetics, and general principles. *Eur J Med Genet.* 2014;57:464–472.

the use of NGS provided a conclusive diagnosis in 18 of 38 families (47%). Diagnostic yields range between 20% and 60%, depending on the homogeneity of the patient population; however, despite all efforts, nearly 50% of patients with arthrogryposis of a genetic origin do not have a precise molecular diagnosis.

Autopsy evaluation is extremely valuable. It should include an extensive workup for visceral anomalies, malformations of cortical development, and the number of anterior horn cells and their size in the spinal cord, with special attention paid to patchy involvement and the presence or absence of tracts at various levels in the spinal cord. Evaluation of the peripheral nerve, eye, and muscle tissue from different muscle groups and the diaphragm is also needed. Tendon attachments, fibrous bands replacing muscle, and cartilaginous or bony fusions can be evaluated, in addition to the presence of other malformations, deformations, or disruptions. Microarray analysis from different tissues and DNA extraction and molecular testing are also possible.

DIFFERENTIAL DIAGNOSIS

There is an ever-expanding list of disorders presenting with arthrogryposis. Almost 50% of fetal akinesia/hypokinesia presentations are neuromuscular in origin, involving all points along the neuromuscular axis (motor neurons, peripheral nerves, neuromuscular junctions, and the skeletal muscle regulatory and contractile apparatus). Mechanosensitive ion channels are another area of interest.

On clinical grounds, from a neuromuscular standpoint, one can recognize severe spinal muscular atrophies (SMA type 0), atypical SMA forms with arthrogryposis and bone fractures (see Chapter 652.2), lower motor neuron diseases (see Chapter 652.3), CMDs with specific attempts to recognize early sclerotic forms of the Ullrich CMD phenotype (Fig. 648.14) (see Chapter 649.6), and CMD with CNS involvement-alpha dystroglycan–related CMD (Fig. 648.15) (see Chapter 648.6). In any infant with contractures and/or facial weakness with a tented upper lip, examination of the mother should be routinely performed for myotonic reactions as a first step for CMD (Fig. 648.16 and Video 648.1) (see also Chapter 649.3). With the same clinical presentation, if the myotonic reaction of the mother is negative, congenital myopathies (Fig. 648.17 and Video 648.2) (see also Chapter 648.3) should be included in the differential diagnosis. Fetal acetylcholine receptor inactivation syndrome is characterized by clinical features ranging from mild facial and bulbar myopathy to arthrogryposis, and *maternal treatment* can improve the outcome (see Chapter 652.1). Some pterygium syndromes may respond to *acetylcholine treatment.*

Prevention or treatment of metabolic disturbances (metabolic acidosis) or treating an inherited metabolic disease may also have a positive impact on the outcome. Carbohydrate-deficient glycoprotein

Fig. 648.14 A 3-mo-old male infant, born with arthrogryposis (A), congenital torticollis (B), proximal knee contractures (C), and distal laxity (D-F), a clinical phenotype consistent with Ullrich congenital muscular dystrophy.

Fig. 648.15 A 3-mo-old female infant with an intrauterine diagnosis of hydrocephalus and arthrogryposis. Ventriculoperitoneal shunt replacement at birth. Note dysmorphic facial features, megalocornea (A), failure to thrive, decrease in muscle mass, and generalized weakness (B). A high serum CK level with CNS malformation on brain MRI led to diagnosis of Walker-Warburg syndrome with *POMT1* gene variant.

syndrome (CDG), perinatal lethal forms of Gaucher disease, glycogen storage disease types IV and VII (phosphofructokinase deficiency), Zellweger syndrome spectrum, adenylosuccinate lyase deficiency, and ARC (arthrogryposis, renal dysfunction, cholestasis) syndrome are among the diseases in this group with an autosomal recessive inheritance.

GENETIC COUNSELING AND PRENATAL DIAGNOSIS

Establishing a molecular diagnosis in an index patient with a genetic form of arthrogryposis is required for appropriate genetic counseling and prenatal diagnosis. Despite maternal care and the availability of prenatal ultrasonography (US), which can confirm abnormal movements and postural findings as early as 11 weeks, 75% of affected individuals with arthrogryposis were reported to be not diagnosed before birth. Real-time US can visualize contractures, the quality of in utero movements, the joint positioning, lung hypoplasia, nuchal edema, the muscle mass, and the bone growth in the first or early second trimester. Prenatal or postnatal MR findings can be used as a complementary adjunct to US, especially for the evaluation of accompanying muscle and joint malformations. The maternal perception of decreased intrauterine movements and high-risk pregnancies should be carefully evaluated. In an effort to improve the detection rate and

Fig. 648.16 Arthrogryposis due to congenital myotonic dystrophy in the newborn period (A), at age 3 mo (B), and at 1 yr (C). Note severe hyperextension of the limbs at birth (A) and facial weakness characterized by tented upper lip (B and C), signs that should lead to physical examination of the mother. See also Video 648.1.

guide the diagnostic strategy, a fetal approach can be applied as early as the first prenatal ultrasound at 12 weeks, in the first trimester (Fig. 648.18).

Timely recognition leads to a further etiologic and diagnostic workup and pregnancy management and creates time for informed choices, in utero stimulation, or early delivery according to the degree of lung maturation. In a case of detection of contractures in a prenatal

Fig. 648.17 Arthrogryposis, respiratory insufficiency, and fractures at birth (**A-C**), with a family history of consanguinity and similarly affected infant at the age of 3 mo with dysmorphic features, severe facial involvement (tented upper lip), frontal bossing, epicanthus (**D**), pectus excavatum deformity, and severe generalized weakness (**E**). Muscle biopsy revealed intracytoplasmic nemaline rods (**F**), leading to a diagnosis of *KHL40*-nemaline myopathy. See also Video 648.2.

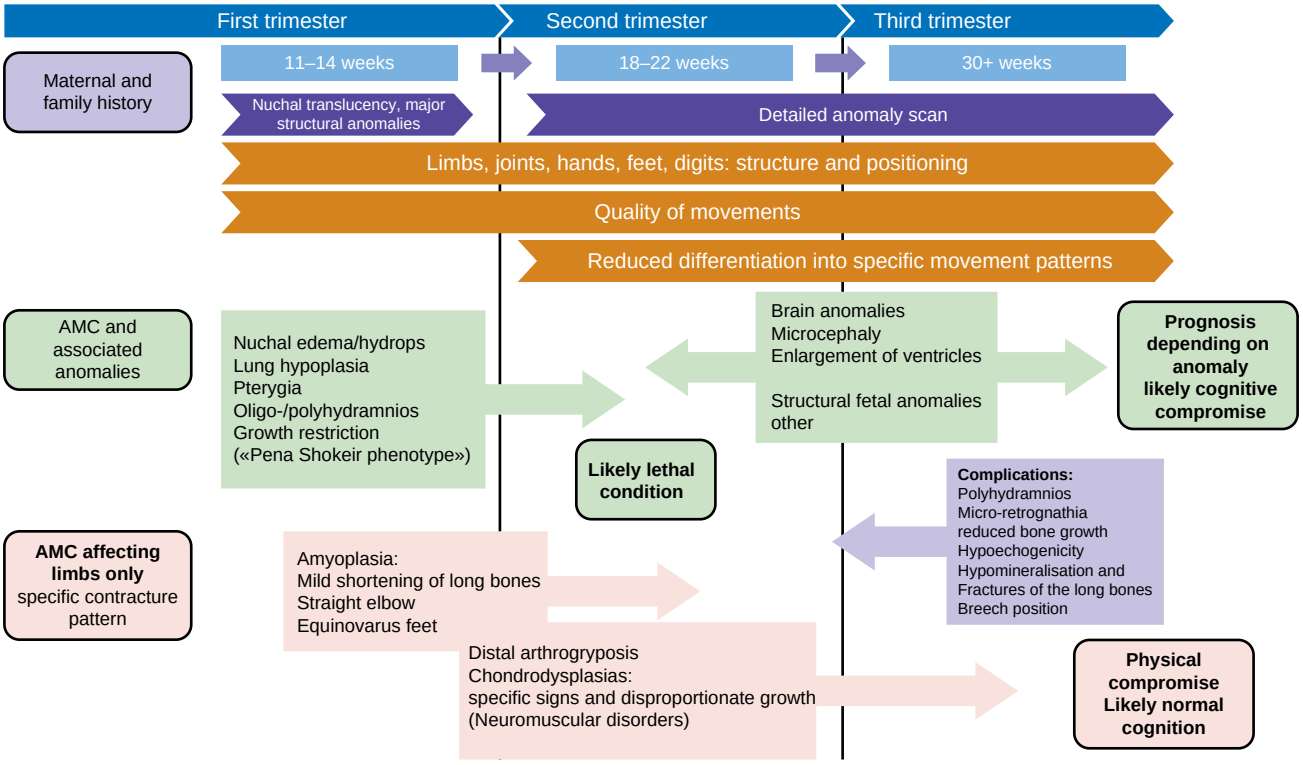

Fig. 648.18 Proposed ultrasound algorithm for improving the detection of AMC in prenatal care. Screening for limb, joints, hand, feet, digit anomalies, and positioning as the quality of movements should start as early as the first trimester and monitored throughout pregnancy. Reduced differentiation into specific movement patterns can likely be appreciated in the second trimester. Depending on the type of findings and the time of appearance during fetal development, a likely diagnosis and prognosis can be provided. Chromosomal microarray analysis is indicated in all fetuses with AMC, and further molecular testing including panel and genome-wide sequencing should be offered depending on the clinical presentation. *(From Filges I, Tercanli S, Hall JG. Fetal arthrogryposis: challenges and perspectives for prenatal detection and management. Am J Med Genet. 2019;181C:327–336. Fig. 2.)*

US study, physicians involved in the care of a pregnant woman should examine her to rule out myotonic dystrophy, in order to prevent serious complications. Due to high rates of infertility, before introducing artificial reproductive techniques, myotonic dystrophy should be considered. Because of genetic anticipation, the diagnosis of the mother may be delayed to the time of giving birth to a severely affected infant with arthrogryposis (see Chapter 649.3). Arthrogryposis with a history of myasthenia gravis in the mother should be evaluated accordingly, because miscarriage, stillbirth, or neonatal death can complicate the picture (see Chapter 652.1).

Chromosomal abnormalities and autosomal recessive, autosomal dominant, X-linked, and mitochondrial inheritance have been all described in the disorders related to arthrogryposis, and genetic counseling should be provided accordingly. If a specific diagnosis is not made, the empirical recurrence risk is defined as 3%, and it is slightly higher (7%) for arthrogryposis plus CNS involvement.

MANAGEMENT

Each affected individual with arthrogryposis is unique, and the natural course of the condition depends on the underlying etiology and management. A multidisciplinary team approach (pediatricians, pediatric orthopedic specialists, plastic or hand surgeons, rehabilitation physicians, occupational therapists, physical therapists, medical geneticists, neurologists) is essential in standard care (see Chapter 723). Management is shifting to a multidisciplinary clinic that provides patient-centered, comprehensive care in a coordinated manner.

In terms of amyoplasia, follow-up is required to identify treatment outcomes such as the development of degenerative arthritis, the need for orthotics for ambulation, or the possibility of becoming overweight in adulthood. Cytokines and other factors released in response to early therapeutic interventions are suggested to facilitate the elongation of pathologic periarticular soft tissues and increase joint motion. The core principle of management in DA is to preserve muscle function. Anesthesia-related complications due to limited jaw opening, restrictive pulmonary function, and the risk of MH should be considered in the setting of multiple surgeries.

Visit Elsevier eBooks+ at eBooks.Health.Elsevier.com for Bibliography.

Chapter 649

Muscular Dystrophies

*Adnan Y. Manzur**

A muscular dystrophy is distinguished from all other neuromuscular diseases by four obligatory criteria: it is a primary myopathy, it has a genetic basis, the course is progressive, and degeneration and death of muscle fibers occur at some stage in the disease. This definition excludes neurogenic diseases such as spinal muscular atrophy, nonhereditary myopathies such as dermatomyositis, nonprogressive and nonnecrotizing congenital myopathies such as congenital muscle fiber–type disproportion, and nonprogressive inherited metabolic myopathies. Some metabolic myopathies can fulfill the definition of a progressive muscular dystrophy but are not traditionally classified as dystrophies (muscle carnitine deficiency).

Many muscular dystrophies might eventually be reclassified as metabolic myopathies once the biochemical defects are better defined. Muscular dystrophies are a group of unrelated diseases, each transmitted by a different genetic trait and each differing in its clinical course and expression (Table 649.1). Identifiable pathogenic variants in some genes may lead to a spectrum of clinical phenotypes, ranging in age of onset, severity, and presence of comorbidities. Some muscular dystrophies are more severe and/or may be present at birth or soon after birth, typically defined as *congenital muscular dystrophies* (Table 649.2), whereas others may have an onset in childhood or even in adulthood. There is a range of severity from those that lead to death in the neonatal period to those that progress gradually over decades, generally with a normal lifespan. Some categories of dystrophies, such as limb-girdle muscular dystrophy (LGMD), are not homogeneous diseases but rather syndromes encompassing several distinct clinical entities and a number of putative genes.

* The editors are grateful to Dr. Diana X. Bharucha-Goebel, much of whose work on previous editions of this chapter is retained here.

649.1 Duchenne and Becker Muscular Dystrophies

Adnan Y. Manzur

Duchenne muscular dystrophy (DMD) is the most common hereditary neuromuscular disease affecting all races and ethnic groups. Its characteristic clinical features are progressive weakness, intellectual impairment, and hypertrophy of the calves, with proliferation of connective tissue and progressive fibrosis in muscle. The incidence is 1 in 3,600 liveborn infant males. This disease is inherited as an X-linked recessive trait. The abnormal gene is at the Xp21 locus and is one of the largest genes. **Becker muscular dystrophy** (BMD) is a disease that is fundamentally similar to DMD, with a genetic defect at the same locus, but clinically it follows a milder and more protracted course.

CLINICAL MANIFESTATIONS

Infant boys with DMD are rarely symptomatic at birth or in early infancy, although some are mildly hypotonic. Early gross motor skills, such as rolling over, sitting, and standing, are usually achieved at the appropriate ages, or may be mildly delayed. Distinctive facies are not an early feature because facial muscle weakness is a late event; in later childhood, a "transverse" or horizontal smile may be seen. Walking is often delayed past 18 months in approximately 50%, and hip girdle weakness may be seen in a subtle form as early as the second year. Toddlers might assume a lordotic posture when standing to compensate for gluteal weakness. An early Gowers sign may be seen by age 3 years, but nearly always is evident by age 5 or 6 years (see Fig. 630.5 in Chapter 630). A Trendelenburg (waddling) gait frequently appears at this time as well. Common presentations in toddlers include delayed walking, frequent falling, toe walking, and trouble running or walking upstairs, developmental delay, and, less often, malignant hyperthermia after anesthesia. A significant minority present with speech or global developmental delay and autistic spectrum traits. Some asymptomatic infants come to attention because of isolated transaminases aspartate transaminase (AST)/alanine transaminase (ALT) elevation, which originates from muscles secondary to sarcolemmal damage, and it is important to perform serum creatinine kinase (CK), which is found to be massively elevated. Non-recognition of this feature leads to hepatology workup and sometimes, an unnecessary muscle biopsy.

The length of time a patient with DMD remains ambulatory varies greatly. Patients may demonstrate increased difficulties with ambulation, due to the proximal lower extremity weakness, that is further confounded by progressive ankle contractures and toe walking. The age of complete loss of ambulation ranges typically from about 10-14 years. The age at which loss of independent ambulation occurs has increased over time with the advent of clinical care guidelines recommending the use of corticosteroids (e.g., prednisone or deflazacort) in boys with DMD (see the section "Treatment"). With orthotic bracing, physiotherapy, and sometimes minor surgery (Achilles tendon lengthening), most are able to walk until age 12 years. Maintenance of ambulation is not only important for preservation of autonomy in activities of daily living (which has psychosocial benefits for the patient and his family), but also provides additional benefits in slowing the progression of scoliosis (that typically worsens after loss of ambulation) and in maintenance of pulmonary health.

The relentless progression of weakness continues into the second decade. The function of distal muscles is usually relatively well enough preserved, allowing the child to continue to use eating utensils, a pencil, and a computer keyboard. As the disease progresses in the teenage years, the upper extremity strength declines further, and patients may have increased difficulties bringing hands to mouth independently, have fatigue with writing, and have worsening contractures, including in the hands and fingers. Respiratory muscle involvement frequently

Chromosomal abnormalities and autosomal recessive, autosomal dominant, X-linked, and mitochondrial inheritance have been all described in the disorders related to arthrogryposis, and genetic counseling should be provided accordingly. If a specific diagnosis is not made, the empirical recurrence risk is defined as 3%, and it is slightly higher (7%) for arthrogryposis plus CNS involvement.

MANAGEMENT

Each affected individual with arthrogryposis is unique, and the natural course of the condition depends on the underlying etiology and management. A multidisciplinary team approach (pediatricians, pediatric orthopedic specialists, plastic or hand surgeons, rehabilitation physicians, occupational therapists, physical therapists, medical geneticists, neurologists) is essential in standard care (see Chapter 723). Management is shifting to a multidisciplinary clinic that provides patient-centered, comprehensive care in a coordinated manner.

In terms of amyoplasia, follow-up is required to identify treatment outcomes such as the development of degenerative arthritis, the need for orthotics for ambulation, or the possibility of becoming overweight in adulthood. Cytokines and other factors released in response to early therapeutic interventions are suggested to facilitate the elongation of pathologic periarticular soft tissues and increase joint motion. The core principle of management in DA is to preserve muscle function. Anesthesia-related complications due to limited jaw opening, restrictive pulmonary function, and the risk of MH should be considered in the setting of multiple surgeries.

Visit Elsevier eBooks+ at eBooks.Health.Elsevier.com for Bibliography.

Chapter 649

Muscular Dystrophies

*Adnan Y. Manzur**

A muscular dystrophy is distinguished from all other neuromuscular diseases by four obligatory criteria: it is a primary myopathy, it has a genetic basis, the course is progressive, and degeneration and death of muscle fibers occur at some stage in the disease. This definition excludes neurogenic diseases such as spinal muscular atrophy, nonhereditary myopathies such as dermatomyositis, nonprogressive and nonnecrotizing congenital myopathies such as congenital muscle fiber–type disproportion, and nonprogressive inherited metabolic myopathies. Some metabolic myopathies can fulfill the definition of a progressive muscular dystrophy but are not traditionally classified as dystrophies (muscle carnitine deficiency).

Many muscular dystrophies might eventually be reclassified as metabolic myopathies once the biochemical defects are better defined. Muscular dystrophies are a group of unrelated diseases, each transmitted by a different genetic trait and each differing in its clinical course and expression (Table 649.1). Identifiable pathogenic variants in some genes may lead to a spectrum of clinical phenotypes, ranging in age of onset, severity, and presence of comorbidities. Some muscular dystrophies are more severe and/or may be present at birth or soon after birth, typically defined as *congenital muscular dystrophies* (Table 649.2), whereas others may have an onset in childhood or even in adulthood. There is a range of severity from those that lead to death in the neonatal period to those that progress gradually over decades, generally with a normal lifespan. Some categories of dystrophies, such as limb-girdle muscular dystrophy (LGMD), are not homogeneous diseases but rather syndromes encompassing several distinct clinical entities and a number of putative genes.

* The editors are grateful to Dr. Diana X. Bharucha-Goebel, much of whose work on previous editions of this chapter is retained here.

649.1 Duchenne and Becker Muscular Dystrophies

Adnan Y. Manzur

Duchenne muscular dystrophy (DMD) is the most common hereditary neuromuscular disease affecting all races and ethnic groups. Its characteristic clinical features are progressive weakness, intellectual impairment, and hypertrophy of the calves, with proliferation of connective tissue and progressive fibrosis in muscle. The incidence is 1 in 3,600 liveborn infant males. This disease is inherited as an X-linked recessive trait. The abnormal gene is at the Xp21 locus and is one of the largest genes. **Becker muscular dystrophy** (BMD) is a disease that is fundamentally similar to DMD, with a genetic defect at the same locus, but clinically it follows a milder and more protracted course.

CLINICAL MANIFESTATIONS

Infant boys with DMD are rarely symptomatic at birth or in early infancy, although some are mildly hypotonic. Early gross motor skills, such as rolling over, sitting, and standing, are usually achieved at the appropriate ages, or may be mildly delayed. Distinctive facies are not an early feature because facial muscle weakness is a late event; in later childhood, a "transverse" or horizontal smile may be seen. Walking is often delayed past 18 months in approximately 50%, and hip girdle weakness may be seen in a subtle form as early as the second year. Toddlers might assume a lordotic posture when standing to compensate for gluteal weakness. An early Gowers sign may be seen by age 3 years, but nearly always is evident by age 5 or 6 years (see Fig. 630.5 in Chapter 630). A Trendelenburg (waddling) gait frequently appears at this time as well. Common presentations in toddlers include delayed walking, frequent falling, toe walking, and trouble running or walking upstairs, developmental delay, and, less often, malignant hyperthermia after anesthesia. A significant minority present with speech or global developmental delay and autistic spectrum traits. Some asymptomatic infants come to attention because of isolated transaminases aspartate transaminase (AST)/alanine transaminase (ALT) elevation, which originates from muscles secondary to sarcolemmal damage, and it is important to perform serum creatinine kinase (CK), which is found to be massively elevated. Non-recognition of this feature leads to hepatology workup and sometimes, an unnecessary muscle biopsy.

The length of time a patient with DMD remains ambulatory varies greatly. Patients may demonstrate increased difficulties with ambulation, due to the proximal lower extremity weakness, that is further confounded by progressive ankle contractures and toe walking. The age of complete loss of ambulation ranges typically from about 10-14 years. The age at which loss of independent ambulation occurs has increased over time with the advent of clinical care guidelines recommending the use of corticosteroids (e.g., prednisone or deflazacort) in boys with DMD (see the section "Treatment"). With orthotic bracing, physiotherapy, and sometimes minor surgery (Achilles tendon lengthening), most are able to walk until age 12 years. Maintenance of ambulation is not only important for preservation of autonomy in activities of daily living (which has psychosocial benefits for the patient and his family), but also provides additional benefits in slowing the progression of scoliosis (that typically worsens after loss of ambulation) and in maintenance of pulmonary health.

The relentless progression of weakness continues into the second decade. The function of distal muscles is usually relatively well enough preserved, allowing the child to continue to use eating utensils, a pencil, and a computer keyboard. As the disease progresses in the teenage years, the upper extremity strength declines further, and patients may have increased difficulties bringing hands to mouth independently, have fatigue with writing, and have worsening contractures, including in the hands and fingers. Respiratory muscle involvement frequently

Table 649.1 Pathophysiologic Classification of Muscular Dystrophy

DISEASE	LOCUS	GENE	MODE OF INHERITANCE
LIMB-GIRDLE MUSCULAR DYSTROPHY (LGMD) CAUSED BY SARCOLEMMA OR CYTOSOLIC PROTEIN DEFECTS			
Duchenne/Becker MD	Xp21	Dystrophin	XR
LGMD 1A (myofibrillar myopathy)	5q31	Myotilin	AD
LGMD 1B (Emery-Dreifuss muscular dystrophy)	1q21	Lamin A/C	AD
LGMD 1C (rippling muscle disease)	3p25	Caveolin	AD
LGMD 1D (D1 DNAJB6-related LGMD)	7q36	DNAJB6	AD
LGMD 1E (myofibrillar myopathy)	6q23	Desmin	AD
LGMD 1F (D2 TNP03-related LGMD)	7q32	Transportin-3	AD
LGMD 1G (D3 HNRNPDL-related LGMD)	2q37	HNRDL	AD
LGMD 1H	3p23-25	Unknown—not confirmed	AD
LGMD 1L (D4 calpain-3–related LGMD)	15q15.1	Calpain-3	
LGMD 2A (R1 calpain-3–related LGMD)	15q15.1	Calpain-3	AR
LGMD 2B (R2 dysferlin–related LGMD)	2p13.1	Dysferlin	AR
LGMD 2C (R5 γ-sarcoglycan–related LGMD)	13q12	γ-Sarcoglycan	AR
LGMD 2D (R3 α-sarcoglycan–related LGMD)	17q21	α-Sarcoglycan	AR
LGMD 2E (R4 β-sarcoglycan–related LGMD)	4q12	β-Sarcoglycan	AR
LGMD 2F (R6 δ-sarcoglycan–related LGMD)	5q33	δ-Sarcoglycan	AR
LGMD 2G (R7-telethonin–related LGMD)	17q11.2	Telethonin (TCAP)	AR
LGMD 2H (R8 TRIM 32–related LGMD)	9q31-q33	Tripartite motif-containing 32 (TRIM32)	AR
LGMD 2I (R9-FKRP–related LGMD)	13q13.3	Fukutin-related protein (FKRP)	AR
LGMD 2J (R10-Titin–related LGMD)	2q31	Titin	AR/AD
LGMD 2K (R11-POMT1–related LGMD)	9q34.1	Protein-O-mannosyltransferase (POMT1)	AR
LGMD 2L (R12-anoctamin 5–related LGMD)	11p14.3	ANO5	AR
LGMD 2M (R13-fukutin–related LGMD)	9q31	Fukutin	AR
LGMD 2N (R14 POMT2–related LGMD)	14q24	POMT2	AR
LGMD 2O (R15 POMGNT1–related LGMD)	1p32	POMGnT1	AR
LGMD 2P (R16 α-dystroglycan–related LGMD)	3p21	DAG1	AR
LGMD 2Q (R17 plectin–related LGMD)	8q24	Plectin 1f	AR
LGMD 2R (myofibrillar myopathy)	2q35	Desmin	AR
LGMD 2S (R18 TRAPPC11–related LGMD)	4q35	TRAPPC11	AR
LGMD 2T (R19 GMPPB–related LGMD)	3p21	GMPPB	AR
LGMD 2U (R20 ISPD–related LGMD)	7p21	ISPD	AR
LGMD 2V (Pompe disease)	17q25	GAA	AR
LGMD 2W (PINCH-2–related myopathy)	2q14	LIMS2	AR
LGMD 2X (BVES-related myopathy)	6p21	BVES	AR
LGMD 2Y (TOR1AIP1-related myopathy)	3q13,33	POGLUT1	AR
LGMD 2Z	6q21	POPDC1	AR
CONGENITAL MUSCULAR DYSTROPHY (CMD) SECONDARY TO GLYCOSYLATION DISORDER			
Fukuyama MD (syndromic)	9q31	Fukutin	AR
Muscle-eye-brain disease (syndromic)	1p34.1	Protein O-linked mannose beta-1,2-N-acetylglucosaminyltransferase (POMGnT1)	AR
Walker-Warburg syndrome (syndromic)	9q34.1	Protein-O-mannosyltransferase (POMT1)	AR
MDC 1A (merosin-negative CMD)	6q22-23	Laminin-a2 (merosin)	
MDC 1B (merosin-positive CMD)	1q42	?	AR

Continued

Table 649.1 Pathophysiologic Classification of Muscular Dystrophy—cont'd

DISEASE	LOCUS	GENE	MODE OF INHERITANCE
MDC 1C	19q13.3	Fukutin-related protein (FKRP)	AR
MC 1D	22q12.3-q13.1	LARGE	AR
OTHER CONGENITAL MUSCULAR DYSTROPHIES			
CMD with early rigid spine (RSS)	1p36	Selenoprotein N-1	AR
CMD with ITGA7 mutations	12q	Integrin α7	AR
Ullrich syndrome/Bethlem myopathy	21q22.3 (A1, A2) 2q37 (A3)	Collagen VI α1, α2, and α3	AD
MUSCULAR DYSTROPHIES SECONDARY TO NUCLEAR ENVELOPE DEFECTS			
Emery-Dreifuss MD X1	Xq28	Emerin	XR
Emery-Dreifuss MD X2	q21.2	Lamin A/C	AD
Emery-Dreifuss MD X3	1q21.2	Lamin A/C	AR
Emery-Dreifuss MD X4	6q25	Synaptic nuclear envelope protein 1 (SYNE1; Nesprin-1)	AD
Emery-Dreifuss MD X5	14q23	SYNE2	AD
Emery-Dreifuss MD X6	Xq26	Four-and-a-half-LIM protein 1 (FHL1)	XR
Emery-Dreifuss MD X7?	3p25.1	LUMA (transmembrane protein 43)	AR
MUSCULAR DYSTROPHIES SECONDARY TO RNA METABOLISM DEFECTS			
Myotonic dystrophy 1 (DM1)	19q13.3	Myotonic dystrophy-associated protein kinase (DMPK)	AD
Myotonic dystrophy 2 (DM2)	3q21	Zinc finger, nucleic acid binding protein (ZNF9)	AD
OTHER MUSCULAR DYSTROPHIES OF UNKNOWN MECHANISM			
Facioscapulohumeral dystrophy (FSHD)	3q21	FRG-1 (FSH region gene 1)	AD
Oculopharyngeal MD	14q11.2-q13	PABPN1	AD

Note: LGMD table: Disease names in parentheses: New nomenclature proposed from 2018 European Neuromuscular Centre Workshop.
AD, Autosomal dominant; AR, autosomal recessive; MD, muscular dystrophy; MDC, muscular dystrophy congenita; XR, X-linked recessive.
From Rocha CT, Escolar DM. Treatment and management of muscular dystrophy. In: Bertorini TE, ed. *Neuromuscular Disorders Treatment and Management*, 2nd ed. Philadelphia: Elsevier; 2022: Table 20.1, p. 493–494.

Table 649.2 Specific Congenital Muscular Dystrophies: Distinguishing Clinical Features

SUBCATEGORY	DISTINGUISHING CLINICAL FEATURES	ASSOCIATED GENES
Collagen VI-related dystrophies	• Proximal muscle weakness in childhood • Severe hypotonia and diffuse weakness in infancy • Infantile onset typically never achieves ambulation • Early-onset proximal contractures diffusely • Distal joint hyperlaxity • Hyperkeratosis pilaris on skin (legs and arms) • Keloids • Atrophic, wide scars • Scoliosis (early) • Very thin body habitus • Severe restrictive lung disease early requiring bilevel ventilation • Normal intellect • CK usually elevated (100–several 1,000 U/L)	*COL6A1, COL6A2, COL6A3*
cLAMA2-related dystrophies	• Proximal muscle weakness in childhood • Severe hypotonia and diffuse weakness in infancy • Infantile onset typically never achieves ambulation • Early-onset proximal contractures diffusely • Brain MRI demonstrates white matter disease (clinically not significant) • Some develop seizures • Very thin body habitus • Severe restrictive lung disease early requiring bilevel ventilation • Nerve conductions demonstrate slowing • Normal intellect • CK usually in the 1,000s	*LAMA2*

Table 649.2 Specific Congenital Muscular Dystrophies: Distinguishing Clinical Features—cont'd

SUBCATEGORY	DISTINGUISHING CLINICAL FEATURES	ASSOCIATED GENES
Dystroglycan-related disorders (dystroglycanopathies, previously known as muscle-eye-brain disease)	• Mild to severe proximal muscle weakness and hypotonia in infancy • Varying degrees of CNS involvement • Brain MRI may be abnormal—lissencephaly, pachygyria, cerebellar hypoplasia, or dysplasia • *FKRP* and *FKTN* may cause a cardiomyopathy, if late onset • Varying degree of eye involvement—severe myopia, retinal hypoplasia • Intellectual delay ranging from normal to severe disability	*POMT1, POMT2, POMGnT1, POMGnT2, FKTN, FKRP, LARGE, ISPD, GTDC2, B3GALNT2, B3GNT1, B4GAT1, TMEM5, POMK, DPM1, DPM2, DPM3, DOLK, GMPPB, RXYLT1, DAG1*
Myofibrillar myopathy	• Distal and proximal muscle weakness developing in adolescence or early adulthood • Respiratory muscle weakness often necessitating noninvasive or invasive ventilatory support • Rigid spine • Possible sensory neuropathy	*BAG3, CRYAB, DES, FLNC, KY, LDB3, MYOT, PYROXD1*
Selenon-related myopathy	• Severe axial weakness • Early-onset scoliosis • Early-onset restrictive lung disease requiring bilevel noninvasive ventilation, before loss of ambulation (characteristic) • Normal intellect	*SEPN1*
LMNA-related dystrophy	• Severe hypotonia and diffuse weakness in infancy • Proximal muscle weakness in childhood • Prominent head drop in infancy (dropped-head syndrome); may achieve ambulation despite head drop • At risk of cardiac arrhythmia • Early diffuse contractures • Severe restrictive lung disease requiring bilevel ventilation	*LMNA*

CK, Creatine kinase; CNS, central nervous system.
From Konersman CG. Hypotonia and weakness. In: Kliegman RM, Toth H, Bordini BJ, Basel D, eds. *Nelson Pediatric Symptom-Based Diagnosis*, 2nd ed. Philadelphia: Elsevier; 2023: Table 35.35, p. 616–617.

manifests as a weak and ineffective cough, frequent pulmonary infections, and decreasing respiratory reserve. Early pulmonary symptoms often include snoring and sleep apnea. Parents or patients may report an increased frequency of headaches, difficulty awakening in the mornings, and increased daytime fatigue as signs of sleep-disordered breathing. Pharyngeal weakness can lead to episodes of aspiration, nasal regurgitation of liquids, and an airy or nasal voice quality. The function of the extraocular muscles remains well preserved. Incontinence due to anal and urethral sphincter weakness is an uncommon and very late event.

Contractures most often involve the ankles, knees, hips, and elbows. As upper extremity weakness progresses, contractures are also seen in neck lateral rotation, shoulders, and fingers. **Scoliosis** is common in patients with DMD. The thoracic deformity further compromises the pulmonary capacity and compresses the heart. It may also lead to more discomfort, and if severe enough, risk for hip dislocation. Scoliosis usually progresses more rapidly after the child becomes nonambulatory. However, in the era of corticosteroid use, there may be a further protective effect on the development of and rate of progression of scoliosis. Enlargement of the calves (pseudohypertrophy) and wasting of thigh muscles are classic features. The enlargement is caused by hypertrophy of some muscle fibers, infiltration of muscle by fat, and proliferation of collagen. After the calves, the next most common site of muscular hypertrophy is the tongue, followed by muscles of the forearm. Abnormalities of the muscle are demonstrated using muscle MRI techniques to assess signal, water content, fat fractions, and even MR spectroscopy profiles (Fig. 649.1). Fasciculations of the tongue do not occur. The voluntary sphincter muscles rarely become involved.

Unless ankle contractures are severe, ankle deep tendon reflexes remain preserved until terminal stages. The knee deep tendon reflexes may be present until about 6 years of age but are less brisk than the ankle jerks and are eventually lost with the progression of weakness.

Cardiomyopathy, including persistent tachycardia and myocardial fibrosis, occurs in a majority of patients with DMD. The severity of cardiac involvement does not necessarily correlate with the degree of skeletal muscle weakness. In patients with DMD, the progression of cardiomyopathy typically occurs after loss of independent ambulation. However, in patients with BMD, patients may develop worsening of cardiomyopathy and even develop severe heart failure despite still being ambulant. Smooth muscle dysfunction, particularly of the gastrointestinal tract, is a minor, but often overlooked, feature.

Intellectual impairment occurs in a majority of patients, although only 20–30% have an IQ <70. There is a range in the extent of intellectual disability, with some patients requiring specialized education and having difficulty with reading and writing, to those less severely affected who may only require some additional tutoring or assistance. The extent of severity of the intellectual disability does not appear to correlate with the severity of the myopathy but may be related to the location of the mutations in the dystrophin gene. Epilepsy is slightly more common than in the general pediatric population, although it is not a salient feature of DMD. Autism-like behavior may develop in some patients. Dystrophin is expressed in brain and retina, as well as in striated and cardiac muscle, though the level is lower in brain than in muscle. This distribution might explain some of the central nervous system manifestations. Abnormalities in cortical architecture and of dendritic arborization may be detected neuropathologically; cerebral atrophy is demonstrated by MRI late in the clinical course. Patients with DMD and BMD may occasionally report myalgias that are often exercise or exertion induced. Calcinosis of muscle is rare.

Death in males with DMD occurs in the late teens to 20s.The causes of death are respiratory failure during sleep, intractable heart failure, pneumonia, or, occasionally, aspiration and airway obstruction. In the recent decade, and with the application of standards of care, survival is prolonged into the 30s in many patients.

In **BMD,** the onset is often after 5 years or 7 years of age, and most boys remain ambulatory into adulthood. Calf pseudohypertrophy, cardiomyopathy, and elevated serum levels of CK are similar to those of patients with DMD. Cramps on exercise and myoglobinuria may be initial presenting features. Given the increased level of activity in BMD patients, the cardiac manifestations, including tachycardia, shortness of breath, or fatigue, may be evident earlier in patients with BMD and even in the setting of independent ambulation. Learning disabilities

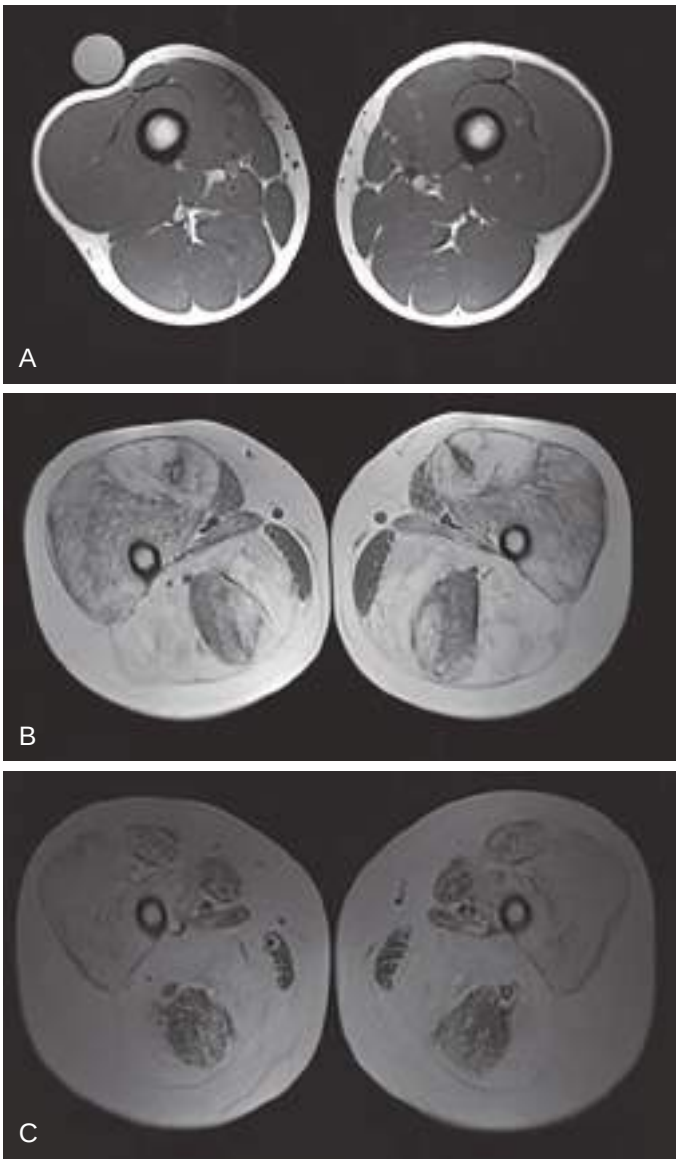

Fig. 649.1 Axial T1-weighted MRI images of the thigh in a healthy 14-yr-old male (**A**), 9-yr-old ambulant male with DMD (**B**), and 14-yr-old ambulant male with DMD (**C**), showing the increased fatty infiltration and muscle atrophy in males with DMD. *(Courtesy Dr. Ami Mankodi, Neurogenetics Branch, NINDS/NIH.)*

are less common. The onset of weakness is later in BMD than in DMD. The lifespan in patients with BMD is typically into the 40s and 50s, with cardiac complications as well as pulmonary complications frequently leading to morbidity.

LABORATORY FINDINGS

The serum CK level is consistently greatly elevated in DMD, even in presymptomatic stages, including at birth. The usual serum concentration is 15,000-35,000 IU/L (normal <160 IU/L). A normal serum CK level is incompatible with the diagnosis of DMD, although in terminal stages of the disease, the serum CK value may be considerably lower than it was a few years earlier because there is less muscle to degenerate. Other lysosomal enzymes present in muscle, such as aldolase and aspartate aminotransferase, are also increased but are less specific.

Cardiac assessment by echocardiography and ECG are essential and should be monitored. The recommendation is for cardiac surveillance every year starting at the time of diagnosis, and then yearly. After the diagnosis of DMD is established, patients should be referred to a pediatric cardiologist who is familiar with the care of DMD patients

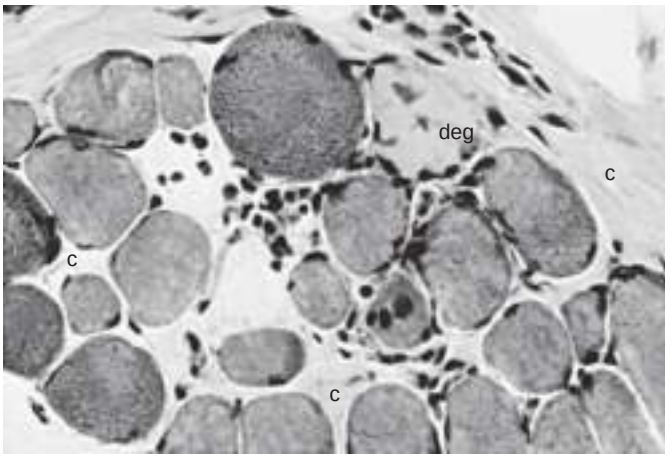

Fig. 649.2 Muscle biopsy of a 4-yr-old male with Duchenne muscular dystrophy. Both atrophic and hypertrophic muscle fibers are seen, and some fibers are degenerating *(deg)*. Connective tissue *(c)* between muscle fibers is increased (hematoxylin and eosin, ×400).

for long-term cardiac care. Cardiac MRI may detect changes such as muscle fibrosis in the heart evident even earlier than the changes seen by echocardiography.

Electromyography (EMG) shows characteristic myopathic features but is not specific for DMD. No evidence of denervation is found. Motor and sensory nerve conduction velocities are normal.

DIAGNOSIS

Genetic evaluation for DMD typically begins with deletion/duplication analysis of the dystrophin gene, using dosage analysis. If negative, then sequencing of the dystrophin gene by next-generation sequencing is performed. If genetic analysis is still negative for a pathogenic variant in the dystrophin gene, but if the suspicion is high based on clinical features and serum CK levels, then muscle biopsy with dystrophin immunohistochemistry may be useful. Immunohistochemical staining of frozen sections of muscle biopsy tissue detects differences in the rod domain, the carboxyl terminus (that attaches to the sarcolemma), and the N terminus or amino terminus (that attaches to the actin myofilaments) of the large dystrophin molecule and may be prognostic of the clinical course as Duchenne or Becker disease. More severe weakness occurs with truncation of the dystrophin molecule at the carboxyl terminus than at the amino terminus. Dystroglycans and other sarcolemmal regional proteins, such as merosin and sarcoglycans, also can be measured because they may be secondarily decreased. Further genetic testing could be done, which may include RNA sequencing from muscle to attempt to identify a variant altering splicing (e.g., one that may not be identified on next-generation sequencing). Accurate assignation of pathogenicity and anticipated severity of a particular dystrophin gene variant can be difficult, and free access to various international databases is most helpful for the clinician; the Leiden pathogenic variant database maintained by the Leiden University Medical Center and ClinVar hosted by the National Center for Biotechnology Information (Bethesda, MD), are good examples.

The **muscle biopsy** is diagnostic and shows characteristic changes (Figs. 649.2 and 649.3). Myopathic changes include endomysial connective tissue proliferation, scattered degenerating and regenerating myofibers, foci of mononuclear inflammatory cell infiltrates as a reaction to muscle fiber necrosis, mild architectural changes in still-functional muscle fibers, and many dense fibers. These hypercontracted fibers probably result from segmental necrosis at another level, allowing calcium to enter the site of breakdown of the sarcolemmal membrane and trigger a contraction of the whole length of the muscle fiber. Calcifications within myofibers are correlated with secondary β-dystroglycan deficiency.

The decision about whether muscle biopsy should be performed to establish the diagnosis sometimes presents problems. If there is a

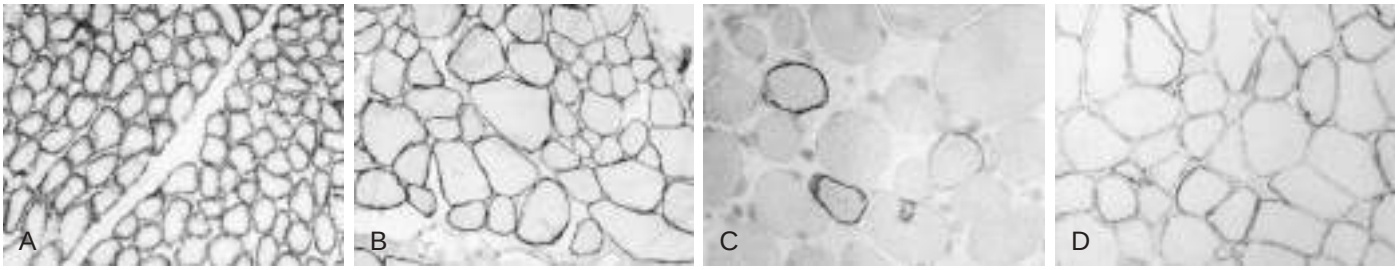

Fig. 649.3 Dystrophin is demonstrated by immunohistochemical reactivity in the muscle biopsies of a normal-term male neonate (**A**), a 10-yr-old male with limb-girdle muscular dystrophy (**B**), a 6-yr-old male with Duchenne muscular dystrophy (**C**), and a 10-yr-old male with Becker muscular dystrophy (**D**). In the normal condition, and also in non–X-linked muscular dystrophies in which dystrophin is not affected, the sarcolemmal membrane of every fiber is strongly stained, including atrophic and hypertrophic fibers. In Duchenne dystrophy, most myofibers express no detectable dystrophin, but a few scattered fibers known as revertant fibers show near-normal immunoreactivity. In Becker muscular dystrophy, the abnormal dystrophin molecule is thin, with pale staining of the sarcolemma, in which reactivity varies not only between myofibers but also along the circumference of individual fibers (×250).

family history of the disease, particularly in the case of an involved brother whose diagnosis has been confirmed, a patient with typical clinical features of DMD and high concentrations of serum CK probably does not need to undergo biopsy. The result of the genetic testing (dystrophin deletion/duplication analysis and sequencing) might also influence whether to perform a muscle biopsy. If there is a doubt about the pathogenicity of the dystrophin gene variant, muscle biopsy is useful in confirming or refuting the diagnosis. The most common muscles sampled are the vastus lateralis and the gastrocnemius.

GENETIC ETIOLOGY AND PATHOGENESIS

Despite the X-linked recessive inheritance in DMD, approximately 30% of cases are new or de novo pathogenic variant, and the mother is not a carrier. The female carrier state usually shows no muscle weakness, but due to skewed X-inactivation, about 8% of carrier females are *manifesting* carriers with some weakness, although typically milder than is seen in affected males. These symptomatic females are explained by the Lyon hypothesis, in which the normal X chromosome becomes inactivated and the one with the gene deletion is active (see Chapter 97). The full clinical picture of DMD has occurred in several females with Turner syndrome in whom the single X chromosome must have had the Xp21 gene deletion.

The asymptomatic carrier state of DMD is associated with elevated serum CK values in about 50% of cases. The level of increase is usually in the magnitude of hundreds or a few thousand but does not have the extreme values noted in affected males. Prepubertal females who are carriers of the dystrophy also have increased serum CK values, with highest levels at 8-12 years of age. If the mother of an affected male has normal CK levels, it is unlikely that her daughter can be identified as a carrier by measuring CK. Muscle biopsy of suspected female carriers can detect an additional 10% in whom serum CK is not elevated; a specific genetic diagnosis using polymerase chain reaction (PCR) on peripheral blood is definitive. Approximately 40% of female carriers may be at risk of developing cardiomyopathy or fibrosis (determined by cardiac imaging of carrier females), even in the absence of skeletal muscle weakness.

A 427-kDa cytoskeletal protein known as *dystrophin* is encoded by the gene at the Xp21.2 locus. This gene contains 79 exons of coding sequence and 2.5 Mb of DNA. This subsarcolemmal protein attaches to the sarcolemmal membrane overlying the A and M bands of the myofibrils and consists of four distinct regions or domains: the amino terminus contains 250 amino acids and is related to the *N*-actin binding site of α-actinin; the second domain is the largest, with 2,800 amino acids, and contains many repeats, giving it a characteristic rod shape; a third, cysteine-rich domain is related to the carboxyl terminus of α-actinin; and the final carboxyl-terminal domain of 400 amino acids is unique to dystrophin and to a dystrophin-related protein encoded by chromosome 6. The absence of dystrophin at the sarcolemma disrupts the membrane cytoskeleton and leads to loss secondarily of other components of the cytoskeleton.

The molecular defects in the dystrophinopathies vary and include intragenic deletions, duplications, or point variants of nucleotides. Approximately 65% of patients have deletions, approximately 10% exhibit duplications, and approximately 10% have point variants or smaller rearrangements. In less than 1% of cases, a deep intronic variant may lead to an alteration of splicing and thereby may impact the reading frame. The site or size of the intragenic abnormality does not always correlate well with the phenotypic severity; in both the Duchenne and Becker forms the variants are mainly near the middle of the gene, involving deletions in regions between exons 45 and 55. Phenotypic or clinical variations are explained by the alteration of the translational reading frame of messenger RNA (mRNA), which results in unstable, truncated dystrophin molecules and severe, classic DMD; variants that preserve the reading frame still permit translation of coding sequences further downstream on the gene and produce a semifunctional dystrophin, expressed clinically as BMD. An even milder form of adult-onset disease, formerly known as **quadriceps myopathy,** is also caused by an abnormal dystrophin molecule. The clinical spectrum of the dystrophinopathies, especially a presentation, not only includes the classic Duchenne and Becker forms but also global developmental delay with autistic spectrum features, failure to thrive, and symptomatic cardiomyopathy.

Analysis of the dystrophin protein requires a muscle biopsy and is demonstrated by Western blot analysis or in tissue sections by immunohistochemical methods using either fluorescence or light microscopy of antidystrophin antisera (see Fig. 649.3). In classic DMD, levels of <3% of normal are found; in BMD, the molecular weight of dystrophin is reduced to 20–90% of normal in 80% of patients, but in 15% of patients the dystrophin is of normal size but reduced in quantity, and 5% of patients have an abnormally large protein caused by excessive duplications or repeats of codons. Selective immunoreactivity of different parts of the dystrophin molecule in sections of muscle biopsy material distinguishes the Duchenne and Becker forms (Fig. 649.4). The demonstration of deletions and duplications also can be made from blood samples by the more rapid PCR, which identifies as many as 98% of deletions by amplifying 18 exons but cannot detect duplications. The diagnosis can thus be confirmed at the molecular genetic level from either the muscle biopsy material or from peripheral blood, although as many as 30% of males with DMD or BMD have a false-normal blood PCR; all cases of dystrophinopathy are detected by muscle biopsy.

The same methods of DNA analysis from blood samples may be applied for carrier detection in female relatives at risk, such as sisters and cousins, and to determine whether the mother is a carrier or whether a new variant occurred in the embryo. Prenatal diagnosis is possible as early as the 12th week of gestation by sampling chorionic villi for DNA analysis by Southern blot or PCR, and in cases of aborted fetuses with DMD, muscle demonstrates abnormal dystrophin staining by immunohistochemistry. Newborn screening for DMD is not currently part of the routine neonatal screening. Nonetheless, a CK-based test is available for families requesting screening.

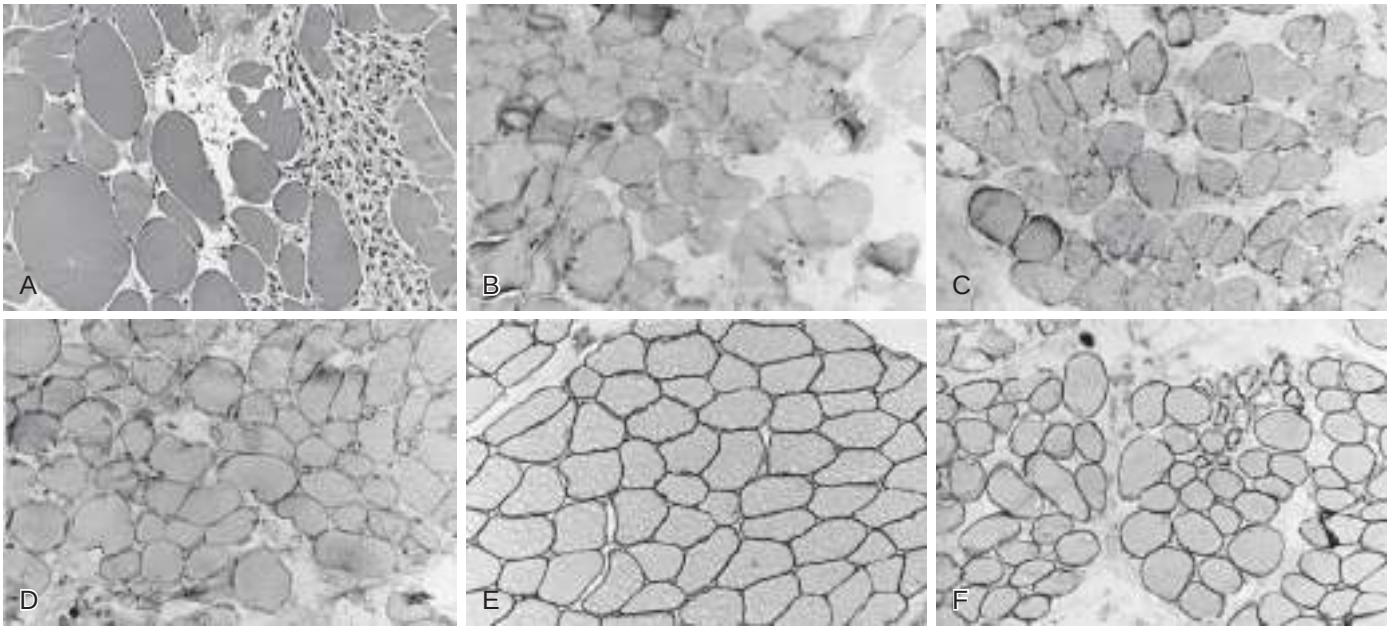

Fig. 649.4 Quadriceps femoris muscle biopsy specimens from a 4-yr-old male with Becker muscular dystrophy. **A,** Myofibers vary greatly in size, with both atrophic and hypertrophic forms; at the right is a zone of degeneration and necrosis infiltrated by macrophages, similar to Duchenne muscular dystrophy (hematoxylin and eosin, ×250). Immunoreactivity using antibodies against the dystrophin molecule in the rod domain **(B),** carboxyl terminus **(C),** and amino terminus **(D)** all show deficient but not totally absent dystrophin expression; most fibers of all sizes retain some dystrophin in parts of the sarcolemma but not around the entire circumference in cross section. Alternatively, the prominence of dystrophin is less, appearing weak, when compared with the simultaneously incubated normal control from another child of similar age **(E). F,** Merosin expression is normal in this patient with Becker dystrophy, in both large and small myofibers, and is lacking only in frankly necrotic fibers. Compare with classic Duchenne muscular dystrophy illustrated in Figures 649.3C and 649.8.

TREATMENT

There is no medical cure for this disease at this time. The mainstay of management for DMD has been supportive care and prevention of complications. Much can be done to treat complications and to improve the quality of life of affected children. Updated, international consensus care guidelines of DMD are available (pulmonary, cardiac, bone) and are a key driver for improvement and management.

Glucocorticoids (prednisone or deflazacort) have been shown to slow the decline in muscle strength and increase the time a patient maintains independent ambulation, and it may have additional benefits on scoliosis progression. Initiation of steroids is indicated when a child shows a plateau in development and/or a regression in motor development as compared with peers. This typically occurs by 4-6 years old. Recommended doses are prednisone 0.75 mg/kg/day or deflazacort 0.9 mg/kg/day. Alternative protocols for steroid administration include weekend-only dosing, alternate-day regimens, or 10-day-on/10-day-off regimens; the daily regimen has been the preferred regimen based upon comparative studies. Long-term complications include weight gain, osteoporosis, delayed puberty, growth retardation, acne, glucose intolerance, and cataracts. Given the improvements with steroids in motor abilities, as well as potentially in pulmonary, orthopedic, and cardiac health, they are recommended for children with DMD. Vamorolone, a novel corticosteroid, may have greater efficacy and fewer adverse events (bone, growth, behavior) compared to conventional steroid therapy; it is approved for children ≥ 2 years old.

Exondys 51 (eteplirsen) is an exon 51 skipping antisense oligonucleotide approach that binds RNA and skips over the defective exon, restoring the reading frame, thereby producing a shorter but potentially functional dystrophin protein. This only applies to patients with pathogenic variants amenable to this repair (~13% of patients). It is given as a weekly IV infusion. Ataluren permits read through of premature stop codons (10–15% of patients) from a nonsense variant, resulting in production of a functional dystrophin. It may have benefits in patients at a certain level of disease progression. Golodirsen (Vyondys 53) and viltolarsen (Viltepso) are additional antisense oligonucleotides that are approved for the ~8% of patients with pathogenic variants in exon 53. Cardiosphere-derived cells, which have immune mediating, antifibrotic, and regenerative properties, are undergoing investigation for DMD.

Elevidys, an FDA approved recombinant gene therapy, delivers a shortened (138kDa vs 427kDa) dystrophin protein that is expressed in muscle in children 4-5 years old after a single intravenous dose.

Cardiac care initially includes angiotensin-converting enzyme (ACE) inhibitors, angiotensin receptor blockers, or β blockers. Other agents used include aldosterone antagonists (e.g., Aldactone or eplerenone). Initiation of cardiac medications at the time of a drop in the left ventricular ejection fraction to <55% or for symptomatic cardiomyopathy is noncontroversial. The prophylactic use of ACE inhibitors and β blockers aiming to delay echocardiographic symptomatic cardiomyopathy is now recommended from age 10 years onward by most consensus care guidelines. This is based on recent data showing MRI changes in the heart preceding the echocardiogram abnormalities, and a potentially cardioprotective effect with agents such as ACE inhibitors. Due to potential risks for hyperkalemic or rhabdomyolytic reactions to anesthesia, it is recommended to avoid agents such as inhaled anesthetics or muscle relaxants.

Pulmonary infections should be promptly treated. Patients should avoid contact with children who have obvious respiratory or other contagious illnesses. Immunizations for influenza virus and other routine vaccinations are indicated. When sleep-disordered breathing is suspected or the forced vital capacity drops below 60% predicted for age, children should undergo sleep studies and the use of bilevel positive airway pressure (BiPAP) should be considered. Additional devices such as lung volume recruitment bag or a cough assist device, proper suctioning, and nebulized therapies may assist with airway clearance as children develop weakness in coughing.

Preservation of a good **nutritional state** is important. DMD is not a vitamin-deficiency disease, and excessive doses of vitamins should be avoided. Adequate vitamin D and calcium intake is important to minimize osteoporosis in boys confined to a wheelchair. However, due to chronic corticosteroid use combined with the loss of ambulation, boys with DMD are at higher risk for osteopenia and osteoporosis, putting them at higher risk for fractures in the setting of even minor injuries or falls. Dual x-ray absorptiometry (DEXA) scans should be done in boys with DMD and vitamin D levels should be optimized. Some patients with low bone density may require additional therapies such as bisphosphonates, or testosterone in cases of pubertal delay. Because of the decreased caloric expenditure in nonambulant children and the

use of corticosteroids, these children tend to eat excessively and gain weight. Obesity makes a patient with myopathy even less functional because part of the limited reserve muscle strength is dissipated in lifting the weight of excess subcutaneous adipose tissue. Dietary restrictions with supervision may be needed.

Physiotherapy delays but does not always prevent contractures. At times, contractures are actually useful in functional rehabilitation. If contractures prevent extension of the elbow beyond 90 degrees and the muscles of the upper limb no longer are strong enough to overcome gravity, the elbow contractures are functionally beneficial in fixing an otherwise flail arm and in allowing the patient to eat and write. Surgical correction of the elbow contracture may be technically feasible, but the result may be deleterious. Stretching and bracing methods may be useful depending on the location of the contracture and level of severity of the contracture. Surgical interventions should be considered with caution and with input from the neurologist, physical therapist, and/or physical medicine and rehabilitation specialists involved in the child's care. Physiotherapy contributes little to muscle strengthening because patients usually are already using their entire reserve for daily functioning, and exercise cannot further strengthen involved muscles. Excessive exercise can actually accelerate the process of muscle fiber degeneration.

Special vigilance should be maintained in watching for scoliosis, which often progresses more rapidly once the patient loses independent ambulation, and coincident with pubertal growth spurt. Early referral to orthopedics is indicated as the definitive treatment for progressive scoliosis is with spinal fusion surgery, and multidisciplinary team management is required to ensure the safety of this major procedure, especially from the respiratory and cardiac perspective.

Visit Elsevier eBooks+ at eBooks.Health.Elsevier.com for Bibliography.

649.2 Emery-Dreifuss Muscular Dystrophy/ Laminopathies

Adnan Y. Manzur

Emery-Dreifuss muscular dystrophy (EDMD) is a form of muscular dystrophy caused by pathogenic variants involving nuclear envelope proteins (see Table 649.1). It was first described as a rare X-linked recessive disorder caused by variant in *EMD* encoding emerin. The locus of its associated genetic abnormality is on the long arm within the large Xq28 region that includes other genes that cause myotubular myopathy, neonatal adrenoleukodystrophy, and the Bloch-Sulzberger type of incontinentia pigmenti. Subsequently, *dominant variants* in *LMNA* located on chromosome 1q21 that encodes for nuclear envelope protein lamin A/C, were found to be abnormal in male and female affected patients. This form can manifest both as a congenital muscular dystrophy (CMD) or one with an onset later in adolescence or adulthood, and it represents a broad phenotypic spectrum (see Table 649.2). In addition to the motor manifestations, which are variable, there is also a risk of sudden death from ventricular fibrillation, which can occur as early as in childhood in some cases.

Clinical manifestations range from a CMD with severe weakness, respiratory insufficiency, and contractures from infancy or children with weakness and a *dropped head syndrome* to the more classic EDMD forms. In the childhood-onset EDMD forms, symptoms may begin between 5 and 15 years of age, but many patients survive to late adult life because of the slow progression of the course of the disease. Muscles *do not* exhibit pseudohypertrophy. Contractures of the elbows, ankles, and neck extensor muscles develop early, and muscle becomes wasted in a scapulohumeroperoneal distribution. Facial weakness *does not* typically occur; this disease is thus distinguished clinically from autosomal dominant scapulohumeral and scapuloperoneal syndromes of *neurogenic* origin. Myotonia is absent. Intellectual function is normal. *Dilated cardiomyopathy* is severe and is often the cause of death, more commonly from conduction defects such as atrial fibrillation/flutter and sudden ventricular fibrillation than from intractable myocardial failure. Stroke is another complication, secondary to the cardiac arrhythmia. Respiratory insufficiency is more prominent in the early and severe forms and may require mechanical ventilation, especially in the severe congenital-onset patients. The serum CK value is only mildly to moderately elevated, further distinguishing this disease from other X-linked recessive muscular dystrophies.

Nonspecific myofiber necrosis and endomysial fibrosis are seen in the muscle biopsy. Many centronuclear fibers and a selective histochemical type I muscle fiber atrophy can cause confusion with myotonic dystrophy.

GENETICS

The defective gene in the X-linked form is called *EMD* or *EDMD* and encodes a protein, emerin. Unlike other dystrophies in which the defective gene is expressed at the sarcolemmal membrane, emerin is expressed at the inner nuclear membrane; this protein stabilizes the nuclear membrane against the mechanical stresses that occur during muscular contraction. It interacts with *Nesprin-1* and *Nesprin-2* genes, also critical for nuclear membrane integrity. Complete deletion of *EDMD* occurs in approximately 25% of cases and results from an inversion in the Xq28 region; total absence of emerin is demonstrated by both Western blotting and immunoreactivity in tissue sections. Another gene, *LMNA,* at the 1q21 locus, is linked to the nuclear envelope and encodes lamin A/C, sometimes termed *laminopathy.* This genetic variant causes a similar clinical phenotype to EMD defects, except that both sexes are affected, and it is transmitted as either an autosomal dominant or recessive trait. Most *EMD* deletions are null variants, whereas more than 80% of *LMNA* alterations are caused by missense variants, and with a minority being nonsense or out-of-frame variants. Desmin protein also may be abnormal and seen to be abnormally expressed in the muscle biopsy. Homozygous nonsense variants in these *lamin A/C* genes are lethal due to cardiomyopathy and conduction disturbances. *There remain many patients with an EDMD phenotype clinically, where the underlying genetic defect remains unknown.*

DIAGNOSTICS

In suspected cases, emerin deficiency may be demonstrated not only in the muscle biopsy by immunoreactivity and Western blotting techniques but also in a variety of other tissues, including circulating lymphocytes in peripheral blood, exfoliative buccal mucosal cells, and skin fibroblasts. Emerin is absent in varying proportions in female carriers. Muscle histology in *LMNA* patients is typically *nonspecific* with myopathic or mild dystrophic changes, with variability in fiber size, increase in connective tissue, and necrotic fibers. Genetic testing of the specific genes is available, and in a patient with typical phenotype may confirm the diagnosis without the need for muscle biopsy. Patients should have careful cardiac evaluation, including an electrocardiogram, echocardiogram, and at least 24-hour Holter monitoring. Serum CK levels may be moderately elevated. Muscle MRI of the glutei and lower extremities may be helpful, particularly in *LMNA* variants. EMG is not definitively diagnostic. Muscle biopsy is diagnostic from the onset of symptoms. In the differential diagnosis, an Emery-Dreifuss–like syndrome with joint contractures, mild weakness, and later-onset cardiac symptoms is caused by *FHL1* variants of *myofibrillar myopathy,* but reducing bodies are absent.

Treatment should be supportive, with special attention to cardiac conduction defects, and can require medications or a pacemaker. Implantable cardioverter-defibrillators are available and have prevented sudden death in some patients with EDMD. In patients with cardiac arrhythmias or a severe decrease in left ventricular function, there may be an increased risk of thromboembolic events, and antithrombotic drugs may be considered. Pulmonary care should include monitoring with pulmonary function tests as well as surveillance for sleep-disordered breathing if clinically indicated. Orthopedic management, use of orthotic devices, or physical therapy to try to minimize or slow down the rate of progression of contractures may be beneficial.

Visit Elsevier eBooks+ at eBooks.Health.Elsevier.com for Bibliography.

649.3 Myotonic Muscular Dystrophy

Adnan Y. Manzur

Myotonic dystrophy is the second most common muscular dystrophy in North America, Europe, and Australia, having an incidence varying from 1 in 20,000 to 1 in 100,000 in the general population. It is inherited as an autosomal dominant trait (see Table 649.1). **Classic myotonic dystrophy (type 1)** (DM1, or Steinert disease) is caused by a CTG trinucleotide expansion on chromosome 19q13.3 in the 3′ untranslated region of *DMPK,* the gene that encodes a serine–threonine protein kinase. **Type 2 (DM2)** is associated with an unstable CCTG tetranucleotide repeat expansion on chromosome 3q21 of an intron of the zinc finger 9 protein gene. A third **late form (DM3)** is identified at locus 15q21-q24.

Myotonic dystrophy is an example of a genetic defect causing dysfunction in multiple organ systems. Not only is striated muscle severely affected, but smooth muscle of the alimentary tract and uterus is also involved, cardiac function is altered, and patients have multiple and variable endocrinopathies, immunologic deficiencies, cataracts, dysmorphic facies, an increased risk for malignancies, intellectual impairment, and other neurologic abnormalities.

CLINICAL MANIFESTATIONS

DM1 becomes symptomatic at any age, but DM2 is rarely expressed in infancy or early childhood. In the usual clinical course, *excluding the severe neonatal form,* DM1 infants can appear almost normal at birth, or facial wasting and hypotonia can already be early expressions of the disease. The facial appearance is characteristic, consisting of an inverted-V–shaped upper lip, thin cheeks, and scalloped, concave temporalis muscles (Fig. 649.5). The head may be narrow, and the palate is high and arched because the weak temporal and pterygoid muscles in late fetal life do not exert sufficient lateral forces on the developing head and face.

In DM1, weakness is often mild in the first few years (childhood-onset form) or may not even become evident until adolescence or early adulthood (classic/adult-onset form). Progressive wasting of distal muscles becomes increasingly evident, particularly in the intrinsic muscles of the hands. The thenar and hypothenar eminences are flattened, and the atrophic dorsal interossei leave deep grooves between the fingers. The dorsal forearm muscles and anterior compartment muscles of the lower legs also become wasted. The tongue is thin and atrophic. Wasting of the sternocleidomastoids gives the neck a long, thin, cylindrical contour. Proximal muscles also eventually undergo atrophy, and scapular winging appears. Difficulty with climbing stairs and Gowers sign are progressive. Tendon stretch reflexes are usually preserved.

The distal distribution of muscle wasting in myotonic dystrophy is an *exception* to the general rule of myopathies having proximal and neuropathies with distal distribution patterns. The muscular atrophy and weakness in myotonic dystrophy are slowly progressive throughout childhood and adolescence and continue into adulthood. It is rare for patients with myotonic dystrophy to lose the ability to walk even in late adult life, although splints or bracing may be required to stabilize the ankles.

Myotonia, *a characteristic feature shared by few other myopathies*, does not occur in infancy and is usually not clinically or even electromyographically evident until about age 5 years. Exceptional patients develop it as early as age 3 years. Myotonia is a very slow relaxation of muscle after contraction, regardless of whether that contraction was voluntary or was induced by a stretch reflex or electrical stimulation. During physical examination, myotonia may be demonstrated by asking the patient to make tight fists and then to quickly open the hands (grip myotonia; Fig. 649.6). It may be induced by striking the thenar eminence with a rubber percussion hammer (percussion myotonia), and it may be detected by watching the involuntary drawing of the thumb across the palm. Myotonia can also be demonstrated in the tongue by pressing the edge of a wooden tongue blade against its dorsal surface and by observing a deep furrow that disappears slowly. The severity of myotonia does not necessarily parallel the degree of weakness, and the weakest muscles often have only minimal myotonia. *Myotonia is not a painful muscle spasm.* Musculoskeletal pain and fatigue are fairly commonly reported in patients with myotonic dystrophy.

The **speech** of patients with myotonic dystrophy is often articulated poorly and is slurred because of the involvement of the muscles of the face, tongue, and pharynx. Both myotonia and weakness can drive the difficulties in patients' speech and swallowing. Difficulties with swallowing sometimes occur, and more severely involved patients may be at risk for aspiration pneumonia. Incomplete external ophthalmoplegia sometimes results from extraocular muscle weakness.

Smooth muscle involvement of the **gastrointestinal tract** results in slow gastric emptying, poor peristalsis, and constipation. Some patients have encopresis associated with anal sphincter weakness. Women with myotonic dystrophy can have ineffective or abnormal uterine contractions during labor and delivery.

Cardiac involvement is usually manifested as heart block in the Purkinje conduction system and arrhythmias (and sudden death) rather than as cardiomyopathy, unlike most other muscular dystrophies. Atrial or ventricular tachyarrhythmias have also resulted in sudden death in adults and older children.

Endocrine abnormalities involve many glands and appear at any time during the course of the disease so that the endocrine status must be reevaluated annually. Hypothyroidism is common; hyperthyroidism occurs rarely. Adrenocortical insufficiency can lead to an addisonian crisis even in infancy. Diabetes mellitus is common in patients with myotonic dystrophy; some children have a disorder of insulin release rather than defective insulin production. The onset of puberty may be precocious or, more often, delayed. Testicular atrophy and testosterone deficiency are common in adults and are responsible for a high incidence of male infertility. Ovarian atrophy is rare. Frontal baldness is also characteristic in male patients and often begins in adolescence.

Immunologic deficiencies are common in myotonic dystrophy. The plasma immunoglobulin G level is often low.

Cataracts often occur in myotonic dystrophy. They may be congenital, or they can begin at any time during childhood or adult life. Early cataracts are detected only by slit-lamp examination; periodic examination by an ophthalmologist is recommended. Visual evoked potentials are often abnormal in children with myotonic dystrophy and are unrelated to cataracts. They are not usually accompanied by visual impairment.

About half of the patients with myotonic dystrophy are **intellectually impaired,** but severe intellectual impairment is unusual. The remainder are of average or occasionally above-average intelligence. Epilepsy is not common. Cognitive impairment might result from accumulations of variant *DMPK* mRNA and aberrant alternative splicing in cerebral cortical neurons. A higher than expected incidence of **autism** occurs in children with DM1.

A severe **congenital form** of myotonic dystrophy appears in a minority of involved infants born to mothers with myotonic dystrophy who may be symptomatic with known diagnosis, or pauci-symptomatic and undiagnosed (see Fig. 649.5). All patients with this severe congenital disease to date have had the DM1 form. Symptoms may present prenatally with polyhydramnios and decreased fetal movements. At birth, patients typically have marked hypotonia, respiratory difficulties or respiratory failure, and feeding difficulties; they may have additional orthopedic manifestations, such as clubfoot deformities or more extensive congenital contractures **(arthrogryposis multiplex congenita)**. Facial wasting is prominent. Infants can require gavage feeding or ventilator support for respiratory muscle weakness or apnea. Those requiring ventilation for <30 days often survive, and those with prolonged ventilation have an infant mortality rate of 25% and a lower likelihood of ventilator-free survival. Children ventilated for <30 days have better motor, language, and daily activity skills than those requiring prolonged ventilation. One or both leaves of the diaphragm may be nonfunctional. The abdomen becomes distended with gas in the stomach and intestine because of poor peristalsis from smooth muscle weakness. The distention further compromises respiration. Inability to empty the rectum can compound the problem. Myotonia is typically

Fig. 649.5 A 6-yr-old with congenital myotonic dystrophy with 1975 cytosine-thymine-guanine (CTG) repeats in the *DMPK* gene showing the characteristic elongated facies, left ptosis, and an open, down-turned (tented) mouth with dental malocclusion. **A,** The tracheostomy scar is evidence of severe respiratory distress requiring intubation at the time of birth. Neonate with congenital myotonic dystrophy (**B**) also with an open, down-turned mouth and frog-leg position of lower extremities. **C,** A neonate with congenital myotonic dystrophy with severe respiratory distress and arthrogryposis. *(**A,** From Konersman C. Hypotonia, weakness, stroke. In: Kliegman RM, Lye PS, Bordini BJ, et al., eds. Nelson Symptom-Based Diagnosis. Philadelphia: Elsevier; 2018. Fig. 29.16; **B,** From Johnston H. The floppy weak infant revisited. Brain Dev. 2003;25:155–158; **C,** From Echenne B, Bassez G. Congenital and infantile myotonic dystrophy. Handbook Clin Neurol. 2013;113:1387–1393.)*

not present in the congenital form during the neonatal period but may be present in childhood (typically after 5 years old).

LABORATORY FINDINGS

The classic myotonic electromyogram is not found in infants but can appear in children in the early school years. The levels of serum CK and other serum enzymes from muscle may be normal or only mildly elevated in the hundreds (never the thousands).

ECG should be performed annually in early childhood. Ultrasound imaging of the abdomen may be indicated in affected infants to determine diaphragmatic function. Radiographs of the chest and abdomen and additional studies of gastrointestinal motility or swallowing studies may be needed.

Endocrine assessment should be undertaken to determine thyroid and adrenal cortical function and to verify carbohydrate metabolism (glucose tolerance test). Immunoglobulins should be examined, and, if needed, more extensive immunologic studies should be performed.

DIAGNOSIS

The primary diagnostic test is a DNA analysis of blood to demonstrate the abnormal expansion of the CTG or CCTG repeat. Prenatal diagnosis also is feasible. The muscle biopsy specimen in older children shows many muscle fibers with central nuclei and selective atrophy of histochemical type I fibers, but degenerating fibers are usually few and widely scattered, and there is little or no fibrosis of muscle. Intrafusal fibers of muscle spindles are also abnormal. In young children with the common form of the disease, the biopsy specimen can even appear normal or at least not show myofiber necroses, which is a striking contrast with DMD. In the severe neonatal form of myotonic dystrophy, the muscle biopsy reveals maturational arrest in various stages of development in some and congenital muscle fiber–type disproportion in others. It is likely that the sarcolemmal membrane of muscle fibers not only has abnormal properties of electrical polarization but is also incapable of responding to trophic influences of the motor neuron. Muscle biopsy is not usually required for diagnosis, which in typical cases can be based on the clinical manifestations, including the family history, and molecular genetic diagnosis. **Neonatal myotonic dystrophy** causing arthrogryposis multiplex and/or severe neonatal hypotonia must be distinguished from amyoplasia, congenital muscular dystrophy with or without merosin expression, congenital myasthenia gravis, spinal muscular atrophy, and arthrogryposis secondary to oligohydramnios.

Fig. 649.6 The patient was asked to squeeze with both of his hands for several seconds and then suddenly release his grasp, and several seconds passed before full relaxation was achieved, an exam finding known as grip myotonia. *(From Hughes BN, Hogue JS, Hsieh DT. Grip and percussion myotonia in myotonic dystrophy type 1. J Pediatr. 2014;164:1234.)*

GENETICS

The genetic defect in myotonic muscular dystrophy is on chromosome 19 at the 19q13 locus. It consists of an expansion of the *DM* gene that encodes a serine–threonine kinase *(DMPK),* with numerous repeats of the CTG codon. Expansions range from 50 to >2,000, with the normal alleles of this gene ranging in size from 5-37; the larger the expansion, the more severe the clinical expression, with the largest expansions seen in the severe neonatal form. Rarely, the disease is associated with no detectable repeats, perhaps a spontaneous correction of a previous expansion but a phenomenon still incompletely understood. Another myotonic dystrophy **(proximal myotonic myopathy)** is a clinical entity linked to at least two different chromosomal loci than classic myotonic dystrophy but to one locus that shares a common unique pathogenesis in being mediated by a variant in mRNA. Defects in RNA splicing explain the insulin resistance in myotonic dystrophies as well as the myotonia.

Clinical and genetic expression can vary between siblings or between an affected parent and child. In the severe neonatal form of the disease, the mother is the transmitting parent in 94% of cases, a fact not explained by increased male infertility alone. Several cases of paternal transmission have been reported, but this is a very rare occurrence. Genetic analysis reveals that symptomatic neonates usually have many more repeats of the CTG codon than do patients with the more classic form of the disease, regardless of which parent is affected. Myotonic dystrophy often exhibits a pattern of **anticipation** in which each successive generation has a tendency to be more severely involved than the previous generation. Prenatal genetic diagnosis of myotonic dystrophy is available.

TREATMENT

There is no specific medical treatment, but the cardiac, endocrine, gastrointestinal, and ocular complications can often be treated. Physiotherapy and orthopedic treatment of contractures in the neonatal form of the disease may be beneficial. Myotonia may improve with exercise (warm-up phenomenon), and avoidance of extreme cold temperatures may be helpful. Cardiac surveillance with an annual ECG as well as Holter studies and an echocardiogram about every 2 years should be pursued. Cardiac pacemaker implantation might be considered for heart block, and antiarrhythmic drugs might be indicated but are needed only rarely in children. Respiratory issues should be addressed; management strategies may include BiPAP, cough assist, and incentive spirometry.

Myotonia may be diminished by drugs that raise the depolarization threshold of muscle membranes, such as mexiletine, phenytoin, carbamazepine, procainamide, and quinidine sulfate. These drugs also have cardiotropic effects; thus cardiac evaluation is important before prescribing them. Phenytoin and carbamazepine are used in doses similar to those when used as antiepileptics (see Chapter 633.6); serum concentrations of 10-20 μg/mL for phenytoin and 5-12 μg/mL for carbamazepine should be maintained. If a patient's disability is caused mainly by weakness rather than by myotonia, these drugs will be of no value. Excess sleepiness is sometimes managed with methylphenidate or modafinil. Low-impact to moderate exercise may be beneficial for myalgias.

Anesthesia precautions should be considered given the higher rates of complications with anesthesia in patients with myotonia. Succinylcholine should be avoided due to the risk of myotonia, and, instead, short-acting nondepolarizing muscle relaxants should be used that are modified in terms of dosing for the extent of muscle wasting. For induction, a modified rapid-sequence induction for intubation should be used. During recovery, neostigmine should be used with caution, and extubation should occur when a patient is more fully awake. Following sedation, patients should be monitored closely because of the risk of aspiration.

OTHER MYOTONIC SYNDROMES

Most patients with myotonia have myotonic dystrophy. However, myotonia is not specific for this disease and occurs in several rarer conditions.

Myotonic chondrodystrophy (Schwartz-Jampel disease) is a rare congenital disease characterized by generalized muscle hypertrophy and weakness. Dysmorphic phenotypic features and the radiographic appearance of long bones are reminiscent of Morquio disease (see Chapter 107), but abnormal mucopolysaccharides are not found. Dwarfism, joint abnormalities, and blepharophimosis are present. Several patients have been the products of consanguinity, suggesting autosomal recessive inheritance. The muscle protein perlecan, encoded by the *SJS1* gene, a large heparan sulfate proteoglycan of basement membranes and cartilage, is defective in some cases of Schwartz-Jampel disease and explains both the muscular hyperexcitability and the chondrodysplasia.

EMG reveals continuous electrical activity in muscle fibers, closely resembling or identical to myotonia. Muscle biopsy reveals nonspecific myopathic features, which are minimal in some cases and pronounced in others. The sarcotubular system is dilated.

Myotonia congenita (Thomsen disease), a *channelopathy,* is the most common of the nondystrophic myotonia syndromes (Tables 649.3-649.6) and is characterized by weakness and generalized muscular hypertrophy so that affected children resemble bodybuilders (Herculean appearance). Myotonia is prominent and can develop at age 2-3 years, earlier than in myotonic dystrophy. The disease is clinically stable and is apparently not progressive for many years. EMG demonstrates myotonia. Muscle biopsy specimens show minimal pathologic changes and is not indicated for diagnosis. Various families are described as showing either autosomal dominant (Thomsen disease) or recessive (Becker disease, not to be confused with BMD or DMD) inheritance. Pathogenic variants may be nonsense, missense, or frameshift. However, specifically, missense variants that alter the activation of the CLC-1 dimer leads to the dominantly inherited forms of the disease. Patients with the recessive form (Becker disease) tend to have more severe disease. The autosomal dominant and autosomal recessive forms of myotonia congenita have been mapped to the same 7q35 locus. This gene is important for the integrity of chloride channels of the sarcolemmal and T-tubular membranes.

Paramyotonia is a *temperature-related* myotonia that is aggravated by cold and alleviated by warm external temperatures. Patients have difficulty when swimming in cold water or if they are dressed inadequately in cold weather. *Paramyotonia congenita* (Eulenburg disease) is a defect in a gene at the 17q13.1-13.3 locus, the identical locus identified in hyperkalemic periodic paralysis. By contrast with myotonia congenita, paramyotonia is a disorder of the voltage-gated sodium channel caused by a pathogenic variant in the α subunit. Myotonic dystrophy also is a sodium channelopathy (see Table 649.5).

In sodium channelopathies, exercise produces increasing myotonia, whereas in chloride channelopathies, exercise reduces the myotonia. This is easily tested during examination by asking patients to close the eyes forcefully and open them repeatedly; it becomes progressively more difficult in sodium channel disorders and progressively easier in chloride channel disorders.

Treatments for the nondystrophic myotonias include mexiletine as the first-line (both for sodium channel and chloride channel myotonias) treatment. Mexiletine has been shown to improve stiffness as well as decrease handgrip myotonia. Other treatment options include carbamazepine, phenytoin, and gabapentin.

Visit Elsevier eBooks+ at eBooks.Health.Elsevier.com for Bibliography.

Table 649.3 Chloride Channel Myopathies

CLINICAL FEATURES	AUTOSOMAL-DOMINANT MYOTONIA CONGENITA OF THOMSEN	AUTOSOMAL-RECESSIVE GENERALIZED MYOTONIA OF BECKER
Inheritance	Dominant	Recessive
Gene defect	Chromosome 7; variant in skeletal muscle chloride channel	Chromosome 7; variant in skeletal muscle chloride channel
Age of onset	Infancy to early childhood	Late childhood; occasionally starts earlier or begins in teens
Myopathy	Muscle hypertrophy frequent; no myopathy, although variants uncommonly develop weakness	Occasional muscle wasting and weakness can occur late; hypertrophy of muscles frequently occurs in legs
Myotonia	Generalized stiffness, especially after rest; improves with exercise; prominent myotonia of eye closure, but not paradoxical myotonia	Generalized stiffness, especially after rest; transient weakness is prominent after complete relaxation for several minutes; myotonia occurs in eyes; no paradoxical myotonia
Provocative stimuli	Prolonged rest or maintenance of the posture	Prolonged rest or maintenance of the same posture
Therapy for symptoms	Exercise; antimyotonia therapy (e.g., mexiletine); Achilles tendon stretching helps prevent need for heel cord–lengthening surgery	Exercise; especially avoiding prolonged rest; antimyotonia therapy (e.g., mexiletine); transient weakness does not improve after mexiletine

From Moxley III RT, Heatwole C. Channelopathies: myotonic disorders and periodic paralysis. In: Swaiman KF, Ashwal S, Ferriero DM, et al., eds. *Swaiman's Pediatric Neurology,* 6th ed. Philadelphia: Elsevier; 2018: Table 151-3.

Table 649.4 Sodium Channel Myotonias Without Periodic Paralysis

CLINICAL FEATURES	ACETAZOLAMIDE-RESPONSIVE SODIUM CHANNEL MYOTONIA	MYOTONIA FLUCTUANS
Inheritance	Dominant	Dominant
Gene defect	Chromosome 17; variant in skeletal muscle sodium channel	Chromosome 17; variant in skeletal muscle sodium channel
Age of onset	First decade	First or second decade
Myopathy	Rare	Rare, muscle hypertrophy common
Myotonia	Face, paraspinal muscles, paradoxical myotonia of eyelids, grip limbs; varies in severity and often there is pain with myotonia	Face, limbs, eyelids; frequently fluctuates in severity; especially after exercise
Provocative stimuli	Fasting, cold, oral potassium, infection	Exercise-rest-exercise, oral potassium
Therapy for symptoms	Acetazolamide, mexiletine; avoid high-potassium diet; monitor during and after surgery for rigidity and rhabdomyolysis	Mexiletine; avoid high-potassium diet; monitor during and after surgery for rigidity and rhabdomyolysis

From Moxley III RT, Heatwole C. Channelopathies: myotonic disorders and periodic paralysis. In: Swaiman KF, Ashwal S, Ferriero DM, et al., eds. *Swaiman's Pediatric Neurology*, 6th ed. Philadelphia: Elsevier; 2018: Table 151-4.

Table 649.5 Sodium Channel Myopathies with Periodic Paralysis

CLINICAL FEATURES	PARAMYOTONIA CONGENITA	PARAMYOTONIA CONGENITA WITH HYPERKALEMIC PERIODIC PARALYSIS	HYPERKALEMIC PERIODIC PARALYSIS WITH MYOTONIA
Inheritance	Dominant	Dominant	Dominant
Gene defect	Chromosome 17; variant in skeletal muscle sodium channel	Chromosome 17; variant in skeletal muscle sodium channel	Chromosome 17; variant in skeletal muscle sodium channel
Age of onset	First decade	First decade	First decade
Myopathy	Very rare	Rare	Infrequent
Myotonia	Especially paradoxical myotonia of the eyelids and grip	Especially paradoxical myotonia of the eyelids and grip	Especially paradoxical myotonia of the eyelids
Provocative stimuli	Cold exposure followed by exercise leads to focal paralysis; occasionally exercise provokes stiffness	Oral potassium load, rest after exercise mainly in morning (hyperkalemic weakness), cold exposure followed by exercise (focal paralysis)	Rest after exercise, cold, oral potassium
Therapy for symptoms	Mexiletine, mild exercise, keep patient warm	Mild exercise, thiazides, mexiletine	Thiazides, acetazolamide, sodium restriction

From Moxley III RT, Heatwole C. Channelopathies: myotonic disorders and periodic paralysis. In: Swaiman KF, Ashwal S, Ferriero DM, et al., eds. *Swaiman's Pediatric Neurology*, 6th ed. Philadelphia: Elsevier; 2018: Table 151-5.

649.4 Limb-Girdle Muscular Dystrophies

Adnan Y. Manzur

LGMDs encompass a heterogeneous group of progressive hereditary muscular dystrophies that mainly affect muscles of the hip and shoulder girdles (Table 649.7). Distal muscles also eventually become atrophic and weak, and in a few subtypes, distal muscles such as calves may have weakness earlier in disease. Hypertrophy of the calves and ankle contractures develop in some forms, causing potential confusion with BMD. Over 30 genetic forms of LGMD are described, each at a different chromosomal locus and expressing different protein defects (see Table 649.1). Some include diseases classified with other traditional groups, such as the lamin A/C defects of the nuclear membrane (see EDMD), and some forms of CMD. **LGMD1** denotes autosomal dominant inheritance and **LGMD2** implies an autosomal recessive trait, but neither term defines the genetic etiology. LGMD2 is mainly a group of several *sarcoglycanopathies*, calpainopathy resulting from a mutation in the *calpain-3* gene (*CAPN3*), α-dystroglycanopathies, or dysferlinopathies that include Miyoshi myopathy (which usually does not become symptomatic until late adolescence into adult life).

The onset of disease is variable, with some patients manifesting by 4-5 years of age (e.g., sarcoglycanopathies), to others presenting in late adolescence to adulthood (e.g., dysferlinopathy or anoctaminopathy). For many LGMDs, the initial clinical manifestations rarely appear before middle or late childhood or may be delayed until early adult life. Low back pain may be a presenting complaint because of the lordotic posture resulting from gluteal muscle weakness. In many of these disorders, loss of independent ambulation may occur, ranging from within the first decade of life to loss of ambulation in early adulthood, highlighting the variability in rate of progression (even for the same disease). Although weakness of neck flexors and extensors is common, weakness of facial, lingual, and other bulbar-innervated muscles are rarely involved. As weakness and muscle wasting progress, tendon stretch reflexes become diminished. Cardiac involvement can occur in some of the subtypes. Intellectual function is generally normal in most, but can be involved to varying degrees, especially in some of the α-dystroglycanopathies (e.g., LGMDs due to gene variants in *POMT2, POMGnT1, GMPPB,* and *ISPD*). The clinical differential diagnosis of LGMD includes juvenile/type 3 spinal muscular atrophy (Kugelberg-Welander disease), myasthenia gravis, and metabolic myopathies.

The EMG and muscle biopsy frequently show confirmatory evidence of muscular dystrophy, but none of the findings are specific enough to make the definitive diagnosis without additional clinical or immunohistochemical criteria. In some cases, α-sarcoglycan

Table 649.6 Channelopathies with Hypokalemic Periodic Paralysis

CLINICAL FEATURES	ANDERSEN SYNDROME: PERIODIC PARALYSIS WITH CARDIAC DYSRHYTHMIA	CALCIUM CHANNEL PERIODIC PARALYSIS	SODIUM CHANNEL PERIODIC PARALYSIS	POTASSIUM CHANNEL PERIODIC PARALYSIS	PERIODIC PARALYSIS WITH THYROID DISEASE
Inheritance	Dominant	Dominant	Dominant	Dominant	Sporadic; occasionally dominant
Age of onset	First or second decade	First to third decade	First to third decade	Not yet determined	Third decade (males 20:1)
Myopathy	Typical; also short stature; dysmorphic features; prolonged QT interval on electrocardiogram; ventricular dysrhythmias	Moderately common late; vacuoles frequently seen on biopsy	Not yet determined	Not yet determined	Infrequent
Myotonia	No	No	No	No	No
Provocative stimuli	Rest after exercise, oral glucose	High-carbohydrate meals, rest after exercise, cold, emotional stress/ excitement	High-carbohydrate meals, rest after exercise, cold, emotional stress/ excitement	Usually by strenuous exercise followed by rest; less consistent provocation after high carbohydrate intake	High-carbohydrate meals, rest after exercise, acetazolamide
Therapy for symptoms	Mild exercise, glucose, high sodium intake, acetazolamide, dichlorphenamide	Acetazolamide, dichlorphenamide, potassium, spironolactone	Acetazolamide, dichlorphenamide, potassium, spironolactone	Acetazolamide	Propranolol, restoration of euthyroid state, oral potassium, spironolactone

From Moxley III RT, Heatwole C. Channelopathies: myotonic disorders and periodic paralysis. In: Swaiman KF, Ashwal S, Ferriero DM, et al., eds. *Swaiman's Pediatric Neurology*, 6th ed. Philadelphia: Elsevier; 2018: Table 151-6.

Table 649.7 Limb-Girdle Muscular Dystrophies

TYPE	INHERITANCE	GENE	PROTEIN	CLINICAL FEATURES
LGMD1A	AD	*TTID*	Myotilin	Adult-onset myofibrillar myopathy; mildly elevated CK; muscle biopsy: rimmed vacuoles, rodlike inclusions, and Z-band streaming
LGMD1B	AD	*LMNA*	Lamin A/C	Onset first and fourth decade of life; contractures, +/− axial weakness, cardiac arrhythmia and/or cardiomyopathy (potentially life-threatening); CK normal or mildly elevated
LGMD1C	AD	*CAV3*	Caveolin	Onset variable: First decade to adulthood; presents with myalgias +/− rippling muscles and proximal weakness; CK 4-25× elevated
LGMD1D	AD	DNAJB6	HSP40	Onset classically adulthood; proximal weakness; CK normal to 5× elevated; gradually progressive
LGMD1E	AD	*DES*	Desmin	Myofibrillar myopathy; cardiomyopathy and cardiac arrhythmias; CK normal or mildly elevated; muscle biopsy: inclusions and desmin accumulation
LGMD1F	AD	*TNPO3*	Transportin	Onset variable: first decade to adulthood; proximal weakness +/− scapular winging; +/− respiratory involvement
LGMD2A	AR	*CAPN3*	Calpain 3	Onset at 8-15 yr, progression variable (variable loss of ambulation in second or third decade); scapular winging common; cardiac spared; CK very high
LGMD2B	AR	*DYSF*	Dysferlin	Onset in adolescence or early adulthood; mild weakness initially; limb-girdle pattern weakness or Miyoshi myopathy (calf weakness) at onset; gradually progressive; cardiac spared; gastric atrophy earlier in disease

Table 649.7 Limb-Girdle Muscular Dystrophies—cont'd

TYPE	INHERITANCE	GENE	PROTEIN	CLINICAL FEATURES
LGMD2C	AR	*SGCG*	γ-Sarcoglycan	Duchenne-like, onset 4-7 yr; CK very high; respiratory failure often in third decade; + cardiac involvement; loss of ambulation by teenage years
LGMD2D	AR	*SGCA*	α-Sarcoglycan (adhalin)	Duchenne-like, onset 2-15 yr; frequent loss of ambulation; quadriceps weakness; rare cardiomyopathy; CK very high
LGMD2E	AR	*SGCB*	β-Sarcoglycan	Phenotype between Duchenne and Becker muscular dystrophies; onset first decade; loss of ambulation 10-25 yr old; occasional cardiomyopathy
LGMD2F	AR	*SGCD*	δ-Sarcoglycan	Onset 2-10 yr old; loss of ambulation by first or second decade; dilated cardiomyopathy; also a milder phenotype described
LGMD2G	AR	*TCAP*	Telethonin	Rare disease; onset in adolescence; CK up to 10× normal
LGMD2H	AR	*TRIM32*	Tripartite motif containing 32	Seen in Hutterite population; onset childhood to young adulthood; proximal weakness; slowly progressive; ambulatory into adulthood
LGMD2I	AR	*FKRP*	Fukutin-related protein	Dystroglycanopathy; variable phenotype: early onset never ambulate to milder and later onset with muscle cramps; cardiomyopathy common; +/− respiratory failure
LGMD2J	AR	*TTN*	Titin	Onset 3-10 yr; variable severity; +/− respiratory insufficiency; progressive with loss of ambulation (some patients with the severe congenital myopathy phenotype may never ambulate); muscle biopsy: variable fiber size; rods; internal nuclei
LGMD2K	AR	*POMT1*	Protein O-mannosyltransferase 1	Onset first decade; mild weakness and fatigue; slow progression; intellectual disability
LGMD2L	AR	*ANO5*	Anoctamin	More common in Northern Europe and Canada; Onset second to third decade; no cardiomyopathy; report of patients with premature ventricular contractions. Limb-girdle or Miyoshi myopathy phenotypes
LGMD2M	AR	*FKTN*	Fukutin	Early onset, high CK, progression over time; variable intellectual disability; vermis hypoplasia and polymicrogyria; some patients develop dilated cardiomyopathy
LNGD2N	AR	*POMT2*	Protein O-mannosyltransferase 2	LGMD phenotype with or without intellectual disability
LGMD2O	AR	*POMGnT1*	*	More likely a congenital muscle disease/Walker-Warburg syndrome or muscle-eye-brain presentation (possible childhood LGMD phenotype)
LGMD2P	AR	*DAG1*	Dystroglycan	Childhood onset (first decade); very high CK; fatigue and proximal weakness; +/− CNS (intellectual disability), respiratory and eye (cataracts) involvement
LGMD2Q	AR	*PLEC1*	Plectin	Childhood onset, loss of ambulation in adulthood
LGMD2R	AR	*DES*	Desmin	Adult-onset weakness; proximal and distal weakness; cardiac: atrioventricular block (may require early pacemaker by 20s); cardiomyopathy (onset in childhood or 20s); with respiratory involvement
LGMD2S	AR	*TRAPPC11*	Transport protein particle complex 11	Onset infancy or childhood; high CK; proximal weakness; fatigue; +/− seizures, spasticity, hyperkinetic movements, intellectual disability
LGMD2T	AR	*GMPPB*	GDP-mannose pyrophosphorylase B	Can manifest as congenital onset or childhood onset LGMD with or without intellectual disability; seizures; cataracts
LGMD2U	AR	*ISPD*	Isoprenoid synthase domain	Can manifest as congenital muscular dystrophy or childhood-onset LGMD with or without intellectual disability; some patients lose independent ambulation; +/− cardiomyopathy; +/− respiratory insufficiency
LGMD2V	AR	*GAA*	α-1,4 glucosidase	Pompe disease (infantile, juvenile, or adult-onset forms): cardiomyopathy (more in infantile form), respiratory insufficiency, weakness. EMG: irritative myopathy (can see myotonia/cone–rod dystrophies and myopathic recruitment)

**POMGnT1* encodes for protein: Protein-O-linked mannose beta-1,2 N-acetylglucosaminyltransferase.
AD, Autosomal dominant; AR, autosomal recessive; CK, creatine kinase; CNS, central nervous system; EMG, electromyography; GDP, guanosine diphosphate; LGMD, limb-girdle muscular dystrophy.

(formerly known as *adhalin*), a dystrophin-related glycoprotein of the sarcolemma, is deficient; this specific defect may be demonstrated in the muscle biopsy by immunocytochemistry, as may deficiency of three other forms of sarcoglycan as well. Increased serum CK level is typical, but the magnitude of elevation varies among families. The ECG is usually unaltered.

A variant in dystrophin-associated protein in the sarcoglycan complex (**sarcoglycanopathy**; **LGMD types 2C, 2E, and 2F**) is responsible for some cases of autosomal recessive LGMD. Most sarcoglycanopathies result from a pathogenic variant in α-sarcoglycan; other LGMDs resulting from deficiencies in β-, γ-, and δ-sarcoglycan also occur. In normal smooth muscle, α-sarcoglycan is replaced by ε-sarcoglycan, and the others are the same. *Dystroglycanopathies* are caused by variants leading to the abnormal glycosylation of α-dystroglycan, and regardless of the gene, all variants seem to be implicated in a common pathway that impacts dystroglycan function. Histochemically, dystroglycanopathies often show defects (loss or reduction) of immunoreactivity to one of two antibodies, VIA41 or IIH6, which recognize carbohydrate moieties of α-dystroglycan. The extent of reduction can vary from subtle to severe.

Another group of LGMDs **(type 2B)** are caused by allelic variants of the dysferlin *(DYSF)* gene, another gene expressing a protein essential to structural integrity of the sarcolemma, though not associated with the dystrophin-glycoprotein complex. *DYSF* interacts with caveolin-3 or calpain-3, and *DYSF* deficiency may be secondary to defects in these other gene products. Dysferlinopathies can present with the classic LGMD pattern of proximal weakness or may present with early weakness in the lower legs, specifically calf weakness, known as Miyoshi myopathy. Primary calpain-3 defect (type 2A) has wide clinical variability, with age of onset ranging from 2-40 years old, and age at loss of independent ambulation ranging from 5 years old to the late 30s. Respiratory compromise can be seen later in the disease but is less severe than in some other LGMDs. Both are slowly progressive myopathies with onset in adolescence or young adult life and can affect distal as well as proximal muscles. Cardiomyopathy is rare. Chronically elevated serum CK in the thousands is found in dysferlinopathies. Ultrastructure shows a thickened basal lamina over defects in the sarcolemma and replacement of the sarcolemma by multiple layers of small vesicles. Regenerating myofibers outnumber degenerating myofibers. Pathogenic variants in *CAV3* can also have a variable neuromuscular phenotype ranging from: limb-girdle phenotype (LGMD1C) to distal myopathy to rippling muscle disease to hyperCKemia and exercise intolerance. There are also reports of patients with rhabdomyolysis with caveolinopathies. These disorders were formerly called *hyperCKemia* and *rippling muscle disease,* the latter sometimes confused with myotonia. An autosomal recessive variant in the calcium-activated chloride channel anoctamin-5 can causes one of the following phenotypes: a proximal LGMD2L, a distal Miyoshi myopathy phenotype, or hyperCKemia. It typically presents in adulthood and is more commonly seen in Northern Europe and Canada. There does not seem to be any associated cardiomyopathy, although there are reports of early premature ventricular contractions (PVCs).

There is genetic overlap of the group of LGMDs with the congenital muscular dystrophies, such as Walker-Warburg syndrome with *POMT*, Fukuyama muscular dystrophy with *FKRP* genetic defects, and *GMPPB*. Patients with pathologic variants in these genes can present with an early CMD-like phenotype to a childhood or later-onset LGMD phenotype, and in both motor phenotypes may or may not have varying degrees of intellectual disability.

Visit Elsevier eBooks+ at eBooks.Health.Elsevier.com for Bibliography.

649.5 Facioscapulohumeral Muscular Dystrophy

Adnan Y. Manzur

Facioscapulohumeral muscular dystrophy (FSHD) is the third most common muscular dystrophy (after Duchenne muscular dystrophy and myotonic dystrophy). Autosomal dominant inheritance is generally the mode of inheritance, and genetic anticipation is often found within several generations of a family, the succeeding more severely involved at an earlier age than the preceding. The genetic mechanism in autosomal dominant **FSHD1** involves integral deletions of a 3.3-kb tandem repeat (D4Z4) in the subtelomeric region at the 4q35 locus. D4Z4 acts as a lamin-dependent insulator, exhibiting both enhancer-blocking and barrier activities, and displaces the telomere toward the nuclear periphery. Normally, there are 11-100 tandem copies or D4Z4 repeats. When there are fewer repeats (<10 repeat units), this enables chromatin remodeling and leads to decreased methylation, thus turning on DUX4 expression (which is normally dormant). In addition, the disease will only manifest in chromosomes that carry a pLAM1 polyadenylate site distal to the last D4Z4 repeat. When these factors all exist, this creates a "permissive" haplotype or state that allows for the expression of DUX4, which is normally repressed. Approximately 5–10% of families with this phenotype do not map to the 4q35 locus. **FSHD2,** although clinically overlapping with FSHD1, is not caused by the contraction in D4Z4 repeats. However, instead, it is caused by pathogenic variants of *SMCHD1* (on chromosome 18p) that can lead to hypomethylation of D4Z4. When these variants exist in the setting of a permissive haplotype and the polyadenylation signal, DUX4 is expressed, again sharing a final common pathway in leading to the same clinical disease. The prevalence varies geographically but ranges from 1:8,000-20,000. Though the clinical onset is generally in later childhood or adult life, early molecular defects arising during myogenesis are demonstrated in the human fetus, and patients can present as early as in the infantile period.

CLINICAL MANIFESTATIONS

Facioscapulohumeral dystrophy (FSHD) shows the earliest and most severe weakness in facial and shoulder girdle muscles (Fig. 649.7). Asymmetric weakness or patchy weakness, when present, should raise suspicion for FSHD. The facial weakness in FSHD differs from that of myotonic dystrophy; rather than an inverted-V–shaped upper lip, the mouth in FSHD is rounded and appears puckered because the lips protrude. Inability to close the eyes completely in sleep is a common expression of upper facial weakness; some patients have extraocular muscle weakness, although ophthalmoplegia is rarely complete. FSHD has been associated with Möbius syndrome on rare occasions. Pharyngeal and tongue weakness may be absent and is never as severe as the facial involvement. Hearing loss, which may be subclinical, and retinal vasculopathy (indistinguishable from Coats disease) are associated features, particularly in severe cases of FSHD with early-childhood onset.

Scapular winging is prominent, often even in infants. Flattening or even concavity of the deltoid contour is seen, and the biceps and triceps brachii muscles are wasted and weak. Muscles of the hip girdle and thighs also eventually lose strength and undergo atrophy, and the Gowers sign and a Trendelenburg gait appear. Contractures of the extremities are rare. Finger and wrist weakness occasionally is the first symptom. Weakness of the anterior tibial and peroneal muscles can lead to foot drop; this complication usually occurs only in advanced cases with severe weakness. Lumbar hyperlordosis and kyphoscoliosis are common complications of axial muscle involvement. Calf pseudohypertrophy is not a usual feature but is described rarely.

There is a great deal of clinical variability, including within families. FSHD can be a mild disease, causing minimal disability. Clinical manifestations might not be expressed in childhood and are delayed into middle adult life. In more severe cases, patients may present early in life. About 20% of patients will lose independent ambulation, and about 10–15% of patients may require noninvasive or invasive respiratory support. Unlike most other muscular dystrophies, asymmetry of weakness is common. About 30% of affected patients are asymptomatic or show only mild scapular winging and decreased tendon stretch reflexes, of which they were unaware until formal neurologic examination was performed.

LABORATORY FINDINGS

Serum levels of CK and other enzymes vary greatly, ranging from normal or near normal to elevations of several thousand. An ECG should be performed, although the anticipated findings are usually normal. EMG reveals nonspecific myopathic muscle potentials. Diagnostic

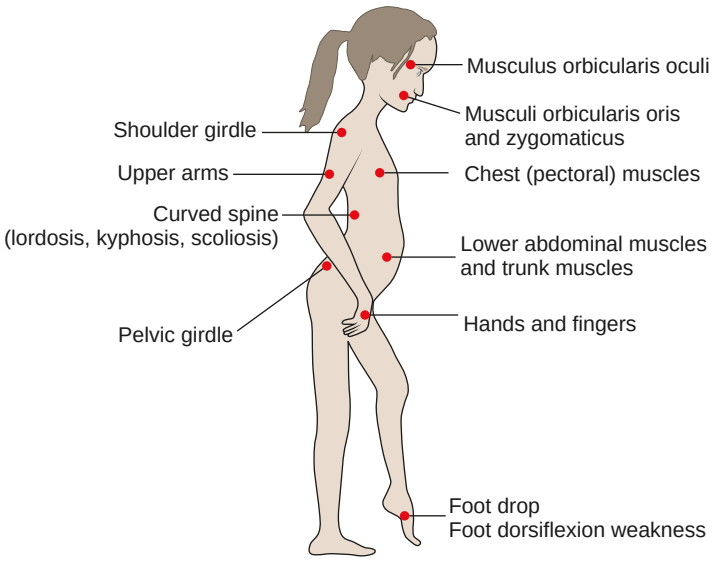

Fig. 649.7 Overview of affected muscles in FSHD. The symptoms tend to start at the upper half of the body and then spread to lower body parts involving the pelvic girdle and the leg muscles. There is a high degree of clinical variability in disease severity, and affected muscles are generally involved asymmetrically regarding the left-right body axis. In some cases, patients with foot drop can be supported by ankle-foot orthotics (AFOs) and knee-ankle-foot orthotics (KAFOs). Surgery to attach the scapula to the ribcage can enhance arm motion or alleviate pain. *(From Schätzl T, Kaiser L, Deigner HP. Facioscapulohumeral muscular dystrophy: genetics, gene activation and downstream signaling with regard to recent therapeutic approaches: an update. Orphanet J Rare Dis. 2021;16:129. Fig. 1.)*

molecular testing in individual cases and within families is indicated for prediction.

DIAGNOSIS AND DIFFERENTIAL DIAGNOSIS

Molecular genetic diagnosis is the most specific confirmation if clinical suspicion is high, with or without a family history of the disease. Muscle biopsy distinguishes more than one form of FSHD, consistent with clinical evidence that several distinct diseases are embraced by the term *facioscapulohumeral dystrophy.* Muscle biopsy and EMG also distinguish the primary myopathy from a neurogenic disease with a similar distribution of muscular involvement. The general histopathologic findings in the muscle biopsy material are extensive proliferation of connective tissue between muscle fibers, extreme variation in fiber size with many hypertrophic as well as atrophic myofibers, and scattered degenerating and regenerating fibers. An *inflammatory* type of FSHD is also distinguished, characterized by extensive lymphocytic infiltrates within muscle fascicles. Despite the resemblance of this form to inflammatory myopathies such as polymyositis, there is no evidence of autoimmune disease, and steroids and immunosuppressive drugs do not alter the clinical course. A precise histopathologic diagnosis has important therapeutic implications. Mononuclear cell *inflammation* in a muscle biopsy sample of infants younger than 2 years old is usually FSHD or, less often, a CMD.

TREATMENT

Pulmonary function should be followed routinely, and if there are concerns for daytime headaches or increased fatigue, a sleep study should be performed to assess for any sleep-disordered breathing or sleep apnea. Light aerobic exercise and stretching regimens may help to prevent deconditioning or disuse atrophy over time. High-intensity training, strength training, or weightlifting are not recommended because they will not help in regaining strength or retarding the progression of weakness or muscle wasting. Foot drop and scoliosis may be treated by orthopedic measures. In selected cases, surgical wiring of the scapulae (scapular fixation surgery) to the thoracic wall provides improved shoulder stability and abduction of the arm, but brachial plexopathy, frozen shoulder, and scapular fractures are reported complications. Additional rehabilitation options for scapular support include kinesiotaping. Chronic pain can be seen commonly in patients with FSHD, and may require further management, including gabapentin, tricyclic antidepressants, or exercise and cognitive behavioral therapy. Cosmetic improvement of the facial muscles of expression may be achieved by reconstructive surgery, which grafts a fascia lata to the zygomatic muscle and to the zygomatic head of the quadratus labii superioris muscle. Exercise of facial muscles can help minimize secondary disuse atrophy. Routine eye exams should be performed (testing for Coats disease), and in young affected children, audiograms should be performed. No effective pharmacologic or genetic treatment is presently clinically available.

Visit Elsevier eBooks+ at eBooks.Health.Elsevier.com for Bibliography.

649.6 Congenital Muscular Dystrophies

Adnan Y. Manzur

The term *congenital muscular dystrophies (CMDs)* refers to a group of hereditary disorders with early (prenatal, neonatal, or early-childhood) onset and histologic features suggestive of a dystrophic process. It is used to encompass several distinct diseases that have a common characteristic of severe involvement at birth or in early childhood but that, ironically, often follow a more benign clinical course than the early onset and histopathologic changes in the muscle biopsy would suggest. A distinguishing feature of the congenital dystrophies, by contrast with other muscular dystrophies, is a high association with **brain malformations**, particularly disorders of cortical development such as lissencephaly/pachygyria and polymicrogyria, often complicated by severe epilepsy (Fig. 649.8). Most of the CMDs are inherited in an autosomal recessive manner (see Table 649.2).

CLINICAL MANIFESTATIONS

In several distinct clinical and genetic diseases grouped under the umbrella term *congenital muscular dystrophies,* infants often have contractures or arthrogryposis at birth and are diffusely hypotonic. In some cases, weakness in infancy may be less significant and initial motor milestones may even be normal. The muscle mass is thin in the trunk and extremities. Head control is often poor due to neck weakness and marked axial hypotonia. Facial muscles may be mildly involved, but ophthalmoplegia, pharyngeal weakness, and weak sucking are not common. A minority has severe dysphagia and requires gavage or gastrostomy. Tendon stretch reflexes may be hypoactive or absent. Distal arthrogryposis is common in all forms of CMD (see Chapter 648.10). Congenital contractures involving axial or proximal joints (including, for example, of the elbows) are often suggestive of **Ullrich CMD** due to pathologic variant(s) in one of the three collagen VI genes *(COL6A1, COL6A2, COL6A3).*

The CMDs can be classified according to the type of protein altered by the specific genetic variants. Diseases of extracellular matrix proteins include LAMA2-related CMD (merosin deficiency, *LAMA2* pathogenic variant at locus 6q22-q23) and COL6-related CMD (Ullrich CMD in the more severe form, to Bethlem myopathy in the milder

form of the disease) (*COL6A1, -A2,* and *-A3* variants at 21q22 and 2q37 loci). A protein of the endoplasmic reticulum (*SEPN1* variant at 1p35) is the basis of rigid spine syndrome. Abnormal glycosylation of α-dystroglycan causes Walker-Warburg syndrome (*POMT1* variant at 9q34), muscle-eye-brain disease of Santavuori (*POMGnT1* variant at 1p32), Fukuyama muscular dystrophy (*FCMD* variant at 8q31-q33 and 9q31), and CMD with secondary merosin deficiency (*FKRP* variant at 19q13). Pathogenic variants in genes that affect the glycosylation of α-dystroglycan can also lead to milder or later-onset LGMD phenotypes (with or without intellectual involvement; see Chapter 649.4). Glycosylation defects (dystroglycanopathies) result in defective neuroblast migration in the fetal brain and also can cause dilated cardiomyopathy. The dystroglycan molecule interacts with both proteins of the plasma (sarcolemmal) membrane and those of the extracellular matrix and basal lamina not only in muscle but also in brain, where defective dystroglycan and poor glycosylation result in gaps in the pial limiting membrane, a discontinuous glia limitans, causing cobblestone lissencephaly and glioneuronal heterotopia of overmigrated neural cells during formation of the cerebral cortex.

The **Fukuyama type** of CMD is the second most common muscular dystrophy in Japan (after DMD); it has also been reported in children of Dutch, German, Scandinavian, and Turkish ethnic backgrounds. In the Fukuyama variety, severe cardiomyopathy and malformations of the brain usually accompany the skeletal muscle involvement. Signs and symptoms related to these organs are prominent: cardiomegaly and heart failure, intellectual disability, seizures, microcephaly, and failure to thrive.

Central neurologic disease can accompany forms of CMD other than Fukuyama disease. The mental and neurologic status is the most variable feature; an apparently normal brain and normal intelligence do not preclude the diagnosis if other manifestations indicate this myopathy. The cerebral malformations that occur are not consistently of one type and vary from severe dysplasias (holoprosencephaly, lissencephaly) to milder conditions (agenesis of the corpus callosum, focal heterotopia of the cerebral cortex and subcortical white matter, cerebellar hypoplasia). Seizures are a frequent complication, as early as the neonatal period, and may include infantile spasms and other severe infantile epilepsies.

CMD is a constant association with cerebral dysgenesis in the **Walker-Warburg syndrome** and in **muscle-eye-brain disease.** The neuropathologic findings are those of neuroblast migratory abnormalities in the cerebral cortex, cerebellum, and brainstem. Studies indicate considerably more genetic overlap between Walker-Warburg, Fukuyama, and muscle-eye-brain forms of CMD that explain mixed and transitional phenotypes, so that, for example, a *Fukutin*-related *(FKRP)* gene can cause a Walker-Warburg or muscle-eye-brain presentation, or *POMGnT1* also can produce phenotypes other than classic Walker-Warburg disease.

LABORATORY FINDINGS

The serum CK level is usually moderately elevated from several hundred to many thousand IU/L; only marginal increases are sometimes found. EMG shows nonspecific myopathic features. Investigation of all forms of CMD should include cardiac assessment and an imaging study of the brain. In the past, muscle biopsy was considered essential for the diagnosis, but currently a confirmed genetic mutation together with a typical phenotype or a confirmed genetic defect in a sibling, allows a confident diagnosis, avoiding a muscle biopsy.

DIAGNOSIS

Muscle biopsy is diagnostic in the neonatal period or thereafter. An extensive proliferation of endomysial collagen envelops individual muscle fibers even at birth, also causing them to be rounded in cross-sectional contour by acting as a rigid sleeve, especially during contraction. The perimysial connective tissue and fat are also increased, and the fascicular organization of the muscle may be disrupted by the fibrosis. Tissue cultures of intramuscular fibroblasts exhibit increased collagen synthesis, but the structure of the collagen is normal. Muscle fibers vary in diameter, and many show central nuclei, myofibrillar splitting, and other cytoarchitectural alterations. Scattered degenerating and regenerating fibers are seen. No inflammation or abnormal inclusions are found.

Immunocytochemical reactivity for merosin (α_2 chain of laminin) at the sarcolemmal region is absent in approximately 40% of cases and normally expressed in the others (Figs. 649.9 and 649.10). Merosin is a protein that binds the sarcolemmal membrane of the myofiber to the basal lamina or basement membrane. Merosin also is expressed in brain and in Schwann cells. The presence or absence of merosin does not always correlate with the severity of the myopathy or predict its course. Adhalin (α-dystroglycan) may be reduced to varying degrees

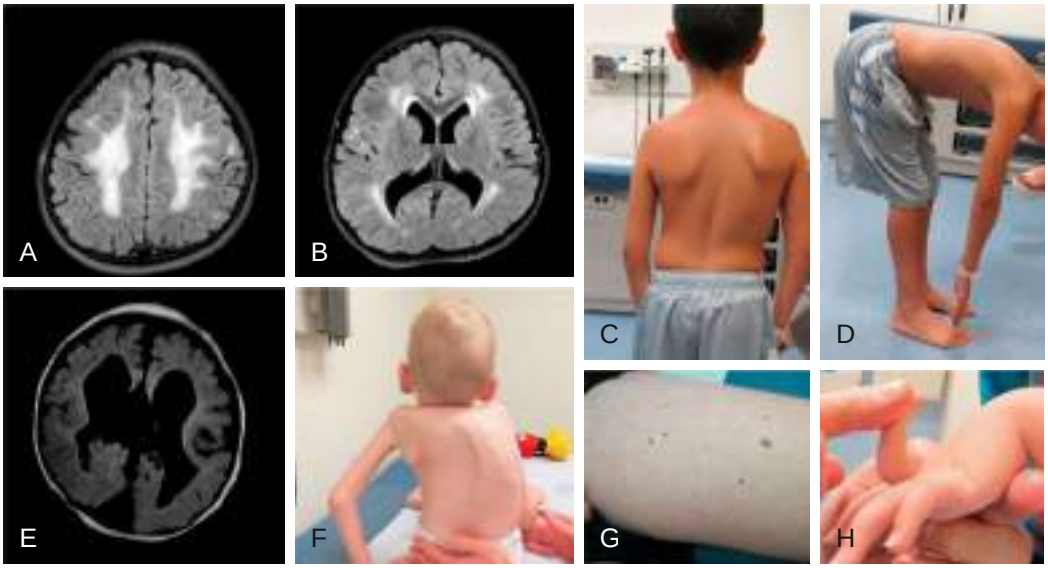

Fig. 649.8 Findings in congenital muscular dystrophies. **A** and **B**, Axial FLAIR brain MRI images showing the increased T2 hyperintensity seen within the white matter in patients with LAMA2 CMD. **C**, Scapular winging and scoliosis in patient with SEPN1 muscular dystrophy. **D**, Rigid spine noted in forward flexion in patient with SEPN1 muscular dystrophy. **E**, Brain MRI in patient with muscle-eye-brain disease with absent corpus callosum, Dandy-Walker malformation, subependymal cysts. **F**, Early and severe kyphoscoliosis in a child with Ullrich CMD. **G**, Keratosis pilaris, a common skin finding in patients with collagen VI–related CMDs. **H**, Distal hyperlaxity seen in patients with collagen VI–related CMDs. *(Courtesy Drs. Carsten Bönnemann and Reghan Foley, Neuromuscular and Neurogenetics Disorders of Childhood Section, NINDS/NIH.)*

in the α-dystroglycanopathies, and there can be secondary reduction of merosin (laminin 211). Collagen VI is selectively reduced, absent, or mislocalized in COL6-related CMDs. Mitochondrial dysfunction may be another secondary defect.

TREATMENT

Supportive care at this time is the mainstay of therapy. A consensus statement on the management of patients with congenital muscular dystrophies was published in 2010 by Wang, et al. Given the high prevalence of respiratory insufficiency in this population, it is important at every visit to screen for respiratory function with pulmonary function testing and eliciting information on the frequency and duration of respiratory illnesses, the frequency of lower respiratory infections, abnormal breathing in sleep, increased daytime fatigue, or headaches. Sleep studies should be performed early (especially in collagen VI CMD and SEPN1 muscular dystrophy), where the respiratory compromise can occur even in ambulant patients because of increased diaphragmatic weakness. Additional respiratory supports may include chest physical therapy, cough assist with suctioning, BiPAP, and, in more advanced stages, invasive ventilation or sip/puff ventilation options for continuous ventilator supports. Weight gain should be optimized to make sure the patient is not losing weight or gaining excess weight. Swallowing should be assessed to screen for dysphagia. Some children will require G-tube feeds due to insufficient oral intake to meet caloric needs, whereas others may require nearly full G-tube feeds due to swallowing difficulties. Speech therapy may be needed for assessment for dysphagia but also because some of these children will have some difficulty with articulation because of oromotor weakness that can affect communication early in life. Constipation occurs frequently and should be medically managed through diet or stool softeners. Physical therapists and physiatrists should be involved in working with the patients on assistive devices and stretching and bracing regimens to try to slow down the progression of or manage contractures. Children may develop scoliosis (or in collagen VI–related CMD, kyphoscoliosis deformities), and should be followed regularly by orthopedic specialists to determine when bracing or surgical interventions are needed. Children with α-dystroglycanopathies with central nervous system involvement may require additional supports, including speech therapies, individualized education plans for learning and intellectual disabilities, seizure management, and spasticity management.

Visit Elsevier eBooks+ at eBooks.Health.Elsevier.com for a Bibliography.

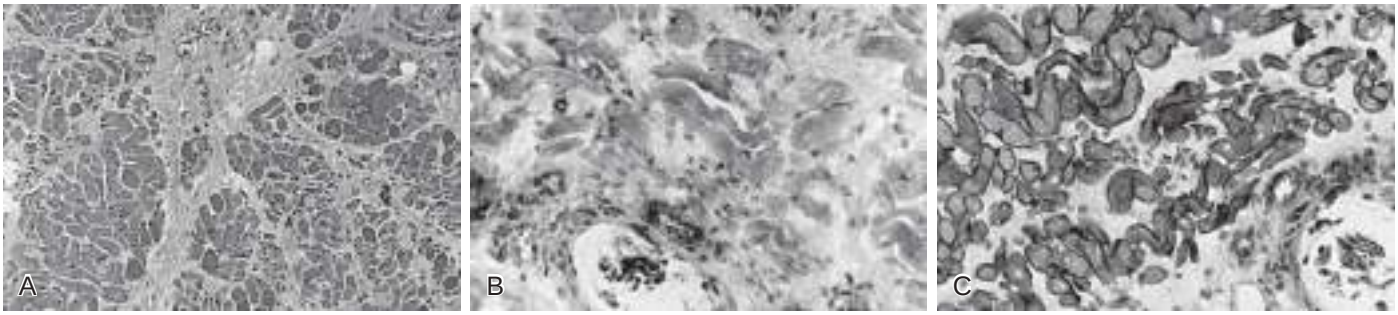

Fig. 649.9 Quadriceps femoris muscle biopsy of a 6-mo-old female with congenital muscular dystrophy associated with merosin (α_2-laminin) deficiency. **A,** Histologically, the muscle is infiltrated by a great proliferation of collagenous connective tissue; myofibers vary in diameter, but necrotic fibers are rare. **B,** Immunocytochemical reactivity for merosin (α_2-laminin) is absent in all fibers, including the intrafusal myofibers of a muscle spindle seen at bottom. **C,** Dystrophin expression (rod domain) is normal. Compare with Figures 649.3, 649.4, and 649.10.

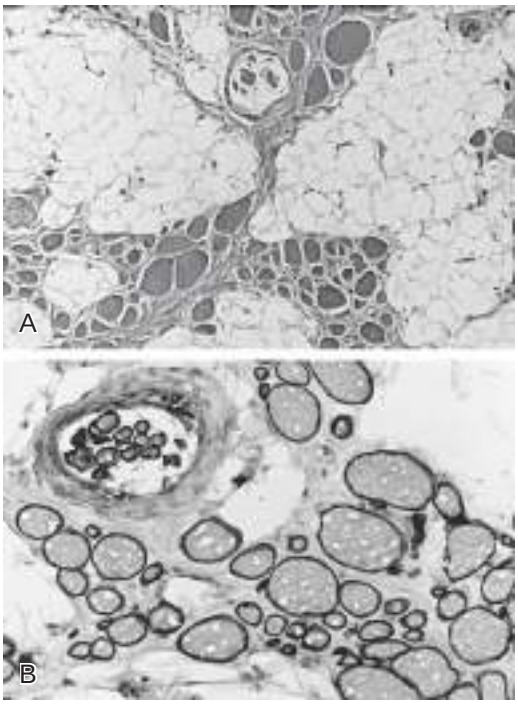

Fig. 649.10 Quadriceps femoris muscle biopsy specimen of a 2-yr-old female with congenital muscular dystrophy. **A,** The fascicular architecture of the muscle is severely disrupted, and muscle is replaced by fat and connective tissue; the remaining small groups of myofibers of variable size are seen, including a muscle spindle at top. **B,** Merosin expression is normal in both extrafusal fibers of all sizes and in intrafusal spindle fibers. The severity of the myopathy does not relate to the presence or absence of merosin in congenital muscular dystrophy. Compare with Figure 649.9.

Chapter 650

Endocrine and Toxic Myopathies

*Adnan Y. Manzur**

THYROID MYOPATHIES

See also Chapters 601-606 and Table 650.1.

Thyrotoxicosis causes proximal weakness and wasting accompanied by myopathic electromyographic changes. Rarely the myopathy may be limited to painless external ophthalmoplegia and proptosis, at least initially. Thyroxine binds to myofibrils and, if in excess, impairs contractile function. Hyperthyroidism can also induce myasthenia gravis and hypokalemic periodic paralysis, the latter mainly affecting East Asian males who have a genetic predisposition. A pathologic variant in the gene *KCNJ18* may be responsible for altering the potassium channel Kir2.6 in up to one third of cases. Potassium supplementation and propranolol are useful in treating thyrotoxic periodic paralysis.

Hypothyroidism, whether congenital or acquired, consistently produces hypotonia and a proximal distribution of weakness. Although muscle wasting is most characteristic, one form of cretinism, Kocher-Debré-Sémélaigne syndrome, is characterized by generalized pseudohypertrophy of weak muscles. Infants can have a Herculean appearance reminiscent of myotonia congenita. The serum creatine kinase (CK) level is elevated in hypothyroid myopathy and returns to normal after thyroid replacement therapy.

Results of muscle biopsy in hypothyroidism reveal acute myopathic changes, including myofiber necrosis and sometimes central cores. In hyperthyroidism, the muscle biopsy specimen shows only mild, nonspecific myopathic changes without necrosis of myofibers. The clinical and pathologic features of hyperthyroid myopathy and hypothyroid myopathy resolve after appropriate treatment of the thyroid disorder. Many of the systemic symptoms of hyperthyroidism, including myopathic weakness and ophthalmoparesis, improve with the administration of β blockers.

Most patients with primary **hyperparathyroidism** (see Chapter 613) develop weakness, fatigability, fasciculations, and muscle wasting that is reversible after removal of the parathyroid adenoma. The serum CK and muscle biopsy remain normal, but electromyography can show nonspecific myopathic features. A minority of patients develop myotonia that could be confused with myotonic dystrophy.

STEROID-HORMONE INDUCED MYOPATHY

Cushing disease and iatrogenic Cushing syndrome from exogenous corticosteroid administration can cause painless, symmetric, progressive proximal weakness, increased serum CK levels, and a myopathic electromyogram and muscle biopsy specimen (see Chapter 619). Myosin filaments may be selectively lost. The 9α-fluorinated steroids, such as dexamethasone, betamethasone, and triamcinolone, are the most likely to produce *steroid myopathy.* Dexamethasone alters the abundance of ceramides in myotubes in developing muscle. In patients with dermatomyositis or other myopathies treated with steroids, it is sometimes difficult to distinguish refractoriness of the disease from steroid-induced weakness, especially after long-term steroid administration. Vitamin D is another factor altering muscle metabolism and particularly its sensitivity to insulin; vitamin D deficiency may be accentuated and contribute to steroid myopathy, especially in type 2 diabetic patients and insulin resistance.

All patients who have been taking steroids for long periods develop reversible type II myofiber atrophy; this is a *steroid effect* but is not steroid myopathy unless it progresses to become a necrotizing myopathy. At greatest risk in the pediatric age-group are children requiring long-term steroid therapy for asthma, rheumatoid arthritis, dermatomyositis, lupus, and other autoimmune or inflammatory diseases or who are being treated for leukemia or other hematologic diseases. In addition to steroids, the drugs listed in Table 650.2 can cause acute or chronic toxic myopathies. An incompletely understood entity known as critical illness myopathy is a progressive weakness of patients with extended illnesses who remain in the intensive care unit; it is associated pathologically with selective loss of thick (myosin) myofilaments; immobility and excessive steroid treatment are believed to be important factors. Various steroids are sometimes used chronically in the treatment of Duchenne muscular dystrophy; they may actually exaggerate the weakness because of steroid myopathy superimposed on the dystrophic process (see Chapter 649).

Hyperaldosteronism is accompanied by episodic and reversible weakness similar to that of periodic paralysis. Another clinical presentation is muscle cramps at rest. The proximal myopathy can become irreversible in chronic cases. Elevated CK levels and even myoglobinuria sometimes occur during acute attacks. Arterial hypertension is a frequent manifestation, and in children, aldosterone-secreting adenomas up to 6 mm in diameter or multiple adrenocortical micronodules of 0.5 mm should be considered in the differential diagnosis of idiopathic hypertension and muscle weakness or cramps. Hereditary primary aldosteronism is due to a pathogenic variant in one of the potassium channel genes *KCNJ5* and *GIRK4*.

Chronic growth hormone excess (sometimes illicitly acquired by adolescent athletes or seen in acromegaly) produces atrophy of some myofibers and hypertrophy of others, and scattered myofiber degeneration. Despite the augmented protein synthesis induced by growth hormone, it impairs myofibrillar adenosine triphosphatase activity and reduces sarcolemmal excitability, with resultant diminished, rather than increased, strength corresponding to the larger muscle mass. It has been used therapeutically in muscular dystrophy with both a positive effect and complications. *Ghrelin* is an intestinal hormone that activates a growth hormone secretagogue receptor and stimulates growth hormone release. In addition to its effect as a "hunger hormone" that involves food intake and fat deposition, it also prevents muscular atrophy by inducing myodifferentiation and myoblast fusion.

STATIN-INDUCED RHABDOMYOLYSIS WITH MYOGLOBINURIA

Myalgias and a self-limited myopathy can be induced in 10–20% of patients taking statin drugs (HMG-CoA reductase inhibitors [HMGCR]). In addition, a less common but more severe statin-associated immune-mediated necrotizing myopathy may occur and is characterized by marked elevated CK levels, muscle edema and necrosis, and the presence of anti-HMGCR antibodies. These widely prescribed drugs are mainly used in adults to lower plasma cholesterol levels but also are sometimes administered to adolescents, particularly in familial cases of hypercholesterolemia. Statins lower the patient's levels of coenzyme-Q10, which is needed for mitochondrial electron transport. Myalgias are usually well tolerated, whereas myopathy requires stopping the statin. The immune-mediated muscle necrosis requires immune suppression with prednisone; steroid-sparing agents included intravenous immunoglobulin (IVIG) and rituximab.

* The editors are grateful to Dr. Harvey B. Sarnat, much of whose work on previous editions of this chapter is retained here.

Table 650.1 Neuromuscular Manifestations of Endocrine Disorders

DIABETES	SYMPTOMS	LABORATORY TEST RESULTS	EMG
Acromegaly	Proximal weakness, CTS, neuropathy, muscle atrophy	Normal CK (may be elevated), elevated growth hormone, IGF-1, TSH	Normal or myopathic
Hypopituitarism	Weakness (may be severe); muscle fatigue	Normal CK; multiple hormone deficiencies	Not defined
Adrenal insufficiency, Addison disease	Proximal weakness, cramps, fatigue	Elevated potassium, reduced cortisol levels, abnormally high corticotropin, normal CK	Normal
Thyrotoxic* periodic paralysis	Weakness with hypokalemia, usually after high-carbohydrate meals (occurs mainly in Asians, more common in men)	Elevated CK during attacks	Normal except for decreased CMAP during attacks, after exercise
Hypothyroidism (adult: Hoffmann syndrome; children: Kocher-Debré Sémélaigne)	Proximal weakness, muscle spasms, pain (adults); myoedema, delayed relaxation of reflexes; peripheral neuropathy, entrapment neuropathies, CTS	Elevated CK, elevated thyrotropin or low T_4	Nonspecific
Hyperthyroidism or thyrotoxic myopathy	Proximal weakness with little atrophy, more common in women; distal weakness in 20%, some bulbar involvement; Graves ophthalmopathy can occur, myasthenia gravis and periodic paralysis may occur; fasciculations and myokymia; peripheral neuropathy	Normal CK, high T_4 and T_3, reduced thyrotropin	Myopathy, with fibrillations and fasciculations
Diabetes	Peripheral polyneuropathy, focal neuropathy; myopathy unusual; muscle infarcts causing unilateral weakness, swelling; proximal muscle weakness (diabetic amyotrophy)	Elevated CK	Motor unit action potentials
Cushing disease (primary or drug induced)	Proximal weakness, myalgia, truncal adipose tissue accumulation, moon face	Normal CK, low potassium, elevated plasma cortisol	May show myopathic motor unit action potentials
Hyperparathyroidism, primary or secondary from renal disease	Proximal weakness and atrophy, muscle cramps, possible hypotonia	Elevated calcium levels, usually low phosphate and high alkaline phosphatase, normal or mildly elevated CK, elevated PTH and vitamin D levels	Small polyphasic motor units or potentials
Hypoparathyroidism	Hypocalcemia-induced tetany (Chvostek, Trousseau signs), cramps	Mildly elevated CK, hypocalcemia, hypomagnesemia	Multiplex discharges

CK, Creatine kinase; CMAP, compound muscle action potential; CTS, carpal tunnel syndrome; EMG, electromyography; IGF-1, insulin-like growth factor-1; PTH, parathyroid hormone; TSH, thyroid stimulating hormone.
*Graves disease most common but also seen in toxic nodular goiter iodine or amiodarone-induced thyrotoxicosis or pituitary adenoma.
Modified from Bassam BA, Bertorini TE. Neuromuscular manifestations of acquired metabolic, endocrine, and nutritional disorders. In: Bertorini TE, ed. *Neuromuscular Disorders Treatment and Management*, 2nd ed. Philadelphia: Elsevier; 2022: Table 650.1, p 529.

MITOCHONDRIAL DYSFUNCTION IN TOXIC MYOPATHIES

Impaired mitochondrial function, enzymatic activity in the five respiratory chain complexes, and alterations in the mitochondrial ultrastructure are a common basis for the clinical effects of many toxic organic compounds and heavy metals that affect both muscle and peripheral nerves. Statin toxicity is mentioned previously. Another example is excessive zinc intake as a dietary supplement (see Chapter 654). These acquired, induced mitochondrial cytopathies can produce weakness and resemble the clinical progression of genetic mitochondrial myopathies plus neuropathy.

Table 650.2 Toxic Myopathies

INFLAMMATORY CAUSES
Cimetidine
D-Penicillamine
Procainamide
L-Tryptophan
L-dopa
NONINFLAMMATORY NECROTIZING OR VACUOLAR CAUSES
Cholesterol-lowering agents (statins)
Chloroquine
Colchicine
Emetine
ε-Aminocaproic acid
Labetalol
Cyclosporine and tacrolimus
Isotretinoic acid (vitamin A analog)
Vincristine
Statins
Alcohol
RHABDOMYOLYSIS AND MYOGLOBINURIA
Cholesterol-lowering drugs (especially statins)
Alcohol
Heroin
Amphetamine
Toluene
Cocaine
ε-Aminocaproic acid
Pentazocine
Phencyclidine
MALIGNANT HYPERTHERMIA
Halothane
Ethylene
Diethyl ether
Methoxyflurane
Ethyl chloride
Trichloroethylene
Gallamine
Succinylcholine
MITOCHONDRIAL CAUSES
Zidovudine
MYOTONIA
2,4-*d*-Chlorophenoxyacetic acid
Anthracene-9-carboxylic acid
Cholesterol-lowering drugs
Chloroquine
Cyclosporine
MYOSIN LOSS
Nondepolarizing neuromuscular blocking agents
Intravenous glucocorticoids

Modified from Goldman L, Ausiello D. *Cecil Textbook of Medicine*, 22nd ed. Philadelphia: WB Saunders; 2004: p 2399.

CRITICAL ILLNESS MYOPATHY

Patients who are in the intensive care unit for extended periods sometimes develop progressive weakness and myalgias that cannot be attributed simply to disuse atrophy. The pathogenesis remains uncertain, but some factors may include inhibition of protein synthesis, mitochondrial dysfunction, oxidative stress, and disruption of intramuscular calcium homeostasis. Patients with severe disease may even develop rhabdomyolysis, with elevated serum CK and myoglobinuria leading to renal damage.

Visit Elsevier eBooks+ at eBooks.Health.Elsevier.com for Bibliography.

Chapter 651

Metabolic Myopathies and Channelopathies*

651.1 Periodic Paralyses and Other Muscle Channelopathies

Adnan Y. Manzur

Episodic, reversible weakness or paralysis, known as **periodic paralysis,** is associated with transient alterations in serum potassium levels, usually hypokalemia but occasionally hyperkalemia. All familial forms of periodic paralysis are caused by pathogenic variants in genes encoding voltage-gated ion channels in muscle: sodium, calcium, and potassium (Table 651.1). Nonhereditary causes of periodic paralysis are caused by a diverse group of disorders that affect potassium balance (Table 651.2).

During attacks of **hypokalemic paralysis,** myofibers are electrically unexcitable, although the contractile apparatus can respond normally to calcium. The genetic disorder is inherited as an autosomal dominant trait. It is precipitated in some patients by a heavy carbohydrate meal, insulin, epinephrine including that induced by emotional stress, hyperaldosteronism or hyperthyroidism, administration of amphotericin B, or ingestion of licorice.

Episodes of hypokalemic paralysis often begin in infancy, particularly in the hyperkalemic form, and the disease is nearly always symptomatic by 10 years of age, affecting both sexes equally. Late childhood or adolescence is the more typical age of onset of the hypokalemic form, Andersen-Tawil syndrome, and paramyotonia congenita. Periodic paralysis is an episodic event; patients are unable to move after awakening and gradually recover muscle strength during the next few minutes or hours. All four extremities are involved. Muscles that remain active in sleep, such as the diaphragm, extraocular muscles (rapid eye movements), and cardiac muscle are not affected. Patients are normal between episodes, but in adult life episodes become more frequent, and the disorder causes progressive myopathy with permanent weakness even between episodes. The usual frequency of episodes in childhood is once a week. The differential diagnosis includes thyrotoxic periodic paralysis, myotonia congenita, and paramyotonia congenita. A triad of periodic paralysis, potentially fatal cardiac ventricular ectopy (caused by a defect in Kir2.1 channels for terminal repolarization), and characteristic physical features is known as **Andersen-Tawil syndrome.**

Alterations in serum potassium levels occur only during acute episodes and are accompanied by T-wave changes in the electrocardiogram. Hypokalemia may be caused by alterations in calcium gradients. The creatine kinase (CK) level may be mildly elevated at those times. Plasma phosphate levels often decrease during symptomatic periods. Muscle biopsy findings are often normal between episodes, but during an episode a vacuolar myopathy is demonstrated. Pathologic changes in the periodic paralyses are similar, whether the disease is the result of a sodium or a potassium channel defect, suggesting that the changes might result from the recurrent paralytic state rather than the specific channelopathy. The vacuoles are dilated sarcoplasmic reticulum and invaginations of the extracellular space into the cytoplasm, and they may be filled with glycogen. Muscle biopsy is

*The editors are grateful to Dr. Harvey B. Sarnat, much of whose work on previous editions of this chapter is retained here.

Table 651.1 Muscle Channelopathies

	MYOTONIA CONGENITA	PARAMYOTONIA CONGENITA	OTHER SODIUM CHANNEL MYOTONIAS	HYPERKALEMIC PERIODIC PARALYSIS	HYPOKALEMIC PERIODIC PARALYSIS	ANDERSEN-TAWIL SYNDROME	THYROTOXIC PERIODIC PARALYSIS	CENTRAL CORE/ MALIGNANT HYPERTHERMIA
Gene	*CLCN1*	*SCN4A*	*SCN4A*	*SCN4A*	*CACNA1S, SCN4A*	*KCNJ2*	*KCNJ18*	*RYR1*
Chromosome	7q35	17q23	17q23	17q23	1q32, 17q23*	17q24	17†	19q 13
Clinical features	Myotonia	Myotonia, episodic weakness	Myotonia	Episodic weakness, myotonia	Episodic weakness	Episodic weakness, premature ventricular contractions, ventricular tachyarrhythmia	Episodic weakness	Weakness, malignant hyperthermia, and rarely myotonia
Triggers	Cold (some patients)	Cold	Potassium (some patients)	Potassium, rest after exercise	Carbohydrates, rest after exercise	Rest after exercise, carbohydrates (some patients), potassium (some patients)	Thyrotoxicosis	Anesthesia
Acute treatment	n/a	n/a	n/a	Carbohydrate/ glucose	Potassium oral, rarely IV	Potassium (if attacks associated with hypokalemia)	Potassium, adrenergic blocking agents	IV fluids, support
Chronic treatment	Mexiletine, phenytoin, procainamide	Mexiletine, phenytoin, procainamide	Mexiletine, phenytoin, procainamide, acetazolamide	Acetazolamide, dichlorphenamide	Potassium, acetazolamide, dichlorphenamide, potassium-sparing diuretic	Potassium (if attacks are associated with hypokalemia), acetazolamide, dichlorphenamide, potassium-sparing diuretic	Treatment of thyrotoxicosis	n/a
Exercise testing	Short exercise test (SET): Postexercise decrement, rapid return to baseline	SET: Postexercise decrement, facilitated by repetition or cold	SET: Often nondiagnostic	Long exercise test (LET): Postexercise decrement	LET: Postexercise decrement	LET: Postexercise decrement	LET: postexercise decrement (when symptomatic)	n/a
Laboratory features	n/a	n/a	n/a	Ictal high potassium‡	Ictal low potassium	Ictal high/low potassium	Ictal low potassium, elevated thyroid hormone	Elevated creatine kinase during malignant hyperthermia
Commercially available genetic testing	Yes	Yes	Yes	Yes	Yes	Yes	No	Yes

*Calcium channel gene chromosome 1, sodium channel gene chromosome 17.
†Exact location not determined.
‡Case reports of families with variants associated with hyperkalemic periodic paralysis and normal potassium.
IV, Intravenous; n/a, nonapplicable.
From Statland JM, Barohn RJ. Muscle channelopathies: the nondystrophic myotonias and periodic paralyses. *Continuum*. 2013;19(6):1598–1614. Table 4.1.

Downloaded for mohamed ahmed (dr.mms2020@gmail.com) at University of Southern California from ClinicalKey.com by Elsevier on April 25, 2024. For personal use only. No other uses without permission. Copyright ©2024. Elsevier Inc. All rights reserved.

Table 651.2 Secondary Causes of Periodic Paralysis

HYPOKALEMIC
Thyrotoxic
Primary hyperaldosteronism (Conn syndrome)
Renal tubular acidosis (e.g., Fanconi syndrome)
Juxtaglomerular apparatus hyperplasia (Bartter syndrome)
Gastrointestinal potassium wastage
Villous adenoma
Laxative abuse
Pancreatic non–insulin-secreting tumors with diarrhea
Nontropical sprue
Barium intoxication
Potassium-depleting diuretics
Amphotericin B
Licorice
Corticosteroids
Toluene toxicity
p-Aminosalicylic acid
Carbenoxolone
HYPERKALEMIC
Addison disease
Hypoaldosteronism
Excessive potassium supplementation
Potassium-sparing diuretics
Chronic renal failure

From Chinnery PF. Muscle diseases. In: Goldman L, Schafer AI, eds. *Goldman's Cecil Medicine*, 24th ed. Philadelphia: Elsevier; 2012: Table 429-8, p. 2415.

not essential to diagnose periodic paralysis, however. Hypoglycemia does not occur. Loci for the majority of periodic paralyses have been demonstrated and the genes at least partially characterized, but many patients with the same clinical phenotype exhibit no variants in the identified genes.

TREATMENT

Paralytic episodes of hypokalemic periodic paralysis are best treated by the oral administration of potassium or even fruit juices that contain potassium. A low sodium intake and the administration of acetazolamide, 5 mg/kg/day bid or tid as a starting dose, often is effective in abolishing episodes or at least reducing their frequency and severity. Dichlorphenamide, a carbonic anhydrase inhibitor, is approved for the treatment of primary hypokalemic and hyperkalemic periodic paralysis syndromes in adults. The drug reduced the frequency, with few side effects (paresthesias, confusion, dysgeusia). Acetazolamide has also been used off label for these conditions.

OTHER MUSCLE CHANNELOPATHIES

Disorders of ion channels other than the well-documented potassium channelopathies also are recognized (see Table 651.1). A rare, severe **neonatal myotonia** is secondary to a pathologic variant of the voltage-gated sodium channel *SCN4A* gene; it is unrelated to neonatal myotonic dystrophy, myotonia congenita, or infantile myofibrillar myopathies. This same gene is also responsible for severe neonatal **episodic laryngospasm.** Mexiletine is effective treatment of the myotonia, but the long-term prognosis remains poor, with death by 2 years of age. Sodium channel blockers, such as carbamazepine, phenytoin, and procainamide, are alternatives.

Neuromyotonia, a continuous muscle activity of neurogenic origin, may be caused by pathogenic variants in genes encoding or antibodies against potassium channels, but is rare in childhood. **Schwartz-Jampel disease,** resulting from an autosomal recessive trait, involves severe muscle stiffness, myotonia, blepharospasm, and chondrodysplasia. It becomes symptomatic in the first year of life and is slowly progressive until midadolescence, after which it is stable. It is no longer considered a variant of myotonic dystrophy and is caused by a pathogenic variant in *HSPG2* which encodes perlecan, the major heparan sulfate proteoglycan of basement membranes. Sodium channel blockers may be useful.

Visit Elsevier eBooks+ at eBooks.Health.Elsevier.com for Bibliography.

651.2 Malignant Hyperthermia

Adnan Y. Manzur

See also Chapters 91 and 648.4.

Malignant hyperthermia susceptibility (MHS) is usually inherited as an autosomal dominant trait. It occurs in all patients with *RYR1*-related central core disease but is not limited to that particular myopathy. The *RYR1* is at the 19q13.1 locus and is responsible for both central core disease and MHS without this specific myopathy. At least 180 separate pathogenic variants in this gene are associated with malignant hyperthermia. The gene programs the ryanodine receptor, a tetrameric calcium-release channel in the sarcoplasmic reticulum, in apposition to the voltage-gated calcium channel of the transverse tubule (see Table 651.1). *RYR1* variants account for up to 75% of cases of malignant hyperthermia reactions. A similar rhabdomyolytic, but not true malignant hyperthermia, reaction occurs rarely in Duchenne and other muscular dystrophies. *CACNA1S* variants are a cause of periodic paralysis but rarely some variance in this gene is associated with MHS. Malignant hyperthermia is also a key risk in *STAC3*-related congenital myopathy, which was initially described in Native American Indians, but has been reported in multiple ethnicities. The key features of *STAC3* disease, also called **Bailey-Bloch congenital myopathy**, are myopathy with cleft palate, skeletal anomalies, delayed motor development, and MHS. MHS has also been observed in various other myopathies, in some children with scoliosis, and in an isolated syndrome not associated with other muscle disease. Affected children sometimes have peculiar facies, described in **King Denborough syndrome**. MHS is present in affected individuals at all ages, including premature infants whose mothers underwent general anesthesia for cesarean section. Overall, MHS affects 1:10,000 to 1:250,000, but prevalence of genetic abnormalities may be as high as 1:400.

Acute malignant hyperthermia episodes are precipitated by exposure to general anesthetics, and in particular the depolarizing muscle relaxant succinylcholine and halogenated inhaled anesthetic gases. Patients suddenly develop extreme fever, rigidity of muscles, masseter muscle spasm and metabolic and respiratory acidosis; the serum CK level rises massively and sometimes over 30,000 IU/L. Life-threatening hyperkalemia is a major risk. Myoglobinuria can result in tubular necrosis and acute renal failure.

The muscle biopsy specimen obtained during an episode of malignant hyperthermia or shortly afterward is not indicated but shows widely scattered necrosis of muscle fibers known as rhabdomyolysis. Between attacks, the muscle biopsy specimen is normal unless there is an underlying chronic myopathy.

It is important to recognize patients at risk of malignant hyperthermia because the attacks may be prevented by administering dantrolene sodium before an anesthetic is given. Patients at risk, such as siblings, are identified by genetic testing or by the caffeine contracture test: a portion of fresh muscle biopsy tissue in a saline bath is attached to a strain gauge and exposed to caffeine and other drugs; an abnormal spasm is diagnostic. The syndrome-associated receptor also may be demonstrated by immunochemistry in frozen sections of the muscle biopsy. The gene defect of the ryanodine receptor is present in 50% of patients; gene testing is available for this and for *STAC3*-related myopathy and MHS. Four other gene loci for MHS are known.

Apart from the genetic disorder of malignant hyperthermia, some drugs can induce acute rhabdomyolysis with myoglobinuria and potential renal failure, but this usually occurs in patients who are predisposed by some other metabolic disease (mitochondrial myopathies). Valproic acid can induce this process in children with mitochondrial cytopathies or with carnitine palmitoyltransferase (CPT) deficiency.

Dantrolene sodium is a specific treatment or preventive if administered to patients at risk before an anesthetic. The pediatrician has a crucial role in identifying the potential MHS, conveying the risk to the anesthetist, and a malignant hyperthermia safe protocol with total intravenous anesthetic is recommended for suspected or proven cases.

Visit Elsevier eBooks+ at eBooks.Health.Elsevier.com for Bibliography.

651.3 Glycogenoses

Adnan Y. Manzur

See Chapter 107.1 and Table 651.3.

Glycogenosis I (von Gierke disease) is not a true myopathy because the deficient liver enzyme glucose-6-phosphatase is not normally present in muscle. Nevertheless, children with this disease are hypotonic and mildly weak for unknown reasons.

Glycogenosis II (Pompe disease) is an autosomal recessively inherited deficiency of the glycolytic lysosomal enzyme α-glucosidase (formerly known as acid maltase) that cleaves the α-1,4 and α-1,6 glycosidic linkages. Of the 12 known glycogenoses, type II is the only one with a defective lysosomal enzyme. The defective gene is at locus 17q23, with more than 200 distinct variants. Two clinical forms are described. The **infantile** form is a severe generalized myopathy and cardiomyopathy. Patients have cardiomegaly and hepatomegaly and are diffusely hypotonic and weak. The serum CK level is greatly elevated. A muscle biopsy specimen reveals a vacuolar myopathy with abnormal lysosomal enzymatic activities such as acid and alkaline phosphatases. Evidence of secondary mitochondrial cytopathy is often demonstrated; it includes electron microscopic demonstration of paracrystalline structures within muscle mitochondria and low concentrations of respiratory chain enzymes. Death in infancy or early childhood is usual; however, enzyme replacement therapy has improved the outcome.

The **late childhood** or **adult** form is a much milder myopathy without cardiac or hepatic enlargement. It might not become clinically expressed until later childhood or early adult life but may be symptomatic as myopathic weakness and hypotonia even in early infancy. Even in late adult-onset acid maltase deficiency, >50% of the patients report difficulties with muscle strength dating from childhood. Ultrastructural evidence of secondary mitochondrial cytopathy also occurs, as with infantile Pompe disease. MRI of muscle may show distinctive changes that differ from other myopathies.

The serum CK level is greatly elevated, and the muscle biopsy findings are diagnostic even in the presymptomatic stage. The diagnosis of glycogenosis II is confirmed by quantitative assay of acid maltase activity in muscle or liver biopsy specimens.

A rare variant of the milder form of acid maltase deficiency can show muscle acid maltase activity in the low normal range with only intermittent decreases to subnormal values; the muscle biopsy findings are similar although milder. In another form, **Danon disease,** transmitted as an X-linked recessive trait at the Xq24 locus, the primary deficiency is lysosomal membrane protein-2 (LAMP2) and results in hypertrophic cardiomyopathy, proximal myopathy, and intellectual disability.

Glycogenosis III (Cori-Forbes disease), a deficiency of debrancher enzyme (amylo-1,6-glucosidase), is more common than is usually diagnosed, and it is generally the least severe. Hypotonia, weakness, hepatomegaly, and fasting hypoglycemia in infancy are common, but these features often resolve spontaneously, and patients become asymptomatic in childhood and adult life. Others experience slowly progressive distal muscle wasting, hepatic cirrhosis, recurrent hypoglycemia, and heart failure. This more serious chronic course is particularly seen in the Inuit population. Minor myopathic findings including vacuolation of muscle fibers are found in the muscle biopsy specimen.

Glycogenosis IV (Andersen disease) is a deficiency of brancher enzyme, resulting in the formation of an abnormal glycogen molecule, amylopectin, in the liver, reticuloendothelial cells, and skeletal and cardiac muscle. Hypotonia, generalized weakness, muscle wasting, and contractures are the usual signs of myopathic involvement. Most patients die before age 4 years because of hepatic or cardiac failure. A few children without neuromuscular manifestations have been described.

Glycogenosis V (McArdle disease) is caused by muscle glycogen phosphorylase deficiency inherited as an autosomal recessive trait at locus 11q13, encoded by *PMGM*. Exercise intolerance is the cardinal clinical feature. Physical exertion results in cramps, weakness, and myoglobinuria, but strength is normal between attacks. The serum CK level is elevated only during exercise. A characteristic clinical feature is lack of the normal rise in serum lactate levels during ischemic exercise because of inability to convert pyruvate to lactate under anaerobic conditions in vivo. Myophosphorylase deficiency may be demonstrated histochemically and biochemically in the muscle biopsy tissue. Some patients have a defect in adenosine monophosphate–dependent muscle phosphorylase β-kinase, a phosphorylase enzyme activator. Muscle phosphorylase deficiency can be diagnosed by MR spectroscopy, which shows that the intramuscular pH does not decrease with exercise and there is no depletion of adenosine triphosphatase but that the phosphocreatine concentration falls excessively. This noninvasive technique may be useful in some patients if the radiologist is experienced with the disease.

A rare **neonatal form of myophosphorylase deficiency** causes feeding difficulties in early infancy, may be severe enough to result in neonatal death, or can follow a course of slowly progressive weakness resembling a muscular dystrophy. The long-term prognosis is good. Patients must learn to moderate their physical activities, but they do not develop severe chronic myopathic handicaps or cardiac involvement.

Glycogenosis VII (Tarui disease) is muscle phosphofructokinase deficiency. Although this disease is rarer than glycogenosis V, the symptoms of exercise intolerance, clinical course, and inability to convert pyruvate to lactate are identical. The distinction is made by biochemical study of the muscle biopsy specimen. It is transmitted as an autosomal recessive trait at the 1cenq32 locus, and some gene variants are particularly prevalent in the Ashkenazi Jewish population.

Visit Elsevier eBooks+ at eBooks.Health.Elsevier.com for Bibliography.

651.4 Mitochondrial Myopathies

Adnan Y. Manzur

See also Chapters 107.4 and 638.2 and Table 651.4.

Several diseases involving muscle, brain, and other organs are associated with structural and functional abnormalities of mitochondria, producing defects in aerobic cellular metabolism, the electron transport chain, and the Krebs cycle (see Table 651.4; Table 651.5). Because mitochondria are found in all cells except mature erythrocytes, the term **mitochondrial cytopathy** is used preferentially to emphasize the multisystemic nature of these diseases. The structural aberrations are best demonstrated by electron microscopy of the muscle biopsy sample, revealing a proliferation of abnormally shaped cristae, including stacked or whorled cristae and paracrystalline structures that occupy the space between cristae and are formed from CK. Muscle biopsies of neonates, infants, and toddlers show more severe involvement of endothelial cells of intramuscular capillaries than of myofibers, unlike the reverse in adults, but endothelial paracrystalline structures are globular rather than brick shaped as in myofibers. The endoplasmic reticulum becomes abnormally adherent to mitochondria. Similar endothelial mitochondrial alterations are seen in the brain in Leigh and other infantile mitochondrial encephalopathies. Histochemical study of the muscle biopsy specimen reveals abnormal clumping of oxidative enzymatic activity and scattered myofibers, with loss of cytochrome-*c* oxidase activity and with increased neutral lipids within myofibers. Ragged red muscle fibers occur in some mitochondrial myopathies, particularly those with a combination of respiratory chain complexes I and IV deficiencies. Accumulations of this membranous material

Table 651.3 Clinical Symptoms and Classification of Muscle Glycogen Storage Diseases

GSD	ENZYMATIC DEFECT	CHROMOSOME	CLINICAL SYNDROME(S)	CHARACTERISTIC FEATURES ON MUSCLE BIOPSY
DEFECTS IN GLYCOGEN METABOLISM				
0	Muscle glycogen synthase	19q13	Cardiomyopathy, exercise intolerance	Lack of glycogen
II (Pompe)	Lysosomal α-1,4-1, 6-glucosidase (acid maltase)	17q25	*Infantile "classic" form:* multiorgan involvement (heart, muscle, liver) *Late-onset form:* myopathy with atrophy and weakness, respiratory insufficiency	PAS-positive vacuoles; secondary changes: increased acid phosphatase reaction, mitochondrial alterations, autophagic vacuoles, neurogenic-like changes
III (Cori-Forbes)	Debranching enzyme (oligo-1,4-1,4-glucanotransferase, amylo-1,6-glucosidase)	1p21	*IIIa:* liver (hepatomegaly, growth retardation, fasting hypoglycemia), myopathy with atrophy and weakness or exercise intolerance *IIIb:* only liver involvement	PAS-positive vacuoles
IV (Andersen)	Branching enzyme (amylo-1,4-1,6-transglucosidase)	3p12	*Congenital form:* myopathy, cardiomyopathy, neuronal involvement *Childhood form:* myopathy, cardiomyopathy *Adult form:* myopathy or APBD	Diastase-resistant PAS-positive deposits; polyglucosan bodies
V (McArdle)	Myophosphorylase	11q13	Exercise intolerance, myopathy with atrophy and weakness (during late disease course), infantile form	PAS-positive deposits; negative phosphorylase staining
IX	Phosphorylase kinase α (muscle) subunit or β-subunit	Xq13 16q13	Exercise intolerance, muscle weakness Liver and muscle involvement	PAS-positive deposits
XIV	Phosphoglucomutase 1	1p31	Exercise intolerance	PAS-positive vacuoles
XV	Glycogenin	3q24	Muscle weakness; cardiac arrhythmia	PAS-positive deposits, polyglucosan bodies
DEFECTS OF GLYCOLYTIC METABOLISM				
VII (Tarui)	Phosphofructokinase (muscle isoform)	12q13.3	Exercise intolerance, chronic hemolysis, infantile form (rare)	PAS-positive deposits; negative PFK staining; polyglucosan bodies
	Phosphoglycerate kinase	Xq13	Exercise intolerance, chronic hemolysis; rare form with CNS involvement (oligophrenia, delayed motor development, epilepsy)	PAS-positive deposits
X	Phosphoglycerate mutase (muscle isoform)	7p12	Exercise intolerance	PAS-positive deposits
XI	Lactate dehydrogenase (muscle isoform)	11p15	Exercise intolerance, dermatologic symptoms	Normal
XII	Aldolase A	16q22-q24	Exercise intolerance, chronic hemolysis	Normal
XIII	β-Enolase	17pter-p12	Exercise intolerance	PAS-positive deposits
	Triosephosphate isomerase		Myopathy with atrophy and weakness, chronic hemolysis	PAS-positive deposits; secondary changes; mitochondrial alterations

APBD, Adult polyglucosan body disease (motor neuron involvement, polyneuropathy, dementia, urinary incontinence); CNS, central nervous system; GSD, glycogen storage disease; PAS, periodic acid–Schiff; PFK, phosphofructokinase.

From Vorgerd M, Deschauer M. Treatment and management of hereditary metabolic myopathies. In: Bertorini TE, ed. *Neuromuscular Disorders Treatment and Management,* 2nd ed. Philadelphia: Elsevier; 2022: Table 23.1, p. 575.

beneath the muscle fiber membrane are best demonstrated by special stains, such as modified Gomori trichrome.

These characteristic histochemical and ultrastructural changes are most consistently seen with point pathogenic variants in mitochondrial transfer RNA. The large mitochondrial DNA (mtDNA) deletions of 5 kb or 7.4 kb (the single mitochondrial chromosome has 16.5 kb) are associated with defects in mitochondrial respiratory oxidative enzyme complexes, if as few as 2% of the mitochondria are affected, but minimal or no morphologic or histochemical changes may be noted in the muscle biopsy specimen, even by electron microscopy. Hence, quantitative biochemical studies of the muscle tissue are needed to confirm the diagnosis. Because most of the subunits of the respiratory chain complexes are encoded by nuclear DNA (nDNA) rather than mtDNA, mendelian autosomal inheritance is possible, rather than maternal transmission as with pure mtDNA point variants. Complex II (succinate dehydrogenase) is the only enzyme complex in which all of its subunits are encoded by nDNA; it is histochemically reactive in all mitochondrial diseases with mtDNA

Table 651.4 Select Mitochondrial Disorders with Hypotonia Classified by Clinical Phenotypes

CLINICAL PHENOTYPE	ASSOCIATED VARIANTS	MODE OF INHERITANCE	COMMON CLINICAL FEATURES
MELAS syndrome (mitochondrial encephalopathy, lactic acidosis, and strokelike episodes)	tRNA point variants: • m.3243A>G in $tRNA^{Leu}$ (~80% of cases) • m.3217T>C in $tRNA^{Leu}$ (~7.5% of cases) • m.13513G>A encoding NADH-ubiquinone (<15% of cases) • m.3252A>G in $tRNA^{Leu}$ (<5% of cases) • Multiple other mtDNA point variants	Maternal	• *Cardinal*: strokelike episodes, intermittent encephalopathy, T2/FLAIR abnormalities on brain MRI that do not respect vascular territory, lactic acidosis • *Other*: hearing loss, diabetes, short stature, gastrointestinal issues
MERRF syndrome (myoclonic epilepsy with ragged red fibers)	tRNA point variants: • m.8344A>G in $tRNA^{Lys}$ (>80% of cases) • m.8356T>C in $tRNA^{Lys}$ • m.8363G>A in $tRNA^{Lys}$ • m.8361G>A in $tRNA^{Lys}$ • Multiple other mtDNA point variants	Maternal	• *Cardinal:* myoclonus, proximal weakness, generalized epilepsy, ataxia • *Other*: multiple lipomatosis, hearing loss, cognitive impairment, neuropathy
KSS (Kearns-Sayre syndrome)	Single large mtDNA deletion (1.1-10-kb) • m.8470_13446del4977 (deletion of 4977 base pairs; most common) • Multiple other mtDNA deletions	Sporadic	• *Cardinal*: multisystemic disease with progressive external ophthalmoplegia, pigmentary retinopathy, cardiomyopathy before age 20 yr • *Other*: short stature, proximal muscle weakness, hearing loss, dementia, ataxia, multiple endocrinopathies (diabetes, hypothyroidism, hypoparathyroidism, hypogonadism)
CPEO (chronic progressive external ophthalmoplegia)	Single large mtDNA deletion (1.1-10 kb)	Sporadic	• *Cardinal*: skeletal muscle disorder with ptosis, ophthalmoparesis, ±proximal muscle weakness
	• m.3243A>G in $tRNA^{Leu}$ (most common; same as MELAS) • Multiple other mtDNA point variants	Maternal	
	• Multiple mtDNA deletions caused by variants in the following nuclear genes: *SLC25A4* encoding ANT1, *C10orf2* encoding twinkle, *POLG1* encoding mtDNA polymerase, *POLG2, OPA1*	Autosomal dominant	
Leigh syndrome (subacute necrotizing encephalomyelopathy)	mtDNA variants: • m.8993T>G or m.8993T>C in *MT-ATP6* (~10% of cases) • Multiple other mtDNA point variants	Maternal	• Hypotonia, spasticity, movement disorders (chorea), cerebellar ataxia, neuropathy, bilateral basal ganglia lesions, seizures, lactic acidosis, psychomotor retardation/regression especially with illness between 3-12 mo of age • Hypertrophic cardiomyopathy
	• m.8470_13446del4977 (deletion of 4977 base pairs; also seen in KSS)	Sporadic	
	Nuclear gene variants resulting in respiratory chain complex deficiencies: • Complex I: *NDUFV1, NDUFS1, NDUFS2, NDUFS3, NDUFS4, NDUFS7, NDUFS8, NDUFA1, NDUFA2, NDUFA10, NDUFA9, NDUFA12, NDUFAF2, NDUFAF5, NDUFAF6, FOXRED1* • Complex II: *SDHA, SDHAF1* • Complex III: *BCS1L, UQCRQ, TTC19* • Complex IV: *SURF1, COX10, COX15, SCO2, NDUFA4, PET100, LRPPRC*	Autosomal recessive	

Continued

Table 651.4 Select Mitochondrial Disorders with Hypotonia Classified by Clinical Phenotypes—cont'd

CLINICAL PHENOTYPE	ASSOCIATED VARIANTS	MODE OF INHERITANCE	COMMON CLINICAL FEATURES
NARP (neurogenic muscle weakness, ataxia, retinitis pigmentosa)	• m.8993T>G or m.8993T>C in *MT-ATP6* (50% of cases)	Maternal	• Proximal neurogenic muscle weakness, sensory neuropathy, seizures, ataxia, pigmentary retinopathy, learning difficulties, dementia with onset usually in childhood
Mitochondrial DNA depletion syndrome	• Homozygous or compound heterozygous variants in *TK2* (thymidine kinase 2), a mitochondrial deoxyribonuclease, resulting in mitochondrial depletion	Autosomal recessive	• Hypotonia, proximal muscle weakness, axial weakness, respiratory insufficiency, marked clinical variability with death in infancy to early adulthood due to respiratory insufficiency

FLAIR, Fluid-attenuated inversion recovery; mtDNA, mitochondrial DNA; NADH, nicotinamide adenine dinucleotide, reduced form; tRNA, transfer RNA.
Data from DiMauro S, Hirano M. MERRF. *GeneReviews* [Internet], June 3, 2003. Seattle: University of Washington; DiMauro S, Hirano M. MELAS. *GeneReviews* [Internet]. February 27, 2001. Seattle: University of Washington; Thorburn DR, Rahman S. Mitochondrial DNA-associated Leigh syndrome and NARP. *GeneReviews* [Internet], October 30, 2003. Seattle: University of Washington; Liang C, Ahmad K, Sue CM. The broadening spectrum of mitochondrial disease: shifts in the diagnostic paradigm. *Biochim Biophys Acta* 2014;1840:1360–1367; Konersman C. Hypotonia, weakness, and stroke. In: Kliegman RM, Lye PS, Bordini BJ, et al., eds. *Nelson Symptom-Based Diagnosis*. Philadelphia: Elsevier; 2018: Table 29.11.

Table 651.5 Clinical Spectrum of Mitochondrial Disease

NERVOUS SYSTEM
Hypotonia
Failure to thrive
Motor regression
Stroke (nonvascular)
Dementia
Episodic encephalopathy (elevated cerebrospinal fluid lactate)
Intellectual disability
Neuropathy (axonal, demyelinating, or sensory ganglionopathy)
Ophthalmoparesis (slowly progressive)
Ptosis (slowly progressive; little diurnal variation; asymmetric at onset)
Optic atrophy
Retinitis pigmentosa (perimacular; vision usually spared)
Ataxia
Central apnea
Epilepsy (focal or multifocal myoclonus; status epilepticus; triggered by sodium valproate)
Migraines
Sensorineural hearing loss (asymmetric; young onset; partial recovery possible)
HEART
Cardiomyopathy
Conduction block or arrhythmia
SKELETAL MUSCLE
Myopathy (proximal, symmetric weakness; myalgia)
Exercise intolerance
Episodic rhabdomyolysis
OTHER
Lactic acidosis
Recurrent bowel obstruction (pseudoobstruction)
Short stature
Diabetes (young onset; nonobese)

Data from Amato A, Russell J. *Neuromuscular Disorders*. New York: McGraw-Hill, 2008; Liang C, Ahmad K, Sue CM. The broadening spectrum of mitochondrial disease: shifts in the diagnostic paradigm. *Biochim Biophys Acta*. 2014;1840:1360–1367.

point variants. Serum lactate is elevated in some diseases, and cerebrospinal fluid lactate is more consistently elevated, even if serum concentrations are normal.

The term primary mitochondrial myopathies encompasses the group of genetic disorders where pathophysiology is impaired oxidative phosphorylation and the primary affected organ is the skeletal muscle. Several distinct or overlapping mitochondrial syndromes that primarily affect striated muscle or muscle and brain are identified. These can be divided clinically, or histopathologically, into the ragged red fiber diseases and non–ragged fiber diseases. The ragged red fiber diseases include Kearns-Sayre, MELAS (*m*itochondrial *e*ncephalopathy, *l*actic *a*cidosis, and *s*trokelike episodes) syndrome, MERRF (*m*yoclonic *e*pilepsy with *r*agged *r*ed *f*ibers) syndrome, and progressive external ophthalmoplegia syndromes, which are associated with a combined defect in respiratory chain complexes I and IV. The non–ragged fiber diseases include Leigh encephalopathy and Leber hereditary optic atrophy; they involve complex I or IV alone or, in children, the common combination of defective complexes III and V. **Kearns-Sayre syndrome** is characterized by the triad of progressive external ophthalmoplegia, pigmentary degeneration of the retina, and onset before age 20 years. Heart block, cerebellar deficits, and a high cerebrospinal fluid protein content are often associated. Visual evoked potentials are abnormal. Patients usually do not experience weakness of the trunk or extremities or dysphagia. Most cases are sporadic.

Chronic progressive external ophthalmoplegia may be isolated or accompanied by limb muscle weakness, dysphagia, and dysarthria. A few patients described as having *ophthalmoplegia plus* have additional central nervous system involvement. Autosomal dominant inheritance is found in some pedigrees, but most cases are sporadic.

MERRF and **MELAS syndromes** are other mitochondrial disorders affecting children. The latter is characterized by stunted growth, episodic vomiting, seizures, and recurring cerebral insults causing hemiparesis, hemianopia, or even cortical blindness, and dementia. The disease behaves as a degenerative disorder, and children die within a few years.

Other diseases of the central nervous system that also involve myopathy with mitochondrial abnormalities include **Leigh subacute necrotizing encephalopathy** (see Chapter 107.4) and **cerebrohepatorenal (Zellweger) disease, primarily a peroxisomal disease with secondary mitochondrial alterations** (see Chapter 106.2). Another recognized mitochondrial myopathy is **cytochrome-*c* oxidase deficiency. Oculopharyngeal muscular dystrophy** is also fundamentally a mitochondrial myopathy.

Mitochondrial depletion syndrome of early infancy is characterized by severely decreased oxidative enzymatic activities in most or all five of the complexes; in addition to diffuse muscle weakness, neonates and young infants can show multisystemic involvement, and the syndrome occurs in several forms: myopathic, encephalomyopathic, hepatoencephalopathic, and intestinal encephalopathic. Cardiomyopathy and sometimes bullous skin lesions or generalized edema also can occur.

One myopathic subgroup of mtDNA maintenance defect is related to the *TK2* gene, which encodes for thymidine kinase 2. The clinical presentation is with floppy infant and childhood-onset progressive limb and bulbar myopathy with restrictive lung disease and respiratory failure. The TK2 enzyme phosphorylates nucleosides in the pathway to generate deoxynucleoside triphosphates required for mtDNA replication and maintenance. Raised serum CK together with raised plasma

lactate is a good diagnostic clue, and the diagnosis can be confirmed by documenting autosomal recessive variants in the *TK2* gene. This group is of particular interest because of the potential for treatment with pyrimidine deoxynucleosides.

Alpers syndrome is genetically homogeneous and is caused by mtDNA depletion and variants in the *POLG1* gene. Several other genes are identified, mostly in later-onset forms; hence, mitochondrial depletion is a syndrome and not a single disease. **Barth syndrome** is an X-linked recessive mitochondrial disorder characterized by cardiomyopathy, myopathy of striated muscle, growth retardation, neutropenia, and high serum and urinary concentrations of 3-methyl-glutaconic acid.

Many rare diseases with only a few case reports are suspected of being mitochondrial disorders. It is also now recognized that secondary mitochondrial defects occur in a wide range of nonmitochondrial diseases, including inflammatory autoimmune myopathies, Pompe disease, and some cerebral malformations, and also may be induced by certain drugs and toxins, so that interpretation of mitochondrial abnormalities as primary defects must be approached with caution.

INVESTIGATIONS

Investigation for mitochondrial cytopathies begins with serum lactate. Lactic acid is not increased in all mitochondrial cytopathies, so that a normal result is not necessarily reassuring; cerebrospinal fluid lactate is increased in some cases in which serum lactate is normal, particularly if there are clinical signs of encephalopathy. Serum 3-methyl-glutaconic acid often is increased in mitochondrial cytopathies in general, demonstrated in more than 50 different genetic pathogenic variants, and is a good screening measurement; it rarely is increased in other metabolic diseases. This product may also be increased in urine. Hepatic enzymes (transaminases) should be measured in blood. Cardiac evaluation is often warranted. Molecular markers in blood for the common diseases with known mtDNA point variants identify many of the mitochondrial cytopathies presenting in adult life or adolescence, but less frequently in children and least in young infants. MRI of the brain may reveal hyperintense lesions of the basal ganglia and MR spectroscopy can demonstrate an increased lactate peak. The muscle biopsy provides the best evidence of all mitochondrial myopathies and should include histochemistry for oxidative enzymes, electron microscopy, and quantitative biochemical assay of respiratory chain enzyme complexes and coenzyme Q10; muscle tissue also can be analyzed for mtDNA. Many mitochondrial disorders also can affect the Schwann cells and axons of peripheral nerves and present clinically with neuropathy; hence, motor and sensory nerve conduction velocities can be measured in selected patients. Sural nerve biopsy is required only rarely if neuropathy is the predominant finding, and the diagnosis is not evident from other studies.

A diagnostic approach is noted in Figure 651.1.

TREATMENT

There is no effective treatment for majority of the mitochondrial cytopathies, but various *cocktails* are often used to try to overcome the metabolic deficits (see Chapter 638.2).

Visit Elsevier eBooks+ at eBooks.Health.Elsevier.com for Bibliography.

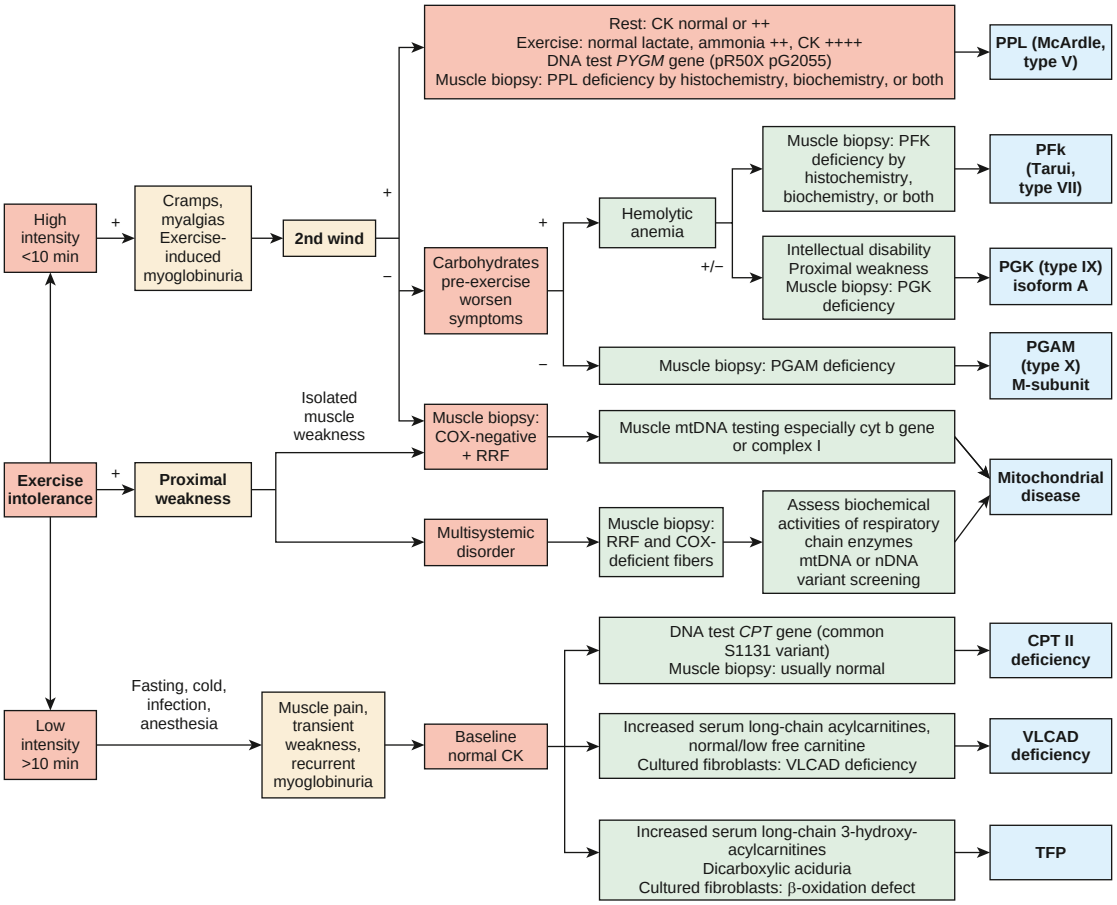

Fig. 651.1 Clinical diagnostic algorithm for patients with exercise intolerance in whom a metabolic myopathy is suspected. CK, Creatine kinase; COX, cytochrome-c oxidase; CPT, carnitine palmitoyltransferase; cyt *b*, cytochrome *b*; mtDNA, mitochondrial DNA; nDNA, nuclear DNA; PFk, phosphofructokinase; PGAM, phosphoglycerate mutase; PGK, phosphoglycerate kinase; PPL, myophosphorylase; RRF, ragged red fibers; TFP, trifunctional protein deficiency; VLCAD, very long-chain acyl-coenzyme A dehydrogenase. *(From Berardo A, Di Mauro S, Hirano M. A diagnostic algorithm for metabolic myopathies. Curr Neurol Neurosci Rep. 2010;10:118–126. Fig. 1.)*

651.5 Lipid Myopathies

Adnan Y. Manzur

See Chapter 106.4.

Skeletal muscles are the most important sites in the body for long-chain fatty acid metabolism because of their large mass and their rich density of mitochondria where fatty acids are metabolized. Fatty acids are the major source of energy for skeletal muscle during sustained exercise or fasting. Hereditary disorders of lipid metabolism that cause progressive myopathy are an important, relatively common, and often treatable group of muscle diseases (Table 651.6). Increased lipid within myofibers is seen in the muscle biopsy of some mitochondrial myopathies and is a constant, rather than an unpredictable, feature of specific diseases. Among the ragged red fiber diseases, Kearns-Sayre syndrome always shows increased neutral lipid, whereas MERRF and MELAS syndromes do not, a useful diagnostic marker for the pathologist. Free fatty acids are converted to acyl-coenzyme A by fatty acyl-coenzyme A synthetases; the resulting long-chain fatty acids bind to carnitine and are transported into mitochondria where β-oxidation is carried out. Disorders of lipid fuel utilization and lipid storage disorders can be divided into defects of transport and oxidation of exogenous fatty acids within mitochondria and defects of endogenous triglyceride catabolism.

Muscle carnitine deficiency is an autosomal recessive disease caused by pathologic variants in the *SLC22A5* gene, involving deficient transport of dietary carnitine across the intestinal mucosa. Carnitine is acquired from dietary sources but is also synthesized in the liver and kidneys from lysine and methionine; it is the obligatory carrier of long- and medium-chain fatty acids into muscle mitochondria.

The clinical course may be one of sudden exacerbations of weakness or can resemble a progressive muscular dystrophy with generalized proximal myopathy and sometimes facial, pharyngeal, and cardiac involvement. Symptoms usually begin in late childhood or adolescence or may be delayed until adult life. Progression is slow but can end in death.

The serum CK level is mildly elevated. Muscle biopsy material shows vacuoles filled with lipid within muscle fibers in addition to nonspecific changes suggestive of a muscular dystrophy. Mitochondria can appear normal or abnormal. Carnitine measured in muscle biopsy tissue is reduced, but the serum carnitine level is normal.

Treatment stops the progression of the disease and can even restore lost strength if the disease is not too advanced. It consists of special diets low in long-chain fatty acids. Steroids can enhance fatty acid transport. Specific therapy with L-carnitine taken orally in large doses overcomes the intestinal barrier in some patients. Some patients also improve when given supplementary riboflavin, and other patients seem to improve with propranolol.

Systemic carnitine deficiency is a disease of impaired renal and hepatic synthesis of carnitine rather than a primary myopathy. Patients with this autosomal recessive disease experience progressive proximal myopathy and show muscle biopsy changes similar to those of muscle carnitine deficiency; the onset of weakness is earlier and may be evident at birth. Endocardial fibroelastosis can also occur. Episodes of acute hepatic encephalopathy resembling Reye syndrome can occur. Hypoglycemia and metabolic acidosis complicate acute episodes. Cardiomyopathy may be the predominating feature in some cases and result in death.

Cerebral infarctions and myopathy occur in children, particularly when accompanied by hypoglycemia. The mean age at presentation is approximately 9 years. A brain MRI shows distinctive changes related to multiple infarcts of various sizes.

The concentration of carnitine is reduced in serum as well as in muscle and liver. L-Carnitine deficiency can be corrected by oral administration of carnitine on a daily basis.

A similar clinical syndrome may be a complication of renal Fanconi syndrome because of excessive urinary loss of carnitine or loss during chronic hemodialysis.

Treatment with L-carnitine improves the maintenance of blood glucose and serum carnitine levels but does not reverse the ketosis or acidosis or improve the exercise capacity.

Muscle CPT deficiency manifests as episodes of cramps after exercise, rhabdomyolysis, coma, and elevated serum CK levels. It is the most commonly identified cause of recurrent myoglobinuria in adults, but myoglobinuria is not a constant feature. CPT transfers long-chain fatty acid acyl-coenzyme A residues to carnitine on the outer mitochondrial membrane for transport into the mitochondria. Exercise intolerance and myoglobinuria resemble glycogenoses V and VII. The degree of exercise that triggers an attack varies among individuals, ranging from casual walking to strenuous exercise. Fasting hypoglycemia can occur. Some patients present only in late adolescence or adult life with myalgias. Genetic transmission is autosomal recessive and is caused by a defect on chromosome 1 at the 1p32 locus. Administration of valproic acid can precipitate acute rhabdomyolysis with myoglobinuria in patients with CPT deficiency; it should be avoided in the treatment of seizures or migraine if they occur. Treatment includes a low fat, high carbohydrate diet. *Very long-chain acyl-coenzyme A dehydrogenase deficiency* has a similar clinical presentation but mainly with adult onset.

Visit Elsevier eBooks+ at eBooks.Health.Elsevier.com for Bibliography.

651.6 Vitamin E Deficiency Myopathy

Adnan Y. Manzur

Deficiency of vitamin E (α-tocopherol, an antioxidant also important in mitochondrial superoxide generation) may produce a progressive myopathy closely resembling a muscular dystrophy. Myopathy and neuropathy are recognized in humans who lack adequate intake of this antioxidant. Patients with chronic malabsorption, those undergoing long-term dialysis, and premature infants who do not receive vitamin E supplements are particularly vulnerable. Treatment with high doses of vitamin E can reverse the deficiency. Myopathy caused by chronic hypervitaminosis E also occurs.

Visit Elsevier eBooks+ at eBooks.Health.Elsevier.com for Bibliography.

Table 651.6 Defects of Lipid Metabolism Resulting in Myopathy

BIOCHEMICAL DEFECT	AFFECTED GENE(S)	TYPICAL MUSCLE PHENOTYPE	CHARACTERISTIC CHANGES OF ACYL-CARNITINE SPECTRUM IN BLOOD	MUSCLE HISTOLOGY
Carnitine palmitoyltransferase II deficiency	*CPT II*	Attacks with myoglobinuria	C16:0 and C18:1 carnitine elevated	Often normal interictally
Multiple acyl-coenzyme A (CoA) dehydrogenase deficiency (glutaric aciduria type 2)	*ETFDH*, *ETFA*, or *ETFB*	Permanent muscle weakness	Multiple acyl-carnitines (C4–C18:1) elevated	Lipid storage
Medium-chain acyl-CoA dehydrogenase deficiency	*MCAD*	Attacks with myoglobinuria; permanent muscle weakness	C8 carnitine elevated	Lipid storage
Very long-chain acyl-CoA dehydrogenase deficiency	*ACADVL*	Attacks with myoglobinuria	C14:1 carnitine elevated	Often normal interictally
Primary muscle carnitine deficiency	Unknown	Permanent muscle weakness	Carnitine rarely reduced	Lipid storage
Primary systemic carnitine deficiency (carnitine transporter defect)	*SLC22A5 (OCTN2)*	Hypotonia, cardiomyopathy	Carnitine reduced	Lipid storage
Trifunctional protein deficiency (deficiency of long-chain 3-hydroxyacyl-CoA dehydrogenase, long-chain 2-enoyl-CoA hydratase, and long-chain 3-ketoacyl-CoA thiolase)	*HADHA* and *HADHB*	Attacks with myoglobinuria	3-hydroxy C16 and C18 acylcarnitine elevated (can be normal interictally)	Often normal interictally
Short-chain acyl-CoA dehydrogenase deficiency	*ACADS*	Hypotonia	C4 carnitine elevated	Sometimes lipid storage
Neutral lipid storage disease with ichthyosis	*ABHD5 (GCI58)*	Permanent muscle weakness	Normal	Abundant lipid storage
Neutral lipid storage disease with myopathy	*PNPLA2*	Permanent muscle weakness	Normal C16:0, C18:0, C18:1	Abundant lipid storage
Carnitine-acylcarnitine-translocase deficiency (CACT deficiency)	*SLC25A20*	Hypotonia	C18:2 carnitine elevated	Not reported
Lipin deficiency	*LPIN1*	Attacks of myoglobinuria, permanent muscle weakness	C14:1 carnitine elevated	Normal interictally
Long-chain acyl-CoA deficiency (LCAD deficiency)	*ACADL*	Attacks of myoglobinuria, permanent muscle weakness	C4 carnitine elevated	Normal interictally
Short-chain L-3-hydroxyacyl-CoA dehydrogenase deficiency (SCHAD deficiency)	*HADH*	Attacks of myoglobinuria, permanent muscle weakness	C4 carnitine elevated	Often normal interictally
Medium-chain 3-ketoacyl-CoA thiolase (MCKAT deficiency)	*MCKAT*	Attacks of myoglobinuria	C12–C16 carnitine elevated	Not reported

From Vorgerd M, Deschauer M. Treatment and management of hereditary metabolic myopathies. In: Bertorini TE, ed. *Neuromuscular Disorders Treatment and Management*, 2nd ed. Philadelphia: Elsevier; 2022: Table 23.2, p. 582.

Chapter 652

Disorders of Neuromuscular Transmission and of Motor Neurons*

652.1 Myasthenia Gravis

Adnan Y. Manzur

AUTOIMMUNE MYASTHENIA GRAVIS

Myasthenia gravis (MG) is a chronic autoimmune disease of the postsynaptic end plate leading to abnormal neuromuscular transmission or blockade, characterized clinically by rapid fatigability of striated muscle, particularly extraocular and palpebral muscles and those of swallowing. It must be distinguished from congenital myasthenic syndrome, a genetic disorder of receptors on the presynaptic and postsynaptic membranes, as well as the synapse of the neuromuscular junction and toxin-induced disorders of neurotransmission, such as botulism (see later). In MG, the release of acetylcholine (ACh) into the synaptic cleft by the axonal terminal is normal, but the postsynaptic muscle membrane (i.e., *sarcolemma*) or *motor end plate* is less responsive than normal. This is due to antibodies against the postsynaptic acetylcholine receptor (AChR), leading to an abnormal architecture/folding pattern of the postsynaptic membrane, as well as a decreased number of receptors to which ACh can bind.

Infants born to *myasthenic mothers* can have a **transient neonatal myasthenic syndrome** secondary to placentally transferred anti-AChR antibodies, distinct from congenital myasthenic syndromes (Tables 652.1-652.3).

Clinical Manifestations

The age of onset for *immune-mediated* MG ranges anywhere from 11 months to 17 years of age. In the prepubertal age-groups, the female:male ratio is about 1.5:1, and in the postpubertal age-groups, the female:male ratio is about 1:1 (Table 652.4). In juvenile autoimmune MG, unilateral or bilateral but usually *asymmetric ptosis* and some degree of extraocular muscle weakness are the earliest and most constant signs. Extraocular weakness is not confined to muscles innervated by just one or two of the three corresponding brainstem nuclei; it is progressive. Older children might complain of diplopia, and young children might hold open their eyes with their fingers or thumbs if the ptosis is severe enough to obstruct vision. Pupillary responses to light are preserved. Dysphagia and facial weakness also are common and, in early infancy, feeding difficulties are frequent as the cardinal sign of myasthenia; in severe cases, aspiration and airway obstruction may occur. Poor head control because of weakness of the neck flexors may be prominent. Involvement initially may appear to be limited to bulbar-innervated muscles, but the disease can be systemic and progressive weakness eventually involves limb-girdle muscles and distal muscles of the hands in many cases. Fasciculations of muscle, myalgias, and sensory symptoms do not occur. Tendon stretch reflexes may be diminished but rarely are lost. *Ocular MG may prove to be transitory over time, but in some patients, weakness never progresses to involve the axial or appendicular muscles.* This disorder accounts for approximately 25% of all juvenile MG patients and is most frequent in children of Chinese and southeastern Asian descent, suggesting an ethnic genetic predisposition. In addition, prepubertal patients are more likely to have *ocular only* myasthenia, whereas a majority of postpubertal patients with myasthenia will have generalized symptoms.

Rapid fatigue of muscles is a characteristic feature of MG that distinguishes it from most other neuromuscular diseases. Ptosis increases progressively as patients are asked to sustain an upward gaze for 30-90 seconds. Holding the head up from the surface of the examining table while lying supine is very difficult (indicative of neck flexion weakness), and gravity cannot be overcome for more than a few seconds. Repetitive opening and closing of the fists produces rapid fatigue of hand muscles, and patients cannot elevate their arms for more than 1-2 minutes because of fatigue of the deltoids. Patients are more symptomatic late in the day or when tired. Dysphagia can interfere with eating, and the muscles of the jaw soon tire when an affected child chews. Reviewing activities of daily living helps determine the severity of symptoms (Table 652.5). Additional triggers for exacerbation of weakness may include heat and intercurrent illness. Application of cold packs over the eyes will reverse ptosis.

Left untreated, MG is usually progressive and can become life-threatening because of respiratory muscle involvement and the risk of aspiration, particularly at times when the child is otherwise unwell, as during an upper respiratory tract infection. Familial myasthenia (congenital myasthenic syndrome) usually is not progressive, but may vary in severity from milder forms, limb-girdle forms, to more severe forms, including those with respiratory failure.

Myasthenic crisis is an acute or subacute severe increase in weakness in patients with MG, usually precipitated by an intercurrent infection, surgery, or even emotional stress. It may require intravenous cholinesterase inhibitors, immunoglobulin, plasma exchange, gavage feeding, and even transient ventilator support. It must be distinguished from **cholinergic crisis** secondary to overdosing with anticholinesterase medications. The muscarinic effects include abdominal cramps, diarrhea, profuse sweating, salivation, bradycardia, increased weakness, and miosis. Cholinergic crisis requires only supportive care and withholding of further doses of cholinergic drugs, and it passes within a few hours; the dose of medication to be restarted should be reconsidered, unless the patient had taken an overdose that was not prescribed.

Approximately 70–80% of adolescents with immune-mediated MG will have elevated AChR antibodies, but anti-AChR antibodies are only occasionally demonstrated in the plasma of prepubertal children. Some with negative titers of anticholinesterase exhibit anti–muscle-specific tyrosine kinase (MuSK) circulating antibodies. MuSK is localized at the neuromuscular junction and appears essential to fetal development of this junction. Additional autoantibodies related to immune MG include LRP4, titin, and ryanodine receptor (RyR) antibodies. In some patients, no antibody is detected (unknown MG etiology).

Infants born to myasthenic mothers can have respiratory insufficiency, inability to suck or swallow, and generalized hypotonia and weakness, a syndrome typically referred to as transient neonatal myasthenia. They might show little spontaneous motor activity for several days to weeks. The onset of symptoms typically occurs within the first 1-3 days of life. Some require ventilatory support and feeding by gavage during this period. Some patients may also require pyridostigmine (acetylcholinesterase [AChE] inhibitor) management transiently. After the abnormal antibodies disappear from the blood and muscle tissue, these infants regain normal strength and are not at increased risk of developing MG in later childhood. Patients usually show full recovery by about 2 months of age. A small minority develops *fetal akinesia sequence* with multiple joint contractures *(arthrogryposis)* that develop in utero from lack of fetal movement. AChR antibodies can usually be demonstrated in maternal blood, but at times maternal antibodies may not be detected. Rates of transient neonatal myasthenia are estimated to be as high as 10–20% of infants born to mothers with MG.

CONGENITAL MYASTHENIC SYNDROMES

A heterogeneous group of genetic diseases of neuromuscular transmission is collectively called **congenital myasthenic syndromes (CMSs).** The etiology and pathogenesis of these syndromes are unrelated to either transitory neonatal myasthenia caused by placental transfer of

*The editors are grateful to Dr. Diana X. Bharucha-Goebel and Dr. Goknur Haliloglu, much of whose work on previous editions of this chapter is retained here.

Table 652.1 Congenital Myasthenic Syndromes: Subtypes and Distinguishing Clinical Features

CMS SUBTYPE[1]		% OF ALL CMS	GENE(S)[2]	DISTINGUISHING CLINICAL FEATURES	RESPONSE TO ACHE INHIBITORS
Postsynaptic CMS	Acetylcholine receptor (AChR) deficiency	50%[3]	*CHRNA1* *CHRNB1* *CHRND* *CHRNE*	*AChR deficiency (AR)* • Early onset • Mild to severe • Ptosis, EOP; bulbar, arm, leg weakness	Improvement
	Slow-channel CMS (SCCMS)			*SCCMS (AD)* • Selective severe neck, wrist, finger extensor weakness • Childhood to adult onset • Mild to severe • Progressive ventilatory insufficiency; may require assisted ventilation	Deterioration
	Fast-channel CMS (FCCMS)			FCCMS (AR): Mild to severe	Improvement
	Defect in AChR clustering pathway	15–20%	*RAPSN*	*Early onset* • Hypotonia, respiratory failure at birth • Episodic apnea • Arthrogryposis multiplex congenita • Mild to severe *Late onset:* • Limb weakness in adolescence or adulthood; as in seronegative myasthenia gravis	Improvement
		10–15%	*DOK7*	Limb-girdle pattern of predominantly proximal weakness, waddling gait, and ptosis but no EOP	Deterioration or ineffective
		<1%	*LRP4*	Respiratory failure at birth, delayed motor milestones, ptosis, ophthalmoparesis, limb weakness	See footnote 4
		<1%	*MUSK*	*Broad phenotype* • Prenatal onset with fetal akinesia deformation sequence • Early onset with ophthalmoplegia and respiratory failure • Isolated vocal cord paralysis • Late-onset limb-girdle weakness	Deterioration or ineffective
	Plectin deficiency	<1%	*PLEC*	*Childhood to adulthood onset:* • Fatigable proximal myopathy and ptosis • With or without skin blistering	Improvement
	Defect in skeletal muscle voltage-gated sodium channel	<1%	*SCN4A*	Phenotype overlapping with *SCN4A*-associated skeletal muscle sodium channelopathies: periodic paralysis, myotonia, myopathy	See footnote 4
Synaptic CMS	End plate AChE deficiency	10–15%	*COLQ*	• Often severe • In some with C-terminal missense pathogenic variants: later presentation, milder clinical course • EOP • General muscle weakness/severe involvement of axial muscles • Slow pupillary light response	Deterioration or ineffective
		1–2%; >14 independent kinships reported	*COL13A1*	• At birth, respiratory distress and dysphagia; may resolve • Recurrent apnea triggered by infections • In adulthood, bilateral nonfatigable ptosis and marked axial weakness • Sometimes improvement of muscle weakness by adulthood	Likely ineffective
	Defects in AChR clustering pathway	<1%	*AGRN*	• Early-onset or late-onset phenotype • Persons with late onset may present with distal muscle weakness and wasting in addition to myasthenia	Deterioration

Downloaded for mohamed ahmed (dr.mms2020@gmail.com) at University of Southern California from ClinicalKey.com by Elsevier on April 23, 2024. For personal use only. No other uses without permission. Copyright ©2024. Elsevier Inc. All rights reserved.

Table 652.1 Congenital Myasthenic Syndromes: Subtypes and Distinguishing Clinical Features—cont'd

CMS SUBTYPE[1]		% OF ALL CMS	GENE(S)[2]	DISTINGUISHING CLINICAL FEATURES	RESPONSE TO ACHE INHIBITORS
Presynaptic CMS	Defect in ACh synthesis	4–5%	*CHAT*	• Hypotonia, respiratory failure at birth • Episodic apnea • Improvement with age	Improvement
	Defects in ACh recycling	<1%	*SLC5A7*	• Early onset • More severe than *CHAT*-related CMS • Arthrogryposis/joint contractures, apneic crisis at birth, marked ptosis, ophthalmoplegia, and muscle fatigability • Some have limited survival, some have milder phenotypes. • Some with learning difficulties	Some improvement
		<1%	*SLC18A3*	Similar to *SLC5A7*	Some improvement
	Defects in synaptic vesicle docking, priming, fusing, and exocytosis	<1%	*SNAP25*	Myasthenia is element of a severe and complex phenotype: • Developmental and epileptic encephalopathy of infancy and childhood with diverse clinical manifestations • Severe ID, cerebellar ataxia, brain atrophy	See footnote 4
		<1%	*VAMP1*	• Early-onset phenotype with severe congenital hypotonia and muscle weakness, feeding difficulties, delayed motor development, ophthalmoparesis. • May have joint contractures or joint laxity • May have respiratory insufficiency	Likely improvement[4]
		<1%	*SYT2*	• AR: Severe congenital-onset hypotonia and weakness, with variable degrees of respiratory involvement; mimics severe congenital myopathy • AD: Mimics distal hereditary motor neuropathy, slowly progressive distal motor neuropathy, and myasthenic syndrome	See footnote 4
		<1%	*PREPL*	• Congenital hypotonia, feeding difficulties, ptosis, and proximal muscle weakness • Growth hormone deficiency • See footnote 5	ACh inhibitors possibly beneficial in infancy[4]
	Defects in axonal transport of proteins	<1%	*MYO9A*	• Early-onset, ptosis, ophthalmoplegia and moderate global weakness, bulbar involvement, respiratory crises • Additional CNS symptoms: ID or learning difficulties, nystagmus, oculomotor apraxia	Improvement[4]
	Defect in mitochondrial citrate carrier	<1%	*SLC25A1*	• Relatively mild CMS phenotype with ID • Subtle mitochondrial abnormalities	Improvement[4]
Pre- and postsynaptic CMS	Limb-girdle myasthenia with glycosylation deficiency	<1%	*ALG2* *ALG14*	Overlap with CDG syndromes	See footnote 4
		1–2%	*DPAGT1* *GFPT1* *GMPPB*	• "Limb-girdle" pattern of weakness with predominantly proximal weakness but usually no ptosis or EOP; tubular aggregates on muscle biopsy in some • ID may occur in *DPAGT1*-associated CMS • *GMPPB* associated with high CK and muscular dystrophy	Improvement

[1]CMS subtypes are grouped by site of defect and mechanism of neuromuscular junction defect.

[2]Additional genes are published as CMS genes or genes with an underlying pathology of the neuromuscular junction, but to date have been reported in only one or two studies. These genes include: postsynaptic proteins *RPH3A*, *MACF1*, and *CHD8*; synaptic proteins *LAMA5*, *LAMB2*, and *UNC13A*; as well as *TOR1AIP1* (encoding the inner nuclear membrane protein, lamin-associated protein 1), and *DES* (the muscle-specific member of the intermediate filament protein family linking the contractile apparatus to the sarcolemmal cytoskeleton, cytoplasmic organelles, and nucleus). *Note:* Neuromuscular end plate pathology has been associated with autosomal recessive loss-of-function variants in *DES* rather than autosomal dominant variants (associated with *DES*-related myopathies).

[3]*CHRNE* is by far the most common causative gene among the AChR-subunit genes *CHRNA1*, *CHRNB1*, *CHRND*, and *CHRNE*.

[4]No or limited data; small number of reported individuals.

[5] Additional non-myasthenic features (cystinuria, learning difficulties, endocrinologic defects, hyperphagia with tendency to obesity) may be associated with homozygous deletions of the two contiguous genes *PREPL* and *SLC3A1* on chromosome 2p21 (hypotonia-cystinuria syndrome; OMIM 606407).

ACh, Acetylcholine; AChE, acetylcholinesterase; AD, autosomal dominant; AR, autosomal recessive; CDG, congenital disorders of glycosylation; CMS, congenital myasthenic syndrome; CNS, central nervous system; EOP, external ophthalmoplegia; ID, intellectual disability.

Modified from Abicht A, Muller JS, Lochmuller H. Congenital myasthenic syndromes overview. In: *GeneReviews* [Internet]. Seattle (WA): University of Washington. 2003 May 9 [updated 2021 Dec 23]. Table 1.

Downloaded for mohamed ahmed (dr.mms2020@gmail.com) at University of Southern California from ClinicalKey.com by Elsevier on April 23, 2024. For personal use only. No other uses without permission. Copyright ©2024. Elsevier Inc. All rights reserved.

Table 652.2 Differential Diagnosis of Myasthenia Gravis

DIAGNOSIS	SIMILARITIES	DIFFERENCES	DIAGNOSTIC TEST
Spinal muscular atrophy	Floppy infant or child with muscle weakness Respiratory and bulbar involvement Contractures (SMA1)	Absence of ptosis, and facial weakness Absent deep tendon reflexes Presence of tongue fasciculation, polyminimyoclonus	SMA genetics
Congenital myotonic dystrophy	Floppy infant or child with muscle weakness Respiratory and bulbar involvement Contractures Ptosis and facial weakness	Mother affected with myotonic dystrophy (may be undiagnosed) EMG shows no decrement on RNS or abnormal jitter/block	Myotonic dystrophy genetics
Congenital myopathy/ muscular dystrophy	Floppy infant or child with muscle weakness Respiratory and bulbar involvement Contractures Facial weakness May have ptosis	Characteristic muscle biopsy abnormalities EMG shows no decrement on RNS or abnormal jitter/block	Muscle biopsy Muscle MRI Genetics
Mitochondrial myopathy	Floppy infant or child with muscle weakness Respiratory and bulbar involvement Contractures Ptosis and facial weakness	May have other system involvement EMG shows decrement on RNS or abnormal jitter/block	Muscle biopsy Genetics
Myasthenia gravis	Fatigable muscle weakness Respiratory and bulbar involvement Ptosis and facial weakness EMG shows decrement on RNS or abnormal jitter/block	Age of onset (rare before 12 mo) Absence of family history Absence of ankle-dorsiflexion weakness Ptosis can be asymmetric	Antibody (RIA and cell-based assay if available) AChR, MuSK, and LRP4
Neonatal myasthenia gravis	Floppy neonate with muscle weakness Respiratory and bulbar involvement Ptosis and facial weakness EMG shows decrement on RNS or abnormal jitter/block	Mother with myasthenia gravis (may be undiagnosed)	Antibody testing of the mother
Limb-girdle muscular dystrophy	Proximal muscle weakness Respiratory involvement Positive family history	EMG shows no decrement on RNS or abnormal jitter/block	Muscle biopsy Muscle MRI Genetics
Chronic fatigue syndrome	History of fatigability with gross motor and fine motor activities	Clear period of prior normal motor function before onset of symptoms Absence of: muscle weakness of formal assessment; ptosis or facial weakness; EMG abnormalities	Clinical diagnosis
Hypermobility syndromes	History of "fatigability" with gross motor and fine motor activities	Absence of: muscle weakness on formal assessment; ptosis or facial weakness; EMG abnormalities	Clinical diagnosis

EMG, Electromyography; RNS, repetitive nerve stimulation; RIA, radioimmunoassay.
From Ramdas S, Beeson D. Congenital myasthenic syndromes: where do we go from here? *Neuromusc Dis.* 2021;31:943–1954. Table 1.

Table 652.3 Typical Distribution of Ocular Symptoms in Different Hereditary and Autoimmune Disorders Involving the Extraocular Muscles

	PTOSIS	OPHTHALMOPARESIS	DIPLOPIA	ASYMMETRY
CONGENITAL MYASTHENIC SYNDROME				
Presynaptic	Yes	No	Rare	No
Synaptic	Yes	Yes	No	No
Postsynaptic	Yes	Yes	Rare	No
Progressive external ophthalmoplegia (mitochondrial deletion syndrome)	Yes	Yes	No	Rare
Myotonic dystrophy	Yes	No	No	No
Autoimmune Lambert-Eaton myasthenic syndrome	Yes	Yes	Yes	Yes
Autoimmune acetylcholine receptor-positive myasthenia gravis	Yes	Yes	Yes	Yes
Autoimmune MuSK-positive myasthenia gravis	Yes	Yes	Yes	Yes
Orbital myositis	Rare	Yes	Yes	Yes
Thyroid orbitopathy	No	Yes	Yes	Yes

From Punga AR, Maddison P, Heckmann JM, et al. Epidemiology, diagnostics, and biomarkers of autoimmune neuromuscular junction disorders. *Lancet Neurol.* 2022;23:176–185. Table 2.

Table 652.4 Pathophysiologic Characteristics of Myasthenia Gravis Subtypes

	ACETYLCHOLINE RECEPTOR MYASTHENIA GRAVIS SUBTYPES			MuSK MYASTHENIA GRAVIS	LRP4 MYASTHENIA GRAVIS	AGRIN MYASTHENIA GRAVIS	SERONEGATIVE MYASTHENIA GRAVIS	LAMBERT-EATON MYASTHENIC SYNDROME SUBTYPES		SERONEGATIVE LAMBERT-EATON MYASTHENIC SYNDROME
	EARLY-ONSET ACETYLCHOLINE RECEPTOR ANTIBODY-POSITIVE MYASTHENIA GRAVIS (ASSOCIATED WITH THYMIC FOLLICULAR HYPERPLASIA)	*THYMOMA-ASSOCIATED MYASTHENIA GRAVIS*	*LATE-ONSET, NON-THYMOMATOUS ACETYLCHOLINE RECEPTOR ANTIBODY-POSITIVE MYASTHENIA GRAVIS*					*NON-PARANEOPLASTIC (40–50%)*	*PARANEOPLASTIC SMALL-CELL LUNG CANCER (50–60%)*	
Antigenic target	Acetylcholine receptor	Acetylcholine receptor	Acetylcholine receptor	MuSK	LRP4	Agrin	Unknown	$Ca_V2{\cdot}1$ VGCCs (P/Q-type)	$Ca_V2{\cdot}1$ VGCCs (P/Q-type)	Unknown
Age at onset	<50 yr	Peak age 50 yr	>50 yr	<50 yr	Early onset	Unknown	Unknown	Bimodal (young females, older males)	>50 yr	Unknown
Gender bias	Yes (Female)	No	Yes (Male)	Yes (Female)	Yes (Female)	Unknown	Yes (Female)	No	Yes (Male)	Unknown
Dominant IgG isotype	IgG1-IgG3	IgG1-IgG3	IgG1-IgG3	IgG4	IgG1-IgG3	Unknown	Unknown	Potentially IgG1-IgG3	Potentially IgG1-IgG3	Unknown
Role of complement	Yes	Yes	Yes	No	Yes	Unknown	Unknown	Potentially yes	Potentially yes	Unknown
HLA association	DR3–B8	No	No consistent association	DR14–DQ5	Unknown	Unknown	Unknown	DR3–B8 and DQ2	No	Unknown
Tumor association	No	Thymoma	No	No	Unknown	Unknown	Unknown	No	Small cell lung cancer	Unknown

Most (about 85%) patients with myasthenia gravis have acetylcholine receptor autoantibodies. MuSK, LRP4, and agrin antibody-positive myasthenia gravis variants are much less prevalent (about 5%, 2%, and <1% of patients with myasthenia gravis, respectively). About 8% of patients with myasthenia gravis are seronegative for all these antibodies. About 15% of patients with Lambert-Eaton myasthenia gravis are seronegative (i.e., they have no detectable VGCC antibodies). Class I direct evidence: Patient antibodies are pathogenic upon passive transfer to animals or upon application in in vitro models. Class II indirect evidence: Active immunization with the antigen causes a myasthenia gravis phenotype in animals or transplacental transfer causes a temporary phenotype
in children. Class III circumstantial evidence: Pathogenicity is expected based on the biological role of the antigen or positive response to immunosuppressive treatments, although direct experimental evidence is lacking. Gender bias refers to overrepresentation of the syndrome in one of two sexes.

HLA, Human leukocyte antigen; LRP4, low-density lipoprotein receptor-related protein 4; MuSK, muscle-specific tyrosine kinase; NA, not applicable; VGCCs, voltage-gated calcium channels.

From Huijbers MG, Marx A, Plomp JJ, et al. Advances in the understanding of disease mechanisms of autoimmune neuromuscular junction disorders. *Lancet Neurol*. 2022;21:163–174.

Downloaded for mohamed ahmed (dr.mms2020@gmail.com) at University of Southern California from ClinicalKey.com by Elsevier on April 23, 2024. For personal use only. No other uses without permission. Copyright ©2024. Elsevier Inc. All rights reserved.

Table 652.5 Myasthenia Gravis Activities of Daily Living Scale (MG-ADL)

GRADE	0	1	2	3
Talking	Normal	Intermittent slurring or nasal speech	Constant slurring or nasal speech, but can be understood	Difficult to understand speech
Chewing	Normal	Fatigue with solid food	Fatigue with soft food	Gastric tube
Swallowing	Normal	Rare episode of choking	Frequent choking, modifications in diet	Gastric tube
Breathing	Normal	Shortness of breath with exertion	Shortness of breath at rest	Ventilator dependence
Impairment of ability to brush teeth or comb hair	None	Extra effort, but no rest periods needed	Rest periods needed	Cannot do one of these functions
Impairment of ability to arise from a chair	None	Mild, sometimes uses arms	Moderate, always uses arms	Severe, requires assistance
Double vision	None	Occurs, but not daily	Daily, but not constant	Constant
Eyelid droop	None	Occurs, but not daily	Daily, but not constant	Constant
TOTAL MG-ADL SCORE				

MG-ADL, Myasthenia Gravis Activities of Daily Living Scale.
From Wolfe GI, Herbelin L, Nations SP, et al. Myasthenia gravis activities of daily living profile. *Neurology*. 1999;52:1487–1489.

maternal antibodies or to autoimmune MG, despite overlap of clinical symptoms. CMSs are nearly always *permanent static* disorders without spontaneous remission (see Table 652.1). Several distinct genetic forms are recognized, nearly all with onset at birth or in early infancy with symptoms that may include hypotonia, external ophthalmoplegia, ptosis, dysphagia, weak cry, facial weakness, easy muscle fatigue generally, and sometimes respiratory insufficiency or failure, the last often precipitated by a minor respiratory infection. In the childhood-onset forms, findings such as fatigability, delayed motor milestones, and fluctuating ocular symptoms (ptosis and extraocular muscle weakness) are common. Cholinesterase inhibitors have a favorable effect in most, but in some forms the symptoms and signs are actually worsened. Children with most types of congenital MG do not experience myasthenic crises and rarely exhibit elevations of anti-ACh antibodies in plasma.

Pathologic gene variants responsible for CMS have been identified in over 30 different genes. The genetic variants are known in *less than half* of children with CMS. The most common genes associated with CMS include *CHAT, CHRNE, DOK7, COLQ, GFPT,* and *RAPSN.* CMS can be caused by pathogenic variants affecting proteins involved in ACh synthesis, vesicle fusion into the synaptic cleft, ACh breakdown in the synaptic cleft, and reuptake of choline, within subunits of the postsynaptic AChR, as well as in postsynaptic glycosylation pathways. Basal lamina-associated proteins can lead to synaptic cleft abnormalities due to variants in the *COLQ, COL13A1,* and *LAMB2* genes. These pathways emphasize the role of the integrity of the extracellular matrix proteins in the formation and maintenance of the synapse. Anti-AChR and anti-MuSK antibodies are usually, but not always, absent in serum, unlike in autoimmune forms of MG affecting older children and adults.

There may be clinical clues that aid in the diagnosis (see Tables 652.1 and 652.3). In patients with apneic episodes, consider *RAPSN, CHAT,* and *COLQ.* Apneic episodes in patients with choline acyltransferase (CHAT) variants can be episodic but can also be life-threatening. Although most CMS syndromes are inherited in a recessive fashion, there are several in which an autosomal dominant pattern of inheritance or de novo dominant pattern of inheritance can be seen, including *CHRNA1, CHRNB1, CHRND, CHRNE,* and *SYT2.* Variants in the *RAPSN* gene can lead to an early-onset hypotonia with respiratory failure and episodic apnea but can also present in milder limb-girdle patterns of weakness with an onset in childhood or adolescence. Genes associated with a more limb-girdle myasthenic syndrome phenotype include *GFPT1, DPAGT1, ALG2, ALG14, GMPPB,* and *PREPL.* Genes affecting the postsynaptic AChR subunits may be associated with a slow-channel CMS in which patients may have variable weakness, typically with worsening with AChE inhibitors, as well as a fast-channel CMS syndrome; they can show improvement in symptoms in response to AChE inhibitors.

RARE OTHER CAUSES OF MYASTHENIA

MG is occasionally associated with hypothyroidism, usually **Hashimoto thyroiditis.** Other collagen vascular diseases and also some centronuclear myopathies may be associated with defects in neuromuscular transmission. Thymomas, noted in some adults, rarely coexist with MG in children. Likewise, lung carcinomas that occur in adults associated with Lambert-Eaton myasthenic syndrome are not seen in children. Lambert-Eaton syndrome in children is rare but has been reported with lymphoproliferative disorders and with neuroblastoma. Postinfectious MG in children is transitory and usually follows a varicella-zoster infection by 2-5 weeks as an immune response.

Laboratory Findings and Diagnosis

MG is one of the few neuromuscular diseases in which electromyography (EMG) is more specifically diagnostic than a muscle or nerve biopsy. A *decremental response* is seen to repetitive nerve stimulation; the muscle potentials diminish rapidly in amplitude until the muscle becomes refractory to further stimulation. Electrophysiologically, this response is due to end plate potentials decreasing with subsequent repetitive stimulations, such that stimuli no longer result in end plate potentials that achieve a threshold resulting in a propagating motor action potential. This results in a cumulative lowering of the compound muscle action potential (CMAP) amplitude with the repeated stimuli. A decline of greater than 10% between waves 1 and 4 on repetitive stimulation is diagnostic for a decremental response, and suggestive of a disorder of neuromuscular transmission. The motor nerve conduction velocity remains normal. This unique EMG pattern is the electrophysiologic correlate of the fatigable weakness observed clinically and is reversed after a cholinesterase inhibitor is administered. A myasthenic decrement may be absent or difficult to demonstrate in muscles that are not involved clinically. This feature may be confusing in early cases or in patients showing only weakness of extraocular muscles. Stimulated single-fiber EMG methodology, when available, measures the variability in neuromuscular transmission as a value called jitter, and is highly sensitive and moderately specific for neuromuscular junction transmission abnormality. Special electrophysiologic studies are required in the classification of CMS and involve estimating the number of AChRs per end plate and in vitro study of end plate function. These special studies and patch-clamp recordings of kinetic properties of channels are performed on special biopsy samples of intercostal muscle strips that include both the origin and insertion of the muscle but are only

performed in specialized centers. If myasthenia is limited to the extraocular, levator palpebrae, and pharyngeal muscles, repetitive nerve stimulation of the distal and proximal muscles (e.g., abductor pollicis brevis muscle or trapezius muscle, respectively), although diagnostic in the generalized disease, is usually normal.

Anti-AChR antibodies should be assayed in the plasma but are inconsistently demonstrated. Antibodies against the MuSK receptor should be sought in children without circulating AChR antibodies, a diagnostic finding when elevated, which further delineates the etiology. Many cases of congenital MG result from failure to synthesize or release ACh at the presynaptic membrane. In some cases, the gene that mediates the enzyme choline acetyltransferase for the synthesis of ACh is identified. In others, there is a defect in the quantal release of vesicles containing ACh. The treatment of such patients with cholinesterase inhibitors is not effective. In some patients, such as those with *COLQ* and *DOK7* variants as well as slow-channel myasthenia, AChE inhibitors (e.g., pyridostigmine) can lead to no response or even worsening of symptoms. Clinical genetic testing for CMS can be done by panels that are commercially available and can test ~14-21 CMS-associated genes.

Other serologic tests of autoimmune disease, such as antinuclear antibodies and abnormal immune complexes, should also be sought. If these are positive, more extensive autoimmune disease involving vasculitis or tissues other than muscle is likely. A thyroid profile should always be examined. The serum creatine kinase (CK) level is normal in MG.

The heart is not involved, and electrocardiographic findings remain normal. Radiographs of the chest often reveal an enlarged thymus, but the hypertrophy is not a thymoma. It may be further defined by CT or MRI of the anterior mediastinum if the radiographic findings are uncertain, but caution should be used when selecting the optimal imaging modalities because of radiation exposure for CT and anesthetic risk in a myasthenic patient if sedated MRI is needed for a younger myasthenic child.

The role of conventional muscle biopsy in MG is limited. It is not required in most cases, but approximately 17% of patients show inflammatory changes, sometimes called *lymphorrhages,* that are interpreted by some physicians as a mixed myasthenia-polymyositis immune disorder. Muscle biopsy tissue in MG shows a nonspecific type II muscle fiber atrophy, similar to that seen with disuse atrophy, steroid effects on muscle, polymyalgia rheumatica, and many other conditions. The ultrastructure of motor end plates shows simplification of the membrane folds; the AChRs are located in these postsynaptic folds, as shown by bungarotoxin (snake venom), which binds specifically to the AChRs.

A clinical test for MG is administration of a short-acting cholinesterase inhibitor, usually edrophonium chloride. Ptosis and ophthalmoplegia improve within a few seconds, and the fatigability of other muscles decreases. The "edrophonium Tensilon test" should be undertaken with extreme caution because of risk of bradyarrhythmias and syncope, and it can cause paradoxical worsening of neuromuscular transmission in COLQ-related CMS. This test is now used rarely in centers where good neurophysiology, antibody, and molecular genetic testing are readily available.

Recommendations on the Use of Cholinesterase Inhibitors as a Diagnostic Test for Myasthenia Gravis in Infants and Children

Children 2 Years of Age and Older

- The child should have a specific fatigable weakness that can be measured, such as ptosis of the eyelids, dysphagia, or inability of the cervical muscles to support the head. Nonspecific generalized weakness without cranial nerve motor deficits is not a criterion.
- This test is recommended to be undertaken on an intensive care unit or high dependency unit setting where facilities for resuscitation are available, in case of adverse reactions to edrophonium.
- An intravenous infusion of normal saline should be started to enable the administration of medications in the event of an adverse reaction.
- Electrocardiographic monitoring is recommended during the test.
- A dose of atropine sulfate (0.01 mg/kg) should be *available* in a syringe, ready for intravenous administration at the bedside during the edrophonium test, to block acute muscarinic effects of the cholinesterase inhibitor, such as abdominal cramps and/or sudden diarrhea from increased peristalsis, profuse bronchotracheal secretions that can obstruct the airway, or, rarely, cardiac arrhythmias. Some physicians pretreat all patients with atropine before administering edrophonium, but this is not recommended unless there is a history of a reaction to tests. Atropine can cause the pupils to be dilated for as long as 14 days after a single dose, and the pupillary effects of homatropine can last 4-7 days.
- Edrophonium chloride (Tensilon) is administered intravenously. The initial test dose is 0.01 mg/kg (no more than 1 mg [for children <30 kg], and no more than 2 mg initial dose [for children >30 kg]). After the initial dose, repeat doses may be given intravenously. For children <30 kg, repeat at a rate of 1 mg every 30-45 seconds to a maximum cumulative dose of 5 mg. For children >30 kg, repeat doses of 1 mg every 30-45 seconds to a maximum cumulative dose of 10 mg. In adults, the average edrophonium dose to show positive responses is approximately 3.3 mg for ptosis and approximately 2.6 mg for oculomotor symptoms. Side effects include nausea and emesis; light-headedness from bradycardia (atropine is the antidote) and bronchospasm are less common side effects. The edrophonium test may be done by intramuscular or subcutaneous injection but may require modification of dosing.
- Effects should be seen within 10 seconds and disappear within 120 seconds. Weakness is measured as, for example, the distance between the upper and lower eyelids before and after administration, degree of external ophthalmoplegia, or ability to swallow a sip of water.
- Long-acting cholinesterase inhibitors, such as pyridostigmine (Mestinon), are generally not as useful for the acute assessment of myasthenic weakness. The neostigmine (Prostigmin) test may be used (as outlined later) but might not be as definitively diagnostic as the edrophonium test.

Children Younger Than 2 Years of Age

- Infants ideally should have a specific fatigable weakness that can be measured, such as ptosis of the eyelids, dysphagia, and inability of the cervical muscles to support the head. Nonspecific generalized weakness without cranial nerve motor deficits makes it less easy to assess results but may be a criterion at times.
- An intravenous line should be started as a rapid route for medications in the event of an adverse effect of the test medication.
- Electrocardiographic monitoring is recommended during the test.
- Pretreatment with atropine sulfate to block the muscarinic effects of the test medication is not recommended, but atropine sulfate should be available at the bedside in a prepared syringe. If needed, it should be administered intravenously in a dose of 0.01 mg/kg.
- *Edrophonium is not recommended for use in infants*; its effect is too brief for objective assessment, and an increased incidence of acute cardiac arrhythmias is reported in infants, especially neonates, with this drug.
- Prostigmin methyl sulfate (neostigmine) is administered intramuscularly at a dose of 0.04 mg/kg. If the result is negative or equivocal, another dose of 0.04 mg/kg may be administered 4 hours after the first dose (a typical dose is 0.5-1.5 mg). The peak effect is seen in 20-40 minutes. Intravenous Prostigmin is **contraindicated** because of the risk of cardiac arrhythmias, including fatal ventricular fibrillation, especially in young infants.
- Long-acting cholinesterase inhibitors administered orally, such as pyridostigmine (Mestinon), are generally not as useful for the acute assessment of myasthenic weakness because the onset and duration are less predictable.

The test should be performed in the emergency department, hospital ward, or intensive care unit; the important issue is preparation for potential complications such as cardiac arrhythmia or cholinergic crisis, as outlined.

Treatment

Some patients with mild MG require no treatment. Cholinesterase-inhibiting drugs are the primary therapeutic agents. Pyridostigmine bromide (Mestinon) may be given orally starting at 0.5-1 mg/kg per

dose every 4-6 hours while the patient is awake to a maximum of 60 mg per dose. The maximum daily recommended dose is 7 mg/kg/day, with most adults achieving effect with total daily doses of <960 mg/day, divided in four to eight doses. Pyridostigmine is given in short-acting forms and can also be used in a long-acting form at bedtime for patients with more weakness upon awakening in the morning. Overdoses of cholinesterase inhibitors produce **cholinergic crises** with symptoms such as increased secretions, diarrhea, and cramping; atropine blocks the muscarinic effects but does not block the nicotinic effects that produce additional skeletal muscle weakness. In the rare familial MG caused by the absence of end plate AChE, cholinesterase inhibitors are not helpful and often cause increased weakness; these patients can be treated with ephedrine or diaminopyridine, both of which increase ACh release from terminal axons.

Because of the autoimmune basis of the disease, long-term steroid treatment with prednisone may be effective. Thymectomy should be considered and might provide a cure. Thymectomy is most effective in patients who have high titers of anti-AChR antibodies in the plasma and who have been symptomatic for <2 years. Thymectomy is ineffective in congenital and familial forms of MG. Treatment of hypothyroidism usually abolishes an associated myasthenia without the use of cholinesterase inhibitors or steroids.

If the specific genetic variant can be identified in a patient with one of the CMSs, specific therapeutic approaches are available for some that differ from the treatments listed earlier (see Tables 652.1 and 652.6).

Plasmapheresis is effective treatment in some children, particularly those who do not respond to steroids, but plasma exchange therapy provides only temporary remission. Intravenous immunoglobulin is beneficial and should be tried before plasmapheresis because it is less invasive. Plasmapheresis and intravenous immunoglobulin appear to be most effective in patients with high circulating levels of anti-AChR antibodies. Refractory patients, as well as patients with MuSK-related MG, might respond more effectively to rituximab, a monoclonal antibody to the B-cell CD20 antigen. Efgartigimod (Vyvgart) is an antibody fragment Fc receptor antagonist, inhibiting the Fc receptor from recycling IgG into the circulation, and is FDA approved for patients ≥18 years of age with severe, generalized AChR antibody–positive MG. Clinical trials have started in children 2-18 years of age.

Neonates with transient maternally transmitted MG require cholinesterase inhibitors for only a few days or occasionally for a few weeks, especially to allow feeding. No other treatment is usually necessary. In non–maternally transmitted congenital MG, identification of the specific molecular defect is important for treatment; Table 652.6 summarizes specific therapies for each type.

Complications

Children with MG do not tolerate neuromuscular-blocking drugs, such as succinylcholine and pancuronium, and may be paralyzed for weeks after a single dose. An anesthesiologist should carefully review myasthenic patients who require a surgical anesthetic, and such anesthetics should be administered only by an experienced physician/anesthesiologist. Also, certain antibiotics can potentiate myasthenia and should be avoided; these include the aminoglycosides, β-blocking agents, procainamide, chloroquine, and fluoroquinolones.

Prognosis

Some patients with autoimmune MG experience spontaneous remission after a period of months or years; others have a permanent disease extending into adult life. Immunosuppression, thymectomy, and treatment of associated hypothyroidism might provide a cure. Genetically determined CMSs may show initial worsening in infancy but then remain static throughout childhood and into adult life.

Table 652.6 Potential Therapies in Congenital Myasthenic Syndromes

SYNDROME	THERAPY
AChE deficiency, COLQ	Ephedrine 3 mg/kg/day in 3 divided doses; begin with 1 mg/kg; not obtainable in several countries If ephedrine is not obtainable, 3,4-diaminopyridine 1 mg/kg/day in 4 divided doses, up to 60 mg/day in adults Avoid AChE inhibitors
AChR deficiency	AChE inhibitors: pyridostigmine bromide (Mestinon) 4-5 mg/kg/day in 4-6 divided doses If necessary, add 3,4-diaminopyridine 1 mg/kg/day in 4 divided doses, up to 60 mg/day in adults
AChR fast channel	AChE inhibitors: pyridostigmine bromide (Mestinon) 4-5 mg/kg/day in 4-6 divided doses If necessary, add 3,4-diaminopyridine 1 mg/kg/day in 4 divided doses, up to 60 mg/day in adults
AChR slow channel	Quinidine sulfate • *Adults*: Begin for 1 wk with 200 mg tid; gradual increase to maintain a serum level of 1-25 μg/mL • *Children*: 15-60 mg/kg/day in 4-6 divided doses; not available in several countries If quinidine sulfate is not available, fluoxetine 80-100 mg/day in adults Avoid AChE inhibitors
ChAT	AChE inhibitors: pyridostigmine bromide (Mestinon) 4-5 mg/kg/day in 4-6 divided doses If necessary, add 3,4-diaminopyridine 1 mg/kg/day in 4 divided doses, up to 60 mg/day in adults
DOK7	Ephedrine 3 mg/kg/day in 3 divided doses; begin with 1 mg/kg; not obtainable in several countries If ephedrine is not obtainable, 3,4-diaminopyridine 1 mg/kg/day in 4 divided doses, up to 60 mg/day in adults Avoid AChE inhibitors
Laminin β_2	Albuterol (Salbutamol): Start with 1 mg 3 times daily. Increase to 2 mg 3 times daily until 10 years age; maximum of 4 mg 3 times daily in older children, as tolerated. Albuterol has largely replaced the use of ephedrine, which is not obtainable in several countries. Reference dose of ephedrine as an alternative to albuterol: ephedrine 3 mg/kg/day in 3 divided doses, starting with 1 mg/kg. Second-line drug is 3,4 diaminopyridine mg/kg/day in 4 divided doses, up to 60 mg/day in adults. Avoid AChE inhibitors
MuSK	AChE inhibitors: pyridostigmine bromide (Mestinon) 4-5 mg/kg/day in 4-6 divided doses 3,4-Diaminopyridine 1 mg/kg/day in 4 divided doses, up to 60 mg/day in adults
Rapsyn	AChE inhibitors: pyridostigmine bromide (Mestinon) 4-5 mg/kg/day in 4-6 divided doses If necessary, add 3,4-diaminopyridine 1 mg/kg/day in 4 divided doses, up to 60 mg/day in adults

AChE, Acetylcholinesterase; AChR, acetylcholine receptor.

Modified from Burke G, Hiscock A, Klein A, et al. Salbutamol benefits children with congenital myasthenic syndrome due to DOK7 mutations. *Neuromuscul Disord*. 2012;23:170–175; Chan HS, Wong VCN, Engel AG. Neuromuscular junction acetylcholinesterase deficiency responsive to albuterol. *Pediatr Neurol* 2012;47:137e140; Engel GA. The therapy of congenital myasthenic syndromes. *Neurotherapeutics*. 2007;4(2):252–257.

OTHER CAUSES OF NEUROMUSCULAR BLOCKADE

Organophosphate chemicals, commonly used as insecticides, can cause a myasthenia-like syndrome in children exposed to these toxins (see Chapter 94).

Botulism results from ingestion of food containing the toxin of *Clostridium botulinum,* a gram-positive, spore-bearing, anaerobic bacillus (see Chapter 256). The incubation period is short, only a few hours, and symptoms begin with nausea, vomiting, and diarrhea. Cranial nerve involvement soon follows, with diplopia, dysphagia, weak suck, facial weakness, and absent gag reflex. The mechanism is cleavage by the botulinum toxin of several of the structural glycoproteins of the wall (i.e., membrane) of synaptic vesicles within axonal terminals. These glycoproteins include synaptobrevin and synaptotagmin, but synaptophysin is resistant.

In **infantile botulism,** which classically presents between the ages of 4 and 7 months, honey as well as spores from dirt (e.g., near construction sites) are common sources of contamination. The earliest signs are usually constipation, poor feeding, and then a weak cry. On evaluation, patients appear hypotonic, with facial weakness, dysphagia, and a poor gag. Generalized weakness with a risk of respiratory failure can occur. Generalized hypotonia and weakness then develop and can progress to respiratory failure. Neuromuscular blockade is documented by EMG with repetitive nerve stimulation. Slow repetitive nerve stimulation may show a decremental response, and baseline CMAP amplitudes may be low. With rapid repetitive nerve stimulation, there is an incremental response. EMG/repetitive nerve stimulation studies may help in confirming a diagnosis if the clinical presentation is not straightforward. However, when suspected, botulinum toxin studies should be sent preferentially from stool samples from the patient, and then treatment should be initiated as soon as possible with Botulinum Immune Globulin IV (Baby-BIG or BIG-IV). BIG-IV, which is human-derived antibotulism toxin antibodies, is approved by the FDA for the treatment of infant botulism types A and B. Early use of BIG-IV has shortened the overall length of hospitalization and improved the time to recovery. Respiratory and feeding/gavage support may be required for days or weeks until the toxin is cleared from the body.

Tick paralysis is a disorder of ACh release from axonal terminals due to a neurotoxin that blocks depolarization. It also affects large, myelinated motor and sensory nerve fibers. This toxin is produced by the wood tick or dog tick, insects common in the Appalachian and Rocky Mountains of North America. The tick embeds its head into the skin, usually the scalp, and neurotoxin production is maximal about 5-6 days later. Motor symptoms include weakness, loss of coordination, and sometimes an ascending paralysis resembling Guillain-Barré syndrome. Tendon reflexes are lost. Sensory symptoms of tingling paresthesias can occur in the face and extremities. The diagnosis is confirmed by identification of the tick, and treatment involves the prompt removal of the entire tick. It is important to monitor patients closely, because some patients may show worsened respiratory symptoms for the first day after tick removal. Most patients will show rapid improvement within a few hours to a few days from the time of tick removal.

Visit Elsevier eBooks+ at eBooks.Health.Elsevier.com for Bibliography.

652.2 Spinal Muscular Atrophies

Adnan Y. Manzur

Spinal muscular atrophy (SMA) is a degenerative disease of motor neurons that begins in fetal life and continues to be progressive in infancy and childhood. Among the autosomal recessive disorders in childhood, SMA is the most common cause of infant mortality, and is second in birth prevalence only to cystic fibrosis. The incidence of SMA is estimated to be 1 in 6,000-10,000 newborns, with a carrier frequency of approximately 1/40-1/60. It is a clinically heterogeneous, panethnic disorder. SMA is caused by a homozygous deletion in the survival motor neuron 1 *(SMN1)* gene on chromosome 5q13. Infrequent families with autosomal dominant inheritance are described, and a rare X-linked recessive form also occurs. There is also a separate group of clinically and genetically heterogeneous non-5q SMA forms (see Chapter 652.3).

The pathologic hallmark of SMA is the progressive denervation of muscle. This is compensated for in part by reinnervation from an adjacent motor unit, but giant motor units are thus created, with subsequent atrophy of muscle fibers when the reinnervating motor neuron eventually becomes involved. Motor neurons of cranial nerves III, IV, and VI to the extraocular muscles, as well as those of the sacral spinal cord innervating striated muscle of the urethral and anal sphincters, are selectively spared. The upper motor neurons (layer 5 pyramidal neurons in the cerebral cortex) also remain normal.

SMA is classified clinically into a severe infantile form, also known as **Werdnig-Hoffmann disease** or SMA type I; a late infantile and more slowly progressive form, SMA type II; a more chronic or juvenile form, **Kugelberg-Welander disease,** or SMA type III; and an **adult-onset form** (SMA type IV). A severe fetal form that is usually fatal in the perinatal period has been described as SMA type 0, with motor neuron degeneration demonstrated in the spinal cord as early as midgestation. These distinctions of types are based upon the age at onset, severity of weakness, maximum motor milestone achieved, and clinical course (Table 652.7). Some patients are transitional between types I and II or between types II and III in terms of clinical function. Of note, the *SMN* gene region comprises a centromeric copy containing the *SMN2* gene. There is a correlation between the severity of disease, age at onset, and *SMN2* copy number, and a higher *SMN2* copy number is associated with milder disease severity.

Muscle biopsy does not distinguish types I and II, though type III shows a more adult than perinatal pattern of denervation and reinnervation. Type 0 can show biopsy features more similar to those of myotubular myopathy because of maturational arrest; scattered myotubes and other immature fetal fibers also are demonstrated in the muscle biopsies of patients with types I and II, but they do not predominate. Autonomic motor neurons of both the sympathetic and parasympathetic systems are not spared, but usually do not show clinical manifestations until late stages. Autonomic deficits may involve the detrusor muscle of the urinary bladder or the smooth muscle urethral and anal sphincters, in all three forms of SMA. In some patients with type I SMA and respiratory distress, there may be severe autonomic dysregulation with dysautonomia and cardiovascular collapse leading to death or to severe ischemic brain damage. The differential diagnosis is noted in Table 652.8.

CLINICAL MANIFESTATIONS AND COURSE

The cardinal features of the classic, most common phenotype, **SMA type I,** can be summarized as a presentation before the age of 6 months with severe hypotonia (Fig. 652.1); symmetric generalized muscle weakness affecting the lower limbs more than the upper limbs, proximal more than distal; frog-leg posture; absence of deep tendon reflexes; tongue fasciculations; and selective involvement of the axial and intercostal muscles but sparing of diaphragm. SMA is in the differential diagnosis list of floppy infant syndrome (see Chapter 648). Due to the involvement of the intercostal respiratory muscles, there is a typical paradoxical abdominal breathing pattern, bell-shaped chest, and weak cough (Video 652.1). Infants lie flaccid with little movement, unable to overcome gravity, and lack head control. These infants rarely achieve improvements of motor function and acquire motor developmental milestones (see Fig. 648.1 in Chapter 648). In contrast to their severe weakness and floppiness, infants with SMA type I have an alert and bright expression with preserved cognitive functions. There is no involvement of the facial and extraocular muscles at presentation, although facial weakness does occur at later stages of the disease.

SMA type I is not homogeneous within itself. At least three clinical subgroups can be defined as (1) severe weakness from birth or the neonatal period and head control is never achieved; (2) presentation after the neonatal period, within the first 2 months, and head control is never achieved; and (3) onset after the neonatal period but head control is achieved, and rarely, some of the infants may gain the ability to sit with support. There may be a range of clinical presentations and courses of respiratory involvement and swallowing and sucking difficulties in this fragile group of SMA type I patients.

Infants with SMA type I develop respiratory failure within the first 2 years of life, and without respiratory and nutritional support, they

Table 652.7 Clinical Motor Neuron Entities with Established Genetic Linkage

CLINICAL ENTITY	GENE	CHROMOSOME	AGE AT ONSET	CLINICAL FEATURES
PROXIMAL SMA: AUTOSOMAL RECESSIVE				
SMA type 0	*SMN*	5q13	Prenatal	Severe Congenital heart defects Death around 30 days
SMA type 1	*SMN*	5q13	<6 mo	Severe Never sit, and fatal before age 2*
SMA type 2	*SMN*	5q13	6-18 mo	Sit independently, never walk* LE predominance
SMA type 3	*SMN*	5q13	>18 mo	Walk independently
Congenital with arthrogryposis	*SMN*	5q13	Congenital	Severe Facial weakness, respiratory failure at birth, contractures Death around 30 days
SMA + congenital fractures Type 1	*TRIP4*	15q22	Prenatal	Severe Pulmonary hypoplasia, congenital heart defects ± facial dysmorphisms Death at 2-16 mo
SMA + congenital fractures Type 2	*ASCC1*	10q22	Prenatal	Severe Pulmonary hypoplasia, congenital heart defects ± facial dysmorphisms Death at 2-16 mo
SMA + myoclonus epilepsy	*ASAH1*	8q22	3-30 yr	Seizures, proximal weakness, tongue fasciculations, respiratory insufficiency later in the disease
SMA + pontocerebellar hypoplasia Type 1A	*VRK1*	14q32	First decade Some prenatal	May walk but then lose ambulation Feeding difficulties Ataxia and nystagmus In severe cases, death before 6 mo
SMA + pontocerebellar hypoplasia Type 1B	*EXOSC3*	9p11	Congenital	Muscle wasting, distal contractures, microcephaly, and oculomotor apraxia
Spinal muscular atrophy with hypomyelination and cerebellar hypoplasia	*EXOSC8*	3q13	2-4 mo	Severe weakness, failure to thrive, hearing and vision impairment, death caused by respiratory failure before 20 mo
PROXIMAL SMA: AUTOSOMAL DOMINANT				
Adult	*VAPB*	20q13	30-60 yr	Proximal LE weakness and atrophy Fasciculations and reduced reflexes Slow progression
SMAJ adult onset	*CHCHD10*	22q11	30-70 yr	Proximal > distal and abdominal weakness Cramps and fasciculations
Bulbar SMA with gynecomastia	?	?	Second to third decade	Asymmetric, proximal weakness + tibialis anterior Nasal voice and tremors Limb and tongue fasciculations
HMN8	*TRPV4*	12q24	Congenital	LE weakness only; proximal > distal Arthrogryposis ± vocal cord paresis
HMSN-P (Okinawa type)	*TFG*	3q12	17-50 yr	Symmetric proximal > distal weakness Progression to severe disability and wheelchair
SMA with LE predominance (SMALED 1)	*DYNC1H1*	14q32	Early childhood	LE weakness and wasting Delayed walking Decreased patellar reflexes
RECESSIVE X-LINKED SMA				
Bulbospinal SMAX 1 (Kennedy disease)	Androgen receptor	Xq12	20-40 yr	Gynecomastia, bulbar involvement, hyperlipoproteinemia
SMAX 2 Infantile	*UBE1*	Xp11	Neonatal–early infantile	Severe Arthrogryposis and fractures
DISTAL SMA: AUTOSOMAL RECESSIVE				
SMA + diaphragm paralysis (SMARD1)	*GHMBP2*	11q13	Infantile	Severe Early respiratory failure
DHMNJ (Jerash type)	?	9p21	6-10 yr	LE weakness progressing to UE Brisk patellar reflexes and absent ankle + Babinski earlier on

Continued

Table 652.7 Clinical Motor Neuron Entities with Established Genetic Linkage—cont'd

CLINICAL ENTITY	GENE	CHROMOSOME	AGE AT ONSET	CLINICAL FEATURES
Type 3	?	11q13	Infancy to early adult	Distal weakness progressing to proximal and truncal weakness
Type 4	*PLEKHG5*	1p36		Generalized weakness, contractures, scapular winging, lordosis Progresses to severe disability over a decade
Type 5	*DNAJB2 (HSJ1)*	2q35	First to fourth decades	Severe, distal, LE weakness (foot drop; bulbar and respiratory weakness later in course)
Distal SMA + ataxia telangiectasia	*ATM*	11q22	Second decade	Distal weakness, LE > UE, resting tremor
Distal SMA + encephalopathy	*TBCE*	1q42	Neonatal to 14 mo	Global developmental delay, distal UE and LE weakness, spasticity, ± ataxia, ± optic atrophy Progressive
DISTAL SMA: AUTOSOMAL DOMINANT				
Calf predominant (HMN2D)	*FBXO38*	5p31	13-48 yr	Calves, hands, and feet weakness Slowly progressive
SMALED2A	*BICD2*	9q22	Congenital	Symmetric, proximal > distal, LE > UE weakness; ankle contractures; most patients are ambulant
Distal SMA + macular changes	*FBLN5*	14q32	First to ninth decades	Macular degeneration and weakness (70%)
Distal SMA + hearing loss	*MYH14*	19q13	4-23 yr	Symmetric distal weakness, hoarseness, and hearing loss
Scapuloperoneal neuropathy	*TRPV4*	12q24		Scapuloperoneal and distal weakness Laryngeal palsy
DISTAL SMA: X-LINKED				
SMAX 3	*ATP7A*	Xq21	1-61 yr	Distal (tibioperoneal) weakness Hand weakness later in disease Slow progression
DISTAL SMA: MITOCHONDRIAL INHERITANCE				
MTATP6 variant syndrome	*MTATP6*	N/A	First to second decade	Distal, LE > UE weakness; progressive Brisk reflexes

*Without treatment.
DHMNJ, Distal hereditary motor neuropathy, Jerash type; HMN8, distal hereditary motor neuronopathy type 8; HMSN-P, hereditary motor and sensory neuropathy with proximal predominance; LE, lower extremities; SMA, spinal muscular atrophy; SMAJ, spinal muscular atrophy, Jokela type; UE, upper extremities.
From Castro D, Henriquez A. Treatment and management of spinal muscular atrophy and congenital myopathies. In: Bertorini TE, ed. *Neuromuscular Disorders Treatment and Management*, 2nd ed. Philadelphia: Elsevier; 2022: Table 13.1, p. 262–263.

usually do not survive beyond their second birthday. A multidisciplinary approach (respiratory, gastrointestinal, and orthopedic interventions) combined with noninvasive ventilatory support (NIV) and enteral feeding have changed the natural course of the disease over the years. To date, the median time to either death or full-time NIV (NIV >16 hr/day) is 13.5 months with improved supportive respiratory and nutritional care. Infants who are symptomatic prenatally or at birth are classified as having a rare phenotype, **SMA type 0** (<1%); they can present with severe muscle weakness, respiratory distress, feeding problems, and cranial nerve involvement. Congenital contractures, ranging from simple clubfoot to generalized arthrogryposis, occur in approximately 10% of severely involved neonates (see Chapter 648.10). There is a perception of decreased intrauterine movements by the mother; these infants usually die within the first months of life. Although motor neurons are primarily affected tissue in SMA, other tissues, including those of the brain, cardiac system, vascular system, and even sensory nerves, may also contribute to the overall phenotype, especially in the most severe forms of the disease. Early-stage developmental congenital heart defects described in severe SMA patients, generally carrying one copy of *SMN2,* include atrial septal defects, a dilated right ventricle, ventricular septal defects, and hypoplastic left heart syndrome. These patients are also prone to possible involvement of the autonomic nervous system, which may result in arrhythmia and sudden death. Vasculopathy can be another rare presentation, and ulceration and necrosis of the fingers and toes have also been described in two severe type I SMA patients.

In **type II SMA,** affected infants are usually able to suck and swallow, and respiration is adequate in early infancy. Developmental delay in gross motor milestones or stagnation of motor development between the ages of 6 and 18 months is rather typical for this form. Proximal muscle weakness is again more prominent in the lower extremities compared with the upper extremities. Patients can sit without support but are unable to walk independently. These children show progressive weakness, but many survive into the school years or beyond, although they are confined to an electric wheelchair and severely handicapped. Nasal speech and problems with deglutition develop later. Respiratory complications are less severe and develop later during the course of the disease. Scoliosis becomes a major complication in many patients with long survival times. Gastroesophageal reflux may lead to malnutrition or to aspiration with acute airway obstruction or pneumonia.

Kugelberg-Welander disease is the mildest **SMA (type III),** and patients can appear normal in infancy. The progressive weakness is proximal in distribution, particularly involving the shoulder girdle muscles. Patients are ambulatory and develop a variable course of proximal muscle weakness after the age of 18 months. A significant proportion of children with SMAIII, especially the ones with onset of symptoms before 3 years of age, suffer loss of ambulation at some point during the course of the disease. Symptoms of bulbar muscle weakness are rare. Patients with SMA III may have muscular hypertrophy rather than atrophy, and it may easily be confused with a muscular dystrophy (Video 652.2). Longevity extends well into adult life. Fasciculations are a specific clinical sign of the denervation of muscle. In thin children, they may be seen in the deltoid and biceps brachii muscles and occasionally the quadriceps femoris muscles, but the continuous, involuntary, wormlike movements may be masked by a thick pad of subcutaneous fat. Fasciculations are best observed in the tongue, where almost no subcutaneous connective tissue

separates the muscular layer from the epithelium. If the intrinsic lingual muscles are contracted, as in crying or when the tongue protrudes, fasciculations are more difficult to see than when the tongue is relaxed. Cramps and myalgias of appendicular and axial muscles are common, especially in later stages, and problems of micturition may be present, though adolescent patients may be too embarrassed to state them unless the physician directly inquires.

Table 652.8 Differential Diagnosis of 5q Spinal Muscular Atrophy

SPINAL CORD DISORDERS
Neoplasms (SMA types I, II, III)
Other myelopathies (SMA types I, II, III)
OTHER MOTOR NEURON DISORDERS
SMARD1 (SMA type I)
Juvenile muscular atrophy of distal upper extremity (Hirayama disease)
Fazio-Londe disease, Brown-Vialetto-Van Laere syndrome
Other non-5q SMAs (SMA types I, II, III)
Juvenile ALS (SMA types I, II, III)
NEUROPATHIES
Congenital hypomyelinating or axonal neuropathies (SMA types I, II)
Hereditary motor and sensory neuropathies (SMA types I, II, III)
CIDP (SMA types II, III)
NEUROMUSCULAR JUNCTION DISORDERS
Botulism (SMA type I)
Congenital myasthenic syndromes (SMA types I, II, III)
Lambert-Eaton myasthenic syndrome (SMA type III)
Autoimmune myasthenia gravis (SMA types II, III)
MYOPATHIES
Congenital myopathies (SMA types I, II, III)
Congenital myotonic dystrophy (SMA type I)
Congenital muscular dystrophies (SMA types I, II)
Muscular dystrophies (DMD/BMD, LGMD) (SMA type III)
Mitochondrial myopathies (SMA types I, II, III)
Acid maltase/Pompe disease (SMA types I, II, III)
Other metabolic myopathies (SMA types I, II, III)
Inflammatory myopathies (SMA type III)
Channelopathies (SMA type III)
OTHER DISORDERS
Chromosomal abnormalities (SMA types I, II, III)
Prader-Willi syndrome (SMA type III)
Central nervous system abnormalities (SMA types I, II, III)
Hexosaminidase A deficiency (SMA types III, IV)

ALS, amyotrophic lateral sclerosis; BMD, Becker muscular dystrophy; CIDP, chronic inflammatory polyneuropathy; DMD, Duchenne muscular dystrophy; LGMD, limb-girdle muscular dystrophy; SMARD1, spinal muscular atrophy with respiratory distress 1.
From Darras BT, Monani UR, De Vivo DC. Genetic disorders affecting the motor neuron: spinal muscular atrophy. In: Swaiman KF, Ashwal S, Ferriero DM, et al., eds. *Swaiman's Pediatric Neurology*, 6th ed. Philadelphia: Elsevier; 2018: Box 139-1.

The outstretched fingers of children with SMA often show a characteristic tremor *(polyminimyoclonus)* due to fasciculations and weakness (Video 652.3). It should not be confused with a cerebellar tremor.

The adult phenotype of the disease is **SMA type IV,** which is characterized by a mild muscle weakness with an onset usually in the second or third decade of life. There may be an intrafamilial variability in the clinical expression of the disease.

The intelligence is normal, and children often appear brighter than their normal peers because the effort they cannot put into physical activities is redirected to intellectual development, and they are often exposed to adult speech more than to juvenile language because of the social repercussions of the disease. Progressive deterioration of ambulation and the high risk of falling and fracturing long bones or the pelvis eventually require use of a wheelchair; an electric wheelchair often is needed because weakness of the upper extremities does not allow the patient to manually push the wheels. Progressive scoliosis is another serious complication and may have a further adverse effect on respiration.

LABORATORY FINDINGS

The CK level may be normal, but more commonly is mildly elevated (up to twofold to fourfold), but usually not more than 10 times the normal upper limit. The chest x-ray in early-onset disease may demonstrate thin ribs. ECG may serve as a simple and practical tool in patients with SMA to demonstrate a baseline tremor as an artifact representing muscle fibrillations more prominent on lead II (Fig. 652.2). Although seen in mainly lower motor neuron diseases (MNDs), including poliomyelitis, recognition of this ECG pattern may prevent further electrophysiologic tests (EMG and nerve conduction studies [NCSs]) in SMA patients. Electrophysiologic studies (EMG-NCS) should be reserved for selected atypical patients. The results of motor NCSs are normal, except for mild slowing in terminal stages of the disease, an important feature distinguishing SMA from peripheral neuropathy. EMG shows fibrillation potentials and other signs of the denervation of muscle. There is no need for a muscle biopsy, which demonstrates a neurogenic pattern with group atrophy in all forms of SMA.

DIAGNOSIS

The simplest, most definitive first-step diagnostic test in a patient with a clinical suspicion of SMA and normal and/or mildly elevated serum CK levels is a molecular genetic marker in the blood for the homozygous deletion in *SMN1* (Table 652.9). The current gold standard is *SMN1* deletion/variant and *SMN2* copy number testing, with a minimal standard of *SMN1* deletion testing. The homozygous absence of *SMN1* exon 7 (with or without deletion of exon 8) confirms the diagnosis of SMA. The genetic test for SMA has a 95% sensitivity and nearly 100% specificity (see Table 652.9). Real-time polymerase chain reaction (PCR) or multiplex ligation-dependent probe amplification (MLPA) tests give rapid and reliable *SMN1* gene copy numbers. Semiquantitative assays improve the diagnostic sensitivity up to 98%. According to different scenarios, if the patient has a single *SMN1* copy, the coding

Fig. 652.1 Type I spinal muscular atrophy (Werdnig-Hoffmann disease). Clinical manifestations of weakness of limb and axial musculature in a 4-mo-old infant with severe weakness and hypotonia. With vertical suspension **(A)**, note the dangling lower limbs with lack of hip flexion, tendency of the upper limbs to slip through the examiner's hands, and lack of neck flexion with resulting head lag. When subject is supine, note the *frog-leg* positioning of the legs and the lack of traction response **(B)** and the lag of head **(C)**, with attempts by the examiner to pull the infant to a sitting position. *(From Oskoui M, Darras BT, De Vivo DC. Spinal muscular atrophy: 125 years later and on the verge of a cure. In: Sumner CJ, Paushkin S, Ko C-P, eds. Spinal Muscular Atrophy: Disease Mechanisms and Therapy. San Diego: Academic Press; 2017. Chapters 1 and 3–19.)*

region of the second undeleted allele should be sequenced to identify the second causative variant, including point variations, insertions, and deletions. Direct sequencing of the gene is also recommended in patients with a clinical diagnosis, two *SMN1* copies, and a consanguineous background.

Muscle biopsy is used more selectively in patients showing equivocal or negative genetic findings. The muscle biopsy in infancy reveals a characteristic pattern of perinatal denervation that is unlike that of mature muscle. Groups of giant type I fibers are mixed with fascicles of severely atrophic fibers of both histochemical types (Fig. 652.3). Scattered immature myofibers resembling myotubes also are demonstrated. In juvenile SMA, the pattern may be more similar to adult muscle that has undergone many cycles of denervation and reinnervation. Neurogenic changes in muscle also may be demonstrated by EMG, but the results are less definitive than by muscle biopsy in infancy. Sural nerve biopsy is performed only occasionally, but shows mild sensory neuropathic changes, and the sensory nerve conduction velocity may be slowed; hypertrophy of unmyelinated axons also is seen. At autopsy, mild degenerative changes are seen in sensory neurons of dorsal root ganglia and in somatosensory nuclei of the thalamus, but these alterations are not perceived clinically as a sensory loss or paresthesias. The most pronounced neuropathologic lesions are the extensive neuronal degeneration and gliosis in the ventral horns of the spinal cord and brainstem motor nuclei, especially the hypoglossal nucleus. On rare instances, the clinical features of an SMA-like presentation may be a feature of mitochondrial diseases (*SCO2, DGUOK,* and *TK2* gene variants). *SCO2* encodes one of the COX assembly proteins, and the latter two gene variants are associated with mitochondrial DNA depletion syndromes. Unexpectedly elevated serum CK levels at some point in the clinical course of these patients, and cognitive developmental delay, can be clues to considering a mitochondrial disease in the differential diagnosis. Depending on the stage and progression of the disease, a muscle biopsy demonstrating ragged red fibers and COX-deficient fibers, may help in the differential diagnosis.

GENETICS

The genetic locus for all three of the common forms of SMA is on chromosome 5, a deletion at the 5q11-q13 locus, confirming that they are variants of the same disease rather than different diseases. The affected *SMN1* gene has a molecular weight of 38 kDa and contains 8 exons that span 20 kb and telomeric and centromeric exons that differ only by 5 bp and produce a transcript encoding 294 amino acids. *SMN1* is duplicated in a highly homologous gene called *SMN2,* and both genes are transcribed. *SMN2* remains present in all patients with SMA but cannot fully compensate for the *SMN1* defect. However, a molecular basis for correlation between the *SMN2* copy number and clinical severity of the SMA is the capability of *SMN2* to encode a small amount of an identical *SMN* protein. The critical difference between *SMN1* and *SMN2* is a cytosine (C) to thymine (T) transition in exon 7 of *SMN2* (Fig. 652.4).

The SMN complex has a role in the formation of small nuclear ribonucleoproteins (snRNPs), through assembly of Sm-proteins (a distinctive family of RNA-associated small proteins) onto small nuclear RNAs (SnRNAs). SMN deficiency and reduced snRNP assembly capacity are hypothesized to cause aberrant splicing or transport of RNPs to motor neurons. Dysregulation of genes involved

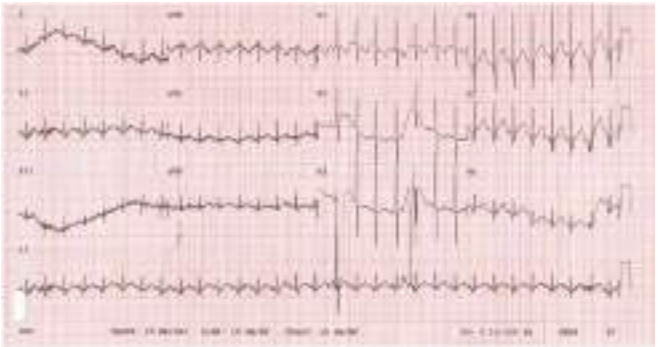

Fig. 652.2 Standard 12-lead EKG (25 mm/s, 10 mV/mm, diagnostic filter 0.05-150 Hz) showed diffuse somatic muscle fibrillations and baseline tremor, more prominent on lead II.

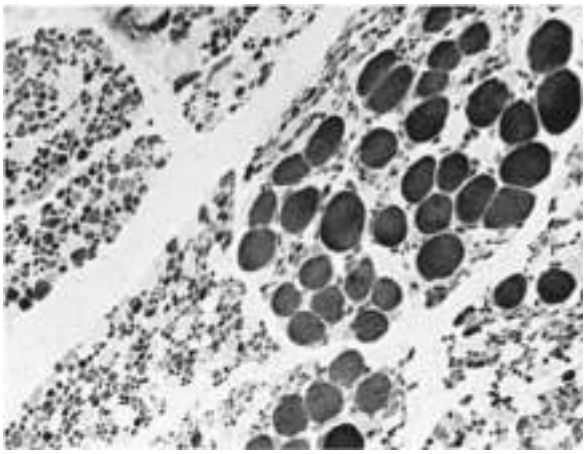

Fig. 652.3 Muscle biopsy of neonate with infantile spinal muscular atrophy. Groups of giant type I (darkly stained) fibers are seen within muscle fascicles of severely atrophic fibers of both histochemical types. This is the characteristic pattern of perinatal denervation of muscle. Myofibrillar adenosine triphosphatase, preincubated at pH 4.6 (×400).

Table 652.9 Molecular Genetic Tests in Spinal Muscular Atrophy

TYPE OF VARIANT	TEST APPLIED	VARIANT DETECTION RATE
Homozygous deletion of exon 7*	*SMN1* Targeted variant analysis Polymerase chain reaction/restriction enzyme analysis or multiplex ligation probe amplification methodologies	Approximately 95–98%
Compound heterozygosity (deletion of *SMN1* exon 7 [allele 1] and an intragenic variant of *SMN1*† [allele 2])	Targeted variant analysis combined with *SMN1* sequence analysis‡	2–5%
SMN2 copy number#	Quantitative polymerase chain reaction analysis and other methodologies¶	Not available

*Testing for exon 8 deletion is not necessary.
†Small intragenic deletions/insertions and nonsense, missense, and splice site variants.
‡Whole-gene deletions/duplications are not detected.
#*SMN2* copy number ranges from 0 to 5.
¶Multiplex ligation-dependent probe amplification (MLPA), long-range polymerase chain reaction (PCR), chromosomal microarray analysis (CMA) that includes the *SMN1, SMN2* chromosomal segment.
From Darras BT. Spinal muscular atrophies. *Pediatr Clin North Am.* 2015;62:743–766; Adapted from Markowitz JA, Singh P, Darras BT. Spinal muscular atrophy: a clinical and research update. *Pediatr Neurol.* 2012;46:1–12.

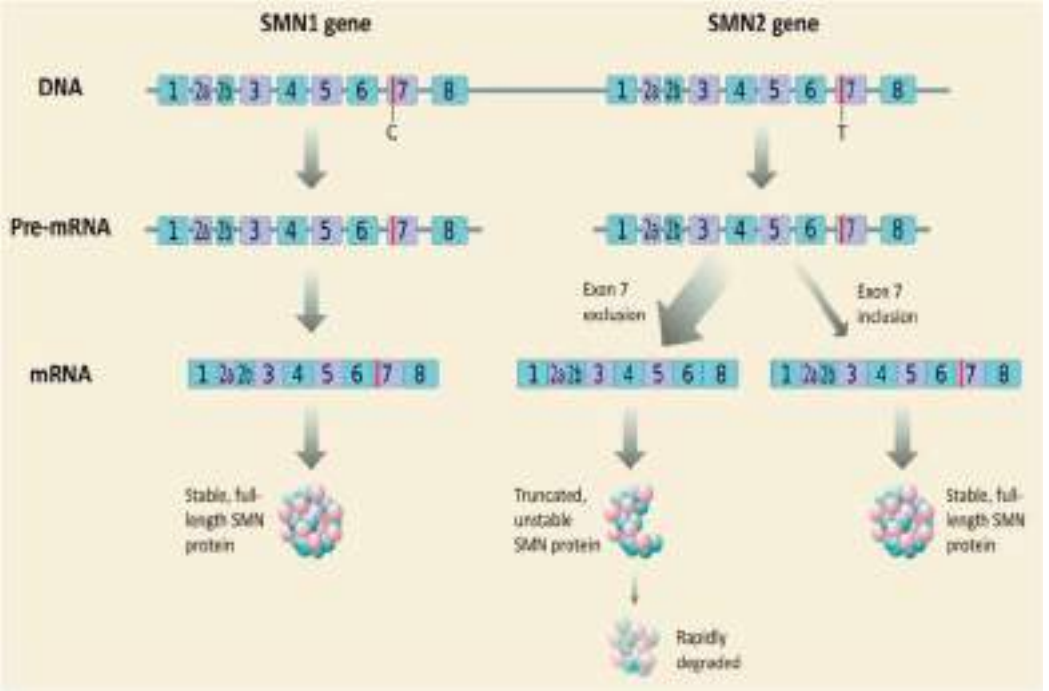

Fig. 652.4 Genetics of spinal muscular atrophy. In humans, the SMN protein is encoded by the *SMN1* and *SMN2* genes. The C to T substitution in exon 7 of *SMN2* is translationally silent but alters splicing such that the majority of *SMN2* transcripts lack exon 7 and the truncated protein is unstable. Normally, *SMN1* produces abundant SMN protein. In SMA, homozygous variants of *SMN1* result in only a small amount of functional SMN protein contributed by the varying copy numbers of *SMN2*. mRNA, messenger RNA; SMN, survival motor neuron. *(From Farrar MA, Park SB, Vucic S, et al. Emerging therapies and challenges in spinal muscular atrophy. Ann Neurol. 2017;81:355–368.)*

in synaptogenesis and the maintenance of neuromuscular junctions in animal studies possibly explains the special vulnerability of motor neurons. A second view is that, independent from snRNPs assembly, SMN may have a motor neuron–specific role such as mRNA transport along the axon. Considering the length of axons, integrity of neuromuscular junctions, and interactions with skeletal muscle, SMN protein deficiency may be detrimental for motor neurons. SMN is localized in bright-dot–like structures, called gems (gemini of Cajal bodies) in the nucleus. It is also present in other cellular structures such as Golgi bodies, cell membranes, and especially the axon and growth cone compartments of motor neurons. Due to its localization in ribonucleoprotein granules in neurites and growth cones in neurons, SMN modulates axonal growth and localization of β-actin messenger ribonucleic acid (mRNA) in growth cones of motor neurons. Early functional impairment of sensory-motor connectivity in animal models showed that motor neuron loss follows afferent synapse loss with the same temporal and topographic pattern, with changes occurring first in motor neurons innervating the proximal muscles and axial muscles, and then the distal muscles. The third view connects SMN function, in a direct or indirect manner, to actin dynamics and actin-dependent processes. There is an expansion in the spectrum of SMN function, including actin dynamics, vesicular transport, protein translation and trafficking, mRNA transport, apoptosis, and many others, which are reflected to widespread pathophysiologic findings described in humans and animal models (Fig. 652.5).

The severity of the disease is inversely correlated with the amount of functional SMN protein. In that sense, other than the *SMN2* copy number, which is the major protective modifier, the severity of the phenotype can be also influenced by other genetic modifiers, including plastin 3 and neurocalcin. Nutritional deficiency, oxidative stress, and hypoxia may contribute to widespread splicing alterations, including *SMN2,* and affect the disease progression.

Carrier testing by dose analysis is available and is based on semiquantitative real-time PCR or MLPA. In this context, limitations of the molecular testing, difficulties in predicting the offspring's phenotype based solely on the *SMN2* copy number, and the effect on reproductive planning should be considered.

Newborn screening is aimed at identifying presymptomatic SMA patients. DNA extraction from newborn blood spots, followed by either liquid microbead array or real-time PCR techniques, helps to identify *SMN1* homozygous deletions. Challenges in newborn screening include the inability to detect carriers of heterozygous deletions of *SMN1*, and *SMN2* copy numbers.

MANAGEMENT

A multidisciplinary and supportive approach is the key in the management of a patient with SMA along with published updated standards of care. Follow-up coordination should be managed by an expert in neuromuscular disorders, and the team ideally should include a pediatric and an adult neurologist, respiratory physicians, geneticists, gastroenterologists, palliative care physicians, rehabilitation specialists, orthopedic surgeons, and allied healthcare professionals. The consensus statement for the standard of care in SMA includes ethical and palliative care sections. Despite increased standards and technologic advances, there is a high variability in terms of ventilatory support, nutritional support, and scoliosis surgery. In terms of advances in disease-modifying treatments that will change the natural course of the disease, care and treatment options should be discussed clearly with the family and/or patients to define expectations, the quality of life, and palliative care issues. Because SMA is a dynamic disease by nature, a proactive plan should be introduced in almost every care subtopic (Table 652.10). Overall, supportive therapy should aim to help the patient to be as functionally independent as possible.

THERAPEUTIC ADVANCES

The prognosis, especially for SMA type I, has been improved due to the use of genetically based treatments with three drugs, nusinersen, onasemnogene, and risdiplam (Table 652.11). These drugs are expensive and may not be available in all countries.

SMN-antisense oligonucleotide (ASO), **nusinersen**, administered intrathecally is approved by the FDA and by the European Medicines Agency for all types of SMA patients. It modifies the splicing of *SMN2* by inducing an increase in exon 7 retention in *SMN2* pre-mRNA, which finally allows a protein product similar to *SMN1*. The initial

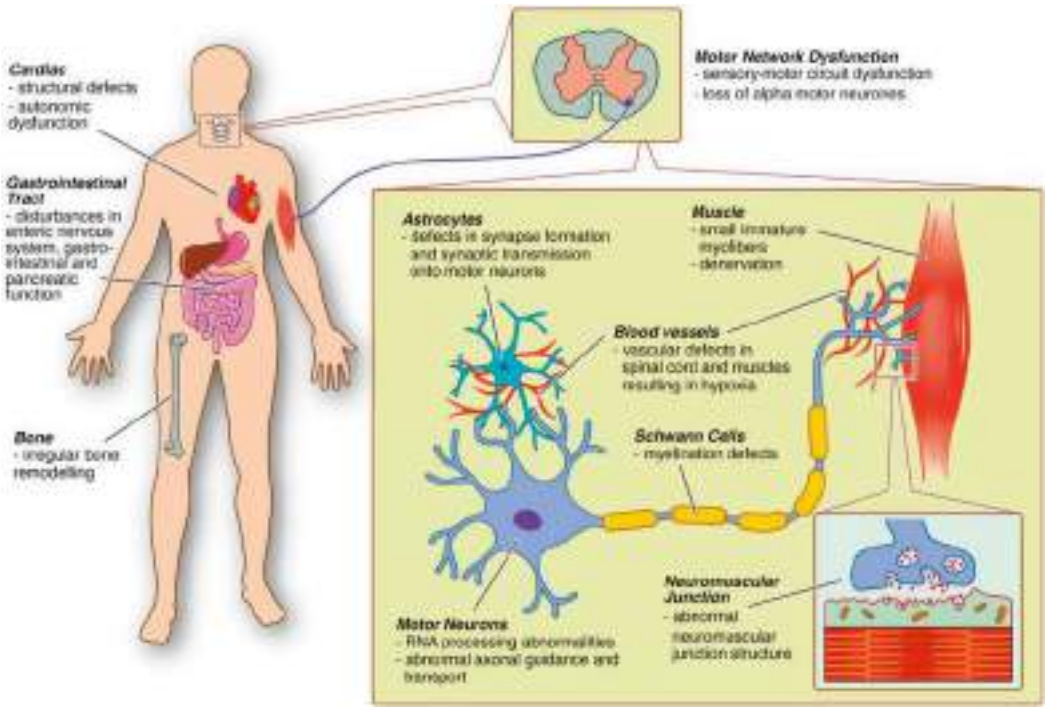

Fig. 652.5 Pathophysiologic findings in spinal muscular atrophy (SMA). Multiple functional abnormalities in motor networks have been identified in SMA mice and humans, including defects in astrocytes, Schwann cells, motor neurons, and skeletal muscle. Disease-associated phenotypes have also been reported across a range of other organs in SMA mice (in some cases supported by data from human patients), including cardiac structural and functional abnormalities, gastrointestinal tract dysfunction, and irregular bone remodeling. One potential unifying factor may be a deficiency in the development of the vasculature in SMA, with the resulting hypoxia likely impacting a range of cell types. *(From Farrar MA, Park SB, Vucic S, et al. Emerging therapies and challenges in spinal muscular atrophy. Ann Neurol. 2017;81:355–368.)*

Table 652.10 Management of Spinal Muscular Atrophy

	PROBLEMS	ASSESSMENTS	INTERVENTIONS
Respiratory	• Respiratory muscle weakness • Paradoxical breathing, bell-shaped chest • Weak cough • Difficulties in mobilization of mucus • Recurrent pulmonary infections • Mucus plugs • Atelectasis • Respiratory failure	• Cough effectiveness • Respiratory muscle function tests • Overnight oximetry • Forced vital capacity (>6 yr) • Overnight polysomnography if disordered breathing suspected • Acute respiratory infections	• Referral to respiratory specialist • Routine immunizations • Annual influenza vaccination • Airway clearance techniques and cough assistance (chest physiotherapy, postural drainage, mechanical or manual cough assistance) • Respiratory devices: noninvasive ventilation (nocturnal and/or daytime if indicated)* • Antibiotics intensified airway clearance • Increased ventilation support*
Nutritional	• Swallowing dysfunction • Failure to thrive • Prolonged feeding times • Gastroesophageal reflux • High risk for aspiration pneumonia • Constipation • Delayed gastric emptying • Increased fat mass and particular risk for becoming overweight (nonambulatory SMA type II patients) • Decreased bone mineral density	• Feeding and swallowing assessment • Assess caloric intake • Assess for signs of reflux or aspiration • Assess for constipation • Assess calcium and vitamin D status	• Nutritional supplementation • Modifying food consistency • Optimizing oral intake • Positioning and seating alterations • Nasogastric, nasojejunal, or percutaneous gastrostomy (as soon as reduced oral intake is recognized) • Nissen fundoplication (if indicated) • Hydration, regular oral aperients • Calcium and vitamin D supplementation (if indicated)
Orthopedic physiotherapy	• Scoliosis, hip subluxation, joint contractures (nonambulatory SMA type II patients) • Pain • Limited mobility	• Posture, mobility, function • Contractures • Scoliosis • Hip subluxation/dislocation	• Equipment to assist with mobility, self-care, and function • Physiotherapy, standing frames, orthoses • Spinal surgery† • Stretching, adequate positioning • Exercises with low resistance or high repetition • Evaluation with functional motor scales developed for SMA patients

Continued

Table 652.10 Management of Spinal Muscular Atrophy—cont'd

	PROBLEMS	ASSESSMENTS	INTERVENTIONS
Other organ involvement	• Reduced muscle mass • Higher risk of hypoglycemia during fasting • Congenital heart failure (SMA type 0) • Obesity, hyperinsulinemia with insulin resistance, and/or impaired glucose metabolism (nonambulatory type II SMA patients)	• Consider hypoglycemia during surgery and febrile episodes • Assess glucose metabolism if indicated	• Appropriate treatment if indicated • Referral to cardiologist • Referral to endocrinologist
Psychologic	• Issues related to quality-of-life index • Evaluation of family matrix	• Assess for depression/anxiety	• Counseling, pharmacotherapy • Appropriate referrals

*The appropriate level of interventional support to prolong life, particularly in spinal muscular atrophy (SMA) type I, is controversial, and the consensus statement recognizes the importance of discussions with the family to explore and define the potential quality of life and palliative care issues. The philosophy and introduction of proactive respiratory support in patients with SMA type I varies considerably and practice varies internationally.

†There is no consensus on management of scoliosis or hip subluxation/dislocation in nonambulant patients. If there is no fast progression of scoliosis, surgery should be delayed until at least 10-12 yr of age to allow for optimum growth. Otherwise, growing rods and vertical expandable prosthetic titanium ribs should be considered. Possibility of intrathecal administration of drugs should be taken into account.

The management of SMA incorporates a multidisciplinary and supportive approach, including neurologists (adult and pediatric), respiratory physicians, geneticists, gastroenterologists, palliative care physicians, rehabilitation specialists, orthopedic surgeons, and allied healthcare professionals.

Modified from Farrar MA, Park SB, Vucic S, et al. Emerging therapies and challenges in spinal muscular atrophy. *Ann Neurol.* 2017;81:355–368; and from Pechman A, Kirschner J. Diagnosis and new treatment avenues in spinal muscular atrophy. *Neuropediatrics.* 2017;48(4):273–281.

Table 652.11 US Food and Drug Administration Approved SMA Therapeutics

MEDICATIONS	APPROVED FOR AGES	ROUTE/DOSING FREQUENCY	MECHANISM OF ACTION	ADVERSE EVENTS
Nusinersen (Spinraza)	All	IT/Loading dose (4 doses in 2 mo), then q 4 mo	ASO promoting inclusion of exon 7 in *SMN2* pre-mRNA	*Common*: LP-related, thrombocytopenia,* proteinuria* *Rare*: Hydrocephalus†
Onasemnogene abeparvovec-xioi (Zolgensma)	≤2 yr 0 d	IV/one-time dose	GRT using AAV9 vector	*Common*: asymptomatic thrombocytopenia, moderate elevation LFTs *Rare*: acute liver failure, TMA
Risdiplam (Evrysdi)	≥2 mo	PO/daily	Small molecule splice modifier promoting inclusion of exon 7 in *SMN2* pre-mRNA	*Common*: fever, diarrhea, rash, oral ulcers *Rare* (animal models only): retinal toxicity, testicular toxicity

*Associated with ASOs.

†Hydrocephalus has rarely been reported in individuals treated with either nusinersen or onasemnogene abeparvovec, and it remains unclear whether this is a rare consequence of SMA or is related to treatment.

AAV, Adeno-associated virus; ASO, antisense oligonucleotide; GRT, gene replacement therapy; IT, intrathecal; IV, intravenous; LFT, liver function test; LP, lumbar puncture; PO, oral; TMA, thrombotic microangiopathy.

From Klotz J, Rocha CT, Young SD, et al. Advances in the therapy of spinal muscular atrophy. *J Pediatr.* 2021;236:13–20. Table 1.

"loading" regime is with four intrathecal doses of nusinersen over the first 2 months, and this is followed by an intrathecal dose every 4 months, anticipated to be continued for life for maintenance of benefit. Nusinersen in phase 1 to phase 3 studies in SMA type I (0-6 months) showed favorable safety and tolerability with statistically significant improvement in survival and motor milestones. Two-year follow-up data on "real-world use" of an Italian clinical cohort reported that sitting was achieved in all the seven patients treated before 210 days of age (100%), in 11 of 23 treated between 210 days and 2 years (55%), and in 3 of 14 treated between 2 and 4 years of age (17.6%). Only one child achieved independent walking. The NURTURE study group has also reported a cohort of 25 presymptomatic infants (15 with two copies of SMN2, and 10 with three copies of SMN2) with a median follow-up of approximately 3 years: all participants achieved the ability to sit without support, 23/25 (92%) achieved walking with assistance, and 22/25 (88%) achieved walking independently. Long-term follow-up is necessary to evaluate the effect of this treatment at different stages of the disease. Scoliosis, surgical interventions, and severe respiratory disease may complicate the lumbar puncture procedure.

The clinical trial data of the use of nusinersen in SMA type II/III patients (2-14 years) has also been very positive, with statistically significant improvement in functional assessment scores and motor milestones. Real-world cohort data from multiple studies of intrathecal nusinersen has reported improvement in walking ability or 6-minute walk distance in SMA3.

Risdiplam is an orally administered small molecule drug that modifies SMN2 pre-mRNA splicing and has been approved by the FDA for the treatment of patients with SMA who are 2 months of age or older. Risdiplam promotes the inclusion of exon 7, thereby increasing the expression of full-length SMN2 mRNA and functional SMN protein.

A phase 2-3 open-label study of risdiplam SMA1 infants age 1-7 months reported that sitting was achieved in 30% of the treated infants. Another study was in open-label extension, with optimized dose of risdiplam; 41 infants were enrolled and after 12 months of treatment, 12 infants (29%) were able to sit without support for at least 5 seconds, a milestone not attained in the natural history of SMA1.

Onasemnogene abeparvovec is a single-dose intravenously administered SMN gene replacement therapy (GRT) to replace *SMN1* and thus increase the production of the full-length SMN protein. It has FDA license for use up to 2 years of age and European medicines Agency approval children up to 21 kg bodyweight, so it primarily addresses the SMA1 population. The adeno-associated viral vector (AAV9) is used to transport a functional copy of *SMN1*, crossing the blood-brain barrier. The phase I clinical trial of intravenously administered GRT in SMA type I patients established a safety profile, but alanine transaminase (ALT) and aspartate transaminase (AST) elevation was noted in the

first month after treatment, indicating an immune-mediated "hepatitis," which requires treatment with prednisolone starting the day before treatment, and weaned off over a period of 3-4 months. *Thrombotic angiopathy* is a rare but life-threatening adverse effect.

The efficacy of onasemnogene has completely altered the natural history of SMA1. In an open-label study, 12 infants received the high (therapeutic) dose of onasemnogene at mean age of 3.4 months and follow-up was reported at median age 25 months; 11 patients sat unassisted, 11 were fed orally and could speak, and 2 walked independently. Five-year follow-up data were available for 10 of the 12 patients in the therapeutic-dose cohort (families of 2 infants refused participation in the follow-up study). All these patients remained alive and without the need for permanent ventilation (permanent ventilation is defined as need for ventilatory support for more than 16 hours per day) and maintained previously acquired motor milestones. Two patients attained the new milestone of "standing with assistance" without the use of nusinersen.

The outcome of single-dose onasemnogene gene therapy for *symptomatic* infantile-onset SMA1 has demonstrated that 14 of 32 patients achieved independent sitting at 18 months of age. Only 1 patient achieved walking. This study had broader inclusion and exclusion criteria compared with others, which resulted in inclusion of patients with more severe disease at baseline, at least in part explaining why the results were not as positive. There are no randomized controlled trials or systematic reviews comparing nusinersen, risdiplam, and onasemnogene, and their use is dictated by patient age, SMA categorization and severity, availability and funding, and patient choice.

Genetic counseling, depending on carrier screening tests, or in the presence of a previously affected child with SMA, may help with reproductive planning (prenatal diagnosis or preimplantation diagnosis). **Prenatal diagnosis** should be offered to families with an index patient in the family (recurrence risk is 25%), and antenatal screening by chorionic villus sampling between the 10th and 12th gestational week of pregnancy may serve for *SMN1* deletion/variant analysis.

Visit Elsevier eBooks+ at eBooks.Health.Elsevier.com for Bibliography.

652.3 Other Motor Neuron Diseases

Adnan Y. Manzur

Motor neuron diseases (MNDs) are a heterogeneous group of *progressive neurodegenerative* disorders characterized by upper and lower neuron dysfunction, with an onset from birth to adulthood. A variety of causes, including hereditary, immune-mediated, infectious, paraneoplastic, and sporadic diseases, should be considered.

Acute flaccid paralysis is the most common presentation of MND in children; it may occur in outbreaks. *Poliomyelitis* used to be a major cause of chronic disability, but with the routine use of polio vaccine, this viral infection is rare (see Chapter 296). Other enteroviruses, such as coxsackievirus and echovirus, or the live polio vaccine virus can also cause an acute infection of motor neurons, with symptoms and signs similar to poliomyelitis, although usually milder. Specific PCR tests and viral cultures of cerebrospinal fluid are diagnostic. A clustering of cases of acute flaccid paralysis has been reported during outbreaks of enterovirus D68 in multiple states in children (mean age 7-11 years). Limb weakness is often *asymmetric* and includes bulbar weakness, as well as cranial nerve VI and VII involvement. MRI may demonstrate longitudinal spinal cord lesions with dominant anterior horn cell involvement (Fig. 652.6). Cerebrospinal fluid pleocytosis and elevated protein are common. Treatments have included steroids and intravenous immunoglobulin; persistent paresis is a common sequela. Motor neuron infection with the West Nile virus also occurs.

In children, an insidious onset, slow progression, and family history can be clues for a genetic basis. Although the most common MND in children is 5q13-associated SMA, with a typical or predominant lower motor neuron phenotype, there is a clinically and genetically heterogeneous group of MNDs that overlap with **hereditary spastic paraplegias (HSPs), hereditary sensory-motor neuropathies (HSMNs),** and **juvenile forms of amyotrophic lateral sclerosis (ALS).**

A less common group of MNDs, not associated with *SMN1,* are called **non–5q13-associated SMAs;** this heterogeneous group can be associated with X-linked, autosomal dominant or autosomal recessive SMAs, **distal SMAs, segmental SMAs,** or **distal hereditary motor neuropathies** or **neuronopathies.** Additional features, such as deafness; epilepsy; encephalopathy; spasticity; visual impairment; or brainstem, cerebellar, gastrointestinal, or rheumatologic disorders may be indicative of a widespread involvement. These **atypical SMA** phenotypes can also be called **SMA-plus syndromes,** and they show extensive phenotypic overlap and molecular genetic heterogeneity (see Table 652.7). Primary involvement of the upper motor neuron, with a progressive upper and lower motor neuron loss, characterize **juvenile amyotrophic lateral sclerosis,** which is rare and ultimately fatal.

There has been an increase in the molecular diagnostic yield and expansion of these clinical phenotypes. This further helps not only to understand the natural course and common pathophysiologic mechanisms involved, but also indicates the appropriate genetic counseling and prenatal diagnosis.

A pattern of weakness, amyotrophy, and progression (proximal or distal, bulbar or respiratory involvement), the presence of spasticity, deep tendon reflexes, and the family history should be evaluated. In contrast to typical SMA, electrophysiologic studies and EMG may serve as important tools to demonstrate a neurogenic basis. Multisystem assessment, including vision, hearing, and cognitive development, is required. Clinical evaluation and recognition of distinctive features will help to classify MND and consider treatable MND forms in the differential diagnosis.

SMA with respiratory distress (SMARD) is a rare autosomal recessive disease due to pathogenic variants in the gene encoding IGHMBP2 on chromosome 11q13. In contrast to classical SMA type I, *predominant distal weakness* with *diaphragmatic palsy* results in severe respiratory failure. There is usually an early presentation between 6 weeks and 6 months of age, with intrauterine growth restriction, a weak cry and suck, and congenital foot deformities. Routine chest x-ray may reveal *diaphragmatic eventration,* which causes early respiratory failure. Atypical patients with peripheral neuropathy and no respiratory involvement have also been described. Beyond the core symptoms, sensory and autonomic dysfunction (excessive sweating, urinary retention, constipation, and cardiac arrhythmia), seizures, and progressive cranial nerve involvement can be additional features.

Brown-Vialetto-Van Laere (BVVL) syndrome is a rare heterogeneous neurodegenerative disorder characterized by involvement of cranial nerves VII-XII, progressive facial weakness, sensorineural deafness, dysphagia, tongue amyotrophy, fasciculations, bulbar palsy, and respiratory insufficiency. It may present at all ages. Weakness of the arms and hands, optic atrophy, and ataxia may be additional presentations. The clinical presentation of **Fazio-Londe syndrome** is the same and characterized by progressive bulbar palsy resulting from motor neuron degeneration more in the brainstem than the spinal cord, *without sensorineural deafness.*

Identification of pathogenic variants in the riboflavin transporter genes provided a targeted therapeutic strategy with oral or intravenous *high-dose riboflavin supplementation* with the starting dose being 10 mg/kg/day. The oral riboflavin dose may need to be sequentially increased to 50 mg/kg/day in pediatric patients and 1500 mg/day in adult patients for maximum benefit. The clinical response in this group may be variable, ranging from a rapid response to gradual improvement over 12 months, clinical stabilization, or rarely no response. Recognition of *abnormal acylcarnitine profiles* mimicking *multiple acyl-CoA dehydrogenase deficiency* in BVVL should also be considered. A biochemical response to treatment is also evident. The common core phenotype of this treatable MND includes progressive axonal sensorimotor neuropathy (manifesting with sensory ataxia and severe weakness of the upper limbs and axial muscles with distinctly preserved muscle power of the lower limbs), hearing loss, optic atrophy, and respiratory insufficiency.

The classic form of **pontocerebellar hypoplasia with SMA (PCH1)** is characterized by severe hypotonia, areflexia, muscle weakness, central visual impairment, dysphagia, respiratory insufficiency, and acquired microcephaly, with a presentation in the first months of life and death in infancy. There is a wide clinical spectrum, with a severe antenatal onset representing the severe end of the spectrum with arthrogryposis and polyhydramnios.

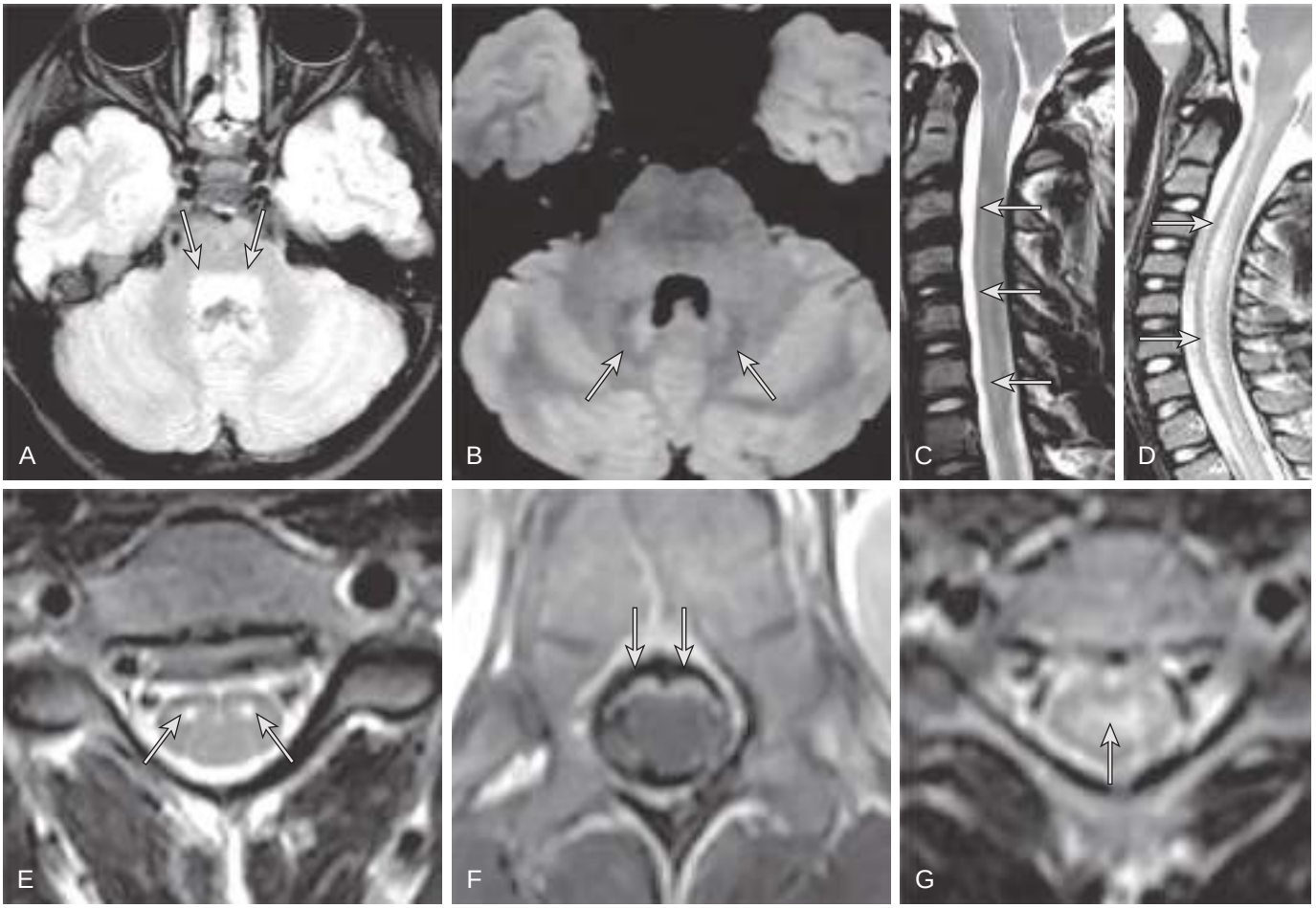

Fig. 652.6 Acute flaccid paralysis. Brain and spinal cord MRI. Axial fluid-attenuated inversion recovery (FLAIR) image at the level of the pons showing increased signal in the tegmentum (**A**; case 2). Axial FLAIR image at the level of the pons showing increased signal in the dentate nuclei, right greater than left, and sagittal T2 weighted image of the cervical spine shows long segment hyperintensity in the ventral cord (**B, C**; case 5). Sagittal T2 weighted image shows extensive increased signal in the central cord and cord swelling (**D**) at presentation (**D-F**; case 1). Five weeks after presentation, axial T2 weighted imaging of the cervical spine shows residual increased signal in the anterior horns (**E**) and an axial T1 weighted postcontrast image shows ventral nerve root enhancement at the level of the conus medullaris (**F**). Axial T2 weighted image of the cervical spine showing increased signal in the central gray matter (**G**; case 6). Cases 2, 5, and 6 were children with enterovirus D68 identified in the nasopharynx. *(From Messacar K, Schreiner TL, Maloney JA, et al. A cluster of acute flaccid paralysis and cranial nerve dysfunction temporally associated with an outbreak of enterovirus D68 in children in Colorado, USA. Lancet. 2015;385:1662–1671. Fig. 3.)*

SMA with progressive myoclonic epilepsy (SMAPME) is characterized by treatment-resistant progressive myoclonic epilepsy combined with proximal muscle weakness, areflexia, atrophy, progressive weakness, and dysphagia, followed by normal developmental milestones. Mild facial weakness, tongue fasciculations, sensorineural hearing loss, and tremor may be additional features. Rare variants include *polyarticular arthritis with SMA, mild SMA without seizures, eyelid myoclonic status epilepticus,* and *absence and atonic seizures* in adolescence.

Lethal arthrogryposis with anterior horn cell disease (LAAHD) and SMA with congenital arthrogryposis and fractures are atypical SMA forms within the fetal akinesia/hypokinesia spectrum (see Chapter 648.10).

A variety of **mitochondrial diseases** may present with an SMA-like clinical phenotype. In addition to hypotonia, weakness, and respiratory failure, there is a more extensive spectrum of multisystem involvement, such as infantile hypertrophic cardiomyopathy, hepatic failure, spasticity, Leigh-like syndrome, encephalopathy, seizures, brainstem dysfunction, global developmental delay, ptosis, and ophthalmoplegia. Lactic acidosis and increased serum CK levels may further help to include genes involved in *COX assembly proteins* and *mitochondrial depletion syndromes* in the molecular genetic workup.

SMA with lower extremity predominance (SMALED) is characterized by congenital or early-onset, proximal lower limb–predominant muscle weakness and atrophy. There is again a wide range of clinical presentations from the antenatal to adulthood periods. Spasticity and cognitive impairment can be a part of the clinical picture in some patients. The most common gene responsible for this phenotype is *DYNC1H1,* and its phenotypic spectrum spans lower extremity–predominant SMA, axonal Charcot-Marie-Tooth disease type 2, neurodevelopmental disorders, malformations of cortical development, learning disability, epilepsy, HSP, and phenotypes may overlap. *DYNC1H1*-related SMALED has a distinctive pattern of lower limb muscle MRI abnormalities, which are of diagnostic help.

Scapuloperoneal SMA is an autosomal dominant condition defined by its selective muscle involvement, progressive distal weakness, and atrophy. Laryngeal palsy, sensorineural deafness, short stature, scoliosis, and mild limb and skeletal dysplasia may accompany the picture.

Motor neurons become involved in several metabolic diseases of the nervous system, such as gangliosidosis (Tay-Sachs disease), ceroid lipofuscinosis (Batten disease), and glycogenosis II (Pompe disease), but the signs of denervation may be minor or obscured by the more prominent involvement of other parts of the central nervous system or of muscle. Amyotrophy related to lower motor neuron degeneration is a prominent future of some multisystem disorders, such as infantile neuroaxonal dystrophy (INAD), achalasia-addisonianism-alacrima (AAA, triple A, or Allgrove syndrome), and Chédiak-Higashi syndrome (CHS).

Visit Elsevier eBooks+ at eBooks.Health.Elsevier.com for Bibliography.

Chapter 653

Hereditary Motor-Sensory Neuropathies

Adnan Y. Manzur*

The hereditary motor-sensory neuropathies (HMSNs) are a group of progressive diseases of peripheral nerves of genetic (and syndrome) etiology (Tables 653.1 and 653.2). HMSNs are the most common group of hereditary neuropathies and the term Charcot-Marie-Tooth disease (CMT) is used interchangeably, and more commonly. Motor components generally dominate the clinical picture, but sensory and autonomic involvement is expressed later. Sural nerve biopsy used to be the most definitive means of diagnosis, but with the expanded knowledge of the molecular genetics of this group of diseases, the diagnosis of most can be confirmed by less invasive genetic testing. Electromyography (EMG) remains a useful adjunct to clinical diagnosis and helps distinguish between **demyelinating** or **hypomyelinating** and **axonal** forms. Clinical clues are noted in Tables 653.3-653.5.

Classification of HMSNs is difficult because no simple unifying scheme is capable of incorporating all the clinical presentations and overlapping genetics (see Tables 653.1 and 653.2). More than 140 genes have been described as causing the HMSN/CMT spectrum. In some neuropathies, a diverse genotype with pathogenic variants in different genes at different chromosomal loci may produce a similar phenotype. One classification identifies the following:

I. Hereditary neuropathies secondary to general diseases
II. Primary neuropathies
  IIa. Hereditary motor sensory neuropathies
  IIb. Distal hereditary motor neuropathies
  IIc. Hereditary sensory ± autonomic neuropathies
III. Syndromic neuropathies, including congenital hypomyelinating neuropathies
IV. Hereditary sensory neuropathy (Refsum disease)

Visit Elsevier eBooks+ at eBooks.Health.Elsevier.com for Bibliography.

653.1 Peroneal Muscular Atrophy (Charcot-Marie-Tooth Disease, HMSN Type IIa)

Adnan Y. Manzur

CMT is the most common genetically determined neuropathy and the most common demyelinating variant, also described as CMT1A, and has an overall prevalence of 3.8/100,000 population and accounts for >50% of cases of HMSN overall. It is transmitted as an autosomal dominant trait with 83% expressivity; the 17p11.2 locus is the site of the abnormal gene. Autosomal recessive transmission also is described but is rarer. The gene product is peripheral myelin protein 22 (PMP22). A much rarer X-linked HMSN type I results from a defect at the Xq13.l locus, causing pathogenic variants in the gap junction protein connexin-32. Other forms, caused by >40 genes, have been reported (see Table 653.1). Both fatty acid binding by PMP22 and the kinetics of its membrane interactions are affected by mutations.

CLINICAL MANIFESTATIONS

Most patients are asymptomatic until late childhood or early adolescence, but young children sometimes manifest gait disturbance as early as the second year of life. The peroneal and tibial nerves are the earliest and most severely affected. Children with the disorder are often described as being clumsy, falling easily, or tripping over their own feet. Application of the Cumberland Ankle Instability Tool for Youth is a means of objectively documenting and following this manifestation. The onset of symptoms may be delayed until after the fifth decade.

Muscles of the anterior compartment of the lower legs become wasted, and the legs have a characteristic storklike contour. The muscular atrophy is accompanied by progressive weakness of dorsiflexion of the ankle and eventual foot drop. The process is bilateral but may be slightly asymmetric. Pes cavus deformities invariably develop as a result of denervation of intrinsic foot muscles, further destabilizing the gait. A small minority of individuals with CMT1A have hip dysplasia. Atrophy of muscles of the forearms and hands is usually not as severe as that of the lower extremities, but in advanced cases contractures of the wrists and fingers produce a claw hand. Proximal muscle weakness is a late manifestation and is usually mild. Axial muscles are not involved.

The disease is slowly progressive throughout life, but patients occasionally show accelerated deterioration of function over a few years. Most patients remain ambulatory and have normal longevity, although orthotic appliances are required to stabilize the ankles.

Sensory involvement mainly affects large, myelinated nerve fibers that convey proprioceptive information and vibratory sense, but the threshold for pain and temperature can also increase. Some children complain of tingling or burning sensations of the feet, but pain is rare. Because the muscle mass is reduced, the nerves are more vulnerable to trauma or compression. Autonomic manifestations may be expressed as poor vasomotor control with blotching or pallor of the skin of the feet and inappropriately cold feet.

Nerves often become palpably enlarged. Tendon stretch reflexes are lost distally. Cranial nerves are not affected. Sphincter control remains well preserved. Autonomic neuropathy does not affect the heart, gastrointestinal tract, or bladder. Intelligence is normal. A unique point variant in *PMP22* causes progressive auditory nerve deafness in addition, but this is usually later in onset than the peripheral neuropathy. X-linked CMT disease (*GJB1* variant) has been associated with an acute disseminated encephalitis-like illness.

Davidenkow syndrome is a variant of HMSN type I with a scapuloperoneal distribution.

LABORATORY FINDINGS AND DIAGNOSIS

Motor and sensory nerve conduction velocities are greatly reduced, sometimes as slow as 20% of the normal conduction time. In new cases without a family history, both parents should be examined, and nerve conduction studies should be performed.

EMG and muscle biopsy are not usually required for diagnosis, but they show evidence of many cycles of denervation and reinnervation. The serum creatine kinase level is normal. The cerebrospinal fluid (CSF) protein may be elevated, but no cells appear in the CSF.

Sural nerve biopsy is diagnostic. Large- and medium-size myelinated fibers are reduced in number, collagen is increased, and characteristic **onion bulb formations** of proliferated Schwann cell cytoplasm surround axons. This pathologic finding is called **interstitial hypertrophic neuropathy.** Extensive segmental demyelination and remyelination also occur. The definitive molecular genetic diagnosis may be made in blood.

TREATMENT

Stabilization of the ankles is a primary concern. In early stages, stiff boots that extend to the midcalf often suffice, particularly when patients walk on uneven surfaces such as ice and snow or stones. As the dorsiflexors of the ankles weaken further, lightweight plastic splints may be custom-made to extend beneath the foot and around the back of the ankle. They are worn inside the socks and are not visible, reducing self-consciousness. External short-leg braces may be required when foot drop becomes complete. Soft tissue/bony foot surgery, or surgical fusion of the ankle may be considered in cases of progressive foot deformity, depending upon age and severity.

* The editors are grateful to Dr. Harvey B. Sarnat and Dr. Diana X. Bharucha-Goebel, much of whose work on previous editions of this chapter is retained here.

Table 653.1 Nonsyndromic Inherited Neuropathies

DISEASE	INHERITANCE PATTERN	GENE OR LOCUS	CLINICAL FEATURES
HEREDITARY MOTOR AND SENSORY NEUROPATHIES (HMSNs)			
Demyelinating			Forearm NCV usually <38 m/sec
CMT1	AD		Young adult onset, NCV 10-35 m/sec
CMT1A		*PMP22* (usually duplication)	Most common (70% of all CMT1) Pathogenic variants also cause CMT3
CMT1B		*MPZ* (P_0)	Pathogenic variants also cause CMT2 and CMT3
CMT1C		*LITAF/SIMPLE*	
CMT1D		*EGR2*	Broad clinical spectrum (also CMT3)
CMT1F		*NEFL*	DSS phenotype common
CMT1 plus		*FBLN5*	Macular degeneration; cutis laxa
CMT1		*PMP2*	Classic CMT1
SNCV/CMT1		*ARHGEF10*	Asymptomatic slowed NCVs
HNPP	AD	*PMP22* (usually deletion)	Adult-onset episodic entrapment neuropathies, mild slowing (NCV 40-50 m/sec)
CMT3			Severe, early-onset demyelinating
DSS	AD/X AR	*CMT1* genes *PRX, MTMR2*	Onset before age 3 yr old
CHN	AD AR	*PMP22, MPZ* *EGR2*	Congenital onset AR-CHN, also known as CMT4E
CMT4	AR		Childhood onset, usually severe
CMT4A		*GDAP1*	Both axonal and demyelinating types
CMT4B1		*MTMR2*	Biopsy shows focally folded myelin
CMT4B2		*SBF2/MTMR13*	Same as above ± early-onset glaucoma
		SBF1/MTMR5	
CMT4C		*SH3TC2*	Scoliosis often severe, also axonal types
CMT4D		*NDRG1*	Dysmorphic features, deafness
CMT4E		*EGR2*	
CMT4F		*PRX*	DSS phenotype
CMT4G		*HK1*	
CMT4H		*FGD4*	
CMT4J		*FIG4*	
		SURF-1	
		CTDP1	
Slow NCV	AD	*ARHGEF10*	Asymptomatic NCV slowing
Intermediate			NCV 25-45 m/sec
CMTX	X		
CMTX1		*GJB1/Cx32*	Similar to CMT1, but males more severely affected, CNS involvement common
CMTX2, Cowchock syndrome		*AIFM1*	MR, deafness, axonal
CMTX5		*PRPS1*	Axonal CMT, deafness, optic atrophy
CMTX6		*PDK3*	Axonal CMT
CMTX		*DRP2*	Intermediate MCVs
CMTDI	AD		
DI-CMTA		10q24	
DI-CMTB		*DNM2*	Neutropenia
DI-CMTC		*YARS*	

Continued

Table 653.1 Nonsyndromic Inherited Neuropathies—cont'd

DISEASE	INHERITANCE PATTERN	GENE OR LOCUS	CLINICAL FEATURES
DI-CMTD		*MPZ*	
DI-CMTE		*IFN2*	Focal segmental glomerulosclerosis
DI-CMTF		*GNB4*	
CMTRI	AR		
CMTR1A		*GDAP1*	
CMTR1B		*KARS*	
CMTR1C		*PLEKHG5*	
CMTR1D		*COX6A1*	
Axonal			NCV >38 m/sec
CMT2	AD		Young adult onset
CMT2A		*MFN2* *KIF1B (rare)*	Most common; also HMSN V (optic atrophy), VI (spasticity), and early onset
CMT2B		*RAB7*	Severe sensory loss like HSAN-1
CMT2C		*TRPV4*	Vocal cord/diaphragm weakness
CMT2D		*GARS*	Arm > leg, motor predominant, similar to dHMN caused by BSCL2 mutations
CMT2E		*NEFL*	Allelic with CMT1E; variable phenotype
CMT2F		*HSP27 (HSPB1)*	Motor predominant
CMT2G		12q12-13.3	Proximal > distal weakness
CMT2H, K		*GDAP1*	Allelic with CMT4A
CMT2I, J		*MPZ (P0)*	Cough, pain, autonomic/pupil, deafness
CMT2L		*HSP22 (HSPB8)*	Motor predominant, allelic with HMNIIa
CMTDIB, CMT2M		*DNM2*	Intermediate or CMT2; cataracts; ophthalmoplegia; ptosis
CMT2N		*AARS*	
CMT2P		*LRSAM1*	
CMT2Q		*DHTKD1*	
CMT2U		*MARS*	Late onset
CMT2V		*NAGLU*	Late-onset painful sensory predominant
CMT2W		*HARS*	
CMT2Y		*VCP*	
CMT2Z		*MORC2*	Pyramidal signs
CMT2			
CMT2 with giant axons		*DCAF8*	Childhood onset
CMT2		*TUBB3*	
CMT2		*DGAT2*	
CMT2		*JAG1*	Vocal fold paralysis
SPG10, CMT2		*KIF5A*	
HMSNP		*TFG*	Proximal > distal
AR-CMT2	AR		
CMT2B1		*LMNA*	Also called CMT2B1 and CMT4C1
CMT2B2		*MED25*	
NMAN		*HINT1*	
CMT2R		*TRIM2*	
CMT2S		*IGHMBP2*	

Table 653.1 Nonsyndromic Inherited Neuropathies—cont'd

DISEASE	INHERITANCE PATTERN	GENE OR LOCUS	CLINICAL FEATURES
CMT2T		*HSJ1*	
CMT2X		*KIAA1840*	
AR-CMT2	AR/AD	*MME*	Dominant pathogenic variants cause late onset
HEREDITARY SENSORY AND AUTONOMIC NEUROPATHIES (HSANS)			
HSAN			Sensory (± autonomic) neuropathy
HSAN1A	AD	*SPTLC1*	Late-onset, slowly progressive sensory axonal neuropathy ± SNHL, weakness
HSAN1B	AD	3p24-p22	Variant with cough, GERD, deafness
HSAN1C	AD	*SPTLC2*	
HSAN1D/SPG3A	AD	*ATL1*	
HSAN2A	AR	*HSN2*	Congenital sensory loss, acral mutilation
HSAN3	AR	*IKBKAP*	Severe dysautonomia, Ashkenazi Jews
HSAN4	AR	*TRKA*	Anhidrosis, acral mutilation, ± CNS
HSAN5	AR	*NGFB*	Congenital insensitivity to pain
HSAN6	AR	*DST*	Severe autonomic dysfunction, death by age 2
HSAN7	AD	*SCN11A*	Congenital insensitivity to pain, hyperhidrosis, GI dysfunction
HSAN8	AR	*PRDM12*	Congenital insensitivity to pain
HEREDITARY MOTOR NEUROPATHIES/NEURONOPATHIES (HMNS)			
HMN/dSMA			Distal wasting and weakness
HMNIIa	AD	*HSPB8(HSP22)*	Adult onset, allelic with CMT2L
HMNIIb	AD	*HSP27(HSPB1)*	Allelic with CMT2F
HMNVa	AD	*GARS*	Upper limb predominant
HMNVb	AD	*BSCL2*	Allelic with SPG17/Silver syndrome
HMNVI	AR	*IGHMBP2*	Severe infantile respiratory distress/SMARD
HMNVIIa	AD	2q14	Adult onset, vocal cord paralysis
HMNVIIb	AD	*DCTN1*	Same as above
HMNX	X	Xq13.1-q21	
HMNJ	AR	9p21.1-p12	Childhood-onset (Jerash type)
SBMA	X	Androgen Receptor (CAG rpt)	Adult-onset bulbar symptoms, proximal weakness, sensory neuronopathy, gynecomastia

This table lists the inherited neuropathies that are generally considered to affect the peripheral nerve exclusively or predominantly, although as shown in the Clinical Features column, many of these diseases affect the CNS and other tissues. For the columns, in the Disease column, the name is usually abbreviated, with full names below; inheritance pattern is listed as autosomal dominant (AD), autosomal recessive (AR), or X-linked (X); and for gene or locus, the affected gene(s) is listed if known; otherwise, the chromosomal locus is listed. In cases where the variant is not a missense variant, the type of variant is listed in parentheses (duplication, deletion, or CAG repeat). The diseases are grouped according to phenotype: HMSN, hereditary motor and sensory neuropathy; HS(A)N, hereditary sensory and (±autonomic) neuropathy; HMN, hereditary motor neuropathy, also called dSMA (distal spinal muscular atrophy); SBMA, spinal bulbar and muscular atrophy. The HMSNs are further divided into demyelinating, axonal, and intermediate forms based on the usual range of nerve conduction velocity (NCV).

CHN, Congenital hypomyelinating neuropathy; CMT, Charcot-Marie-Tooth disease; CMTDI, dominant intermediate CMT; CNS, central nervous system; DSS, Déjèrine-Sottas disease; GERD, gastroesophageal reflux disease; GI, gastrointestinal; HNPP, hereditary neuropathy with liability to form pressure palsies; MCV, motor conduction velocity; MR, mental retardation; rpt, repeat; SMARD, spinal muscular atrophy with respiratory distress; SNHL, sensorineural hearing loss; SPG, hereditary spastic paraplegia (see Table 653.2).

From Motley W, Chaudry V, Lloyd TE. Treatment and management of hereditary neuropathies. In: Bertorini TE, ed. *Neuromuscular Disorders Treatment and Management*, 2nd ed. Philadelphia: Elsevier; 2022: Table 14.2, p. 280–282.

Table 653.2 Syndromic Neuropathies

DISEASE	INHERITANCE PATTERN	GENE OR LOCUS	CLINICAL FEATURES
HNA	AD	*SEPT9*	Recurrent brachial neuritis, dysmorphic features in some
Friedreich ataxia (FRDA)	AR	*Frataxin-GAA repeats*	Ataxia, sensory large fiber axonal neuropathy, positive Babinski sign, cardiomyopathy
AVED	AR	*TTPA*	FRDA-like, vitamin E deficiency
SCAN1	AR	*TDP1*	Spinocerebellar ataxia, sensory neuropathy

Continued

Table 653.2 Syndromic Neuropathies—cont'd

DISEASE	INHERITANCE PATTERN	GENE OR LOCUS	CLINICAL FEATURES
Ataxia-telangiectasia	AR	*ATM*	Ataxia, telangiectasias, malignancy, infections
SCA			Sensory neuropathy variable in most
SCA3/MJD	AD	*ATXN3*	Ataxia, spasticity, severe axonal neuropathy
SCA4	AD	*PLEKHG4*	Prominent axonal sensory neuropathy
SCA10	AD	*ATXN10*	± Sensorimotor neuropathy
SCA25	AD	2p21-p13	Prominent axonal sensory neuropathy
SCA27	AD	*FGF-14*	Mild axonal sensory neuropathy
HSP			"Complicated HSP" with neuropathy
SPG2	X	*PLP*	CNS white matter disease ± neuropathy
SPG7	AR	Paraplegin	± Neuropathy, dysarthria, dysphagia
SPG9	AD	10q23.3-24.1	Amyotrophy, cataracts, GERD
SPG10	AD	*KIF5A*	± Distal atrophy
SPG11	AR	*Spatacsin*	MR, nystagmus, thin corpus callosum
SPG14	AR	3q27-q28	Distal motor neuropathy, MR, visual agnosia
SPG15	AR	*Spastizin*	Pigmented maculopathy, MR, dysarthria
SPG17	AD	*BSCL2*	(Silver syndrome) hand atrophy prominent
SPG20	AR	*Spartin*	(Troyer syndrome) distal atrophy, dysarthria
FAP TTR	AD	*TTR*	Early adult-onset painful sensorimotor and autonomic neuropathy, entrapment neuropathy, cardiomyopathy, GI symptoms
(Iowa)		*ApoAI*	Similar to TTR, but progressive renal failure
(Finnish)		*Gelsolin*	Cranial neuropathies, corneal dystrophy
Fabry	X	*α-Gal-A*	Child-onset painful SFSN, renal failure, cardiac disease, strokes
Leukodystrophies			Some associated with demyelinating neuropathy
GLD/Krabbe	AR	*GALC*	Progressive MR, hyperreflexia, sz, optic atrophy
MLD	AR	*ARSA*	Same as above, though CNS sx less severe
PCWH/Waardenburg	AD	*SOX10*	CHN, central dysmyelination, Waardenburg and Hirschsprung syndrome
Adrenomyeloneuropathy	X	*ABCD1*	Spastic paraparesis, large fiber sensory loss, bowel and bladder incontinence
Merosin deficiency	AR	*LAMA2*	Neuropathy and muscular dystrophy
Refsum disease	AR	*PAHX* *PEX7*	Ataxia, retinitis pigmentosa, demyelinating neuropathy, cardiac, deafness, ichthyosis
AMACR deficiency	AR	*AMACR*	Adult-onset sensory and motor neuropathy, retinitis pigmentosa, seizures, ataxia, developmental delay, acute and relapsing encephalopathy with headache
Mitochondrial diseases			Neuropathy common, axonal or demyelinating
Leigh disease	ARmito	Multiple genes	Early onset CPEO, ptosis, ataxia, MR, pyramidal signs, demyelinating neuropathy
NARP	Mito	*MTATP6*	Sensory neuropathy, ataxia, retinitis pigmentosa
MNGIE	AR	*ECGF1* *POLG*	Ptosis, CPEO, leukoencephalopathy, neuropathy, myopathy, GI dysmotility
Porphyria	AD		
AIP		*PBGD*	Acute neuropathy, abdominal pain, psychosis, sz
Copro		*CPO*	Similar to AIP, but also skin photosensitivity
Variegate		*PPOX*	Similar to AIP, but also skin photosensitivity
Tangiers disease	AR	*ABC1*	Orange tonsils, organomegaly, low HDL, atherosclerosis
Abetalipoproteinemia	AR	*MTTP*	Ataxia, acanthocytosis, steatorrhea, low LDL

Table 653.2 Syndromic Neuropathies—cont'd

DISEASE	INHERITANCE PATTERN	GENE OR LOCUS	CLINICAL FEATURES
Hypobetalipoproteinemia	AD	*Apo-B*	Ataxia, sensory axonal polyneuropathy
GAN	AR	Gigaxonin	MR, kinky hair, biopsy shows giant axons
ACCPN	AR	*KCC3*	Agenesis of corpus callosum, French Canadian
CCFDN	AR	*CTDP1*	Congenital cataracts, facial dysmorphism

This table lists the inherited neuropathies in which the neuropathy is part of a systemic disease. For the columns, in Disease, the name is usually abbreviated, with full names below; in the column Inheritance Pattern, data are listed as autosomal dominant (AD), autosomal recessive (AR), X-linked (X), or mitochondrial (maternal) (mito); and for in the Gene or Locus column, the affected gene(s) is listed if known; otherwise, the chromosomal locus is listed.

ACCPN, Agenesis of the corpus callosum and peripheral neuropathy, also known as Anderman syndrome; AIP, acute intermittent porphyria; AMACR , alpha-methylacyl-CoA racemase; AVED, ataxia with isolated vitamin E deficiency; CCFDN, congenital cataracts, facial dysmorphism, neuropathy; CHN, congenital hypomyelinating neuropathy; CNS, central nervous system; Copro, coproporphyria; CPEO, chronic progressive external ophthalmoplegia; FAP, familial amyloidotic polyneuropathy; GAN, giant axonal neuropathy; GERD, gastroesophageal reflux disease; GI, gastrointestinal; GLD, globoid-cell dystrophy; HDL, high-density lipoprotein; HNA, hereditary neuralgic amyotrophy; HSP, hereditary spastic paraplegia; LDL, low-density lipoprotein; MLD, metachromatic leukodystrophy; MJD, Machado-Joseph disease; MNGIE, mitochondrial neurogastrointestinal encephalopathy syndrome; MR, mental retardation; NARP, neuropathy, ataxia, and retinitis pigmentosa; PCWH, peripheral demyelinating neuropathy, central dysmyelination, Waardenburg syndrome, and Hirschsprung disease; SCA, spinocerebellar ataxia; SCAN1, spinocerebellar ataxia with axonal neuropathy 1; SFSN, small fiber sensory neuropathy; SPG, spastic gait; sx, symptoms; sz, seizures; TTR, transthyretin; Variegate, variegate porphyria.

From Motley W, Chaudry V, Lloyd TE. Treatment and management of hereditary neuropathies. In: Bertorini TE, ed,. *Neuromuscular Disorders Treatment and Management*, 2nd ed. Philadelphia: Elsevier; 2022: Table 14.3, p. 283–284.

Table 653.3 Polyneuropathies with Onset in Infancy

SALIENT CLINICAL FEATURE	CLINICAL PHENOTYPE	GENE	MODE OF INHERITANCE
AXONAL NEUROPATHIES			
Pes cavus with footdrop	CMT2E	*NEFL*	AD, AR
Optic atrophy	CMT2A	*MFN2*	AD, AR
	CMT4A	*GDAP1*	AR
	IOSCA	*C10orf2*	AR
	Infantile neuroaxonal dystrophy	*PLA2G6*	AR
Ophthalmoparesis	Mitochondrial disorders	*SCO2* *C10orf2* *TK2*	AR
Skeletal abnormalities	CMT2C, SPSMA, congenital dSMA	*TRPV4*	AD
Arthrogryposis	Congenital dSMA	*TRPV4*	AD
	SMARD1	*IGHMBP2*	AR
	X-linked SMA	*UBE1*	X-linked
	Pontocerebellar hypoplasia type 1	*EXOSC3, VRK1, TSEN54, RARS2*	AR
	SMA with congenital fractures	*TRIP4* *ASCC1*	Presumed AR
Congenital fractures	X-linked SMA	*UBE1*	X-linked
	SMA with congenital fractures	*TRIP4* *ASCC1*	Presumed AR
Vocal cord paresis	CMT2A	*MFN2*	AD, AR
	CMT2C, SPSMA, congenital dSMA	*TRPV4*	AD
	CMT4A	*GDAP1*	AR
	BVVL/Fazio-Londe disease	*SLC52A3*	AR
Early infantile respiratory failure	SMA1	*SMN1*	AR
	SMARD1	*IGHMBP2*	AR
	X-linked SMA	*UBE1*	X-linked
	Pontocerebellar hypoplasia type 1	*EXOSC3, VRK1, TSEN54, RARS2*	AR
	SMA with congenital fractures	*TRIP4* *ASCC1*	Presumed AR
	Lethal neonatal AR axonal sensorimotor polyneuropathy	Unknown	AR
	Congenital axonal neuropathy with encephalopathy	Unknown	Unknown, presumed AR

Continued

Table 653.3 Polyneuropathies with Onset in Infancy—cont'd

SALIENT CLINICAL FEATURE	CLINICAL PHENOTYPE	GENE	MODE OF INHERITANCE
AXONAL NEUROPATHIES			
Predominant motor involvement	Congenital dSMA, SPSMA	*TRPV4*	AD
	SMA1	*SMN1*	AR
	X-linked SMA	*UBE1*	X-linked
	Pontocerebellar hypoplasia type 1	*EXOSC3, VRK1, TSEN54, RARS2*	AR
	SMA with congenital fractures	*TRIP4* *ASCC1*	Presumed AR
	Mitochondrial disorders	*SCO2, TK2*	AR
Kinky hair hepatopathy	Giant axonal neuropathy	*GAN*	AR
	Mitochondrial disorders	*DGUOK* *C10orf2*	AR
	MTP/LCHAD deficiency	*HADHA/HADHB*	AR
Cardiomyopathy	Mitochondrial disorders	*SCO2*	AR
		TK2	AR
		DGUOK	AR
	MTP/LCHAD deficiency	*HADHA/HADHB*	AR
CNS involvement	Pontocerebellar hypoplasia type 1	*EXOSC3, VRK1, TSEN54, RARS2*	AR
	Giant axonal neuropathy	*GAN*	AR
	Infantile neuroaxonal dystrophy	*PLA2G6*	AR
	HMSN/ACC	*KCC3*	AR
	IOSCA	*C10orf2*	AR
	CMTX1	*GJB1*	X-linked
	Mitochondrial disorders	*SCO2*	AR
		TK2	AR
		DGUOK	AR
	Adrenoleukodystrophy	*ABCD1*	X-linked
Developmental regression	Adrenoleukodystrophy	*ABCD1*	X-linked
Dysautonomia, chronic skin ulceration	HSAN III (Riley-Day syndrome)	*IKBKAP*	AR
DEMYELINATING NEUROPATHIES			
Acute sensory ataxia, walking difficulties in a previously well child	GBS		
Slowly progressive weakness, ataxia in a previously well child; responsive to steroids	CIDP		
Developmental regression	MLD	*ARSA*	AR
	Krabbe disease	*GALC*	AR
Irritable, stiff, crying infant; occasional unexplained fevers	Krabbe disease	*GALC*	AR
Pes cavus with footdrop, marked difficulties walking	CMT1A	*PMP22* point variants or duplication	De novo (AD), AR
	CMT1B	*MPZ*	De novo (AD)
	CMT1F	*NEFL*	AD, AR
	CMT4C	*SH3TC2*	AR
	CMT4E	*EGR2*	AR, AD
	CMT4F	*PRX*	AR
	CMT4H	*FGD4*	AR

Table 653.3 Polyneuropathies with Onset in Infancy—cont'd

SALIENT CLINICAL FEATURE	CLINICAL PHENOTYPE	GENE	MODE OF INHERITANCE
AXONAL NEUROPATHIES			
Early respiratory insufficiency	CMT1A	*PMP22* point variants or duplication	De novo (AD), AR
	CMT1B	*MPZ*	De novo (AD)
	CMT4C	*SH3TC2*	AR
	CMT4E	*EGR2*	AR, AD
Severe scoliosis requiring surgery in infancy	CMT1B	*MPZ*	De novo (AD)
	CMT4C	*SH3TC2*	AR
Facial weakness	CMT4B1	*MTMR2*	AR
	CMT4B2	*SBF2*	AR
	CMT4C	*SH3TC2*	AR
Sensorineural hearing loss	CMT1A	*PMP22* point variants or duplication	De novo (AD), AR
	CMT4C	*SH3TC2*	AR
	CMT4F	*PRX*	AR
Congenital nystagmus	CMT1B	*MPZ*	De novo (AD)
	CMT4C	*SH3TC2*	AR

AD, Autosomal dominant; AR, autosomal recessive; BVVL, Brown-Vialetto-Van Laere syndrome; CMT, Charcot-Marie-Tooth disease; CIDP, chronic inflammatory demyelinating polyneuropathy; CNS, central nervous system; dSMA, distal spinal muscular atrophy; GBS, Guillain-Barré syndrome; HMSN/ACC, hereditary motor and sensory neuropathy with agenesis of the corpus callosum; HSAN, hereditary sensory and autonomic neuropathy; IOSCA, infantile-onset spinocerebellar ataxia; MLD, metachromatic leukodystrophy; MTP/LCHAD, mitochondrial trifunctional protein/long-chain 3-hydroxyacyl-CoA dehydrogenase; SMA, spinal muscular atrophy; SMARD, spinal muscular atrophy with respiratory distress type 1; SPSMA, scapuloperoneal spinal muscular atrophy.

From Konersman C. Hypotonia, weakness, and stroke. In: Kliegman RM, Lye PS, Bordini BJ, et al., eds. *Nelson Symptom-Based Diagnosis.* Philadelphia: Elsevier; 2018: Table 29.19.

Table 653.4 Infantile Demyelinating Neuropathies with CNS Involvement

	INHERITANCE	GENE	OTHER FEATURES
ASSOCIATED WITH CNS HYPOMYELINATION			
Hypomyelination with congenital cataracts (HCC)	AR	*DRCTNNBIA*	Congenital cataracts, pyramidal signs, cerebellar signs, intellectual disability
Peripheral demyelinating neuropathy, central dysmyelinating leukodystrophy, Waardenburg syndrome and Hirschsprung disease (PCWH)	AD	*SOX10*	Waardenburg syndrome, Hirschsprung disease, spasticity, ataxia, dysautonomia, intellectual disability
Pelizaeus-Merzbacher disease	X-linked	*PLP1**	Early nystagmus and titubation, ataxia, spasticity, movement disorder, intellectual disability
Pelizaeus-Merzbacher–like disease	AR	*GJA12*	Nystagmus, ataxia, delayed development
Cockayne syndrome	AR	*ERCC6, ERCC8*	Growth failure, photosensitivity, retinopathy, progressive neurologic impairment
ASSOCIATED WITH ABNORMAL CNS WHITE MATTER			
Metachromatic leukodystrophy	AR	*ARSA*	Psychomotor regression, spasticity, seizures
Krabbe disease	AR	*GALC*	Extreme irritability, spasticity, psychomotor regression
Niemann-Pick disease type C†	AR	*NPC1, NPC2*	Hepatomegaly, vertical gaze palsy, progressive ataxia, dystonia, cataplexy
Merosin-deficient congenital muscular dystrophy	AR	*LAMA2*	Proximal weakness, raised creatine kinase, muscular dystrophy
Navajo neurohepatopathy	AR	*MPV17*	Liver disease, corneal scarring, recurrent metabolic acidosis, recurrent infections, failure to thrive
ASSOCIATED WITH OTHER CNS INVOLVEMENT			
Congenital disorders of glycosylation	AR	Multiple genes	Variable features
Congenital cataracts, facial dysmorphism and neuropathy (CCFDN)	AR	*CTDP1*	Congenital cataracts, microretina, intellectual disability, facial dysmorphism, short stature, hypogonadism

Continued

Table 653.4 Infantile Demyelinating Neuropathies with CNS Involvement—cont'd

	INHERITANCE	GENE	OTHER FEATURES
POLG-related hepatocerebral mtDNA deletion syndromes	AR	*POLG1*	Encephalopathy, refractory seizures, liver dysfunction
Leigh syndrome	AR, X-linked, mitochondrial	Multiple genes	Psychomotor regression, brainstem and basal ganglia signs, raised lactate levels

*Peripheral neuropathy associated with *PLP1* null mutations only.
†Peripheral neuropathy rarely seen in Niemann-Pick disease type.
AD, Autosomal dominant; AR, autosomal recessive; CNS, central nervous system; mtDNA, mitochondrial DNA.
From Yiu EM, Ryan MM. Demyelinating prenatal and infantile developmental neuropathies. *J Peripher Nerve Syst*. 2012;17:32–52. Table 4.

Table 653.5 Characterization of Inherited Loss of Pain Perception Syndrome

GENE (PROTEIN)	PROTEIN FUNCTION	INHERITANCE	CLASSIFICATION	TYPICAL ONSET	PROMINENT AND DISTINGUISHING FEATURES
ARL6IP1 (ARL6IP1)	Organization of endoplasmic reticulum and mitochondrial networks	AR	NC	Congenital	Spastic paraplegia and severe acromutilations
ATL1 (ATL)	Membrane-shaping molecule	AD	HSAN1 (allelic with spastic paraplegia: SPG 3 A)	Adulthood	Impaired sensation of touch, involvement of upper motor neurons (some cases), fractures, and osteomyelitis
ATL3 (ATL3)	Membrane-shaping molecule	AD	HSAN1	Adulthood	Spasticity (some cases), fractures, osteomyelitis, and severely delayed wound healing
CLTCL1 (CH22,CLH-22)	Clathrin-coated vesicles	AR	NC	Congenital	Inability to feel touch and developmental delay
DNMT1 (DNMT1)	Epigenetic regulation	AD	HSAN1 (allelic with autosomal dominant cerebellar ataxia, deafness, and narcolepsy: ADCADN)	Adulthood	Sensorineural hearing loss, progressive dementia, and sleep disorder
DST (DST)	Organization of the cytoskeleton	AR	HSAN6 (allelic with epidermolysis bullosa, isoform-dependent)	Congenital	Severe psychomotor delay, joint contractures, alacrima, feeding difficulties, cardiovascular instability, hypomimia, and muscle weakness
ELP1 (ELP1/1KAP)	Transcription elongation factor complex	AR	HSAN3 (allelic with medulloblastoma predisposition syndrome)	Congenital	Loss of proprioception leading to spinal deformities, alacrima, gastrointestinal dysfunction, cardiovascular instability, and autonomic crises
FAAH-OUT (non-coding RNA. FAAHPl)	Endocarmabinoid signaling	AD/AR	CIP	Congenital	Impaired anxiety
FLVCR1 (FLVCR1)	Heme metabolism	AR	NC (allelic with posterior column ataxia with retinitis pigmentosa: PCARP)	Congenital	Psychomotor delay, delayed wound healing, anemia, and retinitis pigmentosa
GMPPA (GMPPA)	Protein glycosylation	AR	Alacrima, achalasia, and mental retardation syndrome (AAMR)	Congenital	Psychomotor delay, achalasia (swallowing disorder), and alacrima (lack of tears)
KIF1A (KIF1A)	Axonal transport	AR	HSAN2	Childhood	Muscle weakness and autonomic involvement
MADD (MADD)	TNF signaling	AR	Developmental delay with endocrine, exocrine, autonomic, and hematologic abnormalities (DEEAH)	Congenital	Psychomotor delay, exocrine and endocrine dysfunction, and pancreatic insufficiency

Table 653.5 Characterization of Inherited Loss of Pain Perception Syndrome—cont'd

GENE (PROTEIN)	PROTEIN FUNCTION	INHERITANCE	CLASSIFICATION	TYPICAL ONSET	PROMINENT AND DISTINGUISHING FEATURES
MPV17	Maintenance of mitochondrial DNA (mtDNA)	AR	CMT2EE (allelic with mitochondrial DNA depletion syndrome 6: MTDPS6)	Juvenile, adulthood	Distal sensory impairment signs of CMT, restrictive lung disease, steatosis, and muscle weakness
NCF (NGF)	Neurotrophin signaling	AR	HSAN5	Congenital	Variable degree of intellectual disability, fractures, osteomyelitis, corneal lesions, and anhidrosis (lack of sweating leading to hyperthermia and fever episodes)
NTRK1 (TRKA)	Neurotrophin signaling	AR	HSAN4	Congenital	Variable degree of intellectual disability, painless fractures, osteomyelitis, corneal lesions, and anhidrosis (lack of sweating leading to hyperthermia and fever episodes)
PRDM 12 (PRDM12)	Epigenetic regulation	AR	HSAN8	Congenital	Normal intellect, but in a few cases intellectual disability, facial injuries, corneal lesions, and hypohidrosis
RAB7A (RAB7)	Axonal transport	AD	HSAN (also classified as Charcot-Marie-Tooth; CMT2B)	Adulthood	Strong motor involvement
RETREG1 (RETREG1/ FAM134B)	Selective autophagy of the ER (ER-phagy), Golgi	AR	HSAN2	Childhood	Spasticity: muscle weakness may occur, osteomyelitis, and hyper- hidrosis
RFC1 (RFC 1)	DNA synthesis during replication or after damage	AR	Chronic idiopathic axonal polyneuropathy (CIAP)/ HSAN (allelic with CANVAS)	Adulthood	Large clinical spectrum: sensory neuropathy, numbness (sometimes with pain), chronic cough, cerebellar and vestibular dysfunction, afferent ataxia/proprioceptive loss
SCN9A (Na, 1.7)	Voltage-gated sodium channel (neuron excitability)	AR	CIP/HSAN2	Congenital	Anosmia (absent sense of smell) and fractures
SCN11A (Nav l.9)	Voltage-gated sodium channel (neuron excitability)	AR	CIP/HSAN7	Congenital	Pruritus, delayed motor development, joint hypermobility, skin ulcers (cervical region), intestinal dysmotility, and sometimes abdominal pain
SPTLC1 (SPTLCl)	Sphingolipid metabolism	AD	HSAN1 (allelic with ALS)	Adulthood	Mild motor involvement (some cases more pronounced), osteomyelitis, amputations, autonomic involvement rare, shooting and lancinating pain
SPTLC2 (SPTLC2)	Sphingolipid metabolism	AD	HSAN1	Adulthood	Mild motor involvement (some cases more pronounced), osteomyelitis, amputations, autonomic involvement rare, shooting and lancinating pain
TECPR2 (TECPR2)	Autophagy	AR	HSAN9 (allelic with spastic paraplegia: SPG49)	Congenital	Dysautonomia and respiratory failure
WNKl (WNK1)	Kinase activity, ion transport and ER function	AR	HSAN 2	Childhood	Severe acral mutilations
ZFHX2 (ZFHX2)	Transcription	AD	CIP	Congenital	Normal intellect

AD, Autosomal dominant; AR, autosomal recessive; CANVAS, cerebellar ataxia, neuropathy, and vestibular areflexia syndrome; CIP, congenital insensitivity to pain; CMT, Charcot-Marie-Tooth; ALS, amyotrophic lateral sclerosis; ER, endoplasmic reticulum; HSAN, hereditary sensory and autonomic neuropathy; NC, not classified.
From Lischka A, Lassuthova P, Çakar A, et al. Genetic pain loss disorders. *Nat Rev Dis Primers*. 2022;8:41. Table 1.

The leg should be protected from traumatic injury. In advanced cases, compression neuropathy during sleep may be prevented by placing soft pillows beneath or between the lower legs. Burning paresthesias of the feet are not common but are often abolished by phenytoin, carbamazepine, or gabapentin. Progressive resistance exercise for foot dorsiflexion may attenuate the progression of weakness.

Hereditary sensory autonomic neuropathy 1 (HSAN1) has, in preliminary studies, been treated with oral L-serine, with biochemical improvements (lowering of toxic metabolites). Multiple gene replacement therapies for CMT disease are in the experimental stage.

Visit Elsevier eBooks+ at eBooks.Health.Elsevier.com for Bibliography.

653.2 Peroneal Muscular Atrophy (Axonal Type)

Adnan Y. Manzur

Peroneal muscular atrophy is clinically similar to HMSN type I, but the rate of progression in the disability is variable. EMG shows denervation of muscle. Sural nerve biopsy reveals axonal degeneration rather than the demyelination and whorls of Schwann cell processes typical in the demyelinating type I. The most common form of axonal HMSN is caused by pathogenic variants in the *MFN2* gene with locus on chromosome 1 at 1p36. More than 40 genes have been described as causing axonal HMSN, and the inheritance can be dominant or recessive.

An autosomal recessive infantile motor axonal neuropathy can closely mimic infantile spinal muscular atrophy.

Visit Elsevier eBooks+ at eBooks.Health.Elsevier.com for Bibliography.

653.3 Congenital Hypomyelinating Neuropathy and Déjèrine-Sottas Disease (HMSN Type III)

Adnan Y. Manzur

Congenital hypomyelinating neuropathy is an interstitial hypertrophic neuropathy of autosomal dominant transmission, clinically similar to HMSN type I but more severe. Symptoms develop in early infancy and are rapidly progressive, with hypotonia and breathing and feeding difficulties. Pupillary abnormalities, such as lack of reaction to light and *Argyll Robertson pupil,* are common. Kyphoscoliosis and pes cavus deformities complicate approximately 35% of cases. Nerves become palpably enlarged at an early age. Déjèrine-Sottas disease is a more slowly progressive variant with onset usually before age 5 years.

An autosomal recessive form of congenital hypomyelinating neuropathy also is known and may be caused by various pathologic genetic variants, including *MTMR2, PMP22, EGR2,* and *MPZ.* A secondary variant in the *EGR2* gene may intensify the clinical manifestation of Déjèrine disease. Neonatal hypotonia and developmental delay in infancy are hallmark clinical features. Many patients exhibit congenital insensitivity to pain. Cranial nerves are inconsistently involved, and respiratory distress and dysphagia are rare complications. Tendon reflexes are absent. **Arthrogryposis** is present at birth in at least half of the cases.

The onion bulb formations seen in the sural nerve biopsy specimen are pronounced. Hypomyelination also occurs. In the recessive form, hypomyelination may not be accompanied by interstitial hypertrophy in all cases.

The genetic locus of 17p11.2 is identical to that of HMSN type I or CMT disease. Monoallelic variants in *MPZ* (myelin protein zero), *PMP22,* or *EGR2* (early grow response 2) are the most frequent genetic causes. The clinical and pathologic differences may be phenotypic variants of the same disease, analogous to the situation in Duchenne and Becker muscular dystrophies. An autosomal recessive form of Déjèrine-Sottas disease is incompletely documented.

Visit Elsevier eBooks+ at eBooks.Health.Elsevier.com for Bibliography.

653.4 Roussy-Lévy Syndrome

Adnan Y. Manzur

Roussy-Lévy syndrome is defined as a combination of HMSN type II and cerebellar deficit resembling Friedreich ataxia, but it does not have cardiomyopathy.

653.5 Refsum Disease (HMSN Type IV) and Infantile Refsum Disease

Adnan Y. Manzur

See also Chapter 106.2.

Refsum disease is a rare autosomal recessive disease caused by an enzymatic block in β-oxidation of phytanic acid to pristanic acid. Phytanic acid is a branched-chain fatty acid that is derived mainly from dietary sources, such as spinach, nuts, and coffee. Levels of phytanic acid are greatly elevated in plasma, CSF, and brain tissue. Phytanic and very long-chain fatty acids may be lipotoxic by impairing mitochondrial function in the central and peripheral nervous systems. The CSF shows an albuminocytologic dissociation, with a protein concentration of 100-600 mg/dL. Genetic linkage studies identify two distinct loci at 10p13 and 6q22-q24 with *PHYH* and *PEX7* pathogenic variants, respectively. The infantile form also can be caused by the *PEX1, PEX2,* or *PEX26* genes, which produce both clinical and biochemical differences from the classic form, and include minor facial dysmorphism, retinitis pigmentosa, sensorineural hearing loss, hypercholesterolemia, hepatomegaly, and failure to thrive. Phytanic acid accumulation in infantile Refsum disease is secondary to a primary peroxisomal disorder; hence, autosomal recessive Refsum disease is really a different disease.

The clinical onset of classic Refsum disease is usually between 4 and 7 years of age, with intermittent motor and sensory neuropathy. Ataxia, progressive neurosensory hearing loss, retinitis pigmentosa with loss of night vision, ichthyosis, and liver dysfunction also develop in various degrees. Skeletal malformations from birth and cardiac findings of conduction disturbances and cardiomyopathy appear in the majority. Motor and sensory nerve conduction velocities are delayed. Sural nerve biopsy shows loss of myelinated axons. Treatment is by dietary management and periodic plasma exchange. With careful management, life expectancy can be normal. Hearing loss due to acoustic nerve involvement may sometimes be improved with cochlear implantation.

Visit Elsevier eBooks+ at eBooks.Health.Elsevier.com for Bibliography.

653.6 Fabry Disease

Adnan Y. Manzur

See also Chapter 106.4.

Fabry disease, a rare X-linked recessive trait, results in storage of ceramide trihexoside because of deficiency of the enzyme ceramide trihexosidase, which cleaves the terminal galactose from ceramide trihexoside (ceramide-glucose-galactose-galactose), resulting in tissue accumulation of this trihexoside lipid in central nervous system neurons, Schwann cells and perineurial cells, ganglion cells of the myenteric plexus, skin, kidneys, blood vessel endothelial and smooth muscle cells, heart, sweat glands, cornea, and bone marrow. It results from a missense pathogenic variant disrupting the crystallographic structure of α-galactosidase A.

CLINICAL MANIFESTATIONS

The presentation is in late childhood or adolescence, with recurrent episodes of burning pain and paresthesias of the feet and lower legs so severe that patients are unable to walk. These episodes are often precipitated by fever or by physical activity. Objective sensory and motor deficits are not demonstrated on neurologic examination, and reflexes are preserved. Autonomic nerve involvement is almost universal and may cause cardiac rhythm abnormalities, cutaneous mottling, and gastrointestinal peristaltic abnormalities; autonomic expression is variable between patients. Cardiac involvement is not limited to autonomic abnormalities of arrhythmias and conduction defects, but may also include left ventricular hypertrophy, coronary artery disease, and valvular infiltrative myopathy. Characteristic skin lesions are seen in the perineal region, scrotum, buttocks, and periumbilical zone as flat or raised red-black telangiectasias known as **angiokeratoma corporis diffusum.** Hypohidrosis may be present. Corneal opacities, cataracts, and necrosis of the femoral heads are inconstant features. Tortuosity of retinal vessels and of the vertebral and basilar arteries can occur. The disease is progressive. Hypertension and renal failure are usually delayed until early adult life. Recurrent strokes result from vascular wall involvement. Untreated, death often occurs in the fifth decade due to cerebral infarction or renal insufficiency, but a significant morbidity already occurs in childhood despite the absence of major organ failure. Heterozygous female carriers may be asymptomatic or less severely affected than symptomatic males; corneal opacities involve 70–80%, though cataracts are rare.

LABORATORY FINDINGS

Motor and sensory nerve conduction velocities are normal to only mildly slow, showing preservation of large, myelinated nerve fibers. CSF protein is normal. Proteinuria is present early in the course. An electrochemical skin conductance test is abnormal in the majority of Fabry patients as an indication of small sensory nerve and autonomic nerve involvement. Cardiac evaluation should include ECG, echocardiography, and coronary artery assessment in selected cases.

Calcifications often are seen in the pulvinar of the thalamus, as demonstrated by computed tomography (CT) or magnetic resonance imaging (MRI), and are specific imaging findings, believed caused by cerebral hyperperfusion. Positron tomography, by contrast, shows reduced cerebral blood flow velocity and impaired autoregulation because of the glycosphingolipid storage in vascular endothelial cells.

Pathologic features are usually first detected in skin or sural nerve biopsy specimens. Electron microscopy demonstrates crystalline glycosphingolipids, appearing as *zebra bodies,* in lysosomes of endothelial cells, in smooth myocytes of arterioles, and in Schwann cells. Nerves show a selective loss of small, myelinated fibers and relative preservation of large- and medium-sized axons, in contrast to most axonal neuropathies, in which large, myelinated fibers are most involved.

An assay for the deficient enzyme, α-galactosidase-A, may be performed from blood leukocytes, skin fibroblasts, and other tissues. This test may permit detection of the female carrier state; for females, gene sequencing is preferred.

TREATMENT

See Chapter 106.4 for the specific therapy of Fabry disease, including enzyme replacement.

Medical therapy of painful neuropathies includes management of the initiating disease and therapy directed to the neuropathic pain independent of the etiology. Pain may be burning or associated with paresthesia, hyperalgesia (abnormal response to noxious stimuli), or allodynia (induced by nonnoxious stimuli; see Chapter 93). Neuropathic pain is often successfully managed by tricyclic antidepressants; selective serotonin reuptake inhibitors are less effective. Anticonvulsants (carbamazepine, phenytoin, gabapentin, lamotrigine) are effective, as are narcotic and nonnarcotic analgesics. **Enzyme replacement therapy** has improved the short- and long-term prognosis of the clinical neuropathy and also reverses the increased blood flow velocity in the brain. Chaperone therapy with migalastat facilitates trafficking and stabilization of the abnormal enzyme.

Visit Elsevier eBooks+ at eBooks.Health.Elsevier.com for Bibliography.

653.7 Giant Axonal Neuropathy

Adnan Y. Manzur

Giant axonal neuropathy is a rare autosomal recessive disease with onset in early childhood. It is a progressive mixed peripheral neuropathy and degeneration of central white matter similar to leukodystrophies (Table 653.6). Ataxia and nystagmus are accompanied by signs of progressive peripheral neuropathy. A large majority of affected children have frizzy or kinky hair, which microscopically shows variation in the diameter of the shaft and twisting, similar to that in Menkes disease; microscopic examination of a few scalp hairs provides a simple screening tool in suspected cases. Focal axonal enlargements are seen in both the peripheral nervous system and the central nervous system, but the myelin sheath is intact. The disease is a general proliferation of intermediate filaments, including neurofilaments in axons, glial filaments (i.e., Rosenthal fibers) in brain, cytokeratin in hair, and vimentin in Schwann cells and fibroblasts.

Nonsense, missense gene variants, splice site variants, or deletions occur in *GAN,* with allelic heterogeneity at 16q24. These gene variants are responsible for defective synthesis of the protein gigaxonin, a member of the cytoskeletal BTB/kelch superfamily, crucial to linkage between intermediate proteins and the cell membrane. MRI shows white matter lesions of the brain similar to leukodystrophies (Fig. 653.1A,B), and MR spectroscopy demonstrates increased ratios of choline:creatine and myoinositol:creatine, with decreased *N*-acetyl aspartate, indicating demyelination and glial proliferation, as well as axonal loss. Gigaxonin is expressed in a wide variety of neuronal cell types and is localized to the Golgi apparatus and endoplasmic reticulum. *GAN* gene variants have been demonstrated in human cell lines of neoplastic cells and also in a variety of tumors.

The diagnosis is suspected clinically based upon a childhood onset of ataxic gait, findings of neuropathy, and kinky or curly hair (see Fig. 653.1C); it is genetically confirmed by testing of the *GAN* gene. Pathologic findings of enlarged or swollen axons from peripheral nerve biopsy are characteristic. Clinically, the onset of symptoms occurs within the first 5 years of life, and there is progressive ataxia and weakness. As the disease progresses, patients also develop dysphagia, dysarthria, optic neuropathy, respiratory insufficiency, scoliosis (see Fig. 653.1E), and some in later stages will develop seizures. A gene variant of *BAG3,* one of several genes associated with myofibrillar myopathy (see Chapter 648.5), also can cause the finding of giant axons histologically, but clinically it is distinguished from giant axonal neuropathy caused by pathologic variants in the *GAN* gene.

Visit Elsevier eBooks+ at eBooks.Health.Elsevier.com for Bibliography.

653.8 Hypermyelinating (Tomaculous) Neuropathy; Hereditary Neuropathy with Liability to Pressure Palsies

Adnan Y. Manzur

This hereditary neuropathy is characterized by redundant overproduction of myelin around each axon in an irregular segmental fashion so that tomaculous (sausage-shaped) bulges occur in the individual myelinated nerve fibers. Other sections of the same nerve can show loss of myelin. Such nerves are particularly prone to pressure palsies, and patients, usually beginning in adolescence, present with recurrent or intermittent mononeuropathies secondary to minor trauma or entrapment neuropathies, such as carpal tunnel syndrome, peroneal

Table 653.6 Clinical Features of Human Disorders Caused by Pathogenic Variants in Ion Channel and Inflammatory Genes That Lead to Altered Pain Perception and Are Inherited in a Mendelian Manner

DISORDER	GENE (PROTEIN)	TYPE AND EFFECT OF GENE	MAIN PHENOTYPE	ADDITIONAL FEATURES
ION CHANNELS				
Inherited erythromelalgia (primary)	*SCN9A* (Na_v1.7)	Heterozygous, activating GOF, AD	Onset by age 20 yr; episodic pain triggered by warmth; feet affected more frequently than hands; burning distal extremity pain initiated by heat or physical activity	Erythema and warmth; cold relieves symptoms (see Chapter 211.5)
Paroxysmal extreme pain disorder	*SCN9A* (Na_v1.7)	Heterozygous, activating GOF	Onset at birth; episodic pain; sacral region is affected most frequently; face is affected more often than the limbs; physical triggers include defecation	Erythema of the sacrum; tonic attacks
Small-fiber neuropathy	*SCN9A* (Na_v1.7)	Heterozygous, activating GOF	Onset at any age but more common in early adulthood; persistent burning pain; feet affected more frequently than hands	Could be autonomic features
Small-fiber neuropathy	*SCN10A* (Na_v1.8)	Heterozygous, activating GOF	Persistent burning pain	Could be autonomic features
Familial episodic pain syndrome type I	*TRPA1* (TRPA1)	Heterozygous, activating GOF	Onset at birth or in infancy; episodic chest or arm pain; triggers are hunger and cold	—
Familial episodic pain syndrome type III	*SCN11A* (Na_v1.9)	Heterozygous, activating GOF	Onset in first decade; episodic hand and foot pain; triggers are intercurrent illness or exercise	—
INFLAMMATION				
STING-associated vasculopathy infantile onset (SAVI)	*TMEM173 (STING1)* GOF	AD	Onset in infancy Rash → ulcers-necrosis, nose, fingers, toes, ears Exacerbated by cold	Lung and joint involvement
Aicardi-Goutières syndrome	*TREX1* *RNASEH2A* *RNASEH2B* *RNASEH2C* *IFIN1*	AR; rarely AD	Inconsolable crying, jittery, seizures, microcephaly, rashes, poor feeding	—
Familial chilblain lupus	*TREX1* *SAMHD1* *LOF; rarely GOF* *STING*	AD	Cold-induced erythema, onset early childhood Papules, plaques on fingers, nose, toes, ear, cheeks	—

AD, Autosomal dominant; AR, autosomal recessive; GOF, gain of function; LOF, loss of function; Na_v, sodium ion channel.
Modified from Rabbitt AL. The irritable infant. In: Kliegman RM, Toth H, Bordini BJ, Basel D, eds. *Nelson Pediatric Symptom-Based Diagnosis*, 2nd ed. Philadelphia: Elsevier; 2023: Table 30.7, p. 511.

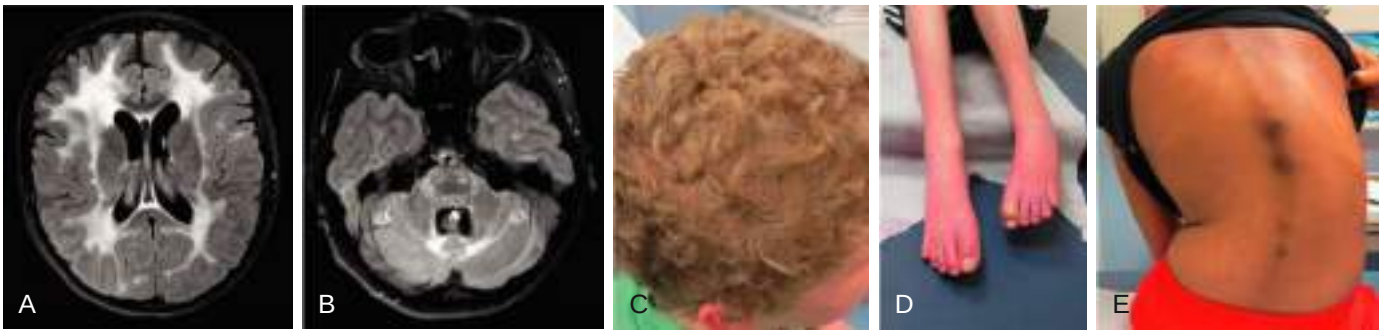

Fig. 653.1 Giant axonal neuropathy (GAN). **A** and **B**, White matter abnormalities on T2/fluid-attenuated inversion recovery (FLAIR) sequences seen diffusely and including the brainstem and cerebellum in a more advanced patient with GAN. There is also mild ex vacuo dilatation of the ventricles due to progressive atrophy. **C**, Typical kinky hair in GAN (i.e., dry and tight curly hair) often evident in patients from birth or early childhood. **D**, Patients with GAN develop distal atrophy and contractures and may have pedal erythema. **E**, Children with GAN often develop scoliosis by 8-10 yr of age.

palsies, and even writer's cramp. Phenotype expression is somewhat variable. It is transmitted as an autosomal dominant trait, with loci identified at 17p11.2 and 17p12, and deletion of exons in *PMP22* (in some patients, only microdeletions). Duplication of the same 17p12 locus leads to CMT disease type 1A, *MPZ* gene variants. Sural nerve biopsy is diagnostic, but special teased fiber preparations should be made to demonstrate the myelin abnormalities most clearly. Skin or conjunctival biopsies also may be diagnostic. Electrophysiologic nerve conduction studies are abnormal but nonspecific. Genetic studies are definitive.

Treatment is supportive and includes avoiding trauma and prolonged nerve compression, including postures when sitting or lying. Surgical release of entrapped nerves is indicated at times, particularly of the ulnar nerve.

Visit Elsevier eBooks+ at eBooks.Health.Elsevier.com for Bibliography.

653.9 Leukodystrophies

Adnan Y. Manzur

Several hereditary degenerative diseases of white matter of the central nervous system also cause peripheral neuropathy. The most important are Krabbe disease (globoid cell leukodystrophy), metachromatic leukodystrophy, and adrenoleukodystrophy (see Chapters 106 and 639). Within the brain, they produce progressive but selective demyelination, affecting the deep white matter of the centrum semiovale with relative sparing of U-fibers around each gyrus. Additional metabolic disorders associated with peripheral neuropathy are noted in Table 653.2.

Visit Elsevier eBooks+ at eBooks.Health.Elsevier.com for Bibliography.

653.10 Congenital Hereditary Sensory Pain Syndromes

Adnan Y. Manzur

Nociception is the result of complex activity in sensory pathways, whereas *pain* is the interaction between nociception, cognition, emotion, and social learning. There are genetic disorders of "nociception," which encompass a range of rare conditions and several genes. These are labeled as "pain" syndromes, which may make clinical assessment difficult.

In understanding genotype-phenotype pathophysiology, there are genes encoding the voltage-dependent sodium channel (Nav channel) 1.7, which is expressed selectively in sensory and autonomic neurons. Inactivating gene variants in SCN9A Nav1.7 result in congenital insensitivity to pain (see Table 653.5), whereas gain-of-function gene variants produce distinct pain syndromes such as inherited erythromelalgia (IEM), paroxysmal extreme pain disorder (PEPD), and small-fiber neuropathy (see Table 653.6).

GENETIC DISORDERS WITH INCREASED PAIN THRESHOLD OR INSENSITIVITY TO PAIN

Congenital insensitivity to pain disorders are diagnosed in infancy or early childhood (see Chapter 655). Table 653.5 provided a summary of some of the phenotypes presenting with abnormal deficiencies in autonomic nervous system function like anhidrosis, recurrent fever, defective tears, and feeding problems.

The collective term *congenital insensitivity to pain* has five underlying causative HSAN. Each are associated with unique clinical features, and all are autosomal recessive, apart from HSAN I, which is autosomal dominant. Figure 653.2 is a composite illustration of clinical images of patients with HSAN. These disorders can involve ion channels (channelopathies) or other key elements of nociception transduction pathways, such as modulators.

HSAN-I

HSAN-I is the most common type of HSAN, and it affects all nerve fiber types. The consequent clinical and sensory deficits are diminished or absent reflexes, distal loss of proprioception, light touch, and sensitivity to noxious thermal stimuli. HSAN-I has an autosomal dominant pattern of inheritance with different causative pathologic gene variants, which mostly involve the *SPTLC1* gene (HSAN-IA) and lead to reduced activity of serine palmitoyltransferase (a key enzyme in sphingolipid synthesis).

The disease is evident in late adolescence to the early thirties and features pupillary abnormalities, loss of corneal reflex and abrasions, deafness, restless legs, cramps, absent reflexes, Charcot joints, and development of painless injuries of the tongue and limbs. The clinical picture may also be complicated with the occurrence of osteomyelitis and sepsis. In this instance, the sensory disturbances of nociception are not a consequence of an ion channel or receptor defect, but down to membrane impairment in signal transduction and variants in the *SPTLC2* gene. Gene variants in the *ATL1* and *ATL3* genes (altered synthesis of axonal proteins), as well as the *DNMT1* gene (DNA methylation protein) have also been reported in HSAN-I.

HSAN-II

HSAN-II has an autosomal recessive inheritance pattern. The age of clinical onset is during infancy. HSAN-II affects all myelinated fibers,

Fig. 653.2 Clinical images of patients with HSAN. These patients may present with a variety of severe clinical symptoms and signs including self-inflicted mutilations of the tongue, lips, and distal phalanges, as well as corneal opacities, foot ulcers, and deformities. Excessive scratching may occur, leading to painless tissue damage. Recurring fractures can result in malposition of bones and joints, here represented by a knee joint in a patient with *SCN11A* gene variant. The affected genes are indicated, respectively. *(From Lischka A, Lassuthova P, Cakar A, et al. Genetic pain loss disorders. Nat Rev Dis Primer. 2022;8:41. Fig. 4; ATL3 from Kornak U, Mademan I, Schinke M, et al. Sensory neuropathy with bone destruction due to a mutation in the membrane-shaping atlastin GTPase 3. Brain. 2014;137(Pt 3):683–692. Fig 3; PRDM12 from Chen YC, Auer-Grumbach M, Matsukawa S, et al. Transcriptional regulator PRDM12 is essential for human pain perception [published correction appears in Nat Genet. 2015 Aug;47(8):962]. Nat Genet. 2015;47(7):803–808. Fig 2; RETREG1 (right panel) from Kurth I, Pamminger T, Hennings JC, et al. Mutations in FAM134B, encoding a newly identified Golgi protein, cause severe sensory and autonomic neuropathy. Nat Genet. 2009;41(11):1179–1181. Fig 1; SCN11A from Leipold E, Liebmann L, Korenke GC, et al. A de novo gain-of-function mutation in SCN11A causes loss of pain perception. Nat Genet. 2013;45(11):1399–1404. Fig 1.)*

and so the clinical and sensory deficits that characterize this condition are diminished or absent reflexes, distal loss of proprioception, light touch, and sensitivity to noxious thermal stimuli.

The four gene variants described are *WNK1, FAM134B, KIF1A,* and *SCN9A*; each are associated with different subtypes of HSAN-II. The *WNK1* gene variant leads to the HSAN-IIA phenotype with marked loss of sensitivity to pressure, proprioception, vibration sensation, and areflexia, decreased corneal reflexes, diffuse hypotonia, and episodic hyperhidrosis. *WNK1* is involved with organizing sodium and chloride ion fluxes and cell membrane excitability, as well as coordinating the expression of *TRPV4,* which is an important cation channel involved in nociception. Recessive gene variants in *KIF1A,* encoding kinesin proteins (axonal transport of synaptic vesicles), can cause other HSAN-II disorders with a more complex neurologic picture.

HSAN-III

HSAN-III includes **Riley-Day syndrome (familial dysautonomia)** and is typically identified during infancy (see Chapter 655). It affects both unmyelinated fibers and large myelinated fibers leading to autonomic deficits including hyperhidrosis, defective tears, postural hypotension, recurrent fevers, and significant feeding problems. Reflexes may be diminished or absent, and the sensory deficits include a general inability to detect noxious stimuli and a diffuse thermal insensitivity.

Riley-Day syndrome (familial dysautonomia) is a neurodevelopmental genetic autosomal recessive disorder due to variants in the *IKBKAP* or *ELP1* gene (9q31.3), which encodes the elongator complex protein 1 (ELP1). ELP1 is a scaffold protein for the transcription of neural key proteins and a regulator for different kinases involved in proinflammatory signaling. There are diffuse changes in pathology that affect myelinated terminals (usually small nerve fibers), dorsal root ganglia, spinal cord lateral root entry zones, Lissauer tracts, and parasympathetic afferents.

HSAN-IV

HSAN-IV is a rare condition and typically diagnosed in infancy because of autonomic dysfunction including anhidrosis and repeated episodes of fever, and sometimes developmental difficulty. HSAN-IV affects both unmyelinated and small myelinated fibers. The reflexes may be diminished, or absent, and sensory deficits include an inability to detect noxious stimuli and diffuse thermal insensitivity. This condition is also referred to as congenital insensitivity to pain with anhidrosis (CIPA). Other possible signs and symptoms are bone lesions, facial dysmorphology, microcephaly, mandibular osteolysis, dental caries and premature tooth loss, recurrent soft tissue and bone infections, urine and fecal incontinence, and growth disturbances.

CIPA is an autosomal recessive condition with a loss-of-function pathogenic variant in the *TRKA* gene encoding the high-affinity tyrosine kinase receptor *NTRK1* for nerve growth factor (NGF). This gene is located on chromosome 1 (1q21-q22) and several mutations have been reported.

HSAN-V

HSAN-V is a very rare autosomal recessive disease that affects only small-myelinated fibers; hence, the condition is characterized by distal insensitivities to noxious and thermal stimuli. HSAN-V is caused by a pathologic variant in the *NGF-β* gene (chromosome 1p13.2). Because the *NGF-β* gene also binds with the *TRKA* gene (HSAN-IV), and is involved with signaling apoptosis of nociceptive sensory neurons, the HSAN-V phenotype can encompass characteristics of HSAN-IV. There may be other phenotypes caused by changes in the NGF/TRKA signaling pathway.

GENETIC DISORDERS WITH PAINFUL PERIPHERAL NEUROPATHIES

The familial forms of painful peripheral neuropathy result from a pathologic gain of function in ion channel gene variants, i.e., some the autosomal dominant channelopathies and some inflammatory disorders (see Table 653.6). The other conditions resulting in pain syndromes are listed below.

Familial Episodic Pain Syndrome Type 1

Familial episodic pain syndrome type 1 (FEPS type 1) is an autosomal dominant disorder due to pathologic variants in the *TRPA1* gene.

It has only been reported in one family, in Colombia in South America. The family has 21 affected members over 4 generations. Onset is evident during infancy and characterized by arm and chest pain, tachycardia, and diaphoresis, which is triggered by cold, hunger (fasting), or physical stress (exertion). Episodes last around 1-2 hours. There is no altered pain sensitivity outside the episodes in the affected individuals.

FEPS type 2 is seen in adults: only three reported, from two independent families. The episodes of pain are in the feet. One case developed episodes of burning and intense itch in the feet in middle age; the patient's son developed a similar phenotype with allodynia and hyperalgesia at an earlier age. The third case from a different family developed stabbing pain in both feet, lower legs, and hands in middle age. These pain attacks of are not associated with cold or other triggering factors, but warmth sometimes relieves the attack.

FEPS type 3 is an autosomal dominant disorder due to pathologic variants in the *SCN11A* gene, producing a small-fiber painful neuropathy, again seen predominantly in adults. It has been reported in over 20 families. Infants may present with recurrent episodes of crying due to limb and distal joint pain. Fatigue, intercurrent illnesses, and weather changes are common triggers. The pain is sometimes relieved by nonsteroidal antiinflammatory drugs (NSAIDs). Most affected individuals report that the severe pain episodes diminish with age.

Paroxysmal Extreme Pain Disorder

PEFD (sometimes called **familial rectal pain syndrome**) is an autosomal dominant condition with painful neuropathy due to pathologic gain-of-function variants in the *SCN9A* gene. Pain may begin from birth and is often stimulated by defecation or perineal stimulation during wiping or use of rectal thermometer. Jaw pain may be provoked by cold fluids, spicy foods, and emotion; ocular pain may be caused by cold wind blowing on the face. The pain is severe, paroxysmal, and associated with harlequin color change, tears, rhinorrhea, and tonic stiffening episodes, which may be confused with seizures, syncope, or hyperekplexia. The painful episodes last seconds to a few minutes. Treatment is difficult and may include carbamazepine, mexiletine, topical lidocaine, and stool softeners (see later).

Inherited Erythromelalgia

IEM, sometimes called erythermalgia, is due to pathologic gain-of-function variants in the *SCN9A* gene and is characterized by recurrent episodes of bilateral burning pain, erythema, and swelling primarily of the feet and hands (see Chapter 211.5). Over time, the face and ears are involved, and the pain may become constant. It is more commonly evident during childhood, but episodes may begin during infancy. Triggers include a warm environment or prolonged standing. Figure 653.3 illustrates some of the clinical and physiologic features in a patient. Treatment includes cooling with a fan or ice; but be aware that ice may produce cold injury if used too often. Medical therapy is similar to that for PEPD. The differential diagnosis includes Fabry disease (which may initially present in infancy with painful feet and hands) and secondary autoimmune causes of erythromelalgia.

Other Pathologic Genetic Variants in SCN2A

Other variants in *SCN2A* can cause benign familial infantile seizures, febrile seizures plus syndrome, and intractable epilepsy of infancy. A gain-of-function gene variant is associated with neonatal seizures, episodic ataxia, myoclonus, and pain.

STING-Associated Vasculopathy Infantile Onset

STING-associated vasculopathy infantile onset (SAVI) is a severe autosomal dominant autoinflammatory disorder due to a pathologic gain-of-function variant in *TMEM173,* which encodes the STING protein (stimulator of interferon genes). Interferon-driven inflammation (**interferonopathy**) results in painful ulcerating lesions (digits, face, nose, ears) that become eschars and necrotic. The associated features

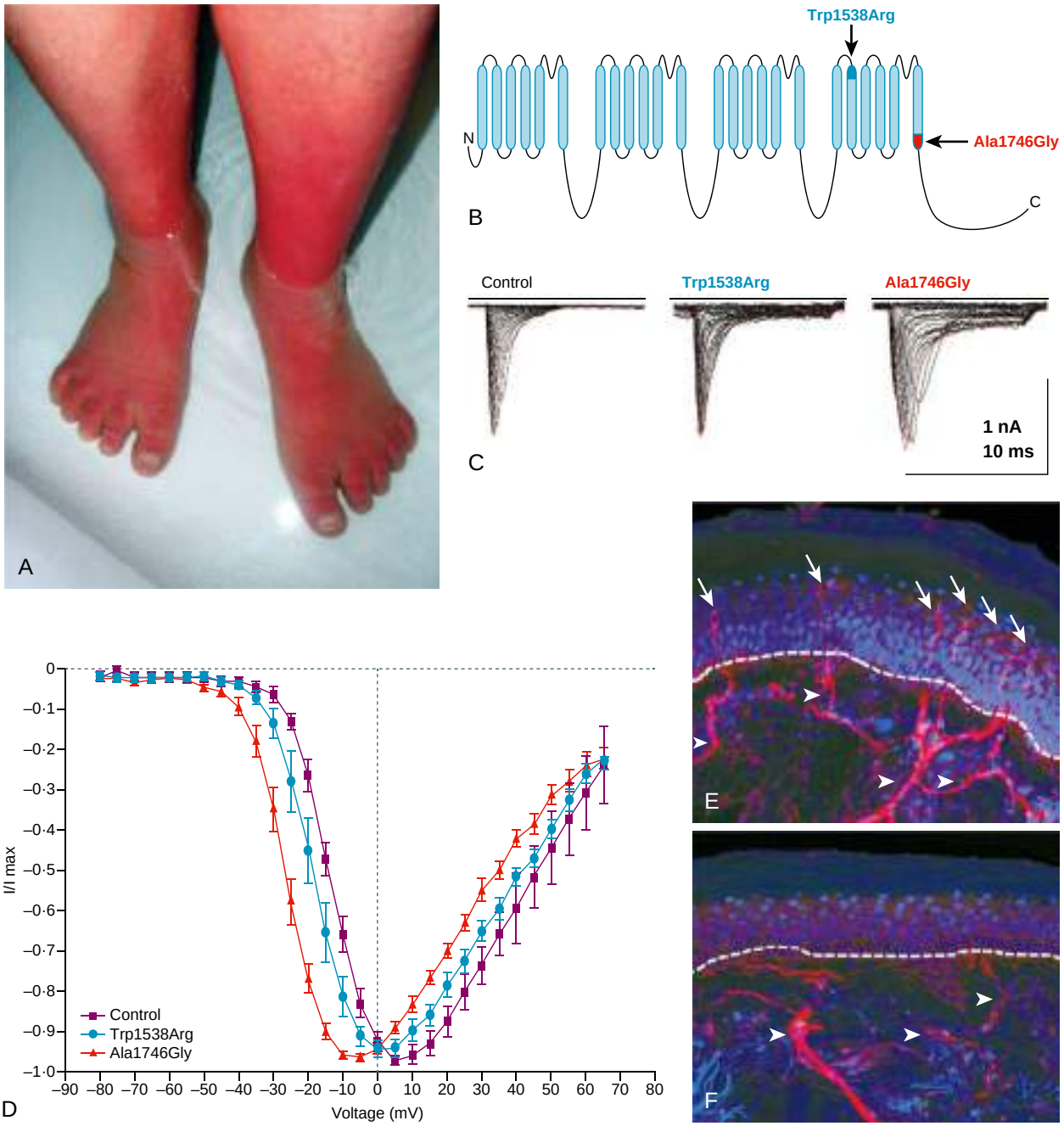

Fig. 653.3 Clinical characteristics and genetic and physiologic features of inherited erythromelalgia and small-fiber neuropathy. **A,** Patient with inherited erythromelalgia and erythema cools feet in cold water in an attempt to relieve pain, which is exacerbated by warmth. **B,** Schematic diagram of the Nav1.7 α subunit. Two mutations are shown in the fourth domain (Trp1538Arg in transmembrane segment 2 and Ala1746Gly in transmembrane segment 6) that cause erythromelalgia with varying clinical phenotypes and that have been characterized biophysically. **C,** Whole cell voltage-clamp recordings in HEK293 cells expressing wild-type Nav1.7 or mutant channels. From a holding potential of −120 mV, currents were evoked by voltage increments of 5 mV from −80 to 40 mV. **D,** Normalized current–voltage plots from recordings in **(C)** show a hyperpolarizing shift in the voltage dependence of activation. This shift is more pronounced in the mutation causing early onset (first decade) of inherited erythromelalgia (Ala1746Gly) rather than late onset (sixth decade; Trp1538Arg). **E,** Inherited erythromelalgia is not associated with sensory nerve-fiber degeneration, in contrast with small-fiber neuropathy. Epidermal innervations in a healthy individual are detected by immunostaining with the pan-neuronal marker PGP9.5 *(red).* Intraepidermal fibers *(arrows)* and dermal fibers *(arrowheads)* are seen. **F,** Gain-of-function mutations in Nav1.7 (distinct from mutations causing inherited erythromelalgia) or Nav1.8 can cause small-fiber neuropathy characterized by degeneration and loss of intraepidermal nerve fibers as shown here. *(**A, E, F** from Bennett DIH, Woods CG. Painful and painless channelopathies. Lancet Neurol. 2014;13:587–599. Fig. 3; **B-D** from Cregg R, Laguda B, Werdehausen R, et al. Novel mutations mapping to the fourth sodium channel domain of Nav1.7 result in variable clinical manifestations of primary erythromelalgia. Neuromolecular Med. 2013;15:265–278.)*

include interstitial lung disease, livedo reticularis, Raynaud phenomenon, and elevated inflammatory biomarkers (e.g., erythrocyte sedimentation rate and C-reactive protein). The differential diagnosis includes juvenile idiopathic arthritis, granulomatosis with polyangiitis, and other infant-onset autoinflammatory diseases.

Aicardi-Goutières Syndrome

Aicardi-Goutières syndrome (AGS) is an autosomal recessive (occasionally autosomal dominant), systemic autoinflammatory interferonopathy that presents in infancy with irritability and progresses to dystonia, seizures, developmental delay, and progressive microcephaly.

Some patients may develop systemic lupus erythematosus (SLE)-like symptoms as well as cold-induced chilblains.

Familial Chilblain Lupus

Familial chilblain lupus (FCL) is another interferonopathy with early childhood onset of acral lesions (i.e., involving fingers, toes, nose, cheeks, ears). This disorder is a monogenetic form of cutaneous lupus with autosomal dominant inheritance (*TREX1, SAMHD1, STING* gene variants)

DIAGNOSIS

All HSANs are characterized by absence of the normal axon flare response to intradermal injection of histamine phosphate (see Chapter 655 for details). There are also descriptions of using nerve conduction studies in the pain disorders. However, the combination of any concerning clinical features (see Tables 653.5 and 653.6) should prompt genetic testing. In developed medical settings a combined panel for mendelian disorders of pain perception, as well as insensitivity to pain or increased pain perception, should include gene testing for the following disorders: congenital insensitivity to pain, IEM, PEPD, small fiber neuropathy, FEPs, HSAN, and forms of HSAN with prominent sensory loss.

TREATMENT

Symptomatic Management of Insensitivity to Pain Syndromes

Treatment is primarily supportive for conditions like HSAN (see Chapter 655). Neuropathic pain medications like pregabalin or gabapentin can improve burning, lancinating pains, and symptoms of restless legs syndrome. Carbidopa, an inhibitor of DOPA-decarboxylase, blocks dopamine synthesis outside the brain and is effective in dysautonomic crisis, and better than benzodiazepines. Unstable hypertension occurring with dysautonomic crisis can be treated with α_2-adrenergic agonists like clonidine and intranasal dexmedetomidine, or diazepam.

Outside of dysautonomic crisis, fluctuations in blood pressure and orthostatic hypotension require head of the bed elevation to avoid supine hypertension, while sufficient water and salt intake, compression devices, exercise, and adrenergic agents like midodrine and droxidopa can improve postural hypotension. Counseling is needed to avoid overheating with the use of cold pack, regular rest, and staying in cool areas for those with prominent anhidrosis, especially in HSAN-IV.

Multidisciplinary management is recommended with involvement of neurology, dermatology, physical and occupational therapy, prosthetics, and orthopedic surgery for optimal skin and limb care. These teams can provide guidance on foot care including daily examinations and cleaning, protective footwear with well-fitted shoes, splinting, stretching, guided exercise programs, and early treatment of injuries. For those with tongue ulceration, smoothing incisors is preferable to dental extraction. Artificial tears, moisture chamber glasses, scleral lenses, tarsorrhaphy, and cautery of tear ducts should be evaluated by ophthalmology to protect anesthetic corneas and increase baseline moisture. Those with early cognitive impairment may benefit from early special education school programs.

Therapies for Genetic Disabling Pain Syndromes

In general, the disabling pain syndromes do not have effective treatments. However, some patients with voltage-gated sodium channel–related FEPS experience pain attacks that may gradually weaken and diminish with age. A similar age-dependent reduction in painful events is seen in patients with *TRPA1*-related FEPS type 1. In contrast, episodic pain does not gradually weaken with age in patients with Nav1.8-related FEPS type 2 and Nav1.9-related FEPS type 3 disorder.

To date, medications such as mexiletine, lidocaine, and carbamazepine have been used as nonselective sodium channel blocking analgesics. There may also be some efficacy in certain pain channelopathies (e.g., Nav1.7-related PEPD). Other antiepilepsy medications have been used with varying effectiveness including lamotrigine, topiramate, tiagabine, and sodium valproate. However, there are no proven positive outcomes for these nonselective anti-epilepsy drugs in FEPS patients; there is also the problem that analgesic dosing may be accompanied by central nervous system side effects such as ataxia, confusion, and sedation.

Visit Elsevier eBooks+ at eBooks.Health.Elsevier.com for Bibliography.

Chapter 654

Toxic Neuropathies

*Adnan Y. Manzur**

Many chemicals (organophosphates), toxins, and drugs can cause peripheral neuropathy (Tables 654.1-654.3). The clinical features may differ depending on the agent (Table 654.4). **Heavy metals** are well-known neurotoxins. Lead poisoning, especially if chronic,

Table 654.1 Toxic Neuropathies

METALS
Arsenic (insecticide, herbicide)
Gold
Lead (paint, batteries, pottery)
Lithium (batteries)
Mercury (metallic, vaporized)
Thallium (rodenticides)
Zinc (chronic excessive intake)
OCCUPATIONAL OR INDUSTRIAL CHEMICALS
Acrylamide (grouting, flocculation)
Carbon disulfide (solvent)
Cyanide
Dichlorophenoxyacetate
Dimethylaminopropionitrite
Ethylene oxide (gas sterilization)
Nitrous oxide (vitamin B12 deficiency)
Hexacarbons (glue, solvents)
Organophosphates (insecticides, petroleum additive)
Polychlorinated biphenyls
Tetrachlorobiphenyl
Trichloroethylene
METABOLIC DISORDERS
Fabry disease
Krabbe disease
Leukodystrophies
Porphyria
Tangier disease
Tyrosinemia
Uremia
BIOLOGIC AND INFECTIOUS NEUROPATHIES
COVID-19
Diphtheria
Herpesviruses
HIV
Leprosy
Lyme disease
Rabies
Serum sickness
West Nile virus
Zika virus

* The editors are grateful to Dr. Harvey B. Sarnat, much of whose work on previous editions of this chapter is retained here.

Table 654.2 Chemotherapy Drugs Commonly Associated with Peripheral Neuropathy

CLASS	DRUG	TYPICAL CLINICAL FEATURES OF NEUROPATHY	ADDITIONAL FEATURES/ NOTES
Platinum compounds	Oxaliplatin*	Pure sensory with ataxia	Acute paresthesias, cramps, fasciculation common after each dose
	Cisplatin*	Pure sensory with ataxia	Coasting common (continued worsening after stopping chemotherapy for 2–3 months) Can cause ototoxicity
Taxanes	Paclitaxel*	Predominantly sensory, often painful	Acute arthralgia and myalgia in 10–30%
	Docetaxel*	Predominantly sensory, often painful	Acute arthralgia and myalgia in 10–30%
Vinca alkaloids	Vincristine*	Distal weakness and sensory symptoms	Autonomic involvement common
Immunomodulatory agents	Thalidomide*	Predominantly sensory, sometimes painful	Cramps may occur Constipation common
Proteasome inhibitors	Bortezomib*	Painful, small-fiber predominant sensory	Autonomic involvement can occur and rarely non–length-dependent patterns
Epothilones	Ixabepilone*	Predominantly sensory, sometimes painful	Not used in UK outside clinical trial setting
Antibody–drug conjugates	Brentuximab vedotin*	Predominantly sensory with ataxia	
	Ado-trastuzumab emtansine†	Predominantly sensory	Limited clinical information in the literature
Immune checkpoint inhibitors	Nivolumab, pembrolizumab, ipilimumab‡	Acute or subacute polyradiculoneuropathy	Usually respond to corticosteroids
BRAF/MEK inhibitors	Dabrafenib, vemurafenib, trametinib†	Length-dependent sensory predominant, or acute/subacute polyradiculopathy	May respond to immunotherapy

*Neuropathy is dose related (more likely with increasing cumulative dose).
†Relationship to dose is unclear/not reported.
‡Neuropathy is likely to be idiosyncratic and unrelated to dose.
MEK, Mitogen-activated protein kinase kinase (or MAP2K).
Modified from Smyth D, Kramarz C, Carr AS, et al. Toxic neuropathies: a practical approach. *Pract Neurol.* 2023;23:120–130. Table 2.

Table 654.3 Medications Associated with Peripheral Neuropathy

DRUG/CLASS	TYPICAL PATTERN OF NEUROPATHY	NOTES/ADDITIONAL FEATURES
IMMUNOSUPPRESANTS		
Tumor necrosis factor inhibitors	Acute or subacute polyradiculoneuropathy (axonal or demyelinating)	Some of the conditions being treated with these drugs are also associated with a neuropathy
Calcineurin inhibitors (tacrolimus, cyclosporine)	Acute or subacute polyradiculoneuropathy (axonal or demyelinating)	Almost exclusively reported in posttransplant patients
Interferon-alpha	Acute, subacute or chronic demyelinating polyradiculoneuropathy	Initial course of immunomodulation usually needed; however, most recover after single course
Leflunomide	Length-dependent sensory or sensorimotor axonal	Renal failure increases risk
ANTIBIOTICS		
Linezolid	Painful predominantly sensory axonal	Dose dependent—mainly with prolonged courses May also cause optic neuropathy
Metronidazole	Painful length-dependent sensory axonal	Dose dependent—mainly with prolonged courses (≥4 weeks) May coexist with ataxia or encephalopathy
Nitrofurantoin	Length-dependent sensorimotor axonal, often rapid onset with clinical weakness	
Dapsone	Motor-predominant axonal	Dose dependent—mainly with prolonged courses

Continued

Table 654.3 Medications Associated with Peripheral Neuropathy—cont'd

DRUG/CLASS	TYPICAL PATTERN OF NEUROPATHY	NOTES/ADDITIONAL FEATURES
Fluoroquinolones (e.g., ciprofloxacin, norfloxacin)	Sensory symptoms, however, detailed clinical features not well documented	Likely to be extremely rare with short courses
ANTITUBERCULOSIS DRUGS		
Isoniazid	Sensory predominant axonal	Prevented with pyridoxine (B_6) supplementation Occasionally causes optic neuropathy
Ethambutol	Sensory predominant axonal (uncommon)	Optic neuropathy
ANTIFUNGALS		
Some triazoles (itraconazole, voriconazole, posaconazole)	Sensory predominant axonal	May also increase risk of neuropathy with vinca alkaloids and calcineurin inhibitors due to CYP3A4 inhibition
ANTIRETROVIRALS		
Some nucleoside reverse transcriptase inhibitors (stavudine, didanosine, zalcitabine)	Sensory predominant axonal	Have largely been superseded by nonneurotoxic agents
CARDIAC DRUGS		
Amiodarone	Distal predominant sensorimotor, often with both sensory ataxia and distal weakness Nerve conduction studies may show demyelinating or axonal changes	Tremor, cerebellar ataxia, optic neuropathy, myopathy may develop
Perhexiline	Severe, demyelinating polyradiculoneuropathy	Very common No longer available in the UK
OTHER DRUGS		
Phenytoin	Mild axonal or demyelinating sensory or sensorimotor Commonly asymptomatic signs or nerve conduction abnormalities	Occasional cases of more significant neuropathy associated with high doses/phenytoin concentrations, often without cerebellar signs Folate supplementation should be given
Levodopa/carbidopa intestinal gel	Sensory predominant axonal neuropathy	Due to impaired absorption/metabolism of pyridoxine and other B vitamins
Colchicine	Mild sensory predominant axonal	Myopathy usually more prominent
Chloroquine	Mild sensory predominant axonal	Myopathy usually more prominent
Disulfiram	Sensorimotor axonal, often with clinical muscle weakness	
Nitrous oxide	Usually length-dependent sensorimotor Can also cause a pure motor/motor-predominant neuropathy	Myelopathy often more prominent
Pyridoxine (vitamin B_6)	Sensory ganglionopathy with prominent large-fiber loss and ataxia	Pyridoxine deficiency can also lead to a sensory predominant neuropathy. Mild elevation in plasma concentration (2-3 times upper limit of normal) common with multivitamin supplementation

From Smyth D, Kramarz C, Carr AS, et al. Toxic neuropathies: a practical approach. *Pract Neurol*. 2023;23:120–130. Table 3.

causes mainly a motor neuropathy selectively involving large nerves, such as the common peroneal, radial, and median nerves, a condition known as mononeuritis multiplex (see Chapter 761). Arsenic produces painful burning paresthesias and motor polyneuropathy. Exposure to industrial and agricultural chemicals is a less common cause of toxic neuropathy in children than in adults, but insecticides are neurotoxins for both insects and humans, and if they are used as sprays in closed spaces, they may be inhaled and induce lethargy, vomiting, seizures, and neuropathy, particularly with recurrent or long-term exposure. Working adolescents and children in developing countries are also at risk. Lithium is widely used in batteries, as well as in medication for the treatment of psychosis and other psychiatric conditions, but can be neurotoxic, especially cumulatively over time. **Puffer fish poisoning,** which can be acquired even when fish contaminated with the venom has been cooked, produces a Guillain-Barré–like syndrome. Ethanol abuse can be neurotoxic and particularly affects the optic nerves, but optic neuritis is not a peripheral neuropathy.

The most frequent cause of toxic neuropathies in children is **prescribed medications,** though street drugs and even some legal over-the-counter products also can be neurotoxic. Antimetabolic and immunosuppressive drugs, such as vincristine, cisplatin, and paclitaxel, produce polyneuropathies as complications of chemotherapy for neoplasms and immunologic disorders, such as juvenile idiopathic arthritis. This *iatrogenic* cause is usually an axonal degeneration rather than primary demyelination, unlike primary autoimmune neuropathies. Excessive vitamin intake of *megavitamins* can be neurotoxic. Zinc compounds are widely sold without prescription as dietary supplements and promoted for treatment of a variety of disorders, both neurologic (e.g., hyposmia) and immunologic, and for various visceral organ systems; most claims are not evidence based. Zinc ions are essential for the conservation of postsynaptic membranes

Table 654.4 Clinical Features of Toxic Neuropathies

NEUROPATHY PHENOTYPE	TOXIC CAUSES TO CONSIDER
Sensory predominant	*Commonly cause predominant sensory ataxia:* Mercury, nitrous oxide, acrylamide Pyridoxine (vitamin B_6), platinum compounds, brentuximab vedotin, amiodarone *Other causes of sensory predominant neuropathy:* Alcohol, cadmium, *n*-hexane/glue-sniffing, allyl chloride, carbon disulfide, ethylene oxide Taxanes, bortezomib, thalidomide, *BRAF*/MEK inhibitors, leflunomide, linezolid, metronidazole, calcineurin inhibitors, isoniazid, ethambutol, triazole antifungals, amiodarone, phenytoin, colchicine, chloroquine, levodopa/carbidopa intestinal gel, fluoroquinolones
Can involve significant distal motor weakness	Nitrous oxide, lead, arsenic, thallium, *n*-hexane/glue-sniffing, organophosphates Vinca alkaloids, *BRAF*/MEK inhibitors, dapsone, nitrofurantoin, disulfiram, amiodarone
Predominant neuropathic pain	Alcohol, mercury, thallium, ciguatoxin Taxanes, bortezomib, thalidomide, linezolid, metronidazole, nitrofurantoin, disulfiram, cotrimoxazole
Acute/subacute sensorimotor neuropathy ("GBS like")	Arsenic, thallium, seafood toxins (saxitoxin, tetrodotoxin), diethylene glycol, *n*-hexane/glue-sniffing (if acute high doses) Immune checkpoint inhibitors, tumor necrosis factor inhibitors, *BRAF*/MEK inhibitors, calcineurin inhibitors, nitrofurantoin, bortezomib (rarely), amiodarone (rarely)
Encephalopathy	Alcohol, lead (mainly in children), arsenic, mercury, *n*-hexane/glue-sniffing, industrial agents (acrylamide, carbon disulfide, diethylene glycol, ethylene oxide). Metronidazole, disulfiram, phenytoin
Tremor	Mercury Calcineurin inhibitors, amiodarone, phenytoin
Optic neuropathy	Nitrous oxide, lead, mercury, thallium Vincristine, calcineurin inhibitors, linezolid, ethambutol, isoniazid, amiodarone, chloroquine, dapsone, disulfiram
Myelopathy	Nitrous oxide
Myopathy	Taxanes, immune checkpoint inhibitors, amiodarone, colchicine, chloroquine
Gastrointestinal disturbance	Lead, arsenic, thallium, seafood toxins, organophosphates
Renal failure	Lead, mercury, cadmium, diethylene glycol Calcineurin inhibitors
Anemia	Chemotherapy drugs, lead (microcytic anemia, basophilic stippling), arsenic, nitrous oxide (megaloblastic anemia)
Mees lines	Arsenic, thallium
Hyperkeratosis	Arsenic, thallium

GBS, Guillain-Barré syndrome; MEK, mitogen-activated protein kinase kinase (or MAP2K).
Modified from Smyth D, Kramarz C, Carr AS, et al. Toxic neuropathies: a practical approach. *Pract Neurol.* 2023;23:120–130. Table 1.

and mitochondria. Chronic excessive zinc intake is cumulative and becomes toxic by impairing synaptic activity and mitochondrial respiratory chain enzymes, especially complex I enzymes, resulting in polyneuropathy, myopathy, and encephalopathy. Mitochondrial dysfunction also is a frequent basis of neuropathy in many other toxic neuropathies.

Chronic uremia is associated with toxic neuropathy and myopathy. The neuropathy is caused by excessive levels of circulating parathyroid hormone (see Chapter 650). Reduction in serum parathyroid hormone levels is accompanied by clinical improvement and a return to normal of nerve conduction velocity. Peripheral nerve axonal damage, particularly of small fibers, can be secondary to mitochondrial loss or dysfunction in toxic neuropathies. Abnormal toxic complex lipids, generated in Schwann cells by deficient mitochondrial respiration, are capable of damaging or destroying neighboring axons, a secondary mitochondrial toxic neuropathy. Small heat-shock proteins can be provoked that also may contribute to toxic neuropathy.

Biologic neurotoxins associated with diphtheria, Lyme disease, West Nile virus disease, leprosy, herpesviruses (Bell palsy), and rabies also produce peripheral nerve–induced or ventral horn cell–induced weakness or paralysis. Human immunodeficiency virus (HIV) infections also produce neuropathy, and this infection is particularly prevalent in children in several African countries, including those who emigrate to western countries as refugees. Tick paralysis, botulism, and paralytic shellfish poisoning cause neuromuscular junction blockade rather than true neuropathy. During the 2020/2021 COVID-19 pandemic, Guillain Barré syndrome and peripheral neuropathy were described in association with SARS-CoV-2 infection. The SARS-CoV-2–associated peripheral neuropathy was considered to be multifactorial and immune mechanisms, preexisting risk factors, antiviral drugs, and bedding-related nerve compression were considered contributing factors. Various inborn errors of metabolism are also associated with peripheral neuropathy from metabolite toxicity or deficiencies (see Part XI and Table 654.1).

Visit Elsevier eBooks+ at eBooks.Health.Elsevier.com for Bibliography.

Chapter 655

Autonomic Neuropathies

Monique M. Ryan

Involvement of small, lightly, or unmyelinated autonomic nerve fibers is seen in many peripheral neuropathies, but their autonomic manifestations are usually mild or subclinical. Some autonomic neuropathies are more symptomatic, causing disturbances of autonomic regulation of the cardiovascular, gastrointestinal, genitourinary, thermoregulatory, sudomotor, and pupillomotor systems.

The differential diagnosis is noted in Table 653.1 (in Chapter 653) and Tables 655.1-655.3. Table 655.4 lists the tests useful in assessing autonomic nervous system function. The treatment of acquired autonomic dysfunction includes both management of the primary disorder (Guillain-Barré syndrome, diabetes) and symptomatic management of organ-specific manifestations (Table 655.5).

655.1 Familial Dysautonomia

Monique M. Ryan

Familial dysautonomia **(Riley-Day syndrome)** is an autosomal recessive disorder most common in Eastern European Jews, in whom its incidence is 1 in 10,000-20,000. It is very rare in other ethnic groups but is, overall, the most common hereditary sensory autonomic neuropathy (HSAN). The variant gene, *IKBKAP* (IκB kinase–associated protein), is at the 9q31-q33 locus. Variants in *IKBKAP* affect the development and maturation of peripheral nerves. This and other autonomic neuropathies are often regarded as **neurocristopathies** because the abnormal tissues are largely derived from the neural crest.

PATHOLOGY

This disease of the peripheral nerves is characterized pathologically by a reduced number of the small unmyelinated nerve fibers that carry pain, temperature, and taste sensation and mediate autonomic functions, including baroreceptors. There is also loss of small and large myelinated fibers from peripheral nerves. The dorsal root ganglia are small, with reduced neurons. The number of parasympathetic ganglion cells in the myenteric plexuses is reduced. Optic nerve involvement, with predominant loss of papillomacular nerve fibers, may impair visual acuity. Fungiform and circumvallate papillae (taste buds) are absent or reduced in the tongue (Fig. 655.1).

CLINICAL MANIFESTATIONS

Clinical manifestations are highly variable. Affected infants and children may be hypotonic, with motor delay and feeding difficulties. Breath-holding spells, followed by syncope, are common in the first 5 years of life. Responses to hypoxia and hypercapnia are reduced. Recurrent pneumonia often leads to chronic lung disease. Affected persons may experience profound postural hypotension without compensatory tachycardia but can also develop extreme hypertension and tachycardia when under emotional and/or physical stress. Temperature dysregulation is reflected by the development of hyperthermia or hypothermia with infections and environmental stressors.

When affected children become older, insensitivity to pain becomes evident and traumatic injuries are frequent. Pain and temperature sensation are reduced, although to a lesser degree than in other HSANs (see Table 655.2). **Alacrima** (absence of tears with emotional crying) is a universal finding. Corneal ulcerations result from decreased corneal sensation and xerophthalmia. Newly erupting teeth cause tongue ulcerations and, in older children, dental trauma; soft tissue mutilation may be prominent. Walking is delayed and appears ataxic, probably as a result of a combination of poor sensory feedback from muscle spindles, vestibular nerve dysfunction, and cerebellar involvement. The deep tendon reflexes are absent. Scoliosis or kyphosis, or both, is seen in most patients and is usually progressive. There is an increased incidence of urinary incontinence. Bradycardia and other cardiac arrhythmias can occur; some patients require a cardiac pacemaker.

Approximately 40% of patients experience seizures; some are triggered by hypoxia during breath holding and some by fever, but some have no obvious precipitants. Emotional lability and learning disabilities are common in school-age children with familial dysautonomia. Puberty is often delayed, especially in females. Short stature can occur but is responsive to treatment with growth hormone.

After 3 years of age, **dysautonomic crises** begin, usually with attacks of cyclic vomiting lasting 24-72 hours or even longer. These repeated episodes of retching and vomiting are associated with tachycardia, hypertension, profuse sweating, blotching of the skin, apprehension, and irritability. Prominent gastric distention can occur, causing abdominal pain and even respiratory distress. Hematemesis can complicate pernicious vomiting.

LABORATORY FINDINGS

ECG shows prolonged corrected QT intervals with lack of appropriate shortening with exercise, reflecting aberrant autonomic regulation of cardiac conduction. Chest radiographs may show atelectasis and chronic inflammatory changes. The urinary vanillylmandelic acid level is decreased, and the homovanillic acid level is increased. The plasma level of dopamine β-hydroxylase (the enzyme that converts dopamine to epinephrine) is diminished. Sural nerve biopsy shows loss of unmyelinated fibers, but nerve conduction studies and electromyography are often normal, because they reflect only the function of large myelinated fibers. Electroencephalography is useful for evaluating seizures.

DIAGNOSIS

All HSANs are characterized by absence of the normal axon flare response to intradermal injection of histamine phosphate. Because the skin of a normal infant reacts more intensely to histamine, a 1:10,000 dilution should be used. Instillation of 2.5% methacholine into the conjunctival sac produces miosis in patients with familial dysautonomia but no detectable effect on a normal pupil; this is a nonspecific sign of parasympathetic denervation from any cause. Methacholine is applied to only one eye in this test, with the other eye serving as a control; the pupils are compared at 5-minute intervals for 20 minutes. The combination of alacrima, absent fungiform papillae, decreased patellar reflexes, and an abnormal histamine test with Ashkenazi Jewish lineage is diagnostic. Because of variable expression and potential overlap with other HSANs, genetic testing should be used to confirm the diagnosis.

TREATMENT

Symptomatic treatment includes special attention to the respiratory and gastrointestinal systems to prevent aspiration and malnutrition, topical ocular lubricants to prevent corneal ulceration, orthopedic management of scoliosis and joint problems, and anticonvulsants where required. Gastrostomy, with or without fundoplication, should be considered in those with recurrent aspiration. Hyperpyrexia from anhidrosis can be life-threatening and should be treated aggressively. Chronic lung disease should be treated symptomatically. Patients should be warned that their insensitivity to hypoxia may place them at risk of complications with underwater swimming, air travel, and travel to high altitudes. Protection from injuries is important because of the lack of pain as a protective mechanism. Some children require a cardiac pacemaker.

Dysautonomic crises respond poorly to standard antiemetics and are usually treated with centrally acting medications such as diazepam and clonidine. Carbidopa, a DOPA decarboxylase inhibitor, is also effective in dysautonomic crises.

PROGNOSIS

Sixty percent of patients die before the age of 20 years, usually of chronic respiratory failure or aspiration. Older patients often develop chronic renal disease related to vasomotor instability and hypertension. The prognosis is improved by treatment in a center familiar with this

Table 655.1 Classifications of Pediatric Autonomic Disorders

ETIOLOGY	TOPOGRAPHY	FREQUENCY	NEUROTRANSMISSION
FUNCTIONAL	GENERALIZED	COMMON	PANDYSAUTONOMIA (ADRENERGIC AND CHOLINERGIC FAILURE)
Reflex (vasovagal) syncope Postural tachycardia syndrome Orthostatic intolerance without tachycardia	Reflex (vasovagal) syncope Postural tachycardia syndrome Orthostatic intolerance without tachycardia Hereditary sensory autonomic neuropathies Other rare genetic disorders Immune-mediated	Reflex (vasovagal) syncope Postural tachycardia syndrome Orthostatic intolerance without tachycardia Obesity Diabetes Anorexia nervosa Other metabolic disorders	Autoimmune autonomic ganglionopathy Acute autonomic and sensory neuropathy Guillain-Barré syndrome Paraneoplastic neuropathies Porphyria
INHERITED			
Hereditary sensory autonomic neuropathies Other rare genetic disorders			
METABOLIC	PUPIL	RARE	PURE ADRENERGIC FAILURE
Obesity Diabetes Anorexia Other metabolic disorders	Argyll Robertson pupil Adie pupil Horner syndrome Pourfour du Petit syndrome	Immune-mediated Traumatic Hereditary sensory autonomic neuropathies Other rare genetic disorders	Dopamine-beta hydroxylase deficiency Pure adrenergic neuropathy
IMMUNE-MEDIATED	FACE		PURE CHOLINERGIC FAILURE
Autoimmune autonomic ganglionopathy Guillain-Barré syndrome Anti-NMDA receptor encephalitis Paraneoplastic autonomic neuropathy Sjögren disease	Cluster headache Harlequin syndrome Gustatory sweating		Botulism Lambert-Eaton syndrome Adie pupil Chagas disease Acute cholinergic neuropathy
INFECTIOUS	LIMBS		
Chagas disease HIV Tetanus	Raynaud phenomenon Acrocyanosis Primary idiopathic hyperhidrosis		
NEOPLASIA			
Catecholamine-secreting tumors Brainstem and posterior fossa tumors			
TRAUMA AND MALFORMATIONS			
Spinal cord injury Traumatic brain injury Syringomyelia Arnold-Chiari malformation			
DRUGS			
POSTSURGICAL OR POSTRADIOTHERAPY USAGES			
Acquired baroreflex failure			

From Palma JA, Norcliffe-Kaufmann, Fuente-Mora C, et al. Disorders of the autonomic nervous system: autonomic dysfunction in pediatric practice. In: Swaiman KF, Ashwal S, Ferriero DM, et al., eds. *Swaiman's Pediatric Neurology*, 6th ed. Philadelphia: Elsevier; 2018: Table 154-1.

disease. Measures to better control vasomotor stability and vomiting improve quality of life, but their effect on longevity is not yet known.

Visit Elsevier eBooks+ at eBooks.Health.Elsevier.com for Bibliography.

655.2 Other Autonomic Neuropathies

Monique M. Ryan

CONGENITAL INSENSITIVITY TO PAIN AND ANHIDROSIS

Congenital insensitivity to **pain** and **anhidrosis,** or HSAN type IV, is an autosomal recessive disorder with onset in infancy (see Table 655.2 and Chapter 653.10). Affected children usually present with episodes of overheating related to warm environmental temperatures because they have absent or reduced sweating. Infantile hypotonia improves with age. Frequent burns and traumatic injuries result from the lack of pain perception, which also causes poor healing of fractures and a tendency for development of chronic osteomyelitis and Charcot joints. Temperature sensation is also markedly impaired. Anhidrosis causes a thick, calloused appearance of the skin, with lichenification of the palms and chronic dystrophic changes in the nails. There is no alacrima, but corneal ulceration may result from hypoesthesia. Almost all patients have behavioral and cognitive deficits. Nerve biopsy reveals an almost total absence of unmyelinated nerve fibers, which usually convey pain, temperature, and autonomic sensation. The diagnosis is confirmed by targeted genetic testing.

Table 655.2 Hereditary Sensory and Autonomic Neuropathies

TYPE	GENE	INHERITANCE	ONSET	AUTONOMIC FEATURES	SENSORY FEATURES	OTHER FEATURES
HSAN 1A	*SPTLC1*	AD	Adult	Varying degrees of distal anhidrosis	Progressive loss of pain, temperature, and fine-touch sensation Varying degrees of sensorineural hearing loss Episodes of lancinating limb pain	One case with congenital presentation reported with severe growth and mental retardation, microcephaly, hypotonia, and respiratory insufficiency
HSAN 1B	3p24-p22 locus					Cough and gastroesophageal reflux
HSAN 1C	*SPTLC2*					Varying degrees of distal muscle weakness
HSAN 1D	*ALT1*			None		—
HSAN 1E	*DMNT1*			None		Early-onset dementia
HSAN 1F	*ATL3*			None		—
HSAN 2A	*WNK1*	AR	Childhood or adolescence	None	Varying degrees of progressive loss of pain, temperature, and fine-touch sensation	
HSAN 2B	*FAM134B*			Varying degrees of hyperhidrosis, urinary incontinence, and pupillary abnormalities		—
HSAN 2C	*KIF1A*			None		—
HSAN 2D	*SCN9A*			Urinary and fecal incontinence, reduced sweating		Lack of fungiform lingual papillae, hyposmia, hearing loss, hypogeusia, and bone dysplasia
HSAN 3	*IKAP (ELP-1)*	AR	Newborn	Impaired lacrimation Orthostatic hypotension Paroxysmal hypertension and vomiting episodes with skin blotching Normal or increased sweating	Impaired pain and temperature sensation with preserved fine-touch sensation	Described in Ashkenazi Jewish ancestry Neonatal hypotonia Respiratory and feeding difficulties Neuropathic joints Optic neuropathy, chronic lung disease, scoliosis, rhabdomyolysis Renal failure Varying degrees of cognitive and behavioral problems
HSAN 4	*NTRK (TRKA)*	AR	Newborn	Anhidrosis Episodic hyperthermia Undetectable plasma norepinephrine	Loss of pain and temperature sensation Preserved fine-touch and vibration sensation	Frequent fractures Neuropathic joints Slow-healing wounds Varying degrees of cognitive and behavioral problems
HSAN 5	*NGFβ*	AR	Newborn	Variable degree of anhidrosis	Loss of pain and temperature sensation Preserved fine-touch and vibration sensation	Frequent fractures Neuropathic joints Tooth loss from gingival disease

Table 655.2 Hereditary Sensory and Autonomic Neuropathies—cont'd

TYPE	GENE	INHERITANCE	ONSET	AUTONOMIC FEATURES	SENSORY FEATURES	OTHER FEATURES
HSAN 6	*DST*	AR	Newborn	Impaired lacrimation Labile blood pressure and heart rate Hyperthermia and skin-blotching episodes	Loss of pain and temperature sensation	Described in Ashkenazi Jewish ancestry Neonatal hypotonia Respiratory and feeding difficulties, delayed psychomotor development, neuropathic joints All described patients died before age 3
HSAN 7	*SCN11A*	AD (only a heterozygous de novo variant described)	Newborn	Hyperhidrosis and gastrointestinal dysfunction	Loss of pain and temperature sensation	Frequent fractures Neuropathic joints Slow-healing wounds

AD, Autosomal dominant; AR, autosomal recessive.
From Palma JA, Norcliffe-Kaufmann, Fuente-Mora C, et al. Disorders of the autonomic nervous system: autonomic dysfunction in pediatric practice. In: Swaiman KF, Ashwal S, Ferriero DM, et al., eds. *Swaiman's Pediatric Neurology*, 6th ed. Philadelphia: Elsevier; 2018: Table 154-2.

Table 655.3 Other Genetic and Metabolic Disorders Causing Autonomic Dysfunction

DISEASE	AUTONOMIC FEATURES
Dopamine beta-hydroxylase deficiency	Ptosis, hypotension, hypothermia; treatment with droxidopa
Aromatic L-amino acid decarboxylase deficiency	Ptosis, poor feeding, hypotension, hypotonia; treatment with dopamine agonists/monoamine oxidase inhibitors
Menkes disease	Orthostatic hypotension; treatment with subcutaneous copper injections
Fabry disease	Hypohidrosis or hyperhidrosis, decreased salivation; treatment by enzyme replacement
Acute intermittent porphyria (AIP)	Tachycardia, hypotension or hypertension; treatment as for AIP
Porphyria variegata	As for AIP
Hirschsprung disease	Tachycardia, hypertension, hyperthermia; treatment symptomatic (see Table 655.5)
Congenital central hypoventilation syndrome (CCHS)	Constipation, pupillary abnormalities, hypothermia; treatment symptomatic
Pitt-Hopkins syndrome	As for CCHS
Rett syndrome	Irregular breathing, abnormal heart rate variability, sudden death; treatment symptomatic
Alexander disease	Constipation, hypothermia, sleep-disordered breathing; treatment symptomatic
Hyperbradykininism	Orthostatic hypotension, purple legs; treatment symptomatic (see Table 655.5)
Panayiotopoulos syndrome	Hypertension, tachycardia, cardiac arrest; treatment symptomatic (see Table 655.5)
Cold-induced sweating syndrome	Unexplained fevers, impaired thermoregulation; treatment symptomatic (see Table 655.5)

Table 655.4 Autonomic Function Testing

The sympathetic and parasympathetic divisions of the autonomic nervous system are involved in all tests of autonomic function
CARDIAC PARASYMPATHETIC NERVOUS SYSTEM FUNCTION
Heart rate variability with deep respiration (respiratory sinus arrhythmia); time-domain and frequency-domain assessments Heart rate response to the Valsalva maneuver Heart rate response to standing
SYMPATHETIC ADRENERGIC FUNCTION
Blood pressure response to upright posture (standing or tilt table) Blood pressure response to Valsalva maneuver Microneurography
SYMPATHETIC CHOLINERGIC FUNCTION
Thermoregulatory sweat testing Quantitative sudomotor-axon reflex test Sweat imprint methods Sympathetic skin response

From Freeman R. Autonomic peripheral neuropathy. *Lancet*. 2005;365:1259–1270.

Table 655.5 Symptomatic Management of Autonomic Dysfunction

PROBLEM	TREATMENT
Orthostatic hypotension	Volume and salt supplements Adequate hydration Pressure garments Fludrocortisone (mineralocorticoid) Midodrine (α agonist)
Aspiration pneumonitis	Gastrostomy with/without fundoplication
Dysautonomic crises	Clonidine, diazepam, carbidopa
Gastroparesis	Prokinetic agents (metoclopramide, domperidone, erythromycin)
Hypomotility	Fiber, laxatives
Urinary dysfunction	Timed voiding; bladder catheterization
Hyperhidrosis	Anticholinergic agents (glycopyrrolate, propantheline) Intracutaneous botulism toxin
Anhidrosis	Cool baths, cooling vests

Fig. 655.1 A, Normal tongue with fungiform papillae present on the tip. B, Dysautonomic tongue. Note absence of the highly vascularized fungiform papillae from the tongue tip, which gives the appearance of a smooth tongue. *(From Axelrod FB, Gold-von Simson G. Hereditary sensory and autonomic neuropathies: Types II, III, and IV. Orphanet J Rare Dis. 2007;2:39. Fig. 4.)*

ALLGROVE SYNDROME (TRIPLE A SYNDROME)

Allgrove syndrome is a rare autonomic neuropathy characterized by early-onset alacrima, feeding difficulties and achalasia, autonomic dysfunction with orthostatic hypotension, altered heart rate variability, hyperreflexia, ataxia, muscle weakness, sensorimotor polyneuropathy, and adrenocorticotropic hormone–resistant adrenal insufficiency, which develops in the first decade. The gene *AAAS* (alacrima-achalasia-adrenal insufficiency neurologic disorder) is located on chromosome 12q13.

Visit Elsevier eBooks+ at eBooks.Health.Elsevier.com for Bibliography.

Chapter 656

Guillain-Barré Syndrome

Monique M. Ryan

Guillain-Barré syndrome (GBS) is an autoimmune disorder that is thought to be a **postinfectious polyneuropathy,** involving mainly motor but also sensory and sometimes autonomic nerves. This syndrome affects people of all ages and is not hereditary. Most GBS patients in the United States and Europe have a demyelinating neuropathy, but primarily axonal degeneration is apparent in some forms of GBS seen mainly in China, Mexico, Bangladesh, and Japan.

CLINICAL MANIFESTATIONS

The onset of weakness usually follows a nonspecific gastrointestinal or respiratory infection by approximately 10 days. The original infection might have caused only gastrointestinal (especially *Campylobacter jejuni,* but also *Helicobacter pylori*), respiratory (especially *Mycoplasma pneumoniae*), or systemic (Zika virus, COVID-19) symptoms. Consumption of undercooked poultry, unpasteurized milk, and contaminated water are the main sources of gastrointestinal infections. West Nile virus also can mimic Guillain-Barré–like syndrome, but more often causes a motor neuron disease similar to poliomyelitis. GBS may follow administration of vaccines against rabies, influenza, and conjugated meningococcal vaccine, particularly serogroup C. Other infectious precursors of GBS include mononucleosis, Lyme disease, cytomegalovirus, the Zika virus and, most recently, COVID-19 infection.

Initial symptoms include numbness and paresthesia, followed by weakness (Fig. 656.1). Radicular back pain and myalgia are common in the initial stages; affected children can be very irritable. Weakness usually begins in the lower extremities and progressively involves the trunk, the upper limbs, and finally the bulbar muscles, but weakness is sometimes proximally prominent. Extraocular muscle involvement is rare, but many children develop facial weakness. In most cases weakness is essentially symmetric. Weakness progresses over days or weeks, the clinical nadir occurring in less than 4 weeks. Approximately 60% of children lose the ability to walk at some point in their illness; a small proportion progress to flaccid tetraplegia. The maximal severity of weakness is reached by 4 weeks after onset. The differential diagnosis of GBS is shown in Tables 656.1 and 656.2.

Bulbar involvement occurs in about 50% of cases and can result in respiratory insufficiency (see Fig. 656.1; Table 656.3). Dysphagia and facial weakness can be signs of impending respiratory failure, interfere with saliva control and swallowing, and increase the risk of aspiration. Vocal cord paralysis may cause dyspnea or a hoarse voice. Severe bulbar and respiratory muscle involvement can lead to death if GBS is not recognized and treated.

The **autonomic nervous system** is also involved in some cases. Lability of blood pressure and heart rate, postural hypotension, episodes of profound bradycardia or tachycardia, and occasional asystole occur more commonly in younger patients or those with severe weakness. Cardiovascular monitoring is important, especially early in the disease course, when rapid progression of weakness, respiratory insufficiency, and autonomic instability can be life-threatening. The tendon reflexes are lost in GBS, usually early, but are sometimes preserved until later; areflexia is more common but hyporeflexia may be seen. As many as 10% of affected children retain their reflexes throughout their course.

Subtypes of GBS include an acute inflammatory demyelinating polyneuropathy and an acute motor axonal neuropathy; these are distinguished by findings on nerve conduction studies and an associated pattern of antiganglioside antibodies (see Table 656.3). Localized forms of GBS also occur and include a pattern of facial diplegia with paresthesias and a pattern of pharyngeal-cervical-brachial weakness. **Miller Fisher syndrome (MFS)** is an uncommon GBS variant associated with acute external (and occasionally internal) ophthalmoplegia, ataxia, and areflexia. The cranial nerve VI is most often involved in MFS. Although areflexia is seen in MFS, patients have no or only very mild lower extremity weakness, compared with GBS. Distal paresthesias are common in MFS. Urinary incontinence or retention is seen in approximately 20% of cases but is usually transient. MFS overlaps clinically with Bickerstaff brainstem encephalitis, which has similar findings with an associated encephalopathy.

Chronic inflammatory demyelinating polyradiculoneuropathy (CIDP, sometimes called *chronic inflammatory relapsing polyneuritis*) is a more chronic, slowly progressive, acquired inflammatory neuropathy with some clinical overlap with GBS (Table 656.4). Symptoms such as weakness and paresthesias develop over more than 4-6 weeks, recur intermittently (relapsing), or progress slowly over periods of months to years. Weakness is generally both proximal and distal, and variably severe. Hyporeflexia or areflexia is almost universal. Motor deficits occur in 94% of cases and sensory paresthesias in 64%, but cranial

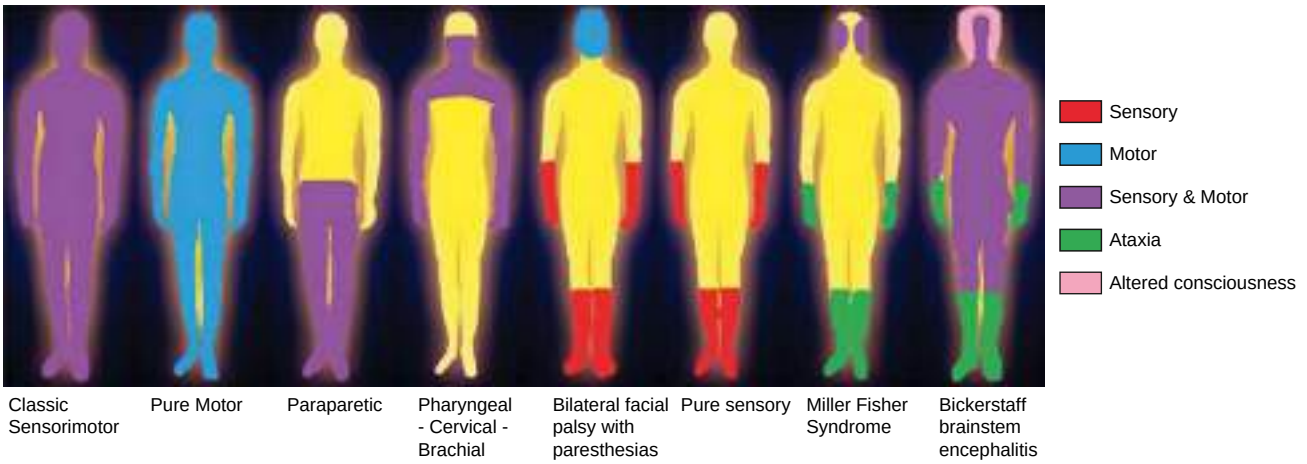

Fig. 656.1 Pattern of symptoms in variants of Guillain-Barré syndrome (GBS). Graphic representation of the pattern of symptoms typically observed in the different clinical variants of GBS. Symptoms can be purely motor, purely sensory (rare), or a combination of motor and sensory. Ataxia can be present in patients with Miller Fisher syndrome, and both decreased consciousness and ataxia can be present in patients with Bickerstaff brainstem encephalitis. Symptoms can be localized to specific regions of the body, and the pattern of symptoms differs between variants of GBS. Although rare, bilateral facial palsy with paresthesias, the pure sensory variant, and Miller Fisher syndrome are included in the GBS spectrum, but they do not fulfill the diagnostic criteria for GBS. *(From El-Abassi RN, Soliman M, Levy MH, et al. Treatment and management of autoimmune neuropathies. In: Bertorini TE, ed. Neuromuscular Disorders Treatment and Management, 2nd ed. Philadelphia: Elsevier; 2022: Fig. 15.1, p. 313.)*

Table 656.1 Differential Diagnosis of Childhood Guillain-Barré Syndrome

SPINAL CORD LESIONS
Acute transverse myelitis (may occur with GBS)
Epidural abscess
Tumors
Poliomyelitis
Enteroviral myelitis
Acute flaccid myelitis
Hopkins syndrome
Vascular malformations
Cord infarction
Fibrocartilaginous embolism
Cord compression from tumors
Acute disseminated encephalomyelitis
Bickerstaff brainstem encephalitis
Anterior spinal artery syndrome
PERIPHERAL NEUROPATHIES
Toxic (See Chapter 654)
Vincristine
Thalidomide
Glue sniffing
Heavy metal: gold, arsenic, lead, thallium, mercury
Organophosphate pesticides
Fluoroquinolones
Isoniazid
Dapsone
Nitrous oxide
Snake venom
Puffer fish
Buckthorn toxin
Carbon monoxide
Immune checkpoint inhibitors
Infections
HIV
Diphtheria
West Nile virus
Cytomegalovirus (radiculitis)
Leprosy
Lyme disease
Zika virus
COVID-19
Inborn errors of metabolism/hereditary
Leigh disease
Tangier disease
Porphyria
Fabry disease
Tyrosinemia
Mitochondrial neuropathies
Critical illness: polyneuropathymyopathy
Eosinophilic granulomatosis with polyangiitis
Granulomatosis with polyangiitis
Sarcoidosis
Systemic lupus erythematosus
Microscopic polyangiitis
Other vasculitides
Nutritional deficiencies
Vitamin B1, B6, B12, E
Riboflavin
NEUROMUSCULAR JUNCTION DISORDERS
Tick paralysis
Myasthenia gravis
Acute flaccid myelitis
Botulism
Hypercalcemia
MYOPATHIES
Periodic paralyses (hypokalemic or hyperkalemic)
Dermatomyositis
Critical illness myopathy/polyneuropathy
OTHER
Conversion disorder
Chronic inflammatory demyelinating polyneuritis (acute onset)

Table 656.2 Differential Diagnosis of Guillain-Barré Syndrome by Anatomic Site and Illness

	DISTINGUISHING CLINICAL FEATURES	CSF FINDINGS	ELECTROMYOGRAPHY FINDINGS	OTHER SUPPORTIVE TESTS
BRAIN				
Encephalitis	Drowsiness, seizures	Pleocytosis	Normal	Brain MRI for hyperintense lesions, EEG for slowing epileptiform discharges
Brainstem stroke	Hyperacute sudden onset, cranial and limb weakness	Normal	Normal	Brain MRI and magnetic resonance angiography for corresponding infarct and vascular occlusion
SPINAL CORD				
Transverse myelitis	Sensory level, brisk reflexes	Normal	Normal	Abnormal spine MRI for hyperintense lesions
Malignant infiltration	Cauda equina syndrome	Malignant cells	Normal	Abnormal spine MRI for enhancing lesions, investigations for primary lesions
ANTERIOR HORN CELL				
Infection with poliovirus, enterovirus 71, or enterovirus D68	Fever, flaccid paralysis	Pleocytosis	Motor neuronopathy	Presence of virus
PLEXUS				
Neuralgic amyotrophy	Asymmetry, pain, and findings limited to affected nerves	Normal	Abnormal in affected nerves	Brachial plexus MRI for nerve enhancement
NERVE ROOTS				
Cytomegalovirus and HIV radiculitis	Subacute presentation	Pleocytosis	Delayed or absent F waves and H waves	HIV and cytomegalovirus serology
Chronic inflammatory demyelinating polyneuropathy	Subacute presentation and relapsing–remitting pattern	Albumin-cytologic dissociation	Demyelinating neuropathy	Nerve ultrasound for enlarged nerve roots
PERIPHERAL NERVES				
Chronic inflammatory demyelinating polyneuropathy	Subacute presentation and relapsing–remitting pattern	Albumin-cytologic dissociation	Demyelinating neuropathy	Nerve ultrasound for enlarged nerve roots, and proximal and distal nerves
Porphyria	Family history, concomitant psychiatric and abdominal pain	Normal	Axonal neuropathy	Increased urinary porphobilinogen
Lyme disease or other tick-borne diseases	History of exposure, characteristic rash (erythema migrans in Lyme disease)	Normal	Axonal neuropathy	Antibodies against *Borrelia burgdorferi* (Lyme disease) or the related tick species
Thiamine deficiency	Predisposing factors (e.g., hyperemesis gravidarum, alcohol misuse, nutritional deficiency, and other neurologic features such as Wernicke encephalopathy)	Normal	Axonal neuropathy	Reduced blood thiamine and erythrocyte transketolase activity
Diphtheria	Laryngeal infection	Increased total protein	Demyelinating neuropathy	Isolation of *Corynebacterium diphtheriae* on cultures
Critical illness polyneuropathy	Prolonged illness or ventilation	Normal	Axonal neuropathy	Overlap with myopathy
Metabolic or electrolyte imbalance	Predisposing factors	Normal	Normal	Low serum concentrations of abnormal electrolyte
NEUROMUSCULAR JUNCTION				
Myasthenia gravis	Fatigable weakness, relapsing–remitting pattern	Normal	Repetitive nerve stimulation for a decremental response	Acetylcholine receptor antibodies
Botulism	Rapid progression, pupillary abnormalities, dysautonomia, and descending paralysis	Normal	Rapid repetitive nerve stimulation for an incremental increase	Botulism toxin

Table 656.2 Differential Diagnosis of Guillain-Barré Syndrome by Anatomic Site and Illness—cont'd

	DISTINGUISHING CLINICAL FEATURES	CSF FINDINGS	ELECTROMYOGRAPHY FINDINGS	OTHER SUPPORTIVE TESTS
Lambert-Eaton syndrome	Proximal weakness, depressed tendon reflexes, and autonomic changes	Normal	Repetitive nerve stimulation for post-tetanic facilitation	Antibodies against voltage-gated calcium channels
MUSCLE				
Inflammatory myositis	Proximal weakness, normal reflexes and sensation	Normal	Normal sensory potentials Myopathic	Increased serum creatine kinase
Critical illness myopathy	Prolonged illness or ventilation	Normal	Normal sensory potentials	Overlap with neuropathy
Hypokalemic periodic paralysis	Transient weakness, family history, triggering factors (e.g., fasting, exercise, and carbohydrate-rich meals)	Normal	Abnormal exercise test	Low serum potassium concentrations, genetic mutation
MISCELLANEOUS				
Functional disorder	Inconsistent, variable presentation	Normal	Normal	Psychologic evaluation

From Shahrizaila N, Lehmann HC, Kuwabara S. Guillain-Barre syndrome. *Lancet*. 2021;397:1214–1226. Table 2.

Table 656.3 Clinical Classification of Guillain-Barré Syndrome

	PATTERNS OF LIMB WEAKNESS	SENSORY INVOLVEMENT	CRANIAL NERVE INVOLVEMENT	CNS INVOLVEMENT	SERIAL NEURAL CONDUCTION	IgG AGAINST GANGLIOSIDE TYPE	PROPORTION OF PATIENTS WITH GUILLAIN-BARRÉ SYNDROME
GUILLAIN-BARRÉ SYNDROME SPECTRUM							
Classic							
Demyelinating	Upper and lower limbs	Yes	Yes	No	AIDP	Unknown	69–90%
Axonal	Upper and lower limbs	Yes in AMSAN, no in AMAN	Yes	No	AMSAN, RCF	GM1, GD1a	<22%
Pure motor	Upper and lower limbs	No	Yes	No	AMAN, RCF	GM1, GD1a	5–70%
Pure sensory	None	Yes	No	No	Abnormal SNAPs	GD1b	<1%
Paraparetic	Lower limbs	Yes	No	No	Axonal	GM1, GD1b	5–10%
Facial diplegia and paresthesia	None	Yes (distal)	Facial	No	AIDP	Unknown	<5%
Pharyngeal, cervical, brachial	Proximal upper limbs	Supportive	Bulbar	No	Equivocal	GT1a, GQ1b	<5%
Acute bulbar palsy	None	Supportive	Bulbar	No	Equivocal	GT1a	<1%
Guillain-Barré syndrome with hyperreflexia	Upper and lower limbs	Yes	Yes	No	Axonal	GM1	<1%
MILLER FISHER SYNDROME SPECTRUM							
Classic	None	Ataxia	Ocular motor nerves	No	Abnormal SNAPs	GQ1b, GT1a	4–25%
Acute ophthalmoplegia	None	Supportive	Ocular motor nerves	No	Normal	GQ1b	<1%
Acute ataxic neuropathy	None	Ataxia	No	No	Axonal	GM1	<5%
Acute ptosis	None	Supportive	Ptosis only	No	Normal	GQ1b	<1%
Acute mydriasis	None	Supportive	Dilated pupils	No	Normal	Unknown	<1%
Acute vestibular syndrome	None	Supportive	Nystagmus	Nystagmus	Normal	GQ1b	<1%

Continued

Table 656.3 Clinical Classification of Guillain-Barré Syndrome—cont'd

	PATTERNS OF LIMB WEAKNESS	SENSORY INVOLVEMENT	CRANIAL NERVE INVOLVEMENT	CNS INVOLVEMENT	SERIAL NEURAL CONDUCTION	IgG AGAINST GANGLIOSIDE TYPE	PROPORTION OF PATIENTS WITH GUILLAIN-BARRÉ SYNDROME
BICKERSTAFF BRAINSTEM ENCEPHALITIS							
Classic	None	Supportive	Ocular motor nerves	Yes	Axonal	GQ1b, GT1a	<5%
Acute ataxic hypersomnolence	None	Ataxia	No	Yes	Normal	GQ1b	<1%

AIDP, acute inflammatory demyelinating polyneuropathy; AMAN, acute motor axonal neuropathy; AMSAN, acute motor and sensory neuropathy; RCF, reversible conduction failure; SNAP, sensory nerve action potential.
From Shahrizaila N, Lehmann HC, Kuwabara S. Guillain-Barre syndrome. *Lancet*. 2021;397:1214–1226. Table 3.

Table 656.4 Differential Diagnosis CIDP

TYPICAL CIDP
- AL amyloidosis, ATTRv polyneuropathy
- Chronic ataxic neuropathy ophthalmoplegia M-protein agglutination disialosyl antibodies (CANOMAD)
- Guillain-Barré syndrome
- Hepatic neuropathy
- HIV-related neuropathy
- Multiple myeloma
- Osteosclerotic myeloma
- POEMS syndrome
- Uremic neuropathy
- Vitamin B12 deficiency—actual or functional (e.g., nitrous oxide poisoning)
- Riboflavin transporter deficiency (*SLC52A2*)

DISTAL CIDP
- Anti-MAG IgM neuropathy
- Diabetic neuropathy
- Hereditary neuropathies (CMT1, CMTX1, CMT4, metachromatic leukodystrophy, Refsum disease, adrenomyeloneuropathy, ATTRv polyneuropathy)
- POEMS syndrome
- Vasculitic neuropathy

MULTIFOCAL AND FOCAL CIDP
- Diabetic radiculopathy/plexopathy
- Entrapment neuropathies
- Hereditary neuropathy with liability to pressure palsies (HNPP)
- Multifocal motor neuropathy (MMN)
- Neuralgic amyotrophy
- Peripheral nerve tumors (such as lymphoma, perineurioma, schwannoma, neurofibroma)
- Vasculitic neuropathy (mononeuritis multiplex)

MOTOR CIDP
- Hereditary motor neuropathies (such as distal hereditary motor neuropathies, spinal muscular atrophy, porphyria)
- Inflammatory myopathies
- Motor neuron disease
- Neuromuscular junction disorders (such as myasthenia gravis, Lambert-Eaton syndrome)

SENSORY CIDP
- Cerebellar ataxia, neuropathy, vestibular areflexia syndrome (CANVAS)
- Chronic immune sensory polyradiculopathy (CISP)
- Dorsal column lesions (such as syphilis, paraneoplastic, copper deficiency, vitamin B_{12} deficiency)
- Hereditary sensory neuropathies
- Idiopathic sensory neuropathy
- Sensory neuronopathy
- Toxic neuropathies (such as chemotherapy and vitamin B_6 toxicity)

AL, amyloid light chain; ATTRv, hereditary transthyretin amyloidosis; CIDP, chronic inflammatory demyelinating polyradiculoneuropathy; MAG, antimyelin-associated glycoprotein; POEMS, polyneuropathy,organomegaly, endocrinopathy, M-protein, skin changes.
Modified from Van den Bergh PYK, van Doorn PA, Hadden RDM, et al. European Academy of Neurology/Peripheral Nerve Society guideline on diagnosis and treatment of chronic inflammatory demyelinating polyradiculoneuropathy: report of a joint task force-second version. *J Peripher Nerv Syst*. 2021;26:242–268. Table 4.

nerve and autonomic involvement is uncommon. The cerebrospinal fluid (CSF) shows no pleocytosis, but the CSF protein is almost always elevated. Nerve conduction studies show variable slowing of nerve conduction; where required, sural nerve biopsy shows patchy myelin loss and focal inflammatory changes. Acute-onset CIDP may be difficult to distinguish from GBS; CIDP may also be difficult to distinguish from GBS with treatment-related symptom fluctuations.

Congenital GBS is very rare, manifesting as generalized hypotonia, weakness, and areflexia in an affected neonate, fulfilling all electrophysiologic and CSF criteria and in the absence of maternal neuromuscular disease. Treatment is not always required.

LABORATORY FINDINGS AND DIAGNOSIS

CSF studies are helpful in diagnosing GBS. The CSF protein is usually elevated to more than twice the upper limit of normal, the glucose level is normal, and there is no pleocytosis; there should be fewer than 10 white blood cells/mm^3. Bacterial cultures are negative, whereas viral studies rarely isolate specific viruses. The dissociation between high CSF protein and a lack of cellular response (cytoalbuminologic dissociation) in a patient with an acute or subacute polyneuropathy is essentially diagnostic of GBS. These findings may not be apparent in the first week after the onset of symptoms (Table 656.5).

On MRI of the spinal cord in GBS, typical findings include thickening of the cauda equina and intrathecal nerve roots with gadolinium enhancement (Fig. 656.2). Atypical findings should prompt consideration of the alternative diagnoses listed in Table 656.1. Imaging in CIDP is similar but may show greater enhancement of spinal nerve roots (Fig. 656.3).

Nerve conduction studies and electromyography are sensitive to early signs of peripheral nerve inflammation in GBS. Motor and sensory nerve conduction velocities are reduced to a variable extent, reflecting the patchy nature of nerve involvement in this disorder, which is also reflected by focal conduction block and dispersed responses. Electromyography may show acute denervation of muscle. Serum creatine kinase levels may be mildly elevated or normal. Serum antiganglioside antibodies against GM_1 and GD_1 are sometimes elevated in GBS, particularly in cases with primarily axonal rather than demyelinating neuropathy, suggesting that they might play a role in disease propagation and/or recovery in some cases (see Table 656.3). Sural nerve biopsy shows segmental demyelination, focal inflammation, and Wallerian degeneration, but is almost never required for diagnosis.

Serologic testing for *Campylobacter* and *Helicobacter* infections helps establish causation if results are positive but does not alter treatment. Stool cultures are rarely positive because the infection is generally self-limited, and the neuropathy follows the acute gastroenteritis.

TREATMENT

Patients in early stages of GBS should be admitted to the hospital for observation because the ascending paralysis can rapidly cause (potentially life-threatening) respiratory failure and autonomic instability (Fig. 656.4). The respiratory effort (measured by bedside testing or spirometry) *must* be monitored for changes predicting onset of hypoventilation and respiratory failure. Patients with milder weakness and slow progression may be treated expectantly, with observation for stabilization and spontaneous remission. Severe or rapidly

Table 656.5 Diagnostic Criteria for Guillain-Barré Syndrome*

FEATURES NEEDED FOR DIAGNOSIS OF GUILLAIN-BARRÉ SYNDROME IN CLINICAL PRACTICE
• Progressive weakness in legs and arms (sometimes initially only in legs) • Areflexia (or decreased tendon reflexes) in weak limbs
ADDITIONAL SYMPTOMS
• Progressive phase lasts days to 4 wk (often 2 wk) • Relative symmetry • Mild sensory symptoms or signs (not present in acute motor axonal neuropathy) • Cranial nerve involvement, especially bilateral weakness of facial muscles • Autonomic dysfunction • Pain (common)
FEATURES THAT SHOULD RAISE DOUBT ABOUT THE DIAGNOSIS OF GUILLAIN-BARRÉ SYNDROME
• CSF: increased number of mononuclear cells or polymorphonuclear cells (>50 cells/μL) • Severe pulmonary dysfunction with little or no limb weakness at onset • Severe sensory signs with little or no weakness at onset • Bladder or bowel dysfunction at onset • Fever at onset • Sharp spinal cord sensory level • Marked, persistent asymmetry of weakness • Persistent bladder or bowel dysfunction • Slow progression of weakness and without respiratory involvement (consider subacute inflammatory demyelinating polyneuropathy or acute-onset chronic inflammatory demyelinating polyneuropathy)
NERVE CONDUCTION STUDIES
• Can be helpful in clinical practice but are generally not required to diagnose Guillain-Barré syndrome • Essential for classification of Guillain-Barré syndrome as acute inflammatory demyelinating polyneuropathy or acute motor axonal neuropathy • Acute inflammatory demyelinating polyneuropathy: features of demyelination (decreased motor nerve conduction velocity, prolonged distal motor latency, increased F-wave latency, conduction blocks, and temporal dispersion) • Acute motor axonal neuropathy: no features of demyelination (one demyelinating feature in one nerve, if distal CMAP amplitude is less than 10% LLN, can be found; distal CMAP amplitude less than 80% LLN in at least two nerves. Transient motor nerve conduction block might be present.

*Classification of Guillain-Barré syndrome as either acute inflammatory demyelinating polyneuropathy or acute motor axonal neuropathy is not required for the diagnosis of Guillain-Barré syndrome. Whether acute inflammatory demyelinating polyneuropathy and acute motor axonal neuropathy require different treatments is unknown. The amount of conduction slowing required to define demyelination differs between classification systems.

CSF, Cerebrospinal fluid; CMAP, compound muscle action potential; LLN, lower limit of normal.

From Willison HJ, Jacobs BC, van Doorn PA. Guillain-Barré syndrome. *Lancet.* 2016;388:717–727. Panel 1.

progressive muscle weakness is treated with intravenous immunoglobulin (IVIG); common protocols include IVIG 0.4 g/kg/day for 5 consecutive days or 1 g/kg/day for 2 days. Plasmapheresis and/or immunosuppressive drugs are alternatives if IVIG is ineffective. Steroids are not effective for weakness but may help with pain. Supportive care, such as respiratory support, prevention of pressure sores and constipation, nutritional support, pain management, prevention of deep vein thrombosis, and treatment of secondary bacterial infections is important.

Neuropathic pain in GBS should be treated aggressively, with narcotic analgesics where necessary, and with medications such as gabapentin.

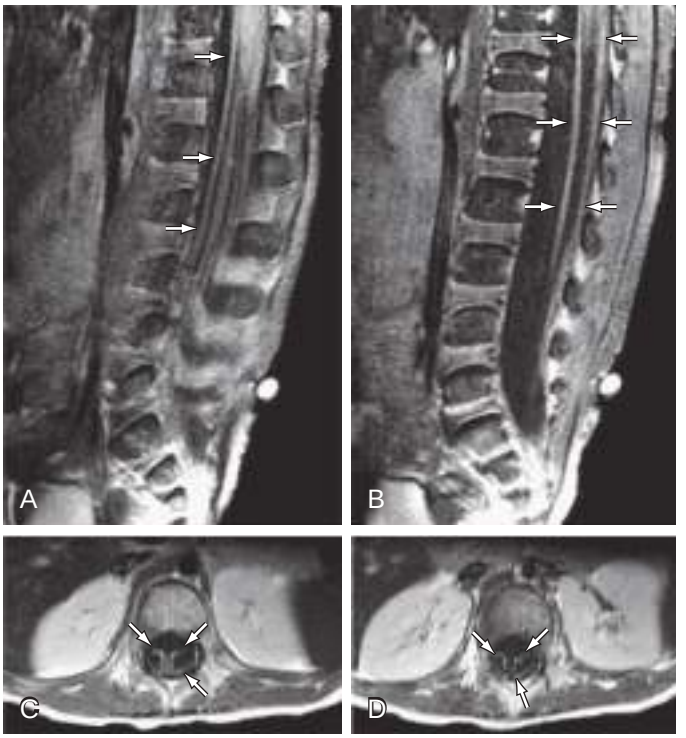

Fig. 656.2 Guillain-Barré syndrome. Sagittal off-midline (**A**) and midline (**B**) postgadolinium T1 weighted fat-saturated images through the lumbar spine of a patient who could not ambulate. **C** and **D**, Axial postcontrast T1 weighted images through the conus medullaris and proximal lumbar nerve roots, respectively. The images show extensive contrast enhancement of nerve roots (*arrows* in **A-D**), in keeping with changes of Guillain-Barré syndrome. *(From Slovis TL, ed. Caffey's Pediatric Diagnostic Imaging, 11th ed. Philadelphia: Mosby; 2008: Fig. 65-6.)*

CIDP can be treated with either oral or pulsed steroids or IVIG, with refractory cases often requiring use of other immunosuppressive medications. Children with relapsing or slowly progressive weakness often need months to years of therapy, but most eventually achieve a sustained remission. The outcome is generally good, but some children have permanent deficits.

PROGNOSIS

GBS is usually a monophasic illness; spontaneous recovery begins within 2-3 weeks but can take months. Therapy with IVIG hastens recovery but not does alter the long-term outcome. As many as 60% of affected children become nonambulant during their illness, but most eventually regain full strength. A minority has some residual weakness, most often of the ankle dorsiflexors. Improvement usually follows a gradient opposite the direction of involvement, with bulbar function recovering first and lower extremity weakness resolving last. The tendon reflexes are usually the last function to recover. Clinical features predicting a severe course and slow (possibly incomplete) recovery include cranial nerve involvement, the need for ventilatory support, and maximum disability at the time of presentation. Neurophysiologic studies do not necessarily predict the long-term outcome, but children with demyelinating forms of GBS generally recover more quickly than those with axonal forms. Bulbar and respiratory muscle involvement can lead to death from GBS if the syndrome is not recognized and treated. Fatigue is the most common long-term residuum of GBS. Relapses occur in about 4% of children with GBS and are generally responsive to immunomodulatory treatment.

Visit Elsevier eBooks+ at eBooks.Health.Elsevier.com for Bibliography.

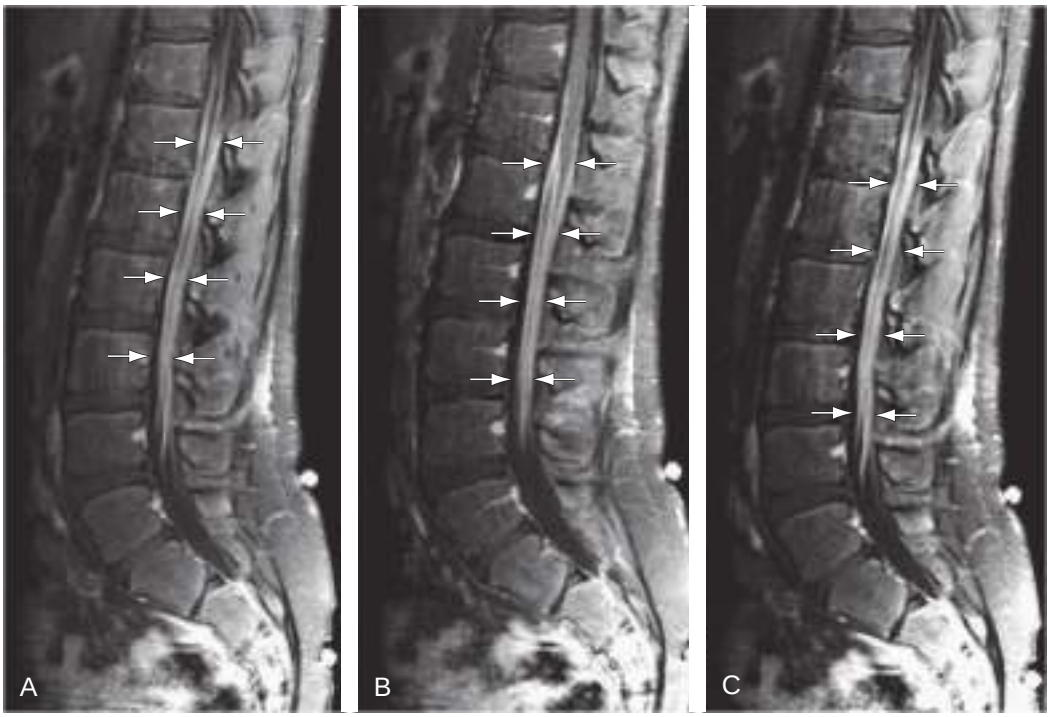

Fig. 656.3 Chronic inflammatory demyelinating polyneuropathy (CIDP) in a 13-yr-old male with peripheral neuropathy and gait disturbance. Sagittal fat-saturated T1 weighted images off the midline to the right **(A)**, at the midline **(B)**, and off the midline to the left **(C)**. *(From Slovis TL, ed. Caffey's Pediatric Diagnostic Imaging, 11th ed. Philadelphia: Mosby; 2008: Fig. 65-7.)*

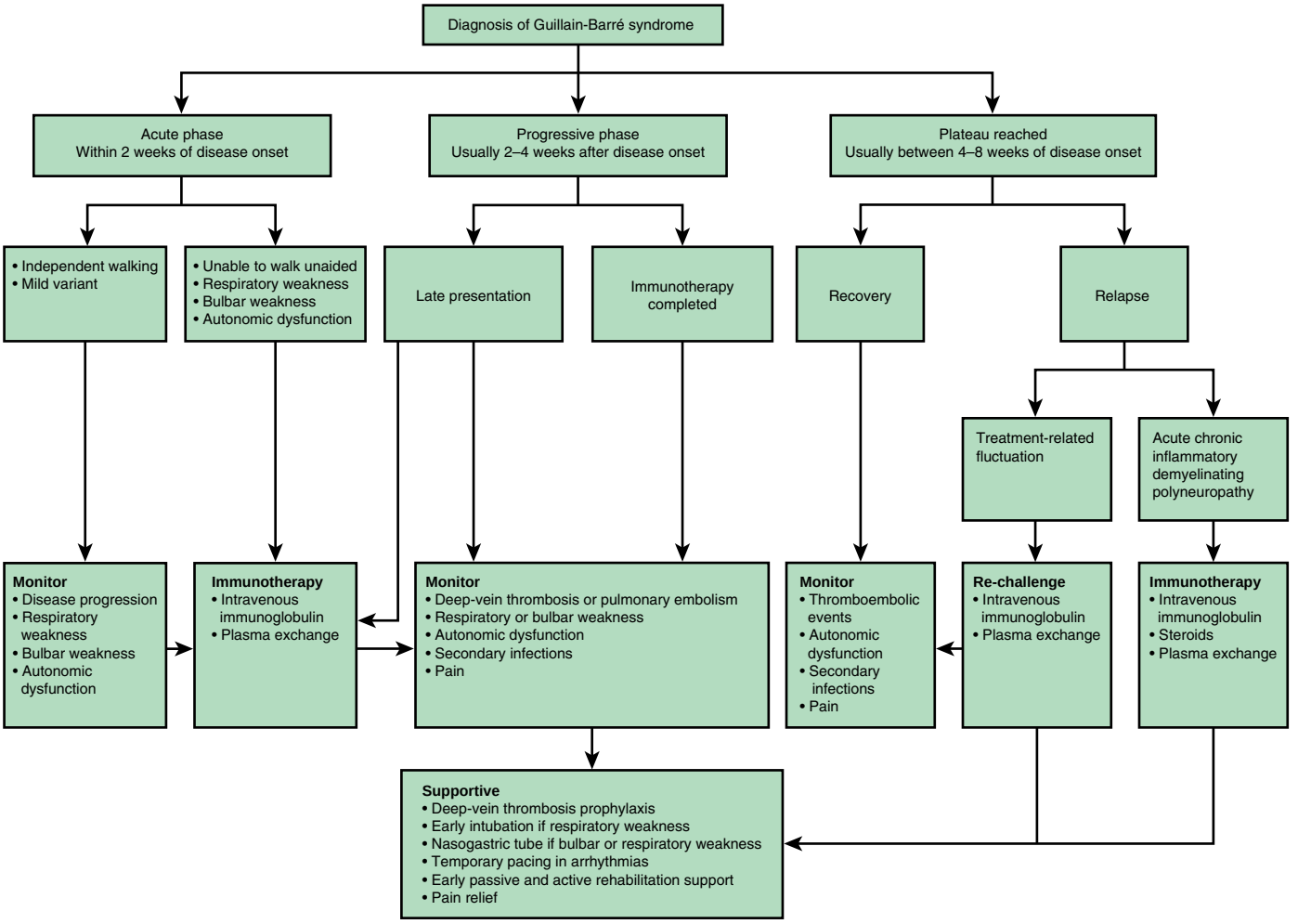

Fig. 656.4 Management algorithm for Guillain-Barré syndrome. Depending on the time of symptom presentation from disease onset, patients can be managed according to the disease phase. Immunotherapy with either intravenous immunoglobulin or plasma exchange is recommended when the patient cannot walk unaided. Supportive management includes monitoring for disease progression and early intervention when there is evidence of autonomic dysfunction, respiratory weakness, or bulbar weakness. Due to prolonged immobility, patients are also at risk of deep vein thrombosis and pulmonary embolism, warranting preventive prophylaxis. After plateau is reached, some patients can have a relapse, which could be due to treatment-related fluctuation, or an acute onset of chronic inflammatory demyelinating polyneuropathy. *(From Shahrizaila N, Lehmann HC, Kuwabara S. Guillain-Barre syndrome. Lancet. 2021;397:1214–1226. Fig. 3.)*

Chapter 657

Bell Palsy

Monique M. Ryan

Bell palsy is an *acute-onset* peripheral facial nerve palsy that is not associated with any other cranial nerve neuropathies or brainstem dysfunction. It is a common disorder at all ages from infancy through adolescence, usually developing suddenly about 2 weeks after a presumed viral infection. Numerous viruses have been linked with Bell palsy (Table 657.1). Active or reactivation of herpes simplex or varicella-zoster virus are the most common causes of Bell palsy (Fig. 657.1). In **Ramsay Hunt syndrome** (herpes zoster oticus), an acute facial nerve palsy is associated with painful vesicles in the external auditory canal or auricle. Hereditary forms of Bell palsy are rare. Bell palsy rarely occurs in the context of systemic hypertension or type 1 diabetes mellitus. *Unilateral or bilateral facial nerve palsy is often a sign of Lyme disease.* In addition, Lyme-associated facial palsy is often preceded by fever, malaise, headache, myalgias or arthralgias, all symptoms uncommon in idiopathic Bell palsy.

CLINICAL MANIFESTATIONS

Pain behind the ear may precede weakness, which develops acutely. Both the upper and lower portions of the face are paretic, and the corner of the mouth droops. Patients are unable to close the eye on the affected side and are hence at risk of exposure keratitis. Taste on the anterior two thirds of the tongue is lost on the involved side in approximately 50% of cases; this finding helps establish the anatomic limits of the lesion as being proximal or distal to the chorda tympani branch of the facial nerve. Lacrimation is spared. Facial numbness and paresthesias are rare, but when present suggest concomitant involvement of the trigeminal nerve. The blood pressure should always be checked in a child with acute facial weakness.

Imaging is not required for *typical* Bell palsy. In children less than 2 years of age or those in whom there is suspicion of other pathologies because of atypical findings or chronic or recurrent weakness, MRI of the facial nerve excludes structural lesions causing facial nerve dysfunction. Serology and other viral studies are generally noncontributory. A full blood count should be considered to exclude leukemia in younger patients or those with atypical findings. Lyme antibody testing is indicated in children from endemic areas.

In patients who do not recover within a few weeks, neurophysiologic examination of the facial nerve helps to determine the severity of the facial neuropathy and the likely speed of recovery. In chronic cases, other causes of facial neuropathy should be considered, including hypertension, diabetes, facial nerve tumors such as schwannomas and neurofibromas, infiltration of the facial nerve by leukemic cells or by a rhabdomyosarcoma of the middle ear, brainstem infarcts or tumors, and traumatic injury of the facial nerve.

TREATMENT

In contrast to adults, the outcome of pediatric Bell palsy is so good that benefit from treatment with corticosteroids, with or without acyclovir, has not been established, although many centers recommend a brief course of oral prednisone. In adults, treatment may include steroids *plus* an antiviral agent (valacyclovir, famciclovir) although this is controversial, and steroids alone have been beneficial, whereas antiviral agents alone have had no benefit. The combination may provide improved outcomes. Protection of the cornea with an ocular lubricant is especially important at night.

PROGNOSIS

Most children experience complete spontaneous recovery from Bell palsy within a few weeks from onset. A small proportion (<10%) has some residual facial weakness. Bilateral Bell palsy is rare, but as many as 15% of children experience recurrent episodes of facial weakness.

Nerve regrowth is occasionally misdirected, resulting in **synkinesis,** where activation of one muscle group may produce activation of another inappropriate muscle group; blinking may result in mouth twitching, smiling may cause eye blinking, and lacrimation (crocodile tears) may occur while eating. This complication is much less common in children than adults.

Table 657.1 Etiologies of Acute Peripheral Facial Palsy

COMMON
Idiopathic
Herpes simplex virus type 1*
Varicella-zoster virus*
Lyme disease (may be bilateral)
LESS COMMON INFECTIOUS CAUSES
Otitis media ± cholesteatoma
Epstein-Barr virus
Cytomegalovirus
Mumps
Human herpesvirus 6
Intranasal influenza vaccine
Mycoplasma
Toxocara
Rickettsia
AIDS/HIV
OTHER LESS COMMON ASSOCIATIONS
Trauma
Schwannoma of facial nerve
Infiltrative tumor
Aneurysm or vascular malformation
Anomalous narrowing of facial nerve canal
Hypertension
Sjögren syndrome
Diabetes mellitus, type 1
Guillain-Barré syndrome
Sarcoidosis
Kawasaki syndrome
Melkersson-Rosenthal syndrome†
Treatment with ribavirin or interferon

*Implicated in idiopathic Bell palsy.
†Noncaseating granulomas with facial (lips, eyelids) edema, recurrent alternating facial paralysis, family history, migraines, or headaches.

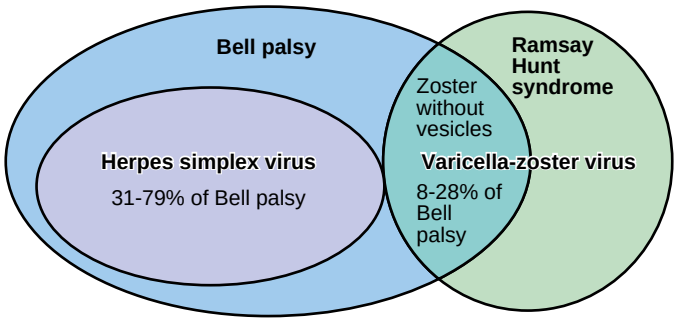

Fig. 657.1 Involvement of herpes simplex and varicella-zoster viruses in acute facial palsy. *(Modified from Hato N, Murakami S, Gyo K. Steroid and antiviral treatment for Bell's palsy. Lancet. 2008;371:1818–1820.)*

Disorders of the Eye

PART XXVII

Chapter 658

Growth and Development of the Eye

Scott E. Olitsky and Justin D. Marsh

The eye of a normal full-term infant at birth is approximately 65% of adult size. Postnatal growth is maximal during the first year, proceeds at a rapid but decelerating rate until the third year, and continues at a slower rate thereafter until puberty, after which little change occurs. The anterior structures of the eye are relatively large at birth but thereafter grow proportionately less than the posterior structures. This results in a progressive change in the shape of the globe such that it becomes more spherical.

In an infant, the sclera is thin and translucent, with a bluish tinge. The cornea is relatively large in newborns (averaging 10 mm) and attains adult size (nearly 12 mm) by the age of 2 years or earlier. Its curvature tends to flatten with age, resulting in a progressive change in the refractive properties of the eye. A normal cornea is perfectly clear. In infants born prematurely, however, the cornea may have a transient opalescent haze. The anterior chamber in a newborn appears shallow, and the angle structures, important in the maintenance of normal intraocular pressure, must undergo further differentiation after birth. The iris, typically light blue or gray at birth in White individuals, undergoes progressive change of color as the pigmentation of the stroma increases in the first 6 months of life. The pupils of a newborn infant tend to be small and are often difficult to dilate. This is the result of an immature iris dilator muscle. Remnants of the **pupillary membrane** (anterior vascular capsule) are often evident on ophthalmoscopic examination, appearing as cobweb-like lines crossing the pupillary aperture, especially in preterm infants.

The lens of a newborn infant is more spherical than that of an adult; its greater refractive power helps to compensate for the relative shortness of the young eye. The lens continues to grow throughout life, as new peripheral fibers continually push older fibers toward the center of the lens. With age, the lens becomes progressively denser and more resistant to the change of shape that occurs during accommodation (focusing of the lens).

The fundus of a newborn's eye is less pigmented than that of an adult; the choroidal vascular pattern is highly visible, and the retinal pigment pattern often has a fine peppery or mottled appearance. In some darkly pigmented infants, the fundus has a gray or opalescent sheen. In a newborn, the macular landmarks, particularly the foveal light reflex, are less well defined due to incomplete maturation of the retinal layers. The peripheral retina appears pale or grayish, and the peripheral retinal vasculature is immature, especially in premature infants. The optic nerve head color varies from pink to slightly pale, sometimes grayish. Within 4-6 months, the appearance of the fundus approximates that of the mature eye.

Superficial retinal hemorrhages may be observed in many newborn infants. These are usually absorbed promptly and rarely leave any permanent effect. The majority of birth-related retinal hemorrhages resolve within 2 weeks, with complete resolution of all such hemorrhages within 4-6 weeks of birth. Conjunctival hemorrhages also may occur at birth and are resorbed spontaneously without consequence.

Remnants of the primitive **hyaloid vascular system** may appear as small tufts or wormlike structures projecting from the disc (Bergmeister papilla) or as a fine strand traversing the vitreous; in some cases, only a small dot (Mittendorf dot) remains on the posterior aspect of the lens capsule.

An infant's eye is somewhat **hyperopic** (farsighted). The general trend is for hyperopia to increase from birth until age 7 years. Thereafter, the level of hyperopia tends to decrease rapidly until age 14 years. Elimination of the hyperopic state may occur during this time. If the process continues, a child may become **myopic** (nearsighted). A slower continuation of the decrease in hyperopia, or increase in myopia, continues into the third decade of life. The refractive state at any time in life depends on the net effect of many factors: the size of the eye, the state of the lens, and the curvature of the cornea.

Newborn infants tend to keep their eyes closed much of the time, but normal newborns can see, respond to changes in illumination, and fixate points of contrast. The visual acuity in newborns is estimated to be approximately 20/400. This poor vision is a result of the immature, multilayered foveal anatomy. Retinal development continues postnatally, maturing completely during the first few years of life. One of the earliest responses to a formed visual stimulus is an infant's regard for the mother's face, evident especially during feeding. By 2 weeks of age, an infant shows more sustained interest in large objects, and by 8-10 weeks of age, a normal infant can follow an object through an arc of 180 degrees. The acuity improves rapidly and may reach 20/30-20/20 by the age of 2-3 years.

Many normal infants may have imperfect coordination of the eye movements and alignment during the early days and weeks, but proper coordination should be achieved by 3-6 months, usually sooner. Persistent deviation of an eye in an infant at 6 months of age requires evaluation.

Tears often are not present with crying until after 1-3 months. Preterm infants have reduced reflex and basal tear secretion, which may allow topically applied medications to become concentrated and lead to rapid drying of their corneas.

Visit Elsevier eBooks+ at eBooks.Health.Elsevier.com for Bibliography.

Chapter 659

Examination of the Eye

Scott E. Olitsky and Justin D. Marsh

The eye exam is a routine part of pediatric well childcare, which begins in the newborn period. The primary care physician plays a critical role in the detection of both obvious and insidious asymptomatic eye diseases. School and community screening programs can also be effective in identifying problems at an early age. The American Academy of Ophthalmology recommends preschool vision screening during well child visits as a means of reducing preventable visual loss (Table 659.1). Referrals to an ophthalmologist should be

made when a significant ocular abnormality or visual acuity deficit is suspected. An ophthalmologist should also examine high-risk children, such as those with a family history of eye disease, or various systemic or genetic disorders, such as Down syndrome or juvenile idiopathic arthritis.

The basic eye exam, whether performed by a pediatrician or an ophthalmologist, must include visual acuity and visual field testing, assessment of pupils, ocular motility and alignment, a general external/facial examination, and finally, examination of the media and fundus via ophthalmoscopy.

The periodicity for visual assessment should occur beginning in the newborn to 6 month age group and continue at ages 6-12 months, 1-3 years, 4-5 years, and 6 years and older. The assessments include an ocular history, inspection of the lids and eyes, red reflex testing, pupil examination, ocular motility testing, and assessment of visual acuity.

When indicated, biomicroscopy (slit-lamp examination), cycloplegic refraction, and tonometry are performed by an ophthalmologist. Special diagnostic procedures, such as ultrasound, fluorescein angiography, electroretinography, or visual evoked response testing, are also indicated for specific conditions.

VISUAL ACUITY

There are various means of assessing visual acuity in the pediatric population. A child's age and ability to cooperate, as well as clinician preference, all factor into deciding which test to use. The most common visual acuity test in infants is an assessment of their ability to fixate and follow a target. If appropriate targets are used, this response can be demonstrated by approximately 6 weeks of age.

The test begins by seating the child comfortably in the caretaker's lap. The object of visual interest, usually a bright-colored toy or target with lights, is slowly moved to the right and to the left. The examiner observes whether the infant's eyes turn toward the object and follow its movements. The examiner can use a thumb or palm of the hand to occlude one of the infant's eyes to test each eye separately. Although a sound-producing object might compromise the purity of the visual stimulus, in practice, toys that squeak or rattle heighten an infant's awareness and interest in the test.

The human face is a better target than test objects. The examiner can exploit this by moving his or her face slowly in front of the infant's face. If the appropriate following movements are not elicited, the test should be repeated with the caretaker's face as the test stimulus. It should be remembered that even children with poor vision can follow a large object without apparent difficulty, especially if only one eye is affected.

An objective measurement of visual acuity is usually possible when children reach the age of 2.5-3 years. Children this age are tested using a schematic picture or other illiterate eye chart. Examples include Allen or Lea symbols and tumbling E. Each eye should be tested separately. It is essential to prevent peeking. The examiner should hold the occluder in place and observe the child throughout the test. The child should be reassured and encouraged throughout the test because many children are intimidated by the process and fear a "bad grade" or punishment for errors. In addition, many children may be too timid to verbally identify figures being tested and may be more willing to participate if given the opportunity to match the presented symbols to identical symbols provided on a handout during the exam. Matching is often preferred at this age, particularly in randomized control trials, because it also allows the clinician to test visual acuity using letters instead of figures, even if a child has not yet learned the alphabet.

An adult-type **Snellen acuity chart** can be used at 5-6 years of age if the child knows letters. A visual acuity of 20/40 is generally accepted as normal for 3-year-old children. At 4 years of age, 20/30 is acceptable. By 5 or 6 years of age, most children attain 20/20 vision.

Optokinetic nystagmus (the response to a sequence of moving targets; "railroad" nystagmus) can also be used to assess vision; this can be calibrated by targets of various sizes (stripes or dots) or by a rotating drum (known as an OKN drum) at specified distances.

The visual evoked response, an electrophysiologic method of evaluating the response to light and special visual stimuli, such as calibrated stripes or a checkerboard pattern, can also be used to study visual function in selected cases.

Preferential looking tests are used for evaluating vision in infants and children who cannot respond verbally to standard acuity tests. This is a behavioral technique based on the observation that, given a choice, an infant prefers to look at patterned rather than unpatterned stimuli. Because these tests require the presence of a skilled examiner, their use is often limited to research protocols involving preverbal children.

VISUAL FIELD ASSESSMENT

Visual field assessment must be geared to a child's age and abilities. Formal visual field examination (perimetry and scotometry) can often be accomplished in school-age children. In younger children and in the pediatrician's office, the examiner must often rely on confrontation techniques and finger counting in quadrants of the visual field. In many such children, only testing by attraction can be accomplished; the examiner observes a child's response to familiar objects brought into each of the four quadrants of the visual field of each eye in turn. The child's bottle, a favorite toy, and lollipops are particularly effective attention-getting items. These gross methods can often detect diagnostically significant field changes such as the bitemporal hemianopia of a chiasmal lesion or the homonymous hemianopia of a cerebral lesion.

COLOR VISION TESTING

Color vision testing can be accomplished when a child is able to name or trace the test figures, which include numbers, shapes, or other symbols. The common color vision testing tools include Ishihara color plates or Hardy Rand Littler. Color vision testing is not frequently necessary in young children; however, parents may request testing, particularly if their child seems to be slow in learning colors or if there is a family history of color vision deficiency. It is important to keep in mind and reassure parents that "color-deficient" children do not misname colors, and that true "color blindness" is very rare and not compatible with normal vision. **Color deficiency** is common in male patients but rare in females because the gene is transmitted in an X-linked manner. **Achromatopsia**, which may be encountered occasionally, is a condition of complete color blindness associated with subnormal visual acuity, nystagmus, and photophobia.

Color discrimination is a means of assessing the intensity of a hue, typically red. Patients describe the intensity of red depicted from the test object. A change in color discrimination (often referred to as color "desaturation") can be a sign of optic nerve or retinal disease.

PUPILLARY EXAMINATION

The pupil exam includes evaluations of both the direct and consensual responses to light, accommodation (a near target), and reduced illumination, noting the size and symmetry of the pupils under each testing condition. Special care must be taken to differentiate the reaction to light from the reaction to near gaze. A child's natural tendency is to look directly at the approaching light, inducing the near gaze reflex when one is attempting to test only the reaction to light; accordingly, every effort must be made to control fixation on a distance target. The swinging flashlight test is especially useful for detecting unilateral or asymmetric prechiasmatic afferent defects in children (see "Marcus Gunn Pupil" in Chapter 662).

OCULAR MOTILITY

Ocular motility testing assesses alignment and extraocular muscle function. This is tested by having a child follow an object in various positions of gaze, known as the *cardinal positions*. The cardinal positions are those in which one extraocular muscle predominantly functions and a deficit can be identified if present. Movements of each eye individually **(ductions)** and of the two eyes together (**versions**, conjugate movements, and convergence) are assessed.

Alignment can be assessed in two ways. The first is symmetry of the corneal light reflexes. The second method is to occlude each eye in an

Table 659.1 Vision Screening Guidelines

FUNCTION	RECOMMENDED TESTS	REFERRAL CRITERIA	COMMENTS
AGES 3-5 YEARS			
Distance visual acuity	Snellen letters Snellen numbers Tumbling E test HOTV test (contains only these 4 letters)	<4 of 6 correct on 20-ft line with either eye tested at 10 ft monocularly (i.e., <10/20 or 20/40), or Two-line difference between eyes, even within the passing range (i.e., 10/12.5 and 10/20 or 20/25 and 20/40)	Tests are listed in decreasing order of cognitive difficulty; the highest test that the child is capable of performing should be used; in general, Lea symbols or the HOTV test should be used for ages 3-5 years and Snellen letters or numbers for ages 6 years and older
	Picture tests		Testing distance of 3 m (10 ft) is recommended for all visual acuity tests
	Allen figures		A line of figures is preferred over a single figure
	Lea symbols		The nontested eye should be covered by an occluder held by the examiner or by an adhesive occluder patch applied to eye; the examiner must ensure that it is not possible to peek with the nontested eye
Ocular alignment	Cross cover test at 3 m (10 ft) or Random dot E stereo test at 40 cm (630 sec of arc)	Any eye movement <4 of 6 correct	
	Simultaneous red reflex test (Bruckner test)	Any asymmetry of pupil color, size, brightness	Direct ophthalmoscope used to view both red reflexes simultaneously in a darkened room from 2-3 ft away; detects asymmetric refractive errors as well
Ocular media clarity (cataracts, tumors, etc.)	Red reflex	White pupil, dark spots, absent reflex	Direct ophthalmoscope, darkened room. View eyes separately at 12-18 inches; white reflex indicates possible retinoblastoma
AGES 6 YEARS AND OLDER			
Distance visual acuity	Snellen letters Snellen numbers Tumbling E test HOTV test	<4 of 6 correct on 4.5 m (15 ft) line with either eye tested at 3 m (10 ft) monocularly (i.e., <10/15 or 20/30)	Tests are listed in decreasing order of cognitive difficulty; the highest test that the child is capable of performing should be used; in general, Lea symbols or the HOTV test should be used for ages 3-5 years and Snellen letters or numbers for ages 6 years and older
	Picture tests	Two-line difference between eyes, even within the passing range (i.e., 10/10 and 10/15 or 20/20 and 20/30)	Testing distance of 3 m (10 ft) is recommended for all visual acuity tests
	Allen figures		A line of figures is preferred over a single figure
	Lea symbols		The nontested eye should be covered by an occluder held by the examiner or by an adhesive occluder patch applied to the eye; the examiner must ensure that it is not possible to peek with the nontested eye
Ocular alignment	Cross cover test at 3 m (10 ft) or Random dot E stereo test at 40 cm (630 sec of arc)	Any eye movement <4 of 6 correct	

alternating fashion and observe for a change in fixation of the viewing eye (see discussion on cover testing for strabismus in Chapter 663).

BINOCULAR VISION

Attaining binocular visual function is one of the primary goals of amblyopia therapy and ocular realignment surgery. Just as there are multiple methods for assessing visual acuity, there are various means of testing the level of binocular vision. The Titmus test is probably the most frequently used test; a series of three-dimensional images are shown to the child while he or she wears a set of polarized glasses. The level of difficulty with which these images can be detected correlates with the degree of binocular vision present.

EXTERNAL EXAMINATION

The external examination begins with general inspection, paying close attention to size, shape, and symmetry of the orbits, in addition to the position and movement of the lids and position and symmetry of the globes. Viewing the eyes and lids in such a manner aids in detecting orbital asymmetry, lid masses, proptosis (exophthalmos), and abnormal pulsations. Palpation is also important in detecting orbital and lid masses. Orbital dermoids and capillary hemangiomas are frequently evaluated during the external examination.

The lacrimal system is assessed by looking for evidence of tear deficiency, overflow of tears (epiphora), erythema, and swelling in the region of the tear sac or gland. The lacrimal gland is located in the superotemporal orbit, beneath the eyebrow. The tear drainage system, which includes the lacrimal sac, is located within the medial wall of the orbit, where the eyelids meet the bridge of the nose. The sac is massaged to check for reflux when obstruction is suspected. The presence and position of the puncta are also checked.

The lids and conjunctivae are specifically examined for focal lesions, foreign bodies, and inflammatory signs; loss and misdirection of lashes should also be noted. When necessary, the lids can be everted in the following manner: (1) instruct the patient to look down; (2) grasp the lashes of the patient's upper lid between the thumb and index finger of one hand; (3) place a probe, a cotton-tipped applicator, or the thumb of the other hand at the upper margin of the tarsal plate; and (4) pull the lid down and outward and evert it over the probe, using the instrument as a fulcrum. Foreign bodies commonly lodge in the concavity just above the lid margin and are exposed only by fully everting the lid.

The anterior segment of the eye is then evaluated with oblique focal illumination, noting the luster and clarity of the cornea, the depth and clarity of the anterior chamber, and the features of the iris. Transillumination of the anterior segment aids in detecting opacities and in demonstrating atrophy or hypopigmentation of the iris; these latter signs are important when ocular albinism is suspected. When necessary, fluorescein dye can be used to aid in diagnosing abrasions, ulcerations, and foreign bodies.

BIOMICROSCOPY (SLIT-LAMP EXAMINATION)

The slit-lamp exam provides a highly magnified view of the various structures of the eye and an optical section through the media of the eye—the cornea, aqueous humor, lens, and vitreous. Lesions can be identified and localized according to their depth within the eye; the resolution is sufficient to detect individual inflammatory cells in the aqueous and anterior vitreous. With the addition of special lenses and prisms, the angle of the anterior chamber and components of the fundus also can be examined with a slit lamp. Biomicroscopy is often crucial in trauma and in examining for iritis. It is also helpful in diagnosing many metabolic and genetic diseases of childhood.

FUNDUS EXAMINATION (OPHTHALMOSCOPY)

The ideal setting for ophthalmoscopy is with a well-dilated pupil unless there are neurologic or other contraindications. Tropicamide (Mydriacyl) 0.5–1% and phenylephrine (Neo-Synephrine) 2.5% are recommended as mydriatics of short duration. These are safe for most children, but the possibility of adverse systemic effects must be recognized. For very small infants, especially 6 months or younger, more dilute preparations may be advisable. Beginning with posterior landmarks, the disc, the macula, and the four quadrants are systematically examined by following each of the major vessel groups to the periphery. Retinal hemorrhages, vascular anomalies, and posterior uveitis are often appreciated during this segment of the examination. Color, cup, and contour of the optic nerve should be noted as well. Abnormalities are frequently followed with further imaging studies such as a CT or MRI or diagnostic testing such as automated perimetry (see "Visual Field Assessment" earlier). The midperipheral retina can be seen if a child is directed to look up and down and to the right and left. Even with care, only a limited fraction of the fundus can be seen with a direct or handheld ophthalmoscope. For examination of the far periphery, an indirect ophthalmoscope is used, and full dilation of the pupil is essential.

REFRACTION

Refraction determines the focusing power of the eye: the degree of nearsightedness (myopia), farsightedness (hypermetropia), or astigmatism. Retinoscopy provides an objective determination of the amount of correction needed and can be performed at any age, including the newborn period. In young children, it is best done with cycloplegia using cyclopentolate 1% eye drops in an ophthalmologist's office. Subjective refinement of refraction involves asking patients for preferences in the strength and axis of corrective lenses; it can be accomplished in many school-age children. Refraction and determination of visual acuity with appropriate corrective lenses in place are essential steps in deciding whether a patient has a visual defect or amblyopia. Photoscreening cameras aid ancillary medical personnel in screening for refractive errors in preverbal children. The accuracy and practical usefulness of these devices are still being investigated.

TONOMETRY

Tonometry is the method of assessing intraocular pressure. It may be performed with a portable, stand-alone instrument or by the applanation method during slit-lamp examination. Alternative methods are pneumatic, electronic, or rebound tonometry. When accurate measurement of the pressure is necessary in a child who cannot cooperate, it may be performed with sedation or general anesthesia. A gross estimate of pressure can be made by palpating the globe with the index fingers placed side by side on the upper lid above the tarsal plate.

Visit Elsevier eBooks+ at eBooks.Health.Elsevier.com for Bibliography.

Chapter 660

Abnormalities of Refraction and Accommodation

Scott E. Olitsky and Justin D. Marsh

Emmetropia is the normal state in which parallel rays of light come to focus on the retina with the eye at rest (nonaccommodating). Even though such an ideal optical state is common, the opposite condition, ametropia, often occurs. Three principal types of **ametropia** exist: **hyperopia** (farsightedness), **myopia** (nearsightedness), and **astigmatism** (Fig. 660.1). Most children are physiologically hyperopic at birth. Nevertheless, myopia and astigmatism may develop early in childhood, particularly when associated with previous prematurity or numerous medical diagnoses. With growth, the refractive state tends to change and should be evaluated periodically.

Measurement of the refractive state of the eye (refraction) can be accomplished both objectively and subjectively. The objective method involves directing a beam of light from a retinoscope onto a patient's retina. Using loose lenses of various strengths held in front of the eye, the retinal light reflex (viewed through the pupil) can be neutralized, yielding a precise refraction. An objective refraction is obtainable at any age because it requires no response from the patient. In infants and children, it is generally more accurate to perform a refraction after instillation of eye drops that produce **mydriasis** (dilation of the pupil) and **cycloplegia** (paralysis of accommodation); those used most commonly are tropicamide (Mydriacyl), cyclopentolate (Cyclogyl), and atropine sulfate. A subjective refraction involves placing lenses in front of the eye and having the patient report which lenses provide the clearest image of the letters on a chart. This method is dependent on a patient's ability to discriminate and communicate, but it can be used for some children and may be helpful in determining the best refractive correction for children who are developmentally capable.

HYPEROPIA

If parallel rays of light come to focus posterior to the retina with the eye in a neutral state, hyperopia or farsightedness exists. This may result from a shorter anteroposterior diameter of the eye or a lower refractive power of the cornea or lens.

In hyperopia, the additional refracting power needed to bring objects into focus at distance and near is generated through the accommodative mechanism. If the accommodative effort required for focus is within that child's accommodative amplitude, the vision is clear. In

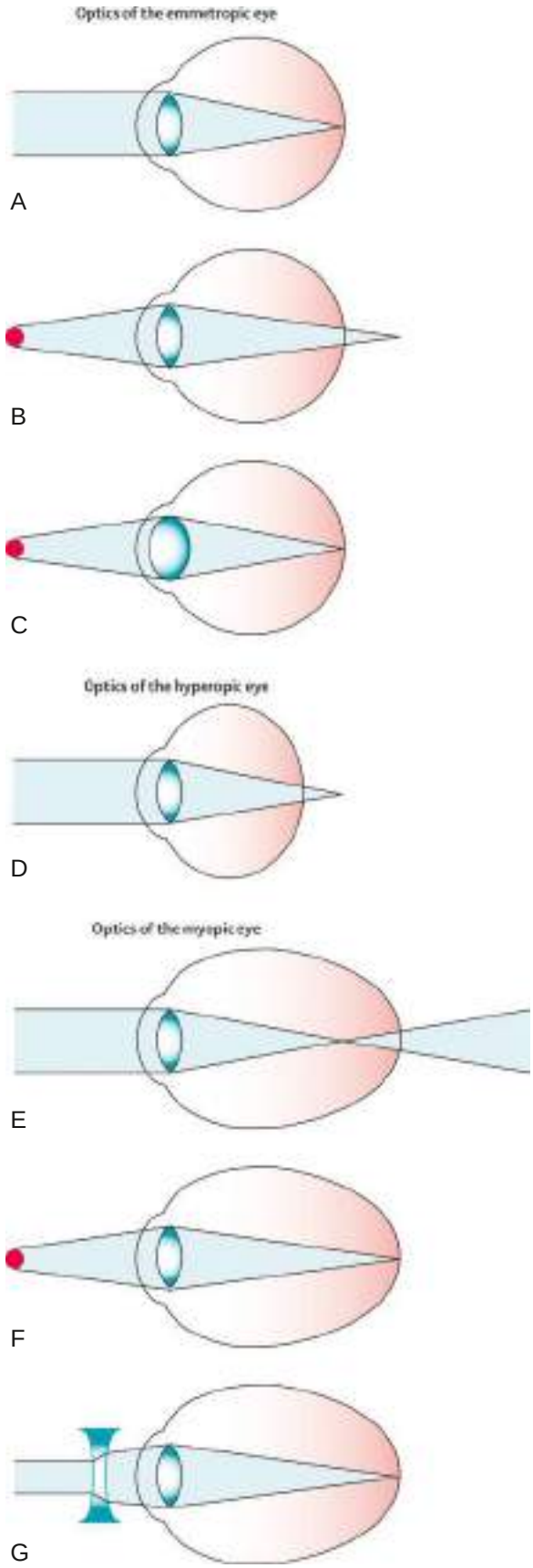

Fig. 660.1 Schematic optics of the eye. **A-C**, Emmetropic eyes. **D**, Hyperopic eyes. **E-G**, Myopic eyes. **A**, In emmetropic eyes, the parallel rays of a distant object are focused on the photoreceptors. **B**, When a closer object is viewed, the image is in focus behind the photoreceptors. The image can be brought forward into focus on the photoreceptors by the process of accommodation—increasing the optical power of the lens **(C)**. In hyperopic eyes **(D)**, the eye is too short, and the image of a distant object is focused behind the photoreceptors and can be brought into focus by accommodation. Myopic eyes are eyes that have grown too long **(E)**, and the image of a distant object falls in front of the photoreceptors and cannot be brought into focus by accommodation. When closer objects are viewed, the image moves back toward the photoreceptors, and at a certain distance (the far point), which is related inverse to the severity of the myopia, it comes into focus **(F)**. Closer objects can then be brought into focus using accommodation. Optical correction for myopia is achieved with concave (diverging) lenses, which move the image into focus on the photoreceptors (G). Contact lenses work in a similar way, whereas refractive surgery reduces the power of the cornea to bring the image of distant objects into focus. For equal corneal power, myopic eyes have longer axial lengths than emmetropic eyes, with deeper anterior and vitreal chambers. Their lenses tend to be thinner and of lower power than those of emmetropic eyes. *(From Morgan IG, Ohno-Matusi K, Saw SM. Myopia. Lancet. 2012;379:1739-1746, Fig. 1, p. 1740.)*

high degrees of hyperopia requiring greater accommodative effort, vision may be blurred, and the child may complain of eyestrain, headaches, or fatigue. Squinting, eye rubbing, and lack of interest in reading are frequent manifestations. If the induced discomfort is great enough, a child may not make the effort to focus and may develop bilateral amblyopia (ametropic amblyopia). Esotropia may also be associated (see discussion on convergent strabismus, accommodative esotropia in Chapter 663). Convex lenses (spectacles or contact lenses) of sufficient strength to provide clear vision and comfort are prescribed when indicated. Even children who have high degrees of hyperopia but who have good vision will happily wear glasses because they provide comfort by eliminating the excessive accommodation required to see well. Preverbal children should also be given glasses for high levels of hyperopia to prevent the development of esotropia or amblyopia. Children with normal levels of hyperopia do not require correction in the majority of cases.

MYOPIA

In myopia, parallel rays of light come to focus anterior to the retina. This is a result of either a long anteroposterior diameter of the eye or a higher refractive power of the cornea or lens. The principal symptom is blurred vision for distant objects. The far point of clear vision varies inversely with the degree of myopia; as the myopia increases, the far point of clear vision moves closer to the eye. For example, an individual with one diopter of myopia has a far point of clear focus that is 1 m from the eye. Any object located farther than 1 m from the eye will begin to appear blurry. Similarly, for an individual with 3 diopters of myopia, the far point of clear vision is now $\frac{1}{3}$ m from the eye, as the far point is the inverse of the power of myopia, as measured in meters. Thus myopic children tend to hold objects and reading material closer, prefer to be close to the blackboard, and may be uninterested in distant activities. Squinting is common because the visual acuity is improved when the lid aperture is reduced, also known as the *pinhole effect.*

Myopia is infrequent in infants and preschool-age children. It is more common in infants with a history of **retinopathy of prematurity.** A hereditary tendency to myopia is also observed, and children of myopic parents should be examined at an early age. Nonsyndromic myopia is associated in some families with variants in the high-grade myopia-1 locus *(MYP1)* as well as in *SLITRK6* and *RASGRF1* genes. The incidence of myopia increases during the school years, especially during the preteen and teen years. The degree of myopia also increases with age during periods of rapid growth.

Concave lenses (spectacles or contact lenses) of appropriate strength are provided to allow for clear vision. Changes are usually needed periodically, from every few months to every 1-2 years. Globally the prevalence of myopia appears to be increasing, leading to heightened interest in myopia prevention treatment. Numerous therapies, including cycloplegic agents (topical atropine sulfate), peripheral defocus contact lenses, and reading addition spectacle lenses (bifocal lenses) are under investigation in an attempt to prevent or slow the progression of myopia.

Excimer laser correction for myopia has been approved for adults since 1995. The laser is applied to the corneal stroma to reshape the cornea, changing its refractive power (Fig. 660.2). Laser-assisted in situ keratomileusis (LASIK) uses either a microkeratome or a femtosecond laser to produce an epithelial-stromal flap, permitting the underlying corneal tissue to be ablated. The flap is then reseated and assumes the altered corneal shape. Photorefractive keratectomy (PRK) requires manual removal of the epithelium after treatment with alcohol to expose the Bowman layer and stroma, allowing the corneal surface to then be treated by the excimer laser. The epithelium regenerates to cover the defect over a period of 4-10 days. Reduction or elimination of refractive error is usually significant and remains stable over time. Risks are greatest with high degrees of myopia (>10 diopters) and include starbursts, halos, and distorted images or multiple images (usually at night). Refractive surgery is not approved for pediatric patients but is occasionally used off-label to treat certain forms of amblyopia or other high refractive error states in children who are unable to wear proper refractive correction.

In most cases, myopia is not a result of pathologic alteration of the eye and is referred to as simple or physiologic myopia. Some children may have **pathologic myopia**, a rare condition caused by a pathologically abnormal axial length of the eye; this is usually associated with thinning of the sclera, choroid, and retina and often with some degree of uncorrectable visual impairment. Tears or breaks in the retina may occur as it becomes increasingly thin, leading to the development of retinal detachments. Myopia may also occur as a result of other ocular abnormalities, such as keratoconus, ectopia lentis, congenital stationary night blindness, and glaucoma. Myopia is also a major feature of Stickler syndrome, a genetic disorder of connective tissue involving problems with vision, hearing, and facial and skeletal development; it is also common in Marfan syndrome, homocystinuria, and Weill-Marchesani syndrome.

ASTIGMATISM

In astigmatism, the refractive powers of the various meridians of the eye differ. Most cases are caused by irregularity in the curvature of the cornea, although some astigmatism results from changes in the lens. Mild degrees of astigmatism are common and may produce no symptoms. With greater degrees, distortion of vision can occur. To achieve a clearer image, a person with astigmatism uses accommodation or squints to obtain a pinhole effect. Symptoms include eyestrain, headache, and fatigue. Cylindrical or spherocylindrical lenses are used to provide optical correction when indicated. Glasses may be needed constantly or only part time, depending on the degree of astigmatism and the severity of the attendant symptoms. In some cases, contact lenses are used.

Infants and children with corneal irregularity resulting from injury, ptosis, or hemangiomas of the periorbita or eyelid are at increased risk of astigmatism and associated amblyopia.

ANISOMETROPIA

When the refractive state of one eye is significantly different from the refractive state of the other eye, **anisometropia** exists. If uncorrected, one eye may always be out of focus, leading to the development of amblyopia. Early detection and correction are essential if normal visual development in both eyes is to be achieved.

ACCOMMODATION

During accommodation, the ciliary muscle contracts, the suspensory fibers of the lens relax, and the lens assumes a more rounded shape, adding power to the lens. The amplitude of accommodation is greatest during childhood and gradually diminishes with age. The physiologic decrease in accommodative ability that occurs with age is called **presbyopia**.

Disorders of accommodation in children are relatively rare. Premature presbyopia is occasionally encountered in young children. The most common cause of paralysis of accommodation in children is

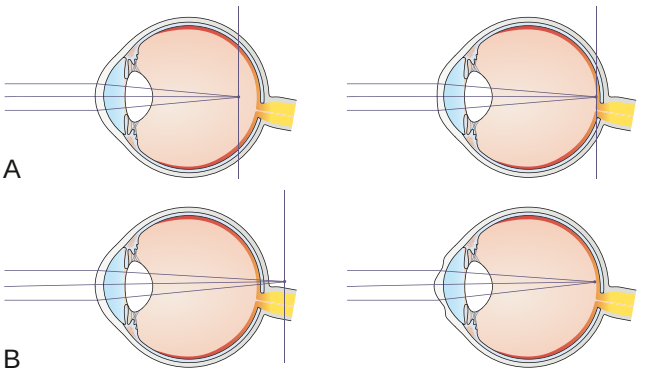

Fig. 660.2 Refractive errors before *(left)* and after *(right)* surgery. A, Refractive eye surgery corrects myopia using central ablation to flatten the corneal curvature (B) and corrects hyperopia using mid-peripheral ablation to steepen the corneal curvature. *(Modified from Kim T, Alió del Barrio, Wilkins M, et al. Refractive surgery. Lancet. 2019;393:2085-2094, Fig. 1, p. 2086.)*

intentional or inadvertent use of cycloplegic substances, topically or systemically; included are all the anticholinergic drugs and poisons, as well as plants and plant substances having these effects. Neurogenic causes of accommodative paralysis include lesions affecting the oculomotor nerve (third cranial nerve) along any part of its course. Differential diagnoses include tumors, degenerative diseases, vascular lesions, trauma, and infectious etiologies. Systemic disorders that may cause impairment of accommodation include botulism, diphtheria, Wilson disease, diabetes mellitus, and syphilis. Adie tonic pupil may also lead to a deficiency of accommodation after some viral illnesses (see Chapter 662). An apparent defect in accommodation may be psychogenic in origin; it is common for a child to feign inability to read when it can be demonstrated that visual acuity and ability to focus are normal.

Visit Elsevier eBooks+ at eBooks.Health.Elsevier.com for Bibliography.

Chapter 661

Disorders of Vision

Scott E. Olitsky and Justin D. Marsh

Severe visual impairment (corrected vision poorer than **6/60**) and blindness in children have many etiologies and may be caused by multiple defects affecting any structure or function along the visual pathways (Tables 661.1, 661.2, 661.3). The overall incidence is approximately 2.5/100,000 children; the incidence is higher in developing countries, in low birthweight infants, and in the first year of life. The most common causes occur during the prenatal and perinatal time periods; the cerebral-visual pathways, optic nerve (hypoplasia, atrophy), and retinal (Leber amaurosis) sites are most often affected. Important prenatal causes include microphthalmia/anophthalmia as well as autosomal recessive (most common), autosomal dominant, and X-linked genetic disorders and hypoxia or chromosomal syndromes. Perinatal/neonatal causes include retinopathy of prematurity, hypoxia-ischemia, and infection. Severe visual impairment starting in older children may be due to central nervous system or retinal tumors, infections, hypoxia-ischemia, injuries, neurodegenerative disorders, or juvenile idiopathic arthritis.

AMBLYOPIA

This is a decrease in visual acuity, unilateral or bilateral, that occurs in visually immature children as a result of a lack of a clear image projecting onto the retina. The unformed retinal image may occur secondary to a deviated eye **(strabismic amblyopia)**, an unequal need for vision correction between the eyes **(anisometropic amblyopia)**, a high refractive error in both eyes **(ametropic amblyopia)**, or a media opacity within the visual axis **(deprivation amblyopia)**.

The development of visual acuity normally proceeds rapidly in infancy and early childhood. Anything that interferes with the formation of a clear retinal image during this early developmental period can produce amblyopia. Amblyopia occurs only during the critical period of development before the cortex has become visually mature, within the first decade of life. The younger the child, the more susceptible he or she is to the development of amblyopia.

The **diagnosis** of amblyopia is confirmed when a complete ophthalmologic examination reveals reduced acuity that is unexplained by an organic abnormality. If the history and ophthalmologic examination do not support the diagnosis of amblyopia in a child with poor vision, consideration must be given to other causes (neurologic, psychologic). *Amblyopia is usually asymptomatic and can avoid detection until vision screening, which may delay diagnosis as screening programs often target school-age children.* This is problematic because amblyopia is more resistant to treatment at an older age, being reversed more rapidly in younger children whose visual system is less mature. Thus one key to the successful treatment of amblyopia is early detection and prompt intervention.

Most often, **treatment** first consists of removing any media opacity or prescribing appropriate glasses, if needed, so that a well-focused retinal image can be produced in each eye. The sound eye is then covered (occlusion therapy) or blurred with glasses (fogging) or drops (penalization therapy) to stimulate proper visual development of the more severely affected eye. Occlusion therapy may provide a more rapid improvement in vision, but some children may better tolerate atropine penalization. The best treatment for any one patient should be selected on an individual basis. The goals of treatment should be thoroughly understood and the treatment carefully supervised. Close monitoring of amblyopia therapy by an ophthalmologist is essential, especially in the very young, to avoid deprivation amblyopia in the good eye. Many families need reassurance and support throughout the trying course of treatment. Although full-time occlusion has historically been considered the best way to treat children with amblyopia, a series of prospective studies has shown that some children can achieve similar results with part-time patching, or the use of atropine drops. Historical thought was that older children would not respond to amblyopia therapy. Studies suggest older children and adolescents deemed visually mature who demonstrate amblyopia, particularly refractive or anisometropic in etiology, can demonstrate improvement in vision with appropriate therapy.

DIPLOPIA

Diplopia, or double vision, is generally a result of a misalignment of the visual axes. Occluding either eye relieves the diplopia if it is binocular in origin. Affected children commonly squint, cover one eye with a hand, or assume an abnormal head posture (a face turn or head tilt) to alleviate the bothersome sensation. These behaviors, especially in preverbal children, are important clues to diplopia. *The onset of diplopia in any child warrants prompt evaluation; it may signal the onset of a serious problem such as increased intracranial pressure, a brain tumor, infection (Lyme disease), migraine, Guillain-Barré syndrome, or an orbital mass* (Fig. 661.1).

Monocular diplopia is less common and results from refractive error, dislocation of the lens, cataract, dry eyes, or some defect in the media or macula. With this type of diplopia, occluding the nondiplopic eye will not relieve the symptoms. Monocular diplopia may also often have psychologic causes.

SUPPRESSION

In the presence of strabismus, diplopia occurs secondary to the same image falling on different regions of the retina in each eye. In a visually immature child, a process may occur in the cortex that eliminates the disability of seeing double. This is an active process and is termed **suppression**. It typically only develops in children. Although suppression eliminates the annoying symptom of diplopia, frequent suppression may not only place the patient at risk for amblyopia but also increase the risk for worsening strabismus. Once suppression develops, it may allow an intermittent strabismus to become constant or strabismus to redevelop later in life, even after successful treatment during childhood.

AMAUROSIS

Amaurosis is partial or total loss of vision; the term is usually reserved for profound impairment, blindness, or near blindness. When amaurosis exists from birth, primary consideration in the differential diagnosis must be given to developmental malformations, damage consequent to gestational or perinatal infection, anoxia or hypoxia, perinatal trauma, and the genetically determined diseases that can affect the eye itself or the visual pathways (see Table 661.3). Often the reason for amaurosis can be readily determined by objective ophthalmic examination; examples are severe microphthalmia, corneal opacification, dense cataracts, chorioretinal scars, macular defects, retinal dysplasia, and severe optic nerve hypoplasia. In other cases, an intrinsic retinal disease may not be apparent on initial ophthalmoscopic examination, or the defect may involve the brain and not the eye. Neuroradiologic (MRI or CT) and electrophysiologic (electroretinography) evaluation are helpful in these cases.

Amaurosis that develops in a child who once had useful vision has different implications. In the absence of obvious ocular disease (cataract, chorioretinitis, retinoblastoma, retinitis pigmentosa), consideration must be given to many neurologic and systemic disorders that can affect the visual pathways (see Table 661.1). Amaurosis of rather

Table 661.1 Causes of Childhood Severe Visual Impairment or Blindness

CONGENITAL	**INFECTIOUS/INFLAMMATORY PROCESSES**
Optic nerve hypoplasia or aplasia	Encephalitis, especially in the prenatal infection syndromes caused by *Toxoplasma gondii*, cytomegalovirus, rubella virus, *Treponema pallidum*, herpes simplex virus, Zika virus
Holoprosencephaly	Meningitis or arachnoiditis
Septo-optic dysplasia	Chorioretinitis
Optic coloboma	Endophthalmitis
Congenital hydrocephalus	Trachoma
Hydranencephaly	Keratitis
Porencephaly	Uveitis
Microcephaly	Sarcoidosis
Encephalocele, particularly occipital	Optic neuritis
Morning glory disc	Hemophagocytic lymphohistiocytosis
Aniridia	Granulomatosis with polyangiitis
Microphthalmia/anophthalmia syndromes	**HEMATOLOGIC DISORDERS**
Persistent pupillary membrane	Leukemia with central nervous system involvement
Cataracts	Langerhans cell histiocytosis
Persistent hyperplastic primary vitreous	**VASCULAR AND CIRCULATORY DISORDERS**
Anterior segment dysgenesis syndromes	Collagen vascular diseases
Peters anomaly	Arteriovenous malformations—intracerebral hemorrhage, subarachnoid hemorrhage
Axenfeld-Rieger anomaly	Central retinal occlusion
Glaucoma syndromes (see Table 661.2)	Retinal vasculitis
PHAKOMATOSES	Coats disease
Tuberous sclerosis	Susac syndrome
Neurofibromatosis (special association with optic glioma)	**TRAUMA**
Sturge-Weber syndrome	Contusion or avulsion of optic nerves, chiasm, globe, cornea
von Hippel-Lindau disease	Cerebral contusion or laceration
TUMORS	Intracerebral, subarachnoid, or subdural hemorrhage
Retinoblastoma	Retinal detachment
Optic glioma	Laser injury
Perioptic meningioma	**DRUGS AND TOXINS**
Craniopharyngioma	Quinine
Cerebral glioma	Ethambutol
Astrocytoma	Methanol
Posterior and intraventricular tumors when complicated by hydrocephalus	Many others
Pseudotumor cerebri	**OTHER**
NEURODEGENERATIVE DISEASES	Retinopathy of prematurity
Cerebral storage disease	Sclerocornea
Gangliosidoses, particularly Tay-Sachs disease, Sandhoff variant, generalized gangliosidosis	Conversion reaction
Other lipidoses and ceroid lipofuscinoses, particularly the late-onset disorders such as those of Jansky-Bielschowsky and of Batten-Mayou-Spielmeyer-Vogt	Osteopetrosis
Mucopolysaccharidoses, particularly Hurler syndrome and Hunter syndrome	Susac syndrome: branch retinal artery occlusions, hearing loss, CNS dysfunction
Leukodystrophies (dysmyelination disorders), particularly metachromatic leukodystrophy and Canavan disease	Coats disease: poor vision, retinal telangiectasias and exudation
Demyelinating sclerosis (myelinoclastic diseases), especially Schilder disease and Devic neuromyelitis optica	
Special types: Dawson disease, Leigh disease, the Bassen-Kornzweig syndrome, Refsum disease	
Retinal degenerations: retinitis pigmentosa and its variants and Leber congenital type (see Table 661.3)	
Optic atrophies: congenital autosomal recessive type, infantile and congenital autosomal dominant types, Leber disease, and atrophies associated with hereditary ataxias: Behr, Marie, and Sanger-Brown	

Modified from Kliegman R. *Practical Strategies in Pediatric Diagnosis and Therapy*. Philadelphia: WB Saunders;1996.

rapid onset may indicate an encephalopathy (hypertension), infectious or inflammatory (optic neuritis) processes, vasculitis, migraine, leukemia, drugs or toxins, eclampsia, or trauma. It may be caused by acute demyelinating disease affecting the optic nerves, chiasm, or cerebrum. In some cases, precipitous loss of vision is a result of increased intracranial pressure, rapidly progressive hydrocephalus, or dysfunction of a ventricular shunt. More slowly progressive visual loss suggests tumor or neurodegenerative disease. Gliomas of the optic nerve and chiasm and craniopharyngiomas are primary diagnostic considerations in children who show progressive loss of vision.

Clinical manifestations of impairment of vision vary with the age and abilities of a child, the mode of onset, and the laterality and severity of the deficit. The first clue to amaurosis in an infant may be **nystagmus** or **strabismus,** with the vision deficit itself passing undetected for some time. Timidity, clumsiness, or behavioral change may be the initial clues in the very young. Deterioration in school progress and indifference to school activities are common signs in an older child. School-age children often try to hide their disability and, in the case of very slowly progressive disorders, may not themselves realize the severity of the problem; some detect and promptly report small changes in their vision.

Any evidence of loss of vision requires prompt and thorough ophthalmic evaluation. Complete delineation of childhood amaurosis and its cause may require extensive investigation involving neurologic evaluation, electrophysiologic tests, neuroradiologic procedures, and sometimes metabolic and genetic studies. Furthermore, attendant special educational, social, and emotional needs must be met.

Table 661.2 Congenital Glaucoma and Anterior Segment Dysgenesis*

OMIM NUMBER	GENE SYMBOL	PROTEIN	PHENOTYPE	MODE OF INHERITANCE	SYNDROMIC (S) OR ISOLATED (I)
105650	*RPS19*	Ribosomal protein S19	Diamond-Blackfan anemia 1	AD	S
137600	*PITX2*	Paired like homeodomain 2	Anterior segment dysgenesis 4	AD	I
175780	*COL4A1*	Collagen type IV alpha 1 chain	Brain small vessel disease with or without ocular anomalies including congenital glaucoma	AD	S
180849	*CREBBP*	CREB binding protein	Rubinstein-Taybi syndrome 1	AD	S
236670	*POMT1*	Protein O-mannosyltransferase 1	Muscular dystrophy-dystroglycanopathy (congenital with brain and eye anomalies), type A, 1; muscular dystrophy-dystroglycanopathy (congenital with cognitive disabilities), type B, 1; muscular dystrophy-dystroglycanopathy (limb-girdle), type C, 1	AR	S
249420	*SH3PXD2B*	SH3 and PX domains 2B	Frank-Ter Haar syndrome with or without glaucoma	AR	S
251750	*LTBP2*	Latent transforming growth factor beta binding protein 2	Weill-Marchesani syndrome 3; glaucoma 3, primary congenital, D; microspherophakia and/or megalocornea, with ectopia lentis and with or without secondary glaucoma	AR	S or I
253280	*POMGNT1*	Protein O-linked mannose N-acetylglucosaminyltransferase 1 (beta 1,2-)	Muscular dystrophy-dystroglycanopathy (congenital with brain and eye anomalies), type A, 3	AR	S
600221	*TEK*	TEK receptor tyrosine kinase	Glaucoma 3, primary congenital, E; Venous malformations, multiple cutaneous and mucosal	AD	S or I
601090	*FOXC1*	Forkhead box C1	Anterior segment dysgenesis 3, multiple subtypes; Axenfeld-Rieger syndrome, type 3	AD	S or I
601631	*FOXC1*	Forkhead box C1	Anterior segment dysgenesis 3, multiple subtypes; Axenfeld-Rieger syndrome, type 3	AD	S or I
601652	*MYOC*	Myocilin	Glaucoma 1A, primary open angle	AD	I
601771	*CYP1B1*	Cytochrome P450 family 1 subfamily B member 1	Anterior segment dysgenesis 6, multiple subtypes; glaucoma 3A, primary open angle, congenital, juvenile, or adult onset	AR	I
602091	*LTBP2*	Latent transforming growth factor beta binding protein 2	Weill-Marchesani syndrome 3; Glaucoma 3, primary congenital, D; microspherophakia and/or megalocornea, with ectopia lentis and with or without secondary glaucoma	AR	S or I
603474	*RPS19*	Ribosomal protein S19	Diamond-Blackfan anemia 1	AD	S
604563	*SBF2*	SET binding factor 2	Charcot-Marie-Tooth disease, type 4B2	AR	S
607423	*POMT1*	Protein O-mannosyltransferase 1	Muscular dystrophy-dystroglycanopathy (congenital with brain and eye anomalies), type A, 1; muscular dystrophy-dystroglycanopathy (congenital with cognitive disabilities), type B, 1; muscular dystrophy-dystroglycanopathy (limb-girdle), type C, 1	AR	S
610192	*GLIS3*	GLIS family zinc finger 3	Diabetes mellitus, neonatal, with congenital hypothyroidism. Additional features include congenital glaucoma	AR	S
610199	*GLIS3*	GLIS family zinc finger 3	Diabetes mellitus, neonatal, with congenital hypothyroidism. Additional features include congenital glaucoma	AR	S

Continued

Table 661.2 Congenital Glaucoma and Anterior Segment Dysgenesis*—cont'd

OMIM NUMBER	GENE SYMBOL	PROTEIN	PHENOTYPE	MODE OF INHERITANCE	SYNDROMIC (S) OR ISOLATED (I)
613150	*POMT2*	Protein O-mannosyltransferase 2	Muscular dystrophy-dystroglycanopathy (congenital with brain and eye anomalies), type A, 2	AR	S
613293	*SH3PXD2B*	SH3 and PX domains 2B	Frank-Ter Haar syndrome with or without glaucoma	AR	S
617315	*CYP1B1*	Cytochrome P450 family 1 subfamily B member 1	Anterior segment dysgenesis 6, multiple subtypes; glaucoma 3A, primary open angle, congenital, juvenile, or adult onset	AR	I

*There are 55 entries in Online Mendelian Inheritance in Man (OMIM, https://www.ncbi.nlm.nih.gov/omim) for congenital glaucoma. This table only lists those with strong association to congenital glaucoma or diseases with congenital glaucoma as one of the major clinical features.
AD, Autosomal dominant; AR, autosomal recessive.
From Chen HY, Lehmann OJ, Swaroop A. Genetics and therapy for pediatric eye diseases. *EBioMedicine*. 2021;67:103360(Table 1b)

Table 661.3 Leber Congenital Amaurosis (LCA)*

OMIM NUMBER	GENE SYMBOL	PROTEIN	PHENOTYPE	MODE OF INHERITANCE	SYNDROMIC (S) OR ISOLATED (I)
204000	*GUCY2D*	Guanylate cyclase 2D, retinal	Leber congenital amaurosis 1	AD or AR	I
601777			Cone-rod dystrophy 6		
204100	*RPE65*	Retinoid isomerohydrolase RPE65	Leber congenital amaurosis 2	AR	I
613794			Retinitis pigmentosa 20		
618697			Retinitis pigmentosa 87 with choroidal involvement	AD	
604232	*SPATA7*	Spermatogenesis associated 7	Leber congenital amaurosis 3; Retinitis pigmentosa, juvenile	AR	I
604393	*AIPL1*	Aryl hydrocarbon receptor interacting protein like 1	Cone-rod dystrophy; Retinitis pigmentosa, juvenile; Leber congenital amaurosis 4	AD or AR	I
604537	*LCA5*	Lebercilin LCA5	Leber congenital amaurosis 5	AR	I
613826	*RPGRIP1*	RPGR interacting protein 1	Leber congenital amaurosis 6	AR	I
613829	*CRX*	Cone-rod homeobox	Leber congenital amaurosis 7	AD	I
613835	*CRB1*	Crumbs cell polarity complex component 1	Leber congenital amaurosis 8	AR	I
600105			Retinitis pigmentosa-12		
608553	*NMNAT1*	Nicotinamide nucleotide adenylyltransferase 1	Leber congenital amaurosis 9	AR	I
611755	*CEP290*	Centrosomal protein 290	Leber congenital amaurosis 10	AR	I or S
610188			Joubert syndrome 5		
610189			Senior-Loken syndrome 6		
613837	*IMPDH1*	Inosine monophosphate dehydrogenase 1	Leber congenital amaurosis 11	AR	I
180105			Retinitis pigmentosa 10	AD	
610612	*RD3*	RD3 regulator of GUCY2D	Leber congenital amaurosis 12	AR	I
612712	*RDH12*	Retinol dehydrogenase 12	Leber congenital amaurosis 13	AD or AR	I
613341	*LRAT*	Lecithin retinol acyltransferase	Retinitis pigmentosa, juvenile; Leber congenital amaurosis 14; Retinal dystrophy, early-onset severe	AR	I
613843	*TULP1*	TUB like protein 1	Leber congenital amaurosis 15	AR	I
600132					

Table 661.3 Leber Congenital Amaurosis (LCA)*—cont'd

OMIM NUMBER	GENE SYMBOL	PROTEIN	PHENOTYPE	MODE OF INHERITANCE	SYNDROMIC (S) OR ISOLATED (I)
614186	*KCNJ13*	Potassium inwardly rectifying channel subfamily J member 13	Leber congenital amaurosis 16	AR	I
615360	*GDF6*	Growth differentiation factor 6	Leber congenital amaurosis 17	AR	I
608133	*PRPH2*	Peripherin 2	Leber congenital amaurosis 18; Retinitis pigmentosa 7 and digenic form	AD or AR	I or S
169150			Macular dystrophy, patterned, 1		
618513	*USP45*	Ubiquitin specific peptidase 45	Leber congenital amaurosis 19	AR	I
617879	*TUBB4B*	Tubulin beta 4B class IVb	Leber congenital amaurosis with early-onset deafness	AD	S
609237	*IQCB1*	IQ motif-containing protein B1	Leber congenital amaurosis	AR	I or S
609254			Senior-Loken syndrome 5	AR	

*There are 101 entries in Online Mendelian Inheritance in Man (OMIM; https://www.ncbi.nlm.nih.gov/omim) for LCA. This table only lists the genes with strong association to LCA or diseases with LCA as one of the major clinical attributes.
AD, Autosomal dominant; AR, autosomal recessive; DR, digenic recessive.
From Chen HY, Lehmann OJ, Swaroop A. Genetics and therapy for pediatric eye diseases. *EBioMedicine* .2021;67:103360(Table 1c)

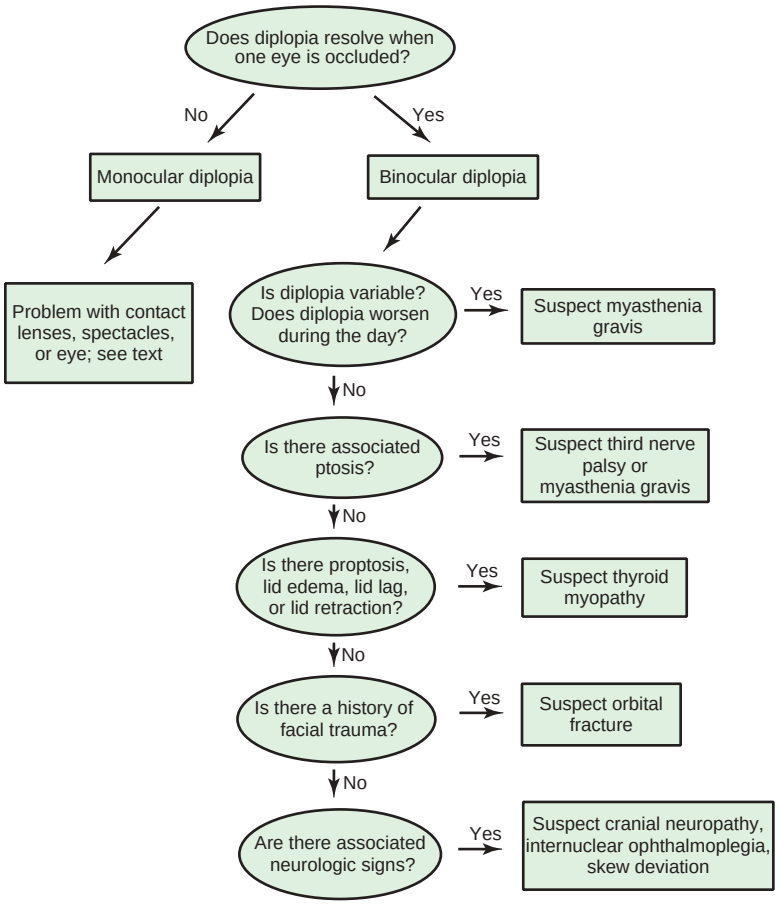

Fig. 661.1 General approach to diplopia. The clinician should first distinguish monocular from binocular diplopia and, in patients with binocular diplopia, address the five questions on the right side of the figure. Only then should the clinician identify which muscle is weak, although this is unnecessary if the clinician already suspects myasthenia (from fatigability) or full third nerve palsy (from weakness of the medial rectus, superior rectus, inferior rectus, and inferior oblique muscles, with or without a dilated pupil). Uncommon causes of diplopia and associated ptosis, not presented in the figure, are botulism, the Fisher variant of Guillain-Barre syndrome, and aberrant regeneration of the third nerve. Uncommon causes of diplopia and associated orbital findings (e.g., proptosis) are carotid-cavernous fistula (which causes an orbital bruit), orbital tumor, and pseudotumor. *(From McGee S. Evidence-Based Physical Diagnosis, 3rd ed. Elsevier; 2012. Fig. 57.1, p. 522.)*

NYCTALOPIA

Nyctalopia, or night blindness, is vision that is defective in reduced illumination. It generally implies impairment in function of the rods, particularly in dark adaptation time and perceptual threshold. Stationary congenital night blindness may occur as an autosomal dominant, autosomal recessive, or X-linked recessive condition. It may be associated with myopia and nystagmus. Children may have excessive problems going to sleep in a dark room, which may be mistaken for a behavioral problem. Progressive night blindness usually indicates primary or secondary retinal, choroidal, or vitreoretinal degeneration (see Chapter 670); it occurs also in vitamin A deficiency or as a result of retinotoxic drugs such as quinine.

PSYCHOGENIC DISTURBANCES

Vision problems of psychogenic origin are common in school-age children. Both conversion reactions and willful feigning are encountered. The usual manifestation is a report of reduced visual acuity in one or both eyes. Another common manifestation is constriction of the visual field. In some cases, the symptom is diplopia or polyopia (see Chapters 35 and 38).

Important clues to the diagnosis are inappropriate affect, excessive grimacing, inconsistency in performance, and suggestibility. A thorough ophthalmologic examination is essential to differentiate organic from functional visual disorders.

Affected children usually fare well with reassurance and positive suggestions. In some cases, mental health care is indicated. In all cases, the approach must be supportive and nonpunitive.

DYSLEXIA

This is the inability to develop the capability to read at an expected level despite an otherwise normal intellect (see Chapter 51). The terms *reading disability* and *dyslexia* are often used interchangeably. Most dyslexic individuals also display poor writing ability. Dyslexia is a primary reading disorder and should be differentiated from secondary reading difficulties caused by intellectual disability, environmental or educational deprivation, and systemic physical or other organic brain or eye diseases. Because there is not one standard test for dyslexia, the diagnosis is usually made by comparing reading ability with intelligence and standard reading expectations. Dyslexia is a language-based disorder and is not caused by any defect in the eye or visual acuity per se, nor is it attributable to a defect in ocular motility or binocular alignment. Although ophthalmologic evaluation of children with a reading problem is recommended to diagnose and correct any concurrent ocular problems such as a refractive error, amblyopia, or strabismus, treatment directed to the eyes themselves cannot be expected to correct developmental dyslexia (see Chapter 51).

Visit Elsevier eBooks+ at eBooks.Health.Elsevier.com for Bibliography.

Chapter 662

Abnormalities of Pupil and Iris

Scott E. Olitsky and Justin D. Marsh

ANIRIDIA

The term *aniridia* is a misnomer because some iris tissue is usually present, although it is hypoplastic (Fig. 662.1). Two-thirds of the cases are dominantly transmitted with a high degree of penetrance. The other third of cases are sporadic and are considered new pathologic genetic variants. The condition is bilateral in 98% of all patients, regardless of the means of transmission, and is found in approximately 1/50,000 persons. Pathologic variants in *PAX6* on 11p13 are typically implicated, and aniridia may be associated with other ocular findings.

Aniridia is a panocular disorder and should not be thought of as an isolated iris defect. Macular and optic nerve hypoplasia are commonly present and lead to decreased vision and sensory nystagmus. The visual acuity is approximately 20/200 in most patients, although the vision may occasionally be better. Other ocular deformities are common and may involve the lens and cornea. The cornea may be small, and a cellular infiltrate (pannus) occasionally develops in the superficial layers of the peripheral cornea (keratopathy). Clinically this appears as a gray opacification. Lens abnormalities include cataract formation and partial or total lens dislocation. **Glaucoma** develops in as many as 75% of individuals with aniridia.

One-fifth of sporadic aniridic patients may develop **Wilms tumor** (see Chapter 548.1). Because of their proximity in location, large deletions may include both *PAX6* and *WT1*, leading to this association. Although it has traditionally been taught that only patients with sporadic aniridia are at risk for developing Wilms tumor, it has also been reported in individuals with familial aniridia. Additionally, genitourinary abnormalities and intellectual disability, when present with aniridia, are strongly associated with Wilms tumor (WAGR syndrome). Wilms tumor usually presents before the fifth year, and these children should be screened using renal ultrasonography every 3-6 months until approximately 5 years of age if there is an 11p13 region deletion placing the child at risk for Wilms tumor.

COLOBOMA OF THE IRIS

A **coloboma** is the defect formed when the embryonic fissure fails to close completely. This unilateral or bilateral developmental defect may present as a defect in a sector of the iris, a hole in the substance of the iris, or a notch in the pupillary margin (Fig. 662.2). Simple (isolated) colobomas may be sporadic but are frequently transmitted as an autosomal dominant trait and may occur alone or in association with other anomalies and syndromes (syndromic) (Table 662.1). Because of the anatomic location of the embryonic fissure, an iris coloboma is always located inferiorly, giving the iris a keyhole appearance. An iris coloboma may be the only externally visible part of a more extensive coloboma that also involves the choroid, retina, and optic nerve. When this occurs, vision is likely to be severely affected. Complications include retinal detachment, cataract formation, and choroidal neovascularization. All children with an iris coloboma should undergo a full ophthalmologic examination.

MICROCORIA

Microcoria (congenital miosis) appears as a small pupil that does not react to light or accommodation and that dilates poorly, if at all, with medication. The condition may be unilateral or bilateral. In bilateral cases, the degree of miosis may be different in each eye. The eye may be otherwise normal or may demonstrate other abnormalities of the

Fig. 662.1 Partial aniridia in a member of an autosomal dominant pedigree. *(From Hoyt CS, Taylor D, eds. Pediatric Ophthalmology and strabismus. 4th ed. Elsevier; 2013; Fig. 32.22, p. 304.)*

NYCTALOPIA

Nyctalopia, or night blindness, is vision that is defective in reduced illumination. It generally implies impairment in function of the rods, particularly in dark adaptation time and perceptual threshold. Stationary congenital night blindness may occur as an autosomal dominant, autosomal recessive, or X-linked recessive condition. It may be associated with myopia and nystagmus. Children may have excessive problems going to sleep in a dark room, which may be mistaken for a behavioral problem. Progressive night blindness usually indicates primary or secondary retinal, choroidal, or vitreoretinal degeneration (see Chapter 670); it occurs also in vitamin A deficiency or as a result of retinotoxic drugs such as quinine.

PSYCHOGENIC DISTURBANCES

Vision problems of psychogenic origin are common in school-age children. Both conversion reactions and willful feigning are encountered. The usual manifestation is a report of reduced visual acuity in one or both eyes. Another common manifestation is constriction of the visual field. In some cases, the symptom is diplopia or polyopia (see Chapters 35 and 38).

Important clues to the diagnosis are inappropriate affect, excessive grimacing, inconsistency in performance, and suggestibility. A thorough ophthalmologic examination is essential to differentiate organic from functional visual disorders.

Affected children usually fare well with reassurance and positive suggestions. In some cases, mental health care is indicated. In all cases, the approach must be supportive and nonpunitive.

DYSLEXIA

This is the inability to develop the capability to read at an expected level despite an otherwise normal intellect (see Chapter 51). The terms *reading disability* and *dyslexia* are often used interchangeably. Most dyslexic individuals also display poor writing ability. Dyslexia is a primary reading disorder and should be differentiated from secondary reading difficulties caused by intellectual disability, environmental or educational deprivation, and systemic physical or other organic brain or eye diseases. Because there is not one standard test for dyslexia, the diagnosis is usually made by comparing reading ability with intelligence and standard reading expectations. Dyslexia is a language-based disorder and is not caused by any defect in the eye or visual acuity per se, nor is it attributable to a defect in ocular motility or binocular alignment. Although ophthalmologic evaluation of children with a reading problem is recommended to diagnose and correct any concurrent ocular problems such as a refractive error, amblyopia, or strabismus, treatment directed to the eyes themselves cannot be expected to correct developmental dyslexia (see Chapter 51).

Visit Elsevier eBooks+ at eBooks.Health.Elsevier.com for Bibliography.

Chapter 662

Abnormalities of Pupil and Iris

Scott E. Olitsky and Justin D. Marsh

ANIRIDIA

The term *aniridia* is a misnomer because some iris tissue is usually present, although it is hypoplastic (Fig. 662.1). Two-thirds of the cases are dominantly transmitted with a high degree of penetrance. The other third of cases are sporadic and are considered new pathologic genetic variants. The condition is bilateral in 98% of all patients, regardless of the means of transmission, and is found in approximately 1/50,000 persons. Pathologic variants in *PAX6* on 11p13 are typically implicated, and aniridia may be associated with other ocular findings.

Aniridia is a panocular disorder and should not be thought of as an isolated iris defect. Macular and optic nerve hypoplasia are commonly present and lead to decreased vision and sensory nystagmus. The visual acuity is approximately 20/200 in most patients, although the vision may occasionally be better. Other ocular deformities are common and may involve the lens and cornea. The cornea may be small, and a cellular infiltrate (pannus) occasionally develops in the superficial layers of the peripheral cornea (keratopathy). Clinically this appears as a gray opacification. Lens abnormalities include cataract formation and partial or total lens dislocation. **Glaucoma** develops in as many as 75% of individuals with aniridia.

One-fifth of sporadic aniridic patients may develop **Wilms tumor** (see Chapter 548.1). Because of their proximity in location, large deletions may include both *PAX6* and *WT1*, leading to this association. Although it has traditionally been taught that only patients with sporadic aniridia are at risk for developing Wilms tumor, it has also been reported in individuals with familial aniridia. Additionally, genitourinary abnormalities and intellectual disability, when present with aniridia, are strongly associated with Wilms tumor (WAGR syndrome). Wilms tumor usually presents before the fifth year, and these children should be screened using renal ultrasonography every 3-6 months until approximately 5 years of age if there is an 11p13 region deletion placing the child at risk for Wilms tumor.

COLOBOMA OF THE IRIS

A **coloboma** is the defect formed when the embryonic fissure fails to close completely. This unilateral or bilateral developmental defect may present as a defect in a sector of the iris, a hole in the substance of the iris, or a notch in the pupillary margin (Fig. 662.2). Simple (isolated) colobomas may be sporadic but are frequently transmitted as an autosomal dominant trait and may occur alone or in association with other anomalies and syndromes (syndromic) (Table 662.1). Because of the anatomic location of the embryonic fissure, an iris coloboma is always located inferiorly, giving the iris a keyhole appearance. An iris coloboma may be the only externally visible part of a more extensive coloboma that also involves the choroid, retina, and optic nerve. When this occurs, vision is likely to be severely affected. Complications include retinal detachment, cataract formation, and choroidal neovascularization. All children with an iris coloboma should undergo a full ophthalmologic examination.

MICROCORIA

Microcoria (congenital miosis) appears as a small pupil that does not react to light or accommodation and that dilates poorly, if at all, with medication. The condition may be unilateral or bilateral. In bilateral cases, the degree of miosis may be different in each eye. The eye may be otherwise normal or may demonstrate other abnormalities of the

Fig. 662.1 Partial aniridia in a member of an autosomal dominant pedigree. *(From Hoyt CS, Taylor D, eds. Pediatric Ophthalmology and strabismus. 4th ed. Elsevier; 2013; Fig. 32.22, p. 304.)*

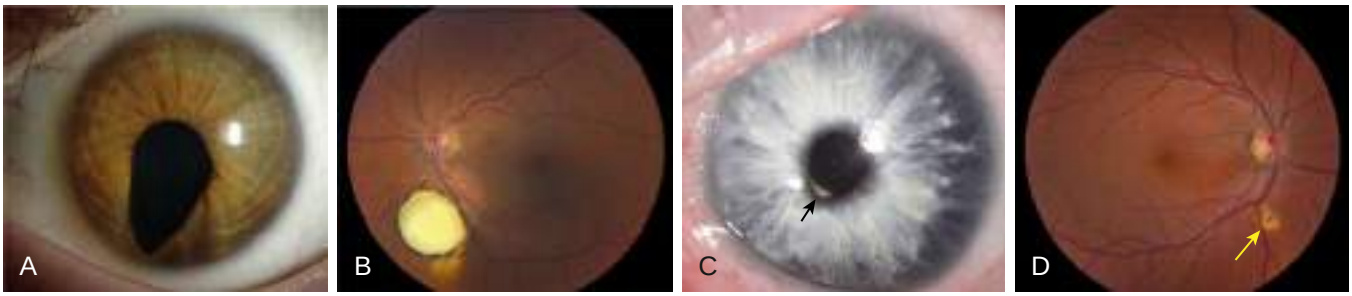

Fig. 662.2 Clinical presentations of uveal coloboma. **A,** Typical iris coloboma of a left eye. Note the inferonasal positioning of the coloboma, corresponding to the position of the optic fissure. **B,** Typical chorioretinal coloboma inferior to the optic nerve in a patient with excellent visual acuity. **C,** Microform of iris coloboma in a patient with Waardenburg syndrome, type 2A. Note slight peaking of the pupil of the inferonasal quadrant *(arrow).* **D,** Microform of a chorioretinal coloboma in the asymptomatic mother of a patient with bilateral nonsyndromic coloboma. *(From George A, Cogliati T, Brooks BP. Genetics of syndromic ocular coloboma: CHARGE and COACH syndromes. Exp Eye Res. 2020;193:107940; Fig. 2).*

Table 662.1 Syndromes Associated with Coloboma

Cat eye syndrome
CHARGE association
COACH
Coloboma with agenesis of corpus callosum
Congenital colobomatous microphthalmia iris coloboma and anal atresia
Congenital disorder of glycosylation type IV
Deletion 4p, 7p, 13q, 2q31.1, 14q24.3, 15q24
Glotz
Goldenhar
Jacobsen
Joubert
Klippel Feil 1,3
Meckel Gruber
Morning glory anomaly
Noonan
Renpenning
Rieger
Rubinstein-Taybi
SOX2-related eye disorders
Temtamy
Trisomy 13, 18, 22
Warburg

Plus >40 single gene pathologic variants.
COACH, Cerebral vermis hypoplasia, oligophrenia, ataxia, coloboma, hepatic fibrosis; CHARGE, coloboma, heart defect, atresia choanae, retarded growth and development, genital hypoplasia, ear anomalies, deafness.

anterior segment. Congenital microcoria is usually transmitted as an autosomal dominant trait, although it may occur sporadically.

CONGENITAL MYDRIASIS

In this disorder, the pupils appear dilated, do not constrict significantly to light or near gaze, and respond minimally to miotic agents. The iris is otherwise normal, and affected children are usually healthy. Trauma, pharmacologic mydriasis, and neurologic disorders should be considered. Congenital mydriasis is one component of the **multisystemic smooth muscle dysfunction syndrome**; associated features include a patent ductus arteriosus and dilation of the aorta. Many apparent cases of congenital mydriasis show abnormalities of the central iris structures and may be considered a form of aniridia.

DYSCORIA AND CORECTOPIA

Dyscoria is abnormal shape of the pupil, and corectopia is abnormal pupillary position. They may occur together or independently as congenital or acquired anomalies.

Congenital corectopia is usually bilateral and symmetric and rarely occurs as an isolated anomaly; it is often accompanied by dislocation of the lens (ectopia lentis et pupillae), and the lens and pupil are commonly dislocated in opposite directions. **Ectopia lentis et pupillae** is transmitted as an autosomal recessive disorder; consanguinity is common. It is associated with pathologic variants in *ADAMTSL4*, which encodes a secreted glycoprotein widely distributed in the eye, which binds fibrillin-1 microfibrils and accelerates microfibril biogenesis.

When acquired, distortion and displacement of the pupil are frequently a result of trauma or intraocular inflammation. Prolapse of the iris after perforating injuries of the eye leads to peaking of the pupil in the direction of the perforation. Posterior synechiae (adhesions of the iris to the lens) are commonly seen when inflammation from any cause occurs in the anterior segment.

ANISOCORIA

Anisocoria occurs when the pupils are of different sizes. This may be a result of local or neurologic disorders. As a rule, if the inequality is more pronounced in the *presence of bright focal illumination* or on near gaze, there is a defect in pupillary constriction and the larger pupil is abnormal. If the anisocoria is worse in *reduced illumination*, a defect in dilation exists and the smaller pupil is abnormal (Figs. 662.3 and 662.4). Neurologic causes of anisocoria (parasympathetic or sympathetic lesions) must be differentiated from local causes such as synechiae (adhesions), congenital iris defects (colobomas, aniridia), and pharmacologic effects. **Horner syndrome** is an important cause of anisocoria (see later). Simple central anisocoria may occur in otherwise healthy individuals.

DILATED FIXED PUPIL

A dilated, unreactive pupil may be caused by internal ophthalmoplegia, Hutchinson pupil of transtentorial herniation, tonic pupil, pharmacologic blockade, and iridoplegia secondary to ocular trauma (see Fig. 662.3).

The most common cause of a dilated unreactive pupil is purposeful or accidental instillation of a cycloplegic agent, particularly atropine and related substances. Central nervous system lesions, such as a pinealoma, may cause internal ophthalmoplegia in children. Because the external surface of the oculomotor nerve carries the fibers responsible for pupillary constriction, compression of the nerve along its intracranial course may be associated with internal ophthalmoplegia, even before the development of ptosis or an ocular motility deficit. Although ophthalmoplegic migraine is a common cause of a third nerve palsy with pupillary involvement in children, an intracranial aneurysm must also be considered in the differential diagnosis. The blown pupil of transtentorial herniation, occurring with increasing intracranial pressure, is generally unilateral, and patients usually are obviously ill. The **pilocarpine test** can help differentiate neurologic iridoplegia from pharmacologic blockade. In the case of neurologic iridoplegia, the dilated pupil constricts within minutes after instillation of 1 or 2 drops of 0.5–1% pilocarpine; if the pupil has been dilated with atropine, pilocarpine has no effect. Because pilocarpine is a long-acting drug, this test is not to be used in acute situations in which pupillary signs must be carefully monitored. Because of the consensual pupil response to light, even complete uniocular blindness does not cause a unilaterally dilated pupil.

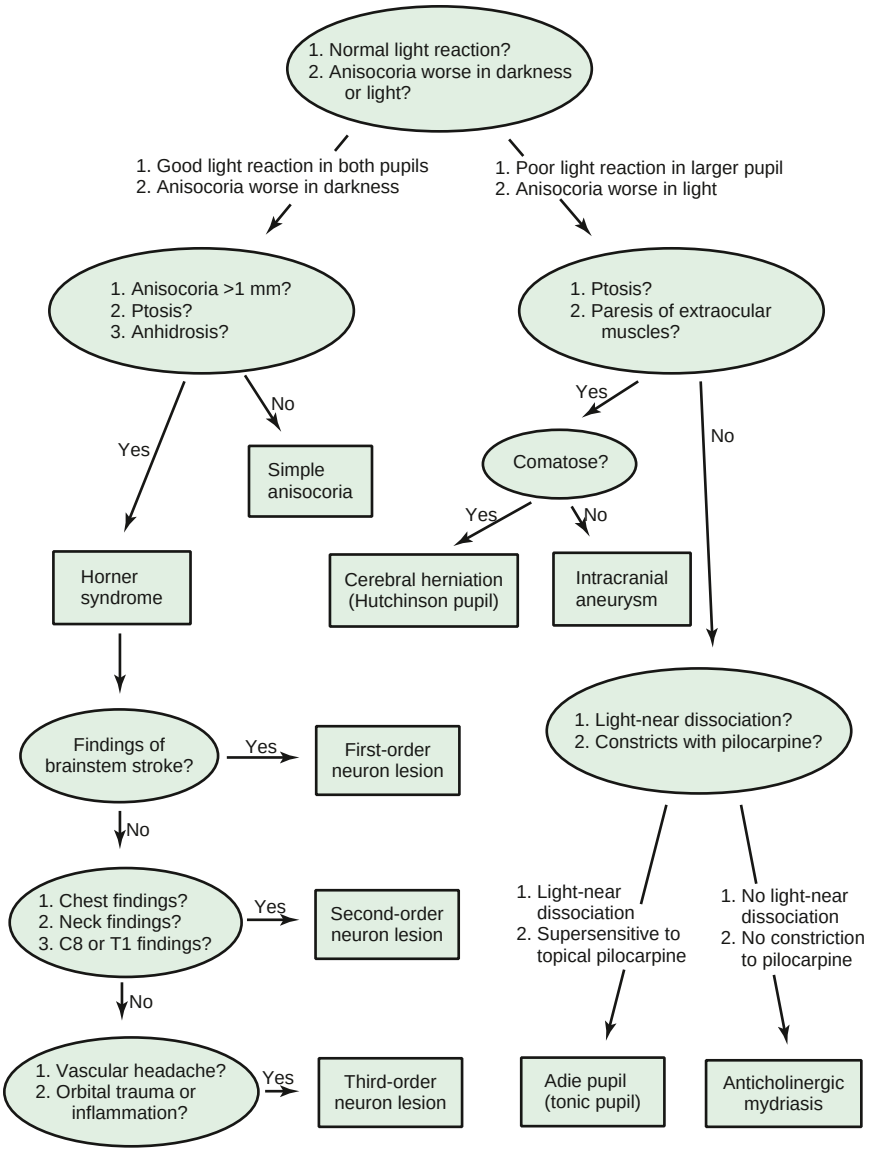

Fig. 662.3 Approach to anisocoria. The first two questions (Is there normal light reaction? And is anisocoria worse in darkness or light?) distinguish problems with the pupillary dilator muscle (i.e., Horner syndrome, simple anisocoria; *left side of figure*) from problems with the pupillary constrictor muscle (i.e., third cranial nerve, iris; *right side of figure*). Two other tests distinguish Horner syndrome from simple anisocoria: the cocaine test and pupillary dilator lag (i.e., the pupil dilates slowly in darkness, as documented in photographs). *(From Czarnecki JSC, Pilley SFJ, Thompson HS. The analysis of anisocoria: the use of photography in the clinical evaluation of unequal pupils. Can J Ophthalmol. 1979;14:297-302; and Thompson HS, Pilley SFJ. Unequal pupils: a flow chart for sorting out the anisocorias. Surv Ophthalmol. 1976;21[1]:45-48.)*

TONIC PUPIL

This is typically a large pupil that reacts poorly to light (the reaction may be very slow or even absent), reacts poorly and slowly to accommodation, and redilates in a slow, tonic manner. The features of tonic pupil are explained by cholinergic supersensitivity of the sphincter after peripheral (postganglionic) denervation and imperfect reinnervation. A distinctive feature of a tonic pupil is its sensitivity to dilute cholinergic agents. Instillation of 0.125% pilocarpine causes significant constriction of the involved pupil and has little or no effect on the unaffected side. The condition is usually unilateral.

Tonic pupil may develop after the acute stage of a partial or complete iridoplegia. It can be seen after trauma to the eye or orbit and may occur in association with toxic or infectious conditions. For those in the pediatric age group, tonic pupil is uncommon. Infectious processes (primarily viral syndromes) and trauma are the primary causes. Features of tonic pupil may also be seen in infants and children with familial dysautonomia (Riley-Day syndrome), although the significance of these findings has been questioned. Tonic pupil has also been reported in young children with Charcot-Marie-Tooth disease. Tonic pupil and other pupillary abnormalities may be noted in ROHHAD syndrome (rapid onset obesity, hypoventilation, hypothalamic dysfunction, and autonomic dysregulation). The occurrence of tonic pupil in association with decreased deep tendon reflexes in young women is referred to as **Adie syndrome.**

Ross syndrome is similar to Adie syndrome and includes decreased deep tendon reflexes and hypohidrosis.

MARCUS GUNN PUPIL

A **relative afferent pupillary defect** (Marcus Gunn pupil) indicates an asymmetric, *prechiasmatic*, afferent conduction defect. It is best demonstrated by the swinging flashlight test, which allows comparison of the direct and consensual pupillary responses in both eyes (Fig. 662.5). With patients fixing on a distant target (to control accommodation), a bright focal light is directed alternately into each eye in turn. In the presence of an afferent lesion, both the direct response to light in the affected eye and the consensual response in the other eye are subnormal. Swinging the light to the better or normal eye causes both pupils to react (constrict) normally. Swinging the light back to the affected eye causes both pupils to redilate to some degree, reflecting the defective conduction. This is a very sensitive and useful test for detecting and confirming optic nerve and retinal disease. This test is only abnormal if there is a "relative" difference in the conduction properties of the optic nerves. Therefore patients with bilateral and symmetric optic nerve

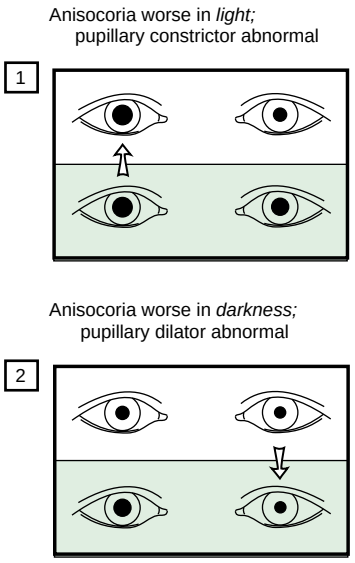

Fig. 662.4 Patient 1 *(top)* has more prominent anisocoria in light than darkness, indicating that the pupillary constrictor of the larger pupil is abnormal (i.e., it fails to constrict in light, *arrow*). Patient 2 has more prominent anisocoria in darkness than light, indicating that the pupillary dilator of the smaller pupil is abnormal (i.e., it fails to dilate in darkness, *arrow*). The diagnosis in patient 1 (abnormal pupillary constrictor) could be a third nerve palsy, tonic pupil, pharmacologic mydriasis, or a disorder of the iris. The diagnosis in patient 2 (abnormal pupillary dilator) could be Horner syndrome or simple anisocoria. In patient 2, both pupils will react to light, whereas the larger pupil of patient 1 does not react well to light. *(From McGee S. Evidence-Based Physical Diagnosis. 3rd ed. Elsevier; 2012; Fig. 20.4, p. 170.)*

disease will not demonstrate an afferent pupillary defect. A subtle relative afferent defect may be found in some children with amblyopia.

HORNER SYNDROME

The principal signs of oculosympathetic paresis (Horner syndrome) are homolateral miosis, mild ptosis, and apparent enophthalmos with slight elevation of the lower lid as a result of the ptosis. Patients may also have decreased facial sweating, increased amplitude of accommodation, and transient decrease in intraocular pressure. If paralysis of the ocular sympathetic fibers occurs before the age of 2 years, heterochromia iridis with hypopigmentation of the iris may occur on the affected side (Fig. 662.6).

Oculosympathetic paralysis may be caused by a lesion (tumor, trauma, infarction) in the midbrain, brainstem, upper spinal cord, neck, middle fossa, or orbit (Table 662.2). Congenital oculosympathetic paresis, often as part of **Klumpke brachial palsy**, is common, although the ocular signs, particularly the anisocoria, may pass undetected for years. Horner syndrome is also seen in some children after thoracic surgery. *Congenital* Horner syndrome may occur in association with vertebral anomalies and with enterogenous cysts. In some infants and children, Horner syndrome is the presenting sign of tumor in the mediastinal or cervical region—specifically neuroblastoma. Rare causes of Horner syndrome, such as vascular lesions or ectopic thymus tissue, also occur in the pediatric age group. In many cases, no cause of congenital Horner syndrome can be identified. Occasionally the condition is familial.

When the cause of Horner syndrome is in question, investigative procedures should be implemented and may include imaging of the head, neck, and chest, as well as 24-hour urinary catecholamine assay. Examining old photographs and old records can sometimes be helpful in establishing the age at onset of Horner syndrome.

The cocaine test is useful in diagnosing oculosympathetic paralysis; a normal pupil dilates within 20-45 minutes after instillation of one or two drops of 4% cocaine, whereas the miotic pupil of an oculosympathetic paresis dilates poorly, if at all, with cocaine. In some cases, there is also denervation supersensitivity of the affected eye to dilute

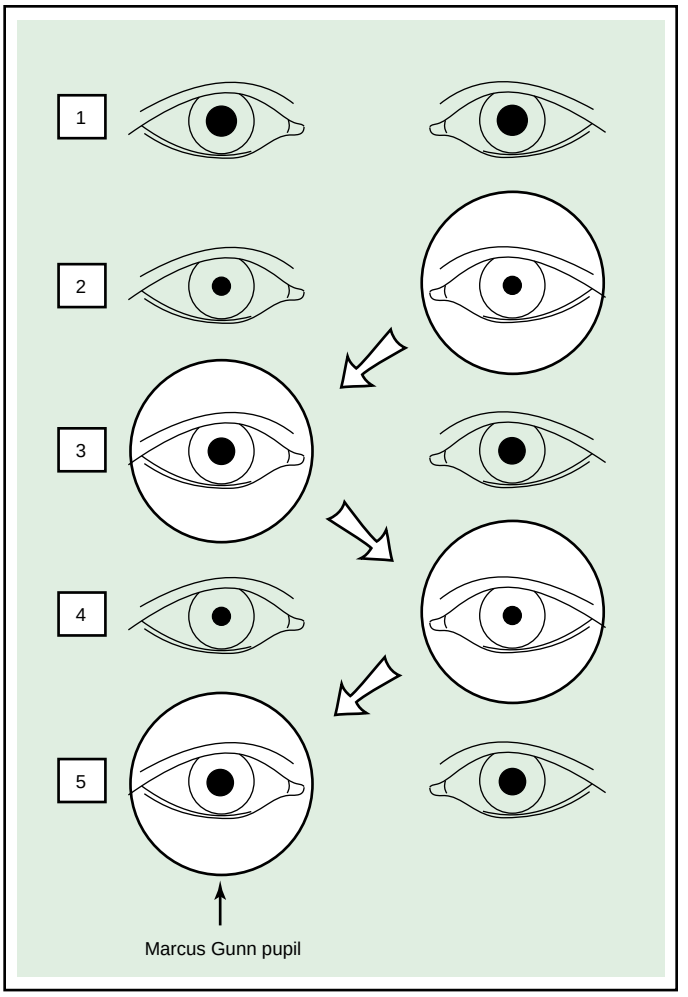

Fig. 662.5 The relative afferent pupillary defect (Marcus Gunn pupil). The figure depicts a patient with an abnormal right optic nerve. Under normal room light illumination (row 1), the pupils are symmetrical. During the swinging flashlight test, the pupils constrict when the normal eye is illuminated (rows 2 and 4) but dilate when the abnormal eye is illuminated (rows 3 and 5). Although both pupils constrict or dilate simultaneously, the clinician is usually focused on just the illuminated pupil. The pupil that dilates during the swinging flashlight test has the "relative afferent pupillary defect" and is labeled the Marcus Gunn pupil. *(From McGee S. Evidence-Based Physical Diagnosis. 3rd ed. Elsevier; 2012; Fig. 20.2, p. 165.)*

Fig. 662.6 Left congenital Horner syndrome showing upper- and lower-lid ptosis and an iris heterochromia, with the lighter eye being the affected eye. In bright light (**A**) and in the dark (**B**). *(From Hoyt CS, Taylor D, eds. Pediatric Ophthalmology and strabismus. 4th ed. Elsevier; 2013; Fig. 63.9, p. 661.)*

Table 662.2 Causes of Horner Syndrome

CENTRAL (FIRST-ORDER NEURON)
Brainstem disease – commonly stroke (e.g. lateral medullary infarction), but also tumor, demyelination
Syringomyelia
Lateral medullary (Wallenberg) syndrome
Cervical spinal cord lesion
Diabetic autonomic neuropathy
PREGANGLIONIC (SECOND-ORDER NEURON)
Pancoast tumor
Carotid and aortic aneurysm and dissection
Thoracic spinal cord lesion
Miscellaneous neck lesions (thyroid tumour, enlarged lymph nodes, trauma, postsurgical)
POSTGANGLIONIC (THIRD-ORDER NEURON)
Internal carotid artery dissection
Nasopharyngeal tumour
Cavernous sinus mass
Otitis media
CLUSTER HEADACHE (MIGRAINOUS NEURALGIA)

From Salman JF: Kanski's Clinical Ophthalmology, 9th ed. London: Elsevier, 2020. Table 19.4

phenylephrine or similar agents. When present, the topical administration of a weak alpha$_1$ agonist may dilate only the affected pupil, leading to a "reversal" of the apparent miosis. Furthermore, instillation of 1% hydroxyamphetamine hydrobromide can help determine the location of sympathetic lesion because it only dilates the pupil if the postganglionic sympathetic neuron is intact.

PARADOXICAL PUPIL REACTION

Some children exhibit paradoxical constriction of the pupils to darkness. An initial brisk constriction of the pupils occurs when the light is turned off, followed by slow redilation of the pupils. The response to direct light stimulation and the near response are normal. The mechanism is not clear, but paradoxical constriction of the pupils in reduced light can be a sign of retinal or optic nerve abnormalities. The phenomenon has been observed in children with congenital stationary night blindness, albinism, retinitis pigmentosa, Leber congenital retinal amaurosis, and Best disease. It has also been observed in those with optic nerve anomalies, optic neuritis, optic atrophy, and possibly amblyopia. Thus children with paradoxical pupillary constriction to darkness should have a thorough ophthalmologic examination.

PERSISTENT PUPILLARY MEMBRANE

Involution of the pupillary membrane and anterior vascular capsule of the lens is usually completed during months 5-6 of fetal development. It is common to see some remnants of the pupillary membrane in newborns, particularly in premature infants. These membranes are nonpigmented strands of obliterated vessels that cross the pupil and may secondarily attach to the lens or cornea. The remnants tend to atrophy in time and usually present no problem. In some cases, however, significant remnants that remain obscure the pupil and interfere with vision. In rare cases, there is patency of the vascular elements; hyphema may result from rupture of persistent vessels.

Intervention must be considered to minimize amblyopia in infants with extensive persistent pupillary membrane of sufficient degree to interfere with vision in the early months of life. In some cases, mydriatics and occlusion therapy may be effective, but in others, surgery may be needed to provide an adequate pupillary aperture.

HETEROCHROMIA

In heterochromia, the two irises are of different color (heterochromia iridium) or a portion of an iris differs in color from the remainder (heterochromia iridis). Simple heterochromia may occur as an autosomal dominant characteristic. Congenital heterochromia is also a feature of Waardenburg syndrome, an autosomal dominant condition characterized principally by lateral displacement of the inner canthi and puncta, pigmentary disturbances (usually a median white forelock and patches of hypopigmentation of the skin), and defective hearing. Change in the color of the iris may occur as a result of trauma, hemorrhage, intraocular inflammation (iridocyclitis, uveitis), intraocular tumor (especially retinoblastoma), intraocular foreign body, glaucoma, iris atrophy, or oculosympathetic palsy (Horner syndrome), which may be associated with a cervical neuroblastoma, melanosis oculi, previous intraocular surgery, and some glaucoma medications.

Fig. 662.7 Red reflex. Normal red reflex in the left eye and white reflex in the right eye. This patient was later diagnosed with retinoblastoma in the right eye. *(From Martin RJ, Fanaroff AA, Walsch MC eds. Fanaroff & Martin's Neonatal-Perinatal Medicine. 10th ed. Vol 2, Elsevier; 2015; Fig. 103.7, p. 1739.)*

OTHER IRIS LESIONS

Discrete nodules of the iris, referred to as **Lisch nodules**, are commonly seen in patients with neurofibromatosis (see Chapter 636.1). Lisch nodules represent melanocytic hamartomas of the iris and vary from slightly elevated pigmented areas to distinct ball-like excrescences. The nodules cause no visual disturbance. Lisch nodules are found in 92–100% of individuals older than 5 years of age who have neurofibromatosis but are rare in infancy. Slit-lamp identification of these nodules may help fulfill the criteria required to confirm the diagnosis of neurofibromatosis.

In leukemia (see Chapter 544), there may be infiltration of the iris, sometimes with **hypopyon**, an accumulation of white blood cells in the anterior chamber, which may herald relapse or involvement of the central nervous system.

The lesion of **juvenile xanthogranuloma** (nevoxanthoendothelioma; see Chapter 711) may occur in the eye as a yellowish fleshy mass or plaque of the iris. Spontaneous **hyphema** (blood in the anterior chamber), glaucoma, or a red eye with signs of uveitis may be associated. A search for the skin lesions of xanthogranuloma should be made in any infant or young child with spontaneous hyphema, although the iris lesions may be present without cutaneous manifestations. In many cases, the ocular lesion responds to topical corticosteroid therapy.

LEUKOCORIA

This includes any white pupillary reflex, or so-called *cat's-eye reflex*. Primary diagnostic considerations in any child with leukocoria are cataract, persistent hyperplastic primary vitreous, cicatricial retinopathy of prematurity, retinal detachment, retinoschisis, larval granulomatosis, and retinoblastoma (Fig. 662.7). Also to be considered are endophthalmitis, organized vitreous hemorrhage, leukemic ophthalmopathy, exudative retinopathy (as in Coats disease), and less-common conditions such as medulloepithelioma, massive retinal gliosis, the retinal pseudotumor of Norrie disease, the so-called *pseudoglioma of the Bloch-Sulzberger syndrome*, retinal dysplasia, and the retinal lesions of the phakomatoses. A white reflex may also be seen with fundus coloboma, large atrophic chorioretinal scars, and ectopic medullation of retinal nerve fibers. *Leukocoria is an indication for prompt and thorough evaluation.*

The diagnosis can often be made by direct examination of the eye by ophthalmoscopy and biomicroscopy. Ultrasonographic and radiologic examinations are often helpful. In some cases, the final diagnosis rests with a pathologist.

Visit Elsevier eBooks+ at eBooks.Health.Elsevier.com for Bibliography.

Chapter 663

Disorders of Eye Movement and Alignment

Scott E. Olitsky and Justin D. Marsh

STRABISMUS

Strabismus, or misalignment of the eyes, is one of the most common eye problems encountered in children, affecting approximately 4% of children younger than 6 years of age. Strabismus can result in vision loss (amblyopia) and can have significant psychologic effects. Early detection and treatment of strabismus are essential to prevent permanent visual impairment. Of children with strabismus, 30–50% develop amblyopia. Restoration of proper alignment of the visual axis must occur at an early stage of visual development to allow these children a chance to develop normal binocular vision. The word strabismus means "to squint or to look obliquely." Many terms are used in discussing and characterizing strabismus (Table 663.1).

Orthophoria is the ideal condition of exact ocular balance. It implies that the oculomotor apparatus is in perfect equilibrium so that the eyes remain coordinated and aligned in all positions of gaze and at all distances. Even when binocular vision is interrupted, as by occlusion of one eye, truly orthophoric individuals maintain perfect alignment. Orthophoria is seldom encountered because the majority of individuals have a small latent deviation (heterophoria).

Heterophoria is a latent tendency for the eyes to deviate. This latent deviation is normally controlled by fusional mechanisms that provide binocular vision or avoid diplopia (double vision). The eye deviates only under certain conditions, such as fatigue, illness, or stress, or during tests that interfere with maintenance of these normal fusional abilities (such as covering one eye). If the amount of heterophoria is large, it may give rise to bothersome symptoms, such as transient diplopia (double vision), headaches, or asthenopia (eyestrain). Some degree of heterophoria is found in normal individuals; it is usually asymptomatic.

Heterotropia is a misalignment of the eyes that is constant. It occurs because of an inability of the fusional mechanism to control the deviation. Tropias may be unilateral or may alternate between either eye, depending on the patient. In an alternating tropia, there is no preference for fixation of either eye, and both eyes drift with equal frequency. Because each eye is used periodically, vision usually develops normally. A unilateral tropia is a more serious situation because only one eye is constantly misaligned. The undeviated eye becomes the preferred eye, resulting in loss of vision or amblyopia of the deviated eye.

It is common in ocular misalignments to describe the type of deviation. This helps to make decisions on the cause and treatment of the strabismus. The prefixes *eso-, exo-, hyper-,* and *hypo-* are added to the terms *phoria* and *tropia* to further delineate the type of strabismus. Esophorias and esotropias are inward or convergent deviations of the eyes, commonly known as *crossed eyes*. Exophorias and exotropias are divergent or outward-facing eye deviations, *walleyed* being the lay term. Hyperdeviations and hypodeviations designate upward or downward, respectively, deviations of an eye. In cases of unilateral strabismus, the deviating eye is often part of the description of the misalignment (left esotropia).

Diagnosis

Many techniques are used to assess ocular alignment and movement of the eyes to aid in diagnosing strabismic disorders. In a child with strabismus or any other ocular disorder, assessment of visual acuity is mandatory. Decreased vision in one eye requires evaluation for a strabismus or other ocular abnormalities, which may be difficult to discern on a brief screening evaluation. Even strabismic deviations of only a few degrees in magnitude, too small to be evident by gross inspection, may lead to amblyopia and significant vision loss.

Corneal light reflex tests are perhaps the most rapid and easily performed diagnostic tests for strabismus. They are particularly useful in children who are uncooperative and in those who have poor ocular fixation. To perform the **Hirschberg corneal reflex test,** the examiner projects a light source onto the cornea of both eyes simultaneously as a child looks directly at the light. Comparison should then be made of the placement of the corneal light reflex in each eye. In straight eyes, the light reflection appears symmetric and, because of the relationship between the cornea and the macula, slightly nasal to the center of each pupil. If strabismus is present, the reflected light is asymmetric and appears displaced in one eye. The Krimsky method of the corneal reflex test uses prisms placed over one or both eyes to align the light reflections. The amount of prism needed to align the reflections is used to measure the degree of deviation. Although it is a useful screening test, corneal light reflex testing may not detect a small angle or an intermittent strabismus.

Cover tests for strabismus require a child's attention and cooperation, good eye movement capability, and reasonably good vision in each eye (Fig. 663.1). If any of these are lacking, the results of these tests may not be valid. These tests consist of the cover-uncover test and the alternate cover test. In the cover-uncover test, a child looks at an object in the distance, preferably 6 m away. An eye chart is commonly used for fixation in children older than 3 years of age. For younger children, a noise-making toy or movie helps hold their attention for the test. As the child looks at the distant object, the examiner covers one eye and watches for movement of the uncovered eye. If no movement occurs, there is no apparent misalignment of that eye. After one eye is tested, the same procedure is repeated on the other eye. When performing the alternate cover test, the examiner rapidly covers and uncovers each eye, shifting back and forth from one eye to the other. If the child has an ocular deviation, the eye rapidly moves as the cover is shifted to the other eye. Both the cover-uncover test and the alternate cover test should be performed at both distance and near fixation. The cover-uncover test differentiates tropias, or manifest deviations, from latent deviations, called **phorias**.

Clinical Manifestations and Treatment

The etiologic classification of strabismus is complex, and the causative types must be distinguished; there are comitant and noncomitant forms of strabismus.

Comitant Strabismus

Comitant strabismus is the most common type of strabismus. The individual extraocular muscles usually have no defect, and extraocular motility is full in all positions of gaze. The amount of deviation is constant, or relatively constant, in the various directions of gaze.

Pseudostrabismus is one of the most common reasons a pediatric ophthalmologist is asked to evaluate an infant. This condition is characterized by the false appearance of strabismus when the visual axes are aligned accurately. This appearance may be caused by a flat, broad nasal bridge, prominent epicanthal folds, or a narrow interpupillary distance, giving the appearance of esotropia despite the eyes being aligned (pseudoesotropia). The observer may see less white sclera nasally than would be expected, and the impression is that the eye is turned in toward the nose, especially when the child gazes to either side. Parents frequently comment that when their child looks to the side, the eye almost disappears from view. Pseudoesotropia can be differentiated from a true misalignment of the eyes when the corneal light reflex is centered in both eyes and when the cover-uncover test shows no refixation movement. Once pseudoesotropia has been confirmed, parents can be reassured that the child will outgrow the appearance of esotropia. As the child grows, the bridge of the nose becomes more prominent and displaces the epicanthal folds, and the medial sclera becomes proportional to the amount visible on the lateral aspect. It is the appearance of crossing that the child will outgrow. Because true esotropia can develop later in children with pseudoesotropia, parents and pediatricians should

be cautioned that reassessment is required if the apparent deviation does not improve.

Esodeviations are the most common type of ocular misalignment in children and represent >50% of all ocular deviations. *Congenital esotropia* is a confusing term. Few children who are diagnosed with this disorder are actually born with an esotropia. For this reason, infants with confirmed onset earlier than 6 months are typically considered to have what was previously classified as congenital esotropia, although the term **infantile esotropia** is perhaps a more accurate description.

Between 2-4 months of age, many infants will exhibit strabismus, including esotropia, which typically resolve spontaneously. Esotropia that resolves without treatment do so before 10-12 weeks of age and have intermittent or variable deviations. Those most likely to benefit from active treatment have persistent esotropia (10 weeks-6 months of age) and constant esotropia (40 PD), in combination with a refractive error ≤ +3.00 D, and the absence of prematurity, developmental delay, meningitis, nystagmus, eye anomalies, and incomitant or paralytic strabismus. The evaluation is noted in Figure 663.2.

Table 663.1 Description of Alignment and Movement

NORMAL OCULAR ALIGNMENT: ORTHOPHORIA
LATENCY
phoria: development of abnormality only during certain conditions (fatigue, illness, cover test)
tropia: abnormality present during normal conditions; deviation may be constant or intermittent
DIRECTION OF DEVIATION
Eso-: inward, horizontal deviation ("crossing")
Exo-: outward, horizontal deviation ("wall eye")
Hyper-: upward, vertical deviation
Hypo-: downward, vertical deviation
Incyclo-: nasal torsional deviation of the superior pole of the cornea
Excyclo-: temporal torsional deviation of the superior pole of the cornea
EQUALITY OF DEVIATION
Concomitant: misalignment is equal in all positions of gaze
Noncomitant: misalignment varies significantly in different positions of gaze
NEUROMUSCULAR DYSFUNCTION
Paralytic: misalignment secondary to a cranial nerve palsy, muscle weakness, or mechanical restriction (usually noncomitant)
Nonparalytic: no underlying neuromuscular dysfunction; usually concomitant but can be noncomitant
TANDEM MOVEMENTS OF BOTH EYES
version: both eyes move in same direction (conjugate); direction of movement: levo- (left), dextro- (right), supra- (up), infra- (down)
vergence: eyes move in opposite directions (disconjugate); convergence (inward movement), divergence (outward movement)

From Costakos D. Eye disorders. In: Kliegman RM, Bordini BJ, Toth H, Basel D, eds. *Nelson Pediatric Symptom-Based Diagnosis.* 2nd ed, Philadelphia: Elsevier; 2022: Table 43.2, p. 787.

The characteristic angle of infantile esodeviations is large and constant (Fig. 663.3). Because of the large deviation, cross-fixation is frequently encountered. This is a condition in which the child looks to the right with the left eye and to the left with the right eye. With cross-fixation, there is no need for the eye to turn away from the nose (abduction) as the adducting eye is used in side gaze; this condition simulates a sixth nerve palsy. Abduction can be demonstrated by the doll's-head maneuver or by patching one eye for a short time. Children with infantile esotropia tend to have refractive errors similar to those of normal children of the same age. This contrasts with the characteristic high level of farsightedness associated with accommodative esotropia. **Amblyopia** is common in children with infantile esotropia.

The primary goal of **treatment** in infantile esotropia is to eliminate or reduce the deviation as much as possible. Ideally this results in normal sight in each eye, in straight-looking eyes, and in the development of binocular vision. Early treatment (before age 2 years) is more likely to lead to the development of binocular vision, which helps maintain long-term ocular alignment. Once any associated amblyopia is treated, surgery is performed to align the eyes. Even with successful surgical alignment, it is common for vertical deviations to develop in children with a history of infantile esotropia. The two most common forms of vertical deviations to develop are inferior oblique muscle overaction and dissociated vertical deviation. In inferior oblique muscle overaction, the overactive inferior oblique muscle produces an upshoot of the eye closest to the nose when the patient looks to the side (Fig. 663.4). In dissociated vertical deviation, one eye drifts up slowly with no movement of the other eye. Surgery may be necessary to treat either or both of these conditions.

It is important that parents realize that early successful surgical alignment is only the beginning of the treatment process. Because many children may redevelop strabismus or amblyopia, they need to be monitored closely during the visually immature period of life.

Accommodative esotropia is defined as a "convergent deviation of the eyes associated with activation of the accommodative (focusing) reflex." It usually occurs in a child who is between 2-3 years of age and who has a history of acquired intermittent or constant crossing. Amblyopia occurs in the majority of cases.

The mechanism of accommodative esotropia involves uncorrected hyperopia, accommodation, and accommodative convergence. The image entering a hyperopic (farsighted) eye is blurred. If the amount of hyperopia is not significant, the blurred image can be sharpened by accommodating (focusing of the lens of the eye). Accommodation is closely linked with convergence (eyes turning inward) because both are required to view an object at near. If a child's hyperopic refractive error

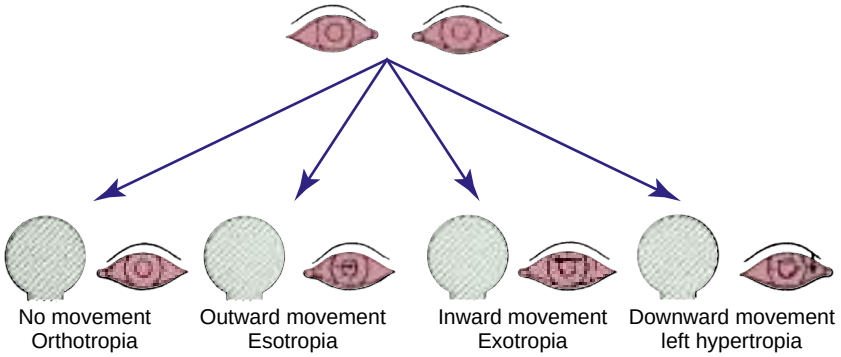

Fig. 663.1 The cover test. In each instance, the occluder is placed over the right eye while the patient is viewing a fixation target and the examiner is watching for movement of the patient's left eye. If the left eye is not aligned, it will need to move to look at the fixation target. If there is no movement of the left eye, the test needs to be repeated by occluding the left eye and watching for movement of the right eye. *(From Kliegman RM, Lye PS, Bordini BJ, Toth H, Basel D, eds. Nelson Pediatric Symptom-Based Diagnosis. Elsevier; 2018: Fig. 32.6, p. 567).*

is large or if the amount of convergence that occurs in response to each unit of accommodative effort is great, esotropia may develop.

The **treatment** for accommodative esotropia is to prescribe the full hyperopic (farsighted) correction. These glasses eliminate a child's need to accommodate and therefore correct the esotropia (Fig. 663.5). Although many parents are initially concerned that their child will not want to wear glasses, the benefits of binocular vision and the decrease in the focusing effort required to see clearly provide a strong stimulus to wear glasses, and they are generally accepted well. The full hyperopic correction sometimes straightens the eye position at distance fixation but leaves a residual deviation at near fixation. This may be observed, treated with bifocal lenses, or treated with surgery.

It is important to warn parents of children with accommodative esotropia that the esodeviation may appear to increase without glasses after the initial correction is worn. Parents frequently state that before wearing glasses, their child had a small esodeviation, whereas after removal of the glasses, the esodeviation becomes quite large. Parents often blame the increased esodeviation on the glasses. This apparent increase is a result of the child using the appropriate amount of accommodative effort after the glasses have been worn. When these children remove their glasses, they continue to use an accommodative effort to bring objects into proper focus and increase the esodeviation.

Most children maintain straight eyes once initially treated. Because hyperopia generally decreases with age, patients may outgrow the need to wear glasses to maintain alignment. In some patients, a residual esodeviation persists even when wearing their glasses. This condition commonly occurs when there is a delay between the onset of accommodative esotropia and treatment. In others, the esotropia may initially be eliminated with glasses, but crossing redevelops and is not correctable with glasses. Any residual component of esotropia that is not fully correctable with glasses is typically referred to as "nonaccommodative," and a child with both accommodative and nonaccommodative components of esotropia is often referred to as having "partially accommodative" esotropia. Surgery for the nonaccommodative portion of the crossing may be indicated to restore binocular vision.

Exodeviations are the second most common type of misalignment. The divergent deviation may be intermittent or constant. Intermittent exotropia is the most common exodeviation in childhood. It is characterized by outward drifting of one eye, which usually occurs when a child is fixating at distance. The deviation is generally more frequent with fatigue or illness. Exposure to bright light may cause reflex closure of the exotropic eye. Because the eyes initially can be kept straight most of the time, visual acuity tends to be good in both eyes and binocular vision is initially normal.

The age at onset of intermittent exotropia varies but is often between age 6 months and 4 years. The decision to perform eye muscle surgery is based on the amount and frequency of the deviation. If the deviation is small and infrequent, it is reasonable to observe the child. If the exotropia is large or increasing in frequency, surgery is indicated to maintain normal binocular vision.

Constant exotropia may rarely be congenital. Congenital exotropia may be associated with neurologic disease or abnormalities of the bony orbit, as in Crouzon syndrome. Exotropia that occurs later in life may represent a deterioration of an intermittent exotropia that was present in childhood. Surgery can restore binocular vision even in longstanding cases.

Noncomitant Strabismus

When an eye muscle is paretic, palsied, or restricted, a muscle imbalance occurs in which the deviation of the eye varies according to the direction of gaze. Recent onset of a paretic muscle can be suggested by the symptom of double vision that increases in one direction, the findings of an ocular deviation that increases in the field of action of the paretic muscle, and an increase in the deviation when the child fixates with the paretic eye. It is important to differentiate a noncomitant strabismus from a comitant deviation because noncomitant forms

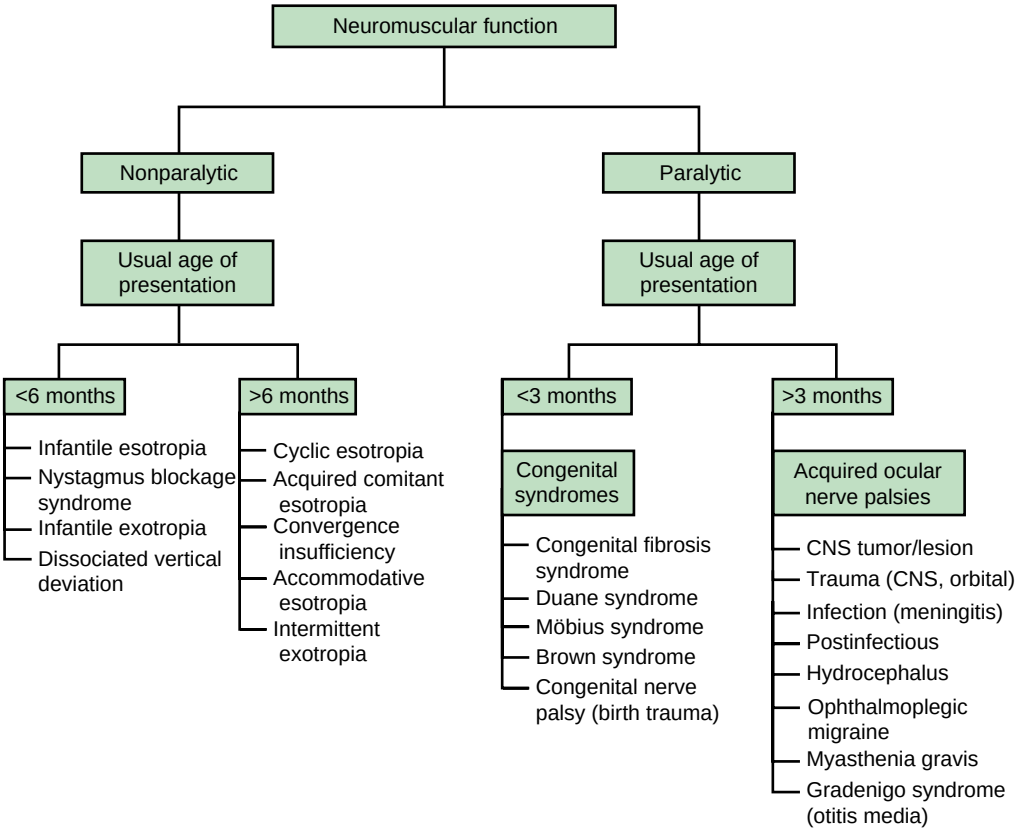

Fig. 663.2 Evaluation of strabismus. CNS, Central nervous system. *(From Costakos D. Eye disorders. In: Kliegman RM, Bordini BJ, Toth H, Basel D, eds. Nelson Pediatric Symptom-Based Diagnosis. 2nd ed. Philadelphia: Elsevier; 2022: Fig. 43.9, p. 789).*

Fig. 663.3 Congenital esotropia. Note the large angle of crossing.

Fig. 663.4 Inferior oblique muscle overaction.

of strabismus are often associated with trauma, systemic disorders, or neurologic abnormalities (Table 663.2).

Third Nerve Palsy

In the pediatric population, third nerve palsies are usually congenital. The congenital form is often associated with a developmental anomaly or birth trauma. Acquired third nerve palsies in children can be an ominous sign and may indicate a neurologic abnormality such as increased intracranial pressure (ICP) and an intracranial neoplasm or aneurysm. Other, less serious causes include an inflammatory or infectious lesion, head trauma, postviral syndromes, and migraines.

A third nerve palsy, whether congenital or acquired, usually results in an exotropia and a hypotropia, or downward deviation of the affected eye, as well as complete or partial ptosis of the upper lid. This characteristic strabismus results from the action of the normal, unopposed muscles, the lateral rectus muscle, and the superior oblique muscle. If

Fig. 663.5 Accommodative esotropia. Control of deviation with corrective lenses.

the internal branch of the third nerve is involved, pupillary dilation may be noted as well. Eye movements are usually limited nasally, in elevation, and in depression. In addition, clinical findings and treatment may be complicated in congenital and traumatic cases of third nerve palsy, owing to misdirection of regenerating nerve fibers, referred to as *aberrant regeneration*. This results in anomalous and paradoxical eyelid, eye, and pupil movement such as elevation of the eyelid, constriction of the pupil, or depression of the globe on attempted medial gaze.

Fourth Nerve Palsy

These palsies can be congenital or acquired. Because the fourth nerve has a long intracranial course, it is susceptible to damage resulting from head trauma. In children, however, fourth nerve palsies are more frequently congenital than traumatic. A palsied fourth nerve results in weakness in the superior oblique muscle, which causes an upward deviation of the affected eye, a hypertropia. Because the antagonist muscle, the inferior oblique, is relatively unopposed, the affected eye demonstrates an upshoot when looking toward the nose. Children typically present with a head tilt to the shoulder opposite the affected eye and may also position their chin down and face turned away from the affected side. This head position places the eye away from the area of greatest action of the affected muscle and therefore minimizes the deviation and the associated double vision. Because the abnormal head posture maintains the child's ocular alignment, amblyopia is uncommon. Because no abnormality exists in the neck muscles, attempts to correct the head tilt by exercises and neck muscle surgery are ineffective. Recognition of a superior oblique paresis can be difficult because deviation of the head and the eye may be minimal. **Treatment** may include eye muscle surgery to improve the ocular alignment and eliminate the abnormal head posture.

Sixth Nerve Palsy

These palsies produce markedly crossed eyes with limited ability to move the afflicted eye laterally. Children frequently present with their head turned toward the palsied muscle, a position that helps preserve binocular vision. The esotropia is largest when the eye is moved toward the affected muscle.

Congenital sixth nerve palsies are rare. Decreased lateral gaze in infants is often associated with other disorders, such as infantile esotropia or Duane retraction syndrome. In neonates, a transient sixth nerve paresis can occur; it usually clears spontaneously by 6 weeks. It

Table 663.2 Less Common Forms of Strabismus

TYPE OF STRABISMUS	PRESENTING SYMPTOMS AND SIGNS	CAUSE	TREATMENT
Duane syndrome	Esotropia with deficient abduction or exotropia with deficient adduction of one eye; head turn	Absence of sixth nerve nucleus and aberrant innervation of lateral rectus muscle from third cranial nerve	Strabismus surgery for correction of large deviations or abnormal head position
Dissociated vertical deviation	One eye turns up intermittently, especially with fatigue	Eye movement abnormality related most commonly to congenital esotropia	Eye muscle surgery on superior rectus and inferior oblique muscles
Brown syndrome	Head tilt; inability to elevate eye in adduction	Restriction of free passage of superior oblique tendon through trochlea	Observation if not severe; superior oblique tendon surgery if severe
Möbius syndrome	Masklike facies; inability to abduct both eyes; difficulty closing eyes	Bilateral sixth and seventh nerve palsies	Protect corneas from exposure; strabismus surgery
Congenital fibrosis syndrome	Chin-up head position; inability to elevate eyes; ptosis	Autosomal dominant gene on chromosome 16 in some patients; superior division of third nerve in others	Surgical release of tight extraocular muscles
Third nerve palsy	Exotropia and hypertropia; ptosis; dilated, nonreactive pupil	Congenital absence of third nerve; trauma; tumor	Ptosis and strabismus surgery
Double elevator palsy	Chin-up head posture; inability to elevate one eye	Paresis of superior rectus muscle	Transposition strabismus surgery
Orbital floor fracture	Vertical diplopia; chin-up head position	Entrapment of orbital tissues in fracture	Repair of floor fracture; release of inferior rectus muscle restriction
Myasthenia: congenital or acquired	Variable ptosis and eye movement abnormalities	Blockage of acetylcholine receptor sites by immune complexes	Treatment of systemic myasthenia; strabismus surgery if patient is stable
Mitochondrial disorders	Ptosis, progressive external ophthalmoplegia, optic neuropathy, cardiomyopathy, peripheral myopathy	Various mitochondrial variants	Supportive

From Costakos D. Eye disorders. In: Kliegman RM, Bordini BJ, Toth H, Basel D, eds. *Nelson Pediatric Symptom-Based Diagnosis.* 2nd ed. Philadelphia: Elsevier; 2022: Table 43.3, p. 790.

is believed that increased ICP associated with labor and delivery is the contributing factor.

Acquired sixth nerve palsies in childhood are often an ominous sign because the sixth nerve is susceptible to increased ICP associated with hydrocephalous and intracranial tumors. Other causes of sixth nerve defects in children include trauma, vascular malformations, meningitis, and Gradenigo syndrome. A benign sixth nerve palsy, which is painless and acquired, can be noted in infants and older children. This is frequently preceded by a febrile illness or upper respiratory tract infection and may be recurrent. Complete resolution of the palsy is common in this scenario, although other causes of an acute sixth nerve palsy should be eliminated before this diagnosis is made.

Strabismus Syndromes

Special types of strabismus have unusual clinical features. Most of these disorders are caused by structural anomalies of the extraocular muscles or adjacent tissues. Most strabismus syndromes produce noncomitant misalignments.

Monocular Elevation Deficiency

A monocular elevation deficit in both abduction and adduction is referred to as *monocular elevation deficiency* (previously called *double-elevator palsy*). It may represent a paresis of both elevators, the superior rectus and inferior oblique muscles, or a possible restriction to elevation from a fibrotic inferior rectus muscle. When an affected child fixates with the nonparetic eye, the paretic eye is hypotropic and the ipsilateral upper eyelid may appear ptotic. Fixation with the paretic eye causes a hypertropia of the nonparetic eye and a disappearance of the ptosis (Fig. 663.6). Because the apparent ptosis is actually secondary to the strabismus, correction of the hypotropia treats the pseudoptosis.

Fig. 663.6 Double-elevator palsy of the right eye. Note the disappearance of the apparent ptosis when fixating with the involved eye.

Duane Syndrome

This congenital disorder of ocular motility is characterized by retraction of the globe on adduction. Duane syndrome occurs more frequently in females and involves the left eye more commonly than the right eye. It is caused by the absence of the sixth nerve nucleus and subsequent anomalous innervation of the lateral rectus muscle, which results in co-contraction of the medial and lateral rectus muscles on attempted adduction of the affected eye. Within the spectrum of Duane syndrome, patients may exhibit impairment of abduction, impairment

of adduction, or upshoot or downshoot of the involved eye on adduction. They may have esotropia, exotropia, or relatively straight eyes. Many children exhibit a compensatory head posture to maintain single vision. Some develop amblyopia. Surgery to improve alignment or to reduce a noticeable face turn can be helpful in selected cases. Duane syndrome usually occurs sporadically, but it can be inherited as an autosomal dominant trait. While typically occurring as an isolated condition, some patients may have various associated ocular and systemic anomalies.

Möbius Syndrome

The distinctive features of Möbius syndrome are congenital facial paresis and abduction weakness. The facial palsy is commonly bilateral, frequently asymmetric, and often incomplete, tending to spare the lower face and platysma. Ectropion, epiphora, and exposure keratopathy may develop. The abduction defect may be unilateral or bilateral. Esotropia is common. The cause is unknown. Whether the primary defect is maldevelopment of cranial nerve nuclei, hypoplasia of the muscles, or a combination of central and peripheral factors is unclear. Some familial cases have been reported. Associated developmental defects may include ptosis, palatal and lingual palsy, hearing loss, pectoral and lingual muscle defects, micrognathia, syndactyly, supernumerary digits, and the absence of hands, feet, fingers, or toes. Surgical correction of the esotropia is indicated and any attendant amblyopia should be treated.

Brown Syndrome

In this syndrome, elevation of the eye in the adducted position is restricted (Fig. 663.7). An associated downward deviation of the affected eye in adduction may also occur. A compensatory head posture may be evident. Brown syndrome occurs as a result of restriction of the superior oblique tendon as it moves through the trochlea. Cases may be congenital or acquired. Acquired Brown syndrome may follow trauma to the orbit involving the region of the trochlea or sinus surgery. It may also occur with inflammatory processes, particularly sinusitis and juvenile idiopathic arthritis.

Acquired inflammatory Brown syndrome may respond to treatment with either nonsteroidal medications or corticosteroids. Surgery may be helpful for selected cases of Brown syndrome.

Parinaud Syndrome

This eponym designates a palsy of vertical gaze, isolated or associated with pupillary or nuclear oculomotor (third cranial nerve) paresis. It indicates a lesion affecting the mesencephalic tegmentum. The ophthalmic signs of midbrain disease include vertical gaze palsy, dissociation of the pupillary responses to light and to near focus, general pupillomotor paralysis, corectopia, dyscoria, accommodative disturbances, pathologic lid retraction, ptosis, extraocular muscle paresis, and convergence paralysis. Some cases have associated spasms of convergence, convergent retraction nystagmus, and vertical nystagmus, particularly on attempted vertical gaze. Combinations of these signs are referred to as the **sylvian aqueduct syndrome**.

A principal cause of vertical gaze palsy and associated mesencephalic signs in children is tumor of the pineal gland or third ventricle. Differential diagnosis includes trauma and demyelinating disease. In children with hydrocephalus, impairment of vertical gaze and pathologic lid retraction are referred to as the *setting-sun sign*. A transient supranuclear disorder of gaze is sometimes seen in healthy neonates.

CONGENITAL OCULAR MOTOR APRAXIA

This congenital disorder of conjugate gaze is characterized by a defect in voluntary horizontal gaze, compensatory jerking movement of the head, and retention of slow pursuit and reflexive eye movements. Additional features are absence of the fast (refixation) phase of optokinetic nystagmus and obligate contraversive deviation of the eyes on rotation of the body. Affected children typically are unable to look quickly to either side voluntarily in response to a command or in response to an eccentrically presented object but may be able to follow a slowly moving target to either side. To compensate for the defect in purposive lateral eye movements, children jerk their head to bring the eyes into the desired position and may also blink repetitively in an attempt to change fixation. The signs tend to become less conspicuous with age.

Fig. 663.7 Brown syndrome of the right eye.

The pathogenesis of congenital ocular motor apraxia is unknown. It may be a result of delayed myelination of the ocular motor pathways. Structural abnormalities of the central nervous system (CNS) have been found in a few patients, including agenesis of the corpus callosum and cerebellar vermis, porencephaly, hamartoma of the foramen of Monro, and macrocephaly. Many children with congenital ocular motor apraxia show delayed motor and cognitive development.

NYSTAGMUS

Nystagmus (rhythmic oscillations of one or both eyes) may be caused by an abnormality in any one of the three basic mechanisms that regulate position and movement of the eyes: the fixation, conjugate gaze, or vestibular mechanism. In addition, physiologic nystagmus may be elicited by appropriate stimuli (Table 663.3).

Congenital sensory nystagmus is generally associated with ocular abnormalities that lead to decreased visual acuity; common disorders that lead to early-onset nystagmus include albinism, aniridia, achromatopsia, congenital cataracts, congenital macular lesions, congenital optic atrophy, and congenital optic nerve hypoplasia. In some instances, nystagmus occurs as a dominant or X-linked characteristic without obvious ocular abnormalities.

Congenital idiopathic motor nystagmus is characterized by horizontal jerky oscillations, often with gaze preponderance. There are no ocular anatomic defects that cause the nystagmus, and the visual acuity is generally near normal. There may be a null point in which the nystagmus damps and the vision improves; a compensatory head posture will develop that places the eyes into the position of least nystagmus. The cause of congenital idiopathic motor nystagmus is unknown; in some instances, this is familial. Eye muscle surgery may be performed to eliminate an abnormal head posture by bringing the point of best vision into straight-ahead gaze.

Acquired nystagmus requires prompt and thorough evaluation. Spontaneous nystagmus is often associated with either peripheral or central vestibular disorders. Peripheral disorders are often acute and benign, but the severity of symptoms is often problematic to the patient (room spinning, unsteady gait, tinnitus, diaphoresis). Central vestibular lesions are more concerning for CNS disorders (vestibular nuclei, brainstem, cerebellum, cortex); symptoms are more chronic and less severe. Worrisome pathologic types are the gaze-paretic or gaze-evoked oscillations of cerebellar, brainstem, or cerebral disease.

Nystagmus retractorius or **convergent nystagmus** is repetitive jerking of the eyes into the orbit or toward each other. It is usually seen with vertical gaze palsy as a feature of Parinaud (sylvian aqueduct) syndrome. The causal condition may be neoplastic, vascular, or inflammatory. In children, nystagmus retractorius suggests particularly the presence of pinealoma or hydrocephalus.

A diagnostic approach to nystagmus is noted in Figures 663.8 and 663.9 and Table 663.4.

Table 663.3 Specific Patterns of Nystagmus

PATTERN	DESCRIPTION	ASSOCIATED CONDITIONS
Latent nystagmus	Conjugate jerk nystagmus toward viewing eye	Congenital vision defects, occurs with occlusion of eye
Manifest latent nystagmus	Fast jerk to viewing eye	Strabismus, congenital idiopathic nystagmus
Periodic alternating	Cycles of horizontal or horizontal-rotary that change direction	Caused by both visual and neurologic conditions
Seesaw nystagmus	One eye rises and intorts as other eye falls and extorts	Usually associated with optic chiasm defects
Nystagmus retractorius	Eyes jerk back into orbit or toward each other	Caused by pressure on mesencephalic tegmentum (Parinaud syndrome)
Gaze-evoked nystagmus	Jerk nystagmus in direction of gaze	Caused by medications, brainstem lesion, or labyrinthine dysfunction
Gaze-paretic nystagmus	Eyes jerk back to maintain eccentric gaze	Cerebellar disease
Downbeat nystagmus	Fast phase beating downward	Posterior fossa disease, drugs
Upbeat nystagmus	Fast phase beating upward	Brainstem and cerebellar disease; some visual conditions
Vestibular nystagmus	Horizontal-torsional or horizontal jerks	Vestibular system dysfunction
Asymmetric or monocular nystagmus	Pendular vertical nystagmus	Disease of retina and visual pathways
Spasmus nutans	Fine, rapid, pendular nystagmus	Torticollis, head nodding; idiopathic or gliomas of visual pathways

From Kliegman R. *Practical Strategies in Pediatric Diagnosis and Therapy.* Philadelphia: WB Saunders;1996.

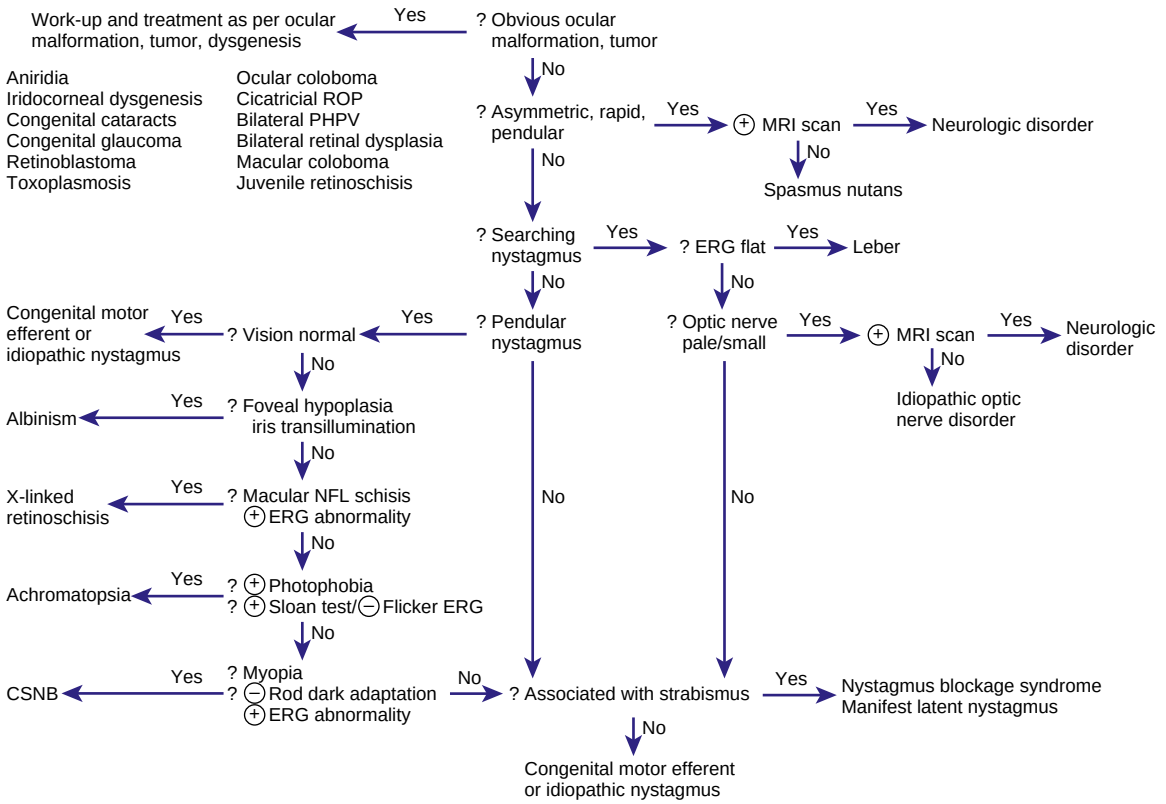

Fig. 663.8 Algorithm for the work-up of an infant with nystagmus. ⊕, Positive; ⊖, negative; CSNB, congenital stationary night blindness; ERG, electroretinogram; NFL, nerve fiber layer; PHPV, persistent hyperplastic primary vitreous; ROP, retinopathy of prematurity. *(From Nelson LB. Harley's Pediatric Ophthalmology. 4th ed. Philadelphia: Saunders; 1998: p. 470.)*

Spasmus nutans is a special type of acquired nystagmus in childhood (see also Chapter 637). In its complete form, it is characterized by the **triad** of pendular nystagmus, head nodding, and torticollis. The nystagmus is characteristically very fine, very rapid, horizontal, and pendular; it is often asymmetric, sometimes unilateral. Signs usually develop within the first year or two of life. Components of the triad may develop at various times. In many cases, the condition is benign and self-limited, usually lasting a few months, sometimes years. The cause of this classic type of spasmus nutans, which usually resolves spontaneously, is unknown. Some children exhibiting signs resembling

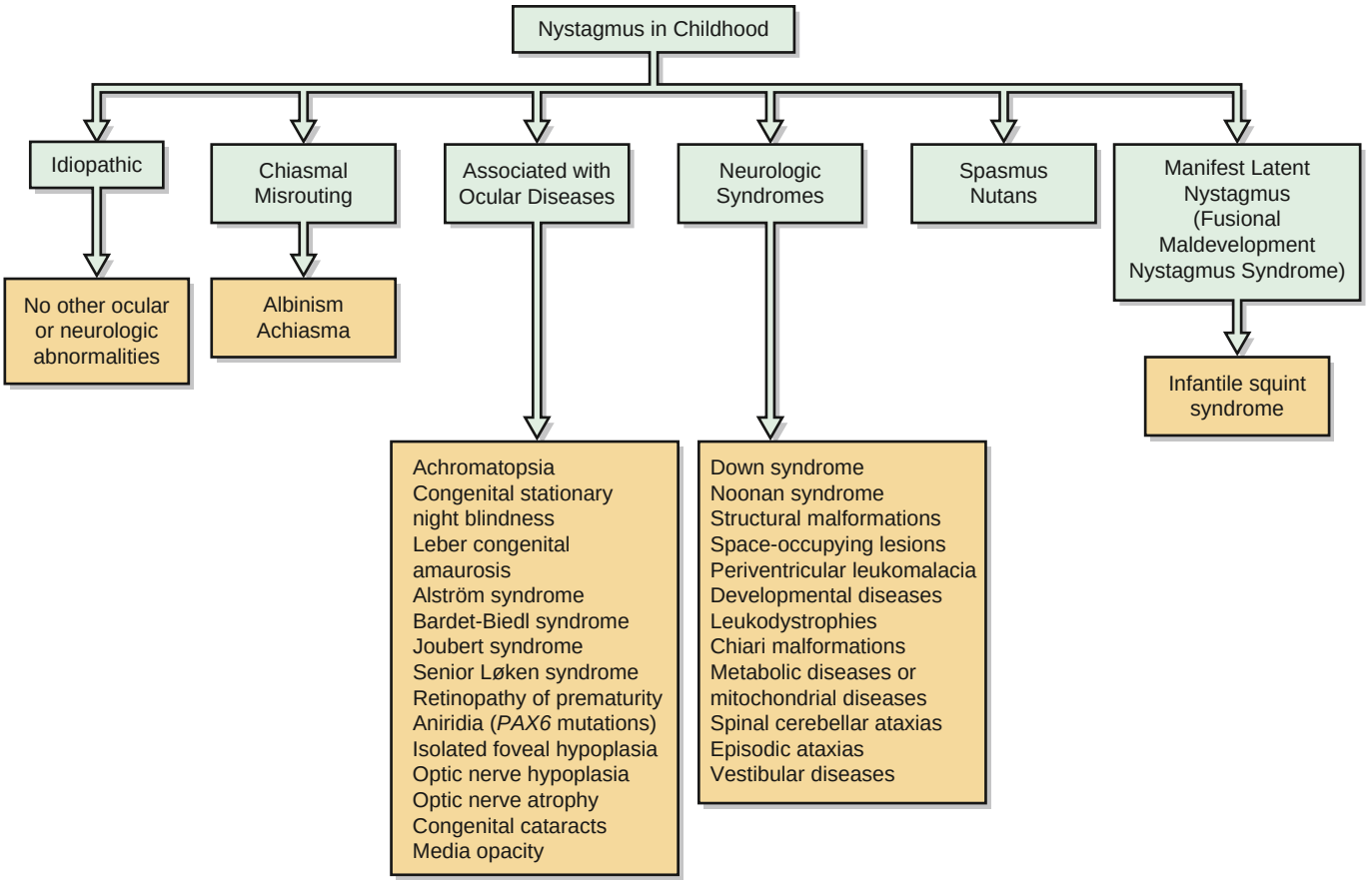

Fig. 663.9 Classification of nystagmus based on associated diseases. *(From Hoyt CS, Taylor D, eds. Pediatric ophthalmology and strabismus. 4th ed. Philadelphia: Elsevier; 2013: Fig. 89.2, p. 910.)*

Table 663.4 Key Distinguishing Features of Peripheral and Central Types of Spontaneous and Positional Nystagmus

TYPE OF NYSTAGMUS	PERIPHERAL (END ORGAN AND NERVE)	CENTRAL (BRAINSTEM AND CEREBELLUM)
Spontaneous	Unidirectional, fast phase away from the lesion, combined horizontal torsional, inhibited with fixation	Bidirectional or unidirectional; often pure horizontal, vertical, or torsional; *not* inhibited with fixation
Static positional	Fixed or changing direction, inhibited with fixation	Fixed or changing direction, *not* inhibited with fixation
Paroxysmal positional	Vertical-torsional, occasionally horizontal-torsional, vertigo prominent, fatigability, latency	Often pure vertical, vertigo less prominent, no latency, nonfatigable

From Goldman L, Schafer AI, eds. *Goldman-Cecil Medicine*. 25 ed. Philadelphia: Elsevier; 2016: Table 424.5, p. 2579.

those of spasmus nutans have underlying brain tumors, particularly hypothalamic and chiasmal optic gliomas. Appropriate neurologic and neuroradiologic evaluation and careful monitoring of infants and children with nystagmus are therefore recommended.

OTHER ABNORMAL EYE MOVEMENTS

To be differentiated from true nystagmus are certain special types of abnormal eye movements, particularly opsoclonus, ocular dysmetria, and flutter (Table 663.5).

Opsoclonus

Opsoclonus and ataxic conjugate movements are spontaneous, nonrhythmic, multidirectional, chaotic movements of the eyes. The eyes appear to be in agitation, with bursts of conjugate movement of varying amplitude in varying directions. Opsoclonus is most often associated with infectious or autoimmune encephalitis. It may be the first sign of neuroblastoma or other tumors producing a paraneoplastic syndrome.

Ocular Motor Dysmetria

This is analogous to dysmetria of the limbs. Affected individuals show a lack of precision in performing movements of refixation, characterized by an overshoot (or undershoot) of the eyes with several corrective to-and-fro oscillations on looking from one point to another. Ocular motor dysmetria is a sign of cerebellar or cerebellar pathway disease.

Table 663.5 Specific Patterns of Nonnystagmus Eye Movements

PATTERN	DESCRIPTION	ASSOCIATED CONDITIONS
Opsoclonus	Multidirectional conjugate movements of varying rate and amplitude	Hydrocephalus, diseases of brainstem and cerebellum, neuroblastoma, paraneoplasia syndrome
Ocular dysmetria	Overshoot of eyes on rapid fixation	Cerebellar dysfunction
Ocular flutter	Horizontal oscillations with forward gaze and sometimes with blinking	Cerebellar disease, hydrocephalus, or central nervous system neoplasm
Ocular bobbing	Downward jerk from primary gaze, remains for a few seconds, then drifts back	Pontine disease
Ocular myoclonus	Rhythmic to-and-fro pendular oscillations of the eyes, with synchronous nonocular muscle movement	Damage to red nucleus, inferior olivary nucleus, and ipsilateral dentate nucleus

From Kliegman R. *Practical Strategies in Pediatric Diagnosis and Therapy*. Philadelphia: Saunders; 1996.

Flutter-Like Oscillations

These intermittent to-and-fro horizontal oscillations of the eyes may occur spontaneously or on change of fixation. They are characteristic of cerebellar disease.

Visit Elsevier eBooks+ at eBooks.Health.Elsevier.com for Bibliography.

Chapter 664

Abnormalities of the Lids

Scott E. Olitsky and Justin D. Marsh

PTOSIS

In blepharoptosis, the upper eyelid droops below its normal level. **Congenital ptosis** is usually a result of a localized dystrophy of the levator muscle in which the striated muscle fibers are replaced with fibrous tissue. The condition may be unilateral or bilateral and can be familial, transmitted as a dominant trait (Figs. 664.1 and 664.2).

Parents often comment that the eye looks smaller because of the drooping eyelid. The lid crease is decreased or absent where the levator muscle would normally insert below the skin surface. Because the levator is replaced by fibrous tissue, the lid does not move downward fully in downgaze (lid lag). If the ptosis is severe, affected children often attempt to raise the lid by lifting their brow or adapting a chin-up head posture to maintain binocular vision.

Marcus Gunn jaw-winking ptosis (maxillopalpebral synkinesis) accounts for 5% of ptosis in children. In this syndrome, an abnormal synkinesis exists between the fifth and third cranial nerves; this causes the eyelid to elevate with movement of the jaw. The wink is produced by chewing or sucking and may be more noticeable than the ptosis itself (Fig. 664.3).

Although ptosis in children is often an isolated finding, it may also be acquired and occur in association with other ocular or systemic disorders (Fig. 664.4). Systemic disorders include myasthenia gravis, muscular dystrophy, Miller Fisher variant of Guillain Barré syndrome, and botulism. Ocular disorders include mechanical ptosis secondary to lid tumors, blepharophimosis syndrome, congenital fibrosis syndrome, combined levator/superior rectus maldevelopment, and congenital or acquired third nerve palsy. Ptosis may be a sign of cerebral herniation. A small degree of ptosis is seen in Horner syndrome (see Chapter 662). A complete ophthalmic and systemic examination is therefore important in the evaluation of a child with ptosis.

Amblyopia may occur in children with ptosis. The amblyopia may be secondary to the lid covering the visual axis (deprivation) or induced astigmatism (anisometropia). When amblyopia occurs, it should generally be treated before treating the ptosis.

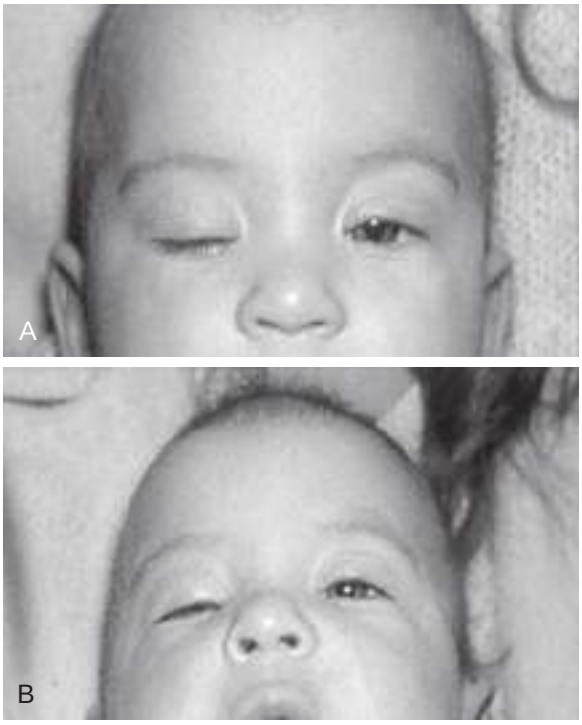

Fig. 664.1 A, Congenital ptosis of the right upper eyelid. B, The child adopted a compensatory chin-up head posture to allow use of both eyes together and did not have amblyopia. *(From Costakos DM. Eye disorders In Kliegman RM, Bordini BJ, Toth H, Basel D, eds. Nelson Pediatric Symptom-Based Diagnosis. 2nd ed. Philadelphia: Elsevier; 2022: Fig. 43.20, p. 805.)*

Treatment of ptosis in a child is indicated for elimination of an abnormal head posture, improvement in the visual field, prevention of amblyopia, and restoration of a normal eyelid appearance. The timing of surgery depends on the degree of ptosis, its cosmetic and functional severity, the presence or absence of compensatory posturing, the wishes of the parents, and the discretion of the surgeon. Surgical treatment is determined by the amount of levator function that is present. A levator resection may be used in children with moderate to good function. In patients with poor or absent function, a frontalis suspension procedure may be necessary. This technique requires that a suspension material be placed between the frontalis muscle and the tarsus of the eyelid. It allows patients to use their brow and frontalis muscle more effectively to raise their eyelid. Amblyopia may still exist even after surgical correction and should be treated if present.

Table 663.5 Specific Patterns of Nonnystagmus Eye Movements

PATTERN	DESCRIPTION	ASSOCIATED CONDITIONS
Opsoclonus	Multidirectional conjugate movements of varying rate and amplitude	Hydrocephalus, diseases of brainstem and cerebellum, neuroblastoma, paraneoplasia syndrome
Ocular dysmetria	Overshoot of eyes on rapid fixation	Cerebellar dysfunction
Ocular flutter	Horizontal oscillations with forward gaze and sometimes with blinking	Cerebellar disease, hydrocephalus, or central nervous system neoplasm
Ocular bobbing	Downward jerk from primary gaze, remains for a few seconds, then drifts back	Pontine disease
Ocular myoclonus	Rhythmic to-and-fro pendular oscillations of the eyes, with synchronous nonocular muscle movement	Damage to red nucleus, inferior olivary nucleus, and ipsilateral dentate nucleus

From Kliegman R. *Practical Strategies in Pediatric Diagnosis and Therapy*. Philadelphia: Saunders; 1996.

Flutter-Like Oscillations

These intermittent to-and-fro horizontal oscillations of the eyes may occur spontaneously or on change of fixation. They are characteristic of cerebellar disease.

Visit Elsevier eBooks+ at eBooks.Health.Elsevier.com for Bibliography.

Chapter 664

Abnormalities of the Lids

Scott E. Olitsky and Justin D. Marsh

PTOSIS

In blepharoptosis, the upper eyelid droops below its normal level. **Congenital ptosis** is usually a result of a localized dystrophy of the levator muscle in which the striated muscle fibers are replaced with fibrous tissue. The condition may be unilateral or bilateral and can be familial, transmitted as a dominant trait (Figs. 664.1 and 664.2).

Parents often comment that the eye looks smaller because of the drooping eyelid. The lid crease is decreased or absent where the levator muscle would normally insert below the skin surface. Because the levator is replaced by fibrous tissue, the lid does not move downward fully in downgaze (lid lag). If the ptosis is severe, affected children often attempt to raise the lid by lifting their brow or adapting a chin-up head posture to maintain binocular vision.

Marcus Gunn jaw-winking ptosis (maxillopalpebral synkinesis) accounts for 5% of ptosis in children. In this syndrome, an abnormal synkinesis exists between the fifth and third cranial nerves; this causes the eyelid to elevate with movement of the jaw. The wink is produced by chewing or sucking and may be more noticeable than the ptosis itself (Fig. 664.3).

Although ptosis in children is often an isolated finding, it may also be acquired and occur in association with other ocular or systemic disorders (Fig. 664.4). Systemic disorders include myasthenia gravis, muscular dystrophy, Miller Fisher variant of Guillain Barré syndrome, and botulism. Ocular disorders include mechanical ptosis secondary to lid tumors, blepharophimosis syndrome, congenital fibrosis syndrome, combined levator/superior rectus maldevelopment, and congenital or acquired third nerve palsy. Ptosis may be a sign of cerebral herniation. A small degree of ptosis is seen in Horner syndrome (see Chapter 662). A complete ophthalmic and systemic examination is therefore important in the evaluation of a child with ptosis.

Amblyopia may occur in children with ptosis. The amblyopia may be secondary to the lid covering the visual axis (deprivation) or induced astigmatism (anisometropia). When amblyopia occurs, it should generally be treated before treating the ptosis.

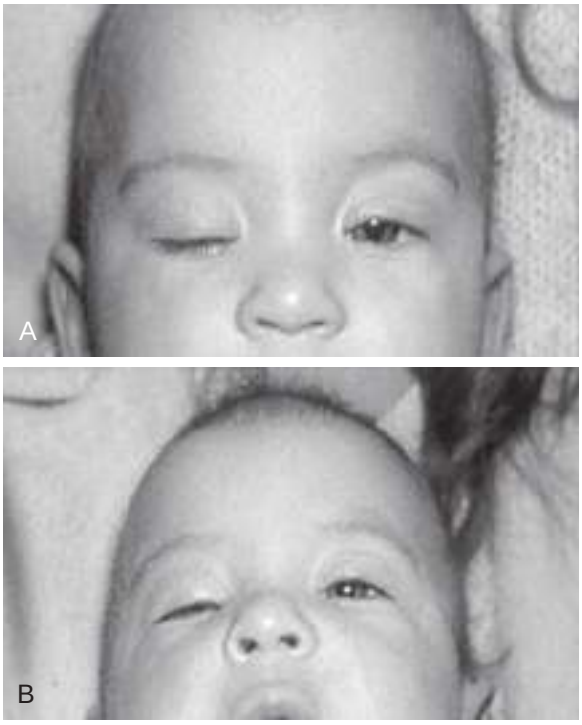

Fig. 664.1 A, Congenital ptosis of the right upper eyelid. B, The child adopted a compensatory chin-up head posture to allow use of both eyes together and did not have amblyopia. *(From Costakos DM. Eye disorders In Kliegman RM, Bordini BJ, Toth H, Basel D, eds. Nelson Pediatric Symptom-Based Diagnosis. 2nd ed. Philadelphia: Elsevier; 2022: Fig. 43.20, p. 805.)*

Treatment of ptosis in a child is indicated for elimination of an abnormal head posture, improvement in the visual field, prevention of amblyopia, and restoration of a normal eyelid appearance. The timing of surgery depends on the degree of ptosis, its cosmetic and functional severity, the presence or absence of compensatory posturing, the wishes of the parents, and the discretion of the surgeon. Surgical treatment is determined by the amount of levator function that is present. A levator resection may be used in children with moderate to good function. In patients with poor or absent function, a frontalis suspension procedure may be necessary. This technique requires that a suspension material be placed between the frontalis muscle and the tarsus of the eyelid. It allows patients to use their brow and frontalis muscle more effectively to raise their eyelid. Amblyopia may still exist even after surgical correction and should be treated if present.

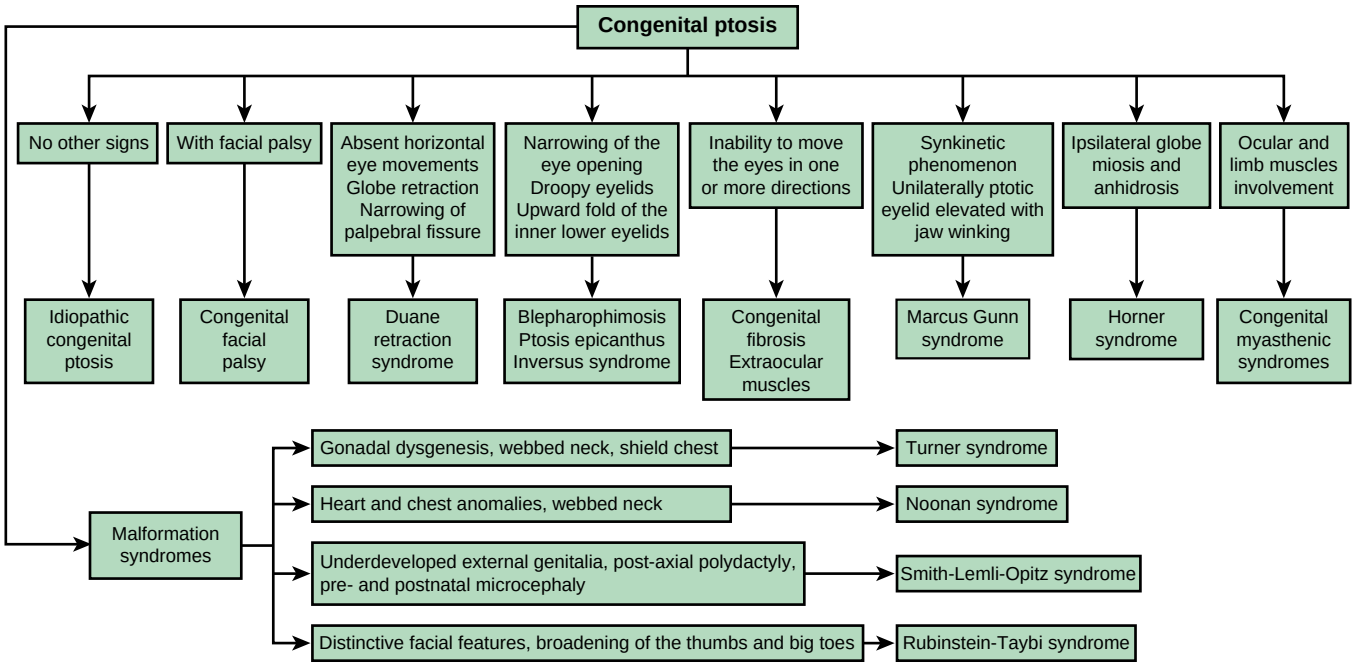

Fig. 664.2 Flow chart outlining congenital types of ptosis. *(From Pavone P, Cho YC, Pratico AD, et al. Ptosis in childhood: A clinical sign of several disorders. Medicine. 2018 Sep;97[36]:e12124, Fig. 8A.)*

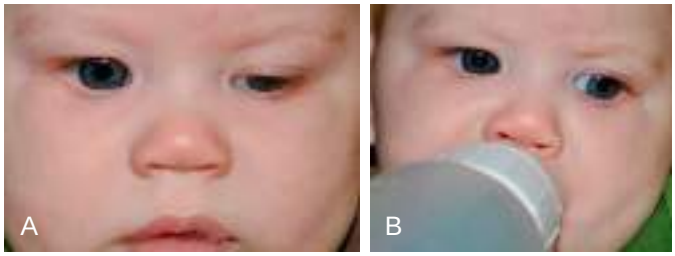

Fig. 664.3 Marcus Gunn jaw-winking phenomenon. **A,** Left upper lid ptosis. **B,** The left lid raises up while the patient sucks from the bottle. *(From Martin RJ, Fanaroff AA, Walsch MC, eds. Fanaroff & Martin's Neonatal-Perinatal Medicine. 10th ed. Philadelphia: Elsevier; 2015: Fig. 103.2.)*

EPICANTHAL FOLDS

These vertical or oblique folds of skin extend on either side of the bridge of the nose from the brow or lid area, covering the inner canthal region. They are present to some degree in most young children and become less apparent with age. The folds may be sufficiently broad to cover the medial aspect of the eye, making the eyes appear crossed (pseudoesotropia). Epicanthal folds are a common feature of many syndromes, including chromosomal aberrations (trisomies) and disorders of single genes.

LAGOPHTHALMOS

This is a condition in which complete closure of the lids over the globe is difficult or impossible. It may be paralytic because of a facial palsy involving the orbicularis muscle, or spastic, as in thyrotoxicosis. It may be structural when retraction or shortening of the lids results from scarring or atrophy consequent to injury (burns) or disease. Children with various craniosynostosis syndromes can have problematic lagophthalmos. Infants with congenital ichthyosis may have lagophthalmos caused by the restrictive effect of the lids. Lagophthalmos may accompany proptosis or **buphthalmos** (enlarged cornea because of elevated intraocular pressure) when the lids, although normal, cannot effectively cover the enlarged or protuberant eye. A degree of physiologic lagophthalmos may occur normally during sleep, but functional lagophthalmos in an unconscious or debilitated patient can be a problem.

In patients with lagophthalmos, exposure of the eye may lead to drying, infection, corneal ulceration, or perforation of the cornea; the result may be loss of vision, even loss of the eye. In lagophthalmos, protection of the eye by artificial tear preparations, ophthalmic ointment, or moisture chambers is essential. Gauze pads are to be avoided because the gauze may abrade the cornea. In some cases, surgical closure of the lids (tarsorrhaphy) may be necessary for long-term protection of the eye.

LID RETRACTION

Pathologic retraction of the lid may be myogenic or neurogenic. Myogenic retraction of the upper lid occurs in **thyrotoxicosis**, in which it is associated with three classic signs: a staring appearance (Dalrymple sign), infrequent blinking (Stellwag sign), and lag of the upper lid on downward gaze (von Graefe sign).

Neurogenic retraction of the lids may occur in conditions affecting the anterior mesencephalon. Lid retraction is a feature of the **syndrome of the sylvian aqueduct**. In children, it is commonly a sign of hydrocephalus. It may occur with meningitis. Paradoxical retraction of the lid is seen in the Marcus Gunn jaw-winking syndrome. It may also be seen with attempted eye movement after recovery from a third nerve palsy if aberrant regeneration of the oculomotor nerve fibers has occurred.

Simple staring and the physiologic or reflexive lid retraction ("eye popping"), in contrast to pathologic lid retractions, occur in infants in response to a sudden reduction in illumination or as a startle reaction.

ECTROPION, ENTROPION, AND EPIBLEPHARON

Ectropion is eversion of the lid margin; it may lead to overflow of tears (epiphora) and subsequent maceration of the skin of the lid, inflammation of exposed conjunctiva, or superficial exposure keratopathy. Common causes are scarring consequent to inflammation, burns, or trauma and weakness of the orbicularis muscle as a result of facial palsy; these forms may be corrected surgically. Protection of the cornea is essential. Ectropion is also seen in certain children who have faulty development of the lateral canthal ligament; this may occur in Down syndrome.

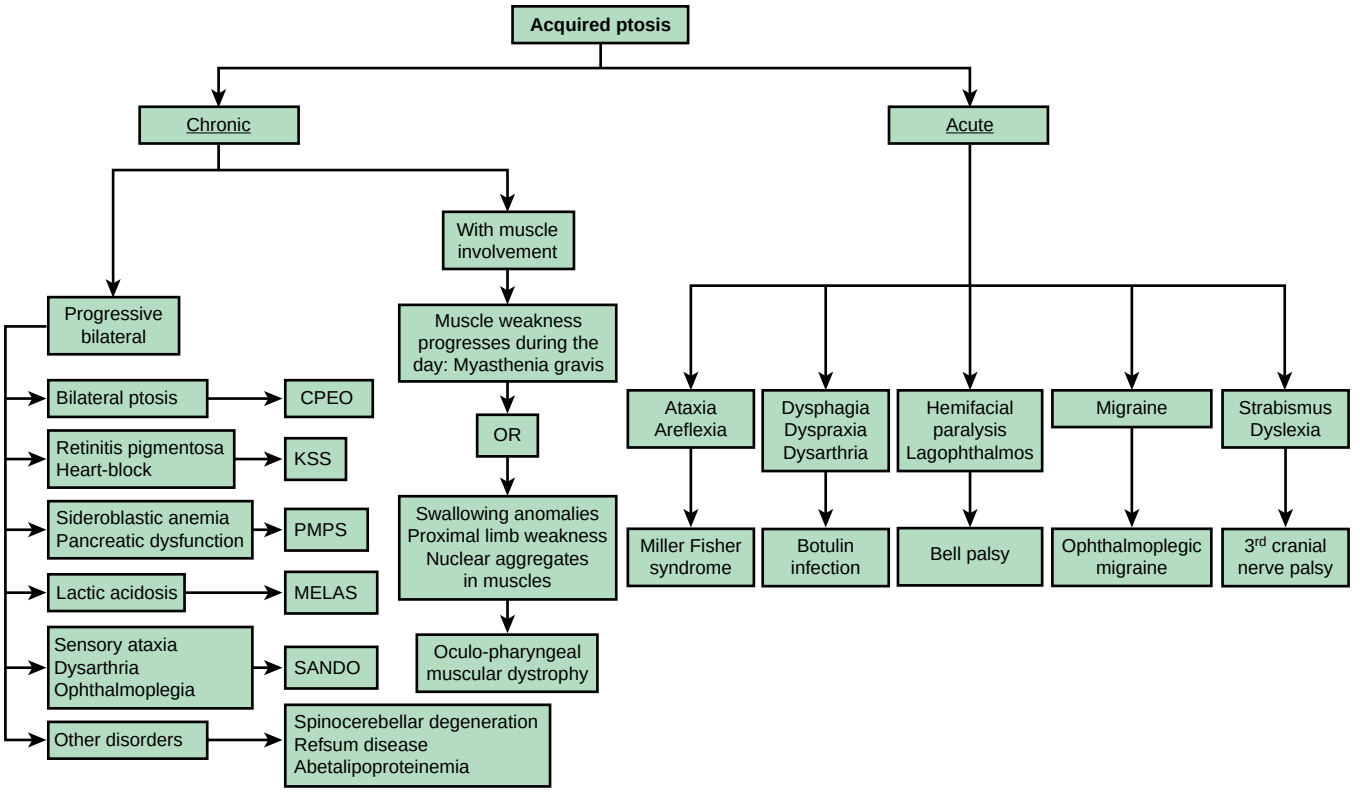

Fig. 664.4 Flow chart outlining acquired types of ptosis. CPEO, Chronic progressive external ophthalmoplegia; KSS, Kearns-Sayre syndrome; MELAS, mitochondrial encephalopathy, lactic acidosis, and strokelike episodes; PMPS, Pearson marrow pancreas syndrome; SANDO, sensory ataxic neuropathy, dysarthria, and ophthalmoparesis. *(From Pavone P, Cho YC, Pratico AD, et al. Ptosis in childhood: A clinical sign of several disorders. Medicine. 2018 Sep;97[36]:e12124, Fig. 8B.)*

Entropion is inversion of the lid margin, which may cause discomfort and corneal damage because of the inward turning of the lashes (trichiasis). A principal cause is scarring secondary to inflammation, such as occurs in trachoma or as a sequela of Stevens-Johnson syndrome. There is also a rare congenital form. Surgical correction is effective in many cases.

Epiblepharon is commonly seen in childhood and may be confused with entropion. In epiblepharon, a roll of skin beneath the lower eyelid lashes causes the lashes to be directed vertically and to touch the cornea (Fig. 664.5). Unlike entropion, the eyelid margin itself is not rotated toward the cornea. Epiblepharon usually resolves spontaneously. When mild symptoms are present, such as mild ocular irritation, lubrication is typically recommended. Rarely, corneal scarring may occur, and surgery may be necessary.

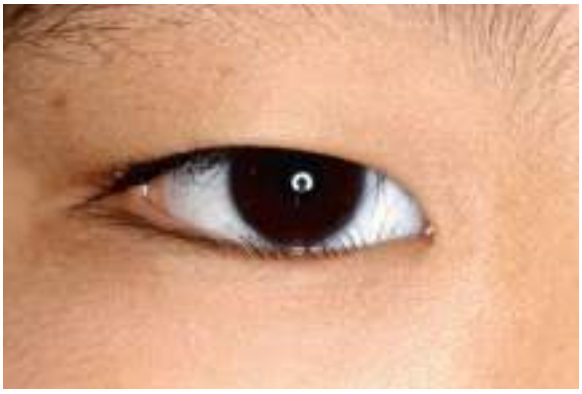

Fig. 664.5 Epiblepharon.

BLEPHAROSPASM

This spastic or repetitive closure of the lids may be caused by irritative disease of the cornea, conjunctiva, or facial nerve; fatigue or uncorrected refractive error; or common tic. Thorough ophthalmic examination for pathologic causes, such as trichiasis, keratitis, conjunctivitis, or foreign body, is indicated. Local injection of botulinum toxin may give relief but frequently must be repeated.

BLEPHARITIS

This inflammation of the lid margins is characterized by erythema and crusting or scaling; the usual symptoms are irritation, burning, and itching. The condition is commonly bilateral and chronic or recurrent. The two main types are **staphylococcal** and **seborrheic.** In staphylococcal blepharitis, ulceration of the lid margin is common, the lashes tend to fall out, and conjunctivitis and superficial keratitis are often associated. In seborrheic blepharitis, the scales tend to be greasy, the lid margins are less red, and ulceration usually does not occur. Commonly blepharitis presents as a combination of the two.

Thorough daily cleansing of the lid margins with a cloth or moistened cotton applicator to remove scales and crusts is important in the **treatment** of both forms. Staphylococcal blepharitis is treated with an antistaphylococcal antibiotic applied directly to the lid margins. When a child also has seborrhea, concurrent treatment of the scalp is important.

Pediculosis of the eyelashes may produce a clinical picture of blepharitis. The lice can be smothered with ophthalmic-grade petrolatum ointment applied to the lid margin and lashes. Nits should be mechanically removed from the lashes. It should be remembered that pediculosis can represent a sexually transmitted disease.

Mites (*Demodex* spp.) are an increasingly recognized cause of blepharitis, including in children and adolescents. Close inspection of the eyelashes often reveals sheathing of the lash at its base. Tea tree oil or products containing tea tree oil may be helpful, in addition to diligent lid hygiene.

HORDEOLUM (STYE)

Infection of the glands of the lid may be acute or subacute; tender focal swelling and redness are noted. The usual agent is *Staphylococcus aureus.* When the meibomian glands are involved, the lesion is referred to as an internal hordeolum; the abscess tends to be large and may point through either the skin or the conjunctival surface. When the infection involves the glands of Zeis or Moll, the abscess tends to be smaller and more superficial and points at the lid margin; it is then referred to as an *external hordeolum* or *stye*.

Treatment is frequent warm compresses and, if necessary, surgical incision and drainage. In addition, topical antibiotic preparations are often used. Untreated, the infection may progress to cellulitis of the lid or orbit, requiring the use of systemic antibiotics.

CHALAZION

A chalazion is a granulomatous inflammation of a meibomian gland characterized by a firm, nontender nodule in the upper or lower lid. This lesion tends to be chronic and differs from internal hordeolum in the absence of acute inflammatory signs. Although many chalazia subside spontaneously, incision and drainage may be necessary if they become large enough to distort vision (by inducing astigmatism by exerting pressure on the globe) or become cosmetically unacceptable. Patients who experience frequent chalazia formation, or those who have significant corneal changes secondary to the underlying blepharitis, may benefit from systemic, low-dose erythromycin or azithromycin treatment.

COLOBOMA OF THE EYELID

This cleftlike deformity may vary from a small indentation or notch of the free margin of the lid to a large defect involving almost the entire lid. If the gap is extensive, ulceration and corneal opacities may result from exposure. Early surgical correction of the lid defect is recommended. Other deformities frequently associated with lid colobomas include dermoid cysts or dermolipomas on the globe; they often occur in a position corresponding to the site of the lid defect. Lid colobomas may also be associated with extensive facial malformation, as in mandibulofacial dysostosis (Franceschetti or Treacher Collins syndrome).

TUMORS OF THE LID

A number of lid tumors arise from surface structures (the epithelium and sebaceous glands). Nevi may appear in early childhood; most are junctional. Compound nevi tend to develop in the prepubertal years and dermal nevi at puberty. Malignant epithelial tumors (basal cell carcinoma, squamous cell carcinoma) are rare in children, but the basal cell nevus syndrome and the malignant lesions of xeroderma pigmentosum and of Rothmund-Thomson syndrome may develop in childhood.

Other lid tumors arise from deeper structures (the neural, vascular, and connective tissues). **Capillary hemangiomas** are especially common in children (Fig. 664.6). Many tend to regress spontaneously, although they may show alarmingly rapid growth in infancy. In many cases, the best management of such hemangiomas is patient observation, allowing spontaneous regression to occur (see Chapter 691). In the case of a rapidly expanding lesion, which may cause amblyopia by obstructing the visual axis or inducing astigmatism, **treatment** should be considered. Systemic propranolol is an effective treatment without the risks associated with corticosteroid use. Other treatment options include topical timolol, corticosteroids (systemically or by direct injection), and surgical excision. Cutaneous capillary malformations (e.g., port-wine stain) can occur as an isolated lesion or in association with other signs of Sturge-Weber syndrome. Affected patients should be monitored for the development of glaucoma. **Lymphangiomas** (lymphatic malformations) of the lid appear as firm masses at or soon after birth and tend to enlarge slowly during the growing years. Associated conjunctival involvement, appearing as a clear, cystic, sinuous conjunctival mass, may provide a clue to the diagnosis. In some cases, there is also orbital involvement. The **treatment** may include sclerosant therapy, percutaneous drainage, or surgical excision.

Fig. 664.6 Capillary hemangioma of the eyelid. *(Courtesy Amy Nopper, MD, and Brandon Newell, MD.)*

Plexiform neuromas of the lids occur in children with neurofibromatosis, often with ptosis as the first sign. The lid may take on an S-shaped configuration. The lids may also be involved by other tumors, such as retinoblastoma, neuroblastoma, and rhabdomyosarcoma of the orbit; these conditions are discussed elsewhere.

Visit Elsevier eBooks+ at eBooks.Health.Elsevier.com for Bibliography.

Chapter 665

Disorders of the Lacrimal System

Scott E. Olitsky and Justin D. Marsh

THE TEAR FILM

The tear film, which bathes the eye, is a complex structure composed of three layers. The innermost mucin layer is secreted by the goblet and epithelial cells of the conjunctiva and the acinar cells of the lacrimal gland. It adds stability and provides an attachment for the tear film to the conjunctiva and cornea. The middle aqueous layer constitutes 98% of the tear film and is produced by the main lacrimal gland and accessory lacrimal glands. It contains various electrolytes and proteins as well as antibodies. The outermost lipid layer is produced largely from the sebaceous meibomian glands of the eyelid and retards evaporation of the tear film. Tears drain medially into the punctal openings of the lid margin and flow through the canaliculi into the lacrimal sac and then through the nasolacrimal duct into

the nose (Fig. 665.1). Preterm infants have reduced tear secretion. This may mask the diagnosis of a nasolacrimal duct obstruction and concentrate topically applied medications. Tear production reaches adult levels at 1-3 months.

DACRYOSTENOSIS

Congenital nasolacrimal duct obstruction (CNLDO), or dacryostenosis, is the most common disorder of the lacrimal system, occurring in up to 20% of newborn infants. It is usually caused by a failure of canalization of the epithelial cells (resulting in membrane formation) that form the nasolacrimal duct as it enters the nose beneath the inferior turbinate (valve of Hasner). Signs of CNLDO may be present at the time of birth, although the condition may not become evident until normal tear production develops. Signs of CNLDO include an excessive tear lake, overflow of tears onto the lid and cheek, and reflux of mucoid material that is produced in the lacrimal sac. Erythema or maceration of the skin may result from irritation and rubbing produced by dripping of tears and discharge. If the blockage is complete, these signs may be severe and continuous. If obstruction is only partial, the nasolacrimal duct may be capable of draining the basal tear film that is produced. However, under periods of increased tear production (exposure to cold, wind, sunlight) or increased closure of the distal end of the nasolacrimal duct (nasal mucosal edema), tear overflow may become evident or may increase.

Infants at increased risk for CNLDO include those with trisomy 21, EEC (ectrodactyly, ectodermal dysplasia, clefting) syndrome, branchiooculofacial syndrome, craniometaphyseal or craniodiaphyseal dysplasias, LADD (lacrimo-auriculo-dento-digital) syndrome, CHARGE (coloboma, heart anomaly, choanal atresia, retardation, genital, and ear anomalies) syndrome, and Goldenhar syndrome (Table 665.1).

Infants with CNLDO may develop acute infection and inflammation of the nasolacrimal sac **(dacryocystitis)**, inflammation of the surrounding tissues **(pericystitis)**, or, rarely, periorbital cellulitis. With dacryocystitis, the sac area is swollen, red, and tender, and patients may have systemic signs of infection such as fever and irritability.

The primary **treatment** of uncomplicated nasolacrimal duct obstruction is a regimen of nasolacrimal massage, usually two or three times daily, accompanied by cleansing of the lids with warm water. Topical antibiotics are used for control of mucopurulent drainage. A bland ophthalmic ointment may be used on eyelids if the skin is macerated. Most cases of CNLDO resolve spontaneously; 96% resolve before 1 year of age. For cases that do not resolve by 1 year, the nasolacrimal duct may be probed, with a cure rate of approximately 80%. Some ophthalmologists intubate the nasolacrimal system at the same time because this may improve the outcome of the procedure.

Acute dacryocystitis (Fig. 665.2) requires prompt treatment with systemic antibiotics. In such cases, some form of definitive surgical intervention is usually indicated.

A **dacryocystocele** (mucocele) is an unusual presentation of a nonpatent nasolacrimal sac that is obstructed both proximally and distally. Dacryocystoceles can be seen at birth or shortly after birth as a bluish subcutaneous mass just below the medial canthal tendon (Figs. 665.3 and 665.4). Initial **treatment** of dacryocystocele is usually conservative, involving massage/digital decompression of the lacrimal sac. If resolution of the dacryocystocele is not achieved with conservative management, surgical probing may be beneficial. At times, the intranasal portion of the nasolacrimal duct becomes distended, causing respiratory compromise. In one study, 9.5% of infants with dacryocystocele had related respiratory compromise, and this may be more common when dacryocystoceles are present bilaterally. These infants benefit from early probing. When left untreated, dacryocystocele may progress to dacryocystitis/cellulitis, requiring systemic antibiotics and often hospitalization. Once the cellulitis has improved, the nasolacrimal system should be probed if spontaneous resolution has not occurred.

Not all tearing in infants and children is caused by nasolacrimal obstruction. Tearing may also be a sign of glaucoma, intraocular inflammation, or external irritation, such as that from a corneal abrasion or foreign body.

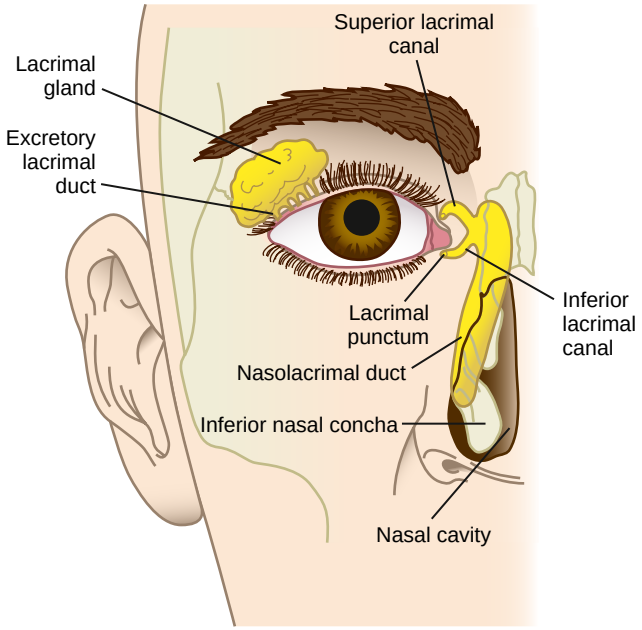

Fig. 665.1 The lacrimal apparatus.

ALACRIMA AND "DRY EYE"

Alacrima refers to a wide spectrum of disorders with reduced or absent tear secretion. Occasionally normal basal tearing occurs with an absence of emotional tearing. Etiologies can be divided into syndromes that have a pathologic association or are inherited. Associated syndromes include familial dysautonomia (Riley-Day syndrome), anhidrotic ectodermal dysplasia, and triple-A syndrome (Allgrove syndrome: achalasia, alacrima, adrenal insufficiency). Examples of pathologic association include aplasia of cranial nerve nuclei and lacrimal gland aplasia/hypoplasia. Both autosomal recessive and autosomal dominant inheritance have been reported in isolated congenital alacrima. In addition, medications with anticholinergic side effects can decrease tear production. The patients with alacrima have variable presentation, including no symptoms, photophobia, foreign body sensation, eye pain, and decreased vision. The symptoms, if present, often occur early in life. Because the dryness can be severe, damage to the cornea and subsequent loss of vision may occur. The goal of treatment is to minimize corneal irritation, corneal scarring, and loss of vision. Aggressive ocular lubrication is used to prevent these sequelae.

An **acquired abnormality** of any layer of the tear film may produce a dry eye. Commonly acquired disorders that may lead to a decreased or unstable tear film include Sjögren syndrome, Stevens-Johnson syndrome, toxic epidermal necrolysis, vitamin A deficiency, viral infections of the lacrimal gland, ocular pemphigoid, trachoma, chemical burns, irradiation, isotretinoin treatment of acne, graft-versus-host disease, and meibomian gland dysfunction. Corneal exposure as a consequence of poor lid closure or other pathologic states can quickly lead to pathologically dry eyes. Examples of conditions leading to such exposure include ichthyosis, xeroderma pigmentosum, and certain

Table 665.1 Syndromes Associated with Congenital Lacrimal Drainage Anomalies

Down syndrome	Branchio-oto-renal syndrome
Ectrodactyly-ectodermal dysplasia clefting (EEC) syndrome	Crouzon syndrome
Treacher Collins syndrome	Klinefelter syndrome
Rubinstein-Taybi syndrome	Fraser syndrome
Lacrimo-auriculo-dento-digital (LADD) or Levy-Hollister syndrome	Goltz-Gorlin syndrome
Hay-Wells syndrome	Wolf-Hirschhorn or 4p-syndrome
ADULT syndrome	Congenital rubella syndrome
Limb-mammary syndrome	Turner syndrome
Rapp-Hodgkin syndrome	Fetal alcohol syndrome
Split-hand/split-foot syndrome	Hallermann-Streiff syndrome
Aplasia of the lacrimal and salivary glands (ALSG) syndrome	Fetal valproate syndrome
Apert syndrome	HPPD syndrome (hypertelorism, preauricular sinus, punctal pits, deafness)
Saethre-Chotzen syndrome	Velocardiofacial (VCFS) syndrome
CHARGE syndrome	Poland-Möbius syndrome
Branchio-oculo-facial (BOF) syndrome	Robinow syndrome
Goldenhar syndrome	Angelman syndrome
Cornelia de Lange syndrome	Waardenburg-Klein syndrome
Congenital arhinia-microphthalmia syndrome	PHACE syndrome
Johanson Blizzard syndrome	Williams-Beuren syndrome
Pashayan syndrome	Peter's plus syndrome
Millers syndrome	Kabuki syndrome
Kallmann syndrome	Angora hair nevus syndrome
Nager syndrome	TARP syndrome
Blepharophimosis syndrome	11q trisomy syndrome
VACTERL association	Barber-Say syndrome

ADULT, acro-dermato-ungual-lacrimal-tooth; CHARGE, coloboma, heart, atresia choanae, growth retardation, genital ear; PHACE, posterior fossa, hemangioma, arterial, cardiac, eye or endocrine; TARP, talipes equinovarus, atrial septal defects, Robin syndrome, persistent left superior vena cava; VACTERL, vertebral, anal atresia, cardiac, tracheo-esophageal atresia, renal, limb.

Modified from Ali MJ. Updates on congenital lacrimal drainage anomalies and their association with syndromes and systemic disorders: A major review. *Ann Anatomy.* 2021;233:151613: Table 665.1.

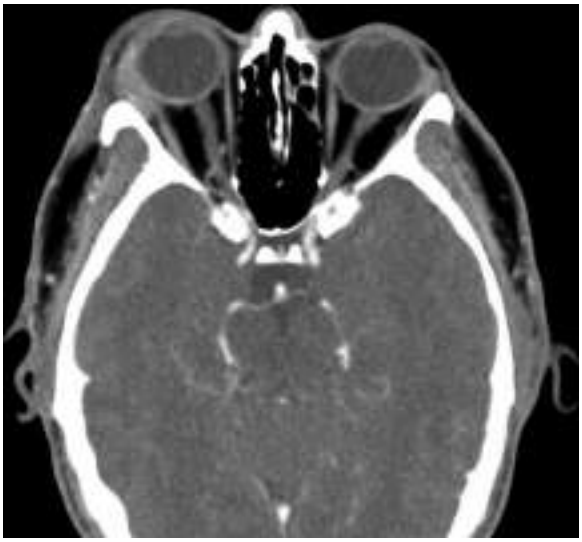

Fig. 665.2 Noncontrast axial CT study exhibiting right acute dacryoadenitis with inflammation adjacent to the lateral orbital wall and lateral rectus muscle. *(From Maamari RN, Couch SM. Nonspecific orbital inflammation. Adv Ophthalmol Optom. 2018;3[1]:315-335, Fig. 3.)*

Fig. 665.3 Dacryocystocele below inner canthus of the right eye.

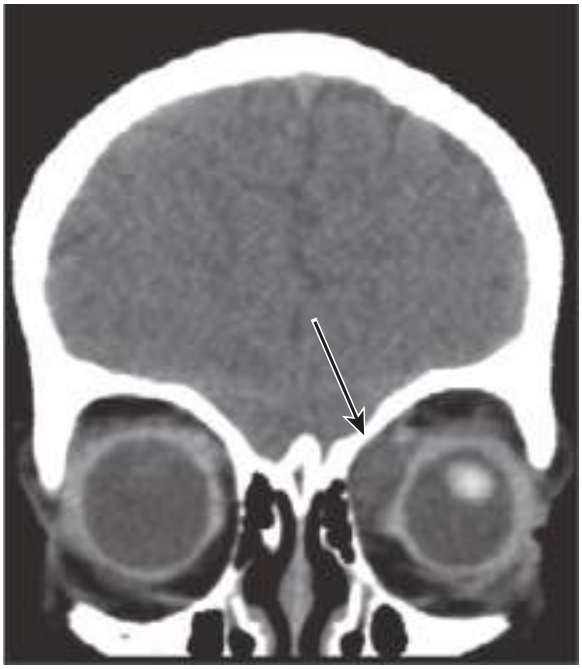

Fig. 665.4 Coronal CT shows a left dacryocystocele *(arrow)*. *(Modified from Coley BD, ed. Caffey's Pediatric Diagnostic Imaging, 13th ed. Philadelphia: Elsevier; 2019: Fig. 5.23, p. 36.)*

craniosynostoses syndromes, such as Crouzon, Apert, or Pfeiffer. Any tear deficiency can lead to corneal ulceration, scarring, or infection. **Treatment** includes correction of the underlying disorder when possible and frequent instillation of an ocular lubricant. In some cases, occlusion of the lacrimal puncta is helpful. In severe cases, tarsorrhaphy may be necessary to protect the cornea.

Visit Elsevier eBooks+ at eBooks.Health.Elsevier.com for Bibliography.

Chapter 666

Disorders of the Conjunctiva

Scott E. Olitsky and Justin D. Marsh

CONJUNCTIVITIS

The conjunctiva reacts to a wide range of bacterial and viral agents, allergens, irritants, toxins, and systemic diseases. Conjunctivitis is common in childhood and may be infectious or noninfectious. The differential diagnosis of a red-appearing eye includes conjunctival disease, as well as other ocular sites (Table 666.1).

Ophthalmia Neonatorum

This form of conjunctivitis, occurring in infants younger than 4 weeks of age, is the most common eye disease of newborns. Its many different causal agents vary greatly in their virulence and outcome. Silver nitrate instillation may result in a mild self-limited chemical conjunctivitis, whereas *Neisseria gonorrhoeae* and *Pseudomonas* are capable of causing corneal perforation, blindness, and death. The risk of conjunctivitis in newborns depends on frequencies of maternal infections, prophylactic measures, circumstances during labor and delivery, and postdelivery exposure to microorganisms.

Epidemiology

Conjunctivitis during the neonatal period is usually acquired during vaginal delivery and reflects the sexually transmitted infections prevalent in the community. The incidence of gonococcal ophthalmia neonatorum can be reduced by widespread use of topical silver nitrate or erythromycin prophylaxis, prenatal screening, and treatment of maternal gonorrhea. Gonococcal ophthalmia neonatorum has an incidence of 0.3/1,000 live births in the United States. In comparison, *Chlamydia trachomatis* is the most common organism causing ophthalmia neonatorum in the United States, with an incidence of 8.2/1,000 births.

Clinical Manifestations

The clinical manifestations of the various forms of ophthalmia neonatorum are not specific enough to allow an accurate diagnosis. Although the timing and character of the signs are somewhat typical for each cause of this condition, there is considerable overlap, and physicians should not rely solely on clinical findings. Regardless of its cause, ophthalmia neonatorum is characterized by redness and chemosis (swelling) of the conjunctiva, edema of the eyelids, and discharge, which may be purulent.

Neonatal conjunctivitis is a potentially blinding condition. The infection may also have associated systemic manifestations that require treatment. Any newborn infant who develops signs of conjunctivitis needs a prompt and comprehensive systemic and ocular evaluation to determine the agent causing the infection and the appropriate treatment.

The onset of inflammation caused by silver nitrate drops usually occurs within 6-12 hours after birth, with clearing by 24-48 hours. The usual incubation period for conjunctivitis caused by *N. gonorrhoeae* is 2-5 days, and for that caused by *C. trachomatis*, 5-14 days. Gonococcal infection may be present at birth owing to prolonged rupture of amniotic membranes or be delayed beyond 5 days of life because of partial suppression by ocular prophylaxis. Gonococcal conjunctivitis may also begin in infancy after inoculation by the contaminated fingers of adults. The time of onset of disease with other bacteria is highly variable.

Gonococcal conjunctivitis begins with mild inflammation and a serosanguineous discharge. Within 24 hours, the discharge becomes thick and purulent, and tense edema of the eyelids with marked chemosis occurs. If proper treatment is delayed, the infection may spread to involve the deeper layers of the conjunctivae and the cornea. Complications include corneal ulceration and perforation, iridocyclitis, anterior synechiae, and, rarely, panophthalmitis. Conjunctivitis caused by *C. trachomatis* (inclusion blennorrhea) may vary from mild inflammation to severe swelling of the eyelids with copious purulent discharge. The process involves mainly the tarsal conjunctivae; the corneas are rarely affected. Conjunctivitis caused by *Staphylococcus aureus* or other organisms is similar to that produced by *C. trachomatis.* Conjunctivitis caused by *Pseudomonas aeruginosa* is uncommon, acquired in the nursery, and a potentially serious process. It is characterized by the appearance on days 5-18 of edema, erythema of the lids, purulent discharge, pannus formation, endophthalmitis, sepsis, shock, and death.

Diagnosis

Conjunctivitis appearing after 48 hours should be evaluated for a possibly infectious cause. Gram stain of the purulent discharge should be performed and tested by polymerase chain reaction (PCR) for gonococcus. If a viral cause is suspected, a swab should be submitted for PCR testing. In chlamydial conjunctivitis, the diagnosis is made by tests for chlamydial antigen or DNA. The differential diagnosis of ophthalmia neonatorum includes dacryocystitis caused by congenital nasolacrimal duct obstruction with lacrimal sac distention (dacryocystocele; see Chapter 665).

Treatment

Treatment of infants in whom gonococcal ophthalmia is suspected where the Gram stain shows the characteristic intracellular Gram-negative diplococci should be initiated immediately with ceftriaxone, 25-50 mg/kg/24 hr for one dose IV or IM, not to exceed 125 mg. The eye should also be irrigated initially with saline every 10-30 minutes, gradually increasing to 2-hour intervals until the purulent discharge has cleared. Treatment (ceftriaxone 25-50 mg/kg/day, IM or IV in a single daily dose for 7 days, with cefotaxime 25 mg/kg q 12 hr substituted if the patient has hyperbilirubinemia) is extended if sepsis or other extraocular sites are involved. Associated meningitis is treated for 10-14 days. Neonatal conjunctivitis secondary to chlamydial infections is treated with oral erythromycin (50 mg/kg/24 hr in four divided doses) for 2 weeks. This cures conjunctivitis and may prevent subsequent chlamydial pneumonia. *Pseudomonas* neonatal conjunctivitis is treated with systemic antibiotics, including an aminoglycoside, plus local saline irrigation and gentamicin ophthalmic ointment. Staphylococcal conjunctivitis is treated with parenteral methicillin and local saline irrigation.

Prognosis and Prevention

Before the institution of topical ophthalmic prophylaxis at birth, gonococcal ophthalmia was a common cause of blindness or permanent eye damage. If properly applied, this form of prophylaxis is highly effective unless infection is present at birth. Drops of 0.5% erythromycin or 1% silver nitrate are instilled directly into the open eyes at birth using wax or plastic single-dose containers. Saline irrigation after silver nitrate application is unnecessary. Silver nitrate is ineffective against active infection and may have limited use against *Chlamydia*. Povidone-iodine (2% solution) may also be an effective prophylactic agent, especially in developing countries.

Identification of maternal gonococcal infection and appropriate treatment has become a standard element of routine prenatal care. An infant born to a woman who has untreated gonococcal infection should receive a single dose of ceftriaxone, 50 mg/kg (maximum 125 mg) IV or IM, in addition to topical prophylaxis. The dose should be reduced for premature infants. Penicillin (50,000 units) should be used if the mother's gonococcal isolate is known to be penicillin sensitive.

Neither topical prophylaxis nor topical treatment prevents the afebrile pneumonia that occurs in 10–20% of infants exposed to *C. trachomatis.* Although chlamydial conjunctivitis is often a self-limiting disease, chlamydial pneumonia may have serious consequences. It is important that infants with chlamydial disease receive systemic treatment. Treatment of colonized pregnant people with erythromycin may prevent neonatal disease.

Table 666.1 The Red Eye

CONDITION	CAUSE	SIGNS/SYMPTOMS	TREATMENT
Bacterial conjunctivitis	*Haemophilus influenzae*, *H. influenzae aegyptius*, *Streptococcus pneumoniae*, *Neisseria gonorrhoeae*, *Staphylococcus aureus*, *Yersinia* species, cat-scratch bacillus less common	Mucopurulent unilateral or bilateral discharge, normal vision, photophobia usually absent Conjunctival injection and edema (chemosis); gritty sensation	Topical antibiotics: systemic ceftriaxone for gonococcus, *H. influenzae*
Viral conjunctivitis	Adenovirus, ECHO virus, coxsackievirus, herpes simplex virus, coronavirus	As above; may be hemorrhagic, unilateral enlarged preauricular lymph nodes	Self-limited
Neonatal conjunctivitis	*Chlamydia trachomatis*, gonococcus, chemical (silver nitrate), *S. aureus*	Palpebral conjunctival follicle or papillae; as above	Ceftriaxone for gonococcus and oral erythromycin for *C. trachomatis*
Allergic conjunctivitis	Seasonal pollens or allergen exposure	Itching, incidence of bilateral chemosis (edema) greater than that of erythema, tarsal papillae	Antihistamines, steroids, cromolyn
Keratitis	Herpes simplex, adenovirus, *S. pneumoniae*, *S. aureus*, *Pseudomonas* species, *Acanthamoeba* species, chemicals	Severe pain, corneal swelling, clouding, limbus erythema, hypopyon, cataracts; contact lens history with amebic infection	Specific antibiotics for bacterial/fungal infections; keratoplasty, acyclovir for herpes
Endophthalmitis	*S. aureus*, *S. pneumoniae*, *Candida albicans*, associated surgery or trauma	Acute onset, pain, loss of vision, swelling, chemosis, redness; hypopyon and vitreous haze	Antibiotics
Anterior uveitis (iridocyclitis)	JIA, reactive arthritis, sarcoidosis, Behçet disease, Kawasaki disease, inflammatory bowel disease	Unilateral/bilateral; erythema, ciliary flush (in circumcorneal area), irregular pupil, iris adhesions; pain, marked photophobia, small pupil, poor vision, no discharge	Topical steroids, plus therapy for primary disease
Posterior uveitis (choroiditis)	Toxoplasmosis, histoplasmosis, *Toxocara canis*	No sign of erythema, decreased vision, no discharge	Specific therapy for pathogen
Episcleritis/ scleritis	Idiopathic autoimmune disease (e.g., SLE, Henoch-Schönlein purpura)	Localized pain, intense erythema, unilateral; blood vessels bigger than in conjunctivitis; scleritis may cause globe perforation, no discharge	Episcleritis is self-limiting; topical steroids for fast relief
Foreign body	Occupational exposure	Unilateral, red, gritty feeling; visible or microscopic size	Irrigation, removal; check for ulceration
Blepharitis	*S. aureus*, *S. epidermidis*, seborrheic, blocked lacrimal duct: rarely, molluscum contagiosum, *Pthirus pubis*, *Pediculosis capitis*	Bilateral, irritation, itching, hyperemia, crusting, affecting lid margins	Topical antibiotics, warm compresses
Dacryocystitis	Obstructed lacrimal sac: *S. aureus*, *H. influenzae*, pneumococcus	Pain, tenderness, erythema, and exudate in area of lacrimal sac (inferomedial to inner canthus); tearing (epiphora); possible orbital cellulitis	Systemic, topical antibiotics; surgical drainage
Dacryoadenitis	*S. aureus*, *Streptococcus* species, CMV, measles, EBV, enteroviruses, trauma, sarcoidosis, leukemia	Pain, tenderness, edema, erythema over gland area (upper temporal lid); fever, leukocytosis	Systemic antibiotics; drainage of orbital abscesses
Orbital cellulitis	Paranasal sinusitis: *H. influenzae*, *S. aureus*, *S. pneumoniae*, other *Streptococcus* species Trauma: *S. aureus* Fungi: *Aspergillus*, *Mucor* species if immunodeficient	Rhinorrhea, chemosis, vision loss, painful extraocular motion, proptosis, ophthalmoplegia, fever, lid edema, leukocytosis	Systemic antibiotics (postseptal cellulitis), drainage of orbital abscesses
Periorbital cellulitis	Trauma: *S. aureus*, *Streptococcus* species Bacteremia: *H. influenzae*, pneumococci, *S. pyogenes*, *S. aureus*	Cutaneous erythema, warmth, normal vision, minimal involvement of orbit, fever, leukocytosis, toxic appearance	Systemic antibiotics (preseptal cellulitis)

CMV, Cytomegalovirus; EBV, Epstein-Barr virus; ECHO, enteric cytopathogenic human orphan; JIA, juvenile idiopathic arthritis; SLE, systemic lupus erythematosus.
Modified from Behrman RE, Kliegman RM. *Nelson Essentials of Pediatrics*. 3rd ed. Philadelphia: WB Saunders; 1998; with data from Rosenbaum JT, Nozik RA. Uveitis: many diseases, one diagnosis. *Am J Med*. 1985;79:545–547; Elkington AR, Khaw PT. The red eye. *BMJ*. 1988;296:1720–1724; Wilhemus KR. The red eye. Infectious conjunctivitis, keratitis, endophthalmitis, and periocular cellulitis. *Infect Dis Clin North Am*. 1988;2:99–116; Forrester JV. Uveitis: pathogenesis. *Lancet*. 1991;338:1498–1501; Gioliotti F. Acute conjunctivitis of childhood. *Pediatr Ann*. 1993;22:353–356.

Acute Purulent Conjunctivitis

This is characterized by more or less generalized (bilateral in 50–75%) conjunctival hyperemia, edema, mucopurulent exudate, glued eyes (lids stuck together after sleeping), and various degrees of ocular pain and discomfort. It is usually a result of bacterial infection. In addition, there is usually little or no pruritus or periauricular lymph node enlargement; the peak season is between December and April. Bacterial conjunctivitis is more common in young children (<5 years), whereas viral conjunctivitis is more common among adolescents and adults. The most frequent causes are nontypeable *Haemophilus influenzae* (60–80%; associated with ipsilateral otitis media), pneumococci (20%), and staphylococci (5–10%). Bacterial purulent conjunctivitis, especially that caused by

pneumococcus or *H. influenzae,* may occur in epidemics. Conjunctival smear and culture are helpful in differentiating specific types. These common forms of acute purulent conjunctivitis usually respond well to warm compresses and topical instillation of antibiotic drops, which shortens the duration of illness and hastens return to school. Topical antibiotics include aminoglycosides (gentamicin, tobramycin), quinolones (ciprofloxacin, ofloxacin, moxifloxacin), and combinations of antibiotics and chloramphenicol (Table 666.2). Brazilian purpuric fever caused by *Haemophilus aegyptius* manifests as conjunctivitis and sepsis. **Hyperacute bacterial conjunctivitis** is caused by gonococcal or meningococcal infection and requires systemic, not topical, antimicrobial therapies. Concerning symptoms that should require an ophthalmology referral include vision loss, severe purulent discharge, corneal involvement, conjunctival scarring, cutaneous-conjunctival involvement (Stevens-Johnson syndrome), recurrent symptoms, severe pain, herpes simplex virus infection, severe photophobia, and involvement with a contact (cosmetic or prescription) lens.

Viral Conjunctivitis

This is generally characterized by a watery discharge. Follicular changes (small aggregates of lymphocytes) are often found in the palpebral conjunctiva. Involvement is often unilateral and associated with periauricular nodes. Viral conjunctivitis occurs more often in the summer and in older children (>5 years). Conjunctivitis resulting from adenovirus infection is relatively common, sometimes with corneal involvement as well as pharyngitis or pneumonia. Outbreaks of conjunctivitis caused by enterovirus are also encountered; this type may be hemorrhagic (Fig. 666.1). Acute hemorrhagic conjunctivitis may be epidemic because of enterovirus CA24 or 70 and is characterized by red, swollen, and painful eyes with a hemorrhagic watery discharge. Conjunctivitis is commonly associated with such systemic viral infections as childhood exanthems, particularly measles. Viral conjunctivitis is usually self-limited.

Epidemic Keratoconjunctivitis

This is caused by adenovirus serotypes 8, 19, or 37, and is transmitted by direct contact. It initially presents as a sensation of a foreign body beneath the lids, with itching and burning. Edema (chemosis) and photophobia develop rapidly, and large oval follicles appear within the conjunctiva. Preauricular adenopathy and a pseudomembrane on the conjunctival surface occur frequently. Subepithelial corneal infiltrates may develop and may cause blurring of vision; these usually disappear but may permanently reduce visual acuity. Corneal complications are less common in children than in adults. Children may have associated upper respiratory tract infection and pharyngitis. No specific medical therapy is available to decrease the symptoms or shorten the course of the disease. Emphasis must be placed on prevention of spread of the disease. A replicating virus is present in 95% of patients 10 days after the appearance of symptoms.

Pharyngoconjunctival fever presents with high fever, pharyngitis, bilateral conjunctivitis, and periauricular lymphadenopathy. It is highly contagious.

Membranous and Pseudomembranous Conjunctivitis

These types of conjunctivitis can be encountered in a number of diseases. The classic membranous conjunctivitis is that of diphtheria, accompanied by a fibrin-rich exudate that forms on the conjunctival surface and permeates the epithelium; the membrane is removed with difficulty and leaves raw bleeding areas. In pseudomembranous conjunctivitis, the layer of fibrin-rich exudate is superficial and can often be stripped easily, leaving the surface smooth. This type occurs with

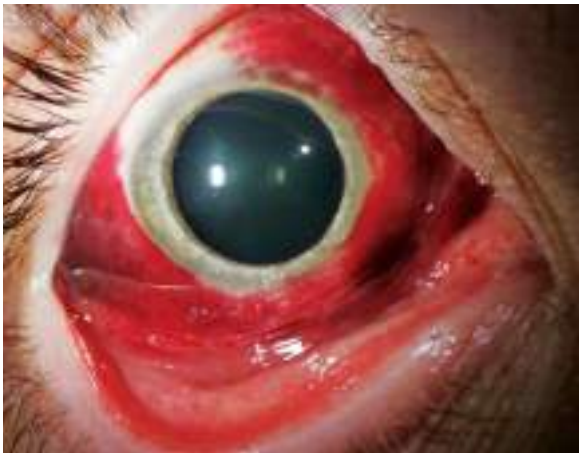

Fig. 666.1 Acute hemorrhagic conjunctivitis (AHC) is a highly contagious conjunctivitis that presents with symptoms of pain, redness, and tearing. Ocular findings include extensive subconjunctival hemorrhages, follicles, and chemosis. Causative agents include coxsackie group A24 (CA24) and enterovirus E70 (EV70). *(From Krachmer JH, Palay DA. Cornea Atlas. 3rd ed. London: Elsevier, 2014: Fig 7-23))*

Table 666.2 Topical Antibiotics Used to Treat Bacterial Conjunctivitis: Adult Dosages

DRUG	DOSAGE
Bacitracin (AK-Tracin, Bacticin) ointment	Apply 0.5 inch in eye q3-4hr
Ciprofloxacin (Ciloxan) 0.3% ophthalmic solution	1-2 gtt in eye q15min × 6 hr, then q30min × 18h, then q1hr × 1 day, then q4hr × 12 days*
Gatifloxacin (Zymar) 0.3% ophthalmic solution	1 gt in eye q2h up to 8 × per day × 2 days, then 1 gt qid × 5 days
Gentamicin (Gentak, Gentasol) 0.3% ophthalmic solution or ointment	Ointment: 0.5 inch applied to eye 2-3 × per day Solution: 1-2 gtt in eye q4hr
Levofloxacin (Quixin) 0.5% ophthalmic solution	1-2 gtt in eye q2hr × 2 days while awake, then q4hr × 5 days while awake
Moxifloxacin (Vigamox) 0.5% ophthalmic solution	1 gt in eye tid × 7 days
Neomycin/polymyxin B/gramicidin (Neosporin) ophthalmic solution	1-2 gtt in eye q4hr × 7-10 days
Ofloxacin (Ocuflox) 0.3% ophthalmic solution	1-2 gtt in eye q2-4hr × 2 days, then 1-2 gtt in eye qid × 5 days
Polymyxin B and trimethoprim (Polytrim) ophthalmic solution	1 gt in eye q3hr × 7-10 days
Sulfacetamide (Isopto Cetamide, Ocusulf-10, Sodium Sulamyd, Sulf-10, AK-Sulf) 10% ophthalmic solution, ointment	Ointment: 0.5-inch ribbon in eye q3-4hr and qhr × 7 days Solution: 1-2 gtt in eye q2-3hr × 7-10 days
Tobramycin (AK-Tob, Tobrex) 0.3% ophthalmic solution	1-2 gtt in eye q4hr

*Exceeds dosage recommended by the manufacturer.
From Bope ET, Kellerman RD, eds. *Conn's Current Therapy*. Philadelphia: Elsevier; 2014: Table 2, p. 321.

many bacterial and viral infections, including staphylococcal, pneumococcal, streptococcal, or chlamydial conjunctivitis, and in epidemic keratoconjunctivitis. It is also found in vernal conjunctivitis and in Stevens-Johnson disease.

Allergic Conjunctivitis

This is usually accompanied by intense itching, clear watery discharge, and conjunctival edema (chemosis) (see Chapter 188). It is commonly seasonal (spring-summer). Cold compresses and topical antihistamine drops give symptomatic relief. Topical mast cell stabilizers or prostaglandin inhibitors may also help. In selected cases, topical corticosteroids are used under an ophthalmologist's supervision but should not be used routinely or for a long time.

Vernal Conjunctivitis

This usually begins in the prepubertal years and may recur for many years. Atopy appears to have a role in its origin, but the pathogenesis is uncertain. Extreme itching and tearing are the usual complaints. Large, flattened, cobblestone-like papillary lesions of the palpebral conjunctivae are characteristic (Fig. 666.2). A stringy exudate and a milky conjunctival pseudomembrane are frequently present. Small elevated lesions of the bulbar conjunctiva adjacent to the limbus (Horner-Trantas dots) may be found. Smear of the conjunctival exudate reveals many eosinophils. Topical corticosteroid therapy and cold compresses afford some relief. Topical mast cell stabilizers or prostaglandin inhibitors are useful when long-term control is needed. The long-term use of corticosteroids should be avoided.

Parinaud Oculoglandular Syndrome

This represents a form of cat-scratch disease and is caused by *Bartonella henselae,* which is transmitted from cat to cat by fleas (see Chapter 255). Kittens are more likely than adult cats to be infected. Humans can become infected when they are scratched by a cat. In addition, bacteria may pass from a cat's saliva to its fur during grooming. The bacteria can then be deposited on the conjunctiva after rubbing one's eyes after handling the cat. Lymphadenopathy and conjunctivitis are hallmarks of the disease. Conjunctival granulomas may develop (Fig. 666.3). The course is generally self-limited, but antibiotics may be used in some cases.

Chemical Conjunctivitis

This can result when an irritating substance enters the conjunctival sac (as in the acute but benign conjunctivitis caused by silver nitrate in newborns). Other common offenders are household cleaning substances (including detergent pods), sprays, smoke, smog, metal halide bulbs, and industrial pollutants. Alkalis tend to linger in the conjunctival tissues and continue to inflict damage for hours or days. Acids precipitate the proteins in tissues and so produce their effect immediately. In either case, prompt, thorough, and copious irrigation is crucial. Extensive tissue damage, even loss of the eye, can result, especially if the offending agent is an alkali.

OTHER CONJUNCTIVAL DISORDERS

Subconjunctival hemorrhage is manifested by bright or dark red patches in the bulbar conjunctiva and may result from injury or inflammation. It commonly occurs spontaneously. It may occasionally result from severe sneezing or coughing. Rarely, it may be a manifestation of a blood dyscrasia. Subconjunctival hemorrhages are self-limiting and require no treatment.

Pinguecula is a yellowish white, slightly elevated mass on the bulbar conjunctiva, usually in the interpalpebral region (Fig. 666.4). It represents elastic and hyaline degenerative changes of the conjunctiva. No treatment is required except for cosmetic reasons, in which case simple excision suffices.

Pterygium is a fleshy triangular conjunctival lesion that may encroach on the cornea. It typically occurs in the nasal interpalpebral region (Fig. 666.5). The pathologic findings are similar to those

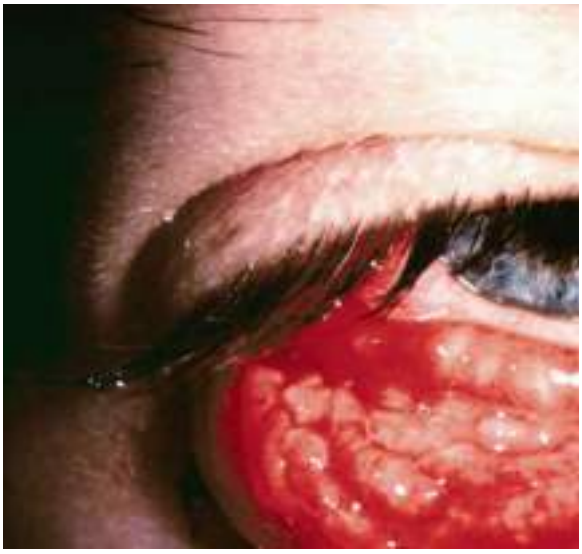

Fig. 666.3 Conjunctival granulomas in Parinaud oculoglandular syndrome.

Fig. 666.2 Vernal conjunctivitis.

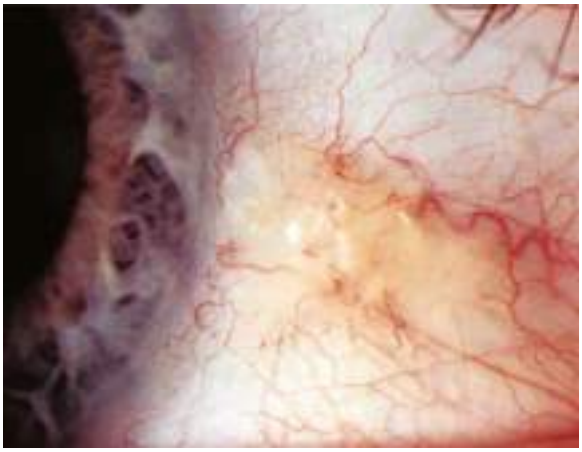

Fig. 666.4 Pinguecula. These lesions are found at the 3 o'clock and 9 o'clock positions and are extremely common, especially in older patients. *(From Palay DA, Krachmer JH. Primary Care Ophthalmology, 2nd ed, Philadelphia: Elsevier Mosby; 2005: Fig. 3.49, p 62.)*

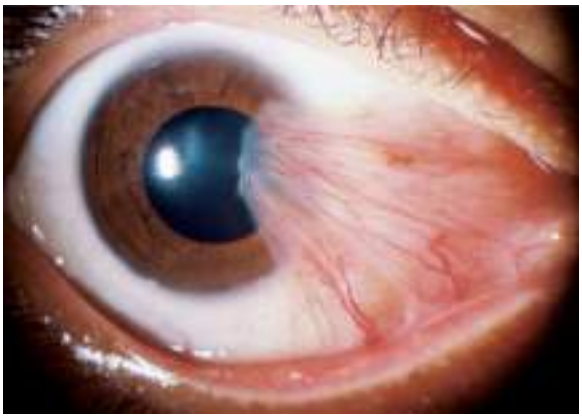

Fig. 666.5 Pterygium. These lesions are found in the horizontal meridian, most common nasally. *(From Palay DA, Krachmer JH. Primary Care Ophthalmology. 2nd ed. Philadelphia: Elsevier Mosby; 2005: Fig. 3.50, p 62.)*

of a pinguecula. The development of pterygia is related to exposure to ultraviolet light, and it therefore is more commonly found among people who live near the equator. Removal is suggested when the lesion encroaches far onto the cornea. Recurrence after removal is common.

Dermoid cyst and **dermolipoma** are benign lesions, clinically similar in appearance. They are smooth, elevated, round to oval lesions of various sizes. The color varies from yellowish white to fleshy pink. The most frequent site is the upper outer quadrant of the globe; they also commonly occur near or straddling the limbus. Dermolipoma is composed of adipose and connective tissue. Dermoid cysts may also contain glandular tissue, hair follicles, and hair shafts. Excision for cosmetic reasons is feasible. Dermolipomas are often connected to the extraocular muscles, making their complete removal impossible without sacrificing ocular motility.

Conjunctival nevus is a small, slightly elevated lesion that may vary in pigmentation from pale salmon to dark brown. It is usually benign, but careful observation for progressive growth or changes suggestive of malignancy is advised.

Symblepharon is a cicatricial adhesion between the conjunctiva of the lid and the globe; the lower lid is usually affected. It follows operation or injuries, especially burns from lye, acids, or molten metals. It is a serious complication of Stevens-Johnson syndrome. It may interfere with motion of the eyeball and may cause diplopia. The adhesions should be separated and the raw surfaces kept from uniting during healing. Grafts of oral mucous membrane may be necessary.

Visit Elsevier eBooks+ at eBooks.Health.Elsevier.com for Bibliography.

Chapter 667

Abnormalities of the Cornea

Scott E. Olitsky and Justin D. Marsh

MEGALOCORNEA

This is a nonprogressive symmetric condition characterized by an enlarged cornea (>12 mm in diameter) and an anterior segment in which there is *no evidence* of previous or concurrent ocular hypertension (glaucoma). High myopia is frequently present and may lead to reduced vision. A frequent complication is the development of lens opacities in adult life. All modes of inheritance have been described, although X-linked recessive is the most common. Systemic abnormalities that may be associated with megalocornea include Marfan syndrome, craniosynostosis, and Alport syndrome. The cause of the enlargement of the cornea and the anterior segment is unknown, but possible explanations include a defect in the growth of the optic cup and an arrest of congenital glaucoma.

Pathologic corneal enlargement caused by glaucoma is to be differentiated from this anomaly. Any progressive increase in the size of the cornea, especially when accompanied by photophobia, lacrimation, or haziness of the cornea, requires prompt ophthalmologic evaluation.

MICROCORNEA

Microcornea, or anterior microphthalmia, is an abnormally small cornea in an otherwise relatively normal eye. It may be familial, with transmission being dominant more often than recessive. More commonly, a small cornea is just one feature of an otherwise developmentally abnormal or microphthalmic eye; associated defects include colobomas, microphakia, congenital cataract, glaucoma, and aniridia.

KERATOCONUS

This is a disease of unclear pathogenesis characterized by progressive thinning and bulging of the central cornea, which becomes cone shaped. Although familial cases are known, most cases are sporadic. It is a common ocular condition with an incidence of 1 in 2,000 adults. Eye rubbing and contact lens wear have been implicated as pathogenic, but the evidence to support this is equivocal. The incidence is increased in individuals with atopy, Down syndrome, Marfan syndrome, and retinitis pigmentosa.

Most cases are bilateral, but involvement may be asymmetric. The disorder usually presents and progresses rapidly during adolescence; progression then slows and stabilizes when patients reach full growth. Descemet's membrane may occasionally be stretched beyond its elastic breaking point, causing an acute rupture in the membrane with resultant sudden and marked corneal edema (acute hydrops, Fig. 667.1) and decrease in vision. The corneal edema resolves as endothelial cells cover the defective area. Some degree of corneal scarring occurs, but the visual acuity is often better than before the initial incident. Signs of keratoconus include Munson sign (bulging of the lower eyelid on looking downward) and the presence of a Fleischer ring (a deposit of iron in the epithelium at the base of the cone). Glasses and contact lenses are the first step in treating the visual distortion caused by keratoconus. Corneal cross-linking is a procedure using riboflavin and UV light and may arrest the progression of keratoconus. If the cornea vaults too severely for the vision to be corrected with contact lenses, then a corneal transplant must be performed to restore vision.

NEONATAL CORNEAL OPACITIES

Loss of the normal transparency of the cornea in neonates may occur secondary to either intrinsic hereditary or extrinsic environmental causes (Table 667.1).

SCLEROCORNEA

In sclerocornea, the normally translucent cornea is replaced by sclera-like tissue. Instead of a clearly demarcated cornea, white, feathery, often ill-defined, and vascularized tissue develops in the peripheral cornea, appearing to blend with and extend from the sclera. The central cornea is usually clearer, but total replacement of the cornea with sclera may occur. The curvature of the cornea is often flatter, similar to the sclera. Potentially coexisting abnormalities include a shallow anterior chamber, iris abnormalities, and microphthalmos. This condition is usually bilateral. In approximately 50% of cases, a dominant or recessive inheritance has been described. Sclerocornea has been reported in association with numerous systemic abnormalities including limb deformities, craniofacial defects, and genitourinary disorders. In generalized sclerocornea, especially if bilateral, early corneal transplantation should be considered in an effort to provide vision.

Fig. 667.1 Acute hydrops from keratoconus with significant corneal edema.

Sclerocornea is classified into one of the congenital corneal opacity disorders with cornea plana if it involves peripheral scleralization or a total sclerocornea disorder such as Peters anomaly.

PETERS ANOMALY

Peters anomaly (irido-corneo-trabecular dysgenesis) is a bilateral central corneal opacity (leukoma) that is present at birth (Fig. 667.2). It is often associated with iridocorneal adhesions that extend from the iris collarette to the border of the corneal opacity. Approximately 50% of patients have other ocular abnormalities, which may include cataracts, glaucoma, and microphthalmia. As many as 80% of cases may be bilateral, and 60% are associated with systemic malformations **(Peters plus syndrome)**, which may include short stature, developmental delay, cleft lip and/or palate, dysmorphic facial features, and cardiac, genitourinary, and central nervous system malformations. Peters plus syndrome is an autosomal recessive (*B3GLCT* gene) disorder.

Some investigators have divided Peters anomaly into two types: a mesodermal or neuroectodermal form (type 1), which does not show

Table 667.1 STUMPED: Differential Diagnosis of Neonatal Corneal Opacities

DIAGNOSIS	LATERALITY	OPACITY	OCULAR PRESSURE	OTHER OCULAR ABNORMALITIES	NATURAL HISTORY	INHERITANCE
S—Sclerocornea	Unilateral or bilateral	Vascularized, blends with sclera, clearer centrally	Normal (or elevated)	Cornea plana	Nonprogressive	Sporadic
T—Tears in endothelium and Descemet's membrane						
Birth trauma	Unilateral	Diffuse edema	Normal	Possible hyphema, periorbital ecchymoses	Spontaneous improvement in 1 mo	Sporadic
Infantile glaucoma	Bilateral	Diffuse edema	Elevated	Megalocornea, photophobia and tearing, abnormal angle	Progressive unless treated	Autosomal recessive
U—Ulcers						
Herpes simplex keratitis	Unilateral	Diffuse with geographic epithelial defect	Normal	None	Progressive	Sporadic
Congenital rubella	Bilateral	Disciform or diffuse edema, no frank ulceration	Normal or elevated	Microphthalmos, cataract, pigment epithelial mottling	Stable, may clear	Sporadic
Neurotrophic exposure	Unilateral or bilateral	Central ulcer	Normal	Lid anomalies, congenital sensory neuropathy	Progressive	Sporadic
M—Metabolic (rarely present at birth) (mucopolysaccharidoses IH, IS; mucolipidosis type IV)*	Bilateral	Diffuse haze, denser peripherally	Normal	Few	Progressive	Autosomal dominant
P—Posterior corneal defect	Unilateral or bilateral	Central, diffuse haze or vascularized leukoma	Normal or elevated	Anterior chamber cleavage syndrome	Stable, sometimes early clearing or vascularization	Sporadic, autosomal recessive
E—Endothelial dystrophy						
Congenital hereditary endothelial dystrophy	Bilateral	Diffuse corneal edema, marked corneal thickening	Normal	None	Stable	Autosomal dominant or recessive
Posterior polymorphous dystrophy	Bilateral	Diffuse haze, normal corneal thickness	Normal	Occasional peripheral anterior synechiae	Slowly progressive	Autosomal dominant
Congenital hereditary stromal dystrophy	Bilateral	Flaky, feathery stromal opacities; normal corneal thickness	Normal	None	Stable	Autosomal dominant
D—Dermoid	Unilateral or bilateral	White vascularized mass, hair, lipid arc	Normal	None	Stable	Sporadic

*Mucopolysaccharidosis IH (Hurler syndrome); mucopolysaccharidosis IS (Scheie syndrome).
From Nelson LB, Calhoun JH, Harley RD. *Pediatric Ophthalmology*. 3rd ed. Philadelphia: WB Saunders; 1991, p. 210.

Fig. 667.2 Peters anomaly. Central opacity in a patient with Peters anomaly.

associated lens changes, and a surface ectodermal form (type 2), which does. Histologic findings include a focal absence of Descemet's membrane and corneal endothelium in the region of the opacity. Peters anomaly may be caused by incomplete migration and differentiation of the precursor cells of the central corneal endothelium and Descemet's membrane, or a defective separation between the primitive lens and cornea during embryogenesis. Peters anomaly may be autosomal recessive (*CYP1B1* gene) or autosomal dominant (*FOXC1*, *PAX6*, *PITX2* genes).

CORNEAL DYSTROPHIES

These are rare inherited disorders that may present at birth, during childhood, or during early adulthood with bilateral involvement (although severity may be asymmetric) and that progress with time (Table 667.2). In most, inheritance is autosomal dominant with variable expression; the most common pathogenic variant is in *TGFB1*, which is associated with the granular corneal dystrophy types 1 and 2, as well as lattice corneal dystrophy. Congenital hereditary endothelial dystrophy is both an autosomal recessive and dominant disorder; the recessive form presents at birth and is more severe (Fig. 667.3; see also Table 667.2); three variants are X-linked.

DERMOIDS

Epibulbar dermoids are choristomas. They are often present at birth and may increase in size with age. They occur most frequently in the lower temporal quadrant. They most commonly straddle the limbus and extend into the peripheral cornea (Fig. 667.4). Rarely, they may be confined entirely to the cornea or conjunctiva. Epibulbar (or limbal) dermoids may cause visual disturbance by encroaching on the visual axis or by contributing to the development of astigmatism, which may lead to amblyopia.

A dermoid usually appears as a well-circumscribed, rounded or oval, gray or pinkish-yellow mass with a dry surface from which short hairs may protrude. It may affect only the superficial layers of the cornea, although full-thickness involvement is common. Associated ocular anomalies include eyelid and iris colobomas, microphthalmos, and retinal and choroidal defects. A total of 30% of dermoids are associated with systemic abnormalities. Many of the associated anomalies involve developmental defects of the first branchial arch (vertebral anomalies, dysostosis of the facial bones, ear anomalies and dental anomalies, and Goldenhar syndrome). Epibulbar dermoids are found in 75% of cases of Goldenhar syndrome.

DENDRITIC KERATITIS

Infection of the cornea with the herpes simplex virus produces a characteristic lesion of the corneal epithelium, referred to as a dendrite; it has a branching, treelike pattern that can be demonstrated by fluorescein staining (Fig. 667.5). The acute episode is accompanied by pain, photophobia, tearing, blepharospasm, and conjunctival injection. Specific treatment may include mechanical debridement of the involved corneal epithelium to remove the source of infection and eliminate an antigenic stimulus to inflammation in the adjacent stroma. Medical treatment may include the use of topical trifluridine, topical ganciclovir, or systemic acyclovir/valacyclovir. In addition, a cycloplegic agent is useful to relieve pain from spasm of the ciliary muscle. Overly aggressive topical antiviral treatment itself can be toxic to the cornea and should be avoided. Recurrent infection and deep stromal involvement can lead to corneal scarring and loss of vision.

Topical use of corticosteroids causes exacerbation of superficial herpetic disease of the eye and may lead to corneal perforation; eye drops combining steroids and antibiotics are therefore to be avoided in treatment of red eye, unless there are clear-cut indications for their use and close supervision during therapy.

Infants born to mothers infected with herpes simplex virus should be examined carefully for signs of ocular involvement. Intravenous acyclovir is required for treatment of ocular herpes in newborns.

CORNEAL ULCERS

The usual signs and symptoms are focal or diffuse corneal haze, hyperemia, lid edema, pain, photophobia, tearing, and blepharospasm. It is important to distinguish a corneal ulcer from that of a corneal abrasion. Although a corneal abrasion involves loss of the epithelial layer of the cornea and subsequently stains with topical fluorescein, a corneal ulcer also has underlying stromal infiltration and appears white or hazy on examination. Corneal ulcers can be infectious or noninfectious in origin. **Hypopyon** (pus in the anterior chamber) is common, particularly when the cause is infection. Regardless of cause, corneal ulcers require prompt treatment. Infectious cases result most frequently from contact lens wear and traumatic lesions that become secondarily infected. Although many organisms are capable of infecting the cornea, *Pseudomonas aeruginosa* can be particularly devastating because it can rapidly destroy stromal tissue and lead to corneal perforation. *Neisseria gonorrhoeae* also is particularly damaging to the cornea. Indolent ulcers may be caused by fungi, often in association with the use of contact lenses. In each case, scrapings of the cornea must be studied in an effort to identify the infectious agent and determine the best therapy. Although aggressive local treatment is generally needed to save the eye, systemic treatment may be necessary in some cases as well. Perforation or scarring resulting from corneal ulceration is an important cause of blindness throughout the world and is estimated to be responsible for 10% of blindness in the United States.

Unexplained corneal ulcers in infants and young children should raise the question of a sensory defect, as in Riley-Day or Goldenhar-Gorlin syndrome, or of a metabolic disorder, such as tyrosinemia (Fig. 667.6). Corneal ulceration can also occur as a consequence of severe vitamin deficiencies, such as those seen with malabsorption in cystic fibrosis or restrictive eating disorders. Peripherally located inflammatory ulcers are commonly associated with blepharitis and typically require both topical antibiotic and corticosteroid treatment.

PHLYCTENULES

These are small, yellowish, slightly elevated lesions usually located at the corneal limbus; they may encroach on the cornea and extend centrally. A small corneal ulcer is often found at the head of the advancing lesion, with a fascicle of blood vessels behind the head of the lesion. Although once thought to represent a sign of systemic tuberculin infection, phlyctenular keratoconjunctivitis is a morphologic expression of delayed hypersensitivity to diverse antigens. In children, it commonly occurs as a result of a hypersensitivity reaction to nonpathogenic staphylococcal strains at the eyelid margin. Treatment usually consists of eliminating the underlying disorder, usually staphylococcal blepharitis or meibomianitis, and suppressing the immune response with the use of topical corticosteroid therapy. A superficial stromal pannus and scarring sometimes remain after treatment.

Table 667.2 Corneal Dystrophies Classified According to IC3D, Second Edition

NAME	LOCUS	GENE	INHERITANCE
EPITHELIAL AND SUBEPITHELIAL DYSTROPHIES			
Epithelial basement membrane dystrophy	5q31	*TGFBI*	AD Mostly sporadic
Epithelial recurrent erosion dystrophies	10q25.1	*COL17A1*	AD
Subepithelial mucinous corneal dystrophy	Unknown	Unknown	AD
Meesmann corneal dystrophy	12 q13 17q12	*KRT3* *KRT12*	AD
Lisch epithelial corneal dystrophy	Xp22.3	Unknown	XLD
Gelatinous drop–like corneal dystrophy	1p32	*TACSTD2*	AR
EPITHELIAL—STROMAL *TGFBI* DYSTROPHIES			
Reis-Bückler corneal dystrophy	5q31	*TGFBI*	AD
Thiel-Behnke corneal dystrophy	5q31	*TGFBI*	AD
Lattice corneal dystrophy	5q31	*TGFBI*	AD
Granular corneal dystrophy type 1	5q31	*TGFBI*	AD
Granular corneal dystrophy type 2	5q31	*TGFBI*	AD
STROMAL DYSTROPHIES			
Macular corneal dystrophy	16q22	*CHST6*	AR
Schnyder corneal dystrophy	1p36	*UBIAD1*	AD
Congenital stromal corneal dystrophy	12q21.33	*DCN*	AD
Fleck corneal dystrophy	2q34	*PIKFYVE*	AD
Posterior amorphous corneal dystrophy	12q21.33	*DCN* *KERA* *LUM* *EPYC*	AD
Central cloudy dystrophy of Francois	Unknown	Unknown	AD
Pre-Descemet's corneal dystrophy	Xp22.31 Unknown	*STS* Unknown	XLR (when associated with x-linked ichthyosis) AD (in isolated corneal dystrophy)
ENDOTHELIAL DYSTROPHIES			
Fuchs endothelial corneal dystrophy (FECD)	1p34.3-p32 18q21.2 10p11.22 20p13	*COL8A2* *TCF4* *ZEB1* *SLC4A11*	AD (early-onset FECD)
Posterior polymorphous corneal dystrophy	20p11.2-q11.2 1p34.3-p32.3 10p11.22	Unknown *COL8A2* *ZEB1*	AD
Congenital hereditary endothelial dystrophy	20p13	*SLC4A11*	AR
X-linked endothelial corneal dystrophy	Xq25	Unknown	XLD

IC3D, International Committee for Classification of Corneal Dystrophies; AD, autosomal dominant; AR, autosomal recessive; XLD, X-linked dominant.
From Bitar M, Hara Y, Sethi D, Couser NL. Genetic abnormalities of the cornea. In Couser NL, ed. *Ophthalmic Genetic Diseases*. Elsevier; 2019: Table 5.1, p. 62.

INTERSTITIAL KERATITIS

This denotes nonulcerative inflammation of the corneal stroma. There is a diverse list of causes of interstitial keratitis (IK), including bacterial, viral, parasitic, and inflammatory etiologies (Table 667.3). In the United States, herpesvirus infections and congenital syphilis account for the majority of cases of IK. Although the corneal findings may regress with time, "ghost vessels," which represent the previous vascular changes, and patchy corneal scarring remain and serve as permanent stigmata of the disease.

Cogan syndrome is an autoimmune IK associated with hearing loss and vestibular symptoms. Although its cause is unknown, a systemic vasculitis is suspected. Prompt treatment is required to avoid permanent hearing loss. Both the corneal changes and the auditory involvement may respond to the use of corticosteroids and immunosuppressive agents.

CORNEAL MANIFESTATIONS OF SYSTEMIC DISEASE

Several metabolic diseases produce distinctive corneal changes in childhood. Refractile polychromatic crystals are deposited throughout the cornea in cystinosis (see Chapter 105.4). Corneal deposits producing various degrees of corneal haze also occur in certain types

Fig. 667.3 Congenital hereditary endothelial dystrophy. This cornea is markedly edematous but has no enlargement. Intraocular pressure was normal. Patient has since undergone corneal transplantation with excellent results. *(From Stamper RL, Lieberman MF, Drake MV, eds. Becker-Shaffer's Diagnosis and Therapy of the Glaucomas. 8th ed. Philadelphia: Mosby; 2009: Fig. 19-21, p. 30).)*

Fig. 667.4 Limbal dermoid. Inferotemporal lesion in a patient with Goldenhar syndrome.

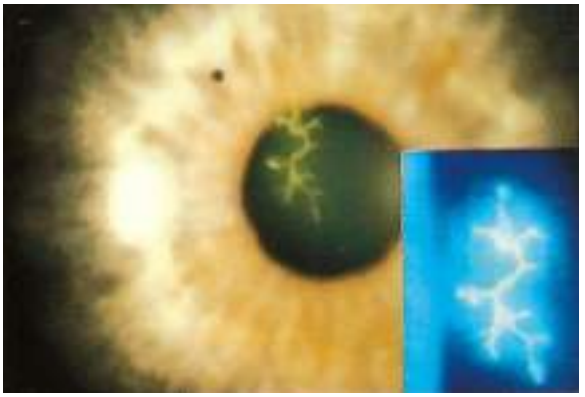

Fig. 667.5 Herpes simplex corneal epithelial keratitis in diffuse light and in light passed through a cobalt blue filter after fluorescein staining *(inset)*. Note the dendritic staining pattern characteristic of herpes simplex. *(From Goldman L, Schafer AI, eds. Goldman-Cecil Medicine. 25th ed. Philadelphia: Elsevier; 2016: Fig. 423.19.)*

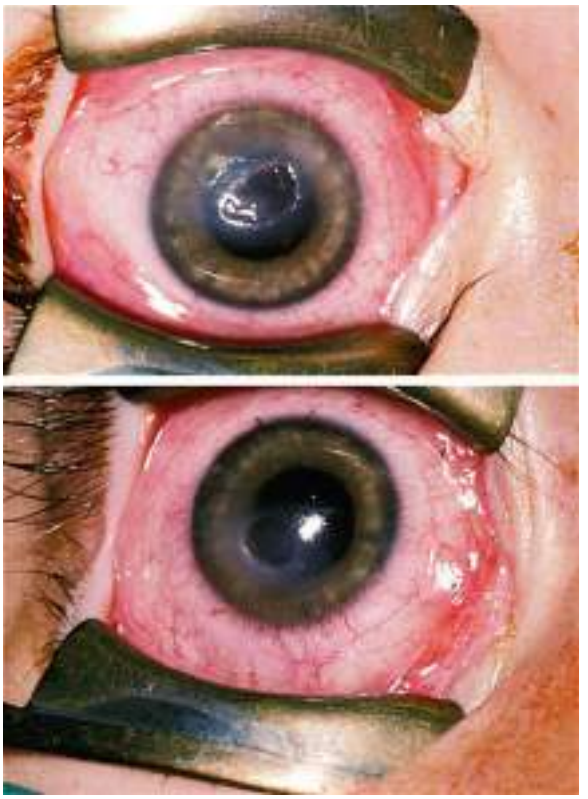

Fig. 667.6 Riley-Day syndrome. This child had a combination of anesthetic corneas and dry eyes that had been treated for several months by topical wetting agents without success. He responded well to a bilateral tarsorrhaphy and lubricant ointment. Later, punctal occlusion allowed enough wetting of his eyes to allow the tarsorrhaphies to be undone. *(From Hoyt CS, Taylor D, eds. Pediatric Ophthalmology and Strabismus, 4th ed. Philadelphia: Elsevier; 2013: Fig. 33.9, p. 315.)*

of mucopolysaccharidosis (MPS; see Chapter 109), particularly MPS IH (Hurler), MPS IS (Scheie), MPS I H/S (Hurler-Scheie compound), MPS IV (Morquio), MPS VI (Maroteaux-Lamy), and sometimes MPS VII (Sly). Corneal deposits may develop in patients with GM_1 (generalized) gangliosidosis (see Chapter 106.4). In Fabry disease, fine opacities radiating in a whorl or fanlike pattern occur, and corneal changes can be important in identifying the carrier state (see Chapter 106.4). A spraylike pattern of corneal opacities may also be seen in the Bloch-Sulzberger syndrome (incontinentia pigmenti; see Chapter 636.7). In Wilson disease (see Chapter 405.2), the distinctive corneal sign is the Kayser-Fleischer ring, a golden-brown ring in the peripheral cornea resulting from changes in Descemet's membrane. Pigmented corneal rings may develop in neonates with cholestatic liver disease. Corneal changes may occur in autoimmune hypoparathyroidism and band keratopathy in patients with hypercalcemia (see Chapters 611 and 613.1). Transient keratitis may occur with measles and sometimes with rubella (see Chapter 294).

Visit Elsevier eBooks+ at eBooks.Health.Elsevier.com for Bibliography.

Table 667.3 Partial List of Causative Agents in Microbial Keratitis

BACTERIA
Gram-Positive Cocci
• *Staphylococcus aureus*
• *Staphylococcus epidermidis*
• *Streptococcus pneumoniae, Streptococcus pyogenes*, viridans streptococci
• *Enterococcus faecalis*
• *Peptostreptococcus* spp.
Gram-Positive Bacilli
• *Bacillus coagulans, Bacillus cereus, Bacillus licheniformis*
• *Brevibacillus (Bacillus) brevis, Brevibacillus (Bacillus) laterosporus*
• *Corynebacterium diphtheriae*
• *Clostridium perfringens, Clostridium tetani*
Gram-Negative Coccobacilli
• *Neisseria gonorrhoeae*
• *Moraxella lacunata, Moraxella nonliquefaciens, Moraxella catarrhalis*
• *Acinetobacter calcoaceticus*
• *Pasteurella multocida*
• *Achromobacter xylosoxidans*
Gram-Negative Bacilli
• *Pseudomonas aeruginosa, Pseudomonas stutzeri, Pseudomonas fluorescens*
• *Burkholderia (Pseudomonas) mallei*
• *Proteus mirabilis*
• *Serratia marcescens*
• *Escherichia coli*
• *Klebsiella pneumoniae*
• *Morganella morganii*
• *Aeromonas hydrophila*
• *Bartonella henselae*
Mycobacteria
• *Mycobacterium tuberculosis, Mycobacterium chelonae, Mycobacterium gordonae, Mycobacterium mucogenicum*
Actinomycetes
• *Nocardia* spp.
Spirochetes
• *Treponema pallidum*
• *Borrelia burgdorferi*
VIRUSES
• Herpes simplex virus
• Varicella-zoster virus
• Adenovirus
• Vaccinia virus
• Epstein-Barr virus
• Rubeola
• Enteroviruses
• Coxsackievirus
FUNGI
• *Fusarium* spp.
• *Candida* spp.
• *Aspergillus* spp.
• *Acremonium* spp.
• *Alternaria* spp.
• *Penicillium* spp.
• *Bipolaris* spp.
• *Nosema* spp.
• *Vittaforma (Nosema) corneae*
• *Encephalitozoon* spp.
• *Edenia gomezpompae*
• *Exophiala phaeomuriformis*
CHLAMYDIA
• *Chlamydia trachomatis*
PARASITES
• *Acanthamoeba polyphaga, Acanthamoeba castellanii*
• *Onchocerca volvulus*
• *Leishmania brasiliensis*
• *Trypanosoma* spp.

From Azar DT, Hallak J, Barnes SD, et al. Microbial keratitis. In: Bennett JE, Dolin R, Blaser MJ, eds. *Mandell, Douglas, and Bennett's Principles and Practices of Infectious Diseases.* 9th ed. Saunders; 2020: Table 113.1, p. 1509.

Chapter 668

Abnormalities of the Lens

Scott E. Olitsky and Justin D. Marsh

CATARACTS

A cataract is any opacity of the lens (Fig. 668.1). Some are clinically unimportant; others significantly affect visual function. The incidence of infantile cataracts is approximately 2-13/10,000 live births. Approximately 60% of cataracts are an isolated defect, 22% are part of a syndrome, and the remaining cases are associated with other unrelated major birth defects. Cataracts are more common in low birthweight infants. Infants who weigh at or below 2,500 g have a three- to fourfold increased odds of developing infantile cataracts. Some cataracts are associated with other ocular or systemic diseases.

Differential Diagnosis

The differential diagnosis of cataracts in infants and children includes a wide range of developmental disorders, infectious and inflammatory processes, metabolic diseases, and toxic and traumatic insults (Table 668.1). Cataracts may also develop secondary to intraocular processes, such as retinopathy of prematurity, persistent hyperplastic primary vitreous, retinal detachment, retinitis pigmentosa, and uveitis. Finally, a fraction of cataracts in children are inherited (Fig. 668.2).

Developmental Variants

Early developmental processes may lead to various congenital lens opacities. Discrete dots or white plaquelike opacities of the lens capsule are common and sometimes involve the contiguous subcapsular region. Small opacities of the posterior capsule may be associated with persistent remnants of the primitive hyaloid vascular system (the common Mittendorf dot), whereas those of the anterior capsule may be associated with persistent strands of the pupillary membrane or vascular sheath of the lens. Congenital cataracts of this type are usually stationary and rarely interfere with vision, but in some cases, progression occurs.

Prematurity

A special type of lens change seen in some preterm newborn infants is the so-called *cataract of prematurity*. The appearance is of a cluster of tiny vacuoles in the distribution of the Y sutures of the lens. They can be visualized with an ophthalmoscope and are best seen with the pupil well dilated. The pathogenesis is unclear. In most cases, the opacities disappear spontaneously, often within a few weeks.

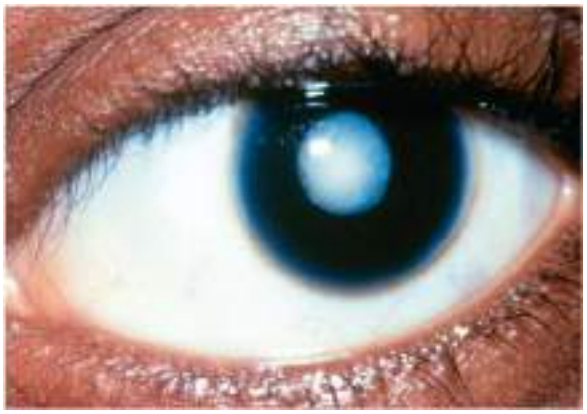

Fig. 668.1 Leukocoria secondary to cataract.

Mendelian Inheritance

Many isolated, idiopathic cataracts unassociated with other diseases are hereditary. There are ~35 genes associated with isolated pediatric cataracts; ~40% are inherited as autosomal dominants, ~20% are autosomal recessive, and ~35% have both dominant and recessive traits. Twelve crystallin gene pathologic variants are the most frequently identified genetic etiologies for both autosomal dominant and recessive inheritance patterns. Other involved genes include transcription factors, membrane proteins, and cytoskeletal proteins.

Congenital Infection Syndrome

Cataracts in infants and children can be a result of prenatal infection. Lens opacity may occur in any of the major congenital infection syndromes (e.g., toxoplasmosis, cytomegalovirus, syphilis, rubella, herpes simplex virus). Cataracts may also occur secondary to other perinatal infections, including measles, poliomyelitis, influenza, varicella-zoster, and vaccinia.

Metabolic Disorders

Cataracts are a prominent manifestation of many metabolic diseases, particularly certain disorders of carbohydrate, amino acid, calcium, and copper metabolism. A primary consideration in any infant with cataracts is the possibility of **galactosemia** (see Chapter 107.2). In classic infantile galactosemia, galactose-1-phosphate uridyltransferase deficiency, the cataract is typically of the zonular type, with haziness or opacification of one or more of the perinuclear layers of the lens. Haziness or clouding of the nucleus also often occurs. In its early stages, the cataract generally has a distinctive oil droplet appearance and is best detected with the pupil fully dilated. Progression to complete opacification of the lens may occur within weeks. With early treatment (galactose-free diet), the lens changes may be reversible.

In **galactokinase deficiency**, cataracts are the sole clinical manifestation. The cataracts are usually zonular and may appear in the first few months of life, first few years of life, or later in childhood.

In children with juvenile-onset diabetes mellitus, lens changes are uncommon. Some develop snowflake-like white opacities and vacuoles of the lens. Others develop cataracts that may progress and mature rapidly, sometimes in a matter of days, especially during adolescence. An antecedent event may be the sudden development of myopia caused by changes in the optical density of the lens. Congenital lens opacities may be seen in children of diabetic and prediabetic mothers (see Chapter 147).

Hypoglycemia in neonates can also be associated with early development of cataracts. Ketotic hypoglycemia is also associated with cataracts.

An association between cataracts and hypocalcemia is well established. Various lens opacities may be seen in patients with hypoparathyroidism (see Chapter 611).

The **oculocerebral renal syndrome of Lowe** is associated with cataracts in infants. Affected male children frequently have dense bilateral cataracts at birth, often in association with glaucoma and miotic pupils. Punctate lens opacities are frequently present in heterozygous females.

The distinctive sunflower cataract of **Wilson disease** is not commonly seen in children. Various lens opacities may be seen in children with certain of the sphingolipidoses, mucopolysaccharidoses, and mucolipidoses, particularly Niemann-Pick disease, mucosulfatidosis, Fabry disease, and aspartylglycosaminuria.

Cerebrotendinous xanthomatosis (CTX) is an autosomal recessive metabolic storage disease involving a pathogenic variant in an enzyme used during bile acid synthesis, leading to accumulation of cholesterol in the brain and elsewhere. In addition to cataract formation in childhood, patients may develop chronic diarrhea in infancy and progressive cognitive and neurologic impairment later in life. Early detection is vital as cataract formation may occur before permanent neurologic impairment, providing a window of time to treat the condition. Treatment typically consists of oral chenodeoxycholic acid.

Table 668.1 Differential Diagnosis of Cataracts

DEVELOPMENTAL VARIANTS Prematurity (Y-suture vacuoles) with or without retinopathy of prematurity Mittendorf dot (remnant of hyaloid artery) Persistent pupillary membrane (remnant of embryonic lens vasculature)	**INBORN ERRORS OF METABOLISM** Abetalipoproteinemia (absent chylomicrons, retinal degeneration) Fabry disease (α-galactosidase A deficiency) Galactokinase deficiency Galactosemia (galactose-1-phosphate uridyltransferase deficiency) Homocystinemia (subluxation of lens, mental retardation) Infantile neuronal ceroid lipofuscinosis Mannosidosis (acid α-mannosidase deficiency) Niemann-Pick disease (sphingomyelinase deficiency) Refsum disease (phytanic acid α-hydrolase deficiency) Wilson disease (accumulation of copper leads to cirrhosis and neurologic symptoms) Zellweger syndrome
GENETIC DISORDERS *Simple Mendelian Inheritance* Autosomal dominant (most common) Autosomal recessive X-linked	**ENDOCRINOPATHIES** Albright hereditary osteodystrophy Hypocalcemia (hypoparathyroidism) Hypoglycemia Diabetes mellitus
Major Chromosomal Defects Trisomy disorders (13, 15, 18, 21) Turner syndrome (45X) Deletion syndromes (1p36, 1q43-44, 5p, 11p13, 18p, 18q, 22q11.2) Duplication syndromes (3q, 20p, 10q)	**CONGENITAL INFECTIONS** Toxoplasmosis Cytomegalovirus infection Syphilis Rubella Perinatal herpes simplex infection Measles (rubeola) Poliomyelitis Influenza Varicella-zoster
Multisystem Syndromic Disorders Alport syndrome (hearing loss, renal disease) Alström syndrome (nerve deafness, diabetes mellitus) Apert disease (craniosynostosis, syndactyly) Branchiooculofacial syndrome Cerebrooculofacial skeletal syndrome Cockayne syndrome (premature senility, skin photosensitivity) Congenital cataracts–facial dysmorphism–neuropathy (CCFDN) syndrome Conradi disease (chondrodysplasia punctata) Crouzon disease (dysostosis craniofacialis) Ectodermal dysplasia Hallermann-Streiff syndrome (microphthalmia, small pinched nose, skin atrophy, and hypotrichosis) Hypohidrotic ectodermal dysplasia (anomalous dentition, hypohidrosis, hypotrichosis) Ichthyosis (keratinizing disorder with thick, scaly skin) Incontinentia pigmenti (dental anomalies, mental retardation, cutaneous lesions) Laurence Moon Bardet Biedl Syndrome Lowe syndrome (oculocerebrorenal syndrome: hypotonia, renal disease) Marfan syndrome Meckel-Gruber syndrome (renal dysplasia, encephalocele) Myotonic dystrophy Nail-patella syndrome (renal dysfunction, dysplastic nails, hypoplastic patella) Marinesco-Sjögren syndrome (cerebellar ataxia, hypotonia) Martsolf syndrome Nevoid basal cell carcinoma syndrome (autosomal dominant, basal cell carcinoma erupts in childhood) Norrie disease Oculofaciocardiodental syndrome Progeria Rothmund-Thomson syndrome (poikiloderma: skin atrophy) Rubinstein-Taybi syndrome (broad great toe, mental retardation) Smith-Lemli-Opitz syndrome (toe syndactyly, hypospadias, mental retardation) Sotos syndrome (cerebral gigantism) Spondyloepiphyseal dysplasia (dwarfism, short trunk) Warburg-Micro syndrome types 1-4 Werner syndrome (premature aging in second decade of life)	**OCULAR ANOMALIES** Peters' anomaly (corneal opacifications with iris-corneal dysgenesis) Rieger syndrome (iris dysplasia, myotonic dystrophy) Microphthalmia Coloboma Aniridia Mesodermal dysgenesis Norrie disease Posterior lenticonus Persistent hyperplastic primary vitreous Primitive hyaloid vascular system Retinitis pigmentosa
	MISCELLANEOUS DISORDERS Atopic dermatitis Drugs (corticosteroids) Radiation Trauma Juvenile idiopathic arthritis Retinopathy of prematurity Spherocytosis
	IDIOPATHIC

Chromosomal Defects

Lens opacities of various types may occur in association with chromosomal defects, including trisomies 13, 18, and 21; Turner syndrome; and a number of deletion and duplication syndromes (Table 668.1).

Drugs, Toxic Agents, and Trauma

Of the various drugs and toxic agents that may produce cataracts, corticosteroids are of major importance in the pediatric age group. Steroid-related cataracts characteristically are posterior subcapsular lens opacities. The incidence and severity vary. The relative significance of dose, mode of administration, duration of treatment, and individual susceptibility is controversial, and the pathogenesis of steroid-induced cataracts is unclear. The effect on vision depends on the extent and density of the opacity. In many cases, the acuity is only minimally or moderately impaired. Reversibility of steroid-induced cataracts may occur in some cases. All children receiving long-term steroid treatment should have periodic eye examinations.

Trauma to the eye is a major cause of cataracts in children (Fig. 668.3). Opacification of the lens may result from blunt or penetrating injury. Cataracts can be an important manifestation of child abuse.

Cataract formation after exposure to therapeutic radiation is dose and duration dependent. Adult research shows 50% occurrence in lens dose of 15 Gy. Delayed onset is the rule.

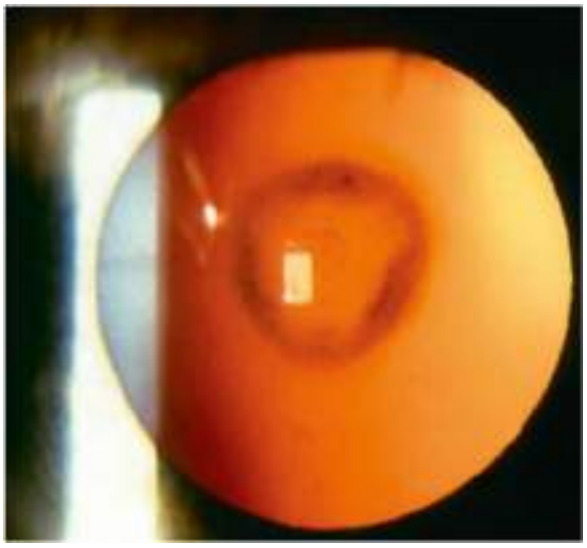

Fig. 668.2 Central lamellar cataract.

Miscellaneous Disorders

The list of multisystem syndromes and diseases associated with lens opacities and other eye anomalies is extensive (see Table 668.1).

Treatment

The treatment of cataracts that significantly interfere with vision includes the following: (1) surgical removal of lens material to provide an optically clear visual axis; (2) correction of the resultant aphakic refractive error with spectacles, contact lenses, or intraocular lens implantation; and (3) correction of any associated sensory deprivation amblyopia. Because the use of spectacles may not be possible in children after cataract removal, the use of contact lenses for visual rehabilitation is sometimes a medical necessity. Intraocular lens implantation is the mainstay for visual rehabilitation in children 2 years or older. A multicenter trial studied the visual outcomes in very young children treated with a contact lens versus an intraocular lens implant. One year after treatment, the children randomized into the intraocular lens implant group had more intraoperative complications, adverse events, and need for additional intraocular surgery. Although the median visual acuity was better in the contact lens group, the difference did not reach statistical significance. Treatment of the amblyopia may be the most demanding and difficult step in the visual rehabilitation of infants or children with cataracts. Not all cataracts require surgical intervention. Cataracts that are not visually significant should be monitored for change, and the child should be monitored for the development of amblyopia.

Prognosis

Prognosis depends on many factors, including the nature of the cataract, the underlying disease, age at onset, age at intervention, duration and severity of any attendant amblyopia, and presence of any associated ocular abnormalities (e.g., microphthalmia, retinal lesions, optic atrophy, glaucoma, nystagmus, and strabismus). Persistent amblyopia is the most common cause of poor visual recovery after cataract surgery in children. Secondary conditions and complications may develop in children who have had cataract surgery, including inflammatory sequelae, secondary membranes, glaucoma, retinal detachment, and changes in the axial length of the eye. All of these should be considered in planning treatment.

ECTOPIA LENTIS

Normally the lens is suspended in place behind the iris diaphragm by the zonular fibers of the ciliary body. Abnormalities of the suspensory system resulting from a developmental defect, disease, or trauma may result in instability or displacement of the lens. Displacement of the lens is classified as luxation, which is complete displacement of the lens (also known as dislocation) (Fig. 668.4), or as subluxation, which is a partial displacement (Fig. 668.5). Symptoms include blurring of vision, which is often the result of refractive changes such as myopia, astigmatism, or aphakic hyperopia. Some patients experience diplopia (double vision). An important sign of displacement is **iridodonesis**, a tremulousness of the iris caused by the loss of its usual support. Also, the anterior chamber may appear deeper than normal. Sometimes the equatorial region ("edge") of the displaced lens may be visible in the pupillary aperture. On ophthalmoscopy, this may appear as a black crescent. Also, the difference between the phakic and aphakic portions can be appreciated when focusing on the fundus.

Fig. 668.3 Diffuse cataract related to blunt trauma.

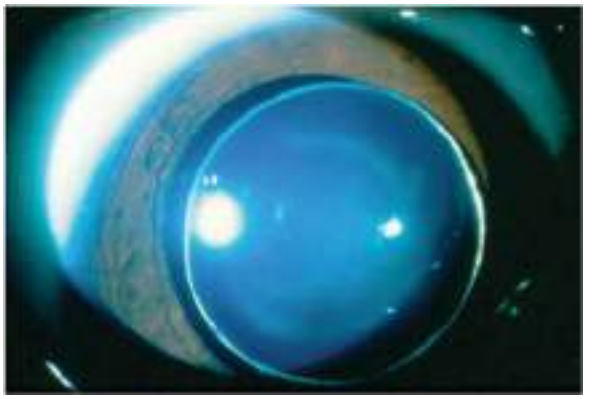

Fig. 668.4 Complete dislocation of lens into the anterior chamber seen in Weill-Marchesani syndrome.

Fig. 668.5 Marfan syndrome. Upward lens subluxation. *(From Hoyt CS, Taylor D. Pediatric Ophthalmology and Strabismus. 4th ed. Philadelphia: Elsevier; 2013: Fig. 35.9A, p. 333.)*

Differential Diagnosis

A major cause of lens displacement is trauma. Displacement may also occur as a result of ocular disease, such as uveitis, intraocular tumor, congenital glaucoma, high myopia, megalocornea, or aniridia, or in association with cataract. Ectopia lentis may also be inherited or associated with systemic disease.

Displacement of the lens occurring as a heritable ocular condition unassociated with systemic abnormalities is referred to as *simple ectopia lentis*. Simple ectopia lentis is usually transmitted as an autosomal dominant condition. The lens is generally displaced upward and temporally. The ectopia may be present at birth or may appear later in life. Another form of heritable dislocation is ***ectopia lentis et pupillae*** (see Chapter 662). In this condition, both the lens and pupil are displaced, usually in opposite directions. This condition is generally bilateral, with one eye being almost a mirror image of the other. *Ectopia lentis et pupillae* is an autosomal recessive condition, although variable expression with some intermingling with simple ectopia lentis has been reported.

Systemic disorders associated with displacement of the lens include Marfan syndrome, homocystinuria, Weill-Marchesani syndrome, and sulfite oxidase deficiency. Ectopia lentis occurs in approximately 80% of patients with Marfan syndrome. In approximately 50% of patients with Marfan syndrome, the ectopia is evident by 5 years of age. In most cases, the lens is displaced superiorly and temporally; it is almost always bilateral and relatively symmetric. In homocystinuria, the lens is usually displaced inferiorly and somewhat nasally. The subluxation of the lens occurs early in life and is often evident by 5 years of age. In Weill-Marchesani syndrome, the displacement of the lens is often downward and forward, and the lens tends to be small and round.

Ectopia lentis is also associated occasionally with other conditions, including Ehlers-Danlos, Sturge-Weber, Crouzon, and Klippel-Feil syndromes; oxycephaly; and mandibulofacial dysostosis. A syndrome of dominantly inherited blepharoptosis, high myopia, and ectopia lentis has also been described.

Treatment and Prognosis

Displacement of the lens often results only in optical problems. In some cases, however, more serious complications may develop, such as glaucoma, uveitis, retinal detachment, or cataract. Management must be individualized according to the type of displacement, its cause, and the presence of any complicating ocular or systemic conditions. For many patients, optical correction by spectacles or contact lenses can be provided. Manipulation of the iris diaphragm with mydriatic or miotic drops may sometimes help improve vision. In selected cases, the best treatment is surgical removal of the lens. In many children, treatment of any associated amblyopia must be instituted early. In addition, for children with ectopia lentis, safety precautions should be taken to prevent injury to the eye.

OTHER DISORDERS OF THE LENS

Microspherophakia

The term *microspherophakia* refers to a small, round lens that may occur as an isolated anomaly (probably autosomal recessive) or in association with other ocular abnormalities, such as ectopia lentis, myopia, or retinal detachment (possibly autosomal dominant). Microspherophakia may also occur in association with various systemic disorders, including Marfan syndrome, Weill-Marchesani syndrome, Alport syndrome, mandibulofacial dysostosis, and Klinefelter syndrome.

Anterior Lenticonus

Anterior lenticonus is a rare bilateral condition in which the anterior capsule of the lens thins, allowing the lens to bulge forward centrally. It may be accompanied by lens opacities or other eye anomalies and is a prominent feature of Alport syndrome. The increased curvature of the central area may cause high myopia. Spontaneous rupture of the anterior capsule may occur, requiring prompt surgical intervention.

Posterior Lenticonus

Posterior lenticonus, which occurs more commonly than anterior lenticonus, is characterized by a circumscribed round or oval bulge of the posterior lens capsule and cortex, involving the central region of the lens. In the early stages, by the red reflex test, this may look like an oil droplet. It occurs in infants and young children and tends to increase with age. Usually the lens material within and surrounding the capsular bulge eventually becomes opacified. Posterior lenticonus usually occurs as an isolated ocular anomaly. It is generally unilateral but may be bilateral. It is believed to be sporadic, although autosomal dominant and X-linked inheritance has been suggested in some cases. Infants or children with posterior lenticonus may require optical correction, amblyopia treatment, and surgery for progressive cataract.

Visit Elsevier eBooks+ at eBooks.Health.Elsevier.com for Bibliography.

Chapter 669

Disorders of the Uveal Tract

Scott E. Olitsky and Justin D. Marsh

UVEITIS (IRITIS, CYCLITIS, CHORIORETINITIS)

The uveal tract (the inner vascular coat of the eye, consisting of the iris, ciliary body, and choroid) (Fig. 669.1) is subject to inflammatory involvement in numerous systemic diseases, both infectious and noninfectious, and in response to exogenous factors, including trauma and toxic agents (Table 669.1). Inflammation may affect any one portion of the uveal tract preferentially or all parts together. Uveitis may be classified as anterior (iris, ciliary body), intermediate (vitreous-choroid locations), posterior (choroid, retina) or panuveitis, with subclassification as infectious, inflammatory, or systemic disease associated and eye limited.

Iritis may occur alone or in conjunction with inflammation of the ciliary body as iridocyclitis or in association with pars planitis. Pain, photophobia, and lacrimation are the characteristic symptoms of acute anterior uveitis, but the inflammation may develop insidiously without disturbing symptoms. Signs of anterior uveitis include conjunctival hyperemia, particularly in the perilimbal region (ciliary flush), and cells and protein ("flare") in the aqueous humor (Figs. 669.2 and 669.3). Inflammatory deposits on the posterior surface of the cornea (keratic precipitates) and congestion of the iris may also be seen. More chronic cases may show degenerative changes of the cornea (band keratopathy), lenticular opacities (cataract), development of glaucoma, and impairment of vision. The cause of anterior uveitis is often idiopathic; primary considerations in children are rheumatoid disease, particularly pauciarticular arthritis, Kawasaki disease, postinfectious reactive arthritis syndrome, tubulointerstitial nephritis (TINU), HLA-B27 associated syndromes, and sarcoidosis. Iritis may be secondary to corneal disease, such as herpetic keratitis or a bacterial or fungal corneal ulcer, or to a corneal abrasion or foreign body. Traumatic iritis and iridocyclitis are especially common in children.

Iridocyclitis that occurs in children with juvenile idiopathic arthritis deserves special mention. Unlike most forms of anterior uveitis, it rarely creates pain, photophobia, or conjunctival hyperemia. Loss of vision may not be noticed until severe and irreversible damage has occurred. Because of the lack of symptoms and the high incidence of uveitis in these children, routine periodic screening is necessary. Ophthalmic screening guidelines are based on 3 factors that predispose children with arthritis to uveitis (Fig. 669.4):

1. Type of arthritis
2. Age of onset of arthritis
3. Antinuclear antibody (ANA) status

Choroiditis, inflammation of the posterior portion of the uveal tract, invariably also involves the retina; when both are obviously affected, the condition is termed *chorioretinitis*. The causes of posterior uveitis are numerous; the more common are toxoplasmosis, histoplasmosis, cytomegalovirus, sarcoidosis, syphilis, tuberculosis, and toxocariasis

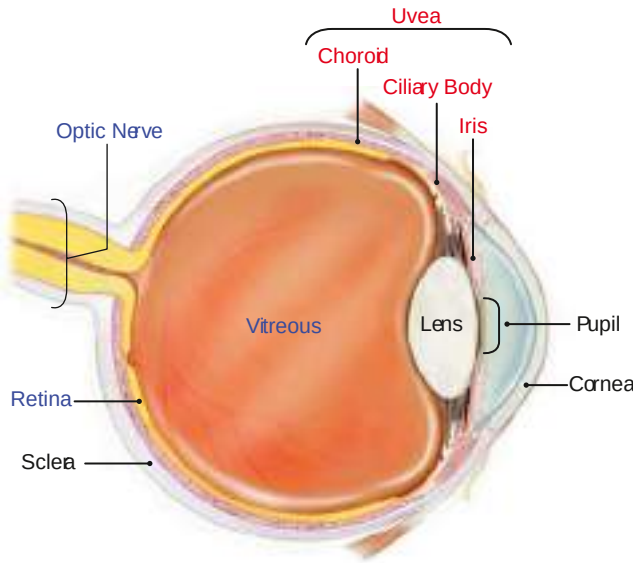

Fig. 669.1 Anatomic locations for uveitis. *(From National Eye Institute: Uveitis. Courtesy National Eye Institute, National Institutes of Health, Bethesda, Maryland.* https://www.nei.nih.gov/learn-about-eye-health/eye-conditions-and-diseases/uveitis*)*

(Fig. 669.5). Depending on the etiology, the inflammatory signs may be diffuse or focal. Vitreous reaction often occurs as well. With many types, the result is atrophic chorioretinal scarring demarcated by pigmentation, often with visual impairment. Secondary complications include retinal detachment, glaucoma, and phthisis.

Panophthalmitis is inflammation involving all parts of the eye. It is frequently suppurative, most often as a result of a perforating injury or of septicemia. It produces severe pain, marked congestion of the eye, inflammation of the adjacent orbital tissues and eyelids, and loss of vision. In many cases, the eye is lost despite intensive treatment of the infection and inflammation. Enucleation of the eye or evisceration of the orbit may be necessary.

Sympathetic ophthalmia is a rare type of uveal inflammatory response that affects the uninjured eye after a perforating injury to the other eye. It may occur weeks, months, or even years after the injury. A hypersensitivity phenomenon is the most probable cause. Loss of vision in the uninjured (sympathizing) eye may result. Removal of the injured eye prevents the development of sympathetic ophthalmia but does not stop the progression of the disease once it has occurred. High-dose intravenous methylprednisolone is the initial treatment of choice. Immune therapy (immune suppression or modulators) may need to be added to steroids; these agents include cyclosporine, azathioprine, mycophenolate mofetil, cytoxan and TNF-alpha blocking agents (infliximab, adalimumab).

Treatment

The various forms of intraocular inflammation are treated according to their underlying systemic causal factors. When infection is proved or suspected, appropriate systemic antimicrobial or antiviral therapy is used. In some cases, intravitreal injection is indicated.

Elimination of the intraocular inflammation is important to reduce the risk of severe, and often permanent, vision loss. Untreated, the inflammatory process may lead to the development of band keratopathy (calcium deposition in the cornea), cataracts, glaucoma, and irreversible retinal damage. Anterior inflammation may respond well to topical corticosteroid treatment. Posterior cases often require systemic therapy. The use of topical and systemic corticosteroids can lead to the development of glaucoma and cataracts. To reduce the need for topical and systemic corticosteroids, systemic immunosuppression is often used in patients requiring long-term treatment. Immunosuppressive agents include methotrexate, cyclosporine, and tumor necrosis factor inhibitors. Multiple agents may be needed in recalcitrant cases.

Table 669.1 Uveitis in Childhood

ANTERIOR UVEITIS
Juvenile idiopathic arthritis (pauciarticular)
Sarcoidosis including Blau syndrome
Trauma
Tuberculosis
Kawasaki disease
MIS-C
Ulcerative colitis
Crohn syndrome
HLA-B27 associated
Reactive postinfectious (enteric or genital) with arthritis and rash
Spirochetal (syphilis, leptospiral)
Lyme disease
Brucellosis
Heterochromic iridocyclitis (Fuchs)
Viral (herpes simplex, herpes zoster)
Ankylosing spondylitis
Stevens-Johnson syndrome
Chronic infantile neurologic cutaneous arthritis syndrome (CINCA)
Familial Mediterranean fever
Hyperimmunoglobulin D syndrome
Tumor necrosis factor receptor–associated periodic syndrome
Muckle-Wells syndrome
Celiac disease
Psoriasis
Multiple sclerosis
Cyclic neutropenia
Chronic granulomatous disease
X-linked lymphoproliferative disease
Hypocomplementemic vasculitis
Tubulointerstitial nephritis and uveitis syndrome
Idiopathic
Drugs (rifabutin, anti-tumor necrosis factor agents, interferon)
INTERMEDIATE AND POSTERIOR UVEITIS (CHOROIDITIS—MAY INVOLVE RETINA)
Toxoplasmosis
Toxocariasis
Sarcoidosis including Blau syndrome
Cat-scratch disease
Tuberculosis
Histoplasmosis
Viral (rubella, herpes simplex, HIV, cytomegalovirus, West Nile)
Subacute sclerosing panencephalitis
Tubulointestinal nephritis and uveitis syndrome
Diffuse unilateral subacute neuroretinitis (DUSN) secondary to *Ancylostoma caninum* or *Baylisascaris procyonis*
Idiopathic
ANTERIOR AND/OR POSTERIOR (PAN) UVEITIS
Sympathetic ophthalmia (trauma to other eye)
Vogt-Koyanagi-Harada syndrome (uveootocutaneous syndrome: poliosis, vitiligo, alopecia, deafness, tinnitus, uveitis, aseptic meningitis, retinitis)
Behçet syndrome
Juvenile xanthogranulomatosis
Lyme disease
Sarcoidosis
UVEO-MENINGEAL SYNDROMES
Vogt-Koyanagi-Harada disease
Behçet
Sarcoidosis
Granulomatosis with polyangiitis
Cat-scratch disease
Whipple disease
Syphilis
Lyme disease
Acute posterior multifocal placoid pigment epitheliopathy
Lymphoma, leukemia
Herpes simplex
Cytomegalovirus

MIS-C, Multisystem inflammatory system in children associated with COVID-19

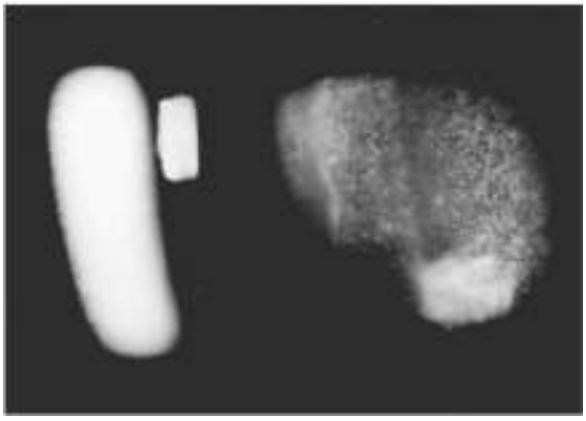

Fig. 669.2 Cell and flare in the anterior chamber. The flare represents protein leakage. *(Courtesy Peter Buch, CRA.)*

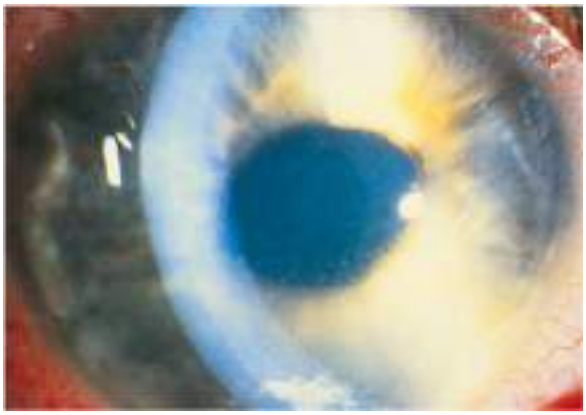

Fig. 669.3 Iritis. Conjunctival injection is most marked immediately around the cornea (ciliary flush). *(From Zitelli BJ, McIntire SC, Nowald AJ, Garrison J, eds. Zitelli and Davis' Atlas of Pediatric Physical Diagnosis. 8th ed. Philadelphia: Elsevier; 2023: Fig. 20.88, p. 721)*

Noninfectious inflammatory uveitis in adolescents has been treated with adalimumab, a human antitumor necrosis factor-α monoclonal antibody resulting in improved vision, lack of disease progression, and an ability to wean steroids. Cycloplegic agents, particularly atropine, are also used to reduce inflammation and to prevent adhesion of the iris to the lens (posterior synechiae), especially in anterior uveitis. Extensive posterior synechiae formation can lead to acute angle closure glaucoma. Other complications are noted in Table 669.2.

Surgery may be required for patients who develop glaucoma because of the underlying disease process or the need for corticosteroid treatment. Cataract surgery should be delayed until the inflammation has been under control for a period of time. Cataract surgery in children with a history of prolonged uveitis can carry significant risk. There is no universal agreement concerning the use of intraocular lenses in these patients.

Pars planitis is an uncommon idiopathic form of intermediate uveitis characterized by anterior chamber involvement, anterior vitreous cells and condensations, and peripheral retinal vasculitis. The average age of onset is 9 years. It is predominately bilateral and seen more frequently in males. Painless decreased vision is the usual presenting sign. The prognosis is good when adequate medical treatment is sought early in the course of the disease.

Masquerade syndromes can sometimes mimic intraocular inflammation. Retinoblastoma, leukemia, retained intraocular foreign body, juvenile xanthogranuloma, and peripheral retinal detachments may produce signs similar to those seen in uveitis. These syndromes should be kept in mind when evaluating a patient with suspected uveitis or if a patient does not respond as anticipated to appropriate treatment.

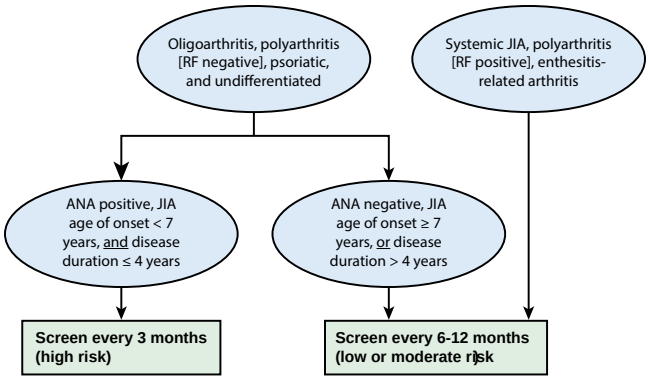

Fig. 669.4 Ophthalmology screening recommendations. ANA, Antinuclear antibody; JIA, juvenile idiopathic arthritis; RF, rheumatoid factor. *(From Angeles-Han ST, Ringold S, Beukelman T, et al. 2019 American College of Rheumatology/Arthritis Foundation guideline for the screening, monitoring, and treatment of juvenile idiopathic arthritis-associated uveitis. Arthritis Care Res (Hoboken). 2019;71:703–716.)*

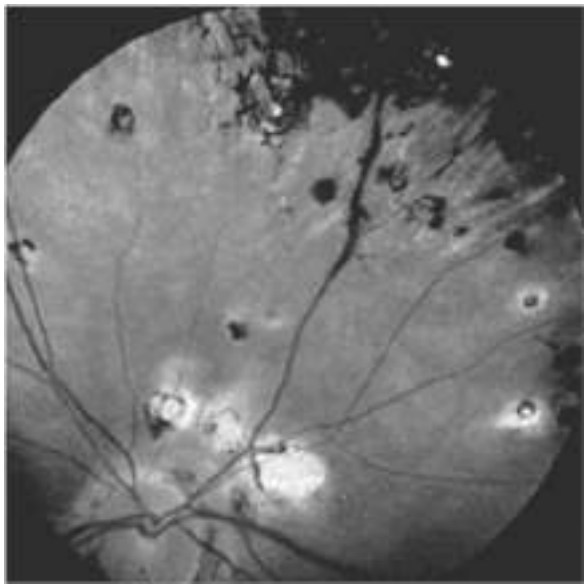

Fig. 669.5 Focal atrophic and pigmented scars of chorioretinitis.

Table 669.2 Comorbidities and Complications of Uveitis in Pediatric Group

Band keratopathy
Posterior synechia
Peripheral anterior synechia
Cataract
Ocular hypertension
Glaucoma
Ocular hypotension
Cystoid macular edema (CME)
Vitreous hemorrhage
Tractional and rhegmatogenous retinal detachment
Epiretinal membrane
Neovascularization of cornea
Neovascular or fibrovascular proliferation on retina or in vitreous
Phthisis bulbi

From Maleki A, Anesi SD, Look-Why S, Manhapra A, Foster CS. Pediatric uveitis: A comprehensive review. *Surv Ophthalmol.* 2022;67(2):510–529. Table 4.

Visit Elsevier eBooks+ at eBooks.Health.Elsevier.com for Bibliography.

Chapter 670

Disorders of the Retina and Vitreous

Scott E. Olitsky and Justin D. Marsh

RETINOPATHY OF PREMATURITY

Retinopathy of prematurity (ROP) is a complex disease of the developing retinal vasculature in infants born prematurely. It may be acute (early stages) or chronic (late stages). Clinical manifestations range from mild, usually transient changes of the peripheral retina to severe progressive vasoproliferation, scarring, and potentially blinding retinal detachment. ROP includes all stages of the disease and its sequelae.

Pathogenesis

Beginning at 16 weeks of gestation, retinal angiogenesis normally proceeds from the optic disc to the periphery, reaching the outer rim of the retina (ora serrata) nasally at about 36 weeks and extending temporally by approximately 40 weeks. Injury to this process results in various pathologic and clinical changes. The first observation in the acute phase is cessation of vasculogenesis. Rather than a gradual transition from a vascularized to avascular retina, there is an abrupt termination of the vessels marked by a line in the retina. The line may then grow into a ridge composed of mesenchymal and endothelial cells. Cell division and differentiation may later resume, and vascularization of the retina may proceed. Alternatively, there may be progression to an abnormal proliferation of vessels out of the plane of the retina, into the vitreous, and over the surface of the retina. Cicatrization and traction on the retina may follow, leading to retinal detachment.

The risk factors associated with ROP are not fully known, but prematurity and the associated retinal immaturity at birth represent the major factors. Oxygenation, respiratory distress, apnea, bradycardia, heart disease, infection, hypercarbia, acidosis, anemia, and the need for transfusion are thought by some to be contributory factors. Generally, the lower the gestational age, the lower the birthweight, and the sicker the infant, the greater the risk for ROP.

The basic pathogenesis of ROP is still unknown. Exposure to the extrauterine environment, including the necessarily high inspired oxygen concentrations, produces cellular damage, perhaps mediated by free radicals. Later in the course of the disease, peripheral hypoxia develops and vascular endothelial growth factors (VEGFs) are produced in the nonvascularized retina. These growth factors stimulate abnormal vasculogenesis, causing neovascularization to occur. Because of poor pulmonary function, a state of relative retinal hypoxia occurs. This causes upregulation of VEGF, which, in susceptible infants, can cause abnormal fibrovascular growth. This neovascularization may then lead to scarring and loss of vision.

Classification

The international classification of ROP describes the location, extent, and severity of the disease. To delineate location, the retina is divided into three concentric zones centered on the optic disc (Fig. 670.1). Zone I, the posterior or inner zone, extends twice the disc-macular distance, or 30 degrees in all directions from the optic disc. Zone II, the middle zone, extends from the outer edge of zone I to the ora serrata nasally and to the anatomic equator temporally. Zone III, the outer zone, is the residual crescent that extends from the outer border of zone II to the ora serrata temporally. The extent of involvement is described by the number of circumferential clock hours involved.

The phases and severity of the disease process are classified into five stages. Stage 1 is characterized by a demarcation line that separates vascularized from avascular retina. This line lies within the plane of the retina and appears relatively flat and white. Often noted is abnormal branching or arcading of the retinal vessels leading into the line. Stage 2 is characterized by a ridge; the demarcation line has grown, acquiring height, width, and volume and extending up and out of the plane of the retina. Stage 3 is characterized by the presence of a ridge and the development of extraretinal fibrovascular tissue (Fig. 670.2A). Stage 4 is characterized by subtotal retinal detachment caused by traction from the proliferating tissue in the vitreous or on the retina. Stage 4 is subdivided into two phases: (1) subtotal retinal detachment not involving the macula and (2) subtotal retinal detachment involving the macula. Stage 5 is total retinal detachment.

When signs of posterior retinal vascular changes accompany the active stages of ROP, the term *plus disease* is used (see Fig. 670.2B and C). Patients reaching the point of dilation and tortuosity of the retinal vessels also frequently demonstrate the associated findings of engorgement of the iris, pupillary rigidity, and vitreous haze.

The Early Treatment for Retinopathy of Prematurity Cooperative has described types 1 and 2 ROP as follows:

Type 1 ROP
- Zone I: Any stage with plus
- Zone I: Stage 3 without plus
- Zone II: Stage 2 to three with plus type 2 ROP
- Zone I: Stage 1 to two without plus
- Zone II: Stage 3 without plus

Clinical Manifestations and Prognosis

In more than 90% of at-risk infants, the course is one of spontaneous arrest and regression, with little or no residual effects or visual disability. Fewer than 10% of infants have progression toward severe disease, with significant extraretinal vasoproliferation, cicatrization, detachment of the retina, and impairment of vision.

Some children with arrested or regressed ROP are left with demarcation lines, undervascularization of the peripheral retina, or abnormal branching, tortuosity, or straightening of the retinal vessels. Some are left with retinal pigmentary changes, dragging of the retina, ectopia of the macula, retinal folds, or retinal breaks. Others proceed to total retinal detachment, which commonly assumes a funnel-like configuration. The clinical picture is often that of a retrolental membrane, producing leukocoria (a white reflex in the pupil). Some patients develop cataract, glaucoma, and signs of inflammation. The end stage is often a painful blind eye or a degenerated phthisical eye. The spectrum of ROP also includes myopia, which is often progressive and of significant degree in infancy. The incidence of anisometropia, strabismus, amblyopia, and nystagmus may also be increased.

Diagnosis

Systematic serial screening ophthalmologic examinations of infants at risk are recommended. Infants with a birthweight of less than 1,500 g or gestational age of 32 weeks or less and selected infants with a birthweight between 1,500 and 2,000 g or gestational age of more than 32 weeks with an unstable clinical course, including those requiring cardiorespiratory support and who are believed by their pediatrician or neonatologist to be at high risk, should have retinal screening examinations. The timing of the initial screening exam is based on the infant's age. Table 670.1 was developed from an evidence-based analysis of the Multicenter Trial of Cryotherapy for ROP. The examination can be stressful to fragile preterm infants, and the dilating drops can have untoward side effects. Infants must be carefully monitored during and after the examination. Some neonatologists and ophthalmologists advocate the use of topical tetracaine and/or oral sucrose to reduce the discomfort and stress to the infant. Follow-up is based on the initial findings and risk factors but is usually 2 weeks or less.

Treatment

In selected cases, laser photocoagulation of the avascular retina reduces the more severe complications of progressive ROP (Table 670.2). Advances in vitreoretinal surgical techniques have had limited success in reattaching the retina in infants with total retinal detachment (stage 5 ROP), but the visual results are often disappointing. The Early Treatment for Retinopathy of Prematurity Cooperative study did find

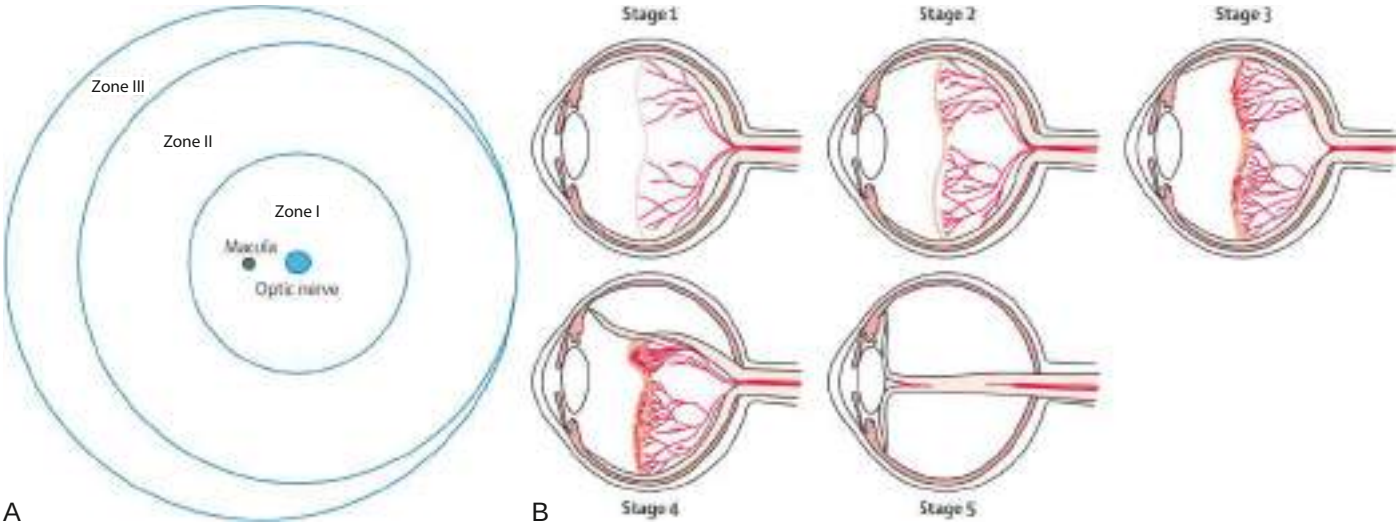

Fig. 670.1 The retina is divided into three zones and the extent or severity of retinopathy in these zones is classified in terms of five stages. **A,** Diagram of right eye. **B,** Stage 1 is characterized by a thin demarcation line between vascularized and nonvascularized retina, stage 2 by a ridge, stage 3 by extraretinal fibrovascular proliferation, stage 4 by partial retinal detachment, and stage 5 by total retinal detachment. In stage 3, extraretinal neovascularization can become severe enough to cause retinal detachment (stages 4-5), which usually leads to blindness. *(**A** from Hellström A, Smith LEH, Dammann O. Retinopathy of prematurity. Lancet. 2013;382:1445–1454, Fig. 3, p. 1450; **B** courtesy Lisa Hård.)*

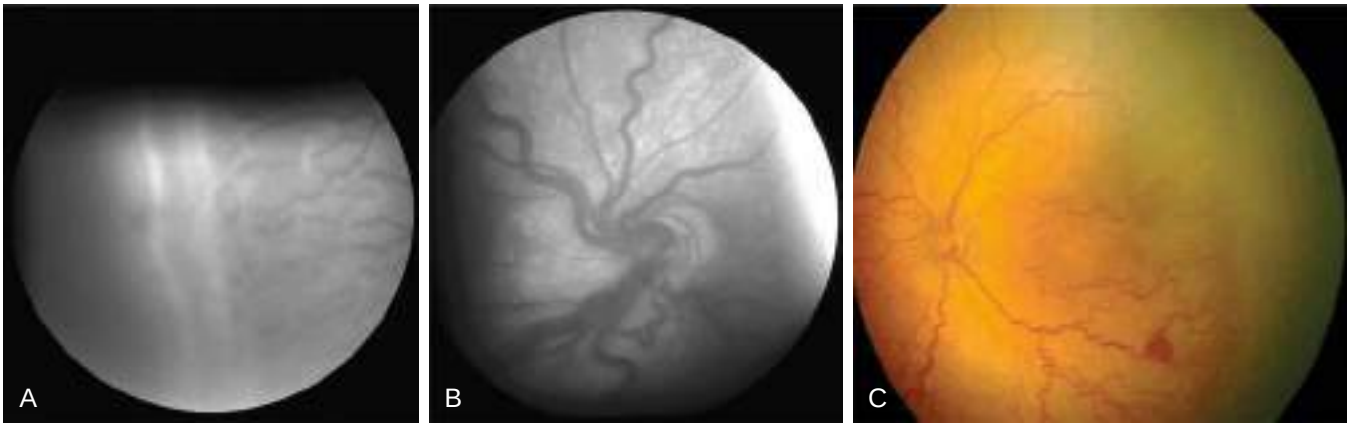

Fig. 670.2 Retinopathy of prematurity (ROP). **A,** In stage 3, there is a ridge and extraretinal vascular tissue. **B,** Retinal vessels are dilated and tortuous in active zone I ROP with plus disease. **C,** Zone I ROP with plus disease.

Table 670.1 Timing of First Eye Examination Based on Gestational Age at Birth

GESTATIONAL AGE AT BIRTH	AGE AT INITIAL EXAMINATION IN WEEKS	
	POSTMENSTRUAL	CHRONOLOGICAL
22	31	9
23	31	8
24	31	7
25	31	6
26	31	5
27	31	4
28	32	4
29	33	4
30	34	4
31	35	4
32	36	4

Table 670.2 Criteria for Peripheral Ablative Therapy for Retinopathy of Prematurity

1. Zone II: Plus disease with stage 2 or 3 ROP
2. Zone I: Plus disease with stage 1 or 2 ROP
3. Zone I: Stage 3 ROP

ROP, Retinopathy of prematurity.
Data from Early Treatment for Retinopathy of Prematurity Cooperative Group: Revised indications for the treatment of retinopathy of prematurity: Results of the Early Treatment for Retinopathy of Prematurity Randomized Trial. *Arch Ophthalmol* 2003;121:1684.

improved structural and visual outcomes with a redefined threshold for treatment. It demonstrated the importance of plus disease and the presence of posterior retinal involvement in the determination of when to treat ROP. Treatment should be considered for any eye with type 1 ROP. Serial examinations are indicated for any eye with type 2 ROP; treatment is considered if type 2 progresses to type 1 or if threshold ROP develops.

Intravitreal injections of VEGF antagonists may be recommended as first or second therapy for ROP, particularly in neonates with disease in zone 1. This treatment rapidly reduces intravitreal VEGF levels, often

improving plus disease and extraretinal fibrovascular tissue (stage 3 disease) within days of treatment. Theoretical advantages of these agents include not only the potential for improved peripheral retinal vascularization after treatment but also an apparent reduction in myopia later in childhood. Because the effects of intravitreal VEGF antagonists are temporary, neonates treated in this manner must be followed closely, often for months, after treatment to ensure additional therapy is not warranted.

Prevention

Prevention of ROP ultimately depends on the prevention of premature birth and its attendant problems (see Chapters 116 and 119.2). However, a number of other potential factors have been studied to decrease the occurrence of ROP in these premature infants. Ambient light had been considered by some to be a potential agent that could hopefully be manipulated. The LIGHT-ROP study definitively found that ambient light reduction had no impact on ROP. The association between ROP and oxygen saturation has been studied for decades. Recent research has focused on maintaining oxygen saturation levels for severely premature infants at levels sufficiently low to minimize the risk of ROP and sufficiently high to optimize survival.

PERSISTENT FETAL VASCULATURE

Persistent fetal vasculature (PFV; formerly called *persistent hyperplastic primary vitreous*) includes a spectrum of manifestations caused by the persistence of various portions of the fetal hyaloid vascular system and associated fibrovascular tissue.

Pathogenesis

During development of the eye, the hyaloid artery extends from the optic disc to the posterior aspect of the lens; it sends branches into the vitreous and ramifies to form the posterior portion of the vascular capsule of the lens. The posterior portion of the hyaloid system normally regresses by the seventh fetal month and the anterior portion by the eighth fetal month. Small remnants of the system, such as a tuft of tissue at the disc (Bergmeister papilla) or a tag of tissue on the posterior capsule of the lens (Mittendorf dot), are common findings in healthy persons. More extensive remnants and associated complications constitute PFV. Two major forms are described: anterior PFV and posterior PFV. Variability is great, and mixed or intermediate forms occur.

Clinical Manifestations

The usual clinical feature of anterior PFV is the presence of a vascularized plaque of tissue on the back surface of the lens in an eye that is microphthalmic or slightly smaller than normal. The condition is usually unilateral and may occur in infants with no other abnormalities and no history of prematurity. The fibrovascular tissue tends to undergo gradual contracture. The ciliary processes become elongated, and the anterior chamber may become shallow. The lens is usually smaller than normal and may be clear, but it often becomes cataractous and may swell or absorb fluid. Large or anomalous vessels of the iris may be present. The anterior chamber angle may have abnormalities. In time, the cornea may become cloudy.

Anterior PFV is usually noted in the first weeks or months of life. The most frequent presenting signs are leukocoria (white pupillary reflex), strabismus, and nystagmus. The course is usually progressive, and the outcome is poor. Major complications are spontaneous intraocular hemorrhage, swelling of the lens caused by rupture of the posterior capsule, and glaucoma. The eye may eventually deteriorate. The spectrum of posterior PFV includes fibroglial veils around the disc and macula, vitreous membranes and stalks containing hyaloid artery remnants projecting from the disc, and meridional retinal folds. Traction detachment of the retina may occur. Vision may be impaired, but the eye is usually retained.

Treatment

Surgery is performed to prevent complications, to preserve the eye and a reasonably good cosmetic appearance, and, in some cases, to salvage vision. Surgical treatment usually involves aspirating the lens and excising the abnormal tissue. If useful vision is to be attained, refractive correction and aggressive amblyopia therapy are required. In some cases, the affected eye is enucleated because distinguishing between this white mass and retinoblastoma can be difficult. Ultrasonography and CT are valuable diagnostic aids.

RETINOBLASTOMA

Retinoblastoma (Fig. 670.3) is the most common primary malignant intraocular tumor of childhood. It occurs in approximately 1/15,000 live births; 250-300 new cases are diagnosed in the United States annually. Hereditary and nonhereditary patterns of transmission occur; there is no predilection for gender or race. The hereditary form occurs earlier and is usually bilateral and multifocal, whereas the nonhereditary form is generally unilateral and unifocal. Fifteen percent of unilateral cases are hereditary. Bilateral cases often present earlier than unilateral cases. Unilateral tumors are often large by the time they are discovered. The average age at diagnosis is 15 months for bilateral cases compared with 27 months for unilateral cases. It is unusual for a child to present with a retinoblastoma after 3 years of age. Rarely, the tumor is discovered at birth, during adolescence, or even in early adulthood.

Clinical Manifestations

The clinical manifestations of retinoblastoma vary depending on the stage at which the tumor is detected. The initial sign in the majority of patients is a white pupillary reflex (leukocoria). Leukocoria results because of the reflection of light off the white tumor. The second most frequent initial sign of retinoblastoma is strabismus. Less frequent presenting signs include pseudohypopyon (tumor cells layered inferiorly in front of the iris) caused by tumor seeding in the anterior chamber of the eye, hyphema (blood layered in front of the iris) secondary to iris neovascularization, vitreous hemorrhage, and signs of orbital cellulitis. On examination, the tumor appears as a white mass, sometimes small and relatively flat, sometimes large and protuberant. It may appear nodular. Vitreous haze or tumor seeding may be evident.

The retinoblastoma gene is a recessive suppressor gene located on chromosome 13 at the 13q14 region. Because of the hereditary nature of retinoblastoma, family members of affected children should undergo a complete ophthalmologic examination and genetic counseling. Newborn siblings and children of affected patients should be referred to an ophthalmologist shortly after birth, when the peripheral retina can be evaluated without the need for an examination under anesthesia.

Diagnosis

Retinoblastoma is diagnosed by direct observation by an experienced ophthalmologist. Ancillary testing such as CT or ultrasonography may help to confirm the diagnosis and demonstrate calcification within the mass. MRI may better detect the presence of an associated pineoblastoma (trilateral retinoblastoma). A definitive diagnosis occasionally cannot be made, and removal of the eye must be considered to avoid the possibility of lethal metastasis of the tumor. Because a biopsy can lead to spread of the tumor, histologic confirmation before enucleation is not possible in most cases. Therefore removal of a blind eye in which the diagnosis of retinoblastoma is likely may be appropriate.

Treatment

Therapy varies, depending on the size and location of the tumor as well as whether it is unilateral or bilateral. Advanced tumors may be treated by enucleation. Other treatment modalities include the use of external beam irradiation, radiation plaque therapy, laser or cryotherapy, and chemoreduction (systemic chemotherapy) followed by local therapies (i.e., laser therapy, cryotherapy, and brachytherapy). During the last decade, there has been a dramatic shift in the treatment of retinoblastomas. Intraarterial chemotherapy involves delivery of chemotherapeutic agents via the ophthalmic artery and has dramatically reduced the need for enucleation in many cases of retinoblastoma.

Nonocular secondary tumors are common in patients with germinal pathogenic variants; they are estimated to occur with an incidence of 1% per years of life. The most common secondary tumor is osteogenic sarcoma of the skull and long bones; the risk is higher in patients

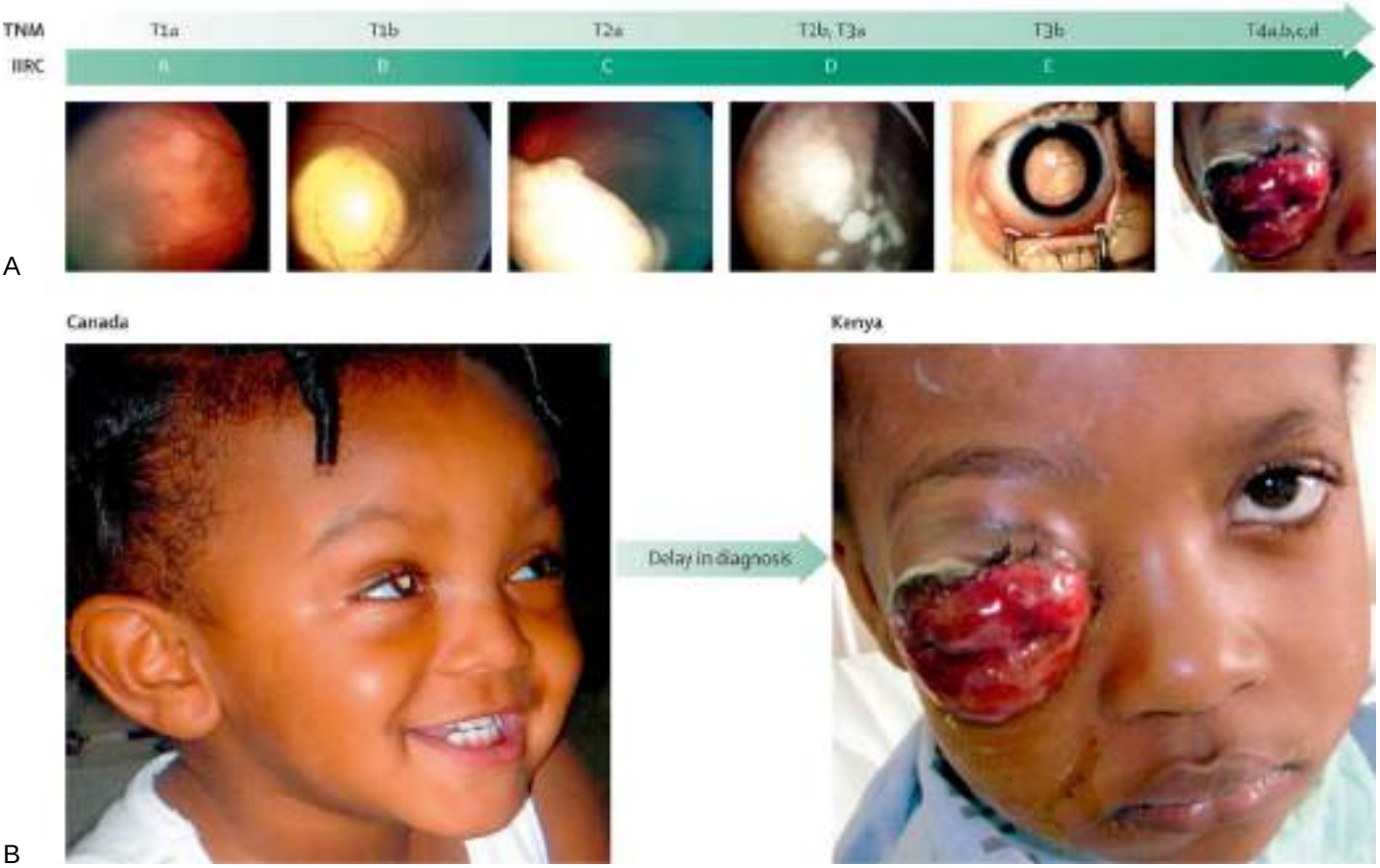

Fig. 670.3 Progression of retinoblastoma from small intraretinal tumors to a massive orbital retinoblastoma probably extending into the brain. **A,** Progression of retinoblastoma from small intraretinal tumors that can be cured by laser treatment and cryotherapy (TNM T1a, IIRC A) to massive orbital retinoblastoma probably extending into the brain (TNM T4a-b). **B,** A difference in age at diagnosis recorded between Canada and Kenya could mean the difference between possible cure and certain death. The Canadian child with leukocoria was diagnosed because of the left-hand image, which was taken by his sister with his mother's mobile phone. IIRC, International Intraocular Retinoblastoma Classification; TNM, tumor node metastasis cancer staging. *(From Dimaras H, Kimani K, Dimba EAO, et al. Retinoblastoma. Lancet. 2012;379:1436–1444, Fig. 1, p. 1438.)*

treated with radiation. Other malignancies include lung, brain, soft tissue, and skin.

The prognosis for children with retinoblastoma depends on the size and extension of the tumor. When confined to the eye, most tumors can be cured. The prognosis for long-term survival is poor when the tumor has extended into the orbit or along the optic nerve.

INHERITED RETINAL DYSTROPHIES

Inherited retinal dystrophies (IRDs) represent a wide spectrum of disorders (~280 affected genes) causing loss of photoreceptors and involving various locations (peripheral vs. macular or central) (Fig. 670.4) and affecting ~1/3,000 people. Most cases are monogenetic or isolated and nonsyndromic (~75%). Inheritance may be autosomal recessive or dominant, X-linked, mitochondrial, uniparental disomy, or digenic. There is significant genetic heterogenicity and overlap of the involved genes (Fig. 670.5). The IRDs are classified as retinitis pigmentosa, macular dystrophies, cone, or cone-rod dystrophies, syndromic (Usher syndrome with deafness), and the Leber congenital amaurosis disorders (>20 genes).

Retinitis Pigmentosa

This progressive peripheral retinal degeneration is the most common IRD and is characterized by pigmentary changes, arteriolar attenuation, usually some degree of optic atrophy, and progressive

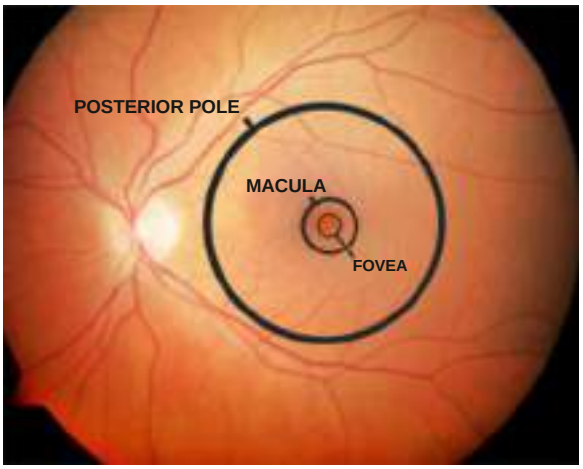

Fig. 670.4 Fundus image of a normal retina. The macula contains a high proportion of cone cells, which are most densely clustered in the fovea. The posterior pole marks the area of the retina between the optic disc (the *bright yellow oval* on the left of the image) and the macula. *(From Broadgate S, Yu J, Downes SM, Halford S. Unraveling the genetics of inherited dystrophies: Past, present, and future. Prog Retinal Eye Res. 2017;59:53–96. Fig. 1, p. 55).*

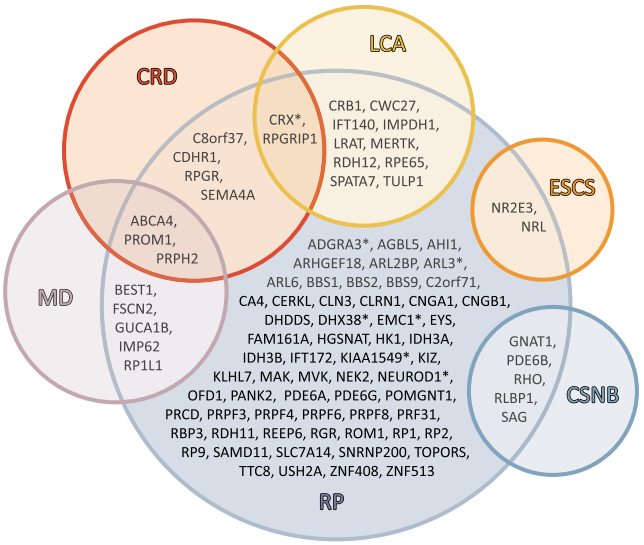

Fig. 670.5 Venn diagram summarizing the genetic overlap between retinitis pigmentosa and other inherited retinal dystrophies. Each circle represents a specific clinical diagnosis. The gene names listed in the overlapping areas indicate that mutations in these genes can lead to different phenotypes. Genes marked with an asterisk are candidate genes for nonsyndromic RP. CRD, cone-rod dystrophy; CSNB, congenital stationary night blindness; ESCS, enhanced S-cone syndrome; LCA, Leber congenital amaurosis; MD, macular dystrophy; RP, retinitis pigmentosa. *(From Verbakel SK, van Huet RAC, Boon CJF, et al. Non-syndromic retinitis pigmentosa. Prog Retin Eye Res. 2018;66:157–186. Fig 1.)*

Fig. 670.6 Retinitis pigmentosa. Fundus photograph shows "bone spicule" pigmentation of the midperipheral fundus, waxy pallor of the optic disc, and attenuated retinal vessels, the most consistent finding in retinitis pigmentosa. *(Courtesy Dr. John I. Loewenstein.)*

impairment of visual function. Dispersion and aggregation of the retinal pigment produce various ophthalmoscopically visible changes ranging from granularity or mottling of the retinal pigment pattern to distinctive focal pigment aggregates with the configuration of bone spicules (Fig. 670.6). Other ocular findings include subcapsular cataract, glaucoma, and keratoconus.

Impairment of night vision (nyctalopia) or dark adaptation is often the first clinical manifestation. Progressive loss of peripheral vision (tunnel vision), often in the form of an expanding ring scotoma or concentric contraction of the field, is usual. There may also be loss of central vision. Retinal function, as measured by electroretinography (ERG), is characteristically reduced. The disorder may be autosomal recessive, autosomal dominant, or X-linked with ~70 affected genes (see Fig. 670.5). Children with autosomal recessive retinitis pigmentosa are more likely to become symptomatic at an earlier age (median age 10.7 years). Those with autosomal dominant retinitis pigmentosa are more likely to present in their 20s.

Another form of nonsyndromic IRD is **Leber congenital retinal amaurosis** (LCA), in which the retinal changes tend to be pleomorphic, with various degrees of pigment disorder, arteriolar attenuation, and optic atrophy. The incidence is approximately 1/81,000 births. Patients develop poor vision, nystagmus, poor pupillary response to light, and a behavioral pattern of eye rubbing. There are pathogenic variants in ~20 different genes producing this early (infancy) onset autosomal recessive severe retinal degenerative disease (see Fig. 670.5). Ten percent have pathogenic variants in the *LRAT* or *RPE65* genes, involved in retinoid metabolism. Although the retina may initially appear normal during infancy, the child typically shows evidence of visual impairment, nystagmus, and poor pupillary reaction soon after birth. ERG findings are abnormal early and confirm the diagnosis. Visual loss can be profound and may progress with age.

Gene replacement therapy via subretinal injections shows promise for *RPE65*-related IRDs, including those phenotypes of retinitis pigmentosa, Leber congenital amaurosis, and other IRD with this pathologic gene variant. Individuals who received subretinal injection of vector genomes of voretigene neparvovec improved in their ability to navigate a dimly lit course when compared with controls, with outcomes measured at 1 year. Similar gene replacement studies have been conducted or are being conducted for other retinal dystrophies, including choroideremia, Stargardt disease, cone-rod dystrophy, and X-linked retinoschisis.

Usher syndrome, an autosomal recessive disorder, is the most common cause of syndromic IRD *and* sensorineural deafness (incidence, 1/25,000). Type 1 Usher syndrome presents at birth with profound hearing loss and poor balance; vision loss progresses more slowly and begins during adolescence. Patients with type 3 disease have normal hearing at birth but develop hearing loss and night blindness around puberty. To date, 11 genetic loci have been located (5 for type 1, 3 for type 2; 1 for type 3).

A similar clinical picture may occur in the setting of secondary pigmentary retinal degenerations, which must be differentiated from retinitis pigmentosa, when associated with a wide variety of metabolic diseases, neurodegenerative processes, and multifaceted syndromes. Examples include the progressive retinal changes of the mucopolysaccharidoses (particularly Hurler, Hunter, Scheie, and Sanfilippo syndromes; see Chapter 109) and certain of the late-onset gangliosidoses (Batten-Mayou, Spielmeyer-Vogt, and Jansky-Bielschowsky diseases; see Chapters 106.4 and 639.2), the progressive retinal degeneration associated with progressive external ophthalmoplegia (Kearns-Sayre syndrome; see Chapter 638.2), and the retinitis pigmentosa–like changes in the Laurence-Moon and Bardet-Biedl syndromes. The retinal manifestations of abetalipoproteinemia (Bassen-Kornzweig syndrome; see Chapter 106) and Refsum disease (see Chapter 106.2) are also similar to those found in retinitis pigmentosa. The diagnosis of the latter two disorders in a patient with presumed retinitis pigmentosa is important because treatment is possible. There is also an association of retinitis pigmentosa and congenital hearing loss, as in Usher syndrome.

STARGARDT DISEASE (FUNDUS FLAVIMACULATUS)

This autosomal recessive IRD/macular dystrophy is characterized by slowly progressive bilateral macular degeneration and impairment of vision. It usually appears at 8-14 years of age, and affected children are often initially misdiagnosed as having functional visual loss. The foveal reflex becomes obtunded or appears grayish, pigment spots develop in the macular area, and macular depigmentation and chorioretinal atrophy eventually occur. Macular hemorrhages may also develop. Some patients also have white or yellow spots beyond the macula or pigmentary changes in the periphery; the term *fundus flavimaculatus* is commonly used for this condition. It is now recognized that Stargardt disease and fundus flavimaculatus represent different entities on the spectrum of the same disease. Central visual acuity is reduced, often to 20/200, but total loss of vision does not occur. ERG findings vary. The condition is not associated with central nervous system abnormalities and is to be differentiated from the macular changes of many

progressive metabolic neurodegenerative diseases. The most common (95%) genetic pathogenic variant (autosomal recessive) responsible for Stargardt macular dystrophy involves the *ABCA4* gene. Pathologic variants in *ELOVL4* are less common and are inherited as an autosomal dominant trait. Gene replacement therapy is being investigated for this condition.

BEST VITELLIFORM DEGENERATION

This macular dystrophy is characterized by a distinctive yellow or orange discoid subretinal lesion in the macula, resembling the intact yolk of a fried egg. Diagnosis is usually made at 3-15 years of age, with a mean age of presentation of 6 years. Vision is usually normal at this stage. The condition may be progressive; the yolklike lesion may eventually degenerate ("scramble") and result in pigmentation, chorioretinal atrophy, and vision impairment. The condition is usually bilateral. There is no association with systemic abnormalities. Inheritance is usually autosomal dominant. The vitelliform macular dystrophy gene *(VMD2)* has been identified, and DNA testing is available. In vitelliform macular degeneration, the ERG response is normal. Electrooculographic findings are abnormal in affected patients and carriers, and this test is useful in diagnosis and genetic counseling.

CHERRY-RED SPOT

Because of the special histologic features of the macula, certain pathologic processes affecting the retina produce an ophthalmoscopically visible sign referred to as a *cherry-red spot*, a bright to dull red spot at the center of the macula surrounded and accentuated by a grayish-white or yellowish halo (Fig. 670.7). The halo is a result of a loss of transparency of the retinal ganglion cell layer secondary to edema, lipid accumulation, or both. Because ganglion cells are not present in the fovea, the retina surrounding the fovea is opacified but the fovea transmits the normal underlying choroidal color (red), accounting for the presence of the cherry-red spot. A cherry-red spot typically occurs in certain sphingolipidoses, principally in Tay-Sachs disease (GM_2 type 1), in the Sandhoff variant (GM_2 type 2), and in generalized gangliosidosis (GM_1 type 1). Similar but less distinctive macular changes occur in some cases of metachromatic leukodystrophy (sulfatide lipidosis), in some forms of neuronopathic Niemann-Pick disease, in galactosialidosis, and in certain mucolipidoses. The cherry-red spot that characteristically occurs as a result of retinal ischemia secondary to vasospasm, ocular contusion, or occlusion of the central retinal artery must be differentiated from the cherry-red spot of neurodegenerative disease (see Chapters 106.4 and 639).

Fig. 670.7 Cherry-red spot seen in a case of Tay-Sachs disease. Because the parafoveal area has many retinal ganglion cells and the fovea has none, the fovea retains its orange-red color but is surrounded by a retina that is whitish. This produces the cherry-red spot in the macula. *(From Cheng KP, Biglan AW. Ophthalmology. In Zitelli BJ, McIntire SC, Nowald AJ, eds. Zitelli and Davis' Atlas of Pediatric Physical Diagnosis, 6th ed. Philadelphia: Saunders, 2012. Fig. 19.102.)*

PHAKOMATOSIS

See also Chapter 636.

These are the herald lesions of the hamartomatous disorders. **Tuberous sclerosis**, the distinctive ocular lesion is a refractile, yellowish, multinodular cystic lesion arising from the disc or retina; the appearance of this typical lesion is often compared with that of an unripe mulberry (Fig. 670.8). Equally characteristic and more common in tuberous sclerosis are flatter, yellow to whitish retinal lesions that vary in size from minute dots to large lesions approaching the size of the disc. These lesions are benign astrocytic proliferations. Rarely, similar retinal phakomas occur in neurofibromatosis. In **von Hippel-Lindau disease** (angiomatosis of the retina and cerebellum), the distinctive fundus lesion is a hemangioblastoma; this vascular lesion usually appears as a reddish globular mass with large, paired arteries and veins passing to and from the lesion. In **Sturge-Weber syndrome** (encephalofacial angiomatosis), the fundus abnormality is a choroidal hemangioma; the hemangioma may impart a dark color to the affected area of the fundus, but the lesion is best seen with fluorescein angiography.

Fig. 670.8 Retinal phakoma of tuberous sclerosis.

RETINOSCHISIS

Congenital hereditary retinoschisis, also referred to as juvenile X-linked retinoschisis, is a bilateral vitreoretinal dystrophy that has a bimodal age of presentation. The first group presents with strabismus and nystagmus at a mean age of 1.5-2 years and is the most severely affected. The second group presents at 6-7 years with poor vision. Retinoschisis is characterized by splitting of the retina into inner and outer layers. The usual ophthalmoscopic finding in affected males is an elevation of the inner layer of the retina, most commonly in the inferotemporal quadrant of the fundus, often with round or oval holes visible in the inner layer. Schisis of the fovea is virtually pathognomonic and is found in almost 100% of patients. Ophthalmoscopically, this appears in early stages as small, fine striae in the internal limiting membrane. These striae radiate outward in a petaloid or spoke-wheel configuration. In some cases, frank retinal detachment or vitreous hemorrhage occurs.

Vision impairment varies from mild to severe; visual acuity may worsen with age, but good vision is often retained. Carrier females are asymptomatic, but linkage studies may be useful to help detect carriers. In some cases, treatment with a topical carbonic anhydrase inhibitor may improve visual acuity.

RETINAL DETACHMENT

A retinal detachment is a separation of the outer layers of the retina from the underlying retinal pigment epithelium (RPE). During embryogenesis, the retina and RPE are initially separated. During ocular development, they join together and are held in apposition to each other by various physiologic mechanisms. Pathologic events leading to a retinal

detachment return the retina–RPE to its former separated state. The detachment can occur as a congenital anomaly but more commonly arises secondary to other ocular abnormalities or trauma. Three types of detachment are described, and each may occur in children. Rhegmatogenous detachments result from a break in the retina that allows fluid to enter the subretinal space. In children, these are usually a result of trauma (such as child abuse) but may occur secondary to myopia or ROP or after surgery for congenital cataract. Tractional retinal detachments result when vitreoretinal membranes pull on the retina. They can occur in diabetes, sickle cell disease, and ROP. Exudative retinal detachments result when exudation exceeds absorption. This can be seen in Coats disease, retinoblastoma, and ocular inflammation.

The presenting sign of retinal detachment in an infant or child may be loss of vision, secondary strabismus or nystagmus, or leukocoria (white pupillary reflex). In addition to direct examination of the eye, special diagnostic studies such as ultrasonography and neuroimaging (CT, MRI) may be necessary to establish the cause of the detachment and the appropriate treatment. Prompt treatment is essential if vision is to be salvaged.

COATS DISEASE

This idiopathic, nonfamilial exudative retinopathy is characterized by telangiectasia of retinal vessels with leakage of plasma to form intraretinal and subretinal exudates and by retinal hemorrhages and detachment (Fig. 670.9). The condition is usually unilateral. It predominantly affects previously healthy males, usually appearing in the first decade. The most frequent presenting signs are blurring of vision, leukocoria, and strabismus. Rubeosis of the iris, glaucoma, and cataract may develop. The differential diagnosis includes retinoblastoma, ROP, Norrie disease, angiomatosis, chorioretinitis (see Table 669.1), systemic vasculitis, and Coats plus syndrome (leukodystrophy, osteopenia, anemia, retinitis) due to pathogenic variants in *CTC1* (autosomal recessive). **Treatment** with photocoagulation, cryotherapy, or VEGF inhibitors may be helpful.

FAMILIAL EXUDATIVE VITREORETINOPATHY

This progressive genetic retinal vascular disorder has clinical and angiographic findings that suggest an aberration of vascular development. Avascularity of the peripheral temporal retina is a significant finding in most cases, with abrupt cessation of the retinal capillary network in the region of the equator. The avascular zone often has a wedge- or V-shaped pattern in the temporal meridian. Glial proliferation or well-marked retinochoroidal atrophy may be found in the avascular zone. Excessive branching of retinal arteries and veins, dilation of the capillaries, arteriovenous shunt formation, neovascularization, and leakage from retinal vessels of the farthest vascularized retina occur. Vitreoretinal adhesions are usually present at the peripheral margin of the vascularized retina. Traction, retinal dragging and temporal displacement of the macula, falciform retinal folds, and retinal detachment are common. Intraretinal or subretinal exudation, retinal hemorrhage, and recurrent vitreous hemorrhages may develop. Patients may also develop cataracts and glaucoma. Vision impairment of varying severity occurs. The condition is usually bilateral. Familial exudative vitreoretinopathy (FEVR) is usually an autosomal dominant condition (*FZD4* or *LRP5*) with incomplete penetrance. Autosomal recessive *(LRP5)* and X-linked *(CNDP)* have also been reported. Asymptomatic family members often display a zone of avascular peripheral retina.

The findings in FEVR may resemble those of ROP in the cicatricial stages, but unlike ROP, the neovascularization of FEVR seems to develop years after birth, and most patients with FEVR have no history of prematurity, oxygen therapy, prenatal or postnatal injury or infection, or developmental abnormalities. FEVR is also to be differentiated from Coats disease, angiomatosis of the retina, peripheral uveitis, and other disorders of the posterior segment.

HYPERTENSIVE RETINOPATHY

In the early stages of hypertension, no retinal changes may be observable. Generalized constriction and irregular narrowing of the arterioles are usually the first signs in the fundus. Other alterations include retinal edema, flame-shaped hemorrhages, cotton-wool spots (retinal nerve fiber layer infarcts), and papilledema (Fig. 670.10). These changes are reversible if the hypertension can be controlled in the early stages, but in long-standing hypertension, irreversible changes may occur. Thickening of the vessel wall may produce a silver- or copper-wire appearance. Hypertensive retinal changes in a child should alert the physician to renal disease, pheochromocytoma, collagen disease, and cardiovascular disorders, particularly coarctation of the aorta.

Fig. 670.9 Coats disease with massive retinal exudation.

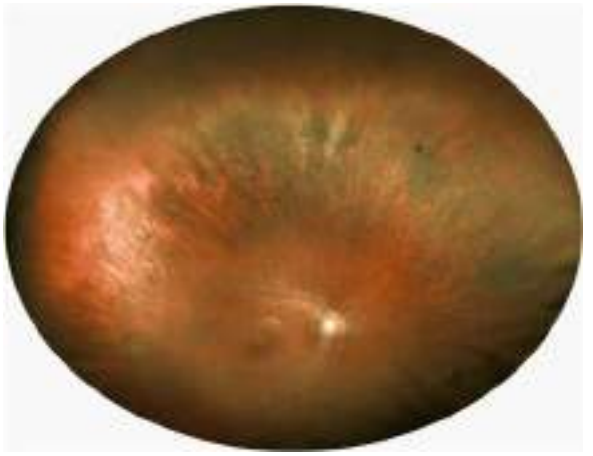

Fig. 670.10 Hypertension retinopathy with narrowed arterioles whose sclerosed walls create the appearance of "nicking" when the arterioles cross venules. *(From Yanoff M, Duker JS, eds. Ophthalmology. Elsevier, 2009.)*

DIABETIC RETINOPATHY

The retinal changes of diabetes mellitus are classified as nonproliferative or proliferative. Nonproliferative diabetic retinopathy is characterized by retinal microaneurysms, venous dilation, retinal hemorrhages, and exudates. The microaneurysms appear as tiny red dots. The hemorrhages may be of both the dot and blot type, representing deep intraretinal bleeding, and the splinter or flame-shaped type, involving the superficial nerve fiber layer. The exudates tend to be deep and to appear waxy. There may also be superficial nerve fiber infarcts called cytoid bodies or cotton-wool spots, as well as retinal edema. These signs may wax and wane. They are seen primarily in the posterior pole, around the disc and macula, or well within the range of direct ophthalmoscopy. Involvement of the macula may lead to decreased vision.

Proliferative retinopathy, the more serious form, is characterized by neovascularization and proliferation of fibrovascular tissue on the

retina, extending into the vitreous. Neovascularization may occur on the optic disc, elsewhere on the retina, or on the iris and in the anterior chamber angle (or rubeosis irides) (Fig. 670.11). Traction on these new vessels leads to hemorrhage and, eventually, scarring. The vision-threatening complications of proliferative diabetic retinopathy are retinal and vitreous hemorrhages, cicatrization, traction, and retinal detachment. Neovascularization of the iris may lead to secondary glaucoma if not treated promptly.

Diabetic retinopathy involves the alteration and nonperfusion of retinal capillaries, retinal ischemia, and neovascularization, but its pathogenesis is not yet completely understood, either in terms of location of the primary pathogenetic mechanism (retinal vessels vs surrounding neuronal or glial tissue) or the specific biochemical factors involved. The better the degree of long-term metabolic control, the lower the risk of diabetic retinopathy.

The prevalence and course of retinopathy relate to a patient's age and to disease duration. Detectable microvascular changes are rare in prepubertal children, with the prevalence of retinopathy increasing significantly after puberty, especially after the age of 15 years. The incidence of retinopathy is low during the first 5 years of disease and increases progressively thereafter, with the incidence of proliferative retinopathy becoming substantial after 10 years and with increased risk of visual impairment after 15 years or more.

Ophthalmic examination guidelines have been proposed by the American Academy of Pediatrics. An initial exam is recommended at age 9 years if the diabetes is poorly controlled. If the diabetes is well controlled, an initial exam 3 years after puberty with annual follow-up is recommended.

In addition to retinopathy, patients with juvenile-onset diabetes may develop optic neuropathy, characterized by swelling of the disc and blurring of vision. Patients with diabetes may also develop cataracts, even at an early age, sometimes with rapid progression.

Treatment

Macular edema is the leading cause of visual loss in diabetic persons. Photocoagulation may be used to decrease the risk of continued vision loss in patients with macular edema.

Proliferative retinopathy causes the most severe vision loss and can lead to total loss of vision and even loss of the eye. Patients who have proliferative disease and who display certain high-risk characteristics should undergo panretinal photocoagulation to preserve their central vision. Neovascularization of the iris is also treated with panretinal photocoagulation to stop the development of neovascular glaucoma.

Vitrectomy and other intraocular surgery may be necessary in patients with nonresolving vitreous hemorrhage or traction retinal detachment. The value of technologic advances, such as insulin infusion pumps and pancreatic transplants, in preventing ocular complications is under investigation (see Chapter 629).

SUBACUTE BACTERIAL ENDOCARDITIS

At some time during the disease, retinopathy is present in approximately 40% of cases of subacute bacterial endocarditis (see Chapter 486). The lesions include hemorrhages, hemorrhages with white centers (Roth spots), papilledema, and, rarely, embolic occlusion of the central retinal artery (Fig. 670.12).

BLOOD DISORDERS

In primary and secondary anemias, retinopathy in the form of hemorrhages and cotton-wool patches may occur. Vision can be affected if hemorrhage occurs in the macular area. The hemorrhages may be light and feathery or dense and preretinal. In polycythemia vera, the retinal veins are dark, dilated, and tortuous. Retinal hemorrhages, retinal edema, and papilledema may be observed. In leukemia, the veins are characteristically dilated, with sausage-shaped constrictions; hemorrhages, particularly white-centered hemorrhages and exudates, are common during the acute stage. In the sickling disorders, fundus changes include vascular tortuosity, arterial and venous occlusions, "salmon patches," refractile deposits, pigmented lesions, arteriolar-venous anastomoses, and neovascularization (with "sea-fan" formations), sometimes leading to vitreous hemorrhage and retinal detachment. Individuals with sickle cell hemoglobin C and sickle cell hemoglobin β-thalassemia hemoglobinopathies are at a higher risk of the development of retinopathy than are those with homozygous hemoglobin S disease. It is thought that the more anemic state of those patients with homozygous hemoglobin S disease offers protection from vascular occlusions in the retina.

TRAUMA-RELATED RETINOPATHY

Retinal changes may occur in patients who suffer trauma to other parts of the body. The occurrence of retinal hemorrhages in infants who have been physically abused is well documented (Fig. 670.13; see Chapter 17). Retinal, subretinal, subhyaloid, and vitreous hemorrhages have been described in infants and young children with inflicted neurotrauma. Often there are no signs of direct trauma to the eye, periocular region, or head. Such cases may result from violent shaking of an infant, and permanent retinal damage may result.

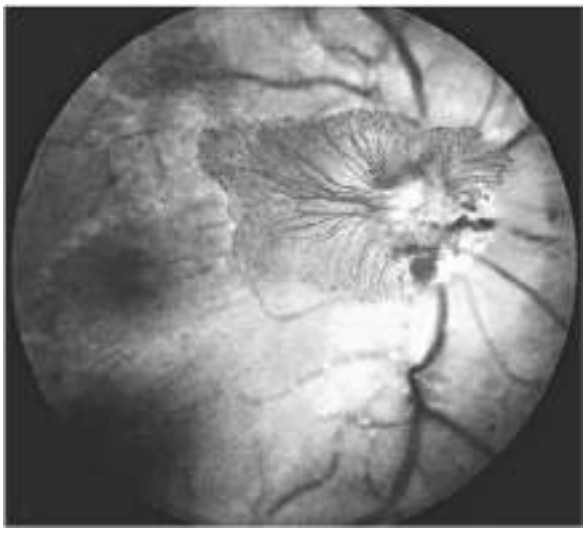

Fig. 670.11 Proliferative diabetic retinopathy with neovascularization of the disc.

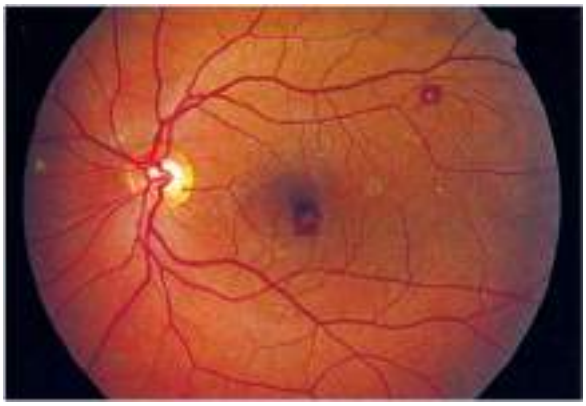

Fig. 670.12 Roth's spots. Multiple white-centered hemorrhages in a man with recurrent subacute bacterial endocarditis. White-centered hemorrhages are also seen with leukemia and diabetes. The small white scars are probably the residua of previous episodes. *(From Goldman L, Schafer AI, eds. Goldman-Cecil Medicine. 25th ed. Philadelphia: Elsevier, 2016. Fig. 423.28, p. 2569.)*

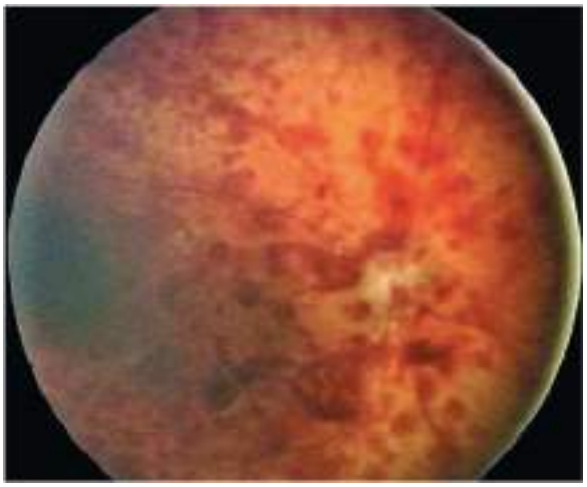

Fig. 670.13 Shaken baby syndrome (inflicted neurotrauma). Retinal hemorrhages in multiple layers too numerous to count into the far periphery.

In patients with severe head or chest compressive trauma, a traumatic retinal angiopathy known as **Purtscher retinopathy** may occur. This is characterized by retinal hemorrhage, cotton-wool spots, possible disc swelling, and decreased vision. The pathogenesis is unclear, but there is evidence of arteriolar obstruction in this condition. A Purtscher-like fundus picture may also occur in several nontraumatic settings, such as acute pancreatitis, lupus erythematosus, and childbirth. **Laser pointers** may produce vision loss with varying findings depending on the retinal area exposed to the nonionizing radiation.

MYELINATED NERVE FIBERS

Myelination of the optic nerve fibers normally terminates at the level of the disc, but in some individuals, ectopic myelination extends to nerve fibers of the retina. The condition is most commonly seen adjacent to the disc, although more peripheral areas of the retina may be involved. The characteristic ophthalmoscopic picture is a focal white patch with a feathered edge or brushstroke appearance. Because the macula is generally unaffected, the visual prognosis is good. A relative or absolute visual field defect corresponding to areas of ectopic myelination is usually the only associated ocular abnormality. Extensive unilateral involvement, however, is associated with ipsilateral myopia, amblyopia, and strabismus. If unilateral high myopia and amblyopia are present, appropriate optical correction and occlusion therapy should be instituted. For unknown reasons, the disorder is more commonly encountered in patients with craniofacial dysostosis, oxycephaly, neurofibromatosis, and Down syndrome.

CHORIORETINAL COLOBOMA

The term *coloboma* describes a defect such as a gap, notch, fissure, or hole (see Chapter 662). The typical fundus coloboma is a result of malclosure of the embryonic fissure, which leaves a gap in the retina, RPE, and choroid, thus baring the underlying sclera. The defect may be extensive, involving the optic nerve, ciliary body, and iris and even the lens, or it may be localized to one or more portions of the fissure. The usual appearance is of a well-circumscribed, wedge-shaped white area extending inferonasally below the disc, sometimes involving or engulfing the disc. In some cases, there is ectasia or cyst formation in the area of the defect. Less extensive colobomatous defects may appear as only single or multiple focal punched-out chorioretinal defects or anomalous pigmentation of the fundus in the line of the embryonic fissure. Colobomas may occur in one or both eyes. A visual field defect usually corresponds to the chorioretinal defect. Visual acuity may be impaired, particularly if the defect involves the disc or macula.

Fundus colobomas may occur in isolation as sporadic defects or as an inherited condition. Isolated colobomatous anomalies are commonly inherited in an autosomal dominant manner with highly variable penetrance and expressivity. Family members of affected patients should receive appropriate genetic counseling. Colobomas may also be associated with such abnormalities as microphthalmia, glioneuroma of the eye, cyclopia, or encephalocele. They occur in children with various chromosomal disorders, including trisomies 13 and 18, triploidy, cat-eye syndrome, and 4p−. Ocular colobomas also occur in many multisystem disorders, including the CHARGE (*C,* coloboma; *H,* heart disease; *A,* atresia choanae; *R,* retarded growth, and development and/or central nervous system anomalies; *G,* genetic anomalies and/or hypogonadism; *E,* ear anomalies and/or deafness) association; Joubert, Aicardi, Meckel, Warburg, and Rubinstein-Taybi syndromes; linear sebaceous nevus; Goldenhar and Lenz microphthalmia syndromes; and Goltz focal dermal hypoplasia.

Visit Elsevier eBooks+ at eBooks.Health.Elsevier.com for Bibliography.

Chapter 671

Abnormalities of the Optic Nerve

Scott E. Olitsky and Justin D. Marsh

OPTIC NERVE APLASIA

This rare congenital anomaly of unknown etiology is typically unilateral. The optic nerve, retinal ganglion cells, and retinal blood vessels are absent. A vestigial dural sheath usually connects with the sclera in a normal position, but no neural tissue is present within this sheath. Optic nerve aplasia typically occurs sporadically in an otherwise healthy person.

OPTIC NERVE HYPOPLASIA

Hypoplasia of the optic nerve is a nonprogressive, idiopathic condition characterized by a subnormal number of optic nerve axons with normal mesodermal elements and glial supporting tissue. In typical cases, the nerve head is small and pale, with a pale or pigmented peripapillary halo or double ring sign (Fig. 671.1).

This anomaly is associated with defects of vision and of visual fields of varying severity, ranging from blindness to normal or near-normal vision. It may be associated with systemic anomalies that most commonly involve the central nervous system (CNS). CNS defects such as hydranencephaly or anencephaly or more focal lesions compatible with continued development may accompany optic nerve hypoplasia, but unilateral or bilateral optic nerve hypoplasia may be found without any concomitant defects.

Optic nerve hypoplasia is a principal feature of **septo-optic dysplasia (SOD),** a developmental disorder characterized by the association of anomalies of the midline structures of the brain

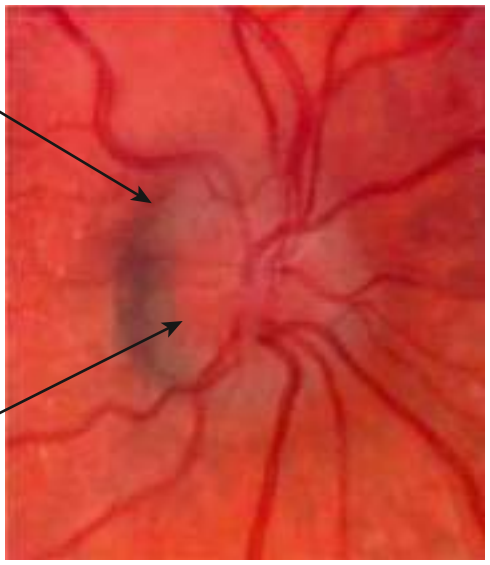

Fig. 671.1 Optic nerve hypoplasia: the "double ring sign." The first ring shows the border of the nerve sheath, and the second ring is formed by the actual border of the optic nerve tissue edge. *(From Martin RJ, Fanaroff AA, Walsh MC, eds. Fanaroff & Martin's Neonatal-Perinatal Medicine. 10th ed. Philadelphia: Elsevier; 2015: Fig. 103.24, p. 1753.)*

with hypoplasia of the optic nerves, optic chiasm, and optic tracts; typically noted are agenesis of the septum pellucidum, partial or complete agenesis of the corpus callosum, and malformation of the fornix, with a large chiasmatic cistern. Patients may have hypothalamic abnormalities and endocrine defects ranging from panhypopituitarism to isolated deficiency of growth hormone, hypothyroidism, or diabetes insipidus. Neonatal hypoglycemia and seizures are important presenting signs in affected infants. In some patients with SOD, pathologic variants in *HESX1*, *SOX2*, *SOX3*, *OTX2,* and *PROKR2* have been identified.

MRI is preferred for evaluating CNS abnormalities in patients with optic nerve hypoplasia. During MRI, special attention should be directed to the pituitary infundibulum, where ectopia of the posterior pituitary may be found. Posterior pituitary ectopia appears on MRI as an absence of the pituitary infundibulum with an abnormal bright spot at the upper infundibulum area. This abnormality is present in approximately 15% of patients and suggests a posterior pituitary hormone deficiency, requiring further endocrinologic workup. Endocrine function should be watched closely in patients with optic nerve hypoplasia. The cause of optic nerve hypoplasia remains unclear.

Children with **periventricular leukomalacia** display an unusual form of optic nerve hypoplasia. The optic nerve demonstrates a large cup within a normal-size optic disc. This form of optic nerve hypoplasia occurs secondary to transsynaptic degeneration of optic axons caused by the primary bilateral lesion in the optic radiation (periventricular leukomalacia).

OPTIC NERVE COLOBOMA

Optic nerve colobomas can be unilateral or bilateral. The visual acuity can range from normal to complete blindness. The coloboma develops secondary to incomplete closure of the embryonic fissure. The defect may produce a partial or total excavation of the optic disc (Fig. 671.2). Chorioretinal and iris colobomas may also occur (see Chapter 662). Optic nerve colobomas may be seen in a multitude of ocular and systemic abnormalities, including the CHARGE (*C,* coloboma; *H,* heart disease; *A,* atresia choanae; *R,* retarded growth and development and/or CNS anomalies; *G,* genetic anomalies and/or hypogonadism; *E,* ear anomalies and/or deafness) association.

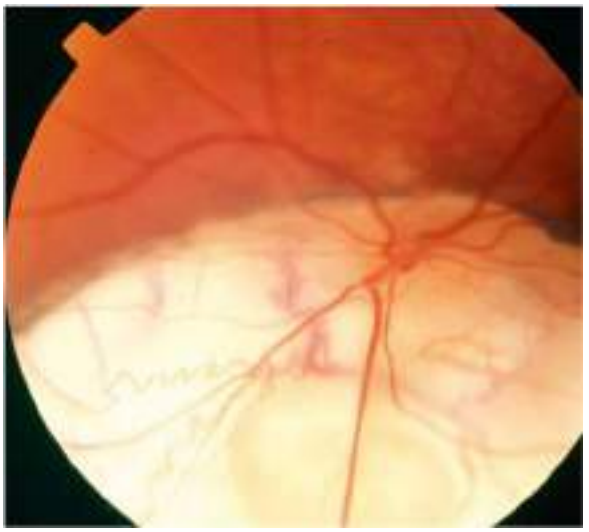

Fig. 671.2 Optic nerve coloboma.

MORNING GLORY DISC ANOMALY

This term describes a congenital malformation of the optic nerve characterized by an enlarged, excavated, funnel-shaped disc with an elevated rim resembling a morning glory flower. White glial tissue is present in the central part of the disc (Fig. 671.3). The retinal vessels are abnormal and appear at the peripheral disc, coursing over the elevated pink rim in a radial fashion. Pigmentary mottling of the peripapillary region is usually seen. Most cases are unilateral. Females are affected twice as often as males. Visual acuity is usually severely reduced. Morning glory disc anomaly has been associated with basal encephalocele in patients with midfacial anomalies. Abnormalities of the carotid circulation can also be seen in patients with morning glory anomaly. Moyamoya disease is a well-described associated finding.

TILTED DISC

In this congenital anomaly, the vertical axis of the optic disc is directed obliquely, so that the upper temporal portion of the nerve head is more prominent and anterior to the lower nasal portion of the disc. The retinal vessels emerge from the upper temporal portion of the disc rather than from the nasal side. Often noted is a peripapillary crescent or conus. Associated visual field defects and myopic astigmatism may be found. Clinical recognition of the tilted disc syndrome is important to avoid confusion of its disc and visual field signs with those of papilledema and intracranial tumor.

DRUSEN OF THE OPTIC NERVE

These globular, acellular bodies are thought to arise from axoplasmic derivatives of disintegrating nerve fibers. Drusen may be buried within the optic nerve, producing elevation of the optic nerve head (pseudopapilledema), or they may be partially or completely exposed, appearing as refractile bodies at the surface of the disc (Fig. 671.4). Visual field defects and spontaneous hemorrhages of the peripapillary nerve fiber layer may occur in association with drusen. Drusen may occur as an autosomal dominant condition with incomplete penetrance. B-scan ultrasonography can help to positively identify drusen suspected on clinical ophthalmic exam in some cases, although drusen in young children may be less likely to be visible with ultrasonography than in adults.

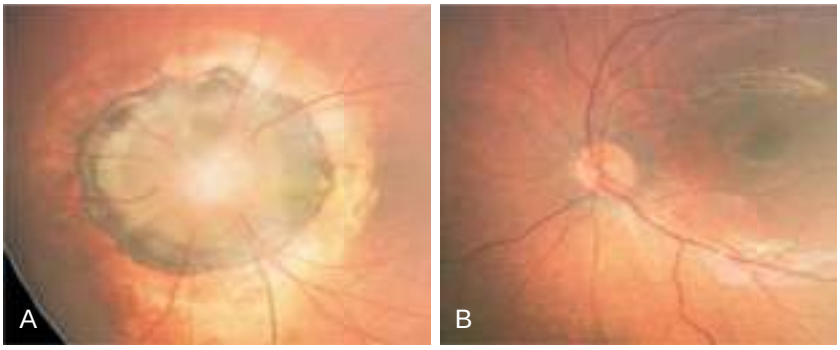

Fig. 671.3 A, Morning glory disc anomaly. The defect looks like a fully opened morning glory flower. B, Normal appearance of scaled fundus photography. *(From Martin RJ, Fanaroff AA, Walsh MC, eds. Fanaroff & Martin's Neonatal-Perinatal Medicine. 10th ed. Philadelphia: Elsevier; 2015: Fig. 103.25, p. 1754.)*

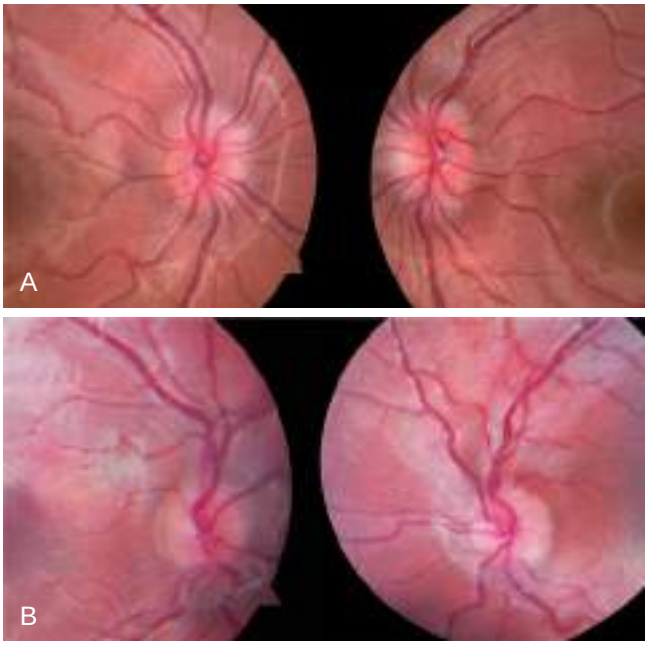

Fig. 671.4 Comparison of optic disc in children with optic disc drusen and papilledema. A, Optic disc photos of a 10-year-old child with bilateral buried optic disc drusen. The disc margins are blurred, but there are no hemorrhages, exudates, or vessel obscuration. B, Optic disc photos of a 5-year-old child with mild papilledema due to increased intracranial pressure. Disc margins are blurred with mild obscuration of vessels, but no hemorrhages or exudates. *(From Chang MY, Pineles SL. Optic disc drusen in children. Surv Ophthalmol. 2016;61:745–758: Fig. 1).*

PAPILLEDEMA

The term *papilledema* is reserved to describe swelling of the nerve head secondary to increased intracranial pressure (ICP). Clinical manifestations of papilledema include edematous blurring of the disc margins, fullness or elevation of the nerve head, partial or complete obliteration of the disc cup, capillary congestion and hyperemia of the nerve head, generalized engorgement of the veins, loss of spontaneous venous pulsation, hemorrhages in the nerve fiber layer around the disc, and peripapillary exudates (see Fig. 671.4 and 630.2). In some cases, edema extending into the macula may produce a fan- or star-shaped figure. In addition, concentric peripapillary retinal wrinkling (Paton lines) may be noted. Transient obscuration of vision may occur, lasting seconds, and is associated with postural changes. Vision, however, is usually normal in acute papilledema. Normally, when the ICP is relieved, the papilledema resolves and the disc returns to a normal or nearly normal appearance within 6-8 weeks. Sustained chronic papilledema or longstanding unrelieved increased ICP may, however, lead to permanent nerve fiber damage, atrophic changes of the disc, macular scarring, and impairment of vision.

The *pathophysiology* of papilledema is probably as follows: elevation of intracranial subarachnoid cerebrospinal fluid (CSF) pressure, elevation of CSF pressure in the sheath of the optic nerve, elevation of tissue pressure in the optic nerve, stasis of axoplasmic flow and swelling of the nerve fibers in the optic nerve head, and secondary vascular changes and the characteristic ophthalmoscopic signs of venous stasis. Associated neuro-ophthalmic signs of increased ICP in infants and children include sixth cranial nerve palsy and attendant esotropia, lid retraction, paresis of upward gaze, tonic downward deviation of the eyes, and convergent nystagmus.

The common **etiologies** of papilledema in childhood are intracranial tumors and obstructive hydrocephalus, intracranial hemorrhage, the cerebral edema of trauma, meningoencephalitis, toxic encephalopathy, idiopathic intracranial hypertension, and certain metabolic diseases. Regardless of the cause, the optic disc signs of increased ICP in early childhood may occasionally be modified by the distensibility of the young skull. In the absence of conditions associated with early closure of sutures and early obliteration of the fontanel (craniosynostosis, Crouzon disease, and Apert syndrome), infants with increased ICP may not develop papilledema.

The **differential diagnosis** of papilledema includes structural changes of the disc (pseudopapilledema, pseudoneuritis, drusen, and myelinated nerve fibers; see Fig. 671.4), with which it may be confused, and the disc swelling of papillitis associated with optic neuritis in addition to the disc changes of hypertension and diabetes mellitus. Unless retinal hemorrhage or edema involves the macular area, the preservation of good central vision and the absence of an afferent pupillary defect (Marcus Gunn pupil) help to differentiate acute papilledema from the edema of the optic nerve head found in acute optic neuritis.

Papilledema is a neurologic emergency. It can be accompanied by other signs of increased ICP, including headaches, nausea, and vomiting. Neuroimaging should be performed; if no intracranial masses are detected, a lumbar puncture and determination of CSF pressure should follow.

OPTIC NEURITIS

This is any inflammation or demyelinization of the optic nerve with attendant impairment of function (see Chapter 640.2). The process is usually acute, with rapidly progressive loss of vision. It may be unilateral or bilateral. Pain on movement or palpation of the globe may precede or accompany the onset of visual symptoms. There is decreased visual activity, decreased color vision and contrast sensitivity, a relative afferent pupillary defect, and a normal macula and peripheral retina.

When the retrobulbar portion of the nerve is affected without ophthalmoscopically visible signs of inflammation at the disc, the term *retrobulbar optic neuritis* is applied. When there is ophthalmoscopically visible evidence of inflammation of the nerve head, the term *papillitis* or *intraocular optic neuritis* is used. When there is involvement of both the retina and the papilla, the term *optic neuroretinitis* is used.

In childhood, optic neuritis may occur as an isolated condition or as a manifestation of a neurologic or systemic disease. Optic neuritis may be secondary to inflammatory diseases (systemic lupus erythematosus, sarcoidosis, Behçet disease); infections (tuberculosis, syphilis, Lyme disease, meningitis, viral encephalitis, HIV, or postinfectious disease); and toxic or nutritional disorders (methanol, ethambutol, vitamin B_{12} deficiency). It may signify one of the many demyelinating diseases of childhood (see Chapter 640.2). Although a significant percentage of adults who experience an episode of optic neuritis eventually develop other symptoms associated with multiple sclerosis (MS), young children with optic neuritis are seemingly at less risk (risk of MS is 19% within 20 years). High-risk features suggestive of MS include visual acuity better than no light perception, periocular pain, acutely normal-appearing optic nerve, no retinal abnormalities, and abnormal MRI suggesting a demyelinating disease. Bilateral optic neuritis in children may be associated with **acute disseminated encephalomyelitis (ADEM)** or **neuromyelitis optica (NMO or Devic disease).** NMO is characterized by rapid and severe bilateral visual loss accompanied by transverse myelitis and paraplegia. Involvement of the brain stem and occasionally the cortex may be seen on MRI. NMO-specific immunoglobulin G (directed to the aquaporin 4 water channel) is the diagnostic test of choice for Devic syndrome. Antibody-negative NMO patients may have anti-MOG (myelin oligodendrocyte glycoprotein) antibodies, suggesting another form of demyelinating optic neuritis. Optic neuritis may also be secondary to an exogenous toxin or drug, as with lead poisoning or as a complication of long-term high-dose treatment with chloramphenicol or vincristine. Extensive pediatric neurologic and ophthalmic investigation, including MRI and lumbar puncture, is usually required. Idiopathic NMO is associated with anti–aquaporin 4 antibodies, otherwise known as NMO antibodies.

In most cases of acute optic neuritis, some improvement in vision begins within 1-4 weeks after onset, and vision may improve to normal or near normal within weeks or months. The course varies with cause. Although central vision may recover fully, it is common to find permanent defects in other areas of visual function (contrast sensitivity, color, brightness sense, and motion perception). Recurrences may occur especially, but not universally, in patients who go on to develop MS.

A **treatment** trial has demonstrated that high-dose intravenous methylprednisolone may help to speed the visual recovery in young adults, and it may prevent the development of MS in those at risk. It is unknown to what degree the results of the aforementioned trial may be extrapolated to optic neuritis in childhood.

LEBER HEREDITARY OPTIC NEUROPATHY

Leber hereditary optic neuropathy (LHON) is characterized by an acute to subacute painless loss of central vision primarily affecting young males (male to female ratio 2.5:1). The incidence is 1:30,000-50,000 people. A characteristic peripapillary telangiectatic microangiopathy occurs not only in the presymptomatic phase of involved eyes but also in a number of asymptomatic females (Fig. 671.5). Disc hyperemia and edema mark the acute phase of central visual loss. One eye is usually affected before the other; the second eye involvement begins 2-3 months later. Visual field loss (blurring, clouding) and impaired color vision are also present. In time, progressive optic atrophy and vision loss usually ensue. The tortuous angiopathy becomes less obvious. Although visual function after the initial loss generally remains stable, partial or less often complete recovery may occur in as many as 20–30% of affected individuals. This recovery may take place years or decades after the initial episode of acute vision loss. The peripapillary angiopathy, the lack of short-term remission and inflammation and MRI, as well as the degree of symmetry or peripheral motor or sensory deficits, serve to distinguish most cases of Leber disease from the optic neuritis of MS.

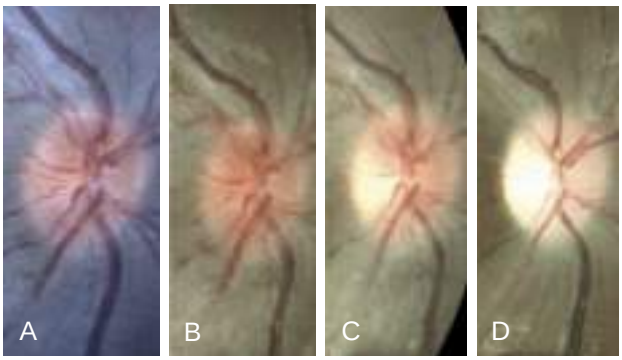

Fig. 671.5 A 9-year-old child with Leber hereditary optic neuropathy (LHON) m.11778 presents with best-corrected visual acuity of 20/20 in the right eye and no symptoms **(A).** At age 12, retinal nerve fiber layer swelling is observed before reduction in vision **(B).** His visual acuity rapidly decreases 1 month later to 20/50 and subtle temporal optic nerve pallor is visible **(C).** Three months later, his visual acuity is <20/400 and diffuse optic nerve pallor is present **(D).** Notice that peripapillary telangiectasia was present at age 9, 3 years before his visual symptoms started. The patient's left eye progressed similarly to the right eye. *(From Pilz YL, Bass SJ, Sherman J. A review of mitochondrial optic neuropathies: from inherited to acquired forms. J Optometry. 2016;10:205–214: Fig. 1, p. 208).*

LHON is maternally inherited and is caused by pathogenic gene variants in mitochondrial DNA (Fig. 671.6). Multiple point variants in the mitochondrial DNA have been identified. Pathogenic variants in *MTND1*, *MTND4* (~70%), and *MTND6* represent ~90% of cases. **LHON plus** is a related mitochondrial disorder affecting skeletal and cardiac muscle disorders, including electrocardiographic abnormalities. Only ~50% of males and 15% of females with a pathogenic gene variant develop symptomatic LHON.

The differential diagnosis includes optic neuritis (Chapter 640.2), other genetic optic neuropathies (Table 671.1; see also Fig. 671.6) and toxic or nutritional neuropathies (Table 671.2).

Gene therapy with intravitreal injection of a vector-*ND4* gene has had success improving vision in patients with LHON.

OPTIC ATROPHY

This term denotes degeneration of optic nerve axons, with attendant loss of function. The ophthalmoscopic signs of optic atrophy are pallor of the disc and loss of substance of the nerve head, sometimes with enlargement of the disc cup. The associated vision defect varies with the nature and site of the primary disease or lesion.

Optic atrophy is the common expression of a wide variety of congenital or acquired pathologic processes (Table 671.3). The cause may be traumatic, inflammatory, degenerative, neoplastic, or vascular; intracranial tumors and hydrocephalus are principal causes of optic atrophy in children. In some cases, progressive optic atrophy is hereditary. **Dominantly inherited infantile optic atrophy** is a relatively mild heredodegenerative type that tends to progress through childhood and adolescence. **Autosomal recessively inherited congenital optic atrophy** is a rare condition that is evident at birth or develops at

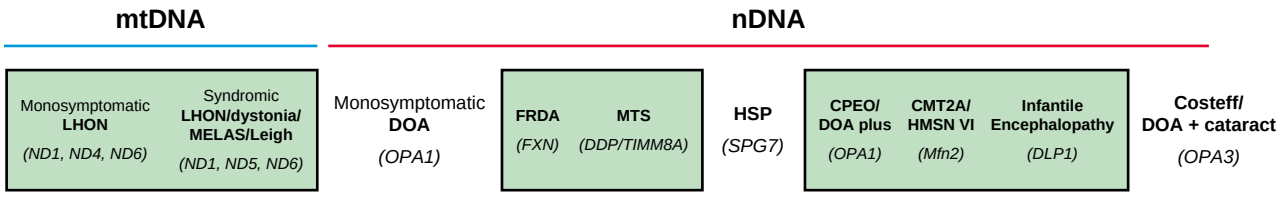

Fig. 671.6 Mitochondrial and nuclear DNA etiologies of inherited optic neuropathies. LHON, Leber hereditary optic neuropathy; DOA, dominant optic atrophy; FRDA, Friedreich ataxia; MTS, Mohr-Tranebjaerg syndrome; HSP, hereditary spastic paraplegia; CPEO, chronic progressive external ophthalmoplegia; CMT2A, Charcot Marie tooth; HMSN VI, hereditary motor and sensory neuropathy; mtDNA, mitochondrial DNA; nDNA, nuclear DNA; MELAS, mitochondrial encephalopathy, lactic acidosis, stroke. *(Modified from Carelli V, La Morgia C, Valentino ML, et al. Retinal ganglion cell neurodegeneration in mitochondrial inherited disorders. Biochim et Biophysic Acta. 2009;1787:518–528: Fig. 2).*

Table 671.1 Genetic and Clinical Features of Primary Hereditary Optic Atrophies and Their Respective Genes

	OPA1	*LHON*	*OPA3*	*TMEM126A*	*WFS1*
Inheritance	Autosomal dominant	Maternal	Autosomal dominant	Autosomal recessive	Autosomal dominant
Age of onset	Childhood	Young adult, male > female	Late childhood	Childhood	Childhood to adult
Ophthalmologic features	Slowly progressive, tritanomaly	Sudden visual loss. Frequently beginning unilateral	Often additional cataract	Early manifestation and progression	Highly variable
Loss of visual acuity	Moderate to severe	Pronounced visual impairment	Moderate	Severe visual loss	Variable
Possible extraocular signs	~20% of patients have neurologic symptoms (e.g., ataxia, neuropathy)	Mild neurologic symptoms possible; multiple sclerosis–like symptoms	Late in life; mild neurologic signs possible late in life	Subclinical hearing impairment	Hearing impairment, disturbed glucose tolerance, behavioral abnormalities

LHON, Leber hereditary optic neuropathy (*mt-ND1, mt-ND4, mt-ND46, mt-ND6*); OPA1, optic atrophy type 1; OPA3, optic atrophy type 3; TMEM126A, optic atrophy type 7; WFS1, Wolfram syndrome (diabetes mellitus, diabetes insipidus, optic neuropathy, deafness).
Modified from Neuhann T, Rautenstrauss B. Genetic and phenotypic variability of optic neuropathies. *Expert Rev Neurother.* 2013;13(4):357–367.

Table 671.2 Causes of Acquired Optic Neuropathies

TOXINS	MEDICATIONS	NUTRITIONAL DEFICIENCIES
Methanol	Ethambutol	Thiamine (Vitamin B_1)
Ethanol	Isoniazid	Riboflavin (Vitamin B_2)
Tobacco	Chloramphenicol	Pyridoxine (Vitamin B_6)
Arsenics	Linezolid	Folic Acid (Vitamin B_9)
Cobalt	Erythromycin	Cobalamin (Vitamin B_{12})
Thallium	Streptomycin	
Carbon disulfide	Ciprofloxacin	
Tetrachloride	Dapsone	
Cyanide	Antiretrovirals	
Ethylene glycol	Amiodarone	
Toluene	Infliximab	
Styrene	Clioquinol	
Perchloroethylene	Pheniprazine	
	Suramin	
	Quinine	

From Pilz YL, Bass SJ, Sherman J. A review of mitochondrial optic neuropathies: From inherited to acquired forms. *J Optometry.* 2016;10:205–214: Table 2.

a very early age; the visual defect is usually profound. **Behr optic atrophy** is a hereditary type associated with hypertonia of the extremities, increased deep tendon reflexes, mild cerebellar ataxia, some degree of mental deficiency, and possibly external ophthalmoplegia. This disorder principally afflicts boys 3-11 years of age. Some forms of heredodegenerative optic atrophy are associated with sensorineural hearing loss, as may occur in some children with juvenile-onset (insulin-dependent) diabetes mellitus. In the absence of an obvious cause, optic atrophy in an infant or child warrants extensive etiologic investigation.

OPTIC NERVE GLIOMA

Optic nerve glioma, more properly referred to as **juvenile pilocytic astrocytoma,** is the most frequent tumor of the optic nerve in childhood (Fig. 671.7). This neuroglial tumor may develop in the intraorbital, intracanalicular, or intracranial portion of the nerve; the chiasm is often involved.

The tumor is a cytologically benign hamartoma that is generally stationary or only slowly progressive. The principal *clinical manifestations* when the tumor occurs in the intraorbital portion of the nerve are unilateral loss of vision, proptosis, and deviation of the eye; optic atrophy or congestion of the optic nerve head may occur. Chiasmal involvement may be attended by defects of vision and visual fields (often bitemporal hemianopia), increased ICP, papilledema or optic atrophy, hypothalamic dysfunction, pituitary dysfunction, and sometimes nystagmus or strabismus. Juvenile pilocytic astrocytomas occur with increased frequency in patients with neurofibromatosis (see Chapter 636.1).

Treatment of optic pathway gliomas is controversial. The best management is usually periodic observation with serial radiography

Table 671.3 Causes of Childhood Optic Atrophy

Compressive intracranial lesions
Compressive bony disorders
Craniosynostosis
Fibrous dysplasia
Hydrocephalus
Postpapilledema optic atrophy
Infectious
Hereditary
Leber hereditary optic neuropathy
Dominant optic atrophy (Kjer)
Recessive optic atrophy
Behr optic atrophy
DIDMOAD (diabetes insipidus, diabetes mellitus, optic atrophy, deafness) (Wolfram) optic atrophy
Toxic or nutritional optic neuropathy
Hypoxia
Trauma
Postoptic neuritis
Radiation optic neuropathy
Paraneoplastic syndromes
Neurodegenerative disorders with optic atrophy
Krabbe disease
Canavan disease
Leigh disease
Mitochondrial encephalomyopathy, lactic acidosis, and strokelike (MELAS) episodes
Neonatal adrenoleukodystrophy
Metachromic leukodystrophy
Riley-Day syndrome
Lactic acidosis
Spinocerebellar degeneration
Mucopolysaccharidosis
Ocular disorders
Glaucoma
Retinal disease
Vascular disease
Uveitis
Optic nerve hypoplasia

From Martin RJ, Fanaroff AA, Walsh MC, eds. *Fanaroff & Martin's Neonatal-Perinatal Medicine*. 10th ed. Philadelphia: Elsevier; 2015. Box 103.5.

Fig. 671.7 Optic nerve glioma (ONG). **A,** ONG in a patient with neurofibromatosis NF1. Axial fat-saturated T2-weighted MR image of the orbits demonstrates bilaterally symmetrically enlarged and tortuous intracanalicular portions of the optic nerves associated *(arrows)*. Areas of signal abnormality within the cerebellar white matter indicate spongiform changes of NF1 *(arrowheads)*. **B,** Isolated right ONG. Axial T2-weighted MR image of the orbits demonstrates an ONG *(arrow)* with similar expansion and tortuosity of the optic nerve to the case in **A** but with unilateral involvement of the right optic nerve and without additional imaging findings of NF1. *(From Coley BD [ed]. Caffey's Pediatric Diagnostic Imaging, 13th ed. Philadelphia: Elsevier, 2019: Fig. 7.8, p. 48.)*

(preferably MRI). Only symptomatic and radiographically progressing optic nerve gliomas require strong consideration for treatment. If a patient has unsightly proptosis with complete or nearly complete loss of vision of the affected eye, surgical removal may be appropriate when the tumor is confined to the intraorbital, intracanalicular, or prechiasmal portion of the nerve. When the chiasm is involved, resection is not usually indicated, and radiation and chemotherapy may be necessary.

TRAUMATIC OPTIC NEUROPATHIES

Injury to the optic nerve may result from both direct and indirect trauma. Direct trauma to the optic nerve is a result of a penetrating injury to the orbit with transection or contusion of the nerve. Blunt trauma to the orbit may also lead to severe visual loss if the traumatic force is transmitted to the optic canal and causes disruption of the blood supply to the intracanalicular portion of the nerve. Treatment with high-dose corticosteroids has not proved to be effective; it has been shown that similar regimens involve an increased relative risk of death when they are given to patients who have experienced significant head injuries.

Visit Elsevier eBooks+ at eBooks.Health.Elsevier.com for Bibliography.

Chapter 672

Childhood Glaucoma

Scott E. Olitsky and Justin D. Marsh

Glaucoma is a general term used to indicate damage to the optic nerve with visual field loss that is caused by or related to elevated pressure within the eye. It is classified according to the age of the affected individual at presentation and the association of other ocular or systemic conditions. Glaucoma that begins within the first 5 years of life is called

Table 672.1 Primary and Secondary Childhood Glaucomas

I. PRIMARY GLAUCOMAS
- A. Congenital open-angle glaucoma
  1. Congenital
  2. Infantile
  3. Late recognized
- B. Autosomal dominant juvenile glaucoma
- C. Primary angle-closure glaucoma
- D. Associated with systemic abnormalities
  1. Sturge-Weber syndrome
  2. Neurofibromatosis type I (NF-1)
  3. Stickler syndrome
  4. Oculocerebrorenal (Lowe) syndrome
  5. Rieger syndrome
  6. Hepatocerebrorenal syndrome
  7. Marfan syndrome
  8. Rubinstein-Taybi syndrome
  9. Infantile glaucoma associated with cognitive disability and paralysis
  10. Oculodentodigital dysplasia
  11. Open-angle glaucoma associated with microcornea and absence of frontal sinuses
  12. Mucopolysaccharidosis
  13. Trisomy 13
  14. Cutis marmorata telangiectasia congenita
  15. Warburg syndrome
  16. Kniest syndrome (skeletal dysplasia)
  17. Michel syndrome
  18. Nonprogressive hemiatrophy
- E. Associated with ocular abnormalities
  1. Congenital glaucoma with iris and pupillary abnormalities
  2. Aniridia
     - a. Congenital glaucoma
     - b. Acquired glaucoma
  3. Congenital ocular melanosis
  4. Sclerocornea
  5. Iridotrabecular dysgenesis
  6. Peters syndrome
  7. Iridotrabecular dysgenesis and ectropion uveae
  8. Posterior polymorphous dystrophy
  9. Idiopathic or familial elevated episcleral venous pressure
  10. Anterior corneal staphyloma
  11. Congenital microcornea with myopia
  12. Congenital hereditary endothelial dystrophy
  13. Congenital hereditary iris stromal hypoplasia

II. SECONDARY GLAUCOMAS
- A. Traumatic glaucoma
  1. Acute glaucoma
     - a. Angle concussion
     - b. Hyphema
     - c. Ghost cell glaucoma
  2. Late-onset glaucoma with angle recession
  3. Arteriovenous fistula
- B. Secondary to intraocular neoplasm
  1. Retinoblastoma
  2. Juvenile xanthogranuloma
  3. Leukemia
  4. Melanoma
  5. Melanocytoma
  6. Iris rhabdomyosarcoma
  7. Aggressive nevi of the iris
- C. Secondary to uveitis
  1. Open-angle glaucoma
  2. Angle-blockage glaucoma
     - a. Synechial angle closure
     - b. Iris bombé with pupillary block
- D. Lens-induced glaucoma
  1. Subluxation-dislocation and pupillary block
     - a. Marfan syndrome
     - b. Homocystinuria
  2. Spherophakia and pupillary block
  3. Phacolytic glaucoma
- E. Secondary to surgery for congenital cataract
  1. Lens material blockage of the trabecular meshwork (acute or subacute)
  2. Pupillary block
  3. Chronic open-angle glaucoma associated with angle defects
- F. Steroid-induced glaucoma
- G. Secondary to rubeosis
  1. Retinoblastoma
  2. Coats disease
  3. Medulloepithelioma
  4. Familial exudative vitreoretinopathy
- H. Secondary angle-closure glaucoma
  1. Retinopathy of prematurity
  2. Microphthalmos
  3. Nanophthalmos
  4. Retinoblastoma
  5. Persistent hyperplastic primary vitreous
  6. Congenital pupillary iris-lens membrane
- I. Glaucoma associated with increased venous pressure
  1. Carotid or dural-venous fistula
  2. Orbital disease
- J. Secondary to maternal rubella
- K. Secondary to intraocular infection
  1. Acute recurrent toxoplasmosis
  2. Acute herpetic iritis

From Nelson LB. *Harley's Pediatric Ophthalmology*. 4th ed. Philadelphia: Saunders; 1998: p. 294.

infantile (congenital); that which begins between the ages of 5 and 30 years is called juvenile.

Primary glaucoma indicates that the cause is an isolated anomaly of the drainage apparatus of the eye (trabecular meshwork). More than 50% of infantile cases are primary glaucoma. In secondary glaucoma, other ocular or systemic abnormalities are associated, even if a similar developmental defect of the trabecular meshwork is also present. Primary infantile glaucoma occurs with an incidence of 0.03% (Table 672.1).

CLINICAL MANIFESTATIONS

The symptoms of infantile glaucoma include the classic triad of epiphora (tearing), photophobia (sensitivity to light), and blepharospasm (eyelid squeezing; Fig. 672.1). Each can be attributed to corneal irritation. Only approximately 30% of affected infants demonstrate the classic symptom complex. Signs of glaucoma include corneal edema, corneal and ocular enlargement, and conjunctival injection (Fig. 672.2).

The sclera and cornea are more elastic in early childhood than later in life. An increase in intraocular pressure (IOP) therefore leads to an expansion of the globe, including the cornea, and the development of buphthalmos ("ox eye"). If the cornea continues to enlarge, breaks occur in the endothelial basement membrane (Descemet's membrane) and may lead to permanent corneal scarring. These breaks in Descemet's membrane (Haab striae) are visible as horizontal edematous lines that cross or curve around the central cornea. They rarely occur beyond 3 years of age or in corneas <12 mm in diameter. The cornea also becomes edematous and cloudy, with increased IOP. The corneal edema leads to tearing and photophobia. If any of these other signs or symptoms are present, glaucoma should be considered in a child suspected of having a nasolacrimal duct obstruction.

Children with unilateral glaucoma generally present early because the difference in the corneal size between the eyes can be noticed. When the disease is bilateral, parents may not recognize the increased corneal size.

Fig. 672.1 Tearing of the right eye caused by glaucoma. Note the increased corneal diameter of the right eye. *(From Nelson LB. Harley's Pediatric Ophthalmology. 4th ed. Philadelphia: WB; 1998; p. 285.)*

Fig. 672.2 Infantile glaucoma. The left cornea is enlarged and edematous.

Many parents view the large eyes as attractive and do not seek help until other symptoms develop.

Cupping of the optic nerve head is detected by ocular examination. The optic nerve of an infant is easily distended by excessive pressure. Deep central cupping readily occurs and may regress with normalization of pressure.

Some infants and children with early-onset glaucoma have more extensive maldevelopment of the anterior segment of the eye. The neurocristopathies, particularly those involving the anterior segment (Axenfeld-Rieger syndrome: *FOXC1, PITX2, CYP1B1, PRDM5* genes), produce early-onset glaucoma. They are usually bilateral and may include abnormalities of the iris, cornea, and lens. Other ocular anomalies that may be associated with glaucoma in infants and children are aniridia, cataract, spherophakia, and ectopia lentis. Glaucoma may also develop secondary to persistent hyperplastic primary vitreous or retinopathy of prematurity.

Trauma, intraocular hemorrhage, ocular inflammatory disease, and intraocular tumor are also important causes of glaucoma in the pediatric population. Systemic disorders associated with glaucoma in infants and children are Sturge-Weber syndrome (see Chapter 636.3), neurofibromatosis (see Chapter 636.1), Lowe syndrome, Marfan syndrome (see Chapter 743), congenital rubella (see Chapters 149 and 294), and a number of chromosomal syndromes (see Chapter 99).

Table 672.2 Differential Diagnosis of Primary Congenital Glaucoma

I. OTHER GLAUCOMAS
A. Glaucoma associated with congenital anomalies
B. Secondary glaucoma
II. OTHER CAUSES OF CORNEAL ENLARGEMENT OR CLOUDING
A. Megalocornea
B. Sclerocornea
C. High myopia
D. Metabolic diseases
1. Cystinosis
2. Mucopolysaccharidoses
a. MPS I H = Hurler's syndrome
b. MPS I S = Scheie's syndrome
c. MPS II = Hunter's syndrome
d. MPS IV = Morquio's syndrome
e. MPS VI = Maroteaux-Lamy syndrome
f. MPS VII = b-Glucuronidase deficiency
3. Hand-Schüller-Christian disease (histiocytosis)
4. Acrodermatitis enteropathica
5. Peroxisomal disorders
6. Zellweger syndrome
E. Posterior polymorphous dystrophy
F. Congenital hereditary endothelial dystrophy
G. Obstetric trauma
H. Inflammation (keratitis, iridocyclitis)
III. OTHER CAUSES OF EPIPHORA OR PHOTOPHOBIA
A. Nasolacrimal duct obstruction
B. Conjunctivitis
C. Corneal abrasion
D. Meesmann's corneal dystrophy
E. Reis-Buckler's dystrophy
IV. OTHER CAUSES OF OPTIC NERVE ABNORMALITIES
A. Pit
B. Coloboma
C. Hypoplasia
D. Tilted disc
E. Large physiologic cup

From Stamper RL, Lieberman MF, Drake MV, eds. *Becker-Shaffer's Diagnosis and Therapy of the Glaucomas.* 8th ed. Philadelphia: Mosby, 2009: Box 19.3, p. 307.

Glaucoma occurs frequently in children with a history of congenital cataracts. Glaucoma may develop in up to 25% of children who have undergone cataract surgery early in life. The cause of aphakic glaucoma is not known but is thought to be the result of a coexistent anterior chamber deformity. Children treated for cataracts must be monitored closely for this complication, which may threaten vision.

DIAGNOSIS AND TREATMENT

The diagnosis of infantile glaucoma is made on recognition of the signs and symptoms. Once the diagnosis is established, treatment is started promptly. Unlike adult glaucoma, in which medication is often the first line of therapy, for infantile glaucoma the treatment is primarily surgical. The differential diagnosis is noted in Table 672.2.

Procedures used to treat glaucoma in children include surgery to establish a more normal anterior chamber angle (goniotomy and trabeculotomy), to create a site for aqueous fluid to exit the eye (trabeculectomy and Seton surgery), or to reduce aqueous fluid production (cyclocryotherapy and cyclophotocoagulation). Many children frequently require several operations to lower and maintain their IOP adequately, and long-term medical therapy may be necessary as well. Patients with multiple ocular abnormalities and those with aphakic glaucoma generally require more surgeries to achieve and maintain adequate IOP control. Although vision may be reduced secondary to glaucomatous optic nerve damage or corneal scarring, amblyopia is the most common cause of loss of vision in these children.

Visit Elsevier eBooks+ at eBooks.Health.Elsevier.com for Bibliography.

Chapter 673

Orbital Abnormalities

Scott E. Olitsky and Justin D. Marsh

HYPERTELORISM AND HYPOTELORISM

Hypertelorism is wide separation of the eyes or an increased interorbital distance, which may occur as a morphogenetic variant, a primary deformity, or a secondary phenomenon in association with developmental abnormalities, such as frontal meningocele or encephalocele or the persistence of a facial cleft. Often-associated conditions are strabismus, exotropia, and sometimes optic atrophy.

Hypotelorism refers to narrowness of the interorbital distance, which may occur as a morphogenetic variant alone or in association with other anomalies, such as epicanthus or holoprosencephaly, or secondary to a cranial dystrophy, such as scaphocephaly.

EXOPHTHALMOS AND ENOPHTHALMOS

Protrusion of the eye is referred to as *exophthalmos* or *proptosis* and is a common indicator of orbital disease. It may be caused by shallowness of the orbits, as in many craniofacial malformations, or by increased tissue mass within the orbit, as with neoplastic, vascular, and inflammatory disorders. Ocular complications include exposure keratopathy, ocular motor disturbances, and optic atrophy with loss of vision.

Posterior displacement or sinking of the eye back into the orbit is referred to as *enophthalmos*. This may occur with orbital fracture or with atrophy of orbital tissue.

ORBITAL INFLAMMATION

Nonspecific Orbital Inflammation/Idiopathic Orbital Inflammation/Orbital Pseudotumor

Nonspecific orbital inflammation (NSOI) is an acute or subacute, usually benign, idiopathic inflammatory process of unknown etiology manifesting in specific orbital structures but usually with no systemic features. After thyroid-associated disease and lymphoproliferative disorders, it is the third most common noninfectious masslike inflammatory lesion of the orbit. It is unilateral in ~80% of patients, who often present with periorbital edema, ptosis, limited extraocular motion, pain, proptosis, conjunctival injection, chemosis or, less often, decreased visual acuity. There are five categories involving specific orbit tissues: dacryoadenitis (Fig. 673.1A), myositis (see Fig. 673.1B), anterior orbit (see Fig. 673.1C), posterior orbit apex (optic nerve; Fig. 673.2), and diffuse. Lacrimal gland inflammation and orbital myositis are the most common manifestations. The apical (**orbital apex syndrome**) often affects visual acuity and cranial nerves III, IV, and VI, as well as the first division of CN V. There is an association with a sclerosing IgG4-related disease variant, which may also manifest with inflammation and fibrosis in extraorbital tissue (pancreas, retroperitoneal); systemic IgG4-related disease is more common in patients with bilateral lacrimal gland involvement.

The differential diagnosis of NSOI includes sarcoidosis, granulomatosis with polyangiitis, lymphoma, and thyroid orbitopathy (Fig. 673.3). In addition, **Tolosa Hunt syndrome** may mimic NSOI; manifestations include unilateral headache, brow and eye pain, and cranial nerve palsies with associated cavernous sinus granulomatosis (Fig. 673.4). Biopsy is not initially needed for patients with NSOI who have a typical presentation (usually myositis) or a higher biopsy risk (orbital apex-optic nerve). Therapy is usually initiated with systemic corticosteroids.

Thyroid-related ophthalmopathy (see Chapter 601) is believed to be secondary to an immune mechanism, leading to inflammation and deposition of mucopolysaccharides and collagen in the extraocular muscles and orbital fat. Involvement of the extraocular muscles may lead to a restrictive strabismus. Lid retraction and exophthalmos may cause corneal exposure and infection or perforation. Involvement of the posterior orbit can compress the optic nerve. Treatment of thyroid-related ophthalmopathy may include the use of systemic corticosteroids, radiation of the orbit, eyelid surgery, strabismus surgery, or orbital decompression to eliminate symptoms and protect vision. The degree of orbital involvement is often independent of the status of the systemic disease.

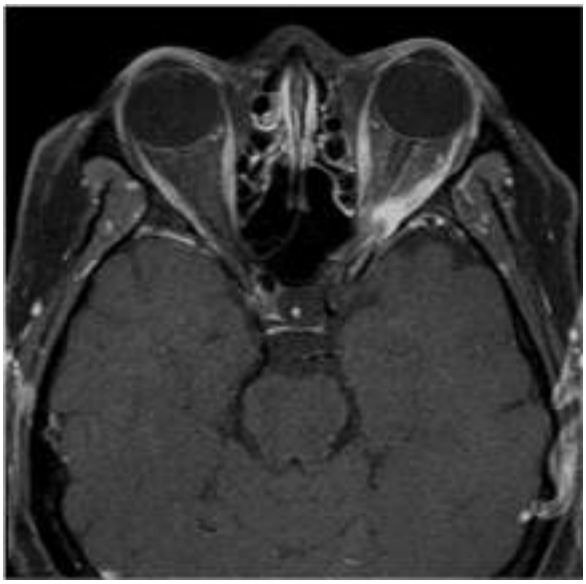

Fig. 673.2 Nonspecific orbital inflammation involving the orbital apex. Contrast-enhanced T1-weighted axial MRI with fat suppression showing inflammatory tissue at the left orbital apex resulting in compression and obliteration of the optic nerve. *(From Maamari RN, Couch SM. Nonspecific orbital inflammation. Adv Ophthalmol Optom. 2018;3:315–335: Fig. 7.)*

Fig. 673.1 Anatomic localization of nonspecific orbital inflammation. **A,** Lacrimal gland (right eye). **B,** Extraocular muscle (left lateral rectus). **C,** Orbital fat (left inferomedial extraconal space). *(From Lee MJ, Planck SR, Choi D, et al. Non-specific orbital inflammation: current understanding and unmet needs. Prog Retinal Eye Res. 2021;81:100885: Fig. 5).*

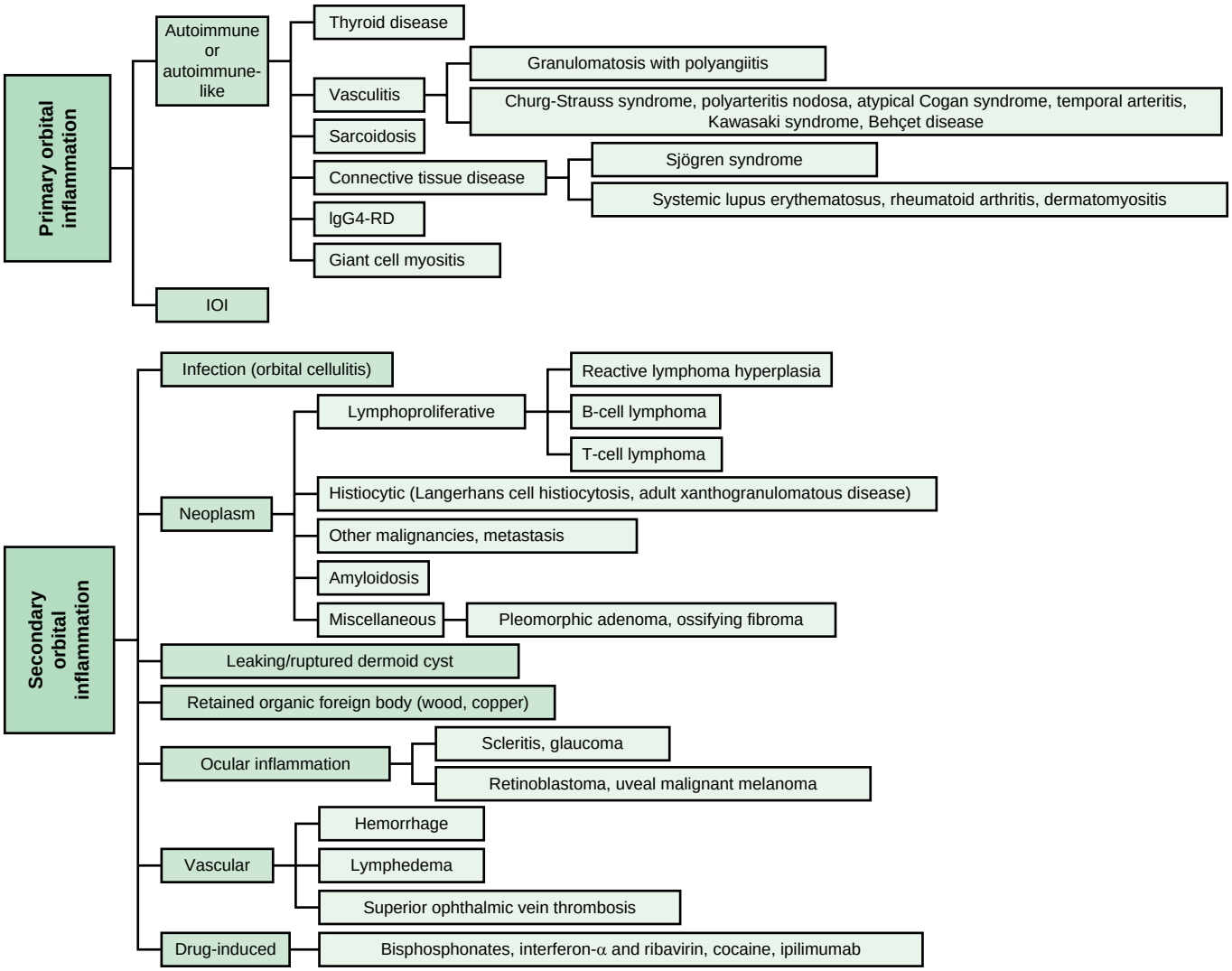

Fig. 673.3 Classification for possible causes of orbital inflammation. NSOI, nonspecific orbital inflammation. *(From Mombaerts I, Rose GE, Garrity JA. Orbital inflammation: biopsy first. Surv Ophthalmol. 2016;61:664–669: Table 1.)*

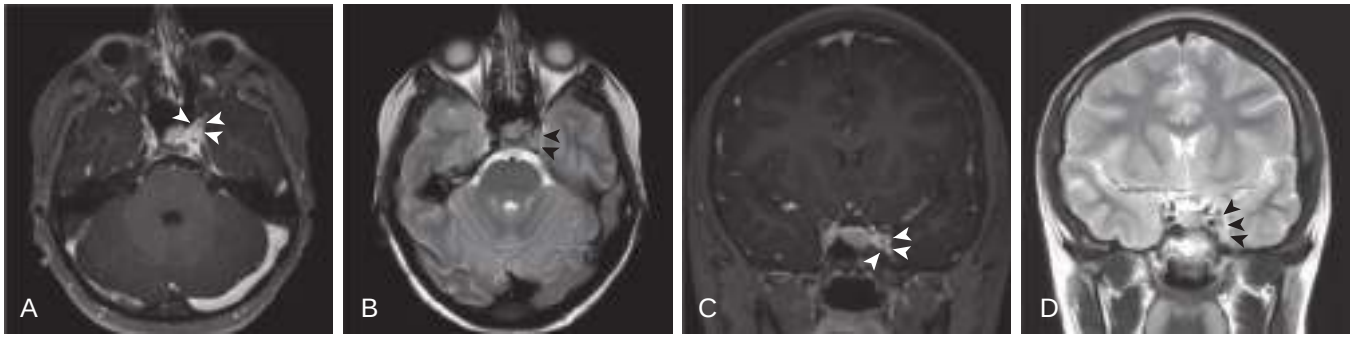

Fig. 673.4 MR scan of the brain showing an enhancing space-occupying lesion within the left cavernous sinus *(arrowheads)*. Postgadolinium T1-weighted (**A**) and T2-weighted (**B**) axial views. Postgadolinium T1-weighted (**C**) and T2-weighted (**D**) coronal views. *(From Pérez CA, Evangelista M. Evaluation and management of Tolosa-Hunt syndrome in children: a clinical update. Pediatr Neurol. 2016;62:18–26: Fig. 2.)*

Other systemic disorders that may cause inflammatory disease within the orbit include lymphoma (see Chapter 545), sarcoidosis (see Chapter 209), amyloidosis (see Chapter 206), polyarteritis nodosa (see Chapter 210.3), systemic lupus erythematosus (see Chapter 199), dermatomyositis (see Chapter 200), granulomatosis with polyangiitis (see Chapter 210), and juvenile xanthogranuloma (see Chapter 556).

TUMORS OF THE ORBIT

Various tumors occur in and about the orbit in childhood. Among benign tumors, the most common are vascular lesions (principally hemangiomas; Fig. 673.5) and dermoids. Among malignant neoplasms, rhabdomyosarcoma, lymphosarcoma, and metastatic neuroblastoma are the most frequent. Optic nerve gliomas (see Chapter 671)

Fig. 673.5 Orbital hemangioma. **A,** Note the proptosis. **B,** CT scan. *(Courtesy Amy Nopper, MD, and Brandon Newell, MD.)*

are most commonly seen in patients with neurofibromatosis and may present with poor vision or proptosis. Retinoblastoma (see Chapter 551) may extend into the orbit if it is discovered late or goes untreated. Teratomas are rare tumors that typically grow rapidly after birth and exhibit explosive proptosis.

The effects of orbital tumors vary with their locations and growth patterns. The principal signs are proptosis, resistance to retroplacement of the eye, and impairment of eye movement. A palpable mass may be found. Other significant signs are ptosis, optic nerve head congestion, optic atrophy, and loss of vision. Bruit and visible pulsation of the globe are important clues to vascular lesions.

Evaluation of orbital tumors includes ultrasonography, MRI, and CT. Pseudotumor of the orbit also must be considered in children with signs of a mass lesion. In selected cases, an incisional or excisional biopsy of the lesion may be warranted.

Visit Elsevier eBooks+ at eBooks.Health.Elsevier.com for Bibliography.

Chapter **674**

Orbital Infections

Scott E. Olitsky, Justin D. Marsh, and Mary Anne Jackson

Orbital infections are common in children. It is important to be able to distinguish the different forms of infection that occur in the orbital region to allow rapid diagnosis and treatment to prevent loss of vision or spread of the infection to the nearby intracranial structures (Table 674.1).

DACRYOADENITIS

Dacryoadenitis is inflammation of the lacrimal gland; it most commonly occurs in the pediatric population and in some young adults and is related to a variety of infectious pathogens or inflammatory processes (see Chapter 673). Pain, redness, swelling, increase in tearing, and discharge over the lacrimal gland are noted and usually visible at the lateral one third of the upper eyelid; concurrent preauricular lymphadenopathy may be noted (Fig. 674.1). It may occur with mumps (in which case it is usually acute and bilateral, subsiding in a few days or weeks), with influenza, infectious mononucleosis, and herpes zoster. *Staphylococcus aureus* may produce a suppurative dacryoadenitis, and other bacterial causes include streptococci and *Neisseria gonorrhoeae*. Chronic dacryoadenitis is associated with certain systemic diseases, particularly sarcoidosis, tuberculosis, and syphilis. Some systemic diseases may produce enlargement of the lacrimal and salivary glands (Mikulicz syndrome).

DACRYOCYSTITIS

Dacryocystitis is an infection of the lacrimal sac and generally requires obstruction of the nasolacrimal system to allow its development. Acute, subacute, and chronic forms are described. Most patients with dacryocystitis present with redness and swelling over the region of the lacrimal sac (Fig. 674.2). It is treated with warm compresses and systemic antibiotics. This helps control the infection, but the obstruction usually requires definitive treatment to reduce the risk of recurrence.

Dacryocystitis may occur in newborns as a complication of a congenital dacryocystocele (see Chapter 665). If present, systemic antibiotics and digital pressure for decompression are recommended. The obstruction of the nasolacrimal system may resolve once the infection clears. If spontaneous resolution does not occur, probing should be considered within a short time frame. An intranasal cyst may be present in conjunction with the dacryocystocele. If this occurs, marsupialization of the cyst may be needed at the time of the probing.

PRESEPTAL CELLULITIS

Inflammation of the lids and periorbital tissues without signs of true orbital involvement (such as proptosis or limitation of eye movement) is generally referred to as *periorbital* or *preseptal cellulitis* and is a form of facial cellulitis. This is a common entity in young children, usually under age 5 years, and may rarely be caused by direct seeding related to bacteremia (usually seen in those <3 years), or more often sinusitis,

Table 674.1 Manifestations of Orbital Cellulitis Associated with Ethmoid Sinusitis

MANIFESTATIONS	CLINICAL AND CT IMAGING DESCRIPTION
1: Inflammatory edema	Eyelid edema and erythema; eye may be swollen shut Fever Painless extraocular muscle movement; full range of motion Visual acuity normal Edema of orbit without abscess formation
2: Orbital cellulitis	Inflammation of orbital contents without discrete abscess formation Fever, malaise
3: Subperiosteal abscess	Purulent exudate beneath medial orbital periosteum of lamina papyracea Pain on extraocular muscle movement Fever, malaise, may have pain with extraocular muscle movement Displacement of globe (down and out)
4: Orbital abscess/ orbital apex syndrome	Purulent collection within orbit Proptosis, chemosis Ophthalmoplegia; pain on extraocular muscle movement Decreased vision Fever, malaise
5: Septic cavernous sinus thrombophlebitis	Bilateral (contralateral) eye findings; ptosis, proptosis, swelling, ophthalmoplegia Severe headaches Meningismus, fever, severe malaise Decreased vision

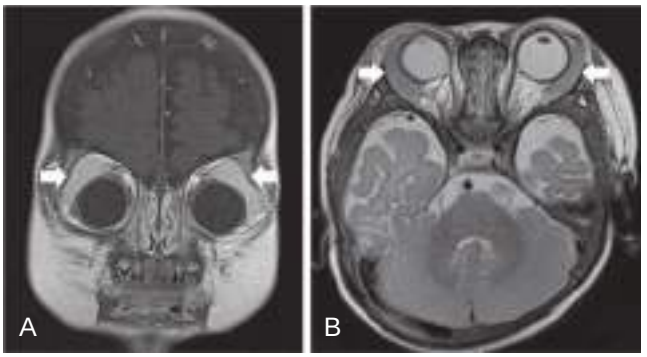

Fig. 674.1 MRI of the bilateral lacrimal glands. **A,** Coronal T1-weighted image. **B,** Axial T2-weighted image. The bilateral lacrimal glands are markedly enlarged *(arrows). (From Hoshino A, Fujii T, Hibino S, Abe Y. Acute infantile dacryoadenitis. J Pediatr. 2014;164:425: Fig. 2))*

Fig. 674.2 Dacrycystitis in a child previously treated for nasolacrimal duct obstruction.

trauma, or other infected wounds in the periorbital region, or an abscess of the lid or periorbital region (pyoderma, hordeolum, conjunctivitis, dacryocystitis, insect bite). Brown recluse spider bites are often associated with considerable local swelling, and in the first 24 hours, the bite itself may not be obvious to the parent or the examiner.

Patients present with eyelid swelling; the edema may be so intense as to make it difficult to evaluate the globe. Before the *Haemophilus influenzae* type B (Hib) vaccine, the most common cause of pediatric preseptal (facial) cellulitis was bacteremia caused by Hib. Group A streptococcus (GAS), pneumococcus, and *S. aureus* (especially if related to an infected wound or bite) are the most common identifiable etiologic agents. Occasionally, young children with herpes simplex virus infection of the periorbital tissues will present first with swelling and redness, followed by the appearance of discrete tiny ulcers.

Clinical examination will show **lack of** proptosis, with normal painless ocular movements, normal vision, and normal pupil responses. CT imaging can demonstrate edema of the lids and subcutaneous tissues anterior to the orbital septum (Fig. 674.3); imaging is not necessary in those without signs of an orbital process. Antibiotic therapy and careful clinical monitoring and evaluation to identify signs of local progression are essential. In well-appearing children with infected traumatic wounds or insect bites associated with periorbital cellulitis, oral antibiotics that target *S. aureus* and GAS may be considered. For young children in whom a hematogenous process is suspected, or in any toxic, ill-appearing child, blood cultures should be obtained, and hospitalization and intravenous antibiotics are required. Most recommend intravenous ampicillin with sulbactam or intravenous clindamycin plus cefotaxime (or ceftriaxone) for hospitalized patients.

Fig. 674.3 CT scan of a patient with preseptal cellulitis.

Periorbital necrotizing fasciitis is a severe, rapidly spreading form of periorbital bacterial infection, involving both superficial and deep fascial planes. The disease may have no preceding events or may follow trauma to the periorbital skin. Initial symptoms resemble periorbital/facial cellulitis but rapidly progress to tissue necrosis, blistering, and significant systemic toxicity. Streptococci and *S. aureus* are the most common pathogens. Treatment includes broad spectrum antibiotics, surgical debridement, and, when available, hyperbaric oxygen therapy.

ORBITAL CELLULITIS

Inflammation of the tissues of the orbit, characterized by the triad of proptosis, painful limitation of movement of the eye (ophthalmoplegia), and potentially decreased visual acuity, is termed *orbital cellulitis* (see Table 674.1). Edema of the conjunctiva (chemosis) and inflammation and swelling of the eyelids may be seen. The mean age is ~7 years, ranges from 1 week to 18 years, and has a 2:1 predilection in males. An increased risk is seen in the winter because complicated obligatory sinusitis often follows respiratory viral infection (e.g., influenza). Patients often feel ill, are febrile, and appear toxic, and leukocytosis sometimes but not always may be appreciated. Practitioners should have an increased clinical suspicion for intracranial extension in those with headache, vomiting, and any focal neurologic findings.

Orbital cellulitis may follow direct infection of the orbit from a wound, hematogenous seeding of organisms during bacteremia, or *more often* direct extension or venous spread of infection from contiguous sites such as the lids, conjunctiva, globe, lacrimal gland, nasolacrimal sac, or *more commonly* from the paranasal (ethmoid) sinuses. The **differential diagnosis** includes idiopathic orbital inflammation, myositis, sarcoidosis, granulomatous vasculitis, leukemia, lymphoma, histiocytic disorders, rhabdomyosarcoma, ruptured dermoid cyst, orbital trauma, and orbital foreign body (see Chapter 673). In some cases, primary or metastatic tumor in the orbit can produce the clinical picture of orbital cellulitis.

Although the most common cause of orbital cellulitis in children is direct extension or venous spread from infected paranasal sinuses, an antecedent history of sinusitis requiring antibiotic therapy is generally not reported. The spread of infection to the orbit from the sinuses is more prevalent in children because of their thinner bony septa and sinus wall, greater porosity of bones, open suture lines, and larger vascular foramina (Fig. 674.4). The spread of infection is also facilitated by the venous and lymphatic communication between the sinuses and surrounding structures, which allow flow in either direction, facilitating retrograde thrombophlebitis. Frequently noted pathogenic organisms include *S. aureus,* streptococcus species (especially *Streptococcus anginosus* also known as the *Streptococcus milleri* group, and *S. pyogenes*), *Streptococcus pneumoniae*, and anaerobes (e.g., *Bacteroides* spp., *Prevotella* spp.).

The potential for complications is high. Visual loss can occur secondary to an increase in orbital pressure that causes retinal artery or ophthalmic vein occlusion or optic neuritis. This is more likely to occur in the presence of an orbital abscess. Extension of infection from the orbit into the cranial cavity may lead to cavernous sinus thrombosis or meningitis, epidural or subdural empyema, or brain abscesses (Fig. 674.5). Additional complications include optic atrophy, exposure keratitis, and retinal or choroidal ischemia. An interdisciplinary team involving an infectious disease specialist, ophthalmologist, otolaryngologist, and, where indicated, a pediatric neurosurgeon should be involved in the care of the patient with orbital infection.

Orbital cellulitis must be recognized promptly and treated aggressively. Hospitalization and systemic antibiotic therapy are indicated. All patients with suspected orbital cellulitis should undergo contrast CT imaging of the orbit, paranasal sinuses, and adjacent cortex. Lumbar puncture should not be considered unless there is a meningitis presentation (and only after CT imaging), assuming there are no signs of elevated intracranial pressure or focal neurologic findings on examination. Parenteral antibiotics should be initiated immediately. Antimicrobial agents should begin with intravenous ampicillin with sulbactam or intravenous clindamycin plus ceftriaxone, cefepime (or cefotaxime); in cases where there is suspicion for intracranial extension, vancomycin plus cefotaxime (or ceftriaxone) plus metronidazole should be given.

If the patient does not show evidence of improvement or if there are signs of progression, sinus and abscess drainage should be considered. The presence of an orbital or unresponsive subperiosteal abscess (see Fig. 674.4) may require urgent drainage of the orbit. The clinical presentation and course of each individual patient should dictate the need and timing of abscess drainage.

Most children (especially those <9 years of age) with a medial **subperiosteal abscess** can initially be managed with intravenous antibiotics, which usually are sufficient for resolution of the subperiosteal abscess. Adjunctive use of corticosteroids is controversial but may hasten resolution. Patients should be examined frequently for signs of visual deterioration or pupillary abnormalities. Most will become afebrile within 48 hours and have examination improvement by 72 hours. If there are pupillary abnormalities, decreased vision, or failure to improve, the subperiosteal abscess should be drained.

Many recommend drainage for a subperiosteal abscess and an orbital abscess in older children. Additionally, abscesses involving the orbital roof with associated frontal sinus disease may require more frequent surgical intervention. Operative procedures should be coordinated with the otolaryngologist to allow for sinus drainage at the same time that the subperiosteal abscess is drained, and cultures should be obtained from the sinus and the abscess. Similarly, if neurosurgical intervention is required, operative coordination should occur with ophthalmology and otolaryngology.

Fig. 674.4 Orbital complications of sinusitis. **A,** Orbital phlegmon and orbital cellulitis. Axial contrast-enhanced computed tomography (CECT) shows left preseptal periorbital soft tissue swelling (STS) and left ethmoid air cell opacification. There is increased density of the left medial extraconal orbital fat *(asterisks),* consistent with phlegmon. The adjacent medial rectus muscle is thickened. There is subtle increased density of the intraconal orbital fat, consistent with orbital cellulitis. **B,** Orbital subperiosteal abscess. Axial CECT shows preseptal periorbital STS *(arrowhead),* extensive left ethmoid air cell opacification, and an elliptical low-density, peripherally enhancing, medial subperiosteal abscess *(a). (Modified from Walters MM, Robertson RL, eds. Pediatric Radiology: The Requisites, 4th ed. Philadelphia: Elsevier, 2017. Fig. 10.37, p. 377.)*

Fig. 674.5 Superior ophthalmic vein (SOV) and cavernous sinus thrombosis (CST). **A,** SOV thrombosis. Axial contrast-enhanced computed tomography (CECT) shows opacification of the partially visualized paranasal sinuses *(arrowhead).* There is a tram-track sign due to lack of enhancement of the thrombosed left SOV *(black arrow).* Compare with the normally enhancing right SOV *(white arrow).* **B,** CST (new patient). Axial computed tomography image demonstrates a sphenoid sinus air–fluid level caused by sphenoid sinusitis. Gas is present within the right cavernous sinus *(arrow)* due to CST. There is resultant right ocular proptosis with minimal reticulation of the right intraconal orbital fat *(asterisk).* **C,** Axial T2-weighted magnetic resonance (same patient) shows low signal intensity within the right cavernous sinus with lateral convexity of its lateral margin *(arrow),* consistent with CST. Note the sphenoid sinus air–fluid level *(s). (From Walters MM, Robertson RL [eds]. Pediatric Radiology: The Requisites. 4th ed. Philadelphia: Elsevier, 2017: Fig. 10.38, p. 377.)*

Table 674.2 Endophthalmitis Categories and the Most Common Pathogens in Each

CATEGORY	COMMON PATHOGENS
Acute postoperative	Coagulase-negative staphylococci
Chronic postcataract	*Propionibacterium acnes*
Postinjection	Viridans streptococci, coagulase-negative staphylococci
Bleb-related	Streptococci, *Haemophilus influenzae*
Posttraumatic	*Bacillus cereus*
Keratitis related	Molds (e.g., *Fusarium*)
Endogenous	*Staphylococcus aureus*, streptococci, gram-negative bacilli
Fungal	Candida, Aspergillus, Fusarium

From Durand ML. Endophthalmitis. In: Bennett JE, Dolin R, Blaser MJ, eds. *Mandell, Douglas, and Bennett's Principles and Practice of Infectious Diseases.* Philadelphia: Elsevier, 2020: Table 114.1, p. 1524.

ENDOPHTHALMITIS

Endophthalmitis is infection of the aqueous and/or vitreous humors and is rare in children; major predisposing factors are noted in Table 674.2. Endogenous hematogenous bacterial (*S. aureus*, streptococci, gram-negative bacilli) and fungal (candida, *Aspergillus* spp., *Fusarium*) may be seen in immunosuppressed and neutropenic patients, whereas histoplasmosis, blastomycosis, coccidiomycosis, and cryptococcus endophthalmitis may rarely be seen as part of disseminated systemic mycotic infection. In addition, ocular toxocariasis may mimic bacterial or fungal endophthalmitis.

The diagnosis requires vitreous sampling because aqueous samples are often negative. The pathogen may be identified by staining, culture, and molecular methods.

Treatment of bacterial endophthalmitis requires intravitreal antibiotics; systemic antibiotics alone are ineffective. Fungal disease often requires combined intraocular and systemic antifungal agents.

Visit Elsevier eBooks+ at eBooks.Health.Elsevier.com for Bibliography.

Chapter 675

Injuries to the Eye

Scott E. Olitsky and Justin D. Marsh

Approximately 30% of all blindness in children results from trauma. Children and adolescents account for a disproportionate number of episodes of ocular trauma. Males ages 11-15 years are the most vulnerable; their injuries outnumber those in females by a ratio of about 4:1. The majority of injuries are related to sports, sticks, stones, fireworks, paint balls, air-powered BB guns, and other projectiles. High-velocity projectiles and fireworks cause particularly devastating ocular and orbital injuries. Much of the trauma is avoidable (see Chapter 14). Any part of the orbit or globe may be affected (Figs. 675.1 and 675.2).

ECCHYMOSIS AND SWELLING OF THE EYELIDS

Ecchymosis and edema of the eyelids are common after blunt trauma (Fig. 675.3). These disorders are self-limiting, absorb spontaneously, and can be treated with iced compresses and analgesics. Periorbital

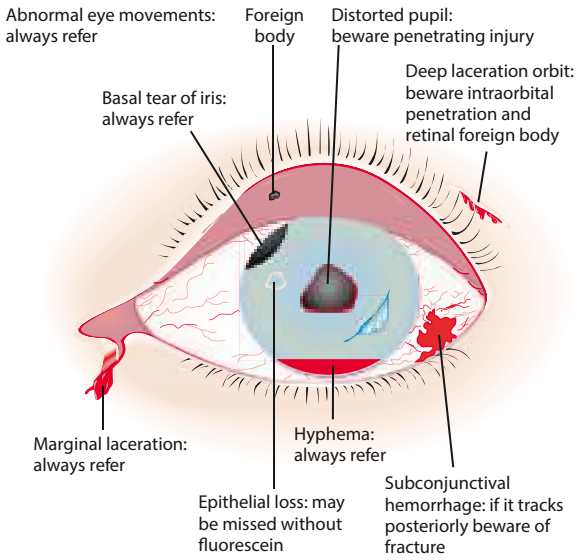

Fig. 675.1 The injured eye. *(From Khaw PT, Shah P, Elkington AR. Injury to the eye. BMJ. 2004;328:36–38.)*

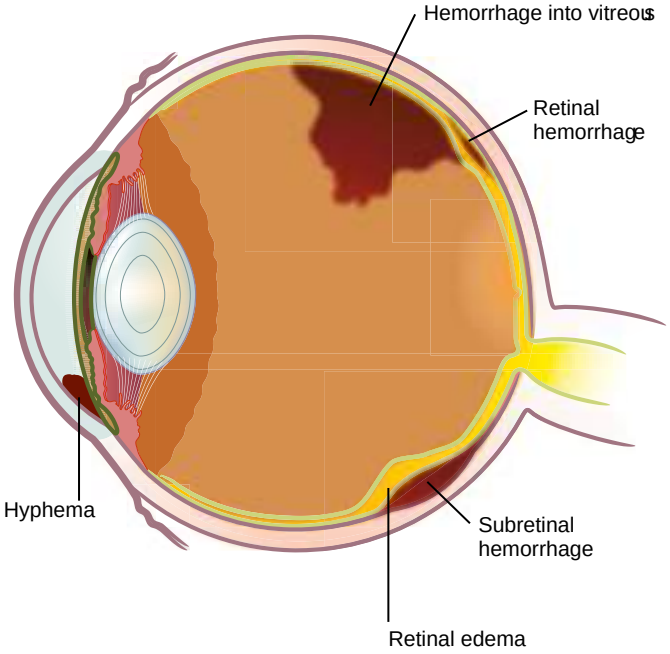

Fig. 675.2 Various types of ocular hemorrhage after blunt trauma to the globe. *(From Reilly BM. Practical Strategies in Outpatient Medicine. 2nd ed. Philadelphia: WB Saunders; 1991:68.)*

Fig. 675.3 Eyelid ecchymosis and subconjunctival hemorrhage.

ecchymosis should prompt careful examination of the eye and surrounding structures for more serious injuries such as orbital bone fracture, intraocular hemorrhage, or rupture of the globe.

LACERATIONS OF THE EYELIDS

Eyelid lacerations may vary from simple to complex. When evaluating an eyelid laceration, key findings include the depth of the laceration, its location, and whether there is involvement of the canaliculus (lacrimal ducts). Most superficial eyelid lacerations may be closed by the primary caregiver, but if a laceration is deep, involves the lid margin, or involves the canaliculus, it should be evaluated by an ophthalmologist. The levator muscle is responsible for elevation of the upper eyelid and runs deep to the skin and orbicularis oculi muscle. If the levator muscle is compromised and not recognized at initial repair, ptosis will occur. Therefore, if orbital fat is visible in the laceration, the laceration has compromised the skin, orbicularis oculi, levator muscles, and orbital septum and must be meticulously repaired to avoid ptosis. Eyelid margin involvement (Fig. 675.4) also requires careful repair to avoid lid malposition and notch formation. These can lead to ocular surface problems in the future, resulting in corneal scarring and loss of vision. Lacerations involving the canaliculus require intubation of the nasolacrimal system, in addition to repair of the laceration of the eyelid to avoid future tearing problems. Proper primary repair of eyelid lacerations often achieves a superior outcome to secondary repair at a later date. As with any eyelid injury, careful examination of the eye and surrounding tissue is required.

SUPERFICIAL ABRASIONS OF THE CORNEA

When the corneal epithelium is scratched, abraded, or denuded, it exposes the underlying epithelial basement layer and superficial corneal nerves. This is accompanied by pain, tearing, photophobia, and decreased vision. Corneal abrasions are detected by instilling fluorescein dye and inspecting the cornea using a blue-filtered light (Fig. 675.5). A slit lamp is ideal for this examination, but a direct ophthalmoscope with a blue filter or a handheld Wood lamp is adequate for young children.

Treatment of a corneal abrasion is directed at promoting healing and relieving pain. Abrasions are treated with frequent applications of a topical antibiotic ointment until the epithelium is completely healed. The use of a semipressure patch does not improve healing time or decrease pain. An improperly applied patch may itself abrade the cornea. A topical cycloplegic agent (cyclopentolate hydrochloride 1%) can relieve the pain from ciliary spasm in patients with large abrasions. Topical anesthetics should not be given at home because they retard epithelial healing and inhibit the natural blinking reflex.

FOREIGN BODY INVOLVING THE OCULAR SURFACE

This usually produces acute discomfort, tearing, and inflammation. Most foreign bodies can be detected by examination in good light with the aid of magnification (Fig. 675.6) or a direct ophthalmoscope set on a high plus lens (+10 or +12). In many cases, slit-lamp examination is necessary, especially if the particle is deep or metallic. Some conjunctival foreign bodies tend to lodge under the upper eyelid, causing the sensation of corneal foreign body, as they make contact with the globe on eyelid movement; they may also produce vertically oriented linear corneal abrasions (Fig. 675.7). Finding these abrasions should lead to a suspicion of such a foreign body, and eversion of the lid may be necessary (see Chapter 659). If a foreign body is suspected but not found, further examination is indicated. If the history suggests injury with a high-velocity particle, radiologic examination of the eye may be needed to explore the possibility of an intraocular foreign body.

Removal of a foreign body can be facilitated by instillation of a drop of topical anesthetic. Many foreign bodies can be removed by irrigation or by gently wiping them away with a moistened cotton-tipped applicator. Embedded foreign bodies or foreign bodies in the central cornea should be treated by an ophthalmologist. Removal of corneal foreign bodies may leave epithelial defects, which are treated as corneal abrasions. Metallic foreign bodies may cause rust to form in the corneal tissues; examination

Fig. 675.4 Eyelid margin laceration.

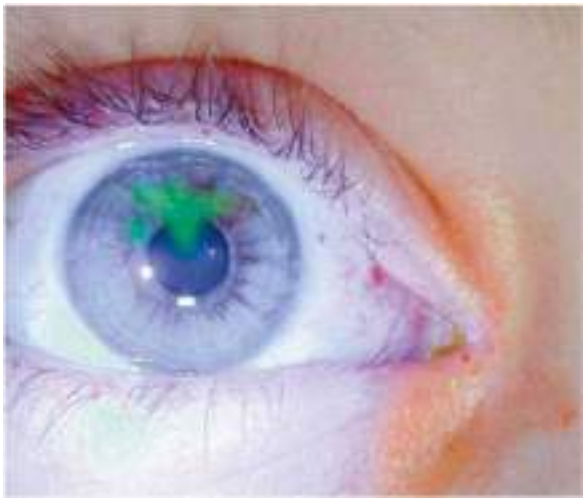

Fig. 675.5 Corneal abrasion with fluorescein staining.

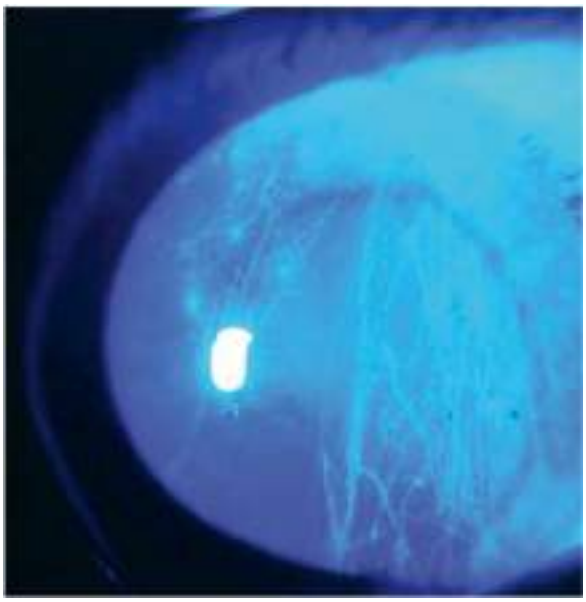

Fig. 675.6 Vertically oriented linear corneal abrasions secondary to a foreign body underneath the upper eyelid.

Fig. 675.7 Superficial corneal foreign body.

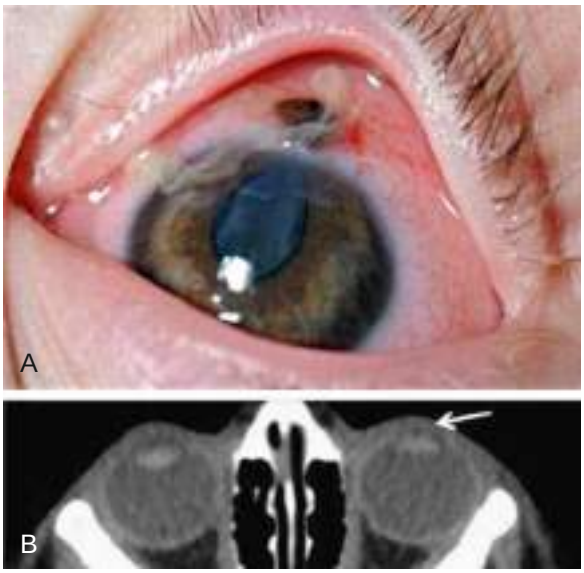

Fig. 675.8 **A,** Photograph of an open globe injury with a peaked pupil because of iris prolapse through the sclera, a shallow anterior chamber, and a traumatic cataract. **B,** CT imaging demonstrating a shallow left anterior chamber when compared to the right *(arrow)* but without evidence of an intraocular foreign body. *(From Hwang RY, Schoenberger SD. Imaging a peaked pupil in a traumatic open globe injury. J Pediatr. 2013;163:1517: Figs. A and B.)*

by an ophthalmologist 1 or 2 days after removal of a foreign body is recommended because a rust ring might require further treatment.

HYPHEMA

This is the presence of blood in the anterior chamber of the eye. It may occur with either a blunt or perforating injury and represents a situation that may threaten vision. Hyphema appears as a bright or dark red fluid level between the cornea and iris, or as a diffuse murkiness of the aqueous humor. Children with hyphema present with acute loss of vision, with or without pain. The treatment of hyphema involves efforts to minimize the vision-threatening sequelae, such as rebleeding, glaucoma, and corneal blood staining. Bedrest is necessary, ideally with elevation of the head of the bed to 30 degrees. A shield (without underlying patch) is placed on the affected eye to prevent repeat trauma, and a cycloplegic agent is used to immobilize the iris. In addition, topical or systemic steroids are used to minimize intraocular inflammation. Antiemetics should be considered if the patient is experiencing nausea. All nonsteroidal anti-inflammatories and aspirin must be avoided. Rarely, hospitalization and sedation may be necessary to ensure compliance in some children. If the intraocular pressure is elevated, topical and systemic pressure-lowering medications are used. If the pressure is not controllable by such measures, then surgical evacuation of the clot may be required to minimize the risk of permanent vision loss. Patients with sickle cell disease or trait are at higher risk of acute loss of vision secondary to elevated intraocular pressure or optic nerve infarction and may require more aggressive intervention. Individuals with a history of traumatic hyphema have an increased incidence of glaucoma later in life and should be monitored on a regular basis throughout their lives.

OPEN GLOBE

A penetrating, perforating, or blunt injury resulting in compromise of the cornea or sclera of the eye is one of the most sight-threatening injuries that can be sustained (Fig. 675.8). An open globe is a true ophthalmologic emergency that requires prompt, careful evaluation and immediate repair to minimize vision loss. Permanent vision loss can result from corneal scarring, loss of intraocular contents, or infection. Evaluation involves careful history, including time and mechanism of the injury, as well as visual acuity and inspection of the eye. A full-thickness corneal wound will often present with prolapsed iris tissue through the wound. If this is not immediately evident, a peaked or irregular pupil may be a sign of full-thickness laceration. Scleral compromise may be more difficult to identify because of overlying structures. The thinnest part of the sclera is at the corneoscleral junction (the limbus) and just posterior to the insertion of the rectus muscles. When an open globe is caused by blunt force injury, these are the two areas most likely involved. A ruptured globe occurs when the compressive traumatic force is high enough to lead to a rupture of the globe itself. Although the term *ruptured globe* is frequently used to describe any open eye, the term should be reserved for this specific form of trauma. The force required to rupture the globe often is severe enough to lead to other permanent injuries to the eye with a resultant poor prognosis even when the rupture itself can be repaired. This specific term denotes a poorer prognosis than many other forms of open globe injuries.

The overlying conjunctiva may not be compromised but a subconjunctival hemorrhage may be present, obscuring the view. In these cases, look for a shallow anterior chamber, low intraocular pressure, or pigment within the involved area. If the patient has been diagnosed with an open globe, the examination should be stopped, an eye shield placed immediately, and the ophthalmologist contacted to minimize further ocular compromise.

OPTIC NERVE TRAUMA

The optic nerve may be injured in both penetrating and blunt trauma. The injury may occur at any point between the globe and the chiasm. Traumatic injury to the optic nerve, regardless of cause or location, results in reduced vision and a pupillary defect. Direct trauma to the intraorbital optic nerve may cause transection, partial transection, or optic sheath hemorrhage. Fractures involving the skull base may cause injury to the intracranial portions of the optic nerve. Treatment decisions are difficult because there are no universally accepted guidelines, and the prognosis for good visual outcome is often poor. Medical management involves observation and the use of high-dose corticosteroids, although the use of corticosteroids has not been proven to improve visual outcomes and has been shown to increase the risk of death in patients with significant head injury. Surgical intervention involves optic nerve sheath decompression for nerve sheath hemorrhages. If compression of the optic nerve is secondary to orbital hemorrhage, prompt lateral canthotomy and cantholysis should be performed to relieve intraorbital pressure. Decompression of the optic canal may be performed if there is compression of the optic nerve by a bone fragment. Optic canal decompression is controversial in the absence of direct bone compression.

CHEMICAL INJURIES

Chemical burns of the cornea and adnexal tissue are among the most urgent of ocular emergencies, and they are most common in toddler and preschool-age children and men. Laundry detergent pods have become an increasingly common source of ocular injury to young children over the last decade. Alkali burns are usually more destructive than acid burns because they react with fats to form soaps, which damage cell membranes, allowing further penetration of the alkali into the eye. Acids generally cause less severe, more localized tissue damage. The corneal epithelium offers moderate protection against weak acids, and little damage occurs unless the pH is 2.5 or less. Most stronger acids precipitate tissue proteins, creating a physical barrier against their further penetration.

Mild acid or alkali burns are characterized by conjunctival injection and swelling and mild corneal epithelial erosions. The corneal stroma may be mildly edematous, and the anterior chamber may have mild to moderate cell and flare reactions. With strong acids, the cornea and conjunctiva rapidly become white and opaque. The corneal epithelium may slough, leaving a relatively clear stroma; this appearance may initially mask the severity of the burn. Severe alkali burns are characterized by corneal opacification.

Emergency treatment of a chemical burn begins with immediate, copious irrigation with water or saline. Local debridement and removal of foreign particles should be performed as irrigation continues. If the nature of the chemical injury is unknown, the use of pH test paper is helpful in determining whether the agent was basic or acidic. Irrigation should continue for at least 30 minutes or until 2 L of irrigant has been instilled in mild cases and for 2-4 hours or until 10 L of irrigant has been instilled in severe cases. At the end of irrigation, the pH should be within a normal range (7.3-7.7). The pH should be checked again approximately 30 minutes after irrigation to ensure that it has not changed. The goal of treatment is to minimize sequelae that may threaten vision, such as conjunctival scarring, corneal scarring/opacification, glaucoma, cataract, and phthisis.

ORBITAL FRACTURES

The orbit is the bony structure surrounding the eye. Any of these bones may fracture in a traumatic incident. Superior and lateral wall fractures are the least common of the fracture sites, but superior orbital fracture is the most significant because of the potential of intracranial injury. The medial wall of the orbit is very susceptible to fracture because of the thin nature of the lamina papyracea. Perhaps the most common site of fracture from blunt trauma is the orbital floor. This is often referred to as blowout fracture. At times, the fracture may act as a trapdoor, entrapping orbital contents within the fracture site. In some cases, there may be very little external evidence of trauma, the so called "white-eyed blow-out fracture."

The patient often presents with a recent history of periorbital trauma and pain. Diplopia, eyelid swelling, eye movement restriction, or hypesthesia may or may not be present. Eye symptoms may be associated with nausea and bradycardia if the inferior rectus is entrapped in the fracture site. A complete ophthalmic examination, including visual acuity, examination of the pupil for ocular alignment, ocular motility, anterior segment, and fundus status, as well as the history of the injury, is required because there are often accompanying ocular injuries. The diagnosis of fracture is suspected if eye misalignment, eye movement restriction, or enophthalmos (sunken eye) are present. The diagnosis can be verified by orbital CT scan, although small areas of entrapped muscle may easily be missed if careful attention is not directed toward the fracture site.

Medical management includes iced compresses to the orbit and elevation of the head of the bed for the first 24-48 hours. Broad-spectrum antibiotics are sometimes recommended for 14 days because of the exposure of the orbital contents to the sinus cavity. In medial wall fractures, instructions not to blow one's nose should be given to the patient to avoid orbital emphysema and subsequent optic nerve compression. Consider neurosurgical consultation in orbital roof fractures. Indications for surgical repair of orbital fractures are diplopia in primary gaze or downgaze that persists for 2 weeks, enophthalmos, or fracture of the orbital floor involving more than half of the floor. Extraocular muscle entrapment often requires prompt surgical repair because affected patients have significant pain, nausea, and vomiting that are difficult to control. Rarely, extraocular muscle entrapment can cause activation of the oculocardiac reflex, requiring urgent fracture repair.

PENETRATING WOUNDS OF THE ORBIT

These demand careful evaluation for possible damage to the eye, optic nerve, orbital contents, or brain. Examination should include investigation for a retained foreign body. Orbital hemorrhage and infection are common with penetrating wounds of the orbit; such injuries must be treated as emergencies.

CHILD ABUSE

See Chapter 17.

This is a major cause of injuries to the eye and orbital region. The possibility of nonaccidental trauma must be considered in any child with ecchymosis or laceration of the lids, hemorrhage in or about the eye, cataract or dislocated lens, retinal detachment, or fracture of the orbit. Inflicted childhood neurotrauma (shaken baby syndrome) occurs secondary to violent, nonaccidental, repetitive, unrestrained acceleration-deceleration head and neck movements, with or without blunt head trauma in children typically younger than 3 years of age. Inflicted childhood neurotrauma accounts for approximately 10% of all cases of child abuse and carries a mortality rate of up to 25%. Detection of abuse is not only important to treat the pathology that is discovered but also to prevent further abuse or even death. The ocular manifestations are numerous and may have a prominent role in recognition of this syndrome. Retinal hemorrhage is the most common ophthalmic finding and occurs at all levels of the retina. The pattern of hemorrhage helps distinguish this disorder from other causes of retinal hemorrhage or from accidental injuries (Fig. 675.9). Retinal hemorrhages can occur without associated intracranial pathology.

FIREWORKS-RELATED INJURIES

Injuries related to the use of fireworks can be the most devastating of all ocular traumas that occur in children. At least 20% of emergency department visits for fireworks-related injuries are for ocular trauma. In the United States, a majority of these injuries take place around Independence Day, and most occur despite adult supervision.

SPORTS-RELATED OCULAR INJURIES AND THEIR PREVENTION

Although sports injuries occur in all age-groups, far more children and adolescents participate in high-risk sports than adults. The greater number of participating children, their athletic immaturity, and the increased likelihood of their using inadequate or improper eye protection account for their disproportionate share of sports-related eye injuries (see Chapter 734).

The sports with the highest risk of eye injury are those in which no eye protection can be worn, including boxing, wrestling, and martial arts. Other high-risk sports include those that use a rapidly moving ball or puck, bat, stick, racquet, or arrow (baseball, hockey, lacrosse, racquet sports, and archery) or involve aggressive body contact (football and basketball). Related to both risk and frequency of participation, the highest percentage of eye injuries are in basketball and baseball.

Protective eyewear, designed for a specific activity, is available for most sports. For basketball, racquet sports, and other recreational activities that do not require a helmet or face mask, molded polycarbonate sports goggles that are secured to the head by an elastic strap are suggested. For hockey, football, lacrosse, and baseball (batter), specific helmets with polycarbonate face shields and guards are available. Children should also wear sports goggles under their helmets. For baseball, goggles and helmets should be worn for batting, catching, and base running; goggles alone are usually sufficient for other positions.

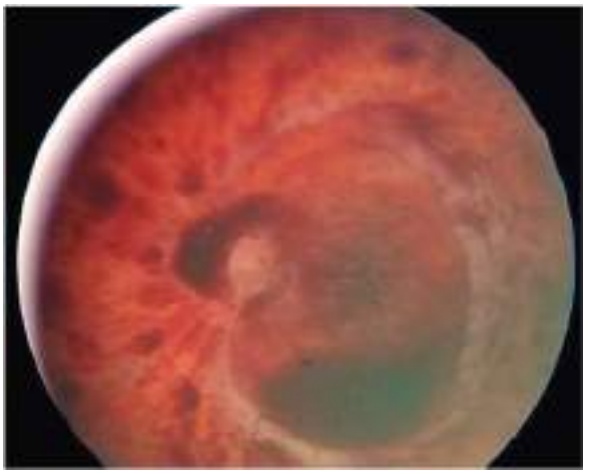

Fig. 675.9 Retinal hemorrhages in an abused child.

HANDHELD LASER RETINAL INJURY

Handheld laser pointers, often purchased to light cigarettes or for other purposes, may produce significant retinal damage if the power output is ≥150 mW. If a person looks directly at the light, direct foveal injury may occur before they have time to blink. Central (foveal) blurring and decreased visual activity are the chief complaints. Retinal injuries include retinal disruption, subretinal edema, and macular holes (Fig. 675.10), which usually require surgical repair.

Visit Elsevier eBooks+ at eBooks.Health.Elsevier.com for Bibliography.

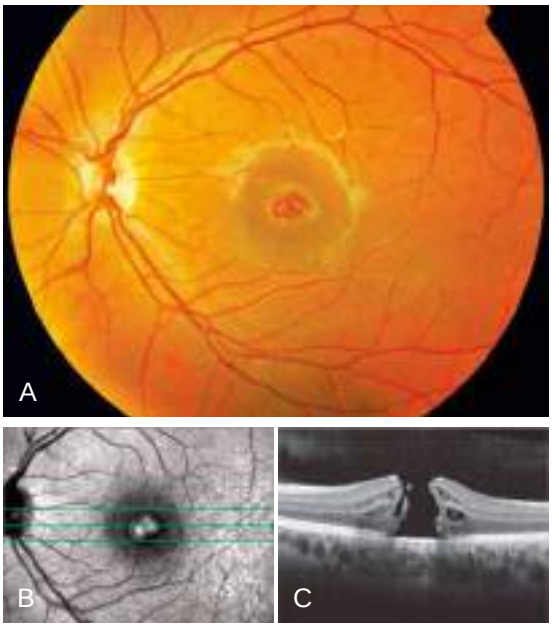

Fig. 675.10 Laser damage to the left eye. **A,** Color photo of the fundus of the left eye showing a macular hole. Note the changes at the retinal pigment epithelium. **B,** Infrared photo of the left fundus. **C,** Optical coherence tomography of the left eye showing the macular hole. *(From Petrou P, Patwary S, Banerjee PJ, et al. Bilateral macular hole from a handheld laser pointer. Lancet. 2014;383:1780.)*

The Ear

PART XXVIII

Chapter 676

General Considerations and Evaluation of the Ear

Joseph Haddad Jr.

CLINICAL MANIFESTATIONS

Diseases of the ear and temporal bone typically manifest with one or more of eight clinical signs and symptoms.

Otalgia usually is associated with inflammation of the middle ear (about 50% of cases) or external ear, but it can represent pain referred from involvement of the teeth, temporomandibular joint, or pharynx (Table 676.1). In young infants, pulling or rubbing the ear along with general irritability or poor sleep, especially when associated with fever, may be the only signs of ear pain. Ear pulling alone is not diagnostic of ear pathology.

Purulent otorrhea is a sign of otitis externa, otitis media (OM) with perforation of the tympanic membrane (TM), drainage from the middle ear through a patent tympanostomy tube, or, rarely, drainage from a first branchial cleft sinus. Bloody drainage may be associated with acute or chronic inflammation (often with granulation tissue and/or an ear tube), trauma, neoplasm, foreign body, or blood dyscrasia. Clear drainage suggests a perforation of the TM with a serous middle-ear effusion or, rarely, a cerebrospinal fluid leak draining through defects (congenital or traumatic) in the external auditory canal or from the middle ear.

Hearing loss results either from disease of the external or middle ear (conductive hearing loss) or from pathology in the inner ear, retrocochlear structures, or central auditory pathways (sensorineural hearing loss [SNHL]); the underlying etiology can be genetic or nongenetic, syndromic or nonsyndromic, or idiopathic. The most common cause of hearing loss in children is OM.

Swelling around the ear most commonly is a result of inflammation (e.g., external otitis, perichondritis, mastoiditis), trauma (e.g., hematoma), benign cystic masses, or neoplasm.

Vertigo is a specific type of dizziness that is defined as any illusion or sensation of motion. **Dizziness** is less specific than vertigo and refers to a sensation of altered orientation in space. Vertigo is an uncommon complaint in children; the child or parent might not volunteer information about balance unless asked specifically. The most common cause of dizziness in young children is eustachian tube–middle-ear disease, but true vertigo also may be caused by labyrinthitis, perilymphatic fistula between the inner and middle ear as a result of trauma or a congenital inner ear defect, cholesteatoma in the mastoid or middle ear, vestibular neuronitis, benign paroxysmal vertigo, Meniere disease, or disease of the central nervous system. Older children might describe a feeling of the room spinning or turning; younger children might express the dysequilibrium only by falling, stumbling, or clumsiness.

Nystagmus may be unidirectional, horizontal, or jerk nystagmus. It is vestibular in origin and usually is associated with vertigo.

Tinnitus rarely is described spontaneously by children, but it is common, especially in patients with eustachian tube–middle-ear disease or SNHL. Children can describe tinnitus if asked directly about it, including laterality and the quality of the sound.

FACIAL PARALYSIS

The facial nerve may be dehiscent in its course through the middle ear as a normal variant in as many as 50% of people. Infection with local inflammation, most commonly in acute OM, can lead to a temporary paralysis of the facial nerve. It also can result from Lyme disease, cholesteatoma, Bell palsy, Ramsay Hunt syndrome (herpes zoster oticus), fracture, neoplasm, or infection of the temporal bone. Congenital facial paralysis can result from birth trauma or congenital abnormality of the seventh nerve or from a syndrome such as Möbius or CHARGE (coloboma, heart defects, atresia choanae, retarded growth, genital hypoplasia, and ear anomalies), or it may be associated with other cranial nerve abnormalities and craniofacial anomalies.

PHYSICAL EXAMINATION

Complete examination with special attention to the head and neck can reveal a condition that can predispose to or be associated with ear disease in children. The facial appearance and the character of speech can give clues to an abnormality of the ear or hearing. Many craniofacial anomalies, such as cleft palate, mandibulofacial dysostosis (Treacher Collins syndrome), and trisomy 21 (Down syndrome), are associated with disorders of the ear and eustachian tube. Mouth breathing and hyponasality can indicate intranasal or postnasal obstruction. **Hypernasality** is a sign of velopharyngeal insufficiency. Examining the oropharyngeal cavity might uncover an overt cleft palate or a submucous cleft (usually associated with a bifid uvula), both of which predispose to OM with effusion. A nasopharyngeal tumor with nasal and eustachian tube blockage may be associated with OM.

The position of the patient for examination of the ear, nose, and throat depends on the patient's age and ability to cooperate, the clinical setting, and the examiner's preference. The child can be examined on an examination table or on the parent's lap. The presence of a parent or assistant usually is necessary to minimize movement and provide better examination results. An examining table may be desirable for uncooperative older infants or when a procedure, such as microscopic evaluation or tympanocentesis, is performed. Lap examination is adequate in most infants and young children; the parent may assist in restraining the child by folding the child's wrists and arms over the child's own abdomen with one hand and holding the child's head against the parent's chest with the other hand. If necessary, the child's legs can be held between the parent's knees. To avoid ear trauma with movement, the examiner should hold the otoscope with the hand placed firmly against the child's head or face, so that the otoscope moves with the head. Pulling up and out on the pinna straightens the ear canal and allows better exposure of the TM.

When examining the ear, inspecting the auricle and external auditory meatus for infection can aid in evaluating complications of OM. External otitis can result from acute OM with discharge, or inflammation of the posterior auricular area can indicate a periostitis or subperiosteal abscess extending from the mastoid air cells. The presence of preauricular pits or skin tags also should be noted because affected children have a slightly higher incidence of SNHL; ear pits can develop chronic infection.

Cerumen is a protective, waxy, water-repellent coating in the ear canal that can interfere with examination. Cerumen usually is removed using the surgical head of the otoscope, which allows passage of a wire loop or a blunt curette under direct visualization. Other methods include gentle irrigation of the ear canal with warm water, which should be performed only if the TM is intact, or instillation of a solution such as diluted hydrogen peroxide in the ear canal (with intact TM only) for a few minutes to soften the wax for suction removal or irrigation. Commercial preparations such as trolamine polypeptide oleate–condensate (Cerumenex) may cause dermatitis of the external canal with chronic use and should be used only under a physician's supervision.

Inflammation of the ear canal with associated pain often indicates external otitis. Abnormalities of the external auditory canal include

Table 676.1 Causes of Otalgia and Sources for Referred Pain

INTRINSIC
External Ear
External otitis
Cerumen impaction
Foreign body
Perichondritis
Preauricular cyst or sinus
Impacted insects
Myringitis
Trauma
Tumor
Middle Ear, Eustachian Tube, and Mastoid
Barotrauma
Middle ear effusion
Negative intratympanic pressure (eustachian tube dysfunction)
Acute otitis media
Mastoiditis
Aditus block
Complication of otitis media
Gradenigo syndrome (otorrhea, CN VI palsy, pain in CN V distribution, petrositis)
Tumor
Eosinophilic granuloma
Granulomatosis with polyangiitis
EXTRINSIC
Trigeminal Nerve
Dental
Jaw
Temporomandibular joint
Oral cavity (tongue)
Infratemporal fossa tumors
Facial Nerve
Bell palsy
Tumors
Herpes zoster
Glossopharyngeal Nerve
Tonsil
Oropharynx
Nasopharynx
Vagus Nerve
Laryngopharynx
Esophagus
Gastroesophageal reflux
Thyroid
Cervical Nerves
Lymph nodes
Cysts
Cervical spine
Neck infections
Miscellaneous
Migraine
Neuralgias
Paranasal sinuses
Central nervous system
Drug induced (mesalazine, sulfasalazine)
Factitious disorder by proxy

From Bluestone CD, Stool SE, Alper CM, et al. *Pediatric Otolaryngology*, 4th ed., vol. 1. Philadelphia: Saunders; 2003:288.

stenosis (common in children with trisomy 21), bony exostoses, otorrhea, and the presence of foreign bodies. Cholesteatoma of the middle ear can manifest in the canal as intermittent foul-smelling drainage, sometimes associated with white debris; cholesteatoma of the external canal can appear as a white, pearl-like mass in the canal skin. White or gray debris of the canal suggests fungal external otitis. Newborn ear canals are filled with vernix caseosa, which is soft and pale yellow and should disappear shortly after birth.

The TM and its mobility are best assessed with a pneumatic otoscope. The normal TM is in a neutral position; a bulging TM may be caused by increased middle-ear air pressure, with or without pus or effusion in the middle ear; a bulging drum can obscure visualization of the malleus and annulus. Retraction of the TM usually indicates negative middle-ear pressure, but it also can result from previous middle-ear disease with fixation of the ossicles, ossicular ligaments, or TM. When retraction is present, the bony malleus appears more prominent, and the incus may be more visible posterior to the malleus.

The normal TM has a silvery gray, "waxed paper" appearance. A white or yellow TM can indicate a middle-ear effusion. A red TM alone might not indicate pathology, because the blood vessels of the membrane may be engorged as a result of crying, sneezing, or nose blowing, though hemorrhagic redness is associated with acute OM. A normal TM is translucent, allowing the observer to visualize the middle-ear landmarks: incus, promontory, round window niche, and often the chorda tympani nerve. If a middle-ear effusion is present, an air-fluid level or bubbles may be visible (Fig. 676.1). Inability to visualize the middle-ear structures indicates opacification of the drum, usually caused by thickening of the TM or a middle-ear effusion or both. Assessment of the light reflex often is not helpful, because a middle ear with effusion reflects light as well as a normal ear. Bullae (blister of the TM) formation is associated with acute OM.

TM mobility is helpful in assessing middle-ear pressures and the presence or absence of fluid (see Fig. 676.1). To best perform pneumatic otoscopy, a speculum of adequate size is used to obtain a good seal and allow air movement in the canal. A rubber ring around the tip of the speculum can help obtain a better canal seal. Normal middle-ear pressure is characterized by a neutral TM position and brisk TM movement to both positive and negative pressures.

Eardrum retraction is most common when negative middle-ear pressure is present; with even moderate negative middle-ear pressure, there is no visible inward movement with applied positive pressure in the ear canal. However, negative canal pressure, which is produced by releasing the rubber bulb of the pneumatic otoscope, can cause the TM to bounce out toward the neutral position. The TM can retract in both the presence and absence of middle-ear fluid, and if the middle-ear fluid is mixed with air, the TM might still have some mobility. Outward eardrum movement is less likely in the presence of severe negative middle-ear pressure or middle-ear effusion.

The TM that exhibits fullness (bulging) moves to applied positive pressure but not to applied negative pressure if the pressure within the middle ear is positive. A full TM and positive middle-ear pressure without an effusion may be seen in young infants who are crying during the otoscopic examination, in older infants and children with nasal obstruction, and in the early stage of acute OM. When the middle-ear–mastoid air cell system is filled with an effusion and little or no air is present, the mobility of the TM is severely decreased or absent in response to both applied positive and negative pressures.

Tympanocentesis, or aspiration of the middle ear, is the definitive (but not usually needed) method of verifying the presence and type of a middle-ear effusion and is performed by inserting an 18-gauge spinal needle attached to a syringe or a collection trap through the inferior portion of the TM (Fig. 676.2). Culturing of the ear canal and alcohol cleansing should precede tympanocentesis and culture of the middle-ear aspirate; a canal culture is taken first to help determine whether organisms cultured from the middle ear are contaminants from the external canal or true middle-ear pathogens.

Further diagnostic studies of the ear and hearing include audiometric evaluation, impedance audiometry (tympanometry), acoustic reflectometry, and specialized eustachian tube function studies. Diagnostic imaging studies, including CT and MRI, often provide further information about anatomic abnormalities and the extent of inflammatory processes or neoplasms. Specialized assessment of labyrinthine function should be considered in the evaluation of a child with a suspected vestibular disorder (see Chapter 682).

Visit Elsevier eBooks+ at eBooks.Health.Elsevier.com for Bibliography.

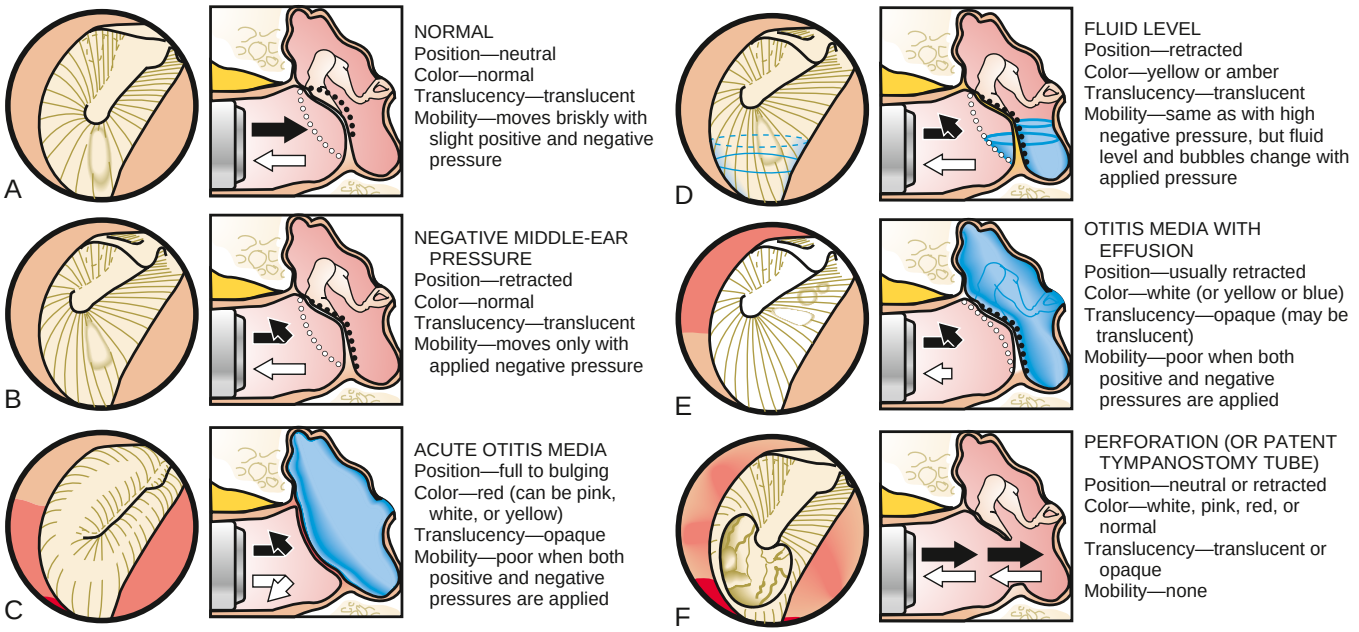

Fig. 676.1 A–F, Common conditions of the middle ear, as assessed with the otoscope. *(From Bluestone CD, Klein JO. Otitis Media in Infants and Children, 3rd ed. Philadelphia: Saunders; 2001:131.)*

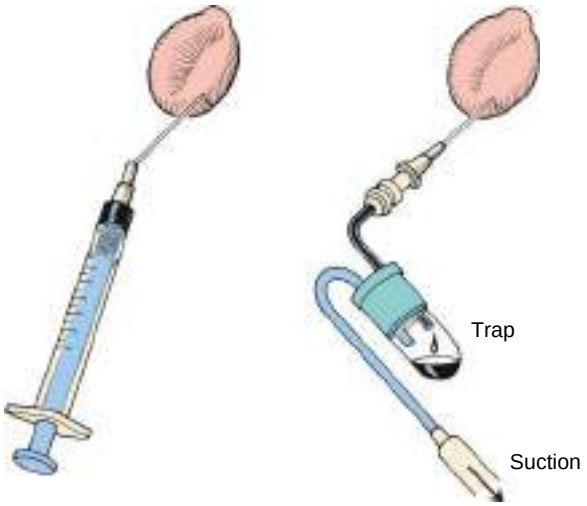

Fig. 676.2 Tympanocentesis can be performed with a needle attached to a tuberculin syringe *(left)* or by using an Alden-Senturia collection trap (Storz Instrument Co, St. Louis). *(From Bluestone CD, Klein JO. Otitis Media in Infants and Children, 2nd ed. Philadelphia: Saunders; 1995:127.)*

Chapter 677

Hearing Loss

Joseph Haddad Jr.

See also Chapter 55.

INCIDENCE AND PREVALENCE

Bilateral neural hearing loss is categorized as **mild** (20-30 dB hearing level [HL]), **moderate** (30-50 dB HL), **moderately severe** (50-70 dB HL), **severe** (75-85 dB HL), or **profound** (>85 dB). The World Health Organization estimates that approximately 360 million people (5% of the world's population, including 32 million children) have disabling hearing loss. An additional 364 million people have mild hearing loss. Half of these cases could have been prevented. In the United States, the average incidence of neonatal hearing loss is 1.6 per 1,000 infants; the rate by state varies from 0.22 to 3.61 per 1,000. Among children and adolescents, the prevalence of mild or greater hearing loss is 3.1% and is higher among persons from lower-income families.

Onset of hearing loss in children can occur at any time in childhood. When less severe hearing loss or the transient hearing loss that commonly accompanies middle-ear disease in young children is considered, the number of affected children increases substantially.

TYPES OF HEARING LOSS

Hearing loss can be peripheral or central in origin. Peripheral hearing loss can be conductive, sensorineural, or mixed. **Conductive hearing loss (CHL)** is the most common type of hearing loss in children and occurs when sound transmission is physically impeded in the external and/or middle ear, most commonly by otitis media (OM) with effusion. **Sensorineural hearing loss (SNHL)** is caused by damage to or maldevelopment of structures of the inner ear, including hair cell destruction, cochlear malformation; perilymphatic fistula of the round or oval window membrane, and failure in development or lesions of the acoustic division of the eighth nerve. Coexistent CHL and SNHL is considered a **mixed hearing loss**.

An auditory deficit originating along the central auditory nervous system pathways from the proximal eighth nerve to the cerebral cortex usually is considered **central** (or **retrocochlear**) **hearing loss**. Tumors or demyelinating disease of the eighth nerve and cerebellopontine angle can cause hearing deficits but spare the outer, middle, and inner ear. These causes of hearing loss are rare in children. Functional disorders of the eighth nerve and/or brainstem pathways may manifest in a variety of clinical defects known collectively as *auditory neuropathy spectrum disorder* (ANSD) or *auditory dyssynchrony,* without abnormalities demonstrable on imaging. Other forms of central auditory deficits, known as **central auditory processing disorders**, include those that make it difficult even for children with normal hearing sensitivity to listen selectively in the presence of noise, to combine information from the two ears properly, to process speech when it is slightly degraded, and to integrate auditory information when it is delivered faster, although they can process it when delivered at a slow rate. These deficits can manifest as specific language disorders or poor attention or as academic or behavior problems

in school. Strategies for coping with such disorders are available for older children, and identification and documentation of the central auditory processing disorder allow parents and teachers to make appropriate accommodations to enhance learning.

ETIOLOGY

Most CHL is acquired, with middle-ear fluid the most common cause. Congenital causes include anomalies of the pinna, external ear canal, tympanic membrane (TM), and ossicles. Rarely congenital cholesteatoma or other masses in the middle ear manifest as CHL. TM perforation (e.g., trauma, OM), ossicular discontinuity (e.g., infection, cholesteatoma, trauma), tympanosclerosis, acquired cholesteatoma, or masses in the ear canal or middle ear (Langerhans cell histiocytosis, salivary gland tumors, glomus tumors, rhabdomyosarcoma) also can manifest as CHL. Uncommon diseases that affect the middle ear and temporal bone and can manifest with CHL include otosclerosis, osteopetrosis, fibrous dysplasia, and osteogenesis imperfecta. Rare autoimmune or inflammatory syndromes may include hearing loss. **Susac syndrome** is manifest as a subacute encephalopathy, visual impairment, and hearing loss. **Cogan syndrome** presents with interstitial keratitis, sudden hearing loss, and vestibular impairment.

SNHL may be congenital or acquired. Acquired SNHL may be caused by genetic, infectious, autoimmune, anatomic, traumatic, ototoxic, and idiopathic factors (Tables 677.1-677.4). The recognized risk factors account for approximately 50% of cases of moderate to profound SNHL.

Infectious Causes

The most common infectious cause of congenital SNHL is **cytomegalovirus (CMV)**, which infects 1 in 100 newborns in the United States (see Chapters 149 and 302). Of these, 6,000-8,000 infants each year have clinical manifestations, including approximately 75% with SNHL. Congenital CMV warrants special attention because it is associated with hearing loss in its symptomatic and asymptomatic forms with bilateral and unilateral hearing loss, respectively; the hearing loss may be progressive. Some children with congenital CMV have suddenly lost residual hearing at 4-5 years of age. Much less common congenital infectious causes of SNHL include toxoplasmosis and syphilis. Congenital CMV, toxoplasmosis, and syphilis also can manifest with delayed onset of SNHL months to years after birth. Rubella, once the most common viral cause of congenital SNHL, is very uncommon because of effective vaccination programs. In utero infection with herpes simplex virus is rare, and hearing loss is not an isolated manifestation.

Other postnatal infectious causes of SNHL include neonatal group B streptococcal sepsis and bacterial meningitis at any age. *Streptococcus pneumoniae* is the most common cause of bacterial meningitis that results in SNHL after the neonatal period and has become less common with the routine administration of pneumococcal conjugate vaccine. *Haemophilus influenzae* type b, once the most common cause of meningitis resulting in SNHL, is rare owing to the *H. influenzae* type b conjugate vaccine. Uncommon infectious causes of SNHL include Lyme disease, parvovirus B19, and varicella. Mumps, rubella, and measles, all once common causes of SNHL in children, are rare owing to vaccination programs. When these infectious etiologies occur, the resulting hearing loss is frequently bilateral and severe.

Genetic Causes

Genetic causes of SNHL probably are responsible for as many as 50% of SNHL cases (see Tables 677.3 and 677.4). These disorders may be associated with other abnormalities, may be part of a named syndrome, or can exist in isolation. SNHL often occurs with abnormalities of the ear and eye and with disorders of the metabolic, musculoskeletal, integumentary, renal, and nervous systems.

Autosomal dominant hearing losses account for approximately 10% of all cases of childhood SNHL. Waardenburg (types I and II) and branchiootorenal syndromes represent two of the most common autosomal dominant syndromic types of SNHL. Types of SNHL are coded with a four-letter code and a number, as follows: **DFN** = deafness, A = dominant, B = recessive, and number = order of discovery (e.g., DFNA 13). Autosomal dominant conditions in addition to those just discussed include DFNA 1-18, 20-25, 30, 36, 38, and pathologic variants in the crystallin gene *(CRYM)*.

Autosomal recessive genetic SNHL, both syndromic and nonsyndromic, accounts for approximately 80% of all childhood cases of

Table 677.1 Indicators Associated with Hearing Loss

INDICATORS ASSOCIATED WITH SENSORINEURAL AND/OR CONDUCTIVE HEARING LOSS

Neonates (Birth to 28 Days) When Universal Screening Is Not Available

- Family history of hereditary childhood sensorineural hearing loss
- In utero infection, such as cytomegalovirus, rubella, syphilis, herpes simplex, or toxoplasmosis
- Craniofacial anomalies, including those with morphologic abnormalities of the pinna, ear canal, ear tags, ear pits, and temporal bone anomalies
- Birth weight <1,500 g (3.3 lb)
- Hyperbilirubinemia at a serum level requiring exchange transfusion
- Ototoxic medications, including but not limited to the aminoglycosides, used in multiple courses or in combination with loop diuretics
- Bacterial meningitis
- Apgar scores of 0-4 at 1 min or 0-6 at 5 min
- Mechanical ventilation lasting ≥5 days; extracorporeal membrane oxygenation
- Stigmata or other findings associated with a syndrome known to include a sensorineural and/or conductive hearing loss; white forelock

Infants and Toddlers (Age 29 Days to 2 Yr) When Certain Health Conditions Develop that Require Rescreening

- Parent or caregiver concern regarding hearing, speech, language, and/or developmental delay
- Bacterial meningitis and other infections associated with sensorineural hearing loss
- Head trauma associated with loss of consciousness or skull fracture
- Stigmata or other findings associated with a syndrome known to include a sensorineural and/or conductive hearing loss; neurofibromatosis, osteopetrosis, and Usher Hunter, Waardenburg, Alport, Pendred, or Jervell and Lange-Nielsen syndrome
- Ototoxic medications, including but not limited to chemotherapeutic agents or aminoglycosides used in multiple courses or in combination with loop diuretics
- Recurrent or persistent otitis media with effusion for 3 mo or longer
- Skeletal dysplasia

Infants and Toddlers (Age 29 Days to 3 Yr) Who Require Periodic Monitoring of Hearing

- Some newborns and infants pass initial hearing screening but require periodic monitoring of hearing to detect delayed-onset sensorineural and/or conductive hearing loss. Infants with these indicators require hearing evaluation at least every 6 mo until age 3 yr and at appropriate intervals thereafter

INDICATORS ASSOCIATED WITH DELAYED-ONSET SENSORINEURAL HEARING LOSS

- Family history of hereditary childhood hearing loss
- In utero infection, such as cytomegalovirus, rubella, syphilis, herpes simplex, or toxoplasmosis
- Neurofibromatosis type 2 and neurodegenerative disorders
- Cogan syndrome (vasculitis: keratitis, uveitis, vertigo, arthritis, dermatitis)

INDICATORS ASSOCIATED WITH CONDUCTIVE HEARING LOSS

- Recurrent or persistent otitis media with effusion
- Anatomic deformities and other disorders that affect eustachian tube function
- Neurodegenerative disorders

Note: At all ages, parents' concern about hearing loss must be taken seriously even in the absence of risk factors.

Adapted from American Academy of Pediatrics, Joint Committee on Infant Hearing. Joint Committee on Infant Hearing 1994 position statement. *Pediatrics.* 1995;95:152.

Table 677.2 Infectious Pathogens Implicated in Sensorineural Hearing Loss in Children

CONGENITAL INFECTIONS
Cytomegalovirus
Lymphocytic choriomeningitis virus
Rubella virus
Toxoplasma gondii
Treponema pallidum
ACQUIRED INFECTIONS
Borrelia burgdorferi (Lyme disease)
Cytomegalovirus
Epstein-Barr virus
Haemophilus influenzae
Herpes simplex
Lassa fever virus
Measles virus
Mumps virus
Neisseria meningitidis
Nonpolio enteroviruses
Plasmodium falciparum
Rubella
Streptococcus pneumoniae
Syphilis
Varicella-zoster virus

From Smith RJH, Bale JF Jr., White KR. Sensorineural hearing loss in children. *Lancet.* 2005;365:879–890.

SNHL. Usher syndrome (types 1, 2, and 3: all associated with blindness and retinitis pigmentosa), Pendred syndrome, and Jervell and Lange-Nielsen syndrome (one form of long QT syndrome) are three of the most common syndromic recessive types of SNHL. Other autosomal recessive conditions include Alström syndrome, type 4 Bartter syndrome, biotinidase deficiency, and DFNB 1-18, 20-23, 26-27, 29-33, 35-40, 42, 44, 46, 48, 49, 53, and 55.

Unlike children with an easily identified syndrome or with anomalies of the outer ear, who may be identified as being at risk for hearing loss and consequently monitored, children with nonsyndromic hearing loss present greater diagnostic difficulty. Pathogenic variants of the connexin-26 and -30 genes are identified in autosomal recessive (DNFB 1) and autosomal dominant (DNFA 3) SNHL and in sporadic patients with nonsyndromic SNHL; up to 50% of nonsyndromic SNHLs may be related to a pathogenic variation of connexin-26. Pathologic variants of the *GJB2* gene co-localize with DFNA 3 and DFNB 1 loci on chromosome 13, are associated with autosomal nonsyndromic susceptibility to deafness, and are associated with as many as 30% of cases of sporadic severe to profound congenital deafness and 50% of cases of autosomal recessive nonsyndromic deafness. In addition, pathogenic variants in *GJB6* are associated with approximately 5% of recessive nonsyndromic deafness. Sex-linked disorders associated with SNHL, thought to account for 1–2% of SNHLs, include Norrie disease, otopalatal digital syndrome, Nance deafness, and Alport syndrome. Chromosomal abnormalities such as trisomy 13-15, trisomy 18, and trisomy 21 also can be accompanied by hearing impairment. Patients with Turner syndrome have monosomy for all or part of one X chromosome and can have CHL, SNHL, or mixed hearing loss. The hearing loss may be progressive. Mitochondrial genetic abnormalities (MELAS, MERRF) also can result in SNHL (see Table 677.3).

Many genetically determined causes of hearing impairment, both syndromic and nonsyndromic, do not express themselves until sometime after birth. Alport, Alström, Down, and Hunter-Hurler syndromes and von Recklinghausen disease are genetic diseases that can have SNHL as a late manifestation.

Physical Causes

Agenesis or malformation of cochlear structures may be genetic; these include Scheibe, Mondini (Fig. 677.1), Alexander, and Michel anomalies, enlarged vestibular aqueducts (in isolation or associated with Pendred syndrome), and semicircular canal anomalies. These anomalies most likely develop before the eighth week of gestation and result from arrest in normal development, aberrant development, or both. Many of these anomalies also have been described in association with other congenital conditions such as intrauterine CMV and rubella infections. These abnormalities are quite common; in as many as 20% of children with SNHL, obvious or subtle temporal bone abnormalities are seen on high-resolution CT scanning or MRI.

Conditions, diseases, or syndromes that include craniofacial abnormalities may be associated with CHL and possibly with SNHL. Pierre Robin sequence, Stickler syndrome, and Treacher Collins, Klippel-Feil, Crouzon, and branchiootorenal syndromes and osteogenesis imperfecta often are associated with hearing loss. Congenital anomalies causing CHL include malformations of the ossicles and middle-ear structures and atresia of the external auditory canal.

SNHL also can occur secondary to exposure to toxins, chemicals, antimicrobials, and noise exposure. Early in pregnancy, the embryo is particularly vulnerable to the effects of toxic substances. Ototoxic drugs, including aminoglycosides, loop diuretics, and chemotherapeutic agents (cisplatin) also can cause SNHL. Congenital SNHL can occur secondary to exposure to these drugs as well as to thalidomide and retinoids. Certain chemicals, such as quinine, lead, and arsenic, can cause hearing loss both prenatally and postnatally. Among adolescents, the use of personal listening devices at high volume settings has been found to be correlated with hearing loss.

Trauma, including temporal bone fractures, inner ear concussion, head trauma, iatrogenic trauma (e.g., surgery, extracorporeal membrane oxygenation), radiation exposure, and noise, also can cause SNHL. Other uncommon causes of SNHL in children include autoimmune disease (systemic or limited to the inner ear), metabolic abnormalities, and neoplasms of the temporal bone.

EFFECTS OF HEARING IMPAIRMENT

The effects of hearing impairment depend on the nature and degree of the hearing loss and on the individual characteristics of the child. Hearing loss may be unilateral or bilateral, conductive, sensorineural, or mixed; mild, moderate, severe, or profound; of sudden or gradual onset; stable, progressive, or fluctuating; and affecting a part or all of the audible spectrum. Other factors, such as intelligence, medical or physical condition (including accompanying syndromes), family support, age at onset, age at time of identification, and promptness of intervention, also affect the impact of hearing loss on a child (see Chapter 55).

Most hearing-impaired children have some useable hearing. Only 6% of those in the hearing-impaired population have bilateral profound hearing loss. Hearing loss very early in life can affect the development of speech and language, social and emotional development, behavior, attention, and academic achievement. Some cases of hearing impairment are misdiagnosed because affected children have sufficient hearing to respond to environmental sounds and can learn some speech and language but when challenged in the classroom cannot perform to full potential.

Even mild or unilateral hearing loss can have a detrimental effect on the development of a young child and on school performance. Children with such hearing impairments have greater difficulty when listening conditions are unfavorable (e.g., background noise and poor acoustics), as can occur in a classroom. The fact that schools are auditory-verbal environments is unappreciated by those who minimize the impact of hearing impairment on learning. Hearing loss should be considered in any child with speech and language difficulties or below-par performance, poor behavior, or inattention in school (Table 677.5).

Children with moderate, severe, or profound hearing impairment and those with other impairing conditions often are educated in classes or schools for children with special needs. There is a strong trend toward integrating a child with hearing loss into the least restrictive learning environment; this approach can only be successful if there are sufficient supportive services available for auditory and other learning needs. The auditory management and choices regarding modes of communication

Table 677.3 Common Types of Early-Onset Hereditary Nonsyndromic Sensorineural Hearing Loss

LOCUS	GENE	AUDIO PHENOTYPE
DFN3*	*POU3F4*	Conductive hearing loss as a result of stapes fixation mimicking otosclerosis; superimposed progressive SNHL.
DFNA1	*DIAPH1*	Low-frequency loss beginning in the first decade and progressing to all frequencies to produce a flat audio profile with profound losses throughout the auditory range.
DFNA2	*KCNQ4* *GJB3*	Symmetric high-frequency sensorineural loss beginning in the first decade and progressing over all frequencies. Symmetric high-frequency sensorineural loss beginning in the third decade.
DFNA3	*GJB2* *GJB6*	Childhood-onset, progressive, moderate to severe high-frequency sensorineural hearing impairment. Childhood-onset, progressive, moderate to severe high-frequency sensorineural hearing impairment.
DFNA6, 14, and 38	*WFS1*	Early-onset low-frequency sensorineural loss; approximately 75% of families dominantly segregating this audio profile carry missense mutations in the C-terminal domain of wolframin.
DFNA8, and 12	*TECTA*	Early-onset stable bilateral hearing loss affecting mainly mid to high frequencies.
DFNA10	*EYA4*	Progressive loss beginning in the second decade as a flat to gently sloping audio profile that becomes steeply sloping with age.
DFNA11	*MYO7A*	Ascending audiogram affecting low and middle frequencies at young ages and then affecting all frequencies with increasing age.
DFNA13	*COL11A2*	Congenital midfrequency sensorineural loss that shows age-related progression across the auditory range.
DFNA15	*POU4F3*	Bilateral progressive sensorineural loss beginning in the second decade.
DFNA20, and 26	*ACTG1*	Bilateral progressive sensorineural loss beginning in the second decade; with age, the loss increases with threshold shifts in all frequencies, although a sloping configuration is maintained in most cases.
DFNA22	*MYO6*	Postlingual, slowly progressive, moderate to severe hearing loss.
DFNB1	*GJB2, GJB6*	Hearing loss varies from mild to profound. The most common genotype, 35delG/35delG, is associated with severe to profound SNHL in about 90% of affected children; severe to profound deafness is observed in only 60% of children who are compound heterozygotes carrying 1 35delG allele and any other *GJB2* SNHL-causing allele variant; in children carrying 2 *GJB2* SNHL-causing missense mutations, severe to profound deafness is not observed.
DFNB3	*MYO7A*	Severe to profound sensorineural hearing loss.
DFNB4	*SLC26A4*	DFNB4 and Pendred syndrome (see Table 677.5) are allelic. DFNB4 hearing loss is associated with dilation of the vestibular aqueduct and can be unilateral or bilateral. In the high frequencies, the loss is severe to profound; in the low frequencies, the degree of loss varies widely. Onset can be congenital (prelingual), but progressive postlingual loss also is common.
DFNB7, and 11	*TMC1*	Severe to profound prelingual hearing impairment.
DFNB9	*OTOF*	*OTOF*-related deafness is characterized by two phenotypes: prelingual nonsyndromic hearing loss and, less frequently, temperature-sensitive nonsyndromic auditory neuropathy spectrum disorder. The nonsyndromic hearing loss is bilateral severe to profound congenital deafness.
DFNB12	*CDH23*	Depending on the type of mutation, recessive mutations of *CDH23* can cause nonsyndromic deafness or type 1 Usher syndrome (USH1), which is characterized by deafness, vestibular areflexia, and vision loss as a result of retinitis pigmentosa.
DFNB16	*STRC*	Early-onset, nonsyndromic, autosomal recessive sensorineural hearing loss.
mtDNA	*MTRNR1* *MTTS1*	Degree of hearing loss varies from mild to profound but usually is symmetric; high frequencies are preferentially affected; precipitous loss in hearing can occur after aminoglycoside therapy; variable penetrance.

*Approximately 45 DFNA genes are inherited as autosomal recessive or dominant and, less often, X-linked.
SNHL, Sensorineural hearing loss.
Adapted from Smith RJH, Bale JF Jr,. White KR. Sensorineural hearing loss in children. *Lancet*. 2005;365:879–890.

and education for children with hearing impairments must be individualized, because these children are not a homogeneous group. A team approach to individual case management is essential because each child and family unit have unique needs and abilities (see Chapter 55).

HEARING SCREENING

Hearing impairment can have a major impact on a child's development, and because early identification improves prognosis, screening programs have been widely and strongly advocated. The National Center for Hearing Assessment and Management estimates that the detection and treatment at birth of hearing loss saves $400,000 per child in special education costs; screening costs approximately $8-$50/child. Data from the Colorado newborn screening program suggest that if hearing-impaired infants are identified and treated by age 6 months, these children (with the exception of those with bilateral profound impairment) should develop the same level of language as their age-matched peers who are not hearing impaired. These data provide compelling support for establishing mandated newborn hearing screening programs for all children. The American Academy of Pediatrics endorses the goal of universal detection of hearing loss in infants before 3 months of age, with appropriate intervention no later than 6 months of age. The Centers for Disease Control and Prevention estimates that of the approximately 4 million infants born in the United States in 2014, 97.9% were screened for hearing loss.

Table 677.4 Common Types of Syndromic Sensorineural Hearing Loss

SYNDROME	GENE	PHENOTYPE
DOMINANT		
Waardenburg (WS1) (may also be recessive)	*PAX3*	Major diagnostic criteria include dystopia canthorum, congenital hearing loss, heterochromic irises, white forelock, and an affected first-degree relative. Approximately 60% of affected children have congenital hearing loss; in 90%, the loss is bilateral.
Waardenburg (WS2) (WS2D) (WS2E) (WS4A) (WS4B)	*MITF*, others *SNAI12* *SOX10* *EDNRB* *EDN3*	Major diagnostic criteria are as for WS1 but without dystopia canthorum. Approximately 80% of affected children have congenital hearing loss; in 90%, the loss is bilateral.
Branchiootorenal	*EYA1* *SIX1* *SIX5*	Diagnostic criteria include hearing loss (98%); preauricular pits (85%); and branchial (70%), renal (40%), and external ear (30%) abnormalities. The hearing loss can be conductive, sensorineural, or mixed and mild to profound in degree.
CHARGE syndrome	*CHD7*	Choanal atresia, colobomas, heart defect, retardation, genital hypoplasia, ear anomalies, deafness. Can lead to sensorineural or mixed hearing loss. Can be autosomal dominant or isolated cases.
Goldenhar syndrome	Unknown	Part of the hemifacial microsomia spectrum. Facial hypoplasia, ear anomalies, hemivertebrae, and parotid gland dysfunction. Can cause conductive or mixed hearing loss. Can be autosomal dominant or sporadic.
Stickler	*COL2A1* *COL11A1* *COL11A2* *COL9A1*	Myopia, cleft palate, hearing loss, joint hypermobility, micrognathia.
RECESSIVE		
Pendred syndrome	*SLC26A4*	Diagnostic criteria include sensorineural hearing loss that is congenital, nonprogressive, and severe to profound in many cases, but can be late-onset and progressive; bilateral dilation of the vestibular aqueduct with or without cochlear hypoplasia; and an abnormal perchlorate discharge test or goiter.
Alport syndrome	*COL4A3, COL4A4,* and *COL4A5* (X-linked)	Nephritis, deafness, lens defects, retinitis. Can lead to bilateral sensorineural hearing loss in the 2,000-8,000 Hz range. The hearing loss develops gradually and is not generally present in early infancy.
Usher syndrome type 1 (USH1)	*USH1A, MYO7A, USH1C, CDH23, USH1E, PCDH15, USH1G*	Diagnostic criteria include congenital, bilateral, and profound hearing loss; vestibular areflexia; and retinitis pigmentosa (commonly not diagnosed until tunnel vision and nyctalopia become severe enough to be noticeable).
Usher syndrome type 2 (USH2)	*USH2A, USH2B, USH2C, WHRN, ADGRV1*	Diagnostic criteria include mild to severe, congenital, bilateral hearing loss and retinitis pigmentosa; hearing loss may be perceived as progressing over time because speech perception decreases as diminishing vision interferes with subconscious lip reading.
Usher syndrome type 3 (USH3)	*USH3* *CLRN1*	Diagnostic criteria include postlingual, progressive sensorineural hearing loss; late-onset retinitis pigmentosa; and variable impairment of vestibular function.
Jervell and Lange-Nielsen syndrome	*KCNQ1* *KCNE1*	Severe hearing loss, prolonged QT interval (ECG), and sudden death.

Adapted from Smith RJH, Bale JF Jr., White KR. Sensorineural hearing loss in children. *Lancet*. 2005;365:879–890.

Hearing screening is mandated in at least 45 states, but until screening programs are universally mandated, some hospitals will continue to use other criteria to screen for hearing loss. Some use the high-risk criteria (see Table 677.1) to decide which infants to screen, some screen all infants who require intensive care, and some do both. The problem with using high-risk criteria to screen is that 50% of cases of hearing impairment will be missed, either because the infants are hearing impaired but do not meet any of the high-risk criteria or because they develop hearing loss after the neonatal period.

The recommended hearing screening techniques are either otoacoustic emissions (OAE) testing or auditory brainstem evoked responses (ABRs). The ABR test, an auditory evoked electrophysiologic response that correlates highly with hearing, has been used successfully and cost-effectively to screen newborns and to identify further the degree and type of hearing loss. OAE tests, used successfully in most universal newborn screening programs, are quick, easy to administer, and inexpensive, and they provide a sensitive indication of the presence of hearing loss. Results are relatively easy to interpret. OAE tests elicit no response if hearing is worse than 30-40 dB, no matter what the cause; children who fail OAE tests undergo an ABR for a more definitive evaluation, as ABR has a higher sensitivity and specificity. It is recommended that both OAE measurement and ABR screening be used in the intensive care unit setting. Screening methods such as observing behavioral responses to uncalibrated noisemakers or using automated systems such as the Crib-o-gram (Canon) or the auditory response cradle (in which movement of the infant in response to sound is recorded by motion sensors) *are not recommended.*

Many children become hearing impaired after the neonatal period and therefore are not identified by newborn screening programs. Often it is not until children are in preschool or kindergarten that further hearing screening takes place; an evidence-based systematic review has identified pure-tone and OAE screening to be effective, with pure-tone screening having higher sensitivity. Among adolescents, high-frequency hearing loss is associated with exposure to loud noises, so

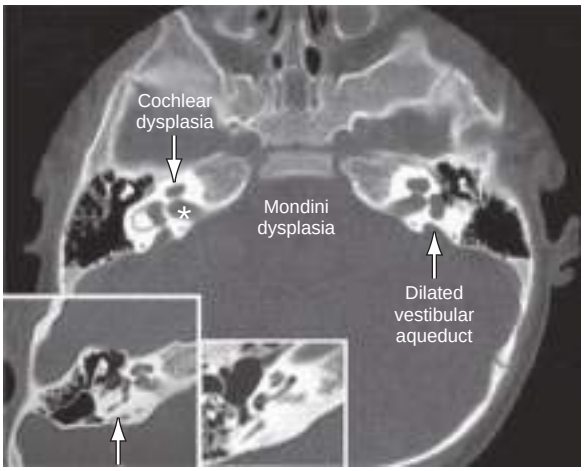

Fig. 677.1 Mondini dysplasia shown by CT of the temporal bone in a child with Pendred syndrome. Both dilation of the vestibular aqueduct and cochlear dysplasia are present in this section. In the larger of the two inset images of a normal temporal bone, the vestibular aqueduct is visible but much smaller *(arrow)*. The cochlea appears normal, and in the smaller inset image of a more inferior axial section, the expected number of cochlear turns can be clearly counted. Internal auditory canal *(asterisk)*. *(From Smith RJH, Bale JF Jr., White KR. Sensorineural hearing loss in children. Lancet. 2005;365:879–890.)*

attention should be paid to those frequencies on a hearing screen; most noise-induced hearing loss is around 4 kHz. Figure 677.2 provides recommendations for postneonatal screening.

IDENTIFICATION OF HEARING IMPAIRMENT

The impact of hearing impairment is greatest on an infant who has yet to develop language; consequently, identification, diagnosis, description, and treatment should begin as soon as possible. Infants with a prenatal or perinatal history that puts them at risk (see Table 677.3) or those who have failed a formal hearing screening should be evaluated by an experienced clinical audiologist until a reliable assessment of auditory sensitivity has been obtained. Primary care clinicians should encourage families to cooperate with the follow-up plan. Infants who are born at risk but who were not screened as neonates (e.g., because of transfer from one hospital to another) should have a hearing screening by age 3 months.

Hearing-impaired infants who are born at risk or are screened for hearing loss in a neonatal hearing screening program account for only a portion of hearing-impaired children. Children who are congenitally deaf because of autosomal recessive inheritance or subclinical congenital infection often are not identified until 1-3 years of age. Usually those with more severe hearing loss are identified at an earlier age, but identification often occurs later than the age at which intervention can provide an optimal outcome, especially in countries lacking technologic resources. Children who hear normally develop extensive receptive and expressive language by 3 years of age (Table 677.6) and exhibit behavior reflecting normal auditory

Table 677.5 Hearing Impairment as a Function of Average Hearing Threshold Level of the Better Ear

AVERAGE THRESHOLD LEVEL (dB) AT 500-2,000 Hz (ANSI)	DESCRIPTION	COMMON CAUSES	WHAT CAN BE HEARD WITHOUT AMPLIFICATION	DEGREE OF IMPAIRMENT (IF NOT TREATED IN FIRST YEAR OF LIFE)	PROBABLE NEEDS
0-15	Normal range	Conductive hearing loss	All speech sounds	None	None
16-25	Slight hearing loss	Otitis media, TM perforation, tympanosclerosis; eustachian tube dysfunction; some SNHL	Vowel sounds heard clearly, may miss unvoiced consonant sounds	Mild auditory dysfunction in language learning Difficulty in perceiving some speech sounds	Consideration of need for hearing aid, speech reading, auditory training, speech therapy, appropriate surgery, preferential seating
26-30	Mild	Otitis media, TM perforation, tympanosclerosis, severe eustachian dysfunction, SNHL	Hears only some speech sounds, the louder voiced sounds	Auditory learning dysfunction Mild language retardation Mild speech problems Inattention	Hearing aid Lip reading Auditory training Speech therapy Appropriate surgery
31-50	Moderate hearing loss	Chronic otitis, ear canal/middle ear anomaly, SNHL	Misses most speech sounds at normal conversational level	Speech problems Language retardation Learning dysfunction Inattention	All of the above, plus consideration of special classroom situation
51-70	Severe hearing loss	SNHL or mixed loss due to a combination of middle-ear disease and sensorineural involvement	Hears no speech sound of normal conversations	Severe speech problems Language retardation Learning dysfunction Inattention	All of the above; probable assignment to special classes
71+	Profound hearing loss	SNHL or mixed	Hears no speech or other sounds	Severe speech problems Language retardation Learning dysfunction Inattention	All of the above; probable assignment to special classes or schools

ANSI, American National Standards Institute; *SNHL*, sensorineural hearing loss; *TM*, tympanic membrane.
Modified from Northern JL, Downs MP. *Hearing in Children*, 4th ed. Baltimore: Williams & Wilkins; 1991.

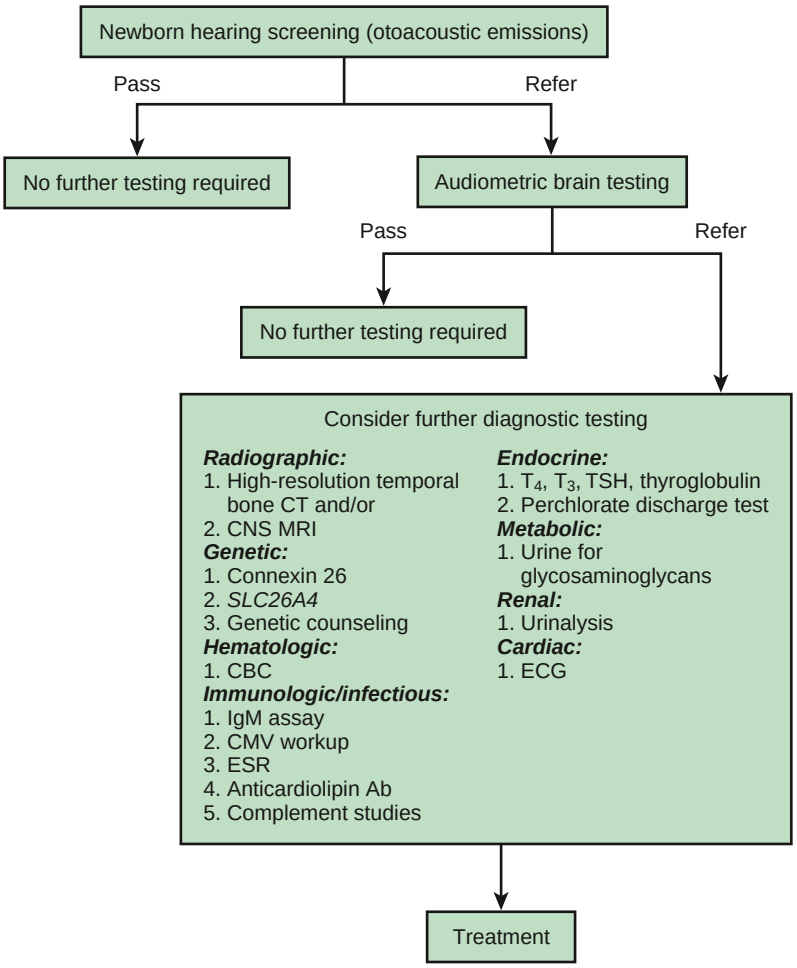

Fig. 677.2 Algorithm for newborn hearing screening. Ab, Antibody; CBC, complete blood count; CMV, cytomegalovirus; CNS, central nervous system; CT, computed tomography; ECG, electrocardiogram; ESR, erythrocyte sedimentation rate; IgM, immunoglobulin M; MRI, magnetic resonance imaging; T3, triiodothyronine; T4, thyroxine; TSH, thyroid-stimulating hormone. *(From Norton SJ, Bhama PK, Perkins JA. Early detection and diagnosis of infant hearing impairment. In: Flint PW, Haughey BH, Lund VJ, et al., eds. Cummings Otolaryngology–Head and Neck Surgery, 5th ed. Philadelphia: Mosby; 2010: Fig. 190.1.)*

Table 677.6 Criteria for Referral for Audiologic and Speech and Language Evaluation

SHOULD ABSOLUTELY REFER FOR A SPEECH-LANGUAGE EVALUATION IF:		
AT AGE (mo)	**RECEPTIVE**	**EXPRESSIVE**
15	Does not look/point at 5-10 objects/people named by parent	Not using three words
18	Does not follow simple directions ("get your shoes.")	Not using Mama, Dada, or other names
24	Does not point to pictures or body parts when they are named	Not using 25 words
30	Does not verbally respond or nod/shake head to questions	Not using unique two-word phrases, including noun-verb combinations
36	Does not understand prepositions or action words; does not follow two-step directions	Vocabulary <200 words; does not ask for things by name; echolalia to questions; regression of language after acquiring two-word phrases

From Schum RL. Language screening in the pediatric office setting. *Pediatr Clin North Am.* 2007;54(3):425–436.

Table 677.7 Guidelines for Referral of Infants/Toddlers with Suspected Hearing Loss

AGE (mo)	NORMAL DEVELOPMENT
0-4	Should startle to loud sounds, quiet to mother's voice, momentarily cease activity when sound is presented at a conversational level
5-6	Should correctly localize to sound presented in a horizontal plane, begin to imitate sounds in own speech repertoire or at least reciprocally vocalize with an adult
7-12	Should correctly localize to sound presented in any plane Should respond to name, even when spoken quietly
13-15	Should point toward an unexpected sound or to familiar objects or persons when asked
16-18	Should follow simple directions without gestural or other visual cues; can be trained to reach toward an interesting toy at midline when a sound is presented
19-24	Should point to body parts when asked; by 21-24 mo, can be trained to perform play audiometry

From Matkin ND. Early recognition and referral of hearing-impaired children. *Pediatr Rev.* 1984;6:151–156.

function (Table 677.7). Failure to fulfill these criteria should be the reason for an audiologic evaluation. Parents' concern about hearing and any delayed development of speech and language should alert the pediatrician, because parents' concern usually precedes formal identification and diagnosis of hearing impairment by 6-12 months.

CLINICAL AUDIOLOGIC EVALUATION

When hearing impairment is suspected in a young child, reliable and valid estimates of auditory function can be obtained using electrophysiologic and age-appropriate behavioral measurement. Successful treatment strategies for hearing-impaired children rely on prompt identification and ongoing assessment to define the dimensions of auditory function. Cooperation among primary care providers and specialists in areas such as audiology, speech and language pathology, education, and child development is necessary to optimize auditory-verbal development. Therapy for hearing-impaired children may include an amplification device, a **frequency modulation** (FM) system in the classroom, close monitoring of hearing and auditory skills, speech and language therapy, counseling of parents and families, advising teachers, and dealing with public agencies.

Audiometry

Audiologic evaluation technique varies as a function of the age and developmental level of the child, the reason for the evaluation, and the child's otologic condition or history. An audiogram provides the fundamental description of hearing sensitivity (Fig. 677.3). Hearing thresholds are assessed as a function of frequency using pure tones (single-frequency stimuli) at octave intervals from 250 to 8,000 Hz. When the child is old enough to accept their placement, earphones typically are used to assess each ear independently. Before this stage, testing may be performed in a sound-treated environment with stimuli delivered via speakers; this approach permits description only of the better-hearing ear.

Air-conducted signals are presented through earphones (or loudspeakers) and are used to provide information about the sensitivity of the entire auditory system. These same test sounds can be delivered to the ear through an oscillator that is placed on the head, usually on the mastoid. Such signals are considered bone-conducted because the bones of the skull transmit vibrations as sound energy directly to the inner ear, essentially bypassing the outer and middle ears. In a normal ear, and also in children with SNHL, the air- and bone-conduction thresholds are equivalent. In those with CHL, bone-conduction thresholds are more sensitive than air- conducted responses; this is called the **air-bone gap**, which indicates the amount of hearing loss attributable to dysfunction in the outer and/or middle ear. In mixed hearing loss, both the bone- and air-conduction thresholds are abnormal, and there is additionally an air-bone gap.

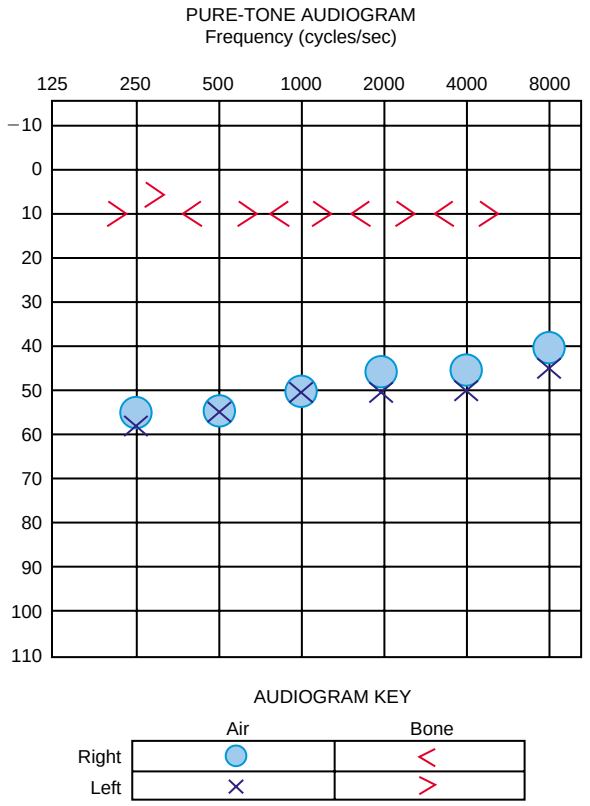

Fig. 677.3 Audiogram showing bilateral conductive hearing loss.

Speech-Recognition Threshold

Another measure useful for describing auditory function is the **speech-recognition threshold (SRT)**, which is the lowest intensity level at which a score of approximately 50% correct is obtained on a task of recognizing spondee words. Spondee words are 2-syllable words or phrases that have equal stress on each syllable, such as *baseball, hotdog,* and *pancake*. Listeners must be familiar with all the words for a valid test result to be obtained. The SRT should correspond to the average of pure-tone thresholds at 500, 1,000, and 2,000 Hz, the pure-tone average. The SRT is relevant as an indicator of a child's potential for development and use of speech and language; it also serves as a check of the validity of a test because children with nonorganic hearing loss (malingerers) might show a discrepancy between the pure-tone average and SRT. An SRT may be obtained in a child with expressive speech or language limitations using modified techniques, such as picture-pointing responses.

The basic battery of hearing tests concludes with an assessment of a child's ability to understand monosyllabic words when presented at a comfortable listening level. Performance on such word recognition tests assists in the differential diagnosis of hearing impairment and provides a measure of how well a child performs when speech is presented at loudness levels similar to those encountered in conversation. For speech recognition as well, a picture-pointing response may be obtained with standardized tests.

Play Audiometry

Hearing testing technique is age dependent. For children at or above the developmental level of a 5- to 6-year-old, conventional test methods can be used. For children 30 months to 5 years of age, play audiometry can be used. Responses in play audiometry usually are conditioned motor activities associated with a game, such as dropping blocks in a bucket, placing rings on a peg, or completing a puzzle. The technique can be used to obtain a reliable audiogram for a preschool child.

Visual Reinforcement Audiometry

For children between the ages of about 6 and 30 months, **visual reinforcement audiometry (VRA)** is commonly used. In this technique, the child is conditioned to turn the head in response to a tonal signal from a speaker in the same location as an animated (mechanical) toy or video reinforcer. If infants are properly conditioned, by presenting sounds associated with the reinforcer, VRA can provide reliable estimates of hearing sensitivity for tonal signals and speech sounds. In most applications of VRA, sounds are presented by loudspeakers in a sound field, so *ear-specific* information is not obtained. Assessment of an infant often is designed to rule out hearing loss that would be sufficient to affect the development of speech and language. Normal sound-field response levels of infants indicate sufficient hearing for this purpose despite the possibility of different HLs in the two ears. When ear-specific information is needed in this age-group, the ABR is conducted under sleep-deprived or sedated conditions.

Behavioral Observation Audiometry

Used as a screening device for infants <5 months of age, **behavioral observation audiometry** is limited to unconditioned, reflexive

responses to complex (not frequency-specific) test sounds such as warble tones, narrow-band noise, speech, or music presented using calibrated signals from a loudspeaker. Response levels can vary widely within and among infants and usually do not provide a reliable estimate of hearing sensitivity. The types of responses observed during this testing may include alterations in sucking behavior, initiation or cessation in crying, pupillary dilatation, and alterations in respiration.

Assessment of a child with suspected hearing loss is not complete until pure-tone hearing thresholds and SRTs (a reliable audiogram) have been obtained in each ear. Behavioral observation audiometry and VRA in sound-field testing give estimates of hearing responsivity in the *better-hearing ear*. When significant hearing loss is suspected in infants, electrophysiologic assessments must be conducted to permit early intervention.

Acoustic Immittance Testing

Acoustic immittance testing is a standard part of the clinical audiologic test battery and includes tympanometry, acoustic reflex threshold measurement, and acoustic reflex decay testing. It is a useful objective assessment technique that provides information about the status of the TM, middle ear, and acoustic reflex arc. Tympanometry can be performed in a physician's office and is helpful in the diagnosis and management of OM with effusion, a common cause of mild to moderate hearing loss in young children.

Tympanometry

Tympanometry provides a graph (tympanogram) of the middle ear's ability to transmit sound energy (admittance or compliance) or impede sound energy (impedance) as a function of air pressure in the external ear canal. Because most immittance test instruments measure acoustic admittance, the term *admittance* is used here. The principles apply to whatever units of measurement are used.

A probe is inserted into the entrance of the external ear canal so that an airtight seal is obtained. A manometer in the probe varies air pressure, while a sound generator presents a tone, and a microphone measures the sound pressure level reflected back. The sound pressure measured in the ear canal relative to the known intensity of the probe signal is used to estimate the acoustic admittance of the ear canal and middle-ear system. Admittance can be expressed in a unit called a millimho (mmho) or as a volume of air (mL) with equivalent acoustic admittance. Additionally, an estimate can be made of the volume of air enclosed between the probe tip and TM. The acoustic admittance of this volume of air is deducted from the overall admittance measure to obtain a measure of the admittance of the middle-ear system alone. Estimating ear canal volume also has a diagnostic benefit, because an abnormally large value is consistent with the presence of an opening in the TM (perforation, pressure equalization tube, or surgical defect).

Once the admittance of the air mass in the external auditory canal has been eliminated, it is assumed that the remaining admittance measure accurately reflects the admittance of the entire middle-ear system. Its value is controlled largely by the dynamics of the TM. Abnormalities of the TM can dictate the shape of tympanograms, thus obscuring abnormalities medial to the TM. In addition, the frequency of the probe tone, the speed and direction of the air pressure change, and the air pressure at which the tympanogram is initiated can all influence the outcome. The effect of the probe tone frequency is well documented, and in young children (<4-6 months) with small ear canals, use of a high-frequency probe tone, either 678 or 1,000 Hz, is recommended.

When air pressure in the ear canal is equal to that in the middle ear, the middle-ear system is functioning optimally. That is, the pressure equalization function of the eustachian tube permits the middle ear to rest at atmospheric pressure, equivalent to the condition in the ear canal. Therefore the ear canal pressure at which there is the greatest flow of energy (admittance) should be a reasonable estimate of the air pressure in the middle-ear space. This pressure is determined by finding the maximum or **peak admittance** on the tympanogram and obtaining its value on the *x* axis. The value on the *y* axis at the tympanogram peak is an estimate of peak admittance based on admittance tympanometry (Table 677.8). This peak measure sometimes is referred to as **static acoustic admittance**, even though it is estimated from a dynamic measure. Normative values for peak admittance as a function of air pressure are well established.

Table 677.8 Norms for Peak (Static) Admittance Using a 226-Hz Probe Tone for Children and Adults

AGE GROUP	ADMITTANCE (mL)	SPEED OF AIR PRESSURE SWEEP	
		≤50 daPa/sec*	200 daPa/sec†
Children (3-5 yr)	Lower limit	0.30	0.36
	Median	0.55	0.61
	Upper limit	0.90	1.06
Adults	Lower limit	0.56	0.27
	Median	0.85	0.72
	Upper limit	1.36	1.38

*Ear canal volume measurement based on admittance at lowest tail of tympanogram.
†Ear canal measurement based on admittance at lowest tail of tympanogram for children and at +200 daPa for adults.
daPa, decaPascals.
Adapted from Margolis RH, Shanks JE. Tympanometry: basic principles of clinical application. In: Rintelman WS, ed. *Hearing Assessment*, 2nd ed. Austin: PRODED; 1991: pp. 179–245.

Tympanometry in Otitis Media with Effusion

Children who have OM with effusion often have reduced peak admittance or high negative tympanometric peak pressures (see Fig. 680.5C). However, in the diagnosis of effusion, the tympanometric measure with the greatest sensitivity and specificity is the shape of the tympanogram rather than its peak pressure or admittance. The tympanogram is classified based on shape and peak admittance location. The greater the stiffening of the TM and ME, the lower the peak. As negative pressure within the middle ear increases, the peak becomes more negatively displaced. The more rounded the peak (or, in an absent peak, a flat tympanogram), the higher is the probability that an effusion is present (see Fig. 680.5B). The stage of OM may affect the tympanometric findings. An immobile TM/ME system based on significant effusion, as reflected in flat tympanogram, may evolve into findings of negative ME pressure and later positive pressure as the OM resolves, returning to a normal tympanogram.

Acoustic Reflex Threshold Test

The acoustic reflex threshold test also is part of the immittance test battery. With a properly functioning middle-ear system, admittance at the TM decreases due to the stiffening action of the middle ear muscles (stapedius and, to a lesser extent, tensor tympani). In healthy ears, the stapedial reflex occurs after exposure to loud sounds as a protective mechanism. Admittance instruments are designed to present reflex-activating signals (pure tones of various frequencies or noise), either to the same ear or the contralateral ear, while measuring the concomitant changes in admittance. Very small admittance changes that are time locked to presentations of the signal are considered to be a result of middle-ear muscle reflexes. Admittance changes may be absent when the hearing loss is sufficient to prevent the signal from reaching the loudness level necessary to elicit the reflex or when a middle-ear condition affects HLs or introduces sufficient stiffening to obscure reading the reflex activity. The acoustic reflex test also is used in the assessment of SNHL and the integrity of the neurologic components of the reflex arc, including crossed and uncrossed activity of cranial nerves VII and VIII.

Auditory Brainstem Response

The auditory brainstem response (ABR) test is used to screen newborn hearing, confirm hearing loss in young children, obtain

ear-specific information in young children, and test children who cannot, for whatever reason, cooperate with behavioral test methods. It also is important in the diagnosis of auditory dysfunction (i.e., estimation of hearing thresholds) and of disorders of the auditory nervous system. The ABR test is a far-field recording of minute electrical discharges from numerous neurons. The stimulus therefore must be able to cause synchronous discharge of the large numbers of neurons involved. Stimuli with very rapid onset, such as clicks or tone bursts, must be used. Unfortunately, the rapid onset required to create a measurable ABR also causes energy to be spread in the frequency domain, reducing the frequency specificity of the response.

The ABR result is not affected by sedation or general anesthesia. Infants and children from about 4 months to 4 years of age routinely are sedated to minimize electrical interference caused by muscle activity during testing. The ABR also can be performed in the operating room when a child is anesthetized for another procedure. Children younger than 4 months of age might sleep for a long enough period after feeding to allow an ABR to be done.

The ABR is recorded as 5-7 waves. Waves I, III, and V can be obtained consistently in all age-groups; waves II and IV appear less consistently. The latency of each wave (time of occurrence of the wave peak after stimulus onset) increases and the amplitude decreases with reductions in stimulus intensity; latency also decreases with increasing age, with the earliest waves reaching mature latency values earlier in life than the later waves. Age-specific normative data have been obtained in several studies.

The ABR test has two major uses in a pediatric setting. As an audiometric test, it provides information on the ability of the peripheral auditory system to transmit information to the auditory nerve and beyond. It also is used in the differential diagnosis or monitoring of central nervous system pathology. For hearing threshold estimation, the goal is to find the minimum stimulus intensity that yields an observable ABR, generally relying on wave V, the most robust aspect of morphology. Plotting latency versus intensity for various waves also aids in the differential diagnosis of hearing impairment. A major advantage of auditory assessment using the ABR test is that ear-specific threshold estimates can be obtained on infants or patients who are difficult to test. ABR thresholds using click stimuli correlate best with behavioral hearing thresholds in the higher frequencies (1,000-4,000 Hz); responsivity in the low frequencies requires different stimuli (tone bursts/pips or filtered clicks) or the use of masking, neither of which isolates the low-frequency region of the cochlea in all cases, and this can affect interpretation.

The ABR test does not assess "hearing." It reflects auditory neuronal electrical responses that can be correlated to behavioral hearing thresholds, but a normal ABR result only suggests that the auditory system, up to the level of the midbrain, is responsive to the stimulus used. Conversely, a failure to elicit an ABR indicates an impairment of the system's synchronous response but does not necessarily mean that there is no "hearing." The behavioral response to sound sometimes is normal when no ABR can be elicited, such as in neurologic demyelinating disease.

Hearing losses that are sudden, progressive, or unilateral are indications for ABR testing. Although it is believed that the different waves of the ABR reflect activity in increasingly rostral levels of the auditory system, the neural generators of the response have not been precisely determined. Each ABR wave beyond the earliest waves probably is the result of neural firing at many levels of the system, and each level of the system probably contributes to several ABR waves. High-intensity click stimuli are used for the neurologic application. The morphology of the response and wave, interwave latencies, and interaural latency differences are examined with respect to age-appropriate forms. Delayed or missing waves in the ABR result often have diagnostic significance.

The ABR and other electrical responses are extremely complex and difficult to interpret. A number of factors, including instrumentation design and settings, environment, degree and configuration of hearing loss, and patients' characteristics, can influence the quality of the recording. Therefore testing and interpretation of electrophysiologic activity as it possibly relates to hearing should be carried out by trained audiologists to avoid the risk that unreliable or erroneous conclusions will affect a patient's care.

Otoacoustic Emissions

During normal hearing, OAEs originate from the outer hair cells in the cochlea and are detected by sensitive amplifying processes. They travel from the cochlea through the middle ear to the external auditory canal, where they can be detected using miniature microphones. Transient evoked OAEs (TEOAEs) may be used to check the integrity of the cochlea. In the neonatal period, detection of OAEs can be accomplished during natural sleep, and TEOAEs can be used as screening tests in infants and children for hearing down to the 30 dB level of hearing loss. They are less time consuming and elaborate than ABRs and may be used when behavioral tests cannot be accomplished. TEOAEs are reduced or absent owing to various dysfunctions in the middle and inner ears. They are absent in patients with >30 dB of hearing loss and are not used to determine the hearing threshold; rather, they provide a screen for whether hearing is present at >30-40 dB. CHL, such as OM or congenitally abnormal middle-ear structures, reduces the transfer of TEOAEs and may be incorrectly interpreted as a cochlear hearing disorder. If a hearing loss is suspected based on the absence of OAEs, the ears should be examined for the evidence of pathology, tympanometry should be conducted, and then ABR testing should be used for confirmation and identification of the type, degree, and laterality of hearing loss.

TREATMENT

With widespread hearing screening within the United States, early diagnosis and treatment of children with hearing loss are common. Testing for hearing loss is possible even in very young children, and it should be done if parents suspect a problem. Any child with a known risk factor for hearing loss should be evaluated in the first 6 months of life.

Once a hearing loss is identified, a full developmental and speech and language evaluation is needed. Counseling and involvement of parents are required in all stages of the evaluation and treatment or rehabilitation. A CHL often can be corrected through treatment of a middle-ear effusion (i.e., ear tube placement) or surgical correction of the abnormal sound-conducting mechanism. Dependent on the level of hearing loss, children with SNHL should be evaluated for possible hearing aid use by a pediatric audiologist. Current guidelines indicate that within 1 month of diagnosis of SNHL, children should be fitted with **hearing aids**, and hearing aids may be fitted for children as young as 1 month of age. Compelling evidence from the hearing screening program in Colorado shows that identification and amplification before age 6 months make a very significant difference in the speech and language abilities of affected children compared with cases identified and amplified after the age of 6 months. In these children, repeat audiologic testing is needed to reliably identify the degree of hearing loss and to fine-tune the use of hearing aids. Hearing aids remain the rehabilitative device of choice, in the context of an individually designed treatment plan, for children with mild, moderate, or moderately severe CHL, mixed HL, or SNHL. For children with severe or profound SNHL, a trial with hearing aids is needed to determine if this approach is sufficient for the development of language; other options may need to be explored if there are indications that speech and language are delayed with a hearing aid in this HL group. Importantly, efficacy of hearing aids depends on their consistent use. There is great variability in how often children wear their hearing aids. Though there is no specific recommendation regarding the minimal number of hours per day that the hearing aids should be worn, parents should be encouraged to have their child use hearing aids full-time in order to facilitate speech and language development.

When it is clear that hearing aids are not providing the auditory stimulation needed to support language development, the parents require counseling to consider alternative treatments. A **cochlear implant** may be necessary to facilitate intelligible oral communication (i.e., oralism). This approach requires years of intensive speech and language training and is dependent on providing the best possible auditory stimulation. This option is very attractive to parents with hearing because it is the most familiar form of communication to them. Although there is a heavy emphasis in the medical world valuing the development of oral language (speech production), parents should also be provided with information about alternatives such as sign language, total communication, and cued speech (see Chapter 55). Each of these communication modalities has advantages and disadvantages. **Sign language** allows the child to develop a language system early and can support academic training. The consequence of this option is that the dominant hearing world does not interact easily with users of sign language, and the child may face significant challenges integrating into hearing society. Such possibilities as academic success and college/graduate school training are not excluded by the use of sign language, but a narrower set of venues may be available to accommodate the child's learning needs. Whereas this option may be acceptable to deaf parents already in the deaf community, many hearing parents are uncomfortable with this path for their child. This option also requires that the parents become fluent in sign language.

Total communication is an educational philosophy in which both sign and oral language as well as other forms of communication are encouraged. In theory, the two systems support and clarify information transfer and enhance academic progress. Depending on the particular school and/or teachers, one system may be emphasized over the other. **Cued speech** is an approach in which the development of oral language is supported by a system of hand gestures near the mouth and throat to disambiguate confusions that result from lip reading alone. This system can be highly successful in supporting spoken language and requires that parents become fluent in the use of the cues. Other factors should be considered in making the choice of communication modality. Significant comorbidities, such as visual impairment or other developmental delays, may limit the ability of a child to derive benefit from some choices. Support for the parents in making this decision may require counseling from an audiologist, social worker, deaf educator, and/or psychologist. Organizations of parents of deaf children, such as the A.G. Bell Association and the John Tracy Clinic, can provide a wealth of support and information to parents in this process.

Infants and young children with profound congenital or prelingual onset of deafness have benefited from **multichannel cochlear implants** (Fig. 677.4). Cochlear implants are systems that combine internal (surgically implanted) and externally worn components. These implants consist of 4 main components: the externals—which include a microphone, a minicomputer sound (speech) processor, and a transmitter—and the internal—an electrode array. These implants bypass injury to the organ of Corti and provide neural stimulation through the digitization of auditory stimuli into digital radiofrequency impulses. Specifically, sound is initially detected by the microphone and then is processed by the speech processor. The speech processor is programmed by an audiologist to implement the manufacturer's proprietary speech processing strategies that are highly sophisticated manipulations of the input signal. Signals from the speech processor are transmitted across the skin by an FM signal to the internal receiver, which converts these signals into electrical impulses. Finally, these electrical impulses are sent to the electrode array located in the cochlea, where electrical fields are created that act on the cochlear nerve. This contrasts with the transmission of sound in a healthy ear, which involves the transmission of sound vibrations to the hair cells of the cochlea, the release of ions and neurotransmitters in the cochlea, and the transmission of neural impulses to the cochlear nerve and then the brain.

Surgical implantation is done under general anesthesia and involves mastoidectomy and widening of the facial recess because the approach to the cochlea is through the facial recess. After fastening the internal stimulator package in the mastoid process, the cochlea must be opened to insert the electrode array, which is most commonly done through an opening made in the round window. Care is taken to avoid contamination of the cochlear fluids by bone dust or blood. After the cochlea is closed, generally with fascia, the wound is closed. An audiologist performs testing in the operating room to verify the functional integrity of the implanted device. These electrophysiologic responses from cranial nerve VIII are critical to determining a starting point for programming the external device after the wound has healed. A plain x-ray is often performed in the operating room as well to document placement of the array in the scala tympani.

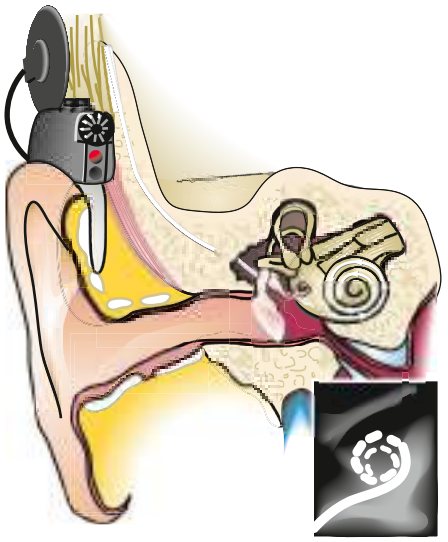

Fig. 677.4 All cochlear implants share key components, including a microphone, speech processor, and transmitter coil, shown in a behind-the-ear position in this diagram. The microphone and speech processor pick up environmental sounds and digitize them into coded signals. The signals are sent to the transmitter coil and relayed through the skin to the internal device embedded in the skull. The internal device converts the code to electronic signals, which are transmitted to the electrode array wrapping around the cochlea. The inset shows the radiographic appearance of the stimulating electrode array. *(From MED-EL Corporation, Innsbruck, Austria. From Smith RJH, Bale JF Jr., White KR. Sensorineural hearing loss in children. Lancet. 2005;365:879–890.)*

The healing process after surgery is approximately 3-4 weeks for a child. During this time, the child cannot hear. When the child is brought in for the first stimulation using the external equipment, programs are developed that provide the first access to sound. The methods to create the programs entail a combination of electrophysiologic measures and behavioral testing that is like the pediatric audiologic assessments described earlier. The initial programs are a starting point, followed by modifications and enhancements that are based on the parents' and audiologist's observations of changing auditory awareness and vocalization.

When parents elect to pursue cochlear implantation for their child, a long-term commitment is necessary to ongoing engagement with a team of rehabilitation specialists. Audiologic management entails consistent monitoring of the child's response to the implant and impact on emerging language skills. Speech and language therapy is necessary to stimulate language and to teach parents skills to support speech development. The child should be in a preschool setting in which speech, language, social, and academic precursor skills are fostered. For some parents, this engagement is very challenging, not only in terms of time required but also in terms of the emotional consequences of attempting to minimize the impact of hearing loss on their child's future; support for the parents is often needed in this process from the team.

Table 677.9 Recommended Pneumococcal Vaccination Schedule for Persons with Cochlear Implants

AGE AT FIRST PCV13 DOSE (mo)*	PCV12 PRIMARY SERIES	PCV13 ADDITIONAL DOSE	PPV23 DOSE
2-6	3 doses, 2 mo apart†	1 dose at 12-15 mo of age‡	Indicated at ≥24 mo of age§
7-11	2 doses, 2 mo apart†	1 dose at 12-15 mo of age‡	Indicated at ≥24 mo of age§
12-23	2 doses, 2 mo apart¶	Not indicated	Indicated at ≥24 mo of age§
24-59	2 doses, 2 mo apart¶	Not indicated	Indicated§
≥60	Not indicated	Not indicated**	Indicated

*A schedule with a reduced number of total 13-valent pneumococcal conjugate vaccine (PCV13) doses is indicated if children start late or are incompletely vaccinated. Children with a lapse in vaccination should be vaccinated according to the catch-up schedule (see Chapter 228).
†For children vaccinated at younger than age 1 yr, minimum interval between doses is 4 wk.
‡The additional dose should be administered 8 wk or more after the primary series has been completed.
§Children younger than age 5 yr should complete the PCV13 series first; 23-valent pneumococcal polysaccharide vaccine (PPV23) should be administered to children 24 mo of age or older 8 wk or more after the last dose of PCV13 (see Chapter 228) (Centers for Disease Control and Prevention Advisory Committee on Immunization Practices: Preventing pneumococcal disease among infants and young children: Recommendations of the Advisory Committee on Immunization Practices [ACIP]. *MMWR Recomm Rep*. 2000;49[RR-9]:1–35, and Licensure of a 13-valent pneumococcal conjugate vaccine [PCV13] and recommendations for use among children—Advisory Committee on Immunization Practices [ACIP]. *MMWR Morb Mortal Wkly Rep*. 2010;59[9]:258–261.)
¶Minimum interval between doses is 8 wk.
**PCV13 is not recommended generally for children age 5 yr or older.
PCV, Pneumococcal conjugate vaccine; PPV, pneumococcal polysaccharide vaccine.
From Centers for Disease Control and Prevention Advisory Committee on Immunization Practices. Pneumococcal vaccination for cochlear implant candidates and recipients: Updated recommendations of the Advisory Committee on Immunization Practices. *MMWR Morb Mortal Wkly Rep*. 2003;52(31):739–740.

A serious possible complication of cochlear implantation is pneumococcal meningitis. All children receiving a cochlear implant must be vaccinated with the pneumococcal polyvalent vaccine PCV13 (Table 677.9), and rates of pneumococcal meningitis have declined considerably since implementation of the vaccine.

The Food and Drug Administration (FDA) has approved cochlear implantation in patients over 9 months of age with severe to profound bilateral hearing loss not benefitting from hearing aids; off-label use of cochlear implants has demonstrated efficacy in younger children and those with residual hearing. Cochlear implantation before age 2 years improves hearing and speech, enabling more than 90% of children to be in mainstream education. Most develop age-appropriate auditory perception and oral language skills. There is increasing evidence to support expansion of the candidacy for cochlear implantation in children to be based on outcomes of advanced testing using speech stimuli, especially in noise. To date, implantation of children with devices that combine acoustic input (like a hearing aid) with electric stimulation from a cochlear implant has not been approved by the FDA. These devices, called *electroacoustic cochlear implants,* or *hybrids,* may offer hope for children using hearing aids but struggling with noise in the classroom or social contexts.

Valganciclovir has been effective in treating hearing deficits in children with congenital CMV and isolated SNHL (see Chapter 302).

GENETIC COUNSELING

Families of children with the diagnosis of SNHL or a syndrome associated with SNHL and/or CHL should be referred for genetic counseling. This will give the parents an idea of the likelihood of similar diagnoses in future pregnancies, and the geneticist can assist in the evaluation and testing of the patient to establish a diagnosis.

677.1 Idiopathic Sudden Sensorineural Hearing Loss

Joseph Haddad Jr.

Sudden SNHL in a previously healthy child is uncommon but may be from OM or other cochlear pathologies such as autoimmunity (Cogan syndrome, others). Usually, these causes are obvious from the history and physical examination. Sudden loss of hearing in the absence of obvious causes may also be the result of a vascular event affecting the cochlear apparatus or nerve, such as embolism or thrombosis (secondary to prothrombotic conditions) or hemorrhage. Additional causes include perilymph fistula, medications, trauma, and the first episode of Meniere syndrome. In adults, sudden SNHL is often idiopathic and unilateral; it may be associated with a sensation of ear fullness, tinnitus, and vertigo. Identifiable causes of sudden SNHL include infections (Epstein-Barr virus, varicella-zoster virus, herpes simplex virus) (see Table 677.2), vascular injury to the cochlea, enlarged vestibular aqueduct, endolymphatic hydrops, and autoimmune inflammatory diseases. In most (~75%) patients with sudden SNHL, no etiology is discovered, and it is termed **idiopathic sudden SNHL**. This entity is defined by a rapid (≤72 hours) onset that may be unilateral (bilateral in 25%) and associated with a hearing loss of ≥30 dB. Patients should be evaluated immediately to exclude other etiologies and obtain a focused MRI of the auditory vestibular region.

Management of **idiopathic sudden SNHL** has included oral prednisone, intratympanic (also called transtympanic) dexamethasone perfusion, or a combination of both; the latter combination may be the most useful. Recovery of hearing is more likely in patients with early treatment and with mild or moderate hearing loss and those with unilateral involvement.

Visit Elsevier eBooks+ at eBooks.Health.Elsevier.com for Bibliography.

Chapter 678

Congenital Malformations of the Ear

Joseph Haddad Jr.

The external and middle ears, derived from the first and second branchial arches and grooves, grow throughout puberty, but the inner ear, which develops from the otocyst, reaches adult size and shape by midfetal development. The ossicles are derived from the first and second arches (malleus and incus), and the stapes arises from the second arch and the otic capsule. The malleus and incus achieve adult size and shape by the 15th week of gestation, and the stapes achieves adult size and shape by the 18th week of gestation. Although the pinna, ear canal, and tympanic membrane (TM) continue to grow after birth, congenital abnormalities of these structures develop during the first half of gestation. Malformed external and middle ears may be associated with serious renal anomalies, mandibulofacial dysostosis, hemifacial microsomia, and other craniofacial malformations (Table 678.1). Facial nerve abnormalities may be associated with any of the congenital abnormalities of the ear and temporal bone. Malformations of the external and middle ears also may be associated with abnormalities of the inner ear and both conductive hearing loss (CHL) and sensorineural hearing loss (SNHL).

Congenital ear problems may be either minor and mainly cosmetic or major, affecting both appearance and function. Any child born with an abnormality of the pinna, external auditory canal, or TM should have a complete audiologic evaluation in the neonatal period. Imaging studies are necessary for evaluation and treatment; in the patient with other craniofacial abnormalities, a team approach with other specialists can assist in guiding therapy.

PINNA MALFORMATIONS

Severe malformations of the external ear are rare, but minor deformities are common. Isolated abnormalities of the external ear occur in approximately 1% of children (Fig. 678.1). A **pitlike** depression just in front of the helix and above the tragus may represent a cyst or an epidermis-lined fistulous tract (Fig. 678.2). These are common, with an incidence of approximately 8 in 1,000 children, and may be unilateral or bilateral and familial. The pits require surgical removal only if there is recurrent infection. Accessory **skin tags**, with an incidence of 1-2/1,000 live births, can be removed for cosmetic reasons by simple ligation if they are attached by a narrow pedicle. If the pedicle is broad based or contains cartilage, the defect should be corrected surgically. An unusually prominent or "lop" ear results from lack of bending of the cartilage that creates the antihelix. It may be improved cosmetically in the neonatal period by applying a firm framework (sometimes soldering wire is used) attached by Steri-Strips to the pinna and worn continuously for weeks to months. Otoplasty for cosmetic correction can be considered in children older than 5 years of age, when the pinna has reached approximately 80% of its adult size.

The term **microtia** may indicate subtle abnormalities of the size, shape, and location of the pinna and ear canal or major abnormalities with only small nubbins of skin and cartilage and the absence of the ear canal opening; **anotia** indicates complete absence of the pinna and ear canal (Fig. 678.3). Microtia can have a genetic or environmental predisposition. Several hereditary forms of microtia have been identified that exhibit either autosomal dominant or recessive mendelian inheritance. In addition, some forms due to chromosomal aberrations have been reported. Most of the responsible genes that have been identified are homeobox genes, which are involved in the development of pharyngeal arches. Microtic ears often are more anterior and inferior in placement than normal auricles, and the location and function of the facial nerve may be abnormal. Surgery to correct microtia is considered for both cosmetic and functional reasons; children who have some pinna can wear regular glasses, a hearing aid, and earrings and feel more normal in appearance. If the microtia is severe, some patients may opt for creation and attachment of a prosthetic ear, which cosmetically closely

Table 678.1 Diseases with Anomalies of the External and Middle Ears Listed by Pathologic Defect and Traditional Name

PATHOLOGIC NAME	EPONYM
4p-syndrome	Wolf-Hirschhorn syndrome
Acrocephalosyndactyly type I	Apert syndrome
Acrocephalosyndactyly type III	Saethre-Chotzen syndrome
Acrocephalosyndactyly type V	Pfeiffer syndrome
Anus imperforate with hand, foot, and ear anomalies	Townes-Brocks syndrome
Arteriohepatic dysplasia	Alagille syndrome
Branchio-oto-renal syndrome	Melnick Fraser syndrome
Brevicollis	Klippel-Feil syndrome
Cervico-oculoacoustic syndrome	Wildervanck syndrome
Cleft palate, microcephaly, large ears, and short stature	Say syndrome
Cleft palate, micrognathia, and glossoptosis	Pierre Robin sequence
Congenital contractural arachnodactyly	Beals syndrome
Congenital facial diplegia	Möbius syndrome
Constitutional aplastic pancytopenia with multiple anomalies	Fanconi syndrome
Craniofacial dysostosis	Crouzon disease
Craniometaphyseal dysplasia	Pyle disease
Dyschondrosteosis	Léri-Weill syndrome
Exomphalos-macroglossia-gigantism syndrome	Beckwith-Wiedemann syndrome
Faciodigitogenital syndrome	Aarskog syndrome
Gargoylism	Hurler syndrome
Gonadal aplasia	Turner syndrome
Hemifacial microsomia (oculoauriculovertebral dysplasia)	Goldenhar syndrome
Lacrimoauriculodentodigital syndrome	Levy-Hollister syndrome
Mandibulofacial dysostosis	Treacher Collins syndrome
Orofaciodigital syndrome type II	Mohr syndrome
Osteodysplasty	Melnick-Needles syndrome
Osteopetrosis	Albers-Schönberg disease
Renal agenesis, bilateral	Potter syndrome
Third and fourth pharyngeal pouch syndrome	DiGeorge syndrome
Trisomy 13-15 syndrome	Patau syndrome
Trisomy 18 syndrome	Edwards syndrome
Trisomy 21 syndrome	Down syndrome

From Lesperance MM, Flint PW, eds. *Cummings Pediatric Otolaryngology.* Philadelphia: Elsevier; 2015, Table 15.1, p. 197.

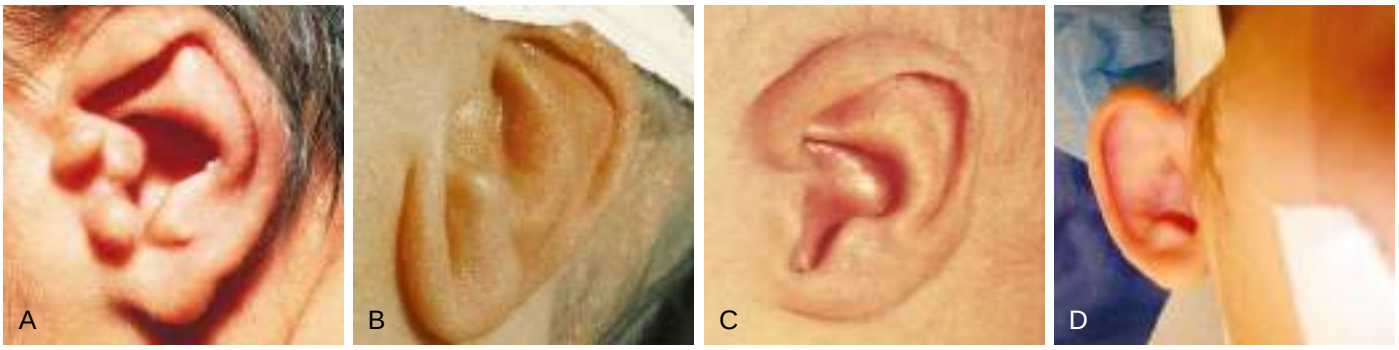

Fig. 678.1 Minor congenital auricular deformities. **A,** In this infant, the superior portion of the helix is folded over, obscuring the triangular fossa; the antihelix is sharply angulated; and there are three preauricular skin tags. **B,** This neonate with orofaciodigital and Turner syndromes has a simple helix and a redundant folded lobule. The ear is low set and posteriorly rotated, and the antitragus is anteriorly displaced. **C,** This infant with Rubinstein-Taybi syndrome has an exaggerated elongated intertragal notch. **D,** Prominent ear in an otherwise normal child. The auricular cartilage is abnormally contoured, making the ear protrude forward. *(C courtesy Dr. Michael E. Sherlock, Lutherville, Maryland; from Zitelli BJ, McIntire SC, Nowalk AJ, eds. Zitelli and Davis' Atlas of Pediatric Physical Diagnosis, 7th ed. Philadelphia: Elsevier; 2018: Fig. 24.17, p. 875.)*

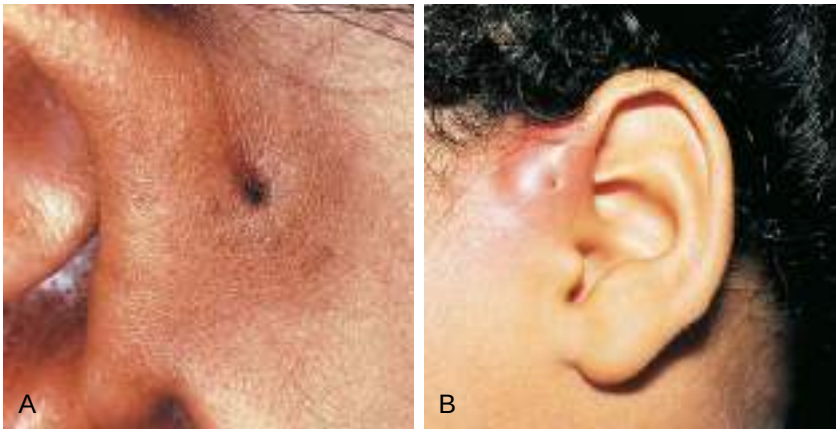

Fig. 678.2 Preauricular sinuses. **A,** These congenital remnants are located anterior to the pinna and have an overlying surface dimple. **B,** In this child, the sinus has become infected, forming an abscess. *(A courtesy Michael Hawke, MD; from Zitelli BJ, McIntire SC, Nowalk AJ, eds. Zitelli and Davis' Atlas of Pediatric Physical Diagnosis, 7th ed. Philadelphia: Elsevier; 2018: Fig. 24.18, p. 876.)*

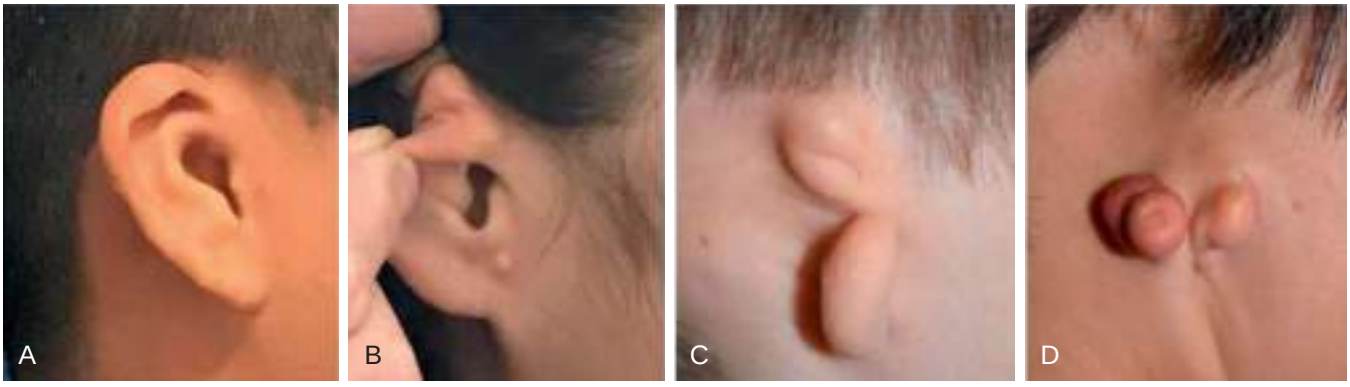

Fig. 678.3 **A,** Type I microtia with constricted ear and minimal tissue deficiency. **B,** Type II microtia, conchal type: absence of superior portions of the ear and preservation of inferior conchal anatomy. **C,** Type III microtia, lobular type: markedly deformed and no identifiable concha and preservation of the lobule. **D,** Type IV, anotia. *(From Lesperance MM, ed. Cummings Pediatric Otolaryngology, 2nd ed, Philadelphia: Elsevier; 2022: Fig. 18.2, p. 250.)*

resembles a real ear. Surgery to correct severe microtia may involve a multistage procedure, including carving and transplantation of autogenous cartilage rib grafts and local soft tissue flaps. Cosmetic reconstruction of the auricle usually is performed between 5 and 7 years of age and is performed before canal atresia repair in children deemed appropriate for this surgery.

CONGENITAL STENOSIS OR ATRESIA OF THE EXTERNAL AUDITORY CANAL

Stenosis or atresia of the ear canal often occurs in association with malformation of the auricle and middle ear. Malformations can occur in isolation or as part of a genetic syndrome. For example, the ear canal is narrow in trisomy 21, and external canal stenosis or atresia is common in branchiooculofacial syndrome, leading to CHL. Audiometric evaluation of these children should be undertaken as early in life as possible. Most children with significant CHL secondary to bilateral atresia wear bone conduction hearing aids for the first several years of life. Diagnosis, evaluation, and surgical planning often are aided by CT, and sometimes MRI, of the temporal bone. Mild cases of ear canal stenosis do not require surgical enlargement unless the patient develops chronic external otitis or severe cerumen impaction that affects hearing.

Reconstructive ear canal and middle-ear surgery for atresia usually is considered for children older than 5 years of age who have bilateral deformities resulting in significant CHL. The aim of reconstructive surgery is to improve hearing to a point where the child may not need a hearing aid or to provide an ear canal and pinna so that the child can derive improved benefit from an air-conduction hearing aid. Hearing results for atresiaplasty range from fair to excellent. CT evidence of an adequate middle-ear cleft, ossicles, and mastoid is required to perform the surgery; the position of the facial nerve, which often is in an abnormal location in these children, also must be considered (Fig. 678.4). The use of bone-anchored hearing aids is a safe, reliable, and low-risk alternative to atresiaplasty, and hearing results are generally excellent. Bone-anchored hearing aids may also be useful for rehabilitation of nonoptimal atresiaplasty hearing results. These devices are approved by the US Food and Drug Administration for surgical placement in children age 5 years and older; before age 5 years, they can be worn with a soft band around the head. Disadvantages include the fact that cosmesis is not very good (a bone-anchored hearing aid has a visible titanium abutment and snap-on hearing aid) and frequent wound care is required. Middle ear implants are effective alternatives for those who cannot tolerate foreign bodies in the ear for medical reasons or rely on good perception of high-frequency sounds.

CONGENITAL MIDDLE-EAR MALFORMATIONS

Children may have congenital abnormalities of the middle ear as an isolated defect or in association with other abnormalities of the temporal bone, especially the ear canal and pinna, or as part of a syndrome. Affected children usually have CHL but may have mixed CHL and SNHL. Most malformations involve the ossicles, with the incus most commonly affected. Other less common abnormalities of the middle ear include persistent stapedial artery, high-riding jugular bulb, and abnormalities of the shape and volume of the aerated portion of the middle ear and mastoid; all present problems for a surgeon. Depending on the type of abnormality and the presence of other anomalies, surgery may be considered to improve hearing.

CONGENITAL INNER EAR MALFORMATIONS

Congenital inner ear malformations are classified as a result of improvements in imaging modalities (Table 678.2). As many as 20% of children with SNHL may have anatomic abnormalities identified on CT or MRI. Congenital malformations of the inner ear usually are associated with SNHL of various degrees, from mild to profound. These malformations are most commonly found in infants and may occur as isolated anomalies or in association with other syndromes, genetic abnormalities, or structural abnormalities of the head and neck (Table 678.3). High-resolution temporal bone CT can identify enlarged vestibular aqueducts and cochlear nerve canal stenosis in association with SNHL. Although no therapy exists for this condition, it may be associated with progressive SNHL in some children; therefore diagnosis may have some prognostic value.

Congenital perilymphatic fistula of the oval or round window membrane may present as a rapid-onset, fluctuating, or progressive SNHL with or without vertigo and often is associated with congenital inner ear abnormalities. Middle-ear exploration may be required to confirm this

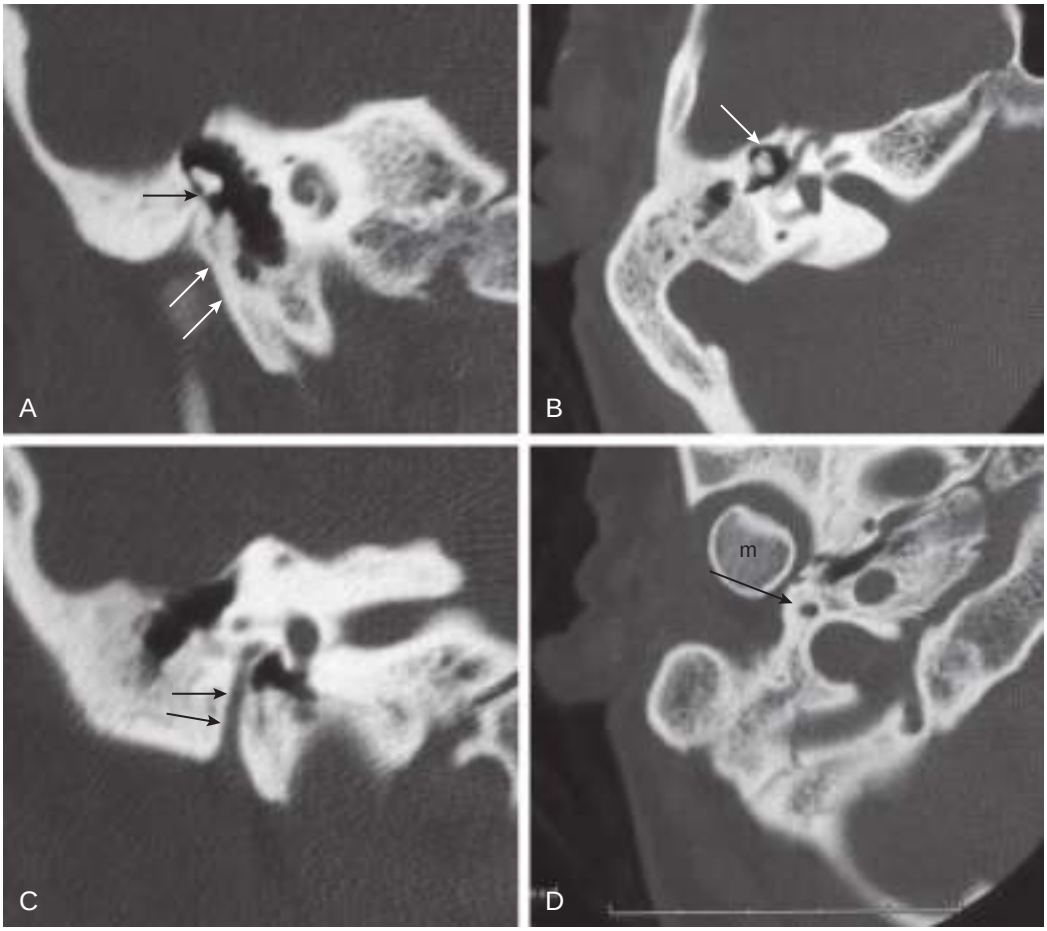

Fig. 678.4 External auditory canal atresia on CT scans. **A,** Coronal scan of right ear shows absent external auditory canal with thick bony atresia plate *(white arrows)*. Malleus neck is rotated and fused to superior portion of atresia plate *(black arrow)*. **B,** Axial scan through attic shows fused ossicular mass *(arrow)*. **C,** Coronal scan more posterior to **(A)** shows mastoid segment of facial nerve canal positioned more anteriorly than normal *(arrows)*. **D,** Axial scan more inferior to **(B)** shows anterior-posterior mastoid segment of the facial nerve en face *(arrow)*. Note abnormally close relationship to mandibular condyle. *(From Faerber EN, Booth TN, Swartz JD. Temporal bone and ear. In Slovis TL, ed. Caffey's Pediatric Diagnostic Imaging, 11th ed. Philadelphia: Mosby; 2008: Fig. 44.7, p. 584.)*

diagnosis, because no reliable nonoperative diagnostic test exists. It may be necessary to repair a perilymphatic fistula to prevent possible spread of infection from the middle ear to the labyrinth or meninges, to stabilize hearing loss, and to improve vertigo when present.

Table 678.2 Classification of Congenital Inner Ear Malformations

MALFORMATIONS LIMITED TO THE MEMBRANOUS LABYRINTH
Complete membranous labyrinthine dysplasia
Limited membranous labyrinthine dysplasia
Cochleosaccular dysplasia (Scheibe)
Cochlear basal turn dysplasia
MALFORMATIONS OF THE OSSEOUS AND MEMBRANOUS LABYRINTH
Complete labyrinthine aplasia (Michel)
Cochlear anomalies
Cochlear aplasia
Cochlear hypoplasia
Incomplete partition (Mondini)
Common cavity
Labyrinthine anomalies
Semicircular canal dysplasia
Semicircular canal aplasia
Aqueductal anomalies
Enlargement of the vestibular aqueduct
Enlargement of the cochlear aqueduct
Internal auditory canal anomalies
Narrow internal auditory canal
Wide internal auditory canal
Eighth cranial nerve anomalies
Hypoplasia
Aplasia

From Lesperance MM, ed. *Cummings Pediatric Otolaryngology*, 2nd ed, Philadelphia: Elsevier; 2022: Box 13.1, p. 178.

CONGENITAL CHOLESTEATOMA

A congenital cholesteatoma (approximately 2–5% of all cholesteatomas) is a nonneoplastic, destructive, cystic lesion that usually appears as a white, round, cystlike structure medial to an intact TM. Cysts are seen most commonly in boys and in the anterior-superior portion of the middle ear, although they can present in other locations and within the TM or in the skin of the ear canal. They can be classified as "open," meaning in direct continuity with mucosa of the middle ear, or "closed." Affected children often have no prior history of otitis media. One theory for the pathogenesis is that the cyst derives from a congenital rest of epithelial tissue that persists beyond 33 weeks of gestation, when it ordinarily would disappear. Other theories include squamous metaplasia of the middle ear, entrance of squamous epithelium through a nonintact eardrum into the middle ear, ectodermal implants between the first and second branchial arch remnants, and residual amniotic fluid squamous debris. Congenital or acquired cholesteatoma should be suspected when deep retraction pockets, keratin debris, chronic drainage, aural granulation tissue, or a mass behind or involving the TM is present. Congenital cholesteatoma is often asymptomatic, whereas acquired cholesteatoma commonly presents with otorrhea. Besides acting as a benign tumor causing local bone destruction, the keratinaceous debris of a cholesteatoma serves as a culture medium, leading to chronic otitis media. Complications include ossicular erosion with hearing loss, bone erosion into the inner ear with dizziness, or exposure of the dura, with consequent meningitis or a brain abscess. Evaluation includes a CT scan (Fig. 678.5) to detect bone erosion and audiometry to assess air and bone conduction and speech reception and discrimination. Treatment includes cholesteatoma removal, repair of damaged small middle ear bones, and mastoidectomy in 50% of congenital and >90% of acquired cholesteatoma cases. A second-look procedure 6-9 months after primary surgery is usually recommended to detect and remove small amounts of residual disease before more extensive recurrence or development of complications. Higher initial stage of disease, erosion of ossicles, cholesteatoma abutting or enveloping the incus or stapes,

Table 678.3 Inner Ear Malformations in Syndromic Hearing Loss

SYNDROME	GENETIC ABNORMALITY	RADIOGRAPHIC ANOMALIES	ASSOCIATED ANOMALIES
Apert	*FGFR2*	Vestibular dysplasia, high-riding jugular bulb	Stapes footplate fixation
Branchio-oto-renal	*EYA1*	Hypoplastic cochlea, enlarged VA	Malleus or incus dysplasia, aberrant facial nerve
CHARGE	*CHD7*	Hypoplastic or absent SCC	Coloboma, heart defects, choanal atresia, growth retardation, genital/urinary abnormalities
Down	Trisomy 21	Hypoplastic cochlea, SCC dysplasia, cochlear nerve canal hypoplasia	Narrow external auditory canal, eustachian tube dysfunction
Edwards	Trisomy 18	Hypoplastic cochlea, absent SCC	Microtia, low-set ears
Pendred	*SLC26A4*	Hypoplastic cochlea, enlarged VA, modiolar deficiency	Goiter, hypothyroidism
Waardenburg type I	*PAX3*	Hypoplastic cochlea and/or SCC, enlarged VA	Telecanthus, white forelock, heterochromia iridum
Waardenburg type II	*MITF, SNAI2, SOX10*	Enlarged vestibule, hypoplastic SCC	White forelock, heterochromia iridum
Waardenburg type III	*PAX3*	Hypoplastic cochlea and/or SCC, enlarged VA	Upper limb abnormalities, white forelock, heterochromia iridum
Waardenburg type IV	*EDNRB, EDN3, SOX10*	Enlarged vestibule, hypoplastic SCC	Hirschsprung disease, white forelock, heterochromia iridum

SCC, Semicircular canal; VA, vestibular aqueduct.
Modified from Lesperance MM, ed. *Cummings Pediatric Otolaryngology*, 2nd ed. Philadelphia: Elsevier; 2022: Table 13.2, p. 189.

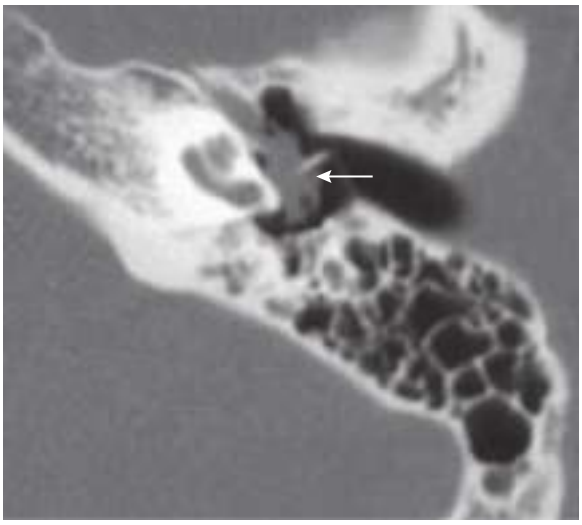

Fig. 678.5 Congenital cholesteatoma. Axial CT of left ear shows soft tissue mass *(arrow)* in the middle ear. This mass was noted otoscopically behind an intact membrane. *(From Faerber EN, Booth TN, Swartz JD. Temporal bone and ear. In Slovis TL, ed. Caffey's Pediatric Diagnostic Imaging, 11th ed. Philadelphia: Mosby; 2008: Fig. 44.31, p. 598.)*

and need for removal of the ossicles are associated with increased likelihood of residual cholesteatoma, which occurs in ~10% of congenital and ~25% of acquired cases. More extensive disease at initial surgery is associated with poorer hearing outcomes. Children with significant inflammation or extensive scarring may require a 2-stage procedure with initial removal of the cholesteatoma and subsequent repair of damaged middle ear structures.

Visit Elsevier eBooks+ at eBooks.Health.Elsevier.com for Bibliography.

Chapter 679

External Otitis (Otitis Externa)

Joseph Haddad Jr.

In an infant, the outer two thirds of the ear canal is cartilaginous and the inner one third is bony. In an older child and adult, the outer one third is cartilaginous and the inner two thirds is bony. The epithelium is thinner in the bony portion than in the cartilaginous portion, there is no subcutaneous tissue, and epithelium is tightly applied to the underlying periosteum; hair follicles, sebaceous glands, and apocrine glands are scarce or absent. The skin in the cartilaginous area has well-developed dermis and subcutaneous tissue and contains hair follicles, sebaceous glands, and apocrine glands. The highly viscid secretions of the sebaceous glands and the watery, pigmented secretions of the apocrine glands in the outer portion of the canal combine with exfoliated surface cells of the skin to form **cerumen**, a protective, waxy, water-repellent coating.

The normal flora of the external canal consists mainly of aerobic bacteria and includes coagulase-negative staphylococci (see Chapter 227.3), *Corynebacterium* (diphtheroids; see Chapter 233), *Micrococcus,* and occasionally *Staphylococcus aureus* (see Chapter 227.1), viridans streptococci (see Chapter 231), and *Pseudomonas aeruginosa* (see Chapter 251.1). **Excessive wetness** (swimming, bathing, increased environmental humidity), **dryness** (dry canal skin and lack of cerumen), the presence of other skin pathologic conditions (previous infection, eczema, or other forms of dermatitis), and trauma (due to digital or foreign body, use of cotton-tipped swabs) make the skin of the canal vulnerable to infection by the normal flora or exogenous bacteria and predispose to colonization with gram-negative bacteria.

ETIOLOGY

External otitis (**swimmer's ear**, although it can occur without swimming) is caused most by *P. aeruginosa* (up to 60%), but *S. aureus*, *Enterobacter aerogenes, Proteus mirabilis, Klebsiella pneumoniae,* streptococci, coagulase-negative staphylococci and diphtheroids, and fungi such as *Candida* and *Aspergillus* also may rarely be isolated. External otitis results from chronic irritation and maceration from excessive moisture in the canal. The loss of protective cerumen may play a role, as may trauma, but cerumen impaction with trapping of water also can cause infection. Inflammation of the ear canal due to herpesvirus, varicella-zoster virus, other skin exanthems, and eczema also may predispose to external otitis.

CLINICAL MANIFESTATIONS

The predominant symptom is acute rapid onset (typically within 48 hours) of ear pain (otalgia), often severe, accentuated by manipulation of the pinna or by pressure on the tragus and by jaw motion. The severity of the pain and tenderness (tragus or pinna, or both) may be disproportionate to the degree of inflammation, because the skin of the external ear canal is tightly adhered to the underlying perichondrium and periosteum. Itching often is a precursor of pain and usually is characteristic of chronic inflammation of the canal or resolving acute otitis externa. Conductive hearing loss (CHL) may result from edema of the skin and tympanic membrane (TM), serous or purulent secretions, or the canal skin thickening associated with chronic external otitis.

Edema of the ear canal, erythema, and thick, clumpy otorrhea are prominent signs of acute disease. The cerumen usually is white and soft in consistency, as opposed to its usual yellow color and firmer consistency (Fig. 679.1). The canal often is so tender and swollen that the entire ear canal and TM cannot be adequately visualized, and complete otoscopic examination may be delayed until the acute swelling subsides. If the TM can be visualized, it may appear either normal or opaque. TM mobility may be normal, or, if the TM is thickened, mobility may be reduced in response to positive and negative pressure.

Other physical findings may include palpable and tender lymph nodes in the periauricular region and erythema and swelling of the pinna and periauricular skin. Rarely, facial paralysis, other cranial nerve abnormalities, vertigo, and/or sensorineural hearing loss are present. If these occur, **necrotizing (malignant) otitis externa**, an invasive infection of the temporal bone and skull base, is probable. Fortunately, this disease is rare in children and is seen only in association with immunocompromise or severe malnourishment. In adults, it is associated with diabetes mellitus.

DIAGNOSIS

Diffuse external otitis may be confused with **furunculosis**, **otitis media (OM)**, and **mastoiditis** (Table 679.1). Furuncles occur in the lateral hair-bearing part of the ear canal; furunculosis usually causes a localized swelling of the canal limited to one quadrant, whereas external otitis is associated with concentric swelling and involves the entire ear canal. In OM, the TM may be perforated, severely retracted, or bulging and immobile; hearing usually is impaired. If the middle ear is draining through a perforated TM or tympanostomy tube, secondary external otitis may occur; if the TM is not visible owing to drainage or ear canal swelling, it may be difficult to distinguish acute OM with drainage from an acute external otitis. Pain on manipulation of the

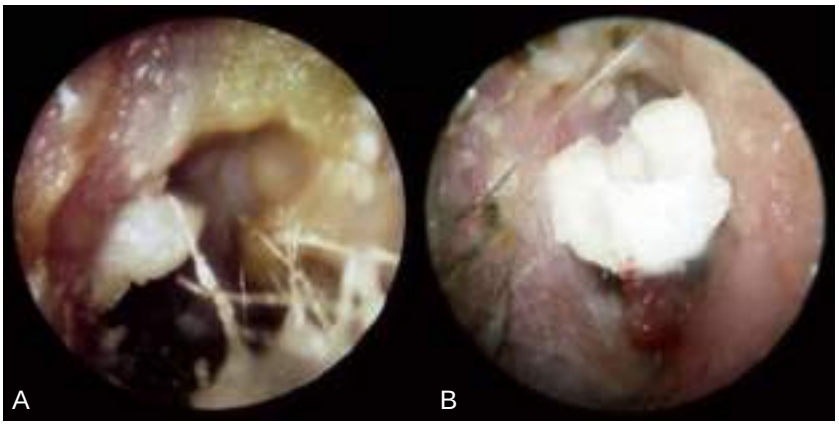

Fig. 679.1 Acute otitis externa. **A,** Erythema, edema, and copious purulent debris. **B,** In some cases an edematous canal with granulation tissue necessitates the placement of an ear wick to assist with topical drug delivery in the acute setting. *(Courtesy Dr. John W. House, Los Angeles.)*

Table 679.1 Differential Diagnosis of Painful External Ear and Auditory Canal Disorders

DISORDER	CLINICAL FEATURES
Acute otitis externa	Diffuse redness, swelling, and pain of the canal with greenish to whitish exudate; often very tender pinna
Necrotizing (malignant) otitis externa (± skull base osteomyelitis)	Rapidly progressive, severe swelling and redness of pinna; pinna may be laterally displaced; risk factors include diabetes mellitus, congenital or acquired immunodeficiency, severe neutropenia
Dermatitis	
Eczema	History of atopy, presence of lesions elsewhere; lesions are scaly, red, pruritic, and weeping
Contact	History of cosmetic use or irritant exposure; lesions are scaly, red, pruritic, and weeping
Seborrhea	Scaly, red, papular dermatitis; scalp may have thick, yellow scales
Psoriasis	History or presence of psoriasis elsewhere; erythematous papules that coalesce into thick, white plaques
Cellulitis	Diffuse redness, tenderness, and swelling of the pinna
Furuncles	Red, tender papules in areas with hair follicles (distal third of the ear canal)
Infected periauricular cyst	Discrete, palpable lesions; history of previous swelling at same site; cellulitis may develop, obscuring cystic structure
Insect bites	History of exposure; lesions are red, tender papules
Herpes zoster oticus	Painful, vesicular lesions in the ear canal and tympanic membrane, hearing loss, vestibulitis; with addition of seventh cranial nerve palsy—Ramsay Hunt syndrome
Perichondritis	Inflammation of the cartilage, usually secondary to cellulitis
Relapsing polychondritis	Recurrent episodes, involves other cartilage sites (nose)
Granulomatosis with polyangiitis	Fever, weight loss, respiratory and/or renal manifestations
Tumors including Langerhans cell histiocytosis	Palpable mass, destruction of surrounding structures
Foreign body	Foreign body may cause secondary trauma to the ear canal or become a nidus for an infection of the ear canal
Trauma	Bruising and swelling of external ear; there may be signs of basilar skull fracture (cerebrospinal fluid otorrhea, hemotympanum)
Red ear syndrome	Paroxysmal unilateral or bilateral burning and reddening. Associated with migraines or trigeminal cephalgias
Erythromelalgia	Burning, erythema from heat exposure relieved by cold; isolated ear involvement unusual

Modified from Kliegman R, Bordini B, Toth H, Basel D, eds. *Nelson Pediatric Symptom-Based Diagnosis,* 2nd ed. Philadelphia: Elsevier; 2022: Table 5.2.

auricle and significant lymphadenitis are not common features of OM, and these findings assist in the differential diagnosis. In some patients with external otitis, the periauricular edema is so extensive that the auricle is pushed forward, creating a condition that may be confused with acute mastoiditis and a subperiosteal abscess. In mastoiditis, the postauricular fold is obliterated, whereas in external otitis, the fold is usually better preserved. In acute mastoiditis, a history of OM and hearing loss is usual; tenderness is noted over the mastoid and not on movement of the auricle; and otoscopic examination may show sagging of the posterior canal wall.

Referred otalgia may come from disease in the paranasal sinuses, teeth, pharynx, parotid gland, neck and thyroid, and cranial nerves

(trigeminal neuralgia; herpes simplex virus, varicella-zoster virus; see Table 676.1).

TREATMENT

Topical otic preparations containing acetic acid, with or without hydrocortisone, or neomycin (active against gram-positive organisms and some gram-negative organisms, notably *Proteus* spp.), polymyxin (active against gram-negative bacilli, notably *Pseudomonas* spp.), or a quinolone (ciprofloxacin), with or without hydrocortisone, are all highly effective in treating most forms of acute external otitis. A nonototoxic (quinolone) antibiotic should be chosen in the setting of known TM perforation or tympanostomy tube. If canal edema is marked, the patient may need referral to a specialist for cleaning and possible wick placement. An otic antibiotic and corticosteroid eardrop is often recommended. A wick can be inserted into the ear canal and topical antibiotics applied to the wick 3 times a day for 24-48 hours. The wick can be removed after 2-3 days, at which time the edema of the ear canal usually is markedly improved and the ear canal and TM are better seen. Topical antibiotics are then continued by direct instillation. When the pain is severe, oral analgesics (e.g., ibuprofen, acetaminophen) may be necessary for a few days.

Someone other than the patient should place the drops in the ear canal while the patient is recumbent with the affected ear facing up. The drops should fill the canal, and the patient should remain in place for 3-5 minutes. Gently moving the ear to and fro may enhance the drops to fill the ear canal. Patients should respond to initial therapeutics in 48-72 hours. Failure to improve in this time frame should prompt assessment of drug delivery and adherence to therapy, consideration for change in therapy, and consideration of alternative diagnoses. Careful evaluation for underlying conditions should also be undertaken in patients with severe or recurrent otitis externa. Figure 679.2 outlines an approach to managing acute external otitis.

As the inflammatory process subsides, cleaning the canal with a suction or cotton-tipped applicator to remove the debris enhances the effectiveness of the topical medications. In subacute and chronic infections, periodic cleansing of the canal is essential. In severe acute external otitis associated with fever and lymphadenitis, oral or parenteral antibiotics may be indicated; an ear canal culture should be done, and empirical antibiotic treatment can then be modified if necessary, based on susceptibility of the organism cultured. A fungal infection of the external auditory canal, or **otomycosis**, is characterized by fluffy white debris, sometimes with black spores seen; treatment includes cleaning and application of antifungal solutions such as clotrimazole or nystatin; other antifungal agents include boric acid powder, m-cresyl acetate 25%, gentian violet 2%, and thimerosal 1:1,000.

Necrotizing otitis externa, commonly caused by *P. aeruginosa* (see Chapter 251.1), requires immediate culture, intravenous antibiotics,

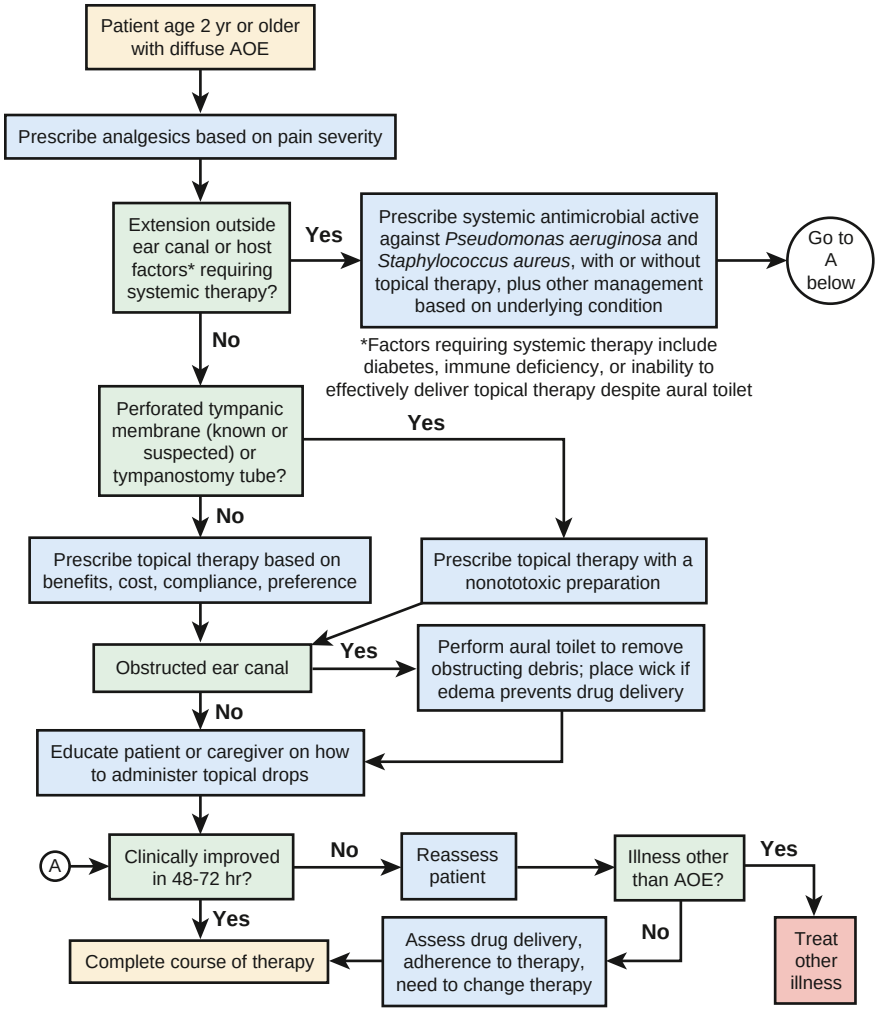

Fig. 679.2 Management algorithm for acute otitis externa (AOE). *(From Rosenfeld RM, Brown L, Cannon CR, et al. Clinical practice guideline: acute otitis externa. Otolaryngol Head Neck Surg. 2006;134:S4–S23. Copyright 2006 American Academy of Otolaryngology—Head and Neck Surgery Foundation, Inc.)*

and imaging studies to evaluate the extent of the disease. Surgical intervention to obtain cultures or debride devitalized tissue may be necessary.

PREVENTION

Preventing external otitis may be necessary for individuals susceptible to recurrences, especially children who swim. The most effective prophylaxis is instillation of dilute alcohol or acetic acid (2%) immediately after swimming or bathing. During an acute episode of otitis externa, patients should not swim, and the ears should be protected from excessive water during bathing. A hair dryer may be used to clear moisture from the ear after swimming as a method of prevention. Cotton-tipped swabs (or another material) may cause trauma to the ear canal, including tympanic membrane perforation, cerumen impaction, or retained foreign body and should be avoided.

OTHER DISEASES OF THE EXTERNAL EAR

Furunculosis

Furunculosis, caused by *S. aureus,* affects only the hair-containing outer third of the ear canal and typically occurs at the inferior entrance to the meatus. Mild forms are treated with oral antibiotics active against *S. aureus.* If an abscess develops, incision and drainage may be necessary.

Acute Cellulitis

Acute cellulitis of the auricle and external auditory canal usually is caused by group A streptococcus and occasionally by *S. aureus.* The skin is red, hot, and indurated, without a sharply defined border. Fever may be present with little or no exudate in the canal. Parenteral administration of penicillin G or a penicillinase-resistant penicillin is the therapy of choice.

Perichondritis and Chondritis

Perichondritis is an infection involving the skin and perichondrium of the auricular cartilage; extension of infection to the cartilage is termed **chondritis**. The ear canal, especially the lateral aspect, also may be involved. Early perichondritis may be difficult to differentiate from cellulitis because both are characterized by skin that is red, edematous, and tender. The main cause of perichondritis/chondritis and cellulitis is trauma (accidental or iatrogenic, laceration or contusion), including ear piercing, especially when done through the cartilage. The most commonly isolated organism in perichondritis and chondritis is *P. aeruginosa,* although other gram-negative and, occasionally, gram-positive organisms may be found. Treatment involves systemic, often parenteral, antibiotics; surgery to drain an abscess or remove nonviable skin or cartilage may also be needed. Removal of all ear jewelry is mandatory in the presence of infection.

Dermatoses

Various dermatoses (seborrheic, contact, infectious eczematoid, or neurodermatoid) are common causes of inflammation of the external canal; scratching and the introduction of infecting organisms cause acute external otitis in these conditions.

Seborrheic dermatitis is characterized by greasy scales that flake and crumble as they are detached from the epidermis; associated changes in the scalp, forehead, cheeks, brow, postauricular areas, and concha are usual.

Contact dermatitis of the auricle or canal may be caused by earrings or by topical otic medications such as neomycin, which may produce erythema, vesiculation, edema, and weeping. Poison ivy, oak, and sumac also may produce contact dermatitis. Hair care products have been implicated in sensitive individuals.

Infectious eczematoid dermatitis is caused by a purulent infection of the external canal, middle ear, or mastoid; the purulent drainage infects the skin of the canal or auricle, or both. The lesion is weeping, erythematous, or crusted.

Atopic dermatitis occurs in children with a familial or personal history of allergy; the auricle, particularly the postauricular fold, becomes thickened, scaly, and excoriated.

Neurodermatitis is recognized by intense itching and erythematous, thickened epidermis localized to the concha and orifice of the meatus.

Treatment of these dermatoses depends on the type but should include application of an appropriate topical medication, elimination of the source of infection or contact when identified, and management of any underlying dermatologic problem. In addition to topical antibiotics (or antifungals), topical steroids are helpful if contact dermatitis (see Chapter 696.1), atopic dermatitis (see Chapter 696), or eczematoid dermatitis is suspected.

Herpes Simplex Virus

See Chapter 299.

Herpes simplex virus may appear as vesicles on the auricle and lips. The lesions eventually become encrusted and dry and may be confused with impetigo. Topical application of a 10% solution of carbamide peroxide in anhydrous glycerol is symptomatically helpful. **Ramsay Hunt syndrome** (herpes zoster oticus with facial paralysis) may present initially with otalgia, with subsequent appearance of vesicles in the ear canal and on the pinna and with facial paralysis and pain. Other cranial nerves may be affected as well, especially the eighth nerve. Treatment of herpes zoster oticus includes systemic antiviral agents, such as acyclovir, and systemic corticosteroids. As many as 50% of patients with Ramsay Hunt syndrome do not completely recover their facial nerve function.

Bullous Myringitis

Commonly associated with an acute upper respiratory tract infection, bullous myringitis presents as an ear infection with more severe pain than usual. On examination, hemorrhagic or serous blisters (bullae) may be seen on the TM. The disease sometimes is difficult to differentiate from acute OM because a large bulla may be confused with a bulging TM. The organisms involved are the same as those that cause acute OM, including both bacteria and viruses. Treatment consists of empiric antibiotic therapy and pain medications. In addition to ibuprofen or codeine for severe pain, a topical anesthetic eardrop may also provide some relief. Incision of the bullae, although not necessary, promptly relieves the pain.

Exostoses and Osteomas

Exostoses represent benign hyperplasia of the perichondrium and underlying bone. Those involving the auditory canal tend to be found in people who swim often in cold water. Exostoses are broad based, often multiple, and bilateral. Osteomas are benign bony growths in the ear canal of uncertain cause (see Chapter 550.2). They usually are solitary and attached by a narrow pedicle to the tympanosquamous or tympanomastoid suture line. Both are more common in males; exostoses are more common than osteomas. Surgical treatment is recommended when large masses cause cerumen impaction, ear canal obstruction, or hearing loss.

Visit Elsevier eBooks+ at eBooks.Health.Elsevier.com for Bibliography.

Chapter 680

Otitis Media

Brittany Player

The term **otitis media (OM)** has two main categories: acute infection, which is termed suppurative or **acute otitis media (AOM)**, and inflammation accompanied by **middle-ear effusion (MEE)**, termed nonsuppurative or **secretory OM**, or **otitis media with effusion (OME)**. These two main types are interrelated: acute infection usually is succeeded by residual inflammation and effusion that, in turn, predispose children to recurrent infection. MEE is a feature of both AOM and OME and is an expression of the underlying middle-ear mucosal inflammation. MEE results in the conductive hearing loss associated with OM, ranging from none to as much as 50 dB of hearing loss (moderate hearing loss).

The peak incidence and prevalence of OM are during the first 2 years of life. More than 80% of children experience at least one episode of OM by the age of 3 years. Conservative estimates for OM-related costs place the annual burden at $3-5 billion per year. Accounting for >10% of pediatric primary care encounters, OM is a leading reason for pediatric visits and use of antibiotics and figures importantly in the differential diagnosis of fever. Recurrent OM is defined as a minimum of three episodes of AOM in 6 months or four episodes of AOM in 12 months with at least one of those episodes occurring in the preceding 6 months. It often serves as the main justification for myringotomy with insertion of tympanostomy tubes and adenoidectomy, the most frequently performed operations in infants and young children. OM is also the most common cause of acquired hearing loss in children. OM has a propensity to become chronic and recur. The earlier in life a child experiences the first episode, the greater the frequency of recurrence, severity, and persistence of MEE.

Accurate diagnosis of AOM in infants and young children may be difficult (Figs. 680.1-680.3). Symptoms may not be apparent, especially in early infancy and in chronic stages of the disease. Accurate visualization of the tympanic membrane (TM) and middle-ear space may be difficult because of anatomy, patient cooperation, or blockage by cerumen, removal of which may be arduous and time consuming. Abnormalities of the eardrum may also be subtle or difficult to appreciate. In the face of these difficulties, both underdiagnosis and overdiagnosis occur.

EPIDEMIOLOGY

Several factors affect the occurrence of OM, including age, gender, genetic background, socioeconomic status, breast milk feeding, degree of exposure to tobacco smoke, degree of exposure to other children, presence or absence of respiratory allergy, season of the year, and pneumococcal vaccination status. Children with certain types of immune deficiencies and congenital craniofacial anomalies (i.e., cleft palate, Down syndrome) are particularly prone to OM.

Age

The age of onset of OM is an important predictor of the development of recurrent and chronic OM, with earlier age of onset having an increased risk for exhibiting these difficulties later in life. The development of at least one episode of OM is reported as 63–85% by 12 months and 66–99% by 24 months of age. The percentage of days with MEE is 5–27% during the first year of life and 6–18% during the second year of life. Across groups, rates are highest at 6-20 months of age. After the age of 2, the incidence and prevalence of OM decline progressively, although the disease remains relatively common into the early school-age years. The most likely reasons for the higher rates in infants and younger children include less well-developed immunologic defenses and less favorable eustachian tubal structure and function.

Gender

Epidemiologic data suggest an incidence of OM greater in males than in females, although some studies have found no gender-related differences in the occurrence of OM.

Genetic Background

That middle-ear disease tends to run in families is a commonplace observation, suggesting that OM may have a heritable component. The degree of concordance for the occurrence of OM is much greater among monozygotic than among dizygotic twins. OM is especially prevalent and severe among Native American, Inuit, and Indigenous Australian children.

Socioeconomic Status

Elements contributing to the association of poverty with OM include crowding, limited hygienic facilities, suboptimal nutritional status, limited access to medical care, and limited resources for complying with prescribed medical regimens.

Breast Milk Compared with Formula Feeding

Most studies have found a protective effect of breast milk feeding against OM. This protective effect may be greater in socioeconomically

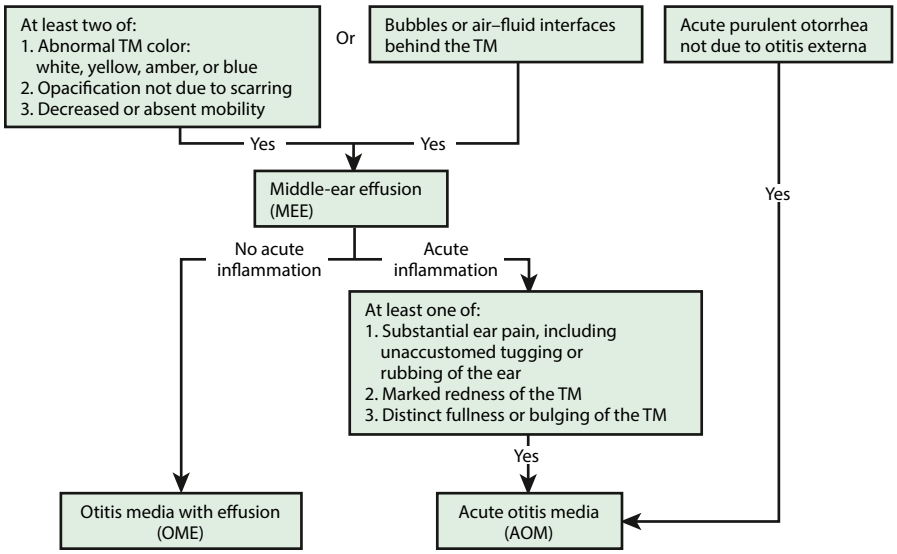

Fig. 680.1 Algorithm for distinguishing between acute otitis media and otitis media with effusion. TM, Tympanic membrane.

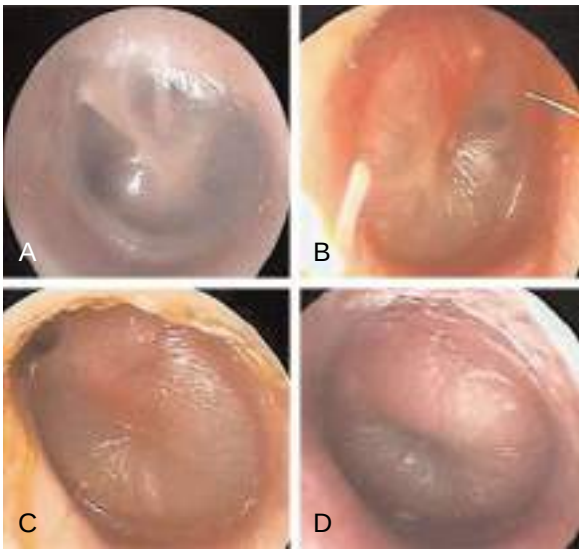

Fig. 680.2 Examples of normal tympanic membrane (A) and of mild bulging (B), moderate bulging (C), and severe bulging (D) of the tympanic membrane from middle-ear effusion. *(Courtesy Alejandro Hoberman, MD.)*

Fig. 680.3 Tympanic membrane in acute otitis media.

disadvantaged children than in more advantaged children. The protective effect is attributable to the milk itself rather than to the mechanics of breastfeeding.

Exposure to Tobacco Smoke

Tobacco smoke exposure is an important preventable risk factor in the development of OM. Studies that have used objective measures to determine infant exposure to secondhand tobacco smoke, such as cotinine levels, have consistently identified a significant linkage between tobacco smoke and OM.

Exposure to Other Children

OM is more common with repeated exposure to other children, whether at home or in out-of-home group daycare. Together, but independently, family socioeconomic status and the extent of exposure to other children appear to constitute two of the most important identifiable risk factors for developing OM.

Season

In keeping with the pattern of occurrence of upper respiratory tract infections in general, the highest rates of occurrence of OM are observed during cold weather months and the lowest rates during warm weather months. In OM, it is likely that these findings strongly depend on the significant association of OM with viral respiratory illnesses.

Congenital Anomalies

OM is universal among infants with unrepaired palatal clefts and is also highly prevalent among children with submucous cleft palate, other craniofacial anomalies, and Down syndrome (see Chapter 57). The common feature in these congenital anomalies is a deficiency in eustachian tube function, which predisposes these children to middle-ear disease.

Other Factors

Pacifier use is linked with an increased incidence of OM and recurrence of OM, although the effect is small. Neither maternal age nor birthweight nor season of birth appears to influence the occurrence of OM once other demographic factors are accounted for. Some suggest an association of OM with bottle feeding in the recumbent position (propped bottle). Children with HIV infection have a high risk for recurrent OM.

ETIOLOGY

Acute Otitis Media

Pathogenic bacteria can be isolated by standard culture techniques from middle-ear fluid in most documented AOM cases. Three pathogens predominate in AOM: *Streptococcus pneumoniae* (see Chapter 228), nontypeable *Haemophilus influenzae* (see Chapter 240), and *Moraxella catarrhalis* (see Chapter 242). The overall incidence of these organisms has changed with the use of the conjugate pneumococcal vaccine. Widespread use of the expanded serotype coverage 13-valent as compared with the 7-valent pneumococcal conjugate vaccine has further reduced the prevalence of *S. pneumoniae* as a cause of AOM, particularly the virulent 19A serotype. Less common pathogens include group A streptococcus (see Chapter 229), *Staphylococcus aureus* (see Chapter 227.1), and gram-negative organisms. Gram-negative organisms and *S. aureus* are found most commonly in neonates and very young infants who are hospitalized; in outpatient settings, the distribution of pathogens in these young infants is similar to that in older infants. Molecular techniques to identify nonculturable bacterial pathogens have suggested the importance of other bacterial species such as *Alloiococcus otitidis.*

Respiratory viruses may also be identified in MEEs of children with AOM, either alone or, more commonly, in association with pathogenic bacteria. Of these viruses, rhinovirus (see Chapter 310) and respiratory syncytial virus (RSV; see Chapter 307) are found most often. AOM is a known complication of bronchiolitis; middle-ear aspirates in children with bronchiolitis regularly contain bacterial pathogens, suggesting that RSV is rarely, if ever, the sole cause of their AOM. Viral pathogens have a negative impact on eustachian tube function, can impair local immune function and increase bacterial adherence, and can change the pharmacokinetic dynamics, reducing the efficacy of antimicrobial medications. However, it remains uncertain whether viruses alone can cause AOM or whether their role is limited to setting the stage for bacterial invasion, and perhaps also to amplify the inflammatory process, thereby interfering with resolution of the bacterial infection.

Otitis Media with Effusion

Using standard culture techniques, the pathogens typically found in AOM are recoverable in only 30% of children with OME. However, using polymerase chain reaction (PCR), MEEs contain evidence of bacterial DNA and viral RNA in much larger proportions of these children. Biofilms of pathogenic bacteria are present on the middle-ear mucosa and adenoid pad in most children with chronic OM. Biofilms consist of aggregated and adherent bacteria, embedded in an extracellular matrix and in neutrophil extracellular traps, allowing for

protection against antimicrobials; their presence may contribute to the persistence of pathogens and the recalcitrance of chronic OM to antibiotic treatment.

PATHOGENESIS

A multifactorial disease process, risk profile, and host-pathogen interactions play important roles in the pathogenesis of OM. Such events as alterations in mucociliary clearance through repeated viral exposure experienced in daycare settings or through exposure to tobacco smoke may tip the balance of pathogenesis in less virulent OM pathogens in their favor, especially in children with a unique host predisposition.

Anatomic Factors

Patients with significant craniofacial abnormalities affecting eustachian tube function have an increased incidence of OM. During the pathogenesis of OM, the eustachian tube demonstrates decreased effectiveness in ventilating the middle-ear space.

Under usual circumstances the eustachian tube is passively closed and is opened by contraction of the tensor veli palatini muscle. In relation to the middle ear, the tube has three main functions: ventilation, protection, and clearance. The middle-ear mucosa depends on a continuing supply of air from the nasopharynx delivered by way of the eustachian tube. Interruption of this ventilatory process by tubal obstruction initiates an inflammatory response that includes secretory metaplasia, compromise of the mucociliary transport system, and effusion of liquid into the tympanic cavity. Measurements of eustachian tube function have demonstrated that the tubal function is suboptimal during the events of OM with increased opening pressures.

Eustachian tube obstruction may result from extraluminal blockage via hypertrophied nasopharyngeal adenoid tissue or tumor or may result from intraluminal obstruction via inflammatory edema of the tubal mucosa, most commonly as a consequence of a viral upper respiratory tract infection. Progressive reduction in tubal wall compliance with increasing age may explain the progressive decline in the occurrence of OM as children grow older. The protection and clearance functions of the eustachian tube may also be involved in the pathogenesis of OM. Thus, if the eustachian tube is patulous or excessively compliant, it may fail to protect the middle ear from reflux of infective nasopharyngeal secretions, whereas impairment of the mucociliary clearance function of the tube might contribute to both the establishment and persistence of infection. The shorter and more horizontal orientation of the tube in infants and young children may increase the likelihood of reflux from the nasopharynx and impair passive gravitational drainage through the eustachian tube.

Children with **craniofacial abnormalities** experience an increased incidence of OM associated with the abnormal eustachian tube function. In children with cleft palate, where OM is a universal finding, a main factor underlying the chronic middle-ear inflammation appears to be impairment of the opening mechanism of the eustachian tube. Possible factors include muscular changes, tubal compliance factors, and defective velopharyngeal valving, which may result in disturbed aerodynamic and hydrodynamic relationships in the nasopharynx and proximal portions of the eustachian tubes. In children with other craniofacial anomalies and with Down syndrome, the high prevalence of OM has also been attributed to structural and/or functional eustachian tubal abnormalities.

Host Factors

The effectiveness of a child's immune system in response to the bacterial and viral infections of the upper airway and middle ear during early childhood probably is the most important factor in determining which children are otitis prone. The maturation of this immune system during early childhood is most likely the primary event leading to the decrease in incidence of OM with increased age. Immunoglobulin A (IgA) deficiency is found in some children with recurrent AOM, but the significance is questionable; many children with IgA deficiency do not experience recurrent episodes of AOM. Selective immunoglobulin G (IgG) subclass deficiencies (despite normal total serum IgG) may be found in children with recurrent AOM in association with recurrent sinopulmonary infection, and these deficiencies probably underlie the susceptibility to infection. Children with HIV infection have recurrent and difficult-to-treat episodes of AOM in the first and second year of life. Children with recurrent OM that is not associated with recurrent infection at other anatomic sites rarely have a readily identifiable immunologic deficiency. Evidence that subtle immune deficits play a role in the pathogenesis of recurrent AOM is provided by studies involving antibody responses to various types of infection and immunization; by the observation that breast milk feeding, as opposed to formula feeding, confers some protection against the occurrence of OM in infants with cleft palate; and by studies in which young children with recurrent AOM achieved a measure of protection from intramuscularly administered bacterial polysaccharide immunoglobulin or intravenously administered polyclonal immunoglobulin. This evidence, along with the documented decrease in incidence of upper respiratory tract infections and OM as children's immune systems develop and mature, is indicative of the importance of a child's innate immune system in the pathogenesis of OM (see Chapter 164).

Viral Pathogens

Although OM may develop and persist in the absence of apparent respiratory tract infection, many, if not most, episodes are initiated by viral or bacterial upper respiratory tract infection. Among children in group daycare, AOM was observed in approximately 30–40% of children with respiratory illness caused by RSV (see Chapter 307), influenza viruses (see Chapter 305), or adenoviruses (see Chapter 309) and in approximately 10–15% of children with respiratory illness caused by parainfluenza viruses (see Chapter 306), rhinoviruses (see Chapter 310), or enteroviruses (see Chapter 297). Viral infection of the upper respiratory tract results in release of cytokines and inflammatory mediators, some of which may cause eustachian tube dysfunction.

Respiratory viruses also may enhance nasopharyngeal bacterial colonization and adherence and impair host immune defenses against bacterial infection.

CLINICAL MANIFESTATIONS

Symptoms of AOM are variable, especially in infants and young children. In young children, evidence of ear pain may be manifested by irritability or a change in sleeping or eating habits and, occasionally, holding or tugging at the ear. *Pulling at the ear alone has a low sensitivity and specificity.* Fever may also be present and may occasionally be the only sign. Rupture of the TM with purulent otorrhea is uncommon. Systemic symptoms and symptoms associated with upper respiratory tract infections also occur; occasionally there may be no symptoms, with the disease having been discovered at a routine health examination. The Acute Otitis Media Severity of Symptom (AOM-SOS) scale is a five-item validated symptom score that has proven beneficial as a tool to monitor AOM symptoms in patients and studies of antimicrobial effectiveness in OM. OME often is not accompanied by overt complaints of the child but can be accompanied by hearing loss. This hearing loss may manifest as changes in speech patterns but often goes undetected if unilateral or mild in nature, especially in younger children. Balance difficulties or disequilibrium can rarely be associated with OME, and older children may complain of mild discomfort or a sense of fullness in the ear.

EXAMINATION OF THE TYMPANIC MEMBRANE

Otoscopy

Two types of otoscope heads are available: **surgical** or **operating** and **diagnostic** or **pneumatic**. The surgical head embodies a lens that can swivel over a wide arc and an unenclosed light source, thus providing ready access of the examiner's instruments to the external auditory canal and TM. Use of the surgical head is optimal for removing cerumen or debris from the canal under direct observation and is necessary for satisfactorily performing tympanocentesis or myringotomy. The

diagnostic head incorporates a larger lens, an enclosed light source, and a nipple for the attachment of a rubber bulb and tubing. When an attached speculum is fitted snugly into the external auditory canal, an airtight chamber is created comprising the vault of the otoscope head, the bulb and tubing, the speculum, and the proximal portion of the external canal. Although examination of the ear in young children is a relatively invasive procedure that is often met with lack of cooperation by the patient, this task can be enhanced if done with as little pain as possible. The outer portion of the ear canal contains hair-bearing skin and subcutaneous fat and cartilage that allow a speculum to be placed with relatively little discomfort. Closer to the TM the ear canal is made of bone and is lined only with skin and no adnexal structures or subcutaneous fat; a speculum pushed too far forward and placed in this area often causes skin abrasion and pain. Using a rubber-tipped speculum or adding a small sleeve of rubber tubing to the tip of the plastic speculum may serve to minimize patient discomfort and enhance the ability to achieve a proper fit and an airtight seal, facilitating pneumatic otoscopy.

Learning to perform **pneumatic otoscopy** is a critical skill in being able to assess a child's ear and in making an accurate diagnosis of AOM. The degree of TM mobility in response to both positive and negative pressure can be estimated by observing as the bulb is alternately squeezed gently and released, thus providing a critical assessment of middle-ear fluid, which is a hallmark sign of both AOM and OME (see Fig. 680.1). With both types of otoscope heads, bright illumination is also critical for adequate visualization of the TM.

Clearing the External Auditory Canal

Children's ears are "self-cleaning" because of squamous migration of ear canal skin. Cleaning of cerumen with cotton-tipped swabs should be avoided, as it often worsens impaction by pushing cerumen deeper into the canal, compacting it. If the TM is obscured by cerumen, the cerumen should be removed. This can be accomplished through direct visualization using a headlight or through the surgical head of the otoscope by using an ear curette or gentle suction with a No. 5 or 7 French ear suction tube. During this procedure, it may be most advantageous to restrain the infant or young child in the prone position, turning the child's head to the left or right as each ear is cleared. In children old enough to cooperate, clearing of the external canal may be achieved more easily and less traumatically by lavage than by mechanical removal, provided one can be certain that a TM perforation is not present.

Tympanic Membrane Findings

Important characteristics of the TM consist of contour, color, translucence, structural changes, if any, and mobility. The TM is anatomically divided into the pars tensa and pars flaccida. The pars tensa comprises the lower two thirds of the drum inferior to the lateral process of the malleus. Its contour is normally **slightly concave**; abnormalities consist of fullness or bulging or, conversely, extreme retraction. The normal color of the pars tensa is **pearly gray**, with the pars flaccida being slightly more vascular in nature. Erythema may be a sign of inflammation or infection, but unless intense, erythema alone may result from crying or vascular flushing. Abnormal whiteness of the membrane may result from either scarring or the presence of effusion in the middle-ear cavity; this effusion also may impart an amber, pale yellow, or, rarely, bluish color. Rarely a persistent focal white area may be indicative of a congenital cholesteatoma in the middle-ear space. Normally, the membrane is translucent, although some degree of opacity may be normal in the first few months of life; later, opacification denotes either scarring or, more commonly, underlying effusion. Structural changes include scars, perforations, and retraction pockets. Retractions or perforations, especially in the posterior-superior quadrant, or pars flaccida, of the TM may be a sign of cholesteatoma formation. Of all the visible characteristics of the TM, mobility is the most sensitive and specific in determining the presence or absence of MEE. Mobility is generally not an all-or-none phenomenon. A total absence of mobility does exist with a TM perforation that can develop after a substantial increase in middle-ear pressure associated with effusion. When a perforation is not present, substantial impairment of mobility is the more common finding with MEE. Bulging of the TM is the most specific finding of AOM (97%) but has lower sensitivity (51%) (see Figs. 680.2 and 680.3).

Diagnosis

A **diagnosis of AOM** should be made in children who present with:

- Moderate to severe bulging of the TM or new-onset otorrhea not caused by otitis externa
- Mild bulging of the TM and recent (<48 hours) onset of ear pain or intense TM erythema

A **diagnosis of AOM** should ***not*** be made in children without MEE.

AOM and OME may evolve into the other without any clearly differentiating physical findings; any schema for distinguishing between them is to some extent arbitrary. In an era of increasing bacterial resistance, distinguishing between AOM and OME is important in determining treatment, because OME in the absence of acute infection does not require antimicrobial therapy. Purulent otorrhea of recent onset is indicative of AOM. Difficulty in distinguishing clinically between AOM and OME is limited to circumstances in which purulent otorrhea is not present. Both AOM without otorrhea and OME are accompanied by physical signs of MEE, namely, the presence of at least two of three TM abnormalities: white, yellow, amber, or (rarely) blue discoloration; opacification other than that caused by scarring; and decreased or absent mobility. Alternatively, in OME, either air-fluid levels or air bubbles outlined by small amounts of fluid may be visible behind the TM, a condition often indicative of impending resolution (see Fig. 680.4).

To support a diagnosis of AOM instead of OME in a child with MEE, distinct fullness or bulging of the TM may be present, with or without accompanying erythema, or, at a minimum, MEE should be accompanied by ear pain that appears clinically important. Unless intense, erythema alone is insufficient because erythema, without other abnormalities, may result from crying or vascular flushing. In AOM, the malleus may be obscured, and the TM may resemble a bagel without a hole but with a central depression (see Fig. 680.3). Rarely, the TM may be obscured by surface bullae or may have a cobblestone appearance. Bullous myringitis is a physical manifestation of AOM and not an etiologically discrete entity. Within days after onset, fullness of the membrane may diminish, even though infection may still be present.

In OME, bulging of the TM is absent or slight or the membrane may be retracted (Fig. 680.4); erythema also is absent or slight but may increase with crying or with superficial trauma to the external auditory canal incurred in clearing the canal of cerumen.

Both before and after episodes of OM and also in the absence of OM, the TM may be retracted as a consequence of negative middle-ear air pressure. The presumed cause is diffusion of air from the middle-ear

Fig. 680.4 Tympanic membrane in otitis media with effusion.

cavity more rapidly than it is replaced via the eustachian tube. Mild retraction is generally self-limited, although in some children it is accompanied by mild conductive hearing loss. More extreme retraction is of concern, as discussed later in the section on sequelae of OM.

Conjunctivitis-Associated Otitis Media

Simultaneous appearance of purulent and erythematous conjunctivitis with an ipsilateral OM is a well-recognized presentation, caused by nontypeable *H. influenzae* in most children. The disease often is present in multiple family members and affects young children and infants. Topical ocular antibiotics are ineffective. In an era of resistant organisms, this clinical association can be important in antibiotic selection, with oral antibiotics (see later) effective against resistant forms of nontypeable *H. influenzae.*

Asymptomatic Purulent Otitis Media

Rarely, a child will present during a routine exam without fever, irritability, or other overt signs of infection, but on exam, the patient will demonstrate an obvious purulent MEE and bulging TM. Although an uncommon presentation of "acute" OM, the bulging nature of the TM and the obvious purulence of the effusion do warrant antimicrobial therapy.

Tympanometry

Tympanometry, or **acoustic immittance testing**, is a simple, rapid, atraumatic test that, when performed correctly, offers objective evidence of the presence or absence of MEE. The tympanogram provides information about **TM compliance** in electroacoustic terms that can be thought of as approximately equivalent to TM mobility as perceived visually during pneumatic otoscopy. The absorption of sound by the TM varies inversely with its stiffness. The stiffness of the membrane is least, and its compliance is greatest, when the air pressures impinging on each of its surfaces—middle-ear air pressure and external canal air pressure—are equal. Anything tending to stiffen the TM, such as TM scarring or middle-ear fluid, reduces the TM compliance, which is recorded as a flattening of the curve of the tympanogram. An ear filled with middle-ear fluid generally has a very noncompliant TM and therefore a flattened tympanogram tracing.

Tympanograms may be grouped into one of three categories (Fig. 680.5). Tracings characterized by a relatively steep gradient, sharp-angled peak, and middle-ear air pressure (location of the peak in terms of air pressure) that approximates atmospheric pressure (see Fig. 680.5A) (type A curve) are assumed to indicate normal middle-ear status. Tracings characterized by a shallow peak or no peak are often termed "flat" or type B (see Fig. 680.5B) and usually are assumed to indicate the presence of a middle-ear abnormality that is causing decreased TM compliance. The most common such abnormality in infants and children is MEE. Tracings characterized by intermediate findings—somewhat shallow peak, often in association with a gradual gradient (obtuse-angled peak) or negative middle-ear air pressure peak (often termed type "C"), or combinations of these features (see Fig. 680.5C)—may or may not be associated with MEE and must be considered nondiagnostic or equivocal with respect to OM. However, type C tympanograms do suggest eustachian tube dysfunction and some ongoing pathology in the middle ear and warrant follow-up.

When reading a tympanogram, it is important to look at the volume measurement. The type B tympanometric response is analyzed within the context of the recorded volume. A flat, "low"-volume (≤1 mL) tracing typically reflects the volume of the ear canal only, representing MEE, which impedes the movement of an intact eardrum. A flat, high-volume (>1 mL) tracing typically reflects the volume of the ear canal and middle-ear space, representing a perforation (or patent tympanostomy tube) in the TM. In a child with a tympanostomy tube present, a flat tympanogram with a volume <1 mL would suggest a plugged or nonfunctioning tube and middle-ear fluid, whereas a flat tympanogram with a volume >1 mL would suggest a patent tympanostomy tube.

Although tympanometry is quite sensitive in detecting MEE, it can be limited by patient cooperation, the skill of the individual administering the test, and the age of the child, with less reliable results in very young children. Use of tympanometry may be helpful in office screening, may supplement the examination of difficult-to-examine patients, and may help to identify patients who require further attention because their tympanograms are abnormal. Tympanometry also may be used to help confirm, refine, or clarify questionable otoscopic findings; to objectify the follow-up evaluation of patients with known middle-ear disease; and to validate otoscopic diagnoses of MEE. Even though tympanometry can predict the probability of MEE, it cannot distinguish the effusion of OME from that of AOM.

PREVENTION

General measures to prevent OM that have been supported by numerous investigations include avoiding exposure to individuals with respiratory infection, appropriate vaccination strategies against pneumococci and influenzae, avoiding environmental tobacco smoke, and breast milk feeding.

IMMUNOPROPHYLAXIS AND VACCINATION STATUS

Heptavalent pneumococcal conjugate vaccine (PCV7) reduced the overall number of episodes of AOM by only 6–8% but with a 57% reduction in serotype-specific episodes. Reductions of 9–23% are seen in children with histories of frequent episodes, and a 20% reduction is seen in the number of children undergoing tympanostomy tube insertion. The 13-valent pneumococcal polysaccharide-protein conjugate vaccine (PCV13) contains the seven serotypes included in PCV7 (serotypes 4, 6B, 9V, 14, 18C, 19F, and 23F) and six additional serotypes (serotypes 1, 3, 5, 6A, 7F, and 19A). Early data indicate a significant reduction in the number of invasive pneumococcal mastoiditis cases since the introduction of PCV13. With the widespread use of PCV13,

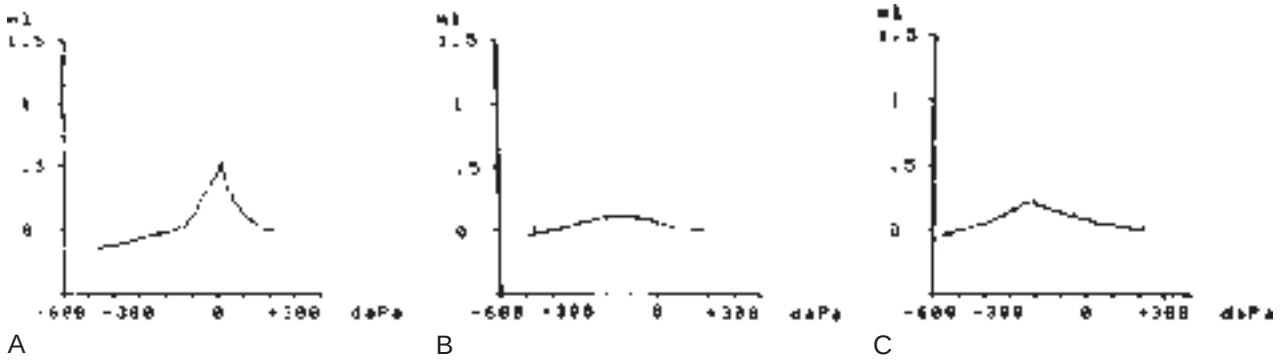

Fig. 680.5 Tympanograms obtained with a Grason-Stadler GSI 33 Middle Ear Analyzer, exhibiting (**A**) high admittance, steep gradient (i.e., sharp-angled peak), and middle-ear air pressure approximating atmospheric pressure (0 decaPascals [daPa]); (**B**) low admittance and indeterminate middle-ear air pressure; and (**C**) somewhat low admittance, gradual gradient, and markedly negative middle-ear air pressure.

continued surveillance will be necessary to detect other emerging serotypes, which are also demonstrating increasing resistance. Although the influenza vaccine also provides a measure of protection against OM, the relatively limited time during which individuals and even communities are exposed to influenza viruses limits the vaccine's effectiveness in broadly reducing the incidence of OM. Limitation of OM disease is only a portion of the benefit realized from the vaccinations for pneumococci and influenza viruses.

TREATMENT

Management of Acute Otitis Media

AOM can be very painful. Whether or not antibiotics are used for treatment, pain should be assessed and, if present, treated (Table 680.1). Individual episodes of AOM have traditionally been treated with antimicrobial drugs, and a sharp decline in complications from AOM during the last half-century seems, at least in part, attributable to the widespread routine use of antimicrobials. However, concerns about increasing bacterial resistance have prompted consideration for withholding antimicrobial treatment in certain, well-defined clinical situations (Table 680.2). Although viral and bacterial pathogens have been cultured from middle-ear fluid obtained by tympanocentesis, two factors may argue in favor of prescribing antimicrobial therapy for children who have AOM. First, symptomatic improvement and resolution of infection may occur more promptly and more consistently with antimicrobial treatment than without, even though most untreated cases eventually resolve. Second, prompt and adequate antimicrobial treatment may prevent the development of suppurative complications. Whereas data from the Netherlands in the 1990s suggested an increased incidence of acute mastoiditis with watchful waiting as the initial approach to treatment of AOM, other studies from several countries have contradicted these findings, demonstrating no increased incidence in acute mastoiditis with changes in recommendations for more conservative antimicrobial prescribing practices.

Given that most episodes of OM will spontaneously resolve, consensus guidelines have been published to assist clinicians who wish to consider a period of "watchful waiting" or observation before treating AOM with antibiotics (see Table 680.2 and Table 680.3; Fig. 680.6). The most important aspect of these guidelines is that close follow-up of the patient must be ensured to assess for lack of spontaneous resolution or worsening of symptoms and that patients should be provided with adequate analgesic medications (acetaminophen, ibuprofen) during the period of observation. When pursuing the practice of watchful waiting in patients with AOM, the certainty of the diagnosis, the patient's age, and the severity of the disease should be considered. For patients <2 years of age, it is recommended to treat all confirmed diagnoses of AOM. In patients, <6 months of age, even presumed episodes of AOM should be treated because of the increased potential of significant morbidity from infectious complications. In children between 6 and 24 months of age who have a questionable diagnosis of OM but severe disease, defined as temperature of >39°C (102°F), significant otalgia, or toxic appearance, antibiotic therapy is also recommended. Children in this age-group with a questionable diagnosis and nonsevere disease can be observed for a period of 2-3 days with close follow-up. In children older than 2 years of age, observation might be considered in all episodes of nonsevere OM or episodes of questionable diagnosis, whereas antibiotic therapy is reserved for confirmed, severe episodes of AOM. Information from Finland suggests that the "watchful waiting" or delayed treatment approach does not worsen the recovery from AOM or increase the complication rates.

Accurate diagnosis is the most crucial aspect of the treatment of OM. In studies using stringent criteria for diagnosis of AOM, the benefit of antimicrobial treatment is enhanced. In addition, subpopulations of patients clearly receive more benefit from oral antimicrobial therapy than others. *Younger children, children with otorrhea, and children with bilateral AOM have a significantly enhanced benefit from antimicrobial therapy in comparison with older children, children without otorrhea, or children with unilateral AOM.*

Table 680.1 Therapy for Otalgia in Acute Otitis Media

APPROACH	RECOMMENDATIONS
Acetaminophen, ibuprofen	Preferred therapy
Benzocaine, antipyrine (topical)	Brief, benefit over acetaminophen in patients older than 5 yr
Topical antibiotics (fluoroquinolones) with or without steroids for chronic suppurative otitis (perforated tympanic membrane)	Preferred treatment with ear canal cleaning; must culture
Homeopathic agents	Not recommended
Narcotic analgesia with codeine or analogs	Not recommended
Tympanostomy/myringotomy	Not recommended for initial approach; an option for otitis media unresponsive to antibiotic therapy

Bacterial Resistance

Persons at greatest risk of harboring resistant bacteria are those who are younger than 2 years of age; who are in regular contact with large groups of other children, especially in daycare settings; or who recently have received antimicrobial treatment. The development of resistant bacterial strains and their rapid spread have been fostered and facilitated by selective pressure resulting from extensive use of antimicrobial drugs, the most common target of which in children is OM. Many strains of each of the pathogenic bacteria that commonly cause AOM are resistant to commonly used antimicrobial drugs.

Although antimicrobial resistance rates vary between countries, in the United States approximately 40% of strains of nontypeable *H. influenzae*

Table 680.2 Recommendations for Initial Management for Uncomplicated Acute Otitis Media*

AGE	OTORRHEA WITH AOM*	UNILATERAL OR BILATERAL AOM* WITH SEVERE SYMPTOMS†	BILATERAL AOM* WITHOUT OTORRHEA	UNILATERAL AOM* WITHOUT OTORRHEA
6 mo to 2 yr	Antibiotic therapy	Antibiotic therapy	Antibiotic therapy	Antibiotic therapy or additional observation
≥2 yr	Antibiotic therapy	Antibiotic therapy	Antibiotic therapy or additional observation	Antibiotic therapy or additional observation‡

*Applies only to children with well-documented AOM with high certainty of diagnosis.
†A toxic-appearing child, persistent otalgia more than 48 hours, temperature ≥39°C (102.2°F) in the past 48 hours, or if there is uncertain access to follow-up after the visit.
‡This plan of initial management provides an opportunity for shared decision-making with the child's family for those categories appropriate for additional observation. If observation is offered, a mechanism must be in place to ensure follow-up and begin antibiotics if the child worsens or fails to improve within 48-72 hr of AOM onset.
NOTE: For infants younger than age 6 mo, a suspicion of AOM should result in antibiotic therapy.
AOM, Acute otitis media.
From Lieberthal AS, Carroll AE, Chonmaitree T, et al. The diagnosis and management of acute otitis media. *Pediatrics*. 2013;131:e964–e999, Table 4.

Table 680.3 Suggested Antibiotics for Treatment of Otitis Media and for Patients Who Have Failed First-Line Antibiotic Treatment

INITIAL IMMEDIATE OR DELAYED ANTIBIOTIC TREATMENT		ANTIBIOTIC TREATMENT AFTER 48-72 HR OF FAILURE OF INITIAL ANTIBIOTIC TREATMENT	
RECOMMENDED FIRST-LINE TREATMENT	**ALTERNATIVE TREATMENT (IF PENICILLIN ALLERGY OR SUSPICION OF β-LACTAMASE–PRODUCING ORGANISMS)**	**RECOMMENDED TREATMENT**	**ALTERNATIVE TREATMENT**
Amoxicillin (pathogens include *Pneumococcus, H. influenzae* non–type B, *Moraxella)*	Cefdinir	Amoxicillin-clavulanate	Ceftriaxone
or	*or*	*or*	
Amoxicillin-clavulanate Ceftriaxone	Cefpodoxime Ceftriaxone Levofloxacin (type I hypersensitivity to penicillin) Clindamycin + third generation cephalosporin (non–type I hypersensitivity to penicillin)	Ceftriaxone	Tympanocentesis*
ANTIBIOTIC DOSAGE			
• Amoxicillin 80-90 mg/kg/day bid for 10 days** • Amoxicillin-clavulanate (ratio 14:1) 80-90 mg/kg/day of amoxicillin component bid for 10 days** • Ceftriaxone 50 mg/kg/day daily IM or IV for 1-3 days • Cefdinir 14 mg/kg/day daily for 10 days** • Cefpodoxime 10 mg/kg/day bid for 10 days** • Levofloxacin 20 mg/kg/day bid if ≤5 yr for 10 days; 10 mg/kg/day bid if >5 yr for 10 days			

*Tympanocentesis for those who fail second-line therapy.
**Durations of antibiotic therapy may vary based on symptom severity and patient age. For patients 2-5 yr old with mild or moderate disease severity, a 7-day course may be appropriate. For patients 6 yr and older, a 5- to 7-day course may be adequate for mild to moderate symptoms.
IM, Intramuscular; IV intravenous; bid, twice daily.

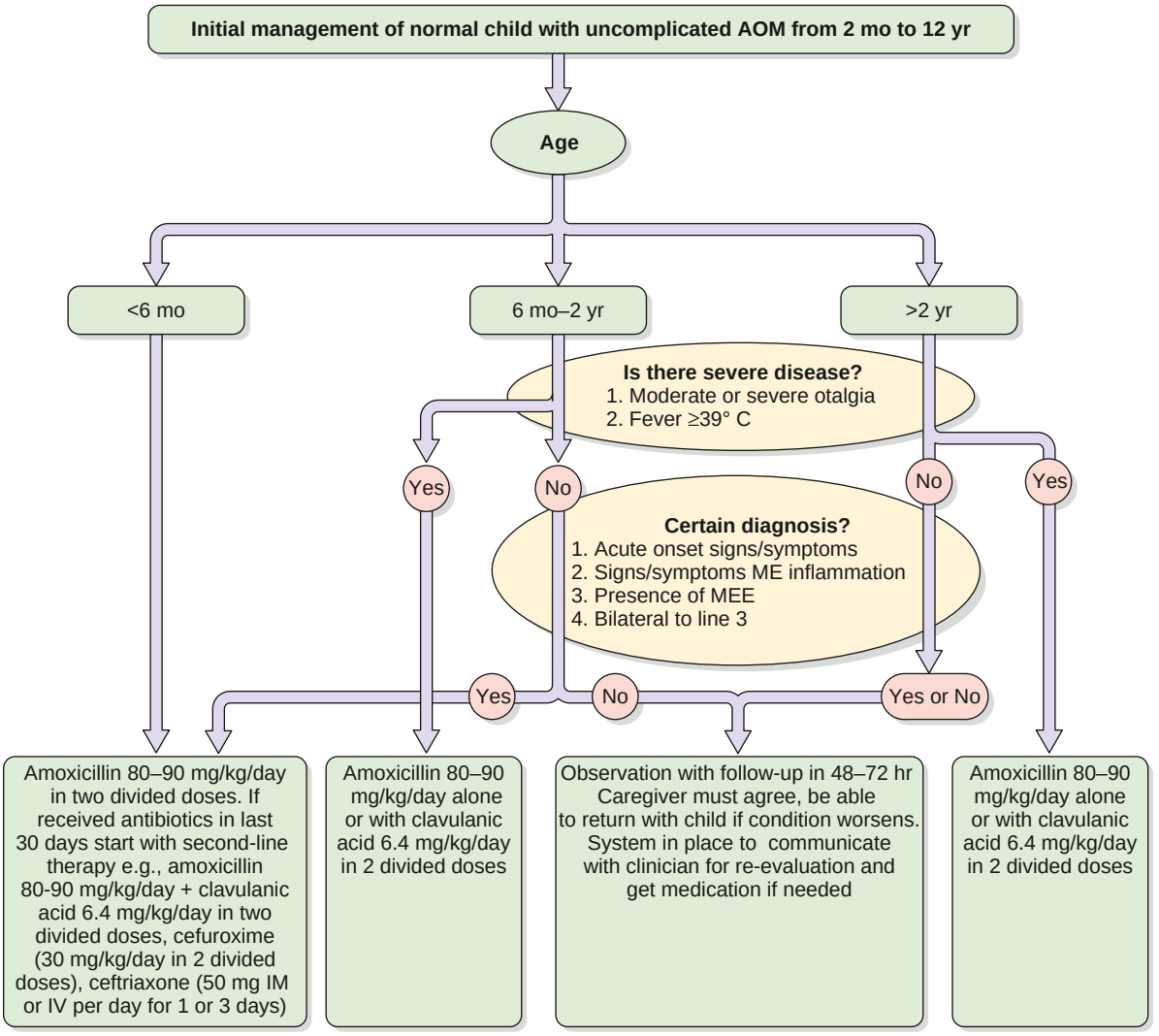

Fig. 680.6 Algorithm for management of acute otitis media. *(From Mazer BD: Otitis media. In: Leung DYM, Szefler SJ, Bonilla FA, et al., eds. Pediatric Allergy: Principles and Practices, 3 ed, Philadelphia: Elsevier; 2016: Fig. 25-3.)*

and almost all strains of *M. catarrhalis* are resistant to aminopenicillins (e.g., ampicillin and amoxicillin). In most cases the resistance is attributable to production of β-lactamase and can be overcome by combining amoxicillin with a β-lactamase inhibitor (clavulanate) or by using a β-lactamase–stable antibiotic. Occasional strains of nontypeable *H. influenzae* that do not produce β-lactamase are resistant to aminopenicillins and other β-lactam antibiotics by virtue of alterations in their penicillin-binding proteins. It is worth noting that bacterial resistance rates in Northern European countries where antibiotic use is not routine are lower (β-lactamase resistance in 6–10% of isolates) than in the United States.

In the United States, approximately 50% of strains of *S. pneumoniae* are penicillin-nonsusceptible, divided approximately equally between penicillin-intermediate and, even more difficult to treat, penicillin-resistant strains. A much higher incidence of resistance is seen in children attending daycare. Resistance by *S. pneumoniae* to the penicillins and other β-lactam antibiotics is mediated not by β-lactamase production but by alterations in penicillin-binding proteins. This mechanism of resistance can be overcome if higher concentrations of β-lactam antibiotics at the site of infection can be achieved for a sufficient time interval. Many penicillin-resistant strains of *S. pneumoniae* are also resistant to other antimicrobial drugs, including sulfonamides, macrolides, and cephalosporins. In general, as penicillin resistance increases, so also does resistance to other antimicrobial classes. Resistance to macrolides, including azithromycin and clarithromycin, by *S. pneumoniae* has increased, rendering these antimicrobials far less effective in treating AOM. One mechanism of resistance to macrolides also results in resistance to clindamycin, which otherwise is effective against resistant strains of *S. pneumoniae.* Unlike resistance to β-lactam antibiotics, macrolide resistance cannot be overcome by increasing the dose.

First-Line Antimicrobial Treatment

Amoxicillin remains the drug of choice for uncomplicated AOM under many circumstances because of its excellent safety record, relative efficacy, palatability, and low cost. Amoxicillin is the most efficacious of available oral antimicrobial drugs against both penicillin-susceptible and penicillin-nonsusceptible strains of *S. pneumoniae*. Increasing the dose from the traditional 40-45 mg/kg/day to 80-90 mg/kg/day will generally provide efficacy against penicillin-intermediate and some penicillin-resistant strains. This higher dose should be used particularly in children younger than 2 years old, in children who have recently received treatment with β-lactam drugs, and in children who are exposed to large numbers of other children because of their increased likelihood of an infection with a nonsusceptible strain of *S. pneumoniae*. A limitation of amoxicillin is that it may be inactivated by the β-lactamases produced by many strains of nontypeable *H. influenzae* and most strains of *M. catarrhalis*. However, episodes of AOM caused by these two pathogens often resolve spontaneously.

Allergies to penicillin antibiotics should be categorized into type I hypersensitivity, consisting of urticaria or anaphylaxis, and those that fall short of type I reactions, such as rash formation. For children with a non–type I reaction in which cross reactivity with cephalosporins is less of a concern, first-line therapy with cefdinir would be an appropriate choice. In children with a type I reaction or known sensitivity to cephalosporin antibiotics, there are far fewer choices. Resistance to trimethoprim-sulfamethoxazole by many strains of both nontypeable *H. influenzae* and *S. pneumoniae* and a reported high clinical failure rate in children with AOM treated initially with this antimicrobial argue against its use. Similarly, increasing rates of macrolide resistance argue against the efficacy of azithromycin. Because of concerns for arthropathy and damage to weight-bearing bones in animal models, fluoroquinolone use in children has been limited; fluoroquinolone use is recommended in certain clinical situations and/or when alternative therapies are deemed suboptimal. Early alternative management in allergic patients with tympanostomy tubes can allow for lessening of the severity of their disease and the use of topical antimicrobials.

Duration of Treatment

The duration of treatment of AOM has historically been set at 10 days, and most efficacy studies examining antimicrobial treatment in AOM have used this duration as a benchmark. Studies comparing shorter with longer durations of antimicrobial treatment have reported higher treatment failure rates in younger children, particularly those younger than 2 years old. Antibiotic courses shorter than 10 days, more severe disease, exposure to larger groups of other children, such as in daycare settings, and in children with a history of OME are also associated with higher treatment failure rates. The clinical practice guidelines published in 2013 by the American Academy of Pediatrics suggest shorter durations of antibiotic therapy may be adequate for treatment of AOM in children older than 2 years. However, compelling evidence substantiating the efficacy of shorter antibiotic courses to treat AOM in older children is limited.

Most patients improve within 72 hours; however, patients should not stop therapy. If there are persistent symptoms after 72 hours of therapy, the child should be reexamined for persistent OM or a complication such as mastoiditis (see Chapter 681).

Follow-Up

The principal goals of follow-up are to assess the outcome of treatment and to differentiate between inadequate response to treatment and early recurrence. The appropriate interval for follow-up should be individualized. Follow-up within days is advisable in the young infant with a severe episode or in a child of any age with continuing pain. Follow-up within 2 weeks is appropriate for the infant or young child who has been having frequent recurrences. At that point, the TM is not likely to have returned to normal, but substantial improvement in its appearance should be evident. In the child with only a sporadic episode of AOM and prompt symptomatic improvement, follow-up 1 month after initial examination is early enough, or in older children, no follow-up may be necessary. The continuing presence of MEE alone after an episode of AOM is not an indication for additional or second-line antimicrobial treatment. However, persisting MEE does warrant additional follow-up to ensure that the effusion resolves and does not lead to persisting hearing loss or other complications.

Unsatisfactory Response to First-Line Treatment

AOM is essentially a closed-space infection, and its resolution depends both on eradication of the offending organism and restoration of middle-ear ventilation. Factors contributing to unsatisfactory response to first-line treatment, in addition to inadequate antimicrobial efficacy, include poor compliance with treatment regimens, concurrent or intercurrent viral infection, persistent eustachian tube dysfunction and middle-ear under-aeration, reinfection from other sites or from incompletely eradicated middle-ear pathogens, and immature or impaired host defenses. The identification of biofilm formation in the middle ear of children with chronic OM also indicates that, in some children, eradication with standard antimicrobial therapy is likely to be unsuccessful. Despite these many potential factors, switching to an alternative or second-line drug is reasonable when there has been inadequate improvement in symptoms or in middle-ear status as reflected in the appearance of the TM or when the persistence of purulent nasal discharge suggests that the antimicrobial drug being used has less-than-optimal efficacy. Second-line drugs may also appropriately be used when AOM develops in a child already receiving antimicrobial therapy, or in an immunocompromised child, or in a child with severe symptoms whose previous experience with OM has been problematic.

Second-Line Treatment

When treatment of AOM with a first-line antimicrobial drug has proven inadequate, numerous second-line alternatives are available (see Table 680.3). Drugs chosen for second-line treatment should be effective against β-lactamase–producing strains of nontypeable *H. influenzae* and *M. catarrhalis* and against susceptible and most nonsusceptible strains of *S. pneumoniae.* Because high-dose amoxicillin (80-90 mg/kg/day) is effective against most strains of *S. pneumoniae* and because the addition of clavulanate extends the effective antibacterial spectrum of amoxicillin to include β-lactamase–producing bacteria, high-dose amoxicillin-clavulanate is particularly well-suited as a

second-line drug for treating AOM. The 14:1 amoxicillin-clavulanate formulation contains twice as much amoxicillin as the previously available 7:1 formulation. Diarrhea, especially in infants and young children, is a common adverse effect and usually is not severe enough to require cessation of treatment. Cefdinir has demonstrated efficacy in treatment, is generally well tolerated with respect to taste, and can be given as a once-daily regimen. The ability to also use cefdinir in most children with mild type I hypersensitivity reactions has further added to its favorable selection as a second-line agent. Intramuscular ceftriaxone has important limitations for use in young children; treatment entails both the pain of intramuscular injection and substantial cost, and the injection may need to be repeated once or twice at 2-day intervals to achieve the desired degree of effectiveness. Nonetheless, use of ceftriaxone is appropriate in severe cases of AOM when oral treatment is not feasible, in highly selected cases after treatment failure using orally administered second-line antimicrobials, or when highly resistant *S. pneumoniae* is found in aspirates obtained from diagnostic tympanocentesis.

Clarithromycin and azithromycin have only limited activity against nonsusceptible strains of *S. pneumoniae* and against β-lactamase–producing strains of nontypeable *H. influenzae.* Macrolide use also appears to be a major factor in causing increases in rates of resistance to macrolides by group A streptococcus and *S. pneumoniae*. Clindamycin is active against most strains of *S. pneumoniae,* including resistant strains, but is not active against nontypeable *H. influenzae* or *M. catarrhalis.*

Other antimicrobial agents that have been traditionally used in the management of AOM have such significant lack of effectiveness against resistant organisms that use seldom outweighs the potential side effects or complications. This includes cefaclor, loracarbef, cefixime, trimethoprim-sulfamethoxazole, and erythromycin-sulfisoxazole. Cefpodoxime has demonstrated reasonable effectiveness in some investigations but is generally poorly tolerated because of its taste.

ANTIMICROBIAL PROPHYLAXIS

In children who have developed frequent episodes of AOM, antimicrobial prophylaxis with subtherapeutic doses of an aminopenicillin or a sulfonamide has been used in the past to provide protection against recurrences of AOM (although not of OME). However, because of the increased incidence of resistant organisms and the contribution of antimicrobial usage to bacterial resistance, the risks of sustained antimicrobial prophylaxis clearly outweigh potential benefits.

Myringotomy and Tympanocentesis

Myringotomy is a long-standing treatment for AOM but is not commonly needed in children receiving antimicrobials. **Indications for myringotomy** in children with AOM include severe, refractory pain; hyperpyrexia; complications of AOM such as facial paralysis, mastoiditis, labyrinthitis, or central nervous system infection; and immunologic compromise from any source. Myringotomy should be considered as third-line therapy in patients who have failed two courses of antibiotics for an episode of AOM. In children with AOM in whom clinical response to vigorous, second-line treatment has been unsatisfactory, either diagnostic tympanocentesis or myringotomy is indicated to enable identification of the offending organism and its sensitivity profile. Either procedure may be helpful in effecting relief of pain. Tympanocentesis with culture of the middle-ear aspirate may also be indicated as part of the sepsis workup in very young infants with AOM who show systemic signs of illness such as fever, vomiting, or lethargy and whose illness accordingly cannot be presumed to be limited to infection of the middle ear. Performing tympanocentesis can be facilitated by use of a specially designed tympanocentesis aspirator. Studies reporting the use of strict, individualized criteria for the diagnosis of AOM that include office tympanocentesis with bacterial culture followed by culture-guided antimicrobial therapy demonstrate significant reduction in the frequency of recurrent AOM episodes and tympanostomy tube surgery. However, many primary care physicians do not feel comfortable performing this procedure, there is the potential for complications, and parents may view this procedure as traumatic. Often, children requiring this intervention have a strong enough history of recurrent OM to warrant the consideration of tympanostomy tube placement, so that the procedure can be performed under general anesthesia.

Early Recurrence After Treatment

Recurrence of AOM after apparent resolution may be caused by either incomplete eradication of infection in the middle ear or upper respiratory tract reinfection by the same or a different bacteria or bacterial strain. Recent antibiotic therapy predisposes patients to an increased incidence of resistant organisms, which should also be considered in choosing therapy, and, generally, initiating therapy with a second-line agent is advisable (see Table 680.3).

Myringotomy and Insertion of Tympanostomy Tubes

When AOM is recurrent, despite appropriate medical therapy, consideration of surgical management of AOM with tympanostomy tube insertion is warranted. Although this surgical procedure may improve the quality of life in patients with recurrent AOM, some studies have suggested the procedure is effective at reducing the rate of AOM, whereas others found postprocedure rates of AOM were no different than patients managed with antibiotics. Individual patient factors, including the risk profile, severity of AOM episodes, child's development and age, presence of a history of adverse drug reactions, concurrent medical problems, and parental wishes, will affect the timing of a decision to consider referral for this procedure. When a patient experiences three episodes of AOM in a 6-month period or four episodes in a 12-month period with one episode in the preceding 6 months, potential surgical management of the child's AOM should be discussed with the parents. Guidelines on tympanostomy tube placement indicate that if MEE is persistent in one or two ears and present at the time of evaluation by the otolaryngologist, then myringotomy is indicated. However, if MEE has cleared, the guidelines recommend holding off on myringotomy and offering observation unless there are additional considerations such as difficulty with tolerating antibiotic therapy (allergic concerns or other tolerance difficulties), severe episodes of acute OM, or other developmental considerations. Not infrequently, one or more of these additional considerations do affect a child's care.

AOM-Associated Tube Otorrhea

Although tympanostomy tubes may reduce the incidence of AOM in some children, patients with tympanostomy tubes may still develop AOM. One advantage of tympanostomy tubes in children with recurrent AOM is that if patients do develop an episode of AOM with a functioning tube in place, these patients will manifest purulent drainage from the tube. By definition, children with functioning tympanostomy tubes without otorrhea do not have bacterial AOM as a cause for a presentation of fever or behavioral changes and should not be treated with oral antibiotics. If tympanostomy tube otorrhea develops, ototopical treatment, and not oral antibiotics, should be considered as first-line therapy. With a functioning tube in place, the infection is able to drain, there is usually negligible pain associated with the infection, and the possibility of developing a serious complication from an episode of AOM is remote. Importantly, strict water precautions after tympanostomy tube placement do not appear to affect the occurrence of posttympanostomy otorrhea, and as such, water precautions are no longer recommended in children with myringotomy tubes. However, when otorrhea does occur, it is important to keep the ear canal dry while ototopical treatment is administered. The current quinolone otic drops approved by the U.S. Food and Drug Administration for use in the middle-ear space in children are formulated with ciprofloxacin/dexamethasone (Ciprodex) and ofloxacin (Floxin). The topical delivery of these otic drops allows them to use a higher antibiotic concentration than can be tolerated by administering oral antibiotics, and they have excellent coverage of even the most resistant strains of common middle-ear pathogens, as well as coverage of *S. aureus* and *Pseudomonas aeruginosa*. The high rate of success of these topical preparations, their broad coverage, the lower likelihood of their contributing to the

development of resistant organisms, the relative ease of administration, the lack of significant side effects, and the lack of ototoxicity make them the first choice for tube otorrhea. Oral antibiotic therapy should be reserved for cases of tube otorrhea that have other associated systemic symptoms, patients who have difficulty in tolerating the use of topical preparations, or, possibly, patients who have failed an attempt at topical otic drops. Despite these advantages of ototopical therapy, survey data have indicated that, compared with otolaryngologists, primary care practitioners are less likely to prescribe ototopicals as first-line therapy in tympanostomy tube otorrhea.

As a result of the relative ease in obtaining fluid for culture and the possibility of the development of fungal otitis, which has shown an increase with the use of broad-spectrum quinolone ototopicals, patients who fail topical therapy should also have culture performed. Other otic preparations are available; although these either have some risk of ototoxicity or have not received approval for use in the middle ear, many of these preparations were widely used before the development of the current quinolone drops and were generally considered reasonably safe and effective. In all cases of tube otorrhea, attention to aural toilet (e.g., cleansing the external auditory canal of secretions and avoidance of external ear water contamination) is important. In some cases, with very thick, tenacious discharge, topical therapy may be inhibited due to lack of delivery of the medication to the site of infection. Suctioning and removal of the secretions, often done through referral to an otolaryngologist, may be quite helpful. When children with tube otorrhea fail to improve satisfactorily with conventional outpatient management, they may require tube removal, hospitalization to receive parenteral antibiotic treatment, or both.

MANAGEMENT OF OTITIS MEDIA WITH EFFUSION

Management of OME depends on an understanding of its natural history and its possible complications and sequelae. Children with OME should be assessed for any baseline sensory, physical, cognitive, or behavioral factors that may portend risk of learning problems from MEE. Moreover, clinicians should evaluate developmentally at-risk children for OME at the time of diagnosis of an at-risk condition such as Down syndrome, autism, speech and language delay, permanent hearing loss, craniofacial syndromes, cleft palate, blindness, or global developmental delay and at 12-18 months of age (if diagnosed as being at risk before this time). However, children who do not have symptoms that could be attributed to OME, such as hearing difficulties, ear discomfort, balance (vestibular) problems, poor school performance, or behavioral problems, and are not at developmental risk should not be routinely screened for OME. When MEE persists for longer than 3 months, an age-appropriate hearing test and consideration of referral to an otolaryngologist are appropriate. In older children (generally older than 4 years) and depending on the expertise in the primary care office, hearing screening may be achieved in primary care. For any child who fails a hearing screening in the primary care office, referral to an otolaryngologist is warranted. In considering the decision to refer the patient for consultation, the clinician should attempt to determine the impact of the OME on the child and educate the family in this regard. Most cases of OME resolve without treatment within 3 months. For children with OME being managed expectantly, the guidelines for management of OME recommend examination should be performed at 3- to 6-month intervals, until the effusion is no longer present, significant hearing loss is identified, or structural abnormalities of the eardrum or middle ear are suspected. Although hearing loss may be of primary concern, OME causes several other difficulties in children that should also be considered. These include predisposition to recurring AOM, pain, disturbance of balance, and tinnitus. In addition, long-term sequelae that have been demonstrated to be associated with OME include pathologic middle-ear changes, atelectasis of the TM and retraction pocket formation, adhesive OM, cholesteatoma formation and ossicular discontinuity, and conductive and sensorineural hearing loss. Long-term adverse effects on speech, language, cognitive, and psychosocial development have also been demonstrated. This impact is related to the duration of effusion present, whether the effusion is unilateral or bilateral, the degree of underlying hearing loss, and other developmental and social factors affecting the child. In considering the impact of OME on development, it is especially important to take into consideration the overall presentation of the child. Although it is unlikely that OME causing unilateral hearing loss in the mild range will have long-term negative effects on an otherwise healthy and developmentally normal child, even a mild hearing loss in a child with other developmental or speech delays certainly has the potential to compound this child's difficulties (Table 680.4). At a minimum, children with OME persisting longer than 3 months deserve close monitoring of their hearing levels with skilled audiologic evaluation, frequent assessment of developmental milestones, including speech and language assessment, and attention paid to their rate of recurrent AOM.

Variables Influencing Otitis Media with Effusion Management Decisions

Patient-related variables that affect decisions on how to manage OME include the child's age, the frequency and severity of previous episodes of AOM and interval since the last episode, the child's current speech and language development, presence of a history of adverse drug reactions, concurrent medical problems, or risk factors such as daycare attendance, and parental wishes. In considering surgical management of OME with tympanostomy tubes, particular benefit is seen in patients with persisting OME punctuated by episodes of AOM, because the tubes may provide resolution of both conditions. Persistence of MEE after recurrent AOM (three episodes in 6 months or four in 12 months) may be treated with tympanostomy tube placement. Disease-related variables that most otolaryngologists consider in the treatment of OME include whether the effusion is unilateral or bilateral, the apparent quantity of effusion, the duration if known, the degree of hearing impairment, the presence or absence of other possibly related symptoms (such as tinnitus, vertigo, or disturbance of balance), and the presence or absence of mucopurulent or purulent rhinorrhea, which, if sustained for longer than 2 weeks, would suggest that concurrent nasopharyngeal or paranasal sinus infection is contributing to continuing compromise of middle-ear ventilation.

Medical Treatment

Antimicrobials have demonstrated limited efficacy in resolving OME, presumably because they help to eradicate nasopharyngeal infection, unapparent middle-ear infection, or both. The most significant effects of antibiotics for OME have been shown with treatment durations of 4 weeks and 3 months. However, with the risk of bacterial antimicrobial resistance, the small potential benefit of antimicrobial therapy is outweighed by the negative potential of treatment and is not recommended. Instead, antibiotic treatment should be limited to cases in which there is evidence of associated bacterial upper respiratory tract infection or untreated middle-ear infection. For this purpose, the most broadly effective drug available should be used as recommended for AOM.

Table 680.4 Sensory, Physical, Cognitive, or Behavioral Factors that Place Children Who Have Otitis Media with Effusion at an Increased Risk for Developmental Difficulties (Delay or Disorder)

Permanent hearing loss independent of otitis media with effusion
Suspected or diagnosed speech and language delay or disorder
Autism spectrum disorder and other pervasive developmental disorders
Syndromes (e.g., Down) or craniofacial disorders that include cognitive, speech, and language delays
Blindness or uncorrectable visual impairment
Cleft palate with or without associated syndrome
Developmental delay

From Rosenfeld RM, Shin JJ, Schwartz SJ, et al. American Academy of Otolaryngology-Head and Neck Surgery Foundation. Clinical practice guideline. Otitis media with effusion (update). *Otolaryngol Head Neck Surg*. 2016;154(2):201–214, Table 3.

The efficacy of corticosteroids in the treatment of OME has been demonstrated to be short term. Therefore the risk-to-benefit ratio for steroids is such that they are no longer recommended for treatment of OME. Antihistamine-decongestant combinations are not effective in treating children with OME and are not indicated. Antihistamines alone, decongestants alone, and mucolytic agents are also ineffective and not recommended. The risk profile for decongestants and antihistamines in children are such that, unless there is some other medical condition such as documented allergic disease for antihistamine therapy, these medications are contraindicated for OME treatment. Randomized controlled trials do not support the use of topical intranasal steroid sprays to treat the manifestations of eustachian tube dysfunction, and their use for OME resolution is also not recommended. Inflation of the eustachian tube by the Valsalva maneuver or other means has not demonstrated long-term efficacy. Other "alternative" therapies, including spinal manipulation, currently have no demonstrated efficacy or role in children with OME.

Myringotomy and Insertion of Tympanostomy Tubes

When OME persists despite an ample period of watchful waiting, generally 3-6 months or perhaps longer in children with unilateral effusion, consideration of surgical intervention with tympanostomy tubes is appropriate. Myringotomy alone, without tympanostomy tube insertion, permits evacuation of MEE and may sometimes be effective, but often the incision heals before the middle-ear mucosa returns to normal, and the effusion soon reaccumulates. Inserting a tympanostomy tube offers the likelihood that middle-ear ventilation will be sustained for at least as long as the tube remains in place and functional. Tympanostomy tubes have a variable duration of efficacy based on design. Tubes that are designed for a shorter duration, 6-12 months, have a lesser impact on disease-free middle-ear spaces in children. Some studies comparing the efficacy of tympanostomy tube types, including shorter-acting tubes, with watchful waiting provide a less helpful assessment of the differences between these approaches. Tubes that are somewhat longer acting, effective for 12-18 months, are generally more appropriate for most children undergoing tube placement. Regardless of type, tympanostomy tube placement nearly uniformly reverses the conductive hearing loss associated with OME. Occasional episodes of obstruction of the tube lumen and premature tube extrusion may limit the effectiveness of tympanostomy tubes, and tubes can also be associated with otorrhea. However, placement of tympanostomy tubes is generally quite effective in providing resolution of OME in children. Tympanostomy tubes generally extrude on their own but rarely require surgical removal after several years in place. Sequelae after tube extrusion include residual perforation of the eardrum, tympanosclerosis, localized or diffuse atrophic scarring of the eardrum (which may predispose to the development of a retraction pocket), residual conductive hearing loss, and cholesteatoma. The more serious of these sequelae are quite infrequent. Recurrence of MEE after the extrusion of tubes does develop, especially in younger children. However, most children without underlying craniofacial abnormalities require only one set of tympanostomy tubes. In developed countries, immunologic maturity and other developmental changes provide improved middle-ear health and resolution of chronic OME by the time of tube extrusion. However, in some populations, including Australian Aboriginal people, Indigenous Nations in the United States, and Alaskan Natives, even with an absence of craniofacial abnormalities, there is a preponderance of chronic OME; these patients should have increased follow-up after tube extrusion. Because persistent OME may clear spontaneously during the summer months, watchful waiting through the summer season may be advisable in children with OME who are otherwise well and without developmental or speech concerns. In considering surgical management of OME in children, primarily in those with bilateral disease and hearing loss, it has been demonstrated that placement of tympanostomy tubes results in a significant improvement in their quality of life.

Adenoidectomy

Adenoidectomy may reduce the risk of subsequent recurrences of both AOM and OME in older children who have undergone tube insertion and in whom, after extrusion of tubes, OM continues to be a problem. Efficacy appears to be independent of adenoid size and probably derives from removal of the focus of infection in the nasopharynx as a site of biofilm formation, chronic inflammation affecting eustachian tube function, and recurrent seeding of the middle ear via the eustachian tube. Current guidelines state that adenoidectomy should not be performed at the time of tympanostomy tube insertion in children younger than 4 years old unless a distinct indication exists (nasal obstruction, chronic adenoiditis). However, in children older than 4 years, one should recommend tympanostomy tubes, adenoidectomy, or both when surgery is performed for OME.

Complications of Acute Otitis Media

Most complications of AOM consist of the spread of infection to adjoining or nearby structures, the development of chronicity, or both. Suppurative complications are relatively uncommon in children in developed countries but occur not infrequently in disadvantaged children whose medical care is limited. The complications of AOM may be classified as either intratemporal or intracranial (Table 680.5).

Intratemporal Complications

Direct but limited extension of AOM leads to complications within the local region of the ear and temporal bone. These complications include dermatitis, TM perforation, chronic suppurative OM (CSOM), mastoiditis, petrositis, brain abscess, hearing loss, facial nerve paralysis, cholesteatoma formation, and labyrinthitis.

Infectious Dermatitis

This is an infection of the skin of the external auditory canal resulting from contamination by purulent discharge from the middle ear. The skin is often erythematous, edematous, and tender. Management consists of proper hygiene combined with systemic antimicrobials and ototopical drops as appropriate for treating AOM and tube otorrhea.

Tympanic Membrane Perforation

Rupture of the TM can occur with episodes of either AOM or OME. Although damage to the TM from these episodes generally heals spontaneously, chronic perforations can develop in a small number of cases and require further surgical intervention.

Chronic Suppurative Otitis Media

CSOM consists of persistent middle-ear infection with discharge through a TM perforation. The disease is initiated by an episode of AOM with rupture of the membrane. The mastoid air cells are invariably involved. The most common etiologic organisms are *P. aeruginosa* and *S. aureus;* however, the typical AOM bacterial pathogens may also be the cause, especially in younger children or in the winter months. Treatment is guided by the results of microbiologic investigation. If an associated cholesteatoma is not present, parenteral antimicrobial treatment combined with assiduous aural cleansing is likely to be successful in clearing the infection, but in refractory cases, tympanomastoidectomy can be required.

Mastoiditis

Mastoiditis is an important complication associated with OM (see Chapter 681).

Facial Paralysis

As it traverses the middle ear and mastoid bone, the facial nerve may be affected by adjacent infection. Facial paralysis occurring as a complication of AOM is uncommon and often resolves after myringotomy and parenteral antibiotic treatment. Facial paralysis in the presence of AOM requires urgent attention because prolonged infection can result in the development of permanent facial paralysis, which can have a devastating effect on a child. Facial paralysis in an infant or child requires complete and unequivocal examination of the TM and middle-ear space. Any difficulty in examination requires urgent consultation with an otolaryngologist. Any examination that demonstrates an ear abnormality also requires urgent referral to an otolaryngologist. If facial paralysis

Table 680.5 Manifestations of the Sequelae and Complications of Otitis Media

COMPLICATION	CLINICAL FEATURES
ACUTE	
Perforation with otorrhea	Immobile tympanic membrane secondary to visible perforation, exudate in ear canal
Acute mastoiditis with periostitis	Tenderness and erythema over mastoid process, no destruction of bony trabeculae
Acute mastoid osteitis	Destruction of bony trabeculae; tenderness and erythema over mastoid process coupled with outward displacement of pinna
Petrositis	Infection of perilabyrinthine cells; may present with otitis, paralysis of lateral rectus, and ipsilateral orbital or facial pain (Gradenigo syndrome)
Facial nerve palsy	Peripheral cranial nerve VII paralysis
Labyrinthitis	Vertigo, fever, ear pain, nystagmus, hearing loss, tinnitus, nausea and vomiting
Lateral (or transverse) sinus thrombosis	Headache, fever, seizures, altered states of consciousness, septic emboli
Meningitis	Fever, headache, nuchal rigidity, seizures, altered states of consciousness
Extradural empyema	Fever, headache, seizures, altered states of consciousness
Subdural empyema	Fever, headache, seizures, altered states of consciousness
Brain abscess	Fever, headache, seizures, altered states of consciousness, focal neurologic examination
Gradenigo syndrome	OM, sixth cranial nerve palsy, pain in first and second distribution of trigeminal nerve.
NONACUTE	
Chronic perforation	Immobile tympanic membrane secondary to perforation
Otitis media with effusion (OME)	Immobile, opaque tympanic membrane
Adhesive otitis	Irreversible conductive hearing loss secondary to chronic OME
Tympanosclerosis	Thickened white plaques may cause conductive hearing loss
Chronic suppurative otitis media	After acute otitis media with perforation, secondary infection with *Staphylococcus aureus, Pseudomonas aeruginosa*, or anaerobes develops, causing chronic otorrhea
Cholesteatoma	White, pearl-like destructive tumor with otorrhea arising near or within tympanic membrane; may be secondary to chronic negative middle ear pressure
Otitic hydrocephalus	Increased intracranial pressure secondary to AOM; signs and symptoms include severe headaches, blurred vision, nausea, vomiting, papilledema, diplopia (abducens paralysis)

AOM, Acute otitis media.
From Kliegman RM, Bordini BJ, Toth H, Basel D, eds. *Nelson Pediatric Symptom-Based Diagnosis*. Philadelphia: Elsevier; 2022: Table 5.6.

develops in a child with mastoid osteitis or with CSOM, mastoidectomy should be undertaken urgently.

Cholesteatoma

Cholesteatoma is a cystlike growth originating in the middle ear, lined by keratinized, stratified squamous epithelium and containing desquamated epithelium and/or keratin (see Chapter 678; Fig. 680.7).

Acquired cholesteatoma develops most often as a complication of long-standing chronic OM. The condition also may develop from a deep retraction pocket of the TM or as a consequence of epithelial implantation in the middle-ear cavity from traumatic perforation of the TM or insertion of a tympanostomy tube. Cholesteatomas tend to expand progressively, causing bony resorption, often extend into the mastoid cavity, and may extend intracranially with potentially life-threatening consequences. Acquired cholesteatoma commonly presents as a chronically draining ear in a patient with a history of previous ear disease. Cholesteatoma should be suspected if otoscopy demonstrates an area of TM retraction or perforation with white, caseous debris persistently overlying this area. Along with otorrhea from this area, granulation tissue or polyp formation identified in conjunction with this history and presentation should prompt suspicion of cholesteatoma. The most common location for cholesteatoma development is in the superior portion of the TM *(pars flaccida)*. Most patients also present with conductive hearing loss on audiologic evaluation. When cholesteatoma is suspected, otolaryngology consultation should be sought immediately. Delay in recognition and treatment can have significant long-term consequences, including the need for more extensive surgical treatment, permanent hearing loss, facial nerve injury, labyrinthine damage with loss of balance function, and intracranial extension. The required treatment for cholesteatoma is tympanomastoid surgery.

Congenital cholesteatoma is an uncommon condition generally identified in younger patients (Fig. 680.8). The etiology of congenital cholesteatoma is thought to be a result of epithelial implantation in the middle-ear space during otologic development in utero. Congenital cholesteatoma most commonly presents in the anterior-superior quadrant of the TM but can be found elsewhere. Congenital cholesteatoma appears as a discrete, white opacity in the middle-ear space on otoscopy. Unlike patients with acquired cholesteatoma, there is generally not a strong history of OM or chronic ear disease, history of otorrhea, or changes in the TM anatomy such as perforation or retraction. Similar to acquired cholesteatoma, many patients do have some degree of abnormal findings on audiologic evaluation, unless identified very early. Congenital cholesteatoma also requires surgical resection.

Labyrinthitis

Labyrinthitis occurs uncommonly as a result of the spread of infection from the middle ear and/or mastoid to the inner ear (see Chapter 682). Cholesteatoma or CSOM is the usual source. Symptoms and signs include vertigo, tinnitus, nausea, vomiting, hearing loss, nystagmus, and clumsiness. Treatment is directed at the underlying condition and must be undertaken promptly to preserve inner-ear function and prevent the spread of infection.

INTRACRANIAL COMPLICATIONS

Meningitis, epidural abscess, subdural abscess, focal encephalitis, brain abscess (see Chapters 643, 644, and 681), transverse (lateral) and sigmoid sinus thrombosis and otitic hydrocephalus each may develop as a complication of acute or chronic middle-ear or mastoid infection through direct extension, hematogenous spread, or thrombophlebitis. Bony destruction adjacent to the dura is often involved, and a cholesteatoma may be present. In a child with middle-ear or mastoid infection, the presence of any systemic symptom, such as high spiking fevers, headache, or lethargy of extreme degree or a finding of meningismus or of any abnormal central nervous system sign on physical examination should prompt suspicion of an intracranial complication.

When an intracranial complication is suspected, lumbar puncture should be performed only after imaging studies establish that there is no evidence of mass effect or hydrocephalus. In addition to examination

Fig. 680.7 A, Primary acquired cholesteatoma in the region of the pars flaccida with scutum erosion. B, Cholesteatoma developing at the margin of perforation (secondary acquired cholesteatoma) with secondary infection. *(From Chole RA, Sudhoff HH. Chronic otitis media, mastoiditis, and petrositis. In: Flint PW, Haughey BH, Lund VJ, et al, eds. Cummings Otolaryngology—Head and Neck Surgery, 5th ed. Philadelphia: Elsevier; 2010: Figs. 139-4, 139-5.)*

Fig. 680.8 Congenital chronic otitis media with cholesteatoma. *(From Chole RA, Sudhoff HH. Chronic otitis media, mastoiditis, and petrositis. In: Flint PW, Haughey BH, Lund VJ, et al., eds. Cummings Otolaryngology—Head and Neck Surgery, 5th ed. Philadelphia: Elsevier; 2010: Fig. 139-6.)*

of the cerebrospinal fluid, culture of middle-ear exudate obtained via tympanocentesis may identify the causative organism, thereby helping to guide the choice of antimicrobial medications. Myringotomy should be performed to permit middle-ear drainage. Concurrent tympanostomy tube placement is preferable to allow for continued decompression of the "infection under pressure" that is the causative event leading to intracranial spread of the infection.

Treatment of intracranial complications of OM requires urgent, otolaryngologic, and often, neurosurgical consultation, intravenous antibiotic therapy, drainage of mastoiditis, and tympanomastoidectomy in patients with coalescent mastoiditis. Many brain abscesses may be managed without drainage but require long-term broad-spectrum antibiotic therapy (see Chapter 644).

Lateral (transverse) or sigmoid sinus thrombosis may be complicated by dissemination of infected thrombi with resultant development of septic infarcts in various organs. Diagnosis is confirmed by MRI. Mastoidectomy may be required even in the absence of osteitis or coalescent mastoiditis, especially in the case of propagation or embolization of infected thrombi. In the absence of coalescent mastoiditis, sinus thrombosis can often be treated with tympanostomy tube placement, anticoagulation, and intravenous antibiotics. Otolaryngology consultation should be obtained before initiating this anticoagulation to coordinate the possible need for surgical intervention before anticoagulation.

Otitic hydrocephalus, a form of **idiopathic intracranial hypertension**, or **pseudotumor cerebri** (see Chapter 645), is an uncommon condition that consists of increased intracranial pressure without dilation of the cerebral ventricles occurring in association with acute or chronic OM or mastoiditis. The condition is commonly also associated with lateral sinus thrombosis, and the pathophysiology is thought to involve obstruction by thrombus of intracranial venous drainage into the neck, producing a rise in cerebral venous pressure and a consequent increase in cerebrospinal fluid pressure. Symptoms are those of increased intracranial pressure. Signs may include, in addition to evidence of OM, paralysis of one or both lateral rectus muscles and papilledema with or without visual acuity loss. MRI can confirm the diagnosis. Treatment measures include the use of antimicrobials and medications such as acetazolamide or furosemide to reduce intracranial pressure, mastoidectomy, repeated lumbar puncture, lumboperitoneal shunt, and ventriculoperitoneal shunt. If left untreated, otitic hydrocephalus may result in loss of vision secondary to optic atrophy.

Physical Sequelae

The physical sequelae of OM consist of structural middle-ear abnormalities resulting from long-standing middle-ear inflammation. In most instances, these sequelae are consequences of severe and/or chronic infection, but some may also result from the noninfective inflammation of long-standing OME. The various sequelae may occur singly or interrelatedly in various combinations.

Tympanosclerosis consists of whitish plaques in the TM and nodular deposits in the submucosal layers of the middle ear. The changes involve hyalinization with deposition of calcium and phosphate crystals. Uncommonly, there may be associated conductive hearing loss. In developed countries, probably the most common cause of tympanosclerosis is tympanostomy tube insertion.

Atelectasis of the TM is a descriptive term applied to either severe retraction of the TM caused by high negative middle-ear pressure or loss of stiffness and medial prolapse of the membrane from long-standing retraction or severe or chronic inflammation. A **retraction pocket** is a localized area of atelectasis. Atelectasis is often transient and usually unaccompanied by symptoms, but a deep retraction pocket may lead to erosion of the ossicles and adhesive otitis and may serve as the nidus of a cholesteatoma. For a deep retraction pocket, and for the unusual instance in which atelectasis is accompanied by symptoms

such as otalgia, tinnitus, or conductive hearing loss, the required treatment is tympanostomy tube insertion and, at times, tympanoplasty. Patients with persisting atelectasis and retraction pockets should have referral to an otolaryngologist.

Adhesive OM consists of proliferation of fibrous tissue in the middle-ear mucosa, which may, in turn, result in severe TM retraction, conductive hearing loss, impaired movement of the ossicles, ossicular discontinuity, and cholesteatoma. The hearing loss may be amenable to surgical correction.

Cholesterol granuloma is an uncommon condition in which the TM may appear to be dark blue secondary to middle-ear fluid of this color. Cholesterol granulomas are rare, benign cysts that occur in the temporal bone. They are expanding masses that contain fluids, lipids, and cholesterol crystals surrounded by a fibrous lining and generally require surgical removal. Tympanostomy tube placement will not provide satisfactory relief. This lesion requires differentiation from bluish middle-ear fluid, which can also rarely develop in patients with the more common OME.

Chronic perforation may rarely develop after spontaneous rupture of the TM during an episode of AOM or from acute trauma, but more commonly results as a sequela of CSOM or as a result of failure of TM closure after extrusion of a tympanostomy tube. Chronic perforations are generally accompanied by conductive hearing loss. Surgical repair of a TM perforation is recommended to restore hearing, prevent infection from water contamination in the middle-ear space, and prevent cholesteatoma formation. Chronic perforations are almost always amenable to surgical repair, usually after the child has been free of OM for an extended period.

Permanent **conductive hearing loss** (see Chapter 677) may result from any of the conditions just described. Rarely, permanent sensorineural hearing loss may occur in association with acute or chronic OM, secondary to spread of infection or products of inflammation through the round window membrane, or as a consequence of suppurative labyrinthitis.

POSSIBLE DEVELOPMENTAL SEQUELAE

Permanent hearing loss in children has a significant negative impact on development, particularly in speech and language. The degree to which OM affects long-term development in children is difficult to assess, and there have been conflicting studies examining this question. Developmental impact is most likely to be significant in children who have greater levels of hearing loss, hearing loss that is sustained for longer periods, or hearing loss that is bilateral and in children who have other developmental difficulties or risk factors for developmental delay (see Table 680.4).

Visit Elsevier eBooks+ at eBooks.Health.Elsevier.com for Bibliography.

Chapter 681

Acute Mastoiditis

Brittany Player

Mastoiditis, a suppurative infection of the mastoid air cell system, is the most common infectious complication of acute otitis media (AOM), typically affecting younger children. Coalescent mastoiditis occurs when the suppurative infection leads to bony breakdown of the fine bony septa separating individual mastoid air cells.

ANATOMY

The temporal bone forms a portion of the skull base and has multiple complex anatomic functions. The mastoid process is a pyramid-shaped outgrowth of the temporal bone. The inferior extent is attached to the sternocleidomastoid muscle. The mastoid process borders the middle cranial fossa, posterior cranial fossa, and sigmoid sinus. It is composed of a system of interlinked mucosa-lined air cells that communicate with the middle ear space and contains the fallopian canal, which includes the facial nerve, the chorda tympani supplying taste to the anterior two thirds of the tongue, and the semicircular canal system. Because the mastoid cavity is anatomically adjacent to the meninges, brain, venous sinuses of the brain, facial nerve, and cervical lymph nodes, mastoiditis often accompanies or precedes intracranial complications of AOM (see Chapter 680).

EPIDEMIOLOGY

In the preantibiotic era, acute mastoiditis was a much more common complication of AOM with high rates of intracranial infectious complications, morbidity, and mortality. Currently, mastoiditis is a rare complication, occurring in approximately 1-4 cases per 100,000 population of children <2 years old and less commonly among older children. A multicenter study with 223 consecutive cases of acute mastoiditis reported 28% of patients were younger than 1 year old, 38% of patients were between 1 and 4 years old, 22% of patients were between 4 and 8 years old, and 8% of patients were between 8 and 18 years old. Some studies reported decreased incidence of acute mastoiditis after introduction of the 7-valent pneumococcal conjugate vaccine (PCV7), whereas others reported no change or nominal increases. One study reported a sharp decrease in acute mastoiditis beginning in 2010, which coincided with licensure and widespread use of the 13-valent pneumococcal conjugate vaccine (PCV13). Another study, which included data from eight hospitals, found that the proportion of PCV13 serotypes isolated from cases of mastoiditis decreased from 50% in 2011 to 29% in 2013, with most of the decrease attributable to decreases in serotype 19A. Changes in rates of mastoiditis are likely related to changing incidence of AOM in response to pneumococcal conjugate vaccines. Other factors influencing the occurrence of mastoiditis include rates of antibiotic prescriptions for AOM, access to healthcare, and rates of antimicrobial resistance. Whereas groups in countries such as the Netherlands and Iceland reported adherence to a watchful waiting strategy for treatment of AOM, this resulted in slightly increased rates of acute mastoiditis compared with countries where antibiotics are routinely used to treat AOM. Other studies from several countries have contradicted these findings, demonstrating no increased incidence in acute mastoiditis, with changes in recommendations for more conservative antimicrobial prescribing practices. Despite large differences in antibiotic prescription rates in different countries, because of the overall low incidence of acute mastoiditis, the number of children needed to be treated with antibiotics to prevent one case of acute mastoiditis ranges from 2,500 to 4,800. Some studies have reported an increase in incidence, which has correlated with an increase in infections with drug-resistant bacteria. All-cause mortality among children with mastoiditis is 0.03%.

MICROBIOLOGY

Streptococcus pneumoniae remains the most common pathogen cultured from cases of acute mastoiditis (Table 681.1). After introduction of PCV7, pneumococcal serotype 19A was commonly associated with acute mastoiditis. This serotype is frequently resistant to

Table 681.1 Etiology of Acute Mastoiditis

BACTERIA	FREQUENCY
Streptococcus pneumoniae	10–51%
Streptococcus pyogenes	0–12%
Staphylococcus aureus	2–10%
Pseudomonas aeruginosa	10%
Haemophilus influenzae	2–3%
No growth	20–40%

penicillin and macrolide antibiotics. PCV13 use has been associated with fewer serotype 19A infections overall; its impact on the etiology of mastoiditis is less clear. Other bacteria commonly cultured include *Streptococcus pyogenes, Staphylococcus aureus, Pseudomonas aeruginosa, Fusobacterium necrophorum,* and *Haemophilus influenzae*. *P. aeruginosa* is more likely in patients with chronic otitis media and/or cholesteatoma, older children, and those with previous tympanostomy tubes, though higher rates of *P. aeruginosa* recovery should suggest consideration of the method of sample collection when interpreting this culture result.

CLINICAL MANIFESTATIONS

Acute mastoiditis and AOM present similarly in children. Ninety-seven percent of children with an acute mastoiditis have a coexisting AOM on the affected side. The remaining 3% of children with acute mastoiditis either had a serous middle ear effusion at the time of presentation or had a history of AOM within the past 2 weeks. Other clinical manifestations include protrusion of the ear (87%), retroauricular swelling and tenderness (67%), retroauricular erythema (87%), fever (60%), otalgia, and hearing loss (Tables 681.2 and 681.3). Prolonged symptoms during the treatment of AOM may suggest concurrent mastoiditis. Children with acute mastoiditis were less likely to have bilateral infection. Some children do not have external signs of infection.

DIAGNOSIS AND IMAGING

Acute mastoiditis is usually diagnosed based on history and clinical findings (see Table 681.2). CT scan of the temporal bone can confirm the diagnosis, whereas head CT can identify intracranial complications (see Chapter 680), including epidural abscess or subdural empyema. Findings of acute mastoiditis include bony demineralization, loss of bony septations in the mastoid cavity (Fig. 681.1), and, occasionally, subperiosteal abscess (Fig. 681.2). CT scans have the advantage of being readily available in most emergency rooms, can quickly evaluate for intracranial complications, and can identify whether there is bony destruction or a drainable fluid collection. Contrast-enhanced CT scan or MRI allows evaluation for vascular thrombosis (Fig. 681.3) and abscess formation. MRI is generally reserved for patients in whom there is a suspected intracranial complication (Figs. 681.4 and 681.5). Incidental detection of mastoid air cell opacification occurs in more than 20% of children (and in 40% of children <2 years old) undergoing MRI for other reasons, so imaging findings must be interpreted in the appropriate clinical context.

There is a limited role for ultrasound in the diagnosis of acute mastoiditis. Ultrasound can be used as a screening test when a postauricular subperiosteal abscess is suspected due to clinical findings such as protrusion of the pinna and retroauricular erythema. If there is a fluid collection on ultrasound or concern for a defect in the cranial vault, further imaging with a CT and/or MRI would be recommended. Because ultrasound cannot identify intracranial complications, its use must be limited to a highly selected patient population.

Table 681.2 Diagnosis of Acute Mastoiditis

Fever, otalgia, postauricular swelling plus redness
- Older child: ear up and out
- Infant: ear down and out

Tympanic membrane: acute otitis media
Radiograph: mastoid air cells coalescent or clouded
Computed tomography, magnetic resonance imaging, or bone scan as needed

From Wald ER, Conway JH. Mastoiditis. In: Long SS, Prober CG, Fischer M, eds. *Principles and Practice of Pediatric Infectious Diseases*, 5th ed. Philadelphia: Elsevier; 2018: p. 227.

MANAGEMENT

Acute mastoiditis is a rare complication of AOM, and there is a large degree of overlap between the presentations of children with both disease processes. For the pediatrician confronted with a majority of uncomplicated AOM, it is difficult to decide when to initiate a more extensive evaluation. Any time there is a purulent middle-ear effusion along with postauricular findings, acute mastoiditis needs to be in the differential diagnosis. In general, children with acute mastoiditis will appear sicker than children with uncomplicated AOM, and many of them have already failed to respond to appropriate antibiotic therapy for AOM. Focal neurologic deficits, including facial paresis, in a child with AOM or mastoiditis suggest intracranial spread of infection. In a child with suspected mastoiditis, it is critical to document normal facial nerve function at the time of the initial exam so that if this complication does develop during treatment, the treating team is able to document this complication.

Table 681.3 Differential Diagnosis of Postauricular Involvement of Acute Mastoiditis with Periostitis/Abscess

	POSTAURICULAR SIGNS AND SYMPTOMS					
DISEASE	CREASE*	ERYTHEMA	MASS	TENDERNESS	EXTERNAL CANAL INFECTION	MIDDLE-EAR EFFUSION
Acute mastoiditis with periostitis	May be absent	Yes	No	Usually	No	Usually
Acute mastoiditis with subperiosteal abscess	Absent	Maybe	Yes	Yes	No	Usually
Periostitis of pinna with postauricular extension	Intact	Yes	No	Usually	No	No
External otitis with postauricular extension	Intact	Yes	No	Usually	Yes	No
Postauricular lymphadenitis	Intact	No	Yes†	Maybe	No	No

*Postauricular crease (fold) between pinna and postauricular area.
†Circumscribed.
From Bluestone CD, Klein JO, eds. *Otitis Media in Infants and Children*, 3rd ed. Philadelphia: WB Saunders; 2001: p. 333.

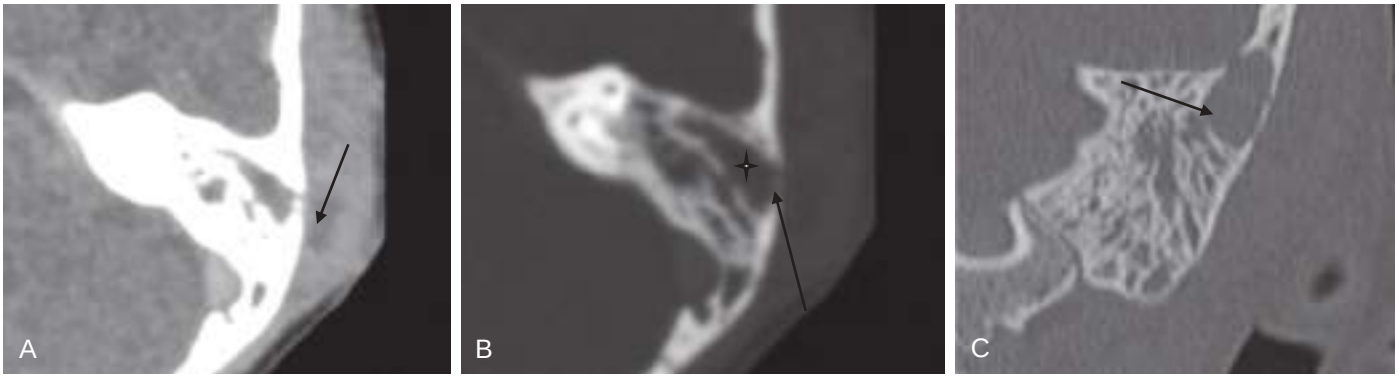

Fig. 681.1 Coalescent mastoiditis with subperiosteal abscess formation. **A** and **B**, Axial CT images with soft tissue windows and bone windows, respectively. *Arrow* in **A** points to the subperiosteal abscess. *Star* in **B** shows the loss of bony septations in the mastoid cavity, and the *arrow* points to the erosion of the bony cortex. **C**, Coronal image shows demineralization of the mastoid tegmen abutting the middle cranial fossa, a precursor to epidural abscess formation.

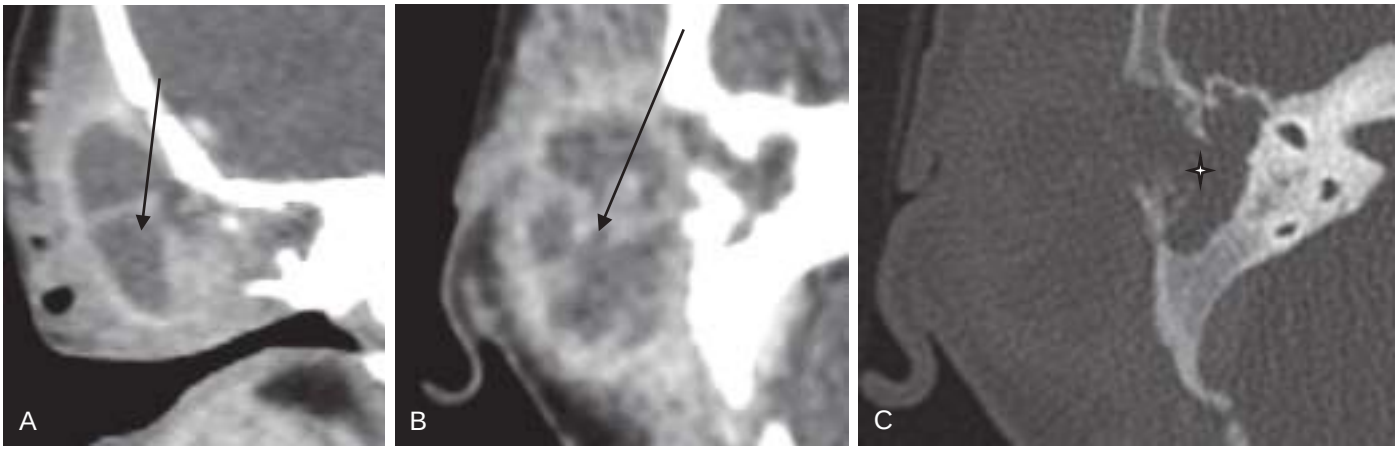

Fig. 681.2 Advanced case of coalescent mastoiditis with subperiosteal abscess formation. Axial (**A**) and coronal (**B**) images; *arrow* points to the subperiosteal abscess **C**, Extensive loss of bony septations in the mastoid cavity (*star).*

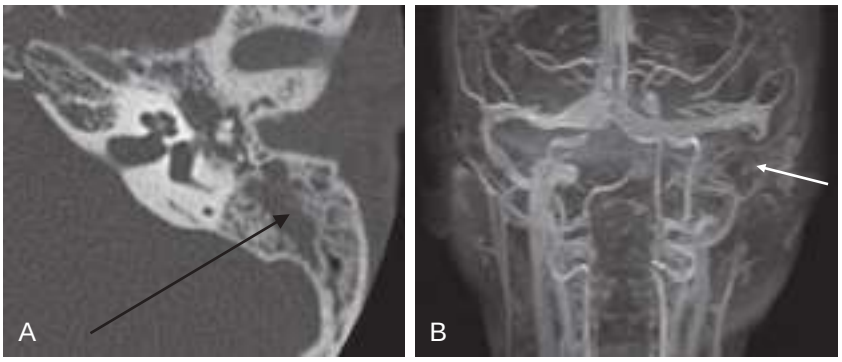

Fig. 681.3 **A**, Axial CT scan with bone windows shows opacification of the mastoid air cells, a small region of coalescence (*arrow),* and opacification of the middle ear space. **B**, CT venogram with a sigmoid sinus thrombosis. The *arrow* points to the area where a patent sigmoid sinus should be present.

Complete blood count typically reveals leukocytosis with neutrophil predominance. C-reactive protein is often highly elevated. If otorrhea is present, implying a perforated tympanic membrane, the fluid should be sent for Gram stain and culture. Blood culture should be considered in any child appearing toxic. For children with postauricular findings consistent with acute mastoiditis, admission to the hospital for intravenous antibiotic therapy and serial exams is recommended.

In highly selected cases, ultrasound may be helpful to differentiate postauricular erythema from a postauricular abscess and avoids the risk of ionizing radiation exposure. However, ultrasound is not as sensitive as CT scanning and will underdiagnose postauricular abscess formation and will provide no information as to whether there is an intracranial complication present such as a brain abscess. Some authors advocate deferring CT scanning in patients with clinically suspected acute mastoiditis and without focal neurologic

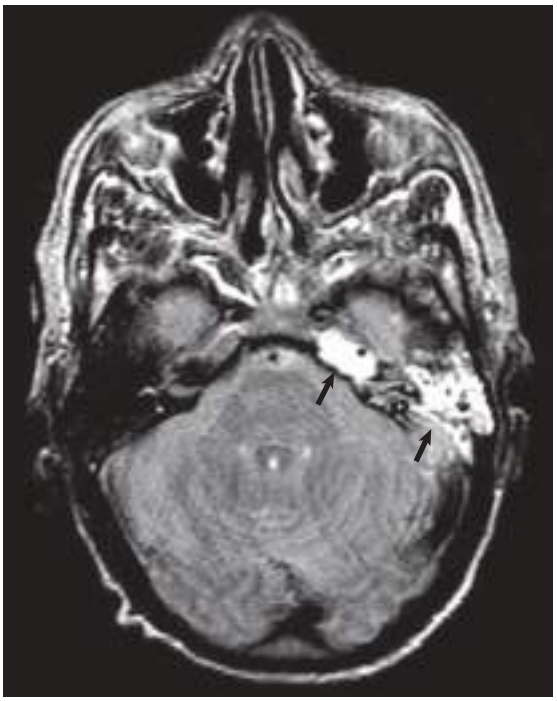

Fig. 681.4 Axial T2-weighted MRI showing left mastoiditis and petrous apicitis *(arrows)* as high signal in mastoid and petrous apex. *(From Budenz CL, El-Kashlan HK. Complications of temporal bone infections. In: Flint PW, Francis HW, Haughey BH, et al, eds. Cummings Otolaryngology Head & Neck Surgery, 7th ed., vol. 2. Philadelphia: Elsevier; 2021: Fig 141.17A.)*

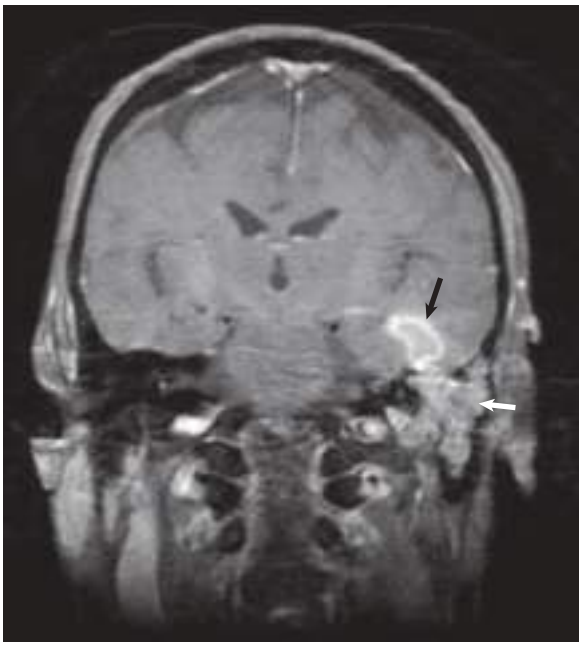

Fig. 681.5 Coronal enhanced T1-weighted MRI of the patient showing enhancing tissue in left mastoid *(white arrow)* and temporal lobe abscess with enhancing capsule *(black arrow)*. *(From Budenz CL, El-Kashlan HK. Complications of temporal bone infections. In: Flint PW, Francis HW, Haughey BH, et al, eds. Cummings Otolaryngology Head & Neck Surgery, 7th ed., vol. 2. Philadelphia: Elsevier; 2021: Fig 141.17D)*

findings to allow for an initial 24- to 48-hour period of inpatient intravenous antibiotic therapy. If there is any concern about the possibility of an intracranial complication, a contrasted CT scan is the most sensitive readily available test and should be ordered upon presentation.

Antibiotic therapy should initially be administered intravenously. Empiric antibiotic selection may include a β-lactam/β-lactamase inhibitor combination (e.g., ampicillin-sulbactam, piperacillin-tazobactam) or third-generation cephalosporin (e.g., cefotaxime, ceftriaxone). In children with chronically draining ears or concern for cholesteatoma, there is an increased incidence of gram-negative infection, and coverage should include antibiotics with activity against *Pseudomonas* spp. (e.g., ceftazidime, cefepime). If intracranial infection is suspected, broader-spectrum antimicrobial coverage (e.g., vancomycin plus a third-generation cephalosporin) should be initiated. In cases of uncomplicated acute mastoiditis (e.g., absence of intracranial complications or localized abscess formation), a 24- to 48-hour trial of intravenous antibiotics may yield clinical improvement without surgical intervention. Therapy should be adjusted when cultures and susceptibilities are available. The total duration of therapy is 4 weeks, with transition from intravenous to oral therapy at discharge for those without intracranial complications. The optimal duration of intravenous therapy is unknown, but some experts recommend a minimum of 7-10 days of intravenous therapy before oral transition, whereas others transition once the patient demonstrates clinical improvement and surgical intervention is no longer required.

Otolaryngology consultation can be helpful to assist with management and to determine whether surgical intervention would be beneficial. Many patients will benefit from tympanostomy tube placement at the time of the acute infection to allow localized ototopical antibiotic treatment and aspiration of middle-ear fluid for culture and sensitivity. In a patient with an additional extracranial complication such as facial paresis, drainage of the middle-ear space with placement of a tympanostomy tube is required and should take place urgently. A small group of patients may necessitate mastoidectomy—surgical removal of diseased bone and granulation tissue in the mastoid cavity. At the time of surgery, a drain is often placed to allow purulent secretions an egress. Indications for mastoidectomy include coalescent mastoiditis, postauricular abscess formation, infectious intracranial complication, and failure to respond to appropriate IV antibiotics. When intracranial complications occur or there are mental status changes, evaluation by otolaryngology and neurosurgery and emergent mastoidectomy are indicated. Most children with mastoiditis make a full recovery. Long-term otologic complications like sensorineural or conductive hearing loss are uncommon. A posttreatment audiogram is often obtained to evaluate the hearing status after an infection.

SPECIAL SITUATIONS

When treating acute mastoiditis, several uncommon situations require particular attention. Selecting empiric antibiotics for unvaccinated and undervaccinated children is challenging, and in this patient population, it is especially important to obtain a sample of middle-ear fluid for Gram stain and culture to guide antibiotic therapy. There is an increased incidence of acute mastoiditis in children with autism spectrum disorder. Immunocompromised patients should be treated with more aggressive and prolonged courses of antibiotic; they may benefit from more aggressive surgical treatment to remove infected tissue. Sigmoid sinus thrombosis can occur secondary to acute mastoiditis. If this does occur, in addition to the standard treatment for acute mastoiditis, consideration should be given to involving hematology and for administering systemic anticoagulation. Otitic hydrocephalus, which is elevated intracranial pressure after middle-ear infection, manifests with emesis, headache, and visual impairment and is associated with lateral or sigmoid sinus thrombosis; management requires antibiotics, anticoagulation, treatment of increased intracranial pressure, and surgical decompression with drainage of the mastoid infection.

Children with **cochlear device implantation** may have a 3.5% incidence of acute mastoiditis. Despite having a foreign body present in the middle ear and inner ear space, the majority of these

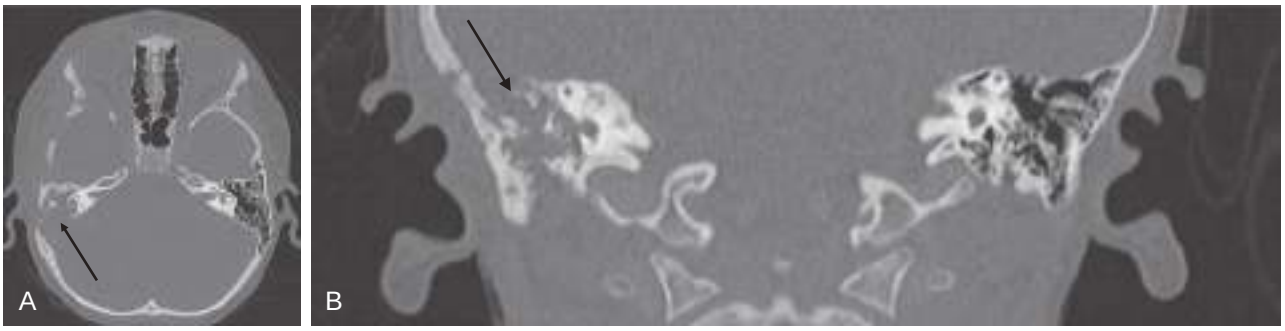

Fig. 681.6 Axial (A) and coronal (B) CT scans of a patient with Langerhans cell histiocytosis of the right temporal bone. A, Opacification of the mastoid with loss of bony septations and erosion of the bone separating the cranial fossa from the mastoid cavity *(arrow)*. B, Bony erosion caused by the tumor and the erosion of the mastoid tegmen *(arrow)*.

acute mastoiditis cases can be managed with tympanostomy tube placement, intravenous antibiotic therapy, and incision and drainage of an abscess without removal of the device.

Although very rare, benign and malignant tumors can affect the temporal bone of children. The presentation mimics that of chronic otitis media and chronic mastoiditis, and this often leads to a delay in diagnosis. Hearing loss, otalgia, and otorrhea are common symptoms. The main differentiating factor is the protracted course of otorrhea and refractory nature of symptoms despite appropriate medical therapy. Aural polyps or a mass lesion may be present on physical exam. Potential causes include rhabdomyosarcoma, nonrhabdomyosarcomatous sarcoma (including chondrosarcoma, chordoma, osteosarcoma, Ewing sarcoma, fibrosarcoma, angiosarcoma, and chloroma), Langerhans cell histiocytosis (formerly histiocytosis X) (Fig. 681.6), lymphoma, and metastasis.

Visit Elsevier eBooks+ at eBooks.Health.Elsevier.com for Bibliography.

Chapter 682

The Inner Ear and Diseases of the Bony Labyrinth

Joseph Haddad Jr.

Genetic factors can affect the anatomy and function of the inner ear. Infectious agents, including viruses, bacteria, and protozoa, also can cause abnormal function, most commonly as sequelae of congenital infection (see Table 677.2) or bacterial meningitis (see Chapter 643.1). Other acquired diseases of the labyrinthine capsule include otosclerosis, osteopetrosis, Langerhans cell histiocytosis (see Chapter 556.1), fibrous dysplasia, and other types of bony dysplasia. All of these can cause both conductive hearing loss (CHL) and sensorineural hearing loss (SNHL), as well as vestibular dysfunction.

OTHER DISEASES OF THE INNER EAR

Labyrinthitis (also called **vestibular neuritis**) may be a complication of direct spread of infection from acute or chronic otitis media or mastoiditis and also can complicate bacterial meningitis as a result of organisms entering the labyrinth through the internal auditory meatus, endolymphatic duct, perilymphatic duct, vascular channels, or hematogenous spread. Clinical manifestations of vestibular neuritis can include a sudden onset of rotatory vertigo, dysequilibrium, postural imbalance (furniture walking) with falls to the affected side, deep-seated ear pain, nausea, vomiting, and spontaneous horizontal (occasionally rotary) nystagmus.

The dizziness may last a few days, but balance issues, particularly after rapid head movements toward the affected ear, may last for months. Vestibular neuritis is usually unilateral and is not associated with other neurologic defects; subjective hearing loss is unusual in vestibular neuritis. If hearing loss is present, idiopathic SNHL should be considered, as well as classical labyrinthitis (vestibular and cochlear nerves). Treatment of vestibular neuritis may include prednisone and vestibular rehabilitative exercises. Recurrent episodes should suggest another diagnosis such as vestibular migraine or benign paroxysmal positional vertigo.

In children, viral labyrinthitis is often associated with hearing loss. **Acute serous labyrinthitis**, characterized by mild symptoms of vertigo and hearing loss, most commonly develops secondary to middle-ear infection without direct invasion. **Acute suppurative labyrinthitis**, characterized by abrupt, severe onset of these symptoms, may be caused by bacterial meningitis or acute middle-ear or mastoid infection via a dehiscent horizontal semicircular canal. In these latter cases, a cholesteatoma is almost always present. Treatment of acute infectious labyrinthitis includes antimicrobial agents in cases of bacterial infection or antiviral agents (acyclovir, valacyclovir) in cases of herpes zoster oticus. Oral corticosteroids reduce labyrinthine inflammation and may prevent sequelae. A short course (≤3 days) of vestibular suppressants (dimenhydrinate 1-2 mg/kg) alleviates acute symptoms such as nausea. If it is secondary to otitis media, otologic surgery may be required to remove underlying cholesteatoma or drain the middle ear and mastoid. **Chronic labyrinthitis**, most often associated with cholesteatoma, manifests with SNHL and vestibular dysfunction that develops over time; surgery is required to remove the cholesteatoma. Chronic labyrinthitis also occurs uncommonly secondary to long-standing otitis media, with the slow development of SNHL, usually starting in the higher frequencies, and possibly with vestibular dysfunction. In addition, and more commonly, children with chronic middle-ear fluid often are unsteady or off balance, a situation that improves immediately when the fluid resolves.

Vertigo and dizziness are common among older children and adolescents. Benign **paroxysmal vertigo**, the most common cause of vertigo in pediatric patients, is characterized by short periods of vertigo or dizziness lasting seconds to a few minutes and associated with imbalance and nystagmus; tinnitus or hearing loss is unusual. **Basilar/vestibular migraine** is a common cause of episodic vertigo or dizziness and is associated with headache (50–70% of patients), rotary or to-and-fro nystagmus, and sensitivity to noise and bright light (see Chapter 635.1). **Benign paroxysmal positional vertigo** is less common in young children and more common with increasing age into adulthood. Particles form in the semicircular canals (canalithiasis), most often the

posterior canal; symptoms occur with position changes of the head and may last seconds to minutes. Vertigo and nystagmus may be demonstrated by changing position (sitting to lying down on the right or left). Treatment involves canalith repositioning maneuvers to shift the debris from the canals into the utricle. Additional etiologies of vertigo include vestibular migraine, trauma, superior semicircular canal dehiscence, isolated autoimmune inner ear disease or syndrome-associated autoimmune diseases including Cogan syndrome (interstitial keratitis, vertigo, hearing loss), Vogt-Koyanagi-Harada syndrome (uveomeningitis, vitiligo, vertigo, hearing loss), Susac syndrome (microangiopathy with retinopathy, encephalopathy, deafness), granulomatosis with polyangiitis, mixed connective tissue disease, and, most rarely, CNS tumor.

Otosclerosis, an autosomal dominant disease that affects only the temporal bones, causes abnormal bone growth that can result in fixation of the stapes in the oval window, leading to progressive hearing loss. In one series in North America, otosclerosis was found in 0.6% of temporal bones of children younger than 5 years of age and 4% of those ages 5-18 years. The hearing loss is usually conductive at first, but SNHL can develop. Females are affected most commonly, with onset of otosclerosis in teenagers or young adults, often associated with pregnancy. Corrective surgery to replace the stapes with a mobile prosthesis often is successful.

Osteogenesis imperfecta is a systemic disease that can involve both the middle and inner ears (see Chapter 742). Hearing loss occurs in approximately 20% of young children and as many as 50% of adults by the age of 50 with this disease. The hearing loss most commonly is conductive but can be sensorineural or mixed. Etiologies of hearing loss include otosclerosis, ossicle fractures, or neural degeneration. If the hearing loss is severe enough, a hearing aid may be a preferable alternative to surgical correction of the fixed stapes, because stapedectomy in children with osteogenesis imperfecta can be technically very difficult, and the disease and the hearing loss may be progressive.

Osteopetrosis, a very uncommon skeletal dysplasia, can involve the temporal bone, including the middle ear and ossicles, usually resulting in a moderate to severe CHL. Recurrent facial nerve paralysis also can occur because of excess bone deposition; with each recurrence, less facial function might return (see Chapter 740).

Visit Elsevier eBooks+ at eBooks.Health.Elsevier.com for Bibliography.

Chapter 683

Traumatic Injuries of the Ear and Temporal Bone

Joseph Haddad Jr.

AURICLE AND EXTERNAL AUDITORY CANAL

Auricle trauma is common in certain sports. Hematoma, with accumulation of blood between the perichondrium and the cartilage, can follow trauma to the pinna and is especially common in teenagers involved in wrestling or boxing. Prompt drainage of a hematoma can prevent irreversible damage. Immediate needle aspiration or, when the hematoma is extensive or recurrent, incision and drainage and a pressure dressing are necessary to prevent perichondritis, which can result in cartilage loss and a "cauliflower ear deformity." Sports helmets should be worn when appropriate during activities when head trauma is possible.

Frostbite of the auricle should be managed by rapidly rewarming the exposed pinna with warm irrigation or warm compresses.

Foreign bodies in the external canal are common in childhood. Often these can be removed in the office setting without general anesthesia if the child is mature enough to understand and cooperate and is properly restrained; if an adequate headlight, surgical head otoscope, or otomicroscope is used for visualizing the object; and if appropriate instruments such as alligator forceps, wire loops or a blunt cerumen curette or suction are used, depending on the shape of the object. Gentle irrigation of the ear canal with body-temperature water or saline may be used to remove very small objects, but only if the tympanic membrane (TM) is intact. Attempts to remove an object from a struggling child or with poor visualization and inadequate tools result in a terrified child with a swollen and bleeding ear canal and can then mandate general anesthesia to remove the object. Difficult foreign bodies, especially those that are large, deeply embedded, or associated with canal swelling, are best removed by an otolaryngologist and/or under general anesthesia. Disk batteries are removed emergently because they leach a basic fluid that can cause severe tissue destruction. Insects in the canal are first killed with mineral oil or lidocaine and are then removed under otomicroscopic examination. Objects retained in the external auditory canal can lead to complications such as otalgia, conductive hearing loss, infection, and aural drainage.

After a foreign body is removed from the external canal, the TM should be inspected carefully for traumatic perforation, middle-ear effusion, abrasions, and bleeding. If a foreign body has resulted in acute inflammation of the canal, topical otic medications as described for acute external otitis should be instituted (see Chapter 679).

TYMPANIC MEMBRANE AND MIDDLE EAR

Traumatic perforation of the TM usually results from sudden external compression, such as a slap, or penetration by a foreign object such as a stick or cotton-tipped swab. The perforation may be linear or stellate. It is most commonly in the anterior portion of the pars tensa when it is caused by compression, and it may be in any quadrant of the TM when caused by a foreign object. Systemic antibiotics and topical otic medications are not required unless suppurative otorrhea is present. Small traumatic TM perforations often heal spontaneously, but it is important to evaluate and monitor the patient's hearing to ensure that spontaneous healing occurs. If the TM does not heal within several months, surgical graft repair should be considered. If a perforation is present, otorrhea can occur from water entering the middle ear from the ear canal during swimming or bathing; appropriate precautions should be taken. Perforations resulting from penetrating foreign bodies are less likely to heal than those caused by compression. Audiometric examination reveals a conductive hearing loss, with larger air-bone gaps seen in larger perforations. Immediate surgical exploration may be indicated if the injury is accompanied by one or more of the following: vertigo, nystagmus, severe tinnitus, moderate to severe hearing loss, or cerebrospinal fluid (CSF) otorrhea. At the time of exploration, it is necessary to inspect the ossicles, especially the stapes, for possible dislocation or fracture and to clear sharp objects that might have penetrated the oval or round windows. Sensorineural hearing loss results if the stapes subluxates or dislocates into the oval window or if either the oval or round window is penetrated. Children should not be given access to cotton-tipped applicators, because the applicators commonly cause ear trauma. Contact with small objects should be limited to times of parental supervision.

Perilymphatic fistula can occur after barotrauma or an increase in CSF pressure. It should be suspected in a child who develops a sudden SNHL or vertigo after physical exertion, deep water diving, air travel, playing a wind instrument, or significant head trauma. The leak characteristically is at the oval (Fig. 683.1) or the round window and may be associated with congenital abnormalities of these structures or an anatomic abnormality of the cochlea or semicircular canals. Perilymphatic fistulas occasionally close

Fig. 683.1 Intraoperative view of traumatic oval window perilymphatic fistula. *(From Kim SH, Kazahaya K, Handler SD. Traumatic perilymphatic fistulas in children: etiology, diagnosis and management. Int J Pediatr Otorhinolaryngol. 2001;60:147–153, Fig. 2.)*

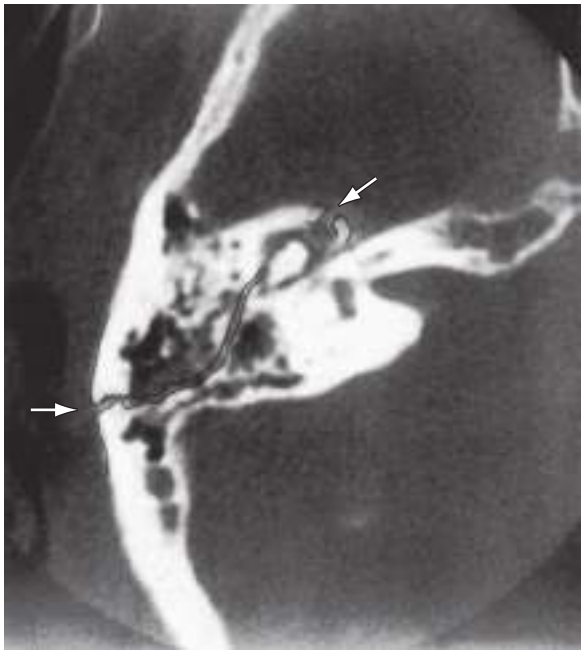

Fig. 683.2 High-resolution axial CT of uncomplicated longitudinal fracture *(arrows)*. A hematoma is present. The course of the fracture has been highlighted. *(From Schubiger O, Valavanis A, Stuckman G, et al. Temporal bone fractures and their complications: examination with high resolution CT. Neuroradiology. 1986;28:93–99.)*

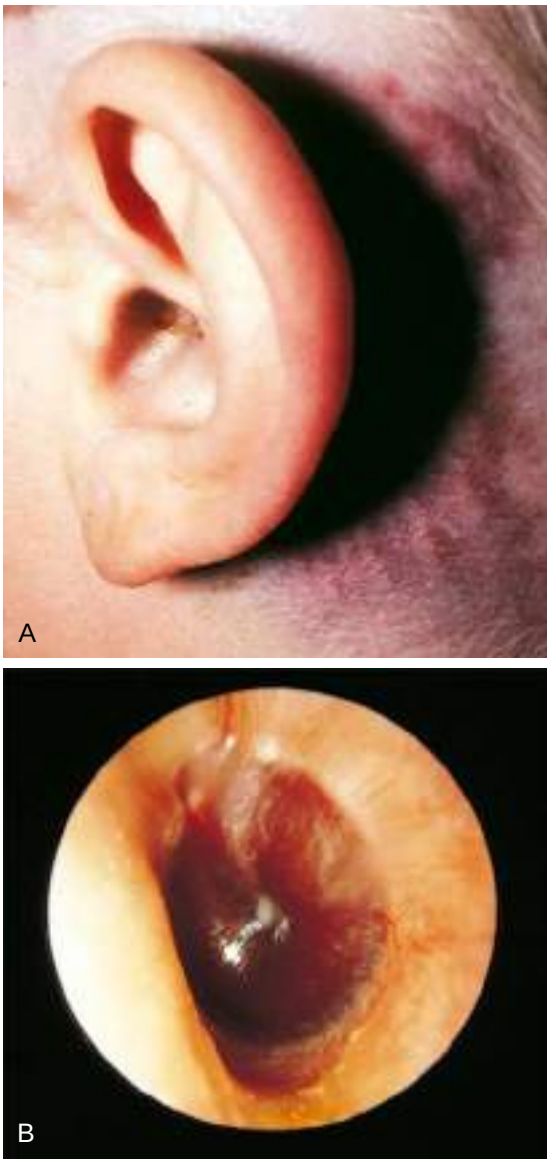

Fig. 683.3 Basilar skull fracture. **A,** Basilar skull fracture involving the temporal bone is often signaled by postauricular ecchymotic discoloration, termed the *Battle sign*. **B,** The force of the blow may also cause tearing of the ear canal or, as shown here, middle ear hemorrhage with hemotympanum. Depending on the timing of examination, this may appear red or blue. *(**B** courtesy Michael Hawke, MD; from Zitelli BJ, McIntire SC, Nowalk AJ, eds. Zitelli and Davis' Atlas of Pediatric Physical Diagnosis, 7th ed. Philadelphia: Elsevier; 2018: Fig. 24-15, p. 874.)*

spontaneously, but immediate surgical repair of the fistula is recommended to control vertigo and to stop any progression of the SNHL; even timely surgery does not usually restore the SNHL. No reliable test is known for perilymphatic fistula, so middle-ear exploration is required for diagnosis and treatment.

TEMPORAL BONE FRACTURES

Children are particularly prone to basilar skull fractures, which usually involve the temporal bone. Temporal bone trauma should be considered in head injuries, and the status of the ear and hearing should be evaluated. Temporal bone fractures are divided into longitudinal (70–80%), transverse (10–20%), and mixed. Longitudinal fractures (Fig. 683.2) are commonly manifested by bleeding from a laceration of the external canal or TM; postauricular ecchymosis **(Battle sign)**; **hemotympanum** (blood behind an intact TM); conductive hearing loss resulting from TM perforation, hemotympanum, or ossicular injury; delayed onset of facial paralysis (which usually improves spontaneously); and temporary CSF otorrhea or rhinorrhea (from CSF running down the eustachian tube) (Fig. 683.3). Transverse fractures of the temporal bone have a graver prognosis than longitudinal fractures and are often associated with immediate facial paralysis and damage to the labyrinth or internal auditory canal. Facial paralysis might improve if caused by edema, but surgical decompression of the nerve is often recommended if there is no evidence of clinical recovery and facial nerve studies are unfavorable. If the facial nerve has been transected, surgical decompression and anastomosis offer the possibility of some functional recovery. Transverse fractures are also associated with severe SNHL, vertigo, nystagmus, tinnitus, nausea, and vomiting associated with

loss of cochlear and vestibular function; hemotympanum; rarely, external canal bleeding; and CSF otorrhea, either in the external auditory canal or behind the TM, which can exit the nose via the eustachian tube.

If temporal bone fracture is suspected or seen on radiographs, gentle examination of the pinna and ear canal is indicated; lacerations or avulsion of soft tissue is common with temporal bone fractures. Vigorous removal of external auditory canal blood clots or tympanocentesis is not indicated, because removing the clot can further dislodge the ossicles or reopen CSF leaks. The effectiveness of prophylactic antibiotics to prevent meningitis in patients with basilar skull fractures and CSF otorrhea or rhinorrhea cannot be determined because studies to date are flawed by biases. If a patient is afebrile and the drainage is not cloudy, watchful waiting without antibiotics is indicated. Surgical intervention is reserved for children who require repair of a nonhealing TM perforation, who have suffered dislocation of the ossicular chain, or who need decompression of the facial nerve. SNHL can also follow a blow to the head without an obvious fracture of the temporal bone (labyrinthine concussion).

ACOUSTIC TRAUMA

Acoustic trauma results from exposure to high-intensity sound (fireworks, gunfire, loud music, heavy machinery) and is initially manifested by a temporary decrease in the hearing threshold, most commonly at 4,000 Hz on an audiometric examination, and tinnitus. If the sound is between 85 and 140 dB, the loss is usually temporary (after a rock concert), but both the hearing loss and the tinnitus can become permanent with chronic noise exposure; the frequencies from 3,000-6,000 Hz are most often involved. Sudden, extremely loud (>140 dB), short-duration noises with loud peak components (gunfire, bombs) can cause permanent hearing loss after a single exposure. Noise-induced hearing loss results from interactions between genes and the environment. A meta-analysis demonstrated that loud music exposure resulted in increased hearing thresholds and decreased otoacoustic emissions in children and adolescents. Ear protection and avoidance of chronic exposure to loud noise are preventive measures. Hearing loss from chronic noise exposure should be entirely preventable. Parents should be made aware of the dangers of acoustic trauma, from the environment and from the use of headphones, and should take measures to minimize exposure. Treatment with high-dose steroids for 1-2 weeks should be considered to treat acute hearing loss related to noise trauma.

Visit Elsevier eBooks+ at eBooks.Health.Elsevier.com for Bibliography.

Chapter 684

Tumors of the Ear and Temporal Bone

Joseph Haddad Jr.

Benign tumors of the external canal include osteomas and monostotic and polyostotic fibrous dysplasia. Osteomas are usually unilateral and located lateral in the bony canal; they require removal only if hearing is impaired or external otitis results. Exostoses (see Chapter 550.2), or localized bony hyperplasias, may be confused with osteomas; however, exostoses are usually bilateral and located in the region of the annulus of the tympanic membrane. Masses occurring over the mastoid bone, such as first branchial cysts, dermoid cysts, and lipomas, may be confused with primary mastoid tumors; imaging can help with the diagnosis and treatment plan.

Eosinophilic granuloma, which can occur in isolation or as part of systemic Langerhans cell histiocytosis (see Chapter 556.1), should be suspected in patients with otalgia, otorrhea (sometimes bloody), hearing loss, abnormal tissue within the middle ear or ear canal, and roentgenographic findings of a sharply delineated destructive lesion of the temporal bone. Definitive diagnosis is made by biopsy. Treatment depends on the site of the lesion and histology. Depending on the site, it may be treated by surgical excision, curettage, or local radiation. If the lesion is part of a systemic presentation of Langerhans cell histiocytosis, chemotherapy in addition to local therapy (surgery with or without radiation) is indicated. Long-term follow-up is necessary whether the temporal bone lesion is a single isolated lesion or part of a multisystem disease.

Rhabdomyosarcoma is the most common malignancy of the temporal bone in children. Symptoms and signs of rhabdomyosarcoma (see Chapter 549) originating in the middle ear or ear canal include a mass or polyp in the middle ear or ear canal, bleeding from the ear, otorrhea, otalgia, facial paralysis, and hearing loss. Other cranial nerves also may be involved. Diagnosis is based on biopsy, but the extent of disease is determined by both CT and MRI of the temporal and facial bones, skull base, and brain (Fig. 684.1).

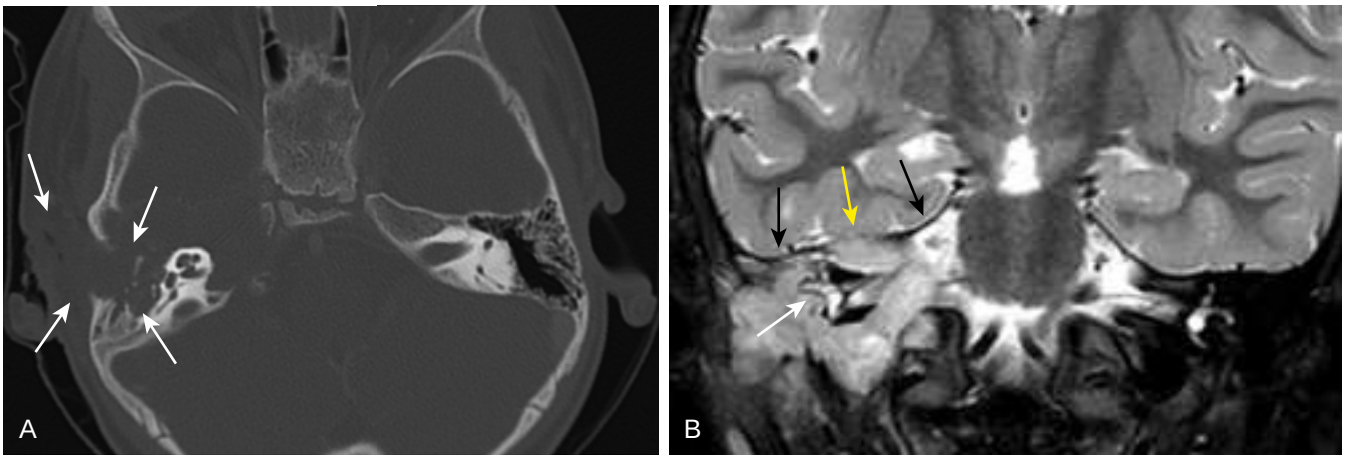

Fig. 684.1 Rhabdomyosarcoma in a 2-yr-old male with hearing loss and right periauricular swelling. **A**, Axial CT shows a large soft tissue mass of the right temporal bone *(arrows)* with extensive osseous destruction. **B**, Coronal STIR MR image shows hyperintense mass of the right temporal bone. Focal loss of integrity of the floor of the right middle cranial fossa *(yellow arrow)* and intact dura *(black arrows)* are shown. Destruction of the bony labyrinth *(white arrow)* by the mass. *(Modified from Koral K. Neoplasia. In: Coley BD, ed. Caffey's Pediatric Diagnostic Imaging, 13th ed, Philadelphia: Elsevier; 2019: Fig. 12.1.)*

Management usually involves a combination of chemotherapy, radiation, and surgery.

Non-Hodgkin lymphoma (see Chapter 545.2) and leukemia (see Chapter 544) also occur rarely in the temporal bone. Although primary neoplasms of the middle ear are very uncommon in children, they include adenoid cystic carcinoma, adenocarcinoma, and squamous cell carcinoma. Benign tumors of the temporal bone include glomus tumors. The initial signs and symptoms of the more common nasopharyngeal neoplasms (angiofibroma, rhabdomyosarcoma, epidermoid carcinoma) may be associated with insidious onset of chronic otitis media with effusion (often unilateral). A high index of suspicion is needed for diagnosing these tumors early.

Visit Elsevier eBooks+ at eBooks.Health.Elsevier.com for Bibliography.

The Skin

PART XXIX

Chapter 685

Morphology of the Skin

Julie M. Dhossche and Yvonne E. Chiu

EPIDERMIS

The mature epidermis is a stratified epithelial tissue composed predominantly of keratinocytes (Fig. 685.1). The epidermis protects the organism from the external environment through physical, chemical, and immunologic barrier functions and prevents water loss. Epidermal differentiation results in the formation of a functional barrier to the external world. The epidermis comprises four histologically recognizable layers, described here from deepest to most superficial. The first or **basal layer** consists of columnar cells that rest on the dermal-epidermal junction. Basal keratinocytes are connected to the dermal-epidermal junction by hemidesmosomes. Basal keratinocytes are attached to themselves and to the cells in the spinous layer by desmosomal, tight, gap, and adherens junctions. The role of the basal keratinocyte is to serve as a continuing supply of keratinocytes for the normally differentiating epidermis and as a reservoir of cells to repair epidermal damage. The second layer is the **spinous layer**, composed of three to four layers of spinous cells. Their role is to synthesize keratin, which makes up the keratin intermediate filament network. The third layer is the **granular layer**, which consists of two to three layers of granular cells. Granular cells contain keratohyalin and lamellar granules, containing the protein and lipid components that make up the cornified layer. The fourth layer, or **cornified layer**, is composed of multiple layers of dead, highly compacted cells. The dead cells are composed mainly of disulfide-bonded keratins cross-linked by filaggrins. The intercellular spaces are composed of hydrophobic lipids, predominantly ceramides, cholesterol, and fatty acids, serving as an effective barrier against water and salt loss as well as permeation of water-soluble substances. As the cornified layer is replenished, the oldest or most superficial layer is shed in a highly regulated process. The normal process of epidermal differentiation, from basal cell to shedding of the cornified layer, takes 28 days.

The epidermis also contains three other cell types. The **melanocytes** are pigment-forming cells, which are responsible for skin color and protection from ultraviolet radiation. Epidermal melanocytes are derived from the neural crest and migrate to the skin during embryonic life. They reside in the interfollicular epidermis and in the hair follicles. Melanocytes produce intracellular organelles (melanosomes) containing melanin, which they transfer via dendrites to the keratinocytes to protect the keratinocyte nucleus from ultraviolet damage. **Merkel** cells are type I slow-adapting mechanosensory receptors for touch that differentiate within the epidermis from epidermal progenitor cells. **Langerhans** cells are dendritic cells of the mononuclear phagocyte system and are uniquely characterized by a specific organelle, the Birbeck granule, which resembles a tennis racket on electron microscopy. These cells are derived from bone marrow and participate in immune reactions in the skin, playing an active part in antigen presentation and processing.

The junction of the epidermis and dermis is the basement membrane zone. This complex structure is a result of contributions from both epidermal and mesenchymal cells. The dermal-epidermal junction extends from the basal cell plasma membrane to the uppermost region of the dermis. Ultrastructurally, the basement membrane appears as a trilaminar structure, consisting of a lamina lucida immediately adjacent to the basal cell plasma membrane, a central lamina densa, and the subbasal lamina on the dermal side of the lamina densa. Several structures within this zone act to anchor the epidermis to the dermis. The plasma membrane of basal cells contains electron-dense plates known as *hemidesmosomes;* tonofilaments course within basal cells to insert at these sites. The **hemidesmosomes** are composed of 180- and 230-kDa bullous pemphigoid antigens (BP180 [BPAG2, type XVII collagen] and BP230 [BPAG1], respectively), $\alpha_6\beta_4$ and $\alpha_3\beta_1$ integrins, and plectin. Anchoring filaments originate in the plasma membrane, primarily near the hemidesmosomes, and insert into the lamina densa. Anchoring fibrils, composed predominantly of type VII collagen, extend from the lamina densa into the uppermost dermis, where they loop through collagen fibrils before reinserting into the lamina densa.

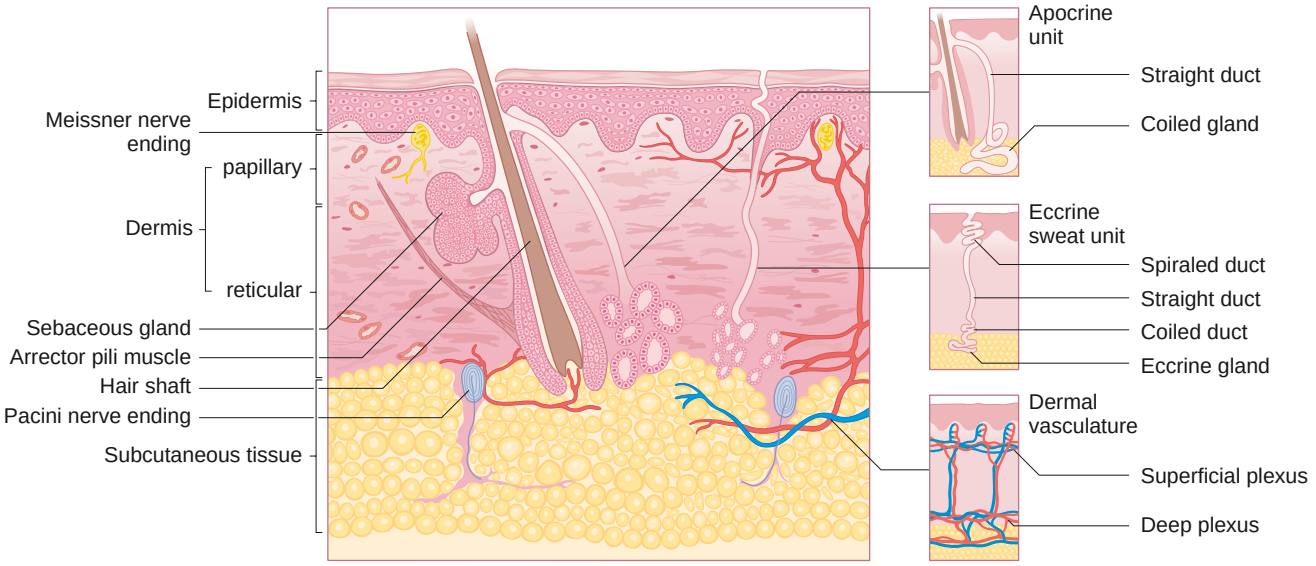

Fig. 685.1 Schematic of skin structure. *(From James WD, Berger T, Elston D. Andrews' Diseases of the Skin: Clinical Dermatology, 12th ed. Philadelphia: Elsevier; 2016: Fig. 1.1.)*

DERMIS

The dermis provides the skin with most of its mechanical properties (see Fig. 685.1). The dermis forms a tough, pliable, fibrous supporting structure between the epidermis and the subcutaneous fat. The predominant dermal cell is a spindle-shaped fibroblast that is responsible for the synthesis of collagen, elastic fibers, and mucopolysaccharides. Phagocytic histiocytes, mast cells, and motile leukocytes are also present. Within the dermis are blood vessels, lymphatics, neural structures, eccrine and apocrine sweat glands, hair follicles, sebaceous glands, and smooth muscle. Morphologically, the dermis can be divided into two layers: the superficial papillary layer that interdigitates with the rete ridges of the epidermis and the deeper reticular layer that lies beneath the papillary dermis. The papillary layer is less dense and more cellular, whereas the reticular layer appears more compact because of the coarse network of interlaced collagen and elastic fibers.

The extracellular matrix of the dermis consists of collagen and elastic fibers embedded in an amorphous ground substance. Collagen provides strength and stability to the dermis, and elastic fibers allow for elasticity. The gelatinous ground substance serves as a supporting medium for the fibrillar and cellular components and as a storage place for a substantial portion of body water.

SUBCUTANEOUS TISSUE

The **panniculus**, or subcutaneous tissue, consists of fat cells and fibrous septa that divide it into lobules and anchor it to the underlying fascia and periosteum (see Fig. 685.1). Blood vessels and nerves are also present in this layer, which serves as a storage depot for lipid, an insulator to conserve body heat, and a protective cushion against trauma.

APPENDAGEAL STRUCTURES

Appendageal structures are derived from aggregates of epidermal cells that become specialized during early embryonic development. Small buds (primary epithelial germs) appear in the third fetal month and give rise to hair follicles, sebaceous and apocrine glands, and the attachment bulges for the arrector pili muscles. Eccrine sweat glands are derived from separate epidermal downgrowths that arise in the second fetal month and are completely formed by the fifth month. Formation of nails is initiated in the third intrauterine month.

Hair Follicles

The pilosebaceous unit includes the hair follicle, sebaceous gland, arrector pili muscle, and, in areas such as the axillae, an apocrine gland. Hair follicles are distributed throughout the skin, except in the palms, soles, lips, and glans penis. Individual follicles extend from the surface of the epidermis to the deep dermis (see Fig. 685.1). The hair follicle is divided into four segments: the infundibulum, which extends from the skin surface to the opening of the sebaceous duct; the isthmus, extending from the sebaceous duct opening to the bulge; the lower follicle between the bulge and the hair bulb; and the hair bulb. The bulge is at the insertion of the arrector pili muscle and is a focus of epidermal stem cells. The bulb is where the matrix cells and the dermal papilla are involved in formation and maintenance of the hair. The growing hair consists of the hair shaft, made of dead keratinocytes, and its supporting inner and outer root sheaths.

Human hair growth is cyclic, with alternate periods of growth (anagen), transition (catagen), and rest (telogen). The length of the anagen phase varies from months to years, whereas catagen and telogen last approximately 3 weeks and 3 months, respectively. At birth, all hairs are in the anagen phase. Subsequent generative activity lacks synchrony, so an overall random pattern of growth and shedding prevails. At any time, approximately 85% of hairs are in the anagen phase. Scalp hair usually grows about 1 cm per month.

The types of hair are lanugo, vellus, and terminal hairs. **Lanugo hair** is thin and short; this hair is shed in utero and is replaced by vellus hair by 36-40 weeks of gestation. **Vellus hair** is short, soft, frequently unpigmented, and distributed over the body. **Terminal hair** is long and coarse and is found on the scalp, beard, eyebrows, eyelashes, and axillary and pubic areas. During puberty, androgenic hormone stimulation causes pubic, axillary, and beard hair to change from vellus hair to terminal hair.

Sebaceous Glands

Sebaceous glands occur in all areas except the palms, soles, and dorsal feet and are most numerous on the head, upper chest, and back (see Fig. 685.1). Their ducts open into the hair follicles except on the eyelids, lips, nipples, prepuce, and labia minora, where they emerge directly onto the skin surface. These holocrine glands are saccular structures that are often branched and lobulated and consist of a proliferative basal layer of small flat cells peripheral to the central mass of lipidized cells. The latter cells disintegrate as they move toward the duct and form the lipid secretion known as *sebum,* which consists of triglycerides, wax esters, squalene, and cholesterol esters. The purpose of sebum production likely relates to hydrophobic skin barrier function. Sebaceous glands depend on hormonal stimulation and are activated by androgens at puberty. Fetal sebaceous glands are stimulated by maternal androgens, and their lipid secretion, together with desquamated stratum corneum cells, constitutes the vernix caseosa.

Apocrine Glands

The apocrine glands are located in the axillae, areolae, perianal and genital areas, and periumbilical region (see Fig. 685.1). These large, coiled, tubular structures continuously secrete an odorless milky fluid that is discharged in response to adrenergic stimuli, usually because of emotional stress. Bacterial biotransformation of apocrine sweat components (fatty acids, thioalcohols, and steroids) accounts for the unpleasant odor associated with perspiration. Apocrine glands remain dormant until puberty, when they enlarge and secretion begins in response to androgenic activity. The secretory coil of the gland consists of a single layer of cells enclosed by a layer of contractile myoepithelial cells. The duct is lined with a double layer of cuboidal cells and opens into the pilosebaceous complex.

Eccrine Sweat Glands

Eccrine sweat glands are distributed over the entire body surface and are most abundant on the palms and soles (see Fig. 685.1). Those on the hairy skin respond to thermal stimuli and serve to regulate body temperature by delivering water to the skin surface for evaporation; in contrast, sweat glands on the palms and soles respond mainly to psychophysiologic stimuli.

Each eccrine gland consists of a secretory coil located in the reticular dermis or subcutaneous fat and a secretory duct that opens onto the skin surface. Sweat pores can be identified on the epidermal ridges of the palm and fingers with a magnifying lens but are not readily visualized elsewhere. Two types of cells constitute the single-layered secretory coil: small dark cells and large clear cells. These rest on a layer of contractile myoepithelial cells and a basement membrane. The glands are supplied by sympathetic nerve fibers, but the pharmacologic mediator of sweating is acetylcholine rather than epinephrine. Sweat from these glands consists of water; sodium; potassium; calcium; chloride; phosphorus; lactate; and small quantities of iron, glucose, and protein. The composition varies with the rate of sweating but is always hypotonic in normal children.

Nails

Nails are specialized protective epidermal structures that form convex, translucent, tight-fitting plates on the distal dorsal surfaces of the fingers and toes. The nail plate, which is derived from a metabolically active matrix of multiplying cells situated beneath the posterior nail fold, is composed of anucleate keratinocytes. Nail growth is relatively slow; complete fingernail regrowth takes 6 months, and complete toenail regrowth requires 12-18 months. The nail plate is bounded by the lateral and posterior nail folds; a thin eponychium (the cuticle) protrudes from the posterior fold over a crescent-shaped white area called the *lunula.* The eponychium serves as a sealant barrier to protect the germinal matrix of the nail plate. The hyponychium refers to the volar surface epithelium of the distal digit and seals the nail bed distally. The pink color beneath the nail reflects the underlying vascular bed. Nail health relies on several factors, including nutrition, hydration, local infection/irritation, and systemic disease.

Visit Elsevier eBooks+ at eBooks.Health.Elsevier.com for Bibliography.

Chapter 686

Dermatologic Evaluation of the Patient

Julie M. Dhossche and Yvonne E. Chiu

HISTORY AND PHYSICAL EXAMINATION

A history and careful physical examination are often necessary for accurate assessment of skin disorders. A good skin exam is essential in dermatologic evaluation and should be performed under adequate illumination. In addition to the skin covering the entire body surface, mucous membranes (conjunctiva, oropharynx, nasal mucosa, and anogenital mucosa), hair, and nails should be examined when appropriate. The color, turgor, texture, temperature, and moisture of the skin and the growth, texture, caliber, and luster of the hair and nails should be noted. Erythema or other color changes may be challenging to appreciate in children with darker skin tones, and other features of the disorder should be relied upon to make the diagnosis. Skin lesions should be palpated, inspected, and classified on the basis of morphology, size, color, texture, firmness, configuration, location, and distribution. One must also decide whether the changes are those of the *primary* lesion itself or whether the clinical pattern has been altered by a *secondary* factor such as infection, trauma, or therapy.

Primary lesions are classified as macules, papules, patches, plaques, nodules, tumors, vesicles, bullae, pustules, wheals, and cysts. A **macule** represents an alteration in skin color but cannot be felt. When the lesion is >1 cm, the term **patch** is used. **Papules** are palpable solid lesions <1 cm. **Plaques** are palpable lesions >1 cm in size and have a flat surface. **Nodules** are palpable lesions >1 cm with a rounded surface. The word **tumor** may be used for a large nodule that is suspected to be neoplastic in origin. **Vesicles** are raised, fluid-filled lesions <1 cm in diameter; when larger, they are called **bullae**. **Pustules** are fluid-filled lesions containing purulent material. **Wheals** are flat-topped, palpable lesions of variable size, duration, and configuration that represent dermal collections of edema fluid. **Cysts** are circumscribed, thick-walled lesions; they are covered by a normal epidermis and contain fluid or semisolid material.

Primary lesions may change into secondary lesions, or secondary lesions may develop over time where no primary lesion existed. Primary lesions are usually more helpful for diagnostic purposes than secondary lesions. Secondary lesions include scales, purpura, petechiae, ulcers, erosions, excoriations, fissures, crusts, and scars. **Scales** consist of compressed layers of stratum corneum cells that are retained on the skin surface. **Purpuras** are the result of bleeding into the skin and have a red-purple color; they may be flat or palpable. **Petechiae** are small (<2-3 mm) purpura. **Erosions** involve focal loss of the epidermis, and they heal without scarring. **Ulcers** extend into the dermis and tend to heal with scarring. Ulcerated lesions inflicted by scratching are often linear or angular in configuration and are called **excoriations**. **Fissures** are caused by splitting or cracking. **Crusts** consist of matted, retained accumulations of blood, serum, pus, and epithelial debris on the surface of a weeping lesion. **Scars** are end-stage lesions that can be thin, depressed, and atrophic; raised and hypertrophic; or flat and pliable. **Lichenification** is a thickening of skin with accentuation of normal skin lines that is caused by chronic irritation (rubbing, scratching) or inflammation.

If the diagnosis is not clear after a thorough examination, one or more diagnostic procedures may be indicated.

BIOPSY OF SKIN

Biopsy of skin is occasionally required for diagnosis. The two most commonly used approaches are the shave biopsy and the punch biopsy. A shave biopsy is primarily used for superficial, raised lesions, whereas a punch biopsy is used when it is indicated to sample the dermis and subcutaneous tissue, as with most inflammatory dermatoses. Both are simple, relatively painless procedures and usually provide adequate tissue for examination if the appropriate lesion is sampled. The selection of a fresh, well-developed primary lesion is extremely important to obtain an accurate diagnosis. In cases of a punch biopsy, the site of the biopsy should have relatively low risk for damage to underlying dermal structures. After cleansing of the site, the skin is anesthetized by intradermal injection of 1–2% lidocaine, with or without epinephrine, with a 27- or 30-gauge needle. For a shave biopsy, a double-edged razor or scalpel is used to remove a thin disk of tissue down to the upper dermis. Hemostasis can be obtained with 20% aluminum chloride solution, and the biopsy site is then covered with petroleum jelly and a bandage. In the case of a punch biopsy, after anesthetizing the skin, a punch tool, usually 3 or 4 mm in diameter, is pressed firmly against the skin and rotated until it sinks to the proper depth. All three layers (epidermis, dermis, and subcutis) should be contained in the plug. The plug should be lifted gently with forceps or extracted with a needle and separated from the underlying tissue with iris scissors. Bleeding abates with firm pressure and with suturing. The biopsy specimen should be placed in 10% formaldehyde solution (Formalin) for appropriate processing.

WOOD LAMP

A Wood lamp emits ultraviolet light mainly at a wavelength of 365 nm. A skin examination under a Wood lamp, which is performed in a darkened room, is useful in accentuating changes in pigmentation and detecting fluorescence in certain infectious disorders. Discrete areas of altered pigment can often be visualized more clearly by using a Wood lamp, particularly if the pigmentary change is epidermal. Hyperpigmented lesions appear darker, and hypopigmented lesions (e.g., those seen in **tuberous sclerosis**) lighter than the surrounding skin. Blue-green fluorescence is detectable at the base of each infected hair shaft in ectothrix infections, such as tinea capitis caused by *Microsporum* species. Scales and crusts may appear pale yellow, but this color is not evidence of a fungal infection. Dermatophyte lesions of the skin (tinea corporis) do not fluoresce; macules of tinea versicolor have a golden fluorescence under a Wood lamp. **Erythrasma**, an intertriginous infection caused by *Corynebacterium minutissimum,* may fluoresce pink-orange, whereas *Pseudomonas aeruginosa* is yellow-green under a Wood lamp.

POTASSIUM HYDROXIDE PREPARATION

Potassium hydroxide (KOH) preparation is a rapid and reliable method for detecting fungal elements of both yeasts and dermatophytes. Scaly lesions should be scraped at the active border for optimal recovery of mycelia and spores. Vesicles should be unroofed, and the blister roof should be clipped and placed on a slide for examination. In tinea capitis, infected hairs must be plucked from the follicle; scales from the scalp do not usually contain mycelia. A few drops of 20% KOH are added to the specimen. Dimethyl sulfoxide is usually in solution with the KOH, negating the need to heat the specimen. If using KOH without dimethyl sulfoxide, the specimen is gently heated over an alcohol lamp or on a hot plate until the KOH begins to bubble. Alternatively, sufficient time (10-20 minutes) can be allowed for dissolution of the keratin at room temperature. The preparation is examined under low-intensity light microscopy for fungal elements.

TZANCK SMEAR

Tzanck smear had been useful in the diagnosis of infections caused by herpes simplex virus or varicella-zoster virus and for the detection of acantholytic cells in pemphigus. An intact, fresh vesicle is ruptured and drained of fluid. The roof and base of the blister are then carefully scraped with a No. 15 scalpel blade, with care taken to avoid drawing a significant amount of blood; the material is smeared on a clear glass slide and air dried. Staining with Giemsa stain is preferable, but Wright stain is acceptable. Balloon cells and multinucleated giant cells are diagnostic of herpes virus infection; acantholytic epidermal cells—large round epidermal cells with hypertrophic nuclei—are characteristic of pemphigus.

Table 686.1 Immunofluorescence Findings in Immune-Mediated Cutaneous Diseases

DISEASE	INVOLVED SKIN	UNINVOLVED SKIN	DIRECT IF FINDINGS	INDIRECT IF FINDINGS	CIRCULATING ANTIBODIES
Dermatitis herpetiformis	Negative	Positive	Granular IgA ± C in papillary dermis	None	IgA antiendomysial and transglutaminase antibodies
Bullous pemphigoid	Positive	Positive	Linear IgG and C band in BMZ, occasionally IgM, IgA, IgE	IgG to BMZ	IgG anti-BP180 and anti-BP230
Pemphigus (all variants)	Positive	Positive	IgG in intercellular spaces of epidermis between keratinocytes	IgG to intercellular spaces of epidermis between keratinocytes	IgG antidesmoglein 1 and 3 (pemphigus vulgaris and foliaceus). IgA antidesmocollin 1 (IgA pemphigus)
Linear IgA bullous dermatosis (chronic bullous dermatosis of childhood)	Positive	Positive	Linear IgA at BMZ, occasionally C	Low titer, rare IgA, anti-BP180	None
Discoid lupus erythematosus	Positive	Negative	Linear IgG, IgM, IgA, and C3 at BMZ (lupus band)	None	Usually ANA-negative
Systemic lupus erythematosus	Positive	Variable; 30–50% of sun-exposed skin; 10–30% of photoprotected skin	Linear IgG, IgM, IgA, and C3 at BMZ (lupus band)	None	ANA Anti-Ro (SSA), anti-La (SSB) Anti-RNP Anti-dsDNA Anti-Sm
IgA vasculitis (Henoch-Schönlein purpura)	Positive	Positive	IgA around vessel walls	None	None

ANA, Antinuclear antibody; BMZ, basement membrane zone at the dermal-epidermal junction; BP, bullous pemphigoid; C, complement; dsDNA, double-stranded deoxyribonucleic acid; IF, immunofluorescence; Ig, immunoglobulin; Sm, Smith; SSA/SSB, Sjögren syndrome A/B; RNP, ribonucleoprotein.

Direct fluorescent assay and polymerase chain reaction tests have largely replaced Tzanck smears in the diagnosis of herpes simplex and varicella-zoster infections. Both of these are rapid, sensitive, and specific, with the polymerase chain reaction even more so. When obtaining specimens for these tests, the vesicles should be ruptured before sample collection with the swab.

IMMUNOFLUORESCENCE STUDIES

Immunofluorescence studies of skin can be used to detect tissue-fixed antibodies to skin components and complement; characteristic staining patterns are specific for certain skin disorders (Table 686.1). Direct immunofluorescence detects autoantibodies bound to cutaneous antigens in the skin, and indirect immunofluorescence detects circulating autoantibodies present in the serum.

Skin biopsy specimens for direct immunofluorescence should be obtained from involved sites except in those diseases for which perilesional skin or uninvolved skin is required. A punch biopsy sample is obtained, and the tissue is placed in a special transport medium or immediately frozen in liquid nitrogen for transport or storage. Thin cryostat sections of the specimen are incubated with fluorescein-conjugated antibodies to the specific antigens.

Serum of patients can be examined by indirect immunofluorescence techniques using sections of normal human skin, guinea pig lip, or monkey esophagus as substrate. The substrate is incubated with fresh or thawed frozen serum and then with fluorescein-conjugated antihuman globulin. If the serum contains antibody to epithelial components, its specific staining pattern can be seen on fluorescence microscopy. By serial dilution, the titer of circulating antibody can be estimated.

686.1 Cutaneous Manifestations of Systemic Diseases

Julie M. Dhossche and Yvonne E. Chiu

Selected diseases have signature skin findings, often as the presenting signs of illness, which can facilitate the assessment of patients with complex medical states (Table 686.2).

CONNECTIVE TISSUE DISEASES

Lupus Erythematosus

Lupus erythematosus (LE; see Chapter 199) is an idiopathic autoimmune inflammatory disease that may be multisystemic (i.e., systemic LE or SLE) or confined to the skin. Distinct cutaneous lupus subtypes seen in children include acute cutaneous LE, subacute cutaneous LE, chronic cutaneous LE (including discoid LE, discussed under "Discoid Lupus Erythematosus"), and neonatal LE (discussed under "Neonatal Lupus Erythematosus").

Systemic Lupus Erythematosus

SLE is a chronic inflammatory multisystem disease with approximately 15–20% of cases diagnosed in childhood. It is diagnosed when 4 of 11 well-defined clinical and 6 immunologic criteria are present (see Chapter 199), where both one clinical and one immunologic criterion each must be met. Four of the clinical criteria are skin findings. **Criterion 1** is acute cutaneous lupus, which may involve the classic malar or "butterfly" rash (Fig. 686.1), bullous lupus lesions, psoriasiform and/or annular polycyclic lupus lesions that resolve without scarring, and photosensitive erythematous macular or papular eruption (Fig. 686.2).

Table 686.2 Characteristics of Cutaneous Signs of Systemic Diseases

DISEASE	AGE OF ONSET	SKIN LESIONS	DISTRIBUTION	DIAGNOSTIC EVALUATION(S) AND FINDINGS	ASSOCIATED SYMPTOMS/ SIGNS	DIFFERENTIAL DIAGNOSIS
Systemic lupus erythematosus	Any	Erythematous patches and plaques; palpable purpura; livedo reticularis; Raynaud phenomenon; urticaria	Photodistribution; "malar" face	ANA panel Anti-dsDNA Leukopenia/ lymphopenia Thrombocytopenia Complement levels Urinalysis	Arthritis Nephritis Cerebritis Serositis	Seborrheic dermatitis Atopic dermatitis Juvenile dermatomyositis
Discoid lupus erythematosus	Any	Annular, scaly plaques; atrophy; dyspigmentation	Photodistribution	ANA	Scarring	Subacute cutaneous lupus Polymorphous light eruption Juvenile dermatomyositis
Neonatal lupus erythematosus	Newborn	Annular, erythematous, scaly plaques	Head/neck	ANA Anti-Ro (SSA), anti-La (SSB)	Heart block Thrombocytopenia	Tinea capitis Atopic dermatitis Seborrheic dermatitis
Juvenile dermatomyositis	Any	Erythematous to violaceous scaly macules; discrete papules overlying joints	Periocular face; shoulder girdle; extensor extremities	ANA AST ALT Aldolase Creatine kinase Lactate dehydrogenase	Fatigue Proximal muscle weakness Calcifications Vasculopathy	Atopic dermatitis Allergic contact dermatitis Lupus erythematosus
Morphea	Any	Sclerotic plaques; resolve with hyperpigmentation and atrophy	Variable	Skin biopsy MRI brain if head and neck involvement	Neurologic (seizures, migraine headaches, focal neurologic deficits, asymptomatic MRI abnormalities) Musculoskeletal (joint contractures, limb length discrepancy, arthritis, arthralgias)	Systemic sclerosis
IgA vasculitis (Henoch-Schönlein purpura)	Childhood and adolescence	Purpuric papules and plaques	Buttocks; lower extremities	Urinalysis Blood urea nitrogen/ creatinine ratio Skin biopsy	Abdominal pain Arthritis	Vasculitis Drug eruption Infantile hemorrhagic edema Viral exanthem
Kawasaki disease	Infancy, childhood	Erythematous maculopapular to urticarial plaques; acral and groin erythema, edema, desquamation, digital cyanosis / gangrene	Diffuse	Leukocytosis ESR C-reactive protein Thrombocytosis	Strawberry tongue Conjunctivitis Lymphadenopathy Cardiovascular complications	Viral syndrome Drug eruption Staphylococcal/ streptococcal illness
Inflammatory bowel disease	Childhood and adolescence	Aphthae; erythema nodosum; pyoderma gangrenosum; lip swelling	Oral and perianal predominate	Skin biopsy Fecal calprotectin, ESR, CRP Gastroenterology evaluation	Abdominal pain Diarrhea Cramping Arthritis Conjunctivitis	Behçet syndrome Vasculitis *Yersinia* colitis
Sweet syndrome	Any	Infiltrated erythematous, edematous plaques	Head and neck predominate	Skin biopsy Leukocytosis ESR	Fever Flulike illness Conjunctivitis	Infection Urticaria Erythema multiforme Urticarial vasculitis Systemic autoinflammatory diseases*

Continued

Table 686.2 Characteristics of Cutaneous Signs of Systemic Diseases—cont'd

DISEASE	AGE OF ONSET	SKIN LESIONS	DISTRIBUTION	DIAGNOSTIC EVALUATION(S) AND FINDINGS	ASSOCIATED SYMPTOMS/ SIGNS	DIFFERENTIAL DIAGNOSIS
Graft-versus-host disease	Any	Acute: erythema, papules, vesicles, bullae	Diffuse with predilection for head/neck and palms/soles	Skin biopsy Liver function tests	Fever Mucositis Hepatitis	Drug eruption Infectious exanthem
Drug rash with eosinophilia and systemic symptoms (DRESS syndrome)	Any	Erythema; urticarial macules and plaques	Diffuse	Liver function Eosinophilia Atypical lymphocytosis	Facial edema Lymphadenopathy Fever Hepatitis	Stevens-Johnson syndrome Infectious exanthem
Serum sickness-like reaction (SSLR)	Any	Edematous, urticarial plaques	Diffuse	None	Fever Lymphadenopathy Arthritis, nephritis	Kawasaki disease Urticaria
Multisystem inflammatory syndrome in children (MIS-C) (see Table 686.3)						
Autoinflammatory diseases (see Table 686.4)						

*NOMID, Neonatal-onset multisystem inflammatory disease and other recurrent fever syndromes.
ALT, Alanine aminotransferase; ANA, antinuclear antibodies; AST, aspartate aminotransferase; dsDNA, double-stranded deoxyribonucleic acid; ESR, erythrocyte sedimentation rate; SSA/SSB, Sjögren syndrome A/B.

Fig. 686.1 Malar rash of systemic lupus erythematosus.

Fig. 686.2 Photosensitive rash of systemic lupus erythematosus.

The malar rash must be distinguished from other causes of a "red face," most notably seborrheic dermatitis, atopic dermatitis, and rosacea. **Criterion 2** is chronic cutaneous lupus, which includes discoid lupus lesions, hypertrophic (verrucous) lupus lesions, and lupus panniculitis, among others. **Criterion 3** is oral or nasal ulcers in the absence of other causes such as vasculitis, Behçet disease, infection (herpes simplex virus [HSV]), or inflammatory bowel disease. **Criterion 4** is nonscarring alopecia, which may include diffuse thinning or hair fragility in the absence of other causes such as alopecia areata, drugs, or iron deficiency. Patients may meet full SLE criteria based on skin findings alone with one immunologic criterion (such as positive antinuclear antibodies [ANA] or anti-dsDNA). Other associated but not diagnostic cutaneous findings include purpuric lesions, livedo reticularis, Raynaud phenomenon, and urticaria.

On histology, cutaneous LE demonstrates varying degrees of epidermal atrophy, plugging of hair follicles, and a vacuolar alteration at an inflamed dermal-epidermal junction. Deposition of immunoglobulins (IgM, IgG) and complement in lesional skin may help confirm the diagnosis. Immune deposits in nonlesional sun-exposed skin are found in the majority of patients with SLE (lupus band test), although clinical use of this test has been mostly abandoned in favor of serologic testing.

The skin lesions often respond to treatment of the SLE with systemic agents. Oral hydroxychloroquine is used most commonly, but many other systemic therapies are effective, including both classic and biologic immunosuppressants. Low- to mid-potency topical corticosteroids, topical calcineurin inhibitors, and intralesional corticosteroid injection may be considered for adjunctive therapy for skin lesions. A multispecialty approach is recommended, as pediatric patients are at significantly higher risk for long-term morbidity than adults.

Neonatal Lupus Erythematosus

Neonatal LE (see Chapter 199.1) manifests at birth or during the first few weeks of life as annular, erythematous, scaly plaques, typically on the head, neck, and upper trunk (Fig. 686.3). Telangiectasias are also common. Ultraviolet light may exacerbate or initiate cutaneous lesions. Passive transplacental transfer of maternal anti-Ro/SSA and anti-La/SSB antibodies causes the transient skin lesions, though most infants are born to mothers without a known rheumatologic diagnosis.

Table 686.3 Mucocutaneous Findings in Multisystem Inflammatory Syndrome in Children

LOCATION	DESCRIPTORS
Generalized, including: Perineal Trunk Face Ears Periorbital area Extremities	Urticarial Papular Maculopapular Macular Morbilliform Desquamative Edematous Erythematous Purpuric Targetoid Retiform Reticular Scarlatiniform Petechiae Livedoid EM-like RIME-like Lipschultz ulcer
Hands and Feet	Edematous Erythematous Desquamative Purpuric Petechiae
Tongue	Papillitis Strawberry tongue De-epithelialized
Lips	Cracked/fissured Erythematous
Eyes	Injected Swollen Nonpurulent discharge

RIME, Reactive infectious mucocutaneous eruption.
From Neale H, Hawryluk EB. COVID-19 pediatric dermatology. *Dermatol Clin.* 39(4):505–519, Table 1, p. 509.

Antibody levels wane by 6 months old, generally resulting in clearance of the rash. Congenital heart block occurs in 30% of affected infants, but only 10% of affected infants have both skin and cardiac abnormalities. Noncardiac extracutaneous manifestations, such as anemia, thrombocytopenia, and cholestatic liver disease, are less common. Neonatal LE is often misdiagnosed as infantile eczema, seborrheic dermatitis, or tinea corporis. Skin lesions are typically managed conservatively, given the transient nature of neonatal LE, and strict sun avoidance and protection are important. If necessary, low- to mid-potency topical corticosteroids may be used. Systemic agents should be avoided. Maternal ANA testing is indicated.

Discoid Lupus Erythematosus

Discoid LE (DLE) is uncommon in early childhood and manifests in late adolescence. The signature skin findings in DLE are chronic, erythematous, scaly, atrophic plaques (Fig. 686.4) on sun-exposed skin that frequently heal with scarring and dyspigmentation. Extracutaneous features may include involvement of the nasal and oral mucosa, eyes, and nails. The differential diagnosis includes other photodermatoses, such as polymorphous light eruption, juvenile springtime eruption, and juvenile dermatomyositis (JDM). There is a distinct overlap between SLE and DLE, with common histopathologic features and photoexacerbation; most patients with DLE have normal laboratory results and do not progress to systemic disease.

First-line treatment of DLE consists of low- to mid-potency topical corticosteroids. Other topical options include calcineurin inhibitors and retinoids. Intralesional corticosteroid injection is also effective for severe localized lesions. Oral hydroxychloroquine is used first-line for severe skin disease or as a second-line agent when lesions are not controlled with topical or local agents. Strict ultraviolet light avoidance is important.

Table 686.4 Dermatologic Manifestations of Monogenic Autoinflammatory Diseases

I. NONSPECIFIC MACULOPAPULAR RASHES WITH RECURRENT EPISODIC FEVER AND ABDOMINAL PAIN (HEREDITARY PERIODIC FEVER SYNDROME)
- A. Recurrent fever attacks of short duration (typically ≤7 days)
  1. Familial Mediterranean fever
  2. Hyperimmunoglobulinemia D with periodic fever syndrome/mevalonate kinase deficiency
- B. Recurrent fever attacks of longer duration (typically >7 days)
  1. Tumor necrosis factor receptor–associated periodic syndrome

II. NEUTROPHILIC URTICARIA (CAPS)
- A. Recurrent fever attacks of short duration (typically <24 hours)
  1. CAPS/familial cold autoinflammatory syndrome
  2. CAPS/Muckle-Wells syndrome
- B. Continuous low-grade fever
  1. CAPS/neonatal-onset multisystem inflammatory disease/CINCA
  2. IL-18–mediated AID and IL-1–mediated AID: NLRC4-related macrophage activation syndrome

III. PUSTULAR SKIN RASHES AND EPISODIC FEVERS
- A. IL-1–mediated pyogenic disorders with sterile osteomyelitis
  1. Deficiency of IL-1 receptor antagonist
  2. Majeed syndrome
- B. Partially IL-1–mediated pyogenic disorders
  1. Pyogenic sterile arthritis, pyoderma gangrenosum, and acne syndrome
  2. Haploinsufficiency of A20 (monogenic form of Behçet disease)
- C. Pyogenic disorders caused by non–IL-1 cytokine dysregulation
  1. Deficiency of IL-36 receptor antagonist
  2. CARD14-mediated psoriasis (monogenic form of psoriasis)
  3. Early-onset inflammatory bowel disease

IV. VASCULOPATHY AND PANNICULITIS/LIPOATROPHY SYNDROMES
- A. Chronic atypical neutrophilic dermatitis with lipodystrophy and elevated temperature syndrome or proteasome-associated autoinflammatory syndrome

V. VASCULOPATHY AND/OR VASCULITIS WITH LIVEDO RETICULARIS SYNDROMES
- A. Without significant CNS disease
  1. STING-associated vasculopathy with onset in infancy
- B. With severe CNS disease
  1. Aicardi-Goutières syndrome
  2. Deficiency of adenosine deaminase 2
  3. Spondyloenchondrodysplasia with immune dysregulation

VI. AUTOINFLAMMATORY DISORDERS WITH GRANULOMATOUS SKIN DISEASES
- A. Without significant immunodeficiency
  1. Blau syndrome (pediatric granulomatous arthritis, pediatric granulomatous arthritis)
- B. With variable features of immunodeficiency and significant CNS disease
  2. PLCγ2-associated antibody deficiency and immune dysregulation: cold-induced urticaria and/or granulomatous rash

VII. OTHER INFLAMMATORY SYNDROMES
- A. LACC1-mediated monogenic Still disease

AID, Autoinflammatory disorder; CAPS, cryopyrin-associated periodic syndromes; CINCA, chronic infantile neurologic cutaneous and articular syndrome; CNS, central nervous system; STING, stimulator of interferon genes.
From Shwin KW, Lee CCR, Goldbach-Mansky. Dermatologic manifestations of monogenic autoinflammatory diseases. *Dermatol Clin.* 2017;35:21–38, Box 1, p. 24–25.

Juvenile Dermatomyositis

Characteristic skin findings are often the presenting sign of JDM (see Chapter 200). An ill-defined, erythematous to violaceous, scaly,

Fig. 686.3 Annular plaque in neonatal lupus erythematosus.

Fig. 686.4 Erythematous scaly plaque of discoid lupus erythematosus.

Fig. 686.5 Gottron papules in juvenile dermatomyositis.

minimally pruritic eruption occurs in photodistributed areas such as the face, upper trunk, and extensor extremities. Circumscribed periocular involvement of this **heliotrope** rash involving the eyelids may take the appearance of "raccoon eyes," particularly in young children. Distinctive erythematous, scaly papules overlying the knuckles and other joints **(Gottron papules)** are helpful in suggesting the diagnosis in the absence of associated muscle weakness (Fig. 686.5). Other cutaneous features include nail fold and gingival margin telangiectasia, palmar hyperkeratosis ("mechanic's hands"), ulceration resulting from vasculopathy or underlying calcinosis, lipodystrophy, and a poikilodermatous (dyspigmentation and telangiectasia) eruption over the shoulder girdle ("shawl sign"). Cutaneous features may precede the systemic illness, which is primarily characterized by muscle weakness and pain. The differential diagnosis includes atopic dermatitis, other connective tissue diseases, lichen planus, medication reactions, and infectious exanthems. Pathology of lesional skin demonstrates epidermal atrophy and vacuolar degeneration at the dermal-epidermal junction, often similar to LE. JDM is distinct from adult dermatomyositis in both presentation and prognosis. Pediatric patients have more difficulty with gastrointestinal (GI) vasculopathy and cutaneous calcifications, and JDM is not a paraneoplastic phenomenon as in adults. A rare clinical variant known as **amyopathic dermatomyositis** occurs when only skin, and not muscle, is involved.

Skin lesions benefit from systemic immunosuppressive therapy, as discussed in detail in Chapter 200. Adjunctive treatment options for skin disease include topical corticosteroids and calcineurin inhibitors. The cutaneous calcinosis of JDM is difficult to manage, with a variety of agents showing limited benefit, and no treatment consensus exists. Strict photoprotection and sunlight avoidance are vital to prevent cutaneous exacerbations.

Systemic Sclerosis

Systemic sclerosis is characterized by diffuse skin hardening and thickening, along with systemic features. It frequently manifests as acral (sclerodactyly, ulceration, nail fold telangiectasia, or Raynaud phenomenon) and facial changes (pinched nose, furrowed perioral skin, or "scleroderma facies") (see Chapter 201). Overlap syndromes such as **mixed connective tissue disease** may include some physical and laboratory features of scleroderma.

Morphea

Morphea, also called *localized scleroderma* (see Chapter 201), is another autoimmune connective tissue disease characterized by skin hardening and thickening. The lesions of morphea are generally more localized, and it is a distinct disorder from systemic sclerosis. There are five subtypes of morphea, including circumscribed (plaque), linear, generalized, pansclerotic, and mixed. Though morphea is not characterized by the degree of systemic involvement that systemic sclerosis has, it can have extracutaneous manifestations. Neurologic findings such as seizures, migraine headaches, focal neurologic deficits, and asymptomatic MRI abnormalities are seen in some patients, predominately those with linear morphea of the head and neck. Musculoskeletal complications can include joint contractures, limb length and girth discrepancies, arthritis, and arthralgias, and these are most common in children with linear morphea of a limb.

VASCULITIDES

The vasculitides (see Chapter 210) encompass a broad group of disorders having considerable overlap with connective tissue diseases. Immune-mediated inflammation of blood vessels of varying size may be caused by an underlying inflammatory state, infection, medication, or malignancy. Common clinical features include **palpable nonthrombocytopenic purpuric** skin lesions, arthritis, fever, myalgia, fatigue, and weight loss as well as an elevated erythrocyte sedimentation rate. Extracutaneous organs that may be involved include the joints, lungs, kidneys, and central nervous system.

Henoch-Schönlein Purpura (Immunoglobulin A Vasculitis)

Henoch-Schönlein purpura (see Chapter 210.1) is a vasculitis that manifests in school-age children as palpable purpuric lesions in gravity-dependent areas, predominantly the buttocks and lower extremities (Fig. 686.6). **Infantile hemorrhagic edema (IHE**; also called *acute hemorrhagic edema of infancy*) shares some clinical features with Henoch-Schönlein purpura but appears in infants and toddlers. IHE is characterized by the sudden onset of circumscribed edema with purpuric papules and plaques on the trunk and extremities but, unlike Henoch-Schönlein purpura, commonly affects the face and lacks other organ involvement. Henoch-Schönlein purpura must also be differentiated from infectious causes of purpuric skin lesions, such as meningococcemia, Rocky Mountain spotted fever, and purpuric viral exanthems such as those caused by enteroviruses, as well as from juvenile rheumatoid arthritis and other vasculitides. Diagnosis is

Fig. 686.6 Purpura of the lower leg in IgA vasculitis (Henoch-Schönlein purpura).

Fig. 686.7 Clinical picture of idiopathic Sweet syndrome. *(From Prat L, Bouaziz JD, Wallach D, et al. Neutrophilic dermatoses as systemic diseases. Clin Dermatol. 2014;32:376–388, Fig. 1.)*

confirmed by histologic confirmation of a small vessel vasculitis with the immunofluorescence finding of IgA in blood vessel walls. Skin lesions are generally managed conservatively and self-resolve in 3–4 weeks. Systemic treatment is discussed in detail in Chapter 210.1.

Kawasaki Disease

Kawasaki disease (see Chapter 208) is a common vasculitis usually seen in children younger than age 5 years. The skin eruption of Kawasaki disease is polymorphic, manifesting variously as maculopapular or morbilliform eruptions, urticaria, targetoid lesions, or psoriasiform lesions on the trunk and extremities. Early involvement with erythema and peeling in the perineum/inguinal region may be an initial clue to the diagnosis. Acral edema and desquamation are also prominent features but typically occur later. Classic mucocutaneous features include erythematous cracked lips, nonpurulent conjunctivitis with sparing of the limbus, and lingual plaques ("white strawberry tongue") that shed to produce denuded, erythematous patches with prominent papilla ("strawberry tongue"). Extracutaneous features include high fever, cervical lymphadenopathy, arthritis, and occasionally cardiac or GI disease. First-line treatment is with aspirin and intravenous immunoglobulin, as discussed in Chapter 208. **Multisystem inflammatory syndrome in children (MIS-C)** (Chapter 311) may resemble Kawasaki disease; cutaneous manifestations are noted in Table 686.3.

Behçet Disease

Behçet disease (see Chapter 202) is a multisystem disease that includes oral and genital ulceration and ocular disease (uveitis, relapsing iridocyclitis) in older children and adults. Recurrent aphthous stomatitis is present in almost all patients and is commonly the presenting symptom. Genital ulcerations may resemble aphthae; can occur on the penis, scrotum, or vulva; and may be particularly painful in females. Perianal ulceration is more common in children than in adults. Additional skin findings may include folliculitis, purpuric lesions, erythema nodosum, and pustule formation after venipuncture or skin trauma **(pathergy)**. Differential diagnosis of oral lesions includes recurrent aphthous stomatitis, herpes simplex, and rare oculocutaneous syndromes (e.g., MAGIC [mouth and genital ulcers with inflamed cartilage] syndrome). Skin biopsy demonstrates nongranulomatous vasculitis in all vessel sizes. Oral lesions may respond to swish and spit/swallow preparations variably, including corticosteroids, antihistamines, antibiotics, and analgesics. Skin lesions are managed with topical corticosteroids, topical anesthetics such as sucralfate, and systemic agents as outlined in Chapter 202.

GASTROINTESTINAL DISEASES

Inflammatory Bowel Disease

Inflammatory bowel disease includes ulcerative colitis (see Chapter 382.1) and Crohn disease (see Chapter 382.2). Skin lesions of inflammatory bowel disease are classified as specific or reactive. Specific cutaneous manifestations have the same histologic features and pathologic mechanism as the underlying inflammatory bowel disease lesions and include aphthous ulcers, granulomatous cheilitis, perianal fistulas and fissures, and metastatic Crohn disease (discussed later). Reactive cutaneous manifestations occur secondary to immune-mediated antigen cross reactivity between gut and skin components; examples include erythema nodosum and pyoderma gangrenosum.

Up to 30% of patients with **ulcerative colitis** present with cutaneous manifestations. Aphthous ulcers are common and may worsen with gastrointestinal exacerbations. Erythema nodosum, occurring in up to 10% of patients, manifests as warm, erythematous nodules, often on the distal lower extremities. Pyoderma gangrenosum is a focal, ulcerative process that has distinctive, inflamed, undermined borders and a purulent, boggy center. Thrombophlebitis also occurs at an increased rate in patients with ulcerative colitis.

Crohn disease classically manifests as perianal fissures and skin tags, abscesses, sinuses, and fistulas; these may be presenting signs. Enlargement of the lips and a cobblestone appearance of oral mucosa may also be present, known as *orofacial granulomatosis* or *cheilitis granulomatosa.* As in ulcerative colitis, aphthae, erythema nodosum, and pyoderma gangrenosum occur with increased frequency and may improve with treatment of the underlying disease. Noncaseating granulomatous inflammation is seen on routine histopathology, and when found in skin not contiguous with the intestinal tract, is labeled **metastatic Crohn disease**. Metastatic lesions may appear as solitary or multiple localized plaques or nodules and may be located on perianal, perioral, or other cutaneous surfaces, including scars and ileostomy sites. In most cases of inflammatory bowel disease–associated skin disease, treatment of the underlying condition improves the cutaneous sequelae.

Rarely, these associated skin findings may be seen without the classic GI manifestations, warranting continued GI surveillance for subsequent disease development. Isolated cutaneous involvement is treated similarly with systemic steroid-sparing and biologic agents with or without topical or intralesional corticosteroids. Azathioprine, a common treatment, causes increased risk for nonmelanoma skin cancers.

CUTANEOUS MANIFESTATIONS OF MALIGNANCY

Skin disease associated with malignancy has a wide variety of presentations, including both metastatic lesions and nonmalignant paraneoplastic conditions. Cutaneous metastases manifest as firm nodules and occur at any cutaneous site. Paraneoplastic reaction patterns are often distinctive and can aid in the diagnosis of the underlying malignancy. Some genetic syndromes have an increased malignancy risk that may be suggested initially by cutaneous signs. Other cutaneous findings that may signal an underlying malignancy include pruritus, ichthyosis, acanthosis nigricans, urticaria, pemphigus, and erythroderma.

Sweet Syndrome

Also known as **acute febrile neutrophilic dermatosis**, Sweet syndrome (see Chapter 213) occurs in several forms, including classical (usually idiopathic or infection-related, Fig. 686.7), malignancy-associated,

immunodeficiency-related, autoinflammatory (recurrent fever) syndromes, and drug-induced. Pathogenesis for all four forms remains unclear; however, new data are emerging implicating a potential interleukin (IL)-1–mediated pathway. Malignancy-associated Sweet syndrome is most commonly associated with hematologic malignancies, especially **acute myelogenous leukemia**. It manifests abruptly before, during, or after the malignancy course and is characterized by tender, erythematous, edematous plaques or nodules that may be pustular or targetoid, often accompanied by fever, anemia, and leukocytosis. Oral ulcers are more common in malignancy-associated Sweet syndrome than in other forms of the disease, and extracutaneous manifestations involving various organ systems may also occur. Diagnosis is confirmed by the presence of a dense neutrophilic infiltrate without evidence of vasculitis. The differential diagnosis includes other neutrophilic dermatoses such as pyoderma gangrenosum as well as cellulitis, erythema multiforme, Behçet disease, and erythema nodosum. First-line treatment for both malignancy-associated and nonmalignancy-associated Sweet syndrome is oral glucocorticoids (prednisone 1-2 mg/kg/day for 2-4 weeks) in combination with high-potency topical or intralesional corticosteroids. Systemic steroid-sparing agents include colchicine and dapsone.

Cutaneous manifestations of other autoinflammatory diseases are noted in Table 686.4.

Langerhans Cell Histiocytosis

Langerhans cell histiocytosis (LCH, see Chapter 556.1) is a neoplastic disorder characterized by proliferation of myeloid dendritic cells. Once thought to be Langerhans cells, which are skin-resident dendritic cells, the cells of LCH are now understood to represent a distinct cell type. LCH can be a single-system or multisystem disease, with the neoplastic infiltrate in organs such as the skin, bone, central nervous system, lung, hematopoietic system, liver, and spleen. When present on the skin, the lesions of LCH can be crusted erosions, scaly papules, or purpura. There is a predilection for the scalp, palms, soles, and intertriginous areas such as axillae and groin. Prognosis and treatment are variable depending on the organ systems involved.

Necrolytic Migratory Erythema (Glucagonoma Syndrome)

Necrolytic migratory erythema is a distinctive migratory erythema that often signals an underlying neoplasm, usually an α-cell pancreatic tumor. Polycyclic, weeping, erythematous patches and plaques on the face, extremities, and groin occur in association with glossitis and cheilitis. The lesions are painful or pruritic, enlarge and coalesce over time, and may develop central clearing with vesicles, crusts, and scales peripherally. Skin biopsy reveals superficial necrolysis with perivascular infiltrate. Elevated glucagon levels, hyperglycemia, and hypoaminoacidemia confirm the diagnosis, and tumor resection leads to resolution of the rash. Other treatments for necrolytic migratory erythema include somatostatin analogs (octreotide) and nutritional support; however, these measures do not affect the underlying tumor burden.

ERYTHROMELALGIA

This disorder may be primary (caused by pathogenic genetic variants in *SCN9A*) or secondary (myeloproliferative disorders, paraneoplastic, autoimmune) and is characterized by the triad of recurrent extremity pain, warmth, and redness. Warmth, exercise, sitting, or wearing shoes or gloves may initiate the episode. Cooling and elevation may relieve symptoms (see Chapter 211.5).

CUTANEOUS REACTIONS IN THE SETTING OF IMMUNOSUPPRESSION

Medication reactions, infectious etiologies, and graft-versus-host disease (GVHD) are included in the differential diagnosis in skin eruptions in immunosuppressed patients; cutaneous and histologic similarities can be confounding.

Medication Reactions

The majority of medication reactions are mild morbilliform or exanthematous eruptions of little clinical consequence. Identifying the suspect medication may be difficult owing to the many medications used in immunosuppressed patients. Features that may help identify suspect medications include rash onset relative to exposure, character of distribution and spread, associated symptoms, and laboratory data. Medication eruptions usually begin on the trunk **7-10 days after exposure**; they spread peripherally and are associated with pruritus and, less commonly, with fever, arthralgia, and lymphadenopathy. Eosinophilia may support a diagnosis of drug eruption but may be absent in the setting of bone marrow suppression. Penicillins, sulfa drugs, cephalosporins, nonsteroidal antiinflammatory drugs (NSAIDs), anticonvulsants, and aminoglycosides are common offenders. Medication eruptions may resolve despite continued use of the offending agent, or they may progress to more severe involvement. A careful drug history, elimination of all nonessential, suspect medications or change to medications of dissimilar class, and treatment of pruritus with emollients, topical steroids, antihistamines, and antipruritics are indicated. Skin biopsies are rarely useful in distinguishing medication eruptions from viral exanthems, although GVHD, if sufficiently advanced, may have signature histopathologic findings.

Fig. 686.8 Lichenoid eruption in chronic graft-versus-host disease.

Graft-Versus-Host Disease

GVHD (see Chapter 179) may have florid cutaneous expression in addition to characteristic extracutaneous features such as fever, mucositis, diarrhea, and hepatitis. It may be either acute or chronic. **Acute GVHD** occurs in 20–70% of hematopoietic stem cell transplants, depending on histocompatibility differences. It may be mistaken for a medication reaction or infectious exanthem because of the nonspecific erythematous maculopapular (morbilliform) eruption that often starts focally and then generalizes. Features that suggest acute GVHD include timing of eruption (typically 1-3 weeks after transplantation, at the time of hematopoietic reconstitution); initial involvement of the head and neck including the ears; and subsequent spread to the trunk, extremities, palms, and soles. In severe cases of acute GVHD, blistering, necrolysis, and erythroderma occur. **Chronic GVHD** occurs in approximately 65% of long-term transplant survivors, who may or may not have experienced prior acute GVHD. Cutaneous manifestations of chronic GVHD are distinctive, with sclerotic, poikilodermic scaly plaques and lichen planus–like papules predominating on the trunk and distal extremities (Fig. 686.8). Sclerotic areas are prone to contracture and chronic wound development. Involvement of the hair, nails, and oral mucosa is also common in chronic GVHD. First-line treatment for GVHD includes systemic glucocorticoids and other immunosuppressants supplemented by mid- to high-potency topical corticosteroids. In mild disease, topical corticosteroids or topical calcineurin inhibitors alone may be effective. Second-line treatment approaches include phototherapy (narrow-band UVB or UVA1) and extracorporeal photopheresis. All patients with GVHD benefit from sunlight protection, emollient use, and topical or oral antipruritics.

Visit Elsevier eBooks+ at eBooks.Health.Elsevier.com for Bibliography.

686.2 Multisystem Medication Reactions

Julie M. Dhossche and Yvonne E. Chiu

See also Chapter 193.

Most cutaneous reactions that result from the use of systemic medications are confined to the skin and resolve without sequelae after discontinuation of the offending agent (Table 686.5). More severe drug eruptions may be life-threatening, making rapid recognition vital (Table 686.6 and see Chapter 695). Genetics and, particularly, ethnicity appear to play a major role in determination of the occurrence of multisystem medication reactions, particularly to anticonvulsants.

DRUG RASH WITH EOSINOPHILIA AND SYSTEMIC SYMPTOMS

Drug rash with eosinophilia and systemic symptoms (DRESS syndrome) is also called *drug hypersensitivity syndrome* or *anticonvulsant hypersensitivity syndrome.* It is classically seen **2-6 weeks after initial exposure** to an anticonvulsant (carbamazepine, phenobarbital, phenytoin, lamotrigine) or other drugs (allopurinol, minocycline, sulfonamides [dapsone, sulfasalazine], other antibiotics) and often manifests as the triad of **fever**, **rash**, and **hepatitis** (Fig. 686.9). The skin rash is initially located on the head, upper trunk, and arms. A diffuse exanthem of pruritic, morbilliform papules

Table 686.5 Drug Eruptions in Pediatric Patients

ERUPTION	KEY DRUGS	LESIONAL PATTERN	MUCOSAL CHANGES
Urticaria	Penicillins, cephalosporins, sulfonamides, minocycline, aspirin/NSAIDs, antiepileptics, monoclonal antibodies, radiocontrast media	Pruritic erythematous wheals (Fig. 686.12)	None
Angioedema	Aspirin/NSAIDs, ACE inhibitors	Swelling of subcutaneous and deep dermal tissues	May be present
Serum sickness–like reaction	Cephalosporins, penicillins, minocycline, sulfonamides, macrolides, rifampin, ciprofloxacin, griseofulvin, itraconazole, bupropion, fluoxetine, rituximab, H1N1 vaccine	Urticarial or erythema multiforme–like (see Fig. 686.11)	None
Exanthematous	Penicillins, sulfonamides, cephalosporins, antiepileptics	Erythematous macules and/or papules	None
Drug hypersensitivity syndrome	Sulfonamides, phenytoin, phenobarbital, carbamazepine, lamotrigine, amoxicillin, allopurinol, sulfonamides, dapsone, minocycline, aspirin, vancomycin, azithromycin, abacavir, nevirapine, Chinese medicine	Edema (especially periorbital); erythematous macules and/or papules; sometimes vesicles or bullae (see Fig. 686.10)	May be present
Lichenoid	Captopril, enalapril, labetalol, nifedipine, propranolol, gold salts, hydrochlorothiazide, furosemide, spironolactone, hydroxychloroquine, ketoconazole, penicillamine, griseofulvin, tetracycline, carbamazepine, phenytoin, NSAIDs, hydroxyurea, imatinib, dapsone, sulfasalazine, allopurinol, iodides and radiocontrast media, IFN-γ, omeprazole, TNF inhibitors, sildenafil, leflunomide, human growth hormone	Discrete flat-topped, reddish-purple papules and plaques	May be present
Fixed drug	Sulfonamides, ibuprofen, acetaminophen, salicylates, tetracyclines, pseudoephedrine, loratadine, teicoplanin, metronidazole, macrolides, barbiturates, lamotrigine, potassium iodide, quinine, phenolphthalein, foods and food flavorings (especially tartrazine)	Solitary to few erythematous, hyperpigmented plaques (see Fig. 686.13)	Unusual
Pustular (AGEP)	β-Lactam antibiotics, cephalosporins, macrolides, clindamycin, terbinafine, paroxetine, hydroxychloroquine, contrast agents	Generalized small pustules and papules (see Fig. 686.14)	None
Acneiform	Corticosteroids, androgens, lithium, iodides, phenytoin, isoniazid, methotrexate	Follicular-based inflammatory papules and pustules predominate	None
Pseudoporphyria	NSAIDs, COX-2 inhibitors, tetracyclines, furosemide	Photodistributed blistering and skin fragility	None
Vasculitis	Penicillins, NSAIDs, sulfonamides, cephalosporins	Purpuric papules, especially on the lower extremities; urticaria, hemorrhagic bullae, digital necrosis, pustules, ulcers	Rarely
Stevens-Johnson/toxic epidermal necrolysis	Sulfonamides, antiepileptics (especially phenytoin, carbamazepine, and lamotrigine), NSAIDs, acetaminophen, allopurinol, dapsone, barbiturates	Target lesions, bullae, epidermal necrosis with detachment (see Figs. 695.3 and 695.4)	Present
Drug-induced lupus	Minocycline, procainamide, hydralazine, isoniazid, penicillamine	Urticarial, vasculitic, erythematous	Rare

ACE, Angiotensin converting enzyme; AGEP, acute generalized exanthematous pustulosis; COX-2, cyclooxygenase-2; IFN, interferon; NSAID, Nonsteroidal antiinflammatory drug; TNF, tumor necrosis factor.

Adapted from Paller AS, Mancini AJ, eds. *Hurwitz Clinical Pediatric Dermatology*, 6th ed. St Louis: Elsevier; 2022: p. 541.

Table 686.6 Main Clinical and Histologic Characteristics of Severe Cutaneous Adverse Reactions

DRUG TO SCAR INTERVAL	GENERAL SYMPTOMS	SKIN FEATURES	LABORATORY VALUES	MAIN ORGANS INVOLVED	HISTOLOGIC FEATURES
SJS and TEN	4-28 days	Fever ≥38°C, Influenza- like syndrome, respiratory tract symptoms	Blisters, large skin detachment, confluent erythema, atypical target lesions, purpura, Nikolsky sign; skin detachment Stevens-Johnson syndrome <10%, toxic epidermal necrolysis ≥30%, SJS-TEN 10–30%; two or more mucous membranes involved	Lymphopenia, transitory neutropenia, mild cytolysis, renal impairment	Full-thickness epidermal necrosis, focal adnexal necrosis, necrotic keratinocytes, mild mononuclear cell dermal infiltrate, negative direct immunofluorescence test
DRESS syndrome	2-6 wk	Fever ≥38°C, Influenza- like syndrome	Maculopapular rash Erythroderma, facial or extremity edema, pustules, focal monopolar mucous membrane involvement	Eosinophilia >700 cells/μL Atypical lymphocytes, elevated transaminase concentration, impaired renal function, herpesvirus reactivation (HHV-6, HHV-7, EBV, CMV), parvovirus B19 reactivation	Lichenoid infiltrate or Eczematous pattern (spongiosis, edema), focal necrotic keratinocytes, mononuclear infiltrate, focal eosinophil and neutrophil infiltrates, mild vasculitis
AGEP	1-11 days	Fever ≥38°C	Intertriginous erythema, edema, widespread nonfollicular sterile pustules, postpustular pinpoint desquamation, Nikolsky sign, rare oral mucous membrane involvement	Hyperleukocytosis, neutrophils ≥7,000 cells/μL, mild eosinophilia	Subcorneal or intraepidermal spongiform or nonspongiform pustules with or without papillary edema, focal necrotic keratinocytes, neutrophilic, sometimes with eosinophils, mild vasculitis

*General symptoms can precede or occur at the same time as skin manifestations.
AGEP, Acute generalized exanthematous pustulosis; CMV, cytomegalovirus; DRESS, drug reaction with eosinophilia and systemic symptoms; EBV, Epstein-Barr virus; HHV, human herpesvirus; SCAR, severe cutaneous adverse reaction; SJS, Stevens-Johnson syndrome; TEN, toxic epidermal necrolysis.
From Duong TA, Valeyrie-Allanore L, Wolkenstein P, et al. Severe cutaneous adverse reactions to drug. *Lancet*. 2017;390: 1996–2011. Table 1.

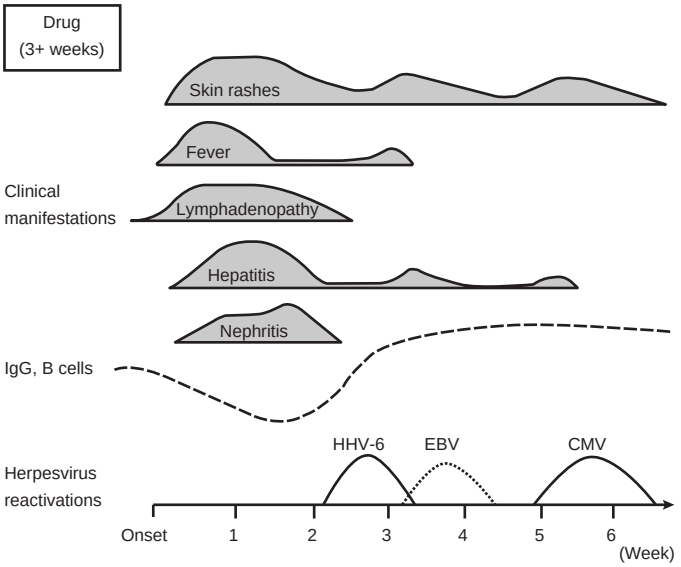

Fig. 686.9 Clinical symptoms and laboratory findings of drug-induced hypersensitivity syndrome/drug rash with eosinophilia and systemic symptoms. CMV, Cytomegalovirus; EBV, Epstein-Barr virus; HHV, human herpesvirus. *(From Kano Y, Ishida T, Hirahara K, Shiohara T. Visceral involvements and long-term sequelae in drug-induced hypersensitivity syndrome. Med Clin N Am. 2010;94:743–759, Fig. 1, p. 745).*

are most common, though any morphology may be present (Fig. 686.10). Exfoliation early in the course, as seen in toxic epidermal necrolysis, is uncommon. If mucous membrane involvement occurs, it is usually mild. Prominent periocular or facial edema, cervical lymphadenopathy, pharyngitis, and malaise accompany this dramatic cutaneous eruption. *Eosinophilia (≥500/μL) and atypical lymphocytosis are common but not always present.* Hepatitis ranging from mild elevation of liver transaminase values to frank hepatic failure may also be accompanied by interstitial nephritis, pneumonitis, myocarditis, shock, and encephalitis; mortality rate from these complications approaches 10%. Late-onset thyroiditis and hypothyroidism may occur months later as a result of antimicrosomal antibodies directed against thyroid peroxidases involved in drug metabolism.

DRESS syndrome is caused by a T-cell response specific to the drug. Reactivation of herpesviruses, especially human herpesvirus 6, also contributes to DRESS syndrome via an unknown pathogenic mechanism. Genetic predisposition with particular HLA allele types has also been implicated with specific ethnic groups and drugs, such as HLA-A*3101 with carbamazepine. The differential diagnosis includes Stevens-Johnson syndrome, viral exanthem, macrophage activation, hemophagocytic syndromes, and GVHD in the appropriate clinical setting. DRESS syndrome is often distinguished from other medication reactions by its later onset after drug exposure and more persistent course.

Withdrawal of the medication is the primary therapeutic intervention. Lymphocyte transformation tests and patch testing may be

Fig. 686.10 A 9-yr-old with cerebral palsy and seizures treated with carbamazepine. Seventeen days after start of therapy he demonstrated fever, rash (exanthematous), lymphadenopathy, and nephritis, all part of a drug-induced hypersensitivity syndrome. *(From Schachner LA, Hansen RC, eds. Pediatric Dermatology, 3rd ed. Philadelphia: Mosby; 2003: p. 1269.)*

helpful for identifying the offending drug when multiple suspect agents are present, but drug discontinuation should not be delayed while awaiting results. Symptomatic treatment of pruritus and pain can be accomplished with emollients and mid- to high-potency topical corticosteroids (twice daily for 1-2 weeks). Systemic corticosteroid therapy is necessary in the setting of rapidly evolving or severe hepatic or renal involvement. Counseling about increased risk with similar medications and in family members is important. DRESS syndrome can have a relapsing course, both in the skin and other organ systems, well after the medication has been withdrawn and initial improvement achieved, necessitating close follow-up for several months.

SERUM SICKNESS–LIKE REACTION

Serum sickness–like reaction (SSLR) manifests as annular, urticarial, sharply marginated, coalescing plaques, often with a lavender hue to the center (Fig. 686.11). In addition, acral erythema/edema, arthritis/arthralgia, lymphadenopathy, and fever are often present. Unlike with true serum sickness (see Chapter 191), laboratory evidence of circulating immune complexes and multisystem involvement of vasculitis are typically absent. The differential diagnosis includes Kawasaki disease, connective tissue diseases, acute annular urticaria, and DRESS syndrome. SSLR is most commonly seen 10-14 days after exposure to various drugs (especially cephalosporins, penicillins, minocycline, and other antibiotics), as well as after certain infections and vaccinations. The cause of drug-related SSLR is unknown, but a toxic metabolite is suspected. In contrast to DRESS syndrome, SSLR typically occurs after repeated drug exposures.

Fig. 686.11 Serum sickness–like reaction is composed of urticarial plaques with an erythematous border and violaceous centers.

Fig. 686.12 Urticaria. Transient well-circumscribed, erythematous wheals occurred in this girl as a reaction to administration of cefixime. Note the edematous center and halo of erythema. Circling a lesion and noting whether it is clear 24 hours later facilitates diagnosis. *(From Paller AS, Mancini AJ, eds. Hurwitz Clinical Pediatric Dermatology, 5th ed. Philadelphia: Elsevier; 2016: Fig. 20-2, p. 469.)*

Fig. 686.13 Multiple fixed-drug eruption.

Medication withdrawal and symptomatic treatment with oral antihistamines and analgesics are recommended. Systemic glucocorticoids are indicated for severe joint involvement or extensive rashes.

Fig. 686.14 Acute generalized exanthematous pustulosis is characterized by the acute onset of fever and generalized erythema with numerous small, discrete, sterile, nonfollicular pustules. Pustules may appear in a few days after the drug therapy is started. Pustules resolve in <15 days, followed by desquamation. *(From Habif TP, ed. Clinical Dermatology, 4th ed. Philadelphia: Mosby; 2004: p. 490.)*

FIXED-DRUG ERUPTION

Fixed-drug eruption (FDE) occurs minutes to hours after exposure to a drug and is characterized by mild pruritus or burning of a well-circumscribed, dusty red, brown, gray or, if severe, violaceous patch appearing on the extremities, trunk, lips, or genitals (Fig. 686.13). There is usually one lesion that, on reexposure to the drug, appears in the same (fixed) location as the previous episode, often appearing more rapidly. On occasion, there may be two or more lesions. Stopping the offending agent is required; the FDE will then resolve within 10-14 days, often with residual hyperpigmentation. Offending medications include sulfonamides, tetracyclines, NSAIDs, and acetaminophen.

ACUTE GENERALIZED EXANTHEMATOUS PUSTULOSIS

Acute generalized exanthematous pustulosis is often drug-related (most commonly aminopenicillins, macrolides, sulfonamides), occurring **within hours to days after drug exposure**. It is characterized by many nonfollicular sterile pustules with underlying edema and erythema, typically beginning on the face and intertriginous regions (Fig. 686.14). Neutrophilia and fever are common, whereas eosinophilia is less common than in DRESS syndrome. The rash may burn or itch; mucous membrane involvement is rare and often mild. Internal organ involvement is not common and often is asymptomatic. A pustular smear is always indicated to rule out infection in the setting of leukocytosis, fever, and a pustular rash. Differential diagnosis includes generalized pustular psoriasis, bullous impetigo, IgA pemphigus, and subcorneal pustular dermatosis. Therapy consists of stopping the causative drug and offering symptomatic relief with moist dressings, emollients, and mid-potency topical corticosteroids (applied twice daily for 1-2 weeks).

Visit Elsevier eBooks+ at eBooks.Health.Elsevier.com for Bibliography.

Chapter 687

Principles of Dermatologic Therapy

Stephen R. Humphrey

Competent skin care requires an appreciation of primary versus secondary lesions, a specific diagnosis, and knowledge of the natural course of the disease. If the diagnosis is uncertain, it is better to err on the side of less aggressive rather than more aggressive treatment.

In the use of topical medication, consideration of vehicle is as important as the specific therapeutic agent. Acute **weeping lesions** respond best to wet compresses, followed by lotions or creams. For **dry, thickened,** scaly skin, or for treatment of a contact allergic reaction possibly the consequence of a component of a topical medication, an ointment base is preferable, as it helps to occlude and moisten the affected area. Gels and solutions are most useful for the scalp and other hairy areas because of their faster absorption. The site of involvement is of considerable importance because the most desirable vehicle may not be cosmetically or functionally appropriate, such as an ointment on the face or hands. A patient's preference should also play a part in the choice of vehicle because compliance is poor if a medication is not acceptable to a patient. Ointments tend to sting less and are the least irritating. Cosmetically acceptable foam delivery systems have been developed, and the number of products and formulations available is increasing.

Most **lotions** are mixtures of water and oil that can be poured. After the water evaporates, the small amount of remaining oil covers the skin. Some shake lotions are a suspension of water and insoluble powder; as the water evaporates, cooling the skin, a thin film of powder covers the skin. **Creams** are emulsions of oil and water that are viscous and do not pour (more oil than in lotions). **Ointments** have oils and a small amount of water or no water at all; they feel greasy, lubricate dry skin, trap water, and aid in occlusion. Ointments without water usually require no preservatives because microorganisms require water to survive. Because of this, ointments often have the lowest number and concentration of ingredients, decreasing the risk of sensitizing the skin.

Therapy should be kept as simple as possible, and specific written instructions about the frequency and duration of application should be provided. Physicians should become familiar with one or two preparations in each category and should learn to use them appropriately. Prescribing nonspecific proprietary medications that may contain sensitizing agents should be avoided. Certain preparations, such as topical antihistamines and sensitizing anesthetics, are never indicated.

WET DRESSINGS

Wet dressings cool and dry the skin by evaporation and cleanse it by removing crusts and exudate, which would cause further irritation if permitted to remain. The dressings decrease pruritus, burning, and stinging sensations and are indicated for acutely inflamed moist or oozing dermatitis. Although various astringent and antiseptic substances may be added to the solution, cool or tepid tap water compresses are just as effective. Dressings of multiple layers of Kerlix, gauze, or soft cotton material may be saturated with water and remoistened as often as necessary. Compresses should be applied for 10-20 minutes at least every 4 hours and should usually be continued for 24-48 hours.

Alternatively, cotton pajamas can be soaked in water and then wrung as dry as possible. These are placed on the child and covered with dry pajamas, preferably sleeper pajamas with feet. The child should sleep in these overnight. This type of dressing can be used nightly for up to 1 week.

Wet dressings or wet wraps in conjunction with topical steroids may also be used in more severe cases of dermatitis (e.g., atopic dermatitis). In this method, a thin layer of the topical steroid is applied to the affected areas, which are then covered with warm, wet wraps

Fig. 686.14 Acute generalized exanthematous pustulosis is characterized by the acute onset of fever and generalized erythema with numerous small, discrete, sterile, nonfollicular pustules. Pustules may appear in a few days after the drug therapy is started. Pustules resolve in <15 days, followed by desquamation. *(From Habif TP, ed. Clinical Dermatology, 4th ed. Philadelphia: Mosby; 2004: p. 490.)*

FIXED-DRUG ERUPTION

Fixed-drug eruption (FDE) occurs minutes to hours after exposure to a drug and is characterized by mild pruritus or burning of a well-circumscribed, dusty red, brown, gray or, if severe, violaceous patch appearing on the extremities, trunk, lips, or genitals (Fig. 686.13). There is usually one lesion that, on reexposure to the drug, appears in the same (fixed) location as the previous episode, often appearing more rapidly. On occasion, there may be two or more lesions. Stopping the offending agent is required; the FDE will then resolve within 10-14 days, often with residual hyperpigmentation. Offending medications include sulfonamides, tetracyclines, NSAIDs, and acetaminophen.

ACUTE GENERALIZED EXANTHEMATOUS PUSTULOSIS

Acute generalized exanthematous pustulosis is often drug-related (most commonly aminopenicillins, macrolides, sulfonamides), occurring **within hours to days after drug exposure**. It is characterized by many nonfollicular sterile pustules with underlying edema and erythema, typically beginning on the face and intertriginous regions (Fig. 686.14). Neutrophilia and fever are common, whereas eosinophilia is less common than in DRESS syndrome. The rash may burn or itch; mucous membrane involvement is rare and often mild. Internal organ involvement is not common and often is asymptomatic. A pustular smear is always indicated to rule out infection in the setting of leukocytosis, fever, and a pustular rash. Differential diagnosis includes generalized pustular psoriasis, bullous impetigo, IgA pemphigus, and subcorneal pustular dermatosis. Therapy consists of stopping the causative drug and offering symptomatic relief with moist dressings, emollients, and mid-potency topical corticosteroids (applied twice daily for 1-2 weeks).

Visit Elsevier eBooks+ at eBooks.Health.Elsevier.com for Bibliography.

Chapter 687

Principles of Dermatologic Therapy

Stephen R. Humphrey

Competent skin care requires an appreciation of primary versus secondary lesions, a specific diagnosis, and knowledge of the natural course of the disease. If the diagnosis is uncertain, it is better to err on the side of less aggressive rather than more aggressive treatment.

In the use of topical medication, consideration of vehicle is as important as the specific therapeutic agent. Acute **weeping lesions** respond best to wet compresses, followed by lotions or creams. For **dry, thickened,** scaly skin, or for treatment of a contact allergic reaction possibly the consequence of a component of a topical medication, an ointment base is preferable, as it helps to occlude and moisten the affected area. Gels and solutions are most useful for the scalp and other hairy areas because of their faster absorption. The site of involvement is of considerable importance because the most desirable vehicle may not be cosmetically or functionally appropriate, such as an ointment on the face or hands. A patient's preference should also play a part in the choice of vehicle because compliance is poor if a medication is not acceptable to a patient. Ointments tend to sting less and are the least irritating. Cosmetically acceptable foam delivery systems have been developed, and the number of products and formulations available is increasing.

Most **lotions** are mixtures of water and oil that can be poured. After the water evaporates, the small amount of remaining oil covers the skin. Some shake lotions are a suspension of water and insoluble powder; as the water evaporates, cooling the skin, a thin film of powder covers the skin. **Creams** are emulsions of oil and water that are viscous and do not pour (more oil than in lotions). **Ointments** have oils and a small amount of water or no water at all; they feel greasy, lubricate dry skin, trap water, and aid in occlusion. Ointments without water usually require no preservatives because microorganisms require water to survive. Because of this, ointments often have the lowest number and concentration of ingredients, decreasing the risk of sensitizing the skin.

Therapy should be kept as simple as possible, and specific written instructions about the frequency and duration of application should be provided. Physicians should become familiar with one or two preparations in each category and should learn to use them appropriately. Prescribing nonspecific proprietary medications that may contain sensitizing agents should be avoided. Certain preparations, such as topical antihistamines and sensitizing anesthetics, are never indicated.

WET DRESSINGS

Wet dressings cool and dry the skin by evaporation and cleanse it by removing crusts and exudate, which would cause further irritation if permitted to remain. The dressings decrease pruritus, burning, and stinging sensations and are indicated for acutely inflamed moist or oozing dermatitis. Although various astringent and antiseptic substances may be added to the solution, cool or tepid tap water compresses are just as effective. Dressings of multiple layers of Kerlix, gauze, or soft cotton material may be saturated with water and remoistened as often as necessary. Compresses should be applied for 10-20 minutes at least every 4 hours and should usually be continued for 24-48 hours.

Alternatively, cotton pajamas can be soaked in water and then wrung as dry as possible. These are placed on the child and covered with dry pajamas, preferably sleeper pajamas with feet. The child should sleep in these overnight. This type of dressing can be used nightly for up to 1 week.

Wet dressings or wet wraps in conjunction with topical steroids may also be used in more severe cases of dermatitis (e.g., atopic dermatitis). In this method, a thin layer of the topical steroid is applied to the affected areas, which are then covered with warm, wet wraps

for approximately 30 minutes to 1 hour 2-3 times daily. This method is especially effective in children with extensive and severe dermatitis.

BATH OILS, COLLOIDS, AND SOAPS

Bath oil has little benefit in the treatment of children. It offers little moisturizing effect but increases the risk of injury during a bath. Bath oil may lubricate the surface of the bathtub, causing an adult or child to fall when stepping into the tub. Tar bath solutions can be prescribed and may be helpful for psoriasis and atopic dermatitis. Colloids such as starch powder and colloidal oatmeal are soothing and antipruritic for some patients when added to the bathwater. Oilated colloidal oatmeal contains mineral oil and lanolin derivatives for lubrication if the skin is dry. These can also lubricate the bathtub surface. Ordinary bath soaps may be irritating and drying if patients have dry skin or dermatitis. Synthetic soaps are much less irritating. Fragrance-free soaps and cleansers are often better tolerated and less likely to irritate skin. Additionally, solid soaps tend to be less irritating, as they do not have as many preservatives as liquid soap might. When skin is acutely inflamed, avoidance of soap is advised.

LUBRICANTS

Lubricants, such as lotions, creams, and ointments, can be used as moisturizers for dry skin and as vehicles for topical agents such as corticosteroids and keratolytics. In general, ointments are the most effective emollients. Numerous commercial preparations are available. Some patients do not tolerate ointments, and some may be sensitized to a component of the lubricant; some preservatives in creams are also sensitizers. These preparations can be applied several times a day if necessary and tolerated. Maximal effect is achieved when they are applied to dry skin 2 or 3 times daily. Lotions containing menthol and camphor in an emollient vehicle can help control pruritus and dryness, but the use of moisturizers in addition to these products is best to decrease skin dryness.

SHAMPOOS

Special shampoos containing sulfur, salicylic acid, zinc, and selenium sulfide are useful for conditions in which there is scaling of the scalp, such as seborrheic dermatitis or psoriasis. Tar-containing shampoos are useful in these conditions. Most shampoos also contain surfactants and detergents. They should be used as frequently as necessary to control scaling. Patients should be instructed to leave the lathered shampoo in contact with the scalp for 5-10 minutes before thorough rinsing.

POWDERS

Powders are hygroscopic and serve as absorptive agents in areas of excessive moisture. When dry, powders decrease friction between two surfaces. They are most useful in the intertriginous areas and between the toes, where maceration and abrasion may result from friction on movement. Coarse powders may cake; therefore they should be of fine particle size and inert, unless medication has been incorporated in the formulation. The use of cornstarch-based powders in inflamed or broken skin may serve as a good growth environment for microorganisms and should be avoided.

PASTES

Pastes contain fine powder in ointment vehicles and are not often prescribed in current dermatologic therapy; in certain situations, however, they can be used effectively to protect vulnerable or damaged skin. A stiff zinc oxide paste is bland and inert and can be applied to the diaper area to prevent further irritation caused by diaper dermatitis. Zinc oxide paste should be applied in a thick layer, completely obscuring the skin, and is removed more easily with mineral oil than with soap and water.

KERATOLYTIC AGENTS

Urea-containing agents are hydrophilic; they hydrate the stratum corneum and make the skin more pliable. In addition, because urea dissolves hydrogen bonds and epidermal keratin, it is effective in treating scaling disorders. Concentrations of 10–40% are available in several commercial lotions and creams, which can be applied once or twice daily as tolerated. Salicylic acid is an effective keratolytic agent and can be incorporated into various vehicles in concentrations up to 6% to be applied 2 or 3 times daily. Salicylic acid preparations should not be used in treating small infants or on large surface areas or denuded skin; percutaneous absorption may result in salicylism. The α-hydroxy acids, particularly lactic acid and glycolic acid, are available in commercial preparations or can be incorporated in an ointment vehicle in concentrations up to 12%. Some creams contain both urea and lactic acid. The α-hydroxy acid preparations are useful for the treatment of keratinizing disorders and may be applied once or twice daily. Some patients complain of burning with the use of these agents; in such cases, the frequency of application should be decreased.

Table 687.1 Potency of Topical Glucocorticosteroids

CLASS 1—SUPER-POTENT
Betamethasone dipropionate, 0.05% gel, ointment
Clobetasol propionate cream, ointment, 0.05%
Halobetasol propionate cream, ointment, 0.05%
CLASS 2—POTENT
Betamethasone dipropionate cream 0.05%
Desoximetasone cream, ointment, gel 0.05% and 0.25%
Fluocinonide cream, ointment, gel, 0.05%
CLASS 3—UPPER MID-STRENGTH
Betamethasone dipropionate cream, 0.05%
Betamethasone valerate ointment, 0.1%
Fluticasone propionate ointment, 0.005%
Mometasone furoate ointment, 0.1%
Triamcinolone acetonide cream, 0.5%
CLASS 4—MID-STRENGTH
Desoximetasone cream, 0.05%
Fluocinolone acetonide ointment, 0.025%
Triamcinolone acetonide ointment, 0.1%
CLASS 5—LOWER MID-STRENGTH
Betamethasone valerate cream/lotion, 0.1%
Fluocinolone acetonide cream, 0.025%
Fluticasone propionate cream, 0.05%
Triamcinolone acetonide cream/lotion, 0.1%
CLASS 6—MILD STRENGTH
Desonide cream, 0.05%
CLASS 7—LEAST POTENT
Topicals with hydrocortisone, dexamethasone, flumethasone, methylprednisolone, and prednisolone

From Weston WL, Lane AT, Morelli JG. *Color Textbook of Pediatric Dermatology*, 4th ed. St. Louis: Mosby; 2007: p. 418.

TAR COMPOUNDS

Tars are obtained from bituminous coal, shale, petrolatum (coal tars), and wood. They are antipruritic and astringent and appear to promote normal keratinization. They may be useful for chronic eczema and psoriasis, and their efficacy may be increased if the affected area is exposed to UV light after the tar has been removed. Tars should not be used for acute inflammatory lesions. Tars are often messy and unacceptable because they may stain and they have an odor. They may be incorporated into shampoos, bath oils, lotions, and ointments. A useful preparation for pediatric patients is liquor carbonis detergens (LCD) 2–5% in a cream or ointment vehicle. Tar gel and tar in light body oil are relatively pleasant cosmetic preparations that cause minimal staining of skin and fabrics. Tars can also be incorporated into a vehicle with a topical corticosteroid. The frequency of application varies from 1-3 times daily, according to tolerance. Many children refuse to use tar preparations because of their odor and staining characteristics.

ANTIFUNGAL AGENTS

Antifungal agents are available as powders, lotions, creams, ointments, and solutions for the treatment of dermatophyte and yeast infections. Nystatin, naftifine, and amphotericin B are specific for *Candida albicans* and are ineffective in other fungal disorders. Tolnaftate is effective against dermatophytes but not against yeast. The spectrum for ciclopirox olamine includes the dermatophytes, *Malassezia furfur,* and *C. albicans.* The azoles clotrimazole, econazole, ketoconazole, miconazole, oxiconazole, and sulconazole have a similar broad spectrum. Butenafine has a similar broad

spectrum and also has antiinflammatory properties. Terbinafine has greater activity against dermatophytes but poorer activity against yeasts than the azoles. The topical antifungal agents should be applied 1-2 times a day for most fungal infections. All have low sensitizing potential; additives such as preservatives and stabilizers in the vehicles may cause allergic contact dermatitis. Ointments containing 6% benzoic acid and 3% salicylic acid are potent keratolytic agents that have also been used for the treatment of dermatophyte infections. Irritant reactions are common.

TOPICAL ANTIBIOTICS

Topical antibiotics have been used for many years to treat local cutaneous infections, although their efficacy, with the exception of mupirocin, fusidic acid, and retapamulin, has been questioned. Ointments are the preferred vehicles (except in the treatment of acne vulgaris; see Chapter 710), and combinations with other topical agents such as corticosteroids are, in general, inadvisable. Whenever possible, the etiologic agent should be identified and treated specifically. Antibiotics in wide use as systemic preparations should be avoided because of the risk of bacterial resistance. The sensitizing potential of certain topical antibiotics, such as neomycin and nitrofurazone, should be kept in mind and avoided when possible. Mupirocin, fusidic acid, and retapamulin are the most effective topical agents currently available and are as effective as oral erythromycin in treatment of mild to moderate impetigo. Polysporin and bacitracin are not as effective.

TOPICAL CORTICOSTEROIDS

Topical corticosteroids are potent antiinflammatory agents and effective antipruritic agents. Successful therapeutic results are achieved in a wide variety of skin conditions. Corticosteroids can be divided into seven different categories on the basis of strength (Table 687.1), but for practical purposes, four categories can be used: low, moderate, high, and super. Low-potency preparations include hydrocortisone, desonide, and hydrocortisone butyrate. Medium-potency compounds include betamethasone, flurandrenolide, fluocinolone, mometasone furoate, and triamcinolone. High-potency topical steroids include fluocinonide and halcinonide. Betamethasone dipropionate, halobetasol, and clobetasol propionate are superpotent preparations and should be prescribed with care. Some of these compounds are formulated in several strengths according to clinical efficacy and degree of vasoconstriction. Physicians using topical steroids should become familiar with preparations within each class.

All corticosteroids can be obtained in various vehicles, including creams, ointments, solutions, gels, and aerosols. Some are available in a foam vehicle. Absorption is enhanced by an ointment or gel vehicle, but the vehicle should be selected on the basis of the type of disorder and the site of involvement. Frequency of application should be determined by the potency of the preparation, the location on the body, and the severity of the eruption. Applying a thin film 2 times daily usually suffices. Adverse local effects include cutaneous atrophy, striae, telangiectasia, acneiform eruptions, purpura, hypopigmentation, and increased hair growth. Systemic adverse effects of high-potency and superpotent topical steroids occur with long-term use and include poor growth, cataracts, and suppression of adrenal function.

The relative skin thickness should be considered in regard to the selection of class of steroid (see Table 687.1). Thin skin such as the eyelids, face, groin, and genitalia will absorb a substantial amount of medication compared to the thickest skin on the palms and soles. One adult fingertip's worth of medication is enough to cover an area the size of an adult palm and is approximately half a gram of medication. Knowing the area being treated and which medication class to prescribe can decrease the potential for side effects.

In selected circumstances, corticosteroids may be administered by intralesional injection (acne cysts, keloids, psoriatic plaques, alopecia areata, persistent insect bite reactions). Only experienced physicians should use this method of administration.

TOPICAL NONSTEROIDAL ANTIINFLAMMATORY AGENTS

Calcineurin-inhibiting antiinflammatory agents that inhibit T-cell activation may be used instead of topical steroids for the treatment of atopic dermatitis and other inflammatory conditions. These agents are pimecrolimus and tacrolimus. They do not have the adverse local effects seen with topical steroids. Stinging with application is the most common complaint and may be lessened by mixing the medication with an ointment such as petrolatum jelly for the initial applications. These agents are only as strong as medium-potency topical steroids. In 2006, the FDA issued a boxed warning for topical calcineurin inhibitors because data from animal experiments and case reports suggested potential for an increased risk of lymphoma with systemic use. No clear link between topical calcineurin inhibitor use and lymphoma risk has been established despite multiple epidemiologic and clinical studies. Crisaborole, a novel PDE4 inhibitor, is now approved for mild to moderate atopic dermatitis, and is another option for nonsteroidal treatments.

SUNSCREENS

Sunscreens are of two general types: (1) those, such as zinc oxide and titanium dioxide, that absorb all wavelengths of the UV and visible spectrums and (2) a heterogeneous group of chemicals that selectively absorb energy of various wavelengths within the UV spectrum. In addition to the spectrum of light that is blocked, other factors to be considered include cosmetic acceptance, sensitizing potential, retention on skin while swimming or sweating, required frequency of application, and cost. Sunscreen ingredients include para-aminobenzoic acid (PABA) with ethanol, PABA esters, cinnamates, and benzophenone. These block transmission of the majority of solar UVB and some UVA wavelengths. Avobenzone and ecamsule are more effective in blocking UVA. Antioxidants may also be found in some sunscreens. Lip protectants that absorb in the UVB range are also available. Some chemical sunscreens (oxybenzone, octocrylene, and octinoxate) have been implicated in harming coral reefs and are banned in certain areas of the world.

Sunscreens are designated by sun protection factor (SPF). The SPF is defined as the amount of time to develop a mild sunburn with the sunscreen compared with the amount of time without the sunscreen. A minimum SPF factor of 30 should be recommended most often. The higher the SPF, the better the protection is against UVB rays. Sunscreens do not include any measurement of the efficacy in blocking UVA. The efficacy of these agents depends on careful attention to instructions for use. Chemical sunscreens should be applied at least 30 minutes before sun exposure to permit penetration into the epidermis, again on arrival at the destination, and every subsequent hour when exposed to direct sunlight. Most patients with photosensitivity eruptions require protection by agents that absorb both UVB and UVA wavelengths (see Chapter 697).

Although sunscreens do confer photoprotection and may decrease the development of nevi, protection is incomplete against all harmful UV light. Midday (10 AM to 4 PM) sun avoidance is the primary method of photoprotection. Clothing, hats, and staying in the shade offer additional sun protection.

LASER THERAPY

The vascular-specific pulsed dye laser therapy is used mainly for the treatment of capillary malformations (port-wine stains). Spider telangiectasia, small facial pyogenic granulomas, superficial and ulcerated hemangioma, and warts may also be treated. Vascular-specific pulsed dye lasers produce light that is readily absorbed by oxyhemoglobin, producing selective photothermolysis of vascular lesions.

Ultraviolet Phototherapy

Phototherapy can be a useful treatment for many cutaneous inflammatory disorders, including atopic dermatitis, psoriasis, pityriasis lichenoides, vitiligo, and a few others. Some benefits of phototherapy include the fact that it is well tolerated, may treat a large area of the body, and may enable a patient to avoid systemic immunosuppressive agents. There are two traditional modalities of treatment: psoralen (a photosensitizer) + UVA (PUVA) or narrow-band UVB phototherapy (NBUVB). NBUVB phototherapy is most often used, typically dosed between 1 and 3 times per week, depending on the condition. There is an increased risk of skin cancers with long-term use of PUVA, but there does not seem to be an increased risk for NBUVB. Risks include burns, though this is quite rare if performed properly.

Visit Elsevier eBooks+ at eBooks.Health.Elsevier.com for Bibliography.

Chapter 688

Dermatologic Diseases of the Neonate

Sarah B. Younger and Kari L. Martin

Minor evanescent lesions of newborn infants, particularly when florid, may cause undue concern. Most of these entities are relatively common, benign, and transient and do not require therapy.

SEBACEOUS HYPERPLASIA

Minute, profuse, yellow-white papules are frequently found on the forehead, nose, upper lip, and cheeks of a term infant; they represent hyperplastic sebaceous glands (Fig. 688.1). These tiny papules diminish gradually in size and disappear entirely within the first few weeks of life; no treatment is required.

MILIA

Milia are superficial epidermal inclusion cysts that contain laminated keratinized material. The lesion is a firm cyst, 1-2 mm in diameter, and pearly, opalescent white. Milia may occur at any age, but in neonates are most frequently scattered over the face and gingivae and on the midline of the palate, where they are called *Epstein pearls.* Milia exfoliate spontaneously in most infants and may be ignored; those that appear in scars or sites of trauma in older children may be gently unroofed and the contents extracted with a fine-gauge needle.

SUCKING BLISTERS

Solitary or scattered superficial bullae present at birth on the upper limbs of infants are presumably induced by vigorous sucking on the affected part in utero. Common sites are the radial aspect of the forearm, thumb, and index finger. These bullae resolve rapidly without sequelae. They may occur in conjunction with sucking pads (calluses), which are found on the lips and are a result of combined intracellular edema and hyperkeratosis. No treatment is required.

CUTIS MARMORATA

When a newborn infant is exposed to low environmental temperatures, an evanescent, lacy, reticulated red and/or blue cutaneous vascular pattern appears over most of the body surface. This vascular change represents an accentuated physiologic vasomotor response that disappears with increasing age, although it is sometimes discernible even in older children. No treatment is needed.

Cutis marmorata telangiectatica congenita presents in a similar fashion but is a vascular anomaly in which the lesions are more intense, may be segmental, and are persistent despite warming of the infant. They may be associated with loss of dermal tissue, epidermal atrophy, and ulceration (Fig. 688.2). The lower extremities are usually affected, with limb atrophy noted on the affected side. Gradual fading of the livid erythema occurs over 3-5 years, but limb asymmetry is permanent. Extracutaneous findings such as ocular and neurologic abnormalities may be associated in 20–80% of cases. There is no specific treatment.

Fig. 688.1 Sebaceous hyperplasia. Minute white-yellow papules on the nose of a newborn.

HARLEQUIN COLOR CHANGE

A dramatic vascular event, harlequin color change occurs transiently in up to 10% of newborns, most commonly on days 2-52 of life. It probably reflects an imbalance in the autonomic vascular regulatory mechanism. When the infant is placed on one side, the body is bisected longitudinally into a pale upper half and a deep red dependent half. The color change lasts only for a few minutes and occasionally affects only a portion of the trunk or face. Changing the infant's position may reverse the pattern. Muscular activity causes generalized flushing and obliterates the color differential. Repeated episodes may occur but do not indicate permanent autonomic imbalance. There is generally no need for treatment. This disorder should be readily distinguishable from harlequin syndrome, which is associated with paroxysmal hemifacial flushing and sweating with or without a Horner syndrome. Symptoms are induced by heat, stress, or exercise. Some cases are secondary to trauma, cervical cord syrinx, or neuroblastoma. Although rarely congenital, most cases occur in older children.

NEVUS SIMPLEX (SALMON PATCH)

Nevus simplex is a small, pale pink, ill-defined, vascular macule that occurs most commonly on the glabella, eyelids, upper lip, and nuchal area of 40–60% of normal newborn infants. These lesions persist for several months and may become more visible during crying or changes in environmental temperature. Most lesions on the face eventually fade and disappear completely, although lesions occupying the entire central forehead often do not. Those on the posterior neck and occipital areas usually persist. Treatment is not usually indicated, though pulsed dye laser treatment can be helpful in lightening lesions that are persistent and cosmetically bothersome. Lesions located in the midline lumbosacral area and associated with other changes such as a sinus or pit, patch of hair, or asymmetric gluteal cleft warrant imaging with ultrasound to evaluate the underlying spinal cord for spinal dysraphism.

Nevus simplex should not be confused with a port-wine stain (capillary malformation), which is a permanent lesion and may be associated with Sturge-Weber syndrome. Nevus simplex is usually symmetric, with lesions on both eyelids or on both sides of the midline. Port-wine stains are often larger and unilateral, and they usually end along the midline (see Chapter 691).

Fig. 688.2 Newborn girl with reticulate erythema/livedo on legs, right arm, and cheeks. *(From Pleimes M, Gottler S, Weibel L. Characteristic congenital reticular erythema: cutis marmorata telangiectatica congenital. J Pediatr. 2013;163:604, Fig. 1.)*

CONGENITAL DERMAL MELANOCYTOSIS (SLATE GRAY NEVUS)

Congenital dermal melanocytosis, which appears as blue or slate-gray macular lesions, has variably defined margins. It occurs most commonly in the sacral area but may be found over the posterior thighs, legs, back, and shoulders (Fig. 688.3). The spots may be solitary or numerous and often involve large areas. The peculiar hue of these macules is a result of the dermal location of melanin-containing melanocytes (mid-dermal melanocytosis) that are presumably arrested in their migration from neural crest to epidermis. They usually fade during the first few years of life as a result of darkening of the overlying skin; no therapy is required. If lesions persist, they may be treated with lasers, if desired. Malignant degeneration does not occur. The characteristic appearance and congenital onset distinguish these spots from the bruises of child abuse. Rarely dermal melanocytosis is associated with Hurler or Hunter syndrome, GM1 gangliosidosis, Niemann-Pick disease, mucolipidosis, and mannosidosis. These lesions have previously been referred to as "Mongolian spots." This term should be avoided, as it derives from racist terminology.

ERYTHEMA TOXICUM

A benign, self-limited, evanescent eruption, erythema toxicum occurs in approximately 50% of full-term infants; preterm infants are affected less commonly. The lesions are firm, yellow-white, 1- to 2-mm papules or pustules with a surrounding erythematous flare (Fig. 688.4). At times, splotchy erythema is the only manifestation. Lesions may be sparse or numerous and either clustered in several sites or widely dispersed over much of the body surface. The palms and soles are usually spared. Peak incidence occurs on the second day of life, but new lesions may erupt during the first few days as the rash waxes and wanes. Onset may occasionally be delayed for a few days to weeks in premature infants. Eosinophils can be demonstrated in Wright-stained smears of the intralesional contents. Cultures are sterile.

The cause of erythema toxicum is unknown. The lesions can mimic pyoderma, candidiasis, herpes simplex, transient neonatal pustular melanosis, and miliaria but can be differentiated by the characteristic infiltrate of eosinophils and the absence of organisms on a stained smear. The course is brief (3-7 days), and lesions generally resolve without pigmentation. No therapy is required. Incontinentia pigmenti and eosinophilic pustular folliculitis also have eosinophilic infiltration but can be distinguished by their distribution, histologic type, and chronicity.

TRANSIENT NEONATAL PUSTULAR MELANOSIS

Pustular melanosis is a transient, benign, self-limited dermatosis of unknown etiology that is characterized by three types of lesions: (1) evanescent superficial pustules, (2) ruptured pustules with a collarette of fine scale, at times with a central hyperpigmented macule, and (3) hyperpigmented macules (Fig. 688.5). Lesions are present at birth, and one or all types of lesions may be found in a profuse or sparse distribution. Pustules represent the early phase of the disorder, and macules, the late phase. The pustular phase rarely lasts more than 2-3 days; hyperpigmented macules may persist for as long as 3 months. Sites of predilection are the anterior neck, forehead, and lower back, although the scalp, trunk, limbs, palms, and soles may be affected.

The active phase shows an intracorneal or subcorneal pustule filled with polymorphonuclear leukocytes, debris, and an occasional eosinophil. The macules are characterized only by increased melanization of epidermal cells. Cultures and smears can be used to distinguish these pustules from those of pyoderma and erythema toxicum, because the lesions of pustular melanosis do not contain bacteria or dense aggregates of eosinophils. No therapy is required.

INFANTILE ACROPUSTULOSIS

Onset of infantile acropustulosis generally occurs at 2-10 months of age; lesions are occasionally noted at birth (Fig. 688.6). The cause is unknown. The lesions are initially discrete erythematous papules that become vesiculopustular within 24 hours and subsequently crust over before healing.

Fig. 688.3 Extensive dermal melanocytosis on the back of a newborn. *(Courtesy Fitzsimons Army Medical Center teaching file.)*

Fig. 688.4 Erythema toxicum on the trunk of a newborn infant.

Fig. 688.5 Transient neonatal pustular melanosis. Multiple papules present at birth on the arm of an infant. *(From Weston WL, Lane AT, Morelli JG, eds. Color Textbook of Pediatric Dermatology, 3rd ed. Philadelphia: Mosby; 2002:331.)*

Fig. 688.6 Acropustulosis of infancy. Multiple tense erythematous papules and pustules on the palm of this 4-mo-old girl. *(From Kliegman RM, Lye PS, Bordini BJ, Toth H, Basel D, eds. Nelson Pediatric Symptom-Based Diagnosis. Philadelphia: Elsevier; 2017: Fig. 47.3, p. 854.)*

They are intensely pruritic. Preferred sites are the palms of the hands and the soles and sides of the feet, where the lesions may be extensive. A less dense eruption may be found on the dorsum of the hands and feet, ankles, and wrists. Pustules occasionally occur elsewhere on the body. Each episode lasts 7-14 days, during which time pustules continue to appear in crops. After a 2- to 4-week remission, a new outbreak follows. This cyclic pattern continues for approximately 2 years; permanent resolution is often preceded by longer intervals of remission between periods of activity. Infants with acropustulosis are otherwise well.

Wright-stained smears of intralesional contents show abundant neutrophils or, occasionally, a predominance of eosinophils. Histologically, well-circumscribed, subcorneal, neutrophilic pustules, with or without eosinophils, are noted.

The differential diagnosis in neonates includes transient neonatal pustular melanosis, erythema toxicum, milia, cutaneous candidiasis, and staphylococcal pustulosis. In older infants and toddlers, additional diagnostic considerations include scabies, dyshidrotic eczema, pustular psoriasis, subcorneal pustular dermatosis, and hand-foot-and-mouth disease. A therapeutic trial of a scabicide is warranted in equivocal cases.

Therapy is directed at minimizing discomfort for infants. Topical mid- to high-potency corticosteroids and/or oral antihistamines may decrease the severity of the pruritus and an infant's irritability. Dapsone (1-2 mg/kg/day by mouth, divided in one to two doses) is effective but has potentially serious side effects, notably, hemolytic anemia and methemoglobinemia; its use should be limited to particularly severe cases.

EOSINOPHILIC PUSTULAR FOLLICULITIS

Eosinophilic pustular folliculitis is defined as recurrent crops of pruritic, coalescing, follicular papulopustules on the face, trunk, and extremities. Fifty percent of patients have peripheral eosinophilia, with eosinophil counts exceeding 5%, and approximately 30% have leukocytosis (>10,000 leukocytes/mm^3).

Infants account for <10% of all cases of eosinophilic pustular folliculitis. The clinical and histologic appearances of this disorder in infants closely resemble those in immunocompetent adults, with minor exceptions. In infants, the lesions are most prominent on the scalp, although they also occur on the trunk and extremities and occasionally are found on the palms and soles. The classic annular and polycyclic appearance with centrifugal enlargement is not seen in infants. The differential diagnosis includes erythema toxicum neonatorum, infantile acropustulosis, localized pustular psoriasis, pustular folliculitis, and transient neonatal pustular melanosis. High-potency topical corticosteroids are the most effective treatment (see Table 687.1).

Visit Elsevier eBooks+ at eBooks.Health.Elsevier.com for Bibliography.

Chapter 689

Cutaneous Defects

Kari L. Martin

SKIN DIMPLES

Cutaneous depressions over bony prominences and in the sacral area, at times associated with pits and creases, may occur both in normal children and in association with dysmorphic syndromes. Skin dimples may develop in utero because of interposition of tissue between a sharp bony point and the uterine wall, which leads to decreased subcutaneous tissue formation.

Dimples may also be present overlying an area of bone hypoplasia. Bilateral acromial skin dimples are usually an isolated finding, but they are also seen in association with deletion of the long arm of chromosome 18. Dimples tend to occur over the patella in congenital rubella, over the lateral aspects of the knees and elbows in prune-belly syndrome, on the pretibial surface in campomelic syndrome, and in the shape of an H on the chin in Freeman-Sheldon ("whistling face") syndrome.

Sacral dimples are common and usually are isolated findings. They may be seen in multiple syndromes or in association with spina bifida occulta and diastematomyelia. Association with a mass or other cutaneous stigma (hair, aplasia cutis, lipoma, hemangioma) should increase concern for underlying **spinal dysraphism** (see Chapter 631). Simple sacral dimples do not predict underlying spinal cord malformations, and spinal ultrasounds should not be performed in these cases because most of the abnormal findings reported in them are of no clinical significance. In infants younger than 3 months who warrant imaging, ultrasound is an initial, cost-effective, noninvasive method. If there is serious concern of an underlying defect, MRI is indicated. *MRI of the spine is the imaging modality of choice for patients older than 3 months if there is a strong suspicion of a spinal dysraphism.*

REDUNDANT SKIN

Loose folds of skin must be differentiated from a congenital defect of elastic tissue or collagen such as cutis laxa, Ehlers-Danlos syndrome, or pseudoxanthoma elasticum. Redundant skin over the posterior part of the neck is common in Turner, Noonan, Down, and Klippel-Feil syndromes and monosomy 1p36; more generalized folds of skin occur in infants with trisomy 18 and short-limbed skeletal dysplasia.

AMNIOTIC CONSTRICTION BANDS

Partial or complete constriction bands that produce defects in extremities and digits are found in 1 in 10,000-45,000 otherwise normal infants. Constrictive tissue bands are caused by primary amniotic rupture, with subsequent entanglement of fetal parts, particularly limbs, in shriveled fibrotic amniotic strands. This event is probably sporadic, with negligible risk of recurrence. Formation of constrictive tissue bands is associated with maternal history of abdominal trauma, amniocentesis, and hereditary defects of collagen such as Ehlers-Danlos syndrome and osteogenesis imperfecta. Treatment traditionally involves multiple surgical elongating procedures such as Z- and W-plasties. A surgical alternative uses lipoinjection and multiple internal incisions on the deep surface of the band.

Adhesive bands involve the craniofacial area and are associated with severe defects such as encephalocele and facial clefts. Adhesive bands result from broad fusion between disrupted fetal tissue and an intact amniotic membrane. The craniofacial defects appear not to be caused by constrictive amniotic bands, but to result from a vascular disruption sequence with or without cephaloamniotic adhesion (see Chapter 100).

The limb–body wall complex involves vascular disruption early in development, affecting several embryonic structures; it includes at least two of the following three characteristics: exencephaly or encephalocele with facial clefts, thoracoschisis and/or abdominoschisis, and limb defects.

PREAURICULAR SINUSES AND PITS

Pits and sinus tracts anterior to the pinna may be a result of imperfect fusion of the tubercles of the first and second branchial arches. These anomalies may be unilateral or bilateral, may be familial, and at times are associated with other anomalies of the ears and face. **Preauricular pits** are present in **branchiootorenal dysplasia 1 syndrome** (*EYA-1* gene), an autosomal dominant disorder that consists of external ear malformations, branchial fistulas, hearing loss, and renal anomalies. When the tracts become chronically infected, retention cysts may form and drain intermittently; such lesions may require excision.

ACCESSORY TRAGI

An accessory tragus typically appears as a single pedunculated, flesh-colored papule in the preauricular region anterior to the tragus. Less commonly, accessory tragi are multiple or bilateral and may be located in the preauricular area, on the cheek along the line of the mandible (Fig. 689.1), or on the lateral aspect of the neck anterior to the sternocleidomastoid muscle. In contrast to the rest of the pinna, which develops from the second branchial arch, the tragus and accessory tragi derive from the first branchial arch. Accessory tragi may occur as isolated defects or in chromosomal first branchial arch syndromes that include anomalies of the ears and face, such as cleft lip, cleft palate, and mandibular hypoplasia. An accessory tragus is consistently found in oculoauriculovertebral syndrome (Goldenhar syndrome). Other associated syndromes include mandibulofacial dysostosis (Treacher Collins syndrome), Townes-Brocks, VACTERL, and Wolf-Hirschhorn syndrome. Surgical excision is appropriate if cosmetically desired.

Studies are controversial on whether patients with accessory tragi and preauricular pits have a higher prevalence of hearing loss and urinary tract anomalies. *Renal ultrasound should be performed when found with at least one of the following: other malformations or dysmorphic features; family history of deafness, auricular, and/or renal malformation; or a maternal history of gestational diabetes.*

BRANCHIAL CLEFT AND THYROGLOSSAL CYSTS AND SINUSES

Cysts and sinuses in the neck may be formed along the course of the first, second, third, or fourth branchial clefts as a result of improper closure during embryonic life. Second branchial cleft cysts are the most common. The lesions may be unilateral or bilateral (2–3%) and may open onto the cutaneous surface or drain into the pharynx. Secondary infection is an indication for systemic antibiotic therapy. These anomalies may be inherited as autosomal dominant traits.

Thyroglossal cysts and fistulas are similar defects located in or near the midline of the neck; they may extend to the base of the tongue. A pathognomonic sign is vertical motion of the mass with swallowing and tongue protrusion. In nearly 50% of affected children, the cyst or fistula manifests as an infected midline upper neck mass. Cysts in the tongue base may be differentiated from an undescended lingual thyroid by radionuclide scanning. Unlike branchial cysts, a thyroglossal duct cyst often appears after an upper respiratory infection (see Chapter 601).

Fig. 689.1 Accessory tragus on cheek along jaw line.

PILONIDAL SINUS AND ABSCESS

The etiology of pilonidal disease remains unknown; three hypotheses explaining its origin have been proposed. The first states that trauma, such as can occur with prolonged sitting, impacts hair into the subcutaneous tissue, which serves as a nidus for infection. The second suggests that in some patients, hair follicles exist in the subcutaneous tissues, perhaps the result of some embryologic abnormality, and that they serve as a focal point for infection, especially with secretion of hair oils. The third speculates that motion of the buttocks disturbs a particularly deep midline crease and works bacteria and hair beneath the skin. This theory arises from the apparent improved short-term and long-term results of operations that close the wound off the midline, obliterating the deep natal cleft.

Pilonidal disease usually manifests in adolescents or young adults with significant hair over the midline sacral and coccygeal areas. It can occur as an acute abscess with a tender, warm, flocculent, erythematous swelling or as draining sinus tracts. This disease does not resolve with nonoperative treatment. An acute abscess should be drained and packed open, using appropriate anesthesia. Oral broad-spectrum antibiotics covering the usual isolates (*Staphylococcus aureus* and *Bacteroides* species) are prescribed, and the patient's family withdraws the packing over the course of a week. When the packing has been totally removed, the area can be kept clean by a bath or shower. The wound usually heals completely in 6 weeks. Once the wound is healed, most pediatric surgeons feel that elective excision should be scheduled to avoid recurrence. There are some reports, however, that this is only necessary if the disease recurs. Usually, patients who present with sinus tracts are managed with a single elective excision.

Most surgeons carefully identify the extent of each sinus tract and excise all skin and subcutaneous tissue involved to the fascia covering the sacrum and coccyx. Some close the wound in the midline; others leave it open and packed for healing by secondary intention. This method has been modified by the application of a vacuum-assisted (VAC sponge) dressing. This is a system that applies continuous suction to a porous dressing. It is usually changed every 3 days and can be done at home with the assistance of a nurse. Some marsupialize the wound by suturing the skin edges down to the exposed fascia covering the sacrum and coccyx. There appears to be improved success with excision and closure in such a way that the suture line is not in the midline. Currently there appears to be enthusiasm for the less radical methods that Bascom has introduced, treating simple sinus tracts with small local procedures and limiting excision to only diseased tissues, while still keeping the incision off the midline. Recurrence or wound-healing problems are relatively common, occurring in 9–27% of cases. The variety of treatments and procedures currently being described indicates that all are associated with significant complications and delays in return to normal activity. Still, it is rare for problems to persist beyond 1-2 years. Recalcitrant cases are treated by a large, full-thickness gluteal flap or skin grafting.

SUPERNUMERARY NIPPLES

Solitary or multiple accessory nipples may occur in a unilateral or bilateral distribution along a line from the anterior axillary fold to the inguinal area. Accessory nipples may or may not have areolae and may be mistaken for congenital nevi. They may be excised for cosmetic reasons, but otherwise, treatment is not necessary. Renal or urinary tract anomalies, malignancies—especially genitourinary cancers—and hematologic abnormalities may rarely occur in children with this finding (see Chapter 588).

APLASIA CUTIS CONGENITA (CONGENITAL ABSENCE OF SKIN)

Developmental absence of skin is usually noted on the scalp as multiple or solitary (70%), noninflammatory, well-demarcated, oval or circular 1- to 2-cm ulcers (Table 689.1). The appearance of lesions varies, depending on when they occurred during intrauterine development. Those that form early in gestation may heal before delivery and appear as atrophic, fibrotic scars with associated alopecia, whereas more recent defects may

Table 689.1 Freiden's Classification of Aplasia Cutis Congenita

GROUP	DEFINITION	INHERITANCE
1	Isolated scalp involvement; may be associated with single defects	AD
2	Scalp ACC with limb reduction defects (Adams-Oliver syndrome); may be associated with encephalocele	AD
3	Scalp ACC with epidermal nevus	Sporadic
4	ACC overlying occult spinal dysraphism, spina bifida, or meningoencephalocele	Sporadic
5	ACC with placental infarcts and/or fetus papyraceus (disappearing twin syndrome)	Sporadic
6	ACC with epidermolysis bullosa; Bart phenotype*	AD or AR
7	ACC localized to extremities without blistering; usually affecting pretibial areas and dorsum of hands and feet	AD or AR
8	ACC caused by teratogens (e.g., varicella, herpes, methimazole, valproic acid, misoprostol)	Sporadic
9	ACC associated with malformation syndromes (e.g., trisomy 13, deletion 4p−, deletion Xp22.1, ectodermal dysplasia, Johanson-Blizzard syndrome, Adams-Oliver syndrome)	Variable

*Bart phenotype ACC with epidermolysis bullosa and dystrophic nails.
ACC, Aplasia cutis congenital; AD, autosomal dominant; AR, autosomal recessive.
Modified from Frieden IJ. Aplasia cutis congenita: a clinical review and proposal for classification. *J Am Acad Dermatol.* 1986;14:646–660.

Fig. 689.2 Solitary scalp vertex lesion of aplasia cutis congenita with hair collar sign.

Fig. 689.3 An elastic protruding hairless nodule measuring up to 1.5 cm in diameter, with a ring of dark, coarse, long hairs surrounding the nodule forming a "hair collar." *(From Chien MM, Chen KL, Chiu HC. The "hair collar" sign. J Pediatr. 2016;168:246.)*

manifest as ulcerations. Most occur at the vertex of the scalp just lateral to the midline, but similar defects may also occur on the face, trunk, and limbs, where they are often symmetric and usually associated with an intrauterine fetal demise of a twin **(fetus papyraceus)**. The depth and size of the ulcer vary. Only the epidermis and upper dermis may be involved, resulting in minimal scarring or hair loss, or less often, the defect may extend to the deep dermis; to the subcutaneous tissue; and, rarely, to the periosteum, skull, and dura. Lesions may be surrounded by a ring of hair known as the **hair collar sign** (Fig. 689.2). The hair collar sign may also be associated with an encephalocele, meningocele, heterotopic glial tissue, or a meningothelial hamartoma.

Diagnosis is made on physical findings indicative of in utero disruption of skin development. Lesions are sometimes mistakenly attributed to scalp electrodes or obstetric trauma. Most are sporadic, but autosomal dominant and recessive cases also occur; some are caused by pathogenic variants in *BMS1*.

Although most individuals with aplasia cutis congenita have no other abnormalities, these lesions may be associated with isolated physical anomalies or with malformation syndromes, including Opitz, Adams-Oliver, oculocerebrocutaneous, Johanson-Blizzard, and 4p(−), X-p22 microdeletion syndromes; trisomy 13-15; and chromosome 16-18 defects (see Table 689.1). Aplasia cutis congenita may also be found in association with an overt or underlying embryologic malformation, such as congenital pulmonary malformations, meningomyelocele, gastroschisis, omphalocele, or spinal dysraphism. Aplasia cutis congenita in association with the vanishing twin syndrome (fetus papyraceus) is apparently caused by ischemic or thrombotic events in the placenta and fetus such as the hypovolemia that occurs with acute transfusion from a surviving to a dying twin. Blistering or skin fragility and/or absence or deformity of nails in association with aplasia cutis congenita is a well-recognized manifestation of epidermolysis bullosa.

Major complications are rare and more often associated with large, stellate lesions of the midline parietal scalp. Hemorrhage, secondary local infection, and meningitis have been reported. If the defect is small, recovery is uneventful, with gradual epithelialization and formation of a hairless atrophic scar over a period of several weeks. Small bony defects usually close spontaneously in the first year of life. Large or numerous scalp defects may require repair, but care must be taken, as abnormal underlying venous structures have complicated surgical repair. Truncal and limb defects, despite being large, usually epithelialize and form atrophic scars, which can later be revised.

Although the hair collar sign is often associated with aplasia cutis, it may also be seen with encephaloceles, meningoceles, heterotopic glial elements, or hamartoma. Brain MRI is often indicated to evaluate for these lesions in patients with the hair collar sign without aplasia cutis (Fig. 689.3).

FOCAL FACIAL DERMAL DYSPLASIAS

The focal facial dermal dysplasias (FFDDs) are a rare group of conditions sharing bitemporal or preauricular lesions resembling scars or aplasia cutis congenita. FFDD1 **(Brauer syndrome)** is inherited in an autosomal dominant fashion and typically has mild associated facial features. FFDD2 **(Brauer-Setleis syndrome)** and FFDD3 **(Setleis syndrome)** are associated with thin, puckered periorbital skin, distichiasis

and/or absent eyelashes, upslanting palpebral fissures, flat nasal bridge, large lips, and redundant facial skin. FFDD2 is inherited in an autosomal dominant fashion, whereas FFDD3 is autosomal recessive and caused by pathogenic variants in *TWIST2;* autosomally dominant cases of FFDD3 have been reported and are caused by chromosome duplication/triplication of the 1p36.22p36.21 region. FFDD4 has no other related skin findings; it is inherited both in autosomal dominant and recessive manners and is caused by pathogenic variants in *CYP26C1*.

FOCAL DERMAL HYPOPLASIA (GOLTZ-GORLIN SYNDROME)

A rare congenital mesoectodermal and ectodermal disorder, focal dermal hypoplasia is characterized by dysplasia of connective tissue in the skin and skeleton. This disorder is an X-linked dominant disorder caused by pathogenic variants in the *PORCN* gene. It manifests as numerous soft tan papillomas. Other cutaneous findings include linear atrophic lesions, reticulated hypopigmentation and hyperpigmentation, telangiectasias, congenital absence of skin, angiofibromas presenting as verrucous excrescences, and papillomas of the lips, tongue, circumoral region, vulva, anus, and the inguinal, axillary, and periumbilical areas. Partial alopecia, sweating disorders, and dystrophic nails are additional, less common ectodermal anomalies. The most frequent skeletal defects are syndactyly, clinodactyly, polydactyly, and scoliosis. **Osteopathia striata** are fine parallel vertical stripes noted on radiographs in the metaphyses of long bones of patients with this disorder; these are highly characteristic of focal dermal hypoplasia but are not pathognomonic. Many ocular abnormalities, the most common of which are colobomas, strabismus, nystagmus, and microphthalmia, are also characteristic. Small stature, enamel hypoplasia, soft tissue anomalies, and peculiar dermatoglyphic patterns are also common. Cognitive impairment occurs occasionally. There is no specific treatment.

DYSKERATOSIS CONGENITA (ZINSSER-ENGMAN-COLE SYNDROME)

Dyskeratosis congenita (DKC), a rare familial syndrome, consists classically of the triad of reticulated hyperpigmentation of the skin (Fig. 689.4), dystrophic nails, and mucous membrane leukoplakia in association with immunologic and hematologic abnormalities. Patients with DKC also show signs of premature aging and increased occurrence of cancer, especially squamous cell carcinoma. DKC may be X-linked recessive (*DKC-1* gene), autosomal dominant (*hTERC* and *TINF2* genes), or autosomal recessive (*NOLA3* gene). Onset occurs in childhood, most commonly as nail dystrophy. The nails become atrophic and ridged longitudinally with progression to pterygia and complete nail loss. Skin changes usually appear after onset of nail changes and consist of reticulated gray-brown pigmentation, atrophy, and telangiectasia, especially on the neck, face, and chest. Hyperhidrosis and hyperkeratosis of the palms and soles, sparse scalp hair, and easy blistering of the hands and feet are also characteristic. Blepharitis, ectropion, and excessive tearing because of atresia of the lacrimal ducts are occasional manifestations. Oral leukokeratosis may give rise to squamous cell carcinoma. Other mucous membranes, including conjunctival, urethral, and genital, may be involved. Infection, malignancy, pulmonary fibrosis, and bone marrow failure are common, and death before age 40 years is typical. No effective treatment exists. Allogenic hemopoietic stem cell transplantation is curative treatment when bone marrow failure occurs.

Fig. 689.4 Reticulated dyspigmentation on neck of patient with dyskeratosis congenita.

CUTIS VERTICIS GYRATA

Cutis verticis gyrata, an unusual alteration of the scalp that is more common in males, may be present from birth or may develop during adolescence. The scalp is characterized by convoluted elevated folds, 1-2 cm in thickness, usually in the fronto-occipital axis. Unlike the lax skin of other disorders, the convolutions cannot generally be flattened by traction. **Primary cutis gyrata** may be associated with intellectual disability, retinitis pigmentosa, sensorineural deafness, and thyroid aplasia. **Secondary cutis gyrata** may be the result of chronic inflammatory diseases, tumors, nevi, and acromegaly.

Visit Elsevier eBooks+ at eBooks.Health.Elsevier.com for Bibliography.

Chapter 690

Ectodermal Dysplasias

Kari L. Martin

Ectodermal dysplasia (ED) is a heterogeneous group of disorders characterized by a constellation of findings involving defects of two or more of the following: teeth, skin, and appendageal structures, including hair, nails, and eccrine and sebaceous glands. Although more than 150 EDs have been described, the majority are rare, with an estimated incidence of 3.5 in 10,000 individuals.

Individuals presenting with a constellation of abnormalities involving the teeth, skin, and nails should raise suspicion for a diagnosis of ED. Table 690.1 provides a general list of abnormalities that may be seen in patients with EDs. Further specifying the specific type of ED can be challenging because there are a large number of subtypes and most are extremely rare (Table 690.2). Exome sequencing may enhance the identification of these rare subtypes.

Table 690.1 Clinical Abnormalities in Ectodermal Dysplasia

Teeth	Small primary teeth, anodontia or hypodontia of secondary teeth, conical or peg teeth, premature loss of teeth, delayed eruption of teeth, defective enamel, small widely spaced teeth, elongated pulp chamber in teeth
Skin	Atopic dermatitis, xerosis, photosensitivity, palmoplantar keratoderma, facial telangiectasias
Hair	Abnormal quantity, structure and quality: thin, brittle, slow-growing, kinky or wooly, fragile, dry, and lusterless hair. Often involves scalp, eyebrows and eyelashes.
Nails	Brittle, dystrophic, absent, ridging, pitting
Sweat	Hypohidrosis, hyperhidrosis of palms and soles
Other	Recurrent sinus infection, nasal congestion, hoarse voice, wheezing

Normal phenotype is also possible for any of these categories.

Table 690.2 Classification for Ectodermal Dysplasias*

DISORDER†	INHERITANCE	GENE	PROTEIN	FUNCTION
EDA/NF-κB PATHWAY				
Hypohidrotic ectodermal dysplasia	XLR	*EDA1*	Ectodysplasin (EDA)	Membrane ligand
Hypohidrotic ectodermal dysplasia	AD	*EDAR*	EDA receptor (EDAR)	Receptor of EDA
		EDARADD	EDAR-associated death domain	Adaptor molecule
Hypohidrotic ectodermal dysplasia	AR	*EDAR*	EDAR	Receptor of EDA
		EDARADD	EDAR-associated death domain	Adaptor molecule
		TRAF6	TNF receptor–associated factor 6	Activates IKK
Hypohidrotic ectodermal dysplasia with immune deficiency (males) ± osteopetrosis (males) ± lymphedema	XLR	*NEMO/IKBKG*	NF-kB essential modulator	NF-kB activation
Incontinentia pigmenti (females)	XLD	*NEMO/IKKγ*	NF-κB essential modulator	NF-κB activation
Hypohidrotic ectodermal dysplasia with immune deficiency	AR	*IkBα*	IkBα	NF-kB activation
P63 PATHWAY				
Ectrodactyly-ectodermal dysplasia-clefting syndrome	AD	*p63*	p63	Transcription factor
Rapp-Hodgkin syndrome	AD	*p63*	p63	Transcription factor
Ankyloblepharon-ectodermal dysplasia-clefting syndrome (AEC)	AD	*p63*	p63	Transcription factor
Acrodermatoungual-lacrimal-tooth (ADULT)	AD	*p63*	p63	Transcription factor
Limb-mammary syndrome	AD	*p63*	p63	Transcription factor
Curly hair, ankyloblepharon, and nail dystrophy (CHAND) syndrome	AR	*RIPK4*	RIPK4	Serine/threonine protein kinase
Popliteal pterygium syndromes (spectrum)	AR, AD	*IRF6*	IRF6	Transcription factor
Popliteal pterygium	AR	*RIPK4*	RIPK4	Kinase
Bartsocas-Papas (Cocoon syndrome)	AR	*CHUK*	CHUK	Kinase
Ectodermal dysplasia	AD	*KDF1*	KDF1	Keratinocyte differentiation factor
Trichodentoosseous syndrome (TDO)	AD	*DLX3*	DLX3	Transcription factor
Clefting-ectodermal dysplasia	AR	*PVRL1*	Nectin 1	Interacts with cadherins, especially at adherens junctions
Ectodermal dysplasia-syndactyly syndrome	AR	*PVRL4*	Nectin 4	Interacts with cadherins, especially at adherens junctions
Hypotrichosis with juvenile macular dystrophy ± ectrodactyly/other ectodermal defects	AR	*CDH3*	Cadherin 3/P-cadherin	Adhesion molecule for cell-cell binding
WNT PATHWAY				
Witkop syndrome	AD	*MSX1*	MSX1	Transcription factor
Focal dermal hypoplasia	X-linked dominant	*PORCN*	PORCN	Regulates Wnt signaling
Oculodentodigital dysplasia (ODDD)	AD	*WNT10A*	Wnt10A	Wnt pathway
Hypohidrotic ectodermal dysplasia	AR, AD	*WNT10A*	Wnt10A	β-catenin-mediated signaling
Schöpf-Schulz-Passarge syndrome	AR	*WNT10A*	Wnt10A	β-catenin-mediated signaling

Table 690.2 Classification for Ectodermal Dysplasias*—cont'd

DISORDER†	INHERITANCE	GENE	PROTEIN	FUNCTION
Ectodermal dysplasia	AR	*KREMEN1*	KREMEN1	Receptor involved in Wnt regulation
STRUCTURAL ELEMENT				
Clouston syndrome	AD	*GJB6*	Connexin 30	Intercellular junctions
Ectodermal dysplasia	AR	*GRHL2*	Grainyhead-like 2	Transcription factor
Oculodentodigital dysplasia (ODDD)	AR	*GJA1*	Connexin 43	Intercellular junctions
Ellis van Creveld syndrome	AR	*EVC, EVC2*	EVC, EVC2	Ciliopathy
Ectodermal dysplasia 4, hair/nail type (ECTD4)	AR	*KRT85*	KRT85	Keratin
Keratitis-ichthyosis-deafness syndrome, autosomal dominant (KID)	AR	*GJB2*	Connexin 26	Intercellular junctions
Ectodermal dysplasia: skin fragility syndrome	AR	*PKP1*	Plakophilin 1	Desmosomal plaque/stability
Naegeli- Franceschetti-Jadassohn syndrome	AD	*KRT14*	KRT14	Keratin
Pachyonychia congenita	AD	*KRT 6a, 6b, 6c, 16, 17*	KRT 6a, 6b, 6c, 16, 17	Keratin

*Many forms of ectodermal dysplasia remain unclassified.
†Some more recently described forms of ectodermal dysplasia are not yet named.
AD, Autosomal dominant; AR, autosomal recessive; IKK, inhibitor of kappa light polypeptide gene enhancer in B-cell kinase; TNF, tumor necrosis factor; XLD, X-linked dominant; XLR, X-linked recessive.
From Paller AS, Mancini AJ. *Hurwitz Clinical Pediatric Dermatology*, 6th ed. Philadelphia: Elsevier; 2022: Table 7.1, p. 165.

HYPOHIDROTIC ECTODERMAL DYSPLASIA

The syndrome known as hypohidrotic ectodermal dysplasia (HED) manifests as a triad of defects: partial or complete absence of sweat glands, anomalous dentition, and hypotrichosis. There are many recognized types of HED; HED-1 (X-linked recessive) is most common, with a frequency of 1 per 17,000 live births.

In HED, affected patients are unable to sweat and may experience episodes of high fever in warm environments, which may be mistakenly considered to be **fevers of unknown origin**. This error is particularly common in infancy when the facial changes are not easily appreciated. Diagnosis at this time may be made using the starch-iodine test or palmar or scalp biopsy. Scalp biopsy is the most sensitive and is 100% specific. It shows a complete lack of eccrine structures. Infants and older children must be protected from high temperatures given their inability to sweat. Cooling devices and clothing can be helpful to increase participation in activities and sports. Aside from patients with *WNT10A* pathogenic variants—who do not have facial dysmorphism—the typical facies are characterized by frontal bossing; malar hypoplasia; a flattened nasal bridge; recessed columella; thick, everted lips; wrinkled, hyperpigmented periorbital skin; and prominent, low-set ears (Fig. 690.1). The skin over the entire body is dry, finely wrinkled, and hypopigmented, often with a prominent venous pattern. Extensive peeling of the skin is a clinical clue to diagnosis in the newborn period. The paucity of sebaceous glands may account for the dry skin. The scalp hair is sparse, fine, and lightly pigmented, and eyebrows and lashes are sparse or absent. Other body hair is also sparse or absent. Sexual hair growth is normal. Anodontia or hypodontia with widely spaced, conical teeth is a consistent feature (see Fig. 690.1). *Co-management with pediatric dentistry familiar with ectodermal dysplasias is critical for oral health, nutrition, and maintenance of the facial bones.* Otolaryngic and ophthalmologic abnormalities secondary to decreased saliva and tear production are seen. The incidence of atopic diseases in children with HED is high. Gastroesophageal reflux is common and may play a role in failure to thrive, which is seen in 20% of cases. Sexual development is usually normal. Historically, the infant mortality rate has been 30%. Carrier females of X-linked HED may have no or less severe clinical manifestations.

Prenatal therapy of X-linked HED with a recombinant protein containing the EDA receptor binding domain has been successful in three patients.

Hypohidrotic ED with immune deficiencies causes similar findings in sweating and hair and nail development, in association with a dysgammaglobulinemia. Significant mortality is seen from recurrent infections. A variety of pathogenic variants of the genes encoding the tumor necrosis factor α (TNFα)–related signaling pathway proteins—key in signal transduction from ectoderm to mesoderm during development—are the molecular basis for this disorder (see Table 690.2).

Treatment of children with HED includes protecting them from exposure to high ambient temperatures. Early dental evaluation is necessary so that prostheses can be provided for cosmetic reasons and for adequate nutrition. The use of artificial tears prevents damage to the cornea in patients with defective lacrimation. Alopecia may necessitate the wearing of a wig to improve appearance.

HIDROTIC ECTODERMAL DYSPLASIA (CLOUSTON SYNDROME)

The salient features of the autosomal dominant disorder hidrotic ED are dystrophic, hypoplastic, or absent nails; sparse hair; and hyperkeratosis of the palms and soles (Table 690.3). Conjunctivitis and blepharitis are common. The dentition and sweating are always normal. Absence of eyebrows and eyelashes, clubbing of the fingers, and hyperpigmentation over the knees, elbows, and knuckles have been noted in some affected individuals. Pathogenic variants in the *GJB6* gene encoding the gap junction protein connexin 30 are responsible for this disorder. A similar disorder associated with deafness has been described with pathogenic variants in the *GJB2* gene encoding the connexin 26 protein. Pathogenic variants in *GJB1* have also been implicated.

Fig. 690.1 Hypohidrotic ectodermal dysplasia is characterized by pointed ears, fine hair, periorbital hyperpigmentation, midfacial hypoplasia, and pegged teeth. *(Courtesy the Fitzsimons Army Medical Center teaching file.)*

Table 690.3 Common Ectodermal Dysplasias: Inheritance and Characteristic Clinical Findings

TYPE	INHERITANCE(S)	CHARACTERISTIC CLINICAL FINDINGS
Hypohidrotic ED	XLR, AD, AR	Distinctive facies: prominent forehead, thick lips and flattened nasal bridge; collodion-like membrane; eczema Hypotrichosis of scalp and trunk, light/brittle/slow-growing hair Hypodontia, conical teeth Hypohidrosis
Hypohidrotic ED-immune deficiency (EDA-ID)	XLR, AD	Seborrheic dermatitis–like rash, intertrigo Hypotrichosis Hypodontia, pointed teeth Hypohidrosis/anhidrosis Recurrent infections Decreased immunoglobulin levels
Hidrotic ED (Clouston)	AD	Hyperpigmented skin over joints; palmoplantar keratoderma, conjunctivitis, blepharitis Milky-white nails in early childhood, nail dystrophy, clubbing Sparse, wiry, brittle, pale scalp hair to total alopecia Normal sweating
Witkop tooth and nail syndrome	AD	Usually normal hair, rarely sparse or fine Normal sweating Small primary teeth, hypodontia causing lower lip eversion (“pouting lower lip”) Thin, slow growing hypoplastic nails (toes > fingers), koilonychia
EEC	AD	Dry skin, aplasia or hypoplasia of skin Normal sweating Coarse, lightly pigmented hair; thick eyebrows Hypodontia (reduced number), taurodontia, premature loss of teeth, dental enamel abnormalities Ectrodactyly more common than syndactyly Nail dystrophy, transverse ridging and pitting Corneal erosion, lacrimal duct abnormality, blepharitis, GU defects, cleft lip or palate

Continued

Table 690.3 Common Ectodermal Dysplasias: Inheritance and Characteristic Clinical Findings—cont'd

TYPE	INHERITANCE(S)	CHARACTERISTIC CLINICAL FINDINGS
AEC (Hay-Wells syndrome) and RHS	AD	Erosive dermatitis, neonatal erythroderma (e.g., scalp, hands), dyspigmentation of skin Coarse, wiry, lightly pigmented hair, patchy alopecia ± Hypohidrosis Hypodontia, conical teeth Nail absence or dystrophy with thickened nails Ectrodactyly more common than syndactyly Lacrimal duct abnormality, hearing loss, cleft lip/palate, ankyloblepharon, reflux
Limb-mammary	AD	Normal hair Hypodontia ± Hypohidrosis Nail dystrophy Ectrodactyly more common than syndactyly Bifid uvula, hypoplastic nipples, joint contracture of hand, lacrimal duct atresia, cleft palate
ADULT	AD	Dry skin, photosensitivity, lentigines Hypodontia, premature loss of teeth Normal sweating Pitting and longitudinal ridging of nails Ectrodactyly and syndactyly No cleft palate or lip Hypoplastic nipples, lacrimal duct atresia,

AD, Autosomal dominant; ADULT, acro-dermato-ungal-lacrimal-tooth; AEC, ankyloblepharon-ectodermal dysplasia-clefting; AR, autosomal recessive; ED, ectodermal dysplasia; EEC, ectrodactyly, ectodermal dysplasia, and cleft lip/palate syndrome; RHS, Rapp-Hodgkin syndrome; XLR, X-linked recessive.

Table 690.4 Disorders Associated with Decreased Sweat Production

CUTANEOUS LESIONS
Congenital absence of sweat glands without ectodermal dysplasia
Incontinentia pigmenti
Burns
MULTISYSTEM DISORDERS
Fabry disease
Crisponi syndrome
Chronic graft-versus-host disease
Sjögren syndrome
NEUROLOGIC DISORDERS
Spinal cord injury
Guillain-Barré syndrome
Hereditary sensory autonomic neuropathy type I, II, IV
Complex regional pain syndrome
Multiple sclerosis
Multiple system atrophy
Ross syndrome
Shy-Drager syndrome
MEDICATIONS
Anticholinergic drugs
Opioids
Botulism toxin
Clonidine
Barbiturate overdose
α_2-Receptor antagonists
OTHER
Idiopathic acquired generalized anhidrosis
Hypothyroidism
Conversion disorder
Heat shock
Sympathectomy

In addition to the EDs, other disorders are associated with absent or decreased sweat production (Table 690.4).

Visit Elsevier eBooks+ at eBooks.Health.Elsevier.com for Bibliography.

Chapter 691

Vascular Anomalies

Kari L. Martin

Nearly all vascular lesions of childhood may be divided into vascular malformations and vascular tumors (Table 691.1). Vascular malformations are developmental disorders of blood vessel formation. Malformations do not regress, but slowly enlarge. They should be named after the predominant vessel(s) forming the lesion: arterial, capillary, lymph, venous, or combinations of these. Vascular tumors exhibit endothelial cell hyperplasia and proliferation. The International Society for the Study of Vascular Anomalies (ISSVA) continues to update the classification structure for vascular disorders as new disorders are identified and as the biology and genetic causes for established disorders are found. The complete classification, associated syndromes, and causative pathogenic variants can be found at www.issva.org.

VASCULAR MALFORMATIONS

Capillary Malformation (Port-Wine Stain)

Capillary malformations (CMs) are present at birth. These vascular malformations consist of mature dilated dermal capillaries. The lesions are macular, sharply circumscribed, pink to purple, and tremendously varied in size (Fig. 691.1). The head and neck region is the most common site of predilection; most lesions are unilateral. The mucous membranes can be involved. As a child matures into adulthood, the CM may become darker in color and pebbly in consistency; it may occasionally develop papules that bleed spontaneously. CM may occur in isolation or in combination with other vessel malformations.

True CM should be distinguished from **nevus simplex**, which, in contrast, is a relatively transient lesion often located in the midline (see Chapter 688). When a CM is lateral and localized to the forehead and upper eyelid, the diagnosis of **Sturge-Weber syndrome** (glaucoma, leptomeningeal venous angioma, seizures, hemiparesis contralateral to the facial lesion, intracranial calcification) must be considered (see Chapter 636.3). Early screening for glaucoma is important to

Table 691.1 Contemporary Classification of Vascular Anomalies (ISSVA 2014 Classification)

VASCULAR TUMORS
Benign
Infantile hemangioma/hemangioma of infancy
Congenital hemangiomas (RICH, NICH, PICH)
Tufted angioma
Spindle cell hemangioma
Epithelioid hemangioma
Pyogenic granuloma
Locally Aggressive or Borderline
Kaposiform hemangioendothelioma
Retiform hemangioendothelioma
Papillary intralymphatic angioendothelioma (Dabska tumor)
Composite hemangioendothelioma
Kaposi sarcoma
Malignant
Angiosarcoma
Epithelioid hemangioendothelioma
VASCULAR MALFORMATIONS
Simple
Capillary (CM) (e.g., port-wine stain, telangiectasia, CMTC, salmon patch/nevus simplex)
Venous (VM) (includes common, familial, glomuvenous, others)
Lymphatic (LM) (includes macrocystic, microcystic, primary lymphedema, others)
Arteriovenous (AVM) and arteriovenous fistula (sporadic or syndromal)
Combined
CM + VM, CM + LM, CM + AVM
LM + VM
CM + LM + VM
CM + LM + AVM, CM + VM + AVM
CM + LM + VM + AVM
Of major named vessels
Affect veins, arteries or lymphatics; usually of large caliber
Associated with other anomalies
Associated with anomalies of bone, soft tissue (usually overgrowth, rarely undergrowth) or viscera

CMTC, Cutis marmorata telangiectatica congenita; *NICH*, noninvoluting congenital hemangioma; *PICH*, partially involuting congenital hemangioma; *RICH*, rapidly involuting congenital hemangioma.
From Paller AS, Mancini AJ. *Hurwitz Clinical Pediatric Dermatology*, 6th ed. Philadelphia: Elsevier; 2022: Box 12.1, p. 327. Created with data from Wassef M, Blei F, Adams D, et al. Vascular anomalies classification: Recommendations from the International Society for the Study of Vascular Anomalies. *Pediatrics*. 2015;136(1):e203–e214.

Fig. 691.1 Capillary malformation. Pink macule on the cheek of an infant.

Table 691.2 Port-Wine Stain–Associated Syndromes

- Sturge-Weber syndrome
- Klippel-Trenaunay syndrome
- Parkes-Weber syndrome
- Phakomatosis pigmentovascularis
- Macrocephaly–capillary malformation (M-CM) syndrome
- Capillary malformation–arteriovenous malformation (CM-AVM) syndrome
- Diffuse capillary malformation with overgrowth (DCMO)
- Bannayan-Riley-Ruvalcaba syndrome
- Von Hippel-Lindau disease
- Rubinstein-Taybi syndrome
- Wyburn-Mason syndrome
- Roberts syndrome
- Coat disease

Modified from Paller AS, Mancini AJ. *Hurwitz Clinical Pediatric Dermatology*, 6th ed. Elsevier: Philadelphia; 2022: Box 12.4, p. 347.

Fig. 691.2 Nodular venous malformation on the leg of an adolescent.

prevent additional damage to the eye. CMs also occur as a component of **Klippel-Trenaunay syndrome** and with moderate frequency in other syndromes, including megalencephaly, capillary malformation, polymicrogyria (MCAP), Cobb (spinal arteriovenous malformation [AVM], port-wine stain), congenital lipomatous, overgrowth, vascular malformations, epidermal nevi, skeletal anomalies (CLOVES), Proteus, Beckwith-Wiedemann, and Bonnet-Dechaume-Blanc syndromes, and others (Table 691.2). In the absence of associated anomalies, morbidity from these lesions may include a poor self-image, hypertrophy of underlying structures, and traumatic bleeding.

The most effective treatment for CM is with the pulsed-dye laser. This therapy is targeted to hemoglobin within the lesion and minimizes thermal injury to the surrounding normal tissue. After such treatment, the texture and pigmentation of the skin are generally improved with low risks of scarring. Therapy can begin in infancy when the surface area of involvement is smaller. There may be advantages to treating within the first year of life. Although this approach is quite effective, redarkening of the stain may occur over time, making ongoing treatments useful. Camouflaging cosmetics may also be used.

Venous Malformation

Venous malformations include vein-only malformations and combination malformations. Malformations consisting of veins only range from nodules containing a mass of venules (Fig. 691.2) to diffuse large vein abnormalities that may consist of either a superficial component resembling varicose veins, deeper venous malformations, or both. Most venous malformations are sporadic, although inherited forms exist as well. Inherited forms and up to 40% of sporadic venous malformations are caused by *TIE2* pathogenic variants. Treatment is reserved for painful or symptomatic lesions. Surgical excision is best for small

or superficial nodular lesions; sclerotherapy or laser ablation is used for larger, diffuse lesions. Localized intravascular coagulopathy can be problematic in these lesions because of the chronic slow flow. This leads to both painful thrombotic episodes and the risk of progression to systemic disseminated intravascular coagulopathy. Pulmonary embolus has been reported in patients with large venous malformations.

LYMPHATIC MALFORMATIONS

See Chapter 538.

ARTERIOVENOUS MALFORMATION

AVMs are direct connections of artery to vein that bypass the capillary bed (Fig. 691.3). AVMs of the skin are very rare. Skin changes are often noted at birth, but they tend to be very subtle, presenting as a red-pink patch. Over time the lesions deepen in color and often result in thickening of the skin and surrounding tissue. They are diagnosed from their obvious arterial palpation. Some AVMs are progressive and can lead to significant morbidity and even mortality, so early diagnosis and evaluation by an experienced multidisciplinary team are essential.

KLIPPEL-TRENAUNAY AND PARKES-WEBER SYNDROMES

Klippel-Trenaunay syndrome is a term historically used to describe complex mixed vascular malformation with overgrowth of bone and soft tissue (Figs. 691.4 and 691.5). The anomaly is present at birth and usually involves a lower limb but may involve more than one limb, as well as portions of the trunk or face. Enlargement of the soft tissues may be gradual and may involve the entire extremity, a portion of it, or selected digits. The vascular lesion most often is a capillary malformation, generally localized to the hypertrophied area. The deep venous system may be absent or hypoplastic. Venous blebs and/or vesicular lymphatic lesions may be present on the malformation's surface. Thick-walled venous varicosities typically become apparent ipsilateral to the vascular malformation after the child begins to ambulate. If there is an associated AVM, the disorder is called **Parkes-Weber syndrome**.

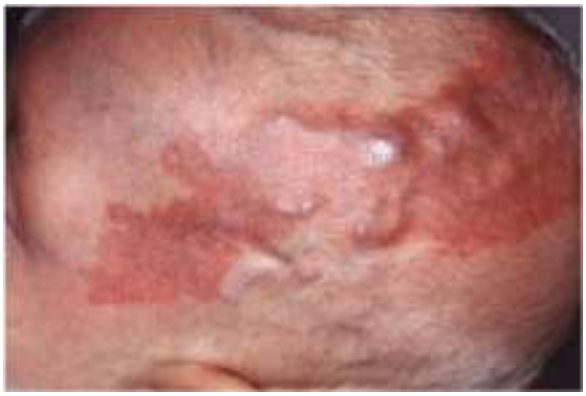

Fig. 691.3 Arteriovenous malformation in conjunction with a port-wine stain of the scalp of a newborn.

Fig. 691.4 Overgrowth of the right arm and hand in an adolescent with Klippel-Trenaunay syndrome.

Somatic pathogenic activating variants in multiple genes have been associated with vascular malformations and limb overgrowth (Fig. 691.6 and Table 691.3).

These disorders can be confused with Maffucci syndrome or, if the surface vascular lesion is minimal, with Milroy disease. Pain, limb swelling, and cellulitis may occur. Thrombophlebitis, dislocations of joints, hematuria secondary to angiomatous involvement of the urinary tract, rectal bleeding from lesions of the gastrointestinal tract, pulmonary lesions, and malformations of the lymphatic vessels are infrequent complications. MRI may delineate the extent of the anomaly, but surgical correction or palliation is often difficult. Sclerotherapy or endovenous laser ablation may be of benefit when a venous component is the dominant vessel in the malformation. The indications for radiologic studies of viscera and bones are best determined by clinical evaluation. Supportive care includes compression bandages for varicosities; surgical treatment may help carefully selected patients. Leg-length differences should be treated with orthotic devices to prevent the development of spinal deformities. Corrective bone surgery may eventually be needed to treat significant leg-length discrepancy.

Angiokeratoma Circumscriptum

Several forms of angiokeratoma have been described. Angiokeratomas are characterized by ectasia of superficial lymphatic vessels and capillaries with hyperkeratosis of the overlying epidermis. Angiokeratoma circumscriptum is a rare disorder consisting of a solitary lesion or multiple lesions that manifest as a plaque or plaques of blue-red crusted papules or nodules. The limbs are the sites of predilection. **If therapy is desired, surgical excision is the treatment of choice.**

Cutis Marmorata Telangiectatica Congenita

Cutis marmorata telangiectatica congenita, a benign vascular anomaly apparent at birth, is composed of dilated superficial capillaries and veins. Involved areas of skin have a reticulated red or purple hue that resembles physiologic cutis marmorata but is more pronounced and relatively unvarying (Fig. 691.7). The lesions may be restricted to a single limb and a portion of the trunk or may be more widespread. The lesions become more pronounced during changes in environmental temperature, physical activity, or crying. In some cases, the underlying subcutaneous tissue is atrophic, and ulceration may occur within the reticulated bands. Rarely, defective growth of bone and other congenital abnormalities may be present. No specific therapy is indicated. Mild vascular-only cases may show gradual improvement. Cutis marmorata telangiectatica congenita may be associated with CM, Adams-Oliver syndrome, patent ductus arteriosus, and a variety of other anomalies. It must be differentiated from reticulate CM and physiologic cutis marmorata.

Blue Rubber Bleb Nevus Syndrome

Blue rubber bleb nevus is a rare syndrome consisting of numerous venous malformations of the skin, mucous membranes, and gastrointestinal tract caused by somatic pathogenic variants in *TEK* in some patients. Typical lesions are blue-purple and rubbery in consistency; they vary in size from a few millimeters to a few centimeters in diameter. They are sometimes painful or tender. The compressible nodules may be present at birth but usually are progressive during childhood. New lesions may continue to develop throughout life. Large disfiguring and irregular blue marks may also occur. The lesions, which can rarely be located in the liver, spleen, and central nervous system in addition to the skin and gastrointestinal tract, do not involute spontaneously. Recurrent gastrointestinal hemorrhage caused by lesions in the gastrointestinal tract may lead to severe anemia. Palliation can be achieved by excision of involved bowel.

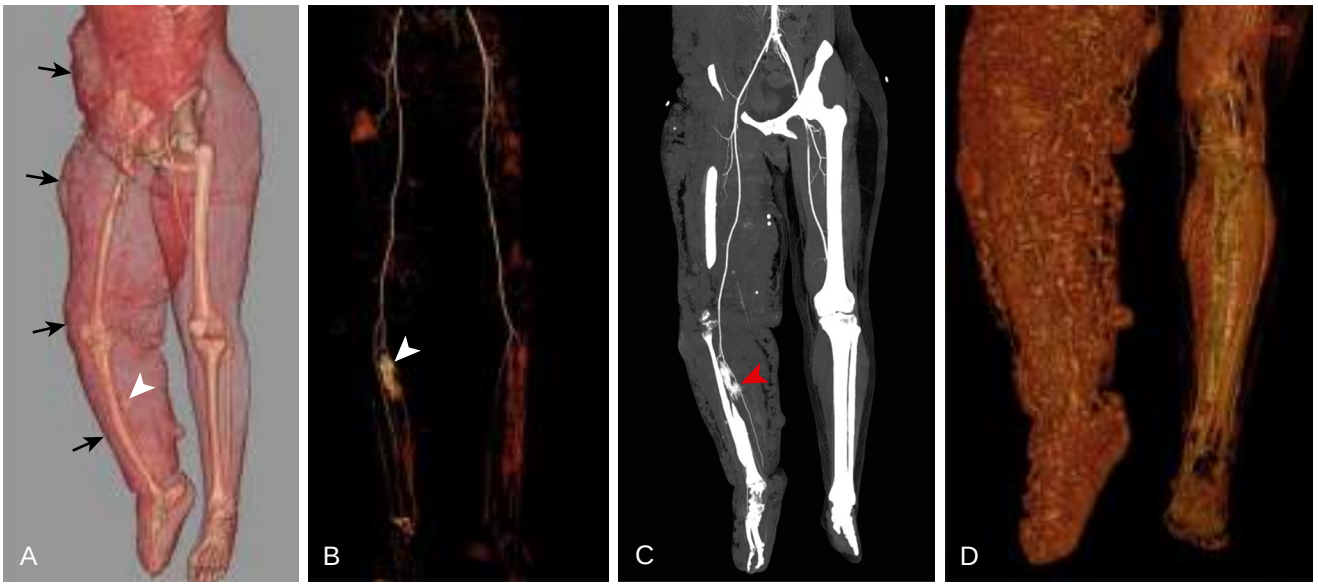

Fig. 691.5 Parkes-Weber syndrome. **A,** Three-dimensional volume-rendering CT angiography image of the limbs shows overgrowth of the right limb *(arrows)* with an arterial blush adjacent to the posterior tibial artery (*arrowhead*), consistent with a high-flow vascular malformation. **B,** Three-dimensional volume-rendering CT angiography image of the limbs shows arterial blush adjacent to the posterior tibial artery *(arrowhead)*. **C,** Coronal CT angiography image of the limb shows arterial blush adjacent to the posterior tibial artery *(arrowhead)*. **D,** Venous phase CT of the limb reveals varicose veins in the right limb. *(From Ufuk F. Limb overgrowth with vascular anomalies. J Pediatr. 2020;240:308–309, Fig, p. 309)*

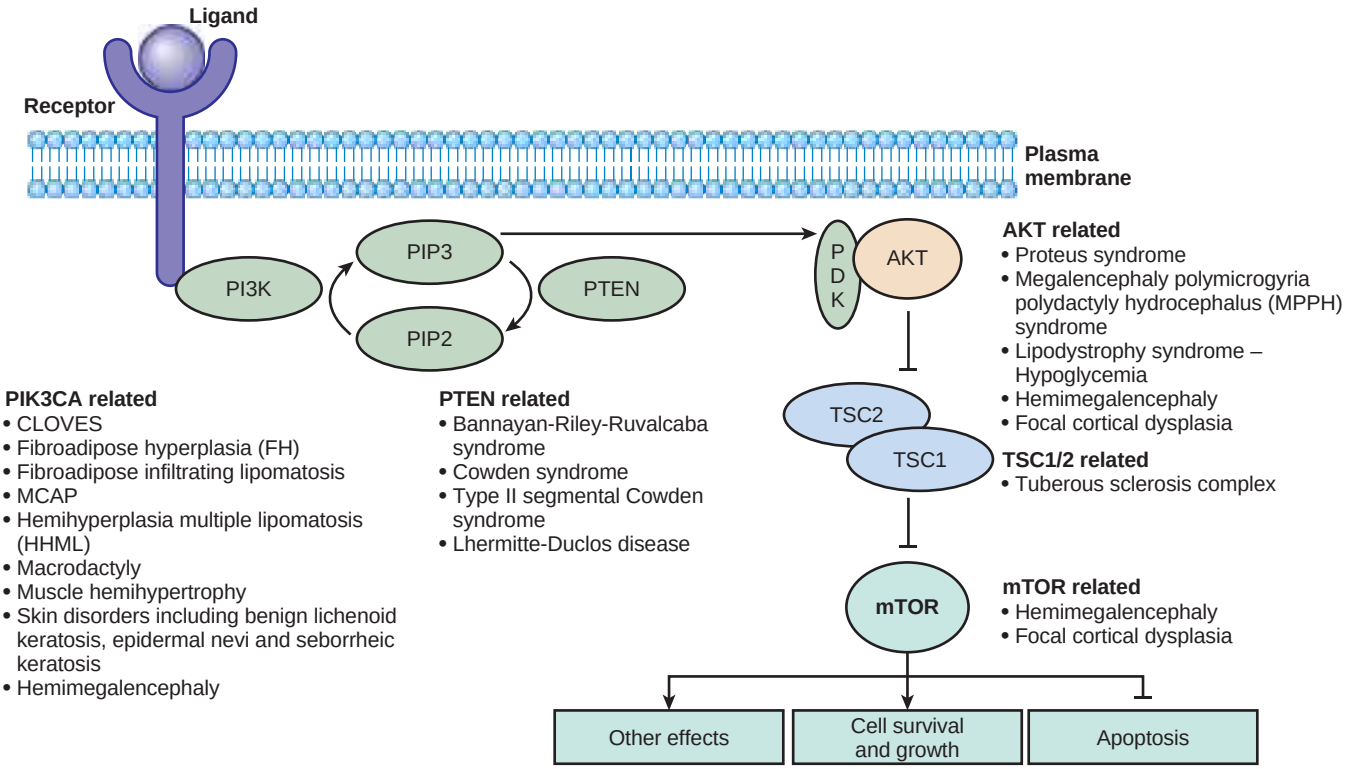

Fig. 691.6 Simplified PIK3CA-AKT-mTOR pathway and associated clinical overgrowth disorders. PIP, Phosphatidylinositol polyphosphate; PTEN, phosphatase and tensin homolog; PDK, phosphatidylinositol-dependent kinase. *(From Kang HC, Baek ST, Song S, Gleeson JG. Clinical and genetic aspects of the segmental overgrowth spectrum due to somatic mutations in PIK3CA. J Pediatr. 2015;167[5]:957–962, Fig, p. 959)*

PHAKOMATOSIS PIGMENTOVASCULARIS

Phakomatosis pigmentovascularis is a rare disorder characterized by the association of a capillary malformation and melanocytic lesions. Typically, the capillary malformation is extensive, and associated pigmentary lesions may include dermal melanocytosis, café-au-lait macules, or a nevus spilus (speckled nevus). Nonpigmented skin lesions that may occur in this setting include nevus anemicus and epidermal nevi. Systemic anomalies are seen in rare cases.

NEVUS ANEMICUS

Although present at birth, nevus anemicus may not be detectable until early childhood. The nevus consists of solitary or numerous sharply

Table 691.3 Clinical Diagnostic Criteria for *PIK3CA*-Related Overgrowth Spectrum (PROS)

REQUIRED CRITERIA

1. The presence of somatic *PIK3CA* pathogenic variant (if the pathogenic variant cannot be defined, then the disease is regarded as a presumptive PROS disorder)
2. Congenital or early childhood onset
3. Sporadic, without family history and mosaic distribution
4. Affected patients can have one or more findings from category A or B

CATEGORY A (MORE THAN 2 FEATURES)*	CATEGORY B (ISOLATED FEATURES)
1. Adipose, muscle, nerve, and skeletal overgrowth	1. Large, isolated LM
2. Capillary, venous, arteriovenous, and/or LMs	2. Isolated macrodactyly,† overgrown and splayed feet/hands, or overgrown limbs
3. Epidermal nevus	3. Truncal adipose overgrowth
	4. Hemi- or bilateral dysplastic megalencephaly or focal cortical dysplasia type 2
	5. Epidermal nevus
	6. Seborrheic keratosis
	7. Benign lichenoid keratoses

*Typically progressive. Can manifest as scoliosis (kyphosis), limb overgrowth, central nervous system (hydrocephalus, cerebellar tonsillar ectopia, Chiari, megalencephaly, mega corpus callosum), regional lipomatous undergrowth with overgrowth, infiltrating lipomatosis, or Wilms tumor/ovarian cystadenoma.

†Other terms include macrodystrophia lipomatosa, macrodactylia fibrolipomatosis, and gigantism.

From Kang HC, Baek ST, Song S, Gleeson JG. Clinical and genetic aspects of the segmental overgrowth spectrum due to somatic mutations in *PIK3CA*. *J Pediatr*. 2015;167(5):957–962, Table 1.

Fig. 691.7 Mottled pattern of cutis marmorata telangiectatica congenita on the right hand.

delineated, pale macules or patches that are most often on the trunk but may also occur on the neck or limbs. These nevi may simulate plaques of vitiligo, leukoderma, or nevoid pigmentary defects, but they can be readily distinguished because of their response to firm stroking. Stroking evokes an erythematous line and flare in normal surrounding skin, but the skin of a nevus anemicus does not redden. They can also be diagnosed by diascopy, in which pressure of the skin with a glass slide will obscure the borders of a nevus anemicus. Although the cutaneous vasculature appears normal histologically, the blood vessels within the nevus do not respond to injection of vasodilators. It has been postulated that the persistent pallor may represent a sustained localized adrenergic vasoconstriction.

VASCULAR TUMORS

Vascular tumors include infantile hemangiomas (IHs), tufted angiomas, kaposiform hemangioendotheliomas (KHEs), congenital hemangiomas, and additional more rare entities.

Infantile Hemangioma

IHs are proliferative benign vascular tumors of vascular endothelium that may be present at birth or, more commonly, may become apparent in the first or second week of life, predictably enlarge, and then spontaneously involute. IHs are the most common tumor of infancy, occurring in 5% of newborns. Risk factors include prematurity, low birthweight, female gender, and White race. IHs should be classified as superficial, deep, or mixed (Fig. 691.8). The terms *strawberry* and *cavernous* should not be used to describe hemangiomas. The immunohistochemical marker GLUT-1 is specifically expressed in an IH, which helps distinguish it histologically from other vascular anomalies. Superficial IHs are bright red, protuberant, compressible, sharply demarcated lesions that may occur on any area of the body (Fig. 691.9, see also Fig. 691.8). Although sometimes present at birth, they more often appear in the first or second month of life and are heralded by an erythematous or blue mark or an area of pallor, which subsequently develops a fine telangiectatic pattern before the growth phase (see Fig. 691.9). The presenting sign may occasionally be an ulceration of the perineum or lip. Favored sites are the face, scalp, back, and anterior chest; lesions may be solitary or multiple. Patterns of facial involvement include frontotemporal, maxillary, mandibular, and frontonasal regions. IHs that are more deeply situated are more diffuse and are less defined than superficial IHs. The lesions are cystic, firm, or compressible, and the overlying skin may appear normal in color or may have a bluish hue (Fig. 691.10).

Most IHs are mixed, having both superficial and deep components. IHs undergo a phase of rapid expansion, followed by a stationary period and finally by spontaneous involution (Fig. 691.11). Regression may be anticipated when the lesion develops pale gray areas centrally. The course of a particular lesion is unpredictable, but approximately 60% of these lesions reach maximal involution by 5 years of age and 90–95% by 9 years. Spontaneous involution cannot be correlated with size or site of involvement, but lip lesions seem to persist most often. Complications include impairment of a vital function, ulceration, secondary infection, and permanent disfigurement. The location of a lesion may interfere with a vital function (e.g., on an eyelid interfering with vision, on the urethra with urination, on the airway with respiration). IHs in a "beard" distribution may be associated with upper airway or subglottic involvement. Stridor should suggest a tracheobronchial lesion. Large visceral (hepatic) IHs may be complicated by coexistent hypothyroidism because of type 3 iodothyronine deiodinase; symptoms may be difficult to detect in this age-group. Table 691.4 lists other concerning features.

In the usual patient with an IH who has no serious complications or extensive growth resulting in tissue destruction and severe disfigurement, treatment consists of expectant observation. Because almost all lesions regress spontaneously, therapy is rarely indicated. Parents require repeated reassurance and support. After spontaneous involution, many patients are left with small cosmetic defects, such as telangiectasia, hypopigmentation, fibrofatty deposits, and scars if the lesion has ulcerated. Residual telangiectasias may be treated with pulsed dye laser therapy. Other defects can be treated or minimized by judicious surgical repair if desired.

In the rare case in which intervention is required, topical timolol solution (1 drop of 0.5% gel-forming solution applied twice each day) is effective, especially in small, superficial, nonulcerating, and nonmucosal IH. Topical timolol treatment is a very safe alternative to observation alone for a superficial IH. Timolol solution may also be used with caution in the treatment of an ulcerated IH, with or without occlusion.

In a disfiguring, life- or vision-threatening, or ulcerated IH that is not responding to other treatment, oral propranolol is the first-line treatment. IHs typically respond with growth arrest and often early signs of involution within a couple of weeks of treatment initiation. Dosing varies ranging from 1 to 3 mg/kg/day, though best outcomes occur at 3 mg/kg/day with no increase in side effects. Some recommend inpatient initiation of propranolol for infants younger than 8 weeks gestational age or those with comorbid conditions. The dose is initiated at 1 mg/kg/day divided into three doses with heart rate and blood pressure monitoring at 1 and 2 hours after each dose. If that dose is tolerated, the dose is increased to 2 mg/kg/day divided

Fig. 691.8 Types of infantile hemangiomas according to anatomic location. **A,** Bright red, superficial hemangioma. **B,** Bluish, deep hemangioma. **C,** Mixed type. *(From Léaute-Labréze C, Harper JI, Hieger PH. Infantile haemangioma. Lancet. 2017;390:85–94, Fig. 4, p. 88.)*

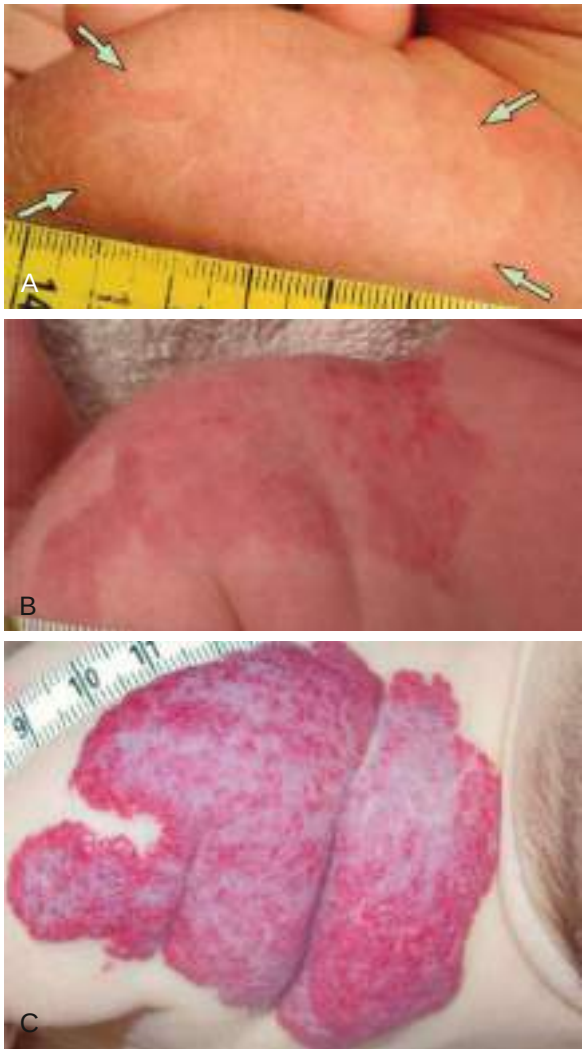

Fig. 691.9 Precursor lesions of infantile hemangioma. Figure shows a sharply demarcated, so-called anemic spot on the left shoulder. **A,** Day 3. **B,** Day 21. **C,** Day 90. *(From Léaute-Labréze C, Harper JI, Hieger PH. Infantile haemangioma. Lancet. 2017;390:85–94, Fig. 3, p. 87.)*

Fig. 691.10 Deep infantile hemangioma of the chest.

Fig. 691.11 Spontaneous regression of infantile hemangioma. **A,** Hemangioma on right lower arm, age 14 wk. **B,** Residual telangiectasia at age 23 mo. *(From Léaute-Labréze C, Harper JI, Hieger PH. Infantile haemangioma. Lancet. 2017;390:85–94, Fig. 5, p. 88.)*

into three doses. The outpatient initiation assumes good social support and access to the hospital. The initial dose and monitoring are similar to the inpatient plan; if the dose is tolerated for 3-7 days, the dose is increased to 1.5 mg/kg/day. If the latter dose is tolerated after 3-7 days, the dose is increased to 2 mg/kg/day. In all situations, propranolol must be given a minimum of 6 hours after the last dose. Risks of propranolol treatment include hypoglycemia, bradycardia, hypotension, gastroesophageal reflux disease or

Table 691.4 Clinical "Red Flags" Associated with Hemangiomas

CLINICAL FINDING	RECOMMENDED EVALUATION
Facial hemangioma involving significant area of face (>5 cm)	Evaluate for PHACES (posterior fossa abnormalities, hemangioma, and arterial, cardiac, eye, and sternal abnormalities): MRI and MRA of brain, neck, orbit
	Cardiac, ophthalmologic evaluation
	Evaluate for midline abnormality: supraumbilical raphe, sternal atresia, cleft palate, thyroid abnormality
Cutaneous hemangiomas in beard distribution	Evaluate for airway hemangioma, especially if manifesting with stridor
Periocular hemangioma	MRI of orbit Ophthalmologic evaluation
Paraspinal midline vascular lesion	Ultrasonography or MRI to evaluate for occult spinal dysraphism
Multifocal infantile hemangiomas (>5 cm)	Evaluate for parenchymal hemangiomas, especially hepatic/central nervous system Guaiac stool test, liver ultrasound
Large hemangioma, especially hepatic	Ultrasonography with Doppler flow study
	MRI
	TSH to detect associated hypothyroidism
Thrill and/or bruit associated with hemangioma	Consider cardiac evaluation and echocardiography to rule out diastolic reversal of flow in aorta
	MRI to evaluate extent and flow characteristics
Perineal segmental hemangioma	MRI of spine, kidneys to detect LUMBAR/PELVIS/SACRAL syndrome

LUMBAR, Lower body infantile hemangiomas and other skin defects, urogenital anomalies and ulceration, myelopathy, bony deformities, anorectal malformations and arterial anomalies, renal anomalies; PELVIS, perineal hemangioma, external genital malformations, lipomyelomeningocele, vesicorenal anomalies, imperforate anus, skin tag; SACRAL, spinal dysraphism, anogenital anomalies, cutaneous anomalies, renal/urologic anomalies, angioma in lumbosacral location.
Modified from Blei F. Vascular anomalies: from bedside to bench and back again. *Curr Probl Pediatr Adolesc Health*. 2002;32:67–102.

worsening of existing disease, hyperkalemia, and bronchospasm/wheezing. Nonetheless, reports of side effects of propranolol used for IH treatment are rare. Increased propranolol levels occur with inhibitors of CYP2D6 (cimetidine, amiodarone, fluoxetine, quinidine, ritonavir) and CPY1A2 (cimetidine, ciprofloxacin, isoniazid, ritonavir, theophylline); decreased blood levels occur with inducers of hepatic drug metabolism (rifampin, phenytoin, phenobarbital).

In patients unable to tolerate propranolol, or if the IH has not responded after a couple of weeks of treatment, systemic oral corticosteroids may be used. Termination of growth and sometimes regression may be evident after 2-4 weeks of therapy. When a response is obtained, the dose should be decreased gradually, though most patients will require treatment until about 1 year of age.

Intralesional corticosteroid injection by an experienced physician can also induce rapid involution of a localized IH but has risks of ulceration, tissue atrophy, and blindness if used near the orbit. Vincristine is used by some oncologists to treat significant IH. Interferon-α therapy may also be effective, but spastic diplegia is seen in 10% of cases. Use of these therapies has become less necessary since the introduction of propranolol.

Fig. 691.12 Large segmental infantile hemangioma of the face in a 2-mo-old infant with definite PHACE. *(From Garzon MC, Epstein LG, Heyer GL, et al. PHACE syndrome: consensus-derived diagnosis and care recommendations. J Pediatr. 2016;178:24–33, Fig. 1, p. 25.)*

In patients with large segmental IH of the face, **PHACES** syndrome should be considered (Fig. 691.12 and Table 691.5). PHACES stands for **p**osterior fossa brain defects such as Dandy-Walker malformation or cerebellar hypoplasia, large segmental facial infantile **h**emangioma, **a**rterial cerebrovascular abnormalities such as aneurysms and stroke, **c**oarctation of the aorta, and **e**ye abnormalities. **S**ternal raphe defects such as pits, scars, or **s**upraumbilical raphe are infrequently observed. Evaluation of children at risk for PHACES is important both to detect any underlying abnormalities and before starting systemic therapy, which may be indicated given the size and location of the IH typically associated with this syndrome. PHACES children with cervical and intracranial arterial abnormalities are at increased risk of cerebrovascular accidents, and specialized care by an experienced multidisciplinary team is essential.

Multifocal Infantile Hemangioma

Diffuse neonatal hemangiomatosis (or benign neonatal hemangiomatosis) is a historical term to describe a condition in which numerous or multifocal vascular lesions are widely distributed (Fig. 691.13). Several distinct diagnoses have been previously lumped together under this clinical phenotype with mortality cited as high as 60–80%. Upon further analysis, this group of disorders has been found to comprise several distinct entities, which are important to distinguish from one another, given their varying prognoses and management strategies. Therefore the term *multifocal IH* is more accurate and leads to correct treatments and prognosis for these patients with more than one cutaneous (and/or visceral) IH.

Multifocal IHs may occur in the skin and visceral organs, but remain GLUT-1–positive when biopsied, have a relatively good prognosis with low morbidity, and respond to systemic propranolol just as solitary cutaneous IH. Patients with more than five cutaneous IH should undergo an abdominal physical exam and possibly liver ultrasound to detect liver IH, which can grow quite large (Fig. 691.14).

Multifocal lymphangioendotheliomatosis (also known as cutaneovisceral angiomatosis) also presents with many vascular tumors in the skin and visceral organs but is GLUT-1–negative and complicated by

Table 691.5 PHACES Diagnostic Criteria: Revised

ORGAN SYSTEMS	MAJOR CRITERIA	MINOR CRITERIA
Arterial anomalies	Anomaly of major cerebral or cervical arteries* Dysplasia† of the large cerebral arteries Arterial stenosis or occlusion with or without moyamoya collaterals Absence or moderate-severe hypoplasia of the large cerebral and cervical arteries Aberrant origin or course of the large cerebral or cervical arteries except common arch variants such as bovine arch Persistent carotid-vertebrobasilar anastomosis (proatlantal segmental, hypoglossal, otic, and/or trigeminal arteries)	Aneurysm of any of the cerebral arteries
Structural brain	Posterior fossa brain anomalies Dandy-Walker complex Other hypoplasia/dysplasia of the mid and/or hind brain	Midline brain anomalies Malformation of cortical development
Cardiovascular	Aortic arch anomalies Coarctation of the aorta Dysplasia* Aneurysm Aberrant origin of the subclavian artery with or without a vascular ring	Ventricular septal defect Right aortic arch/double aortic arch Systemic venous anomalies
Ocular	Posterior segment abnormalities Persistent hyperplastic primary vitreous Persistent fetal vasculature Retinal vascular anomalies Morning glory disc anomaly Optic nerve hypoplasia Peripapillary staphyloma	Anterior segment abnormalities Microphthalmia Sclerocornea Coloboma Cataracts
Ventral/midline	Anomaly of the midline chest and abdomen • Sternal defect • Sternal pit • Sternal cleft • Supraumbilical raphe	Ectopic thyroid hypopituitarism Midline sternal papule/hamartoma

DEFINITE PHACE

Hemangioma >5 cm in diameter of the head including scalp PLUS one major criteria or two minor criteria

Hemangioma of the neck, upper trunk, or trunk and proximal upper extremity PLUS two major criteria

POSSIBLE PHACE

Hemangioma >5 cm in diameter of the head including scalp PLUS one minor criteria

Hemangioma of the neck, upper trunk, or trunk and proximal upper extremity PLUS one major or two minor criteria

No hemangioma PLUS two major criteria

*Internal carotid artery, middle cerebral artery, anterior cerebral artery, posterior cerebral artery, or vertebrobasilar system.
†Includes kinking, looping, tortuosity, and/or dolichoectasia.
From Garzon MC, Epstein LG, Heyer GL, et al. PHACE syndrome: consensus-derived diagnosis and care recommendations. *J Pediatr.* 2016;178:24–33, Table II.

severe thrombocytopenia and gastrointestinal bleeding with high mortality. Accurate diagnosis in patients who present with multifocal vascular tumors is critical so early, appropriate management may be initiated.

Congenital Hemangioma

Congenital hemangiomas are benign vascular tumors that are present typically at birth. They are most often red or blue hued with telangiectasia and may have a ring of pallor. They do not undergo further growth after delivery as IHs do. Changes after delivery occur along a spectrum, and the lesion may stay stable **(noninvoluting congenital hemangiomas [NICH])**, partially involute (**partially involuting congenital hemangiomas [PICH]**), or decrease rapidly in size, leaving fibrofatty residual tissue behind **(rapidly involuting congenital hemangiomas [RICH])**. They are distinguishable from IH because of their clinical course and negative GLUT-1 markers on histopathology. It is also important to note the difference because CH do not respond to propranolol.

Kaposiform Hemangioendothelioma

KHE is a rare and potentially life-threatening vascular tumor. KHE classically presents as a red to purple firm plaque on the lateral neck, axilla, trunk, or extremities. Visceral tumors occur as well. Lesions may occasionally get smaller over time but rarely resolve completely. Tufted angioma, once thought to be a separate tumor on the same clinical spectrum as KHE, is considered under the umbrella term of KHE (Fig. 691.15). The main complication of these tumors is the development of **Kasabach-Merritt phenomenon (KMP)**, which may be fatal; therefore early diagnosis and treatment are important. Oral sirolimus may be helpful to stabilize and sometimes shrink these tumors. Retroperitoneal or intrathoracic lesions in the absence of cutaneous lesions are uncommon but are often associated with KMP.

Kasabach-Merritt Phenomenon

KMP is a life-threatening combination of a rapidly enlarging KHE, thrombocytopenia, microangiopathic hemolytic anemia, and an acute

or chronic consumption coagulopathy. The clinical manifestations are usually evident during early infancy. The vascular lesion is usually cutaneous and is only rarely located in viscera. The associated thrombocytopenia may lead to precipitous hemorrhage accompanied by ecchymoses, petechiae, and a rapid increase in the size of the vascular lesion. Severe anemia from hemorrhage or microangiopathic hemolysis may ensue. Thrombocytopenia is present, but the bone marrow contains increased numbers of normal or immature megakaryocytes. The thrombocytopenia has been attributed to sequestration or increased destruction of platelets within the lesion. Hypofibrinogenemia and decreased levels of consumable clotting factors are relatively common (see Chapter 533.6).

Treatment includes surgical excision of small lesions, although this is often difficult because of coagulopathy. Additional pharmacologic treatments include systemic steroids with or without vincristine as first-line therapy in most cases. Antiplatelet, antifibrinolytic, and other chemotherapeutic agents have been used with mixed results. Initial studies of sirolimus therapy have been promising. The mortality rate overall once patients have KMP is significant.

Fig. 691.13 Multifocal cutaneous and systemic (liver) infantile hemangiomas. *(From Eichenfield LF, Frieden IJ, Esterly NB. Textbook of Neonatal Dermatology, 2nd ed. Philadelphia: Saunders; 2008:359.)*

Pyogenic Granuloma (Lobular Capillary Hemangioma)

A pyogenic granuloma (PG) is a small, red, glistening, sessile, or pedunculated papule that often has a discernible epithelial collarette (Fig. 691.16). The surface may be weeping and crusted or completely epithelialized. PGs initially grow rapidly, may ulcerate, and bleed easily

Fig. 691.15 Nodular tufted angioma on the left thigh.

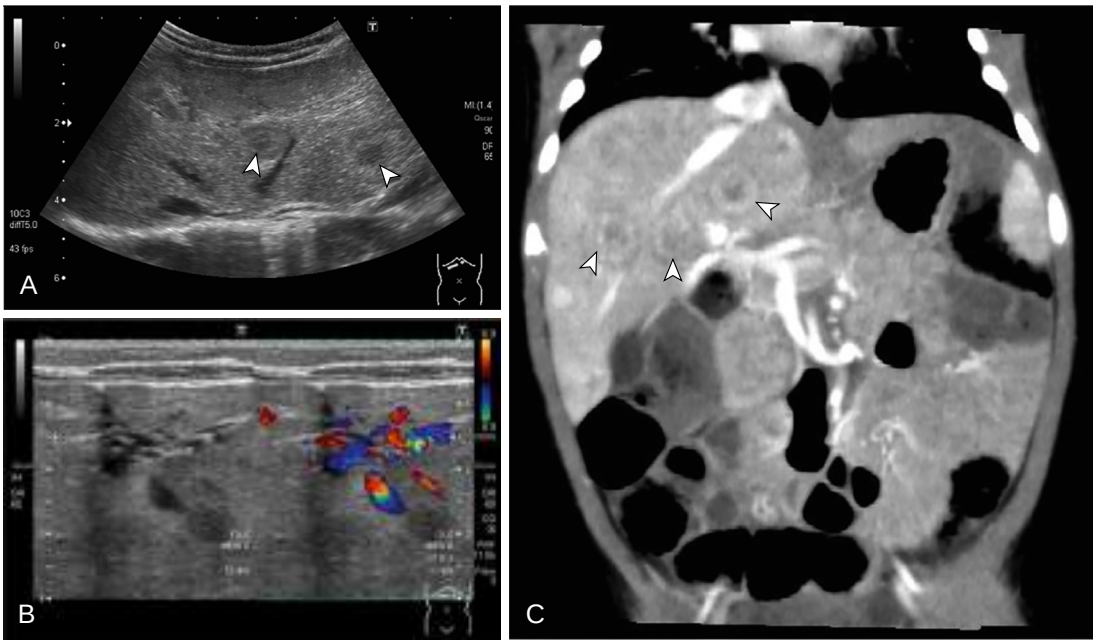

Fig. 691.14 Multifocal infantile hemangioma. A, Multiple hypoechoic lesions *(arrowheads)*. B, Arteriovenous shunting on ultrasound. C, Multiple hypervascular masses in the liver on computed tomography *(arrowheads)*. *(From Uda K, Okubo Y, Matushima T, et al. Multifocal infantile hemangioma. J Pediatr. 2019;210:238, Fig. 2, p. 238.e1.)*

Fig. 691.16 Pyogenic granuloma on the left cheek.

Fig. 691.17 Spider angioma with visible central arteriole component.

when traumatized because they consist of exuberant granulation tissue. They are relatively common in children, particularly on the face, arms, and hands. Such a lesion located on a finger or hand may appear as a subcutaneous nodule. PGs may arise at sites of injury, but a history of trauma often cannot be elicited.

PGs are benign but a nuisance because they bleed easily with trauma and may recur if incompletely removed. Numerous satellite papules have developed after surgical excision of PGs from the back, particularly in the interscapular region. Small lesions may regress after cauterization with silver nitrate; larger lesions require excision and electrodesiccation of the base of the granuloma. Small (<5 mm) lesions may be treated successfully with pulsed dye laser therapy.

Angiokeratoma of Mibelli

Angiokeratoma of Mibelli is characterized by 1- to 8-mm red, purple, or black scaly, verrucous, occasionally crusted papules and nodules that appear on the dorsum of the fingers and toes and on the knees and the elbows. Less commonly, palms, soles, and ears may be affected. In many patients, onset has followed frostbite or chilblains. These nodules bleed freely after injury and may involute in response to trauma. They may be effectively eradicated by cryotherapy, electrofulguration, excision, or laser ablation.

Spider Angioma

A vascular spider (nevus araneus) consists of a central feeder artery with many dilated radiating vessels and a surrounding erythematous flush, varying from a few millimeters to several centimeters in diameter (Fig. 691.17). Pressure over the central vessel causes blanching; pulsations visible in larger nevi are evidence for the arterial source of the lesion. Spider angiomas are associated with conditions in which there are increased levels of circulating estrogens, such as cirrhosis and pregnancy, but they also occur in up to 15% of normal preschool-age children and 45% of school-age children. Sites of predilection in children are the dorsum of the hand, forearm, nose, infraocular region, lips, and ears. Lesions often regress spontaneously after puberty. If removal is desired, pulsed dye laser therapy is the mode of choice; resolution is achieved in 90% of cases with a single treatment.

Fig. 691.18 Hereditary hemorrhagic telangiectasia. Telangiectases are found on the lips, oral mucosa, nasal mucosa, skin, and conjunctiva. Epistaxis is the most common manifestation of the disease. Blood transfusions may be required. *(From Habif TP. Clinical Dermatology: A Color Guide to Diagnosis and Therapy, 4th ed. Philadelphia: Mosby; 2004: Fig. 23.22, p. 831.)*

Maffucci Syndrome

The association of spindle cell hemangiomas with nodular enchondromas in the metaphyseal or diaphyseal cartilaginous portion of long bones is known as *Maffucci syndrome.* Maffucci syndrome is caused by somatic mosaic pathogenic variants in the *IDH1* and *IDH2* genes. Vascular lesions are typically soft, compressible, asymptomatic, blue to purple subcutaneous masses that grow in proportion to a child's growth and stabilize by adulthood. Mucous membranes or viscera may also be involved. Onset occurs during childhood. Bone lesions may produce limb deformities and pathologic fractures. Malignant transformation of enchondromas (chondrosarcoma, angiosarcoma) or primary malignancies (ovarian, fibrosarcoma, glioma, pancreatic) may be a complication (see Chapter 550).

Hereditary Hemorrhagic Telangiectasia (Osler-Weber-Rendu Disease)

Hereditary hemorrhagic telangiectasia (HHT), which is inherited as an autosomal dominant trait, occurs in two types. The gene in **HHT-1** encodes *ENG,* a membrane glycoprotein on endothelial cells that binds transforming growth factor-β. **HHT-2** is caused by pathogenic variants in the *ACVRL1* gene and is associated with increased risk for hepatic involvement and pulmonary hypertension. **HHT-juvenile polyposis syndrome** is caused by a pathogenic variant in *SMAD4.*

Affected children usually experience recurrent epistaxis before detection of the characteristic skin and mucous membrane lesions. The mucocutaneous lesions, which usually develop at puberty, are 1- to 4-mm, sharply demarcated, red to purple macules, papules, or spider-like projections, each composed of a tightly woven mat of tortuous telangiectatic vessels (Fig. 691.18). The nasal mucosa, lips, and tongue are usually involved; less commonly, cutaneous lesions occur on the face, ears, palms, and nail beds. Vascular ectasias may also arise in the conjunctivae, larynx, pharynx, gastrointestinal tract, bladder, vagina, bronchi, brain, and liver. Diagnostic criteria include spontaneous recurrent epistaxis, telangiectasias (oral, nose, fingers), visceral lesions (gastrointestinal telangiectasias,

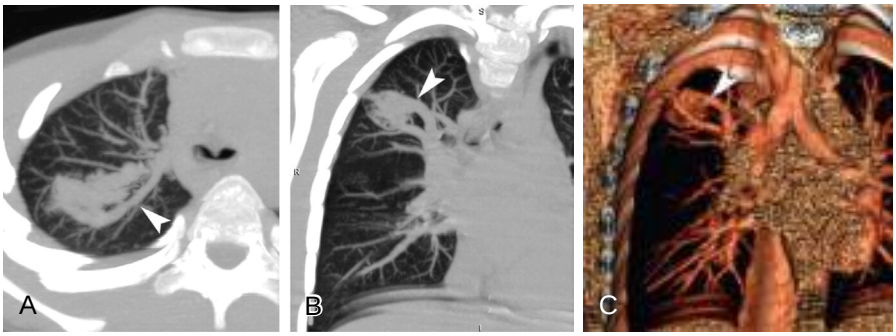

Fig. 691.19 Chest multislice spiral CT in a patient showing a large pulmonary arteriovenous malformation in the posterior segment of right upper lobe *(arrowhead)*. **A,** Axial maximum intensity projection image. **B,** Coronal maximum intensity projection image. **C,** Three-dimensional volume rendering. *(From Giordano P, Lenato GM, Suppressa P, et al. Hereditary hemorrhagic telangiectasia: arteriovenous malformations in children. J Pediatr. 2013;163:179–186, Fig. 1, p. 182.)*

Fig. 691.20 Infant with CM-AVM syndrome and a typical-appearing CM-AVM stain of the left chest. This lesion demonstrates high flow on Doppler evaluation, differentiating it from classic CM. In CM-AVM syndrome, the lesions tend to be multifocal, with more arising over time. *(From Eichenfield LF, Frieden IJ, eds. Neonatal and Infant Dermatology, 3rd ed. Philadelphia: Elsevier; 2015: Fig. 22.14, p. 363.)*

pulmonary or hepatic or cerebral AVMs), and first-degree relative with HHT.

Massive hemorrhage is the most serious complication of HHT and may result in severe anemia. Bleeding may occur from the nose, mouth, gastrointestinal tract, genitourinary tract, or lungs; epistaxis is often the only complaint, occurring in 80% of patients. Approximately 15–20% of patients with AVMs in the lungs present with stroke due to embolic abscesses (Fig. 691.19). Hepatic encephalopathy in the presence of normal liver function may occur with a hepatic AVM. Persons with HHT have normal levels of clotting factors and an intact clotting mechanism. In the absence of serious complications, the life span of a person with HHT is normal. Local lesions may be ablated temporarily with chemical cautery or electrocoagulation. More drastic surgical measures may be required for lesions in critical sites, such as the lung or gastrointestinal tract. Bevacizumab, an anti–vascular endothelial growth factor agent, has been effective in treating affected patients with HHT who have high cardiac output secondary to hepatic AVMs. The nasal spray form of bevacizumab may be beneficial therapy for epistaxis.

Capillary Malformation–Arteriovenous Malformation Syndrome (CM-AVM)

CM-AVM is an autosomal dominant disorder caused by pathogenic variants in *RASA1* (CM-AVM-1) or *EPHB4* (CM-AVM-2) and is characterized by multiple atypical-appearing macules or patches that are present at birth, suggestive of microcutaneous AVMs that look like capillary malformations (Fig. 691.20). Lesions that are present at birth will enlarge and darken with increasing age. Some lesions have peripheral pallor (**halo effect**). In addition, associated high-flow AVMs may be present in the brain, spinal cord, or skin. Arteriovenous fistulas have also been reported. Pulse dye laser treatment may be effective for cutaneous lesions, whereas embolization is indicated for AVMs.

Ataxia-Telangiectasia

See Chapter 637.1.

Ataxia-telangiectasia is transmitted as an autosomal recessive trait because of a pathogenic variant in the *ATM* gene. The characteristic telangiectasias develop at approximately 3 years of age, first on the bulbar conjunctivae and later on the nasal bridge, malar areas, external ears, hard palate, upper anterior chest, and antecubital and popliteal fossae. Additional cutaneous stigmata include café-au-lait spots, premature graying of the hair, and sclerodermatous changes. Progressive cerebellar ataxia, neurologic deterioration, sinopulmonary infections, and malignancies are also seen.

Angiokeratoma Corporis Diffusum (Fabry Disease)

See Chapter 106.4.

An inborn error of glycolipid metabolism (α-galactosidase), angiokeratoma corporis diffusum is an X-linked recessive disorder that is fully penetrant in males and is of variable penetrance in carrier females. Angiokeratomas appear before puberty and occur in profusion over the genitalia, hips, buttocks, and thighs and in the umbilical and inguinal regions. They consist of 0.1- to 3.0-mm, red to blue-black papules that may have a hyperkeratotic surface. Telangiectasias are seen in the mucosa and conjunctiva. On light microscopy, these angiokeratomas appear as blood-filled, dilated, endothelium-lined vascular spaces. Granular lipid deposits are demonstrable in dermal macrophages, fibrocytes, and endothelial cells.

Additional clinical manifestations include recurrent episodes of fever and agonizing pain, cyanosis and flushing of the acral limb areas, paresthesias of the hands and feet, corneal opacities detectable on slit-lamp examination, and hypohidrosis. Renal involvement and cardiac involvement are the usual causes of death. The biochemical defect is a deficiency of the lysosomal enzyme α-galactosidase, with accumulation of ceramide trihexoside in tissues, particularly vascular endothelium, and excretion in urine (see Chapter 106.4 for therapy). Similar cutaneous lesions have also been described in another lysosomal enzyme disorder, α-L-fucosidase deficiency, and in sialidosis, a storage disease with neuraminidase deficiency.

Visit Elsevier eBooks+ at eBooks.Health.Elsevier.com for Bibliography.

Chapter 692

Cutaneous Nevi

Kari L. Martin

Nevus skin lesions are characterized histopathologically by collections of well-differentiated cell types normally found in the skin. Vascular nevi are described in Chapter 691. Melanocytic nevi are subdivided into two broad categories: those that appear after birth (acquired nevi) and those that are present at birth (congenital nevi).

ACQUIRED MELANOCYTIC NEVUS

Melanocytic nevi are benign clusters of melanocytic nevus cells that arise as a result of alteration and proliferation of melanocytes at the epidermal-dermal junction.

Epidemiology

The number of *acquired* melanocytic nevi increases gradually during childhood and more slowly in early adulthood. The number reaches a plateau in the third or fourth decade and then slowly decreases thereafter. The mean number of melanocytic nevi in an adult varies depending on genetics, skin color, and sun exposure. The greater the number of nevi present, the greater the risk for development of melanoma, though the majority of melanomas arise de novo. Sun exposure during childhood, particularly intermittent, intense exposure of an individual with light skin, and a propensity to burn and freckle rather than tan are important determinants of the number of melanocytic nevi that develop. Red-haired children, despite their light skin and propensity to freckle and sunburn, have fewer nevi than other children. Increased numbers of nevi are also associated with immunosuppression and administration of chemotherapy.

Clinical Manifestations

Melanocytic nevi have a well-defined life history and are classified as junctional, compound, or dermal in accordance with the location of the nevus cells in the skin. In childhood, >90% of nevi are junctional; melanocyte proliferation occurs at the junction of the epidermis and dermis to form nests of cells. Junctional nevi appear anywhere on the body in various shades of brown; they are relatively small, discrete, flat, and variable in shape. Although some nevi, particularly those on the palms, soles, and genitalia, remain junctional throughout life, most become compound as melanocytes migrate into the papillary dermis to form nests at both the epidermal-dermal junction and within the dermis. If the junctional melanocytes stop proliferating, nests of melanocytes remain only within the dermis, forming an intradermal nevus. With maturation, compound and intradermal nevi may become raised, dome-shaped, verrucous, or pedunculated. Slightly elevated lesions are usually compound. Distinctly elevated lesions are usually intradermal. With age, the dermal melanocytic nests regress and nevi gradually disappear.

Prognosis and Treatment

Acquired pigmented nevi are benign, but a very small percentage undergo malignant transformation. Suspicious changes are indications for excision and histopathologic evaluation. This includes rapid increase in size; unusual colors such as red, black, varying shades of brown, gray, and white; bleeding; textures such as scaling, erosion, ulceration, and induration; and regional lymphadenopathy. Most of these changes are from irritation, infection, or maturation; darkening and gradual increase in size and elevation normally occur during adolescence and should not be cause for concern. Two common benign changes are clonal nevi (fried-egg moles) and eclipse nevi. A **clonal nevus** is light brown with a dark, raised center representing a clonal change of a subset of nevus cells within the lesion. **Eclipse nevi** are flat and light brown with dark brown rims. They are seen primarily in the scalp (Fig. 692.1). Consideration should be given to the presence of risk factors for development of melanoma and the patient's parents' wishes about removal of the nevus. If doubt remains about the benign nature of a nevus, excision is a safe and simple outpatient procedure that may be justified to allay anxiety.

ATYPICAL MELANOCYTIC NEVUS

Atypical melanocytic nevi occur both in an autosomal dominant familial melanoma-prone setting (familial mole–melanoma syndrome, dysplastic nevus syndrome, BK mole syndrome) and as a sporadic event. Only 2% of all pediatric melanomas occur in individuals with a familial syndrome; melanoma develops before age 20 years in 10% of individuals with the syndrome. Malignant melanoma has been reported in children with dysplastic nevus syndrome as young as 10 years old. Risk for development of melanoma is essentially 100% in individuals with dysplastic nevus syndrome who have two family members who have had melanomas. The term *atypical mole syndrome* describes lesions in those individuals without an autosomal dominant familial history of melanoma but with more than 50 nevi, some of which are atypical. The lifetime risk of melanoma associated with dysplastic nevi in this context is estimated to be 5–10%.

Atypical nevi tend to be large (5-15 mm) and round to oval. They have irregular margins and variegated color, and portions of them are elevated. These nevi are most common on the posterior trunk, suggesting that intermittent, intense sun exposure has a role in their genesis. They may also occur in sun-protected areas such as the breasts, buttocks, and scalp. Atypical nevi do not usually develop until puberty, although scalp lesions may be present earlier. Atypical nevi demonstrate disordered proliferation of atypical intraepidermal melanocytes, lymphocytic infiltration, fibroplasia, and angiogenesis. It may be helpful to obtain histopathologic documentation of dysplastic change by biopsy to identify these individuals. It is prudent to excise borderline atypical nevi in immunocompromised children or in those treated with irradiation or chemotherapeutic agents. Although chemotherapy is associated with the development of a greater number of melanocytic nevi, it has not been directly linked to increased risk for development of melanoma. The threshold for removal of clinically atypical nevi is also lower at sites that are difficult to observe, such as the scalp. Children with atypical nevi should undergo a complete skin examination every 6-12 months. In these children, photographic mole mapping serves as a useful adjunct in following nevus change. Parents must be counseled about the importance of sun protection and avoidance and should be instructed to look for early signs of melanoma on a regular basis, approximately every 3-4 months.

CONGENITAL MELANOCYTIC NEVUS

Congenital melanocytic nevi are present in 2–3% of newborn infants. These nevi have been categorized by size: giant congenital nevi are >40 cm in diameter (adult size) or >5% of the body surface; large nevi are 20-40 cm, medium nevi are 1.5-20 cm, and small nevi are <1.5 cm in diameter (Fig. 692.2). Congenital nevi are characterized by the

Fig. 692.1 Eclipse nevi (rim moles) in the scalp.

Fig. 692.2 Congenital melanocytic nevus. Changing appearance with time of a congenital melanocytic nevus of small-to-medium size on the trunk when the patient was 9 months old (**A**) and 10 years old (**B**). *(From Anderson-Vildosola J, Hernandez-Martin A. Addressing frequently asked questions and dispelling myths about melanocytic nevi in children. Dermatol Clin. 2022;40:51–59, Fig. 5)*

presence of nevus cells in the lower reticular dermis; between collagen bundles; surrounding cutaneous appendages, nerves, and vessels in the lower dermis; and occasionally extending to the subcuticular fat. Large and giant congenital nevi often harbor *NRAS* pathogenic variants, and *BRAF* pathogenic variants typically seen in regular melanocytic nevi are most common in small or medium congenital nevi. Identification is often uncertain, however, because they may have the histologic features of ordinary junctional, compound, or intradermal nevi. Some nevi that were not present at birth display histopathologic features of congenital nevi; these should not be considered congenital, but may be called congenital nevus–like nevi (CNLN). Furthermore, congenital nevi may be difficult to distinguish clinically from other types of pigmented lesions, adding to the difficulty that parents may have in identifying nevi that were present at birth. The clinical differential diagnosis includes dermal melanocytosis, café-au-lait macules, and smooth muscle hamartomas.

Sites of predilection for small congenital nevi are the lower trunk, upper back, shoulders, chest, and proximal limbs. The lesions may be flat, elevated, verrucous, or nodular and may be various shades of brown, blue, or black. Given the difficulty in identifying small congenital nevi with certainty, data regarding their malignant potential are controversial and likely overstated. The true incidence of melanoma in congenital nevi, especially small and medium-sized lesions, is unknown. Removal of all small congenital nevi is not warranted because the development of melanoma in a small congenital nevus is an exceedingly rare event before puberty. A number of factors must be weighed in the decision about whether or not to remove a nevus, including its location, the ability to monitor it clinically, the potential for scarring, the presence of other risk factors for melanoma, and the presence of atypical clinical features.

Giant congenital pigmented nevi (<1 in 20,000 births) occur most commonly on the posterior trunk (Fig. 692.3) but may also appear on the head or extremities. These nevi are of special significance because

Fig. 692.3 "Bathing suit" large congenital melanocytic nevus.

of their association with leptomeningeal melanocytosis (neurocutaneous melanocytosis) and their predisposition for development of malignant melanoma.

Leptomeningeal involvement occurs most often when the nevus is located on the head or midline on the trunk, particularly when associated with multiple "satellite" melanocytic nevi (>20 lesions). Nevus cells within the leptomeninges and brain parenchyma may cause increased intracranial pressure, hydrocephalus, seizures, intellectual disability, and motor deficits and may result in melanoma. Malignancy can be identified by careful cytologic examination of the cerebrospinal fluid for melanin-containing cells. MRI demonstrates asymptomatic leptomeningeal melanosis in 30% of individuals with giant congenital nevus of the type described earlier. The overall incidence of malignant melanoma arising in a giant congenital nevus is 1–2%. The median age at diagnosis of the melanomas that arise within a giant congenital nevus is 7 years. The mortality rate approaches 100%. The risk of melanoma is greater in patients in whom the predicted adult size of the nevus is >40 cm, lesions are on the trunk, and satellite lesions are present. Management of giant congenital nevi remains controversial and should involve the parents, pediatrician, dermatologist, and plastic surgeon. If the nevus lies over the head or spine, MRI may allow detection of neural melanosis, the presence of which makes gross removal of a nevus from the skin a futile effort. In the absence of neural melanosis, early excision and repair aided by tissue expanders or grafting may reduce the burden of nevus cells and thus the potential for development of melanoma, but at the cost of many potentially disfiguring operations. Nevus cells deep within subcutaneous tissues may evade excision. Random biopsies of the nevus are not helpful, but biopsy of newly expanding nodules is indicated. Follow-up every 6 months for 5 years and every 12 months thereafter is recommended. Serial photographs of the nevus may aid in detecting changes.

MELANOMA

Malignant melanoma is the most common skin cancer in children, and approximately 1% of all melanomas occur before 20 years of age. An estimated 400 cases of pediatric melanoma are diagnosed each year. The incidence of melanoma in the pediatric population increases with age, from 1-2 cases per 1 million in children under age 10 to 16.9 cases in children age 15-19 years. The incidence of pediatric melanoma has increased by an average of 2% per year between 1973 and 2009. This increase was especially notable in females between the ages of 15 and 19. In this age-group, melanoma accounts for 6% of all childhood cancers. Melanoma develops primarily in White individuals, on the head and trunk in males, and on the extremities in females. In preadolescent patients, melanoma is more likely to present on the head and neck than in other locations. Risk factors for the development of melanoma include the presence of familial atypical mole–melanoma syndrome or xeroderma pigmentosum; an increased number of acquired melanocytic nevi, or atypical nevi; fair complexion; excessive sun exposure, especially intermittent exposure to intense sunlight; a personal or family (first-degree relative) history of a previous melanoma; giant

congenital nevus; and immunosuppression (Table 692.1). In previously well children, UV radiation is responsible for most melanomas. Less than 5% of childhood melanomas develop within giant congenital nevi or in individuals with familial atypical mole–melanoma syndrome. Approximately 40–50% of the time, melanoma develops at a site where there was no apparent nevus. The mortality rate from melanoma is related primarily to tumor thickness and the level of invasion into the skin. About 75% of pediatric cases are localized and have an excellent outcome. Ninety percent of pediatric patients diagnosed with melanoma are expected to be alive in 5 years. In patients with nodal disease, the outcomes are intermediate, with about 60% expected to survive long-term.

There is variability in prognosis depending on the age of diagnosis in pediatric patients. Children younger than 10 with melanoma often have poor prognostic features. They are more often non-White, have head and neck primary tumors, thicker primary lesions, a higher incidence of spitzoid morphology, vascular invasion and nodal metastases, and more often have syndromes that predispose them to melanoma. The treatment of melanomas, as in adult patients, is surgical excision with 1-cm margins for tumors <1 mm deep, 1- to 2-cm margins for tumors >1 mm and <2 mm deep, and 2-cm margins for tumors >2 mm deep. Sentinel lymph node biopsy has become a widespread practice in pediatric melanoma. It should be considered in lesions >1 mm and in thin lesions with ulceration, mitotic rate greater than 1 mm^2, and young age. Though pediatric patients are more likely to have nodal metastases than their adolescent counterparts, this has not been associated with a decrease in overall survival. Alternatively, in adolescents, nodal disease is a significant negative prognostic factor. Increased tumor thickness and ulceration are associated with lymph node positivity. If the sentinel node is positive, a lymph node dissection can be considered. Patients with regional lymph node involvement can be offered treatment with interferon alfa-2b or ipilimumab (FDA approved for 12 years of age and older). *BRAF* and *MEK* inhibitors are not currently available for pediatric patients; however, phase 1 and 2 clinical trials are currently ongoing for adolescent patients.

Given the lack of effective therapy for melanoma, prevention and early detection are the most effective measures. Emphasis should be given to avoidance of intense midday sun exposure between 10 AM and 3 PM; wearing of protective clothing such as a hat, long sleeves, and pants; and use of sunscreen. Adolescents should be counseled not to use tanning booths. Early detection includes frequent clinical and photographic examinations of patients at risk (dysplastic nevus syndrome) and prompt response to rapid changes in nevi (size, shape, color, inflammation, bleeding or crusting, and sensation). The ABCDE rule (asymmetry, border irregularities, color variability, diameter >6 mm, evolving), which is a useful screening tool for adults, may not be as effective for children. Unlike adult melanomas, which are usually pigmented, pediatric melanomas are often amelanotic and can mimic benign lesions such as warts and pyogenic granulomas. They are also more likely to have regular borders and to be less than 6 mm in diameter. They often present as papules or papulonodules. To highlight these differences from adult melanomas, an **ABCDE rule for pediatric melanoma** has been proposed: **A**melanotic, **B**leeding, **B**umps, uniform **C**olor, small **D**iameter, **D**e novo, and in **E**volution.

HALO NEVUS

Halo nevi occur primarily in children and young adults, most commonly on the back (Fig. 692.4). Development of the lesion may coincide with puberty or pregnancy. Several pigmented nevi frequently develop halos simultaneously. Subsequent disappearance of the central nevus over several months is the usual outcome, and the depigmented area usually repigments. Excision and histopathologic examination of the lesion is indicated only when the nature of the central lesion is in question. An acquired melanocytic nevus occasionally develops a peripheral zone of depigmentation over a period of days to weeks. There is a dense inflammatory infiltrate of lymphocytes and histiocytes in addition to the nevus cells. The pale halo reflects disappearance of the melanocytes. This phenomenon is associated with congenital nevi, blue nevi, Spitz nevi, dysplastic nevi, neurofibromas, primary and secondary malignant melanoma, and occasionally with poliosis, **Vogt-Koyanagi-Harada** syndrome, and pernicious anemia. Patients with vitiligo have an increased incidence of halo nevi. Individuals with halo nevi have circulating antibodies against the cytoplasm of melanocytes and nevus cells.

SPITZ NEVUS (SPINDLE AND EPITHELIOID CELL NEVUS)

Spitz nevus manifests most commonly in the first 2 decades of life as a pink to red, smooth, dome-shaped, firm, hairless papule on the face, shoulder, or upper limb (Fig. 692.5). Most are <1 cm in diameter, but they can achieve a size of 3 cm. Rarely, they occur as numerous grouped lesions. Visually similar lesions include pyogenic granuloma, hemangioma, nevocellular nevus, juvenile xanthogranuloma, and basal cell carcinoma, but these entities are histologically distinguishable. Classic-appearing Spitz nevi can be monitored with regular clinical and dermoscopic examination, and multiple dermoscopy studies

Table 692.1 Summary of Clinical and Histologic Features by Subtypes of Pediatric Melanoma

	SPITZOID MELANOMA	MELANOMA ARISING IN CMN	CONVENTIONAL MELANOMA
Clinical	Papule or nodule; frequently amelanotic, but can be any color (e.g., pink-red to blue-black); distribution is not limited to sun-exposed skin	New, rapidly growing nodule arising in the deep dermis or subcutaneous tissues of a CMN; commonly solitary and ulcerated; by comparison, proliferative nodules commonly occur in multiples and are not ulcerated	Children: typically papules or nodules of any color, but often amelanotic; most do not follow ABCD criteria; nodular subtype most common Adolescents: similar to presentation in adults with lesions having ABCD criteria
Histologic	Primary differential diagnosis is Spitz nevus vs atypical Spitz tumor; most cells have abundant eosinophilic cytoplasm and characteristic spitzoid cytomorphology; nuclear atypia is typically high grade; growth in the form of expansile nodules or sheets; ulceration, epidermal consumption, brisk deep mitotic activity, and poor maturation are often seen; epidermal hyperplasia might be seen on the surface, but Kamino bodies are relatively uncommon	The primary differential diagnosis is benign proliferative nodules arising in congenital nevi; compared with benign proliferative nodules, melanomas typically have epithelioid or small, blue cell, tumor-like morphology, with sheets of melanocytes with high-grade nuclear atypia; mitotic activity is high (often >3/mm^2); zones of necrosis or ulceration can be helpful in establishing a diagnosis	Nodular melanoma: similar to adult nodular melanoma; no horizontal growth phase present; superficial spreading melanoma: similar to superficial spreading melanoma in adults with a preceding horizontal growth phase, pagetosis, lentiginous growth, and junctional confluence with frequent alteration of the epidermal contour; precursor nevus is common

CMN, Congenital melanocytic nevi; ABCD, asymmetry, border irregularity, color variegation, diameter >6 mm.
From Merkel EA, Mohan LS, Shi K, et al. Paediatric melanoma: clinical update, genetic basis, and advances in diagnosis. *Lancet Child Adoles.* 2019;3:646–654, Table 1).

Fig. 692.4 Well-developed halo nevus.

Fig. 692.5 Dome-shaped red Spitz nevus.

have demonstrated a tendency for these benign lesions to develop a reticular or homogeneous pattern and/or regress over time. Guidelines recommend excision be reserved for suspicious lesions (>8-10 mm, with excessive growth, asymmetry, or ulceration) in children over 12 years of age and for suspicious lesions in all ages when melanoma cannot be excluded. If a nevus arouses clinical suspicion that it may be a melanoma, an excisional biopsy of the entire lesion is recommended. If the margins of excision of a Spitz nevus are positive but the biopsy sample suggested a typical Spitz nevus, reexcision of the site is no longer routinely recommended. Because Spitz nevi may be difficult to distinguish histopathologically from malignant melanoma, immunohistochemistry and genomic alteration studies can be useful adjunct tools. Atypical Spitz tumors are Spitz nevi with atypical histologic features or unknown malignant potential. Management for these tumors is not clearly defined and may range from clinical monitoring to yearly nodal ultrasonography to potentially sentinel lymph node biopsy and lymphadenectomy. Improving genetic profiling of these tumors may provide better prognostic information soon. Prognostic implication of positive sentinel lymph node biopsy has not been established, and given the potential morbidity of the procedure, it is often avoided.

ZOSTERIFORM LENTIGINOUS NEVUS (AGMINATED LENTIGINES)

Zosteriform lentiginous nevus is a unilateral, linear, bandlike collection of numerous 2- to 10-mm brown or black macules on the face, trunk, or limbs. The nevus may be present at birth or may develop during childhood. There are higher numbers of melanocytes in elongated rete ridges of the epidermis.

NEVUS SPILUS (SPECKLED LENTIGINOUS NEVUS)

Nevus spilus is a flat brown patch within which are darker flat or raised brown melanocytic elements with a prevalence of 2–3% (Fig. 692.6). It varies considerably in size and can occur anywhere on the body. The color of the macular component may vary from light to dark brown,

Fig. 692.6 Nevus spilus.

and the number of darker lesions may be low or high. Nevus spilus is rare at birth and is commonly acquired in late infancy or early childhood. Dark elements within the nevus are usually present initially and tend to increase in number gradually over time. The darker macules represent nevus cells in a junctional or dermal location; the patch has increased numbers of melanocytes in a lentiginous epidermal pattern. The malignant potential of these nevi is uncertain; nevus spilus is found more commonly in individuals with melanoma than in matched control subjects. Like congenital melanocytic nevi, the risk of melanoma developing within a nevus spilus is thought to be proportionate to the size of the lesion as a whole. The nevi need not be excised unless atypical features or recent clinical changes are noted.

NEVUS OF OTA AND NEVUS OF ITO

Nevus of Ota is more common among females and Asian and Black patients. This nevus consists of a permanent patch composed of partially confluent blue, black, and brown macules. Enlargement and darkening may occur with time. Occasionally, some areas of the nevus are raised. The macular nevi resemble the more common dermal melanocytosis of the lower back and buttocks in color and occur unilaterally in the areas supplied by the first and second divisions of the trigeminal nerve. Nevus of Ota differs from a more common dermal melanocytosis patch not only by its distribution but also by having a speckled rather than a uniform appearance. Both are forms of mid-dermal melanocytosis. Nevus of Ota also has a greater concentration of elongated, dendritic dermal melanocytes located in the upper rather than the lower portion of the dermis. This nevus is sometimes present at birth; in other cases, it may arise during the first or second decade of life. Patchy involvement of the conjunctiva, hard palate, pharynx, nasal mucosa, buccal mucosa, or tympanic membrane occurs in some patients. Malignant change is exceedingly rare. Laser therapy may effectively decrease the pigmentation but can be unpredictable.

Nevus of Ito is localized to the supraclavicular, scapular, and deltoid regions. This nevus tends to be more diffuse in its distribution and less mottled than nevus of Ota. It is also a form of mid-dermal melanocytosis. The only available treatments are masking with cosmetics and laser therapy.

BLUE NEVI

The common blue nevus is a solitary, asymptomatic, smooth, dome-shaped, blue to blue-gray papule <10 mm in diameter on the dorsal aspect of the hands and feet. Rarely, common blue nevi form large plaques. Blue nevus is nearly always acquired, often during childhood and more commonly in females. Microscopically, it is characterized by groups of intensely pigmented, spindle-shaped melanocytes in the dermis. This nevus is benign.

The cellular blue nevus is typically 1-3 cm in diameter and occurs most frequently on the buttocks and in the sacrococcygeal area. In addition to collections of deeply pigmented dermal dendritic melanocytes, cellular islands composed of large spindle-shaped cells are noted in the dermis and may extend into the subcutaneous fat. A histologic continuum may be seen from blue nevi to cellular blue nevi. A combined nevus is the association of a blue nevus with an overlying melanocytic nevus.

The blue-gray color that is characteristic of these nevi is an optical effect caused by dermal melanin. Longer wavelengths of visible light penetrate to the deep dermis and are absorbed there by melanin; shorter-wavelength blue light cannot penetrate deeply but instead is reflected back to the observer.

NEVUS DEPIGMENTOSUS (ACHROMIC NEVUS)

Nevi depigmentosi are usually present at birth; they are localized macular hypopigmented patches or streaks, often with irregular borders (Fig. 692.7). They can resemble hypomelanosis of Ito clinically, except that they are more localized and often unilateral. Small lesions may also resemble the ash leaf macules of tuberous sclerosis. Nevi depigmentosi appear to represent a focal defect in transfer of melanosomes to keratinocytes.

EPIDERMAL NEVI

Epidermal nevi may be visible at birth or may develop in the first few months or years of life. They affect both sexes equally and usually occur sporadically. Epidermal nevi are hamartomatous lesions characterized by hyperplasia of the epidermis and/or adnexal structures in a focal area of the skin.

Epidermal nevi are classified into a number of variants, depending on the morphology and extent of the individual nevus and the predominant epidermal structure (Table 692.2). An epidermal nevus may appear initially as a discolored, slightly scaly patch that, with maturation, becomes more linear, thickened, verrucous, and hyperpigmented. *Systematized* refers to a diffuse or extensive distribution of lesions, and *ichthyosis hystrix* indicates that the distribution is extensive and bilateral (Fig. 692.8). Morphologic types include pigmented papillomas, often in a linear distribution; unilateral hyperkeratotic streaks involving a limb and perhaps a portion of the trunk; velvety hyperpigmented plaques; and whorled or marbled hyperkeratotic lesions in localized plaques or over extensive areas of the body along Blaschko lines. An inflammatory linear verrucous variant is markedly pruritic and tends to become erythematous, scaling, and crusted. Many have *RAS* pathogenic variants.

Fig. 692.7 Large nevus depigmentosus of the abdomen.

The histologic pattern evolves as an epidermal nevus matures, but epidermal hyperplasia of some degree is apparent in all stages of development. One or another dermal appendage may predominate in a particular lesion. These nevi must be distinguished from lichen striatus, lymphangioma circumscriptum, shagreen patch of tuberous sclerosis, congenital hairy nevi, linear porokeratosis, linear lichen planus, linear psoriasis, the verrucous stage of incontinentia pigmenti, and nevus sebaceus (Jadassohn). Keratolytic agents such as retinoic acid and salicylic acid may be moderately effective in reducing scaling and controlling pruritus, but definitive treatment requires full-thickness excision; recurrence is usual if more superficial removal is attempted. Alternatively, the nevus may be left intact. Epidermal nevi are occasionally associated with other abnormalities of the skin and soft tissues; eyes; and nervous, cardiovascular, musculoskeletal, and urogenital systems. In these instances, the disorder is referred to as epidermal nevus syndrome. This syndrome, however, is not a distinct clinical entity.

Nevus Sebaceus (Jadassohn)

A relatively small, sharply demarcated, oval or linear, elevated, yellow-orange plaque that is usually devoid of hair, nevus sebaceus occurs on the head and neck of infants (Fig. 692.9). Although the lesion is characterized histopathologically by an abundance of sebaceous glands, all elements of the skin are represented. It is frequently flat and inconspicuous in early childhood. With maturity, usually during adolescence, the lesions become verrucous and studded with large rubbery nodules. The changing clinical appearance reflects the histologic pattern, which is characterized by a variable degree of hyperkeratosis, hyperplasia of the epidermis, malformed hair follicles, and often a profusion of sebaceous glands and

Table 692.2 Epidermal Nevi and Their Associated Genetic Syndromes

LESION	PATHOGENIC GENE VARIANT
KERATINOCYTIC NEVI	
Epidermal nevus	*FGFR3* *FGFR2* *HRAS* *KRAS* *NRAS* *PIK3CA*
Epidermolytic ichthyosis	*KRT1* *KRT10* *KRT2*
CHILD syndrome	*NSDHL*
PTEN nevus	*PTEN*
Proteus syndrome and epidermal nevi	*AKT1*
PIK3CA-related overgrowth spectrum/ CLOVES	*PIK3CA*
Acantholytic dyskeratotic epidermal nevus	*ATP2A2* *GJB2*
Inflammatory linear verrucous epidermal nevus	*Not identified to date*
ADNEXAL NEVI	
Nevus sebaceous/nevus sebaceous syndrome	*FGFR2* *HRAS* *KRAS* *NRAS*
Porokeratotic adnexal ostial nevus	*GJB2 (connexin 26)*
Nevus comedonicus/nevus comedonicus syndrome	*NEK9* *FGFR2*
Becker nevus/Becker nevus syndrome	*ACTB (beta-actin)*

CHILD, Congenital hemidysplasia with ichthyosiform erythroderma and limb defects; CLOVES, congenital lipomatous overgrowth and vascular and skeletal anomalies.

Fig. 692.8 Epidermal nevus (ichthyosis hystrix type).

Fig. 692.9 Orange-yellow nevus sebaceus of the scalp.

Fig. 692.10 Becker nevus on the shoulder of an adolescent male.

Fig. 692.11 Large smooth muscle hamartoma of the buttock.

the presence of ectopic apocrine glands. Sebaceous nevi are caused by somatic mosaic pathogenic variants in *HRAS* and *KRAS*. The disruption of these oncogenes helps explain the 14% incidence of these lesions developing tumors throughout a patient's lifetime. Most tumors are benign (trichoblastomas, syringocystadenoma papilliferum, trichilemmomas), but basal cell carcinoma can occur as well. Lesions may be monitored or excised if the family is unable to or uncomfortable with monitoring alone. Sebaceous nevi associated with central nervous system, skeletal, and ocular defects represent a variant of the epidermal nevus syndrome.

Becker Nevus (Becker Melanosis)

Becker nevus develops predominantly in males, during childhood or adolescence, initially as a hyperpigmented patch. The lesion commonly develops hypertrichosis, limited to the area of hyperpigmentation, and evolves into a unilateral, slightly thickened, irregular, hyperpigmented plaque. The most common sites are the upper torso and upper arm (Fig. 692.10). The nevus shows an increased number of basal melanocytes and variable epidermal hyperplasia. Becker melanosis is commonly associated with a smooth muscle hamartoma, which may appear as slight perifollicular papular elevations or slight induration. Stroking of such a lesion may induce smooth muscle contraction and make the hairs stand up **(pseudo-Darier sign)**. The nevus is benign, has no risk for malignant change, and is rarely associated with other anomalies.

NEVUS COMEDONICUS

An uncommon organoid nevus of epithelial origin, nevus comedonicus consists of linear plaques of plugged follicles that simulate comedones; they may be present at birth or may appear during childhood. The horny plugs represent keratinous debris within dilated, malformed pilosebaceous follicles. The lesions are most often unilateral and may develop at any site. Rarely, they are associated with other congenital malformations, including skeletal defects, cerebral anomalies, and cataracts. Although these lesions are often asymptomatic, some affected individuals experience recurrent inflammation, resulting in cyst formation, fistulas, and scarring. There is no effective treatment except full-thickness excision; palliation of larger lesions may be achieved by regular applications of a retinoic acid preparation.

CONNECTIVE TISSUE NEVUS

Connective tissue nevus is a hamartoma of collagen, elastin, and/or glycosaminoglycans of the dermal extracellular matrix. It may occur as a solitary defect or as a manifestation of an associated disorder. These nevi may occur at any site but are most common on the back, buttocks, arms, and thighs. They are skin-colored, ivory, or yellow plaques, 2-15 cm in diameter, composed of many tiny papules or grouped nodules that are frequently difficult to appreciate visually because of the subtle color changes. The plaques have a rubbery or cobblestone consistency on palpation. Biopsy findings are variable and include increased amounts and/or degeneration or fragmentation of dermal collagen, elastic tissue, or ground substance. Similar lesions occurring with tuberous sclerosis are called shagreen patches; however, shagreen patches consist only of excessive amounts of collagen. The association of many small papular connective tissue nevi with osteopoikilosis is called *dermatofibrosis lenticularis disseminata* **(Buschke-Ollendorff syndrome)**.

SMOOTH MUSCLE HAMARTOMA

Smooth muscle hamartoma is a developmental anomaly resulting from hyperplasia of the smooth muscle (arrector pili) associated with hair follicles. It is usually evident at birth or shortly thereafter as a flesh-colored or lightly pigmented plaque with overlying hypertrichosis on the trunk or limbs (Fig. 692.11). Transient elevation or a rippling movement of the lesion, caused by contraction of the muscle bundles, can sometimes be elicited by stroking of the surface (pseudo-Darier sign). Smooth muscle hamartoma can be mistaken for congenital pigmented nevus, but the distinction is important because the former has no risk for malignant melanoma and need not be removed.

Visit Elsevier eBooks+ at eBooks.Health.Elsevier.com for Bibliography.

Chapter 693

Hyperpigmented Lesions

Joel C. Joyce

DISORDERS OF PIGMENTATION

Pigmentation of the skin requires migration of melanoblasts from the neural crest to the dermal-epidermal junction, enzymatic processes to form pigment, structural components to contain the pigment (melanosomes), and transfer of pigment to the surrounding keratinocytes. Increased skin color may be generalized or localized and may result from various defects in any of these requirements. Some of these aberrations are a manifestation of systemic disease, others represent generalized or focal developmental or genetic defects, and still others may be nonspecific and the result of cutaneous inflammation.

EPHELIDES (FRECKLES)

Ephelides (freckles) are well-demarcated macules—light or dark brown, round, oval, or irregularly shaped—that occur in sun-exposed areas such as the face, upper back, arms, and hands. They are usually less than 3 mm in diameter and are induced by exposure to sun, particularly during the summer, and may fade or disappear during the winter. They are a result of increased sun-induced melanogenesis and melanosome transport from melanocytes to keratinocytes and not from increased numbers of melanocytes. They are more common in redheads and fair-haired individuals and first appear in the preschool years. Histologically, they are marked by increased melanin pigment in epidermal basal cells, which have more numerous and larger dendritic processes than the melanocytes of the surrounding paler skin. The lack of melanocytic proliferation or elongation of epidermal rete ridges distinguishes them from **lentigines**. Ephelides have been identified as a marker for increased risk for ultraviolet (UV)-induced neoplasia and hence melanoma independent of melanocytic nevi. Treatment is not required, but regular and consistent sun protection can slow ephelis development.

LENTIGINES

Lentigines, often mistaken for ephelides or junctional nevi, are small (usually <5 mm but occasionally 1-2 cm), round, dark-brown macules that can appear anywhere on the body. They can be solitary or grouped. Onset can be at an early age, particularly when associated with genetic syndromes, but can appear at any age. They are more common in darkly pigmented than in lightly pigmented individuals. They do not vary in coloration seasonally and remain permanently. Histologically they have elongated, club-shaped epidermal rete ridges with increased numbers of melanocytes and dense epidermal deposits of melanin. No nests of melanocytes are found. Lentigines are benign and, when few, may be viewed as a normal occurrence. They are seen most commonly on the lower lip and sun-exposed skin but may occur elsewhere, particularly when associated with syndromes, inadvertent or therapeutic radiation exposure, or patterned (inherited-tendency).

Eruptive/generalized lentiginosis (lentiginosis profusa) involves innumerable small pigmented macules that are present at birth or appear during childhood. There are no associated abnormalities, and mucous membranes are spared. Carney complex is an autosomal dominant syndrome characterized by multiple lentigines and neoplasms, including myxomas of the skin, heart (atrial), and breast; psammomatous melanotic schwannomas; epithelioid blue nevi of skin and mucosae; growth hormone–producing pituitary adenomas; and testicular Sertoli cell tumors. Components of the Carney complex have been described previously as the NAME (nevi, atrial myxoma, myxoid neurofibroma, ephelides) and LAMB (lentigines, atrial myxoma, mucocutaneous myxoma, blue nevi) syndromes. The complex is inherited in an autosomal dominant pattern and caused by an inactivating pathogenic variant of the *PRKAR1A* gene.

Multiple lentigines syndrome (formerly LEOPARD) is an autosomal dominant entity consisting of a generalized, symmetric distribution of *l*entigines (Fig. 693.1) in association with *e*lectrocardiographic *a*bnormalities, *o*cular hypertelorism, *p*ulmonary stenosis, *a*bnormal genitals (cryptorchidism, hypogonadism, hypospadias), growth *r*etardation, and sensorineural *d*eafness (type 1, *PTPN11* gene; type 2, *RAF1* gene). Other features include hypertrophic obstructive cardiomyopathy and pectus excavatum or carinatum.

Peutz-Jeghers syndrome is characterized by melanotic macules on the lips and mucous membranes and by gastrointestinal (GI) polyposis. It is inherited as an autosomal dominant trait caused by pathogenic variants of *STK11*. Onset is noted in infancy and early childhood when pigmented macules appear on the lips and buccal mucosa. The macules are usually a few millimeters in size but may be as large as 1-2 cm. Macules also occasionally appear on the palate, gums, tongue, and vaginal mucosa. Cutaneous macules may develop on the nose, hands, and feet; around the mouth, eyes, and umbilicus; and as longitudinal bands or diffuse hyperpigmentation of the nails. Pigmented macules often fade from the lips and skin during puberty and adulthood but generally do not disappear from mucosal surfaces. Buccal mucosal macules are the most constant feature of the disorder; in some families, occasional members may be affected only with the pigmentary changes. Indistinguishable pigmentary changes beginning in adult life, without intestinal involvement, also occur sporadically in individuals.

Polyposis usually involves the jejunum and ileum but may also occur in the stomach, duodenum, colon, and rectum (see Chapter 393). Episodic abdominal pain, diarrhea, melena, and intussusception are frequent complications. Patients have a significantly increased risk of GI tract and non–GI tract tumors at a young age. GI cancer has been reported in 2–3% of patients; the lifetime relative risk for GI malignancy is 13-15. The relative risk of non–GI tract malignancies, including ovarian, cervical, and testicular tumors, is 9. **Peutz-Jeghers syndrome** must be differentiated from other syndromes associated with multiple lentigines (Laugier-Hunziker syndrome), from ordinary freckling, from Gardner syndrome, and from Cronkhite-Canada syndrome, a disorder characterized by GI polyposis, alopecia, onychodystrophy, and diffuse pigmentation of the palms, volar aspects of the fingers, and dorsal hands. Treatment of Peutz-Jeghers melanotic macules is not required, but various lasers have been effective for cosmesis in some cases.

CAFÉ-AU-LAIT MACULES

Café-au-lait macules (CALMs) are uniformly hyperpigmented, sharply demarcated macular lesions, the hues of which vary with the normal degree of pigmentation of the individual: they are tan or light brown in White individuals and may be dark brown in Black children (Figs. 693.2 and 693.3). CALMs vary tremendously in size and may be large, covering a significant portion of the trunk or limb. The borders are usually

Fig. 693.1 Multiple lentigines in LEOPARD (*l*entigines in association with *e*lectrocardiographic *a*bnormalities, *o*cular hypertelorism, *p*ulmonary stenosis, *a*bnormal genitals [cryptorchidism, hypogonadism, hypospadias], growth *r*etardation, and sensorineural *d*eafness) syndrome.

smooth (ovoid), but some have exceedingly irregular borders. They are characterized by increased numbers of melanocytes and melanin in the epidermis but lack the clubbed rete ridges that typify lentigines. One to three CALMs are common in the general population, and up to 27% of children have a solitary CALM, depending on ancestry. The spots may be present at birth or may develop during childhood. The spots themselves are benign and may fade with age.

Large, often asymmetric café-au-lait spots with irregular borders are characteristic of patients with **McCune-Albright syndrome** (*GNAS1* gene; see Chapter 600.6). This disorder includes polyostotic fibrous dysplasia of bone, leading to pathologic fractures; precocious puberty; and numerous hyperfunctional endocrinopathies. The macular hyperpigmentation has an irregular border and may be present at birth or may develop late in childhood (see Fig. 693.3). The lesions are often unilateral and migrate along the lines of Blaschko. Cutaneous pigmentation is typically most extensive on the side showing the most severe bone involvement.

Fig. 693.2 Multiple café-au-lait macules on a child with neurofibromatosis type 1. *(From Eichenfield LF, Frieden IJ, Esterly NB. Textbook of Neonatal Dermatology. Philadelphia: Saunders; 2001:372.)*

Neurofibromatosis Type 1 (Von Recklinghausen Disease)

The CALM is the most familiar cutaneous hallmark of the autosomal dominant neurocutaneous syndrome known as **neurofibromatosis type 1** (*NF1*, see Fig. 693.2 and Chapter 636.1). Included in the criteria for this diagnosis is the presence of six or more CALMs (>5 mm in diameter in prepubertal patients and >15 mm in diameter in postpubertal patients; Table 693.1). Multiple CALMs commonly produce a freckled appearance of non–sun-exposed areas such as the axillae (Crowe sign), the inguinal and inframammary regions, and under the chin. CALMs can also be seen in segmental NF1, which results from somatic mosaicism arising from postzygotic pathogenic genetic variants in the *NF1* gene such that the clinical manifestations of NF1 are present only in a localized body segment. Another variant of NF1 is hereditary spinal neurofibromatosis, which is a rare disorder that generally presents with multiple CALM and multiple symmetric spinal root neurofibromas, but other stigmata of NF1 are typically absent.

CALM may be seen in **Watson syndrome**, an NF1 allelic variant (CALM, pulmonic stenosis intellectual disability, short stature), mosaic NF1, and **Legius syndrome** *(SPRED1)*. Differentiation of these disorders is noted in Figure 693.4 and Table 693.2.

CALMs also occur with certain other disorders, including other types of neurofibromatosis, but in many of these disorders the CALMs are not the defining diagnostic feature (see Table 693.2).

INCONTINENTIA PIGMENTI (BLOCH-SULZBERGER DISEASE)

See Chapter 636.7.

POSTINFLAMMATORY PIGMENTARY CHANGES

Either hyperpigmentation or hypopigmentation can occur as a result of cutaneous inflammation. Alteration in pigmentation usually follows a severe inflammatory reaction but may result from mild dermatitis. Dark-skinned individuals are more likely than fair-skinned children to show these changes. Although altered pigmentation may persist for weeks to months, patients can be reassured that these lesions are usually temporary. Sun protection and treatment of the underlying dermatitis can shorten duration.

Visit Elsevier eBooks+ at eBooks.Health.Elsevier.com for Bibliography.

Fig. 693.3 Coast of Maine café-au-lait macules. Irregularly bordered café au lait macules that tend not to cross the midline are characteristic of McCune-Albright syndrome. *(Modified from Collins MT, Singer FR, Rugster E. McCune-Albright syndrome and the extraskeletal manifestations of fibrous dysplasia. Orphanet J Rare Dis. 2012;7[Suppl. 1]:S4, Fig. 2.)*

Table 693.1 Previous and Recently Updated National Institutes of Health Diagnostic Criteria for Neurofibromatosis Type 1

CARDINAL CLINICAL FEATURES (ANY TWO OR MORE ARE REQUIRED FOR DIAGNOSIS)	NEW CHANGES
1. Six or more café-au-lait macules more than 5 mm in greatest diameter in prepubertal individuals and more than 15 mm in greatest diameter in postpubertal individuals	Must be bilateral (both sides of the body)*
2. Freckling in the axillary or inguinal regions	Must be bilateral (both sides of the body)*
3. Two or more neurofibromas of any type or one plexiform neurofibroma	No change
4. Two or more Lisch nodules	Or two or more choroidal abnormalities
5. Optic pathway glioma	No change
6. A distinctive osseous lesion such as sphenoid wing dysplasia	Added anterolateral bowing of tibia (tibial dysplasia) or pseudarthrosis of a long bone
7. First-degree relative (e.g., mother, father, sister, brother) with NF1	Changed to a parent with NF1 by the aforementioned criteria
	New criteria: A pathogenic NF1 variant

*If only café-au-lait macules and freckling are present, the diagnosis is most likely NF1, but exceptionally, the person might have another diagnosis such as Legius syndrome. At least one of the two pigmentary findings (café-au-lait macules or freckling) should be bilateral.
NIH, National Institutes of Health.
From Albaghdadi M, Thibodeau ML, Lara-Corrales I. Updated approach to patients with multiple café au lait macules. *Dermatol Clin.* 2022;40:9–23, Table 1.

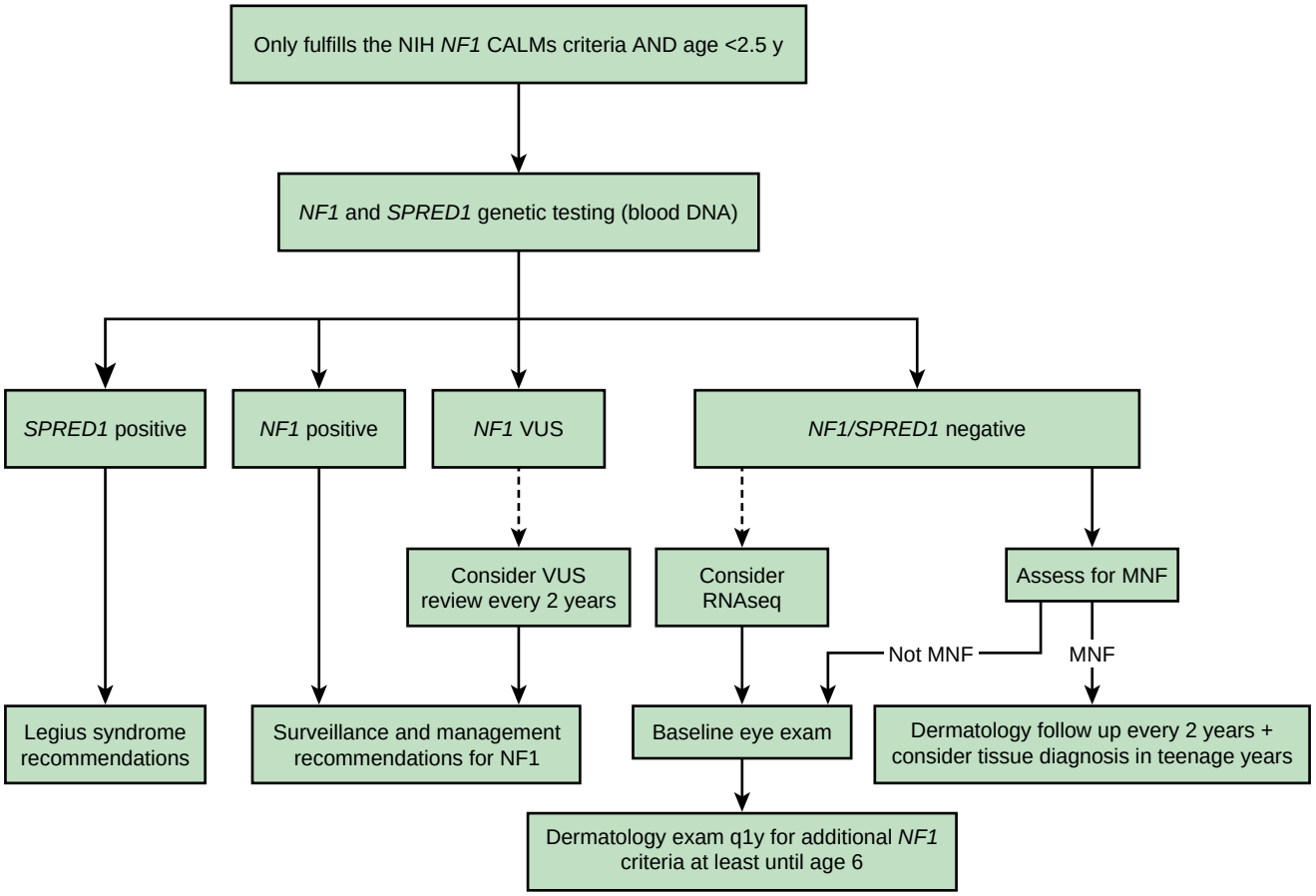

Fig. 693.4 Approach to the genetic diagnosis of young children who solely meet the CALM NIH criteria. MNF, Mosaic neurofibromatosis; NFI, neurofibromatosis; RNAseq, RNA sequencing; SPRED1, sprouty-related EVH1 domain-containing 1; VUS, variant of unknown significance. *(From Albaghdadi M, Thibodeau ML, Lara-Corrales I. Updated approach to patients with multiple café au lait macules. Dermatol Clin. 2022;40:9–23, Fig. 7.)*

Table 693.2 Conditions Featuring Café au Lait Macules

CONDITION	GENE (INHERITANCE)	ASSOCIATED FEATURES*	ADDITIONAL TESTING TO CONSIDER
Ataxia telangiectasia	*ATM* (AR)	Progeric changes in skin and hair, hypopigmented macules, progressive neurologic impairment, cerebellar ataxia, radiosensitivity, malignancy, immunocompromise, premature aging, and oculocutaneous telangiectasia	Karyotype* Serum AFP*
Cardiofaciocutaneous syndrome	*BRAF, MAP2K1/2* (AD)	Follicular hyperkeratosis, sparse, slow-growing, curly hair, ulerythema ophryogenes, melanocytic nevi, infantile hemangiomas, distinctive craniofacial features, cardiac anomalies, psychomotor delay, failure to thrive, and skin abnormalities	Gene panel for RASopathies
Constitutional mismatch repair deficiency syndrome	*MLH1, MSH2, MSH6, PMS2, EPCAM* (AR)	Adenomatous colonic polyps, multiple malignancies including colonic adenocarcinoma, glioblastoma, medulloblastoma, lymphoma, and a positive family history of Lynch syndrome–associated malignancies on both sides of the family	Gene panel for Lynch syndrome genes
Multiple café-au-lait spots	N/A (AD)	Six or more CALMs in multiple generations without NF1-associated features	No genetic testing available
Familial progressive hyperpigmentation and hypopigmentation syndrome	*KITLG* (AR)	Progressive, diffuse, partly blotchy, hyperpigmented lesions with scattered hypopigmented spots and lentigines	*KITLG* gene testing
Fanconi anemia	*FANCA* and other genes (AR)	Faint, ill-defined CALMs "shadow spots," hypopigmented macules, skinfold freckle-like macules, progressive bone marrow failure, short stature, hypogonadism, thumb or other radial ray abnormalities, and skeletal malformations	DNA breakage studies Gene panel for bone marrow failure syndromes
Legius syndrome	*SPRED1* (AD)	Six or more CALMs, intertriginous freckling, lipomas, macrocephaly, and learning disabilities	*SPRED1* gene testing
Noonan syndrome with lentigines	*PTPN11* (AD)	Small brown lentigines, café noir spots, CALMs, dysmorphic facial features, obstructive cardiomyopathy, pulmonary stenosis, growth abnormalities, and sensorineural hearing loss	*PTPN11* gene testing
McCune-Albright syndrome	*GNAS* (sporadic)	Coast of Maine CALMs associated with the lines of Blaschko, fibrous dysplasia, and endocrinopathies	*GNAS* gene testing from affected tissue (not blood)
Neurofibromatosis type 1	*NF1* (AD)	Six or more CALMs, skinfold freckling, neurofibromas, plexiform neurofibromas, Lisch nodules, optic gliomas, skeletal dysplasia, macrocephaly, nevus anemicus, and juvenile xanthogranuloma	*NF1* gene testing (DNA) ± RNA sequencing
Neurofibromatosis type 2	*NF2* (AD)	Schwannomas, cutaneous plaques with hypertrichosis, light irregularly bordered CALMs, subcutaneous nodular tumors, peripheral neuropathy, and ophthalmologic lesions	*NF2* gene testing (DNA) ± RNA sequencing
Noonan syndrome	*PTPN11, SOS2,* and other genes (AD)	Skin hyperlaxity, easy bruising, keratosis pilaris, temporal alopecia, distinctive facial features, developmental delay, learning difficulties, short stature, congenital heart disease, renal anomalies, lymphatic malformations	Gene panel for RASopathies
Piebaldism	*KIT* (AD)	Hypopigmented patches of skin and hair, hyperpigmentation of skin, CALMs, and axillary/inguinal freckling	*KIT* gene testing
PTEN hamartoma tumor syndrome	*PTEN* (AD)	Hamartomas, trichilemmomas, papillomatous papule, acral and plantar keratoses, lipomas, autism spectrum disorder, and macrocephaly	*PTEN* gene testing
Ring chromosome syndrome 7, 11, 12, 15, and 17	Sporadic	Depends on which chromosome but may include CALMs, nevus flammeus, dark pigmented nevi, patchy hypopigmented areas, microcephaly, mental delay, short stature, and skeletal abnormalities	Karyotype

Continued

Table 693.2 Conditions Featuring Café au Lait Macules—cont'd

CONDITION	GENE (INHERITANCE)	ASSOCIATED FEATURES*	ADDITIONAL TESTING TO CONSIDER
RSS	11p15 locus Chromosome 7 (sporadic) *CDKN1C, IGF2, PLAGL2, HMGA2* (AD)	Growth restriction, relative macrocephaly, craniofacial abnormalities, mild cognitive impairment, and delay	Molecular and methylation testing of 11p15 and uniparental disomy 7 ± RSS gene panel testing
Tuberous sclerosis	*TSC1, TSC2* (AD)	Facial angiofibromas, ash leaf macules, thumbprint-like macules, confetti-like skin lesions, shagreen patch, Koenen tumors, hamartomas, multisystem lymphangioleiomyomatosis, epilepsy, cognitive deficits	*TSC1* and *TSC2* gene testing

*All disorders listed have had multiple CALMs associated with them.

AD, Autosomal dominant; AFP, alpha fetoprotein; AR, autosomal recessive; ATM, ataxia telangiectasia variant gene; BRAF, B-RAF proto-oncogene; CDKN1C, cyclin-dependent kinase inhibitor 1C; EPCAM, epithelial cell adhesion molecule; FANCA, FA complementation group A; GNAS, GNAS complex locus; HMGA2, high mobility group AT-hook 2; IFG2, insulin-like growth factor 2; KIT, KIT proto-oncogene receptor tyrosine kinase; KITLG, *KIT* ligand; MAP2K1/2; mitogen-activated protein kinase 1, MLH1; MutL, *Escherichia coli* homolog of 1; MSH2; MutS, *E. coli* homolog of 2; MSH6, MutS , *E. coli* homolog of 6; NF1, neurofibromin 1; NF2, neurofibromin 2; PLAGL2, PLAG1-like zinc finger 2; PTEN, phosphate and tensin homolog; *PMS2,* postmeiotic segregation increased *Saccharomyces cerevisiae* 2; PTPN11, protein tyrosine phosphatase nonreceptor type 11; RSS, Russel-Silver syndrome; SPRED 1, sprouty-related EVH1 domain-containing protein 1; SOS2, SOS RAS/RAC guanine nucleotide exchange factor 2; TSC1, TSC1 gene; TSC2, TSC2 gene.

From Albaghdadi M, Thibodeau ML, Lara-Corrales I. Updated approach to patients with multiple café au lait macules. *Dermatol Clin.* 2022;40:9–23, Table 2.

Chapter 694

Hypopigmented Lesions

Joel C. Joyce

ALBINISM

Congenital oculocutaneous albinism (OCA) consists of partial or complete failure of melanin production in the skin, hair, and eyes despite the presence of normal number, structure, and distribution of melanocytes. These disorders are autosomal recessive in inheritance and result from pathogenic variants in genes related to melanin synthesis or the transport and storage of melanin within cells (Table 694.1). Tyrosinase is the copper-containing enzyme that catalyzes multiple steps in melanin biosynthesis (see Chapter 105.2), and gene variants resulting in abnormal function of tyrosinase and associated transporter proteins result in various OCA phenotypes. Gene variants resulting in abnormal structure and function of several cellular organelles may result in OCA with other extracutaneous complications.

Oculocutaneous Albinism with Abnormal Melanin Production

Oculocutaneous albinism type 1 (OCA1) is characterized by great reduction in or absence of tyrosinase activity caused by pathogenic gene variants in *TYR*. OCA1-A, the most severe form, is characterized by a lack of visible pigment in hair, skin, and eyes (Fig. 694.1). This manifests as photophobia, nystagmus, defective visual acuity, white hair, and white skin. The irises are blue-gray in oblique light and prominent pink in reflected light. OCA1-B, or yellow **albinism**, manifests at birth as white hair, pink skin, and gray eyes. This type is particularly prevalent in Amish communities. Progressively the hair becomes yellow-red, the skin tans lightly on exposure to the sun, and the irises may accumulate some brown pigment, with a resultant improvement in visual acuity. Photophobia and nystagmus are present but mild. OCA-TS is a temperature-sensitive type of albinism. The abnormal tyrosinase has decreased activity at 35–37°C (95–98.6°F). Therefore cooler regions of the body such as the limbs and head pigment to some degree, whereas other areas remain depigmented.

Oculocutaneous albinism type 2 (OCA2) ranges from nearly normal to closely resembling type 1 albinism. This is the most common form of albinism seen worldwide. Little or no melanin is present at birth, but pigment, particularly red-yellow pigment, may accumulate during childhood to produce straw-colored or light brown skin in White individuals. Pigmented nevi may develop. Progressive improvement in visual acuity and nystagmus occurs with aging. Black individuals may have yellow-brown skin, dark-brown freckles in sun-exposed areas, and brown coloration of the irises. Brown OCA is an allelic variant of OCA2. Prader-Willi and Angelman syndromes, which include hypopigmentation, have deletions that include the gene *(OCA2)* involved in OCA2.

Oculocutaneous albinism type 3 (OCA3), also known as *rufous albinism,* is seen predominantly in patients of African descent. It is characterized by red hair, reddish-brown skin, pigmented nevi, freckles, reddish-brown to brown eyes, nystagmus, photophobia, and decreased visual acuity. Vision abnormalities tend to be milder than in other forms of OCA. Abnormal gene variants in *TYRP1* are typically associated with development of OCA3.

Oculocutaneous albinism type 4 (OCA4) is a rare OCA with clinical findings similar to those in OCA2. Gene variants in *SLC45A2* are known to cause OCA4.

Additional rare variants of OCA exist that may present with similar clinical features to those noted earlier. See Table 694.1.

Cross-McKusick-Breen syndrome consists of tyrosinase-positive albinism with ocular abnormalities, cognitive impairment, spasticity, and athetosis. The genetic defect is unidentified.

Because of the absence of normal protection by adequate amounts of epidermal melanin, persons with albinism are predisposed to development of actinic keratoses and cutaneous carcinoma secondary to skin damage by ultraviolet light. Protective clothing and a broad-spectrum sunscreen (see Chapter 697) should be worn during exposure to sunlight.

Oculocutaneous Albinism with Organelle Dysfunction

Hermansky-Pudlak syndrome is a collection of autosomal recessive genetic disorders characterized by OCA, ceroid accumulation in lysosomes, and platelet dysfunction, resulting in prolonged bleeding time (Table 694.2). Ceroid accumulation over time can cause damage to the lung, kidneys, and gastrointestinal tract, with risk of development of granulomatous colitis and/or pulmonary fibrosis. Abnormalities in the development of platelet-dense granules lead to platelet dysfunction.

Table 693.2 Conditions Featuring Café au Lait Macules—cont'd

CONDITION	GENE (INHERITANCE)	ASSOCIATED FEATURES*	ADDITIONAL TESTING TO CONSIDER
RSS	11p15 locus Chromosome 7 (sporadic) *CDKN1C, IGF2, PLAGL2, HMGA2* (AD)	Growth restriction, relative macrocephaly, craniofacial abnormalities, mild cognitive impairment, and delay	Molecular and methylation testing of 11p15 and uniparental disomy 7 ± RSS gene panel testing
Tuberous sclerosis	*TSC1, TSC2* (AD)	Facial angiofibromas, ash leaf macules, thumbprint-like macules, confetti-like skin lesions, shagreen patch, Koenen tumors, hamartomas, multisystem lymphangioleiomyomatosis, epilepsy, cognitive deficits	*TSC1* and *TSC2* gene testing

*All disorders listed have had multiple CALMs associated with them.

AD, Autosomal dominant; AFP, alpha fetoprotein; AR, autosomal recessive; ATM, ataxia telangiectasia variant gene; BRAF, B-RAF proto-oncogene; CDKN1C, cyclin-dependent kinase inhibitor 1C; EPCAM, epithelial cell adhesion molecule; FANCA, FA complementation group A; GNAS, GNAS complex locus; HMGA2, high mobility group AT-hook 2; IFG2, insulin-like growth factor 2; KIT, KIT proto-oncogene receptor tyrosine kinase; KITLG, *KIT* ligand; MAP2K1/2; mitogen-activated protein kinase 1, MLH1; MutL, *Escherichia coli* homolog of 1; MSH2; MutS, *E. coli* homolog of 2; MSH6, MutS , *E. coli* homolog of 6; NF1, neurofibromin 1; NF2, neurofibromin 2; PLAGL2, PLAG1-like zinc finger 2; PTEN, phosphate and tensin homolog; *PMS2,* postmeiotic segregation increased *Saccharomyces cerevisiae* 2; PTPN11, protein tyrosine phosphatase nonreceptor type 11; RSS, Russel-Silver syndrome; SPRED 1, sprouty-related EVH1 domain-containing protein 1; SOS2, SOS RAS/RAC guanine nucleotide exchange factor 2; TSC1, TSC1 gene; TSC2, TSC2 gene.

From Albaghdadi M, Thibodeau ML, Lara-Corrales I. Updated approach to patients with multiple café au lait macules. *Dermatol Clin.* 2022;40:9–23, Table 2.

Chapter 694

Hypopigmented Lesions

Joel C. Joyce

ALBINISM

Congenital oculocutaneous albinism (OCA) consists of partial or complete failure of melanin production in the skin, hair, and eyes despite the presence of normal number, structure, and distribution of melanocytes. These disorders are autosomal recessive in inheritance and result from pathogenic variants in genes related to melanin synthesis or the transport and storage of melanin within cells (Table 694.1). Tyrosinase is the copper-containing enzyme that catalyzes multiple steps in melanin biosynthesis (see Chapter 105.2), and gene variants resulting in abnormal function of tyrosinase and associated transporter proteins result in various OCA phenotypes. Gene variants resulting in abnormal structure and function of several cellular organelles may result in OCA with other extracutaneous complications.

Oculocutaneous Albinism with Abnormal Melanin Production

Oculocutaneous albinism type 1 (OCA1) is characterized by great reduction in or absence of tyrosinase activity caused by pathogenic gene variants in *TYR*. OCA1-A, the most severe form, is characterized by a lack of visible pigment in hair, skin, and eyes (Fig. 694.1). This manifests as photophobia, nystagmus, defective visual acuity, white hair, and white skin. The irises are blue-gray in oblique light and prominent pink in reflected light. OCA1-B, or yellow **albinism**, manifests at birth as white hair, pink skin, and gray eyes. This type is particularly prevalent in Amish communities. Progressively the hair becomes yellow-red, the skin tans lightly on exposure to the sun, and the irises may accumulate some brown pigment, with a resultant improvement in visual acuity. Photophobia and nystagmus are present but mild. OCA-TS is a temperature-sensitive type of albinism. The abnormal tyrosinase has decreased activity at 35–37°C (95–98.6°F). Therefore cooler regions of the body such as the limbs and head pigment to some degree, whereas other areas remain depigmented.

Oculocutaneous albinism type 2 (OCA2) ranges from nearly normal to closely resembling type 1 albinism. This is the most common form of albinism seen worldwide. Little or no melanin is present at birth, but pigment, particularly red-yellow pigment, may accumulate during childhood to produce straw-colored or light brown skin in White individuals. Pigmented nevi may develop. Progressive improvement in visual acuity and nystagmus occurs with aging. Black individuals may have yellow-brown skin, dark-brown freckles in sun-exposed areas, and brown coloration of the irises. Brown OCA is an allelic variant of OCA2. Prader-Willi and Angelman syndromes, which include hypopigmentation, have deletions that include the gene *(OCA2)* involved in OCA2.

Oculocutaneous albinism type 3 (OCA3), also known as *rufous albinism,* is seen predominantly in patients of African descent. It is characterized by red hair, reddish-brown skin, pigmented nevi, freckles, reddish-brown to brown eyes, nystagmus, photophobia, and decreased visual acuity. Vision abnormalities tend to be milder than in other forms of OCA. Abnormal gene variants in *TYRP1* are typically associated with development of OCA3.

Oculocutaneous albinism type 4 (OCA4) is a rare OCA with clinical findings similar to those in OCA2. Gene variants in *SLC45A2* are known to cause OCA4.

Additional rare variants of OCA exist that may present with similar clinical features to those noted earlier. See Table 694.1.

Cross-McKusick-Breen syndrome consists of tyrosinase-positive albinism with ocular abnormalities, cognitive impairment, spasticity, and athetosis. The genetic defect is unidentified.

Because of the absence of normal protection by adequate amounts of epidermal melanin, persons with albinism are predisposed to development of actinic keratoses and cutaneous carcinoma secondary to skin damage by ultraviolet light. Protective clothing and a broad-spectrum sunscreen (see Chapter 697) should be worn during exposure to sunlight.

Oculocutaneous Albinism with Organelle Dysfunction

Hermansky-Pudlak syndrome is a collection of autosomal recessive genetic disorders characterized by OCA, ceroid accumulation in lysosomes, and platelet dysfunction, resulting in prolonged bleeding time (Table 694.2). Ceroid accumulation over time can cause damage to the lung, kidneys, and gastrointestinal tract, with risk of development of granulomatous colitis and/or pulmonary fibrosis. Abnormalities in the development of platelet-dense granules lead to platelet dysfunction.

Table 694.1 Forms of Oculocutaneous Albinism

TYPE	PERCENTAGE OF PATIENTS WORLDWIDE	GENETIC VARIANT	FUNCTION OF AFFECTED GENE	COMMENTS
OCA1A	50%	TYR (absence) = tyrosinase negative	Rate-limiting steps in melanin formation; hydroxylates L-tyrosine to L-DOPA and L-DOPA to DOPA-quinone	1:40,000; most severe cutaneous and ocular defects; highest risk of skin cancer; most common type in Whites
OCA1B		TYR (decreased)	Critical enzyme in melanin formation	Subtypes: yellow (yellow hair); platinum (metallic tinge); minimal pigment (only eyes darken)
OCA1-TS		TYR (variant site functions at higher temperatures)	Temperature sensitive	Melanin at cooler sites (arms, legs) Occurs in Siamese cats
OCA2	30%	P protein	Transmembrane protein that is key for melanosome biogenesis and normal processing and transport of TYR and *TRYP1*	1:36,000 (Whites); TYR-positive; includes brown albinism (1:3,900-1:10,000; most common form in patients of African origin; more pigment with advancing age); also includes red OCA2 with concomitant *MC1R* pathogenic variant and red hair
OCA3 (Rufous)	3%	*TRYP1*	Catalyzes oxidation of 5,6-dihydroxyindole-2-carboxylic acid monomers into melanin and stabilizes TYR so it can leave endoplasmic reticulum for incorporation into melanosomes	1:8,500 Africans; reddish-bronze color to skin and hair
OCA4	17%	*MATP/SLC45A2*	Membrane transporter in melanosomes and regulates pH	Rare (Whites); 27% of OCA in Japan; resembles OCA2
OCA5		Unknown (4q24)	—	One Pakistani family
OCA6		*SLC24A5*	$Na^+/K^+/Ca^+$ + solute carrier protein involved in melanosome maturation and melanin biosynthesis	Heterogeneous extent of pigmentation
OCA7		*LRMDA*	Melanocyte differentiation	Rare; skin color lighter only when compared with relatives

LRMDA, Leucine-rich melanocyte differentiation associated protein; MATP, membrane-associated transporter protein; OCA, oculocutaneous albinism; P protein, pink-eyed dilution protein; TS, temperature sensitive; TYR, tyrosinase; TRYP1, tyrosinase-related protein 1.
From Paller AS, Mancini AJ. *Hurwitz Clinical Pediatric Dermatology*, 6th ed. Philadelphia: Elsevier; 2022: Table 11.1, p. 291.

Fig. 694.1 White hair and skin in oculocutaneous albinism type 1 (OCA1).

Chédiak-Higashi syndrome (see Chapter 170) is another genetic abnormality associated with dysfunction of lysosome-related organelles. Patients with Chédiak-Higashi syndrome have hypopigmentation of the skin, eyes, and hair; prolonged bleeding times and easy bruising; recurrent infections; abnormal natural killer cell function; and peripheral neuropathy. Chédiak-Higashi syndrome is caused by pathogenic gene variants in the *CHS1/LYST* gene, which is a lysosomal trafficking regulatory gene.

MELANOBLAST MIGRATION ABNORMALITIES

Piebaldism

A congenital autosomal dominant disorder, piebaldism is characterized by sharply demarcated amelanotic patches that occur most frequently on the forehead, anterior scalp (producing a white forelock), ventral trunk, elbows, and knees. Islands of normal or darker-than-normal pigmentation may be present within the amelanotic areas (Fig. 694.2). The plaques are a result of a permanent localized absence of melanocytes as a result of a defect in the *KIT* protooncogene, which encodes the cell surface receptor transmembrane tyrosine kinase. The pattern of depigmentation arises from defective melanoblast migration from the neural crest during development. The reason that piebaldism is a localized and not a generalized process remains unknown. Piebaldism must be differentiated from vitiligo, which may be progressive and is not usually congenital, nevus depigmentosus, and Waardenburg syndrome.

Waardenburg Syndrome

Waardenburg syndrome also manifests at birth as localized areas of depigmented skin and hair. There are four main types of Waardenburg syndrome with additional subtypes identified. The hallmark of **Waardenburg type 1** (WS1) is the white forelock, which is seen in

Table 694.2 Clinical Features of Hermansky-Pudlak Syndrome

TYPE	PATHOGENIC VARIANT	UNDERLYING CAUSE	FINDINGS ASSOCIATED WITH THE CUTANEOUS PIGMENT DILUTION
HPS-1 HPS-4	*HPS1* (82% of HPS in Puerto Ricans; 37% in non–Puerto Ricans) *HPS4*	BLOC-3 deficiency: HPS1 and HPS4 associate in a complex (BLOC-3) that regulates biogenesis of melanosomes, platelet-dense bodies, and the lung lamellar body	Nystagmus, decreased visual acuity; prolonged bleeding; pulmonary fibrosis (typical onset in young adults); granulomatous colitis (up to one third of patients)
HPS-2 HPS-10	*AP3B1* (~10% of non–Puerto Ricans) and *AP3D1* (rare)	AP-3 deficiency: *AP3B1* and APSD1 encode subunits of AP-3, which mediates protein trafficking into transport vesicles of the lysosome (and is thus also involved in immune function)	Nystagmus, decreased visual acuity; prolonged bleeding; congenital neutropenia and impaired NK cell cytotoxicity; recurrent bacterial and viral infections; conductive hearing loss; fibrosing lung disease (30–50%) beginning during childhood; seizures in HPS-10
HPS-3 HPS-5 HPS-6	*HPS3* (~20% in Puerto Ricans and ~12% in non–Puerto Ricans) *HPS5* (~9% in non–Puerto Ricans) *HPS6* (~16% in non–Puerto Ricans)	BLOC-2 deficiency: HPS3, HPS5, and HPS6 are associated in a complex (BLOC-2) that localizes tyrosinase and *TRYP1*, allowing them to function normally	Nystagmus, decreased visual acuity; mild extraocular manifestations (bleeding, skin pigmentation)
HPS-7 HPS-8 HPS-9	*DTNBP1* *BLOC1S3* *BLOC1S6/PLDN*	BLOC-1 deficiency: Dysbindin, BLOC1S3, and BLOC1S6 are subunits of BLOC-1 and also involved in skin melanosome biogenesis and platelet function	Nystagmus, decreased visual acuity; prolonged bleeding (may not be a feature with *BLOC1S6* pathogenic variant)

BLOC, Biogenesis of lysosome-related organelles complex; DTNBP1, dystrobrevin binding protein 1; HPS, Hermansky-Pudlak syndrome.
From Paller AS, Mancini AJ. *Hurwitz Clinical Pediatric Dermatology*, 6th ed. Philadelphia: Elsevier; 2022: Table 11.2, p. 295.

Fig. 694.2 Depigmented macule with islands of hyperpigmentation in piebaldism.

20–60% of patients. Only 15% of patients have areas of depigmented skin. Deafness occurs in 9–37%, heterochromia irides in 20%, and unibrow (synophrys) in 17–69% of those affected. Dystopia canthorum (i.e., telecanthus) is seen in all patients with WS1. **Waardenburg type 2** is similar to type 1, except that patients with type 2 lack dystopia canthorum, but they also have a higher incidence of deafness. **Waardenburg type 3** is similar to WS1, except that patients also have limb abnormalities. It is also called *Klein-Waardenburg syndrome*. **Waardenburg type 4** is also called *Shah-Waardenburg syndrome*. Patients with this type all have Hirschsprung disease. Dystopia canthorum is seldom seen in these patients. Multiple pathogenic variants in multiple genes have been identified as causative of the various types of **Waardenburg syndrome** (Table 694.3).

Tuberous Sclerosis Complex (*TSC1*, *TSC2* Genes)

See Chapter 636.2 for a discussion of this complex.

Hypomelanosis of Ito

Hypomelanosis of Ito is a rare congenital skin disorder affecting children that can have associated defects in several organ systems. There is no evidence for genetic transmission; chromosomal mosaicism and chromosomal translocations have been reported. Hypomelanosis of Ito is a descriptive diagnosis. Blaschkoid or mosaic hypomelanosis may be better descriptive terms. It is also known as *incontinentia pigmenti achromians*.

The skin lesions of hypomelanosis of Ito are generally present at birth but may be acquired in the first 2 years of life. The lesions are similar to a negative image of those present in incontinentia pigmenti, consisting of patterned, hypopigmented macules arranged over the body surface in sharply demarcated whorls, streaks, and patches that follow the lines of Blaschko (Fig. 694.3). The palms, soles, and mucous membranes are spared. The hypopigmentation remains unchanged throughout childhood but fades during adulthood. The degree of depigmentation varies from hypopigmented to achromic. Neither inflammatory nor vesicular lesions precede the development of the pigmentary changes as in incontinentia pigmenti. The hypopigmented areas demonstrate fewer and smaller melanocytes and a decreased number of melanin granules in the basal cell layer than normal. Inflammatory cells and pigment incontinence are lacking.

The majority of patients with hypomelanosis of Ito have no associated abnormalities, but involvement of other organ systems can rarely occur. The most commonly associated abnormalities involve the nervous system, including intellectual disability (70%), seizures (40%), microcephaly (25%), and muscular hypotonia (15%). The musculoskeletal system is the second most frequently involved system, affected by scoliosis and thoracic and limb deformities. Minor ophthalmologic defects (strabismus, nystagmus) are present in 25% of patients, and 10% have cardiac defects. These frequencies are likely to be overestimated because patients with isolated skin disease often do not seek further evaluation. The differential diagnosis includes systematized nevus depigmentosus, which is a stable leukoderma not associated with systemic manifestations. Differentiation from incontinentia pigmenti, particularly the hypopigmented fourth stage, is critical for genetic counseling because incontinentia pigmenti, unlike hypomelanosis of Ito, is inherited.

Table 694.3 Subtypes of Waardenburg Syndrome

DISORDER	INHERITANCE	GENE(S)	OTHER COMMENTS
WS1	AD	*PAX3*	Most common form; dystopia canthorum
WS2	AD	*MITF, SOX10, SLUG, KITLG, KIT*	No facial dysmorphism; high risk of hearing loss; iris heterochromia
WS3	AD/AR	*PAX3*	Associated limb abnormalities
WS4A	AD/AR	*EDNRB*	Aganglionic megacolon
WS4B	AD/AR	*EDN3*	Aganglionic megacolon
WS4C	AD	*SOX10*	Aganglionic megacolon
PCWH	AD	*SOX10*	Severe hypotonicity with central nervous system and peripheral nerve abnormalities

AD, Autosomal dominant; AR, autosomal recessive; EDN, endothelin; EDNRB, endothelin receptor beta; PCWH, peripheral demyelinating neuropathy, central dysmyelination, Waardenburg syndrome, and Hirschsprung disease.
From Paller AS, Mancini AJ. *Hurwitz Clinical Pediatric Dermatology*, 6th ed. Philadelphia: Elsevier; 2022: Table 11.4, p. 298.

Fig. 694.3 Marbled hypopigmented streaks on the abdomen in hypomelanosis of Ito.

Vitiligo

Epidemiology and Etiology

Vitiligo is an *acquired* macular depigmentation disorder associated with the destruction of melanocytes. The disorder represents a clinical end-point resulting from a complex interaction of environmental, genetic, and immunologic factors. Autoimmune, genetic, autocytotoxic, and neural theories have been postulated. The prevalence is 0.5–2% of most populations.

There is an autoimmune component to vitiligo. Eighty percent of patients with active disease have anti-melanocyte antibodies to one of several antigens on melanocytes. These antibodies appear to be cytotoxic for melanocytes. There is also a correlation between disease activity and the titer of serum anti-melanocyte antibody. Melanocyte-specific $CD8^+$ T lymphocytes are also involved in the pathogenesis of vitiligo. These antibodies and T cells recognize a variety of melanocyte enzymatic and structural proteins.

The genetic epidemiology of vitiligo is part of a broader genetically determined autoimmune and autoinflammatory diathesis. Between 15 and 20% of patients with generalized vitiligo have one or more affected first-degree relatives. In these families the genetic pattern is suggestive of polygenic, multifactorial inheritance. In the other patients, the disease occurs sporadically. Genome-wide association studies in patients with vitiligo have identified a substantial number of associated genes, of which consistent association is seen with *DDR1*, *XBP1*, *NLRP1*, *PTPN22*, and *COMT*, although many other genes have been implicated.

Table 694.4 Vitiligo Subgroups

DERMATOMAL OR SEGMENTAL	NONDERMATOMAL OR NONSEGMENTAL
Onset in childhood	Can begin in childhood; 50% before 20 yr of age
Less common	More common
Rapid onset; stabilizes in ~1 yr	Progressive, with flare-ups; lifelong
Involves hair after onset	Involves hair in later stages
Autoimmune diseases uncommon	Personal or family history of autoimmunity* common
Often occurs on the face or upper extremities	Occurs at sites sensitive to pressure, friction, or trauma; Koebner phenomenon
Responsive to autologous grafting, with repigmentation	Relapses after autologous grafting
Difficult to distinguish from nevus depigmentosus	Associated with halo nevus formation

*Autoimmune thyroid diseases, type 1 diabetes, psoriasis, pernicious anemia, systemic lupus erythematosus, Addison disease, alopecia areata.

Fig. 694.4 Sharply demarcated, symmetric, depigmented areas of vitiligo.

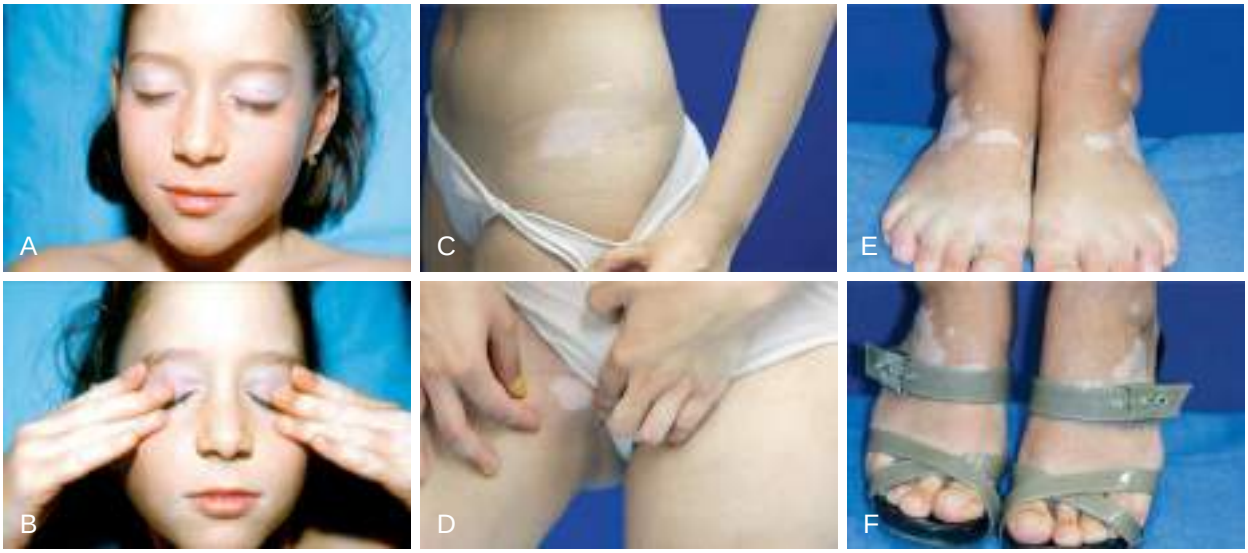

Fig. 694.5 Koebner phenomenon in relation to daily living activities. **A** and **B**, Eye rubbing. **C** and **D**, Underwear print. **E** and **F**, Shoe print. *(From Ezzedine K, Eleftheriadou V, Whitton M, van Geel N. Vitiligo. Lancet. 2015;386:74–82, Fig. 5.)*

Many authorities believe that the cause of melanocyte destruction in vitiligo is an interferon gamma–based immune destruction and melanocyte apoptosis. It has also been suggested that melanocytes are destroyed because of the accumulation of a toxic melanin synthesis intermediate and/or lack of protection from hydrogen peroxide and other oxygen radicals. There is in vitro evidence that some of these metabolites may be lethal to melanocytes.

Clinical Manifestations

There are two subtypes of vitiligo, generalized (nonsegmental) and segmental, which likely are distinctly different diseases (Table 694.4). Generalized vitiligo (85–90% of cases) may be divided into widespread (type A) and localized (type B). Approximately 50% of all patients with vitiligo have onset before 18 years of age, and 25% demonstrate depigmentation before age 8 years. Most children have the generalized form, but the segmental type is more common among children than among adults. Patients with the generalized form usually present with a remarkably symmetric pattern of white macules and patches (Fig. 694.4); the margins may be somewhat hyperpigmented. The patches tend to be acral and/or perioriﬁcial. Occasionally, almost the entire skin surface becomes depigmented. Vitiligo lesions may develop in areas of traumatized skin (Koebner phenomenon) (Fig. 694.5).

There are several varieties of localized vitiligo. One form is halo nevus phenomenon, whereby benign moles develop depigmented rings at the periphery (see Chapter 692). Premature graying of scalp hair (canities) has also been considered a form of localized vitiligo. In segmental vitiligo, depigmented areas are typically limited to a dermatomal distribution. This type of vitiligo has a rapid onset and progression in a localized area without the development of depigmentation in other areas.

A number of **autoimmune diseases** occur in up to 20% of patients with vitiligo, including Addison disease, Hashimoto thyroiditis, pernicious anemia, diabetes mellitus, hypoparathyroidism, and polyglandular autoimmune syndrome with selective immunoglobulin A deficiency. In addition, other diseases with possible immune defects, such as alopecia areata and morphea, have been seen in patients with vitiligo.

Vogt-Koyanagi-Harada syndrome is vitiligo associated with uveitis, dysacusia, meningoencephalitis, and depigmentation of the skin, scalp hair, eyebrows, and eyelashes. In **Alezzandrini syndrome**, vitiligo is associated with tapetoretinal degeneration and deafness. It is typically unilateral. Light microscopic examination of early lesions shows mild inflammatory change. Over time, degenerative changes occur in melanocytes, leading to their complete disappearance.

The differential diagnosis of vitiligo includes other causes of widespread acquired leukoderma. The two most common alternative diagnoses are pityriasis versicolor and postinflammatory hypopigmentation.

Treatment

Localized areas of vitiligo may respond to a potent topical steroid (class I or II) and/or topical calcineurin inhibitor (tacrolimus or pimecrolimus), depending on the location of involvement. Therapy with Janus kinase inhibitors has been effective in adults with vitiligo. In patients with more extensive involvement, narrow-band ultraviolet light B (NBUVB) [UVB311] is the treatment of choice. Treatment with NBUVB is often undertaken simultaneously with topical therapy. Systemic therapy and whole-body depigmentation are rarely used in children, although systemic corticosteroids can be given to slow the rate of change in rapidly progressive depigmentation. In all forms of vitiligo, response to therapy may be slow, taking many months to years. For those not interested in treatment, cover-up cosmetics may be used. All areas of vitiligo are susceptible to sun damage, and care should be taken to minimize sun exposure of affected areas. Spontaneous remission may be seen in a small percentage of cases.

Visit Elsevier eBooks+ at eBooks.Health.Elsevier.com for Bibliography.

Chapter 695

Vesiculobullous Disorders

Joel C. Joyce

Many diseases are characterized by vesiculobullous lesions; they vary considerably in cause, age of onset, and pattern. The morphology and distribution of the blisters in these **blistering disorders** often provides a visual clue to the location of the lesion within the skin. Blisters localized to the epidermal layers are thin-walled, relatively flaccid, and easily ruptured. Subepidermal blisters are tense, thick-walled, and more durable. Biopsies of blisters can be diagnostic because the level of cleavage within the skin and associated findings, such as the nature of the inflammatory infiltrate, are characteristic for a particular disorder. Other diagnostic procedures, such as direct immunofluorescence on affected tissue and indirect immunofluorescence from a patient's serum to detect circulating antibodies, can often help to distinguish vesiculobullous disorders that have nearly identical histopathologic findings (Table 695.1).

695.1 Erythema Multiforme

Joel C. Joyce

ETIOLOGY

Among the numerous factors implicated in the etiology of erythema multiforme (EM), infection with herpes simplex virus (HSV) is the most common. Other viral infections, as well as vaccinations, have been implicated as triggers. Infection with *Mycoplasma pneumoniae* and other pathogens may produce a similar lesion, particularly in children and young adults; differentiation from Stevens-Johnson syndrome and reactive infectious mucocutaneous eruptions (RIMEs; see Chapter 695.2) can be difficult. HSV labialis and, less commonly, HSV genitalis are implicated in 60–70% of episodes of EM and are believed to trigger nearly all episodes of *recurrent* (six or more episodes per year) EM, frequently in association with sun exposure. HSV antigens and DNA are present in skin lesions of EM but are absent in nonlesional skin. The presence of the human leukocyte antigens A33, B62, B35, DQw3 (DQB1*0301 split), and DR53 is associated with an increased risk of HSV-induced EM, particularly the recurrent form. Most patients experience a single self-limited episode of EM. Lesions of HSV-induced recurrent EM typically develop 10-14 days after onset of recurrent HSV eruptions and have a similar appearance from episode to episode, but they may vary in frequency and duration in a given patient. Not all episodes of recurrent HSV evolve into EM in susceptible patients.

Drug-related EM is less common (<10% of patients) and may be associated with nonsteroidal antiinflammatory agents, including acetaminophen, sulfonamides, and other antibiotics. The differential diagnosis in drug-related EM should include severe cutaneous adverse reactions such as Stevens-Johnson syndrome (see Chapter 695.3) and drug hypersensitivity syndrome (sometimes called drug reaction [rash] with eosinophilia and systemic symptoms [DRESS] or drug-induced hypersensitivity syndrome [DIHS]) (see Chapter 686.2).

CLINICAL MANIFESTATIONS

EM has numerous morphologic manifestations on the skin, varying from erythematous macules, papules, vesicles, bullae, or urticarial plaques to patches of confluent erythema. The eruption appears most commonly in patients between the ages of 10 and 40 years (with highest incidence in males in the second decade) and usually is asymptomatic, although a burning sensation or pruritus may be present. The diagnosis of EM is established by finding the classic lesion: doughnut-shaped, **targetoid** (target-like, iris, or bull's-eye) papules with an erythematous outer border, an inner pale ring, and a dusky purple to necrotic center (which sometimes blisters and erodes; Figs. 695.1 and 695.2).

EM is characterized by an abrupt, symmetric cutaneous eruption, most commonly on the extensor upper extremities; lesions are relatively sparse on the face, trunk, and legs. Lesions can be seen on the palms and soles. The eruption often appears initially as red macules or urticarial plaques that evolve and expand centrifugally to form lesions up to 2 cm in diameter with a dusky to necrotic center. Lesions of a particular episode typically appear within 72 hours and remain fixed in place (average duration: 7 days). Oral lesions may occur with a predilection for the vermilion border of the lips and the buccal mucosa, but other mucosal surfaces are usually spared. EM may manifest initially as urticaria-like lesions, but in contrast to urticaria, a given lesion of EM does not fade within 24 hours. Prodromal symptoms are generally absent. Prognosis is favorable with limited long-term morbidity. Lesions typically resolve without sequelae in approximately 2 weeks, but in darker pigmented individuals, pigmentary alterations at the site of lesions can be long-standing. *Progression to Stevens-Johnson syndrome does not occur.* Many authors distinguish between **EM minor** (mainly cutaneous typical or atypical **targetoid** lesions affecting <10% body surface area plus no or limited mucosal involvement, often limited to one site, such as the mouth) and **EM major** (same cutaneous involvement pattern as EM minor plus two or more mucosal sites with more severe oral involvement). EM major and Stevens-Johnson syndrome are separate entities.

Fig. 695.1 Early fixed papules with a central dusky zone on the dorsum of the hand of a child with erythema multiforme caused by herpes simplex virus. *(From Weston WL, Lane AT, Morelli J. Color Textbook of Pediatric Dermatology, 3rd ed. St. Louis: Mosby; 2002:156.)*

Fig. 695.2 "Target" or "iris" lesions with characteristic central dusky zone on palms of a child with erythema multiforme caused by herpes simplex virus. *(From Weston WL, Lane AT, Morelli J. Color Textbook of Pediatric Dermatology, 3rd ed. St. Louis: Mosby; 2002:156.)*

Table 695.1 Sites of Blister Formation and Diagnostic Studies for the Vesiculobullous Disorders

DISORDER	BLISTER CLEAVAGE SITE	DIAGNOSTIC STUDIES
Acrodermatitis enteropathica	IE	Serum zinc level
Bullous impetigo	GL	Smear, culture
Bullous pemphigoid	SE (junctional)	Direct and indirect immunofluorescence
Candidiasis	SC	KOH preparation, culture
Dermatitis herpetiformis	SE	Direct immunofluorescence
Dermatophytosis	IE	KOH preparation, culture
Dyshidrotic eczema	IE	Routine histopathology
EB simplex	IE	Electron microscopy, immunofluorescence mapping, genetic testing
Junctional EB	SE (junctional)	Electron microscopy, immunofluorescence mapping, genetic testing
Recessive dystrophic EB	SE	Electron microscopy, immunofluorescence mapping, genetic testing
Dominant dystrophic EB	SE	Electron microscopy, immunofluorescence mapping, genetic testing
Epidermolytic ichthyosis	IE	Routine histopathology
Erythema multiforme	SE	Routine histopathology
Erythema toxicum	SC, IE	Smear for eosinophils
Incontinentia pigmenti	IE	Smear for eosinophils Routine histopathology
Insect bites	IE	Routine histopathology
Kindler syndrome	IE, SE	Electron microscopy, immunofluorescence mapping, genetic testing
Linear IgA dermatosis	SE	Direct immunofluorescence
Mastocytosis	SE	Routine histopathology
Miliaria crystallina	IC	Routine histopathology
Neonatal pustular melanosis	SC, IE	Smear for neutrophils
Pemphigus foliaceus	GL	Direct and indirect immunofluorescence studies
		Tzanck smear
Pemphigus vulgaris	Suprabasal	Direct and indirect immunofluorescence studies
		Tzanck smear
Scabies	IE	Skin scraping
Staphylococcal scalded skin syndrome	GL	Routine histopathology
Toxic epidermal necrolysis	SE	Routine histopathology
Viral blisters	IE	Viral PCR (preferred) or direct immunofluorescence testing for HSV and VZV Routine histopathology

EB, Epidermolysis bullosa; GL, granular layer; HSV, herpes simplex virus; IC, intracorneal; IE, intraepidermal; KOH, potassium hydroxide; PCR, polymerase chain reaction; SC, subcorneal; SE, subepidermal; VZV, varicella-zoster virus.

Pathogenesis

The pathogenesis of EM is unclear, but it may be a host-specific, cell-mediated immune response to an antigenic stimulus, resulting in damage to keratinocytes. The HSV *Pol1* gene expressed in HSV-induced recurrent EM lesions upregulates/activates the transcription factor SP1 and inflammatory cytokines. These cytokines, released by activated mononuclear cells and keratinocytes, may contribute to epidermal cell death and constitutional symptoms.

Pathology

Microscopic findings in EM are variable but may aid in diagnosis. Early lesions typically have slight intercellular edema, rare dyskeratotic keratinocytes, and basal vacuolation in the epidermis, as well as a perivascular lymphohistiocytic infiltrate with edema in the upper dermis. More mature lesions demonstrate accentuation of these characteristics and the development of lymphocytic exocytosis, as well as an intense, perivascular, and interstitial mononuclear infiltrate in

the upper third of the dermis. In severe cases, the entire epidermis becomes necrotic.

Differential Diagnosis

The differential diagnosis of EM also includes RIME, bullous pemphigoid, pemphigus vulgaris, linear immunoglobulin (Ig) A dermatosis, graft-versus-host disease, fixed-drug eruption, bullous drug eruption, urticaria, viral infections such as HSV, reactive arthritis syndromes, Kawasaki disease, Sweet syndrome, Behçet disease, vasculitis, erythema annulare centrifugum, and polymorphous drug eruption. EM that primarily involves the oral mucosa may be confused with Stevens-Johnson syndrome, bullous pemphigoid, pemphigus vulgaris, vesiculobullous or erosive lichen planus, Behçet syndrome, recurrent aphthous stomatitis, and primary herpetic gingivostomatitis. In contrast to EM, Stevens-Johnson syndrome manifests with erythematous or purpuric macules (no papules) and usually begins on the trunk. Serum sickness–like reaction to cefaclor (or other antibiotics) may also manifest as EM-like lesions; the lesions may develop a dusky to purple center, but in most cases, the eruption of cefaclor-induced serum sickness–like reaction is pruritic, transient, and migratory and is probably urticarial rather than true EM.

Treatment

Treatment of EM is supportive. If secondary to underlying infection, the infection should be treated. Topical emollients, systemic antihistamines, and nonsteroidal antiinflammatory agents do not alter the course of the disease but may provide symptomatic relief. For individuals with severe mucosal disease, opioids can be used to control pain, and diligent oral hygiene is essential. No controlled, prospective studies support the use of corticosteroids in the management of EM. Prophylactic oral acyclovir given for 6 months may be effective in controlling *recurrent episodes of HSV-associated EM*. On discontinuation of acyclovir, both HSV and EM may recur, although episodes may be less frequent and milder. For recurrent cases not responsive to antiviral therapy, steroid-sparing agents used to decrease frequency of recurrence include azathioprine, mycophenolate mofetil, and dapsone. Appropriate laboratory monitoring is recommended. See Chapter 695.2.

Visit Elsevier eBooks+ at eBooks.Health.Elsevier.com for Bibliography.

695.2 Reactive Infectious Mucocutaneous Eruption

Joel C. Joyce

Originally named *Mycoplasma*-induced rash and mucositis (MIRM), RIME may also be caused by other infectious agents such as *Chlamydophila,* enterovirus, COVID-19, and others. It is believed to be a distinct entity not classified as EM or Stevens-Johnson syndrome/toxic epidermal necrosis (SJS/TEN).

RIME presents 1-2 weeks after a prodrome characterized by fever, malaise, headache, and cough or features more characteristic of a specific infection (pneumonia secondary to *M. pneumoniae* or COVID-19). The dominant feature is severe mucositis (Fig. 695.3, Table 695.2) most often involving the oral (~95%), ocular (~80%), and urogenital mucosa. Rash may be absent in ~30%, but when present is sparse; lesions are vesiculobullous (~75%) or atypical targeted (~45%), papules, macules, or morbilliform. Lesions involve <10% of body surface area but rarely may be extensive in severe RIME.

The differential diagnosis includes EM, which manifests with an acral rash that evolves from macules to papules to plaques and target lesions. In addition, severe RIME may resemble SJS/TEN, which presents with macules, purpura, erythroderma, atypical target lesions, and extensive blistering.

Treatment includes mouth care and pain management. Azithromycin is used when there is evidence of *Mycoplasma* infection (positive PCR plus IgM) or *Chlamydophila* infection. Steroids have been used, as has etanercept, for more severe disease. In general, RIME is a self-limiting disease that heals without residua. Recurrences are rare.

Visit Elsevier eBooks+ at eBooks.Health.Elsevier.com for Bibliography.

695.3 Stevens-Johnson Syndrome

Joel C. Joyce

ETIOLOGY

Drugs, particularly sulfonamides, nonsteroidal antiinflammatory agents, antibiotics (particularly β-lactams), and anticonvulsants, are the most common precipitants of the blistering drug rashes known as Stevens-Johnson syndrome (SJS) and toxic epidermal **necrolysis** (TEN). SJS and TEN exist along a spectrum: SJS is defined as affected body surface area <10%, SJS-TEN overlap syndrome as affected body surface area between 10% and 30%, and TEN as affected body surface area >30%. TEN is the most severe disorder in the clinical spectrum of the disease, involving considerable constitutional toxicity and extensive necrolysis of the mucous membranes and >30% of the body surface area. Approximately 80% of cases are classified as SJS. In children in the United States, the risk of death is 0.3–1.5%. Human leukocyte antigen (HLA)-B*1502 and HLA-B*5801 are implicated in the development of these two disorders in Han Chinese patients receiving carbamazepine and in Japanese patients receiving allopurinol, respectively. Current thinking defines most cases of classic SJS as secondary to medications.

Clinical Manifestations

Cutaneous lesions in SJS generally consist initially of erythematous macules that rapidly and variably develop central necrosis to form vesicles, bullae, and areas of denudation on the face, trunk, and extremities. The **Nikolsky sign** (denudation of the skin with gentle

Fig. 695.3 Manifestations of mycoplasma-induced rash and mucositis. **A,** Bilateral conjunctivitis. **B,** Oral mucositis. **C,** Cutaneous targetoid vesicles; sutures are visible at sites where skin biopsy sample was taken. *(From Sandhu R, Mareddy C, Itskowitz M, et al. Mycoplasma-induced rash and mucositis in a young patient with red eyes, oral mucositis, and targetoid cutaneous vesicles. Lancet Infect Dis. 2017;17:562.)*

Table 695.2	Mucocutaneous Lesions of *Mycoplasma pneumoniae*–Induced Rash and Mucositis
ORAL	
Erosions	
Ulcers	
Vesiculobullae	
Denudation	
Hemorrhagic crusting	
OCULAR	
Conjunctival injection	
Conjunctivitis	
Photophobia	
Eyelid edema	
Lid margin ulceration	
Conjunctival pseudomembranes	
Corneal involvement (rare)	
UROGENITAL	
Erosions	
Ulcerations	
Vesiculobullae	
Oro-esophageal	
Mucositis	
ANAL	
Mucositis	
CUTANEOUS	
Vesiculobullae	
Targetoid	
Papules	
Macules	
Morbilliform	

From Ramien ML. Reactive infectious mucocutaneous eruption: Mycoplasma pneumoniae-induced rash and mucositis and other parainfectious eruptions. *Clin Exper Dermatol.* 2021;46:420–429.

tangential pressure) may be positive. The skin lesions are typically more widespread than in EM and are accompanied by involvement of two or more mucosal surfaces, namely the eyes, oral cavity, upper airway or esophagus, gastrointestinal tract, or anogenital mucosa (Fig. 695.4). A burning sensation, edema, and erythema of the lips and buccal mucosa are often the presenting signs, followed by development of bullae, ulceration, and hemorrhagic crusting. Lesions may be preceded by a flulike upper respiratory illness. Pain from mucosal ulceration is often severe, but skin tenderness is minimal to absent in SJS, in contrast to pain in TEN. Corneal ulceration, anterior uveitis, panophthalmitis, bronchitis, pneumonitis, myocarditis, hepatitis, enterocolitis, polyarthritis, hematuria, and acute tubular necrosis leading to renal failure may occur. Disseminated cutaneous bullae and erosions may result in increased insensible fluid loss and a high risk of bacterial superinfection and sepsis. New lesions occur in crops, and complete healing may take 4-6 weeks, and ocular scarring, visual impairment, and strictures of the esophagus, bronchi, vagina, urethra, or anus may remain. Nonspecific laboratory abnormalities in SJS include leukocytosis, elevated erythrocyte sedimentation rate, and, occasionally, increased liver transaminase levels and decreased serum albumin values.

Pathogenesis

Pathogenesis is related to drug-specific $CD8^+$ cytotoxic T cells, with perforin/granzyme B and granulysin triggering keratinocyte apoptosis. This process is followed by expanded enactment of apoptosis involving the interaction of soluble Fas ligand with Fas receptor. Consideration has been given to the role that macrophages/monocytes play in the development of SJS/TEN via tumor necrosis factor-α, tumor necrosis factor–related apoptosis-inducing ligand (TRAIL), and tumor necrosis factor–inducer of apoptosis weak (TWEAK) signaling pathways. It is likely that many affected individuals have yet unrecognized underlying genetic predispositions.

Fig. 695.4 Bullae are present on the conjunctivae (A) and in the mouth (B) with Stevens-Johnson syndrome. C, Sloughing, ulceration, and necrosis in the oral cavity interfere with eating. Genital lesions cause dysuria and interfere with voiding. *(From Habif TP, ed. Clinical Dermatology, 4th ed. Philadelphia: Mosby; 2004:631.)*

Differential Diagnosis

The differential diagnosis of SJS includes TEN, urticaria, RIME, DRESS (sometimes called DIHS; see Chapter 686), other drug eruptions, and viral exanthems, as well as Kawasaki disease. SJS has rarely been reported in patients with systemic lupus erythematosus.

Treatment

Management of SJS is supportive and symptomatic. Potentially offending drugs must be discontinued as soon as possible. *Ophthalmologic consultation is mandatory because ocular sequelae such as corneal scarring can lead to vision loss.* Application of cryopreserved amniotic membrane to the ocular surface during the acute phase of the disease limits the destructive and long-term sequelae. Early topical steroid treatment may also reduce ocular sequelae. Oral lesions should be managed with mouthwashes and glycerin swabs. Urogenital lesions should be observed closely and treated to prevent stricture or fusion. Topical (oral) anesthetics (diphenhydramine, dyclonine, viscous lidocaine) may provide relief from pain, particularly when applied before eating. Denuded skin lesions can be cleansed with saline or Burrow solution compresses. Treatment may require admission to an intensive care unit, IV fluids,

nutritional support, sheepskin or air-fluid bedding, daily saline or Burrow solution compresses, paraffin gauze or colloidal gel (Hydrogel) dressing of denuded areas, saline compresses on the eyelids, lips, or nose, analgesics, and urinary catheterization (when needed). A daily examination for infection and ocular lesions, which constitute the major cause of long-term morbidity, is essential. Systemic antibiotics are indicated for documented urinary or cutaneous infections and for suspected bacteremia (*Staphylococcus aureus* or *Pseudomonas aeruginosa*) because infection is the leading cause of death. Prophylactic systemic antibiotics are not necessary. Systemic antiinflammatory and immunosuppressive therapies have been controversial. A large systematic review concluded that patients who received IV immunoglobulin (IVIG) and systemic corticosteroids had better outcomes than supportive care alone. Other publications have found that these agents have not improved outcomes such as decreased time to healing or shortened hospital stay. Nevertheless, advocates for use remain, and IVIG (1.5-2.0 g/kg/day × 3 days) may be considered in early disease. Total dose >2 g/kg has shown improved but not statistically significant outcomes in children compared with adults. Case reports/series have demonstrated rapid efficacy with cyclosporine (3 mg/kg/day divided twice daily), as well as with infliximab (5 mg/kg intravenously for one dose) or with etanercept (0.8 mg/kg injection once and then a second dose 1 week later). Emerging evidence has supported the use of anti–tumor necrosis factor therapy in the acute setting, particularly in adults but also in children.

Visit Elsevier eBooks+ at eBooks.Health.Elsevier.com for Bibliography.

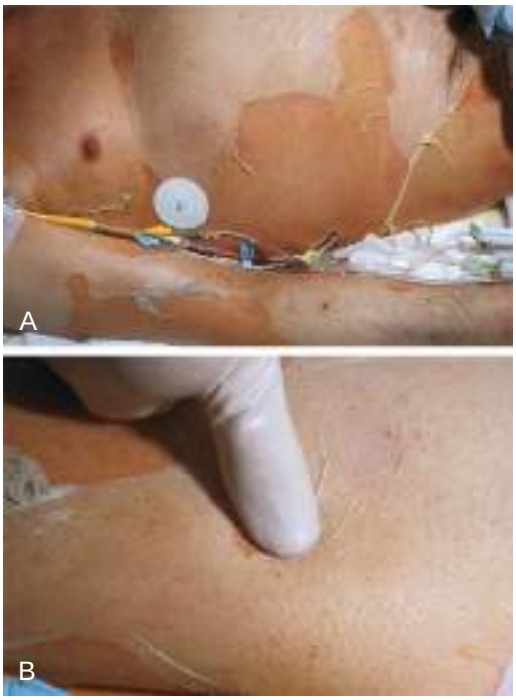

Fig. 695.5 A, Large sheets of full-thickness epidermis are shed. B, Toxic epidermal necrolysis begins with diffuse, hot erythema. In hours the skin becomes painful, and with slight thumb pressure, the skin wrinkles, slides laterally, and separates from the dermis (Nikolsky sign). *(From Habif TP, ed. Clinical Dermatology, 4th ed. Philadelphia: Mosby; 2004:633.)*

695.4 Toxic Epidermal Necrolysis

Joel C. Joyce

EPIDEMIOLOGY AND ETIOLOGY

The pathogenesis of toxic epidermal necrolysis (TEN) is not proven but may involve a hypersensitivity phenomenon that results in damage primarily to the basal cell layer of the epidermis. Epidermal damage appears to result from keratinocyte apoptosis. This condition, typically attributed as a drug rash, is triggered by many of the same factors that are thought to be responsible for SJS (see Chapter 695.3), principally drugs such as the sulfonamides, β-lactam antibiotics, anticonvulsants, and allopurinol. TEN is defined by (1) widespread blister formation and morbilliform or confluent erythema, associated with skin tenderness; (2) absence of target lesions; (3) sudden onset and generalization within 24-48 hours; and (4) histologic findings of full-thickness epidermal necrosis and a minimal-to-absent dermal infiltrate. Skin involvement should be 30% or greater in contrast to SJS (10% or less) or SJS-TEN overlap (10–30%). These criteria categorize TEN as a separate entity from EM.

CLINICAL MANIFESTATIONS

The prodrome consists of fever, malaise, localized skin tenderness, and diffuse erythema. Inflammation of the eyelids, conjunctivae, mouth, and genitals may precede skin lesions. Flaccid bullae may develop, although this is not a prominent feature. Characteristically, full-thickness epidermis is lost in large sheets (Fig. 695.5). The **Nikolsky sign** (denudation of the skin with gentle tangential pressure) is present, but only in the areas of erythema (see Fig. 695.5). Healing takes place over 14 or more days. Scarring, particularly of the eyes, may result in corneal opacity. The course may be relentlessly progressive, complicated by severe dehydration, electrolyte imbalance, shock, and secondary localized infection and septicemia. Loss of nails and hair may also occur. Long-term morbidity includes alterations in skin pigmentation, eye problems (lack of tears, conjunctival scarring, loss of lashes), and strictures of mucosal surfaces.

Differential Diagnosis

The differential diagnosis includes staphylococcal scalded skin syndrome, in which the blister cleavage plane is intraepidermal; graft-versus-host disease; chemical burns; drug eruptions; toxic shock syndrome; and **pemphigus**. The use of skin histopathology to differentiate SJS-TEN from other similar **blistering disorders** can be difficult, but early full-thickness epidermal necrosis tends to portend a worse clinical prognosis.

Drug hypersensitivity syndrome (sometimes called DRESS or DIHS; see Chapter 686), is a multisystem reaction that appears approximately several weeks to 3 months after the start of therapy with the offending agent. The skin eruption is variable but can be a red-pink morbilliform eruption often associated with facial swelling; lymphadenopathy; fever; hepatic, renal, and pulmonary disease; eosinophilia; atypical lymphocytosis; and leukocytosis.

TREATMENT

Appreciation of the specific etiologic factor is crucial in the treatment of TEN. Because most cases are drug-induced, cessation of the offending agent as soon as possible is critical. Management is similar to that for severe burns and may be best accomplished in a burn unit (see Chapter 89). It may include strict reverse isolation, meticulous fluid and electrolyte therapy, use of an air-fluid bed, and daily cultures. Systemic antibiotic therapy is indicated when secondary infection is evident or suspected. Skin care consists of cleansing with isotonic saline or Burrow solution. Biologic or colloid gel (Hydrogel) dressings alleviate pain and reduce fluid loss. Opiates are often required for pain relief. Mouth and eye care, as for EM major and SJS, may be necessary. Similar considerations as in the treatment of SJS (see Chapter 695.3) with systemic agents may be considered, although controversies remain over relative efficacy and best treatment regimens.

Visit Elsevier eBooks+ at eBooks.Health.Elsevier.com for Bibliography.

695.5 Mechanobullous Disorders

Joel C. Joyce

EPIDERMOLYSIS BULLOSA

Diseases categorized under the general term epidermolysis bullosa (EB) are a heterogeneous group of congenital, genetic **blistering disorders**. They differ in severity and prognosis, clinical and histologic features, and inheritance patterns but are all characterized by induction of blisters by trauma and exacerbation of blistering in warm weather. The disorders can be categorized under three major headings with multiple subgroupings: **epidermolysis bullosa simplex** (EBS), **junctional epidermolysis bullosa** (JEB), and **dystrophic epidermolysis bullosa** (DEB) (Tables 695.3-695.8). **Kindler syndrome**, which includes poikiloderma and photosensitivity, as well as easy blistering, is also considered a separate form of EB. **Epidermolysis bullosa acquisita** is an autoimmune disorder producing antibodies to the α chain of type VII collagen. It is rare in children. It is often acquired secondary to other autoimmune diseases or malignancy but has rare congenital forms. Affected mothers may pass the autoantibody to the fetus, resulting in similar but transient lesions in the newborn.

EPIDERMOLYSIS BULLOSA SIMPLEX

EBS is a nonscarring, autosomal dominant or recessive disorder. The defect in *most common* types of EBS is in keratin 5 or 14, which makes up intermediate filaments of the basal keratinocytes (see Table 695.6). The intraepidermal bullae result from cytolysis of the basal cells. There are multiple other rare variants with defects that also result in intraepidermal blistering (see Table 695.3).

Table 695.3 Epidermolysis Bullosa Simplex (EBS) Clinical Subtypes

MOST COMMON EBS CLINICAL SUBTYPES	TARGETED PROTEIN(S)
AUTOSOMAL DOMINANT EBS	
Localized	Keratin 5, keratin 14
Intermediate	Keratin 5, keratin 14
Severe	Keratin 5, keratin 14
With mottled pigmentation	Keratin 5*
Migratory circinate erythema	Keratin 5
Intermediate	Plectin
Intermediate with cardiomyopathy	**Kelch-like member 24**
AUTOSOMAL RECESSIVE EBS	
Intermediate or severe	Keratin 14, keratin 5
Intermediate	Plectin
Localized or intermediate with BP230 deficiency	Bullous pemphigoid antigen 230 (BP230) (syn. BPAG1e)
Localized or intermediate with exophilin-5 deficiency	Exophilin-5 (syn. Slac2-b)
Intermediate with muscular dystrophy	**Plectin**
Severe with pyloric atresia	**Plectin**
Localized with nephropathy	**CD151 (CD151 antigen) (syn. tetraspanin 24)**

*Typical recurrent mutation in keratin 5, but cases with other keratin 5, keratin 14 or exophilin-5 mutations have been reported; syndromic EBS subtypes in **bold**.
From Has C, Bauer JW, Bodemer C, et al: Consensus reclassification of inherited epidermolysis bullosa and other disorders with skin fragility. *Br J Dermatol* 2020;183:614-617; Table 3, p. 617.)

Localized EBS (formerly Weber-Cockayne disease) predominantly affects the hands and feet and often manifests when a child begins to walk; onset may be delayed until puberty or early adulthood, when heavy shoes are worn or the feet are subjected to increased trauma. Bullae are usually restricted to the hands and feet (Fig. 695.6); rarely, they occur elsewhere, such as the dorsal aspect of the arms and the shins. The disorder ranges from mildly incapacitating to crippling at times, with severe exacerbations. Blisters should be drained by puncturing, but the blister top should be left intact to protect the underlying skin. Erosions may be covered with a semipermeable dressing. Diligent wound care and protection of areas subject to pressure are beneficial. Observation for infection is important and should be treated promptly.

In **intermediate EBS (formerly Koebner type)**, blisters are usually present at birth or during the neonatal period. Sites of predilection are the hands, feet, elbows, knees, legs, and scalp. Intraoral lesions are minimal, nails rarely become dystrophic and usually regrow even when they are shed, and dentition is normal. Bullae heal with minimal to no scar or milia formation. Secondary infection is the primary complication. The propensity to blister decreases with age, and the long-term prognosis is good. Treatment is similar to that noted earlier.

Severe EBS (formerly EBS Dowling-Meara or EBS herpetiformis) is characterized by grouped blisters resembling those of herpes simplex (Fig. 695.7). During infancy, blistering may be severe and extensive, may involve mucous membranes, and may result in shedding of nails, formation of milia, and mild pigmentary changes, without scarring. After the first few months of life, warm temperatures do not appear to exacerbate blistering. Hyperkeratosis and hyperhidrosis of the palms and soles may develop, but generally, the condition improves with age. Maintenance of nutritional status and treatment of infections is important, particularly in infancy. Day-to-day management may involve wound care techniques as described.

JUNCTIONAL EPIDERMOLYSIS BULLOSA

Severe JEB (formerly Herlitz syndrome) is an autosomal recessive condition that is life threatening (see Tables 695.5 and 695.6). Blisters appear at birth or develop during the neonatal period, particularly on the perioral area, scalp, legs, diaper area, and thorax. Nails eventually become dystrophic and then often permanently lost. Mucous membrane involvement may be severe, and ulceration of the respiratory, gastrointestinal, and genitourinary epithelium has been documented in many affected children, although less frequently than in severe recessive DEB. Healing is delayed, and vegetating granulomas may persist for a long time. Large, moist, erosive plaques (Fig. 695.8) may provide a portal of entry for bacteria, and septicemia is a frequent cause of death. Mild atrophy may be seen in areas of recurrent blistering. Defective dentition with early loss of teeth as a result of rampant caries is characteristic. Growth retardation and recalcitrant anemia are almost invariable. In addition to infection, cachexia and circulatory failure are common causes of death. Most patients die within the first years of life.

Intermediate JEB (formerly non-Herlitz syndrome) is a heterogeneous group of disorders. Blistering may be severe in the neonatal period, making differentiation from severe JEB difficult. All conditions associated with severe JEB may be seen but are usually milder. **Localized JEB** and **JEB with pyloric atresia** are similar disorders.

In all types of JEB, a subepidermal blister is found on light microscopic examination, and electron microscopy demonstrates a cleavage plane in the lamina lucida, between the plasma membranes of the basal cells and the basal lamina. Absence or a great reduction of hemidesmosomes is seen on electron micrographs in severe JEB and some cases of intermediate JEB. The defect in severe JEB is in laminin 332 (pathogenic gene variants in *LAMA3, LAMB3,* or *LAMC2*), a glycoprotein associated with anchoring filaments beneath the hemidesmosomes. In intermediate JEB, defects have also been described in other hemidesmosomal components, such as type XVII collagen (BP180) (gene variants of *COL17A1*). In JEB with pyloric atresia, the defect is in the $\alpha_6\beta_4$ integrin (gene variants of *ITGA6* or *ITGB4*).

Treatment for JEB is supportive. The diet should provide adequate calories and *supplemental iron*. Infections should be treated promptly. Transfusions of packed red blood cells may be required if the patient shows no response to iron and erythropoietin therapy. Strict adherence to wound care regimens is essential. Wound care regimens include highly specialized nonadherent bandages designed specifically for children with chronic skin fragility. Tissue-engineered skin grafts (artificial skin derived from human keratinocytes and fibroblasts) may be beneficial. Birch bark extract topical gel containing betulin is approved by the European Union and promotes wound healing and controls inflammation.

Table 695.4 Characteristics of Major Forms of Epidermolysis Bullosa Simplex

TYPE	CLINICAL MANIFESTATIONS
Localized EBS (formerly Weber-Cockayne)	Easy blistering on palms and soles May be focal keratoderma of palms and soles in adults 25% show oral mucosal erosions Rarely show reticulated pigmentation, especially on arms and trunk and punctate keratoderma (EBS with mottled pigmentation)
Intermediate EBS (formerly Koebner)	Generalized blistering Variable mucosal involvement Focal keratoderma of palms and soles Nail involvement in 20% Improves with advancing age
Severe EBS (formerly Dowling-Meara or EB herpetiformis)	Most severe in neonate, infant; improves beyond childhood Large, generalized blisters; later, smaller (herpetiform) blisters Mucosal blistering, including esophageal Nails thickened, shed but regrow May have natal teeth
EBS with mottled pigmentation	Reticulated hyperpigmentation, especially on arms and trunk Punctate keratoses and keratoderma

EBS, Epidermolysis bullosa simplex.
From Paller AS, Mancini AJ. *Hurwitz Clinical Pediatric Dermatology*, 6th ed. Philadelphia: Elsevier; 2022: Table 13.2, p. 319.

Table 695.6 Characteristics of Major Forms of Junctional Epidermolysis Bullosa

TYPE	CLINICAL MANIFESTATIONS
JEB, severe (formerly Herlitz)	50% of patients die by 2 yr old Blisters heal with atrophic scarring but no milia Periungual and fingerpad blistering, erythema Blistering of oral and esophageal mucosae Laryngeal and airway involvement with early hoarseness Later, perioral granulation tissue with sparing of lips Anonychia Dental enamel hypoplasia, excessive caries Growth retardation Anemia
JEB, intermediate (formerly non-Herlitz)	Less severe, but similar manifestations to Herlitz type, including dental, nail, and laryngeal involvement Granulation tissue is rare Perinasal cicatrization Less mucosal involvement Alopecia Anemia but not as severe as JEB, generalized severe
JEB, localized	Localized blisters without residual scarring or granulation tissue Minimal mucosal involvement Dental and nail abnormalities as in JEB, generalized severe
JEB, with pyloric atresia	Usually lethal in neonatal period Generalized blistering, leading to atrophic scarring May be born with large areas of cutis aplasia No granulation tissue Nail dystrophy or anonychia Pyloric atresia, genitourinary malformations Rudimentary ears Dental enamel hypoplasia (survivors) Variable anemia, growth retardation, mucosal blistering

JEB, Junctional epidermolysis bullosa.
From Paller AS, Mancini AJ. *Hurwitz Clinical Pediatric Dermatology*, 6th ed. Philadelphia: Elsevier; 2022: Table 13.4, p. 321.

Table 695.5 Junctional Epidermolysis Bullosa (JEB) Clinical Subtypes

MOST COMMON JEB CLINICAL SUBTYPES	TARGETED PROTEIN(S)
Severe	Laminin 332*
Intermediate	Laminin 332
Intermediate	Type XVII collagen
With pyloric atresia	**Integrin α6β4**
Localized	Laminin 332, type XVII collagen, integrin α6β4, integrin α3 subunit
Inversa	Laminin 332
Late onset	Type XVII collagen
LOC syndrome	Laminin α3A
With interstitial lung disease and nephrotic syndrome	**Integrin α3 subunit**

*JEB severe is rarely caused by pathogenic variants affecting the type XVII collagen gene; syndromic JEB subtypes in **bold**.
LOC, laryngo–onycho–cutaneous.
From Has C, Bauer JW, Bodemer C, et al: Consensus reclassification of inherited epidermolysis bullosa and other disorders with skin fragility. *Br J Dermatol* 2020;183:614-617; Table 4, p. 617.)

Table 695.7 Dystrophic Epidermolysis Bullosa (DEB) Clinical Subtypes

DEB SUBTYPES	TARGETED PROTEIN
AUTOSOMAL DOMINANT DEB (DDEB)	
Intermediate	Type VII collagen
Localized	
Pruriginosa	
Self-improving	
AUTOSOMAL RECESSIVE DEB (RDEB)	
Severe	Type VII collagen
Intermediate	
Inversa	
Localized	
Pruriginosa	
Self-improving	
DOMINANT AND RECESSIVE (COMPOUND HETEROZYGOSITY)	
DEB, severe	Type VII collagen

bold, most common subtypes.
From Has C, Bauer JW, Bodemer C, et al: Consensus reclassification of inherited epidermolysis bullosa and other disorders with skin fragility. *Br J Dermatol* 2020;183:614-617; Table 5, p. 617.)

Table 695.8 Characteristics of Major Forms of Dystrophic Epidermolysis Bullosa

TYPE	CLINICAL MANIFESTATIONS
Dominant dystrophic	Onset at birth to early infancy Blistering predominates on dorsum of hands, elbows, knees, and lower legs Milia associated with scarring Some patients develop scarlike lesions, especially on the trunk 80% have nail dystrophy
Recessive dystrophic, severe generalized	Present at birth Widespread blistering, scarring, milia Deformities: pseudosyndactyly, joint contractures Severe involvement of mucous membranes, nails; alopecia Growth retardation, poor nutrition Anemia Mottled, carious teeth Osteoporosis, delayed puberty, cardiomyopathy, glomerulonephritis, renal amyloidosis, IgA nephropathy Predisposition to squamous cell carcinoma in heavily scarred areas
Recessive dystrophic, generalized intermediate	Generalized blisters from birth with milia, scarring Less anemia, growth retardation, mucosal but more esophageal issues with advancing age

IgA, Immunoglobulin A.
From Paller AS, Mancini AJ. *Hurwitz Clinical Pediatric Dermatology*, 6th ed. Philadelphia: Elsevier; 2022: Table 13.6, p. 323.

DYSTROPHIC EPIDERMOLYSIS BULLOSA

All forms of DEB result from pathogenic variants in collagen VII, a major component of anchoring fibrils that tether the basement membrane and overlying epidermis to its dermal foundation (see Tables 695.7 and 695.8). The blister is subepidermal in all types of DEB. The type and location of the pathogenic gene variant within *COL7A1* dictate the severity of the phenotype.

Dominant DEB is the most common type. The spectrum of dominant DEB is varied. Blisters may be manifest at birth and are often limited and characteristically form over acral bony prominences.

Fig. 695.6 Bullae of the feet in localized epidermolysis bullosa simplex.

Fig. 695.7 Grouped vesicle on an erythematous base in severe epidermolysis bullosa simplex.

Fig. 695.8 Nonhealing granulation tissue in junctional epidermolysis bullosa.

The lesions heal promptly, with the formation of soft, wrinkled scars; milia; and alterations in pigmentation (Fig. 695.9). Abnormal nails and nail loss are common. In many cases, the blistering process is mild, causing little restriction of activity and not impairing growth and development. Mucous membrane involvement tends to be minimal.

Recessive DEB, severe generalized (formerly recessive DEB–Hallopeau-Siemens syndrome) is the most incapacitating form of EB, although the clinical spectrum is wide. Some patients have blisters, scarring, and milia formation primarily on the hands, feet, elbows, and knees (Fig. 695.10). Others have extensive erosions and blister formation at birth that seriously impede their care and feeding. Mucous membrane lesions are common and may cause severe nutritional

Fig. 695.9 Scarring with milia formation over the knee in dominant dystrophic epidermolysis bullosa.

Fig. 695.10 Severe scarring of the hands and knees in recessive dystrophic epidermolysis bullosa.

Fig. 695.11 Mitten-hand deformity of recessive dystrophic epidermolysis bullosa.

deprivation, even in older children, whose growth may be restricted. During childhood, esophageal erosions and strictures, scarring of the buccal mucosa, flexion contractures of joints secondary to scarring of the integument, development of cutaneous squamous cell carcinomas, and the development of digital fusion may significantly limit the quality of life (Fig. 695.11). Squamous cell carcinomas and infection are major causes of morbidity and mortality.

Although the skin becomes less sensitive to trauma with aging in patients with recessive DEB, the progressive and permanent deformities complicate management, and the overall prognosis is poor. *Foods that traumatize the buccal or esophageal mucosa should be avoided.* If esophageal scarring develops, a semiliquid diet and esophageal dilatations may be required. Stricture excision or colonic interposition may be needed to relieve esophageal obstruction. In infants, severe oropharyngeal involvement may necessitate the use of special feeding devices such as a gastrostomy tube. Iron therapy for anemia, intermittent antibiotic therapy for secondary infections, and periodic surgery for release of digits may reduce morbidity. Wound care dressings, including nonstick dressings made from silicone, are a mainstay of treatment and the daily maintenance of the skin barrier to reduce new skin trauma and promote healing. Compounds for treating itch, reducing inflammation, and fighting infection, particularly with antimicrobial peptides, aid in promoting more effective wound healing when dressings are used, therefore reducing morbidity.

Beyond wound care and care of comorbid conditions in EB, a number of new technologies offer a wider array of practical and hypothetical treatment options for EB patients. Tissue-engineered skin grafts containing keratinocytes and fibroblasts are of some benefit. Skin grafts that have undergone gene editing may show promise. Pluripotent stem cells, taken from areas of revertant mosaicism of a patient's own skin, provide personalized options for treatments for affected patients. Redosable gene therapy with a herpes simplex virus type 1 vector carrying the *COL7A1* gene is FDA approved for patients ≥6 months of age. The therapy is applied directly to wounds and produces normal collagen type VII alpha chains. Allogeneic bone marrow transplantation has been shown to be beneficial in some cases but warrants further study.

KINDLER SYNDROME

Kindler syndrome, often considered a distant subtype of EB, contains features of both EB, such as congenital blistering, and congenital poikilodermas, such as Rothmund-Thomson syndrome and Bloom syndrome (see Chapter 697), which include photosensitivity, congenital poikiloderma, and progressive cutaneous atrophy. Blisters tend to appear on acral sites in infancy or early childhood and are provoked by trauma. Photosensitivity can appear as increased susceptibility to sunburn. Both blistering and photosensitivity can improve greatly with advancing age, but poikilodermatous changes can be progressive. Sclerodermoid-like changes and nail abnormalities of the hands and feet, as well as dental abnormalities, have been reported.

Kindler syndrome is an autosomal recessive disorder caused by pathogenic gene variants in *KIND1* (also known as *FERMT1*), which encodes kindlin-1, a protein thought to regulate interactions between the extracellular matrix and actin filaments. Blister formation has been shown to occur within the epidermis, within the basement membrane zone, and below the basement membrane. Because Kindler syndrome is often confused with EB, at least initially, it can be confirmed by electron microscopy, immunostaining for anti–kindlin-1 antibodies within the skin, or genetic analysis of the *KIND1* gene.

Treatment is similar to that for EB, with efforts to reduce trauma to the skin, meticulous wound care, and treatment of skin infections. In addition, sun avoidance measures are beneficial because they can slow the rate of the development of poikiloderma.

Visit Elsevier eBooks+ at eBooks.Health.Elsevier.com for Bibliography.

695.6 Pemphigus

Joel C. Joyce

PEMPHIGUS VULGARIS

Etiology/Pathogenesis

Pemphigus vulgaris (PV) is a rare autoimmune blistering disorder caused by circulating antibodies to desmoglein III that results in suprabasal cleaving with consequent blister formation. Desmoglein III is a 30-kDa glycoprotein that is complexed with plakoglobin, a plaque protein of desmosomes. The desmogleins are a subfamily of the cadherin family of cell adhesion molecules.

Clinical Manifestations

PV usually first appears as painful oral ulcers, which may be the only evidence of the disease for weeks or months. Subsequently, large, flaccid bullae emerge on nonerythematous skin, most commonly on the face, trunk, pressure points, groin, and axillae. The **Nikolsky sign** is present. The lesions rupture and enlarge peripherally, producing painful, raw, denuded areas that have little tendency to heal. When healing occurs, it is without scarring, but hyperpigmentation is common. Malodorous, verrucous, and granulomatous lesions may develop at sites of ruptured bullae, particularly in the skinfolds; as this pattern becomes more pronounced, the condition may be more properly referred to as **pemphigus vegetans**. Because the course may rapidly lead to debility, malnutrition, and death, prompt diagnosis is essential. **Neonatal PV** develops in utero as a result of placental transfer of maternal antidesmoglein antibodies from women who have active PV, although it may occur when the mother is in remission. High antepartum maternal titers of PV antibodies and increased maternal disease activity correlate with a poor fetal outcome, including demise.

Pathology

Biopsy of a fresh small blister reveals a suprabasal (intraepidermal) blister containing loose, acantholytic epidermal cells that have lost their intercellular bridges and thus their contact with one another. Immunofluorescence staining with an IgG antibody produces a characteristic pattern ("chicken wire") on direct immunofluorescence preparations of both involved and uninvolved skin of essentially all patients. Serum IgG antibody titers to desmoglein correlate with the clinical course in many patients; thus serial determinations may have predictive value.

Differential Diagnosis

PV must be differentiated from EM, bullous pemphigoid (BP), SJS, and TEN.

Treatment

The disease is best treated initially with systemic methylprednisolone 1-2 mg/kg/day. Azathioprine, cyclophosphamide, mycophenolate mofetil, and methotrexate therapy all have been useful in maintenance regimens. IVIG given in cycles may be beneficial to patients whose disease does not respond to steroids. Rituximab with IVIG replacement has been very effective in the management of severe PV. Excellent control of the disease may be obtained, but relapse is common. It has been successfully used in children.

PEMPHIGUS FOLIACEUS

Etiology/Pathogenesis

Pemphigus foliaceus is caused by circulating antibodies to a 50-kDa portion of the 160-kDa desmosomal glycoprotein desmoglein I, which result in subcorneal cleavage leading to superficial erosions. This extremely rare disorder is characterized by subcorneal blistering; the site of cleavage is high in the epidermis rather than suprabasal as in PV.

Clinical Manifestations

The superficial blisters rupture quickly, leaving erosions surrounded by erythema that heal with crusting and scaling (Fig. 695.12). The

Fig. 695.12 Superficial erosions in pemphigus foliaceus.

Nikolsky sign is present. Focal lesions are usually localized to the scalp, face, neck, and upper trunk. Mucous membrane lesions are minimal or absent. Pruritus, pain, and a burning sensation are frequent complaints. The clinical course varies but is generally more benign than that of PV. **Fogo selvagem (endemic pemphigus foliaceus)**, which is endemic in certain areas of Brazil, is identical clinically, histopathologically, and immunologically to pemphigus foliaceus. Anti–desmoglein-1 antibodies in individuals with fogo selvagem cross react with sand fly (*Lutzomyia* sp.) salivary proteins, suggesting an environmental trigger for this autoimmune disease.

Pathology

An intraepidermal acantholytic bulla high in the epidermis is diagnostic. It is imperative to select an early lesion for biopsy. Immunofluorescent staining with an IgG antibody reveals a characteristic intercellular staining pattern similar to that of PV but higher in the epidermis.

Differential Diagnosis

When generalized, pemphigus foliaceus may resemble an exfoliative dermatitis or any of the chronic blistering disorders; localized erythematous plaques simulate seborrheic dermatitis, psoriasis, impetigo, eczema, and systemic lupus erythematosus.

For localized disease, super-potent topical corticosteroids used twice a day may be all that is needed for control until remission. For more generalized disease, long-term remission is usual after suppression of the disease by systemic methylprednisolone (1 mg/kg/day) therapy. Dapsone (25-100 mg/day) also may be used, with appropriate laboratory monitoring.

BULLOUS PEMPHIGOID

Etiology/Pathogenesis

BP is caused by circulating antigens to either the 180-kDa or 230-kDa BP antigen that result in a subepidermal blister. The 230-kDa protein (BP230) is part of the hemidesmosome, whereas the 180-kDa protein (BP180, now known as type XVII collagen) localizes to both the hemidesmosome and the upper lamina lucida and is a transmembrane collagenous protein.

Clinical Manifestations

The blisters of BP typically arise in crops on a normal, erythematous, eczematous, or urticarial base. Bullae appear predominantly on the flexural aspects of the extremities, in the axillae, and on the groin and central abdomen. Infants have involvement of the palms, soles, and face more frequently than older children do. Individual lesions vary greatly in size, are tense, and are filled with serous fluid that may become hemorrhagic or turbid. Oral lesions occur less frequently and are less severe than in PV. Pruritus, a burning sensation, and subcutaneous edema may accompany the eruption, but constitutional symptoms are not prominent.

Pathology

Biopsy material should be taken from an early bulla arising on an erythematous base. A subepidermal bulla and a dermal

inflammatory infiltrate, predominantly of eosinophils, can be identified histopathologically. In sections of a blister or perilesional skin, a band of Ig (usually IgG) and C3 can be demonstrated in the basement membrane zone by direct immunofluorescence. Indirect immunofluorescence studies of serum have positive results in ~70% of cases for IgG antibodies to the basement membrane zone; however, the titers do not correlate well with the clinical course.

Diagnosis and Differential Diagnoses

BP rarely occurs in children but must be considered in the differential diagnosis of any chronic blistering disorder. The differential diagnosis includes bullous EM, PV, linear IgA dermatosis, bullous drug eruption, dermatitis herpetiformis (DH), herpes simplex infection, and bullous impetigo, which can be differentiated by histologic examination, immunofluorescence studies, and cultures. The large, tense bullae of BP can generally be distinguished from the smaller, flaccid bullae of PV.

Treatment

Localized BP can be successfully suppressed with super-potent topical corticosteroids (clobetasol propionate) twice a day. Generalized disease usually requires systemic methylprednisolone (1 mg/kg/day) therapy. Doxycycline has some benefits but is not as effective as prednisone. Rarely are other immunosuppressive treatments necessary, such as azathioprine or mycophenolate mofetil. Refractory cases have been treated with rituximab, but the condition usually remits within a year in most children.

Visit Elsevier eBooks+ at eBooks.Health.Elsevier.com for Bibliography.

695.7 Dermatitis Herpetiformis

Joel C. Joyce

ETIOLOGY/PATHOGENESIS

In dermatitis herpetiformis (DH), IgA antibodies are directed at epidermal transglutaminase (transglutaminase 3). **Gluten-sensitive enteropathy (celiac disease)** is found in all patients with DH, although the majority are asymptomatic or have minimal gastrointestinal symptoms (see Chapter 384). The severity of the skin disease and the responsiveness to gluten restriction do not correlate with the severity of the intestinal inflammation. An antibody to smooth muscle endomysium is found in 70–90% of patients with DH. Ninety percent of patients with the disease express HLA-DQ2. HLA-DQ2–negative patients with DH usually express HLA-DQ8.

CLINICAL MANIFESTATIONS

DH is characterized by symmetric, grouped, small, tense, erythematous, stinging, intensely pruritic papules and vesicles. The eruption is pleomorphic, including erythematous, urticarial, papular, vesicular, and bullous lesions. Sites of predilection are the knees, elbows, shoulders, buttocks, forehead, and scalp; mucous membranes are usually spared. Hemorrhagic lesions may develop on the palms and soles. When pruritus is severe, excoriations may be the only visible sign (Fig. 695.13).

PATHOLOGY

Subepidermal blisters composed predominantly of neutrophils are found in dermal papillae. The presence of granular IgA on direct immunofluorescence in the dermal papillary tips is diagnostic.

DIFFERENTIAL DIAGNOSIS

DH may mimic other chronic blistering disorders and may also resemble scabies, papular urticaria, insect bites, contact dermatitis, and papular eczema.

Fig. 695.13 Multiple excoriations around the elbows in dermatitis herpetiformis.

TREATMENT

Patients with DH show response within weeks to months to a gluten-free diet. Oral administration of dapsone (0.5-2.0 mg/kg/day daily or divided twice daily) provides immediate relief from the intense pruritus but must be used with caution because of possible serious side effects (methemoglobinemia, hemolysis, and drug hypersensitivity syndrome [sulfone syndrome]). Dapsone alone may not relieve the intestinal inflammation of celiac disease. Local antipruritic measures may also be useful. Jejunal biopsy is indicated to diagnose gluten-sensitive enteropathy because cutaneous manifestations may precede malabsorption. The disease is chronic, and either a gluten-free diet or dapsone must be continued indefinitely to prevent relapse.

Visit Elsevier eBooks+ at eBooks.Health.Elsevier.com for Bibliography.

695.8 Linear Immunoglobulin A (IgA) Dermatosis (Chronic Bullous Dermatosis of Childhood)

Joel C. Joyce

ETIOLOGY/PATHOGENESIS

Linear IgA dermatosis is a heterogeneous autoimmune disorder with antibodies targeting multiple antigens. It has been reported to be the most common autoimmune blistering disorder in children. It is caused by circulating IgA antibodies, most commonly to LABD97 and LAD-1, which are degradation proteins of BP180 (type XVII collagen). Linear IgA dermatosis may also be seen as a drug eruption. Most cases of drug-induced linear IgA dermatosis are related to vancomycin, although anticonvulsants, ampicillin, cyclosporine, and captopril are implicated.

CLINICAL MANIFESTATIONS

This rare dermatosis is most common in the first decade of life, with a peak incidence during the preschool years. The eruption consists of many large, symmetrically located, tense bullae filled with clear or hemorrhagic fluid. The bullae are often clustered together and develop on a normal or erythematous urticarial base. Areas of predilection are the genitals and buttocks (Fig. 695.14), the perioral region, and the scalp. Sausage-shaped bullae may be arranged in an annular or rosette-like fashion around a central crust (Fig. 695.15). Erythematous plaques with gyrate margins bordered by intact bullae may develop over larger areas. Pruritus may be absent or very intense, and systemic signs or symptoms are absent.

PATHOLOGY

The subepidermal bullae are infiltrated with a mixture of inflammatory cells. Neutrophilic abscesses may be noted in the dermal papillary tips,

Fig. 695.14 Erosion on an erythematous base after loss of blister roof in linear IgA dermatosis.

Fig. 695.15 Linear IgA bullous dermatitis. *(Modified from Gouveia AI, Teixeira A, Freitas JP, et al. Linear immunoglobulin A bullous dermatosis. J Pediatr. 2016;170:338, Fig. 1A.)*

indistinguishable from those of DH. The infiltrate may also be largely eosinophilic, resembling that in BP. Therefore direct immunofluorescence studies are required for a definitive diagnosis of linear IgA dermatosis; perilesional skin demonstrates linear deposition of IgA and sometimes IgG and C3 at the dermal-epidermal junction. Immunoelectron microscopy has localized the immunoreactants to the sublamina densa, although a combined sublamina densa and lamina lucida pattern has also been seen.

DIFFERENTIAL DIAGNOSIS

The eruption can be distinguished by histopathologic and immunofluorescence studies from PV, BP, DH, scabies, and EM. Gram stain and culture preclude the diagnosis of bullous impetigo.

TREATMENT

Many cases of linear IgA dermatosis respond favorably to oral dapsone (see treatment of DH) or sulfapyridine. Other antibiotics, including erythromycin and dicloxacillin, have been used, but the response is often transient. Children who show no response to dapsone may benefit from oral therapy with methylprednisolone (1 mg/kg/day) or a combination of these drugs. The usual course is 2-4 years, although some children have persistent or recurrent disease; there are typically no long-term sequelae. IgA nephropathy is a rare complication.

Visit Elsevier eBooks+ at eBooks.Health.Elsevier.com for Bibliography.

Chapter 696

Eczematous Disorders

Julie M. Dhossche and Yvonne E. Chiu

Eczematous disorders are a broad group of cutaneous eruptions characterized by erythema, edema, and pruritus. Acute eczematous lesions demonstrate erythema, weeping, oozing, and the formation of microvesicles within the epidermis. Chronic lesions are generally thickened, dry, and scaly, with coarse skin markings (lichenification) and altered pigmentation. Many types of eczema occur in children; the most common is **atopic dermatitis** (see Chapter 186), although seborrheic dermatitis, allergic and irritant contact dermatitis, nummular eczema, and acute palmoplantar eczema (dyshidrosis) are also relatively common in childhood.

Once the diagnosis of eczema has been established, it is important to further classify the eruption more specifically for proper management. Pertinent historical data often provide the clue. In some instances, the subsequent course and character of the eruption permit classification. Histologic changes are relatively nonspecific, but all types of eczematous dermatitis are characterized by intraepidermal edema known as *spongiosis*.

696.1 Contact Dermatitis

Julie M. Dhossche and Yvonne E. Chiu

The form of eczema known as contact dermatitis can be subdivided into irritant dermatitis, in which nonspecific injury to the skin causes immediate inflammation, and allergic contact dermatitis, resulting from a delayed hypersensitivity reaction. Irritant dermatitis is more frequent in children, particularly during the early years of life. Allergic reactions increase in frequency upon maturation of the immune system.

IRRITANT CONTACT DERMATITIS

Irritant contact dermatitis can result from prolonged or repetitive contact with physical, chemical, or mechanical irritants, including saliva, urine, feces, fragrance, detergents, dyes, henna, plants, caterpillars, abrasive materials, and chafing.

Irritant contact dermatitis may be difficult to distinguish from atopic dermatitis or allergic contact dermatitis. A detailed history and consideration of the sites of involvement, the age of the child, and contactants usually provide clues to the etiologic agent. The propensity for development of irritant dermatitis varies considerably among children; some may respond to minimal injury, making it difficult to identify the offending agent through history. Children with atopic dermatitis are more prone to irritant contact dermatitis as an exacerbating factor. Irritant contact dermatitis usually clears after removal of the stimulus and temporary treatment with a topical corticosteroid preparation (see Chapter 687). Education of patients and parents about the causes of contact dermatitis is crucial to successful therapy.

Dry skin dermatitis results from repetitive wet-to-dry behaviors such as lip licking (Fig. 696.1), thumb sucking, frequent handwashing, or excessive sweating. Involved skin is erythematous and fissured, localized to the area of exposure. Treatment of dry skin dermatitis begins with eliminating the offending wet-to-dry behavior. A thick moisturizer (cream or ointment based) applied twice daily decreases transepidermal water loss and replenishes skin lipids to improve hydration. A topical steroid is usually necessary to treat the inflammation.

Juvenile plantar dermatosis occurs mainly in prepubertal children with hyperhidrosis who wear occlusive synthetic footwear. Weight-bearing surfaces of the foot may be pruritic or painful and develop a fissured or glazed appearance (Fig. 696.2). Immediate application of a thick emollient when socks and shoes are removed or immediately after swimming usually minimizes juvenile plantar dermatosis. Severe inflammatory cases may require short-term (1-2 weeks) application of a medium- to high-potency topical steroid.

Fig. 696.1 Perioral irritant contact dermatitis from lip licking.

Fig. 696.2 Red, scaly juvenile plantar dermatosis.

Fig. 696.3 Severe, erosive diaper dermatitis.

DIAPER DERMATITIS

Diaper dermatitis refers to any rash in the diaper region; the most common of these is irritant diaper dermatitis. Elevated pH in the diaper area and synergistic activity of urinary and fecal enzymes lead to inflammation, which disrupts the normal skin barrier and increases susceptibility to other irritants and organisms. Additional factors are occlusion, friction, and use of diaper wipes and topical preparations. Loose or frequent stooling predisposes an infant to diaper dermatitis. Diaper dermatitis presents with erythema and scaling in a patchy or confluent pattern and, in severe cases, may have papulovesicular or bullous lesions, fissures, and/or erosions (Fig. 696.3). The genitocrural folds are often spared because concave areas are relatively protected. Chronic hypertrophic, flat-topped papules and infiltrative nodules may occur. **Candidal infection** typically represents a secondary process. It is characterized by "beefy" red-pink, tender skin that has numerous 1- to 2-mm pustules and satellite papules and involves both concave and convex areas. Discomfort may be marked because of intense inflammation. Allergic contact dermatitis, seborrheic dermatitis, psoriasis, candidiasis, atopic dermatitis, child abuse, and rare disorders such as Langerhans cell histiocytosis, nutritional deficiencies, and acrodermatitis enteropathica should be considered when the eruption is persistent or is recalcitrant to simple therapeutic measures (Table 696.1).

Diaper dermatitis often responds to simple measures; some infants are predisposed to diaper dermatitis, and management may be difficult. The damaging effects of overhydration of the skin and prolonged contact with feces and urine can be obviated by frequent changing of the diapers and periods of "rest" free of diaper use. Cleansing of affected skin is best accomplished with a soft cloth and lukewarm water, patted dry. Overwashing should be avoided because it leads to chapping and may worsen the dermatitis. Disposable diapers containing a superabsorbent material may help to maintain a relatively dry environment. First-line therapy for diaper dermatitis is application of a protective barrier agent (ointment or paste) containing petroleum or zinc oxide at every diaper change. Topical sucralfate is an effective barrier with some antibacterial activity and is useful for recalcitrant cases. Low-potency nonhalogenated topical corticosteroids, such as 2.5% hydrocortisone, may be used for short periods (3-5 days). Treatment with a topical anticandidal agent is indicated for secondary candidal infection. Topical preparations containing triamcinolone-nystatin and betamethasone dipropionate-clotrimazole are generally inappropriate for diaper dermatitis in infants because of the higher potency of the corticosteroid component. If using multiple topical agents, the protective barrier should be applied last. When diaper dermatitis does not respond to typical prevention and treatment strategies, non–diaper-associated causes must be considered.

ALLERGIC CONTACT DERMATITIS

Allergic contact dermatitis is a delayed hypersensitivity cutaneous reaction to environmental allergens and should be considered in any child with recalcitrant eczema. It has been estimated to affect 16.4% of all children in the United States, though children are likely underdiagnosed, especially those with concomitant atopic dermatitis. Children of all ages may develop allergic contact dermatitis, though it is more common in older children. Allergic contact dermatitis is a T-cell–mediated hypersensitivity reaction that is provoked by application of an antigen to the skin surface. The antigen penetrates the skin, where it is conjugated with a cutaneous protein, and the hapten-protein complex is transported to the regional lymph nodes by antigen-presenting Langerhans cells. A primary immunologic response occurs locally in the nodes and becomes generalized, presumably because of dissemination of sensitized T cells. Sensitization requires several days and, when followed by a fresh antigenic challenge, manifests as allergic contact dermatitis. Generalized distribution may also occur if enough antigen finds its way into the circulation, such as by consumption. Once sensitization has occurred, each new antigenic challenge may provoke an inflammatory reaction within 8-12 hours; sensitization to a particular antigen usually persists for many years.

Acute allergic contact dermatitis is an erythematous, intensely pruritic, eczematous dermatitis. Acute cases may be edematous and vesiculobullous. The chronic condition has the features of long-standing eczema: lichenification, scaling, fissuring, and pigmentary change. Distinguishing allergic contact dermatitis from other eczematous disorders can be challenging, especially with irritant contact dermatitis, which can be clinically identical. The distribution of the eruption often provides a clue to the diagnosis. Airborne sensitizers usually affect exposed areas, such as the face and arms. Jewelry, topical agents, shoes, clothing, henna tattoo dyes, plants,

Table 696.1 Diaper Dermatitis

DISEASE	CLINICAL MANIFESTATION	OTHER FEATURES	TREATMENT
Friction	Inner surface of thighs, genitalia, buttocks, abdomen	Course waxes and wanes Aggravated by talc	Responds well to diaper changes Avoidance of diapers
Irritant	Mild erythema with shiny surface and occasional papules Confined to convex surfaces Spares intertriginous areas	Exacerbated by heat, moisture, and sweat retention	Gentle cleansing Regular diaper changes Barrier creams (zinc oxide, Vaseline) Low-potency topical steroids can help
Allergic contact	Typically confined to convex surfaces Skin involved is in direct contact with offending agent *Mild cases:* diffuse erythema, papules, vesicles, scaling *Severe cases:* papules, plaques, psoriasiform lesions, ulcerations, infiltrative nodules	Often related to topical antibiotics (neomycin, bacitracin) Certain emulsifiers in topical products Preservatives in wet wipes can be an offender	Remove offending agent Judicious use of low-potency topical steroids Barrier creams/ointments
Seborrheic dermatitis	Salmon-colored patches Often have yellow, greasy scale Fissures, erosions, maceration, and weeping can be seen	Axillae, ear creases, and neck are often involved "Cradle cap" on scalp Hypopigmentation often seen in patients with darker skin tones	Low-potency topical steroids If coexistent infection—antifungal or antibacterial agents
Candidiasis	Usually involves intertriginous areas and convex surfaces Bright-red papules and plaques Satellite lesions on abdomen and thighs	Oral thrush may be present Often occurs after treatment with systemic antibiotics or local topical steroid use	Topical anticandidal agent, including nystatin
Intertrigo	Well-demarcated, macerated plaques with weeping Gluteal cleft and fleshy folds of thighs	May be associated with miliaria	Avoiding excessive heat Cool clothing
Psoriasis	Bright red, scaly, well-demarcated plaques Can persist for months Less responsive to topical treatment	Red, sometimes scaly Can be present on extremities or trunk Nail changes seen Family history	Low-potency topical steroids Moisturizers
Staphylococcal infection	Many thin-walled pustules with pink-red base Collarette of scale after rupturing		Antistaphylococcal therapy
Acrodermatitis enteropathica (zinc deficiency)	Early lesions are vesicular and pustular Become confluent, pink, dry, scaly, crusty plaques	Perioral skin typically also involved Irritability or listlessness Failure to thrive, alopecia, diarrhea	Secondary to zinc deficiency or inborn error of zinc transporter Treat with zinc replacement
Langerhans cell histiocytosis	May mimic candidiasis or seborrheic dermatitis Persistent, does not improve with standard treatments Clusters of infiltrative, crusted, hemorrhagic papules Ulceration can be seen	Involvement of groin, axillae, periauricular skin, hairline, and scalp Anemia, thrombocytopenia, hepatosplenomegaly, and osseous lesions	Chemotherapy

From Humphrey S. Congenital cutaneous lesions and infantile rashes. In: Kliegman RM, Toth H, Bordini BJ, Basel D, eds. *Nelson Pediatric Symptom-Based Diagnosis*, 2nd ed. Philadelphia: Elsevier; 2023: Table 60.2, p. 1144.

and even toilet seats cause dermatitis at points of contact. Careful evaluation of environmental exposures, cultural customs, daily activity, animal exposures, ear piercing, tattooing, and personal product usage in the patient and all caregivers is essential. Other potential diagnoses to consider include herpes simplex virus, impetigo, cellulitis, and dermatophytoses.

Rhus dermatitis (poison ivy, poison sumac, poison oak), a response to the plant allergen urushiol, is the most common allergic contact dermatitis. It is often vesiculobullous and may be distinguished by linear streaks of vesicles where the plant leaves have brushed against the skin (Fig. 696.4). Fluid from ruptured cutaneous vesicles does not spread the eruption; antigen retained on skin, clothing, or under fingernails initiates new plaques of dermatitis if not removed by washing with soap and water. Antigen may also be carried by animals on their fur. "Black spot" poison ivy dermatitis is a rare variant that results from oxidation of concentrated urushiol left on the skin and manifests as small discrete black lacquer–like glossy papules with surrounding erythema and edema. Sensitization to one plant produces cross reactions with the others. Spontaneous resolution occurs in 1-3 weeks, with the most common complication being secondary bacterial infection with normal skin flora. Exposure avoidance and thorough washing after exposure are the mainstays for prevention. Barrier creams or organoclay compounds such as bentoquatam may be effective if applied before expected exposure.

Nickel dermatitis develops from contact with jewelry, metal closures on clothing, or even cell phones. Metal closures on pants frequently cause periumbilical dermatitis (Fig. 696.5). Some children are exquisitely sensitive to nickel, with even the trace amounts found in gold jewelry provoking eruptions. The most frequently involved sites from jewelry are the earlobes from nickel-containing earrings. Early ear piercing increases risk of sensitization, and it is recommended to delay piercing until after 10 years of age. Patch testing for nickel sensitivity is unreliable in infants and toddlers and should only be performed if there is high clinical suspicion.

Shoe dermatitis typically affects the dorsum or soles of the feet and toes, sparing the interdigital spaces; it is usually symmetric. Other forms of allergic contact dermatitis, in contrast to irritant dermatitis, rarely involve the palms and soles. Common allergens are the antioxidants and accelerators in shoe rubber, adhesives, and the chromium salts in tanned leather or shoe dyes. Excessive sweating often leaches these substances from their source.

Apparel contains a number of sensitizers, including dyes, dye fixative, fabric finishes, fibers, resins, and cleaning solutions. Dye may be poorly

Fig. 696.4 Linear lesions in poison ivy.

Fig. 696.5 Chronic periumbilical nickel dermatitis.

fixed to clothing and so may be leached out with sweating, as can partially cured formaldehyde resins. The elastic in garments is a frequent cause of clothing dermatitis, and contact allergy to the ink "tag" of tagless baby clothing has been reported. Exposure to other items with fabric, such as infant car seats, may induce reactions similar to clothing.

Topical medications and cosmetics may be unsuspected as allergens, particularly if a medication is being used for a preexisting dermatitis. The most common offenders are neomycin, topical antihistamines, topical anesthetics, fragrances, topical corticosteroids, oxybenzone and octocrylene in chemical sunscreens, preservatives, dye in temporary tattoos, and ethylenediamine, a stabilizer present in many medications. All types of cosmetics can cause facial dermatitis; involvement of the eyelids is characteristic for nail polish sensitivity. Another pediatric allergen has been methylisothiazolinone (MI), a chemical preservative found in rinse-off products including liquid soaps and shampoos, as well as paints and glues, which may be used in making homemade "slime" and lead to hand dermatitis.

Neomycin sulfate is present in many nonprescription topical antibiotic preparations, and thus children are frequently exposed at an early age. It is one of the most common causes of allergic contact dermatitis, and use of combination products of neomycin with other antibiotics, antifungals, or corticosteroids may induce co-reactivity with these chemically unrelated substances.

As mentioned previously, diagnosis of allergic contact dermatitis is usually based on history; however, patch testing may be helpful, especially in older children. Identification and avoidance of the offending agent is the mainstay of managing allergic contact dermatitis. First-line treatment for acute eruption is a mid-potency topical corticosteroid ointment for 2-3 weeks and symptom management with nonsensitizing and fragrance-free emollients/moisturizers, wet dressings, and sedating antihistamines to allow for sleep. Systemic corticosteroids are used when >10% of skin is involved (0.5-1.0 mg/kg prednisone to a maximum of 60 mg/day for 7-10 days, followed by a 7-10 day taper). More chronic allergic contact dermatitis is treated with low- to mid-potency topical corticosteroids. Desensitization therapy is rarely indicated. Topical calcineurin inhibitors, such as tacrolimus, may be a potential steroid-sparing alternative agent in select patients.

Visit Elsevier eBooks+ at eBooks.Health.Elsevier.com for Bibliography.

696.2 Nummular Eczema

Julie M. Dhossche and Yvonne E. Chiu

Nummular eczema is characterized by coin-shaped, severely pruritic, eczematous plaques, commonly involving the extensor surfaces of the extremities (Fig. 696.6), buttocks, and shoulders with facial sparing. The plaques are relatively discrete, boggy, vesicular, slightly scaly, and exudative; when chronic, they often become thickened and lichenified and may develop central clearing. Nummular eczema may be an atypical morphology in someone with underlying atopic dermatitis or may be an independent disorder. Flares are generally sporadic but may be precipitated by xerosis, irritants, allergens, or occult staphylococcal infection. Most frequently, these lesions are mistaken for tinea corporis, but plaques of nummular eczema are distinguished by the lack of a raised, sharply circumscribed border, the lack of fungal organisms on a potassium hydroxide (KOH) preparation, and frequent weeping or bleeding when scraped. First-line treatment is with emollients, wet dressings, and potent topical corticosteroids. Steroid-impregnated tapes may simultaneously treat and provide barrier protection to these circumscribed eczematous plaques. An oral antihistamine may be helpful, particularly a sedating antihistamine at night. Antibiotics are indicated for secondary infection. Methotrexate and dupilumab have been described as systemic treatments.

Visit Elsevier eBooks+ at eBooks.Health.Elsevier.com for Bibliography.

696.3 Pityriasis Alba

Julie M. Dhossche and Yvonne E. Chiu

Pityriasis alba occurs mainly in children and causes lesions that are hypopigmented, ill-defined, round or oval patches (Fig. 696.7). They may be mildly erythematous and finely scaly. Lesions occur on the face, neck, upper trunk, and proximal portions of the arms and are most pronounced on darker skin tones or after tanning of surrounding skin. Itching

Fig. 696.6 Discrete, boggy plaque of nummular dermatitis.

is minimal or absent. The cause is unknown, but the eruption appears to be exacerbated by dryness and is often regarded as a mild form of atopic dermatitis. Pityriasis alba is frequently misdiagnosed as vitiligo, tinea versicolor, or tinea corporis. The lesions wax and wane but eventually disappear, and normal pigmentation often takes months to return. Application of a lubricant or emollient may ameliorate the condition, and avoidance of sun exposure and daily sunscreen use can help reduce the appearance of existing lesions by allowing for natural lightening of adjacent unaffected skin. If pruritus is troublesome or if the lesions are active with erythema and fine scale, a low-potency topical steroid or calcineurin inhibitor may be used.

Visit Elsevier eBooks+ at eBooks.Health.Elsevier.com for Bibliography.

696.4 Lichen Simplex Chronicus

Julie M. Dhossche and Yvonne E. Chiu

Lichen simplex chronicus is a secondary skin disorder resulting from excessive scratching or rubbing. It is characterized by a chronic pruritic, eczematous, circumscribed plaque that is usually lichenified and hyperpigmented (Fig. 696.8). All affected areas must be accessible to scratching, with the most common sites being the posterior neck, genitalia, wrists, ankles, and dorsal feet. Although the initiating event may be a transient lesion such as an insect bite, trauma from rubbing and scratching accounts for persistence of the plaque. Lichen simplex chronicus may also be seen in other chronic eczematous dermatoses such as atopic dermatitis, typically when poorly controlled. Pruritus must be controlled to permit healing; thus a covering to prevent scratching may be necessary. A high-potency topical corticosteroid under occlusion is often helpful and hastens resolution. Second-line therapy includes adding 6% salicylic acid gel to the topical corticosteroid preparation.

696.5 Acute Palmoplantar Eczema

Julie M. Dhossche and Yvonne E. Chiu

A recurrent, sometimes seasonal, blistering disorder of the hands and feet, acute palmoplantar eczema (also known as dyshidrotic eczema or pompholyx) occurs in all age-groups but is uncommon in infancy. The pathogenesis is unknown, although possible predisposing factors include a history of atopy, exposure to contact allergens (especially metals) or irritants, or IV immunoglobulin therapy. The disease is characterized by recurrent crops of small, deep-seated, "tapioca-like" vesicles, which are intensely pruritic and may coalesce into tense bullae (Fig. 696.9). Sites of predilection are the palms, soles, and lateral aspects of the fingers and toes. Primary lesions are noninflammatory and are filled with clear fluid, which, unlike sweat, has a physiologic pH and contains protein. Maceration and secondary infection are frequent because of scratching. The chronic phase is characterized by thickened, fissured plaques that may cause considerable discomfort and dystrophic nails. Although acute

Fig. 696.7 Patchy hypopigmented lesions with diffuse borders characteristic of pityriasis alba.

Fig. 696.8 Thickened plaque of lichen simplex chronicus.

palmoplantar eczema is frequently seen in patients with hyperhidrosis, histologic examination reveals an eczematous reaction around sweat ducts, without any structural or functional abnormalities of the sweat ducts themselves. The diagnosis is made clinically. The disorder may be confused with allergic contact dermatitis, which usually affects the dorsal rather than the volar surfaces, and with dermatophytosis, which can be distinguished by a KOH preparation of the roof of a vesicle and by appropriate cultures.

Acute palmoplantar eczema responds to wet dressings, liberal emollient use, and potent topical corticosteroid ointment applied twice daily for 2-4 weeks. Weeping skin benefits from twice-daily soaking in an astringent solution, such as aluminum subacetate. Second-line treatment includes phototherapy and systemic immunomodulators. Severe disease may require oral corticosteroids with a 2-week taper. Secondary bacterial infection should be treated systemically with an appropriate antibiotic. Patients should be told to expect recurrence and should protect their hands and feet from the damaging effects of excessive sweating, chemicals, harsh soaps, and adverse weather. Unfortunately, it is impossible to prevent recurrence or to predict its frequency.

Visit Elsevier eBooks+ at eBooks.Health.Elsevier.com for Bibliography.

696.6 Seborrheic Dermatitis

Julie M. Dhossche and Yvonne E. Chiu

ETIOLOGY

Seborrheic dermatitis is a chronic inflammatory disease most common in infancy and adolescence that parallels the distribution, size, and activity of the sebaceous glands. The cause is unknown, as is the role of the sebaceous glands in the disease. *Malassezia furfur* is implicated as a causative agent,

Fig. 696.9 Vesicular palmar lesions of acute palmoplantar eczema with large bullae.

Fig. 696.10 Cradle cap in an infant.

although it remains unclear whether dermatitis results from the action of the fungus, its by-products, or an exaggerated response of the host. In adolescence, seborrheic dermatitis typically occurs after puberty, indicating a possible role for sex hormones.

It is also unknown whether infantile seborrheic dermatitis and adolescent seborrheic dermatitis are the same or different entities. There is no evidence that children with infantile seborrheic dermatitis will experience seborrheic dermatitis as adolescents.

CLINICAL MANIFESTATIONS

The disorder may begin in the first month of life and typically self-resolves by 1 year. Diffuse or focal scaling and crusting of the scalp, sometimes called *cradle cap* (Fig. 696.10), may be the initial and, at times the only, manifestation. A greasy, scaly, erythematous papular dermatitis, which is usually nonpruritic in infants, may involve the face, neck, retroauricular areas, axillae, umbilicus, and diaper area. The dermatitis may be patchy and focal or may spread to involve almost the entire body (Fig. 696.11). Postinflammatory pigmentary changes are common, particularly in infants with darker skin. When the scaling becomes pronounced, the condition may resemble psoriasis and, at times, can be distinguished only with difficulty. The possibility of coexistent atopic dermatitis must be considered when there is an acute weeping dermatitis with pruritus, and the two are often clinically inseparable at an early age. An intractable seborrhea-like dermatitis with chronic diarrhea and failure to thrive may reflect systemic dysfunction of the immune system. A chronic treatment-resistant seborrhea-like pattern may also result from cutaneous histiocytic infiltrates in infants with Langerhans cell histiocytosis. Seborrheic dermatitis is a common cutaneous manifestation of AIDS in young adults and is characterized by thick, greasy scales on the scalp and large hyperkeratotic erythematous plaques on the face, chest, and genitals.

During adolescence, seborrheic dermatitis is more localized and may be confined to the scalp, chest, and intertriginous areas. Also noted may be marginal blepharitis and involvement of the external auditory canal. Scalp changes vary from diffuse, brawny scaling to focal areas of thick, oily, yellow crusts with underlying erythema. Loss of hair is uncommon, and pruritus may be absent to marked. When the dermatitis is severe, erythema and scaling occur at the frontal hairline, the medial aspects of the eyebrows, and in the nasolabial and retroauricular folds. Red, scaly plaques may appear in the axillae, inguinal region, gluteal cleft, and umbilicus. On the extremities, seborrheic plaques may be more eczematous and less erythematous and demarcated. Unlike infantile seborrheic dermatitis, adolescent seborrheic dermatitis generally does not self-resolve and has a chronic relapsing course.

DIFFERENTIAL DIAGNOSIS

The differential diagnosis of seborrheic dermatitis includes psoriasis, atopic dermatitis, dermatophytosis, Langerhans cell histiocytosis, and candidiasis. Secondary bacterial infections and superimposed candidiasis are common.

TREATMENT

Initial management for infantile seborrheic dermatitis is generally conservative given the self-limited nature of this condition.

Fig. 696.11 Seborrheic dermatitis may occasionally be more widespread. *(From Tom WL, Eichenfield LF. Eczematous disorders. In: Eichenfield LF, Frieden IJ, eds. Neonatal and Infant Dermatology, 3rd ed. Philadelphia: Elsevier; 2015: Fig. 15.11, p. 225.)*

Emollients, baby oil, gentle shampooing with nonmedicated baby shampoo, and gentle use of a soft brush to remove scales are usually effective measures. Persistent lesions may be treated with low-potency topical corticosteroids if inflamed (applied once daily for 1 week) and a topical antifungal (e.g., ketoconazole 2% cream twice daily). Antifungal shampoos such as ketoconazole 2% shampoo should be used cautiously because they are not tear-free.

First-line therapy for children and adolescents with scalp seborrheic dermatitis is antifungal shampoo used several times weekly to daily (selenium sulfide, ketoconazole, ciclopirox, zinc pyrithione, salicylic acid, or tar). Mid-potency topical corticosteroids such as fluocinolone 0.01% oil or triamcinolone 0.1% lotion may also be used for inflamed lesions, applied once daily for 2-4 weeks. Nonscalp lesions are treated with topical corticosteroid cream (low-potency for facial lesions, mid-potency elsewhere), as well as topical antifungals such as ketoconazole 2% cream or ketoconazole 2% shampoo used as a body or face wash. Second-line therapy for seborrheic dermatitis includes topical calcineurin inhibitors and keratolytic agents such as urea. Severe adult cases improve with oral antifungal agents; however, pediatric studies are lacking. Once acute disease is controlled, antifungal shampoo used on a twice-weekly basis is effective maintenance to reduce the risk of relapse.

Visit Elsevier eBooks+ at eBooks.Health.Elsevier.com for Bibliography.

Chapter 697

Photosensitivity

Julie M. Dhossche and Yvonne E. Chiu

Photosensitivity denotes an abnormal cutaneous reaction to UV radiation, either in sunlight or artificial light. The UV light spectrum contains UVA (320-400 nm wavelength), UVB (290-320 nm wavelength), and UVC (100-290 nm wavelength) subtypes. Transmitted radiation <300 nm is largely absorbed in the epidermis, whereas >300 nm is mostly transmitted to the dermis after variable epidermal melanin absorption. Children vary in susceptibility to UV radiation, depending on their skin type (i.e., its amount of pigment; Table 697.1).

ACUTE SUNBURN REACTION

The most common photosensitive reaction seen in children is acute sunburn, which is caused mainly by UVB radiation. Sunlight contains many times more UVA than UVB radiation, but UVA must be encountered in much larger quantities than UVB radiation to produce sunburn. Immediate pigment darkening is caused by UVA radiation–induced photo-oxidative darkening of existing melanin and its transfer from melanocytes to keratinocytes. This effect generally lasts for a few hours and is not photoprotective. UVB-induced effects appear 6-12 hours after initial exposure and reach a peak in 24 hours. Effects include redness, tenderness, edema, and blistering (Fig. 697.1). Severe sunburn induces systemic symptoms of fever, nausea, and headache. Reactive oxidation species generated by UVB induce keratinocyte membrane damage and are involved in the pathogenesis of sunburn. A portion of the vasodilation seen in UVB-induced erythema is mediated by prostaglandins E_2, E_3, and F_{2A}. Other inflammatory cytokines induced by UVB include interleukins 1, 6, and 8 and tumor necrosis factor-α. Acute sunburn is a self-limited condition that resolves within 1 week with desquamation and without scarring. Delayed melanogenesis as a result of UVB radiation begins in 2-3 days and lasts several days to a few weeks. Manufacture of new melanin in melanocytes, transfer of melanin from melanocytes to keratinocytes, increase in size and arborization of melanocytes, and activation of quiescent melanocytes produce delayed melanogenesis and pigment darkening (tanning). This effect reduces skin sensitivity to future UV-induced erythema. The amount of protection afforded depends on the skin type of the patient. Additional effects and possible complications of sun exposure include increased thickness of the stratum corneum, recurrence or exacerbation of herpes simplex labialis, lupus erythematosus, and many other conditions (Table 697.2).

Acute sunburn should be managed conservatively with cool compresses, aloe vera products, and calamine lotion. Oral analgesics such as ibuprofen and acetaminophen may decrease pain. Topical corticosteroids are only helpful in the acute phase and generally should not be used to treat sunburn once peak erythema has been reached (~24 hours). Topical anesthetics are relatively ineffective and potentially hazardous because of their propensity to cause contact dermatitis. A bland emollient, such as plain petrolatum, is effective in the desquamative phase.

The long-term sequelae of chronic and intense sun exposure are not often seen in children, but most individuals receive >50% of their lifetime UV dose by age 20 years; therefore pediatricians have a pivotal role in educating patients and their parents about the harmful effects, potential malignancy risks, and irreversible skin damage that result from prolonged exposure to the sun and tanning lights. Premature aging, senile elastosis, actinic keratoses, squamous and basal cell carcinomas, and melanomas all occur with greater frequency in sun-damaged skin. In particular, blistering sunburns in childhood and adolescence significantly increase the risk for development of malignant melanoma.

Sun protection is best achieved by sun avoidance, which includes minimizing time in the midday sun (10 AM to 4 PM), staying in the shade, and wearing protective clothing including wide-brimmed hats. Protection is enhanced by a wide variety of sunscreen agents. Physical sunscreens (zinc oxide, titanium dioxide) that block UV light are preferred, whereas chemical sunscreens (para-aminobenzoic acid [PABA], PABA esters, salicylates, benzophenones, avobenzone, cinnamates, and ecamsule) absorb damaging radiation. Some of these products may be systemically absorbed and achieve levels higher than permitted by the FDA. Most chemical sunscreens are effective for only UVB wavelengths but benzophenones and avobenzone provide protection in both the UVA and UVB ranges; ecamsule is a UVA sunscreen. Stabilizers such as octocrylene and diethyl 2,6-naphthalate increase the time of function of the chemical sunscreens. "Broad-spectrum" sunscreens are combination products that absorb both UVA and UVB, and families should be advised to use products labeled as "broad spectrum" with a sun protective factor (SPF) of at least 30, reapply liberally at least every 2 hours while outdoors, and reapply after swimming. Infants younger than 6 months of age should not be exposed to direct sunlight but may have SPF 15 physical sunscreens applied to small areas of skin if sunlight avoidance is not possible. SPF is defined as the minimal dose of sunlight required to produce cutaneous erythema after application of a sunscreen, divided by the dose required with no use of sunscreen. SPF applies only to UVB protection; there is no associated rating for UVA protection in the United States aside from the "broad spectrum" designation.

Table 697.1 Sun-Reactive Skin Types

FITZPATRICK SKIN TYPE	SUNBURN, TANNING HISTORY
I	Always burns easily, no tanning
II	Usually burns, minimal tanning
III	Sometimes burns, gradual light brown tan
IV	Minimal to no burning, always tans
V	Rarely burns, tans profusely dark brown
VI	Never burns, pigmented black

PHOTOSENSITIVE REACTIONS

Photosensitizers in combination with a particular wavelength of light (typically UVA) cause dermatitis that can be classified as phototoxic or photoallergic reactions. Contact with the photosensitizer may occur externally on the skin, internally by enteral or parenteral administration, or through host synthesis of photosensitizers in response to an administered drug.

Photoallergic reactions occur in only a small percentage of persons exposed to photosensitizers and light and require a time interval for sensitization to take place. Thereafter, dermatitis appears within 24 hours of reexposure to the photosensitizer and light. Typically, patients present with an eczematous eruption in sun-exposed areas with sparing behind the ear, under the chin, and under clothing. Photoallergic dermatitis is a T-cell–mediated delayed hypersensitivity reaction in which the drug, acting as a hapten, may combine with a skin protein to form the antigenic substance. Table 697.2 lists some of the important classes of drugs and chemicals responsible for photosensitivity reactions. The most common photoallergens are chemicals present in sunscreens.

Phototoxic reactions occur in all individuals who accumulate adequate amounts of a photosensitizing drug or chemical within the skin. UV radiation excites the agent to a state capable of causing cell or tissue damage through reactive oxygen species formation. Prior sensitization is not required. Dermatitis develops within hours after exposure to radiation in the range of 285-450 nm. The eruption is confined to light-exposed areas and often resembles exaggerated sunburn, but it

Fig. 697.1 Sunburn. Well-demarcated, severe erythema.

may be urticarial or bullous. It results in postinflammatory hyperpigmentation. All the drugs that cause photoallergic reactions may also cause a phototoxic dermatitis if given in sufficiently high doses. Several additional drugs and contactants cause phototoxic reactions (see Table 697.2). Postinflammatory hyperpigmentation develops rapidly and can be the presenting sign. Contact with furocoumarin-containing plants causes a nonallergic disorder called **phytophotodermatitis** (Figs. 697.2 and 697.3). The most common phytophotodermatitis seen in children is caused by lime juice, which presents as hyperpigmentation in streaky patterns on sun-exposed skin consistent with dripping juice or handprints (see Table 697.2).

Diagnosis of photosensitive reactions caused by drugs or chemicals relies on a high index of suspicion, an appreciation of the distribution pattern of the eruption, and a history of application or ingestion of a known photosensitizing agent. Phototesting and photopatch testing are also helpful when available. First-line treatment for both photoallergy and phototoxicity consists of discontinuation of the offending agent and good sun protection practices, including avoidance of sun exposure. Photoallergic reactions are treated similarly to contact dermatitis, with a topical corticosteroid to alleviate pruritus when necessary. Severe reactions may necessitate a 2- to 3-week course of systemic corticosteroid therapy. Phototoxic reactions are treated similarly to sunburn, with comfort measures such as cool compresses, emollients, and oral analgesics.

PORPHYRIAS

See Chapter 112.

Porphyrias are acquired or inborn disorders due to genetic variants of specific enzymes in the heme biosynthetic pathway. Some have childhood photosensitivity as a consistent feature. The pathogenesis of photosensitivity in porphyria relates to deposition of excess porphyrins in the skin; UV radiation excites these molecules, causing cell and tissue damage via generation of reactive oxygen species. Signs and symptoms may be negligible during the winter, when sun exposure is minimal.

Congenital erythropoietic porphyria (Günther disease) is a rare autosomal recessive disorder affecting the enzyme uroporphyrinogen III synthase. It may cause hydrops fetalis, but more typically manifests in the first few months of life as hemolytic anemia and exquisite sensitivity to light, which may induce repeated severe bullous eruptions that result in mutilating scars (Fig. 697.4). Hyperpigmentation, hyperkeratosis, vesiculation, and fragility of skin, as well as various nail changes, develop in light-exposed areas. Light therapy for an affected neonate presenting with jaundice may inadvertently induce skin manifestations. Hirsutism in areas of mild involvement, scarring alopecia in severely affected areas, pink to red urine, brown teeth (erythrodontia), splenomegaly, and corneal ulceration are additional characteristic manifestations. Laboratory findings include uroporphyrin I and coproporphyrin I in urine, plasma, and erythrocytes and coproporphyrin I in feces. Teeth and urine from affected patients fluoresce reddish pink under a Wood lamp as a result of the presence of porphyrins. **Hepatoerythropoietic porphyria**, a separate entity, has skin findings that closely resemble those seen in congenital erythropoietic porphyria; this extremely rare disorder presents in early childhood and is discussed in greater depth in Chapter 112.

Table 697.2 Cutaneous Reactions to Sunlight

Sunburn
Photoallergic Drug Eruptions • Systemic drugs include tetracyclines, psoralens, chlorothiazides, sulfonamides, barbiturates, griseofulvin, thiazides, quinidine, phenothiazines • Topical agents include coal tar derivatives, psoralens, halogenated salicylanilides (soaps), perfume oils (e.g., oil of bergamot), sunscreens (e.g., PABA, cinnamates, benzophenones)
Phototoxic Drug Eruptions • Systemic agents include nalidixic acid, furosemide, nonsteroidal antiinflammatory agents (naproxen, piroxicam), and high doses of agents causing photoallergic eruptions • Topical agents include 5-fluorouracial, furocoumarins and high doses of agents causing photoallergic eruptions
Phytophotodermatosis • Furocoumarin-containing plants: fig tree leaves and sap, limes, celery, fennel, carrots, parsley, dill, parsnips
Genetic Disorders with Photosensitivity • Xeroderma pigmentosum • Bloom syndrome • Cockayne syndrome • Rothmund-Thomson syndrome • Trichothiodystrophy • Smith-Lemli-Opitz syndrome • Kindler syndrome
Inborn Errors of Metabolism • Porphyrias • Hartnup disease and pellagra
Infectious Diseases Associated with Photosensitivity • Recurrent herpes simplex infection • Viral exanthems (accentuated photodistribution; e.g., varicella)
Skin Diseases Exacerbated or Precipitated by Light • Lichen planus • Darier disease • Lupus erythematosus, including neonatal • Dermatomyositis • Psoriasis • Erythema multiforme • Atopic dermatitis • Hailey-Hailey disease
Deficient Protection Because of a Lack of Pigment • Vitiligo • Oculocutaneous albinism • Phenylketonuria • Chédiak-Higashi syndrome • Hermansky-Pudlak syndrome • Waardenburg syndrome • Piebaldism

PABA, para-aminobenzoic acid.

Erythropoietic protoporphyria may be autosomal dominant, autosomal recessive, or X-linked and most commonly involves the enzyme ferrochelatase (FECH), the final enzyme in the heme synthetic pathway. Symptoms develop in early childhood and manifest as intense pain, tingling, or pruritus within 30 minutes of sun exposure, followed by erythema, edema, urticaria, or mild systemic symptoms; these acute manifestations resolve completely within days. The absence of blistering distinguishes erythropoietic protoporphyria from the other cutaneous porphyrias. Nail changes consist of opacification of the nail plate, onycholysis, pain, and tenderness. Recurrent sun exposure produces a subtle chronic eczematous dermatitis with thickened, lichenified skin, especially over the finger joints (Fig. 697.5A), as well as mild facial scarring (see Fig. 697.5B). Pigmentation, hypertrichosis, skin fragility, and mutilation are not seen. Gallstones develop frequently; however, severe liver disease occurs in <5% of patients. Protoporphyrin is detected in plasma, erythrocytes, and feces. **X-linked protoporphyria**

is a similar disorder to erythropoietic protoporphyria but is due to a pathogenic genetic variant in 5-aminolevulinic acid synthetase (the first and rate-controlling enzyme of heme synthesis) and therefore does not have iron overload or associated anemia.

The wavelengths of light mainly responsible for eliciting cutaneous reactions in porphyria are in the region of 400 nm (UVA light). Window glass, including that in automobiles, transmits wavelengths >320 nm and is not protective, and fluorescent indoor lights may be pathogenic. Patients must avoid direct sunlight, wear protective clothing, and use a sunscreen agent that effectively blocks UVA light. Oral beta-carotene also provides some photoprotective benefit. Afamelanotide, an alpha-melanocyte–stimulating hormone (α-MSH) analog, is approved by the FDA for treatment of erythropoietic protoporphyria to increase pain-free light exposure. This drug serves to increase skin pigmentation by increasing melanin production by melanocytes, resulting in increased UV tolerance.

Cutaneous porphyria symptoms are typically constant throughout life, and secondary bacterial infections commonly complicate the disease course. Cutaneous porphyrias do not appear to increase the risk for skin malignancies. Additional diagnostic and treatment recommendations for the porphyrias are outlined in Chapter 112.

Fig. 697.2 Phytophotodermatitis (fig tree leaves). *(From Papazoglou A, Mantadakis E. Fig tree leaves phytophotodermatitis. J Pediatr. 2021;239:244–245, Fig.1A.)*

Pseudoporphyria is a porphyria-like reaction characterized by erythema, blistering, and scarring on sun-exposed skin seen occasionally in patients with juvenile idiopathic arthritis taking nonsteroidal anti-inflammatory agents.

COLLOID MILIUM

Colloid milium is a rare, asymptomatic disorder that occurs on the face (nose, upper lip, and upper cheeks) and may extend to the dorsum of the hands and the neck as a profuse eruption of tiny, ivory to yellow, firm, grouped papules. Lesions appear before puberty on otherwise normal skin, unlike the adult variant that develops on sun-damaged skin. Onset may follow an acute sunburn or long-term sun exposure. Most cases reach maximal severity within 3 years and remain unchanged thereafter, although the condition may remit spontaneously after puberty. Treatment is usually not necessary.

HYDROA VACCINIFORME

Hydroa vacciniforme is a vesiculobullous disorder with unclear etiology, although chronic or latent Epstein-Barr virus infections or lymphoproliferative disorders have been implicated. It begins in early childhood and may remit at puberty, with peak incidence in the spring and summer. Erythematous, pruritic macules develop symmetrically within hours of sun exposure over the ears, nose, lips, cheeks, and dorsal surfaces of the hands and forearms. Lesions progress to stinging tender papules and hemorrhagic vesicles and bullae, resembling chickenpox. They become umbilicated, ulcerated, and crusted, eventually healing with pitted scars and telangiectasias. Associated features are rare but include fever, malaise, hypersensitivity to mosquito bites, conjunctivitis, and other ocular symptoms. This eruption should be distinguished

Fig. 697.4 Crusted ulcerations in an infant with congenital erythropoietic porphyria.

Fig. 697.3 Phytophotodermatitis (lime). **A,** Linear hyperpigmentation on the left cheek. **B,** A linear streak of hyperpigmentation on the right dorsal hand along with irregular hyperpigmentation of the bilateral dorsal fingers. *(From Dreher K, Evans MS. Linear hyperpigmentation in chronic phytophotodermatitis from limes. J Pediatr. 2021;239:245–246.)*

Fig. 697.5 Erythropoietic protoporphyria. **A**, Erythematous thickening over the metacarpal phalangeal joints. **B**, Linear crusts and scarring.

from erythropoietic protoporphyria, which rarely shows vesicles. Typical lesions have been reproduced with repeated doses of UVA or UVB light. First-line treatment includes sun avoidance, broad-spectrum sunscreens, and other sun-protective habits. Other potential therapies include mid-potency topical corticosteroids for inflamed lesions, low-dose courses of narrow-band UVB (NB-UVB) therapy, beta-carotene, hydroxychloroquine, or antiviral agents such as acyclovir.

SOLAR URTICARIA

Solar urticaria is a rare disorder induced by UV or visible irradiation. The disorder is mediated by immunoglobulin E antibodies to either an abnormal photoallergen present only in affected patients (type I) or a normal photoallergen ordinarily present in skin (type II), leading to mast cell degranulation and histamine release. Classic urticarial lesions consisting of erythematous pruritic wheals develop on sun-exposed skin (Fig. 697.6) within 5-10 minutes of sun exposure and fade within 24 hours. Severe reactions involving large areas of skin may lead to systemic symptoms or anaphylaxis. Diagnosis is achieved by history alone or with phototesting. First-line treatment is an oral H_1 antihistamine, plus sun avoidance and protection. Second-line therapy possibilities include oral or topical corticosteroids, photodesensitization using NB-UVB, omalizumab, or intravenous immunoglobulin.

POLYMORPHOUS LIGHT ERUPTION

Polymorphous light eruption (PMLE) is a common photosensitivity reaction that develops most commonly in females. The first eruption typically appears in the spring after the first episode of prolonged sun exposure of the season. Onset of the eruption is delayed by hours to days after sun exposure and lasts for days to sometimes weeks. PMLE usually resolves with increased sun exposure throughout the spring and summer. Areas of involvement tend to be symmetric and are characteristic for a given patient, including some, but not all, of the exposed or lightly covered skin on the face, neck, upper chest, and distal extremities. Lesions have various morphologies but most commonly are pruritic, 2- to 5-mm, grouped, erythematous papules or papulovesicles or >5-cm edematous plaques; lesions are nonscarring. A PMLE variant known as **juvenile spring eruption** characteristically occurs

Fig. 697.6 Urticaria after 5 min of exposure to artificial ultraviolet A radiation.

on affected boys' ears each spring, and **pinpoint papular PMLE** is a variant characterized by pinpoint-sized lesions occurring in darker-skinned individuals. Most PMLE cases involve sensitivity to UVA radiation, although some are UVB induced. PMLE most likely results from a delayed-type hypersensitivity reaction to a photo-induced antigen within the skin, with individuals having a genetic predisposition. Provocative phototesting, as well as skin biopsy (showing epidermal spongiosis and superficial and deep lymphocytic infiltrate), aid in diagnosis. Treatment is aimed at prevention with sun avoidance, protective clothing, and broad-spectrum sunscreens. Topical corticosteroids (low-potency for facial lesions, high-potency for lesions elsewhere) can be used for mild eruptions. Second-line approaches include prophylactic NB-UVB phototherapy or hydroxychloroquine in early spring and short-course systemic glucocorticoids for severe flares.

ACTINIC PRURIGO

Actinic prurigo, often classified as a variant of PMLE, is a chronic familial photodermatitis inherited as an autosomal dominant trait seen most commonly in Native Americans of North and South America. Human leukocyte antigen (HLA) DRB1*0407 (60–70%) and HLA DRB1*0401 (20%) are strongly associated with actinic prurigo. Most patients are female and are sensitive to UVA radiation. The first episode generally occurs in early childhood, several hours to 2 days after intense sun exposure. The papulonodular lesions are intensely pruritic, erythematous, and crusted. Areas of predilection include the face (Fig. 697.7), lower lip, distal extremities, and, in severe cases, buttocks. Facial lesions may heal with minute pitted or linear scarring. Lesions often become chronic, without periods of total clearing, merging into eczematous plaques that become lichenified and occasionally secondarily infected. Associated features that distinguish this disorder from other photoeruptions and atopic dermatitis include cheilitis, conjunctivitis, and traumatic alopecia of the outer half of the eyebrows. Actinic prurigo is a chronic condition that generally persists into adult life, although it may improve spontaneously in the late teenage years. Sun avoidance, protective clothing, and broad-spectrum sunscreens may be helpful in preventing the eruption. Mid- to high-potency topical corticosteroids and antihistamines palliate the pruritus and inflammation. Severe acute eruptions may require oral glucocorticoids. Treatment with NB-UVB beginning in springtime has shown improved tolerance of sunlight during summer months; however, it may induce symptoms in some patients. Thalidomide 50-100 mg/day is very effective, but its use is limited by toxicity, especially severe birth defects when taken by pregnant females. Dupilumab is described in case reports to be helpful.

COCKAYNE SYNDROME

Cockayne syndrome is a rare autosomal recessive disorder. Onset occurs at 1 year of age and is characterized by facial erythema in a butterfly distribution after sun exposure. Later characteristics include loss of adipose tissue and development of thin, atrophic, hyperpigmented

Fig. 697.7 Erythematous, excoriated papules in actinic prurigo.

Fig. 697.8 Dyspigmentation and actinic keratoses in child with xeroderma pigmentosum.

skin, particularly over the face. Associated features include stunted growth; dwarfism; microcephaly; progressive neurologic dysfunction (caused by leukodystrophy); mental retardation; progressive dementia; distinct facies (aged look, pinched nose, sunken eyes, large protuberant ears); long limbs; disproportionately large hands and feet; cool and cyanotic extremities; carious teeth; unsteady gait with tremor; limitation of joint mobility; progressive deafness; cataracts; retinal degeneration; optic atrophy; decreased sweating and tearing; and premature graying of the hair. Complications include diabetes and hepatic or renal impairment. Diffuse extensive demyelination of the peripheral and central nervous systems ensues, and patients generally die of atheromatous vascular disease or infections (especially pneumonia) before the third decade. There are two types of Cockayne syndrome. **Type I (*CSA* gene)** is less severe than **type II (*CSB* gene)**. Patients may have xeroderma pigmentosum–Cockayne syndrome overlap, which is phenotypically more like Cockayne syndrome and is due to genetic variants in *XPB, XPD,* or *XPG* genes. Photosensitivity in Cockayne syndrome is a result of deficient nucleotide excision repair of UV-induced damage, specifically within actively transcribing regions of DNA (transcription-coupled DNA repair). The etiology of neurologic and other associated features remains unclear; however, evidence points toward a mitochondriopathy. The syndrome is distinguished from progeria (see Chapter 111) by the presence of photosensitivity and ocular abnormalities and from xeroderma pigmentosum by the fact that patients with Cockayne syndrome do not develop sun-induced pigmentation or increased risk of skin cancers. Diagnosis is accomplished by genetic testing and performing various tests on cultured fibroblasts. The mainstay of treatment for the photosensitivity of Cockayne syndrome is strict sunlight avoidance and protective measures.

XERODERMA PIGMENTOSUM

Xeroderma pigmentosum is a rare autosomal recessive disorder that results from a defect in nucleotide excision repair. Eight genetic groups have been recognized on the basis of each group's separate defect in ability to repair (xeroderma pigmentosum A through G) or replicate (xeroderma pigmentosum V [variant]) damaged DNA. The wavelength of light that induces the DNA damage ranges from 280 to 340 nm. Skin changes are first noted during infancy or early childhood in sun-exposed areas, though lesions may occur at other sites, including the scalp. The skin lesions consist of erythema, scaling, bullae, crusting, ephelides (freckles), telangiectasia, keratoses (Fig. 697.8), basal and squamous cell carcinomas, and malignant melanomas. Interestingly, although most patients experience exaggerated acute sunburn reactions after minimal UV exposure, up to half of affected patients do not and instead develop progressive freckling. This difference in presentation depends on genetic subtype. Ocular manifestations include photophobia, lacrimation, blepharitis, symblepharon, keratitis, corneal opacities, tumors of the lids, and possible eventual blindness. Neurologic abnormalities such as cognitive deterioration and sensorineural deafness develop in approximately 20% of patients.

This disease is a serious mutilating disorder, and the life span of an affected patient is often brief. Affected families should have genetic counseling. Xeroderma pigmentosum is detectable in cells cultured from amniotic fluid or DNA analysis of chorionic villous samples. Cultured skin fibroblast tests and genetic testing after birth also confirm diagnosis. Affected children should be totally protected from sun exposure; protective clothing, sunglasses, and opaque broad-spectrum sunscreens should be used even for mildly affected children. Light from unshielded fluorescent bulbs and sunlight passing through glass windows (including vehicle windows) are also harmful; thus applied window films are recommended. Early detection and removal of malignancies is mandatory, and oral isotretinoin may be used to prevent nonmelanoma skin cancers. Average age of death of these patients is 32 years. There is crossover between several subtypes of xeroderma pigmentosum and both Cockayne syndrome and trichothiodystrophy.

ROTHMUND-THOMSON SYNDROME

Rothmund-Thomson syndrome is also known as **poikiloderma congenitale** because of the striking skin changes (Fig. 697.9). It is inherited as an autosomal recessive trait. Pathogenic genetic variants in the *RECQL4* gene, which encodes a DNA helicase involved in repair and replication of DNA and telomeres, are found in approximately 65% of patients. The other genetic variants causing Rothmund-Thomson syndrome are unknown. Skin changes are noted as early as 3 months of age and begin on the face. Plaques of erythema and edema appear in a butterfly distribution and on the forehead, ears, neck, dorsal portions of the hands, extensor surfaces of the arms, and buttocks. These are replaced gradually by **poikiloderma** (reticulated, atrophic, hyperpigmented, and hypopigmented telangiectatic patches or plaques). Palmoplantar hyperkeratosis develops in one third of patients. Light sensitivity is present in many cases, and exposure to the sun may provoke formation of bullae. Areas of involvement, however, are not strictly photodistributed. Short stature; small hands and feet; sparse eyebrows, eyelashes, and pubic and axillary hair and sparse, fine, prematurely gray scalp hair or alopecia; dystrophic nails; various tooth and skeletal abnormalities; and hypogonadism are common. One of the more distinguishing features is an increased incidence of juvenile subcapsular bilateral cataracts. Most patients have normal mental development. Keratoses and later squamous cell carcinomas may develop on exposed skin. The most worrisome association is osteosarcoma, which occurs in 30% of those patients with Rothmund-Thomson syndrome and *RECQL4* pathogenic genetic variants. Genetic testing aids in diagnosis. Management of dermatologic findings begins with sun avoidance and protection behaviors, and telangiectatic lesions have been shown to respond to pulsed dye laser therapy. In the absence of malignancy, life expectancy is normal.

Fig. 697.9 Poikiloderma on the arm of an infant with Rothmund-Thomson syndrome.

BLOOM SYNDROME

Bloom syndrome is inherited in an autosomal recessive manner, most commonly in the Ashkenazi Jewish population. It is caused by pathogenic genetic variants in the *BLM/RECQL3* gene encoding a DNA helicase. Patients are sensitive to UV radiation, with increased rates of chromosomal breaks and sister chromatid exchanges. Erythema and telangiectasia develop during infancy in a butterfly distribution on the face after exposure to sunlight. A bullous eruption on the lips and telangiectatic erythema on the cheeks, hands, and forearms may develop. Café-au-lait spots and hypopigmented macules may be present. Intrauterine growth deficiency developing into short stature, referred to as "proportionate dwarfism," and a distinctive facies consisting of a prominent nose and ears and a small, narrow face are generally found. Intellect is average to low average. Immunodeficiency is seen in all patients, manifesting as recurrent ear and pulmonary infections. Gastrointestinal malabsorption, gastroesophageal reflux, and hypogonadism are common. Affected children have an unusual tendency to develop both solid tumors (especially of the skin) and lymphoreticular malignancies, which often result in death during childhood or early adulthood. Sister chromatid exchange analysis is generally performed to confirm diagnosis. The only effective measures to reduce skin disease are sun protection and avoidance.

HARTNUP DISEASE

See Chapter 105.5.

Hartnup disease is a rare inborn error of metabolism with autosomal recessive inheritance. Neutral amino acids, including tryptophan, are not transported across the brush border epithelium of the intestine and kidneys due to a pathogenic variant in the *SLC6A19* gene encoding the transporter. This results in deficiency of nicotinamide synthesis and causes a photo-induced **pellagra-like syndrome**. The urine contains increased amounts of monoamine monocarboxylic amino acids, distinguishing Hartnup disease from dietary pellagra. Cutaneous signs, which precede neurologic manifestations, initially develop during the early months of life. An eczematous, occasionally vesiculobullous, eruption occurs on the face and extremities in a glove-and-stocking photodistribution. Hyperpigmentation and hyperkeratosis may supervene and are intensified by further exposure to sunlight. Episodic flares may be precipitated by febrile illness, sun exposure, emotional stress, and poor nutrition. In most cases, mental development is normal, but some patients display emotional instability and episodic cerebellar ataxia. Neurologic symptoms are fully reversible. Administration of nicotinamide and protection from sunlight result in improvement of both cutaneous and neurologic manifestations.

Visit Elsevier eBooks+ at eBooks.Health.Elsevier.com for Bibliography.

Chapter 698

Diseases of the Epidermis

698.1 Psoriasis

Julie M. Dhossche and Yvonne E. Chiu

Psoriasis affects 2–4% of the U.S. population, and pediatric psoriasis accounts for approximately one third of all cases.

ETIOLOGY/PATHOGENESIS

Psoriasis is an inflammatory autoimmune-related disease characterized by inflammation and keratinocyte proliferation (Fig. 698.1). Within the dermis, dendritic cells are activated by self-antigens and release cytokines such as interferon-γ, tumor necrosis factor, and interleukin (IL)-12, IL-17, IL-22, and IL-23, which recruit T cells. Once activated, the T cells release cytokines that induce proliferation and abnormal differentiation of epidermal keratinocytes; in turn, more cytokines are produced to perpetuate the cycle. Psoriasis has a complex multifactorial genetic basis. Family history of psoriasis is present in ~50% of patients, typically a first-degree relative. The major psoriasis-susceptibility gene *(PSORS1)* is human leukocyte antigen (HLA)-CW*0602, encoding a class I major histocompatibility complex protein involved in recognition of self-antigens. Numerous other psoriasis susceptibility genes have been identified.

Factors contributing to disease onset/flares in some patients include bacterial and viral infections, trauma, physical or emotional stress, tobacco use/secondhand exposure, and certain medications.

CLINICAL MANIFESTATIONS

This common chronic skin disorder is first evident within the first 2 decades of life for approximately 30% of affected individuals. **Plaque psoriasis**, the most common (>80%) subtype, is characterized by erythematous papules that coalesce to form plaques with sharply demarcated, irregular borders (Fig. 698.2A-D). If they are unaltered by treatment, a thick silvery or yellow-white scale (resembling mica) develops (see Fig. 698.2A). Removal of the scale may result in pinpoint bleeding **(Auspitz sign)**. The **Koebner phenomenon**, in which new lesions appear at sites of trauma, is a valuable diagnostic feature. Lesions may occur anywhere, but preferred sites are the scalp, knees, elbows, umbilicus, superior intergluteal fold, genitalia, and ear canal. Nail involvement, a valuable diagnostic sign, is characterized by pitting of the nail plate, detachment of the plate (onycholysis), yellowish-brown subungual discoloration, and accumulation of subungual debris (see Fig. 698.2G, H, and M). Plaques are generally asymptomatic; however, pruritus is more common in children than in adults.

Guttate psoriasis, a variant that occurs predominantly in children, is characterized by an acute eruption of many oval or round papules smaller than 1.5 cm that are morphologically identical to the larger plaques of psoriasis (see Fig. 698.2N-Q). Sites of predilection are the trunk, face, and proximal portions of the limbs. The onset usually follows a few weeks after a **streptococcal** infection such as pharyngitis; thus throat culture and serologic titers should be obtained. Guttate psoriasis has also been observed after perianal streptococcal infection, viral infections, sunburn, and withdrawal of systemic corticosteroid therapy or tumor necrosis factor (TNF)-α inhibitors. Clinical course ranges from spontaneous resolution to chronic disease.

Pustular psoriasis is a multisystem autoinflammatory disease characterized by recurrent episodes with the sudden onset of fever, malaise, extracutaneous organ involvement, and a diffuse erythematous-pustular exanthema. It may be associated with plaque psoriasis in some patients; unregulated cytokine production as a result of pathogenic genetic variants in the *IL36RN, AP1S3,* and *CARD14* genes are implicated in a subset of patients.

Psoriasis is rare in infants but may be severe and recalcitrant and may pose a diagnostic problem. Psoriatic diaper rash is a common

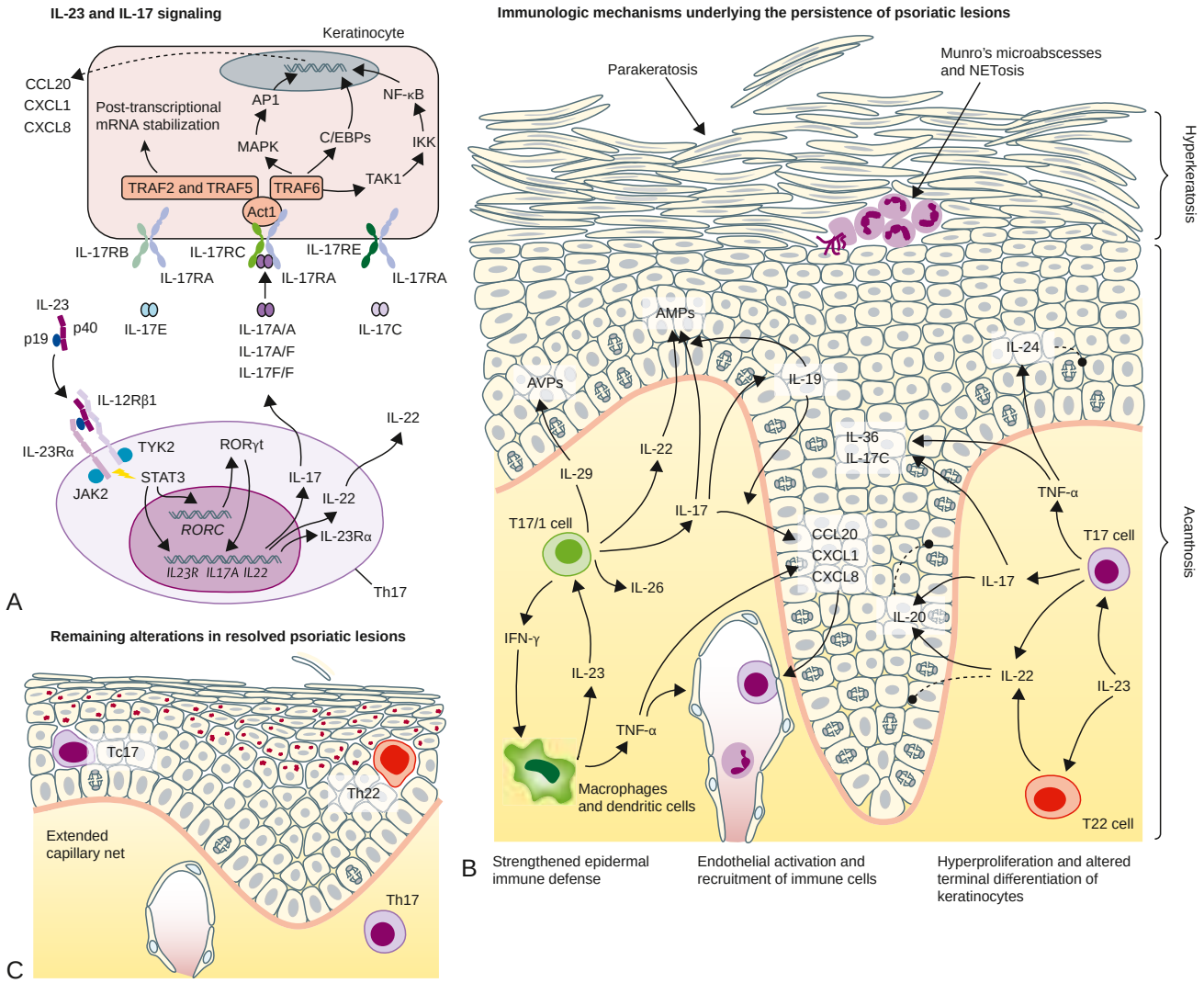

Fig. 698.1 Immune pathogenesis of psoriasis. The IL-23 and IL-17 pathway in psoriasis with elements of their signaling. **A**, IL-23 acts on Th17 cells via the transmembrane receptor complex composed of IL-12Rβ1 and IL-23Rα and intracellular JAK–STAT signaling and induces the expression of IL-17A, IL-17F, and IL-22, which act on epithelial cells through distinct receptor and signaling pathways. **B**, In psoriatic skin IL-23 is essential for the stabilization of the phenotype of IL-17–producing lymphocytes, activates these cells, and enhances their cytokine production and pathogenicity. IL-17 mostly acts synergistically with other cytokines, leading to massive activation of immunologic pathways and cytokines such as IL-22, IL-20, and IL-24, promoting the epidermal changes. **C**, After successful antipsoriatic treatment, potentially pathogenetic T cells remain in the resolved psoriatic skin. Blood capillaries extend during psoriatic inflammation by angiogenic signals and recede slowly. AMP, antimicrobial protein; AVP, antiviral protein; C/EBP, CCAAT-enhancer-binding protein; T17, Th17 and Tc17; T1, Th1 and Tc1; T22, Th22 and Tc22; Th, T helper cell; Tc, cytotoxic T cell; NETosis, activation and release of neutrophil extracellular traps. *(From Ghoreschi K, Balato A, Enerbäck C, Sabat R. Therapeutics targeting the IL-23 and IL-17 pathway in psoriasis. Lancet. 2021;397:754–766, Fig. 2.)*

presentation in children younger than 2 years old. Other rare forms include psoriatic erythroderma (>90% body surface area involvement), linear psoriasis, palmoplantar psoriasis, and inverse psoriasis (occurring in intertriginous areas). Children may also develop juvenile psoriatic arthritis, with or without skin lesions.

Psoriasis may be triggered by mild trauma (piercing, tattoos), sun or chemical burns, medications (β blockers, NSAIDs), or HIV infection. Comorbid conditions include arthritis, Crohn disease, depression, and nonalcoholic fatty liver disease.

DIFFERENTIAL DIAGNOSIS

Psoriasis is a clinical diagnosis. The differential diagnosis of plaque-type psoriasis includes nummular dermatitis, tinea corporis, seborrheic dermatitis, postinfectious arthritis syndromes, and pityriasis rubra pilaris. Scalp lesions may be confused with seborrheic dermatitis, atopic dermatitis, or tinea capitis. Diaper area psoriasis may mimic seborrheic dermatitis, eczematous diaper dermatitis, perianal streptococcal disease, candidiasis, or allergic contact dermatitis. Guttate psoriasis can be confused with viral exanthems, secondary syphilis, pityriasis rosea, and pityriasis lichenoides chronica (PLC). Nail psoriasis must be differentiated from onychomycosis, lichen planus, and other causes of onychodystrophy.

PATHOLOGY

When the diagnosis is in doubt, histopathologic examination of an untreated lesion can be helpful. Characteristic changes of psoriasis include parakeratosis, acanthosis, elongated rete ridges, neutrophilic infiltrate in the epidermis sometimes forming microabscesses, dilated dermal blood vessels, and lymphocytic infiltrate in the dermis.

Fig. 698.2 Clinical manifestations of psoriasis. Typical erythematous plaques with silvery scales (**A**) can be scattered (**B**, psoriasis nummularis), cover larger areas of the skin (**C**, psoriasis geographica), or affect the entire body surface (**D**, erythrodermic psoriasis). Scalp involvement might be accompanied by nonscarring alopecia (**E**). Psoriatic arthritis affects up to 30% of all patients (**F**, thumb interphalangeal joint). Nail changes are frequent and range from pitting and yellow or brown discoloration (**G**) to complete dystrophy (**H**). Psoriasis inversa occurs in intertriginous areas and is usually devoid of scales (**I**). Pustular psoriasis might occur in a generalized form (**J** and **K**) or localized (**L**, palmoplantar type and **M**, acrodermatitis continua suppurativa type). In children, the onset as guttate psoriasis might follow streptococcal infection of the upper respiratory tract (**N**) and affect any site of the body (**O-Q**). *(From Boehncke WH, Schön MP. Psoriasis. Lancet. 2015;386:983–992, Fig. 1, p. 984.)*

TREATMENT

The therapeutic approach varies with the age of the child, type of psoriasis, sites of involvement, and extent of the disease. Physical and chemical trauma to the skin should be avoided as much as possible to prevent Koebner-response lesions. The treatment of psoriasis should be viewed as a four-tier process. Efficacy varies with each therapy (Table 698.1).

The first tier is topical therapy. The first-line topical agents for lesions on the body are emollients, vitamin D analogs (calcipotriene or calcitriol, although calcitriol is less irritating for children), and mid- to high-potency corticosteroids (see Chapter 687). A proprietary formulation containing both calcipotriene and betamethasone dipropionate (a high-potency topical corticosteroid) exists in ointment and solution forms. The preparation that is least potent but effective should be applied twice a day. Second-line topical options for lesions on the body include retinoids (tazarotene), tar preparations, anthralin, and keratolytics (salicylic acid or urea). Facial or intertriginous lesions may be treated with low-potency topical corticosteroids and/or topical vitamin D analogs or calcineurin inhibitors as corticosteroid-sparing agents. For scalp lesions, applications of a phenol and saline solution (e.g., Baker Cummins P&S liquid) or salicylic acid shampoo followed by a tar shampoo are effective in the removal of scales. A high-potency to superpotency corticosteroid in a foam, solution, or lotion base may be applied when the scaling is diminished. Nail lesions are difficult to treat topically; the first-line approach is a high-potency topical corticosteroid to the proximal nail fold.

The second tier of therapy is phototherapy. Narrow-band ultraviolet B (311 nm; NB-UVB) is an effective and well-tolerated alternative in pediatric patients with plaque and guttate psoriasis poorly controlled with topical treatments. Excimer (308 nm) laser UVB irradiation may be used for localized treatment-resistant plaques. Exposure to natural sunlight is often effective for less severe psoriasis.

The third tier is systemic therapy for children with moderate to severe, recalcitrant or generalized psoriasis. Methotrexate (0.2-0.7 mg/kg/wk to a maximum of 25 mg/week) is the first-line systemic agent for children; other options include oral retinoids (0.5-1.0 mg/kg/day to a maximum of 50 mg/day) and cyclosporine (modified formulation, 3-5 mg/kg/day). Oral retinoids may be cautiously combined with phototherapy, although doses may need to be decreased because of the photosensitizing effects of the medication. Oral retinoids are also considered for generalized pustular and diffuse guttate psoriasis.

Biologic response modifiers are increasingly used in place of traditional oral agents. TNF-α inhibitors such as etanercept, infliximab, and adalimumab have increasingly been used for pediatric psoriasis. Etanercept has FDA approval for those 4 years and older with psoriasis. One study reported a significant improvement in psoriatic lesions at 12 weeks with 57% versus 11% of patients receiving etanercept or placebo, respectively, achieving a 75% improvement in Psoriasis Area and Severity Index-75 (PASI-75, a metric to evaluate psoriasis severity). Ustekinumab, a human monoclonal antibody that blocks IL-12 and IL-23 and their cell-surface receptors, is approved for those 6 years and older with moderate to severe psoriasis. Biologic IL-17 inhibitors

Table 698.1 Recommendations for Pediatric Psoriasis

RECOMMENDATION	STRENGTH OF RECOMMENDATION	LEVEL OF EVIDENCE
Topical corticosteroids are recommended for the treatment of pediatric psoriasis as an off-label therapy	B	II
The use of ultra-high-potency topical corticosteroids as monotherapy is effective for short-term treatment of localized psoriasis in pediatric patients	C	II
Tacrolimus 0.1% ointment is recommended for off-label use as monotherapy for pediatric psoriasis of the face and genital region	C	II-III
Calcipotriene/calcipotriol is recommended as a treatment option for childhood plaque psoriasis	B	II
Because of the theoretical risk of increased calcium absorption and systemic effects of hypercalcemia, occlusion of calcipotriene/calcipotriol applied to large body surface areas is not recommended	B	III
Monitoring of vitamin D metabolites may be considered during calcipotriene/calcipotriol therapy when applied to a large body surface area	B	I-II
The combination of calcipotriol/betamethasone dipropionate ointment applied once daily for up to 4 weeks at a time is recommended as a safe and effective treatment for children ages 12 yr and older with mild to moderate plaque psoriasis	B	I-II
The combination of calcipotriol/betamethasone dipropionate suspension applied once daily for up to 8 wk at a time is recommended as a safe and effective treatment for children ages 12 yr and older with mild to moderate plaque psoriasis of the scalp	B	II
The use of emollients (at the same time or different time of day) with topical calcipotriene may be considered to reduce irritation and enhance the efficacy of calcipotriene	C	III
Rotational therapy with topical vitamin D analogues, topical calcineurin inhibitors, emollients, tar-based therapies, and topical corticosteroids may be considered in children as steroid-sparing regimens that may reduce potential adverse effects from overreliance on topical steroid therapy	C	II
The off-label use of topical tazarotene may be recommended as monotherapy or in combination with topical corticosteroids for the treatment of localized pediatric skin or nail psoriasis	C	III
Long-term use (12 wk or longer) of topical anthralin is recommended for the treatment of mild to moderate psoriasis. Short-contact anthralin protocols are recommended to limit adverse effects	B	II
Coal tar preparations can be used as a monotherapy or combined with other topical therapies for the treatment of pediatric psoriasis	C	II-III
The use of coal tar preparations in conjunction with phototherapy is effective for the treatment of psoriasis in children but may be limited by the theoretical long-term risk of carcinogenesis	B	II-III
NB-UVB is recommended as a treatment option for moderate to severe pediatric plaque and guttate psoriasis	B	II-III
The use of excimer laser or PUVA therapy in children with psoriasis may be efficacious and well tolerated but has limited supporting evidence	C	III
Methotrexate is recommended as an effective systemic therapy for moderate to severe plaque psoriasis and other psoriasis subtypes in children	B	II-III
Methotrexate is recommended as an effective systemic therapy for pustular psoriasis in children	B	III
Methotrexate weight-based dosing is recommended in younger children, ranging from 0.2 to 0.7 mg/kg/wk (maximum, 25 mg/wk)	B	III
Folic acid supplementation daily or six times weekly during treatment with methotrexate is recommended	B	II
Routine clinical and laboratory monitoring is recommended before and during treatment with methotrexate	B	III
Cyclosporine is recommended as an effective systemic therapy for moderate to severe plaque psoriasis in children	B	II-III
Cyclosporine is recommended as an effective systemic therapy for moderate to severe pustular psoriasis in children	B	III
Cyclosporine is recommended for short-term crisis management of severe or unstable plaque, erythrodermic, or pustular psoriasis until the patient can be transitioned to a medication appropriate for long-term use	C	III
Routine blood pressure clinical and laboratory monitoring is recommended during therapy with cyclosporine	A	III
Modified cyclosporine (for microemulsion in capsules or solution) is recommended for use and is not interchangeable with unmodified forms of cyclosporine	C	III

Continued

Table 698.1 Recommendations for Pediatric Psoriasis—cont'd

RECOMMENDATION	STRENGTH OF RECOMMENDATION	LEVEL OF EVIDENCE
Acitretin is recommended as an effective, nonimmunosuppressive systemic therapy for children with extensive guttate or moderate to severe (ideally thin plaque) psoriasis vulgaris at a dosage of 0.1-1 mg/kg/d	B	II
Acitretin is recommended as an effective systemic therapy for pustular psoriasis in children	B	II-III
Acitretin combined with NB-UVB therapy may be synergistic for plaque and pustular psoriasis in childhood and allows for a reduction in dosing of both agents	C	III
Acitretin may be combined with other systemic therapies such as methotrexate or cyclosporine, or biologics, depending on the individual clinical situation	C	III
Routine clinical and laboratory monitoring is recommended during therapy with acitretin	C	III
Fumaric acid esters may be considered as a potentially effective alternative therapy for pediatric patients with moderate to severe psoriasis who are candidates for systemic therapy	C	II-III
Clinical and laboratory monitoring is recommended during treatment with fumaric acid esters	C	III
Etanercept is recommended as an effective therapy for moderate to severe psoriasis in children 6 yr of age and older	A	I-III
Etanercept dosing is typically once weekly and is dosed subcutaneously at 0.8 mg/kg with a maximum of 50 mg weekly	A	I, III
Adalimumab is recommended for off-label use as an effective therapy in children and adolescents with moderate to severe psoriasis	B	I, III
The dose of adalimumab is 0.8 mg/kg (maximum, 40 mg) at weeks 0 and 1 and then is given every other week; adalimumab administered at a dose of 0.8 mg/kg is more efficacious than at a dose of 0.4 mg/kg	B	I
Infliximab can be recommended as monotherapy or in combination with methotrexate for use in pediatric patients with severe plaque or pustular psoriasis that is unresponsive to other systemic medications, rapidly progressive, unstable, and/or life threatening	C	III
The starting dose of infliximab is an infusion of 5 mg/kg administered on weeks 0, 2, and 6 and then every 8 weeks	C	III
Ustekinumab is recommended as an effective therapy for adolescents 12 yr and older with moderate to severe plaque psoriasis	A	I, III
Ustekinumab can be used as an effective therapy for pediatric patients younger than 12 yr old with moderate to severe plaque psoriasis	C	III
Ustekinumab is given at weeks 0, 4, and 16 and then every 12 weeks with weight-based dosing as follows: 0.75 mg/kg if < 60 kg, 45 mg if 60 to 100 kg, and 90 mg if > 100 kg	B	I
Biologics may be safely combined with topical corticosteroids, with or without a vitamin D analogue, to augment effectiveness for the treatment of moderate to severe plaque psoriasis	C	III
The major risk for biologics in children is injection site reaction, but patients should be monitored for their increased risk of infection	B	II

Data from Menter A, Cordoro KM, Davis DMR, et al. Joint American Academy of Dermatology–National Psoriasis Foundation guidelines of care for the management and treatment of psoriasis in pediatric patients. *J Am Acad Dermatol.* 2020;82(1):161–201, Tables XX–XLVIII, pp. 173–189.

secukinumab and ixekizumab are also FDA approved for those 6 and older. The safety and efficacy data of these biologic agents show they are generally well tolerated and efficacious in the treatment of moderate to severe plaque psoriasis. The primary risk is injection site reaction. A small-molecule inhibitor of phosphodiesterase 4, apremilast, is also used for pediatric psoriasis. IL-23 inhibitors may also have a role in the treatment of severe disease and are being studied in pediatric populations.

PROGNOSIS

Prognosis is best for children with limited disease. Psoriasis is a lifelong disease characterized by remissions and exacerbations. Arthritis or various eye diseases may be extracutaneous complications. Metabolic and cardiovascular disorders also occur with increased frequency in patients with psoriasis. For example, an increasing degree of obesity and the associated metabolic syndrome (hyperglycemia, hyperlipidemia, and hypertension) correlates with psoriasis severity. Patients with psoriasis also have increased rates of stroke, myocardial infarction, and other vascular diseases later in adult life. A proposed mechanism involves the systemic proinflammatory state induced by both psoriasis and these associated conditions, although the direction of causality remains unclear. Furthermore, children suffering from psoriasis have a greater risk of taking psychotropic medications for anxiety or depression and are more likely to report impairment in quality of life due to their chronic disease.

Visit Elsevier eBooks+ at eBooks.Health.Elsevier.com for Bibliography.

698.2 Pityriasis Lichenoides

Julie M. Dhossche and Yvonne E. Chiu

Pityriasis lichenoides encompasses a disease spectrum ranging from PLC to pityriasis lichenoides et varioliformis acuta (PLEVA; Mucha-Habermann disease). The designation of pityriasis

Fig. 698.3 Widespread plaques with fine scale in pityriasis lichenoides chronica.

Fig. 698.4 Necrotic lesion with erythematous halo in pityriasis lichenoides et varioliformis acuta.

lichenoides as acute or chronic refers to the morphologic appearance of the lesions rather than to the duration of the disease. No correlation is found between the type of lesion at the onset of the eruption and the duration of the disease. Many patients have both acute and chronic lesions simultaneously, and transition of lesions from one form into another occurs occasionally. As a result, some authors advocate using pityriasis lichenoides as the general diagnosis rather than differentiating between PLC and PLEVA. Febrile ulceronecrotic Mucha-Habermann disease (FUMHD) is a rare subtype of PLEVA that is more severe and potentially life-threatening.

ETIOLOGY/PATHOGENESIS

Two main theories exist for the etiology of pityriasis lichenoides. The first is that it arises in a genetically susceptible individual as a hypersensitivity reaction to an infection. The second is that it represents a monoclonal T-cell lymphocytic proliferation on the pathway to cutaneous T-cell dyscrasia.

CLINICAL MANIFESTATIONS

Pityriasis lichenoides most commonly manifests in the second and third decades of life; 30% of cases manifest before age 20 years, with peaks of incidence at 5 and 10 years of age. The overall eruption persists for months to years with a tendency to eventually remit.

PLC manifests gradually as generalized, multiple, brown-red papules to plaques that are covered by a fine grayish scale (Fig. 698.3). Lesions may be asymptomatic or may cause minimal pruritus and occasionally become vesicular, hemorrhagic, crusted, or superinfected. Individual papules become flat and brownish in 2-6 weeks, ultimately leaving hyperpigmented or hypopigmented macules and patches. Scarring is unusual. Various stages of lesions are present, most commonly on the trunk and extremities and generally spare the face, palmoplantar surfaces, scalp, and mucous membranes.

PLEVA manifests as an abrupt eruption of numerous 2- to 3-mm papules that have a vesiculopustular and then a purpuric center, are covered by a dark adherent hemorrhagic or necrotic crust, and are surrounded by an erythematous halo (Fig. 698.4). Constitutional symptoms, such as fever, malaise, headache, and arthralgias, may be present for 2-3 days after the initial outbreak. Lesions are distributed diffusely on the trunk and extremities, as in PLC. Individual lesions heal within a few weeks, sometimes leaving a varioliform scar, and successive crops of papules produce the characteristic polymorphous appearance of the eruption, with lesions in various stages of evolution.

FUMHD manifests as high fever and ulceronecrotic nodules up to a few centimeters in diameter, which are most common on the anterior trunk and flexor surfaces of the proximal upper extremities. Histopathology of lesions is consistent with PLEVA. Hemorrhagic bullae, mucosal ulcers, arthritis, cardiomyopathy, vasculitis, abdominal complaints, hematologic abnormalities (megaloblastic anemia, pancytopenia, and diffuse intravascular coagulation), and superinfection of cutaneous lesions with *Staphylococcus aureus* may also develop. These patients may have a history of previous PLEVA diagnosis. Although there is no reported standardized treatment and there have been reports of fatalities, typically the ulceronecrotic lesions heal with hypopigmented scarring in a few weeks.

PATHOLOGY

PLC histologically shows a parakeratotic, thickened corneal layer; epidermal spongiosis; a superficial perivascular infiltrate of macrophages and predominantly CD8 lymphocytes that may extend into the epidermis; and small numbers of extravasated erythrocytes in the papillary dermis.

The histopathologic changes of PLEVA and FUMHD reflect their more severe nature. Intercellular and intracellular edema in the epidermis may lead to degeneration of keratinocytes. A dense perivascular mononuclear cell infiltrate, endothelial cell swelling, and extravasation of erythrocytes into the epidermis and dermis are additional characteristic features.

DIFFERENTIAL DIAGNOSIS

The differential diagnosis of pityriasis lichenoides includes guttate psoriasis, pityriasis rosea, drug eruptions, secondary syphilis, viral exanthems, lymphomatoid papulosis, and lichen planus. The chronicity of pityriasis lichenoides helps preclude pityriasis rosea, viral exanthems, and some drug eruptions. A skin biopsy can help distinguish pityriasis lichenoides from other entities in the differential diagnosis.

TREATMENT

Pityriasis lichenoides should be considered a benign condition that does not alter the health of the child. A lubricant to remove excessive scaling may be all that is necessary if the patient is asymptomatic. If treatment is required, first-line agents are oral antiinflammatory antibiotics such as erythromycin (30-50 mg/kg/day to a maximum of 4000 mg/day for 2-3 months) or doxycycline for children >8 years. Topical corticosteroids (mid-potency, applied twice daily) and topical calcineurin inhibitors may help the pruritus and inflammation but do not alter the course of the disease. Phototherapy (NB-UVB) is the second-line treatment option. Methotrexate should be reserved for severely symptomatic cases. The rare FUMHD usually requires inpatient treatment; initially, systemic corticosteroids, methotrexate, intravenous immunoglobulin, or cyclosporine may be necessary, with eventual transition to another form of treatment, as mentioned earlier, once the disease improves and stabilizes.

Visit Elsevier eBooks+ at eBooks.Health.Elsevier.com for Bibliography.

Fig. 698.5 Keratotic follicular plugs with surrounding erythema in keratosis pilaris.

698.3 Keratosis Pilaris

Julie M. Dhossche and Yvonne E. Chiu

Keratosis pilaris is a common papular eruption resulting from keratin plugging of hair follicles. It displays an autosomal dominant transmission with variable penetrance. Typical areas of involvement include the upper extensor surfaces of the arms and thighs, cheeks, and buttocks. The lesions may resemble gooseflesh; they are noninflammatory, scaly, follicular papules that do not coalesce. They are generally asymptomatic but may be pruritic. Irritation of the follicular plugs occasionally causes erythema surrounding the keratotic papules (Fig. 698.5). A subset of patients has keratosis pilaris associated with facial telangiectasia and ulerythema ophryogenes, a rare cutaneous disorder characterized by inflammatory keratotic facial papules that may result in scars, atrophy, and alopecia. Because the lesions of keratosis pilaris are associated with and accentuated by dry skin, they are often more prominent during the winter. Keratosis pilaris is more frequent in patients with atopic dermatitis and is most common during childhood and early adulthood, tending to subside in the third decade of life. Treatment of keratosis pilaris is optional. Measures to decrease pruritus include moisturization with a bland emollient. Regular applications of a 10–40% urea cream or an alpha-hydroxy acid preparation such as 12% lactic acid cream or lotion can improve the appearance of keratosis pilaris but may further contribute to pruritus and irritation. Therapy may improve the condition but does not cure it.

698.4 Lichen Spinulosus

Julie M. Dhossche and Yvonne E. Chiu

Lichen spinulosus is an uncommon disorder that occurs principally in children and more frequently in boys. The cause is unknown. The lesions consist of sharply circumscribed irregular plaques of spiny, keratotic, follicular plugs. Plaques may occur anywhere on the body and are often distributed symmetrically on the trunk, elbows, knees, and extensor surfaces of the limbs. Although sometimes erythematous or pruritic, the lesions are usually skin colored and asymptomatic.

Treatment is usually unnecessary. For patients who regard the eruption as a cosmetic defect, urea-containing lubricants (10–40%) are often effective in flattening the projections. The plaques usually disappear spontaneously after several months or years.

698.5 Pityriasis Rosea

Julie M. Dhossche and Yvonne E. Chiu

Pityriasis rosea is a common benign papulosquamous disorder typically affecting adolescents and young adults 15-30 years of age. The disease is more commonly seen in the winter and is usually self-limited.

Fig. 698.6 Herald patch and surrounding pityriasis rosea.

ETIOLOGY/PATHOGENESIS

The cause of pityriasis rosea is unknown; a viral agent is suspected, with a current focus on human herpesviruses 6 and 7. Supporting evidence for an infectious etiology includes the tendency for it to occur in (familial) case clusters, presence of a prodrome and seasonal variation, and infrequent recurrences, although the rash itself does not appear to be contagious.

CLINICAL MANIFESTATIONS

This benign, common eruption occurs most frequently in children and young adults. Although a prodrome of fever, malaise, arthralgia, and pharyngitis may precede the eruption, children rarely complain of such symptoms. A **herald patch** classically precedes the generalized eruption and may occur anywhere on the body. Herald patches are generally larger than other lesions and vary from 1 to 10 cm in diameter; they are annular in configuration and have a raised border with fine, adherent scales. Approximately 5-10 days after the appearance of the herald patch, a widespread, symmetric eruption involving mainly the trunk and proximal limbs becomes evident (Fig. 698.6). In the inverse form of pityriasis rosea, the face, scalp, and distal limbs may be preferentially involved. Lesions may appear in crops for several days. Typical lesions are oval or round, <1 cm in diameter, slightly raised, and pink to brown. The developed lesion is covered by a fine scale, which gives the skin a crinkly appearance. Some lesions clear centrally and produce a collarette of scale that is attached only at the periphery. Papular, vesicular, urticarial, hemorrhagic, large annular, and mucosal lesions are unusual variants. The long axis of each lesion is usually aligned with the cutaneous cleavage lines, a feature that creates the so-called **Christmas tree pattern** on the back. Conformation to skin lines is often more discernible in the anterior and posterior axillary folds and supraclavicular areas. The lesions most commonly are asymptomatic but may be mildly to severely pruritic. Duration of the eruption varies from 2 to 12 weeks, with self-resolution. After the eruption has resolved, postinflammatory hypopigmentation or hyperpigmentation may be pronounced, particularly in dark-skinned patients. These changes disappear in subsequent weeks to months.

DIFFERENTIAL DIAGNOSIS

The herald patch may be mistaken for tinea corporis, a pitfall that can be avoided if microscopic evaluation of a potassium hydroxide preparation of scrapings of the lesion is performed. The generalized eruption resembles a number of other diseases; secondary syphilis is the most important. Drug eruptions, viral exanthems, guttate psoriasis, PLC, and nummular dermatitis can also be confused with pityriasis rosea.

TREATMENT

Therapy is unnecessary for asymptomatic patients with pityriasis rosea. If scaling is prominent, a bland emollient may suffice. Pruritus may be suppressed by a lubricating lotion containing menthol and camphor or by an oral antihistamine for sedation, particularly at night, when itching may be troublesome. Occasionally, a mid-potency topical corticosteroid preparation may be necessary to alleviate pruritus. Exposure to natural sunlight and NB-UVB phototherapy may reduce disease duration and severity. Acyclovir has been used in some cases to treat symptoms and shorten duration.

Visit Elsevier eBooks+ at eBooks.Health.Elsevier.com for Bibliography.

698.6 Pityriasis Rubra Pilaris

Julie M. Dhossche and Yvonne E. Chiu

ETIOLOGY/PATHOGENESIS

The cause of pityriasis rubra pilaris remains unclear. Pityriasis rubra pilaris can be subdivided into six clinical subtypes based on age of onset, characteristics, and other features. Most cases are sporadic, but familial forms are commonly seen in the fifth subtype, with gain-of-function variants in the *CARD14* gene. The sixth subtype occurs in those with HIV infection. Some studies have indicated a role for TNF-α in disease development, whereas other hypotheses for causal factors include abnormal vitamin A metabolism, trauma, infections, immunosuppression, and UV light exposure.

CLINICAL MANIFESTATIONS

This rare inflammatory dermatosis is known for its variability in clinical presentation and course of disease. It often has an insidious onset with diffuse scaling and erythema of the scalp, which is indistinguishable from the findings in seborrheic dermatitis, and with thick hyperkeratosis of the palms and soles (Fig. 698.7A). Lesions over the elbows and knees are also common (see Fig. 698.7B), and generalized erythroderma develops in some patients. The characteristic primary lesion is a firm, dome-shaped, tiny, acuminate, pink to red papule, which has a central keratotic plug pierced by a vellus hair. Masses of these papules coalesce to form large, erythematous, sharply demarcated orange-pink plaques with overlying scale, within which islands of normal skin can be distinguished. Typical papules on the dorsum of the proximal phalanges are readily palpated. Gray plaques or papules resembling lichen planus may be found in the oral cavity. Dystrophic changes in the nails may occur and mimic those of psoriasis. Lesions are commonly pruritic. In childhood, the prognosis for eventual resolution is relatively good.

DIFFERENTIAL DIAGNOSIS

Differential diagnosis includes ichthyosis, seborrheic dermatitis, keratoderma of the palms and soles, and psoriasis. The "Wong" variant of dermatomyositis may present with a pityriasis rubra pilaris–like eruption.

Fig. 698.7 Pityriasis rubra pilaris. **A**, Orange palmar hyperkeratosis. **B**, Elbow lesions.

HISTOLOGY

Skin biopsy revealing follicular plugging, epidermal acanthosis, perivascular infiltrate, checkerboard pattern of orthokeratosis and parakeratosis, and an intact granular layer may differentiate this condition from psoriasis and seborrheic dermatitis.

TREATMENT

The numerous therapeutic regimens recommended are difficult to evaluate because pityriasis rubra pilaris has a capricious course with exacerbations and remissions. Moisturization alone is useful in mild cases. Topical agents, such as mid- to high-potency corticosteroids, keratolytics (urea, salicylic acid), vitamin D analogs (calcipotriene), retinoids (tazarotene, tretinoin), and tar, are used in combination with systemic agents for widespread disease and as monotherapy for localized disease. When further treatment is necessary, oral retinoids (isotretinoin or acitretin 0.5-1 mg/kg/day; maximum daily dose of isotretinoin is 80 mg/day and acitretin is 50 mg/day) are used as first-line agents, whereas methotrexate is used as a second-line agent. Third-line treatment options include biologic TNF-α inhibitors, cyclosporine, azathioprine, and NB-UVB phototherapy. Ustekinumab and secukinumab have also been described as efficacious.

Visit Elsevier eBooks+ at eBooks.Health.Elsevier.com for Bibliography.

698.7 Darier Disease (Keratosis Follicularis)

Julie M. Dhossche and Yvonne E. Chiu

ETIOLOGY/PATHOGENESIS

A rare genetic disorder, Darier disease is inherited as an autosomal dominant trait and is caused by pathogenic genetic variants in the *ATP2A2* gene. This gene encodes a cellular calcium pump, SERCA2, and dysfunction results in loss of adhesion between epidermal cells and abnormal keratinization.

CLINICAL MANIFESTATIONS

Onset usually occurs in late childhood and persists throughout life. Typical lesions are small, firm, skin-colored, warty papules that are not always follicular in location. The lesions eventually acquire yellow, malodorous, greasy crusts and coalesce to form large, gray-brown, vegetative plaques (Fig. 698.8). The scalp, face, neck, shoulders, chest, back, axillae, limb flexures, and groin are symmetrically involved. Papules, fissures, crusts, and ulcers may appear on the mucous membranes of the lips, tongue, buccal mucosa, pharynx, larynx, and vulva. Hyperkeratosis of the palms and soles and nail dystrophy with subungual hyperkeratosis and longitudinal red and white banding are variable features. Severe pruritus, secondary infection, offensive odor, and pain may occur. Several exacerbating triggers have been identified: sweating, UV light exposure, heat, friction, surgery, and infections; thus Darier disease has a chronic relapsing course that usually worsens in summertime.

HISTOLOGY

Histologic changes seen in Darier disease are diagnostic. Hyperkeratosis with keratin plugging, intraepidermal separation (acantholysis) with formation of suprabasal clefts, and dyskeratotic epidermal cells are characteristic features.

DIFFERENTIAL DIAGNOSIS

Darier disease is most likely to be confused with seborrheic dermatitis, acanthosis nigricans, flat warts, or Hailey-Hailey disease.

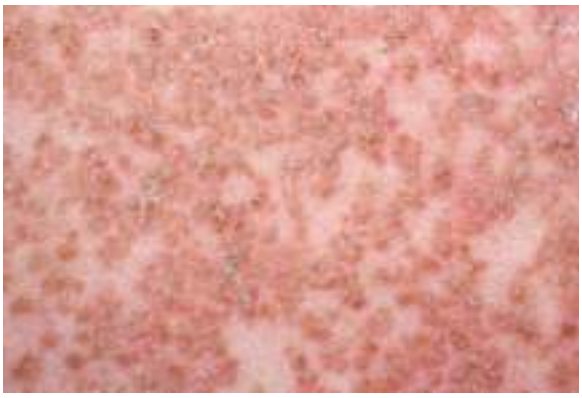

Fig. 698.8 Papules coalescing into a large plaque on the back of a patient with Darier disease.

TREATMENT

Treatment is nonspecific and begins with emollients and avoidance of triggers. First-line treatment for mild/localized disease is low- to mid-potency corticosteroids; second-line treatment are topical retinoids. Further treatment options include topical keratolytic agents (urea, lactic acid), antiseptic washes (triclosan, chlorhexidine gluconate, or bleach), or calcineurin inhibitors. More severe/generalized disease is treated with oral isotretinoin or acitretin (0.5-1.0 mg/kg/day for 3-4 months; maximum daily dose of isotretinoin is 80 mg/day and acitretin is 50 mg/day). Secondary infections are common and must be treated appropriately. Novel treatments currently being investigated include anti–IL-6 antibodies, cyclooxygenase-2 (COX2) inhibitors and miglustat (a glucosylceramide synthase inhibitor).

Visit Elsevier eBooks+ at eBooks.Health.Elsevier.com for Bibliography.

698.8 Lichen Nitidus

Julie M. Dhossche and Yvonne E. Chiu

ETIOLOGY/PATHOGENESIS

The etiology of lichen nitidus is unknown but has been linked to immune alteration.

CLINICAL MANIFESTATIONS

This uncommon, chronic, benign, papular eruption is characterized by minute (1-2 mm), flat-topped, shiny, firm papules of uniform size. The papules are most often skin-colored but may be pink or red. In darker-skinned individuals, they are usually hypopigmented (Fig. 698.9). Sites of predilection are the genitals, abdomen, chest, forearms, wrists, and inner aspects of the thighs. The lesions may be sparse or numerous and may form large plaques; careful examination usually discloses linear papules in a line of a scratch (Koebner phenomenon), a valuable clue to the diagnosis because it occurs in only a few diseases. Lichen nitidus occurs in all age-groups but is most prevalent in school-age children and young adults. Patients with lichen nitidus are usually asymptomatic and constitutionally well, although pruritus may be severe. The lesions may be confused with those of lichen planus, and lichen nitidus can rarely occur concurrently with lichen planus.

DIFFERENTIAL DIAGNOSIS

Widespread keratosis pilaris can also be confused with lichen nitidus, but the follicular localization of the papules and the absence of Koebner phenomenon in the former distinguish them. Verruca plana (flat warts), if small and uniform in size, may occasionally resemble lichen nitidus.

Fig. 698.9 Slightly hypopigmented, uniform papules of lichen nitidus.

HISTOLOGY

Although the diagnosis can be made clinically, a biopsy is occasionally indicated. The lichen nitidus papule consists of sharply circumscribed nests of lymphocytes and histiocytes in the upper dermis enclosed by clawlike epidermal rete ridges.

TREATMENT

The course of lichen nitidus spans months to years, but the lesions eventually involute completely. No treatment is necessary, but mid- to high-potency topical steroids may be used for pruritus.

Visit Elsevier eBooks+ at eBooks.Health.Elsevier.com for Bibliography.

698.9 Lichen Striatus

Julie M. Dhossche and Yvonne E. Chiu

ETIOLOGY/PATHOGENESIS

Lichen striatus is hypothesized to be caused by a combination of a genetic predisposition present in a mosaic manner in the skin (following the lines of Blaschko) and an infectious trigger.

CLINICAL MANIFESTATIONS

A benign, self-limited eruption, lichen striatus consists of a continuous or discontinuous linear band of papules in a Blaschkoid distribution. The primary lesion is a flat-topped, hypopigmented or pink papule covered with fine scale. Aggregates of these papules form multiple bands or plaques. The papules are gradually replaced by hypopigmented macules, which may be the presenting lesion in some cases. The eruption evolves over a period of days or weeks in an otherwise healthy child, remains stationary for weeks to months, and finally remits without sequelae, usually within 2 years. Symptoms are usually absent, although some children complain of itching. Nail dystrophy may occur when the eruption involves the proximal nail fold and matrix (Fig. 698.10).

DIFFERENTIAL DIAGNOSIS

Lichen striatus is occasionally confused with other disorders. The initial plaque may resemble papular eczema or lichen nitidus until the linear configuration becomes apparent. Linear lichen planus and linear psoriasis are usually associated with typical individual lesions elsewhere on the body. Linear epidermal nevi are permanent lesions that often become more hyperkeratotic and hyperpigmented than those of lichen striatus.

TREATMENT

Treatment is not necessary and generally not very effective. A low-potency topical corticosteroid preparation or topical calcineurin

Fig. 698.10 Lichen striatus with nail dystrophy.

Fig. 698.11 Flat-topped, purple polygonal papules of lichen planus.

inhibitor can be used when pruritus is a problem in a patient with lichen striatus.

Visit Elsevier eBooks+ at eBooks.Health.Elsevier.com for Bibliography.

698.10 Lichen Planus

Julie M. Dhossche and Yvonne E. Chiu

ETIOLOGY/PATHOGENESIS

The cause of lichen planus is unknown, but an immune attack on the skin by cytotoxic T cells is postulated. A genetic predisposition may exist, and other proposed triggers include metal exposure, certain medications, liver disease, vaccinations (especially hepatitis B vaccination), and infections (especially hepatitis C virus).

CLINICAL MANIFESTATIONS

This is a rare disorder in young children and uncommon in older ones. The classic form of lichen planus is the most common subtype in children, often exhibiting an acute eruptive onset. The lesions erupt in an explosive fashion, much like a viral exanthem, and spread to involve most of the body surface. The primary lesion is a violaceous, sharply demarcated, polygonal papule with fine white lines (Wickham's striae) or scale on the surface. Papules may coalesce to form large plaques (Fig. 676.11). The papules are intensely pruritic, and additional papules are often induced by scratching (Koebner phenomenon) so that lines of them are detected. Sites of predilection are the flexor surfaces of the wrists, the forearms, the inner aspects of the thighs, and the ankles.

Hypertrophic, linear, bullous, atrophic, annular, follicular, erosive, ulcerative, and actinic forms of lichen planus may also occur in children. Characteristic lesions of mucous membranes consist of pinhead-size white papules that coalesce to form reticulated and lacy patterns on the buccal mucosa. Erosive ulcers are also common in the oral mucosa and may also involve the gastrointestinal tract. Nail involvement causes nail dystrophy. The disorder may persist for months to years, but self-resolution eventually occurs in most cases. Intense hyperpigmentation frequently persists for a long time after the resolution of lesions.

HISTOLOGY

The histopathologic findings in lichen planus are specific, consisting of hyperkeratosis, irregular acanthosis, wedge-shaped hypergranulosis, apoptotic keratinocytes in the lower epidermis and upper dermis, and basal cell degeneration with a bandlike lymphocytic infiltrate at the epidermal-dermal junction. Pigment incontinence is frequently seen. Biopsy is indicated if the diagnosis is unclear.

TREATMENT

Treatment is directed at alleviation of the intense pruritus and amelioration of the skin lesions. First-line treatment with a high-potency topical corticosteroid applied twice daily is effective for localized disease on the trunk or extremities; lesions on the face and genitals may be treated with low- to mid-potency corticosteroids. Alternatives to topical steroids include topical calcineurin inhibitors or vitamin D analogs. Thick lesions may require intralesional corticosteroid injection. Oral antihistamines (hydroxyzine) are often added for the pruritus. Short courses of systemic glucocorticoids or phototherapy (NB-UVB) are used as second-line approaches for rare cases of widespread, intractable lesions. Other medications with reported efficacy include oral retinoids (acitretin), dapsone, metronidazole, griseofulvin, and methotrexate.

Visit Elsevier eBooks+ at eBooks.Health.Elsevier.com for Bibliography.

698.11 Porokeratosis

Julie M. Dhossche and Yvonne E. Chiu

ETIOLOGY/PATHOGENESIS

Porokeratoses are a group of uncommon dermatoses due to abnormal epidermal keratinization. Genetic variants in the mevalonate pathway with autosomal dominant transmission, chronic sun exposure (particularly with the disseminated superficial actinic form), and immunosuppression (particularly organ transplantation) may contribute.

CLINICAL MANIFESTATIONS

Porokeratosis is a rare, chronic, progressive disease of keratinization. The prototypical lesion is an atrophic papule or plaque with a surrounding ridge of hyperkeratosis, called *cornoid lamella.* Several forms have been delineated: solitary plaques, linear porokeratosis, hyperkeratotic lesions of the palms and soles, disseminated eruptive lesions, and superficial actinic porokeratosis. **Classic porokeratosis of Mibelli** begins in childhood and is more common in males. Sites of predilection are the limbs, face, genitals, mucous membranes, palms, and soles. The primary lesion is a small, keratotic papule that slowly enlarges peripherally so that the center becomes depressed, with the edge forming an elevated wall or collar (Fig. 698.12). The configuration of the plaque may be round, oval, or gyrate. The elevated border is split by a thin groove from which minute cornified projections protrude. The central atrophic area is yellow, gray, or tan and sclerotic, smooth, and dry, whereas the hyperkeratotic border is a darker gray, brown, or black. **Linear porokeratosis** is also more common in childhood and typically follows the lines of Blaschko. The disease is slowly progressive but relatively asymptomatic; some patients experience pruritus or pain.

Fig. 698.12 Large plaque of porokeratosis of Mibelli with raised border and depressed center.

HISTOLOGY
A skin biopsy is usually unnecessary but will disclose the characteristic cornoid lamella (plug of stratum corneum cells with retained nuclei), which is responsible for the invariable linear ridge of the lesion. The granular layer is absent beneath the cornoid lamella.

DIFFERENTIAL DIAGNOSIS
The differential diagnosis of porokeratosis includes warts, epidermal nevi, lichen planus, granuloma annulare, tinea corporis, nummular eczema, pityriasis rosea, and elastosis perforans serpiginosa.

TREATMENT
No treatment is uniformly successful; thus therapeutic decisions depend largely on lesion size, location, symptoms, and patient preference. Most lesions are asymptomatic and do not require any intervention; however, when treatment is necessary, options include pharmacologic management (topical vitamin D analogs, topical retinoids, topical 5-fluorouracil, topical imiquimod, or oral retinoids [severe cases only]); destructive therapy (liquid nitrogen cryotherapy, electrodessication and curettage, or various lasers); and surgical removal. In general, the less invasive topical agents should be attempted first. Good UV protection should also be encouraged. Patients should be monitored for malignant transformation.

PROGNOSIS
Typically, the course of porokeratosis is slowly progressive, with an increase in size and number of individual lesions. Some cases undergo spontaneous resolution, and infrequently porokeratosis lesions may undergo malignant transformation into squamous cell carcinoma. At-risk lesions appear to be long-standing (average 33.5 years duration), large size, and location on limbs.

Visit Elsevier eBooks+ at eBooks.Health.Elsevier.com for Bibliography.

698.12 Gianotti-Crosti Syndrome (Papular Acrodermatitis)

Julie M. Dhossche and Yvonne E. Chiu

ETIOLOGY/PATHOGENESIS
The pathogenesis of Gianotti-Crosti syndrome, also known as *papular acrodermatitis,* is unclear, but an immunologic reaction to viral infections and immunizations has been postulated. Historically, the most common associations are with Epstein-Barr virus, hepatitis B virus (primarily in countries without routine childhood vaccination programs), coxsackievirus A16, and parainfluenza virus, as well as with many childhood immunizations.

Fig. 698.13 Numerous flat-topped, red papules in Gianotti-Crosti syndrome.

CLINICAL MANIFESTATIONS
This distinctive eruption is benign and predominantly occurs in children younger than 5 years old about 1 week after a viral illness. Cases are usually sporadic, but epidemics have been recorded. Skin lesions are monomorphic, firm, dusky, or coppery red papules ranging in size from 1 to 10 mm (Fig. 698.13), although there is considerable variation in lesion appearance between patients. The papules often have the appearance of vesicles; however, when opened, no fluid is obtained. The papules sometimes become hemorrhagic. Lines of papules **(Koebner phenomenon)** may be noted on the extremities after minor local trauma. The papules occur in crops and may become profuse and coalesce into plaques, forming a symmetric eruption on the face, ears, buttocks, and limbs, including the palms and soles. The trunk is relatively spared, as are the scalp and mucous membranes. The eruption is occasionally associated with malaise and low-grade fever but few other constitutional symptoms. The underlying viral infection may cause signs and symptoms, such as lymphadenopathy and hepatomegaly in patients with hepatitis B viremia. The eruption resolves spontaneously but may take up to 2 months. Some residual pigment change may occur but is not scarring.

HISTOLOGY
Skin biopsy in Gianotti-Crosti syndrome is not specific, being characterized by a dermal perivascular mononuclear cell infiltrate, capillary endothelial swelling, and epidermal spongiosis and parakeratosis.

DIFFERENTIAL DIAGNOSIS
Gianotti-Crosti syndrome can be confused with other viral exanthems, erythema infectiosum, lichen planus, erythema multiforme, and Henoch-Schönlein purpura (IgA vasculitis).

TREATMENT
The lesions are typically asymptomatic and resolve spontaneously, thus requiring no treatment. If present, pruritus may be relieved by emollients or calamine lotion. Mid-potency topical steroids may relieve pruritus but do not alter disease course. Sedating antihistamines at bedtime are also helpful.

Visit Elsevier eBooks+ at eBooks.Health.Elsevier.com for Bibliography.

698.13 Acanthosis Nigricans

Julie M. Dhossche and Yvonne E. Chiu

See also Chapter 65.

ETIOLOGY/PATHOGENESIS
The skin lesions of acanthosis nigricans may be genetic due to variants in the fibroblast growth factor receptor gene or acquired as a manifestation of insulin resistance. In familial cases, acanthosis nigricans

Fig. 698.14 Velvety hyperpigmentation of the axilla in acanthosis nigricans.

Fig. 698.15 Confluent and reticulated papillomatosis. Reticulate tan papules, patches, and plaques involving the epigastrium, inframammary areas, and sternum. *(From Paller AS, Mancini AJ. Hurwitz Clinical Pediatric Dermatology, 6th ed. Philadelphia: Elsevier; 2022, Fig. 23.34, p. 641.)*

is inherited as an autosomal dominant trait and develops in infancy. Insulin resistance with compensatory hyperinsulinism may lead to insulin binding to and activation of insulin-like growth factor receptors, promoting epidermal and fibroblast growth. Common causes of insulin resistance in children are obesity and diabetes mellitus, with acanthosis nigricans seen in >60% of children with a body mass index >98%. Other endocrinopathies such as pituitary hypogonadism, Cushing syndrome, polycystic ovarian syndromes, thyroid disease, and acromegaly, as well as certain drugs (insulin, oral contraceptives and other sex hormones, nicotinic acid, corticosteroids, and heroin) are also implicated as potential underlying causes. In the paraneoplastic form (rare in children), tumor-secreted growth factors induce acanthosis nigricans.

CLINICAL MANIFESTATIONS

Acanthosis nigricans is characterized by symmetric, hyperpigmented, velvety, hyperkeratotic plaques with exaggerated skin lines in intertriginous areas. The most common locations are the posterior neck and axillae (Fig. 698.14), but it is also seen in the inframammary areas, groin, inner thighs, and anogenital region. Before plaque development, patients notice a "dirty" appearance of affected skin that does not wash clean. Skin lesions remain asymptomatic unless maceration or secondary infection occurs. The clinical severity and histopathologic features of acanthosis nigricans correlate positively with the degree of hyperinsulinism and with the degree of obesity. The differential diagnosis includes **confluent and reticulated papillomatosis (CARP)**, Addison disease, pellagra, and erythrasma. CARP is an idiopathic disorder characterized by hyperpigmented papules with reticulation peripheral to the papules and is commonly distributed in the intermammary region (Fig. 698.15) and the epigastrium and upper back; less often it involves the axilla (Fig. 698.16) or neck and face.

HISTOLOGY

The histologic changes are those of papillomatosis and hyperkeratosis rather than acanthosis or excessive pigment formation. A mild dermal inflammatory infiltrate may be present.

TREATMENT

Treatment is aimed at the underlying disorder. Acanthosis nigricans in the obese child is associated with risk factors for glucose homeostasis abnormalities, and counseling families on its causes and consequences may motivate them to make healthy lifestyle changes that can decrease the risk for development of cardiac disease and diabetes mellitus. In children with obesity-related acanthosis nigricans, weight loss should be the primary goal. If a drug or malignancy is suspected, removal of that agent or treatment of cancer typically results in resolution. Appearance of skin lesions responds poorly to local medical management; some patients benefit from topical keratolytic agents (40% urea cream or 12% ammonium lactate cream) and agents that inhibit keratinocyte proliferation (topical retinoids and vitamin D analogs).

Fig. 698.16 Confluent and reticulated papillomatosis. Hyperpigmented thin plaques, which were confluent centrally and reticulated at the periphery, were present in the bilateral axillae of this 16-year-old male patient who also had classic acanthosis nigricans affecting the neck folds. These axillary changes resolved completely with oral minocycline and lactic acid–containing emollients. *(From Paller AS, Mancini AJ. Hurwitz Clinical Pediatric Dermatology, 6th ed. Philadelphia: Elsevier; 2022, Fig. 23.35, p. 641.)*

Visit Elsevier eBooks+ at eBooks.Health.Elsevier.com for Bibliography.

Chapter 699

Disorders of Keratinization

Kari L. Martin

DISORDERS OF CORNIFICATION

Mendelian disorders of cornification (ichthyoses) are a primary group of inherited conditions characterized clinically by patterns of scaling and histopathologically by hyperkeratosis. They are usually distinguishable by inheritance patterns, clinical features, associated defects, and histopathologic changes (Tables 699.1, 699.2, and 699.3). The two main categories of ichthyotic diseases are whether they are limited to the skin or have syndromic associations.

COLLODION BABY

Collodion baby is not a single entity, but a newborn phenotype that is most often seen in babies who eventually demonstrate lamellar ichthyosis or congenital ichthyosiform erythroderma (CIE). Less commonly, collodion babies evolve into babies with Gaucher disease or neutral lipid storage disease with ichthyosis, Loricrin keratoderma, trichothiodystrophy, Sjögren-Larsson syndrome, Conradi-Hünerman syndrome, or harlequin ichthyosis. A small subset become otherwise healthy babies without chronic skin disease (self-healing collodion baby).

Collodion babies are covered at birth by a thick, taut membrane resembling oiled parchment or collodion (Fig. 699.1), which is subsequently shed. Affected neonates have ectropion (eversion of the eyelid away from the globe), flattening of the ears and nose, and fixation of the lips in an O-shaped configuration. Hair may be absent or may perforate the abnormal covering. The membrane cracks with initial respiratory efforts and, shortly after birth, begins to desquamate in large sheets. Admission to a neonatal intensive care unit and a high-humidity environment and application of nonocclusive lubricants facilitate shedding of the membrane. Complete shedding may take several weeks, and a new membrane may occasionally form in localized areas.

Neonatal morbidity and mortality may be due to cutaneous infection, aspiration pneumonia (squamous material), hypothermia, or hypernatremic dehydration from excessive transcutaneous fluid losses as a result of increased skin permeability. The outcome is uncertain, and accurate prognosis depends on identification of the underlying ichthyosis.

NONSYNDROMIC ICHTHYOSES

Ichthyosis Vulgaris

Etiology/Pathogenesis

Autosomal dominant or recessive pathogenic variants in the filaggrin gene cause ichthyosis vulgaris. Filaggrin is a filament-aggregating protein that assembles the keratin filament cytoskeleton, causing collapse of the granular cells into a classic flattened squamous cell shape. Pathogenic variants in filaggrin lead to absence of or marked reductions in keratohyalin granules (see Table 699.2).

Clinical Manifestations

Ichthyosis vulgaris is *the most common* of the disorders of keratinization, with an incidence of 1/250 live births. Onset generally occurs in the first year of life. In most cases, it is trivial, consisting only of slight roughening of the skin surface. Scaling is most prominent on the extensor aspects of the extremities, particularly the legs (Fig. 699.2). Flexural surfaces are spared, and the abdomen, neck, and face are relatively uninvolved. Keratosis pilaris—particularly on the upper arms and thighs, accentuated markings, and hyperkeratosis on the palms and soles—and atopy are relatively common. Scaling is most pronounced during the winter months and may abate completely during warm weather. There is no accompanying disorder of hair, teeth, mucosal surfaces, or other organ systems; however, patients are at increased risk of atopy.

Treatment

Scaling may be diminished by daily applications of an emollient or a lubricant containing urea (10–40%), salicylic acid, or an alpha-hydroxy acid such as lactic acid (5–12%).

X-Linked Ichthyosis

Etiology/Pathogenesis

X-linked ichthyosis involves a deficiency of steroid sulfatase, which hydrolyzes cholesterol sulfate and other sulfated steroids to cholesterol. Cholesterol sulfate accumulates in the stratum corneum and plasma. In the epidermis this accumulation causes malformation of intercellular lipid layers, leading to barrier defects and delay of corneodesmosome degradation, resulting in corneocyte retention.

Clinical Manifestations

Skin peeling may be present at birth but typically begins at 3-6 months of life. Scaling is most pronounced on the sides of the neck, lower face, preauricular areas, anterior trunk, and the limbs, particularly the legs. The elbow (Fig. 699.3) and knee flexures are generally spared but may be mildly involved. The palms and soles may be slightly thickened but are also usually spared. The condition gradually worsens in severity and extent. Keratosis pilaris is not present, and there is no increased incidence of atopy. Deep corneal opacities that do not interfere with vision develop in late childhood or adolescence and are a useful marker for the disease because they may also be present in carrier females. Some patients have larger deletions on the X chromosome that encompass neighboring genes, generating *contiguous gene deletion syndromes*. These include Kallmann syndrome (*KAL1* gene), which consists of hypogonadotrophic hypogonadism and anosmia, X-linked chondroplasia punctata (*ARSE* gene), short stature, and ocular albinism. The rate of testicular cancer may be increased in patients with coexistent Kallmann syndrome. There is also an increased risk of attention-deficit/hyperactivity disorder and autism owing to a contiguous gene defect in neuroligin 4.

Reduced steroid sulfatase enzyme activity can be detected in fibroblasts, keratinocytes, and leukocytes and, prenatally, in amniocytes or chorionic villus cells. In affected families, an affected male can be detected by restriction enzyme analysis of cultured chorionic villus cell DNA or amniocytes or by in situ hybridization, which identifies steroid sulfatase gene deletions prenatally in chorionic villus cells. A placental steroid sulfatase deficiency in carrier mothers may result in low urinary and serum estriol values, prolonged labor, and insensitivity of the uterus to oxytocin and prostaglandins.

Treatment

Daily application of emollients and a urea-containing lubricant (10–40%) is usually effective. Glycolic or lactic acid (5–12%) in an emollient base and propylene glycol (40–60%) in water with occlusion overnight are alternative forms of therapy.

AUTOSOMAL RECESSIVE CONGENITAL ICHTHYOSES

Harlequin Ichthyosis

Etiology/Pathogenesis

Harlequin ichthyosis is caused by pathogenic variants in the *ABCA12* gene. Pathogenic variants in the gene lead to defective lipid transport, and *ABCA12* activity is required for the generation of long-chain ceramides that are essential for the development of the normal skin barrier.

Clinical Manifestations

At birth, markedly thickened, ridged, and cracked skin forms horny plates over the entire body, disfiguring the facial features and constricting the digits. Severe ectropion and chemosis obscure the orbits, the nose and ears are flattened, and the lips are everted and gaping. Nails

Table 699.1 Inherited Ichthyoses – Syndromic

DISORDER	PREVIOUS NAME	MIM #	INHERITANCE	CUTANEOUS FINDINGS	EXTRACUTANEOUS FINDINGS	GENE DEFECT(S)	PROTEIN(S)
X-LINKED ICHTHYOSIS SYNDROMES							
RXLI (recessive X-linked ichthyosis) syndromic presentation		308100	XR	Large, dark scales Sparing of body folds	Prolongation of labor Cryptorchidism Corneal opacities, asymptomatic	*STS* Larger deletions with contiguous gene defects	Steroid sulfatase
IFAP syndrome (ichthyosis-follicularis-atrichia-photophobia)		398205	XR	Spiny follicular ichthyosis Nail dystrophy Alopecia	Photophobia Psychomotor delay Short stature	*MBTPS2*	Membrane-bound transcription factor peptidase, site 2
Conradi-Hünermann-Happle syndrome (CDPX2)	X-linked chondrodysplasia punctata (Conradi-Hünermann syndrome)	302960	XD	Striated ichthyosiform hyperkeratosis Follicular atrophoderma Alopecia	Cataracts Frontal bossing Short proximal limbs	*EBP*	Emopamil-binding protein
CHILD syndrome		308050	XD	Unilateral ichthyosiform erythroderma	Chondrodysplasia punctata Cataracts Limb reduction defects Asymmetric organ hypoplasia	*NSDHL*	3-β-hydroxysteroid-Δ8,Δ7-isomerase
AUTOSOMAL ICHTHYOSIS SYNDROMES WITH PROMINENT HAIR ABNORMALITIES							
NS (Netherton syndrome)		256500	AR	Erythroderma in infancy Ichthyosis linearis circumflexa Alopecia	Atopic diathesis Food allergies Structural hair defects (trichorrhexis invaginata) Growth delay	*SPINK5*	LETKI
IHS (ichthyosis hypotrichosis syndrome)		610765	AR	Adherent platelike scale Hypohidrosis Hypotrichosis	Photophobia Pingueculum	*ST14*	Serine protease 14
IHSC syndrome (ichthyosis-hypotrichosis-sclerosing cholangitis)		607626	AR	Fine thin scale Hypotrichosis with coarse thick hair	Sclerosing cholangitis Congenital paucity of bile ducts	*CLDN1*	Claudin 1
TTD (trichothiodystrophy)		601675	AR	May have collodion membrane Can vary from mild scaling to marked adherent plaques	Photosensitivity Brittle hair with "tiger tail" pattern Decreased fertility Short stature Susceptibility to infection	*ERCC2, XPD ERCC3, XPB GTF2H5, TTDA*	Xeropigmentosum group D protein Xeropigmentosum group B protein
TTD (not associated with congenital ichthyosis)		234050	AR	Delayed onset Fine scale	Nonphotosensitive Brittle hair Short stature Decreased fertility	*C7Orf11, (TTDN1)*	M-phase–specific PLK1-interacting protein, (TTD non-photosensitive 1 protein)
AUTOSOMAL ICHTHYOSIS SYNDROMES WITH FATAL DISEASE COURSE							
Gaucher syndrome, type 2		230900	AR	Collodion baby, mild scaling later	Hepatosplenomegaly retroflexion of the head, strabismus, dysphagia, choking spells, hypertonicity Death usually occurs in the first year	*GBA*	Acid β-glucosidase

Continued

Downloaded for mohamed ahmed (dr.mms2020@gmail.com) at University of Southern California from ClinicalKey.com by Elsevier on April 22, 2024. For personal use only. No other uses without permission. Copyright ©2024. Elsevier Inc. All rights reserved.

Table 699.1 Inherited Ichthyoses – Syndromic—cont'd

DISORDER	PREVIOUS NAME	MIM #	INHERITANCE	CUTANEOUS FINDINGS	EXTRACUTANEOUS FINDINGS	GENE DEFECT(S)	PROTEIN(S)
Multiple sulfatase deficiency		272200	AR	Mild scale	Mental retardation Mucopolysaccharidosis Metachromatic leukodystrophy Death within first year of life	*SUMF1*	Sulfatase-modifying factor-1
CEDNIK syndrome (cerebral dysgenesis-neuropathy-ichthyosis-palmoplantar keratoderma)		609528	AR	Coarse platelike white scale Fine, sparse hair	Sensorineural deafness Cerebral dysgenesis Neuropathy Microcephaly Neurogenic muscle atrophy Optic nerve atrophy Cachexia Lethal within first decade	*SNAP29*	Synaptosomal-associated protein, 29kDA
ARC syndrome (arthrogryposis-renal dysfunction-cholestasis)		208085	AR	Fine scale	Arthrogryposis Intrahepatic bile duct hypoplasia with cholestasis Renal tubular degeneration Metabolic acidosis Abnormal platelet function Death within first year of life	*VPS33B*	Vacuolar protein sorting–associated protein 33B
AUTOSOMAL ICHTHYOSIS SYNDROMES WITH OTHER ASSOCIATED SIGNS							
SLS (Sjögren-Larsson syndrome)		270200	AR	Fine lamellar scale	Diplegia or tetraplegia Retinal glistening white dots	*ALDH3A2*	Long-chain aldehyde dehydrogenase
RS (Refsum syndrome) (HMSN4: hereditary motor sensory neuropathy type 4)	Refsum disease	266500	AR	Late onset, fine scale	Retinitis pigmentosa Cardiac failure	*PAHX* or *PHYH* *PEX7*	Phytanoyl-CoA hydroxylase Peroxin-7
KID syndrome (keratitis-ichthyosis-deafness syndrome)	KID; includes HID syndrome	242150 602540	AD	Verrucous plaques Stippled pattern of keratoderma	Keratitis Sensorineural deafness	*GJB2 (GJB6)*	Connexin 26
Neutral lipid storage disease with ichthyosis	Chanarin-Dorfman syndrome (also termed NCIE2)	275630	AR	Fine scales with occasional background erythema	Myopathy Hepatosplenomegaly	*ABHD5*	CGI-58
IPS (ichthyosis prematurity syndrome)		608649	AR	White caseous scale, attenuated on scalp and eyebrows Follicular keratosis	Atopic manifestations	*SLC27A4*	Long-chain fatty acid transport protein 4
CHIME syndrome		280000	AR	Ichthyotic erythema Occasionally migratory plaques	Colobomas Conductive hearing loss Mental retardation	NK	NK
MEDNIK syndrome (mental retardation-enteropathy-deafness-neuropathy-ichthyosis-keratodermia)		Not on OMIM	AR	Rough, thickened skin	Congenital sensorineural deafness Psychomotor and growth retardation Chronic diarrhea	*AP1S1*	Adapter-related protein complex 1 sigma-1A subunit

AD, Autosomal dominant; AR, autosomal recessive; XD, X-linked dominant; XR, X-linked recessive.
Modified from Foley CC, Paller AS, Irvine AD. Disorders of cornification (ichthyosis). In: Eichenfield LF, Frieden IJ, eds. *Neonatal and Infant Dermatology*, 3rd ed. Philadelphia: Elsevier; 2015: Table 19.1, p. 283–284.

Downloaded for mohamed ahmed (dr.mms2020@gmail.com) at University of Southern California from ClinicalKey.com by Elsevier on April 22, 2024. For personal use only. No other uses without permission. Copyright ©2024. Elsevier Inc. All rights reserved.

Table 699.2 Inherited Ichthyoses – Nonsyndromic

DISORDER	PREVIOUS NAME	MIM #	INHERITANCE	CUTANEOUS FINDINGS	EXTRA-CUTANEOUS FINDINGS	GENE DEFECT(S)	PROTEIN(S)
COMMON ICHTHYOSES							
IV (ichthyosis vulgaris)		146700	AD (autosomal semidominant)	Fine, white scale Accentuated palmoplantar markings	Strong association with atopic manifestations	*FLG*	Filaggrin
RXLI (recessive X-linked ichthyosis) (nonsyndromic presentation)		308100	XR	Large, dark scales Sparing of body folds	Prolongation of labor Cryptorchidism Corneal opacities, asymptomatic	*STS*	Steroid sulfatase
AUTOSOMAL RECESSIVE CONGENITAL ICHTHYOSIS (ARCI)							
MAJOR TYPES							
HI (harlequin ichthyosis)		242500	AR	Rigid plates Severe erythema Hypohidrosis Scarring alopecia	Ectropion Eclabion Contractures Failure to thrive Short stature	*ABCA12*	ATP-binding cassette, subfamily a, member 12
LI (lamellar ichthyosis)		242300 601277 604777	AR	Large adherent plates Hypohidrosis	Ectropion Eclabium Short stature if severe	*TGM1, ABCA12, PNPLA1, LIPN*	Transglutaminase 1, ABCA12 transporter, PNPLA1, lipase N
CIE (congenital ichthyosiform erythroderma)		242100	AR	Fine white scales Background erythema Hypohidrosis Mild PPK White nails	Failure to thrive Short stature if severe Occasional neurologic deficits	*TGM1, ALOX12B, ALOXE3, ABCA12, CYP4F22, NIPAL4*	Transglutaminase 1 Arachidonate lipoxygenases, cytochrome P450 enzyme, ichthyin, ABCA12 transporter
MINOR VARIANTS							
SHCB (self-healing collodion baby)		242300	AR	Collodion baby at birth, not subsequent ichthyotic phenotype	None	*TGM1, ALOX12B, ALOXE3*	Keratinocyte transglutaminase 1
Acral SHCB (self-healing collodion baby)		242300	AR	Acral collodion membranes that heal	None	*TGM1*	Transglutaminase 1
BSI (bathing suit ichthyosis)		242300	AR	Collodion membrane at birth, extremities heal	None	*TGM1*	Transglutaminase 1
KERATINOPATHIC ICHTHYOSIS (KPI)							
MAJOR TYPES							
EI (epidermolytic ichthyosis)	BCIE/EH	113800	AD, rarely AR	Widespread skin blistering in neonates Warty hyperkeratosis	Growth failure if severe	*KRT1, KRT10*	Keratins 1 and 10
SEI (superficial EI)	Ichthyosis bullosa of Siemens	146800	AD	Mild flexural hyperkeratosis Adherent fine scale Pruritus	None	*KRT2E*	Keratin 2
MINOR VARIANTS							
AEI (annular epidermolytic ichthyosis)		607602	AD	Intermittent annular, polycyclic erythematous scaly plaques		*KRT1, KRT10*	Keratins 1 and 10
ICM (ichthyosis Curth-Macklin)	Ichthyosis hystrix	146590 146600	AD	Spiky hyperkeratosis	None	*KRT1*	Keratin 1
Epidermolytic epidermal nevi		Not in OMIM	Somatic pathogenic variants			*KRT1, KRT10*	Keratins 1 and 10

Continued

Table 699.2 Inherited Ichthyoses – Nonsyndromic—cont'd

DISORDER	PREVIOUS NAME	MIM #	INHERITANCE	CUTANEOUS FINDINGS	EXTRA-CUTANEOUS FINDINGS	GENE DEFECT(S)	PROTEIN(S)
OTHER FORMS							
LK (loricrin keratoderma)		604117	AD	Collodion baby Mild, fine, white scale Diffuse PPK	None	*LOR*	Loricrin
EKV (erythrokeratoderma variabilis)		133200	AD	Transient, migratory erythematous patches Hyperkeratosis Diffuse PPK	None	*GJB3, GJB4*	Connexins 31, 30.3
PSD (peeling skin disease)		270300	AR		None	*CDSN, TGM5*	Corneodesmin, Transglutaminase 5
CRIE (congenital reticular ichthyosiform erythroderma)		609165	AD (isolated cases)		None	*KRT10*	Keratin
KLICK (keratosis linearis-ichthyosis congenita-keratoderma)		Not in OMIM	AR	Linear keratoses in skin folds Sclerosing PPK	None	*POMP*	Proteasome maturation protein

AD, Autosomal dominant; AR, autosomal recessive; XR, X-linked recessive.
Modified from Foley CC, Paller AS, Irvine AD. Disorders of cornification (ichthyosis). In: Eichenfield LF, Frieden IJ, eds. *Neonatal and Infant Dermatology,* 3rd ed. Philadelphia: Elsevier; 2015: Table 19.2, p. 285–286.

Table 699.3 Differential Diagnosis of Netherton Syndrome: Disorders with Ichthyosis and Alopecia (Hereditary Disorders Only)*

DISORDER	INHERITANCE	GENE	FEATURES RESEMBLING NETHERTON SYNDROME	DIFFERENTIATION FROM NETHERTON SYNDROME
SAM syndrome	AR Loss-of-function pathogenic variants	*DSG1*	CIE with PPK, no collodion membrane; failure to thrive; hypernatremia; barrier defect; dermatitis; high IgE; malabsorption; eosinophilic esophagitis; multiple food allergies; recurrent infections; hypotrichosis; hypoalbuminemia	May have microcephaly, growth hormone deficiency, developmental delay, cardiac defects; psoriasiform dermatitis with acantholysis in skin sections; absence of desmoglein
ADAM17 deficiency	AR Loss-of-function pathogenic variants	*ADAM17*	Psoriasiform erythroderma/widespread pustules; failure to thrive; malabsorption; short, broken hair; recurrent infections	Bloody diarrhea; cardiomyopathy/ cardiomyositis
EGFR deficiency	AR Loss-of-function pathogenic variants	*EGFR*	Erythema, scaling, and widespread pustules; alopecia; failure to thrive, watery diarrhea, high IgE and eosinophils, hypernatremia, hypoalbuminemia; recurrent bronchiolitis	Cardiovascular issues
Trichothiodystrophy	AR Loss-of-function pathogenic variants	*ERCC2, ERCC3, GTF2H5, C7Orf11*	CIE-like ichthyosis; short, brittle hair; "tiger tail" hair shaft defect under polarized microscopy	May have impaired intelligence, decreased fertility, short stature, and photosensitivity
IHS (also called autosomal recessive ichthyosis with hypotrichosis [ARIH] syndrome)	AR Loss-of-function pathogenic variants	*ST14* (encodes matriptase); abnormal filaggrin processing	Generalized, congenital ichthyosis with sparing of face, palms, and soles; diffuse nonscarring alopecia of scalp, eyelashes, and eyebrows from birth, but improves to sparse, unruly hair during adolescence and merely recession of the frontal hair line by adulthood	May have patchy follicular atrophoderma and hypohidrosis; photophobia from corneal abnormalities; blepharitis; dental abnormalities; hair microscopy may show pili torti or pili bifurcati
IHSC (or NISCH) syndrome	AR Loss-of-function pathogenic variants	*CLDN1* (encodes claudin 1, structural protein of tight junctions)	Congenital generalized scaling, predominantly on the limbs and abdomen and sparing skinfolds, palms, and soles; coarse, curly hair with frontotemporal cicatricial alopecia	Congenital paucity of bile ducts or sclerosing cholangitis leads to neonatal jaundice with hepatomegaly; oligodontia, and enamel dysplasia; blood smears show small eosinophils and keratinocyte vacuoles without lipid contents

*Netherton syndrome must also be distinguished from severe atopic dermatitis and immunodeficiency disorders.
AR, Autosomal recessive; CIE, congenital ichthyosiform erythroderma; Ig, immunoglobulin; IHS, ichthyosis hypotrichosis syndrome; IHSC, ichthyosis-hypotrichosis-sclerosing cholangitis; NISCH, neonatal ichthyosis sclerosing cholangitis; PPK, palmoplantar keratoderma; SAM, severe dermatitis, multiple allergies, and metabolic wasting.

Fig. 699.1 Typical appearance of a collodion baby.

Fig. 699.2 Scale over the shin in ichthyosis vulgaris.

Fig. 699.3 Sparing of the antecubital fossa in X-linked ichthyosis.

and hair may be absent. Joint mobility is restricted, and the hands and feet appear fixed and ischemic. Affected neonates have respiratory difficulty, suck poorly, and are subject to severe cutaneous infection. Harlequin ichthyosis used to be uniformly fatal in the neonatal period, but with the use of oral retinoids, more patients survive (~80%) beyond infancy and have severe ichthyosis usually resembling lamellar ichthyosis or nonbullous CIE as adolescents and adults. Those with a compound heterozygous genotype have a better prognosis. Prenatal diagnosis has been accomplished by fetoscopy, fetal skin biopsy, and microscopic examination of cells from amniotic fluid.

Treatment

Initial treatment includes high fluid intake to avoid dehydration from transepidermal water loss and use of a humidified heated incubator, emulsifying ointments, careful attention to hygiene, and oral retinoids.

Fig. 699.4 Generalized scaling of lamellar ichthyosis.

Intubation may be required until nares are patent and parenteral nutrition required until eclabium has resolved. Consultation with ophthalmology is often required given the extensive ectropion. If constrictive bands are around the digits, debridement may be performed to prevent ischemia.

Lamellar Ichthyosis and Congenital Ichthyosiform Erythroderma (Nonbullous Congenital Ichthyosiform Erythroderma)

Lamellar ichthyosis and CIE (nonbullous congenital ichthyosiform erythroderma; non-harlequin ichthyosis autosomal recessive congenital ichthyoses [ARCI]) are the most common types of autosomal recessively inherited ichthyosis. Both forms are present at or shortly after birth. Most infants with these forms of ichthyosis present with erythroderma and scaling, but among collodion babies, most turn out to have one of these ichthyosis variants.

Etiology/Pathogenesis

Six genes have been identified that cause non-harlequin ichthyosis ARCI: *TGM* (the gene encoding transglutaminase), *ABCA12, NIPAL4* (also known as *ICHTHYIN*), *CYP4F22,* and the lipoxygenase genes *ALOX12B* and *ALOXE3*. Transglutaminase pathogenic variants lead to abnormalities in the cornified envelope, whereas defects in *ABCA12* cause abnormal lipid transport and those in *CYP4F22* produce abnormal lamellar granules. The lipoxygenases are likely to play a role in epidermal barrier formation by affecting lipid metabolism.

Clinical Manifestations

After shedding of the collodion membrane, if present, lamellar ichthyosis evolves into large, quadrilateral, dark scales that are free at the edges and adherent at the center. Scaling is often pronounced and involves the entire body surface, including flexural surfaces (Fig. 699.4). The face is often markedly involved, including ectropion and small, crumpled ears. The palms and soles are generally hyperkeratotic. The hair may be sparse and fine, but the teeth and mucosal surfaces are normal. Unlike in CIE, there is little erythema.

In CIE, erythroderma tends to be persistent, and scales, although they are generalized, are finer and whiter than in lamellar ichthyosis (Fig. 699.5). Hyperkeratosis is particularly noticeable around the knees, elbows, and ankles. Palms and soles are uniformly hyperkeratotic. Patients have sparse hair, cicatricial alopecia, and nail dystrophy. Neither form includes blistering.

Treatment

Pruritus may be severe and responds minimally to antipruritic therapy. The unattractive appearance of the child and the bad odor from bacterial colonization of macerated scales may cause severe emotional distress. A high-humidity environment in winter and air conditioning in summer reduce discomfort. Generous and frequent applications of emollients and keratolytic agents such as lactic or glycolic acid (5–12%), urea (10–40%), tazarotene (0.1% gel), and retinoic acid (0.1% cream) may lessen the scaling to some extent, although these agents

Fig. 699.5 Prominent erythema and scale in congenital ichthyosiform erythroderma.

Fig. 699.6 Superficial erosions and hyperkeratosis in epidermolytic hyperkeratosis.

produce stinging if applied to fissured skin. Oral retinoids have a beneficial effect in these conditions but do not alter the underlying defect and therefore must be administered indefinitely. The long-term risks of these compounds (teratogenic effects and toxicity to bone) may limit their usefulness. Ectropion requires ophthalmologic care and, at times, plastic surgical procedures.

KERATINOPATHIC ICHTHYOSES

Epidermolytic Ichthyosis (Bullous Congenital Ichthyosiform Erythroderma; Epidermolytic Hyperkeratosis)

Etiology/Pathogenesis

Epidermolytic ichthyosis is an autosomal dominant trait that has been shown to be due to defects in either keratin 1 or keratin 10. These keratins are required to form the keratin-intermediate filaments in cells of the suprabasilar layers of the epidermis.

Clinical Manifestations

The clinical manifestations are initially characterized by the onset at birth of widespread blisters and erosions on a background of generalized erythroderma (Fig. 699.6). Recurrent blistering may be widespread in neonates and may cause diagnostic confusion with other blistering disorders. With time, the blister formation ceases, erythema decreases, and generalized hyperkeratosis develops. The scales are small, hard, and verrucous. Distinctive, parallel hyperkeratotic ridges develop over the joint flexures, including the axillary, popliteal, and antecubital fossae, and on the neck and hips. Palmoplantar keratoderma (PPK) is associated with keratin 1 defects. The hair, nails, mucosa, and sweat glands are normal. Malodorous secondary bacterial infection is common and requires appropriate antibiotic therapy.

Fig. 699.7 Erythrokeratoderma variabilis. **A,** Fixed, hyperkeratotic plaques. **B,** Migratory, erythematous lesion.

Histopathology

The histopathology is diagnostic of epidermolytic ichthyosis, consisting of hyperkeratosis, degeneration of the epidermal granular layer with an increased number of keratohyalin granules, clear spaces around nuclei, and indistinct cellular boundaries of cells in the upper epidermis. On electron microscopic examination, keratin-intermediate filaments are clumped, and many desmosomes are attached to only one keratinocyte instead of connecting neighboring keratinocytes. Localized forms of the disease may resemble epidermal nevi or keratoderma of the palms and soles but share the distinctive histopathologic changes of epidermolytic ichthyosis.

Treatment

Treatment of epidermolytic ichthyosis is difficult. Morbidity is increased in the neonatal period as a result of prematurity, sepsis, and fluid and electrolyte imbalance. Bacterial colonization of macerated scales produces a distinctive bad odor that can be controlled somewhat by use of an antibacterial cleanser. Intermittent oral antibiotics are generally necessary. Keratolytic agents are often poorly tolerated. Oral retinoids may produce significant improvement. Prenatal diagnosis for affected families is possible by examination of DNA extracts from chorionic villus cells or amniocytes, provided that the specific pathogenic variant in the affected parent is known.

OTHER NONSYNDROMIC ICHTHYOSES

Erythrokeratoderma Variabilis

Etiology/Pathogenesis

An autosomal dominant disorder, erythrokeratoderma variabilis (EKV), is caused by pathogenic variants in connexins 31 and 30.3. Connexins are proteins that form gap junctions between cells that allow for transport and signaling between neighboring epidermal cells.

Clinical Manifestations

EKV usually manifests in the early months of life, progresses in childhood, and stabilizes in adolescence. It is characterized by two distinctive manifestations: sharply demarcated, hyperkeratotic plaques (Fig. 699.7A)

and transient figurate erythema (see Fig. 699.7B). The distribution is generalized but sparse; sites of predilection are the face, buttocks, axillae, and extensor surfaces of the limbs. The palms and soles may be thickened, but hair, teeth, and nails are normal.

Treatment
There are case reports that topical tazarotene gel 0.1% and oral retinoids are effective for treatment of EKV.

Symmetric Progressive Erythrokeratoderma
Etiology/Pathogenesis
Symmetric progressive erythrokeratoderma is an autosomal dominant disorder caused by pathogenic variants in the gene encoding loricrin. Loricrin is a major component of the epidermal cornified cell envelope.

Clinical Manifestations
The disorder manifests in childhood as large, fixed, geographic and symmetric, fine, scaling, hyperkeratotic, erythematous plaques primarily on the extremities, buttocks, face, ankles, and wrists. The primary feature distinguishing this disorder from EKV is the lack of variable erythema seen in the latter condition.

Treatment
Symmetric progressive erythrokeratoderma is a very rare disorder, but reports of response to topical and oral retinoids exist.

SYNDROMIC ICHTHYOSES
Sjögren-Larsson Syndrome
Etiology/Pathogenesis
The autosomal recessive inborn error of metabolism known as Sjögren-Larsson syndrome is an abnormality of fatty alcohol oxidation that results from a deficiency of fatty aldehyde dehydrogenase *(FALDH3A2)*, a component of the fatty alcohol–nicotinamide adenine dinucleotide oxidoreductase enzyme complex (see Table 699.1).

Clinical Manifestations
The clinical picture of Sjögren-Larsson syndrome consists of ichthyosis, cognitive impairment, and spasticity. The ichthyosis is generalized but is accentuated on the flexures and the lower abdomen and consists of erythroderma, fine scaling, larger platelike scales, and dark hyperkeratosis. The degree of scale varies markedly from patient to patient. Most individuals have palmoplantar hyperkeratosis. The skin changes may be identical to the other forms of ichthyosis, and diagnosis is often delayed until the onset of neurologic symptoms. Pruritus is severe, and hypohidrosis is common. Glistening dots in the foveal area are a cardinal ophthalmologic sign. About half the patients have primary retinal degeneration. Motor and speech developmental delays are usually noted before 1 year of age, and spastic diplegia or tetraplegia, epilepsy, and intellectual disability generally become evident in the first to third years of life. Some patients may walk with the aid of braces, but most are confined to wheelchairs. This deficiency can be demonstrated in cultured skin fibroblasts of affected patients and carriers and, prenatally, in cultured chorionic villus cells and amniocytes from affected fetuses. Elevation of urinary leukotriene B4 (LTB4) may provide an easier approach to diagnosis.

Treatment
Treatment is similar to the other forms of ichthyosis (humectants, emollients, topical or oral retinoids); 5-lipoxygenase inhibitors have been used to decrease pruritus.

Netherton Syndrome
Etiology/Pathogenesis
A rare autosomal recessive disorder, Netherton syndrome is caused by pathogenic variants in the *SPINK 5* gene, which encodes a serine protease inhibitor *(LEKT1)*.

Clinical Manifestations
Netherton syndrome is characterized by ichthyosis (usually ichthyosis linearis circumflexa, but occasionally the lamellar or congenital types of ichthyosiform erythroderma), trichorrhexis invaginata and other hair shaft anomalies, and atopic diathesis. The disorder manifests at birth or in the first few months of life as generalized erythema and scaling. The trunk and limbs have diffuse erythema and superimposed migratory, polycyclic, and serpiginous hyperkeratotic lesions (Fig. 699.8), some with a distinctive double-edged margin of scale. Lichenification or hyperkeratosis tends to persist in the antecubital and popliteal fossae. The face and scalp may remain erythematous and scaling. Many hair shaft deformities, most notably trichorrhexis invaginata, have been described in most patients with Netherton syndrome.

Fig. 699.8 Serpiginous, erythematous, hyperkeratotic lesions of ichthyosis linearis circumflexa.

Fig. 699.9 Very short scalp hair and thick scale in Netherton syndrome.

The ichthyosis is present in the first 10 days of life and may be especially marked around the eyes, mouth, and perineal area. The erythroderma is often intensified after infection. Infants may suffer from failure to thrive, recurrent bacterial and candidal infections, elevated serum immunoglobulin IgE values, and marked hypernatremic dehydration. The most frequent allergic manifestations are urticaria, angioedema, atopic dermatitis, and asthma. Scalp hair is sparse and short and fractures easily (Fig. 699.9); eyebrows, eyelashes, and body hair are also abnormal. The characteristic hair abnormality can be identified with light microscopy; in the newborn, it may best be identified in eyebrow hair. The differential diagnosis is noted in Table 699.3.

Treatment
Owing to the inflammatory nature of the skin disease, oral antihistamines and topical steroids, as used in the treatment of atopic dermatitis, are helpful for Netherton syndrome.

Refsum Syndrome
See Chapters 106.2 and 653.5.

Etiology/Pathogenesis
There are two types of Refsum syndrome. The classic form is autosomal recessive and caused by pathogenic variants in the *PAHX* gene that result in an increase in phytanic acid. The infantile forms of Refsum syndrome are also autosomal recessive and caused by pathogenic variants in the *PEX1, PEX2,* or *PEX26* genes. These are peroxisomal abnormalities that lead to an increase in very long-chain fatty acids, di- and tri-hydroxycholestanoic acid, and pipecolic acid, as well as phytanic acid.

Clinical Manifestations
Refsum syndrome is a multisystem disorder that becomes symptomatic in the second or third decade of life. The ichthyosis may be generalized, is relatively mild, and resembles ichthyosis vulgaris. The ichthyosis may also be localized to the palms and soles. Chronic polyneuritis with progressive paralysis and ataxia, retinitis pigmentosa, anosmia, deafness, bony abnormalities, and electrocardiographic changes are the most characteristic features. The condition is diagnosed through lipid analysis of the blood or skin, which shows elevated phytanic acid values.

The infantile form begins, as suggested by the name, early in life, and in addition to the changes seen in the classic form, affected patients have hepatomegaly, abnormal bile acid profiles, developmental delay, and cognitive impairment.

Treatment
Phytanic acid is exclusively derived from dietary chlorophyll. Lifelong dietary avoidance of phytanic acid–containing products leads to clinical improvement in classic Refsum syndrome.

Chondrodysplasia Punctata
See Chapter 106.2.

Etiology/Pathogenesis
Chondrodysplasia punctata (CPD) is a clinically and genetically heterogeneous condition. X-linked dominant CPD, also known as *Conradi-Hünermann syndrome,* is the best-characterized form. There is also an X-linked recessive form caused by a pathogenic variant in the *ARSE* gene. Rhizomelic CPD type 1 is an autosomal recessive disorder caused by pathogenic variants in the *PEX7* gene, which encodes the *PTS2* receptor. CPD can also be caused by maternal vitamin K deficiency or warfarin teratogenicity.

Clinical Manifestations
These heterogeneous disorders are marked by ichthyosis and bone changes. Nearly all patients with the X-linked dominant form and approximately 25% of those with the recessive type have cutaneous lesions, ranging from severe, generalized erythema and scaling to mild hyperkeratosis. Rhizomelic CPD is associated with cataracts, hypertelorism, optic nerve atrophy, disproportionate shortening of the proximal extremities, psychomotor retardation, failure to thrive, and spasticity; most affected patients die in infancy. Patients with the X-linked dominant form have asymmetric, variable shortening of the limbs and a distinctive ichthyosiform eruption at birth. Thick, yellow, tightly adherent, keratinized plaques are distributed in a whorled pattern over the entire body. The eruption typically resolves in infancy and may be superseded by a follicular atrophoderma and patchy alopecia.

Additional features in all variants include cataracts and abnormal facies with saddle nose and frontal bossing. The pathognomonic defect, termed CPD, is stippled epiphyses in the cartilaginous skeleton. This defect, which is seen in various settings and inherited disorders, often in association with peroxisomal deficiency and disturbance of cholesterol biosynthesis, disappears by 3-4 years of age.

Fig. 699.10 Limb dysplasia and ichthyosiform eruption in CHILD (congenital hemidysplasia with ichthyosiform erythroderma and limb defects) syndrome.

Fig. 699.11 Palmar keratoderma with epidermolytic changes seen on biopsy.

OTHER SYNDROMES WITH ICHTHYOSIS
A number of other rare syndromes with ichthyosis as a consistent feature include the following: keratitis with ichthyosis and deafness (KID syndrome, connexin 26 gene), ichthyosis with defective hair having a banded pattern under polarized light and a low sulfur content (trichothiodystrophy), multiple sulfatase deficiency, neutral lipid storage disease with ichthyosis (Chanarin-Dorfman syndrome; *CGI58* gene), and CHILD syndrome (Fig. 699.10; congenital hemidysplasia with ichthyosiform erythroderma and limb defects; *NSDHL* gene).

Palmoplantar Keratodermas
Excessive hyperkeratosis of the palms and soles may occur as a manifestation of a focal or generalized congenital hereditary skin disorder or may result from such chronic skin diseases as psoriasis, eczema, pityriasis rubra pilaris, lupus erythematosus, or postinfectious arthritis syndrome.

Diffuse Hyperkeratosis of Palms and Soles (Unna-Thost, Vorner)
Unna-Thost and Vorner type PPKs, although clinically inseparable, were thought to be separate entities. They were separated histologically by the presence (Vorner) or absence (Unna-Thost) of epidermolytic hyperkeratosis. They represent the clinical spectrum of the same disease caused by pathogenic variants in keratin (*KRT1* and *KRT9* genes). This autosomal dominant disorder manifests in the first few months of life as erythema that

gradually progresses to sharply demarcated, hyperkeratotic, scaling plaques over the palms (Fig. 699.11) and soles. The margins of the plaques often remain red; plaques may extend along the lateral aspects of the hands and feet and onto the volar wrists and the heels. Hyperhidrosis is usually present, but hair, teeth, and nails are usually normal. Striate (*DSG1*, *DSP*, *KRT1* genes) and punctate forms of palmar and plantar hyperkeratosis represent distinct entities.

Mal De Meleda (*SLURP-1* Gene)

A rare, progressive autosomal recessive condition, mal de Meleda is characterized by erythema and thick scales on the palms, fingers, soles, and flexor aspects of the wrists, knees, and elbows. Hyperhidrosis, nail thickening or koilonychia, and eczema may also occur.

Vohwinkel Palmoplantar Keratoderma (Mutilating Keratoderma)

Vohwinkel PPK is a progressive autosomal dominant disease consisting of honeycombed hyperkeratosis of palms and soles, sparing the arches; starfish-like and linear keratoses on the dorsum of the hands, fingers, feet, and knees; and ainhum-like constriction of the digits that sometimes leads to autoamputation. Varying degrees of alopecia may be seen. Two forms have been identified. Vohwinkel PPK with ichthyosis is caused by pathogenic variants in the loricrin gene, and Vohwinkel PPK with deafness by pathogenic variants in connexin 26.

Papillon-Lefèvre Syndrome (Cathepsin C Gene)

An autosomal recessive erythematous hyperkeratosis of the palms and soles, Papillon-Lefèvre syndrome sometimes extends to the dorsal hands and feet, elbows, and knees later in childhood. The PPK may be either diffuse, striate, or punctuate. This syndrome is characterized by periodontal inflammation, leading to loss of teeth by age 4-5 years if untreated.

Other Syndromes

Keratoderma of palms and soles also occurs as a feature of some forms of ichthyosis and ectodermal dysplasia. Richner-Hanhart syndrome is an autosomal recessive focal PPK with corneal ulcers, progressive mental impairment, and a deficiency of tyrosine aminotransferase, which leads to tyrosinemia. **Pachyonychia congenita** is transmitted as an autosomal dominant trait with variable expressivity. The classic type I form (Jadassohn-Lewandowski syndrome) is due to pathogenic variants in the gene for keratin 16. Major features of the syndrome are onychogryphosis; PPK; follicular hyperkeratosis, especially of the elbows and knees; and oral leukokeratosis. The nail dystrophy is the most striking feature and may be present at birth or develop early in life. The nails are thickened and tubular, projecting upward at the free edge to form a conical roof over a mass of subungual keratotic debris. Repeated paronychial inflammation may result in shedding of the nails. The feature seen most consistently among patients with this condition is keratoderma of the palms and soles. Additional associated features include hyperhidrosis of the palms and soles and bullae and erosions on the palms and soles. Some patients have shown a selective cell-mediated defect in recognition and processing of *Candida*. Surgical removal of the nails and excision of the nail matrix have been helpful in some patients.

Treatment

Treatment for PPK is the same no matter what its cause. In mild cases, emollient therapy may suffice. Keratolytic agents such as salicylic acid, lactic acid, and urea creams may be required. Oral retinoids are the treatment of choice for severe cases unresponsive to topical therapy.

Visit Elsevier eBooks+ at eBooks.Health.Elsevier.com for Bibliography.

Chapter 700

Diseases of the Dermis

Jacquelyn R. Sink and Yvonne E. Chiu

KELOID

Etiology and Pathogenesis

Keloids are usually induced by trauma and commonly follow ear piercing, burns, scalds, and surgical procedures. The resulting keloid is larger than the initial area of trauma to the skin. Certain individuals are predisposed to keloid formation; a familial tendency (recessive or dominant inheritance) or the presence of foreign material in the wound may have a pathogenic role. Keloids are a rare feature of Ehlers-Danlos syndrome, Rubinstein-Taybi syndrome, and pachydermoperiostosis. Keloids result from an abnormal fibrous wound-healing response in which tissue repair and regeneration-regulation control mechanisms are lost. Collagen production is 20 times that seen in normal scars, and the type I:III collagen ratio is abnormally high. In keloids, tissue levels of tumor growth factor-β and platelet-derived growth factor are elevated; fibroblasts are more sensitive to their effects, and their degradation rate is decreased.

Clinical Manifestations

A *keloid* is a sharply demarcated, benign, dense growth of connective tissue that forms in the dermis after trauma. The lesions are firm, raised, pink to hyperpigmented, and rubbery; they may be tender or pruritic. Sites of predilection are the face, earlobes (Fig. 700.1), neck, shoulders, upper trunk, sternum, and lower legs. Unlike hypertrophic scars, keloids frequently recur after attempted removal and outgrow the original boundaries of the wound.

Histology

A keloid consists of whorled and interlaced hyalinized collagen fibers.

Differential Diagnosis

Keloids should be differentiated from *hypertrophic scars,* which remain confined to the site of injury and may involute over time.

Fig. 700.1 Keloid of earlobe after piercing.

Treatment
Treatment of keloids is difficult. Young keloids may diminish in size if injected intralesionally at 4-week intervals with triamcinolone suspension (10-40 mg/mL). At times, a more concentrated suspension is required. Large or old keloids may require surgical excision followed by serial intralesional injections of corticosteroid; however, recurrence rates are high. Earlobe keloids may respond favorably to surgical excision followed by use of pressure earrings and serial intralesional steroid injections. Silicone scar sheeting may help in some patients. Other therapeutic modalities that have been used with variable success include laser therapy, radiation therapy, and intralesional injection of bleomycin, interferon, verapamil, or fluorouracil.

STRIAE CUTIS DISTENSAE (STRETCH MARKS)
Etiology and Pathogenesis
Striae formation is common in adolescence. The most frequent causes are rapid growth, pregnancy, obesity, Cushing disease, and prolonged use of systemic or topical corticosteroid therapy. They may also be seen in patients with Ehlers-Danlos syndrome. The pathogenesis is unknown, but alterations in collagen and elastic fibers are thought to play a role.

Clinical Manifestations
Striae appear as linear, depressed, pink bands of atrophic skin that eventually become silvery, opalescent, and smooth. They occur most frequently in areas subject to distention, such as the lower back (Fig. 700.2), buttocks, thighs, breasts, abdomen, and shoulders.

Differential Diagnosis
Striae distensae resemble atrophic scars.

Treatment
Striae tend to spontaneously become less conspicuous as the color fades with time, and treatment is not necessary.

CORTICOSTEROID-INDUCED ATROPHY
Etiology and Pathogenesis
Both topical and systemic corticosteroid treatment can result in cutaneous atrophy. This is particularly common when a potent or superpotent topical corticosteroid is applied under occlusion or to an intertriginous area for a prolonged period. Keratinocyte growth is decreased, but epidermal maturation is accelerated, resulting in thinning of the epidermis and stratum corneum. Fibroblast growth and function are also decreased, leading to dermal changes. The mechanism involves inhibition of synthesis of collagen type I, noncollagenous proteins, and total protein content of the skin, along with progressive reduction of dermal proteoglycans and glycosaminoglycans.

Clinical Manifestations
Affected skin is thin, fragile, smooth, and semitransparent, with telangiectasia, prominent veins, and loss of normal skin markings.

Histology
On histology, thinning of the epidermis is present. Spaces between dermal collagen and elastic fibers are small, producing a more compact yet thin dermis.

Treatment
Optimal treatment is prevention by monitoring and educating on the proper use of topical steroids to avoid side effects.

GRANULOMA ANNULARE
Etiology and Pathogenesis
The cause of granuloma annulare (GA) is unknown. A possible association with diabetes mellitus has been proposed, particularly with the generalized form of GA; however, this hypothesis is controversial and has not been confirmed in children.

Clinical Manifestations
This common dermatosis occurs predominantly in healthy children and young adults. Typical lesions begin as firm, smooth, erythematous papules. They gradually enlarge to form annular plaques with a papular border and a normal, slightly atrophic or discolored central area up to several centimeters in size. Lesions may occur anywhere on the body, but mucous membranes are notably spared. Favored sites include the dorsum of the hands (Fig. 700.3) and feet. The disseminated papular form is rare in children. Subcutaneous GA tends to develop on the scalp and limbs, particularly in the pretibial area. These lesions are firm, usually nontender, skin-colored nodules. Perforating GA is characterized by the development of grouped papules, some with a yellowish, crusted, or scaly center, and occur because of transepidermal elimination of altered collagen.

Differential Diagnosis
Annular lesions are often mistaken for tinea corporis due to the elevated, advancing border; however, GA characteristically lacks scale. Papular lesions may simulate rheumatoid nodules, particularly when grouped on the fingers and elbows.

Histology
The lesions of GA demonstrate granuloma formation on histology with a central area of necrotic collagen, mucin deposition, and a peripheral palisading infiltrate of lymphocytes, histiocytes, and foreign body giant cells. The pattern resembles that of necrobiosis lipoidica and rheumatoid nodules, but subtle histologic differences usually permit differentiation.

Treatment
The eruption persists for months to years, but spontaneous resolution without residual change is typical; approximately 50% of lesions clear within 2 years. Application of a potent or superpotent topical corticosteroid preparation or intralesional injections (5-10 mg/mL)

Fig. 700.2 Striae on the back of an adolescent.

Fig. 700.3 Annular lesion with a raised papular border and depressed center, characteristic of granuloma annulare.

of corticosteroid may hasten involution, but nonintervention is also appropriate.

NECROBIOSIS LIPOIDICA

Etiology and Pathogenesis

The cause of necrobiosis lipoidica (NL) is unclear, but 50–75% of patients have diabetes mellitus, though NL occurs in less than 1% of all diabetic patients. NL has also been noted in patients with obesity, hypertension, and dyslipidemias. Its presence may signify a higher risk for diabetic complications such as nephropathy and retinopathy.

Clinical Manifestations

This disorder manifests as erythematous papules that evolve into irregularly shaped, sharply demarcated, erythematous to yellow, sclerotic plaques with central telangiectasias and a violaceous border. Scaling, crusting, and ulceration may occur. Lesions develop most commonly on the anterior tibial surfaces (Fig. 700.4). Slow extension of a given lesion over the years is usual, but long periods of quiescence or complete healing with scarring may occur.

Histology

Poorly defined areas of necrobiotic collagen are seen on microscopic evaluation, primarily low in the dermis with mucin deposition. Surrounding the necrobiotic, disordered areas of collagen is a palisading lymphohistiocytic granulomatous infiltrate. Some lesions are more characteristically granulomatous, with limited necrobiosis of collagen.

Differential Diagnosis

NL must be differentiated clinically from xanthomas, morphea, GA, erythema nodosum, and pretibial myxedema.

Treatment

The lesions of NL usually persist despite good control of the diabetes but may improve minimally after applications of high-potency topical steroids or local injection of a corticosteroid. Ulcerated areas should be managed with meticulous wound care. Pentoxifylline and antiplatelet therapy with aspirin have also been used.

LICHEN SCLEROSUS

Etiology and Pathogenesis

Lichen sclerosus (LS) is a chronic inflammatory dermatosis whose cause is largely unknown. Several studies have identified the presence of autoantibodies against the glycoprotein extracellular matrix protein 1 (ECM-1).

Clinical Manifestations

Lichen sclerosus (LS) manifests as shiny, ivory-colored, flat-topped papules, often with a violaceous halo. The surface shows prominent dilated pilosebaceous or sweat duct orifices that may contain yellow or brown follicular plugs. The papules coalesce to form irregular plaques of variable size, and hemorrhagic bullae can be seen in the margins. In the later stages, atrophy results in a depressed plaque with a wrinkled surface. This disorder occurs more commonly in girls than in boys. Sites of predilection in girls are the vulvar (Fig. 700.5), perianal, and perineal skin. Extensive involvement may produce an atrophic plaque of hourglass configuration; shrinkage of the labia and stenosis of the introitus may result. Erythema and purpura are possible. Vaginal discharge precedes vulvar lesions in approximately 20% of patients. In boys, the prepuce and glans penis are often involved, usually in association with phimosis *(balanitis xerotica obliterans)*; most boys with the disorder were not circumcised early in life. Commonly involved extragenital sites include the upper trunk, neck, axillae, flexor surfaces of wrists, and areas around the umbilicus and the eyes. Pruritus, pain, and dysuria may be severe, and constipation due to withholding may occur.

Differential Diagnosis

In children, LS is most frequently confused with focal morphea (see Chapter 201), with which it may coexist. In the genital area, it may be mistakenly attributed to sexual abuse, irritant dermatitis, or vulvovaginitis. The vitiligoid form associated with depigmentation must be differentiated from vitiligo or postinflammatory hypopigmentation.

Histology

Biopsy is rarely necessary but shows hyperkeratosis with follicular plugging, hydropic degeneration of basal cells, a bandlike dermal lymphocytic infiltrate, homogenized collagen, and thinned elastic fibers in the upper dermis.

Treatment

Vulvar LS in childhood usually improves with puberty but does not always resolve completely, and symptoms can recur throughout life. Long-term observation for the development of squamous cell carcinoma is necessary in patients with later disease onset or persistence beyond puberty. Superpotent topical corticosteroids are the treatment of choice, including for the genital area, providing relief from pruritus and producing clearing of lesions. Topical tacrolimus and pimecrolimus have also been used. It is not known how response to treatment affects long-term cancer risk.

MORPHEA

Etiology and Pathogenesis

Morphea is an autoimmune sclerosing condition of the dermis and subcutaneous tissue of unknown etiology.

Clinical Manifestations

Morphea is characterized by solitary, multiple, or linear circumscribed areas of erythema that evolve into indurated, sclerotic, atrophic plaques, with or without a lilac border (Fig. 700.6). Affected areas may resolve

Fig. 700.4 Yellow sclerotic plaque of necrobiosis lipoidica on the shin.

Fig. 700.5 Ivory-colored perivaginal plaque with hemorrhage.

Fig. 700.6 Erythematous, hyperpigmented plaque of early morphea.

Fig. 700.7 Linear morphea with involvement over the ankle.

without sequelae or with subsequent atrophy and/or pigment change. Morphea is seen more commonly in females. Five types of morphea have been described: circumscribed, linear, generalized, mixed, and pansclerotic; the most common types in children are circumscribed and linear. Morphea can affect any area of skin. When confined to the frontal scalp, forehead, and midface in a linear band, it is referred to as **en coup de sabre**. When located on one side of the face, it is termed **progressive hemifacial atrophy**, also known as **Parry-Romberg syndrome**. These forms of morphea carry a poorer prognosis because of the associated underlying central nervous system involvement or musculoskeletal atrophy that can be cosmetically disfiguring. Linear morphea over a joint may lead to limb undergrowth or restriction of mobility (Fig. 700.7). Pansclerotic morphea is a rare, severe, disabling variant.

Differential Diagnosis

The differential diagnosis of morphea includes GA, NL, LS, and late-stage European Lyme borreliosis (acrodermatitis chronica atrophicans).

Histology

Thickening or sclerosus of the dermis with collagen degeneration is seen.

Treatment

Morphea tends to persist, with gradual outward expansion for months to years until spontaneous cessation of the inflammatory phase occurs. Topical calcipotriene, alone or in combination with high-potency to superpotency topical steroids or topical tacrolimus, has been used for less severe disease. For severe morphea, methotrexate with or without pulsed intravenous or oral glucocorticosteroids may halt progression and help shorten the disease course. Ultraviolet A-1 (UVA-1) phototherapy, mycophenolate mofetil, and other therapies are also used. Physical therapy is recommended in linear morphea involving a joint to maintain mobility. Significant postinflammatory pigment alteration may persist for years.

SCLEREDEMA (SCLEREDEMA ADULTORUM, SCLEREDEMA OF BUSCHKE)

Etiology and Pathogenesis

The cause of scleredema is unknown. There are three types. **Type 1** (55% of cases) is preceded by a febrile illness, often related to an upper or lower respiratory infection (most commonly streptococcus). **Type 2** (25%) is associated with paraproteinemia, including multiple myeloma. **Type 3** (20%) is seen in diabetes mellitus.

Clinical Manifestations

Fifty percent of patients with scleredema are younger than 20 years old. Onset of type 1 is sudden, with brawny edema of the face and neck that spreads rapidly to involve the thorax and arms in a sweater distribution; the abdomen and legs are usually spared. The face acquires a waxy, masklike appearance. The involved areas feel indurated and woody, are nonpitting, and are not sharply demarcated from normal skin. The overlying skin is normal in color and is not atrophic.

Type 2 and type 3 scleredema may occur insidiously. Systemic involvement, which is uncommon and usually associated with types 2 and 3, is marked by thickening of the tongue, dysarthria, dysphagia, restriction of eye and joint movements, and pleural, pericardial, and peritoneal effusions. Electrocardiographic changes may also be observed. Laboratory data are not helpful.

Differential Diagnosis

Scleredema must be differentiated from scleroderma (see Chapter 201), morphea, myxedema, trichinosis, dermatomyositis, sclerema neonatorum, and subcutaneous fat necrosis.

Histology

Skin biopsy demonstrates an increase in dermal thickness due to swelling and homogenization of the collagen bundles, which are separated by large interfibrous spaces. Special stains can identify increased amounts of mucopolysaccharides in the dermis of patients with scleredema.

Treatment

In type 1 scleredema, the active phase of the disease persists for 2-8 weeks. Spontaneous and complete resolution usually occurs after 6 months to 2 years. Recurrent attacks are unusual. In types 2 and 3, the disease is slowly progressive. There is no specific therapy.

LIPOID PROTEINOSIS (URBACH-WIETHE DISEASE, HYALINOSIS CUTIS ET MUCOSAE)

Etiology and Pathogenesis

Lipoid proteinosis is an autosomal recessive disorder caused by pathogenic variants in the *ECM-1* gene, which encodes ECM-1. ECM-1 has a functional role in the structural organization of the dermis by binding to perlecan, matrix metalloproteinase 9, and fibulin. Pathogenesis involves infiltration of hyaline material into the skin, oral cavity, larynx, and internal organs.

Clinical Manifestations

Lipoid proteinosis presents initially in early infancy as hoarseness due to vocal cord involvement. Skin lesions appear during childhood and consist of yellowish papules and nodules that may coalesce to form plaques. The classic sign is a string of beaded papules on the eyelids. Lesions also occur on the face, forearms, neck, genitals, dorsum of the fingers, and scalp, where they result in patchy alopecia. Similar deposits are found on the lips, leading to eversion of the lips, as well as the undersurface of the tongue, fauces, uvula, epiglottis,

and vocal cords. The tongue becomes enlarged and feels firm on palpation. The patient may be unable to protrude the tongue. Pocklike, atrophic scars may develop on the face. Hypertrophic, hyperkeratotic nodules and plaques occur at sites of friction, such as the elbows and knees; the palms may be diffusely thickened. The disease progresses until early adult life, but the prognosis is good. Symmetric calcification lateral to the sella turcica in the medial temporal region, identifiable roentgenographically as bilateral bean-shaped opacities, is pathognomonic but is not always present. Involvement of the larynx can lead to respiratory compromise, particularly in infancy, necessitating tracheostomy. Associated anomalies include dental abnormalities, epilepsy, and recurrent parotitis because of infiltrates in the Stensen duct. Virtually any organ can be involved.

Histology
The distinctive histologic pattern in lipoid proteinosis includes dilation of dermal blood vessels and infiltration of homogeneous eosinophilic extracellular hyaline material along capillary walls and around sweat glands. Hyaline material in homogeneous bundles, diffusely arranged in the upper dermis, produces a thickened dermis. The infiltrates appear to contain both lipid and mucopolysaccharide substances.

Treatment
There is no specific treatment for lipoid proteinosis.

MACULAR ATROPHY (ANETODERMA)
Etiology and Pathogenesis
Anetoderma is characterized by circumscribed areas of slack skin associated with loss of dermal substance. This disorder may have no associated underlying disease (primary macular atrophy) or may develop after an inflammatory skin condition. Secondary macular atrophy may be a result of direct destruction of dermal elastin or elastolysis on an immunologic basis, especially in the presence of antiphospholipid antibodies, which are related to autoimmune disorders. The elastolysis may then be a result of release of elastase from inflammatory cells.

Clinical Manifestations
Lesions vary from 0.5 to 1.0 cm in diameter and, if inflammatory, may initially be erythematous. They subsequently become thin, wrinkled, and blue-white or hypopigmented. The lesions often protrude as small outpouchings that, on palpation, may be readily indented into the subcutaneous tissue because of the dermal atrophy. Sites of predilection include the trunk, thighs, upper arms, and, less commonly, the neck and face. Lesions remain unchanged for life; new lesions often continue to develop for years.

Histology
All types of macular atrophy show focal loss of elastic tissue on histopathologic examination, a change that may not be recognized unless special stains are used.

Differential Diagnosis
Lesions of anetoderma occasionally resemble morphea, LS, focal dermal hypoplasia, atrophic scars, or end-stage lesions of chronic bullous dermatoses.

Treatment
There is no effective therapy for macular atrophy.

PSEUDOXANTHOMA ELASTICUM
Etiology and Pathogenesis
Pseudoxanthoma elasticum (PXE) is a genetic metabolic disease linked to pathogenic variants in the *ABCC6* gene. The primary abnormality seen in PXE is mineralization of tissue in the skin, Bruch membrane in the retina, and vessel walls. Cutaneous manifestations of PXE may be present in generalized arterial calcification of infancy.

Fig. 700.8 Confluent plaque of pebbly skin in pseudoxanthoma elasticum.

Clinical Manifestations
Onset of skin manifestations often occurs during childhood, but the changes produced by early lesions are subtle and may not be recognized. The characteristic pebbly, "plucked chicken skin" cutaneous lesions are 1- to 2-mm, asymptomatic, yellow papules arranged in a linear or reticulated pattern or in confluent plaques. Preferred sites are the flexural neck (Fig. 700.8), axillary and inguinal folds, umbilicus, thighs, and antecubital and popliteal fossae. As the lesions become more pronounced, the skin acquires a velvety texture and droops in lax, inelastic folds. The face is usually spared. Mucous membrane lesions may involve the lips, buccal cavity, rectum, and vagina. There is involvement of the connective tissue of the media and intima of blood vessels, Bruch membrane of the eye, and endocardium or pericardium, which may result in visual disturbances, angioid streaks in the Bruch membrane, irregular mottling of the retinal epithelium, intermittent claudication, cerebral and coronary occlusion, hypertension, and hemorrhage from the gastrointestinal tract, uterus, or mucosal surfaces. Women with PXE have an increased risk of miscarriage in the first trimester. Arterial involvement generally manifests in adulthood, but claudication and angina have occurred in early childhood.

Pathology
Histopathologic examination shows fragmented, swollen, and clumped elastic fibers in the middle and lower third of the dermis. The fibers stain positively for calcium. Collagen near the altered elastic fibers is reduced in amount and is split into small fibers. Aberrant calcification of the elastic fibers of the internal elastic lamina of arteries in PXE leads to narrowing of vessel lumina.

Treatment
There is no effective treatment for PXE, although laser therapy, with or without intravitreal injection of vascular endothelial growth factor antagonists, may help prevent retinal hemorrhage. The use of oral phosphate binders has shown mixed results in decreasing calcification of elastic fibers.

ELASTOSIS PERFORANS SERPIGINOSA
Etiology and Pathogenesis
Elastosis perforans serpiginosa (EPS) is characterized by the extrusion of altered elastic fibers through the epidermis. The primary abnormality is probably in the dermal elastin, which provokes a cellular response that ultimately leads to extrusion of the abnormal elastic tissue.

Clinical Manifestations
This is an unusual skin disorder in which 1- to 3-mm, firm, skin-colored, keratotic papules tend to cluster in arcuate and annular patterns on the posterolateral neck and limbs (Fig. 700.9) and occasionally on the face and trunk. Onset usually occurs in childhood or

Fig. 700.9 Arcuate keratotic papule of elastosis perforans serpiginosa.

Fig. 700.10 Hyperkeratotic papules in reactive perforating collagenosis.

adolescence. A papule consists of a circumscribed area of epidermal hyperplasia that communicates with the underlying dermis by a narrow channel. There is a great increase in the amount and size of elastic fibers in the upper dermis, particularly in the dermal papillae. Approximately 30% occur in association with osteogenesis imperfecta, Marfan syndrome, PXE, Ehlers-Danlos syndrome, Rothmund-Thomson syndrome, scleroderma, acrogeria, and Down syndrome. EPS has also occurred in association with penicillamine therapy.

Histology
Histopathology reveals a hyperplastic epidermis with extrusion of abnormal elastic fibers and a lymphocytic superficial infiltrate.

Differential Diagnosis
The differential diagnosis of EPS includes tinea corporis, perforating GA, reactive perforating collagenosis, lichen planus, creeping eruption, and porokeratosis of Mibelli.

Treatment
Treatment of EPS is ineffective; however, the lesions are asymptomatic and may disappear spontaneously.

REACTIVE PERFORATING COLLAGENOSIS
Etiology and Pathogenesis
The primary process in reactive perforating collagenosis represents transepidermal elimination of altered collagen. A familial autosomal recessive form has been described.

Clinical Manifestations
Reactive perforating collagenosis usually manifests in early childhood as small papules on the dorsal areas of the hands and forearms, elbows, knees, and, sometimes, the face and trunk. Over a period of several weeks, the papules enlarge to 5-10 mm, become umbilicated, and develop keratotic plugs centrally (Fig. 700.10). Individual lesions resolve spontaneously in 2-4 months, leaving hypopigmented macules or scars. Lesions may recur in crops, linearly as a part of the Koebner phenomenon, or in response to cold temperatures or superficial trauma such as abrasions, insect bites, and acne lesions.

Histology
Collagen in the papillary dermis is engulfed within a cup-shaped perforation in the epidermis. The central crater contains pyknotic inflammatory cells and keratinous debris.

Differential Diagnosis
EPS and Kyrle disease may mimic reactive perforating collagenosis.

Treatment
Reactive perforating collagenosis resolves spontaneously in 6-8 weeks. Narrow-band ultraviolet B (UVB) light may help with pruritus and hasten resolution.

XANTHOMAS
See Chapter 105.

FABRY DISEASE
See Chapter 653.6.

MUCOPOLYSACCHARIDOSES
See Chapter 109.

Several of the mucopolysaccharidoses are characterized by thickened, rough, inelastic skin, particularly on the extremities, and generalized hypertrichosis but are nonspecific features. Extensive and persistent dermal melanocytosis has been described in children with Hurler and Hunter syndromes. Telangiectasias on the face, forearms, trunk, and legs have been observed in Scheie and Morquio syndromes. In some patients with Hunter syndrome, ivory-colored, distinctive, firm dermal papules and nodules with corrugated surface texture are grouped into symmetric plaques on the upper trunk (Fig. 700.11), arms, and thighs. Onset of these unusual lesions occurs in the first decade of life, and spontaneous disappearance has been noted.

MASTOCYTOSIS
Etiology and Pathogenesis
Mastocytosis encompasses a clinical spectrum of disorders that range from solitary cutaneous nodules to diffuse infiltration of skin associated with involvement of internal organs (Table 700.1). All of the disorders are characterized by aggregates of mast cells in the dermis. There are four types of mastocytosis: mastocytomas (three or fewer lesions), urticaria pigmentosa (more than three lesions, also known as *maculopapular cutaneous mastocytosis*), diffuse cutaneous mastocytosis, and telangiectasia macularis eruptiva perstans (TMEP). Increased expression of stem cell factor (also called *kit ligand* or *mast cell growth factor*) stimulates the proliferation of mast cells and increases the production of melanin by melanocytes. Some forms of mastocytosis are associated with activating pathogenic variants (most commonly the *D816V* variant) in the *KIT* gene. The local and systemic manifestations of the disease are at least partly a result of the release of histamine and heparin from mast cell granules; although heparin is present in significant amounts in mast cells, coagulation disturbances occur only rarely. The vasodilator prostaglandin D_2 or its metabolite appears to exacerbate the flushing response. Serum tryptase values may be elevated, but not consistently.

Fig. 700.11 Ivory-colored papules on the upper back in Hunter syndrome.

Table 700.1 Mastocytosis Classification
CUTANEOUS MASTOCYTOSIS
Urticaria pigmentosa/maculopapular cutaneous mastocytosis
Diffuse cutaneous mastocytosis
Solitary mastocytoma
SYSTEMIC MASTOCYTOSIS
Indolent mastocytosis
Smoldering mastocytosis
Aggressive mastocytosis
Systemic mastocytosis with associated hematologic non–mast cell lineage (AHN) disease
Mast cell leukemia
MAST CELL SARCOMA

Modified from Valent P, Akin C, Metcalfe D. Mastocytosis: 2016 Updated WHO classification and novel emerging treatment concepts. *Blood.* 2017;129:1420–1427, Table 2.

Clinical Manifestations

Mastocytomas are usually 1-5 cm in diameter. Lesions may be present at birth or may arise in early infancy at any site. The lesions may manifest as recurrent, evanescent wheals or bullae; in time, an infiltrated, pink, yellow, or tan, rubbery plaque develops at the site of whealing or blistering (Fig. 700.12). The surface acquires a pebbly, orange peel–like texture, and hyperpigmentation may become prominent. Mechanical irritation of the lesion may lead to urtication (Darier sign) within a few minutes due to local histamine release; rarely, systemic signs of histamine release become apparent.

Urticaria pigmentosa is the most common form of mastocytosis in children. In the first type of urticaria pigmentosa, the **classic infantile type**, lesions may be present at birth but more often erupt in crops in the first several months to 2 years of age. New lesions seldom arise after age 3-4 years. In some cases, early bullous or urticarial lesions fade, only to recur at the same site, ultimately becoming fixed and hyperpigmented. In others, the initial lesions are hyperpigmented. Vesiculation usually abates by 2 years of age. Individual lesions range in size from a few millimeters to several centimeters and may be macular, papular, or nodular. They range in color from yellow-tan to red-brown and often have ill-defined borders (see Fig. 700.12). Larger nodular lesions, like solitary mastocytomas, may have a characteristic *peau d'orange* (orange peel–like) texture. Lesions of urticaria pigmentosa may be sparse or numerous and are often symmetrically distributed. Palms, soles, and face are usually spared, as are the mucous membranes. The rapid appearance of erythema and wheals in response to vigorous stroking of a lesion can usually be elicited; dermographism of intervening normal skin is also common. Affected children can have intense pruritus. Systemic signs of histamine release, such as anaphylaxis-like episodes, hypotension, syncope, headache, episodic flushing, tachycardia, wheezing, colic, and diarrhea, are uncommon and occur most frequently in the more severe types of mastocytosis. Flushing is by far the most common symptom.

The **second type** of urticaria pigmentosa may begin in childhood but typically develops in adulthood. This type does not resolve, and new lesions continue to develop throughout life. Patients with this type of mastocytosis may develop systemic involvement.

Systemic mastocytosis is marked by an abnormal increase in the number of mast cells in numerous organ systems and is uncommon in children. Bone lesions are often silent (but may be painful) and are detectable radiologically as osteoporotic or osteosclerotic areas, principally in the axial skeleton. Gastrointestinal tract involvement may lead to abdominal pain, nausea, vomiting, diarrhea, steatorrhea, and bloating. Mucosal infiltrates may be detectable by barium studies or by small bowel biopsy. Peptic ulcers also occur. Hepatosplenomegaly due to mast cell infiltrates and fibrosis has been described, as has mast cell proliferation in lymph nodes, kidneys, periadrenal fat, and bone marrow. Abnormalities in the peripheral blood, such as anemia, leukocytosis, and eosinophilia, are noted in approximately 30% of patients. Mast cell leukemia may occur.

Diffuse cutaneous mastocytosis is characterized by diffuse involvement of the skin rather than discrete hyperpigmented lesions. Affected patients are usually normal at birth and demonstrate features of the disorder after the first few months of life. Rarely, the condition may present with intense generalized pruritus in the absence of visible skin changes. The skin usually appears thickened, pink to yellow in color, doughy, or with a *peau d'orange* texture. Surface changes are accentuated in flexural areas. Recurrent bullae (see Fig. 700.12), intractable pruritus, and flushing attacks are common, as is systemic involvement.

Telangiectasia macularis eruptiva perstans (TMEP) is a variant of mastocytosis that consists of telangiectatic, hyperpigmented macules usually localized to the trunk. These lesions do not urticate when stroked. This form of the disease is seen primarily in adolescents and adults.

Differential Diagnosis

The differential diagnosis of solitary mastocytomas includes recurrent bullous impetigo, herpes simplex, congenital melanocytic nevi, and juvenile xanthogranuloma.

Urticaria pigmentosa can be confused with drug eruptions, postinflammatory pigmentary change, juvenile xanthogranuloma, pigmented nevi, ephelides, xanthomas, chronic urticaria, insect bites, and bullous impetigo. Diffuse cutaneous mastocytoma may be confused with epidermolytic hyperkeratosis. TMEP must be differentiated from other causes of telangiectasia.

The systemic manifestations of mastocytosis may mimic pheochromocytoma, carcinoid syndrome, vasoactive intestinal peptide–secreting tumors, vasculitis, autoinflammatory diseases, hyper-IgE syndrome, somatization disorder, autonomic dysfunction, angioedema, chronic urticaria, and anaphylaxis.

Prognosis

Spontaneous involution usually occurs in patients with solitary mastocytomas and classic infantile urticaria pigmentosa. The incidence of systemic manifestations in these patients is very low. The mean duration of urticaria pigmentosa is around 10 years. A larger number of lesions early in life may lead to later resolution.

Treatment

Solitary mastocytomas usually do not require treatment. Lesions that blister may be treated with topical steroids after each blistering episode.

In urticaria pigmentosa, flushing can be precipitated by excessively hot baths, vigorous rubbing of the skin, and certain drugs, such as

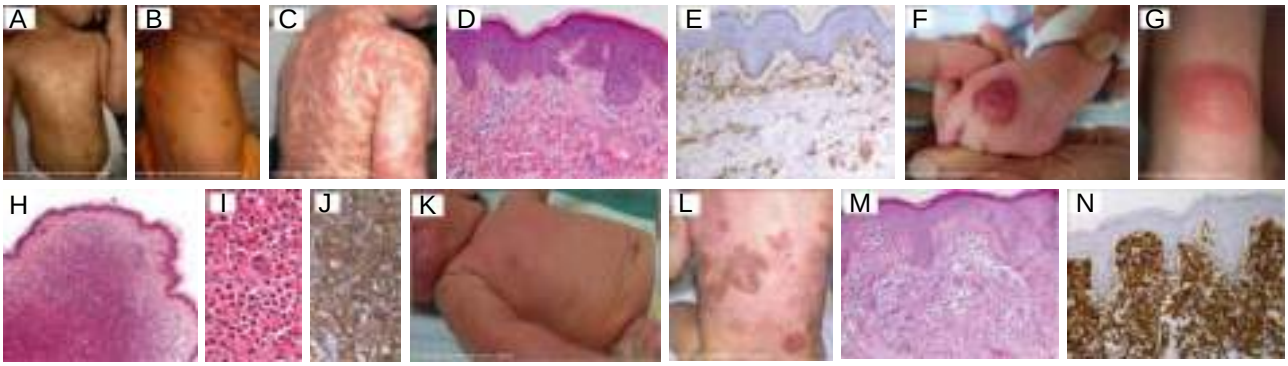

Fig. 700.12 Clinical features and histologic findings in childhood mastocytosis. Diagnosis of mastocytosis in children is often obvious, and skin biopsy is rarely performed. The histologic diagnosis of cutaneous mastocytosis must consider the increased number and proportion of mast cells compared to other inflammatory cells. Mast cells can be rounded, cuboidal, fusiform, or histiocyte-like. Eosinophils may be observed in all mastocytosis subtypes. The epidermis may be hyperpigmented in urticaria pigmentosa (UP) and diffuse cutaneous mastocytosis (DCM), whereas it is normal in mastocytoma. **A-E,** Types of urticaria pigmentosa. **A,** Maculopapular UP. **B,** Plaque-type UP. **C,** Extensive UP with plaques and macules. **D,** Skin biopsy: increased number and proportion of mast cells around the vessels or scattered into the dermis, dilatation of the capillaries of the superficial dermis. **E,** c-Kit staining. **F-J,** Mastocytoma. **F,** Mastocytoma localized on the hand. **G,** Mastocytoma localized on the forearm. **H, I,** Skin biopsy: abundant and diffuse infiltration of mast cells throughout the dermis. Mast cells are always recognizable, with a large, pink, and granular cytoplasm and a round, dense, central nucleus. **J,** c-Kit staining. **K-N,** DCM. **K,** Diffuse infiltration of skin. **L,** Extensive bullous lesions associated with infiltration on the back. **M,** Skin biopsy: diffuse dermal infiltration of mast cells associated with some fibrosis and dilated capillaries. **N,** c-Kit staining. *(From Méni C, Bruneau J, Georgin-Lavialle S, et al. Paediatric mastocytosis: a systematic review of 1747 cases. Br J Dermatol. 2015;172:642–651, Fig. 1, p. 643.)*

Table 700.2 Pharmacologic Agents and Physical Stimuli that May Exacerbate Mast Cell Mediator Release in Patients with Mastocytosis

Venoms (bee stings, jellyfish stings, snake bites)
Complement-derived anaphylatoxins
Biologic peptides (substance P, somatostatin, vasoactive intestinal polypeptide)
Polymers (dextran)
Physical stimuli (heat, cold, exertion, friction, trauma, vibration, sunlight)
Acetylsalicylic acid (aspirin), ibuprofen, and related nonsteroidal analgesics*
Alcohol
General anesthetics (D-tubocurarine, scopolamine, decamethonium, gallamine, pancuronium)
Polymyxin B
Local anesthetics (lidocaine, tetracaine procaine, methylparaben preservative)
Sympathomimetics
Opiates (codeine, morphine)*
Radiographic dyes (iodine-containing)
Other drugs (papaverine, dipyridamole, trimethaphan, amphotericin B, quinine, thiamine, dextromethorphan, lactam, antibiotics, vancomycin)
Stress (sleep deprivation, anxiety, pain)

*Appears to be a problem in <10% of patients.
Modified from Carter MC, Metcalfe DD. Paediatric mastocytosis. *Arch Dis Child.* 2002;86:315–319, Table 4.

codeine, aspirin, morphine, atropine, ketorolac, alcohol, tubocurarine, iodine-containing radiographic dyes, and polymyxin B (Table 700.2). Avoidance of these triggering factors is advisable; it is notable that general anesthesia may be safely performed with appropriate precautions.

For patients who are symptomatic, oral antihistamines may be palliative. H_1 receptor antagonists are the initial drugs of choice for systemic signs of histamine release. If H_1 antagonists are unsuccessful, H_2 receptor antagonists may be helpful in controlling pruritus or gastric hypersecretion. Topical steroids are of benefit in controlling skin urtication and blistering. Oral mast cell–stabilizing agents, such as cromolyn sodium or ketotifen, may also be effective for diarrhea or abdominal cramping and with systemic symptoms such as headache or muscle pain. Midostaurin, an inhibitor of receptor tyrosine kinase KIT, may be effective in patients with systemic mastocytosis associated with hematologic malignancy. A premeasured epinephrine pen kit may be considered for those individuals at higher risk for anaphylaxis such as systemic disease, extensive cutaneous disease, high baseline tryptase levels, and known allergies.

For patients with diffuse cutaneous mastocytosis, treatment is similar to urticaria pigmentosa. Phototherapy with narrow-band UV (UVB or UVA-1) or psoralen with UVA treatment may be useful.

Lesions of TMEP may be cautiously treated with vascular pulsed dye lasers.

Visit Elsevier eBooks+ at eBooks.Health.Elsevier.com for Bibliography.

700.1 Mast Cell Activation Syndrome

James J. Nocton

Mast cell activation (MCA) occurs in several defined conditions, including primary mast cell disorders, allergic reactions, systemic inflammatory diseases, and drug reactions, and results in the release of multiple proinflammatory mediators, including tryptase, histamine, prostaglandins, and leukotrienes. The effects of these mediators lead to the clinical symptoms of MCA, which may range from mild to severe and may involve multiple organ systems, including the cutaneous, gastrointestinal, respiratory, and cardiovascular systems (Table 700.3). The term *mast cell activation syndrome (MCAS)* has been used to describe a condition associated with symptoms, signs, and laboratory abnormalities that are consistent with the effects of mast cell mediators; it is recurrent, usually severe, and involves multiple organ systems and responds to treatment with medications that are known to inhibit mast cells or secreted mast cell mediators. Consensus criteria for the diagnosis and

Table 700.3 Common Symptoms in Patients with Mast Cell Mediator Disorders

Cardiovascular: chest pain, hypotension, hypotensive syncope, tachycardia
Dermatologic: angioedema, dermatographism, flushing, pruritus, urticaria pigmentosa
Gastrointestinal: abdominal cramping/pain, bloating, diarrhea, esophagitis, nausea, vomiting
Musculoskeletal: bone/muscle pain, degenerative disc disease, osteoporosis/osteopenia
Naso-ocular: nasal congestion, pruritus, tearing
Neurologic: headache, memory and concentration difficulties (brain fog), paresthesia, peripheral neuropathy
Respiratory: hoarseness, sore throat, stridor, throat swelling, wheezing
Systemic: anaphylaxis, fatigue

From Theoharides TC, Tsilioni I, Ren H. Recent advances in our understanding of mast cell activation – or should it be mast cell mediator disorders? *Expert Rev Clin Immunol.* 2019;15(6):639–656, Table 1.

Table 700.4 Consensus Criteria for the Diagnosis of Mast Cell Activation Syndrome (MCAS)*

Criterion A: Typical clinical signs of severe, recurrent (episodic) systemic MCA are present (often in the form of anaphylaxis) (definition of systemic: involving at least two organ systems)
Criterion B: Involvement of MC is documented by biochemical studies: preferred marker: increase in serum tryptase level from the individual's baseline to plus 20% + 2 ng/mL†
Criterion C: Response of symptoms to therapy with MC-stabilizing agents, drugs directed against MC mediator production or drugs blocking mediator release or effects of MC-derived mediators‡

*All three MCAS criteria (A + B + C) must be fulfilled to call a condition MCAS.
†Other MC-derived markers of MCA (histamine and histamine metabolites, PGD_2 metabolites, and heparin) have also been proposed but are less specific compared to tryptase.
‡Example: histamine receptor blockers.
From Valent P, Akin C, Bonadonna P, et al. Proposed diagnostic algorithm for patients with suspected mast cell activation syndrome (MCAS). *J Allergy Clin Immunol Pract.* 2019;7(4):1125–1133, Table I, p. 1126.

Table 700.5 Facial Flushing Etiologies

FLUSHING WITH FOOD
- Alcohol
- Monosodium glutamate (MSG)
- Sulfites
- Scrombroidosis
- Auriculotemporal syndrome (Frey syndrome gustatory flushing)
- Postherpetic gustatory flushing
- Nitrates
- Capsaicin
- Tyramine-containing foods

ENDOCRINE
- Carcinoid
- Pheochromocytoma and paraganglioma
- Medullary thyroid carcinoma
- Pancreatic neuroendocrine tumors (VIP)
- Cushing syndrome
- Perimenopause
- Thyrotoxicosis

OTHER
- Mastocytosis
- Urticaria pigmentosa
- Mast cell activation syndrome
- Harlequin syndrome
- Congenital Horner syndrome
- Idiopathic anaphylaxis
- Panic attacks
- Blushing/anxiety
- Spinal cord injury/autonomic dysregulation
- Niacin supplements

classification of MCAS have been developed (Table 700.4). Under this classification, MCAS is designated primary when it is associated with a defined mast cell disorder such as systemic or cutaneous **mastocytosis**; it is termed secondary when it is recognized in the context of an allergen or another disease known to be associated with MCA; and it is designated idiopathic when neither a primary mast cell disorder nor another associated disease is present.

Patients fulfilling the consensus criteria for MCAS must have *recurrent* clinical manifestations *consistent with MCA*. Cutaneous symptoms have included urticaria, angioedema, itching, and frequent skin **flushing** (Table 700.5). Gastrointestinal symptoms such as abdominal pain, nausea, vomiting, and diarrhea are common. Tachycardia, sometimes with hypotension and syncope, may be frequent, and some patients have wheezing episodes and rhinitis. Nonspecific and constitutional symptoms have also been described, including headache, fatigue, chronic pain, paresthesias, anxiety, and depression. These nonspecific symptoms most likely represent comorbidities.

Patients diagnosed with MCAS have biochemical evidence indicating mast cell mediator release. **Laboratory abnormalities** that might indicate MCA include elevated serum tryptase and increases in 24-hour urinary histamine metabolites (N-methylhistamine), the prostaglandin D_2 metabolite 2,3-dinor-11-β-$PGF_{2\text{-}\alpha}$, or the leukotriene metabolite LTE_4. The current consensus criteria for the diagnosis of MCAS includes an increase in serum tryptase as the preferred measurement documenting mast cell mediator release (see Table 700.4). Additional biochemical markers have been proposed but remain either of unknown or questionable reliability as markers of MCA.

MCAS has been classified into three groups: primary, secondary, and idiopathic. Primary MCAS refers to patients with *clonal proliferation* of mast cells resulting from pathogenic variants in the *KIT* gene and is usually associated with systemic or cutaneous mastocytosis. A small percentage of those with primary MCAS have clonal proliferation of mast cells but may not completely fulfill the criteria to diagnose systemic or cutaneous mastocytosis. Secondary MCAS refers to patients with either an IgE-dependent allergy, a non–IgE-mediated hypersensitivity disorder, or another inflammatory disease associated with MCA. Idiopathic MCAS refers to patients who do not have clonal mast cells and who do not have an underlying disorder but who nonetheless fulfill the consensus criteria for MCAS with characteristic clinical symptoms and signs, specific abnormal laboratory test results, and a response to treatment that inhibits mast cells or the effect of mast cell mediators.

The **differential diagnosis** of MCAS is broad, reflecting the protean symptoms and signs that have been associated with the syndrome. Cardiovascular conditions may be considered in those with syncope; thyroid disease, adrenal insufficiency, infectious diseases, intoxications, chronic pain syndromes, somatization secondary to anxiety or depression, hypereosinophilic syndromes, hereditary angioedema, and dysautonomias are also considerations in patients with symptoms that appear to be potentially related to MCA. There is also an overlap with idiopathic anaphylaxis and MCAS (see Chapter 190 and Fig. 190.4).

When episodes of cutaneous flushing are the primary symptom and sign, the differential diagnosis is likewise broad. Flushing refers to transient episodes of erythema, most commonly on the face, accompanied by a sensation of warmth. Wet flushing is associated with *increased sweating* and is typical of autonomic nervous system activation, whereas dry flushing occurs without sweating. Wet flushing is more likely caused by panic attacks, pain syndromes, dysautonomia, medications, or toxins. Dry flushing is associated with a more extensive list of

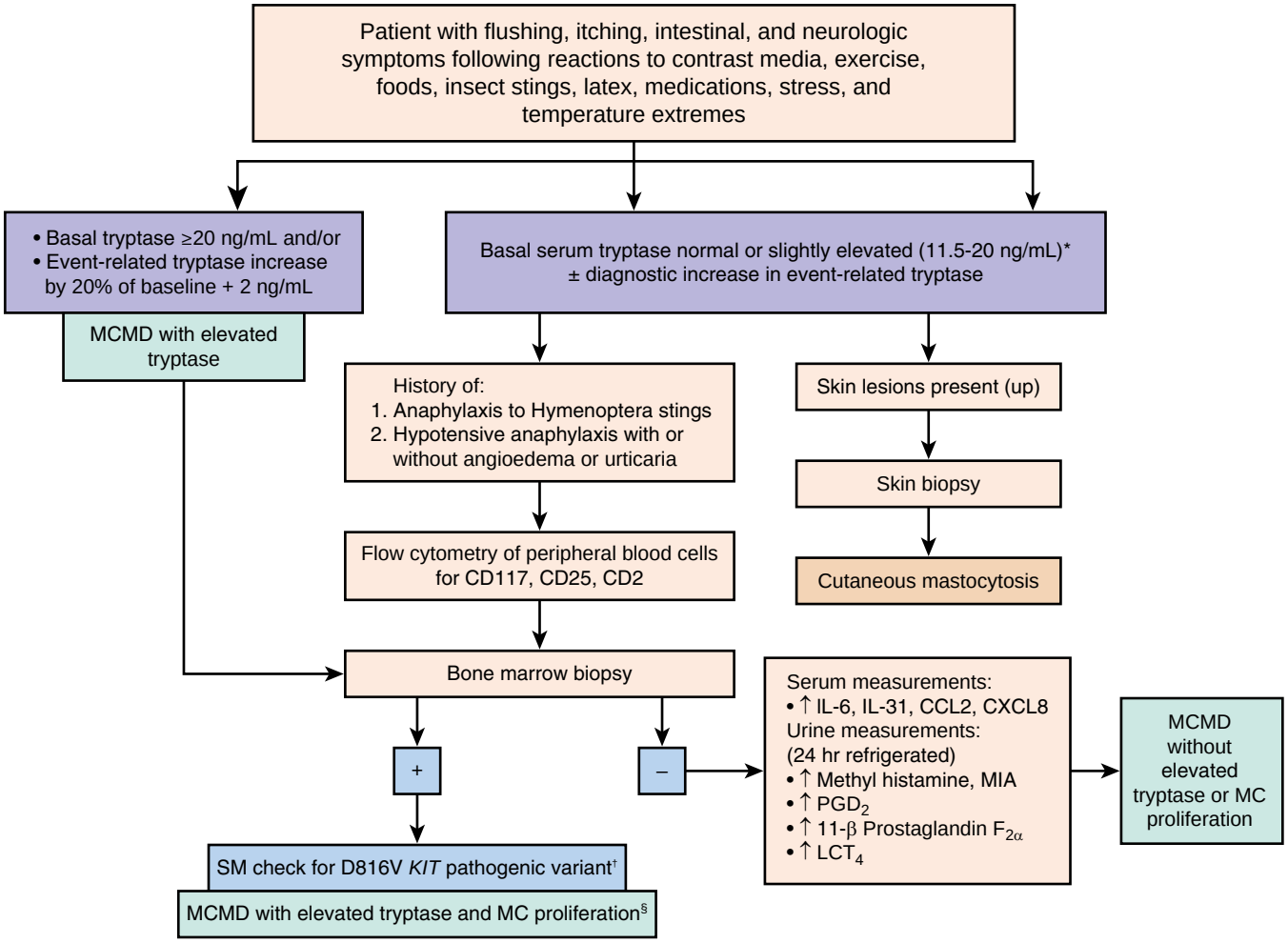

Fig. 700.13 Diagnostic algorithm for mast cell disorders. Diagrammatic representation of a proposed diagnostic rubric for mast cell mediator disorders with emphasis on clonal and nonclonal subtypes and the presence or absence of elevated serum tryptase. MC, Mast cells; MCMD, mast cell mediator disorder; SM, systemic mastocytosis. *This range varies among different laboratories. †KIT pathogenic variants should be investigated. §A patient with elevated basal tryptase should also have BM biopsy; most of these patients have SM. *(From Theoharides TC, Tsilioni I, Ren H. Recent advances in our understanding of mast cell activation – or should it be mast cell mediator disorders? Expert Rev Clin Immunol. 2019;15[6]:639–656, Fig. 1.)*

possible diagnoses, including MCAS, thyroid disease, foods and other ingestions, some interferonopathies and channelopathies, and tumors such as pheochromocytoma, neuroendocrine tumors, and medullary carcinoma of the thyroid.

When evaluating a patient with symptoms consistent with MCA, if the symptoms are severe, episodic, and respond to mast cell–directed therapy, then the likelihood of MCAS is high. In this setting, further evaluation with serum tryptase measurements should be performed. If the patient fulfills all three diagnostic criteria for MCAS (see Table 700.4), a potential underlying cause should then be sought. This investigation might include genetic analysis of the *KIT* gene in those suspected of having clonal disease such as cutaneous or systemic mastocytosis, a search for potential allergens, or further evaluation for an underlying chronic inflammatory disease (Fig. 700.13). The MCAS can then be classified as primary, secondary, or idiopathic and appropriate management initiated.

The management of MCAS includes medications that interfere with the effects of mast cell mediators, such as the antihistamines cetirizine, loratadine, and fexofenadine; the antileukotrienes montelukast and zafirlukast; and medications that interfere with degranulation such as the mast cell stabilizer cromolyn. Recently, the tyrosine kinase inhibitor midostaurin has also demonstrated efficacy by inhibiting histamine release and increasing apoptosis of mast cells. Management of any identified associated disease is paramount. Prognosis is favorable for most individuals with MCAS but is also dependent on potential associated disease and comorbidities.

Visit Elsevier eBooks+ at eBooks.Health.Elsevier.com for Bibliography.

Chapter 701

Diseases of Subcutaneous Tissue

Jacquelyn R. Sink and Yvonne E. Chiu

Diseases involving the subcutis are usually characterized by necrosis and/or inflammation; they may occur either as a primary event or as a secondary response to various stimuli or disease processes. The principal diagnostic criteria relate to the appearance and distribution of the lesions, associated symptoms, results of laboratory studies, histopathology, and natural history and exogenous provocative factors of these conditions.

CORTICOSTEROID-INDUCED ATROPHY

Intradermal or subcutaneous injection of a corticosteroid can produce deep atrophy accompanied by surface pigmentary changes and telangiectasia (Fig. 701.1). These changes occur approximately 2-8 weeks after injection and may last for months.

RAYNAUD PHENOMENON

An exaggerated vascular response to cold temperatures or emotional stress, Raynaud phenomenon is characterized by sudden-onset, sharply demarcated, transient color changes of the skin of the digits (see Chapter 201). This condition can occur as a primary condition or may be associated with an underlying disorder, such as systemic lupus erythematosus (SLE) or systemic sclerosis. It is thought to be caused by abnormal vasoconstriction of the digital blood vessels.

701.1 Panniculitis and Erythema Nodosum

Jacquelyn R. Sink and Yvonne E. Chiu

Inflammation of the fibrofatty subcutaneous tissue may primarily involve the fat lobule (lobular panniculitis) or the fibrous septum that compartmentalizes the fatty lobules (septal panniculitis). Histopathologic evaluation is usually necessary to confirm the diagnosis. Lobular panniculitis that spares the subcutaneous vasculature includes infectious panniculitis, traumatic panniculitis (including cold and post-steroid panniculitis), connective tissue disease panniculitis, pancreatic panniculitis, α_1 antitrypsin deficiency, subcutaneous fat necrosis (SCFN) of the newborn, sclerema neonatorum, subcutaneous sarcoidosis, and factitial panniculitis. Lobular panniculitis associated with vasculitis occurs in erythema induratum and occasionally as a feature of Crohn's disease (see Chapter 382.2). Septal panniculitis, sparing the vasculature, may be seen in erythema nodosum (Table 701.1 and Fig. 701.2), necrobiosis lipoidica, progressive systemic sclerosis (see Chapter 201), and subcutaneous granuloma annulare (see Chapter 700). Septal panniculitis that includes inflammation of the vessels is found primarily in leukocytoclastic vasculitis and polyarteritis nodosa (see Chapter 210).

Fig. 701.1 Localized fat atrophy with overlying erythema after steroid injection.

ERYTHEMA NODOSUM

Etiology and Pathogenesis

No underlying cause is found in 30–50% of pediatric cases of erythema nodosum; Table 701.1 lists numerous potential etiologies. The most common etiology in children is group A β-hemolytic streptococcal infection. Other causes include *Yersinia enterocolitica* gastroenteritis, medications (cephalosporins, penicillins, macrolides), and inflammatory disorders (inflammatory bowel disease); sarcoidosis should be considered in young adults.

Clinical Manifestations

Erythema nodosum is a nodular erythematous hypersensitivity reaction that typically appears as multiple lesions on the lower legs (favoring the pretibial area) and less often in other areas, including the extensor surfaces of the arms and thighs. The lesions vary in size from 1 to 6 cm and are symmetric and oval, with the longer axis parallel to the extremity. Lesions initially appear bright or dull red but progress to a brown or purple; they are painful and usually do not ulcerate (see Fig. 701.2). Initial lesions may resolve in 1-2 weeks, but new lesions may continue to appear for 2-6 weeks. Repeat episodes may occur over weeks to months. Before or immediately at the onset of lesions, there may be systemic manifestations, including fever, malaise, arthralgias (50–90%), and rheumatoid factor–negative arthritis.

Histology

A septal panniculitis occurs acutely with thickening of the septa and an inflammatory cell infiltrate composed of neutrophils. Monocytes and histiocytes predominate in chronic erythema nodosum.

Treatment

Treatment is directed at the underlying cause. Nonsteroidal antiinflammatory agents (ibuprofen, naproxen, salicylates) may be prescribed for symptomatic relief, along with bed rest and leg elevation. Supersaturated solution of potassium iodide (oral), colchicine, and intralesional corticosteroids can be considered as alternative treatments for persistent symptoms. Oral steroids have been employed for the treatment of severe, persistent, or recurrent lesions. The idiopathic form

Table 701.1 Etiology of Erythema Nodosum

VIRUSES Epstein-Barr, hepatitis B, mumps
FUNGI Coccidioidomycosis, histoplasmosis, blastomycosis, sporotrichosis, *Trichophyton mentagrophytes*
BACTERIA AND OTHER INFECTIOUS AGENTS Group A streptococcus,* tuberculosis,* *Yersinia, Shigella, Escherichia coli,* cat-scratch disease, leprosy, leptospirosis, tularemia, mycoplasma, Whipple disease, lymphogranuloma venereum, psittacosis, brucellosis, meningococcosis, neisserial infection, syphilis
OTHER Sarcoidosis, inflammatory bowel disease,* estrogen-containing oral contraceptives,* systemic lupus erythematosus, Behçet syndrome, severe acne, celiac disease, Hodgkin disease, lymphoma, sulfonamides, bromides, echinacea, Sweet syndrome, pregnancy, idiopathic*

*Common.

Fig. 701.2 Tender red nodules with indistinct borders in a teenage girl with erythema nodosum. *(From Weston WL, Lane AT, Morelli J. Color Textbook of Pediatric Dermatology, 3rd ed. St. Louis: Mosby; 2002, p. 212.)*

is a self-limited disorder. Protracted or recurrent cases may warrant further workup, including antistreptolysin O/deoxyribonuclease ASO/(DNase) B titer, complete blood count (CBC), throat culture, QuantiFERON-TB gold assay but not a tuberculosis (TB) skin test, chest radiograph, erythrocyte sedimentation rate, and C-reactive protein.

POST-STEROID PANNICULITIS

Etiology and Pathogenesis

The mechanism of the inflammatory reaction in the fat in post-steroid panniculitis is unknown.

Clinical Manifestations

Most cases of post-steroid panniculitis have been reported in children. The disorder occurs in children who have received high-dose corticosteroids, particularly after rapid discontinuation. Within 1-2 weeks after discontinuation of the drug, multiple subcutaneous nodules usually appear on the cheeks, although other areas may be involved. Nodules range in size from 0.5 to 4.0 cm, are erythematous or skin-colored, and may be pruritic or painful.

Histology

A lobular panniculitis is seen with a mixed infiltrate of lymphocytes, histiocytes, and neutrophils. Scattered, swollen adipocytes with eosinophilic, needle-shaped crystals are also seen. The epidermis, dermis, and fibrous septa of the fat are normal. Vasculitis is not seen.

Treatment

Treatment of post-steroid panniculitis is unnecessary because the lesions remit spontaneously over a period of months without scarring.

LUPUS ERYTHEMATOSUS PROFUNDUS (LUPUS ERYTHEMATOSUS PANNICULITIS)

Etiology and Pathogenesis

The pathophysiology of lupus erythematosus profundus is largely unknown. This variant of chronic cutaneous lupus erythematosus is rare in childhood. Only 2–5% of patients with lupus erythematosus profundus have associated SLE. It can occur in association with other

Fig. 701.3 Deep nodule of lupus profundus with overlying hyperkeratotic lesion of discoid lupus erythematosus.

forms of cutaneous lupus or as an isolated condition. The mean age of onset in reported pediatric cases is 9.8 years.

Clinical Manifestations

Lupus erythematosus profundus manifests as one to several firm, tender, well-defined, purple plaques or nodules 1-3 cm in diameter. Most pediatric cases involve the head/neck and proximal extremities. This condition may precede or follow the development of other cutaneous lesions and/or SLE. The overlying skin is usually normal but may be erythematous, atrophic, poikilodermatous, ulcerated, or hyperkeratotic (Fig. 701.3). On healing, a shallow depression generally remains or, rarely, soft pink areas of anetoderma result.

Histology

The histopathologic changes in lupus erythematosus profundus are distinctive and may allow the clinician to make the diagnosis in the absence of other cutaneous features of lupus erythematosus. The panniculitis is characterized by a mostly nodular, dense infiltrate of lymphocytes and plasma cells. Necrosis of the fat lobule is characteristic. A dense perivascular and periappendiceal lymphocytic infiltrate is seen in the dermis. Lichenoid changes may be identified at the epidermal-dermal junction. Histopathologic differentiation from subcutaneous panniculitis–like T-cell lymphoma may be difficult and requires T-cell rearrangement studies.

Treatment

Nodules tend to be persistent and frequently ulcerate. Long-term follow-up to evaluate for systemic disease is warranted; approximately 5–10% of patients with lupus erythematosus profundus will have SLE. There is no consensus on the utility of laboratory testing. Antinuclear antibody is positive in only a small subset of patients. A few case reports show slight neutropenia, leukopenia, and mildly elevated liver function tests. Hydroxychloroquine (2-5 mg/kg/day) is the treatment of choice for lupus erythematosus profundus. Systemic corticosteroids may be helpful, but topical corticosteroids are typically ineffective. Intralesional corticosteroids may worsen the lipoatrophy and lead to ulceration. Immunosuppressive agents are indicated only for the treatment of other severe manifestations of SLE. Avoidance of sun exposure and trauma is also important.

α_1-ANTITRYPSIN DEFICIENCY

Etiology and Pathogenesis

Individuals with α_1-antitrypsin deficiency have severe homozygous deficiency (ZZ genotype) or, rarely, a partial deficiency of the protease inhibitor α_1-antitrypsin, which inhibits trypsin activity and the activity of elastase, serine proteases, collagenase, factor VIII, and kallikrein (see Chapter 442). Panniculitis is rare and usually occurs with severe α_1-antitrypsin deficiency.

Clinical Manifestations

Cellulitis-like areas or one or more warm, tender, red nodules occur on the trunk or proximal extremities. Nodules tend to ulcerate

spontaneously and discharge an oily yellow fluid. Panniculitis may be associated with other manifestations of the disease, such as panacinar emphysema, noninfectious hepatitis, cirrhosis, persistent cutaneous vasculitis, cold contact urticaria, and acquired angioedema. Diagnosis can be substantiated by a decreased level of serum α_1-antitrypsin activity.

Histology
Extensive septal and lobular neutrophilic infiltrate with necrosis of the fat is observed.

Treatment
Panniculitis associated with α_1-antitrypsin deficiency typically resolves over several weeks after treatment with intravenous exogenous enzyme replacement therapy.

PANCREATIC PANNICULITIS
Etiology and Pathogenesis
The pathogenesis of pancreatic panniculitis appears to be multifactorial, involving liberation of the lipolytic enzymes lipase, trypsin, and amylase into the circulation, which leads to adipocyte membrane damage and intracellular lipolysis. There is no correlation, however, between the occurrence of panniculitis and the serum concentration of pancreatic enzymes.

Clinical Manifestations
Pancreatic panniculitis manifests most commonly on the pretibial regions, thighs, or buttocks as tender, erythematous nodules that may be fluctuant and occasionally discharge an oily brown or yellowish liquid. It appears most often in males with alcoholism but may also occur in patients with pancreatitis because of cholelithiasis or abdominal trauma, rupture of pancreatic pseudocysts, pancreatic ductal adenocarcinoma, or pancreatic acinar cell carcinoma. Associated features may include polyarthritis **(pancreatitis-panniculitis-polyarthritis syndrome)**. In almost 65% of patients, abdominal signs are absent or mild, making the diagnosis difficult.

Histology
Characteristic histopathologic changes include lobular panniculitis with necrosis of fat cells and ghost cells with thick, shadowy walls and no nuclei.

Treatment
The primary pancreatic disorder must be treated. The arthritis may be chronic and responds poorly to treatment with nonsteroidal antiinflammatory drugs and oral corticosteroids.

SUBCUTANEOUS FAT NECROSIS
Etiology and Pathogenesis
SCFN in infants may be a result of ischemic injury from various perinatal complications, such as maternal preeclampsia, birth trauma, asphyxia, meconium aspiration, and prolonged hypothermia. Whole-body cooling for neonatal hypoxemic-ischemic encephalopathy is increasingly associated with SCFN. Susceptibility is attributed to differences in composition between the subcutaneous tissue of young infants and that of older infants, children, and adults. Neonatal fat solidifies at a relatively high temperature because of its relatively greater concentration of high-melting-point saturated fatty acids, such as palmitic and stearic acids.

Clinical Manifestations
This benign, self-limited inflammatory disorder of adipose tissue occurs primarily in the first few days to weeks of life in apparently healthy, full-term or postterm infants. Some lesions may be present at birth. Typical lesions are asymptomatic, indurated, erythematous to violaceous, sharply demarcated plaques or nodules located primarily on the cheeks, buttocks, back, thighs, or upper arms (Fig. 701.4). Lesions may be focal or extensive and are generally asymptomatic, although they may be tender during the acute phase. Uncomplicated lesions involute spontaneously within weeks to months, usually without scarring or atrophy. Calcium deposition may occasionally occur within areas of fat necrosis, which may sometimes result in rupture and drainage of liquid material. These areas may heal with atrophy. A potentially serious complication of SCFN is **hypercalcemia**. It typically manifests before 2 months of age, but can present up to 6 months of age, with lethargy, poor feeding, vomiting, failure to thrive, irritability, seizures, shortening of the QT interval on electrocardiography, and/or renal failure. The origin of the hypercalcemia is unknown, but an accepted hypothesis is that macrophages produce 1,25-dihydroxyvitamin D_3 which, in turn, increases calcium uptake. Infants with SCFN should be monitored for several months after lesion resolution for delayed-onset hypercalcemia.

Fig. 701.4 Red-purple nodular infiltration of the skin of the chest caused by subcutaneous fat necrosis.

Histology
Histopathologic changes in SCFN are diagnostic, consisting of necrosis of fat; a granulomatous cellular infiltrate composed of lymphocytes, histiocytes, multinucleated giant cells, and fibroblasts; and radially arranged clefts of crystalline triglyceride within fat cells and multinucleated giant cells. Calcium deposits are commonly found in areas of fat necrosis.

Differential Diagnosis
SCFN can be confused with sclerema neonatorum, panniculitis, cellulitis, and hematoma.

Treatment
Because the lesions are self-limited, therapy is not required for uncomplicated cases of SCFN. Needle aspiration of fluctuant lesions may prevent rupture and subsequent scarring but is rarely needed. Treatment of hypercalcemia is aimed at enhancing renal calcium excretion with hydration and furosemide (1-2 mg/kg/dose) and at limiting dietary intake of calcium and vitamin D. Reduction of intestinal calcium absorption and alteration of vitamin D metabolism may be accomplished by administering corticosteroids (0.5-1.0 mg/kg/day). Bisphosphonates have been used in severe cases.

SCLEREMA NEONATORUM
Etiology and Pathogenesis
Although the cause of sclerema neonatorum remains unknown, multiple theories have been proposed. The hardening of the subcutaneous fat may occur as a response to a decrease in body temperature because of circulatory shock, a defect in lipolytic enzymes or in lipid transport, association with an underlying severe disease, or a special form of edema affecting the connective tissue supporting the adipocytes.

Clinical Manifestations
This uncommon panniculitis manifests abruptly in preterm, gravely ill infants as diffuse, yellowish white, woody indurations of the skin. It begins on the legs and buttocks and then quickly progresses to other areas, sparing the palms and soles. Affected skin becomes stony in

consistency, cold, and nonpitting. The face assumes a masklike expression, and joint mobility may be compromised because of inflexibility of the skin.

Histology
Histopathologic changes in sclerema neonatorum consist of increased size of fat cells and width of the fibrous connective tissue septa. In contrast to SCFN, fat necrosis, inflammation, giant cells, and calcium crystals are generally absent.

Treatment
Sclerema neonatorum is almost always associated with serious illness, such as sepsis, congenital heart disease, multiple congenital anomalies, or hypothermia. The appearance of sclerema in a sick infant should be regarded as an ominous prognostic sign. There is no specific therapy for the condition. The outcome depends on the response of the underlying disorder to treatment.

COLD PANNICULITIS
Etiology and Pathogenesis
The pathogenic mechanism of cold panniculitis may be likened to that of SCFN, involving a greater propensity of fat to solidify in infants than in older children and adults because of the higher percentage of saturated fatty acids in the subcutaneous fat of infants. Lesions occur in infants after prolonged cold exposure, especially on the cheeks, or after prolonged application of a cold object such as an ice cube, ice bags, cooling blankets, or popsicles to any area of the skin.

Clinical Manifestations
Ill-defined, erythematous to bluish, painful, indurated plaques or nodules arise within hours to a few days in areas exposed to cold (face, arms, legs); the lesions persist for 2-3 weeks and heal without residua.

Histology
Histopathologic examination reveals an infiltrate of lymphoid and histiocytic cells around blood vessels at the dermal-subdermal junction and in the fat lobules; by the third day, some of the fat cells in the subcutis may have ruptured and coalesced into cystic structures.

Differential Diagnosis
Cold panniculitis may be confused with facial cellulitis caused by *Haemophilus influenzae* type b. As opposed to buccal cellulitis, the area may be cold to the touch, and the patient is afebrile and appears well. **Familial cold autoinflammatory syndrome** manifests with urticaria on exposure to cold environments; associated features include conjunctivitis, myalgias, fatigue, and elevated inflammatory markers. **Cold urticaria**, in contrast, occurs on direct contact with cold objects, resulting in urticaria at the site, which can be reproduced with the ice cube test.

Treatment
Treatment is unnecessary because cold panniculitis resolves spontaneously. Recurrence of the lesions is common, emphasizing the importance of parental education.

CHILBLAINS (PERNIO)
Etiology and Pathogenesis
Vasospasm of arterioles from damp cold exposure with resultant hypoxemia and localized perivascular mononuclear inflammation appears to be responsible for chilblains (see Chapter 90). The disease is most commonly idiopathic but may be associated with cryoglobulins, antiphospholipid antibodies, anorexia nervosa, or a thin body habitus. There are reports of chilblain-like rash occurring during the COVID-19 pandemic.

Clinical Manifestations
The condition is characterized by initial blanching followed by localized, symmetric, erythematous to violaceous, edematous plaques and nodules in areas exposed to cold, typically acral sites (distal hands and feet, ears, face). Lesions develop 12-24 hours after cold exposure and may be associated with numbness, tingling, itching, burning, or pain. Blister formation and ulceration are rare (see Chapter 90).

Histology
Histopathologic examination reveals marked dermal edema and a perivascular and periappendiceal, predominantly T-cell lymphocytic infiltrate in the papillary and reticular dermis.

Differential Diagnosis
Raynaud phenomenon is a more acute condition than chilblains, with characteristic color changes and no chronic lesions. Frostbite due to extreme cold exposure is painful and involves freezing of the tissue, with resultant tissue necrosis.

Treatment
Most cases of chilblains resolve spontaneously, but the condition can last up to 2-3 weeks. Prevention is the treatment of choice. Nifedipine (0.25-0.5 mg/kg 3 times a day, maximum 10 mg/dose) may be used in severe cases. Unusual or persistent cases of perniosis in children may warrant further workup, including antinuclear antibody titer, cryoglobulins, antiphospholipid antibodies, CBC with differential, and cold agglutinins.

FACTITIAL PANNICULITIS
Etiology and Pathogenesis
Factitial panniculitis results from subcutaneous injection of a foreign substance by the patient or a proxy. The most common substances are organic materials such as milk and feces; drugs, such as the opiates and pentazocine; oily materials, such as mineral oil and paraffin; and the synthetic polymer povidone.

Clinical Manifestations
Indurated plaques, ulcers, or nodules that liquefy and drain may be noted clinically in factitial panniculitis.

Histology
The histopathology is variable, depending on the injected substance, but may include the presence of birefringent crystals, oil cysts surrounded by fibrosis and inflammation, and an acute inflammatory reaction with fat necrosis. Vessels are characteristically spared.

Treatment
Treatment of factitial panniculitis must address the primary reason for the performance of this self-destructive act. Munchausen syndrome by proxy should be considered in young children (see Chapter 17.2).

Visit Elsevier eBooks+ at eBooks.Health.Elsevier.com for Bibliography.

701.2 Lipodystrophy
Leah Lalor

Lipodystrophies are conditions that share a common finding of reduction in subcutaneous fat, often with accompanying lipohypertrophy in other areas. They may be inherited or acquired. Several lipodystrophy syndromes have been described, which are extremely rare disorders of deficient body fat associated with many metabolic complications. Lipoatrophy is selective loss of fat (whereas lipodystrophy is redistribution of fat) and is associated with medications, HIV infection, trauma or pressure, autoimmune disorders, and after inflammation of fat.

Lipodystrophies are defined by etiology (congenital or acquired) and distribution of fat loss (generalized or partial). This results in four main types of lipodystrophy: congenital generalized lipodystrophy, familial partial lipodystrophy, acquired generalized lipodystrophy, and acquired partial lipodystrophy.

GENERALIZED LIPODYSTROPHY
Generalized lipodystrophy may be congenital or acquired and is characterized by loss of fat affecting the whole body.

Congenital generalized lipodystrophy (CGL): This is an autosomal recessive disorder characterized by nearly complete lack of subcutaneous fat starting at birth or in infancy with prominent musculature, phlebomegaly, acanthosis nigricans, hepatomegaly, umbilical prominence, and voracious appetite in childhood. There are several known genetic causes, each with unique clinical features. Metabolic complications are frequent and may be severe.

Acquired generalized lipodystrophy (AGL): This typically presents before adolescence with progressive fat loss of the whole body, including palms and soles, and is more common in females (3:1 female:male). There may be fat accumulation in the face, neck, and/or axillae. There are frequent and often severe metabolic complications, and this is associated with autoimmune disease.

PARTIAL LIPODYSTROPHY

Partial lipodystrophy is when part of the body has loss of fat with frequent excess fat accumulation elsewhere in the body. It may be inherited or acquired.

Familial partial lipodystrophy (FPLD): This is a group of autosomal dominant disorders in which fat loss affects the limbs, buttocks, and hips with excess fat accumulation in other areas dependent on particular subtype. Fat distribution is often normal in childhood with development of progressive loss of fat around puberty. There is often associated muscular hypertrophy and metabolic complications in adulthood, particularly cardiac.

Acquired partial lipodystrophy (APL): As in AGL, this is more common in females (4:1 female:male) and begins in childhood with progressive loss of fat in a cranial-to-caudal distribution. Fat accumulation may appear in the hips, buttocks, and legs. Metabolic complications are uncommon, but it is associated with autoimmune diseases, in particular, membranoproliferative glomerulonephritis.

Diagnosis

Diagnosis of lipodystrophy is based on history, physical examination, body composition, and metabolic status, and confirmatory genetic testing may be helpful in suspected familial cases, but formal diagnostic criteria have not been established. Lipodystrophy should be suspected in patients with regional or generalized lack of adipose tissue outside the normal range and in children with failure to thrive. Additional physical features include prominent muscles and veins; severe acanthosis nigricans; eruptive xanthomas; and Cushingoid, acromegaloid, or progeroid appearance. Familial forms can be suspected when there is a clear familial pattern.

Differential diagnosis includes other conditions that present with severe weight loss, including malnutrition, eating disorders, uncontrolled diabetes mellitus, thyrotoxicosis, adrenocortical deficiency, cancer cachexia, HIV-associated wasting, and chronic infections.

Screening for Comorbidities

Metabolic comorbidities are common in many forms of lipodystrophy, and all patients should be screened for dyslipidemia, diabetes, nonalcoholic fatty liver disease, and cardiovascular and reproductive dysfunction. Those with APL are at lower risk for metabolic issues.

Dyslipidemia: Triglycerides should be measured at least annually and with new-onset abdominal pain or appearance of cutaneous xanthomas. Fasting lipid panel should be measured at diagnosis and yearly after age 10 years.

Diabetes mellitus: Screening should be formed annually following the guidelines of the American Diabetes Association, which includes fasting plasma glucose, oral glucose tolerance test, or glycosylated hemoglobin.

Liver disease: Alanine aminotransferase (ALT) and aspartate aminotransferase (AST) should be measured yearly with liver ultrasound performed at diagnosis and then clinically as indicated based on symptoms or laboratory abnormalities. Liver biopsy should be performed as indicated clinically.

Reproductive dysfunction: Early adrenarche, true precocious puberty, or central hypogonadism may occur in children with generalized lipodystrophy, and oligo/amenorrhea, decreased fertility, and polycystic ovary syndrome are common in women with lipodystrophy. Measurement of gonadal steroids and gonadotropins, and pelvis ultrasonography should be performed as clinically indicated with pubertal staging performed annually for children.

Cardiac disease: Hypertension is common in lipodystrophy syndromes, even in children. Blood pressure should be measured at least yearly. ECG and echocardiogram should be done yearly in CGL and progeroid disorders and at diagnosis and as clinically indicated in FPLD and AGL.

Kidney disease: Protenuria is common. Urine protein should be measured yearly using 24-hour collection or spot urine protein-to-creatinine ratio. Kidney biopsy should be done as indicated clinically.

Malignancy: Lymphomas occur in AGL. Appropriate screening has not been established but could include yearly skin and lymph node exam. Generalized lipodystrophy has been reported as a paraneoplastic phenomenon in pilocytic astrocytoma in some children who recovered body fat after treatment. Some progeroid syndromes are associated with increased malignancy risk.

Treatment of Lipodystrophy

There is no cure for lipodystrophy, and no treatment that can regrow lost adipose tissue; however, there are some ways to prevent or improve the associated comorbidities. Diet is the cornerstone of therapy for the metabolic complications of lipodystrophies, and a dietician should be consulted for children with these diagnoses. Medium-chain triglyceride oil formulas can provide energy and reduce triglycerides in infants. Most patients with lipodystrophy should be encouraged to be physically active, though some should have a cardiac evaluation before engaging in an intense exercise regimen.

Metreleptin is recombinant human methionyl leptin and is the only approved medication for lipodystrophy. It is a first-line treatment for metabolic and endocrine abnormalities in generalized lipodystrophy and may be used for prevention of these complications in children. Treatment for specific metabolic complications can be reviewed elsewhere.

Consideration should be given to referral to plastic surgeons and/or cosmetic dermatologists for patients with distress related to their body appearance. Mental health professionals may also be helpful.

HIV/ART-ASSOCIATED LIPODYSTROPHY

This is the most common form of *nonlocalized* lipodystrophy and is linked to protease inhibitors and nucleoside analogue reverse transcriptase inhibitors. It may affect up to 40% of patients within 1-2 years of antiretroviral therapy (ART) initiation. Typical manifestations include lipoatrophy of peripheral sites (face, limbs, heel pads, buttocks), central lipohypertrophy (particularly dorsocervical, supraclavicular, breast, intraabdominal, and visceral), and metabolic abnormalities (insulin resistance, type 2 diabetes mellitus, dyslipidemia, hypertension, lactic acidosis). These changes are progressive and largely irreversible, can be disfiguring and stigmatizing, and may result in a lack of adherence to treatment.

LOCALIZED LIPOATROPHY

Localized lipoatrophy can be idiopathic or secondary to subcutaneous medication injections, pressure, and panniculitis. Unlike generalized or partial lipodystrophy, localized lipoatrophy involves a small part of the body and has no accompanying metabolic derangements. Idiopathic and pressure-induced lipoatrophy manifest as annular atrophy at the ankles; a bandlike semicircular depression 2-4 cm in diameter on the thighs, abdomen, and/or upper groin; or a centrifugally spreading, depressed, bluish plaque with an erythematous margin. Medication-induced lipoatrophy is most common with insulin and injected corticosteroids, though others have been reported. **Insulin lipoatrophy** usually occurs approximately 6 months to 2 years after the initiation of relatively high doses of insulin. A dimple or well-circumscribed depression at or surrounding the site of injection is typically seen. Lesions may be prevented by frequent rotation of injection sites or a switch to insulin pump.

Visit Elsevier eBooks+ at eBooks.Health.Elsevier.com for Bibliography.

Chapter 702

Disorders of the Sweat Glands

Kari L. Martin

Eccrine glands are found over nearly the entire skin surface and provide the primary means, through evaporation of the water in sweat, of cooling the body. These glands, which have no anatomic relationship to hair follicles, secrete a relatively large amount of odorless aqueous sweat. In contrast, apocrine sweat glands are limited in distribution to the axillae, anogenital skin, mammary glands, ceruminous glands of the ear, Moll glands in the eyelid, and selected areas of the face and scalp. Each apocrine gland duct enters the pilosebaceous follicle at the level of the infundibulum and secretes a small amount of a complex, viscous fluid that, on alteration by microorganisms, produces a distinctive body odor. Some disorders of these two types of sweat glands are similar pathogenetically, whereas others are unique to a given gland.

ANHIDROSIS

Neuropathic anhidrosis results from a disturbance in the neural pathway from the control center in the brain to the peripheral efferent nerve fibers that activate sweating. Disorders in this category, which are characterized by generalized anhidrosis, include **congenital insensitivity to pain with anhidrosis (CIPA)**, tumors of the hypothalamus, and damage to the floor of the third ventricle. Pontine or medullary lesions may produce anhidrosis of the ipsilateral face or neck and ipsilateral or contralateral anhidrosis of the rest of the body. Peripheral or segmental neuropathies, caused by leprosy, amyloidosis, diabetes mellitus, alcoholic neuritis, or syringomyelia, may be associated with anhidrosis of the innervated skin. Various autonomic disorders are also associated with altered eccrine sweat gland function.

At the level of the sweat gland, anticholinergics (drugs such as atropine and scopolamine) may paralyze the sweat glands. Acute intoxication with barbiturates or diazepam has produced necrosis of sweat glands, resulting in anhidrosis with or without erythema and bullae. Eccrine glands are largely absent throughout the skin or are present in a localized area among patients with **hypohidrotic ectodermal dysplasia (HED)** or **localized congenital absence of sweat glands**, respectively. Infiltrative or destructive disorders that may produce atrophy of sweat glands by pressure or scarring include scleroderma, acrodermatitis chronica atrophicans, radiodermatitis, burns, Sjögren syndrome, multiple myeloma, and lymphoma. Obstruction of sweat glands may occur in miliaria and in a number of inflammatory and hyperkeratotic disorders, such as the ichthyoses, psoriasis, lichen planus, pemphigus, porokeratosis, atopic dermatitis, and seborrheic dermatitis. Occlusion of the sweat pore may also occur with the topical agents aluminum and zirconium salts, formaldehyde, or glutaraldehyde.

Diverse disorders that are associated with anhidrosis by unknown mechanisms include dehydration, uremia, cirrhosis, endocrine disorders such as Addison disease, diabetes mellitus, diabetes insipidus, and hyperthyroidism, toxic overdose with lead, arsenic, thallium, fluorine, or morphine, and inherited conditions such as autonomic neuropathies, Fabry disease, Franceschetti-Jadassohn syndrome, which combines features of incontinentia pigmenti and HED, CIPA, and familial anhidrosis with neurolabyrinthitis.

Anhidrosis may be complete, but in many cases, what appears clinically to be anhidrosis is actually hypohidrosis caused by anhidrosis of many, but not all, eccrine glands. Compensatory, localized hyperhidrosis of the remaining functional sweat glands may occur, particularly in diabetes mellitus and miliaria. The primary complication of anhidrosis is *hyperthermia,* seen primarily in anhidrotic ectodermal dysplasia or in otherwise normal preterm or full-term neonates who have immature eccrine glands.

HYPERHIDROSIS

Etiology and Pathogenesis

Hyperhidrosis is excessive sweating beyond what is physiologically necessary for temperature control and occurs in 3% of the population, with about half having axillary hyperhidrosis. The numerous disorders that can be associated with increased production of eccrine sweat may also be classified into those with neural mechanisms involving an abnormality in the pathway from the neural regulatory centers to the sweat gland and those that are nonneurally mediated and occur by direct effects on the sweat glands (Table 702.1).

Clinical Manifestations

The average age at onset of hyperhidrosis is 14-25 years. The excess sweating may be continuous or may occur in response to emotional stimuli. In severe cases, sweat may be seen to drip constantly from the hands.

Treatment

Excessive sweating of the palms and soles (volar hyperhidrosis) and axillary sweating may respond to 20% aluminum chloride in anhydrous ethanol applied under occlusion for several hours, iontophoresis, injection with botulinum toxin, therapy with oral anticholinergics and antimuscarinic drugs (oxybutynin), or in severe, refractory cases, cervicothoracic or lumbar sympathectomy. Reports of successful treatment of hyperhidrosis with ultrasound and microwave technology are available, but studies are faulted with small sample size and/or lack of controls.

MILIARIA

Etiology and Pathogenesis

Miliaria results from retention of sweat in occluded eccrine sweat ducts. The eruption is most often induced by hot, humid weather, but it may also be caused by high fever. Infants who are dressed too warmly may demonstrate this eruption indoors, even during the winter.

Clinical Manifestations

In miliaria crystallina, asymptomatic, noninflammatory, pinpoint, clear vesicles may suddenly erupt in profusion over large areas of the body surface, leaving brawny desquamation on healing (Fig. 702.1). This type of miliaria occurs most frequently in newborn infants because of the relative immaturity and delayed patency of the sweat duct and the tendency for infants to be nursed in relatively warm, humid conditions. It may also occur in older patients with hyperpyrexia or hypernatremia.

Miliaria rubra is a less superficial eruption characterized by erythematous, minute papulovesicles that may impart a prickling sensation. The lesions are usually localized to sites of occlusion or to flexural areas, such as the neck, groin, and axillae, where friction may have a role in their pathogenesis. Involved skin may become macerated and eroded. However, lesions of miliaria rubra are extrafollicular.

Repeated attacks of miliaria rubra may lead to miliaria profunda, which is caused by rupture of the sweat duct deeper in the skin, at the level of the dermal-epidermal junction. Severe, extensive miliaria rubra or miliaria profunda may result in disturbance of heat regulation. Lesions of miliaria rubra may become infected, particularly in malnourished or debilitated infants, leading to development of **periporitis staphylogenes**, which involves extension of the process from the sweat duct into the sweat gland.

Histology

Histologically, miliaria crystallina reveals an intracorneal or subcorneal vesicle in communication with the sweat duct, whereas in miliaria rubra, one sees focal areas of spongiosis and spongiotic vesicle formation in close proximity to sweat ducts that generally contain a keratinous plug.

Table 702.1 Causes of Hyperhidrosis

CORTICAL	Cardiovascular
Emotional	Heart failure
Familial dysautonomia	Shock
Congenital ichthyosiform erythroderma	Vasomotor
Epidermolysis bullosa	Cold injury
Nail-patella syndrome	Raynaud phenomenon
Jadassohn-Lewandowsky syndrome	Rheumatoid arthritis
Pachyonychia congenita	Neurologic
Palmoplantar keratoderma	Abscess
Stroke	Familial dysautonomia
HYPOTHALAMIC	Postencephalitic
Drugs	Tumor
Alcohol	Absence of corpus callosum
Antipyretics	Miscellaneous
Cocaine	Chédiak-Higashi syndrome
Emetics	Compensatory
Insulin	Lymphoma
Opiates (including withdrawal)	Phenylketonuria
Ciprofloxacin	Vitiligo
Exercise	Frey syndrome
Infection	MEDULLARY
Defervescence	Physiologic gustatory sweating
Chronic illness	Encephalitis
Metabolic	Granulosis rubra nasi
Carcinoid syndrome	Syringomyelia
Debility	Thoracic sympathetic trunk injury
Diabetes mellitus	SPINAL
Hyperpituitarism	Cord transection
Hyperthyroidism	Syringomyelia
Hypoglycemia	CHANGES IN BLOOD FLOW
Obesity	Maffucci syndrome
Pheochromocytoma	Arteriovenous fistula
Porphyria	Klippel-Trénaunay syndrome
Pregnancy	Glomus tumor
Rickets	Blue rubber-bleb nevus syndrome
Infantile scurvy	

Differential Diagnosis

The clarity of the fluid, superficiality of the vesicles, and absence of inflammation permit differentiation of miliaria crystalline from other blistering disorders. Miliaria rubra may be confused with or superimposed on other diaper area eruptions, including candidiasis and folliculitis.

Treatment

All forms of miliaria respond dramatically to cooling of the patient by regulation of environmental temperatures and by removal of excessive clothing; administration of antipyretics is also beneficial to patients with fever. Topical agents are usually ineffective and may exacerbate the eruption.

BROMHIDROSIS

Bromhidrosis, characterized by excessive odor, may result from alteration of either apocrine or eccrine sweat. Apocrine bromhidrosis develops after puberty as a result of the formation of short-chain fatty acids and ammonia by the action of anaerobic diphtheroids on axillary apocrine sweat. Eccrine bromhidrosis is caused by microbiologic degradation of stratum corneum that has become softened by excessive eccrine sweat. The soles of the feet and the intertriginous areas are the primary affected sites. Hyperhidrosis, warm weather, obesity, intertrigo, and diabetes mellitus are predisposing factors. Treatments that may be helpful include cleansing with germicidal soaps, topical clindamycin or erythromycin, or topical application of aluminum or zirconium. In addition, more invasive surgical and laser treatments have been used. Treatment of any associated hyperhidrosis is mandatory.

Fig. 702.1 Superficial clear vesicles of miliaria crystallina.

HIDRADENITIS SUPPURATIVA

Etiology and Pathogenesis

Hidradenitis suppurativa (HS) is a disease of the apocrine gland–bearing areas of the skin. The pathogenesis of hidradenitis suppurativa is controversial. It is believed that it is a primary inflammatory disorder of the hair follicle and not solely an alteration of apocrine glands. It is considered a part of the follicular occlusion tetrad, along with acne conglobata, dissecting cellulitis of the scalp, and pilonidal sinus. The natural history of the disease involves progressive dilation below the follicular obstruction, leading to rupture of the duct, inflammation, sinus tract formation, and destructive scarring. It has been associated with Sjögren syndrome, inflammatory bowel disease, obesity, smoking, diabetes mellitus, and thyroid disease. It is also known to occur in other family members and may be associated with loss-of-function pathogenic variants in multiple genes in some patients (Fig. 702.2). HS has been one manifestation of autoinflammatory syndromes, including pyoderma gangrenosum-acne-HS (PASH) (*PSTPIP1* promoter), pyoderma gangrenosum-acne-pyogenic arthritis-HS (PAPASH) *(PSTPIP1)*, and psoriatic arthritis-pyoderma gangrenosum-acne-HS (PsAPASH).

Clinical Manifestations

HS is a chronic, inflammatory, suppurative disorder of the follicular units in the axillae, anogenital area, and, occasionally, the scalp, posterior aspect of the ears, inframammary folds (female), and periumbilical area (Fig. 702.3). Onset of clinical manifestations is sometimes preceded by pruritus or discomfort and usually occurs during puberty or early adulthood. Solitary or multiple painful erythematous nodules, deep abscesses, and contracted scars are sharply confined to areas of skin containing apocrine glands. When the disease is severe and chronic, sinus tracts, ulcers, and thick, linear fibrotic bands develop. HS tends to persist for many years, punctuated by relapses and partial remissions. Complications include cellulitis, ulceration, and burrowing abscesses that may perforate adjacent structures, forming fistulas to the urethra, bladder, rectum, or peritoneum. Episodic inflammatory arthritis develops in some patients. Obesity and smoking may worsen or trigger symptoms. Patients with HS have an increased risk of adverse cardiovascular outcomes and a long-term risk of squamous cell carcinoma.

The autoinflammatory associated disorders present with fever, joint pain, cutaneous lesions (severe painful acne), and elevated inflammatory markers (ESR, CRP).

Differential Diagnosis

Early lesions of HS are often mistaken for infected epidermal cysts, furuncles, scrofuloderma, actinomycosis, cat-scratch disease, granuloma inguinale, or lymphogranuloma venereum. However, sharp localization to areas of the body that bear apocrine glands should suggest hidradenitis. When involvement is limited to the anogenital region, the condition may be difficult to distinguish from Crohn's disease.

Treatment

Conservative management includes cessation of smoking, weight loss, and avoidance of irritation of the affected area. Warm compresses and topical antiseptic or antibacterial soaps may also be helpful. For mild, early disease, topical clindamycin 1% may be helpful. For more severe disease, therapy may be initiated with doxycycline (100 mg bid) or minocycline (100 mg bid) in adolescents and young adults. Some patients require intermittent or long-term antibiotic treatment. Combination therapy with clindamycin and rifampin is helpful in some patients. Oral retinoids for 5-6 months may also be effective, although disease may recur. Oral contraceptive agents, which contain a high estrogen:progesterone ratio and low androgenicity of the progesterone, are another alternative along with spironolactone. Laser hair ablation has proven helpful in some studies as well. Systemic immunosuppressants (infliximab, adalimumab, cyclosporine, anakinra) and medications targeted at glucose metabolism and metabolic syndrome (metformin) have been helpful in patients resistant to more traditional measures. Adalimumab, a tumor necrosis factor-alpha (TNF-α) inhibitor, is the only FDA-approved medication for the treatment of moderate-to-severe HS. Surgical measures, including deroofing procedures and full excision, may be a helpful adjuvant to medical therapy, especially in recalcitrant cases.

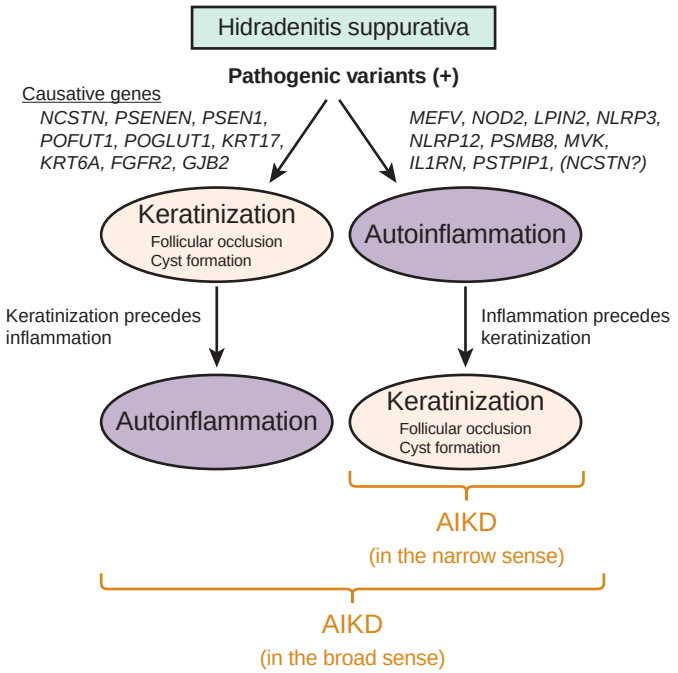

Fig. 702.2 Hidradenitis suppurativa and autoinflammatory keratinization disease (AIKD). Genes responsible for hidradenitis suppurativa can be divided into two groups. One includes *NCSTN, PSENEN, PSEN1, POFUT1, POGLUT1, KRT17, KRT6A, FGFR2*, and *GJB2*, whose pathogenic variants result in autoinflammation preceded by keratinization. This hidradenitis suppurativa subtype can be regarded as an autoinflammatory keratinization disease in the broad sense. The other group includes *MEFV, NOD2, LPIN2, NLRP3, NLRP12, PSMB8, MVK, IL1RN, PSTPIP1*, and possibly *NCSTN*, whose pathogenic variants lead to keratinization preceded by autoinflammation. This hidradenitis suppurativa subtype can be regarded as an autoinflammatory keratinization disease in the narrow sense. *(From Nomura T. Hidradenitis suppurativa as a potential subtype of autoinflammatory keratinization disease. Front Immunol. 2020;11:847, Fig. 1.).*

FOX-FORDYCE DISEASE

Etiology and Pathogenesis

The cause of Fox-Fordyce disease is unknown, but it is related to blockage of apocrine sweat glands.

Clinical Manifestations

This disease is most common in females and manifests during puberty to the third decade of life as pruritus primarily in the axillae, although the areolae, pubic, and perineal regions can also be affected. Pruritus is exacerbated by emotional stress and stimuli that induce apocrine sweating. Dome-shaped, skin-colored to slightly hyperpigmented, follicular papules develop in the pruritic areas.

Treatment

Fox-Fordyce disease is difficult to treat. Oral contraceptive pills and topical treatments, including corticosteroids, antibiotics, or retinoids, may help some patients. Systemic isotretinoin and ablative lasers have shown varying efficacy. Mechanical destruction and removal of apocrine glands have been used in recalcitrant cases. Partial response has been seen in one study using botulinum toxin type A.

Visit Elsevier eBooks+ at eBooks.Health.Elsevier.com for Bibliography.

Fig. 702.3 Hidradenitis suppurativa. **A,** This young man had recurrent inflammatory papules and nodulocystic lesions in the axillae and groin for 5 years. Although lesions initially improved with oral antibiotics, he subsequently developed draining sinus tracts. **B,** This young woman had multiple indurated sinus tracts, nodules, and ulcers with purulent and necrotic drainage in her axillae. *(From Rachidi S, Bender AM, Cohen BA. Disorders of the hail and nails. In: Cohen BA, ed. Pediatric Dermatology, 5th ed. Philadelphia: Elsevier; 2022, Fig. 8.42.)*

Chapter 703

Disorders of Hair

Kari L. Martin

Disorders of hair in infants and children may be a result of intrinsic disturbances of hair growth, underlying biochemical or metabolic defects, inflammatory dermatoses, or structural anomalies of the hair shaft. Excessive and abnormal hair growth is referred to as hypertrichosis or hirsutism. **Hypertrichosis** is excessive hair growth at inappropriate locations; **hirsutism** is an androgen-dependent male pattern of hair growth in women (see Chapter 589). **Hypotrichosis** is deficient hair growth. Hair loss, partial or complete, is called **alopecia**. Alopecia may be classified as nonscarring or scarring; the latter type is rare in children and, if present, is most often caused by prolonged or untreated inflammatory conditions such as pyoderma and tinea capitis.

HYPERTRICHOSIS

Hypertrichosis is rare in children and may be localized or generalized and permanent or transient. Tables 703.1 and 703.2 list some of the many causes of hypertrichosis.

HYPOTRICHOSIS AND ALOPECIA

Table 703.3 lists some of the disorders associated with hypotrichosis and alopecia. True alopecia is rarely congenital; it is more often related to an inflammatory dermatosis, mechanical factors, drug ingestion, infection, endocrinopathy, nutritional disturbance, or disturbance of the hair cycle. Any inflammatory condition of the scalp, such as atopic dermatitis or seborrheic dermatitis, if severe enough, may result in partial alopecia. Unless the hair follicle has been permanently damaged, hair growth returns to normal if the underlying condition is treated successfully.

Hair loss in childhood should be divided into the following four categories: congenital diffuse, congenital localized, acquired diffuse, and acquired localized.

Table 703.1 Causes of Hypertrichosis and Associated Conditions

INTRINSIC FACTORS
Racial and familial forms such as hairy ears, hairy elbows, intraphalangeal hair, or generalized hirsutism
EXTRINSIC FACTORS
Local trauma Malnutrition Anorexia nervosa Long-standing inflammatory dermatoses Drugs: Diazoxide, phenytoin, corticosteroids, Cortisporin, cyclosporine, androgens, anabolic agents, hexachlorobenzene, minoxidil, psoralens, penicillamine, streptomycin, danazol, omeprazole, valproic acid
HAMARTOMAS OR NEVI
Congenital pigmented nevocytic nevus, hair follicle nevus, Becker nevus, congenital smooth muscle hamartoma, fawn-tail nevus associated with diastematomyelia
ENDOCRINE DISORDERS
Virilizing ovarian tumors, Cushing syndrome, acromegaly, hyperthyroidism, hypothyroidism, congenital adrenal hyperplasia, adrenal tumors, gonadal dysgenesis, male pseudohermaphroditism, nonendocrine hormone–secreting tumors, polycystic ovary syndrome, pigmentary hypertrichosis with non-autoimmune diabetes mellitus *(SLC29A3)*
CONGENITAL AND GENETIC DISORDERS (SEE TABLE 703.2)

Acquired localized hair loss is the most common type of hair loss in childhood. Three conditions—traumatic alopecia, alopecia areata, and tinea capitis—are predominantly seen (Tables 703.4 and 703.5).

TRAUMATIC ALOPECIA (TRACTION ALOPECIA, HAIR PULLING, TRICHOTILLOMANIA)

Traction Alopecia

Traction alopecia is common and is seen in almost 20% of school-aged females with coily or kinky hair. It is caused by trauma to the hair follicles from tight braids or ponytails, headbands, rubber bands, curlers, weaves, or rollers (Fig. 703.1). There is a greater risk of traction alopecia if hair trauma is combined with chemically relaxed hair. Broken hairs and inflammatory follicular papules in circumscribed patches at the scalp margins are characteristic and may be accompanied by regional lymphadenopathy. Children and parents must be encouraged to avoid devices that cause trauma to the hair and, if necessary, to alter the hairstyle. Otherwise scarring of hair follicles may occur. Treatment with topical phenylephrine, an α_1-adrenergic receptor agonist, facilitates contraction of arrector pili smooth muscle and shows promise in decreasing hair loss and increasing the force needed for epilation.

Hair Pulling

Hair pulling in childhood is usually an acute reactional process related to emotional stress, or it may be a habit (especially in young children). It may also be seen in trichotillomania (obsessive-compulsive disorder) and as part of more severe psychiatric disorders, usually in adolescents.

Table 703.2 Congenital Syndromes Associated with Generalized Hypertrichosis

Acromegaloid facial appearance syndrome (affected genes: *PGM1, GLO1, IGHG3, HP*)
Barber-Say syndrome *(KMT2A)*
Cantú syndrome (hypertrichosis with osteochondrodysplasia) (*ABCC9, KCNJ8*)
Coffin-Siris syndrome (BAF complex genes)
Cornelia de Lange (Brachmann-de Lange) syndrome (*NIPBL, SMC1A, SMC3, RAD21, HDAC8*)
Craniofacial dysostosis
Eye disorders
- With amaurosis congenital, cone-rod type
- With congenital lamellar cataracts and mental retardation
- With pigmentary retinopathy

Gorlin-Chaudhry-Moss (oculo-facio-cardio-dental) syndrome *(BCOR)*
Gingival hyperplasia
- Congenital generalized hypertrichosis with gingival hyperplasia
- Zimmerman-Laband syndrome

Hemimaxillofacial dysplasia
Lipodystrophies
- Berardinelli-Seip syndrome (*BSCL*)
- Donohue syndrome (leprechaunism) (*INSR*)

Mitochondrial encephalopathy, lactic acidosis, and strokelike episodes (MELAS) syndrome
Mucopolysaccharidoses
- Hunter syndrome
- Hurler syndrome
- Sanfilippo syndrome

Porphyrias
- Erythropoietic porphyria (Gunther disease)
- Familial porphyria cutanea tarda
- Hepatoerythropoietic porphyria

Rubinstein-Taybi syndrome (*CREBBP, EP300*)
Schinzel-Giedion syndrome (*SETBP1* [MAJ359])
Stiff skin syndrome
Toxin exposure
- Fetal alcohol syndrome
- Fetal hydantoin syndrome

Weidemann-Steiner syndrome (*KMT2A*)
Winchester (Torg-Winchester) syndrome (*MMP2*)

From Paller AS, Mancini AJ. *Hurwitz Clinical Pediatric Dermatology*, 6th ed. Philadelphia: Elsevier; 2022, Box 7.8, p. 191.

Trichotillomania

Etiology and Pathogenesis. The *Diagnostic and Statistical Manual of Mental Disorders*, 5th edition (DSM-5) classifies trichotillomania in the category of obsessive-compulsive and related disorders. The diagnostic criteria for trichotillomania include visible hair loss attributable to pulling; mounting tension preceding or during hair pulling; gratification or release of tension after hair pulling; and absence of hair pulling attributable to hallucinations, delusions, or an inflammatory skin condition.

Clinical Manifestations. Compulsive pulling, twisting, and breaking of hair produces irregular areas of incomplete hair loss, most often on the crown and in the occipital and parietal areas of the scalp. Occasionally eyebrows, eyelashes, and body hair are traumatized. Trichotillomania often begins during periods of inactivity (going to bed, watching TV) and is frequently unobserved by the parents. Some plaques of alopecia may have a linear outline. The hairs remaining within the areas of loss are of various lengths (Fig. 703.2) and are typically blunt-tipped because of breakage. The scalp usually appears normal, although hemorrhage, crusting (Fig. 703.3), and chronic folliculitis may also occur. Long-term repeated trauma may result in irreversible damage and permanent alopecia. Trichophagy, resulting in trichobezoars, may complicate this disorder.

Differential Diagnosis. Acute reactional hair pulling, tinea capitis, and alopecia areata must be considered in the differential diagnosis of trichotillomania (see Tables 703.4 and 703.5).

Treatment. Trichotillomania is closely related to obsessive-compulsive disorder and may be an expression of it for some children. When trichotillomania occurs secondary to obsessive-compulsive disorder, clomipramine 50-150 mg/day or a selective serotonin reuptake inhibitor (SSRI) such as fluoxetine may be helpful, particularly when combined with behavioral interventions (see Chapter 37). *N*-Acetylcysteine may also be helpful.

Table 703.3 Disorders Associated with Alopecia and Hypotrichosis

Congenital total alopecia: Atrichia with papules, Moynahan alopecia syndrome
Congenital localized alopecia: Aplasia cutis, triangular alopecia, sebaceous nevus
Hereditary hypotrichosis: Marie-Unna syndrome, hypotrichosis with juvenile macular dystrophy, hypotrichosis (Mari type), ichthyosis with hypotrichosis, cartilage-hair hypoplasia, Hallermann-Streiff syndrome, trichorhinophalangeal syndrome, ectodermal dysplasia, "pure" hair and nail and other ectodermal dysplasias
Diffuse alopecia of endocrine origin: Hypopituitarism, hypothyroidism, hypoparathyroidism, hyperthyroidism
Alopecia of nutritional origin: Marasmus, kwashiorkor, iron deficiency, zinc deficiency (acrodermatitis enteropathica), gluten-sensitive enteropathy, essential fatty acid deficiency, biotinidase deficiency
Disturbances of the hair cycle: Telogen effluvium
Toxic alopecia: Anagen effluvium
Autoimmune alopecia: Alopecia areata
Traumatic alopecia: Traction alopecia, trichotillomania
Cicatricial alopecia: Lupus erythematosus, lichen planopilaris, pseudopelade, morphea (*en coup de sabre*) dermatomyositis, infection (kerion, favus, tuberculosis, syphilis, folliculitis, leishmaniasis, herpes zoster, varicella), acne keloidalis, follicular mucinosis, sarcoidosis
Hair shaft abnormalities: Monilethrix, pili annulati, pili torti, trichorrhexis invaginata, trichorrhexis nodosa, woolly hair syndrome, Menkes disease, trichothiodystrophy, trichodento-osseous syndrome, uncombable hair syndrome (spun-glass hair, pili trianguli et canaliculi)

ALOPECIA AREATA

Etiology and Pathogenesis

Alopecia areata is a T-cell–driven autoimmune disorder producing nonscarring alopecia. The cause is unknown. It is hypothesized that in genetically susceptible individuals, loss of immune privilege of the hair follicle allows for T-cell inflammation against anagen hairs and follicles, leading to stoppage of hair growth.

Clinical Manifestations

Alopecia areata is characterized by rapid and complete loss of hair in round or oval patches on the scalp (Fig. 703.4), eyebrows, eyelashes, and on other body sites. In alopecia totalis, all the scalp hair is lost (Fig. 703.5); alopecia universalis involves all body and scalp hair. The lifetime incidence of alopecia areata is 0.1–0.2% of the population. More than half of affected patients are younger than 20 years of age.

The skin within the plaques of hair loss appears normal. Alopecia areata is associated with atopy and with nail changes such as pits (Fig. 703.6), longitudinal striations, and leukonychia. Autoimmune diseases such as Hashimoto thyroiditis, Addison disease, pernicious anemia, ulcerative colitis, myasthenia gravis, collagen vascular diseases, and vitiligo may also be seen. An increased incidence of alopecia areata has been reported in patients with Down syndrome (5–10%).

Differential Diagnosis

Tinea capitis, seborrheic dermatitis, trichotillomania, traumatic alopecia, and lupus erythematosus should be considered in the differential diagnosis of alopecia areata (see Tables 703.4 and 703.5).

Treatment

The course is unpredictable, but spontaneous resolution in 6-12 months is usual, particularly when relatively small, stable patches of alopecia are present. Recurrences are common. Onset at a young age, extensive or prolonged hair loss, and numerous episodes are usually poor prognostic signs. Alopecia universalis, alopecia totalis, and alopecia ophiasis (Fig. 703.7)—a type of alopecia areata in which hair loss is circumferential—are also less likely to resolve. Therapy is difficult to evaluate because the course is erratic and unpredictable. The use of highly potent or superpotent topical corticosteroids is effective in

Table 703.4 Helpful Historical Clues in the Diagnosis of Hair Disorders

HISTORICAL CONSIDERATIONS	TELOGEN EFFLUVIUM	TRICHOTILLOMANIA	TINEA CAPITIS	ALOPECIA AREATA
Are the spots itchy?	Negative	Negative	Positive	Usually negative
Do the spots come and go?	Negative	Sometimes positive	Negative	Sometimes positive
Is the hair falling out in clumps?	Positive	Negative	Negative	Usually negative
Are there any anxiety disorders or obsessive-compulsive tendencies?	Negative	Positive	Negative	Negative

From Lio PA. What's missing from this picture? An approach to alopecia in children. *Arch Dis Child Educ Pract Ed.* 2007;92:193–198.

Table 703.5 Helpful Physical Examination Clues in the Diagnosis of Hair Disorders

PHYSICAL FINDINGS	TELOGEN EFFLUVIUM	TRICHOTILLOMANIA	TINEA CAPITIS	ALOPECIA AREATA
Scarring?	Negative	Negative	Usually negative	Negative
Exclamation-point hairs?	Negative	Negative	Negative	Positive
Irregular pattern with mixed length and stubbly hairs?	Negative	Positive	Negative	Negative
Scaling, pustules, or kerion?	Negative	Negative	Positive	Negative
Positive hair-pull test result?	Positive	Negative	Negative	Usually negative
Nail pitting or grooves?	Negative	Negative	Negative	Positive

From Lio PA. What's missing from this picture? An approach to alopecia in children. *Arch Dis Child Educ Pract Ed.* 2007;92:193–198.

Fig. 703.1 Traction alopecia.

Fig. 703.2 Hair pulling. Hairs are broken off at various lengths.

Fig. 703.3 Hemorrhage and crusting secondary to hair pulling.

Fig. 703.4 Circular patch of alopecia areata with normal-appearing scalp.

Fig. 703.5 Alopecia totalis: total loss of scalp hair.

Fig. 703.6 Multiple nail pits in alopecia areata.

Fig. 703.7 Ophiasis pattern of alopecia areata.

Table 703.6	Possible Etiology of Anagen Effluvin
CANCER THERAPY	
Chemotherapy	
Radiation therapy	
TOXIC METAL (SEE CHAPTER 760)	
Lead (see Chapter 761)	
Mercury	
Arsenic (rat, insect poison)	
Thallium (rat poison)	
Bismuth	
TOXIC CHEMICALS	
Boric acid (pesticide, cleaning agent)	
Warfarin	
Colchicine	

some patients. Intradermal injections of steroid (triamcinolone 5 mg/mL) every 4-6 weeks may also stimulate hair growth locally, but this mode of treatment is impractical in young children or in patients with extensive hair loss. Systemic corticosteroid therapy (prednisone 1 mg/kg/day) is associated with good results; the permanence of cure is questionable, however, and the side effects of chronic oral corticosteroids are a serious deterrent. Some patients may maintain hair growth by switching to a more appropriate long-term immunosuppressant such as methotrexate. Additional therapies that are sometimes effective include short-contact anthralin, topical minoxidil, and contact sensitization with squaric acid dibutylester or diphenylcyclopropenone. Janus kinase inhibitors, both oral and topical, may also be used. In general, parents and patients can be reassured that spontaneous remission of alopecia areata usually occurs. New hair growth may initially be of finer caliber and lighter color, but replacement by normal terminal hair can be expected.

ACQUIRED DIFFUSE HAIR LOSS

Telogen Effluvium

Telogen effluvium manifests as sudden loss of large amounts of hair, often with brushing, combing, and washing of hair. Diffuse loss of scalp hair occurs from premature conversion of growing, or anagen, hairs, which normally constitute 80–90% of hairs, to resting, or telogen, hairs. Hair loss is noted 6 weeks to 3 months after the precipitating cause, which may include childbirth; a febrile episode; surgery; acute blood loss, including blood donation; sudden severe weight loss; discontinuation of high-dose corticosteroids or oral contraceptives; hypothyroidism or hyperthyroidism; and psychiatric stress. Telogen effluvium also accounts for the loss of hair by infants in the first few months of life; friction from bed sheets, particularly in infants with pruritic, atopic skin, may exacerbate the problem. There is no inflammatory reaction; the hair follicles remain intact, and telogen bulbs can be demonstrated microscopically on shed hairs. Because >50% of the scalp hair is rarely involved, alopecia is usually not severe. Parents should be reassured that normal hair growth will return within approximately 3-6 months.

Toxic Alopecia (Anagen Effluvium)

Anagen effluvium is an acute, severe, diffuse inhibition of growth of anagen follicles, resulting in the loss of >80–90% of scalp hair. Hairs become dystrophic, and the hair shaft breaks at the narrowed segment. Loss is diffuse, rapid (1-3 weeks after treatment), and temporary, as regrowth occurs after the offending agent is discontinued. Causes of anagen effluvium include radiation; cancer chemotherapeutic agents such as antimetabolites, alkylating agents, and mitotic inhibitors; thallium; thiouracil; heparin; the coumarins; boric acid; and hypervitaminosis A (see Table 703.6).

CONGENITAL DIFFUSE HAIR LOSS

Congenital diffuse hair loss is defined as congenitally thin hair diffusely related to either hypoplasia of hair follicles or to structural defects in hair shafts.

Structural Defects of Hair

Structural defects of the hair shaft may be congenital, reflect known biochemical aberrations, or be related to damaging grooming practices. All the defects can be demonstrated by microscopic examination of affected hairs, particularly with scanning and transmission electron microscopy, although many can even be seen by simple trichography done in the office.

Trichorrhexis Nodosa

Congenital trichorrhexis nodosa is an autosomal dominant condition. The hair is dry, brittle, and lusterless, with irregularly spaced, grayish white nodes on the hair shaft. Microscopically, the nodes have the appearance of two interlocking brushes (Fig. 703.8A). The defect results from a fracture of the hair shaft at the nodal points caused by disruption of the cells in the hair cortex. Trichorrhexis nodosa has also been observed in some infants with Menkes syndrome, trichothiodystrophy, citrullinemia, and argininosuccinic aciduria.

Acquired Trichorrhexis Nodosa

Acquired trichorrhexis nodosa, the most common cause of hair breakage, occurs in two forms. Proximal defects are found most frequently in children with coily or kinky hair, whose complaint is not of alopecia but of failure of the hair to grow. The hair is short, and longitudinal splits, knots, and whitish nodules can be demonstrated in hair mounts. Easy breakage is demonstrated by gentle traction on the hair shafts. A history of other affected family members may be obtained. The problem may be caused by a combination of genetic predisposition and the cumulative mechanical trauma of rough combing and brushing, hair-straightening procedures, and "permanents." Patients must be cautioned to avoid damaging grooming techniques. A soft, natural-bristle brush and a wide-toothed comb should be used. The condition is self-limited, with resolution in 2-4 years, if patients avoid damaging practices. Distal trichorrhexis nodosa is seen more frequently in children with loose curly or straight hair types. The distal portion of the hair shaft is thinned, ragged, and faded; white specks, sometimes mistaken for nits, may be noted along the shaft. Hair mounts reveal the paintbrush defect and the sites of excessive fragility and breakage. Localized areas of the moustache or beard may also be affected. Avoidance of traumatic grooming, regular trimming of affected ends, and the use of cream rinses to lessen tangling ameliorate this condition.

Pili Torti

Patients with pili torti present with spangled, brittle, coarse hair of different lengths over the entire scalp. There is a structural defect in which the hair shaft is grooved and flattened at irregular intervals and is twisted on its axis to various degrees. Minor twists that occur in normal hair should not be misconstrued as pili torti. Curvature of the hair follicle apparently leads to the flattening and rotation of the

Fig. 703.8 A, Microscopic hair fracture in trichorrhexis nodosa. B, Beading of hair in monilethrix. C, Cuplike abnormality of hair in Netherton syndrome.

hair shaft. The genetic defect in isolated pili torti is unknown, and both autosomal dominant and recessive forms have been described. Syndromes in which the hair shaft abnormalities of pili torti are seen in association with other cutaneous and systemic abnormalities include Menkes kinky hair syndrome, Björnstad syndrome (pili torti with deafness; *BCS1L* gene), and multiple ectodermal dysplasia syndromes.

Menkes Kinky Hair Syndrome (Trichopoliodystrophy)

Males with Menkes kinky hair syndrome, an X-linked recessive trait, are born to an unaffected mother after a normal pregnancy. Neonatal problems include hypothermia, hypotonia, poor feeding, seizures, and failure to thrive. Hair is normal to sparse at birth but is replaced by short, fine, brittle, light-colored hair that may have features of trichorrhexis nodosa, pili torti, or monilethrix. The skin is hypopigmented and thin, cheeks typically appear plump, and the nasal bridge is depressed. Progressive psychomotor retardation is noted in early infancy. Pathogenic variants in the *ATP7A* gene, encoding a copper-transporting adenosine triphosphatase protein, cause Menkes kinky hair syndrome. It is a result of maldistribution of the copper in the body. Copper uptake across the brush border of the small intestine is increased, but copper transport from these cells into the plasma is defective, resulting in low total body copper stores. Parenteral administration of copper-histidine is helpful if begun in the first 2 months of life.

Monilethrix

The hair shaft defect known as monilethrix is inherited as an autosomal dominant trait with variable age of onset, severity, and course. Pathogenic variants in the hair keratins *KRT81* (hHb1), *KRT83* (hHb3), and *KRT86* (hHb6) have been identified in autosomal dominant cases, and pathogenic variants in desmoglein 4 are found in autosomal recessive cases. The hair appears dry, lusterless, and brittle, and it fractures spontaneously or with mild trauma. Eyebrows, lashes, body and pubic hair, and scalp hair may be affected. Monilethrix may be present at birth, but the hair is usually normal at birth and is replaced in the first few months of life by abnormal hairs; the condition is sometimes first apparent in childhood. Follicular papules may appear on the nape of the neck and the occiput and, occasionally, over the entire scalp. Short, fragile beaded hairs that emerge from the horny follicular plugs give a distinctive appearance. Keratosis pilaris and koilonychia of fingernails and toenails may also be present. Microscopically, a distinctive, regular beading pattern of the hair shaft is evident, characterized by elliptic nodes that are separated by narrower internodes (see Fig. 703.8B). Not all hairs have nodes, and both normal and beaded hairs may break. Patients should be advised to handle the hair gently to minimize breakage. Treatment is generally ineffective, although oral retinoids and topical minoxidil have produced some improvement.

Trichothiodystrophy

Hair in trichothiodystrophy is sparse, short, brittle, and uneven; the scalp hair, eyebrows, or eyelashes may be affected. Microscopically, the hair is flattened, folded, and variable in diameter; it has longitudinal grooving and nodal swellings that resemble those seen in trichorrhexis nodosa. Under a polarizing microscope, distinctive alternating dark and light bands are seen. The abnormal hair has a cystine content that is <50% of normal because of a major reduction in and altered composition of constituent high-sulfur matrix proteins. Trichothiodystrophy is caused by pathogenic variants in DNA repair/transcription genes (*XPD, XPB, TTDN1,* and *TTDA*) and may occur as an isolated finding or in association with various syndrome complexes that include intellectual impairment, short stature, ichthyosis, nail dystrophy, dental caries, cataracts, decreased fertility, neurologic abnormalities, bony abnormalities, and immunodeficiency. Some patients are photosensitive and have impaired DNA repair mechanisms, similar to that seen in groups B and D xeroderma pigmentosum; the incidence of skin cancers, however, is not increased. Patients with trichothiodystrophy tend to resemble one another, with a receding chin, protruding ears, raspy voice, and sociable, outgoing personality. Trichoschisis, a fracture perpendicular to the hair shaft, is characteristic of the many syndromes that are associated with trichothiodystrophy. Perpendicular breakage of the hair shaft has also been described in association with other hair abnormalities, particularly monilethrix.

Trichorrhexis Invaginata (Bamboo Hair)

Short, sparse, fragile hair without apparent growth is characteristic of trichorrhexis invaginata, which is found primarily in association with Netherton syndrome (see Chapter 699). It has also been reported in other ichthyosiform dermatoses. The distal portion of the hair is invaginated into the cuplike proximal portion, forming a fragile nodal swelling (see Fig. 703.8C).

Pili Annulati

Alternating light and dark bands of the hair shaft characterize pili annulati. When viewed under the light microscope, the region of the hair shaft that appeared bright in reflected light instead appears dark in the transmitted light as a result of focal aggregates of abnormal air-filled cavities within the shaft. The hair is not fragile. The defect may be autosomal dominant or sporadic in inheritance and usually begins after age 2. Pseudopili annulati is a variant of normal blond hair; an optical effect caused by the refraction and reflection of light from the partially twisted and flattened shaft creates the impression of banding.

Woolly Hair Disease

Woolly hair diseases manifest at birth as peculiarly tight, curly, abnormal hair in a person who is not Black. Autosomal dominant and recessive (*PKRY5* gene) types have been described along with the genodermatoses Naxos disease and Carvajal syndrome, which are associated with cardiomyopathy. Woolly hair nevus, a sporadic form, involves only a circumscribed portion of the scalp hair. The affected hair is fine, tightly curled, and light-colored, and it grows poorly. Microscopically, an affected hair is oval and shows twisting of 180 degrees on its axis.

Uncombable Hair Syndrome (Spun-Glass Hair)

The hair of patients with uncombable hair syndrome appears disorderly, is often silvery blond (Fig. 703.9), and may break because of

Fig. 703.9 Complicated combing. Blond, frizzy, and glistening hair in uncombable hair syndrome. *(From Drivenes JL, Betz RC, Bygum A. A girl with unruly locks: molecular genetics makes a diagnosis of uncombable hair syndrome. Lancet. 2022;399:1079.)*

repeated, futile efforts to control it. Eyebrows and eyelashes are normal. A longitudinal depression along the hair shaft is a constant feature, and most hair follicles and shafts are triangular (pili trianguli et canaliculi). The shape of the hair varies along its length, however, preventing the hairs from lying flat.

The disorder is associated with pathogenic variants in *PAD13*, *TCHH*, and *TGM3* genes. Most patients have no other findings, but in some there may be associated brachydactyly, ectodermal dysplasia, cataracts, and oligodontia.

Visit Elsevier eBooks+ at eBooks.Health.Elsevier.com for Bibliography.

Table 704.1 White Nail or Nail Bed Changes

DISEASE	CLINICAL APPEARANCE
Anemia	Diffuse white
Arsenic	Mees lines: transverse white lines
Cirrhosis	Terry nails: most of nail, zone of pink at distal end (see Fig. 704.6)
Congenital leukonychia (autosomal dominant; variety of patterns)	Syndrome of leukonychia, knuckle pads, deafness; isolated finding; partial white
Darier disease	Longitudinal white streaks
Half-and-half nail	Proximal white, distal pink azotemia
High fevers (some diseases)	Transverse white lines
Hypoalbuminemia	Muehrcke lines: stationary paired transverse bands
Hypocalcemia	Variable white
Malnutrition	Diffuse white
Pellagra	Diffuse milky white
Punctate leukonychia	Common white spots
Tinea and yeast	Variable patterns
Thallium toxicity (rat poison)	Variable white
Trauma	Repeated manicure: transverse striations
Zinc deficiency	Diffuse white

From Habif TP, ed. *Clinical Dermatology*, 4th ed. Philadelphia: Mosby; 2004:887.

Chapter 704

Disorders of the Nails

Kari L. Martin

Nail abnormalities in children may be manifestations of generalized skin disease, skin disease localized to the periungual region, systemic disease, drugs, trauma, or localized bacterial and fungal infections (Table 704.1). Nail anomalies are also common in certain congenital disorders (Table 704.2).

ABNORMALITIES IN NAIL SHAPE OR SIZE

Anonychia is absence of the nail plate, usually a result of a congenital disorder or trauma. It may be an isolated finding or may be associated with malformations of the digits. **Koilonychia** is flattening and concavity of the nail plate with loss of normal contour, producing a spoon-shaped nail (Fig. 704.1). Koilonychia occurs as an autosomal dominant trait or in association with iron-deficiency anemia, Plummer-Vinson syndrome, hemochromatosis, various genodermatoses, and occupational trauma. The nail plate is relatively thin for the first year or two of life and, consequently, may be spoon-shaped in otherwise normal children.

Congenital nail dysplasia, an autosomal dominant disorder, manifests at birth as longitudinal streaks and thinning of the nail plate. There is platyonychia and koilonychia, which may overgrow the lateral folds and involve all nails of the toes and fingers.

Table 704.2 Congenital Diseases with Nail Defects

Large nails	Pachyonychia congenita, Rubinstein-Taybi syndrome, hemihypertrophy
Smallness or absence of nails	Ectodermal dysplasias, nail-patella, dyskeratosis congenita, focal dermal hypoplasia, cartilage-hair hypoplasia, COIF, Ellis–van Creveld, Larsen, epidermolysis bullosa, incontinentia pigmenti, Rothmund-Thomson, Turner, Coffin-Siris, popliteal web, trisomies (8, 13, 18), Apert, Gorlin-Pindborg, long arm 21 deletion, otopalatodigital, elfin facies, anonychia, Noonan, acrodermatitis enteropathica, teratogens (alcohol, warfarin, hydantoin)
Other	Congenital malalignment of the great toenails, familial dystrophic shedding of the nails

COIF, Congenital onychodysplasia of index fingers.

Nail-patella syndrome is an autosomal dominant disorder in which the nails are 30–50% of their normal size and often have triangular or pyramidal lunulae. The thumbnails are always involved, although in some cases only the ulnar half of the nail may be affected or may be missing. Nail involvement is symmetric, and the nails from the index finger to the little finger are progressively less damaged. The patella is also smaller than usual or absent, and this anomaly may lead to knee instability. Iliac horns, bony spines arising from the posterior aspect of the iliac bones; overextension of joints; skin laxity; ocular anomalies;

Fig. 704.1 Spoon nails (koilonychia). Most cases are a variant of normal. *(From Habif TP, ed. Clinical Dermatology, 4th ed. Philadelphia: Mosby; 2004:885.)*

Fig. 704.2 Finger clubbing. The distal phalanges are enlarged to a rounded bulbous shape. The nail enlarges and becomes curved, hard, and thickened. *(From Habif TP, ed. Clinical Dermatology, 4th ed. Philadelphia: Mosby; 2004:885.)*

Table 704.3 Clubbing in Children*

HISTORY	SYMPTOM	DISEASE
ACQUIRED		
Generalized	Pulmonary	Cystic fibrosis Bronchiectasis Tuberculosis, aspergillosis Asthma complicated by lung infections Sarcoidosis Pulmonary fibrosis Tumors
	Cardiovascular	Cyanotic congenital heart disease Subacute bacterial endocarditis Myxomas
	Gastrointestinal	Inflammatory bowel disease Gardner's syndrome Parasitosis Cirrhosis Chronic active hepatitis
	Endocrine	Diamond's syndrome (myxedema, exophthalmos and clubbing) Hypervitaminosis A Malnutrition
Limited to one or more digits		Aortic/subclavian artery aneurysm Brachial plexus injury Trauma Maffucci's syndrome Gout Sarcoidosis Severe herpetic whitlow
Hereditary		Pachydermoperiostosis Familial, isolated Apert's syndrome Pfeiffer's syndrome Rubinstein-Taybi syndrome
Pseudoclubbing*		

*Broad distal phalanges with normally shaped nails.
Modified from Baran R, Dawber RPR. *Diseases of the Nails and Their Management.* Oxford: Blackwell Science; 1984:29.

and nephropathy, the most serious feature, may also be present. Nail-patella syndrome is caused by pathogenic variants in the transcription factor *LMX1B* gene.

For a discussion of pachyonychia congenita, see Chapter 699.

Habit tic deformity consists of a depression down the center of the nail with numerous horizontal ridges extending across the nail from it. One or both thumbs are usually involved as a result of chronic rubbing and picking at the nail with an adjacent finger. Treatment aims at cessation of trauma to the nail via massaging with bland ointments, physical barriers, or cyanoacrylate adhesive.

Clubbing of the nails is characterized by swelling of each distal digit, an increase in the angle between the nail plate and the proximal nail fold (Lovibond angle) to >180 degrees, and a spongy feeling when one pushes down and away from the interphalangeal joint because of an increase in fibrovascular tissue between the matrix and the phalanx (Fig. 704.2). The pathogenesis is not known. Nail clubbing is seen in association with diseases of numerous organ systems, including pulmonary, cardiovascular (cyanotic heart disease), gastrointestinal (celiac disease, inflammatory bowel disease), and hepatic (chronic hepatitis) systems, and in healthy individuals as an idiopathic or familial finding (Table 704.3).

CHANGES IN NAIL COLOR

Leukonychia is a white opacity of the nail plate that may involve the entire plate or may be punctate or striate (see Table 704.1). The nail plate itself remains smooth and undamaged. Leukonychia can be traumatic or associated with infections such as leprosy and tuberculosis, dermatoses such as lichen planus and Darier disease, malignancies such as Hodgkin disease, anemia, and arsenic poisoning (Mees lines). Leukonychia of all nail surfaces is an uncommon hereditary autosomal dominant trait that may be associated with congenital epidermal cysts and renal calculi. Paired parallel white bands that do not change position with growth of the nail, fade with pressure, and thus reflect a change in the nail bed are associated with hypoalbuminemia and are called *Muehrcke lines.* When the proximal portion of the nail is white and the distal 20–50% of the nail is red, pink, or brown, the condition is called *half-and-half nails* or *Lindsay nails;* this is seen most commonly in patients with renal disease but may occur as a normal variant. White nails of cirrhosis, or Terry nails (Fig. 704.3), are characterized by a white ground-glass appearance of the entire or the proximal end of the nail and a normal pink distal 1-2 mm of the nail; this finding can also be associated with congestive heart failure and adult-onset diabetes and can be normal in children less than 4 years old.

Fig. 704.3 Terry nails. The nail bed is white with only a narrow zone of pink at the distal end. *(From Habif TP, ed. Clinical Dermatology, 4th ed. Philadelphia: Mosby; 2004:885.)*

Fig. 704.4 Green/black discoloration at the edge of the nails secondary to *Pseudomonas* infection.

Black pigmentation of an entire nail plate or linear bands of pigmentation **(melanonychia striata)** is most common in individuals with Fitzpatrick type IV-VI skin. Most often, the pigment is melanin, which is produced by melanocytes of a junctional nevus in the nail matrix and nail bed and is of no consequence. Extension or alteration in the pigment should be evaluated by biopsy because of the possibility of malignant change.

Bluish black to greenish nails may be caused by *Pseudomonas* infection (Fig. 704.4), particularly in association with onycholysis or chronic paronychia. The coloration is caused by subungual debris and pyocyanin pigment from the bacterial organisms.

Yellow nail syndrome manifests as thickened, excessively curved, slow-growing yellow nails without lunulae. All nails are affected in most cases. Associated systemic diseases include bronchiectasis, recurrent bronchitis, chylothorax, and focal edema of the limbs and face. Deficient lymphatic drainage, caused by hypoplastic lymphatic vessels, is believed to lead to the manifestations of this syndrome.

Splinter hemorrhages most often result from minor trauma but may also be associated with subacute bacterial endocarditis, vasculitis, Langerhans cell histiocytosis, severe rheumatoid arthritis, peptic ulcer disease, hypertension, chronic glomerulonephritis, cirrhosis, scurvy, trichinosis, malignant neoplasms, and psoriasis (Fig. 704.5 and Table 704.4).

NAIL SEPARATION

Onycholysis indicates separation of the nail plate from the distal nail bed. Common causes are trauma, long-term exposure to moisture, hyperhidrosis, cosmetics, psoriasis, fungal infection (distal onycholysis), atopic or contact dermatitis, porphyria, drugs (bleomycin, vincristine, retinoid agents, indomethacin, chlorpromazine [Thorazine]), and drug-induced phototoxicity from tetracyclines (Fig. 704.6) or chloramphenicol (Table 704.5).

Fig. 704.5 Splinter hemorrhage of the distal nail bed due to trauma. *(From Hordinsky M, Sawaya ME, Scher RK. Atlas of Hair and Nails. London: Churchill Livingstone; 1999.)*

Table 704.4 Disorders Associated with Subungual Hemorrhage

	SPLINTER-SHAPED	HEMATOMAS
Normal variant	+	–
Blood dyscrasias	+	+
Collagen diseases (lupus erythematosus)	+	+
Trichinosis	+	–
Trauma	+	+
Child abuse	+	+
Cryoglobulinemia	+	–
Drug eruptions	+	–
Dialysis	+	–
Endocarditis (SBE)	+	–
Emboli	+	+
Langerhans cells histiocytosis	+	–
Arterial lines or punctures	+	–
Sarcoidosis	+	–
Sepsis	+	–
Thyroid disease	+	–
Vasculitis	+	–
Phototoxicity (tetracyclines)	+	–

From Silverman R, Baran R. Nail and appendageal abnormalities. In: Schachner LA, Hansen RC, eds. *Pediatric Dermatology*, 4th ed. Philadelphia: Mosby; 2011, Table 12.9, p. 813.

Beau lines are transverse grooves in the nail plate (Fig. 704.7) that represent a temporary disruption of formation of the nail plate. The lines first appear a few weeks after the event that caused the disruption in nail growth. A single transverse ridge appears at the proximal nail fold in most 4- to 6-week-old infants and works its way distally as the nail grows; this line may reflect metabolic changes after delivery. At

Fig. 704.6 Distal onycholysis secondary to oral tetracycline usage and ultraviolet light exposure.

Fig. 704.7 Beau lines. Longitudinal disruption of the nail.

Fig. 704.8 Onychomadesis. Proximal nail bed separation.

Table 704.5 Underlying Causes of Onycholysis

CHEMICAL IRRITANTS
Cosmetics, especially with formaldehyde
Depilatories
Detergents
Nail polish removers
Organic solvents
INFLAMMATORY DISORDERS
Alopecia areata
Atopic dermatitis
Contact dermatitis
Lichen planus
Psoriasis
INFECTIOUS DISORDERS
Bacterial paronychia
Candidiasis
Herpes simplex (whitlow)
Onychomycosis
Verrucae
MEDICATIONS
Anticonvulsants (valproic acid)
Chemotherapeutic agents (especially taxanes)
Griseofulvin
Retinoids (isotretinoin)
Tetracyclines (photoonycholysis)
Thiazides (photoonycholysis)
SYSTEMIC DISORDERS
Iron-deficiency anemia
Rheumatic disease
Thyroid disease (hyperthyroidism or hypothyroidism)
Kawasaki disease
MIS-C
TRAUMA
Compulsive subungual cleaning
Sportsman toe

MIS-C, multisystem inflammatory syndrome in children.
From Paller AS, Mancini AJ. *Hurwitz Clinical Pediatric Dermatology,* 6th ed. Philadelphia: Elsevier; 2022, Box 7.9, p. 201.

other ages, Beau lines are usually indicative of periodic trauma or episodic shutdown of the nail matrix secondary to a systemic disease such as hand-foot-and-mouth disease, measles, mumps, pneumonia, or zinc deficiency. Onychomadesis is an exaggeration of Beau lines leading to proximal separation of the nail bed (Fig. 704.8).

NAIL CHANGES ASSOCIATED WITH SKIN DISEASE

Nail changes may be particularly associated with various other diseases. Nail changes of psoriasis most characteristically include pitting, onycholysis, yellow-brown discoloration, and thickening. Nail changes in lichen planus include violaceous papules in the proximal nail fold and nail bed, leukonychia, longitudinal ridging, thinning of the entire nail plate, and pterygium formation, which is abnormal adherence of the cuticle to the nail plate or, if the plate is destroyed focally, to the nail bed. Postinfectious reactive arthritis syndromes may include painless erythematous induration of the base of the nail fold; subungual parakeratotic scaling; and thickening, opacification, or ridging of the nail plate. Dermatitis that involves the nail folds may produce dystrophy, roughening, and coarse pitting of the nails. Nail changes are more common in atopic dermatitis than in other forms of dermatitis that affect the hands. Darier disease is characterized by red or white streaks that extend longitudinally and cross the lunula. Where the streak meets the distal end of the nail, a V-shaped notch may be present. Total leukonychia may also occur. Transverse rows of fine pits are characteristic of alopecia areata. In severe cases, the entire nail surface may be rough. Patients with acrodermatitis enteropathica may have transverse grooves (Beau lines) and nail dystrophy as a result of periungual dermatitis.

TRACHYONYCHIA (20-NAIL DYSTROPHY)

Trachyonychia is characterized by longitudinal ridging, pitting, fragility, thinning, distal notching, and opalescent discoloration of all the nails (Fig. 704.9). Patients can have no associated skin or systemic diseases and no other ectodermal defects. Its occasional association with alopecia areata has led some authorities to suggest that trachyonychia may reflect an abnormal immunologic response to the nail matrix, whereas histopathologic studies have suggested that it may be a manifestation of lichen planus, psoriasis, or spongiotic (eczematous) inflammation of the nail matrix. The disorder must be differentiated from fungal infections, psoriasis, nail changes of alopecia areata, and nail dystrophy secondary to eczema. Eczema and fungal infections rarely produce changes in all the nails simultaneously. The disorder is self-limited, can be treated with potent topical steroids or topical retinoids, and eventually remits by adulthood.

NAIL INFECTION

Fungal infection **(onychomycosis)** of the nails has been classified into four types. White superficial onychomycosis manifests as diffuse or speckled white discoloration of the surface of the toenails. It is caused primarily by *Trichophyton mentagrophytes,* which invades the nail plate. The organism

Fig. 704.9 Dystrophy of all nails in trachyonychia.

Fig. 704.10 Discoloration, hyperkeratosis, and crumbling of nail secondary to dermatophyte infection.

may be scraped off the nail plate with a blade, but treatment is best accomplished by the addition of a topical azole antifungal agent. Distal subungual onychomycosis, the most common type, involves foci of onycholysis under the distal nail plate or along the lateral nail groove, followed by development of hyperkeratosis and yellow-brown discoloration. The process extends proximally, resulting in nail plate thickening, crumbling (Fig. 704.10), and separation from the nail bed. *Trichophyton rubrum* and, occasionally, *T. mentagrophytes* infect the toenails; fingernail disease is almost exclusively caused by *T. rubrum,* which may be associated with superficial scaling of the plantar surface of the feet and often of one hand. The dermatophytes are found most readily at the most proximal area of the nail bed or adjacent ventral portion of the involved nail plates. Topical therapies such as ciclopirox 8% lacquer, amorolfine 5% lacquer, or bifonazole-urea 1%/40% ointment may be effective for solitary nail infection. Topical efinaconazole 10% and topical tavaborole 5% solution may also be effective; laser treatment is an expensive but safe alternative to oral therapy. Because of its long half-life in the nail, oral itraconazole may be effective when given as pulse therapy (1 week of each month for 3-4 months). Dosage is weight-dependent. Oral daily terbinafine is also quite effective. Either agent is superior to griseofulvin, fluconazole, or ketoconazole. The risks, the most concerning of which is hepatic toxicity, and costs of oral therapy are minimized with the use of pulsed dosing.

Proximal white subungual onychomycosis occurs when the organism, generally *T. rubrum,* enters the nail through the proximal nail fold, producing yellow-white discoloration of portions of the undersurface of the nail plate. The surface of the nail is unaffected. This occurs almost exclusively in immunocompromised patients and is a well-recognized manifestation of AIDS. Treatment includes oral terbinafine or itraconazole.

Candidal onychomycosis involves the entire nail plate in patients with chronic mucocutaneous candidiasis. It is also commonly seen in patients with AIDS. The organism, generally *Candida albicans,* enters distally or along the lateral nail folds; rapidly involves the entire thickness of the nail plate; and produces thickening, crumbling, and deformity of the plate. Topical azole antifungal agents may be sufficient for treatment of candidal onychomycosis in an immunocompetent host, but oral antifungal agents are necessary for treatment of patients with immune deficiencies. Table 704.6 outlines the differential diagnosis of onychomycosis.

Table 704.6 Differential Diagnosis of Onychomycosis

Psoriasis
- As in onychomycosis: onycholysis, subungual hyperkeratosis, splinter hemorrhages, leukonychia, dystrophy
- Pitting
- Oil drop sign (a translucent yellow-red discoloration seen in the nail bed)
- Other cutaneous features of psoriasis, family history of psoriasis

Lichen planus
- Cutaneous disease at other sites
- Thin nail plate and ridging
- Dorsal pterygium—scarring at proximal aspect of nail

Trauma
- Nail plate can appear abnormal
- Nail bed should be normal
- Distal onycholysis with repeated trauma
- Single nail affected, shape of nail changed, homogenous alteration of nail color

Eczema
- Irregular buckled nails with ridging
- Cutaneous signs of eczema

Yellow nail syndrome
- Nail plate is discolored green-yellow
- Nails are hard with elevated longitudinal curvature
- Nails may be shed, painful
- Associations with bronchiectasis, lymphedema, and chronic sinusitis

Lamellar onychoschizia (lamellar splitting)
- History of repeated soaking in water
- Usually distal portion of nail
- Periungual squamous cell carcinoma/Bowens disease
- Single nail, warty changes of nail fold; ooze from edge of nail

Malignant melanoma
- Black discoloration of nail plate or nail bed
- Pigment can extend onto nail fold
- Can get associated bleeding

Myxoid (mucous) cyst
- Cyst at base of nail, groove in nail extending length of nail

Alopecia areata
- Pits, longitudinal ridging, brittleness
- Hair loss

From Eisman S, Sinclair R. Fungal nail infection: diagnosis and management. *BMJ.* 2014;348:g1800.

PARONYCHIAL INFLAMMATION

Paronychial inflammation may be acute or chronic and generally involves one or two nail folds on the fingers. Acute paronychia manifests as erythema, warmth, edema, and tenderness of the proximal nail fold, most commonly as a result of pathogenic staphylococci, streptococci, or *Candida* (Fig. 704.11). Warm soaks and oral agents are generally effective; incision and drainage may occasionally be necessary. Development of chronic paronychia follows prolonged immersion in water (Fig. 704.12), such as occurs in finger or thumb sucking; exposure to irritating solutions; nail fold trauma; or diseases including Raynaud phenomenon, collagen vascular diseases, and diabetes. Swelling of the proximal nail fold is followed by separation of the nail fold from the underlying nail plate and suppuration. Foreign material, embedded in the dermis of the nail fold, becomes a nidus for inflammation and secondary infection with *Candida* species and mixed bacterial flora. A combination of attention to predisposing factors, meticulous drying of the hands, and long-term topical antifungal agents and potent topical corticosteroids may be required for successful treatment of chronic paronychia.

Ingrown nail occurs when the lateral edge of the nail, including spicules that have separated from the nail plate, penetrates the soft tissue of

Fig. 704.11 Acute paronychia secondary to *Staphylococcus aureus.*

Fig. 704.12 Chronic paronychia with erythema and lateral nail fold separation.

Fig. 704.13 Clinical features of an 8-yr-old boy upon initial presentation to a dermatology clinic. Findings included yellowish-brown discoloration, hyperkeratosis, transverse ridging, and lateral deviation of the bilateral great toenails. *(From Pollack K, Zlotoff B, Wilson B. Hyperkeratosis and discoloration of the toenails in an 8-year-old. J Pediatr. 2017;189:233.)*

the lateral nail fold. Erythema, edema, and pain, most often involving the lateral great toes, are noted acutely; recurrent episodes may lead to formation of granulation tissue. Predisposing factors include (1) congenital malalignment (especially of the great toes) (Fig.704.13); (2) compression of the side of the toe from poorly fitting shoes, particularly if the great toes are abnormally long and the lateral nail folds are prominent; and (3) improper cutting of the nail in a curvilinear manner rather than straight across. Management includes proper fitting of shoes; allowing the nail to grow out beyond the free edge before cutting it straight across; warm water soaks; oral antibiotics if cellulitis affects the lateral nail fold; and, in severe, recurrent cases, application of silver nitrate to granulation tissue, nail avulsion, or excision of the lateral aspect of the nail followed by matricectomy.

PARONYCHIAL TUMORS

Tumors in the paronychial area include pyogenic granulomas, mucous cysts, subungual exostoses, and junctional nevi. Periungual fibromas that appear in late childhood should suggest a diagnosis of tuberous sclerosis.

Visit Elsevier eBooks+ at eBooks.Health.Elsevier.com for Bibliography.

Chapter 705

Disorders of the Mucous Membranes

Leah Lalor

The mucous membranes may be involved in developmental disorders, genodermatoses, infections, acute and chronic skin diseases, and benign or malignant tumors. This chapter includes some of the more common and more distinctive conditions of the mucous membranes, but is not exhaustive (see also Chapter 695 for erythema multiforme, Stevens-Johnson syndrome, and reactive infectious mucocutaneous eruption [RIME]).

ANGULAR CHEILITIS

Angular cheilitis **(perlèche)** is characterized by inflammation and fissuring at the corners of the mouth, often with associated erosion, maceration, and crusting (Fig. 705.1). Chapping or moisture collection at the angles of the mouth predispose children to developing angular cheilitis. Children who are chronic lip lickers or who have excessive salivation or drooling related to neurologic deficits, orthodontic appliances, or mouth breathing are at increased risk. Atopic dermatitis or contact dermatitis related to toothpaste, chewing gum, mouthwash, or cosmetics are also common causes. Nutritional deficiencies are a less frequent etiology. Protection can be provided by frequent application of a bland ointment such as petrolatum. Candidiasis should be treated with an appropriate antifungal agent, and contact dermatitis of the perioral skin should be treated with a low-potency topical corticosteroid ointment preparation and frequent use of petrolatum or a similar emollient along with avoidance of the offending agent. Correction of the underlying predisposing factors (if possible) will prevent recurrence.

APHTHOUS STOMATITIS (CANKER SORES)

Aphthous stomatitis consists of solitary or multiple painful ulcerations occurring on the labial (Fig. 705.2), buccal, lingual, sublingual, palatal, or gingival mucosa (see Chapter 361). Lesions may manifest initially as erythematous, indurated papules that erode rapidly to form sharply circumscribed, necrotic ulcers with a gray fibrinous exudate and an erythematous halo. Minor aphthous ulcers are 2-10 mm in diameter and heal spontaneously in 7-10 days. Major aphthous ulcers are >10 mm in diameter, take from 10 to 30 days to heal, and may heal with scarring. A third type of aphthous ulceration is herpetiform in appearance,

Fig. 705.1 Angular cheilitis.

Fig. 705.2 Aphthous ulceration on lower lip.

manifesting as a few to numerous grouped 1- to 2-mm lesions, which tend to coalesce into plaques and heal over 7-10 days. Approximately 30% of patients with recurrent lesions have a family history of the disorder (see Chapter 361 for the differential diagnosis).

The etiology of aphthous stomatitis is multifactorial; the condition probably represents an oral manifestation of a number of conditions, including viral infection, inflammatory bowel disease, cyclic neutropenia, and others. Altered local regulation of the cell-mediated immune system, after activation and accumulation of cytotoxic T cells, may contribute to the localized mucosal breakdown. It is a common misconception that aphthous stomatitis is a manifestation of herpes simplex virus infection. Recurrent herpes infections remain localized to the lips and rarely cross the mucocutaneous junction; involvement of the oral mucosa occurs only in primary infections.

Treatment of aphthous stomatitis is supportive. The majority of mild cases do not require therapy. Relief of pain, particularly before eating, may be achieved with the use of a topical anesthetic such as viscous lidocaine or an oral rinse with a combined solution of elixir of diphenhydramine, viscous lidocaine, and an oral antacid. Caution must be taken to avoid hot food and drink after topical anesthetic use. A superpotent topical corticosteroid in a mucosa-adhering agent may help to reduce inflammation, and topical tetracycline mouthwash may also hasten healing. In severe, debilitating cases, systemic therapy with corticosteroids, colchicine, dapsone, or thalidomide may be helpful.

FORDYCE SPOTS

Fordyce spots (Fordyce granules) are clusters of asymptomatic, 1- to 3-mm, yellow-white macules and papules on the vermilion lips and buccal mucosa. They are a common clinical finding and represent a normal anatomic variant of sebaceous glands. They can present in either sex from infancy to adulthood and may become more prominent during puberty due to the influence of androgens. No therapy is required.

EPSTEIN PEARLS (GINGIVAL CYSTS OF THE NEWBORN)

Epstein pearls are white, keratin-containing cysts on the palatal or alveolar mucosa of approximately 60–85% of neonates. They are epidermal inclusion cysts that form when the soft and hard palates fuse and are analogous to facial milia. They cause no symptoms and are generally shed within a few weeks; no therapy is necessary.

MUCOCELE

Mucus retention cysts are painless, fluctuant, tense, 2- to 10-mm, bluish papules on the lips (Fig. 705.3), tongue, palate, or buccal mucosa. Traumatic severance of the duct of a minor salivary gland leads to submucosal retention of mucus secretion. Lesions on the floor of the mouth are known as *ranulas* when the sublingual or submandibular salivary gland ducts are involved. Fluctuations in size are typical, and the lesions may disappear temporarily after traumatic rupture. Recurrence is prevented by surgical excision of the mucus deposit and associated salivary gland(s).

Fig. 705.3 Mucocele on lower lip.

FISSURED TONGUE

Fissured tongue (scrotal tongue, or lingua plicata) is a common benign developmental anomaly of the tongue. The dorsal tongue has many folds with deep grooves and a pebbled appearance. Fissured tongue can be seen in individuals with Melkersson-Rosenthal syndrome and Down syndrome, and it is often seen in association with geographic tongue. Food particles and debris may become trapped in the fissures, resulting in irritation, inflammation, and halitosis. Careful cleansing with a mouth rinse and soft-bristled toothbrush is recommended.

GEOGRAPHIC TONGUE (BENIGN MIGRATORY GLOSSITIS)

Geographic tongue consists of single or multiple sharply demarcated, irregular, smooth, red patches surrounded by an elevated yellowish-white serpiginous border on the dorsum of the tongue. Onset is rapid, and the pattern may change over hours to days. The smooth patches correspond to atrophic filiform papillae, and the elevated margins represent hypertrophic papillae (Fig. 705.4). The etiology of this condition remains unclear, though it is associated with some inflammatory disorders of the skin like psoriasis. Lesions are typically asymptomatic, but some patients may experience a burning sensation or sensitivity to spicy, hot, or cold foods. No therapy other than reassurance is necessary.

Fig. 705.4 Geographic tongue.

BLACK HAIRY TONGUE

Black hairy tongue is a dark coating on the dorsum of the tongue caused by hyperplasia and elongation of the filiform papillae; overgrowth of chromogenic bacteria and fungi and entrapped pigmented residues that adsorb to microbial plaque and desquamating keratin may contribute to the dark coloration. Changes often begin posteriorly and extend anteriorly on the dorsum of the tongue. The condition is most common in adults but may also manifest during adolescence. Poor oral hygiene, lack of oral feeding, treatment with systemic antibiotics such as tetracycline (which promote the growth of *Candida* spp.), and smoking are predisposing factors. Improved oral hygiene and brushing with a soft-bristled toothbrush may be all that is necessary for treatment.

ORAL HAIRY LEUKOPLAKIA

Oral hairy leukoplakia occurs in approximately 25% of patients with AIDS but is rare in the pediatric population. It manifests as corrugated and shaggy white plaques on the lateral margins of the tongue, which cannot be removed by rubbing. The lesions occasionally may spread to the ventral tongue surface, floor of the mouth, tonsillar pillars, and pharynx. The condition is caused by Epstein-Barr virus, which is present in the upper layer of the affected epithelium. The plaques have no malignant potential. The disorder occurs predominantly in HIV-infected patients but may also be found in individuals who are immunosuppressed for other reasons, such as organ transplantation, leukemia, chemotherapy, and long-term use of inhaled steroids. The condition is generally asymptomatic and does not require therapy.

ACUTE NECROTIZING ULCERATIVE GINGIVITIS (VINCENT STOMATITIS, FUSOSPIROCHETAL GINGIVITIS, TRENCH MOUTH)

Acute necrotizing ulcerative gingivitis manifests as painful, punched-out ulceration, necrosis, and bleeding of the interdental papillae. A grayish-white pseudomembrane may cover the ulcerations. Lesions may spread to involve the buccal mucosa, lips, tongue, tonsils, and pharynx and may be associated with dental pain, a bad taste, low-grade fever, and lymphadenopathy. It occurs most commonly in the second or third decade, particularly in the context of poor dental hygiene, poor nutrition, smoking, and stress.

NOMA

Noma is a severe form of fusospirillary gangrenous stomatitis that occurs primarily in malnourished, impoverished children 2-5 years of age who have had a preceding illness such as measles, scarlet fever, tuberculosis, malignancy, or immunodeficiency. The disease is most prevalent in Africa but also occurs in Asia and Latin America. Sporadic cases associated with immunodeficiency have been reported in developed countries. It manifests as a painful, red, indurated papule on the alveolar margin, followed by ulceration and mutilating gangrenous destruction of tissue in the oronasal region. The process may also involve the scalp, neck, shoulders, perineum, and vulva. Noma neonatorum manifests in the first month of life as gangrenous lesions of the lips, nose, mouth, and anal regions. Affected infants are usually small for gestational age, malnourished, premature, and frequently ill (particularly with *Pseudomonas aeruginosa* sepsis). Care consists of nutritional support, conservative debridement of necrotic soft tissues, empirical broad-spectrum antibiotics such as penicillin and metronidazole, and, in the case of noma neonatorum, antipseudomonal antibiotics (see Chapter 62).

PTEN HAMARTOMA SYNDROME (COWDEN SYNDROME)

PTEN hamartoma syndrome is an autosomal dominant condition caused by loss-of-function pathogenic variants in the *PTEN* tumor-suppressor gene. Mucocutaneous lesions typically appear in the second or third decade. Oral papillomas are 1- to 3-mm, smooth, pink or whitish papules on the palatal, gingival, buccal, and labial mucosae and may coalesce into a cobblestone appearance. Numerous flesh-colored papules also develop on the face, particularly around the mouth, nose, and ears. These papules are most commonly trichilemmomas, a benign neoplasm of the hair follicle. Associated findings may include acral keratoses, thyroid adenoma, goiter, gastrointestinal polyps, fibrocystic breast nodules, and carcinoma of the breast or thyroid.

Herpes Simplex Virus Infection

Herpes simplex virus (HSV) types 1 and 2 commonly cause primary and recurrent infection, resulting in grouped vesicles on oral, nasal, and genital mucosae.

Erythema Multiforme

Erythema multiforme (EM) is an uncommon disorder of mucocutaneous blistering typically on the labial mucosa and acral skin as a reaction to HSV infection. Please see Chapter 695.1 for more detail.

Stevens-Johnson Syndrome

Stevens-Johnson syndrome (SJS) is an uncommon disorder of skin sloughing that occurs primarily after exposure to a medication. It can have extensive mucosal involvement in addition to skin. Please see Chapter 695.3 for more detail.

Reactive Infectious Mucocutaneous Eruption (Formerly Mycoplasma-Induced Rash and Mucositis)

This condition is on the spectrum of SJS and toxic epidermal necrolysis (TEN), but tends to be triggered by various infections and has more mucosal involvement than cutaneous. Please see Chapter 695.2 for more detail.

Lichen Sclerosus

Lichen sclerosus is a rare disorder of genital mucosa typically seen in young girls and elderly women. It manifests as pink and white atrophic genital mucosa that can be associated with pain, dysuria, constipation, and bleeding. Please see Chapter 586 for more details.

Visit Elsevier eBooks+ at eBooks.Health.Elsevier.com for Bibliography.

Chapter 706

Cutaneous Bacterial Infections

706.1 Impetigo

Stephen R. Humphrey

ETIOLOGY/PATHOGENESIS

Impetigo is the most common skin infection in children throughout the world. Invasive *Staphylococcus aureus* has a global incidence of approximately 20-50 cases/100,000 population per year. There are two classic forms of impetigo: nonbullous and bullous.

S. aureus is the predominant organism of **nonbullous impetigo** in the United States (see Chapter 227); group A β-hemolytic streptococci (GABHS) are implicated in the development of some lesions (see Chapter 229). The staphylococcal types that cause nonbullous impetigo are variable but are not generally from phage group 2, the group that is associated with scalded skin and toxic shock syndromes. Staphylococci generally spread from the nose to normal skin and then infect the skin. In contrast, the skin becomes colonized with GABHS an average of 10 days before development of impetigo. The skin serves as the source for acquisition of GABHS and is the probable primary source for the spread of impetigo. Lesions of nonbullous impetigo that grow staphylococci in culture cannot be distinguished clinically from those that grow pure cultures of GABHS.

Bullous impetigo is always caused by *S. aureus* strains that produce exfoliative toxins. The staphylococcal exfoliative toxins (ETA, ETB, ETD) blister the superficial epidermis by hydrolyzing human desmoglein 1, resulting in a subcorneal vesicle. This is also the target antigen of the autoantibodies in pemphigus foliaceus.

CLINICAL MANIFESTATIONS

Nonbullous Impetigo

Nonbullous impetigo accounts for more than 70% of cases. Lesions typically begin on the skin of the face or on extremities that have been traumatized. The most common lesions that precede nonbullous impetigo are insect bites, abrasions, lacerations, chickenpox, scabies pediculosis, and burns. A tiny vesicle or pustule forms initially and rapidly develops into a honey-colored crusted plaque that is generally <2 cm in diameter (Fig. 706.1). The infection may be spread to other parts of the body by the fingers, clothing, and towels. Lesions are associated with little to no pain or surrounding erythema, and constitutional symptoms are generally absent. Pruritus occurs occasionally, regional adenopathy is found in up to 90% of cases, and leukocytosis is present in approximately 50%.

Fig. 706.1 Multiple crusted and oozing lesions of impetigo.

Bullous Impetigo

Bullous impetigo is mainly an infection of infants and young children. Flaccid, transparent bullae develop most commonly on skin of the face, buttocks, trunk, perineum, and extremities. **Neonatal bullous impetigo** can begin in the diaper area. Rupture of a bulla occurs easily, leaving a narrow rim of scale at the edge of a shallow, moist erosion. Surrounding erythema and regional adenopathy are generally absent. Unlike those of nonbullous impetigo, lesions of bullous impetigo are a manifestation of localized staphylococcal scalded skin syndrome and develop on intact skin.

Differential Diagnosis

The differential diagnosis of **nonbullous impetigo** includes viruses (herpes simplex, varicella-zoster), fungi (tinea corporis, kerion), arthropod bites, and parasitic infestations (scabies, pediculosis capitis), all of which may become impetiginized.

The differential diagnosis of **bullous impetigo** in neonates includes epidermolysis bullosa, bullous mastocytosis, herpetic infection, and early staphylococcal scalded skin syndrome. In older children, allergic contact dermatitis, burns, erythema multiforme, linear immunoglobulin A dermatosis, pemphigus, and bullous pemphigoid must be considered, particularly if the lesions do not respond to therapy.

COMPLICATIONS

Potential but *very rare* complications of either nonbullous or bullous impetigo include bacteremia with subsequent osteomyelitis, septic arthritis, pneumonia, and septicemia. Positive blood culture results are *very rare* in otherwise healthy children with localized lesions. Cellulitis has been reported in up to 10% of patients with nonbullous impetigo and rarely follows the bullous form. Lymphangitis, suppurative lymphadenitis, guttate psoriasis, and scarlet fever occasionally follow streptococcal disease. There is no correlation between the number of lesions and clinical involvement of the lymphatics or development of cellulitis in association with streptococcal impetigo.

Infection with nephritogenic strains of GABHS may result in **acute poststreptococcal glomerulonephritis** (see Chapter 559.4). The clinical character of impetigo lesions does not predict the development of poststreptococcal glomerulonephritis. Children 3-7 years of age are most commonly affected. The latent period from onset of impetigo to development of poststreptococcal glomerulonephritis averages 18-21 days, which is longer than the 10-day latency period after pharyngitis. Poststreptococcal glomerulonephritis occurs epidemically after either pharyngeal or skin infection. Impetigo-associated epidemics have been caused by M groups 2, 49, 53, 55, 56, 57, and 60. Strains of GABHS that are associated with endemic impetigo in the United States have little or no nephritogenic potential. Acute rheumatic fever does not occur as a result of impetigo.

TREATMENT

The decision on how to treat impetigo depends on the number of lesions and their locations. Topical therapy with mupirocin 2% and retapamulin 1% 2-3 times a day for 10-14 days is acceptable for localized disease caused by *S. aureus,* though there are resistant strains to these topical antibiotics.

Systemic therapy with oral antibiotics should be prescribed for patients with streptococcal or widespread involvement of staphylococcal infections; when lesions are near the mouth, where topical medication may be licked off; or in cases with evidence of deep involvement, including cellulitis, furunculosis, abscess formation, or suppurative lymphadenitis. Cephalexin 25-50 mg/kg/day in three to four divided doses for 7 days is an excellent choice for initial therapy. A culture should be performed, as the emergence of methicillin-resistant *S. aureus* (MRSA) typically requires a different antibiotic choice based on antibiotic susceptibility patterns. If MRSA is suspected, clindamycin, doxycycline, or sulfamethoxazole-trimethoprim is indicated. No evidence suggests that a 10-day course of therapy is superior to a 7-day course; twice-daily

sulfamethoxazole trimethoprim for 3 days has been comparable to once daily for 5 days. Benzathine benzylpenicillin IM has been used when compliance with multiple-dose and -day oral antibiotics may be poor.

Visit Elsevier eBooks+ at eBooks.Health.Elsevier.com for Bibliography.

706.2 Subcutaneous Tissue Infections

Stephen R. Humphrey

The principal determinations for soft tissue infection are whether it is *nonnecrotizing* or *necrotizing* and *purulent* or *nonpurulent*. Nonnecrotizing, nonpurulent lesions respond to antibiotic therapy alone, whereas necrotizing or purulent (abscess) lesions require prompt surgical removal of all devitalized tissue in addition to antimicrobial therapy. Necrotizing soft tissue infections are life-threatening conditions that are characterized by rapidly advancing local tissue destruction and systemic toxicity, including shock. Tissue necrosis distinguishes soft tissue infections from cellulitis. In cellulitis, an inflammatory infectious process involves subcutaneous tissue but does not destroy it. Necrotizing soft tissue infections may initially manifest with a paucity of early cutaneous signs relative to the rapidity and degree of destruction of the subcutaneous tissues.

CELLULITIS

Etiology

Cellulitis is characterized by infection and inflammation of loose connective tissue, with limited involvement of the dermis and relative sparing of the epidermis. A break in the skin from previous trauma, insect bite, surgery, or an underlying skin lesion predisposes to cellulitis. Cellulitis is also more common in individuals with lymphatic stasis, diabetes mellitus, or immunosuppression.

S. aureus and *Streptococcus pyogenes* (group A streptococcus) are the most common etiologic agents. In patients who are immunocompromised or have diabetes mellitus, other bacterial or fungal agents may be involved, notably *Pseudomonas aeruginosa; Aeromonas hydrophila* and, occasionally, other Enterobacteriaceae; *Legionella* spp.; the Mucorales, particularly *Rhizopus* spp., *Mucor* spp., and *Absidia* spp.; and *Cryptococcus neoformans.* Children with relapsed nephrotic syndrome may experience cellulitis caused by *Escherichia coli.* In children 3 months to 5 years of age, *Haemophilus influenzae* type b was once an important cause of facial cellulitis, but its incidence has declined significantly since the institution of immunization against this organism.

Environmental risk factors include exposure to fish, shellfish, and meats *(Erysipelothrix rhusiopathiae)*; salt water, or brackish inland waterways *(Vibrio vulnificus)*; penetrating trauma (mixed pathogens including *Clostridium perfringens*); and human or animal bites (see Chapter 765) (Table 706.1).

Table 706.1 Special Considerations for Causes of Cellulitis

SETTING OR EXPOSURE	CAUSES OF CELLULITIS
Cat or dog bites	*Pasteurella* species, *Capnocytophaga canimorsus*
Penetrating trauma	*Staphylococcus aureus*
Freshwater immersion	*Aeromonas hydrophila*
Saltwater immersion	*Vibrio* species
Freshwater, saltwater fish	*Streptococcus iniae*
Swine, poultry, fish	*Erysipelothrix rhusiopathiae*
Periorbital or facial cellulitis	*Haemophilus influenzae, Streptococcus pneumoniae*
Neutropenia	*Pseudomonas aeruginosa*, other gram-negative bacilli
Human immunodeficiency virus infection	*Helicobacter cinaedi*
Acute varicella	*Streptococcus pyogenes*
Immunosuppression	*Cryptococcus neoformans*

From Long SS, Prober CG, Fischer M. *Principles and Practice of Pediatric Infectious Diseases*, 5th ed. Philadelphia: Elsevier; 2018: Table 68.3, p. 444.

Clinical Manifestations

Cellulitis manifests clinically as a localized area of edema, warmth, erythema, and tenderness. The lateral margins tend to be indistinct because the process is deep in the skin, primarily involving the subcutaneous tissues in addition to the dermis. Application of pressure may produce pitting. Although distinction cannot be made with certainty in any particular patient, cellulitis due to *S. aureus* tends to be more localized and may suppurate, whereas infections caused by *S. pyogenes* (group A streptococci) tend to spread more rapidly and may be associated with lymphangitis. Regional adenopathy and constitutional signs and symptoms such as fever, chills, and malaise are common. Complications of cellulitis are uncommon but include subcutaneous abscess, bacteremia, osteomyelitis, septic arthritis, thrombophlebitis, endocarditis, and necrotizing fasciitis. Lymphangitis or glomerulonephritis can also follow infection with *S. pyogenes.*

Diagnosis

Cellulitis in a neonate should prompt assessment for invasive bacterial infection, including blood culture; lumbar puncture is also usually performed, though its necessity for mild cases of cellulitis is controversial in this age-group. In older children, cultures of blood or cutaneous aspirates, biopsies, or swabs are not routinely recommended. However, blood cultures should be considered if the patient is younger than 1 year of age, if signs of systemic toxicity are present, if an adequate examination cannot be carried out, or if an immunocompromising condition (e.g., malignancy, neutropenia, or neutrophil functional defects) is present. Aspirates from the site of inflammation, skin biopsy, and blood cultures allow identification of the causal organism in approximately 25% of cases of cellulitis. Yield of the causative organism is approximately 30% when the site of origin of the cellulitis is apparent, such as an abrasion or ulcer. An aspirate taken from the point of maximum inflammation yields the causal organism more often than a leading-edge aspirate. Lack of success in isolating an organism stems primarily from the low number of organisms present within the lesion. Ultrasonography can be performed if an associated subcutaneous abscess is suspected and may be helpful in cases where there is uncertainty if there a drainable fluid collection is present.

The differential diagnosis includes an exuberant immune-allergic reaction to insect bites, particularly mosquito bites (Skeeter syndromes) (see Chapter 187). **Skeeter syndrome** is characterized by swelling disproportionate to erythema; there is pruritus but usually no tenderness. In addition, **cold panniculitis** may appear as an erythematous, but usually nontender, swelling after exposure to cold, such as sledding or eating a cold Popsicle (see Chapter 701.1).

Treatment

Empirical antibiotic therapy for cellulitis and the initial route of administration should be guided by the age and immune status of the patient, history of the illness, and location and severity of the cellulitis.

Neonates should receive an intravenous antibiotic with a β-lactamase–stable antistaphylococcal antibiotic such as nafcillin, cefazolin, or vancomycin, and an aminoglycoside such as gentamicin or a third-generation cephalosporin such as cefotaxime.

In infants and children older than 2 months with mild to moderate infections, particularly if fever, lymphadenopathy, and other constitutional signs are absent, treatment of cellulitis may be initiated orally on an outpatient basis with a penicillinase-resistant penicillin such as dicloxacillin or a first-generation cephalosporin such as cephalexin or, if MRSA is suspected, with clindamycin. Some recommend trimethoprim-sulfamethoxazole, although it does not provide ideal

coverage against *S. pyogenes,* a potential cause of cellulitis *without* abscess.

Intravenous antibiotics may be necessary if improvement is not noted or the disease progresses significantly in the first 24-48 hours of therapy. Infants and children older than 2 months with signs of systemic infection, including fever, lymphadenopathy, or constitutional signs, also require hospitalization and treatment with intravenous antibiotics effective against *S. pyogenes* and *S. aureus,* such as clindamycin or a first-generation cephalosporin (cefazolin). If the child is severely ill or toxic appearing, consideration should be given to the addition of clindamycin or vancomycin if these antibiotics were not started initially. Other agents for complicated skin and skin structure infections caused by MRSA or *S. pyogenes* have been approved by the U.S. Food and Drug Administration (FDA) in adults, including dalbavancin (IV given once weekly), ceftaroline (IV), telavancin (IV), linezolid (oral or IV), tedizolid (oral or IV), and oritavancin (IV). Dalbavancin also provides activity against vancomycin-resistant enterococci.

In unimmunized patients, antibiotic treatment may include a third-generation cephalosporin (cefepime, ceftriaxone, or, if available, cefotaxime) or a β-lactam/β-lactamase inhibitor combination (e.g., ampicillin-sulbactam), which provides coverage for *H. influenzae* type b and *Streptococcus pneumoniae*.

Once the erythema, warmth, edema, and fever have decreased significantly, a 5- to 7-day total course of treatment may be completed on an outpatient basis, though treatment should be extended if the infection has not substantially improved with this period. Elevation of an affected limb, particularly early in the course of therapy, may help reduce swelling and pain. If present, a subcutaneous abscess should be drained.

NECROTIZING FASCIITIS

Etiology

Necrotizing fasciitis is a subcutaneous tissue infection that involves the deep layer of superficial fascia but may spare adjacent epidermis, deep fascia, and muscle.

Relatively few organisms possess sufficient virulence to cause necrotizing fasciitis when acting alone. Most (55–75%) cases of necrotizing fasciitis are polymicrobial **(synergistic or type 1 necrotizing fasciitis)**, with an average of four different organisms isolated. The organisms most commonly isolated in polymicrobial necrotizing fasciitis are *S. aureus,* streptococcal species, *Klebsiella* species, *E. coli,* and anaerobic bacteria.

The rest of the cases **(type 2)** and the most fulminant infections, associated with toxic shock syndrome and a high case-fatality rate, are usually caused by *S. pyogenes* (group A streptococcus) (see Chapter 229). Streptococcal necrotizing fasciitis may occur in the absence of toxic shock-like syndrome and is potentially fatal and associated with substantial morbidity. Necrotizing fasciitis can occasionally be caused by *S. aureus; C. perfringens; Clostridium septicum; P. aeruginosa; Vibrio* spp., particularly *V. vulnificus;* and fungi of the order Mucorales, particularly *Rhizopus* spp., *Mucor* spp., and *Absidia* spp. Necrotizing fasciitis has also been reported on rare occasions to result from nongroup A streptococci such as group B, C, F, or G streptococci; *S. pneumoniae;* or *H. influenzae* type b.

Infections caused by any organism or combination of organisms cannot be distinguished clinically from one another, although development of *crepitus* signals the presence of gas-forming organisms: *Clostridium* spp. or gram-negative bacilli such as *E. coli, Klebsiella, Proteus,* or *Aeromonas.*

Clinical Manifestations

Necrotizing fasciitis may occur anywhere on the body but most often on the extremities or areas of trauma. The incidence of necrotizing fasciitis is highest in hosts with systemic or local tissue immunocompromise, such as those with diabetes mellitus, neoplasia, or peripheral vascular disease, and those who have recently undergone surgery, who use IV drugs, or who are undergoing immunosuppressive treatment, particularly with corticosteroids. The infection can also occur in healthy individuals after minor puncture wounds, abrasions, or lacerations; blunt trauma; surgical procedures, particularly of the abdomen, gastrointestinal or genitourinary tracts, or the perineum; or hypodermic needle injection.

There is a resurgence of fulminant necrotizing soft tissue infections caused by *S. pyogenes,* which may occur in previously healthy individuals. Streptococcal necrotizing fasciitis is classically located on an extremity. There may be a history of recent trauma to or operation in the area. Necrotizing fasciitis due to *S. pyogenes* may also occur after superinfection of varicella lesions. Children with this disease have tended to display onset, recrudescence, or persistence of high fever and signs of toxicity after the third or fourth day of varicella. Common predisposing conditions in neonates are omphalitis and balanitis after circumcision.

Necrotizing fasciitis begins with acute onset of local, and at times tense, edema with erythema, tenderness, and heat. Fever is usually present, and pain, tenderness, and constitutional signs are disproportionate to cutaneous signs, especially with involvement of fascia and muscle. Tachycardia is out of proportion to the fever. Lymphangitis and lymphadenitis may or may not be present. The infection advances along the superficial fascial plane, and initially there may be few cutaneous signs to herald the serious nature and extent of the subcutaneous tissue necrosis that is occurring. Skin changes may appear over 24-48 hours as nutrient vessels are thrombosed and cutaneous ischemia develops. Early clinical findings include ill-defined cutaneous erythema and edema that extends beyond the area of erythema. *There is intense pain on movement.* Additional signs include formation of bullae filled initially with straw-colored and later bluish to hemorrhagic fluid and darkening of affected tissues from red to purple to blue. Skin anesthesia and, finally, frank tissue gangrene and slough develop owing to the ischemia and necrosis. Vesiculation or bulla formation, ecchymoses, crepitus, anesthesia, and necrosis are ominous signs indicative of advanced disease. Children with varicella lesions may initially show no cutaneous signs of superinfection with invasive *S. pyogenes,* such as erythema or swelling. Significant systemic toxicity may accompany necrotizing fasciitis, including shock, organ failure, and death. Advance of the infection in this setting can be rapid, progressing to death within hours. Patients with involvement of the superficial or deep fascia and muscle tend to be more acutely and systemically ill and have more rapidly advancing disease than those with infection confined solely to subcutaneous tissues above the fascia. There is often hyponatremia (<135 mg/L), an elevated CRP (>20 mg/L), and extreme leukocytosis. In an extremity, **compartment syndrome** may develop, manifesting as tight edema, pain on motion, and loss of distal sensation and pulses; this is a surgical emergency (see Chapter 80).

Diagnosis

Definitive diagnosis of necrotizing fasciitis is made by surgical exploration, which should be undertaken as soon as the diagnosis is suspected. Necrotic fascia and subcutaneous tissue are gray and offer little resistance to blunt probing. Although MRI aids in delineating the extent and tissue planes of involvement, these procedures should not delay surgical intervention. Frozen-section incisional biopsy specimens obtained early in the course of the infection can aid management by decreasing the time to diagnosis and helping to establish the margins of involvement. Gram staining of tissue can be particularly useful if chains of gram-positive cocci, indicative of infection with *S. pyogenes,* are seen.

Treatment

Early supportive care, surgical debridement, and parenteral antibiotic administration are mandatory for necrotizing fasciitis. All devitalized tissue should be removed to freely bleeding edges, and repeat exploration is generally indicated within 24-36 hours to confirm that no necrotic tissue remains. This procedure may need to be repeated on several occasions until devitalized tissue has ceased to form. Meticulous daily wound care is also paramount.

Parenteral antibiotic therapy should be initiated as soon as possible with broad-spectrum agents against all potential pathogens. Initial empirical therapy should be instituted with vancomycin, linezolid,

or daptomycin to cover gram-positive organisms and piperacillin-tazobactam to cover gram-negative organisms. An alternative is to add ceftriaxone with metronidazole to cover mixed aerobic-anaerobic organisms. Definitive therapy should then be based on sensitivity of isolated organisms. Penicillin with clindamycin is indicated for necrotizing fasciitis caused by either group A streptococcus or *Clostridium* spp. For group A streptococcus infections, clindamycin is administered until the patient is hemodynamically stable and no longer requires surgical debridement. Unlike penicillin, the effectiveness of clindamycin is not influenced by the infectious burden or bacterial stage of growth; thus its addition early in the course of infection may lead to more rapid bacterial killing. Doxycycline plus either ciprofloxacin or ceftazidime is recommended for *V. vulnificus* necrotizing fasciitis. Duration of therapy for necrotizing fasciitis depends on the course of the illness. Antibiotics are generally continued for at least 5 days after signs and symptoms of local signs and symptoms have resolved; the typical duration of therapy is 4 weeks. Many centers employ hyperbaric oxygen therapy, although it should not delay resuscitation of shock or surgical debridement.

Prognosis

The combined case-fatality rate among children and adults with necrotizing fasciitis and syndrome due to polymicrobial infection or *S. pyogenes* has been as high as 60%. However, death is less common in children and in cases not complicated by toxic shock–like syndrome.

Visit Elsevier eBooks+ at eBooks.Health.Elsevier.com for Bibliography.

706.3 Staphylococcal Scalded Skin Syndrome (Ritter Disease)

Stephen R. Humphrey

ETIOLOGY AND PATHOGENESIS

Staphylococcal scalded skin syndrome is caused predominantly by phage group 2 staphylococci, particularly strains 71 and 55, which are present at localized sites of infection. Foci of infection include the nasopharynx and, less commonly, the umbilicus, urinary tract, a superficial abrasion, conjunctivae, and blood. The clinical manifestations of staphylococcal scalded skin syndrome are mediated by hematogenous spread in the absence of specific antitoxin antibody of staphylococcal epidermolytic or exfoliative toxins A or B. The toxins have reproduced the disease in both animal models and human volunteers. Decreased renal clearance of the toxins may account for the fact that the disease is most common in infants and young children, as well as a lack of protection from antitoxin antibodies. Epidermolytic toxin A is heat stable and is encoded by bacterial chromosomal genes. Epidermolytic toxin B is heat labile and is encoded on a 37.5-kb plasmid. The site of blister cleavage is subcorneal. The epidermolytic toxins produce the split by binding to and cleaving desmoglein 1. Intact bullae are consistently sterile, unlike those of bullous impetigo, but culture specimens should be obtained from all suspected sites of localized infection and from the blood to identify the source for elaboration of the epidermolytic toxins.

CLINICAL MANIFESTATIONS

Staphylococcal scalded skin syndrome, which occurs predominantly in infants and children younger than 5 years of age, includes a range of disease from localized bullous impetigo to generalized cutaneous involvement with systemic illness. Onset of the rash may be preceded by malaise, fever, irritability, and exquisite tenderness of the skin. **Scarlatiniform erythema** develops diffusely and is accentuated in flexural and periorificial areas. The conjunctivae are inflamed and occasionally become purulent. The brightly erythematous skin may rapidly acquire a wrinkled appearance, and in severe cases, sterile, flaccid blisters and erosions develop diffusely. Circumoral erythema is characteristically prominent, as is radial crusting and fissuring around the eyes, mouth, and nose. At this stage, areas of the epidermis may separate in response to gentle shear force (Nikolsky sign; Fig. 706.2). As large sheets of epidermis peel away, moist, glistening, denuded areas become apparent, initially in the flexures and subsequently over much of the body surface (Fig. 706.3). This development may lead to secondary cutaneous infection, sepsis, and fluid and electrolyte disturbances. The desquamative phase begins after 2-5 days of cutaneous erythema; healing occurs without scarring in 10-14 days. Patients may have pharyngitis, conjunctivitis, and superficial erosions of the lips, but intraoral mucosal surfaces are spared. Although some patients appear ill, many are reasonably comfortable except for the marked skin tenderness.

DIFFERENTIAL DIAGNOSIS

A presumed forme fruste of the disease manifests as diffuse, scarlatiniform, tender erythroderma that is accentuated in the flexural areas but does not progress to blister formation. In patients with this form, Nikolsky sign may be absent. Although the exanthem is similar to that of streptococcal scarlet fever, strawberry tongue and palatal petechiae are absent. Staphylococcal scalded skin syndrome may be mistaken for a number of other blistering and exfoliating disorders, including

Fig. 706.2 Nikolsky sign. With slight thumb pressure the skin wrinkles, slides laterally, and separates from the dermis. *(From Habif TP, ed. Clinical Dermatology, 4th ed. Philadelphia: Mosby; 2004.)*

Fig. 706.3 Infant with staphylococcal scalded skin syndrome.

bullous impetigo, epidermolysis bullosa, epidermolytic hyperkeratosis, pemphigus, drug eruption, erythema multiforme, and drug-induced toxic epidermal necrolysis. Toxic epidermal necrolysis can often be distinguished by a history of drug ingestion, the presence of Nikolsky sign only at sites of erythema, the absence of perioral crusting, full-thickness epidermal necrosis, and a blister cleavage plane in the lowermost epidermis.

HISTOLOGY

A subcorneal, granular layer split can be identified on skin biopsy. Absence of an inflammatory infiltrate is characteristic. Histology is identical to that seen in pemphigus foliaceus, bullous impetigo, and subcorneal pustular dermatosis.

TREATMENT

Systemic therapy, given either orally in cases of localized involvement or parenterally with a semisynthetic antistaphylococcal penicillin (e.g., nafcillin), first-generation cephalosporin (e.g., cefazolin), clindamycin, or vancomycin if MRSA is considered, should be prescribed. Clindamycin is typically used *in addition* to other agents to inhibit bacterial protein (toxin) synthesis; however, it may not provide any additional coverage compared with cephalosporins unless there is high MRSA community prevalence. The skin should be gently moistened and cleansed. Application of an emollient provides lubrication and decreases discomfort. Topical antibiotics are unnecessary. In neonates, or in infants or children with severe infection, hospitalization is mandatory, with attention to fluid and electrolyte management, infection control measures, pain management, and meticulous wound care with contact isolation. In particularly severe disease, care in an intensive care or burn unit is required. Recovery is usually rapid, but complications, such as excessive fluid loss, electrolyte imbalance, faulty temperature regulation, pneumonia, septicemia, and cellulitis, may cause increased morbidity.

Visit Elsevier eBooks+ at eBooks.Health.Elsevier.com for Bibliography.

706.4 Ecthyma

Stephen R. Humphrey

See also Chapters 227, 229, and 251.

Ecthyma resembles nonbullous impetigo in onset and appearance but gradually evolves into a deeper, more chronic infection. The initial lesion is a vesicle or vesicular pustule with an erythematous base that erodes through the epidermis into the dermis to form an ulcer with elevated margins. The ulcer becomes obscured by a dry, heaped-up, tightly adherent crust (Fig. 706.4) that contributes to the persistence of the infection and scar formation. Lesions may be spread by autoinoculation, may be as large as 4 cm, and occur most frequently on the legs. Predisposing factors include the presence of pruritic lesions, such as insect bites, scabies, or pediculosis, that are subject to frequent scratching; poor hygiene; and malnutrition. Complications include lymphangitis, cellulitis, and, rarely, poststreptococcal glomerulonephritis. The causative agent is usually GABHS; *S. aureus* is also cultured from most lesions but is probably a secondary pathogen. Crusts should be softened with warm compresses and removed. Systemic antibiotic therapy, as for impetigo, is indicated; almost all lesions are responsive to treatment with penicillin.

Ecthyma gangrenosum is a necrotic ulcer covered with a gray-black eschar. It is usually a sign of *P. aeruginosa* infection, most often occurring in immunosuppressed patients. Neutropenia is a risk factor for ecthyma gangrenosum, including variants such as chronic, cyclic, and transient neutropenia. Ecthyma gangrenosum occurs in up to 6% of patients with systemic *P. aeruginosa* infection but can also occur as a primary cutaneous infection by inoculation. The lesion begins as a red or purpuric macule that vesiculates and then ulcerates. There is a surrounding rim of pink to violaceous skin. The punched-out ulcer develops raised edges with a dense, black, depressed, crusted center.

Fig. 706.4 Dry, tightly adherent crust in ecthyma.

Lesions may be single or multiple. Patients with bacteremia commonly have lesions in apocrine areas. Clinically similar lesions may also develop as a result of infection with other agents, such as *S. aureus, A. hydrophila, Enterobacter* spp., *Proteus* spp., *Burkholderia cepacia, Serratia marcescens, Aspergillus* spp., Mucorales, *E. coli,* and *Candida* spp. There is bacterial invasion of the adventitia and media of dermal veins but not arteries. The intima and lumina are spared. Blood and skin biopsy specimens for culture should be obtained, and empirical broad-spectrum, systemic therapy that includes coverage for *P. aeruginosa* (e.g., antipseudomonal penicillin or cephalosporin and an aminoglycoside) should be initiated as soon as possible.

Visit Elsevier eBooks+ at eBooks.Health.Elsevier.com for Bibliography.

706.5 Other Cutaneous Bacterial Infections

Stephen R. Humphrey

BLASTOMYCOSIS-LIKE PYODERMA (PYODERMA VEGETANS)

Blastomycosis-like pyoderma is an exuberant cutaneous reaction to bacterial infection that occurs primarily in children who are malnourished and immunosuppressed. The organisms most commonly isolated from lesions are *S. aureus* and group A streptococcus, but several other organisms have been associated with these lesions, including *P. aeruginosa, Proteus mirabilis,* diphtheroids, *Bacillus* spp., and *C. perfringens.* Crusted, hyperplastic plaques on the extremities are characteristic, sometimes forming from the coalescence of many pinpoint, purulent, crusted abscesses (Fig. 706.5). Ulceration and sinus tract formation may develop, and additional lesions may appear at sites distant from the site of inoculation. Regional lymphadenopathy is common, but fever is not. Histopathologic examination reveals pseudoepitheliomatous hyperplasia and microabscesses composed of neutrophils and/or eosinophils. Giant cells are usually lacking. The differential diagnosis includes deep fungal infection, particularly blastomycosis (Fig. 706.6) and tuberculous and atypical mycobacterial infection. Underlying immunodeficiency should be ruled out, and the selection of antibiotics should be guided by susceptibility testing because the response to antibiotics is often poor.

BLISTERING DISTAL DACTYLITIS

Blistering distal dactylitis is a superficial blistering infection of the volar fat pad on the distal portion of the finger or thumb that typically affects infants and young children (Fig. 706.7). More than one finger may be involved, as may the volar surfaces of the proximal phalanges, palms, and toes. Blisters are filled with a watery purulent fluid; polymorphonuclear leukocytes and gram-positive cocci are identified on Gram stain. Patients commonly have no preceding history of trauma, and systemic symptoms are generally absent. Poststreptococcal

Fig. 706.5 Large vegetating lesion of pyoderma vegetans.

Fig. 706.6 Cutaneous blastomycosis. Verrucous, crusted, erythematous plaque on the chin in a 15-yr-old boy with respiratory symptoms and bone pain. *(From Paller AS, Mancini AJ, eds. Hurwitz Clinical Pediatric Dermatology, 3rd ed. Philadelphia: Saunders; 2006, Fig. 14.13.)*

Fig. 706.7 Blistering dactylitis. Edema and a tense bulla on the thumb of this 7-yr-old girl. Culture of the blister fluid yielded *Staphylococcus aureus* rather than the more commonly seen group A β-hemolytic streptococcus. *(From Paller AS, Mancini AJ, eds. Hurwitz Clinical Pediatric Dermatology, 3rd ed. Philadelphia: Saunders; 2006, Fig. 14.14.)*

glomerulonephritis has not occurred after blistering distal dactylitis. The infection is caused most commonly by group A streptococcus but has also occurred as a result of infection with *S. aureus.* If left untreated, blisters may continue to enlarge and extend to the paronychial area. The infection responds to incision and drainage and a 10-day course of an antibiotic effective against group A streptococcus and *S. aureus* (e.g., amoxicillin-clavulanate, clindamycin, cephalexin); patients may require initial IV antibiotic therapy.

Fig. 706.8 Perianal streptococcal dermatitis. Bright red erythema with a moist, tender surface. *(From Paller AS, Mancini AJ, eds. Hurwitz Clinical Pediatric Dermatology, 3rd ed. Philadelphia: Saunders; 2006, Fig. 17.38.)*

PERIANAL INFECTIOUS DERMATITIS

Perianal infectious dermatitis presents most commonly in boys (70% of cases) between the ages of 6 months and 10 years as perianal dermatitis (90% of cases) and pruritus (80% of cases; Fig. 706.8). The incidence of perianal infectious dermatitis is not known precisely but ranges from 1 in 2,000 to 1 in 218 patient visits. When GABHS is suspected, it is often referred to as *perianal streptococcal dermatitis.* The rash is superficial, erythematous, well marginated, nonindurated, and confluent from the anus outward. Acutely (<6 weeks), the rash tends to be bright red, moist, and tender to touch. At this stage, a white pseudomembrane may be present. As the rash becomes more chronic, the perianal eruption may consist of painful fissures, a dried mucoid discharge, or psoriasiform plaques with yellow peripheral crust. In girls, the perianal rash may be associated with vulvovaginitis. In boys, the penis may be involved. Approximately 50% of patients have rectal pain, most commonly described as burning inside the anus during defecation, and 33% have blood-streaked stools. Fecal retention is a frequent behavioral response to the infection. Patients also have presented with guttate psoriasis. Although local induration or edema may occur, constitutional symptoms, such as fever, headache, and malaise, are absent, suggesting that subcutaneous involvement, as in cellulitis, is absent. Familial spread of perianal infectious dermatitis is common, particularly when family members bathe together or use the same water.

Perianal infectious dermatitis is usually caused by GABHS, but it may also be caused by *S. aureus.* The index case and family members should undergo culture; follow-up cultures to document bacteriologic cure after a course of treatment are recommended.

The differential diagnosis of perianal infectious dermatitis includes psoriasis, seborrheic dermatitis, candidiasis, pinworm infestation, sexual abuse, and inflammatory bowel disease.

For GABHS perianal infectious dermatitis, treatment with a 7-day course of cefuroxime (20 mg/kg/day in two divided doses) is superior to treatment with penicillin. Concomitant topical mupirocin ointment two to three times a day also may be used. If *S. aureus* is cultured, treatment should be based on sensitivities.

ERYSIPELAS

See Chapter 229.

Fig. 706.9 Folliculitis. Multiple follicular pustules.

FOLLICULITIS

Folliculitis, or superficial infection of the hair follicle, is most often caused by *S. aureus*. The lesions are typically small, discrete, dome-shaped pustules with an erythematous base, located at the ostium of the pilosebaceous canals (Fig. 706.9). Hair growth is unimpaired, and the lesions heal without scarring. Favored sites include the scalp, buttocks, and extremities. Poor hygiene, maceration, drainage from wounds and abscesses, and shaving of the legs can be provocative factors. Folliculitis can also occur as a result of tar therapy or occlusive wraps. The moist environment encourages bacterial proliferation. In HIV-infected patients, *S. aureus* may produce confluent erythematous patches with satellite pustules in intertriginous areas and violaceous plaques composed of superficial follicular pustules in the scalp, axillae, or groin. The differential diagnosis includes *Candida,* which may cause satellite follicular papules and pustules surrounding erythematous patches of intertrigo (particularly in groin/buttocks), and *Malassezia furfur,* which produces 2- to 3-mm, pruritic, erythematous, perifollicular papules and pustules on the back, chest, and extremities, particularly in patients who have diabetes mellitus or are taking corticosteroids or antibiotics. Diagnosis is made by examining potassium hydroxide–treated scrapings from lesions. Detection of *Malassezia* may require a skin biopsy, demonstrating clusters of yeast and short, branching hyphae ("macaroni and meatballs") in widened follicular ostia mixed with keratinous debris.

Topical antibiotic therapy (e.g., clindamycin 1% lotion or solution twice a day) is usually all that is needed for mild cases, but more severe cases may require the use of a systemic antibiotic such as dicloxacillin or cephalexin. Bacterial culture should be performed in treatment-resistant cases. In chronic recurrent folliculitis, daily application of a benzoyl peroxide 5% gel or wash may facilitate resolution. Dilute bleach baths may also be effective in reducing recurrence.

Folliculitis barbae (sycosis barbae) is a deeper, more severe recurrent inflammatory form of folliculitis caused by *S. aureus* that involves the entire depth of the follicle. Erythematous follicular papules and pustules develop on the chin, upper lip, and angle of the jaw, primarily in young Black males. Papules may coalesce into plaques, and healing may occur with scarring. Affected individuals are frequently found to be *S. aureus* carriers. Treatment with warm saline compresses and topical antibiotics, such as mupirocin, generally clear the infection. More extensive, recalcitrant cases may require therapy with β-lactamase–resistant systemic antibiotics for several weeks and elimination of *S. aureus* from the sites of carriage.

Pseudomonal folliculitis (hot tub folliculitis) is attributable to *P. aeruginosa,* predominantly serotype O-11. It occurs after exposure to poorly chlorinated hot tubs/whirlpools and swimming pools and to a contaminated water slide or loofah sponge. The lesions are pruritic papules and pustules or deeply erythematous to violaceous nodules that develop 8-48 hours after exposure and are most dense in areas covered by a bathing suit (Fig. 685.10). Patients occasionally experience fever, malaise, and lymphadenopathy. The organism is readily cultured from pus. The eruption usually resolves spontaneously in 1-2 weeks, often leaving postinflammatory hyperpigmentation. Consideration should be given to the use of systemic antibiotics (ciprofloxacin) in adolescent patients with constitutional symptoms. Immunocompromised children are susceptible to complications of *Pseudomonas* folliculitis (cellulitis) and should avoid hot tubs.

ABSCESSES AND FURUNCLES

Etiology

The causative agent in furuncles ("boils") and carbuncles is usually *S. aureus,* which penetrates abraded perifollicular skin. Furuncles are nodules that develop from a single follicle, whereas carbuncles are a coalescence of multiple follicles and are more extensive. Conditions predisposing to furuncle formation include obesity, hyperhidrosis, maceration, friction, and preexisting dermatitis. Furunculosis is also more common in individuals with low serum iron levels, diabetes, malnutrition, HIV infection, or other immunodeficiency states. Recurrent furunculosis is frequently associated with carriage of *S. aureus* in the nares, axillae, or perineum or close contact with someone such as a family member who is a carrier. Other bacteria or fungi may occasionally cause furuncles or carbuncles.

Community-acquired MRSA **abscesses** can also complicate folliculitis-related carbuncles or are acquired from penetrating cutaneous trauma unrelated to folliculitis. Community-acquired MRSA infections commonly affect children and young adults, especially athletes, where spread of the infection is enhanced by skin-to-skin contact. Infection can also be spread by crowding conditions, shared personal hygiene items, and a compromised skin barrier. They may occur in any location; however, they are most common on the lower abdomen, buttocks, and legs.

Clinical Manifestations

This follicular lesion may originate from a preceding folliculitis or may arise initially as a deep-seated, tender, erythematous, perifollicular nodule. Although lesions are initially indurated, central necrosis and suppuration follow, leading to rupture and discharge of a central core of necrotic tissue and destruction of the follicle (Fig. 706.11). Healing occurs with scar formation. Sites of predilection are the hair-bearing areas on the face, neck, axillae, buttocks, and groin. Pain may be intense if the lesion is situated in an area where the skin is relatively fixed, such as in the external auditory canal or over the nasal cartilages. Patients with furuncles usually have no constitutional symptoms; bacteremia may occasionally ensue. Rarely, lesions on the upper lip or cheek may lead to cavernous sinus thrombosis. Infection of a group of contiguous follicles, with multiple drainage points, accompanied by inflammatory changes in surrounding connective tissue is a carbuncle. Carbuncles may be accompanied by fever, leukocytosis, and bacteremia. Hidradenitis suppurativa should be considered in individuals who have recurrent abscesses.

Treatment

Treatment for furuncle and carbuncle includes regular bathing with antimicrobial soaps (chlorhexidine) and wearing of loose-fitting clothing to minimize predisposing factors for furuncle formation. Frequent application of a hot, moist compress may facilitate the drainage of lesions. Large lesions should be drained by a small incision. Carbuncles and large or numerous furuncles should be treated with systemic antibiotics chosen based on culture and sensitivity testing results.

Abscesses are treated with incision and drainage and oral antibiotics for 7-10 days. Antibiotics with coverage against MRSA are recommended and commonly include oral clindamycin (10-30 mg/kg/day in divided doses) or trimethoprim-sulfamethoxazole (8-10 mg trimethoprim/kg/day in divided doses every 12 hours). Children older than 8 years may receive doxycycline. To reduce colonization and hence reinfection in children with recurrent infections, mupirocin intranasally (twice daily) and either chlorhexidine (in lieu of soap during showers) or diluted bleach baths (1 teaspoon per gallon of water or 1/4 cup per 1/4 tub [~13 gallons] of water) once daily for 5 days in patients and in family members has been recommended. Recolonization often occurs, typically within 3 months of the decolonization attempt.

Fig. 706.10 Papules and pustules in hot tub folliculitis.

Fig. 706.11 Rupture and discharge of pus in a furuncle.

PITTED KERATOLYSIS

Pitted keratolysis occurs most frequently in humid tropical and subtropical climates, particularly in individuals whose feet are moist for prolonged periods, for example, as a result of hyperhidrosis, prolonged wearing of boots, or immersion in water. It occurs most commonly in young males from early adolescence to the late 20s. The lesions consist of 1- to 7-mm, irregularly shaped, superficial erosions of the horny layer on the soles, particularly at weight-bearing sites (Fig. 706.12). Brownish discoloration of involved areas may be apparent. A rare variant manifests as thinned, erythematous to violaceous plaques in addition to the typical pitted lesions. The condition is frequently malodorous and is painful in approximately 50% of cases. The most likely etiologic agent is *Corynebacterium (Kytococcus) sedentarius.* Treatment of hyperhidrosis is mandatory with prescription-strength aluminum chloride products or 40% formaldehyde in petrolatum ointment. Avoidance of moisture and maceration produces slow, spontaneous resolution of the infection. Topical or systemic erythromycin and topical imidazole creams are standard therapy.

ERYTHRASMA

Erythrasma is a benign chronic superficial infection caused by *Corynebacterium minutissimum.* Predisposing factors include heat, humidity, obesity, skin maceration, diabetes mellitus, and poor hygiene. Approximately 20% of affected patients have involvement of the toe webs. Other frequently affected sites are moist, intertriginous areas such as the groin and axillae. The inframammary and perianal regions are occasionally involved. Sharply demarcated, irregularly bordered, slightly scaly, brownish red patches are characteristic of the disease. Mild pruritus is the only constant symptom. *C. minutissimum* is a complex of related organisms that produce porphyrins that fluoresce brilliant coral red under ultraviolet light. The diagnosis is readily made, and erythrasma is differentiated from dermatophyte infection and from tinea versicolor on Wood lamp examination. However, bathing

Fig. 706.12 Superficial erosions of the horny layer in pitted keratolysis.

within 20 hours of Wood lamp examination may remove the water-soluble porphyrins. Staining of skin scrapings with methylene blue or Gram stain reveals the pleomorphic, filamentous coccobacillary forms.

Effective treatment can be achieved with topical erythromycin, clindamycin, miconazole, or a 10- to 14-day course of oral erythromycin or an oral tetracycline (in those older than 8 years of age).

ERYSIPELOID

A rare cutaneous infection, erysipeloid is caused by inoculation of *E. rhusiopathiae* from handling contaminated animals, birds, fish, or their products. The localized cutaneous form is most common, characterized by well-demarcated, diamond-shaped, erythematous to violaceous patches at sites of inoculation. Local symptoms are generally not severe, constitutional symptoms are rare, and the lesions resolve spontaneously after weeks but can recur at the same site or develop elsewhere weeks to months later. The diffuse cutaneous form manifests as lesions at several areas of the body in addition to the site of inoculation. It is also self-limited. The systemic form, caused by hematogenous spread, is accompanied by constitutional symptoms and may include endocarditis, septic arthritis, cerebral infarct and abscess, meningitis, and pulmonary effusion. Diagnosis is confirmed by skin biopsy, which reveals the gram-positive organisms, and culture. The treatment of choice for localized cutaneous infection is oral penicillin for 7 days; ciprofloxacin or a combination of erythromycin and rifampin may be used for penicillin-allergic patients. Severe diffuse cutaneous or systemic infection may require parenteral penicillin or ceftriaxone.

TUBERCULOSIS OF THE SKIN

See Chapters 261 and 263.

Cutaneous tuberculosis infection occurs worldwide, particularly in association with HIV infection, malnutrition, and poor sanitary conditions. Primary cutaneous tuberculosis is rare in the United States. Cutaneous disease is caused by *Mycobacterium tuberculosis, Mycobacterium bovis,* and, occasionally, by the bacillus Calmette-Guérin (BCG), an attenuated vaccine form of *M. bovis.* The manifestations caused by a given organism are indistinguishable from one another. After invasion of the skin, mycobacteria either multiply intracellularly within macrophages, leading to progressive disease, or are controlled by the host immune reaction.

Primary cutaneous tuberculosis (tuberculous chancre) results when *M. tuberculosis* or *M. bovis* gains access to the skin or mucous membranes through trauma in a previously uninfected individual without immunity to the organism. Sites of predilection are the face, lower extremities, and genitals. The initial lesion develops 2-4 weeks after introduction of the organism into the damaged tissue. A red-brown papule gradually enlarges to form a shallow, firm, sharply demarcated ulcer. Satellite abscesses may be present. Some lesions acquire a crust resembling impetigo, and others become heaped up and verrucous at the margins. The primary lesion can also manifest as a painless ulcer on the conjunctiva, gingiva, or palate and occasionally as a painless acute paronychia. Painless regional adenopathy may appear several

weeks after the development of the primary lesion and may be accompanied by lymphangitis, lymphadenitis, or perforation of the skin surface, forming **scrofuloderma**. Untreated lesions heal with scarring within 12 months but may reactivate, may form lupus vulgaris (sharply defined red-brown nodules with a gelatinous consistency that represent progressive infection), or, rarely, may progress to the acute miliary form. Therefore antituberculous therapy is indicated (see Chapter 261).

M. tuberculosis or *M. bovis* can be cultured from the skin lesion and local lymph nodes, but acid-fast staining of histologic sections, particularly of a well-controlled infection, often does not reveal the organism. The differential diagnosis is broad, including a syphilitic chancre; deep fungal or atypical mycobacterial infection; leprosy; tularemia; cat-scratch disease; sporotrichosis; nocardiosis; leishmaniasis; reaction to foreign substances such as zirconium, beryllium, silk or nylon sutures, talc, and starch; papular acne rosacea; and lupus miliaris disseminatus faciei.

Scrofuloderma results from enlargement, cold abscess formation, and breakdown of a lymph node, most frequently in a cervical chain, with extension to the overlying skin from underlying foci of tuberculous infection. Linear or serpiginous ulcers and dissecting fistulas and subcutaneous tracts studded with soft nodules may develop. Spontaneous healing may take years, eventuating in cordlike keloid scars. Lupus vulgaris may also develop. Lesions may also originate from an underlying infected joint, tendon, bone, or epididymis. The differential diagnosis includes syphilitic gumma, deep fungal infections, actinomycosis, and hidradenitis suppurativa. The course is indolent, and constitutional symptoms are typically absent. Antituberculous therapy is indicated (see Chapter 261).

Direct cutaneous inoculation of the tubercle bacillus into a previously infected individual with a moderate to high degree of immunity initially produces a small papule with surrounding inflammation. **Tuberculosis verrucosa cutis** (warty tuberculosis) forms when the papule becomes hyperkeratotic and warty, and several adjacent papules coalesce or a single papule expands peripherally to form a brownish red to violaceous, exudative, crusted verrucous plaque. Irregular extension of the margins of the plaque produces a serpiginous border. Children have the lesions most commonly on the lower extremities after trauma and contact with infected material such as sputum or soil. Regional lymph nodes are involved only rarely. Spontaneous healing with atrophic scarring takes place over months to years. Healing is also gradual with antituberculous therapy.

Lupus vulgaris is a rare, chronic, progressive form of cutaneous tuberculosis that develops in individuals with a moderate to high degree of tuberculin sensitivity induced by previous infection. The incidence is greater in cool, moist climates, particularly in females. Lupus vulgaris develops as a result of direct extension from underlying joints or lymph nodes; through lymphatic or hematogenous spread; or, rarely, by cutaneous inoculation with the BCG vaccine. It most commonly follows cervical adenitis or pulmonary tuberculosis. Approximately 33% of cases are preceded by scrofuloderma, and 90% of cases manifest on the head and neck, most commonly on the nose or cheek. Involvement of the trunk is uncommon. A typical solitary lesion consists of a soft, brownish red papule that has an apple-jelly color when examined by diascopy. Peripheral expansion of the papule or, occasionally, the coalescence of several papules forms an irregular lesion of variable size and form. One or several lesions may develop, including nodules or plaques that are flat and serpiginous, hypertrophic and verrucous, or edematous in appearance. Spontaneous healing occurs centrally, and lesions characteristically reappear within the area of atrophy. Chronicity is characteristic, and persistence and progression of plaques over many years are common. Lymphadenitis is present in 40% of those with lupus vulgaris, and 10–20% have infection of the lungs, bones, or joints. Extensive deformities may be caused by vegetative masses and ulceration involving the nasal, buccal, or conjunctival mucosa; the palate; the gingiva; or the oropharynx. Squamous cell carcinoma, with a relatively high metastatic potential, may develop, usually after several years of the disease. After a temporary impairment in immunity, particularly after measles infection (lupus exanthematicus), multiple lesions may form at distant sites as a result of hematogenous spread from a latent focus of infection. The histopathology reveals a tuberculoid granuloma without caseation; organisms are extremely difficult to demonstrate. The differential diagnosis includes sarcoidosis, atypical mycobacterial infection, blastomycosis, chromoblastomycosis, actinomycosis, leishmaniasis, tertiary syphilis, leprosy, hypertrophic lichen planus, psoriasis, lupus erythematosus, lymphocytoma, and Bowen disease. Small lesions can be excised. Antituberculous drug therapy usually halts further spread and induces involution.

Orificial tuberculosis (tuberculosis cutis orificialis) appears on the mucous membranes and periorificial skin after autoinoculation of mycobacteria from sites of progressive infection. It is a sign of advanced internal disease and carries a poor prognosis, and it occurs in a sensitized host with impaired cellular immunity. Lesions appear as painful, yellowish or red nodules that form punched-out ulcers with inflammation and edema of the surrounding mucosa. Treatment consists of identification of the source of infection and initiation of antituberculous therapy.

Miliary tuberculosis (hematogenous primary tuberculosis) rarely manifests cutaneously and occurs most commonly in infants and in individuals who are immunosuppressed after chemotherapy or infection with measles or HIV. The eruption consists of crops of symmetrically distributed, minute, erythematous to purpuric macules, papules, or vesicles. The lesions may ulcerate, drain, crust, and form sinus tracts or may form subcutaneous gummas, especially in malnourished children with impaired immunity. Constitutional signs and symptoms are common, and a leukemoid reaction or aplastic anemia may develop. Tubercle bacilli are readily identified in an active lesion. A fulminant course should be anticipated, and aggressive antituberculous therapy is indicated.

Single or multiple metastatic tuberculous abscesses **(tuberculous gummas)** may develop on the extremities and trunk by hematogenous spread from a primary focus of infection during a period of decreased immunity, particularly in malnourished and immunosuppressed children. The fluctuant, nontender, erythematous subcutaneous nodules may ulcerate and form fistulas.

Vaccination with BCG characteristically produces a papule approximately 2 weeks after vaccination. The papule expands in size, typically ulcerates within 2-4 months, and heals slowly with scarring. In 1-2 per million vaccinations, a complication caused specifically by the BCG organism occurs, including regional lymphadenitis, lupus vulgaris, scrofuloderma, and subcutaneous abscess formation. Delayed reactivation with inflammation at the site of BCG vaccination has been reported with Kawasaki disease and multisystem inflammatory syndrome in children (MIS-C), as well as immunization with the COVID-19 and influenza vaccines.

Tuberculids are skin reactions that exhibit tuberculoid features histologically but do not contain detectable mycobacteria. The lesions appear in a host who usually has moderate to strong tuberculin reactivity, has a history of previous tuberculosis of other organs, and usually shows a therapeutic response to antituberculous therapy. The cause of tuberculids is poorly understood. Most affected patients are in good health with no clear focus of disease at the time of the eruption. The most commonly observed tuberculid is the papulonecrotic tuberculid. Recurrent crops of symmetrically distributed, asymptomatic, firm, sterile, dusky-red papules appear on the extensor aspects of the limbs, the dorsum of the hands and feet, and the buttocks. The papules may undergo central ulceration and eventually heal, leaving sharply delineated, circular, depressed scars. The duration of the eruption is variable, but it usually disappears promptly after treatment of the primary infection. Lichen scrofulosorum, another form of tuberculid, is characterized by asymptomatic, grouped, pinhead-sized, often follicular pink or red papules that form discoid plaques, mainly on the trunk. Healing occurs without scarring.

Atypical mycobacterial infection may cause cutaneous lesions in children. Interestingly, there may be some seasonable variation in incidence. It has been postulated that vitamin D may play a role. *Mycobacterium marinum* is found in saltwater, freshwater, and diseased fish. In the United States, it is most commonly acquired from tropical fish tanks and swimming pools. Traumatic abrasion of the skin serves as a portal of entry for the organism. Approximately 3 weeks after inoculation, a single reddish papule develops and enlarges slowly to form a violaceous nodule or, occasionally, a warty plaque (Fig. 706.13). The lesion occasionally breaks down to form a crusted ulcer or a suppurating

Fig. 706.13 Violaceous, warty plaque of *Mycobacterium marinum* infection.

abscess. Sporotrichoid erythematous nodules along lymphatics may also suppurate and drain. Lesions are most common on the elbows, knees, and feet of swimmers and on the hands and fingers in persons with aquarium-acquired infection. Systemic signs and symptoms are absent. Regional lymph nodes occasionally become slightly enlarged but do not break down. Rarely, the infection becomes disseminated, particularly in an immunosuppressed host. A biopsy specimen of a fully developed lesion demonstrates a granulomatous infiltrate with tuberculoid architecture. Treatment with two active agents is generally recommended, with a combination of clarithromycin and ethambutol providing a reasonable balance between effectiveness and tolerability. Rifampin should be added to clarithromycin and ethambutol for deep tissue involvement. Other agents with activity against *M. marinum* include trimethoprim-sulfamethoxazole, doxycycline, minocycline, and ciprofloxacin. Although azithromycin has been used as an alternative to clarithromycin for some mycobacterial infections, its effectiveness against *M. marinum* is not known. Treatment should continue for 1-2 months after resolution of lesions with a minimum treatment duration of 6 months. The application of heat to the affected site may be a useful adjunctive therapy (see Chapter 263).

Mycobacterium kansasii primarily causes pulmonary disease; skin disease is rare, often occurring in an immunocompromised host. Most commonly, sporotrichoid nodules develop after inoculation of traumatized skin. Lesions may develop into ulcerated, crusted, or verrucous plaques. The organism is relatively sensitive to antituberculous medications, which should be chosen on the basis of susceptibility testing.

Mycobacterium scrofulaceum causes cervical lymphadenitis (scrofuloderma) in young children, typically in the submandibular region. Nodes enlarge over several weeks, ulcerate, and drain. The local reaction is nontender and circumscribed, constitutional symptoms are absent, and there generally is no evidence of lung or other organ involvement. Other atypical mycobacteria may cause a similar presentation, including *Mycobacterium avium* complex, *M. kansasii,* and *Mycobacterium fortuitum.* Treatment is accomplished by excision and administration of antituberculous drugs (see Chapter 263).

Mycobacterium ulcerans (Buruli ulcer or Bairnsdale ulcers) causes a painless subcutaneous nodule after inoculation of abraded skin. Most infections occur in children in tropical rainforests. The nodule usually ulcerates, develops undermined edges, and may spread over large areas, most commonly on an extremity. Local necrosis of subcutaneous fat, producing a septal panniculitis, is characteristic. Ulcers persist for months to years before healing spontaneously with scarring, sometimes with contractures (if over a joint) and lymphedema. Constitutional symptoms and lymphadenopathy are absent. Diagnosis is made by culturing the organism at 32–33°C (89.6–91.4°F). **Treatment of choice** is an 8-week course of rifampin and streptomycin with surgical debridement for larger lesions. Local heat therapy and oral chemotherapy may benefit some patients.

M. avium complex, composed of more than 20 subtypes, most commonly causes chronic pulmonary infection. Cervical lymphadenitis and osteomyelitis occur occasionally, and papules or purulent leg ulcers occur rarely by primary inoculation. Skin lesions may be an early sign of disseminated infection. The lesions may take various forms, including erythematous papules, pustules, nodules, abscesses, ulcers, panniculitis, and sporotrichoid spread along lymphatics. For treatment, see Chapter 263.

M. fortuitum complex causes disease in an immunocompetent host principally by primary cutaneous inoculation after traumatic injury, injection, or surgery. A nodule, abscess, or cellulitis develops 4-6 weeks after inoculation. In an immunocompromised host, numerous subcutaneous nodules may form, break down, and drain. Treatment is based on identification and susceptibility testing of the organism. Isolates are usually susceptible to fluoroquinolones, doxycycline, minocycline, sulfonamides, cefoxitin, and imipenem; macrolides should be used with caution because many *M. fortuitum* isolates have the erythromycin methylase *(erm)* gene, which confers inducible resistance to macrolides despite "susceptible" minimum inhibitory concentrations.

Visit Elsevier eBooks+ at eBooks.Health.Elsevier.com for Bibliography.

Chapter 707

Cutaneous Fungal Infections

Stephen R. Humphrey

TINEA VERSICOLOR

A common, innocuous, chronic fungal infection of the stratum corneum, tinea versicolor is most often caused by the dimorphic yeast *Malassezia globosa,* with *Malassezia furfur* and *Malassezia sympodialis* as less frequent causative agents. The synonyms *Pityrosporum ovale* and *Pityrosporum orbiculare* were used previously to identify the causal organism.

Etiology

M. globosa is part of the normal indigenous skin flora, predominantly in the yeast form, and is found particularly in areas of skin that are rich in sebum production. Proliferation of filamentous forms occurs in the disease state. Predisposing factors include a warm, humid environment, excessive sweating, occlusion, high plasma cortisol levels, immunosuppression, malnourishment, and genetically determined susceptibility. The disease is most prevalent in adolescents and young adults.

Clinical Manifestations

The lesions of tinea versicolor vary widely in color. In lighter skin, they are typically reddish brown, whereas in darker skin, they may be either hypopigmented or hyperpigmented. The characteristic macules are covered with a fine scale. They often begin in a perifollicular location, enlarge, and merge to form confluent patches, most commonly on the neck, upper chest, back, and upper arms (Fig. 707.1). Facial lesions are common in adolescents; lesions occasionally appear on the forearms, dorsum of the hands, and pubis. There may be little or no pruritus. Involved areas do not tan after sun exposure. A papulopustular perifollicular variant of the disorder may occur on the back, chest, and sometimes the extremities. These pustules tend to be monomorphic.

Differential Diagnosis

Examination with a Wood lamp discloses a yellowish gold fluorescence. A potassium hydroxide (KOH) preparation of scrapings is diagnostic, demonstrating groups of thick-walled spores and myriad short, thick,

Fig. 707.1 Hyperpigmented, sharply demarcated macules of varying sizes on the upper trunk characteristic of tinea versicolor.

Fig. 707.2 Id reaction. Papular eruption of the face associated with severe tinea infection of the hand.

angular hyphae resembling macaroni/spaghetti and meatballs. Skin biopsy, including culture and special stains for fungi (periodic acid–Schiff), are often necessary to make the diagnosis in cases of primarily follicular involvement. Microscopically, organisms and keratinous debris can be seen within dilated follicular ostia.

Tinea versicolor must be distinguished from dermatophyte infections, seborrheic dermatitis, pityriasis alba, pityriasis rosea, and secondary syphilis. Tinea versicolor may mimic nonscaling pigmentary disorders, such as postinflammatory pigmentary change, if a patient has removed the scales by scrubbing. *M. globosa* folliculitis must be distinguished from the other forms of folliculitis.

Treatment

Many therapeutic agents can be used to treat this disease successfully. The causative agent, a normal human saprophyte, is not eradicated from the skin, however, and the disorder recurs in predisposed individuals. Appropriate topical therapy may include one of the following: selenium 2% shampoo applied for 10 minutes before rinsing for 1 week, ketoconazole 2% shampoo once daily for 3 days, and terbinafine spray once to twice daily for 1-2 weeks. Antifungal creams are available and can be used; however, these can be impractical to apply given the large surface of skin involved. Oral therapy may be more convenient and may be achieved successfully with fluconazole 300 mg/wk for 2-4 weeks or itraconazole 200 mg/24 hr for 5-7 days. Recurrent episodes continue to respond promptly to these agents. Oral therapy is particularly helpful in those with severe disease or recurrent disease or in those where topical therapies have failed. Maintenance therapy with selenium sulfide shampoo or ketoconazole 2% shampoo once a week may be used.

DERMATOPHYTOSES

Dermatophytoses are caused by a group of closely related filamentous fungi with a propensity for invading the stratum corneum, hair, and nails. The three principal genera responsible for infections are *Trichophyton, Microsporum,* and *Epidermophyton.*

Etiology

Trichophyton spp. cause lesions of all keratinized tissue, including skin, nails, and hair. *Trichophyton rubrum* is the most common dermatophyte pathogen. *Microsporum* spp. principally invade the hair, and the *Epidermophyton* spp. invade the intertriginous skin. Dermatophyte infections are designated by the word **tinea** followed by the Latin word for the anatomic site of involvement. The dermatophytes are also classified according to source and natural habitat. Fungi acquired from the soil are called *geophilic*. They infect humans sporadically, inciting an inflammatory reaction. Dermatophytes that are acquired from animals are *zoophilic*. Transmission may be through direct contact or indirectly by infected animal hair or clothing. Infected animals are frequently asymptomatic. Dermatophytes acquired from humans are referred to as *anthropophilic*. These infestations range from chronic low-grade to acute inflammatory disease. *Epidermophyton* infections are transmitted only by humans, but various species of *Trichophyton* and *Microsporum* can be acquired from both human and nonhuman sources.

Epidemiology

Host defense has an important influence on the severity of the infection. Disease tends to be more severe in individuals with diabetes mellitus, lymphoid malignancies, immunosuppression, and states with high plasma cortisol levels, such as Cushing syndrome. Some dermatophytes, most notably the zoophilic species, tend to elicit more severe, suppurative inflammation in humans. Some degree of resistance to reinfection is acquired by most infected persons and may be associated with a delayed hypersensitivity response. However, no relationship has been demonstrated between antibody levels and resistance to infection. The frequency and severity of infection are also affected by the geographic locale, the genetic susceptibility of the host, and the virulence of the strain of dermatophyte. Additional local factors that predispose to infection include trauma to the skin, hydration of the skin with maceration, occlusion, and elevated temperature.

Occasionally, a secondary skin eruption, referred to as a dermatophytid or "id" reaction, appears in sensitized individuals and has been attributed to circulating fungal antigens derived from the primary infection. The eruption is characterized by grouped papules (Fig. 707.2) and vesicles and, occasionally, by sterile pustules. Symmetric urticarial lesions and a more generalized maculopapular eruption also can occur. Id reactions are most often associated with tinea pedis, but they also occur with tinea capitis.

Tinea Capitis

Clinical Manifestations

Tinea capitis is a dermatophyte infection of the scalp most often caused by *Trichophyton tonsurans,* occasionally by *Microsporum canis*, and, much less commonly, by other *Microsporum* and *Trichophyton* spp. It is particularly common in children age 3-7 years old. In *Microsporum* and some *Trichophyton* infections, the spores are distributed in a sheathlike fashion around the hair shaft (**ectothrix** infection), whereas *T. tonsurans* produces an infection within the hair shaft (endothrix). **Endothrix** infections may continue past the anagen phase of hair growth into telogen and are more chronic than infections with ectothrix organisms that persist only during the anagen phase. *T. tonsurans* is an anthropophilic species acquired most often by contact with infected hairs and epithelial cells that are on such surfaces as theater seats, hats, and combs. Dermatophyte spores may also be airborne within the immediate environment, and high carriage rates have been demonstrated in noninfected schoolmates and household members. *M. canis* is a zoophilic species that is acquired from cats and dogs.

The clinical presentation of tinea capitis varies with the infecting organism. Endothrix infections such as those caused by *T. tonsurans* create a

Fig. 707.3 Black-dot ringworm with hairs broken off at the scalp.

Fig. 707.4 Tinea capitis mimicking seborrheic dermatitis.

Fig. 707.5 Lymphadenopathy associated with tinea capitis.

pattern known as "black-dot ringworm," characterized initially by many small circular patches of alopecia in which hairs are broken off close to the hair follicle (Fig. 707.3). Another clinical variant manifests as diffuse scaling, with minimal hair loss secondary. It strongly resembles seborrheic dermatitis, psoriasis, or atopic dermatitis (Fig. 707.4). *T. tonsurans* may also produce a chronic and more diffuse alopecia. Lymphadenopathy is common (Fig. 707.5). A severe inflammatory response produces elevated, boggy granulomatous masses **(kerion)**, which are often studded with pustules (Fig. 707.6A). Fever, pain, and regional adenopathy are common, and permanent scarring and alopecia may result (see Fig. 707.6B). The zoophilic organism *M. canis* or the geophilic organism *Microsporum gypseum* also may cause kerion formation. The pattern produced by

Fig. 707.6 A, Kerion. Boggy granulomatous mass of the scalp. B, Scarring after kerion.

Microsporum audouinii, the most common cause of tinea capitis in the 1940s and 1950s, is characterized initially by a small papule at the base of a hair follicle. The infection spreads peripherally, forming an erythematous and scaly circular plaque **(ringworm)** within which the infected hairs become brittle and broken. Numerous confluent patches of alopecia develop, and patients may complain of severe pruritus. *M. audouinii* infection is no longer common in the United States. **Favus** is a chronic form of tinea capitis that is rare in the United States and is caused by the fungus *Trichophyton schoenleinii*. Favus starts as yellowish red papules at the opening of hair follicles. The papules expand and coalesce to form cup-shaped, yellowish, crusted patches that fluoresce dull green under a Wood lamp. Other species, such as *Trichophyton violaceum* and *Trichophyton soudanense* are becoming more common with resettlement and emigration.

Differential Diagnosis

Tinea capitis can be confused with seborrheic dermatitis, psoriasis, alopecia areata, trichotillomania, and certain dystrophic hair disorders. When inflammation is pronounced, as in kerion, primary or secondary bacterial infection must also be considered. In adolescents, the patchy, moth-eaten type of alopecia associated with secondary syphilis may resemble tinea capitis. If scarring occurs, discoid lupus erythematosus and lichen planopilaris must also be considered in the differential diagnosis.

The important diagnostic procedures for the various dermatophyte diseases include examination of infected hairs with a Wood lamp, microscopic examination of KOH preparations of infected material, and identification of the etiologic agent by culture. Hairs infected with common *Microsporum* spp. fluoresce a bright blue-green. Most *Trichophyton*-infected hairs do not fluoresce.

Microscopic examination of a KOH preparation of infected hair from the active border of a lesion discloses tiny spores surrounding the hair shaft in *Microsporum* infections and chains of spores within the hair shaft in *T. tonsurans* infections. Fungal elements are not usually seen in scales. A specific etiologic diagnosis of tinea capitis may be obtained by planting broken-off infected hairs on Sabouraud medium with reagents to inhibit growth of other organisms. Such identification may require 2 weeks or more.

Treatment

Oral administration of griseofulvin microcrystalline (20-25 mg/kg/day with a maximum daily dose of 1000 mg, or 10-15 mg/kg/day with a maximum daily dose of 750 mg if the ultramicrosize form is used) is typically the recommended treatment for all forms of tinea capitis. Absorption of griseofulvin is enhanced by the ingestion of a fatty meal and should be recommended for the patient. A minimum of 8 weeks of treatment is usually required, though longer courses are sometimes needed. Repeat fungal cultures may help guide treatment length. Treatment for 1 month after a negative culture result minimizes the risk of recurrence. Adverse reactions to griseofulvin are rare but include nausea, vomiting, headache, blood dyscrasias, phototoxicity, and hepatotoxicity. Terbinafine dosing is weight-based. Off-label use is 125 mg daily for 6 weeks if under 25 kg. From 25 to 35 kg, the dose is 187.5 mg daily for 6 weeks. For patients greater than 35 kg, the dose is 250 mg daily for 6 weeks. It is possibly effective in pulse therapy, although it has limited activity against *M. canis*, but better activity than griseofulvin for *T. tonsurans.* The oral granule formulation of terbinafine is approved by the U.S. Food and Drug Administration (FDA) for tinea capitis in children 4 years of age and older. Oral itraconazole is useful in instances of griseofulvin resistance, intolerance, or allergy. Itraconazole is given for 4-6 weeks at a dosage of 5 mg/kg/24 hr with food. This is off-label and length of course depends on organism. Capsules are preferable to the syrup, which may cause diarrhea. Itraconazole is not approved by the FDA for treatment of dermatophyte infections in the pediatric population. Topical therapy alone is ineffective, but it may be an important adjunct because it may decrease the shedding of spores and should be recommended in all patients. Asymptomatic dermatophyte carriage in family members is common. Because one in three families have at least one member who is a carrier, treatment of both patient and potential carriers with a sporicidal shampoo may hasten clinical resolution. Vigorous shampooing with a 2.5% selenium sulfide, zinc pyrithione, or ketoconazole shampoo is helpful. It is not necessary to shave the scalp.

Tinea Corporis

Clinical Manifestations

Tinea corporis, defined as infection of the glabrous skin, excluding the palms, soles, and groin, can be caused by most of the dermatophyte species, although *T. rubrum* and *Trichophyton mentagrophytes* are the most prevalent etiologic organisms. In children, infections with *M. canis* are also common. Tinea corporis can be acquired by direct contact with infected persons or by contact with infected scales or hairs deposited on environmental surfaces. *M. canis* infections are usually acquired from infected pets.

The most typical clinical lesion begins as a dry, mildly erythematous, elevated, scaly papule or plaque that spreads centrifugally and clears centrally to form the characteristic annular lesion responsible for the designation of ringworm (Fig. 707.7). At times, plaques with advancing borders may spread over large areas. Grouped pustules are another variant. Most lesions clear spontaneously within several months, but some may become chronic. Central clearing does not always occur (Fig. 707.8), and differences in host response may result in wide variability in the clinical appearance; for example, granulomatous lesions called **Majocchi granuloma**, which are caused by the penetration of organisms along the hair follicle to the level of the dermis, produce a fungal folliculitis and perifolliculitis (Fig. 707.9) and the kerion-like lesions referred to as *tinea profunda.* Majocchi granuloma is more common after inappropriate treatment with topical corticosteroids, especially the superpotent class.

Differential Diagnosis

Many skin lesions, both infectious and noninfectious, must be differentiated from the lesions of tinea corporis. Those most frequently confused are granuloma annulare, nummular eczema, pityriasis rosea, psoriasis, seborrheic dermatitis, erythema chronicum migrans, and tinea versicolor. Microscopic examination of KOH wet mount preparations and cultures should always be performed when fungal infection is considered. Tinea corporis usually does not fluoresce with a Wood lamp.

Fig. 707.7 Annular plaque of tinea corporis with central clearing.

Fig. 707.8 Minimal central clearing with tinea corporis.

Fig. 707.9 Follicular papule and pustule in Majocchi granuloma after use of a superpotent topical steroid.

Treatment

Tinea corporis usually responds to treatment with one of the topical antifungal agents (e.g., imidazoles, terbinafine, butenafine, naftifine) twice daily for 2-4 weeks. In unusually severe or extensive disease, a course of therapy with oral griseofulvin microcrystalline may be required for 4 weeks. Terbinafine for 2 weeks can also be used. Itraconazole has produced excellent results in many cases with a 1- to 2-week course of oral therapy. Combination topical corticosteroid/antifungal preparations should not be used, as they may result in worsening or persistent infection.

Tinea Cruris

Clinical Manifestations

Tinea cruris, or infection of the groin, occurs most often in adolescent males and is usually caused by the anthropophilic species *Epidermophyton floccosum* or *T. rubrum,* but occasionally by the zoophilic species *T. mentagrophytes.*

The initial clinical lesion is a small, raised, scaly, erythematous patch on the inner aspect of the thigh. This spreads peripherally, often developing numerous tiny vesicles at the advancing margin. It eventually forms bilateral, irregular, sharply bordered patches with hyperpigmented scaly centers. In some cases, particularly in infections with *T. mentagrophytes,* the inflammatory reaction is more intense and the infection may spread beyond the crural region. The scrotum and labia are usually not involved in the infection, which is an important distinction from candidiasis. Pruritus may be severe initially but abates as the inflammatory reaction subsides. Bacterial superinfection may alter the clinical appearance, and erythrasma or candidiasis may coexist. Tinea cruris is more prevalent in obese persons and in persons who perspire excessively and wear tight-fitting clothing. It is a good idea to examine a patient's feet, which can be a source for tinea cruris.

Differential Diagnosis

The diagnosis of tinea cruris is confirmed by culture and by demonstration of septate hyphae on a KOH preparation of epidermal scrapings. The disorder must be differentiated from intertrigo, allergic contact dermatitis, candidiasis, and erythrasma. Bacterial superinfection must be precluded when there is a severe inflammatory reaction.

Treatment

Patients should be advised to wear loose cotton underwear. Topical treatment with an imidazole twice a day for 3-4 weeks is recommended for severe infection, especially because these agents are effective in mixed candidal-dermatophytic infections. Oral treatments, as mentioned earlier, may also be used.

Tinea Pedis

Clinical Manifestations

Tinea pedis (athlete's foot), infection of the toe webs and soles of the feet, is uncommon in young children but occurs with some frequency in preadolescent and adolescent males. The usual etiologic agents are *T. rubrum, T. mentagrophytes,* and *E. floccosum.*

Most commonly, the lateral toe webs (third to fourth and fourth to fifth interdigital spaces) and the subdigital crevice are fissured, with maceration and peeling of the surrounding skin (Fig. 707.10). Severe tenderness, itching, and a persistent foul odor are characteristic. These lesions may become chronic. This type of infection may involve overgrowth by bacterial flora, including *Kytococcus sedentarius, Brevibacterium epidermidis,* and gram-negative organisms. Less commonly, a chronic diffuse hyperkeratosis of the sole of the foot occurs with only mild erythema (Fig. 707.11). In some cases, two feet and one hand are involved. This type of infection is more refractory to treatment and tends to recur. An inflammatory vesicular type of reaction may occur with *T. mentagrophytes* infection. This type is most common in young children. The lesions involve any area of the foot, including the dorsal surface, and are usually circumscribed. The initial papules progress to vesicles and bullae that may become pustular (Fig. 707.12). A number of factors, such as occlusive footwear and warm, humid weather, predispose to infection. Tinea pedis may be transmitted in shower facilities and swimming pool areas.

Differential Diagnosis

Tinea pedis must be differentiated from simple maceration and peeling of the interdigital spaces, which is common in children. Infection with *Candida albicans* and various bacterial organisms (erythrasma) may cause confusion or may coexist with primary tinea pedis. Contact dermatitis, vesicular foot dermatitis, atopic dermatitis, and juvenile plantar dermatitis also simulate tinea pedis. Fungal mycelia can be seen on microscopic examination of a KOH preparation or by culture.

Treatment

Treatment for mild infections includes simple measures such as avoidance of occlusive footwear, careful drying between the toes after bathing, and the use of an absorbent antifungal powder such as zinc undecylenate. Topical therapy with an imidazole is curative in most cases. Each of these agents is also effective against candidal infection. Several weeks of therapy may be necessary, and low-grade, chronic infections, particularly those caused by *T. rubrum,* may be refractory. In refractory cases, oral griseofulvin therapy may effect a cure, but recurrences are common.

Fig. 707.11 Diffuse, minimally erythematous tinea pedis.

Fig. 707.10 Interdigital tinea pedis.

Fig. 707.12 Vesicobullous tinea pedis.

Tinea Unguium

Clinical Manifestations

Tinea unguium (onychomycosis) is a dermatophyte infection of the nail plate. It occurs most often in patients with tinea pedis, but it may occur as a primary infection. It can be caused by a number of dermatophytes, of which *T. rubrum* and *T. mentagrophytes* are the most common.

The most superficial form of tinea unguium (i.e., white superficial onychomycosis) is caused by *T. mentagrophytes.* It manifests as irregular single or numerous white patches on the surface of the nail unassociated with paronychial inflammation or deep infection. *T. rubrum* generally causes a more invasive, subungual infection that is initiated at the lateral distal margins of the nail and is often preceded by mild paronychia. The middle and ventral layers of the nail plate, and perhaps the nail bed, are the sites of infection. The nail initially develops a yellowish discoloration and slowly becomes thickened, brittle, and loosened from the nail bed (Fig. 707.13). In advanced infection, the nail may turn dark brown to black and may crack or break off.

Differential Diagnosis

Tinea unguium must be differentiated from various dystrophic nail disorders. Changes as a result of trauma, psoriasis, lichen planus, eczema, and trachyonychia can all be confused with tinea unguium. Nails infected with *C. albicans* have several distinguishing features; most prominently, a pronounced paronychial swelling. Thin shavings taken from the infected nail, preferably from the deeper areas, should be examined microscopically with KOH and cultured. Repeated attempts may be required to demonstrate the fungus. Histologic evaluation of nail clippings with special stains for dermatophytes can be diagnostic.

Treatment

Systemic antifungals are more effective at treating onychomycosis than topical antifungals. The long half-life of itraconazole in the nail has led to promising trials of intermittent short courses of therapy (double the normal dose for 1 week of each month for 3-4 months). Oral terbinafine is also used for the treatment of onychomycosis. Terbinafine once daily for 12 weeks is more effective than itraconazole pulse therapy. Pulse terbinafine treatment has also been used in adults and has been effective. Topical antifungals may be an acceptable treatment for mild disease without matrix involvement, and typically children have a better response to topical therapy than adults, likely because of faster growth of the nails. Several topical agents have been FDA approved for the treatment of onychomycosis in adults, including ciclopirox, efinaconazole, and tavaborole. Small clinical trials have demonstrated efficacy of ciclopirox in children. Efinaconazole and tavaborole can be used in children 6 and older as well.

Tinea Nigra Palmaris

Tinea nigra palmaris is a rare but distinctive superficial fungal infection that occurs principally in children and adolescents. It is caused by the dimorphic fungus *Phaeoannellomyces werneckii,* which imparts a gray-black color to the affected palm. The characteristic lesion is a well-defined hyperpigmented macule. Scaling and erythema are rare, and the lesions are asymptomatic. Tinea nigra is often mistaken for a junctional nevus, melanoma, or staining of the skin by contactants. Treatment is with an imidazole antifungal. *Keratolytic agents, such as salicylic acid, once to twice daily* can also be used.

Fig. 707.13 Hyperkeratotic nail in onychomycosis.

CANDIDAL INFECTIONS (CANDIDIASIS AND MONILIASIS)

See Chapter 280.

The dimorphic yeasts of the genus *Candida* are ubiquitous in the environment, but *C. albicans* usually causes candidiasis in children. This yeast is not part of the indigenous skin flora, but it is a frequent transient on skin and may colonize the human alimentary tract and the vagina as a saprophytic organism. Certain environmental conditions, notably elevated temperature and humidity, are associated with an increased frequency of isolation of *C. albicans* from the skin. Many bacterial species inhibit the growth of *C. albicans,* and alteration of normal flora by the use of antibiotics may promote overgrowth of the yeast.

Chronic mucocutaneous candidiasis is associated with a diverse group of primary immunodeficiency diseases (Table 707.1). Chronic mucocutaneous candidiasis is characterized by chronic or recurrent *Candida* infections of the oral cavity, esophagus, genitals, nails, and skin. Chronic mucocutaneous candidiasis may also be seen as an acquired infection in patients with HIV infection and during immunosuppressive treatments.

Oral Candidiasis (Thrush)

See Chapter 280.

Vaginal Candidiasis

See Chapters 163 and 280.

C. albicans is an inhabitant of the vagina in 5–10% of women, and vaginal candidiasis is not uncommon in adolescent girls. A number of factors can predispose to this infection, including antibiotic therapy, corticosteroid therapy, diabetes mellitus, pregnancy, and the use of oral contraceptives. The infection manifests as cheesy white plaques on an erythematous vaginal mucosa and a thick white-yellow discharge. The disease may be relatively mild or may produce pronounced inflammation and scaling of the external genitals and surrounding skin with progression to vesiculation and ulceration. Patients often complain of severe itching and burning in the vaginal area. Before treatment is initiated, the diagnosis should be confirmed by microscopic examination and/or culture. The infection may be eradicated by insertion of nystatin or imidazole vaginal tablets, suppositories, creams, or foam. If these products are ineffective, the addition of one dose of fluconazole (150 mg) is effective for adolescents.

Congenital Cutaneous Candidiasis

See Chapter 280.

Candidal Diaper Dermatitis

Candidal diaper dermatitis is a ubiquitous problem in infants and, although relatively benign, is often frustrating because of its tendency to recur. Predisposed infants usually carry *C. albicans* in their intestinal tracts, and the warm, moist, occluded skin of the diaper area provides an optimal environment for its growth. A seborrheic, atopic, or primary irritant contact dermatitis usually provides a portal of entry for the yeast.

The primary clinical manifestation consists of an intensely erythematous, confluent plaque with a scalloped border and a sharply demarcated edge. It is formed by the confluence of numerous papules and vesicular pustules. Satellite pustules, those that stud the contiguous skin, are a hallmark of localized candidal infections. The perianal skin, inguinal folds, perineum, and lower abdomen are usually involved (Fig. 707.14). In males, the entire scrotum and penis may be involved, with an erosive balanitis of the perimeatal skin. In females, the lesions may be found on the vaginal mucosa and labia. In some infants, the process is generalized, with erythematous lesions distant from the diaper

Table 707.1 Primary Immunodeficiencies Underlying Candida and Other Fungal Infections

DISEASE	ASSOCIATED INFECTIONS	IMMUNOLOGIC PHENOTYPE	GENE, TRANSMISSION
CMC			
SCID	Bacteria, viruses, fungi, mycobacteria	No T cells, with or without B and/or NK cell lymphopenia	>30 genes: *IL2RG*, X-linked; *JAK3*, autosomal recessive; *RAG1*, autosomal recessive; *RAG2*, autosomal recessive; *ARTEMIS*, autosomal recessive; *ADA*, autosomal recessive; *CD3*, autosomal recessive, etc.
CID			
CD25 deficiency	Viruses and bacteria	T-cell defect	*IL2RA*, autosomal recessive
NEMO or iκBγ deficiency	Pyogenic bacteria, mycobacteria, viruses		*NEMO* or *IKBG* X-linked
IκBα GOF pathogenic variant			*IKBA*, autosomal dominant
DOCK8 deficiency	Viruses, bacteria and fungi		*DOCK8*, autosomal recessive
TCR-α deficiency	Viruses and bacteria		*TCRA*, autosomal recessive
CRACM1 deficiency	Viruses, mycobacteria, bacteria and fungi		*CRACM1*, autosomal recessive
MST1/STK4 deficiency	Viruses and bacteria		*MST1/STK4*, autosomal recessive
MHC class II deficiency	Viruses, bacteria and fungi		*CIITA*, *RFXANK*, *RFXC*, *RFXAP*, all autosomal recessive
Idiopathic CD4 lymphopenia	*Pneumocystis*, *Cryptococcus*, virus	CD4 T cells <300 cells/mm^3	*UNC119*, autosomal dominant, *MAGT1* X-linked, *RAG1*, autosomal recessive
SYNDROMIC CMC			
Interleukin-12Rβ1 and interleukin-12p40 deficiencies	*Mycobacteria*, *Salmonella*	Deficit of interleukin-17–producing T cells	*IL12RB1*, autosomal recessive, *IL12B*, autosomal recessive
STAT3 deficiency (autosomal dominant-HIES)	*Staphylococcus aureus*, *Aspergillus*	Hyperimmunoglobulin E, deficit of interleukin-17–producing T cells	*STAT3*, autosomal dominant
APECED/APS-1	No	Neutralizing antiinterleukin-17A, antiinterleukin-17F, and/or antiinterleukin-22 autoantibodies	*AIRE*, autosomal recessive
CARD9 deficiency	Dermatophytes, *Candida*, brain abscess	Deficit of interleukin-17–producing T cells	*CARD9*, autosomal recessive
CMCD			
Complete interleukin-17RA deficiency	*S. aureus*	No interleukin-17 response	*IL17RA*, autosomal recessive
Partial interleukin-17F deficiency	*S. aureus*	Impaired interleukin-17F, interleukin-17A/F function	*IL17F*, autosomal dominant
STAT1 GOF pathogenic variants	Bacteria, viruses, fungi, mycobacteria	Low interleukin-17–producing T cells	*STAT1*, autosomal dominant

CMC, Chronic mucocutaneous candidiasis; SCID, severe combined immunodeficiency; NK, natural killer; CID, combined immunodeficiency; NEMO, nuclear factor κβ essential modulator; iκBγ, inhibitor of nuclear factor of kappa light polypeptide gene enhancer in B cells, gamma; IκBα, inhibitor of nuclear factor of kappa light polypeptide gene enhancer in B cells, alpha; GOF, gain-of-function; DOCK8, dedicator of cytokinesis 8; TCR, T-cell receptor; CRACM1, calcium release-activated calcium modulator 1; MST1, macrophage stimulating 1; STK4, serine/threonine protein kinase 4; MHC, major histocompatibility complex; STAT, signal transducer and activator of transcription; HIES, hyperimmunoglobulin E syndrome; APECED, autoimmune polyendocrinopathy–candidiasis–ectodermal dystrophy; APS-1, autoimmune polyendocrinopathy syndrome type 1; AIRE, autoimmune regulator; CARD9, caspase recruitment domain-containing protein 9; CMCD, chronic mucocutaneous candidiasis disease.

From Lanternier F, Cypowyj S, Picard, C, et al. Primary immunodeficiencies underlying fungal infections. *Curr Opin Pediatr*. 2013;25:736–747.

area. In some cases, the generalized process may represent a fungal id (hypersensitivity) reaction.

The differential diagnosis of candidal diaper dermatitis includes other eruptions of the diaper area that may coexist with candidal infection. For this reason, it is important to establish a diagnosis by means of KOH preparation or culture.

Treatment consists of applications of an imidazole cream 2 times daily. The combination of a corticosteroid and an antifungal agent may be justified if inflammation is severe but may confuse the situation if the diagnosis is not firmly established. Corticosteroids should not be continued for more than a few days. Protection of the diaper area by an application of thick zinc oxide paste overlying the anticandidal preparation may be helpful. The paste is more easily removed with mineral oil than with soap and water. Fungal id reactions gradually abate with successful treatment of the diaper dermatitis or may be treated with a mild corticosteroid preparation. When

Fig. 707.14 Erythematous confluent plaque caused by candidal infection.

Fig. 707.15 Intertriginous candidiasis of the neck.

recurrences of diaper candidiasis are frequent, it may be helpful to prescribe a course of oral anticandidal therapy to decrease the yeast population in the gastrointestinal tract. Some infants seem to be receptive hosts for *C. albicans* and may reacquire the organism from a colonized adult.

Intertriginous Candidiasis

Intertriginous candidiasis occurs most often in the axillae and groin, on the neck (Fig. 707.15), under the breasts, under pendulous abdominal fat folds, in the umbilicus, and in the gluteal cleft. Typical lesions are large, confluent areas of moist, denuded, erythematous skin with an irregular, macerated, scaly border. Satellite lesions are characteristic and consist of small vesicles or pustules on an erythematous base. With time, intertriginous candidal lesions may become lichenified, dry, scaly plaques. The lesions develop on skin subjected to irritation and maceration. Candidal superinfection is more likely to occur under conditions that lead to excessive perspiration, especially in obese children and in children with underlying disorders, such as diabetes mellitus. A similar condition, interdigital candidiasis, commonly occurs in individuals whose hands are constantly immersed in water. Fissures occur between the fingers and have red denuded centers, with an overhanging white epithelial fringe. Similar lesions between the toes may be secondary to occlusive footwear. Treatment is the same as for other candidal infections.

Perianal Candidiasis

Perianal dermatitis develops at sites of skin irritation as a result of occlusion, constant moisture, poor hygiene, anal fissures, and pruritus from pinworm infestation. It may become superinfected with *C. albicans,* especially in children who are receiving oral antibiotic or corticosteroid medication. The involved skin becomes erythematous, macerated, and excoriated, and the lesions are identical to those of candidal intertrigo or candidal diaper rash. Application of a topical antifungal agent in conjunction with improved hygiene is usually effective. Underlying disorders such as pinworm infection must also be treated (see Chapter 339).

Candidal Paronychia and Onychia

See Chapter 704.

Candidal Granuloma

Candidal granuloma is a rare response to an invasive candidal infection of skin. The lesions appear as crusted, verrucous plaques and hornlike projections on the scalp, face, and distal limbs. Affected patients may have single or numerous defects in immune mechanisms, and the granulomas are often refractory to topical therapy. A systemic anticandidal agent may be required for palliation or eradication of the infection.

Visit Elsevier eBooks+ at eBooks.Health.Elsevier.com for Bibliography.

Chapter 708

Cutaneous Viral Infections

Lamiaa Hamie and Stephen R. Humphrey

WART (VERRUCA)

Etiology

Human papillomaviruses (HPVs) cause a spectrum of diseases from warts (verrucae vulgaris) to squamous cell carcinoma of the skin and mucous membranes, including the larynx (see Chapter 438.2). The HPVs are classified by genus, species, and type. More than 200 types are known, and the entire genomes of approximately 100 are completely sequenced. The incidence of all types of warts is highest in children and adolescents. HPV is spread by direct contact and autoinoculation; transmission within families and by fomites also occurs. The clinical manifestations of infection develop 1 month or longer after inoculation and depend on the HPV type, the size of the inoculum, the immune status of the host, and the anatomic site.

Clinical Manifestations

Cutaneous warts develop in 5–10% of children. **Common warts** (verruca vulgaris), caused most commonly by HPV types 2 and 4, occur most frequently on the fingers, dorsum of the hands (Fig. 708.1), paronychial areas, face, knees, and elbows. They are well-circumscribed papules with an irregular, roughened, keratotic surface. When the surface is pared away, many black dots representing thrombosed dermal capillary loops are often visible. **Periungual warts** are often painful and may spread beneath the nail plate, separating it from the nail bed (Fig. 708.2). **Plantar warts (verruca plantaris)**, although similar to the common wart, are caused by HPV type 1 and are usually flush with the surface of the sole because of the constant pressure from weight bearing. When plantar warts become hyperkeratotic (Fig. 708.3), they may be painful. Similar lesions (palmar-verruca palmaris) can also occur on the palms. They are sharply demarcated, often with a ring of thick callus. The surface keratotic material must sometimes be removed before the boundaries of the wart can be appreciated. Several

Fig. 708.1 Verrucous papules on the back of the hand.

Fig. 708.2 Periungual wart with disruption of nail growth.

Fig. 708.3 Hyperkeratotic plantar wart.

Fig. 708.4 Multiple flat warts on the face with lesions in line of trauma.

Fig. 708.5 Condylomata acuminata in the perianal area of a toddler.

contiguous warts (HPV type 4) may fuse to form a large plaque, known as the *mosaic wart*. **Flat warts (verruca plana)**, caused by HPV types 3 and 10, are slightly elevated, minimally hyperkeratotic papules that usually remain <3 mm in diameter and vary in color from pink to brown. They may occur in profusion on the face, arms, dorsum of the hands, and knees. The distribution of several lesions along a line of cutaneous trauma (koebnerization) is a helpful diagnostic feature (Fig. 708.4). Lesions may be disseminated in the beard area and on the legs by shaving and from the hairline onto the scalp by combing the hair. **Epidermodysplasia verruciformis** (*EVER1, EVER2* genes), caused primarily by HPV types 5 and 8 (β-papillomaviruses, species 1), manifests as many diffuse verrucous papules. Wart types 9, 12, 14, 15, 17, 25, 36, 38, 47, and 50 may also be involved. Inheritance is thought to be primarily autosomal recessive, but an X-linked recessive form has also been postulated. Warts progress to **squamous cell carcinoma** in 10% of patients with epidermodysplasia verruciformis.

Genital HPV infection occurs in sexually active adolescents, most commonly as a result of infection with HPV types 6 and 11. **Condylomata acuminata** (mucous membrane warts) are moist, fleshy, papillomatous lesions that occur on the perianal mucosa (Fig. 708.5), labia, vaginal introitus, and perineal raphe and on the shaft, corona, and glans penis. Occasionally, they can obstruct the urethral meatus or the vaginal introitus. Because they are located in intertriginous areas, they may become moist and friable. When left untreated, condylomata proliferate and become confluent, at times forming large cauliflower-like masses. Lesions can also occur on the lips, gingivae, tongue, and conjunctivae. Genital warts in children may occur after inoculation during birth through an infected birth canal, as a consequence of sexual abuse, or from incidental spread from cutaneous warts. A significant proportion of genital warts in children contain HPV types that are usually isolated from cutaneous warts. HPV infection of the cervix is a major risk factor for the development of carcinoma, particularly if the infection is caused by HPV type 16, 18, 31, 33, 35, 39, 45, 52, 59, 67, 68, or 70. Immunization against types 6, 11, 16, 18, 31, 33, 45, 52, and 58 is available (see Chapter 438.2). Laryngeal (respiratory) papillomas contain the same HPV types as in anogenital papillomas. Transmission is believed to occur from mothers with a genital HPV infection to

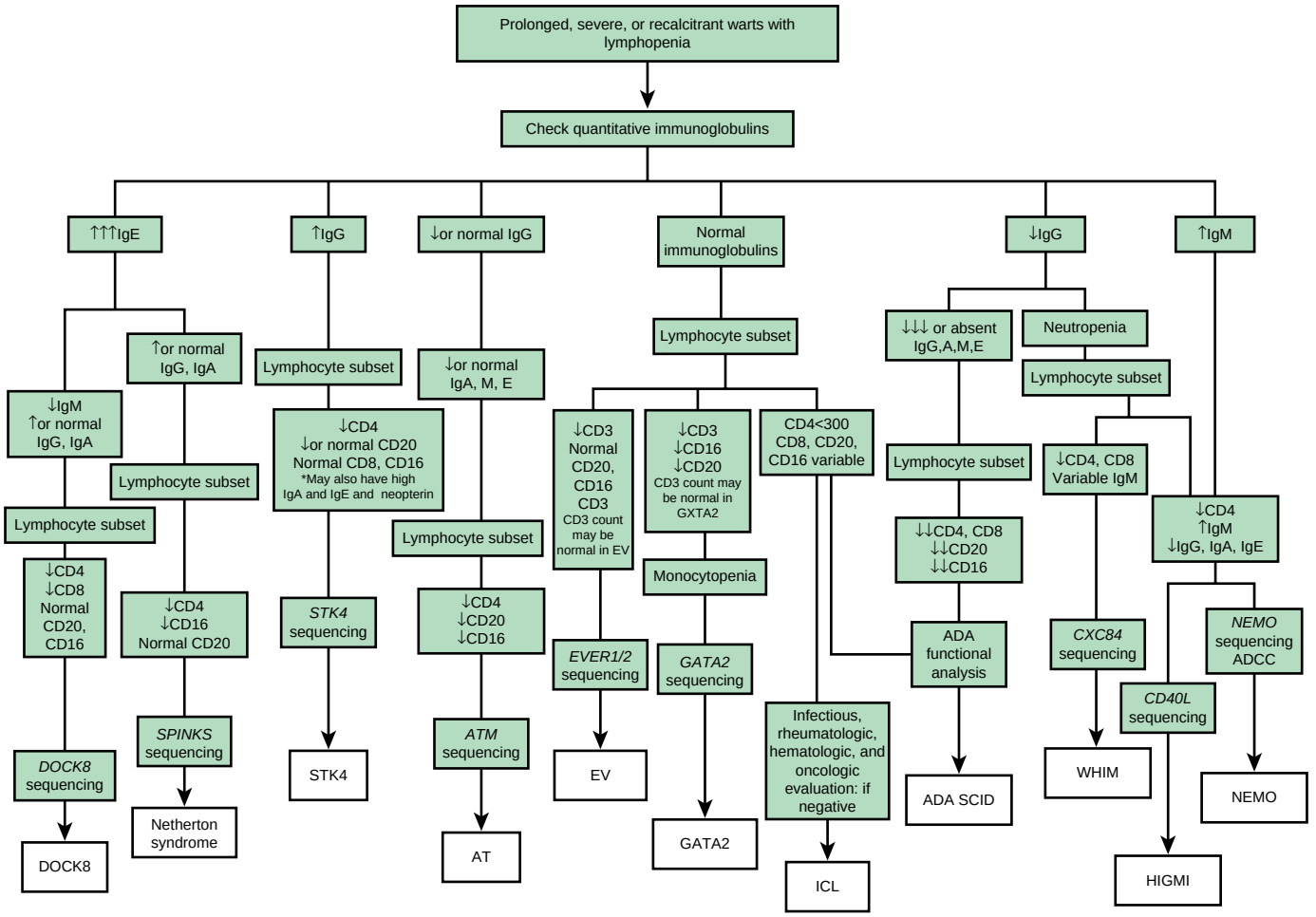

Fig. 708.6 Algorithm for diagnosis of primary immune deficiency with warts and lymphopenia. ADA SCID, adenosine deaminase severe combined immunodeficiency; AT, ataxia-telangiectasia; DOCK8, Dedicator of cytokinesis 8; EV, epidermodysplasia verruciformis; ICL, idiopathic CD4 lymphopenia; NEMO, nuclear factor κB essential modulator deficiency; STK4, serine/threonine kinase 4 deficiency; WHIM, warts, hypogammaglobulinemia, recurrent bacterial infections, and myelokathexis; XHIGM1, x-linked hyper IgM syndrome type 1/CD40L deficiency. *(From Lieding JW, Holland SM. Warts and all: HPV in primary immunodeficiencies. J Allergy Clin Immunol. 2012;130[5]:1030–1048, Fig. 3, p. 1043.)*

neonates who aspirate infectious virus during birth and may subsequently develop laryngeal papillomatosis.

Differential Diagnosis

Common warts are most often confused with molluscum contagiosum. Plantar and palmar warts may be difficult to distinguish from punctate keratoses, corns, and calluses. In contrast to calluses, warts obliterate normal skin markings. Juvenile flat warts mimic lichen planus, lichen nitidus, angiofibromas, syringomas, milia, and acne. Condylomata acuminata may resemble condylomata lata of secondary syphilis. Patients with recurrent, multiple, difficult-to-treat or disseminated warts may have a primary immune deficiency disorder (Fig. 708.6).

Treatment

Various therapeutic measures are effective in the treatment of warts. More than 65% of warts disappear spontaneously within 2 years. Warts are epidermal lesions and do not produce scarring unless subjected to surgical procedures or overly aggressive treatments. Hyperkeratotic lesions (common, plantar, and palmar warts) are more responsive to therapy if the excess keratotic debris is gently pared with a scalpel until thrombosed capillaries are apparent; further paring may induce bleeding. Treatment is most successful when performed regularly and frequently (every 2-4 weeks).

Common warts can be eradicated by applications of liquid nitrogen or by laser therapy, such as carbon dioxide or pulsed dye laser. Daily application of salicylic acid in flexible collodion or as a stick is a slow but painless method of removal that is effective in some patients. Plantar and palmar warts may be treated with 40% salicylic acid plasters. These should be applied for 5 days at a time with a 2-day rest period between applications. After removal of the plaster and prolonged soaking in hot water, keratotic debris can be removed with an emery board or pumice stone. Condylomata respond best to weekly applications of 25% podophyllin in tincture of benzoin. The medication should be left on the warts for 4-6 hours and then removed by bathing. Keratinized warts near the genitals (buttocks) do not respond to podophyllin. Imiquimod (5% cream) applied 3 times weekly is also beneficial. Imiquimod is not only indicated for genital warts but also has been used successfully to treat warts in other locations; however, it can cause inflammation and irritation, particularly in occluded areas. For nongenital warts, imiquimod should be applied daily. Cimetidine 30-40 mg/kg/day by mouth has been used in children with multiple warts unresponsive to other treatment, though its efficacy remains unclear. Immunotherapy with intralesional candida, MMR (measles, mumps, and rubella)

Fig. 708.7 Grouped molluscum.

Fig. 708.8 Molluscum with surrounding dermatitis.

vaccine or *Trichophyton* antigen may also be employed, especially when lesions are numerous or resistant to other therapies. Immunotherapy is performed in clinic, and multiple treatments at 1-month intervals (at least three to four) are usually required. With all types of therapy, care should be taken to protect the surrounding normal skin from irritation. Other treatments include 5-fluorouracil, a chemotherapy agent, which can be helpful, particularly when used with occlusion and sometimes in combination with salicylic acid. Topical cidofovir, an antiviral agent, and intralesional bleomycin, have also been used in refractory cases.

MOLLUSCUM CONTAGIOSUM

Etiology

The poxvirus that causes molluscum contagiosum is a large double-stranded DNA virus that replicates in the cytoplasm of host epithelial cells. Type 1 virus causes most infections. The disease is acquired by direct contact with an infected person or from fomites and is spread by autoinoculation. Children age 2-6 years who are otherwise well and individuals who are immunosuppressed are most commonly affected. The incubation period is estimated to be 2 weeks or longer.

Clinical Manifestations

Discrete, pearly, skin-colored, smooth, dome-shaped papules vary in size from 1 to 5 mm. They typically have a central umbilication from which a plug of cheesy material can be expressed. Although these papules can emerge anywhere on the body, they have a predilection for sites such as the face, eyelids, neck, axillae, and thighs (Fig. 708.7). They may be found in clusters on the genitals or in the groin of adolescents and may be associated with other venereal diseases in sexually active individuals. Lesions commonly involve the genital area in children but are not acquired by sexual transmission in most cases. Mild surrounding erythema or an eczematous dermatitis may accompany the papules (Fig. 708.8). Lesions on patients with AIDS tend to be large and numerous, particularly on the face. Exuberant lesions may also be found in children with leukemia and other immunodeficiencies. Children with atopic dermatitis are susceptible to widespread involvement in areas of dermatitis. A pustular eruption can develop at the site of individual molluscum lesions (Fig. 708.9). It is not a secondary bacterial infection, but rather an immunologic reaction to the molluscum virus; hence treatment with antibiotics is unnecessary. Atrophic scars may often follow this type of reaction.

Differential Diagnosis

The differential diagnosis of molluscum contagiosum includes trichoepithelioma, basal cell carcinoma, ectopic sebaceous glands, syringoma, hidrocystoma, keratoacanthoma, juvenile xanthogranulomas, and warty dyskeratoma. In individuals with AIDS, cryptococcosis may be indistinguishable clinically from molluscum contagiosum. Rarely, coccidioidomycosis, histoplasmosis, or *Penicillium marneffei* infection masquerades as molluscum-like lesions in an immunocompromised host.

Fig. 708.9 Inflamed molluscum. Crusted papule at the site of a previous molluscum.

Treatment

Molluscum contagiosum is a self-limited disease, with an average duration of 6-9 months. However, lesions can persist for years, spreading to distant sites and potentially transmitting to others. Affected patients should be advised to avoid shared baths and towels until the infection is clear. In cases of atopic dermatitis or immunodeficiency, infection may rapidly spread, leading to the development of hundreds of lesions in children. *Immunotherapy with either* Candida *or* Trichophyton *antigen is the most commonly used treatment*. This is repeated every 4 weeks until resolution. If lesions are limited in number, then depending on the age of the patient, individual lesions can be treated with liquid nitrogen cryotherapy. For younger children, cantharidin may be applied to the lesions and covered with adhesive bandages to prevent unwanted spread of the blistering agent. A blister forms at the application site, facilitating the removal of the molluscum. However, it's important to note that cantharidin should not be applied to the face. Cantharidin availability is either very limited or completely unavailable in the United States. Imiquimod has not been proven more effective than placebo in randomized trials. Considering that molluscum is an epidermal disease, caution should be exercised to avoid excessive treatment that may result in scarring.

Visit Elsevier eBooks+ at eBooks.Health.Elsevier.com for Bibliography.

Chapter 709

Arthropod Bites and Infestations

709.1 Arthropod Bites

Lamiaa Hamie and Stephen R. Humphrey

Arthropod bites are a common affliction of children and occasionally pose a problem in diagnosis. A patient may be unaware of the source of the lesions or may deny being bitten, making interpretation of the eruption difficult. In these cases, knowledge of the habits, life cycle, and clinical signs of the more common arthropod pests of humans may help lead to a correct diagnosis (Table 709.1).

CLINICAL MANIFESTATIONS

The type of reaction that occurs after an arthropod bite depends on the insect species and the age-group and reactivity of the human host. Arthropods may cause injury to a host by various mechanisms, including mechanical trauma, such as the lacerating bite of a tsetse fly; invasion of host tissues, as in myiasis; contact dermatitis, as seen with repeated exposure to cockroach antigens; granulomatous reaction to retained mouthparts; transmission of systemic disease; injection of irritant cytotoxic or pharmacologically active substances, such as hyaluronidase, proteases, peptidases, and phospholipases in sting venom; and induction of anaphylaxis. Most reactions to arthropod bites depend on antibody formation to antigenic substances in saliva or venom. The type of reaction is determined primarily by the degree of previous exposure to the same or a related species of arthropod. When someone is bitten for the first time, no reaction develops. An immediate petechial reaction is occasionally seen. After repeated bites, sensitivity develops, producing a pruritic papule (Fig. 709.1) approximately 24 hours after the bite. This is the most common reaction seen in young children. With prolonged, repeated exposure, a wheal develops within minutes after a bite, followed 24 hours later by papule, vesicle, or bullae formation. By adolescence or adulthood, only a wheal may form, unaccompanied by the delayed papular reaction. Thus adults in the same household as affected children may be unaffected. Ultimately, as a person becomes insensitive to the bite, no reaction occurs at all. This stage of nonreactivity is maintained only as long as the individual continues to be bitten regularly. Individuals in whom papular urticaria develops are in the transitional phase between development of a primarily delayed papular reaction and development of an immediate urticarial reaction.

Arthropod bites may occur as solitary, numerous, or profuse lesions, depending on the feeding habits of the perpetrator. Fleas tend to sample their host several times within a small localized area, whereas mosquitoes tend to attack a host at more randomly scattered sites. Delayed

Fig. 709.1 Pruritic papules after bed bug bites.

Table 709.1 Bed Bugs Versus Other Arthropod Bites: Main Clinical and Epidemiologic Features*

ARTHROPOD	CLINICAL FEATURES ON EXAMINATION	LOCATION	TIMING OF PRURITUS	CONTEXT
Bed bugs	3-4 bites in a line or curve	Uncovered areas	Morning	Traveling
Fleas	3-4 bites in a line or curve	Legs and buttocks	Daytime	Pet owners or rural living
Mosquitoes	Nonspecific urticarial papules	Potentially anywhere	*Anopheles* spp. night; *Culex* spp. night; *Aedes* spp. day	Worldwide distribution
Head lice	Live lice on the head associated with itchy, scratched lesions	Scalp, ears, and neck	Any	Children, parents, or contact with children
Body lice	Excoriated papules and hyperpigmentation; live lice inside clothes	Back	Any	Unhoused people
Sarcoptes scabiei mites (scabies)	Vesicles, burrows, nodules, and nonspecific secondary lesions	Interdigital spaces, forearms, breasts, genitals	Night	Sexually transmitted, households or institutions
Ticks	Erythema migrans or ulcer	Potentially anywhere	Asymptomatic	Pet owners or hikers
Pyemotes ventricosus	Comet sign, a linear, erythematous, macular tract	Under clothes	Any time when inside habitat	People exposed to woodworm-contaminated furniture (*Pediculoides ventricosus* is a woodworm parasite)
Spiders	Necrosis (uncommon)	Face and arms	Immediate pain, no itching	Rural living

*It is difficult to diagnose a bite. Diagnosis relies on an array of arguments, none of which is specific by itself; it is the association of elements that is suggestive. Any arthropod bite can be totally asymptomatic.

From Bernardeschi C, Le Cleach L, Delaunay P, Chosidow O. Bed bug infestation [published correction appears in *BMJ*. 2013;346:F1044]. *BMJ*. 2013;346:f138.

Fig. 709.2 Red-brown papules in papular urticaria.

hypersensitivity reactions to insect bites—the predominant lesions in the young and uninitiated—are characterized by firm, persistent papules that may become hyperpigmented and are often excoriated and crusted. Pruritus may be mild or severe, transient or persistent. A central punctum is usually visible but may disappear as the lesion ages or is scratched. The immediate hypersensitivity reaction is characterized by an evanescent, erythematous wheal. If edema is marked, a tiny vesicle may surmount the wheal. Certain beetles produce bullous lesions through the action of cantharidin, and various insects, including beetles and spiders, may cause hemorrhagic nodules and ulcers. Bites on the lower extremities are more likely to be severe or persistent or become bullous than those located elsewhere. Complications of arthropod bites include development of impetigo, folliculitis, cellulitis, lymphangitis, and severe anaphylactic hypersensitivity reactions, particularly after the bite of certain hymenopterans. The histopathologic changes are variable, depending on the arthropod, the age of the lesion, and the reactivity of the host. Acute urticarial lesions tend to show central vesiculation in which eosinophils are numerous. Papules most commonly show dermal edema and a mixed superficial and deep perivascular inflammatory infiltrate, often including a number of eosinophils. At times, however, the dermal cellular infiltrate is so dense that a lymphoma is suspected. Many young children demonstrate extensive dermal but nonerythematous, nontender edema in response to mosquito bites **(Skeeter syndrome)**, which responds to oral antihistamines; this must be distinguished from cellulitis, which tends to be painful, tender, and red. Retained mouthparts may stimulate a foreign body type of granulomatous reaction.

Papular urticaria occurs principally in the first decade of life. It may occur at any time of the year. The most common culprits are species of fleas, mites, bed bugs, gnats, mosquitoes, chiggers, and animal lice. Individuals with papular urticaria have predominantly transitional lesions in various stages of evolution between delayed-onset papules and immediate-onset wheals. The most characteristic lesion is an edematous, red-brown papule (Fig. 709.2). An individual lesion frequently starts as a wheal that, in turn, is replaced by a papule. A given bite may incite an id reaction at distant sites of quiescent bites in the form of erythematous macules, papules, or urticarial plaques. After a season or two, the reaction progresses from a transitional to a primarily immediate hypersensitivity urticarial reaction.

One of the most commonly encountered arthropod bites is that resulting from human, cat, or dog fleas (family Pulicidae). Eggs, which are generally laid in dusty areas and cracks between floorboards, give rise to larvae that then form cocoons. The cocoon stage can persist for up to 1 year, and the flea emerges in response to vibrations from footsteps, accounting for the assaults that frequently befall the new owners of a recently reopened dwelling. Adult dog fleas can live without a blood meal for approximately 60 days. Attacks from fleas are more likely to occur when the fleas do not have access to their usual host; cat or dog fleas are more voracious and problematic when one visits an area frequented by the pet than when the pet is encountered directly. Flea bites tend to be grouped in lines or irregular clusters on the lower extremities. Fleas are often not seen on the body of a pet. Diagnosis of flea bites is aided by examination of debris from the animal's bedding material. The debris is collected by shaking the bedding into a plastic bag and examining the contents for fleas or their eggs, larvae, or feces.

Table 709.2 Patient Education to Eliminate Bed Bugs

DETECTION
• Look for brown insects no bigger than apple seeds on the mattress, sofa, and curtains and in darker places in the room (especially cracks in the walls, crevices in box springs, and furniture)
• Look for black spots on the mattress or blood traces on the sheets
ELIMINATION
• Contact a pest management company
• Wash clothes at 60°C (140°F) or freeze delicate clothing, vacuum, and clean your home before the pest manager visits
• Collaborate with professionals who are used to dealing with bed bug infestation to increase eradication efficacy
PREVENTION
• Carefully examine secondhand furniture to assure the absence of bed bugs before purchase so as not to contaminate your home
• When sleeping in a hotel, even an upmarket establishment, lift mattresses to look for bed bugs or black spots
• Do not leave luggage in dark places, near furniture, or close to your bed. Before going to bed, close suitcases and put them in the bathroom—in the bathtub or shower stall

From Bernardeschi C, Le Cleach L, Delaunay P, Chosidow O. Bed bug infestation [published correction appears in *BMJ*. 2013;346:F1044]. *BMJ*. 2013;346:f138.

TREATMENT

Treatment is directed at alleviation of pruritus by oral antihistamines and cool compresses. Potent topical corticosteroids are helpful. Topical antihistamines are potent immunologic sensitizers and have no role in the treatment of insect bite reactions. A short course of systemic steroids may be helpful if many severe reactions occur, particularly around the eyes. Insect repellents containing *N,N*-diethyl-3-methylbenzamide (DEET) may afford moderate protection against mosquitoes, fleas, flies, chiggers, and ticks, but are relatively ineffective against wasps, bees, and hornets. DEET must be applied to exposed skin and clothing to be effective. The most effective protection against mosquitoes, the human body louse, and other blood-feeding arthropods is the use of DEET and permethrin-impregnated clothing. However, these measures are not effective against the phlebotomine sand fly, which transmits leishmaniasis. Because of the potential for toxicity, the lowest effective DEET dose should be selected. Additional insect repellents include picaridin (flies, mosquitoes, chiggers, ticks), IR3535 (mosquitoes), oil of lemon, eucalyptus (mosquitoes), and citronella (mosquitoes). Table 709.2 lists methods to eliminate bed bugs.

An effort should be made to identify and eradicate the etiologic agent. Pets should be carefully inspected. Crawl spaces, eaves, and other sites of the house or outbuildings frequented by animals and birds should be decontaminated, and baseboard crevices, mattresses, rugs, furniture, and animal sleeping quarters should be decontaminated. Agents that are effective for ridding the home of fleas include lindane, pyrethroids, and organic thiocyanates. Flea-infested pets may be treated with powders containing rotenone, pyrethroids, malathion, or methoxychlor. Lufenuron, an agent that prevents fleas from reproducing, is effective for animals in oral and injectable formulations. Fipronil is effective as a topical agent for the prevention of flea infestation.

Visit Elsevier eBooks+ at eBooks.Health.Elsevier.com for Bibliography.

709.2 Scabies

Lamiaa Hamie and Stephen R. Humphrey

Scabies is caused by burrowing and release of toxic or antigenic substances by the female mite *Sarcoptes scabiei* var. *hominis*. The most

Table 709.3 Different Presenting Forms of Scabies

PRESENTING FORMS OF SCABIES	SPECIFIC HIGH-RISK POPULATIONS	CLINICAL MANIFESTATIONS	LIMITED DIFFERENTIAL DIAGNOSES
Classic scabies (scabies vulgaris)	Infants and children; sexually active adults; men who have sex with men	Intense generalized pruritus, worse at night; inflammatory pruritic papules localized to finger webs, flexor aspects of wrists, elbows, axillae, buttocks, genitalia, female breasts; lesions and pruritus spare the face, head, and neck; secondary lesions include eczematization, excoriation, impetigo	Dermatitis herpetiformis, drug reactions, eczema, pediculosis corporis, lichen planus, pityriasis rosea
Scalp scabies	Infants and children; institutionalized older adults; AIDS patients; patients with preexisting crusted scabies	Atypical crusted papular lesions of the scalp, face, palms, and soles	Dermatomyositis, ringworm, seborrheic dermatitis
Crusted scabies (Norwegian scabies, scabies norvegica, scabies crustosa)	Institutionalized older adults; institutionalized developmentally disabled (Down syndrome); unhoused persons, especially HIV-positive; all immunocompromised patients, particularly those with AIDS or positive for HIV or HTLV-1; transplant recipients; patients on prolonged systemic corticosteroids and chemotherapy	Psoriasiform hyperkeratotic papular lesions of the scalp, face, neck, hands, feet, with extensive nail involvement; eczematization and impetigo common	Contact dermatitis, drug reactions, eczema, erythroderma, ichthyosis, psoriasis
Nodular scabies	Sexually active adults; men who have sex with men; HIV-positive men > HIV-positive women	Violaceous pruritic nodules localized to male genitalia, groin, axillae, representing hypersensitivity reaction to mite antigens	Acropustulosis, atopic dermatitis, Darier disease, lupus erythematosus, lymphomatoid papulosis, papular urticaria, necrotizing vasculitis, secondary syphilis

HTLV-1, Human T-cell lymphotropic virus type 1.
From Bennett JE, Blaser MJ, Dolin R, et al., eds. *Mandell, Douglas, and Bennett's Principles and Practice of Infectious Diseases*, 8th ed. Philadelphia: Saunders; 2015: Table 295.1, p. 3252.

important factor that determines spread of scabies is the extent and duration of physical contact with an affected individual. Children and sexual partners of affected individuals are most at risk. Scabies is transmitted only rarely by fomites because the isolated mite dies within 2-3 days.

ETIOLOGY AND PATHOGENESIS

An adult female mite measures approximately 0.4 mm in length; has four sets of legs; and has a hemispheric body marked by transverse corrugations, brown spines, and bristles on the dorsal surface. A male mite is approximately half her size and is similar in configuration. After impregnation on the skin surface, a gravid female exudes a keratolytic substance and burrows into the stratum corneum, often forming a shallow well within 30 minutes. She gradually extends this tract by 0.5-5.0 mm/24 hours along the boundary with the stratum granulosum. She deposits 10-25 oval eggs and numerous brown fecal pellets (scybala) daily. When egg laying is completed, in 4-5 weeks, she dies within the burrow. The eggs hatch in 3-5 days, releasing larvae that move to the skin surface to molt into nymphs. Maturity is achieved in approximately 2-3 weeks. Mating occurs, and the gravid female invades the skin to complete the life cycle.

CLINICAL MANIFESTATIONS

In an immunocompetent host, scabies is frequently heralded by intense pruritus, particularly at night (Table 709.3). The first sign of the infestation often consists of 1- to 2-mm red papules, some of which are excoriated, crusted, or scaling. Threadlike burrows are the classic lesion of scabies (Figs. 709.3 and 709.4) but may not be seen in infants. In infants, bullae and pustules are relatively common. The eruption may also include wheals, papules, vesicles, and a superimposed eczematous dermatitis (Fig. 709.5). The palms, soles, and scalp are often affected. In older children and adolescents, the clinical pattern is similar to that in adults, in whom preferred sites are the interdigital spaces; wrist flexors; anterior axillary folds; ankles, buttocks, umbilicus and belt line; groin; genitals in men; and areolas in women. The head, neck, palms, and soles are generally spared. Infants will often have a diffuse eczematous eruption that will involve the scalp, neck, and face. Red-brown nodules, most often located in covered areas such as the axillae, groin, and genitals, predominate in the less common variant called *nodular scabies.* Additional clues include facial sparing, affected family members, poor response to topical antibiotics, and transient response to topical steroids. Untreated, scabies may lead to eczematous dermatitis, impetigo, ecthyma, folliculitis, furunculosis,

Fig. 709.3 Classic scabies burrow.

cellulitis, lymphangitis, and id reaction. Glomerulonephritis has developed in children from streptococcal impetiginization of scabies lesions. In some tropical areas, scabies is the predominant underlying cause of pyoderma. A latent period of approximately 1 month follows an initial infestation. Thus itching may be absent and lesions may be relatively inapparent in contacts who are asymptomatic carriers. However, on reinfestation, reactions to mite antigens are noted within hours.

DIFFERENTIAL DIAGNOSIS

The differential diagnosis of scabies can often be made clinically but is confirmed by microscopic identification of mites (Fig. 709.6A), ova, and scybala (see Fig. 709.6B) in epithelial debris. Scrapings most often test positive when obtained from burrows or fresh papules. A reliable method is application of a drop of mineral oil on the selected lesion, scraping of it with a No. 15 blade, and transferring the oil and scrapings to a glass slide.

The differential diagnosis depends on the types of lesions present. **Burrows** are virtually pathognomonic for human scabies. **Papulovesicular lesions** are confused with papular urticaria, canine scabies, chickenpox, viral exanthems, drug eruptions, dermatitis herpetiformis, and folliculitis. **Eczematous lesions** may mimic atopic dermatitis and seborrheic dermatitis, and the less common bullous disorders of childhood may be suspected in infants with predominantly bullous lesions. **Nodular scabies** is frequently misdiagnosed as urticaria pigmentosa and Langerhans cell histiocytosis. The histopathologic appearance of nodular scabies, consisting of a deep, dense, perivascular infiltrate of lymphocytes, histiocytes, plasma cells, and atypical mononuclear cells, may mimic malignant lymphoid neoplasms.

TREATMENT

The treatment of choice for scabies is permethrin 5% cream (Elimite) applied to the entire body from the neck down, with particular attention to intensely involved areas, which is also standard therapy (Table 709.4). Scabies is frequently found above the neck in infants (younger than 2

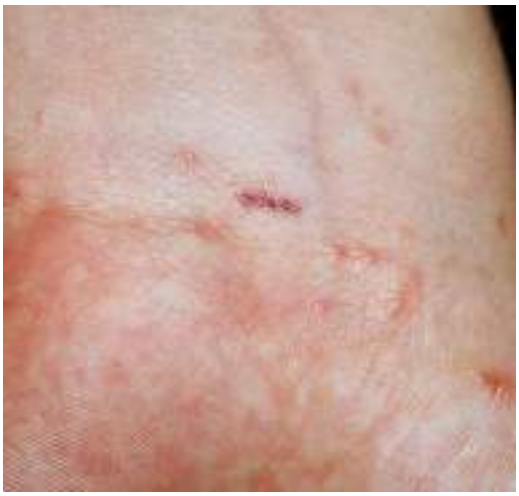

Fig. 709.4 Scabies. Felt-tipped ink pen has penetrated and highlighted a burrow. The ink is retained after the surface is wiped clean with an alcohol swab. *(From Habif TP, ed. Clinical Dermatology, 6th ed. Philadelphia: Mosby; 2016: Fig 15-16.)*

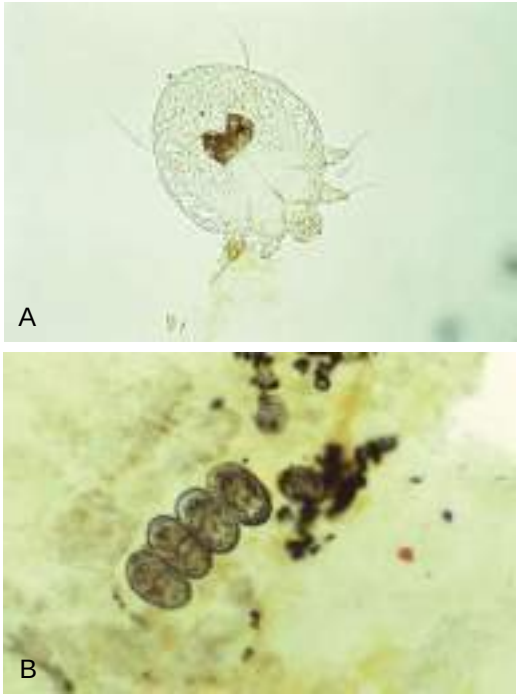

Fig. 709.6 A, Human scabies mite obtained from scraping. B, Scabies ova and scybala.

Fig. 709.5 A, Diffuse scabies on an infant. The face is clear. The lesions are most numerous around the axillae, chest, and abdomen. B, Scabies. Infestation of the palms and soles is common in infants. The vesicular lesions have all ruptured. *(From Habif TP, ed. Clinical Dermatology, 4th ed. Philadelphia: Mosby; 2004: Figs. 15.8 and 15.9.)*

Table 709.4 Currently Recommended Treatment for Scabies

SCABICIDES	FDA APPROVED?	PREGNANCY CATEGORY*	DOSING SCHEDULE	SAFETY PROFILE	CONTRAINDICATIONS
5% Permethrin cream (Actin, Nix, Elimite)	Yes	B	Apply from neck down; wash off after 8-14 hr; good residual activity, but second application recommended after 1 wk	Excellent; itching and stinging on application	Prior allergic reactions; infants <2 mo of age; breastfeeding
1% Lindane lotion or cream	Yes	B	Apply 30-60 mL from neck down; wash off after 8-12 hr; no residual activity; increasing drug resistance	Potential for central nervous system toxicity from organochloride poisoning, usually manifesting as seizures, with overapplication and ingestions	Preexisting seizure disorder; infants and children <6 mo of age; pregnancy; breastfeeding
10% Crotamiton cream or lotion (Eurax)	Yes	C	Apply from neck down on 2 consecutive nights; wash off 24 hr after second application	Excellent; not very effective; exacerbates pruritus	None
2–10% Sulfur in petrolatum ointments	No	C	Apply for 2-3 days, then wash	Excellent; not very effective	Preexisting sulfur allergy
10–25% Benzoyl benzoate lotion	No	None	Two applications for 24 hr with 1-day to 1-wk interval	Irritant; exacerbates pruritus; can induce contact irritant dermatitis and pruritic cutaneous xerosis	Preexisting eczema
0.5% Malathion lotion (Ovide), 1% malathion shampoo (unavailable in the United States)	No	B	95% ovicidal; rapid (5 min) killing; good residual activity; increasing drug resistance	Flammable 78% isopropyl alcohol vehicle stings eyes, skin, mucosa; increasing drug resistance; organophosphate poisoning risk with overapplication and ingestions	Infants and children <6 mo of age; pregnancy; breastfeeding
Ivermectin (Stromectol)	Yes	C	200-μg/kg single PO dose, may be repeated in 14-15 days; not ovicidal, second dose on day 14 or 15 highly recommended; recommended for endemic or epidemic scabies in institutions and refugee camps	Excellent; may cause nausea and vomiting; take on empty stomach with water	Safety in pregnancy uncertain; probably safe during breastfeeding; not recommended for children younger than 5 yr of age or weighing <15 kg

*U.S. Food and Drug Administration safety in pregnancy categories: A, safety established; B, presumed safe; C, uncertain safety; D, unsafe; X, highly unsafe.
From Bennett JE, Blaser MJ, Dolin R, et al., eds. *Mandell, Douglas, and Bennett's Principles and Practice of Infectious Diseases*, 8th ed. Philadelphia: Saunders; 2015: Table 295.2, p. 3253.

years old), necessitating treatment of the scalp. The medication is left on the skin for 8-12 hours and should be reapplied in 1 week for another 8- to 12-hour period. Additional therapies include sulfur ointment 5–10%, and crotamiton 10% lotion or cream. Lindane 1% lotion or cream should only be used as an alternative therapy, given the risk of systemic toxicity. For severe infestations or in immunocompromised patients, ivermectin 200 μg/kg per dose given orally for two doses 2 weeks apart can be used (off-label use). Single-dose ivermectin (200 μg/kg) has also been effective in immunocompetent patients, with improvement (cure) noted in 60% at 2 weeks and 89% at 4 weeks after treatment (see Table 709.4).

Transmission of mites is unlikely more than 24 hours after treatment. Pruritus, which is a result of hypersensitivity to mite antigens, may persist for a number of days to weeks, and may be alleviated by a topical corticosteroid preparation. If pruritus persists for >2 weeks after treatment and new lesions are occurring, the patient should be reexamined for mites. Nodules are extremely resistant to treatment and may take several months to resolve. The entire family should be treated, as should caretakers of the infested child. Clothing, bed linens, and towels should be washed in hot water and dried using high heat. Clothing or other items (e.g., stuffed animals) that cannot be washed may be dry cleaned or stored in bags for 3 days to 1 week, as the mite will die when separated from the human host.

CRUSTED SCABIES

The Norwegian variant of human scabies is highly contagious and occurs mainly in individuals who are cognitively and physically debilitated, particularly those who are institutionalized and those with Down syndrome; in patients with poor cutaneous sensation (leprosy, spina bifida); in patients who have severe systemic illness (leukemia, diabetes); and in immunosuppressed patients (HIV infection). Affected individuals are infested by a myriad of mites that inhabit the crusts and exfoliating scales of the skin and scalp (Fig. 709.7). The nails may become thickened and dystrophic. The subungual debris is densely populated by mites. The infestation is often accompanied by generalized lymphadenopathy and eosinophilia. There is massive orthokeratosis and parakeratosis with numerous interspersed mites, psoriasiform epidermal hyperplasia, foci of spongiosis, and neutrophilic abscesses. Norwegian scabies is thought to represent a deficient host immune response to the organism. Management is difficult, requiring scrupulous isolation measures, removal of the thick scales, and repeated but careful applications of permethrin 5% cream. Ivermectin (200-250 μg/kg) has been used successfully as single-dose therapy in refractory cases, particularly in HIV-infected patients. A second dose may be needed a week later. The U.S. Food and Drug Administration has not approved this agent for the treatment of scabies.

Fig. 709.7 Norwegian scabies. A and B, Right side of the head and neck and right leg before treatment showing diffuse, scaly hyperkeratotic rash, crusts, and fissures with areas of skin erythema *(arrow)* caused by hyperinfestation after infection with *Sarcoptes scabiei* in a patient with Down syndrome. *(Modified from Lee K, Heresi G, Hammond RA. Norwegian scabies in a patient with Down syndrome. J Pediatr. 2019;209:253.)*

CANINE SCABIES

Canine scabies is caused by *S. scabiei* var. *canis,* the dog mite that is associated with mange. The eruption in humans, which is most frequently acquired by cuddling an infested puppy, consists of tiny papules, vesicles, wheals, and excoriated eczematous plaques. Burrows are not present because the mite infrequently inhabits human stratum corneum. The rash is pruritic and has a predilection for the arms, chest, and abdomen, the usual sites of contact with dogs. Onset is sudden and usually follows exposure by 1-10 days, possibly resulting from development of a hypersensitivity reaction to mite antigens. Recovery of mites or ova from scrapings of human skin is rare. The disease is self-limited because humans are not a suitable host. Bathing and changing clothes are generally sufficient. Removal or treatment of the infested animal is necessary. Symptomatic therapy for itching is helpful. In rare cases in which mites are demonstrated in scrapings from an affected child, they can be eradicated by the same measures applicable to human scabies.

OTHER TYPES OF SCABIES

Other mites that occasionally bite humans include the chigger or harvest mite *(Eutrombicula alfreddugesi),* which prefers to live on grass, shrubs, vines, and stems of grain. Larvae have hooked mouthparts, which allow the chigger to attach to the skin, but not to burrow, to obtain a blood meal, most commonly on the lower legs. Avian mites may affect those who come into close contact with chickens or pet gerbils. Humans may occasionally be assaulted by avian mites that have infested a nest outside a window, an attic, heating vents, or an air conditioner. The dermatitis is variable, including grouped papules, wheals, and vesicular lesions on the wrists, neck, breasts, umbilicus, and anterior axillary folds. A prolonged investigation is often undertaken before the cause and source of the dermatitis are discovered.

Visit Elsevier eBooks+ at eBooks.Health.Elsevier.com for Bibliography.

709.3 Pediculosis

Lamiaa Hamie and Stephen R. Humphrey

Three types of lice are obligate parasites of the human host: body or clothing lice *(Pediculus humanus corporis),* head lice *(Pediculus humanus capitis),* and pubic or crab lice *(Phthirus pubis).* Only the body louse serves as a vector of human disease (typhus, trench fever, relapsing fever). Body and head lice have similar physical characteristics. They are approximately 2-4 mm in length. Pubic lice are only 1-2 mm in length and are greater in width than in length, giving them a crablike appearance. Female lice live for approximately 1 month and deposit 3-10 eggs daily on the human host. However, body lice generally lay eggs in or near the seams of clothing. The ova or nits are glued to hairs or fibers of clothing but not directly on the body. Ova hatch in 1-2 weeks and require another week to mature. Once the eggs hatch, the nits remain attached to the hair as empty sacs of chitin. Freshly hatched larvae die unless a meal is obtained within 24 hours and every few days thereafter. Both nymphs and adult lice feed on human blood, injecting their salivary juices into the host and depositing their fecal matter on the skin. Symptoms of infestation do not appear immediately but develop as an individual becomes sensitized. The hallmark of all types of pediculosis is pruritus.

Pediculosis corporis is rare in children except under conditions of poor hygiene, especially in colder climates when the opportunity to change clothes on a regular basis is lacking. The parasite is transmitted mainly on contaminated clothing or bedding. The primary lesion is a small, intensely pruritic, red macule or papule with a central hemorrhagic punctum, located on the shoulders, trunk, or buttocks. Additional lesions include excoriations, wheals, and eczematous, secondarily infected plaques. Massive infestation may be associated with constitutional symptoms of fever, malaise, and headache. Chronic infestation may lead to "vagabond's skin," which manifests as lichenified, scaling, hyperpigmented plaques, most commonly on the trunk. Lice are found on the skin only transiently when they are feeding. At other times, they inhabit the seams of clothing. Nits are attached firmly to fibers in the cloth and may remain viable for up to 1 month. Nits hatch when they encounter warmth from the host's body when the clothes are worn again. Therapy consists of improved hygiene and hot water laundering of all infested clothing and bedding. A uniform temperature of 65°C (149°F), wet or dry, for 15-30 minutes kills all eggs and lice. Alternatively, eggs hatch and nymphs starve if clothing is stored for 2 weeks at 23.9–29.4°C (75–85°F).

Pediculosis capitis is an intensely pruritic infestation of lice in the scalp hair. It is the most common form of lice to affect children, in particular those between the ages of 3 and 12 years. Fomites and head-to-head contact are important modes of transmission. In summer months in many areas of the United States and in the tropics at all times of the year, shared combs, brushes, or towels have a more important role in louse transmission. Translucent 0.5-mm eggs are laid near the proximal portion of the hair shaft and become adherent to one side of the shaft (Fig. 709.8). A nit cannot be moved along or knocked off the hair shaft with the fingers. Secondary pyoderma, after trauma from scratching, may result in matting together of the hair and cervical and occipital lymphadenopathy. Hair loss does not result from pediculosis but may accompany the secondary pyoderma. Head lice are a major cause of numerous pyodermas of the scalp, particularly in tropical environments. Lice are not always visible, but nits are detectable on the hairs, most commonly in the occipital region and above the ears, rarely on beard or pubic hair. Dermatitis may also be noted on the neck and pinnae. An **id reaction**, consisting of erythematous patches and plaques, may develop, particularly on the trunk.

In cases of resistance (which is common) of head lice to pyrethroids, malathion 0.5% in isopropanol is the treatment of choice and should be applied to dry hair until hair and scalp are wet and left on for 12 hours. A second application 7-9 days after the initial treatment may be necessary. This product is flammable, so care should be taken to avoid open flames. Malathion, like lindane shampoo, is not indicated for use in neonates and infants; however, additional approved therapies include spinosad (if >6 months), benzyl alcohol lotion (if >6 months), and ivermectin for difficult-to-treat head lice (Table 709.5). All household members should be treated at the same time. Nits can be removed

Fig. 709.8 Phthiriasis palpebrarum. Dermoscopy examination of eyelashes in a 27-mo-old boy, showing nits and parasites *(arrow)*. *(From Ouedraogo M, Ventejou S, Leducq S, et al. Crusts on the eyelashes. J Pediatr. 2019;209:254.)*

Table 709.5 Drugs for Head Lice

DRUG	RESISTANCE	FDA-APPROVED LOWER AGE OR WEIGHT LIMIT	DOSAGE AND ADMINISTRATION	COST*/SIZE
Ivermectin 0.5% lotion—Sklice (Arbor)	No	6 mo	Apply to dry hair and scalp for 10 min, then rinse†	$297.60/4 oz
Ivermectin tablets‡—Stromectol (MSD)	No	15 kg§	200-400 μg/kg PO once; repeat 7-10 days later	$9.30#
Spinosad 0.9% suspension—Natroba (ParaPro)	No	6 mo	Apply to dry hair for 10 min, then rinse; repeat 7 days later if necessary¶	$246.10/4 oz
Benzyl alcohol 5% lotion—Ulesfia (Lachlan)	No	6 mo	Apply to dry hair for 10 min, then rinse; repeat 7 days later**	$181.30/8 oz
Pyrethrins with piperonyl butoxide shampoo‡—Generic Rid (Bayer)	Yes	2 yr	Apply to dry hair for 10 min, then shampoo; repeat 7-10 days later	$15.00/8 oz‡‡ $20.00/8 oz‡‡
Permethrin 1% creme rinse‡—Generic Nix (Insight)	Yes	2 mo	Apply to shampooed, towel-dried hair for 10 min, then rinse; repeat 7 days later	$18.00/4 oz‡‡ $21.00/4 oz‡‡
Malathion 0.5% lotion—Generic Ovide (Taro)	Not in the United States	6 yr§§	Apply to dry hair for 8-12 hr, then shampoo; repeat 7-9 days later if necessary##,¶¶	$221.70/2 oz $246.40/2 oz
Abametapir lotion 0.74% (Xeglyze)	No	6 mo	Apply to dry hair for 10 min on day 0 and then rinse with water	Not available yet

*Approximate WAC for the indicated size. WAC represents a published catalogue or list price and may not represent an actual transactional price. Source: AnalySource Monthly. November 5, 2016. Reprinted with permission by First Databank, Inc. All rights reserved. Copyright 2016. www.fdbhealth.com/policies/drug-pricing-policy. Total cost of treatment may vary based on hair length and number of applications required to completely eradicate lice.
†The manufacturer recommends using up to one single-use, 4-oz tube of topical ivermectin lotion per application.
‡Not FDA approved for treatment of head lice.
§The safety and effectiveness of oral ivermectin have not been established in children weighing <15 kg.
#Cost of two 3-mg tablets (one dose for a 30-kg child at the lowest dosage).
¶The manufacturer recommends using up to one 4-oz (120-mL) bottle of spinosad 0.9% suspension per application.
**The amount of benzoyl alcohol 5% lotion recommended per application depends on hair length.
‡‡Approximate cost according to Walgreens.com. Accessed November 10, 2016.
§§The safety and effectiveness of malathion lotion have not been established in children <6 yr old; it is contraindicated in children <24 mo old.
##In clinical trials, patients used a maximum of 2 fl oz of malathion lotion per application.
¶¶One or two 20-min applications have also been effective (Meinking TL, Vicaria M, Eyerdam DH, et al: Efficacy of a reduced application time of Ovide lotion [0.5% malathion] compared to Nix creme rinse [1% permethrin] for the treatment of head lice. *Pediatr Dermatol* 21:670–674, 2004.)
††Available without a prescription.
FDA, U.S. Food and Drug Administration; MSD, Merck Sharp Dohme; WAC, wholesaler acquisition cost or manufacturer's published price to wholesalers.
From The Medical Letter. Drugs for head lice. *Med Lett Drugs Ther*. 2016;58:150–152.

Fig. 709.9 Intact nits on human hairs.

with a fine-toothed comb after application of a damp towel to the scalp for 30 minutes. Clothing and bed linens should be laundered in very hot (54.4°C [>130°F]) water and then dried for at least 10 minutes at the highest setting or dry-cleaned; brushes and combs should be discarded or coated with a pediculicide for 15 minutes and then thoroughly cleaned in boiling water. If the object cannot be washed, it can be sealed in a plastic bag for 48 hours. Children may return to school after the initial treatment.

Pediculosis pubis is transmitted by skin-to-skin or sexual contact with an infested individual; the chance of acquiring the lice with one sexual exposure is 95%. The infestation is usually encountered in adolescents, although small children may occasionally acquire pubic lice on the eyelashes (see Fig. 709.8). Patients experience moderate to severe pruritus and may develop a secondary pyoderma from scratching. Excoriations tend to be shallow, and the incidence of secondary infection is lower than in pediculosis corporis. Maculae ceruleae are steel-gray spots, usually <1 cm in diameter, which may appear in the pubic area and on the chest, abdomen, and thighs. Oval translucent nits, which are firmly attached to the hair shafts, may be visible to the naked eye or may be readily identified by a hand lens or by microscopic examination (Fig. 709.9). Grittiness, as a result of adherent nits, may sometimes be detected when the fingers are run through infested hair. Adult lice are more difficult to detect than head or body lice because of their lower level of activity and smaller, translucent bodies. Because pubic lice occasionally may wander or may be transferred to other sites on fomites, terminal hair on the trunk, thighs, axillary region, beard area, and eyelashes should be examined for nits. The coexistence of other venereal diseases should be considered. Treatment with a 10-minute application of a pyrethrin preparation is usually effective. Retreatment may be required in 7-10 days. Infestation of eyelashes is eradicated by petrolatum applied 3-5 times per 24 hours for 8-10 days. Clothing, towels, and bed linens may be contaminated with nit-bearing hairs and should be thoroughly laundered or dry-cleaned.

Visit Elsevier eBooks+ at eBooks.Health.Elsevier.com for Bibliography.

709.4 Seabather's Eruption

Lamiaa Hamie and Stephen R. Humphrey

Seabather's eruption is a severely pruritic dermatosis of inflammatory papules that develops within about 12 hours of bathing in saltwater, primarily on body sites that were covered by a bathing suit. The eruption has been described primarily in connection with bathing in the waters of Florida and the Caribbean. Lesions, which may include pustules, vesicles, and urticarial plaques, are more numerous in individuals who keep their bathing suits on for an extended period after leaving the water. The eruption may be accompanied by systemic symptoms of fatigue, malaise, fever, chills, nausea, and headache; in one large series, ~40% of children younger than 16 years of age had fever. Duration of the pruritus and skin eruption is 1-2 weeks. Lesions consist of a superficial and deep perivascular and interstitial infiltrate of lymphocytes, eosinophils, and neutrophils. The eruption appears to be caused by an allergic hypersensitivity reaction to venom from larvae of the thimble jellyfish *(Linuche unguiculata)*. Treatment is largely symptomatic. Potent topical corticosteroids have been shown to provide relief to some patients.

Chapter 710
Acne

Leah Lalor

ACNE VULGARIS

Acne is a chronic inflammatory disorder of the pilosebaceous unit with a multifactorial pathogenesis that affects at least 85% of adolescents but can occur in any age-group.

Pathogenesis

There are four main pathogenic factors leading to the development of acne: (1) increased sebum production; (2) abnormal keratinization of the follicular infundibulum; (3) *Cutibacterium acnes* (formerly *Propionibacterium acnes*)–mediated responses; and (4) inflammation.

The initial lesion of acne is a microcomedone, which progresses to a comedone. A comedone is a dilated, epithelium-lined follicular sac filled with lamellated keratinaceous material, lipid, and bacteria. An open comedone, known as a **blackhead**, has a patulous pilosebaceous orifice that permits visualization of the plug. An open comedone becomes inflammatory less commonly than does a closed comedone, or **whitehead**, which has only a pinpoint opening. An inflammatory papule or nodule develops from a comedone that has ruptured and extruded its follicular contents into the subadjacent dermis, inducing a neutrophilic inflammatory response. If the inflammatory reaction is close to the surface, a **papule or pustule** develops. If the inflammatory infiltrate develops deeper in the dermis, a **nodule** forms. Suppuration and an occasional giant cell reaction to keratin and hair are the cause of **nodulocystic** lesions. These are not true cysts but liquefied masses of inflammatory debris.

Comedonal acne (Fig. 710.1), particularly of the forehead and central face, is frequently the first sign of pubertal maturation. Most patients with acne do not have endocrine abnormalities. Many women with acne (25–50%) note acne flares about 1 week before menstruation.

Fig. 710.1 Primarily comedonal acne in a 7-yr-old female.

Fig. 710.2 Inflammatory papules and pustules.

Fig. 710.3 Severe nodulocystic acne.

Clinical Manifestations

Acne vulgaris is characterized by four basic types of lesions: open and closed comedones, papules, pustules (Fig. 710.2), and nodulocystic lesions (Fig. 710.3 and Table 710.1). One or more types of lesions may predominate. In its mildest form, which is often seen early in adolescence, lesions are limited to comedones on the central area of the face. Lesions may also involve the chest, upper back, and deltoid areas. A predominance of lesions on the forehead, particularly closed comedones, is common in early acne but can also be seen with prolonged use of greasy hair preparations (pomade acne) (Fig. 710.4). Marked involvement on the trunk is most often seen in males. Lesions often heal with temporary postinflammatory erythema and hyperpigmentation. Pitted, atrophic, or hypertrophic scars may be interspersed, depending on the severity, depth, and chronicity of the process.

Diagnosis of acne is rarely difficult, although flat warts, folliculitis, and other types of acne (drug-induced or exacerbated: glucocorticoid agents, anabolic steroids, gold, dactinomycin, isoniazid, iodides, bromides, cyclosporin, interferon beta, epidermal growth factor inhibitors, lithium, phenobarbital, phenytoin, progestins/Depo-Provera) may be confused with acne vulgaris. Definable autoinflammatory syndromes and androgen excess disorders are often associated with difficult-to-treat acne or when acne is noted with other cutaneous or systemic symptoms (Fig. 710.5). The differential diagnosis includes sarcoidosis, angiofibromas, keratosis pilaris, chloracne, rosacea, and fibrofolliculomas.

Treatment

An effective treatment strategy targets multiple pathogenic factors. There is no single treatment that addresses all four pathogenic factors other than the systemic retinoid isotretinoin; thus a **combination approach is typically preferred**. Therapy must be individualized based on acne lesion assessment and severity and aimed at preventing comedone formation. Inflammatory acne is frequently underdiagnosed in people of color, as the characteristic erythema may be masked by darker skin pigment. Careful evaluation of acne type is warranted to ensure appropriate treatment is selected.

Initial control requires 10-12 weeks of regular daily use of medications. Acne can be controlled and severe scarring prevented by judicious maintenance therapy that is continued until the disease process has abated spontaneously (Table 710.2 and Fig. 710.6).

It is also important to address the potentially severe emotional impact of acne on adolescents. The pediatrician must be aware of the frequently poor correlation between acne severity and psychosocial impact, particularly in adolescents. As adolescents become preoccupied with their appearance, offering treatment even to the youngster whose acne is mild may enhance self-image.

Table 710.1 One Approach to the Classification of Acne

SEVERITY	DESCRIPTION
Mild	Comedones (noninflammatory lesions) are the main lesions. Papules and pustules may be present but are small and few in number (generally <10).
Moderate	Moderate numbers of papules and pustules (10-40) and comedones (10-40) are present. Mild disease of the back and trunk may also be present.
Moderately severe	Numerous papules and pustules are present (40-100), usually with many comedones (40-100) and occasional larger, deeper nodular inflammatory lesions (up to 5). Widespread affected areas usually involve the face, chest, and back.
Severe	Nodulocystic acne and conglobate acne, including many large inflammatory, painful nodular or pustular lesions along with many smaller papules, pustules, and comedones.

The American Academy of Dermatology acknowledges that there is no universally agreed upon grading/severity classification for acne.
Modified from James WD. Clinical practice: Acne. *N Engl J Med.* 2005;352:1463–1472.

Diet

Little evidence shows that the ingestion of particular foods can trigger acne flares, though high nonfat milk ingestion and high-glycemic-load diets may be contributory. When a patient is convinced that certain

dietary items exacerbate acne, it is prudent for the patient to omit those foods, provided that such omissions do not lead to excessive dietary restrictions.

Climate

Climate appears to influence acne in that improvement frequently occurs in summer and flares are more common in winter. Remission in summer may relate partly to the relative absence of stress. Emotional tension and fatigue seem to exacerbate acne in many individuals; the mechanism is unclear but has been proposed to relate to an increased adrenocortical response.

Cleansing

Cleansing with soap and water removes surface lipid and renders the skin less oily in appearance. It is generally recommended to wash with a gentle cleanser twice daily, followed by moisturizing with a noncomedogenic emollient, for all acne patients. Repetitive cleansing can be harmful because it irritates the skin, and use of harsh scrubs is not recommended. Greasy cosmetic and hair preparations must be discontinued because they exacerbate preexisting acne and cause further plugging of follicular pores. Manipulation and squeezing of facial lesions can lead to scarring and should be avoided.

Fig. 710.4 Pomade acne along the hairline.

Topical Therapy

All topical preparations must be used for 10-12 weeks before their effectiveness can be assessed (Table 710.3). Retinoids are first-line therapy and may be used alone for mild acne, but combination therapy is frequently more effective. A popular and effective combination is use of a benzoyl peroxide preparation in the morning and a retinoid at night. Recommendations for specific acne presentations are presented in Tables 710.2 and 710.3.

Retinoids. A topical retinoid should be the primary treatment for acne vulgaris. Topical retinoids have multiple actions, including inhibition of the formation and number of microcomedones, reduction of mature comedones, reduction of inflammatory lesions, and production of normal desquamation of the follicular epithelium. Retinoids should be applied nightly to all affected areas. The main side effects of retinoids are irritation and dryness. Not all patients initially tolerate daily use of a retinoid. It may be prudent to begin therapy every other or every third day and slowly increase the frequency of application as tolerated. Tretinoin, adapalene, tazarotene, and trifarotene (Table 710.4) are the available retinoids. They vary in strength and efficacy, although adapalene tends to be less irritating and tazarotene is more irritating but may be more effective.

Benzoyl Peroxide. Benzoyl peroxide is primarily an antimicrobial agent and does have mild comedolytic activity. It has an advantage over topical antibiotics in that it does not enhance antimicrobial resistance. It is available in multiple formulations and concentrations. The gel formulations are preferred, owing to better stability and more consistent release of the active ingredient. Washes and cleansers are useful for covering large surface areas such as the chest and back. As with retinoids, the main side effects are irritation and drying. Benzoyl peroxide can also bleach clothing, which sometimes limits the use of leave-on preparations like gels.

Topical Antibiotics. Topical antibiotics are indicated for the treatment of inflammatory acne. Clindamycin is the most commonly used. It is not as effective as oral antibiotics. It should never be used as monotherapy because it does not inhibit microcomedone formation and has the potential to induce antimicrobial resistance. Irritation and dryness are generally less than with retinoids or benzoyl peroxide. Topical antibiotics should not be used as monotherapy and can be prescribed as a combination product or separately. The most common combination product is benzoyl peroxide/clindamycin. A combination tretinoin/clindamycin product may also be used.

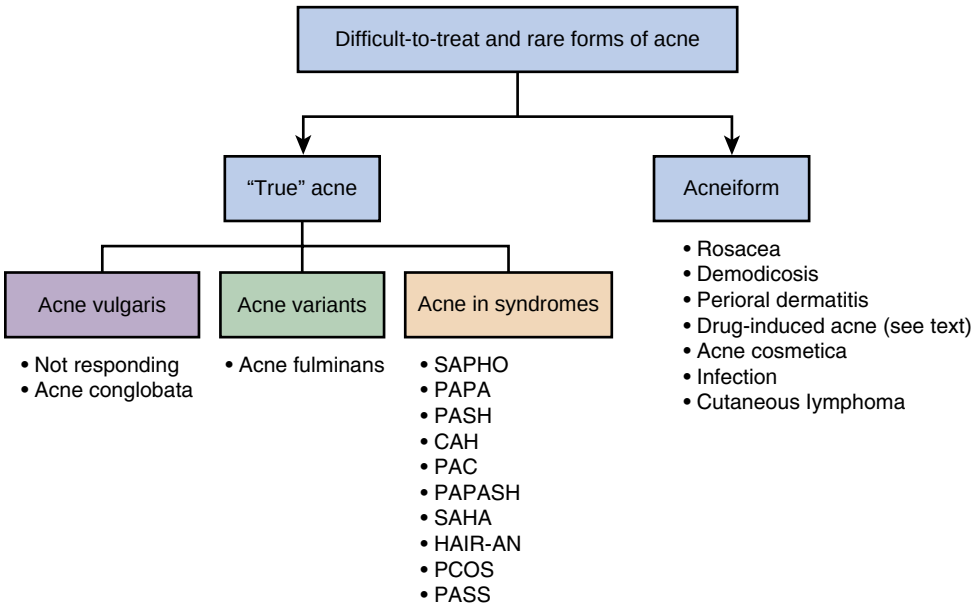

Fig. 710.5 Rare and difficult forms of acne. CAH, Congenital adrenal hyperplasia; PAPA, pyogenic sterile arthritis, pyoderma gangrenosum, acne syndrome; PASH, pyoderma gangrenosum, acne, and suppurative hidradenitis syndrome; SAPHO, synovitis, acne, pustulosis, hyperostosis, osteitis syndrome; PAC, pyoderma gangrenosum, acne, ulcerative colitis; PAPASH, pyogenic arthritis, pyoderma gangrenosum, acne, suppurative hidradenitis; SAHA, seborrhea, acne, hirsutism, androgenic alopecia; HAIR-AN, hyperandrogenism, insulin resistance, acanthosis nigricans; PCOS, polycystic ovarian syndrome; PASS, pyoderma gangrenosum acne, spondyloarthritis. *(Modified from Dessinioti C, Katsambas A. Difficult and rare forms of acne. Clin Dermatol. 2017;35[2]:138–146.)*

Table 710.2 Acne Treatment Algorithm

THERAPY	SEVERITY (LESION TYPE)				
	MILD (COMEDONAL)	MILD (INFLAMMATORY/ MIXED)	MODERATE (INFLAMMATORY/ MIXED)	SEVERE (INFLAMMATORY/ MIXED)	SEVERE (NODULAR/ SCARRING)
Initial therapy options*,†	Topical retinoid BP Salicylic acid cleanser	BP/retinoid combo BP/antibiotic combo Antibiotic/retinoid combo + BP	BP/retinoid combo BP/antibiotic combo ± topical retinoid Antibiotic/retinoid combo + BP ± oral antibiotic	BP/retinoid combo + oral antibiotic BP/antibiotic combo + topical retinoid + oral antibiotic Antibiotic/retinoid combo + BP + oral antibiotic	Isotretinoin
Alternative therapy options*,†,‡	Add BP or retinoid if not already prescribed BP/antibiotic combo BP/retinoid combo Antibiotic/retinoid combo	Substitute another combo product Add missing component (e.g., topical retinoid, BP, topical antibiotic) Change type, strength, or formulation of topical retinoid	Substitute another combo product Add missing component (i.e., topical retinoid, BP, topical antibiotic, oral antibiotic) Change type, strength, or formulation of topical retinoid Consider hormonal therapy§ for female patients Consider oral isotretinoin	Consider changing oral antibiotic Consider isotretinoin Consider hormonal therapy§ for female patients	Consider hormonal therapy§ for female patients
Maintenance therapy	Topical retinoid or BP/ retinoid combo	Topical retinoid or BP/ retinoid combo	Topical retinoid or BP/ retinoid combo	Topical retinoid or BP/ retinoid combo	Topical retinoid or BP/ retinoid combo

*If combination products not available to patient, consider substitution of individual components as separate prescriptions.
†Topical dapsone may be considered in place of topical antibiotic.
‡If needed as determined by physician assessment and patient satisfaction.
§Combined oral contraceptive or oral spironolactone.
BP, Benzoyl peroxide.
Adapted from Zaenglein AL, Thiboutot DM. Expert committee recommendations for acne management. *Pediatrics* 2006;118(3):1188–1199; Thiboutot D, Gollnick H, Bettoli V, et al. New insights into the management of acne: An update from the Global Alliance to Improve Outcomes in Acne Group. *J Am Acad Dermatol*. 2009;60:S1–50; Eichenfield LF, Krakowski AC, Piggott C, et al. Evidence-based recommendations for the diagnosis and treatment of pediatric acne. *Pediatrics*. 2013;131(3):S163–S186; Thiboutot DM, Gollnick HP. Treatment considerations for inflammatory acne: Clinical evidence for adapalene 0.1% in combination therapies. *J Drugs Dermatol*. 2006;5(8):785–794; Gollnick H, Cunliffe W, Berson D, et al. Management of acne: A report from a Global Alliance to Improve Outcomes in Acne. *J Am Acad Dermatol*. 2003;49(Suppl 1):S1–S37; and Zaenglein AL, Pathy AL, Schlosser BJ, et al. Guidelines of care for the management of acne vulgaris. *J Am Acad Dermatol*. 2016;74:945–973. From Paller AS, Mancini AJ. *Hurwitz Clinical Pediatric Dermatology*, 6th ed. Philadelphia: Elsevier; 2022, Table 8.1, p. 210.

Azelaic Acid. Azelaic acid (20% cream) has mild antimicrobial and keratolytic properties. It can also help expedite resolution of postinflammatory hyperpigmentation and is less irritating than many other topical acne treatments.

Clascoterone. Clascoterone 1% cream is a topical androgen antagonist, a first in its class, and is approved for use in males and females 12 years and older. It has shown efficacy in improving both inflammatory and noninflammatory acne in trials, but how this medication will be used under real-world circumstances is yet to be determined.

Systemic Therapy

Antibiotics, especially tetracycline and its derivatives (see Table 710.4), are indicated for the treatment of patients whose acne has not responded to topical medications, who have moderate to severe inflammatory papulopustular and nodulocystic acne, and who have a propensity for scarring (Table 710.5). Tetracycline and its derivatives act by reducing the growth and metabolism of *C. acnes*. They also have antiinflammatory properties. For most adolescent patients, therapy may be initiated twice daily, for at least 6-8 weeks, in combination with a judicious topical regimen, and should not be used for longer than 3-6 months. The drugs should always be administered in combination with a topical retinoid and topical benzoyl peroxide but not with topical antibiotics. Doxycycline is the preferred oral antibiotic in acne because of its high efficacy and lower risk of long-term side effects compared with similar medications. Minocycline and doxycycline should be taken with food. Side effects of tetracycline and derivatives are rare and include vaginal candidiasis, particularly in those who take tetracycline concurrently with oral contraceptives; gastrointestinal irritation; phototoxic reactions, including onycholysis and brown discoloration of nails; esophageal ulceration; inhibition of fetal skeletal growth; and staining of growing teeth, precluding its use during pregnancy and in those younger than 8 years of age. Doxycycline is the most photosensitizing of the tetracycline derivatives and is also more likely to cause pill esophagitis. Rarely, minocycline causes dizziness, intracranial hypertension, bluish discoloration of the skin and mucous membranes, hepatitis, a lupus-like syndrome, and drug hypersensitivity. A possible complication of prolonged systemic antibiotic use is proliferation of gram-negative organisms—particularly *Enterobacter, Klebsiella, Escherichia coli,* and *Pseudomonas aeruginosa*—producing severe refractory folliculitis.

Females who have acne and hormonal abnormalities, whose acne is unresponsive to antibiotic therapy, or who are not candidates for isotretinoin therapy should be considered for a trial of hormonal therapy. Combined oral contraceptive pills are the primary form of hormonal therapy. Spironolactone has also shown effectiveness. Young women with acne that is refractory to conventional therapy and have other signs of hyperandrogenism should be evaluated for polycystic ovarian syndrome.

Isotretinoin (13-*cis*-retinoic acid) is indicated for *severe nodulocystic acne and moderate to severe acne that has not responded to conventional*

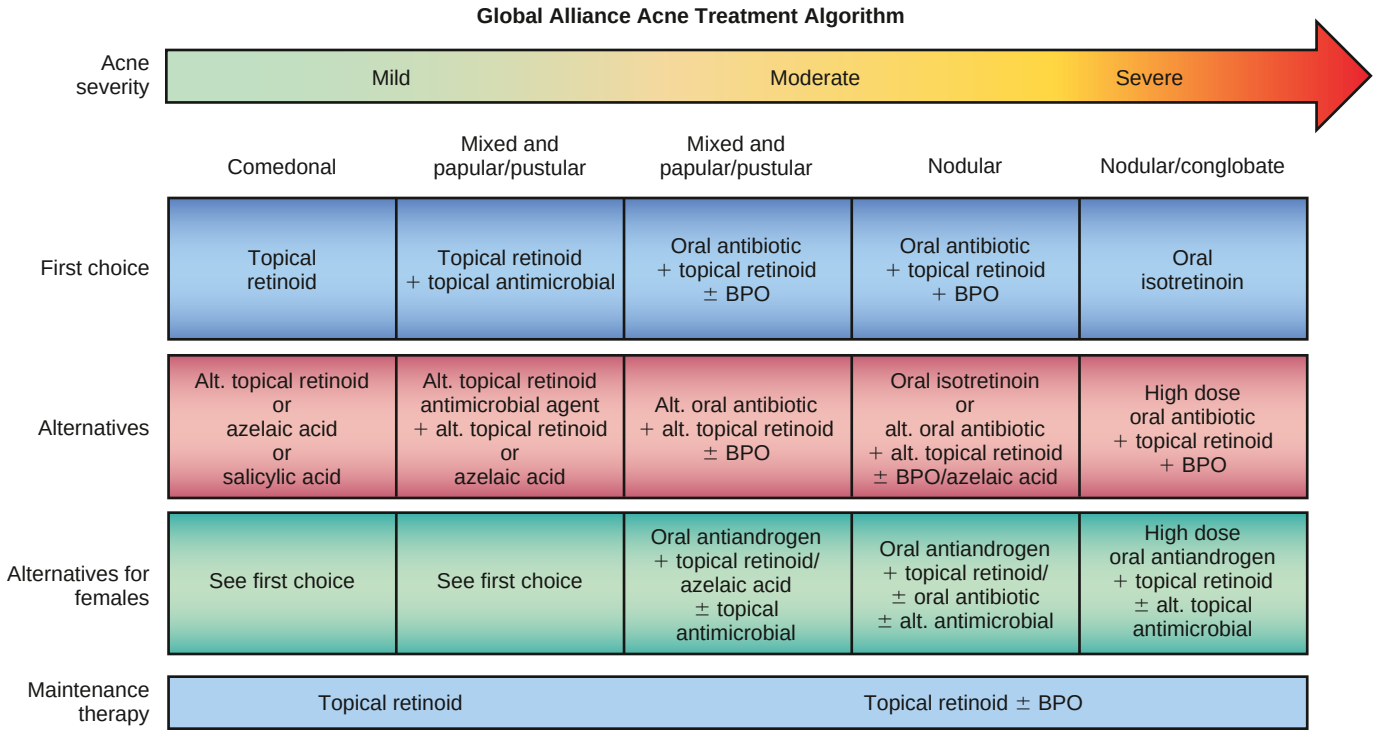

Fig. 710.6 Acne treatment algorithm. BPO, Benzoyl peroxide. *(From Thiboutot D, Gollnick H; Global Alliance to Improve Acne, et al. New insights into the management of acne: an update from the Global Allegiance to Improve Outcomes in Acne. J Am Acad Dermatol. 2009;60:S1–S50.)*

Table 710.3 Recommendations for Topical Therapies

- Benzoyl peroxide or combinations with erythromycin or clindamycin are effective acne treatments and are recommended as monotherapy for mild acne, or in conjunction with a topical retinoid, or systemic antibiotic therapy for moderate to severe acne.
- Benzoyl peroxide is effective in the prevention of bacterial resistance and is recommended for patients on topical or systemic antibiotic therapy.
- Topical antibiotics (e.g., erythromycin and clindamycin) are effective acne treatments but are not recommended as monotherapy because of the risk of bacterial resistance.
- Topical retinoids are important in addressing the development and maintenance of acne and are recommended as monotherapy in primarily comedonal acne or in combination with topical or oral antimicrobials in patients with mixed or primarily inflammatory acne lesions.
- Treatment with multiple topical agents that affect different aspects of acne pathogenesis can be useful. Combination therapy should be used in the majority of patients with acne.
- Topical adapalene, tretinoin, and benzoyl peroxide can be safely used in the management of preadolescent acne in children.
- Azelaic acid is a useful adjunctive acne treatment and is recommended in the treatment of postinflammatory dyspigmentation.
- Topical dapsone 5% gel is recommended for inflammatory acne, particularly in adult females with acne.
- There is limited evidence to support recommendations for sulfur, nicotinamide, resorcinol, sodium sulfacetamide, aluminum chloride, and zinc in the treatment of acne.

From Zaenglein AL, Pathy AL, Scholsser BJ, et al. Guidelines of care for the management of acne vulgaris. *J Am Acad Dermatol*. 2016;74(5):945–973, Table V, p. 951.

therapy. The recommended dosage is 0.5-1.0 mg/kg/day. A standard course in the United States lasts 16-20 weeks or until acne is clear. At the end of one course of isotretinoin, 70–80% of patients are cured, 10–20% need conventional topical and/or oral medications to maintain adequate control, and 10–20% have relapses and need an additional course of isotretinoin. Isotretinoin addresses all four pathogenic mechanisms of acne, is highly effective, and only has very rare treatment failures.

Isotretinoin use has many side effects. It is highly **teratogenic** and is **absolutely contraindicated** in pregnancy. Pregnancy should be avoided for 4 weeks after discontinuation of therapy. Two forms of birth control are required, or a confirmation of total abstinence, as are monthly pregnancy tests. *Concerns over cases of pregnancy despite warnings have prompted a manufacturer registration program, iPLEDGE (www.ipledgeprogram.com), which requires physician enrollment and careful patient pregnancy screening to prescribe isotretinoin.* Many patients also experience cheilitis, xerosis, periodic epistaxis, and blepharoconjunctivitis. Increased serum triglyceride and cholesterol levels are also common. It is important to rule out preexisting liver disease and hyperlipidemia before initiating therapy and to recheck laboratory values when the dosage is established. Less common but significant side effects include arthralgias, myalgias, temporary thinning of the hair, paronychia, increased susceptibility to sunburn, formation of pyogenic granulomas, and colonization of the skin with *Staphylococcus aureus,* leading to impetigo, secondarily infected dermatitis, and scalp folliculitis. Rarely, hyperostotic lesions of the spine develop after more than one course of isotretinoin. Concomitant use of an oral tetracycline and isotretinoin is contraindicated because either drug, but particularly when they are used together, can cause benign intracranial hypertension. Although no cause-and-effect relationship has been established, drug-induced mood changes and depression and/or suicide have mandated close attention to psychiatric well-being before and during isotretinoin prescription. An increased risk of inflammatory bowel disease with the use of isotretinoin is debated.

Surgical Therapy

Intralesional injection of low-dose (3-5 mg/mL) midpotency glucocorticoids (e.g., triamcinolone) with a 30-gauge needle on a tuberculin syringe may hasten the healing of individual painful nodulocystic lesions. Dermabrasion or laser peel to minimize scarring should be considered only after the active process is quiescent. Figure 710.7 describes the management of scarring.

The role of pulsed dye laser in the treatment of inflammatory acne is controversial and inconclusive.

Table 710.4 Medications for the Treatment of Acne

DRUG	DOSE	SIDE EFFECTS	OTHER CONSIDERATIONS
TOPICAL AGENTS			
Retinoids			
Tretinoin	Applied once nightly; strengths of 0.025–0.1% available*	Irritation (redness and scaling)	Generics available.
Adapalene	Applied once daily, at night or in the morning; 0.1% and 0.3%*	Minimal irritation	0.1% generic available.
Tazarotene†	Applied once nightly; 0.05% and 0.1%*	Irritation	Limited data suggest tazarotene is more effective than alternatives.
Trifarotene	Applied once nightly; 0.005% cream	Mild irritation	Labeled for trunk use.
Antimicrobials			
Benzoyl peroxide, 2.5–10%	Applied once or twice daily	Benzoyl peroxide can bleach clothing and bedding	Available over the counter; 2.5–5% concentrations as effective as and less drying than 10% concentration.
Clindamycin, erythromycin‡	Applied once or twice daily	Propensity to resistance	Most effective for inflammatory lesions (rather than comedones); resistance a concern when used alone.
Minocycline	Applied once or twice daily; 4% foam	None	Brand name, expensive.
Combination benzoyl peroxide and clindamycin or erythromycin; combination tretinoin and clindamycin	Applied once or twice daily	Side effects from benzoyl peroxide (bleach clothing or bedding) and from topical antibiotics (propensity to resistance)	Combination more effective than topical antibiotics alone; limits development of resistance; use of individual products in combination less expensive and appears similarly effective.
Other Topical Agents			
Azelaic acid‡	Applied twice daily; 20% cream	Well tolerated	Helpful for postinflammatory dyspigmentation; 10% cream available over the counter
Salicylic acid	Applied once or twice daily	Peeling, irritation	Low efficacy
Dapsone	Applied once daily; 5% and 7.5% gel	Mild irritation	Evidence of particular efficacy in skin of color
Clascoterone	Applied twice daily; 1% cream	Mild irritation	Brand name, expensive.
ORAL ANTIBIOTICS§			
Tetracycline#	250-500 mg once or twice daily	Gastrointestinal upset, intracranial hypertension	Inexpensive; dosing limited by need to take on empty stomach.
Doxycycline#	50-100 mg once or twice daily	Phototoxicity, intracranial hypertension, pill esophagitis, gastrointestinal upset	20-mg dose antiinflammatory only; limited data on efficacy.
Minocycline#	50-100 mg once or twice daily	Hyperpigmentation of teeth, oral mucosa, and skin; lupus-like reactions with long-term treatment, intracranial hypertension, drug hypersensitivity	
Sarecycline	Daily for 12 wk based on weight; 60-mg, 100-mg, 150-mg tablets	Intracranial hypertension, lightheadedness, candidiasis, nausea	Newest antimicrobial agent
Trimethoprim-sulfamethoxazole	One dose (160 mg trimethoprim, 800 mg sulfamethoxazole) twice daily	Toxic epidermal necrolysis and allergic eruptions	Trimethoprim may be used alone in a 300-mg dose twice daily; limited data available; not generally recommended.
Erythromycin‡	250-500 mg twice daily	Gastrointestinal upset	Resistance problematic; efficacy is limited.

Table 710.4 Medications for the Treatment of Acne—cont'd

DRUG	DOSE	SIDE EFFECTS	OTHER CONSIDERATIONS
HORMONAL AGENTS[¶]			
Spironolactone[#]	50-200 mg in 1-2 divided doses	Temporary menstrual irregularities and breast tenderness; possible potassium elevations in those with renal or cardiac disease	Higher doses more effective but cause more side effects; best given in combination with oral contraceptives.
Estrogen-containing oral contraceptives	Daily	Potential side effects include thromboembolism	Several approved specifically for acne, but all COCs have efficacy in acne treatment
ORAL RETINOID			
Isotretinoin[**]	0.5-1.0 mg/kg/day in 2 divided doses	Birth defects; adherence to pregnancy prevention program outlined by drug manufacturer, including two initial negative pregnancy tests, is essential; hypertriglyceridemia, elevated results on liver function tests, abnormal night vision, benign intracranial hypertension, dryness of the lips, ocular, nasal, and oral mucosa and skin, secondary staphylococcal infections, arthralgias, and mood disturbances are possible common or important side effects; laboratory testing of lipid profiles and liver function tests when dosage established	Relapse rate higher if patient is younger than age 16 yr at initial treatment, if acne is of high severity and involves the trunk, or if drug is used in adult women

*As cream or gel.
†Tazarotene is in pregnancy category X: contraindicated in pregnancy.
‡Clindamycin, erythromycin, and azelaic acid are in pregnancy category B: no evidence of risk in humans.
§Oral antibiotics are indicated for moderate to severe disease; for the treatment of acne on the chest, back, or shoulders; and in patients with inflammatory disease in whom topical combinations have failed or are not tolerated.
#This drug is in pregnancy category D: positive evidence of risk in humans.
¶Hormonal agents are for use in women only.
**Isotretinoin is in pregnancy category X: contraindicated in pregnancy. It should be used only in patients with severe acne that does not clear with combined oral and topical therapy.
Modified from James WD. Clinical practice: Acne. *N Engl J Med.* 2005;352:1463–1472.

Table 710.5 Recommendations for Systemic Antibiotics

- Systemic antibiotics are recommended in the management of moderate and severe acne and forms of inflammatory acne that are resistant to topical treatments.
- Doxycycline and minocycline are more effective than tetracycline.
- Although oral erythromycin or azithromycin can be effective in treating acne, its use should be limited to those who cannot use the tetracyclines (i.e., pregnant women or children <8 years of age). Erythromycin use should be restricted because of its increased risk of bacterial resistance.
- Use of systemic antibiotics other than the tetracyclines and macrolides is discouraged because there are limited data for their use in acne. Trimethoprim-sulfamethoxazole and trimethoprim use should be restricted to patients who are unable to tolerate tetracyclines or to treatment-resistant patients.
- The use of systemic antibiotics should be limited to the shortest possible duration. Reevaluate at 3-4 mo to minimize the development of bacterial resistance. Monotherapy with systemic antibiotics is not recommended.
- Concomitant topical therapy with benzoyl peroxide or a retinoid should be used with systemic antibiotics and for maintenance after completion of systemic antibiotic therapy.

From Zaenglein AL, Pathy AL, Scholsser BJ, et al. Guidelines of care for the management of acne vulgaris. *J Am Acad Dermatol.* 2016;74(5):945–973, Table VI, p. 952.

DRUG-INDUCED ACNE

Pubertal and postpubertal patients who are receiving systemic corticosteroid therapy are predisposed to steroid-induced acne. This monomorphous folliculitis occurs primarily on the face, neck, chest (Fig. 710.8), shoulders, upper back, arms, and, rarely, on the scalp. Onset follows the initiation of steroid therapy by approximately 2 weeks. The lesions are small, erythematous papules or pustules that may erupt in profusion and are all in the same stage of development. Comedones may occur subsequently, but nodulocystic lesions and scarring are rare. Pruritus is occasional. Although steroid acne is relatively refractory if the medication is continued, the eruption may respond to the use of tretinoin and a benzoyl peroxide gel.

Other drugs that can induce acneiform lesions in susceptible individuals include isoniazid, phenytoin, phenobarbital, trimethadione, lithium carbonate, androgens (anabolic steroids), and vitamin B_{12}.

Other causes of acne, including halogens and chloracne, are rare and typically obvious with judicious history-taking.

NEONATAL CEPHALIC PUSTULOSIS (FORMERLY NEONATAL ACNE)

Approximately 20% of normal neonates demonstrate pustules and red papules on the face in the first 6 weeks of life. Small inflammatory papules and pustules predominate on the cheeks and forehead (Fig. 710.9); comedones are absent. The cause of neonatal acne is unknown, but it has been theorized that it may be an inflammatory reaction to *Pityrosporum* species rather than true acne. Other theories include placental transfer of maternal androgens, hyperactive neonatal adrenal glands, and a hypersensitive neonatal end-organ response to androgenic hormones. The eruption involutes spontaneously over a few months. Treatment is usually unnecessary. If desired, the lesions can be treated effectively with topical antifungals and/or benzoyl peroxide.

Icepick (V)	Rolling (U)	Boxcar (M)	Keloids	Hypertrophic
Punch excision (deep bases) Elevation and grafting Laser resurfacing/ dermabrasion (many scars close together) Spot TCA peel	**Combined therapy** Micrograft and subcision + ± Filler Resurfacing microdermabrasion Deep-spot TCA peel	**Shallow** ≤3 mm diameter-laser skin resurfacing >3 mm diameter-laser skin resurfacing ± punch elevation **Deep** ≤3 mm diameter-punch excision >3 mm diameter-punch excision or punch elevation Fractional thermolysis (deep or shallow) Dermabrasion CO_2 laser resurfacing	Intralesional corticosteroids Intralesional 5-FU Intralesional bleomycin Compression Imiquimod after intralesional excision Cryotherapy Pulsed-dye laser Excision + electrotherapy	Intralesional steroids Intralesional 5-FU Vascular laser Intralesional bleomycin Compression Imiquimod after intralesional excision
Adjunctive treatment: Topical retinoids 2 wk before and after treatment, sunscreens, moisturizers				

Nonablative lasers for mild disease; ablative and fractional lasers for moderate scarring

Fig. 710.7 Treatment options for acne scars. CO_2, Carbon dioxide; FU, fluorouracil; TCA, trichloroacetic acid. *(From Thiboutot D, Gollnick H; Global Alliance to Improve Acne, et al. New insights into the management of acne: an update from the Global Allegiance to Improve Outcomes in Acne. J Am Acad Dermatol. 2009;60:S1–S50.)*

INFANTILE ACNE

Infantile acne usually manifests between 6 weeks and 2 years of age, more commonly in males than in females (Fig. 710.10). Open and closed comedones predominate on the face. Papules and pustules occur frequently, but only occasionally do nodulocystic lesions develop. Pitted scarring is seen in 10–15%. The course may be relatively brief, or the lesions may persist for many months or years, although the eruption generally resolves by 4 years of age. Use of topical benzoyl peroxide gel and topical retinoid, as would be recommended for typical acne, is effective but off-label. Some acne medications are approved down to age 9 years but none for infants. Oral erythromycin is occasionally necessary, and isotretinoin can be used in severe cases. A child with refractory acne or other signs of pubertal development warrants a search for an abnormal source of androgens, such as a virilizing tumor or congenital adrenal hyperplasia.

MID-CHILDHOOD ACNE

Acne that begins between 1 and 7 years of age is not considered normal. Although the neonatal adrenal gland secretes high levels of androgens through the first year of life, it becomes quiescent until adrenarche, which occurs around age 7. Underlying endocrine abnormality should be investigated in those presenting with acne in middle childhood. Precocious puberty, late-onset congenital adrenal hyperplasia, or an androgen-secreting tumor may underlie acne in this age-group. Workup for androgen excess is indicated.

ACNE FULMINANS (ACUTE FEBRILE ULCERATIVE ACNE)

Acne fulminans is characterized by abrupt onset of extensive inflammatory, tender, ulcerative acneiform lesions in typically male teenagers and may be related to recent initiation of isotretinoin. The distinctive feature is the tendency for large nodules to form exudative, necrotic, ulcerated, crusted plaques. Lesions heal with extensive scarring. A preceding history of mild papulopustular or nodular acne is noted in most patients. Constitutional symptoms and signs are common, including fever, debilitation, arthralgias, myalgias, weight loss, and leukocytosis. Blood cultures are sterile. Lesions of erythema nodosum sometimes develop on the shins. Osteolytic bone lesions may develop in the clavicle, sternum, and epiphyseal growth plates; affected bones appear normal or have slight sclerosis or thickening on healing. Salicylates may be helpful for the myalgias, arthralgias, and fever. Treatment should be directed by a dermatologist and includes systemic corticosteroids and isotretinoin. Antibiotics are not indicated unless there is evidence of secondary infection.

Fig. 710.8 Monomorphous papular eruption of steroid acne.

Fig. 710.9 Comedonal acne in a neonate.

Fig. 710.10 Inflammatory infantile acne.

Pyogenic Arthritis with Pyoderma Gangrenosum and Acne (PAPA Syndrome) (see Fig. 710.5, Chapter 204, and Chapter 702).

Chronic Recurrent Multifocal Osteomyelitis/Synovitis Acne Pustulosis Hyperostosis Osteitis (SAPHO) Syndrome (see Chapter 204).

Visit Elsevier eBooks+ at eBooks.Health.Elsevier.com for Bibliography.

Chapter 711

Tumors of the Skin

Kari L. Martin

See also Chapter 636.

INFUNDIBULAR FOLLICULAR CYST

Infundibular follicular cysts (more commonly referred to as *epidermoid cysts* or *sebaceous cysts*) are the nodules most commonly seen in children. Such a cyst is a sharply circumscribed, dome-shaped, firm, freely movable, skin-colored nodule (Fig. 711.1), often with a central dimple or punctum that is a plugged, dilated pore of a pilosebaceous follicle. Follicular cysts form most frequently on the face, neck, chest, or upper back and may periodically become inflamed and infected secondarily, particularly in association with acne vulgaris. The cyst wall may also rupture and induce an inflammatory reaction in the dermis. The wall of the cyst is derived from the follicular infundibulum. A mass of layered keratinized material that may have a cheesy consistency fills the cavity. Cysts may arise from occlusion of pilosebaceous follicles (acneiform cysts), implantation of epidermal cells into the dermis as a result of an injury that penetrates the epidermis (epidermal inclusion cysts), and rests of epidermal cells (epidermoid cysts). Multiple epidermoid cysts may be present in Gardner syndrome and nevoid basal cell carcinoma syndrome. Excision of the cyst with removal of the entire sac and its contents is indicated, particularly if the cyst becomes recurrently inflamed. A fluctuant cyst should be incised and drained and, if there is surrounding erythema, treated with antibiotics or intralesional corticosteroids. After the inflammation subsides, the cyst may be removed.

MILIUM

A milium is a 1- to 2-mm, firm, pearly white or yellowish subepidermal keratin cyst. Milia in newborns are discussed in Chapter 688. Secondary milia occur in association with subepidermal blistering diseases and after dermabrasion or other injury to the skin. They are retention cysts caused by hyperproliferation of injured epithelium and are indistinguishable histopathologically from primary milia. Those that develop after blistering usually arise from the eccrine sweat duct, but they may develop from the hair follicle, sebaceous duct, or epidermis. A milium body differs from an infundibular follicular cyst only in its small size and superficial location.

FIBROFOLLICULOMAS

These lesions usually appear in late adolescence or in young adults and are characterized by multiple dome-shaped, clear-white papules appearing on the nose, cheeks, and neck, and at times the trunk or ears (Fig. 711.2). They are associated with the familial cancer syndrome of **Birt-Hogg-Dubé**, an autosomal dominant disorder that results from a pathogenic variant in the folliculin *(FLCN)* tumor suppressor gene. Associated features include pulmonary cysts, pneumothorax, renal cell carcinoma, and other benign or malignant tumors.

PILAR CYST (TRICHILEMMAL CYST)

A pilar cyst may be clinically indistinguishable from an infundibular follicular cyst. It manifests as a smooth, firm, mobile nodule, predominantly on the scalp (Fig. 711.3). Pilar cysts occasionally develop on the face, neck, or trunk. A cyst may become inflamed and may occasionally suppurate and ulcerate. The cyst wall is composed of stratified squamous epithelium with indistinct intercellular bridges. The peripheral cell layer of the wall shows a palisade arrangement, which is not seen in an epidermoid cyst. No granular layer is present. The cyst cavity contains dense homogeneous eosinophilic keratinous material, and foci of calcification are seen in 25% of cases. The propensity for development of pilar cysts may be inherited in an autosomal dominant manner. More than one cyst generally develops in a patient. Numerous pilar and epidermoid cysts, desmoid tumors, fibromas, lipomas, or osteomas may be associated with colonic polyposis or adenocarcinoma in Gardner syndrome. Pilar cysts shell out easily from the dermis.

PILOMATRICOMA (PILOMATRIXOMA)

The second most common nodule seen in children, pilomatricoma is a benign tumor that manifests as a 3- to 30-mm, firm, solitary, deep dermal or subcutaneous tumor on the head, neck, or upper extremities. The overlying epidermis is usually normal. The tumor may occasionally be located more superficially, however, tinting the overlying skin blue-red (Fig. 711.4). Multiple pilomatricomas are seen in myotonic dystrophy, Gardner syndrome, Rubinstein-Taybi syndrome, and Turner syndrome. In general, however, pilomatricomas are not hereditary. Histopathologically, irregularly shaped islands of epithelial cells with eosinophilic, anucleate "ghost cells" are embedded in a cellular stroma. Calcium deposits are found in 75% of tumors. Pilomatricomas are caused by pathogenic variants in β-catenin.

TRICHOEPITHELIOMA

A 2- to 8-mm, smooth, round, firm, skin-colored papule, trichoepithelioma is derived from an immature hair follicle.

Fig. 711.1 Flesh-colored cyst on the forehead.

Fig. 711.2 Multiple dome-shaped, whitish papules on the nose and cheeks in a 31-yr-old carrier of an *FLCN* pathogenic variant. *(From Menko FH, van Steensel MAM, Giraud S, et al. Birt-Hogg-Dubé syndrome: diagnosis and management. Lancet. 2009;10:1199–1206, Fig. 1.)*

Fig. 711.3 Pilar cyst of the anterior scalp.

Trichoepitheliomas generally occur singly on the face in childhood or early adulthood. Multiple trichoepitheliomas are inherited autosomal dominantly (type 1: *CYLD* gene; type 2: 9p21 gene currently unidentified), appear in childhood or at puberty, and gradually increase in number on the nasofacial folds, nose, forehead, and upper lip; occasionally they occur on the scalp, neck, and upper trunk. Microscopically, these benign tumors are characterized by horn cysts composed of a fully keratinized center surrounded by basophilic cells in an adenoid network. Topical imiquimod therapy may be beneficial. Surgical excision has been used for therapy, as have cryotherapy, electrosurgery, and laser vaporization.

Fig. 711.4 Pilomatricoma. Firm tumor with overlying bluish discoloration of the skin.

ERUPTIVE VELLUS HAIR CYSTS

Eruptive vellus hair cysts are 1- to 3-mm, asymptomatic, soft, skin-colored follicular papules on the central chest (Fig. 711.5). They may become crusted or umbilicated. Abnormal vellus hair follicles become occluded at the level of the infundibulum, resulting in retention of hairs within an epithelium-lined cystic dilation of the proximal part of the follicle. Most cases are chronic, but spontaneous regression has been reported.

STEATOCYSTOMA MULTIPLEX

An autosomal dominant (*KRT17* gene) condition, steatocystoma multiplex usually manifests in adolescence or early adulthood as numerous soft to firm cystic nodules that are adherent to the underlying skin and are 3 mm to 3 cm in diameter. When punctured, the cysts may drain oily or cheesy material. Sites of predilection include the sternal region, axillae, arms, and scrotal skin. The multiply folded cyst wall is lined on the luminal side with a thick, homogeneous, eosinophilic horny layer; there is no granular layer. Flattened sebaceous gland lobules are often visible in the cyst wall, and lanugo hairs may be present in a cystic cavity that appears otherwise empty (a processing artifact).

SYRINGOMA

The benign tumors known as syringomas are soft, small, skin-colored or yellowish-brown papules that develop on the face, particularly in the periorbital regions (Fig. 711.6). Other sites of predilection include the axillae and umbilical and pubic areas. They often develop during puberty and are more frequent in females. Eruptive syringomas develop in crops over the anterior trunk during childhood or adolescence. A syringoma is derived from an intraepidermal sweat gland duct. Syringomas are of cosmetic significance only. Sparse lesions may be excised, but they are often too numerous to remove.

INFANTILE DIGITAL FIBROMA

Infantile digital fibroma is a smooth, firm, erythematous or skin-colored nodule on the dorsal or lateral surface of a distal phalanx of a finger or toe. More than 80% of tumors occur in infancy or may be present at birth. Lesions may be solitary or multiple and may manifest as "kissing" tumors on opposing digits. They are usually asymptomatic, but flexion deformity of the digits may occur. Clinically the lesion resembles a fibroma, leiomyoma, angiofibroma, acquired digital fibrokeratoma, accessory digit, or mucous cyst. The diagnosis is confirmed by the finding of numerous spindle-shaped fibroblasts that contain small, round, dense eosinophilic cytoplasmic inclusion bodies composed of collections of actin microfilaments. Local recurrence after simple excision of this tumor has been reported in 75% of patients. Because the tumor does not metastasize and may regress spontaneously in 2-3 years, a course of expectant observation is advised. If functional impairment or flexion deformity of the digit becomes apparent, prompt full excision of the tumor is indicated.

Fig. 711.5 Eruptive vellus hair cysts. Multiple papules on the chest.

Fig. 711.7 Dermatofibroma. Red-brown nodular variant.

Fig. 711.6 Syringomas. Multiple yellow papules near the eye.

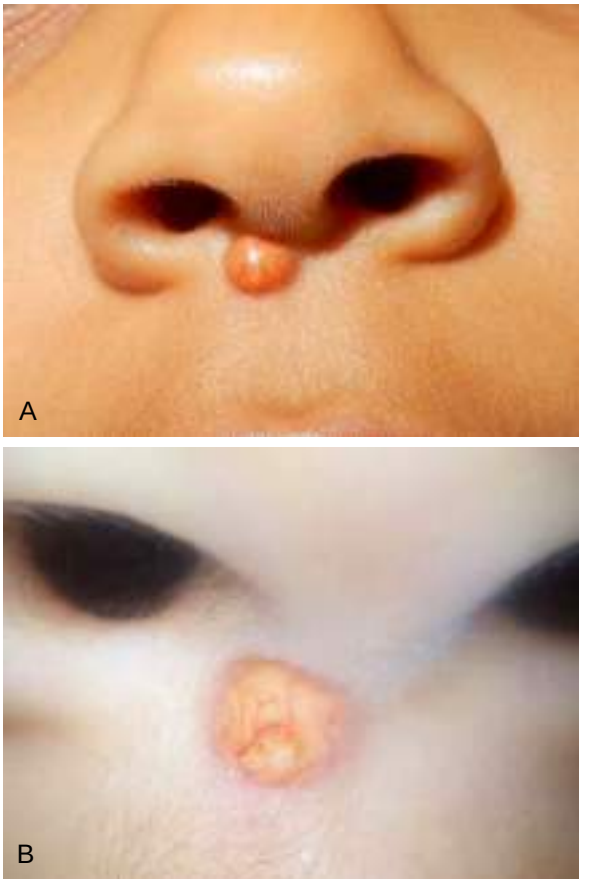

Fig. 711.8 A, Juvenile xanthogranuloma. A 4-mm, apricot-colored, dome-shaped, firm papule with overlying telangiectasias below the nasal columella. B, Pink-red rim in a "setting-sun" pattern seen by dermoscopy. *(From Bell KA, Marathe K, Burke KT, Cardis MA. A persistent pimple in a 5-year-old girl. J Pediatr. 2020;224:172–173, Figs. 1 and 2, p. 172).*

DERMATOFIBROMA

A benign dermal tumor, dermatofibroma may be pedunculated, nodular (Fig. 711.7), or flat and is usually well circumscribed and firm but occasionally feels soft on palpation. The overlying skin is usually hyperpigmented; it may be shiny or keratotic and dimples when the tumor is pinched. Dermatofibromas range in size from 0.5 to 10.0 mm, arise most frequently on the limbs, and are usually asymptomatic but may occasionally be pruritic. They are composed of fibroblasts, young and mature collagen, capillaries, and histiocytes in varying proportions, forming a nodule in the dermis that has poorly defined edges. The cause of these tumors is unknown, but trauma such as an insect bite or folliculitis appears to induce reactive fibroplasia. The differential diagnosis includes epidermal inclusion cyst, juvenile xanthogranuloma, hypertrophic scar, and neurofibroma. Dermatofibromas may be excised or left intact, according to the patient's preference. They usually persist indefinitely.

JUVENILE XANTHOGRANULOMA

A firm, dome-shaped, yellow, pink, or orange papule or nodule (Fig. 711.8), juvenile xanthogranuloma varies from 5 mm to approximately 4 cm in diameter. The average age at onset is 2 years. These nodules are 10 times more common in White than in Black individuals. Sites of predilection are the scalp, face, and upper trunk, where they may erupt in profusion or remain as solitary lesions. Nodular lesions may appear on the oral mucosa. The diagnosis is usually made clinically. Mature lesions are characterized histopathologically by a dermal infiltrate of lipid-laden histiocytes, admixed inflammatory cells, and Touton giant cells. Clinically the lesions may resemble papulonodular urticaria pigmentosa, dermatofibromas, or xanthomas of hyperlipoproteinemia, but they can be distinguished from these entities histopathologically.

Affected infants are nearly always otherwise normal, and blood lipid values are not elevated. Café-au-lait macules are found on 20% of

patients with juvenile xanthogranuloma. Xanthogranulomatous infiltrates occur occasionally in the iris or other ocular tissues. This process may result in glaucoma, hyphema, uveitis, heterochromia iridis, iritis, or sudden proptosis. When seen in patients <2 years of age, multiple lesions and periocular location may heighten concerns for intraocular involvement. There appears to be an association among juvenile xanthogranuloma, neurofibromatosis, and childhood leukemia, most frequently juvenile chronic myelogenous leukemia. There is no need to remove the benign lesions of juvenile xanthogranuloma because most of them regress spontaneously in the first few years. Residual dyspigmentation and atrophy may result.

LIPOMA

A benign collection of fatty tissue, lipoma appears on the trunk, neck, or proximal portions of the limbs. Lipomas are soft, compressible, lobulated subcutaneous masses. Multiple lesions may occur occasionally, as in Gardner syndrome. Atrophy, calcification, liquefaction, or xanthomatous change may sometimes complicate their course. A lipoma is composed of normal fat cells surrounded by a thin connective tissue capsule. Lipomas represent a cosmetic defect and may be surgically excised. Multiple lipomas, identical to those that occur singly, are inherited in an autosomal dominant fashion and often appear by the third decade in patients with familial multiple lipomatosis. Lipomas may appear intraabdominally, intramuscularly, and subcutaneously. Congenital lipomatosis manifests in the first few months of life as large subcutaneous fatty masses on the chest with extension into skeletal muscle. Congenital lipomatosis can also be a manifestation of **Proteus syndrome** (overgrowth/hyperplasia skin, connective tissue, pathogenic variant in *AKT1*). Angiolipomas usually manifest as numerous painful subcutaneous nodules on the arms and trunk.

CLOVES syndrome (congenital lipomatous overgrowth, vascular malformations, epidermal nevi, and scoliosis/skeletal and spinal anomalies) is usually a sporadic disorder caused by a pathogenic variant in the ***PIK3CA*** gene with an asymmetric truncal lipomatous mass present at birth. Additional features include macrodactyly, vascular malformations (low flow), linear epidermal nevus, and renal anomalies. The differential diagnosis includes Proteus, Klippel-Trenaunay, and Bannayan-Riley-Ruvalcaba syndromes.

PIK3CA somatic pathogenic variants and those in the related AKT-mTOR pathway (*PIK3CA*-related overgrowth spectrum [PROS]) are associated with segmental overgrowth syndromes (Fig. 711.9; see also Fig. 691.6). In addition to regional/localized tissue overgrowth, there is a spectrum of malformations (hemimegaloencephaly, macrodactyly, lymphatic, muscle hemihypertrophy, epidermal nevi, capillary, polydactyly, syndactyly).

BASAL CELL CARCINOMA

Basal cell carcinoma is very rare in children in the absence of a predisposing condition, such as nevoid basal cell carcinoma syndrome, xeroderma pigmentosum, nevus sebaceus of Jadassohn, arsenic intake, or exposure to irradiation. The lesions are smooth, pearly, pink telangiectatic papules that enlarge slowly and may bleed or ulcerate. Sites of predilection are the face, scalp, and upper back. The differential diagnosis includes pyogenic granuloma, nevocellular nevus, epidermal inclusion cyst, closed comedo, dermatofibroma, and adnexal tumor. Depending on the site of occurrence and associated disease of the host, electrodesiccation and curettage or simple excision of basal cell carcinoma is usually curative. When the tumor is recurrent, >2 cm in diameter, located on problematic anatomic areas such as the midface or ears, or is an aggressive histopathologic type, Mohs microscopically controlled surgery may be the most appropriate treatment.

NEVOID BASAL CELL CARCINOMA SYNDROME (BASAL CELL NEVUS SYNDROME, GORLIN SYNDROME)

The autosomal dominant entity known as nevoid basal cell carcinoma syndrome is caused by pathogenic variants in the *PTCH1*, *PTCH2* ("patched"), and *SUFU* genes. These tumor-suppressor genes, part of the hedgehog signaling pathway, are important in determining embryonic patterning and cell fate in a number of structures in the developing embryo. Pathogenic variants in these genes produce dysregulation of several genes involved in organogenesis and

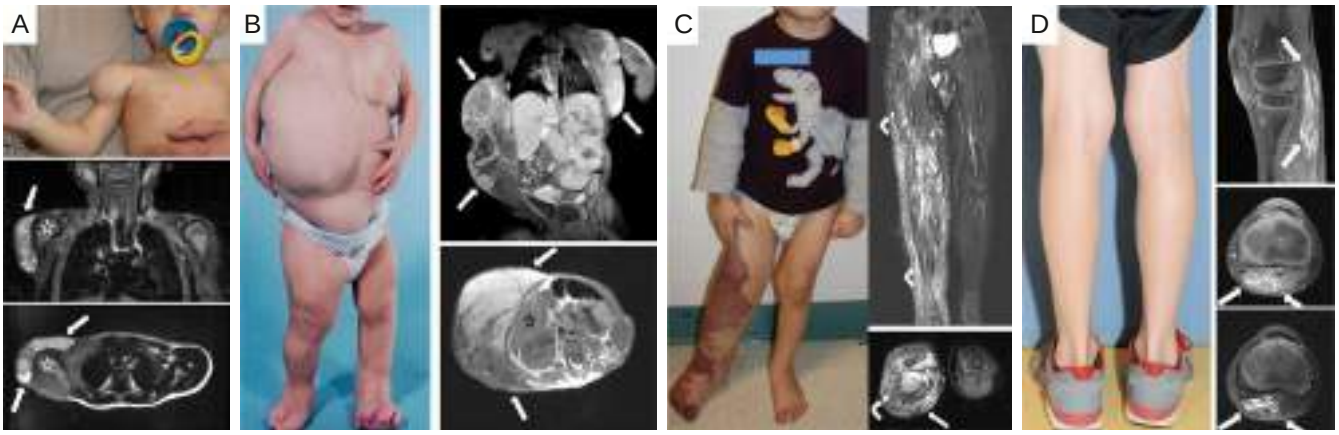

Fig. 711.9 Photographs and MRIs of participants with isolated LM, CLOVES, KTS, and FAVA. **A,** An 8-mo-old boy (LM1) with isolated LM. Note swelling in deltoid region without cutaneous vascular signs. Coronal and sagittal fat-saturated T2-weighted MRI demonstrates macrocystic LM (a multilocular cystic mass) involving the anterolateral aspects of the right shoulder without muscular infiltration *(arrows)*; humeral head *(asterisk)*. **B,** A 19-mo-old female (CL12) with CLOVES syndrome. Note asymmetric distribution of truncal lipomatous masses and bilateral lower extremity involvement. Coronal fat-saturated T1-weighted MRI after contrast administration demonstrates moderate heterogeneous enhancement of the bilateral truncal masses *(arrows)*. Axial T1-weighted MRI without contrast depicts truncal lipomatous overgrowth *(arrows)*; segment VI of the liver *(asterisk)*. **C,** A 3-yr-old boy (KT4) with KTS. Note capillary LM and overgrowth involving the right lower extremity. Coronal and axial fat-saturated T2-weighted MRI shows the persistent marginal vein system *(bent arrows)* and marked enlargement of the subcutaneous tissues due to a combination of lymphatic fluid and fat *(straight arrow)*. There are also intramuscular venous malformations. **D,** A 9-yr-old boy (F8) with FAVA of the left gastrocnemius muscle; note absence of overgrowth and cutaneous vascular anomalies. Sagittal fat-saturated T1-weighted MRI after contrast administration demonstrates the longitudinal distribution of the diffuse FAVA *(arrows)*. Axial fat-saturated T2-weighted MRI with *(upper)* and without *(lower)* contrast. Note that the right head of the gastrocnemius muscle is diffusely replaced by a contrast-enhancing heterogeneous soft tissue lesion *(arrows)*. CLOVES, Congenital lipomatous overgrowth with vascular, epidermal, and skeletal anomalies; FAVA, fibroadipose vascular anomaly; KTS, Klippel-Trenaunay syndrome; LM, lymphatic malformation. *(From Luks VL, Kamitaki N, Vivero MP, et al. Lymphatic and other vascular malformative/overgrowth disorders are caused by somatic pathogenic variants in PIK3CA. J Pediatr. 2015;166:1048–1054, Fig. 1, p. 1051.)*

carcinogenesis. Consequently, the syndrome includes a wide spectrum of defects involving the skin, eyes, central nervous and endocrine systems, and bones. The predominant features are early-onset basal cell carcinomas and mandibular cysts. Approximately 20% of those in whom a basal cell carcinoma develops before age 19 years have this syndrome. Basal cell carcinomas appear between puberty and age 35 years, erupting in crops of tumors that vary in size, color, and number; they may be difficult to distinguish from other types of skin lesions. Sites of predilection are the periorbital skin, nose, malar areas, and upper lip, but the lesions can also develop on the trunk and limbs and are not restricted to sun-exposed areas. Ulceration, bleeding, crusting, and local invasion can occur. Small milia, epidermal cysts, pigmented lesions, hirsutism, and palmar and plantar pits are additional cutaneous findings.

The facies of patients with this syndrome are characterized by temporoparietal bossing, prominent supraorbital ridges, a broad nasal root, ocular hypertelorism or dystopia canthorum, and prognathism. Keratinized cysts (odontogenic keratocysts) in the maxilla and mandible occur in most patients. These cysts range in size from a few millimeters to several centimeters; may result in maldevelopment of the teeth; and cause pain, swelling of the jaw, facial deformity, bone erosion, pathologic fractures, and suppurating sinus tracts. Osseous defects such as anomalous rib development, spina bifida, kyphoscoliosis, and brachymetacarpalism occur in 60% of patients, and ocular abnormalities—including cataracts, glaucoma, coloboma, strabismus, and blindness—occur in approximately 25%. Some males have hypogonadism, and the testes are absent or undescended. Kidney malformations have also been reported. Neurologic manifestations include calcification of the falx, seizures, mental retardation, partial agenesis of the corpus callosum, hydrocephalus, and nerve deafness. The incidence of medulloblastoma, ameloblastoma of the oral cavity, fibrosarcoma of the jaw, teratoma, cystadenoma, cardiac fibroma, ovarian fibroma, and fetal-onset rhabdomyoma is higher in patients with nevoid basal cell carcinoma syndrome.

Treatment of these patients requires the participation of various specialists according to individual clinical problems. Basal cell carcinomas should not be treated with irradiation. Most of the basal cell carcinomas have a clinically benign course, and it is often impossible to remove them all. Those with an aggressive growth pattern and those on the central areas of the face, however, should be removed promptly. Treatment options include surgery, Mohs micrographic surgery, laser ablation, cryotherapy, photodynamic therapy, topical 5% imiquimod and oral retinoids (0.5-1.0 mg/kg/day). Vismodegib, which inhibits smoothened protein in the hedgehog pathway, is a targeted therapy available for unresectable basal cell carcinomas. Genetic counseling is also indicated.

MELANOMA

See Chapter 692.

MUCOSAL NEUROMA SYNDROME (MULTIPLE ENDOCRINE NEOPLASIA TYPE IIB)

Mucosal neuroma syndrome, an autosomal dominant trait, is characterized by an asthenic or marfanoid habitus with scoliosis, pectus excavatum, pes cavus, and muscular hypotonia. The syndrome is caused by pathogenic variants in the tyrosine kinase domain of the *RET* gene. Patients have thick, patulous lips and soft tissue prognathism simulating acromegaly. Multiple mucosal neuromas or neurofibromas appear as pink, pedunculated, or sessile nodules on the anterior third of the tongue, at the commissures of the lips, and on the buccal mucosa and palpebral conjunctiva. Various ophthalmologic defects and intestinal ganglioneuromatosis with recurrent diarrhea are additional common findings. There is a high incidence of medullary thyroid carcinoma in association with high calcitonin levels, pheochromocytoma, and hyperparathyroidism in patients with this syndrome. Periodic screening tests for the associated malignant tumors are mandatory.

Visit Elsevier eBooks+ at eBooks.Health.Elsevier.com for Bibliography.

Chapter 712
Nutritional Dermatoses

Joel C. Joyce

OVERVIEW

There are many cutaneous manifestations of nutritional deficiencies (Table 712.1). For more details see Chapters 64-72.

ACRODERMATITIS ENTEROPATHICA

Acrodermatitis enteropathica is a rare autosomal recessive disorder caused by an inability to absorb sufficient zinc from the diet. The genetic variant is in the intestinal zinc-specific transporter gene *SLC39A4*. Initial signs and symptoms usually occur in the first few months of life, often after weaning from breast milk to cow's milk. The cutaneous eruption consists of vesiculobullous, eczematous, dry, scaly, or psoriasiform skin lesions symmetrically distributed in the perioral, acral, and perineal areas (Fig. 712.1) and on the cheeks, knees, and elbows (Fig. 712.2). The hair often has a peculiar, reddish tint, and alopecia of some degree is characteristic. Ocular manifestations include photophobia, conjunctivitis, blepharitis, and corneal dystrophy detectable by slit-lamp examination. Associated manifestations include chronic diarrhea, stomatitis, glossitis, paronychia, nail dystrophy, growth retardation, irritability, delayed wound healing, intercurrent bacterial infections, and superinfection with *Candida albicans*. Lymphocyte function and free radical scavenging are impaired. Without treatment the course is chronic and intermittent but often relentlessly progressive. When the disease is less severe, only growth retardation and delayed development may be apparent.

The diagnosis is established by the constellation of clinical findings and detection of a low plasma zinc concentration. A serum zinc level less than 50 μg/dL is suggestive, but not diagnostic, of **acrodermatitis enteropathica**. Levels of alkaline phosphatase, a zinc-dependent enzyme, may also be decreased. Histopathologic changes in the skin are nonspecific and include parakeratosis and pallor of the upper epidermis. The variety of manifestations of the syndrome may stem from the fact that zinc has a role in numerous metabolic pathways—including those of copper, protein, essential fatty acids, and prostaglandins—and that zinc is incorporated into many zinc metalloenzymes. Other nutritional deficiencies may produce similar findings (see Table 712.1), although the classic findings are highly suggestive of acrodermatitis enteropathica.

Oral therapy with zinc compounds is the treatment of choice. Replacement for individuals with inherited acrodermatitis enteropathica is with elemental zinc 3 mg/kg/24 hr in the form of zinc sulfate, gluconate, or acetate (i.e., 220 mg of zinc sulfate contains 50 mg of elemental zinc). Zinc gluconate carries less risk of gastrointestinal distress. However, plasma zinc levels should be monitored every 3-6 months so as to individualize the dosage. Zinc therapy rapidly abolishes the manifestations of the disease. Supplementation is for life. A syndrome resembling acrodermatitis enteropathica has been observed in patients with secondary zinc deficiency resulting from long-term total parenteral nutrition without supplemental zinc or to chronic malabsorption syndromes. A rash similar to acrodermatitis enteropathica has also been reported in infants fed breast milk that is low in zinc and in those with maple syrup urine disease, organic aciduria, methylmalonic acidemia, biotinidase deficiency, essential fatty acid deficiency, severe protein malnutrition (kwashiorkor), and cystic fibrosis. Cutaneous manifestations tend to appear in more severe forms. For those individuals with acquired zinc deficiency, oral replacement with elemental zinc, 0.5-1.0 mg/kg/24 hr, should be undertaken and the cause of underlying malnutrition should be addressed.

Table 712.1 Distinctive Skin Changes of Nutritional Disorders and Selected Differential Diagnosis

SKIN CHANGE	NUTRITIONAL DISORDER	SELECTED DIFFERENTIAL DIAGNOSIS
Exfoliative erythroderma	Kwashiorkor	Atopic dermatitis, psoriasis, staphylococcal scalded skin syndrome
Phrynoderma	Vitamin A deficiency, vitamin B–complex deficiencies, vitamin C deficiency, essential fatty acid deficiency	Keratosis pilaris, pityriasis rubra pilaris
Petechiae, purpura	Vitamin K deficiency, vitamin C deficiency (perifollicular petechiae)	Consumptive coagulopathy, coagulation disorder, thrombocytopenia, vascular fragility syndrome (Ehlers-Danlos), cutaneous vasculitis (e.g., Henoch-Schoenlein purpura)
Yellow-orange discoloration	Carotenemia	Jaundice, quinacrine-induced
Hyperpigmentation	Vitamin B12 deficiency, folate deficiency	Addison disease
Photodistributed dermatitis	Vitamin B3 deficiency (pellagra), vitamin B6 deficiency	Connective tissue disease (systemic lupus erythematosus, dermatomyositis), polymorphous light eruption
Seborrheic dermatitis–like changes	Vitamin B–complex deficiencies	Seborrheic dermatitis, psoriasis
Angular stomatitis	Vitamin B–complex deficiencies, iron deficiency	Angular cheilitis with candidal overgrowth
Glossitis	Vitamin B–complex deficiencies, zinc deficiency, iron deficiency	Sjogren syndrome, oral lichen planus, syphilis
Diaper dermatitis	Zinc deficiency, vitamin B–complex deficiencies	Irritant or allergic contact dermatitis, seborrheic dermatitis, inverse psoriasis, Langerhans cell histiocytosis
Lightening of hair	Kwashiorkor, marasmus, vitamin B–complex deficiencies, copper deficiency	Poliosis, vitiligo
Corkscrew hairs	Vitamin C deficiency	
Nail changes	Koilonychia: iron deficiency Longitudinal hyperpigmented streaks: vitamin B3 deficiency (pellagra)	Koilonychia: chronic irritant, lichen planus, psoriasis, Plummer–Vinson syndrome, transient in young children Longitudinal hyperpigmented streaks: physiologic, drug-induced, trauma

From Wong CY, Chu DH. Cutaneous signs of nutritional disorders. *Inter J Women Dermatol*. 2021;7:647–652: Table 1, p. 649.

ESSENTIAL FATTY ACID DEFICIENCY

Essential fatty acid deficiency causes a generalized scaly dermatitis composed of thickened, erythematous, desquamating plaques. Individuals may also show failure to thrive, growth retardation, alopecia, thrombocytopenia, and poor wound healing. The eruption has been induced experimentally in animals fed a fat-free diet and has been observed in patients with chronic severe malabsorption, as in short-gut syndrome, and in those sustained on a fat-free diet or fat-free parenteral alimentation. Linoleic acid (18:2 n-6) and arachidonic acid (20:4 n-6) are deficient, and an abnormal metabolite, 5,8,11-eicosatrienoic acid (20:3 n-9), is present in the plasma. Alterations in the triene/tetraene ratio are diagnostic (arachidonic acid/eicosatrienoic acid ratio >0.4 or linoleic acid/arachidonic acid ratio >2.3). The horny layer of the skin contains microscopic cracks, the barrier function of the skin is disturbed, and transepidermal water loss is increased. Topical application of linoleic acid, which is present in sunflower seed and safflower oils, may ameliorate the clinical and biochemical skin manifestations, although absorption can be inconsistent. Oral and/or parenteral therapy can also be considered. Appropriate nutrition should be provided, with the recommendation that 1–4% of total calories should be from linoleic acid.

KWASHIORKOR

Severe protein and essential amino acid deprivation in association with adequate caloric intake can lead to **kwashiorkor**, particularly at the time of weaning to a diet that consists primarily of corn, rice (or rice milk), or beans (see Chapter 64). Children can be fed such a restricted diet for cultural reasons or because of misdiagnosis on the part of the child's parents or healthcare providers of perceived food allergies. Diffuse, fine, reddish-brown scaling (enamel/flaky paint sign) is the classic cutaneous finding. In severe cases, erosions and linear fissures develop (Fig. 712.3). Nails are thin and soft, and hair is sparse, thin, and depigmented, sometimes displaying a "flag sign" consisting of alternating light and dark bands that reflect alternating periods of adequate and inadequate nutrition. The cutaneous manifestations may closely resemble those of acrodermatitis enteropathica; however, edema of the extremities and face ("moon facies") and a protuberant abdomen ("pot belly") are key features uniformly observed in kwashiorkor. The serum zinc level is often deficient; in some cases, skin lesions of kwashiorkor heal more rapidly when zinc is applied topically. See Chapter 64 for treatment recommendations.

CYSTIC FIBROSIS

See Chapter 454.

Protein-calorie malnutrition develops in 5–10% of patients with cystic fibrosis. Rash in infants with cystic fibrosis and malnutrition is rare but may appear by age 6 months. The initial eruption consists of scaling, erythematous papules and progresses in 1-3 months to extensive desquamating plaques. The rash is accentuated around the mouth and perineum and on the extremities (lower greater than upper). Alopecia may be present, but mucous membranes and nails are uninvolved.

Fig. 712.1 A, Periorificial eruption. B, Diaper rash. The skin findings are typical of zinc deficiency, in this case caused by low levels of zinc in breast milk. *(From Eichenfield LF, Frieden IJ, Esterly NB. Textbook of Neonatal Dermatology. Philadelphia: Saunders; 2001: Fig. 14.14.)*

PELLAGRA

See Chapter 67.3.

Pellagra manifests as edema, erythema, and burning of sun-exposed skin on the face, neck, and dorsal aspects of the hands, forearms, and feet. Lesions of pellagra may also be provoked by burns, pressure, friction, and inflammation. The eruption on the face frequently follows a butterfly distribution, and the dermatitis encircling the neck has been termed "Casal's necklace." Blisters and scales develop, and the skin increasingly becomes dry, rough, thickened, cracked, and hyperpigmented. Skin infections may be unusually severe. Pellagra develops in patients with insufficient dietary intake or malabsorption of niacin and/or tryptophan. Administration of isoniazid, 6-mercaptopurine, or 5-fluorouracil may also produce **pellagra**. **Hartnup disease** (see Chapter 105), caused by a pathogenic gene variant in *SLC6A19,* which encodes a neutral amino acid transporter, is a rare autosomal recessive disorder that presents in infancy with a "pellagra-like syndrome" as a result of decreased absorption of tryptophan. Nicotinamide supplementation and sun avoidance are the mainstays of therapy in pellagra. See Chapter 67.3 for treatment recommendations.

Fig. 712.3 Erosions and scaling in kwashiorkor.

Fig. 712.2 A, Psoriasiform lesion of zinc deficiency dermatitis on the ankles. B, Similar lesions on the elbows.

SCURVY (VITAMIN C OR ASCORBIC ACID DEFICIENCY)

See Chapter 68.

Scurvy manifests initially as follicular hyperkeratosis, or coiling of the hair on the upper arms, back, buttocks, and lower extremities (Fig. 712.4). Other features are perifollicular erythema and hemorrhage, particularly on the legs and advancing to involve large areas of hemorrhage; swollen, erythematous gums (Fig. 712.5); stomatitis; and subperiosteal hematomas. In children, the most common risk factors are behavioral or psychiatric disease resulting in poor nutrition. The best method of confirmation of a clinical diagnosis of scurvy is a trial of vitamin C supplementation. Treatment is with 100-200 mg/day of vitamin C supplementation orally or parenterally for up to 3 months.

VITAMIN A DEFICIENCY

See Chapter 66.

Fig. 712.4 Scurvy. *(Photo courtesy Albert Yan, MD.)*

Fig. 712.5 Clinical photograph showing inflamed marginal gingiva in scurvy. *(From Agarwal A, Shaharyar A, Kumar A, et al. Scurvy in pediatric age group – a disease often forgotten? J Clin Ortho Trauma. 2015;6:101–107, Fig. 1, p. 103.)*

Vitamin A deficiency manifests initially as impairment of visual adaptation to the dark. Cutaneous changes include xerosis and hyperkeratosis and hyperplasia of the epidermis, particularly the lining of hair follicles and sebaceous glands. In severe cases, desquamation may be prominent. See Chapter 66 for treatment recommendations.

Visit Elsevier eBooks+ at eBooks.Health.Elsevier.com for Bibliography.

Bone and Joint Disorders

PART XXX

Section 1

Orthopedic Problems

Chapter 713

Orthopedic Growth and Development

Brendan A. Williams and Lawrence Wells

There is a wide spectrum of normal orthopedic growth and development in children. Normal values are often defined as those that fall within 2 standard deviations of the mean value for the population, a range that accounts for approximately 95% of values. *Statistically normal* should not be confused with *ideal* in any given person's or parent's mind. Table 713.1 lists terms used to describe some common deviations from normal. Congenital anomalies can be categorized into production problems and packaging problems. Production problems include abnormalities caused by malformation, dysplasia, or disruption that will not spontaneously resolve (see Chapter 100). Packaging problems include deformations caused by mechanical causes, including in utero positioning and molding, and they usually resolve with time.

Table 713.1 Terminologies for Deviations

TERMINOLOGY	DESCRIPTION
Congenital	Anomaly that is apparent at birth
Deformation	A normally formed structure that is pushed out of shape by mechanical forces
Deformity	A body part altered in shape from normal, outside the normal range
Developmental	A deviation that occurs over time; one that might not be present or apparent at birth
Disruption	A structure undergoing normal development that stops developing or is destroyed or removed
Dysplasia	A tissue that is abnormal or wrongly constructed
Malformation	A structure that is wrongly built; failure of embryologic development or differentiation resulting in abnormal or missing structures

IN UTERO POSITIONING

In utero positioning produces temporary joint and muscle contractures and affects the torsional alignment of the long bones, particularly those of the lower extremities. Normal full-term newborns can have up to 20- to 30-degree hip and knee flexion contractures. These contractures tend to resolve by 4-6 months of age. The newborn hip externally rotates in extension up to 80-90 degrees and has limited internal rotation to approximately 0-10 degrees. The lower leg often has inward rotation (internal tibial torsion). The face may also be distorted; the spine and upper extremities are less affected by the in utero position. The effects of in utero positioning, therefore, are physiologic in origin and resolve by 3-4 months of age.

GROWTH AND DEVELOPMENT

Consideration of growth and development helps formulate treatment strategies designed to preserve or restore normal growth potential. Growth is subject to many variables, including genetics, nutrition, general health, endocrine status, mechanical forces, and physiologic age. Growth also varies between two anatomic regions and even between two bones of the same region.

Bone formation or ossification occurs in two different ways. In **endochondral ossification**, mesenchymal cells undergo chondrogenesis to form cartilage that matures to become bone. Most bones in the axial and appendicular skeleton are formed in this manner. In **intramembranous ossification**, osteoblasts are formed by direct differentiation of mesenchymal cells into bone. Flat bones of the skull and clavicle are examples of this pattern of bone formation.

CENTERS OF OSSIFICATION

At the beginning of the fetal period, the chondrocytes in the midshaft of the long bones form the **primary** centers of growth from which the bone eventually lengthens. **Secondary** centers of ossification appear in the chondroepiphysis and mostly appear postnatally. They direct the formation of bone throughout growth, particularly joint development. The ossification centers that are typically present at birth are the distal femur, proximal tibia, calcaneus, and talus (Fig. 713.1).

Anatomic Locations: Descriptive Terms

Typical **long bones** are divided into the physis, epiphysis, metaphysis, diaphysis, and perichondrial ring (Figs. 713.2 and 713.3). The physis is the growth plate located at the end of bone. The epiphysis is typically a secondary ossification center that contributes to joint development. The metaphysis is the bone adjacent to the physis on the side away from the joint. The diaphysis is the central part or shaft of long bones. The perichondrial ring contributes to appositional growth.

The articular cartilage also contributes to the growth of the epiphysis. The perichondrial ring, which surrounds the physes, and the perichondrium around the epiphyses and periosteum, which surrounds the metaphysis and diaphyseal regions of the bone, contribute to appositional or circumferential growth. Bones without physes (pelvis, scapulae, carpals, tarsals) grow by appositional bone growth from their surrounding perichondrium and periosteum. Other bones (metacarpals, metatarsals, phalanges, spine) grow by a combination of appositional and endochondral ossification.

Important Growth and Developmental Milestones

Table 713.2 summarizes some important musculoskeletal growth considerations.

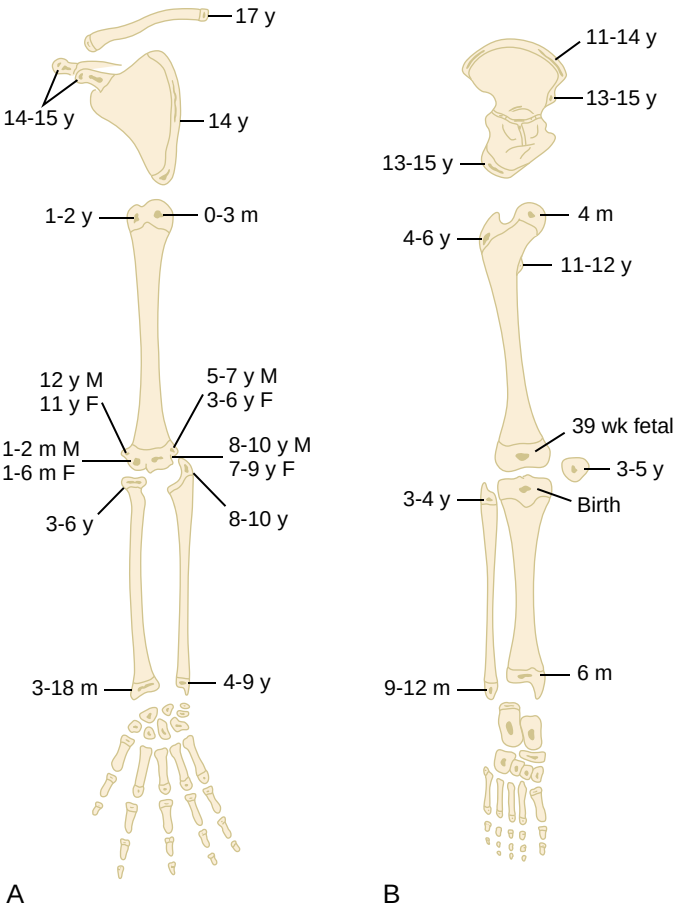

Fig. 713.1 Ages of onset of secondary (epiphyseal and apophyseal) ossification of the major bones of the upper (A) and lower (B) extremity. F, Female; M, male; m, month; wk, week; y, year. *(From Caffey J. Pediatric X-ray Diagnosis, 8th ed. Chicago: Year Book, 1985.)*

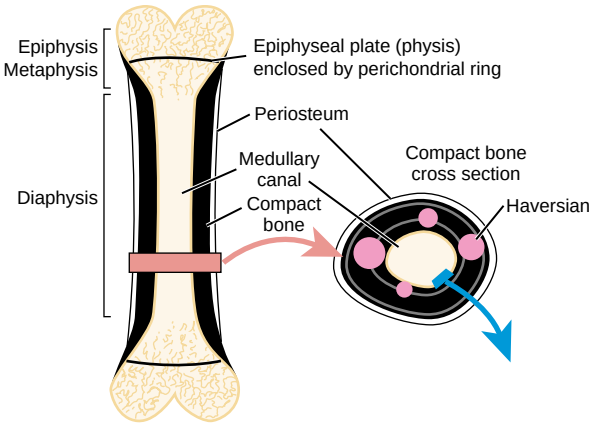

Fig. 713.2 Diagram showing typical long bone divisions.

Growth Patterns in Upper and Lower Extremities

The upper extremity grows longitudinally, primarily from physes of the proximal humeral physis and the distal radial and ulnar physes. In the lower extremity, most of the longitudinal growth occurs around the knee, in the distal femoral and the proximal tibial physes (Fig. 713.4).

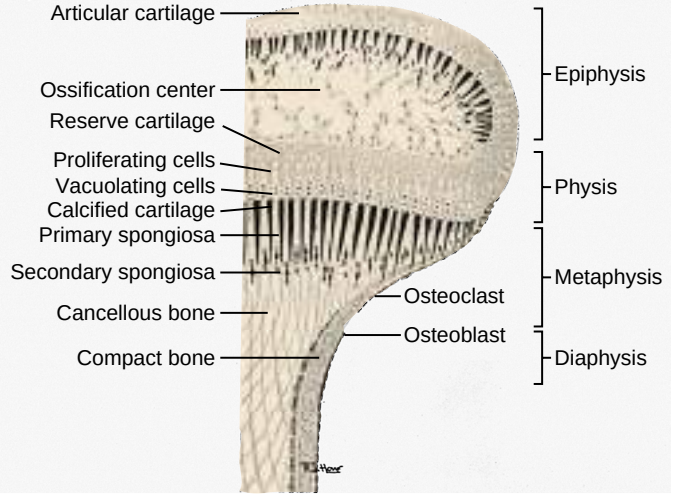

Fig. 713.3 Functional components of the growing end of a tubular bone and their anatomic substrate. *(From Kan JH, Strouse PJ. Embryology, anatomy, and normal findings. In: Coley BD, ed. Caffey's Pediatric Diagnostic Imaging, 13th ed. Philadelphia: Elsevier, 2019: Fig. 128.5)*

Table 713.2 Skeletal Growth Considerations

- Abnormal stature can be assessed as "proportionate" or "disproportionate" based on comparing the ratio of sitting height with sub-ischial height (lower limbs).
- Normally the arm span is almost equal to standing height.
- The head is disproportionately large at birth, and the ratio of head height to total height is approximately 1:4 at birth, which changes to 1:7.5 at skeletal maturity.
- Lower extremities account for approximately 15% of height at birth and 30% at skeletal maturity.
- The rate of height and growth increase is not constant and varies with growth spurts.
- By age 5, birth height usually doubles, and the child is approximately 60% of adult height. The child is approximately 80% of final height at 9 yr old. During puberty, the standing height increases by approximately 1 cm/mo.
- Bone age is more important than chronological age in determining future growth potential.

In the hip joint, the acetabulum forms with the convergence of three primary ossification centers: ischium, ilium, and pubis.

GAIT/FUNCTIONAL MATURATION

Functional mobility develops in infants in a predictable fashion (Table 713.3). Failure to achieve functional milestones is an indication for referral to a neurologist to determine if a central nervous system (CNS) problem exists. CNS maturation contributes significantly to the development of gait. In early ambulation (at 8-15 months), the child usually has a wide-based gait with hyperflexion of hips and knees, and initial contact with the heel. By the age of 2 years, the wide gait diminishes, reciprocal arm swing begins, and there is increased stride length and velocity. Adult fluid gait patterns usually start developing by 3 years and mature to an adult-like pattern by age 7 years.

Visit Elsevier eBooks+ at eBooks.Health.Elsevier.com for Bibliography.

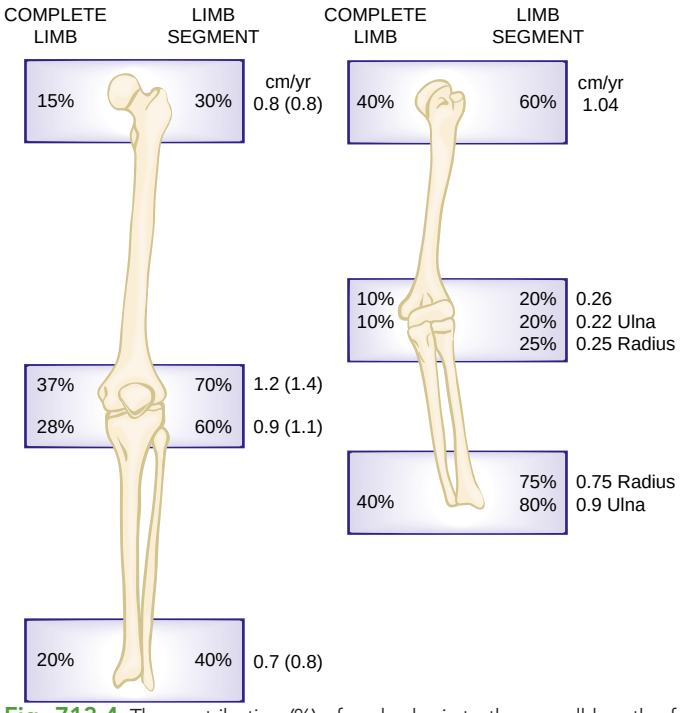

Fig. 713.4 The contribution (%) of each physis to the overall length of the extremities. *(From Morrissy R, Weinstein S, eds. Lovell and Winter's Pediatric Orthopedics, 5th ed. Philadelphia: Lippincott Williams & Wilkins, 2001.)*

Table 713.3 Functional Milestones

MILESTONE	ACHIEVED BY
Head control	3-6 mo
Sitting	6-9 mo
Crawling	8 mo
Pulling to stand	8-12 mo
Ambulating	12-18 mo

Chapter 714

Orthopedic Evaluation of the Child

Kathleen J. Maguire and Lawrence Wells

A detailed history and thorough physical examination are critical to the evaluation of a child with an orthopedic problem. The child's family and acquaintances are important sources of information, especially in younger children and infants. Appropriate radiographic imaging and, occasionally, laboratory testing may be necessary to support the clinical diagnosis.

HISTORY

A comprehensive history should include details about the prenatal, perinatal, and postnatal periods. Prenatal history should include information about maternal health, including smoking history, use of prenatal vitamins, use of drugs or opiates, alcohol consumption, diabetes, immunization status (including receipt of rubella vaccine), and sexually transmitted infections. The child's prenatal and perinatal history should include information about the length of pregnancy, length of labor, type of labor (induced or spontaneous, Cesarean or vaginal delivery), presentation of fetus (cephalic or breech), birth trauma, evidence of any fetal distress at delivery, requirement for supplemental oxygen after the delivery, birth length and weight, Apgar score, muscle tone at birth, feeding history, and period of hospitalization. In older infants and young children, evaluation of developmental milestones for posture, locomotion, dexterity, social activities, and speech are important. Specific orthopedic questions should focus on joint, muscular, appendicular, or axial skeleton complaints. Information regarding pain or other symptoms in any of these areas should be elicited (Table 714.1). The family history can give clues to heritable disorders. It also can forecast expectations of the child's future development and allow appropriate interventions as necessary.

Table 714.1 Characterization of Pain and Presenting Symptom

Location: Whether pain is localized to a particular segment or involves a larger area.
Intensity: Usually on a pain scale of 1-10 to indicate severity.
Quality: Tumor pain is often unrelenting, progressive, and present during the night. Pain at night particularly suggests osteoid osteoma. Pain in inflammation and infection is usually continuous.
Onset: Was it acute and related to specific trauma or was it insidious? Acute pain and history of trauma are more commonly associated with fractures.
Duration: Whether transient, only lasting for minutes, or lasting for hours or days. Pain lasting for longer than 3-4 weeks suggests a serious underlying problem.
Progress: Whether static, increasing, or decreasing.
Radiation: Pain radiating to upper or lower extremities or complaints of numbness, tingling, or weakness require appropriate workup.
Aggravating factors: Relationship to any activities, movements, or particular positions.
Alleviating factors: Is the pain relieved by rest, heat/ice, and/or medication? Conditions such as spondylolysis, Scheuermann disease, inflammatory spondyloarthropathy, muscle pulls, or overuse are improved by bed rest.
Gait and posture: Disturbances associated with pain.

PHYSICAL EXAMINATION

The orthopedic physical examination includes a thorough examination of the musculoskeletal system along with a comprehensive neurologic examination. The examination may vary depending on the age of the child. The musculoskeletal examination includes inspection, palpation, and evaluation of motion, strength, stability, and gait. A basic neurologic examination includes sensory examination, motor function, and reflexes. The orthopedic physical examination requires basic knowledge of anatomy of joint range of motion, alignment, and stability. Many common musculoskeletal disorders can be diagnosed by the history and physical examination alone. One screening tool that has been useful in children is the pediatric gait, arms, legs, spine (pGALS) test, the components of which are shown in Figure 714.1.

Inspection

Initial examination of the child begins with inspection. The patient should be *comfortable with adequate exposure and well-lit surroundings* (lest some important physical findings be missed). Infants or young children may be examined on their parent's lap so that they feel more secure and are more likely to be cooperative. The clinician should use the guidelines listed in Table 714.2 during inspection.

Palpation

Palpation of the involved region should include assessment of local temperature and tenderness; assessment for a swelling or mass, lymphadenopathy, spasticity or contracture, and bone or joint deformity; and evaluation of anatomic axis of limb and of limb lengths.

Gait

A "Walk on your tip-toes." *Observe the child walking

B "Walk on your heels." *Observe the child walking

Arms

C "Put your hands out in front of you."

D "Turn your hands over and make a fist. Pinch your index finger and thumb together."

E "Touch the tips of your fingers with your thumb."

F Squeeze metacarpophalangeal joints

G "Put your hands together."*

H "Put your hands back to back."*

I "Reach up and touch the sky.* Look at the ceiling."

J "Put your hands behind your neck."

Legs

K Feel for effusion at the knee

L "Bend and then straighten your knee." (active movement of knees and examiner feels for crepitus)

M Passive flexion (90 degrees) with internal rotation of hip

Spine

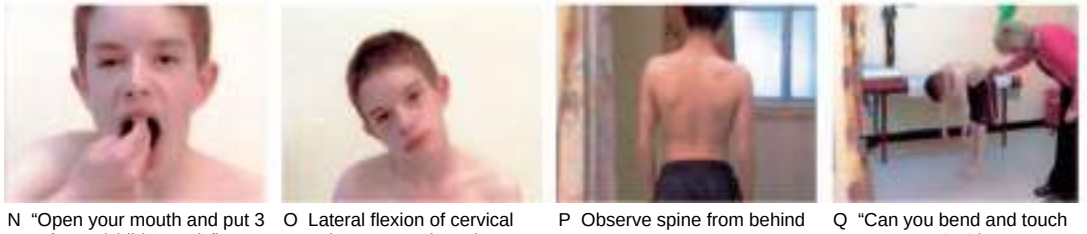

N "Open your mouth and put 3 of your (child's own) fingers in your mouth."*

O Lateral flexion of cervical spine: "Try and touch your shoulder with your ear."

P Observe spine from behind

Q "Can you bend and touch your toes?" Observe curve of spine from side and behind

Fig. 714.1 The components of pediatric gait, arms, legs, spine (pGALS) screen, with illustration of movement. Screening questions: (1) Do you have any pain or stiffness in your joints, muscles, or back? (2) Do you have any difficulty getting yourself dressed without any help? (3) Do you have any difficulty going up and down stairs? *Additions and amendments to the original adult gait, arms, legs, spine screen. *(From Foster HE, Kay LJ, Friswell M, et al. Musculoskeletal screening examination [pGALS] for school-age children based on the adult GALS screen. Arthritis Rheum. 2006;55:709–716.)*

Table 714.2 Guidelines During Inspection of a Child with Musculoskeletal Problem

- It is important to inspect how the patient moves about in the room before and during the examination, as well as during various maneuvers. *Balance, posture,* and *gait pattern* should also be evaluated.
- *General examination* findings should include inspection for skin rashes, café-au-lait spots, hairy patches, dimples, cysts, tuft of hair, or evidence of spinal midline defects that can indicate serious underlying problems that need review.
- *General body habitus,* including signs of cachexia, pallor, and nutritional deficiencies, should be noted.
- *In the setting of trauma,* inspection of the injured limb should note deformity, swelling, erythema, and ecchymosis about a joint and/or long bone of the appendicular skeleton.
- Inspect the appendicular skeleton for evidence of *deformity.* Note if the deformity appears centered at a joint, bone, or within soft tissue. Attempt correction of the deformity to assess if it is correctible/flexible or fixed.
- Note any obvious spinal asymmetry, axial deformities, trunk decompensation, and evidence of muscle spasm or contractures. The *forward bending test* is valuable in assessing asymmetry and movement of the spine.
- Any *discrepancies in limb lengths,* as well as *muscle atrophy,* should be recorded.

Table 714.3 Beighton Grading for Hypermobility

DESCRIPTION	BILATERAL TESTING	SCORE (MAX. POINTS)
Passive dorsiflexion of the fifth metacarpophalangeal joint to >90 degrees	Yes	2
Passive hyperextension of the elbow >10 degrees	Yes	2
Passive hyperextension of the knee >10 degrees	Yes	2
Passive apposition of the thumb to the flexor side of the forearm, while shoulder is flexed 90 degrees, elbow is extended, and hand is pronated	Yes	2
Forward flexion of the trunk, with the knees straight, so that the palms of the hands rest easily on the floor	No	1
Total		9

From Smits-Engelsman, B, Klerks M, Kirby A. Beighton Score: a valid measure for generalized hypermobility in children. *J Pediatr.* 2011;158:119–123. Table 1.

Contractures are a loss of mobility of a joint from congenital or acquired causes and are caused by periarticular soft tissue fibrosis or involvement of muscles crossing the joint. Congenital contractures are common in **arthrogryposis** (see Chapter 723). Spasticity is an abnormal increase in tone associated with hyperreflexia and is common in cerebral palsy.

Deformity of the bone or joint is an abnormal fixed shape or position from congenital or acquired causes. It is important to assess the type of deformity, its location, and degree of deformity on clinical examination. It is also important to assess whether the deformity is fixed or can be passively or actively corrected, and whether there is any associated muscle spasm, local tenderness, or pain on motion. Classification of the deformity depends on the plane of deformity: **varus** (apex away from midline) or **valgus** (apex toward midline), or **flexion and extension** (in the sagittal plane). In the axial skeleton, especially the spine, deformity can be defined as scoliosis, kyphosis, hyperlordosis, and kyphoscoliosis (see Chapter 720).

Range of Motion

Active and passive joint motion should be assessed, recorded, and compared with the opposite side. Baseline flexibility or hypermobility beyond the range of normal motion should be noted. The **Beighton score** for hyperflexibility has been validated in children and serves to establish underlying laxity in the pediatric population (Table 714.3). Objective evaluation should be done with a goniometer and recorded.

Vocabulary for direction of joint motion is as follows:

Abduction: Away from the midline
Adduction: Toward the midline
Flexion: Movement of bending from the starting position
Extension: Movement from bending to the starting position
Hyperextension: Movement in extension beyond the starting position
Supination: Rotating the forearm to face the palm upward
Pronation: Rotating the forearm to face the palm downward
Inversion: Turning the hindfoot inward
Eversion: Turning the hindfoot outward
Plantar flexion: Pointing the toes away from the body (toward the floor)
Dorsiflexion: Pointing the toes toward the body (toward the ceiling)
Internal rotation: Turning inward toward the axis of the body
External rotation: Turning outward away from the axis of the body

Table 714.4 Normal Upper Extremity Motion in Children in Degrees

MOTION	VALUE (IN DEGREES)
Shoulder elevation	180
Shoulder internal rotation	50-60
Shoulder external rotation	40-45
Shoulder extension	45-55
Shoulder internal rotation at 90 degrees of abduction	70
Shoulder external rotation at 90 degrees of abduction	100
Elbow flexion	145-150
Elbow extension	4-7

Adapted from Payares-Lizano M, Pino C. Pediatric orthopedic examination. *Pediatr Clin North Am.* 2020;67(1):1–21. Table 5; with additional data from McKay MJ, Baldwin JN, Ferreira P, et al. Normative reference values for strength and flexibility of 1,000 children and adults. *Neurology.* 2017;88(1):36–43.

Normal ranges of motion for the appendicular skeleton are noted in Table 714.4 (upper extremity), Table 714.5 (hip), and Table 714.6 (lower extremity).

NEUROLOGIC EVALUATION

A careful neurologic evaluation is part of every pediatric musculoskeletal examination (see Chapter 630). The assessment should include evaluation of developmental milestones, muscle strength (Table 714.7), sensory assessment, muscle tone, and deep tendon reflexes. The neurologic evaluation should also assess the spine and identify any deformity, such as scoliosis and kyphosis, or abnormal spinal mobility. The hips and feet should also be examined specifically, along with torsional

Table 714.5 Normal Hip Range of Motion in Children in Degrees

MOTION	AGE 2-5 (MALE/FEMALE)	AGE 6-10 (MALE/FEMALE)	AGE 11-17 (MALE/FEMALE)
Abduction	51/53	43/51	34/44
Adduction	17/18	15/18	14/17
Flexion	118/121	118/122	113/120
Extension	21/21	19/21	15/22
Internal rotation in flexion	45/47	40/41	35/35
External rotation in flexion	51/49	44/48	40/46
Internal rotation in extension	47/51	42/47	36/42
External rotation in extension	47/50	42/45	39/44

From Sankar WN, Laird CT, Baldwin KD. Hip range of motion in children: what is the norm? *J Pediatr Orthop*. 2012;32(4):399–405. Table 1.

Table 714.6 Normal Lower Extremity Motion in Children in Degrees

MOTION	AGE 3-9 (MALE/FEMALE)	AGE 10-19 (MALE/FEMALE)
Knee flexion	145/144	140/142
Knee extension	4/4	2/2
Ankle dorsiflexion	33/31	32/31
Ankle plantarflexion	63/63	58/63

Adapted from McKay MJ, Baldwin JN, Ferreira P, et al. Normative reference values for strength and flexibility of 1,000 children and adults. *Neurology*. 2017;88(1):36–43. Table e-4.

Table 714.7 Medical Research Council (MRC) Scale for Muscle Strength

MUSCLE GRADE	DESCRIPTION
Grade 5	Normal
Grade 4	Movement against gravity and resistance
Grade 3	Movement against gravity over (almost) full range
Grade 2	Movement of the limb with gravity eliminated
Grade 1	Visible contraction without movement of the limb
Grade 0	No visible contraction

Data from Medical Research Council.

Table 714.8 Ashworth Scale of Spasticity

0	No increase in muscle tone
1	Slight increase in muscle tone, usually a catch or minimal resistance at end range of motion
2	Moderate tone throughout range of motion
3	Considerable increase in tone; passive range of motion difficult
4	Rigid in flexion or extension

Table 714.9 Clinical Scale of Extremity Motor Control

GRADE	DEFINITION
1	Hypotonic, no volitional motion
2	Hypertonic, no volitional motion
3	Mass flexion or extension in response to a stimulus
4	Patient can initiate movement but results in mass flexion or extension
5	Slow volitional movement; stress or rapid movement results in mass action
6	Volitional control of specific joints/muscles

abnormalities of the lower extremity, which are vastly more common in the neurologically involved population. Specific peripheral nerve examinations may be necessary.

When the nervous system matures, the developing cerebral cortex normally inhibits rudimentary reflexes that are often present at birth (see Chapter 630). Therefore, persistence of these reflexes can indicate neurologic abnormality. The most commonly performed deep tendon reflex tests include biceps, triceps, quadriceps, and gastrocnemius and soleus tendons. Upper motor neuron signs should also be noted. The **Ashworth scale** is often used to grade spasticity (Table 714.8). Upper-extremity motor control is often graded, and these grades are useful both diagnostically and prognostically. Passive range of motion should be assessed to determine extremity motor control (Table 714.9). Localized or diffuse weakness must be determined and documented. A thorough assessment and grading of muscle strength is mandatory in all cases of neuromuscular disorders (see Table 714.7).

Gait Assessment

Children typically begin walking between 8 and 16 months of age. Early ambulation is characterized by short stride length, a fast cadence, and slow velocity with a wide-based stance. The gait cycle is a single sequence of functions that starts with heel strike, foot flat, heel off, toe off, and swing. These events describe one gait cycle and include two phases: stance and swing. The stance phase is the period during which the foot is in contact with the ground. The swing phase is the portion of the gait cycle during which a limb is being advanced forward without ground contact. Normal gait is a symmetric and smooth process. Deviation from the norm indicates potential abnormality and should trigger investigation.

Neurologic maturation is necessary for the development of gait and the normal progression of developmental milestones. A child's

Table 714.10 Causes of Gait Disturbances

MECHANICAL
Acute injuries (accidental or nonaccidental)
Overuse conditions (mainly sports-related)
Dysplastic lesions
Limb length discrepancy
OSSEOUS
Legg-Calvé-Perthes disease
Osteochondritis dissecans of knee and talus
Slipped capital femoral epiphysis
Osteomyelitis
Spondylodiscitis
Osteoid osteoma or other primary bone tumor
ARTICULAR
Developmental hip dysplasia
Septic arthritis
Transient synovitis
Rheumatic disease (juvenile idiopathic arthritis, systemic lupus erythematosus)
Hemophilia-related hemorrhage
Ankylosis of a joint
NEUROLOGIC
Guillain-Barré syndrome and other peripheral neuropathies
Intoxication
Cerebellar ataxia
Brain tumor
Lesion occupying spinal cord space
Posterior column spinal cord disorders
Myopathy
Hemiplegia
Complex regional pain syndrome
Cerebral palsy
HEMATOLOGIC/ONCOLOGIC
Sickle cell pain crisis
Leukemia, lymphoma
Metastatic tumor
Langerhans cell histiocytosis
OTHER
Soft tissue infection
Myositis
Fasciitis
Bursitis
Kawasaki disease
Conversion disorder
Gaucher disease
Phlebitis
Scurvy
Rickets
Peritonitis

From Kliegman RM, Lye PS, Bordini BJ, et al., eds. *Nelson Pediatric Symptom-Based Diagnosis*. Philadelphia: Elsevier, 2018: Table 34.1, p. 615.

Table 714.11 Differential Diagnosis of Limping in Children by Age

AGE GROUP	DIAGNOSTIC CONSIDERATIONS
Early walker: 1-3 yr	PAINFUL LIMP Septic arthritis and osteomyelitis Transient synovitis Fracture Occult trauma (toddler's fracture) Intervertebral diskitis Malignancy Abuse (nonaccidental trauma) Rheumatologic disorders (e.g., juvenile idiopathic arthritis) PAINLESS LIMP Developmental dysplasia of the hip Neuromuscular disorder Polio Cerebral palsy Lower extremity length inequality
Child: 3-10 yr	PAINFUL LIMP Septic arthritis, osteomyelitis, myositis Transient synovitis Trauma, fracture Rheumatologic disorders Spondylodiscitis Malignancy PAINLESS LIMP Developmental dysplasia of the hip Legg-Calvé-Perthes disease Lower extremity length inequality Neuromuscular disorder (e.g., muscular dystrophy) Polio Cerebral palsy
Adolescent: 11 yr to maturity	PAINFUL LIMP Septic arthritis, osteomyelitis, myositis Trauma (including overuse injuries and fractures) Rheumatologic disorder Slipped capital femoral epiphysis (acute, unstable) Malignancy Osteochondritis dissecans PAINLESS LIMP Slipped capital femoral epiphysis (chronic, stable) Developmental dysplasia of the hip (acetabular dysplasia) Lower extremity length inequality Neuromuscular disorder

Modified from Marcdante K, Kliegman R, eds. *Nelson Essentials of Pediatrics*, 7th ed. Philadelphia: Saunders, 2015.

gait changes with neurologic maturation. Toddlers normally walk with greater hip and knee flexion, flexed arms, and a wider base of gait than older children. As the neurologic system continues to develop in the cephalocaudal direction, the efficiency and smoothness of gait increase. The gait characteristics of a 7-year-old child are similar to those of an adult. When the neurologic system is abnormal (e.g., cerebral palsy), gait can be disturbed, exhibiting pathologic reflexes and abnormal movements.

Deviations from normal gait occur in a variety of orthopedic conditions. Disorders that result in muscle weakness (e.g., spina bifida, muscular dystrophy), spasticity (e.g., cerebral palsy), or contractures (e.g., arthrogryposis) lead to abnormalities in gait. Other causes of gait disturbances include limp, pain, torsional variations (in-toeing and out-toeing), toe walking, joint abnormalities, and leg-length discrepancy (Tables 714.10 and 714.11).

LIMPING

A thorough history and clinical examination are the first steps toward early identification of the underlying problem causing a limp. Limping can be considered either *painful* ***(antalgic)*** or *painless*, with the differential diagnosis ranging from benign to serious causes (e.g., septic hip, tumor). In a painful gait, the stance phase is shortened as the child decreases the time spent on the painful extremity. In a painless gait, which indicates underlying proximal muscle weakness or hip instability, the stance phase is equal between the involved and uninvolved sides, but the child leans or shifts the center of gravity over the involved extremity for balance. A bilateral disorder produces a waddling gait. **Trendelenburg gait** (i.e., trunk lists to the affected side with each step) is produced by weak abnormal hip abductors. When the patient stands on one foot, a **Trendelenburg sign** (i.e., sagging rather than rising of

the unsupported buttock) can often be elicited when abductors are weak.

Disorders most commonly responsible for an abnormal gait generally vary based on the age of the patient. The differential diagnosis of limping varies based on age group (see Table 714.11) or mechanism. Neurologic disorders, especially spinal cord, muscle, or peripheral nerve disorders, can also produce limping and difficulty walking. Antalgic gait is predominantly a result of trauma, infection, or pathologic fracture. Trendelenburg gait is generally caused by congenital, developmental, or muscular disorders. In some cases, limping also may be caused by nonskeletal causes, such as testicular torsion, inguinal hernia, and appendicitis.

BACK PAIN

Children frequently have a specific skeletal pathology as the cause of back pain. The most common causes of back pain in children are trauma, spondylolysis, spondylolisthesis, and infection (see Chapter 720.5). Tumor and tumor-like lesions that cause back pain in children are likely to be missed unless a thorough clinical assessment and adequate workup are performed when required. Nonorthopedic causes of back pain include urinary tract infections, nephrolithiasis, and pneumonia.

RADIOGRAPHIC ASSESSMENT

Plain radiographs are the first step in evaluation of most musculoskeletal disorders. Advanced imaging includes MRI, nuclear bone scans, ultrasonography, CT, and positron emission tomography. Rapid short tau inversion recovery (STIR) MRI is a valuable screening test if a specific location is not well defined.

Plain Radiographs

Routine radiographs consist of anteroposterior and lateral views of the involved area with inclusion of one joint above and below the site of symptoms. Comparison views of the opposite side, if uninvolved, may be helpful in difficult situations but are not always necessary. Specialized views for each joint, such as oblique views, may offer more specific and tailored imaging for an individual fracture or other condition. It is important for the clinician to be aware of normal radiographic variants of the immature skeleton, including when to expect to see development and ultimately closure of growth centers about the joints. Several synchondroses may be mistaken for fractures. A patient with "normal" plain radiographic appearance but having persistent pain or symptoms might need to be evaluated further with additional imaging studies.

Ultrasonography

Ultrasonography is useful to evaluate suspected fluid-filled lesions such as popliteal cysts and hip joint effusions. Major indications for ultrasonography are fetal studies of the extremities and spine (including detection of congenital anomalies like spondylocostal dysostosis or osteogenesis imperfecta), developmental dysplasia of the hip in children 6 weeks to 6 months of age, joint effusions, occult neonatal spinal dysraphism, foreign bodies in soft tissues, and popliteal cysts of the knee.

Magnetic Resonance Imaging

MRI is the imaging modality of choice for defining the exact anatomic extent of most musculoskeletal lesions (particularly if the structure is soft tissue). MRI avoids ionizing radiation and does not cause any known harmful effects. It produces excellent anatomic images of the musculoskeletal system, including the soft tissue, bone marrow cavity, spinal cord, and brain. It is especially useful for defining the extent of soft tissue lesions, infections, and injuries. Tissue planes are well delineated, allowing more accurate assessment of tumor invasion into adjacent structures. Cartilage structures can be visualized and differentiated (e.g., articular cartilage of the knee can be distinguished from the fibrocartilage of the meniscus). MRI is also helpful in visualizing unossified joints in the pediatric population, including the shoulders, elbows, and hips of young infants.

Magnetic Resonance Angiography

Magnetic resonance angiography (MRA) has largely replaced routine angiography in the preoperative assessment of vascular lesions and bone tumors. MRA provides good visualization of peripheral vascular branches and tumor neovascularity in patients with primary bone tumors.

Computed Tomography

CT has enhanced the evaluation of multiple musculoskeletal disorders. Coronal, sagittal, and axial imaging is possible with CT, including three-dimensional reconstructions that can be beneficial in evaluating complex lesions of the axial and appendicular skeleton. It allows for visualization of the detailed bone anatomy and the relationship of bones to contiguous structures. CT is useful to readily evaluate tarsal coalition, accessory navicular bone, infection, growth plate arrest, osteoid osteoma, pseudoarthrosis, femoroacetabular impingement, complex fracture patterns (periarticular and intra-articular), bone and soft tissue tumors, spondylolysis, and spondylolisthesis. CT is superior to MRI for assessing bone involvement and cortical destruction (even subtle changes), including calcification or ossification and fracture (particularly if displacement of an articular fracture is suspected).

Nuclear Medicine Imaging

A bone scan displays physiologic information rather than pure anatomy and relies on the emission of energy from the nucleotide injected into the patient. Indications include early septic arthritis, osteomyelitis, avascular necrosis, tumors (osteoid osteoma), metastatic lesions, occult and stress fractures, and cases of nonaccidental trauma.

Total-body radionuclide scan (technetium-99) is useful to identify bony lesions, inflammatory tumors, and stress fractures. Tumor vascularity can also be inferred from the flow phase and the blood pool images. Gallium or indium scans have high sensitivity for local infections. Thallium-201 chloride scintiscans have >90% sensitivity and 80–90% accuracy in detecting malignant bone or soft tissue tumors. *MRI has supplanted nuclear medicine imaging in many circumstances.*

LABORATORY STUDIES

Laboratory tests are occasionally necessary in the evaluation of a child with musculoskeletal disorder. These may include a complete blood cell count; erythrocyte sedimentation rate; C-reactive protein assay; Lyme titers; and blood, wound, joint, periosteum, or bone cultures for infectious conditions such as septic arthritis or osteomyelitis. Rheumatoid factor, antinuclear antibodies, and human leukocyte antigen B27 may be necessary for children with suspected rheumatologic disorders. Creatine kinase, aldolase, aspartate aminotransferase, and dystrophin testing are indicated in children with suspected disorders of striated muscle, such as Duchenne muscular dystrophy.

Visit Elsevier eBooks+ at eBooks.Health.Elsevier.com for Bibliography.

Chapter 715

The Foot and Toes

Christine M. Goodbody, Jennifer J. Winell, and Richard S. Davidson

Abnormalities affecting the osseous and articular structures of the foot may be congenital, developmental, neuromuscular, inflammatory, or acquired. Problems with the foot and/or toes may be associated with a host of connective tissue diseases and syndromes, and overuse syndromes are commonly observed in young athletes. Symptoms may include pain and difficulty with shoe wear, and cosmetic concerns are common. The foot may be divided into the **forefoot** (toes and metatarsals), the **midfoot** (cuneiforms, navicular, cuboid), and the **hindfoot** (talus and calcaneus). Although the tibiotalar joint (ankle) provides plantarflexion and dorsiflexion, the subtalar joint (between the talus and calcaneus) is oriented obliquely, providing inversion and eversion. Inversion represents a combination of plantarflexion and varus, whereas eversion involves dorsiflexion and valgus. The subtalar joint is especially important for walking on uneven surfaces. Inversion of the transverse tarsal (Chopart) joint locks the midfoot to provide a stable base on which to perform toe-off during the gait cycle. Eversion of the transverse tarsal joint unlocks the **hindfoot** to provide accommodation during heel strike of the of the gait cycle. The talonavicular and calcaneocuboid joints connect the midfoot with the hindfoot.

715.1 Metatarsus Adductus

Christine M. Goodbody, Jennifer J. Winell, and Richard S. Davidson

Metatarsus adductus involves adduction of the forefoot relative to the hindfoot. When the forefoot is adducted, and sometimes in supination, the deformity is termed *metatarsus varus* (Fig. 715.1). The disorder is common in newborns, most frequently caused by intrauterine molding (deformation); the deformity is bilateral in 50% of cases. A careful hip and neck examination must always be performed to look for other abnormalities associated with intrauterine positioning.

CLINICAL MANIFESTATIONS

The forefoot is adducted (occasionally supinated), whereas the midfoot and hindfoot are normal. The lateral border of the foot is convex, and the base of the fifth metatarsal appears prominent. Range of motion at the ankle and subtalar joints is normal. Both the magnitude and the degree of flexibility should be documented. When the normal foot is viewed from the plantar surface, a line through the midpoint of (and parallel to) the heel should extend through the second toe. In metatarsus adductus, the line extends laterally to the second toe. Flexibility is assessed by stabilizing the hindfoot and midfoot in a neutral position with one hand and applying pressure over the first metatarsal head with the other. Correction with little pressure is indicative of a more flexible deformity. In the walking child with an uncorrected metatarsus adductus deformity, an in-toe gait and abnormal shoe wear may occur. A subset of patients will also have a dynamic adduction deformity of the great toe (hallux varus), which is often most noticeable during ambulation. This usually improves spontaneously and does not require treatment.

RADIOGRAPHIC EVALUATION

Radiographs are not performed routinely in infants with metatarsus adductus. Older children with residual deformity should have anteroposterior (AP) and lateral weight-bearing or simulated weight-bearing radiographs. The AP radiographs demonstrate adduction of the metatarsals at the tarsometatarsal articulation and an increased intermetatarsal angle between the first and second metatarsals.

TREATMENT

The treatment of metatarsus adductus is based on the rigidity of the deformity, but most children respond to nonoperative treatment. Deformities that are flexible and overcorrect into abduction with passive manipulation may be observed. Those feet that correct just to a neutral position may benefit from stretching exercises, which can be demonstrated to the parents in the office. In a walking child, the parents can try reversing the shoes as well. If this is not effective, reverse-last shoes can be prescribed to maintain the abducted position of foot. These are worn full-time (22 hours/day), and the condition is reevaluated in 4-6 months. The position of the heel bisector can be followed over the course of observation or treatment to monitor for improvement. If improvement occurs, treatment can be continued for an additional year or more. If there is no improvement, serial plaster casts should be considered. When stretching a foot with metatarsus adductus, care should be taken to maintain the hindfoot in neutral to slight varus alignment to avoid creating hindfoot valgus. Feet that cannot be corrected to a neutral position may benefit from initial serial casting; the best results are obtained when treatment is started before 8 months of age. In addition to stretching the soft tissues, the goal is to alter physeal growth and stimulate remodeling, resulting in permanent correction. Once flexibility and alignment are restored, orthoses, corrective shoes, or wearing shoes on opposite feet is generally recommended for 6-12 months. A dynamic hallux varus usually improves spontaneously, and no active treatment is required.

Surgical treatment may be considered in the small subset of patients with symptomatic residual deformities who have not responded to treatment. Surgery is generally delayed until children are 4-6 years of age. Cosmesis is often a concern, and pain and/or the inability to wear certain types of shoes may occasionally lead patients to consider surgery.

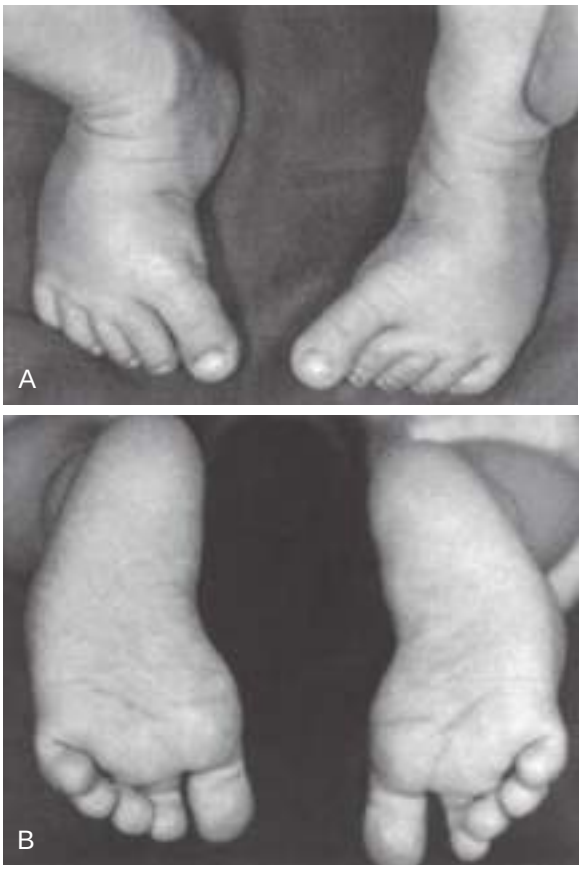

Fig. 715.1 Bilateral mild metatarsus adductus. **A,** Dorsal view showing medial deviation of all the metatarsals. **B,** Plantar view showing the "bean-shaped" foot. This type of foot is easily corrected with serial casting. *(From Ricco AI. Disorders of the foot. In: Herring JA, ed. Tachdjian's Pediatric Orthopaedics, 6th ed. Philadelphia: Elsevier; 2022: Fig. 19-19.)*

Options for surgical treatment include either soft tissue releases or osteotomies depending on age, anatomy, deformity flexibility, and other patient-specific factors. An osteotomy (midfoot or multiple metatarsals) is most likely to result in permanent restoration of alignment.

Visit Elsevier eBooks+ at eBooks.Health.Elsevier.com for Bibliography.

715.2 Calcaneovalgus Feet

Christine M. Goodbody, Jennifer J. Winell, and Richard S. Davidson

A common finding in the newborn, the calcaneovalgus foot occurs secondary to in utero positioning (deformation). Excessive dorsiflexion and eversion are observed in the hindfoot, and the forefoot may be abducted. There may be an associated external tibial torsion (see Chapter 716).

CLINICAL MANIFESTATIONS

The infant typically presents with the foot dorsiflexed and everted, and occasionally the dorsum of the foot or toes will be in contact with the anterolateral surface of the lower leg (Fig. 715.2). Dimpling may be indicative of reduced subcutaneous fat at the dorsolateral ankle. Plantarflexion and inversion are often restricted. A careful hip examination should be performed, and if there is any concern, hip ultrasonography should be considered. When comparing risk for developmental dysplasia of the hip (DDH) with other congenital foot deformities, congenital calcaneovalgus has the highest association, with 6.1–19.4% of patients having coexisting DDH. The calcaneovalgus foot may be confused with a congenital vertical talus and may rarely be associated with a posteromedial bow of the tibia. A calcaneovalgus deformity also may be seen in older patients, typically those with a neuromuscular imbalance involving weakness or paralysis of the gastrocsoleus muscle (e.g., polio, myelomeningocele).

RADIOGRAPHIC EVALUATION

Radiographs are usually not required but should be ordered if the deformity fails to correct spontaneously or with early treatment. AP and lateral radiographs along with a lateral radiograph of the foot in maximal plantarflexion may help distinguish calcaneovalgus from a congenital vertical talus or congenital oblique talus. Evaluation of the position of the talus in relation to the navicular in both the lateral and maximally plantarflexed lateral view can help to diagnose congenital vertical or oblique talus. If a posteromedial bow of the tibia is suspected, AP and lateral radiographs of the tibia and fibula are necessary. In posteromedial bowing of the tibia, the deformity is located in the tibia with the apex of deformity positioned posterior and medial. All three conditions may be confused clinically with calcaneovalgus feet.

TREATMENT

Mild cases of calcaneovalgus foot, in which full passive range of motion is present at birth, require no active treatment. These usually resolve within the first few weeks of life. A gentle stretching program focusing on plantarflexion and inversion is recommended for cases with some restriction in motion. For cases with a greater restriction in mobility, serial casts may be considered to restore motion and alignment, although casting is rarely required in the treatment of calcaneovalgus feet. Unresponsive cases should be evaluated for associated neuromuscular or other etiologies.

Visit Elsevier eBooks+ at eBooks.Health.Elsevier.com for Bibliography.

715.3 Talipes Equinovarus (Clubfoot)

Christine M. Goodbody, Jennifer J. Winell, and Richard S. Davidson

Clubfoot or congenital talipes equinovarus (CTEV) is the term used to describe a deformity involving malalignment of the calcaneo-talar-navicular complex. Components of this deformity may be best understood using the mnemonic **CAVE** (cavus:midfoot, adductus:forefoot, varus:heel, equinus:hindfoot). Although this is predominantly a hindfoot deformity, it involves plantarflexion (cavus) of the first ray (the first metatarsal and first cuneiform) and adduction of the forefoot/midfoot on the hindfoot. The hindfoot is in varus and equinus. The clubfoot deformity may be positional, congenital, associated with a variety of underlying diagnoses (neuromuscular or syndromic), or a focal dysplasia of musculoskeletal tissue distal to the knee.

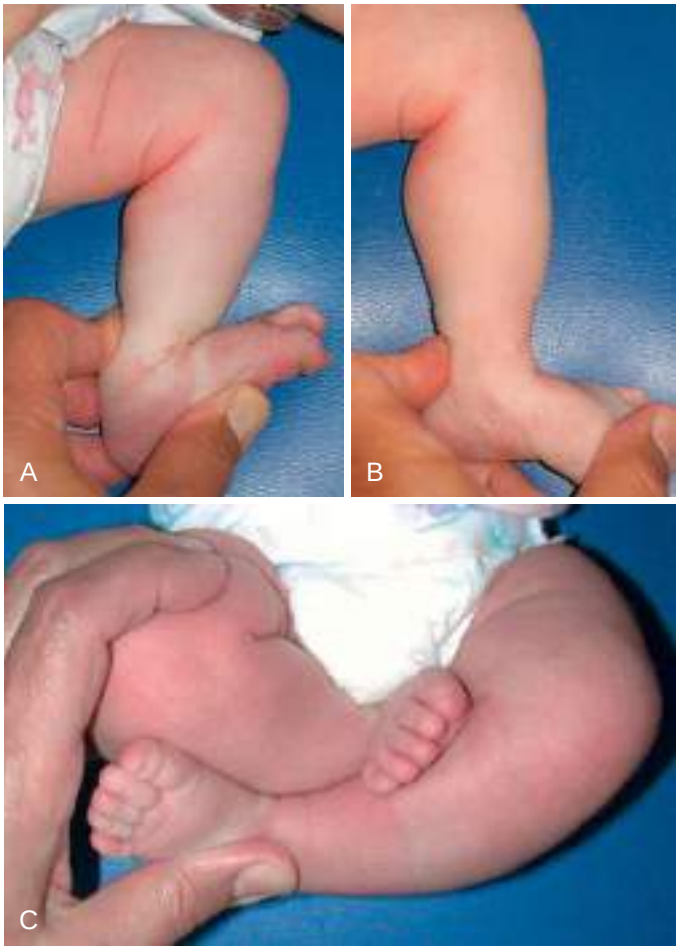

Fig. 715.2 Clinical picture of calcaneovalgus foot (A) that is passively correctable (B) and is due to intrauterine positioning (C).

The **positional (or postural) clubfoot** is a normal foot that has been held in a deformed position in utero and is found to be flexible on examination in the newborn nursery. The nonpositional **congenital clubfoot** can either be idiopathic or syndromic. There is a spectrum of severity, but clubfoot associated with neuromuscular diagnoses or syndromes is typically rigid and more difficult to treat. Clubfoot is also extremely common in patients with myelodysplasia, arthrogryposis, and chromosomal syndromes such as trisomy 18 and chromosome 22q11 deletion syndrome (see Chapter 99).

Congenital clubfoot is seen in approximately 1-2 in 1,000 births and most likely results from a complex multifactorial polygenic inheritance. The risk is ~25% when both a parent and one sibling have clubfeet. It occurs more commonly in males (2:1) and is bilateral in 50% of cases. The pathoanatomy involves both abnormal tarsal morphology (plantar and medial deviation of the head and neck of the talus) and abnormal relationships between the tarsal bones in all three planes, as well as associated contracture of the soft tissues on the plantar and medial aspects of the foot.

CLINICAL MANIFESTATIONS

A complete physical examination should be performed to rule out coexisting musculoskeletal and neuromuscular problems. The spine should be inspected for signs of occult dysraphism. Examination of the infant

clubfoot demonstrates forefoot cavus and adductus and hindfoot varus and equinus (Fig. 715.3). The degree of flexibility varies, and all patients will exhibit calf atrophy. Internal tibial torsion, foot length shortening, and leg-length discrepancy (shortening of the ipsilateral extremity) will be observed in a subset of cases. Although classically not associated with DDH (see Chapter 719.1), there is a higher association of CTEV and DDH than in the general population.

RADIOGRAPHIC EVALUATION

AP and lateral radiographs are not recommended for idiopathic clubfoot. For arthrogrypotic or syndromic feet, x-rays may be helpful but must be performed with the foot held in the maximally corrected position. The lateral x-ray should be a trans-malleolar view. Multiple radiographic measurements can be made to describe malalignment between the tarsal bones. The navicular bone does not ossify until 3-6 years of age, so the focus of radiographic interpretation is the relationship between segments of the foot, forefoot to hindfoot. A common radiographic finding is "parallelism" between lines drawn through the axis of the talus and the calcaneus on the lateral radiograph, indicating hindfoot varus. X-ray may be particularly useful for older children with persistent or recurrent deformities that are difficult to assess.

TREATMENT

Nonoperative treatment is initiated in all infants and should be started as soon as possible following birth. Techniques have included taping and strapping, manipulation and serial casting, and functional treatment. Historically, a significant percentage of patients treated by manipulation and casting required a surgical release, which was usually performed between 3 and 12 months of age. Although many feet remain well aligned after surgical releases, a significant percentage of patients require additional surgery for recurrent or residual deformities, and stiffness remains a concern at long-term follow-up. While pain is uncommon in childhood and adolescence, symptoms may appear during adulthood. These concerns have led to considerable interest in less-invasive methods for treating the deformity.

The Ponseti method of clubfoot treatment, which is the standard of initial treatment, involves a specific technique for manipulation and serial casting, and may be best described as minimally invasive rather than nonoperative (Fig. 715.4). The order of correction follows the mnemonic CAVE. Weekly cast changes are performed; 5-10 casts are typically required. The most difficult deformity to correct is the hindfoot equinus, and ~90% of patients will require a percutaneous tenotomy of the heel cord under local anesthesia as an outpatient. Following the tenotomy, a long leg cast with the knee flexed 90 degrees and the foot in maximal abduction (up to 70 degrees) with 0-10 degrees of dorsiflexion is worn for 3-4 weeks. The patient then begins a bracing program. An abduction brace (bars and shoes) is worn 22 hours a day for 3 months and then at nighttime until the age of 3-5 years. A small subset of patients (up to 20%) with recurrent, dynamic supination deformity will require transfer of the tibialis anterior tendon to the lateral cuneiform. The results of the Ponseti method are excellent at up to 40 years of follow-up. Despite casting, children do not have much dysfunction or delay in achieving normal motor milestones. Compliance with the bracing program is essential as recurrence is common if the brace is not worn as recommended. Minimally invasive methods are most successful when treatment is begun at birth or during the first few months of life, and with good compliance with postmanipulation bracing.

Aggressive surgical realignment has a definite role in the management of clubfeet, especially in the minority of *congenital* clubfeet that have failed nonoperative or minimally invasive methods, and for the neuromuscular and rigid syndromic clubfeet. In such cases, minimally invasive methods such as the Ponseti technique may potentially be of value in decreasing the need for surgery or the magnitude of surgery required. Common surgical approaches include a release of the involved joints (realignment of the tarsal bones), a lengthening of the shortened posteromedial musculotendinous units, and usually pinning of the foot in the corrected position. The "a la carte" method allows the surgeon to apply the principles of deformity correction to be tailored to the unique characteristics of each deformity. For older children with untreated clubfeet or those in whom a recurrence or residual deformity is observed, bony procedures (osteotomies) may be required in addition to soft tissue surgery. Triple arthrodesis is reserved as salvage for painful, deformed feet in adolescents and adults.

Visit Elsevier eBooks+ at eBooks.Health.Elsevier.com for Bibliography.

715.4 Congenital Vertical Talus

Christine M. Goodbody, Jennifer J. Winell, and Richard S. Davidson

Congenital vertical talus is an uncommon foot deformity in which the midfoot is dorsally dislocated on the hindfoot and the ankle is in fixed equinus. A variant form, called oblique talus, refers to subluxation of

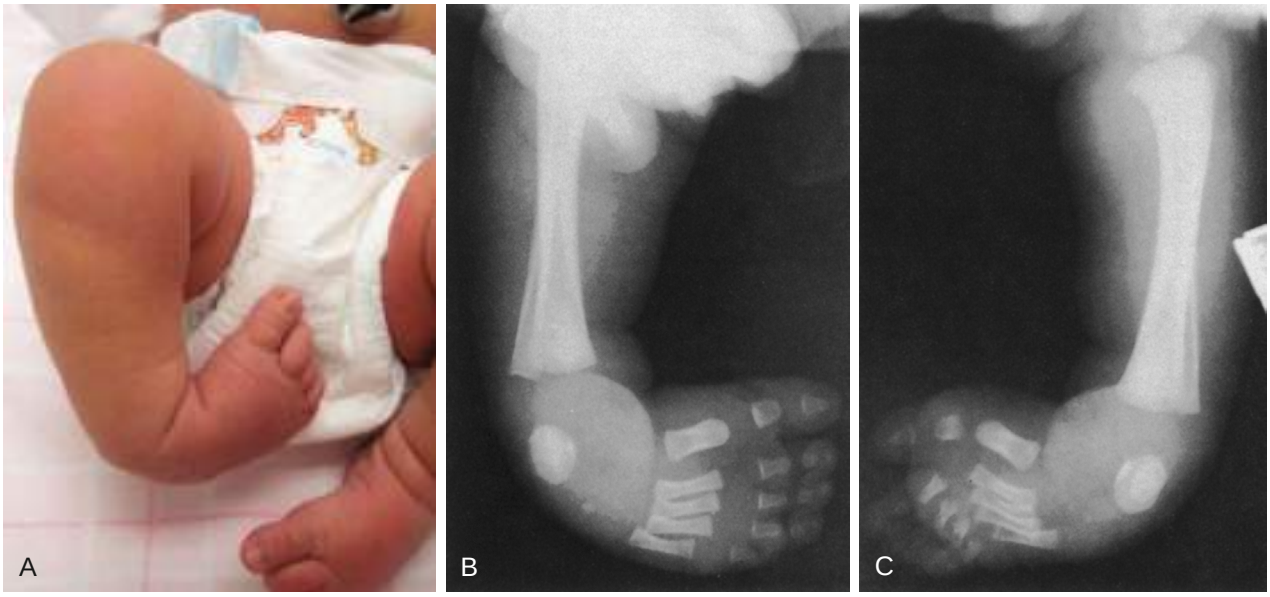

Fig. 715.3 Talipes equinovarus in a newborn. **A,** Clinical appearance of an untreated clubfoot. **B** and **C,** Initial radiographic appearance of bilateral untreated clubfeet. *(From Ricco AI. Disorders of the foot. In: Herring JA, ed. Tachdjian's Pediatric Orthopaedics, 6th ed. Philadelphia: Elsevier; 2022: Fig. 19-42.)*

Fig. 715.4 Ponseti method of clubfoot treatment. Ponseti casts show *serial* correction of the patient (**A-F**). The last cast (**E** and **F**) was applied after percutaneous heel cord tenotomy. *(From Ricco AI. Disorders of the foot. In: Herring JA, ed. Tachdjian's Pediatric Orthopaedics, 6th ed. Philadelphia: Elsevier; 2022: Fig. 19.47, p. 717.)*

the talonavicular joint and is usually neuromuscular in origin. There is nearly an even split between idiopathic cases and cases with an underlying neuromuscular condition or a syndrome. Neurologic causes include myelodysplasia, tethered cord, and sacral agenesis. Other associated conditions include arthrogryposis, Larsen syndrome, multiple pterygium syndrome, and chromosomal abnormalities (trisomy 13-15, 19; see Chapter 99). Depending on the age at diagnosis, the differential diagnosis may include a calcaneovalgus foot, oblique talus (talonavicular joint reduces passively), flexible flatfoot with a tight Achilles tendon, and tarsal coalition.

CLINICAL MANIFESTATIONS

Congenital vertical talus has also been described as a **rocker-bottom foot** (Fig. 715.5). The plantar surface of the foot is convex, and the talar head is prominent along the medial border of the midfoot. The forefoot is dorsiflexed (dorsally dislocated) and abducted relative to the hindfoot, and the hindfoot is in equinus and valgus. There is an associated contracture of the anterolateral (toe extensors) and the posterior (Achilles tendon, peroneals) soft tissues, which may overpower a weakened posterior tibialis and toe flexors. The deformity is typically rigid in vertical talus and flexible in oblique talus. Physical examination is required to identify any coexisting neurologic and/or musculoskeletal abnormalities.

RADIOGRAPHIC EVALUATION

AP, lateral, and maximal plantarflexion, and dorsiflexion lateral radiographs should be obtained when the diagnosis is suspected. The maximum plantarflexion view helps determine whether the dorsal subluxation or dislocation of the midfoot on the hindfoot can be reduced passively, that is, if the navicular can be aligned with the talus. The dorsiflexion lateral view confirms the equinus contracture of the ankle. Although the navicular does not ossify until 3-6 years of age, in younger patients the relationship between the talus and the first metatarsal may be evaluated.

TREATMENT

The initial management consists of serial manipulation and casting, which is started shortly after birth. A *reverse* Ponseti method of casting is particularly useful in stretching out the dorsiflexion and valgus deformities. Open reduction and pin fixation can then stabilize the midfoot, allowing simultaneous heel cord tenotomy and dorsiflexion with casting to correct the ankle equinus.

Fig. 715.5 Congenital vertical talus. **A,** Pronation of the forefoot. **B,** Valgus of the heel. **C,** Absence of an arch, the rocker bottom deformity. **D,** Elevation of the lateral toes and tight peroneal tendons. *(From Ricco AI. Disorders of the foot. In: Herring JA, ed. Tachdjian's Pediatric Orthopaedics, 6th ed. Philadelphia: Elsevier; 2022: Fig. 19-67.)*

In recalcitrant cases, the competing deformities of the midfoot and the hindfoot make conservative treatment difficult. Initially an attempt is made to reduce the dorsal dislocation of the forefoot/midfoot on the hindfoot. Once this has been achieved, attention can be directed toward stretching the hindfoot contracture. These deformities are typically rigid, and surgical intervention is required in the majority of cases. In such cases, casting still helps to stretch out the contracted soft tissues to minimize the magnitude of surgical correction required. Surgery is generally performed between 3 and 12 months of age as a one-stage procedure. This involves release/lengthening of the contracted anterior soft tissues in concert with an open reduction and wire fixation of the talonavicular joint, followed by a posterior release with lengthening of the contracted musculotendinous units. Fixation with Kirschner wires is commonly performed to maintain alignment. Postoperatively, casting is employed for a variable period of time, and afterward patients often require the use of an orthosis for extended periods, depending on the underlying diagnosis. Salvage options for recurrent or residual deformities in older children include a subtalar or triple arthrodesis.

Visit Elsevier eBooks+ at eBooks.Health.Elsevier.com for Bibliography.

715.5 Hypermobile Pes Planus (Flexible Flatfeet)

Christine M. Goodbody, Jennifer J. Winell, and Richard S. Davidson

Flatfoot is a common diagnosis, and it has been estimated that up to 23% of the public may be affected, depending on the diagnostic criteria employed. Three types of flatfeet may be identified: a flexible flatfoot, a flexible flatfoot with a tendo-Achilles contracture, and a rigid flatfoot. Flatfoot describes a change in foot shape, and there are several abnormalities in alignment between the tarsal bones. There is eversion of the subtalar complex, valgus alignment of the hindfoot, and midfoot sag at the naviculocuneiform and/or the talonavicular joints. Additionally, the forefoot is abducted relative to the hindfoot, and the head of the talus is uncovered and prominent along the plantar and medial border of the midfoot/hindfoot. Although hypermobile or flexible pes planus represents a common source of concern for parents, these children are rarely symptomatic. Flatfeet are common in neonates and toddlers and are associated with physiologic ligamentous laxity. Improvement or correction is seen as the longitudinal arch develops between 5 and 10 years of age in the vast majority of children. Flexible flatfeet persisting into adolescence and adulthood are usually associated with **familial ligamentous laxity (hypermobility syndromes)** and often can be identified in other family members.

Patients typically have a normal longitudinal arch when examined in a non–weight-bearing position or standing on the toes, but the arch flattens when weight-bearing. The hindfoot collapses into valgus, and the midfoot sag becomes evident. The forefoot is supinated in weight-bearing. Generalized hypermobility and ligamentous laxity are often observed. Range of motion should be assessed at both the subtalar and the ankle joints. If the heel cord is tight, the flexible flatfoot may become painful. When assessing range of motion at the ankle, the hindfoot should always be inverted while testing dorsiflexion to lock subtalar eversion and apparent dorsiflexion. If the foot is neutral or everted, spurious dorsiflexion may occur through the midfoot, masking a tendo-Achilles contracture. If subtalar motion is restricted, the flatfoot is considered "rigid," and other diagnoses, such as tarsal coalition and juvenile rheumatoid arthritis, must be considered. On occasion, there may be tenderness and/or callus formation under the talar head medially. The shoes should be assessed as well and may have evidence of excessive wear along the medial border.

RADIOGRAPHIC EVALUATION

Routine radiographs of asymptomatic flexible flatfeet are usually not indicated. If obtained for diagnostic reasons, weight-bearing radiographs (AP and lateral) are required to assess the deformity. The foot should be positioned in the child's normal stance as medial rotation and hindfoot inversion may falsely correct the flatfoot. On the AP radiograph, there is widening of the angle between the longitudinal axis of the talus and the calcaneus, indicating excessive heel valgus, as well as talonavicular uncoverage and forefoot abduction. The lateral

view shows decreased calcaneal pitch to the tibia and distortion of the normal straight-line relationship between the long axis of the talus and the first metatarsal (i.e., Meary angle) with sag, either of the talonavicular or naviculocuneiform joint, resulting in flattening of the normal medial longitudinal arch (Fig. 715.6).

TREATMENT

Although the natural history of the flexible flatfoot remains unknown, there is little evidence to suggest that this condition results in long-term problems or disability. As such, treatment is reserved for the small subset of patients who develop symptoms. Patients may complain of hindfoot pain, difficulty with shoe wear, or fatigue after long walking. These patients may benefit from a nonprescription orthosis, such as a medial arch support. However, tight heel cords, when present, must be corrected before using arch supports. Severe cases, often associated with an underlying connective tissue disorder such as Ehlers-Danlos syndrome (see Chapter 744) or Down syndrome (see Chapter 99), may benefit from a custom orthosis such as the UCBL (University of California Biomechanics Laboratory) orthosis to better control the hindfoot and prevent collapse of the arch. Although an orthosis may relieve symptoms, there is no evidence to suggest any permanent change in the shape of the foot or alignment of the tarsal bones. Patients with a flexible flatfoot and a tight tendo-Achilles should be treated with stretching exercises. Often patients are referred to physical therapy to ensure that they are stretching appropriately. For the few patients with persistent pain despite conservative measures, surgical correction of the flatfoot can be considered. This typically involves a lateral column lengthening, which addresses all components of the deformity. The procedure involves an osteotomy of the calcaneus, with placement of a trapezoidal bone graft. A lengthening of the tendo-Achilles is often required, sometimes with a plantarflexion osteotomy of the medial cuneiform if the first ray remains supinated or in varus to restore the tripod surface of the foot. This procedure preserves the mobility of the hindfoot joints, in contrast to a subtalar or triple arthrodesis. Although a hindfoot arthrodesis may correct the deformity adequately, the subsequent stress transfer to neighboring joints may result in late-onset, painful degenerative changes.

Visit Elsevier eBooks+ at eBooks.Health.Elsevier.com for Bibliography.

715.6 Tarsal Coalition

Christine M. Goodbody, Jennifer J. Winell, and Richard S. Davidson

Tarsal coalition, also known as **peroneal spastic flatfoot**, is characterized by a painful, rigid flatfoot deformity and peroneal (lateral calf) muscle spasm without true spasticity. It represents a congenital fusion or failure of segmentation between two or more tarsal bones. Any condition that alters the normal gliding and rotatory motion of the subtalar joint may produce the clinical appearance of a tarsal coalition. Thus congenital malformations, arthritis, inflammatory disorders, infection, neoplasms, and trauma can be possible causes.

The most common tarsal coalitions occur between the talus and calcaneus at the medial talocalcaneal facet (subtalar or talocalcaneal coalition) and between the calcaneus and navicular (calcaneonavicular coalition). Coalitions can be fibrous, cartilaginous, or osseous. Tarsal coalition occurs in approximately 1% of the general population and appears to be inherited as an autosomal dominant trait with nearly full penetrance. Approximately 60% of calcaneonavicular and 50% of medial facet talocalcaneal coalitions are bilateral.

CLINICAL MANIFESTATIONS

Approximately 25% of patients will become symptomatic, typically during the second decade of life. Although the flatfoot and a decrease in subtalar motion may have been present since early childhood, the onset of symptoms may correlate with the additional restriction in motion that occurs as a cartilaginous bar ossifies, reducing flexibility. Recurrent "ankle sprains" often accompany the presenting symptoms. The timing of ossification varies between the talonavicular (3-5 years of age), the calcaneonavicular (8-12 years of age), and the talocalcaneal (12-16 years of age) coalitions. Hindfoot pain is commonly observed, especially in the region of the sinus tarsi and under the head of the talus. Symptoms are activity related and are often increased with running or prolonged walking, especially on uneven surfaces. There may be tenderness over the site of the coalition and/or pain with testing of subtalar motion. The clinical appearance of a flatfoot is seen in both the weight-bearing and non–weight-bearing positions. There is a restriction in subtalar motion.

RADIOGRAPHIC EVALUATION

AP and lateral weight-bearing radiographs and an oblique radiograph of the foot should be obtained as well as a Harris or "heel" view (Table 715.1). A calcaneonavicular coalition is seen best on the oblique radiograph. On the lateral radiograph, there may be elongation of the anterior process of the calcaneus, known as the "anteater sign" (Fig. 715.7). A talocalcaneal coalition may be seen on a Harris (axial) view of the heel. On the lateral radiograph, there may be narrowing of the posterior facet of the subtalar joint or a C-shaped line along the medial outline of the talar dome and the inferior outline of the sustentaculum tali ("C sign"; Fig. 715.8). Beaking (or spur formation) of the anterior aspect of the talus on the lateral view is seen with some frequency and results from an alteration in the distribution of stress. Irregularity in the subchondral bony surfaces may be seen in patients with a cartilaginous coalition, in contrast to a well-formed bony bridge in those with an osseous coalition. A fibrous coalition may require additional imaging studies to diagnose. Although plain films may be diagnostic, a CT scan is considered the "gold standard" imaging modality when a coalition is suspected (see Fig. 715.8). In addition to securing the diagnosis, this study helps define the degree of joint involvement in patients with a talocalcaneal coalition. Although uncommon, more than one tarsal coalition may be observed in the same patient. MRI is also very accurate at detecting tarsal coalition, with a high rate of agreement with CT, and

Fig. 715.6 Lateral weight-bearing radiograph demonstrating features of flatfoot.

Table 715.1 Radiographic Secondary Signs Associated with Tarsal Coalition

Talar beaking
Posterior subtalar facet narrowing
Rounding and flattening of the lateral talar process
Hypoplasia of the talus, shortening of the talar neck
Anterior nose sign
Ball-and-socket ankle joint
Continuous C-sign
Flatfoot deformity
Altered navicular morphology (wide or laterally tapering)
Dysmorphic sustentaculum tali (enlarged and ovoid on lateral radiograph)

From Slovis T, ed. *Caffey's Pediatric Diagnostic Imaging*, 11th ed. Philadelphia: Mosby; 2008: p. 2604.

Fig. 715.7 Calcaneonavicular coalition in a child with the anteater sign *(arrow)* and talar beak *(dashed arrow)*. Elongation of the anterior calcaneus resembling the nose of an anteater is present. *(From Kan JH, Laor T. Congenital anomalies of bone. In: Coley BD, ed. Caffey's Pediatric Diagnostic Imaging, 13th ed. Philadelphia: Elsevier; 2019: Fig. 131.11, p. 1250.)*

may be useful when other diagnoses for pain are suspected and CT is diagnostically suboptimal, or in young children whose tarsal bones are not ossified. MRI offers less radiation exposure but requires more time and may necessitate sedation.

TREATMENT

The treatment of symptomatic tarsal coalitions varies according to the type and extent of coalition, the age of the patient, and the presence and magnitude of symptoms. Treatment is required only for symptomatic coalitions, and the initial management consists of activity restriction and nonsteroidal antiinflammatory medications, often with a shoe insert such as the UCBL orthosis. Immobilization in a short leg walking cast for 4-6 weeks may be required in patients with more pronounced symptoms or those who do not respond to initial measures. For patients with chronic pain despite an adequate trial of nonoperative therapy, surgical treatment should be considered as persistently symptomatic patients who are treated surgically are less likely to report persistent problems at long-term follow-up. Options include resection of the coalition, osteotomy, and/or, in extensive coalitions, arthrodesis. For the calcaneonavicular coalition, resection, and interposition of fat, bone wax, or of the extensor digitorum brevis muscle has been successful. Often, concomitant hindfoot valgus and contracture of the gastrocnemius-soleus are present. In these patients, more reliable pain relief can be obtained with resection of the coalition, correction of the hindfoot valgus by calcaneal lengthening osteotomy with bank bone graft and lengthening of the gastrocnemius-soleus complex. For those with extensive involvement of the joint and/or degenerative changes, a triple arthrodesis may be the best option; this is rarely needed in adolescents.

Visit Elsevier eBooks+ at eBooks.Health.Elsevier.com for Bibliography.

715.7 Cavus Feet

Christine M. Goodbody, Jennifer J. Winell, and Richard S. Davidson

Cavus is a deformity involving plantarflexion of the forefoot or midfoot on the hindfoot and may involve the entire forepart of the foot or just the medial column. The result is an elevation of the medial longitudinal arch (Fig. 715.9). A deformity of the hindfoot will often develop to compensate for the primary forefoot abnormality. Although familial cavus may occur, most patients with this deformity will have an underlying neuromuscular etiology. The initial goal is to rule out, and if present, treat, any underlying causes. These diagnoses may relate to abnormalities of the spinal cord (occult dysraphism, tethered cord, polio, myelodysplasia, etc.) and peripheral nerves (hereditary motor and sensory neuropathies [see Chapter 653], such as Charcot-Marie-Tooth [CMT] disease, Dejerine-Sottas disease, or

Fig. 715.8 Talocalcaneal coalition. **A,** A lateral radiograph demonstrates the C sign *(arrows)*, ovoid, elongated sustentaculum tali, and pes planus. **B,** Computed tomography with coronal reformats in a different patient demonstrates bilateral middle facet subtalar coalitions *(arrowheads)*. *(From Laor T, Kan JH. Congenital anomalies of bone. In: Coley BD, ed. Caffey's Pediatric Diagnostic Imaging, 13th ed. Philadelphia: Elsevier; 2019: Fig. 131-13.)*

Refsum disease). Although a unilateral cavus foot is most likely to result from an occult intraspinal anomaly, bilateral involvement usually suggests an underlying nerve or muscle disease. Cavus is commonly observed in association with a hindfoot deformity. Two thirds of patients with pes cavovarus have CMT, and conversely, 80% of CMT patients have pes cavovarus. In patients with hereditary motor and sensory neuropathies, progressive weakness and muscle imbalance result in plantarflexion of the first ray and medial column. To obtain a plantigrade foot, the hindfoot must roll into varus. With equinocavus, the hindfoot is in equinus, whereas in calcaneocavus (usually seen in polio or myelodysplasia), the hindfoot is in calcaneus (excessive dorsiflexion).

TREATMENT

Any underlying diagnosis must be identified, as this knowledge also helps address the specific disorder and formulate the proper management strategy. With mild deformities, stretching through physical therapy or serial casting of the plantar fascia and contracted muscles with exercises to strengthen weakened muscles may help delay progression. An ankle-foot orthosis may be necessary to stabilize the foot and improve ambulation. Surgical treatment is indicated for progressive or symptomatic deformities that have failed to respond to nonoperative measures or in the foot that is no longer braceable. The specific procedures recommended depend on the degree of deformity and the underlying diagnosis. In the case of a progressive neuromuscular condition, recurrence of deformity is commonly observed, and additional procedures may be required to maintain a plantigrade foot. Families should be counseled in detail regarding the disease process and the expected gains from the surgery. The goal of surgery is to restore motion and alignment, and to improve muscle balance. For milder deformities, a soft tissue release of the plantar fascia, often combined with a tendon transfer, may suffice. For patients with a fixed bony deformity of the forefoot, midfoot, and/or hindfoot, one or more osteotomies may be required for realignment. A triple arthrodesis (calcaneocuboid,

Fig. 715.9 Clinical picture demonstrating pes cavus.

talonavicular, and subtalar) may be required for severe or recurrent deformities in older patients. Long-term bracing is usually helpful in preventing recurrence.

Visit Elsevier eBooks+ at eBooks.Health.Elsevier.com for Bibliography.

715.8 Osteochondroses/Apophysitis

Christine M. Goodbody, Jennifer J. Winell, and Richard S. Davidson

Osteochondroses are idiopathic avascular necroses of bones, which may involve tarsal bones as well. Although rare, they may be observed in the tarsal navicular **(Köhler disease)** or the second or third metatarsal head **(Freiberg infraction**; Fig. 715.10). These are generally self-limited conditions that commonly result in activity-related pain, which can at times be disabling. The treatment is based on the degree of symptoms and most often includes restriction of activity. The diagnosis is made by history and physical examination in conjunction with concordant radiographic findings. The navicular is particularly sensitive, as it is the last tarsal bone to ossify, which may lead to compression from adjacent ossified bones. For patients with Köhler disease, nonsurgical treatment with a short leg cast or controlled ankle motion (CAM) boot for 6-8 weeks may provide significant relief. Patients with Freiberg infraction may benefit from a period of casting and/or shoe modifications such as a rocker-bottom sole, a stiff-soled shoe, or a metatarsal bar (not pads) to offload the forefoot. Degenerative changes and collapse of the metatarsal head will occasionally occur following the gradual healing process, and surgical intervention is required in a small subset of cases. Procedures have included joint debridement, bone grafting, redirectional osteotomy, subtotal or complete excision of the metatarsal head, and joint replacement.

Apophysitis represents inflammation or stress injury to the areas on or around growth plates in children and adolescents from repetitive tensile loading and is most often observed during periods of rapid growth. Enthesopathy refers to injury or inflammation at attachment points of tendons to bones. Calcaneal apophysitis **(Sever disease)** is the most common cause of heel pain in children; treatment includes activity modification, nonsteroidal antiinflammatory medications, heel cord stretching exercises, and heel cushions or arch supports. **Iselin disease** represents an apophysitis at the fifth metatarsal base where the peroneus brevis attaches and is less common. Even though the mandate for imaging heel pain in all children remains controversial, radiographs should be considered when the symptoms are unilateral or fail to respond to treatment. Gentle stretching, a period of rest (6-8 weeks), and avoidance of sports will often resolve symptoms, although recurrence is common until maturity when the apophyses close.

Fig. 715.10 Radiographs of Köhler disease (A) and Freiberg infraction (B).

Visit Elsevier eBooks+ at eBooks.Health.Elsevier.com for Bibliography.

715.9 Puncture Wounds of the Foot

Christine M. Goodbody, Jennifer J. Winell, and Richard S. Davidson

Most puncture wound injuries to the foot may be adequately managed in the clinic or emergency department. Treatment involves a thorough irrigation and a tetanus booster, if appropriate, and many clinicians will recommend antibiotics. Using this approach, the majority will heal without complication. A subset of cases may develop cellulitis, most often caused by *Staphylococcus aureus*, and require intravenous antibiotics with or without surgical drainage if an abscess develops. Persistent signs of infection should be investigated more thoroughly. Deep infection is uncommon and may be associated with septic arthritis, infectious chondritis, or osteomyelitis. The most common organisms are *S. aureus* and *Pseudomonas aeruginosa*; the treatment involves a thorough surgical debridement followed by a short course (10-14 days) of systemic antibiotics. Although plain radiographs will demonstrate any metallic fragments or other radiopaque foreign bodies, ultrasonography (or CT or MRI) may be necessary to identify radiolucent objects such as glass, plastic, or wood. Routine empiric exploration and removal of foreign bodies is not required but may be necessary when symptoms are present or when an infection is suspected. Pain and/or gait disturbance is more likely with superficial objects under the plantar surface of the foot.

A special situation occurs when a puncture wound from a nail comes through a rubber sneaker or running shoe. This situation presents a high risk of a *Pseudomonas* infection, and consideration should be given to a thorough irrigation and debridement under general anesthesia followed by systemic antibiotics for 10-14 days. Foreign-body entrapment of rubber may also occur.

Visit Elsevier eBooks+ at eBooks.Health.Elsevier.com for Bibliography.

715.10 Toe Deformities

Christine M. Goodbody, Jennifer J. Winell, and Richard S. Davidson

JUVENILE HALLUX VALGUS (BUNION)

Juvenile hallux valgus is approximately 10-fold more common in females than in males. A family history is common and is typically associated with familial ligamentous laxity. The etiology is multifactorial, and important factors include genetic factors, ligamentous laxity, pes planus, wearing shoes with a narrow toe box, and occasionally spasticity (e.g., in the setting of cerebral palsy). Bunion refers to the

bump that occurs with chronic rubbing against the prominent first metatarsal head medially.

Clinical Manifestations

There is prominence of the first metatarsophalangeal (MTP) joint medially and often erythema and callus from chronic irritation (Fig. 715.11). The great toe metatarso-phalangeal joint is in valgus and is usually pronated. There is splaying (widening) of the forefoot. Pes planus, with or without an associated heel cord contracture, is also observed commonly. Although cosmesis is perhaps the most common concern, patients may have pain in the region of the first MTP joint and/or difficulty with shoe wear.

Radiographic Evaluation

Weight-bearing AP and lateral radiographs of the feet should be obtained. On the AP view, common measurements include the angular relationships between the first and second metatarsals (intermetatarsal angle, <10 degrees is normal) and between the first metatarsal and the proximal phalanx (hallux valgus angle, <25 degrees is normal) (see Fig. 715.11). The orientation of the first metatarsal–medial cuneiform joint is also documented. On the lateral radiograph, the angular relationship between the talus and the first metatarsal helps identify a midfoot break associated with pes planus. Radiographs are more helpful in surgical planning than in establishing the diagnosis.

Treatment

Conservative management of adolescent bunions consists primarily of shoe modifications. It is important that footwear accommodate the width of the forefoot, or pressure on the medial prominence can lead to callouses and pain. Patients should avoid wearing shoes with a narrow toe box and/or a high heel. Shoe modifications, such as a soft upper, bunion last, or heel cup, also may be recommended. In the presence of flexible pes planus, an orthotic to restore the medial longitudinal arch may be beneficial. If the flatfoot is rigid, further evaluation for tarsal coalition should be pursued. If a tendo-Achilles contracture is present, stretching exercises are recommended. The value of night splinting remains unproven. Surgical treatment is reserved for those patients with persistent and disabling pain who have failed a course of nonoperative therapy. Surgery is not advised purely for cosmesis. Surgery is usually delayed until skeletal maturity to decrease the risk of either recurrence or overcorrection, although guided growth via hemiepiphysiodesis in skeletally immature symptomatic patients is gaining popularity. Radiographs are essential in preoperative planning to assess both the magnitude of deformity (hallux valgus angle, intermetatarsal angle, distal metatarsal articular angle) and associated features such as obliquity of the first metatarsal–medial cuneiform joint. Surgical treatment often involves a soft tissue release and/or rebalancing procedure at the first MTP joint, and a single or double osteotomy of the first metatarsal to decrease foot width and realign the joints along the medial column of the forefoot. If there is deformity in the medial cuneiform, medial cuneiform opening wedge osteotomy and bone graft placement can correct the proximal alignment. An arthrodesis of the first MTP joint may be indicated in patients with spasticity to prevent recurrence.

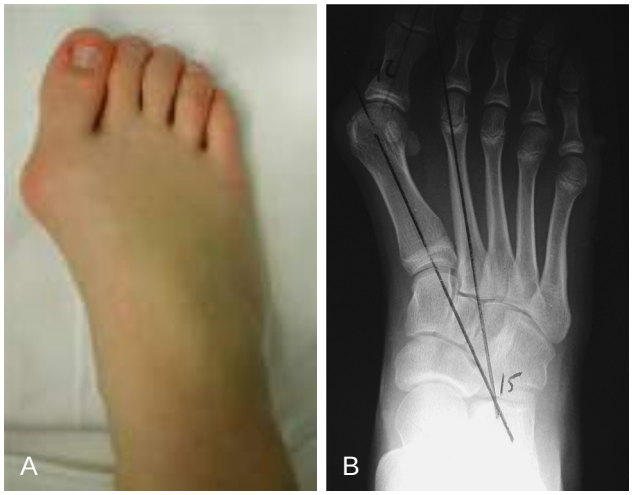

Fig. 715.11 Juvenile hallux valgus (bunion). **A,** Clinical appearance of the right foot of an 11-yr-old with hallux valgus. **B,** Radiograph shows an intermetatarsal angle of 15 degrees. The hallux valgus angle measures 42 degrees. It is the angle formed by a line drawn along the axis of the proximal phalanx and a second line drawn along the shaft of the first metatarsal. *(From Ricco AI. Disorders of the foot. In: Herring JA, ed. Tachdjian's Pediatric Orthopaedics, 6th ed. Philadelphia: Elsevier, 2022; Fig. 19-111.)*

CURLY TOES

Curly toes, or varus deformity, is caused by contracture of the flexor digitorum longus resulting in flexion at the MTP and interphalangeal (IP) joints and medial deviation of the toe. It is extremely common and is often seen in the parents of affected patients. The toe usually lies underneath its neighbor, and the third, fourth, and fifth toes are most commonly involved (Fig. 715.12). The deformity very rarely causes symptoms, and active treatment (stretching, splinting, or taping) is not required. Most cases improve over time, and a subset will resolve completely. For the rare case in which there is chronic pain or skin irritation, release of the flexor digitorum longus tendon at the distal IP joint may be considered. Osteotomy in the older child may rarely be considered.

OVERLAPPING FIFTH TOE

Congenital digitus minimus varus, or varus fifth toe, involves dorsiflexion and adduction of the fifth toe. The fifth toe typically overlaps the fourth. There is also a rotatory deformity of the toe, and the nail tends to point outward. Mild congenital shortness of the fifth metatarsal is common. The deformity is usually bilateral and may have a genetic basis. Symptoms are frequent and involve pain over the dorsum of the toe from shoe wear. Nonoperative treatment has not been successful. For symptomatic patients, several different options for reconstruction have been described. Common features of operative intervention include releasing the contracted extensor tendon and the MTP joint capsule (dorsal, dorsomedial, or complete), and plastic alteration of the tight skin. An alternative procedure involves creation of a syndactyly between the fourth and fifth toes.

POLYDACTYLY

Polydactyly is the most common congenital toe deformity and is seen in approximately 2 in every 1,000 births; it is bilateral in 50% of cases. Polydactyly may be preaxial (great toe) or postaxial (fifth toe), and occasionally one of the central toes is duplicated. Associated anomalies are found in approximately 10% of postaxial and 20% of preaxial polydactyly and may be present in over half of patients with more rare forms of polydactyly. One third of patients will also have polydactyly of the hand. Conditions that may be associated with polydactyly include Ellis-Van Creveld (chondroectodermal dysplasia), longitudinal deficiency of the tibia, and Down syndrome. The extra digit may be either rudimentary or well formed, and plain radiographs of the foot help define the anatomy and evaluate any coexisting bony anomalies. Treatment is indicated for cosmesis and to allow for fitting with standard shoes. This involves surgical removal of the extra digit, and the procedure is generally performed between 9 and 12 months of age. Rudimentary digits may be surgically excised earlier but should not be "tied off," as this may leave painful residual scars or bone masses. For surgical treatment, radiographic evaluation is critical to properly plan reconstruction for a properly shaped and stable foot at maturity.

Fig. 715.12 Curly third, fourth, and fifth toes. *(From Ricco AI. Disorders of the foot. In: Herring JA, ed. Tachdjian's Pediatric Orthopaedics, 6th ed. Philadelphia: Elsevier; 2022. Fig. 19-133.)*

Fig. 715.13 Clinical picture of polysyndactyly involving the great toe.

SYNDACTYLY

Syndactyly involves webbing of the toes, which may be simple (soft tissue only) or complex (involving bone). The syndactyly may be incomplete or complete (extends to the tip of the toes), and the toenails may be confluent. There is often a positive family history, and the third and fourth toes are most frequently involved. Symptoms are extremely rare, and cosmetic concerns are infrequent. Treatment is only required for a subset of cases in which there is an associated polydactyly (Fig. 715.13). Complex syndactyly may be seen in patients with Apert syndrome.

HAMMER TOE

A hammer toe is a flexion deformity of the lesser toes that involves the proximal IP (PIP) joint. This deformity may be distinguished from a curly toe by the absence of rotation. The second toe is most often involved, and a painful callus may develop over the dorsum of the toe where it rubs on the shoe or the tip of the toe which is directed against the sole of the shoe. Nonoperative therapy is rarely successful, and surgery is recommended for symptomatic cases. A release of the flexor tendons will suffice in most cases. Some authors recommend a transfer of the flexor tendon to the extensor tendon. For severe cases with significant rigidity, especially in older patients, a partial or complete resection of the proximal phalanx and a PIP joint fusion may be required.

MALLET TOE

Mallet toe involves a flexion contracture at the distal IP (DIP) joint and results from congenital shortening of the flexor digitorum longus tendon. Patients may develop a painful callus on the plantar surface of the tuft or dorsal aspect of the DIP joint. As nonoperative therapy is usually unsuccessful, surgery is required for patients with chronic symptoms. For flexible deformities in younger children, stretching or release of the flexor digitorum longus tendon is recommended. For stiffer deformities in older patients, resection of the head of the middle phalanx, or arthrodesis of the DIP joint, may be considered.

CLAW TOE

A claw toe deformity involves hyperextension at the MTP joint and flexion at both the PIP and DIP joints, often associated with dorsal subluxation of the MTP joint. *This condition must be distinguished from hyperextension of the MTP joint due to ground reaction where the stiff flexed toe in stance pushes the MTP joint into hyperextension. If the MTP does hyperextend, this is a claw toe.* The majority are associated with an underlying neurologic disorder and must be evaluated. The etiology is usually muscle imbalance, and the extensor tendons are recruited to substitute for weakening of the tibialis anterior muscle. If treatment is elected, surgery is required. Transfer of the extensor digitorum (or hallucis) tendon to the metatarsal neck is commonly performed along with a dorsal capsulotomy of the MTP joint and fusion of the PIP joint (IP joint of the great toe).

ANNULAR BANDS

Bands of amniotic tissue associated with amniotic disruption syndrome (early amniotic rupture sequence, congenital constriction band syndrome, annular band syndrome) may become entwined along the extremities, resulting in a spectrum of problems from in utero amputation (Fig. 715.14) to a constriction ring along a digit (Fig. 715.15; see Chapter 100). These rings, if deep enough, may result in impairment of arterial or venous blood flow as well as severe damage to the muscles, tendons, and bone growth distal to the band. Even though concerns regarding tissue viability are less common, swelling from impairment in venous return is often an urgent problem. The treatment of annular bands usually involves observation; however, circumferential release of the band may be required emergently if arterial inflow is obstructed or electively to relieve venous congestion. Physical therapy and bracing may help prevent future contractures and deformities.

MACRODACTYLY

Macrodactyly represents an enlargement of the toes and may occur as an isolated problem or in association with a variety of other conditions such as Proteus syndrome (Fig. 715.16), neurofibromatosis, tuberous sclerosis, and Klippel-Trenaunay-Weber syndrome. This condition results from a deregulation of growth, and there is hyperplasia of one or more of the underlying tissues (osseous, nervous, lymphatic, vascular, fibrofatty). Macrodactyly of the toes may be seen in isolation (localized gigantism) or with enlargement of the entire foot or leg. In addition to cosmetic concerns, patients may have difficulty wearing standard shoes. The initial treatment is observation, if possible. This is a difficult condition to treat surgically, and complications are frequent. For involvement of a single toe, the best option may be a resection of the ray (including the metatarsal). For greater degrees of involvement, debulking of the various tissues is required. Often a growth arrest of the underlying osseous structures is performed. Stiffness and wound problems are common. The rate of recurrence is high, and more than one debulking may be required. Patients may elect to have an amputation if the process cannot be controlled by less extensive procedures. Leg length inequality is common and must be looked for and treated if needed.

SUBUNGUAL EXOSTOSIS

A subungual exostosis is a benign bone mass that projects out from the dorsal and medial surface of a distal toe phalanx, under the nail. The etiology is unknown but may relate to minor, repetitive trauma. The great toe is involved most often. Patients present with discomfort, and the toenail may be deformed and elevated. The lesion may be demonstrated on plain radiographs and histologically involves normal bone with a fibrocartilaginous cap. The treatment for symptomatic lesions is excision, and the recurrence rate is approximately 10%.

INGROWN TOENAIL

Ingrown toenails are relatively common in infants and young children and usually involve the medial and/or lateral border of the great toe. Symptoms include chronic irritation and discomfort. Recurrent infection is seen in some cases. Parents should be instructed when cutting toenails to cut straight across the distal aspect of the nail, rather than

Fig. 715.14 Constriction band syndrome with congenital amputation.

Fig. 715.15 Constriction band syndrome with foot involvement.

Fig. 715.16 Macrodactyly of the great toe in a case of Proteus syndrome.

curve inward at the nail edges. If conservative measures, including shoe modifications, warm soaks, and appropriate nail trimming fail to control the symptoms, surgical removal of a portion of the nail should be considered.

Visit Elsevier eBooks+ at eBooks.Health.Elsevier.com for Bibliography.

Table 715.2 Differential Diagnosis of Foot Pain According to Age

AGE GROUP	DIAGNOSTIC CONSIDERATIONS
0-6 yr	Poorly fitting shoes Fracture Puncture wound Foreign body Osteomyelitis Cellulitis Juvenile idiopathic arthritis Hair tourniquet Dactylitis Leukemia
6-12 yr	Poorly fitting shoes Trauma (fracture, sprain) Juvenile idiopathic arthritis (enthesopathy) Puncture wound Sever disease (calcaneal apophysitis) Accessory tarsal navicular bone Hypermobile flatfoot Tarsal coalition Oncologic (Ewing sarcoma, leukemia)
12-18 yr	Poorly fitting shoes Stress fracture Trauma (fracture, sprain) Foreign body Ingrown toenail Metatarsalgia Plantar fasciitis Achilles tendinopathy Accessory ossicles (navicular, os trigonum) Tarsal coalition Avascular necrosis of metatarsal (Freiberg infarction) or navicular (Köhler disease) bones Plantar warts

From Marcdante KJ, Kliegman RM, Schuh AM. *Nelson Essentials of Pediatrics*, 9th ed. Philadelphia: Elsevier; 2023.

715.11 Painful Foot

Christine M. Goodbody, Jennifer J. Winell, and Richard S. Davidson

Table 715.2 shows a differential diagnosis for foot pain in different age ranges. In addition to the history and physical examination, plain radiographs are most helpful in establishing the diagnosis. Occasionally more sophisticated imaging modalities such as CT or MRI will be required.

715.12 Shoes

Christine M. Goodbody, Jennifer J. Winell, and Richard S. Davidson

In toddlers and children, a well-fitting shoe with flexible soles is recommended. This recommendation is in part based on studies suggesting that the development of the longitudinal arch seems to be best in societies in which shoes are not worn, and flatfeet are more common in shod children. Well-cushioned, shock-absorbing shoes are helpful in the child and adolescent athlete to decrease the chances of developing an overuse injury. Otherwise, shoe modifications are generally reserved for abnormalities in either alignment between segments of the foot or symptoms from an underlying condition (e.g., a limb-length discrepancy). Numerous modifications are available.

As a rule, shoes protect the foot from abnormal temperature as well as rough surfaces and sharp objects but have not been shown to help the normal foot develop. Poorly fitting shoes may create problems.

Visit Elsevier eBooks+ at eBooks.Health.Elsevier.com for Bibliography.

Chapter 716

Torsional and Angular Deformities of the Limb

Brendan A. Williams, Jennifer J. Winell, and Lawrence Wells

716.1 Normal Limb Development

Brendan A. Williams, Jennifer J. Winell, and Lawrence Wells

During the seventh week of intrauterine life, the lower limb rotates medially to bring the great toe toward the midline. The hip joint forms by the eleventh week; the proximal femur and acetabulum continue to develop until physeal closure in adolescence. The first component of rotation is the femoral neck, which is rotated approximately 40 degrees anteriorly at birth. This anterior rotation is referred to as **anteversion** (the angle between the axis of the femoral neck and the transcondylar axis). The increased anteversion results in increased internal rotation of the hip. In most children, femoral anteversion decreases to 15-20 degrees by 8-10 years of age. Conditions such as cerebral palsy that involve spasticity of the lower extremities can result in the persistence of fetal anteversion. This results in torsional abnormalities of the lower limb and gait disturbances. The second component of limb rotation is found in the tibia. Tibial torsion is the angular difference between the axis of the knee and the transmalleolar axis. Infants can have 30 degrees of medial rotation of the tibia. When skeletally mature, the rotation is between 5 degrees of medial rotation and 15 degrees of lateral rotation (Fig. 716.1). Excessive medial rotation of the tibia is referred to as **medial tibial torsion**. This is very common and, although concerning to parents, very rarely requires treatment. The medial or lateral rotation beyond ±2 SDs from the mean is considered abnormal rotation. The third component of rotational (axial) abnormalities of the lower extremity derives from the foot. Metatarsus adductus can cause the foot to curve medially, pointing the toes inward. It is assessed by observing the medial and lateral borders of the foot.

Torsional deformity may be simple, involving a single component, or complex, involving multiple components. Complex deformities may be additive (internal tibial torsion and internal femoral torsion are additive) or compensatory (external tibial torsion and internal femoral torsion are compensatory).

The normal tibiofemoral angle at birth is 10-15 degrees of physiologic varus. The alignment changes to 0 degrees by 18 months, and physiologic valgus up to 12 degrees is reached in between 3 and 4 years of age. The normal valgus of 7 degrees is achieved by 5-8 years of age (Fig. 716.2). Persistence of varus beyond 2 years of age may be pathologic and is seen in conditions such as Blount disease. Overall, 95% of developmental physiologic genu varum and genu valgum cases resolve with growth. Persistent genu valgum or valgus into adolescence is considered pathologic and deserves further evaluation.

Visit Elsevier eBooks+ at eBooks.Health.Elsevier.com for Bibliography.

716.2 Limb Evaluation

Brendan A. Williams, Jennifer J. Winell, and Lawrence Wells

When evaluating concerns regarding the limb, the provider should obtain a history documenting onset, progression, functional limitations, previous treatment, evidence of neuromuscular disorder, and any significant family history. The examination should assess the exact torsional profile and include (1) foot progression angle, (2) femoral anteversion, (3) tibial version with thigh-foot angle, and (4) assessment of foot adduction and abduction.

FOOT PROGRESSION ANGLE

Limb position during gait is expressed as the **foot progression angle** and represents the angular difference between the axis of the foot with the direction in which the child is walking. Its value is usually estimated by asking the child to walk in the clinic hallway (Fig. 716.3). Inward rotation of the foot is assigned a negative value, and outward rotation is designated with a positive value. The normal foot progression angle in children and adolescents is 10 degrees (range: −5 to 20 degrees). The foot progression angle delineates whether there is an in-toeing or out-toeing gait.

FEMORAL ANTEVERSION

Hip rotation is measured with the child in the prone position, the hip in neutral flexion or extension, thighs together, and the knees flexed to 90 degrees (Fig. 716.4). Both hips are assessed at the same time. Internal rotation of the hip is measured by rotating the leg ipsilaterally, and external rotation is measured by rotating the leg contralaterally. Excessive anteversion has increased internal rotation, whereas retroversion has increased external rotation. The amount of anteversion can be approximately estimated by palpating the greater trochanter of the hip while internally rotating the limb. Femoral anteversion should be measured at the point when the greater trochanter is most prominent laterally during this rotation (Craig test).

TIBIAL ROTATION

Tibial rotation is measured using the **transmalleolar angle.** The transmalleolar angle is the angle between the longitudinal axis of the thigh with a line perpendicular to the axis of the medial and lateral malleolus (Fig. 716.5). In the absence of foot deformity, the **thigh-foot angle** is preferred (Fig. 716.6). It is measured with the child lying prone. The angle is formed between the longitudinal axis of the thigh and the longitudinal axis of the foot. It measures the tibial and hindfoot rotational status. Inward rotation is assigned a negative value, and outward rotation is assigned a positive value. Inward rotation indicates medial tibial torsion, whereas outward rotation represents lateral tibial torsion. Infants have a mean angle of −5 degrees (range: −35 to 40 degrees) as a consequence of normal in utero position. In mid-childhood through adult life, the mean thigh-foot angle is 10 degrees (range: −5 to 30 degrees).

FOOT SHAPE AND POSITION

The foot is observed for any deformities in prone and standing position. The **heel bisector line** (HBL) is used to evaluate the foot adduction and abduction deformities. The HBL is a line that divides the heel in two equal halves along the longitudinal axis (Fig. 716.7). It normally extends through the center of the second toe. When the HBL points medial to the second toe, the forefoot is abducted, and when the HBL is lateral to the second toe, the forefoot is adducted. Other lower-extremity problems, such as heel varus or valgus, can make assessment of axial plane issues more difficult.

It is also important to screen children with these foot deformities for associated hip dysplasia and neuromuscular problems (e.g., cerebral palsy).

Visit Elsevier eBooks+ at eBooks.Health.Elsevier.com for Bibliography.

716.3 Torsional Deformities

Brendan A. Williams, Jennifer J. Winell, and Lawrence Wells

FEMORAL ANTEVERSION

In-toeing gait most commonly results from excessive femoral anteversion. It occurs more commonly in females than males (2:1) in children 3-6 years of age and is congenital, resulting from persistent infantile

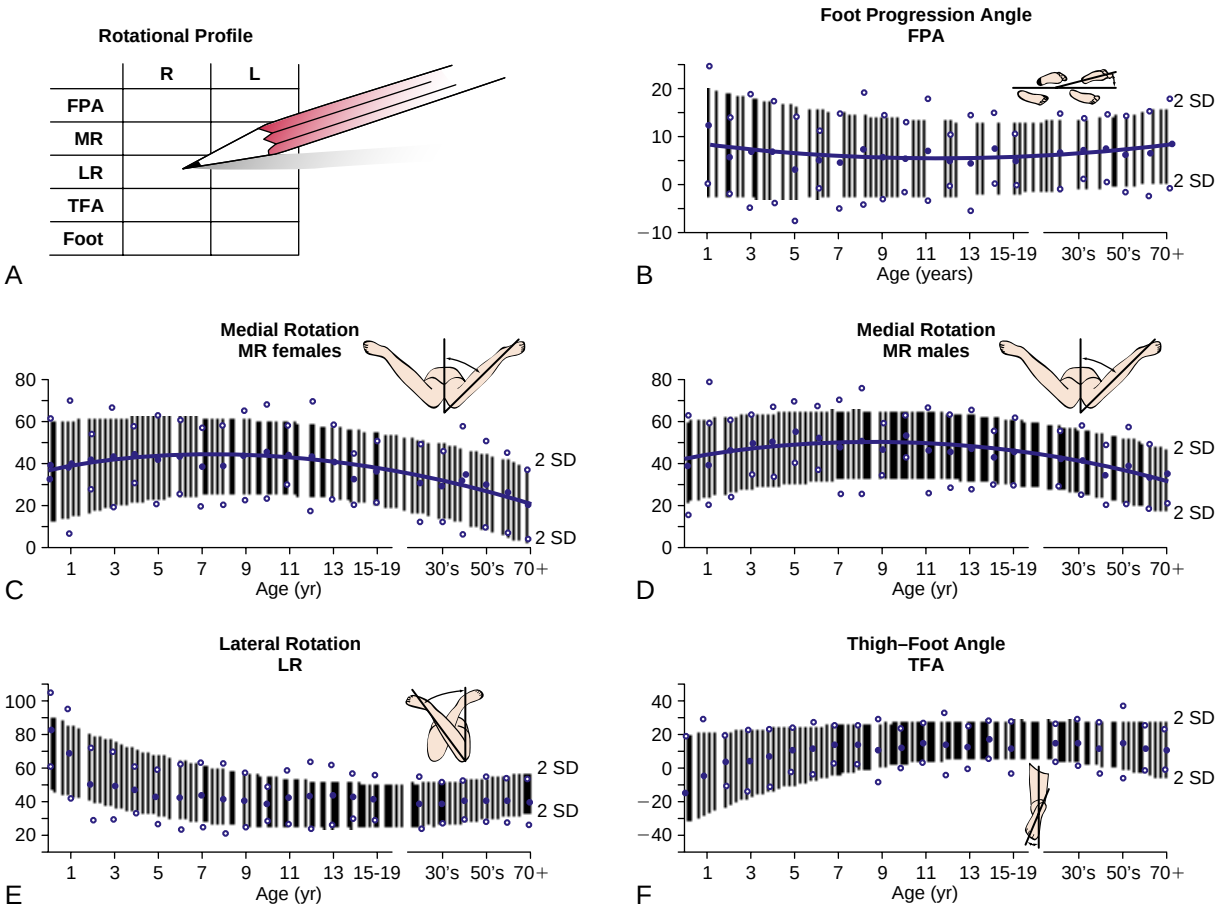

Fig. 716.1 A-F, The rotational profile from birth to maturity is depicted graphically. All graphs include 2 SD from the mean for the foot progression angle *(FPA)* for femoral medial rotation *(MR)* and lateral rotation *(LR)* (for males and females), and the thigh-foot angle *(TFA)*. *(From Morrissey RT, Weinstein SL, eds. Lovell and Winter's Pediatric Orthopaedics, 3rd ed. Philadelphia: Lippincott Williams & Wilkins; 1990.)*

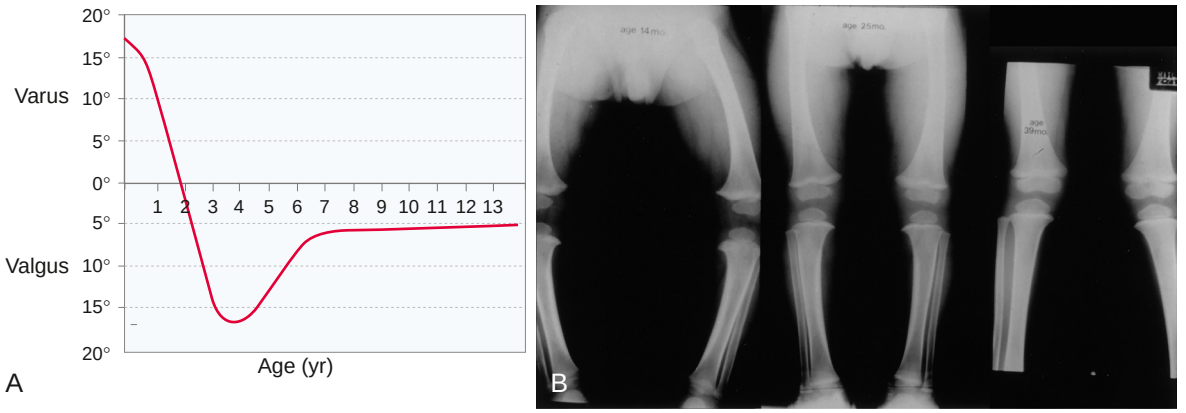

Fig. 716.2 A, Development of the tibiofemoral angle during growth (after Salenius). B, Serial radiographs demonstrating normal transition from varus alignment at 14 months to neutral position at 25 months to valgus tibiofemoral alignment at 39 months. *(From Wimberly RL. Disorders of the leg. In: Herring JA, ed. Tachdjian's Pediatric Orthopaedics, 6th ed. Philadelphia: Elsevier; 2022: Fig 18.13.)*

anteversion. On examination, many children with this condition will have **generalized ligamentous laxity**. Gait examination reveals that the entire leg is inwardly rotated. Internal hip rotation is increased beyond 70 degrees, and consequently the external rotation is restricted to 10-20 degrees. Clinically, the patellae point inward when the foot is straight, and compensatory external rotation of the tibia is demonstrated. This is frequently mistaken as "genu valgum." The amount of anteversion can be roughly estimated by palpating the greater trochanter of the hip while internally rotating the limb. The point of maximal prominence of the greater trochanter laterally during this rotation corresponds to the degree of femoral anteversion.

Diagnosis is made clinically on examination; CT can provide objective measurements but is rarely indicated. The treatment is predominantly observation and reassurance. The torsion usually corrects with longitudinal growth by 8-10 years of age. Although rare, persistent deformity, unacceptable cosmesis, functional impairment, anteversion

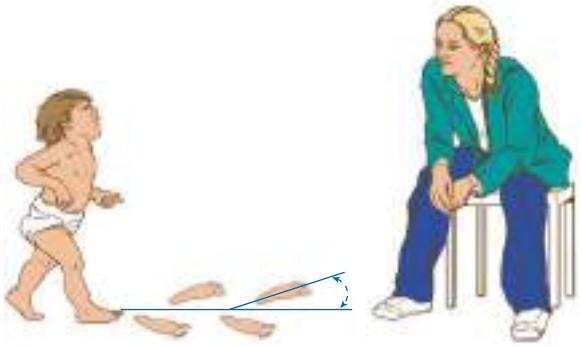

Fig. 716.3 Foot progression angle. The long axis of the foot is compared with the direction in which the child is walking. If the long axis of the foot is directed outward, the angle is positive. If the foot is directed inward, the angle is negative and indicates in-toeing. *(From Thompson GH. Gait disturbances. In: Kliegman RM, ed. Practical Strategies in Pediatric Diagnosis and Therapy. Philadelphia: WB Saunders; 2004.)*

Fig. 716.4 Anteversion measured by medial rotation of hip (A) and lateral rotation of hip (B). In this patient, internal rotation is nearly 90 degrees, suggestive of excessive femoral anteversion.

>45 degrees, and no external rotation beyond neutral are indications for operative intervention. Surgery involves a derotation osteotomy of the femur.

MEDIAL TIBIAL TORSION

Medial (internal) tibial torsion manifests with **in-toeing gait.** It is commonly associated with metatarsus adductus, genu valgum, or femoral anteversion. This condition is usually seen during the second year of life. It is often noticed after the child begins to walk independently. Many parents are concerned with a "bowed" appearance of the legs. Normally at birth, the medial malleolus lies behind the lateral malleolus, but by adulthood, it is reversed, with the tibia in 15 degrees of external rotation. The treatment is observation and reassurance because spontaneous resolution with normal growth and development can be anticipated. Correction can be seen as early as 4 years of age and in some children by 8-10 years of age. Persistent deformity with functional impairment is treated with supramalleolar derotation osteotomy, but this is rarely necessary.

Fig. 716.5 Measurement of transmalleolar angle (TMA). *(From Guler O, Isyar M, Karataş D, et al. Investigating the relationship between internal tibial torsion and medial collateral ligament injury in patients undergoing knee arthroscopy due to tears in the posterior one third of the medial meniscus. Knee. 2016;23[4]:655–658, Fig 2.)*

EXTERNAL FEMORAL TORSION

Femoral retrotorsion, when of idiopathic origin, is usually bilateral. The disorder is associated with an **out-toeing gait** and increased incidence of degenerative arthritis. The clinical examination of external femoral torsion shows excessive hip external rotation and limitation of internal rotation. The hip will externally rotate up to 70-90 degrees and internally rotate to only 0-20 degrees. External femoral torsion can also follow a **slipped capital femoral epiphysis (SCFE)**. There should be a low threshold to perform radiographs of the hips in children older than 10 years of age who present with hip or knee pain and decreased internal rotation of the hip on clinical examination. If a SCFE is detected, it is treated surgically. Occasionally, persistent femoral retroversion after SCFE can produce functional impairment resulting in a severe out-toed gait and difficulty opposing one's knees in the sitting position. The latter can be disabling to adolescent females. Should this occur, a Southwick osteotomy or surgical realignment might be necessary.

LATERAL TIBIAL TORSION

Lateral (external) tibial torsion is less common than medial rotation and is often associated with a **calcaneovalgus foot**. It can be compensatory to persistent femoral anteversion or secondary to a tight iliotibial band. Natural growth rotates the tibia externally, and therefore external tibial torsion can become worse with time. Clinically, the patella faces outward when the foot is straight. The thigh-foot angle and the transmalleolar angle are increased. There may be associated patellofemoral instability with knee pain. Although some correction can occur with growth, extremely symptomatic children may need a supramalleolar osteotomy, which is usually done by 10-12 years of age.

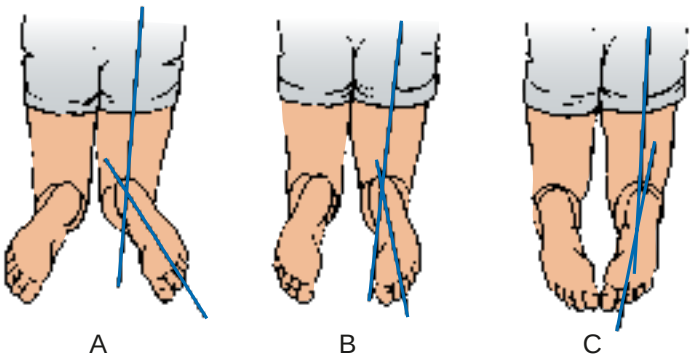

Fig. 716.6 Thigh-foot angle. With the child in the prone position and the knees flexed and approximated, the long axis of the foot can be compared with the long axis of the thigh. The long axis of the foot bisects the heel and the third or middle toe. **A,** External tibial torsion produces excessive outward rotation. **B,** Normal alignment is characterized by slight external rotation. **C,** Internal tibial torsion produces inward rotation. *(From Zolkoske AC, Fehr SD. Gait disturbances. In: Kliegman RM, Toth H, Bordini BJ, Basel D, eds. Nelson Pediatric Symptom-Based Diagnosis, 2nd ed. Philadelphia: Elsevier; 2023: Fig 45.6.)*

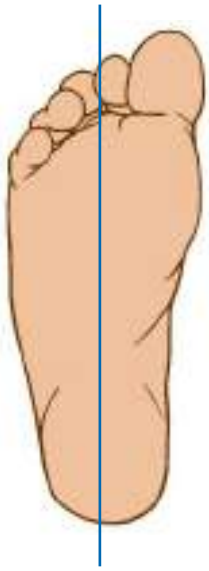

Fig. 716.7 Schematic demonstration of heel bisector line.

METATARSUS ADDUCTUS

Metatarsus adductus (see Chapter 715.1) manifests with forefoot adduction and medial rotation of all metatarsals. Of children with metatarsus adductus, 10–15% have hip dysplasia. The prognosis is good because the majority get better with nonoperative intervention. Feet that correct actively with stimulation of the lateral border of the foot are treated with stretching exercises alone. Feet that are flexible and correctable to neutral with manipulation are treated with stretching, reverse last shoes, or serial casting. Feet that do not correct fully with conservative care or rigid deformities are treated with medial capsulotomy of the first metatarsal cuneiform joint and soft tissue release by 2 years of age. Osteotomies of the base of the metatarsal may be performed after 6 years of age.

Visit Elsevier eBooks+ at eBooks.Health.Elsevier.com for Bibliography.

716.4 Coronal Plane Deformities

Brendan A. Williams, Jennifer J. Winell, and Lawrence Wells

Genu varum and genu valgum are common pediatric deformities of the knee. Figure 716.2 presents the age-appropriate normal values for knee angle. Tibial bowing is common during the first year, bowlegs are common during the second year, and knock-knees are most prominent between 3 and 4 years of age.

GENU VARUM

Physiologic bowleg is a common torsional combination that is secondary to normal in utero positioning (Fig. 716.8). Spontaneous resolution with normal growth and development can be anticipated. Persistence of varus beyond 2 years of age may be pathologic. Causes of pathologic bowing include metabolic bone disease (vitamin D deficiency, rickets, hypophosphatasia), asymmetric growth arrest (trauma, infection, tumor, Blount disease), bone dysplasia (dwarfism, metaphyseal dysplasia), and congenital and neuromuscular disorders (Table 716.1). It is important to differentiate physiologic bowing from Blount disease (Table 716.2). Physiologic bowing should also be differentiated from rickets and skeletal dysplasia. Rickets has classic bony changes seen on plain radiographs with trumpeting widening and fraying of the metaphysis along with widening of the physis (see Chapter 69).

TIBIA VARA

Idiopathic tibia vara, or **Blount disease**, is a developmental deformity resulting from abnormal endochondral ossification of the medial aspect of the proximal tibial physis leading to varus angulation and medial rotation of the tibia (Fig. 716.9). The incidence is greater in Black patients and in overweight toddlers. It is also higher in patients who have an affected family member or started walking early in life. Idiopathic tibia vara has been classified into three types, depending on the age at onset: infantile (1-3 years of age), juvenile (4-10 years of age), and adolescent (11 years or older). The juvenile and adolescent forms are commonly combined as late-onset tibia vara. The exact cause of tibia vara remains unknown, although it is thought to result from abnormal growth of the physis due to excessive weight.

The **infantile** form of tibia vara is the most common. There is a predominance in Black females. Approximately 80% are bilateral with a prominent medial metaphyseal beak, internal tibial torsion, and leg-length discrepancy. The characteristics of the **juvenile** and **adolescent** (late-onset) forms include predominance in Black males, obesity, normal or greater than normal height, less frequent bilateral involvement (approximately 50%), slowly progressive genu varum deformity, pain rather than deformity as the primary initial complaint, no palpable proximal medial metaphyseal beak, minimal internal tibial torsion, mild medial collateral ligament laxity, and mild lower extremity length discrepancy. The infantile group has the greatest potential for progression.

An anteroposterior (AP) standing radiograph of both lower extremities with patellae facing forward and a lateral radiograph of the involved extremity should be obtained (Fig. 716.10). Weight-bearing radiographs are preferred and allow maximal presentation of the clinical deformity. The metaphyseal-diaphyseal angle (Drennan angle) can be measured and is useful in distinguishing between physiologic genu varum and early tibia vara (Fig. 716.11). This angle can aid in predicting the risk of progression. Angles greater than 16 degrees carry an increased risk of progression, whereas those less than 10 degrees are likely to resolve spontaneously. Patients with Drennan angles of 11-16 degrees should be monitored for progressive tibia vara.

The Langenskiöld classification, which describes six stages on radiographs for infantile Blount disease (Fig. 716.12), is the most widely

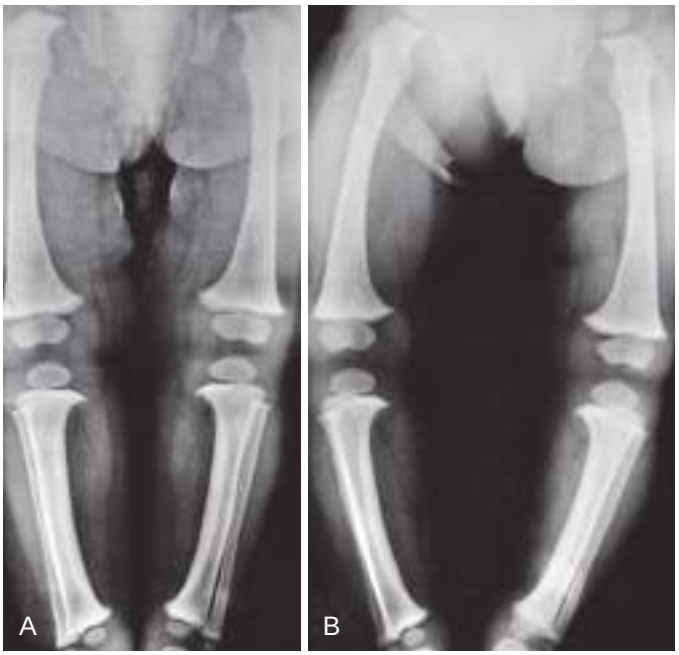

Fig. 716.8 Genu varum. **A,** In recumbent position, tibia and femora are bowed, but the legs do not appear bowed. **B,** In erect position during weight bearing and with ankles in apposition, the legs are bowed. *(From Coley BD, ed. Caffey's Pediatric Diagnostic Imaging, 13th ed. Philadelphia: Elsevier; 2019.)*

Table 716.1 Classification of Genu Varum (Bowlegs)

PHYSIOLOGIC
Asymmetric growth
Tibia vara (Blount disease)
• Infantile
• Juvenile
• Adolescent
Focal fibrocartilaginous dysplasia
Physeal injury
Trauma
Infection
Tumor
METABOLIC DISORDERS
Vitamin D deficiency (nutritional rickets)
Vitamin D–resistant rickets
Hypophosphatasia
SKELETAL DYSPLASIA
Metaphyseal dysplasia
Achondroplasia
Enchondromatosis

Modified from Thompson GH. Angular deformities of the lower extremities. In: Chapman MW, ed. *Operative Orthopedics*, 2nd ed. Philadelphia: JB Lippincott; 1993: Table 222-1, p. 3132.

Table 716.2 Differentiation of Leg Bowing

PHYSIOLOGIC BOWING	BLOUNT DISEASE
Gentle and symmetric deformity	Asymmetric, abrupt, and sharp angulation
Metaphyseal-diaphyseal angle <11 degrees	Metaphyseal-diaphyseal angle >11 degrees
Normal appearance of the proximal tibial growth plate	Medial sloping of the epiphysis Widening of the physis Fragmentation of the metaphysis
No significant lateral thrust	Significant lateral thrust

cited classification system, although other radiographic and MRI-based systems have been described. Langenskiöld differentiates based on fragmentation of the epiphysis, beaking of the medial tibial epiphysis, depression of the medial tibial plateau, and formation of a bony bar. CT with three-dimensional reconstructions and MRI can also be useful to assess the meniscus; the articular surface of the proximal tibia, including the posteromedial slope; or the integrity of the proximal tibial physis.

Management is based on the stage of the disease, the age of the child, and the nature of presentation (primary or recurrent deformity). In children younger than 3 years and Langenskiöld stage <3, bracing is effective and can prevent progression in 50% of patients. A maximal trial of 1 year of orthotic management is recommended. If complete correction is not obtained after 1 year or if progression occurs during this time, a corrective osteotomy is indicated. Surgical treatment is also indicated in children >4 years of age, those at Langenskiöld stage >3, and those with severe deformities. A proximal tibial valgus osteotomy and associated fibular diaphyseal osteotomy are usually the procedures of choice. In late-onset tibia vara, correction is also necessary to restore the mechanical axis of the knee. Hemiplateau elevation with correction of posteromedial slope has been established as a treatment modality in relapsed cases.

GENU VALGUM (KNOCK-KNEES)

The appearance of symmetric bilateral genu valgum most pronounced around age 4 years of age is part of the normal physiologic process of leg development. However, variation of up to 15 degrees of valgus is possible until 6 years of age. The majority of physiologic valgus has a good chance of correction until this age. The intermalleolar distance with the knees approximated is normally <2 cm, and in a severe valgus deformity, it could measure >10 cm. Pathologic conditions leading to valgus are metabolic bone disease (e.g., rickets or renal osteodystrophy), skeletal dysplasia, posttraumatic physeal arrest, tumors, and infection. The increased valgus at the knee causes lateral deviation of the mechanical axis with stretching of the medial aspect of the knee leading to knee pain. Deformities >15 degrees and occurring after 6 years of age are unlikely to correct with growth and require surgical management. In the skeletally immature, medial tibial epiphyseal hemiepiphysiodesis or stapling (guided growth) is attempted for correction. In the skeletally mature, osteotomy is necessary at the center of rotation of angulation and is usually situated in the distal femur. Long-length AP radiographs of the leg in a weight-bearing stance are necessary for preoperative planning.

Visit Elsevier eBooks+ at eBooks.Health.Elsevier.com for Bibliography.

716.5 Congenital Angular Deformities of the Tibia and Fibula

Brendan A. Williams, Jennifer J. Winell, and Lawrence Wells

POSTEROMEDIAL TIBIAL BOWING

Congenital posteromedial bowing is typically associated with a calcaneovalgus foot and rarely with secondary valgus of the tibia. The exact cause is unknown. Early operative intervention is not indicated because this bowing generally corrects with growth. However, despite the correction of angulation, there can be residual shortening in the tibia and fibula. The mean growth inhibition is 12–13% (range: 5–27%). The mean leg length discrepancy at maturity is 4 cm (range: 3-7 cm). The diagnosis of bowing is confirmed on radiographs, which show the posteromedial angulation without any other osseous abnormalities. The calcaneovalgus deformity of the foot improves with stretching or modified shoe wear and occasionally ankle-foot orthosis. Predicted leg length discrepancy <4 cm is managed with age-appropriate epiphysiodesis of the normal leg. Leg length discrepancy >4 cm is managed with combination of contralateral epiphysiodesis and ipsilateral lengthening. A corrective osteotomy for distal valgus may be required and can be done in the same setting while correcting leg length discrepancy.

Fig. 716.9 Blount disease in a 5-year-old child. **A** and **B**, Preoperative clinical appearance. Note the abrupt medial deviation of the tibia just below the knee. Lateral "thrust" of the knee during weight bearing exacerbates the "limp." **C**, Radiograph demonstrating abrupt angulation at the epiphyseal-metaphyseal junction and medial metaphyseal radiolucency and beaking with apparent lateral subluxation of the proximal end of the tibia. *(From Johnston CE, Young M. Disorders of the leg. In: Herring JA, ed. Tachdjian's Pediatric Orthopaedics, 6th ed. Philadelphia: Elsevier; 2022: Fig 18.14.)*

Fig. 716.10 Anteroposterior radiograph of both knees in Blount disease.

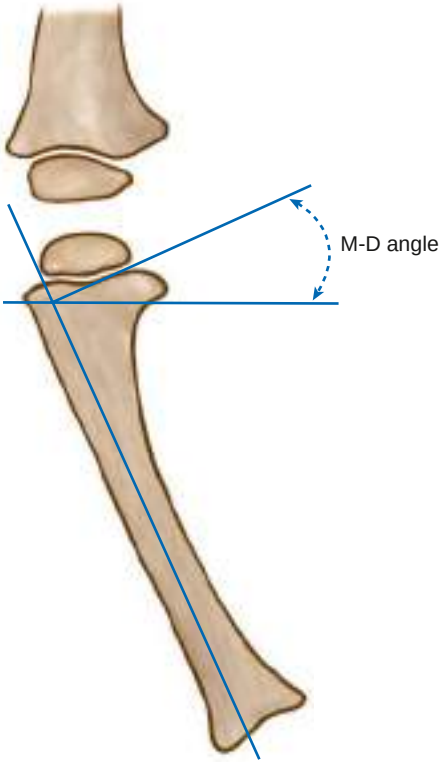

Fig. 716.11 Metaphyseal-diaphyseal *(M-D)* angle. Draw a line on the radiograph through the proximal tibial physis. Draw another line along the lateral tibial cortex. Last, draw a line perpendicular to the shaft line as demonstrated in the diagram. *(From Morrissey RT, Weinstein SL, eds. Lovell and Winter's Pediatric Orthopaedics, 3rd ed. Philadelphia: Lippincott Williams & Wilkins, 1990.)*

ANTEROMEDIAL TIBIAL BOWING (POSTAXIAL HEMIMELIA)

Fibular hemimelia is the most common cause of anteromedial bowing of the tibia. The fibular deficiency can occur with complete absence of fibula or with partial fibular development both proximally and distally. It is associated with deformities of femur, knee, tibia, ankle, and foot. The femur is short and has lateral condylar hypoplasia, causing patellar instability and genu valgum deformity. The tibia has anteromedial bowing with reduced growth potential. The keys for management are addressing the ankle stability and foot deformities. The ankle resembles a ball-and-socket joint with lateral instability. The foot deformities are characterized by the absence of lateral digits, equinocavovarus foot, and tarsal coalition.

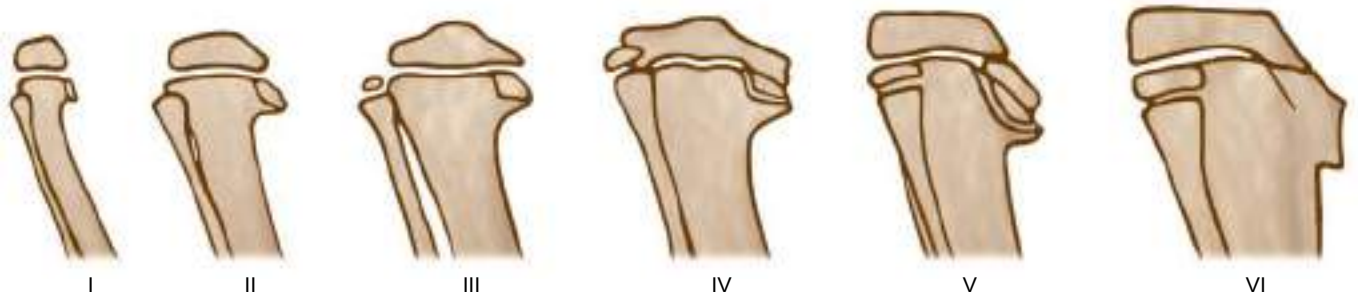

Fig. 716.12 Depiction of the stages of infantile Blount disease. *(From Langeskiöld A. Tibia vara [osteochondrosis deformans tibiae]: a survey of 23 cases. Acta Chir Scand. 1952;103:1.)*

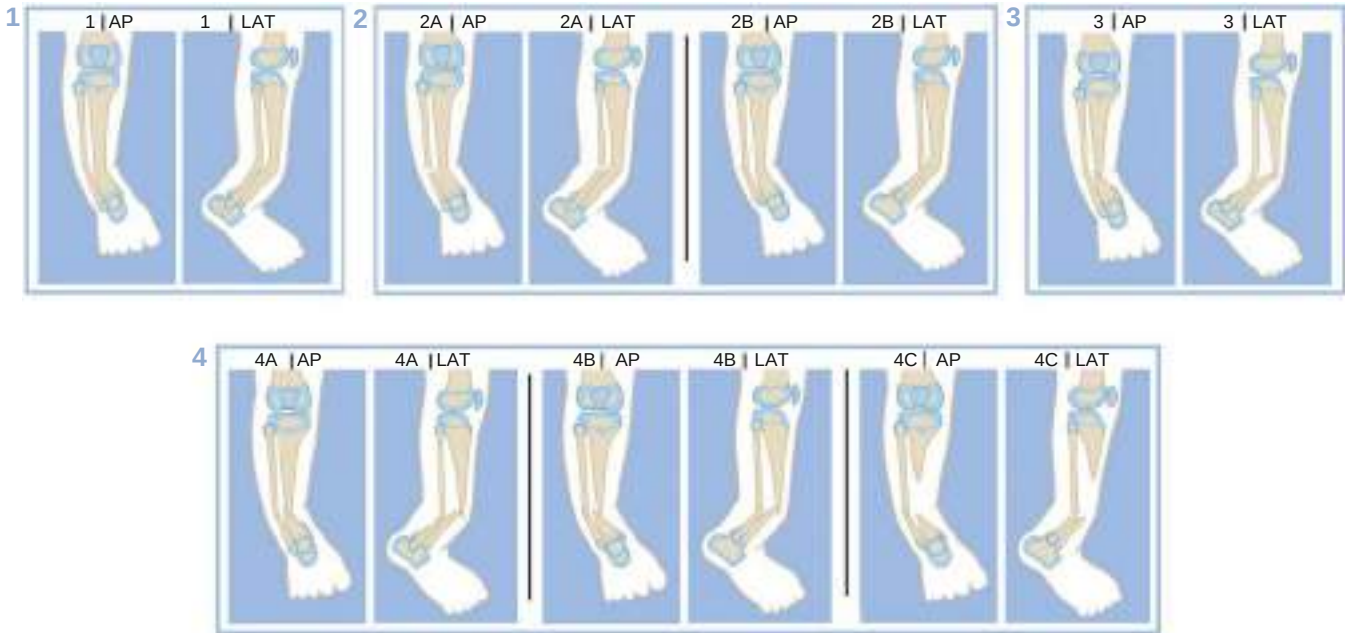

Fig. 716.13 Paley classification of congenital pseudoarthrosis of the tibia. Paley: type 1, no fractures; type 2, no fracture tibia, fracture fibula with fibula *(2A)* at station *(2B)* proximal migration; type 3, fracture tibia, no fracture fibula; type 4, fracture tibia and fibula with fibula *(4A)* at station *(4B)* proximal migration *(4C)* bone defect tibia with proximal migration fibula AP, Anteroposterior; LAT, lateral. (Reproduced with permission by the Paley Foundation.) *(From Paley D. Congenital pseudarthrosis of the tibia: biological and biomechanical considerations to achieve union and prevent refracture. J Child Orthop. 2019;13:120–133.)*

Various surgical options have been described, and the treatment is tailored to the patient's needs and parents' acceptance. A severely deformed foot may be best managed with Syme or Boyd amputation and prosthesis as early as 1 year of age. In the salvageable foot, leg length discrepancy can be treated with contralateral leg epiphysiodesis or ipsilateral limb lengthening.

ANTEROLATERAL TIBIAL BOWING

Anterolateral tibial bowing is associated with **congenital pseudarthrosis of the tibia (CPT)**. Previous estimates suggest that 50–60% of patients with CPT have **neurofibromatosis**; however, this prevalence may be underestimated as the diagnostic criteria for neurofibromatosis often become evident after CPT has been diagnosed. Overall, less than 10% of patients with neurofibromatosis have this lesion. The pseudarthrosis or site of nonunion is typically situated at the middle third and distal third of the tibia. The Boyd's classification identifies six types of CPT with increasing severity depending on the presence of cystic and dysplastic changes. The Paley classification is another frequently employed system (Fig. 716.13). The treatment for this condition has been very frustrating with poor results. Bracing has been recommended to prevent fracture early in the course but does not usually obviate need for later surgical intervention. Numerous treatment protocols and surgical procedures have been described to achieve union, such as single- and dual-onlay grafting with rigid internal fixation, intramedullary nailing with or without bone grafting, and circular frame fixation. With the growing use of microsurgery in orthopedics, vascularized fibular autograft also has been used with varying results. Due to the rate of complications occurring during reconstructive treatment, a below-knee amputation with early rehabilitation is also an accepted treatment strategy for some of these patients.

TIBIAL LONGITUDINAL DEFICIENCY

Tibial longitudinal deficiency, or tibial hemimelia, follows an autosomal dominant inheritance pattern. Multiple classification systems have been described, all of which largely categorize patients based on which portion(s) of the tibia is deficient. The other associated anomalies are foot deformities, hip dysplasia, and symphalangism of the hand. Traditionally, treatment has been guided by the Jones classification, which describes presence of a proximal tibial anlage and a functional quadriceps mechanism. In type Ia deformity, the proximal tibial anlage is absent, and knee disarticulation with prosthesis is recommended. In types Ib and II, the tibial anlage is present, and the management consists of an early Syme amputation, followed later by synostosis of the fibula with the tibia, and a below-knee prosthesis. Type III is rare, and the principal management is with Syme amputation and a prosthesis. Type IV deformity is associated with ankle diastasis, which requires stabilization of the ankle and correction of leg length discrepancy at a later stage. Due to the varied pathology of this condition and its rarity, treatment options and recommendations continue to evolve.

Visit Elsevier eBooks+ at eBooks.Health.Elsevier.com for Bibliography.

Chapter 717

Leg-Length Discrepancy

Christine M. Goodbody and Richard S. Davidson

A discrepancy in leg lengths may result from a variety of congenital or acquired conditions (Table 717.1). Although up to 25% of adults may have a difference of more than 1 cm, only a small percentage have more than a 2 cm difference, for which the main consequence is gait asymmetry. An increase in vertical pelvic motion is observed, and more energy must be expended during ambulation. Although a small compensatory lumbar curvature may develop, a small leg-length discrepancy (<2 cm) is unlikely to result in back pain, structural scoliosis, or degenerative arthritis. There is some evidence to suggest that larger, long-standing discrepancies may be associated with hip or knee arthritis, structural scoliosis, and spine degenerative changes. The goal of treatment is to have a discrepancy of <2-2.5 cm at skeletal maturity, and several treatment methods are available to achieve this objective. Knowledge of the underlying etiology, coupled with regular follow-up to assess limb growth and skeletal maturity, allows the treating physician to project the discrepancy at skeletal maturity and to plan treatment. A subset of patients will have coexisting abnormalities in the viscera or musculoskeletal system that must also be identified and treated.

DIAGNOSIS AND CLINICAL FINDINGS

Gait asymmetry is the most frequent complaint. The long leg is often kept flexed at the knee and hip in stance to level the pelvis. The diagnosis is made on physical examination, and specialized radiographs help to quantify the existing discrepancy and predict what the discrepancy will be at maturity. The discrepancy may be caused by hypoplasia, hyperplasia, or angular deformity (structural discrepancy), by soft-tissue contracture at the hips, knees, or ankles (apparent or functional shortening), or by a combination of these conditions. Other contributing factors include joint subluxation or dislocation (hip), a decrease in the height of the foot (congenital or neuromuscular), or structural disorders of the pelvis. A careful physical examination is required to identify all factors contributing to the discrepancy. Muscle contracture about the hip will also create the appearance of leg-length inequality. For example, to bear weight on an abducted hip, the patient must hike up the contralateral hip and pelvis, making the contralateral leg appear short.

There are several clinical methods for measuring the extent of the limb-length discrepancy. The preferred method is to perform a standing examination in which blocks of various sizes are placed under the short leg until the pelvis is leveled (Fig. 717.1). An alternate method is to measure the length of each leg with the patient supine; the examiner first extends the patient's legs and examines the soles of the feet for asymmetry before flexing the patient's hip to 90 degrees to evaluate for discrepant knee height (Galeazzi sign). Using a tape measure is very inaccurate because of several variables, including the line of measurement used, muscle atrophy, and moving patients. The range of motion at the hip, knee, and ankle must also be assessed to identify any causes of apparent discrepancy. A 10-degree fixed abduction (or adduction) contracture of the hip may create an apparent leg-length discrepancy of 2-3 cm. Similarly, a flexion contracture of the hip and/or knee will create apparent shortening of the extremity, whereas an equinus contracture at the ankle will create apparent lengthening of the extremity. A rigid lumbar scoliosis (suprapelvic contracture) will create pelvic obliquity and an associated apparent limb length inequality. Once a discrepancy is quantified in a child, it must be followed at regular intervals until maturity. Assessments at 6- to 12-month intervals are most common depending on the rate of change.

Leg-length discrepancy may be associated with various **genetic overgrowth syndromes** (see Table 717.1). If there are features other than leg-length discrepancy, specific diagnostic tests for Beckwith-Wiedemann syndrome and *PIK3CA* pathogenic variants must be included in the patient's evaluation. In these disorders, the leg overgrowth tends to increase over time.

RADIOGRAPHIC EVALUATION

Radiologic evaluation complements the clinical examination; both are typically used when making treatment decisions. For an accurate assessment, it is important that the child not move and keep their legs extended; a lift may help. Five different techniques are available. The **teleoroentgenogram** is a single radiographic exposure of both lower extremities (standing) and requires a long cassette. A ruler is placed on the film, and direct measurements are made, factoring in a 6% magnification error, which is usually accounted for using a radiographic marker of known diameter to calibrate the image. One advantage is that angular deformities may be assessed. Its primary indication is for young children. Unfortunately, because only one exposure is used for the leg and because the ankle is less dense than the hip, it may be difficult to "see" the whole leg. In addition, because the x-ray source is at the knee projecting up to the hip and down to the ankle, this method projects the hip and ankle along the ruler, making the leg appear longer than it really is, particularly in obese patients. The **orthoroentgenogram** consists of three separate exposures of the hips, knees, and ankles on a long cassette. The patient is supine, and a ruler is placed on the cassette for measurement of bone length. However, the patient must lie still for the three exposures, which is often difficult to achieve in younger children. Because the x-ray beam is pointed at the hip, knee, and ankle in each of the three exposures, the length measurement is accurate and each of the three joints can be exposed properly. The x-rays expose from the top of the pelvis to the mid femur, from the mid femur to the mid tibia, and from the mid tibia to below the foot for each of the three exposures, respectively, permitting angular deformity assessment in the frontal plane only. The **scanogram** also consists of separate exposures of the hips, knees, and ankles on a cassette with a radiographic ruler; a chest-sized film cassette is used (Fig. 717.2). There is no magnification error; patients must remain still for the three exposures, and angular deformities cannot be assessed. Although CT is an accurate technique, the assessment is time-consuming, and the patient receives a larger dose of radiation. In addition, a radiologist must normalize the axis of the leg to the screen to accurately measure the limbs. An advantage of CT is that limb and segment lengths can be measured even if there are soft tissue contractures or deformity in the sagittal plane. Another popular technique is called **EOS**. EOS is a proprietary low-dose x-ray scanner that can simultaneously take orthogonal full-body images in a standing position and is therefore able to reconstruct three-dimensional (3D) images of the bony anatomy in question (Fig. 717.3). The advantages of EOS are that it has a much lower radiation dose than standard x-rays, it can capture frontal and sagittal planes quickly and simultaneously, and there is no magnification error. The disadvantages are that it requires a trained radiology technician to correctly align the limbs for computer measurement, and not all centers have access to the technology at this time. Regardless of the technique, it is critical that the patellae be pointed forward, that measurements be made in the plane of the limb, that the legs be extended, and that the same method be used in sequential measurements to be compared.

In the presence of flexion or extension deformities where 3D imaging is not employed, each bone should be x-rayed individually with a ruler where the x-ray beam is perpendicular to the bone and the ruler parallel to the bone.

In addition to quantifying the discrepancy, it is essential to determine skeletal age (bone age) to assess how much growth a patient has left and to assist in estimating the size of discrepancy at maturity. An anteroposterior radiograph of the hand and wrist is usually obtained at each visit and compared with the standards in the Greulich and Pyle Atlas to estimate skeletal age. Although more accurate techniques are available, most are time-consuming and impractical for routine clinical

Table 717.1 Causes of Lower Extremity Length Discrepancy

SHORTENING	LENGTHENING
CONGENITAL Hemiatrophy* Skeletal dysplasias Short femur Proximal focal femoral deficiency* Fibular, tibial hemimelia Developmental dysplasia of the hip*	CONGENITAL Hemihypertrophy* Local vascular malformation
TUMOR Developmental Neurofibromatosis Multiple exostosis Enchondromatosis (Ollier disease) Osteochondromatosis Fibrous dysplasia (Albright syndrome) Punctate epiphyseal dysplasia Dysplasia epiphysealis hemimelica (Trevor disease) Radiation therapy before skeletal maturity (physeal arrest)* Resection of benign or malignant neoplasm	TUMOR Developmental Neurofibromatosis Soft tissue hemangioma Arteriovenous malformation Hemihypertrophy with Wilms tumor Aneurysm
INFECTION Osteomyelitis* Septic arthritis Tuberculosis	INFECTION Inflammation Metaphyseal osteomyelitis Rheumatoid arthritis Hemarthrosis (hemophilia)
TRAUMA Physeal injury* Failed joint replacement Osteotomy, atrophic nonunion Overlapping, malposition of fracture fragments* Burns	TRAUMA Metaphyseal, diaphyseal fracture Diaphyseal operations (bone grafts, osteosynthesis, periosteal stripping)
NEUROMUSCULAR DISEASE Poliomyelitis Cerebral palsy* Myelomeningocele Peripheral neuropathy Focal cerebral lesions (hemiplegia)	
OTHER Legg-Calvé-Perthes disease* Slipped capital femoral epiphysis	LATERALIZED OVERGROWTH (HEMIHYPERTROPHY / HEMIHYPERPLASIA SYNDROMES) Beckwith-Wiedemann syndrome *PIK3CA* related overgrowth spectrum (PROS) Klippel-Trenaunay syndrome CLOVES (congenital lipomatous overgrowth, vascular malformations, epidermal nevi, scoliosis/skeletal, spinal) Isolated lymphatic malformation Fibroadipose vascular anomaly Megalencephaly—capillary malformation Hemimegalencephaly /dysplastic megalencephaly/focal cortical dysplasia Muscular hemihyperplasia Fibroadipose hyperplasia or overgrowth CLAPO syndrome (capillary malformation of lower lip, lymphatic malformation of face and neck, asymmetry of face and limbs and partial or generalized overgrowth)

*Common.
Modified from Moseley C. Leg-length discrepancy. *Pediatr Clin North Am.* 1986;33(6):1385.

application. The range of variability using the atlas is approximately 9 months, so the method is most accurate when multiple data points have been collected. Apps to calculate the discrepancy at maturity and timing of treatment are available.

TREATMENT

Options for treatment include observation, a shoe lift or custom orthosis, a limb-shortening procedure (acute shortening and internal fixation versus gradual shortening by growth arrest or guided growth), a limb-lengthening procedure (with internal or external fixation), or a combination of these. Deformity correction is often accomplished simultaneously. In the congenital deficiencies (femur, tibia, fibula) in which the predicted limb-length inequality will require more than three lengthening operations (more than 20 cm), an early foot amputation may be the best option to achieve an optimal functional outcome. In addition to the magnitude of discrepancy predicted at skeletal maturity, both the anticipated adult height of the patient (estimated from family members) and the desires of the patient and the patient's family are important considerations.

Discrepancies of up to 2.5 cm may be treated by observation or a shoe lift. With regard to a shoe lift, up to 1 cm may be placed within the shoe, and up to 5 cm may be placed on the outside of the shoe. Complete correction of inequality is not required, and the height of the lift should be adjusted based on the patient's gait and comfort. An orthotic may be used as a temporizing measure before definitive treatment. For extended discrepancies, "foot in foot" extension prostheses are a reasonable alternative until limb lengthening can be accomplished or for patients who cannot or do not wish to undergo surgical correction.

For patients with a predicted ultimate discrepancy between 2 and 5 cm, an **epiphysiodesis** is offered in skeletally immature patients, and an acute shortening may be performed in a skeletally mature patient. Epiphysiodesis refers to a temporary or permanent cessation of growth at one or more physes. A permanent growth arrest is most commonly performed when sufficient data are available with which to accurately predict when to perform the procedure. Approximately 65% of the growth of the lower extremity comes from the distal femur (37%, 9 mm/year) and proximal tibia (28%, 6 mm/year). Males typically grow until 16 years of age, whereas females grow until 14 years of age. As such, performing an epiphysiodesis of both the distal femur and the proximal tibia in a patient with 3 years of growth remaining should achieve approximately 4.5 cm of correction. Techniques used to determine the timing of epiphysiodesis are the Menelaus method ("rule of thumb"), the Green and Anderson method, the Moseley straight-line graph, and the multiplier method (Figs. 717.4-717.6). Apps to make calculations are available. The most common surgical technique for permanent growth arrest is the percutaneous epiphysiodesis, in which the physis is ablated with a drill and curetted under image intensification. This is an outpatient procedure with few complications. Insertion of plates and screws or just screws across the physis is an alternative but usually requires a second operation to remove the hardware. For patients for whom sufficient data are unavailable or those for whom the underlying diagnosis is associated with an unpredictable pattern

Fig. 717.1 Clinical assessment of limb length inequality with the aid of graduated blocks. (**A**) True leg length inequality (or fixed functional discrepancy) results in asymmetric iliac crest or posterior iliac spine heights with the patient standing erect. The examiner must be sure that the patient is standing evenly on the legs, with the knees straight and the feet flat on the floor. (**B**) A reasonably accurate estimation of leg length inequality can be made by having the patient stand erect on sufficient graduated blocks under the shorter limb to level the pelvis. *(From Podeszwa D. Limb length discrepancy. In: Herring JA, ed. Tachdjian's Pediatric Orthopaedics, 6th ed. Philadelphia: Elsevier, 2022: Fig 20.3.)*

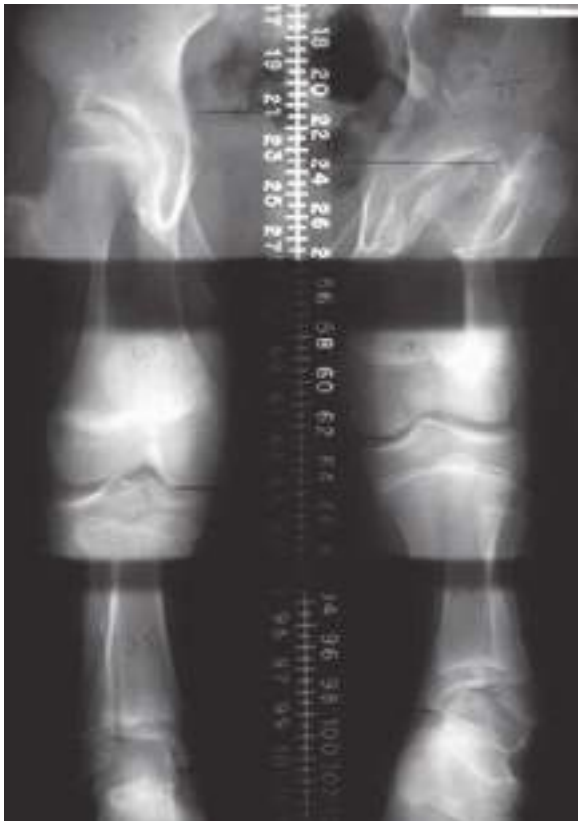

Fig. 717.2 Scanogram to demonstrate exact leg-length discrepancy.

Fig. 717.3 2D Biplanar Whole Body EOS Imaging. *(From Garg B, Mehta N, Bansal T, Malhotra R. EOS Imaging: concept and current applications in spinal disorders. J Clin Orthop Trauma. 2020;11:786–793. Fig. 2.)*

of growth, then a reversible technique, such as staples, plates, and/or screws, may be considered. Once equalization has been achieved, the hardware can be removed, allowing growth to resume. When the patient is skeletally mature or if it is deemed appropriate to wait until maturity before treatment, depending on the magnitude of deformity and patient/family preference, acute shortening may be the best option. Acute shortening is typically performed at the femur (several techniques have been described), given the increased risk of complications associated with shortening of the tibia and fibula including compartment syndrome and neurovascular problems.

For discrepancies >5 cm after maturity, or for smaller ones depending on patient/family preference, lengthening of the short limb is the procedure of choice. An exception would be a discrepancy secondary to overgrowth of one limb, in which acute or gradual shortening of the abnormal limb would be preferred so as to preserve body proportions. Patients with anticipated discrepancies >8-10 cm often require one or more limb-lengthening procedures (several years apart), with or without an epiphysiodesis to mitigate the size of the ultimate discrepancy and need for more than one lengthening. The most common technique used for limb lengthening involves placement of an intramedullary magnetic lengthening nail or an external fixator, either a ring fixator such as the Ilizarov device or a monolateral device (Fig. 717.7). The bone is cut at the metaphyseal-diaphyseal junction, and lengthening is achieved gradually through distraction at the corticotomy. The usual rate

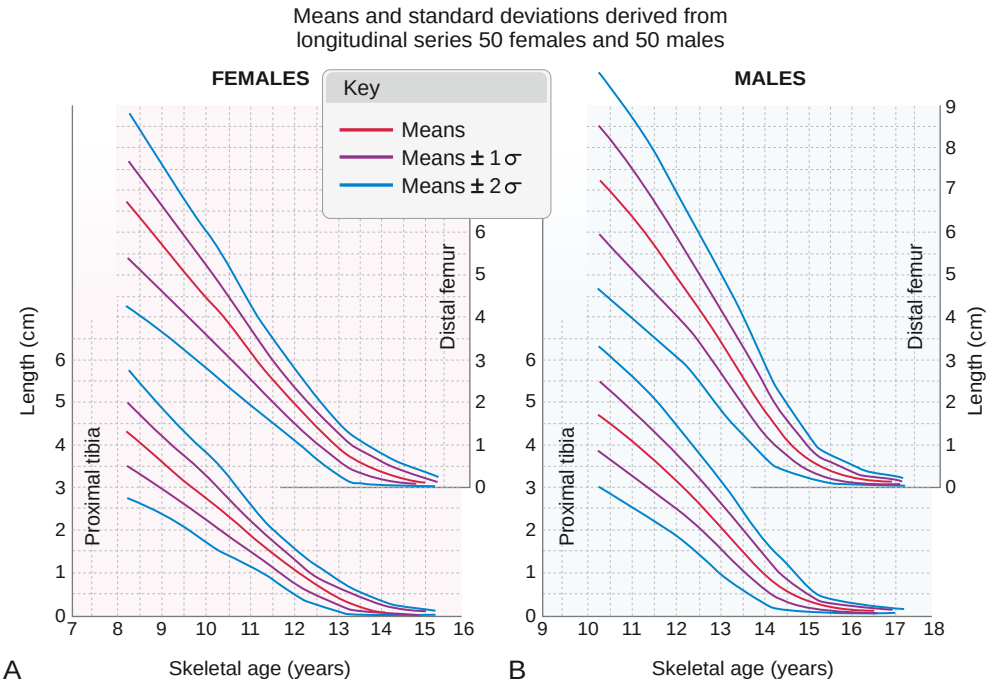

Fig. 717.4 Growth remaining charts for the distal femur and proximal tibia for females (A) and males (B). These charts are based on the growth data and an estimate of the contribution to growth of the distal femur (70%) and the proximal tibia (56%) to the total length of the respective bone. Data are presented relative to skeletal age from age 8 yr to skeletal maturity. *(From Podeszwa D. Limb length discrepancy. In: Herring JA, ed. Tachdjian's Pediatric Orthopaedics, 6th ed. Philadelphia: Elsevier, 2022: Fig 20.13.)*

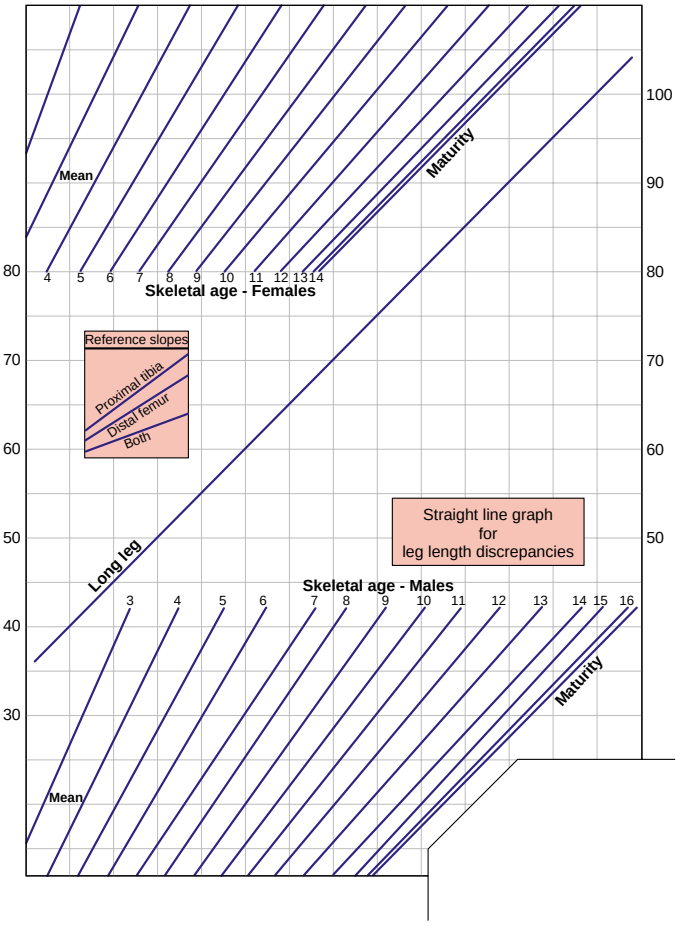

Fig. 717.5 The Moseley straight-line graph for the assessment of leg-length inequalities. This allows simultaneous correlation of the normal leg, short leg, and bone age of the child. It will accurately predict lengths of each extremity at skeletal maturity. The reference slopes are used as a guide in determining when appropriate treatment should be performed. *(From Moseley CF. A straight-line graph for leg-length discrepancies. J Bone Joint Surg Am. 1977;59:174–179.)*

Multiplier for Males and Females (Paley et al, 1999)

Males		Females	
Age	**Multiplier**	**Age**	**Multiplier**
0	5.08	0	4.63
0.4	4.01	0.3	4.01
1	3.24	1	2.97
1.3	2.99	2	2.39
2	2.59	3	2.05
3	2.23	3.3	2.00
4	2.00	4	1.83
5	1.83	5	1.66
6	1.68	6	1.53
7	1.57	7	1.43
8	1.47	8	1.33
9	1.38	9	1.26
10	1.31	10	1.19
11	1.24	11	1.13
12	1.18	12	1.07
13	1.12	13	1.03
14	1.07	14	1.00
15	1.03	15	1.00
16	1.01	16	1.00
17	1.00		
18	1.00		

LLD Prediction Formulas

Prenatal LLD (congenital)
$\Delta_m = \Delta \times M$

Postnatal LLD (developmental)
$\Delta_m = \Delta + I \times G$

Inhibition $\approx I = 1 - \frac{S - S^{\bullet}}{L - L^{\bullet}}$

Growth remaining $= G = L(M - 1)$

Δ_m = LLD at maturity

Δ = Current LLD

L & S = Current length of long and short leg

$L^{\bullet}$ & $S^{\bullet}$ = Length of long and short leg at any other date since LLD began

Fig. 717.6 Paley multiplier. This is a simple method of determining the leg-length discrepancy (LLD) at maturation. This is applicable for shortening conditions in which growth retardation is consistent. *(From Paley D, Bhave A, Herzenberg JE, et al. Multiplier methods for predicting limb-length discrepancy. J Bone Joint Surg Am. 2000;82;1432–1446.)*

of lengthening is 1 mm/day in the femur and 0.75 mm/day in the tibia, and it takes approximately 1 month of wearing the fixator for each centimeter of length gained with a minimum of 3 months in the fixator. Additional time in the fixation device may be required for pathologic bone or for metabolic diseases affecting bone formation. A maximum of 15–25% of the original length of the bone may be gained at each session and is limited by tolerance of the soft tissues and nearby neurovascular structures. An advantage of

Fig. 717.7 Ilizarov device demonstrating bone lengthening by distraction osteogenesis.

Fig. 717.9 Anteroposterior radiograph of fibular hemimelia with leg-length discrepancy.

Fig. 717.8 Extension prosthesis leg-length discrepancy (A) and compensated with extension prosthesis (B).

the circular fixator or multiaxial external fixators is the ability to correct coexisting angular deformities at the same time. Technologic advances have allowed the development of totally implantable intramedullary lengthening rods driven by external magnets. Internal lengthening has become the procedure of choice for patients whose age and anatomy are appropriate for the procedure, especially in the femur where external fixation is more poorly tolerated. These devices may provide improvements in patient satisfaction and reduced complications, including a lower rate of contracture and absence of pin site infection. New technologies for internal lengthening in skeletally immature patients whose physes cannot safely be violated by a rigid nail are actively under study. Complications of limb lengthening include pin tract infection (most common), wound infection, hypertension, joint subluxation, muscle contracture, stretch-induced nerve palsy, premature consolidation, delayed union, implant-related problems, and fractures after implant removal.

Early amputation and prosthetic fitting may provide the best long-term function in patients with projected discrepancies in excess of 18-20 cm, especially when there are coexisting deformities or deficiencies of the ipsilateral foot (Figs. 717.8 and 717.9). The alternative would be multiple reconstructive procedures throughout childhood and adolescence. The cultural and personal values of the child and family, as well as the impact of multiple procedures on the child's psychosocial development, must also be kept in mind when formulating the treatment plan in these complex cases.

Visit Elsevier eBooks+ at eBooks.Health.Elsevier.com for Bibliography.

Chapter 718

The Knee

Anne M. Coyle and J. Todd R. Lawrence

NORMAL DEVELOPMENT OF THE KNEE

The knee is a synovial joint and forms between the third and fourth months of fetal development. Secondary ossification centers form between the sixth and ninth fetal months at the distal femur and between the eighth fetal month and the first postnatal month at the proximal tibia. The patellar ossification center does not appear until 2-4 years of age in females and 3-5 years of age in males.

ANATOMY AND RANGE OF MOTION

The knee is the largest joint in the body and acts primarily as a modified hinge. The distal femur is cam shaped, with the medial and lateral femoral condyles having slightly different shapes. The shape of the articular surfaces allows the femur to glide posteriorly on the tibial plateau during knee flexion and also permits approximately 8-12 degrees of rotation through the flexion and extension arc. The normal range of motion of the knee is from neutral (or fully straight) to 140 degrees of flexion. Increased ligament laxity, including hyperextension of up to 10-15 degrees, can be normal in many children. Most activities can be performed in the flexion arc of 0-70 degrees.

The knee consists of three articulations: *patellofemoral*, *tibiofemoral*, and *tibiofibular*. The anterior and posterior cruciate ligaments as well as medial and lateral collateral ligaments stabilize the knee during movement. The medial and lateral menisci provide support under compressive forces, helping to redistribute the forces from the more rounded distal femur to the flatter proximal tibia. The medial patellofemoral ligament is the primary static soft tissue restraint against lateral patellar displacement. There are also several bursae located about the knee to cushion and reduce friction on tendons acting across the knee joint.

718.1 Discoid Lateral Meniscus

Anne M. Coyle and J. Todd R. Lawrence

Discoid lateral meniscus (DLM) is a congenital anatomic variation of the lateral meniscus that may be asymptomatic or cause the classic **snapping knee syndrome**. Many cases are asymptomatic for years, making the true incidence difficult to determine. DLM is estimated to occur in 3–5% of children and adolescents and is bilateral in about 20% of cases.

Anatomically, the normal meniscus (Fig. 718.1A) is attached around its periphery and at the tips of the "C" anteriorly and posteriorly onto the tibia. During knee motion, the meniscus translates anteriorly and posteriorly to match the slight rollback of the lateral femoral condyle on the tibia with knee flexion. However, with DLM, the meniscal tissue trapped between the articular surfaces is pushed anteriorly as the knee flexes. These abnormal forces, over time, result in tears in the meniscal tissue, the peripheral attachments, or both. Tearing or stretching of this tissue allows for excessive meniscal displacement during knee range of motion. Usually a pop is heard or sensed when flexing at about 90-120 degrees of knee flexion as the meniscus is extruded anteriorly and a loud click or clunk is heard when extending the knee in the last 30 degrees of extension as the meniscus reduces back between the joint surfaces.

The **Watanabe classification system** defines three types of DLM based on arthroscopic appearance. A type I, or **complete discoid lateral meniscus**, is characterized by a thickened lateral meniscus with complete coverage of the tibial surface (see Fig. 718.1B). Because meniscus tissue is always between the joint surfaces with this type of discoid meniscus, it is the type most commonly associated with the knee snapping characteristic of DLM. A type II, or **incomplete discoid lateral meniscus**, is of variable size and covers a lower percentage of the tibial surface (see Fig. 718.1C) compared to the complete type. Although the meniscus can become stretched or torn over time, both the complete and the incomplete types are thought to develop with normal peripheral attachments. A type III, or **Wrisberg variant lateral meniscus**, has no peripheral attachments posteriorly. Instead, it is stabilized posteriorly only by a prominent meniscofemoral ligament, or ligament of Wrisberg, that secures the posterior horn of the lateral meniscus to the lateral surface of the medial femoral condyle (see Fig. 718.1D). As a result, the Wrisberg ligament type of DLM is extremely mobile. Although its shape is not necessarily discoid, the hypermobility of the posterior portion of the meniscus allows it to be extruded anteriorly with flexion and for it to pop back into place with extension, allowing it to present with the same snapping knee pain characteristic of the other DLM variants.

CLINICAL MANIFESTATIONS AND DIAGNOSIS

All types of DLM can be asymptomatic, especially if they have stable peripheral attachments and no tears (see Fig. 718.1). Patients with *symptomatic* DLM usually present with complaints of lateral knee pain and examination findings consistent with a meniscal tear or meniscal instability because of absent peripheral attachments, allowing for anterior extrusion during flexion and reduction with extension thus producing the classic snapping knee. Although patients can present as early as 2 years of age, presentation after 6 years of age is typical, with the highest incidence of presentation during the teenage years.

Younger children usually present with no history of trauma or acute inciting event but rather with a complaint of popping in the knee with occasional swelling as a result of peripheral tears or instability of the meniscus. Older children and adolescents often can recall an inciting event and will sometimes report a history of the mechanical popping. However, they more often note lateral joint line pain and knee swelling. Weight gain during the adolescent growth spurt places increased static and dynamic loads on the tissue, especially during high-level sports. In these patients, degeneration in the central portion of the DLM with direct weight-bearing makes the meniscus highly susceptible to injury and tears, producing the lateral pain and swelling in the knee. Often, the classic popping is not appreciated in these patients.

Physical examination often shows a mild effusion and tenderness over the lateral joint line. For patients with an unstable meniscus, when the knee is fully flexed, a pop with a slight protuberance along the lateral joint line anteriorly can sometimes be appreciated as the meniscus is extruded anteriorly. When the knee is brought back into extension at approximately 20-30 degrees short of full extension, the meniscus can be felt to snap back in place and the protuberance at the lateral joint line disappears.

A high level of suspicion is necessary based on history and clinical examination findings because many patients will present with a complaint that their knee is "dislocating." Radiographs including standard anteroposterior (AP), lateral, merchant (patellar), and 45 degrees flexed posteroanterior (PA) (tunnel) views should be obtained if this diagnosis is considered. Radiographs may appear normal or show findings that include widening of the lateral aspect of the knee joint, flattening of the lateral femoral condyle (resulting in a squared-off appearance), lateral tibial spine hypoplasia, and cupping of the lateral aspect of the tibial plateau. Because these findings are very nonspecific, with any history or physical examination findings suggestive of DLM, evaluation using MRI will provide a definitive diagnosis. Diagnosis on MRI is made if the ratio of the minimal meniscal width to the maximal tibial width in the coronal plane is >20% and/or if continuity between the anterior and posterior horns of the meniscus is present on three or more consecutive slices in the sagittal plane.

TREATMENT

Patients with asymptomatic or incidentally found DLM without evidence of a tear or meniscal instability do not require treatment. They should be educated on symptoms to anticipate, but activity restriction

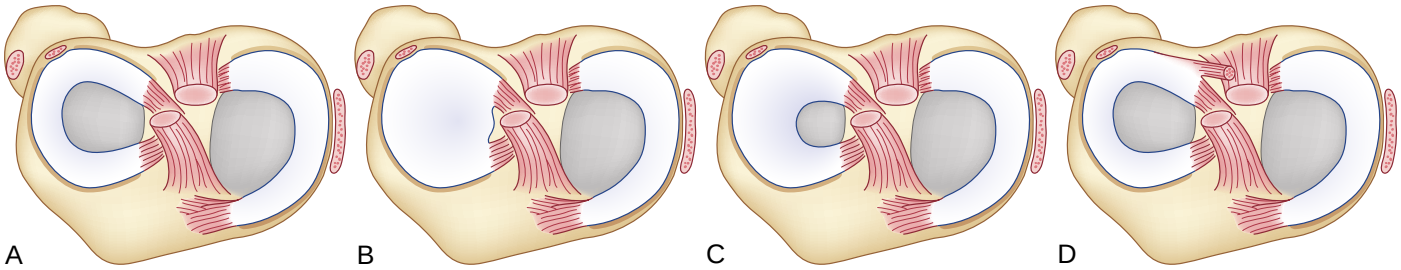

Fig. 718.1 The anatomy of the normal meniscus and discoid variants. **A,** The lateral meniscus normally has a C shape with circumferential and root attachments. **B,** A type I, or complete, discoid lateral meniscus covers the entire tibial plateau and has normal attachments. **C,** A type II, or incomplete, discoid lateral meniscus partially covers the tibial plateau and also has normal attachments. **D,** A type III, or Wrisberg ligament type, appears similar in shape to a normal lateral meniscus but lacks sufficient attachments posteriorly resulting in a hypermobile meniscus. The ligament of Wrisberg secures the posterior horn of the meniscus to the lateral aspect of the medial femoral condyle.

is not usually necessary. If knee pain or mechanical symptoms are persistent and limit activity or if a meniscal tear develops, surgical intervention should be considered. Partial meniscectomy, referred to as **saucerization**, is often performed to reshape the meniscus arthroscopically with the goal of obtaining an anatomically normal-appearing meniscus (Fig. 718.2). Tears remaining in what would be the normal rim of meniscal tissue are either repaired or excised. Meniscal instability is also addressed with repairs as appropriate. Because tears that extend from the center of the meniscal tissue all the way to the peripheral rim are difficult to repair and removing this much meniscal tissue leaves the joint surfaces unprotected, leading to early osteoarthritis, addressing DLM tears as soon as they develop and before they extend to the periphery is preferred. Approximately 9–17% of patients require repeat operation, which is almost always due to repeated tear of the meniscus. Patients with symptomatic DLM are 4.5 times more likely to eventually require surgical treatment on their other knee.

Visit Elsevier eBooks+ at eBooks.Health.Elsevier.com for Bibliography.

718.2 Popliteal Cysts (Baker Cysts)

Anne M. Coyle and J. Todd R. Lawrence

Popliteal cysts or Baker cysts are simple cystic masses filled with gelatinous material that develops in the popliteal fossa, the shallow depression located at the posterior part of the knee. They are considered rare in children. They most commonly occur in the region of the medial head of the gastrocnemius and semimembranosus muscles as an isolated fluid-filled bursa or via herniation through the posterior joint capsule of the knee into this same location. Histologically, the cysts are classified as fibrous, synovial, inflammatory, or transitional. Typically, popliteal cysts resolve spontaneously, although the process may take several years.

CLINICAL MANIFESTATIONS AND DIAGNOSIS

Patients commonly present with a unilateral mass behind the knee that may be fairly large when first noted. Typically, there is no associated history of trauma or knee injury. Physical examination reveals a firm but compressible mass in the popliteal fossa, often medially located and distal to the popliteal crease. The mass is usually most prominent when the knee is extended. Transillumination of the cyst on physical examination is a simple diagnostic test. Knee radiographs are normal but should be obtained to rule out other lesions, such as osteochondromas, osteochondritis dissecans, and malignancies. Ultrasonography, MRI, or aspiration may confirm the diagnosis. Ultrasound can be used to confirm a simple cystic lesion in the expected anatomic location and is often the only diagnostic test necessary with these reassuring findings. However, if a solid mass, vascular lesion, or complex cystic lesion is identified on ultrasound, an MRI may be used to further evaluate the mass. Additionally, in the presence of a knee effusion, an MRI should be considered to evaluate for knee intraarticular pathology that may be

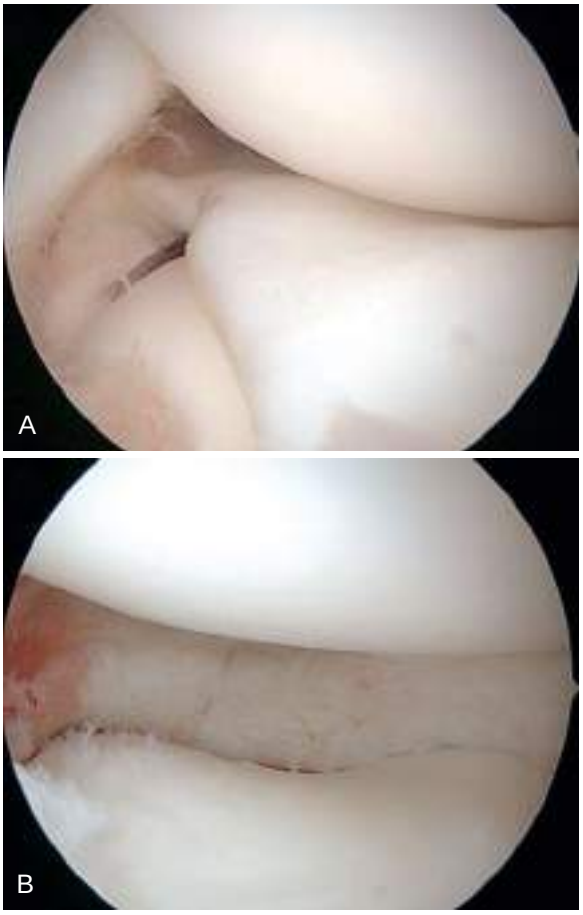

Fig. 718.2 Surgical treatment of discoid lateral meniscus. Arthroscopic images of a complete discoid lateral meniscus before **(A)** and after **(B)** partial meniscectomy.

causing the swelling. These children should also be assessed for other pathology that may cause recurrent or intermittent knee effusions, including Lyme disease, juvenile idiopathic arthritis, or other autoimmune processes. The presence of a solid mass detected on ultrasound or MRI warrants additional diagnostic testing and referral for biopsy.

TREATMENT

In most cases, reassurance is all that is needed for popliteal cysts because they often resolve spontaneously. Rest and leg elevation can be suggested to promote drainage of the fluid accumulating within the cyst. In rare cases in which the cyst is persistently symptomatic, treatment options include aspiration to reduce the size of the cyst and/or corticosteroid injection to reduce inflammation. However, because

cysts often recur after treatment, the risk of these procedures is not usually worth the benefits. Surgical excision of a popliteal cyst is indicated only when symptoms are debilitating and have not resolved after an extended period of conservative treatment. If surgical excision is pursued, concurrent arthroscopic treatment of underlying joint pathology is typically recommended to significantly decrease recurrence rates.

Visit Elsevier eBooks+ at eBooks.Health.Elsevier.com for Bibliography.

718.3 Juvenile Osteochondritis Dissecans

Anne M. Coyle and J. Todd R. Lawrence

Osteochondritis dissecans (OCD) is a localized pathologic process of the subchondral bone that secondarily affects the overlying articular cartilage and can progress to instability of the lesion with cartilage separation and fragmentation. Although OCD may occur in different joints, including the elbow and ankle, 75% of lesions are seen in the knee. Emerging evidence suggests that the cause of OCD is vascular insult to the developing knee that is unable to heal because of repetitive microtrauma. The disorder is being seen with rising frequency in children and adolescents, with a higher incidence in patients >12 years old, likely in large part because of the increased sports participation of young athletes. OCD is more common in active children, and about 60% of cases occur in participants of high-level athletics. The natural history of juvenile OCD is not the same as that seen in adults. In the knee, OCD most commonly affects the lateral aspect of the medial femoral condyle; however, the lateral femoral condyle and patella may also be affected. Failure of both the bone and the cartilage surface to heal completely is associated with an increased risk for developing premature osteoarthritis. Although the exact incidence of OCD is unknown, it is estimated to occur bilaterally in 14–20% of patients.

CLINICAL MANIFESTATIONS AND DIAGNOSIS

The most common presenting complaint is a vague or deep knee pain that is often activity related with no history of significant trauma to the knee. If the osteochondral fragment becomes unstable, the patient may also develop mechanical symptoms, such as catching or locking. Physical examination findings include effusion, tenderness to palpation over the femoral condyles, quadriceps atrophy, and diminished range of motion. It is important to conduct a thorough history and physical examination because several other conditions can present similarly in the pediatric population, including torn meniscus, patellofemoral pain syndrome, and hip pathologies such as Legg-Calvé-Perthes disease and slipped capital femoral epiphysis.

Imaging evaluation of OCD typically includes plain radiographs and MRI. Radiographs can establish the diagnosis and can be used to evaluate the treatment response. Because most OCD lesions are located more on the posterior aspect of the femoral condyle, a PA radiograph with a 45-degree flexed knee (tunnel view) is often required to evaluate for the presence of an OCD. Many of these patients also have some degree of patellar-related pain, necessitating merchant (patellar) view plain films. Thus standard radiographic evaluation of nontraumatic adolescent knee pain should routinely include AP, lateral, tunnel, and merchant radiographs of the knee. An early lesion may appear as a small radiolucency at the articular surface. A more advanced lesion may have a well-demarcated segment of subchondral bone with a lucent line demonstrating separation from the condyle. The clinical significance of irregularities in the ossification center of the developing epiphysis in children younger than 10 years is unclear.

MRI is useful for both diagnosing and characterizing OCD lesions. It can be used to determine the size and stability of the OCD, the integrity of the articular cartilage, and the presence of loose bodies. Fluid observed between the fragment and subchondral bone suggests an unstable lesion and a high risk for detachment. Any linear signal through the articular cartilage or displacement of the fragment indicates a potentially unstable lesion as well. Cysts surrounding the OCD can indicate instability if there are multiple or they are large in size. However, when deciding treatment, it is important to consider both the clinical and radiographic findings as the ability of MRI to predict OCD stability in the pediatric population has been reported to be only 30–92% accurate. For an unstable-appearing OCD, based on either the patients' symptoms and signs or the imaging, arthroscopy is considered the gold standard to determine stability and should be performed to evaluate the status of the lesion.

TREATMENT

Treatment for juvenile OCD includes nonoperative and surgical management, with treatment decisions being based on many factors, including the growth status and skeletal maturity of the patient, the presence of symptoms, the size of the lesion, whether the lesion appears intact and stable, or if there is any suggestion of instability. The rate of juvenile OCD healing without surgical intervention is estimated to be 30–60%. Skeletal immaturity (i.e., younger age), smaller lesion size, and the absence of mechanical symptoms or pain have been associated with a higher likelihood of OCD healing with nonoperative treatment. Unstable OCD lesions will not usually heal with conservative treatment and thus almost always require surgical intervention.

Young patients with stable lesions, as evidenced by an intact articular surface on imaging (Fig. 718.3A), are deemed to have an acceptable probability of healing and are often initially managed conservatively with a period of restricted weight-bearing and immobilization, followed by a period of strict activity restriction and physical therapy for 3-6 months. OCD healing is followed with radiographs, usually at intervals of approximately 1.5-3 months, until lesion healing has been noted. If healing has not been radiographically confirmed in 3-6 months, surgical intervention is often considered. Because of the low rate of healing in skeletally mature patients, even intact lesions are not usually managed conservatively in this patient population, and surgery is recommended.

Although nonsurgical treatment may be successful in stable lesions, surgical treatment of these lesions is often more successful. Surgery also seems to induce healing at a faster rate than conservative treatment. Because surgical treatment has a very low complication rate and a time frame of recovery that closely parallels a course of conservative treatment, some patients may choose to pursue early surgical intervention instead of trying nonoperative treatment first. For stable and intact lesions, surgical management involves arthroscopic evaluation of the joint followed by either a transarticular or retroarticular drilling to stimulate bony healing by creating channels in the subchondral bone that allow revascularization to occur.

More advanced and unstable lesions with findings of edema beneath the fragment, subchondral cyst formation, and partial (see Fig. 718.3B) or complete (see Fig. 718.3C) fragment detachment on arthroscopy are potentially salvageable and should be treated surgically. Treatment involves drilling or fixation with possible bone grafting. OCD lesions may progress and become unstable and dislodge into the joint space (see Fig. 718.3D). Removal of the loose body in addition to cartilage repair and restoration are typically performed for unstable, unsalvageable lesions. In the postoperative period, patients usually require physical therapy to regain strength and range of motion, with a gradual return to baseline activity levels once full healing has been observed. Early identification and treatment of OCD lesions often prevents recurrent symptoms in adulthood and reduces the risk of early-onset osteoarthritis.

Visit Elsevier eBooks+ at eBooks.Health.Elsevier.com for Bibliography.

718.4 Osgood-Schlatter Disease and Sinding-Larsen-Johansson Syndrome

Anne M. Coyle and J. Todd R. Lawrence

In skeletally immature patients, the tibial tubercle apophysis is an extension of the proximal tibial epiphysis. As the femur rapidly grows in length, patients often develop tight musculature, particularly of the quadriceps, across the knee joint. These patients also develop

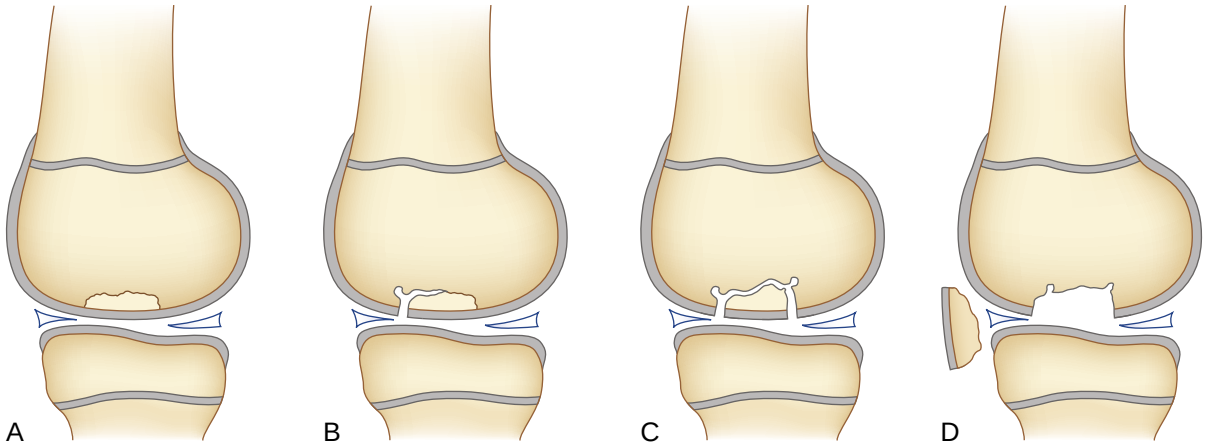

Fig. 718.3 The spectrum of osteochondritis dissecans (OCD) pathology of the knee. **A,** A stable and intact lesion without breach of the overlying articular cartilage. **B,** An OCD with fluid beneath the fragment, subchondral cyst formation, and partial fragment detachment. **C,** An unstable but located lesion with fluid beneath the fragment, multiple subchondral cysts, and complete fragment detachment. **D,** A dislodged OCD lesion, resulting in a loose body within the knee joint space.

movement patterns that preferentially place stress on the knees during physical activity instead of distributing that stress across other joints in the lower extremity. The repetitive tensile microtrauma sustained during sports or other athletic activities creates traction injuries at the weak points in the extensor mechanism at the knee, as the stress exceeds the developing skeleton's ability to repair the damage.

Sinding-Larsen-Johansson (SLJ) syndrome and **Osgood Schlatter (OS) disease** are *overuse injuries* that occur at the most common "weak points" in the system and are two of the most common causes of anterior knee pain in children and adolescents. SLJ syndrome is an **insertional periostitis** at the inferior pole of the patella. OS disease is an irritation of the patellar tendon at its insertion into the tibial tubercle or a **traction apophysitis** of the tibial tubercle growth plate. These conditions typically present during periods of relative accelerated growth and self-resolve within 12-24 months. SLJ syndrome tends to occur in a slightly younger patient population most commonly ages 9-13 years, whereas OS disease presents in slightly older patients with most symptomatic between the ages of 10-15 years. These conditions are most common in very physically active children particularly those that participate in sports such as basketball, volleyball, and soccer, in which jumping, kicking, and squatting puts repetitive strain on the patellar tendon.

CLINICAL MANIFESTATIONS AND DIAGNOSIS

Anterior knee pain, very specifically localized to the inferior pole of the patella (SLJ syndrome) or over the tibial tubercle (OS disease), is the most common patient complaint. Localized soft tissue swelling, along with an eventual firm and fixed increased prominence at the tibial tubercle, may occur with OS disease and may also be part of the initial complaint (Fig. 718.4). There is typically no acute traumatic inciting event, and the history of an acute traumatic onset of symptoms should raise the possibility of a tibial tubercle fracture or patellar sleeve fracture. The pain is aggravated by sports activities but may often persist with regular daily activities and even at rest. Physical examination reveals point tenderness over the inferior pole of the patella (SLJ) or over the tibial tubercle (OS disease). The presence of a knee effusion should raise the possibility of other intraarticular pathology. Diagnosis is usually made clinically, but radiographs may reveal fragmentation of the tibial tubercle and soft tissue swelling consistent with OS disease (Fig. 718.5) and be used to rule out other pathologies.

Another cause of patellar pain is **fat pad impingement syndrome** (Hoffa disease), which is characterized by inflammation and swelling of the infrapatellar fat pad, most often due to trauma or recent surgery. Patients may have pain when extending the knee against resistance.

TREATMENT

In most patients, SLJ syndrome and OS disease are self-limited processes and resolve with rest. Patients are treated with increasing levels

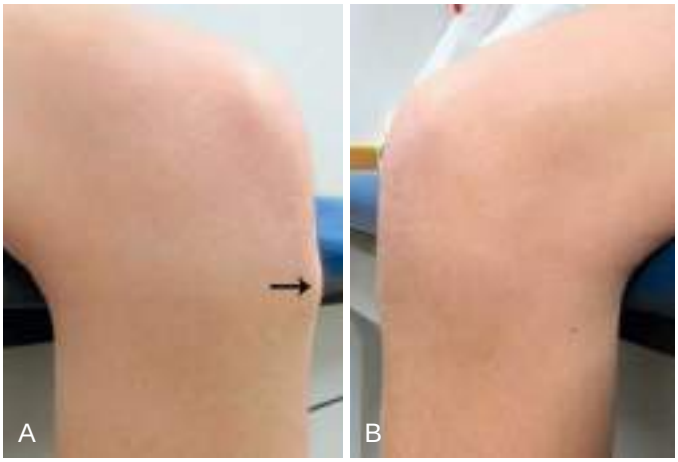

Fig. 718.4 Clinical manifestations of Osgood-Schlatter disease. The increased prominence of the tibial tubercle, indicated by the *arrow,* **(A)** from traction apophysitis in a 15-yr-old male's knee is contrasted with the normal appearance of the tibial tubercle **(B)** in his contralateral, unaffected knee.

of activity restriction or immobilization to get them to a pain-free state before advancing their activities. For instance, if they have pain only with running, but are pain free with normal daily activities, they may be restricted from running but perform daily activities for 2 weeks before advancing. In more severe cases, a knee immobilizer or even crutches with restricted weight-bearing are required to help the patient reach a pain-free state. Patients are usually advised to maintain this pain-free level of activity for 1-2 weeks before attempting to advance their activities. Sports and other dynamic activities are restricted until the patient is pain free with palpation and during daily activities for at least 2 weeks. During this rest period, addressing some of the contributing factors, such as muscular tightness, can help prevent a recurrence with activity resumption. A self-directed stretching regimen, concentrating on the quadriceps and hamstrings, may be provided. Some patients and resistant cases may benefit from formal instruction in these exercises with a physical therapist. Adjunctive therapy with ice (20 minutes every 2-4 hours and after activity) and NSAIDs (topical or oral) is common.

Communication with the patient and family members about the disease and prognosis is an important component of treatment. Reassurance may be appropriate because some patients and parents fear that the swollen tubercle may be a sign of a more significant pathology. Patients and family members should be advised that the tibial tubercle swelling will likely not fully resolve. Additionally, some evidence has suggested that a subgroup of patients who are competitive athletes may

Fig. 718.5 Radiographic findings of Osgood-Schlatter disease. **A,** Lateral radiograph of the knee of a 13-yr-old male demonstrates a sliver of new bone formation *(arrow)* at the tibial tubercle. **B,** Lateral radiograph of the same child at 15 yr of age demonstrates characteristic fragmentation *(arrow)* of the tibial tubercle.

experience long-term pain, and therefore options of treatment strategies and goals regarding participation in competitive sports may need to be discussed.

Treatment with hyperosmolar dextrose local injections may improve outcomes in patients with recalcitrant OS disease. However, corticosteroid injections are not recommended because of the risk of rupture of the patellar tendon due to steroid-induced atrophy. In the rare situation in which young adults have persistent and disabling symptoms, surgical removal of ossicles from the tubercle or reduction of an enlarged tibial tubercle may be warranted. Complications are rare and include early closure of the tibial tubercle with recurvatum or hyperextension, deformity, and, rarely, patellar tendon rupture or avulsion fracture of the tibial tubercle. Although rare, these complications can have significant long-term consequences and should thus prompt counseling to avoid playing through the pain.

Visit Elsevier eBooks+ at eBooks.Health.Elsevier.com for Bibliography.

718.5 Patellofemoral Pain Syndrome

Anne M. Coyle and J. Todd R. Lawrence

Also known as **anterior knee pain syndrome**, patellofemoral pain syndrome (PFPS) is one of the most common causes of knee pain and is characterized by pain located around or behind the patella that is elicited during activities that load the patella during knee flexion and weight-bearing such as squatting and running. PFPS affects 6–7% of the general adolescent population and up to 25% of teens who participate in sports. Females are estimated to account for 55–62% cases. Previously, PFPS was thought to arise from a deranged patellar articular surface; however, increasing evidence shows that anterior knee pain is frequently present even with normal articular cartilage of the patella. Even though abnormal patellar tracking may have a role in in the pathogenesis, the precise etiology of the knee pain remains unknown and is likely multifactorial. In adolescents, repetitive loading of the knee joint without adequate time for recovery is thought to be a key factor in developing PFPS.

CLINICAL MANIFESTATIONS AND DIAGNOSIS

Pain is usually described as being beneath or near the patella. The pain is worse with bent knee activities, such as walking up and down stairs, because these activities put the patella under high compressive loads. Squatting, running, and other vigorous physical activities also exacerbate the anterior knee pain. Sitting in a flexed knee position for an extended period of time, the so-called **theater sign**, is another common complaint and is often relieved through knee extension. The onset of symptoms in usually gradual, with no history of trauma. If a traumatic etiology is noted, consideration for other etiologies should be entertained. Buckling or a sense of the knee *giving way* can occur, but there is rarely any true patellar or knee instability. Swelling is not common and, if present, should prompt further investigation.

On physical examination, reproduction of the patient's pain with palpation about the medial or lateral aspects of the patella and pain during squatting have the highest sensitivity for PFPS. With the knee extended and the quadriceps relaxed, placing pressure on the patella and translating it distally into the top of the trochlear groove, the **grind test**, often also causes pain. Two tests, the patellar tilt test and the patellar apprehension test, have been found to have low sensitivity but the highest specificity for PFPS. The **patellar tilt test** is performed while holding the patella between two fingers, and with the knee extended, the medial patella is compressed posteriorly while simultaneously trying to elevate the lateral aspect of the patella. A fixed lateral aspect of the patella indicates tight lateral structures. With the **patellar apprehension test**, there is resistance to forced lateral displacement of the patella. Reproduction of the patient's pain with these maneuvers is an important component of the examination. Active and passive range of motion of the knee, alignment of the lower extremity, knee ligamentous stability, patellar tracking, and gait should be evaluated to identify any obvious causes of malalignment or an unstable patella. These patients often have tight quadriceps, hamstrings, and heel cords, along with weak hip musculature and poor overall balance. A single leg squat can often highlight the hip weakness and balance and alignment issues that contribute to this condition.

Radiographs are not required for diagnosis as there are no structural defects in PFPS; however, routine radiographs of the knee, including AP, lateral, tunnel (PA with 45-degree flexed knee), and merchant (patellar) views, are sometimes obtained to eliminate other etiologies of vague knee pain, such as OCD. Radiographs of the hip should be considered to rule out hip pathology, such as a slipped capital femoral epiphysis, which can manifest as ill-defined knee pain in adolescents as well. An MRI is not routinely required for evaluation but should be considered in any patient with a history of mechanical symptoms or an effusion. MRI should be considered in cases refractory to standard treatments as well.

TREATMENT

Several methods of nonoperative treatment are used to address PFPS. The mainstay of treatment is continued physiotherapy, involving overall lower-extremity stretching and strengthening, including short-arc quadriceps strengthening, hip and core strengthening, and exercises designed to address balance and overall body positioning during dynamic activities. Home exercise programs can be effective for the properly disciplined and motivated patient, but formal physical therapy should be considered in resistant cases or in patients who are unable to adhere to a self-directed program. Combining physiotherapy with activity modification and load management during treatment is associated with an increased rate of return to sports. Orthoses, including patellar taping, knee sleeves, customized knee braces, or even shoe inserts are often used in conjunction with physical therapy. Knee taping alone does not improve pain; however, exercise therapy in combination with knee taping has a greater reduction in pain than exercise therapy alone. Evidence for long-term benefit from other orthotic use is unclear. Treatment with botulinum toxin injections, nonsteroidal antiinflammatory medications, or therapeutic ultrasound is not substantiated. Despite these efforts, 40% of adolescents will have some pain that continues into early adulthood and significantly affects their quality of life, knee function, and physical activity. Surgical treatment of PFPS is rarely necessary.

Visit Elsevier eBooks+ at eBooks.Health.Elsevier.com for Bibliography.

718.6 Patellofemoral Instability

Anne M. Coyle and J. Todd R. Lawrence

The stable tracking of the patellofemoral joint in the front of the knee depends on a balance of the static restraints and the dynamic forces

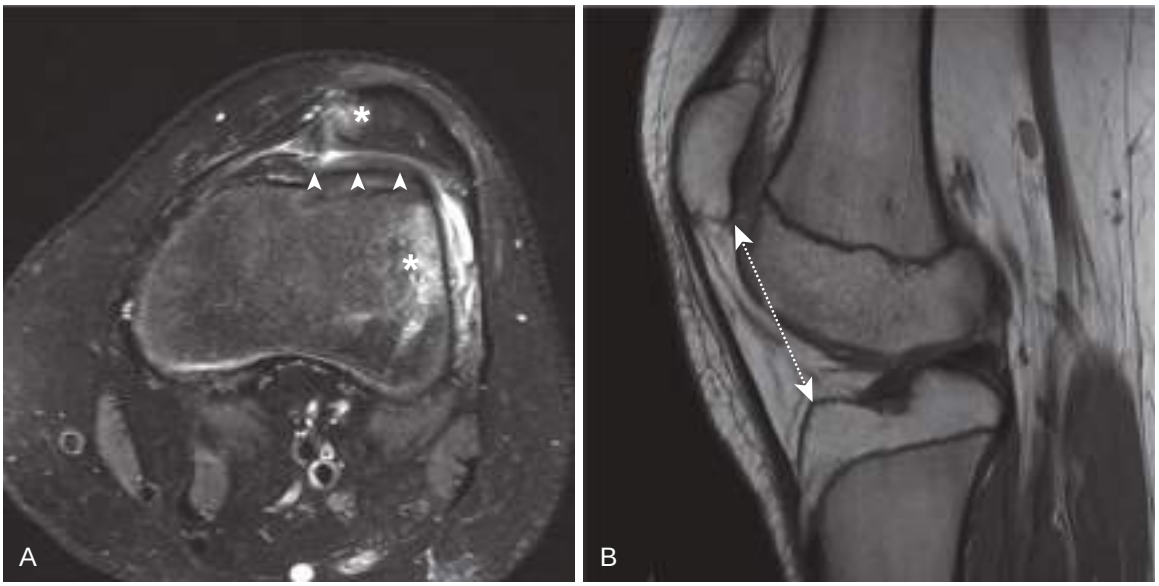

Fig. 718.6 A 14-yr-old female with patellar instability. **A,** A T2-weighted fat suppression axial image through the mid-patella and proximal trochlea demonstrates the characteristic bone bruise pattern on the medial patella and along the lateral femoral condyle that occurs when the dislocated medial patella impacts the lateral femur *(asterisks)*. Injury to the patellar attachment of the medial patellofemoral ligament is also visible at the medial patella. The patella is laterally subluxated in a dysplastic trochlea that is flat to slightly convex *(arrowheads)* instead of having a normal concave shape. **B,** A proton density weighted sagittal image through the center of the knee and patella demonstrates patella alta, with the distance from the anterior tibia to the inferior aspect of the patellar cartilage *(dotted line)* being much longer than the length of the patellar cartilage.

acting on the patella. These include the restraining ligaments and the articular anatomy of the patellofemoral groove that serve to balance the dynamic forces of the quadriceps mechanism and overall limb positioning. During knee flexion, the pull of the quadriceps mechanism tends to place an overall lateral displacing force at the patella. The **Q angle** refers to the deviation between the angle of the patellar tendon and the line of the quadriceps. Wider hips and valgus (knock-kneed) positioning increase the Q angle and thus the lateral force applied at the patella. In extension, the static restraints, including the medial restraining ligaments, primarily the medial patellofemoral ligament, are responsible for guiding the patella into the trochlear groove in the distal femur. Once in the trochlea, the bony congruity becomes the primary restraint to the net lateral forces.

Factors that contribute to patellofemoral instability are multifactorial, including ligamentous laxity; trochlear dysplasia, creating a shallow sulcus; condylar hypoplasia; patella alta (a high-riding patella); or malalignment that effectively increases the Q angle, such as genu valgum, increased femoral anteversion, or a lateralized tibial tubercle.

Acute patellofemoral dislocation is the most common acute knee disorder in children and adolescents between ages 10-19 years and often occurs after a sudden valgus strain during sports participation, but it may also be the result of direct trauma. **Recurrent patellofemoral subluxation** is more than one episode of patellar subluxation without frank dislocation. Lateral malalignment of the extensor mechanism and trochlear dysplasia are the most common etiologic factors. **Habitual dislocation of the patella** describes patellar dislocation occurring during every knee flexion/extension cycle. A dysplastic knee with contracture of the lateral portion of the quadriceps mechanism is often associated. Several syndromes are associated with patellar instability, including Down syndrome (see Chapter 57), Turner syndrome (see Chapter 626.1), Kabuki syndrome (see Chapter 102.2), and Rubinstein-Taybi syndrome (see Chapter 102.3).

CLINICAL MANIFESTATIONS AND DIAGNOSIS

With an **acute patellar dislocation**, patients will recall the acute event and the sensation that their kneecap was out of place. A focused, detailed history is important for characterizing the instability. Straightening the knee is all that is usually required to reduce the patella, but sometimes this requires medical attention. Swelling is typically apparent immediately after the injury and appreciable on examination as a large effusion. Pain along the knee from the medial patella to the medial epicondyle of the femur is common. Lateral patellar translocation with the knee extended should be tested with the **patellar apprehension test**. In the acute setting, there will be increased translation and pain and a feeling of insecurity. Patellar tracking is also an important component of the examination but may not be possible due to pain in the acute setting. The **J sign** refers to the inverted J-path the patella takes, beginning in a laterally subluxated position and then suddenly shifting medially to engage the femoral groove with early knee flexion. The torsional profile of the extremity is also important to assess to rule out possible rotational abnormalities of the femur or tibia.

Radiographs of a patient with patellar instability should include AP, lateral, and merchant views (obtained with the knee bent 45 degrees, with the beam of the x-ray through the knee from head to toe) of the patella. In children and adolescents with acute patellar dislocations, osteochondral injuries are present in up to 75% of cases. Radiographs should also be carefully examined for occult fractures. In the presence of a significant knee effusion, mechanical symptoms, acute traumatic patellar dislocation, or uncertainty in the diagnosis, further investigation should include an MRI to evaluate for loose bodies or cartilage damage. MRI will demonstrate bone bruise patterns typical of patellar dislocation at the medial patellar facet and at the lateral femoral condyle and a tear in the medial patellofemoral ligament (Fig. 718.6). Risk factors for recurrent instability include skeletal immaturity, ligamentous laxity, patella alta (see Fig. 718.6), trochlear dysplasia (see Fig. 718.6), and lateralized tibial tubercle (particularly one situated outside the lateral trochlear ridge).

TREATMENT

Nonoperative management that includes activity restriction, bracing, and physical therapy with return to full activity within in 3-4 months is initially recommended for first-time, acute patellar dislocation and recurrent patellar subluxation, unless a large osteochondral fracture or additional intraarticular pathology is seen on imaging studies. Short-term immobilization for 3 weeks in extension with a posterior splint has been shown to significantly decrease the risk of redislocation. After this, transition to a patellar stabilizing brace usually improves symptoms. Successful treatment is usually achieved with formal physical therapy aimed at improving extensor muscle tone, particularly the vastus medialis obliquus, activity-related body positioning, stretching the iliotibial band, and hip and core

muscle strengthening. Current criteria to return to full activity after conservative management requires absence of pain, recurring patellar instability, and knee effusion, as well as full range of motion, adequate core strength and endurance, psychologic readiness, hop test showing limb symmetry >85%, and satisfactory performance on sport-specific drills. Recurrent, ipsilateral patellofemoral instability is reported in up to 36% of skeletally mature patients. However, the reported redislocation rate in skeletally immature patients is as high as 69%. Risk factors for recurrence include younger age at time of first dislocation, ligamentous laxity, open physes, trochlear dysplasia (shallow trochlea), and extensor mechanism malalignment. Patients at high risk for recurrent dislocation may elect to undergo surgical stabilization early to prevent additional traumatic cartilage damage from a repeat dislocation, but early stabilization after the first dislocation is not currently a mainstay of treatment.

Failure to improve after nonoperative treatment and persistent patellar subluxation or experiencing a recurrent dislocation are the major indications for surgical intervention. Patients are considered surgical candidates for early intervention if there are loose bodies, osteochondral fractures, or chondral damage to prevent mechanical blocking of motion. Many different types of surgical procedures exist to prevent dislocation of the patella, but almost all include reconstruction of the medial patellofemoral ligament. Distal realignment of the patellar tendon insertion with a tibial tubercle osteotomy can help improve overall alignment and is often included as part of the stabilization procedure in skeletally mature adolescents. In skeletally immature patients, surgical reconstruction with physeal-sparing techniques can be performed. Guided growth techniques can be used in patients with growth remaining (typically 6 months–1 year) to correct overall alignment. The surgical approach should be patient specific depending on the pathoanatomy contributing to the recurrent instability for best outcomes. Return to full activity criteria is similar to that for nonsurgical management but the timeline may be adjusted based on underlying pathology and bone healing. Recurrence of patellofemoral instability after surgical intervention is estimated to be around 20%.

Visit Elsevier eBooks+ at eBooks.Health.Elsevier.com for Bibliography.

718.7 Anterior Cruciate Ligament Rupture

Anne M. Coyle and J. Todd R. Lawrence

Anterior cruciate ligament (ACL) tears account for more than half of all knee injuries. Young age is a known risk factor with peak incidence at 16-18 years old. Pediatric ACL reconstruction has become more prevalent as ACL tears in skeletally immature patients have greatly increased in recent years. This increase is likely due to increased sports participation, increased intensity of training and competition, and participation on multiple teams. Heightened awareness and improved methods for diagnosis are also likely contributing factors to the growing awareness of ACL injuries in children and adolescents.

Females are known to have up to a twofold increased risk for ACL injury compared to males playing the same sport. The gender-specific discrepancy appears to be caused mostly by insufficient neuromuscular activation patterns in females, resulting in increased dynamic **genu valgum** (knock-knee), biased limb alignment when landing, and therefore a heightened tendency toward landing or stopping in an injury-prone position. Other nonmodifiable risk factors include generalized joint laxity, knee recurvatum (hyperextension), femoral anteversion, and contralateral ACL injury. Various pediatric ACL injury prevention programs have shown benefits in not only reducing the rate of injuries but also in increasing athletic strength and performance. Studies also indicate that universal implementation of injury prevention programs can be a cost-effective prevention strategy.

CLINICAL MANIFESTATIONS AND DIAGNOSIS

Most ACL tears occur as a result of a noncontact injury involving a rapid pivoting, cutting, landing, or stopping maneuver. Patients with an acute knee injury from one of these activities who present with knee effusion and report a "pop" have a 70% chance of an ACL tear. The pop sensation occurs at the time of injury with later development of swelling, limited range of motion, and sometimes a sensation of instability. After the initial injury, patients may have surprisingly little pain. On physical examination, the **anterior drawer sign** or **Lachman test** may indicate increased anterior tibial translation. The Lachman examination is performed by applying an anteriorly directed force to the proximal tibia with the femur stabilized and the knee flexed 20-30 degrees. The amount of translation and the end point are assessed, with increased translation and an indistinct end point indicating a positive test. A **pivot shift test** can also be performed to confirm the diagnosis, but it is rarely tolerated in the conscious patient. It is conducted by gently bending the knee while just supporting the lower leg. A gentle valgus stress and slight internal rotation can enhance the shift. Assessment for concurrent injury to the medial collateral ligament and medial or lateral menisci should be considered as concurrent tears can be present in up to 45% of ACL tears.

Radiographs of the knee are performed, including AP, lateral, tunnel (PA with 45 degrees flexed knee), and merchant (patellar) views, to assess for other potential injuries common in pediatric and adolescent patients, such as tibial spine avulsion fractures or OCD. In acute traumatic injuries, internal and external oblique radiographs can also be helpful. Ultimately, knee MRI is usually necessary to confirm the presence of an intrasubstance ACL tear and any associated meniscal or chondral pathology (Fig. 718.7). Arthroscopic evaluation is the gold standard for diagnosis and treatment.

TREATMENT

The management of ACL injury in this patient population can be challenging, and the severity of the ACL tear and the degree of knee instability are important in directing treatment. Incomplete or partial ACL tears with a firm endpoint on examination may be treated nonoperatively, and the patient's and family's understanding and willingness to adhere to a protocol of bracing and activity restriction are important factors in optimizing outcomes. For complete tears of the ACL, surgical reconstruction is the preferred treatment for patients who are physically, mentally, and emotionally capable of maintaining precautions and complying with the long rehabilitation course after the procedure. Increasing evidence suggests that optimal timing for surgical intervention is within 3 months of injury to reduce the likelihood of additional damage occurring in the knee. While timing does not seem to affect recovery of knee stability, the risk of meniscal injury is up to 4.5 times higher when surgical intervention is delayed. Use of autologous tissue for ACL reconstruction is usually recommended for young active patients due to a lower risk of reinjury compared to allograft tissue. Growth-respecting ACL reconstruction techniques, such as all-epiphyseal, partial transphyseal, or traditional transphyseal reconstruction techniques, are used based on the skeletal maturity of the patient to minimize the risk for growth disturbance across the distal femoral and proximal tibial physes. The ultimate treatment course is an individual decision for the patient and family to make in consultation with their physician.

Depending on the technique used for reconstruction and any associated meniscal pathology addressed, weight-bearing is initially restricted, and a brace is used for the first 4-6 weeks postoperatively. Physical therapy is started postoperatively and continued until strength and functional testing are equal to the contralateral, unaffected limb. Injury prevention through neuromuscular training is built into the final phases of the rehabilitation and final screening tests to try to minimize the risk of reinjury. Most patients regain full range of motion and report no pain by 12 weeks after surgery. Patients return to sports typically at a minimum of 9-12 months postoperatively and are followed on a yearly basis thereafter until skeletal maturity to monitor progress and for any signs of growth disturbance. The majority of athletes are able to return to their same level of competition. The role of using a brace following ACL reconstruction is not established. Rehabilitation programs focused on strengthening, proximal control exercises, and incorporation of various exercise genres have significantly reduced the recurrence in female athletes. However, despite extensive prevention

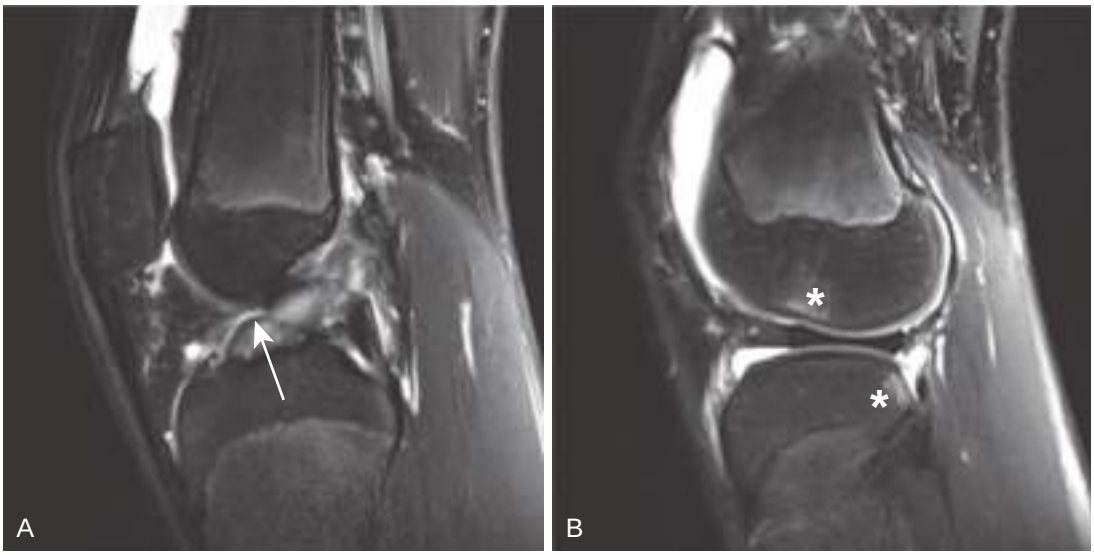

Fig. 718.7 A 14-yr-old female with full-thickness anterior cruciate ligament (ACL) tear. **A,** A T2-weighted fat-suppression sagittal image through the center of the knee demonstrates a full-thickness tear of the ACL with a folded stump near the tibial attachment. *(arrow).* **B,** A T2-weighted fat-suppression sagittal image through the lateral compartment demonstrates the characteristic kissing contusion pattern in the distal femoral condyle and posterior tibial plateau related to the anterior pivot shift that occurs during the ACL injury *(asterisks).*

efforts, secondary injury rates within 24 months of ACL reconstruction remain very high when patients elect to return to risky sports. The sports with the greatest risk for ACL tears are soccer, basketball, and lacrosse for females and football, soccer, and lacrosse for males. Revision of ACL reconstructions has been associated with increased complications.

Visit Elsevier eBooks+ at eBooks.Health.Elsevier.com for Bibliography.

Chapter 719

The Hip

Wudbhav N. Sankar, Jennifer J. Winell, B. David Horn, and Lawrence Wells

Anatomically, the hip joint is a ball-and-socket articulation between the femoral head and acetabulum. The hip joint is a pivotal joint of the lower extremity, and its functional demands require both stability and flexibility.

GROWTH AND DEVELOPMENT

The hip joint begins to develop at about the seventh week of gestation, when a cleft appears in the mesenchyme of the primitive limb bud. These precartilaginous cells differentiate into a fully formed cartilaginous **femoral head** and **acetabulum** by the eleventh week of gestation (see Chapter 21). At birth, the neonatal acetabulum is completely composed of cartilage, with a thin rim of fibrocartilage called the **labrum**.

The very cellular hyaline cartilage of the acetabulum is continuous with the triradiate cartilages, which divide and interconnect the three osseous components of the pelvis (the **ilium**, **ischium**, and **pubis**). The concave shape of the hip joint is determined by the presence of a spherical femoral head.

Several factors determine acetabular depth, including interstitial growth within the acetabular cartilage, appositional growth under the perichondrium, and growth of adjacent bones (the ilium, ischium, and pubis). In the neonate, the entire proximal femur is a cartilaginous structure, which includes the femoral head and the greater and lesser trochanters. The three main growth areas are the physeal plate, the growth plate of the greater trochanter, and the femoral neck isthmus. Between the fourth and seventh month of life, the proximal femoral ossification center (in the center of the femoral head) appears. This ossification center continues to enlarge, along with its cartilaginous anlage, until adult life, when only a thin layer of articular cartilage remains. During this period of growth, the thickness of the cartilage surrounding this bony nucleus gradually decreases, as does the thickness of the acetabular cartilage. The growth of the proximal femur is affected by muscle pull, the forces transmitted across the hip joint with weight bearing, normal joint nutrition, circulation, and muscle tone. Alterations in these factors can cause profound changes in the development of the proximal femur.

VASCULAR SUPPLY

The blood supply to the capital femoral epiphysis is complex and changes with growth of the proximal femur. The proximal femur receives its arterial supply from intraosseous (primarily the medial femoral circumflex artery) and extraosseous vessels (Fig. 719.1). The **retinacular vessels** (extraosseous) lie on the surface of the femoral neck but are intracapsular because they enter the epiphysis from the periphery. This makes the blood supply vulnerable to damage from septic arthritis, trauma, thrombosis, and other vascular insults. Interruption of this tenuous blood supply can lead to avascular necrosis of the femoral head and permanent deformity of the hip.

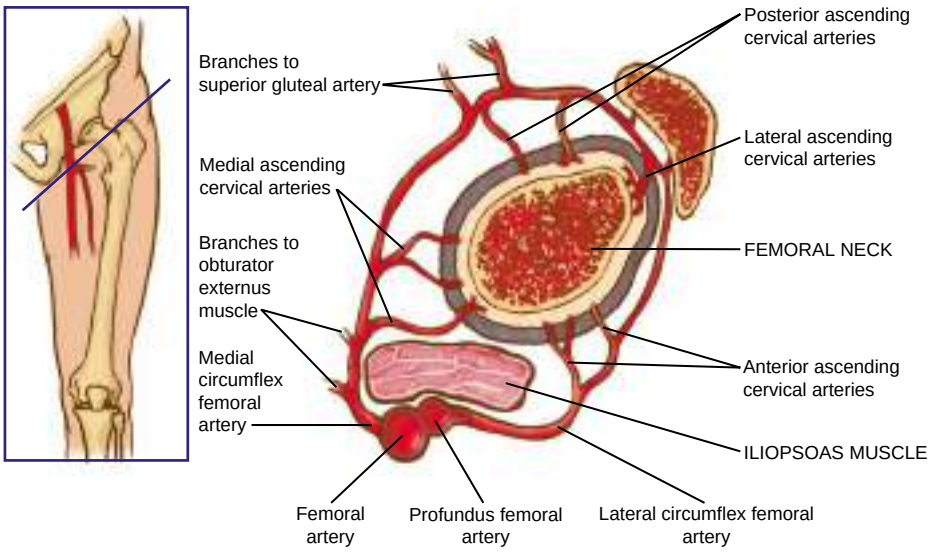

Fig. 719.1 Diagram of vascular anatomy of the proximal femur.

719.1 Developmental Dysplasia of the Hip

Wudbhav N. Sankar, B. David Horn, Jennifer J. Winell, and Lawrence Wells

Developmental dysplasia of the hip (DDH) refers to a spectrum of pathology in the development of the immature hip joint. Formerly called *congenital dislocation of the hip*, DDH more accurately describes the variable presentation of the disorder, encompassing mild dysplasia as well as frank dislocation.

CLASSIFICATION

Acetabular **dysplasia** refers to abnormal morphology and development of the acetabulum. Hip **subluxation** is defined as only partial contact between the femoral head and acetabulum. Hip **dislocation** refers to a hip with no contact between the articulating surfaces of the hip. DDH is classified into two major groups: typical and teratologic. **Typical DDH** occurs in otherwise normal patients or those without defined syndromes or genetic conditions. **Teratologic hip dislocations** usually have identifiable causes, such as arthrogryposis or a genetic syndrome, and occur before birth.

ETIOLOGY AND RISK FACTORS

Although the etiology remains unknown, the final common pathway in the development of DDH is increased laxity of the joint, which fails to maintain a stable femoroacetabular articulation. This increased laxity is probably the result of a combination of hormonal, mechanical, and genetic factors. A positive family history for DDH is found in 12–33% of affected patients. DDH is more common among female patients (80%), which is thought to be because of the greater susceptibility of female fetuses to maternal hormones, such as relaxin, which increases ligamentous laxity. Although only 3–4% of all babies are born in breech presentation, the incidence of DDH in these patients is 16–25%.

Any condition that leads to a tighter intrauterine space and, consequently, less room for normal fetal motion may be associated with DDH. These conditions include oligohydramnios, large birth weight, and first pregnancy. The high rate of association of DDH with other intrauterine molding abnormalities, such as torticollis and metatarsus adductus, supports the theory that the *crowding phenomenon* has a role in the pathogenesis. The left hip is the most commonly affected hip. In the most common fetal position, the left hip is usually forced into adduction by the mother's sacrum.

Tight swaddling with the hips in the extended position has been identified as an important risk factor for the development of hip dysplasia. Population studies of cultures that prefer immobilizing children in hip extension have shown that swaddling in such a way that prevents an infant from naturally drawing their hips to their chest (so called "M" position) is detrimental for hip development.

EPIDEMIOLOGY

Although most newborn screening studies suggest that some degree of hip instability can be detected in 1 in 100 to 1 in 250 babies, actual dislocated or dislocatable hips are much less common, being found in 1-1.5 of 1,000 live births.

There is marked geographic and racial variation in the incidence of DDH. These differences may result from environmental factors, such as child-rearing practices, rather than genetic predisposition. African and Asian caregivers have traditionally carried babies against their bodies in a shawl so that a child's hips are flexed, abducted, and free to move. This keeps the hips in the optimal position for stability and for dynamic molding of the developing acetabulum by the cartilaginous femoral head. Children in Native American and Eastern European cultures, which have a relatively high incidence of DDH, have historically been swaddled in confining clothes that bring their hips into extension. This position increases the tension of the psoas muscle-tendon unit and might predispose the hips to displace and eventually dislocate laterally and superiorly.

PATHOANATOMY

In DDH, several secondary anatomic changes can prevent reduction. Both the fatty tissue in the depths of the socket, known as the pulvinar, and the ligamentum teres can hypertrophy, blocking reduction of the femoral head. The transverse acetabular ligament usually thickens as well, which effectively narrows the opening of the acetabulum. In addition, the shortened iliopsoas tendon becomes taut across the front of the hip, creating an hourglass shape to the hip capsule, which limits access to the acetabulum. Over time, the dislocated femoral head places pressure on the acetabular rim and labrum, causing the labrum to infold and become thick.

The shape of a normal femoral head and acetabulum depends on a concentric reduction between the two. The more time that a hip spends dislocated, the more likely that the acetabulum will develop abnormally. Without a femoral head to provide a template, the acetabulum will become progressively shallow, with an oblique acetabular roof and a thickened medial wall.

CLINICAL FINDINGS

The Neonate

DDH in the neonate is asymptomatic and must be screened for in all newborns by specific maneuvers. Physical examination must be carried out with the infant unclothed and placed supine in a warm, comfortable setting on a flat examination table.

The **Barlow** provocative maneuver assesses the potential for dislocation of an initially nondisplaced hip. The examiner adducts the flexed hip and gently pushes the thigh posteriorly in an effort to dislocate the femoral head (Fig. 719.2). In a positive test, the hip is felt to slide out of the acetabulum. As the examiner relaxes the proximal push, the hip can be felt to slip back into the acetabulum.

The **Ortolani** test is the reverse of the Barlow test: The examiner attempts to reduce a hip that is dislocated at rest (Fig. 719.3). The examiner grasps the child's thigh between the thumb and index finger and, with the fourth and fifth fingers, lifts the greater trochanter while simultaneously abducting the hip. When the test is positive, the femoral head will slip into the socket with a delicate clunk that is palpable but usually not audible. It should be a gentle, nonforced maneuver.

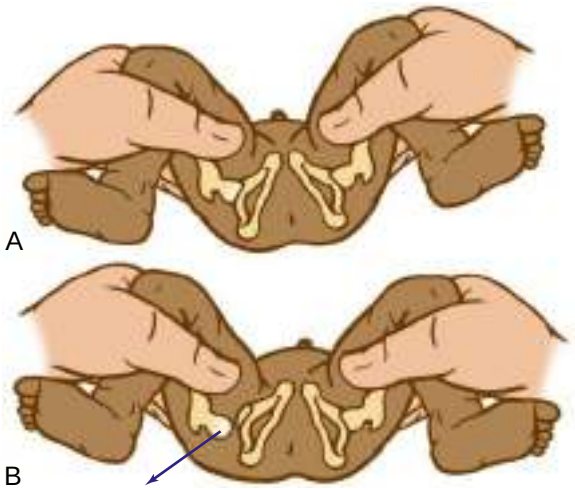

Fig. 719.2 The Barlow provocative test is performed with the patient's knees and hips flexed. A, Holding the patient's limbs gently, with the thigh in adduction, the examiner applies a posteriorly directed force. B, This test is positive in a dislocatable hip.

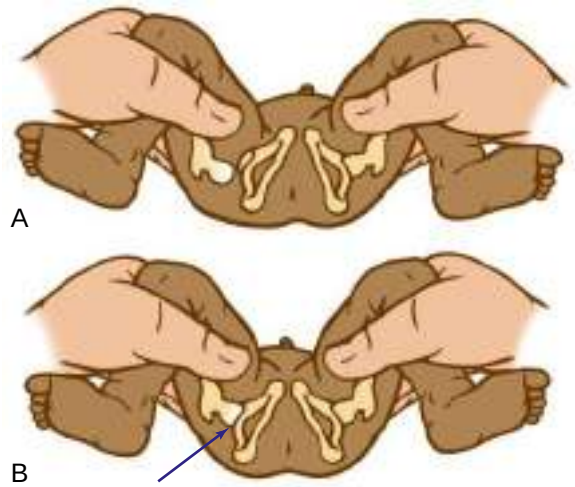

Fig. 719.3 The Ortolani maneuver is the sign of the ball of the femoral head moving in and out of the acetabulum. A, The examiner holds the patient's thigh and gently abducts the hip while lifting the greater trochanter with two fingers. B, When the test is positive, the dislocated femoral head falls back into the acetabulum with a palpable clunk as the hip is abducted.

A **hip click** is the high-pitched sensation (or sound) felt at the very end of abduction during testing for DDH with Barlow and Ortolani maneuvers. A hip click can be differentiated from a **hip clunk**, which is felt as the femoral head goes in and out of joint. Hip clicks usually originate in the ligamentum teres or occasionally in the fascia lata or psoas tendon and do not indicate a significant hip abnormality.

The Infant

As the baby enters the second and third month of life, the soft tissues begin to tighten, and the Ortolani and Barlow tests are no longer reliable. In this age-group, the examiner must look for other specific physical findings, including limited hip abduction, apparent shortening of the thigh, proximal location of the greater trochanter, asymmetry of the gluteal or thigh folds (Fig. 719.4), and positioning of the hip. Limitation of abduction is the most reliable sign of a dislocated hip in this age-group.

Shortening of the thigh, the **Galeazzi sign**, is best appreciated by placing both hips in 90 degrees of flexion and comparing the height of the knees, looking for asymmetry (Fig. 719.5). Asymmetry of gluteal skin creases may be a sign of hip dysplasia. Another helpful test is the **Klisic test**, in which the examiner places the third finger over the greater trochanter and the index finger of the same hand on the anterior superior iliac spine. In a normal hip, an imaginary line drawn between the two fingers points to the umbilicus. In the dislocated hip, the trochanter is elevated, and the line projects halfway between the umbilicus and the pubis (Fig. 719.6).

Fig. 719.4 Asymmetry of thigh folds in a child with developmental dysplasia of the hip.

Fig. 719.5 Positive Galeazzi sign noted in a case of untreated developmental dysplasia of the hip.

The Walking Child

The walking child often presents to the physician after the family has noticed a limp, a waddling gait, or a leg-length discrepancy. The affected side appears shorter than the normal extremity, and the child toe-walks on the affected side. The **Trendelenburg sign** (see Chapter 714) is positive in these children, and an abductor lurch is usually observed when the child walks. As in the younger child, there is limited hip abduction on the affected side and the knees are at different levels when the hips are flexed (the Galeazzi sign). Excessive lordosis, which develops secondary to altered hip mechanics, is common and is often the presenting complaint.

DIAGNOSTIC TESTING

Ultrasonography

Because it is superior to radiographs for evaluating cartilaginous structures, ultrasonography is the diagnostic modality of choice for DDH before the appearance of the femoral head ossific nucleus (4-6 months). During the early newborn period (0-4 weeks), however, physical examination is preferred over ultrasonography because there is a high incidence of false-positive sonograms in this age-group. Therefore, waiting to obtain an ultrasound until the infant is at least 6 weeks of age is recommended unless the child has a strongly positive physical examination. In addition to elucidating the static relationship of the femur to the acetabulum, ultrasonography provides dynamic information about the stability of the hip joint. The ultrasound examination can be used to monitor acetabular development, particularly of infants in Pavlik harness treatment; this method can minimize the number of radiographs taken and might allow the clinician to detect treatment failure earlier.

In the Graf technique, the transducer is placed over the greater trochanter, which allows visualization of the ilium, the bony acetabulum, the labrum, and the femoral epiphysis (Fig. 719.7). The angle formed by the line of the ilium and a line tangential to the bony roof of the acetabulum is termed the α **angle** and represents the depth of the acetabulum. Values >60 degrees are considered normal, and those <60 degrees imply acetabular dysplasia. The **β angle** is formed by a line drawn tangential to the labrum and the line of the ilium; this represents the cartilaginous roof of the acetabulum. A normal β angle is <55 degrees; as the femoral head subluxates, the β angle increases. Another useful test is to evaluate the position of the center of the head compared with the vertical line of the ilium. If the line of the ilium falls lateral to the center of the head, the epiphysis is considered reduced. If the line falls medial to the center of the head, the epiphysis is uncovered and is either subluxated or dislocated.

Screening for DDH with ultrasound remains controversial. Although routinely performed in Europe, meta-analyses indicate that data are insufficient to give clear recommendations. In the United States, the current recommendations are that every newborn undergo a clinical examination for hip instability. Children who have findings suspicious for DDH should be followed up with ultrasound. Most authors agree that infants with risk factors for DDH (breech position, family history, torticollis) should be screened with ultrasound regardless of the clinical findings.

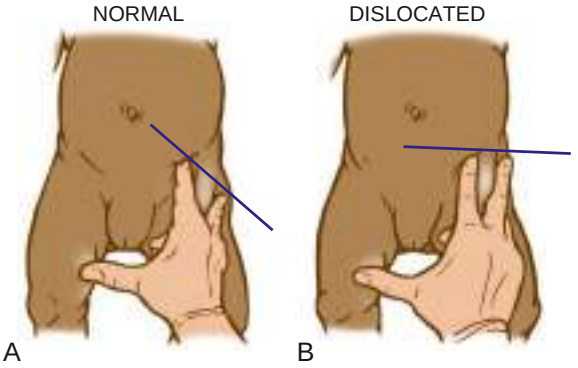

Fig. 719.6 Klisic test. **A,** In a normal hip, an imaginary line drawn down through the tip of an index finger placed on the patient's iliac crest and the tip of the long finger placed on the patient's greater trochanter should point to the umbilicus. **B,** In a dislocated hip, this line drawn through the two fingertips runs below the umbilicus because the greater trochanter is abnormally high.

Radiography

Radiographs are recommended for an infant once the proximal femoral epiphysis ossifies, usually by 4-6 months. In infants of this age, radiographs have proven to be more effective, less costly, and less operator dependent than an ultrasound examination. An anteroposterior (AP) view of the pelvis can be interpreted with the aid of several classic lines drawn on it (Fig. 719.8).

Hilgenreiner's line is a horizontal line drawn through the top of both triradiate cartilages (the clear area in the depth of the acetabulum). **Perkins line** is a vertical line through the most lateral ossified margin of the roof of the acetabulum, drawn perpendicular to Hilgenreiner's line. The ossific nucleus of the femoral head should be located in the medial lower quadrant of the intersection of these two lines. **Shenton's line** is a curved line drawn from the medial aspect of the femoral neck to the lower border of the superior pubic ramus. In a child with normal hips, this line is a continuous contour. In a child with hip subluxation or dislocation, this line consists of two separate arcs and is described as "broken."

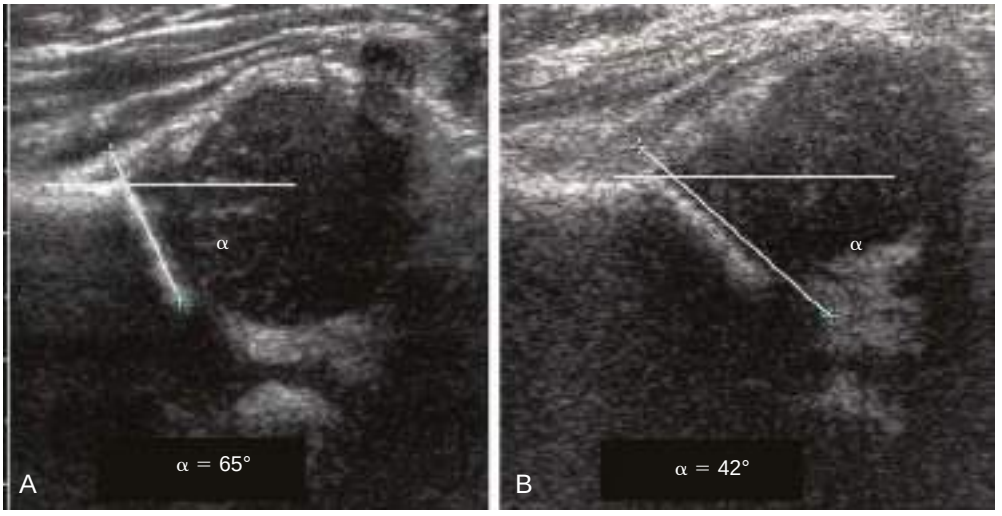

Fig. 719.7 **A,** Normal ultrasonographic image of the hip in an infant. The α angle is >60 degrees. Note that a line drawn tangential to the ilium falls lateral to the center of the femoral head. **B,** In this child with developmental dysplasia of the hip, the left hip demonstrates an α angle of 42 degrees, and a line drawn tangential to the ilium shows that <50% of the femoral head is contained within the acetabulum.

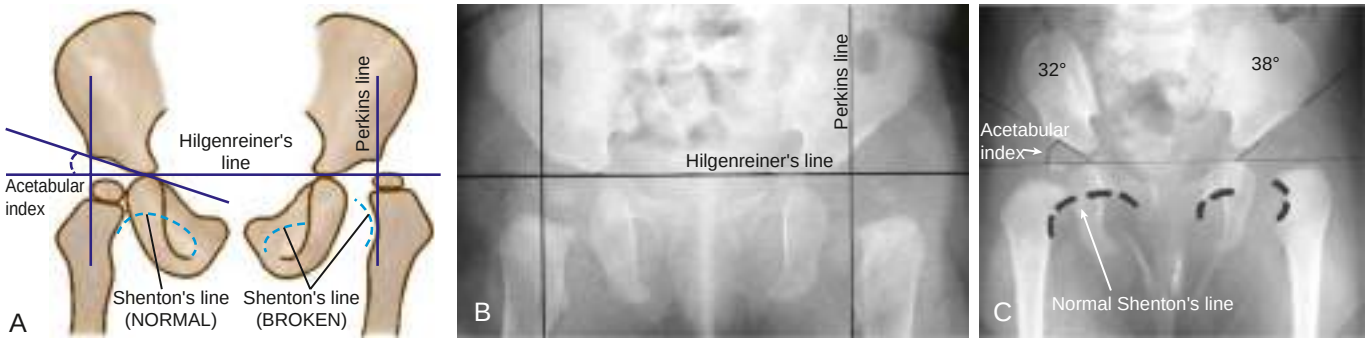

Fig. 719.8 A-C, Radiographic measurements are useful in evaluating developmental dysplasia of the hip. Hilgenreiner's line is drawn through the triradiate cartilages. Perkins line is drawn perpendicular to Hilgenreiner's line at the lateral edge of the acetabulum. The ossific nucleus of the femoral head should be located in the medial lower quadrant of the intersection of these two lines. Shenton's line curves along the femoral metaphysis and connects smoothly to the inner margin of the pubis. In a child with hip subluxation or dislocation, this line consists of two separate arcs and is described as broken. The acetabular index is the angle between a line drawn along the margin of the acetabulum and Hilgenreiner's line; in normal newborns, it averages 27.5 degrees and decreases with age.

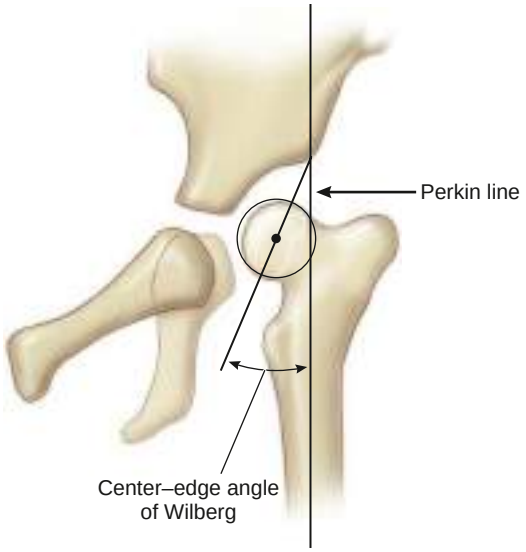

Fig. 719.9 Center–edge angle of Wilberg, which is the angle that is formed between the Perkin's line and a line drawn from the lateral lip of the acetabulum through the center of the femoral head. This angle, which is a useful measure of hip position in older children, is considered normal if it is more than 19 degrees in children between the ages of 6 and 13 years. It increases with age. *(From Kim HK, Herring JA. Developmental dysplasia of the hip. In: Herring JA, ed. Tachdjian's Pediatric Orthopaedics, 6th ed. Philadelphia: Elsevier; 2022: Fig.13.31.)*

The **acetabular index** is the angle formed between Hilgenreiner's line and a line drawn from the depth of the acetabular socket to the most lateral ossified margin of the roof of the acetabulum. This angle measures the development of the osseous roof of the acetabulum. In the newborn, the acetabular index can be up to 40 degrees; by 4 months in the normal infant, it should be no more than 30 degrees. In the older child, the **center-edge angle of Wilberg** is a useful measure of femoral head coverage. This angle is formed at the juncture of the Perkins line and a line connecting the lateral margin of the acetabulum to the center of the femoral head (Fig. 719.9). In children 6-13 years, an angle >19 degrees is normal, whereas in children 14 years and older, an angle >25 degrees is considered normal.

TREATMENT

The goals in the management of DDH are to obtain and maintain a concentric reduction of the femoral head within the acetabulum to provide the optimal environment for the normal development of both the femoral head and acetabulum. The later the diagnosis of DDH is made, the more difficult it is to achieve these goals, the less potential there is for acetabular and proximal femoral remodeling, and the more complex the required treatments.

Newborns and Infants Younger Than 6 Months

Newborns' hips that are Barlow positive (reduced but dislocatable) or Ortolani positive (dislocated but reducible) should generally be treated with a Pavlik harness as soon as the diagnosis is made. The management of newborns with dysplasia who are younger than 4 weeks of age is less clear. A significant proportion of these hips normalize within 3-4 weeks; consequently, many physicians prefer to reexamine these newborns after a few weeks before making treatment decisions. A study of newborns with mildly dysplastic hips based on the results of an ultrasound (alpha angles between 43 and 50 degrees) and who were randomly assigned to receive immediate abduction splinting or active sonographic surveillance from birth with Frejka splinting (if treatment was subsequently needed) revealed no difference in radiologic findings at 6 years of age.

Triple diapers or abduction diapers have *no place* in the treatment of DDH in the newborn; they are usually ineffective and give the family a false sense of security. Acetabular dysplasia, subluxation, or dislocation can all be readily managed with the Pavlik harness. Although other braces are available (von Rosen splint, Ilfeld splint, Frejka pillow), the Pavlik harness remains the most commonly used device worldwide (Fig. 719.10). By maintaining the Ortolani-positive hip in a Pavlik harness on a full-time basis for 6 weeks, hip instability resolves in approximately 75% of cases. After 6 months of age, the failure rate for the Pavlik harness is >50% because it is difficult to maintain the increasingly active and crawling child in the harness. Frequent examinations and readjustments are necessary to ensure that the harness is correctly fitted. The anterior straps of the harness should be set to maintain the hips in flexion (usually ~90-100 degrees); excessive flexion is discouraged because of the risk of femoral nerve palsy. The posterior straps are designed to encourage abduction. These are generally set to allow adduction just to neutral, because forced abduction by the harness can lead to avascular necrosis of the femoral epiphysis.

If follow-up examinations and ultrasounds do not demonstrate concentric reduction of the hip after 3-4 weeks of Pavlik harness treatment, the harness should be abandoned. Continued use of the harness beyond this period in a persistently dislocated hip can cause **Pavlik harness disease** or wearing away of the posterior aspect of the acetabulum, which can make the ultimate reduction less stable.

Children 6 Months to 2 Years of Age

The principal goals in the treatment of late-diagnosed dysplasia are to obtain and maintain reduction of the hip without damaging the femoral head. Closed reductions are performed in the operating room under general anesthesia. The hip is moved to determine the range of motion (ROM) in which it remains reduced. This is

Fig. 719.10 Photograph of a Pavlik harness.

Fig. 719.12 Arthrogram of a reduced hip for evaluating the stability of reduction.

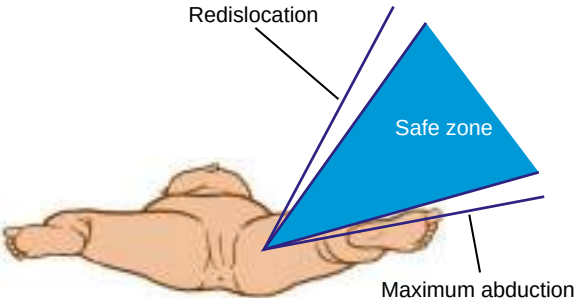

Fig. 719.11 Diagram of the safe zone of Ramsey.

compared to the maximal ROM to construct a "safe zone" (Fig. 719.11). An arthrogram obtained at the time of reduction is very helpful for evaluating the depth and stability of the reduction (Fig. 719.12). The reduction is maintained in a well-molded spica cast, with the "human position" of moderate flexion and abduction being the preferred position. After the procedure, single-cut CT or MRI may be used to confirm the reduction. Twelve weeks after closed reduction, the plaster cast is removed; an abduction orthosis is often used at this point to encourage further remodeling of the acetabulum. Failure to obtain a stable hip with a closed reduction indicates the need for an open reduction. In patients younger than 18 months of age, a concomitant acetabular or femoral procedure is rarely required. The potential for acetabular development after closed or open reduction is excellent and continues for 4-8 years after the procedure.

Children Older Than 2 Years

Children 2-6 years of age with a hip dislocation usually require an open reduction. In this age-group, a concomitant femoral shortening osteotomy is often performed to reduce the pressure on the proximal femur and minimize the risk of osteonecrosis. Because the potential for acetabular development is markedly diminished in these older children, a pelvic osteotomy is usually performed in conjunction with the open reduction. Postoperatively, patients are immobilized in a spica cast for 6-12 weeks.

COMPLICATIONS

The most important complication of DDH is **avascular necrosis** of the femoral epiphysis. Reduction of the femoral head under pressure or in extreme abduction can result in occlusion of the epiphyseal vessels and produce either partial or total infarction of the epiphysis. Revascularization soon follows, but if the physis is severely damaged, abnormal growth and development can occur. Management, as previously outlined, is designed to minimize this complication. With appropriate treatment, the incidence of avascular necrosis for DDH is reduced to 5–15%. Other complications in DDH include redislocation, residual subluxation, acetabular dysplasia, pressure ulcers from prolonged casting, and postoperative complications, including wound infections.

Visit Elsevier eBooks+ at eBooks.Health.Elsevier.com for Bibliography.

719.2 Transient Monoarticular Synovitis (Toxic Synovitis)

Wudbhav N. Sankar, Jennifer J. Winell, B. David Horn, and Lawrence Wells

Transient synovitis (toxic synovitis) is thought to be a reactive arthritis and is one of the most common causes of hip pain in young children.

ETIOLOGY

The cause of transient synovitis remains unknown. It has been variously described as a nonspecific inflammatory condition or as a post-viral immunologic synovitis because it tends to follow recent viral illnesses.

CLINICAL MANIFESTATIONS

Although transient synovitis can occur in all age-groups, it is most prevalent in children between 3 and 8 years of age, with a mean onset at age 6 years. Approximately 70% of all affected children have had a nonspecific upper respiratory tract infection the 7-14 days before symptom onset. Symptoms often develop acutely (~3 days) and usually consist of pain in the groin, anterior thigh, or knee, which may be referred from the hip. These children are usually able to bear weight on the affected limb and typically walk with an antalgic gait with the foot externally rotated. The hip is not held flexed, abducted, or laterally rotated unless a significant effusion is present. They are often afebrile or have a low-grade fever (≤38°C).

DIAGNOSIS

Transient synovitis is a diagnosis of exclusion, and laboratory and radiographic tests can be useful to rule out other more serious conditions. In transient synovitis, infection laboratory tests (ESR: <20 mm/hr, serum CRP: normal or ≤2 mg/dL, and WBC: <12,000 cells/mm^3) are relatively normal, but on occasion a mild elevation in the ESR is observed. AP and Lauenstein (frog-leg) lateral radiographs of the pelvis may be acquired and are also usually found to be normal. Ultrasonography of the hip is the preferred imaging modality and often demonstrates a small joint effusion.

The most important condition to exclude before confirming a diagnosis of toxic synovitis is septic arthritis. Children with septic arthritis usually appear more systemically ill and have more pain than those with transient synovitis, often refusing to walk or move their hip at all. High fever, refusal to walk, and elevations of the ESR, serum CRP, and WBC all suggest a diagnosis of septic arthritis. If the clinical scenario is suspicious for septic arthritis, an ultrasound-guided aspiration of the hip joint should be performed to make the definitive diagnosis (see Chapter 726). An exception to these criteria is hip septic arthritis due to *Kingella kingae or Lyme disease*, which may have minimal inflammation and low-grade or no fever. Synovial fluid white blood cell counts are low in toxic synovitis (<25,000) and much higher in Lyme and septic arthritis (50,00-200,000). MRI may be needed to evaluate for an associated osteomyelitis if the patient has concerning examination or laboratory findings (see Chapter 725).

TREATMENT

The treatment of transient monoarticular synovitis of the hip is symptomatic. Recommended therapies include activity limitation and relief of weight bearing until the pain subsides. Antiinflammatory agents and analgesics can shorten the duration of pain. Most children improve in 5-7 days and recover completely within 3-6 weeks.

Visit Elsevier eBooks+ at eBooks.Health.Elsevier.com for Bibliography.

719.3 Legg-Calvé-Perthes Disease

Wudbhav N. Sankar, Jennifer J. Winell, B. David Horn, and Lawrence Wells

Legg-Calvé-Perthes disease (LCPD) is a hip disorder of unknown etiology that results from temporary interruption of the blood supply to the proximal femoral epiphysis, leading to osteonecrosis and femoral head deformity.

ETIOLOGY

Although the underlying etiology remains obscure, most authors agree that the final common pathway in the development of LCPD is disruption of the vascular supply to the femoral epiphysis, which results in ischemia and osteonecrosis. Infection, trauma, and transient synovitis have all been proposed as causative factors but are unsubstantiated. Factors leading to thrombophilia, an increased tendency to develop thrombosis, and a reduced ability to lyse thrombi have been identified. Factor V Leiden mutation, deficiency of proteins C and S, lupus anticoagulant, anticardiolipin antibodies, antitrypsin, and plasminogen activator might play a role in the abnormal clotting mechanism. These abnormalities in the clotting cascade are thought to increase blood viscosity and the risk for venous thrombosis. Poor venous outflow leads to increased intraosseous pressure, which, in turn, impedes arterial inflow, causing ischemia and cell death. LCPD is rarely due to pathogenic variants in *COL2A1*, which is usually sporadic (de novo) and manifests as an autosomal dominant trait.

EPIDEMIOLOGY

The incidence of LCPD in the United States is 1 in 1,200 children, with males 4-5 times more likely to be affected than females. The peak incidence of the disease is between the ages of 4 and 8 years. Bilateral involvement is seen in approximately 10% of the patients, but the hips are usually in different stages of collapse.

PATHOGENESIS

Early pathologic changes in the femoral head are the result of ischemia and necrosis; subsequent changes result from the repair process. The disease course may have four stages, although variations have been described. The **initial stage** of the disease, which lasts an average of 6 months, is characterized by synovitis, joint irritability, and early necrosis of the femoral head. Revascularization then leads to osteoclastic-mediated resorption of the necrotic segment. The necrotic bone is replaced by fibrovascular tissue rather than new bone, which compromises the structural integrity of the femoral epiphysis. The second stage is the **fragmentation stage**, which typically lasts 8 months. During this stage, the femoral epiphysis begins to collapse, usually laterally, and begins to extrude from the acetabulum. The **healing stage**, which lasts approximately 4 years, begins with new bone formation in the subchondral region. Reossification begins centrally and expands in all directions. The degree of femoral head deformity depends on the severity of collapse and the amount of remodeling that occurs. The final stage is the **residual stage**, which begins after the entire head has reossified. A mild amount of remodeling of the femoral head still occurs until the child reaches skeletal maturity. LCPD often damages the proximal femoral physis, leading to a short neck (coxa breva) and trochanteric overgrowth.

CLINICAL MANIFESTATIONS

The most common presenting symptom is a limp of varying duration. Pain, if present, is usually activity related and may be localized in the groin or referred to the anteromedial thigh or knee region. *Failure to recognize that thigh or knee pain in a child may be secondary to hip pathology can cause further delay in the diagnosis.* Less commonly, the onset of the disease may be much more acute and may be associated with a failure to ambulate.

Antalgic gait (a limp characterized by a shortening of gait phase on the injured side to alleviate weight-bearing pain) may be particularly prominent after strenuous activity at the end of the day. Hip motion, primarily internal rotation and abduction, is limited. Early in the course of the disease, the limited abduction is secondary to synovitis and muscle spasm in the adductor group; however, with time and the subsequent deformities that can develop, the limitation of abduction can become permanent. A mild hip flexion contracture of 10-20 degrees may be present. Atrophy of the muscles of the thigh, calf, or buttock from disuse secondary to pain may be evident. An apparent leg-length inequality may be caused by an adduction contracture or true shortening on the involved side from femoral head collapse.

DIAGNOSIS

Routine plain radiographs are the primary diagnostic tool for LCPD. AP and Lauenstein (frog-leg) lateral views are used to diagnose, stage, provide prognosis for, and follow the course of the disease (Fig. 719.13). It is important when evaluating disease progression that all radiographs be viewed sequentially and compared with previous radiographs to assess the stage of the disease and to determine the true extent of epiphyseal involvement.

In the initial stage of LCPD, the radiographic changes include a decreased size of the ossification center, lateralization of the femoral head with widening of the medial joint space, a subchondral fracture, and physeal irregularity. In the fragmentation stage, the epiphysis appears fragmented, and there are scattered areas of increased radiolucency and radiodensity. During the reossification stage, the bone density returns to normal via new (woven) bone formation. The residual stage is marked by the reossification of the femoral head, gradual remodeling of head shape until skeletal maturity, and remodeling of the acetabulum.

In addition to these radiographic changes, several classic radiographic signs have been reported that describe a "head at risk" for severe deformity. Lateral extrusion of the epiphysis, a horizontal physis, calcification lateral to the epiphysis, subluxation of the hip, and a

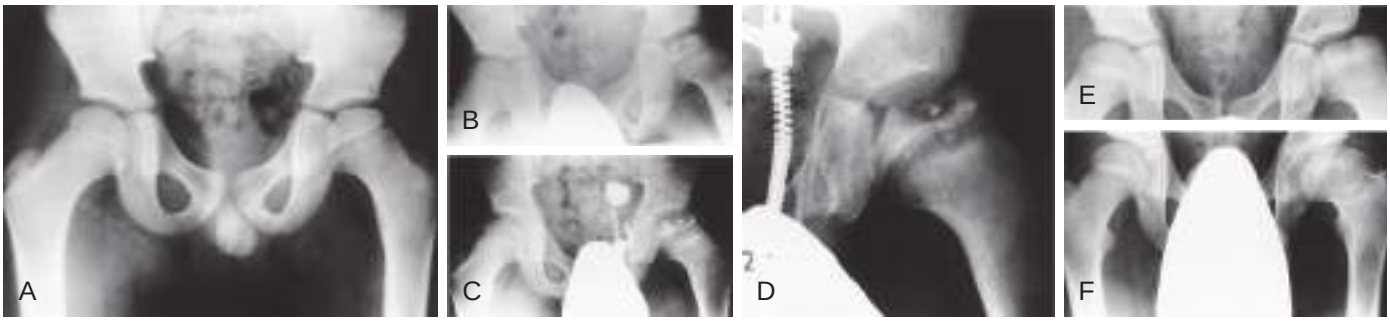

Fig. 719.13 Radiographic evolution of Legg-Calvé-Perthes disease, with onset in a male at 10-yr, 11-mo of age. Despite the late age of onset, the femoral head remodels well as the patient approaches skeletal maturity. **A,** Anteroposterior (AP) radiograph obtained at onset of the disorder shows increased density in the femoral head and apparent widening of the joint space (Waldenström's initial stage). **B,** AP radiograph obtained 9 mo after onset shows the head entering the fragmentation stage. The central fragment remains dense and has collapsed relative to the lateral portion (lateral pillar) of the femoral head. The lateral pillar is lucent but has not collapsed, and the hip is classified as group B in the lateral pillar classification system. The joint space has widened further. **C,** AP radiograph obtained 17 mo after onset shows early reossification of the femoral head (the healing stage). **D,** A closer view of the femoral head at 22 mo after onset of disease. There is still widening of the joint space, and the acetabulum has a bicompartmental appearance. **E,** AP radiograph obtained 4 yr after onset. The femoral head is healed and in the residual state. There is still widening of the joint space and incongruity of the head with the acetabulum. **F,** AP radiograph obtained 6 yr after onset shows improved roundness of the femoral head and better joint congruity. *(From Kim HK, Herring JA. Legg-Calvé-Perthes disease. In: Herring JA, ed. Tachdjian's Pediatric Orthopaedics, 6th ed. Philadelphia: Elsevier; 2022: Fig. 14.19.)*

radiolucent horizontal V in the lateral aspect of the physis (Gage's sign) are all associated with a poor prognosis.

In the absence of changes on plain radiographs, particularly in the early stages of the disease, MRI is useful to diagnose early infarction and determine the degree of impaired perfusion. It is being used more in early stages to help determine prognosis. During the remodeling or residual stages, MRI is extremely helpful to define the abnormal anatomy and determine the extent of intraarticular injury. Arthrography can be useful to dynamically assess the shape of the femoral head, demonstrate whether a hip can be contained, and diagnose hinge abduction. Table 719.1 outlines the differential diagnosis.

Table 719.1 Differential Diagnosis of Legg-Calvé-Perthes Disease

OTHER CAUSES OF AVASCULAR NECROSIS
Sickle cell disease
Other hemoglobinopathies (e.g., thalassemia)
Chronic myelogenous leukemia
Steroid medication
Sequela of traumatic hip dislocation
Treatment of developmental dysplasia of the hip
Septic arthritis
Systemic lupus erythematosus (SLE)
SKELETAL DYSPLASIAS MIMICKING PERTHES
Multiple epiphyseal dysplasia
Spondyloepiphyseal dysplasia
Mucopolysaccharidoses
Hypothyroidism
OTHER SYNDROMES
Osteochondromatosis
Metachondromatosis
Schwartz-Jampel syndrome
Trichorhinophalangeal syndrome
Maroteaux-Lamy syndrome
Martsolf syndrome
Stickler syndrome

From Kim HKW, Herring JA. Legg-Calvé-Perthes disease. In: Herring JA, ed. *Tachdjian's Pediatric Orthopaedics,* 6th ed. Philadelphia: Elsevier; 2022: Box 14.6, p. 561.

CLASSIFICATION

A four-group classification is based on the amount of femoral epiphysis involvement and a set of radiographic "head at-risk" signs**. Group I** hips have anterior femoral head involvement of 25%, no sequestrum (an island of dead bone within the epiphysis), and no metaphyseal abnormalities. **Group II** hips have up to 50% involvement and a clear demarcation between involved and uninvolved segments. Metaphyseal cysts may be present. **Group III** hips display up to 75% involvement and a large sequestrum. In **group IV**, the entire femoral head is involved. Use of this classification system has been limited because of a high degree of interobserver variability.

The **Herring lateral pillar classification** is the most widely used radiographic classification system for determining treatment and prognosis during the active stage of the disease (Fig. 719.14). The Herring classification has a high degree of interobserver reliability. Classification is based on several radiographs taken during the early fragmentation stage. The lateral pillar classification system for LCPD evaluates the shape of the femoral head epiphysis on AP radiograph of the hip. The head is divided into three sections or pillars. The lateral pillar occupies the lateral 15–30% of the head width, the central pillar is approximately 50% of the head width, and the medial pillar is 20–35% of the head width. The degree of involvement of the lateral pillar can be subdivided into three groups. In **group A**, the lateral pillar is radiographically normal. In **group B**, the lateral pillar has some lucency, but >50% of the lateral pillar height is maintained. In **group C**, the lateral pillar is more lucent than in group B, and <50% of the pillar height remains. Herring has added a B/C border group to the classification system to describe patients with approximately 50% collapse of the lateral pillar.

NATURAL HISTORY AND PROGNOSIS

Children who develop signs and symptoms of LCPD before the age of 6 years tend to recover with fewer residual problems. Patients older than 9 years of age at presentation usually have a poor prognosis. The reason for this difference is that the remodeling potential of the femoral head is higher in younger children. Greater extent of femoral head involvement and duration of the disease process are additional factors associated with a poor prognosis. Hips classified as Catterall groups III and IV and lateral pillar group C generally have a poor prognosis.

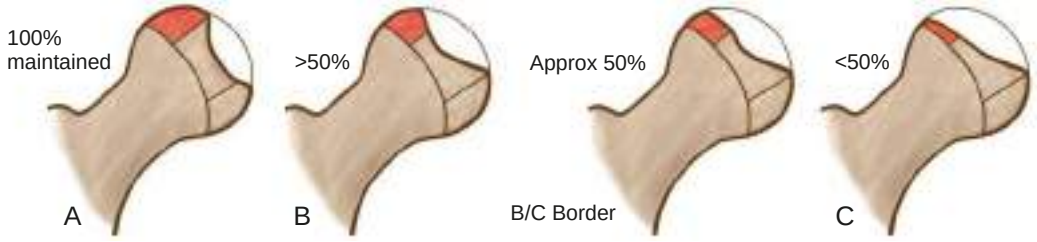

Fig. 719.14 Lateral pillar classification for Legg-Calvé-Perthes disease. **A,** There is no involvement of the lateral pillar. **B,** More than 50% of the lateral pillar height is maintained. **B/C Border,** Lateral pillar is narrowed or poorly ossified with approximately 50% height maintained. **C,** Less than 50% of the lateral pillar height is maintained.

TREATMENT

The goal of treatment in LCPD is preservation of a spherical, well-covered femoral head and maintenance of hip ROM that is close to normal. Although the treatment of LCPD remains controversial, most authors agree that the general approach to these patients should be guided by the principle of containment. This principle is predicated on the fact that while the femoral head is fragmenting, and therefore in a softened condition, it is best to contain it entirely within the acetabulum; by doing so, the acetabulum acts as a mold for the regenerating femoral head. Conversely, failure to contain the head permits it to deform, with resulting extrusion and impingement on the lateral edge of the acetabulum. To be successful, containment must be instituted early while the femoral head is still moldable; once the head has healed, repositioning the femoral epiphysis will not aid remodeling and can, in fact, worsen symptoms.

Initial options to manage symptoms include activity limitation, protected weight bearing, and nonsteroidal antiinflammatory medications. Nonoperative containment can be achieved by using a Petrie cast to restore abduction and to direct the femoral head deeper into the acetabulum. Petrie casts are two long-leg casts that are connected by a bar and can be helpful to keep the hips in abduction and internal rotation (the best position for containment). Casting is generally done in conjunction with an arthrogram to confirm containment and a tenotomy of the adductor tendons. After 6 weeks, patients can be transitioned into an abduction orthosis with limited weight bearing. Several older studies did not support the efficacy of casting and long-term bracing as a means of containment, but a subsequent large series reported excellent results with this form of treatment.

Surgical containment may be approached from the femoral side, the acetabular side, or both sides of the hip joint. A varus osteotomy of the proximal femur is the most common procedure. Pelvic osteotomies in LCPD are divided into three categories: acetabular rotational osteotomies, shelf procedures, and medial displacement or Chiari osteotomies. Any of these procedures can be combined with a proximal femoral varus osteotomy when severe deformity of the femoral head cannot be contained by a pelvic osteotomy alone.

After healing of the epiphysis, surgical treatment shifts from containment to management of the residual deformity. Patients with hinge abduction or joint incongruity might benefit from a valgus-producing proximal femoral osteotomy. Coxa breva and overgrowth of the greater trochanter can be managed by performing an advancement of the trochanter. This helps restore the length-tension relationship of the abductor mechanism and can alleviate abductor fatigue. Patients with femoroacetabular impingement from irregularity of the femoral head often can be helped with an osteoplasty or cheilectomy of the offending prominence.

Visit Elsevier eBooks+ at eBooks.Health.Elsevier.com for Bibliography.

719.4 Slipped Capital Femoral Epiphysis

Wudbhav N. Sankar, Jennifer J. Winell, B. David Horn, and Lawrence Wells

Slipped capital femoral epiphysis (SCFE) is a hip disorder that affects adolescents, most often between 10-16 years of age, and involves failure of the physis and displacement of the femoral head relative to the neck.

CLASSIFICATION

SCFEs may be classified temporally, according to onset of symptoms (acute, chronic, acute-on-chronic); functionally, according to the patient's ability to bear weight (stable or unstable); or morphologically, as the extent of displacement of the femoral epiphysis relative to the neck (mild, moderate, or severe), as estimated by measurement on radiographic or CT images.

An **acute** SCFE is characterized as one occurring in a patient who has prodromal symptoms for ≤3 weeks and should be distinguished from a purely traumatic separation of the epiphysis in a previously normal hip (a true Salter-Harris type I fracture; see Chapter 724). The patient with an acute slip usually has some prodromal pain in the groin, thigh, or knee, and usually reports a relatively minor injury (a twist or fall) that is not sufficiently violent to produce an acute fracture of this severity.

Chronic SCFE is the most common form of presentation. Typically, an adolescent presents with a few months' history of vague groin, thigh, or knee pain and a limp. Radiographs show a variable amount of posterior and inferior migration of the femoral epiphysis and remodeling of the femoral neck in the same direction.

Children with **acute-on-chronic** SCFE can have features of both acute and chronic conditions. Prodromal symptoms have been present for >3 weeks with a sudden exacerbation of pain. Radiographs demonstrate femoral neck remodeling and further displacement of the capital epiphysis beyond the remodeled point of the femoral neck.

The stability classification separates patients based on their ability to ambulate and is more useful in predicting prognosis and establishing a treatment plan. The SCFE is considered *stable* when the child is able to walk with or without crutches. A child with an *unstable* SCFE is unable to walk with or without walking aids. Patients with unstable SCFE have a much higher prevalence of osteonecrosis (up to 50%) compared to those with stable SCFE (nearly 0%). This is most likely because of the vascular injury caused at the time of initial displacement.

SCFE may also be categorized by the degree of displacement of the epiphysis on the femoral neck. The head-shaft angle difference is <30 degrees in mild slips, between 30 and 60 degrees in moderate slips, and >60 degrees in severe slips, compared to the normal contralateral side.

SCFE is one of many etiologies of acquired **coxa vara** defined by an abnormal decrease in the femoral neck shaft angle (Table 719.2).

Table 719.2 Classification of Coxa Vara

ACQUIRED COXA VARA
Slipped capital femoral epiphysis
Sequela of avascular necrosis of the femoral epiphysis
Legg-Calvé-Perthes disease
Traumatic coxa vara
Femoral neck fracture
Traumatic hip dislocation
Sequela of reduction for developmental dysplasia of the hip
Septic necrosis
Other causes of avascular necrosis of the immature femoral head
Coxa vara associated with pathologic bone disorders
Osteogenesis imperfecta
Fibrous dysplasia
Renal osteodystrophy
Osteopetrosis
Other bone-softening conditions affecting the femoral neck
Congenital femoral deficiency with coxa vara
DEVELOPMENTAL COXA VARA
Isolated (may be bilateral)
Associated with a skeletal dysplasia
Cleidocranial dysostosis
Metaphyseal dysostosis
Other skeletal dysplasias

From Sucato DJ. Congenital coxa vara. In: Herring JA, ed. *Tachdjian's Pediatric Orthopaedics*, 6th ed. Philadelphia: Elsevier; 2022: Box 16.1, p. 617.

Fig. 719.15 Clinical examination of a patient with a stable slipped capital femoral epiphysis. Hip flexion and external rotation are limited. With flexion of the affected hip, the limb rotates externally. *(From Podesczwa D. Slipped capital femoral epiphysis. In: Herring JA, ed. Tachdjian's Pediatric Orthopaedics, 6th ed. Philadelphia: Elsevier; 2022: Fig.15.5.)*

ETIOLOGY AND PATHOGENESIS

SCFEs are most likely caused by a combination of mechanical and endocrine factors. The plane of cleavage in most SCFEs occurs through the hypertrophic zone of the physis. During normal puberty, the physis becomes more vertically oriented, which converts mechanical forces from compression to shear. In addition, the hypertrophic zone becomes elongated in pubertal adolescents due to high levels of circulating hormones. This widening of the physis decreases the threshold for mechanical failure. Normal ossification depends on a number of different factors, including the thyroid hormone, vitamin D, and calcium. Consequently, it is not surprising that SCFEs occur with increased incidence in children with medical disorders, such as hypothyroidism, hypopituitarism, and renal osteodystrophy. Obesity, one of the largest risk factors for SCFE, affects both the mechanical load on the physis and the level of circulating hormones. The combination of mechanical and endocrine factors results in gradual failure of the physis, which allows posterior and inferior displacement of the head in relation to the femoral neck.

EPIDEMIOLOGY

The annual incidence of SCFE is 2 per 100,000 in the general population. Obesity is the most closely associated risk factor in the development of SCFE; approximately 65% of the patients are in the >90th percentile in weight-for-age profiles. There is a predilection for males to be affected more often than females and for the left hip to be affected more often than the right. Bilateral involvement has been reported in as many as 60% of cases, nearly half of which may be present at the time of initial presentation.

CLINICAL MANIFESTATIONS

The classic patient presenting with a SCFE is an obese male between the ages of 11 and 16 years. Females present earlier, usually between 10 and 14 years of age. Patients with chronic and stable SCFEs tend to present after weeks to months of symptoms. Patients usually limp to some degree and have an externally rotated lower extremity. Physical examination of the affected hip reveals a restriction of internal rotation, abduction, and flexion. Commonly, the examiner notes that as the affected hip is flexed, the thigh tends to rotate progressively into more external rotation with increased flexion (Fig. 719.15). Most patients complain of groin symptoms, but isolated thigh or knee pain is a common presentation from referred pain along the course of the obturator nerve. Missed or delayed diagnosis often occurs in children who present with knee pain and do not receive appropriate imaging of the hip. Patients with unstable SCFEs usually present in an urgent fashion. Children typically refuse to allow any ROM of the hip; much like a hip fracture, the extremity is shortened, abducted, and externally rotated.

DIAGNOSTIC STUDIES

AP and frog-leg lateral radiographic views of both hips are usually the only imaging studies needed to make the diagnosis. Because approximately 25% of patients have a contralateral slip on initial presentation, it is critical that both hips be carefully evaluated by the treating physician. Radiographic findings include widening and irregularity of the physis, a decrease in epiphyseal height in the center of the acetabulum, a crescent-shaped area of increased density in the proximal portion of the femoral neck, and the "blanch sign of Steel" corresponding to the double density created from the anteriorly displaced femoral neck overlying the femoral head. In an unaffected patient, Klein's line, a straight line drawn along the superior cortex of the femoral neck on the AP radiograph, should intersect some portion of the lateral capital femoral epiphysis. With progressive displacement of the epiphysis, Klein's line no longer intersects the epiphysis (Fig. 719.16). Although some of these radiographic findings can be subtle, most diagnoses can be readily made on the frog-leg lateral view, which reveals the characteristic posterior and inferior displacement of the epiphysis in relation to the femoral neck (Fig. 719.17).

TREATMENT

Once the diagnosis is made, the patient should be admitted to the hospital immediately and placed on bed rest. Allowing the child to go home without definitive treatment increases the risk that a stable SCFE will become an unstable SCFE and that further displacement will occur. Children with atypical presentations (younger than 10 years of age, thin body habitus) should have screening labs sent to rule out an underlying endocrinopathy.

The goal of treatment is to prevent further progression of the slip and to stabilize (i.e., close) the physis. Although various forms of treatment have been used in the past, including spica casting, the current gold standard for the treatment of SCFE is in situ pinning with a single large screw (Fig. 719.18). The term *in situ* implies that no attempt is made to reduce the displacement between the epiphysis and femoral neck because doing so increases the risk of

osteonecrosis. Screws are typically placed percutaneously under fluoroscopic guidance. Postoperatively, most patients are allowed partial weight bearing with crutches for 4-6 weeks, followed by a gradual return to normal activities. Patients should be monitored with serial radiographs to be sure that the physis is closing and that the slip is stable. After healing from the initial stabilization, patients with severe residual deformity may be candidates for proximal femoral osteotomy to correct the deformity, reduce impingement, and improve range of motion.

Because 20–40% of children will develop a contralateral SCFE at some point, many orthopedists advocate prophylactic pin fixation of the contralateral (normal) side in patients with a unilateral SCFE. The benefits of preventing a possible slip must be balanced with the risks of performing a potentially unnecessary surgery. Several recent studies have attempted to analyze decision models for prophylactic pinning, but controversy remains regarding the optimal course of treatment. If prophylactic pinning is not performed, patients and their families must be instructed to return immediately if they develop contralateral hip or leg pain.

COMPLICATIONS

Osteonecrosis and chondrolysis are the two most serious complications of SCFE. Osteonecrosis, or avascular necrosis, usually occurs as a result of injury to the retinacular vessels. This can be caused by an initial force of injury, particularly in unstable slips, forced manipulation of an acute or unstable SCFE, compression from intracapsular hematoma, or as a direct injury during surgery. Partial forms of osteonecrosis can also appear after internal fixation; this can be caused by a disruption of the intraepiphyseal blood vessels. Chondrolysis, on the other hand, is an acute dissolution of articular cartilage in the hip. There are no clear causes of this complication, but it is thought to be associated with more severe slips, to occur more commonly in females, and to be associated with pins or screws protruding out of the femoral head.

Visit Elsevier eBooks+ at eBooks.Health.Elsevier.com for Bibliography.

Fig. 719.16 Illustration of Klein's line.

Fig. 719.18 Preoperative (**A**) and postoperative (**B**) radiographs demonstrating the in situ pinning in a case of slipped capital femoral epiphysis.

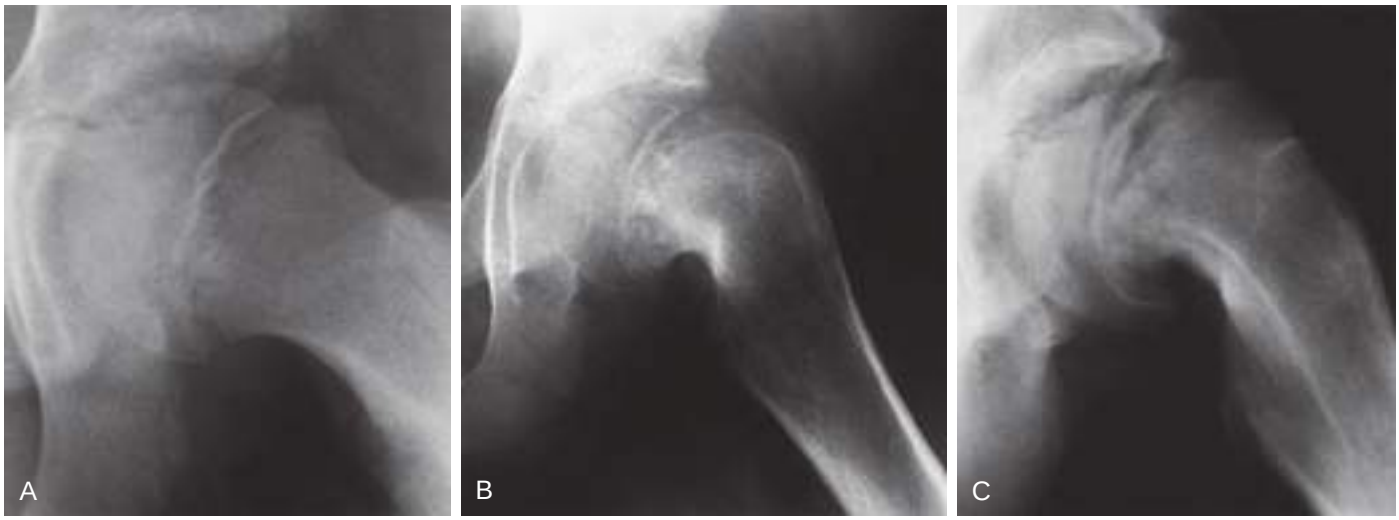

Fig. 719.17 Radiographic appearance of slipped capital femoral epiphysis (SCFE) on presentation. **A,** Appearance of acute SCFE on a frog-leg lateral view. The displacement of the epiphysis is suggestive of a Salter-Harris type I fracture of the upper femoral physis. There are no secondary adaptive changes noted in the femoral neck. **B,** Frog-leg lateral radiographs in a patient with many months of thigh discomfort and a chronic slipped epiphysis. Adaptive changes in the femoral neck predominate, and the epiphysis is centered on the adapted femoral neck. **C,** Frog-leg lateral radiographs of a patient with acute-on-chronic SCFE. The patient had several months of vague thigh pain, with sudden, severe exacerbation of that pain. The acute displacement of the epiphysis is evident. Unlike in acute SCFE (see **A**), secondary adaptive remodeling changes are also present in the femoral neck, beyond which the epiphysis has acutely displaced. *(From Podeszwa D. Slipped capital femoral epiphysis. In: Herring JA, ed. Tachdjian's Pediatric Orthopaedics, 6th ed. Philadelphia: Elsevier; 2022: Fig. 15.1, p. 583.)*

Chapter 720

The Spine

R. Justin Mistovich, Keith D. Baldwin, and David A. Spiegel

Abnormalities of the spine can result from a variety of causes, including congenital, developmental, and traumatic. In addition to spinal deformities, back pain is also prevalent in children and adolescents and may be caused by a number of serious or relatively benign pathologies.

NORMAL SPINAL CURVATURES

A normal spinal column is straight in the anteroposterior (AP, coronal) plane but has curvatures in the lateral (sagittal) plane. Normal cervical lordosis, thoracic kyphosis, and lumbar lordosis regions are biomechanically advantageous as they maintain relationships of the body relative to the forces of gravity, which is important for balance. These curvatures also help to conserve energy by minimizing the amount of muscular activity required to maintain an upright posture.

Abnormalities affecting these normal curvatures, termed *sagittal plane imbalances*, can be measured on a lateral spine radiograph. A vertical line, or *plumb line*, drawn from the center of the seventh cervical vertebra should normally fall through the posterosuperior corner of the sacrum. Disorders affecting sagittal alignment include thoracic hyperkyphosis and lumbar hyperlordosis. In contrast, although scoliosis is *actually* a three-dimensional deformity not limited to a single anatomic plane, it is most commonly *described* as a frontal or coronal plane deformity with curvatures away from the midline in this plane.

OVERVIEW OF ABNORMAL SPINAL CURVATURES

The most common spinal deformities are scoliosis and kyphosis. Early diagnosis is important, as a subset of patients may be candidates for early interventions to prevent curve progression. Bracing has been proven to reduce the number of patients with curve progressing to require surgery in **adolescent idiopathic scoliosis (AIS).**

Scoliosis may be idiopathic, due to congenital bony deformities, or may be associated with a variety of underlying conditions, including neuromuscular diseases, connective tissue diseases, or genetic syndromes. Oftentimes, the pediatrician is the first to diagnose these conditions.

Although parents and families are often most concerned about potential cosmetic abnormalities, the physician diagnosing a patient with a spinal deformity must carefully consider both the potential for underlying causes requiring treatment and the patient's long-term prognosis. Progressive curvatures in the neuromuscular population may result in respiratory insufficiency in addition to a loss of sitting balance. Other conditions such as neurofibromatosis are associated with a specific dystrophic curve pattern that can rapidly progress. Sometimes, a spinal deformity might be the first sign of an underlying syndrome. Parents and the patient need an understanding of the deformity, how it may progress, and potential complications associated with the diagnosis. A classification of common spinal abnormalities is presented in Table 720.1.

720.1 Idiopathic Scoliosis

R. Justin Mistovich, Keith D. Baldwin, and David A. Spiegel

Scoliosis is a complex, three-dimensional spinal deformity, defined in the coronal plane as a curve of at least 10 degrees on a posteroanterior (PA) radiograph of the spine. Affected vertebrae are axially rotated, causing a visible prominence to be noted on the **Adams forward bend test**. The sagittal plane is also affected, leading to abnormalities such as decreased thoracic kyphosis.

ETIOLOGY

By definition, the etiology of idiopathic scoliosis remains unknown despite a considerable body of research. It is likely that the disease is multifactorial, with genetic, hormonal, cellular, and anatomic contributions.

A genetic link has been proposed with sex-linked dominant, autosomal dominant, and polygenetic inheritance patterns all suggested. Genetic involvement has been substantiated in studies of twins, demonstrating a 73% concordance rate for AIS in monozygotic twins compared to a 36% concordance rate in dizygotic twins.

AIS is 2 to 10 times more common in females than males. Investigators have attempted to explain this difference as a genetic effect: it has been hypothesized that males are not as susceptible to the involved genes as females. Therefore, affected males must inherit a larger number of susceptibility genes to have a scoliosis phenotype. Males would pass more susceptibility genes onto their children and would therefore have more affected children. Fathers with AIS transmit the gene to 80% of their children, but mothers with AIS transmit it to only 56% of their children.

Exome sequencing has identified pathogenic variants in the *COL11A2* collagen gene in 32% of AIS cases. COMP promotor methylation has been correlated with a younger age and larger main curve magnitude. Other gene variants have been found to demonstrate an association with AIS, including *PAX1*, *POC5*, the Bsml polymorphism in the vitamin D receptor gene, and *FBN1*. Additionally, females who have first-degree relatives with AIS have been found to have more severe curves and longer arm spans than females who have a spontaneous case.

Cellular structures may be involved in the disease process. Calmodulin, a regulator of the contractile properties of muscle, occurs at increased levels in the platelets of patients with progressive AIS. On a more cellular level, differences in the mRNA expression of H19 and ADIPOQ have been described in the paraspinal musculature from the concave to the convex side of a curvature. Other functional evaluations of patients with AIS have noted abnormalities in proprioception and postural balance.

MRI studies of the brain in patients with AIS versus controls have found that the cerebellum of affected patients is hypertrophied in areas involving the somatosensory tracts, motor control, and response to visual stimulation. These areas of hypertrophy may be a compensation for impaired balance resulting from malalignment of the spine.

Approximately 30% of females with AIS have osteopenia on DEXA studies, and of these, 80% will have lifelong osteopenia. Osteopenia has been linked to an increased risk of curve progression. Insufficient vitamin D levels have been reported in over 90% of patients with operative AIS.

EPIDEMIOLOGY

Idiopathic scoliosis is the most common type of spinal curvature; 80% of cases are idiopathic. The overall prevalence of idiopathic scoliosis in skeletally immature patients ranges from 1–3% of the population. Most curves are mild and do not require treatment, with only 0.5% being >20 degrees and 0.3% exceeding 30 degrees. Curves of ≤10 degrees occur equally between males and females; however, those requiring an intervention occur in a 7:1 female-to-male ratio.

CLASSIFICATION OF IDIOPATHIC SCOLIOSIS

Idiopathic scoliosis is classified according to the age at onset. Patients with curves that are present before age 8-10 years have **early-onset scoliosis (EOS)**. Although EOS can have several etiologies, young patients without a clearly identified cause are classified as having idiopathic EOS. The subgroup of *infantile idiopathic EOS* refers to patients diagnosed before age 3 years and accounts for only 0.5–4% of cases of AIS. AIS affects patients 10 years of age and older and comprises 70–80% of all cases of idiopathic scoliosis.

Table 720.1 Classification of Spinal Deformities

SCOLIOSIS
Idiopathic
Infantile
Juvenile
Adolescent
Congenital
Failure of formation
Wedge vertebrae
Hemivertebrae
Failure of segmentation
Unilateral bar
Block vertebra
Mixed
Neuromuscular
Neuropathic diseases
Upper motor neuron
Cerebral palsy
Spinocerebellar degeneration (Friedreich ataxia, Charcot-Marie-Tooth disease)
Syringomyelia
Spinal cord tumor
Spinal cord trauma
Lower motor neuron
Poliomyelitis
Spinal muscular atrophy
Myopathies
Duchenne muscular dystrophy
Arthrogryposis
Other muscular dystrophies
Syndromes
Neurofibromatosis
Marfan syndrome
Compensatory
Leg-length discrepancy
KYPHOSIS
Postural kyphosis (flexible)
Scheuermann disease
Congenital kyphosis
Failure of formation
Failure of segmentation
Mixed

Adapted from the Terminology Committee, Scoliosis Research Society. A glossary of scoliosis terms. *Spine*. 1976;1:57.

CLINICAL PRESENTATION OF IDIOPATHIC SCOLIOSIS

When evaluating a patient with a structural spinal curvature, a thorough history and physical examination are required because idiopathic scoliosis is a diagnosis of exclusion. All other potential causes, including congenital bone malformations, neuromuscular and syndromic diseases, and tumors must systematically be excluded.

The curvature is frequently found on a positive screening by primary care physicians, through a school screening program, or because patients (or their family or friends) have noticed a cosmetic deformity. Citing the need for early identification of scoliosis to reduce the risk of operative complications with correction of large, neglected curves, the Scoliosis Research Society advocates for school screening. The BrAIST study, which definitively demonstrated that patients treated with Boston braces for 18 hours a day have a significantly lower incidence of curves progressing to the surgical range, supports the potential value of early detection through screening programs. Although the United States Preventive Services Task Force previously recommended against school screening programs, their updated 2018 recommendation statement concluded that evidence was insufficient to recommend for or against screening.

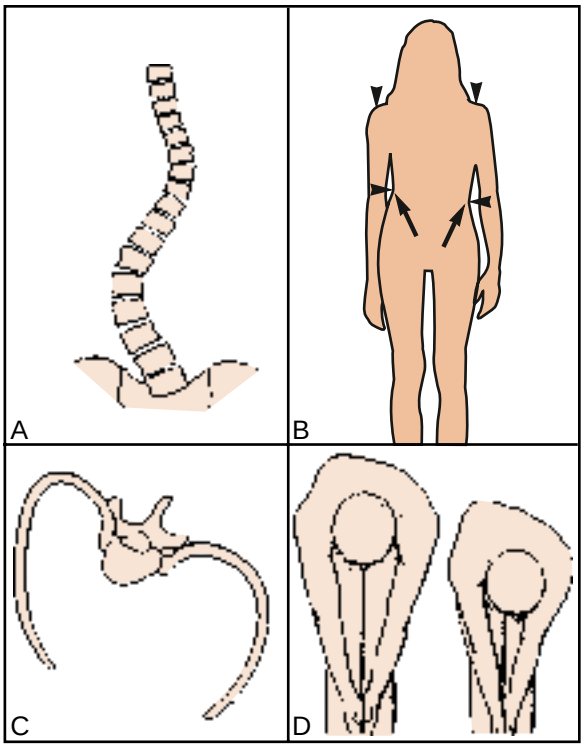

Fig. 720.1 Structural changes in idiopathic scoliosis. **A,** As curvature increases, alterations in body configuration develop in both the primary and compensatory curve regions. **B,** Asymmetry of shoulder height, waistline, and elbow-to-flank distance are common findings. **C,** Vertebral rotation and associated posterior displacement of the ribs on the convex side of the curve are responsible for the characteristic deformity of the chest wall (rib hump) in scoliosis patients. **D,** In the school screening examination for scoliosis, the patient bends forward at the waist. Rib asymmetry of even a small degree is obvious. *(From Scoles PV. Spinal deformity in childhood and adolescence. In: Behrman RE, Vaughn VC III, eds. Nelson Textbook of Pediatrics, update 5. Philadelphia: WB Saunders; 1989.)*

Back pain is not commonly a primary presenting complaint of patients with scoliosis, though when questioned, at least 30% of adolescents with idiopathic scoliosis will report some degree of back discomfort at some point in time. To keep this finding in perspective, a similar number of healthy adolescents complain of episodes of low back pain and discomfort. If a child presents with back pain associated with a curvature, it is important to do a careful history and physical exam, check spine radiographs, and rule out any diagnostic red flags (see Chapter 720.5). Look for other causes of pain in these patients, including spondylosis, spondylolisthesis, tethered cord, syrinx, herniated disk, or tumor such as osteoid osteoma or spinal cord tumor.

PHYSICAL EXAMINATION OF IDIOPATHIC SCOLIOSIS

Evaluate the patient in the standing position, from both the front and the side, to identify any asymmetry in the chest wall, trunk, or shoulders.

Begin the examination focusing on the back. The earliest abnormality noted on physical exam in patients with scoliosis is asymmetry of the posterior chest wall on forward bending. This test, called the Adams forward-bending test (Fig. 720.1), is performed by observing the patient's back while he or she is bending 45 degrees forward. This test can also be augmented with a scoliometer placed at the apex of the deformity. An inclination measuring 7 degrees or more has been suggested as the cutoff for orthopedic referral. Scoliosis is a three-dimensional deformity; patients develop a posterior rib hump on the convex side of the spinal curve as a result of the rotational component of the deformity. The anterior chest wall may be prominent on the

concavity of the curve due to outward rib rotation. Other associated findings may include shoulder imbalance, a lateral shift of the trunk, or an apparent leg-length discrepancy due to pelvic obliquity. A primary **limb length discrepancy** may also present as a lumbar spinal deformity. This lumbar curvature is compensatory and flexible, with the apex toward the shorter leg.

Next, examine the patient from the side to evaluate the degree of kyphosis and lordosis. The upper thoracic spine normally has a smooth, gently rounded kyphotic curve with an apex in the midthoracic region. The cervical spine and lower lumbar spine have concave, or lordotic curves. The magnitude of these sagittal contours varies with age. Children have less cervical lordosis and more lumbar lordosis than do adults or adolescents. When examining a patient with idiopathic scoliosis, a common finding is a loss of the normal thoracic kyphosis, resulting in what is called a relative thoracic lordosis or hypokyphosis.

Another common, benign finding in normal adolescent thoracic spines not associated with scoliosis is a flexible round back, or postural kyphosis. This can be corrected voluntarily when the patient extends his or her spine. This is different from sharp, abrupt, or accentuated forward angulation in the thoracic or thoracolumbar region, which is indicative of a pathologic kyphotic deformity.

The final exam component is a careful neurologic examination because scoliosis may be associated with an underlying neurologic diagnosis. Check superficial abdominal reflexes, extremity deep tendon reflexes, muscle strength, and atrophy and examine for clonus. Also, remember to examine the patient's feet because a cavovarus foot can be associated with a tethered cord. A high suspicion is necessary in patients with infantile and juvenile idiopathic scoliosis because up to 25% have an associated intraspinal abnormality such as a tethered spinal cord or syringomyelia. The index of suspicion for neurologic involvement is further raised in the presence of back pain or neurologic symptoms, bowel or bladder symptoms, café-au-lait spots, a sacral dimple, midline cutaneous abnormalities such as a hair patch or skin tag, unilateral foot deformity, or an atypical curve pattern.

RADIOGRAPHIC EVALUATION OF IDIOPATHIC SCOLIOSIS

Standing, high-quality PA and lateral radiographs of the *entire* spine are recommended at the initial evaluation for patients with clinical findings suggestive of a spinal deformity. Many children's hospitals have low-dose stereoradiographic imaging systems rather than conventional radiographs, which can minimize radiation exposure and also provide three-dimensional reconstructions of spinal deformity. On the PA radiograph, the degree of curvature is determined by the **Cobb angle**, in which the angle between the superior and inferior vertebrae most tilted into the curve is measured (Fig. 720.2).

Although the indications for performing an MRI are variable, it is helpful when an *underlying* cause for scoliosis such as a spinal cord abnormality is being considered. Patients with early-onset scoliosis have a higher incidence of associated cord anomalies. Other considerations include abnormal findings on the history or physical examination and atypical radiographic features, including abnormal curve patterns. Atypical radiographic findings include curve patterns such as a left thoracic curve, double thoracic curves, or high thoracic curves. Other radiographic abnormalities include widening of the spinal canal and erosive or dysplastic changes in the vertebral body or ribs. On the lateral radiograph, an increase in thoracic kyphosis or an absence of segmental lordosis may be suggestive of an underlying neurologic abnormality.

NATURAL HISTORY OF IDIOPATHIC SCOLIOSIS

Treatment decisions are based on the natural history of idiopathic scoliosis. Infantile idiopathic early-onset scoliosis may spontaneously resolve in 20–90% of cases. Patients with infantile scoliosis who have cognitive disabilities, curves presenting after 1 year of age, and larger magnitude curves are more likely to progress. A radiographic parameter called the Mehta angle can also be used to predict curve progression in infantile scoliosis. This measurement examines the vertebra at the apex of the thoracic curve. It measures the angle formed by a line

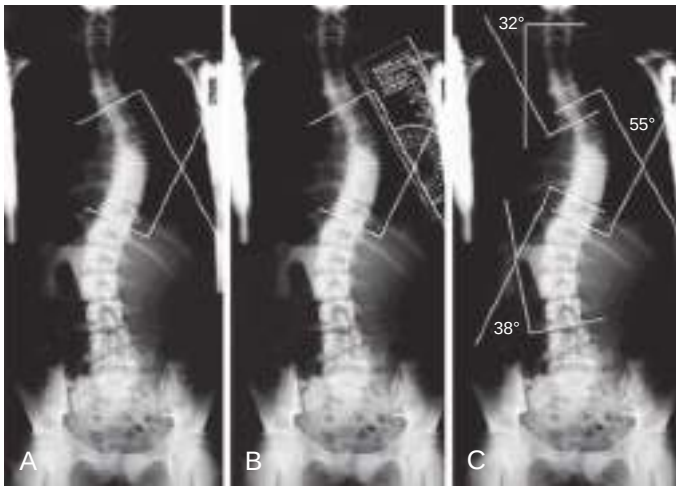

Fig. 720.2 A-C, Cobb angles measurements. *(From Morrissey RT, Weinstein SL, eds. Lovell and Winter's Pediatric Orthopaedics, 3rd ed. Philadelphia: Lippincott Williams & Wilkins; 1990.)*

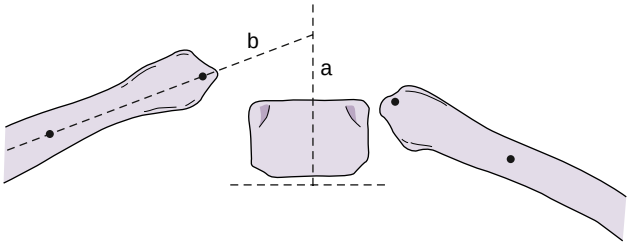

Fig. 720.3 Measuring the rib-vertebra angle difference (RVAD). A line is drawn perpendicular to the inferior end plate of the apical thoracic vertebra. Another line is drawn between two points that bisect the head and neck of the rib articulating with the apex. The angle between the perpendicular line *(a)* and the rib line *(b)* is measured. The same procedure is repeated for the rib on the opposite side. The concave–convex side angles are equal to the RVAD. *(Modified from Mehta MH. The rib-vertebra angle in the early diagnosis between resolving and progressive infantile scoliosis. J Bone Joint Surg Br. 1972;54[2]:230–243.)*

perpendicular from the vertebral end plate and a line down the center of the rib. The measurement is calculated on the convex and concave side, and the final **rib vertebral angle difference** (RVAD) is calculated by subtracting the convex side from the concave side (Fig. 720.3). A curve with an RVAD <20 degrees will resolve in about 80% of cases, whereas one with an RVAD >20 degrees will progress in over 80% of cases. Curves that resolve typically do so before 2 years of age.

Several factors affect the rate of curve progression in patients with AIS. Curves are more likely to progress in more skeletally immature patients with significant growth remaining. Findings associated with significant growth remaining are younger age, premenarchal status, Tanner stage I or II, Risser sign (a radiographic measurement of ossification of the iliac crest) of 0 or 1, and Sanders Maturity Scale values of 1-4. The Sanders Skeletal Maturity Staging System examines skeletal maturity using a single PA radiograph of the left hand and associates this value with current curve magnitude. Patients are staged from S1-S8, with S1 being the most immature and S8 indicating early maturity. Higher magnitude curves in more skeletally immature patients are more likely to progress.

Other factors affecting curve progression are the current curve magnitude, curve pattern, and patient sex. Three-dimensional spinal measurements of vertebral wedging, axial rotation, and torsion have been correlated to curve progression. In general, female patients are more likely than males to have curves that progress. Younger, premenarchal

females with curves between 20 and 30 degrees have a significantly higher risk of progression than do females 2 years after menarche with similar curves, demonstrating the significance of age on progression. In fact, the older group is unlikely to have any progression at all whereas premenarchal females with the same curve are likely to progress. Thoracic curves <30 degrees rarely progress after skeletal maturity, while those >45 degrees may progress approximately 1-2 degrees annually past skeletal maturity, and surgical stabilization is commonly offered.

Functionally, there are not many significant, clinically detrimental effects of smaller curves. There is conflicting literature regarding the exact curve magnitude and curve morphology in idiopathic thoracic scoliosis that leads to cardiopulmonary impairment. Thoracic curves of 50-70 degrees and greater have been associated with pulmonary impairment, although magnitude of curve alone cannot fully predict pulmonary function. Exercise capacity indicators, including heart rate, peak oxygen intake, and work rate, were not affected by thoracic curve magnitude, while FEV_1 was influenced in a prospective study of AIS patients. Factors such as thoracic kyphosis, curve stiffness, location of curve apex, and degree of vertebral rotation may also impact pulmonary function. Surgical correction is correlated with improved total lung capacity in patients with severe restrictive pulmonary function preoperatively.

Long-term studies have demonstrated that back pain is common in patients with scoliosis, although there is no definitive connection between pain and the curve magnitude or location. Furthermore, nearly 70% of patients with pain reported low or moderate severity of symptoms, stating that the pain does not interfere with normal activities.

TREATMENT OF IDIOPATHIC SCOLIOSIS

Treatment options include observation for small curves, bracing, and surgical care. Vitamin D deficiency is common in patients with adolescent idiopathic scoliosis, so evaluation and supplementation if appropriate should be considered. Brace treatment decreases the incidence of curve progression. The BrAIST study, examining the effect of Boston braces in patients treated for 18 hours a day, was stopped before study completion because the benefits of bracing became so clear that it was unethical to continue patients in the nonbraced control arm of the study. Treatment success (preventing curve progression to 50 degrees) in the bracing group was 72%, whereas only 48% of those patients observed without bracing avoided progression to the surgical range. Other types of bracing have also been used, including the Providence night bending brace and the Rigo Chêneau Brace. When discussing bracing with families, is important to understand that bracing in AIS does not lead to curve resolution or other measures of decreased magnitude but rather limits further progression. Additionally, while ~30% of patients who are braced will still require surgery, this does not necessarily mean that bracing was unsuccessful: without a brace, the curve may have progressed more rapidly or to an even higher magnitude, potentially requiring either an earlier surgery or more extensive fusion.

The bracing success rate depends on the amount of growth remaining. For example, patients with infantile or juvenile scoliosis are much more likely to require a surgical procedure than those with adolescent scoliosis and limited remaining growth. Patients at Risser 0 who are very skeletally immature are at a higher risk of surgery even if they are braced. It is recommended that these skeletally immature patients with curves that are otherwise thought of as small magnitude (>30 degrees) should be braced full time for a minimum of 18 hours daily. In addition to the effect of skeletal maturity, adherence with the recommended protocol for wearing the brace will influence the outcome. Adherence can be a challenge in the adolescent population. To better counsel parents and patients on their adherence, braces can be fitted with sensors to monitor duration of wear, and surgeons can review this data with families during follow-up appointments.

Braces are offered for treatment of skeletally immature patients with curves >30 degrees at the first visit or in patients who are being followed and have developed progression of their curvature beyond 25 degrees. Bracing is ineffective in curvatures >45 degrees because these patients have already reached the threshold for surgical intervention. The brace is worn until complete cessation of growth in males, but in females, weaning from the brace may be considered when the patient is more than 2 years postmenarchal, is a Risser 4 or greater, and has grown less than a centimeter over the previous 6 months. Some practitioners will continue with the bracing beyond these parameters and base their weaning on the Sanders scale and/or assessment of the maturity of the distal radius and ulna, especially when the curve is more than 40 degrees because these curves are thought to have a significant incidence of progression after bracing has been completed. There also has been interest in using the Schroth method, which involves physical therapy in addition to a bracing program. While several studies have suggested that the Schroth method may enhance the success of a bracing program, further study will be required to make definitive recommendations.

Serial body casting **(Mehta casting)** can be performed in patients with early-onset scoliosis to minimize the risk of curve progression and potentially delay the necessity of growing spine procedures. In some cases, the scoliosis can be permanently corrected without the need for long-term bracing or surgery. Although most patients can tolerate casting well, the treatment is labor intensive, and there may be a negative impact on health-related quality of life for patients and their caregivers during and potentially after casting. Nonetheless, this quality-of-life effect must be carefully weighed against the risk of increased complications in patients who begin earlier growth-sparing spine surgery. One study found the risk of unplanned reoperation was 3 times higher in those who had growth-sparing spine surgery before age 3 when compared with those who were able to delay surgery.

Traditional surgical treatment involves spinal instrumentation and fusion and is usually recommended for skeletally immature patients with progressive curves >45 degrees and skeletally mature patients with curves >50 degrees. Some surgeons will also consider surgery for lumbar curves >35 degrees, particularly if associated with truncal imbalance. The goals of surgery are to arrest progression of the deformity, to improve cosmesis, and to achieve a balanced spine, all while minimizing the number of vertebral segments that are stabilized and thereby preserving as much motion as possible.

Implants including pedicle screws, sublaminar wires or bands, and hooks are attached to two longitudinal rods (Fig. 720.4). All implants function by allowing the application of mechanical forces to the spine, correcting the deformity in both the frontal and lateral planes to achieve normal frontal and sagittal spinal balance. Pedicle screw constructs also allow for derotational maneuvers, correcting the rib prominences associated with the axial component of the deformity. After instrumentation, the spine is decorticated, and bone graft is placed for the fusion portion of the procedure. The strength of modern spinal implants maintains correction without requiring a postoperative brace in most cases.

Most procedures are performed posteriorly using pedicle screw fixation, which affords excellent correction, especially of the rotational component of the deformity. Posterior osteotomies are often added to enhance flexibility and improve the degree of correction in stiffer curves. Anterior spinal releases requiring a thoracotomy are performed infrequently as a result of the efficacy of pedicle screw instrumentation. Open anterior thoracic and thoracolumbar procedures violate the chest wall and often the diaphragm. Pulmonary function may take up to 2 years to return to normal values. Although thoracoscopic techniques may be used to perform anterior spinal release with or without instrumentation and fusion, their use has been limited because of the efficacy of posterior pedicle screw constructs. However, patients with conditions such as neurofibromatosis and myelomeningocele have a higher likelihood of achieving a nonunion of their fusion, and an anterior fusion may be considered in addition to the posterior fusion in these groups. Additionally, patients with severe, neglected deformities may still benefit from combined anterior and posterior procedures.

Younger patients, in whom the triradiate cartilage remains open, are at risk for "crank shafting," or progressive deformity due to continued anterior spinal growth, after a posterior fusion. Traditionally, these patients were treated by simultaneous anterior fusion to remove this growth potential; however, the rigidity of pedicle screw constructs has negated the need for this additional surgery. While an anterior fusion

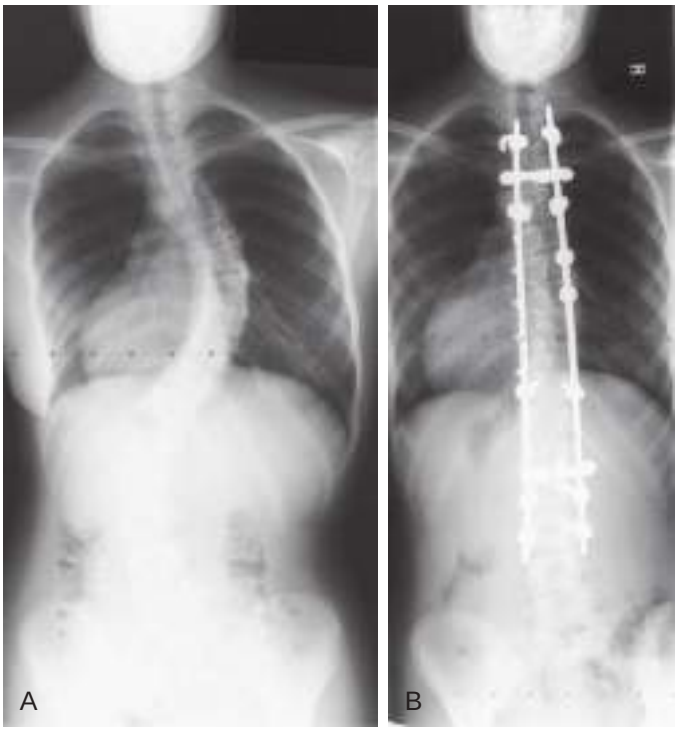

Fig. 720.4 Preoperative standing posteroanterior radiograph of a 14-yr-old female who was skeletally immature and developed a 68-degree right thoracic and a 53-degree left lumbar scoliosis (**A**). Her trunk was shifted to the right, and the left shoulder was slightly depressed. Based on the risk of future progression, she was treated by an instrumented posterior spinal fusion from T3 to L3 with correction of the right thoracic curve to 20 degrees and the left lumbar curve to 10 degrees (**B**). Coronal spinal balance was restored, and shoulder height was maintained.

Fig. 720.5 A postoperative lateral radiograph of a skeletally immature patient with severe syndromic scoliosis after placement of growing rods.

with instrumentation can be considered for idiopathic thoracolumbar and lumbar curves, the posterior approach with pedicle screw fixation is being used more frequently to avoid the need for anterior surgery and chest wall violation.

Very young patients with growing spines are not candidates for definitive **posterior spinal fusion**, as this will limit their lung capacity. A commonly employed simple measurement of thoracic height (a vertical line drawn from T1-T12) can help guide treatment decisions, with fusion not recommended for patients with a thoracic height <22 cm.

In patients with remaining thoracic growth, growing spine procedures are recommended when surgical intervention is required. The most commonly used implants are **growing rods** (traditional and magnetic) and the **vertical expandable prosthetic titanium rib (VEPTR)**.

Growing rods have fixation points placed at the proximal and distal ends of the spinal deformity, which are then linked to subcutaneous expandable rods, spanning the length of the deformity (Fig. 720.5). These fixation points can be pedicle screws or hooks that affix to the posterior elements of the spine. Traditional growing rods require additional minor operations to lengthen the rods, performed about every 6-8 months. **Magnetically controlled growing rods (MCGRs)**, once inserted, can be lengthened in the clinic using an external device, thereby eliminating the need for further surgeries. Even with MCGR, complications are relatively common, with 39% of patients experiencing at least one complication, including rod breakage, screw/hook failure, failure of the rod to lengthen, and surgical site infection (though the risk of infection is lower than in traditional growing rods). Whether patients have traditional or magnetic growing rods, a final fusion is usually necessary once they have sufficient thoracic height or attain skeletal maturity. In selected cases in which the device is stable and the curve is well controlled once patients have achieved adequate pulmonary maturity and chest wall growth, observation has been selected rather than definitive fusion. Minimal correction is achieved when converting growth sparing implants to definitive spinal fusion because there is local osteopenia and usually fibrous or osseous fusions at a subset of spinal segments. In patients who have elected observation rather than conversion to a fusion, the indications for conversion would include implant failure/loss of correction and/or progression of curvature.

The VEPTR (Fig. 720.6) helps young children with thoracic insufficiency syndrome and is also used for early-onset scoliosis in patients with congenital or neuromuscular diagnoses. Long-term survival rates are favorable for these extremely severe deformity patients treated by VEPTR, though the risk of implant-related complications is substantial. Surgery in these young syndromic patients carries a substantial risk of complications, and one study reported a complication rate of nearly 85% with a mortality rate of over 15% over the entire course of operative treatment for early-onset scoliosis.

Significant interest remains in developing surgical techniques to treat AIS that can avoid spinal fusion. One fusionless technique currently used is anterior vertebral body tethering, consisting of a flexible cord attached with screws to affected vertebrae, allowing for correction of a curve dynamically by limiting growth on the curve convexity. Although the device most certainly limits motion to some extent, one would expect greater motion than patients treated with fusion. The ideal indications for tethering remain unclear, though commonly employed criteria are patients age 9-15 years with thoracic curves of 40-67 degrees and Risser stage of ≤1.

A meta-analysis of tethering found that pooled complication rates were 26% for patients treated with a tether versus 0.6% for those treated with a standard posterior spinal fusion. Additionally, the mean reoperation rates in studies that had at least 3 years of follow-up were 24.7% in patients treated with tethers versus 1.8% in posterior spinal fusion patients. Patients treated with posterior spinal fusion have a mean revision rate at 10 years of 7.5% (i.e., >90% are definitively treated with a single procedure).

Another novel fusionless treatment is the ApiFix, which is an expandable, ratcheting, hinged rod connected to a cluster of pedicle screws above and below a curve. The device is placed posteriorly and can allow more motion than traditional fusion techniques, but this has been associated with a 50% complication rate within 2 years, including

Fig. 720.6 A postoperative posteroanterior radiograph of a patient with Jeune syndrome after placement of a right rib-to-rib VEPTR (vertical expandable prosthetic titanium rib).

implant breakage, failure of the ratchet mechanism, osteolysis, and bacterial seeding of implants.

Visit Elsevier eBooks+ at eBooks.Health.Elsevier.com for Bibliography.

720.2 Congenital Scoliosis

R. Justin Mistovich, Keith D. Baldwin, and David A. Spiegel

Congenital scoliosis is a spinal deformity that results from abnormal development of the vertebrae. Asymmetric spinal growth due to one or more vertebral anomalies leads to spinal curvature. Although the malformation is present at birth, it may not become clinically apparent until a later time as growth progresses.

ETIOLOGY

Embryologic development of the spine begins at the fifth week of gestation. An insult to the normal developmental process occurs, resulting in abnormal growth of one or more vertebrae. Oftentimes, this abnormal development is associated with additional developmental anomalies or known syndromic conditions, including Alagille, Jarcho-Levin, Klippel-Fiel, Goldenhar, and VACTERL syndromes.

ASSOCIATED CONDITIONS

It is common for children with congenital scoliosis to have associated malformations in other organ systems that must be ruled out. Genitourinary abnormalities are identified in 20–40% of children with congenital scoliosis and include unilateral renal agenesis, ureteral duplication, horseshoe kidney, and genital anomalies. Approximately 2% of these patients have a silent obstructive uropathy. Renal ultrasonography should be performed early on in all children with congenital scoliosis; other studies such as CT or MRI may also be required.

Cardiac anomalies are identified in 10–54% of patients. A thorough cardiac examination should be performed as well as a referral to pediatric cardiology for consideration of echocardiography.

Intraspinal anomalies are identified in approximately 15–40% of patients. Spinal dysraphism is the general term applied to such lesions (see Chapters 631 and 689). Examples include diastematomyelia, split cord malformations, intraspinal lipomas, arachnoid cysts, teratomas, dermoid sinuses, fibrous bands, and a tight filum terminale. **Cutaneous findings** that may be seen in patients with closed spinal dysraphism include hair patches, skin tags or dimples, sinuses, and hemangiomas. Infants with these cutaneous abnormalities overlying the spine may benefit from ultrasonography to rule out an occult spinal dysraphic condition. MRI is often delayed in older patients until a clinical indication is present, such as tethering of the spinal cord, which may present as back or leg pain, calf atrophy, progressive unilateral foot deformity (especially cavovarus), and problems with bowel or bladder function.

CLASSIFICATION OF CONGENITAL SCOLIOSIS

Congenital scoliosis is classified by the type of developmental abnormality: either a **failure of formation** or a **failure of segmentation**. The deformities are then further described by the anatomic features of the affected vertebrae. Failure of formation results in wedge vertebrae or hemivertebrae. Failure of segmentation results in unilateral bar vertebrae or block vertebrae. Some instances of congenital scoliosis result from a combination of both failure of formation and failure of segmentation (Fig. 720.7). One or more bony anomalies may occur in isolation or in combination.

NATURAL HISTORY OF CONGENITAL SCOLIOSIS

The risk of progression depends on the growth potential of each anomaly, which may vary considerably. Close radiographic follow-up is required. Progression of these curves is most pronounced during periods of rapid growth associated with the first 2-3 years of life and adolescence.

The anatomic characteristics of the malformed vertebra play a significant role in the progression of deformity. The most severe form of congenital scoliosis is a *unilateral* unsegmented bar with a contralateral hemivertebra. In this anomaly, the spine is fused to the side of the unsegmented bar but also has a growth center on the other side at the location of the hemivertebra at the same level. This combination of deformities in the bony spine results in a rapidly progressive curve. All affected patients usually require surgical stabilization. A unilateral unsegmented bar is also associated with significant progression and in most cases will require surgical intervention. An isolated hemivertebra must be followed closely, and many, but not all, of these will be associated with a progressive deformity that requires surgical intervention. In contrast, an isolated block vertebra has little growth potential and rarely requires treatment.

TREATMENT OF CONGENITAL SCOLIOSIS

Early diagnosis and prompt treatment of progressive curves are essential. Bracing is not traditionally indicated for most congenital curves due to their structural nature, except in rare cases to control additional curves not associated with the bony abnormality or to attempt to delay surgery until a safer age for a surgical procedure. Once a bony abnormality is identified that is likely to progress, surgery is recommended before progression occurs, preventing development or further inevitable progression of spinal deformity. If the deformity has already developed, surgical correction is difficult to achieve and the risk of neurologic complications is high.

Surgical techniques depend on the curve anatomy, flexibility, patient age, and surgeon preference. Young patients with growing spines may benefit from a growing spine procedure to allow further growth while limiting curve progression. In terms of definitive fusion, an anterior and posterior spinal fusion was often historically required, though with pedicle screw constructs, a posterior fusion can be sufficient. A convex hemiepiphysiodesis is an option for selected cases with milder curves and younger patients, fusing only one side of the spine to allow some correction of the deformity by permitting growth on the noninvolved side of the curve. Complete excision of a hemivertebra along with fusion of a short segment of the spine through a posterior approach has been performed with greater frequency and often in early childhood. A definitive fusion is still required for many progressive curvatures at skeletal maturity.

Adolescents with a congenital etiology of their spinal deformities are at higher risk of developing in-hospital complications than those with

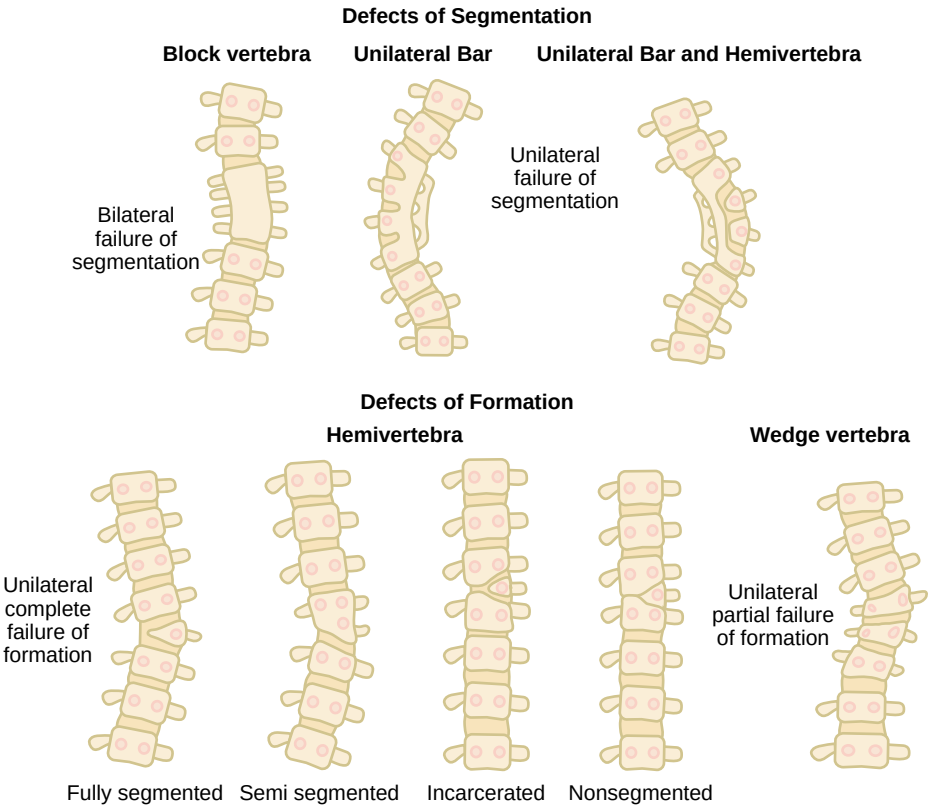

Fig. 720.7 The defects of segmentation and formation that can occur during spinal development. *(From McMaster MJ. Congenital scoliosis. In Weinstein SL, ed. The Pediatric Spine: Principles and Practice, 2nd ed. Philadelphia: Lippincott Williams & Wilkins; 2001:163.)*

idiopathic scoliosis, including shock, infection, and acute respiratory distress syndrome.

SPECIAL CIRCUMSTANCE: THORACIC INSUFFICIENCY SYNDROME

When multiple levels of the thoracic spine are involved in the presence of fused ribs, a progressive three-dimensional deformity of the chest wall may impair lung development and function. This development is termed **thoracic insufficiency syndrome**, when the chest wall is unable to support normal respiration, which can result in decreased life expectancy (Chapter 467.5).

Thoracic insufficiency syndrome may be seen in patients with several recognized conditions such as **Jarcho-Levin syndrome** (spondylocostal or **spondylothoracic dysplasia**) and **Jeune syndrome** (asphyxiating thoracic dystrophy) as well as patients with early-onset scoliosis (idiopathic, neuromuscular, or congenital) and severe spinal deformities in older patients. These difficult cases are treated with **expansion thoracoplasty**, in which the thoracic cage is gradually expanded over time by progressive lengthening of the chest wall on the concavity of the spinal deformity (or in some cases on both sides of the spine). The procedure involves an opening wedge thoracostomy, followed by placement of a VEPTR. The implant is then lengthened at regular intervals (Fig. 720.8). The primary goal is to gradually correct the chest wall deformity to improve pulmonary function, and a secondary goal is correction of an associated spinal deformity. In patients with associated fused ribs, insertion of a VEPTR with an opening wedge thoracostomy results in improved pulmonary function. VEPTR also has been used successfully in patients with early-onset congenital scoliosis. Complications are frequent, and multiple procedures are required; however, this strategy offers hope for many patients with complex, challenging cases. The decision of whether to proceed with a final spinal arthrodesis once chest wall and pulmonary development are thought to be adequate will depend on the specifics of each case. Some patients may elect to be followed even after skeletal maturity if the implant remains in stable position. Further research will be required to answer this and other questions.

Visit Elsevier eBooks+ at eBooks.Health.Elsevier.com for Bibliography.

720.3 Neuromuscular Scoliosis, Genetic Syndromes, and Compensatory Scoliosis

R. Justin Mistovich and David A. Spiegel

NEUROMUSCULAR SCOLIOSIS

Scoliosis is frequently identified in children with neuromuscular diseases such as cerebral palsy, muscular dystrophies, myopathies, spinal muscular atrophy, Friedreich's ataxia, myelomeningocele, polio, and arthrogryposis. Children with spinal cord injuries are also at high risk to develop a progressive curvature. The etiology and natural history of these patients differ from idiopathic and congenital scoliosis. Most cases result from weakness and/or imbalance of the trunk musculature. Spasticity may also contribute to spinal curvatures. In some cases, such as myelomeningocele, coexisting congenital vertebral anomalies may be present, further contributing to curve development.

A spinal deformity is more common in patients with higher degrees of neurologic impairment, particularly those who are nonambulatory with inadequate control of their trunk. It is diagnosed in more than 70% of nonambulatory patients with cerebral palsy and over 90% of patients with Duchenne muscular dystrophy.

The diagnosis is suspected on physical examination. In nonambulatory patients, the most common curve pattern is a long, sweeping C-shaped thoracolumbar or lumbar curve (Fig. 720.9). The curve is typically associated with pelvic obliquity, which may have an impact on seating balance. In contrast, ambulatory patients with diagnoses such as Friedreich ataxia may have curve patterns more similar to that of idiopathic scoliosis.

In ambulatory patients, the examination is similar to the physical examination for idiopathic scoliosis. In nonambulatory patients, the back is inspected with the patient sitting upright. Any asymmetry should be noted. These patients often need manual support to maintain an upright position. If any progressive asymmetry is observed, sitting

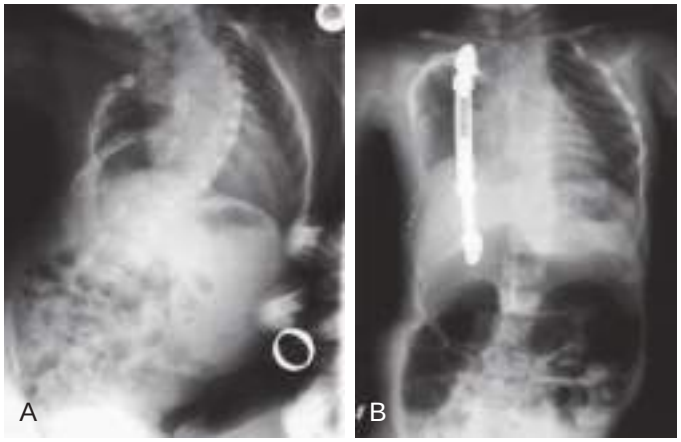

Fig. 720.8 **A,** Anteroposterior preoperative radiograph of a 7-mo-old infant with congenital scoliosis and fused ribs. A three-dimensional reconstruction of a CT scan of the chest of this infant estimated his lung volume to be 173.2 mL^3. **B,** Anteroposterior radiograph after implantation of a vertically expandable prosthetic titanium rib and several expansions over 33 mo. The lung volume now measures 330.3 mL^3, an increase of 90.7%. *(From Gollogly S, Smith JT, Campbell RM. Determining lung volume with three-dimensional reconstructions of CT scan data: a pilot study to evaluate the effects of expansion thoracoplasty on children with severe spinal deformities. J Pediatr Orthop. 2004;23:323–328.)*

Fig. 720.9 Imaging shows a long C-shaped curve with convexity to the left side and significant pelvic obliquity, a curve pattern often seen in patients with neuromuscular scoliosis. *(From Pruthi S. Scoliosis. In: Coley BD, ed. Caffey' Pediatric Diagnostic Imaging, 12th ed. Philadelphia: WB Saunders; 2013: Fig 135-10B.)*

PA and lateral radiographs should be obtained. Because prophylactic treatment or bracing cannot alter the natural history of the disease, our own preference is to establish the diagnosis clinically and obtain radiographs if the curve is noted to progress.

The clinical course of patients with neuromuscular scoliosis depends on the severity of neuromuscular involvement as well as the nature of the underlying disease process. Progressive diseases are often associated with progressive curvatures. The consequences of a progressive scoliosis in the neuromuscular population involve function, especially sitting and standing balance, and ease of hygiene and personal care. Pulmonary dysfunction may be expected with the gradual deformation of the rib cage and vertebra-pelvic axis, as well as collapse of the spine with the pelvis impinging on the rib cage. Diaphragmatic function is impaired, and changes in chest volume and chest wall architecture will undoubtedly exacerbate the pulmonary dysfunction owing to underlying muscle weakness. Pulmonary function may be difficult to document in some patient populations, especially those with severe cerebral palsy. Additionally, patients with initial marginal ambulatory function may lose the ability to walk altogether as their scoliosis advances. Curves associated with pelvic obliquity result in asymmetric seating pressures, which may limit sitting endurance and may cause skin breakdown and decubitus ulcers. Patients may also experience pain from impingement of the rib cage on the iliac crest.

The treatment of neuromuscular scoliosis depends on the age of the patient, the underlying diagnosis, and the magnitude of the deformity. The goal is to achieve or maintain a straight spine over a level pelvis, especially in the nonambulatory population, and to intervene early before curve magnitude and rigidity become severe. Neuromuscular curves often continue to progress after skeletal maturity. Curves of >40-50 degrees will continue to worsen over time. Brace treatment does not affect the natural history of neuromuscular scoliosis, and standard braces used for idiopathic scoliosis are poorly tolerated in neuromuscular patients. A **soft spinal orthosis** may improve sitting balance and ease of care, although it does not ultimately change the natural history of the curvature.

A spinal **arthrodesis** should be offered to patients with progressive curvatures over 40-50 degrees. The indications will differ somewhat based on the underlying diagnosis. For example, patients with Duchenne muscular dystrophy are often offered surgery when their curves progress beyond 20-30 degrees, before their anticipated decline in pulmonary or cardiac function makes the procedure riskier or precludes their ability to tolerate surgery. Ambulatory patients with curvatures similar to those seen in idiopathic scoliosis are managed by principles similar to those used with idiopathic etiologies. Patients who are nonambulatory with pelvic obliquity are usually managed by a long spinal fusion extending from the upper thoracic spine to the pelvis, or the lower lumbar spine in selected cases. A brace is not required after this procedure. Treatment decisions must be individualized in nonambulatory patients with spastic quadriplegia and are based on loss of function, the potential to improve hygiene or personal care, and the desires of the family and/or caregivers. These treatment decisions are complex, and research has demonstrated the benefit of formal decision aids for families to assist with understanding treatment risks and benefits.

Although complications are relatively frequent in comparison to patients with nonneuromuscular curves, the available literature suggests that most patients benefit in terms of function and ease of care. Additionally, data suggest that corrective surgery for patients with neuromuscular scoliosis may improve weight gain postoperatively. It is important to identify risk factors for perioperative complications. Research studies have identified nonambulatory patients and those with curves ≥60 degrees as having a significantly increased risk of postoperative major complications, including ileus, pneumonia, infection, and wound problems. Gastrostomy (G)-tube dependence and increased blood loss were also found to be risk factors for postoperative complications. Baclofen pumps have not been associated with increased risk of complications. ASA classification ≥3, BMI ≥95th percentile, and extension of fusion to the pelvis have been found to be associated with postoperative infections. One study subclassified patients with Gross Motor Function Classification System (GMFCS) level 5 in terms of their risk for complications from spinal fusion. These patients have severe functional limitations and are at a high risk of perioperative complications, although not all are identical in terms of risk factors. They identified four subgroups, based on the associated presence of a G-tube, tracheostomy, history of seizures, and nonverbal status. Patients with none of these risk factors were subclassified as 5.0; one associated risk factor was 5.1; two were 5.2; and three or more were 5.3. The rate of major complications for patients with 5.0 GMFCS levels

was 12%, whereas patients with 5.3 GMFCS level had a 49% rate of major complications.

SYNDROMES AND GENETIC DISORDERS

This diverse group of diagnoses includes **neurofibromatosis** (see Chapter 636.1), **osteogenesis imperfecta** (see Chapter 742), connective tissue diseases such as **Marfan syndrome** (see Chapter 743) and **Ehlers-Danlos syndrome** (see Chapter 744), and **Prader-Willi syndrome** (see Chapter 99). Patients with these diagnoses should have their spine examined routinely during visits to their primary care physician. The follow-up and treatment are based on the age of the patient, the degree of deformity, whether progression has been documented, and the underlying diagnosis. Growth-sparing surgical strategies are appropriate in these diverse patient populations depending on curve onset. Each has unique aspects to their medical and surgical care, often with anatomic abnormalities such as dysplastic bone and dural ectasia, and as a group these diseases have a higher rate of complications related to bleeding, wound healing, infection, neurologic dysfunction, nonunion, and the development of progressive curvatures above or below the instrumented segments in comparison with patients requiring surgery for idiopathic scoliosis. Knowledge of the patient's genetic disorder, including prognosis and life expectancy, is important when determining whether surgical correction is appropriate.

COMPENSATORY SCOLIOSIS

Leg-length inequality is a common clinical diagnosis and is usually associated with a small compensatory lumbar curvature (see Chapter 717). This is one cause of false-positive screening examinations. Patients with leg-length inequality may have the pelvis become tilted toward the shorter limb and subsequently develop an associated lumbar curve. The apex of the curve points toward the short leg. There is little evidence to suggest that a small compensatory lumbar curve places the patient at risk of progression or back pain. However, children with leg-length inequality may also have idiopathic or congenital scoliosis. A standing radiograph may be obtained with a block under the foot on the short side, which corrects the leg-length discrepancy and levels the pelvis. If the curvature disappears when the limb-length discrepancy is corrected, a diagnosis of a compensatory curve is made. An alternative imaging study is a PA radiograph with the patient seated.

In neuromuscular disorders such as polio (see Chapter 296) or cerebral palsy (see Chapter 638.1), an adduction or abduction contracture of the hip, described as a fixed infrapelvic contracture, may have an associated compensatory lumbar scoliosis to maintain standing balance. For patients who ambulate, a 10-degree fixed contracture will result in up to 3 cm of apparent leg-length discrepancy.

Visit Elsevier eBooks+ at eBooks.Health.Elsevier.com for Bibliography.

720.4 Kyphosis

R. Justin Mistovich, Keith D. Baldwin, and David A. Spiegel

The normal thoracic spine has 20-50 degrees of kyphosis from T3-T12 using the Cobb method on a standing lateral radiograph of the spine. A thoracic kyphosis in excess of the normal range of values is termed **hyperkyphosis**. Patients with hyperkyphosis may present with cosmetic concerns, back pain, or both. A flexible or postural kyphosis may be overcorrected voluntarily or with postural adjustment; however, a rigid kyphosis cannot be corrected passively. Causes of rigid kyphosis include **Scheuermann disease** and congenital kyphosis, among others. Table 720.2 lists conditions associated with hyperkyphosis.

Table 720.2 Conditions Associated with Hyperkyphosis

- Trauma causing spinal fractures
- Spinal infections resulting from bacteria, tuberculosis, and fungi
- Metabolic diseases such as osteogenesis imperfecta or osteoporosis
- Iatrogenic (laminectomy, spinal irradiation)
- Neuromuscular diseases
- Neoplasms
- Congenital/developmental
  - Disorders of collagen such as Marfan syndrome
  - Dysplasias such as neurofibromatosis, achondroplasia, and mucopolysaccharidoses

The evaluation and treatment depend on the underlying diagnosis, the degree of deformity, curve flexibility, whether the deformity is progressive, and severity of associated symptoms.

FLEXIBLE KYPHOSIS (POSTURAL KYPHOSIS)

Postural kyphosis is a common cosmetic concern and is most often recognized by parents or peers. Adolescents with postural kyphosis can correct the curvature voluntarily. A standing lateral radiograph will show an increase in kyphosis but no pathologic changes of the involved vertebrae. There is no evidence that postural kyphosis progresses to a structural deformity. Although mild aching discomfort is sometimes reported, there is no evidence that the condition leads to long-term symptoms, alterations in function, or reduced quality of life. The mainstay of treatment is reassurance. Physical therapy can be considered for muscular discomfort. Although core strengthening is certainly beneficial to most patients, no data suggest that a permanent alteration in alignment can be maintained. Neither bracing nor surgery plays a role in the management of this condition.

STRUCTURAL KYPHOSIS

Scheuermann Disease

Scheuermann disease is the most common form of structural hyperkyphosis and is defined by wedging of >5 degrees of three or more consecutive vertebral bodies at the apex of the deformity on a lateral radiograph. In addition, the apex of the thoracic kyphosis is lower than expected. Other radiographic findings include irregularities of the vertebral end plates and **Schmorl nodes**, which are herniations of the vertebral disk into the surface of the vertebral body. The etiology remains unknown but most likely involves the influence of mechanical forces in a genetically susceptible individual. Histologic specimens taken of patients with Scheuermann disease have shown a disordered pattern of endochondral ossification. However, it remains unclear whether these findings are the primary result of a genetic or metabolic pathologic process, or simply the secondary result of mechanical overload. The reported incidence varies from 0.4% to 10%, affecting males three times more frequently than females.

Physical Exam and Clinical Manifestations

The patient should be examined from the side. Hyperkyphosis of the thoracic spine will typically be associated with a sharp contour. The apex of the deformity will often be in the lower thoracic spine. Patients are unable to correct the deformity voluntarily. Pain is a relatively common complaint. It is typically mild and near the apex of the kyphosis. The symptoms are intermittent, rarely severe, and occasionally limit certain activities. Neurologic symptoms are uncommon.

Fig. 720.10 Standing lateral radiograph of a 14-yr-old boy with severe Scheuermann kyphosis. This measures 92 degrees between T3 and T12. Note the wedging of the vertebrae at T6, T7, T8, and T9. The normal thoracic kyphosis is ≤40 degrees.

Radiographic Evaluation

The standard imaging protocol includes standing PA and lateral radiographs (Fig. 720.10). A specific, standardized technique in which the arms are folded across the chest is recommended for the lateral view. In addition to the diagnostic findings noted earlier, a mild scoliosis is commonly seen. Less frequently, a spondylolisthesis may be identified on the lateral radiograph.

Natural History

Treatment depends on the age of the patient, the degree of deformity, and whether any symptoms are present. Adolescent patients with Scheuermann kyphosis may have more complaints of back pain compared to other adolescents, but this often improves after skeletal maturity. A long-term follow-up study noted continued curve progression at about half a degree annually and poorer health-related quality of life compared to normative population values. Kyphotic deformities >90 degrees are more likely to be esthetically unacceptable, symptomatic, and progressive. Deformities more than 100 degrees may be associated with restrictive pulmonary dysfunction.

Treatment

There are few absolute guidelines for treatment, and decisions must therefore be individualized. Skeletally immature patients with mild deformity may benefit from a hyperextension exercise program, but the effects of this strategy on pain relief and spinal alignment, or the natural history, remain unknown. Patients with more than 1 year of growth remaining and a kyphosis of >55-60 degrees may benefit from a bracing program. A Milwaukee brace, which extends up to the neck, is recommended for curves with an apex above T7, whereas curves with a lower apex may often be treated by a thoracolumbar orthosis. The brace should be worn for up to 23 hours daily. Consideration may also be given to a serial casting or stretching program to gain flexibility before instituting the brace program. The goal of the brace is to prevent progression. A permanent improvement in alignment is seen less frequently. Skeletally mature patients with little or no pain and acceptable cosmesis are not treated. In patients with progressive deformity >70-80 degrees who are dissatisfied with their cosmetic appearance or have persistent back pain despite nonoperative measures, a spinal fusion may be considered. Patients treated operatively have less pain and greater satisfaction with their outcome compared to those treated nonoperatively.

An instrumented posterior spinal fusion from the upper thoracic to the mid-lumbar spine is commonly performed, with spinal osteotomies to allow compression of the posterior elements to facilitate deformity correction. These osteotomies allow for shortening of the spine, which should reduce the risks of neurologic complications. An alternative that was used with frequency in the past is combining an anterior spinal release (diskectomies and fusion) with the posterior spinal fusion. This strategy has been used less frequently because of increased complications, length of stay, and costs, in addition to the satisfactory outcomes associated with posterior only surgery. Procedures for kyphosis carry a higher risk than fusions performed for AIS.

CONGENITAL KYPHOSIS

Congenital kyphosis results from congenital anomalies of the vertebrae. In an anterior failure of formation **(type I),** a portion of the vertebral body fails to form. The resulting kyphosis is typically identified after birth and carries a high risk of progression and neurologic dysfunction. Spinal cord dysfunction commonly results from compression at the apex of the deformity. The second type of congenital kyphosis involves an anterior failure of segmentation, in which two vertebrae are fused **(type II)**. The posterior elements of the spine continue to grow, but the anterior spine does not, resulting in a variably progressive kyphosis and a much lower risk of neurologic dysfunction. Patients must be followed closely, and treatment is required in a significant number of cases. Similar to congenital scoliosis, abnormalities of other organ systems should be ruled out.

The treatment depends on the type of malformation, the degree of deformity, and whether neurologic symptoms are present. Bracing is ineffective, and surgical treatment is the only option for progressive curves. Because the natural history is poor for type I deformities and neurologic deterioration is likely, spinal fusion is usually performed shortly after the diagnosis is made. The surgical goals are to prevent or treat kyphotic deformities to restore adequate spinal alignment, while avoiding neurologic deterioration and complications and maximizing spinal growth to the extent possible. This usually involves some form of limited spinal fusion, which may include anterior and/or posterior components, with or without resection of the vertebral remnant, and spinal instrumentation. Ideally, only a short segment of the spine will be fused to try to maximize trunk height. Deformities resulting from anterior failure of segmentation also require spinal stabilization in some cases, but progression is typically slower, and patients are often followed over years to determine whether surgical stabilization will be required.

Visit Elsevier eBooks+ at eBooks.Health.Elsevier.com for Bibliography.

720.5 Back Pain in Children

R. Justin Mistovich, Keith D. Baldwin, and David A. Spiegel

Back pain is a frequent complaint in pediatric and adolescent patients, with studies demonstrating single-year prevalence rates between 7% and 58% of adolescents. An epidemiologic cross-sectional survey found 33.7% of children 10-18 years old experienced back pain within the prior year, with 8.9% of them describing the pain as severe. Risk factors for back pain include increasing growth, female sex, family history, overuse injury resulting from sport participation, manual labor, mobile phone usage of more than 10 hours per week (back and neck pain), and possibly carrying a heavy backpack. Patients with scoliosis commonly have back pain; up to 25% may rate this as severe. The pain may be linked to anxiety, depression, and/or substance misuse (smoking, alcohol); psychosocial factors are often underappreciated. Younger patients are felt to have a greater likelihood of a pathologic diagnosis, and therefore a more aggressive workup has been suggested. The incidence of both pediatric and adolescent back pain has increased, whereas the proportion of patients having diagnosable pathology is decreasing, with 75–80% of patients having a negative workup. These trends add further complexity to determining the proper approach to diagnosis and treatment. The differential diagnosis is extensive (Table 720.3). Although the likelihood of serious pathology is low, a complete history and careful physical exam must be performed on all patients (Table 720.4).

CLINICAL EVALUATION

Providers should take a full history, identifying the location, character, and duration of symptoms. Any history of acute trauma or repetitive physical activities should be sought. It is important to identify patients with at-risk athletic pursuits, including football linemen or gymnasts who have a high incidence of spondylolysis and spondylolisthesis. Symptoms consistent with a neoplastic or infectious etiology include pain that is constant or unrelenting, not relieved by rest, and wakes the patient from sleep. Fevers, chills, night sweats, or constitutional symptoms of weight loss or malaise are additional red flags for infectious or neoplastic processes (see Table 720.4).

Symptoms of neurologic dysfunction must also be uncovered. Patients should be questioned about the presence of any radicular symptoms, gait disturbance, muscle weakness, alterations in sensation, muscle atrophy, and changes in bowel or bladder function.

The physical examination includes a complete musculoskeletal and neurologic assessment. The patient should be adequately undressed for the clinical exam. The provider should inspect the patient from the back and the side, identifying any changes in alignment in the frontal or sagittal plane. Assessment of range of motion in flexion, extension, and lateral bending should be performed. Recall that pain with extension suggests pathology within the posterior elements of the spine, such as spondylolysis. Forward flexion will exacerbate pain linked to abnormalities of the anterior column of the spine (vertebral body or disk), such as a herniated disk or diskitis.

Palpation will reveal any areas of point tenderness over the posterior bony elements of the spinal column or the muscles and identify muscle spasm or strain.

Because pain may be referred from a nonspine region, an abdominal examination should be performed, and a gynecologic evaluation should also be considered. Pathology at the sacroiliac joint may also mimic low back pain. This joint should be stressed by compression of the iliac wings or by external rotation at the hip (Faber test).

A detailed neurologic examination should be performed, including manual muscle testing, sensation, proprioception, and reflexes. The patient should be examined for myelopathy by performing the Babinski test, assessing for hyperreflexia, and checking for sustained (more than three beats) of clonus. The superficial cutaneous abdominal reflex should be tested by gently stroking the skin on each of the four quadrants surrounding the umbilicus. Normally, the umbilicus will move toward the area stimulated. A normal examination includes symmetry in the response on both sides of the midline, even if the reflex cannot be elicited on either side. An abnormal test suggests the presence of a subtle abnormality of spinal cord function, most commonly syringomyelia. A straight leg

Table 720.3 Differential Diagnosis of Back Pain

INFECTIOUS AND INFLAMMATORY DISEASES
Spondylodiscitis*
Vertebral osteomyelitis (pyogenic, tuberculosis)
Spinal epidural abscess
Transverse myelitis
Pyelonephritis*
Perinephric abscess
Pancreatitis
Paraspinal muscle abscess, myositis
Psoas abscess
Endocarditis
Pelvic osteomyelitis or myositis
Pelvic inflammatory disease
RHEUMATOLOGIC DISEASES
Pauciarticular juvenile idiopathic arthritis*
Reactive arthritis
Ankylosing spondylitis
Psoriatic arthritis
Inflammatory bowel disease
Fibrositis, fibromyalgia
DEVELOPMENTAL DISEASES
Spondylolysis*
Spondylolisthesis*
Scheuermann kyphosis*
Scoliosis
Chiari malformation type 1 with or without syringomyelia
Spinal dysraphism
Cauda equina syndrome
MECHANICAL TRAUMA AND ABNORMALITIES
Muscle strain/sprain*
Hip/pelvic anomalies (sacroiliac joint dysfunction)
Herniated disk (rare)
Juvenile osteoporosis (rare)
Overuse syndromes (facet syndrome)*
Vertebral stress fractures
Vertebral compression fractures
Limbus vertebra
Lumbosacral sprain*
Seatbelt injury
Trauma (direct injury; e.g., motor vehicle crash)*
Strain from heavy knapsacks
Radiculopathy (sciatica)
NEOPLASTIC DISEASES
Primary vertebral tumors (osteogenic sarcoma, Ewing sarcoma)
Metastatic tumor (neuroblastoma, rhabdomyosarcoma)
Primary spinal tumor (neuroblastoma, lipoma, cysts, astrocytoma, ependymoma)
Malignancy of bone marrow (ALL, lymphoma)
Benign tumors (eosinophilic granuloma, osteoid osteoma, osteoblastoma, bone cyst)
OTHER
Disk space calcification (idiopathic, after diskitis)
Conversion reaction
Sickle cell anemia*
Nephrolithiasis
Hemolysis (acute)
Hematocolpos
Postprocedure pain after lumbar puncture

*Common.
ALL, Acute lymphocytic leukemia.
Modified from Marcdante KJ, Kliegman RM, Schuh AM. *Nelson Essentials of Pediatrics*, 9th ed. Philadelphia: Elsevier; 2023:774.

Table 720.4	Red Flags: Most Common Indications from History and Examination for Pathologic Findings Needing Special Attention and Sometimes Immediate Action

- Children younger than 18 yr old with considerable pain
- History of violent trauma
- Nonmechanical nature of pain (i.e., constant pain not affected by movement; pain at night)
- History of cancer
- Systemic steroid use
- Drug use
- HIV infection or other immunocompromised patients
- Unintentional weight loss
- Systemically ill, particularly signs of infections such as fever or night sweats
- Persisting severe restriction of motion or intense pain with minimal motion
- Structural deformity including scoliosis, Chiari malformation, tethered cord
- Difficulty with micturition (urinary retention)
- Loss of anal sphincter tone or fecal incontinence
- Progressive motor weakness or gait disturbance, paresthesias, pes cavus, foot drop, saddle anesthesia
- Marked morning stiffness
- Peripheral joint involvement
- Iritis, skin rashes, colitis, urethral discharge, or other symptoms of rheumatologic disease
- Inflammatory disorder such as ankylosing spondylitis suspected
- Family history of rheumatologic disease or structural abnormality

raise test should be done to check for nerve root tension secondary to a herniated disk, slipped vertebral apophysis, or other pathology. This examination should reproduce any neurologic symptoms distal to the knee.

MEDICAL DECISION-MAKING

A detailed history and physical exam are the most important components of the initial evaluation and should focus on identifying "red flags" and differentiating between mechanical and nonmechanical back pain (see Table 720.4). Findings consistent with a nonmechanical etiology warrant a more aggressive evaluation and/or prompt referral.

Patients with mechanical or muscular back pain and symptoms that are activity related and improve with rest are typically treated by rest for a few days or activity restrictions and nonnarcotic analgesics. Physical therapy for core strengthening should be considered if the acute symptoms do not resolve or if the pain is chronic. The patient should be asked to return for a follow-up appointment after 4-6 weeks. Plain radiographs are commonly obtained at the discretion of individual practitioners. However, if no red flags are present, providers may defer radiographs because of the cumulative adverse effects of radiation exposure. Patients presenting with red flags or those who have not improved after 6 weeks of conservative care necessitate further investigation.

RADIOGRAPHIC AND LABORATORY EVALUATION

When further workup is indicated, PA and lateral radiographs of the involved region of the spine are the initial images of choice. Some clinicians will also use oblique radiographs of the lumber spine when spondylolysis is in the differential diagnosis. If plain radiographs are normal, advanced imaging modalities should be considered, including a three-phase technetium bone scan, a bone scan with single-photon emission computed tomography (SPECT) if spondylolysis is suspected, CT for viewing osseous detail, and MRI for viewing soft tissue detail or bony areas of inflammation.

When systemic signs or constitutional symptoms are present, a CBC, ESR, and CRP should be ordered. In certain cases, laboratory tests to evaluate for inflammatory diseases such as juvenile idiopathic arthritis, seronegative spondyloarthropathies, and ankylosing spondylitis are indicated.

Visit Elsevier eBooks+ at eBooks.Health.Elsevier.com for Bibliography.

720.6 Spondylolysis and Spondylolisthesis

R. Justin Mistovich, Keith D. Baldwin, and David A. Spiegel

Spondylolysis represents a defect in the pars interarticularis, the segment of bone connecting the superior and inferior articular facets in the vertebra. It is thought to result from repetitive hyperextension stresses, in which compressive forces are transmitted from the inferior articular facet of the superior vertebra to the pars interarticularis of the inferior vertebra. Supporting the mechanical theory, spondylosis has never been described in nonambulatory adults. However, there may be a genetic association with 19–69% of affected patients having a first-degree relative also affected. A stress fracture, unilateral or bilateral, may progress to a spondylolysis. In many cases, this stress fracture does not heal, resulting in a pseudarthrosis, or false joint, and thereby allowing motion through this bony area where motion should not normally exist.

Spondylolysis is common in athletes who engage in repetitive spinal hyperextension, especially gymnasts, football interior linemen, weightlifters, and wrestlers. Approximately 4–8% of the entire pediatric population is affected, making it the most common cause of back pain in adolescents when a diagnosis can be established. Patients with excessive lordosis in the lumbar spine may be predisposed to developing a spondylolysis, and a genetic component has also been suggested. The lesion is most common at L5, but it may be identified at upper lumbar levels as well.

Spondylolisthesis represents a forward slippage of one vertebra on another and is identified in approximately 4–5% of the population. The multiple causes of spondylolisthesis include dysplastic/congenital defects, isthmic (due to a pars stress fracture), trauma, and neoplasm. In children and adolescents, the most common types are dysplastic and isthmic. Between 5% and 15% of patients with spondylolysis will develop spondylolisthesis.

Spondylolisthesis is assessed on a standing lateral radiograph of the lumbosacral junction according to (1) the percentage of forward translation of one vertebra on the other, (2) the slip angle, measuring the rotation of the involved vertebrae in the sagittal plane, and (3) relative position of the sacrum during upright posture. A grade 1 slip of L5 on S1 has <25% of the width of the vertebral body of L5 translated anteriorly on S1. Similarly, grade 2 is 25–50%, grade 3 is 50–75%, and grade 4 is 75–100%. **Spondyloptosis,** or grade 5 spondylolisthesis, describes a complete displacement of one vertebral body on the level below. The slip angle, which demonstrates the degree to which the superior vertebra is flexed forward relative to the underlying vertebra, and the verticality of the sacrum both have a significant effect on sagittal balance or the relationship of the sagittal weight-bearing axis to the body segments. Abnormalities in sagittal spinal balance may be associated with compensatory flexion of the knees during ambulation, hamstring spasm and/or contracture, and back pain.

CLINICAL MANIFESTATIONS

Spondylolysis may occasionally be asymptomatic and diagnosed incidentally on imaging obtained for other reasons. It usually presents with mechanical low back pain that may radiate to the buttocks, with or without spasm of the hamstring muscles. Neurologic symptoms are rare in patients with spondylolysis. However, patients with spondylolisthesis may experience neurologic symptoms from compression or stretching of the nerve roots, causing radiculopathy or even the surgical emergency of cauda equina in which bowel and bladder function is affected.

PHYSICAL EXAM

Patients with spondylolysis often have discomfort with spinal extension or hyperextension. Provocative testing may include keeping the spine extended for 10-20 seconds to see if back pain can be reproduced. There may be discomfort with palpation of the spinous process of the involved vertebra. Patients with higher grades

of spondylolisthesis demonstrate loss of lumbar lordosis, flattening of the buttocks on visual inspection, and a vertical sacrum resulting from posterior rotation of the pelvis. A step-off may be palpated between the spinous processes of the involved vertebrae. Hamstring contracture is tested by measuring the popliteal angle. The hip is flexed to 90 degrees while fully extending the contralateral hip to the level the pelvis. The knee is then passively extended, and the popliteal angle represents the angle between the thigh (vertical) and the lower leg axis. A careful, complete neurologic examination is essential because diagnosis of spondylolysis and spondylolisthesis is often delayed.

RADIOGRAPHIC EVALUATION

The initial evaluation of the lumbar region should include high-quality AP and lateral radiographs. Some authors also prefer to obtain oblique radiographs, which demonstrate the classic "Scotty dog" finding on the pars interarticularis. The lumbar spine in oblique radiograph projections normally appears to form the figure of a "Scotty dog" (i.e., Scottish terrier), with the transverse process forming the nose, the pedicle forming the eye, and the pars interarticularis forming the neck; in spondylolysis, the pars interarticularis will have a defect or a break, mimicking a "collar" on the radiograph. Standing PA and lateral radiographs of the entire spine are obtained if findings suggestive of scoliosis or hyperkyphosis are also present (Figs. 720.11 and 720.12). In patients with normal plain films, traditional imaging studies included a bone scan with SPECT to diagnose a spondylolysis during the earliest stage of a stress reaction, before the formation of a stress fracture or an established pseudarthrosis. The radiation exposure from this test, though, is substantial—bone scans have 7-9 times the radiation dose of two-view plain films. In comparison, CT scans carry only 2 times the radiation dose of two-view plain films. The sensitivity of MRI using STIR imaging is comparable to SPECT and led to a recommendation for MRI STIR rather than bone scans in acute cases in which plain films could not make a diagnosis. MRI sequences will demonstrate inflammation associated with an acute spondylolysis while avoiding radiation exposure. A CT scan with thin cuts may provide additional information to establish the presence of a pars defect and may be indicated in chronic, refractory cases. MRI is also indicated in the presence of signs or symptoms of cauda equina or nerve root involvement.

TREATMENT

The asymptomatic patient with spondylolysis requires no treatment. Patients with pain are treated initially by activity modification, physical therapy for core strengthening, and analgesic medications. The use of a lumbosacral orthosis, which immobilizes the spine in slight flexion to decompress the posterior elements, may lead to a faster resolution of symptoms, though a recent SRS Evidence Based Medicine Committee report determined that the benefit of bracing is not well established. This orthosis is typically worn for 3-4 months. Participation in sports or other activities that exacerbate pain should be restricted until the symptoms have resolved. Providers should consider checking a vitamin D level in patients with spondylolysis and treating if deficient.

Most patients experience resolution of their symptoms even though the spondylolysis heals in only a small number of patients. Surgery should be offered for chronic, refractory back pain when conservative measures have failed. For those with spondylolysis at L5, a posterior spinal fusion from L5 to S1 is indicated as the mobility at this joint is limited relative to that observed at higher levels in the spine. For the infrequent cases in which the defect is at higher levels in the lumbar spine, techniques for repairing the pseudarthrosis without fusion are considered.

Recommendations for the management of spondylolisthesis depend on the age of the patient, the presence of pain or neurologic symptoms, and the degree of deformity. For low-grade lesions, the management is similar to that for spondylolysis. Significant progressive slippage may occur in 3–5% of skeletally immature patients, and patients must be followed through skeletal maturity. Progression of deformity is increased in higher grade slips and in cases of dysplastic spondylolisthesis. However, there is only a 1.4% incidence of progression after adolescence. Guidelines for the timing of follow-up, and whether or not to obtain routine radiographs at each follow-up, differ between individuals and institutions; we typically follow asymptomatic patients yearly with a standing lateral of the lumbosacral junction. Nonoperative management in minimally symptomatic or asymptomatic patients is appropriate, and delaying surgical treatment does not appear to worsen outcomes.

For low-grade slips with persistent symptoms despite nonoperative measures, an in situ posterior spinal arthrodesis is suggested. Additionally, patients with a more kyphotic slip angle have been shown to have poorer prognosis, although operative treatment did not significantly improve their outcome. The surgical approach for high-grade slips varies between surgeons and institutions. The main

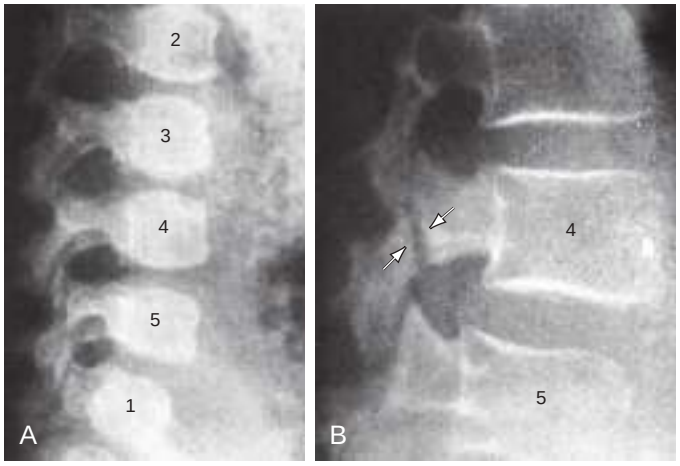

Fig. 720.11 **A,** Normal spine at 9 months of age. **B,** Spondylolysis in the L4 vertebra at 10 yr of age. *(From Silverman FN, Kuhn JP. Essentials of Caffrey's Pediatric X-ray Diagnosis. Chicago: Year Book Medical Publishers; 1990:94.)*

Fig. 720.12 Defect in the pars interarticularis *(arrow)* of the neural arch of L5 (spondylolysis) that has permitted the body of L5 to slip forward (spondylolisthesis) on the body of S1. *(From Silverman FN, Kuhn JP. Essentials of Caffrey's Pediatric X-ray Diagnosis. Chicago: Year Book Medical Publishers; 1990:95.)*

principle is to stabilize the unstable segment of the spine, avoid neurologic complications, and restore adequate sagittal balance to the spine. The typical components of these complex procedures include (1) posterior decompression of the L5 and S1 nerve roots (laminectomy and takedown of pseudarthrosis), (2) instrumented posterior spinal fusion from L4 or L5 to S1 and occasionally the pelvis is included in the instrumentation, (3) diskectomy at L5-S1 with placement of anterior column support (transforaminal cage or fibular allograft from sacrum to L5), and (4) reduction of the slippage by positioning the hips in extension or by an "instrumented reduction" using the spinal implants. Adding the anterior column support enhances rates of fusion. Reduction improves radiographic outcomes but may increase the risk of unplanned surgeries, pseudarthrosis (failure of fusion), and neurologic complications.

Visit Elsevier eBooks+ at eBooks.Health.Elsevier.com for Bibliography.

720.7 Spine Infection

R. Justin Mistovich, Keith D. Baldwin, and David A. Spiegel

Spondylitis, meaning inflammation of the vertebrae, is most commonly due to infectious or autoimmune processes. **Spondylodiscitis** is defined as a primary infection of the intervertebral disk **(diskitis)** with spread to the vertebrae **(osteomyelitis)**. Based on MRI, some think the infection begins in the vertebral body with subsequent rupture into the disk space. The most common etiology is hematogenous seeding of bacteria, with the original infection of the well-perfused end plate extending into the disk and vertebral body. Spondylodiscitis is more commonly seen in children younger than 5 years of age but can occur at any age; it is often associated with vertebral body osteomyelitis. Patients in the younger age range have vascular channels between the vertebral end plate and the disk space, explaining the prevalence of diskitis with osteomyelitis.

Staphylococcus aureus is the most common organism causing spine infections. Other organisms include ***Kingella kingae*** and less often group A streptococcus and *Escherichia coli*. Rare causes of vertebral bone infection include tuberculosis (often multiple vertebral bodies), *Serratia marcescens*, brucellosis, and cat-scratch disease. Blood cultures have a sensitivity of only 30%. Percutaneous or less often open biopsy of the disk space is positive only 50–85% of the time; polymerase chain reaction is indicated for the diagnosis of *Kingella*. The differential diagnosis includes chronic recurrent multifocal osteomyelitis.

CLINICAL MANIFESTATIONS

A high index of suspicion is required to establish the diagnosis of infectious spondylodiscitis. Patients may experience back pain, abdominal pain, fever, or malaise. Fever is less common and may be present in only 30% of patients. Toddlers may develop a limp or refuse to walk, stand, or sit. In an effort to reduce the pain associated with spinal motion, the child will hold the spine in a rigid position. There may also be a paraspinal muscle spasm. Local point tenderness over the affected spinous process is common. There may be a "list" or leaning of the trunk when the patient is viewed from the front or back, and from the side there may be a loss of lumbar lordosis. Neurologic manifestations are rare and, if present, suggest that an epidural abscess may be present. The infection may drain beyond the spine to the paravertebral space and psoas muscles.

Spine flexion compresses the anterior elements of the spine and will elicit an increase in pain. Asking a child to pick up an object from the ground is a simple way to elicit this provocative test.

Although the white blood count may remain normal, the ESR is elevated in 80% of cases, and the CRP is also elevated.

Fig. 720.13 Spondylodiscitis. Sagittal T2-weighted (**A**) and coronal short tau inversion recovery (**B**) images demonstrate destruction of T7-T8 intervertebral disk with abnormal marrow signal in the adjacent vertebral bodies and associated paravertebral soft tissue phlegmon. *(From Bosemani T, Huisman TAGM. Spine imaging. In: Walters MM, Robertson RL, eds. Pediatric Radiology: The Requisites, 4th ed. Philadelphia: Elsevier; 2017: Fig. 9.31, p. 345.)*

RADIOGRAPHIC EVALUATION

The earliest radiographic finding is a postural loss of lumbar lordosis. Later characteristic features on plain radiographs are disk space narrowing, or loss of disk height, and irregularity of the adjacent vertebral end plates. However, these findings do not develop until 2-3 weeks after the onset of symptoms. The diagnosis may be established earlier using MRI. MRI is the most sensitive and specific imaging to diagnose osteomyelitis and to identify abscesses and/or neural compression (Figs. 720.13 and 720.14).

TREATMENT

Once the diagnosis is suspected clinically, the treatment involves symptomatic care and empiric anti-staphylococcal antibiotics, as *S. aureus* is the most common pathogen isolated. *Kingella kingae* is recognized as a common pathogen in patients from 6 months to 4 years of age. A first-generation cephalosporin (e.g., cefazolin) or semisynthetic antistaphylococcal penicillin (e.g., oxacillin) is recommended in areas where methicillin-resistant *S. aureus* (MRSA) is not prevalent. Clindamycin should be considered in areas where MRSA is more common. Some areas of the world report increasing clindamycin resistance among both methicillin-resistant and methicillin-susceptible *S. aureus* isolates, leading to consideration of vancomycin or linezolid. Blood cultures should be obtained *before* the administration of antibiotics. The antibiotic agent may be modified if blood cultures are positive. Symptomatic care includes rest and analgesics, antiinflammatory medications, and a spinal orthosis may also be considered. The typical antibiotic course is from 4-6 weeks. Data in osteomyelitis suggest that conversion from intravenous to oral agents may be acceptable after several days depending on the clinical course (see Chapter

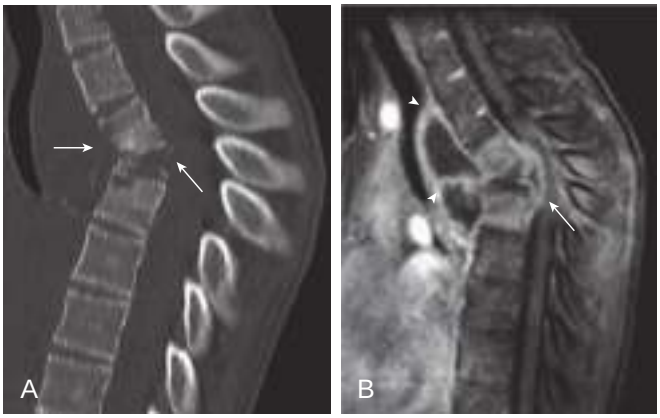

Fig. 720.14 Tuberculous vertebral osteomyelitis in 13-yr-old female with progressive loss of strength and coordination in legs. (**A**) Sagittal reformatted soft-tissue window images from a CT of the spine (**B**) sagittal fat-saturated postcontrast T1-weighted MR images of the thoracic spine demonstrate marked kyphosis at site of bony collapse at the level of the midthoracic spine (*arrows* in **A** and **B**), as well as surrounding soft tissue abscess (*arrowheads* in **B**) predominately anteriorly, at the same level. *(Modified from Maddocks ABR, Pollock AN. Infections of the spine and spinal cord. In: Coley BD, ed. Caffey's Pediatric Diagnostic Imaging, 13th ed. Philadelphia: Elsevier; 2019: Fig. 44.8AC, p. 422.)*

725). A CT-guided needle biopsy of the disk space can be considered. Although the diagnostic yield on cultures is low (20–40%), the pathologic findings may show acute inflammatory cells to establish the diagnosis (≥1 neutrophil per high power field). This intervention is often reserved for patients who do not respond to empiric antibiotics or when there are questionable diagnostic features. Surgical treatment is rarely required, and indications include establishing the diagnosis in patients who fail to respond to empiric antibiotics, and those in whom an abscess and/or neurologic involvement are identified.

Visit Elsevier eBooks+ at eBooks.Health.Elsevier.com for Bibliography.

720.8 Intervertebral Disk Herniation/ Slipped Vertebral Apophysis

R. Justin Mistovich, Keith D. Baldwin, and David A. Spiegel

Intervertebral disk herniation is the result of a tear in the outer layer of the vertebral disk, called the annulus fibrosus, which then allows for protrusion of the inner nucleus pulposus. At times, a free fragment of disk can rupture and compress the nerve roots or spinal cord. Bulging of the annulus without rupture may also be observed, resulting in back pain and occasionally radicular symptoms. Symptoms are due to either direct mechanical compression or a local inflammatory response.

Slipped vertebral apophysis, also called a posterior ring apophysis separation, is due to an injury and is only found in skeletally immature patients. A small fragment of bone from the posterior corner of the vertebral body apophysis avulses and may cause direct mechanical compression to the spinal cord or nerve root, similar to a disk herniation. (An apophysis is a normal outgrowth of bone with its own physis, or growth plate. Another example is the tibial tubercle.) Both disk herniations and ring apophysis separations can cause back pain, radicular symptoms (nerve root compression or irritation), or spinal cord compression.

ETIOLOGY

Predisposing activities for both conditions include heavy lifting, repetitive axial loading activities, and occasionally traumatic injury such as a fall. Approximately 30–60% of patients with symptomatic herniated disks have a history of a trauma or sports-related injury. Other associations include preexisting disk degeneration, congenital malformation, and genetic or environmental factors. There may be a potential association between disk degeneration and the herpes virus. Missense pathogenic variants in collagen-encoding genes may be present in 80% of young patients with symptomatic lumbar disk herniations.

CLINICAL MANIFESTATIONS

Symptoms of intervertebral disk herniation or slipped vertebral apophysis in adolescents are similar to adult herniated disk symptoms. The major complaint is back pain, present in nearly 90% of patients. Over 30% of patients complain of **radicular symptoms** or radiating sciatic-type pain into the legs. The back pain is often made worse by coughing, a Valsalva maneuver, or sitting. Pain may be relieved by standing or back extension, which increases the disk space between vertebral bodies. Providers should inquire about weight loss, fever, or other constitutional symptoms to rule out an infectious or neoplastic etiology.

On physical examination, both paraspinal muscle spasm and a generalized spinal stiffness are common. Patients may lean toward the unaffected side to increase the size of the affected neural foramen, thereby partially relieving symptoms. This results in a reactive scoliosis—not a true spinal curve—that improves with symptom resolution. Although overt signs of neurologic involvement are absent in most patients, a positive straight leg raise test, causing radicular pain to shoot down the affected leg, is usually present. Pain is also worsened by spinal flexion.

It is critical to perform a full neurologic evaluation, including sensation to light touch, pinprick, and proprioception; muscle strength; and reflexes. Providers must also evaluate for perineal numbness, or saddle anesthesia. This finding, combined with changes in bowel or bladder function, is indicative of cauda equina syndrome, a surgical emergency in which the nerve roots at the caudal end of the spinal cord are compressed or damaged.

RADIOGRAPHIC EVALUATION

Radiographs often show loss of lumbar lordosis, which is due to muscle spasm, and sometimes a mild lumbar scoliosis. Other radiographic findings include degenerative changes and a loss of intervertebral disk height. MRI is the best study to establish the diagnosis of a disk herniation (Fig. 720.15). CT is especially helpful to visualize a partially ossified fragment associated with a slipped apophysis.

TREATMENT

The initial treatment is nonoperative in the vast majority of patients—even if symptoms or findings of radiculopathy are observed. Treatment focuses on rest, activity modification, NSAIDs, and physical therapy. An orthosis may provide additional symptomatic relief. Complete bed rest is not recommended. Epidural steroid injection (ESI) may be discussed with patients after approximately 6 weeks of symptomatic treatment if symptoms persist, though the evidence is not yet definitive. However, if patients elect to undergo an ESI, they should not have more than a single injection if the first did not provide any relief. Clinical experience has demonstrated that multiple injections are no more likely to provide relief than a single injection and expose patients to additional risks of infection, scarring, and neural injury. If a patient experiences substantial relief from an ESI and has a later recurrence of symptoms, consideration may be given for a repeat injection after performing a complete physical exam and ruling out any new pathology.

Surgical treatment should be considered when nonoperative measures have failed or when a profound neurologic deficit such as cauda equina syndrome is present or evolving. Unfortunately, children and adolescents respond less favorably to nonoperative therapy compared with adults, and a significant percentage will require surgical intervention. Although patients with disk herniation may improve with reduction in the local inflammatory response around the nerve root and also as the disk material loses water volume and shrinks, which eliminates mechanical compression, patients with symptomatic ring apophyseal separations have a bony fragment causing their symptoms and are unlikely to improve spontaneously.

The surgical technique involves removing a small area of the lamina via a posterior approach, called a **laminotomy**, which allows exposure

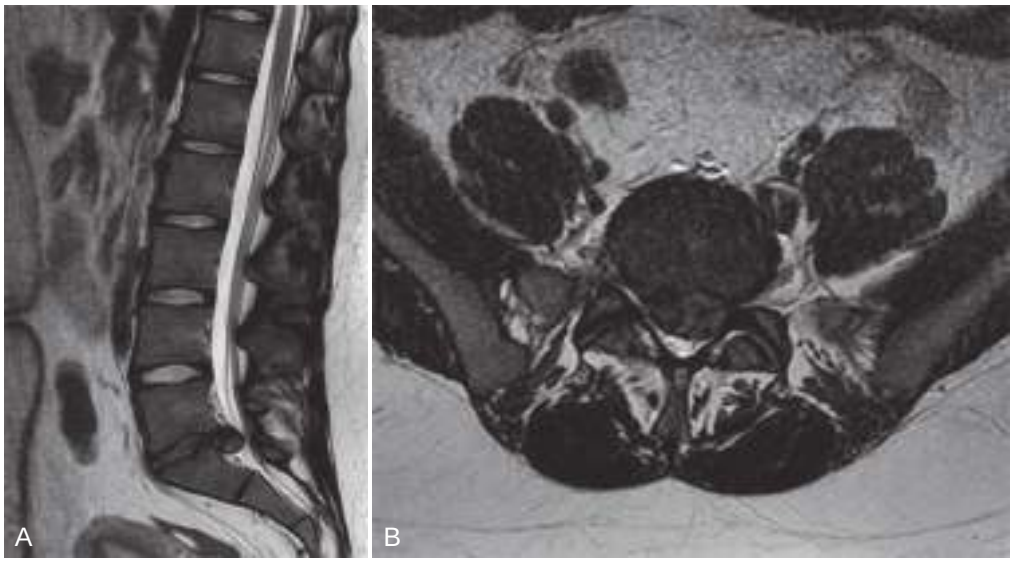

Fig. 720.15 Lumbar disk herniation. Sagittal (**A**) and axial T2-weighted (**B**) images demonstrate a disk extrusion at L5-S1 level with near-complete infilling of bilateral lateral recesses, left greater than right, and effacement of the thecal sac. *(From Bosemani T, Huisman TAGM. Spine imaging. In: Walters MM, Robertson RL, eds. Pediatric Radiology: The Requisites, 4th ed. Philadelphia: Elsevier; 2017: Fig. 9.30, p. 345.)*

of the neural elements and underlying disk. Any loose fragments are removed. A bulging disk may also be opened surgically to decompress the area compressing the neural elements, although a complete diskectomy is inadvisable. The surgical approach is similar in the case of a slipped vertebral apophysis, in which fragments of bone and cartilage must also be removed. This often requires a bilateral laminotomy to completely address the pathology. Patients with congenital lumbar spinal stenosis may be more likely to require surgical treatment and also may require a posterior decompression in addition to the discectomy.

The initial results are excellent in the majority of patients. Approximately 30% may have recurrent herniations and resultant symptoms of back or leg pain at longer-term follow-up. These recurrences are initially treated nonoperatively; however, repeat discectomy may be required, and if so, a significant number of patients may require a spinal arthrodesis to stabilize the damaged motion segment. A spinal fusion may also be required for instability associated with spondylolisthesis or other etiology.

Visit Elsevier eBooks+ at eBooks.Health.Elsevier.com for Bibliography.

720.9 Tumors

R. Justin Mistovich, Keith D. Baldwin, and David A. Spiegel

Back pain may be the most common presenting complaint in children who have a tumor involving the vertebral column or the spinal cord. Other associated symptoms may include weakness of the lower extremities, scoliosis, and loss of sphincter control. The majority of tumors are benign (see Chapter 550), including osteoid osteoma, osteoblastoma, aneurysmal bone cyst, and eosinophilic granuloma. Malignant tumors involving the vertebral column may be osseous, such as osteosarcoma or Ewing sarcoma. They may involve the spinal cord and sympathetic or parasympathetic nerves in cases of ganglioneuroma, ganglioneuroblastoma, and neuroblastoma. Tumors from other primary sites can also metastasize to the spine.

High-quality plain radiographs may show **vertebra plana**, or symmetric collapse of a single vertebra with preserved disk space; this is most commonly seen with eosinophilic granuloma (Fig. 720.16). Other useful imaging modalities include bone scans, which help with localization and identification of other lesions; MRI, which is helpful to identify soft tissue extension and neurologic compression; and CT, which provides excellent bony detail.

Fig. 720.16 (**A**) Lateral radiograph of the lumbar spine of a 6-yr-old female with a painful osteolytic lesion of the L2 vertebral body with vertebral plana deformity. CT-guided frozen section biopsy showed eosinophilic granuloma; intralesional methylprednisolone injection was performed. (**B**) Lateral radiograph of the lumbar spine shows complete reconstitution of the lesion 7 years after diagnosis and treatment. *(From Angelini A, Mavrogenis AF, Rimondi E, et al. Current concepts for diagnosis and management of eosinophilic granuloma of bone. J Orthop Traumatol. 2017;18:83-90. Fig. 3.)*

A biopsy is usually required to establish the diagnosis. Treatment of tumors of the spinal column may require a multidisciplinary approach. These cases should ideally be managed in centers with experience in the care of patients with these lesions. Many lesions are surgically treated by laminectomy, and postoperative surveillance is essential to identify cases of postlaminectomy kyphosis or other spinal deformities, which when progressive may require an instrumented spinal fusion to stabilize.

Visit Elsevier eBooks+ at eBooks.Health.Elsevier.com for Bibliography.

Chapter 721

The Neck

R. Justin Mistovich, Keith D. Baldwin, and David A. Spiegel

721.1 Torticollis

R. Justin Mistovich, Keith D. Baldwin, and David A. Spiegel

Torticollis, literally meaning "twisted neck," is not a diagnosis but rather a clinical manifestation of a variety of underlying conditions (Table 721.1). Common names associated with this condition include "wry-neck" and "cock-robin" deformity. Although congenital muscular torticollis is the most common diagnosis in cases presenting at or close to the time of birth, the differential diagnosis for acquired torticollis is large. Therefore a thorough evaluation is required to identify the underlying cause.

CONGENITAL MUSCULAR TORTICOLLIS

Congenital muscular torticollis (CMT) is due to a contracture of the sternocleidomastoid (SCM) muscle, which results in a *tilting* of the head and neck *toward* the side of the contracted muscle with *rotation* of the head to the *opposite* side (Fig. 721.1). In most cases (75%), the right SCM muscle is involved, causing the patient's face and chin to point to the left side.

CMT is thought to result from an intrauterine deformation or compression and is more common in children of primigravida mothers. CMT may be associated with the presence of a palpable mass or nodule of fibrous tissue within the substance of the SCM muscle in approximately 50% of cases (Figs. 721.2 and 721.3). Findings on muscle biopsies and MRI studies led to the hypothesis that SCM muscle injury from compression or stretch may create localized ischemia, which in turn results in fibrosis and subsequent contracture—essentially an intramuscular compartment syndrome. In rare cases, the condition can result from hereditary muscle aplasia.

Associated findings with CMT include plagiocephaly, facial asymmetry, and positional musculoskeletal deformities such as metatarsus adductus (15%) and calcaneovalgus feet. Hip dysplasia may be identified in 8–20% of affected patients. In addition to routine screening by physical examination for hip dysplasia, providers should consider obtaining either an ultrasound at 6 weeks of age or a plain radiograph of the pelvis at 4-6 months of age in children with CMT even if the physical exam is normal and there are no other risk factors for DDH.

The cornerstone of treatment for CMT is physical therapy and a home stretching program in which caregivers are instructed to gently stretch the contracted SCM by rotating the infant's chin to the ipsilateral shoulder and simultaneously tilting the head toward the contralateral shoulder. The best results occur when treatment is started within the first 3 months of life, leading to resolution in nearly all cases. Patients who start their physical therapy later can expect a more prolonged course, and a subset will not achieve a normal range of motion. Recently, single frequency microcurrent has been used as an adjunct to physical therapy with the goal of reducing the time of treatment and also addressing the challenges of patients presenting at a later age. Botulinum toxin injections may also be considered as an adjunct, especially in resistant cases in older patients. Plagiocephaly commonly accompanies CMT, and patients may be referred to a craniofacial clinic or specialist for discussion of treatment with a cranial remolding helmet. Early restoration of motion reduces the likelihood that patients will have persistent facial asymmetry or cranial molding abnormalities.

Although firm guidelines for imaging the cervical spine have not been established, anteroposterior (AP) and lateral radiographs of the cervical spine may be obtained when the typical clinical features associated with congenital muscular torticollis are absent or if the deformity does not respond to the stretching treatment, because torticollis in infants may also be due to **congenital vertebral anomalies**.

Surgical release of the SCM is considered in patients with *persistent deformity* after failure of conservative treatment. The muscle may be released at its insertion on the clavicle (unipolar release) or at both its origin and insertion (bipolar release). There is no agreement as to the most appropriate time for the surgical release, but surgical treatment is typically delayed until at least 18 months of age; some even suggest waiting until the child is approaching school age. Although range of motion can be improved after surgical release even during the teenage years, remodeling of facial asymmetry and plagiocephaly may be less predictable in patients older than infancy. Surgical management results in satisfactory function and acceptable cosmesis in more than 90% of patients; however, with early diagnosis and treatment, surgery should be required in only a minority of cases. Patients who have residual or untreated CMT beyond a year of age may develop secondary skeletal abnormalities such as a mild cervicothoracic scoliosis or rotational malalignment and tilting of upper and lower cervical vertebrae (especially at the atlantoaxial joint). It is presumed that such malalignment will improve with release of contracture, but in older patients, skeletal deformities may persist.

Table 721.1 Differential Diagnosis of Torticollis

CONGENITAL
Muscular torticollis
Positional deformation
Hemivertebra (cervical spine)
Unilateral atlanto-occipital fusion
Klippel-Feil syndrome
Unilateral absence of sternocleidomastoid
Pterygium colli
TRAUMA
Muscular injury (cervical muscles)
Fibromatosis coli (sternocleidomastoid tumor of infancy)
Atlanto-occipital subluxation
Atlantoaxial subluxation
C2-3 subluxation
Rotary subluxation
Fractures
Foreign body
INFLAMMATION
Cervical lymphadenitis
Retropharyngeal abscess
Cervical vertebral osteomyelitis
Grisel syndrome (nontraumatic subluxation of the atlantoaxial joint due to local inflammation)
Juvenile idiopathic arthritis
Lemierre syndrome
Upper lobe pneumonia
NEUROLOGIC
Visual disturbances (nystagmus, superior oblique or lateral rectus paresis)
Dystonic drug reactions (phenothiazines, haloperidol, metoclopramide)
Cervical cord tumor
Posterior fossa brain tumor
Syringomyelia
Wilson disease
Dystonia musculorum deformans
OTHER
Acute cervical disk calcification
Sandifer syndrome (gastroesophageal reflux, hiatal hernia)
Benign paroxysmal torticollis
Bone tumors (eosinophilic granuloma)
Soft tissue tumor
Psychogenic

Fig. 721.1 Congenital muscular torticollis. **A,** Torticollis secondary to a contracted left sternocleidomastoid (SCM) muscle. **B,** Mass in right SCM *(arrow)* of a newborn. Note intrauterine folding deformity of the right ear. **C,** Flattening of the left occipital area and left ear formation resulting from supine positioning of a child with right congenital torticollis. *(From Johnson CE. Disorders of the neck. In: Herring JA, ed. Tachdjian's Pediatric Orthopaedics, 6th ed. Philadelphia: Elsevier; 2022: Fig 8.6, p. 93.)*

Fig. 721.2 Clinical presentation of a 2- × 2-cm firm, left-sided neck mass. *(From Baik G, Blask A, Reilly BK. Unilateral neck mass in a neonate. J Pediatr. 2018;202:329, Fig. 1.)*

OTHER CAUSES OF TORTICOLLIS

The evaluation of torticollis becomes more complex when the typical findings associated with CMT are absent, the usual clinical response is not observed, or the deformity presents at a later age. In addition to a careful history and physical examination, consultation with an ophthalmologist and neurologist will be helpful. Plain radiographs should be obtained, and MRI of the brain and cervical spine will be required in a subset of cases.

The differential diagnosis is extensive (see Table 721.1). **Neurogenic torticollis** is uncommon and results from tumors of the posterior fossa or brainstem, syringomyelia, and Arnold-Chiari malformation. In addition to the neurologic examination, MRI of the brain and cervical spine is required to establish the diagnosis. **Benign paroxysmal torticollis** of infancy is also uncommon and may be due to vestibular dysfunction. Episodes may last from minutes to days, and the side of the deformity may alternate. The condition is self-limiting, and no specific treatment is required other than ruling out other treatable causes. Torticollis may also be seen in association with diskitis or vertebral osteomyelitis; juvenile idiopathic arthritis; cervical disk calcification; visual problems, such as congenital nystagmus or paresis of the superior oblique or lateral rectus muscle; benign or malignant bone tumors; and in cerebral palsy and chronic gastroesophageal reflux from a hiatal hernia **(Sandifer syndrome).**

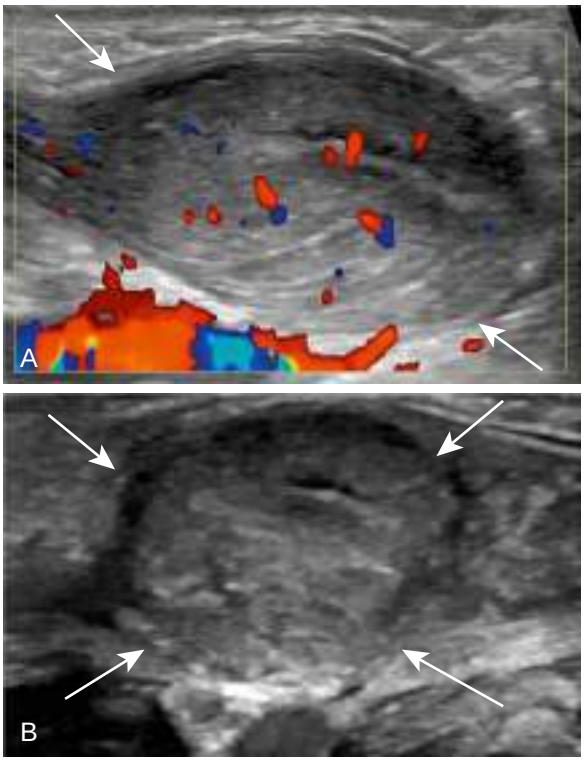

Fig. 721.3 Sonographic image of the symptomatic left neck in a 3-wk-old neonate with fibromatosis colli of the left sternocleidomastoid muscle. **A,** Longitudinal image of the sternocleidomastoid muscle showing enlargement with a fusiform configuration and masslike focus within the expanded segment of the muscle *(arrows)*. The echotexture of the mass is mildly heterogenous and echogenic compared with the normal muscle on the contralateral side. Color flow is preserved within the mass. **B,** The mass has a more rounded configuration on the transverse ultrasound image *(arrows)*. *(From Baik G, Blask A, Reilly BK. Unilateral neck mass in a neonate. J Pediatr. 2018;202:329, Fig. 2.)*

ATLANTOAXIAL ROTATORY DISPLACEMENT

Atlantoaxial rotatory displacement (AARD) represents a spectrum of pathology involving axial alignment (rotational) and motion between C1 and C2. The vertebrae may be partially displaced (subluxated) or completely displaced (dislocated) in the neutral or resting position with head facing forward. Motion between the vertebrae may

be normal (reducible with full range of motion), "sticky" (partially reducible with loss of motion), or fixed (irreducible with no motion between C1 and C2). Loss of motion at the C1-C2 joint results in 50% loss of cervical rotation. Prompt diagnosis and treatment are essential as the malalignment may become irreducible after several weeks. If the displacement persists, the facet of C2 will become deformed (resulting in increased forward slope), which increases the risk of C1 facet sliding off of the C2 facet leading to relapse of deformity.

AARD may complicate infection or inflammation of the tissues of the upper airway, neck, or pharynx **(Grisel syndrome)**, minor traumatic injuries, and surgical procedures in the oropharynx, ear, or nose. The diagnosis is most often made clinically, with the SCM muscle on the *contralateral* side (away from the head tilt) in spasm and prominent. Additionally, patients with AARD often have pain at rest and with head manipulation, features not seen with CMT. Plain radiographs are difficult to interpret given the head tilt, and AARD is best appreciated on a dynamic rotational CT scan, in which axial images are obtained through the upper cervical spine with the head at neutral and rotated maximally toward both the right and the left. The patient must be relaxed and comfortable for images to be successfully obtained. MRI may demonstrate edema or inflammation of the supporting ligaments. Clinicians may choose to treat a patient empirically if the history and clinical findings are characteristic, reserving advanced imaging for patients who have not responded clinically. If the patient is seen within a few days of the onset of symptoms, a trial of analgesics and a soft collar may be attempted. Patients with symptoms that persist or have been present for more than a week are often admitted to the hospital for analgesia, muscle relaxants, and a period of soft cervical traction. If this fails to reduce the displacement, halo traction may be attempted. If the joint can be reduced, patients are typically immobilized for at least 6 weeks in a halo vest. The treatment course is more challenging and outcomes less favorable for patients presenting more than 4 weeks after symptom onset. In such cases traction is typically employed to reduce the joint and then a halo vest used for up to 3-4 months to maintain the reduction. Some have used manipulation under anesthesia to obtain reduction before manipulation. The longer period of immobilization in these chronic cases allows for remodeling of the C2 facet, therefore reducing the risks of relapse after treatment. For those who fail these nonoperative treatment strategies, the most common treatment is a C1-C2 arthrodesis. A less common approach has been to perform an open reduction of the joint followed by either immobilization or by surgical fusion.

Visit Elsevier eBooks+ at eBooks.Health.Elsevier.com for Bibliography.

721.2 Klippel-Feil Syndrome

R. Justin Mistovich, Keith D. Baldwin, and David A. Spiegel

Klippel-Feil syndrome (KFS) includes the classic triad of a low posterior hairline, short neck, and decreased cervical range of motion (Fig. 721.4). However, these clinical findings are present in <50% of patients with KFS. Limited cervical motion may be the most common finding, present in 64.5% of patients, whereas only 9.7% of patients had all three findings. Patients have a congenital fusion **(failure of segmentation)** of one or more cervical motion segments at the craniocervical junction and/or in the subaxial spine and often have additional associated congenital anomalies of the cervical spine and other organ systems.

Additional findings in the cervical spine include occipitocervical synostosis, odontoid abnormalities, basilar invagination (proximal migration of the C2 vertebra above the foramen magnum), and Chiari malformation. Other associations include **Sprengel's deformity** (congenital elevation of the scapula), congenital scoliosis, genitourinary anomalies (25–35%), sensorineural hearing loss (5%), and congenital heart disease (5–10%). Renal abnormalities include double collecting systems, renal aplasia, and horseshoe kidney. The cervical spine anomalies seen in patients with KFS may also be seen with Goldenhar syndrome, Mohr syndrome, VACTERL syndrome, and fetal alcohol syndrome. Clinical problems are more common in adults and include pain or neurologic symptoms from spinal instability or stenosis. Although the incidence has been estimated at 1 in 40,000-42,000 births, many patients with this condition are undiagnosed

ETIOLOGY AND CLASSIFICATION

Most cases are sporadic, but four genetic forms have been described, two of which are autosomal dominant and two are autosomal recessive. A number of chromosomal abnormalities have also been associated with KFS. Pathogenic variants have been reported in the mesenchymal homeobox 1 gene (*MEOX1*, regulates segmentation of vertebrae), the growth differentiating factor 3 or 6 genes *(GDF)*, and the myosin 18 *(MYO18B)* gene.

One classification system is the most practical and has three types, namely a single fused segment (I), multiple noncontiguous fusions (II), and multiple contiguous fused segments (III). Patients with type I tend to have axial pain, whereas while those with types II/III are more likely to have neurologic symptoms.

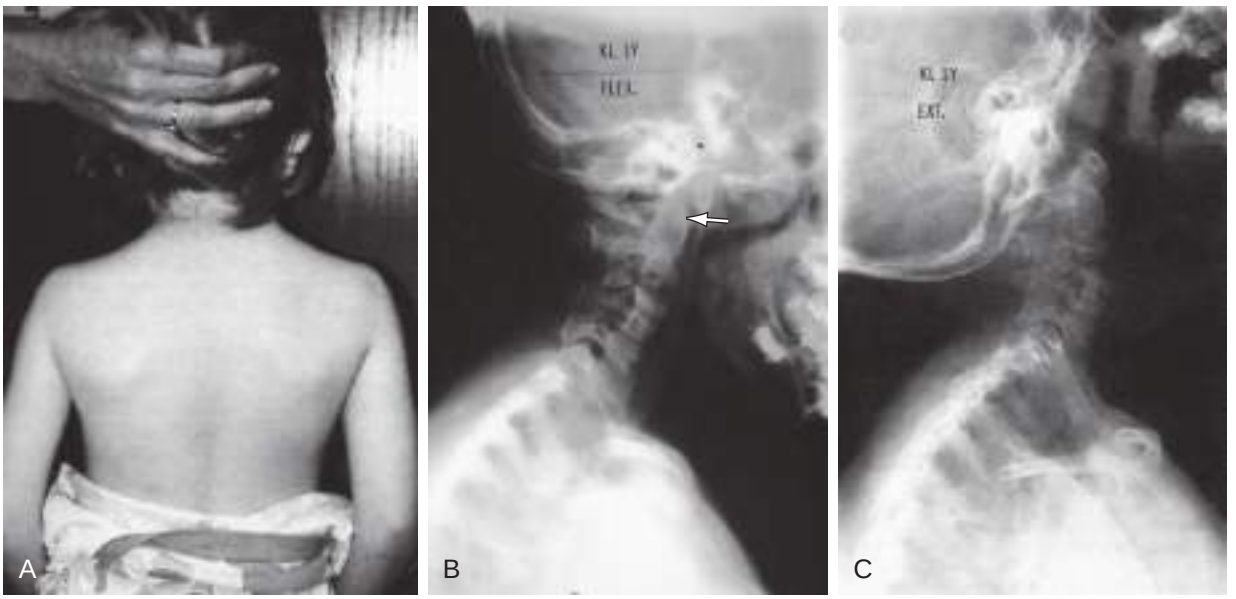

Fig. 721.4 Clinical picture of a 5-yr-old with Klippel-Feil syndrome. **A,** Note short neck and low hairline. **B** and **C,** Radiographs of the cervical spine (**B,** flexion; **C,** extension) demonstrate congenital fusion and evidence of spinal instability *(arrow). (From Drummond DS. Pediatric cervical instability. In: Weisel SE, Boden DS, Wisnecki RI, eds. Seminars in Spine Surgery. Philadelphia: WB Saunders; 1996;292–309.)*

CLINICAL PRESENTATION

KFS is present at birth but does not usually become clinically apparent until the second or third decades. Patients at this point present with pain, loss of motion, or neurologic symptoms. Pain is extremely common by adulthood and may be referred to the neck, occiput, and shoulders/upper back. The source of discomfort may be musculoskeletal and/or neurologic. The pain is greater in patients with more extensive involvement. Headache, dizziness, and fatigue have also been reported. Given that the same physiologic stresses are applied to a smaller number of mobile spinal segments, patients are at risk for the development of hypermobility and often instability, especially at motion segments adjacent to the fused vertebrae. Weakness or clumsiness consistent with **myelopathy** may be the presenting symptoms.

PHYSICAL EXAMINATION

A comprehensive musculoskeletal and neurologic examination is required, given associated anomalies in the musculoskeletal and visceral systems. **Scoliosis** is present in more than 50% of patients with KFS, and congenital anomalies may be identified in other regions of the spine as well. The neurologic exam focuses on identifying any signs of radiculopathy or myelopathy. Spinal cord compression, or myelopathy, may result from stenosis or instability. A physical exam will demonstrate upper motor neuron signs such as hyperreflexia, Hoffman's sign, Babinski's sign, and sustained clonus, with more than three beats considered pathologic. Nerve root compression, or radiculopathy, may be due to stenosis and is identified by weakness or decreased sensation in the muscles or dermatomes served by a particular nerve root.

RADIOLOGIC INVESTIGATION

Initial radiologic evaluation should include an AP, lateral, and oblique view of the cervical spine. The characteristic finding is a congenital fusion of two or more vertebrae resulting from a failure of segmentation; however, multiple vertebrae may be involved. Because congenital anomalies may exist in more than one region of the spine, radiographs of the thoracic and lumbosacral spine should be routinely obtained. Flexion-extension lateral views of the cervical spine may help to identify segments with excessive motion. Referral to an orthopedist is appropriate once the diagnosis is established. Patients with this condition usually undergo CT and MRI of the spine to accurately characterize the bony anomalies and also identify any coexisting neural pathology. A renal ultrasound is routinely obtained to identify associated anomalies (e.g., duplicated collecting system, absence of a kidney, horseshoe kidney). Additional imaging, such as echocardiogram, may identify cardiovascular anomalies, mainly septal defects.

Audiologic evaluation is indicated for patients diagnosed with KFS; hearing impairment may be identified in up to one third of affected patients.

TREATMENT

The three patterns commonly associated with instability include (1) C2/C3 fusion with occipitocervical synostosis, (2) extensive fusion over multiple levels with an abnormal occipitocervical junction, and (3) two fused segments separated by an open joint space.

Pain may often be controlled by activity restriction, intermittent immobilization, or other nonoperative modalities. Patients who are chronically symptomatic, have instability with positive neurologic symptoms or exam findings, or are thought to be at increased risk for neurologic deterioration are candidates for surgical treatment. Operative interventions include decompression of nerve roots or the spinal cord itself and/or spinal fusion to address cervical spinal instability.

Visit Elsevier eBooks+ at eBooks.Health.Elsevier.com for Bibliography.

Table 721.2 Causes of Pediatric Cervical Instability

CAUSES	SUBTYPES
Congenital	Cranio-occipital defects (occipital vertebrae, basilar impression, occipital dysplasias, condylar hypoplasia, occipitalized atlas)
	Atlantoaxial defects (aplasia of atlas arch, aplasia of odontoid process)
	Subaxial anomalies (failure of segmentation and/or fusion, spina bifida, spondylolisthesis)
	Syndromic disorders (e.g., Down syndrome, Klippel-Feil syndrome, 22q11.2 deletion syndrome, Larsen syndrome, Marfan syndrome, Ehlers-Danlos syndrome)
Acquired	Trauma
	Infection (pyogenic/granulomatous)
	Tumor (including neurofibromatosis)
	Inflammatory conditions (e.g., juvenile idiopathic arthritis)
	Osteochondrodysplasias (e.g., achondroplasia, diastrophic dysplasia, metatropic dysplasia, spondyloepiphyseal dysplasia)
	Storage disorders (e.g., mucopolysaccharidoses)
	Metabolic disorders (rickets)
	Miscellaneous (including osteogenesis imperfecta, after surgery)

721.3 Cervical Anomalies and Instabilities

R. Justin Mistovich, Keith D. Baldwin, and David A. Spiegel

Anomalies of the craniovertebral junction or lower cervical spine may be seen in isolation or in association with other conditions. These include genetic syndromes, skeletal dysplasias, connective tissue disorders, and metabolic disorders. These anomalies may be congenital or developmental. Although most anomalies remain asymptomatic and undiagnosed, a subset will place the patient at risk of neurologic injury as a result of instability or spinal canal stenosis. The most frequently encountered causes of cervical spine instability in children can be categorized etiologically (Table 721.2). Patients with conditions that have known associations involving the cervical spine should have a complete evaluation, including history, physical examination, and initial radiographic examination. Lateral radiographs in flexion and extension may be helpful to evaluate instability, and advanced imaging such as CT or MRI may be required to further characterize any abnormalities noted on plain radiographs.

Patients may complain of neck pain or neurologic symptoms. Radicular symptoms include pain, weakness, and numbness within the distribution of a nerve root. Myelopathic symptoms include generalized weakness, gait disturbance, increased fatigue with ambulation, upper extremity clumsiness, and abnormalities in bowel or bladder function. Other symptoms such as headaches, dizziness, or vertigo have also been described. Physical exam findings may include restricted cervical mobility, cervical tenderness or spasm, and neurologic abnormalities.

Although the upper cervical spine has limited flexion and extension, roughly 50% of cervical rotation occurs at the atlantoaxial (C1-2) joint. The main constraints to motion in the upper cervical spine are soft tissue (ligaments and joint capsules) rather than osseous. Excessive motion or instability may result in a compressive injury to the brainstem or spinal cord. Anomalies at the craniovertebral junction include congenital fusion of the occiput to C1 (**occipitalization** of the atlas), basilar impression and invagination (proximal migration of the C2 vertebra as the result of softening of the bones and with normal bones, respectively), and accessory vertebrae. Aplasia or hypoplasia of the atlas or the axis may result in atlantoaxial instability.

OS ODONTOIDEUM

Os odontoideum is the most common anomaly of the odontoid, or dens, and radiographically appears as an oval-shaped, well-corticated bony ossicle that is positioned cephalad to the body of the axis. There is a discontinuity, and the upper portion of the dens moves with the ring of C1, narrowing the space available for the spinal cord and placing it at risk for injury. The body of the dens is mesenchymal in origin and originates from the first cervical vertebra. Subsequent separation allows it to then fuse with the C2 vertebra. It is formed by two separate ossification centers, one on either side of the midline that eventually fuse and are visible at birth. The os odontoideum may be in a normal anatomic position (orthotopic) or adjacent to the occipital bone (dystopic). Although the etiology remains unclear, both traumatic (nonunion of a fracture, repetitive shear stresses from hypermobility on growing cartilage) and developmental (failure of fusion of the ossification centers) theories have been proposed.

Symptoms may include pain and/or neurologic dysfunction. Myelopathy may develop from neural stretch, ischemia, or bony impingement, whereas vertebrobasilar findings may result from ischemia due to stretching or thrombosis of the vertebral arteries. Neurologic examination may reveal a combination of both upper and lower motor neuron signs. Some patients are completely asymptomatic with the anomaly noted incidentally on a lateral cervical spine radiograph.

The radiographic evaluation begins with AP, lateral, and open mouth odontoid views, which may be supplemented by flexion and extension lateral radiographs. CT provides the best bony detail and is useful in defining each anomaly. MRI, including dynamic images in flexion and extension, is best for evaluating neurologic impingement.

Patients who are asymptomatic with no instability may be managed by observation with serial radiographs, activity restriction, and taking special precautions if they require intubation/general anesthesia. Those with neurologic symptoms and instability require surgical stabilization by an instrumented posterior arthrodesis between C1 and C2.

Down Syndrome

Ligamentous hyperlaxity is a characteristic feature of Down syndrome and may result in hypermobility or instability at the occipitoatlantal or the atlantoaxial joints in 4–30% of patients (see Chapter 57). These patients may also have coexisting congenital or developmental anomalies of the cervical spine, such as occipitalization of the atlas, atlantal arch hypoplasia, basilar invagination, and os odontoideum.

Although the natural history of this spectrum of pathology remains unknown, a small subset of patients will develop instability with neurologic dysfunction. The clinical diagnosis of neurologic dysfunction may be challenging because patients often present with subtle findings such as decreased exercise tolerance, tripping/falling, or other gait abnormalities. The challenge lies in the early identification of such cases, especially in patients who plan to participate in activities with increased risk of trauma to the head or neck such as tumbling or other sports.

All patients with Down syndrome require screening by history and physical examination at regular intervals. The guidelines for health supervision for children with Down syndrome suggest that routine radiographic screening is not indicated in asymptomatic patients and that a lateral radiograph in neutral alignment should be obtained for all patients with symptoms of possible atlantoaxial instability (neck pain, radicular pain, weakness, spasticity/change in tone, gait difficulties, hyperreflexia, or change in bowel or bladder function). Dynamic images are suggested when abnormalities

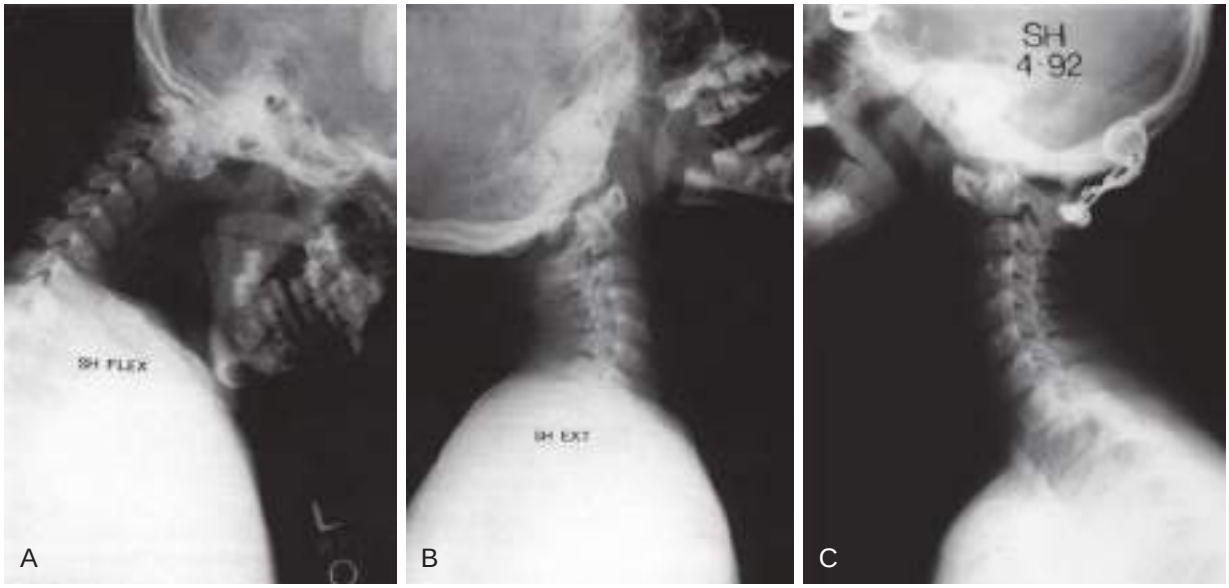

Fig. 721.5 Flexion (A) and extension (B) radiographs of a case of Down syndrome demonstrating atlanto-occipital hypermobility and subluxation. C, Instability and symptoms were relieved by an occipitoaxial arthrodesis.

Fig. 721.6 Radiographs of the cervical spine in a child with 22q11.2 deletion syndrome showing evidence of platybasia, occipitocervical, and atlantoaxial instability. **A,** Neutral radiograph. **B,** Flexion. **C,** Extension. *(From Drummond DS. Pediatric cervical instability. In: Weisel SE, Boden DS, Wisnecki RI, eds. Seminars in Spine Surgery. Philadelphia: WB Saunders; 1996:292–309.)*

are present on the initial lateral radiograph. Although variations in practice patterns likely exist and recommendations may vary between states, radiographic screening is required before participation in the Special Olympics. Patients with coexisting os odontoideum are candidates for routine radiographic surveillance because they are at greater risk for progression of displacement and neurologic injury.

Plain radiographs are ideally obtained in children older than 3 years unless clinical findings mandate earlier evaluation, consisting of an AP and lateral in neutral alignment, usually supplemented by a lateral view in flexion and extension. The atlanto-dens interval (ADI) is used to evaluate the relationship between C1 and C2 (atlantoaxial joint) and is measured as the space between the dens and the anterior ring of C1 on lateral radiographs in neutral, flexion, and extension (Fig. 721.5). Although the ADI should be 3 mm or less in the population without Down syndrome, a normal ADI in children with Down syndrome is <4.5 mm. Hypermobility is diagnosed as an ADI between 6 and 10 mm, whereas an ADI >10 mm represents frank instability and carries greater risk of neurologic injury. Evaluating the space available for the spinal cord is also important, and a measurement of ≤14 mm between the posterior odontoid and posterior arch is felt to be abnormal. Progression from hypermobility to instability on surveillance radiographs is uncommon. In one series of patients with Down syndrome screened routinely, an ADI of ≥6 mm was identified in 4.4%, and 1.6% were noted to progress to hypermobility/instability over 4 years. MRI in flexion and extension is indicated to evaluate for impingement and/or neurologic injury in patients with appropriate clinical symptoms or findings and/or those with radiographic instability, and an increase in signal intensity within the spinal cord at the level of excessive motion is diagnostic of neurologic injury.

Although hypermobility at the occipitoatlantal joint is present in >50% of children with Down syndrome, most patients do not develop instability or neurologic symptoms. The relationships at this articulation are difficult to measure reliably on plain radiographs. An MRI in flexion and extension is required to evaluate any questionable radiographic findings, especially in the presence of clinical symptoms. Involvement of the subaxial spine is less common and is typically encountered in the adult population of patients with Down syndrome. Degenerative changes or instability may result in pain, radiculopathy, and/or myelopathy.

Specific treatment recommendations have not been standardized, but patients diagnosed with hypermobility may be restricted from participation in contact sports and other activities that increase the risk of trauma to the cervical spine. Patients with C1-2 instability with or without neurologic findings are candidates for an atlantoaxial fusion.

22Q11.2 Deletion Syndrome

The chromosome deletion of 22q11.2 is a common genetic syndrome, with an overall prevalence of 1 in 5,950 births and encompasses a wide spectrum of abnormalities. There are characteristic facial features, cleft palate, and cardiac anomalies. Cervical spine anomalies are also common. At least one developmental variation of the occiput or cervical spine is noted in all patients. The occipital variations observed include **platybasia**, an abnormal flattening of the base of the skull, and **basilar impression**. Variations in anatomy of C1 include dysmorphic shape, an open posterior arch, and occipitalization, while axis variations include a dysmorphic dens and "C2 swoosh" (upswept lamina and posterior elements). A range of cervical vertebral fusions is noted in these patients, the most common being at the C2-3 level. Increased segmental motion is commonly observed, but symptomatic instability is quite uncommon. With frequent occurrence of upper cervical spine anomalies in patients with 22q11.2 deletion syndrome (Fig. 721.6), advanced imaging of the upper cervical spine is suggested to characterize the anomalies. Regular follow-up is required as a small subset of patients may develop instability. A flexion-extension MRI of the cervical spine may be considered for evaluation of symptomatic patients to rule out instability and/or neurologic injury.

Visit Elsevier eBooks+ at eBooks.Health.Elsevier.com for Bibliography.

Chapter 722

The Upper Limb

Robert B. Carrigan

SHOULDER

The shoulder is a ball-and-socket joint that is similar to the hip; however, there are several anatomic differences between the two. The shoulder is a very shallow ball-and-socket joint compared to the hip and is more prone to dislocation than the hip. In addition, shoulder

range of motion (ROM) is much greater than that of the hip. This is due to the size of the humeral head relative to the glenoid and the presence of scapulothoracic motion. The shoulder positions the hand along the surface of a theoretical sphere in space, with its center at the glenohumeral joint.

Sprengel Deformity

Sprengel deformity, or congenital elevation of the scapula, is a disorder of development that involves a high scapula and limited scapulothoracic motion. The scapula originates in early embryogenesis at a level posterior to the fourth cervical vertebra. It descends during development to below the seventh cervical vertebra. Failure of this descent, either unilateral or bilateral, is the Sprengel deformity. The severity of the deformity depends on the location of the scapula and associated anomalies. The scapula in mild cases is simply rotated, with a palpable or visible bump corresponding to the superomedial corner of the scapula. Function is generally good. In moderate cases, the scapula is higher on the neck and connected to the spine with an abnormal omovertebral ligamentous or bony connection. Shoulder motion, particularly abduction, is limited. In severe cases, the scapula is small and positioned on the posterior neck. The neck may be webbed. Most patients with Sprengel deformity have associated anomalies of the musculoskeletal system, especially in the spine (Klippel-Feil syndrome), making spinal evaluation important.

Treatment

In mild cases, treatment is generally unnecessary. A prominent and unsightly superomedial corner of the scapula can be excised. In more severe cases, surgical repositioning of the scapula with rebalancing of parascapular muscles can significantly improve both function and appearance.

Congenital Pseudarthrosis of the Clavicle

The clavicle is a tubular S-shaped bone that articulates with the sternum and acromion. It acts as a strut to keep the shoulder from protracting forward. Congenital pseudoarthrosis of the clavicle is a failure of the two primary ossification centers of the clavicle to fuse during embryogenesis (Fig. 722.1). The condition presents exclusively on the right side and may be confused for an acute clavicle fracture sustained during birth. A thorough history and physical exam will help to distinguish between the two conditions. Although both a birth-related clavicle fracture and a congenital pseudoarthrosis will present with a bump or prominence over the midclavicle, a birth-related clavicle fracture will be tender to palpation on exam. The parents may also report that the child is fussy with feeding and changing. Congenital pseudoarthrosis of the clavicle will be painless on exam. Radiographically the congenital pseudoarthrosis clavicle will have two rounded edges at the midportion with signs of hypertrophy.

Fig. 722.1 Radiograph of congenital pseudoarthrosis of the clavicle.

Treatment

There is not a clear consensus regarding treatment of congenital pseudoarthrosis of the clavicle. Surgery is indicated for patients with symptoms of **thoracic outlet syndrome** (impingement of the clavicle on the brachial plexus and subclavian vessels). However, most patients are asymptomatic with few functional limitations and do not require surgical repair. Surgical treatment may be considered for patients with unacceptable cosmetic deformity, pain, or functional deficits.

The operative treatment of congenital pseudoarthrosis of the clavicle consists of opening the pseudoarthrosis site, preserving the periosteum, debriding the hypertrophic ends, bone grafting, and stabilization.

ELBOW

The elbow is the most congruent joint in the body. The stability of the elbow is imparted via this bony congruity and through the medial and radial collateral ligaments. Where the shoulder positions the hand along the surface of a theoretical sphere, the elbow positions the hand within that sphere. The elbow allows extension and flexion through the ulnohumeral articulation and pronation and supination through the radiocapitellar articulation.

Panner Disease and Osteochondritis of the Capitellum

Panner disease is a disruption of the blood flow to the subchondral bone and articular cartilage of the capitellum (Fig. 722.2). It typically occurs in males between the ages of 5 and 13 years. Presenting symptoms include lateral elbow pain, loss of motion, and, in advanced cases, mechanical symptoms of the elbow (loose bodies).

The mechanism of injury can be impaction or overloading of the joint, as seen with sports such as gymnastics and baseball. It can also be idiopathic. Radiographs of the elbow may be normal or may show a small lucency within the subchondral bone of the capitellum. MRI is the study of choice to evaluate a suspected capitellar lesion. MRI can demonstrate the extent of the involvement in the subchondral bone and the integrity of the cartilage of the articular surface.

Treatment

Treatment is typically conservative. Rest, activity modification, and patient education are initial treatment options. In cases in which the articular cartilage fragments and loose bodies form, arthroscopy of the elbow is warranted to remove the loose bodies. When the cartilage defect in the capitellum is large and symptomatic, procedures for restoration of the articular cartilage may be considered. These procedures include drilling of the subchondral bone (microfracture) to promote scar cartilage and osteochondral autograft transplantation (OATS).

Radial Longitudinal Deficiency

Radial longitudinal deficiency of the forearm comprises a spectrum of conditions and diseases that have resulted in hypoplasia or absence of the radius (Table 722.1). Clinical characteristics consist of a small, shortened limb with the hand and wrist in excessive radial deviation. Partial or complete absence of the radial structures of the forearm and hand are observed (Fig. 722.3).

Radial longitudinal deficiency can range in severity from mild to severe and has been classified into four types according to Bayne and Klug (Table 722.2). Radial longitudinal deficiency can be associated with other syndromes such as **Holt-Oram** and **Fanconi anemia**. Complete and thorough workup of these associated conditions is important for the long-term health of the child.

Treatment

The goals for the treatment of radial longitudinal deficiency include centralizing the hand and wrist on the forearm, balancing the wrist, and maintaining appropriate thumb and digital motion. Shortly after

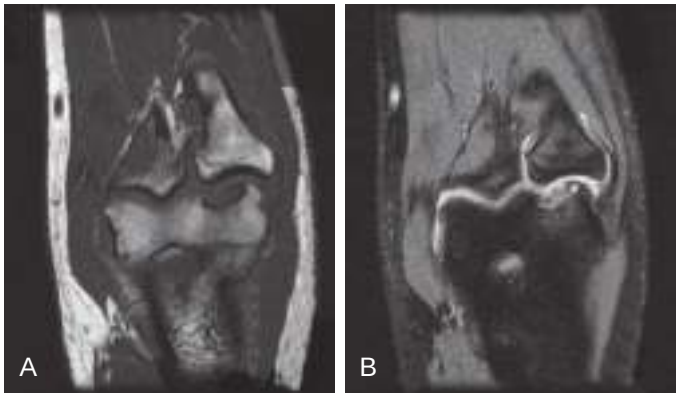

Fig. 722.2 T1 (A) and T2 (B) coronal MRI images of the elbow depicting Panner disease of the elbow.

Table 722.1 Syndromes Commonly Associated with Radial Deficiency

SYNDROME	CHARACTERISTICS
Holt-Oram syndrome	Heart defects, most commonly atrial septal defects Absent thumb or long finger-like thumb
Thrombocytopenia-absent radius syndrome	Thrombocytopenia present at birth but improves over time Thumbs present, radii absent
VACTERL association	Vertebral abnormalities, anal atresia, cardiac abnormalities, tracheoesophageal fistula, esophageal atresia, renal defects, radial dysplasia, lower limb abnormalities
Fanconi anemia	Aplastic anemia does not present at birth, develops about 6 yr of age; fatal without bone marrow transplant Chromosomal breakage challenge test and genetic testing available for early diagnosis Thumb hypoplasia but present

From Trumble T, Budoff J, Cornwall R, eds. *Core Knowledge in Orthopedics: Hand, Elbow, Shoulder*. Philadelphia: Elsevier; 2005:425.

birth, stretching and splinting of the wrist and hand should be started to elongate the contracted radial soft tissues.

Surgery for correction of the wrist deformity is focused on addressing the tight structures and varies by age and level of involvement. The classic surgical technique for children with good elbow motion is centralization of the wrist on the forearm, which is often associated with recurrence of the deformity. When considering a centralization procedure, the preoperative plan begins with careful examination of the patient; considerations regarding thumb and elbow function must be made before surgery. The surgery typically occurs when the child is 1 year of age. Correction of the radial deviation as well as centralization of the wrist can be accomplished with a variety of different surgical techniques. These techniques include open release, capsular reefing, and tendon rebalancing. External fixation techniques and free tissue transfers also have been described.

Nursemaid's Elbow

Nursemaid's elbow is a subluxation and interposition of the annular ligament of the elbow. It is often confused for a subluxation or dislocation of the radial head. The proximal end of the radius, or radial head, is anchored to the proximal ulna by the annular ligament. It wraps around like a leash from the ulna, around the radial head, and back to the ulna. If the radius is pulled distally, the annular ligament can slip proximally off the radial head and into the joint between the radial head and the humerus (Fig. 722.4). The injury is typically produced when a longitudinal traction force is applied to the arm, such as when a falling child is caught by the hand, or when a child is pulled by the hand. The injury usually occurs in toddlers and rarely occurs in children older than 5 years of age. Subluxation of the annular ligament produces immediate pain and limitation of supination. Flexion and extension of the elbow are not limited. Swelling is generally absent. The diagnosis is made by history and physical examination because radiographs are typically normal.

Treatment

The annular ligament is reduced by rotating the forearm into supination while holding pressure over the radial head. A palpable click or clunk can be felt. The child recovers active supination and usually has relief of discomfort. Sometimes pain may persist after reduction maneuvers. Immobilization is not required, but recurrence can happen. Parents should avoid activities that apply traction to the elbows. Parents can learn reduction maneuvers for recurrent episodes to avoid trips to the emergency department or pediatrician's office. Recurrence beyond 5 years of age is rare.

WRIST

The wrist is composed of the two forearm bones (radius and ulna) as well as the eight carpal bones. The wrist allows flexion, extension, and radial and ulnar deviation through the radiocarpal and midcarpal articulations. Pronation and supination occur at the wrist through the distal radial ulnar joint (DRUJ). The wrist is a complex joint with numerous ligamentous and soft tissue attachments. It has complex kinematics that allows for its generous ROM, but when these kinematics are altered, significant dysfunction can occur.

Madelung Deformity

Madelung deformity is a deformity of the wrist that is characterized as radial and palmar angulations of the distal aspect of the radius (Fig. 722.5). Growth arrest of the palmar and ulnar aspect of the distal radial physis is the underlying cause of this deformity. Bony physeal lesions and an abnormal radiolunate ligament **(Vicker's ligament)** have been implicated. The deformity can be bilateral and affects females more than males.

Treatment

Treatment of Madelung deformity is typically observation. Mild deformities can be observed until skeletal maturity. Moderate to severe deformities that either are painful or limit function may be candidates for surgical intervention. Surgical treatment for Madelung deformity is often motivated by appearance. Patients and their families may be concerned about the palmar angulation of the wrist and the resulting prominent distal ulna.

There are a multitude of surgical options for treating Madelung deformity. For the skeletally immature patient, resection of the tethering soft tissue (Vicker's ligament) and physiolysis (fat grafting of any bony lesion seen within the physis) is often the first option. When Madelung deformity is encountered in skeletally mature patients, an osteotomy may be considered. Dorsal closing wedge, dome, and ulnar shortening osteotomies may be used alone or in combination to achieve the desired result.

Long-term considerations of Madelung deformity concern the incongruity of the DRUJ and resulting premature DRUJ arthritis.

Gymnast's Wrist

Gymnast's wrist refers to the changes observed in the physis of the distal radius in the setting of repetitive stress associated with gymnastics

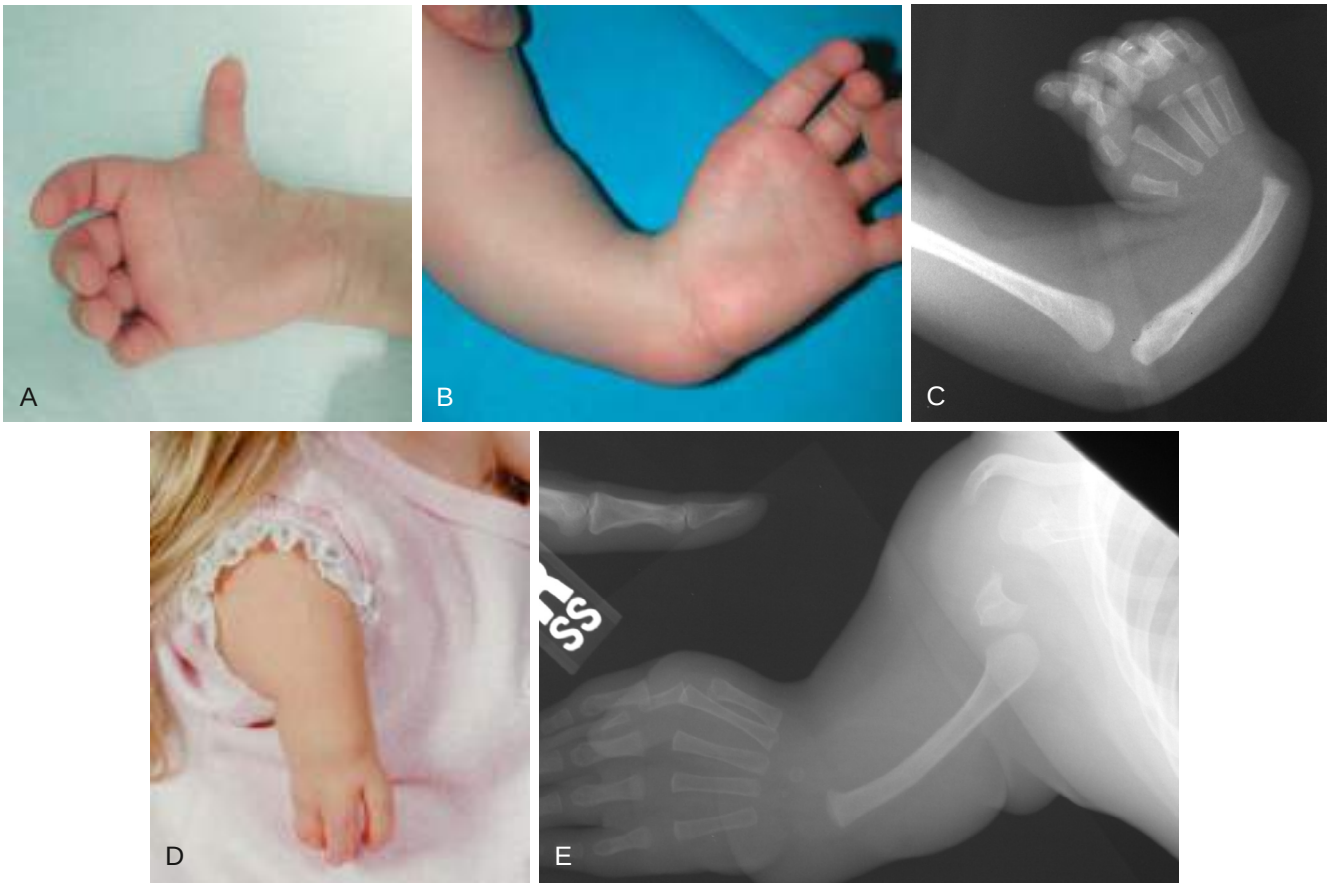

Fig. 722.3 Spectrum of phenotypes of radial dysplasia. **A,** Type 1 radius with a hypoplastic thumb. **B,** Type IV radius with an absent thumb. **C,** Radiograph of a type IV radius. **D** and **E,** Phocomelic radial deficiency. *(From Oishi S, Stutz C, Lake A. Disorders of the upper extremity. In: Herring JA, ed. Tachdjian's Pediatric Orthopaedics, 6th ed. Philadelphia: Elsevier; 2022: Fig. 12.72, p. 337.)*

Table 722.2 Modified Classification of Radial Longitudinal Deficiency

TYPE	THUMB	CARPUS	DISTAL RADIUS	PROXIMAL RADIUS
N	Hypoplastic or absent	Normal	Normal	Normal
0	Hypoplastic or absent	Absence, hypoplasia, or coalition	Normal	Normal, radioulnar synostosis, or congenital dislocation of the radial head
1	Hypoplastic or absent	Absence, hypoplasia, or coalition	>2 mm shorter than the ulna	Normal, radioulnar synostosis, or congenital dislocation of the radial head
2	Hypoplastic or absent	Absence, hypoplasia, or coalition	Hypoplasia	Hypoplasia
3	Hypoplastic or absent	Absence, hypoplasia, or coalition	Physis absent	Variable hypoplasia
4	Hypoplastic or absent	Absence, hypoplasia, or coalition	Absent	Absent

From James MA, McCarroll HR Jr, Manske PR. The spectrum of radial longitudinal deficiency: a modified classification. *J Hand Surg Am*. 1999;24:1145–1155.

(Fig. 722.6). Symptoms include pain with weight bearing, swelling, and loss of motion (mainly wrist extension). The pain is typically mild at first and worsens with time and increased activity. Children will have pain over the distal radial physis on palpation. The child should also be examined for coexisting wrist pathology including DRUJ instability and triangular fibrocartilage complex (TFCC) tears. Radiographs are often normal but may show chronic changes in the distal radial physis, including widening, sclerosis, and partial physeal arrest. Ulnar positive variance may also be observed because of partial growth arrest of the radius. MRI may be useful to examine the extent of physeal involvement as well as TFFC pathology

Treatment

Treatment of gymnast's wrist begins with rest. Typically, the child is prohibited from weight-bearing activities for a period of 6 weeks or until symptoms resolve. The child is slowly progressed back to their routine. If symptoms return during the recovery phase, rest is reinitiated. It is not uncommon for relapses to occur when returning to competition. This may be difficult for the child and parents to understand, as gymnasts and gymnast's families are often very motivated to continue their sport. Use of braces, such as Tiger Paws, may help limit the amount of force transmitted to the wrist and in turn help with injury prevention.

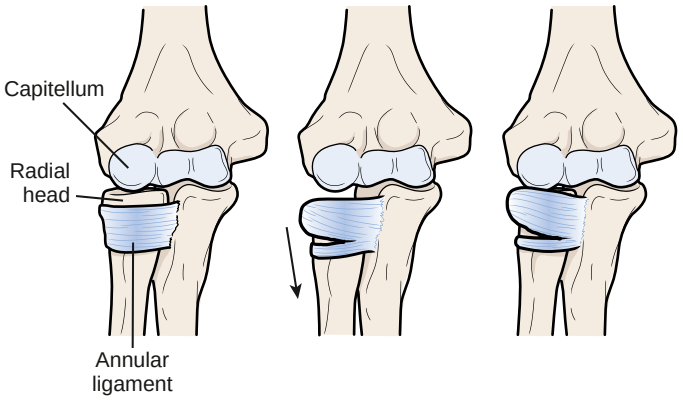

Fig. 722.4 Nursemaid's elbow. Illustration depicting subluxation of the radial head inferior to the annular ligament, with interposition of the ligament to the radiocapitellar joint space. This entity is sometimes in the differential in the setting of upper extremity injury in a small child. Radiographs are negative and serve only to exclude the presence of bony injury when the diagnosis is not clear. *(From Walters MM, Robertson RL, eds. Pediatric Radiology: The Requisites, 4th ed. Philadelphia: Elsevier; 2017: Fig. 7.102.)*

Fig. 722.5 Radiograph of an adolescent with Madelung deformity.

In cases where significant damage is seen in the distal radius physis, surgery may be indicated to prevent future morphologic changes in the wrist. Surgery may include epiphysiodesis of the radius and ulna, shortening of the ulna, and TFCC repair.

Ganglion

The wrist joint articulation is lubricated with synovial fluid, which is produced by the synovial lining of the joint and maintained within the joint by the joint capsule. A defect in the capsule can allow fluid to leak from the joint into the soft tissues, resulting in a ganglion. The term *cyst* is a misnomer, because this extraarticular collection of fluid does not have its own true lining. The defect in the capsule can occur as a traumatic event, although trauma is rarely a feature of the presenting history. The fluid usually exits the joint in the interval between the scaphoid and lunate, resulting in a ganglion located at the dorsoradial aspect of the wrist. Ganglia can occur at other locations, such as the volar aspect of the wrist, or in the palm because of leakage of fluid from the flexor tendon sheaths. Pain is not commonly associated with ganglia in children, and when it is, it is unclear whether the cyst is the cause of the pain. The diagnosis is usually evident on physical examination, especially if the lesion transilluminates. Extensor tenosynovitis and anomalous muscles can mimic ganglion cysts, but radiography or MRI is not routinely required. Ultrasonography is an effective, noninvasive tool to support the diagnosis and reassure the patient and family.

Treatment

Regarding the treatment of ganglia in children, consider the vowels AEIOU.

Aspiration: Simple aspiration of the fluid has a high recurrence rate and is painful for children given the large-bore needle required to aspirate the gelatinous fluid. However, in older children who would like to try and decompress the cyst before considering surgery, this may be reasonable.

Excision: Surgical excision, including excision of the stalk connecting the ganglion to its joint of origin, has a high success rate, although the ganglion can recur.

Injection: Aspiration of the cyst and a simultaneous injection of a corticosteroid have been shown to be effective in treating recurrence in children.

Observation: Up to 80% of ganglia in children <10 years of age resolve spontaneously within 1 year of being noticed. If the ganglion is painful or bothersome and the child is >10 years of age, treatment may be warranted.

Ultrasound: For children's parents who are concerned about the mass and want a radiographic study to confirm the diagnosis, ultrasound is a noninvasive test to confirm the diagnosis.

HAND

The hand and fingers allow for complex and fine manipulations. An intricate balance among extrinsic flexors, extensors, and intrinsic

Fig. 722.6 Gymnast's wrist. **A** and **B**, Posteroanterior radiographs of the bilateral wrists show widening and irregularity of the distal radial physis. Abnormal linear lucency is seen in the metaphyses, with surrounding sclerosis noted. Findings reflect disrupted growth at the physes. **C**, Coronal T1 and **D**, coronal T2 magnetic resonance images with fat saturation show similar abnormality at the distal radial physis, along with abnormal increased fluid signal along the metaphysis. *(From Walters MM, Robertson RL, eds. Pediatric Radiology: The Requisites, 4th ed. Philadelphia: Elsevier; 2017: Fig. 7.107.)*

Table 722.3 Classification of Camptodactyly

TYPE	CHARACTERISTICS
I	Congenital, no sex bias, small finger only
II	Acquired between 7-11 yr, typically progressive
III	Severe, significant contracture, bilateral and associated with other musculoskeletal syndromes

Adapted from Kozin SH. Pediatric hand surgery. In: Beredjiklian PK, Bozentka DJ, eds. *Review of Hand Surgery*. Philadelphia: WB Saunders; 2004:223–245.

muscles allows these complex motions to occur. Congenital anomalies of the hand and upper extremity rank just behind cardiac anomalies in incidence. Like cardiac anomalies, if they are not properly identified and remedied, may have long-term consequences.

Camptodactyly

Camptodactyly is a nontraumatic flexion contracture of the proximal interphalangeal joint that is often progressive. The small and ring fingers are most often affected. Bilateralism is observed two thirds of the time. The etiology of camptodactyly is varied. Several different hypotheses have been offered as to the cause of this condition. Camptodactyly can be divided into three different types (Table 722.3).

Treatment

Nonsurgical treatment is the primary treatment of camptodactyly. Mild contractures of less than 30 degrees are usually well tolerated and do not need treatment. Serial casting or static and dynamic splinting can prevent contractures from worsening.

Surgical treatment is limited to the treatment of severe contractures. At the time of surgery, all contracted and anomalous structures are released. Results of contracture release for camptodactyly are mixed; often a loss of flexion results from an attempt to improve extension.

Clinodactyly

Angular deformity of the digit in the coronal plane, distal to the metacarpophalangeal joint is clinodactyly. The most observed finding is a mild radial deviation of the small finger at the level of the distal interphalangeal joint. This is often due to a triangular or trapezoidal middle phalanx. In some cases, a disruption of the physis at the middle phalanx produces a longitudinal epiphysial bracket. This bracket is thought to be the underlying cause for the formation of the "delta phalanx" that is often observed in clinodactyly. Clinodactyly has been observed in other fingers, including the thumb (Fig. 722.7) and ring finger.

Treatment

The initial treatment for clinodactyly is observation. For severe deformities and for those affecting the thumb, surgery may be indicated. Surgery is technically demanding. Bracket resections, corrective osteotomies, and growth plate ablations are the most common procedures performed to correct the observed angular deformities. Results are good, and recurrences are few.

Polydactyly

Polydactyly or duplication of a digit can occur either as a radial deformity (involving the thumb), central (index, middle, or ring), or as an ulnar deformity (involving the small finger) (Table 722.4). Each has an inherited and genetic component. Transmission is typically in an autosomal dominant pattern and has been linked to differences in genes localized to chromosome 2.

Duplication of the thumb has been subdivided into seven types by Flatt and Wassel based on the degree of duplication (Table 722.5). Small finger duplication has been further subdivided into two types.

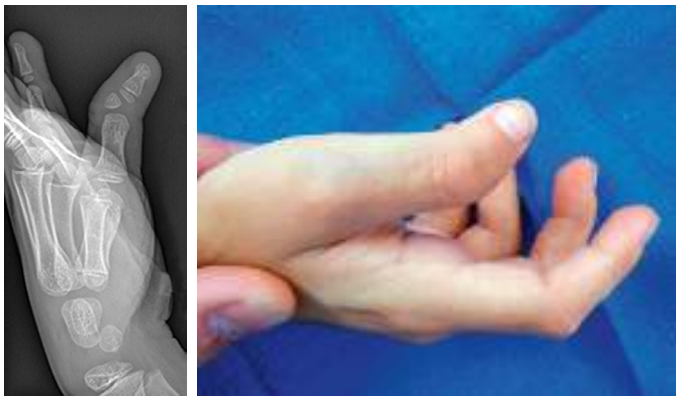

Fig. 722.7 Clinodactyly of the thumb.

Table 722.4 Syndromes Associated with Polydactyly*

Carpenter syndrome
Ellis-van Creveld syndrome
Meckel-Gruber syndrome
Polysyndactyly
Trisomy 13
Orofaciodigital syndrome
Rubinstein-Taybi syndrome
Bardet-Biedl syndrome
Meckel-Gruber syndrome
Pallister-Hall syndrome
Short Rib-polydactyly syndromes (type I, II)

*There are many syndromes with polydactyly; this is a partial list.

Table 722.5 Wassel Classification of Thumb Duplication

TYPE	CHARACTERISTICS
I	Bifid distal phalanx
II	Duplicate distal phalanx
III	Bifid proximal phalanx
IV	Duplicate proximal phalanx
V	Bifid metacarpal
VI	Duplicate metacarpal
VII	Triphalangeal component

Data from Wassel, HD. The results of surgery for polydactyly of the thumb: a review. *Clin Orthop*. 1969;125:175–193.

Type A is a well-formed digit. Type B is a small, often underdeveloped supernumerary digit.

Treatment

Thumb and small finger duplication are typically treated with ablation of the supernumerary digit. Treatment options vary based on the degree of involvement. Less well-formed digits can be treated with suture ligation. Well-formed digits require reconstructive procedures that preserve important structures such as the collateral ligaments and nail folds (Fig. 722.8).

Thumb Hypoplasia

Hypoplasia of the thumb is a challenging condition for both the patient and the doctor. The thumb represents ~40% of hand function. A less-than-optimal thumb can severely limit a patient's function as they grow and develop. Hypoplasia of the thumb can range from being mild with slight shortening and underdeveloped musculature to complete

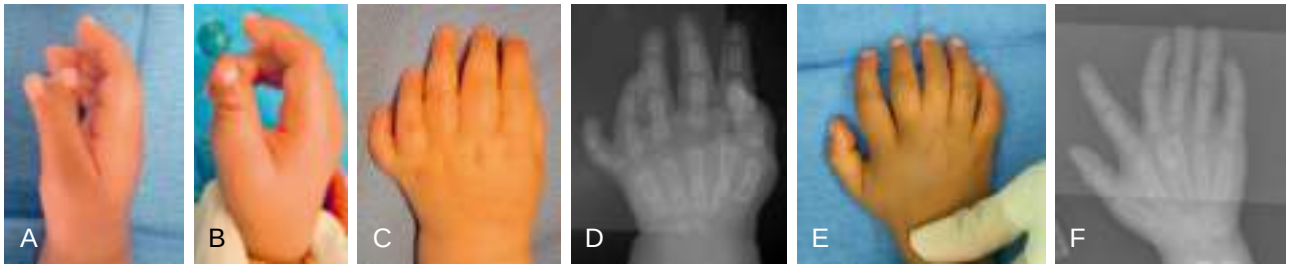

Fig. 722.8 A and B, Preoperative and postoperative pictures of a Wassel II thumb duplication. C, Clinical photograph. D, Radiograph postaxial polydactyly. E, Clinical photograph. F, Radiograph of central polydactyly.

absence of the thumb. Radiographs are useful to help determine osseous abnormalities. The most important finding on physical exam is the presence or absence of a stable carpometacarpal (CMC) joint. This finding helps guide surgical treatment.

Treatment

If the thumb has a stable CMC joint, reconstruction is advised. Key elements of thumb reconstruction include rebuilding the ulnar collateral ligament of the metacarpophalangeal joint, tendon transfers to aid thumb abduction, and procedures to deepen the web space.

If a stable CMC joint is not present or the thumb is completely absent (Fig. 722.9A), pollicization (surgical construction of a thumb from a finger) is the definitive treatment (see Fig. 722.9B). Pollicization is a complex procedure rotating the index finger along its neurovascular pedicle to form a thumb. This procedure is typically performed at around 1 year of age and may be followed by subsequent procedures to deepen the web space or augment abduction.

Syndactyly

Failure of the individual digits to separate during development produces syndactyly. Syndactyly is one of the more common anomalies observed in the upper limb (Table 722.6). It is seen in 0.5 of 1,000 live births. Syndactyly can be classified as simple (skin attachments only), complicated (bone and tendon attachments), complete (fusion to the tips, including the nail), or incomplete (simple webbing).

Treatment

Division of conjoined digits should be considered before the second year of life. Border digits should be divided earlier (3-6 months) because of concern for tethered growth of digits of unequal length. Digits of similar size, such as the index, middle, and ring, may wait until the child is older to consider separation. Reconstruction of the web space and nail folds as well as appropriate skin-grafting techniques must be used to ensure the best possible functional and cosmetic result (Fig. 722.10).

Fingertip Injuries

Young children commonly sustain crush injuries to the fingertips from doorjambs, car doors, and other tight spaces. Injury can range from a simple subungual hematoma to complete amputation of part or the entire fingertip. Radiographs are important to rule out fractures. Physeal fractures associated with nailbed injuries are open fractures with a high risk of osteomyelitis, growth arrest, and deformity if not treated correctly.

The treatment of the soft tissue injury depends on the type of injury. For suture repairs, only absorbable sutures should be used. Removal of sutures from a young child's fingertip can be difficult and may require sedation or general anesthesia. If a subungual hematoma exists but the nail is normal and no displaced fracture is present, the nail need not be removed for nailbed repair. If the nail is torn or avulsed, the nail should be removed, and the nailbed and skin should be inspected and repaired with absorbable sutures where appropriate

If the fingertip is completely amputated, treatment depends on the level of amputation and the age of the child. Distal amputations

Fig. 722.9 A, Congenital absence of the thumb. B, Postsurgical image after pollicization.

of skin and fat in children <2 years of age can be replaced as a composite graft with a reasonable chance of surviving. Similar amputations in older children can heal without replacing the skin if no bone is exposed and the amputated area is small. A variety of coverage procedures exist for amputations through the midportion of the nail. Amputations at or proximal to the proximal edge of the fingernail should be referred emergently to a replant center for consideration for microvascular replantation. When referring, all amputated parts should be saved, wrapped in saline-soaked gauze, placed in a watertight bag, and then placed in ice water. Ice should never directly contact the part because it can cause severe osmotic and thermal injury.

Trigger Thumb and Fingers

The flexor tendons for the thumb and fingers pass through fibrous tunnels made up of a series of pulleys on the volar surface of the digits.

These tunnels can become tight at the most proximal or first annular pulley. Swelling of the underlying tendon occurs, and the tendon no longer glides under the pulley. In children, the most common digit involved is the thumb. Trigger thumbs are not congenital deformities but rather are developmental and most frequently occur before 2 years of age. The incidence of trigger thumb is approximately 3 per 1,000 children at 1 year of age. A history of trauma is rare, and the condition is often painless. Overall function is rarely impaired. A trigger thumb typically manifests with the inability to fully extend the thumb interphalangeal joint. A palpable nodule can be felt in the flexor pollicis longus tendon at the base of the thumb metacarpal phalangeal joint volarly. Other conditions can mimic trigger thumb, including the thumb-in-palm deformity of cerebral palsy. Similar findings in the fingers (index through small) are much less common and may be associated with inflammatory conditions such as juvenile idiopathic arthritis (Fig. 722.11).

Table 722.6 Syndromes Associated with Syndactyly*

Apert syndrome
Carpenter syndrome
Chotzen syndrome
de Lange syndrome
Fanconi pancytopenia
Fetal hydantoin syndrome
Holt-Oram syndrome
Laurence-Moon-Biedl syndrome
Noack syndrome
Orofaciodigital syndrome
Pfeiffer syndrome
Poland syndrome
Polysyndactyly
Trisomy 13
Trisomy 18
Trisomy 21

*There are many more syndromes associated with syndactyly; this list is not all-inclusive.

Treatment

Trigger thumbs spontaneously resolve in up to 30% of children who are diagnosed before 1 year of age. Spontaneous resolution beyond that age is uncommon. Corticosteroid injections are effective in adults but are not effective in children and risk injury to the nearby digital nerves. Surgical release of the first annular pulley is curative and is generally performed between 1 and 3 years of age. Treatment of trigger fingers other than the thumb in children involves evaluation and treatment of any underlying inflammatory process and in some cases surgical decompression of the flexor sheath and possible flexor tendon partial excision.

Visit Elsevier eBooks+ at eBooks.Health.Elsevier.com for Bibliography.

Fig. 722.10 Preoperative (A and B) and postoperative (C and D) pictures of a simple syndactyly.

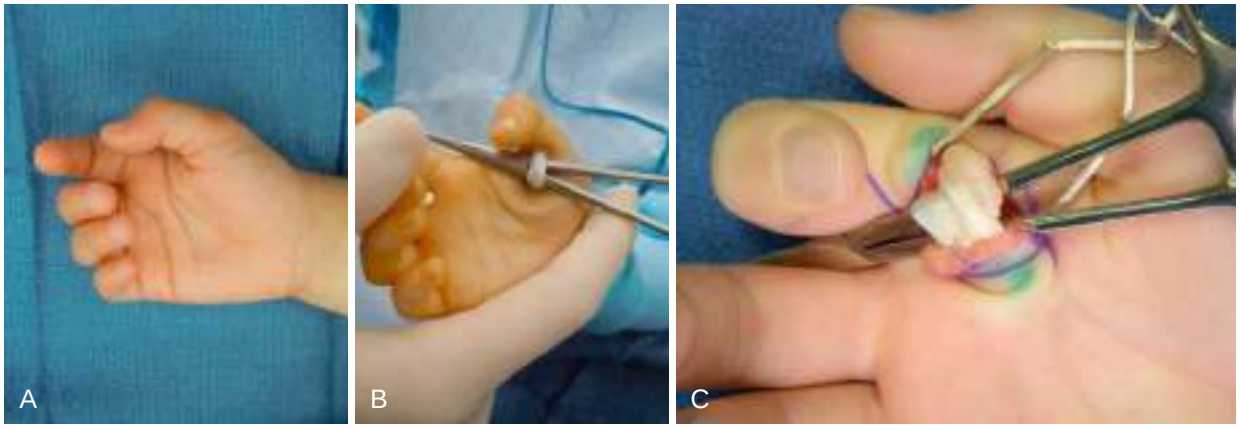

Fig. 722.11 A, Clinical picture of trigger thumb in a 2 yr old; note flexed posture of the interphalangeal joint. B, Intraoperative picture of flexor tendon following release of A1 pulley. C, Intraoperative picture of benign growth along flexor tendon causing triggering in an index finger.

Chapter 723

Arthrogryposis

Christine M. Goodbody, Helen M. Horstmann, and Richard S. Davidson

Arthrogryposis multiplex congenita refers to a heterogeneous group of muscular, neurologic, and connective tissue anomalies that present with two or more joint nonprogressive contractures at birth, as well as muscle weakness. It is associated with abnormal contraction of muscle fibers, causing reduced mobility with a decreased active and passive arc of motion. Arthrogryposis is not a specific diagnosis but a descriptive term with various etiologies and complex clinical features, including multiple congenital contractures of various limb joints. It is associated with over 300 different disorders encompassing malformation, malfunction, and neurologic deficiency (see Chapter 648.10).

Approximately 1% of all births show some form of contractures of the joints ranging from unilateral clubfoot to amyoplasia (the most severe), a condition characterized by pervasive, crippling contractures involving many joints. The overall incidence of arthrogryposis is 1/5,000-10,000 live births with equal gender ratios.

Although children with arthrogryposis may have many other problems, such as micrognathia and feeding issues, focus is on the orthopedic problems frequently seen in this group of children. In the absence of central nervous system lesions, many children have normal intelligence.

ETIOLOGY

The main cause of arthrogryposis is fetal akinesia or decreased fetal movement. The associated pattern of abnormalities is often referred to as the **fetal akinesia deformation sequence**. This sequence manifests as multiple joint contractures, oligohydramnios, craniofacial anomalies (e.g., micrognathia), and pulmonary hypoplasia because of lack of movement of the diaphragm and intercostal muscles. Intrinsic and extrinsic causes of fetal akinesia are categorized into six groups (Fig. 723.1) and include a multitude of disorders (Table 723.1).

Neurologic Abnormalities

Neurologic abnormalities are present in 70–80% of cases. Patchy damage to the anterior horn cells of the spinal cord can lead to characteristic limb posturing of arthrogryposis. Neurologic disorders, such as spinal muscular atrophy and anterior horn disease, are associated with arthrogryposis; however, the type of anterior horn cell involvement is usually not from spinal muscular atrophy syndrome. Other less common neurologic disorders include neonatal myasthenia, myotonic dystrophy, olivo-ponto-cerebellar disorders, and neuronal migration anomalies.

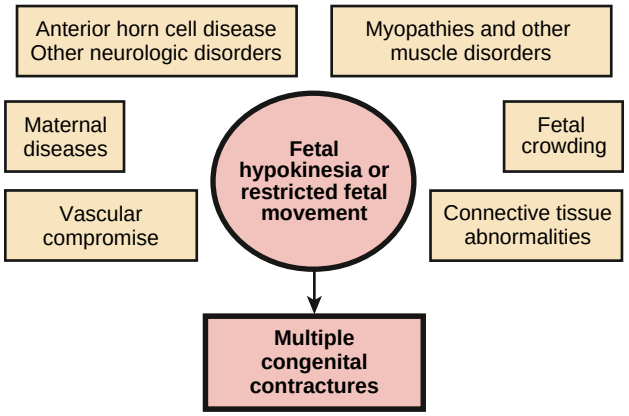

Fig. 723.1 Etiology of arthrogryposis. *(Data from Hall JG. Arthrogryposis multiplex congenital: etiology, genetics, classification, diagnostic approach, and general aspects. J Pediatr Orthop B. 1996;6:159–166.)*

Muscular Abnormalities

These rare abnormalities affect the function and structure of the muscles. **Amyoplasia**, the most common form of arthrogryposis, is associated with abnormally decreased fetal movement and is characterized by underdeveloped, contracted muscles causing joint deformity. The involved skeletal muscle is replaced by fatty or fibrous tissue. Some muscular diseases associated with arthrogryposis are muscular dystrophies, congenital myopathies (central core, nemaline, centronuclear), intrauterine myositis, and mitochondrial diseases.

Limited Intrauterine Spacing

Uterine constraint is rarely the primary cause of arthrogryposis. Maternal uterine anomalies will occasionally increase contractures of fetal limbs with arthrogryposis already existing. Other known causes are lack of amniotic fluid within the uterus, and tumors, such as fibroids, that can prevent movement by impinging on uterine space.

Connective Tissue Abnormalities

When the tendons, bones, joints, and joint lining develop atypically, the resulting decrease in fetal movement causes congenital contractures. Diseases such as **diastrophic dysplasia**, **campomelic dysplasia**, and **metatropic dysplasia** result from connective tissue not developing properly. These are specific diagnoses resulting in limited joint motion and not true distal arthrogryposis. In some cases, the connective tissue develops normally but does not attach to the proper location around a bone or joint, and the subsequent abnormal movement results in distal joint involvement.

Maternal Diseases

Maternal diseases, such as multiple sclerosis, diabetes mellitus, myasthenia gravis, maternal hyperthermia, infection (Zika virus), drugs, and trauma, are associated with an increased incidence of arthrogryposis. In approximately 10% of neonates born to mothers with myasthenia gravis, maternal antibodies enter the fetal circulation through the placenta, causing transient myasthenia gravis; this inhibits fetal acetylcholine receptors, which leads to damaged fetal muscles.

Intrauterine Vascular Compromise

Abnormal fetal blood supply may be associated with arthrogryposis. This occurs when inadequate vascular supply to the fetus causes fetal hypoxia resulting in anterior horn cell death, which, in turn, decreases neurologic and myologic function. The result is fetal akinesia and secondary joint contractures. Multiple congenital contractures have been reported in individuals after bleeding throughout pregnancy or after a failed attempt at terminating the pregnancy.

CLASSIFICATION

Arthrogryposis multiplex congenita is divided into subgroups with different signs, symptoms, and causes as a practical way to make a differential diagnosis. However, given the wide spectrum of disease presentation and etiology, no one classification system exists that is entirely comprehensive. Disorders involving primarily the limbs, such as amyoplasia and distal arthrogryposis, are the most common subgroups. Disorders involving limbs and other body parts typically represent a form of **multiple pterygium syndrome**, which is characterized by weblike membranes that form across joints, affecting a child's ability to extend those joints and causing fixed flexion deformities. Disorders with limb involvement and abnormal neurologic function are caused by atypical central nervous system development, peripheral nervous system abnormalities, damaged or absent anterior horn cells, or a combination thereof.

Amyoplasia, also known as *classic arthrogryposis,* is a sporadic symmetric disorder that causes fibrotic replacement of the muscles. Symptoms include internally rotated and adducted shoulders, extended

Table 723.1 Associated Etiologies of Arthrogryposis

ARTHROGRYPOSIS CAUSED BY NERVOUS SYSTEM DISORDERS • Focal anterior horn cell deficiency • Generalized anterior horn cell deficiency • Structural brain disorder/damage • Uncertain location (Spastic conditions are excluded)
DISTAL ARTHROGRYPOSIS SYNDROMES • Type I dominant distal • Type IIa dominant distal (Freeman-Sheldon syndrome) • Digitotalar dysmorphism • Trismus pseudocamptodactyly • Distal distribution, type not specified
PTERYGIUM SYNDROMES • Multiple pterygium syndrome • Lethal multiple pterygium syndrome • Popliteal pterygium syndrome • Ptosis, scoliosis, pterygia • Antecubital webbing syndrome (Liebenberg)
MYOPATHIES • Emery-Dreifuss muscular dystrophy • Hypotonia, myopathy, mild contractures
ABNORMALITIES OF JOINTS AND CONTIGUOUS TISSUE • Congenital contractural arachnodactyly • Freeman-Sheldon syndrome • Laxity or hypertonicity with intrauterine dislocation and contractures • Larsen syndrome • Spondyloepimetaphyseal dysplasia with joint laxity • Trisomy 18, extended breech position with bilateral hip dislocation • Siblings with bifid humeri, hypertelorism, and hip and knee joint dislocations
SKELETAL DISORDERS • Diastrophic dysplasia • Parastremmatic dysplasia • Kniest dysplasia • Metatropic dysplasia • Campomelic dysplasia • Schwartz syndrome • Fetal alcohol syndrome with synostoses • Osteogenesis imperfecta with bowing/contractures
INTRAUTERINE/MATERNAL FACTORS • Fetal alcohol syndrome with contractures • Infections • Untreated maternal systemic lupus erythematosus • Intrauterine fetal constraint • Deformity (pressure) • Amniotic fluid leakage • Multiple pregnancies • Intrauterine tumors • Disruption (bands)
MISCELLANEOUS • Pseudotrisomy 18 with contractures • Roberts pseudothalidomide syndrome • Deafness with distal contractures • VACTERL association • Multiple abnormalities and contractures not otherwise specified • ARC
SINGLE JOINT • Campomelia • Symphalangism • "Trigger" finger

ARC, Arthrogryposis, renal tubular acidosis, cholestasis; VACTERL, vertebral defects, imperforate anus, congenital heart disease, tracheoesophageal fistula, renal and limb defects.

Modified from Mennen U, Van Heest A, Ezaki MB, et al. Arthrogryposis multiplex congenita. *J Hand Surg Br*. 2005;30(5):468–474. Copyright 2005 The British Society for Surgery of the Hand.

elbows, pronated forearms, flexed fingers and wrists, dislocated hips, feet with severe equinovarus contractures, and extended knees. Involved muscles are hypoplastic and fibrotic. Often, patients have midfacial hemangioma. Intelligence is usually normal (Figs. 723.2 and 723.3).

Distal arthrogryposis is an autosomal dominant disorder that primarily affects the distal joints of the limbs. Characteristics of the upper limbs are medially overlapping fingers, clenched fists, ulnar deviation of fingers, camptodactyly, and hypoplasia. Lower limbs show talipes equinovarus, calcaneovalgus, vertical talus, or metatarsus varus (Fig. 723.4), in addition to limited motion at the involved joints. Ten different types of distal arthrogryposis have been categorized based on specific traits they share with each other (Table 723.2).

MANAGEMENT OF ORTHOPEDIC PROBLEMS OF ARTHROGRYPOSIS

When a child is born with arthrogryposis, the many stiff or dislocated joints pose issues of timing and best practices of management. The overarching goal of management in the lower extremities are plantigrade feet and joints that function to optimize ambulatory potential, whereas in the upper extremity, the aim is largely the ability to grasp, feed, and toilet independently. A child may have stiff elbows, dislocated hips; dislocated, hyperextended, or contracted knees; and clubfeet (Fig. 723.5). The stiffness and deformity need to be aggressively addressed through a combination of modalities. A team of clinicians, including therapists for the upper and lower extremities, orthotists, and orthopedic surgeons, will be involved.

Initially, passive range-of-motion exercises and judicious splinting directed and assisted by physical and occupational therapy will help to address the various deformities. Splinting and casting can be augmented by a taping program that can be taught to the family so that the taping can be redone frequently to take advantage of improved range of motion. The ingenuity of the therapists and/or orthotists to create the right splints and braces using appropriate thermoplastics, neoprene, Velcro, and other materials can be effective (Fig. 723.6).

The therapeutic and orthopedic goal for the child with arthrogrypotic limb deformities is to achieve maximal joint motion and to optimize joint position for function. In the lower extremities, the foot needs to be plantigrade. The knees need to have optimal motion for sitting and standing. Hips need to be stabilized, especially if the child has walking potential. In the upper extremities, in cases where there is extreme stiffness, the goals should include positioning of one arm for feeding and the other for toileting. Two-handed activities require some symmetry, which can be a challenging goal with extreme contractures and limited muscle strength. Serial casting may be beneficial in correcting joint contractures. Although scoliosis is common, it usually does not become a problem until adolescence (see Chapter 720).

FOOT PROBLEMS

Clubfoot deformities are the most commonly seen deformities with arthrogryposis (Fig. 723.7). A clubfoot has components of hindfoot equinus, midfoot varus, and forefoot adduction. Clubfeet in arthrogryposis tend to be more resistant to improvement than in idiopathic cases, but the traditional methods of treatment are nevertheless employed. Casting is begun shortly after birth in a method known as the Ponseti method. Casts are changed weekly until a plateau is reached, then heel cord lengthening is needed. Other deformities such as vertical talus are also seen and are addressed in a similar approach, although with case-appropriate differences in casting techniques (see Chapter 715).

Persistent stiffness often leads to more comprehensive soft tissue releases. This is typically done around age 6-12 months and is followed by 3 months of further casting and additional bracing as needed, especially as the foot is growing. When deformities are not corrected in early childhood, additional bony surgery may be needed later. Some of the approaches to this involve bony wedge osteotomies, lateral column lengthening, bone decancellation, or talectomy. Ring or multiaxial monolateral external fixation with or without osteotomies are used in late correction of residual deformities.

Fig. 723.2 Infant with stiff elbows, wrists, fingers, dislocated left hip, valgus stiff knees, and clubfeet.

Fig. 723.3 Infant with stiff elbows, wrists, fingers, dislocated left hip, clubfeet, and micrognathia.

Children with significant deformities are often in ankle foot orthoses through much of their lives to avoid deformity recurrence and to augment the standing base caused by weak leg muscles. A plantigrade, pain-free, stable foot is the goal of foot management. Foot stiffness is anticipated and unavoidable in arthrogryposis involving the foot.

Fig. 723.4 Infant with club feet, stiff knees, dislocated hips, stiff fingers, and facial hemangioma.

KNEE PROBLEMS

Knee issues in patients with arthrogryposis may include knee extension or flexion contracture, subluxation, and stiffness. Knee flexion contracture is more common in arthrogryposis and is often resistant to nonsurgical treatment. It can be structurally complex and associated with skin webbing known as pterygiums, which require Z-plasty lengthenings. In the case of a flexion contracture, the quadriceps musculature is often deficient and weak. When a trial of casting and splinting of the knee contractures is insufficient, surgical intervention with hamstring lengthenings and posterior knee capsular releases are often needed. Soft tissue relaxation by femoral shortening has also shown benefit.

In the case of knee hyperextension, the quadriceps are sometimes fibrotic and weak despite seeming to overpower the hamstrings. Casting and splinting should begin shortly after birth, which can be done in conjunction with clubfoot casting as needed following the principles of Ponseti. If splinting and therapy fail, lengthening of the quadriceps can be achieved through a number of surgical techniques that may include detachment of the rectus femoris and lengthening of the quadriceps either percutaneously or through a mini open procedure, which may minimize scarring.

Long-standing stiffness may lead to joint surface flattening and other bony abnormalities that can permanently reduce the arc of motion. Repositioning the arc of motion through bony osteotomies may improve sitting or standing. Follow-up bracing can help to compensate for weak, fibrotic muscles of the legs. Use of guided growth plates and screws may also be of benefit.

HIP PROBLEMS

Teratologic hip dislocations are common within the spectrum of arthrogryposis and usually require open reduction of the hip. Hips in a child with less upper-extremity involvement and more supple hips that are not pathologically stiff may respond to early treatment with a Pavlik harness. Coexisting knee hyperextension should

Table 723.2 A Classification System and Clinical Features of Distal Arthrogryposes

TYPE	DESCRIPTION
I	Characteristic clinical features are camptodactyly and talipes equinovarus with possible concomitant shoulder and hip contractures. The DA1 variant is determined by a gene located on chromosome 9.
II	The phenotype was first described in 1938 as the Freeman-Sheldon syndrome, where contractures of fingers and toes are accompanied by kyphosis, scoliosis, and malformations of the facial skeleton with characteristic facial appearance: narrow mouth, wide cheeks, an H-shaped chin dimple, small wide-based nose, high palate, and small tongue. Growth retardation, inguinal hernia, and cryptorchidism have also been reported. Another name of this syndrome is "whistling face" syndrome. The Freeman-Sheldon syndrome is currently classified as DA2A, as a separate DA2B subtype, known as Sheldon-Hall syndrome has been described; this syndrome combines clinical features of DA1 (hand and foot contractures) and some features of DA2 (prominent nasolabial folds, slanted down-facing eyes, and narrow mouth) and is currently considered to be probably the most common type of distal arthrogryposis.
III	Also known as Gordon syndrome, this rare syndrome is characterized by low stature and palatoschisis.
IV	Rare. Contractures with severe scoliosis.
V	Contractures with ocular signs and symptoms such as limited eye motion, ptosis, strabismus, and the absence of typical hand flexion creases. Chest wall muscle abnormalities have also been observed, potentially causing restricted respiratory movements and, consequently, pulmonary hypertension.
VI	Similar to DA3, DA4; very rare, characterized by sensorineural auditory abnormalities.
VII	Difficulties in mouth opening (trismus) and pseudocamptodactyly: wrists position in palmar flexion with MCP joints in extension. Sometimes accompanied by low stature and knee flexion contractures.
VIII	Autosomal dominant multiple pterygium syndrome.
IX	Beals syndrome, i.e., congenital arachnodactyly with contractures of small joints of the fingers. Patients with this type of arthrogryposis are tall and slender, phenotypically resembling Marfan syndrome but without cardiovascular abnormalities.
X	Congenital plantar flexion contractures of the foot.

From Kowalczyk B, Feluś J. Arthrogryposis: an update on clinical aspects, etiology, and treatment strategies. *Arch Med Sci.* 2016;12(1):10–24. Table 1.

Fig. 723.5 Child with stiff elbows, wrists, knees, and clubfeet.

Fig. 723.6 Infant with splints to extend metatarsophalangeal joints, wrists, and knees.

first be treated with physical therapy and serial casting to allow for appropriate Pavlik harness fitting. However, careful observation of the hip during knee flexion is necessary because tightening of the quadriceps and hip flexors can push the hip into posterior dislocation. Once some knee flexion has been achieved, the Pavlik harness can be useful in further flexing the knee and maintaining hip stability in the infant. Most often, the hips are stiff and not reducible by closed means. For these, open reduction with pelvic reconstruction and femoral osteotomy are commonly required, typically at 1 year of age. There is some controversy about reducing bilateral hip dislocations because a high failure rate can result in asymmetry of the pelvis, pain, leg length inequality, and stiffness. If a child has little

Fig. 723.7 Clubfeet in infant with arthrogryposis.

ambulatory potential, they may do as well retaining the bilateral hip dislocations and positioning the hips for sitting. Management decisions should be made in conjunction with the family and guided by a pediatric hip surgeon.

Ambulation

As would be expected, walking is more difficult for children with arthrogryposis because of the muscle weakness and limited joint motion. Children with arthrogryposis who walk have lower activity levels and take fewer steps than their peers. Not surprisingly, muscle fatigue and pain on exertion are common.

UPPER EXTREMITY PROBLEMS

If splinting and a movement exercise program do not result in optimally functional upper extremities, surgical management may improve use of the arms of the child with arthrogryposis. A typical child with arthrogrypotic involvement of the upper extremities has internally rotated arms, extended elbows, flexed wrists, and thumb-in-palm or clasp-thumb deformities (see Figs. 723.2 and 723.3).

Treatment is geared toward optimizing use of the arms and hands, particularly for critical activities of daily living, such as feeding and toileting. Therapy to improve motion of the joints is started immediately after birth. Pediatric hand therapists are the optimal leaders of the mobility treatment program. Therapy is augmented by use of splints so that less-extensive surgery will ultimately be required. The elbow is the critical length adjuster of the arm, allowing the arm to reach out as is necessary for toileting or to approach the mouth for feeding. If necessary, lack of these motions can be compensated for with modified silverware and other adaptive equipment, including arm extenders for grabbing.

Surgery of the Upper Extremity

Surgical correction of arthrogrypotic upper extremity contractures should be started after 1-3 months and completed by age 12 months so that the child can optimize his or her motor development. This allows for improved results by optimizing the joint growth remodeling plasticity. One-stage procedures yield the best results. Delays in surgery result in more problems of intraarticular adhesions as well as fixed joint incongruity.

Shoulder

Because of the rotational capacity of the shoulder, derotation osteotomy of the humerus is only occasionally needed. This is usually done in later childhood.

Elbow

A stiff elbow that does not respond to therapy requires surgical intervention starting with soft tissue and capsular release. Capsulotomy of the posterior elbow combined with a V-Y or Z reconstructive lengthening of the triceps allows improved elbow flexion. Muscle transfer to the forearm can permit active elbow flexion; however, each child needs individual assessment as to an available flexor source. The triceps is commonly used, but caution must be exerted into the overall muscle balance because use of the triceps can create elbow flexion overpowering and an opposite contracture.

Wrist

Wrist flexion deformity is improved with soft tissue balancing as well as partial carpectomies. The carpectomies need to be trapezoidal with more removed from the dorsum and the radial side to balance the wrist flexion contracture as well as the tendency for ulnar deviation. Thumb adduction may require an adductor release with an opponensplasty. Tendon transfers such as transfer of the extensor indicis pollicis to the extensor pollicis longus is helpful for improved function of the thumb in clasp thumb deformity.

Finger stiffness and wrist contractures often respond to therapy and bracing without need for surgery.

Scoliosis

Scoliosis develops in some children with arthrogryposis, with the reported incidence ranging from 2.5–66%. Scoliosis can be congenital or paralytic. It is often accompanied by hip contractures associated with hip dislocation and compensatory lumbar lordosis. Curves <30 degrees can be treated initially with bracing in a thoracolumbar spinal orthosis (TLSO brace). After 40 degrees, spinal fusion is generally warranted.

Surgical Staging

Surgical treatment of the lower limbs usually begins distally and works proximally. The feet are corrected around 6 months of age, the knees around 8 months of age, and the hips around 12 months of age because pelvic osteotomy is often needed to stabilize the hips properly.

The upper extremities are corrected during infancy when the child is seen early. Hand, physical, and occupational therapy are a critical part of the team to optimize function before and after surgery. Further surgery during childhood may be needed to optimize functional use of the upper and lower extremities.

Prognosis

Although most patients with arthrogryposis are ambulatory into adulthood, fewer are entirely independent, and many have pain or limitations in walking and standing. Surgical advancements in upper extremity positioning have improved function, and procedures to correct lower extremity contractures, including not only surgery but also casting for clubfeet, have increased long-term ambulatory potential. However, there is significant variability in this population, and further work must be done to optimize intervention techniques and their appropriate utilization.

Visit Elsevier eBooks+ at eBooks.Health.Elsevier.com for Bibliography.

Chapter 724

Common Fractures

Jason B. Anari, Alexandre Arkader, and Lawrence Wells

Trauma is a leading cause of death and disability in children older than 1 year of age (see Chapter 14). Several factors make fractures of the immature skeleton different from those involving the mature skeleton. The anatomy, biomechanics, and physiology of the pediatric skeletal system differ from those of adults, resulting in different fracture patterns (Fig. 724.1), diagnostic challenges, and management techniques. Children have a high functional demand and expectations while carrying concerns regarding remaining skeletal growth and development.

Epiphyseal lines, rarefaction, dense growth lines, congenital fractures, and pseudofractures may appear on radiographs, which make it challenging to identify and differentiate an acute fracture. Although most fractures in children heal well, some fractures have poor outcomes if handled with insufficient expertise. The differences in the pediatric skeletal system predispose children to injuries different from those of adults. Important differences are the presence of periosseous cartilage, **physes**, and a thicker, stronger, more osteogenic periosteum that produces new bone, called **callus**, more rapidly and in greater amounts. The pediatric bone is less dense and more porous than adult bone. The low density is from lower mineral content, and the increased porosity is the result of an increased number of haversian canals and vascular channels. These differences result in a comparatively lower modulus of elasticity and lower bending strength. The bone in children can fail either in tension or in compression; because the fracture lines do not propagate as in adults, there is less chance of comminuted fractures. Hence, pediatric bone can crush, splinter, and break incompletely (e.g., buckle fracture, greenstick fracture), as opposed to adult bone which generally breaks like glass and may comminute.

A common teaching is that joint injuries, dislocation, and ligament disruptions are infrequent in children. Damage to the physis is more likely. Although this is generally true, MRI studies show that ligament damage in ankle injuries may be more common than once thought. Interdigitating mammillary bodies and the perichondrial ring enhance the strength of the physes. Biomechanically, the physes are not as strong as the ligaments or metaphyseal bone. The physis is most resistant to traction and least resistant to torsional forces. The periosteum is loosely attached to the shaft of bone and adheres densely to the physeal periphery. The periosteum is essentially injured in all fractures, but it is less likely to have complete circumferential rupture because of its loose attachment to the shaft. This intact hinge or sleeve of periosteum lessens the extent of fracture displacement and assists in reduction and maintenance of fracture reduction. The thick periosteum, however, may act as an impediment to reduction, particularly if the fracture has penetrated the periosteum, or in reduction of a displaced growth plate fracture.

724.1 Unique Characteristics of Pediatric Fractures

Jason B. Anari, Alexandre Arkader, and Lawrence Wells

FRACTURE REMODELING

Remodeling is the third and final phase in the biology of fracture healing; it is preceded by the inflammatory and reparative phases. This occurs from a combination of appositional bone deposition on the concavity of deformity, resorption on the convexity, and asymmetric physeal growth. Thus reduction accuracy is somewhat less important than it is in adults (exceptions include intraarticular fractures) (Fig. 724.2). The three major factors that have a bearing on the potential for angular correction are skeletal age, distance from the physis, and orientation to the joint axis. Rotational deformity and angular deformity not in the axis of the joint motion have less potential for remodeling. Remodeling is greatest when the child has many years of growth remaining and when the fracture occurs close to the physis, has less deformity to remodel, and is adjacent to a rapidly growing physis (e.g., the proximal humerus or distal radius). Remodeling typically occurs over several months after the fracture until skeletal maturity. Generally, skeletal maturity is reached in postmenarchal females between 13 and 15 years of age and in males between 15 and 17 years of age.

OVERGROWTH

Physeal stimulation from the hyperemia associated with fracture healing may also cause overgrowth. It is usually more prominent in lower extremity long bones such as the femur. The growth acceleration is usually present for 6 months to 1 year after the injury. Femoral fractures in children younger than 10 years of age may overgrow up to 1-3 cm. If external fixation or casting is employed, bayonet apposition of bone may be preferred for younger children to compensate for the expected overgrowth. This overgrowth phenomenon will result in equal or near equal limb lengths at the conclusion of fracture remodeling if the fracture shortens less than 2 cm. After 10 years of age, overgrowth does not tend to occur, and anatomic alignment is recommended. In physeal injuries, growth stimulation is associated with use of implants or fixation hardware that can cause stimulus for longitudinal growth.

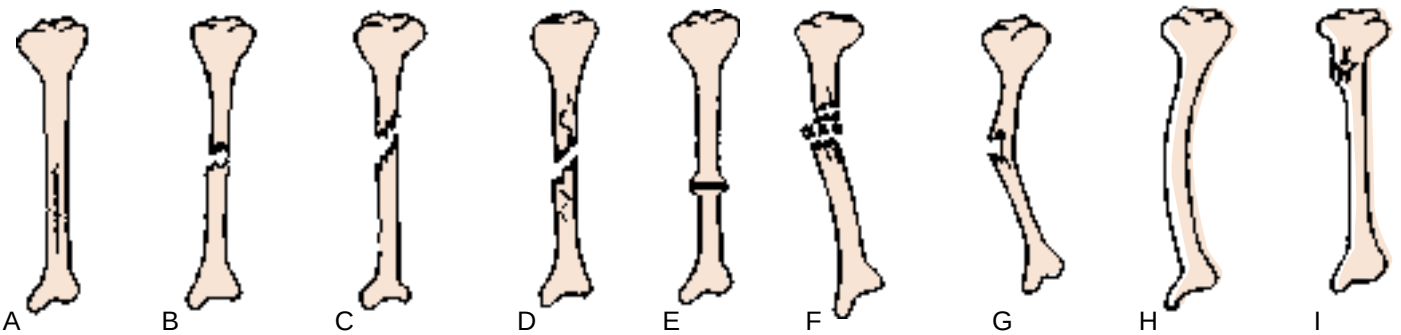

Fig. 724.1 Illustration of fracture patterns. **A,** Longitudinal fracture line parallel to bony axis. **B,** Transverse fracture line perpendicular to bony axis. **C,** Oblique fracture line at angle to bony axis. **D,** Spiral fracture line runs a curvilinear course to the bony axis. **E,** Impacted fractured bone ends compressed together. **F,** Comminuted fragmentation of bone into three or more parts. **G,** Greenstick bending of bone with incomplete fracture of convex side. **H,** Bowing bone plastic deformation. **I,** Torus buckling fracture. *(From White N, Sty R. Radiological evaluation and classification of pediatric fractures. Clin Pediatr Emerg Med. 2002;3:94–105.)*

Fig. 724.2 Remodeling in children is often extensive, as in this proximal tibial fracture (**A**) and as seen 1 yr later (**B**). *(From Dormans JP. Pediatric Orthopedics: Introduction to Trauma. Philadelphia: Mosby; 2005:38.)*

PROGRESSIVE DEFORMITY

Injuries to the physes can be complicated by permanent or temporary growth arrest, leading to progressive limb deformity. The most common cause is complete or partial closure of the growth plate. This can occur in any long bone but is particularly seen in fractures involving the distal ulna, distal femur, and proximal tibia growth plates. An MRI is helpful for early diagnosis of growth arrest, as well as measurement of the percent of physeal closure after such an injury. Harris growth arrest lines may be observed in the setting of asymmetric growth and will point toward the area of growth arrest (Fig. 724.3). If these lines are parallel to the physis, this finding indicates that the growth plate is healthy. As a consequence of growth arrest, angular deformity or shortening, or both, can occur. The partial arrest may be peripheral, central, or combined. The magnitude of deformity depends on the specific physis involved, the degree of involvement, and the amount of growth remaining.

RAPID HEALING

Children's fractures heal more quickly than adults as a result of children's growth potential and thicker, more active periosteum. When children approach adolescence and maturity, the rate of healing slows and mirrors that of an adult.

Visit Elsevier eBooks+ at eBooks.Health.Elsevier.com for Bibliography.

724.2 Pediatric Fracture Patterns

Jason B. Anari, Alexandre Arkader, and Lawrence Wells

The different pediatric fracture patterns are the reflection of a child's characteristic skeletal system. The majority of pediatric fractures can be managed by closed methods and heal well.

PLASTIC DEFORMATION

Plastic deformation is unique to children. It is most commonly seen in the forearm and occasionally the fibula. The fracture results from a force that produces microscopic failure on the tensile side of bone and does not propagate to the concave side (Fig. 724.4). The concave side of bone also shows evidence of microscopic failure in compression. The bone is angulated beyond its elastic limit, but the energy is insufficient to produce a fracture. Thus no fracture line is visible radiographically (Fig. 724.5). Although the plastic deformation is permanent, it is important to remember that children have great remodeling capability; for example, a 20-degree bend in the ulna of a 4-year-old child is expected to correct completely with growth. These findings inform "acceptability" of fracture alignment.

Fig. 724.3 **A**, Harris growth arrest lines on either side of the femur pointing centrally in the femur indicating a central growth arrest. **B**, Corresponding MRI image showing central growth arrest. *(**A**, Courtesy Dr. Keith D. Baldwin, Children's Hospital of Philadelphia.)*

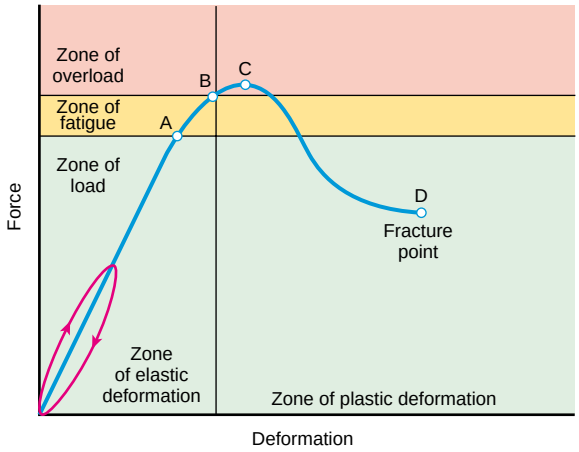

Fig. 724.4 Graphic relation of bony deformation (bowing) and force (longitudinal compression) showing that the limit of an elastic response is not a fracture but plastic deformation. If the force continues, a fracture results. *A*, Reversible bowing with stress; *B*, microfractures occur; *C*, point of maximal strength; between C and *D*, bowing fractures; and *D*, linear fracture occurs. *(Modified from Borden S IV. Roentgen recognition of acute plastic bowing of the forearm in children. Am J Roentgenol Radium Ther Nucl Med. 1975;125:524–530.)*

BUCKLE OR TORUS FRACTURE

Buckle, or torus, fractures represent a failure in compression of the bone, usually occurring at the junction of the metaphysis and diaphysis. The distal radius is the most common location, but it may occur in other areas as well (Fig. 724.6). They are inherently stable, usually associated with an acceptable amount of angulation, and heal in 3-4 weeks with simple immobilization.

GREENSTICK FRACTURE

These fractures occur when the bone is bent and there is failure on the tensile (convex) side of the bone. The fracture line does not propagate to the concave side of the bone (Fig. 724.7). The concave side shows evidence of microscopic failure with plastic deformation. If the angulation at the fracture site is unacceptable, it is usually necessary to break the bone on the concave side because the plastic deformation recoils it back to the deformed position. It is important to distinguish this unicortical fracture pattern from buckle fractures, as these fractures are at greater risk of loss of reduction and often require a longer period of immobilization.

COMPLETE FRACTURES

Fractures that propagate completely through the bone are called complete fractures. These fractures may be classified as spiral, transverse, or oblique, depending on the direction and shape of the fracture lines. A rotational force is responsible for spiral fractures. Most spiral fractures

Fig. 724.5 Plastic deformation is a microfailure in tension without a visible fracture line. *(Courtesy Dr. John Flynn, Children's Hospital, Philadelphia.)*

Fig. 724.6 Buckle fracture is a partial failure in compression. Anteroposterior (**A**) and lateral (**B**) radiographs of the distal radius. *(From Dormans JP. Pediatric Orthopedics: Introduction to Trauma. Philadelphia: Mosby; 2005:37.)*

are stable and heal quickly due to the large surface area; however, spiral fractures occurring as a result of a high-energy trauma may present with shortening of the bone and loss of alignment. Oblique fractures are defined by a 30-degree angle to the axis of the bone and are often unstable. The transverse fracture pattern occurs following a three-point bending force and is amenable to successful reduction by using the intact periosteum from the concave side as a hinge.

Fig. 724.7 Greenstick fractures of the radial and ulnar diaphyses in an 8-yr-old boy. The fracture lines only extend through part of the cortex. *(From Pai DR, Strouse PJ. Skeletal trauma. In: Coley BD ed. Caffey's Pediatric Diagnostic Imaging, 13th ed. Philadelphia: Elsevier; 2019: Fig. 142.5, p. 1435.)*

Table 724.1 Salter-Harris Classification

SALTER-HARRIS TYPE	CHARACTERISTICS
I	Separation through the physis, usually through the zones of hypertrophic and degenerating cartilage cell columns
II	Fracture through a portion of the physis but extending through the metaphyses
III	Fracture through a portion of the physis extending through the epiphysis and into the joint
IV	Fracture across the metaphysis, physis, and epiphysis
V	Crush injury to the physis

EPIPHYSEAL FRACTURES

Fractures involving the epiphysis often involve the growth plate (physis); therefore the potential for growth disturbance leading to deformity or discrepancy exists, and long-term observation is necessary. The distal radial physis is the most injured physis. Salter and Harris (SH) classified physeal injuries into five groups (Table 724.1 and Fig. 724.8). This classification helps to predict the outcome of the injury and offers guidelines in formulating treatment. Most SH type I and II fractures usually can be managed by closed reduction techniques and do not require perfect alignment because they tend to remodel with growth, as long as there is enough growth remaining. One classic exception is the distal femur, where SH type II fractures are unstable and require anatomic reduction with adequate fixation. The SH type III and IV epiphyseal fractures involve the articular surface and require anatomic alignment (<2 mm displacement) to prevent any step off and realign the growth cells of the physis. SH type V fractures are usually not diagnosed initially. They manifest in the future with growth disturbance. Other injuries to the epiphysis are avulsion injuries of the tibial spine and muscle attachments to the pelvis. Osteochondral fractures are also defined as physeal injuries that do not involve the growth plate.

CHILD ABUSE

See also Chapter 17.

Fractures are the second most common manifestation of child abuse after skin injury (bruises, burns/abrasions). The orthopedic surgeon sees 30–50% of all nonaccidental traumas. Child abuse should be suspected in nonambulatory children with lower-extremity long-bone fractures. No fracture pattern or types are pathognomonic for

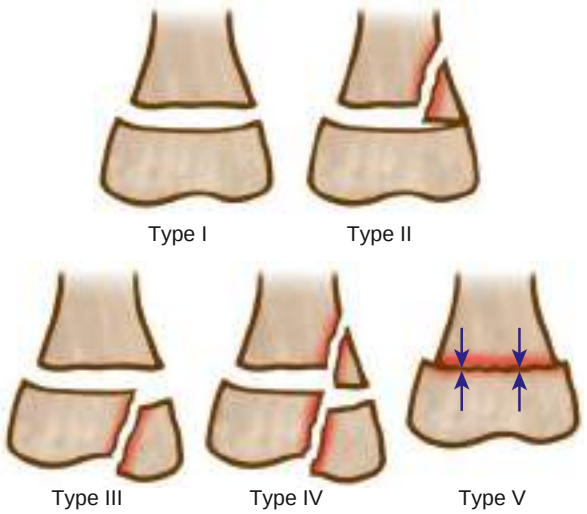

Fig. 724.8 Salter-Harris classification of physeal fractures, types I-V.

child abuse; any type of fracture can result from nonaccidental trauma (Table 724.2). **Transverse fractures** in long bones are the most prevalent, and **corner fractures** in the metaphysis are the most classic. The fractures that suggest nonaccidental injury include femur fractures in nonambulatory children (younger than age 18 months), distal femoral metaphyseal corner fractures, posterior rib fractures, scapular spinous process fractures, and proximal humeral fractures. Fractures that were unwitnessed or carry a suspicious or changing story or delayed presentation also warrant investigation. A full skeletal survey is essential in every suspected case of child abuse because it can demonstrate other fractures in different stages of healing. Radiographically, some systemic diseases mimic signs of child abuse, such as osteogenesis imperfecta, osteomyelitis, Caffey disease, vitamin C deficiency, and fatigue fractures. Many hospitals have a multidisciplinary team to evaluate and treat patients who are victims of child abuse; these teams are critical to engage early and preferably in the emergency room setting, as difficulty arises managing these emotionally charged issues in a clinic setting. Dedicated teams are most well equipped to identify and manage these issues. It is mandatory to report these cases to social welfare agencies.

Visit Elsevier eBooks+ at eBooks.Health.Elsevier.com for Bibliography.

Table 724.2 Skeletal Injuries from Child Abuse

HIGH-SPECIFICITY FINDINGS
• Classic metaphyseal lesions
• Posterior rib fracture
• Scapular fracture
• Sternal fracture
• Spinous process fracture
• First rib fracture
MODERATE-SPECIFICITY FINDINGS
• Multiple fractures
• Fractures of differing age
• Spine fracture
• Complex skull fracture
• Physeal fractures of the long bones
• Digital fractures
LOW-SPECIFICITY FINDINGS
• Diaphyseal fractures of the long bones
• Simple skull fractures
• Clavicle fracture
• Subperiosteal new bone formation

From Coley BD, ed. *Caffey's Pediatric Diagnostic Imaging*, 13th ed. Philadelphia: Elsevier; 2019: Box 143.2, p. 1455; modified from Kleinman PK. *Diagnostic Imaging of Child Abuse*, 2nd ed. St. Louis, MO: Mosby; 1998.

724.3 Upper Extremity Fractures

Jason B. Anari, Alexandre Arkader, and Lawrence Wells

PHALANGEAL FRACTURES

Finger fractures are among the most common fracture types in children. The different phalangeal fracture patterns in children include physeal, diaphyseal, and tuft fractures. The mechanism of injury varies from a direct blow to the finger to a finger trapped in a door (see Chapter 722). Crush injuries of the distal phalanx manifest with severe comminution of the underlying bone (tuft fracture), disruption of the nail bed, and significant soft tissue injury. These injuries are best managed with irrigation, tetanus prophylaxis, and antibiotic prophylaxis; antibiotics effective against staphylococci (e.g., first-generation cephalosporins) are usually appropriate, although the mechanism of injury may warrant other antibiotic coverage. Radiographs in patients with fingertip crush injuries should be scrutinized for evidence of a **Seymour fracture**, an open physeal fracture of the distal phalanx with possible interposition of the nail matrix. These patients are at higher risk of nail plate deformity and infection without surgical treatment. A **mallet finger** deformity is the inability to extend the distal portion of the digit and is caused by a hyperflexion injury. It represents an avulsion fracture of the physis of the distal phalanx. The treatment is continuous splinting of the digit in extension for 6 weeks. The physeal injuries of the proximal and middle phalanx are similarly treated with cast immobilization. The most common physeal finger fracture results from an abduction injury to the small finger. These fractures often require a closed reduction before immobilization. Diaphyseal fractures may be oblique, spiral, or transverse in fracture geometry. They are assessed for angular and rotational deformity with the finger in flexion. The patient should be asked to make a fist. All fingers should point toward the scaphoid. If they do not, a malrotation is suspected, even in the presence of x-rays in which the bones appear minimally displaced. Malrotation or angular deformity may require correction to avoid finger crossover and to optimize hand function. These deformities are corrected with closed reduction, and, if unstable, they need surgical fixation with a percutaneous pin.

HAND FRACTURES

Metacarpal fractures are commonly seen in children or adolescents who strike a person or object with a closed fist. When metacarpal fractures are not displaced, they can be managed with splinting and/or casting. Displaced fractures are typically managed with closed reduction and casting. If reduction cannot be maintained, surgical stabilization may be required.

Fractures of carpal bones are rare in young children but become more common in adolescence. Most carpal bones are stable and can be treated with immobilization in a splint or cast. The scaphoid is the most commonly fractured carpal bone and presents with tenderness at the anatomic snuffbox. **Scaphoid fractures** may be difficult to visualize on initial radiographs; if clinical suspicion for fracture is high, the patient with negative initial radiographs should be placed in a thumb spica splint with a plan to repeat imaging in 14-21 days.

FOREARM FRACTURES

Fractures of the wrist and forearm are very common in children, accounting for nearly half of all fractures seen in the skeletally immature. The most common mechanism of injury is a fall on the outstretched hand. Of forearm fractures, 80% involve the distal radius and ulna, 15% involve the middle third, and the rest are rare fractures of the proximal third of the radius or ulnar shaft (Fig. 724.9). Most forearm fractures in younger children are torus or greenstick fractures. The torus fracture is an impacted fracture, and there is minimal soft tissue swelling or hemorrhage. They may be managed in either a short

Fig. 724.9 Common pediatric fracture patterns. **A,** Posteroanterior and **(B)** lateral radiographs of the wrist demonstrate a buckle fracture of the distal radial metaphysis *(arrows).* **C,** Radiograph of the forearm demonstrates a greenstick fracture of the radial shaft, with the fracture extending through a single cortex. **D,** Anteroposterior radiograph of the forearm shows an oblique fracture through the distal radial shaft, with plastic bowing deformity of the adjacent distal ulna. *(From Walters MM, Robertson RL, eds. Pediatric Radiology: The Requisites, 4th ed. Philadelphia: Elsevier; 2017: Fig. 7.90.)*

arm (below the elbow) cast or removable wrist splint and usually heal within 3-4 weeks.

Diaphyseal fractures can be more difficult to treat because the limits of acceptable reduction are much more stringent than for distal radial fractures. A significant malunion of a forearm diaphyseal fracture can lead to a permanent loss of pronation and supination, leading to functional difficulties. This is particularly true with malrotation of the fragments. Diaphyseal fractures are vulnerable to rotational malalignment because of insertion of the pronator muscle groups and the supinator groups. This malalignment is particularly hard to assess because the deformity is in the axial plane and is evaluated with anteroposterior (AP) and lateral radiographs (Fig. 724.10). The physical examination focuses on soft tissue injuries and ruling out any neurovascular involvement. The AP and lateral radiographs of the forearm and wrist confirm the diagnosis. Displaced and angulated fractures require manipulative closed reduction under general anesthesia or conscious sedation. They are immobilized in an above-elbow cast for at least 6 weeks. Bone fractures in older children and adolescents (>10 years of age) must be followed carefully as they often lose reduction. Loss of reduction and unstable fractures require open reduction and internal fixation. Fixation may be with intramedullary nails or plate fixation, which yield similar results.

DISTAL HUMERAL FRACTURES

Fractures around the elbow receive more attention because more aggressive management is needed to achieve an excellent result. Many injuries are intraarticular, involve the physeal cartilage, and can result in malunion or nonunion. Because the distal humerus develops from a series of ossification centers, these ossification centers can be mistaken for fractures by inexperienced eyes. Careful radiographic evaluation is an essential part of diagnosing and managing distal humeral injuries. It is important to remember that the distal humerus is only responsible for 20% of the growth of the humerus; therefore there is very low potential for remodeling. Observation of soft tissue swelling and tenderness is critical to pick up subtle injuries. Common fractures include separation of the distal humeral epiphysis (transphyseal

Fig. 724.10 A rotationally malaligned forearm fracture that initially had good alignment but lost reduction in the cast. Note that the radial styloid is visible, but the biceps tuberosity is not. The two should normally be 180 degrees from one another. These landmarks are sometimes hard to appreciate in children but were visible on other views in this child.

fracture), **supracondylar fractures** of the distal humerus, and epiphyseal fractures of the lateral condyle or medial epicondyle. The mechanism of injury is most frequently a fall on an outstretched arm. The physical examination includes noting the location and extent of soft tissue swelling, ruling out any neurovascular injury, specifically anterior interosseous nerve involvement or evidence of compartment syndrome. *A transphyseal fracture in a very young child who does not have the reflex to keep the arm outstretched to break a fall should raise suspicion of child abuse.* AP and lateral radiographs of the involved extremity are necessary for the diagnosis. If the fracture is not visible, but there is an altered relationship between the humerus and the radius and ulna or the presence of a posterior fat pad sign, a transphyseal fracture or an occult fracture should be suspected (Fig. 724.11). Imaging studies such as oblique radiographs, CT, MRI, and ultrasonography may be required for further confirmation. Displaced supracondylar fractures may be associated with concomitant neurovascular injury (Fig. 724.12) or, rarely, a compartment syndrome. Ulnar nerve injury is identified by decreased sensation over the cutaneous innervation of the lateral aspects of the hand as well as a motor deficit of abduction and adduction of the fingers. Neurologic injury may also appear in the postoperative period. Careful neurologic examination of the hand before and after is needed to document and treat nerve injury. Most nerve injuries associated with displaced supracondylar fractures are neuropraxias and will resolve in several months.

In general, distal humeral fractures need restoration of anatomic alignment. This is necessary to prevent deformity and to allow for normal growth and development. Closed reduction alone, or in association with percutaneous fixation, is the preferred method. Open reduction is indicated for fractures that cannot be reduced by closed methods, fractures with vascular compromise after closed reduction, open fractures, or interarticular fractures, particularly in older children. Inadequate reductions can lead to loss of motion, cubitus varus, cubitus valgus, and rare nonunion or elbow instability. Elbow stiffness is not as common as in adult fractures but may occur with fractures which are severe or intraarticular.

PROXIMAL HUMERUS FRACTURES

Fractures of the proximal humerus account for <5% of fractures in children. They usually result from a fall onto an outstretched arm or direct trauma. The fracture pattern tends to vary with the age group. Physeal and metaphyseal fractures are both common. Among physeal fractures of the proximal humerus, children younger than 5 years of age most commonly have SH I injuries, those 5-10 years of age have metaphyseal fractures, and children older than 11 years of age have SH II injuries. Examination includes a thorough neurologic evaluation, especially of the axillary nerve. The diagnosis is made on AP radiographs of the shoulder. An axillary view is obtained to rule out

Fig. 724.11 Supracondylar humerus fracture. **A,** Lateral radiograph of the elbow demonstrates a type II supracondylar humerus fracture, with disruption of the anterior humeral line *(black line)*. This line normally passes through the middle third of the capitellum. Here the capitellum is displaced behind the line. A large joint effusion is noted. **B,** Anteroposterior radiograph of the elbow shows a type III supracondylar humerus fracture. There is no cortical continuity and significant displacement and overlap of fracture fragments. *(From Walters MM, Robertson RL, eds. Pediatric Radiology: The Requisites, 4th ed. Philadelphia: Elsevier; 2017: Fig. 7.97.)*

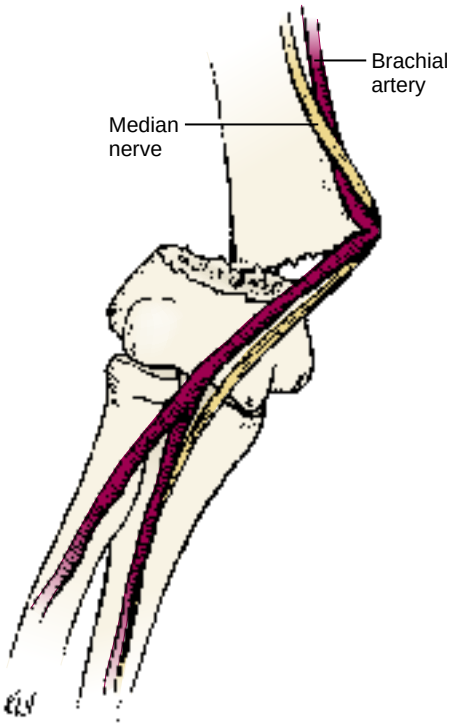

Fig. 724.12 Posterolaterally displaced type III (extension-type) supracondylar humeral fracture. The proximal fragment displaces anteromedially, thus placing the brachial artery and median nerve at risk. *(From Ho C. Upper extremity injuries. In: Herring JA, ed. Tachdjian's Pediatric Orthopaedics, 6th ed. Philadelphia: Elsevier; 202: Fig. 29.30, p. 1194.)*

any dislocation, whereas a scapular-Y view or an axillary view assesses angular deformity in an orthogonal plane. Many children are too uncomfortable to tolerate an axillary view; thus, in this case, a Velpeau axillary can be obtained while the arm remains in a sling. SH I injuries do not require reduction because they have excellent remodeling capacity, and simple immobilization in a sling for 2-3 weeks is sufficient. Metaphyseal fractures usually do not need reduction unless the angulation is >50 degrees. In general, sling immobilization is all that is required. SH II fractures with <30 degrees of angulation and <50% displacement are managed in a sling. Displaced fractures are treated with closed reduction and further stabilization if unstable. Occasionally, open reduction is required because of button-holing of the fracture spike through the deltoid or interposition of the tendon of biceps. The majority of longitudinal growth (80%) of the limb comes from the proximal humeral physis. Additionally, the glenohumeral joint is capable of a large amount of motion. As such, this area is extremely tolerant to deformity. Indications for open reduction are rare. However, as adolescents approach adulthood, these fractures will remodel less.

CLAVICULAR FRACTURES

Neonatal fractures occur as a result of direct trauma during birth, most often through a narrow pelvis or following shoulder dystocia. They can be missed initially and can appear with pseudoparalysis. Childhood fractures are usually the result of a fall on the affected shoulder or direct trauma to the clavicle. The most common site for fracture is the junction of the middle and lateral third clavicle. Tenderness over the clavicle will make the diagnosis. *A thorough neurovascular examination is important to diagnose any associated brachial plexus injury.* Biceps function is critical to assess, as it is a prognostic indicator for future function.

An AP radiograph of the clavicle demonstrates the fracture and can show overlap of the fragments. Physeal injuries occur through the medial or lateral growth plate and are sometimes difficult to differentiate from dislocations of the acromioclavicular or sternoclavicular joint. Further imaging such as a CT scan may be necessary to further define the injury. Posterior medial clavicular physeal injuries are particularly problematic due to their proximity to the great vessels and the trachea. Closed versus open reduction with a cardiac/thoracic team on standby is necessary. This can be delayed if there is no sign of vascular or respiratory compromise.

The treatment of most clavicle fractures consists of an application of a figure-of-8 clavicle strap or a simple sling. A figure-of-8 strap will extend the shoulders and minimize the amount of overlap of the fracture fragments. Evidence exists for adults that fractures that are shortened or displaced result in strength loss of the shoulder without anatomic reduction and fixation. Many centers are extending that indication to older adolescents; however, a 2019 report suggests similar satisfaction and outcomes with less complications in nonoperatively treated adolescent clavicle fractures when compared with operatively treated injuries. If a fracture is open, tenting the skin, or resulting in neurovascular compromise, surgery is indicated. The physeal fractures are treated with simple sling immobilization without any reduction attempt. Often, anatomic alignment is not achieved, nor is it necessary. Clavicle fractures heal rapidly, typically in 3-6 weeks. A palpable mass of callus is usually visible in thin children, and this remodels satisfactorily in 6-12 months. Complete restoration of shoulder motion and function is uniformly achieved.

Visit Elsevier eBooks+ at eBooks.Health.Elsevier.com for Bibliography.

724.4 Lower Extremity Fractures

Jason B. Anari, Alexandre Arkader, and Lawrence Wells

HIP FRACTURES

Hip fractures in children account for <1% of all pediatric fractures. These injuries result from high-energy trauma and can be associated with injury to the chest, head, or abdomen. Treatment of hip fractures in children is associated with a complication rate of up to 60%, including an overall avascular necrosis rate of 50% and a malunion rate of up to 30%. The unique blood supply to the femoral head accounts for the high rate of avascular necrosis. Fractures are classified by the Delbet classification as transphyseal separations, transcervical fractures, cervicotrochanteric fractures, and intertrochanteric fractures. The management principles include urgent anatomic reduction (either open or closed), stable internal fixation (avoiding the physis if possible), and

spica casting if the child is younger. Urgent management has been associated with a lower rate of avascular necrosis and superior overall outcomes. Capsular decompression also has been advocated as decreasing overall pressure on the epiphyseal vessels and has been demonstrated experimentally; the clinical results, however, remain mixed.

FEMORAL SHAFT FRACTURES

Fractures of the femur in children are common. All age groups, from early childhood to adolescence, can be affected. The mechanism of injury varies from low-energy twisting type injuries to high-velocity injuries in vehicular accidents. *Femur fractures in children younger than age 2 years should raise concern for child abuse.* A thorough physical examination is necessary to rule out other injuries and assess the neurovascular status. In the case of high-energy trauma, any signs of hemodynamic instability should prompt the examiner to look for other sources of bleeding. AP and lateral radiographs of the femur demonstrate the fracture. An AP radiograph of the pelvis is obtained to rule out any associated pelvic fracture. Treatment of shaft fractures varies with the age group, as described in Table 724.3.

PROXIMAL TIBIA FRACTURES

Proximal tibia fractures can be physeal injuries, metaphyseal injuries, or avulsion injuries of the tibial spine or tubercle. Physeal injuries can be either isolated or as part of tibial tubercle fracture. If the distal segment is displaced posteriorly the trifurcation of the popliteal vessels may be involved. Careful neurovascular examination is warranted both pre- and postreduction. Anatomic reduction and pin fixation is preferred with unstable fractures or displaced SH III or IV fractures.

Proximal tibial metaphyseal fractures, or the Cozen fracture, are most common in the 3- to 6-year-old age group. They may result in a late valgus deformity even if anatomically reduced. This deformity tends to remodel within 1-2 years but can cause great distress to parents and treating clinicians.

Tibial eminence fractures are fractures of the bony prominence that is the attachment of the anterior cruciate ligament. The mechanism of injury is similar to an anterior cruciate ligament tear in an adult. Displaced fractures require surgical reduction and fixation. This may be done either open or arthroscopically.

Tibial tubercle fractures are common in patients with Osgood-Schlatter syndrome. Care must be taken to observe for compartment syndrome as the injury is associated with injury of the recurrent anterior tibial artery. The injury may be treated nonoperatively if the fracture is displaced <2 mm and the patient has no extensor lag (rare). Open reduction and internal fixation is preferred otherwise.

TIBIA AND FIBULA SHAFT FRACTURES

The tibia is the most commonly fractured bone of the lower limb in children. This fracture generally results from a direct injury. Most tibial fractures are associated with a fibular fracture, and the mean age of presentation is 8 years. The child presents with pain, swelling, and deformity of the affected leg and is unable to bear weight. Distal neurovascular examination is important in assessment. The AP and lateral radiographs should include the knee and ankle. Closed reduction and immobilization are the standard method of treatment. Most fractures heal well, and children usually have excellent results. Open fractures need to undergo irrigation and debridement as well as antibiotic treatment. The tibia is a subcutaneous bone, so if severe soft tissue loss occurs with an open fracture, the patient may need plastic surgery consultation. Definitive external fixation versus internal fixation and simultaneous soft tissue coverage are alternative treatment strategies to minimize infection. Tibia fractures are associated with compartment syndrome. Vigilance is necessary to avoid disastrous outcomes associated with missed compartment syndrome. *Emergent fasciotomy is indicated as soon as compartment syndrome is diagnosed.* Several return trips to the operating room are often necessary to close, versus cover, the fasciotomy wounds.

TODDLER FRACTURES

Toddler fractures occur in young ambulatory children. The age range for this fracture is typically around 1-4 years (Fig. 724.13). The injury often occurs after a seemingly harmless twist or fall and is often unwitnessed. It is a result of a torsional injury. The children in this age group are usually unable to articulate the mechanism of injury clearly or to describe the area of injury well. The radiographs may show no fracture; in these cases, the diagnosis is made by physical examination. The classic symptom is refusal to bear weight, which can manifest as pulling up the affected extremity or florid display of protest. The other common sign is point tenderness at the fracture site. The AP and lateral views of the tibia-fibula might show a nondisplaced spiral fracture of the distal tibial metaphysis. An oblique view is often helpful because the fracture line may be visible in only one of the three views. Often the fracture

Fig. 724.13 Toddler's fracture of the tibia in a 2-yr-old child presenting with a limp and no history of trauma. **A,** Lateral radiograph of the lower leg shows a subtle, nondisplaced, oblique fracture through the tibial shaft *(arrows)*. **B,** Anteroposterior radiograph obtained 10 days later shows healing, with subperiosteal new bone formation along the tibial shaft *(arrows)*. *(From Walters MM, Robertson RL, eds. Pediatric Radiology: The Requisites, 4th ed. Philadelphia: Elsevier; 2017: Fig. 7.117, p. 256.)*

Table 724.3 Femoral Shaft Fracture: Treatment Options by Age

TREATMENT OPTIONS	0-2 YR	3-5 YR	6-10 YR	>11 YR
Spica cast	x	x		
Traction and spica cast		x	x	x
Intramedullary rod		x	x	x
External fixator		x*	x*	x*
Screw or plate		x	x	x

*Open fracture.
Modified from Wells L. Trauma related to the lower extremity. In: Dormans JP, ed. *Pediatric Orthopaedics: Core Knowledge in Orthopaedics.* Philadelphia: Mosby; 2005:93.

line is not visualized until 2-3 weeks later, when periosteal reaction and resorption at the fracture site allow better visualization. Inflammatory markers may be ordered to rule out infectious processes if the diagnosis is in doubt. Bone scans were employed in the past but impart a large amount of radiation to the child. The fracture can be safely treated with a below-knee cast or a controlled ankle motion (CAM) walking boot for approximately 3 weeks.

TRIPLANE AND TILLAUX FRACTURES

Triplane and Tillaux fracture patterns occur at the end of the growth period and are based on relative strength of the bone-physis junction and asymmetric closure of the tibial physis. The triplane fractures are so named because the injury has coronal, sagittal, and transverse components (Fig. 724.14). The Tillaux fracture is an avulsion fracture of the anterolateral aspect of the distal tibial epiphysis. Radiographs and further imaging with CT and three-dimensional reconstructions are necessary to analyze the fracture geometry. The triplane fracture involves the articular surface and hence anatomic reduction is necessary. The reduction is further stabilized with internal fixation. The Tillaux fracture is treated by closed reduction. Open reduction is recommended if a residual intraarticular step-off persists.

Fig. 724.14 The triplane fracture is a transitional fracture: anteroposterior (A) and lateral (B) radiographs. *(From Dormans JP. Pediatric Orthopedics: Introduction to Trauma. Philadelphia: Mosby; 2005:38.)*

METATARSAL FRACTURES

Metatarsal fractures are common in children. They usually result from direct trauma to the dorsum of the foot. High-energy trauma or multiple fractures of the metatarsal base are associated with significant swelling. A high index for compartment syndrome of the foot must be maintained and compartment pressures must be measured if indicated. Diagnosis is obtained by AP, lateral, and oblique radiographs of the foot. Most metatarsal fractures can be treated by closed methods in a below-knee cast or walking boot. Weight-bearing is allowed as tolerated. The Jones fracture of the proximal fifth metatarsal is an exception as it lies at a watershed area of vascular supply and thus has an increased risk of nonunion. Patients with Jones fractures should initially be nonweightbearing and should be referred to an orthopedics specialist. Displaced fractures can require closed or open reduction with internal fixation. Percutaneous, smooth Kirschner wires (K-wires) generally provide sufficient internal fixation for these injuries.

TOE PHALANGEAL FRACTURES

Fractures of the lesser toes are common and are usually secondary to direct blows. They commonly occur when the child is barefoot. The toes are swollen, ecchymotic, and tender. There may be a mild deformity. Diagnosis is made radiographically. Bleeding suggests the possibility of an open fracture. The lesser toes usually do not require closed reduction unless significantly displaced. If necessary, reduction can usually be accomplished with longitudinal traction on the toe. Casting is not usually necessary. Buddy taping of the fractured toe to an adjacent stable toe usually provides satisfactory alignment and relief of symptoms. Crutches and heel walking may be beneficial for several days until the soft tissue swelling and the discomfort decrease.

Visit Elsevier eBooks+ at eBooks.Health.Elsevier.com for Bibliography.

724.5 Operative Treatment of Fractures

Jason B. Anari, Alexandre Arkader, and Lawrence Wells

Surgery is required for 4–5% of pediatric fractures. The common indications for operative treatment in children and adolescents include displaced physeal fractures, displaced intraarticular fractures, unstable fractures, multiple injuries, open fractures, failure to achieve adequate reduction in older children, failure to maintain an adequate reduction, and certain pathologic fractures.

The aim of operative intervention is to obtain anatomic alignment and relative stability. Rigid fixation is not necessary as it is in adults for early mobilization. The relatively stable construct can be supplemented with external immobilization such as a cast, splint, or CAM walking boot. SH types III and IV injuries require anatomic alignment, and if they are unstable, internal fixation is used (smooth K-wires, preferably avoiding the course across the growth plate). Multiple closed reductions of an epiphyseal fracture are contraindicated because they can cause permanent damage to the physis.

Table 724.4 Common Indications for External Fixation in Pediatric Fractures

Grades II and III open fractures
Fractures associated with severe burns
Fractures with soft tissue loss requiring free flaps or skin grafts
Fractures requiring distractions such as those with significant bone loss
Unstable pelvic fractures
Fractures in children with associated head injuries and spasticity
Fractures associated with vascular or nerve repairs or reconstruction

SURGICAL TECHNIQUES

It is important to take great care with soft tissues and skin. The other indications for open reduction and internal fixation are unstable fractures of the spine, ipsilateral fractures of the femur and tibia, neurovascular injuries requiring repair, and open fractures. Closed reduction and minimally invasive fixation are specifically used for supracondylar fractures of the distal humerus and most phalangeal fractures. Failure to obtain anatomic alignment by closed means is an indication for an open reduction. Percutaneous techniques such as intramedullary fixation and minimally invasive plate osteosynthesis are increasingly popular as well.

As children become older, surgical techniques become more similar to adult techniques. The classic example of this is the femoral shaft fracture. Newborns may be treated with a soft dressing or Pavlik harness; young children may have a spica cast; older children will often be treated with flexible nails. Adolescents will frequently be treated with rigid intramedullary fixation similar to their adult counterparts.

Table 724.4 summarizes the main indications for external fixation. The advantages of external fixation include rigid immobilization of the fractures, access to open wounds for continued management, and easier patient mobilization for treatment of other injuries and transportation for diagnostic and therapeutic procedures. The majority of

complications with external fixation are pin tract infections, chronic osteomyelitis, and refractures after pin removal.

Visit Elsevier eBooks+ at eBooks.Health.Elsevier.com for Bibliography.

724.6 Complications of Fractures in Children

Jason B. Anari, Alexandre Arkader, and Lawrence Wells

Complications of fractures in children can be categorized as (1) complications of the injury itself, (2) complications of treatment, and (3) late complications resulting from growth disturbance or deformity.

COMPLICATIONS RESULTING FROM INJURY

Growth arrest is possible in physeal fractures, particularly widely displaced physeal fractures about the distal femur, proximal tibia, or distal ulna. Fractures about the hip may cause **avascular necrosis** or premature physeal closure, particularly when the fracture involves the proximal femoral physis. Unacceptable alignment may cause loss of motion or limb malalignment. Fracture malunion may cause cosmetically unappealing bumps or curves in the limb, and at times functional impairment. **Compartment syndrome** can occur, particularly in diaphyseal tibia fractures or high energy or open both bone forearm fractures. Supracondylar humerus fractures, distal femur fractures, and proximal tibia fractures may result in neurovascular compromise. Nonunions are rare in children but can be seen with intraarticular fractures, such as distal humerus lateral condyle fractures. Malunions or missed Monteggia fracture dislocations about the elbow can cause permanent stiffness and loss of function if the deformity is not corrected. Displaced intraarticular fractures can result in posttraumatic arthritis and early joint degeneration. Open fractures can result in infection and osteomyelitis if inadequately treated. Older children with severe injuries of the lower extremity can be vulnerable to **deep vein thrombosis**.

COMPLICATIONS OF TREATMENT

Treatment may complicate fractures. Cast immobilization can result in **cast ulcers**, either from inadequate padding of bony prominences or from patients placing objects in the cast. Casts that are too tight can cause neurovascular compromise and compartment syndrome. Patients can get cast saw burns from using cast saws that are too dull to remove the cast. Safe operation of a cast saw requires monitoring of blade temperature. The saw blade should be intermittently cooled by taking a break to avoid overheating and thermal injury to the skin. Improperly placed casts can promote fracture displacement and malunion. Surgical treatment can be complicated by blood loss, neurovascular compromise, iatrogenic physeal damage, and hardware complications such as infection or hardware failure. Symptomatic hardware may require later removal.

LATE COMPLICATIONS OF TRAUMA

Late effects of trauma can be from partial or complete closure of the physis or malunion of the fracture. This can lead to limb angular deformity, shortening, or incongruency. Angular deformities can be treated by hemiepiphysiodesis or osteotomy. Joint incongruency may be a very difficult problem to deal with and may ultimately lead to early degenerative joint disease. Reflex sympathetic dystrophy is another poorly understood late effect of trauma but can be debilitating. Distal radius fractures have an above average rate of reflex sympathetic dystrophy relative to other injuries. Physical and occupational therapists are very helpful in managing this condition. Limited evidence exists that vitamin C may be useful in the acute setting of high-risk injuries to prevent this complication.

Chapter 725 Osteomyelitis

Samir S. Shah

Osteomyelitis, or infection of the bone, may be classified as acute or chronic. These clinical definitions correspond with treatment recommendations. **Acute osteomyelitis** is defined as the diagnosis of bone infection within 4 weeks after onset of clinical signs or symptoms in a previously uninfected bone. **Chronic osteomyelitis** is defined as a protracted and indolent disease process with presence of a sequestrum or relapse of infection at the same site following apparently successful treatment; sequestra may arise as a complication of treated or untreated acute hematogenous osteomyelitis.

ETIOLOGY

Bacteria are the most common pathogens in acute skeletal infections. *Staphylococcus aureus* (see Chapter 227.1) is the most common infecting organism in osteomyelitis among all age groups, including newborns. The prevalence of community-acquired methicillin-resistant *S. aureus* (CA-MRSA) as a cause of osteomyelitis varies substantially by region.

Group B streptococcus (see Chapter 230) and gram-negative enteric bacilli (*Escherichia coli,* see Chapter 246) are prominent pathogens in neonates; group A streptococcus (see Chapter 229) constitutes <10% of all cases in this group. After 6 years of age, most cases of osteomyelitis are caused by *S. aureus,* group A streptococci, or *Pseudomonas aeruginosa* (see Chapter 251.1). Cases of *Pseudomonas* infection are related almost exclusively to puncture wounds of the foot, with direct inoculation of *P. aeruginosa* from the foam padding of the shoe into bone or cartilage, which develops as osteochondritis. *Salmonella* spp. (see Chapter 244) and *S. aureus* are the two most common causes of osteomyelitis in children with sickle cell disease (see Chapter 511.1). *Streptococcus pneumoniae* (see Chapter 228) most commonly causes osteomyelitis in children younger than 24 months of age and in children with sickle cell disease, but its frequency has declined because of pneumococcal conjugate vaccines. *Bartonella henselae* (see Chapter 255) can cause osteomyelitis of any bone but is most often seen in pelvic and vertebral bones.

Kingella kingae (see Chapter 239) is the second most common cause of osteomyelitis in children younger than 4 years of age. The organism causes osteomyelitis, spondylodiscitis, and septic arthritis (see Chapter 726) in this age group, especially when there is a subacute presentation. *K. kingae* can be difficult to detect unless polymerase chain reaction (PCR) testing is used.

Infection with atypical mycobacteria (see Chapter 263), *S. aureus,* or *Pseudomonas* can occur after penetrating injuries. These organisms, as well as coagulase-negative staphylococci or gram-negative enteric bacteria, may cause bone infection related to implanted materials such as orthopedic hardware. Fungal infections usually occur as part of multisystem disseminated disease; *Candida* (see Chapter 280) osteomyelitis sometimes complicates fungemia in neonates with or without indwelling vascular catheters. Blastomycosis causes multiple bone lesions in endemic areas.

EPIDEMIOLOGY

The median age of children with musculoskeletal infections is approximately 6 years. Bone infections are more common in males than females.

Minor closed trauma is a common preceding event in cases of osteomyelitis, occurring in approximately 30% of patients. Impaired host defenses (e.g., hemoglobinopathies, human immunodeficiency virus, or chronic granulomatous disease) also increase the risk of skeletal infection. Table 725.1 lists other risk factors.

Table 725.1 Microorganisms Isolated from Patients with Osteomyelitis and Their Clinical Associations

MOST COMMON CLINICAL ASSOCIATION	MICROORGANISM
Frequent microorganism in any type of osteomyelitis	*Staphylococcus aureus* (susceptible or resistant to methicillin)
Associated with septic arthritis, spondylodiscitis, long or unusual bones, age <4 yr, mild symptoms	*Kingella kingae*
Foreign body–associated infection	Coagulase-negative staphylococci, other skin flora, atypical mycobacteria, fungi
Common in nosocomial infections	*Enterobacteriaceae, Pseudomonas aeruginosa, Candida* spp.
Decubitus ulcer or ulceration associated with sensory autonomic neuropathies	*S. aureus*, streptococci, gram-negative enterics, and/or anaerobic bacteria; polymicrobial infections are common
Sickle cell disease	*Salmonella* spp., *S. aureus*, or *Streptococcus pneumoniae*
Exposure to kittens	*Bartonella henselae*
Human or animal bites	*Pasteurella multocida* or *Eikenella corrodens*
Immunocompromised patients	*Aspergillus* spp., *Candida albicans*, or *Mycobacteria* spp.
Populations in which tuberculosis is prevalent	*Mycobacterium tuberculosis*
Populations in which these pathogens are endemic	*Brucella* spp., *Coxiella burnetii*, fungi found in specific geographic areas (coccidioidomycosis, blastomycosis, histoplasmosis)

Modified from Lew DP, Waldvogel FA. Osteomyelitis. *Lancet*. 2004;364:369–379.

PATHOGENESIS

Bacteria reach bone matrices most commonly via hematogenous spread (primary bacteremia). Less common mechanisms include direct inoculation (i.e., trauma or procedures) or contiguous spread from infection of adjacent sites such as synovial fluid or soft tissues.

The unique anatomy and circulation of the ends of long bones result in the predilection for localization of bloodborne bacteria. In the metaphysis, nutrient arteries branch into non-anastomosing capillaries under the physis, which make a sharp loop before entering venous sinusoids draining into the marrow. Low-velocity blood flow in this area predisposes to bacterial invasion. Once a bacterial focus is established, phagocytes migrate to the site and produce an inflammatory exudate (metaphyseal abscess). The generation of proteolytic enzymes, toxic oxygen radicals, and cytokines results in decreased oxygen tension, decreased pH, osteolysis, and tissue destruction. As the inflammatory exudate progresses, pressure increases spread through the porous metaphyseal space via the Haversian system and Volkmann canals into the subperiosteal space. Purulence beneath the periosteum may lift the periosteal membrane of the bony surface, further impairing blood supply to the cortex and metaphysis.

In newborns and young infants, transphyseal blood vessels connect the metaphysis and epiphysis, so it is common for pus from the metaphysis to enter the joint space. This extension through the physis has the potential to result in abnormal growth and bone or joint deformity. During the latter part of the first year of life, the physis forms, obliterating the transphyseal blood vessels. Joint involvement can occur where the metaphysis is intraarticular (hip, ankle, shoulder, and elbow), and subperiosteal pus ruptures into the joint space.

In later childhood, the periosteum becomes more adherent, favoring pus to decompress through the periosteum. Once the growth plate closes in late adolescence, hematogenous osteomyelitis more often begins in the diaphysis and can spread to the entire intramedullary canal. Septic arthritis contiguous with a site of osteomyelitis is also seen in older children with *S. aureus* osteomyelitis, which may be related to simultaneous hematogenous inoculation of bone and joint space. Septic arthritis may also result from infected material entering the synovial space from an adjacent osteomyelitis.

CLINICAL MANIFESTATIONS

The earliest signs and symptoms of acute osteomyelitis, often subtle and nonspecific, generally depend on patient age. Neonates might exhibit *pseudoparalysis* or pain with movement of the affected extremity (e.g., diaper changes). Half of neonates do not have fever and might not appear ill. Older infants and children are more likely to have pain, fever, and localizing signs such as edema, erythema, and warmth. With involvement of the lower extremities, limp or refusal to walk is seen in approximately half of patients.

Focal tenderness over a long bone can be an important finding. Local swelling and redness with osteomyelitis suggests spread of infection beyond the metaphysis and into the subperiosteal space, representing a secondary soft tissue inflammatory response. Pelvic osteomyelitis can manifest with subtle findings such as hip, thigh, groin, or abdominal pain. Vertebral osteomyelitis typically presents as back pain with or without tenderness to palpation over the vertebral processes (Chapter 720.7).

Long bones are principally involved in osteomyelitis (Table 725.2); the femur and tibia are equally affected and together constitute almost half of all cases. The bones of the upper extremities account for 25% of all cases. Flat bones are less commonly affected.

Usually, a single site of bone or joint is involved, although multifocal osteomyelitis may be noted in up to 20% of children with *S. aureus* infections. In neonates, two or more bones are involved in almost half of the cases. Multifocal disease may also be seen with tuberculosis, cat-scratch disease, and brucellosis. Clinical manifestations of chronic infection are more indolent, and fever is unusual. Children with *subacute* symptoms and focal findings in the metaphyseal area (usually of the tibia) might have a **Brodie abscess**, with a well-defined radiographic lucency and surrounding reactive bone. The contents of Brodie abscesses are often sterile, but *S. aureus* is often the most common pathogen (Fig. 725.1).

Some patients with osteomyelitis due to *S. aureus* infection develop a deep venous thrombosis adjacent to the affected bone that can produce septic pulmonary emboli; these patients are often critically ill. Uncomplicated disease should be distinguished from more complicated osteomyelitis (Table 725.3).

DIAGNOSIS

The diagnosis of osteomyelitis begins with clinical suspicion and requires appropriate cultures and imaging studies. *Blood cultures should be performed in all suspected cases before administration of antibiotic therapy.* Blood cultures are positive in ~30% of patients. Blood culture contamination rates are low, generally <5%; microbes such as coagulase-negative staphylococci, α-streptococci (except *S. pneumoniae* and *S. anginosus* group), *Bacillus* species, *Corynebacterium*, and *Cutibacterium* are usually considered contaminants when identified in blood culture from a patient with acute or subacute hematogenous osteomyelitis.

Depending on the results of imaging studies, aspiration or biopsy of bone or subperiosteal abscess for Gram stain, standard bacterial culture, PCR for *K. kingae,* and possibly bone histology provides the optimal specimen for culture to confirm the diagnosis and significantly increases the yield compared with blood culture alone. These specimens, which identify a causative bacteria in ~60% of cases, are often obtained by the interventional radiologist or at the time of surgical

Table 725.2 Site of Involvement in Acute Hematogenous Osteomyelitis

SITE	%
TUBULAR BONE	
Femur	25
Tibia	24
Humerus	13
Phalanges	5
Fibula	4
Radius	4
Ulna	2
Metatarsal	2
Clavicle	0.5
Metacarpal	0.5
CUBOIDAL BONE	
Calcaneus	5
Talus	0.8
Carpals	0.5
Cuneiform	0.5
Cuboid	0.3
IRREGULAR BONE	
Ischium	4
Ilium	2
Vertebra	2
Pubis	0.8
Sacrum	0.8
FLAT BONE	
Skull	1
Rib	0.5
Sternum	0.5
Scapula	0.5
Maxilla	0.3
Mandible	0.3

Data from Krogstad P. Osteomyelitis. In: Cherry JD, Harrison GJ, Kaplan SL, et al., eds. *Feigin and Cherry's Textbook of Pediatric Infectious Diseases*, 8th ed. Philadelphia: Elsevier, 2019: Table 55.2.

drainage by the orthopedic surgeon. Direct inoculation of clinical specimens into aerobic blood culture bottles can improve the recovery of *K. kingae,* particularly if held for 1 week. PCR is the most sensitive technique to detect *K. kingae*, even up to 6 days after antibiotics are initiated. Anaerobic, fungal, and mycobacterial cultures may be performed if risk factors are identified by history or physical examination.

There are no specific laboratory tests for osteomyelitis. Laboratory evaluation of children with suspected osteomyelitis may include a complete blood count and C-reactive protein (CRP). A complete blood count may contribute to assessment of infection severity (e.g., anemia, thrombocytopenia) and suggest an alternative diagnosis (e.g., hematologic malignancy). The initial CRP is elevated in most children with acute osteomyelitis. CRP is nonspecific and does not establish the diagnosis of osteomyelitis, but serial monitoring of an elevated CRP may be of value in assessing response to therapy or identifying complications. Erythrocyte sedimentation rate (ESR) is no longer routinely recommended in cases of acute hematogenous osteomyelitis. Data on procalcitonin are insufficient.

RADIOGRAPHIC EVALUATION

Radiographic studies play a crucial role in the evaluation of osteomyelitis. Conventional radiographs and MRI are the primary modalities. Ultrasonography, CT, and radionuclide studies can also contribute to establishing the diagnosis in selected cases.

Plain Radiographs

Within 72 hours of onset of symptoms of osteomyelitis, plain radiographs of the involved site using soft tissue technique and compared with the opposite extremity, if necessary, can show displacement of the deep muscle planes from the adjacent metaphysis caused by deep-tissue edema. Lytic bone changes are not visible on radiographs until 30–50% of the bony matrix is destroyed. Tubular long bones do not show lytic changes for 7-14 days after onset of infection. Infection in flat and irregular bones can take longer to appear. Radiographs in children with possible osteomyelitis are important to exclude other possible causes (e.g., fracture) of the presenting symptoms and signs.

Magnetic Resonance Imaging and Computed Tomography

MRI is more sensitive than CT or radionuclide imaging in acute osteomyelitis and is the best radiographic imaging technique for identifying abscesses and for differentiating between bone and soft tissue infection. MRI provides precise anatomic detail of subperiosteal pus and accumulation of purulent debris in the bone marrow and metaphyses for possible surgical intervention. In acute osteomyelitis, purulent debris and edema appear dark, with decreased signal intensity on T1-weighted images, with fat appearing bright (Figs. 725.2 and 725.3). The opposite is seen in T2-weighted images. The signal from fat can be diminished with fat-suppression techniques to enhance visualization. Gadolinium administration can also enhance MRI. Cellulitis and sinus tracts appear as areas of high signal intensity on T2-weighted images. Short tau inversion recovery (STIR) MRI is a rapid imaging modality for osteomyelitis (Fig. 725.4). MRI can also demonstrate contiguous or isolated septic arthritis, pyomyositis, or venous thrombosis. *Whole body rapid STIR MRI is an effective alternative to radionuclide imaging where multiple sites of infection are suspected or the site of infection cannot be clearly localized on exam.* CT can demonstrate osseous and soft tissue abnormalities and is ideal for detecting gas in soft tissues but has poor sensitivity for detecting the presence of osteomyelitis.

Radionuclide Studies

Radionuclide imaging, an alternative to MRI, may be useful if multiple foci are suspected. Technetium-99 (^{99m}Tc) methylene diphosphonate, which accumulates in areas of increased bone turnover, is the preferred agent for radionuclide bone imaging (three-phase bone scan). Any areas of increased blood flow or inflammation can cause increased uptake of ^{99m}Tc in the first and second phases, but osteomyelitis causes increased uptake of ^{99m}Tc in the third phase (4-6 hours). Three-phase imaging with ^{99m}Tc has excellent sensitivity (84–100%) and specificity (70–96%) in hematogenous osteomyelitis and can detect osteomyelitis within 24-48 hours after onset of symptoms. The sensitivity in neonates is much lower because of poor bone mineralization. Advantages include infrequent need for sedation and the ability to image the entire skeleton for detection of multiple foci. Disadvantages include exposure to radiation, inability to image surrounding soft tissues, and overall lack of detail, which limits the tests' utility for preoperative planning.

DIFFERENTIAL DIAGNOSIS

Distinguishing osteomyelitis from cellulitis or trauma (unintentional or abuse) may be difficult, particularly when the history is limited. Myositis or pyomyositis can also appear similar to osteomyelitis with fever, warm and swollen extremities, and limping; tenderness to palpation of the affected soft tissue area is generally more diffuse than noted in acute osteomyelitis. Myositis and pyomyositis may be isolated but are often found adjacent to an osteomyelitis on MRI. **Pyomyositis** is most often caused by *S. aureus,* followed by group A streptococcus. The pelvic muscles are a common site of pyomyositis and can mimic a pelvic osteomyelitis. MRI is the definitive

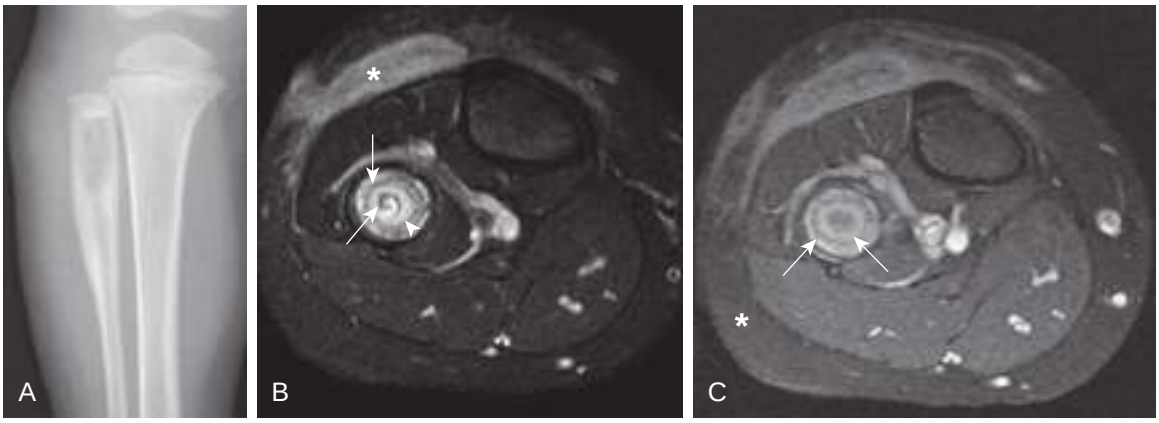

Fig. 725.1 A, Radiograph demonstrates a lytic lesion in the proximal fibula with laminated thick periostitis. Axial T2-weighted fat-saturated MR image (B) shows a layered appearance with intermediate signal *(arrowhead)* between inner and outer rims of lower signal intensity *(arrows)* and a more central hyperintense region. Also note the soft tissue phlegmon/early abscess formation *(asterisk)*. On an axial T1-weighted, fat-saturated, postgadolinium MR image (C), a rim of low signal sclerosis *(outer arrow)* surrounds an inner rim of enhancing granulation tissue *(inner arrow)*, which surrounds the nonenhancing abscess. *(From Kan JH, Meyers AB, Azouz EM. Musculoskeletal infections. In: Coley BD, ed. Caffey's Pediatric Diagnostic Imaging, 13th ed. Philadelphia: Elsevier; 2019: Fig. 137.17.)*

Table 725.3 Characteristics of Uncomplicated vs Complicated Osteomyelitis*

CHARACTERISTIC	UNCOMPLICATED	COMPLICATED
Sites of infection	Single bone	Two or more bones involved Additional soft tissue sites of infection beyond the bone (e.g., muscle [myositis or pyomyositis], pneumonia, and liver abscess)
Clinical response to medical and surgical treatment	Rapid (within 3-5 days), including signs of sepsis or septic shock	Slow, prolonged response, or lack of clinical response Need for more than one surgery for source control
Course of bacteremia when present	Rapid resolution of bacteremia (serial blood cultures become negative when obtained within 1-2 days after the initiation of therapy and source control)	Prolonged bacteremia (3 or more days), suggestive of uncontrolled infection/distant site(s) of infection
Acute sequelae of infection	None	Venous thrombosis or septic thrombophlebitis Endocarditis
Late sequelae of infection	No findings that suggest risk of physis injury or other short- or long-term osteoarticular sequelae of infection	Findings concerning for physeal injury with potential impacts on bone growth with long-term sequelae Presence of or concern for pathologic fracture

*This set of criteria is consensus based with primary focus on clinical findings and course. It may be reasonable to include additional laboratory tests such as the serum C-reactive protein (CRP) in making a determination of an uncomplicated vs complicated course. Concepts such as (1) rapid fall of the CRP concentration within 48 hr of initiation of treatment or (2) a 50% or more decline from peak CRP concentration within 3-5 days of admission or first surgical debridement may be considered. Further research into the various components and functionality of this definition, and any added utility of the CRP or other laboratory markers, will have value and is encouraged.

From Woods CR, Bradley JS, Chatterjee A, et al. Clinical practice guideline by the Pediatric Infectious Diseases Society of America: 2021 guideline on diagnosis and management of acute hematogenous osteomyelitis in pediatrics. *J Pediatric Infect Dis Soc.* 2021;10(8):801–844. Table 1.

study to identify and localize pelvic pyomyositis (Fig. 725.5). An **iliopsoas abscess** can manifest with thigh pain, limp, and fever and must be considered in the differential diagnosis of osteomyelitis. The iliopsoas abscess may be primary (hematogenous: *S. aureus*) or secondary to infection in adjacent bone *(S. aureus)*, kidney *(E. coli)* or intestine (*E. coli*, *Bacteroides* spp.). *Mycobacterium tuberculosis* has been reported in patients with HIV infection. Any child with negative x-ray imaging and a negative hip aspiration who presents with fever, limp, and elevated inflammatory markers should be evaluated for pyomyositis.

Appendicitis, urinary tract infection, and gynecologic disease are among the conditions in the differential diagnosis of pelvic osteomyelitis. Children with leukemia commonly have bone pain or joint pain as an early symptom. Neuroblastoma with bone involvement may be mistaken for osteomyelitis. Primary bone tumors need to be considered, but fever and other signs of illness are generally absent except in Ewing sarcoma. In patients with sickle cell disease, distinguishing bone infection from infarction may be challenging.

Chronic recurrent multifocal osteomyelitis (CRMO) (also called chronic nonbacterial osteomyelitis, CNO) is a nonpyrogenic, sterile inflammatory bone disease that is considered an autoinflammatory disorder (see Chapter 204). It may also be associated with a family history of autoimmune disease; the affected patient may have other inflammatory diseases such as Crohn disease, Sweet syndrome, psoriasis, and palmar plantar pustulosis. CRMO in children has many similarities with synovitis, acne, pustulosis, hyperostosis, and osteitis syndrome (SAPHO), seen in adults. CRMO also has similarities to Majeed syndrome, an autosomal recessive disorder with a microcytic dyserythropoietic anemia, and with a deficiency of interleukin-1 receptor antagonist (DIRA), an autosomal recessive autoinflammatory disease.

In contrast to infectious osteomyelitis, CRMO is multifocal, recurrent, and may involve bones not typical of osteomyelitis (spine, pelvis, clavicle, mandible, and calcaneus). Plain radiographs reveal osteolytic lesions or sclerosis; whole body STIR MRI imaging is the diagnostic study of choice (Fig. 725.6).

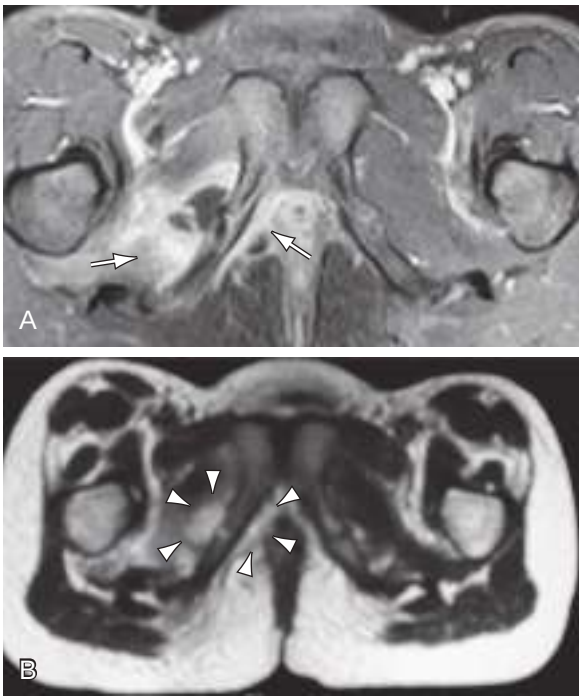

Fig. 725.2 MRI of an 8-year-old female with acute pelvic hematogenous osteomyelitis. **A,** Axial T1-weighted contrast-enhanced MRI with fat saturation reveals a nonenhancing fluid collection adjacent to the inflamed pubic synchondrosis. **B,** The fluid collection appears hyperintense on the corresponding T2-weighted image *(arrowheads)*. In addition, a contrast enhancement within the adjacent internal obturator muscle is seen *(arrow)*, indicating acute pelvic hematogenous osteomyelitis with complicating adjacent abscess formation and soft tissue inflammation. *(From Weber-Chrysochoou C, Corti N, Goetschel P, et al. Pelvic osteomyelitis: a diagnostic challenge in children. J Pediatr Surg. 2007;42:553–557.)*

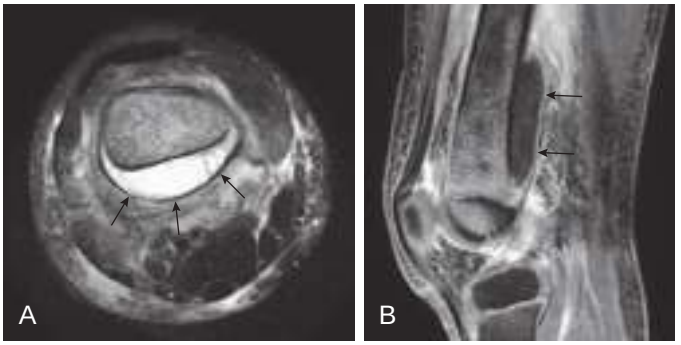

Fig. 725.3 Acute osteomyelitis of the distal femur in a 5-yr-old male. **A,** T2-weighted fat-saturated axial MRI shows a large subperiosteal abscess *(arrows)* at the posterior aspect of the femur. Increased signal is seen within the bone, and there is adjacent soft tissue edema. **B,** T1-weighted fat-saturated postgadolinium sagittal MRI shows the longitudinal extent of the subperiosteal abscess with enhancing wall *(arrows)*. *(From Kan JH, Azouz EM. Musculoskeletal infections. In: Coley BD, ed. Caffey's Pediatric Diagnostic Imaging, 13th ed. Philadelphia: Elsevier; 2019: Fig. 137.13.)*

Pain in CRMO is usually insidious and noted at night; fever is not always present. The mean age of onset is 10 years. The CRP may be elevated but is not as high as in bacterial osteomyelitis. Pain usually responds to nonsteroidal antiinflammatory drugs. Second-line treatments include systemic corticosteroids or tumor necrosis factor-α inhibitors.

Fig. 725.4 Coronal STIR MR image demonstrates a salt-and-pepper appearance of marrow edema and periosteal reaction *(arrow)*. *(From Kan JH, Azouz EM. Musculoskeletal infections. In: Coley BD, ed. Caffey's Pediatric Diagnostic Imaging, 13th ed. Philadelphia: Elsevier; 2019: Fig. 137.14.)*

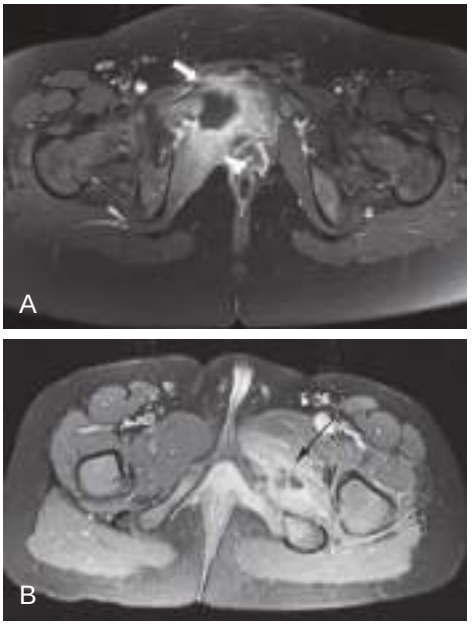

Fig. 725.5 **A,** Pelvic pyomyositis in a 10-yr-old male presenting with limping. Pelvis MRI demonstrates an avid contrast enhancement of the internal obturator muscle *(arrowhead)* with an abscess on T1-weighted fat-saturated postcontrast axial image *(arrow)*. **B,** Pyomyositis in a 7-yr-old male with left pelvic pain and fever. Axial T1 fat-saturated postcontrast image through the inferior ramus of the obturator ring demonstrates multiloculated, rim-enhancing fluid collections in the adductor muscles *(arrow)*, which is characteristic of pyomyositis. *(**A** from Bartoloni A, Gómez A, Pilar M, et al. Imaging of the limping child. Eur J Radiol. 2018;109:155–170. Fig 13; **B** from Pruthi S, Thapa MM. Infectious and inflammatory disorders. Magn Reson Imaging Clin North Am. 2009;17:423. Fig 7.)*

Fig. 725.6 MRI in a patient with chronic recurrent multifocal osteomyelitis. **A,** Whole body image showing multiple foci of osteomyelitis *(arrows)*, some of which are distributed symmetrically. **B,** Image of the ankle showing inflammatory metaphyseal and epiphyseal lesions. **C,** Image of the left femur showing involvement of the diaphysis with a soft tissue reaction. *(From Wipff J, Adamsbaum C, Kahan A, Job-Deslandre C. Chronic recurrent multifocal osteomyelitis. Joint Bone Spine. 2011;78:555–560. Fig. 3, p. 557.)*

TREATMENT

Optimal treatment of skeletal infections requires collaborative efforts of pediatricians, orthopedic surgeons, and interventional radiologists. Obtaining a blood culture *before* antibiotics are given is essential. Most patients with osteomyelitis have an indolent, non–life-threatening condition, and in these circumstances antibiotics may be deferred until a decision about whether to obtain additional diagnostic cultures (periosteal abscess, bone) has been made. A short duration of antibiotic pretreatment (<48 hours) for osteomyelitis caused by *S. aureus* has minimal impact on culture yield from abscess or bone specimens. In critically ill patients, empirical antimicrobial therapy should be initiated without delay.

Antimicrobial Therapy

The initial empirical antimicrobial therapy is based on knowledge of likely bacterial pathogens at various ages, the results of the Gram stain of aspirated material, and additional considerations (Table 725.4). In neonates, an antistaphylococcal penicillin, such as nafcillin or oxacillin (100-200 mg/kg/24 hr divided q6hr IV), and a broad-spectrum cephalosporin, such as cefepime (100-150 mg/kg/24 hr divided q12hr IV), provide coverage for the methicillin-susceptible *S. aureus* (MSSA), group B streptococcus, and gram-negative bacilli. If methicillin-resistant *Staphylococcus* (MRSA) is suspected, clindamycin or vancomycin is substituted for nafcillin. If the neonate is a premature infant or has a central vascular catheter, the possibility of nosocomial bacteria (gram-negative enteric, *Pseudomonas,* or *S. aureus*) or fungi (*Candida* spp.) should be considered. In older infants and children, the principal pathogens are *S. aureus, K. kingae,* and group A streptococcus.

Cefazolin (100-150 mg/kg/24 hr divided q6hr IV) or nafcillin (100-200 mg/kg/24 hr divided q6hr) is the agent of choice for parenteral treatment of osteomyelitis caused by MSSA and is the backbone of empirical treatment for acute hematogenous osteomyelitis. A major factor influencing the selection of empirical therapy is the rate of methicillin resistance among community *S. aureus* isolates. In areas where the prevalence of CA-MRSA is >10–20%, clindamycin (30-40 mg/kg/24 hr divided q6-8hr) or vancomycin (40-60 mg/kg/24 hr divided q6-8hr IV) should be used as empirical treatment. Clindamycin is often preferred over vancomycin when the rate of clindamycin resistance is low among community *S. aureus* isolates given the renal toxicity associated with vancomycin. Because β-lactams are superior to clindamycin and vancomycin for the treatment of MSSA, dual drug therapy in critically ill children should be continued until the causative organism is identified and susceptibilities are known. Rapid molecular diagnostic tests that can accurately differentiate MRSA from MSSA within hours of blood culture positivity can help to avoid prolonged exposure to multiple agents. Clindamycin is the best studied alternative therapy for susceptible isolates of MRSA and for MSSA when a β-lactam cannot otherwise be used.

Penicillin is first-line therapy for treating osteomyelitis caused by susceptible strains of *S. pneumoniae* and all group A streptococci. Cefotaxime or ceftriaxone is recommended for pneumococcal isolates with resistance to penicillin and for most *Salmonella* spp.

Special situations dictate deviations from the usual empirical antibiotic selection. In patients with sickle cell disease with osteomyelitis, gram-negative enteric bacteria *(Salmonella)* are common pathogens, as well as *S. aureus,* so a broad-spectrum cephalosporin such as cefepime (150 mg/kg/24 hr q8hr IV) is used in addition to clindamycin or vancomycin. Clindamycin is a useful alternative drug for patients allergic to β-lactam drugs. In addition to good antistaphylococcal activity, clindamycin has broad activity against anaerobes and is useful for treating infections secondary to penetrating injuries or compound fractures. For immunocompromised patients, combination therapy is usually initiated, such as with vancomycin and ceftazidime, cefepime, or piperacillin-tazobactam, with or without an aminoglycoside. *K. kingae* responds to β-lactam antibiotics, including penicillin and cephalosporins, but some isolates produce a β-lactamase. Thus a first-generation cephalosporin (cefazolin) is a reasonable component of empirical therapy in children younger than 4 years of age. Although

Table 725.4 Antibiotic Choice and Duration of Therapy for Uncomplicated Pediatric Acute Hematogenous Osteomyelitis Caused by *Staphylococcus aureus*[*,†]

PATHOGEN	PARENTERAL THERAPY	ORAL CONVALESCENT THERAPY	DURATION[‡]
Staphylococcus aureus, methicillin susceptible	*Preferred:*[§] Cefazolin Semisynthetic penicillin,[#] e.g., oxacillin and nafcillin	*Preferred:* Cephalexin	3-4 weeks if uncomplicated
	Alternatives:[#] Clindamycin Vancomycin Ceftaroline	*Alternative:* Clindamycin	3-4 weeks if uncomplicated
S. aureus, methicillin resistant, susceptible to clindamycin	*Preferred:* Clindamycin	*Preferred:* Clindamycin	3-4 weeks if uncomplicated
	Alternatives: Vancomycin Daptomycin Ceftaroline Linezolid	*Alternatives:*[¶] Linezolid	No data
S. aureus, methicillin resistant, resistant to clindamycin	*Preferred:* Vancomycin	*Preferred:* Linezolid	No data
	Alternatives: Daptomycin Ceftaroline Linezolid	*Alternatives:* Insufficient clinical data for the treatment of AHO to recommend other oral antibiotics with in vitro activity against *S. aureus*	No data

*Uncomplicated AHO is defined as the presence of infection in a single site with rapid clinical response to antimicrobial therapy (i.e., resolution of fever and marked improvement in clinical signs within 3-5 days), with no more than a single early surgical procedure required as source control for the infection. Complicated infections may require a longer duration of treatment than uncomplicated infections, particularly if multiple surgeries are needed to establish source control.

†Not all antibiotics listed have been prospectively evaluated in clinical trials of acute bacterial osteomyelitis. Prospective studies to evaluate the effectiveness of a range of antibiotic doses in various degrees of severity of uncomplicated and complicated osteomyelitis, with or without surgery, have not been performed, although retrospective data have been reported for many antibiotics in the treatment of pediatric osteomyelitis.

‡The suggested duration of therapy should be based on clinical course (pace of resolution of fever and clinical signs and symptoms, noting the need for surgical intervention[s] required, if any), supported by decline of inflammatory markers.

§Preferred and alternative agents are selected based on published data regarding in vitro activity, clinical efficacy, and safety. Agents are generally listed in order of preference.

#Many of the β-lactamase-stable penicillins cause significant phlebitis in peripheral veins with infusion; administration through a central venous catheter is preferred.

¶Alternative antibiotics that may display in vitro activity against *S. aureus* have not been evaluated prospectively in AHO. However, linezolid has been evaluated in prospective controlled clinical trials for invasive methicillin-resistant *S. aureus* nosocomial pneumonia in adults and is more likely to provide adequate therapy of invasive *S. aureus* AHO, compared with trimethoprim-sulfamethoxazole, which is not recommended for children with AHO by the Infectious Diseases Society of America (IDSA) Clinical Practice Guidelines for Treatment of Methicillin-Resistant *Staphylococcus aureus* Infections in Adults and Children.

AHO, Acute hematogenous osteomyelitis.

From Woods CR, Bradley JS, Chatterjee A, et al. Clinical practice guideline by the Pediatric Infectious Diseases Society of America: 2021 guideline on diagnosis and management of acute hematogenous osteomyelitis in pediatrics. *J Pediatric Infect Dis Soc.* 2021;10(8):801–844. Table 4.

the efficacy of treating osteomyelitis caused by *B. henselae* is uncertain, azithromycin plus rifampin may be considered.

When the pathogen is identified and antibiotic susceptibilities are determined, appropriate adjustments should be made to use the antibiotic with the narrowest spectrum, lowest adverse effect profile, and most favorable host tolerance. If a pathogen is not identified and a patient's condition is improving, therapy is continued with the initially selected antibiotic or an agent with a comparable spectrum of coverage. This selection is more complicated owing to the presence of MRSA isolates in the community. If a pathogen is not identified and a patient's condition is not improving, repeat aspiration or biopsy and the possibility of a noninfectious condition should be considered.

Duration of antibiotic therapy is individualized depending on the organism isolated and clinical course. Most acute cases of osteomyelitis, including those caused by *S. aureus,* can be treated with antibiotics for 21-28 days provided that the patient shows prompt resolution of signs and symptoms (within 5-7 days) and the CRP has normalized; a total of 4-6 weeks of therapy may be required for those with substantially slower resolution of symptoms or normalization of CRP. For group A streptococcus, *S. pneumoniae,* or *Haemophilus influenzae* type b, treatment duration may be shorter. A total of 7-10 postoperative days of treatment is adequate for *Pseudomonas* osteochondritis from a foot puncture wound, when curettage of infected tissue has been performed. Immunocompromised patients generally require prolonged courses of therapy, as do patients with mycobacterial or fungal infection.

For typical cases, antimicrobial agents may be changed from intravenous to oral administration when a patient's condition clearly has improved, the child is afebrile, and bacteremia has resolved. Oral cephalexin (75-100 mg/kg/24 hr divided q8hr) may be used for susceptible staphylococcal or streptococcal infections. Oral clindamycin (30-40 mg/kg/24 hr divided q6-8hr) can be used to complete therapy for children with clindamycin-susceptible CA-MRSA or for patients who are seriously allergic or cannot tolerate β-lactam antibiotics. The oral regimen decreases the risk of complications related to prolonged intravenous therapy, is more comfortable for patients, and permits treatment outside the hospital if adherence to treatment can be ensured. Outpatient intravenous antibiotic therapy via a central venous catheter can be used for completing therapy at home for (1) patients unable or unwilling to take oral medication; (2) patients with underlying medical conditions that make enteral

drug absorption unreliable; (3) patients without comparable oral antibiotic options (e.g., resistant bacteria, drug allergy); and (4) patients with disseminated infection (e.g., endocarditis, pulmonary septic emboli). Catheter-related complications, including infection or mechanical problems, can lead to readmission or emergency department visits.

In children with venous thrombosis complicating osteomyelitis, administration of anticoagulants under the supervision of a hematologist until the thrombus has resolved is a generally accepted practice, although high-quality evidence to support this practice is lacking; antibacterial therapy alone may be sufficient.

Surgical Therapy

When frank pus is obtained from subperiosteal or metaphyseal aspiration or is suspected based on MRI findings, a surgical drainage procedure is usually indicated. Surgical intervention is also often indicated after a penetrating injury and when a retained foreign body is possible. In selected cases, catheter drainage performed by an interventional radiologist is adequate.

Treatment of chronic osteomyelitis consists of surgical removal of sinus tracts and sequestrum, if present. Surgical implantation of antibiotics is not generally recommended. Antimicrobial therapy, typically administered orally, is continued for several months or longer until clinical and radiographic findings suggest that healing has occurred. Normalization of CRP and ESR is expected in successful treatment of chronic osteomyelitis but does not by itself indicate clearance of the underlying infection. Many patients with chronic osteomyelitis have a normal CRP and ESR even at the onset of illness.

Physical Therapy

The major role of physical therapy is a preventive one. If a child is allowed to lie in bed with an extremity in flexion, limitation of extension can develop within a few days. The affected extremity should be kept in extension with sandbags, splints, or, if necessary, a temporary cast. Casts are also indicated when there is a potential for pathologic fracture. After 2-3 days, when pain is easing, passive range-of-motion exercises are started and continued until the child resumes normal activity. In neglected cases with flexion contractures, prolonged physical therapy is required.

Prognosis

When pus is drained and appropriate antibiotic therapy is given, the improvement in signs and symptoms is rapid. Failure to improve or worsening by 48-72 hours requires review of the appropriateness of the antibiotic therapy, the need for surgical intervention, or the accuracy of the diagnosis. Acute phase reactants may be useful as monitors. In acute osteomyelitis, the serum CRP typically decreases below 2 mg/dL within 7-10 days after starting treatment, whereas the ESR typically rises for 5-7 days and then falls slowly, dropping sharply after 10-14 days. Failure of CRP to follow the usual course should raise concerns about the adequacy of therapy. Recurrence of disease and development of chronic infection after treatment occur in <10% of patients.

Because children are in a dynamic state of growth, sequelae of skeletal infections might not become apparent for months or years; therefore long-term follow-up is necessary, with close attention to range of motion of joints and bone length. Although firm data about the impact of delayed treatment on outcome are not available, it appears that initiation of medical and surgical therapy within 1 week of onset of symptoms provides a better prognosis than delayed treatment.

Visit Elsevier eBooks+ at eBooks.Health.Elsevier.com for Bibliography.

Chapter 726

Septic Arthritis

Samir S. Shah

Without early recognition and prompt institution of appropriate medical and surgical therapy, septic arthritis in infants and children has the potential to damage the synovium, adjacent cartilage, and bone and may cause permanent disability.

ETIOLOGY

Staphylococcus aureus (see Chapter 227.1) is the most common cause of bacterial arthritis in all age groups. Methicillin-resistant *S. aureus* (MRSA) accounts for a high proportion (>25%) of community *S. aureus* isolates in many areas of the United States and throughout the world. Group A streptococcus (see Chapter 229) and ***Streptococcus pneumoniae*** (pneumococcus; see Chapter 228) historically cause 10–20%; *S. pneumoniae* is most likely in the first 2 years of life, but its frequency has declined since the introduction of the pneumococcal conjugate vaccines. ***Kingella kingae*** is recognized as a relatively common etiology with improved culture and polymerase chain reaction (PCR) methods in children younger than 4 years (see Chapters 239 and 725). In sexually active adolescents, **gonococcus** (see Chapter 238) is a common cause of septic arthritis and tenosynovitis, usually of small joints or as a monoarticular infection of a large joint (knee). ***Neisseria meningitidis*** (see Chapter 237) can cause either a septic arthritis that occurs in the first few days of illness or a reactive arthritis that is typically seen several days after antibiotics have been initiated. **Group B streptococcus** (see Chapter 230) is an important cause of septic arthritis in neonates. Q fever and brucellosis should be considered in endemic areas and with an exposure risk.

Fungal infections usually occur as part of multisystem disseminated disease; *Candida* arthritis can complicate systemic infection in neonates with or without indwelling vascular catheters. Primary viral infections of joints are rare, but arthritis accompanies many viral (parvovirus, mumps, rubella live vaccines) syndromes, suggesting an immune-mediated pathogenesis.

A microbial etiology is confirmed in approximately 65% of cases of septic arthritis. In addition, some cases treated as bacterial arthritis are actually postinfectious (gastrointestinal or genitourinary) **reactive arthritis** (see Chapter 198) rather than primary infection. **Lyme disease** produces an arthritis more like a rheumatologic disorder and not typically suppurative.

EPIDEMIOLOGY

Septic arthritis is more common in young children. Half of all cases occur by 2 years of age, and 75% of all cases occur by 5 years of age. Adolescents and neonates are at risk of gonococcal septic arthritis.

Most infections in otherwise healthy children arise hematogenously. Less commonly, infection of joints can follow penetrating injuries or procedures such as trauma, arthroscopy, prosthetic joint surgery, intraarticular steroid injection, and orthopedic surgery. Immunocompromised patients and those with rheumatologic joint disease are also at increased risk of joint infection.

PATHOGENESIS

Septic arthritis primarily occurs as a result of hematogenous seeding of the synovial space. Less often, organisms enter the joint space by direct inoculation or extension from a contiguous focus. The synovial membrane has a rich vascular supply and lacks a basement membrane, providing an ideal environment for hematogenous seeding. The presence of bacterial products (endotoxin or other toxins) within the

joint space stimulates cytokine production (tumor necrosis factor-α, interleukin-1) within the joint, triggering an inflammatory cascade. The cytokines stimulate chemotaxis of neutrophils into the joint space, where proteolytic enzymes and elastases are released by neutrophils, damaging the cartilage. Proteolytic enzymes released from the synovial cells and chondrocytes also contribute to destruction of cartilage and synovium. Bacterial hyaluronidase breaks down the hyaluronic acid in the synovial fluid, making the fluid less viscous and diminishing its ability to lubricate and protect the joint cartilage. Damage to the cartilage can occur through increased friction, especially for weight-bearing joints. The increased pressure within the joint space from accumulation of purulent material can compromise the vascular supply and induce pressure necrosis of the cartilage. Synovial and cartilage destruction results from a combination of proteolytic enzymes and mechanical factors.

CLINICAL MANIFESTATIONS

Most septic arthritides are monoarticular. The signs and symptoms of septic arthritis depend on the age of the patient. Early signs and symptoms may be subtle, particularly in neonates. As with osteomyelitis, neonates might exhibit **pseudoparalysis** or pain that limits voluntary movement of the affected extremity (e.g., diaper changes). Septic arthritis in neonates and young infants is often associated with adjacent osteomyelitis caused by transphyseal spread of infection, although osteomyelitis contiguous with an infected joint can be seen at any age (see Chapter 725).

Older infants and children might have fever and pain, with localizing signs such as swelling, erythema, and warmth of the affected joint. With involvement of joints of the pelvis and lower extremities, limp or refusal to walk often occurs.

Erythema and edema of the skin and soft tissue overlying the site of infection are seen earlier in septic arthritis than in osteomyelitis because the bulging infected synovium is usually more superficial, whereas the metaphysis is located more deeply. Septic arthritis of the hip is an exception because of the deep location of the hip joint. With Lyme arthritis, joint swelling is typically quite prominent and may be disproportionate to the relatively lesser degree of pain and limited range of motion when compared with suppurative arthritis. Lyme arthritis has a predilection for large joints, particularly the knees and hips, and may be either monoarticular or pauciarticular at presentation.

Joints of the lower extremity constitute 75% of all cases of septic arthritis (Table 726.1). The elbow, wrist, and shoulder joints are involved in approximately 25% of cases, and small joints are uncommonly infected, except in gonococcal arthritis. Suppurative infections of the hip, shoulder, elbow, and ankle in infants and children may be associated with an adjacent osteomyelitis of the proximal femur, proximal humerus, proximal radius, and distal tibia because the metaphysis extends intraarticularly. Concomitant osteomyelitis is less common in older children and adolescents as their anatomy and physiology become more adult-like.

Table 726.1 Distribution of Hematogenous Bacterial Arthritis*

BONE	PERCENT (%)
Knee	~35
Hip	~25
Ankle	~10
Elbow	~10
Wrist	~4
Shoulder	~5
Small joints	~1–2

*Excludes Lyme disease and immune-complex postinfectious arthritis. Viral (rubella, mumps, chikungunya) infectious arthritis is often small and multiple joints. Septic bursitis (shoulder, prepatellar) may be confused with bacterial joint infections.

DIAGNOSIS

The white blood cell count (WBC) and differential, ESR, and CRP are generally elevated in children with joint infections, but elevations are nonspecific and might not be helpful in distinguishing between infection and other inflammatory processes. Most children with septic arthritis will have normal leukocyte counts and ESR at presentation, and normal test results do not preclude the diagnosis of septic arthritis. A CBC, however, may assist with assessment of illness severity (e.g., anemia, thrombocytopenia) or with identification of other causes of the patient's symptoms (e.g., leukemia).

Blood cultures should be performed in all cases of suspected septic arthritis but are positive in ~20% of proven or probable septic arthritis. Cervical, anal, and throat cultures should be obtained when gonococcus is suspected. Aspiration of the joint fluid provides the optimal specimen to confirm the diagnosis. Most large joint spaces are easy to aspirate, but the hip can pose technical problems; ultrasound guidance facilitates aspiration. Although yield for joint aspirate cultures is higher than from blood cultures, the overall culture yield when combining both methods remains less than 50%. Multiplex bacterial PCR panels have a yield around 50% from joint fluid specimens, but this increase over culture is almost entirely because of their enhanced ability to detect *K. kingae.* Other strategies to increase detection of *K. kingae* include prompt inoculation onto solid media and inoculation of the joint fluid in blood culture bottles. A diagnosis of Lyme arthritis is made via a two-step test of an ELISA or IFA followed by a reflex Western blot for samples that are positive or equivocal by the first methodology. Patients with Lyme arthritis are seropositive because arthritis is a late manifestation of infection. PCR is rarely necessary but can detect *Borrelia burgdorferi* in joint aspirate specimens in cases of Lyme arthritis.

Synovial fluid analysis for cell count, differential, protein, and glucose has limited utility in diagnosing infectious arthritis. Joint fluid WBC counts >50,000 cells/mm^3 (often >100,000 cells/mm^3) suggest bacterial infection as the most likely etiology, but this finding is neither sensitive nor specific enough to exclude or confirm a bacterial infection in isolation. When the results of joint aspirate cell counts and culture are not strongly suggestive of a joint infection, but the clinical presentation is worrisome for a bacterial etiology, infectious causes of sympathetic joint effusions such as adjacent pyomyositis and osteomyelitis should be investigated by MRI (see Chapter 725).

Monitoring elevated CRP may be of value in assessing response to therapy or identifying complications. In addition, patients with adjacent infections complicating septic arthritis more frequently have a CRP >10-13 mg/dL compared with patients with septic arthritis alone. Other findings such as older age, prolonged symptoms, bacteremia, alterations in other lab values (such as elevated absolute neutrophil count or thrombocytopenia), and failure to rapidly improve with therapy have been less consistently associated with adjacent infection. Nonetheless, adjacent infection should be considered in patients demonstrating multiple risk factors.

Radiographic Evaluation

Radiographic studies play a crucial role in evaluating septic arthritis. Conventional radiographs and ultrasonography are performed as part of the routine workup. CT, MRI, and radionuclide studies can all contribute to establishing the diagnosis in selected cases (Fig. 726.1).

Plain Radiographs

Plain films can suggest the diagnosis of septic arthritis by showing widening of the joint capsule, soft tissue edema, and obliteration of normal fat lines. Plain films can also help to exclude other causes of joint pain such as fractures. Plain films of the hip can show medial displacement of the obturator muscle into the pelvis (the obturator sign), lateral displacement or obliteration of the gluteal fat lines, and elevation of Shenton's line with a widened arc.

Fig. 726.1 MRI of staphylococcal septic arthritis of left hip, with fluid collections between planes of gluteal muscles. *Arrows* indicate fluid collection. *(From Matthews CJ, Weston VC, Jones A, et al. Bacterial septic arthritis in adults. Lancet. 2010;375:846–854.)*

Ultrasonography

Ultrasonography is included with plain films in routine evaluations because it is particularly helpful in detecting joint effusion and fluid collection in the soft tissue and subperiosteal regions. Ultrasonography is highly sensitive in detecting joint effusion, particularly for the hip joint, where plain radiographs are normal in more than 50% of cases of septic arthritis of the hip. Ultrasonography can serve as an aid in performing hip aspiration.

Magnetic Resonance Imaging and Computed Tomography

MRI and CT can confirm the presence of joint fluid in patients with suspected osteoarthritis infections but are not routinely indicated. MRI is useful in evaluating for adjacent osteomyelitis or pyomyositis but is typically reserved for cases when the index of suspicion for these conditions is high. Considerations include patient factors such as younger age, the clinical presentation (e.g., protracted pain preceding joint swelling), the results of laboratory investigations such as joint aspiration and CRP, and response to therapy.

DIFFERENTIAL DIAGNOSIS

The differential diagnosis of septic arthritis depends on the joint or joints involved and the age of the patient. For the hip, transient synovitis, pyomyositis, Legg-Calvé-Perthes disease, slipped capital femoral epiphysis, psoas abscess, and proximal femoral, pelvic, or vertebral osteomyelitis, as well as diskitis, should be considered. Transient synovitis (toxic synovitis) is a postinfectious arthritis of the hip that is often seen in young children after a viral infection (see Chapter 719.2). For the knee, distal femoral or proximal tibial osteomyelitis, pauciarticular rheumatoid arthritis, and referred pain from the hip should be considered. Knee or thigh pain may be referred from the hip. Other conditions such as trauma, cellulitis, pyomyositis, sickle cell disease, hemophilia, Lyme arthritis, leukemia, serum sickness, and IgA vasculitis (Henoch-Schönlein purpura) can mimic purulent arthritis. When several joints are involved, serum sickness, collagen vascular disease, rheumatic fever, and IgA vasculitis should be considered. Arthritis is one of the extraintestinal manifestations of inflammatory bowel disease. Reactive arthritis after a variety of bacterial (gastrointestinal or genital) and parasitic infections, streptococcal pharyngitis, or viral hepatitis can resemble acute septic arthritis (see Chapter 198).

TREATMENT

Optimal treatment of septic arthritis requires coordination between primary care physicians, orthopedic surgeons, and radiologists.

Surgical Therapy

Drainage and irrigation of the infected joint via arthroscopy or arthrotomy is typically performed to decompress the joint and remove inflammatory debris. The decision to proceed to one of these procedures after arthrocentesis is based on the gross appearance of the joint fluid, or joint fluid WBC and differential, in the context of the clinical presentation and the specific joint that is infected. Infection of the hip is generally considered a surgical emergency because of the vulnerability of the blood supply to the head of the femur. For joints other than the hip, daily aspirations of synovial fluid may be required. In general, one or two subsequent aspirations suffice. If fluid continues to accumulate after 4-5 days, arthrotomy or video-assisted arthroscopy is needed. At the time of surgery, the joint is flushed with sterile saline solution. Antibiotics are not instilled because they are irritating to synovial tissue, and adequate amounts of antibiotic are achieved in joint fluid with systemic administration.

Antimicrobial Therapy

Empiric antimicrobial therapy should be started immediately in a child with presumed septic arthritis who is ill-appearing or has a rapidly progressive infection. Antibiotic therapy may be deferred until initial joint aspirate has been collected for diagnostic purposes in a child with presumed septic arthritis who does not appear clinically ill.

The initial empirical antimicrobial therapy is based on likely bacterial pathogens at various ages, the results of the Gram stain of aspirated material, and additional considerations. In neonates, an antistaphylococcal penicillin, such as nafcillin or oxacillin (100-200 mg/kg/24 hr divided q6hr IV), and a broad-spectrum cephalosporin, such as cefepime (100-150 mg/kg/24 hr divided q12hr IV), provide coverage for the *S. aureus,* group B streptococcus, and gram-negative bacilli. If MRSA is a concern, clindamycin or vancomycin is selected instead of nafcillin or oxacillin. If the neonate is a small premature infant or has a central vascular catheter, the possibility of nosocomial bacteria (*S. aureus*, gram-negative enterics, or *Pseudomonas aeruginosa*) or fungi *(Candida)* should be considered.

In children with septic arthritis, empirical therapy to cover for *S. aureus* and streptococci includes at minimum nafcillin (100-200 mg/kg/24 hr divided q6hr). In preschool-age children (i.e., 6 months to 4 years), empiric therapy should include an antibiotic with activity against *Kingella kingae* as well as *S. aureus*, such as cefazolin (100-150 mg/kg/24 hr divided q8hr).

In areas where methicillin resistance is noted in ≥10–15% of community-acquired methicillin-resistant *S. aureus* (CA-MRSA) strains, adding an antimicrobial that is effective against local CA-MRSA isolates is suggested. Vancomycin (15 mg/kg q6hr IV) is preferred in patients who are ill-appearing, suspected to be bacteremic, or if local clindamycin resistance is more than 10–15%. Clindamycin (30-40 mg/kg/24 hr divided q6-8hr) is a good alternative when treating CA-MRSA infections. For immunocompromised patients, combination therapy is usually initiated, such as with vancomycin and ceftazidime, cefepime, or piperacillin/tazobactam, with or without an aminoglycoside. Adjunct therapy with dexamethasone has been shown in some studies to decrease the duration of fever and promote a more rapid decline in inflammatory markers, but this is not yet part of routine care. **Lyme arthritis** is treated with oral doxycycline (4.4 mg/kg/24 hr divided q12hr) for 28 days in children >8 years old. For children <8 years old, oral amoxicillin (50 mg/kg/24 hr divided q8hr) or cefuroxime (30 mg/kg/24 hr divided q12hr) is recommended. A second 28-day course may be considered for patients with persistent or recurrent symptoms after completing the initial course of treatment. Intravenous ceftriaxone (50 mg/kg q24hr IV) for 14-28 days may be considered as an initial or second course of therapy for severe or refractory cases.

Empirical antimicrobials are narrowed to targeted therapy when the pathogen is identified. If a pathogen is not identified and a patient's condition is improving, therapy is continued with the antibiotic selected

initially. If a pathogen is not identified and a patient's condition is not improving, consideration should be given to the need for repeat aspiration, the presence of an extraarticular infection requiring surgical debridement, or the possibility of a noninfectious etiology. In such cases, MRI may be performed to assist with subsequent management decisions.

Duration of antibiotic therapy is individualized depending on the organism isolated and the clinical course. A total of 10-14 days is usually adequate for streptococci, *S. pneumoniae*, and *K. kingae;* longer therapy may be needed for *S. aureus* and gram-negative infections (3 weeks), concomitant osteomyelitis (4 weeks), extensive disease, or slow response to treatment. Normalization of CRP in addition to a normal examination supports discontinuing antibiotic therapy. The prognostic significance of an improved but still minimally elevated ESR in the third or fourth week of therapy is not clear if all other clinical and laboratory parameters are favorable. In selected patients, obtaining a plain radiograph of the joint before completing therapy can provide evidence (typically periosteal new bone) of a previously unappreciated contiguous site of osteomyelitis that would likely prolong antibiotic treatment. Oral antibiotics can be used to complete therapy once the patient is afebrile for 48-72 hours and is clearly improving.

Surgically administered intraarticular antibiotics are not recommended.

PROGNOSIS

Improvement in signs and symptoms occurs rapidly after joint drainage and antibiotic administration. Failure to improve or worsening by 48-72 hours requires review of the appropriateness of the antibiotic therapy, the need for surgical intervention, and the correctness of the diagnosis. CRP may be useful to monitor response to therapy. Failure of CRP to decline should raise concerns about the adequacy of therapy. Recurrence of disease and development of chronic infection after treatment occur in <10% of patients.

Septic arthritis can lead to numerous long-term sequelae in children, including leg-length discrepancy or angular deformity from growth arrest, limitations in range of motion due to chondral damage, and avascular necrosis of the femoral head from septic arthritis of the hip. The overall rate of these sequelae with current therapies is <5%. However, children are in a dynamic state of growth, so these abnormalities might not become apparent for months or years; therefore long-term follow-up is necessary, with close attention to range of motion of joints and bone length. Involvement of the hip is associated with a higher rate of sequelae. Initiation of medical and surgical therapy within 1 week of onset of symptoms provides a better prognosis than delayed treatment.

Visit Elsevier eBooks+ at eBooks.Health.Elsevier.com for Bibliography.

Section 2

Sports Medicine

Chapter 727

Prevention of Injuries

Gregory L. Landry and Andrew M. Watson

The Centers for Disease Control and Prevention, the American College of Sports Medicine, and the American Academy of Pediatrics all recommend daily moderate to vigorous physical activity for all adolescents. Physical activity has favorable effects on blood pressure, body composition, and serum lipid levels in youths and is associated with lower rates of cardiovascular disease, type 2 diabetes mellitus, osteoporosis, and colon and breast cancer among adults.

Pediatricians should promote physical activity to their patients, especially those with lower rates of physical activity and sports participation, including children with special healthcare needs (see Chapter 756) and those from lower socioeconomic groups. Physicians also have the responsibility of providing medical clearance for participation in physical activity and sports as well as for the diagnosis and rehabilitation of injuries.

Approximately 30 million children and adolescents participate in organized sports in the United States. Around 3 million sport-related injuries occur annually in young athletes, if injury is defined as time lost from the sport. Deaths in sports are rare, with the majority of nontraumatic deaths caused by cardiac diseases (see Chapter 485). Nonetheless, approximately 30% of life-threatening injuries in children presenting to an emergency room are sports related. Overall, injury rates and injury severity in sports increase with age and pubertal development, related to the greater speed, strength, and intensity of competition.

Identifying mechanisms of injury and establishing and enforcing rules that reduce the likelihood of that mechanism of injury, including penalizing dangerous play, have reduced catastrophic injury rates. Injury rates also have been reduced by removing environmental hazards, such as trampolines in gymnastics and stationary (versus breakaway) bases in softball, and by modifying heat injury rates in soccer tournaments by adding water breaks and reducing the playing time. Certain types of equipment can mitigate the risk of some injuries, such as the use of mouth guards to reduce dental injuries. The most consistently identified risk factor for injury is prior injury. In other words, although reinjury may often be due to insufficient recovery and rehabilitation of a prior injury, appropriate rehabilitation reduces injury risk. Preseason training for adolescent athletes, with an emphasis on speed, agility, core strength, landing mechanics, and flexibility, is associated with lower injury rates in soccer and fewer serious knee injuries in female athletes. Traditional stretching maneuvers or massage have not been demonstrated to reduce the risk of injury or muscle soreness, but ankle taping and use of lace-up ankle braces are helpful in preventing ankle injuries. One setting for implementing some of these prevention strategies and for detecting unrehabilitated injuries and medical problems that could affect participation in sports is the preparticipation sports examination (PSE).

PREPARTICIPATION SPORTS EXAMINATION

The PSE is performed with a directed history and physical examination, including a screening musculoskeletal examination (see Table 485.2 in Chapter 485). It identifies possible problems in 1–8% of athletes and excludes fewer than 1% from participation. The PSE is not a substitute for the recommended comprehensive annual evaluation, which looks at behaviors that are potentially harmful to teens, such as sexual activity, drug use, and violence, and assesses for depression and suicidal ideation and addresses broader issues of prevention. Table 727.1 identifies the purposes of the PSE. If possible, the PSE should be combined with the comprehensive annual health visit with an emphasis on preventive healthcare (see Chapters 13 and 28).

State requirements for how often a young athlete needs a PSE differ, ranging from annually to entry to a new school level (middle school, high school, college). At a minimum, a focused, annual interim evaluation should be done on an otherwise healthy young athlete. The PSE is optimally performed 3-6 weeks before the start of practice.

History and Physical Examination

The essential components of the PSE are the history and focused medical and musculoskeletal screening examinations. Identified problems require more investigation (Table 727.2). While many medical conditions should not limit sports participation, many specialty organizations have released recommendations regarding sports participation (Table 727.3). In the absence of symptoms, no screening laboratory tests are required. Return to sports after COVID-19 infection is based on the severity of infection (mild, moderate, or ICU admission and/or MIS-C), and the intensity of follow-up, especially for those with active cardiac involvement during the acute phase of the illness (Fig. 727.1).

Seventy-five percent of significant findings are identified by the history; a standardized questionnaire given to the parent and athlete is important

Table 727.1 Objectives of the Preparticipation Sports Examination

- Determination of the general health of the athlete
- Disclosure of defects that may limit participation
- Detection of conditions that may predispose the athlete to injury
- Determination of optimal level of performance
- Classification of the athlete according to individual qualifications
- Fulfillment of legal and insurance requirements for organized athletic programs
- Evaluation of size and level of maturation of younger athletes
- Improvement of fitness and performance
- Provision of opportunities for students to compete who have either physiologic or pathologic health conditions that may preclude blanket approval
- Provision of the opportunity to counsel youths and answer health and personal questions
- Entry of the athlete into the local sports medicine system, establishing a doctor-patient relationship that continues

From Sanders B, Blackburn TA, Boucher B. Preparticipation screening-the sports physical therapy perspective. *Int J Sports Phys Ther*. 2013;8(2):180–193. Table 1.

Table 727.2 Preparticipation Sports Examination

COMPONENT OF THE PHYSICAL EXAMINATION	CONDITION TO BE DETECTED
Vital signs	Hypertension, cardiac disease, bradycardia or tachycardia
Height and weight	Obesity, eating disorders, malabsorption
Vision and pupil size	Legal blindness, absent eye, anisocoria, amblyopia
Lymph node	Infectious diseases, malignancy
Cardiac (performed standing and supine)	Heart murmur, prior surgery, dysrhythmia, femoral pulses
Pulmonary	Recurrent and exercise-induced bronchospasm, chronic lung disease
Abdomen	Organomegaly, abdominal mass
Skin	Contagious diseases (impetigo, herpes, staphylococcal, streptococcal)
Genitourinary	Varicocele, undescended testes, tumor, hernia
Musculoskeletal	Acute and chronic injuries, physical anomalies (scoliosis)

Table 727.3 Sports Participation Recommendations by Condition

CONDITION	RECOMMENDATION
Hemophilia	Restrict contact or collision sports until evaluation by a hematologist who can assess degree of hemostatic abnormality and the sport-specific risk
Sickle cell disease	Individual decision-making given variation in phenotypic expression
Diabetes mellitus	No restrictions
Skin infections (herpes gladiatorum, tinea gladiatorum, impetigo, molluscum contagiosum, warts, and MRSA)	Prevent transmission by: • Covering infected site • Using prophylactic medications as prescribed • No sharing of personal items • Thorough cleaning of equipment
Mononucleosis infection	Light, noncontact activity may be introduced as tolerated 3 weeks after illness onset with avoidance of contact/collision sports until 4 weeks after illness onset
Blood-borne infections (hepatitis B, hepatitis C, HIV)	No restrictions
COVID-19 infection	See Fig. 727.1
Heat illness, history of	Gradual acclimatization to heat over 7-14 days, avoid participation while ill (fever, skin rash, viral symptoms), ensure free access to fluids at all times, consume sodium-containing food/fluids to replace insensible losses, rest periods of at least 3 hours before practice or games
Down syndrome	Individual decision-making based on the presence of congenital heart disease or atlantoaxial instability

Data from Herman D, Gadi N, Peck E. Team medical coverage. In Miller MD, Thompson SR, eds. *DeLee, Drez, & Miller's Sports Medicine*, 5th ed. Philadelphia: Elsevier, 2020.

because the young athlete might not know or might forget important aspects of the history. The questionnaire should include questions about the family history and the patient's previous medical, surgical, cardiac, pulmonary, neurologic, dermatologic, visual, psychologic, musculoskeletal, and endocrinologic problems, as well as about prior heat illness, medications, allergies, immunizations, and diet. The most commonly identified problems are *unrehabilitated injuries*. An investigation of previous injuries, including diagnostic tests, treatment, and present functional status, is indicated.

Sudden death during sports can result from undetected cardiac disease, such as hypertrophic or other **cardiomyopathies** (see Chapter 488), **anomalous coronary vessels** (see Chapter 481.2), or a ruptured aorta in **Marfan syndrome** (see Chapter 743). In many cases, the underlying heart disease is not suspected, and death is the first sign of underlying heart disease (see Chapter 485). However, in approximately 25–50% of cases, preceding symptoms of dizziness, chest pain, syncope, palpitations, shortness of breath, and/or a family history of early, unexpected death are identified retrospectively. Chest radiographs, electrocardiograms, and echocardiograms are not recommended as routine screening tests in the United States, but screening electrocardiograms are recommended in a number of other countries and are becoming more commonly used among higher risk groups in the United States, such as collegiate and professional athletes. If there is a suspicion of heart disease, such as a history of syncope, presyncope, palpitations, or excessive dyspnea with exercise, or a family history of a condition such as hypertrophic cardiomyopathy or prolonged QT or Marfan syndrome, the evaluation should be complete and include a 12-lead electrocardiogram, an echocardiogram, Holter or event-capture monitoring, and a stress test with electrocardiographic monitoring. Recommendations for participation with identified cardiac disease should be made in consultation with a cardiologist.

Sports may also be classified by intensity (Fig. 727.2) and contact (Table 727.4). Athletes may seek to participate in sports against medical advice and have done so successfully for professional sports. Section 504(a) of the Rehabilitation Act of 1973 prohibits discrimination against disabled athletes if they have the capabilities or skills required to play a competitive sport. This was reinforced through the Americans with Disabilities Act of

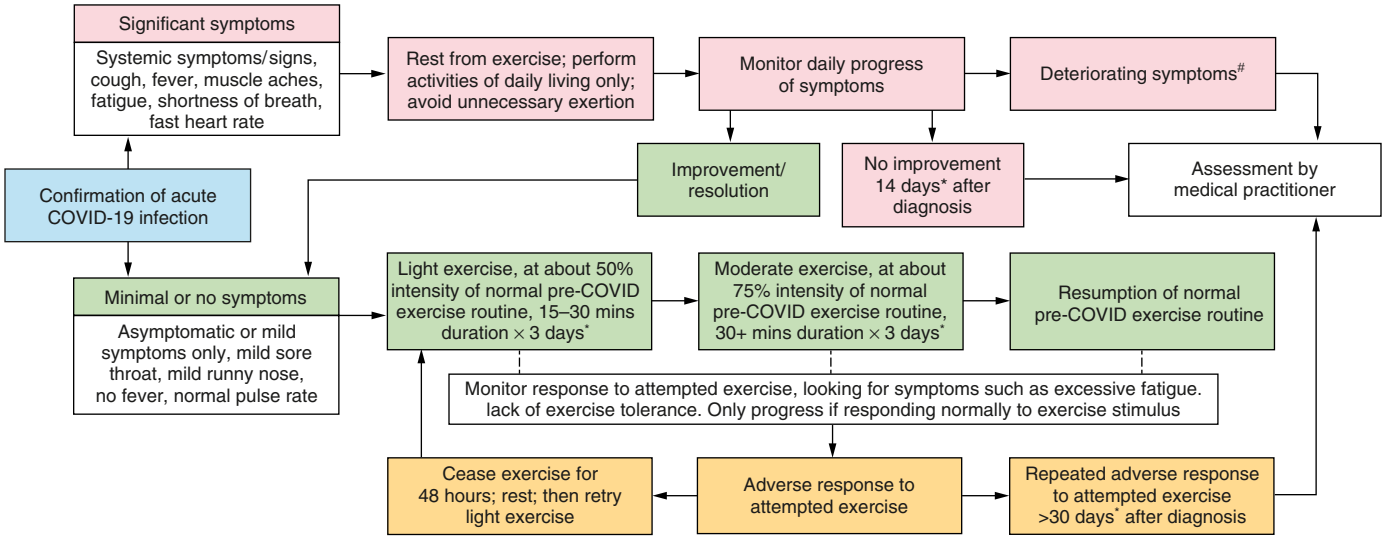

- Dry, post-viral cough may persist beyond the acute COVID-19 infection
- Individuals should be 10 days post diagnosis or onset of symptoms (or have negative RAT on days 6 & 7), before rejoining group / team activities
- *Number of days at each step may be modified in high performance sport, where athletes have the benefit of close medical supervision
- Those with medical comorbidities should adopt a more cautious approach to return to exercise
- # **Cardiac symptoms should be treated as a medical emergency: Pressure, tightness, squeezing pain in chest, arms, neck, jaw, or back, cold sweat, difficulty breathing, collapse, sudden dizziness**

Fig. 727.1 Graduated return to exercise after COVID-19 infection. RAT, rapid home antigen test. *(From Hughes DC, Orchard JW, Partridge EM, et al. Return to exercise post-COVID-19 infection: a pragmatic approach in mid-2022. J Sci Med Sport. 2022;25:544–547. Fig. 1.)*

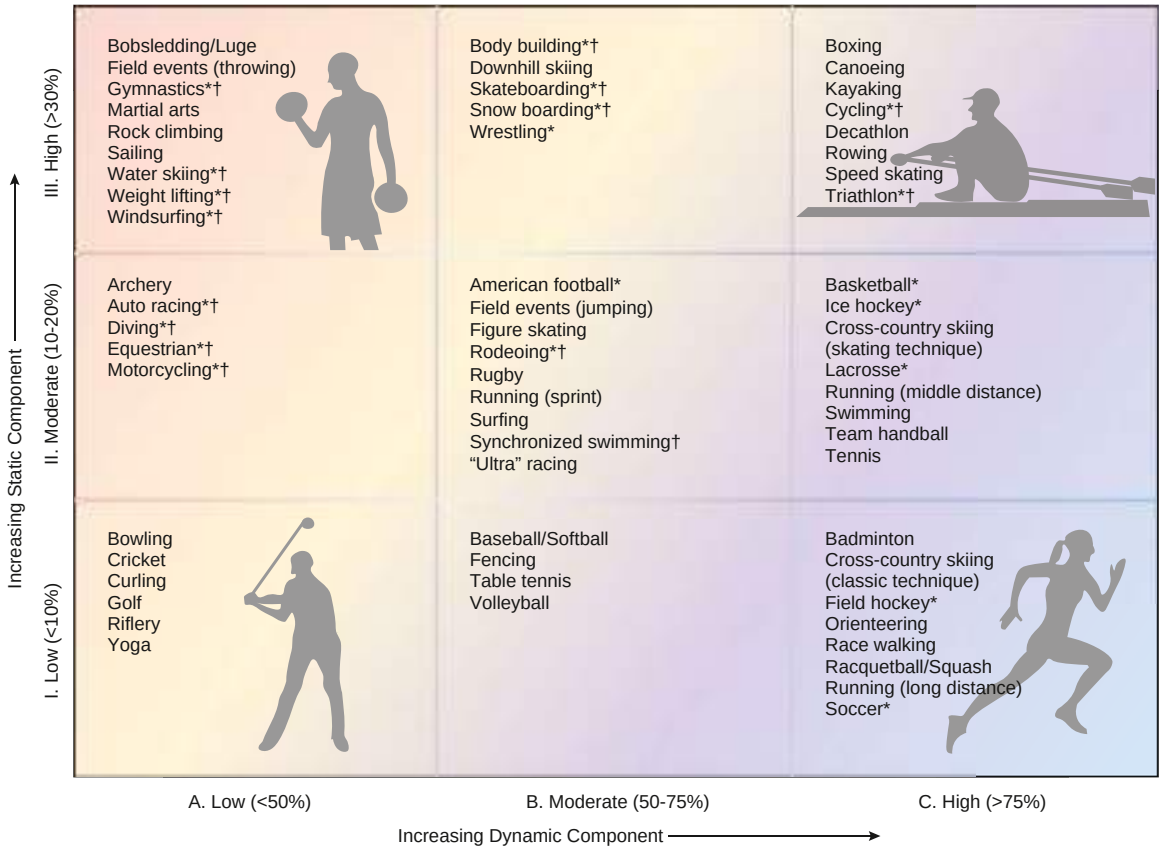

Fig. 727.2 Classification of sports. This classification is based on peak static and dynamic components achieved during competition; however, higher values may be reached during training. The increasing dynamic component is defined in terms of the estimated percentage of maximal oxygen uptake ($\dot{V}O_{2max}$) achieved and results in an increasing cardiac output. The increasing static component is related to the estimated percentage of maximal voluntary contraction reached and results in an increasing blood pressure load. The lowest total cardiovascular demands (cardiac output and blood pressure) are shown in the palest color, with increasing dynamic load depicted by increasing blue intensity and increasing static load by increasing red intensity. Note the graded transition between categories, which should be individualized on the basis of player position and style of play. *Danger of bodily collision (see Table 727.4 for more detail on collision risk). †Increased risk if syncope occurs. *(Modified from Mitchell JH, Haskell W, Snell P, et al. 36th Bethesda conference. Task force 8: classification of sports. J Am Coll Cardiol. 2005;45:1364–1367.)*

Table 727.4 Sports According to Risk of Impact and Educational Background

	JUNIOR HIGH SCHOOL	HIGH SCHOOL/COLLEGE
Impact expected	American football Ice hockey Lacrosse Wrestling Karate/judo Fencing Boxing	American football Soccer Ice hockey Lacrosse Basketball Wrestling Karate/judo Downhill skiing Squash Fencing Boxing
Impact may occur	Soccer Basketball Field hockey Downhill skiing Equestrian Squash Cycling	Field hockey Equestrian Cycling Baseball/softball Gymnastics Figure skating
Impact not expected	Baseball/softball Cricket Golf Riflery Gymnastics Volleyball Swimming Track and field Tennis Figure skating Cross-country skiing Rowing Sailing Archery Weightlifting Badminton	Cricket Golf Riflery Volleyball Swimming Track and field Tennis Cross-country skiing Rowing Sailing Archery Weightlifting Badminton

From Levine BD, Baggish AL, Kovacs RJ, et al. Eligibility and disqualification recommendations for competitive athletes with cardiovascular abnormalities: Task force 1: classification of sports: dynamic, static, and impact: a scientific statement from the American Heart Association and American College of Cardiology. *J Am Coll Cardiol.* 2015;66(21):2350–2355.

1990. Participation in competitive sports is considered a privilege, not a right. *Knapp v Northwestern University* established that "difficult medical decisions involving complex medical problems can be made by responsible physicians exercising prudent judgment (which will be necessarily conservative when definitive scientific evidence is lacking or conflicting) and relying on the recommendations of specialist consultants or guidelines established by a panel of experts."

Visit Elsevier eBooks+ at eBooks.Health.Elsevier.com for Bibliography.

Chapter 728

Management of Musculoskeletal Injury

Gregory L. Landry and Andrew M. Watson

MECHANISM OF INJURY

Acute Injuries

Sprains, strains, and contusions account for the majority of musculoskeletal injuries. A **sprain** is an injury to a ligament or joint capsule. Most sprains are graded I-III. A *grade I* sprain is defined as mild damage to a ligament or ligaments without instability of the affected joint. A *grade II* sprain is considered a partial tear to the ligament, such that it exhibits excessive laxity but has a firm endpoint on examination. A *grade III* sprain is a complete tear of the ligament with instability to the affected joint and without a firm endpoint on examination. A **strain** is an injury to a muscle or tendon, and these are also graded I-III. *Grade I* muscle strains involve disruption of only a few muscle fibers, pain is mild to moderate, and range of motion and strength are at or near normal. *Grade II* strains represent a more significant, partial tear of the muscle and frequently involve loss of range of motion and strength. *Grade III* strains are defined as complete rupture of the musculotendinous unit. On examination, *grade III* strains, and often *grade II* strains, present with ecchymosis and a palpable step-off at the site of injury. A **contusion** is a crush injury to any soft tissue. The history of the injury is especially helpful in assessing musculoskeletal trauma. More severe injuries, including fractures or internal derangement of a joint, may have acute signs and symptoms such as immediate swelling, deformity, numbness or "give-way" weakness, a loud painful pop, mechanical locking of the joint, or instability.

Overuse Injuries

Overuse injuries are caused by repetitive microtrauma that exceeds the body's rate of repair. This can occur in muscles, tendons, bone, bursae, cartilage, and nerves. Overuse injuries can occur in all sports but are more commonly seen in sports emphasizing repetitive motion such as swimming, running, tennis, baseball pitching, and gymnastics. Factors leading to overuse injuries can be categorized as extrinsic (i.e., training errors, poor equipment, or workout surface) and intrinsic (i.e., athlete's anatomy or medical conditions). Training error is the most commonly identified factor. For example, at the beginning of the training program, athletes might violate the "10% rule" by increasing the duration or intensity of workouts by more than 10% per week. This may exceed the body's capacity to recover between bouts of activity, leading to accumulated microtrauma that manifests as an overuse injury. Intrinsic factors include abnormal biomechanics that may be due to underlying anatomic causes (e.g., leg-length discrepancy, pes planus, pes cavus, tarsal coalition, valgus heel, external tibial torsion, and femoral anteversion), muscle imbalance, inflexibility, and medical conditions (deconditioning, nutritional deficits, amenorrhea, and obesity). To identify the cause of an overuse injury, the athlete should be questioned about the specifics of their training. Specifically, runners, for example, should be asked about their shoes, orthotics, running surface, weekly mileage or time spent running per week, speed or hill workouts, and previous injuries and rehabilitation. When causative factors are identified, they can be modified or eliminated so that after rehabilitation the athlete does not suffer a recurrent overuse injury.

For athletes engaged in excessive training that causes an overuse injury, curtailing all exercise may not be necessary. Treatment incorporates a reduction of training load (relative rest) combined with a rehabilitation program designed to return athletes to their sport as soon as possible while minimizing risk of re-injury. Early identification of an overuse injury requires less alteration of the workout regimen. In addition, proper sleep, nutrition, and stress management can optimize recovery between bouts of activity, promoting physiologic adaptation and reducing the risk of accumulated damage that leads to injury.

It has become more commonplace for young athletes to *specialize* in a single sport and engage in year-round training. Families should be advised about the risks of specialization in young athletes because this is associated with burnout, decreased motivation and enjoyment, and increased risk of overuse injuries. This is especially evident among baseball pitchers, in whom repeated exposure to the highly repetitive and forceful throwing motion can damage the tissues in the elbow and shoulder in a growing athlete. These athletes and their parents should be counseled to diversify their sport participation at younger ages, which may increase their enjoyment and performance in sport, as well as reduce the risk of overuse injury.

The goals of treatment in overuse injuries are to control pain and spasm to rehabilitate flexibility, strength, endurance, and proprioceptive deficits (Table 728.1). In many overuse injuries, the role of inflammation in the process is minimal. For most injuries to tendons, the term

Table 728.1 Staging of Overuse Injuries

GRADE	GRADING SYMPTOMS	TREATMENT
I	Pain only after activity Does not interfere with performance or intensity Generalized tenderness Disappears before next session	Modification of activity, consider cross-training, home rehabilitation program
II	Minimal pain with activity Does not interfere with performance More localized tenderness Disappears before next session	Modification of activity, cross-training, home rehabilitation program
III	Pain interferes with activity and performance Definite area of tenderness Usually disappears between sessions	Significant modification of activity, strongly encourage cross-training, home rehabilitation program, and outpatient physical therapy
IV	Pain with activities of daily living Pain does not disappear between sessions Marked interference with performance and training intensity	Discontinue activity temporarily, cross-training only, oral analgesic, home rehabilitation program, and intensive outpatient physical therapy
V	Pain interferes with activities of daily living Signs of tissue injury (e.g., edema) Chronic or recurrent symptoms	Prolonged discontinuation of activity, cross-training only, oral analgesic, home rehabilitation program, and intensive outpatient physical therapy

tendinitis is no longer used because there is little or no inflammation on histopathology of the affected tendons. Rather, there is evidence of microscopic trauma to the tissue and a disorientation of the tendon fibers. Most of these entities are more appropriately called **tendinosis**; when the tendon tissue is scarred and when markedly abnormal, **tendinopathy**. With tendinosis, there is less of a role for antiinflammatory medication in the treatment, except as an analgesic.

Novel treatments are emerging for the effective treatment of chronic tendinopathies. Under ultrasound guidance, pathologic areas of tendon tissue can be targeted with injections of autologous blood or platelet-rich plasma to stimulate a proinflammatory and more robust healing response. Platelet-rich plasma is a controversial therapy with a mixed body of evidence related to its effectiveness for certain acute and chronic tendinopathies; there is a lack of consensus regarding its role in the standard of care. Pathologic tissue can also be targeted with percutaneous needle fenestration or tenotomy, and tendon-fat pad adhesions can also be addressed through mechanical needle scraping or hydrodissection techniques using ultrasound.

INITIAL EVALUATION OF THE INJURED EXTREMITY

Initially, the examiner should determine the quality of the peripheral pulses and capillary refill rate, as well as the gross motor and sensory function to assess for neurovascular injury. The first priorities are to maintain vascular integrity and skeletal stability.

Criteria for immediate attention and rapid orthopedic consultation include vascular compromise, nerve compromise, and open fracture. With the latter, the exposed wound should be covered with sterile saline-soaked gauze, the injured limb should be padded and splinted, and systemic antibiotics should be administered. Pressure should be applied to any site of excessive bleeding. Additional criteria include deep laceration over a joint, unreducible dislocation, grade III (complete) tear of a muscle-tendon unit, and displaced, significantly angulated fractures.

TRANSITION FROM IMMEDIATE MANAGEMENT TO RETURN TO PLAY

Rehabilitation of a musculoskeletal injury should be initiated on the day of the injury.

Phase 1

Limit further injury, control swelling and pain, and minimize strength and flexibility losses. **PRICE** principles (**P**rotection, **R**est, **I**ce, **C**ompression, and **E**levation) need to be applied. Crutches, air stirrups for ankle sprains, slings for arm injuries, and elastic wraps (4-8 inches) for compression are a helpful inventory of medical supplies. Ice can be placed directly over the injury as tolerated for 20 minutes continuously 3 or 4 times per day until the swelling resolves. Compression limits further bleeding and swelling but should not be so tight that it limits perfusion. Elevation of the extremity promotes venous return and limits swelling. A nonsteroidal antiinflammatory drug (NSAID) or acetaminophen are indicated for analgesia.

Pain-free isometric strengthening and range of motion exercises should be initiated as soon as tolerable. Pain inhibits full muscle contraction; deconditioning results if the pain and resultant disuse persist for days to weeks, thus delaying recovery. Education about the nature of the injury and the specifics of rehabilitation exercises, including handouts with written instructions and drawings demonstrating the exercises, are helpful.

Phase 2

Improve strength and range of motion (e.g., flexibility) while allowing the injured structures to heal. Protective devices are removed when the patient's strength and flexibility improve and activities of daily living are pain-free. Flexibility can then be addressed by a program of specific stretches, held for 15-30 seconds for three to five repetitions, once or twice daily. A physical therapist or athletic trainer is invaluable in guiding the athlete through this process. Protective devices might need to be used upon return to sports participation. Swimming, water jogging, and stationary cycling are good, low-impact aerobic exercises that can allow the injured lower extremity to be used pain-free while maintaining cardiovascular fitness.

Phase 3

Achieve near-normal strength and flexibility of the injured structures and further improve or maintain cardiovascular fitness. Strength and endurance are improved under controlled conditions using elastic bands and closed kinetic chain exercises (movement of multiple joints and limb segments with foot fixed to a static surface, such as the floor or wall) at this point and then progressing next to using exercise equipment followed by free weights. Additional sensory proprioceptive training allows the athlete to redevelop the kinesthetic sense critical to joint function and stability during activity.

Phase 4

Return to exercise or competition without restriction. When the athlete has reached normal range of motion, strength, proprioception, and endurance, the athlete can initiate sports-specific exercises. The athlete will transition from the rehabilitation program to functional rehabilitation appropriate for the sport. Substituting sports participation for rehabilitation is inappropriate; rather, there should be progressive stepwise

functional return to a full activity or play program. For instance, a basketball player recovering from an ankle injury might begin a walk-run-sprint-cut program before returning to competition. At any point in this progression, if pain is experienced, the athlete needs to stop, apply ice, avoid running for 1-2 days, continue to perform ankle stabilizing exercises, and then resume running at a lower intensity and progress accordingly.

Relative Rest and Return-to-Play Guidelines

Relative rest refers to the concept that the athlete participates in rehabilitation and return to sport activities provided the injured structures do not hurt during or within 24 hours of the activity. Exercising beyond the pain threshold delays recovery.

IMAGING

Traditional imaging modalities such as x-ray, ultrasound, MRI, and CT are well-established in the routine diagnostic workup of musculoskeletal injury. An obvious advantage of ultrasound is a lack of radiation. It is also better tolerated by younger children who may have difficulty complying with MRI or CT protocols. Dynamic movement or stressing of a limb, joint, or structure can provide valuable diagnostic information and can easily be compared to the contralateral side for comparison. Snapping or popping sensations, suspected intramuscular hematomas, stress fractures, and prognostic scrutiny of strains, sprains, and tendinopathies are all high-yield applications of diagnostic musculoskeletal sonography. Ultrasound imaging can also increase the accuracy of therapeutic injections, improving injection efficacy while simultaneously reducing adverse outcomes by erroneous needle placement.

DIFFERENTIAL DIAGNOSES OF MUSCULOSKELETAL PAIN

Traumatic, rheumatologic, infectious, hematologic, psychologic, congenital, and oncologic processes—especially under the age of 12 years old —can result in a presenting complaint of musculoskeletal pain. Symptoms such as fatigue, weight loss, rash, multiple joint complaints, fever, chronic or recent illness, pain out of proportion to the nature of the injury, and persistent pain despite conservative care suggest a diagnosis other than sports-related trauma. The possibility of child abuse, including sexual abuse, should not be overlooked. Incongruity between the patient's history and physical examination findings should lead to further evaluation. A negative review of systems with an injury history consistent with the physical findings suggests a sports-related etiology.

Visit Elsevier eBooks+ at eBooks.Health.Elsevier.com for Bibliography.

728.1 Growth Plate Injuries

Gregory L. Landry and Andrew M. Watson

Approximately 20% of pediatric sports injuries seen in the emergency department are fractures, and 25% of those fractures involve an epiphyseal growth plate or physis (see Chapter 724). Growth in long bones occurs in three areas and is susceptible to injury. Immature bone can be acutely injured at the physis (e.g., Salter-Harris fractures, see Chapter 724.2), the articular surface (e.g., osteochondritis dissecans [OCD]), or the apophysis (e.g., avulsion fractures). Males suffer nearly twice as many physeal fractures as females, with the highest incidence of fracture occurring during peak height velocity (females: age 12 ± 2.5 years; males: age 14 ± 2 years). The physis is a pressure growth plate and is responsible for longitudinal growth in bone. The apophysis is a bony outgrowth at the attachment of a tendon and is a traction physis. The epiphysis is the end of a long bone, distal or proximal to the long bone, and contains articular cartilage at the joint.

Physeal injuries of the upper extremity are most commonly seen at the distal radius in the growing child or adolescent and are typically due to excessive force applied to the upper extremity. Injuries of this nature can be seen in athletes, including those participating in gymnastics, cheerleading, ice skating, hockey, and weightlifting. Mechanisms of injury include falls onto an outstretched hand or repetitive dorsiflexion and axial loading through the distal radius (see Chapter 734). Chronic wrist pain can be seen in up to 79% of young gymnasts—particularly female gymnasts between the ages of 12-14 years—and is commonly termed **gymnasts' wrist** (see Chapter 722). With repetitive axial loading, temporary metaphyseal ischemia may be induced, preventing cartilage calcification and causing the physis to widen. With widening of the distal radial physis, microfractures can develop. Clinical features include radial wrist pain (particularly dorsal) that is aggravated with passive and active hyperextension activities and relieved with suspension of the offending activity. Tenderness or focal pain around the circumference of the distal radius is often noted. Differential diagnosis includes metacarpal fractures, scaphoid fracture and, in the older child or adolescent, de Quervain tenosynovitis. Juvenile idiopathic arthritis, malignancy, and infection need to be considered in a child with a painful, swollen wrist without a history of trauma. X-rays of the wrist can be helpful, particularly when compared to the contralateral extremity. Radiographs can show physeal widening with cystic changes involving the metaphyseal segment, breaking of the distal epiphysis, and, in later stages, positive ulnar variance (longer ulna compared to the radius). MRI is often helpful for stress fractures when radiographs are inconclusive and will show signs of stress reaction (bone marrow edema, periosteal reaction, etc.), even if a fracture line is not evident. PRICE principles are followed with nonnarcotic pain management. Salter-Harris fractures types I and II can be treated with closed reduction and immobilization. Ulnar-shortening osteotomy may be necessary in the athlete with significant ulnar positive variance. Physeal injuries at the knee (distal femur, proximal tibia) are rare, whereas those at the ankle (distal fibula most commonly) are more frequent—typically occurring as a result of an inversion injury—and predominantly consist of Salter-Harris I fractures.

Growth disturbance following a growth plate injury is a function of location of the physeal fracture. This influences the probability that a physeal bar will form, resulting in growth arrest. In the upper extremity, the areas making the largest contribution to longitudinal growth are the proximal humerus and distal radius and ulna; in the lower extremities, the distal femur and the proximal tibia and fibula are the greatest contributors to longitudinal growth. Injuries to these areas are more likely to cause growth disturbance compared with physeal injuries at the other end of these long bones. The type of physis fracture relative to the risk of growth disturbance is described by the Salter-Harris classification system (see Table 724.1). A grade I injury is least likely to result in growth disturbance, and grade V is the most likely fracture to result in growth disturbance.

Osteochondritis dissecans (OCD) affects the subchondral bone and overlying articular surface (see Chapter 718.3). With avascular necrosis of subchondral bone, the articular surface can flatten, soften, or break off in fragments. The etiology may be related to repetitive stress injury in some patients. OCD most commonly presents in the lower extremities at the knee, affecting the lateral aspect of the medial femoral condyle in 70% of patients, the lateral femoral condyle in 20%, and the patella in 10%. In the upper extremities, it is most frequently seen at the elbow (Fig. 728.1)—affecting the capitellum—and is often associated with repetitive overhead throwing or swinging activities (e.g., baseball). Other sites where OCD lesions are seen are the ankle (talus) and radial head. OCD classically affects athletes in their second decade. The most common presentation is poorly localized, vague joint pain. There is rarely a history of recent acute trauma. Some OCD lesions are asymptomatic and incidental—diagnosed on "routine" radiographs—whereas others manifest as joint effusion, pain, decreased range of motion, and mechanical symptoms (e.g., locking, popping, or catching). Activity usually worsens the pain.

Physical examination might show no specific findings. Sometimes tenderness over the involved condyle can be elicited by deep palpation. Diagnosis is usually made with plain radiographs. Treatment of OCD includes both nonoperative and surgical management (Chapter 718.3). Long-term sequelae can be seen in up to 25% with atypical lesions, older age, effusion, and lesions of large size.

Fig. 728.1 Osteochondritis dissecans in the elbow. *(Copyright Laurel Sauer, 2017.)*

Fig. 728.2 Anterior inferior iliac spine avulsion. *(Copyright Laurel Sauer, 2017.)*

Fig. 728.3 Calcaneal apophysitis (Sever disease). *(Copyright Laurel Sauer, 2017.)*

Avulsion fractures occur when a forceful muscle contraction dislodges the apophysis from the bone. They occur most commonly around the hip (Fig. 728.2) and are typically treated nonsurgically if no significant displacement of the avulsed fragment is present. Acute fractures to other apophyses (i.e., knee and elbow) require urgent orthopedic consultation. Chronically increased traction at the muscle-apophysis attachment can lead to repetitive microtrauma and pain at the apophysis. The most common areas affected are the knee (**Osgood-Schlatter** and **Sinding-Larsen-Johansson disease**), the ankle **(Sever disease)** (Fig. 728.3), the proximal fifth metatarsal **(Iselin disease)**, and the medial epicondyle **(Little Leaguer's elbow)**. Traction apophysitis of the knee and ankle can often be treated in a primary care setting. The main goal of treatment is to minimize the intensity and incidence of pain and disability. Exercises that increase the strength, flexibility, and endurance of the muscles attached at the apophysis, using the relative rest principle, are appropriate. The use of a patellar strap can provide benefit in reducing the traction force placed upon the tibial apophysis during activity. Symptoms can last for 12-24 months if untreated. As growth slows, symptoms abate.

Visit Elsevier eBooks+ at eBooks.Health.Elsevier.com for Bibliography.

728.2 Shoulder Injuries

Gregory L. Landry and Andrew M. Watson

Shoulder pain associated with radiating symptoms down the arm should raise the possibility of a neck injury (see Chapter 730). Neck pain and tenderness or limitation of cervical range of motion requires cervical spine immobilization and transfer of the athlete for further evaluation. If there is no neck pain, tenderness, or limitation of motion of the cervical spine, the shoulder is likely the site of the primary injury.

CLAVICLE FRACTURES

Clavicle fracture is one of the most common shoulder injuries (see Chapter 724.3). Injury is usually sustained by a fall on the lateral side of an adducted shoulder, on an outstretched hand, or by direct blow. Approximately 80% of fractures occur in the middle third of the clavicle. With younger children, plastic bowing of the clavicle may be present instead of an overt fracture but should be treated in the same fashion. Treatment is conservative and includes the use of an arm sling or figure-of-8 brace for comfort and protection. An arm sling is preferred because it is generally more comfortable and easier to apply with similar clinical outcomes. Healing time is shorter in comparison to that in adults—generally 3-6 weeks. An additional 2- to 3-week period of protection from contact/collision activities is recommended after clinical and radiographic healing is achieved to prevent re-injury. If nondisplaced, most medial and lateral clavicular fractures can be managed similar to middle-third clavicular fractures. Displaced lateral and medial third fractures require orthopedic consultation because of a higher incidence of acromioclavicular (AC) osteoarthritis (lateral), and physeal involvement (medial). **Distal clavicular osteolysis** is likely an overuse injury associated with slow dissolution and resorption of

bone. The cause of injury is unclear, appearing most consistent with a stress reaction or fracture at the site of considerable force. This lesion is commonly seen in weightlifting athletes and can be seen in older children. Nonoperative treatment, including activity limitations, ice, NSAIDs, and cortisone injections, can be helpful. For weightlifters, narrowing their hand spacing on the barbell and slowing descent phase of the bench press to end 4-6 cm above the chest are recommended activity modifications. For those not willing to modify weightlifting activity or those with persistent symptoms despite conservative care, surgery can be very successful and involves removal of the distal clavicle (approximately 1 cm) with no loss of strength and full return to activity anticipated.

ACROMIOCLAVICULAR JOINT SEPARATION

An AC joint separation most commonly occurs when an athlete sustains a direct blow to the acromion with the humerus in an adducted position, forcing the acromion inferiorly and medially. Force is directed toward the AC joint and coracoclavicular ligaments because of the inherent stability of the sternoclavicular joint. Patients have point tenderness at the AC joint, pain with lifting their arms above the level of their shoulder, and possibly an apparent step-off between the distal clavicle and the acromion (Fig. 728.4).

Type I AC joint injuries involve isolated sprain of the AC ligament with the periosteal sleeve intact (Fig. 728.5). There is no visible deformity, and the radiographs are normal. Pain is elicited with adduction of the humerus across the chest and palpation of the AC joint. **Type II** injuries involve disruption of the AC and coracoclavicular ligaments, as well as partial disruption of the periosteal sleeve. Radiographs may show slight widening of the AC joint, though the distance between the clavicle and the coracoid process is unchanged in comparison to the uninjured shoulder. Treatment of type I and type II AC injuries is conservative and consists of ice, NSAIDs, and a sling for immobilization. Shoulder range of motion exercises and strengthening of the rotator cuff, deltoid, and trapezius musculature are incorporated early in the rehabilitative course once pain-free range of motion is achieved in order to prevent residual joint stiffness. A short course of physical therapy may be helpful if range of motion limitations are present 2-4 weeks out from injury. Consideration for return to play is made when the patient no longer has focal AC joint tenderness, exhibits full, painless range of motion, has strength sufficient to be functionally protected from a collision or fall, and can perform maneuvers required within their sport. Typically, return to play from a type I AC injury is 1-2 weeks, and 2-4 weeks for type II.

Fig. 728.4 Palpitation of acromioclavicular joint. *(From Anderson SJ. Sports injuries. Curr Probl Pediatr Adolesc Health. 2005;35:105–176.)*

Type III AC joint injury is more severe, involving further tearing of the AC and coracoclavicular ligaments and disruption of the periosteal sleeve with instability of the distal clavicle because of deltotrapezial fascial detachment. Radiographs will commonly show superior displacement of the distal clavicle from the coracoid of 25–100%. The treatment of type III AC injuries is controversial. Many can be treated nonoperatively—similar to that described for types I and II AC injuries—if there is no damage to the overlying skin or neurovascular compromise to the injured limb. The patient should be counseled that this injury is likely to result in a noticeable defect to ascertain whether this is acceptable. Surgery for type III AC injuries is uncommon and primarily for athletes involved with throwing sports or for cosmesis. **Types IV**, **V**, **and VI** AC joint injuries have progressive worsening of ligamentous and fascial disruption with varied locations of the clavicular displacement. These injuries should be referred to an orthopedist for consultation and operative repair.

ANTERIOR GLENOHUMERAL DISLOCATION

The most common mechanism of injury causing an anterior glenohumeral dislocation is contact with the shoulder abducted to 90 degrees and forcefully externally rotated. Patients complain of severe pain and that their shoulder "popped out of place" or "shifted." Patients with an unreduced anterior dislocation have a hollow region inferior to the acromion and a bulge in the anterior portion of the shoulder caused by anterior displacement of the humeral head. Abnormal sensation of the lateral deltoid region and the extensor surface of the proximal forearm should be assessed to evaluate for concomitant injury to the radial or musculocutaneous nerves, respectively.

Reduction of a dislocated shoulder should be made expediently, assuming that there is no crepitus to suggest a fracture. Numerous safe methods for closed reduction have been described, including the traction–counter traction technique, the **Stimson maneuver**, and the abduction maneuver. Postreduction radiographs are helpful and may show evidence of a posterior lateral humeral head impaction fracture **(Hill-Sachs lesion)**. Injuries to the surrounding soft tissues, including the anterior capsule and labrum, are best evaluated by MRI—often with an accompanying arthrogram of the glenohumeral joint. Once reduced, initial treatment of a dislocation includes placing the patient into an arm sling for comfort and protection. The duration of immobilization is controversial and may last from a few days to 6 weeks. The most significant risk after an acute traumatic dislocation is recurrence. Most sports medicine practitioners encourage early range of motion and strengthening exercises as tolerated. Rehabilitation focuses on progressive strengthening of the rotator cuff, deltoid, and periscapular muscles at increasing degrees of abduction and external rotation. Strengthening of the rotator cuff muscles is extremely important because they are the dynamic stabilizers of the glenohumeral joint and are integral to the prevention of future dislocation. Plyometric exercises also may be incorporated near the end of rehabilitation to improve proprioceptive function in preparation for return to athletics. Patients can return to play when strength, range of motion, and proprioception are equal to the uninjured shoulder to the extent that they are able to protect the shoulder and perform sports-specific activities without pain. Surgery is to be considered in cases of recurrent dislocations or in those individuals that fail to heal adequately after prolonged rehabilitation. Additionally, early operative repair should be considered for athletes participating in contact or collision sports that inherently have higher recurrence rates.

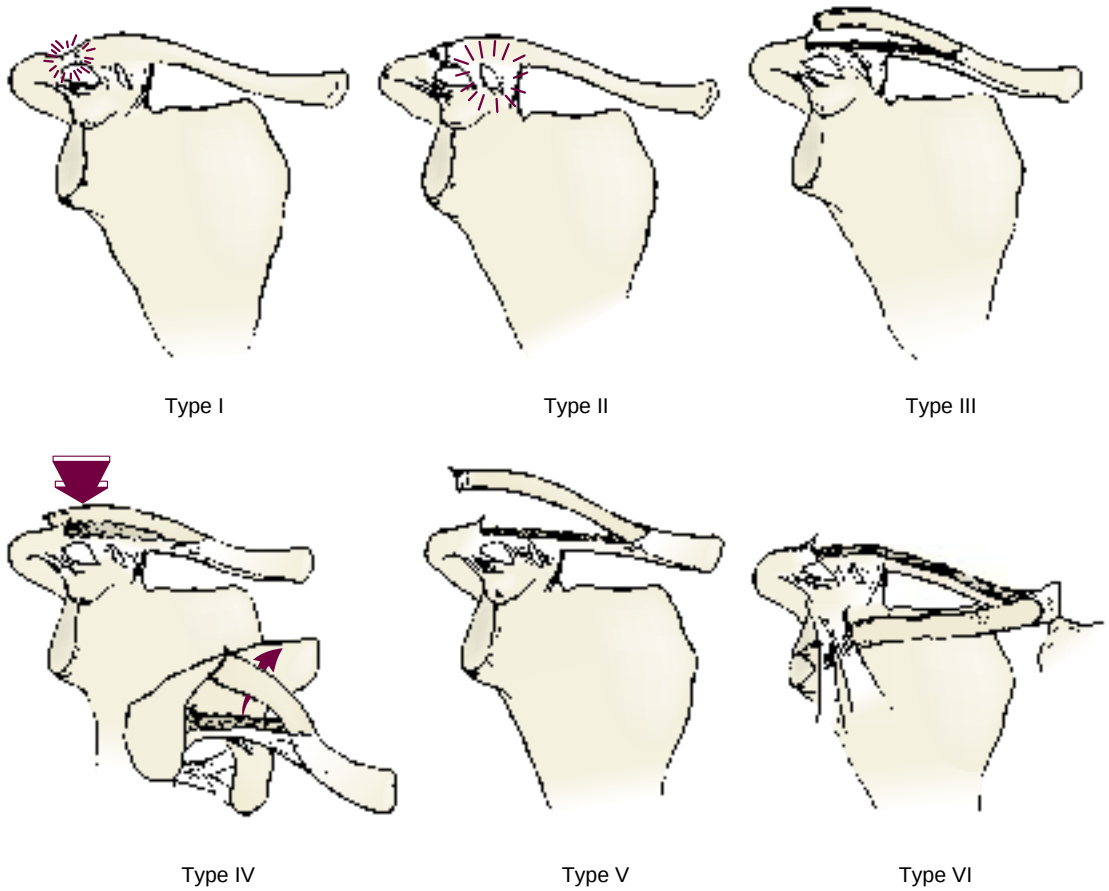

Fig 728.5 Rockwood's classification of acromioclavicular (AC) joint injuries in children. *Type 1*, sprain of the AC ligaments without disruption of the periosteal tube. *Type II*, partial disruption of the periosteal tube. This may produce some AC instability. *Type III*, large split in the periosteal tube allowing superior displacement of the lateral clavicle. *Type IV*, large split in the periosteal tube *(large arrow)* with posterior displacement of the lateral clavicle through the trapezius muscle *(curved arrow)*. *Type V*, complete disruption of the periosteal tube with displacement of the clavicle through the deltoid and trapezius muscles into the subcutaneous tissues. *Type VI*, inferior dislocation of the distal clavicle below the coracoid process. *(Redrawn from Sanders JO, Rockwood CA, Curtis RJ. Fractures and dislocations of the humeral shaft and shoulder. In Rockwood CA, Wilkins KE, Beaty JH, eds. Fractures in Children. Vol 3. Philadelphia, PA: Lippincott-Raven; 1996:974.)*

ROTATOR CUFF INJURY

The muscles of the rotator cuff consist of the supraspinatus, infraspinatus, teres minor, and subscapularis. The function of these muscles is to rotate the humerus and stabilize the humeral head against the glenoid. The supraspinatus is most commonly injured, either by an acute traumatic injury or chronic tendinosis from overuse. Specifically, rotator cuff tendinosis commonly presents with the complaint of pain with overhead arc of motion, such as with throwing, lifting, or reaching for objects above one's head. Pain is often poorly localized about the shoulder, although it may be referred to the deltoid. The onset of pain is often insidious and is commonly associated with increased frequency or duration of overhead throwing or lifting activities. Pain is exacerbated with overhead activities but is often present at rest as well; nighttime pain occurs in more severe cases. On exam, manual muscle testing of the rotator cuff muscles often produces pain and in some cases weakness in comparison to the uninjured shoulder. Supraspinatus tendinosis produces pain with active abduction against resistance in which the patient abducts the arm to 90 degrees, forward flexes to 30 degrees anterior to the parasagittal plane, and internally rotates the humerus.

The treatment of rotator cuff tendinosis includes relative rest from athletics or activities causing pain as well as the use of ice, analgesia, and/or NSAIDs. Strengthening of the rotator cuff and scapular stabilizer musculature, modifications of technique, and core strengthening are important components of rehabilitation often supervised by a physical therapist. In the young athlete, rotator cuff pain is most commonly a result of glenohumeral instability and not rotator cuff impingement syndrome. The latter is more commonly seen in adults and is caused by impingement of the rotator cuff by the bony structures superior to it. As a result, treatment focusing on stretching alone can make symptoms worse. Return to play often includes gradual increases in load placed upon the rotator cuff as the patient resumes prior activities, such as an interval throwing program in baseball.

Glenoid labrum tears may present in similar insidious fashion to rotator cuff tendinosis or may be associated with an acute traumatic dislocation. This frequently manifests with pain in the glenohumeral joint and may be associated with mechanical sensations of clicking or catching in the shoulder. This can frequently be reproduced on exam. One of the most common lesions is a superior labrum anterior and posterior (SLAP) lesion. Throwing athletes are at particular risk. The mechanism of injury is thought to be related to a traction injury along the long head of the biceps at its attachment at the superior glenoid labrum, occurring during the throwing cycle. Radiographs are usually normal. MRI with arthrogram is the best study to identify glenoid labrum pathology (Fig. 728.6).

Proximal humeral stress fracture (epiphysiolysis) is an uncommon cause of proximal shoulder pain and is suspected when shoulder pain does not respond to routine measures. Gradual onset of deep shoulder pain occurs in a young athlete involved in repetitive overhead motion, such as in baseball, tennis, or swimming, but with no history of trauma. Tenderness is noted over the proximal humerus; the diagnosis is confirmed by detecting a widened epiphyseal plate on plain

Fig. 728.6 Coronal intermediate-weighted MRI showing superior labral tear *(arrow)* and tendinosis of the supraspinatus tendon *(arrowhead)*. There is no adjacent perilabral edema, suggesting chronic injury. *(From Chang, I-Yuan J, Polster JM. Pathomechanics and magnetic resonance imaging of the thrower's shoulder. Radiol Clin N Am. 2016;54[5]:801-805. Fig. 13.)*

radiographs, increased uptake on nuclear scan, or edema of the physis on MRI. Treatment is total rest from throwing for at least 6-8 weeks.

Non–sports-related conditions that need to be considered in any child with a painful shoulder include an undiagnosed Sprengel deformity. This deformity involves the scapula, which fails to descend from its cervical region overlying the first through fifth ribs. Children often present with a shortened neckline and a lack of normal scapular thoracic motion. Malpositioning of a glenoid can cause limited forward flexion and abduction of the shoulder. An omovertebral bar is present in up to 50% of cases. This bar connects the superior medial angle of the scapula and the cervical spine and consists of fibrous cartilaginous tissue or bone. Other regional abnormalities can include scoliosis with a prominent scapula on the convex side, congenital rib anomalies, and undiagnosed Klippel-Feil syndrome. Winging of the scapula raises the question of facioscapulohumeral muscular dystrophy. Family histories can be most helpful. Primary bone tumors (see Chapter 550) common to the upper extremities include Ewing sarcoma of the scapula and osteogenic sarcoma of the proximal humerus, in addition to osteoblastomas and chondroblastomas common to the diaphysis and epiphysis of long bones. The most common presenting manifestations of osteosarcoma are pain, upper limb dysfunction, and swelling. Similar presentations can be seen in Ewing sarcoma, along with weight loss and fever. Symptoms not responding to conservative treatment require further investigation and specialty consultation.

Visit Elsevier eBooks+ at eBooks.Health.Elsevier.com for Bibliography.

728.3 Elbow Injuries

Gregory L. Landry and Andrew M. Watson

ACUTE INJURIES

The most commonly dislocated joint in childhood is the elbow. Radial head subluxation, or "nursemaid's elbow," comprises the majority of these (see Chapter 722). Posterior dislocation is the next most common type of **elbow dislocation**, typically resulting from falling backward onto an outstretched arm with the elbow in extension. The dislocation may be complete or incomplete—termed "perched"—with the trochlea subluxed upon the top of the coronoid process. The ulnar collateral ligament (UCL) is commonly disrupted along with other components of the soft tissue capsule about the elbow. Fractures of the olecranon (>80% occurrence) or medial epicondyle may be present as well. An obvious deformity is visualized with the olecranon process displaced prominently behind the distal humerus. Careful examination of the distal radius and ulnar pulses to assess vascular integrity of the distal upper arm is important because of the potential for injury to the brachial artery. Sensation to the distal extremity should also be assessed because of possible injury to the radial, median, and ulnar nerves. Reduction should be performed as soon as possible before significant swelling and muscle spasm potentially complicate the procedure. Longitudinal traction is applied to the forearm with gentle upward pressure on the distal humerus so that the coronoid process clears the trochlea. If reduction is unable to be performed, the arm should be placed in a padded splint and sling and the patient transported to an emergency facility.

Fig. 728.7 Deflection of the supracondylar fat pad with a joint effusion (fat pad sign) *(arrows)* showing evidence of a fracture. *(Copyright Laurel Sauer, 2017.)*

Supracondylar humeral fractures can result from the same mechanism of injury as elbow dislocations and can be difficult to distinguish on exam from a posterior dislocation because of significant swelling about the elbow joint. These, too, can be complicated by concomitant injury to the brachial artery and to a lesser extent the median, radial, and ulnar nerves. The injury typically occurs in the first decade of life, which is associated with peak hyperlaxity of the elbow joint in children between the ages of 5-8 years. An acute compartment syndrome can develop after these fractures, which is associated with a fat pad sign on radiographs (Fig. 728.7). These fractures should be referred for orthopedic consultation and are discussed in more depth in Chapter 724.

Direct trauma to the elbow can cause bleeding and inflammation in the olecranon bursa resulting in **olecranon bursitis**. Aspiration is rarely required, and this injury can be managed with ice, compressive dressing, and analgesia (PRICE principles). An overlying elbow pad provides comfort during activity and prevents re-injury.

Chronic Injuries

Overuse injuries in the upper extremities occur primarily in throwing sports, sports that require repetitive wrist flexion or extension, or sports that demand weight-bearing on hands (gymnastics).

Little Leaguer's elbow is a broad term for several different elbow problems. Throwing overhand creates valgus stress to the elbow with medial opening of the joint and lateral compressive forces. **Medial elbow pain** is a common complaint of young throwers, resulting from repetitive valgus overload of the wrist flexor-pronator muscle groups and their attachment on the medial apophysis. In preadolescents who still have maturing secondary ossification centers, traction apophysitis of the medial epicondyle is likely. Patients have tenderness along the medial epicondyle; pain is exacerbated by valgus stress or resisted wrist flexion and pronation. Wrist pain may be present in more severe cases. Radiographs may show widening of the growth plate at the medial

apophysis in comparison to the uninjured elbow. Treatment includes no throwing for 4-6 weeks and pain-free strengthening and stretching of the flexor-pronator group followed by a 1-2 week progressive functional throwing program with careful rehabilitation. Incorporation of core strengthening and scapular stabilizing exercises, as well as addressing proper throwing mechanics (to reduce the load upon the medial elbow), are important components of the rehabilitation program. Little Leaguer's elbow has to be treated with a period of rest from throwing because of the risk of nonunion of the apophysis and chronic pain. If pain occurs acutely, an avulsion fracture of the medial epicondyle must be considered. Radiographs should be taken in any thrower with acute elbow pain. If the medial epicondyle is avulsed (Fig. 728.8), orthopedic consultation is indicated.

In older adolescents and young adults with a fused apophysis, the structure at the elbow vulnerable to injury is the UCL. UCL sprains/tears are common in sports requiring high-velocity throwing or overhead activities. Medial elbow pain that is worst during the acceleration phase of throwing is common. A loss of throwing velocity and control, as well as a sensation of elbow joint "opening" during throwing is also frequently described. On exam, focal tenderness to palpation over the UCL is present. Additionally, laxity may be appreciated with valgus stress of the elbow when flexed to 30 and/or 90 degrees. Radiographs are generally unremarkable. Diagnostic ultrasonography or MRI with arthrography is often necessary to assess the integrity of the UCL. Partial tears can be treated with a period of time off from throwing (2-4 weeks) followed by careful progressive rehabilitation as discussed earlier for medial elbow pain. If there is a complete tear, surgical repair is indicated if the athlete desires to continue a pitching career.

Fig. 728.8 The many faces of little Leaguer's elbow in a 14-yr-old pitcher. **A,** AP radiograph and coronal oblique fat-saturated T2-weighted MRI demonstrate features of chronic medial epicondyle stress injury *(yellow arrow)* as well as findings of capitellar osteochondritis dissecans *(white arrowhead)*. Proximal medial ulnar collateral ligament edema/grade 1 sprain also noted at the humeral attachment *(red arrow)*. **B,** Sagittal short tau inversion recovery and fat-saturated T1-weighted MR arthrogram images emphasize the classic features of injury to the "metaphyseal equivalent" bone deep to the disorganized and obliterated secondary physis of the ossifying capitellum. *(From Braithwaite KA, Marshall KW. The skeletally immature and newly mature throwing athlete. Radiol Clin N Am. 2016;54[5]:841–855. Fig. 11.)*

Medial epicondylitis, or golfer's elbow**,** is another common cause of medial elbow pain in the individual with fused apophyses. It is commonly caused by overuse of the flexor pronator muscle groups at their origin at the medial humeral epicondyle. This occurs frequently in athletics or activities with repetitive wrist flexion. Tenderness is noted over the medial epicondyle and exacerbated by passive wrist extension or resisted wrist flexion. Treatment includes rest from the inciting activity, ice, stretching and strengthening of the wrist flexors, forearm straps, counterforce bracing, and analgesia. Local injection of corticosteroids can be considered as an adjunctive treatment if initial conservative measures fail. Ulnar nerve dysfunction can be a complication of valgus overload and can occur with any of the diagnoses previously discussed. Persisting paresthesia or motor weakness in the ulnar nerve distribution should be evaluated with electromyography and nerve conduction studies. Diagnostic ultrasonography can also be of use to assess for focal thickening of the nerve, as a sign of irritation, as well as dynamically visualizing the nerve through the arc of elbow flexion to assess for subluxation over the medial epicondyle (Fig. 728.9).

Lateral elbow pain can be caused by compression during the throwing motion at the radiocapitellar joint. **Panner disease** is osteochondrosis of the capitellum that occurs between ages 7 and 12 years (Fig. 728.10). **OCD** of the capitellum occurs at age 13-16 years (see Fig. 728.1). Although patients with both conditions present with insidious onset of lateral elbow pain exacerbated by throwing, patients with OCD have mechanical symptoms (popping, locking) and, more commonly, decreased range of motion. Patients with Panner disease have no mechanical symptoms and often have normal range of motion. The prognosis of Panner disease is excellent, and treatment consists of relative rest (no throwing), brief immobilization, and repeat radiographs in 6-12 weeks to assess bone remodeling. In OCD, radiographs show a more focal lesion in the capitellum with eventual flattening and potentially fragmentation. MRI can be very helpful in early diagnosis and with subsequent staging. A diagnosis of OCD requires orthopedic consultation, with treatment depending on the severity of the lesion and fragmentation.

Lateral epicondylitis, or "tennis elbow," is the most common overuse elbow injury in adults but is relatively uncommon in children and adolescents (Fig. 728.11). It is a tendinosis of the extensor muscle origin at the lateral humeral epicondyle, which is commonly found in individuals performing activities requiring repetitive or prolonged grip. Tenderness is localized over the upper lateral epicondyle and is worsened with passive wrist flexion or resisted wrist extension. Treatment includes relative rest, analgesia, and specific stretching and strengthening exercises for the elbow and forearm. As with medial epicondylitis, corticosteroid injection can be considered as an adjunctive treatment if initial conservative measures fail. Improper equipment (i.e., wrong grip size or overstrung racket) and poor technique can contribute to the onset of symptoms. Return to play should be gradual and progressive to prevent re-injury.

Elbow injuries can be minimized but not necessarily prevented by preseason stretching and strengthening exercises. The importance of core strengthening and scapular stabilization with respect to preventing elbow and shoulder injuries in the throwing athlete cannot be overstated. The most important consideration for preventing elbow injuries in throwers is limitation of the number of pitches and advising players, coaches, and athletes that they should stop immediately when they experience elbow pain. If it persists, they need medical evaluation. It has been recommended that a young pitcher have age-specific limits

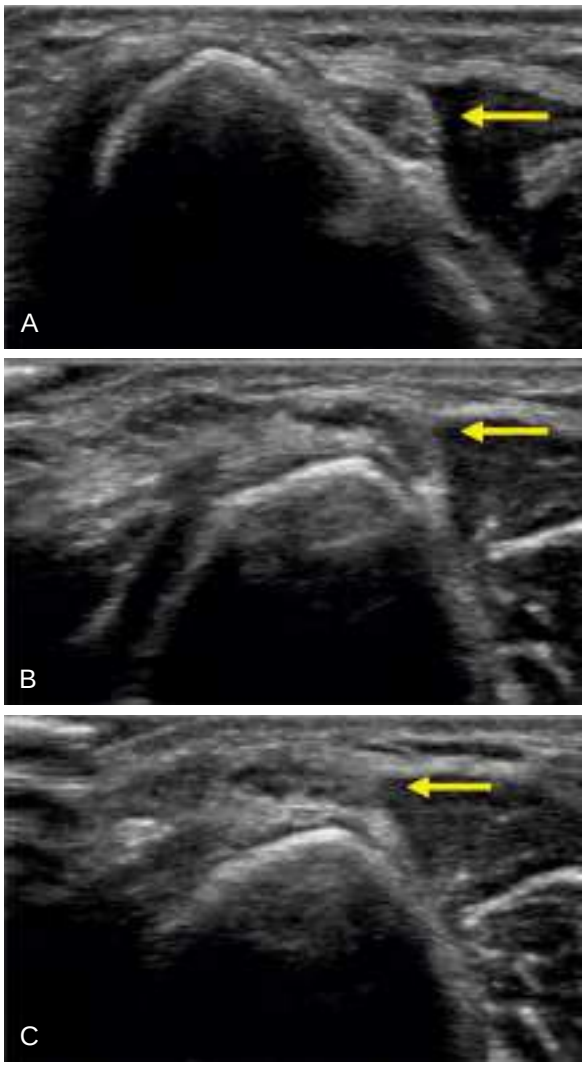

Fig. 728.9 Ulnar nerve subluxation. Dynamic ultrasound imaging of the ulnar nerve (arrow) in the ulnar groove at the elbow. **A,** The ulnar nerve positioned appropriately in the ulnar groove with the elbow extended. With elbow flexion, **(B)** the nerve becomes perched upon the medial epicondyle. As the elbow moves into terminal flexion, **(C)** the nerve is completely dislocated anteriorly over the medial epicondyle. *(Courtesy Nicholas Goyeneche, MD, ultrasound clinic files, Ochsner Clinic Medical Center.)*

on pitch counts, including the number of pitches thrown per game and per week, as well as maintaining appropriate days off between games pitched. A good rule of thumb is that the maximal number of pitches per game should be approximately 6 times the pitcher's age in years.

Other less-common problems that cause elbow pain are ulnar neuropathy/subluxation, tricipital or bicipital tendonitis (distal), olecranon apophysitis, and loose bodies. Non–sports-related injuries that need to be considered in the child with a painful elbow include undiagnosed congenital conditions such as radial dysplasia, including radial ulnar synostosis and mild persistent brachial plexus palsy. The elbow is not an uncommon site for inflammatory arthritides, including juvenile idiopathic arthritis, sepsis, hemophilia, and sickle cell disease. Neoplasia to consider includes osteoblastomas and chondroblastomas, which are common in the diaphysis and epiphysis of longer bones, in addition to osteosarcoma. As always, in the child with persistent symptoms who is not responding to conservative care, further diagnostic workup is indicated.

Visit Elsevier eBooks+ at eBooks.Health.Elsevier.com for Bibliography.

Fig. 728.10 Panner disease. Note fragmentation of the humeral capitellum and flattening of the articular surface *(arrow). (Copyright Laurel Sauer, 2017.)*

728.4 Low Back Injuries

Gregory L. Landry and Andrew M. Watson

SPONDYLOLYSIS, SPONDYLOLISTHESIS, AND FACET SYNDROME

Spondylolysis

Spondylolysis, a common cause of back pain in athletes, is a stress fracture of the pars interarticularis (see Chapter 720.6). It can occur at any vertebral level but is most likely at L5. Complete spondylolysis has never been found in the newborn. Its occurrence increases between the ages of 5.5 and 6.5 years to a rate of 5%. Prevalence in adolescent athletes evaluated for low back pain is 13–47%. Besides hyperextension that causes an acute fracture, the mechanism of injury is either a congenital defect or hypoplastic pars. This is exacerbated by repetitive lumbar extension loading. Ballet, weightlifting, gymnastics, and football are examples of sports in which repetitive extension loading of the lumbar spine frequently occurs.

Patients often present with pain of insidious onset. However, there may be a precipitating injury, such as a fall, or a single episode of hyperextension. The pain is worse with extension, may radiate to the buttocks, and can eventually affect activities of daily living. Rest or supine positioning usually alleviates the pain.

On examination, the pain is reproduced with lumbar extension while standing, especially when standing on one leg (single-leg hyperextension test). Limited forward spinal flexion and tight hamstrings may be seen. Neurologic examination is generally normal. There is often well-localized tenderness to deep palpation just lateral to the involved spinous process.

The diagnosis can be confirmed by finding a pars defect on an oblique lumbar spine radiograph. The defect is rarely seen on anteroposterior

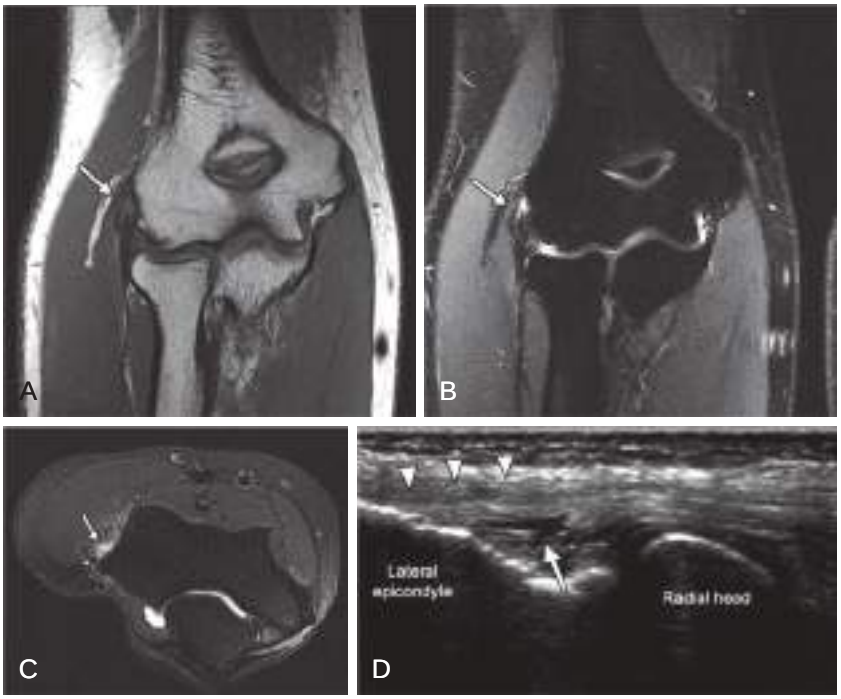

Fig. 728.11 A 22-yr-old tennis player with persistent lateral elbow pain despite 3 months of physical therapy. **A,** Coronal T1 sequence shows thickening and intermediate signal in the common extensor tendon (CET; *arrow*). **B,** Coronal T2 fat suppression (FS) (CET; *arrow*) and **(C)** axial proton density FS sequences reveal fluid signal within the CET and discontinuity of tendon fibers, consistent with a partial-thickness tear (CET; *arrow*). **D,** Corresponding long axis ultrasound image shows an anechoic fluid cleft *(arrow)* in the undersurface of the CET *(arrowheads). (From Gustas CN, Lee KS. Current imaging concepts and image-guided treatments for the injured thrower's elbow. Radiol Clin N Am. 2016;54[5]:817–839. Fig. 2.)*

(AP) and lateral views. MRI or bone single-photon emission CT (SPECT) is needed to confirm diagnosis if radiographs are normal and spondylolysis is suspected. A plain CT scan can help identify the degree of bony involvement and is sometimes used to assess healing.

Treatment includes pain relief and activity restriction. Rehabilitation consisting of trunk strengthening, hip flexor stretching, and hamstring stretching is important in most cases. A thoracic lumbar sacral orthotic may be considered for symptom management in cases in which conservative measures fail, but the overall benefit of bracing on healing is unclear.

Spondylolisthesis and Facet Syndrome

Spondylolysis, spondylolisthesis, and facet syndrome are injuries to the posterior elements of the vertebrae. Spondylolisthesis occurs when bilateral pars defects exist and forward displacement or slippage of a vertebra occurs upon the vertebra inferior to it (see Chapter 720.6). Facet syndrome has history and physical examination findings similar to those of spondylolysis. It is caused by instability or injury to the facet joint, posterior to the pars interarticularis and at the interface of the inferior and superior articulating processes. Facet syndrome can be established by identifying facet abnormalities on CT or by exclusion, if a radiograph and MRI rule out spondylolysis.

Treatment of posterior element injuries is conservative and directed at reducing the extension-loading activity, often for 2-3 months. Body mechanics, posture principals, core strengthening, and lumbar pelvic stabilization routines can be very helpful in the functional recovery of the motivated athlete. Walking, swimming, and cycling can be appropriate exercises during the rehabilitation phase. Rarely, spinal segmental fusion can be indicated in the athlete with spondylolisthesis and persistent symptomatic segmental instability despite conservative care.

LUMBAR DISK HERNIATION, STRAIN, AND CONTUSION

Intervertebral disk injury in children and adolescents is uncommon. Symptoms include pain with prolonged standing and prolonged periods of lumbar flexion, such as sitting in a car. Presentation is variable, and patients may report an acute pain onset with an obvious inciting event or an insidious onset with a history of heavy lifting or repetitive axial load activities. In contrast to the selective motor and sensory deficits often observed in adults with disk herniation, athletes younger than 20 years of age less commonly have pain or tenderness over the course of the sciatic nerve. Physical examination findings may be minimal but usually include pain with forward flexion and lateral bending. It is unusual to have a positive straight leg test or any neurologic deficit in the young athlete with an injured disk. There may be tenderness of the vertebral spinous process at the level of the disk injury. A general aching sensation in the lower back or upper buttocks may be present. MRI usually confirms a clinical diagnosis. Assuming the herniation is not large and the pain is not intractable, treatment is conservative with analgesia and physical therapy. Surgery is rarely necessary.

Acute lumbar strain or contusion can be seen in the younger athlete and is usually associated with precipitating activity often outside of the normal routine. Physical examination reveals tenderness in the paraspinal and lateral soft tissues often associated with recreating the mechanism of injury. Thoracic and lumbar strain in the school-age child is frequently associated with obesity, deconditioning, positive family history, and poorly supervised and equipped recreational activity. Up to 20% of youths have experienced back pain at some point in their life before the age of 15 years. The backpack is the most common cause of back pain of a benign nature in children, with up to 74% of school backpack–wearers experiencing pain. Back pain is more common with the heavy backpack (>10–20% of body weight), female sex, large body mass index, and single shoulder strap.

Treatment is conservative and includes analgesia, myofascial release, massage, and physical therapy, as tolerated. The natural history of acute back strain in adults is that 50% are better in 1 week, 80% in 1 month, and 90% in 2 months, regardless of therapy. The course of back pain in young athletes is likely similar given the elimination of obvious precipitating influence and/or activities, as discussed previously.

Sacroiliitis manifests as pain over the sacroiliac joints; it is usually chronic but is occasionally associated with a history of trauma. Patients

have a positive result with the **Patrick test**, performed in the supine position by resting the foot of the affected side across the opposite knee ("figure-4" position), stabilizing the contralateral iliac crest, and externally rotating the hip on the affected side (pushing the knee down and lateral). Symptomatic improvement with knee-to-chest maneuvers and subsequent posterior pelvic tilt may be present. A radiograph of the sacroiliac joints is indicated, and if results are positive, exploration for a rheumatologic disease (ankylosing spondylitis [see Chapter 197], juvenile idiopathic arthritis [see Chapter 196], or inflammatory bowel disease [see Chapter 382]) is warranted.

Treatment is with relative rest, NSAIDs, and physical therapy. Ankylosing spondylitis is more likely if the onset of lower back pain is before 40 years of age, if there is morning stiffness demonstrating improvement with activity, a family history is present, there is clear benefit from antiinflammatory medication, and if the pain has a gradual onset having lasted longer than 3 months.

OTHER CAUSES

Non–sports-related causes of low back pain in the young athlete are numerous and include infection (osteomyelitis, diskitis) and neoplasia (see Chapter 720.5). These should be considered in patients with fever, weight loss, other constitutional signs, or lack of response to initial therapy. Osteomyelitis of the lower back or pelvis is often, but not always, associated with fever. Undiagnosed Scheuermann disease needs to be considered with a history of chronic back pain; it is more common in males and younger adolescents and should be distinguished from symptomatic postural roundback and congenital decompensating kyphosis. Atypical Scheuermann disease or thoracolumbar apophysitis can progress and become the pediatric equivalent of an adult compression fracture. Benign tumors of the spine include osteoid osteoma, which presents with intense focal nighttime pain that is not activity related and is almost always relieved by aspirin or NSAIDs. Undiagnosed osteoblastoma, eosinophilic granuloma, aneurysmal bone cyst, and fibrous dysplasia are additional benign tumors not to be excluded. Malignant spinal tumors include Ewing sarcoma (onion skin appearance) and osteogenic sarcoma (sunburst pattern); both are associated with the *Codman triangle*, which is the triangular area of new subperiosteal bone seen on radiographs when a tumor raises the periosteum away from the bone. Metastatic tumors of the spine include neuroblastoma, spinal cord tumors, leukemia, and lymphoma. Wilms tumor can also metastasize to the spine and be associated with hemihypertrophy. Referred pain to the spine always needs to be considered. Conditions that can refer pain include pyelonephritis, renal osteodystrophy, pneumonia, endocarditis, cholecystitis, nephrolithiasis, pancreatitis, megacolon, constipation/ileus, hiatal hernia/reflux, pelvic inflammatory disease, and sickle cell crisis. Undiagnosed pregnancy is a consideration in the age-appropriate female. Psychogenic pain and fibromyalgia can be seen in children. Child abuse can present in the spine, with soft tissue injuries more common than fractures. Posterior rib and spinous process fractures can be seen in up to 30% of abused children.

Visit Elsevier eBooks+ at eBooks.Health.Elsevier.com for Bibliography.

728.5 Hip and Pelvis Injuries

Gregory L. Landry and Andrew M. Watson

Injuries to the hip and pelvis represent a small percentage of sports injuries, but they are potentially severe and require prompt diagnosis. Hip pathology can manifest as knee pain with normal findings on knee examination.

In children, **transient synovitis** (see Chapter 719.2) is the most common nontraumatic cause of hip pain. It usually manifests with acute onset of a limp, with the child refusing to use the affected leg and painful range of motion on examination. There may be a history of minor trauma or a recent viral infection. This is a self-limiting condition that usually resolves in 48-72 hours.

Legg-Calvé-Perthes disease (avascular necrosis of the femoral head) also presents in childhood with insidious onset of limp and hip pain (see Chapter 719.3).

Until skeletal maturity (Table 728.2), younger athletes are susceptible to apophyseal injuries (e.g., the anterior superior iliac spine). **Apophysitis** develops from overuse or from direct trauma. **Avulsion fractures** occur in adolescents playing sports requiring sudden, explosive bursts of speed (see Fig. 728.2). Large muscles contract and create force greater than the strength of the attachment of the muscle to the apophysis. Biomechanical susceptibility of the pelvis allows separation to occur in the cartilaginous region between the apophysis and the adjoining bone. The most common sites of pelvic avulsion fractures are the anterior superior iliac spine (sartorius and tensor fasciae lata), anterior inferior iliac spine (rectus femoris), lesser femoral trochanter (iliopsoas), ischial tuberosity (hamstrings), and the iliac crest (abdominal muscles). Symptoms include localized pain and swelling with decreased strength and range of motion. Bilateral radiographs are important for comparison to assess for displacement, if any, of the fracture fragment. Significant displacement or the presence of a large fragment may require orthopedic consultation. Initial treatment includes ice, analgesics, rest, and pain-free range of motion exercises. Crutches are usually needed initially for ambulation. Surgery is not typically indicated because most of these fractures—even large or displaced ones—heal well. Direct contact to the bone around the hip and pelvis causes exquisitely tender subperiosteal hematomas called "**hip pointers**." These injuries are more commonly seen around the anterior superior iliac spine and the iliac crest. Limited active range of motion can be identified about the hip, brought on by contracture of locally attached musculature such as hip flexors and hip abductors. Symptomatic care includes rest, ice, analgesia, and protection from re-injury.

Slipped capital femoral epiphysis usually occurs among 11- to 15-year-olds during the time of rapid linear bone growth (see Chapter 719.4) and often presents with complaints of pain in the groin area or, on occasion, referred pain felt at the knee. Bilateral hip radiographs confirm the diagnosis.

A **femoral neck stress fracture** can manifest as vague progressive hip pain in an endurance athlete. Females are at higher risk. This diagnosis should be suspected in the running athlete with vague anterior

Table 728.2 Age of Appearance and Fusion of Apophyses in Hip and Pelvis

APOPHYSIS	APPEARANCE (YR)	FUSION (YR)	RELATED MUSCLE GROUP(S)
Anterior inferior iliac spine	13-15	16-18	Quadriceps
Anterior superior iliac spine	13-15	21-25	Sartorius
Lesser trochanter	11-12	16-17	Iliopsoas
Greater trochanter	2-3	16-17	Gluteal
Ischial tuberosity	13-15	20-25	Hamstrings
Iliac crest	13-15	21-25	Abdominal obliques Latissimus dorsi

From Waite BL, Krabak BJ. Examination and treatment of pediatric injuries of the hip and pelvis. *Phys Med Rehabil Clin N Am.* 2008;19:305–318.

thigh pain without a history of trauma or acute injury. On examination, there may be pain with passive stretch of the hip flexors and pain with hip rotation. If radiographs do not demonstrate a periosteal reaction consistent with a stress fracture, MRI may be indicated to confirm the suspected diagnosis and determine the location of the fracture. Orthopedic consultation is necessary in femoral neck stress fractures because of their predisposition to nonunion and displacement with minor trauma or continued weight-bearing. These fractures carry increased risk of avascular necrosis of the femoral head. Whereas compression (inferomedial) side femoral neck stress fractures can typically be treated conservatively with non–weight-bearing, tension side (superolateral femoral neck) fractures may be at particular risk of progression and often require surgical fixation.

Osteitis pubis is an inflammation at the pubic symphysis that may be caused by excessive side-to-side rocking of the pelvis. It can be seen in an athlete in any running sport and is more common in sports requiring additional use of the adductor muscles such as ice hockey, soccer, and inline skating. Athletes typically present with vague groin pain that may be unilateral or bilateral. On physical examination, there is tenderness over the symphysis and sometimes over the proximal adductors. Adduction strength testing causes discomfort. Radiographic evidence (irregularity, sclerosis, widening of the pubic symphysis with osteolysis) may not be present until symptoms are present for 6-8 weeks; MRI is more sensitive to early changes. Relative rest for 6-12 weeks may be required. Some patients require corticosteroid injection as adjunctive therapy. Ultrasound needle guidance may be used to improve the accuracy of the injection while simultaneously avoiding injury to surrounding structures, such as the bladder, and vascular structures of the genitalia.

Acetabular labrum tears can occur in the hip, similar to glenoid labrum tears in the shoulder. Athletes may have a history of trauma and complain of sharp anterior hip pain associated with a clicking or catching sensation. Clinical diagnosis is often difficult; magnetic resonance arthrography is the gold standard for diagnosis, but MRI may be useful as well.

Snapping hip syndrome is caused by the iliopsoas musculotendinous unit riding over the pectineal eminence of the pelvis, anterior hip capsule, or the iliotibial band (ITB) over the greater trochanter. Lack of flexibility in these muscles results in snapping, as the musculotendinous unit slides over the associated bony prominence. It is most commonly seen in ballet dancers and runners, and it can occur as an acute or, more commonly, overuse injury. Athletes present with either a painful or painless click or snap in the hip, usually located lateral or anterior and deep within the joint. Examination often reproduces the symptoms. Radiographs are not usually needed in the workup. Ultrasound examination can be useful to visualize the anatomic structures in question causing the snapping sensation. Core weakness may be present, leading to excessive movement about the hip girdle contributing to increased sliding of the tight muscle over the boney prominence. Treatment involves analgesia, relative rest, biomechanical assessment, core flexibility, and stretching/strengthening of the involved soft tissue. Patients with concomitant greater trochanteric bursitis may benefit from a corticosteroid injection into the inflamed bursa to improve pain control and facilitate rehabilitation. The athlete may return to activity as tolerated. Common soft tissue injuries around the hip and pelvis include strain and tendinosis of the hip flexors (groin) and hamstrings in addition to quadriceps contusions and greater trochanteric bursitis.

The term **athletic pubalgia** is commonly used to describe a number of different pathologies that may cause lower abdominal or groin pain. Often called a sports hernia, this is a source of confusion as no true hernia exists through the inguinal canal or abdominal wall. The pathophysiology stems from tissue injury to the structures that comprise the pubic aponeurosis, most commonly the tendinous attachment of the abdominal and hip adductor musculature. Like a true hernia, pain may radiate into the anterior thigh, inguinal region, perineum, and/or scrotum. Physical exam may exhibit tenderness over, or adjacent to, the pubic ramus and/or reproduction of pain with resisted abdominal flexion or hip adduction. MRI, CT scan, and bone scan can be helpful in ruling out other diagnoses but usually are negative. Some radiology departments may have MRI protocols specific for athletic pubalgia that provide more detailed imaging of the pathologic area. Patients who continue with symptoms despite conservative care, such as physical therapy, may be candidates for surgical intervention.

Femoroacetabular impingement (FAI) may coexist with athletic pubalgia to produce groin pain. FAI is defined as an abnormal contact between the femoral neck and the acetabulum as a result of excessive bone on the acetabular rim, the femoral neck, or both. X-rays and MRI can be diagnostic. As in athletic pubalgia, a period of rest and rehabilitation should be attempted, and those who fail conservative treatment should be referred to a sports medicine specialist.

Undiagnosed **non–sports-related conditions** need to be considered. Differential diagnoses may include the epiphyseal dysplasias, congenital or developmental hip dysplasia, additional causes of avascular necrosis, including sickle cell disease, Gaucher disease, rheumatoid arthritis, and other collagen disorders and steroid therapy. Inguinal hernia should be recognized in those patients with groin pain exacerbated with coughing/Valsalva maneuver and a palpable mass in the groin. Traumatic hip dislocations are relatively rare in children but should not be overlooked. Leg-length discrepancies (usually >1 cm) can be symptomatic at the hip in an otherwise healthy child. Common tumors in the lower extremities include osteosarcoma along with osteoblastoma, aneurysmal bone cysts, and fibrous dysplasia (more common in the pelvis). Metastatic tumors to the lower extremities include neuroblastoma, lymphoma, and leukemic infiltration with joint arthralgia. Child abuse always needs to be considered in a young patient with musculoskeletal pain.

Visit Elsevier eBooks+ at eBooks.Health.Elsevier.com for Bibliography.

728.6 Knee Injuries

Gregory L. Landry and Andrew M. Watson

Knee pain is common among adolescents. Acute knee injuries that cause immediate disability and/or effusion are likely to be due to fracture, patellar dislocation, anterior or posterior cruciate ligament injury, or meniscal tear. The mechanism of injury is usually a weight-bearing event. Physeal injuries tend to predominate in younger patients, whereas more skeletally mature adolescents tend to sustain ligamentous injuries. If the knee swells more immediately (within several hours of injury), the swelling is likely caused by a hemarthrosis and more severe injury. The injury most likely to occur with a hemarthrosis is an **anterior cruciate ligament (ACL)** injury. This injury (rare in children younger than 12 years) is usually caused by direct contact, landing off-balance from a jump, quickly changing direction while running, or hyperextension. Instability is often present but may be hard to detect in the presence of significant swelling. Females are more than twice as likely as males to disrupt their ACL, often during sports such as basketball or soccer. Occasionally, these injuries are associated with an avulsion injury of the anterior tibial spine. Most athletes with significant ACL injury need orthopedic consultation with consideration of ACL reconstruction. Chronic ACL insufficiency may increase the risk of meniscal injury, early osteoarthritis, and further joint dysfunction. Physeal-sparing reconstructions with minimal risk of growth arrest or angular deformity have been reported with success in children younger than 12 years and adolescents.

Posterior cruciate ligament (PCL) injury occurs from a direct blow to the region of the proximal tibia when the knee is flexed, such as might occur with a dashboard injury or a fall to the knees in volleyball. PCL injuries are rare and are usually treated nonsurgically.

Medial collateral ligament injuries typically result from a valgus blow to the outside of the knee. Isolated **lateral collateral ligament** injuries are uncommon and result from significant varus knee stress. Because they are extra-articular, lateral collateral and medial collateral ligament injuries should not produce a significant knee effusion and

are generally less disabling. Isolated medial and lateral collateral injuries are generally managed nonsurgically with conservative care and appropriate rehabilitation.

Meniscal tears generally occur by the same mechanisms as ACL injuries. They are often associated with less hemarthrosis, significant joint line pain, and increased pain with full knee flexion. MRI will usually yield the diagnosis; conservative care, including PRICE principles, is therapeutic for smaller injuries. Orthopedic consultation is indicated for meniscus tears in children and adolescents, and surgery may be indicated for larger tears, displaced tears, or those not healing with conservative care over 6-8 weeks. An isolated meniscal tear in a child younger than 10 years of age is unusual. The surgical choice is often repair of the meniscus rather than resection because of the increased potential in children for cartilaginous healing. Discoid meniscus (an anatomic variant covering lateral tibial plateau) should be considered in children younger than 12 years of age and those with a suspected meniscus injury without a history of notable trauma.

Patellar dislocation occurs most often as a noncontact injury when the quadriceps muscles forcefully contract to extend the knee while the tibia is externally rotated in relation to the femur. Patellar dislocation is the second most common cause of hemarthrosis. The patella is almost always dislocated laterally, and this motion tears the medial patellar retinaculum, causing bleeding in the joint. Recurrent episodes of patellar instability are associated with less swelling. Patellar dislocations are often associated with genu valgum, external tibial torsion, and general ligamentous hyperlaxity. Exercises to strengthen the quadriceps, particularly the vastus medialis, and the use of patella-tracking braces may be helpful. Recurrent instability can require surgical intervention. Surgical stabilization of the medial patellar tissues and lateral retinacular release can be helpful in more difficult cases.

INITIAL TREATMENT OF ACUTE KNEE INJURIES

The physician should inspect for an effusion and obvious deformities; if any deformity is present, the physician should assess neurovascular status and transfer the patient for emergency care as indicated. If no gross deformities are present and neurovascular integrity is intact, initial maneuvers include full passive extension and gentle valgus and varus stress to the knee while in extension. *Any laxity to varus or valgus stress in full extension implies a multiligamentous injury*. Comparison to the noninjured knee is always helpful for assessing degrees of laxity and range of motion. The patient's ability to contract the quadriceps should be noted. Pain occurring with quadriceps contraction, or the inability to contract the quadriceps muscle, implies an injury to the extensor mechanism. Tenderness over the medial patella, medial retinaculum, or above the adductor tubercle is associated with a patellar dislocation (usually lateral). Point tenderness is consistent with fracture or injury to the underlying structure. Meniscal tears usually manifest as tenderness along the joint line, accentuated with flexion of the knee beyond 90 degrees. Pain or limitation in either flexion or extension while rotating the tibia implies a meniscal injury. Ligament injury is manifested as pain or laxity with the appropriate maneuver (Fig. 728.12).

If a patient cannot weight-bear without pain, or has clinical signs of instability, significant swelling, or any other major concern, the knee should be immobilized and crutches provided. The Ottawa knee rule, which has been validated for children over 5 years of age, helps determine which patients with mild knee injuries require radiographs. X-rays should be obtained if *any* of the following apply: 55 years or older, point tenderness of fibular head, tenderness of the patella, inability to flex knee to 90 degrees, or inability to bear weight (inability to take four steps) both immediately after the injury and in the emergency department.

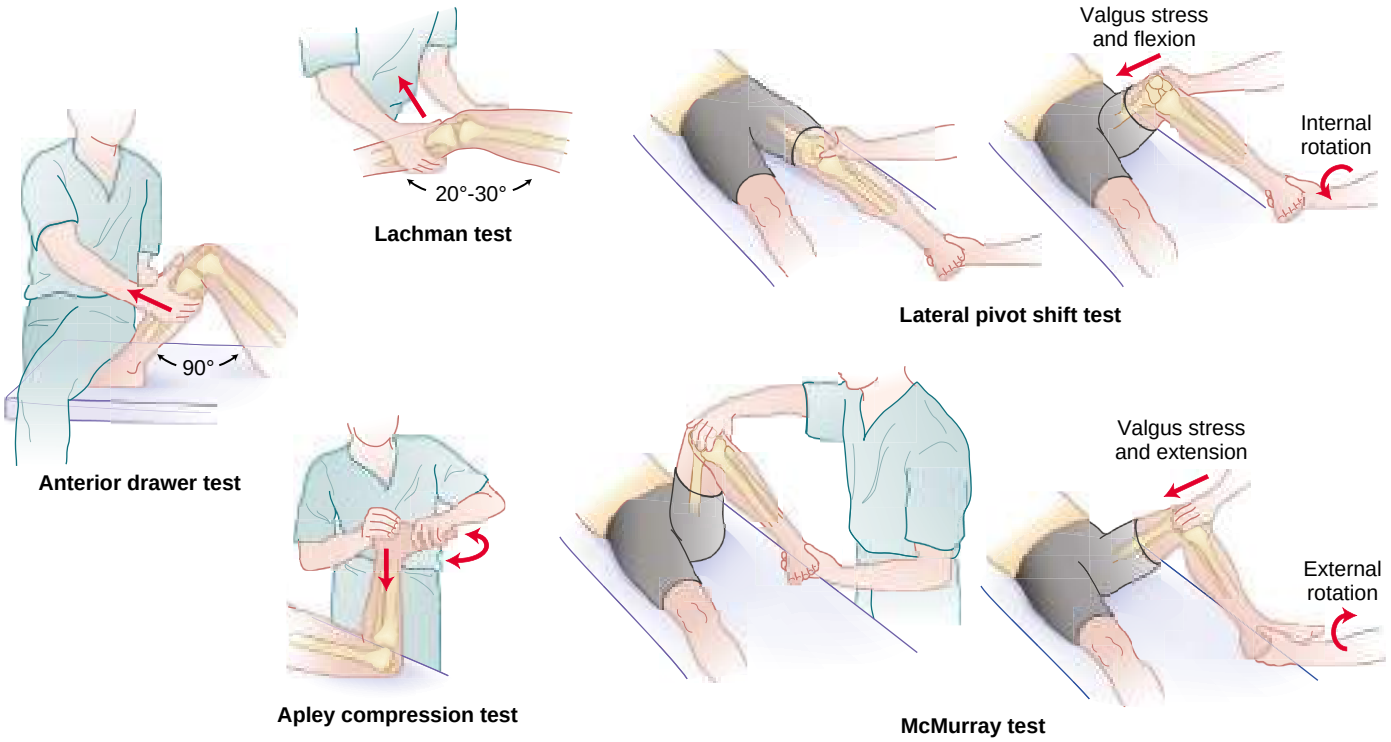

Fig. 728.12 Examination maneuvers include the Lachman, anterior drawer, lateral pivot shift, Apley compression, and McMurray tests. The Lachman test, performed to detect anterior cruciate ligament (ACL) injuries, is conducted with the patient supine and the knee flexed 20-30 degrees. The anterior drawer test detects ACL injuries and is performed with the patient supine and the knee in 90 degrees of flexion. The lateral pivot shift test is performed with the patient supine, the hip flexed 45 degrees, and the knee in full extension. Internal rotation is applied to the tibia while the knee is flexed to 40 degrees under a valgus stress (pushing the outside of the knee medially). The Apley compression test, used to assess meniscal integrity, is performed with the patient prone and the examiner's knee over the patient's posterior thigh. The tibia is externally rotated while a downward compressive force is applied over the tibia. The McMurray test, used to assess meniscal integrity, is performed with the patient supine and the examiner standing on the side of the affected knee.

If the patella is dislocated, reduction may be achieved with gentle active assistive knee extension. Straight-leg immobilizers offer no structural support and are only used for comfort and reminding the patient to be careful with any weight-bearing. A derotational hinge brace may be indicated for stabilization, such as after an injury involving both the ACL and medial collateral ligament. The leg should be elevated, and an elastic wrap can be applied for compression (PRICE principles).

CHRONIC INJURIES

Patellofemoral Stress Syndrome

Patellofemoral stress syndrome (PFSS), or runner's knee, is the most common cause of anterior knee pain. PFSS is also known as **patellofemoral pain syndrome** or **patellofemoral dysfunction** (see Chapter 718.5). It is a diagnosis of exclusion used to describe anterior knee pain that has no other identifiable pathology. Chondromalacia may be seen in association with softening of the articular cartilage underneath the patellar surface. Pain is usually difficult to localize. Patients indicate a diffuse area over the anterior knee as the source, or they might feel as if the pain is originating from underneath the patella. Bilateral pain is common, and pain is often worse going up stairs, after sitting for prolonged periods, or after squatting or running. There should be a negative history for significant swelling or true mechanical symptoms, which would indicate a more serious injury. History of change in activity is common, such as altered training surface or terrain, increased training regimen, or performance of new tasks.

Examination should include evaluation of stance and gait for lower limb alignment, musculature, and midfoot hyperpronation. Flexibility of the hamstrings, iliotibial band, and gastrocnemius should be assessed, because stress is increased across the patellofemoral joint when these structures are excessively tight. Hip range of motion should be assessed to rule out hip pathology. Medial patellar tenderness or pain with compression of the patellofemoral joint confirms the diagnosis in the absence of a significant effusion and other positive findings. PFSS is a clinical diagnosis usually managed without imaging.

Treatment focuses on assessing and improving flexibility, strength, and gait abnormalities. In the presence of midfoot hyperpronation (ankle valgus), new shoes or the use of arch supports can improve patellofemoral mechanics and alleviate pain. Ice and analgesics can be used to help control pain. Reduced overall activity or training is important initially in rehabilitation. Short arc quadriceps strengthening exercises can be helpful: active knee extension with or without resistance between 0 and 30 degrees of knee flexion. Hip and core strengthening exercises are also beneficial. Therapeutic taping techniques to improve patella tracking within the trochlear groove can be helpful with the assistance of a sports physical therapist. The use of a patellar stabilizing brace with a lateral buttress to maintain patellar alignment may be of benefit in more chronic cases as well.

Osgood-Schlatter Disease

Osgood-Schlatter disease is a traction apophysitis occurring at the insertion of the patellar tendon on the tibial tuberosity (see Chapter 718.4). Because it is also related to overuse of the extensor mechanism, Osgood-Schlatter disease is treated like PFSS. A protective pad to protect the tibial tubercle from direct trauma can be used. Therapeutic taping of the tibial tubercle may provide comfort, along with well-fitted knee sleeves and/or straps. NSAIDs are often prescribed for comfort. Stretching focused on the quadriceps and hamstrings is recommended, and PRICE principles apply. Patients and parents should be made aware that resolution is usually slow, often requiring 12-18 months. Complications are rare and can include growth arrest with recurvatum deformity and rupture or avulsion of the patellar tendon/tibial tubercle.

Other Chronic Injuries

Sinding-Larsen-Johansson disease is a traction apophysitis occurring at the inferior pole of the patella. It occurs most often in volleyball and basketball athletes. Treatment is similar to PFSS and Osgood-Schlatter disease.

Patellar tendinosis, or jumper's knee, is caused by repetitive microtrauma of the patellar tendon, usually at the inferior pole of the patella. In approximately 10% of cases, the quadriceps tendon above the patella is affected. It is associated with jumping sports but may occur in runners as well. Treatment is similar to that for PFSS, with an emphasis on eccentric strengthening in physical therapy. Relative rest is more important in patellar tendinosis because chronic pain can be associated with irreversible changes in the tendon. In these cases, recalcitrant to rest, activity modifications, and physical therapy, there may be a role of biologic injections such as platelet-rich plasma to the pathologic area. Surgical techniques also have a good success rate if needed.

Iliotibial band (ITB) friction syndrome is the most common cause of chronic lateral knee pain. Generally, it is not associated with swelling or instability. It is from friction of the ITB along the lateral knee, resulting in bursitis. Tenderness is elicited along the ITB as it courses over the lateral femoral condyle or at its insertion at Gerdy's tubercle along the lateral tibial plateau. Tightness of the ITB is also noted using the Ober test. To perform an Ober test, the athlete lies on one side, the inferior hip is flexed, and the superior hip is extended with the knee flexed. The examiner holds the superior foot in midair, and if the superior knee drops inferiorly toward the exam table, it implies a flexible ITB and a negative Ober test. If the knee and leg stay in midair, the Ober test is positive, suggesting a tight ITB. Treatment principles follow those for PFSS, except the emphasis is on improving flexibility of the ITB.

Other soft tissue injuries to be considered include prepatellar and pes anserine **bursitis**, plical syndromes, and Hoffa syndrome. The pes anserine bursa lies just under the conjoined tendon of the sartorius, gracilis, and semitendinosus muscles as it attaches medially to the proximal tibia. In **Hoffa syndrome**, the fat pad beneath the patella and posterior to the patella ligament becomes pinched with anterior pain on knee extension. These conditions are generally more common in adolescents, those with genu recurvatum, and long-distance runners. Undiagnosed non–sports-related conditions always need to be considered in the context of any child with a painful knee, particularly those younger than 12 years old. These include conditions such as OCD (see Chapter 718.3), which is most common on the lateral aspect of the medial femoral condyle. Inflammatory and infectious arthritis, Baker cyst (see Chapter 718.2), and hip pain referred to the knee are additional considerations. Tumors more common to the knee joint include osteogenic sarcoma (distal femoral and proximal tibial), Langerhans cell histiocytosis in the diaphysis, and eosinophilic granuloma in the epiphysis of long bones. Metastatic tumors to the lower extremities include neuroblastoma and lymphoma. As with any musculoskeletal injury in a child not responding to conservative care, more in-depth diagnostic pursuit for alternative pathology is mandatory.

Visit Elsevier eBooks+ at eBooks.Health.Elsevier.com for Bibliography.

728.7 Lower Leg Exertional Pain: Shin Splints, Stress Fractures, and Chronic Compartment Syndrome

Gregory L. Landry and Andrew M. Watson

Stress injury to the bones of the lower leg occurs on a continuum from mild injury (shin splints) to stress fracture. All occur by an overuse mechanism.

Medial tibial stress syndrome, or shin splints, manifests with pain along the medial tibia and is the most common overuse injury of the lower leg. The pain initially appears toward the end of exercise, and if exercise continues without rehabilitation, the pain worsens and occurs earlier in the exercise period. There is diffuse tenderness over the lower third to half of the distal medial tibia. Any focal tenderness of the tibia is suspicious for a **tibial stress fracture**. A stress fracture tends to be associated with more severe pain and is painful during the entire workout. Shin splints and stress fractures represent a continuum of stress injury to the tibia and are thought to be related to traction of the soleus

on the tibia. Eccentric contraction of the medial aspect of the soleus is required to control pronation from initial contact to mid-stance with running. This contraction increases the stress of the fascial origin of the soleus, possibly through Sharpey fibers, causing disruption to the tibial periosteum and fibrocartilaginous attachments.

The diagnosis can be made by history and physical examination. Findings on plain radiographs of the tibia are typically unremarkable with shin splints, as well as with tibial stress fractures within the first 2 weeks of injury. Beyond this time frame, radiographs may demonstrate periosteal reaction if a stress fracture is present but may still be unremarkable. Sensitivity of plain radiographs can be increased by obtaining four views of the tibia: AP, lateral, and both oblique views. MRI is the most sensitive test to diagnose stress injuries as it can reveal both a stress fracture and stress reaction in the affected bone. Stress reactions may include bone marrow edema or periosteal reaction without a fracture line but represent an impending progression to a fracture if the offending stress is not reduced or eliminated.

The treatment of shin splints involves relative rest, correcting training errors, and addressing muscle imbalances and abnormal mechanical alignment. Orthotics and/or new shoes may be useful in patients who hyperpronate. Fitness can be maintained with non–weight-bearing activities, such as swimming, cycling, and water jogging. With shin splints, after 7-10 days, patients can usually start on the walk-jog program. If pain worsens, 2-3 pain-free days are required before resuming the walk-jog program. Ice should be used daily, and an analgesic should be used for pain control. Stretching the plantar flexors and hamstrings and strengthening the ankle dorsiflexors may be useful. Therapeutic taping and wrapping techniques to support the soft tissue attachments have been useful in some when directed by a skilled sports therapist. Being pain free for 7-10 days is recommended before exercises are commenced. Individuals with pain at rest and who are not responsive to treatment require continued evaluation for stress fracture. Treatment of tibial stress fractures is similar but requires more prolonged avoidance of running and jumping, usually 6-8 weeks.

Chronic compartment syndrome occurs in an athlete in a running sport, usually during a period of heavy training. It is caused by muscle hypertrophy and increased intracompartmental pressure with exercise. There is typically a pain-free period of about 10 minutes at the beginning of a workout before onset of constant throbbing pain that is difficult to localize. It lasts for minutes to hours after exercise and is relieved by ice and elevation. Classically, there is numbness of the foot associated with high pressure within the corresponding muscle compartment. The most common compartment affected is the anterolateral compartment with compression of the fibular nerve followed by the deep posterior compartment. The physical examination in the office is often normal, but weakness of the extensor hallucis longus (anterolateral compartment) and decreased sensation between the first and second toe may be present. Symptoms may be elicited through exercise in or near the examination room (jogging in place, stair climbing, etc.), and prompt evaluation after symptom onset may aid in diagnosis. Radiologic evaluation is typically negative and used primarily to rule out other conditions. Compartment pressure measurements are the test of choice. Treatment involves reduction of activity, antiinflammatory medication, orthotics (hyperpronation), heel cord stretching, light strengthening of distal musculature, optimal footwear, and cross-training (swimming, cycling, and water jogging). Cryotherapy and superficial heat can also be of help. Persistent systems, despite conservative care, may require fasciotomy.

Popliteal artery entrapment syndrome occurs when the popliteal artery is compressed by the medial head of the gastrocnemius muscle and the fascial band of the soleus with activity; the entrapment may be anatomic or functional (from hypertrophy). Patients may have claudication and paresthesia (involvement of the tibial nerve), and calf swelling (primary venous obstruction). Most patients have exertional leg pain with no symptoms at rest; pain may be unilateral or bilateral depending on the type of entrapment syndrome. The tibial or dorsalis pedis pulse may be reduced or absent with passive ankle dorsiflexion with the knee extended. Doppler exam in the neutral and flexion position confirms the diagnosis in most patients; magnetic resonance angiography or CT angiography may be needed if the Doppler exam is inconclusive. Surgical correction is the treatment of choice and involves medical gastrocnemius fasciotomy, take down of the soleus tibial attachments, and resection of the fibula soleus band. If the artery is injured, it requires bypass surgery.

Visit Elsevier eBooks+ at eBooks.Health.Elsevier.com for Bibliography.

728.8 Ankle Injuries

Gregory L. Landry and Andrew M. Watson

Ankle injuries are the most common acute athletic injury. Approximately 85% of ankle injuries are ankle sprains, and 85% of these are inversion injuries (foot planted with the lateral fibula moving toward the ground), 5% are eversion injuries (foot planted with the medial malleolus moving toward the ground), and 10% are combined.

EXAMINATION AND INJURY GRADING SCALE

In obvious cases of fracture or dislocation, evaluating neurovascular status with as little movement as possible is the initial priority. If no deformity is obvious, the next step is inspection for edema, ecchymosis, and anatomic variants. Key sites to palpate for tenderness are the entire length of the fibula; the medial malleolus; the base of the fifth metatarsal; the anterior, medial, and lateral joint lines; the navicular; and the Achilles tendon complex. Assessment of active range of motion (patient alone) in dorsiflexion, plantar flexion, inversion, and eversion along with gentle resisted range of motion can be helpful.

Provocative testing attempts to evaluate the integrity of the ligaments. In a patient with a markedly swollen, painful ankle, provocative testing is difficult because of muscle spasm and involuntary guarding. It is more useful on the field before much bleeding and edema have occurred. The anterior drawer test assesses for anterior translation of the talus and competence of the anterior talofibular ligament. The inversion stress test examines the competence of the anterior talofibular and calcaneofibular ligaments (Fig. 728.13). In the acute setting, the integrity of the tibiofibular ligaments and syndesmosis can be examined by the syndesmosis squeeze test. Pain at the ankle joint with squeezing the superior aspect of the lower leg implies injury to the interosseous membrane and syndesmosis between the tibia and fibula—suspicious for a high ankle sprain or more severe injury. Athletes with this injury cannot bear any weight and have severe pain with dorsiflexion and external rotation of the foot. Occasionally, the peroneal tendon dislocates from the fibular groove simultaneously with an ankle sprain. To assess for peroneal tendon instability, the examiner applies pressure from behind the peroneal tendon with resisted eversion and plantar

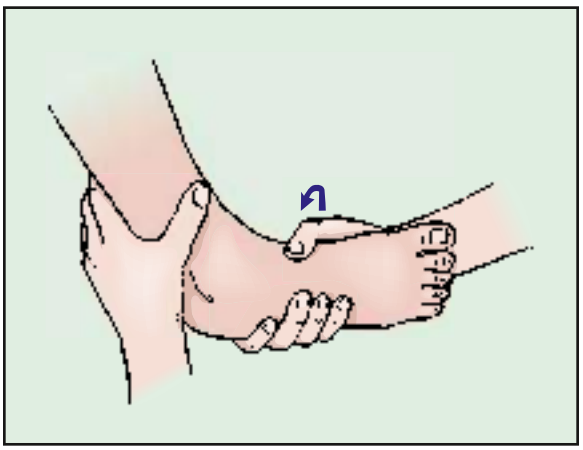

Fig. 728.13 Inversion stress tilt test for ankle instability. *(From Hergenroeder AC. Diagnosis and treatment of ankle sprains: a review. Am J Dis Child. 1990;144:809–814.)*

flexion, and the tendon pops anteriorly. If either a significant syndesmotic injury or an acute peroneal dislocation is suspected, orthopedic consultation should be sought.

RADIOGRAPHS

AP, lateral, and mortise views of the ankle are obtained when patients have pain in the area of the malleoli, are unable to bear weight, or have focal bone tenderness over the distal tibia or fibula. The **Ottawa ankle rules** help define who requires radiographs (Fig. 728.14). A foot series (AP, lateral, and oblique views) should be obtained when patients have pain in the area of the midfoot or bone tenderness over the navicular or fifth metatarsal, and/or an inability to bear weight. It is important to differentiate an **avulsion fracture** of the fifth metatarsal base (dancer's fracture) from the more distal **Jones fracture** of the proximal fifth metatarsal (located about 2 cm distal to the proximal end). The former is treated like an ankle sprain; the latter fracture has an increased risk of nonunion and requires orthopedic consultation. Injury to the deltoid ligament of the medial ankle is rare but should raise the question of proximal fibular fracture. In this circumstance more proximal tibial imaging may be necessary. A **talar dome fracture** may present as an ankle sprain that does not improve. Radiographs on initial presentation can have subtle abnormalities. Any suspicion on the initial radiographs of a talar dome fracture warrants orthopedic consultation and further imaging. In the early adolescent, always look carefully at the tibial epiphysis. Nondisplaced Salter III fractures can be subtle and need to be recognized early and referred to an orthopedic surgeon promptly. Diagnostic ultrasound, when available at the point of care, can efficiently provide prognostic information by direct visualization of injured ligaments. Additionally, dynamic stress can be applied during ligament visualization to assess for gaping of the joint, which is indicative of more complete tearing with an increased duration of expected recovery.

INITIAL TREATMENT OF ANKLE SPRAINS

Ankle sprains need to be treated with PRICE principles. This should be followed for the first 48-72 hours after the injury to minimize bleeding and edema. For an ankle injury, this may consist of crutches and an elastic wrap, although other compression devices, such as an air stirrup splint, are also effective. This allows early weight-bearing with protection and can be removed for rehabilitation. It is important to start a rehabilitation program as soon as possible.

Rehabilitation

Rehabilitation should begin the day of injury; for patients who have pain with movement, isometric strengthening can be started. Early-phase intervention includes restoration of functional range of motion, strengthening with emphasis on peroneal musculature, and early sensory proprioceptive training. Later intervention includes higher-level balance activities, advanced proprioception exercises, and endurance training. When determining when an athlete is ready for running, there must be full range of motion and nearly full strength compared to the uninjured side. While standing on the uninjured side only, the athlete is instructed to hop 8-10 times, if possible. When this can be achieved without pain on the injured side, the athlete can begin to run, starting out with jogging and gradually progressing in speed. The athlete must stop if there is significant pain or limp. Finally, before returning to sport, the athlete must be able to sprint and change directions off the injured ankle comfortably. Performing some sport-related tasks is also helpful in determining readiness for return to play.

Recurrent ankle injuries are more likely in patients who have not undergone complete rehabilitation. Ankle sprains are less likely in players wearing high-top shoes or lace-up ankle braces. Proper taping of the ankle with adhesive tape can provide functional support but loosens with use and is often unavailable. Surgery is a consideration for chronic mechanical instability with lateral complex ligamentous laxity in the failure of more conservative care. Salter-Harris grade I distal fibular fractures need careful consideration, particularly in the child younger than 12 years of age. The physeal plates are generally the weakest link in the musculoskeletal chain and tend to slide or pull apart before the surrounding soft tissue and/or ligaments tear in this younger population.

OTHER CAUSES OF ANKLE PAIN

Toddler's fracture needs to be considered in young children with ankle pain, especially in those younger than 6 years (see Chapter 724.4). The proposed mechanism involves sheer stress with lack of displacement because of the periosteum that is relatively strong compared to the elastic bone in younger children. Initial radiographs may be inconspicuous (a faint spiral oblique line) or even normal. The condition can be mistaken for osteomyelitis, transient synovitis, or even child abuse. Toddler's fracture usually occurs in the lower third of the tibia, whereas nonaccidental injury typically affects the upper two-thirds or midshaft

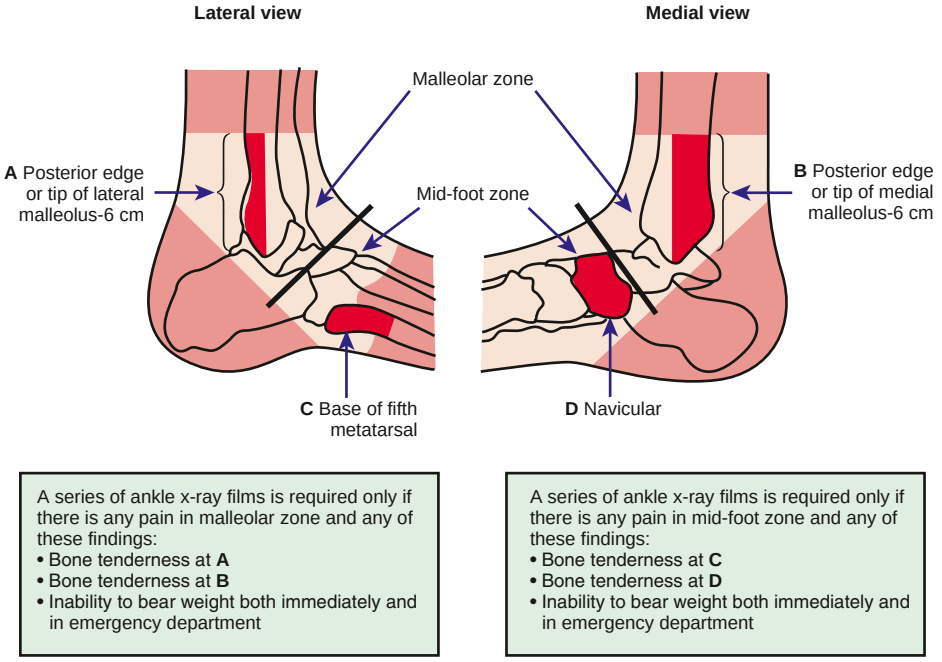

Fig. 728.14 Ottawa ankle rules. *(From Bachmann LM, Kolb E, Koller MT, et al. Accuracy of Ottawa ankle rules to exclude fractures of the ankle and mid-foot; systematic review. BMJ. 2003;326:417–419.)*

of the tibia. Other less common conditions that cannot be excluded include os fibulare, a congenital unfused secondary ossification center of the distal fibula. This can be seen in younger patients with recurrent ankle sprains, particularly as their body weight and activity increase during the early academic years. Undiagnosed tarsal coalitions can also be seen in the presence of ankle sprains in younger children (most commonly talocalcaneal and calcaneal navicular). Muscular strains and/or tendinoses are more prevalent in the older child and adolescent, and include peroneal, posterior tibialis, and gastrocnemius/Achilles types. Tarsal tunnel syndrome (entrapment of the posterior tibial nerve) is more prevalent in the adolescent/younger adult and is commonly associated with medial ankle pain and burning or tingling into the sole of the foot.

Visit Elsevier eBooks+ at eBooks.Health.Elsevier.com for a complete Bibliography.

728.9 Foot Injuries

Gregory L. Landry and Andrew M. Watson

Metatarsal stress fractures can occur in any running athlete. The history is often one of insidious pain with activity that is getting worse. Examination reveals point tenderness over the mid-shaft of the metatarsal, most commonly the second or third metatarsal. Radiographs might not show the periosteal reaction before pain has been present for 2 weeks or more. Treatment is relative rest for 6-8 weeks. Shoes with good arch supports reduce stress to the metatarsals.

Vague dorsal foot pain in an athlete in a running sport can represent a **navicular stress fracture**. Unlike other stress fractures, it might not localize well on examination. If there is any tenderness around the navicular, a stress fracture should be suspected. This stress fracture can take many weeks to show up on plain radiographs, so MRI should be done to confirm the diagnosis. Because this fracture is at high risk of nonunion, immobilization and non–weight-bearing for 8-12 weeks is the usual treatment. A CT scan should be obtained to document full healing after the period of immobilization.

Sever disease (calcaneal apophysitis) occurs at the insertion of the Achilles tendon on the calcaneus and manifests as activity-related pain (see Fig. 728.3). It is more common in males, is often bilateral, and usually occurs between ages 8 and 13 years. Tenderness is elicited at the insertion of the Achilles tendon into the calcaneus, especially with squeezing the heel (positive squeeze test). Sever disease is associated with tight Achilles tendons and mid-foot hyperpronation that puts more stress on the plantar flexors of the foot. Treatment includes relative rest, ice, massage, stretching, and strengthening the Achilles tendon. Correcting the mid-foot hyperpronation with orthotics, arch supports, or stabilizing shoe wear is important in most athletes with Sever disease. If the foot is neutral or there is mild hyperpronation, cushioned heel lifts can be helpful to unload the Achilles tendon and its insertion. With optimal management, symptoms frequently improve in 4-8 weeks. Generally, if there is no limp during the athletic activity, young athletes with Sever disease should be allowed to play.

Plantar fasciitis is an overuse injury resulting in degeneration of the plantar aponeurosis. Rare in prepubertal children, this diagnosis is more likely seen in the adolescent or young adult. Athletes report heel pain with activity that is worse with the first steps of the day or after several hours of non–weight-bearing. Tenderness is elicited on the medial calcaneal tuberosity. Relative rest from weight-bearing activity is helpful. Athletes get plantar fasciitis when shoes are worn with inadequate arch supports. New shoes or use of semirigid arch supports often lessen the pain. Stretching the calves and plantar fascia helps, assisted at times with therapeutic ultrasound treatment. Some patients benefit from night splints even though they can make sleep difficult. As long as there is no limping with athletic activity, the athlete may continue participation. Complete recovery is usually seen at 6 months. Corticosteroid injection, extracorporeal shock-wave therapy, or injections of platelet-rich plasma can be considered in those cases recalcitrant to conservative treatments.

Calcaneal stress fracture is seen in the older adolescent or young adult involved in a running sport. There is heel pain with any weight-bearing activity. The physical examination reveals pain with squeezing the calcaneus. Sclerosis can show up on the AP and lateral radiographs after 2-3 weeks of pain. MRI may need to be performed to confirm the diagnosis in some cases. The calcaneus is an uncommon location for a stress fracture and is often associated with osteopenia. Treatment is rest from running and other weight-bearing activity for at least 8 weeks. Immobilization is rarely necessary.

Pes planus, or "flat feet," may be termed "flexible" or "rigid." Flexible pes planus is usually asymptomatic and is the most common type found in children (see Chapter 715.5). Foot orthotics may be helpful for older children with foot pain or associated muscle cramping. Rigid pes planus is a congenital deformity associated with other anomalies in 50% of cases. It is caused by failure of the tarsal bones to separate, leaving a bony cartilaginous or fibrous bridge or coalition between two or more tarsal bones (see Chapter 715.6). Talocalcaneal coalitions are more symptomatic between 12 and 16 years of age, whereas calcaneonavicular coalitions are more symptomatic between 8 and 12 years of age. Symptoms are insidious with occasional acute arch, ankle, and mid-foot pain, which is at times brought on with sports-related activities. The hindfoot often does not align in its normal varus position on tiptoe maneuvers. Patients are predisposed to ankle sprains secondary to limited subtalar motion, and stress to the subtalar and transverse tarsal joints frequently causes pain. CT scans are diagnostic, and initial treatment is conservative with short leg casting and/or molded orthoses and rest. In the case of failure of conservative care, surgical intervention is usually necessary. Rigid cavus feet can also be associated with metatarsalgia, clawing, and intrinsic muscle atrophy, which are all possible in the young athlete (see Chapter 715.7). With a cavus foot, undiagnosed neurologic conditions, such a Charcot-Marie-Tooth disease, spinal dysraphism, Friedrich ataxia, or spinal tumor, need to be considered. Custom-molded orthotics may be helpful, and family history can be critical. Symptomatic, accessory navicular bones and sesamoiditis can be considered when these areas are painful and do not have evidence of fracture or prior trauma. These conditions are more common in the adolescent or younger adult and can be exacerbated with sporting activities.

Other conditions causing foot pain include **Lisfranc sprain** and/or dislocation, which is more common in football linemen or other athletes requiring heavy loading on the mid-foot and forefoot joints, and gymnasts using the balance beam. The Lisfranc joint is the tarsal metatarsal articulation of the three cuneiform bones and the cuboid with the five proximal metatarsals. Turf toe can be seen, particularly in the older child and/or adolescent running on artificial or synthetic surfaces. It results from hyperextension through the first metatarsal phalangeal joint, spraining the ligaments surrounding the joint often in a football and/or soccer activity.

Iselin apophysitis is an apophysitis that occurs at the tuberosity of the fifth metatarsal. The apophysis at this site appears between the ages of 9 and 14 years and is located within the insertion of the peroneus brevis tendon. This condition can be a predisposing factor to dancer's fracture (see Chapter 728.8). **Freiberg disease**, which involves the collapse of the articular service and subchondral bone, usually of the second metatarsal, and **Kohler disease**, which involves irregular ossification of the tarsal navicular joint with localized pain and increased density, should always be considered in the evaluation **osteochondroses of the foot** (see Chapter 715.8). Freiberg disease is more common in girls between the ages of 12 and 15 years, whereas Kohler disease occurs in younger individuals, age 2-9 years, and is frequently reversible with conservative care, including orthoses and casting.

Visit Elsevier eBooks+ at eBooks.Health.Elsevier.com Bibliography.

Chapter 729

Sports-Related Traumatic Brain Injury (Concussion)

Alex M. Taylor, William P. Meehan III, and Mark R. Proctor

Concussion is a form of **traumatic brain injury** (TBI) caused by sudden acceleration, deceleration, or rotational forces to the brain, which can occur with a blow to the head, neck, face, or body. The resulting pathophysiologic state is associated with a constellation of signs and symptoms that, for **sport-related concussions (SRCs)**, typically self-resolve within 7-10 days. A minority of children can experience **persistent postconcussion symptoms** (PPCS) that extend beyond 28 days and limit functional ability, cause social isolation, reduce school attendance and performance, and can lead to anxiety, mood alteration, and lower quality of life. Accurate diagnosis and appropriate management of concussion is needed to safely return children to school and sports and to avoid the potential for worse outcomes.

DEFINITION/TERMINOLOGY

The spectrum of TBI ranges from mild to severe. Classification is typically determined by score on the Glasgow Coma Scale (see Chapter 79), with severe = ≤8, moderate = 9-12, and mild = 13-15. Although concussion and **mild TBI (mTBI)** are sometimes used interchangeably, concussion may be best understood as the *clinical syndrome* that is associated with mTBI. There are several agreed on features:

- Concussion may be caused by a direct blow to the head, face, neck, or elsewhere on the body with an "impulsive" force transmitted to the head.
- Concussion typically results in the rapid onset of short-lived impairment of neurologic function that resolves spontaneously. However, in some cases, signs and symptoms may evolve over minutes to hours.
- Concussion may result in neuropathologic changes, but the acute clinical signs and symptoms largely reflect a *functional* disturbance rather than a structural injury and, as such, no abnormality is seen on standard structural neuroimaging studies.
- Concussion results in a range of clinical signs and symptoms that may or may not involve loss of consciousness (Fig. 729.1). Resolution of the clinical and cognitive features typically follows a sequential course. However, in some cases, symptoms may be prolonged.

To be defined as a concussion, the clinical signs and symptoms cannot be explained by drug, alcohol, or medication use, other injuries (such as cervical injuries, peripheral vestibular dysfunction), or other comorbidities (e.g., psychologic factors or coexisting medical conditions).

EPIDEMIOLOGOY

According to the Centers for Disease Control and Prevention (CDC), as many as 3.8 million sport-related TBIs may occur in the United States annually with 70–90% of these injuries classified as concussion. One study suggested that current surveillance systems may capture only one out of every nine concussions.

Approximately 20% of middle and high school children report a lifetime prevalence of concussion. Sports participation is the most common mechanism of injury. An estimated 1.1-1.9 million recreational and sports-related concussions occur each year in children 18 years or younger. In gender comparable sports, female athletes report higher rates of concussion than males, and both groups are more likely to suffer a concussion in competition than at practice. Among males, the incidence of concussion is highest in collision (contact) sports, including rugby, American football, ice hockey, lacrosse, basketball, soccer, and wrestling. Among females, the incidence of concussion is highest in soccer, lacrosse, and field hockey. Other sports and recreational activities in which concussions frequently occur include bicycling, skateboarding, skiing, and snowboarding. Younger children may have playground-associated concussions.

PATHOPHYSIOLOGY

The constellation of symptoms associated with concussion are not caused by observable structural injury or hemorrhage; clinical imaging studies (MRI/CT) typically are normal. However, there is a proposed cascade of events that lead to the clinical syndrome. A sudden acceleration, deceleration, or rotation of the brain is thought to result in parenchymal shear stress and strain that disrupts neuronal function in a cascade of ionic and metabolic fluctuations. Affected neurons experience massive depolarization and then require additional adenosine triphosphate (ATP) to restore cellular homeostasis. Glucose levels dramatically increase to fuel ATP production, which ultimately causes lactic acid accumulation. At the same time this process occurs, there is a decrease in cerebral blood flow, which may persist for several weeks. Consequently, less glucose is available when it is most needed to fuel ATP for ionic recovery. The signs and symptoms of concussion are thought to reflect the energy crisis or mismatch between the demand and availability of fuel in the brain after trauma.

SIGNS AND SYMPTOMS

Signs and symptoms of concussion can be classified into five categories, including somatic, vestibular, cognitive, emotional, and sleep related (Table 729.1). Acutely, headache is the most commonly reported symptom, followed by dizziness, difficulty concentrating, and confusion. Sleep disturbance, anxiety, and mood-related symptoms are more likely to occur several weeks post-injury. Brief loss of consciousness occurs in less than 5% of SRCs and is not associated with injury severity or time to recover. The most reliable predictor of recovery is initial symptom burden; children who experience greater symptom load and severity are at increased risk of PPCS. However, several noninjury–related factors can also affect recovery, including female sex, history of migraines, history of prior concussion, poorer preinjury child adjustment, family dysfunction, neurodevelopmental disorder (e.g., learning disability, attention-deficit/hyperactivity disorder [ADHD]), and psychiatric illness (e.g., anxiety, depression).

Although concussion typically results in an immediate onset of short-lived neurologic dysfunction that resolves spontaneously, signs and symptoms may develop over several minutes to hours. The diagnosis can be challenging and further complicated by the presence of concussion-like symptoms in noninjured athletes. Children with preexisting neurodevelopmental disorders, mental health concerns, history of prior concussion, or headaches/migraines may endorse concussion-like symptoms in the absence of injury. A reasonable mechanism of injury needs to be identified as well as a measurable change from baseline symptoms. To this end, age-appropriate symptom scales or checklists may be useful in assessing SRC and monitoring recovery (Table 729.1). Many symptom rating scales are available, and some are incorporated into sideline assessment tools, including the Sport Concussion Assessment Tool version 6 (SCAT6), which is approved for age 13 years and older. It is important to use a developmentally appropriate scale for younger children (e.g., Child-SCAT6 for children age 5-12 years) and to use the same tool in subsequent assessments to allow for tracking of symptoms over time.

INITIAL ASSESSMENT AND TOOLS

The initial diagnosis and management of concussion often begins on the field, rink, or court. Whether on the sideline and/or at a medical clinic, the first step is to rule out an injury that requires immediate attention. Acute care should include cervical spine stabilization, evaluation of airway, breathing, and circulation, and motor and sensory neurologic testing. Once a spinal cord injury or more severe injury to the brain is ruled out, it is important to: (1) perform a detailed evaluation of the athlete's mental status, (2) assess signs and symptoms, and (3) identify risks for delayed recovery (i.e., neurodevelopmental disorders, mental health concerns, history of prior concussion, or headaches/migraines). *This process is facilitated by use of a validated sideline*

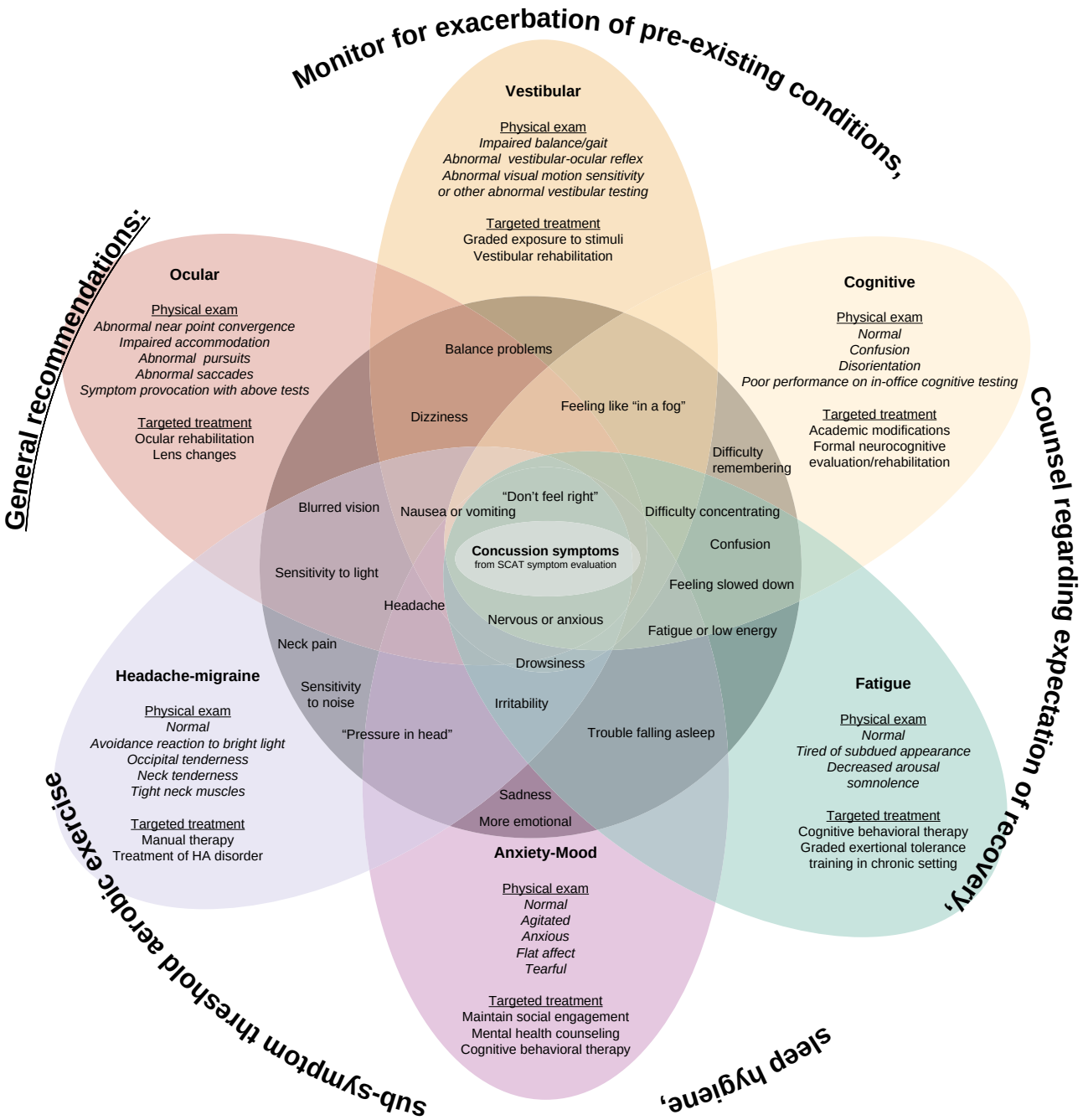

Fig. 729.1 Constellation of symptoms after concussion. Overlapping clinical domains to monitor and facilitate individualized management after concussion. *(From Harmon KG, Clugston JR, Dec K, et al. American Medical Society for Sports Medicine position statement on concussion in sport. Br J Sports Med. 2019;53[4]:213–225.)*

assessment tool. SCAT6 is recommended and includes standardized methods for recording relevant demographics, observable signs of injury, postconcussion symptoms, and memory function (excluding children <12 years), as well as the GCS, cervical spine assessment, brief neurologic exam, and the modified Balance Error Scoring System (m-BESS). Another often-used sideline assessment is the Sideline Assessment of Concussion, which includes a mental status exam, brief neurologic exam, and cognitive screen.

The Balance Error Scoring System (BESS) measures postural stability or balance and consists of six stances, three on a firm surface and the same three stances on an unstable (medium density foam) surface. The modified BESS (m-BESS) is frequently used because it does not rely on availability of medium-density foam for administration. Both include three stances: feet shoulder width apart, a tandem stance (one foot in front of the other), and a single-leg stance on the person's nondominant leg, which are performed for 20 seconds with eyes closed and hands on the iliac crests. An error is recorded each time athletes lift their hands off their hips, open their eyes, step, stumble, fall, remain out of the test position for more than 5 seconds, move hips into more than 30 degrees of flexion or abduction, or lift their forefoot or heel. Normative data are available for comparison, although preseason balance screening provides more precise, individualized data. Furthermore, most evidence suggests that balance impairments generally resolve within 3 days postinjury.

Clinicians should screen for vision problems after concussion. In addition to visual acuity and visual field testing, the Vestibular Ocular Motor Screening Assessment (VOMS) is another tool that is increasingly used to evaluate concussion. It involves a standardized method to

Table 729.1 Postconcussion Symptom Scale

	NONE	MILD		MODERATE		SEVERE	
Headache	0	1	2	3	4	5	6
"Pressure in head"	0	1	2	3	4	5	6
Neck pain	0	1	2	3	4	5	6
Nausea or vomiting	0	1	2	3	4	5	6
Dizziness	0	1	2	3	4	5	6
Blurred vision	0	1	2	3	4	5	6
Balance problems	0	1	2	3	4	5	6
Sensitivity to light	0	1	2	3	4	5	6
Sensitivity to noise	0	1	2	3	4	5	6
Feeling slowed down	0	1	2	3	4	5	6
Feeling like "in a fog"	0	1	2	3	4	5	6
"Don't feel right"	0	1	2	3	4	5	6
Difficulty concentrating	0	1	2	3	4	5	6
Difficulty remembering	0	1	2	3	4	5	6
Fatigue or low energy	0	1	2	3	4	5	6
Confusion	0	1	2	3	4	5	6
Drowsiness	0	1	2	3	4	5	6
More emotional	0	1	2	3	4	5	6
Irritability	0	1	2	3	4	5	6
Sadness	0	1	2	3	4	5	6
Nervous or anxious	0	1	2	3	4	5	6
Trouble falling asleep	0	1	2	3	4	5	6

From Echemendia RJ, Meeuwisse W, McCrory P, et al. Sport concussion assessment tool—5th edition. *Br J Sports Med.* 2017;51:851–858.

assess smooth pursuits, horizontal and vertical saccades, convergence, horizontal vestibular ocular reflex, and visual motion sensitivity. Findings on the VOMS have been shown to distinguish children with concussion from uninjured controls, and vestibular-ocular dysfunction may have a particularly deleterious effect on academics.

Neuropsychologic assessment quantifies cognitive symptoms of concussion and can help to identify comorbidities that can complicate the diagnosis. The areas identified as most vulnerable to injury include attention and executive function (e.g., speed of processing), new learning and memory, and reaction time. Obtaining preseason or "baseline" data enables clinicians to accurately detect cognitive impairment after injury and aids interpretation of data for athletes with preexisting or contextual factors that affect cognitive function (e.g., neurodevelopmental disorder, sleep, anxiety, and depression). Computer-administered neurocognitive tests are frequently used because the cost and availability of trained neuropsychologists to administer and interpret more comprehensive tests are prohibitive. Further, testing may be of additional benefit in determining appropriate school and home interventions for children who go on to experience PPCS.

The application of neuropsychologic assessment varies depending on the time of referral. Research generally supports the use of brief cognitive screens acutely (~3 days postinjury) such as those incorporated into the SCAT and SAC. Computerized administered neurocognitive assessment or a hybrid approach that includes paper and pencil measures of function are most often administered subacutely (~4-30 days postinjury) to assist in return-to-play decision-making, documenting lingering cognitive deficits, and providing rationale for academic supports or accommodations. The purpose of neuropsychologic assessment for patients with prolonged or chronic postconcussion symptoms (30+ days) is to provide the referring clinician and patient with additional insight into injury and noninjury factors affecting recovery, as well as their impact on cognitive function. Symptoms of comorbidities, including sleep deprivation, deconditioning, and pain, closely resemble postconcussion symptoms and similarly influence health-related status and cognition. Research also indicates that anxiety and depression, family functioning, and caregiver adjustment, as well as neurodevelopmental disorders (e.g., learning disability or ADHD) are strong predictors of prolonged symptoms.

In addition to ruling out more severe injury, the primary goal of both sideline assessment and/or office-based assessment is to prevent concussed athletes from returning to play prematurely. The brain is likely more vulnerable to reinjury immediately after concussion and until ionic and metabolic functioning normalizes. Consistent with this, most reinjuries occur within the first 10 days of an initial concussion. Thus, if a concussion is suspected, it is often wise to remove younger athletes from play for 24 hours or until the diagnosis of concussion can be confidently ruled out. Athletes who experience prolonged loss of consciousness, focal neurologic deficits, excessive somnolence, progressively worsening headache pain, repeated vomiting, slurred speech, and significant confusion may need to be seen in the emergency department where brain imaging can be conducted to rule out more severe head injury.

A blood test (Brain Trauma Indicator) is FDA approved for patients ≥18 years of age with concussion who have normal mental status) to help identify patients in need of cranial imaging. The test measures brain proteins, glial fibrillary acid protein, and ubiquitin C-terminal hydroclase-1, and may also be useful in detecting concussion in children.

MANAGEMENT

After diagnosis and removal from play, the initial management strategy is education of the child and parents about concussion, including the signs and symptoms, effects on cognition, and expected trajectory of recovery. Early limited, subsymptom levels of physical activity may improve recovery, whereas complete rest beyond 2-3 days is associated with delayed recovery. Children (symptomatic or asymptomatic) who can tolerate light exercise soon after injury should be encouraged to do so because it prevents deconditioning and can help with sleep and mood regulation. Importantly, early moderate and intense exercise is associated with symptom exacerbation and longer recovery times, and exercise of any intensity is deferred if it provokes symptoms in the first few days postinjury. Most children will begin to achieve some level of activity tolerance within 2-3 days. Management plans should then focus on gradually and progressively resuming noncontact, low-risk physical activity until full recovery (Table 729.2).

Most children who sustain a concussion will experience full recovery with adherence to relative rest, followed by graduated return to physical and cognitive activity. Nonetheless, some athletes require targeted symptom management, particularly when they are slow to improve (Table 729.3; see Fig. 729.1). Acetaminophen or NSAIDs may help to reduce acute headache pain. Prescription medications are sometimes warranted, including topiramate, amitriptyline, or cyproheptadine for posttraumatic headaches, peripheral nerve blocks for occipital or cervicogenic headaches, and gabapentin for headaches with a neuropathic component. Otolaryngology referral or vestibular therapy is recommended for management of dizziness, vertigo, and imbalance. For children with visual disturbance, assessment and visual rehabilitation therapy managed by an optometrist or ophthalmologist is appropriate. Psychologic assessment and intervention, particularly cognitive behavioral therapy, is recommended

Table 729.2 Graduated Return to Play Protocol

STAGE	AIM	ACTIVITY	GOAL OF EACH STEP
1	Symptom-limited activity	Daily activities that do not provoke symptoms	Gradual reintroduction of work/school activities
2	Light aerobic exercise	Walking or stationary cycling at slow to medium pace. No resistance training	Increase heart rate
3	Sport-specific exercise	Running or skating drills. No head impact activities	Add movement
4	Noncontact training drills	Harder training drills (e.g., passing drills). May start progressive resistance training	Exercise, coordination, and increased thinking
5	Full contact practice	After medical clearance, participate in normal training activities	Restore confidence and assess functional skills by coaching staff
6	Return to sport	Normal game play	

NOTE: An initial period of 24-48 hr of both relative physical rest and cognitive rest is recommended before beginning the return to sport progression.
There should be at least 24 hr (or longer) for each step of the progression. If any symptoms worsen during exercise, the athlete should go back to the previous step. Resistance training should be added only in the later stages (stage 3 or 4 at the earliest). If symptoms are persistent (e.g., more than 10-14 days in adults or more than 1 mo in children), the athlete should be referred to a healthcare professional who is an expert in the management of concussion.
From Patricios JS, Schneider KJ, Dvorak J, et al. Consensus statement on concussion in sport: the 6th International Conference on Concussion in Sport–Amsterdam, Oct 2022. *Br J Sports Med.* 2023;57:695.

Table 729.3 Common Potential Interventions for Specific Symptoms After Pediatric Concussion

SPECIFIC SYMPTOMS	POTENTIAL INTERVENTIONS
Headache	Lifestyle modifications (water intake, meal schedule, sleep, and exercise), cervicovestibular therapy, acute medications, preventive medications, and avoiding overuse of acute medications
Light-Headedness or Exercise Intolerance	Increase water and salt intake and gradual increase in exercise
Dizziness or Neck Pain	Vestibular therapy and cervical spine therapy
Balance or Coordination Difficulties	Neuromuscular training
Sleep Difficulties	Lifestyle modifications (bedtime routine, white noise, avoid caffeine, and exercise earlier), and melatonin
Anxiety or Mood Problems	Counselling, antidepressants, and anxiolytics
Cognitive Difficulties	Cognitive testing and academic accommodations

From Beauchamp MH, Degeilh F, Rose SC: Improving outcome after paediatric concussion: challenges and possibilities. *Lancet Child Adolesc* 2023;7:728-738 (Panel 2, p. 733).

for athletes who experience worsening or newly developed symptoms of anxiety or depression. Both are potentially heightened as a direct consequence of concussion as well as the resulting limitations on everyday activities and social interaction. A multidisciplinary and collaborative approach to target specific treatments is advised for children whose symptoms do not show improvement with standard behavioral interventions.

Return to School

Of particular importance to children and their families is the effect of concussion on cognitive function and school performance. Children and adolescents exposed to greater levels of cognitive stress endorse worse symptoms and experience longer recovery after concussion. Students who experience postconcussion symptoms report difficulty in school. There is also evidence that overly restricting cognitive exertion and school participation can delay recovery. Current recommendations focus on using self-reported symptoms to determine school readiness, followed by increasing exposure to classroom learning, tests, and assignments (Table 729.3). In general, children and adolescents are encouraged to attend school, even if on a modified schedule, in 2-3 days or sooner, with a program of academic adjustments and modifications that allow for ongoing learning to occur with minimal symptom provocation. Clinicians should provide documentation to schoolteachers and administrators requesting compressed assignments, more time to complete tests or assignments, deferred examinations, rest breaks, audiobooks, oral teaching, large font printed material, or preprinted notes where indicated.

Return to Play

There is a six-stage return-to-play (RTP) protocol for a safe return to activities (see Table 729.2). Starting with physical rest, athletes are progressed to light aerobic exercise, moderate levels of sport-specific exercise, noncontact training drills, full contact practice, and normal game play. Athletes should be completely asymptomatic, free of medications used to treat concussion symptoms, at full school, and back to baseline functioning on all domains tested before the injury before returning to contact or collision sports. Children and adolescents should remain at each stage of rehabilitation for no less than 24 hours before advancing to the next level. Thus a minimum of 5 days should pass before consideration of full return to competition. If symptoms return at any stage of exertion, the athlete should rest until the symptoms resolve and then return to the previous level of exertion. The final decision for RTP should be made by a licensed clinical provider with experience in the evaluation and management of sports-related concussions. Note that some states or schools require an extended minimum number of symptom-free days before RTP, so clinicians need to be aware of the laws or local recommendations regarding RTP.

Risks for Persistent Postconcussion Symptoms

From 80–90% of children and adolescents diagnosed with concussion will clinically recover within 4 weeks. Factors associated with prolonged recovery include a history of prior concussions, female

Table 729.4 Graduated Return to School Strategy

STAGE	AIM	ACTIVITY	GOAL OF EACH STEP
1	Daily activities at home that do not give the child symptoms	Typical activities of the child during the day as long as they do not increase symptoms (e.g., reading, texting, screen time). Start with 5-15 min at a time and gradually build up	Gradual return to typical activities
2	School activities	Homework, reading, or other cognitive activities outside of the classroom	Increase tolerance to cognitive work
3	Return to school part-time	Gradual introduction of schoolwork. May need to start with a partial school day or with increased breaks during the day	Increase academic activities
4	Return to school full time	Gradually progress school activities until a full day can be tolerated	Return to full academic activities and catch up on missed work

From Patricios JS, Schneider KJ, Dvorak J, et al. Consensus statement on concussion in sport: the 6th International Conference on Concussion in Sport–Amsterdam, Oct 2022. *Br J Sports Med.* 2023;57:695.

sex, history of migraines, neurodevelopmental disorder (e.g., ADHD, learning disability), successive concussion soon after recovery, and acute symptom severity and burden. Female sex and initial symptom severity are the factors associated with more persistent symptoms in adolescents.

Retiring Young Athletes

Retirement from contact sports is rare but sometimes indicated, even in younger athletes. Indications for retirement include chronic neuropsychologic deficit, increased recovery times for successive injuries, decreased threshold for repeat concussions, and multiple concussions over the course of an athletic career.

COMPLICATIONS/LONG-TERM EFFECTS

Second impact syndrome, seen more frequently in younger athletes than adults, refers to a rare, catastrophic neurologic injury involving diffuse cerebral swelling that purportedly occurs in athletes who sustain a second head injury before full recovery from a concussion. Although second impact syndrome is rare, its occurrence highlights the importance of removing children with concussion from play and other activities that place them at increased risk of head injury until fully recovered. Pathogenic variants in *CACNA1A* have been associated with delayed and severe cerebral edema after minor head trauma.

Some literature suggests that young athletes who suffer repetitive head impacts and multiple concussions may be at risk for neurodegenerative diseases, such as chronic traumatic encephalopathy (CTE) or Alzheimer disease. CTE describes pathologic changes in the brain observed postmortem, which are hypothesized to be associated with changes in mood, behavior, and cognition function. At present, there is no way to diagnose CTE in living persons and its incidence and prevalence are unknown.

PREVENTION

The strongest evidence for concussion prevention is in support of concussion education initiatives, age limits on contact, fair play, and adherence to rules of the game or competition. Additionally, there is some evidence that neck strengthening may reduce the risk of concussion. Current research shows no proven benefit to personal protective equipment (i.e., helmets, mouthguards) or dietary supplements in reducing the risk of concussion or its severity, although it is important for athletes to wear properly fitted sport specific protective equipment to prevent *more serious* head injury and maxillofacial and dental trauma.

Visit Elsevier eBooks+ at eBooks.Health.Elsevier.com for Bibliography.

Chapter 730

Cervical Spine Injuries

Julie M. Kerr and Joseph A. Congeni

Sports participation has surpassed motor vehicle crashes as the number one cause of cervical spine injuries (primarily involving soft tissue) in youth older than 8 years of age. American football, hockey, wrestling, and gymnastics have the highest incidence in the United States; internationally, rugby is nearly as high. Catastrophic cervical spine injuries fortunately are rare but can occur as a result of the scrum or tackling in rugby and tackling plays in American football.

The normal cervical spine has a lordotic curve, allowing it to absorb shock and dissipate force with application of an axial force. When the neck is flexed forward, the spine straightens, losing this shock-absorbing property. An axial load to the top of the head in this flexed position transmits force through the spine.

SOFT TISSUE INJURY

The most frequent injury resulting from trauma to the head and neck involves the muscles, tendons, and ligamentous structures. Even though strains, sprains, and contusions are common and are managed with cervical, scapulothoracic, and shoulder-strengthening exercises, thorough evaluation is required to rule out more serious injuries. Even without bony abnormalities, the cervical spine may become unstable secondary to soft tissue injury.

Spinal laxity results when most restraining ligaments are injured. When compared with adjacent vertebra, laxity should horizontally be less than 3.5 mm and angular displacement less than 11 degrees on plain flexion/extension films. However, younger athletes have more baseline laxity, making the criteria less applicable, and muscle spasm can acutely mask instability. If subluxation is remotely suspected, a hard cervical collar should be placed and flexion/extension views obtained again at 2-4 weeks when inflammation and spasm have subsided. A loss of lordosis on lateral x-ray is associated with significant weakness of cervical muscles, particularly the cervical extensors. Disk injuries are rare in pediatric patients. Rupture or herniation must be considered in any cervical pain differential (see Chapter 81).

SPEAR TACKLER'S SPINE

This clinical entity is characterized by progressive spinal changes secondary to incorrect tackling form. Findings on plain x-ray consist of (1) narrowing of cervical spinal canal, (2) loss or reversal of normal cervical lordosis, and (3) preexisting minor posttraumatic x-ray evidence of bony

or ligamentous injury. Although rule changes in collision and contact sports have limited the practice of contacting an opponent with a "head-down" neck position, this condition persists. Most experts argue that this condition disqualifies athletes from return to play.

CERVICAL FRACTURES

All significant neck injuries should be treated seriously until cleared with appropriate examination and imaging. Although many cervical fractures are stable, improper management or inadequate evaluation could produce catastrophic results. *Until formally evaluated, the patient should be immobilized and treated as if the patient has an unstable cervical fracture* (see Chapter 81).

STINGERS (BURNERS)

Stingers are unilateral *(never bilateral)* peripheral nerve injuries occurring at an anatomic location between the cervical nerve root and the brachial plexus. Three proposed mechanisms include traction or tensile stretch injury, compressive injury, and direct trauma. A typical presentation is a transient episode of unilateral burning pain, with or without numbness, that radiates from the shoulder, down the upper arm, and into the hand. Symptoms of C5 and C6 root injury with deltoid and biceps weakness are the most common presentation. These symptoms may last for several minutes to days but do not result in permanent neurologic deficit or abnormal imaging evaluations. Examination should assess for weakness, especially shoulder abduction, external rotation, and elbow flexion. The cervical spine should have full and pain-free range of motion and no tenderness to palpation.

The Spurling Compression test helps to assess for cervical radiculopathy as a cause of upper extremity pain. The patient is seated with their neck tilted to the affected side. In a positive test, the pain is reproduced with gentle axial compression. The test has high specificity (~93%) but relatively low sensitivity (~30%), meaning that positive tests indicate likely cervical radiculopathy but many patients with cervical radiculopathy will not have a positive test.

Return to play may be considered the same day if the exam is reassuring. This requires complete resolution of symptoms, full range of motion, and normal strength. Multiple stingers, bilateral symptoms, or symptoms persisting for longer than one hour should prompt further evaluation with cervical spine radiographs and other imaging modalities as indicated before resumption of any physical activities.

BURNING HANDS SYNDROME

The athlete with this syndrome presents with intense paresthesia and associated hand and arm weakness in both upper extremities. This is suggestive of a central cord syndrome with cord compression of the spinothalamic and corticospinal tracts. As with stingers, most of these episodes resolve in minutes to days. Persistent symptoms or repeated episodes warrant further evaluation and imaging.

TRANSIENT QUADRIPARESIS

Transient quadriparesis is a temporary neurologic episode encompassing sensory symptoms with or without motor changes. Transient quadriparesis is also known as *cervical cord neurapraxia*, *commotio spinalis*, and *spinal cord concussion*. Transient quadriparesis can be divided into three types: plegia (complete loss of motor function), paresis (motor weakness), and paresthesia (sensory symptoms only). There is also a three-part grading system: grade 1 symptoms lasting less than 15 minutes, grade 2 symptoms lasting 15 minutes to 24 hours, and grade 3 symptoms persisting beyond 24 hours. Transient quadriparesis must be differentiated from a stinger, and the player should be removed from activity and spinal cord injury considered.

Mechanisms of injury include hyperextension, hyperflexion, and axial loading. Anatomically, when the neck is hyperflexed or hyperextended, the spinal canal is narrowed by up to 30%, increasing the likelihood of cord injury.

Evaluation should start with plain flexion and extension films if stable. CT should be used if cervical fracture is suspected. MRI should then be used to evaluate for intrinsic spinal cord abnormalities or ongoing cord or root compression.

Table 730.1 Return to Play

NO CONTRAINDICATION TO RTP	
Healed fractures	Healed C1 or C2 fracture with normal cervical spine ROM Healed subaxial fracture without sagittal plane deformity Asymptomatic clay-shoveler's (C7) spinous process avulsion fracture
Congenital conditions	Klippel-Feil (single-level anomaly not C0/C1 articulation) Spina bifida occulta
Degenerative/ postsurgical conditions	Cervical disk disease (no change in baseline neurologic status) Single-level ACF with/without instrumentation Single- or multiple-level posterior cervical laminotomy
Recurrent stingers	Fewer than three episodes lasting <24 hours Must have full cervical range of motion No persisting neurologic deficit
Transient quadriparesis	Single episode Full cervical range of motion Normal neurologic exam No radiologic instability Normal spinal reserve (as evidenced on MRI)
RELATIVE CONTRAINDICATION TO RTP	
Stingers/burners	Prolonged symptomatic burner/stinger Three or more stingers
Transient quadriparesis	Transient quadriparesis lasting >24 hours More than 1 episode with symptoms of any duration
Postsurgical	Healed two-level ACF PCF with/without instrumentation
ABSOLUTE CONTRAINDICATION TO RTP	
Transient quadriparesis and any one or more of	Cervical myelopathy Continued neck discomfort Reduced ROM Neurologic deficit from baseline after injury
Surgical procedures	C1 + C2 fusion Cervical laminectomy Three-level ACF or PCF
Soft tissue injuries	Asymptomatic ligamentous laxity (>11 degrees of kyphotic deformity) C1 + C2 hypermobility with anterior dens >3.5 mm (adult), >4 mm (child), i.e., Down syndrome Symptomatic cervical disk herniation
Other conditions	Spear tackler's spine Multilevel Klippel-Feil anomaly (see Chapter 721.2) Healed subaxial fracture with sagittal kyphosis, coronal plane abnormality, or cord encroachment Ankylosing spondylitis Rheumatoid arthritis with spinal abnormalities Spinal cord abnormality (cord edema, compression, etc.) Arnold-Chiari syndrome Basilar invagination Occipital-C1 assimilation (occipitalization or connection) Spinal stenosis (canal width <13 mm between C3 and C7)

ACF, Anterior cervical fusion; PCF, posterior cervical fusion; ROM, range of motion; RTP, return to play.

Adapted from Cantu R, Li YM, Abdulhamid M, et al. Return to play after cervical spine injury in sports. *Curr Sports Med Rep*. 2013;12:14–17.

Fig. 730.1 An MRI (sagittal) demonstrating spinal cord contusion (edema in central portion of spinal cord). *(From Krabak BJ, Kanarek SL. Cervical spine pain in the competitive athlete. Phys Med Rehabil Clin N Am. 2011;22:459–471. Fig. 2).*

Return to play for transient quadriparesis is heavily debated and lacks data to guide decision-making. Some experts argue that one episode is a contraindication to return to contact sports, whereas others agree with using the Return to Play Table (Table 730.1) for absolute and relative contraindications for return. If allowed to return to play and a second episode of transient quadriparesis occurs, the complete workup must be repeated.

CONGENITAL SPINAL STENOSIS

Developmental narrowing of the cervical spinal canal predisposes an athlete to higher risk of spinal cord injury. This condition can be found incidentally while working up other conditions. Currently, the "gold standard" imaging modality is an MRI measuring a canal width of <13 mm between C3 and C7 to define stenosis, with "normal" being greater than 15 mm.

Functional stenosis can be seen with dynamic MRI in flexion and extension to determine whether the canal space decreases with movement. The positioning of the canal in flexion or extension causes narrowing from movement of the vertebra and ligament, respectively. The measured diameter may be irrelevant if disk protrusion or ligament hypertrophy causes compression. This narrow "reserve space" around the spinal cord puts the athlete at greater risk for injury as compared with the same force applied to a normal spine.

SPINAL CORD INJURY

Spinal cord injury is the most devastating complication of cervical trauma. Hemorrhage and transection are considered irreversible and associated with complete cord injury, whereas contusion and edema are considered to have more potential for recovery (Fig. 730.1). These severe injuries should be managed by providers with expertise in this area.

Visit Elsevier eBooks+ at eBooks.Health.Elsevier.com for Bibliography.

Chapter 731

Heat Injuries

Gregory L. Landry and Andrew M. Watson

Heat illness is among the leading causes of death in U.S. high school athletes. It is a continuum of clinical signs and symptoms that can be mild (heat stress) to fatal (heat stroke). Children are more vulnerable to heat illness than adults because they have a greater ratio of surface area to body mass and produce greater heat per kilogram of body weight during activity. The sweat rate is lower in children, and the temperature at which sweating occurs is higher. Although there is considerable interindividual variability, children can take longer to acclimatize to warmer, more humid environments (typically 8-12 near-consecutive days of 30- to 45-minute exposures). Children also have a blunted thirst response compared with adults and might not consume enough fluid during exercise in hot, humid environments to prevent dehydration. In addition, certain medications may predispose to heat-related injury (Table 731.1).

Three major categories for heat illness are generally used: heat cramps, heat exhaustion, and heat stroke (Table 731.2). However, symptoms of heat illness overlap and progress as the core temperature rises. **Heat cramps** are the most common heat injury and usually occur in mild dehydration and/or salt depletion, typically affecting the calf and hamstring muscles. They tend to occur later in activity, as muscle fatigue is reached and water loss and sodium loss worsen. Heat cramps will normally respond to oral rehydration with electrolyte solution and with gentle stretching. The athlete can return to play when the ability to perform is not impaired. Other minor heat illnesses include heat syncope, heat edema, and heat tetany. **Heat syncope** is fainting after prolonged exercise, attributed to poor vasomotor tone and depleted intravascular volume; it responds to fluids, cooling, and supine positioning. **Heat edema** is mild edema of the hands and feet during initial exposure to heat; it resolves with acclimatization. **Heat tetany** is carpopedal tingling or spasms caused by heat-related hyperventilation during short periods of exposure to intense heat. It responds to moving to a cooler environment and decreasing respiratory rate (or rebreathing by breathing into a bag).

Heat exhaustion is a moderate illness with a core temperature of 37.7–40°C (100–104°F). It is manifested as weakness, fatigue, headache, nausea, vomiting, dizziness, orthostasis, piloerection, and possibly syncope. Central nervous system dysfunction is mild, if present. Treatment includes moving to a cool environment, cooling the body with fans, removing excess clothing, and placing ice over the groin and axillae. If a patient is not able to tolerate oral rehydration, IV fluids are indicated. Patients should be monitored, including rectal temperature, for signs of heat stroke. If rapid improvement is not achieved, transport to an emergency facility is recommended.

Heat stroke is a severe illness manifested by central nervous system disturbances and potential tissue damage. It is a medical emergency; *the mortality rate is up to 50%*. Sports-related heat stroke is characterized by profuse sweating and is related to intense exertion, whereas "classic" heatstroke with dry, hot skin is of slower onset (days) in elderly or chronically ill persons. Rectal temperature is usually >40°C (104°F). Significant damage to the heart, brain, liver, kidneys, and muscle occurs, with possible fatal consequences if untreated. Treatment is immediate whole-body cooling via cold water immersion (Table 731.3). Airway, breathing, circulation, core temperature, and central nervous system status should be monitored constantly. Rapid cooling should be ceased when core temperature is approximately 38.3–38.9°C (101–102°F). IV fluid at a rate of 800 mL/m^2 in the first hour with normal saline or lactated Ringer solution improves

Table 731.1 Medications and Drugs That May Increase the Risk of Heat-Related Injury

MEDICATIONS
Anticholinergic agents (including antihistamines)
β Blockers
Antipsychotics (including SSRIs, TCAs)
Lithium
Diuretics
Salicylates
Sympathomimetic agents
Calcium channel blockers
Antiseizure medications (topiramate, zonisamide)
DRUGS OF MISUSE/SUPPLEMENTS
Amphetamines (including ephedra)
Cocaine
Ecstasy
Phencyclidine
Cathinone (synthetic marijuana) agents
LSD
Alcohol
Anabolic steroids

SSRI, selective serotonin reuptake inhibitors; LSD, lysergic acid diethylamide; TCA, tricyclic antidepressants.

Table 731.2 Spectrum of Heat Illness

HEAT CRAMPS AND DEHYDRATION: *CAUTIOUS RETURN TO PLAY*
Muscle cramps
Thirst
Fatigue
Light-headedness
Sweating
Flushed face
HEAT EXHAUSTION: *REMOVE FROM PLAY*
Dizziness
Rapid pulse
Headaches
Nausea
Vomiting
Loss of coordination
Profuse sweating
Core temperature less than 40°C (104°F)
HEAT STROKE: *MEDICAL EMERGENCY, CALL 911*
Core temperature of 40°C (104°F) or higher
Hot dry skin
Multiple system failure
Delirium
Convulsions
Abnormal vital signs

From Merkel DL, Molony JT Jr. Medical sports injuries in the youth athlete: emergency management. *Int J Sports Phys Ther.* 2012;7:242–251. Table 4.

Table 731.3 Current Therapy for Heat-Related Illness

- Acclimatization is key for prevention of exertional heat illness.
- Heat illness is most effectively managed by immediate recognition of the signs and symptoms and proper diagnosis.
- Core body temperature measurement *must* be done with a rectal thermometer.

EXERCISE-ASSOCIATED COLLAPSE

- Continue walking after race to prevent development.
- Position the patient in the supine or Trendelenburg position and start fluid administration.

HEAT EXHAUSTION

- Provide rapid cooling with ice bags to areas adjacent to large vasculature (groin, neck, axilla).
- Administer oral or intravenous (IV) fluid to correct for hydration deficit.

HEAT STROKE

- Ensure the ability to maintain adequate circulation, airway, and breathing.
- *Ice-water immersion is the most effective way to provide rapid cooling.*
- The goal of cooling is to reduce and maintain a temperature below 38.3°C (101°F).
- Transport to the hospital may be required if the patient's temperature is not reduced effectively or the patient does not return to normal mental status after 30 minutes of medical treatment.

From Cleland P. Heat illness. In: Kellerman RD, Rakel DP, Heidelbaugh JJ, Lee EM, eds. *Conn's Current Therapy 2023.* Philadelphia: Elsevier, 2023: p. 1390.

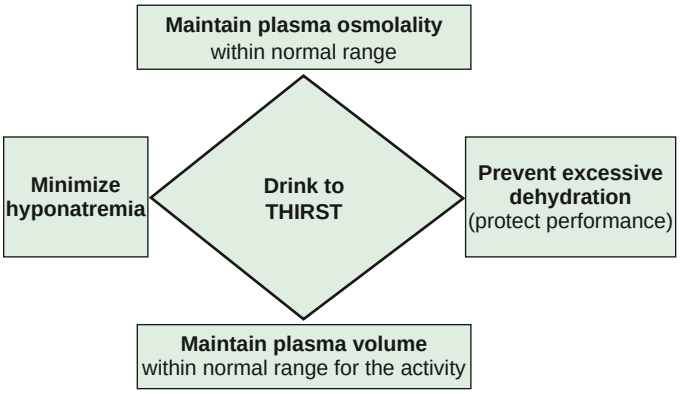

Fig. 731.1 Primary recommended fluid intake strategy to prevent symptomatic exercise-associated hyponatremia. *(From Hew-Butler T, Rosner MH, Fowkes-Godek S, et al. Statement of the third international exercise-associated hyponatremia consensus development conference, Carlsbad, California, 2015. Clin J Sport Med. 2015;25:303–320. Fig. 1.)*

intravascular volume and the body's ability to dissipate heat. Immediate transport to an emergency facility is necessary. Physician clearance is required before return to exercise.

Dehydration is common to all heat illness; consequently, measures to prevent dehydration may also prevent heat illness. Thirst is usually an adequate indicator of hydration status; excessive hypotonic fluid replacement beyond sweat and urine losses can lead to hyponatremia. Endurance athletes should be cautioned not to drink beyond thirst. Mild dehydration (2–3%) does not usually affect performance and itself does not cause cramping, fatigue, or heat stroke.

Exercise-associated hyponatremia (Na < 135 mmol/L) may be asymptomatic or symptomatic (lightheadedness, nausea, headache, confusion, cerebral edema) and is often seen in endurance sports (marathon, triathlon, cycling, swimming), hiking, football, and police or military drills. Major risk factors include overdrinking water or hypotonic sports drinks, weight gain during exercise, exercise duration >4 hours, readily available fluids, and inexperienced or slow pace. Athletes are advised to be hydrated before exercise and should drink to thirst (Fig. 731.1). Fluids should contain sodium and not be ingested in excess.

During a football practice, for example, scheduled breaks every 20-30 minutes with helmets off can decrease the cumulative amount of heat exposure. Practices and competitions should be scheduled in the early morning or late afternoon to avoid the hottest part of the day. Guidelines have been published about modifying activity related to temperature and humidity (Fig. 731.2). Proper clothing such as shorts and T-shirts without helmets can improve heat dissipation. Prepractice and postpractice weight can be helpful in determining the amount of fluid necessary to replace (8 oz for each pound of weight loss). When practicing or performing in a warm environment, gradual acclimatization is recommended.

NWS Heat index — Temperature (°F)

Relative humidity (%)	80	82	84	86	88	90	92	94	96	98	100	102	104	106	108	110
40	80	81	83	85	88	91	94	97	101	105	109	114	119	124	130	136
45	80	82	84	87	89	93	96	100	104	109	114	119	124	130	137	
50	81	83	85	88	91	95	99	103	108	113	118	124	131	137		
55	81	84	86	89	93	97	101	106	112	117	124	130	137			
60	82	84	88	91	95	100	105	110	116	123	129	137				
65	82	85	89	93	98	103	105	114	121	128	136					
70	83	86	90	95	100	105	112	119	126	134						
75	84	88	92	97	103	109	116	124	132							
80	84	89	94	100	106	113	121	129								
85	85	90	96	102	110	117	126	135								
90	86	91	98	105	113	122	131									
95	86	93	100	108	117	127										
100	87	95	103	112	121	132										

Likelihood of heat disorders with prolonged exposure or strenuous activity

Caution — Extreme caution — Danger — Extreme danger

Classification	Heat index	Effect on the body
Caution	80°F - 90°F	Fatigue possible with prolonged exposure and/or physical activity
Extreme danger	90°F - 103°F	Heat stroke, heat cramps, or heat exhaustion possible with prolonged exposure and/or physical activity
Danger	103°F - 124°F	Heat cramps or heat exhaustion likely, and heat stroke possible with prolonged exposure and/or physical activity
Extreme danger	125°F or higher	Heat stroke highly likely

Fig. 731.2 Heat index. To determine the heat index using this chart, air temperature and the relative humidity need to be known. For example, if the air temperature is 100°F and the relative humidity is 55%, the heat index will be 124°F. When the relative humidity is low, the apparent temperature can actually be lower than the air temperature. *(Courtesy National Weather Service, United States National Oceanic and Atmospheric Administration. https://www.weather.gov/ama/heatindex.)*

Fluids with electrolytes and carbohydrates are important during exercise lasting longer than 1 hour. Salt supplements should not be used by most people because of the risk of causing hypernatremia and delayed gastric emptying. If excessive fluid intake contributes to hyponatremia, salt supplements will not avoid the decline in serum sodium. They may be useful in a person with a high sweat rate or recurrent heat cramps.

Visit Elsevier eBooks+ at eBooks.Health.Elsevier.com for Bibliography.

Chapter 732

Nutrition and Endocrine Conditions in Athletes

Gregory L. Landry and Andrew M. Watson

Excessive physical training in young women can adversely affect reproductive function and bone mineral status, especially when combined with calorie restriction (Fig. 732.1; see Chapters 41 and 159).

The majority of bone mass is acquired by the end of the second decade of life (see Chapter 749). Approximately 60–70% of adult bone mass is genetically determined, and the remaining is influenced by three modifiable factors: exercise, calcium intake, and sex steroids (primarily estrogen). Exercise promotes bone mineralization in the majority of young women and should be encouraged. In females with eating disorders and those who exercise to the point of excessive weight loss with **amenorrhea** or **oligomenorrhea**, exercise can be detrimental to bone mineral acquisition, resulting in reduced bone mineral content, or **osteopenia**. In males, prolonged negative energy balance can similarly result in bone demineralization, although this may be more occult without the obvious sign of menstrual cycle disruption.

Specifically, bone mineralization is negatively affected by amenorrhea (absence of menstruation for 3 or more consecutive months). This may be influenced by abnormal eating patterns, or disordered eating, that results in insufficient caloric intake. When occurring together, disordered eating, amenorrhea, and osteoporosis represent the **female athlete triad**. A more inclusive definition refers to the interrelationships among energy availability, endocrine function, and bone mineral

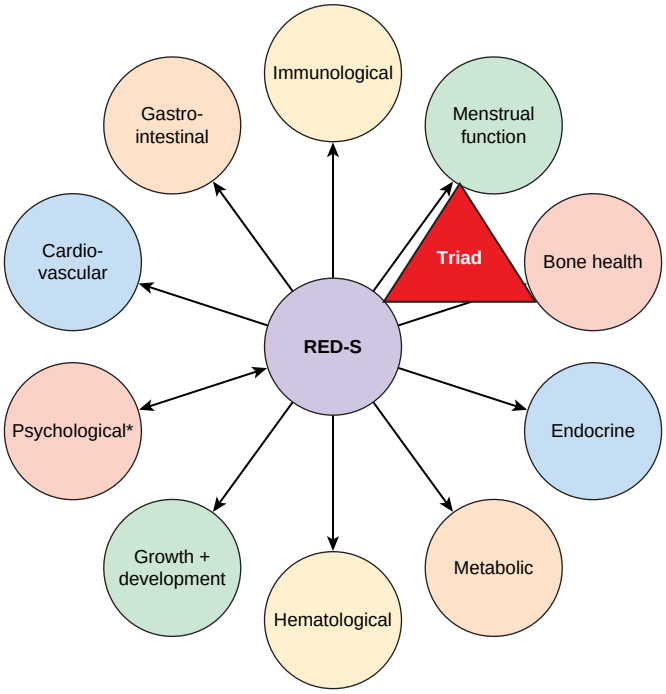

Fig. 732.1 Health consequences of relative energy deficiency in sport (RED-S) showing an expanded concept of the Female Athlete Triad to acknowledge a wider range of outcomes and the application to male athletes. *Psychologic consequences can either precede RED-S or be the result of RED-S. *(Courtesy Dr. Naama W. Constantini, Shaare Zedek Medical Center, Hebrew University, Israel.)*

density, as athletes are distributed along a spectrum of health and disease. The **male athlete triad** describes the impact of these interrelated problems in male athletes. In addition, the International Olympic Committee introduced the concept of **relative energy deficiency in sport** (RED-S), outlining the myriad physiologic, psychologic, and performance consequences of low energy availability in both male and female athletes (see Fig 732.1). At health supervision visits and the preparticipation physical examination, special attention should be given to screening for any unhealthy features of the female or male athlete triads (Tables 732.1 and 732.2).

In both male and female athletes, low energy availability can result in disruption of the hypothalamic-pituitary-gonadal axis. Menstrual abnormalities (including amenorrhea) result from

Table 732.1 Recommended Screening Questions for the Female Athlete Triad*

- Have you ever had a menstrual period?
- How old were you when you had your first menstrual period?
- When was your most recent menstrual period?
- How many periods have you had in the past 12 months?
- Are you presently taking any female hormones (estrogen, progesterone, birth control pills)?
- Do you worry about your weight?
- Are you trying to or has anyone recommended that you gain or lose weight?
- Are you on a special diet or do you avoid certain types of foods or food groups?
- Have you ever had an eating disorder?
- Have you ever had a stress fracture?
- Have you ever been told you have low bone density (osteopenia or osteoporosis)?

*The Triad Consensus Panel recommends asking these screening questions at the time of the sport preparticipation evaluation.

From Constantini NW. Medical concerns of the dancer. Book of Abstracts. XXVII FIMS World Congress of Sports Medicine, Budapest, Hungary, 2002. p. 151.

Table 732.2 Recommended Screening Questions for the Male Athlete Triad

- Do you worry about your weight?
- Are you trying or has anyone recommended that you lose or gain weight?
- Are you on a special diet, or do you avoid certain types of foods or food groups?
- Have you ever had an eating disorder?
- Have you ever had a stress fracture?
- Have you ever been told that you have low bone density or osteoporosis?
- Have you ever been diagnosed with low testosterone levels?
- Do you have low libido (sex drive)?
- Do you have morning erections?*
- Do you need to shave your facial hair less frequently?*

*Recommend inclusion on only preparticipation physical examinations for postpubertal athletes.

From Fredericson M, Kussman A, Misra M, et al. The male athlete triad – a consensus statement from the Female and Male Athlete Triad Coalition part II: diagnosis, treatment, and return-to-play. *Clin J Sport Med.* 2021;31(4):349–366. Box 1.

suppression of the spontaneous hypothalamic pulsatile secretion of gonadotropin-releasing hormone (Fig. 732.2; see Chapter 159.1). It is believed that the amenorrhea results from reduced energy availability, defined as energy intake minus expenditure. Energy availability below a threshold of 30 kcal/kg/day lean body mass is thought to result in menstrual disturbances, whereas availability at or above 45 kcal/kg/day is generally considered sufficient for optimal physiologic function. Other causes of menstrual cycle irregularities to be ruled out are pregnancy (see Chapter 161), pituitary tumors, thyroid abnormalities, polycystic ovary syndrome (see Chapter 589), anabolic-androgenic steroid use (see Chapters 157 and 733), and other medication side effects. Negative energy balance also appears to disrupt thyroid function and appetite-regulating hormones (e.g., leptin, ghrelin), increase resistance to growth hormone, decrease insulin and insulin-like growth factor 1, and increase cortisol levels. Although a threshold has yet to be established, low energy availability in males may also lead to decreased levels of testosterone and luteinizing hormone.

The low estrogen state of amenorrhea predisposes the female athlete to osteopenia and increases the risk of stress fractures, especially of the spine and lower extremity. If left unchecked, bone loss may be partially irreversible despite resumed menses, estrogen replacement, or calcium supplements. Similarly, low energy availability in males reduces bone turnover and can contribute to bone demineralization. Routine bone mineral density screening is not recommended but can help guide treatment and return to activity in severe cases.

Three eating disorders can occur in athletes, contributing to low energy availability. **Anorexia nervosa** manifests as weight <85% of estimated ideal body weight with evidence of starvation manifesting as bradycardia, hypothermia, and orthostatic hypotension or orthostatic tachycardia. **Bulimia nervosa** manifests as recurrent episodes (at least once weekly) of binge eating with a sense of lack of control over eating during an episode with recurrent episodes of compensatory behaviors, such as induced vomiting or excessive exercise. A third category, **unspecified feeding or eating disorder (UFED)**, is a general description for disorders failing to meet the criteria for the two previous disorders. Many young people who previously were diagnosed with UFED have a specific diagnosis of anorexia or bulimia. Signs of an eating disorder are weight loss, food restriction, depression, fatigue, worsened athletic performance, and preoccupation with calories and weight. The athlete might avoid events surrounding food consumption or might hide and discard food. Signs and symptoms include fat depletion, muscle wasting, bradycardia worsened from baseline, orthostatic hypotension, constipation, cold intolerance, hypothermia, gastric motility problems, and in some cases lanugo (see Chapter 41). Electrolyte abnormalities can lead to cardiac dysrhythmias. Psychiatric problems (depression [see Chapter 39], anxiety [see Chapter 38], and suicide risk [see Chapter 40]) are of higher incidence in this population.

For treatment of eating disorders, control of the symptoms is a central theme. The first step is confronting the athlete about the abnormal behavior and unhealthy weight. In general, exercise is not recommended if body weight is <85% of estimated ideal body weight, although there are exceptions, especially if the athlete is eumenorrheic. If the athlete is unable to gain weight with nutrition and medical counseling alone, then psychologic consultation is sought (Fig. 732.3).

Most athletes will not initially admit a problem, and many are unaware of the serious physical consequences. In some cases, athletes may have pursued athletic participation (e.g., in endurance activities) as a means to reduce or maintain a low body weight. A helpful technique in talking to these athletes is to sensitively point out performance issues. Education about decreased strength, endurance, and concentration can be a motivating factor for treatment. Often, the athlete's family needs to be involved, and the athlete should be encouraged to reveal necessary information to them. Psychology or psychiatry referral is important in the multidisciplinary approach to treatment of disordered eating. It is important for the physician to monitor the athlete's physical health while the mental health professional is caring for the mental aspects of the eating disorder.

Visit Elsevier eBooks+ at eBooks.Health.Elsevier.com for Bibliography.

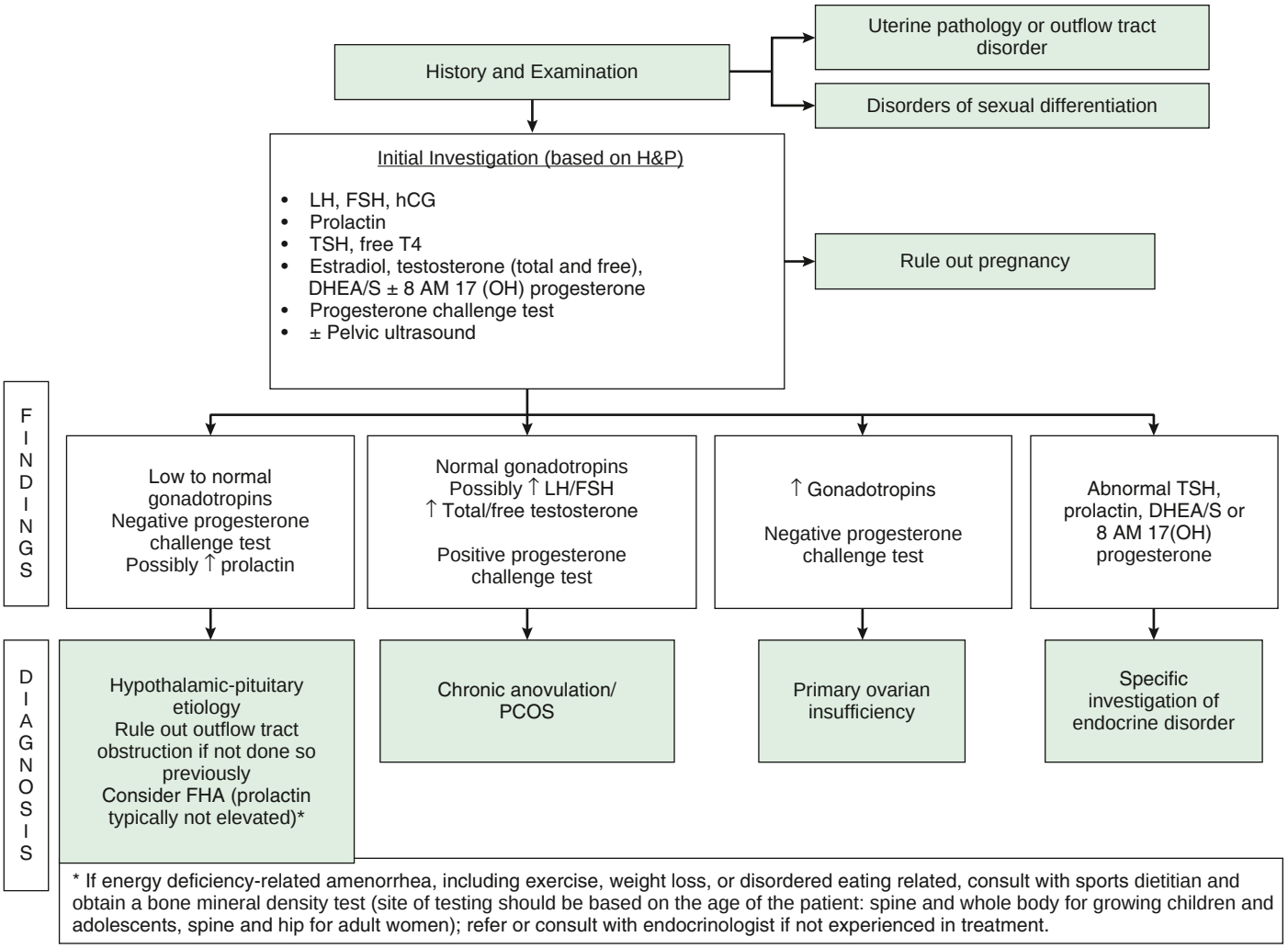

Fig. 732.2 Amenorrhea algorithm. Recommended clinical evaluation of an athlete with primary or secondary amenorrhea, or prolonged oligomenorrhea, includes a history and physical examination, initial and follow-up laboratory testing, and diagnosis by a physician. Referral or consultation with endocrinology is recommended if the diagnosing physician is not experienced with treatment of functional hypothalamic amenorrhea or other etiologies of amenorrhea. DHEA/S, Dehydroepiandrosterone sulfate; FHA, functional hypothalamic amenorrhea; FSH, follicle-stimulating hormone; hCG, human chorionic gonadotropin; LH, luteinizing hormone; PCOS, polycystic ovarian syndrome; TSH, thyroid-stimulating hormone. *(Modified from Jameson JL, De Groot LJ, Illingworth P. Amenorrhea, anovulation, and dysfunctional uterine bleeding. In: Jameson JL, De Groot LJ, eds. Endocrinology Adult and Pediatric, 6th ed. St. Louis: Saunders, 2010: pp. 2341–2355.)*

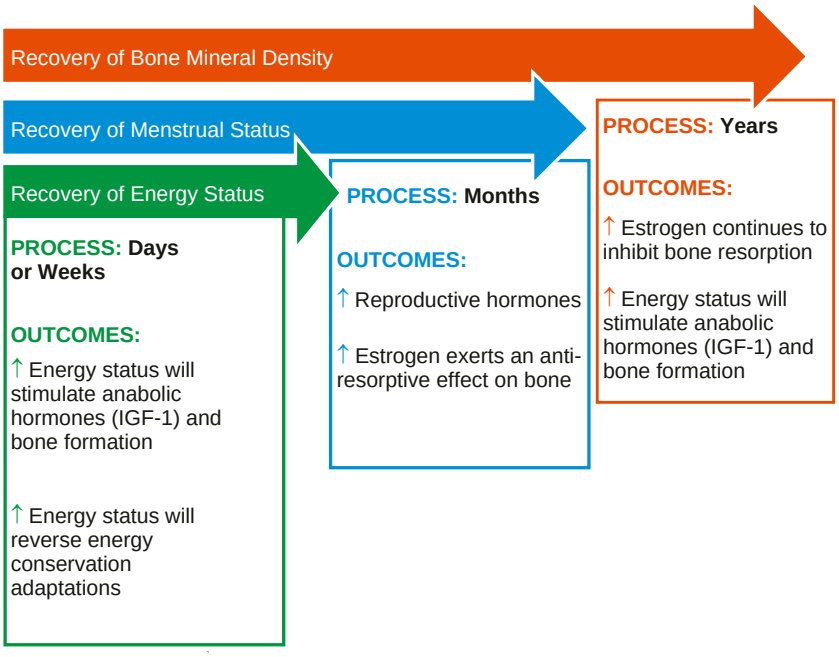

Fig. 732.3 Treatment of the female athlete triad. The three components of the triad recover at different rates with the appropriate treatment. Recovery of energy status is typically observed after days or weeks of increased energy intake and/or decreased energy expenditure. Recovery of menstrual status is typically observed after months of increased energy intake and/or decreased energy expenditure, which improves energy status. Recovery of bone mineral density may not be observed until years after recovery of energy status and menstrual status has been achieved. IGF-1, Insulin-like growth factor-1. *(From De Souza MJ, Nattiv A, Joy E, et al. 2014 Female Athlete Triad Coalition consensus statement on treatment and return to play of the female athlete triad. Br J Sports Med. 2014;48:289. Fig. 3.)*

Chapter 733

Performance-Enhancing Aids

Gregory L. Landry and Andrew M. Watson

See also Chapter 157.

Ergogenic aids are substances used for performance enhancement, most of which are unregulated supplements (Table 733.1). Many agents have significant side effects without proven ergogenic properties. The 2004 Controlled Substance Act outlawed the purchase of steroidal supplements, such as androstenediol and androstenedione, with the exception of dehydroepiandrosterone (DHEA).

The prevalence of lifetime steroid use is highest among males in the United States; among a large representative sample, 3–4% of males in middle school and 5–6% of those in high school report having used steroids for muscle enhancement. The European School Survey Project on Alcohol and Other Drugs found that 1% of European youth reported any use of steroids. Steroids in oral, injectable, and skin cream form are taken in various patterns. *Cycling* is a term used to describe taking multiple doses of steroids for a period, ceasing, and then starting again. *Stacking* refers to the use of different types of steroids in both oral and injectable forms. *Pyramiding* involves slowly increasing the steroid dose to a peak amount and then gradually tapering down.

Anabolic-androgenic steroids have been used in supraphysiologic doses for their ability to increase muscle size and strength and decrease body fat. An evidence base does support the increase in muscle mass and strength; the effects appear to be related to the myotrophic action at androgen receptors, as well as competitive antagonism at catabolism-mediating corticosteroid receptors. However, they have significant endocrinologic side effects, such as decreased sperm count and testicular atrophy in men and menstrual irregularities and virilization in women. Hepatic problems include elevated aminotransaminases and γ-glutamyl transferase, cholestatic jaundice, peliosis hepatitis, and a variety of tumors, including hepatocellular carcinoma. There is evidence that anabolic-androgenic steroids might predispose to a number of cardiovascular risk factors as well, including higher blood pressure, lower high-density lipoprotein, higher low-density lipoprotein, higher homocysteine, and decreased glucose tolerance. The possible psychologic effects include aggression, several personality disorders, and a variety of other psychologic problems (anxiety, paranoia, mania, depression, psychosis). Physical findings that may accompany anabolic-androgenic steroid use in males include gynecomastia, testicular shrinkage, jaundice, male pattern baldness, acne, and marked striae. Women can develop hirsutism, voice deepening, clitoral hypertrophy, male-pattern baldness, acne, and marked striae.

Testosterone precursors (also known as *prohormones*) include androstenedione and DHEA. Their use in the adolescent population has increased markedly in conjunction with reports of high-profile athletes' use. They are androgenic but have not been proven to be anabolic. If they are anabolic at all, they work by increasing the production of testosterone. They also increase production of estrogenic metabolites. The side effects are similar to those of anabolic-androgenic steroids and far outweigh any ergogenic benefit. These substances cannot be sold without prescription.

Creatine is an amino acid mostly stored in skeletal muscle as creatine phosphate or phosphocreatine. Phosphocreatine has the ability to rephosphorylate adenosine diphosphate through the donation of its phosphate group, yielding creatine and adenosine triphosphate. Creatine phosphate is then reconstituted through oxidative phosphorylation. The exogenous provision of creatine can therefore allow for a greater concentration of phosphocreatine in muscle, increasing muscle performance. The use of creatine as an ergogenic aid has increased, especially since other supplements have been withdrawn from the market. Thirty percent of high school football players have used creatine. There is evidence that creatine, as a source of increased energy, enhances strength and maximal exercise performance when used during training.

Caffeine is an active ingredient in energy drinks and some endurance sport supplements that has been shown to have ergogenic effects in both aerobic and anaerobic efforts. It acts primarily as an antagonist at the adenosine receptor, resulting in a number of potentially ergogenic effects such as reduced fatigue and increased muscle power. Although moderate doses of caffeine are considered relatively safe, when included in an energy drink combined with alcohol, excessive caffeine ingestion may result in tachycardia, gastritis, nausea, vomiting, and central nervous system excitation. Overdoses of caffeine may result in seizures, arrhythmias, and hypotension.

Visit Elsevier eBooks+ at eBooks.Health.Elsevier.com for Bibliography.

Table 733.1 Characteristics of Common Performance-Enhancing Substances

PERFORMANCE-ENHANCING SUBSTANCE	DESIRED EFFECTS	MAJOR ADVERSE EFFECTS	MINOR ADVERSE EFFECTS	STATUS	ROUTE OF ADMINISTRATION
Anabolic-androgenic steroids*	Increase muscle size, strength, lean body mass; decrease body fat	Testicular atrophy, CV disease, atherosclerosis, myocardial disease, liver dysfunction, cancer	Acne, gynecomastia	Banned by IOC and all major sporting bodies	Oral, topical, injectable
Creatine	Increase in strength, power output, sprint performance, total work to fatigue, peak force/power; decrease lactate threshold; increase weight and lean body mass	Heatstroke	Dehydration	Allowed	Oral

Continued

Table 733.1 Characteristics of Common Performance-Enhancing Substances—cont'd

PERFORMANCE-ENHANCING SUBSTANCE	DESIRED EFFECTS	MAJOR ADVERSE EFFECTS	MINOR ADVERSE EFFECTS	STATUS	ROUTE OF ADMINISTRATION
Human growth hormone†	May increase lean body mass and decrease fat mass	Carpal tunnel syndrome, intracranial hypertension, CV disease, hyperlipidemia, insulin resistance	Arthralgias	Banned by IOC and International Federations	Injectable
Amphetamines/stimulants‡,§	Increase in alertness and metabolism; may increase strength, muscular power, speed, acceleration, aerobic power, anaerobic capacity, endurance	Arrhythmias, heat exhaustion, seizures, myocardial infarction, sudden death	Agitation, GI upset, nausea, headaches, insomnia, hallucinations	Banned by IOC, NCAA, NFL	Oral, injectable, inhalable
Erythropoietin/blood doping	Increase in oxygen-carrying capacity, endurance	Hypertension, myocardial infarction, pulmonary embolism, immune reaction	Headaches	Banned by IOC and all major sporting bodies	Injectable
Beta-hydroxy-beta-methylbutyrate	May increase lean body mass, muscle strength, power; enhance recovery	Unknown	Unknown	Allowed	Oral
Protein supplements	Increase lean body mass, improve healing	Unknown in previously healthy athletes	Unknown	Allowed	Oral

*Including selective androgen receptor modulators and aromatase inhibitors or estrogen receptor modulators.
†Including various growth factors (IGF-1, etc.).
‡Caffeine is commonly used and remains permitted by WADA.
§Includes various beta-2-agonists prohibited by WADA, except when needed for therapy of asthma but within therapeutic limits.
CV, Cardiovascular; GI, gastrointestinal; IOC, International Olympic Committee; LDH, lactate dehydrogenase; N/A, not applicable; NCAA, National Collegiate Athletic Association; NFL, National Football League; WADA, World Anti-Doping Agency.
Modified from Momaya A, Fawal M, Estes R. Performance-enhancing substances in sports: a review of the literature. *Sports Med.* 2015;45:517–531. Table 1.

Chapter 734

Specific Sports and Associated Injuries

Gregory L. Landry and Andrew M. Watson

SPORTS PARTICIPATION, EARLY SPECIALIZATION, INJURY RISK, AND BURNOUT

It is estimated that 60 million youth, age 6-18 years, participate in organized athletics, with 44 million participating in multiple sports. It has also been estimated that 69% of females and 75% of males age 8-17 years participate in at least one organized sport team or club. Participating in sport gives children the opportunity to develop self-esteem and leadership skills, promote peer socialization, and improve general health and fitness. Some parents encourage their children to participate in a *single sport* because they think this will allow the athlete more time to focus on sport-specific skills and will increase the likelihood that their child will be selected for elite teams, a college scholarship, or professional contract. They may also feel pressure from coaches. However, only 0.2–0.5% of U.S. high school athletes rise to the professional level; Olympic-level athletes start training in their main sport at an older age than their less elite peers and on average participate in two other sports before, or in parallel with, their main sport. A study at the collegiate level revealed that 70% of surveyed athletes did not specialize in their sport until 12 years of age, and 88% participated in more than one sport at some point during childhood. *Multisport* athletes, in general, have a more diverse skill set, can transfer skills from one sport to another, have a decreased risk of **overuse injury**, have lower rates of **burnout**, and thus are less likely to quit sports at a younger age. Exposure to multiple sports also allows these athletes to identify the sport they most enjoy.

Risk of injury in sports increases with age and training volume. In general, there is an increased risk of injury if young athletes participate in more weekly organized sport hours than their age. When young athletes exceed a 2:1 ratio of weekly hours in organized sports to weekly hours in unorganized free play, they are more likely to suffer a serious overuse injury. Overuse injuries unique to young athletes include apophyseal injuries and physeal stress injuries secondary to decreased muscle mass, increased joint hypermobility, and imbalances in growth and strength (see Chapter 728). Overuse injuries and fractures are more likely to occur during adolescent growth spurts as physes, apophyses, and articular surfaces in a rapid phase of growth are less resistant to tensile, shear, and compressive forces than either mature bone or more immature prepubescent bone, and because of decreased blood flow to

the physes. When this underlying vulnerable physiology is combined with overscheduling secondary to participation in a large number of competitive events at young ages, the risk of overuse injury increases. These events often include tournaments, which may consist of multiple games in a short period of time. This type of schedule does not allow enough time for rest and recovery.

Sports specialization is traditionally defined as "participating in a single sport for greater than eight months per year, choosing a single main sport, and/or quitting all other sports to focus on one sport." Athletes who specialize early sometimes report increased anxiety and stress secondary to worrying about failure, trying to meet adult expectations, or experiencing parental pressure to participate or perform at a certain level, and often feel as though they have a lack of control in sport decision-making. These feelings can contribute to burnout, which can lead to quitting sports early and ultimately increased inactivity as an adult. To reduce the risk of overuse injury and burnout, one should limit weekly and yearly participation time, limit sport-specific repetitive movements, and ensure adequate rest and recovery periods. Thus it has been recommended that "intense training in a single sport to the exclusion of others should be delayed until adolescence in order to optimize success while minimizing injury, stress, and burnout."

FOOTBALL

Football is the sport with the greatest number of participants in the United States, especially at the high school level, and with the highest number and rate of injuries. Most of these injuries are relatively minor, and compared with injuries in many other sports, are less severe, as evidenced by fewer days lost from injury. Age, weight, and position played contribute to injury risk, with older and heavier players, running backs, and linebackers having higher injury rates. The most common football injuries include joint sprains, muscle strains, and contusions, with the lower extremities injured most frequently.

Although the majority of catastrophic sports injuries in the United States have occurred in football, these injuries are rare. Catastrophic injury is defined as a fatal injury or a severe injury with or without permanent severe functional disability. Disabling injuries include cervical spine and cerebral injuries.

Head and neck injuries in football include concussion, neck sprain, and brachial plexopathy. Compared to other sports, brain injury (concussion) (see Chapter 729) occurs with the highest rate in football, a result of the frequent exposure to contact during practices and games, although more concussions occur in games than practices. When compared to other sports, cervical spine injuries occur at higher rates in football given the increased risk of high-velocity contact, neck flexion, and axial loading. Proper blocking and tackling form with the neck extended rather than flexed is essential to help reduce the risk of cervical spine injury. Although not shown to reduce the concussion rate, helmets can help reduce facial and dental trauma and provide some protection from side head blows. A **"stinger"** or **"burner"** represents a brachial plexus neurapraxia (see Chapter 730). This is the most common nerve injury in football and results from traction, compression, or a direct blow to the upper cervical nerve roots of the brachial plexus caused by forceful lateral neck bending.

Heat illness is possible in pediatric athletes given physiologic factors, including increased heat production per body weight, less efficient heat dissipation, and higher body temperatures associated with dehydration. Dehydration and associated electrolyte abnormalities and poor acclimatization increase the risk of heat illness. Heat illness risk can be reduced with proper hydration prepractice, during, and postpractice, avoiding practice in high heat or humidity, wearing breathable, light-colored clothing, removing the helmet between plays, and avoiding certain medications such as antihistamines, anticholinergics, stimulants, and supplements (see Chapter 731).

Contusions to the arm or thigh muscles can result in the development of a large hematoma if not treated aggressively in the acute stage, resulting in prolonged time away from football. Large hematomas and those allowed to persist are at risk for development of **myositis ossificans**.

Low back pain can be caused by **spondylolysis**, especially in players with repetitive hyperextension of the spine (see Chapter 720.6). Education on tackling mechanics, core strengthening, and hamstring flexibility are important in prevention of and/or recovery from a spondylolysis injury. Shoulder trauma can cause glenohumeral joint dislocations, the majority of which are anterior dislocations and have a high rate of recurrence; acromioclavicular joint sprains; and fractures to the clavicle or humerus (see Chapter 724). Knee injuries (see Chapter 728.6) are common and include **anterior cruciate ligament (ACL)** tears and, less frequently, medial collateral ligament (MCL) tears. Knee bracing in high school football players is controversial and lacks significant evidence.

Ankle sprains occur frequently, with lateral ankle sprains resulting in less time away from the sport than high ankle sprains. The risk of re-injury may be reduced by rehabilitation, including strengthening and range of motion, and the use of a lace-up ankle brace (see Chapter 728.8). **Turf toe**, a sprain to the first metatarsophalangeal joint, is caused by forceful dorsiflexion of the toe while wearing soft, lightweight, flexible shoes. Calcaneal apophysitis at the insertion of the Achilles tendon on the calcaneus, also known as **Sever disease**, is an overuse injury that typically presents as heel pain in a cleated athlete who is still growing (typically age 7-10 years).

BASEBALL/SOFTBALL

Baseball- and softball-related injury sites are most commonly the shoulder, elbow, ankle, and hip. Facial injuries and concussions are also seen. The most common mechanisms of injury include pitching repetition and being hit by a ball or a bat.

Throwing injuries of the shoulder and elbow are typically seen in pitchers secondary to overuse, with contributory factors, including high pitch count, pitch type, and inadequate rest. **Little League shoulder** is a repetitive microtrauma injury to the open proximal humeral physis, and **Little League elbow** is a repetitive microtrauma injury to one or more of the six ossification centers in the elbow (see Chapter 728.3). Little League shoulder is the most common injury seen in softball windmill pitching, with similar shoulder stress as seen in overhand pitching. Poor core strength and alteration in biomechanics, especially when fatigued, may contribute to injury risk (Fig. 734.1). Age-related **pitch count** and rest guidelines, "Pitch Smart," are available online and are endorsed by the Little League. Curve balls and sliders should not be thrown by players younger than 14 years of age. Current recommendations also advise against participating in multiple leagues and participating in year-round baseball, given the increased risk of injury with this volume of play. Adherence to the guidelines is the responsibility of the athlete, parents, and coaches. Counseling athletes (and coaches) to stop all throwing activities if the player experiences shoulder or elbow pain, with medical evaluation if no resolution with rest, is essential. If injured, a gradual return to throwing protocol under the direction of a physical therapist with additional focus on strengthening and throwing mechanics should be considered. Catchers are more vulnerable to traumatic sprains of the interphalangeal and metacarpal phalangeal joints, head injuries, including concussions from the ball striking the mask, and knee injuries associated with the deep squatting posture. Knee savers are pads attached to the shin guards that increase the angle between the knee and thigh and prevent hyperflexion of the knees. No scientific studies have been done to assess their effectiveness.

Death or serious injury in baseball is rare but may result from direct contact by the ball or bat, causing serious head injury or **commotio cordis**, which is a direct blow to the chest during a critical time in the cardiac cycle resulting in a possibly fatal arrhythmia. Batting helmets, with consideration of faceguards, must be worn properly to help prevent face and head injuries. Modifications to the hardness of baseballs used with younger athletes may also be helpful. Chest protectors have not been shown to reduce the risk of commotio cordis.

Sliding causes the most injuries in base runners, including head injury and lower limb injuries. If sliding is allowed, correct sliding technique must be taught because many injuries are secondary to timing

issues. Head-first sliding is controversial and is not recommended for players younger than 10 years of age.

BASKETBALL/VOLLEYBALL

When combining male and female sports participation, basketball has one of the highest injury rates, even though it is considered a "safe sport" from a contact perspective. Common maneuvers of basketball and volleyball include jumping, pivoting, running, and sudden acceleration and deceleration, which increase the risk for knee and ankle injuries. Similarly, injury to the fingers may result from the passing, catching, and striking of the ball inherent in these sports. Scaphoid fractures may result from falling on an outstretched hand. Injuries to the face and eyes can also occur.

Ankle sprains are the most common injury and are usually caused by inversion with plantar flexion, placing the lateral ligaments at risk. An avulsion fracture of the base of the fifth metatarsal at the insertion of the peroneus brevis tendon is another sequela of inversion ankle injuries. A **high ankle sprain** or syndesmosis ligament injury typically results from an excessive external rotation in a dorsiflexed position, and these athletes have pain out of proportion to examination findings.

Foot pain may be secondary to calcaneal apophysitis (Sever disease), retrocalcaneal bursitis, posterior tibialis tendinosis, accessory tarsal navicular, sesamoiditis, blisters, subungual hematoma, and paronychia (see Chapter 704). Achilles tendinosis is also a common overuse injury.

Knee injuries include those caused by overuse, such as traction apophysitis at the insertion of the patella tendon on the tibial tubercle **(Osgood-Schlatter disease)** (see Chapter 718.4), traction apophysitis at the distal patella **(Sinding-Larsen-Johansson syndrome)** and patellar tendinosis **(jumper's knee)** (see Chapter 728.6).

ACL injury occurs in both male and female participants; however, among children 12-17 years old, the frequency of ACL injury in female participants is slightly higher. The exact reason for this discrepancy is unclear; however, some data suggest that female athletes do not exhibit the same neuromuscular adaptions that male athletes exhibit during pubertal growth spurts. Multiple studies on the effect of neuromuscular training and strengthening programs focused on ACL injury prevention in females suggest that these types of programs may reduce the risk of ACL injury. As with other jumping sports, other acute ligament sprains (MCL with or without ACL) can occur. For all participants, a program focused on the sport-specific strengthening of hip, core, and hamstring muscles to prevent dynamic valgus when landing can help to reduce knee injury rates.

The overhead nature of volleyball can result in overuse shoulder injuries, including rotator cuff tendinosis, shoulder impingement syndrome, labral tears, and glenohumeral instability. Players may want to limit the number of overhead spikes and serves they perform, similar to pitch count limits in baseball, to help reduce the risk of overuse injuries. Finger injuries seen in both basketball and volleyball participants include sprains, dislocations, and fractures.

Eye injuries, although rare, can be reduced by wearing protective eyewear. Facial injuries typically result from an elbow or hand hitting the opponent's face during rebounding or defending. Head injury can occur in both sports when the player makes contact with another player, the floor, or equipment (such as the net pole in volleyball).

TENNIS

Injury rates in high-level youth tennis players are higher than in adults. Tennis injuries occur twice as often in the lower extremity as in the upper extremity. Lower extremity injuries tend to be more acute, whereas upper extremity and trunk injuries tend to be more chronic, and the incidence of overuse injury is high. Overall injury rates are similar for males and females. However, male players age 5-10 years were more likely to sustain injuries to the head and neck and suffer injuries as a result of contact with the net, ball, or racket than other groups.

The most common injury in tennis players is to the ankle, although the knee and thigh are vulnerable as well. Lower extremity injuries are related to the frequent directional changes, creating significant concentric and eccentric loads. Overuse injuries include iliopsoas tendonitis or bursitis, patellofemoral stress syndrome, patellar tendinosis, Osgood-Schlatter disease, medial gastrocnemius strain ("**tennis leg**"), Achilles tendonitis, and Sever disease. Stress fractures in the lower extremity in elite players are most common at the tarsal navicular, metatarsals, and tibia.

In the upper extremities, **tennis elbow** (lateral epicondylosis with extensor carpi radialis brevis tendinosis) and **extensor carpi ulnaris (ECU) tendinosis** with or without subluxation, are particularly prevalent in the recreational player and are thought to be most likely related to overuse and improper technique (see Fig. 728.11). With repetitive overload of the wrist flexor–pronator muscle groups, traction apophysitis at the medial humeral epicondyle and medial epicondylar fragmentation of the humerus, especially in younger males, can occur. This can secondarily involve the ulnar collateral ligament and ulnar nerve. Shoulder pain often results from **labral injury**, a common site of injury for overhead athletes. Anteroposterior glenohumeral instability, glenohumeral internal rotation deficit with impingement, rotator cuff strain, and scapular dyskinesis are all possible. Wrist problems include an enlarged dorsal ganglion cyst, radiocarpal joint capsular impingement or synovitis, chronic degenerative tears of the triangular fibrocartilage complex, and acute fracture of the hook of the hamate. Stress fractures may occur in the metacarpals (second metacarpal in particular) and less commonly in the humerus, ulna, and radius.

It has been hypothesized that repeated loading during service, particularly using a "topspin" serve at a young age, may contribute to the

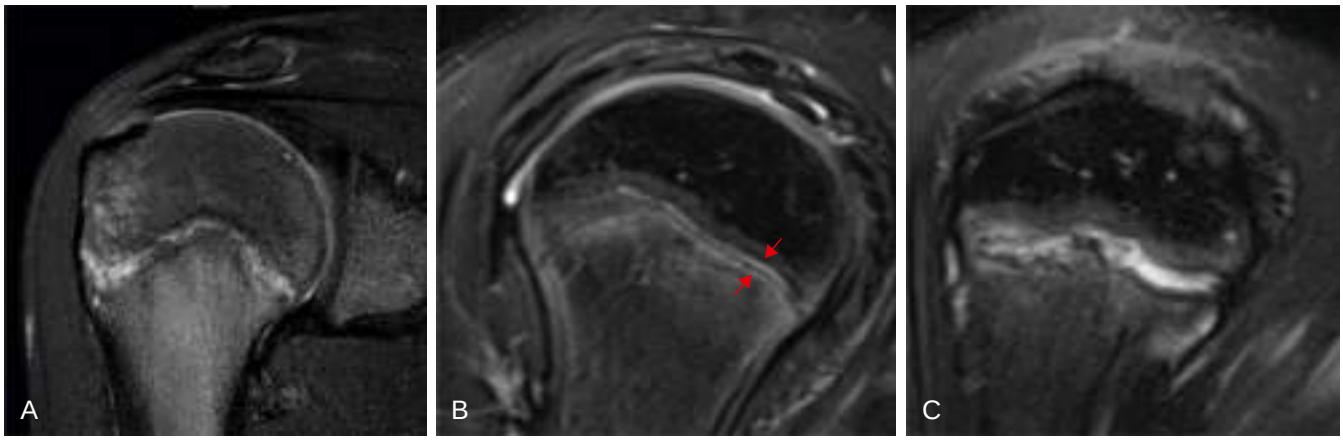

Fig. 734.1 Little League shoulder MRI findings. **A,** Coronal oblique fat-saturated T2 weighted image in a 12-yr-old pitcher demonstrates diffuse proximal humeral primary physeal widening and undulation with bone marrow edema within the metaphysis and lateral epiphysis. **B** and **C** Sagittal oblique fat-saturated T2 weighted images obtained in a 13-yr-old pitcher demonstrate preservation of the normal anterior medial humeral physis *(arrows)* in contrast to the widened irregular physis posteriorly and laterally. *(From Braithwaite KA, Marshall KW. The skeletally immature and newly mature throwing athlete. Radiol Clin N Am. 2016;54:841–855.)*

development of **spondylolysis (pars interarticularis fracture)** or spondylolisthesis. However, the most common back injury in tennis is lumbar muscle strain.

LACROSSE

Lacrosse is one of the fastest growing sports for both male and female youth, high school, and college level athletes. Protective equipment and rules are different for male and female players. Required equipment for male players includes mouth guard, helmet, gloves, and elbow and shoulder pads. Required equipment for female players includes eye wear and mouth guard. **Checking** is allowed in men's lacrosse but is not permitted in youth or women's games.

Injury rates are nearly three times higher in competition than in practice. The most common injuries for all players include lower extremity injuries, primarily ankle and knee sprains, and head injuries. Ankle sprains typically occur in the setting of cutting, dodging, and twisting activities. The likelihood of subsequent injury may be reduced with bracing. ACL tears are a common knee injury and typically occur in noncontact cutting or pivoting. Prepractice training should include balance, lower extremity strengthening, and neuromuscular feedback activities, as these have been proven to help reduce the ACL injury rate.

Head injury occurs in both male and female players. Player-to-player contact is the typical mechanism for head injury in male players. Incidental contact with the stick is the typical mechanism for head injury in female players. Eyewear for female athletes has been shown to reduce the risk of significant eye injury.

Upper extremity injuries include **acromioclavicular sprains** and hand and thumb fractures, particularly in games that permit contact and checking. Shoulder and elbow injuries are typically secondary to contact injury.

As with any sport with significant protective equipment that impedes heat loss, heat illness can occur. Players and coaches should be mindful of hydration, temperature, humidity, and duration of play. Commotio cordis is a rare but possible risk. The use of chest protectors has been evaluated and has not been shown to reduce risk.

SWIMMING/DIVING

In competitive swimming, injuries to the shoulder are most common and are generally a result of chronic overuse. **Swimmer's shoulder** is a general term for shoulder overuse in a swimmer and is typically a combination of subacromial impingement/bursitis and tendinosis of the rotator cuff and long head of the bicep tendon. Commonly, a narrowed subacromial space, increased laxity of the shoulder capsule, and relative weakness of the scapular stabilizers result in protracted shoulder posture, which contributes over time to the insidious onset of shoulder pain and possible **scapulohumeral dyskinesis**. Freestyle, back, and butterfly strokes tend to exacerbate the pain. Prevention includes monitoring training load, proper technique, and strengthening exercises. The multiaxial instability of the glenohumeral joint common in swimmers is addressed with rehabilitation focusing on strengthening of the rotator cuff and scapular stabilizer musculature. Knee and hip/groin pain can be exacerbated with breaststroke given the whip kick motion required in this stroke.

Swimmer's ear, or **otitis externa**, presents with pain and often drainage from the external auditory canal. It is caused by bacterial, or less commonly, fungal infection of the external auditory canal as a result of chronic, excessive wetness (see Chapter 679).

Diving is a sport that many athletes start at a young age with early sport-specific, specialized training. The most common injury for divers is shoulder strain, given overhead activity and the significant force taken by the shoulder, which is dependent on the angle of entry into the water. Low back pain can be seen in divers and may be associated with lumbar hyperextension to compensate for limited shoulder flexibility when entering the water, which can lead to spondylolysis. Diving is also associated with a risk of cervical spinal cord injury secondary to axial loading; according to the National Spinal Cord Injury Statistical Center, diving is the fifth leading cause of spinal cord injury in the United States.

SOCCER

Soccer enjoys a very high level of popularity and participation among youth worldwide. In the United States, the annual rate of injury in soccer more than doubled between 1990 and 2014, and almost three million children were seen in U.S. emergency departments for injuries related to soccer during those years. Mechanisms of injury include noncontact, body-to-body contact, falls, or ball-to-body contact. Although lower extremity injuries are by far the most common, younger children are more likely to injure an upper extremity, and upper extremity injuries are most likely to be fractures. Torso and significant abdominal injuries can occur. Low back symptoms are relatively less common and are most often muscular in nature.

Injuries in youth soccer occur predominately in the lower extremity and include joint and ligament injuries, abrasions, contusions, muscle strains, and fractures of the ankle, knee, and thigh. Ligamentous injuries to the ACL and MCL at the knee and the **anterior talofibular ligament** at the ankle can occur because of the cutting and pivoting maneuvers required during play or as a result of contact with another player. ACL injuries, particularly in females, have gained attention in recent years. ACL injuries are more common in high school girls' soccer than in other girls' sports. Risk factors may include genetics, hormones, age, sex, previous injury, and anthropomorphic factors. **Overuse syndromes** such as patellofemoral dysfunction, Osgood-Schlatter, Sinding-Larsen-Johansson, and Sever disease frequently occur. Hip problems include the **hip pointer (iliac crest contusion)**, iliac crest apophysitis, and chronic groin pain (muscle strain, **sports hernia**, **osteitis pubis**). The terms *sportsman's hernia, inguinal insufficiency,* and *conjoint tendon tear* may comprise a constellation of different pathologic processes producing similar groin pain. These injuries may occur with the combined forceful rotation of the torso and kicking motion. Femoral neck stress fractures, slipped femoral capital epiphysis, and avulsion fractures of the pelvis or femur should also be considered in the differential. Neuromuscular factors, such as quadriceps dominance, muscle activation patterns and dynamic stability, may be modifiable; thus the American Academy of Pediatrics (AAP), and other organizations support neuromuscular training programs aimed at risk reduction for both sexes.

Concussion is common in soccer, primarily as a result of contact between players, player and goal post, and player and ground. Recent evidence suggests that intentional heading of the ball rarely results in a concussion, although the long-term effect of repeated subconcussive impacts for intentional heading remains unknown. The U.S. Soccer Concussion Initiative updated recommendations to reduce head injury risk in youth soccer players, including a ban on heading the ball for age 10 and under and limited heading of the ball for 11-13 year olds. It remains unknown if this has reduced the number or severity of concussions. Padded headbands have not been shown to reduce the risk of concussion in youth soccer players.

ICE HOCKEY

Ice hockey is a fast-paced collision sport associated with injuries caused by contact from other players, the ice, or the boards, as well as from the puck or stick. With injury rates similar to other high school full-contact sports, concussions, contusions, fractures, ligament sprains, muscle strains, lacerations, joint separations, dislocations, and subluxations are commonly reported. Injuries are more likely to occur in competition than in practice, and overall injury rates appear to be on the rise, possibly related to increased participation.

Concussion was the most commonly reported injury in U.S. high school ice hockey athletes, with head and face injuries accounting for 34% of all of the reported injuries. Injuries to the shoulder and arm are also common and include contusions, strains, acromioclavicular separations, and clavicle fractures. Over 50% of upper extremity fractures occur in the forearm, wrist, and hand. Other specific hockey injuries include hip pain secondary to **femoroacetabular impingement (FAI)**, high ankle sprains, hip adductor strain, and osteitis pubis.

The role of factors such as age, size, level of skill, player position, and sex in injury risk is inconclusive, although evidence suggests that concussion may be more frequent in females and fractures more common in males.

Body checking is the single most common mechanism of injury. In Canada, 11- and 12-year-old Pee Wee hockey players who were allowed

to body check had a threefold greater risk of injury than those who were not. USA Hockey rules of play do not allow body checking in the 12-year and under youth leagues. Body checking is not allowed in girls'/women's leagues of any age. The AAP recommends the expansion of nonchecking programs and the restriction of body checking to elite levels of boys' play after 15 years of age. AAP recommendations also include the use of protective equipment (helmets and full-face shields or cages), rules to eliminate dangerous play with a zero-tolerance policy for head contact and body contact from behind, and safer play education for coaches and athletes.

FIELD HOCKEY

Field hockey is played worldwide by both male and female athletes. Protective equipment, including mouth, shin, and ankle guards, is recommended but not required. Players are twice as likely to be injured in game versus practice. Lower limb injuries, particularly inversion ankle sprains, are the most common. Bracing may help with ankle re-injury rates. Other lower extremity injuries include hamstring strain, ACL tears, and contusions. The most common upper limb injury occurs when the hand is struck by a stick or a ball, as field hockey does not require the use of padded gloves for protection. Head injury and facial lacerations occur at a very high rate and are typically caused by contact with the stick or ball. Injury types and rates may differ based on the position played; however, specific data are lacking.

Injury prevention is important in this sport and can be attained via the use of protective equipment, including permitted head or face protection, and sport-specific training, including balance, strengthening, and proprioceptive training activities.

SKIING AND SNOWBOARDING

Injury frequency in skiing, snowboarding, and related winter sports has declined over the past several decades, largely secondary to improved equipment (boots, bindings, poles) and slope conditions. Of concern, however, is that severe head and spinal cord injuries are on the rise due to increased speed and the addition of acrobatic maneuvers (terrain parks, half pipes, aerial tricks). Head and neck injuries are the primary cause of fatal injury. Of the World Cup events, freestyle skiers (particularly aerials and slope style) have a higher incidence of head injury than snowboard and alpine events. Overall, the risk of injury is higher in snowboarders, males, beginners, and those with improper equipment.

Lower extremity injuries are more commonly associated with skiing, while head, internal organ, upper extremity, and ankle injuries are more common in snowboarders. The most common lower extremity injury in skiing is ligamentous (ACL, MCL, and LCL) at the knee. Lower-extremity injuries in skiers also include contusions, knee dislocation, femur fractures, spiral fractures of the tibia **("boot top" fractures)**, and high ankle sprains. Snowboarders are at a unique risk for fracture of the lateral process of the talus, which is often initially misdiagnosed as an ankle sprain.

Upper-extremity injuries are more common in snowboarding because both of the snowboarder's feet are strapped onto the same board and, without poles, there is an increased risk of falls on outstretched arms. Common injuries include distal radial, ulnar, and metacarpal fractures, sprains, and contusions. Other high-incidence upper extremity injuries in snowboarding include shoulder soft tissue injuries, clavicle fractures, acromioclavicular sprains, and glenohumeral joint dislocations. A unique skiing injury is **skier's thumb**, a sprain of the ulnar collateral ligament of the thumb, which typically results from a fall with the thumb in abduction and hyperextension around a ski pole. Phalanx fractures and bony avulsions can also be associated with this injury.

Snow sport athletes may experience visceral injuries to the spleen, liver, and kidney. Spine injuries, including fracture and strain, may also occur.

It is strongly advised that individuals of all ages wear helmets for skiing and snowboarding. Wrist protectors are also recommended for snowboarders. Care should be taken to ensure up-to-date and properly fitted and adjusted equipment. Preventive measures endorsed by the AAP include participation in formal instruction, such as in a ski school, having adequate supervision, and exercising responsible speed and technique. Cardiovascular fitness, endurance, and muscle strength are believed to be critical components in injury prevention; however, there is limited supportive literature.

SKATEBOARDING

Injuries associated with skateboarding are predominantly acute, including contusions, lacerations, sprains, and fractures, affecting the wrists, forearms, and to a lesser extent, the ankles and head. Fractures involving the upper extremities are more common in younger skateboarders, often from a fall onto an outstretched arm. Lower-extremity fractures and head injuries predominate in the adolescent population, which is likely because of higher complexity of the airborne maneuvers and tricks often attempted. Loss of balance leading to a fall when failing to perform a particular maneuver, especially when catching a wheel, is generally the primary cause of injury. These falls can occur at high velocities (up to 40 mph), placing the skateboarder at risk for serious injuries.

Traumatic brain injuries do occur within this sport; the incidence increases with age and is more common in males than females. In older children and adolescents, the neglected use of helmets and the increased speed of their skating contribute to this fact.

In addition to helmet use, other safety measures recommended include wrist guards as well as elbow and knee pads. The building of skateboard parks has been a recent strategy to remove skateboarders from pedestrians, bicyclists, and motor vehicle traffic, while also encouraging adult supervision.

CYCLING AND MOTOCROSS

Bicycle riding has been a beloved childhood recreational activity for decades. Cycling options have expanded to include a variety of events such as track and road racing as well as mountain biking, mountain bike terrain parks or "free-riding," cyclo-cross, and freestyle BMX. As increased speed, jumps, and other human-made obstacles have been added, risk for injury has increased. Motocross, beginning as early as 4 years of age, adds further complexity as it uses two-wheeled motorized cycles racing through designed outdoor courses.

Recreational bicycling injuries include abrasions, lacerations, contusions, and fractures. Head and face as well as genitourinary injuries are common. Helmet use is strongly encouraged to reduce the risk of serious head injury. Upper extremity fractures predominate in mountain bikers and mountain terrain park riders. Risk of injury is increased in mountain biking males between 10 and 14 years and in those who admit to riding faster than usual. Motocross riders sustain more serious injuries. Head injuries include skull fractures and a variety of intracranial bleeds that may occur even when using a helmet.

WRESTLING

Wrestlers may have great fluctuations in weight to meet weight-matched competition standards. Such fluctuations are sometimes associated with fasting, dehydration, and then binging. Counseling wrestlers and their parents regarding impaired performance from these components of disordered eating, especially with respect to decreased speed and strength, is important to deter athletes from incorporating them into routine practice. Most states have rules in place to mitigate this risk by limiting the amount of weight loss for each wrestler.

Wrestling moves apply a variety of torques or forces to the extremities and spine, potentially resulting in a number of common injuries. Takedown maneuvers and subsequent impact with the mat can produce concussions, neck strain/sprain, or spinal cord injury. Spondylolysis (see Chapter 720.6) is a concern in wrestlers given repetitive lumbar extension.

Stingers and **burners**—also seen among football players—are caused by stretching or pinching of the brachial plexus (see Chapter 730). Overall, the two most common sites of injury in wrestling are the shoulder and knee.

At the shoulder, subluxation is common. This generally occurs anteriorly with the shoulder forcibly abducted and extended. Patients are commonly aware of their shoulder slipping in and out. Injuries to the hand are less common and typically include metacarpophalangeal and proximal interphalangeal joint sprains.

Knee injuries (see Chapter 728.6) are also common, and include **prepatellar bursitis**, medial and lateral collateral ligament sprains, and medial and lateral meniscus tears. Acute or recurrent traumatic impact to the mat can result in prepatellar bursitis. If the overlying skin is broken, septic bursitis may occur, resulting in swelling, redness, and warmth over the anterior knee.

Dermatologic problems associated with wrestling include herpes simplex (see Chapter 299: **herpes gladiatorum**), impetigo (see Chapter 706.1), staphylococcal furunculosis or folliculitis, superficial fungal infections, and contact dermatitis. Herpes gladiatorum and superficial bacterial skin infections are contraindications to wrestling until the lesions have resolved. Washing of the wrestling mats with appropriate antibacterial and antifungal solution is required after daily wrestling sessions to keep the mats disinfected and prevent the spread of dermatologic contagion.

Auricular hematoma is caused by friction or direct trauma to the auricle (see Chapter 683). If allowed to remain without evacuation, irreversible deformity of the auricle often results, termed cauliflower ear. Properly fitted headgear is the best means of prevention, and early aspiration of the accumulated blood may reduce the risk of deformity.

RUNNING

Running for sport and exercise has increased in popularity for children and adolescents. Running problems are typically caused by overuse injury related to muscle imbalance; a minor skeletal deformity; repetitive overload; and/or poor flexibility, strength, endurance, or proprioception. With each step while running, the foot impact ranges from 3-8 times the athlete's body weight. Errors in training, including increasing the distance or intensity of workouts too rapidly, often result in injury to the runner. Minor variations (e.g., malalignment) in anatomy that do not cause problems at rest can predispose to injury at specific sites, such as **over-pronation** contributing to increased **patellofemoral stress**. Muscle fatigue, environmental temperature (see Chapter 731), and running surface (grass vs unyielding concrete) also contribute to injury. **Barefoot** or **minimalist running** shoes may promote greater weight distribution through the forefoot during running, and biomechanical research suggests reduced joint forces through the knee and hip. However, increased forces can occur through the foot, ankle, and lower leg in individuals not accustomed to this style of running. Prevention of injuries is possible by muscle-strengthening exercises, incorporating periods of rest into training plans, and the use of good-quality running shoes that match an athlete's foot type.

Shin splints, or **medial tibial stress syndrome**, is a descriptive term for pain located diffusely over the distal medial tibia and should be distinguished from tibia stress fracture and chronic exertional compartment syndrome. Medial tibial stress syndrome is a periosteal stress reaction at the insertion of the soleus muscle. It can be seen in new runners, runners that have markedly increased their training duration in a short period of time, and runners with higher body mass indices (BMIs). Continued loading and stress of medial tibial stress syndrome can lead to a **stress fracture**. Stress fractures in runners (see Chapter 724.4) have been documented at the femoral neck, inferior pubic rami, subtrochanteric area, proximal femoral shaft, proximal tibia, fibula, calcaneus, tarsal navicular, metatarsals, and sesamoids. The most common are in the metatarsals, tibia, and fibula. The anterior proximal tibia, femoral neck (tension or superior side), tarsal navicular, and sesamoids are most at risk for nonunion.

Muscle strains most frequently affect the hamstrings, followed by the quadriceps, hip adductors, soleus, and gastrocnemius muscles. Lower extremity tendon injuries are more common than apophyseal injuries in young, skeletally immature runners. Tendon injury is most common in the Achilles tendon, followed by the posterior tibial, peroneal, iliopsoas, and proximal hamstring tendons. Achilles tendinosis should be distinguished from retrocalcaneal bursitis.

Knee pain in the runner is frequently anterior in location and is commonly caused by **patellofemoral pain syndrome (runner's knee)**, which results from excessive dynamic, usually lateral, motion of the patella in relationship to the femoral intracondylar groove (see Chapter 728.6). The athlete's body habitus (i.e., increased Q-angle, over-pronation) and presence of core and hip abductor weakness may contribute to this overuse injury. Posterior knee pain can be caused by gastrocnemius strain, while posteromedial pain may be caused by proximal tibial stress fracture or semimembranosus/semitendinosus tendinosis. Lateral knee pain is commonly caused by **iliotibial band syndrome** and less so by **popliteal tendinosis**, which may be precipitated by running downhill. Iliotibial band syndrome may combine a component of both bursitis and tendinosis owing to mechanical friction of the iliotibial band (an extension of the tensor fasciae latae) over the lateral femoral epicondyle. Vague knee pain that worsens with activity or traumatic event, particularly if associated with joint swelling, should raise suspicion for **osteochondritis dissecans**, most commonly located at the lateral aspect of the medial femoral condyle.

Chronic exertional compartment syndrome can involve any of the muscle compartments, but the most common is the anterior compartment. There is typically poorly localized throbbing pain that begins 10-15 minutes into a run. Pain typically prevents further training, thus limiting the risk of nerve injury (see Chapter 728.7).

Plantar fasciitis is an inflammation of the supporting structures of the longitudinal arch of the foot due to repetitive cyclic loading with foot strike. Pain is typically worst with the first step out of bed in the morning and with running and is located on the medial aspect of the heel. Pes planus and over-pronation are common in these patients. Calcaneal stress fracture should be considered, especially in the amenorrheic distance runner (see Chapter 732).

The **female and male athlete triads (or relative energy deficiency in sport)**, referring to abnormalities in energy availability, endocrine function, and bone health, are well documented in adolescent running literature and are important education topics for the runner, parents, and coaches (see Chapter 732).

CHEERLEADING

Like other sports, cheerleading has become increasingly popular and evolved to become more competitive and athletic. Cheerleading can begin as early as 3-6 years of age and includes skill levels ranging from recreational to sideline, competition to professional. The sport includes advanced gymnastic tumbling and "stunts" involving athletes lifting and throwing other athletes overhead. This requires repetitive flexion, hyperextension, and rotation of the spine as well as compressive loading on landings, and the risk of athlete contact and falls.

Stunting injuries account for the majority of injuries, with bases (the athletes who lift, throw, and catch another athlete) at higher risk of injury than fliers (athletes who are lifted and thrown). The primary mechanism of injury is contact with another athlete. Injuries sustained in tumbling are the second most common.

The overall injury rate in cheerleading is low at 1/1,000 athletic exposures. However, injuries may be severe; of all female sports, the risk of catastrophic injury is the highest in cheerleading. Following a period of increasing incidence of injury, it appears that injury rates have stabilized.

Head and facial injury accounts for almost one third of injuries sustained. Head trauma primarily results from falls while stunting or from a pyramid formation, which includes the base cheerleaders as well. After concussion, strains and sprains account for the most likely injuries, with ankle the most common site followed by wrist and trunk. Fractures are more likely to occur in the upper extremity. Overuse injuries are common.

Strategies to reduce the risk of injury include designating cheerleading as an official sport, ensuring athletes undergo preparticipation exams, participating in conditioning and strength training, using proper lifting technique, avoiding stunting over hard surfaces, and educating coaches and trainers about sport safety, including specific rules for the execution of technical skills. The American Association of Cheerleading Coaches and Administrators and others have also set up rules to limit the type of stunts performed, and the National Federation of State High School Associations annually updates rules for spirit events with the intent of improving cheerleading safety.

GYMNASTICS

Typically, males and females begin gymnastics participation at 4-5 years of age. The highest level of competition is in the mid-teens followed by retirement, often by 20 years of age for females and mid-20s for males. Both acute and chronic injuries, with a high incidence of overuse-related injuries, are seen in gymnasts and commonly involve the wrists, shoulders, ankles, and back. Injury types and rates in the acrobatic and circus arts are similar to those seen in traditional gymnastics.

The injury rate is similar in male versus female gymnasts. Lower-extremity injuries are more common in female gymnasts, whereas upper body injuries occur with higher frequency in male gymnasts.

Apparatus competed upon accounts for this discrepancy, such as the horizontal bar and ring exercises for male gymnasts, which place a great deal of stress upon the shoulders, and floor exercise, vault, and balance beam for female gymnasts, stressing the feet and ankles. In addition to mechanical or traumatic injuries, female gymnasts may have delayed menarche and can be at risk for hypothalamic amenorrhea or oligomenorrhea, as well as low body weight for height, which is related to disordered eating. Despite the presence of these two components of the **female athlete triad** (see Chapter 732), the third component, reduced bone density or osteoporosis, is not commonly seen. In fact, bone density tends to be high in most gymnasts, which is thought to be secondary to their performance involving repetitive high-impact activities. Nevertheless, **stress fractures**, in both the upper and lower extremities, are a significant problem. The short stature associated with male and female gymnasts is probably caused by selection bias and not the result of gymnastics training.

The amount of weight bearing through the upper extremities in gymnastics can contribute to the development of both traumatic and overuse injuries. During upper extremity weight bearing, the wrist, particularly over the radial physis, is subjected to a force almost twice the athlete's body weight and up to 16 times the body weight during high-impact loading activities. This, along with repetitive motion, axial compression, and torsional forces, contributes to the increasing frequency of wrist pain and injury in gymnastics and acrobatics. Wrist pain and injury is also correlated with training intensity, based on skill level and number of hours of training per week. Wrist injuries typically seen include **distal radial epiphysitis (gymnast's wrist)**, triangular fibrocartilage complex tears, scaphoid fractures, **scapholunate dissociation**, dorsal ganglion cysts, and wrist sprains (see Chapter 722). Individualized training regimens, including gradual increase in training load and reduced training during growth spurts, as well as the use of wrist orthoses, should be considered for these athletes.

Ankle sprain remains the most common injury in gymnastics, secondary to forces seen in landing and dismounting. Ankle sprains that have not responded to conservative management should be further evaluated for osteochondral defects of the talar dome. Heel pain may be secondary to plantar fasciitis, Sever disease, or calcaneal stress fracture. Patellar tendinopathy may contribute to knee pain in a gymnast.

Spine injuries are notable for a high incidence of **spondylolysis**, a stress fracture of the pars interarticularis, and, in less frequent cases, spondylolisthesis, both related to repetitive extension loading of spine (see Chapter 720.6). Other potential sources of back pain in a gymnast include intervertebral disk pathology, **Scheuermann disease** (juvenile kyphosis) (see Chapter 720.4), and mechanical back pain secondary to biomechanical imbalances.

DANCE

Dance, including ballet, modern dance, or drill line, is a highly demanding activity that may be associated with delayed menarche in females and disordered eating in both female and male dancers (see Chapter 732). Acute injuries commonly involve the lower extremities. Overuse injuries are common, due to the repetitive nature of maneuvers incorporated into training and performance and occur at the same rate in amateur male and female dancers. Injuries seen in modern/contemporary dance are similar in type and incidence to those seen in traditional ballet.

Frequently, kinetic chain dysfunction contributes to injury and should be considered when evaluating the dancer. Common mistakes in technique can cause injury, such as forcing excessive "turnout" (external rotation at the hip) in ballet resulting in undue stress placed upon the hip and knees (see Chapter 728.6).

Foot problems are common and include metatarsal stress fractures, subungual hematomas, **sesamoiditis**, **tenosynovitis** (especially of the flexor digitorum longus), plantar fasciitis, Achilles tendinitis, retrocalcaneal bursitis, calluses, and bunions (see Chapter 728.7). A **dancer's fracture** is an avulsion fracture of the distal shaft of the fifth metatarsal. This fracture is at risk for delayed healing as a result of the tenuous blood supply in the area and may necessitate surgical fixation. Common ankle injuries and pain include acute sprains, anterior and posterior impingement syndromes, and osteochondral defects of the talus. Soft tissue impingement between the lateral malleolus and talus can cause persistent pain after an inversion injury. Medial tibial stress syndrome ("shin splints") and tibial stress fractures are noted in the lower leg. Achilles tendinopathy is seen due to the demands of running and jumping. Patellar malalignment or hypermobility can result in patellofemoral pain syndrome or, less frequently, patellar subluxation/dislocation. Patellar tendinopathy is widely reported. **Internal snapping hip syndrome**, caused by the iliopsoas tendon riding over the anterior hip capsule and iliopectineal eminence, and hip flexor (rectus femoris and iliopsoas) tendinosis are commonly noted in traditional ballet. Gluteal region pain with sciatica may be a result of piriformis syndrome, which occurs because of the repetitive external hip rotation required in ballet (see Chapter 728.5).

The proper time to allow a ballet dancer to go en pointe is a common question asked by dancers and parents alike. The average age to go en pointe is 12 years. A functional test should be part of that decision: if the young dancer is able to perform a passé steadily away from the barre and maintain an en pointe position without pain or instability, the dancer is likely ready to begin dancing en pointe. **Posterior impingement syndrome** of the ankle can be seen with dancing en pointe, given compression between bony or soft tissue structures during terminal plantarflexion. An **os trigonum** is commonly the cause of bony-related posterior impingement syndrome.

ADAPTIVE SPORTS

Participation in sports and recreational activities helps to minimize deconditioning; improve strength, endurance, and cardiopulmonary fitness; and promote companionship, sense of achievement, and self-esteem (see Chapter 756). Participation can also support the development of the child's motor coordination and adjustment to physical limitations. However, children with disabilities tend to participate less in physical activity for myriad reasons, including lack of access to activities or opportunities for participation, lack of self-confidence, and fear of injury by the child, parent, or physician. Direction into appropriate sports/physical activity rather than excluding them should be guided by the child's physical or mental challenge, physical abilities, preparticipation exam, and consideration of the American Academy of Orthopedic Surgeons "participation possibility chart," which outlines recommended sports and recreation based on physical disability.

Fear of injury remains a barrier to participation for many; however, the risk of injury for an adaptive sport athlete is no greater than for an athlete without disability. Injuries in the adaptive sport athlete are influenced by the specific disability, equipment used, and prosthetic or orthotics worn. Acute soft tissue injuries, including skin abrasions, contusions, sprains, and strains, tend to be the most common injuries; fractures and dislocations tend to be uncommon, given the lower participation in contact sports. Overuse injuries commonly occur in this athlete population. Lower limb injuries are more common in athletes with amputations or cerebral palsy, and upper limb injuries are more common in spinal cord injury and wheelchair-based athletes. Appropriate training to support muscle balance and avoid muscle imbalance, as well as the management of **spasticity** and properly fitting prosthetics and orthotics can help to reduce the risk of overuse injuries. Pressure sores are common in wheelchair-based athletes and can be avoided with vigilant skin care and monitoring and weight shifting.

Consideration of the athlete's disability and medications is essential because they may have increased propensity for abnormalities in, for example, thermoregulation, resulting in heat illness, and fluid and electrolyte derangements. This should be discussed and monitored with the athlete, parents, athletic trainers, and coaches, as appropriate.

Visit Elsevier eBooks+ at eBooks.Health.Elsevier.com for Bibliography.

Section 3

The Skeletal Dysplasias

Chapter 735

General Considerations in Skeletal Dysplasias

Julie E. Hoover-Fong and Daniah Albokhari

Genetic skeletal disorders include skeletal dysplasias, as well as metabolic bone conditions, dysostoses, and other skeletal malformations (Table 735.1).

The **chondroosteodysplasias**, also known as **skeletal dysplasias** or bone dysplasias, are a genetically and clinically heterogeneous group of disorders with an estimated prevalence of 1/4,000 births. The chondroosteodysplasias can be divided into the chondrodysplasias and osteodysplasias. The former includes genetic disorders of cartilage and results in deficient linear growth, typified by achondroplasia. The **osteodysplasias** are marked by abnormal bone structure, with a classic example of osteogenesis imperfecta (see Chapter 742). The clinical picture of the chondroosteodysplasias is dominated by generalized skeletal abnormalities with frequent involvement of nonskeletal elements. The disorders range in severity from lethal in utero to such mild features as to go undetected. Metabolic bone conditions, such as rickets or hypophosphatasia, are because of abnormal bone mineralization, whereas the dysostoses affect a single bone (e.g., craniosynostosis). Many complex genetic syndromes include skeletal malformations as part of the overall phenotype.

The chondrodysplasias are distinguished from other forms of short stature by skeletal disproportion between the length of the torso and the limbs. There are two basic categories of skeletal dysplasias: those with predominantly short limbs versus short trunks. Figure 735.1 notes the importance of cartilage in bone formation. Efforts to define the extent of clinical heterogeneity has resulted in the delineation of well

Table 735.1 Nosology of Genetic Skeletal Disorders: 2023

GROUP #	NAME	EXAMPLES*
01	FGFR3 chondrodysplasias	Achondroplasia, hypochondroplasia, thanatophoric dysplasia type 1, 2
02	Type 2 collagen disorders	Achondrogenesis (*COL2A1*), Kniest dysplasia, Stickler syndrome (*COL2A1* related)
03	Type 11 collagen	Stickler syndrome (*COL11A1*, *COL11A2*), Marshall syndrome
04	Sulfation disorders	Achondrogenesis (*SLC26A2*), diastrophic dysplasia, spondyloepimetaphyseal dysplasia
05	Dysplasias with multiple joint dislocations	Ehlers-Danlos syndrome types 1 and 2, SEMD with joint laxity
06	Filamins and related disorders	Frontometaphyseal dysplasias (multiple types), Larsen syndrome
07	Proteoglycan core protein disorders	Spondyloepiphyseal dysplasias (multiple types)
08	TRPV4 disorders	Metatropic dysplasia, spondyloepiphyseal dysplasia, SEMD
09	Pseudoachondroplasia and the multiple epiphyseal dysplasias	Sticker syndromes (multiple types), MED (multiple types)
10	Skeletal disorders caused by abnormalities of cilia or ciliary signaling	Short-rib polydactyly syndromes (Jeune syndromes multiple types), Ellis-Van-Creveld syndrome, Meckel syndrome
11	Metaphyseal dysplasias	Metaphyseal dysplasia (multiple types)
12	Spondylometaphyseal dysplasias	Spondylometaphyseal dysplasias (multiple types)
13	Spondyloepi(meta)physeal dysplasias	Multiple types
14	Severe spondylodysplastic dysplasias	Achondrogenesis (*TRIP11*), spondylometaphyseal dysplasia (*GPX4*, *SBDS*, *PAM16*)
15	Mesomelic and rhizo-mesomelic dysplasias	Robinow syndrome (multiple types), mesomelic dysplasia (multiple types)
16	Acromesomelic dysplasias	Multiple types
17	Acromelic dysplasias	Geleophysic dysplasias, acromicric dysplasias, Weill-Marchesani syndrome (multiple types)
18	Brachydactylies (isolated)	Multiple types
19	Brachydactylies (syndromic)	Multiple types, Coffin-Siris syndrome (multiple types)
20	Bent bones dysplasias	Campomelic dysplasia, bent bone dysplasia
21	Primordial dwarfism and slender bones	Microcephalic osteodysplastic primordial dwarfism (multiple types)
22	Lysosomal storage diseases with skeletal involvement	Mucopolysaccharidosis types 1, 2, 3, 4, 6, 7, 10
23	Chondrodysplasia punctata (CDP)	Rhizomelic CDP (multiple types)

Continued

Table 735.1 Nosology of Genetic Skeletal Disorders: 2023—cont'd

GROUP #	NAME	EXAMPLES*
24	Osteopetrosis and related osteoclast disorders	Osteopetrosis (multiple types)
25	Osteosclerotic disorders	Caffey disease and dysplasia, craniometaphyseal dysplasias
26	Osteogenesis imperfecta (OI) and bone fragility	OI (multiple types), osteoporosis (multiple types)
27	Disorders of bone mineralization	Hypophosphatasia, hypophosphatemic rickets (multiple types)
28	Skeletal disorders of parathyroid hormone signaling	Metaphyseal dysplasia (*PTHR1*, *SIK3*)
29	Osteolysis	Progeria, mandibuloacral dysplasias (multiple types)
30	Disorganized development of skeletal components	Cherubism, fibrodysplasia ossificans progressiva
31	Overgrowth and segmental overgrowth	Marfan syndrome, Loey-Dietz syndrome, Sotos syndrome, Proteus syndrome
32	Genetic inflammatory or rheumatoid-like osteoarthropathies	Neonatal onset multisystem inflammatory disease
33	Cleidocranial dysplasias (CD)	CD (*RUNX2*, *CBFB*)
34	Syndromes with craniosynostosis	Carpenter syndromes, Crouzon syndromes, Pfeiffer syndromes
35	Craniofacial dysostosis	Treacher Collins syndrome (multiple types), frontonasal dysplasias; mandibulofacial dysostosis (multiple types)
36	Vertebral and costa dysostosis	Spondylocostal dysostosis (multiple types), Klippel-Feil syndrome (multiple types)
37	Patellar dysostosis	Nail patella syndrome, Holt-Oram syndromes
38	Limb hypoplasia (reduction defects)	Holt-Oram, Cornelia de Lange syndrome (multiple types) Rothmund-Thompson syndrome, Poland syndrome, TAR syndrome
39	Split hand / foot ± other manifestations	Ectrodactyly-ectodermal dysplasia-cleft palate, split hand-foot malformation (multiple types)
40	Polydactyly-syndactyly triphalangism	Preaxial polydactyly (multiple types), syndactyly types 1, 3, 4, 5
41	Defects in joint formation and synostosis	Multiple synostosis syndrome (multiple types), radio-ulnar synostosis (multiple types)

*Examples are not all inclusive; incomplete list.
SEMD, spondyloepimetaphyseal dysplasia; MED multiple epiphyseal dysplasia; ( ) gene notations in italics; TAR, thrombocytopenia absent radius.
Data from Unger S, Ferreira CR, Mortier GR, et al. Nosology of genetic skeletal disorders: 2023 revision. *Am J Med Genet* 2023;1-46 (Table 1).

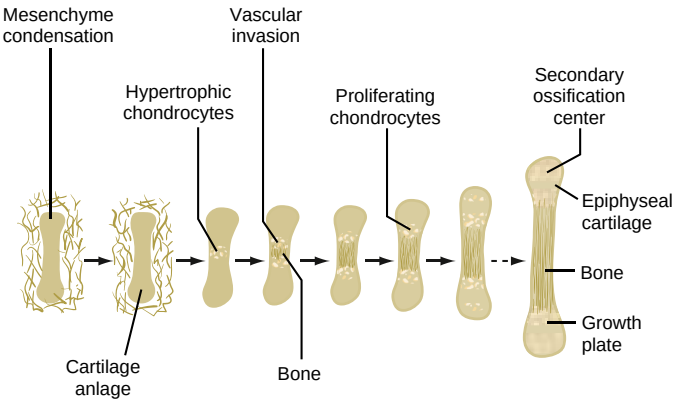

Fig. 735.1 The importance of cartilage in bone formation. *(From Horton WA. Skeletal development: insights from targeting the mouse genome. Lancet. 2005;362:560.)*

over 200 distinct entities (Table 735.2). Many of these disorders result from pathogenic variants of a relatively small group of genes, the *chondrodysplasia genes*. The better-defined chondrodysplasia groups, such as the *FGFR3* and type II collagenopathy groups, contain graded series of disorders that range from severe to mild. This severity spectrum is increasingly appreciated in other skeletal dysplasia groups as more pathogenic variants have been discovered and their associated phenotypes defined. For some genes, such as *COL2A1*, pathogenic variants are distributed throughout the gene, and the clinical phenotypes merge into one another across a broad range. There is much less phenotypic overlap in other genes, such as *FGFR3*, in which the distribution of pathogenic variants is more discrete.

Most chondrodysplasias require the analysis of information from the history, physical examination, skeletal radiographs, family history, and laboratory testing to make a diagnosis. The process involves recognizing complex patterns that are characteristic of the different disorders (Tables 735.3-735.6). Metaphyseal dysplasias, for example, often are characterized by short stature, bowing of the legs, and a waddling gait. Most metaphyseal dysplasias have normal serum levels of calcium and phosphate, alkaline phosphatase activity, and vitamin D metabolites. In addition, subtypes of metaphyseal dysplasias exist and have their own unique features. Metaphyseal chondrodysplasia (**Jansen type;** see Chapter 737) is typified by cupped and ragged metaphyses, which develop mottled calcification at the distal ends of bone over time (Fig. 735.2). Hypercalcemia can occur. The **Schmid type** of metaphyseal chondrodysplasia is less severe, although the radiographic appearance of the knees and extreme bowing of the lower limbs resemble that in patients with familial hypophosphatemia. This condition is associated with defects in collagen type X (*COL10A1*), and the hip abnormalities are more debilitating than in Jansen metaphyseal chondrodysplasia. Patients with both types of metaphyseal chondrodysplasia have short stature.

Table 735.2 Genetics of Some Skeletal Dysplasias

GENE LOCUS	PROTEIN	PROTEIN FUNCTION	CLINICAL PHENOTYPE	INHERIT
COL2A1	Type II collagen α_1 chain	Cartilage matrix protein	Achondrogenesis II	AD*
			Hypochondrogenesis	AD*
			SED congenita	AD
			Kniest dysplasia	AD
			Late-onset SED	AD
			Stickler dysplasia	AD
ACG1	Aggrecan	Cartilage matrix protein	SED Kimberley	AD
			SEMD Aggrecan type	AR
SEDL	Sedlin	Intracellular transporter	X-linked SED tarda	XLR
COL11A1	Type XI collagen α_1 chain	Cartilage matrix protein	OSMEDA	AD
COL11A2	Type XI collagen α_2 chain	Cartilage matrix protein	OSMEDB	AR
COMP	Cartilage oligomeric matrix protein	Cartilage matrix protein	Pseudoachondroplasia	AD
			EDM1 (MED)	AD
COL9A2	Type IX collagen α_2 chain	Cartilage matrix protein	EDM2 (MED)	AD
COL9A3	Type IX collagen α_3 chain	Cartilage matrix protein	EDM3 (MED)	AD
MATN3	Matrilin-3	Cartilage matrix protein	EDM5 (MED)	AD
COL10A1	Type X collagen α_1 chain	Hypertrophic cartilage matrix protein	Schmid metaphyseal chondrodysplasia	AD
FGFR3	FGF receptor 3	Tyrosine kinase receptor for FGFs	Thanatophoric dysplasia I	AD*
			Thanatophoric dysplasia II	AD*
			Achondroplasia	AD
			Hypochondroplasia	AD
PTHR1	PTHrP receptor	G protein–coupled receptor for PTH and PTHrP	Jansen metaphyseal chondrodysplasia	AD
DTDST	DTD sulfate transporter	Transmembrane sulfate transporter	Achondrogenesis 1B	AR*
			Atelosteogenesis II	AR*
			Diastrophic dysplasia	AR
SOX9	SRY box 9	Transcription factor	Campomelic dysplasia	AD
RUNX2†	Runt-related transcription factor 2	Transcription factor	Cleidocranial dysplasia	AD
LMX1B		Transcription factor	Nail-patella dysplasia	AD
CTSK	Cathepsin K	Enzyme	Pyknodysostosis	AR
RMPR	Mitochondrial RNA-processing endoribonuclease	RNA-processing enzyme	CHH	AR
DYNC2H1	Dynein, cytoplasmic two, heavy chain 1	Cytoplasmic cilia-related protein	ATD	AR
			SRPIII	AR
TRPV4	Calcium-permeable TRP ion channel	Transmembrane channel protein	Brachyolmia type 3	AD
			SMDK	AD
			Metatropic dysplasia	AD

*Usually lethal.
†Also called CBFA1.
AD, Autosomal dominant; SED, spondyloepiphyseal dysplasia; SEMD, spondyloepimetaphyseal dysplasia; AR, autosomal recessive; EDM (MED), multiple epiphyseal dysplasia; FGF, fibroblast growth factor; OSMEDA, otospondylomegaepiphyseal dysplasia autosomal dominant; OSMEDB, otospondylomegaepiphyseal dysplasia autosomal recessive; PTHrP, parathyroid hormone-related protein; PTH, parathyroid hormone; DTD, diastrophic dysplasia; SRY, sex-determining region of the Y chromosome; CHH, cartilage-hair hypoplasia; ATD, Jeune asphyxiating thoracic dystrophy; SRPIII, short rib polydactyly syndrome type III; TRPV4, transient receptor potential vanilloid family 4; SMDK, spondyloepimetaphyseal dysplasia Kozlowski type.

Table 735.3 Major Problems Associated with Skeletal Dysplasias

PROBLEM	EXAMPLE
Lethality*	Thanatophoric dysplasia
Associated anomalies†	Ellis-van Creveld syndrome
Short stature	Common to almost all
Cervical spine dislocations	Larsen syndrome
Severe limb bowing	Metaphyseal dysplasia, Schmid type
Spine curvatures	Metatropic dysplasia
Clubfeet	Diastrophic dysplasia
Fractures	Osteogenesis imperfecta
Pneumonias, aspirations	Campomelic dysplasia
Spinal cord compression	Achondroplasia
Joint problems (hips, knees)	Most skeletal dysplasias
Hearing loss	Common (greatest with cleft palate)
Myopia/cataracts	Stickler syndrome
Immunodeficiency	Cartilage-hair hypoplasia, Schimke immunoosseous dysplasia, spondyloenchondromatosis, pathogenic variants in *PEM3, EXTL3, ADA*
Poor body image	Variable, but common to all
Sex reversal	Campomelic dysplasia

*Mostly a result of severely reduced size of thorax.
†See Table 735.4.

Table 735.4 Associated Anomalies in Skeletal Dysplasias

ANOMALY	EXAMPLE
Heart defects	Ellis-van Creveld syndrome, Jeune syndrome
Polydactyly	Short rib polydactyly, Majewski type
Cleft palate	Diastrophic dysplasia
Ear cysts	Diastrophic dysplasia
Spinal cord compression	Achondroplasia
Encephalocele	Dyssegmental dysplasia
Hemivertebrae	Dyssegmental dysplasia
Micrognathia	Campomelic dysplasia
Nail dysplasia	Ellis-van Creveld syndrome
Conical teeth, oligodontia	Ellis-van Creveld syndrome
Multiple oral frenula	Ellis-van Creveld syndrome
Dentinogenesis imperfecta	Osteogenesis imperfecta
Pretibial skin dimples	Campomelic dysplasia
Cataracts, retinal detachment	Stickler syndrome
Intestinal atresia	Saldino-Noonan syndrome
Renal cysts	Saldino-Noonan syndrome
Camptodactyly	Diastrophic dysplasia
Craniosynostosis	Thanatophoric dysplasia
Ichthyosis	Chondrodystrophia punctata
Hitchhiker thumb	Diastrophic dysplasia
Sparse scalp hair	Cartilage-hair hypoplasia
Hypertelorism	Robinow syndrome
Hypoplastic nasal bridge	Acrodysostosis
Clavicular agenesis	Cleidocranial dysplasia
Genital hypoplasia	Robinow syndrome
Tail	Metatropic dysplasia
Omphalocele	Beemer-Langer syndrome
Blue sclera	Osteogenesis imperfecta

Comprehensive descriptions of disorders and references can be found at the Online Mendelian Inheritance in Man (OMIM) website (http://omim.org/about), along with the most recent nosology for genetic skeletal conditions.

CLINICAL MANIFESTATIONS

Growth

The hallmark of the chondrodysplasias is disproportionate short stature. Although this refers to a disproportion between the limbs and the trunk, most disorders exhibit some shortening of both, and subtle degrees of disproportion may be difficult to appreciate, especially in premature, obese, or edematous infants. Disproportionate shortening of the limbs should be suspected if the upper limbs do not reach the mid-pelvis in infancy or the upper thigh after infancy. Disproportionate shortening of the trunk is indicated by a short neck, small chest, and protuberant abdomen. Skeletal disproportion is usually accompanied by short stature (length and height below the third percentile); these measurements are occasionally within the low-normal range early in the course of certain conditions.

There may also be disproportionate shortening of different segments of the limbs; the specific pattern can provide clues for diagnoses. Shortening is greatest in the proximal segments (upper arms and legs) in achondroplasia; this is termed **rhizomelic shortening.** Disproportionate shortening of the middle segments (forearms and lower legs) is called **mesomelic shortening; acromelic** shortening involves the hands and feet.

With some exceptions, there is a strong correlation between the age when shortening is appreciated and the clinical severity of the condition. Many of the lethal neonatal chondrodysplasias are evident during routine fetal ultrasound examinations performed at the end of the first trimester of gestation (see Table 735.5). Gestational standards exist for long-bone lengths, and discrepancies are often detected between biparietal diameter of the skull and long-bone lengths. Many disorders become apparent around the time of birth whereas others manifest during the first year of life. A number of disorders manifest in early childhood and a few in late childhood or later.

Non–Growth-Related Manifestations

Most patients also have problems unrelated to growth. Skeletal deformities, such as abnormal joint mobility, protuberances at and around joints, and angular deformities, are common and usually symmetric. Skeletal abnormalities can adversely affect nonskeletal tissues. Impaired growth at the base of the skull and of vertebral pedicles reduces the size of the spinal canal in achondroplasia and can contribute to spinal cord compression. Short ribs reduce thoracic volume, which can compromise breathing in patients with short trunk chondrodysplasias. Cleft palate (see Chapter 356) is common to many disorders, presumably reflecting defective palatal growth.

Manifestations may be unrelated to the skeleton; they reflect the expression of pathogenic gene variants in nonskeletal tissues. Examples include retinal detachment in spondyloepiphyseal

Table 735.5	Lethal Neonatal Skeletal Dysplasias
USUALLY FATAL*	
Achondrogenesis (different types)	
Thanatophoric dysplasia	
Short rib polydactyly (different types)	
Homozygous achondroplasia	
Campomelic dysplasia	
Dyssegmental dysplasia, Silverman-Handmaker type	
Osteogenesis imperfecta, type II	
Hypophosphatasia (perinatal form)	
Chondrodysplasia punctata (rhizomelic form)	
OFTEN FATAL	
Asphyxiating thoracic dysplasia (Jeune syndrome)	
OCCASIONALLY FATAL	
Ellis-van Creveld syndrome	
Diastrophic dysplasia	
Metatropic dwarfism	
Kniest dysplasia	

*A few prolonged survivors have been reported in most of these disorders.

Table 735.6	Usually Nonlethal Dwarfing Conditions Recognizable at Birth or Within the First Few Months of Life
MOST COMMON	
Achondroplasia	
Osteogenesis imperfecta (types I, III, IV)	
Spondyloepiphyseal dysplasia congenita	
Diastrophic dysplasia	
Ellis-van Creveld syndrome	
LESS COMMON	
Chondrodysplasia punctata (some forms)	
Kniest dysplasia	
Metatropic dysplasia	
Langer mesomelic dysplasia	

dysplasia congenita, sex reversal in campomelic dysplasia, congenital heart malformations in Ellis-van Creveld syndrome, immunodeficiency in cartilage-hair hypoplasia, and renal dysfunction in asphyxiating thoracic dysplasia. These nonskeletal problems provide valuable clues to specific diagnoses and must be managed clinically (see Table 735.4).

Family and Reproductive History

A family history might identify relatives with the condition, and a Mendelian inheritance pattern may be elicited. Because the presentation can vary in some disorders within and among families, features that might be related to the disorder should be identified. Special attention should be given to mild degrees of short stature, disproportion, deformities, and other manifestations (e.g., precocious osteoarthritis) because they may be overlooked. Physical examination of relatives may be useful, as may the review of their photographs, radiographs, and medical and laboratory records.

A reproductive history might reveal previous stillbirths, fetal losses, and other abnormal pregnancy outcomes resulting from a skeletal dysplasia. Pregnancy complications, such as polyhydramnios or reduced fetal movement, are common in bone dysplasias, especially neonatal lethal variants.

Even though most of the skeletal dysplasias are genetic, it is common for an affected individual to be the first in their family to have the diagnosis. New pathogenic variants are common for autosomal dominant disorders, especially lethal disorders in the perinatal period (e.g., thanatophoric dysplasia, osteogenesis imperfecta). In achondroplasia, the most common short stature skeletal dysplasia, ~80% of all individuals have a new pathogenic variant in *FGFR3*. Germ cell mosaicism, in which a parent has clones of mutant germ cells, has been observed in osteogenesis imperfecta, achondroplasia, and in other dominant disorders. A negative family history is usually seen in recessive disorders unless consanguinity is present. A few of the short stature skeletal dysplasias are X-linked in origin. Prenatal diagnosis is available for disorders that have a known genetic etiology. Appropriateness of the testing depends on many factors, and genetic counseling is warranted for these families.

Fig. 735.2 Radiographic findings in Jansen-type metaphyseal chondrodysplasia. **A,** At age 1 yr, there is severe metaphyseal cupping and splaying at the wrists and also in the hand bones. **B,** At age 7 yr, there is increasing metaphyseal change at the wrists with enlarged epiphysis; enlarged epiphyses with wide epiphyseal plates are also present in the hands. **C,** At age 1 yr, there are severe metaphyseal irregularities at the knees and ankles (femur, tibia, and fibula) and enlarged, rounded epiphyses. **D,** At age 7 yr, there are severely fragmented, sclerotic metaphyses, wide epiphyseal plates, and enlarged epiphyses. Radiographic findings in Jansen-type metaphyseal chondrodysplasia. *(From Slovis T, ed. Caffey's Pediatric Diagnostic Imaging, 11th ed. Philadelphia: Mosby, 2008.)*

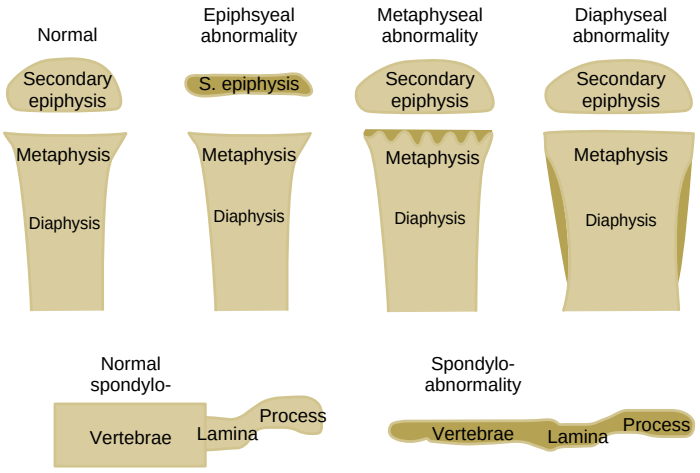

Fig. 735.3 Demonstration of the different portions of the appendicular skeleton that manifest radiographic abnormalities that aid in the clinical classification of the skeletal dysplasias. *(From Krakow D, Rimoin DL. The skeletal dysplasias. Genet Med. 2010;12:327–341. Fig. 2.)*

Table 735.7 Dynamic Classification of Bone Dysplasias

I. EPIPHYSEAL DYSPLASIAS
A. Epiphyseal hypoplasias 1. Failure of articular cartilage: spondyloepiphyseal dysplasia congenita and tarda 2. Failure of ossification center: multiple epiphyseal dysplasia congenita and tarda
B. Epiphyseal hyperplasia 1. Excess of articular cartilage; dysplasia epiphysealis hemimelica
II. PHYSEAL DYSPLASIAS
A. Cartilage hypoplasias 1. Failure of proliferating cartilage: achondroplasia congenita and tarda 2. Failure of hypertrophic cartilage: metaphyseal dysostosis congenita and tarda
B. Cartilage hyperplasias 1. Excess of proliferating cartilage: hyperchondroplasia 2. Excess of hypertrophic cartilage: enchondromatosis
III. METAPHYSEAL DYSPLASIAS
A. Metaphyseal hypoplasias 1. Failure to form primary spongiosa: hypophosphatasia congenita and tarda 2. Failure to absorb primary spongiosa: osteopetrosis congenita and tarda 3. Failure to absorb secondary spongiosa: craniometaphyseal dysplasia congenita and tarda
B. Metaphyseal hyperplasias 1. Excessive spongiosa: multiple exostoses
IV. DIAPHYSEAL DYSPLASIAS
A. Diaphyseal hypoplasias 1. Failure of periosteal bone formation: osteogenesis imperfecta congenita and tarda 2. Failure of endosteal bone formation: idiopathic osteoporosis congenita and tarda
B. Diaphyseal hyperplasias 1. Excessive periosteal bone formation: progressive diaphyseal dysplasia 2. Excessive endosteal bone formation: hyperphosphatasemia

From Rubin P. *Classification of bone dysplasias*. Chicago: Year Book Medical Publishers, 1964. p. 82.

Radiographic Features

Radiographic evaluation for a chondrodysplasia should include plain films of the entire skeleton. Efforts should be made to identify which bones and which parts of bones (i.e., epiphyses, metaphyses, diaphyses) are most affected (Figs. 735.3 and Fig. 735.4 and Table 735.7). If possible, films taken at different ages should be examined because the radiographic changes evolve with time. Films taken before puberty are generally more informative because pubertal closure of the epiphyses obliterates many of the signs needed for a radiographic diagnosis. Prenatal diagnosis may also be possible with fetal ultrasound.

DIAGNOSIS

If an infant or child is short with disproportionate features, a diagnosis is established by matching the observed clinical picture (defined primarily from clinical, family, and gestational histories; physical examination; and radiographic evaluation) with clinical phenotypes of well-documented disorders. A number of reference texts and online databases provide information about the disorders and comprehensive lists of current references (http://www.ncbi.nlm.nih.gov/books/NBK1116/). Consultation with experts in medical genetics, orthopedics, endocrinology, or the bone dysplasia field is recommended.

Genetic testing for chondrodysplasias is very useful, especially for disorders in which recurrent pathogenic variants occur (typical achondroplasia has the same *FGFR3* pathogenic variant). Pathogenic variant testing for achondroplasia is available, although the diagnosis can be made clinically. The greatest utility for testing may be for prenatal diagnosis for couples where both parents have typical *(heterozygous)* achondroplasia. Their children are at a 25% risk of the much more severe *homozygous* achondroplasia (also known as *double dominant*), which can be detected by pathogenic variant analysis. Preimplantation genetic testing can be used to identify zygotes with two pathogenic variants in *FGFR3*. Another example of the utility of genetic testing is in disorders resulting from pathogenic variants in *DTDST*. These disorders are inherited in an autosomal recessive manner, and a limited number of mutant alleles have been found. If the pathogenic variants are identified in the patient, they should be detectable in the parents and potentially used for prenatal diagnosis. Pathogenic variant analysis is commercially available for many of the skeletal dysplasias and is increasingly used to confirm clinical diagnosis and for future pregnancy planning.

Many of the chondrodysplasias have distinct histologic changes of the skeletal growth plate. Sometimes, such tissues obtained at biopsy or discarded from a surgical procedure are helpful diagnostically. It is uncommon to make a diagnosis histologically if it was not already suspected on clinical or radiographic grounds.

MOLECULAR GENETICS OF SKELETAL DYSPLASIAS

A number of chondrodysplasia genes have been identified (see Table 735.2). They encode several categories of proteins, including cartilage matrix proteins, transmembrane receptors, ion transporters, and transcription factors. The number of identified gene loci is smaller than anticipated from the number of recognized clinical phenotypes. The majority of patients have disorders that map to fewer than 10 loci, and

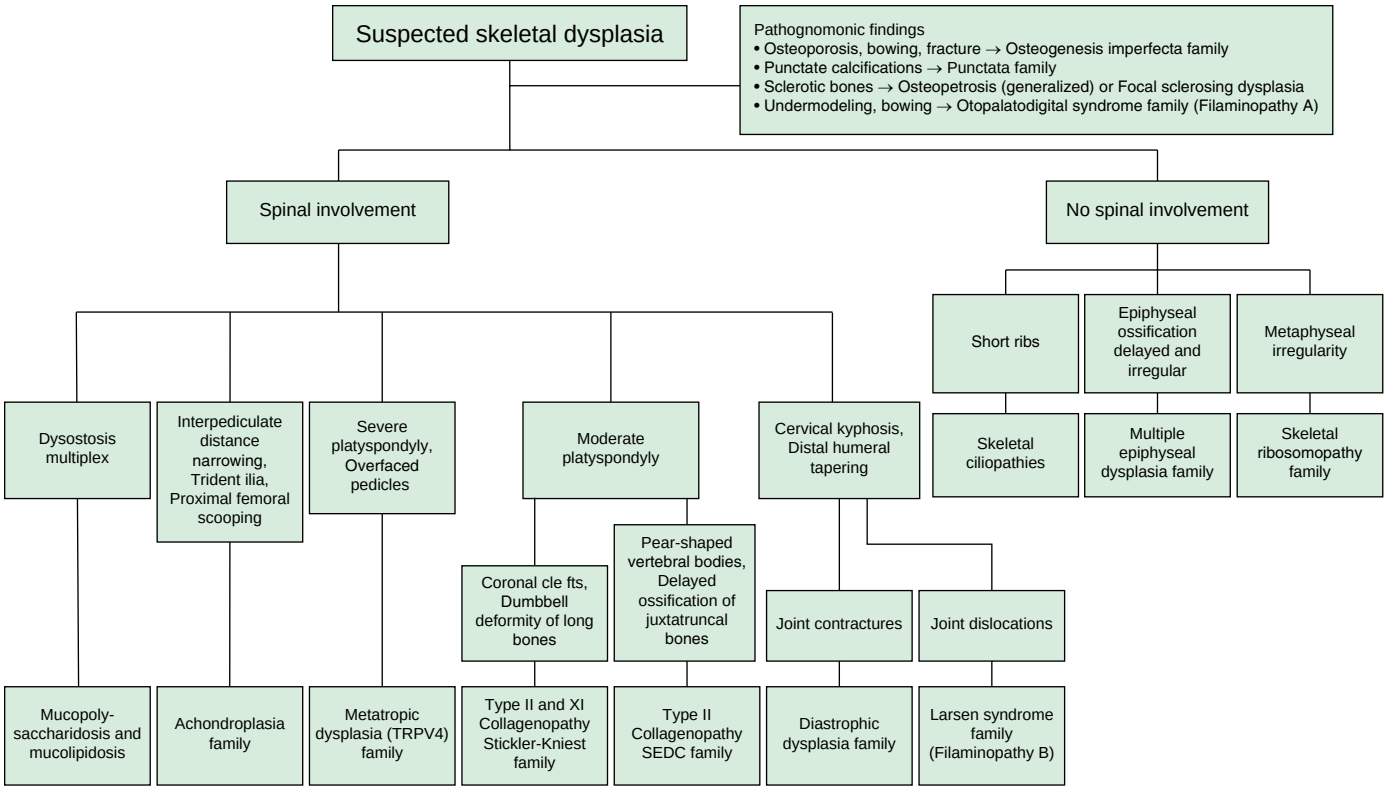

Fig. 735.4 Diagnostic algorithm for the major skeletal dysplasias. TRPV4, transient receptor potential vanilloid 4. *(From Handa A, Grigelioniene G, Nishimura G: Skeletal dysplasia families: a stepwise approach to diagnosis. RadioGraphics 2023;43(5), Fig. 1.)*

pathogenic variants at two loci (*COL2A1* and *FGFR3*) account for more than half of all cases. There may be a limited number of genes whose function is critical to skeletal development, especially linear bone growth, and pathogenic variants in these genes give rise to a wide range of chondrodysplasia clinical phenotypes. New genes harboring pathogenic variants that cause chondrodysplasias continue to be identified with advances in technology.

Pathogenic variants of *COL2A1* and *FGFR3* illustrate different genetic characteristics. *COL2A1* pathogenic variants are distributed throughout the gene, with few instances of recurrence in unrelated persons. In contrast, *FGFR3* pathogenic variants are restricted to a few locations within the gene, and the occurrence of new pathogenic variants at these same sites in unrelated persons is the rule. There is a strong correlation between clinical phenotype and pathogenic variant site for *FGFR3,* but not *COL2A1*.

PATHOPHYSIOLOGY

Chondrodysplasias are caused by pathogenic variants in genes that encode abnormal proteins and disrupt normal endochondral ossification, the biologic process responsible for the development and linear growth of the skeleton (see Fig. 735.1). These genetic variants act through different mechanisms. Most pathogenic variants involving cartilage matrix proteins cause disease when only one of the two copies (alleles) of the relevant gene is mutated. These pathogenic variants usually act through a *dominant negative mechanism* in which the protein products of the mutant allele interfere with the assembly and function of multimeric molecules that contain the protein products of both the normal and mutant alleles. The type II collagen molecule is a triple helix composed of three collagen chains, which are the products of the type II collagen gene *COL2A1*. When chains from both normal and mutant alleles are combined to form triple helices, most molecules contain at least one mutant chain. It is not known how many mutant chains are required to produce a dysfunctional molecule, but, depending on the pathogenic variant, it theoretically could be as few as one.

Pathogenic variants in the gene encoding type X collagen differ from the model above. They map to the region of the chain that is responsible for chain recognition; the chains must recognize each other before they can assemble into collagen molecules. Disease-causing variants are thought to disrupt this process. As a result, none of the mutant chains are incorporated into molecules. This mechanism is *haploinsufficiency* because the products of the mutant allele are functionally absent, and the normal allele is insufficient for normal function. Genetic variants involving ion transport genes also act through a *loss of function* of the transporters. Pathogenic variants of transmembrane receptors studied to date appear to act through a *gain of function*; the mutant receptors initiate signals in a constitutive manner independent of their normal ligands. A pathogenic variant in *FGFR3* is another example of a *gain of function* mechanism of disease. At baseline, *FGFR3* is a negative regulator of endochondral bone formation. If the pathogenic variant associated with achondroplasia is present in this gene, the clinical manifestations of this condition are caused by enhanced inhibition of endochondral bone formation and growth, independent of normal ligands.

TREATMENT

The first step is to establish the correct diagnosis. This allows one to provide a prognosis and to anticipate the medical and surgical problems associated with a particular disorder. Establishing a diagnosis helps to distinguish between lethal disorders and nonlethal disorders in a premature or newborn infant (see Tables 735.5 and 735.6). A poor prognosis for long-term survival might argue against initiating extreme lifesaving measures for thanatophoric dysplasia or achondrogenesis types Ib or II, whereas such measures may be indicated for infants with spondyloepiphyseal dysplasia congenita or diastrophic dysplasia, which have a good prognosis if the infant survives the newborn period.

Overall, management of patients with short stature skeletal dysplasias is directed at preventing and correcting skeletal deformities (spinal stenosis, kyphosis, scoliosis), treating nonskeletal complications (other anomalies, immunodeficiencies), providing genetic counseling, and

helping patients and families learn to cope. Each disorder has its own unique set of problems, and consequently, management must be tailored to each disorder.

There are a number of problems common to many chondrodysplasias for which general recommendations can be made. Children with most chondrodysplasias should avoid contact sports and other activities that cause injury or stress to joints. Good dietary habits should be established in childhood to prevent or minimize obesity in adulthood. Dental care should be started early to minimize the crowding and malalignment of teeth. Children and relatives should be given the opportunity to participate in support groups, such as the Little People of America (http://www.lpaonline.org) and Human Growth Foundation (http://www.hgfound.org).

Three controversial approaches have been used to increase bone length. Surgical limb lengthening has been employed for a few disorders. Its greatest success has been in achondroplasia in which nonskeletal tissues tend to be redundant and easily stretched. The procedure is usually performed during adolescence. Pharmacologic doses of human growth hormone comparable to those used to treat Turner syndrome have also been tried in several disorders; the results have been equivocal. Animal studies suggest that C-type natriuretic peptide (CNP) promotes linear bone growth in achondroplasia. One CNP analogue (vosoritide) is approved to increase height in children with achondroplasia (≥5 years old) before the growth plates are closed. Palovarotene is undergoing clinical trials for fibrodysplasia ossificans and resveratrol for pseudoachondroplasia. Enzyme replacement therapy is available for hypophosphatasia and Morquio A syndrome. Many new therapies are based on the gene or pathway involved in the specific disease (see Chapters 736-742). Clinicaltrials.gov is a resource to access information about these and all other clinical trials.

Visit Elsevier eBooks+ at eBooks.Health.Elsevier.com for Bibliography.

Chapter 736

Disorders Involving Cartilage Matrix Proteins

Daniah Albokhari and Julie E. Hoover-Fong

Disorders of cartilage matrix proteins resulting in bone and joint disorders can be classified according to the defective proteins: collagens (types 2, 9, 10, 11) and the noncollagenous proteins COMP (cartilage oligomeric matrix protein), matrilin-3, and aggrecan. The clinical phenotypes and clinical severity differ between and within the groups, especially the spondyloepiphyseal dysplasia (SED) group, which is made up largely of type collagenopathies (see also Table 735.1).

TYPE 2 COLLAGENOPATHIES

The term *spondyloepiphyseal dysplasia* refers to a heterogeneous group of disorders characterized by shortening of the trunk and, to a lesser extent, the limbs. Severity ranges from most severe and often lethal perinatally, such as achondrogenesis type II, hypochondrogenesis, and platyspondylic dysplasia, Torrance type, to severe/moderately severe neonatal presentation, such as Kniest dysplasia (which is apparent at birth and usually nonlethal) and SED congenita, to mild SED with premature-onset arthrosis (which might not be detected until adolescence or later) (Table 736.1). The radiographic hallmarks are abnormal development of the vertebral bodies and of epiphyses, the extent of which corresponds with clinical severity. Most of the SEDs result from heterozygous pathogenic variants of *COL2A1* and are autosomal dominant disorders. The pathogenic variants are dispersed throughout the gene with imperfect correlation between the variant location and resultant clinical phenotype. Molecular testing/confirmation is readily available commercially. Prenatal diagnosis is possible if the pathogenic variant is known.

Lethal Spondyloepiphyseal Dysplasias

Achondrogenesis type II is characterized by severe shortening of the neck and trunk and especially the limbs, and by a large, soft head. Fetal hydrops and prematurity are common, and infants are stillborn or die shortly after birth. **Hypochondrogenesis** refers to a clinical phenotype intermediate between achondrogenesis type II and SED congenita. It is typically lethal in the newborn period. **Platyspondylic dysplasia, Torrance type** is characterized by disproportionate short stature, short limbs, and coarse facial features. The majority of infants die at or shortly after birth.

The severity of radiographic changes correlates with clinical severity. These conditions manifest short, broad tubular bones with cupped metaphyses. The cranial bones are not well mineralized, and the vertebral bodies are poorly ossified in the entire spine in achondrogenesis type II, and in the cervical and sacral spine in hypochondrogenesis. In both conditions, the pelvic bones are hypoplastic, and the pedicles are ossified. In Torrance type, the platyspondyly is strikingly severe, with iliac hypoplasia, short sacrosciatic notches, and preserved ossification of the pubic bones. The three types can be detected prenatally and confirmed by molecular testing.

KNIEST DYSPLASIA

The Kniest dysplasia variant of SED manifests at birth with a short trunk and limbs associated with a flat face, prominent eyes, enlarged joints, cleft palate, and clubfoot (Fig. 736.1). Radiographs show vertebral defects and short tubular bones with epiphyseal irregularities and metaphyseal enlargement that gives rise to a dumbbell appearance.

Motor development is often delayed because of the joint deformities, although intelligence is normal. Hearing loss and myopia commonly develop during childhood, and retinal detachment is a common complication. Joint enlargement progresses during childhood and becomes painful. It is accompanied by flexion contractures and muscle atrophy, which may be incapacitating by adolescence.

Spondyloepiphyseal Dysplasia Congenita

The phenotype of this group, SED congenita, is apparent at birth. The hands and feet are usually normal. Craniofacial features may present, including malar hypoplasia, hypertelorism, and cleft palate. The neck is short, and the chest is barrel shaped (Fig. 736.2). Kyphosis and exaggeration of the normal lumbar lordosis are common. The proximal segments of the limbs are shorter than the hands and feet, which often appear normal. Some infants have clubfoot and/or exhibit hypotonia.

Skeletal radiographs of the newborn reveal short tubular bones, delayed ossification of vertebral bodies, and proximal limb bone epiphyses (Fig. 736.3). Hypoplasia of the odontoid process, a short, square pelvis with a poorly ossified symphysis pubis, and mild irregularity of metaphyses are apparent.

Infants usually have normal developmental milestones with a waddling gait typically appearing in early childhood. Childhood complications include respiratory compromise from tracheomalacia, spinal deformities, and spinal cord compression because of cervicomedullary instability. The disproportion and shortening become progressively worse with age, and adult heights range from 95-128 cm. Myopia is typical; adults are predisposed to retinal detachment. Precocious osteoarthritis (OA) occurs in early adulthood and requires surgical joint replacement.

Table 736.1 Collagen Disorders

DISORDER	INHERITANCE	GENE
TYPE 2 COLLAGEN DISORDERS		
Achondrogenesis (formerly type 2, type Langer-Saldino)	AD	*COL2A1*
Hypochondrogenesis	AD	*COL2A1*
Platyspondylic dysplasia, type Torrance	AD	*COL2A1*
Spondyloepiphyseal dysplasia congenita	AD, AR	*COL2A1*
Spondyloepimetaphyseal dysplasia	AD	*COL2A1*
Kniest dysplasia	AD	*COL2A1*
Spondyloperipheral dysplasia	AD	*COL2A1*
SED with metatarsal shortening	AD	*COL2A1*
Stickler syndrome	AD	*COL2A1*
Dysplasia of the proximal femoral epiphyses	AD	*COL2A1*
TYPE 11 COLLAGEN DISORDERS		
Stickler syndrome	AD, MOS	*COL11A1*
Marshall syndrome	AS	*COL11A1*
Stickler syndrome (nonocular type)	AD	*COL11A2*
Fibrochondrogenesis	AR, AD	*COL11A1*
Fibrochondrogenesis	AR, AD	*COL11A2*
Otospondylomegaepiphyseal dysplasia	AR	*COL11A2*
Otospondylomegaepiphyseal dysplasia	AD	*COL11A2*

Data from Unger S, Ferreira CR, Mortier GR, et al. Nosology of genetic skeletal disorders: 2023 revision. *Am J Med Genet.* 2023;191A:1164-1209 (Table 1, Group 2 and 3, pp 1166-1167).

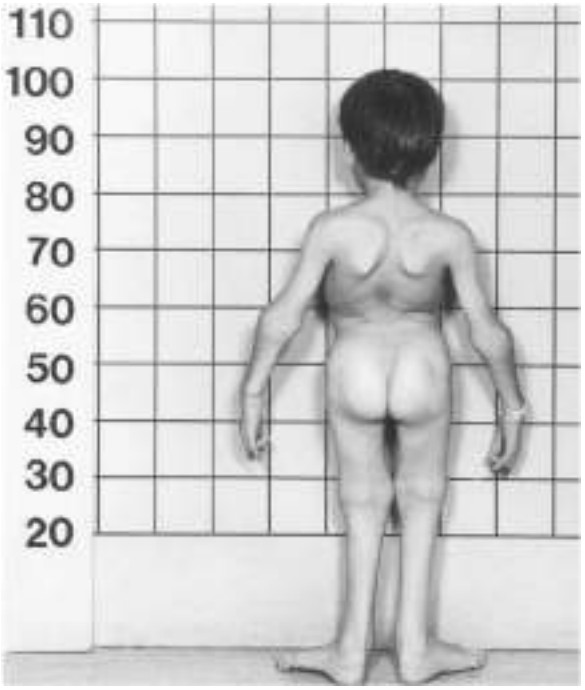

Fig. 736.1 Patient with Kniest dysplasia. The trunk is short, the epiphyses are broad, and there is contracture of the fingers. *(From Traboulsi EI. Skeletal and connective tissue disorders with anterior segment manifestations. In Krachmer JH, Mannis MJ, Holland EJ, eds. Cornea, 3rd ed. Philadelphia: Elsevier, 2011. Fig. 60.9.)*

Mild Spondyloepiphyseal Dysplasia with Premature-Onset Arthrosis

Late-onset SED is a mild clinical phenotype characterized by slightly short stature, progressive joint pain, and diminished range of movement, associated with mild epiphyseal and vertebral abnormalities on radiographs. It is typically detected during childhood or adolescence but can go unrecognized until adulthood when precocious OA appears. The vision and hearing are usually normal. This designation is nosologically distinct from SED tarda, which is clinically similar but results from pathogenic variant of the X-linked gene *SEDL (TRAPPC2)*.

Stickler Syndrome/Dysplasia (Hereditary Progressive Arthro-Ophthalmopathy)

Short stature is not a feature of Stickler dysplasia. This condition resembles SED because of its joint and eye manifestations. Pathogenic variants of genes encoding type II *(COL2A1)*, type XI *(COL11A1, COL11A2)*, and type IX *(COL9A1, COL9A2, COL9A3)* collagens have been identified in Stickler-like disorders. Stickler dysplasia is often identified in the newborn because of cleft palate and micrognathia (**Pierre Robin** anomaly; see Chapter 357). Of patients with Stickler syndrome, 25% have Pierre Robin anomaly, and 18% of patients with Pierre Robin anomaly have Stickler syndrome. Children with Stickler syndrome are often identified in craniofacial clinics. Infants typically have severe myopia and additional ophthalmologic complications, including cataracts, glaucoma, and choroidoretinal and vitreous degeneration, with retinal detachment common during childhood requiring multiple surgical interventions (Fig. 736.4). Special attention must be given to eye complications even in childhood to preserve vision for these individuals. Hearing loss is a common feature that arises during adolescence. Sensorineural hearing loss is the most common form; however, conductive hearing loss may also be seen. Osteoarticular manifestations include joint hypermobility (especially hip), which resolves in adulthood, metaphyseal broadening of the femoral neck, hypoplastic iliac wings, Schmorl nodes, muscle hypotonia, metaphyseal-epiphyseal dysplasia, precocious progressive OA of the spine and peripheral joints (which may require hip replacement surgery before age 30 years), and decreased bone density. Similar manifestations may be seen in other diseases with pathogenic variants in type II and XI collagen genes (Table 736.2).

PSEUDOACHONDROPLASIA AND MULTIPLE EPIPHYSEAL DYSPLASIA

Pseudoachondroplasia and the most common form of multiple epiphyseal dysplasia (MED) are two distinct phenotypes that are grouped together because they result from pathogenic variants of the gene encoding COMP. The pathogenic variants are heterozygous in both, and they are autosomal dominant traits. The clinical phenotypes are restricted to musculoskeletal tissues. Newborns with pseudoachondroplasia are average in size and appearance. Gait abnormalities and short stature mainly affect the limbs and become apparent in late infancy. Short stature becomes marked as the child grows and is associated with generalized joint laxity (Fig. 736.5). The hands are short, broad, and deviated in an ulnar direction; the forearms are bowed. Developmental milestones and intelligence are usually normal. Lumbar lordosis and deformities of the knee develop during childhood; the latter often requires surgical correction. Pain is common in weight-bearing joints during childhood and adolescence, and OA develops late in the second decade of life, which may require hip replacement by mid-30s. Adult height ranges from 105-128 cm. Skeletal radiographs show distinctive abnormalities of vertebral bodies and of both epiphyses and metaphyses of tubular bones (Fig. 736.6).

The MED phenotype has skeletal abnormalities that predominantly affect the epiphyses as noted on radiographs. Two forms, the severe Fairbank type and the mild Ribbing type, are no longer used in classification. Because of overlap in clinical features, and because COMP pathogenic variants are found in both types, they are now considered part of a clinical spectrum. The more severe clinical

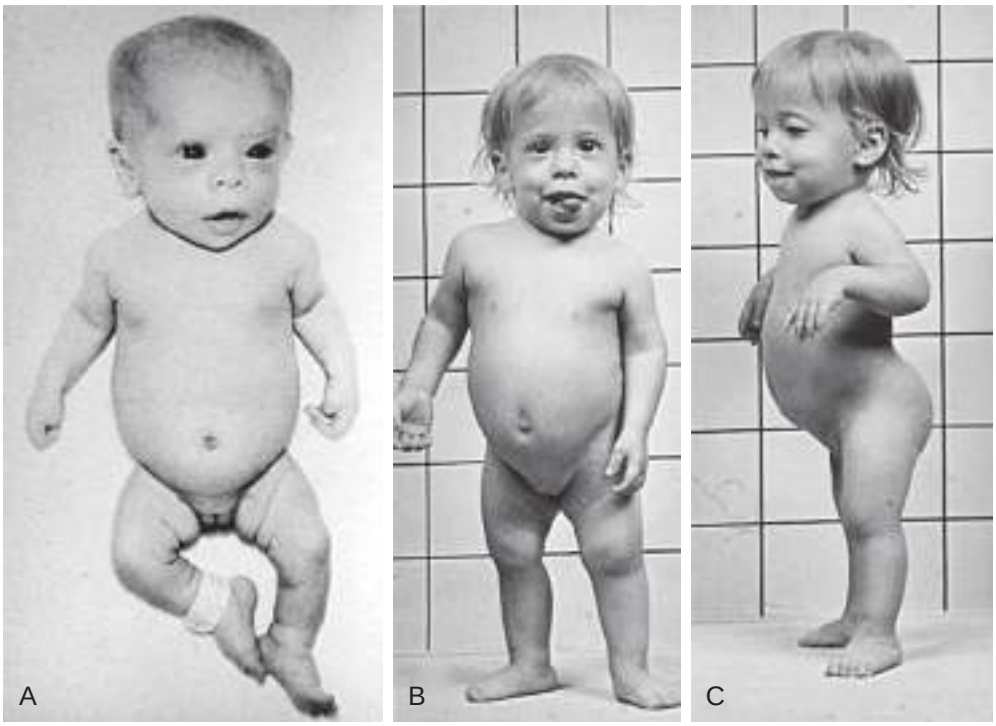

Fig. 736.2 Spondyloepiphyseal dysplasia congenita is shown in infancy (**A**) and early childhood (**B**, **C**). Note the short extremities, relatively normal hands, flat facies, and exaggerated lordosis.

Fig. 736.3 Spondyloepiphyseal dysplasia. Platyspondyly, delayed epiphyseal ossification (especially femoral heads), dens hypoplasia. *(From Campeau P, Schlesinger AE. Skeletal dysplasias. [Updated 2017 Jan 30]. In: De Groot LJ, Chrousos G, Dungan K, et al., eds. Endotext [internet]. South Dartmouth, MA, 2000, MDText.com, Inc. Fig. 5. Available from* https://www.ncbi.nlm.nih.gov/books/NBK279130/*.)*

phenotype of MED has its onset during childhood, with mild short-limbed short stature, pain in weight-bearing joints, and a waddling gait. Radiographs show delayed and irregular ossification of epiphyses. A typical finding is the double-layered patella (pathognomonic). In more mildly affected patients, the disorder might not be recognized until adolescence or adulthood. Radiographic changes may be limited to the capital femoral epiphyses. In the latter case, mild MED must be distinguished from bilateral Legg-Calvé-Perthes disease (see Chapter 719.3). Precocious OA of hips and knees is the major complication in adults with MED. Adult heights range from 136-151 cm.

There are families with clinical and radiographic manifestations of MED that are not caused by pathogenic variants of COMP. Pathogenic variants in the genes encoding all three of the type IX collagen chains have been reported. It has been suggested that COMP and type IX collagen interact functionally in cartilage matrix, thus explaining why pathogenic variants of different genes produce similar pictures. Pathogenic variants of the genes coding for another cartilage matrix protein, matrilin-3 *(MATN3)*, and the diastrophic dysplasia sulfate transporter *(SLC26A)* have also been found in patients with autosomal dominant and recessive MED, respectively. For familial cases of pseudoachondroplasia and MED resulting from pathogenic variant in COMP, prenatal diagnosis is available.

Spondyloepimetaphyseal dysplasia, Borochowitz-Cormier-Daire type

Spondyloepimetaphyseal dysplasia, Borochowitz-Cormier-Daire type is a rare more severe spondylo-epi-metaphyseal dysplasia (SEMD)-like phenotype characterized by short-limb dwarfism with spinal,

Fig. 736.4 Face and profile of a mother and daughter with Stickler syndrome type I. Note in the daughter the flat nasal bridge, the mild epicanthal folds, and discrete micrognathia. At first sight, the mother shows no clear facial characteristics of Stickler syndrome. *(From Baijens LWJ, De Leenheer EMR, Weekamp HH, et al. Stickler syndrome type I and Stapes ankylosis. Int J Pediatr Otorhinolaryngol. 2004;68:1573–1580. Fig. 2.)*

Table 736.2 Other Genetic Diseases Associated with Pathogenic Variants in Type II and Type XI Collagen Genes, with Clinical Presentations Similar to That of Stickler Syndrome

PHENOTYPES ASSOCIATED WITH *COL2A1* PATHOGENIC VARIANTS
Achondrogenesis type II
Hypochondrogenesis
Spondyloepiphyseal dysplasia congenita
Spondyloepimetaphyseal dysplasia, Strudwick type
Kniest dysplasia
Platyspondylic skeletal dysplasia, Torrance type
Spondyloperipheral dysplasia
Czech dysplasia
Spondyloepiphyseal dysplasia, Stanescu type
Dysplasia with altered vertebral contours
Some of the juvenile joint diseases
PHENOTYPES ASSOCIATED WITH *COL11A1* PATHOGENIC VARIANTS
Marshall syndrome
Fibrochondrogenesis 1
Autosomal dominant deafness
PHENOTYPES ASSOCIATED WITH *COL11A2* PATHOGENIC VARIANTS
Otospondylometaphyseal dysplasia
Weissenbacher-Zweymüller syndrome
Fibrochondrogenesis 2
Some cases of isolated sensorineural deafness

Table adapted from Couchouron T, Masson C. Early-onset progressive osteoarthritis with hereditary progressive ophthalmology or Stickler syndrome. *Joint Bone Spine.* 2011;78:45–49. Table 1, p. 48; with additional data from Mortier GR, Cohn DH, Cormier-Daire V, et al. Nosology and classification of genetic skeletal disorders: 2019 revision. *Am J Med Genet A.* 2019;179(12):2393–2419.

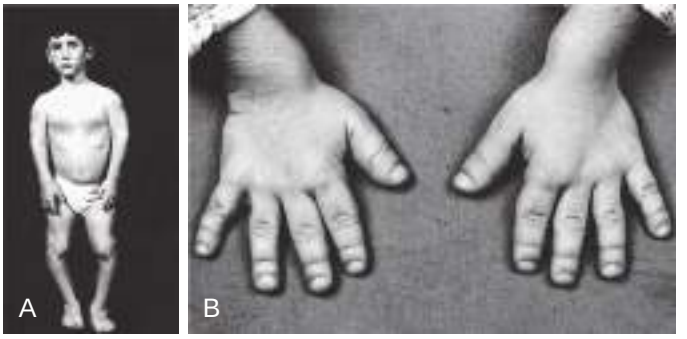

Fig. 736.5 Pseudoachondroplasia in an adolescent male. **A,** The facies and head circumference are normal. There is shortening of all extremities and bowing of the lower extremities. **B,** Photograph of hands, demonstrating short stubby fingers.

epiphyseal, and metaphyseal abnormalities. There are only three families described in the literature caused by autosomal recessive pathogenic variant in the gene encoding matrilin-3 (*MATN3*). Radiographic examination showed flat, ovoid vertebral bodies, short with a stocky appearance, long tubular bones, wide metaphysis with lateral spurs, irregular epiphysis of knee, unossified proximal femur epiphysis, squaring of pelvis, and narrow greater sciatic notch.

SCHMID METAPHYSEAL DYSPLASIA

Schmid metaphyseal dysplasia is one of several chondrodysplasias in which metaphyseal abnormalities dominate the radiographic features. It typically manifests in early childhood with mild short stature, bowing of the legs, and a waddling gait (Fig. 736.7). Joints, such as the wrist, may be enlarged. Radiographs show flaring and irregular mineralization of the metaphyses of tubular bones of the proximal

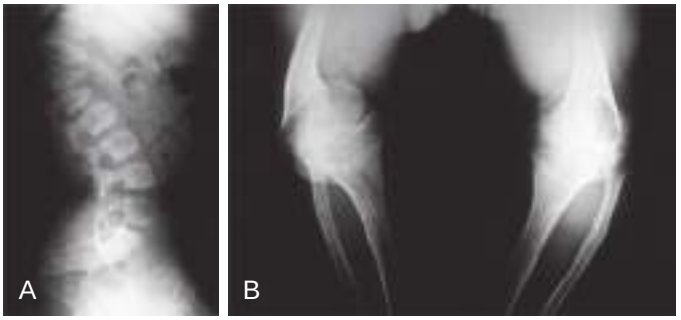

Fig. 736.6 A, Lateral thoracolumbar spine radiograph of a patient with pseudoachondroplasia showing central protrusion (tonguing) of the anterior aspect of upper lumbar and lower thoracic vertebrae. Note reduced vertebral body heights (platyspondyly) and secondary lordosis. B, Lower-extremity radiograph of a patient with pseudoachondroplasia showing large metaphyses, poorly formed epiphyses, and marked bowing of the long bones.

Fig. 736.7 Female patient with metaphyseal dysplasia, type Schmid. The facies are normal, and the stature is mildly reduced. Mild tibia vara is present.

limbs (Fig. 736.8). Coxa vara is usually present and can require surgical correction. Short stature becomes more evident with age and affects the lower extremities more than the upper extremities. Overall, manifestations are limited to the skeleton. Schmid metaphyseal chondrodysplasia is caused by heterozygous pathogenic variants

Fig. 736.8 Radiograph of lower extremities in Schmid metaphyseal dysplasia showing short tubular bones and metaphyseal flaring and irregularities, abnormal capital femoral epiphyses, and femoral necks. The epiphyses are normal. Coxa vara is present.

in the gene encoding type X collagen *(COL10A1)* as an autosomal dominant condition. The distribution of type X collagen is restricted to the region of growing bone in which cartilage is converted into bone. This might explain why radiographic changes are confined to the metaphyses.

Aggrecan-Related Spondyloepiphyseal Dysplasias

Pathogenic variants of aggrecan have been detected in three SED-like conditions. SED-Kimberley is relatively mild, with short stature, stocky build, and early-onset OA of weight-bearing joints. Autosomal dominant pathogenic variants are etiologic. Autosomal recessive pathogenic variants cause a more severe and generalized clinical phenotype, **spondyloepimetaphyseal dysplasia–aggrecan type**. Radiographic changes include irregular epiphyses and widened metaphyses. A mild condition, **familial osteochondritis dissecans,** is characterized by multiple osteochondritic lesions (separation of cartilage and subchondral bone from the surrounding tissue and primarily affecting the knee, ankle, and elbow joints) in knees and/or hips and/or elbows, disproportionate short stature, and early-onset OA. Autosomal dominant pathogenic variants have been found in familial cases.

Visit Elsevier eBooks+ at eBooks.Health.Elsevier.com for Bibliography.

Chapter 737

Disorders Involving Transmembrane Receptors

Daniah Albokhari and Julie E. Hoover-Fong

Heterozygous pathogenic variants of genes encoding *FGFR3* (fibroblast growth factor receptor 3) and *PTHR1* (parathyroid hormone-1 receptor) result in disorders involving transmembrane receptors. The pathogenic variants cause the receptors to become activated in the absence of physiologic ligands, which accentuates normal receptor function of negatively regulating bone growth. The pathogenic variants act by gain of negative function. In the *FGFR3* pathogenic variant group, in which the clinical phenotypes range from severe to mild, the severity appears to correlate with the extent to which the receptor is activated. *PTHR1* and especially *FGFR3* pathogenic variants tend to recur in unrelated individuals (Table 737.1; see also Table 735.1).

FGFR3 CHONDRODYSPLASIA GROUP

The achondroplasia group represents a substantial percentage of patients with chondrodysplasias and contains thanatophoric dysplasia (TD), the most common lethal chondrodysplasia, with a birth prevalence of 1 in 35,000 births and achondroplasia, the most common nonlethal chondrodysplasia, with a birth prevalence of 1 in 15,000–25,000 births. Also in this group are severe achondroplasia with developmental delay and acanthosis nigricans (SADDAN), hypochondroplasia, and camptodactyly, tall stature, and hearing loss syndrome (CATSHL). All five have pathogenic variants in a small number of locations in the *FGFR3* gene. There is a strong correlation between the pathogenic variant site and the clinical phenotype.

Thanatophoric Dysplasia

TD manifests before or at birth. In the former situation, ultrasonographic examination in mid-gestation or later reveals a large head and very short limbs; the pregnancy is often accompanied by polyhydramnios and premature delivery. Very short limbs, short neck, long narrow thorax, and large head with midfacial hypoplasia dominate the clinical phenotype at birth (Fig. 737.1). The cloverleaf skull deformity known as **kleeblattschädel** is sometimes found. If the affected fetus survives pregnancy, the newborn will have severe respiratory distress because of the small thorax. Although this distress can be treated by intense respiratory care, the long-term prognosis is poor.

Skeletal radiographs distinguish two slightly different forms called TD I and TD II. In the more common TD I, radiographs show large calvarium with a small cranial base, marked thinning and flattening of vertebral bodies (platyspondyly) visualized best on lateral view, very short ribs, severe hypoplasia of pelvic bones, and very short and bowed tubular bones with flared metaphyses (Fig. 737.2). The femurs are curved and shaped like a telephone receiver. TD II differs mainly in that there are longer and straighter femurs.

The TD II clinical phenotype is associated with pathogenic variants that map to codon 650 of *FGFR3*, causing the substitution of a lysine with glutamic acid. This activates the tyrosine kinase activity of a receptor that transmits signals to intracellular pathways. The pathogenic variant of the same lysine 650 to methionine is also associated with a clinical phenotype intermediate between TD and achondroplasia, referred to as **SADDAN (severe achondroplasia with developmental delay and acanthosis nigricans)**, where affected cases often do not require ventilatory support and survive beyond infancy. Pathogenic variants of the TD I phenotype mainly map to two regions in the extracellular domain of the receptor, where they substitute cysteine residues for other amino acids. Free cysteine residues are thought to form disulfide bonds promoting dimerization of receptor molecules, leading to activation and signal transmission. TD I and TD II typically present as new pathogenic variants in offspring born to unaffected, average stature parents. The recurrence risk is low. Because the variant codons in TD are pathogenic for unknown reasons and because of the theoretical risk of germ cell mosaicism, parents are offered prenatal diagnosis for subsequent pregnancies.

Table 737.1 *FGFR3* Chondrodysplasia Group

GROUP/NAME OF DISORDER	INHERITANCE	OMIM	GENE
Thanatophoric dysplasia type I (TD I)	AD	187600	*FGFR3*
Thanatophoric dysplasia type II (TD II)	AD	187601	*FGFR3*
Severe achondroplasia with developmental delay and acanthosis nigricans (SADDAN)	AD	616482	*FGFR3*
Achondroplasia	AD	100800	*FGFR3*
Hypochondroplasia	AD	146000	*FGFR3*
Camptodactyly, tall stature, and hearing loss syndrome (CATSHL)	AD	610474	*FGFR3*

Please also refer to group 33 from Mortier et al nosology for craniosynostoses syndromes linked to FGFR3 pathogenic variants, as well as LADD syndrome in group 41 for another FGFR3-related phenotype.

OMIM, Online Mendelian Inheritance in Man (omim.org).

From Campeau P, Schlesinger AE: Skeletal dysplasias. [Updated 2017 Jan 30]. In: De Groot LJ, Chrousos G, Dungan K, et al. (eds). *Endotext [internet]*. South Dartmouth, MA, 2000, MDText.com, Inc. Available from https://www.ncbi.nlm.nih.gov/books/NBK279130/.

Achondroplasia

Achondroplasia is the prototype chondrodysplasia. It typically manifests at birth with short limbs, a long narrow trunk, and a large head with midfacial hypoplasia and prominent forehead (Fig. 737.3). The limb shortening is greatest in the proximal segments (rhizomelia), and the fingers often display a trident configuration. Most joints are hyperextensible, but extension is restricted at the elbow. A thoracolumbar gibbus is typically found in newborns but improves as they start walking with no intervention in 90% of the cases. Birth length may be slightly less than normal but often plots within the low-normal range.

Diagnosis

Skeletal radiographs confirm the diagnosis (Fig. 737.4; see also Fig. 737.3). The calvarial bones are large, whereas the cranial base and facial bones are small. The vertebral pedicles are short throughout the spine as noted on a lateral radiograph. The interpedicular distance, which normally increases from the first to the fifth lumbar vertebra, decreases in achondroplasia. The iliac bones are short and round, and the acetabular roofs are flat. The tubular bones are short with mildly irregular and flared metaphyses. The fibula is disproportionately long compared with the tibia, which is often bowed, causing genu varum.

Clinical Manifestations

Infants usually exhibit delayed motor milestones, often not walking alone until 18-24 months. This is because of hypotonia and mechanical difficulty balancing the large head on a normal-sized trunk and short extremities. Intelligence is normal unless central nervous system complications develop. As the child begins to walk, the gibbus usually gives way to an exaggerated lumbar lordosis.

Infants and children with achondroplasia progressively fall below normal standards for length and height. They can be plotted against standards established for achondroplasia. Adult heights typically are 118-145 cm for men and 112-136 cm for women. C-type natriuretic

Fig. 737.1 Identical twins with type I thanatophoric dysplasia. Disproportionately large head, bell-shaped chest, and micromelia. *(From Gilbert-Barness E, Kapur RP, Oligny LL, Siebert JR, eds. Potter's Pathology of the Fetus, Infant and Child, 2nd ed. Philadelphia: Elsevier, 2007. Fig. 20-47.)*

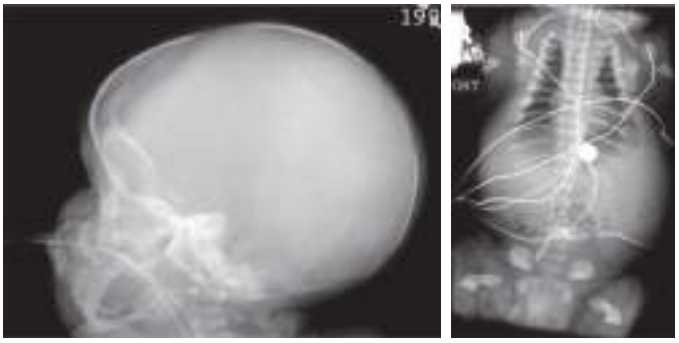

Fig. 737.2 Thanatophoric dysplasia type I. Severe platyspondyly, very short ribs, narrow thorax, short broad pelvis, large skull, very short and bent long bones. *(From Campeau P, Schlesinger AE. Skeletal dysplasias. [Updated 2017 Jan 30]. In De Groot LJ, Chrousos G, Dungan K, et al., eds. Endotext [internet]. South Dartmouth, MA, 2000, MDText.com, Inc., Fig. 1. Available from https://www.ncbi.nlm.nih.gov/books/NBK279130/.)*

Fig. 737.3 Achondroplasia phenotype at different ages. **A,** Infant with achondroplasia with macrocephaly, frontal bossing, midface hypoplasia, small chest, rhizomelic shortening of all the limbs, redundant skinfolds, and extreme joint laxity. Note the trident hand with short fingers and abducted hips. **B,** Typical radiographic findings from a child with achondroplasia. All of the tubular bones are short, but the fibula is relatively long compared with the tibia. There is protrusion of the epiphysis into the metaphysis of the distal femur, creating the chevron deformity, and—to a lesser extent—of the proximal tibia. The iliac bones are rounded, the acetabular roof is horizontal, and the sacrosciatic notches are small. **C,** A 3-yr-old with achondroplasia with the typical features shown in **(A).** Note that the redundant skinfolds are no longer present and that joint laxity has improved. Rhizomelic shortening of the extremities is more pronounced and accompanied by tibial bowing. *(From Horton WA, Hall JG, Hecht JT. Achondroplasia. Lancet. 2007;370:162–172.)*

peptide analogue (vosoritide), administered as a daily subcutaneous injection is the first approved treatment for children ≥5 years of age with achondroplasia; treatment with vosoritide produced an increase of annual growth velocity with no significant side effect. In addition, vosoritide maintains this annual growth velocity up to 2 years along with an improvement in body segment proportion. Clinical trials are underway to study other compounds such as soluble FGFR3 decoy receptors, and tyrosine kinase inhibitors, which may restore bone growth in achondroplasia based on studies in animal models. Other possible future treatments of achondroplasia include fibroblast growth factor aptamers and meclizine, which showed improvement of the skeletal phenotype of the mutant mice. Surgical limb lengthening and human growth hormone treatment have been used to increase height; however, both are controversial.

Virtually all infants and children with achondroplasia have large heads, although only a fraction have true hydrocephalus. Head circumference should be carefully monitored using standards developed for achondroplasia, as should neurologic function in general. The spinal canal is stenotic, and spinal cord compression can occur at the foramen magnum and in the lumbar spine. The former usually occurs in infants and small children and may be associated with hypotonia, failure to thrive, quadriparesis, central and obstructive apnea, and sudden death. Surgical correction may be required for severe stenosis. Lumbar spinal stenosis usually does not occur until early adulthood. Symptoms include paresthesias, numbness, and claudication in the legs. Loss of bladder and bowel control may be late complications. Bowing of the legs is common in patients with achondroplasia and might need to be corrected surgically. Other common problems include dental crowding, articulation difficulties, obesity, and frequent episodes of otitis media, which can contribute to hearing loss.

Genetics

All patients with typical achondroplasia have pathogenic variants at *FGFR3* codon 380. This pathogenic variant is located in the transmembrane domain of the receptor and is thought to stabilize receptor dimers that enhance receptor signals, the consequences of which inhibit linear bone growth. Achondroplasia behaves as an autosomal dominant condition; most cases arise from a new pathogenic variant to average stature parents.

Fig. 737.4 Achondroplasia. Small rounded iliac bones, horizontal acetabula, decreasing interpediculate distance, normal vertebral body height, short ribs. *(From Campeau P, Schlesinger AE. Skeletal dysplasias. [Updated 2017 Jan 30]. In De Groot LJ, Chrousos G, Dungan K, et al., eds. Endotext [internet]. South Dartmouth, MA, 2000, MDText.com, Inc., Fig. 2. Available from https://www.ncbi.nlm.nih.gov/books/NBK279130/.)*

Because of the high frequency of achondroplasia among short stature skeletal dysplasias, it is relatively common for adults with achondroplasia to marry. Such couples have a 50% risk of transmitting their condition, heterozygous achondroplasia, to each offspring, as well as a 25% risk of **homozygous achondroplasia**. The latter condition exhibits intermediate severity between TD and heterozygous achondroplasia and is usually lethal in the newborn period and is often referred to as "double dominant" inheritance. Prenatal diagnosis is available and has been used to diagnose homozygous achondroplasia. Preimplantation genetic testing can be used to identify double dominant pathogenic variants.

Hypochondroplasia

Hypochondroplasia resembles achondroplasia but is milder. Usually, it is not apparent until childhood, when mild short stature affecting the limbs becomes evident. Children have a stocky build, disproportionately short extremities, and slight frontal bossing of the head. Learning disabilities may be more common in this condition. Radiographic changes are mild and consistent with the mild achondroplastic phenotype. Complications are rare; in some patients, the condition is never diagnosed. Adult heights range from 131-154.5 cm for men and 124-138 cm for women. An *FGFR3* pathogenic variant at codon 540 is the most pathogenic variant found in patients with more severe hypochondroplasia. Genetic heterogeneity exists in hypochondroplasia; that is, *SHOX* pathogenic variants are associated with a very similar clinical phenotype. Recombinant growth hormone therapy may enhance growth and improve body disproportion but is still considered controversial with limited evidence of increased final adult height.

JANSEN METAPHYSEAL DYSPLASIA

Jansen metaphyseal chondrodysplasia is a rare, dominantly inherited chondrodysplasia characterized by severe shortening of limbs associated with an unusual facial appearance (see Chapter 735). Sometimes it is accompanied by clubfoot and **hypercalcemia** with serum calcium values of 13-15 mg/dL. At birth, a diagnosis can be made from these clinical findings, and radiographs that show short tubular bones with characteristic metaphyseal abnormalities that include flaring, irregular mineralization, fragmentation, and widening of the physeal space. The epiphyses are normal. The joints become enlarged and limited in mobility with age. Flexion contractures develop at the knees and hips, producing a bent-over posture. The spine can also be deformed by the irregular growth of vertebrae. Intelligence is normal, although there may be hearing loss.

Jansen metaphyseal chondrodysplasia is caused by activating pathogenic variants of *PTHR1*. This G-protein–coupled transmembrane receptor serves as a receptor for both parathyroid hormone and parathyroid hormone-related peptide. Signaling through this receptor serves as a brake on the terminal differentiation of cartilage cells at a critical step in bone growth. Because the pathogenic variants activate the receptor, they enhance the braking effect and thereby slow bone growth. In contrast, loss-of-function pathogenic variants of *PTHR1* are observed in Blomstrand chondrodysplasia, whose clinical features are the mirror image of Jansen metaphyseal chondrodysplasia.

Visit Elsevier eBooks+ at eBooks.Health.Elsevier.com for Bibliography.

Chapter 738

Disorders Involving Ion Transporters

Daniah Albokhari and Julie E. Hoover-Fong

Five genes related to ion transporters have been reported to be involved in skeletal dysplasia conditions, including the *SLC39A13* gene causing Ehlers-Danlos syndrome, spondylodysplastic type, the *SLCO2A1* gene causing hypertrophic osteoarthropathy (OA), the *SLC10A7* gene causing multiple joint dislocations with amelogenesis imperfecta, and the *SLC34A3* gene causing hypophosphatemic rickets with hypercalciuria (HHRH). This chapter will focus on pathogenic variants in the sulfate transporter gene *(SLC26A2)*, also known as **diastrophic dysplasia sulfate transporter *(DTDST),*** which is the most common ion transporter gene causing sulphation disorders skeletal dysplasia. It encompasses a spectrum of both lethal and nonlethal chondrodysplasia, including, in order of decreasing severity, achondrogenesis type 1B, atelosteogenesis type II, diastrophic dysplasia, and a rare recessive form of multiple epiphyseal dysplasia (rMED). The gene product sulfate transporter is important to uptake sulfate ions into cells and is important for cartilage cells that add sulfate moieties to newly synthesized proteoglycans destined for cartilage extracellular matrix. Matrix proteoglycans are responsible for many of the properties of cartilage that allow it to serve as a template for skeletal development. The clinical manifestations result from defective sulfation of cartilage proteoglycans (see also Table 735.1).

A number of pathogenic alleles have been found for the *DTDST* gene; they variably disturb transporter function. The disorders are recessive traits requiring the presence of bi-allelic pathogenic variants. The phenotype is determined by the combination of abnormal alleles with some alleles present in more than one disorder.

Achondrogenesis Type 1B and Atelosteogenesis Type 2

Achondrogenesis type 1B and atelosteogenesis type 2 are rare recessive lethal chondrodysplasias. The most serious is achondrogenesis type 1B, which demonstrates a severe lack of skeletal development usually detected in utero or after a miscarriage. The limbs are extremely short, the head is soft, the thorax is narrow, and the abdomen protuberant. Skeletal radiographs show poor to missing ossification of skull bones, vertebral bodies, fibulas, and ankle bones. The pelvis is hypoplastic, and the ribs are short and slightly thin. The femurs are short and exhibit a trapezoid shape with irregular metaphyses.

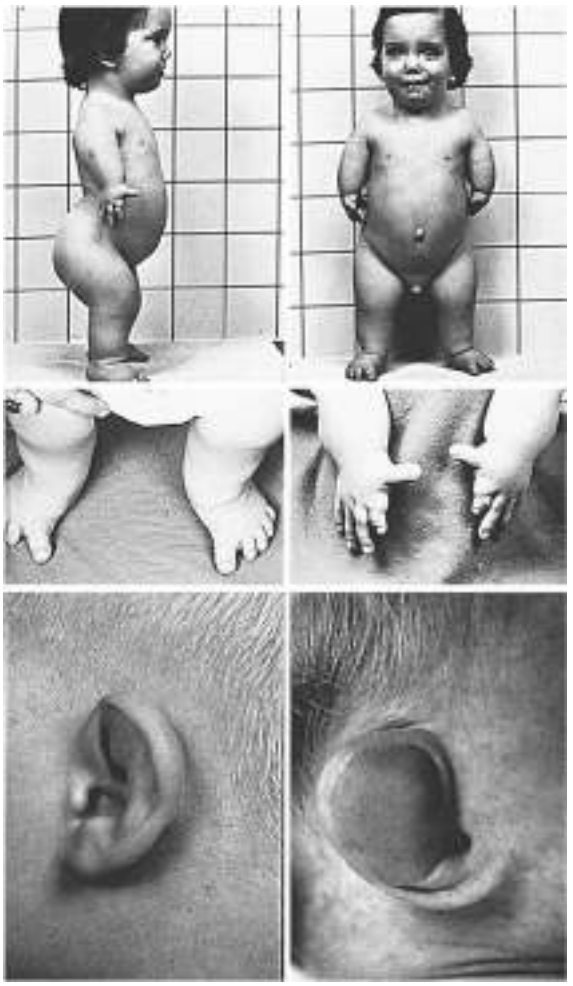

Fig. 738.1 Child with diastrophic dysplasia. The extremities are dramatically shortened *(top)*. Clubfoot is commonly observed *(middle left)*. The fingers are short, especially the index finger; the thumb characteristically is proximally placed and has a hitchhiker appearance *(middle right)*. The upper helix of the ears becomes swollen 3-4 wk postnatally *(lower left)*, and this inflammation spontaneously resolves, leaving a cauliflower deformity of the pinnae *(lower right)*.

Infants with atelosteogenesis type II are stillborn or die soon after birth; prematurity is common. They exhibit very short limbs, especially the proximal segments with normal size head and midface hypoplasia. Clubfoot and dislocations of the elbows and knees may be detected. Hypoplasia of vertebral bodies, especially in the cervical and lumbar spine, and hypoplastic ilia with flat acetabulum are found on radiographs. The femora and humeri are hypoplastic and display a club-shaped appearance. The distal limb bones, including the ulna and fibula, are poorly ossified.

Both disorders have a 25% recurrence risk and are potentially detectable in utero by pathogenic variant analysis if the mutant alleles are identified in the parents. Prenatal diagnosis is possible with fetal imaging and/or pathogenic variant testing, which is commercially available.

Diastrophic Dysplasia

Diastrophic dysplasia is a well-characterized disorder recognized at birth by the presence of very short extremities, normal head size, clubfoot, and short hands, with proximal displacement of the thumb producing a hitchhiker appearance (Fig. 738.1). The hands are usually deviated in an ulnar direction. Bony fusion of the metacarpophalangeal joints (symphalangism) is common, as is restricted movement of many joints, including the hips, knees, and elbows. The external ears often become inflamed soon after birth. The inflammation resolves spontaneously but leaves the ears fibrotic and contracted (cauliflower ear deformity). Many newborns have a cleft palate.

Fig. 738.2 Radiograph of hands in diastrophic dysplasia. The metacarpals and phalanges are irregular and short. The first metacarpal is ovoid.

Radiographs reveal short and broad tubular bones with flared metaphyses and flat, irregular epiphyses (Fig. 738.2). The capital femoral epiphyses are hypoplastic, and the femoral heads are broad. The ulnas and fibulas are disproportionately short. Carpal centers may be developmentally advanced with the first metacarpal typically ovoid, and the metatarsals twisted medially. There may be vertebral abnormalities, including clefts of cervical vertebral lamina and narrowing of the interpedicular distances in the lumbar spine.

Complications are primarily orthopedic and tend to be severe and progressive, leading to joint contractures, spine deformity and early onset OA. The clubfoot deformity in the newborn resists usual treatments, and multiple corrective surgeries are common. Scoliosis typically develops during early childhood. It often requires multiple surgical procedures to control, and it sometimes compromises respiratory function in older children. Despite the orthopedic problems, patients typically have normal intelligence, have normal life span, and reach adult heights in the 105-130 cm range, depending on the severity of scoliosis. Growth curves are available for diastrophic dysplasia. Respiratory insufficiency may present in neonates because of the small rib cage and tracheal instability and collapsibility. In these cases, supportive measures such as mechanical ventilation may be required. Cervical kyphosis is seen in most newborns, which improves spontaneously in childhood. However, some may experience severe cervical kyphosis leading to spinal cord compression.

Some patients are mildly affected and exhibit slight short stature and joint contractures, no clubfoot or cleft palate, and correspondingly mild radiographic changes. The mild phenotype tends to recur within families. The recurrence risk of this autosomal recessive condition is 25%. Ultrasonographic examination can be employed for prenatal diagnosis, but if *DTDST* pathogenic variants can be identified in the patients or parents, molecular genetic diagnosis is possible.

AUTOSOMAL RECESSIVE MULTIPLE EPIPHYSEAL DYSPLASIA

Although previously regarded as a multiple epiphyseal dysplasia, according to the new nosology, rMED is now classified among other sulfation disorders. rMED typically presents during adolescence with the gradual onset of hip and knee pain that might resemble rheumatoid arthritis. Later on, patients present with hand, feet, and knee deformities and scoliosis. Fifty percent of individuals present during infancy with club feet and external ear abnormalities. Stature is normal during childhood, but final height might be slightly decreased compared with unaffected siblings and ranges from 150-180 cm. Radiographic findings include flat epiphysis, mild brachydactyly, and double-layered patella. Diagnosis is clinical, based on presentation and radiologic findings, but molecular confirmation is available with a detection rate over 90%. Management includes physical therapy, pain control, and orthopedic interventions.

Visit Elsevier eBooks+ at eBooks.Health.Elsevier.com for Bibliography.

Chapter 739

Disorders Involving Transcription Factors

Julie E. Hoover-Fong and Daniah Albokhari

Transcription factors are proteins that control the transcription of DNA into RNA to make proteins essential for cellular function. Pathogenic variants in the genes that make transcription factors can result in disease by "turning on" or "turning off" downstream genes to result in disease. Of the estimated 1,500 known transcription factors in humans, four are associated with well-delineated bone dysplasias. Campomelic dysplasia (CD), cleidocranial dysplasia (CCD), and SHOX gene-related conditions are considered dysplasias, whereas nail-patella syndrome (NPS) is classified as a dysostosis (meaning a skeletal disorder limited to individual bones or group of bone rather than the entire skeleton, as in a skeletal dysplasia) (see also Table 735.1).

Pathogenic variants in genes that encode transcription factors that cause disease are *SOX9, RUNX2 (CBFA1)*, *SHOX,* and *LMX1B*, respectively. *SOX9* is a member of the SOX family of transcription factors related to the SRY (sex-determining region of the Y chromosome) gene; *RUNX2 (CBFA1)* belongs to the runt family of transcription factor genes; *SHOX* is part of the homeobox gene family; and *LMX1B* is part of the LIM homeodomain gene family. Each results in a disorder caused by haploinsufficiency of the respective gene products. CD, CCD, and NPS are all autosomal dominant conditions, whereas *SHO*X-related conditions are inherited in a pseudoautosomal fashion.

CAMPOMELIC DYSPLASIA

Campomelic dysplasia is apparent in newborn infants and characterized by short, bowed long bones (especially in the lower legs), respiratory distress, cervical spine anomalies, Pierre-Robin sequence, and variable involvement of the central nervous system, heart, and kidneys. In some cases, femoral bowing is minimal (i.e., acampomelic campomelic dysplasia). Additionally, 75% of XY individuals have some degree of gonadal dysgenesis that ranges from normal female phenotype through ambiguous genitalia and lack of determination of testicular tissue with undervirilization. 46,XX individuals have an expected female phenotype with normal ovarian differentiation. *Therefore karyotype analysis is indicated in every female with campomelia*. These features are because of the role of *SOX9* in the differentiation of testicular tissue downstream of *SRY*. Compared with SOX9 haploinsufficiency, duplications cause gonadal tissue to differentiate into testicular tissue in 46,XX individuals, highlighting the dosage sensitivity of *SOX9* in gonadal differentiation. Radiographs confirm long bone bowing and often show hypoplasia of the scapulae and pelvic bones (Fig. 739.1). Affected infants often die of respiratory distress in the neonatal period because of tracheomalacia, small thoracic volume, and early scoliosis. Complications in children and adolescents who survive include cervical instability, short stature with progressive kyphoscoliosis, recurrent apnea and respiratory infections, hearing loss, and learning difficulties. Because of a deficiency of gonadal differentiation, 46,XY individuals with female genitalia often present with absent thelarche and primary amenorrhea. Pathogenic variant testing is commercially available and has a >95% detection rate. Nearly all individuals with CD represent a de novo pathogenic variant in *SOX9*.

Fig. 739.1 Campomelic dysplasia. Bell-shaped thorax, hypoplastic scapula, bowed femurs, widely spaced ischial bones. *(From Campeau P, Schlesinger AE. Skeletal dysplasias [Fig. 12]. [Updated 2017 Jan 30]. In: De Groot LJ, Chrousos G, Dungan K, et al., eds. Endotext [internet]. South Dartmouth, MA, 2000, MDText.com, Inc. Fig 12. Available at https://www.ncbi.nlm.nih.gov/books/NBK279130/.)*

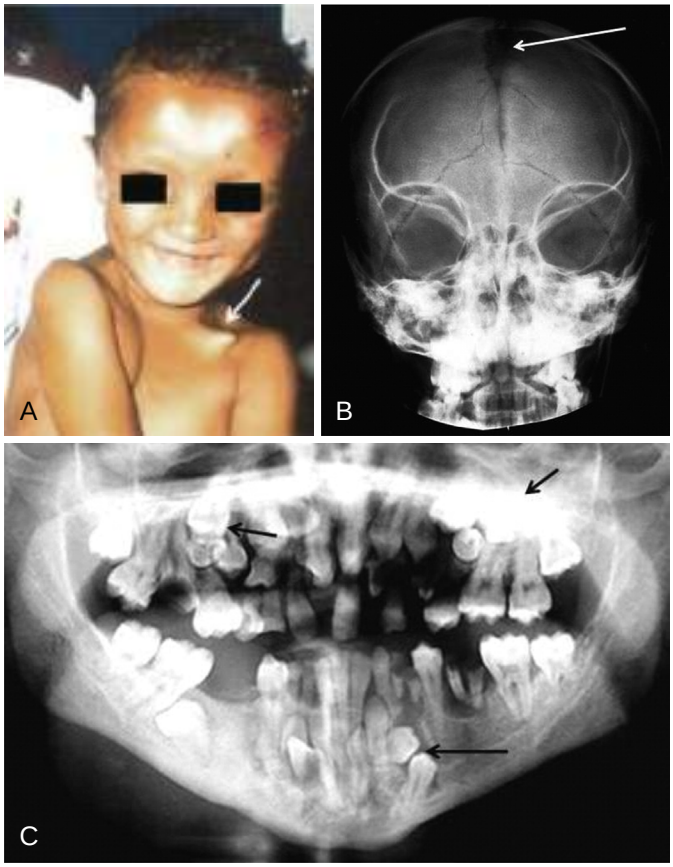

Fig. 739.2 Features of cleidocranial dysplasia displayed. **A,** The forehead is bulky with a central depression, the eyes are widely spaced, and the jaw is pointed. The clavicle is misshapen *(arrow)*. **B,** Note patency of the anterior fontanelle. **C,** Hyperdontia pantomogram of an affected male showing supernumerary teeth. *(From Roberts T, Stephen L, Beighton P. Cleidocranial dysplasia: a review of the dental, historical, and practical implications with an overview of the South African experience. Oral Surg Oral Med Oral Pathol Oral Radiol. 2013;115[1]:46–55. Figs. 1, 4, and 6.)*

CLEIDOCRANIAL DYSPLASIA

Cleidocranial dysplasia can be recognized in infants because of sloping shoulders, wide fontanelles, and prominent forehead. Birth length is normal, but mild short stature and dental abnormalities are evident during childhood (Fig. 739.2). The shoulders of patients

Fig. 739.3 Nail-patella syndrome. **A,** Adolescent showing nail hypoplasia, especially of thumbs, and displacement of small patellae. **B,** Two affected children showing nail dysplasia. **C,** Incomplete extension of the elbows. *(From Jones KL, Jones MC, Del Campo M, eds. Smith's Recognizable Patterns of Human Malformation, 7th ed. Philadelphia: Saunders, 2013. Fig. 1, p. 574.)*

with CD can collapse to meet in the midline because of hypoplasia or absence of the clavicles. Radiographs will reveal the abnormal clavicles, delayed ossification of cranial bones with multiple ossification centers (Wormian bones), and delayed ossification of pelvic bones. The anterior fontanelle is wide and may remain open into adulthood. The course is relatively uncomplicated except for dislocations and variable diffuse joint pain (especially of the shoulders), dental anomalies (e.g., supernumerary and/or retained primary teeth) that require dental treatment, and risk of hearing loss because of infections. Affected individuals are shorter than unaffected siblings and have an increased risk of genu valgum, pes planus, and scoliosis. Diagnosis is based on clinical and radiographic presentation, but molecular confirmation is available with a detection rate of >70%. The proportion of cases caused by de novo pathogenic variants is high. Management includes prevention of ear infections, speech therapy, dental, and orthopedic interventions as indicated.

SHOX GENE-RELATED CONDITIONS

The *SHOX* gene is located on the pseudoautosomal region of the X and Y chromosomes (i.e., Xp22.33/Yp11.32). Because of crossover during meiotic replication, a *SHOX* variant can segregate on both sex chromosomes, thereby allowing inheritance to occur from male to male, male to female, female to female, and female to male (i.e., sex chromosome gene location while appearing to have autosomal inheritance; pseudoautosomal). Haploinsufficiency of the *SHOX* gene (i.e., loss of one copy of the gene) through deletion, single nucleotide variant, or abnormal regulation of adjacent genes causes Leri-Weill dyschondrosteosis (LWD) and idiopathic short stature (ISS) and contributes to Turner syndrome features when included in the absent X-chromosome material. Features of LWD include short stature, mesomelia, and Madelung deformity of the wrists. ISS does not have other phenotypic features of an abnormal *SHOX* gene other than short stature. This distinguishes ISS from Turner syndrome in which the entire X chromosome is typically missing in affected females, causing short stature, pubertal delay/absence, cardiac anomalies, nuchal folds, and other anomalies. Growth hormone injections can provide effective treatment for short stature associated with a *SHOX* gene abnormality.

NAIL-PATELLA SYNDROME

Dysplasia of the nails, absence or hypoplasia of the patella, abnormalities of the elbow, and spurs or "horns" extending from the iliac bones characterize NPS, also called *osteo-onychodysostosis*. Penetrance is high, but clinical presentation is extremely variable with a wide spectrum of severity. Some patients present in early childhood, whereas others are asymptomatic as adults. Nail abnormalities are almost universal with a wide variety of manifestations, including absence, hypoplasia, clefts, ridged, thin, or hypertropic nails, all of which may worsen in severity moving in the ulnar to radial direction. Elbow abnormalities include limitation of movement, cubits valgus, and pterygium. The patella can be hypoplastic or absent (Fig. 739.3). Iliac horns project posterior-laterally from the center of the iliac bone. A total of 30% of patients have nephritis that resembles chronic glomerulonephritis that presents with proteinuria with or without hematuria; 5% of cases progress to end-stage renal disease. There is an increased risk of glaucoma for NPS patients. NPS is often inherited with 12% of cases being *de novo*. Diagnosis is based on clinical presentation, and molecular confirmation is available with a 95% detection rate. Management includes treatment of orthopedic complications, surveillance and treatment of renal disease, and ophthalmologic follow-up.

Visit Elsevier eBooks+ at eBooks.Health.Elsevier.com for Bibliography.

Chapter 740

Osteopetrosis and Other Disorders Involving Defective Bone Resorption

Julie E. Hoover-Fong and Daniah Albokhari

Bone dysplasias displaying increased bone density are rare. Osteopetrosis, which has many subtypes, pycnodysostosis, and dysosteosclerosis are the principal members of this disease category. The clinical features and complications of these conditions are the result of abnormal osteoclast formation and function, resulting in defective bone resorption (Table 740.1).

Table 740.1 Osteopetrosis and Related Osteoclast Disorders

GROUP / DISORDER	INHERITANCE	GENE OR LOCUS
Osteopetrosis, neonatal or infantile form	AR	*TCIRG, CLCN, SNX10*
Osteopetrosis, infantile form, with nervous system involvement	AR	*OSTM1*
Osteopetrosis, infantile form, osteoclast-poor with immunoglobulin deficiency	AR	*TNFRSF11A*
Osteopetrosis, intermediate form	AR	*TCIRG1, TNFSF11, PLEKHM1, CLCN7*
Osteopetrosis, late-onset, dominant form	AD	*CLCN7*
Osteopetrosis with renal tubular acidosis	AR	*CA2*
Osteopetrosis with ectodermal dysplasia and immune defect (OLEDAID)	XL	*IKBKG*
Osteopetrosis, moderate form	AR	*SLC4A2*
Osteopetrosis, moderate form with defective leucocyte adhesion	AR	*FERMT3, RASGRP2*
Osteosclerotic metaphyseal dysplasia	AR	*LRRK1*
Pyknodysostosis	AR	*CTSK*
Dysosteosclerosis	AR	*SLC29A3, TNFRSF11A*
Dysosteosclerosis with degenerative encephalopathy and brain malformation	AR	*CSF1R*

Data from Unger S, Ferreira CR, Mortier GR, et al. Nosology of genetic skeletal disorders: 2023 revision. *Am J Med Genet* 2023;191A:1164-1209 (Table 1, Group 24, pp 1184-1185).

OSTEOPETROSIS

The term *osteopetrosis* derives from the Greek root "osteo," meaning bone, and "petrosis," meaning stone. Osteopetrosis is marked by *increased* bone mass caused by abnormal osteoclast formation or function. The dense bone in osteopetrosis invades the marrow space, causing anemia and pancytopenia, and impinges on nerves traversing cranial and other skeletal foramina, causing deafness, blindness, and palsies. Although the skeleton is dense in osteopetrosis, the bone quality is poor and may be prone to fracture because of imbalanced bone turnover.

To date, genes known to cause osteopetrosis include: *CLCN7, TCIRG1, OSTM1, SNX10, CA2, PLEKHM1, TNFRSF11A, TNFSF11, IKBKG, SLC4A2, FERMT3, and RASGRP2.* Pathogenic variants in *CLCN7, TCIRG1, OSTM1, SNX10, CA2,* and *PLEKHM1* prevent normal osteoclast function to resorb bone while *TNFRSF11A, TNFSF11* encode proteins (RANK and RANKL, respectively) that are essential to the formation of osteoclasts. Pathogenic variants in *CLCN7* may cause disease in an autosomal dominant or recessive fashion and variants in *IKBKG* are X-linked, whereas all others here cause recessive osteopetrosis. CLCN7-related autosomal dominant osteopetrosis occurs in 1 in 20,000 births, while collectively, the recessive form of osteopetrosis occurs in 1 in 250,000 births. Pathogenic variants in *CLCN7* are the most common cause of osteopetrosis overall, causing a wide spectrum of disease severity ranging from late childhood/adolescent-onset autosomal dominant osteopetrosis II (ADOII) to more involved intermediate autosomal osteopetrosis (IAO) to the most severe autosomal recessive osteopetrosis (ARO) with onset at birth. In general, the other recessive forms of osteopetrosis are also severe, usually detected in infancy because of macrocephaly, hepatosplenomegaly, deafness, blindness, and severe anemia.

CLINICAL MANIFESTATIONS

Most of the manifestations of osteopetrosis are because of failure to remodel growing bones. This leads to narrowing of cranial nerve foramina and encroachment on marrow spaces, which results in secondary complications, such as optic and facial nerve dysfunction, and anemia accompanied by compensatory extramedullary hematopoiesis in the liver and spleen (Table 740.2). The unusually dense bones are weak, leading to increased risk of fractures.

In the severe recessive infancy-onset form, patients present with macrocephaly, hepatosplenomegaly, deafness, blindness, and severe anemia. Radiographs reveal diffuse bone sclerosis and *hypocalcemia* may be present. Later radiographs show the characteristic bone-within-bone appearance throughout the skeleton (Figs. 740.1 and 740.2). With time, infants typically fail to thrive and show psychomotor delay and worsening of cranial neuropathies and anemia. Dental problems, osteomyelitis of the mandible, and pathologic fractures are common. The most severely affected patients die during infancy; less severely affected patients rarely survive beyond the second decade but often only after treatment with bone marrow transplant. Those who survive beyond infancy usually have learning disabilities but might have normal intelligence despite hearing and vision loss.

The autosomal dominant form of osteopetrosis (Albers-Schönberg disease, osteopetrosis tarda, or marble bone disease) usually manifests during childhood or adolescence with fractures and mild anemia and, less often, as cranial nerve dysfunction, dental abnormalities, or osteomyelitis of the mandible. Skeletal radiographs reveal a generalized increase in bone density and clubbing of metaphyses. Alternating lucent and dense bands produce a sandwich appearance to vertebral bodies. The radiographic changes are sometimes incidental findings in otherwise asymptomatic adolescents and adults.

Table 740.2 Complications of Osteopetrosis by Subspeciality

SUBSPECIALTY	COMPLICATION
Endocrinology	Osteopetrorickets Hypocalcemia
Ophthalmology	Papilledema Ptosis Strabismus Paralysis of extraocular muscles Optic nerve atrophy Exophthalmos Nystagmus Retinal degeneration Tearing (from nasolacrimal duct obstruction)
Dentistry	Delay/failure of tooth eruption Malformed crowns/roots Periodontal ligament defects Odontoma Tooth agenesis Enamel hypoplasia Tooth decay/caries Thickened lamina dura Osteomyelitis (most frequently of the mandible)
Orthopedics	Skeletal deformities Scoliosis Spondylolisthesis Fractures (particularly of the long bones) Delayed union/nonunion Degenerative arthritis Spondylolysis
Neurology/ neurosurgery	Compressive cranial neuropathies (often optic and facial nerves, but can involve any of cranial nerves I–VIII) Increased intracranial pressure Craniosynostosis Arnold–Chiari I malformation Neuromuscular scoliosis Developmental delay/regression, seizures (*OSTM1* mutation) Calcifications of the basal ganglia, thalami (*CAII* deficiency) Hydrocephalus Cerebrovascular stenosis/occlusion Acquired encephalocele
Otolaryngology	Conductive hearing loss Recurrent otitis media Chronic congestion (poorly pneumatized sinuses) Rhinorrhea Choanal atresia Rhinosinusitis Obstructive sleep apnea
Hematology	Thrombocytopenia with bleeding Anemia Leukopenia with frequent infections Hepatosplenomegaly Transfusion dependence
Nephrology	Renal tubular acidosis, nephrocalcinosis, and nephrolithiasis (*CAII* deficiency)

From Wu CC, Econs MJ, DiMeglio LA, et al. Diagnosis and management of osteopetrosis: consensus guidelines from the osteopetrosis working group. *J Clin Endocrinol Metab* 2017;102(9):3111-3123 (Table 2, p. 3116).

TREATMENT

Most of the bone manifestations in severe osteopetrosis caused by intrinsic osteoclast defects can be prevented or reversed by hematopoietic stem cell transplantation (HSCT), if carried out before development of irreversible secondary complications, such as visual impairment. RANKL replacement therapy may be useful in patients with RANKL deficiency caused by *TNFSF11* bi-allelic pathogenic variants, who do not benefit from HSCT. Interferon-γ is used to delay progression in patients with severe malignant infantile osteopetrosis. Symptomatic care, such as dental care, transfusions for anemia, and antibiotic treatment of infections, is important for patients who survive infancy.

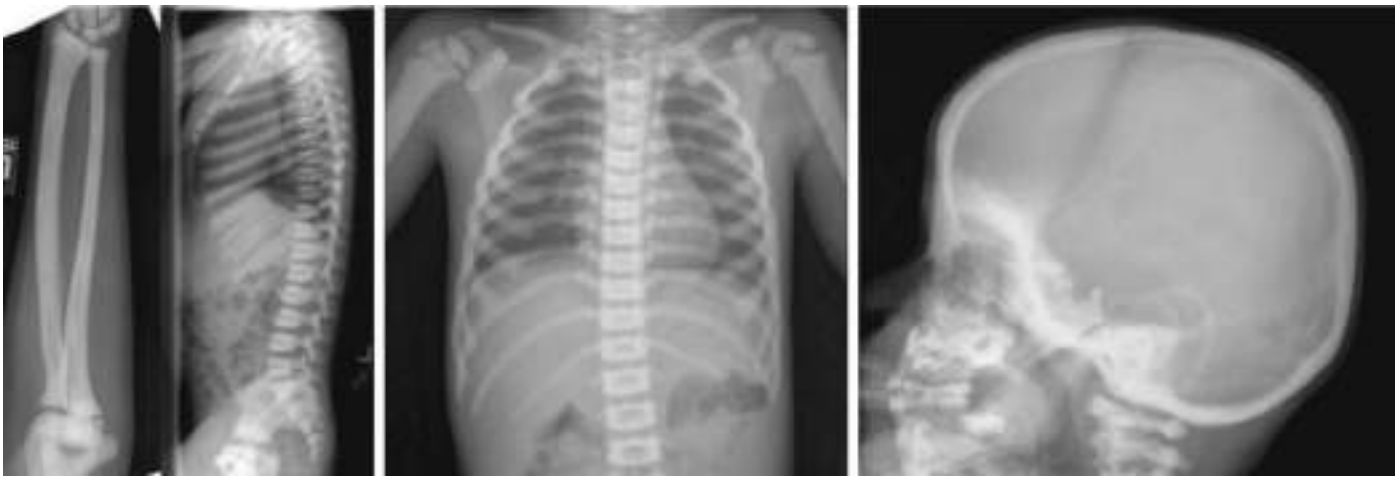

Fig. 740.1 Osteopetrosis. Thick dense bones, alternating bands of sclerosis, and normal density bone in long bones, rugger jersey spine, dense base of skull. *(From Campeau P, Schlesinger AE. Skeletal dysplasias. [Updated 2017, Jan 30]. In De Groot LJ, Chrousos G, Dungan K, et al, eds. Endotext [internet]. South Dartmouth, MA, 2000, MDText.com, Inc. Fig. 14. Available at https://www.ncbi.nlm.nih.gov/books/NBK279130/.)*

Fig. 740.2 Osteopetrosis. Right-hand radiograph obtained at 2 weeks of age. Note metaphyseal lucent bands in the distal ulna and radius *(arrows)* and short tubular bones. *(From Stark Z, Savarirayan R. Osteopetrosis. Orphanet J Rare Dis. 2009;4:5.)*

PYCNODYSOSTOSIS AND DYSOSTEOSCLEROSIS

Pycnodysostosis

An autosomal recessive bone dysplasia related to osteopetrosis, pycnodysostosis manifests in early childhood with short limbs, characteristic facies, an open anterior fontanel, a large skull with frontal and occipital bossing, acroosteolysis, and dental abnormalities. The hands and feet are short and broad, and the nails may be dysplastic. The sclerae may be blue. Minimal trauma often leads to fractures. Treatment is symptomatic and focused mainly on the management of dental problems and fractures. Although some patients have a persistently open anterior fontanelle (i.e., even into adulthood), others with pycnodysostosis have craniosynostosis. The overall prognosis for these patients is generally good, and they typically reach 130-150 cm in height. Skeletal radiographs show a generalized increase in bone density. In contrast to many disorders in this group, the metaphyses are normal. Other changes include wide sutures and Wormian bones in the skull, a small mandible, and osteolysis of the distal phalanges. Homozygous or compound heterozygous missense, nonsense, insertions, deletions, and splicing variants have been described in the gene *CTSK,* which encodes cathepsin K. This is a lysosomal protease that is involved in bone resorption and remodeling. *CTSK* is highly expressed in osteoclasts, and pathogenic variants prevent degradation of bone matrix proteins (e.g., type I and II collagen), which is necessary for normal bone remodeling and resorption. Growth hormone therapy has been used to improve growth.

Dysosteosclerosis

Dysosteosclerosis is another rare bone disease with generalized increased bone density plus widening of tubular bones and vertebral flattening. It is caused by pathogenic variants in three genes: *SLC9A3, CSF1R,* and *TNFRSF11A* (which is allelic with osteopetrosis). Affected individuals have short stature and cranial nerve involvement caused by impingement of the foramina by the abnormally dense bone. No disease-specific treatment has been developed.

There are several other conditions marked by hyperostotic and fragile bones but also other anomalies or conditions distinguishing them from osteopetrosis, pycnodysostosis, and dysosteosclerosis (Table 740.3).

Visit Elsevier eBooks+ at eBooks.Health.Elsevier.com for Bibliography.

Table 740.3 Other Conditions with Hyperostotic Fragile Bones

GENE	DISORDER	CLINICAL CHARACTERISTICS	FEATURES DISTINGUISHING THIS DISORDER FROM *CLCN7*-RELATED ARO
CA2	ARO w/renal tubular acidosis (RTA) (OMIM 259730)	Generalized osteosclerosis. Cerebral calcifications are typical and may be associated with ID.	Onset of ARO with RTA is usually later than in infantile malignant form of ARO and disease course is milder.
OSTM1	*OSTM1*-related ARO (OMIM 259720)	~4% of ARO is caused by pathogenic variants in *OSTM1*. Extremely severe form of ARO with CNS involvement that is indistinguishable from most severe forms of *CLCN7*-related ARO.	*OSTM1*-related ARO is frequently associated with structural brain anomalies.
PLEKHM1	*PLEKHM1*-related ARO (OMIM 611497)	Very rare, can look like ADOII.	*PLEKHM1*-related ARO appears to be very mild and can regress with ↑ age. One person with *PLEKHM1*-related ARO caused by a heterozygous pathogenic variant has been described.
SNX10	*SNX10*-related ARO (OMIM 615085)	~4% of ARO is caused by pathogenic variants in *SNX10*; in particular, "Västerbottenian osteopetrosis" is caused by *SNX10* pathogenic variants. Loss of vision, anemia, and bone fragility are frequently observed, warranting use of HSCT.	*SNX10*-related ARO appears to be slightly less severe than *CLCN7*-related ARO.
TCIRG1	*TCIRG1*-related ARO (OMIM 259700)	>50% of ARO is caused by pathogenic variants in *TCIRG1*.	Higher frequency of neurodevelopmental delay and seizures in *CLCN7*-related ARO than in *TCIRG1*-related ARO. Noncoding *TCIRG1* variants can cause milder phenotype that resembles ADOII.
TNFRSF11A	Osteoclast-poor ARO (OMIM 612301)	Characterized by onset within first year of life and typical ARO manifestations. Investigation of bone biopsy is prerequisite for reliable diagnosis.	*TNFSF11* pathogenic variants cause a slight T-cell defect, and *TNFRSF11A* pathogenic variants can lead to hypogammaglobulinemia similar to a common variable immune deficiency. It is crucial to rule out *TNFSF11*- and *TNFRSF11A*-related ARO, as HSCT is not successful in these persons.
TNFSF11	Osteoclast-poor ARO (OMIM 259710)		

ADOII, Autosomal dominant osteopetrosis type II; ARO, autosomal recessive osteopetrosis; CNS, central nervous system; ID, intellectual disability; HSCT, hematopoietic stem cell transplantation

From Sobacchi C, Villa A, Schulz A, Kornak U. *CLCN7*-Related Osteopetrosis. 2007 Feb 12 [updated 2022 Jan 20]. In: Adam MP, Ardinger HH, Pagon RA, et al., eds. GeneReviews [Internet]. Seattle (WA): University of Washington, Seattle; 1993–2022.

Chapter 741

Other Inherited Disorders of Skeletal Development

Julie E. Hoover-Fong and Daniah Albokhari

Advances in understanding have led to the delineation of the genetic basis of disorders that were previously poorly understood. Some of these conditions are now classified into gene families based on their molecular and clinical findings, as outlined in the most recent nosology and classification of genetic skeletal disorders and previous chapters. Additional important skeletal dysplasias that do not fit into one of the previous categories are discussed in this chapter.

ELLIS-VAN CREVELD SYNDROME

The Ellis-van Creveld syndrome, also known as **chondroectodermal dysplasia**, is a skeletal *and* an ectodermal dysplasia. This skeletal dysplasia presents at birth with short limbs, especially the middle and distal segments, accompanied by postaxial polydactyly of the hands and sometimes of the feet (Fig. 741.1). Nail dysplasia and dental anomalies (including neonatal, absent, premature loss of teeth, and upper lip defects) constitute the ectodermal dysplasia. Additional common manifestations include atrial septal defects and other congenital heart defects.

Skeletal radiographs reveal short tubular bones with clubbed ends, especially the proximal tibia and ulna (Fig. 741.2). Carpal bones display extra ossification centers and fusion; cone-shaped epiphyses are evident in the hands. A bony spur is often noted above the medial aspect of the acetabulum.

Ellis-van Creveld syndrome is an autosomal recessive condition that occurs with increased frequency in the Amish and Finnish founder populations than in the general population. Pathogenic variants have been identified in one of two genes, *EVC (EVC1)* or *EVC2 (LIMBIN)*, which map in a head-to-head configuration to chromosome 4p. Disease-causing variants of *EVC2* are detected in the allelic condition **Weyers acrofacial dysostosis**. EVC and EVC2 proteins are thought to influence hedgehog signaling in cilia by constitutively associating in a ringlike pattern in the ciliary transition zone and transducing extracellular signals to the nucleus via hedgehog signaling. Fgf18 may also play a significant role. This disorder is classified under the **ciliopathies** with major skeletal involvement (see Chapter 101.3).

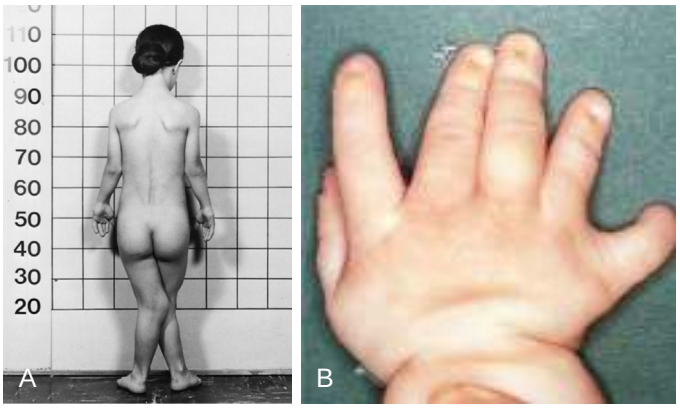

Fig. 741.1 **A,** Ellis-van Creveld syndrome in a young female. Note short stature, joint contractures at the elbows, and marked genu valgum. **B,** Multiple digits (polydactyly) in a different patient with Ellis-van Creveld syndrome. *(**A** from Zipes DP, Libby P, Bonow R, Braunwald E, eds. Braunwald's Heart Disease: a textbook of cardiovascular medicine, 7th ed. Philadelphia: WB Saunders, 2004. Fig 70.6; **B** from Beerman LB, Kreutzer J, Allada V. Cardiology. In: Zitelli BJ, McIntire SC, Nowalk AJ, eds. Zitelli and Davis' Atlas of Pediatric Physical Diagnosis, 6th ed. Philadelphia: Elsevier, 2012. Fig 5.6.)*

Fig. 741.2 Radiograph of lower extremities in Ellis-van Creveld syndrome. Tubular bones are short, and proximal fibula is short. Ossification is retarded in lateral tibia epiphyses, causing a knock-knee deformity.

Approximately 30% of patients die of cardiac or respiratory problems during infancy. Life span is otherwise normal; adult heights range from 119-161 cm.

ASPHYXIATING THORACIC DYSTROPHY

See also Chapter 467.3.

Asphyxiating thoracic dystrophy, or **Jeune syndrome**, is an autosomal recessive chondrodysplasia. Newborn infants present with a long, narrow thorax and respiratory insufficiency associated with pulmonary hypoplasia. Neonates often die. Other neonatal manifestations include slightly short limbs and postaxial polydactyly. This condition results from a disturbance of primary cilia, most often from pathogenic variants of the gene encoding cytoplasmic dynein 2 heavy chain 1 *(DYNC2H1)*. This disorder is classified under **ciliopathies** with major skeletal involvement (see Chapter 101.3).

Skeletal radiographs show very short ribs with anterior expansion. Tubular limb bones are short with bulbous ends; cone-shaped epiphyses occur in hand bones. The iliac bones are short and square with a spur above the medial aspect of the acetabulum (Fig. 741.3).

If infants survive the neonatal period, respiratory function usually improves as the rib cage grows. Surgery that produces lateral thoracic expansion improves rib growth and enhances chest wall dimensions. Progressive renal dysfunction often develops during childhood. Intestinal malabsorption and hepatic dysfunction have also been reported.

SHORT-RIB POLYDACTYLY SYNDROMES

These conditions, which share the clinical features of constricted thoracic cage, short ribs, polydactyly, very short extremities, lethality during the newborn period and autosomal recessive inheritance. Pathogenic variants that map to cilia-related genes—*DYNC2H1, IFT80, IFT81, WDR34, WDR60, DYNC2LI1, NEK1, IFT122, WDR19, INTU, TRAF3IP1*—are found in this group of disorders.

CARTILAGE-HAIR HYPOPLASIA-ANAUXETIC SPECTRUM DISORDERS

Cartilage-hair hypoplasia (CHH), also known as **metaphyseal chondrodysplasia–McKusick type,** is part of a spectrum of disorders with metaphyseal involvement that includes metaphyseal dysplasia without hypotrichosis and anauxetic dysplasia. All disorders are characterized by severe disproportionate short stature, which is usually recognized at birth; the short limbs can lead to prenatal detection. They all show autosomal recessive inheritance and are caused by pathogenic variants in *RMRP*, a gene coding for a large untranslated RNA component of an enzyme complex involved in processing mitochondrial RNA. Loss of this gene product interferes with processing of both messenger RNA and ribosomal RNA and correlates with the extent of bone dysplasia, whereas loss of messenger RNA processing correlates with the degree of hair hypoplasia, immunodeficiency, and hematologic abnormality. Molecular testing confirms the diagnosis, and prenatal diagnosis is available if the pathogenic variant is identified either in the patient or the parents.

CHH is recognized during the second year because of growth deficiency affecting the limbs, accompanied by flaring of the lower rib cage, a prominent sternum, and bowing of the legs. The hands and feet are short, and the fingers are very short with extreme ligamentous laxity. The hair is thin, sparse, and light colored; the nails are hypoplastic; and the skin can be hypopigmented.

Radiographs show short tubular bones with flared, irregularly mineralized, and cupped metaphyses (Fig. 741.4). The knees are more affected than are the hips, and the fibula is disproportionately longer than the tibia. The metacarpals and phalanges are short and broad. Spinal radiographs reveal mild platyspondyly.

Nonskeletal manifestations associated with CHH include immunodeficiency (T-cell abnormalities, neutropenia, leukopenia, and susceptibility to varicella zoster virus infections; children also may have complications from smallpox and polio vaccinations), malabsorption, celiac disease, and Hirschsprung disease. Adults are at risk for malignancy, especially non-Hodgkin lymphoma and skin tumors. Adult height ranges from 107-157 cm.

The highest birth prevalence is in the Amish and Finnish populations because of a founder effect. Carrier frequency in the Amish is 1:19 with 1 per 1,300 births affected compared to a carrier frequency of 1:76 and 1 per 23,000 births affected in Finland. The exact prevalence in the general population is not known, but CHH

is relatively rare. However, two allelic conditions, metaphyseal dysplasia without hypotrichosis and anauxetic dysplasia, expand the phenotypic spectrum. Children with a growth disorder and abnormal hair should be evaluated for *RMRP* pathogenic variants.

TRPV4-SPECTRUM DISORDERS

Pathogenic variants in *TRPV4* cause a spectrum of conditions including metatropic dysplasia, spondylometaphyseal dysplasia (SMD), Kozlowski type, brachyolmia, and familial digital arthropathy with brachydactyly. Metatropic dysplasia and SMD, Kozlowski type are expanded on next. **Brachyolmia** is dominated by progressive scoliosis and platyspondyly on x-rays and familial digital arthropathy with brachydactyly, which is characterized by deforming painful osteoarthritis of the interphalangeal, metacarpophalangeal, and metatarsophalangeal joints starting after the first decade of life. The rest of the skeleton is unaffected in this condition. It should also be noted that pathogenic variants in *TRPV4* are also responsible for a large group of neuromuscular disorders including **Charcot-Marie-Tooth disease type 2C**, scapuloperoneal spinal muscular atrophy, and congenital distal spinal muscular atrophy. Though there is considerable overlap of the phenotypes of the conditions within the skeletal group and the neuromuscular group, there are only rare instances currently recognized of individual patients with both features.

METATROPIC DYSPLASIA

Metatropic dysplasia is an autosomal dominant disorder resulting from heterozygous pathogenic variants of transient receptor potential vanilloid family 4 (TRPV4), which encodes a calcium-permeable cation channel. Newborn infants present with a long narrow trunk and short extremities. A tail-like appendage sometimes extends from the base of the spine. Odontoid hypoplasia is common and may be associated with cervical instability. Kyphoscoliosis appears in late infancy and progresses through childhood, often becoming severe enough to compromise cardiopulmonary function. The joints are large and become progressively restricted in mobility, except in the hands. Contractures often develop in the hips and knees during childhood. Although severely affected infants can die at a young age from respiratory failure, patients usually survive, although they can become disabled as adults from the progressive musculoskeletal deformities. Adult heights range from 110-120 cm.

Skeletal radiographs show characteristic changes dominated by severe platyspondyly and short tubular bones with expanded and deformed metaphyses that exhibit a dumbbell appearance (Fig. 741.5). The pelvic bones are hypoplastic and exhibit a halberd appearance because of a small sacrosciatic notch and a notch above the lateral margin of the acetabulum.

Fig. 741.4 Radiograph of lower extremities in cartilage-hair hypoplasia. The tubular bones are short, and the metaphyses are flared and irregular. The fibula is disproportionately long compared with the tibia. The femoral necks are short.

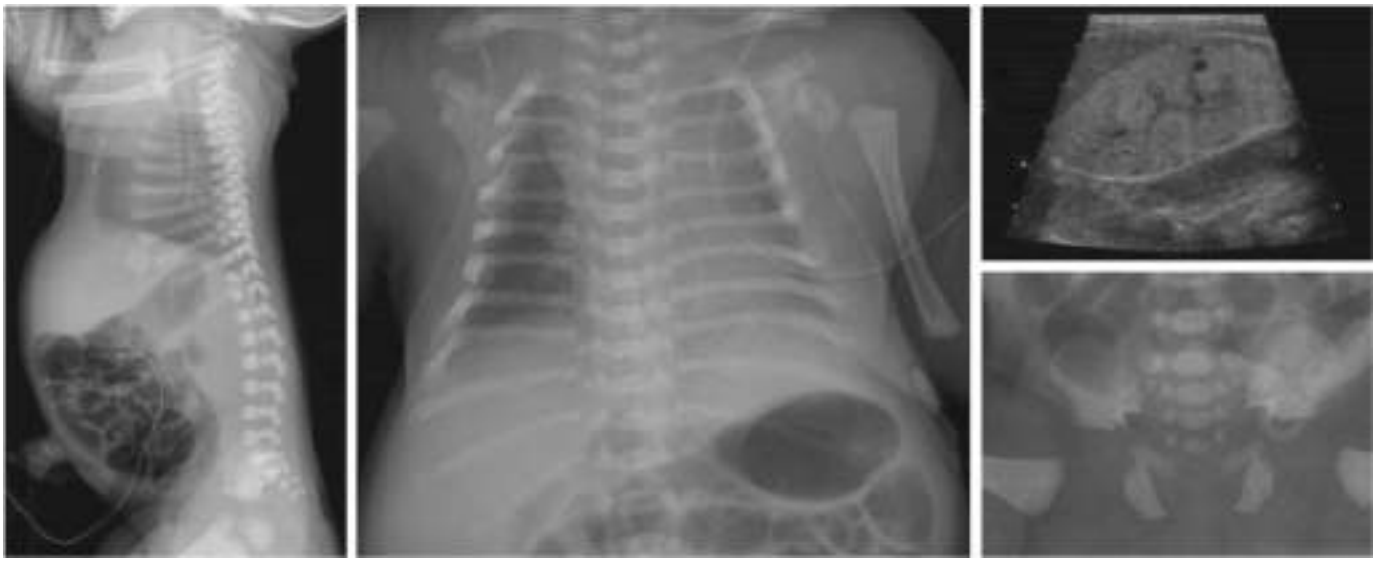

Fig. 741.3 Asphyxiating thoracic dystrophy. Short ribs, long and narrow chest, small pelvis, trident acetabula, no platyspondyly (helps differentiate from thanatophoric dysplasia), cystic renal disease. *(From Campeau P, Schlesinger AE. Skeletal dysplasias. [Updated 2017 Jan 30]. In: De Groot LJ, Chrousos G, Dungan K, et al., eds. Endotext [internet]. South Dartmouth, MA, 2000,* MDText.com*, Inc., Fig 6. Available at:* https://www.ncbi.nlm.nih.gov/books/NBK279130/*)*

SPONDYLOMETAPHYSEAL DYSPLASIA, KOZLOWSKI TYPE

Kozlowski type of spondylometaphyseal dysplasia is an autosomal dominant allelic disorder to metatropic dysplasia caused by *TRPV4* variants.

Kozlowski type of spondylometaphyseal dysplasia manifests in early childhood with mild short stature involving mostly the trunk and a waddling gait. The hands and feet may be short and stubby. Radiographs show flattening of vertebral bodies. The metaphyses of tubular bones are widened and irregularly mineralized, especially at the proximal femur. The pelvic bones manifest mild hypoplasia. Scoliosis can develop during adolescence. The disorder is otherwise uncomplicated, and manifestations are limited to the skeleton. Adults reach heights of 130-150 cm.

DISORDERS INVOLVING FILAMINS

Pathogenic variants of genes encoding filamin A and filamin B proteins have been detected in diverse disorders of skeletal development: filamin A pathogenic variants in otopalatodigital syndromes type 1 and 2, frontometaphyseal dysplasia, Melnick-Needles syndrome and terminal osseous dysplasia with pigmentary defects and filamin B pathogenic variants in Larsen syndrome and perinatal lethal atelosteogenesis types 1 and 3, spondylo-carpal-tarsal dysplasia and Boomerang dysplasia. Filamins functionally connect extracellular to intracellular structural proteins, thereby linking cells to their local microenvironment, which is essential for skeletal development and growth.

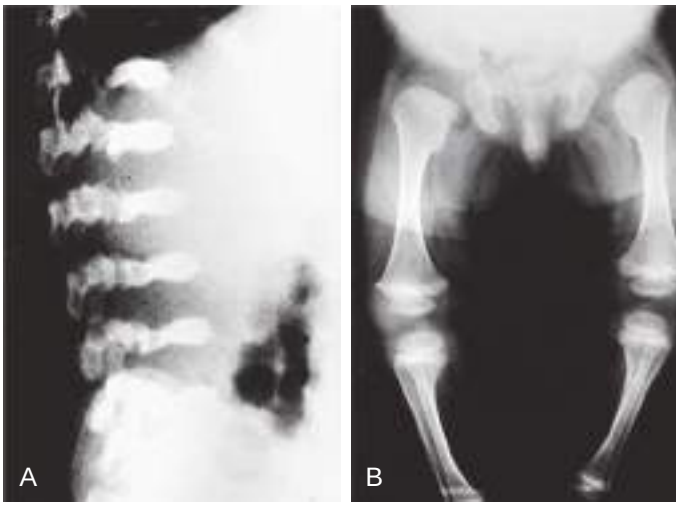

Fig. 741.5 A, Radiograph of the lateral thoracolumbar spine in metatropic dysplasia showing severe platyspondyly. B, Radiograph of lower extremities in metatropic dysplasia showing short tubular bones with widened metaphyses. The femurs have a dumbbell appearance.

JUVENILE OSTEOCHONDROSES

The juvenile osteochondroses are a heterogeneous group of disorders in which regional disturbances in bone growth cause noninflammatory arthropathies. Table 741.1 summarizes the juvenile osteochondroses. Some have localized pain and tenderness (Freiberg disease, Osgood-Schlatter disease [see Chapter 718.4], osteochondritis dissecans [see Chapter 718.3]), whereas others present with painless limitation of joint movement (Legg-Calvé-Perthes disease [see Chapter 719.3], Scheuermann disease [see Chapter 720.4]). Bone growth may be disrupted, leading to deformities. The diagnosis is usually confirmed radiographically, and treatment is symptomatic. The pathogenesis of these disorders is believed to involve ischemic necrosis of primary and secondary ossification centers. Although familial forms have been reported, these disorders usually occur sporadically.

CAFFEY DISEASE (INFANTILE CORTICAL HYPEROSTOSIS)

This is a rare disorder of unknown etiology characterized by cortical hyperostosis with inflammation of the contiguous fascia and muscle. It is often sporadic, but both autosomal dominant and autosomal recessive forms have been reported. Pathogenic variants in *FAM111A* and *TBCE* have been identified in the autosomal dominant and recessive forms, respectively. **Sanjad-Sakati syndrome** (hypoparathyroidism, intellectual disability, dysmorphism) is also caused by pathogenic variants in *TBCE*. Caffey dysplasia is classified in the slender bone dysplasia group.

Prenatal and more often postnatal onsets have been described. Prenatal onset may be mild (autosomal dominant) or severe (autosomal recessive). Severe prenatal disease is characterized by typical bone lesions, polyhydramnios, hydrops fetalis, severe respiratory distress, prematurity, and high mortality. Onset in infancy (younger than 6 months; average: 10 weeks) is most common; manifestations include the sudden onset of irritability, swelling of contiguous soft tissue that precedes the cortical thickening of the underlying bones, fever, and anorexia. The swelling is painful with a woodlike induration but with minimal warmth or redness; suppuration is absent. There are unpredictable remissions and relapses; an episode can last 2 weeks to 3 months. The most common bones involved include the mandible (75%) (Fig. 741.6), the clavicle, and the ulna. If swelling is not prominent or visible, the diagnosis might not be evident.

Laboratory features include elevated erythrocyte sedimentation rate and serum alkaline phosphatase as well as, in some patients, increased serum prostaglandin E levels. There may be

Table 741.1 Juvenile Osteochondroses

EPONYM	AFFECTED REGION	AGE AT PRESENTATION
Legg-Calvé-Perthes disease	Capital femoral epiphysis	3-12 yr
Osgood-Schlatter disease	Tibial tubercle	10-16 yr
Sever disease	Os calcaneus	6-10 yr
Freiberg disease	Head of second metatarsal	10-14 yr
Scheuermann disease	Vertebral bodies	Adolescence
Blount disease	Medial aspect of proximal tibial epiphysis	Infancy or adolescence
Osteochondritis dissecans	Subchondral regions of knee, hip, elbow, and ankle	Adolescence

Fig. 741.6 Facies in infantile cortical hyperostosis. In almost all cases, the changes have appeared before the fifth month of life. Unilateral swelling of the left cheek and left side of the jaw in an infant 12 weeks of age. *(From Slovis T, ed. Caffey's Pediatric Diagnostic Imaging, 11th ed. Philadelphia: Mosby, 2008.)*

Fig. 741.7 A, Radiograph of a 5-mo-old infant showing hyperostosis of the mandible. B, Radiograph of a 5-mo-old infant showing hyperostosis of both legs. *(From Kamoun-Goldrat A, le Merrer M. Infantile cortical hyperostosis [Caffey disease]: a review. J Oral Maxillofac Surg. 2008;66:2145–2150. Figs. 1 and 2.)*

thrombocytosis and anemia. The radiographic features include soft tissue swelling and calcification and cortical hyperostosis (Fig. 741.7). All bones may be affected except the phalanges or vertebral bodies. The differential diagnosis includes other causes of hyperostosis such as chronic vitamin A intoxication, prolonged prostaglandin E infusion in children with ductal dependent congenital heart disease, primary bone tumors, and scurvy.

Complications are unusual but include pseudoparalysis with limb or scapula involvement, pleural effusions (rib), torticollis (clavicle), mandibular asymmetry, bone fusion (ribs or ulna and radius), and bone angulation deformities (common with severe prenatal onset). Treatment includes indomethacin and prednisone (if there is a poor response to indomethacin).

FIBRODYSPLASIA OSSIFICANS PROGRESSIVA

Fibrodysplasia ossificans progressiva (FOP) is a rare and severely disabling disorder characterized by progressive extraskeletal heterotopic bone formation in soft connective tissues including muscles, tendons, ligaments, fascia, and aponeuroses. With the exception of deformity of the large toes, infants are normal at birth. Episodes of painful soft tissue swelling with inflammation usually begin in early childhood initially involving the upper back and neck, and later the entire trunk and extremities. Repeated episodes (flare-ups) slowly transform the soft tissues into bands or plates of bone that span joints and progressively limit movement and mobility. Episodes are often triggered by injury, intramuscular injections, and viral infection. Most patients are wheelchair bound by their late teens. The average life span is approximately 40 years, with death usually resulting from complications of thoracic insufficiency.

FOP results from heterozygous activating pathogenic variants of the gene *(ACVR1)* encoding the bone morphogenetic protein (BMP) type I receptor, activin A receptor type I *(ALK2)*. Patients with classic FOP have the same missense *ACVR1* pathogenic variant, which enhances BMP signaling, which, in turn, induces inflammation and aberrant endochondral ossification through mechanisms that are poorly understood. Environmental factors, such as injury, play an important role in triggering these events. *ACVR1* pathogenic variants usually occur sporadically, but autosomal dominant transmission has rarely been observed. FOP is classified in the disorganized development of skeletal components group.

There is currently no definitive treatment for FOP. Supportive care includes avoidance of injury-prone physical activities, intramuscular injections including immunizations, and overstretching of the jaw during dental procedures. Corticosteroids and other anti-inflammatory agents reduce inflammation and pain during flare-ups but are unable to prevent heterotopic bone formation. Studies in FOP animal models suggest that BMP type I kinase inhibitors and retinoic acid receptor γ agonists, which block chondrogenesis—the initial step in endochondral ossification—may be useful therapies in the future. An animal FOP study has indicated that mutant ALK2 responds to activin A, induces canonical BMP signaling, and leads to heterotopic bone formation, providing an additional possible therapeutic target. The retinoic acid receptor γ agonist palovarotene was approved by the US Food and Drug Administration in 2023 for treatment of FOP for females ages 8 years and older and for males ages 10 years and older.

Visit Elsevier eBooks+ at eBooks.Health.Elsevier.com for Bibliography.

Chapter 742

Osteogenesis Imperfecta

Joan C. Marini

Osteoporosis is fragility of the skeletal system and a susceptibility to fractures of the long bones or vertebral compressions from mild or inconsequential trauma (see Chapter 749). **Osteogenesis imperfecta (OI)** (brittle bone disease), the most common genetic cause of osteoporosis, is a generalized disorder of connective tissue. The spectrum of OI is extremely broad, ranging from forms that are lethal in the perinatal period to a mild form in which the diagnosis may be equivocal in an adult (Table 742.1).

ETIOLOGY

Structural or quantitative defects in type I collagen cause the full clinical spectrum of OI (types I-IV). Defects in processing either the N- or C-terminal propeptides of type I collagen cause distinctive bone fragility syndromes. Type I collagen is the primary component of the extracellular matrix of bone and skin. Between 15% and 20% of patients clinically indistinguishable from OI do not have a molecular defect in type I collagen. These cases are typically caused by defects in genes whose protein products interact with type I collagen. One group of patients has overmodified collagen, with similar biochemical findings to those with collagen structural defects and severe or lethal OI bone dysplasia. These cases are caused by recessive null pathogenic variants in any of the three components of the collagen prolyl 3-hydroxylation complex, prolyl 3-hydroxylase 1 (encoded by *LEPRE1*) or its associated protein, CRTAP, or cyclophilin B (CyPB, encoded by *PPIB*). A second set of cases without collagen defects have biochemically normal collagen. Defects in *IFITM5* and *SERPINF1* account for defects in mineralization in types V and VI OI, while pathogenic variants in *SERPINH1*, encoding the collagen chaperone HSP47, and *FKBP10*, encoding the peptidyl-prolyl *cis-trans* isomerase FKBP65, cause types X and XI OI, respectively. Rare pathogenic variants in *BMP1,* the enzyme that processes the C-propeptide of type I collagen, also cause a recessive form of OI (type XIII). The newest set of genes added to the recessive OI causative panel (*SP7*, type XII OI; *TMEM38B*, type XIV OI; *WNT1*, type XV OI; *CREB3L1*, type XVI OI, *SPARC*, type XVII OI, and *MBTPS2*, type XVIII OI) are not only involved in osteoblast differentiation but also affect collagen synthesis and cross linking. There are currently very few individuals with OI whose genetic defect is not in a known causative gene.

EPIDEMIOLOGY

The autosomal dominant forms of OI occur equally in all racial and ethnic groups, whereas recessive forms occur predominantly in ethnic groups with consanguineous marriages or as a founder effect in an isolated population. The West African founder pathogenic variant for type VIII OI has a carrier frequency of 1 in 200-300 among Black individuals. The collective incidence of all types of OI detectable in infancy is approximately 1 in 20,000. There is a similar incidence of the mild form OI type I.

PATHOLOGY

The pathogenic structural collagen variants in OI cause the bones to be globally abnormal. The bone matrix contains abnormal type I collagen fibrils and relatively increased levels of types III and V collagen. Several noncollagenous proteins of bone matrix are also reduced. Bone cells also contribute to OI pathology, with abnormal osteoblast differentiation and increased numbers of active bone resorbing osteoclasts. The hydroxyapatite crystals deposited on this matrix are poorly aligned with the long axis of fibrils, and there is paradoxical hypermineralization of bone.

PATHOGENESIS

Type I collagen is a heterotrimer composed of two α_1(I) chains and one α_2(I) chain. The chains are synthesized as procollagen molecules with short globular propeptide extensions on both ends of the central helical domain. The helical domain is composed of uninterrupted repeats of the sequence Gly-X-Y, where Gly is glycine, X is often proline, and Y is often hydroxyproline. The presence of glycine at every third residue is crucial to helix formation because its small side chain can be accommodated in the interior of the helix. The chains are assembled into trimers at their carboxyl ends, and helix formation then proceeds linearly in a carboxyl to amino direction. Concomitant with helix assembly and formation, helical proline and lysine residues are hydroxylated by prolyl 4-hydroxylase and lysyl hydroxylase 1, and some of the hydroxylysine residues are subsequently glycosylated. After secretion, the propeptides are cleaved in the pericellular space by specific N- and C-terminal propeptidases.

Collagen structural defects are predominantly of two types: 80% are pathogenic missense variants causing substitutions of helical glycine residues or crucial residues in the C-propeptide by other amino acids, and 20% are single exon splicing defects. The clinically mild OI type I has a quantitative defect, with null pathogenic variants in one α_1(I) allele leading to a reduced amount of normal collagen. Deficiency of type I procollagen caused by a C-propeptide removal causes a paradoxical high bone mass form of OI with mild or severe skeletal fragility depending on whether the defect is in the cleavage site or the cleaving peptidase. Impaired removal of the N-propeptide causes an overlap syndrome of Ehlers-Danlos and OI (OI/EDS) with variable skeletal fragility.

Glycine substitutions in the two α chains have distinct genotype-phenotype relationships, but there is also striking phenotype variability caused by independent pathogenic variants at the same site. In general, glycine substitutions in the α_1 chain are more lethal than those in the α_2(I) chain. Two lethal regions in α_1(I) align with major ligand binding regions of the collagen helix.

Classical OI (Sillence types I-IV) is an autosomal dominant disorder, as is type V OI. Some familial recurrences of OI are caused by parental mosaicism for dominant collagen pathogenic variants. Recessive OI accounts for 10–15% of newly diagnosed OI in North America. Three recessive types are caused by null pathogenic variants in the genes coding for the components of the collagen prolyl 3-hydroxylation complex in the endoplasmic reticulum (*LEPRE1*, *CRTAP*, or *PPIB)*. Murine models indicate that it is the absence of the complex components, rather than the absence of the Pro986 modification, that is critical for development of OI. Other recessive types are caused by null pathogenic variants in genes whose products are involved in collagen folding *(SERPINH1, FKBP10)*, bone mineralization *(SERPINF1)*, or defects in osteoblast differentiation and function *(SP7, TMEM38B, WNT1, CREB3L1, SPARC, MBTPS2)*.

CLINICAL MANIFESTATIONS

Classical OI was described with the triad of fragile bones, blue sclerae, and early deafness, although most cases do not have all three features. The Sillence classification divides OI into four types based on clinical and radiographic criteria. Types V and VI were later proposed based on histologic distinctions. Subsequent types VII-XVIII were based on identification of the molecular defect, followed by clinical description.

Osteogenesis Imperfecta Type I (Mild)

OI type I is sufficiently mild that it is often found in large pedigrees. Many type I families have blue sclerae, recurrent fractures in childhood, and presenile (i.e., beginning in early adulthood) hearing loss (30–60%). Both types I and IV are divided into A and B subtypes, depending on the absence (A) or presence (B) of **dentinogenesis imperfecta,** a type of dentin dysplasia resulting in discolored (often blue-gray or amber), translucent teeth that wear down rapidly or break. Other possible connective tissue abnormalities include hyperextensible joints, easy bruising, thin skin, joint laxity, scoliosis, wormian bones, hernia, and mild short stature compared with family members. Fractures result from mild to moderate trauma but decrease after puberty.

Table 742.1 Osteogenesis Imperfecta

DISORDER	INHERITANCE	GENE	PREVIOUS NAMES / NOTATION
Osteogenesis imperfecta, non-deforming (Sillence type 1)	AD	*COL1A1, COL1A2*	OMIM as OI type I
Osteogenesis imperfecta, severe perinatal form (Sillence type 2)	AD	*COL1A1, COL1A2*	OMIM as OI type II
	AR	*CRTAP*	OMIM as OI type VII
	AR	*P3H1*	OMIM as OI type VIII
	AR	*PPIB*	OMIM as OI type IX
Osteogenesis imperfecta, progressively deforming (Sillence type 3)	AD	*COL1A1, COL1A2, IFITM5*	OMIM as OI type III
	AD	*SERPINF1*	In OMIM as OI type VI
	AR	*CRTAP, P3H1*	OMIM as OI type VII
	AR	*PPIB*	OMIM as OI type IX
	AR	*SERPINH1*	OMIM OI as type X
	AR	*FKBP10*	OMIM as OI type XI
	AR	*TMEM38B*	OMIM as OI type XIV
	AR	*BMP1*	OMIM as OI type XIII
	AR	*WNT1*	OMIM as OI type XV Variants may result in AD osteoporosis.
	AR	*CREB3L1*	OMIM as OI type XVI Ehlers-Danlos-like
	AR	*SPARC*	OMIM as OI type XVII
	AR	*TENT5A*	OMIM as OI type XVIII
	XLR	*MBTPS2*	OMIM as OI type XIX
	AR	*MESD*	OMIM as OI type XX
	AR	*KDELR2*	OMIM as OI type XXL
	AR	*CCD134*	OMIM as OI type XXII
Osteogenesis imperfecta, moderate form (Sillence type 4)	AD	*COL1A1, COL1A2, IFITM5*	OMIM as OI type IV
	AR	*WNT1*	OMIM as OI type XV
	AR	*CRTAP*	OMIM as OI type VII
	AD	*PP1B*	OMIM as OI type IX
	AR	*FKBP10*	OMIM as OI type XI
	AR	*SP7*	OMIM as OI type XII
Osteogenesis imperfecta with calcification of interosseous membranes and/or hypertrophic callus (OI type 5)	AD	*IFITM5*	May mimic progressively deforming or moderate OI (Sillence types 3 and 4)
Osteogenesis imperfecta with craniosynostosis (Cole- Carpenter syndrome)	AD	*P4HB*	Craniosynostosis is not well documented.
	AR	*SEC24D*	Most patients do not have craniosynostosis but rather large fontanels.
Osteoporosis – X-linked form	XL	*MBTPS2*	OMIM as OI type XIX
Osteoporosis – dominant form	AD	*WNT1*	OMIM as OI type XV

Data from Unger S, Ferreira CR, Mortier GR, et al: Nosology of genetic skeletal disorders: 2023 revision. *Am J Med Genet* 2023;191A:1164-1209 (Table 1, Group 26, pp. 1187-1190).

Osteogenesis Imperfecta Type II (Perinatal Lethal)

Infants with OI type II may be stillborn or die in the first years of life. Birthweight and length are small for gestational age. There is extreme fragility of the skeleton and other connective tissues. There are multiple intrauterine fractures of long bones, which have a crumpled appearance on radiographs. There are striking micromelia and bowing of extremities; the legs are held abducted at right angles to the body in the frogleg position. Multiple rib fractures create a beaded appearance, and the small thorax contributes to respiratory insufficiency. The skull is large for body size, with enlarged anterior and posterior fontanels. Sclerae are dark blue-gray. The cerebral cortex has multiple neuronal migration and other defects (agyria, gliosis, periventricular leukomalacia).

Fig. 742.1 Infant with type III osteogenesis imperfecta displays shortened bowed extremities, thoracic deformity, and relative macrocephaly.

Fig. 742.2 Typical features of type III osteogenesis imperfecta radiographs in a 6-yr-old child. A, Lower long bones are osteoporotic, with metaphyseal flaring, "popcorn" formation at growth plates, and placement of intramedullary rods. B, Vertebral bodies are compressed and osteoporotic.

Osteogenesis Imperfecta Type III (Progressive Deforming)

OI type III is the most severe nonlethal form of OI and results in significant physical disability. Birthweight and length are often low normal. Fractures usually occur in utero. There is relative macrocephaly and triangular facies (Fig. 742.1). Postnatally, fractures occur from inconsequential trauma and heal with deformity. Disorganization of the bone matrix results in a "popcorn" appearance at the metaphyses (Fig. 742.2). The rib cage has flaring at the base, and pectus deformity is frequent. Virtually all type III patients have scoliosis and vertebral compression. Growth falls below the curve by the first year; all type III patients have extreme short stature. Scleral hue ranges from white to blue. Dentinogenesis imperfecta, hearing loss, and kyphoscoliosis may be present or develop over time.

Osteogenesis Imperfecta Type IV (Moderately Severe)

Patients with OI type IV can present at birth with in utero fractures or bowing of lower long bones. They can also present with recurrent fractures after ambulation and have normal to moderate short stature. Most children have moderate bowing even with infrequent fractures. Children with OI type IV require orthopedic and rehabilitation intervention, but they are usually able to attain community ambulation skills. Fracture rates decrease after puberty. Radiographically, they are osteoporotic and have metaphyseal flaring and vertebral compressions. Scleral hue may be blue or white.

Defects in the Processing of Type I Procollagen Propeptides

Autosomal dominant pathogenic variants in the C-propeptide cleavage site of procollagen or recessive defects in BMP1, the enzyme responsible for its cleavage, cause bone fragility with normal or elevated dual-energy x-ray absorptiometry bone density *z* scores. Individuals with dominant pathogenic variants have normal stature, white sclerae and teeth, and mild to moderate OI. Null pathogenic variants in *BMP1* lead to a more severe skeletal phenotype with short stature, scoliosis, and bone deformity because *BMP1* has other substrates in addition to type I collagen.

Defects in removal of the type I procollagen N-propeptide cause a distinctive combination of Ehlers-Danlos syndrome and OI. Deletion of exon six, containing the cleavage site, causes EDS type VII. Glycine substitutions near the cleavage site impair processing by altering the site configuration, causing hyperextensibility of large and small joints and variable bone fragility.

Osteogenesis Imperfecta Type V (Hyperplastic Callus) and Type VI Hyperosteoidosis (Mineralization Defect)

Types V and VI OI patients clinically have OI similar in skeletal severity to types IV and III, respectively, but they have distinct findings on bone histology. Type V patients also usually have some combination of hyperplastic callus, calcification of the interosseous membrane of the forearm, and/or a radiodense metaphyseal band. They constitute <5% of OI cases. All type V OI patients are heterozygous for the same pathogenic variant in *IFITM5*, which generates a novel start codon for the bone protein BRIL. Ligamentous laxity may be present; blue sclera or dentinogenesis imperfecta are not present. Patients with type VI OI have progressive deforming OI that does not manifest at birth. They have distinctive bone histology with broad osteoid seams and fish-scale lamellation under polarized light, caused by deficiency of pigment epithelium derived factor, encoded by *SERPINF1*. Types V and VI are connected in intracellular osteoblast pathways—*SERPINF1* transcripts are increased in type V OI, while *IFITM5* transcripts are decreased in type VI OI.

Osteogenesis Imperfecta Types VII, VIII, and IX (Autosomal Recessive)

Types VII and VIII patients overlap clinically with types II and III OI but have distinct features including white sclerae, rhizomelia, and small to normal head circumference. Surviving children have severe osteochondrodysplasia with extreme short stature and dual-energy x-ray absorptiometry L1-L2 *z* score in the −6 to −7 range. Type IX OI is very rare; most cases are lethal, but some have moderate skeletal severity without rhizomelia, and white sclerae.

Osteogenesis Imperfecta Types X and XI (Autosomal Recessive)

There have been several reports of severe to lethal type X OI caused by defects affecting the serine-type endopeptidase inhibitor domain of HSP47. This domain is responsible for the HSP47 chaperone function that helps to maintain the folded state of procollagen heterotrimers. HSP47 and FKBP65, the protein responsible for type XI OI, cooperate in collagen synthesis. Type XI OI is a more prevalent recessive form with a moderate to severe skeletal phenotype, including white sclerae and normal teeth. Congenital contractures of large joints may occur with the same pathogenic variants that cause only skeletal fragility, even in sibships. At the opposite end of the spectrum, a deletion of a single tyrosine residue causes Kuskokwim syndrome, a congenital contracture disorder with very mild vertebral findings and osteopenia. Defects in *FKBP10* decrease collagen crosslinking in matrix because FKBP65 is the foldase for lysyl hydroxylase 2, which hydroxylates collagen telopeptide residues important for cross linking.

Defects in Osteoblast Differentiation (Types XIII-XXII OI)

The most recent functional grouping of genes causing recessive OI (types XIII to XXII) affect osteoblast differentiation and are collagen related. *SP7* (type XIII OI) regulates osteoblast differentiation and is critical for bone formation. *TMEM38B* (type XIV OI) defects are clinically indistinguishable from type IV OI. *TMEM38B* encodes the endoplasmic reticulum membrane cation channel TRIC-B, which affects calcium flux from the endoplasmic reticulum to the cytoplasm. Since many enzymes involved in collagen metabolism are calcium dependent, collagen synthesis is globally dysregulated in the absence of TRIC-B, with significant intracellular retention. Collagen posttranslational modification is also impaired, leading to underhydroxylation of the collagen helix. Recessive *WNT1* (type XV OI) defects cause severe progressive deforming OI. Notably, Wnt signaling pathway activation through the Frizzled receptor on the osteoblast surface increases bone mass, and deficiency of Wnt decreases it. SPARC (type XVII OI), also known as osteonectin, is a glycoprotein component of extracellular matrix. Defects in residues important for SPARC binding to collagen were reported in two cases of moderate to severe OI.

The genes *MBTPS2* and *CREB3L1*, causing types XVIII and XVI OI, respectively, encode proteins involved in regulated intramembrane proteolysis (RIP). *MBTPS2* encodes the transmembrane Golgi protein site-2 protease (S2P), that acts in succession with S1P to activate regulatory molecules in times of cell stress. OASIS, encoded by *CREB3L1*, is an RIP substrate.

Interestingly, missense substitutions in S2P in OI patients result in underhydroxylation of the collagen lysine residue important for crosslinking of collagen in matrix, thus impairing bone strength. In OASIS-null mice, collagen transcription has been shown to be impaired.

Defects in *TENT5A, MESD, KDELR2,* and *CCDC134* have been reported in small numbers of individuals with lethal or severe OI skeletal phenotypes. The products of these genes are not known to interact directly with collagen. *TENT5A* encodes FAM46A, a cytoplasmic poly(A) polymerase with an unexpected role in bone mineralization, likely related to its role as a binding partner for SMADs, modulating BMP signaling. *MESD* acts along the Wnt pathway, serving as an endoplastic reticulum chaperone for the low-density lipoprotein receptors LRP5 and LRP6. Oligodontia and intellectual disability occur in some patients. Bone histology shows enlarged osteocytes and irregular matrix mineralization.

Pathogenic variants in *KDELR2* cause neurodevelopmental and severe skeletal defects. Pathogenic variants in *CCDC134* add to the skeletal effects by impacting the mitogen-activated protein kinase/extracellular signal-regulated kinase (MAPK/ERK) pathway. Expression of type I collagen is reduced, as is osteoblast in vitro mineralization, but histomorphometry is atypical for OI.

LABORATORY FINDINGS

DNA sequencing is the first diagnostic laboratory test, and several Clinical Laboratory Improvement Amendments (CLIA)-certified sequencing labs offer panels to test for dominant and recessive OI. Pathogenic variant identification is useful to determine the type with certainty and to facilitate family screening and prenatal diagnosis. It is also possible to screen for type VI OI by the determination of serum pigment epithelium-derived factor level, which is severely reduced in this type.

If dermal fibroblasts are obtained, they can be useful for determining the level of transcripts of the candidate gene and for collagen biochemical testing, which is positive for overmodification in most cases of types I-IV and IX OI, and in all cases of VII/VIII OI, and for undermodification in type XIV. In OI type I, the reduced amount of type I collagen results in an increase in the ratio of type III to type I collagen on gel electrophoresis.

Severe OI can be detected prenatally by level II ultrasonography as early as 16 weeks of gestation. OI and thanatophoric dysplasia may be confused. Fetal ultrasonography might not detect OI type IV and rarely detects OI type I. For recurrent cases, chorionic villus biopsy can be used for biochemical or molecular studies. Amniocytes produce false-positive biochemical studies but can be used for molecular studies in appropriate cases.

In the neonatal period, the normal to elevated alkaline phosphatase levels present in OI distinguish it from hypophosphatasia. During the school-age period, children with type VI OI have notably elevated serum alkaline phosphatase.

COMPLICATIONS

The morbidity and mortality of OI are cardiopulmonary. Recurrent pneumonias and declining pulmonary function occur in childhood, and cor pulmonale is seen in adults.

Neurologic complications include basilar invagination, brainstem compression, hydrocephalus, and syringohydromyelia. Many children with OI types III and IV have basilar invagination, but brainstem compression is uncommon. Basilar invagination is best detected with spiral CT of the craniocervical junction (Fig. 742.3).

TREATMENT

There is no cure for OI. For severe nonlethal OI, active physical rehabilitation in the early years allows children to attain a higher functional level than orthopedic management alone. Children with OI type I and

Fig. 742.3 Typical feature of basilar invagination shown in the sagittal MRI of an asymptomatic child with type III osteogenesis imperfecta. There is invagination of the odontoid above the Chamberlain line, causing compression and kinking at the pontomedullary junction *(arrow)*.

some with type IV are spontaneous ambulators. Children with types III, IV, V, VI, and XI OI benefit from gait aids and a program of swimming and conditioning. Severely affected patients require a wheelchair for community mobility but can acquire transfer and self-care skills. Teens with OI can require psychologic support with body image issues. Growth hormone improves bone histology in growth-responsive children (usually types I and IV).

Orthopedic management of OI is aimed at fracture management and correction of deformity to enable function. Fractures should be promptly splinted or cast; OI fractures heal well, and cast removal should be aimed at minimizing immobilization osteoporosis. Correction of long-bone deformity requires an osteotomy procedure and placement of an intramedullary rod.

A several-year course of treatment of children with OI with bisphosphonates (IV pamidronate or oral olpadronate or risedronate) confers some benefits. Bisphosphonates decrease bone resorption by osteoclasts; OI patients have increased bone volume that still contains the defective collagen. Bisphosphonates are more beneficial for vertebrae (trabecular bone) than long bones (cortical bone). Treatment for 1-2 years results in increased L1-L4 dual-energy x-ray absorptiometry and, more importantly, improved vertebral compressions and area. However, follow-up of bisphosphonate-treated children has shown that the incidence of scoliosis is unchanged even in children treated early, although there was a modest delay in progression in type III OI. The relative risk of long-bone fractures is modestly decreased by several years of bisphosphonates. However, the material properties of long bones are weakened by prolonged treatment and nonunion after osteotomy is increased. There is no effect of bisphosphonates on mobility scores, muscle strength, or bone pain. Limiting treatment duration to 2-3 years in mid-childhood can maximize the benefits and minimize the detriment to cortical material properties. Benefits appear to persist several years after the treatment interval, and alternation of treatment intervals and drug holidays may be beneficial. Side effects include abnormal long-bone remodeling, increased incidence of fracture nonunion, and osteopetrotic-like brittleness to bone.

Antibodies to sclerostin and TGF-β stimulate osteoblasts to produce bone matrix. They have shown promise in murine models for OI and are currently in trials for children with OI. TGF-beta signaling may be a pathogenic mechanism in OI. Fresolimumab, a TGF-beta neutralizing antibody, treatment in adults with OI type IV demonstrated increases in lumbar spine bone mineral density.

PROGNOSIS

OI is a chronic condition that may limit both life span and functional level. Infants with OI type II usually die within months to 1 year of life. An occasional child with radiographic type II and extreme growth deficiency survives to the teen years. Persons with OI type III have a reduced life span with clusters of mortality from pulmonary causes in early childhood, the teen years, and the 40s. OI types I, IV, and V OI are compatible with a full life span. The oldest reported individuals with type VIII are in their third decade, and some with type XI are in their fourth decade. The long-term prognosis for most recessive types is still emerging, and many adults with OI have not had molecular testing.

Individuals with OI type III are usually wheelchair dependent. With aggressive rehabilitation, they can attain transfer skills and household ambulation. OI type IV children usually attain community ambulation skills either independently or with gait aids.

GENETIC COUNSELING

For autosomal dominant OI, the risk of an affected individual passing the gene to the individual's offspring is 50%. An affected child usually has about the same severity of OI as the parent; however, there is variability of expression, and the child's condition can be either more or less severe than that of the parent. The empirical recurrence risk to an apparently unaffected couple of having a second child with OI is 5–7%; this is the statistical chance that one parent has germline mosaicism. The collagen pathogenic variant in the mosaic parent is present in some germ cells and may be present in somatic tissues. If a parent is a mosaic carrier, the risk of recurrence may be as high as 50%.

For recessive OI, the recurrence risk is 25% per pregnancy. No known individual with severe nonlethal recessive OI has had a child. For X-linked type XVIII OI, the risk to male offspring of carrier women is generally 50%.

Visit Elsevier eBooks+ at eBooks.Health.Elsevier.com for Bibliography.

Section 4

Connective Tissue Disorders

Chapter 743

Marfan Syndrome

Jefferson J. Doyle and Harry C. Dietz III

Marfan syndrome (MFS) is an inherited systemic, connective tissue disorder caused by pathogenic variants in the *FBN1* gene encoding the extracellular matrix (ECM) protein fibrillin-1. It is primarily associated with skeletal, cardiovascular, and ocular pathology. The diagnosis is based on clinical findings, some of which are age dependent.

EPIDEMIOLOGY

The incidence is estimated at 1 in 10,000 live births, and approximately 25% of cases are sporadic. The disorder shows autosomal dominant inheritance, with high penetrance but variable expression. Both interfamilial and intrafamilial clinical variation are common. There is no racial or gender preference.

PATHOGENESIS

MFS is associated with abnormal production, matrix deposition, and/or stability of fibrillin-1, a 350-kd ECM protein that is the major constituent of microfibrils, with prominent disruption of microfibrils and elastic fibers in diseased tissues. The fibrillin-1 *(FBN1)* gene is composed of 65 exons. Linkage analysis has suggested an absence of locus heterogeneity, and the involvement of *FBN1* is demonstrated in >90% of cases, with more than 1,000 disease-causing pathogenic variants identified to date (the majority of which are pathogenic missense variants unique to a given family). With the exception of early-onset and severe presentations of the disease associated with pathogenic variants in exons 26-27 and 31-32, no clear genotype-phenotype correlation has been identified. Given that there is considerable intrafamilial variability, genetic, epigenetic, environmental, or other unidentified factors may influence expression of the disease.

The transforming growth factor beta (TGF-β) family of cytokines influences a diverse repertoire of cellular processes, including cell proliferation, migration, differentiation, survival, and synthetic activity. The TGF-β ligands (TGF-β1, TGF-β2, or TGF-β3) are synthesized as inactive precursor complexes and sequestered by ECM proteins, including fibrillin-1. Mice heterozygous for a pathogenic variant in the fibrillin-1 gene, typical of those that cause MFS in humans, display many of the classic features of MFS, including aortic root aneurysm, which associates with a tissue signature for increased TGF-β signaling, suggesting that pathogenic variants in fibrillin-1 lead to increased TGF-β activation and signaling. Furthermore, pharmacologic antagonism

of TGF-β signaling initiated after the first few weeks of life ameliorates aortic aneurysm in mouse models of MFS, demonstrating that high TGF-β signaling is a cause rather than a consequence of disease progression.

Increased TGF-β signaling has been observed in other tissues in MFS mice, including the developing lung, mitral valve, and skeletal muscle. Treatment of these mice with agents that antagonize TGF-β attenuates or prevents pulmonary emphysema, myxomatous degeneration of the mitral valve, and skeletal muscle myopathy. The prominent role of TGF-β dysregulation in the pathogenesis of MFS was further validated by the discovery and characterization of another related aortic aneurysm syndrome, **Loeys-Dietz syndrome (LDS)**, in which patients have pathogenic variants in the genes encoding positive effectors of TGF-β signaling, including the ligands TGF-β2 or TGF-β3, either subunit of the TGF-β receptor (TβRI or TβRII) or the intracellular signaling intermediates SMAD2 or SMAD3. Patients with LDS share many overlapping clinical features with MFS (see the section on "Differential Diagnosis"). This is further supported by data showing that **Shprintzen-Goldberg syndrome (SGS)**, which shows phenotypic overlap with both MFS and LDS, is caused by pathogenic variants in *SKI*, a known repressor of the TGF-β transcriptional response.

CLINICAL MANIFESTATIONS

MFS is a multisystem disorder, with cardinal manifestations in the skeletal, cardiovascular, and ocular systems.

Skeletal System

Overgrowth of the long bones **(dolichostenomelia)** is often the most obvious manifestation of MFS and may produce a reduced upper segment–to–lower segment ratio (UL/LS) or an arm span–to–height ratio >1.05 times. Abnormal ratios are US/LS <1 for age 0-5 years, US/LS <0.95 for 6-7 years, US/LS <0.9 for 8-9 years, and US/LS <0.85 above age 10 years. Anterior chest deformity is likely the result of excessive rib growth, pushing the sternum either outward **(pectus carinatum)** or inward **(pectus excavatum)**. Abnormal curvatures of the spine (most commonly thoracolumbar scoliosis) may also partly result from increased vertebral growth. Other skeletal features include an inward bulging of the acetabulum into the pelvic cavity (protrusio acetabuli), flat feet (pes planus), and joint hypermobility (Fig. 743.1) or joint contractures. Long and slender fingers in relation to the palm of the hand **(arachnodactyly)** are generally a subjective finding. The combination of arachnodactyly and hypermobile joints is examined by the Walker-Murdoch or wrist sign, which is positive if there is full overlap of the distal phalanges of the thumb and fifth finger when wrapped around the contralateral wrist (see Fig. 743.1), and the Steinberg or thumb sign, which is present when the distal phalanx of the thumb fully extends beyond the ulnar border of the hand when folded across the palm (see Fig. 743.1). Contracture of the fingers **(camptodactyly)** and elbows is commonly observed. A selection of craniofacial manifestations may be present, including a long narrow skull (dolichocephaly), deeply set eyes (enophthalmos), recessed lower mandible (retrognathia) or small chin (micrognathia), flattening of the midface **(malar hypoplasia)**, a high-arching palate, and downward-slanting palpebral fissures (Fig. 743.2).

Cardiovascular System

Thickening of the atrioventricular valves is common and often associated with valvular prolapse. Variable degrees of regurgitation may be present. In children with early-onset and severe MFS, insufficiency of the mitral valve can lead to heart failure, pulmonary hypertension, and death in infancy. This manifestation is the leading cause of morbidity and mortality in young children with the disorder. Supraventricular arrhythmias may be seen in association with mitral valve dysfunction. Ventricular dysrhythmias have also been described in children with MFS, and there is an increased prevalence of prolonged QT interval. Dilated cardiomyopathy occurs with increased prevalence in patients with MFS, most often attributed to volume overload imposed by valve regurgitation. Aortic valve dysfunction is generally a late occurrence and attributed to stretching of the aortic annulus by an expanding aortic root aneurysm.

Aortic aneurysm, **dissection**, **and rupture**, principally at the level of the sinuses of Valsalva (also known as the aortic root), remain the most life-threatening manifestations of MFS, prompting lifelong monitoring by echocardiography or other imaging modalities. In severe cases, the aneurysm may be present in utero, but in mild examples it may be absent or never exceed dimensions that require clinical intervention. Aortic dimensions must be interpreted in comparison to age-dependent nomograms. The most important risk factor for aortic dissection is the maximal aortic root size and a positive family history. The characteristic histologic findings from aortas of patients with MFS include cystic medial necrosis of the tunica media and disruption of

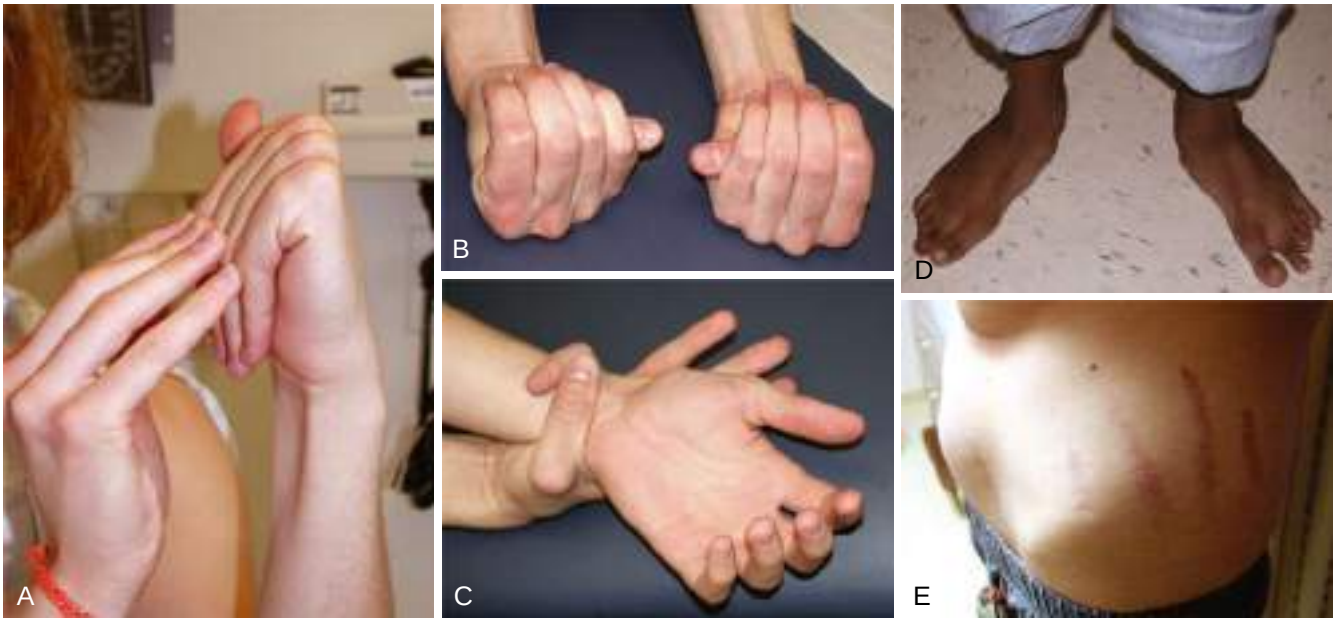

Fig. 743.1 Marfan syndrome. Note the joint laxity (A), Steinberg thumb sign (B), ability to join thumb and fifth finger around the wrist (Walker-Murdoch sign) (C), pes planus (D), and striae over hips and back (E). *(From Jones KL, Jones MC, Del Campo M. Smith's Recognizable Patterns of Human Malformation, 8th ed. Philadelphia: Elsevier, 2022; Fig. 2, p. 664.)*

Fig. 743.2 Marfan syndrome. Note the long slim limbs, pectus excavatum, narrow face, and reduced elbow extension. *(From Jones KL, Jones MC, Del Campo M. Smith's Recognizable Patterns of Human Malformation, 8th ed. Philadelphia: Elsevier, 2022: Fig. 1A, p. 662.)*

elastic lamellae. Cystic medial necrosis describes the focal apoptosis and disappearance of vascular smooth muscle cells and elastic fibers from the tunica media of the aortic wall, and subsequent deposition of mucin-like material in the cystic space. These changes produce a thicker, less distensible and stiffer aorta, which is more prone to aortic dissection. Most patients experiencing acute aortic dissection present with classic symptoms, including sudden-onset, severe, tearing chest pain, often radiating into the back. The dissection typically starts at the aortic root and may remain confined to the ascending aorta (type II) or continue into the descending aorta (type I). Acute-onset heart failure may occur if aortic valve function is compromised, and patients may suffer cerebrovascular injury, depending on the involvement of the carotid arteries. Involvement of the coronary arteries may herald sudden cardiac death, secondary to myocardial infarction or rupture into the pericardial sac with subsequent pericardial tamponade. Chronic aortic dissection usually occurs more insidiously, often without chest pain. Dilatation of the main pulmonary artery is common but does not typically cause any clinical sequelae. Enlargement of the descending thoracic or abdominal aorta can also occur, although relatively rarely.

Ocular System

Dislocation of the ocular lens **(ectopia lentis, EL)** occurs in around 60–70% of patients, although it is not unique to the disorder. Other ocular manifestations include early and severe myopia, thin and flat cornea, increased axial length of the globe, and iris dilator muscle hypoplasia, which results in poor dilation (miosis). Patients are also predisposed to retinal detachment, early cataracts, glaucoma, strabismus, and amblyopia.

Table 743.1 Diagnostic Criteria for Marfan Syndrome

IN THE ABSENCE OF A FAMILY HISTORY OF MFS, A DIAGNOSIS CAN BE ESTABLISHED IN FOUR DISTINCT SCENARIOS: 1. Aortic root *z* score ≥2 AND ectopia lentis* 2. Aortic root *z* score ≥2 AND a bona fide *FBN1* pathogenic variant (see Table 743.2) 3. Aortic root *z* score ≥2 AND a systemic score ≥7* (see Table 743.3) 4. Ectopia lentis AND a bona fide *FBN1* pathogenic variant known to cause aortic disease
IN THE PRESENCE OF A FAMILY HISTORY OF MFS, A DIAGNOSIS CAN BE ESTABLISHED IN THE PRESENCE OF: 1. Ectopia lentis 2. A systemic score ≥7* 3. Aortic root *z* score ≥2 if older than 20 years or ≥3 if younger than 20 years*
IN THE ABSENCE OF A FAMILY HISTORY OF MFS, ALTERNATIVE DIAGNOSES INCLUDE: 1. Ectopia lentis ± systemic score AND *FBN1* pathogenic variant not known to associate with aortic aneurysm or no *FBN1* pathogenic variant = Ectopia lentis syndrome 2. Aortic root *z* score <2 AND a systemic score ≥5 (with at least one skeletal feature) without ectopia lentis = MASS phenotype 3. Mitral valve prolapse AND aortic root *z* score <2 AND a systemic score <5 without ectopia lentis = Mitral valve prolapse syndrome

*Denotes caveat that features suggestive of an alternative diagnosis must be excluded and appropriate alternative molecular testing should be performed. Other syndromes include Shprintzen-Goldberg, Loeys-Dietz, or vascular Ehlers Danlos (see Table 743.4 for genes).

Other Systems

There is an increased incidence of pulmonary disease in MFS; progressive anterior chest deformity or thoracic scoliosis may contribute to a restrictive pattern of lung disease. Furthermore, a widening of the distal airspaces predisposes patients to spontaneous pneumothorax, which occurs in up to 15% of patients. Assessment of pulmonary volumes and function should account for long-bone overgrowth affecting the lower extremities, which can lead to a reduction in the normalized forced vital capacity and total lung capacity. If normalized to thoracic size or sitting height, pulmonary function testing is often normal in patients with the disorder.

MFS patients typically have normal skin texture and elasticity. The most common skin finding is stretch marks—pinkish, scarlike lesions that later become white **(striae atrophicae)**, which occur in about one third of patients (Fig. 743.1). These may occur in the absence of obesity, rapid gain in muscle mass, or pregnancy, and at sites not associated with increased skin distention (i.e., the anterior shoulder or lower back). Another common manifestation is congenital or acquired inguinal hernia. There is also an increased risk of surgical and recurrent hernias in the Marfan population.

Widening of the dural sac or root sleeves (dural ectasia) is present in 63–92% of MFS patients. Although dural ectasia can result in lumbar back pain, it is often asymptomatic and should be assessed by lumbosacral imaging with CT or MRI.

DIAGNOSIS

Given the complexity of the clinical examination in MFS and the relevant differential diagnoses, evaluation should be coordinated by a professional with extensive experience, such as a geneticist, cardiologist, or ophthalmologist. The diagnosis is based on a defined set of clinical criteria drawn up by an international panel of experts (the revised Ghent nosology for the MFS; Table 743.1).

In the absence of a conclusive family history of MFS, the diagnosis can be established in four distinct scenarios:

1. The presence of either aortic root dilatation when standardized to age and body size (an aortic root *z* score ≥2) or aortic dissection combined with ectopia lentis allows for the unequivocal diagnosis of MFS, irrespective of the presence or absence of any systemic features (see Table 743.1), except when these are indicative of an alternative diagnosis.

Table 743.2 Criteria for Causal *FBN1* Pathogenic Variant

- Pathogenic variant previously shown to segregate in a Marfan family
- Any one of the following de novo pathogenic variants (with proven parentage and absence of disease in parents):
  - Nonsense pathogenic variant
  - In-frame and out-of-frame deletion/insertion
  - Splice site pathogenic variants affecting canonical splice sequence or shown to alter splicing on mRNA/cDNA level
  - Missense pathogenic variant affecting/creating cysteine residues
  - Missense pathogenic variant affecting conserved residues of the EGF consensus sequence ((D/N)X(D/N)(E/Q)Xm(D/N)Xn(Y/F) with *m* and *n* representing variable number of residues; D aspartic acid, N asparagine, E glutamic acid, Q glutamine, Y tyrosine, F phenylalanine)
  - Other missense pathogenic variants: segregation in family if possible AND absence in 400 ethnically matched control chromosomes; if no family history, absence in 400 ethnically matched control chromosomes
  - Linkage of haplotype for $n \geq 6$ meioses to the *FBN1* locus

From Loeys BL, Dietz HC, Braverman AC, et al. The revised Ghent nosology for the Marfan syndrome. *J Med Genet*. 2010;47:476–485.

Table 743.3 Scoring of Systemic Features in Points

- Wrist AND thumb sign = 3 (wrist OR thumb sign = 1)
- Pectus carinatum deformity = 2 (pectus excavatum or chest asymmetry = 1)
- Hind foot deformity = 2 (plain pes planus = 1)
- Pneumothorax = 2
- Dural ectasia = 2
- Protrusio acetabuli = 2
- Reduced US/LS AND increased arm/height AND no severe scoliosis = 1
- Scoliosis or thoracolumbar kyphosis = 1
- Reduced elbow extension = 1
- Facial features (3/5) = 1 (dolichocephaly, enophthalmos, downslanting palpebral fissures, midface hypoplasia, retrognathia)
- Skin striae = 1
- Myopia >3 diopters = 1
- Mitral valve prolapse (all types) = 1

Maximum total: 20 points; score ≥7 indicates systemic involvement.
US/LS, Upper segment/lower segment ratio.

2. The presence of aortic root dilatation (*z* score ≥2) or aortic dissection and the identification of a bona fide *FBN1* pathogenic variant (Table 743.2) are sufficient to establish the diagnosis even if ectopia lentis is absent.
3. When aortic root dilatation (an aortic root *z* score ≥2) or aortic dissection is present, but ectopia lentis is absent and the *FBN1* status is either unknown or negative, the diagnosis may be confirmed by the presence of sufficient systemic findings (a systemic score ≥7 points; Table 743.3). However, features suggestive of an alternative diagnosis must be excluded, and the appropriate alternative molecular testing should be performed.
4. In the presence of ectopia lentis, but absence of aortic root dilatation or aortic dissection, an *FBN1* pathogenic variant, which has previously been associated with aortic disease, is required before the diagnosis can be made. If the *FBN1* pathogenic variant is not unequivocally associated with cardiovascular disease in either a related or unrelated proband, the patient should be classified as "isolated ectopia lentis syndrome" (see the section on "Differential Diagnosis").

Despite these diagnostic criteria, on occasion sporadic cases in individuals <20 years old may not fit in one of the four proposed scenarios detailed above. If insufficient systemic features (systemic score <7) and/or borderline aortic root measurements (*z* score <3) are present without documented evidence of a bona fide *FBN1* pathogenic variant, the term "nonspecific connective tissue disorder" is recommended. In those instances in which an *FBN1* pathogenic variant is identified, the term *potential MFS* should be used instead.

In an individual with a positive family history of MFS (in which a family member has been independently diagnosed using the previously described criteria), the diagnosis can be established in the presence of:
1. Ectopia lentis
2. A systemic score ≥7 points (see Table 743.3)
3. Aortic root dilatation with *z* score ≥2 in adults (≥20 years old) or *z* score ≥3 in individuals <20 years old

In the case of scenarios 2 and 3, previously, features suggestive of an alternative diagnosis must again be excluded and appropriate alternative molecular testing should be performed.

DIFFERENTIAL DIAGNOSIS

The differential diagnosis of MFS includes disorders with aortic aneurysm (LDS, familial thoracic aortic aneurysm syndrome, and SGS), ectopia lentis (ectopia lentis syndrome, Weil-Marchesani syndrome, and homocystinuria), or systemic manifestations of MFS (congenital contractural arachnodactyly [CCA] and mitral valve, aorta, skin, skeletal [MASS] phenotype); Table 743.4).

Aortic Aneurysm Syndromes

LDS is a systemic connective tissue disorder characterized by the triad of arterial tortuosity and aggressive aneurysm disease, hypertelorism, and bifid uvula or cleft palate, as well as many of the craniofacial and skeletal features found in MFS. Distinction between MFS and LDS is important because aneurysms tend to dissect at younger ages and smaller dimensions in LDS patients, necessitating more aggressive management. LDS was originally classified into type 1 or type 2, depending on whether the pathogenic variant is present in the *TGFBR1* or *TGFBR2* gene, which encode the type 1 or type 2 TGF-β receptor subunits, respectively. LDS type 3 is caused by heterozygous pathogenic variants in the gene encoding the TGF-β–dependent intracellular signaling molecule SMAD3. LDS type 4 is caused by heterozygous pathogenic variants in the extracellular TGF-β receptor ligand TGF-β2, whereas LDS type 5 is caused by heterozygous pathogenic variants in the extracellular TGF-β receptor ligand TGF-β3. LDS type 6 is caused by heterozygous pathogenic variants in the gene encoding the TGF-β–dependent intracellular signaling molecule SMAD2. As a general rule, the severity of disease associated with the different forms of LDS can be summarized: LDS1 = LDS2 > LDS3 > LDS4 = LDS5 > LDS6. There are exceptions to this rule, mandating careful monitoring of all patients with LDS. Notably, there can be wide clinical variation within each subtype, including between family members harboring the identical pathogenic variant.

Like MFS, **familial thoracic aortic aneurysm syndrome** segregates as an autosomal dominant trait characterized by aortic root aneurysm and dissection. However, other systemic manifestations of MFS are typically absent, and the disorder has reduced penetrance. Disease-causing heterozygous pathogenic variants have been identified in several genes with roles in the vascular smooth muscle contractile apparatus, including *MYH11*, *ACTA2*, and *MYLK*, which encode smooth muscle myosin heavy chain 11, vascular smooth muscle α-actin, and myosin light chain kinase. However, these genes account for only a fraction of cases of *nonsyndromic* familial thoracic aortic aneurysm. In most cases, the management principles that have been generated for MFS have proved effective for this form of familial aortic aneurysm.

SGS is a systemic connective tissue disorder that includes virtually all the craniofacial, skeletal, skin, and cardiovascular manifestations of MFS and LDS, with the additional findings of developmental delay and severe skeletal muscle hypotonia. Most cases are caused by heterozygous pathogenic variants in the *SKI* gene, which encodes an intracellular repressor of TGF-β signaling. Vascular involvement tends to be less prevalent and less severe when compared with MFS or LDS.

Table 743.4 Differential Diagnosis of Marfan Syndrome

DIFFERENTIAL DIAGNOSIS (GENES)	CARDIAC FEATURES	VASCULAR FEATURES	SYSTEMIC FEATURES
AORTIC ANEURYSM SYNDROMES			
Loeys-Dietz syndromes (types I-V) (OMIM: 609192) *TGFBR1, TGFBR2, SMAD3, TGFB2, TGFB3*	• Patent ductus arteriosus • Atrial septal defect • Bicuspid aortic valve	• Aortic root aneurysm • Arterial tortuosity • Widespread aneurysms • Vascular dissection at relatively young ages and small aortic dimensions	• Hypertelorism • Cleft palate • Broad or bifid uvula • Craniosynostosis • Midface hypoplasia • Blue sclerae • Arachnodactyly • Pectus deformity • Scoliosis • Joint hypermobility • Pes planus • Rarely easy bruising • Dystrophic scars • Translucent skin • Rarely developmental delay
Familial thoracic aortic aneurysm (OMIM: 132900) *TGFBR2, ACTA2*, others	• Generally none • Rare forms with patent ductus arteriosus	• Aortic root aneurysm • Ascending aortic aneurysm	• Generally none • Rarely livedo reticularis and iris flocculi
Shprintzen-Goldberg syndrome (OMIM: 182212) *SKI*, unknown others	None	Aortic root aneurysm	• Hypertelorism • Craniosynostosis • Arched palate • Arachnodactyly • Pectus deformity • Scoliosis • Joint hypermobility • Developmental delay
Bicuspid aortic valve with aortic aneurysm (OMIM: 109730) *ACTA2*	Bicuspid aortic valve	• Aortic root aneurysm • Ascending aortic aneurysm	
Ehlers-Danlos syndrome, type IV (OMIM: 130050) *COL3A1*	Mitral valve prolapse	• Aneurysm and rupture of any medium to large muscular artery • No predisposition for aortic root enlargement	• Joint hypermobility • Atrophic scars • Translucent skin • Easy bruising • Hernias • Rupture of hollow organs
ECTOPIA LENTIS SYNDROMES			
Familial ectopia lentis (OMIM: 129600) *FBN1, LTBP2, ADAMTSL4*	None	None	Nonspecific skeletal features
Homocystinuria (OMIM: 236200) *CBS*	Mitral valve prolapse	Intravascular thrombosis	• Tall stature • Ectopia lentis • Long-bone overgrowth • Developmental delay
SYNDROMES WITH SYSTEMIC MANIFESTATIONS OF MFS			
MASS (mitral valve, aorta, skeleton, skin) phenotype (OMIM: 604308) *FBN1*	Mitral valve prolapse	Borderline or nonprogressive	• Nonspecific skin and skeletal findings • Myopia

Ectopia Lentis Syndromes

Both **ectopia lentis syndrome** and **Weill-Marchesani syndrome (WMS)** may also be caused by heterozygous pathogenic variants in *FBN1*. Compound heterozygous or homozygous pathogenic variants at a second locus, *ADAMTSL4* cause ectopia lentis syndrome associated with slightly younger age at diagnosis. Interestingly, some *FBN1* pathogenic variants can be associated with classic MFS, ectopia lentis syndrome, and ectopia lentis combined with skin, but not cardiovascular, manifestations of MFS, suggesting that these presentations are part of a spectrum of clinical features of the same disease, and highlighting the potential contribution of genetic modifiers of disease.

WMS is a systemic connective tissue disorder characterized by skin, skeletal, and ocular abnormalities, including microspherophakia, ectopia lentis, and myopia. Features inconsistent with the diagnosis of MFS include short stature and brachydactyly. In addition to *FBN1* pathogenic variants (type 2), the syndrome may be caused by biallelic pathogenic variants in *ADAMTS10* (type 1) or in *LTBP2* (type 3), which encode ADAM metallopeptidase with thrombospondin type 1 motif 10 and latent TGF-β binding protein 2, respectively.

Homocystinuria is a metabolic disorder caused by homozygous or compound heterozygous pathogenic variants in the gene encoding cystathionine β-synthase, which leads to increases in both homocysteine and methionine. The clinical features of untreated homocystinuria include ectopia lentis and skeletal abnormalities resembling MFS. However, in contrast to MFS, affected persons often suffer from developmental delay, a predisposition to

thromboembolic events, and a high incidence of coronary artery disease. Patients with homocystinuria are not at increased risk for aortic aneurysm.

Syndromes with Systemic Manifestations of MFS

Congenital contractural arachnodactyly (CCA) is a connective tissue disorder caused by heterozygous pathogenic variants in the gene encoding fibrillin-2 *(FBN2)*. There are a number of clinical features overlapping with MFS, including dolichostenomelia, anterior chest deformity, scoliosis, joint contractures, and arachnodactyly, as well as some craniofacial malformations, including highly arched palate and retrognathia. In addition, both may suffer from severe cardiovascular abnormalities leading to premature death, but the specific cardiac anomalies are different; valvular insufficiency and aortic root dilation are common with MFS, whereas congenital heart defects are more common in CCA. Patients with CCA also suffer from crumpled auricular helices (a hallmark of this condition).

Many patients referred for possible MFS are found to have evidence of a systemic connective tissue disorder, including long limbs, deformity of the thoracic cage, striae atrophicae, mitral valve prolapse, and borderline but nonprogressive dilatation of the aortic root, but do not meet diagnostic criteria for MFS. This constellation of features is referred to by the acronym **MASS phenotype**, emphasizing the *m*itral, *a*ortic, *s*kin, and *s*keletal manifestations. The MASS phenotype can segregate in large pedigrees and remain stable over time. The diagnosis is particularly challenging in the context of a young, sporadic patient in whom careful follow-up is needed to distinguish MASS phenotype from early MFS. Familial mitral valve prolapse syndrome can also be caused by pathogenic variants in the gene encoding fibrillin-1 and include subdiagnostic systemic manifestations.

LABORATORY FINDINGS

Laboratory studies should document a negative urinary cyanide nitroprusside test or specific amino acid studies to exclude cystathionine β-synthase deficiency (homocystinuria). Although it is estimated that most, if not all, people with classic MFS have a *FBN1* pathogenic variant, the large size of this gene and the extreme allelic heterogeneity in MFS have frustrated efficient molecular diagnosis. The yield of pathogenic variant screening varies based on technique and clinical presentation. It remains unclear whether the "missing" pathogenic variants are simply atypical in character or location within *FBN1* or located in another gene. Other differential diagnoses, such as MASS phenotype, EL, and WMS have been associated with pathogenic variants in the *FBN1* gene. Furthermore, it is often difficult or impossible to predict the phenotype from the nature or location of a *FBN1* pathogenic variant in MFS. Hence molecular genetic techniques can contribute to the diagnosis, but they do not substitute for comprehensive clinical evaluation and follow-up. Consequently, the absence or presence of a *FBN1* pathogenic variant is not sufficient to exclude or establish the diagnosis, respectively.

MANAGEMENT

Management focuses on preventing complications and genetic counseling. Referral to a multidisciplinary center where a geneticist with experience in MFS works in concert with subspecialists to coordinate a rational approach to monitoring and treatment is advisable, given the complex nature of some patients' disease. Yearly evaluations for cardiovascular disease, scoliosis, or ophthalmologic problems are imperative.

CURRENT THERAPIES

Most therapies currently available or under investigation aim to diminish cardiovascular complications, which can be categorized into activity restrictions, aortic surgery, endocarditis prophylaxis, and current pharmacologic approaches.

Activity Restrictions

Physical therapy can improve cardiovascular performance, neuromuscular tone, and psychosocial health, and so aerobic exertion in moderation is recommended. However, strenuous physical exertion, competitive or contact sports, and particularly isometric activities such as weightlifting, which invoke a Valsalva maneuver, should be avoided.

Aortic Surgery

Surgical outcome is more favorable if undertaken on an elective rather than an urgent or emergent basis (mortality of 1.5% vs 2.6% and 11.7%, respectively). Therefore aortic surgery should be recommended for adult patients when their aortic root diameter approaches 50 mm, and early intervention should be considered for those with a rapid rate of enlargement (>5-10 mm/yr) or a family history of early aortic dissection. There are no definitive criteria guiding the timing of surgery in children in whom dissection is extremely rare, irrespective of aortic size. This has prompted many centers to adopt the adult criterion of 50 mm, although early surgery may be undertaken in the presence of a rapid rate of growth (>10 mm/yr) or the emergence of significant aortic regurgitation. Preserving the native aortic valve at the time of repair is desirable to avoid the need for lifelong anticoagulation. Mitral valve repair or replacement is advised for severe mitral valve regurgitation with associated symptoms or progressive left ventricular dilatation or dysfunction.

Pregnancy

There is higher risk of aortic dissection during pregnancy and particularly in the early postpartum period in women with MFS. However, improved awareness and data have indicated the risk is low in patients with an aortic root diameter <40 mm. Prophylactic aortic root replacement can minimize the risk of aortic dissection and death in women with MFS who wish to become pregnant, but the risk of more distal ascending or descending aortic dissection would not be modified by this intervention. Work in mouse models of MFS and other vascular connective tissue disorders has associated postpartum aortic rupture with lactation and specifically the activity of the hormone oxytocin. This complication can be diminished or even avoided in some mouse models by avoiding lactation through pup removal or a pharmacologic antagonist of the oxytocin receptor. Although more work needs to be done in this area, we discuss the potential negative implications of lactation with women with MFS that choose to become pregnant and are deemed to be at particularly high risk based on the personal or family history.

Endocarditis Prophylaxis

The Professional Advisory Board of the National Marfan Foundation believes that patients with MFS should continue to receive prophylaxis for bacterial endocarditis, in part because it remains unknown, but possible, that the myxomatous valves typical of MFS are a preferred substrate for bacterial infection.

Current Pharmacologic Approaches

β-Blockers

β-Adrenergic receptor blockers have historically been considered the standard of care in MFS, and multiple small observational studies have suggested there is a protective effect on aortic root growth, with the dose typically titrated to achieve a heart rate <100 beats/min during submaximal exercise. Given the putative role of hemodynamic stress in aortic dilatation and aortic dissection in MFS, these effects are attributed to the negative inotropic and chronotropic effects of β-blockade.

Angiotensin II Receptor Type 1 Blockers

There is extensive evidence linking angiotensin II signaling to TGF-β activation and signaling. In a mouse model of MFS, the angiotensin II receptor type 1 blocker (ARB) losartan was shown to completely prevent pathologic aortic root growth and to normalize both aortic wall thickness and architecture, findings that were absent in placebo-treated and propranolol-treated mice. These data suggest the potential for productive aortic wall remodeling in MFS after TGF-β inhibition.

In support of its relevance to humans, a retrospective study assessing the effect of ARBs in a small cohort of pediatric patients with MFS who had severe aortic root enlargement despite previous alternative medical therapy, showed that ARBs significantly slowed the rate of aortic root and sinotubular junction dilatation (both of which occur in MFS), whereas the distal ascending aorta (which does not normally become dilated in MFS) remained unaffected. Further evidence of a beneficial effect from losartan therapy has been provided by three prospective clinical trials demonstrating that losartan treatment alone or in combination with β-blockade slowed the progression of aortic root dilation in patients with MFS.

A comparison clinical trial assessing the therapeutic benefit of losartan versus atenolol in patients with MFS concluded that both drugs provided significant protection against aortic growth, with no significant difference in therapeutic effect between the two drugs despite the use of conventional dose losartan (FDA-approved dose for hypertension) and an atypically high dose of atenolol (average dose of atenolol was 1.5 times and the maximum dose was 2 times the FDA approved upper limit for the treatment of hypertension). Both treatment arms in this trial showed a very slow rate of aortic root growth and a significant decline in aortic root *z* score over time, a performance superior to that observed in untreated Marfan patients or in patients treated with conventional dose atenolol (1–2 mg/kg/day). These data strongly suggest that both modalities have therapeutic roles in patients with MFS.

Additional prospective studies have demonstrated therapeutic benefit of ARBs. A meta-analysis integrating seven randomized prospective trials and over 1,500 patients concluded that ARBs are both efficacious and safe in MFS, either when used alone (in comparison to placebo) or in combination with β-blockers (in comparison to β-blockers alone). An 8-year follow-up of a Dutch study exploring the use of ARBs in adults with MFS suggested that this treatment not only suppressed pathologic aortic growth but also positively influenced important patient outcomes, including risk of surgery, aortic dissection, and all-cause mortality.

PROGNOSIS

The major cause of mortality is aortic root dilatation, dissection, and rupture, with the majority of fatal events occurring in the third and fourth decades of life. A reevaluation of life expectancy in MFS suggested that early diagnosis and refined medical and surgical management has greatly improved the prognosis for patients with the condition. Nevertheless, MFS continues to be associated with significant morbidity, and selected subgroups are refractory to therapy and continue to show early mortality. In a review of 54 patients diagnosed during infancy, 89% had serious cardiac pathology, and cardiac disease was progressive despite standard care (22% died during childhood, 16% before age 1 year). In the classic form of MFS, it is estimated that more than 90% of individuals will have a cardiovascular event during their lifetime, placing both physical and mental stresses on patients and their families. Awareness of these issues and referral for support services can facilitate a positive perspective toward the condition.

GENETIC COUNSELING

The heritable nature of MFS makes recurrence risk (genetic) counseling mandatory. Fathers of these sporadic cases are, on average, 7-10 years older than fathers in the general population. This paternal age effect suggests that these cases represent new dominant pathogenic variants with minimal recurrence risk to additional future offspring of the normal parents. Owing to rare reports of gonadal mosaicism in a phenotypically normal parent, the recurrence risk for parents of a sporadic case can be reported as low but not zero. Each child of an affected parent, however, has a 50% risk of inheriting the MFS pathogenic variant and thus being affected. Recurrence risk counseling is best accomplished by professionals with expertise in the issues surrounding the disorder.

Visit Elsevier eBooks+ at eBooks.Health.Elsevier.com for Bibliography.

Chapter 744

Ehlers-Danlos Syndrome

Donald Basel

Ehlers-Danlos syndrome (EDS) is a heterogeneous group of heritable connective tissue disorders that are grouped into three broad pathoetiologic categories and more specifically divided into fourteen subtypes (Table 744.1). Affected individuals are considered to have an overlapping phenotype of abnormally soft, extensible skin, which often heals poorly, in association with joint hypermobility and occasional instability believed to be rooted in a disruption of normal collagen function (Tables 744.2 and 744.3). All organ systems contain connective tissue elements, and many of these elements are involved in supporting the function of feedback receptors such as mechanoreceptors in lumen or vessel walls or stretch receptors in tendons. The myriad of symptoms, variability of expression, modes of inheritance, and unique phenotypic elements distinguish the subtypes from one another while establishing their common origins. The hypermobility type (hEDS) is the most common form and has no clear molecular etiology.

The connective tissue matrix is complex (Fig. 744.1), and the interplay of cells, collagen and elastin fibers, proteins, and cell signaling molecules remains poorly understood. However, dysfunction at both structural and functional levels more than likely explains the complex medical associations typically encountered in this population, with complaints ranging from joint instability and tissue fragility to chronic pain, autonomic dysfunction, and chronic fatigue (see Table 744.3).

CLASSIFICATION OF THE SIX MOST COMMON SUBTYPES OF EHLERS-DANLOS SYNDROME

Classic (Genes: *COL5a1, COL5a2, COL1a1*; Previously EDS Type I—Gravis, EDS Type II—Mitis)

Classic EDS is the second most common form of EDS and is an autosomal dominant connective tissue disorder characterized by skin hyperelasticity (Fig. 744.2), widened atrophic scars (skin fragility), and joint hypermobility. Other features include easy bruising, which is often associated with hemosiderin staining of the tissues (particularly over regions exposed to frequent trauma, like the shins). The skin is "velvet" to the touch and is particularly fragile, with minor lacerations forming gaping wounds that leave broad, atrophic, papyraceous ("cigarette paper") scars (Fig. 744.3; see also Table 744.2). Additional cutaneous manifestations include molluscoid pseudotumors over pressure points from accumulations of connective tissue and piezogenic papules (Fig. 744.4). Joints are hypermobile, often with joint instability (Fig. 744.5). Scoliosis frequently presents in adolescence, and mitral valve prolapse is common. Life expectancy is generally not reduced, although rare rupture of large arteries has been reported. Similar noncutaneous nonarticular comorbidities, as seen in hypermobile EDS, are found, in particular pain and gastrointestinal dysfunction (see Table 744.3). Premature birth caused by rupture of membranes of an affected offspring is not uncommon. The diagnosis is made by clinical findings and sequencing of *COL5A1* and *COL5A2* genes.

Hypermobile (Cause Unknown, Previously EDS Type III)

Hypermobile EDS (hEDS) is the most prevalent form of EDS with an estimated population frequency of between 0.75–3%. It is an autosomal dominant disorder, but the causative molecular pathoetiology remains elusive. Fewer than 3% of patients with a hEDS phenotype are associated with heterozygous tenascin X gene loss of function, and likewise, only a minority of cases are linked to other findings, such as the association with mosaic type 1 collagen

Table 744.1 Classification of Ehlers-Danlos Syndrome

TYPE	GENE	SKIN FINDINGS	JOINT CHANGES	INHERITANCE	OTHER COMMENTS
Classic	*COL5A1, COL5A2* (usually haploinsufficiency)	Hyperextensibility, bruising, velvety skin, widened atrophic scars, molluscoid pseudotumors, spheroids	Hypermobility and its complications, joint dislocations	AD	Mitral valve prolapse, hernias
	COL1A1 Specific pathogenic variant; c.934C>T			AD	Blue sclerae, short stature, osteopenia/fractures; may have late arterial rupture
CLASSIC VARIANTS					
Cardiac valvular	Biallelic loss of function for *COL1A2*	Classic EDS features		AR	Severe cardiac valve issues as adult
Periodontal	*C1R* *C1S*	Can have classic EDS features	Can have hypermobility	AD	Periodontitis, marfanoid habitus, prominent eyes, short philtrum
Classic-like	*TNXB*	Hyperextensibility, marked hypermobility, severe bruising, velvety skin, no scarring tendency	Hypermobility	AR	Parents (especially mothers) with one *TNXB* pathogenic variant; can have joint hypermobility
	AEBP1	Joint hypermobility, extensible and redundant skin, abnormal scarring	Hypermobility	AR	Biallelic loss of function variants. Highly variable.
Hypermobility	Unknown	Mild hyperextensibility, scarring, textural change	Hypermobility, chronic joint pain, recurrent dislocations	AD	Sometimes confused with joint hypermobility syndrome
Vascular	*COL3A1* Rare variants in *COL1A1*	Thin, translucent skin, bruising, early varicosities, acrogeria	Small joint hypermobility	AD	Abnormal type III collagen secretion; rupture of bowel, uterus, arteries; typical facies; pneumothorax
Kyphoscoliosis	*PLOD* (deficient lysyl hydroxylase) *FKBP14*	Soft, hyperextensible skin, bruising, atrophic scars	Hypermobility	AR	Severe congenital muscle hypotonia that improves a little in childhood; congenital kyphoscoliosis, scleral fragility and rupture, marfanoid habitus, osteopenia, sensorineural hearing loss
VARIANTS WITH KYPHOSCOLIOSIS					
Spondylocheirodysplastic form	*SLC39A13,* which encodes the ZIP13 zinc transporter *B4GALT7* or *B3GALT6,* encoding galactosyltransferase I or II, key enzymes in GAG synthesis	Similar to kyphoscoliotic form		AR	Spondyloepimetaphyseal dysplasia; can have bone fragility and severe progressive kyphoscoliosis without congenital hypotonia; moderate short stature, loose facial skin, wrinkled palms with thenar and hypothenar atrophy, blue sclerae, curly hair, alopecia
Brittle cornea syndrome	ZNF469 or PRDM5	Skin hyperextensibility	Joint hypermobility	AR	Kyphoscoliosis; characteristic thin, brittle cornea, ocular fragility, blue sclera, keratoconus
Musculocontractural	*CHST14* (encoding dermatan 4-O-sulfotransferase) *DSE* (encoding dermatan sulfate epimerase)	Fragile, hyperextensible skin with atrophic scars and delayed wound healing	Hypermobility	AR	Progressive kyphoscoliosis; adducted thumbs in infancy, clubfoot, arachnodactyly, contractures, characteristic facial features, hemorrhagic diathesis
Myopathic	*COL12A1*	Soft, hyperextensible	Hypermobile small joints, large joint contractures (hip, knees, elbows)	AD or AR	Characterized by muscle hypotonia and weakness

Table 744.1 Classification of Ehlers-Danlos Syndrome—cont'd

TYPE	GENE	SKIN FINDINGS	JOINT CHANGES	INHERITANCE	OTHER COMMENTS
Arthrochalasis	Exon 6 deletion of *COL1A1* or *COL1A2*	Hyperextensible, soft skin with or without abnormal scarring	Marked hypermobility with recurrent subluxations	AD	Congenital hip dislocation, arthrochalasis, multiplex congenita, short stature
Dermatosparaxis	Type I collagen N-peptidase *ADAMTS2*	Severe fragility, sagging, redundant skin		AR	Also occurs in cattle

AD, Autosomal dominant; AR, autosomal recessive; EDS, Ehlers–Danlos syndrome; GAG, glycosaminoglycan.
From Malfait F, Francomano C, Byers P, et al. The 2017 International Classification of the Ehlers–Danlos syndromes. *Am J Med Genet C Semin Med Genet.* 2017;175(1):8–26.

Table 744.2 Common and Uncommon Features of Classic Ehlers-Danlos Syndrome

SKIN
Hyperextensible
Velvety
Fragile, thin, poor tensile strength
Atopic scarring ("cigarette-paper" scars)
Striae
Bruising and bleeding (hemosiderin staining of skin)
Piezogenic papules, subcutaneous sphenoids
Wound dehiscence/incisional hernia
MUSCULOSKELETAL/JOINTS
Hypermobile ± joint dislocations
Pes planus
Chronic musculoskeletal pain, sprains
Late walking, hypotonia
OTHER ORGAN INVOLVEMENT
Chiari type I malformation
Gastrointestinal (nausea, reflux, constipation)
Umbilical hernia
Hiatal hernia
Mitral valve prolapse
Aortic root dilation
CSF leak/headache
Pelvic organ prolapse
Premature rupture of fetal membranes
Cervical incompetence
Stress incontinence
Hyperkyphosis
Scoliosis
High arched palate
Femur anteversion ("W" sitting position)
Hollow organ rupture, diverticula
Occipitoatlantoaxial hypermobility

Table 744.3 Associated Features in Ehlers-Danlos/Hypermobility Spectrum Disorders

AUTONOMIC AND NEUROLOGIC DYSFUNCTION
Postural orthostatic tachycardia syndrome (POTS)
Dizziness
Palpitations
Gastroparesis
Diarrhea
Constipation
Sleep dysfunction
Chronic fatigue
Headache (migraine, new daily headache)
Urinary stress incontinence
Somatosensory amplification
Irritable bowel syndrome
Neuropathic pain
MUSCULOSKELETAL PAIN
Chronic regional pain syndrome
Fibromyalgia

defects. There are currently no diagnostic biomarkers, and the inter- and intrafamilial variation has clouded the ability to clearly define large study populations with sufficient phenotypic alignment. An editorial highlighted the impact of sex hormones and associations of certain symptom complexes to environmental exposures or "trigger events," which begs the question of a more complex gene-environment or epigenetic influence.

The primary clinical finding in hEDS is generalized joint hypermobility with less prominent skin manifestations. There is inconsistency in the literature as to what defines hypermobility, but generally a score of ≥6 on the Beighton hypermobility scale (Fig. 744.6, Table 744.4) would qualify as hypermobility in prepubertal children and adolescents, ≥5 for postpubertal individuals up to the age of 50, and ≥4 for all adults beyond the age of 50. Children <6 years of age generally tend toward a hypermobile state, and the Beighton score may not be a reliable indicator of connective tissue laxity in these children (Table 744.5). Joint instability with frequent dislocations is common but not universal; joints are predisposed to osteoarthritis in adults.

Patients with hEDS have significant nonarticular comorbidities associated with functional disorders. These present as complex pain, dysautonomia, chronic fatigue, anxiety, and sleep dysfunction (see Table 744.3). The complexity of hEDS most likely originates from the fact that it is genetically heterogeneous and represents an overlapping spectrum of disorders. Although joint hypermobility is the common denominator, symptoms may range from isolated familial joint hypermobility to the extreme multisystem disorder, which significantly impacts daily quality of life. Life expectancy is not reduced. Mild aortic root dilatation has been reported in up to 20% of affected adults. However, this mild dilatation is nonprogressive and not associated with aortic root dissection.

Vascular (vEDS) (Gene: *COL3A1*; Previously EDS Type IV)

vEDS is an autosomal dominant disorder that shows the most pronounced dermal thinning of all types of EDS. Consequently, the skin is translucent, and the underlying venous network is prominent, most notably over the chest region. The skin has minimal hyperextensibility but has a "velvet" texture and is often described as "doughy." The joints show increased mobility, often with instability. Congenital club foot and hip dislocation are frequently associated. Tissue fragility and arterial rupture cause significant morbidity and mortality. The majority of affected individuals experience a major vascular event before 20 years of age. Premature birth, extensive ecchymoses from trauma, a high incidence of bowel rupture (especially the colon), uterine rupture during pregnancy (~5% risk), rupture of the great vessels (80% by 40 years of age), dissecting aortic aneurysm, and stroke all contribute to the increased morbidity and

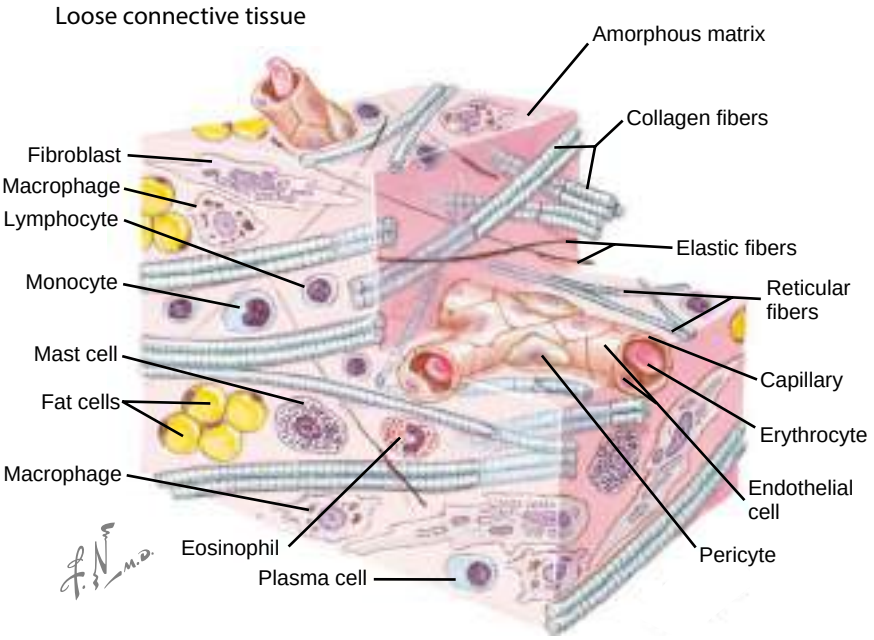

Fig. 744.1 Complex connective tissue macroenvironment illustrated by intermingled collagen and elastin fibers, nerves, mast cells, and capillaries. Both structure and function can be impacted by an abnormal connective tissue matrix. *(Courtesy Netter Images, Image ID 13192. https://netterimages.com/loose-connective-tissue-ovalle-histology-figure-31-labeled-ovalle-histology-frank-h-netter-13192.html)*

Fig. 744.2 Ehlers-Danlos syndrome (EDS). Skin hyperextensibility on the arm. *(From Paller AS, Mancini AJ, eds. Hurwitz Clinical Pediatric Dermatology, 5th ed. Philadelphia: Elsevier, 2016: Fig. 6.1, p. 121.)*

Fig. 744.3 Ehlers-Danlos syndrome (EDS). The Gorlin sign is 5 times more common in EDS than in normal individuals. Note the scars on the forehead. *(From Paller AS, Mancini AJ, eds. Hurwitz Clinical Pediatric Dermatology, 5th ed. Philadelphia: Elsevier, 2016: Fig. 6.2, p. 121.)*

Fig. 744.4 Piezogenic papules on the medial aspects of the heels in a 41-yr-old patient with Ehlers-Danlos syndrome *(top)* and his 2-yr-old daughter *(bottom)*. *(From Poppe H, Hamm H. Piezogenic papules in Ehlers-Danlos syndrome. J Pediatr. 2013;63:1788.)*

shortened life span associated with this condition. The median age of death is estimated at 50 years. Patients are generally counseled regarding the risks associated with pregnancy and advised to avoid activities that raise intracranial or intrathoracic pressure as a result of a Valsalva maneuver (such as weight training or trumpet playing). Skin protection in childhood is important to minimize trauma (shin guards). Celiprolol, a β1 antagonist and a β2 agonist (vasodilator), may reduce vascular events but is not approved by the U.S. Food and Drug Administration (FDA) for use in the United States. The diagnosis is clinical and confirmed by gene sequencing of *COL3A1*.

Kyphoscoliosis (Gene: *PLOD* [Lysyl Hydroxylase Deficiency]; Previously EDS Type VI)

The kyphoscoliotic form of EDS is distinguished by the severe kyphoscoliosis that develops early in childhood. It is an autosomal recessive disorder with phenotypic overlap with the classical type of EDS in that the skin is soft and fragile, joints are hyperextensible, and easy bruising is notable from a young age. Unique characteristics include marked hypotonia and keratoconus, with corneal fragility and globe rupture also reported. In addition, there is a higher risk for rupture of medium-sized arteries. The severity of the kyphoscoliosis may lead to restrictive lung disease with secondary pulmonary hypertension and reduced life expectancy. The diagnosis is clinical and confirmed by urine screening for an increased ratio of deoxypyridinoline to pyridinoline cross linking as well as gene sequencing of *PLOD*.

Fig. 744.5 Despite joint hyperextensibility, this patient does not meet Beighton score criteria for the extreme hypermobility seen with hypermobile Ehlers-Danlos syndrome.

Arthrochalasia (Gene: *COL1a1*, *COL1a2*; Previously EDS Types VIIA and B)

This type of EDS is inherited as an autosomal dominant disorder and characterized by severe joint instability in infancy. Joints show marked hyperextensibility with painless dislocation; the skin bruises easily and is soft and hyperextensible. Congenital hypotonia with gross motor delay is common, and kyphoscoliosis can develop in childhood. The diagnosis is clinical and confirmed by gene sequencing of *COL1A1* and *COL1A2*.

Dermatosparaxis (Type 1 Collagen N-Peptidase; Previously EDS Type VIIC)

This type of EDS is a rare autosomal recessive condition characterized by redundant skin that is soft, fragile, and bruises easily. Affected children often have a characteristic facial appearance, with skin sagging into jowls and fullness around the eyes ("puffy"). Premature rupture of membranes is common; closure of fontanels is delayed. Additional unique features reported in this group include short limbs with brachydactyly (short fingers), frequent

Fig. 744.6 Beighton score. The range of motion of several key small and large joints is measured to provide an overview of joint hypermobility. Instability is not assessed. Scoring: 2 points for each bilateral measure in Nos. ***1*** to ***4*** and 1 point for No. ***5***, equaling a total possible score of 9. Hypermobility is considered significant with a score of ≥6 between the ages of 6 and 35. *(Modified from Smits-Engelsman B, Klerks M, Kirby A. Beighton Score: a valid measure for generalized hypermobility in children. J Pediatr 2011;158:119–123.e4.)*

Table 744.4 The Nine-Point Beighton Hypermobility Score

THE ABILITY TO:	RIGHT	LEFT
1. Passively dorsiflex the fifth metacarpophalangeal joint to ≥90 degrees	1	1
2. Oppose the thenar aspect of the thumb to the volar aspect of the ipsilateral forearm	1	1
3. Hyperextend the elbow to ≥10 degrees	1	1
4. Hyperextend the knee to ≥10 degrees	1	1
5. Place hands flat on the floor without bending the knees	1	
		Total: 9

One point may be gained for each side for maneuvers 1-4, so the hypermobility score will have a maximum of 9 points if all are positive.
From Hakim A, Grahame R. Joint hypermobility. *Best Pract Res Clin Rheumatol.* 2003;17:989–1004, Table 1.

Table 744.5 A Five-Part Questionnaire for Identifying Hypermobility

1. Can you now (or could you ever) place your hands flat on the floor without bending your knees?
2. Can you now (or could you ever) bend your thumb to touch your forearm?
3. As a child did you amuse your friends by contorting your body into strange shapes *or* could you do the splits?
4. As a child or teenager did your shoulder or kneecap dislocate on more than one occasion?
5. Do you consider yourself double-jointed?

Answers in the affirmative to two or more questions suggest hypermobility with sensitivity 80–85% and specificity 80–90%.

From Hakim A, Grahame R. Joint hypermobility. *Best Pract Res Clin Rheumatol.* 2003;17:989–1004. Table 3.

Table 744.6 Genetic / Mendelian Conditions Presenting with Joint Hypermobility

HEREDITARY (SOFT/NONOSSIFIED) CONNECTIVE TISSUE DISORDERS
Ehlers-Danlos syndromes and related disorders
Fibrillinopathies (Marfan and Beals syndromes) and other disorders of the transforming growth factor-b pathway (e.g., Loeys-Dietz syndrome, Shprintzen-Goldberg syndrome)
Hereditary cutis laxae
SKELETAL DYSPLASIAS
Achondroplasia and hypochondroplasia
Dysplasias with multiple dislocations (e.g., Larsen and Desboquis syndromes, *CST3*-related and gPAPP-related disorders)
Some spondyloepimetaphyseal dysplasias
Some *COL2A1*-related and *COL11*-related disorders
Diastrophic dysplasia
Trichorhinophalangeal dysplasia
HEREDITARY MYOPATHIES
COL6-related disorders
SEPN1-related and *RYR1*-related disorders
MYH7-related and *TTN*-related disorders
Limb girdle muscular dystrophy 2E with joint hypermobility and contractures
CHROMOSOMAL AND GENOMIC DISORDERS
Trisomy 21
47,XXY and 47,XXX
Some microdeletion and microduplication syndromes
MULTIPLE CONGENITAL ANOMALIES/INTELLECTUAL DISABILITY DISORDERS (SELECTED)
RASopathies
Kabuki syndrome
FG syndrome
Fragile X syndrome

From Castori M, Hakim A. Contemporary approach to joint hypermobility and related disorders. *Curr Opin Pediatr.* 2017;29:640–649. Table 3.

hernias (umbilical, inguinal), blue sclerae, and bladder rupture. Joints are hypermobile. The diagnosis is confirmed by sequencing of *ADAMTS2*.

DIFFERENTIAL DIAGNOSIS

EDS represents a portion of the hereditary connective tissue disorders, many of which have unique features that enable clinical differentiation. The primary differential diagnosis would include Loeys-Dietz syndrome, which has features of both vEDS and Marfan syndrome (see Chapter 743). EDS has also been confused with MASS syndrome (mitral valve prolapse, aortic root dilation, skeletal changes, skin changes), cutis laxa (see Chapter 745), and pseudoxanthoma elasticum. In general, the skin of patients with cutis laxa hangs in redundant folds, whereas the skin of those with EDS is hyperextensible and snaps back into place when stretched. Other disorders that impact the integrity of the connective tissues—such as exposure to corticosteroids and osteogenesis imperfecta or mild myopathic disorders (Bethlem myopathy, Ullrich congenital muscular dystrophy)—can be indistinguishable in the early stages of disease (Table 744.6).

GENERAL APPROACH TO MANAGEMENT

In addition to the EDS type-specific therapies discussed under each disease, there are general approaches to help improve symptoms and avoid complications.

Musculoskeletal pain, which initially involves the joints, eventually may become generalized and requires a combination of physical therapy and nonpharmacologic approaches (Fig. 744.7). Physical therapy should focus on enhancing the strength of the muscles supporting the affected joints. With severe recurrent sprains or dislocations, bracing may be necessary. Pain medication for low- to moderate-intensity pain could include nonsteroidal antiinflammatory drugs (however, their platelet-inhibiting action may increase the risk of cutaneous bleeding). Higher-intensity pain may require other agents, such as selective serotonin receptor inhibitors or low-dose tricyclic antidepressants. Muscle relaxants or antiepileptic agents should be avoided because they may increase fatigue. Surgery for joint dislocations should be avoided if possible as should prolonged periods of inactivity (which result in rapid muscle deconditioning) (Table 744.7). If surgery is needed for any complication, the sutures should approximate the margins, suture tension should be avoided, and the sutures should be retained longer than usual. Other approaches to pain include cognitive behavioral therapy, acupuncture, and transepidermal electrical nerve stimulation (TENS).

Chronic fatigue should be approached by supporting good sleep hygiene and avoiding sedating medications (see Table 744.7). Patients at risk for arterial bowel or uterine rupture should be counseled about preventive measures, appropriate medications (see specific subtype), and early warning signs of organ rupture.

Visit Elsevier eBooks+ at eBooks.Health.Elsevier.com for Bibliography.

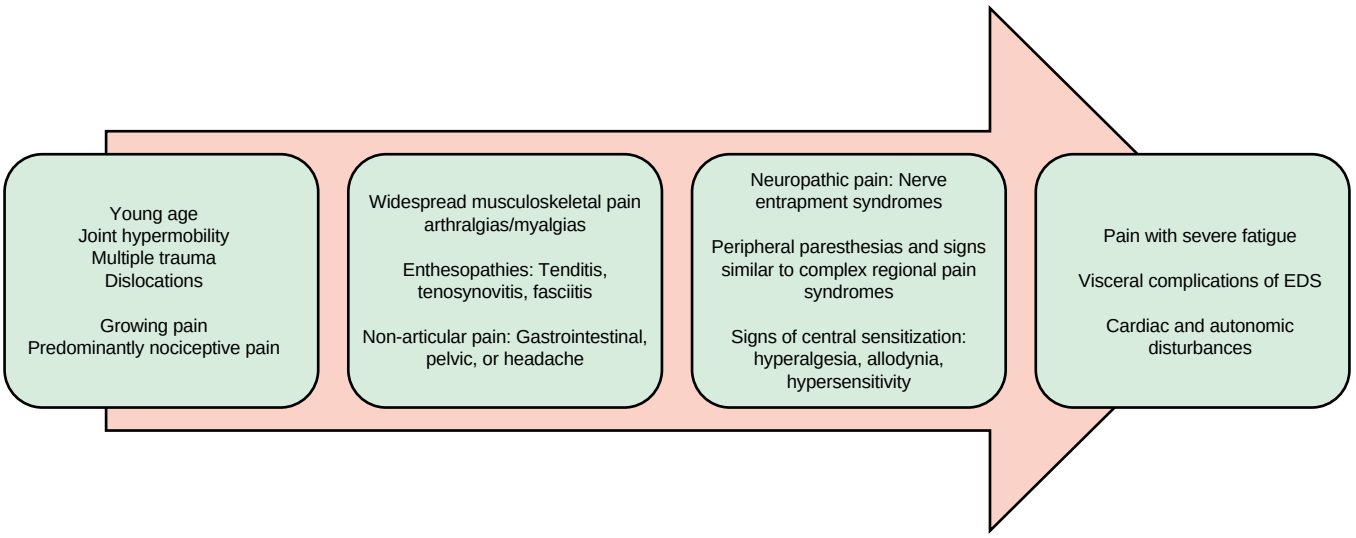

Fig. 744.7 Characteristics of pain in Ehlers-Danlos syndrome that progress in clinical stages. *(From Zhou Z, Rewari A, Shanthanna H. Management of chronic pain in Ehlers-Danlos syndrome. Medicine. 2018;97:e13115.)*

Table 744.7 Lifestyle Recommendations for Hypermobile Ehlers-Danlos Syndrome

Promote regular aerobic fitness
Promote fitness support with strengthening, gentle stretching, and proprioception exercise
Promote postural and ergonomic hygiene, especially during sleep, at school, and in the workplace
Promote weight control (body mass index [BMI] <25)
Promote daily relaxation activities
Promote lubrication during sexual intercourse
Promote early treatment of malocclusion
Avoid high-impact sports/activities
Avoid low environmental temperatures
Avoid prolonged sitting positions and prolonged recumbency
Avoid sudden head-up postural change
Avoid excessive weightlifting/carrying
Avoid large meals (especially of refined carbohydrates)
Avoid hard foods intake and excessive jaw movements (e.g., ice, gums)
Avoid bladder irritant foods (e.g., coffee and citrus products)
Avoid nicotine and alcohol intake

Note: these recommendations are intended as flexible indications for ameliorating quality of life and do not represent lifesaving solutions.
Adapted from Castori M, Morlino S, Celletti C, et al. Management of pain and fatigue in the joint hypermobility syndrome (aka Ehlers-Danlos syndrome, hypermobility type): principles and proposal for a multidisciplinary approach. *Am J Med Genet.* 2012;158:2055–2070.

Chapter 745

Cutis Laxa

Leah Lalor

Cutis laxa syndromes encompass a group of rare multisystem disorders that include loose redundant skinfolds as hallmark clinical feature (Fig. 745.1). Cutis laxa results from impaired elastic fiber assembly and homeostasis, and the known underlying gene defects affect different extracellular matrix proteins, intracellular trafficking, or cellular metabolism.

Cutis laxa (CL) may present in **autosomal recessive** (ARCL1A, ARCL1B, ARCL1C, ARCL2A, ARCL2B), **autosomal dominant** (ADCL), **X-linked** or acquired forms (Fig. 745.2, Tables 745.1 and 745.2). Acquired CL may develop after a febrile illness, inflammatory skin diseases such as lupus erythematosus or erythema multiforme, amyloidosis, urticaria, angioedema, hypersensitivity reactions to penicillin, or in neonates born to women who were taking penicillamine.

Fig. 745.1 Pendulous folds of skin of an infant with cutis laxa.

CLINICAL MANIFESTATIONS

CL may demonstrate widespread folds of **loose skin**, or changes may be mild and limited in extent, resembling anetoderma. Patients with severe cutis laxa have characteristic facial features; they present with an aged appearance with sagging jowls ("bloodhound" appearance; see Fig. 745.1), a hooked nose with everted nostrils, a short columella, a long upper lip, and everted lower eyelids. The skin is also lax elsewhere on the body and has been described as resembling an ill-fitting suit. Hyperelasticity and hypermobility of the joints as seen in the Ehlers-Danlos syndromes are not present. Many infants have a hoarse cry, probably as a result of laxity of the vocal cords. Tensile strength of the skin is normal. Other features are noted in Table 745.3.

The **autosomal dominant** form of CL (ADCL) is typically caused by pathogenic variants in *ELN*, which encodes elastin, an essential extracellular matrix protein responsible for maintenance of skin elasticity. ADCL has predominant skin involvement but can have risk for aortic aneurysm and emphysema. It typically manifests in infancy; it may be associated with intrauterine growth restriction, ligamentous laxity, and delayed closure of the fontanels.

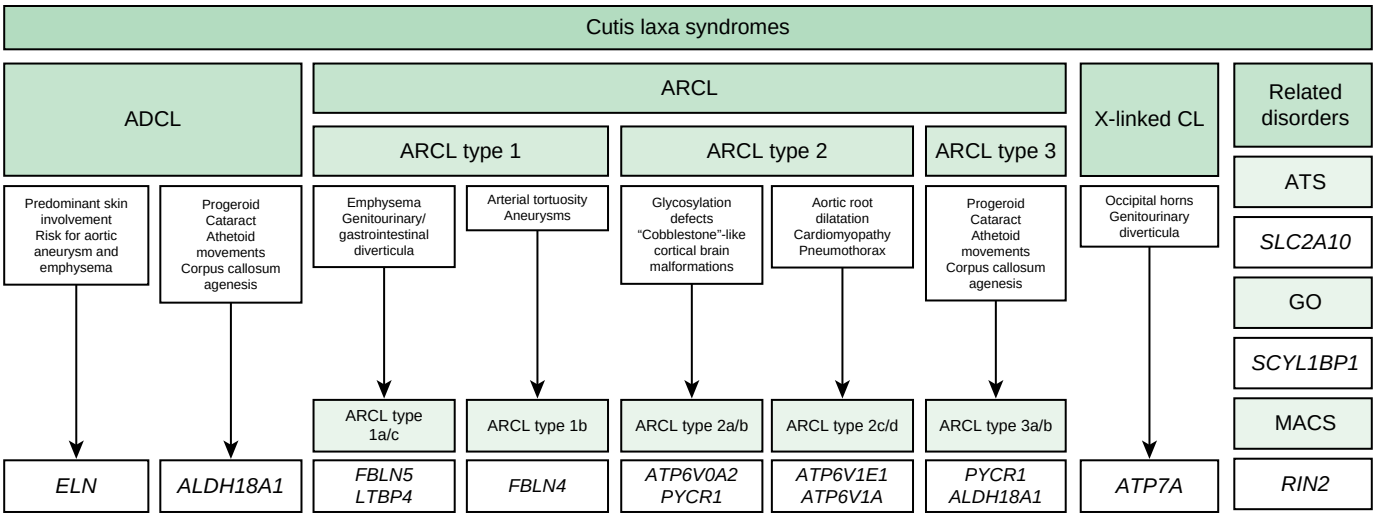

Fig. 745.2 The spectrum of cutis laxa disorders. ADCL, Autosomal dominant cutis laxa; ARCL, autosomal recessive cutis laxa; ATS, arterial tortuosity syndrome; GO, geroderma osteodysplasticum; MACS, macrocephaly-alopecia-cutis laxa-scoliosis. *(From Beyens A, Boel A, Symoens S, et al. Cutis laxa: a comprehensive overview of clinical characteristics and pathophysiology. Clin Genet. 2021;99:53–66. Fig.1.)*

Table 745.1 Disorders to Consider in the Differential Diagnosis of Cutis Laxa

				CLINICAL FINDINGS			
DISEASE NAME	**GENE SYMBOL**	**MIM #**	**INHERITANCE**	**CUTIS LAXA**	**EMPHYSEMA**	**ANEURYSMS**	**DEVELOPMENTAL DELAY**
ALDH18A1-related cutis laxa	*ALDH18A1*	612652	AR	+	–	–	++
FBLN5 -related cutis laxa	*FBLN5*	219100	AR	+++	+++	–	–
EFEMP2-related cutis laxa	*EFEMP2 (FBLN4)*	219100	AR	++	++	+++	–
Autosomal recessive cutis laxa type 2A	*ATP6V0A2*	278250 219200	AR	++	–	–	++
Autosomal dominant cutis laxa	*ELN or FBLN5*	123700	AD	+	+	+	–
Gerodermia osteodysplastica	*GORAB*	231070	AR	+ +	–	–	–
De Barsy syndrome (*PYCR1*-related progeroid syndrome)	*PYCR1*	219150	AR	+	–	–	+++
Autosomal recessive cutis laxa type 2B	*PYCR1*	612940	AR	+	–	_	+++
LTBP4-related cutis laxa	*LTBP4*	613177	AR	+	++	+	+
RIN2-related cutis laxa	*RIN2*	613075	AR	+	–	–	±

Reproduced with permission from Van Maldergem L, Dobyns W, Kornak U. ATP6V0A2-Related Cutis Laxa. 2009 Mar 19 [Updated 2011 May 10]. In: Pagon RA, Bird TD, Dolan CR, et al., eds. GeneReviews[Internet]. Seattle (WA): University of Washington, Seattle; 1993. Available from http://www.ncbi.nlm.nih.gov/books/NBK5200/

Pathogenic variants in *ALDH18A1*, which encodes delta-1-pyrroline-5-carboxylate synthetase (P5CS), a key enzyme in the synthesis of proline (an abundant amino acid in elastin), can cause autosomal dominant or recessive CL. Notably, pathogenic variants in *PYCR1*, which encodes pyrroline-carboxylate reductase 1, another enzyme in this pathway, cause recessive CL (ARCL3). Each of these proline synthesis-related CL subtypes can also present with progeroid features, cataracts, athetoid movements, and corpus callosum anomalies.

Autosomal recessive CL is divided into three general subtypes: type 1 (ARCL1), with cardiopulmonary complications, type 2 (ARCL2), with CNS and skeletal anomalies, and type 3 (ARCL3; de Barsy syndrome), which adds ocular findings to the type 2 features. Overall, these individuals can present with multiple hernias, rectal prolapse, diaphragmatic

Table 745.2 Associations with Acquired Cutis Laxa

Infections
Toxocara canis (cat-scratch)
Treponema pallidum (syphilis)
Borrelia burgdorferi (Lyme disease)
Onchocerca volvulus (onchocerciasis)
Medications
Isoniazid
Penicillins
D-penicillamine
Inflammatory diseases
Celiac disease
Sarcoidosis
Dermatitis herpetiformis
Sweet syndrome
Rheumatic disorders
Systemic lupus erythematosus
Rheumatoid arthritis
Others
α_1-antitrypsin deficiency
Mastocytosis
Nephrotic syndrome
Amyloidosis
Malignancy

From Paller AS, Mancini AJ. *Hurwitz Clinical Pediatric Dermatology*, 6th ed. Philadelphia: Elsevier, 2022: Box 6.6, p. 151.

Table 745.3 Most Common Other Features of Cutis Laxa

- Facial dysmorphism
- Aortic dilatation
- Pulmonary artery stenosis
- Pulmonary emphysema
- Diverticulae: gastrointestinal, genitourinary
- Uterine or rectal prolapse
- Ventral, hiatal, inguinal hernias

Modified from Paller AS, Mancini AJ. *Hurwitz Clinical Pediatric Dermatology*, 6th ed. Philadelphia: Elsevier, 2022: Box 6.4, p. 148.

atony, diverticula of the gastrointestinal and genitourinary tracts, cor pulmonale, emphysema, pneumothoraces, peripheral pulmonary artery stenosis, and aortic dilation. Characteristic facial features include downward-slanting palpebral fissures, a broad, flat nose, and large ears. Skeletal anomalies, dental caries, growth retardation, and developmental delay also occur. Such patients often have a shortened life span.

ARCL1 is comprised of three subtypes. Subtypes ARCL1a and ARCL1c (Urban-Rifkin-Davis syndrome), caused by dominant pathogenic variants in *FBLN5* and *LTPB4*, respectively, are similar disorders and, in addition to skin findings, more frequently develop emphysematous lung changes and mechanical insufficiency of the gastrointestinal and genitourinary tract wall. Subtype ARCL1b, caused by pathogenic variants in *FBLN4*, in addition to skin findings, typically develops elongation, tortuosity, and aneurysms of the large- and middle-sized arteries.

ARCL2 often presents with delays in neuromotor development and can include epilepsy and cortical or cerebellar malformations. Recessive pathogenic variants in *ATP6V0A2* (ARCL 2a) are more common and include N- or O-glycosylation defects and pathogenic variants *PYCR1* (ARCL2b).

ARCL2 with recessive pathogenic variants in ATP6V1E1 (ARCL2c) and ATP6V1A (ARCL2d), genes encoding key enzymes in acidification of intracellular organelles, can include N- or O-glycosylation defects and demonstrate increased frequency of aortic root dilatation, cardiomyopathy, and pneumothorax.

X-linked CL, also referred to as **occipital horn syndrome**, is caused by pathogenic variants of *ATP7A* that encodes a Cu^{2+}-transporting adenosine triphosphatase, α-polypeptide. This clinical presentation is allelic with Menkes disease (see Chapter 639.5) but is at the milder end of that spectrum.

Cutis laxa–like skin changes may also be seen in association with multiple other syndromes, including Lenz-Majewski syndrome, hyperostotic dwarfism, SCARF (**s**keletal abnormalities, **c**utis laxa, **c**raniostenosis, **a**mbiguous genitalia, **r**etardation, **f**acial abnormalities) syndrome, wrinkling skin syndrome, arterial tortuosity syndrome (ATS), gerodermia osteodysplasia, macrocephaly alopecia cutis laxa scoliosis syndrome (MACS), and Costello syndrome.

HISTOLOGY

Histologically, elastic tissue is reduced throughout the dermis, with fragmentation, distention, and clumping of the elastic fibers. This often results in bare microfibrils of random directionality. The light microscopic appearance of elastic fibers in CL patients is typically not able to discern between different subtypes as they appear reduced and fragmented in all.

TREATMENT

Treatment of the skin findings in cutis laxa is largely supportive, although textural improvement and symptomatic relief using resurfacing lasers for acquired CL has been reported.

Regarding medical management, as a general rule, unrelated to the underlying subtype, elastic fiber defects warrant regular assessment of pulmonary, cardiovascular, and urinary systems. Yearly echocardiography is recommended in dominant CL, ARCL1a/c, and ARCL2c. More intensive echocardiographic follow-up is needed in ARCL1b and ATS (every 3 months in ARCL1b; every 3 months until the age of 5 in ATS), while in the remaining subtypes an examination every 3-5 years is sufficient. In ARCL1, MRI head-to-pelvis should be repeated yearly (ARCL1b) or every 3-5 years (ARCL1a/c and ATS).

Visit Elsevier eBooks+ at eBooks.Health.Elsevier.com for Bibliography.

Section 5

Metabolic Bone Disease

Chapter 746

Bone Structure, Growth, and Hormonal Regulation

Rebecca J. Gordon and Catherine M. Gordon

See also Chapters 69 and 610.

Bone is a rigid organ but metabolically active in that it is constantly being formed **(modeled)** and reformed **(remodeled)**. It is capable of rapid turnover, bearing weight, and withstanding the stresses of various physical activities. Bone is the major body reservoir for calcium, phosphorus, and magnesium. Other functions of bone include organ protection, structure, movement, and sound transmission. It is also an endocrine organ that produces fibroblast growth factor 23 (FGF23), which regulates renal phosphate handling. Disorders that affect this organ and the process of mineralization are designated **metabolic bone diseases**.

The human skeleton consists of a protein matrix, largely composed of a collagen-containing protein, osteoid, on which is deposited a crystalline mineral phase. Collagen-containing osteoid accounts for 90% of bone protein; other proteins, including osteocalcin, which

contains γ-carboxyglutamic acid, are also present. Synthesis of osteocalcin depends on vitamin K and vitamin D; in states with high bone turnover, serum osteocalcin values are often elevated. Osteocalcin appears to enhance insulin secretion and sensitivity and reduce fat stores.

The microfibrillar matrix of osteoid permits deposition of highly organized calcium phosphate crystals, including hydroxyapatite [$Ca_{10}(PO_4)_6(OH)_2$] and octacalcium phosphate [$Ca_8H_2(PO_4)_6{\cdot}5H_2O$], plus less-organized amorphous calcium phosphate, calcium carbonate, sodium, magnesium, and citrate. Hydroxyapatite is deep within bone matrix, whereas amorphous calcium phosphate coats the surface of newly formed or remodeled bone.

Because bone growth and turnover rates are high during childhood, many clinical and osseous features of metabolic bone diseases are more prominent in children than in adults. The growth pattern of bones is an acceleration of bone growth (length) of the limbs during prepubescence, increased growth (length) of the trunk (spine) during early adolescence, and increased bone mineral deposition in late adolescence.

The use of dual-energy x-ray absorptiometry (DXA) or quantitative CT permits measurement of both mineral content and bone density in healthy subjects and children with metabolic bone disease. DXA exposes the patient to less radiation than a chest radiograph and significantly less than quantitative CT and is therefore most commonly used in clinical practice (see Chapter 749). **Bone growth** occurs in children by the process of calcification of the cartilage cells present at the ends of bone. In accord with the prevailing extracellular fluid calcium and phosphate concentrations, mineral is deposited in chondrocytes or cartilage cells set to undergo mineralization. The main function of the vitamin D–parathyroid hormone (PTH)–FGF23–endocrine axis is to maintain the extracellular fluid calcium and phosphate concentrations at appropriate levels to permit mineralization.

Other hormones also appear to regulate the growth and mineralization of cartilage, including growth hormone acting through insulin-like growth factors, thyroid hormones, insulin, leptin, ghrelin, and androgens and estrogens during the pubertal growth spurt. Supraphysiologic concentrations of glucocorticoids impair cartilage function and bone growth and augment bone resorption.

Rates of bone formation are coordinated with alterations in mineral metabolism in both the intestine and kidneys, where a number of hormones regulate the processes. Inadequate dietary intake or intestinal absorption of calcium causes a fall in serum levels of calcium and its ionized fraction. This decrease serves as the signal for PTH synthesis and secretion, resulting in greater bone resorption (which raises the serum calcium level) and enhanced distal tubular reabsorption of calcium. It also promotes higher rates of renal synthesis of 1,25-dihydroxyvitamin D [$1,25(OH)_2D$] or calcitriol, the most active metabolite of vitamin D (Fig. 746.1). **Calcium homeostasis** is thus controlled by the intestine because the availability of $1,25(OH)_2D$ ultimately determines the fraction of ingested calcium that is absorbed.

Phosphate homeostasis is regulated by the kidneys because intestinal phosphate absorption is nearly complete, and renal excretion determines the serum level of phosphate. Excessive intestinal phosphate absorption causes a fall in serum levels of ionized calcium and a rise in PTH secretion, resulting in phosphaturia, thus lowering the serum phosphate level and permitting the calcium level to rise. Hypophosphatemia blocks PTH secretion and promotes renal $1,25(OH)_2D$ synthesis. This latter compound also promotes greater intestinal phosphate absorption. The important role of FGF23 in phosphate homeostasis is described later.

Vitamin D can be synthesized in the skin under the influence of ultraviolet (UV) irradiation, or it can be absorbed from the diet. It is converted to 25(OH)D3 (vitamin D3) in the liver and then further converted by the kidney. The skin contains 7-dehydrocholesterol, which is converted to vitamin D3 [25(OH)D3] by UV radiation; other inactive vitamin D sterols are also produced (see Chapter 69). Vitamin D3 is then transported in the bloodstream to the liver by a vitamin D–binding protein (DBP); DBP binds all forms of vitamin D. The plasma concentration of free or nonbound vitamin D is much lower than the level of DBP-bound vitamin D metabolites.

Vitamin D also can enter the metabolic pathway by ingestion of dietary vitamin D2 (ergocalciferol) or vitamin D3 (cholecalciferol), the latter of which is more potent, and both of which are absorbed from the intestine because of the action of bile salts. After absorption, ingested vitamin D is

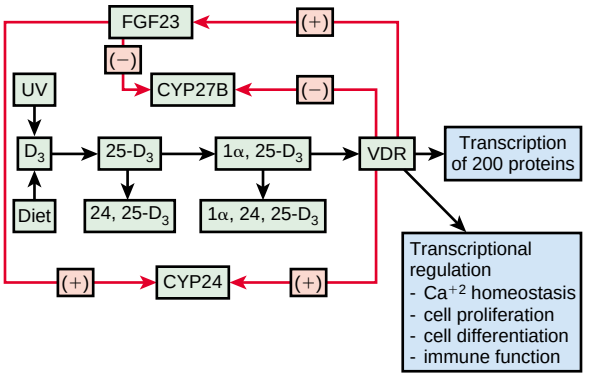

Fig. 746.1 Vitamin D metabolism. Vitamin D can be synthesized in the skin under the influence of ultraviolet (UV) irradiation, or it can be absorbed from the diet. It is converted to 25(OH)D3 (vitamin D3) in the liver and then further converted by the kidney. The enzyme cytochrome P450 (CYP) 27B converts 25(OH)D3 to $1\alpha,25\text{-}(OH)_2D3$. $1,25(OH)_2D3$ binds to vitamin D receptor (VDR), which, after transport to the nucleus, acts to induce the transcription of more than 200 proteins. The functions of some of the proteins are indicated. VDR activation leads to productions of fibroblast growth factor 23 (FGF23). FGF23 induces phosphaturia (not shown), upregulates CYP 24, and downregulates CYP 27B.

transported by chylomicrons to the liver, where, along with skin-derived vitamin D3, it is converted to 25-hydroxyvitamin D [25(OH)D]. The 25(OH)D is next transported by DBP to the kidneys, where it undergoes further metabolism. 25(OH)D is the main circulating vitamin D metabolite in humans (Table 746.1). Because the synthesis of 25(OH)D is weakly regulated by feedback, its plasma level rises in summer and decreases during winter. High vitamin D intake raises the plasma level of 25(OH)D to many times above normal, but the parent vitamin D compound itself is absorbed by adipose tissue.

In the kidneys, 25(OH)D undergoes further hydroxylation, depending on the prevailing serum concentration of calcium, phosphate, PTH, and FGF23. If the calcium or phosphate level is reduced or the PTH level is elevated, the enzyme 25(OH)D-1-hydroxylase is activated and $1,25(OH)_2D$ is formed. $1,25(OH)_2D_3$ binds to a vitamin D receptor, which after transport to the nucleus, acts to induce the transcription of 200-400 proteins and peptides. The functions of some of the proteins are known.

Another class of proteins important in the regulation of mineral balance and vitamin D synthesis are the **phosphatonins**. Among these are FGF23, sFRP-4 (secreted Frizzled-related protein 4), and MEPE (matrix extracellular phosphoglycoprotein). Overexpression of FGF23 results in hypophosphatemia, phosphaturia, reduced serum $1,25(OH)_2D$ values, and some forms of rickets. Disorders of phosphate balance, including hyper- and hypophosphatemia, can relate to loss or gain of function of these phosphatonins (see Fig. 746.1).

Vitamin D receptor activation by $1,25(OH)_2D$ leads to production of FGF23. FGF23 is produced by osteocytes and targets another organ, the kidney, to promote phosphaturia. FGF23 reduces expression/insertion of two sodium phosphate transporters into the renal proximal tubule, resulting in higher levels of urinary phosphate excretion. This bone-derived hormone also inhibits renal hydroxylase activity (CYP 27B1) and promotes 24-hydroxylase activity, with resultant decrease in $1,25(OH)_2D$ levels.

The active metabolite, $1,25(OH)_2D$, circulates at a level that is only 0.1% of the level of 25(OH)D (see Table 746.1) and acts on the intestine to increase the active transport of calcium and stimulate phosphate absorption. Because 1α-hydroxylase is a mitochondrial enzyme that is tightly feedback regulated, the synthesis of $1,25(OH)_2D$ declines after serum calcium or phosphate values return to normal. Excessive $1,25(OH)_2D$ is converted to an inactive metabolite. In the presence of normal or elevated serum calcium or phosphate concentrations, the renal 25(OH) D-24-hydroxylase is activated, producing 24,25-dihydroxyvitamin D [$24,25(OH)_2D$], which is a pathway for the removal of excess vitamin D; serum levels of $24,25(OH)_2D$ (1-5 ng/mL) increase after ingestion of large amounts of vitamin D (see Fig. 746.1) or in the presence of increased concentrations of FGF23. Although hypervitaminosis D and production of

Table 746.1 Vitamin D Metabolic Values in Plasma of Normal Healthy Subjects

METABOLITE	PLASMA VALUE
Vitamin D2	1-2 ng/mL
Vitamin D3	1-2 ng/mL
25(OH)D2	4-10 ng/mL
25(OH)D3	26-70 ng/mL
TOTAL 25(OH)D	20-80 ng/mL*
24,25(OH)2D	1-4 ng/mL
1,25(OH)2D	
Infancy	70-100 pg/mL
Childhood	30-50 pg/mL
Adolescence	40-80 pg/mL
Adulthood	20-35 pg/mL

*The Institute of Medicine states that a value of 25(OH)D of 20 ng/mL is the lower limit of normal for the general population. In contrast, the Endocrine Society defines vitamin D *deficiency* as having a serum level of less than 20 ng/mL, and *insufficiency* as a serum level between 21-29 ng/mL.

inactive metabolites can occur after oral dosing, extensive skin exposure to sunlight does not usually produce toxic levels of 25(OH)D3, suggesting natural regulation of the production of this metabolite in cutaneous tissue.

Serum 1,25(OH)$_2$D levels are higher in children than in adults, are not as subject to seasonal variability, and peak during the first year of life and again during the adolescent growth spurt. These values must be interpreted in light of the prevailing serum calcium, phosphate, and PTH values, and with regard to the entire vitamin D metabolite profile.

Mineral deficiency prevents the normal process of bone mineral deposition. If mineral deficiency occurs at the growth plate, growth slows and bone age is retarded, a condition called **rickets**. Poor mineralization of trabecular bone resulting in a greater proportion of unmineralized osteoid is the condition of osteomalacia. Rickets is found only in growing children before fusion of the epiphyses, whereas osteomalacia is present at all ages. All patients with rickets have osteomalacia, but not all patients with osteomalacia have rickets. These conditions should not be confused with osteoporosis, a condition of equal loss of bone volume and mineral (see Chapter 749).

Rickets may be classified as calcium-deficient or phosphate-deficient rickets. Because both calcium and phosphate ions constitute bone mineral, the insufficiency of either type in the extracellular fluid that bathes the mineralizing surface of bone results in rickets and osteomalacia. The two types of rickets are distinguishable by their clinical manifestations (Table 746.2). Rickets can also occur in the face of mineral

Table 746.2 Clinical Variants of Rickets and Related Conditions

TYPE	SERUM CALCIUM LEVEL	SERUM PHOSPHORUS LEVEL	ALKALINE PHOSPHATASE ACTIVITY	URINE CONCENTRATION OF AMINO ACIDS	GENETICS	GENE DEFECT KNOWN
CALCIUM DEFICIENCY WITH SECONDARY HYPERPARATHYROIDISM*						
Lack of Vitamin D						
Lack of exposure to sunlight	N or L	L	E	E		
Dietary deficiency of vitamin D	N or L	L	E	E		
Congenital	N or L	L	E	E		
Other Deficiencies						
Malabsorption of vitamin D	N or L	L	E	E		
Liver diseases	N or L	L	E	E		
Anticonvulsant drug	N or L	L	E	E		
Renal osteodystrophy	N or L	E	E	V		
Vitamin D–dependent type I	L	N or L	E	E	AR	Y
PRIMARY PHOSPHATE DEFICIENCY (NO SECONDARY HYPERPARATHYROIDISM)						
Genetic primary hypophosphatemia	N	L	E	N	XL, AD, AR	Y
X-linked hypophosphatemic rickets					XL	Y
Autosomal dominant hypophosphatemic rickets					AD	Y
Autosomal recessive hypophosphatemic rickets					AR	Y
Fanconi Syndrome						
Cystinosis	N	L	E	E	AR	Y
Tyrosinosis	N	L	E	E	AR	Y
Lowe syndrome	N	L	E	E	XL	Y
Acquired	N	L	E	E		
Phosphate Deficiency or Malabsorption						
Parenteral hyperalimentation	N	L	E	N		
Low phosphate intake	N	L	E	N		

Continued

Table 746.2 Clinical Variants of Rickets and Related Conditions—cont'd

TYPE	SERUM CALCIUM LEVEL	SERUM PHOSPHORUS LEVEL	ALKALINE PHOSPHATASE ACTIVITY	URINE CONCENTRATION OF AMINO ACIDS	GENETICS	GENE DEFECT KNOWN
Other						
Renal tubular acidosis, type II proximal	N	L	E	N		Y
Tumor-induced osteomalacia	N	L	E	N		Y
END-ORGAN RESISTANCE TO 1,25(OH)$_2$D3						
Vitamin D-dependent type II (several variants)	L	L or N	E	E	AR	Y
RELATED CONDITIONS RESEMBLING RICKETS						
Hypophosphatasia	N	N	L	Phosphoethanolamine elevated	AR	Y
Metaphyseal Dysostosis						
Jansen type	E	N	E	N	AD	Y
Schmid type	N	N	E	N	AD	Y

*Deficiency of vitamin D; low 25(OH)D and no stimulation of higher 1,25(OH)$_2$D values.
AD, Autosomal dominant; AR, autosomal recessive; E, elevated; L, low; N, normal; V, variable; XL, X-linked; Y, yes.

deficiency, despite adequate vitamin D stores. True dietary calcium deficiency rickets are found in some parts of Africa but rarely in North America or Europe. A form of phosphate-deficiency rickets can occur in infants, given prolonged administration of phosphate-sequestering aluminum salts as a treatment for colic or gastroesophageal reflux. This results in the phosphate depletion syndrome.

Visit Elsevier eBooks+ at eBooks.Health.Elsevier.com for Bibliography.

Chapter 747

Hypophosphatasia

Nourah N. Almutlaq and Linda A. DiMeglio

Hypophosphatasia (HPP) is a rare inborn error of metabolism in which tissue-nonspecific (liver, bone, kidney) alkaline phosphatase isoenzyme (TNSALP) activity is deficient, although activity of the intestinal and placental isoenzymes is normal. Decreased serum alkaline phosphatase (ALP) concentrations are the hallmark of HPP.

Pathogenic variants in the *ALPL* gene reduce the TNSALP enzyme activity to below the level essential for normal bone and teeth mineralization. More than 340 variants have been identified to date. Missense variants are the most common; however, splice-site, small deletions, and frameshift variants also have been found. The high heterogeneity of the disease is related to the inheritance pattern and different missense variants' varied TNSALP activity effects. Although the genotype/phenotype correlation is not very consistent, the more severe forms are recessively inherited and milder disease is dominantly inherited.

The clinical spectrum of HPP ranges from a very severe, typically lethal, perinatal form to a mild form with late-adult onset presenting with nonpathognomonic symptoms such as arthropathy and musculoskeletal pain. A nosology describing seven forms of the condition, ranging from neonatal lethal disease to odontohypophosphatasia, which only affects teeth with no skeletal deformities, is employed. (Subtypes and features of HPP are shown in Table 747.1.) The most common signs across subtypes are bone demineralization and premature loss of teeth with intact roots in the setting of low ALP.

The most severe **perinatal HPP** cases are lethal in utero or shortly after birth in untreated newborns. Infants have profound skeletal hypomineralization with short bones that lead to chest deformities and subsequent hypoplastic lungs. Infants may also have anemia with intracranial hemorrhage, periodic apnea, and pyridoxine-dependent seizures (Fig. 747.1A). **Infantile HPP** is next on the continuum. These infants present before 6 months of age with overlapping symptoms to perinatal HPP, including respiratory distress from severe lung hypoplasia. They can also have irritability and failure to thrive explained by the hypercalcemia/hypercalciuria (leading to nephrocalcinosis) and premature craniosynostosis (can lead to increased intracranial pressure). X-rays reveal irregular ossification, punched-out areas, and metaphyseal cupping. Before the availability of enzyme replacement therapy with asfotase alfa, mortality was estimated at 50% and survivors had significant disability. This subset of patients can also improve spontaneously as affected children mature, although early death from renal failure or flail chest leading to pneumonia can occur.

Of note, a **benign prenatal** form of hypophosphatasia also exists. It is seen in newborns with low ALP and skeletal abnormalities in utero or at birth that improve spontaneously over time.

The next category of hypophosphatasia manifests in childhood (after 6 months of life) or late adolescence **(hypophosphatasia tarda)** (see Fig. 747.1B). These children present with premature exfoliation of primary teeth (with the root intact because of poorly mineralized dental cementum), mild skeletal deformities, fracture, and variable short stature. Some children have symptoms of skeletal pain and muscle weakness. Long bones can have characteristic "tongues" of radiolucency (Fig. 747.2).

An **adult hypophosphatasia** form manifests in middle age (although some patients recount a history of early deciduous tooth loss or rickets). It is characterized by nonspecific symptoms and a milder course than pediatric forms. This form may be diagnosed after affected individuals present with osteopenia/osteoporosis, recurrent metaphyseal stress fractures (particularly of the metatarsals and tibiae), and femoral pseudofractures. Affected individuals can also have psychiatric symptoms (depression/anxiety) chondrocalcinosis, osteoarthritis, myopathy, nephrocalcinosis, and permanent tooth loss between 40-60 years of age.

Rarely, patients presenting with identical clinical and radiographic patterns have normal serum alkaline phosphatase activity but increased concentrations of phosphoethanolamine, inorganic phosphate, and pyridoxal-5-phosphate. Their disease has been labeled **pseudohypophosphatasia** and might represent the presence of a variant alkaline

Table 747.1 Hypophosphatasia Main Subtypes and Features

SUBTYPE	ONSET	INHERITANCE	CLINICAL FEATURES
Perinatal severe	Perinatal	Recessive	• Lethal in all cases without enzyme replacement • Prenatal US: absent skeletal mineralization, bowed/short long bones, fractures, osteochondral spurs, and pretibial dimpling • Death from respiratory distress from chest deformities and lung hypoplasia • Vitamin B6-dependent seizures
Prenatal benign	Perinatal	Dominant and recessive	• Skeletal deformity in utero without fractures ("bent not broken") • Improves spontaneously, benign course
Infantile	≤ 6 mo	Recessive	• Lethal in approximately 50% of cases without enzyme replacement • Appear normal at birth • Severe bone demineralization leads to rachitic chest deformities and resultant pulmonary hypoplasia • Hypercalcemic hypercalciuria (leads to nephrocalcinosis) • Craniosynostosis
Childhood	6 mo-18 yr	Dominant and recessive	• Premature loss of deciduous teeth with root intact in children <5 yr • Rickets/fractures/skeletal deformities • "Tongues" of radiolucency on x-ray • Chronic joint/bone pain • Short stature
Adult	Adulthood	Dominant and recessive	• Mild • Osteoporosis • Stress fractures, osteomalacia, and chondrocalcinosis
Odontohypophosphatasia	Childhood	Dominant and recessive	• Mildest form of HPP • No skeletal deformities; premature exfoliation of primary and/or permanent teeth • Severe dental caries

Fig. 747.1 **A,** Fetus with congenital lethal hypophosphatasia showing thin wavy ribs, platyspondyly, missing cervical vertebrae, ossification, and bent femurs. **B,** A 7-yr-old with hypophosphatasia tarda showing osteopenia, bent tibias, and punched-out metaphyseal lesions.

phosphatase isoenzyme that catalyzes artificial substrates in an alkaline environment (e.g., a test tube), but not in vivo with natural substrates.

Because of the heterogenous clinical manifestations of HPP, which often mimics other skeletal disorders, delays and misdiagnosis are common. Clinical features and radiologic findings in the setting of low ALP for age or other biomarkers of the disorder should raise suspicion. Initially the diagnosis might be suspected in the presence of a low serum ALP (adjusted for age and natal sex) and supported with an increased urinary phosphoethanolamine PEA level or high vitamin B6 concentrations. However, other etiologies for low ALP should be ruled out (Fig. 747.3 and Table 747.2).

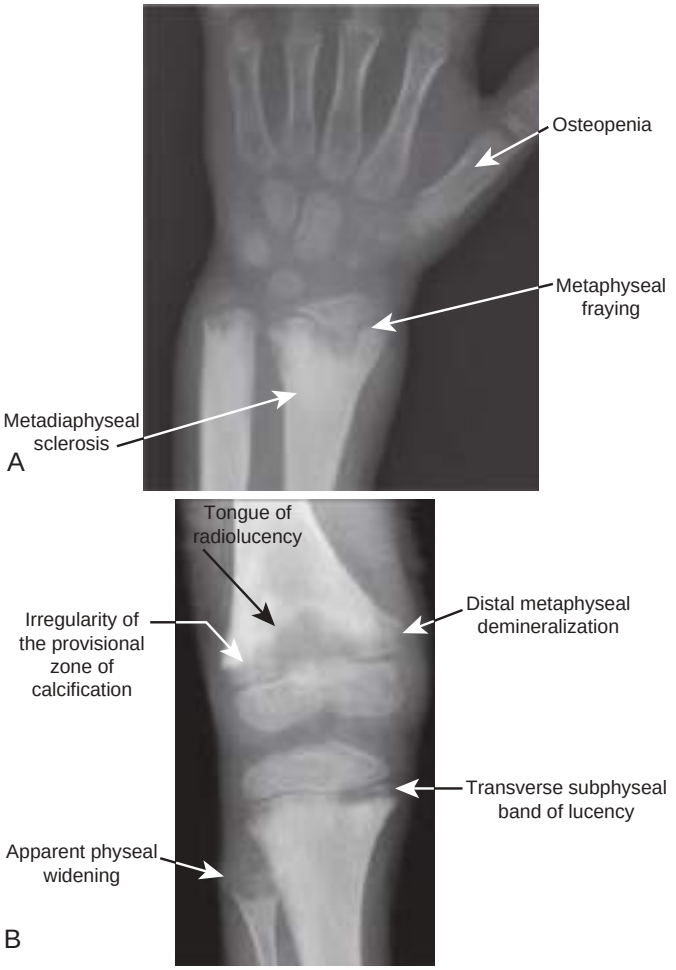

Fig. 747.2 Skeletal features of untreated hypophosphatasia. Untreated, the radiographic features of hypophosphatasia of the wrist **(A)** and knee **(B)** in children include osteopenia, metaphyseal fraying, metaphyseal flaring, metadiaphyseal sclerosis, characteristic "tongues" of radiolucency, irregularity of the provisional zone of calcification, distal metaphyseal demineralization, transverse subphyseal band of lucency, and apparent physeal widening. *(From Whyte MP, Madson KL, Phillips D, et al. Asfotase alfa therapy for children with hypophosphatasia. JCI Insight.2016;1:e85971, Fig. 2.)*

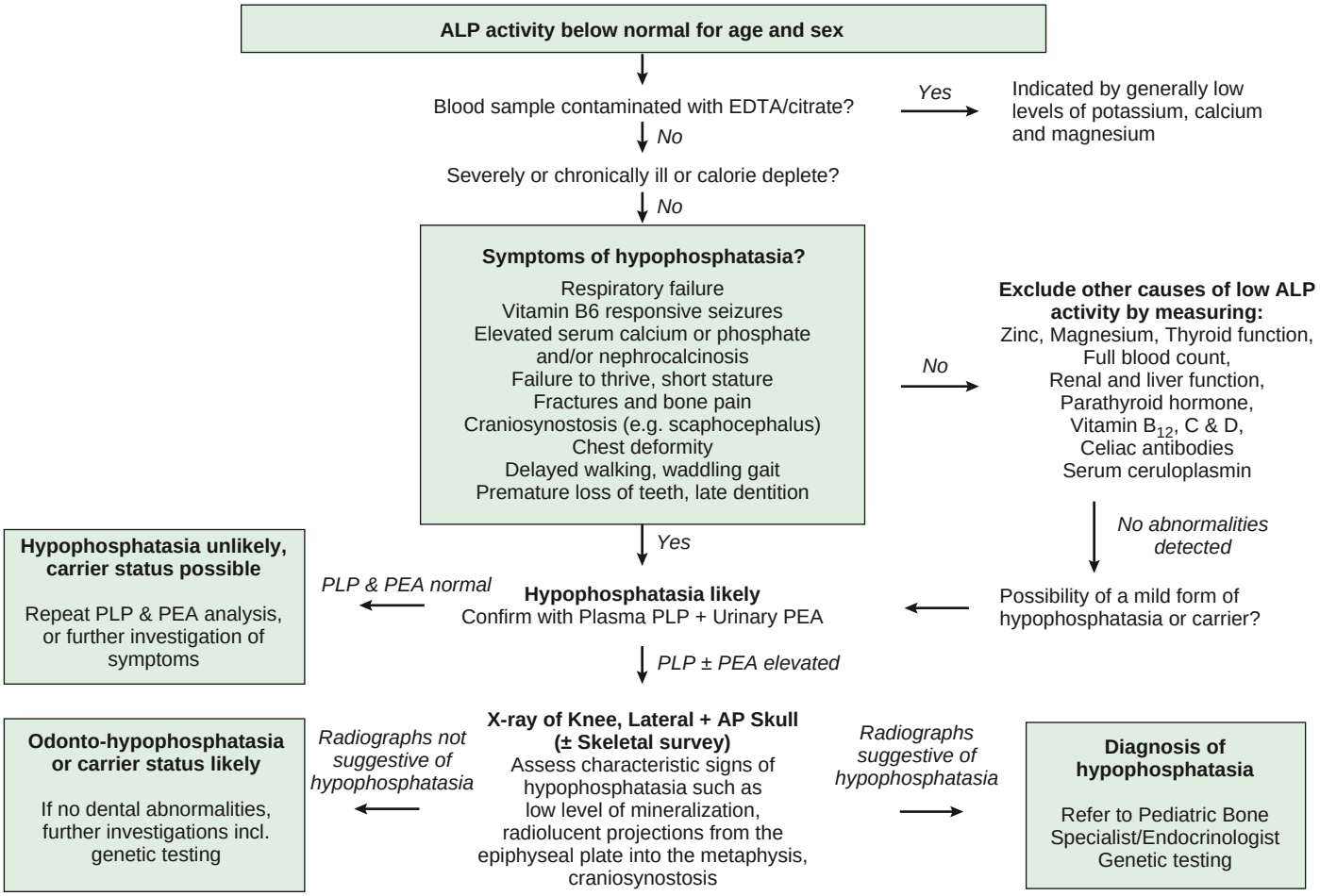

Fig. 747.3 Diagnostic algorithm for the investigation of children presenting with low ALP activity and/or symptoms of hypophosphatasia. For patients with low ALP, other conditions such as nutritional deficiencies (protein/calorie, zinc, folic acid, magnesium, vitamins B6, B12, and C), vitamin D excess, hypothyroidism, hypoparathyroidism, celiac disease, recent significant blood transfusions, renal osteodystrophy, cardiac surgery and cardiopulmonary bypass, posthepatic resection and transplantation, achondroplasia, and Wilson disease need to be excluded. AP, Anteroposterior; PEA, phosphoethanolamine; PLP, pyridoxal-5′-phosphate. *(From Saraff V, Narayanan VK, Lawson AJ, et al. A diagnostic algorithm for children with low alkaline phosphatase activities: lessons learned from laboratory screening for hypophosphatasia. J Pediatr. 2016;172:181–186. Fig. 3.)*

Table 747.2 Causes of Hypophosphatasemia

Cardiac bypass surgery	Milk-Alkali syndrome
Celiac disease	Multiple myeloma
Clofibrate therapy	Osteogenesis imperfecta, type II
Cleidocranial dysplasia	Pernicious or profound anemia
Cushing syndrome	Radioactive heavy metals
Hypophosphatasia	Starvation
Hypothyroidism	Vitamin C deficiency
Improperly collected blood (oxalate, EDTA)	Vitamin D intoxication
	Wilson's disease
Inappropriate reference range	Zn^{++} or Mg^{++} deficiency
Massive transfusion	

EDTA, Ethylenediaminetetraacetic acid
From Whyte MP. Hypophosphatasia: an overview for 2017. *Bone*. 2017;102:15–25. Table 1.

Some mild HPP forms require only symptomatic and supportive treatment. The primary treatment for more severe HPP is enzyme replacement therapy with recombinant human TNSALP (asfotase alfa). This therapy decreases the mortality rate in prenatal HPP and improves skeletal healing and mineral content, pulmonary status, and overall physical activity in other symptomatic forms.

Visit Elsevier eBooks+ at eBooks.Health.Elsevier.com for Bibliography.

Chapter 748

Hyperphosphatasia

Nourah N. Almutlaq and Linda A. DiMeglio

Hyperphosphatasia is a set of conditions characterized by hyperphosphatasemia (elevated serum alkaline phosphatase [ALP]). Increases in alkaline phosphatase are most commonly because of hepatobiliary disease or bone disorders characterized by high osteoblast activity, including nutritional rickets. Distinguishing liver from bone etiologies requires fractionating alkaline phosphatase isoenzymes or measuring bone-specific alkaline phosphatase as well as other laboratory assessments of liver function and bone turnover/vitamin D status. ALP activity varies by age and gender; therefore, specific reference ranges should be employed. It is usually higher in pediatric populations than adults, peaking at times of high bone formation including in the first 6 months and during pubertal growth.

In children younger than 5 years, marked increases in alkaline phosphatase without clinical or laboratory evidence of liver or bone disease is most often because of **benign transient hyperphosphatasemia** generally detected as an incidental finding during screening laboratory evaluations or evaluations performed to assess a specific complaint. The cause may be related to excess sialylation of alkaline phosphatase, which slows clearance. Cases often follow viral illness, including SARS-CoV-2 infection. Serum alkaline phosphatase values as high as 3,000-6,000 IU/L may be encountered. Liver and bone isoenzyme fractions are both elevated; there are no other clinical or laboratory signs of hepatic or bone disease. Diagnosis is confirmed by a careful clinical history plus laboratory assessments of calcium, phosphorus, creatine, AST, ALT, GGT, bilirubin, PTH, and 25-hydroxyvitamin D. A CBC should also be drawn to rule out oncologic processes. Alkaline phosphatase should be followed serially (every 2-3 months) until resolution is documented. The condition usually resolves within 16 weeks without intervention and does not recur.

Juvenile Paget disease (familial hyperphosphatasemia, idiopathic hyperphosphatasia or IHH) is a rare autosomal recessive bone disease hallmarked biochemically by marked serum ALP activity elevation. Most cases are because of loss-of-function variants in the tumor necrosis factor receptor superfamily, member 11B gene (TNFRSF11B) that encodes osteoprotegerin (OPG). OPG inhibits osteoclastogenesis and osteoclast activity by preventing receptor activator of nuclear factor κ-B (RANK) ligand (RANKL) from binding to its receptor RANK. Affected children are asymptomatic at birth and gradually develop progressive long bone deformity (including kyphoscoliosis), bone pain, and significant fractures. X-rays show bowing and diaphyseal thickening, along with osteopenia (Fig. 748.1). Radiographically, the bony texture is variable; dense areas (showing a teased cotton-wool appearance) are interspersed with radiolucent areas and general demineralization. Long bones appear cylindrical, lose metaphyseal modeling, and contain pseudocysts that show a dense, bony halo. Children with juvenile Paget disease have short stature, large skulls with a thickened cranium (widened diploë) that may be deformed, and progressive and profound hearing loss. There is substantial phenotype variability; some cases are diagnosed in infancy and others in late childhood. This disorder is distinct from adult Paget disease (osteitis deformans) because bone histology reveals a lack of normal cortical bone remodeling and an absence of the classic mosaic pattern of lamellar bone found in the adult condition. Given the rarity of this disorder, there is no strong evidence surrounding optimal clinical management; however, antiresorptive therapy with bisphosphonates is associated with clinical, biochemical, and radiographic improvement.

Fig. 748.1 Juvenile Paget disease showing bowing and thickening of the diaphyses and osteopenia. *(From Slovis T, ed. Caffey's Pediatric Diagnostic Imaging, 11th ed. Philadelphia: Mosby, 2008. Fig. 167–226, p. 2744.)*

Other rare forms of hyperphosphatasia include **expansile skeletal hyperphosphatasia (ESH)** caused by dominant variants in the *TNFRSF11A* gene encoding receptor activator of RANK, which regulates osteoclastogenesis, and **hyperphosphatasia-mental retardation syndrome** caused by recessive variants in *PIGV* in the glycosylphosphatidylinositol (GPI)-anchor biosynthesis pathway.

Visit Elsevier eBooks+ at eBooks.Health.Elsevier.com for Bibliography.

Chapter 749

Osteoporosis

Rebecca J. Gordon and Catherine M. Gordon

Osteoporosis, the most common bone disorder in adults, is relatively uncommon in children and adolescents; the criteria that underlie this diagnosis in young patients are a source of debate. This disorder is characterized by diminished bone volume and a marked increase in the prevalence of fractures. In contrast to osteomalacia, which shows undermineralization and normal bone volume, histologic sections of bone in all forms of osteoporosis reveal a normal degree of mineralization but a reduction in the volume of bone, especially trabecular bone (vertebral bone). The **diagnosis of osteoporosis in children and adolescents** requires evidence of skeletal fragility with: (1) a clinically significant fracture history, which is defined as at least two long bone fractures in children less than 10 years old, at least three long bone fractures by 19 years old, or any vertebral fractures; and (2) low bone density, with age, sex, and ancestry-matched bone mineral density (BMD) Z-score ≤ –2.0, assessed by dual-energy x-ray absorptiometry (DXA).

Blood values of minerals (e.g., calcium, phosphorus), vitamin D metabolites, alkaline phosphatase, and parathyroid hormone are usually normal. Evaluation of bone mineral content and areal bone density by DXA is the clinical gold standard for measuring BMD. DXA evaluation in patients 15 years of age or younger includes total body less head and lumbar spine, and in those 16 years and older includes lumbar spine and hip. In certain clinical scenarios, it may be useful to obtain alternative sites, such as the distal femur or forearm scan. Additional research modalities allow for the assessment of bone microarchitecture (e.g., trabecular versus cortical bone), quality, and strength, such as peripheral quantitative CT and trabecular bone score.

In the pediatric age group, osteoporosis may be primary or secondary (Table 749.1, Fig. 749.1). The primary osteoporoses can be divided into heritable disorders of connective tissue, including osteogenesis imperfecta (see Chapter 742), Bruck syndrome, osteoporosis-pseudoglioma syndrome, Ehlers-Danlos syndrome (see Chapter 744), Marfan syndrome (see Chapter 743), homocystinuria, and idiopathic juvenile osteoporosis. Secondary forms of osteoporosis include various neuromuscular disorders, chronic illness, endocrine disorders, and drug-induced and inborn errors of metabolism, including lysinuric protein intolerance and Gaucher disease.

When no obvious primary or secondary cause can be detected, **idiopathic juvenile osteoporosis** should be considered, especially if the following clinical features are evident: onset before puberty, long bone and lower back pain, vertebral fractures, long bone and metatarsal fractures, a washed-out appearance of the spine and appendicular skeleton on standard radiographs, and improvement of bone density after puberty. Trabecular bones such as the spine and metatarsals are particularly affected by atraumatic fractures. Several modes of therapy (including oral calcium supplements, calcitriol, bisphosphonates, and calcitonin) have been used with some success in individual conditions, but the effect of these treatments is difficult to gauge because spontaneous recovery occurs after the onset of puberty in more than 75% of cases.

Osteoporosis-pseudoglioma syndrome is an autosomal recessive disorder manifested by variable age at onset, low bone mass, fractures in childhood, and abnormal eye development. It is caused by pathogenic loss of function variants in *LRP5*, which encodes the low-density lipoprotein receptor-related protein 5. Interestingly, gain-of-function pathogenic variants to this gene result in increased bone density.

The life-cycle implications of either significant demineralization or osteoporosis in childhood need to be stressed. Events in childhood influence peak bone mass, and late adolescence is a period of rapid bone mineral accretion. Peak bone mass is typically achieved by 20-25 years of age (depending on the bone measured), and the contribution during childhood is considerable. A number of measures influence bone mass including adequate calcium intake, vitamin D sufficiency, weight-bearing physical activity, and body mass index (BMI) within a healthy range. General recommendations include achieving the recommended daily allowance (RDA) of calcium for age. Excellent and convenient sources of dietary calcium include dairy products, but also bony fish, green vegetables, and calcium-supplemented drinks (e.g., orange juice). Yogurt and hard cheeses can be used in many lactase-deficient children. Also, a serum 25-hydroxyvitamin D level between 30-50 ng/mL in those with known threats to bone health can be beneficial to maximize calcium absorption and ensure normal range parathyroid hormone. Weight-bearing exercise

Table 749.1 Diagnoses That Confer Increased Risk for Osteoporosis

ENDOCRINE DISORDERS	CONNECTIVE TISSUE/BONE DISORDERS
Female Hypogonadism	Idiopathic juvenile osteoporosis
Turner syndrome	Osteogenesis imperfecta
Hypothalamic amenorrhea (female athletic triad)	Ehlers-Danlos syndrome
Anorexia nervosa	Marfan syndrome
Premature ovarian insufficiency	Homocystinuria
Depot medroxyprogesterone acetate therapy	Fibrous dysplasia
Estrogen receptor α (ESR1) pathogenic variants	Previous or recurrent low impact fractures
Hyperprolactinemia	Early-onset osteoporosis with *WNT1* pathogenic variants
Male Hypogonadism	X-linked osteoporosis with fractures with *PLS3* pathogenic variants
Primary gonadal failure (Klinefelter syndrome)	DRUGS
Secondary gonadal failure (idiopathic hypogonadotropic hypogonadism)	Alcohol
Delayed puberty	Heparin
Hyperthyroidism	Glucocorticoids
Hyperparathyroidism	Thyroxine
Hypercortisolism (therapeutic or Cushing disease)	Anticonvulsants
Growth hormone deficiency	Gonadotropin-releasing hormone agonists
Thyrotoxicosis	Cyclosporine
INFLAMMATORY DISORDERS	Chemotherapy
Dermatomyositis	Tobacco cigarettes
Chronic hepatitis	MISCELLANEOUS DISORDERS
Juvenile idiopathic arthritis	Immobilization (cerebral palsy, spinal muscular atrophy, Duchenne muscular dystrophy)
Systemic lupus erythematosus	Chronic renal disease
GASTROINTESTINAL DISORDERS	Glycogen storage disease type 1
Malabsorption syndromes (cystic fibrosis, celiac disease, biliary atresia)	Chronic hepatitis
True or perceived lactose intolerance	Hypophosphatasia
Inflammatory bowel disease	Low calcium dietary intake
Chronic obstructive jaundice	Gaucher disease
Primary biliary cirrhosis and other cirrhoses	Severe congenital neutropenia
Alactasia	
Subtotal gastrectomy	
BONE MARROW DISORDERS	
Bone marrow transplant	
Lymphoma	
Leukemia	
Hemolytic anemias (sickle cell anemia, thalassemia)	
Systemic mastocytosis	

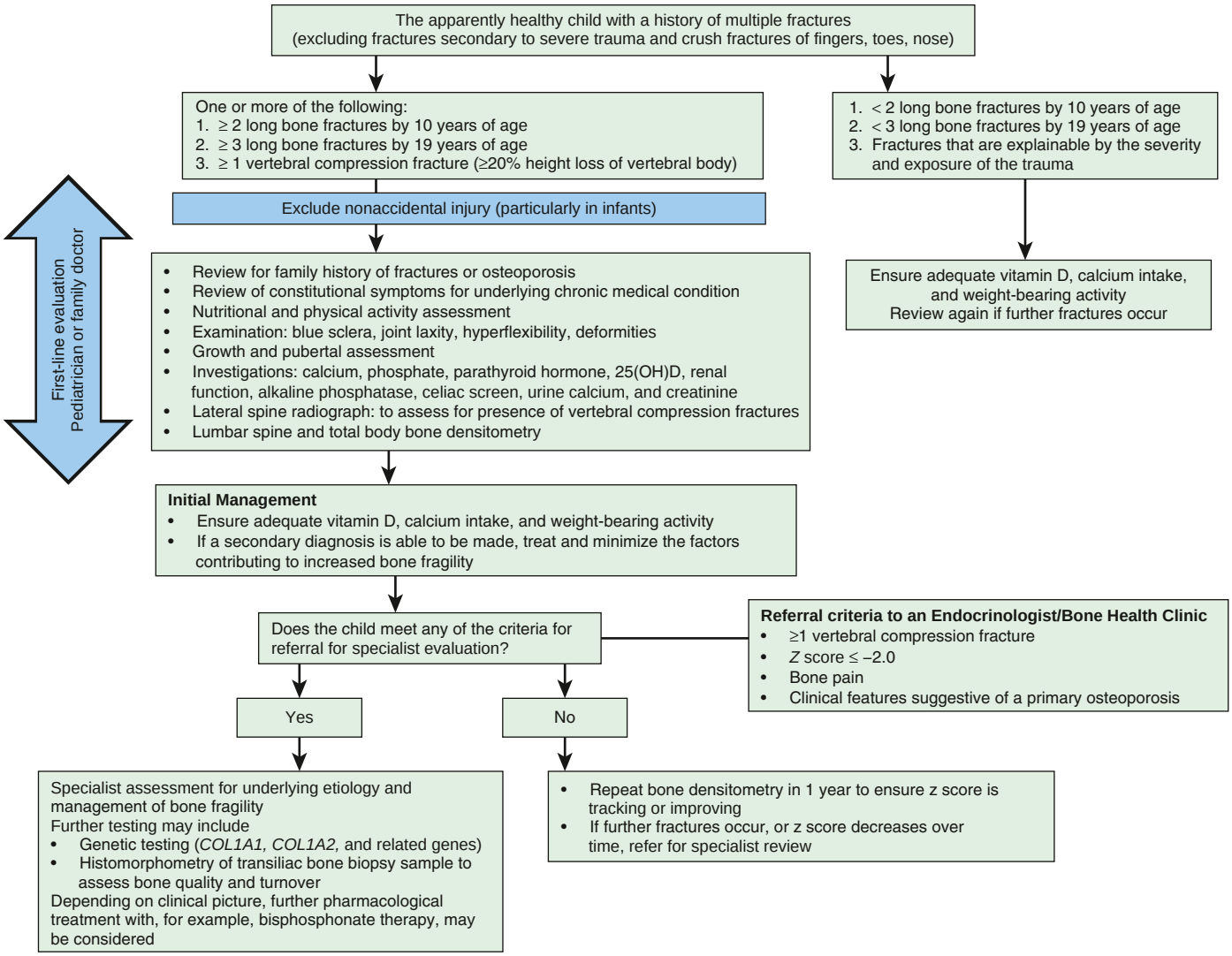

Fig. 749.1 An algorithm for the management of a child presenting with a clinically significant fracture history. The algorithm outlines the initial evaluation, management, and when to consider referral for specialist review. *(Data from Mayranpaa MK, Viljakainen HT, Toiviainen-Salo S, et al. Impaired bone health and asymptomatic vertebral compressions in fracture-prone children: a case-control study. J Bone Miner Res. 2012;27:1413–1424; and Bishop N, Arundel P, Clark E, et al. Fracture prediction and the definition of osteoporosis in children and adolescents: the ISCD 2013 pediatric official positions. J Clin Densitom. 2014;17:275–280.)*

enhances bone formation and reduces bone resorption. Factors that can prevent acquisition of peak bone mass include the use of alcohol and tobacco. Because it appears that adult-onset osteoporosis stems primarily from genetic factors, representing a complex trait interaction, specific interventions during childhood to augment bone mass are not available.

The treatment of secondary osteoporosis is best achieved by treating the underlying disorder when feasible (see Fig. 749.1). Hypogonadism should be treated with hormone replacement therapy, but in adolescent girls, nutritional issues should first be addressed and, ultimately, prescription of transdermal over oral estrogen (see Chapter 732). Calcium intake should be increased to 1,500-2,000 mg/day. In glucocorticoid-induced osteoporosis, an emphasis is placed on the lowest possible dose to prevent disease activity (e.g., in children with inflammatory bowel disease) with alternate-day dosing or, when appropriate, topical (e.g., eczema) or inhaled (e.g., asthma) glucocorticoids. Special diets for inborn errors of metabolism are also appropriate, as well as enzymatic replacement for diseases such as hypophosphatasia, a genetic disorder leading to deficient endogenous alkaline phosphatase production and defective bone mineralization. Screening for celiac disease should be carried out in unexplained cases of low bone mass, as adherence to a gluten-free diet can significantly enhance bone health in these patients (see Chapter 384).

Treatment with bisphosphonates that inhibit bone resorption in certain secondary (e.g., glucocorticoid-induced) and adult-onset osteoporosis has been successful. Bisphosphonate therapy can also be beneficial for children and adolescents and has historically been used with osteogenesis imperfecta and cerebral palsy. The use of bisphosphonates has expanded to additional patient populations with secondary osteoporosis, such as recurrent fractures and low bone mineral density, and high risk for skeletal fragility because of their underlying medical conditions. In consultation with a metabolic bone expert, bisphosphonate treatment should be considered in the following patient populations: Duchenne muscular dystrophy, spinal muscular atrophy, and other nonambulatory patients (i.e., cerebral palsy, metabolic disorders). All modifiable risk factors should be addressed, including adequate calcium intake; sufficient vitamin D; weight-bearing physical activity, such as time within a stander and physical therapy; healthy range BMI; and evaluation of overall heath (i.e., regular menstrual periods in adolescent girls, no other endocrinopathies, and optimizing the treatment status of the underlying medical condition).

Visit Elsevier eBooks+ at eBooks.Health.Elsevier.com for Bibliography.

Rehabilitation Medicine

PART XXXI

Chapter 750

Rehabilitation for Traumatic Brain Injury

Chong-Tae Kim and J. Michael King

Traumatic brain injury (TBI) is a major cause of pediatric disability in children older than 1 year old in the United States (see Chapter 82). According to data from the Centers for Disease Control and Prevention (2006–2010), TBI due to falls (72.8%) is most common in the 0-4 age range. **Nonaccidental TBI** remains a significant cause of TBI at this age (20-30 cases/100,000) (see Chapter 17). Falls (35.1%) and being struck by or against an object (34.9%) are most common in those 5-14 years of age. Assaults, falls, and motor vehicle injuries make up to 85% of the TBI experienced in those 15-24 years of age. TBI is more common in males than females at all ages.

PATHOPHYSIOLOGY

TBI is the consequence of primary and secondary injury (see Chapter 82). Primary injury results from direct physical impact. Secondary injury is the consequence of aberrant neurochemical homeostasis after primary injury (Fig. 750.1). This injury mechanism helps explain why individuals may experience global dysfunction of the brain despite relatively small or focal brain lesions on imaging studies. Minimizing secondary injury is critical to preventing further brain insult after the primary injury.

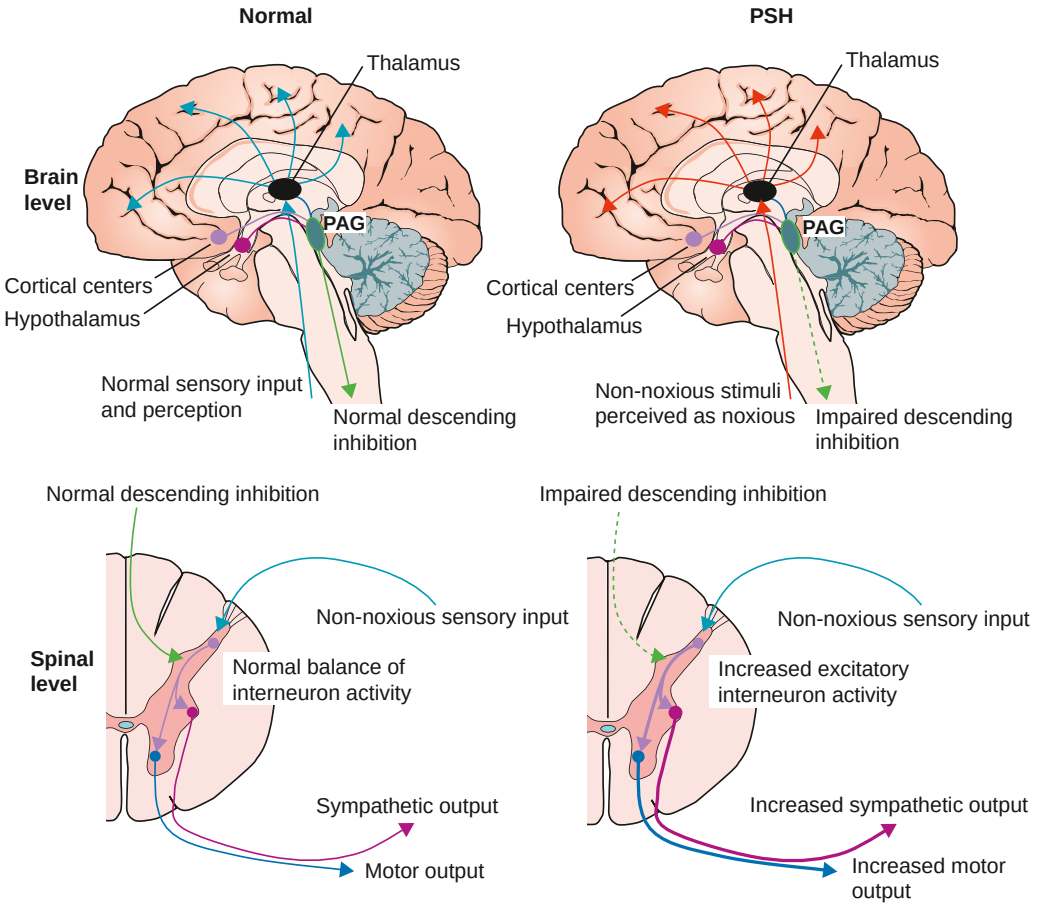

Fig. 750.1 Excitatory:inhibitory ratio model of the pathogenesis of PSH. In normal circumstances, various cortical, hypothalamic, thalamic, and other subcortical inputs modulate activity within brainstem centers—the PAG is shown here as one of the key brainstem hubs in this process. These brainstem nuclei provide inhibitory drive to spinal-reflex arcs, thereby maintaining balance between inhibitory and excitatory interneuron influences on motor and sympathetic efferents, allowing normal sensory stimuli to be perceived as nonnoxious. In the excitatory:inhibitory ratio model of PSH, disconnection of descending inhibition produces maladaptive dendritic arborization and spinal-circuit excitation, with nonnoxious stimuli triggering increased motor and sympathetic output (spinally) and potentially becoming perceived as noxious (centrally). PAG, Periaqueductal grey. PSH, paroxysmal sympathetic hyperactivity. *(From Meyfroidt G, Baguley IJ, Menon DK. Paroxysmal sympathetic hyperactivity: the storm after acute brain injury. Lancet. 16:721–729, 2017 [Fig. 2].)*

Very young children who have not yet closed their cranial sutures accommodate some increase in intracranial pressure that may result from TBI. However, young children have a relatively large head size compared with their body, higher brain water content, and less myelination, all of which may contribute to greater brain distortion and injury than from a comparable injury experienced by an adult.

SEVERITY

The acute severity of TBI is typically classified with the **Pediatric Glasgow Coma Scale** (GCS) (see Chapter 82). GCS scores of 13-15 are considered mild TBI, 9-12 moderate TBI, and 3-8 severe TBI. Additional parameters may be helpful in classifying severity. The longer the duration of loss of consciousness (i.e., <30 min, <24 hr, or >24 hr), the more severe the TBI. Longer duration of posttraumatic amnesia (<1 day, 1-7 days, or >7 days) is also reflective of a more severe TBI. Biomarkers (chemicals sensitive to nerve tissues) are being investigated as potential indicators of severity.

MEDICAL COMPLICATIONS

Disorders of Consciousness

Children with severe TBI manifest various levels of altered consciousness (Table 750.1). They may progress from coma to unresponsive wakefulness syndrome (formerly vegetative state) and/or minimally conscious state. The longer the period of impaired consciousness, the poorer the functional recovery. Rapid transition from coma/unresponsive wakefulness syndrome to a minimally conscious state increases the possibility of better recovery. As patients recover from impaired consciousness, they may have altered circadian sleep–wake patterns. In this phase, it is particularly important to **avoid overstimulation at night**, such as with procedures, and to avoid sedative medications during the day. **A sleep diary** over a period of several days to a week is a useful measure to monitor sleep patterns and determine the effectiveness of medications. **Neurostimulators** (e.g., amantadine, bromocriptine, methylphenidate, or L-dopa) may be used to improve arousal during the day. Trazodone or melatonin may help facilitate sleep onset or maintenance at night, respectively. Modafinil or donepezil can be tried if the above neurostimulators are ineffective. Paradoxically zolpidem has been reported to improve alertness in several cases.

Cognitive-Behavioral Disorders

The management and outcome of mild TBI (concussion) are discussed in Chapter 729. As patients with severe TBI recover from initial low levels of consciousness, they may demonstrate significant cognitive-behavioral disorders, such as agitation, aggression, decreased frustration tolerance, impulsivity, inattention, emotional lability, perseveration, impaired working memory, and poor safety awareness and judgement. Agitation is common in the early stages of recovery. The first line of management for agitation is to decrease excessive environmental, visual, auditory, and tactile stimulation. Physical constraint is typically implemented as a last resort to prevent harm to the patient and others, and it should be removed as soon as the danger has resolved. The **Rancho Los Amigo scale** (RLAS) (Table 750.2) may be used to evaluate the level of this impairment. It is important to exclude potential exacerbating factors or medical causes of impaired mental status and behavior, including electrolyte abnormalities, infection, and concomitant injuries in patients who incur multiple traumas including severe TBI. Posttraumatic amnesia can be particularly debilitating because it may limit the acquisition and retention of new learning skills. The **Children's Orientation and Amnesia Test** may be helpful in determining when a patients' posttraumatic amnesia has ended, after which these children may be candidates for cognitive rehabilitation. This test assesses **general orientation** (name, age, birthdate, school, etc.), **temporal orientation** (current time, day of the week, year, etc.), and **memory** (verbal and nonverbal).

Most patients who have moderate or severe TBI will have varying degrees of long-term residual cognitive impairments, which can include impaired judgment, attention deficits, and impaired working memory (see Chapter 49). The most rapid recovery in cognitive skills tend to occur in the first year after the TBI. Children with more severe injuries and children from lower socioeconomic status (SES) families tend to have more significant long-term deficits after a TBI.

Table 750.1 Level of Consciousness

	COMA	UNRESPONSIVE WAKEFULNESS SYNDROME	MINIMALLY CONSCIOUS STATE (–)	MINIMALLY CONSCIOUS STATE (+)
Eye opening	None	Spontaneous or to stimulus	Spontaneous	Spontaneous
Brain stem reflexes	None	Present	Present	Present
Orientation	None	None	Inconsistent	Consistent
Purposeful response	None	None	Trivial responses with localization (visual fixation or tracking, localization to pain)	Evident reliable responses with verbal, behavioral, and/or motor

Table 750.2 Rancho Los Amino Scale

LEVEL	COGNITIVE-BEHAVIORAL CHARACTERISTICS	CLINICAL FEATURES
I	No response	Comatose state
II	Generalized response	Nonpurposeful, reflexive, stereotyped response to simulations
III	Localized response	Specifically localized (head turn, blink eye, grasp), consistent response to stimulations
IV	Confused-agitated	Confused and hyperactive or bizarre behavior
V	Confused-inappropriate	Less agitated and able to follow simple instructions consistently but difficult to follow complicated ones
VI	Confused-appropriate	Still impaired recent memory, needs assistance for unfamiliar situations
VII	Automatic-appropriate	Able to do daily routine independently but has difficulty solving problems
VIII	Purposeful-appropriate	Independent and functional in activities at home and community but may have some difficulties in stressful situations

Posttraumatic Seizure

The incidence of posttraumatic seizure (PTS) is dependent on injury severity and age. About 30–35% of children with severe TBI will experience a PTS. Very early-onset PTS may develop within 24 hours after a TBI, early-onset PTS within 7 days, and late onset more than 7 days after a TBI. Early-onset PTS is more common in children, and late-onset PTS is more common in adults. The risk of late-onset PTS is increased in particularly severe TBI, those caused by penetrating injury, the presence of subdural hematoma, in injuries occurring in children younger than 5 years, and in patients with a history of early-onset PTS. Prophylactic treatment with an antiepileptic medication for 7 days after a TBI is commonly prescribed (see Chapter 82). However, treatment with an antiepileptic medication beyond 1 week offers no further benefit as a prophylactic agent. The risk of PTS decreases to the same incidence as in the general population after 5 years from TBI.

Paroxysmal Sympathetic Hyperactivity

Paroxysmal sympathetic hyperactivity (PSH) is a constellation of symptoms manifested by hyperthermia, tachycardia, tachypnea, diaphoresis, and increased tone, including dystonic posturing. It is primarily attributable to autonomic dysregulation. The mechanism has not been clearly defined but is thought to be because of disruption of the inhibitory function of the mesencephalon on the diencephalon (see Fig. 750.1). Some drug-related symptoms may mimic the features of PSH and may require discontinuation and the use of alternative medication; for example, haloperidol and chlorpromazine may cause neuroleptic malignant syndrome, and phenytoin may precipitate a fever. The assessment measure pediatric PSH-AM is suggested to improve diagnostic sensitivity (Tables 750.3, 750.4, and 750.5). There is no current established standard of care for management of PSH, but bromocriptine, propranolol or labetalol, clonidine, amantadine, intrathecal baclofen, morphine, benzodiazepine, and gabapentin have been prescribed with variable success. Morphine, fentanyl, propofol, propranolol, and gabapentin have consistently been effective in adult patients for both prevention and treatment. Most patients require more than one class of medication (opioid, beta blockers, alpha 2 agonists, neuromodulators, benzodiazepines, sarcolemmal calcium release blockers). Oral baclofen, Dilantin, and carbamazepine are reported to be ineffective for PSH. PSH is a negative factor for short-term but not long-term functional outcomes.

Neuroendocrine Disorders

Hypothalamic-pituitary injury that occurs with TBI can cause various endocrine disorders. Growth hormone deficiency is the most common and results in growth retardation. Precocious puberty, more common in females than males, may result from loss of neural inhibition on gonadotropin release. Three different types of salt and water metabolism derangements, diabetes insipidus (DI), syndrome of inappropriate secretion of antidiuretic hormone (SIADH), and cerebral salt wasting (CSW) can develop after a severe TBI (see Chapter 82).

Spasticity

Spasticity is a major complication that develops in children with severe TBI (see Chapter 752).

OUTCOME ASSOCIATED WITH SEVERE TRAUMATIC BRAIN INJURY

Given different mechanisms of injury, younger children who incur a severe brain injury tend to have better functional outcomes than older children. However, given the same severity of TBI, the outcome of very young children is poorer than that of older children. The age defined as "very young children" (2-5 years) is variable depending on the studies. The specific reason for this difference in outcomes has not been identified, but a plausible explanation is that although very young children demonstrate a higher potential for neuroplasticity with focal brain injuries, their immature and developing brains are more vulnerable to the diffuse effects on the brain of most forms of TBI.

The GCS score is a strong prognostic factor for mortality and functional outcome in the acute injury phase but not for functional outcome in the subacute or chronic phase for children within the severe TBI group. Duration of posttraumatic amnesia or time to follow commands are better prognostic factors for long-term functional outcomes.

Cognitive and behavioral impairments (poor memory-learning and executive skills, hyperactivity, depression, awareness deficits) are the most common and long-lasting sequelae of TBI. These deficits can inhibit successful school reentry and participation in social activities.

Given the same severity, the long-term functional outcome of children who sustain nonaccidental (inflicted) trauma is worse than that of children with other forms of TBI. Children who incur nonaccidental trauma are typically very young. If developmentally delayed before their brain injury, they are likely to have poorer long-term functional outcomes. The

Table 750.3 Pediatric PSH-AM Pediatric Clinical Feature Scale (PCFS)

	AGE (YR)	0	1	2	3
Heart rate	1-4	<110	100-124	125-139	≥140
	5-15	<100	100-119	120-139	≥140
Respiratory rate	1-4	<30	30-34	35-39	≥40
	5-15	<25	25-29	30-34	≥35
Systolic BP	1-4	<100	100-109	110-119	≥120
	5-15	<120	120-129	130-139	≥140
Diastolic BP	1-4	<65	65-72	73-79	≥80
	5-15	<75	75-82	83-89	≥90
Temperature		37	37-37.9	38-38.9	≥39
Sweating		Normal	Increased sweating	Localized diaphoresis	Generalized diaphoresis
Posturing (muscle tone) during episode		None	Mild increase	Neat increase	Generalized spasticity/opisthotonos

Severity of CF (subtotal score of PCFS): Nil =0, Mild 1-6, Moderate 7-12, Severe ≥13
BP, Blood pressure; PSH-AM, paroxysmal sympathetic hyperactivity-assessment measure.

Table 750.4 Pediatric Diagnosis Likelihood Tool (PDLT)

	PRESENT/ABSENT (1/0)
1. Clinical features occur simultaneously	
2. Episodes are paroxysmal in nature	
3. Sympathetic overactivity to normally nonpainful stimuli	
4. Features persist > 3 consecutive days	
5. Features persist > 1 week postinjury	
6. Features persist despite treatment of alternative differential diagnoses	
7. At least single episode daily	
8. Medication administered to decrease sympathetic features	
9. Absence of parasympathetic features during episodes	
10. Absence of other presumed cause of features	
11. Antecedent acquired brain injury	

Table 750.5 Pediatric PSH-AM

PSH DIAGNOSTIC LIKELIHOOD	COMBINED TOTAL (PCFS + PDLT)
Unlikely	<8
Possible	8-16
Probable	>17

PSH-AM, paroxysmal sympathetic hyperactivity assessment measure; PCFS, pediatric clinical feature scale; PDLT, pediatric diagnosis likelihood tool.

long-term functional outcome of children who sustain a TBI is better than those who sustain a nontraumatic (anoxic) brain injury.

Visit Elsevier eBooks+ at eBooks.Health.Elsevier.com for Bibliography.

Chapter 751

Spinal Cord Injury and Autonomic Dysreflexia Management

Ashlee M. Jaffe and Abigail Case

See Chapter 81.

Individuals from birth to 21 years of age account for 25% of all cases of traumatic **spinal cord injury (SCI)**. Children are more susceptible to lap-belt injuries, upper cervical injuries, SCIs without radiologic abnormalities **(SCIWORA)**, and delayed onset of neurologic deficits, ranging from 30 minutes to 4 days. A population-based study found the epidemiology of pediatric spinal injury in the US varies greatly by age, ethnicity, and payor. Low-income populations are more likely to sustain spinal cord injury due to firearms than other populations.

The most accurate way to evaluate a patient who has sustained an SCI is by performing a standardized physical examination, as endorsed by the International Standards for Neurological and Functional Classification of SCI, recommended for children 6 years of age and older (Fig. 751.1). Life expectancy is related to the neurologic level of injury and the American Spinal Injury Association (ASIA) impairment scale classification.

CLINICAL MANIFESTATIONS

Immediately after an SCI, there is typically a period of **spinal shock** with low tone and absent reflexes. Eventually, signs of an **upper motor neuron** lesion may emerge, including spasticity and involuntary muscle spasms. However, if there is a substantial segment of spinal cord infarction present, patients may have persistent flaccid paralysis.

Children with neurologic levels of injury at T6 or above are at particular risk for interruption and decentralization of the autonomic nervous system. The most common manifestations include bradycardia, hypotension, temperature dysregulation, and, once spinal shock has resolved, **autonomic dysreflexia (AD)**. AD is a sustained sympathetic response as a result of a noxious stimulus *below* the level of injury. Symptoms resulting from AD typically include hypertension, bradycardia, headache, and flushing of the skin above the level of injury, although vague symptoms such as fatigue, irritability, or crying may be the presenting symptoms in younger patients. Noxious stimuli resulting from bladder or rectal distention is a common cause of AD, but there are a large number of other causes that need to be considered (Table 751.1). Children and adolescents with cervical and upper thoracic level SCI have lower baseline blood pressures (BPs) compared with the general population. Therefore caution should be used when referencing age-appropriate BPs because BP elevations of even 20-40 mm Hg above this lower baseline may be suggestive of AD. *Identification and treatment of the noxious stimulus is typically associated with resolution of symptoms without the use of antihypertensive medication.* If necessary, antihypertensive agents with a rapid onset and short duration, such as nifedipine and nitropaste, are advocated to treat elevated BP while the underlying cause is identified (Fig. 751.2). Emergent management of AD is necessary because of the risk of stroke and additional organ damage resulting from sustained hypertension. Consideration of a medical alert bracelet, education of supervising adults, and carrying of an AD emergency reference card is recommended (Fig. 751.3).

Patients with SCI are particularly vulnerable to **deep venous thrombosis** and **pulmonary embolism** because of immobilization of their affected limbs and venous stasis during the first 90 days after an injury. Deep venous thromboses are more common in postpubertal children >14 years old than in younger children. Mechanical prophylaxis (graduated compression stockings and sequential calf compression devices) are recommended for all children with acute SCI; adolescents should also start anticoagulant thromboprophylaxis, especially if additional risk factors like lower extremity fractures are present (unless contraindicated because of the risk of bleeding or prior allergic response). Late-occurring deep venous thrombosis most commonly occurs with prolonged immobilization related to illness or surgery, and prophylactic measures should be continued during these situations as well.

Consequent of SCI, patients often present with varying degrees of bowel and bladder incontinence. After an SCI, the bladder can be areflexic or hyperreflexic, and detrusor sphincter dyssynergia may occur. Clean intermittent catheterization (CIC) of the bladder is typically performed up to 4-6 times/day to prevent urinary retention and vesicoureteral reflux. Constipation can negatively impact the success of a CIC program. Anticholinergic medications may improve bladder storage capacity and prevent urinary incontinence between bladder catheterizations. *Antibiotics are only recommended for symptomatic urinary tract infections; asymptomatic bacteriuria, without vesicoureteral reflux, is generally due to colonization and typically not treated.* If intermittent catheterization is required, one can begin teaching the skills necessary for independent catheterization as early as 3 years of age with a goal of obtaining complete independence by 5-7 years old reflecting the progression toward independent bladder management of the child's able-bodied peers.

Bowel continence programs can be successfully introduced around 2-4 years old. There should be an attempt to distinguish between upper motor neuron (UMN) and lower motor neuron (LMN) bowel dysfunction because the management and bowel agents chosen may vary

Table 750.4 Pediatric Diagnosis Likelihood Tool (PDLT)

	PRESENT/ABSENT (1/0)
1. Clinical features occur simultaneously	
2. Episodes are paroxysmal in nature	
3. Sympathetic overactivity to normally nonpainful stimuli	
4. Features persist > 3 consecutive days	
5. Features persist > 1 week postinjury	
6. Features persist despite treatment of alternative differential diagnoses	
7. At least single episode daily	
8. Medication administered to decrease sympathetic features	
9. Absence of parasympathetic features during episodes	
10. Absence of other presumed cause of features	
11. Antecedent acquired brain injury	

Table 750.5 Pediatric PSH-AM

PSH DIAGNOSTIC LIKELIHOOD	COMBINED TOTAL (PCFS + PDLT)
Unlikely	<8
Possible	8-16
Probable	>17

PSH-AM, paroxysmal sympathetic hyperactivity assessment measure; PCFS, pediatric clinical feature scale; PDLT, pediatric diagnosis likelihood tool.

long-term functional outcome of children who sustain a TBI is better than those who sustain a nontraumatic (anoxic) brain injury.

Visit Elsevier eBooks+ at eBooks.Health.Elsevier.com for Bibliography.

Chapter 751

Spinal Cord Injury and Autonomic Dysreflexia Management

Ashlee M. Jaffe and Abigail Case

See Chapter 81.

Individuals from birth to 21 years of age account for 25% of all cases of traumatic **spinal cord injury (SCI)**. Children are more susceptible to lap-belt injuries, upper cervical injuries, SCIs without radiologic abnormalities **(SCIWORA)**, and delayed onset of neurologic deficits, ranging from 30 minutes to 4 days. A population-based study found the epidemiology of pediatric spinal injury in the US varies greatly by age, ethnicity, and payor. Low-income populations are more likely to sustain spinal cord injury due to firearms than other populations.

The most accurate way to evaluate a patient who has sustained an SCI is by performing a standardized physical examination, as endorsed by the International Standards for Neurological and Functional Classification of SCI, recommended for children 6 years of age and older (Fig. 751.1). Life expectancy is related to the neurologic level of injury and the American Spinal Injury Association (ASIA) impairment scale classification.

CLINICAL MANIFESTATIONS

Immediately after an SCI, there is typically a period of **spinal shock** with low tone and absent reflexes. Eventually, signs of an **upper motor neuron** lesion may emerge, including spasticity and involuntary muscle spasms. However, if there is a substantial segment of spinal cord infarction present, patients may have persistent flaccid paralysis.

Children with neurologic levels of injury at T6 or above are at particular risk for interruption and decentralization of the autonomic nervous system. The most common manifestations include bradycardia, hypotension, temperature dysregulation, and, once spinal shock has resolved, **autonomic dysreflexia (AD)**. AD is a sustained sympathetic response as a result of a noxious stimulus *below* the level of injury. Symptoms resulting from AD typically include hypertension, bradycardia, headache, and flushing of the skin above the level of injury, although vague symptoms such as fatigue, irritability, or crying may be the presenting symptoms in younger patients. Noxious stimuli resulting from bladder or rectal distention is a common cause of AD, but there are a large number of other causes that need to be considered (Table 751.1). Children and adolescents with cervical and upper thoracic level SCI have lower baseline blood pressures (BPs) compared with the general population. Therefore caution should be used when referencing age-appropriate BPs because BP elevations of even 20-40 mm Hg above this lower baseline may be suggestive of AD. *Identification and treatment of the noxious stimulus is typically associated with resolution of symptoms without the use of antihypertensive medication.* If necessary, antihypertensive agents with a rapid onset and short duration, such as nifedipine and nitropaste, are advocated to treat elevated BP while the underlying cause is identified (Fig. 751.2). Emergent management of AD is necessary because of the risk of stroke and additional organ damage resulting from sustained hypertension. Consideration of a medical alert bracelet, education of supervising adults, and carrying of an AD emergency reference card is recommended (Fig. 751.3).

Patients with SCI are particularly vulnerable to **deep venous thrombosis** and **pulmonary embolism** because of immobilization of their affected limbs and venous stasis during the first 90 days after an injury. Deep venous thromboses are more common in postpubertal children >14 years old than in younger children. Mechanical prophylaxis (graduated compression stockings and sequential calf compression devices) are recommended for all children with acute SCI; adolescents should also start anticoagulant thromboprophylaxis, especially if additional risk factors like lower extremity fractures are present (unless contraindicated because of the risk of bleeding or prior allergic response). Late-occurring deep venous thrombosis most commonly occurs with prolonged immobilization related to illness or surgery, and prophylactic measures should be continued during these situations as well.

Consequent of SCI, patients often present with varying degrees of bowel and bladder incontinence. After an SCI, the bladder can be areflexic or hyperreflexic, and detrusor sphincter dyssynergia may occur. Clean intermittent catheterization (CIC) of the bladder is typically performed up to 4-6 times/day to prevent urinary retention and vesicoureteral reflux. Constipation can negatively impact the success of a CIC program. Anticholinergic medications may improve bladder storage capacity and prevent urinary incontinence between bladder catheterizations. *Antibiotics are only recommended for symptomatic urinary tract infections; asymptomatic bacteriuria, without vesicoureteral reflux, is generally due to colonization and typically not treated.* If intermittent catheterization is required, one can begin teaching the skills necessary for independent catheterization as early as 3 years of age with a goal of obtaining complete independence by 5-7 years old reflecting the progression toward independent bladder management of the child's able-bodied peers.

Bowel continence programs can be successfully introduced around 2-4 years old. There should be an attempt to distinguish between upper motor neuron (UMN) and lower motor neuron (LMN) bowel dysfunction because the management and bowel agents chosen may vary

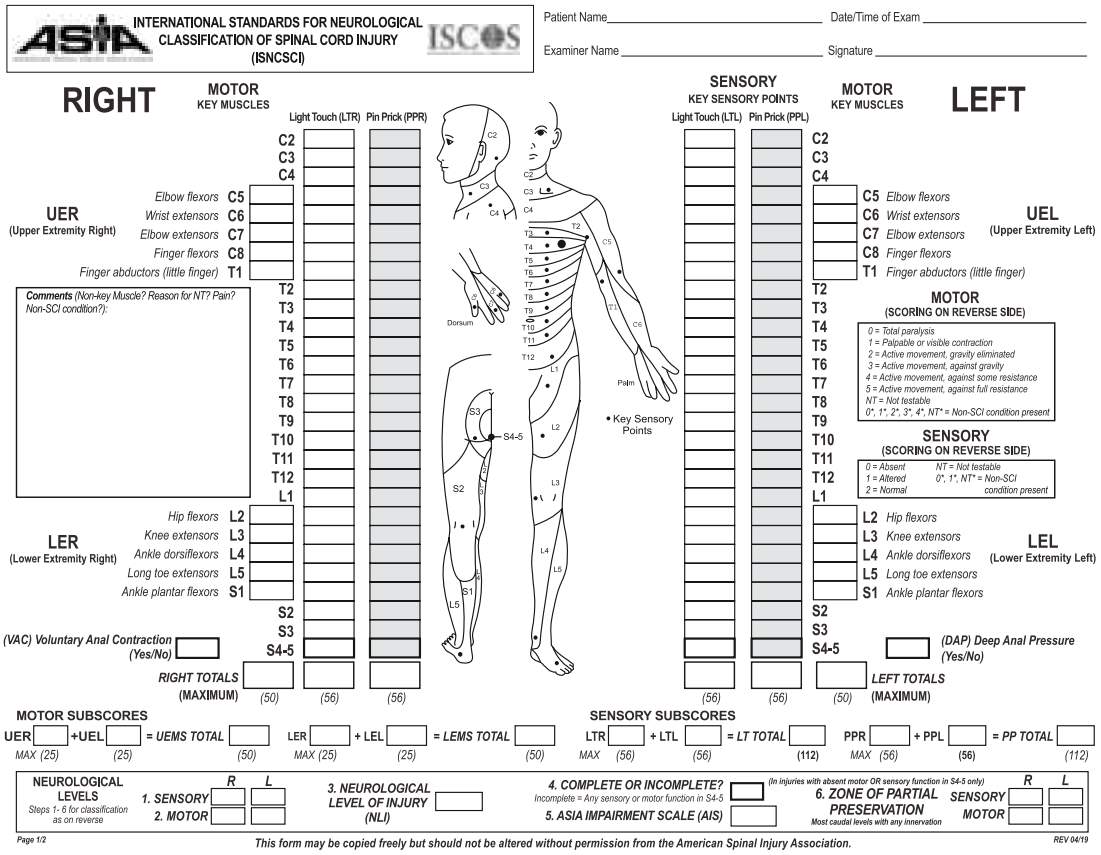

Muscle Function Grading

0 = Total paralysis

1 = Palpable or visible contraction

2 = Active movement, full range of motion (ROM) with gravity eliminated

3 = Active movement, full ROM against gravity

4 = Active movement, full ROM against gravity and moderate resistance in a muscle specific position

5 = (Normal) active movement, full ROM against gravity and full resistance in a functional muscle position expected from an otherwise unimpaired person

NT = Not testable (i.e. due to immobilization, severe pain such that the patient cannot be graded, amputation of limb, or contracture of > 50% of the normal ROM)

0*, 1*, 2*, 3*, 4*, NT* = Non-SCI condition present [a]

Sensory Grading

0 = Absent **1** = Altered, either decreased/impaired sensation or hypersensitivity

2 = Normal **NT** = Not testable

0*, 1*, NT* = Non-SCI condition present [a]

[a] Note: Abnormal motor and sensory scores should be tagged with a '*' to indicate an impairment due to a non-SCI condition. The non-SCI condition should be explained in the comments box together with information about how the score is rated for classification purposes (at least normal / not normal for classification).

When to Test Non-Key Muscles:

In a patient with an apparent AIS B classification, non-key muscle functions more than 3 levels below the motor level on each side should be tested to most accurately classify the injury (differentiate between AIS B and C).

Movement	Root level
Shoulder: Flexion, extension, adbuction, adduction, internal and external rotation **Elbow:** Supination	C5
Elbow: Pronation **Wrist:** Flexion	C6
Finger: Flexion at proximal joint, extension **Thumb:** Flexion, extension and abduction in plane of thumb	C7
Finger: Flexion at MCP joint **Thumb:** Opposition, adduction and abduction perpendicular to palm	C8
Finger: Abduction of the index finger	T1
Hip: Adduction	L2
Hip: External rotation	L3
Hip: Extension, abduction, internal rotation **Knee:** Flexion **Ankle:** Inversion and eversion **Toe:** MP and IP extension	L4
Hallux and Toe: DIP and PIP flexion and abduction	L5
Hallux: Adduction	S1

ASIA Impairment Scale (AIS)

A = Complete. No sensory or motor function is preserved in the sacral segments S4-5.

B = Sensory Incomplete. Sensory but not motor function is preserved below the neurological level and includes the sacral segments S4-5 (light touch or pin prick at S4-5 or deep anal pressure) AND no motor function is preserved more than three levels below the motor level on either side of the body.

C = Motor Incomplete. Motor function is preserved at the most caudal sacral segments for voluntary anal contraction (VAC) OR the patient meets the criteria for sensory incomplete status (sensory function preserved at the most caudal sacral segments S4-5 by LT, PP or DAP), and has some sparing of motor function more than three levels below the ipsilateral motor level on either side of the body. (This includes key or non-key muscle functions to determine motor incomplete status.) For AIS C – less than half of key muscle functions below the single NLI have a muscle grade ≥ 3.

D = Motor Incomplete. Motor incomplete status as defined above, with at least half (half or more) of key muscle functions below the single NLI having a muscle grade ≥ 3.

E = Normal. If sensation and motor function as tested with the ISNCSCI are graded as normal in all segments, and the patient had prior deficits, then the AIS grade is E. Someone without an initial SCI does not receive an AIS grade.

Using ND: To document the sensory, motor and NLI levels, the ASIA Impairment Scale grade, and/or the zone of partial preservation (ZPP) when they are unable to be determined based on the examination results.

AMERICAN SPINAL INJURY ASSOCIATION

INTERNATIONAL STANDARDS FOR NEUROLOGICAL CLASSIFICATION OF SPINAL CORD INJURY

Steps in Classification

The following order is recommended for determining the classification of individuals with SCI.

1. Determine sensory levels for right and left sides.
The sensory level is the most caudal, intact dermatome for both pin prick and light touch sensation.

2. Determine motor levels for right and left sides.
Defined by the lowest key muscle function that has a grade of at least 3 (on supine testing), providing the key muscle functions represented by segments above that level are judged to be intact (graded as a 5).
Note: in regions where there is no myotome to test, the motor level is presumed to be the same as the sensory level, if testable motor function above that level is also normal.

3. Determine the neurological level of injury (NLI).
This refers to the most caudal segment of the cord with intact sensation and antigravity (3 or more) muscle function strength, provided that there is normal (intact) sensory and motor function rostrally respectively.
The NLI is the most cephalad of the sensory and motor levels determined in steps 1 and 2.

4. Determine whether the injury is Complete or Incomplete.
(i.e. absence or presence of sacral sparing)
*If voluntary anal contraction = **No** AND all S4-5 sensory scores = **0***
*AND deep anal pressure = **No**, then injury is **Complete**.*
*Otherwise, injury is **Incomplete**.*

5. Determine ASIA Impairment Scale (AIS) Grade.
Is injury Complete? If YES, AIS=A
NO ↓
Is injury Motor Complete? If YES, AIS=B
NO ↓ (No=voluntary anal contraction OR motor function more than three levels below the motor level on a given side, if the patient has sensory incomplete classification)

Are at least half (half or more) of the key muscles below the neurological level of injury graded 3 or better?
NO ↓ AIS=C **YES ↓ AIS=D**

If sensation and motor function is normal in all segments, AIS=E
Note: AIS E is used in follow-up testing when an individual with a documented SCI has recovered normal function. If at initial testing no deficits are found, the individual is neurologically intact and the ASIA Impairment Scale does not apply.

6. Determine the zone of partial preservation (ZPP).
The ZPP is used only in injuries with absent motor (no VAC) OR sensory function (no DAP, no LT and no PP sensation) in the lowest sacral segments S4-5, and refers to those dermatomes and myotomes caudal to the sensory and motor levels that remain partially innervated. With sacral sparing of sensory function, the sensory ZPP is not applicable and therefore "NA" is recorded in the block of the worksheet. Accordingly, if VAC is present, the motor ZPP is not applicable and is noted as "NA".

Fig. 751.1 American Spinal Injury Association standards worksheet. *(From the American Spinal Injury Association: International standards for neurological and functional classification of spinal cord injury [ISNCSCI]. Richmond, Virginia, 2019,* https://asia-spinalinjury.org/international-standards-neurological-classification-sci-isncsci-worksheet/*.)*

Table 751.1 Potential Etiologies of Noxious Stimuli Causing Autonomic Dysreflexia

URINARY SYSTEM
• Bladder distention
• Bladder or kidney stones
• Blocked/kinked catheter
• Detrusor sphincter dyssynergia
• Urinary tract infection
• Urologic instrumentation
• Shock wave lithotripsy
GASTROINTESTINAL SYSTEM
• Bowel distention
• Bowel impaction
• Gallstones
• Appendicitis
• Gastric ulcers
• Gastritis
• Gastrointestinal instrumentation
• Hemorrhoids
INTEGUMENTARY SYSTEM
• Constrictive clothing, shoes, or orthotics
• Blisters
• Burns, sunburn, or frostbite
• Ingrown toenail
• Insect bites
• Pressure ulcers
MUSCULOSKELETAL SYSTEM
• Fractures
• Heterotopic ossification
• Functional electrical stimulation
REPRODUCTIVE SYSTEM—MALE
• Epididymitis
• Scrotal compression (sitting on scrotum)
• Sexual intercourse
• Sexually transmitted infections
REPRODUCTIVE SYSTEM—FEMALE
• Menstruation
• Pregnancy, especially labor and delivery
• Vaginitis
• Sexual intercourse
• Sexually transmitted infections
HEMATOLOGIC SYSTEM
• Deep vein thrombosis
• Pulmonary embolus
OTHER SYSTEMIC CAUSES
• Boosting (an episode of autonomic dysreflexia intentionally caused by an athlete with spinal cord injury in an attempt to enhance physical performance)
• Excessive alcohol intake
• Excessive caffeine or diuretic intake
• Over-the-counter or prescribed stimulants
• Substance abuse

From Consortium for Spinal Cord Medicine: Acute management of autonomic dysreflexia: individuals with spinal cord injury presenting to health-care facilities, Washington, DC, 2001, Paralyzed Veterans of America, 10–11.

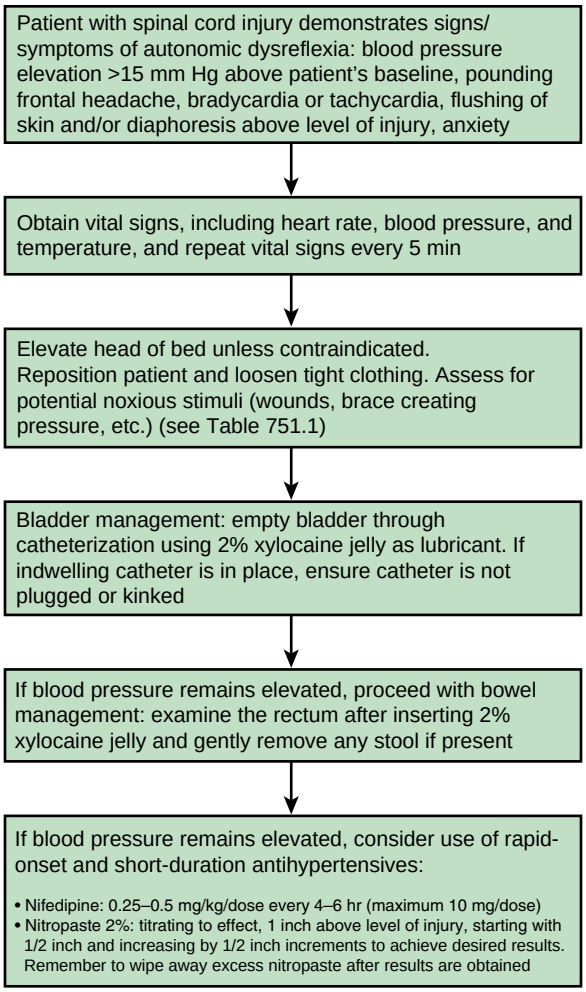

Fig. 751.2 Algorithm for the management of autonomic dysreflexia.

significantly. Lesions at or proximal to the conus medullaris typically result in UMN bowel dysfunction, whereas lesions distal to the conus typically result in LMN bowel dysfunction characterized by an areflexic bowel lacking peristalsis. Management of **bowel incontinence** requires the use of diet modifications, bowel medications, and planned evacuations. Emptying is facilitated by use of the gastrocolic reflex, digital stimulation, suppositories, and enemas in those with UMN bowel dysfunction. Individuals with LMN bowel dysfunction often require manual removal because peristalsis and reflexes are not intact.

Individuals with SCI have increased risk for dysphagia, delayed gastric emptying, ileus, gastric ulcerations, pancreatitis, and superior mesenteric artery syndrome. Presentation of an acute abdomen in SCI is challenging to identify because a patient may be incapable of feeling the pain intensity typically associated with an intraabdominal disorder. As a result, an acute abdomen may be manifested by nonspecific signs and symptoms, such as vomiting, poorly localized dull pain, restlessness, fever, and leukocytosis.

Frequent monitoring for **skin breakdown** and **pressure ulcers** is necessary, both acutely as well as lifelong. Pressure ulcers may heal more slowly in patients with SCI and can significantly impact function. Common locations include the occiput, elbows, sacrum, ischium, and heels. Devices such as halo vests and splints increase the risk of developing a pressure sore. Frequent inspection and repositioning for pressure relief when in bed and when sitting are important measures to minimize the risk of pressure ulcer development.

Depending on the level of the lesion, paralysis of the diaphragm or intercostal and abdominal muscles can result in restrictive ventilatory impairment and ineffective coughing. Respiratory muscle training, abdominal binders, and noninvasive ventilation and airway clearance devices, such as the insufflator–exsufflator cough assist device, should be considered in select patients.

Spasticity typically increases with noxious stimulation and can interfere with sleep, comfort, positioning, and care (see Chapter 752). Untreated spasticity can lead to contracture development and functional limitations. Management includes pharmacologic therapy, stretching, splinting, and positioning to reduce tone. Focal spasticity can be treated with chemodenervation by injecting botulinum toxin into select hypertonic muscles or phenol perineurally. Intrathecal baclofen may be an option for severe generalized spasticity or spasticity that is predominately in the lower extremities.

Increased bone resorption occurs as a result of prolonged immobilization. If excessive calcium is not adequately excreted by the kidneys, insidious onset of abdominal pain, nausea, vomiting, lethargy, polydipsia, polyuria, and behavior changes may occur. This **immobilization**

"ATTENTION PHYSICIAN"

- Sit patient upright (up to 90 degrees).
- Monitor BP every 2-3 min.
- Quick exam to include abdomen for distended bladder/bowel and any other organ system below the level of injury that can be the source of dysreflexia.
- If an indwelling urinary catheter is not in place, catheterize the individual. If indwelling catheter is in place, check system for kinks, folds, constrictions, or obstructions.
- If systolic BP:
  >120 in children under 5 yrs
  >130 in children 6-12 yrs
  >140 in adolescents
  give an antihypertensive with rapid onset and short duration while cause of AD is being investigated.
- **Nitro Paste**—1/2" (<13y) or 1" (≥13y), apply every 30 min, topically above level of injury, wipe off when BP stable, reapply as needed.
- **Nifedipine** (if Nitro paste NOT available)—0.25-0.5mg/kg per dose (<13y) or 10mg per dose (≥13y), squirt immediate release form sublingually or ask patient to chew, may repeat every 20-30 min as needed.
- **IV Antihypertensives**—only in a monitored setting (I.C.U.)
- Monitor symptoms and BP for at least 2 hrs after the resolution of an AD episode.
- All can lead to seizures, stroke, or death!

MY INFORMATION

Name:

MEDICAL HISTORY

Baseline Blood Pressure:

Baseline Body Temperature:

Neurological Location of Injury:

Primary Healthcare Provider:

Phone Number:

Allergies:

EMERGENCY CONTACT

In Case of Emergency Call:

Relationship:

Phone Number:

Pediatric Edition

AUTONOMIC DYSREFLEXIA (AD)

WHAT IT IS:

A blood pressure is the measurement of how well blood moves from the heart to the rest of the body. Autonomic Dysreflexia (AD) affects the blood pressure of people with a spinal cord injury above the thoracic T6 level. Their body gets confused when something harmful or painful is hurting them and they are not able to tell what it is. This causes their body to panic and makes their blood pressure go up. It is unsafe for their blood pressure to get too high. It is important to figure out what is hurting them and take it away. But fixing this can be dangerous and make that person very sick.

Autonomic Dysreflexia is a Medical Emergency!

COMMON CAUSES:

- Full bladder
- Full bowel/ constipation
- Wounds
- Broken bones
- Skin burns
- Infections
- Ingrown toenails
- Any condition or procedures that may cause pain or discomfort but is located below neurologic injury level.

COMMON SIGNS & SYMPTOMS

ABOVE LEVEL OF INJURY

- Hypertension (*A first increase in blood pressure, 15 mm Hg systolic higher than usual in children and 15-20 mm Hg systolic higher than usual in adolescents*)
- Bradycardia (*slow heart rate*) or Tachycardia (*fast heart rate*)
- Big headache
- Feeling nervous/anxiety/scared
- Red cheeks/neck/shoulders
- Blurry vision
- Stuffy nose
- Sweating
- Goosebumps
- Tingling

BELOW LEVEL OF INJURY

- Upset stomach, feels like you need to throw up
- Chills without fever
- Clammy or cold and sweaty
- Cool
- Pale

WHAT TO DO

- **Sit up**—Sit up or raise your head 90 degrees.
  IMPORTANT: Stay sitting up until blood pressure is normal.
- **Take off**—Take off or loosen anything tight.
- **Check blood pressure**—Take your blood pressure every 5 minutes. If it's still higher than normal (15 mm above usual pressure Hg in children, and 15-20 mm Hg above usual pressure in adolescents). Make sure the right size blood pressure cuff is being used.
- **Check bladder**—Empty your bladder (i.e., catheterize your bladder). If you have an indwelling catheter, check if it's bent or kinked.
- **Check bowel**—Check your bowel after using numbing jelly or ointment.
- **Check skin**—See if your skin has any new wounds, sores, bruises, burns, bumps, cuts, insect bites, etc.
- **Find other source**—Look for anything else that may be hurting you. If symptoms have not resolved.
- **Find help**—If not able to promptly make the symptoms go away on your own, call your doctor's office to get more help or go to the nearest emergency room.

IMPORTANT: If you go to the hospital, tell the doctors and nurses you may have dysreflexia, need your blood pressure checked, need to stay sitting up, and need to find what's causing it.

CHRISTOPHER & DANA REEVE FOUNDATION PARALYSIS RESOURCE CENTER

636 Morris Turnpike
Suite 3A
Short Hills, NJ 07078
Phone: (800) 539-7309
Fax: (973) 467-8845
www.paralysis.org

International Center for Spinal Cord Injury at Kennedy Krieger Institute

707 North Broadway
Baltimore, MD 21205
Phone: (443) 923-9230
Fax: (443) 923-9215
www.spinalcordrecovery.org

Fig. 751.3 Example of pediatric autonomic dysreflexia emergency card, which can be downloaded in multiple languages for free from the Christopher & Dana Reeve Foundation Paralysis Resource Center website (https://www.christopherreeve.org/living-with-paralysis/free-resources-and-downloads/wallet-cards).

hypercalcemia is managed with IV normal saline and the bisphosphonate pamidronate. Failure to manage the immobilization hypercalcemia may result in nephrocalcinosis, urolithiasis, or renal failure. Loss of bone mineral density begins immediately after an SCI occurs and osteopenia plateaus 6-12 months later. This may result in **pathologic fractures,** with the most common sites of fracture including the supracondylar region of the femur and the proximal tibia. Precautions are necessary because fractures may occur with minor trauma, range of motion exercises, and gait training. Treatment should include the use of removable splints or casts that are well padded over bony prominences to prevent skin breakdown, which is more likely with insensate skin under the cast. Prevention through progressive weight bearing, if feasible and safe, and calcium and vitamin D supplementation is encouraged.

The risk of development of spinal deformities and scoliosis is about 25% in patients sustaining SCI both before and during puberty, and some of these children will require surgical correction. Because of the high incidence of scoliosis in patients younger than 15 at the time of their injury, radiographs of the thoracolumbar-sacral spine should generally be obtained every 6 months before skeletal maturity and every 12 months thereafter. Children who sustain injuries before puberty are also susceptible to hip dislocation and require periodic screening for this condition. Although neurologic **heterotopic ossification** is less prevalent in children compared with adults, it may occur on average about 4 months, but up to 14 months, after the initial injury. The most common site of heterotopic ossification is the hip, but it may also occur in the knee, elbow, and shoulder.

Children and adolescents with SCI are at risk for decreased muscle mass, insulin resistance, decreased glucose transport, dyslipidemia, obesity, and decreased bone health as they age. Long term, patients with SCI have a 3-5-fold greater odds of cardiovascular disease compared with able-bodied individuals. Nutrition education and monitoring are important for decreasing long-term morbidities. Promoting exercise and physical activity and fitness are important for well-being. Youth with SCI may develop latex allergy thought to be a result of repeated, early exposure to latex products; thus a latex-free environment and degree of suspicion for allergies to bananas, kiwis, avocados, or chestnuts is advised.

Psychologic adjustment to SCI is influenced by the developmental age at the time of injury. SCI will impact the child's psychosocial development, so adjustment should be monitored closely. Long-term outcomes related to coping, depression, and anxiety are better in adults who sustained their injury during childhood, compared with those who sustained their injuries in adulthood. Positive coping strategies and strong social supports are associated with greater social participation. Education regarding sexual development and function with SCI injury should be provided.

PROGNOSIS

Prognosis for functional recovery after an SCI depends on the neurologic level of injury and the level of completeness. Examination at least 72 hours after injury has been determined to be a better indicator of the prognosis than earlier examinations. Reexamination after recovery from spinal shock provides additional prognostic information. It is prudent for those determining and communicating the diagnosis to understand the limitations of the anorectal examinations, and thus completeness of injury, unique to children. Those individuals with an initial incomplete injury have an increased likelihood of eventual neurologic recovery. The neurologic level of injury can be helpful in determining the level of independence with functional activities (Table 751.2). The use of technology in rehabilitation encourages the pediatric patient to become more engaged in their own care and advance their

Table 751.2 Projected Functional Outcomes at 1 Year After Injury and/or Diagnosis According to Neurologic Level of Injury

	C1-C4	C5	C6	C7	C8- T1
Feeding	Dependent	Independent with adaptive equipment	Independent	Independent	Independent
Dressing—Upper Body	Dependent	Independent with adaptive equipment	Independent	Independent	Independent
Dressing—Lower Body	Dependent	Independent with adaptive equipment	Independent with adaptive equipment	Independent with adaptive equipment	Independent with adaptive equipment
Bathing	Dependent	Dependent	Dependent	Some assistance to independent with equipment	Independent
Bed mobility	Dependent	Dependent	Some assistance to independent	Independent	Independent
Transfers— Level Surface	Dependent	Dependent	Some assistance to independent	Independent	Independent
Wheelchair Propulsion	Independent with power; dependent with manual	Independent with power; may be independent with manual on level surfaces	Independent	Independent	Independent
Driving	Dependent	May be independent with adaptations	Independent	Independent	Independent
	T2-T9		**T10-L2**		**L3-L5**
Activities of daily living (feeding, dressing bathing)	Independent		Independent		Independent
Transfers	Independent		Independent		Independent
Ambulation	Standing in frame, tilt table, or standing wheelchair Exercise only		Household ambulation with orthosis		Community ambulation is possible

Adapted from Hornyak J, Wernimont C: Spinal cord injuries. In: Murphy K, McMahon M, Houtrow A eds. Pediatric Rehabilitation: Principles and Practice, 6th ed. New York: Demos Medical Publishing, 2021.

independence, which is correlated with higher quality of life. Common technology includes therapeutic and functional stimulation, EMG biofeedback and EMG-triggered stimulation, assistive technology for computer access, and implanted functional electrical stimulation system including phrenic nerve stimulators.

Visit Elsevier eBooks+ at eBooks.Health.Elsevier.com for Bibliography.

Chapter 752

Spasticity

Joyce L. Oleszek and Loren T. Davidson

Spasticity is a component of the upper motor neuron syndrome characterized by velocity-dependent resistance to passive range of motion, resulting in tonic stretch reflexes and accompanied by exaggerated tendon jerks. Spasticity management is determining what degree of spasticity may be tolerable and of functional benefit versus detrimental.

When devising a treatment plan, both the positive and negative effects of spasticity on function must be considered. Treatment should maximize function, independence, comfort, and quality of life while minimizing sedation and adverse effects. Management strategies including systemic medications, injections, and surgery are reviewed.

SYSTEMIC MEDICATIONS

Systemic medications are used as a treatment for generalized spasticity (Table 752.1). Although efficacy of certain antispasmodics has been demonstrated, their use should be contingent on functional benefit because adverse effects are quite common. Frequently used medications include baclofen, benzodiazepines, dantrolene sodium, tizanidine, clonidine, and trihexyphenidyl.

GABAergic Medications

γ-Aminobutyric acid (GABA) is an inhibitory neurotransmitter of the central nervous system. The two most relevant GABA receptors for the purposes of pharmacologic management of spasticity are $GABA_A$ and $GABA_B$. **Benzodiazepines** exert their effect by increasing the affinity of GABA for the $GABA_A$ receptor. This results in presynaptic inhibition and a net inhibitory effect at both spinal and supraspinal levels. Of the benzodiazepines, diazepam is a commonly used medication to treat spasticity because of its long half-life and need for less frequent administration. In children younger than 2 years of age, clonazepam is a good option because of the availability of a liquid formulation and dosing guidelines. Sedation and cognitive slowing limit the usefulness of this class of medications in children. However, benzodiazepines can be helpful for dystonic storms or disturbed sleep in children with cerebral palsy (CP). The use of benzodiazepines may lead to physiologic dependence; thus abrupt discontinuation should be avoided to prevent withdrawal.

Baclofen is a $GABA_B$ agonist and a preferred agent in the treatment of spasticity of spinal origin. Baclofen exerts an inhibitory effect on both monosynaptic and polysynaptic spinal reflexes, but its supraspinal receptor sites can result in sedation as is common to all GABAergic medications. Daytime dosing of oral baclofen is often better tolerated than benzodiazepines with regard to sedation. Intrathecal administration of baclofen via an intrathecal baclofen (ITB) pump (see later) allows greater selectivity of spasticity reduction while minimizing adverse cognitive effects. Oral baclofen is considered a first-line medication for the management of dystonia in CP with common indications including pain or difficulty sleeping associated with dystonia. Abrupt cessation of oral or ITB baclofen must be avoided because of withdrawal potential.

α_2-Adrenergic Agents

Clonidine and **tizanidine** are examples of centrally acting α_2-adrenergic agonists that decrease spasticity and have an antinociceptive effect. Clonidine is used more frequently as an antihypertensive. Clonidine exerts its effect on spasticity via both presynaptic inhibition of sensory afferents as well as release of glutamate at the level of the spinal cord. In comparison to clonidine, tizanidine has less-potent hemodynamic effects, which is desirable when used primarily for spasticity reduction. However, tizanidine is extensively metabolized by the liver, so hepatic impairment may have a significant effect on its pharmacokinetics. Although clonidine and tizanidine are used widely as antispasmodics in practice, there is limited evidence for their use in reducing spasticity in children with CP. Tizanidine's antispasticity effect has been demonstrated in adults with multiple sclerosis and spinal cord injury. Clonidine has been shown to be effective for disturbed sleep associated with severe hypertonia. The adverse effect profile of these agents can limit their use.

Peripherally Acting Calcium Blockers

Dantrolene sodium works at the level of skeletal muscle to block calcium release from the sarcoplasmic reticulum. Despite its peripheral site of action, dantrolene may induce sedation, although to a lesser degree than other centrally acting agents. A few small studies have shown that dantrolene decreases clonus and spasticity but can also decrease strength. Dantrolene is often well tolerated in children, but its risk of hepatotoxicity requires monitoring of liver function tests. Hepatotoxicity risk increases with age, increasing dose, and female gender (see Table 752.1).

INJECTION MANAGEMENT

Injection management of spasticity should be considered when spasticity causes significant functional impairments that are refractory to more conservative options. Combining treatment options such as injections and systemic medications can be very effective.

Botulinum toxin (BoNT) and phenol injections are used to treat localized spasticity. OnabotulinumtoxinA (Botox) and AbobotulinumtoxinA (Dysport) have obtained U.S. Food and Drug Administration (FDA) approval for both upper and lower limb spasticity in pediatrics. RimabotulinumtoxinB (Myobloc) and IncobotulinumtoxinA (Xeomin) both have FDA approval but neither have a pediatric indication. BoNT is derived from the bacteria *Clostridium botulinum,* and there are seven immunologically distinct serotypes designated A through G. Its mechanism of action involves a light chain protein binding to synaptobrevin at the neuromuscular junction, inhibiting vesicles from anchoring to the cell membrane and preventing acetylcholine release from the presynaptic membrane. This interferes with nerve impulse transmission and results in weakness of the muscle injected. Onset of action is within 2 weeks of administration, duration is 3-6 months, and effects wane as the neuromuscular junction reestablishes its original function. Injections should be administered no more frequently than every 3 months to reduce neutralizing antibody formation, which occurs in 1–2% of treated individuals. BoNT-A is a safe and effective treatment for spasticity in the upper and lower extremities in children with CP, but the effects on long-term functional improvement with repeated injections are less well known. The combination of BoNT-A injections to the gastrocnemius muscles and serial casting has been shown to improve ankle range of motion and gait. BoNT-A can also improve ease of care and comfort in nonambulatory children with CP. The most common adverse events (AEs) include localized pain and weakness, unsteadiness and increased falls, fatigue, urinary incontinence, and dysphagia. Systemic AEs

independence, which is correlated with higher quality of life. Common technology includes therapeutic and functional stimulation, EMG biofeedback and EMG-triggered stimulation, assistive technology for computer access, and implanted functional electrical stimulation system including phrenic nerve stimulators.

Visit Elsevier eBooks+ at eBooks.Health.Elsevier.com for Bibliography.

Chapter 752

Spasticity

Joyce L. Oleszek and Loren T. Davidson

Spasticity is a component of the upper motor neuron syndrome characterized by velocity-dependent resistance to passive range of motion, resulting in tonic stretch reflexes and accompanied by exaggerated tendon jerks. Spasticity management is determining what degree of spasticity may be tolerable and of functional benefit versus detrimental.

When devising a treatment plan, both the positive and negative effects of spasticity on function must be considered. Treatment should maximize function, independence, comfort, and quality of life while minimizing sedation and adverse effects. Management strategies including systemic medications, injections, and surgery are reviewed.

SYSTEMIC MEDICATIONS

Systemic medications are used as a treatment for generalized spasticity (Table 752.1). Although efficacy of certain antispasmodics has been demonstrated, their use should be contingent on functional benefit because adverse effects are quite common. Frequently used medications include baclofen, benzodiazepines, dantrolene sodium, tizanidine, clonidine, and trihexyphenidyl.

GABAergic Medications

γ-Aminobutyric acid (GABA) is an inhibitory neurotransmitter of the central nervous system. The two most relevant GABA receptors for the purposes of pharmacologic management of spasticity are $GABA_A$ and $GABA_B$. **Benzodiazepines** exert their effect by increasing the affinity of GABA for the $GABA_A$ receptor. This results in presynaptic inhibition and a net inhibitory effect at both spinal and supraspinal levels. Of the benzodiazepines, diazepam is a commonly used medication to treat spasticity because of its long half-life and need for less frequent administration. In children younger than 2 years of age, clonazepam is a good option because of the availability of a liquid formulation and dosing guidelines. Sedation and cognitive slowing limit the usefulness of this class of medications in children. However, benzodiazepines can be helpful for dystonic storms or disturbed sleep in children with cerebral palsy (CP). The use of benzodiazepines may lead to physiologic dependence; thus abrupt discontinuation should be avoided to prevent withdrawal.

Baclofen is a $GABA_B$ agonist and a preferred agent in the treatment of spasticity of spinal origin. Baclofen exerts an inhibitory effect on both monosynaptic and polysynaptic spinal reflexes, but its supraspinal receptor sites can result in sedation as is common to all GABAergic medications. Daytime dosing of oral baclofen is often better tolerated than benzodiazepines with regard to sedation. Intrathecal administration of baclofen via an intrathecal baclofen (ITB) pump (see later) allows greater selectivity of spasticity reduction while minimizing adverse cognitive effects. Oral baclofen is considered a first-line medication for the management of dystonia in CP with common indications including pain or difficulty sleeping associated with dystonia. Abrupt cessation of oral or ITB baclofen must be avoided because of withdrawal potential.

α_2-Adrenergic Agents

Clonidine and **tizanidine** are examples of centrally acting α_2-adrenergic agonists that decrease spasticity and have an antinociceptive effect. Clonidine is used more frequently as an antihypertensive. Clonidine exerts its effect on spasticity via both presynaptic inhibition of sensory afferents as well as release of glutamate at the level of the spinal cord. In comparison to clonidine, tizanidine has less-potent hemodynamic effects, which is desirable when used primarily for spasticity reduction. However, tizanidine is extensively metabolized by the liver, so hepatic impairment may have a significant effect on its pharmacokinetics. Although clonidine and tizanidine are used widely as antispasmodics in practice, there is limited evidence for their use in reducing spasticity in children with CP. Tizanidine's antispasticity effect has been demonstrated in adults with multiple sclerosis and spinal cord injury. Clonidine has been shown to be effective for disturbed sleep associated with severe hypertonia. The adverse effect profile of these agents can limit their use.

Peripherally Acting Calcium Blockers

Dantrolene sodium works at the level of skeletal muscle to block calcium release from the sarcoplasmic reticulum. Despite its peripheral site of action, dantrolene may induce sedation, although to a lesser degree than other centrally acting agents. A few small studies have shown that dantrolene decreases clonus and spasticity but can also decrease strength. Dantrolene is often well tolerated in children, but its risk of hepatotoxicity requires monitoring of liver function tests. Hepatotoxicity risk increases with age, increasing dose, and female gender (see Table 752.1).

INJECTION MANAGEMENT

Injection management of spasticity should be considered when spasticity causes significant functional impairments that are refractory to more conservative options. Combining treatment options such as injections and systemic medications can be very effective.

Botulinum toxin (BoNT) and phenol injections are used to treat localized spasticity. OnabotulinumtoxinA (Botox) and AbobotulinumtoxinA (Dysport) have obtained U.S. Food and Drug Administration (FDA) approval for both upper and lower limb spasticity in pediatrics. RimabotulinumtoxinB (Myobloc) and IncobotulinumtoxinA (Xeomin) both have FDA approval but neither have a pediatric indication. BoNT is derived from the bacteria *Clostridium botulinum,* and there are seven immunologically distinct serotypes designated A through G. Its mechanism of action involves a light chain protein binding to synaptobrevin at the neuromuscular junction, inhibiting vesicles from anchoring to the cell membrane and preventing acetylcholine release from the presynaptic membrane. This interferes with nerve impulse transmission and results in weakness of the muscle injected. Onset of action is within 2 weeks of administration, duration is 3-6 months, and effects wane as the neuromuscular junction reestablishes its original function. Injections should be administered no more frequently than every 3 months to reduce neutralizing antibody formation, which occurs in 1–2% of treated individuals. BoNT-A is a safe and effective treatment for spasticity in the upper and lower extremities in children with CP, but the effects on long-term functional improvement with repeated injections are less well known. The combination of BoNT-A injections to the gastrocnemius muscles and serial casting has been shown to improve ankle range of motion and gait. BoNT-A can also improve ease of care and comfort in nonambulatory children with CP. The most common adverse events (AEs) include localized pain and weakness, unsteadiness and increased falls, fatigue, urinary incontinence, and dysphagia. Systemic AEs

Table 752.1 Dosing Guidelines, Pharmacologic Actions, and Adverse Event Profile of Commonly Prescribed Oral Antispasmodic Medications for Children

MEDICATION/DOSING GUIDELINES	PHARMACOLOGIC ACTIONS	ADVERSE REACTIONS/PRECAUTIONS
BACLOFEN 0.125-1 mg/kg/day *2-7 yr:* 2.5-10 mg tid-qid (10-40 mg/day) *8-12 yr:* 5 mg-15 mg tid-qid (15-60 mg/day) *12-16 yr:* 5-20 mg tid-qid (20-80 mg/day) Note: Caution advised with renal impairment; consider reducing dose.	• Centrally acting, structural analog of GABA • Binds to $GABA_B$ receptors causing presynaptic inhibition of mono/polysynaptic spinal reflexes • Rapid absorption, blood level peaks in 1 hr, half-life 5.5 hr. • Renal excretion (70–80% unchanged) • Hepatic excretion (15%)	• CNS depression (sedation, fatigue) • Nausea • Headache • Dizziness • Confusion • Euphoria • Hallucinations • Hypotonia • Ataxia • Paraesthesias Note: Abrupt withdrawal may cause seizures, hallucinations, rebound muscle spasms, and hyperpyrexia.
DIAZEPAM 0.12-0.8 mg/kg/day *6 mo-12 yr:* 0.12-0.8 mg/kg/day PO divided q 6-8h *>12 yr:* 2-10 mg PO bid-qid Note: Starting a qhs dose only or proportionately larger dose at bedtime may limit excessive daytime sedation.	• Centrally acting, binds to $GABA_A$ receptors mediating presynaptic inhibition in brainstem reticular formation and spinal polysynaptic pathways • Rapid absorption, blood level peaks in 1 hr, with half-life of 30-60 hr	• CNS depression (sedation, impaired memory, and impaired attention) • Ataxia • Dependence/potential for substance abuse/overdose • Withdrawal syndrome (including anxiety, agitation, irritability, tremor, muscle twitching, nausea, insomnia, seizures, hyperpyrexia) • Increased potential for adverse effects with low albumin levels due to being 98% protein bound
DANTROLENE SODIUM 3-12 mg/kg /day *>5 yr:* 6-8 mg/kg/d PO divided bid-qid Start 0.5 mg/kg qd-bid for 7 days, then 0.5 mg/kg tid for 7 days, then 1 mg/kg tid for 7 days, then 2 mg/kg tid to a maximum of 12 mg/kg/d or 400 mg/day.	• Peripheral action, blocking release of calcium from sarcoplasmic reticulum with uncoupling of nerve excitation and skeletal muscle contraction • Blood level peaks in 3-6 hr (active metabolite 4-8 hr), half-life of approx. 15 hr	• Malaise • Fatigue • Nausea • Vomiting • Diarrhea • Muscle weakness with high dose **Note:** Hepatotoxicity (baseline liver function tests MUST be checked before starting dantrolene, tested weekly during dose titration and regularly every 1-2 months thereafter). Drug *should be discontinued promptly* if liver enzymes become elevated.
TIZANIDINE *<10 yr:* Initiate 1 mg orally at bedtime initially, increasing to 0.3-0.5 mg/kg in 4 divided doses *>10 yr:* Commence 2 mg orally at bedtime initially, increased according to response, maximum 24 mg/day in 3-4 divided doses	• Centrally acting, $alpha_2$ adrenoceptor agonist activity at both spinal and supraspinal sites. Prevents release of excitatory amino acids, facilitating presynaptic inhibition • Good oral absorption, blood level peaks in 1-2 hr, half-life of 2.5 hr	• Dry mouth • Drowsiness • Headache • Dizziness • Insomnia • Anxiety • Aggression • Mood swings • Visual hallucinations • Risk of hypotension (although 10 times less anti-hypertensive potency than clonidine) • Nausea/vomiting • Constipation • Liver function tests should be monitored; baseline and 1 month after maintenance dose achieved.
CLONIDINE 0.025-0.1 mg/day in 2-3 divided doses.	• Centrally acting, mixed alpha adrenoceptor agonist with predominant alpha-2 activity causing membrane hyperpolarization at multiple sites in brain, brainstem, and dorsal horns of spinal cord. • Rapidly absorbed orally, blood level peaks in 1-1½ hr, half-life of 6-20 hr.	• Drowsiness • Dry mouth • Bradycardia • Orthostatic hypotension • Abrupt cessation may result in rebound hypertension.

can occur in up to 3.6% of children with CP receiving BoNT-A, and those with a history of dysphagia and/or aspiration pneumonia are at increased risk. The FDA requires black box labeling on BoNT products, cautioning of a rare but potentially life-threatening complication of BoNT effects spreading beyond the injection site. Co-administration of BoNT and other agents interfering with neuromuscular transmission, such as aminoglycosides and curare-like agents, should be performed with caution because the effect of the toxin may be potentiated.

Phenol neurolysis can be used in combination with BoNT injections to allow treatment of more affected muscles while remaining within the safe dose range of BoNT. Phenol causes nonselective denaturing of proteins upon exposure to the nerve, thereby causing nerve injury by precipitating and dehydrating the protoplasm. This, in turn, interferes with nerve conduction and impairs innervation to muscles. Phenol injections are typically used to target nerves to large proximal muscles (musculocutaneous, obturator and sciatic nerves), and the duration of clinical effect may be longer than BoNT. There is limited evidence on the use of phenol in children with CP, but a few small studies show safety and efficacy. Phenol injection of the anterior branch of the obturator nerve in children with CP has been found to be safe and effective. AEs include pain, swelling and inflammation, and dysesthesias. The low cost of phenol incurs a significant advantage over BoNT, but the need for electrical stimulation or ultrasound guidance and general anesthesia may negate this benefit.

SURGICAL MANAGEMENT

Intrathecal baclofen (ITB) is approved to treat spasticity of cerebral origin. ITB is delivered to the intrathecal space by a catheter connected to a subfascially implanted pump. This mechanism of delivery produces much higher local concentrations in the cerebrospinal fluid at a fraction of the equivalent systemic dose of baclofen, thereby minimizing the CNS depressive effects. Catheter tips are typically positioned at C5-T2 but can be placed intraventricularly for severe dystonia. ITB pumps require refills at 2-6–month intervals depending on dose rate and pump size and need to be replaced every 5-7 years for end of battery life. The frequent maintenance required can be prohibitive to some families. Before ITB pump placement, a single bolus dose of baclofen can be delivered via lumbar puncture to evaluate responsiveness and impact on functional abilities. ITB is effective in reducing spasticity and dystonia in CP and may improve the ease of care and quality of life of children with CP. Continuous ITB treatment is superior to placebo on attainment of individual treatment goals in children with Gross Motor Function Classification System (GMFCS) level IV and V CP (Fig. 752.1). Serious AEs can occur with ITB. One 14-year study of 430 patients found at least one complication in 25% of patients: infection in 9.3%, CSF leak in 4.9%, catheter problem in 15.1%, and a pump-related problem in 1%. Electromagnetic interference and MRI may cause transient operational changes to the ITB pump and changes to the flow rate; thus the pump should be interrogated by a programmer after MRI as a precaution. **ITB withdrawal** is a medical emergency and needs to be identified early and managed aggressively. Sequelae can include high fever, altered mental status, exaggerated rebound spasticity, and muscle rigidity that, in rare cases, can advance to rhabdomyolysis, multiple organ–system failure, and death. Caregivers need to be educated on the early symptoms of baclofen withdrawal. Prevention of abrupt discontinuation of ITB requires careful attention to programming and monitoring of the infusion system, refill scheduling, and pump alarms.

Selective dorsal rhizotomy (SDR) is a surgical procedure that decreases muscle spasticity by sectioning hyperexcitatory sensory nerve rootlets that innervate the lower extremities. The surgical technique involves single or multilevel osteoplastic laminectomies exposing the L2-S1 nerve roots, and sensory rootlets are chosen for sectioning using intraoperative electromyography. The most ideal candidates are thought to be children 3-8 years of age with spastic diplegic CP, minimal upper limb involvement, good selective motor control and strength with the ability to rise from the floor independently, minimal contractures, and good cognitive skills.

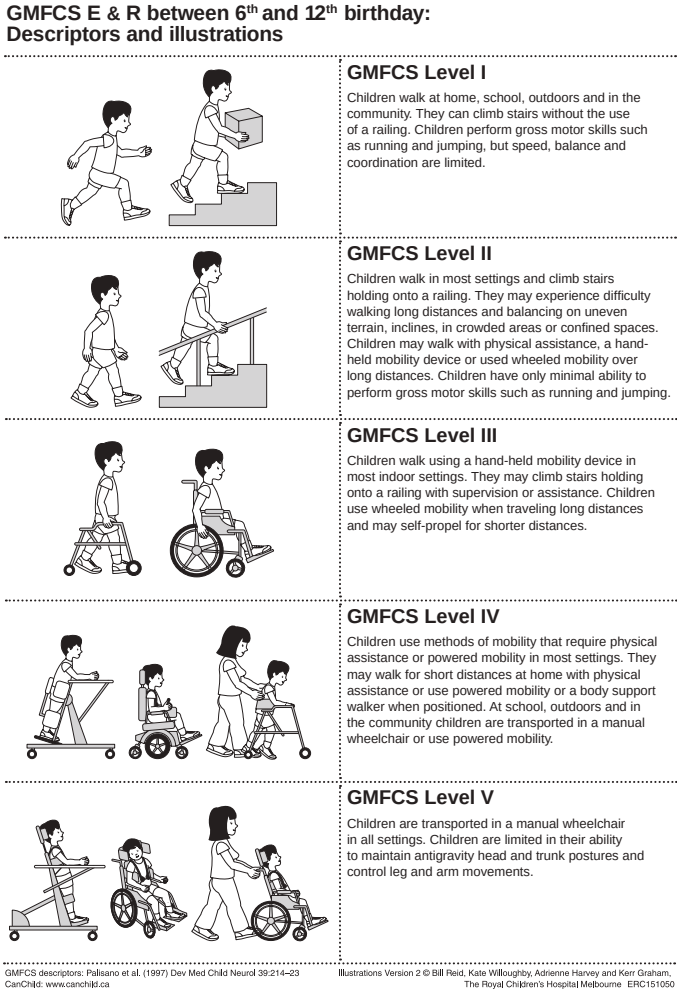

Fig. 752.1 Gross Motor Function Classification System Expanded and Revised (GMFCS E & R). *(Descriptors: ©Palisano et al, 1997 – Dev Med Child Neurol., 39:214-23 (CanChild: www.canchild.ca); Illustrations Version 2 © Bill Reid, Kate Willoughby, Adrienne Harvey and Kerr Graham, The Royal Children's Hospital Melbourne)*

Ambulatory children with CP have better function and quality of life in the 24 months after SDR. A prospective gait analysis study in adults with CP 20 years after SDR showed improved locomotor function with increased gait speed. SDRs are performed to a lesser extent in children with spastic quadriplegic CP, and goals in this population are often to decrease lower limb spasticity while improving comfort, care, and positioning. A study in nonambulatory children with severe CP showed improvements in daily care and comfort at a mean follow-up of 19 months after SDR, although unmasking of prior dystonia can occur. AEs after SDR include bladder or bowel dysfunction, sensory dysesthesias, and back pain; however, these occur infrequently and are typically transient. A systematic review of spinal deformities after SDR in children with CP found scoliosis to be the most common deformity occurring in approximately 30% of children, but this risk has never been satisfactorily shown to be higher than the risk in those children who have not undergone SDR. Studies have reported higher rates of spondylolysis and spondylolisthesis after SDR than would be expected in the general CP population. Spine radiographs should be obtained routinely after SDR to monitor for spinal deformity.

Visit Elsevier eBooks+ at eBooks.Health.Elsevier.com for Bibliography.

Chapter 753

Birth Brachial Plexus Palsy

Maureen R. Nelson and Nicholas L. Fleming

Birth brachial plexus palsy (BBPP) may cause significant arm weakness and subsequent functional deficits in children. The nerves to the arm are affected with variable degrees of weakness and sensory loss. Most children will have good recovery spontaneously, but functional deficits will remain in 20–30% of children with BBPP.

The mechanism for BBPP is lateral stretch of the plexus for the vast majority of cases. Anatomic variations in bones, blood vessels, and tendons lead to a very small number of cases. The incidence of BBPP is reported as 0.5-4.6 per 1,000 live births, with variability thought to be attributable to the type of obstetric care and the size of infants around the world.

Risk factors for BBPP include prior infants with BBPP, shoulder dystocia, birthweight >4 kg, multiparous mothers, mothers with excessive weight gain, and diabetic mothers. Delivering twins or triplets, as well as cesarean sections, have been described as protective from BBPP. Factors with a higher risk of poor outcome are birthweight greater than 4 kg, Horner syndrome, cephalic presentation, and induction or augmentation of labor.

Nerve injuries include neurapraxia, neurotmesis, and axonotmesis. **Neurapraxia** is the least severe of these types and is a reversible loss of nerve conduction. This type will recover. **Neurotmesis** is the most severe and is a total and complete disruption of the nerve. An *avulsion* describes a **neurotmesis** that is a preganglionic lesion, and a *rupture* describes the same event for a postganglionic lesion. **Axonotmesis** is the intermediate form and the most difficult to delineate. There is disruption of the epineurium with variable injury to the axons creating the diagnostic and prognostic difficulties (Fig. 753.1). For these reasons, it is advisable to urgently seek out consultation from specialty clinics or specializing physicians in your geographic area for close monitoring and treatment considerations, including surgical candidacy.

Not only is there variability in the degree of nerve injury, but there is also variability in location. The brachial plexus consists of the anterior primary rami, or roots, from C5, C6, C7, C8, and T1. These roots will combine and then branch to form the trunks, divisions, and branches before separating distally to individual peripheral nerves as illustrated by Figure 753.2.

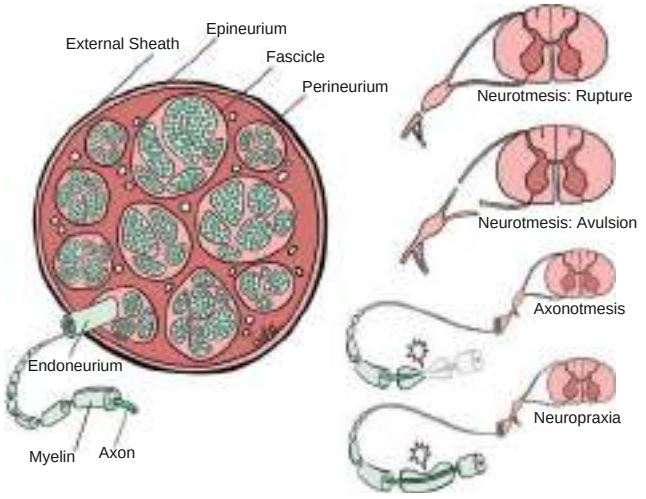

Fig. 753.1 Anatomy of peripheral nerve and injury type. *(Courtesy Kendall Hulk, DO.)*

There is variable impact on motor and sensory systems as well. The sensory fibers are relatively protected compared with the motor fibers because the sensory fibers run together until they are outside of the spinal cord into the dorsal root ganglion, where their cell bodies lie. The motor fibers have the cell bodies within the spinal cord and so are not as cohesive in their path. Therefore the sensory fibers may be spared, while motor fibers show clinical deficits.

Narakas is a commonly used classification system (Table 753.1). Erb palsy is generally described as the upper trunk or C5-C6 palsy. It is by far the most common injury seen in BBPP. When C7 is included in the injury, it may be referred to as *extended Erb palsy*. Together, these forms of Erb palsy make up 75% of all BBPP. These two groups also demonstrate the greatest recovery rate, at 80% and 60%, respectively, resulting in a functional arm. **Klumpke palsy**, C8-T1, is extremely rare in BBPP, likely not occurring except in the case of anatomic variation. If a baby presents with a C8-T1 deficit, the baby most likely originally had a complete C5-T1 BBPP and then had recovery of the upper portion of the plexus. This can happen because C4, C5, C6, and sometimes C7 are protected coming out from the spinal cord, held in a gutter along the transverse processes by connective tissue, whereas C8 and T1 are not. The phrenic nerve may also be involved with its innervation from C3, C4, and C5, with potential respiratory concerns. The differential diagnosis of an infant with a weak or less functional arm is broad, and there should be consideration for other neurologic injury (stroke, spinal cord injury, underlying congenital or metabolic diagnosis), musculoskeletal issues (fracture, muscular torticollis, anomalous rib impinging nerves), infection, tumor, and other sources of pain or pathology that could lead to developmental disregard or a learned nonuse of an extremity. **Phrenic nerve** (4th cervical and C3-C5) injury may also be present and result in ipsilateral diaphragm paralysis and respiratory distress.

PHYSICAL EXAMINATION

Motor movement evaluation is the focus of this exam. The Active Movement Scale is a reliable passive assessment of muscle strength that is widely used for infant examination of BBPP. Mallet scores, which assess shoulder abduction and external rotation deficits, are likewise useful but are more pertinent for examination of the toddler or older children. Examination for sensation, particularly sharp sensation, useful in its own right, will also frequently help with active motor evaluation in infants. Assessment of muscle stretch reflexes is important, in that infants with brachial plexus palsy will be areflexive or hyporeflexive in the involved arm. Evaluation of primitive reflexes, particularly the Moro reflex, is helpful, because most of these infants will have C5-C6 involvement, and therefore the Moro may show shoulder abduction and elbow flexion on one side but not the involved side. Range-of-motion examination is critical. Deficits are commonly seen because of the imbalance of muscles that are active and those that are not. Shoulder adduction and internal rotation is a common position, as is elbow flexion, forearm pronation, and wrist and finger flexion. Torticollis is commonly present and almost always with the face turned away from the involved arm. **Horner syndrome** (ptosis, miosis, and anhidrosis) may be present ipsilaterally and is an indicator of severity. In children with very severe deficits, the arm may be cooler because of the sympathetic nervous system outflow at T1. The size of the involved arm eventually is usually smaller, about 95% of the uninvolved arm, because of muscle atrophy and smaller diameter and length of the bone.

Among older infants and children, compensatory movements of the arm may be noted. Common examples are use of trunk momentum to move (particularly to rotate) the proximal arm, hyperlordosis of the lumbar spine to position the arm more advantageously, use of the pectoralis muscle to flex the shoulder, and use of the knee while sitting to physically flex the elbow. Examination of the back for symmetry, along with the scapulae for winging, is also relevant. Scapular winging can be problematic both socially and clinically. Having the older child manipulate buttons, snaps, or zippers, throw

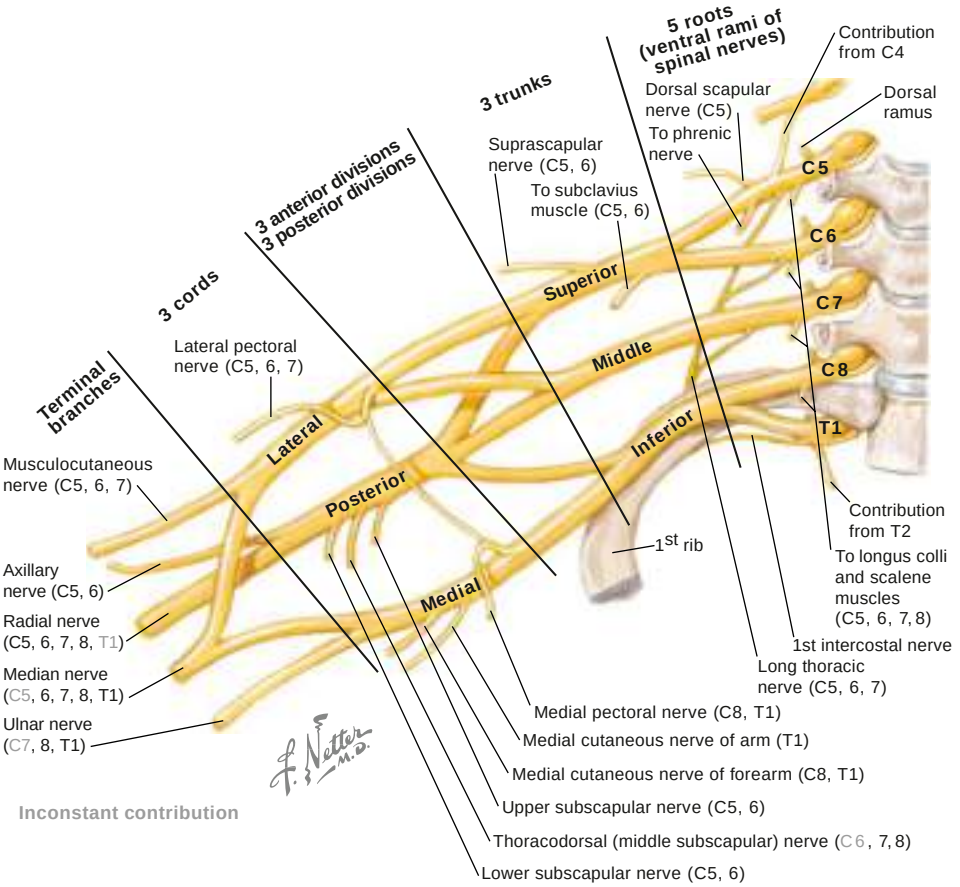

Fig. 753.2 Schematic of the brachial plexus. *(Netter illustration from www.netterimages.com. Elsevier Inc.)*

Table 753.1 Narakas Classification

GROUP	NAME	ROOTS	CLINICAL DESCRIPTION
I	Erb palsy	C5-6	Paralysis of shoulder and biceps with should abduction, external rotation, and elbow flexion
II	Extended Erb palsy	C5-7	As above with paralysis of wrist
III	Total palsy	C5-8, T1	Complete flaccid paralysis
IV	Total palsy with Horner syndrome	C5-8, T1	Complete flaccid paralysis with Horner syndrome

and catch a ball, and write, print, or color may be revealing, along with how they remove their shirt for examination.

When hand function was evaluated with testing of children with upper-plexus involvement, 80% of the children had significantly decreased performance compared with the contralateral hand. This indicates the hand function is impaired even in children who only have upper plexus involvement.

EVALUATION

Radiographic evaluation may be needed. Plain films can be viewed immediately if there is reason to consider clavicle or humerus fracture, infection, osteomyelitis, or tumor. Ultrasound (US) can be used to evaluate for shoulder dislocation. CT myelogram had been the mainstay diagnostic tool for brachial plexus evaluation despite its radiation dose and invasive lumbar puncture. However, MRI lacks these drawbacks and provides a more accurate and reliable evaluation.

US and electrodiagnostic evaluation (EDX) can also be helpful in evaluation of the brachial plexus. US is an ever-improving technology but does not yet evaluate the deeper nerve root avulsions or ruptures, making isolated US imaging inappropriate. However, US can be useful for postganglionic injury evaluation, specifically for the upper plexus. EDX may be supplemental and is especially helpful as a confirmatory test for lower plexus avulsion injuries given its strong specificity and MRI's weaker diagnostic accuracy for these lower plexus injuries.

EDX includes both nerve conduction studies (NCS) and electromyography (EMG) and should be performed by someone who is experienced in the examinations of infants and young children, both for the most precise evaluation and the most comfortable experience for the youngster. The following EDX pearls should be noted:

1. Normal electrical sensory response in areas where the child cannot feel indicates a *preganglionic neurotmesis* (avulsion).
2. Motor nerve conduction studies are useful to check for continuity of nerve fibers to muscles that are weak or paralyzed.
3. F waves are useful in evaluating proximally because these responses go from peripheral nerves to the spinal cord and back.
4. Somatosensory evoked potentials are difficult to perform on infants while awake, because of motor artifact obliterating the responses

with movement, and are imprecise because of overlapping responses to peripheral stimulation. These are useful intraoperatively because stimulation can be performed on the nerve roots themselves to determine proximal continuity.

5. EMG can show activation in muscles with paralysis or severe weakness.
6. The absence of biceps motor unit potentials at 1 month of age predicts future lack of clinical biceps recovery, although biceps EMG at 3 months has been reported to overestimate recovery potential.

TREATMENT

Early referral or consultation with a specialty clinic or specialized physician is paramount and should be completed as early as possible or by 1 month of age for close monitoring and consideration of possible microsurgery. Postoperative improvement in hand and arm function has been shown to have a negative correlation with age at time of primary surgery. Infants who do not show satisfactory improvement in muscle strength are candidates for such primary surgeries, which may include nerve transfers, in which branches from an uninvolved nerve are microsurgically transferred to the distal peripheral nerves supplied by the injured nerve roots and/or nerve grafting, in which one or more of the nonavulsed roots is attached distally to the trunk, cord, or peripheral nerve by means of an autogenous graft (commonly the sural nerve of the leg) or synthetic nerve conduits. There is general consensus that primary nerve surgeries should be performed at 3 months of age for Narakas type III and type IV. Those with upper-plexus (Narakas type I and type II) involvement are monitored closely, and there is surgical consideration for primary nerve surgery between 3 and 6 (or even 9) months of age. Classically, observed elbow flexion less than 3/5 at 6 months of age or a positive "cookie test" (child cannot bring cookie to mouth without bending neck forward more than 45 degrees) at 9 months would prompt decision to undergo primary surgery in these populations. The surgical focus for a complete palsy or "flail arm" is reinnervation of the hand, whereas the surgical goals of an upper-plexus reconstruction include, in descending priority, elbow flexion, glenohumeral abduction, shoulder stability, and shoulder external rotation. It should be noted that the goals of surgery are not to regain normal arm function but rather to have a more functional arm.

Regarding primary nerve surgeries, some have reported better outcomes with nerve transfer rather than nerve graft procedures. However, the heterogenous nature of BBPP, variable surgical techniques, and available nerve options often dictate what can be performed. Spinal accessory to suprascapular nerve transfer and radial nerve (long head of triceps branch) to axillary nerve transfer has been reported as the most common dual nerve transfer procedure. Other common nerve transfers include median or ulnar nerve to the musculocutaneous nerve (MCN), medial pectoral nerve to MCN, intercostal nerve to MCN, and contralateral or cross cervical nerve root transfers. Nerve graft procedures typically include harvesting of the sural (purely sensory) nerve or using synthetic nerve grafts. These grafts are typically used to reestablish the conduit of the suprascapular nerve, graft C5-to-posterior division, or graft C3/C4-to-upper trunk.

Regardless of whether primary surgery is pursued, treatment begins on the initial evaluation with instruction to the parents for positioning and early stretching exercises to begin at 2 weeks, or at 3-4 weeks if a humerus or clavicle fracture is present. They are also told of the critical task of maintaining infant awareness of the involved arm, initially by manually mimicking activities with the affected arm that the baby performs with the contralateral arm and by using a wrist rattle on the arm. Lack of awareness of the arm, sometimes called *developmental disregard*, in children can result in less active use of the arm, with functional loss, as a consequence. The parents also are informed of the higher risk of BBPP for future infants, and so the families are encouraged to speak with the obstetrician about optimal management in future deliveries.

The baby will start with occupational or physical therapy at approximately 2 weeks of age with focus on maintaining joint motion, maximizing strength, promoting sensory awareness, and supporting age-appropriate development. Parent education should be reinforced and a home program including daily stretching, positioning, and strengthening techniques should be constructed. Therapeutic taping may be done for supination, wrist extension, or, most commonly, for shoulder positioning to minimize an adducted, internally rotated posture. Neuromuscular electrical stimulation to the muscles minimizes atrophy and promotes increased size, and therefore strength, of muscle fibers. Ideal parameters for its use have not yet been determined, but a 20-30–minute twice-daily program is effective and has been shown to increase bone density.

The therapist or physician may consider a brace or splinting. Splints can be prescribed in conjunction with a physical or occupational therapist's guidance and are often worn the majority of the day (e.g., 22 hours/day). Common splinting strategies include supporting wrist extension with a baby with wrist-drop and/or extending the fingers and abducting the thumb as well, providing straps to assist with supination (Sup) of the forearm and even braces focused on positioning the shoulder in external rotation (ER). Protocols for splinting strategies such as the "Sup-ER orthosis" have been created and studied in small populations; however, there is currently no general consensus on implementation of such protocols. Early, close monitoring is not only important for surgical considerations, but it is also important for monitoring for secondary problems that can increase the negative impact of functional deficits in children with BBPP. Contractures of the elbow, shoulder, forearm, wrist, and fingers may occur. Although muscle imbalance and fibrosis can contribute to contracture, the evidence suggests a physiologic response related to muscle denervation leading to a failure of growth in the sarcomeres of these affected muscles. Early shoulder dislocations have been described in severe presentations. Botulinum toxin injections help balance out muscles that are overpowering weak muscles and such an intervention can minimize contractures and even prevent or help reduce a shoulder dislocation in these severe cases.

For older babies and children, muscle, tendon, and bony procedures are generally performed. These are often called *secondary surgeries*. Monitoring for shoulder deformity and dislocation is an important part of long-term follow-up. Because the shoulder joint develops as the infant and toddler grows, deficits frequently develop. Glenohumeral dysplasia, sometimes with shoulder dislocation, occurs in 60–80% of those with BBPP. Muscular imbalance across the developing shoulder results in deformity of the skeletally immature glenohumeral joint. The weakness of shoulder external rotation, combined with strong internal rotation, leads to this difficulty. The natural history of this deformity is progression if left untreated. This leads to further functional limitations, even with a strong hand. Treatment aims to minimize this progression. Treatment options include botulinum toxin injections, arthroscopic or open anterior capsule release or release of contracture, musculotendinous lengthening, tendon transfers (e.g., latissimus dorsi to increase external rotation and abduction strength), muscle transfers (e.g., gracilis muscle can be transferred to allow for elbow flexion and/or wrist extension), and, for severe deficits, a derotational humeral osteotomy.

Visit Elsevier eBooks+ at eBooks.Health.Elsevier.com for Bibliography.

Chapter 754

Meningomyelocele (Spina Bifida)

Pamela E. Wilson and Tess S. Simpson

See also Chapter 631.

Meningomyelocele, or spina bifida (SB), is a congenital neural tube defect that results in the malformation of the spine and a potential dysplastic spinal cord. The severity of defect ranges from SB occulta (see Chapter 631.2) upward to anencephaly (see Chapter 631.6). SB without anencephaly is the most prevalent nonchromosomal central nervous system (CNS) defect in the United States. For unknown reasons, Hispanic women have the highest rate of SB (3.80/10,000 live births), followed by non-Hispanic White women (3.09/10,000 live births); the lowest rate is in non-Hispanic Black women (2.73/10,000 live births).

ETIOLOGY

See Chapter 631.1.

PREVENTION

See Chapter 631.1.

PRENATAL SCREENING

Prenatal screening is recommended for all pregnant women to detect neural tube defects. A blood test is done in the second trimester to evaluate alpha-fetal protein (AFP). If a neural tube defect is present, the AFP is often elevated, and further screening using high-resolution ultrasound is indicated. Ultrasound may reveal not only the spinal defect but also abnormal brain development, suggested by the "lemon and banana signs." The lemon sign is a medial indentation and scalloping of the frontal bones in the skull, whereas the banana sign is associated with hindbrain herniation of the cerebellum into the foramen magnum. The importance in early identification allows families to plan for delivery and consider fetal interventions, mainly prenatal surgical closure of the defect. Prenatal closure decreases the need for a ventricular shunt and lowers the incidence of severe Arnold-Chiari malformations, along with improved motor outcomes. However, there is an increased incidence of preterm delivery and a risk for uterine dehiscence; these risks may be reduced with fetoscopic procedures.

CLINICAL IMPLICATIONS

Meningomyelocele is a multisystem condition that includes characteristic abnormalities within the CNS. The neurologic lesion is assessed by the most caudal intact nerve segment with a motor test of grade 3. Lesions associated with SB are often grouped together as thoracic, upper lumbar (L1-L2), midlumbar (L3), lower lumbar (L4-L5), and sacral. Based on this information, a clinician can make inferences on the functional capabilities of the child and answer pertinent questions during the initial encounters (Table 754.1). The most basic question all families ask is: "Will my child walk?"

Initial surgical interventions are related to closure of the open defect. This is generally done the first day of life. Once the back is closed, the child will be monitored to see if hydrocephalus develops. Hydrocephalus is very common and related to hindbrain herniation and obstruction of the fourth ventricle. Hydrocephalus may occur at any time but most frequently within the first few months. Ventricular dilation may precede a change in head circumference or signs of increased intracranial pressure. The occurrence of hydrocephalus is approximately 77–95% and does appear to have an association with level of lesion. Treatment of ventriculomegaly, if mild, may be limited initially to clinical observation. Surgical placement of a ventricular shunt or endoscopic third ventriculostomy is indicated when occipital frontal circumference (OFC) is increasing. The risk for shunt revision in the first 2 years is 30–50%, which then decreases to 10%.

Hindbrain herniation or the **Chiari type II malformation** is seen in 80–90% of individuals with meningomyelocele. The classic manifestations include caudal displacement of the cerebellum, pons, and medulla and elongation of the fourth ventricle. The Chiari II malformation can be symptomatic (from brainstem herniation/compression) in approximately 20% of children. Respiratory symptoms associated with a Chiari malformation include stridor, vocal cord dysfunction, and central or obstructive apnea. Swallowing and feeding problems may require gastrostomy tube placement. If the child has a symptomatic Chiari II malformation, surgical

Table 754.1 Prognosticating in Meningomyelocele

MOTOR LEVEL SPINAL CORD SEGMENT	CRITICAL MOTOR FUNCTION PRESENT	MOBILITY: SCHOOL AGE	RANGE: ADULT	ACTIVITY: ADOLESCENT
T12	Totally paralyzed lower limbs	Standing brace, wheelchair	Wheelchair	Wheelchair, no ambulation
L1-L2	Hip flexor muscles	Crutches, braces, wheelchair	Wheelchair, household ambulation	Wheelchair, nonfunctional ambulation
L3-L4	Quadriceps muscles	Crutches, braces, household ambulation, wheelchair	Crutches, household ambulation, wheelchair	50% Wheelchair, household ambulation with crutches
L5	Medical hamstrings, anterior tibial muscles	Crutches, braces, community ambulation	Crutches, community ambulation	Community ambulation with crutches
S1	Lateral hamstring and peroneal muscles	Community ambulation	Community ambulation	Community ambulation 50% crutch or cane
S2-S3	Mild loss of intrinsic foot muscles possible	Normal	Normal	Limited endurance because of late foot deformities

From Braddon RL, ed. *Physical Medicine & Rehabilitation*, 4th ed. Philadelphia: Saunders; 2011: Table 54.1.

decompression is indicated. All children with SB are at risk for **tethered cord syndrome** (see Chapter 646.1). After shunt malfunction, this is the second most common cause for neurologic decline. Clinical manifestations of tethered cord syndrome include any change in gait, change in bowel or bladder function, increasing scoliosis, back pain, or orthopedic changes. Surgical detethering procedures are indicated in those with neurologic decline, but the success rate is variable.

The **orthopedic complications** of myelomeningocele are common and have predictable patterns. The spine deformities include scoliosis, lordosis, and kyphosis (see Chapter 720). The development of scoliosis has an association with the neurologic level. Children with thoracic level meningomyeloceles have an 80–100% risk, whereas those with a sacral level are at very low risk. Spine deformities tend to increase more rapidly during growth, especially puberty. Treatment of scoliosis includes both nonsurgical and surgical options. Braces, such as thoracic-lumbar-sacral orthotics (TLSO), therapy, and proper seating options may be beneficial. Surgically implanted growing rods to support the developing spine have been used in younger children. Spine surgery should be considered if the scoliotic spine curvature reaches 45 degrees; the child who is nearing skeletal maturity is a better candidate for spine surgery. Realistic expectations need to be discussed with the child and family. Correction of the spine may improve sitting, posture, and pelvic obliquity but may have a negative impact on function and ambulation.

The **development of the hip** is also influenced by neurologic level (see Chapter 719). The risk for dislocation is highest for those with lesions at the L3 level, followed by L1-L2. Unilateral hip dislocations should be fixed surgically because they may result in pelvic obliquity and problems with sitting, whereas bilateral dislocations generally do not require interventions. Contractures of soft tissues are commonly seen in children with higher lesion levels. Hip flexors and knee flexors are commonly involved.

Abnormalities in the foot occur in approximately 90% of children and adolescents. The goal of treatment is to achieve a plantar grade foot for weight bearing and to allow shoe wear. Clubfoot deformities are common in babies, and treatment includes serial casting and orthotics (see Chapter 715.3). The results are often suboptimal, and surgery may be needed. In addition, congenital vertical talus (rocker-bottom feet) is often encountered and needs to be addressed (see Chapter 715.4).

Osteoporosis (see Chapter 749) begins to develop in childhood and is more severe in higher-level meningomyelocele. Fractures of the lower extremities are most common in the femur, followed by the tibia. Preventive treatment includes nutritional approaches such as the use of supplemental calcium and vitamin D. Those with documented fractures should undergo a diagnostic evaluation (see Table 749.1), including dual-energy x-ray absorptiometry (DEXA). The use of bisphosphonates may be considered if the diagnostic evaluation does not reveal other underlying causes. The utility of early weight bearing has been advocated, but passive standing may have little impact on bone density.

Neurogenic bladder and bowel can be anticipated. The goals of treatment interventions are to protect kidney function and achieve social continence. For continence of urine, clean intermittent catheterization (CIC) is the mainstay of management. It is not atypical for newborn babies to be started on a CIC program. Urodynamics and renal ultrasounds are routinely used to monitor for hydronephrosis and track intravesicular pressures. Medications may be used to reduce bladder contractions and improve volume capacity. Surgical techniques are being used to improve continence, including bladder augmentation, urethral surgeries, and catheterizable channels. Poor CIC technique and/or urinary reflux may lead to urinary tract infection (UTI), which is diagnosed by having two findings: a urinalysis with white cell count of >10 and urinary culture >100,000 cfu/mL. A multicomponent bowel program is generally needed to achieve bowel continence. Nonsurgical interventions include adequate hydration, dietary manipulation, fiber regulation, and use of laxatives and enemas. Surgical interventions, such as the antegrade continence enema (ACE), have improved continence in many children and adolescents with SB.

Latex allergies are common. The etiology is likely multifactorial, but increased early exposure may play a role in the development of severe reactions (see Chapter 190). Care providers need to be keenly aware of products that contain latex or that have a cross reactivity, such as foods mixed with avocado, bananas, or kiwi fruit. Radioallergosorbent testing is used for identification of potential severe allergens.

People with SB show a wide range of **neuropsychologic abilities**. Many show a complex neuropsychologic profile that includes strengths in some areas and weaknesses in other areas. Common areas of strengths include vocabulary, word reading, spelling, and certain types of memory. Common weaknesses include motor skills, attention, organization, math, reading comprehension, and executive functioning skills. Overall cognitive functioning typically falls within the average range for children with SB; however, neurologic factors such as a Chiari II malformation or the presence of hydrocephalus increase the risk for neuropsychologic challenges. Neuropsychologic assessment is recommended to identify any potential gaps in cognition and social or emotional skills. This assessment can provide helpful information related to a child or adolescent's education and employment needs and assist with development of an individualized educational plan (IEP) or vocational rehabilitation plan. Appropriate early intervention and support programs should be initiated through an IEP or 504 plan if indicated (see Chapter 56). Effective interventions both at school and the home should be structured, explicit, and individualized. Parents and teachers can support learning goals by progressing in an orderly fashion from one learning target to the next and by modeling how to approach problems or tasks, often with step-by-step instructions and supervised practice.

ADOLESCENCE AND TRANSITION TO ADULTHOOD

Improved and expanded clinical care has increased the life span of individuals with SB, with the majority of individuals now living well into adulthood. Secondary conditions associated with SB (e.g., UTIs, skin breakdown, learning challenges) and more difficulty accessing healthcare services compared with their age-matched peers make adolescents and young adults with SB less likely to achieve emerging adult milestones such as leaving home, attending college, or finding employment.

The primary care clinician, in conjunction with specialty services, plays a pivotal role in developing future planning. It is important to discuss early on strategies to encourage developmentally appropriate independence and self-management skills. Individualized, comprehensive transition care that includes care coordination, decision-making support, education and employment resources, and independent living support is recommended for providers caring for children and adolescents with SB.

Visit Elsevier eBooks+ at eBooks.Health.Elsevier.com for Bibliography.

Chapter 755

Upper and Lower Extremity Assistive Devices

Abigail Case and Sarah Helen Evans

Assistive devices, such as orthoses, prostheses, walkers, crutches, and wheelchairs, are key components of intervention for individuals with physical disabilities, and with the continued advancement in technology, robotic forms of these devices are also important to consider. The type of device chosen depends on the underlying diagnosis, functional abilities of the individual, prognosis for functional improvement or decline, tone abnormalities, range of motion, strength, and the overall gait pattern. Physicians, licensed independent practitioners, and physical therapists perform the evaluation of a child requiring an assistive device.

ORTHOSES

An **orthosis** is a device that is applied to the surface of the body to maintain alignment or position, to prevent or assist movement of the body part, or to provide support. Named for the body parts covered, orthoses can be static, made of rigid material, and designed to immobilize joints to inhibit movement, or they can be dynamic, allowing movement of the limb to occur. For example, **AFO** stands for *ankle-foot orthosis*, a brace worn on the foot that extends from the toes to the mid-calf position, supporting the foot and ankle joints (Fig. 755.1). Prefabricated orthoses are available, but many children require custom-made orthoses for optimal fit. Orthoses are modified or replaced during periods of growth or changes in function and can be obtained either directly through the orthotist or through the child's physical therapist. In most of the United States, braces must be prescribed by a physician or licensed independent practitioner to obtain insurance coverage, and it is best practice to have a prescription.

The use of an upper limb orthosis can be more conspicuous than its lower limb counterparts, and physicians should analyze the user's psychosocial well-being and tolerance for such device. In addition to patient goals and outcomes, the therapeutic intent of the upper limb orthosis must be considered. The efficacy of the orthosis may be measured by the reduction of the effects of the three Ps: paralysis, pain, and position.

Fig. 755.1 Hinged ankle-foot orthosis. *(Courtesy Ultraflex Systems, Inc., Pottstown, PA.)*

The type of lower-extremity orthosis prescribed is based on the child's diagnosis, functional status, prognosis, and the goals of treatment, with the prescription frequently modified over time as the child changes. Before writing a prescription, the provider performs an examination, which may include an evaluation of the child's gait, strength, tone, and range of motion. There are many types of braces that have specific functions to improve gait. Table 755.1 lists examples of these orthoses and their potential uses.

The most prescribed braces are solid and articulated AFOs. Solid AFOs are used for children with hypertonicity because they help to biomechanically reduce tone and provide stability with standing and walking. Children who are nonambulatory also benefit from wearing solid AFOs to maintain range of motion of the ankle.

Articulated (hinged) AFOs allow the child to have ankle dorsiflexion by permitting forward movement of the tibia and supporting the foot for heel strike. This design makes ambulating on uneven surfaces and using stairs easier because of the movement allowed at the ankle, while still supporting the foot position and maintaining medial-lateral stability of the ankle. Articulated AFOs should not be used in children with cerebral palsy, spina bifida, or other disorders if they have a crouched gait pattern because the hinge in the ankle joint may allow further crouching. In crouched gait, the hips and knees are held in flexion and ankles in dorsiflexion throughout the gait cycle, leading to an inefficient gait pattern.

PROSTHESES

A prosthesis is a device that replaces a missing body part, such as an arm or a leg. Lower-extremity prostheses are used to improve mobility, but upper-limb prostheses are not always needed to improve function because children can be quite independent with a single upper limb. Children with congenital upper limb amputations or deficiencies need to have prosthetic devices fit at the time they begin to sit for them to use the prosthesis functionally, and because, developmentally, young children are not ready to learn to use complicated devices, teaching them to use a mechanical prothesis requires intensive occupational therapy. Myoelectric protheses are too heavy and too hard to use at this age. Children with acquired upper limb amputations may be more likely to adjust to the use of a prosthetic arm.

Lower-limb prostheses are used in children with acquired amputations as a result of trauma or cancer and also in congenital transverse amputations or for those who have undergone surgical correction, as often occurs with longitudinal fibular deficiency or proximal femoral focal deficiency.

There are multiple components to lower-limb prostheses, which include the socket and foot, but may also include a hip and knee joint, depending on the level of amputation. A prosthetist works with the child and family to fabricate the prosthesis. A physician or licensed independent practitioner with experience in prostheses provides the prescription for this device.

The type of prosthesis depends on the age of the child, the level of the amputation, and the status of the residual limb. In very young children, use of a lower-extremity prosthesis follows developmental milestones, with the first prosthesis prescribed at the time the child should be pulling to stand. Addition of joints to the prosthesis also occurs when developmentally appropriate, such as use of a knee joint around the age of 3 years when the child is learning to use stairs.

Advances in technology are helping children who use prostheses achieve a fluid gait pattern that makes their prosthetic use virtually undetectable to the untrained eye. New components and designs allow amputees to lead active lifestyles that may include running, swimming, biking, and mountain climbing.

ASSISTIVE MOBILITY DEVICES

The function of assistive mobility devices is to provide a wider base of support to improve stability during ambulation, reduce the possibility

Table 755.1 Orthotic Options

ORTHOSIS	FUNCTION	COMMENTS
Neoprene thumb abductor	Places thumb in abduction to promote functional use of hand	Will not overcome severe cortical thumb position
Thumb spica	Immobilizes and protects the thumb and provides a stable post against which the index finger can pinch	Need to allow for full metacarpophalangeal (MCP) flexion of the fingers
Resting hand	Preserves balance between extrinsic and intrinsic musculature and provides joint stability; prevents contracture	Pressure at the MCP joint or proximal phalanx should be avoided because it can injure the MCP joint. This splint is to be used for positioning, not function
Wrist cock-up	Supports, immobilizes, or stabilizes wrist in extension, which allows for mechanical advantage in grasp	Must maintain full MCP flexion and thumb motion
Elbow extension	Increases extensor end range of motion (ROM)	Not for severe flexor tone with contracture or fluctuating tone; in that case, use a drop out cast or splint
Gunslinger	Supports shoulder girdle and prevents subluxation	Make sure the edges of splint are not cutting into hip area; check in standing and supine
Myomo	Sensor-activated, power-driven upper limb orthosis can train the arm and hand while providing assistance with bimanual activities	Heavy Minimal growth with a child
Foot orthosis (FO)	Provides support of foot only to keep ankle in subtalar neutral	Not typically customized but can be with a UCBL*
Supramalleolar orthosis (SMO)	Provides medial-lateral support of foot to prevent excessive pronation, supination, or instability	Appropriate for children with low tone such as in Down syndrome. Also useful for young children with equinovarus posture or mediolateral instability
Ankle-foot orthosis (AFO)	Provides support at the ankle and reduces foot drop or plantarflexion tone by keeping the ankle in a neutral position	Commonly used for ambulatory and nonambulatory children Assists with dorsiflexion and inhibits plantarflexion. Requires rocker bottom shoe for rollover in gait
FES activated AFO	Uses functional electrical stimulation to assist dorsiflexion at the appropriate time in the gait cycle	Cannot inhibit plantarflexion Less restrictive than a solid or hinged AFO Can be used with an SMO to provide mediolateral stability at the ankle
Ground reaction ankle-foot orthosis (GRAFO)	Provides knee extension moment to reduce crouching or collapsing into dorsiflexion during standing or walking	Appropriate for children with spina bifida or who have weakness in the plantar flexors who crouch when walking
Knee-ankle-foot orthosis (KAFO)	Provides support at the knee when there is quadriceps weakness to promote an upright posture with standing or walking	Less commonly used because of large size of brace but may be appropriate for child with spina bifida or spinal cord injury
Walking assistance exoskeleton	Bionic robot for use in paraplegic patients	Heavy. Very expensive. Does not grow with a patient. Cannot be used in patients with spared sensation in the legs

*UCBL – University of California Berkley Laboratories, where this maximum control foot orthosis was developed.

of falls, and improve efficiency of gait. The least supportive device is a traditional single-point cane commonly used after an orthopedic injury. For most children with gait abnormalities secondary to neurologic disorders, this is not a functional option because a cane does not provide enough stability. More supportive gait aids, such as forearm (Lofstrand) crutches, are appropriate in children with neurologic disorders; however, use of these devices requires good coordination and strength. Children with cerebral palsy and spina bifida may benefit from these devices.

Walkers provide more support than crutches and canes; they do not require as much strength and coordination to operate. Children with cerebral palsy, for example, may use a reverse walker, which they pull behind them. This reverse configuration provides a wide base of support and stability, helps maintain an erect posture, and allows the child to engage with the environment without the barrier of the walker in front of them. Having the walker behind them also reduces the risk for more serious injury from a forward fall.

For children who require a significant amount of support because of poor head and trunk control, **gait trainers** are often used. These devices allow the child to work on leg movements while the trunk and pelvis are stabilized (Fig. 755.2). Although gait trainers provide a child with moderate to severe motor impairments upright supportive mobility, "gait trainer" is a misnomer in that it is not intended to train a child to walk independently.

WHEELCHAIR

Wheelchairs should be considered as a means of mobility when ambulation is not possible or is difficult outside of the home setting. Children with spinal cord injuries, spina bifida, neuromuscular diseases, or cerebral palsy may benefit from the use of a wheelchair. The goal is to provide a wheelchair that will allow the child to move independently about the environment, including home, school, and the community. Children as young as age 2 years can self-propel a manual wheelchair and operate a power wheelchair. The type of wheelchair prescribed will depend on the child's underlying diagnosis, cognition, vision, motor skills (such as head and trunk control), strength and endurance of upper limbs, musculoskeletal deformities, if present, and medical comorbidities. One must also consider future growth or

Fig. 755.2 Gait trainer. *(Photo copyright 2013 by Rifton Equipment, http://www.rifton.com.)*

anticipated changes in function over time, as well as the family's ability to transport the chair. An important consideration when ordering a pediatric wheelchair is the adjustability to accommodate growth. A typical wheelchair may last 3-5 years with periodic adjustments to growth by a seating specialist. There are many components that can be added to provide more support in the wheelchair, including head rests, lateral trunk support, hip guides, antitippers that prevent the wheelchair from tipping backward, and specialized tires. The seating system is considered a separate item from the wheelchair itself and is, in fact, a seating orthosis. It should be properly fit for the child's current size and seating needs. The function of a seating system is to promote the upright positioning of the head and trunk as well as control of the position of the legs, especially the hips, in sitting. Children with good trunk control will require a simple seat back, while a child with poor trunk control, such as someone with a high cervical spinal cord injury, will require a system that includes a head rest and lateral thoracic supports. The seat itself must be customized to provide a stable base on which the trunk can align. Restraint at the pelvis, such as a seatbelt or bar, helps maintain proper positioning in the chair. Specialized cushions are needed for those with decreased sensation to prevent pressure-related skin sores.

ROBOTIC DEVICES

Rehabilitation robotics is a subspecialty field that is helping to increase independence for individuals with disabilities. Robots are currently defined as machines programmable by a computer and capable of carrying out a complex series of activities automatically. Although there is a wide range of the types of robots used in rehabilitation, a subset of robots provide assistance in the form of adaptive equipment. Most of these robots are wearable; notable exceptions are fully automated voice-controlled feeding systems and speech generating devices. Lower limb devices are designed to help a child progress toward a typical gait pattern and range in complexity from exoskeletons to programable AFOs that provide electrical stimulation to muscles that control foot position and strength across the ankle joint. Upper limb devices are designed to increase the use of a minimally functional arm and hand. Programmable prostheses, such as myoelectric arms and hands, respond to input from the user's neuromuscular system while bionic limbs respond to sensors implanted in the brain. The use of robotic assistive devices is less common than mechanical devices, in part because of availability and in part because of higher cost. The advantage of most robotic assistive devices compared with their mechanical counterparts is the ability of the device to train the user to need it less while providing the assistance required in the moment.

Visit Elsevier eBooks+ at eBooks.Health.Elsevier.com for Bibliography.

Chapter 756

Health and Wellness for Children with Disabilities

Meghan A. Klawonn, David M. Kanter, and Margaret A. Turk

DISABILITY

Children with Special Healthcare Needs

The expansion of the *disability* definition to include children with special healthcare needs (CSHCN), chronic conditions, and activity limitations from any cause (e.g., limitations in usual daily activities such as age-appropriate self-care, mobility, communication, and cognition) has made the health issues of the more *traditional* childhood disability types (e.g., cerebral palsy, intellectual disability, spina bifida, congenital musculoskeletal disorders) more difficult to identify. U.S. data note continued increasing prevalence of developmental disabilities and identify developmental, emotional, and behavioral conditions as the leading conditions. Physical health conditions comprise a smaller proportion of disabilities, although mobility and motor control issues may be noted among the aforementioned developmental, behavioral, and emotional conditions. These disabilities contribute to continued economic and health problems into adulthood. Childhood and adolescent health promotion interventions can decrease functional impairment across the life span. Monitoring children with disabilities throughout their development is essential for identifying times when support to children, adolescents, and/or their families is needed to promote positive health outcomes.

Health Promotion Definitions and Background for Disability

The World Health Organization (WHO) defines *health promotion* as "the process of enabling people to increase control over, and to improve, their health." For people with disabilities, this concept is important because they are both underserved and have comparatively large health disparities. The WHO further defines health promotion approaches as including more than health education and consisting of community action, supportive and accessible environments, policy changes, health service modifications, and development of personal skills. Health and wellness programs also include traditional preventive management strategies, such as anticipatory guidance. There is ample evidence that engaging in specific areas of health promotion results in improvement, although the evidence for its influence on adult health is less robust.

Children with disabilities encounter many barriers to healthy behaviors (Table 756.1). Both broad and focused health promotion programs consider severity of condition, barriers and resources, and self-efficacy to achieve health-promoting behaviors. Children with disabilities may also require modeling or assistance to apply healthy behaviors to their particular disability or economic, social, and environmental circumstances.

Individuals with disabilities and their families often view health differently than those without disabilities. Disability may influence health and

Table 756.1 Barriers and Facilitators for Children to Engage in Healthy Behaviors

SELF	FAMILY	INSTITUTION
BARRIERS	BARRIERS	BARRIERS
1. Lack of knowledge and skills 2. Fear of injury or failure 3. Personal choices 4. Fatigue 5. Lack of initiative 6. Limited functional capability	1. Negative attitudes by parents, peers, healthcare providers 2. Limited parental healthy behaviors 3. Stress in the close family network 4. Economic restrictions	1. Inaccessible facilities or resources 2. Needing adult or aide assistance 3. Policies and procedures of facilities or programs 4. Noninclusive providers 5. Transport challenges
FACILITATORS	FACILITATORS	FACILITATORS
1. Education or knowledge about heathy behaviors 2. Engaging child in discussions and decisions 3. Desire to be active 4. Making activities a part of the routine—repetition and consistency promote ongoing activities	1. Promotion of activities by rehabilitation and other healthcare professionals 2. Family support and participation 3. Involvement of friends and peers in activities 4. Models or directions for participation with adaptions 5. Creative and knowledgeable professionals	1. Accessible facilities and opportunities with knowledgeable staff 2. Policies and resources promoting participation 3. Welcoming and inclusive providers: Adaptable approaches

vice versa, but their perception of their own health and wellness does not equate with their level of disability. Experiences as a child with a disability often foreshadow adult behaviors, especially negative attitudes toward therapy, exercise, and activity. Beliefs of parents, families, and healthcare providers also influence the views of health by children with disabilities. Health promotion programs for these children must (1) understand and support the role and well-being of parents, (2) recognize that parents of children with more functional limitations may require more resources and support, (3) involve children with disabilities in the design of programs and decisions about participation, and (4) address barriers to participation, perceived and real (see Table 756.1).

An effective health and wellness program should involve multiple approaches and opportunities for success by considering novel and inclusive approaches, including partnerships with families, school staff, and rehabilitation providers. Effectiveness requires addressing any mismatch between the child's positive sense of health and well-being and that expected by the healthcare providers; recognizing limitations of an education-only model; engaging the child in discussions about the importance of healthy behaviors, ways to engage in healthy behaviors related to the child's disability and circumstances, and decisions about participation; promoting self-efficacy and self-management of health and wellness in preparation for adult healthcare when possible; and parent and family involvement coupled with sensitivity for the high level of support a family may already be providing for a child with a disability.

Anticipatory Guidance, Counseling, and Preventive Care

Preventive healthcare through health education, anticipatory guidance, and participation in screening and immunization schedules is the mainstay of pediatric public health programs (see Chapter 12). *Bright Futures,* developed by the American Academy of Pediatrics and their collaborators and supported by the Maternal and Child Health Bureau, Health Resources, and Services Administration, provides a knowledge base for pediatric healthcare providers and the public about anticipatory guidance, health promotion, and prevention for children and adolescents with a section in the 4th edition titled "Promoting Health for Children and Youth with Special Health Care Needs." For the general population, 25% of parents receive no information, and <50% receive all recommended guidance. Although parents of CSHCNs report similar or better receipt of general preventive information, it is not clear whether those with higher severity of functional limitations receive this guidance or counseling, and whether it is provided in the context of disability and other circumstances.

CSHCNs require typical prevention, as well as more specific counseling or screening related to their disability. Some of this more specific counseling can be managed by specialty care providers, although CSHCNs often have difficulty obtaining appropriate specialty outpatient services. Additional barriers to care, especially with increasing age of the child, are the lack of accessible medical equipment and facilities. Planning for transitions to adult care should begin early, with consideration of environmental access, preparedness for self-management when possible, and knowledge and skills of local healthcare providers. Although discussions of health risks with adolescents about smoking, drinking, and protected sexual activity should be undertaken, the discussions may require a different focus for adolescents with disabilities. Higher violence and abuse rates toward children with disabilities are reported, for which providers must be vigilant. Internet and social media use increases the risk of bullying and other negative experiences. It appears adolescent females with disabilities are more vulnerable than males to this victimization.

The recommendation is to recognize the need for modifications to typical guidance and to be alert for any signs of emotional disturbances. CSHCNs experience family issues with separation/divorce, mental health and substance abuse problems, incarceration, domestic or neighborhood violence, discrimination, parental death, and maltreatment more than those without special needs. Counseling should be broadened to include questions and discussions about conditions associated with the specific disabilities (e.g., epilepsy or cognitive impairments often seen with cerebral palsy, or neurogenic bladder and bowel in spinal cord dysfunction) or secondary conditions, such as pain, osteoporosis/fractures, or the fatigue seen in many CSHCNs. Early recognition of emotional and psychiatric disorders, at early ages and especially during times of transition, can help to address nationally acknowledged unmet mental healthcare needs. There are also signs of comorbidities commonly seen in adulthood, such as cardiovascular and renal conditions, in children with disability.

Physical Activity and Exercise

National health guidelines recommend at least 60 minutes of physical activity daily for children, but any activity increase from sedentary levels to even moderate activity (30-40 minutes of moderate intensity or 20 minutes of more strenuous activity) provides some health benefit. Health professionals should give specific advice about how children with disabilities can increase their level of activity. Exercise and activity increase aerobic capacity, functional ability, and quality of life for children with many kinds of disabilities and chronic diseases. National 24-hour movement guidelines have been established in Canada and Australia, with age-specific recommendations regarding lengths of time to sleep, perform physical activity, and sedentary time. It has been shown that individuals with disabilities meet the 24-hour movement guidelines at lower rates compared to the general population, which in turn may affect mental health. And yet, many healthcare providers and families accept sedentary lifestyles for children and adolescents with disabilities, whatever their functional abilities. Video gaming systems that involve movement can help to overcome this lack of activity because they can provide another way to increase movement. For children with disabilities, school physical education and recess programs can support activities at or greater than the recommendation, and school requirements can reinforce activity expectations; however, there should be monitoring for possible negative affect, poor sense of belonging, and presence of victimization during open recess opportunities. School-based interventions for adolescents with intellectual and developmental disabilities have been shown to increase healthy behaviors, such as engagement in physical activity and increased consumption of fruit and vegetables. Healthy behaviors are in turn associated with improvement in mental health. The need for exercise beyond physical therapy should be clarified to help children understand the benefits and purpose of both. The activities in which youth with disabilities wish to participate can be supported, and shared decision-making should be invoked. Children with disabilities who participate in physical activities report social benefits, such as developing friendships, building a support system, gaining knowledge of self, and acquiring a sense of accomplishment. These factors also contribute to higher adherence to activities. Children with disabilities may also be more likely to participate in physical activities when those activities are supervised and organized, as opposed to free play in an open room. For children with disabilities to engage in physical activity in supported environments, school and public playgrounds must be made sufficiently accessible to support community physical activity. A number of agencies have endorsed the Commit to Inclusion campaign to promote building healthy, inclusive communities for people of all ages with disability (e.g., the President's Council on Fitness, Sports, and Nutrition, along with the National Center on Health, Physical Activity, and Disability; the American Association on Health and Disability; and the Center on Disability at the Public Health Institute).

Physical activity for children and adolescents improves fitness and quality of life for youth with developmental disabilities (Table 756.2). These exercise and fitness programs require 2-3 months of participation, at least twice a week, to achieve any changes, and many of the changes achieved are longer lasting than expected. These programs are not traditional therapy, and participation in therapy is not a substitute. These focused fitness and

Table 756.2 Examples of Effective Exercise Programs for Children with Disabilities

CENTER-BASED FITNESS PROGRAM AND HOME PROGRAM	GROUP AQUATIC AEROBICS	GROUP TRAINING CLASS	ONLINE EXERCISE PRESCRIPTION TOOL
• Children with a variety of disabilities • Group exercise: 2×/wk for 14 wk, warm-up, aerobics, strengthening, cool-down • Home program: 2×/wk for 12 wk using video exercises • *Outcomes:* improved walking efficiency, strength, general function[a]	• Children with a variety of disabilities, 50% able to walk 2×/wk • Recreation to achieve target heart rate; aquatic strengthening program • *Outcomes:* improved walk/run[b]	• Children with cerebral palsy able to walk 2×/wk for 14 wk • Warm-up, circuit training stations (treadmill, balance stairs, closed-chain exercises) • *Outcomes:* improved muscle strength, mobility, function[c]	• Children with a variety of disabilities • 8 wk home exercise program delivered using Physitrack, an online exercise prescription tool • *Outcomes:* equivalent adherence to traditional paper-based method, more easily accessible[d,e]
• Strength • Training	• Walking-jogging program	• Treadmill training program	• Skill-related fitness (SRF)
• Children with cerebral palsy including a majority able to walk with assistive devices 3×/wk for 6 wk • Progressive training program, conducted in the home • *Outcomes:* improved perceptions of strength, walking, stair management, improved psychologic benefits[f]	• Children with down syndrome • 3×/wk for 10 wk, 30 min sessions, achieving 65–70% peak heart rate • *Outcomes:* improved peak exercise time and grade, improved walking capacity[g]	• Children with intellectual disabilities daily for 2 months • Progressive treadmill use with goal of 20-30 min • *Outcomes:* improved heart rate with and without activities[h]	• Adolescents with intellectual disabilities • SRF is a physical fitness component related to sports performance, used to enhance participation with peers in leisure activities • *Outcomes:* positive exercise training effects on agility, power RT, and speed[i]

[a]From Fragala-Pinkham MA, Haley SM, Rabin J, Kharasch VS. A fitness program for children with disabilities. *Phys Ther.* 2005;85(11):1182–1200.
[b]From Fragala-Pinkham M, Haley SM, O'Neil ME. Group aquatic aerobic exercise for children with disabilities. *Dev Med Child Neurol* 2008;50(11):822–827.
[c]From Blundell SW, Shepherd RB, Dean CM, Adams RD, Cahill BM. Functional strength training in cerebral palsy: A pilot study of a group circuit training class for children age 4-8 years. *Clin Rehabil* 2003;17(1):48–57.
[d]From Johnson RW, Williams SA, Gucciardi DF, Bear N, Gibson N. Can an online exercise prescription tool improve adherence to home exercise programmes in children with cerebral palsy and other neurodevelopmental disabilities? A randomised controlled trial. *BMJ Open.* 2020;10(12):e040108.
[e]From Johnson RW, Williams SA, Gucciardi DF, Bear N, Gibson N. Evaluating the effectiveness of home exercise programmes using an online exercise prescription tool in children with cerebral palsy: protocol for a randomised controlled trial. *BMJ Open.* 2018;8(1):e018316.
[f]From McBurney H, Taylor NF, Dodd KJ, Graham HK. A qualitative analysis of the benefits of strength training for young people with cerebral palsy. *Dev Med Child Neurol.* 2003;45(10):658–663.
[g]From Millar AL, Fernhall B, Burkett LN. Effects of aerobic training in adolescents with Down syndrome. *Med Sci Sports Exerc.* 1993;25(2):270–274.
[h]From Lotan M, Isakov E, Kessel S, Merrick J. Physical fitness and functional ability of children with intellectual disability: effects of a short-term daily treadmill intervention. *Sci World J* 2004;4:449–457.
[i]From Jeng SC, Chang C-W, Liu W-Y, Hou Y-J, Lin Y-H. Exercise training on skill-related physical fitness in adolescents with intellectual disability: A systematic review and meta-analysis. *Disabil Health J.* 2017;10(2):198–206.

exercise programs generally require the support and direction of rehabilitation professionals, although programs can be community based in nonmedical surroundings.

Recreation and organized sports are other areas where children and adolescents with disabilities can engage successfully, at times with modifications. Participation improves cardiopulmonary parameters, motor function, social competence, and general sense of well-being. Many children with disabilities require 1-on-1 instruction for development of skills, with a goal of participation in activities with their peers. Perceived barriers to participation in sports differ based on the source: children were concerned about dependency; parents required more information about possible sport participation. Programs through Special Olympics International are an opportunity for children and adolescents to engage in supportive and monitored environments for sport and recreation.

Rehabilitation professionals can assist with problem-solving activity participation, such as by using computerized technologies for "exergaming" (e.g., Wii, Xbox, PlayStation), developing individual or group challenges with mobile devices (e.g., activity trackers), adapting equipment (e.g., modified upper-limb prosthesis to allow baseball glove use or modified bicycle equipment), and knowing of adapted recreation programs in the area (e.g., horseback riding, winter/water sports). Technologies that allow for exercise as part of gaming provide new opportunities for moderate to vigorous exercise in people with disabilities, especially in those with limited use of the lower limbs. Youth with greater functional limitations may not be able to achieve moderate to vigorous exercise, but even light intensity exercise may be enough to give them some health benefits. "Exergaming" programs are viewed as more fun than traditional exercises, which may increase likelihood of participation.

Sleep and Pain

Poor sleep quality or the presence of pain will have an impact on physical activity and general performance in children and youth with disabilities. Regular inquiry about sleep and pain is important because of the higher prevalence of problems in these areas in children with disabilities. Common sleep disturbances include difficulty initiating sleep, frequent sleep disruptions, and reduced sleep duration. Causes are often complex and multifactorial, with some associations with disability type (e.g., obstructive sleep apnea with Down or Prader-Willi syndromes, disrupted sleep patterns with autism, negative bedtime behaviors with attention-deficit/hyperactivity disorder, pain as trigger with cerebral palsy) and comorbidities (e.g., epilepsy, gastroesophageal reflux). Frontline approaches are sleep hygiene and behavioral interventions, and further evaluation may be warranted for targeted interventions (see Chapter 31).

Pain has been described as a cause for behavioral changes, poor sleep, activity interference, and change in school performance in children with a variety of disabilities. Children with cerebral palsy have been most closely studied, with high prevalence of both acute and chronic pain. Routine screening is important for early identification and evaluation for cause, and interventions should be tailored to address the biopsychosocial model of pain management.

Nutrition and Obesity

See also Chapter 65.

Managing the combination of nutrition and physical activity is the key ingredient of weight control. Estimates suggest that children with physical activity limitations were twice as likely as the general population to be overweight, and youth with cognitive impairments are at increased risk. It is unclear if obesity is a cause for the activity limitations or is a result of the limited activity, which may be an important distinction in developing interventions. The concern with obesity contrasts with early life weight gain needs of many children with disabilities, and it may be confusing for parents and families when the focus changes to weight decrease. Confounding factors related to monitoring percent body fat in children with disability include (1) the propensity for some disabilities, often those that are genetically mediated, to be associated with obesity; (2) standards of measurement may not be appropriate for certain diagnoses or disability types (e.g., inaccurate weight [limb deficiencies/amputation, scale inaccessibility], inaccurate height [unable to stand, contractures], no standards related to short stature or muscle wasting); (3) obesity may be a side effect of medication, and this effect must be balanced against the drug benefits (e.g., antipsychotics, steroids); and (4) the social network of family, friends, schools, and healthcare providers may unwittingly negatively influence health habits, including use of food as reward for behavior management. Both children and their parents should be a part of the conversations related to obesity or any weight-related topic. Information must be presented in a direct and understandable way and modified for the child's and parents' needs. Discussion of promoting health through nutrition and physical activity, while problem solving challenges to participation, may be a better approach than explaining body composition and metabolic pathways.

Emotional Health and Leisure Activities

Emotional health is often overlooked in children with disabilities. Youth and adolescents with disabilities appear to be at higher risk for feeling low, stressed, or anxious (especially those with higher levels of limitations), and those with mental health needs may have lower adaptive functioning or a family history of mental illness. While children and young adults diagnosed with autism have received much attention related to emotional support needs, there are increasing reports of this need with most childhood-onset disability conditions, including at ages before teenage years. Sexuality, gender identity, and other sex-related issues can also be reasons for emotional turmoil. Adolescents with physical disabilities participate in fewer social activities, have fewer close or intimate friends, and have fewer plans for ongoing education. There is a risk for continued isolation into adulthood. Passive social media use may exacerbate this problem. Novel programs to improve self-concept and build resilience based on psychoeducational therapy principles, typically developed through interdisciplinary teams, and involving peer groups, parents, and family members, have been shown to successfully promote positive outcomes. Medications may be considered, but effectiveness is not guaranteed, and unwanted side effects may produce more health challenges. Counseling requires insurance support or discretionary funding. There is some early work on using apps to try and help track mental health issues.

Leisure and recreational activities provide social supports, additional stress-coping mechanisms, and ability to develop social skills and a stronger personal identity. Although the negative aspects of social media are often discussed, there are also positive aspects. Adolescents with disabilities may more easily communicate and socialize with peers online, improving their mental well-being. Females with disabilities tend to engage in social or skill-based activities, and males in physical activities, with decreasing participation with increasing age. In general, encouraging socialization through leisure activities, recreation, or sports and physical activity can be a part of counseling in a routine health visit.

Dental Care

Dental care is a frequently unmet healthcare need for children with disabilities, especially for those in low-income families or with more severe impairments. The principal deficits are in receipt of specific dental care (not preventive services). Condition severity may also predict the degree to which parents are interested in oral health–related education and actually engage in oral health efforts. Parents and caregivers play a critical role in oral health support. Challenging behaviors often limit dental care, and the use of behavior management techniques and education programs have been effective in allowing dental care. Dental treatment under anesthesia may be necessary to provide effective oral healthcare.

Role of Healthcare Providers

Primary care and other healthcare providers should be mindful of discussing and promoting health and healthy behaviors with children and adolescents with disabilities and their families (Table 756.3). Initial discussions and preventive screening, including exploration for early signs of cardiovascular or renal diseases and assessing the need for emotional support, are a responsibility of primary care providers individually or in conjunction with specialty care providers. Children with a wide range of impairments should be included in multi-method inclusive research. Innovative strategies for engaging

Table 756.3 Targeting Healthy Behaviors for Children with Disabilities

GENERAL PREVENTION	PHYSICAL ACTIVITY	NUTRITION AND OBESITY
• Recognize risks for less healthy behaviors and facilitators of behavior changes and participation. • Cover typical topics for all children counsel regarding disability or situation context. • Specifically monitor for abuse and violence. • Provide typical age-appropriate adolescent information about smoking, drinking, substance abuse, sexual contacts; refer if unable to provide. • Monitor for disability-specific health conditions; many require referral.	• Promote exercise and activity with an expectation for activity. • Ensure that family and child/adolescent are knowledgeable about benefits and possible adaption. • Review need for possible dietary changes. • Consider referral to community programs and/or rehabilitation professionals	• Recognize obesity can cause limitations and can be the result of poor dietary habits and limited activity. • Follow percent body fat in a consistent way, recognizing the need for accurate measures or limitations of measures (e.g., weight, body mass index [BMI], skinfold thickness, other traditional measures) in many disability conditions. • Ensure that family and child/adolescent are knowledgeable about healthy nutrition. • Consider referral to nutritionist or other professional to engage patient and family in education and behavior change counseling • Review need for increased activity level with dietary intervention.
EMOTIONAL	**HEALTH, RECREATION, AND LEISURE**	**DENTAL**
• Question for sense of anxiety/feeling low, stress management and ability to adapt, and social supports. • Consider medications and counseling based on expected effect, monitor effects/side effects; consider referral, making sure that insurance/payment coverage is available. • Consider recreation and leisure activities to promote social support and ability to develop social skills. • Recommend use of social media in positive ways to enhance connections.	• Question about social activities outside the home: highlight the importance of developing social skills, sense of self, and support networks • Consider referral to community programs or rehabilitation professionals. • Consider recommending online support groups, social groups.	• Discuss more than preventive dental care. • Suggest behavior strategies if there are problems engaging in dental appointments and refer for this service as needed.

children with disabilities have been identified and offer much hope for the future. Parents are more likely to positively engage with a referral to healthcare professionals with expertise in providing a more tailored approach to health promotion after initial advice and support. Strategizing with parents about accessible environments or opportunities can promote inclusive community opportunities for participation. Providers should be willing to discuss intimate relationships and sex-related issues at appropriate times as they do with youth without disabilities—and refer when unable to meet those needs. Family-centered and coordinated care, commonly found in medical homes, can support healthy behaviors and emergency planning for unforeseen events.

Visit Elsevier eBooks+ at eBooks.Health.Elsevier.com for Bibliography.

Environmental Health

PART XXXII

Chapter 757

Overview of Environmental Health and Children

Ruth A. Etzel

GLOBAL CLIMATE CHANGE

Pediatricians' primary goal is prevention. One dominant prevention challenge of the 21st century is the climate crisis. The Intergovernmental Panel on Climate Change concluded that the Earth is undergoing adverse global climate change and that anthropogenic (human-made) contributions are significant. These climate changes are creating conditions that have already affected public health, with disproportionate impacts on certain life stages, including children. Children are especially vulnerable to the impacts of climate change because their bodies are growing and developing, they have unique behaviors and interactions with their environment, and they must rely on parents or caregivers to provide for their basic needs. Climate change affects children's health as a result of their exposure to elevated temperatures; more frequent, severe, or longer-lasting extreme weather events; transmission rates of food-borne, waterborne, and vector-borne diseases; increases in air pollution from molds, pollens, and the burning of fossil fuels; and mental health stressors (Fig. 757.1). Natural disasters such as floods and hurricanes, damp housing, and mycotoxin-related illnesses are worsening as temperatures and sea levels rise. The impacts are being felt most among young children and those who are living in poverty. The need to reduce carbon dioxide in the environment has compelled many countries to sign the Paris Agreement. This agreement promises to keep the global temperature rise well below 2°C above preindustrial levels, and to try to limit the temperature increase to 1.5°C. Even though the Paris Agreement began in 2016, its promises have not been kept and the temperature is already 1.2°C higher than in the preindustrial era. Individual actions are another necessary step in carbon dioxide reduction. Parents and caregivers can work to reduce their family's burning of fossil fuels. They also can protect children's health by checking the air quality index and pollen counts and considering a limit to children's outdoor play time if levels are high. Parents can watch for signs of dehydration or overheating in their children and can prevent tick and mosquito bites by using insect repellent and protective clothing. Pediatricians and those who care for children can be highly effective advocates for an urgent governmental response to the climate crisis by speaking out at the community, national, and international level.

LOCALIZED ENVIRONMENTAL HAZARDS

Localized exposures to a wide variety of chemical, biologic, and physical agents can also harm children. Numerous epidemics of disease from chemical, biologic, and physical agents (both natural and human-made) over the past 80 years have documented a variety of adverse outcomes among children (Table 757.1). Some epidemics, such as those caused by the nighttime release of methyl isocyanate from a factory in Bhopal, India, the nuclear meltdown in Chernobyl, and the melamine contamination of infant formula in China, received widespread attention and heightened the awareness of parents and pediatricians about hazards in the environment. For many people, the word *epidemic* conjures up images of hospital isolation wards, poor sanitation, and rapidly spreading infectious diseases. Epidemics of environmental origin often have served to elucidate new hazards for children. Many of the routinely used chemicals understood to be toxic to children were initially identified when a cluster of children was exposed and developed symptoms during a relatively short period of time. Unfortunately, the children served as the "canaries in the coal mine" to indicate that specific chemicals (including thallium, mercury, arsenic, and lead) contained in products for children such as diaper rinses, teething powders, and depilatory agents, posed a threat to their health. The comparison of children to canaries is apt: following underground mine explosions, canaries were used by miners throughout recent history to help detect elevated levels of carbon monoxide gas. Canaries were useful "carbon monoxide detectors" because of their rapid breathing rate and high metabolism, making them more sensitive to the effects of gases, including carbon monoxide. Likewise, young children have a rapid breathing rate and a high metabolic rate and may be more sensitive than adults to chemicals in the environment.

Table 757.1 summarizes major incidents of environmental poisoning that affected children. The characteristics of environmental exposure and the age and developmental stage of the child affect the likelihood of developing health problems. After the release of methyl isocyanate (used in the production of some pesticides) at Bhopal in 1984, an estimated 200,000 children living near the Bhopal chemical plant were affected by the gas release (see Table 757.1). Methyl isocyanate gas is 1.4 times heavier than air; thus higher concentrations of the gas were found near the ground or floor. Because of their short stature, children's breathing zones are closer to the ground or floor than adults' breathing zones; therefore children likely inhaled higher concentrations of the toxic gas. Children exposed to the same levels of methyl isocyanate as adults may have received larger doses because they have relatively greater lung surface area to body weight ratios and higher minute volume to weight ratios. Based on each of the poisoning events listed in Table 757.1, additional precautions were taken to avoid children's unnecessary exposure to the specific product or chemical implicated.

Although major poisonings such as those listed in Table 757.1 have caused substantial morbidity and mortality among children, environmental health hazards may also result in more subtle effects that may not manifest until later in life. In addition to the exposures received during large outbreaks, children receive smaller doses of chemicals on an almost daily basis through the water they drink, the food they eat, and the air they breathe. Because of their unique vulnerability, they may exhibit symptoms from these exposures earlier than do adults.

TOXINS VERSUS TOXICANTS

A toxin is a poisonous substance produced naturally by a living organism (e.g., aflatoxin). A toxicant is a poisonous substance made by humans or introduced into the environment by human activity (e.g., dioxins). Synthetic chemicals are referred to as toxicants.

MYCOTOXINS

Children's exposures to mycotoxins, the toxins produced by certain fungi on grains, nuts, and other crops, will likely increase as the

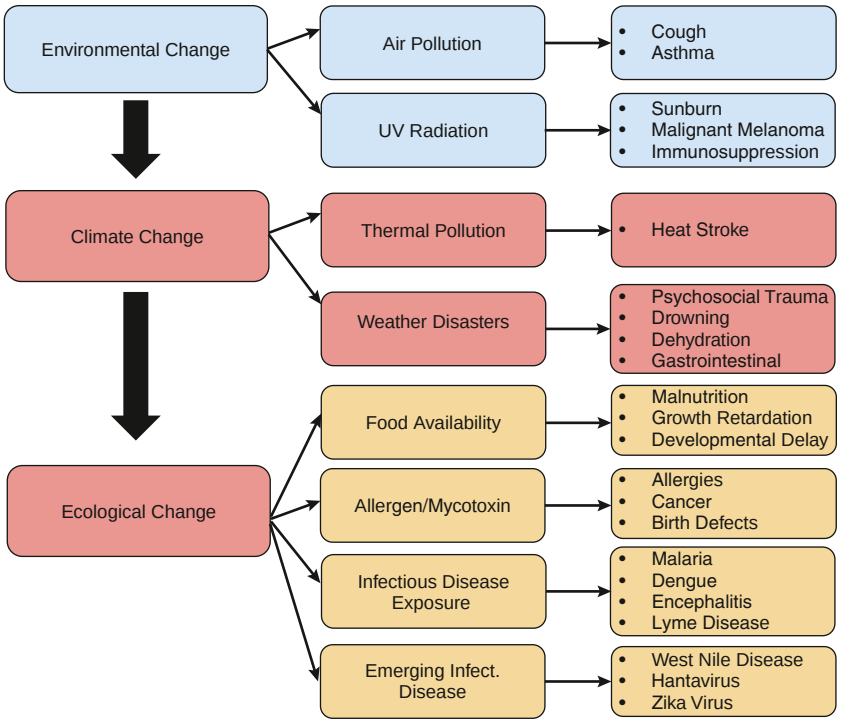

Fig. 757.1 The relationship between environmental change, climate change, ecologic change, and child health. *(Adapted from Bunyavanich S, Landrigan CP, McMichael AJ, et al. The impact of climate change on child health. Ambul Pediatr. 2003;3:44–52. Fig. 2.)*

Table 757.1 Epidemics of Environmental Disease Affecting Children

CONTAMINANT	VEHICLE	DATE	COUNTRY	APPROX. # SICKENED	ILLNESS	APPROX. # WHO DIED
Thallium	Depilatory agents	1930	Grenada	16	Thallotoxicosis	13
Methylmercury	Fish and shellfish	1956	Japan	2,265	Cerebral palsy	1,784
Arsenic	Contaminated milk powder	1955	Japan	11,778	Fever, diarrhea darkened skin, swollen abdomen	113
Hexachlorobenzene	In human milk after pregnant women ate HCB-treated seed grain	1957	Turkey	~200	Pembe yara (pink sore) rash, weakness convulsions	<2 yr ~200
Methyl isocyanate	Leak from chemical plant	1984	India	<15 yr: 200,000	Coughing, eye irritation choking death	All ages 2,500-5,000
Dioxin	Chemical plant explosion	1976	Italy	193 (88%)	Chloracne	0
Radiation	Chernobyl	1986	Ukraine	<18 yr: 4,000	Thyroid cancer	~8
Radiation	Scrapped medical machine stolen from hospital	1987	Goiânia, Brazil	249	Acute radiation syndrome	4 (1 child)
Fungi	Water-damaged homes	1990s	Ohio, US	30	Pulmonary hemorrhage	5
Aflatoxin	Grain	2004	Kenya	317	Aflatoxicosis	125
Melamine	Infant formula	2008	China	290,000	Kidney stones	6
Lead	Small-scale gold mining	2010	Nigeria	>2,000	Seizures, death	200

climate changes because their production is influenced by temperature, humidity, and rainfall. Exposure to mycotoxins results in different health outcomes dependent on the route of exposure. Exposure from eating or drinking may lead to gastrointestinal illness, tremors, and cancer in adulthood; exposure via breathing may result in acute respiratory illness during infancy. There also is emerging evidence linking mycotoxin exposures among children, especially those in developing countries, to stunted growth.

Pediatric Conditions Linked to Mycotoxin Exposures

Exposures to mycotoxins have been linked to at least two conditions that affect children: neural tube defects and acute pulmonary hemorrhage.

Neural Tube Defects

Studies of an epidemic of birth defects in 1990 in south Texas suggested an association between maternal ingestion during pregnancy of high levels of fumonisin, universally present in corn and in corn-based products, and birth defects such as anencephaly and spina bifida. Fumonisins are known to interfere with cellular folate uptake.

Infant Pulmonary Hemorrhage

Several studies of a 1994 epidemic of acute pulmonary hemorrhage in Cleveland, Ohio, documented a novel association between life-threatening pulmonary hemorrhage and the presence of the toxigenic mold *Stachybotrys* in the water-damaged homes in which the infants were living. *Stachybotrys* produces mycotoxins that are lipid soluble and readily absorbed by the airways, as well as a hemolysin and several proteinases that can degrade vascular collagen. In subsequent years, *Stachybotrys* and other toxigenic fungi including *Trichoderma* have been associated with acute pulmonary hemorrhage among infants in other areas of the United States, Canada, and New Zealand. The rapidly growing lungs of infants are especially vulnerable to the effects of the trichothecene mycotoxins produced by *Stachybotrys* and *Trichoderma*.

FOOD-BORNE DISEASES CAUSED BY ENVIRONMENTAL EXPOSURES

Contamination of food with viruses and bacteria is a major cause of childhood food-borne diseases (see Chapter 387), and children are also at risk from a variety of noninfectious food-borne hazards in the environment, which include natural hazards such as mycotoxins and synthetic persistent organic pollutants such as dioxins (see Chapter 759; Table 757.2).

Table 757.2 Food-Borne Illnesses (Noninfectious)

ETIOLOGY	INCUBATION PERIOD	SIGNS AND SYMPTOMS	DURATION OF ILLNESS	ASSOCIATED FOODS	LABORATORY TESTING	TREATMENT
Antimony	5 min to 8 hr usually <1 hr	Vomiting, metallic taste	Usually self-limited	Metallic container	Identification of metal in beverage or food	Supportive care
Arsenic	Few hours	Vomiting, colic, diarrhea	Several days	Contaminated food	Urine; may cause eosinophilia	Gastric lavage BAL (dimercaprol)
Cadmium	5 min to 8 hr usually <1 hr	Nausea, vomiting, myalgia, increase in salivation, stomach pain	Usually self-limited	Seafood, oysters, clams, lobster, grains, peanuts	Identification of metal in food	Supportive care
Ciguatera fish poisoning (ciguatera toxin)	2-6 hr	**GI:** abdominal pain, nausea, vomiting, diarrhea	Days to weeks to months	A variety of large reef fish, grouper, red snapper, amberjack, and barracuda (most common)	Radioassay for toxin in fish or a consistent history	Supportive care, IV mannitol; children more vulnerable
	3 hr	**Neurologic:** paresthesias, reversal of hot and cold, pain, weakness				
	2-5 days	**Cardiovascular:** bradycardia, hypotension, increase in T-wave abnormalities				
Copper	5 min to 8 hr usually <1 hr	Nausea, vomiting, blue or green vomitus	Usually self-limited	Metallic container	Identification of metal in beverage or food	Supportive care
Mercury	1 wk or longer	Numbness, weakness of legs, spastic paralysis, impaired vision, blindness, coma Pregnant women and developing fetuses are especially vulnerable	May be protracted	Fish exposed to organic mercury, grains treated with mercury fungicides	Analysis of blood, hair	Supportive care
Mushroom toxins, short-acting (museinol, muscarine, psilocybin, coprius artemetaris, ibotenic acid)	<2 hr	Vomiting, diarrhea, confusion, visual disturbance, salivation, diaphoresis, hallucinations, disulfiram-like reaction	Self-limited	Wild mushrooms (cooking may not destroy these toxins)	Typical syndrome and mushroom identified or demonstration of the toxin	Supportive care

Continued

Table 757.2 Food-Borne Illnesses (Noninfectious)—cont'd

ETIOLOGY	INCUBATION PERIOD	SIGNS AND SYMPTOMS	DURATION OF ILLNESS	ASSOCIATED FOODS	LABORATORY TESTING	TREATMENT
Mushroom toxin, long-acting (amanitin)	4-8 hr diarrhea; 24-48 hr liver failure	Diarrhea, abdominal cramps, leading to hepatic and renal failure	Often fatal	Mushrooms	Typical syndrome and mushroom identified and/or demonstration of the toxin	Supportive care, life-threatening, may need life support
Nitrite poisoning	1-2 hr	Nausea, vomiting, cyanosis, headache, dizziness, weakness, loss of consciousness, chocolate brown–colored blood	Usually self-limited	Cured meals, any contaminated foods, spinach exposed to excessive nitrification	Analysis of food, blood	Supportive care, methylene blue
Pesticides (organophosphates or carbamates)	Few minutes to few hours	Nausea, vomiting, abdominal cramps, diarrhea, headache, nervousness, blurred vision, twitching, convulsions, salivation, and meiosis	Usually self-limited	Any contaminated food	Analysis of food, blood	Atropine: 2-PAM (pralidoxime) is used when atropine is not able to control symptoms and is rarely necessary in carbamate poisoning
Puffer fish (tetrodotoxin)	<30 min	Paresthesias, vomiting, diarrhea, abdominal pain, ascending paralysis, respiratory failure	Death usually in 4-6 hr	Puffer fish	Detection of tetrodotoxin in fish	Life-threatening, may need respiratory support
Scombroid (histamine)	1 min to 3 hr	Flushing, rash, burning sensation of skin, mouth, and throat, dizziness, urticaria, paresthesias	3-6 hr	Fish: bluefin, tuna, skipjack, mackerel, marlin, escolar, and mahi mahi	Demonstration of histamine in food or clinical diagnosis	Supportive care, antihistamines
Shellfish toxins (diarrheic, neurotoxic, amnesic)	Diarrheic shellfish poisoning (DSP)—30 min to 2 hr	Nausea, vomiting, diarrhea, and abdominal pain accompanied by chills, headache, and fever	Hours to 2-3 days	A variety of shellfish, primarily mussels, oysters, scallops, and shellfish from the Florida coast and the Gulf of Mexico	Detection of the toxin in shellfish; high-pressure liquid chromatography	Supportive care, generally self-limiting
	Neurotoxic shellfish poisoning (NSP)—few minutes to hours	Tingling and numbness of lips, tongue, and throat, muscular aches, dizziness, reversal of the sensations of hot and cold, diarrhea, and vomiting				
	Amnesic shellfish poisoning (ASP)—24-48 hr	Vomiting, diarrhea, abdominal pain and neurologic problems such as confusion, memory loss, disorientation, seizure, coma				
Shellfish toxins (paralytic shellfish poisoning)	30 min to 3 hr	Diarrhea, nausea, vomiting leading to paresthesias of mouth, lips, weakness, dysphasia, dysphonia, respiratory paralysis	Days	Scallops, mussels, clams, cockles	Detection of toxin in food or water where fish are located; high-pressure liquid chromatography	Life-threatening, may need respiratory support

Table 757.2 Food-Borne Illnesses (Noninfectious)—cont'd

ETIOLOGY	INCUBATION PERIOD	SIGNS AND SYMPTOMS	DURATION OF ILLNESS	ASSOCIATED FOODS	LABORATORY TESTING	TREATMENT
Sodium fluoride	Few minutes to 2 hr	Salty or soapy taste, numbness of mouth, vomiting, diarrhea, dilated pupils, spasms, pallor, shock, collapse	Usually self-limited	Dry foods (e.g., dry milk, flour, baking powder, cake mixes) contaminated with sodium fluoride–containing insecticides and rodenticides	Testing of vomitus or gastric washings, analysis of food	Supportive care
Thallium	Few hours	Nausea, vomiting, diarrhea, painful paresthesias, motor polyneuropathy, hair loss	Several days	Contaminated foods	Urine, hair	Supportive care
Tin	5 min to 8 hr, usually <1 hr	Nausea, vomiting, diarrhea	Usually self-limited	Metallic container	Analysis of food	Supportive care
Vomitoxin	Few minutes to 3 hr	Nausea, headache, abdominal pain, vomiting	Usually self-limited	Grains such as wheat, corn, barley	Analysis of food	Supportive care
Zinc	Few hours	Stomach cramps, nausea, vomiting, diarrhea, myalgias	Usually self-limited	Metallic container	Analysis of food, blood, and feces, saliva, or urine	Supportive care

BAL, Bronchoalveolar lavage; GI, gastrointestinal; IV, intravenous.
Adapted from Centers for Disease Control and Prevention. Diagnosis and management of foodborne illnesses: a primer for physicians and other health care professionals. *MMWR*. 2004;53(No. RR-4):1–33.

Aflatoxins

Aflatoxins are poisonous substances that are formed as a result of mold growth on peanuts, corn, figs, oil-seeds, tobacco, and other products. The International Agency for Research on Cancer (IARC) has classified aflatoxin B1 as a group I carcinogen (known to be carcinogenic to humans). Ingestion of elevated levels of aflatoxin also can result in acute aflatoxicosis, characterized by vomiting, abdominal pain, hepatitis, and sometimes death.

Ochratoxin A

The mycotoxin ochratoxin A, produced by many different species of *Aspergillus* molds, is toxic to the kidneys. Ochratoxin A contaminates many foods, including barley, rye, and other cereals, cereal-derived foods, dry fruits, beans, cocoa, coffee, beer, wine, poultry, eggs, pork, and milk. Ochratoxin A is teratogenic, immunotoxic, genotoxic, and mutagenic. The IARC has indicated that ochratoxin is a possible human carcinogen (category 2B).

Fumonisins

Fumonisins are mycotoxins that may contaminate cornmeal and cereals. The fumonisins are known to interfere with sphingolipid metabolism. Consuming foods contaminated with fumonisins during pregnancy has been linked to an increased risk of having a child with a neural tube defect and an increased risk of esophageal cancer in adulthood.

Deoxynivalenol

This mycotoxin, often called *vomitoxin* because its predominant effect is vomiting, can be present in foods made from wheat and corn. Even after the grain is baked or cooked, vomitoxin retains its toxicity. Multiple epidemics of vomiting illness that occurred in China during 1961 to 1985 were associated with ingesting grain contaminated with vomitoxin. In India in 1987, almost 100 people started vomiting after they ate wheat products that contained vomitoxin and other mycotoxins. For infants, the estimated tolerable daily intake is 1.5 μg/kg body weight. A suspected epidemic of vomitoxin-related illness that affected about 1,700 school children in the United States in 1997-98 was linked to burritos that had measurable levels of vomitoxin of 0.3 parts per million (ppm; the advisory level set by the U.S. Food and Drug Administration for adults is 1 ppm).

Visit Elsevier eBooks+ at eBooks.Health.Elsevier.com for Bibliography.

Chapter 758

Biologic Effects of Ionizing Radiation on Children

Samuel L. Brady and Donald P. Frush

DIAGNOSTIC IMAGING, RADIATION THERAPY

Ionizing radiation is produced when energy is absorbed within an atom such that a bound electron is liberated, and the atom becomes ionized. Exposure to ionizing radiation is characterized by three

categories: (1) **absorbed dose**, (2) **equivalent dose**, and (3) **effective dose**. In terms of radiation interaction with humans, absorbed dose is defined as the energy imparted (i.e., absorbed) within a mass of tissue from a radiation source. Absorbed dose is calculated based on the attenuation properties of the irradiated tissue (e.g., attenuation is greater in bony tissue due to its higher electron density and mass than water equivalent, soft tissue organs). The units of absorbed dose, as defined by the International Commission of Radiation Units, are the **Gray** (Gy), the preferred unit, and the older radiation absorbed dose **(rad)**. There are different types of radiation including x-ray, γ-ray, α particles (helium nucleus stripped of all electrons), β particles (unbound electrons), neutrons, and protons. Not all radiation has the same effect on biologic tissue for a given absorbed dose; for example, β particles are quite superficial, protons deposit most of their energy deeper within the body, and α particles and neutrons cause significantly more damage than x-rays or γ-rays. Diagnostic imaging uses x-rays and γ-rays. The therapeutic use of radiation for cancer treatment primarily uses x-rays, β particles, and protons depending on their application and location of disease within the body. **Equivalent dose** is a term used to define the relative effectiveness to cause biologic damage. The International Commission on Radiological Protection (ICRP) gives x-rays, γ-rays, and β particles a relative weighting of 1, protons a weighting of 2, neutrons a weighting of 2.5-20 (neutron weighting factor depends on the energy of the neutron), and α particles a weighting of 20. Thus, for the same level of radiation exposure to an organ, the equivalent dose, i.e., the relative level of biologic damage, would be higher for absorbed doses from protons compared with x-rays. **Effective dose** is a term that represents "the sum of the weighted [applying organ and tissue weighting factors] equivalent doses for the radiosensitive tissues and organs of the body" (National Council on Radiation Protection and Measurements). A list of relative organ and tissue weighting factors defined by the ICRP is provided in Table 758.1. Equivalent dose and effective dose are measured in units of **sievert** (Sv), with levels in diagnostic imaging typically in millisieverts (mSv), and the **rem** (older unit) (Table 758.2). Effective dose is not applied as a metric of dose to an individual but is a population average. Effective dose is not adjusted based on real or potential radiation susceptibilities for tissues for either gender or age.

Nuclear medicine and PET imaging examinations are described by the amount of radioactivity given, commonly injected intravenously. Administered radioactivity is referred to as the administered radiopharmaceutical dose, commonly defined in millicuries (mCi) or megabecquerels (MBq). Radiopharmaceutical dose may be converted to effective dose by applying correction factors provided in ICRP reports 53, 80, 106, and 128.

For the average adult, ionizing radiation exposure occurs from both natural (60%) and medical (40%) sources, and for the average pediatric-age individual, ionizing radiation exposure occurs primarily from natural sources (91%) as compared to medical sources (9%) (National Council on Radiation Protection and Measurements). Radon gas accounts for the majority of natural radiation exposure. For the adult population, the percentage contribution from medical imaging to the total ionizing radiation exposure had been increasing in the late 20th and early 21st century, but is now declining since 2006. As of 2016, for the average adult, CT imaging comprised 63% of the total of ionizing radiation procedures (Fig. 758.1A), but medical imaging accounted for only 42% of the average adult population exposure to ionizing radiation; this has decreased slightly in the past decade due to technologic advances in imaging equipment and how we use the equipment in practice. For the pediatric patient population, CT remains the primary source of medical radiation exposure, accounting for 84% of the total medical exposure (annual per capita exposure) from ionizing radiation (see Fig. 758.1B). Despite efforts to educate the medical community and the public on radiation safety and the guiding principle of keeping radiation dosing "as low as reasonably achievable (ALARA)," understanding of sources, amounts, and potential risks of ionizing radiation can still be limited. Some imaging procedures do not produce ionizing radiation (Table 758.3), and not all ionizing radiation-producing modalities expose a child to the same amount of radiation (Table 758.4). To facilitate choosing the appropriate imaging modality for a patient's clinical indications, American College of Radiology appropriateness criteria have been published (https://www.acr.org/Clinical-Resources/ACR-Appropriateness-Criteria) to assist referring physicians in making the most appropriate imaging or treatment decision for a specific clinical condition.

Table 758.1 Tissue Radiosensitive Weighting Factors; ICRP Report 103

TISSUE	TISSUE WEIGHTING FACTOR (W_T)	$\sum w_T$
Red bone marrow, colon, lung, stomach, breast, remainder tissues*	0.12	0.72
Gonads	0.08	0.08
Bladder, esophagus, liver, thyroid	0.04	0.16
Bone surface, brain, salivary glands, skin	0.01	0.04
Total		1.00

*Remainder tissues: Adrenal glands, extrathoracic region, gallbladder, heart, kidneys, lymphatic nodes, muscle, oral mucosa, pancreas, prostate, small intestine, spleen, thymus, uterus/cervix

BIOLOGIC EFFECTS OF RADIATION

Biologic effects of radiation are divided into **tissue reactions** (previously known as **deterministic effects**) and **stochastic effects**. Tissue reactions do not occur below a threshold absorbed dose, and severity is directly related to the magnitude once the threshold is exceeded. No evidence of tissue reactions has been demonstrated from radiation dose levels typical of diagnostic imaging examinations (i.e., <100 mGy), but complicated interventional procedures have on rare occasions led to these effects. Typical tissue reactions can present as temporary hair loss (epilation) and skin reddening (erythema), which occur in regions of peak dose of >2 Gy (Table 758.5). Cataracts have been reported to occur with acute exposure of >0.5 Gy.

The second type of biologic effect is the **stochastic effects** that are of concern because they are assumed to potentially occur at any dose; that is, there is no threshold. Stochastic effects are most commonly discussed as cancer risk but also include heritable effects. The probability of a stochastic effect increases with rising level of absorbed dose, but not the severity. Cancer, if radiation induced, is not more severe with higher doses. It is generally accepted by the scientific and medical community that stochastic effects may be caused by any level of radiation striking vulnerable tissue (most importantly DNA, but cytoplasm also may be at risk) and causing irreversible damage. The most widely accepted model representing stochastic effects is the **linear no (dose) threshold (LNT) model**. This model maintains that any level of radiation dose has a potential risk, although this risk is currently uncertain at effective dose levels below 50-100 mSv. Greater than this range, there is a recognized, although very small, statistically significant risk of a stochastic effect. In the LNT model, no level of radiation exposure is assumed to be safe.

Table 758.2 Radiation Measurements

UNITS	RADIOACTIVITY	ABSORBED DOSE	EFFECTIVE DOSE	EXPOSURE
Common units	Curie (Ci)	rad	rem	Roentgen (R)
SI units*	Becquerel (Bq)	Gray (Gy)	Sievert (Sv)	Coulombs/kg
CONVERSION EQUIVALENTS 1 millicurie (mCi) = 37 megabecquerels (MBq) 100 rad = 1 Gy (1 rad = 1 cGy) 100 rem = 1 Sv (1 rem = 10 mSv) Background radiation dose is approximately 10 μGy/day (1 millirad/day)				

*SI units: International System of Units.

Radiation can cause permanent cell injury leading to carcinogenesis, genetic variants, or cell death. The biologic effects of radiation result primarily from damage to DNA. **Direct effect** reactions occur mainly through interactions of high **linear energy transfer (LET)** particles, such as α particles or neutrons, directly with the DNA structure. A similar mechanism also can occur with x-ray or γ-ray photons by directly liberating an electron from atoms (called a recoil electron) near the DNA structure. The kinetic energy of the recoil electron or high LET particles may directly cleave chemical bonds in the DNA structure.

An **indirect effect** is caused by the formation of free radicals. This is the more common mechanism with x-rays and γ-rays used in medical imaging. Approximately 80% of the cell is water, so most of the energy deposited in a cell results in the production of aqueous free radicals. This occurs when the absorbed x-ray or γ-ray photon energy is converted to recoil electrons that create ion radicals (H_2O^+ and H_2O^-). The ion radicals promptly decay (10^{-18} to 10^{-3} seconds) into free radical species (OH^-, H^+, H_3O^+). Approximately two thirds of DNA damage is believed to be caused by this indirect effect through creation of hydroxyl (OH^-) free radicals, which then primarily reacts with DNA by attaching to the hydrogen bound to the deoxyribose carbon resulting in a base release from the DNA structure and strand break of the DNA helix. The biochemical changes that follow either direct or indirect effects take hours or days to manifest, whereas the physiologic changes leading to the likely complex cascade of a variety of factors for cancer induction may take years to decades to manifest.

The results from DNA injury are variable. The cell containing the damaged DNA almost always repairs itself and continues as a viable cell for miotic division. In some instances, the cell might die; one form of cell death is called **apoptosis**, which is a common pathway to eliminate heavily damaged and potentially mutable cells. Damage to a single base pair from radiation exposure is the most prevalent and least significant effect. Ninety percent of single-strand DNA breaks are repaired within an hour by naturally occurring DNA repair processes; therefore they usually have little biologic significance because each strand is repaired with use of the opposite strand as a template. Though less likely, a pathogenic variant can result from single-strand break repair if inaccurate repairs occur; however, large regions of the DNA genome on somatic cells are not active or do not have genes that are expressed. Inaccurate repair in these regions of the genome lead to minimal biologic effect and are sufficient to produce viable cells.

Breakage of both strands of DNA (i.e., double-strand break) is the least common event, but more problematic. The ultimate outcome for cell viability depends on the proximity of the break in each strand. If widely separated (greater than 10 base pairs), which is essentially two remote single-strand breaks, repairs occur rather seamlessly. If the breaks in the two strands are opposite or near each other (separated by less than 10 base pairs), repair is more difficult as there is no reciprocal base pair to serve as a "memory" template. Radiation-induced double-stranded breaks generally lead to cell death or **chromosomal misrepair,** potentially leading to pathogenic gene variants that may result in carcinogenesis.

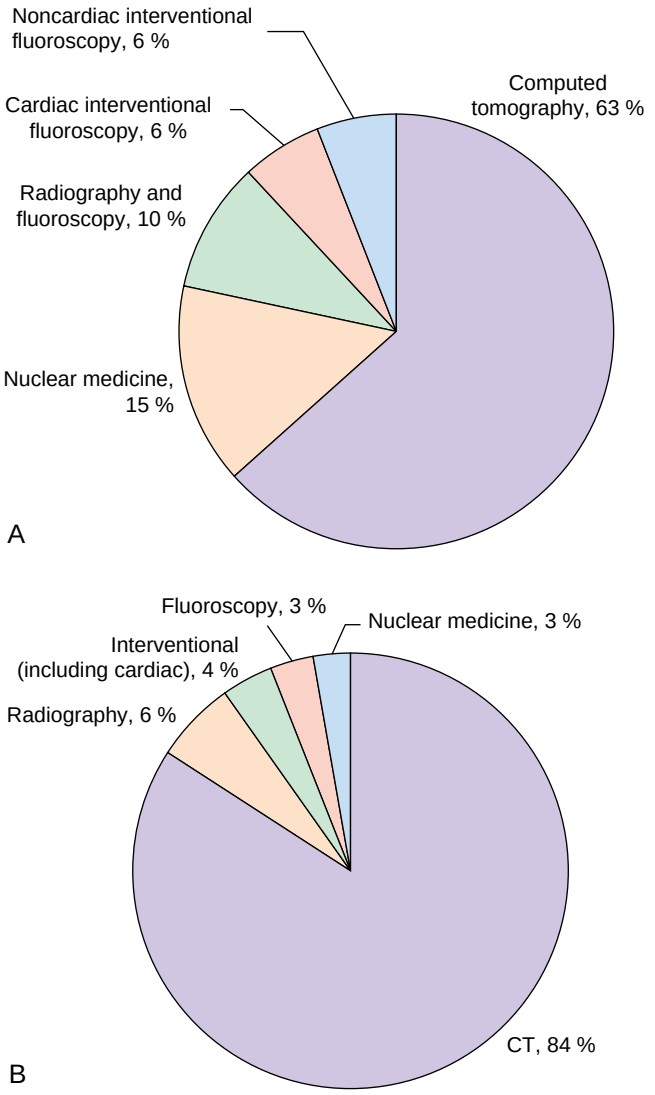

Fig. 758.1 Percentage radiation exposure by diagnostic imaging modality for (A) adult and (B) pediatric populations. *(Adapted with permission of the National Council on Radiation Protection and Measurements, Report 184: Medical Radiation Exposure of Patients in the United States, 2019. Figs. 14.3 and 12.2.)*

When misrepaired DNA damage occurs, aberrations may then be produced in chromosomes, resulting in an *unstable aberration* (usually lethal to dividing cells) or a *stable aberration.* Stable aberrations can result in failure of chromosomes to reunite (leading to deletions) or in abnormal rearrangement of chromosomes, such

as reciprocal translocation or aneuploidy. Although it is logical to think that these abnormalities in chromosomes lead to variants that can activate oncogenes or protooncogenes, or cause variants in tumor-suppressor genes (see Chapter 541), few radiation-induced cancers show specific translocations such as would be associated with activation of specific oncogenes or known tumor-suppressor genes. An exception is the radiation induction of papillary thyroid carcinoma in children, which probably results from activation of the RET oncogene (see Chapter 607).

A longitudinal study of the lifetime risks of excess cancer mortality to irradiation has been evaluated in atomic bomb survivors. More than 120,000 survivors since 1950 have been followed since exposure; additionally, 3,600 in utero survivors and their 77,000 progeny have been followed since 1945. Individual radiation doses were estimated by considering the person's location in relation to distance from the epicenter and individual shielding situations (such as line of sight with respect to buildings and terrain). Radiation types were mixed, and most of the exposure was direct gamma irradiation; neutron exposure was out to approximately 2,000 m. Age at exposure, lifestyle, and other factors were considered in the analytic models when calculating cancer occurrence (Fig. 758.2).

The pediatric population is approximately two to three times more sensitive to radiation-induced carcinogenesis compared with middle-age adults; however, the risk even in this population is indirectly related to age where the neonate is more sensitive than the older child to an identical radiation exposure. Because of the higher risks associated with breast and thyroid cancer, females are also more sensitive than males. It must be understood that cancer rates in this study are mortality figures; the incidence of cancer is approximately twice that of the mortality incidence for all ages. The Centers for Disease Control and Prevention (CDC) reports no scientific evidence demonstrating noncancerous effects (e.g., malformations, growth, intellectual disability, etc.) from in utero exposure <50 mGy, an exposure level that is greater than essentially any single diagnostic examination using ionizing radiation. Additionally, noncancerous effects may only increase slightly with exposure levels between 50 and 500 mGy. In utero radiation exposure is associated with an excess risk of developing (all types) childhood cancer: 1% (<100 mGy), 1–6% (100-500 mGy), and >6% (>500 mGy) as compared to 0.7% naturally. Children are at increased risk of stochastic risks for identical levels of exposure seen in adults because (1) children are growing rapidly, with many

Table 758.3 Imaging Modalities

MODALITY	SOURCE
Radiography (digital plain film x-ray)	Radiation (x-ray)
Fluoroscopy and fluoroscopically guided procedures	Radiation (x-ray)
Ultrasonography	Sound beams
Computed tomography	Radiation (x-ray)
Magnetic resonance imaging	Magnetic field with radiofrequency
Nuclear medicine (including positron emission tomography)	Radiation (administered isotope)

Table 758.4 Average Radiation Dose by Imaging Test for Pediatric Population*

EXAMINATION (0-18 YEARS)	EFFECTIVE DOSE (mSv)
Interventional fluoroscopy: AP and lateral abdomen	0.2-1.1 mSv/min
Interventional fluoroscopy: head	0.02-0.08 mSv/min
Interventional fluoroscopy: cardiac	0.1-1 mSv/min
Digital radiography: 2-view chest	0.04-0.06
Digital radiography: 2-view abdomen	0.1-0.6
Computed tomography: brain	0.8-2
Computed tomography: chest	0.5-4
Computed tomography: abdomen/pelvis†	1-9
Nuclear medicine (^{99m}Tc methylene diphosphonate: bone)	2-5
Positron emission tomography (^{18}F-FDG; whole body)	2-11

*Background radiation reference = 0.01 mSv/day or 3 mSv/yr.
†Radiation dose upper limit includes young adult age population.

Table 758.5 Tissue Reaction Dose Levels

INJURY	APPROXIMATE THRESHOLD
SKIN	
Transient erythema	2 Gy (200 rad)
Dry desquamation	8 Gy (800 rad)
Moist desquamation	15 Gy (1,500 rad)
Temporary epilation	2 Gy (200 rad)
Permanent epilation	7 Gy (700 rad)
EYES	
Cataracts (acute)	2 Gy (200 rad)*

*Has been reported as occurring between 0.5 and 1 Gy.

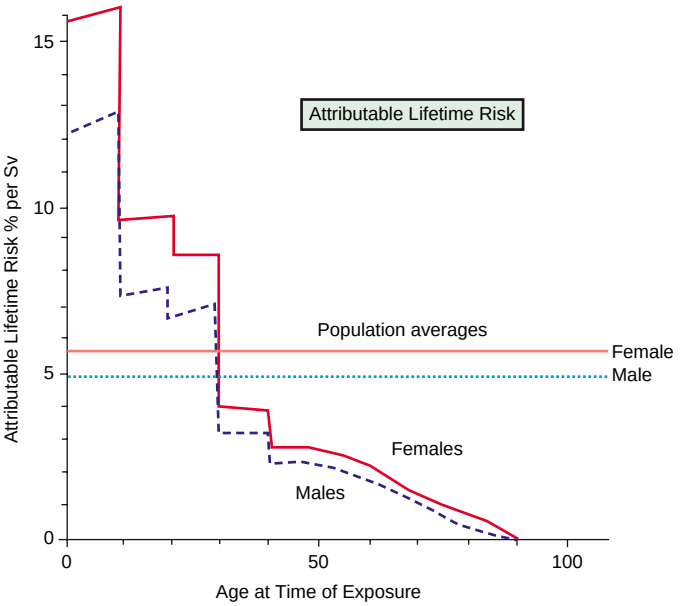

Fig. 758.2 Lifetime risk of excess cancer per sievert (Sv) as a function of age at the time of exposure. Data from the atomic bomb survivors. The average risk across all ages in a population is approximately 5% per Sv, but the risk varies considerably with age: children are much more sensitive than adults. At early ages, girls are more sensitive than boys. *(From Hall EJ. Introduction to session I: Helical CT and cancer risk. Pediatr Radiol. 2002;32:225–227.)*

Table 758.6 Inherited Human Syndromes Associated with Sensitivities to X-Rays

Ataxia-telangiectasia	Fanconi anemia
Basal cell nevoid syndrome	Gardner syndrome
Cockayne syndrome	Nijmegen breakage syndrome
Down syndrome	Usher syndrome

Modified from Davis JT, Frush DP. Biologic effects of diagnostic radiation on children. In: Coley BD, ed. *Caffey's Pediatric Diagnostic Imaging*, 13th ed. Philadelphia: Elsevier; 2019: p. 5; and Hall EJ. *Radiobiology for the Radiologist*, 6th ed. Philadelphia: Lippincott Williams & Wilkins; 2006: p. 41.

cells undergoing mitotic activity dependent on undamaged DNA and chromosomes, and (2) radiation-induced tumors (except leukemia) take a relatively long time to develop and children have a longer lifetime. Policies relating to the use of therapeutic abortion have been established by the ICRP and American College of Obstetricians and Gynecologists, which state that fetal doses <100 mGy should not be considered a reason for terminating pregnancy, and that every woman should be counseled that exposure from a single diagnostic procedure does not result in tissue effects to the fetus.

Most childhood tumors occur sporadically, but 10–15% of cases have a strong familial association. Familial tumors have specific chromosomal deletions in common. In some of these tumors (e.g., retinoblastoma), the two-hit hypothesis is apparent (see Chapter 541). Individuals with certain congenital diseases are at higher risk for the development of tumors after irradiation. Table 758.6 lists diseases that are associated with sensitivity to radiation.

RADIATION EXPOSURE IN DIAGNOSTIC IMAGING OF CHILDREN

Imaging modalities utilizing ionizing radiation for diagnostic purposes (e.g., CT, nuclear medicine, PET, radiography, and fluoroscopy or fluoroscopically guided procedures) are commonly utilized; however, increased awareness of the long-term risk for cancer induction and mortality has led to declining pediatric CT use over the past decade. The European EPI-CT study found a significant dose-response relationship between CT-related radiation exposure and brain cancer as well as hematologic malignancies in a large international study cohort, supporting the concept that stochastic effects are a dose-dependent probability, with the probability of an effect increasing with radiation dose. Therefore it is important that we use the lowest dose necessary to get sufficient diagnostic images. Various federal agencies, healthcare accrediting bodies, and national professional organizations support this goal and provide recommendations or requirements for all imaging examinations to have some retrievable radiation dose estimate, and for institutions and clinics that provide ionizing radiation imaging services to track and review patient examination dose levels annually, comparing these dose levels with expected dose ranges and external benchmarks.

Dose reporting and aggregating software provides the ability to collect and analyze individual examination doses and gives healthcare providers a powerful tool to correct outlier examinations (i.e., over exposures), over utilization, and address other systemic errors present in imaging clinics (such as radiation dose creep with time).

DECREASING UNNECESSARY DIAGNOSTIC RADIATION IN CHILDREN WHILE STILL OBTAINING DIAGNOSTIC IMAGES

Ultimately, the lowest radiation dose examination is the imaging examination performed without ionizing radiation. For an increasing number of indications, utilization of nonionizing radiation modalities such as ultrasound or MRI may be the first consideration for diagnosis. Selecting the correct examination is the responsibility of the requesting healthcare provider and may involve consultation with the radiologist, preferably with pediatric expertise. Clinical decision support algorithms are also available to assist with examination appropriateness (e.g., American College of Radiology's Appropriateness Criteria). The risk of using ionizing radiation for imaging should be weighed against other risks during imaging. CT (depending on the indication and region examined) may detect as many abnormalities as MRI, but CT involves ionizing radiation. However, sedation is often required to successfully obtain MRI imaging in young children; in these cases, consideration of the relative risks of cognitive impairment from moderate sedation and anesthetic versus potential radiation risks use should come into play.

Reducing Radiation from the CT Examination

The most common source of medical radiation for all ages is CT. CT offers the ability to acquire high-quality volumetric imaging datasets in seconds. For many years, adult parameters for CT settings were used for children, which led to dosages for children much higher than the dosage for adults. This occurs because lower energy x-rays that would have been absorbed in the near field in an adult pass into the entire child, with relatively greater organ irradiation for the same exposure. When comparing dosages given to newborns and adults during CT scanning of the head, with the same parameters in both groups, the dosage given to newborns can be four times that of the dosage given to adults; with abdominal imaging, the dosage is increased by 60%. It is the role of the radiologist and technologist, with the help of a medical physicist, to develop and monitor protocols that tailor the examination to the individual indication and for the variabilities in sizes found in the pediatric population.

Modern CT scanners have many tools to help administer the appropriate amount of radiation dose to a pediatric patient and acquire the necessary diagnostic image quality from the imaging examination. Radiologists should work in conjunction with medical physicists and vendor supplied application specialists to tailor specific examination protocols to the pediatric patient population by establishing appropriate scan parameters such as the kilovoltage (kV). Scan range should be limited to only the necessary area for diagnosis (e.g., a chest only scan should begin at the lung apices and extend to no more than a little below the lowest lung base). Multiphasic scanning should be only obtained when justified; for example, in pediatric abdominopelvic CT multiple phases should be necessary in no more than approximately 5% of examinations.

Technologic advances for modern CT scanners are using reconstruction algorithms, such as statistical iterative reconstruction (IR), model-based IR, and deep learning reconstruction (DLR), as well as photon counting technology. These algorithms have been shown to allow the reduction of radiation dose for IR algorithms by 15-30% and DLR algorithms by 44-83% in some patient populations while maintaining equivalent diagnostic confidence to the pre-dose reduced image datasets. Other practical steps to reduce pediatric population radiation dose include replacing older CT scanners with technologically advanced scanners; monitoring institution dose values, which can be compared with available benchmarks, such as **diagnostic reference levels (DRLs)**; and performing only examinations that are justified. Advances in technology and attention to proper performance of examinations have contributed to overall reductions in pediatric patient population doses by >50% during the past two decades.

RADIATION THERAPY: ACUTE AND LATE EFFECTS

Radiation therapy uses high doses to kill malignant cells. The sensitivity of normal cells is quite close to that of malignant cells, and to achieve significant cure rates, radiation oncologists must accept a given percentage of serious complications (5–10%). Radiation causes tissue loss plus injury to the underlying vasculature. The vascular change may be progressive, leading to arteriocapillary fibrosis and irreparable injury, in turn leading to further tissue loss.

The acute effects of therapy (occurring less than 3 months after therapy begins) are usually related to the area of the body being irradiated (except fatigue, which can begin during this time period). These acute effects include radiation-induced pneumonitis, dermatitis, mucositis and esophagitis, cerebral edema, and swelling of the organ irradiated. There may be changes in bowel movement patterns. Of these, one of the most severe acute reactions is pneumonitis. It can manifest within

Table 758.7 Late Effects of Radiation Therapy in Children Treated for Cancer

SYSTEM	LATE EFFECT	DOSE (GY)
Musculoskeletal	Muscular hypoplasia	>20
	Scoliosis, kyphosis, lordosis	>20
	Osteocartilaginous exostosis/ osteochondroma	>12
Neuroendocrine (cranial or cranial spinal)	Impaired growth hormone	>15
	Adrenocorticotropic hormone deficiency	>30
	Thyrotropin-releasing deficiency	>40
	Precocious puberty (females mostly)	>18
	Gonadotropin deficiency	>30
Gonad failure	Ovarian failure	>10
	Testicular failure	>3
Central nervous system dysfunction	Structured changes	>18
	Cognitive changes/Processing speed	Variable
Other	Pulmonary fibrosis	>15
	Nephropathy	>20
	Liver disease	>30 (>60% liver volume)
	Cerebral arteriopathy	>50
	Eye impairment (cataracts, legally blind, double vision, dry eyes)	>5
	Hearing loss	>30
	Dental abnormalities	>20
	Cardiac impairment	>30

24 hours of irradiation when there is an exudation of proteinaceous material into the alveoli and interalveolar edema. Most often, however, radiation pneumonitis begins 2-6 months after the beginning of radiation with a clinical presentation of fever, cough, congestion, and pruritic pain. The late effects of therapy (beginning more than 3 months after therapy) are numerous (Table 758.7). The most common are abnormalities of musculoskeletal development, endocrine/reproductive function, pulmonary function, neurocognition, hearing loss, cardiac function, eye impairment, and dental abnormalities.

As of 2020, there are more than 500,000 childhood cancer survivors in the United States. The risk of developing a second cancer among cancer survivors is over fivefold higher than the general population. Second cancers account for 2.3% of all cancers in children; this reflects an overall standard incidence rate (SIR) of 5.5%. Primary malignancies with the highest cumulative incidence of a second neoplasm in the order of frequency are retinoblastoma (10.4%), CNS cancers (7.4%), cancers of bone (7.2%), soft tissue sarcomas (6.5%), hepatic cancer (5.9%), and neuroblastoma (5.9%) [data from the U.S. Surveillance, Epidemiology, and End Results program (SEER)]. Table 758.8 relates second cancers to primary cancer and latency period. Almost 70% of the second neoplasms are in the field of the original irradiation. Radiation therapy increases the risk of second cancers in a dose-dependent manner for nongenetic neoplasms.

The exact complications depend on the location of the treatment field. In children, because of the location of many childhood tumors, the normal brain is commonly in the treatment field. Standard irradiation of the brain in children results in cortical atrophy in more than half of patients who receive 20-60 Gy; 26% are left with white matter changes (leukoencephalopathy) and 8% with calcifications. The younger the child is at the time of irradiation, the greater the atrophy. Some patients also demonstrate mineralizing microangiopathy. Radiation-induced changes of the brain are potentiated by methotrexate administered before, during, or after radiation therapy.

Cerebral necrosis is a serious complication of radiation-induced vascular disease. It is usually diagnosed 1-5 years after irradiation but can occur up to a decade later. Brain necrosis may manifest as headache, increased intracranial pressure, seizures, sensory deficits, and psychotic changes.

Spinal cord irradiation may result in **radiation myelitis,** which may be either transient or permanent. Acute transient myelitis often appears 2-4 months after irradiation. Patients with myelitis usually present with **Lhermitte sign,** a sensation of little electrical shocks radiating down the spine into the arms and legs, occurring with neck flexion or other movements that stretch the spinal cord. Reversal of transient myelopathy usually occurs between 8 and 40 weeks and does not necessarily progress to delayed necrosis.

Delayed myelopathy occurs after a mean latent period of 20 months but can occur earlier if the total dose or the dose per fraction is high. It usually manifests as discontinuous deterioration and is irreversible. In the cervical and thoracic regions, sensory dissociation develops, followed by spastic and then flaccid paresis. In the lumbar cord, flaccid paresis is dominant. The mortality for high thoracic and cervical lesions reaches 70% with death commonly being due to pneumonia and urinary tract infections.

CNS irradiation may affect growth by compromising function of the pituitary-hypothalamic axis and leading to diminishing growth hormone production and release. Non–growth hormone tropins may also be affected by CNS irradiation, leading to gonadotropin deficiency or precocious puberty. Central hypothyroidism can also develop. CNS irradiation also compromises bone mineral deposition both locally (in the radiation field) and systemically.

Irradiation has other effects specific to children. Scoliosis and hypoplasia of bones may occur if fractionated treatment schemes exceed 4,000 rad. Fractionated doses higher than 25 Gy can result in slipped capital femoral epiphyses. An increase in the incidence of benign osteochondromas has been reported after childhood irradiation. Chest wall irradiation in females (besides causing breast cancer) may impair breast development and/or cause fibrosis and atrophy of breast tissue.

WHOLE BODY IRRADIATION

Uncontrolled Large- or Small-Scale Exposure to Radiation

Large-scale exposure to radiation can occur in an event of nuclear accidents, war, or terrorist attacks (Fig. 758.3). Radiation as well as explosive and thermal injury need to be considered.

Clinical Manifestations

A large single exposure of penetrating radiation can result in **acute radiation syndrome** (Table 758.9). The signs and symptoms of this syndrome result from damage to major organ systems that have different levels of radiation sensitivity, modulated by the rate at which the radiation exposure occurred. Delivery of 1 Gy in 1 minute would be symptomatic, but delivery of 1 cGy/day for 100 days would not be symptomatic.

The **hematopoietic syndrome** results from acute whole body doses >0.7-10 Gy; where healthy patients will almost always recover from doses <2 Gy. The dose that kills 50% of a population in 60 days is approximately 3.5-4.5 Gy, where effective blood transfusions and antibiotics may extend the dose range to 5-8 Gy. Doses >8 Gy almost always lead to hematopoietic-induced death. Symptoms of exposure consist of a *prodromal phase* during which the patient will experience nausea/vomiting, diarrhea, and fatigue within the first 12 hours, with symptoms usually lasting up to 48 hours. A *latent period* of 2-3 weeks, during which patients may feel quite well, follows. Although patients are asymptomatic, bone marrow impairment has occurred. The most obvious laboratory finding is lymphocyte depression (Table 758.10). Maximal bone marrow depression occurs approximately 30 days after exposure, when hemorrhage and infection can be major problems. If the bone marrow was not completely eradicated, a *recovery phase* then ensues. This radiation effect is similar to what occurs when whole body irradiation (given as 12 Gy in two treatments) is used

Table 758.8 Second Cancers and Their Relationship with Primary Cancers

SECOND CANCERS	PRIMARY CANCERS	LATENCY (MEDIAN IN YEARS)	RISK FACTORS
Brain tumors	ALL; brain tumors; HD	9-10	Radiation; younger age
Myelodysplastic syndromes/ acute myelogenous leukemia	ALL; HD; bone tumors	3-5	Topoisomerase II inhibitors; alkylating agents
Breast cancer	HD; bone tumors; soft tissue sarcomas; ALL; brain tumors; Wilms tumors; NHL	15-20	Radiation; female gender
Thyroid cancer	ALL: HD; neuroblastoma; soft tissue sarcomas; bone tumors; NHL	13-15	Radiation; younger age; female gender
Bone tumors	Retinoblastoma (heritable); other bone tumors; Ewing sarcoma; soft tissue sarcomas; ALL	9-10	Radiation; alkylating agents; removal of the spleen
Soft tissue sarcomas	Retinoblastoma (heritable); soft tissue sarcomas; HD; Wilms tumors; bone tumors; ALL	10-11	Radiation; younger age; anthracyclines

ALL, Acute lymphocytic leukemia; HD, Hodgkin disease; NHL, non-Hodgkin lymphoma.
From Bhatia S, Sklar S. Second cancers in survivors of childhood cancer. *Nat Rev Cancer*. 2002;2:124–132.

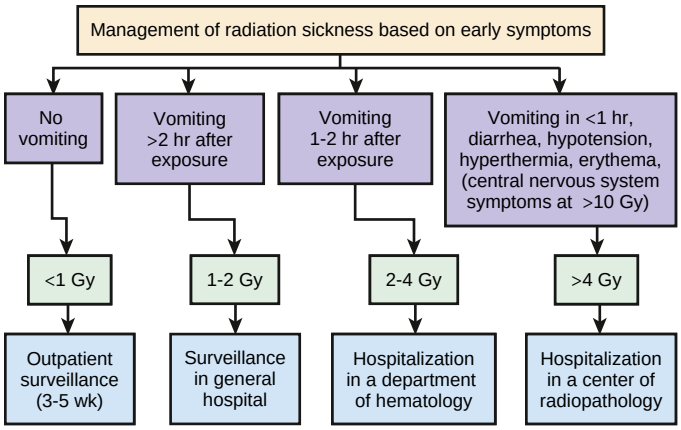

Fig. 758.3 Management algorithm for radiation sickness at different levels of medical care, depending on the appearance of early symptoms and the estimated radiation dose to the whole body. *(From Turai I, Veress K, Günalp B, et al. Medical response to radiation incidents and radionuclear threats. BMJ. 2004;328:568–572.)*

to obliterate the bone marrow in children with leukemia before bone marrow transplantation.

The **gastrointestinal (GI) syndrome** occurs from acute whole body doses >6-10 Gy. Prompt onset of nausea, vomiting, and diarrhea follows. There is a latent period of approximately 1 week if intense medical treatment is administered. Following the latent period, recurrence of GI symptoms, sepsis, and electrolyte imbalance occurs, which results in death at about 2 weeks postexposure from GI tract and bone marrow destruction.

At dose levels exceeding 20-50 Gy, the **cardiovascular/CNS syndrome** predominates. Nausea, vomiting, prostration, hypotension, ataxia, and convulsions are almost immediate. The latent period occurs between 4 and 6 hours postexposure followed by severe manifestation of the initial illness stage leading to eventual coma and death within 2-3 days.

Treatment

For the hematopoietic and GI syndromes, treatment is supportive involving transfusions and Neupogen (filgrastim), Neulasta (pegfilgrastim) and other hematopoietic growth factors, fluids, and, if infected antibiotics and antiviral agents. Stem cell (bone marrow) transplantation may be needed in severe cases.

Localized Irradiation

Clinical Manifestations

Because localized exposure involves a small amount of tissue, systemic manifestations may be less severe, and patients may survive even if locally absorbed doses are very high. The hand is the most common site for accidental localized irradiation injuries, usually as a result of picking up or playing with lost radiation sources. The second most common accidental site is the thigh and buttocks, predominantly from placing unsuspected highly radioactive sources in the pockets.

Table 758.11 lists the skin changes that occur after a single acute, localized irradiation. As opposed to other forms of thermal burns, signs of irradiation appear a period of days *after* the exposure. Vascular insufficiency may appear months to years later and cause ulcerations or necrosis in formerly healed areas. The penetrability of the radiation is an important factor in the outcome of local radiation injury. Beta particles from heavy radiation fallout can cause superficial skin burns because they have low penetrability.

Some tissues that may receive localized radiation exposure are relatively radiosensitive. **Cataract formation** (see Chapter 668) may occur with single γ-ray exposures in the range of <1 Gy. Such cataracts usually take from 2 months to several years to develop. **Oligospermia** may take up to 2 months to develop. Transient infertility in men may result from doses as low as 0.15 Gy, and permanent sterility may occur in males at dose levels between 3 and 6 Gy.

Treatment

Skin therapy is directed at prevention of infections. Treatment of localized injuries usually involves class II to III topical steroids and plastic surgery and grafting, if the radiation exposure was not deeply penetrating (see Chapter 89). The nature of the surgery depends on the dose at various depths in tissue and the location of the lesion. The full expression of radiation injury often is not apparent for 1-2 years due to slow arteriolar narrowing that can cause delayed necrosis. After relatively penetrating radiation, amputation may be necessary because of obliterative changes in small vessels.

INTERNAL CONTAMINATION

Epidemiology

Accidents involving internal contamination are rare and are usually the result of misadministration in hospital settings or voluntary ingestion of unsuspected contaminated radioactive materials. Other possible causes of internal contamination of children include ingestion of breast milk from mothers who have had diagnostic nuclear medicine scans and radiation exposure when a parent or sibling receives a therapeutic dose of iodine-131.

Table 758.9 Acute Radiation Syndrome

SYNDROME	DOSE*	PRODROMAL STAGE	LATENT STAGE	MANIFEST ILLNESS STAGE	RECOVERY
Hematopoietic (bone marrow)	>0.7 Gy (>70 rads) *(mild symptoms may occur as low as 0.3 Gy or 30 rads)*	• Symptoms are anorexia, nausea and vomiting • Onset occurs 1 hr to 2 days after exposure • Stage lasts for minutes to days	• Stem cells in bone marrow are dying, although patient may appear and feel well • Stage lasts 1-6 wk	• Symptoms are anorexia, fever, and malaise • Drop in all blood cell counts occurs for several weeks • Primary cause of death is infection and hemorrhage • Survival decreases with increasing dose • Most deaths occur within a few months after exposure	• In most cases, bone marrow cells will begin to repopulate the marrow • There should be full recovery for a large percentage of individuals from a few weeks up to 2 yr after exposure • Death may occur in some individuals at 1.2 Gy (120 rads) • The $LD_{50}/60$† is about 2.5-5 Gy (250-500 rads)
Gastrointestinal (GI)	>10 Gy (>1,000 rads) *(some symptoms may occur as low as 6 Gy or 600 rads)*	• Symptoms are anorexia, severe nausea, vomiting, cramps, and diarrhea • Onset occurs within a few hours after exposure • Stage lasts about 2 days	• Stem cells in bone marrow and cells lining GI tract are dying, although patient may appear and feel well • Stage lasts <1 wk	• Symptoms are malaise, anorexia, severe diarrhea, fever, dehydration, and electrolyte imbalance • Death is due to infection, dehydration, and electrolyte imbalance • Death occurs within 2 wk of exposure	• The LD_{100}‡ is about 10 Gy (1,000 rads)
Cardiovascular (CV)/ central nervous system (CNS)	>50 Gy (5,000 rads) *(some symptoms may occur as low as 20 Gy or 2,000 rads)*	• Symptoms are extreme nervousness and confusion; severe nausea, vomiting, and watery diarrhea; loss of consciousness; and burning sensations of the skin • Onset occurs within minutes of exposure • Stage lasts for minutes to hours	• Patient may return to partial functionality • Stage may last for hours but often is less	• Symptoms are return of watery diarrhea, convulsions, and coma • Onset occurs 5-6 hr after exposure • Death occurs within 3 days of exposure	• No recovery is expected

*The absorbed doses quoted here are "gamma equivalent" values. Neutrons or protons generally produce the same effects as γ-, β-, or x-rays but at lower doses. If the patient has been exposed to neutrons or protons, consult radiation experts on how to interpret the dose.
†The $LD_{50}/60$ is the dose necessary to kill 50% of the exposed population in 60 days.
‡The LD_{100} is the dose necessary to kill 100% of the exposed population.
From Centers for Disease Control and Prevention. Acute radiation syndrome: a fact sheet for clinicians. Table 1. https://www.cdc.gov/nceh/radiation/emergencies/arsphysicianfactsheet.htm.

Table 758.10 Expected Outcome Based on Absolute Lymphocyte Count After Acute Penetrating Whole Body Irradiation

MINIMAL LYMPHOCYTE COUNT WITHIN FIRST 48 HR AFTER EXPOSURE	PROGNOSIS
1,000-3,000 (normal range)	No significant injury
1,000-1,500	Significant but probably nonlethal injury, good prognosis
500-1,000	Severe injury, fair prognosis
100-500	Very severe injury, poor prognosis
<100	Lethal without compatible bone marrow donor

Clinical Manifestations

The hazards from internal contamination depend on the nature of both the radionuclide (particularly in terms of its solubility in water, half-life, biologic half-life, and radioactive emission) and the chemical compound.

Treatment

The most effective treatment requires knowledge of both the radionuclide and the chemical form. Treatment must be instituted quickly to be effective (Table 758.12). **Removal treatment** involves cleaning a contaminated wound and performing gastric lavage or administration of cathartics in the case of ingestion. Administration of alginate-containing antacids (e.g., Gaviscon) also usually helps in removal by decreasing absorption in the GI tract. An example of **blocking therapy** is the administration of potassium iodine or other stable iodine-containing compounds to patients with known internal contamination with radioactive iodine. The stable iodine effectively blocks the thyroid, although its effectiveness decreases rapidly as time elapses after the contamination. The recommended dose of potassium iodine is 16 mg

for neonates (up to 1 month of age); 32 mg for children ages 1 month to 3 years; 65 mg for children ages 3-18 years (if less than 70 kg), and 130 mg for adults and adolescents >70 kg. Each dose protects for only 1 day. **Dilution therapy** is used in cases of tritium (radioactive hydrogen as water) contamination. Forcing fluids promotes excretion. Cases of internal contamination with transuranic elements (americium and plutonium) may require **chelation therapy** with calcium diethylenetriamine pentaacetate.

Prussian blue is a drug approved by the FDA for patients with internal contamination with cesium or thallium. It can speed fecal elimination of radioactive cesium from the body. It acts by intercepting the cesium coming into the gut from the bile. Prussian blue prevents

Table 758.11 Skin Changes After a Single, Acute, Localized Radiation Exposure

APPROXIMATE THRESHOLD (GY)	CHANGE
2-4	Primary erythema within hours of exposure (appears more quickly after larger doses)
3	Second phase erythema (develops during the manifestation phase of local radiation injury); appears 14-21 days after exposure
3	Temporary epilation (14-18 days after exposure)
7	Definitive epilation (25-30 days after exposure)
10	Dry desquamation (20-28 days after exposure)
15	Moist desquamation, possible ulceration (15-25 days after exposure)
25	Desquamation with blistering, ulceration, and necrosis (>21 days after exposure)

Data from the International Atomic Energy Agency. *Safety Reports Series, No. 101: Medical management of radiation injuries*, 2020. https://www-pub.iaea.org/MTCD/Publications/PDF/PUB1891_web.pdf

Table 758.12 Decontamination of Common Elements in Industrial and Medical Accidents

ELEMENT	EMISSIONS	CRITICAL ORGAN	EFFECTIVE $T_{1/2}$*	DECONTAMINATION
Cesium-137	Beta, gamma	Total body	70 days	Prussian blue (Radiogardase) 3 g po 3 times/day (adults and adolescents); 1 g po 3 times/day (2-12 yr old); consider lavage and purgatives
Cobalt-60	Beta, gamma	Total body	10 days	Lavage, purgatives, penicillamine
Iodine-125, iodine-131	Beta, gamma	Thyroid	Iodine-125, 42 days; iodine-131, 8 days	Potassium iodide: 0-1 mo, 16 mg/day >1 mo to 3 yr, 32 mg/day >3 mo to 3 yr, 32 mg/day >3 to 12 yr and <70 kg, 65 mg/day adults or ≥70 kg, 130 mg/day; consider lavage
Iridium-192	Beta, gamma	Lung	74 days	Lavage for large quantities
Technetium-99 m	Gamma	Total body	5 hours	Potassium perchlorate to reduce thyroid dose
Tritium-3	Beta	Total body	12 days	Forced fluids
Uranium-235, uranium-238	Alpha	Kidney,† bone, liver, lung	Can be permanent if in bone	Bicarbonate to alkalinize the urine

*Effective $t_{1/2}$ combines radioactive and chemical properties and rates of elimination without decontamination efforts.
†The kidney is most vulnerable to large amounts of uranium because of the chemical properties of this heavy metal. Uranium can ultimately be deposited in bone.
po, Per os; *qd*, once per day.
Data from U.S. Food and Drug Administration. Prussian blue, Radiogardase, package insert. Available at: http://www.fda.gov/cder/drug/infopage/prussian_blue/default.htm; U.S. Food and Drug Administration. Guidance: Potassium iodide as a thyroid blocking agent in radiation emergencies. Available at: http://www.fda.gov/cder/guidance/4825fnl.htm; *Management of Persons Accidentally Contaminated with Radionuclides*. NCRP Report No. 65. Bethesda, MD: National Council on Radiation Protection and Measurements; 1980; and Jarrett D, ed. *Medical Management of Radiation Casualties: Handbook*. 2nd ed. AFRRI Special Publication 03-1. Bethesda, MD: Armed Forces Radiobiology Research Institute; 2003. Available at: http://www.afrri.usuhs.mil.
From Linder JA, Linder LS: Radiation accident—dispersed exposure. In Ciottone GR (ed). *Ciottone's Disaster Medicine*, 2nd ed. Philadelphia: Elsevier, 2016. Table 108-1.

Table 758.13 Nuclear Regulatory Commission Guidelines on Breastfeeding During the Period During a Nuclear Medicine Examination

RADIOPHARMACEUTICAL	BREASTFEEDING CESSATION
^{11}C, ^{13}N, ^{15}O, ^{82}Rb	None
^{18}F-labeled	12 hr
^{68}Ga-labeled	12 hr
^{99m}Tc-labeled	24 hr
^{123}-I Sodium iodide	7 days
^{111}In-leukocytes	7 days
^{99m}-Tc labeled	No interruption*
^{201}Tl chloride	14 days
^{67}Ga and ^{89}Zr	28 days
^{177}Lu, diagnostic	35 days
^{131}I-NaI	Stop breastfeeding
^{177}Lu, therapeutic	Stop breastfeeding
^{223}Ra and all alpha emitters	Stop breastfeeding

*The guideline for ^{99m}Tc compounds is a 24-hr interruption for >1110 MBq administered, 12 hr for 444-1110 MBq, and no interruption for <444 MBq administered. The normally administered activity is below activities that require any interruption.

From Dilsizian V, Metter D, Palestro C, Zanaonico P. The Advisory Committee on Medical Uses of Isotomes (ACMUI) Sub-Committee on Nursing Mother Guidelines for the Medical Administration of Radioactive Materials, 2018, p. 12. https://www.nrc.gov/docs/ML1803/ML18033B034.pdf

cesium from being absorbed again from the gut. Prussian blue can be given days after ingestion, unlike potassium iodine, which must be given initially in the first 12-24 hours after exposure.

In the case of breastfeeding after a nuclear medicine procedure, two primary concerns are considered: (1) the internal dose to the infant passed through the excreted milk and (2) the dose from the radiopharmaceutical absorption in the female breast that exposes the infant to external γ-rays while undergoing decay. Most imaging radiopharmaceuticals are below the activity calculated to expose the infant to a dose of 1 mSv via either internal or external mode of exposure. Table 758.13 provides a comprehensive list of radiopharmaceuticals and the recommended period for breastfeeding cessation by the U.S. Nuclear Regulatory Commission. In the case of delaying breastfeeding, pumped milk may be stored for the times indicated in Table 758.13, after which they will be safe to feed the infant.

EXTERNAL CONTAMINATION

The presence of external radioactive contamination on a patient's skin is not an immediate medical emergency. Management involves removing and controlling the spread of radioactive materials. If a patient has suspected surface contamination and no physical injuries, decontamination can be performed relatively easily. If substantial physical trauma or other life-threatening injuries are combined with external contamination, surface decontamination should proceed only after the patient has been stabilized physiologically. In many accident situations, essential medical care may be delayed inappropriately by hospital emergency staff because of fear of radiation or spread of contamination in the hospital. After a radiation accident, triaging of patients is critical and is based on exposure and symptoms (see Fig. 758.3).

Visit Elsevier eBooks+ at eBooks.Health.Elsevier.com for Bibliography.

Chapter 759

Chemical Pollutants

Joel A. Forman and Lauren M. Zajac

More than 85,000 new synthetic chemicals have been developed in the past 75 years. These chemicals are used in millions of products, ranging from food packaging to clothing, building materials, motor fuels, cleaning products, cosmetics, medical products, toys, and baby bottles.

Synthetic chemicals are widely disseminated in the environment. The Toxic Release Inventory of the U.S. Environmental Protection Agency (EPA) reports that in 2021, of 29.3 billion pounds of production-related chemical waste managed, nearly 3.3 billion pounds (11%) were discharged into air, water, and land in the United States. These chemicals are detected today in even the most remote corners of the planet, such as the polar icecaps and in the ocean depths.

All people are at daily risk of exposure to synthetic chemicals, and children are especially likely to be exposed to the nearly 3,000 chemicals that are produced in amounts of 1 million pounds or more per year, designated by the EPA as high-production-volume chemicals. Biomonitoring data on blood and urine levels of more than 400 high-production-volume chemicals are obtained annually by the Centers for Disease Control and Prevention in a sample of the U.S. population through the National Health and Nutrition Examination Survey (NHANES). These data document that most Americans, including children, are routinely exposed to scores of synthetic chemicals; exposure often falls disproportionately on poor children and children of color. Examples are wide ranging and include lead, air pollutants, endocrine disrupting chemicals like phthalates, and many others.

Toxic chemicals are exported in ever-increasing quantities to the world's poorer countries as these countries undergo industrial development. Environmental safeguards in those countries are typically not as stringent as in high-income countries, and the potential for serious exposure is therefore high. Examples of tragedies that have resulted from the movement of toxic chemicals to low- and middle-income countries include the Bhopal disaster in India, in which hundreds were killed and thousands injured by methylisocyanate gas released by an explosion in a pesticide production facility, and the ongoing export each year of more than 2 million tons of newly produced asbestos to the world's poorest countries, where this asbestos is responsible for nearly 200,000 deaths annually from asbestosis, lung cancer, and malignant mesothelioma.

SYNTHETIC CHEMICALS AND HUMAN HEALTH

A recurrent pattern is that chemicals are brought to market with great enthusiasm, presumed harmless, and undergo little or no premarket safety testing. Then years or decades later, after they had come into wide use, the chemicals were found to be harmful to children's health.

Often the first cases of disease caused by these chemicals are clinically severe, but as time passes, evidence of widespread subclinical toxicity comes to light.

Classic historical examples of epidemics caused by inadequately tested toxic chemicals include the following:

- *Tetraethyl lead:* This was added to gasoline in the United States from the early 1920s until 1980. It was responsible for widespread lead poisoning, initially evident as an epidemic of acute toxicity manifesting as encephalopathy, seizures, and even death, but later demonstrated to have caused subclinical neurotoxicity and reduction in IQ across two generations of U.S. children (see Chapter 761).
- *Dichlorodiphenyltrichloroethane (DDT):* This pesticide very nearly led to extinction of the osprey and the American bald eagle and more recently has been linked to increased risk for breast cancer among women exposed decades ago in utero.

- *Polychlorinated biphenyls (PCBs)*: These are highly persistent pollutants banned from production in the United States in 1977, which continue today to contaminate major lakes and rivers and have been found also to be responsible for loss of IQ and disruption of behavior in children.
- *Chlorofluorocarbons:* These destroy the ozone.

Other examples of synthetic chemicals that came into wide use with little assessment of their safety and are now recognized as causing harm to children's health include the following:

- *Phthalates:* These chemicals are added to plastics, cosmetics, medical equipment like intravenous tubing, and common household products that are now linked to increased risk for reproductive abnormalities in male infants and heightened risk of behavioral abnormalities such as attention-deficit/hyperactivity disorder (see Chapter 50).
- *Polybrominated diphenyl ethers:* These are used as flame retardants in carpets, furniture, and electronic equipment and are now linked to persistent loss of intelligence and disruption of behavior in children.
- *Bisphenol A:* A plastics chemical linked to neurodevelopmental disorders.

These chemicals are all produced in volumes of millions of tons per year, are widely disseminated in the environment, and are detectable in the bodies of nearly all Americans. Only decades after their introduction are these chemicals' risks to children beginning to be recognized.

CHILDREN'S UNIQUE SUSCEPTIBILITY TO SYNTHETIC CHEMICALS

The health effects of synthetic chemicals are especially serious when exposure occurs during windows of vulnerability in early life such as during pregnancy, infancy, and early childhood. Children are highly vulnerable to chemical pollutants for several reasons:

1. Children have proportionally greater exposure to environmental pollutants than adults. Because they drink more water, eat more food, and breathe more air per kilogram of body weight, children are more heavily exposed to pollutants in water, food, and air. Children's hand-to-mouth behavior and their play close to the ground further magnify their exposures.
2. Children's metabolic pathways, especially in the first few months after birth, are immature. Although in some instances children are better able than adults to cope with environmental toxicants because they cannot metabolize these chemicals to their active forms, more commonly children are not as able as adults to detoxify and excrete chemical pollutants.
3. Infants and children are growing and developing, and their complex, fast-moving, and highly choreographed developmental processes are exquisitely sensitive to disruption by chemical pollutants. Exposures to even minute doses of toxic chemicals during windows of vulnerability in early development have been shown to cause a wide array of diseases in childhood and to increase risk for chronic disease and disability lifelong (Table 759.1).
4. Because children have many future years of life, they have time for the development of multistage chronic diseases that may be triggered by early exposures.

Table 759.1 Effects of Selected Chemical Pollutants on Infants and Children

CHEMICAL POLLUTANT	EFFECT(S)
Air pollution	Asthma, other respiratory diseases, sudden infant death syndrome
Asbestos	Mesothelioma and lung cancer
Benzene, nitrosamine, vinyl chloride, ionizing radiation	Cancer
Environmental tobacco smoke	Increased risk of sudden infant death syndrome and asthma
Ethyl alcohol	Fetal alcohol syndrome after intrauterine exposure
Lead	Neurobehavioral toxicity from low-dose exposure
Methyl mercury	Developmental neurotoxicity
Organophosphate insecticides	Developmental neurotoxicity
Per- and poly-fluoroalkyl substances (PFAS)	Increased cholesterol levels, altered liver function tests, decreased antibody response to childhood vaccines
Polychlorinated biphenyls	Developmental neurotoxicity
Polybrominated diphenyl ethers	Developmental neurotoxicity
Phthalates	Developmental neurotoxicity and reproductive impairment
Trichloroethylene	Elevated risk of leukemia after intrauterine exposure

SAFETY TESTING OF SYNTHETIC CHEMICALS

Legally mandated testing of chemicals for safety and toxicity coupled with strict controls on dangerous chemicals are the linchpins of chemical safety. Strong chemical safety policies are needed to protect children against disease and death caused by chemicals. A fundamental problem in environmental pediatrics today is that chemical safety policies in many countries are weak. Only approximately 65% of high-production-volume chemicals have been tested for their safety or potential hazard to human health, and fewer than 30% have been assessed for their pediatric or developmental toxicity.

Failure to test chemicals for safety and toxicity reflects the chemical industry's unwillingness to take responsibility for the products they produce coupled with long-standing failure of the previous U.S. federal law on chemical safety, the Toxic Substances Control Act (TSCA). Only five chemicals were banned or controlled under the original TSCA law: PCBs, the ozone-destroying chlorofluorocarbons, and three known human carcinogens—dioxin, asbestos, and hexavalent chromium.

To address the problem of exposure to untested chemicals, countries have enacted stronger chemical safety legislation. In 2007, the European Union enacted the Registration, Evaluation, Authorization, and Restriction of Chemical Substances (REACH) legislation. This law places responsibility on industry to generate data on potential risks of commercial chemicals and to register this information with the European Chemical Agency in Helsinki. The European Union is using this information to craft regulations to protect children's health. Since 2009 REACH has restricted more than 1,000 toxic substances.

In June 2016, the United States passed legislation to revamp TSCA. This law—the Frank R. Lautenberg Chemical Safety for the 21st Century Act—requires the EPA to assess the safety of any new chemical before it is allowed to enter the market, to prioritize safety testing of existing chemicals, and to use a risk-based standard to evaluate chemical safety that considers only hazards to health and is blind to the costs of protective action. This law holds much promise for improving the protection of children's health against toxic chemicals, but it also includes a federal preemption clause that could inhibit state-based protective regulations. Transparency, oversight, and advocacy is critical to ensuring that the law is implemented in a timely manner that is true to the intent to prioritize children's health.

The UN Environment Programme (UNEP) is the United Nations agency responsible for chemical safety. UNEP has called for "a global commitment to the sound management of chemicals. The agency supports and tracks the progress of international agreements and treaties limiting the manufacture, environmental release and global transport of persistent pollutants, pesticides, hazardous waste, and mercury." The Strategic Approach to International Chemicals Management, a program supported by UNEP, provides a platform for coordinating international control of toxic chemicals and hazardous waste across a broad

range of stakeholders. UNEP has worked closely with the World Health Organization (WHO) to coordinate the removal of lead from gasoline in countries around the world.

SYNTHETIC CHEMICALS AND DISEASE IN CHILDREN

A large and growing body of evidence documents that toxic chemicals can cause disease, disability, and death in children. High-dose exposures can cause acute, clinically evident disease. Lower-dose exposures can cause subclinical injury (injury that is very real but detectable only through special testing), such as decreases in intelligence, shortening of attention span, reductions in fertility, and slowing of lung growth. When exposure to a neurotoxic pollutant is widespread, the resulting widespread subclinical neurotoxicity can reduce the intelligence, creativity, and economic productivity of entire societies.

Exposures to toxic chemicals in early life are linked not only to increased risks of disease in childhood, but also to increased risks of disease in later life. This recognition, termed the *developmental origins of health and disease concept*, derives from studies conducted by Barker and colleagues who found that undernutrition in utero is associated decades later with increased risks for hypertension, obesity, diabetes, and cardiovascular disease. Epigenetic programming of gene expression during windows of vulnerability in early development appears to be the underlying mechanism. Increased risks for disease in adult life have now been associated also with early-life exposures to toxic chemicals and appear to be mediated through epigenetic changes in gene expression. Among the health problems linked to toxic chemical exposures in early life are decreased cognition in adults who were exposed as children to lead, neurobehavioral disorders in children exposed to a range of developmental neurotoxicants, and cancer.

CHEMICAL POLLUTANTS OF MAJOR CONCERN

Air Pollutants

Air pollution—ambient air pollution and household air pollution—is the world's largest environmental threat to health and, according to the WHO, is responsible for an estimated 6.7 million deaths each year. The air pollutants of greatest concern for children's health are particulate matter (especially fine particulates less than 2.5 microns in aerodynamic diameter), photochemical oxidants (especially ozone), oxides of nitrogen, sulfur oxides, and carbon monoxide; these are the "criteria air pollutants" regulated by the U.S. EPA in the Clean Air Act. In the United States, approximately 60% of children live in areas that do not meet national ambient air quality standards (NAAQS), most commonly particulate matter and ozone. Globally, ambient levels of air pollutants can be magnitudes higher than the United States.

Fuel combustion is the principal source of air pollution. In high- and middle-income countries, combustion of fossil fuels—coal, oil, and gas—accounts for most air pollution. In low-income and lower middle-income countries, the major source is burning of biomass, such as wood, dung, straw, and charcoal. Coal is the single most highly polluting fossil fuel and the most important source of the greenhouse gas emissions that drive global climate change, but fixed and mobile oil and gas combustion are also major contributors. As the climate changes, wildfires are becoming more common and are further contributing to air pollution and climate change.

Elevated levels of ambient air pollutants are associated with respiratory problems in children, including decreased expiratory volume, wheezing, exacerbations of asthma, and slowed lung growth. Slowed lung growth leads to decreased lung volume and increases risk for respiratory disease in childhood, adolescence, and adult life. Long-term improvements in ambient air quality, especially reductions in levels of particulates and oxides of nitrogen, are associated with statistically and clinically significant improvements in lung growth in children, effects that appear likely to persist into adulthood and to reduce lifetime risk of pulmonary and cardiovascular disease.

Aside from the criteria air pollutants, other pollutants emitted from mobile, stationary, and area sources are considered *hazardous air pollutants* (HAPs), which are known or suspected to cause cancer, reproductive effects, or birth defects. Some common examples are metals such as mercury (neurotoxin), asbestos (mesothelioma, lung cancer), and volatile organic compounds such as polychloroethylene (reproductive effects, cancer). Diesel exhaust is a particularly concerning source of air pollution as it contains fine and ultrafine particulates (capable of reaching alveoli and getting absorbed into bloodstream) and multiple HAPs (e.g., formaldehyde), and has been classified by the International Agency for Research on Cancer as a known human carcinogen.

The effects of household air pollution on children's health are magnified by the fact that many children spend 80–90% of their time indoors, and pollutant levels can be 2-5 times higher indoors especially in poorly ventilated spaces. In 2020, the WHO estimated that 237,000 children <5 years old died from illnesses attributable to household air pollution. Secondhand tobacco smoke (SHS) is an especially hazardous constituent of indoor air pollution and a powerful trigger for asthma (see Chapter 759.1). Household products, particularly some disinfectants, cleaners, paints, and floor finishes, have also been connected to respiratory tract irritation and increased asthma morbidity. Allergens in indoor air can contribute to respiratory problems and include cockroach, mite, mold, and cat and dog allergens.

HEALTH HAZARDS OF UNCONVENTIONAL NATURAL GAS DEVELOPMENT (FRACKING)

Unconventional natural gas development (UNGD) using high-volume horizontal hydraulic fracturing (fracking) has made possible the cost-effective extraction of natural gas from previously inaccessible underground shale deposits and has catalyzed a 16-fold increase in fracking wells in the United States between 2000 and 2020. Natural gas has surpassed coal to become the major source of electricity generation in North America.

In fracking, large volumes of water containing a mix of chemicals (whose composition is a closely guarded secret) are injected at very high pressure through deep wells into shale deposits to break apart the rock and allow release of gas. The gas is brought up to the wellhead through return pipes, collected, and sent to market. In some areas, gas and oil occur together, and the gas may be burned off (flared) at the wellhead while the more valuable oil is piped to market.

The hazards of fracking to children's health include:

- *Toxic air pollution by volatile organic compounds released from fracking wells such as benzene, ethyl-benzene, hydrogen sulfide (H_2S), n-hexane, and methane:* Benzene and ethyl-benzene are known human carcinogens, H_2S and n-hexane are neurotoxicants, and methane is a climate pollutant that contributes to greenhouse gas emissions.
- *Traffic-related air pollution resulting from the large volumes of diesel truck traffic required to bring piping, chemicals, and water to drilling operations:* Diesel exhaust contains coarse and fine particulates, polycyclic aromatic hydrocarbons (PAHs), and formaldehyde, and has been classified by the International Agency for Research on Cancer as a known human carcinogen.
- *Water pollution by toxic chemicals:* Leaks of toxic materials into waterways occur commonly during fracking operations; in addition, much of the water injected into the wells returns to the surface containing proprietary injected chemicals, along with high concentrations of salt dissolved from underground deposits and naturally occurring radioactive materials. These chemicals have been shown to contaminate both ground and surface waters. Water pollution is a particularly severe problem in arid regions with limited water supplies.
- *Radon released from underground deposits:* Radon has been shown to contaminate air near wellheads, and high concentrations of radon have been identified in shipped gas. Additional, nonchemical hazards of fracking include incessant noise, high risk of vehicular injury to children from fast-moving heavy trucks on poorly maintained rural roads, societal disruption in rural communities, and extensive degradation of the environment.

Lead

See Chapter 761.

Mercury

See Chapter 760.

Asbestos

Between 1947 and 1973, asbestos was sprayed as insulation on classroom walls and ceilings in approximately 10,000 schools in the United States. It was also widely utilized in homes as pipe insulation and in floor tiles. Subsequent deterioration or unsafe removal of this asbestos can release asbestos fibers into the air. Asbestos is not a health hazard so long as it is intact, but once it becomes airborne, it can be inhaled by children to produce adverse health effects. Asbestos is a human carcinogen, and the two principal cancers caused by asbestos are lung cancer and mesothelioma. U.S. federal law requires that all schools be inspected periodically for asbestos and that the results be made public. Removal by an EPA-certified contractor is required only when asbestos is visibly deteriorating or is within the reach of children. In most cases, placement of barriers (drywall walls or drop ceilings) provides appropriate protection.

Pesticides

Pesticides are a diverse group of chemicals used to control insects, weeds, fungi, and rodents, and are used in large quantities in agriculture, homes, schools, parks, gardens, and recreational areas. Children are at risk of exposure when pesticides are used inside or outside in places where children live, learn, and play, and in rural areas they can be exposed to pesticide drift from fields that have been sprayed. Children employed in agriculture or living in migrant farm camps are at risk of direct exposure to pesticides. Diet is another major route of exposure because children are exposed to residual levels of multiple pesticides on fruit and vegetables, especially fruits and vegetables imported from countries where pesticide use is heavier than in the United States. Children can be acutely overexposed to pesticides and clinically evident poisoning results. High-dose exposure to neurotoxic insecticides such as the organophosphate and carbamate pesticides can cause acute neurotoxicity. Both classes of pesticides act through inhibition of acetylcholinesterase and are responsible for the largest number of acute poisoning cases. Symptoms include meiosis, excess salivation, abdominal cramping, vomiting, diarrhea, and muscle fasciculation. In severe cases, the child may experience loss of consciousness, cardiac arrhythmias, and death by respiratory arrest. The war gas sarin is an organophosphate. See Chapter 94 for treatment of poisoning from drugs, chemicals, and plants.

Pesticides can also cause a range of chronic toxic effects that include polyneuropathy and central nervous system (CNS) dysfunction (organophosphates), hormonal disruption and reproductive impairment (DDT, kepone, dibromochloropropane), cancer (aldrin, dieldrin, chlorophenoxy herbicides [2,4,5-T]), and pulmonary fibrosis (paraquat).

Prenatal exposure to the organophosphate pesticide **chlorpyrifos** at levels that produce no evident toxicity in pregnant women has been associated with neurodevelopmental disability in children with reduced cognitive function (lowered IQ), disordered executive function, and functional and anatomic changes in the brain discernible by functional magnetic resonance imaging (fMRI).

Two classes of pesticides of concern are synthetic herbicides and the neonicotinoid insecticides. Herbicides account for about 48% of total pesticide use, and their application is increasing. A major use of herbicides is in production of *genetically modified (GM) food crops*, mainly corn and soybeans that are engineered to be tolerant to **glyphosate (Roundup)**, the most used herbicide worldwide. Herbicides can be sprayed on herbicide-resistant crops throughout the growing season, and glyphosate-resistant, "Roundup-Ready," GM crops account for more than 90% of all corn and soybeans planted in the United States.

Studies of agricultural workers exposed occupationally to glyphosate and other herbicides have found evidence for increased incidence of non-Hodgkin lymphoma. On the basis of these studies and convergent results from toxicologic studies, the International Agency for Research on Cancer has determined that glyphosate is a "probable human carcinogen." Measurable levels of glyphosate metabolites are commonly detected in the urine of Americans.

The **neonicotinoids** are a class of neurotoxic pesticides developed in the 1980s to replace the organophosphates and carbamates. Use of neonicotinoids rose dramatically in the early 2000s, and the neonicotinoid insecticide, imidacloprid, is one of the most widely used insecticides in the world. A growing body of evidence indicates that neonicotinoids are toxic to bees and other pollinators at concentrations found currently in agricultural areas, and neonicotinoids are suspected of contributing to bee colony collapse disorder. In 2020, the EPA proposed a number of restrictions and precautions for neonicotinoid use. More than a dozen states have also introduced legislation limiting neonicotinoids, and several European countries have banned or severely restricted their use. Almost no information is available on the possible developmental or pediatric toxicity of the neonicotinoids. This is another example of a new pesticide in widespread use without prior testing for health impacts on children.

Children's exposures to pesticides can be reduced by minimizing applications to lawns, gardens, schools, and playgrounds; adapting techniques of integrated pest management; and reducing pesticide applications to food crops. Pediatricians and parents can look to resources including the National Pesticide Information Center (NPIC) and the EPA for guidance on integrated pest management and safer use of pesticides in and around the home. Consumption of organic produce has been shown to dramatically reduce pesticide exposure in school-age children. Families can choose organic produce when available and cost-competitive but should not avoid a diet rich in fruits and vegetables if organic options are not feasible.

Persistent Organic Pollutants: Per- and Poly-fluoroalkyl Substances and Chlorinated Hydrocarbons

Per- and Poly-fluoroalkyl Substances. Per- and poly-fluoroalkyl substances (PFAS) are a group of synthetic chemicals that have been used in industrial processes and consumer products because they are resistant to water and heat, and do not break down in the environment. In addition, they can move through soil into drinking water sources and can build up in fish and wildlife (bioaccumulate). They may make clothing stain resistant and also reduce friction. PFAS are also known as "forever chemicals" due to their persistence in the environment, as their strong carbon-fluorine chain is resistant to degradation. NHANES has documented universal exposure to some PFAS due to their ubiquity in consumer products (e.g., nonstick pans, take-out food containers, water-resistant textiles) and the food chain. PFAS have also been detected in drinking water sources (both municipal systems and private wells) across the United States. In March 2023, the EPA proposed a draft of enforceable maximum contaminant levels (MCLs) for six different PFAS chemicals in public drinking water systems; the final regulations are expected by the end of 2023. Several states have enacted their own MCLs for various PFAS compounds; these state MCLs will have to become at least as stringent as the federal MCLs (once finalized).

Ingestion of contaminated food, water, or household dust is the major route of exposure to these chemicals. PFAS can cross the placenta and enter breastmilk. The half-life in the body can be days to decades, depending on the specific PFAS compound. Epidemiologic studies suggest a link between PFAS exposure and increased cholesterol levels, altered liver function tests, decreased antibody response to childhood vaccines, increased risk of preeclampsia/high blood pressure during pregnancy, and cancer (kidney and testicular). Health outcome studies in highly exposed communities are ongoing.

Chlorinated Hydrocarbons. The chlorinated hydrocarbons are a large and diverse class of chemicals that include insecticides (DDT), plastics (polyvinyl chloride), electrical insulators (PCBs), and solvents (trichloroethylene). Highly toxic chlorinated dioxins and furans are formed during synthesis of chlorinated herbicides or as by-products of plastic combustion. These materials are widely dispersed and highly persistent in the environment. Dioxins and furans are known human carcinogens. Brominated flame retardants are used in carpets, furniture, and computers and are environmentally persistent.

The embryo, fetus, and young child are at particularly high risk of injury from halogenated hydrocarbons. All of these compounds are lipid soluble. They readily cross the placenta, and they accumulate in breast milk. Intrauterine exposure to PCBs and brominated flame retardants has been linked to persistent neurobehavioral dysfunction

in children manifested by cognitive impairment (reduced IQ), shortening of attention span, and behavioral disorders.

Consumption of fish from contaminated waters is a major source of children's exposure to PCBs. Children can be exposed in utero or through breast milk. To protect children and pregnant women against PCBs in fish, government agencies have issued advisories concerning fish consumption for certain lakes and rivers. Combustion of medical wastes containing polyvinyl chloride and the use of chlorine to bleach paper products are major preventable sources of environmental dioxin emissions and should be discouraged. Older fluorescent light ballasts that were installed decades ago in schools in the United States are another source of PCB exposure. PCB-containing ballasts should be removed from schools as soon as possible to prevent environmental contamination. Removal must be performed by trained workers.

Endocrine Disruptors

Endocrine disruptors are synthetic chemicals that mimic, block, or alter the actions of normal hormones such as estrogen, testosterone, growth hormone, insulin, and thyroid hormone. Synthetic endocrine disruptors are manufactured in volumes of millions of pounds per year. They include phthalates, bisphenol A, perchlorate, certain pesticides, brominated flame retardants, certain metals, and dioxins. These chemicals are widespread today in consumer products such as soaps, shampoos, perfumes, and plastics. They are widely disseminated in the environment and encountered in air, food, and drinking water.

Exposures to endocrine disruptors in early human development are especially hazardous. Even extremely low-dose exposures during critical early periods can lead to lasting impairments in organ function and to increased risk of disease. Reproductive effects are one consequence of early life exposures to endocrine disruptors. Endocrine disruption is implicated in the epidemiologic observations of a trend toward earlier thelarche and menarche in females, with rising rates of testicular cancer and hypospadias, and with diminishing sperm counts. Among the most clearly documented reproductive effects of early life exposures to endocrine disruptors are adenocarcinoma of the vagina in women and cryptorchidism in men whose mothers took diethylstilbestrol (DES). Another well-documented effect is shortening of the anogenital distance, a measure of in utero feminization, in infant males whose mothers had elevated exposures to phthalates during pregnancy.

Early life exposures to endocrine disruptors can have adverse effects on brain development. Prenatal exposure to low molecular weight phthalates is associated with shortening of attention span in children 4-9 years old, as well as with increased risk for autistic behaviors. Prenatal exposure to bisphenol A has also been linked to behavioral anomalies.

Endocrine disruptors have been reported to have adverse impacts on lipid metabolism and to increase the risk for obesity. Higher urinary levels of bisphenol A are associated with obesity-related outcomes, such as cardiovascular disease, in a cross-sectional analysis of NHANES 2003-2004 data in adults.

Early life exposures to endocrine disruptors, most notably DDT, are linked with increased risk for cancer. A long-term epidemiologic study of women in California found that those who were exposed in utero to high levels of DDT have increased risk for breast cancer in adult life 40-50 years later.

Environmental Carcinogens

Leukemia and brain cancer, the two most common forms of pediatric malignancy in the United States, both increased in incidence from 1972 to 2018, despite declining mortality. The cumulative increase in incidence for childhood leukemia was more than 20%, and for brain and CNS cancer more than 40%. In the same time period, testicular cancer in young men, ages 15-30 years, more than doubled in incidence and is occurring at younger ages. These increases are too rapid to be of genetic origin and are not likely due to better diagnostic capabilities. They are most probably the result of still undefined exposures in the environment. Cancer is now the second-leading cause of death in American children, surpassed only by injuries.

Children may be exposed to carcinogenic pollutants in utero or after birth. Children appear more sensitive than adults to certain chemical carcinogens and also to ionizing radiation (see Chapter 758). The potential for chemical carcinogenesis in utero was initially recognized with the discovery that clear cell adenocarcinoma of the vagina could develop in young women who were exposed in utero to DES.

Carcinogenesis may be associated with exposures in the home and community. Children of asbestos workers and children who have grown up near asbestos plants have been found to have an elevated incidence of mesothelioma. Children who attended elementary school in communities containing synthetic rubber plants have been shown to be at increased risk of leukemia as a result of their exposure to 1,3-butadiene, a known human carcinogen and a major component of synthetic rubber. Children who grow up on farms have elevated rates of leukemia; pesticides are suspected of playing an etiologic role. Intrauterine exposure to trichloroethylene via contaminated drinking water has been associated with an increased incidence of leukemia among females living near an industrial facility and industrial waste site.

Routes of Exposure

Transplacental. Heavy metals such as lead and mercury, fat-soluble compounds such as PCBs and DDT, and endocrine disruptors such as phthalates, readily cross the placenta. They may have serious and irreversible toxic effects on the developing nervous, endocrine, and reproductive organs, even at very low levels. The American College of Obstetricians and Gynecologists have recognized the hazards of environmental exposures during pregnancy and provide detailed guidance for counseling to reduce these exposures in their 2021 statement Reducing Prenatal Exposure to Toxic Environmental Agents (Table 259.2).

Water. Approximately 200 chemicals have been detected at various levels in water supplies including contaminants like lead, solvents, pesticides, and emerging chemicals like PFAS. Lead is an especially common contaminant. Water supplies are generally lead-free at the source but can become contaminated by lead that dissolves from lead pipes and from lead-containing plumbing fixtures. Lead is especially likely to dissolve from pipes and plumbing when the water is acidic, as happened in Flint,

Table 759.2 Toxic Chemicals or Pollutants and Reported Association with Adverse Reproductive Health Outcomes*

CHEMICAL OR POLLUTANT WITH REPORTED ADVERSE ASSOCIATION	POTENTIAL HEALTH EFFECT
Antineoplastic drugs, bisphenol A (BPA), cigarette smoke, ethylene oxide, formaldehyde, polybrominated diphenyl ether (PBDE) flame retardants, solvents	Infertility and miscarriage
Air pollutants from fracking, ambient air pollutants, antineoplastic drugs, cigarette smoke, ethylene oxide, formaldehyde, perfluorochemicals (PFAS),* pesticides, phthalates, PBDEs, toluene	Preterm birth and low birthweight
Ambient air pollutants, BPA, lead, mercury, pesticides, phthalates, PBDE flame retardants, polychlorinated biphenyls (PCBs)	Neurodevelopmental impairment

*Associations noted are from reports of animal and limited human studies. Although there are reported associations between exposures and adverse obstetric outcomes, an association does not necessarily mean that the exposure is a cause of the outcome. More research is needed to understand if there is causality and, if so, at what level of exposure or use of a specific product.

Modified from American College of Obstetricians and Gynecologists' Committee on Obstetric Practice. Reducing prenatal exposure to toxic environmental agents: ACOG Committee Opinion, Number 832. *Obstet Gynecol*. 2021;138(1):e40–e54. Table 1.

Michigan, in 2014. The highest levels of lead occur in water that has been standing in lead pipes overnight. It is wise therefore to run water for 2-3 minutes each morning before making up infant formula. Solvents and components of gasoline such as methyl tertiary-butyl ether and benzene are commonly encountered in groundwater. Chemical contaminants from gas drilling can contaminate water in areas where fracking is taking place. Herbicides, such as glyphosate and atrazine, are commonly found contaminants in drinking water in agricultural areas.

In the United States, the EPA regulates approximately 90 drinking water contaminants including organic chemicals, inorganic chemicals, radionuclides, and infectious agents in public water systems. The municipal water systems are responsible for ensuring that the regulated contaminants are below MCLs and will notify customers of any exceedance and steps to address the issue. Those families using private wells, however, are responsible for testing their water on a regular basis. Families with well water can be directed to the EPA private well website or their local health department for guidance on the recommended tests.

Air. Vehicular emissions are the major source of urban air pollution, notably ground-level ozone and particulate matter. Diesel exhaust is a human carcinogen. Coal-fired power plants are another major source of outdoor air pollution. In rural areas, wood smoke can contribute to air pollution. Pediatricians and parents can follow local air quality alerts that include recommendations to reduce risk especially for sensitive groups (airnow.gov). Children living in the vicinity of smelters and chemical production plants can be exposed to toxic industrial emissions such as lead, benzene, and 1,3-butadiene. Specific information about toxic air pollution release in a community can be obtained via the Toxics Release Inventory (www.epa.gov/toxics-release-inventory-tri-program).

Food. Many chemicals are intentionally added to food to improve appearance, taste, texture, or preservation, but many such chemicals have been poorly tested for potential toxicity. Residues of many pesticides are found in both raw and processed foods. Levels of pesticides are lower in organic produce than in conventionally grown fruits and vegetables. Children who consume organic produce have substantially lower urinary pesticide levels than children who eat conventional produce. Elevated levels of methylmercury can be found in large predator fish such as swordfish, shark, king mackerel, and tuna sushi; families should be encouraged to follow fish advisories. Baby foods can contain trace amounts of metals, and rice and rice-based products (especially those made of brown rice) can have inorganic arsenic.

Breast Milk. Breast milk provides many benefits to infants including protection from illness, reduction in allergic diseases like asthma, and reduced risk of obesity, among many others. Breast milk can also be a route of exposure to environmental chemicals including fat-soluble persistent organic pollutants, pesticides, and metals. In almost all situations, the benefits of breastfeeding outweigh the risks of these exposures, and numerous professional organizations support breast milk as the first choice for infant feeding. In addition, chemical regulation can further reduce unnecessary exposure through this route.

Work Clothes. Illnesses in children sometimes may be traced to contaminated dust from parents' work clothes; toxicity from lead, beryllium, dioxin, organophosphate pesticides, and asbestos has occurred. Such exposure (termed *fouling the nest*) can be prevented by providing facilities at work for changing and showering. If facilities are not available, caregivers can be advised to change clothes and shoes before returning home and wash work clothes separately from household laundry. Some work activities and hobbies that occur at home can also expose children to toxins including metals like lead and solvents.

School. Children may be exposed in schools, kindergartens, and nurseries to lead paint, molds, asbestos, tobacco smoke, pesticides, and hazardous arts and crafts materials. Substantial opportunities for prevention exist in the school environment, and pediatricians are often consulted for advice. The EPA has school related environmental health materials (www.epa.gov/schools) that can be shared with stakeholders.

Child Labor. Four to five million children and adolescents in the United States work for pay, and child labor is widespread around the world. Working children are at high risk of physical trauma and injury. They also may be exposed to a wide range of toxic chemicals, including pesticides in agriculture and lawn work, asbestos in construction and building demolition, and benzene in pumping gasoline.

THE PHYSICIAN'S ROLE

Pediatricians have time and again played key roles in the initial recognition of diseases caused by toxic chemicals. Every pediatrician needs to be an "alert clinician" open to the possibility of discovering new diseases in children caused by hazardous exposures in the environment. In considering the origins of noninfectious disease, pediatricians should ask about the home environment, parental occupation, unusual exposures, and neighborhood factories. An environmental cause is particularly likely when several unusual cases of disease or constellations of findings occur together. Any adolescent with a traumatic injury may have been injured at work.

The history is the single most important instrument for obtaining information on environmental exposures (Table 759.3). Information about current and past exposures (including questions about work and travel to or residence in developing countries) should be sought routinely for every new patient. The age of the patient can help focus questions and provide anticipatory guidance on key exposures of concern, such as screening for common sources of lead exposure in young children. Patients with asthma should be evaluated for exposure to common allergens (mold, cockroaches, dust mites) and irritants (tobacco smoke, strong odors). Children with neurodevelopmental disorders should be assessed for pica and other behaviors that increase their risk of toxic exposures. Consider targeted environmental health history questions in patients with illness of unclear causation. Changes in patterns of exposure or new exposures may be especially important. If suspicious information is elicited, more detailed follow-up should be pursued. Referral to a state or local health department or to a Pediatric Environmental Health Specialty Unit may be indicated (https://www.pehsu.net/). Accurate diagnosis of an environmental cause of disease can lead to better care of sick children and prevention of disease in other children.

Visit Elsevier eBooks+ at eBooks.Health.Elsevier.com for Bibliography.

759.1 Tobacco

Judith A. Groner

Cigarette smoking is the single most preventable cause of morbidity and mortality, contributing to over 480,000 annual deaths in the United States. The most common reason that people smoke is nicotine addiction, and people who start smoking at an earlier age are more likely to develop a severe addiction than those who start when they are older. In 2022, 4.5% of middle school students and 16.5% of high school students reported current tobacco use (see Chapter 157.2). While youth use a variety of tobacco products, e-cigarettes are the most common. E-cigarettes work by heating liquid to produce an aerosol that is then inhaled into the lungs; this process is called **vaping**. While the long-term health effects of vaping are still being evaluated, the 2019 E-cigarette or Vaping Use-Associated Lung Injury (EVALI) epidemic drew attention to the dangers associated with e-cigarette use (see Chapter 450).

COMPOSITION OF SECONDHAND SMOKE AND TOXICITIES

Along with active tobacco use, secondhand tobacco smoke (SHS) exposure is a very serious health hazard for both children and adults. SHS is a mixture of approximately 7,000 chemicals and is made up of the mainstream smoke exhaled by the smoker and side-stream smoke expelled from the end of a lit tobacco product. At least 70 carcinogens have been identified in SHS, along with 250 chemicals that are toxic to the CNS, immune system, heart, and liver.

SHS also contains particulate matter, which is an independent health hazard. Particulate matter is microscopic solid and liquid matter suspended in air, which can be inhaled and enter the circulation. The most studied of these include polycyclic aromatic hydrocarbons (PAHs) and the tobacco-specific nitrosamines, which are both carcinogenic. Most particulate matter in side-stream smoke is unfiltered by the smoker

Table 759.3 Clinical Tools for Incorporating Environmental Health into Patient Care

Tips for implementing a focused environmental health history:

1. *Age:* Patient age can help direct screening questions and anticipatory guidance on key exposures of concern, such as lead screening questions for young children. Refer to American Academy of Pediatrics (AAP) Bright Futures or the Pediatric Environmental Health Toolkit for age-specific information.
2. *Location*: Local environmental conditions can help direct environmental guidance. For example, in rural communities with high prevalence of private wells for drinking water, families can be counseled on the importance of routine well water testing.
3. *Symptoms*: Consider environmental exposures in the differential diagnosis. For example, carbon monoxide exposure should be on the differential for families presenting with headaches and flulike symptoms (afebrile, no cough).
4. *Asthma*: assess for common environmental asthma triggers in the home such as mold, cockroaches, mice, environmental tobacco smoke, furry pets, cleaning chemicals, strong odors/fragrances
5. *Neurodevelopmental disorders*: assess for pica behavior and other risk factors that may increase the likelihood of exposures (e.g., lead); assess for use of alternative medications

Components of environmental health history (can be adapted based on patient scenario):

General home health and safety:
- Age and condition of home (lead paint in pre-1978 home)
- Carbon monoxide and fire alarms
- Heat and cooking sources (stove ventilation, safe space heater use)
- Tobacco smoke
- Radon (test basement and first/second floors)
- Cleaning products-safe storage and use (e.g., bleach)

Common indoor allergens:
- Water leaks/mold
- Pests (cockroaches, mice) and pesticide use

Water and food:
- Drinking water source (well water requires routine testing)
- Fish advisories (methylmercury) for pregnant persons and children
- Fresh produce (rinse well before eating)
- Rice-based products (vary grains to reduce arsenic exposure)

Jobs and hobbies:
- Caregiver jobs (contaminant transfer from clothing, shoes)
- Adolescent jobs (safety)
- Hobbies in the home (paints, chemicals)
- Sun protection outdoors
- Noise from headphones, toys

Resources and tools for clinical practice:

Environmental history forms:
- National Environmental Education Foundation (NEEF) has a general environmental history and an asthma-focused environmental history (English and Spanish): www.neefusa.org/resource/pediatric-environmental-history
- World Health Organization (WHO) Paediatric Environmental Health History (Green Page) provides a series of concise questions to assess potential exposures: https://www.who.int/publications/m/item/children-s-environmental-record--green-page

Evidence-based clinical resources:
- The Green Book: American Academy of Pediatrics. *Pediatric Environmental Health*. 4th ed. Etzel RA, Balk SJ, eds. Elk Grove Village, IL: American Academy of Pediatrics; 2019.
- Pediatric Environmental Health Specialty Unit (PEHSU). One PEHSU is located in each of the 10 federal regions in the United States. The PEHSUs provide online classroom materials, resources, and access to network of experts in pediatric and reproductive environmental health: www.pehsu.net
- The Pediatric Environmental Health Toolkit is an online clinical tool that providers can use to access information on common exposures, including identification of sources of exposure and provision of targeted anticipatory guidance: https://peht.ucsf.edu.
- Bright Futures provides guidance for well child care for children and adolescents (includes key environmental anticipatory guidance): https://brightfutures.aap.org/.
- American College of Obstetricians and Gynecologists (ACOG). Reducing Prenatal Exposure to Toxic Environmental Agents: https://pubmed.ncbi.nlm.nih.gov/34259492/

Resources for patients:
- Prescriptions for Prevention are tools that link patients to evidence-based simple steps to reduce or prevent common environmental exposures (English and Spanish): https://nyscheck.org/rx
- National Institute of Environmental Health Sciences (NIEHS). Environmental health topics: https://www.niehs.nih.gov/health/topics/index.cfm

and is in the submicron (<1 μm diameter) range, meaning that it is classified as fine particulate matter. These are smaller than the particles in mainstream smoke and can penetrate deeper into the lungs, resulting in higher toxicity through oxidative stress and inflammation. Short- and long-term exposure to fine particulate matter contributes to the aggravation of asthma and other respiratory diseases, lung and other cancers, cardiovascular disease, and death.

SHS concentration in the indoor environment depends on the number of cigarettes smoked in a period, the volume of the room, the ventilation rate, and other processes that eliminate pollutants from the air. There are multiple mechanisms by which SHS causes injury to the respiratory tract, and injury to the cardiovascular system is due to endothelial cell dysfunction due to smoke exposure and its prothrombotic effects.

THIRDHAND SMOKE

Thirdhand smoke (THS) was defined in 2011 as consisting of the residual tobacco smoke pollutants that remain on surfaces and in dust after tobacco has been smoked. These toxins are reemitted into the gas phase or react with oxidants and other compounds in the environment to yield secondary pollutants. These residual pollutants can be detected in the indoor environment well after being generated. About half the particulate matter from SHS is still airborne after 5-6 hours. Many chemicals, such as nicotine and some PAHs, exist in both the gaseous and the particulate phase of SHS. Classified as "semi-volatile," their ability to change form according to environmental conditions means that they remain detectable in the indoor environment for longer periods after active smoking has ceased. These components in dust and on surfaces can be ingested, inhaled, or even absorbed through the skin. The health implications of THS are not well understood, but there is growing evidence both in vitro and in vivo of health harms of THS exposure, particularly respiratory symptoms. Young children are at higher risk of health issues due to THS absorption because of their hand to mouth behaviors, crawling near surfaces, time spent in the home, and increased respiratory rate.

TOBACCO USE AND EXPOSURE IS A HEALTH RISK DISPARITY

Tobacco use, and hence childhood exposure, is found disproportionately among socially disadvantaged low-income populations, who can least afford tobacco and SHS-related illness and evidenced-based treatment for nicotine addiction. There has been a profound decrease in smoking rates among the middle and upper classes within the United States since the 1960s (83% decrease), but the rate of decrease is much less (39%) among lower income groups. The smoking rate for the overall U.S. population is approximately 12.5%, but it is as high as 32% among adults with a high school equivalency degree. Because of these disparities in smoking rates among adults, children born into low-income homes are more likely to be exposed to SHS. More than 38% of U.S. children age 3-11 years were exposed to tobacco smoke from 2017 to 2018, based on a biologic marker of exposure, serum cotinine levels. Children from low-income homes have the highest rates of biologically measured SHS exposure; for every decrease in family income ratio, serum cotinine levels increase by 1.18 ng/L among children. Having a parent who smokes has also been shown to be an independent risk factor for food insecurity in children.

MATERNAL SMOKING DURING PREGNANCY AND TOBACCO SMOKE EXPOSURE DURING PREGNANCY

The effects of maternal smoking on the fetus are profound and can be divided into pregnancy-related and long-term effects. Fetal exposure is one of the most important modifiable risk behaviors for childhood and long-term health.

Pregnancy-Related Effects

Maternal smoking increases the risk of placenta-associated complications of pregnancy, with an increased rate of placental abruption and placenta previa among maternal smokers. Both active maternal smoking and secondhand maternal tobacco smoke exposure have been shown to reduce birthweight and to increase the risk of preterm birth. In utero tobacco exposure from either maternal active tobacco product use or maternal SHS exposure increases the rate of stillbirth. Smoking both during and after pregnancy is a risk factor for **sudden infant death syndrome (SIDS)**; one study found that any smoking during pregnancy was associated in a doubling of SIDS risk and that there was a linear correlation between the average number of cigarettes smoked daily and an increased risk for SIDS. These associations are modifiable by public policy. Several countries in Europe have shown decreased perinatal complications after comprehensive smoke-free laws; within the United States, pregnancy complications and SIDS are inversely related to tobacco taxation levels.

Long-Term Effects

Maternal smoking in early pregnancy is considered causal for orofacial clefts (Surgeon General Report 2014).

Both active smoking during pregnancy and SHS exposure of the mother increases the *child's* later risk of being overweight or obese. This finding may appear surprising due to the long-known relationship between smoking during pregnancy and low birthweight. This relationship has been shown in multiple epidemiologic studies and is robust to adjustment for potential confounders, such as parental body mass index (BMI), breastfeeding, family diet, and lifestyle.

Maternal smoking during pregnancy has been associated with both an increased risk of learning problems and neurobehavioral issues during childhood. The adverse effects of prenatal smoking on child neurodevelopment include poor language development and reduction in cognitive functioning. Prenatal exposure to smoking may also reduce the child's motor performance, mental development (measured by the Bayley Scales of Infant Development), IQ scores, and language development through age 3 years. This exposure may also increase the risks of several child behavioral problems, including externalization of aggressive and hyperactive behavior, prolonged periods of verbal or physical aggression and socially undesirable behavior (conduct disorder) throughout childhood, and delinquency in later childhood. In one study, a dose-response relationship with increasing severity of poor school performance was related to the number of cigarettes the mother smoked during pregnancy.

Maternal Smoking During Pregnancy and Lung Development

Smoking during pregnancy is associated with poor lung growth and function in the offspring and with a greater risk for wheezing between age 2-4 years. According to the Surgeon General Report (2014), there is sufficient evidence to consider this relationship to be causal.

POSTNATAL SECONDHAND SMOKE EXPOSURE—EFFECTS ON THE CHILD

Respiratory

Children exposed to SHS have a higher rate of asthma prevalence and greater asthma severity. The Surgeon General Report (2006) concluded that there is a causal relationship between parental smoking and cough, phlegm, wheezing, and breathlessness, along with asthma, among school-age children. Children with SHS exposure have a weakened response to inhaled corticosteroids. Children with asthma who are SHS-exposed are more likely to have an acute care visit, an overnight hospital stay, and a higher number of hospital admissions than children with asthma and no SHS exposure. The rate of hospital readmissions for asthma has been associated with the level of the child's saliva cotinine, a biomarker of smoke exposure, and this is true even at very low levels of exposure.

Tobacco smoke exposure is a cause of lower respiratory tract infection in children. Findings of the Surgeon General in 2006 were updated by a systemic review of parental and household smoking and risk of lower respiratory tract infections in infancy in 2011. The strongest relationship was for bronchiolitis, where the risk of any household smoke exposure was increased in the first two years of life.

SHS exposure during childhood increases the rate of middle ear disease, including acute, recurrent otitis media and chronic middle ear effusion. The Surgeon General Report (2006) rated this evidence as sufficient to infer a causal relationship between parental smoking and middle ear disease in children.

Cardiovascular Effects

Tobacco smoke exposure during adulthood has been linked to an increased risk of cardiovascular disease. Evidence links childhood exposure to findings of preclinical atherosclerosis. These include increased carotid intima-media thickness and decreased flow-mediated dilation, both indirect tests for preclinical changes leading to atherosclerosis during adulthood. Other findings have included increased inflammation as measured by C-reactive protein, abnormal lipid profiles, higher blood pressure, and increased rates of metabolic syndrome among SHS-exposed children and youth.

Infection

Childhood exposure to SHS is related to increased rates of invasive meningococcal disease in children less than 5 years old. SHS in the home doubled the risk of invasive meningococcal disease with some evidence of a dose-response relationship. The strongest effect was seen in children under 5 years, with SHS exposure more than doubling the rate of meningococcal disease. This relationship was seen both with prenatal smoking and postnatal exposure.

SHS exposure has also been shown to increase the severity of influenza among children hospitalized for the disease. Children with SHS exposure were 4.7 times more likely to be admitted to intensive care and had a 70% longer length of stay than nonexposed children, after controlling for multiple potential confounding factors.

Healthcare Utilization

Children and teens age 3-19 years who are SHS-exposed had higher healthcare utilization compared with nonexposed peers based on an analysis of NHANES data from 2009–2012. Children with high SHS exposure based on serum cotinine were almost three times more likely to have an overnight hospital stay and two times as likely to have a higher number of total hospital admissions as children with no exposure.

Special Vulnerable Pediatric Populations

There is evidence that SHS exposure exacerbates disease processes among children with significant chronic health conditions. Children with sickle cell disease who are exposed to SHS have increased morbidity, specifically increased rates of emergency department visits, and hospitalizations for vasoocclusive crisis and acute chest syndrome (see Chapter 511.1). In addition, tobacco smoke exposure is also associated with pulmonary function abnormalities among children with sickle cell disease, independent of their baseline disease.

Children with cystic fibrosis (CF) are another vulnerable population in which SHS exposure presents an additive threat to overall health. Core health issues for this group of children include problems with growth, lung function, and pulmonary infections (see Chapter 454). SHS-exposed children with CF had decreased growth between 4 and 12 months compared with non–SHS exposed infants. Furthermore, tobacco smoke exposure was associated with increased bronchodilator responsiveness and air trapping, and with increased methicillin-resistant *Staphylococcus aureus* and anaerobic growth on respiratory culture. Tobacco smoke exposure can be considered a modifiable risk factor for children with sickle cell disease and CF.

TREATMENT FOR TOBACCO USE AND SECONDHAND TOBACCO SMOKE EXPOSURE

There is no risk-free level of youth tobacco use or SHS exposure. Thus the best method to treat tobacco use and SHS exposure is to eliminate this exposure by helping adolescents and their caregivers quit smoking. Methods to reduce exposure such as "smoking outside" or wearing a "smoking jacket" have not been shown to eliminate biochemically confirmed SHS exposure. A meta-analysis of six controlled trials aimed specifically at SHS exposure reduction for children (not parental smoking cessation) showed some reduction in tobacco smoke pollution post intervention. However, all homes had significant tobacco-related air pollution at the end of the study period.

The pediatric office has long been considered an excellent venue for pediatricians to screen for youth tobacco use as well as children's SHS exposure and to intervene with youth and their caregivers. The American Academy of Pediatrics (AAP) recommends that providers:

1. Inquire about tobacco use and tobacco smoke exposure as part of health supervision visits and visits for diseases that may be caused or exacerbated by tobacco smoke exposure.
2. Include tobacco use prevention as part of anticipatory guidance.
3. Address parent/caregiver tobacco dependence as part of pediatric healthcare.
4. Offer tobacco dependence treatment and/or referral to adolescents who want to stop smoking.

The United States Preventative Services Task Force also recommends that primary care clinicians provide school-age children and adolescents who have not started to use tobacco with interventions (including education or brief counseling) to prevent initiation of tobacco use. The "Ask-Counsel-Treat" (ACT) model developed by the AAP provides tips on addressing youth tobacco use in the office (available at https://www.aap.org/en/patient-care/tobacco-control-and-prevention/youth-tobacco-cessation/tobacco-use-considerations-for-clinicians/); it is recommended that screening begin at age 11. The Clinical Effort Against Secondhand Smoke Exposure (CEASE) is a program that trains pediatricians and their office staff to systematically provide cessation counseling and interventions to caregivers who smoke. The CEASE model is (1) **ask** if anyone in the home or who cares for the child smokes; (2) **assist** the patient or caregiver with quitting by providing brief counseling, pharmacotherapy, or appropriate referrals; and (3) **refer** the smoker to evidence based cessation treatments, including telephone-based Quitlines or Text to Quit services. The CEASE model (found at https://www.massgeneral.org/children/cease-tobacco) involves training pediatricians to provide smoking cessation pharmacotherapy to caregivers who wish to quit smoking; it includes tools to both identify caregivers who smoke and facilitate pediatric healthcare providers' delivery of counseling, medications, and referral for tobacco treatment.

Despite the AAP recommendations for pediatricians to incorporate these methods into practice, a meta-analysis in 2016 of controlled trials in routine healthcare settings of child SHS exposure reduction did not show an intervention effect. However, three controlled trials of maternal postpartum smoking relapse prevention did demonstrate beneficial outcomes of the intervention.

Decreasing smoking initiation among youth will prevent the children of the future from SHS exposure. Ninety percent of smokers initiate use before 19 years of age, and 80% of youth who are smokers persist in smoking in adulthood. Of those, half will die earlier than their nonsmoking peers. After many years of individual states working to enact stricter tobacco laws, new federal legislation known as Tobacco 21 was signed in 2019 that raised the minimum age for sale of tobacco products from 18 to 21 years nationwide. By increasing the age of tobacco purchase to 21 years, there is hope that a whole generation of smoking can be prevented.

Visit Elsevier eBooks+ at eBooks.Health.Elsevier.com for Bibliography.

759.2 Marijuana Smoke Exposure

Karen M. Wilson

Unlike tobacco smoke exposure, which has long been recognized as a cause of morbidity and mortality among nonsmokers, marijuana smoke exposure is far less well studied. In 2021, 13.2 million persons age 12 years or older used marijuana on a daily or almost daily basis in the past 12 months, an increase from the 5.7 million daily or almost daily users in 2013 (see Chapter 157.3). The use of marijuana has been increasing in both acceptability and legality in the past 20 years. Current use of marijuana is more common among males and younger adults (18-34 years vs 35 years or older), and those with less than a high school degree. As of 2023, 38 states allow the legal use of marijuana for medical reasons, and 24 states plus Washington DC and Guam have legalized its recreational use. Analysis of poison control center calls for exposure to marijuana for children under 6 years of age showed an increase of 148% from 2006 to 2013; from 4.2/1 million children to 10.4/1 million. Tobacco-smoking parents with young children residing in the home are four times more likely to use marijuana as compared with nontobacco smoking parents. About 38% of young children in the United States are exposed to tobacco smoke, compared to an estimate of 15% of children exposed to marijuana smoke. Studies examining the presence of biomarkers of marijuana smoke exposure have found an exposure prevalence of 16% in young children hospitalized for bronchiolitis in Colorado, and 21% in children 0-3 years being seen at a clinic in New York City.

COMPONENTS OF MARIJUANA SMOKE

While marijuana can also be aerosolized or ingested as hash oil or leaf, combusted marijuana is still the most common form. A recent analysis of data from the U.S. National Health and Nutrition Examination Survey (NHANES) finds that daily marijuana users have higher levels of combustion biomarkers (e.g., volatile organic compounds and polycyclic aromatic hydrocarbons (PAHs) than nonusers. In addition to the particulates and other chemicals of combustion, marijuana comprises two primary active chemicals: Δ9-tetrahydrocannabinol (THC) and cannabidiol (CBD). Exposure to combustion products likely extends to adjacent nonusers, as has been shown for tobacco smoke. Most states with legal marijuana use do not have any restrictions on combustible marijuana use in the presence of children.

IMPACT OF MARIJUANA SMOKE EXPOSURE

While there is clear research on the dangers of secondhand tobacco smoke (SHS), there have been very few studies examining the impact of marijuana smoke exposure. Secondhand marijuana smoke contains particulate matter that is known to be harmful when inhaled, in addition to other toxic and carcinogenic chemicals such as volatile organic compounds, PAHs, and aromatic amines. Studies in adults have demonstrated that it is possible to get a "contact high" from intense exposure. Even brief exposures have been found to impair vascular endothelial function in animal models. Children can be exposed to secondhand and thirdhand marijuana smoke when parents or other household contacts smoke indoors, similar to children living with tobacco smokers. Also similar to tobacco, children could be exposed to marijuana smoke through incursions from neighboring apartments; in a New York City sample, 31% of parents reported marijuana incursions, whereas 34% reported tobacco incursions. Neonates can be exposed to marijuana prenatally or through breast milk. Prenatal exposure has been linked to growth restriction and neonatal intensive care admissions, as well as behavioral issues such as impulsivity. Prenatal exposure has also been linked to impaired executive functioning in young adulthood. One study examined the role of indoor cannabis smoke and health; although they found increased particulates in homes with cannabis use, there was no statistically significant difference in health outcomes.

TREATMENT

In the absence of convincing data showing that marijuana is not harmful, parents should be counseled to avoid exposing their children to marijuana smoke, to lock marijuana in a safe place out of reach of any children, to avoid edibles in appealing or non–child proof packaging, and to be cautious about their own level of impairment if they do choose to use legal marijuana.

Visit Elsevier eBooks+ at eBooks.Health.Elsevier.com for Bibliography.

Chapter 760

Heavy Metal Intoxication

Prashant V. Mahajan

Lead, mercury, arsenic, and cadmium, four of the World Health Organization's (WHO) "Ten chemicals of greatest public health concern," are the heavy metals posing the greatest threats to humans. The most prevalent of these exposures is lead (see Chapter 761).

Heavy metal intoxication results in multiorgan toxicity through widespread disruption of vital cellular functions. A meticulous history of environmental exposure may be necessary to correctly identify heavy metals as the source of the protean manifestations associated with such exposure. Arsenic exposure can occur from contaminated food or water; globally, more than 140 million people are estimated to be chronically exposed to drinking water containing high arsenic levels. Mercury exposure occurs primarily through food; fish is a major source of methyl mercury exposure.

ARSENIC

Arsenic is a metalloid that exists in four forms: elemental arsenic, arsine gas, inorganic arsenic salts (pentavalent arsenate form or trivalent arsenite form), and organic arsenic compounds. Toxic manifestations are higher in the more soluble and higher-valence compounds. **Arsine gas** is the most toxic form of arsenic. Mass poisonings from exposure to arsenic have occurred throughout history, including one in 1998 in Wakayama, Japan, in which 70 people were poisoned. Children may be poisoned after exposure to inorganic arsenic found in pesticides, herbicides, dyes, homeopathic medicines, and certain contaminated folk remedies from China, India, and Southeast Asia (see Chapter 94). Soil deposits contaminate artesian well water. Groundwater contamination with arsenic is a common problem in developing countries and has been reported to be a common well contaminant in many areas of the United States as well (Fig. 760.1). The Southwest has the highest arsenic concentrations in the country with more than 16% of sampled wells exceeding the maximum contaminant level. Food products (e.g., rice, organic brown rice syrup, fruit juices) cooked in contaminated water may absorb arsenic, thus concentrating it in the food (Fig. 760.2). The WHO and United States Environmental Protection Agency (EPA) have set 10 μg/L as the upper limit of safety. In many parts of Asia and South America, this limit is frequently exceeded. Arsenic concentrations in a quarter of the wells in Bangladesh exceed 50 μg/L, and 35-77 million of the 125 million inhabitants of Bangladesh regularly consume arsenic-contaminated water. Occupational exposure may occur in industries involved in the manufacturing, mining, smelting, or refining of glass, pottery, electronic and semiconductor components, and lasers. Although arsenic is no longer produced in the United States, it is produced in many countries and is imported into the United States for industrial use. Organic arsenic compounds may be found in seafood, pesticides, and some veterinary pharmaceuticals. In contrast to mercury, the organic forms of arsenic found in seafood are nontoxic.

Pharmacokinetics

Elemental arsenic is insoluble in water and bodily fluids, and thus is insignificantly absorbed and nontoxic. Inhaled arsine gas is rapidly absorbed through the lungs. The inorganic arsenic salts are well absorbed through the gastrointestinal tract, lungs, and skin. The organic arsenic compounds are well absorbed through the gastrointestinal tract. After acute exposure, arsenic initially is bound to the protein portion of hemoglobin in the red blood cells (RBCs) and rapidly distributed to all tissues. Inorganic arsenic is methylated and is eliminated predominantly by the kidneys, with approximately 95% excreted in the urine and 5% excreted in the bile. Most of the arsenic is eliminated in the first few days, with the remainder slowly excreted over a period of several weeks. Arsenic concentrates in hair, nails, and skin. Arsenic can also accumulate in the fetus, as it can cross the placenta. Measurement of the distance of **Mees lines** (transverse white striae on the nail) from the nailbed can provide an estimate of time of exposure (nails grow at the rate of 0.4 mm/day) (Fig. 760.3).

Pathophysiology

After exposure to arsine gas, absorbed arsine enters RBCs and is oxidized to arsenic dihydride and elemental arsenic. Complexing of these derivatives with red cell sulfhydryl groups results in cell membrane instability and massive hemolysis. The inorganic arsenic salts poison enzymatic processes vital to cellular metabolism. Trivalent arsenic binds to sulfhydryl groups, resulting in decreased production of

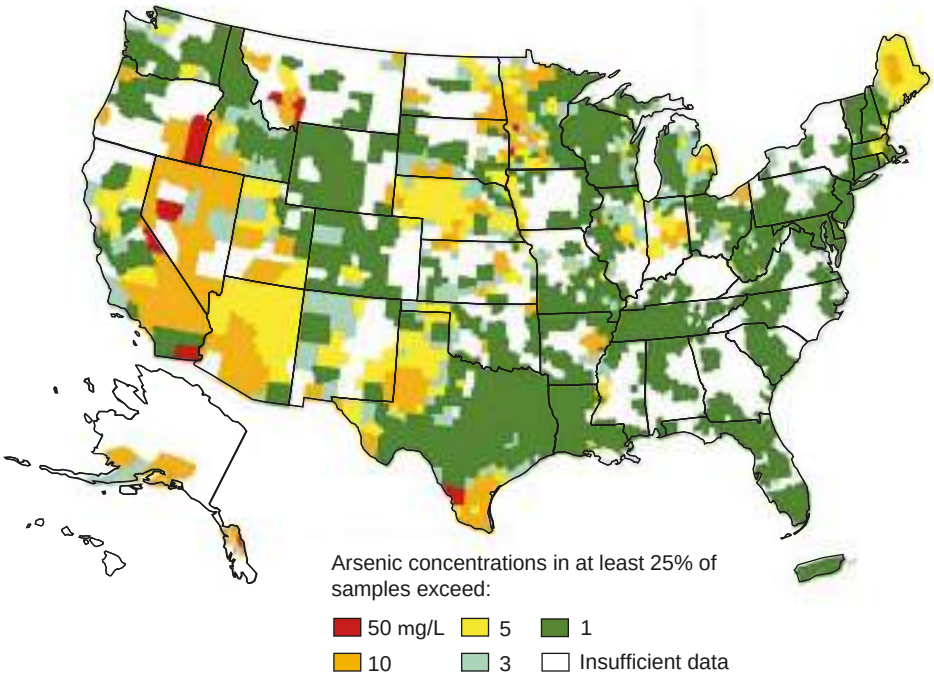

Fig. 760.1 U.S. Geological Survey map of arsenic in groundwater. Groundwater may also contain elevated concentrations of arsenic from agricultural runoff, contamination from runoff from wood preservatives containing arsenic, improperly disposed arsenical chemicals, or mining. For the latest on the US Geological survey: https://www.usgs.gov/mission-areas/water-resources/science/arsenic-and-drinking-water#overview. *(Modified from Agency for Toxic Substances and Disease Registry: Arsenic toxicity. What Are the Routes of Exposure for Arsenic? Fig 1.* https://www.atsdr.cdc.gov/csem/arsenic/what_routes.html.*)*

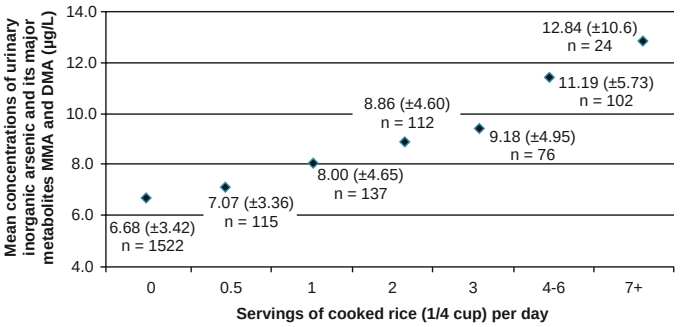

Fig. 760.2 Mean concentrations of urinary inorganic arsenic and its major metabolites monomethylarsonic acid (MMA) and dimethylarsinic acid (DMA) by categories of rice intake in children ages 6-17, National Health and Nutrition Examination Survey (NHANES) 2003-2008, excluding subjects with recent seafood consumption. *(From Lai PY, Cottingham KL, Steinmaus C, et al. Arsenic and rice: Translating research to address health care providers' needs. J Pediatr. 2015;167[4]:797–803. Fig. 1.)*

Fig. 760.3 Mees lines. Transverse white bands are clearly visible on the nails. *(From Chauhan S, D'Cruz S, Singh R, et al. Mees' lines. Lancet. 2008;372[9647]:1410.)*

adenosine triphosphate through the inhibition of enzyme systems such as the pyruvate dehydrogenase and α-ketoglutarate complexes. Pentavalent arsenic may be biotransformed to trivalent arsenic or substituted for phosphate in the glycolytic pathway, resulting in uncoupling of oxidative phosphorylation.

Clinical Manifestations

Arsine gas is colorless, odorless, nonirritating, and highly toxic. Inhalation causes no immediate symptoms. After a latent period of 2-24 hours, exposed individuals experience massive hemolysis, malaise, headache, weakness, dyspnea, nausea, vomiting, abdominal pain, hepatomegaly, pallor, jaundice, hemoglobinuria, and renal failure (Table 760.1). Acute ingestion of arsenic produces gastrointestinal toxicity within minutes to hours and is manifested as nausea, vomiting, abdominal pain, and diarrhea. Hemorrhagic gastroenteritis with extensive fluid loss and third spacing may result in hypovolemic shock. Cardiovascular toxicity includes QT interval prolongation, polymorphous ventricular tachycardia, congestive cardiomyopathy, pulmonary edema, and cardiogenic shock. Acute neurologic toxicity includes delirium, seizures, cerebral edema, encephalopathy, and coma. Lethal doses of arsenates are 5-50 mg/kg; lethal doses of arsenites are <5 mg/kg.

Table 760.1 Effects of Arsenic on Organ Systems

ORGAN SYSTEM	EFFECTS OF ARSENIC
Gastrointestinal system	Submucosal vesicles, watery or bloody diarrhea, severe hematemesis, pancreatitis, jaundice, toxic hepatitis
Cardiovascular system	Reduced myocardial contractility, prolonged QT intervals, tachyarrhythmias, torsades de pointes, pericarditis Vasodilation, hypotension, shock
Kidneys	Hematuria, proteinuria, oliguria, renal failure
Nervous system	Toxic encephalopathy with seizures, headache, cerebral edema, and coma Chronic exposure: peripheral painful sensorimotor neuropathy, paresthesias
Hematologic and lymphatic system	Anemia, leukopenia, and thrombocytopenia; acute hemolysis with arsine gas, basophilic stippling
Liver	Fatty degeneration with central necrosis
Skin	Desquamation, alopecia, hyperkeratosis, nail changes (Mees lines), brown pigmentation Chronic exposure: hyperkeratosis, hyperpigmentation
Teratogenic	Neural tube defects in the fetus
Oncologic	Urologic cancer, other malignancies

Late sequelae include hematuria, proteinuria, and acute kidney injury. A delayed sensorimotor peripheral neuropathy may appear days to weeks after acute exposure, secondary to axonal degeneration. Neuropathy manifests as painful dysesthesias followed by diminished vibratory, pain, touch, and temperature sensation; decreased deep tendon reflexes; and in the most severe cases, an ascending paralysis with respiratory failure mimicking Guillain-Barré syndrome (see Chapter 656). Adult survivors of infant arsenic poisoning experience higher mortality from disorders of the nervous system compared with adults without such exposure.

Subacute toxicity is characterized by prolonged fatigue, malaise, weight loss, headache, chronic encephalopathy, peripheral sensorimotor neuropathy, leukopenia, anemia, thrombocytopenia, chronic cough, and gastroenteritis. Mees lines in the nails become apparent 1-2 months after exposure in approximately 5% of patients. Dermatologic findings include alopecia, oral ulceration, peripheral edema, a pruritic macular rash, and desquamation.

Chronic arsenic toxicity causes significant morbidity in children resulting in skin lesions, lung disease, and deficits in intellectual function. **Chronic exposure** to low levels of arsenic is usually from environmental or occupational sources. Over the course of years, dermatologic lesions develop, including hyperpigmentation, hypopigmentation, hyperkeratoses (especially on the palms and soles), squamous and basal cell carcinomas, and **Bowen disease** (cutaneous squamous cell carcinoma in situ). Encephalopathy and peripheral neuropathy may be present. Hepatomegaly, hypersplenism, noncirrhotic portal fibrosis, and portal hypertension occur. **Blackfoot disease** is an obliterative arterial disease of the lower extremities associated with chronic arsenic exposure that has been described in Taiwan. Carcinogenicity of chronic arsenic exposure is reflected in increased rates of cancers of the skin, lung, liver, bladder, and kidney as well as of angiosarcomas. Arsenic is carcinogenic, possibly through epigenetic dysregulation. The effects of prenatal exposure to arsenic are uncertain but may include low birthweight.

Laboratory Findings

The diagnosis of arsenic intoxication is based on characteristic clinical findings, a history of exposure, and elevated urinary arsenic values, the last of which confirm the exposure. A spot urine arsenic level should be determined for symptomatic patients before chelation, although initially the result may be negative. Because urinary excretion of arsenic is intermittent, definitive diagnosis depends on a 24-hour urine collection. Concentrations greater than 50 μg/L in a 24-hour urine specimen are consistent with arsenic intoxication (Table 760.2). Urine specimens must be collected in metal-free containers. Ingestion of seafood containing nontoxic arsenobetaine and arsenocholine can cause elevations of urinary arsenic. Blood arsenic levels rarely are helpful because of their high variability and the rapid clearance of arsenic from the blood in acute poisonings. Elevated arsenic values in the hair or nails must be interpreted cautiously because of the possibility of external contamination. Abdominal radiographs may demonstrate ingested radiopaque arsenic.

Later in the course of illness, a complete blood cell count may show anemia, thrombocytopenia, and leukocytosis, followed by leukopenia, karyorrhexis, and basophilic stippling of RBCs. The serum concentrations of creatinine, bilirubin, and transaminases may be elevated; urinalysis may show proteinuria, pyuria, and hematuria; and examination of the cerebrospinal fluid may show protein elevations.

MERCURY

Mercury exists in three forms: elemental mercury, inorganic mercury salts, and organic mercury (Table 760.3). **Elemental mercury** is present in thermometers, sphygmomanometers, barometers, batteries, gold or silver smelting processes, and some latex paints produced before 1991. Workers in industries producing these products may expose their children to the toxin when mercury is brought home on contaminated clothing. Vacuuming of carpets contaminated with mercury and breaking of mercury fluorescent light bulbs may result in elemental mercury vapor exposure. Severe inhalation poisonings have resulted from attempts to separate gold from gold ore by heating mercury and forming a gold-mercury amalgam. Elemental mercury has been used in folk remedies by Asian and Mexican populations for chronic stomach pain, by Latin Americans and Caribbean natives in occult practices, and as a skin-lightening agent. Dental amalgams containing elemental mercury release trace amounts of mercury. An expert panel for the National Institutes of Health concluded that existing scientific evidence does not indicate that dental amalgams pose a health risk and should not be replaced merely to decrease mercury exposure. A 2009 WHO expert panel concluded that a global near-term ban on amalgam would be problematic for public and dental health. However, this committee recommended that alternatives to amalgam should be sought as part of a phase-out of the use of mercury-containing amalgams.

Inorganic mercury salts are found in pesticides, disinfectants, antiseptics, pigments, dry batteries, and explosives and as preservatives in some medicinal preparations. **Organic mercury** in the diet, especially fish containing methyl mercury, is a major source of mercury exposure among the general population. Industries that may produce mercury-containing effluents include chlorine and caustic soda production, mining and metallurgy, electroplating, chemical and textile manufacturing, paper and pharmaceutical manufacturing, and leather tanning. Mercury compounds in the environment are methylated to methyl mercury by soil and water microorganisms. Methyl mercury in the water rapidly accumulates in fish (swordfish, king mackerel, fresh tuna, tile fish, shark) and other aquatic organisms, which are in turn consumed by humans. To address concerns that maternal consumption of large quantities of fish during pregnancy may expose the fetus to concentrations of mercury with adverse consequences, the longitudinal Seychelles Child Development Study has been ongoing since the late 1980s. The first cohort of the study involved nearly 800 mother–child pairs, with subsequent cohorts enrolled. Despite a high maternal fish intake (mean of 12 fish meals per week), follow-up of children at least through 9 years of age has revealed no consistent adverse developmental effects. Well-known large outbreaks of methyl mercury intoxication include the incidents in Japan in the 1950s (**Minamata disease,** from consumption of contaminated seafood) and in Iraq in 1971 (from consumption of grain treated with a methyl mercury fungicide).

Thimerosal is a mercury-containing preservative used in some vaccines. Thimerosal contains 49.6% mercury by weight and is metabolized to ethyl mercury and thiosalicylate. During an ongoing review of biologic products in response to the U.S. Food and Drug Administration (FDA) Modernization Act of 1997, the FDA determined that infants who received thimerosal-containing vaccines at multiple visits might have been exposed to more mercury than recommended by federal guidelines. As a precautionary measure, the American Academy of Pediatrics, American Academy of Family Physicians, Advisory Committee on Immunization Practices, and U.S. Public Health Service issued a joint recommendation in 1999 that thimerosal be removed from vaccines as quickly as possible. *In the United States, thimerosal has been removed from all vaccines in the recommended childhood immunization schedule.* Infants and children who have received thimerosal-containing vaccines do not need to undergo blood, urine, or hair testing for mercury because the concentrations of mercury would be quite low and would not require treatment. The larger risks of not vaccinating children far outweigh any known risk of exposure to thimerosal-containing vaccines. Studies do *not* demonstrate a link between thimerosal-containing vaccines and autism spectrum disorders (see Chapter 58), and no evidence supports a change in the standard of practice regarding administration of thimerosal-containing vaccines in areas of the world where they are used. A rise in blood mercury levels following a single dose of hepatitis vaccine was seen in preterm infants, but the clinical significance is unknown.

Pharmacokinetics

Inhaled elemental mercury vapor is 80% absorbed by the lungs and is distributed rapidly to the central nervous system because of its high lipid solubility. The elemental mercury is oxidized by catalase to the mercuric ion, which is the reactive form that causes cellular toxicity. Elemental mercury liquid is poorly absorbed from the gastrointestinal tract, with less than 0.1% being absorbed. The half-life of elemental mercury in the tissues is approximately 60 days, with most of the excretion occurring in the urine.

Inorganic mercury salts are approximately 10% absorbed from the gastrointestinal tract and cross the blood-brain barrier to a lesser extent than elemental mercury. Mercuric salts are more soluble than mercurous salts and therefore produce greater toxicity. Elimination occurs primarily in the urine, with a half-life of approximately 40 days.

Table 760.2 Acceptable and Toxic Levels of Arsenic and Mercury

	ARSENIC	MERCURY
Molecular weight	74.9 Da	200.59 Da
Acceptable blood level	<5 μg/L (<0.665 nmol/L)	<10 μg/L (<50 nmol/L)
Acceptable urine level	<50 μg/L (<6.65 nmol/L) 24-hr urine sample	<20 μg/L (<100 nmol/L)
Intervene at blood level		>35 μg/L (>175 nmol/L)
Intervene at urine level	>100 μg/L (>13.3 nmol/L) 24-hr urine sample	>150 μg/L (>750 nmol/L)

Table 760.3 Differential Characteristics of Mercury Exposure

	ELEMENTAL	INORGANIC (SALT)	ORGANIC (ALKYL)
Primary route of exposure	Inhalation	Oral	Oral
Primary tissue distribution	CNS, kidney	Blood (transient, acute), kidney, CNS (delayed)	CNS, kidney, liver, blood, hair
Clearance	Kidney, GI	Kidney, GI	Methyl: GI Aryl: kidney, GI
CLINICAL EFFECTS CNS	Tremor	Tremor, erethism (irritability)	Paresthesias, ataxia, tremor, tunnel vision, dysarthria
Pulmonary	+++	—	—
Gastrointestinal	+	+++ (caustic)	+
Renal	+	+++ (acute tubular necrosis)	+
Acrodynia	+	++	—
Therapy	BAL, succimer	BAL, succimer	Succimer (early)

+, mild; ++, moderate; +++, severe; BAL, British antilewisite (also known as dimercaprol); CNS, central nervous system; GI, gastrointestinal.
From Sue YJ. Mercury (heavy metals). In: Nelson LS, Howland MA, Lewin NA, et al., eds. *Goldfrank's Toxicologic Emergencies*, 11th ed. New York: McGraw-Hill; 2019: Table 95.3.

Methyl mercury is the most avidly absorbed of the organic mercury compounds, with approximately 90% absorbed from the gastrointestinal tract. The lipophilic, short-chain alkyl structure of methyl mercury allows it to distribute rapidly across the blood-brain barrier and placenta. Methyl mercury is approximately 90% excreted in the bile, with the remainder being excreted in the urine. The half-life is 70 days.

Pathophysiology

After absorption, mercury is distributed to all tissues, particularly the central nervous system and kidneys. Mercury reacts with sulfhydryl, phosphoryl, carboxyl, and amide groups, resulting in disruption of enzymes, transport mechanisms, membranes, and structural proteins. Widespread cellular dysfunction or necrosis results in the multiorgan toxicity characteristic of mercury poisoning.

Clinical Manifestations

Five syndromes describe the clinical presentation of mercury poisoning. **Acute inhalation of elemental mercury vapor** results in rapid onset of cough, dyspnea, chest pain, fever, chills, headaches, and visual disturbances. Gastrointestinal findings include metallic taste, salivation, nausea, vomiting, and diarrhea. Depending on the severity of the exposure, the illness may be self-limited or may progress to necrotizing bronchiolitis, interstitial pneumonitis, pulmonary edema, and death from respiratory failure. Younger children are more susceptible to pulmonary toxicity. Survivors may demonstrate restrictive lung disease. Renal dysfunction and neurologic disturbances (ataxia, persistent weakness, emotional lability) may develop subacutely. Chronic exposure to volatilized elemental mercury in dental amalgams has not been found to be of any clinical significance.

Acute ingestion of inorganic mercury salts (typically secondary to ingestion of a button battery) can manifest in a few hours as corrosive gastroenteritis, signified by metallic taste, oropharyngeal burns, nausea, hematemesis, severe abdominal pain, hematochezia, acute tubular necrosis, cardiovascular collapse, and death.

Chronic inorganic mercury intoxication produces the classic triad consisting of tremor, neuropsychiatric disturbances, and gingivostomatitis. The syndrome may result from long-term exposure to elemental mercury, inorganic mercury salts, or certain organic mercury compounds, all of which may be metabolized to mercuric ions. The tremor starts as a fine intention tremor of the fingers that is abolished during sleep but that may later involve the face and progress to choreoathetosis and spasmodic ballismus. Mixed sensorimotor neuropathy and visual disturbances may also be present. The neuropsychiatric disturbances include emotional lability, delirium, headaches, memory loss, insomnia, anorexia, and fatigue. Renal dysfunction ranges from asymptomatic proteinuria to nephrotic syndrome.

Acrodynia, or **pink disease**, is a rare idiosyncratic hypersensitivity reaction to mercury that occurs predominantly in children exposed to mercurous powders. The symptom complex includes generalized pain, paresthesias, and an acral (hands, feet) rash that may spread to involve the face. The rash typically is red-pink, papular, pruritic, and painful; it may progress to desquamation and ulceration. Morbilliform, vesicular, and hemorrhagic variants have been described. Other important features include anorexia, apathy, photophobia, and hypotonia, especially of the pectoral and pelvic girdles. Irritability, tremors, diaphoresis, insomnia, hypertension, and tachycardia may be present. Some cases initially were diagnosed as pheochromocytoma. The outcome is good after removal of the source of mercury exposure.

Methyl mercury intoxication (also known as **Minamata disease** after the widespread mercury poisoning that occurred at Minamata Bay in Japan in people who had ingested contaminated fish) manifests as delayed neurotoxicity that appears after a latent period of weeks to months. It is characterized by ataxia; dysarthria; paresthesias; tremors; movement disorders; impairment of vision, hearing, smell, and taste; memory loss; progressive dementia; and death. Infants exposed in utero are the most severely affected, with low birthweight, microcephaly, profound developmental delay, cerebral palsy, deafness, blindness, and seizures. Although there is significant residual morbidity from methyl mercury neurotoxicity, observations on long-term follow-up of children exposed in Iraq reveal complete or partial resolution in most cases.

Laboratory Findings

The diagnosis of mercury intoxication is based on characteristic clinical findings, a history of exposure, and elevation of whole blood or urine mercury values, the last of which confirms the exposure. Thin-layer and gas chromatographic techniques can be used to distinguish organic from inorganic mercury. Blood should be collected in special tubes for trace elements from laboratories that capably perform those tests. Levels <10 μg/L in whole blood and <20 μg/L in a 24-hour urine specimen are considered normal (see Table 760.2). Although blood mercury levels may reflect acute exposure, they decrease as mercury redistributes into the tissues. Urine mercury levels are most useful for identifying long-term exposures, except in the case of methyl mercury, which undergoes minimal urinary excretion. Urinary mercury levels are used in monitoring efficacy of chelation therapy, whereas blood levels are used primarily in monitoring organic mercury poisonings. Hair analysis for mercury is not reliable because hair reflects

both endogenous and exogenous mercury exposure (hair avidly binds mercury from the environment). Abdominal radiographs may demonstrate ingested radiopaque mercury.

Urinary markers of early nephrotoxicity include microalbuminuria, retinol-binding protein, β_2-microglobulin, and *N*-acetyl-β-D-glucosaminidase. Early neurotoxicity may be detected with neuropsychiatric testing and nerve conduction studies, whereas severe central nervous system toxicity is apparent on CT or MRI.

TREATMENT OF ARSENIC AND MERCURY INTOXICATION

The principles of management for arsenic and mercury intoxication include prompt removal from the source of poisoning, aggressive stabilization and supportive care, decontamination, and chelation therapy when appropriate. Once the diagnosis is suspected, the local poison control facility should be contacted, and care coordinated with physicians who are familiar with the management of heavy metal poisoning.

Supportive care for patients exposed to arsine gas requires close monitoring for signs of hemolysis, including evaluation of the peripheral blood smear and urinalysis. Transfusion of packed RBCs may be necessary, as may administration of intravenous fluids, sodium bicarbonate, and mannitol to prevent renal failure secondary to the deposition of hemoglobin in the kidneys. After inhalation of elemental mercury vapor, patients require careful monitoring of respiratory status, which may include pulse oximetry, arterial blood gas analysis, and chest radiography. Supportive care involves administration of supplemental oxygen and, in severe cases, intubation and mechanical ventilation.

Acute ingestion of inorganic arsenic and mercury salts results in hemorrhagic gastroenteritis, cardiovascular collapse, and multiorgan dysfunction. Fluid resuscitation, pressor agents, and transfusion of blood products may be required for management of cardiovascular instability. Severe respiratory distress, coma with loss of airway reflexes, intractable seizures, and respiratory paralysis are indications for intubation and mechanical ventilation. Renal function must be monitored carefully for signs of renal failure and the need for hemodialysis.

Gastrointestinal decontamination after ingestion of inorganic arsenic and mercury salts has not been well studied. Because of the corrosive effects of these compounds, induced emesis is not recommended, and endoscopy may be considered before gastric lavage. Arsenic and mercury are not well adsorbed to activated charcoal, but its use may be helpful if coingestants are suspected. Whole bowel irrigation is used to remove any radiopaque material remaining in the gastrointestinal tract.

Chelation for acute arsenic and mercury poisoning is most effective when administered as soon as possible after exposure. Chelation should be continued until 24-hour urinary arsenic or mercury levels return to normal (<50 μg/L for arsenic and <20 μg/L for mercury), the patient is symptom-free, or the remaining toxic effects are believed to be irreversible. The efficacy of chelation in long-term exposures is reduced because heavy metal in the tissue compartment is relatively nonexchangeable and some degree of irreversible toxicity has already occurred.

Dimercaprol, also known as *2,3-dimercaptopropanol* or *British antilewisite (BAL)*, is the chelator of choice for a patient who cannot tolerate oral therapy, as often is true for critically ill patients and after ingestion of the corrosive inorganic arsenic and mercury salts. Dimercaprol is available in 3-mL ampules at a concentration of 100 mg/mL for deep intramuscular (IM) injection. It is formulated in a peanut oil and benzyl benzoate suspension; as such, it is not suitable for patients with peanut allergy. For **arsenic poisoning**, the recommended regimen of dimercaprol is 2.5 mg/kg IM q4 hours for six doses, then every 6 hours for four doses, then every 8 hours for three doses, then every 12 hours for two doses, followed by once daily for 10 days. For severe arsenic poisoning, the dose of dimercaprol is increased to 3.5-5 mg/kg; the same dosing interval is followed. The dose of dimercaprol for **inorganic mercury poisoning** is 5 mg/kg every 4 hours IM for 24-48 hours, and then 2.5 mg/kg IM q12 hours for 10 days. The dimercaprol–heavy metal complex is excreted in the urine and bile. A period of 5 days between courses of chelation is recommended. Adverse effects of dimercaprol include pain at the injection site, hypertension, tachycardia, diaphoresis, nausea, vomiting, abdominal pain, a burning sensation in the oropharynx, and a feeling of constriction in the chest. Dimercaprol may cause hemolysis in glucose-6-phosphate dehydrogenase–deficient individuals. It is important to note that dimercaprol is contraindicated for chelation of methyl mercury because dimercaprol redistributes methyl mercury to the brain from other tissue sites, resulting in increased neurotoxicity.

Table 760.4 Potential Strategies for Reducing Exposure of Arsenic in Rice

1. Diversify the diet
   - Eat a well-balanced diet and a variety of grains[†,‡,§]
   - Identify children at risk for high consumption of rice and rice products (e.g., gluten-free diets, highly allergic)
2. Consider alternatives to rice for first food
   - Start infants on barley, oats, or other grains[†,‡]
   - If rice cereal must be used for infants, limit to one serving per day[§]
3. Adopt strategies that help minimize exposure
   - Rinse rice in a colander before cooking[§]
   - Cook rice like pasta, with plenty of extra water[§]
   - Choose lower-arsenic varieties of rice (e.g., basmati)[§]
   - Avoid or limit use of rice milk or other rice beverages for infants[‡] and children under 5 yr old[§,¶]
   - Read labels of processed foods: choose alternatives to foods sweetened with brown rice syrup or thickened with rice products
4. Regulatory action
   - Federal agencies should establish regulatory limits for arsenic content in rice and rice products[§]

[†]U.S. Food and Drug Administration.
[‡]American Academy of Pediatrics.
[§]Consumer Reports.
[¶]United Kingdom Food Standard Agency.
From Lai PY, Cottingham KL, Steinmaus C, et al. Arsenic and rice: translating research to address health care providers' needs. *J Pediatr.* 2015;167(4):797–803.

Oral chelating agents are used to replace the painful dimercaprol injections when the patient is stable enough to tolerate oral therapy and prolonged chelation is necessary. **Succimer**, also known as *2,3-dimercaptosuccinic acid* (DMSA), is an orally administered water-soluble derivative of dimercaprol. DMSA is available in 100 mg capsules. The recommended regimen of DMSA for both arsenic and mercury poisoning is 10 mg/kg orally every 8 hours for 5 days followed by 10 mg/kg orally every 12 hours for 14 days. The DMSA–heavy metal complex is excreted in the urine and bile. A period of 2 weeks between courses of chelation is recommended. Mild adverse effects include nausea, vomiting, diarrhea, loss of appetite, and transient elevations in liver enzyme levels. DMSA also may cause hemolysis in glucose-6-phosphate dehydrogenase–deficient patients.

D-**Penicillamine** is an orally administered chelator that has been used in the past for less-severe mercury poisoning or as an adjunct to dimercaprol therapy in arsenic poisoning. Its use is largely restricted because of the potential for significant leukopenia, thrombocytopenia, and proteinuria along with the improved tolerability of succimer.

Patients with ingestion of elemental mercury require no follow-up unless there is an underlying disease that decreases the gastrointestinal transit time. Serial abdominal radiographs to document the progression of the metal are recommended. Acute inhalation of mercury fumes and ingestion of inorganic mercury require hospitalization to monitor the respiratory and gastrointestinal status, respectively. Therapeutic abortion may be considered in pregnant patients because of the teratogenic effect of mercury.

Strategies to reduce arsenic exposure in rice are noted in Table 760.4.

Visit Elsevier eBooks+ at eBooks.Health.Elsevier.com for Bibliography.

Chapter 761

Lead Poisoning

Morri Markowitz

Lead is a metal that exists in four isotopic forms. Clinically it is purely a toxicant; no organism has an essential function that is lead dependent. Chemically its low melting point and ability to form stable compounds have made it useful in the manufacture of hundreds of products; this commercial attractiveness has resulted in the processing of millions of tons of lead ore, leading to widespread dissemination of lead in the human environment.

The **blood lead level (BLL)** is the gold standard for determining risk of health effects. The threshold level at which lead begins to cause biochemical, subclinical, or clinical disturbance remains to be determined. In 2021, the Centers for Disease Control and Prevention (CDC) designated 3.5 μg/dL as the *"reference value based on the 97.5th percentile of the population of US children aged 1-5 years."* It is the BLL that identifies the 2.5% of children with the highest BLLs. As a measure of the distribution of BLLs in young American children rather than a toxicity threshold, this number will change in a manner dependent on the epidemiology of BLLs. Surveillance by the CDC has shown that the prevalence of elevated BLLs has declined markedly. Approximately 500,000 U.S. children ages 1-5 years currently have BLLs ≥3.5 μg/dL. Fortunately, children with levels high enough to be life-threatening (>100 μg/dL) are rarely seen in the United States, though deaths continue to occur in other areas of the world. Although BLL ≥3.5 μg/dL is stated as a reference value, it is likely that clinicians and departments of health will consider this a threshold for action.

PUBLIC HEALTH HISTORY

In the late 1970s, nearly all preschool-age children in the United States had BLLs above the current reference value of 3.5 μg/dL. Over the next 25 years, government regulations resulted in the significant reduction of three main contributors to lead exposure by means of (1) the elimination of the use of tetraethyl lead as a gasoline additive, (2) the banning of lead-containing solder to seal food- and beverage-containing cans, and (3) the application of a federal rule that limited the amount of lead allowed in paint intended for household use to less than 0.06% by weight (further reduced by the Consumer Product Safety Commission to 0.009% in 2008). Factors identified by the CDC in the late 1970s that indicate increased risk of lead poisoning, in addition to preschool age, include low socioeconomic status; living in older housing, built primarily before 1960; urban location; and Black race. Another high-risk group that has been identified consists of recent immigrants from less wealthy countries, including adoptees. These risk factors largely persist currently, as indicated by an analysis of over 1 million BLLs obtained from U.S. children between October 2018 and February 2020 and analyzed in a commercial lab. In addition, these data indicated that over half of the children still have measurable BLLs, i.e., ≥1 μg/dL.

Progress is also being made globally. In Mexico, the introduction of unleaded gasoline in 1990 was associated with a decline in BLLs among first-grade students, from 17 μg/dL in 1990 to 6.2 μg/dL in 1997. Algeria, the last country to use leaded gasoline for cars and trucks, phased out its use in 2021. In Malta, after the import of red lead paint was banned and the use of lead-treated wood for fuel in bakeries was prohibited, mean BLLs of pregnant women and newborns decreased by 45%. After it was documented that children living in the neighborhood of a battery factory in Nicaragua had a mean BLL of 17.2 μg/dL, but children in the control community had a mean BLL of 7.4 μg/dL, the factory was closed. Despite these advances, in 2021 the World Health Organization (WHO), citing research for UNICEF by the Institute for Health Metrics and Evaluation, estimated that 815 million children globally may have elevated BLLs above 5 mg/dL. The majority live in developing countries, where in some regions BLLs may be 10- to 20-fold higher than in developed countries.

Unfortunately, local lead-related harms continue to occur. When the water source for Flint, Michigan, was changed (2014) to the Flint River and utilized a water treatment plant with poor corrosion control, the lead level of Flint tap water increased, as did the BLLs of children <5 years of age. Flint is not unique; many other cities have lead pipes that can result in water contamination. In 2021 the US government allocated $15 billion for lead pipe removal.

In 2010, the CDC and WHO identified numerous lead-contaminated villages in northern Nigeria. The grinding of ore to extract gold caused widespread leaded dust dissemination. It is likely that hundreds of children died because of this activity, and all remaining children in some of the villages assessed were lead poisoned, with 97% having a BLL ≥45 μg/dL, the threshold for chelation therapy in the United States. Unfortunately, such disasters continue to occur in Nigeria and neighboring countries from similar metal extraction activities.

SOURCES OF EXPOSURE

Lead poisoning may occur in utero because lead readily crosses the placenta from maternal blood. The spectrum of toxicity is similar to that experienced by children after birth. The source of maternal blood lead content is either redistribution from endogenous stores (i.e., the mother's skeleton) or lead newly acquired from ongoing environmental exposure.

Several hundred products contain lead, including paint, batteries, cable sheathing, cosmetics, mineral supplements, plastics, toys (Table 761.1), and traditional medicines (Table 761.2). Major sources of exposure vary among and within countries; the major source of exposure in the United States remains old lead-based paint. Approximately 34.6 million homes, mainly built before 1950, have lead-based paint (2021 estimate), of which the CDC has estimated that 22.3 million are in a hazardous state. As paint deteriorates, it chalks, flakes, and turns to dust. Improper rehabilitation work of painted surfaces (e.g., sanding) can result in dissemination of lead-containing dust throughout a home. The dust can coat all surfaces, including children's hands. All of these forms of lead can be ingested. If heat is used to strip paint, then lead vapor concentrations in the room can reach levels sufficient to cause lead poisoning via inhalation. There is an increased awareness that tap water in both homes and schools may have substantial amounts of lead. The latter arose from the discovery of contaminated water in most New York City public schools. Moreover, this occurrence raised questions about the safety of the US Environmental Protection Agency (EPA) lead-in-water-standard of 15 parts per billion (ppb; μg of Pb/L of water) that water distribution companies must meet in at least 90% of homes in their service areas. This standard was not based on achieving health safety but rather on what the water companies felt was financially feasible. After review, in 2021 the EPA recommended lowering the "trigger" level to 10 ppb. Breaching this value requires water companies to prepare an intervention plan should the level subsequently go over 15 ppb. It does not require action to reduce the amount of lead in that water supply. Even 10 ppb is still much greater than the 1 ppb recommended by the American Academy of Pediatrics as the limit for allowable lead in drinking water. It should be noted that the EPA lead in water standard does not apply to schools, although many states have set their own standards.

In other parts of the world, especially in poorer countries, additional sources can be found. These include contaminated neighborhoods as the result of car/truck battery lead recycling, aluminum cookware made with recycled metals, spices, and traditional medicines.

METABOLISM

The nonnutritive hand-to-mouth activity of young children is the most common pathway for lead to enter the body. In most cases, lead is ingested either as a component of dust licked off of surfaces or in swallowed paint chips, through water contaminated by its flow through lead pipes or brass fixtures, or from otherwise contaminated foods or liquids. Cutaneous contamination with inorganic lead compounds, such as those found in pigments, does not result in a substantial amount of absorption. Organic lead compounds, such as tetraethyl lead, may penetrate through skin; however, these are rarely encountered.

The percentage of lead absorbed from the gut depends on several factors: particle size, pH, other material in the gut, and nutritional status of

Table 761.1 Sources of Lead

Paint chips
Dust
Soil
Parent's or household contact's occupational exposure (auto repair, smelting, construction, remodeling, plumbing, gun/bullet (firing range) exposure, painting, e-scrap)
Glazed ceramics
Herbal remedies (e.g., Ayurvedic medications)
Home remedies, including antiperspirants, deodorants (litargirio)
Jewelry (toys or parents')
Stored battery casings or recycling (or living near a battery smelter)
Lead-based gasoline (in aviation fuel for propeller planes)
Moonshine alcohol
Mexican candies; Ecuadorian chocolates
Ceremonial spices
Indoor firing ranges
Retained bullet fragments
Imported spices (svanuri marili, zafron, kuzhambu)
Lead-based cosmetics (kohl, surma, kajal)
Lead plumbing (water)
Imported foods in lead-containing cans
Domestic foods (applesauce pouches, others)
Imported toys
Home renovations
Antique toys or furniture
Kratom

Table 761.2 Cases of Lead Encephalopathy Associated with Traditional Medicines by Type of Medication

TRADITIONAL MEDICAL SYSTEM	NO. (%) CASES OF LEAD ENCEPHALOPATHY	NO. (%) PEDIATRIC CASES WITHIN CAM SYSTEM OR MEDICATION
Ayurveda	5 (7)	1 (20)
Ghasard	1 (1)	1 (100)
Traditional Middle Eastern practices	66 (87)	66 (100)
Azarcon and Greta	2 (3)	2 (100)
Traditional Chinese medicine	2 (3)	2 (100)
Total	76 (100)	72 (95)

CAM, Complementary and alternative medicines.
From Karri SK, Saper RB, Kales SN. Lead encephalopathy due to traditional medicines. *Curr Drug Saf.* 2008;3:54–59.

essential elements. Large paint chips are difficult to digest and are mainly excreted; this chemical characteristic of lead compounds is fortunate, as a single chip may contain a potentially lethal dose of lead. Fine dust can be dissolved more readily, especially in an acid medium. Lead eaten on an empty stomach is better absorbed than that taken with a meal. The presence of **calcium** and **iron** may decrease lead absorption by direct competition for binding sites; iron (and probably calcium) deficiency results in enhanced lead absorption, retention, and toxicity.

After absorption, lead is disseminated throughout the body via blood. It circulates bound to erythrocytes; approximately 97–99% of lead in blood is bound on or in the red blood cells. The plasma fraction is too small to be measured by conventional techniques employing atomic absorption spectroscopy or anodic stripping voltammetry; it is presumably the plasma portion that may leave the blood compartment to enter cells and induce toxicity. Thus clinical laboratories report the BLL, not the serum or plasma lead level. The increasing availability and decreasing cost of inductively coupled plasma mass spectrometry, which is capable of measuring lead in ng/dL quantities, may eventually result in clinical availability of tools to measure plasma lead, a more proximal measure to where toxicity is actually occurring.

Most retained lead accumulates in bone, where it resides for years. But in all cells, lead has multiple effects. It binds to enzymes, particularly those with available sulfhydryl groups, changing the contour and diminishing function. For example, three of eight enzymes in the ubiquitously distributed heme pathway are susceptible to lead inhibitory effects. The accumulation of excess amounts of heme precursors is also toxic. The last enzyme in this pathway, ferrochelatase, enables protoporphyrin to chelate iron, thus forming heme. **Erythrocyte protoporphyrin (EP)** levels higher than 35 μg/dL (laboratory dependent) are abnormal and are consistent with lead poisoning, iron deficiency, or recent inflammatory disease. Measurement of the EP level is thus a useful tool for monitoring biochemical lead toxicity. EP levels begin to rise several weeks after BLLs have reached 20 μg/dL in a susceptible portion of the population and are elevated in nearly all children with BLLs higher than 50 μg/dL. A drop in EP levels also lags behind a decline in BLLs by several weeks because it depends on both cell turnover and cessation of further overproduction by marrow red blood cell precursors. The test can be ordered either as the free EP or the zinc protoporphyrin. Results are reported in μg/dL. When reported in μmol/mmol this likely indicates that the analysis has been standardized to a hematocrit of 45, an unwarranted assumption in young children.

A second mechanism of lead toxicity works via its competition with calcium. Many calcium-binding proteins have a higher affinity for lead than for calcium. Lead bound to these proteins may alter function, resulting in abnormal intracellular and intercellular signaling. Neurotransmitter release is, in part, a calcium-dependent process that is adversely affected by lead.

Although these two mechanisms of toxicity may be reversible, a third mechanism prevents the development of the normal tertiary brain structure. In immature mammals the normal neuronal pruning process that results in elimination of multiple intercellular brain connections is affected by lead. Failure to construct the appropriate tertiary brain structure during infancy and childhood may result in a permanent abnormality. In a longitudinal study of childhood lead poisoning, MRI examinations of the participants when in their 20s found smaller areas of brain in the prefrontal cortex and hippocampus regions, areas involved in decision-making and memory formation.

CLINICAL EFFECTS

The BLL is the best-studied measure of the lead burden in children. Although subclinical and clinical findings correlate with BLLs in populations, there is considerable interindividual variability in this relationship. **Lead encephalopathy** is more likely to be observed in children with BLLs higher than 100 μg/dL; however, one child with a BLL of 300 μg/dL may have no symptoms, whereas another with the same level may be comatose. Susceptibility may be associated with polymorphisms in genes coding for lead-binding proteins, such as Δ-aminolevulinic acid dehydratase, an enzyme in the heme pathway.

Several **subclinical effects** of lead have been demonstrated in cross-sectional epidemiologic studies. Hearing and height are inversely related to BLLs in children; in neither case, however, does the lead effect reach a level that would bring an individual child to medical attention. As BLLs increase in the study populations, more sound (at all frequencies) is needed to reach the hearing threshold. Children with higher BLLs are shorter than those with lower levels; for every 10 μg increase in the BLL, the children are 1 cm shorter. Chronic lead exposure also may delay puberty.

Several longitudinal studies have followed cohorts of children for decades after birth and examined the relationship between BLLs and cognitive test scores over time. In general, there is agreement that BLLs, expressed either as levels obtained concurrently with cognitive testing or as a measure that integrates multiple BLLs drawn from subjects over time, are inversely related to cognitive test scores. From these studies, no BLL above 0 μg/dL appears safe. On average, for each 1 μg/dL elevation in BLL, the cognitive score is approximately 0.25-0.50 points lower, though the relationship is not linear across the BLL spectrum.

Because the BLLs from early childhood are predictors of the cognitive test results performed years later, this finding implies that the effects of lead can be permanent.

The effect of in utero lead exposure is less clear. Scores on the Bayley Scale of Mental Development were obtained repeatedly every 6 months for the first 2 years of life in a cohort of infants born to middle-class families. Results correlated inversely with cord BLLs, a measure of in utero exposure. However, after 2 years of age, all other cognitive tests performed on the cohort over the next 10 years correlated with the BLLs at age 2 years but not with cord BLLs, indicating that the effects of prenatal lead exposure on brain function were superseded by early childhood events and later BLLs. Later studies, performed in cohorts of Mexican children monitored from the prenatal period, confirm the association between in utero lead exposure and later cognitive outcomes. In these studies, maternal plasma lead levels, obtained especially during the first trimester, were more strongly associated with cognitive scores in the offspring than with the traditionally measured maternal whole BLLs.

Behavior also is adversely affected by lead exposure. Hyperactivity is noted in young school-age children with histories of lead poisoning or with concurrent elevations in BLL. Older children with higher bone lead content are more likely to be aggressive and to have behaviors that are predictive of later juvenile delinquency. One report supports the concept of long-term effects of early lead exposure. In this longitudinal study, the mothers of a cohort were enrolled during their pregnancies. BLLs were obtained early in pregnancy, at birth, and then multiple times in the offspring during the first 6 years. The investigators report that the later relative rate of arrests, especially for violent crimes, increased significantly in relationship to the presence of these BLLs early in life. For every 5 μg/dL increase in BLL, the adjusted arrest rate was 1.40 for prenatal BLLs and 1.27 for 6-year BLLs. Epidemiologic data support the findings in this observational study. In an analysis that combined two national datasets, total annual leaded gasoline use (U.S. Geological Survey) and total reported violent criminal acts (U.S. Department of Justice), the amount of leaded gasoline used yearly was found to be strongly associated with violent criminal behavior with a lag time of 23 years; that is, early childhood exposure was followed two decades later by violent behavior rising and falling in close tandem. A similar association was found, this time between urban air lead levels and later violent crime, with a similar best-fit model employing a lag of approximately 22 years.

An intervention study, in which children with moderate lead poisoning and initial BLLs of 20-55 μg/dL were aggressively managed over 6 months, addressed the issue of the effects of treatment on cognitive development. Components of treatment included education regarding sources of lead and its abatement, nutritional guidance, multiple home and clinic visits, and for a subset, chelation therapy. Average BLLs declined, and cognitive scores were inversely related to the change in BLLs. For every 1 μg/dL fall in BLLs, cognitive scores were 0.25 point higher. A randomized placebo-controlled treatment study of 2-year-old children with initial BLLs of 20-44 μg/dL that employed the chelating agent succimer administered over 6 months found no difference in mean cognitive scores at age 4 years. However, as in the earlier treatment study, regression analysis did find an inverse relation between *change* scores; that is, a change in BLLs was associated with an inverse change in cognitive scores.

Whether the behavioral effects of lead are reversible is unclear. In one small, short-term study, 7-year-old hyperactive children with BLLs in the 20s were randomly allocated to receive a chelating agent (penicillamine), methylphenidate, or placebo. Teacher and parent ratings of behavior improved for the first two groups but not the placebo group. BLLs declined only in the chelated group. Two-year-old lead-poisoned children enrolled in a placebo-controlled trial of the chelating agent succimer showed no mean difference in behavior at 4 or 7 years of age. However, mean BLLs were also not different in the two groups at those ages.

These studies support the concept that early exposure to lead can result in long-term deficits in cognition and behavior; they also hold out the possibility that reductions in lead burden may be associated with improvement in cognitive test scores.

CLINICAL SYMPTOMS

Gastrointestinal symptoms of lead poisoning include anorexia, abdominal pain, vomiting, and constipation, often occurring and recurring over a period of weeks. Children with BLLs higher than 20 μg/dL are twice as likely to have gastrointestinal complaints as those with lower BLLs. **Central nervous system** symptoms are related to worsening cerebral edema and increased intracranial pressure. Headaches, change in mentation, lethargy, papilledema, seizures, and coma leading to death are rarely seen at levels lower than 100 μg/dL but have been reported in children with a BLL as low as 70 μg/dL. The last-reported death directly attributable to lead toxicity in the United States was in 2006 in a child with a BLL of 180 μg/dL. There is no clear cutoff BLL value for the appearance of hyperactivity, but it is more likely to be observed in children who have levels higher than 20 μg/dL.

Other organs also may be affected by lead toxicity, but symptoms usually are not apparent in children. At high levels (>100 μg/dL), renal tubular dysfunction is observed. Lead may induce reversible Fanconi syndrome. In addition, at high BLLs, red blood cell survival is shortened, possibly contributing to a hemolytic anemia, although most cases of anemia in lead-poisoned children are a result of other factors, such as iron deficiency and hemoglobinopathies. Older patients may develop peripheral neuropathy leading to wrist drop and foot drop, as well as hypertension.

DIAGNOSIS

Screening

It is estimated that 99% of lead-poisoned children are identified by screening procedures rather than through clinical recognition of lead-related symptoms. Until 1997, universal screening by blood lead testing of all children at ages 12 and 24 months was the standard in the United States. Given the national decline in the prevalence of lead poisoning, the recommendations have been revised to target blood lead testing of high-risk populations. High risk is based on an evaluation of the likelihood of lead exposure. Departments of health are responsible for determining the local prevalence of lead poisoning, as well as the percentage of housing built before 1950, the period of peak leaded paint use. When this information is available, informed screening guidelines for practitioners can be issued. For instance, in New York State, where a large percentage of housing was built before 1950, the Department of Health mandates that all children be tested for lead poisoning via blood analyses. *In the absence of such data, the practitioner should continue to test all children at both 12 and 24 months*. In areas where the prevalence of lead poisoning and old housing is low, targeted screening may be performed on the basis of a risk assessment. Three questions form the basis of most published questionnaires (Table 761.3), and items that are pertinent to the locale or individual may be added. If there is a lead-based industry in the child's neighborhood, the child is a recent immigrant from a country that until recently still permitted the use of leaded gasoline, or the child has **pica** (pattern of eating non-food materials) or developmental delay, blood lead testing would be appropriate. All Medicaid-eligible children should be screened by blood lead testing. Venous sampling is preferred to capillary sampling because the chances of false-positive and false-negative results are less with the former. However, capillary screening can be performed rapidly in the office with a point of care (POC) instrument; use of such instruments in primary care offices substantially increases screening rates. Other screening guidelines vary by federal, state, and even local governmental agencies. Contacting your local Department of Health is one way to determine local primary care obligations.

The threshold for lead effects and the reference level for risk management purposes are not the same. Laboratory issues make the interpretation of values more difficult at low levels. Most labs achieve quality control of ±2 μg/dL for reports of BLL, but federal regulations allow laboratories that perform BLL testing to operate with an allowable error of ±4 μg/dL. A capillary screening value ≥3.5 μg/dL requires a venous sample for confirmation (Table 761.4). If the diagnostic (venous) test

Table 761.3 Minimum Personal Risk Questionnaire

1. Does the child live in or regularly visit a house that was built before 1950? (Include settings such as daycare, babysitter's, or relative's home.)
2. Does the child live in or regularly visit a house built before 1978 with recent (past 6 months) or ongoing renovations or remodeling?
3. Does the child have a sibling or playmate who has or did have lead poisoning?

From Screening young children for lead poisoning. Guidance for state and local public health officials. Atlanta: Centers for Disease Control and Prevention, 1997.

Table 761.4 Recommended Schedule for Obtaining a Confirmatory Venous Sample

BLOOD LEAD LEVEL (µg/dL)	TIME TO CONFIRMATION TESTING*
≥3.5-9	Within 3 mo
10-19	Within 1 mo
20-44	Within 2 wk
≥45	Within 48 hr

*The higher the blood lead level is on the initial screening capillary test, the more urgent it is to get a venous sample for confirmatory testing.
Courtesy Centers for Disease Control and Prevention, 2022. https://www.cdc.gov/nceh/lead/advisory/acclpp/actions-blls.htm#anchor_86654

confirms that the BLL is elevated, then further testing is required by the recommended schedule (Table 761.5). A confirmed venous BLL of 45 µg/dL or higher requires prompt chelation therapy.

Other Tools for Assessment

BLL determinations remain the gold standard for evaluating children because of ready availability and its correlation with health outcomes in populations. Techniques are available to measure lead in other tissues and body fluids. Experimentally, the method of x-ray fluorescence (XRF) allows direct and noninvasive assessment of bone lead stores. XRF methodology was used to evaluate a population that had long-term exposure to lead from a polluting battery-recycling factory. The study found that the school-age children had elevated lead levels in bone but not in venous blood, a finding that is consistent with our understanding of the slow turnover of lead in bone, which is measurable in years, in contrast to that in blood, which is measurable in weeks. It also indicates that children may have substantial lead in their bodies that is not detected by routine blood lead testing. This stored lead may be released to toxic levels if bone resorption rates suddenly increase, as occurs with prolonged immobilization of longer than a week and during pregnancy. Thus children with histories of elevated BLLs are potentially at risk for recrudescence of lead toxicity long after ingestion has stopped and may pass this lead to the next generation. XRF methodology is not available for clinical use in children.

Lead also can be measured in urine. Spontaneous excretion, even in children with high BLLs, is usually low. Lead excretion may be stimulated by treatment with chelating agents, and this property of these drugs forms the basis of their use as a component of lead treatment. It also has been used to develop a test that differentiates children with lead burdens responsive to chelation therapy, the **lead mobilization test**. In this test, a timed urine collection follows one or two doses of chelating agent, and the lead content is determined. However, this test is no longer recommended.

Lead in hair, nails, and saliva also is measurable but has problems of contamination and interpretability; thus these have no clinical utility. Radiographs of long bones may show dense bands at the metaphyses ("**lead lines**"), which may be difficult to distinguish from growth arrest

Table 761.5 Schedule for Follow-Up Blood Lead Testing

VENOUS BLOOD LEAD CONCENTRATIONS (µg/dL)	EARLY FOLLOW-UP TESTING (2-4 TESTS AFTER INITIAL TEST ABOVE SPECIFIC VENOUS BLLs)	LATER FOLLOW-UP TESTING AFTER BLL DECLINING
≥3.5-9	3 mo*	6-9 mo
10-19	1-3 mo*	3-6 mo
20-44	2 wk to 1 mo	1-3 mo
≥45	As soon as possible	As soon as possible

BLL, Blood lead level.
Courtesy Centers for Disease Control and Prevention, 2022. https://www.cdc.gov/nceh/lead/advisory/acclpp/actions-blls.htm

Fig. 761.1 Anteroposterior radiograph of the abdomen demonstrates retention of radiopaque lead-based paint chips within bowel, predominantly clustered in the ascending colon. Other etiologies resembling "paint chips" include certain medications, eggshells, other heavy metals including iron- and calcium-containing supplements. Dense "lead lines" are noted in the proximal femoral metaphyses. *(From Swenson DW, Walters MM. Musculoskeletal imaging. In: Walters MM, Robertson RL, eds. Pediatric Radiology: The Requisites, 4th ed. Philadelphia: Elsevier; 2017: Fig. 7.50, p. 214.)*

lines but, if caused by lead, are indicative of months to years of exposure (Fig. 761.1). For children with acute symptoms, when a BLL result is not immediately available, a **kidneys-ureters-bladder (KUB) radiograph** may reveal **radiopaque flecks** in the intestinal tract, a finding that is consistent with recent ingestion of lead-containing plaster or paint chips (see Fig. 761.1). However, the absence of radiographic findings does not rule out lead poisoning.

Because BLLs reflect recent ingestion or redistribution from other tissues but do not necessarily correlate with the body burden of lead or lead toxicity in an individual child, tests of lead effects also may be useful. After several weeks of lead accumulation and a BLL higher than 20 µg/dL, increases in EP values to more than 35 µg/dL may occur. An elevated EP value that cannot be attributed to iron deficiency or recent inflammatory illness is both an indicator of lead effect and a useful means of assessing the success of the treatment; the EP level will begin to fall a few weeks after successful interventions that reduce lead ingestion and increase lead excretion. Because EP is light sensitive, whole blood samples should be covered in aluminum foil (or equivalent) until analyzed.

TREATMENT

All BLLs ≥3 μg/dL should be reported to state or local health departments. Once lead is in bone, it is released slowly and is difficult to remove even with chelating agents. Because the cognitive/behavioral effects of lead may be irreversible, the main effort in treating lead poisoning is to prevent it from occurring and to prevent further ingestion by already-poisoned children. The main components in the effort to eliminate lead poisoning are universally applicable to all children (and adults) and are as follows: (1) identification and elimination of environmental sources of lead exposure, (2) behavioral modification to reduce nonnutritive hand-to-mouth activity, and (3) dietary counseling to ensure sufficient intake of the essential elements calcium and iron and their supporting vitamins, D and C. For the small minority of children with more severe lead poisoning, drug treatment is available that enhances lead excretion. How effective these interventions may be at reducing BLLs or improving cognitive function remains unclear at the lower BLLs commonly observed currently in young children in the United States.

During health maintenance visits a limited risk assessment is warranted, which includes questions pertaining to the most common sources of lead exposure: the condition of old paint, secondary occupational exposure via an adult living in the home, and/or proximity to an industrial source of pollution. If such a source is identified, its elimination usually requires the assistance of public health and housing agencies as well as education for the parents. It would be safest for the family to move out of a lead-contaminated apartment until repairs are completed. During repairs, repeated washes of surfaces and the use of high-efficiency particle accumulator (HEPA) vacuum cleaners help reduce exposure to lead-containing dust. Careful selection of a contractor who is certified to perform lead abatement work is necessary. Sloppy work can cause dissemination of lead-containing dust and chips throughout a home or building and result in further elevation of a child's BLL. After the work is completed, dust wipe samples should be collected from floors and windowsills or wells to verify that the risk from lead has abated. The standards for what are considered acceptable lead dust levels have recently been modified by the EPA to lower limits that are more protective.

A single case of lead poisoning is often discovered in a household with multiple family members, including other young children, and even in a household with a common source of exposure such as peeling lead-based paint. The mere presence of lead in an environment does not produce lead poisoning. Parental efforts at reducing the hand-to-mouth activity of the affected child are necessary to reduce the risk of lead ingestion. Handwashing with soap and water effectively removes lead, but in a home with lead-containing dust, lead rapidly begins to reaccumulate on the child's hands after washing. Therefore handwashing is best limited to the period immediately before nutritive hand-to-mouth activity occurs.

Because there is competition between lead and essential metals, it is reasonable to promote a healthy diet that is sufficient in calcium and iron. The recommended daily intakes of these metals vary somewhat with age. In general, for children 1 year of age and up, a calcium intake of about 1 g/day is sufficient and convenient to remember (roughly the calcium content of a quart of milk [~1,200 mg/qt] or calcium-fortified orange juice). Calcium absorption is vitamin D dependent; milk is fortified with vitamin D, but other nutritional sources of calcium often are not. A multivitamin containing vitamin D may be prescribed for children who do not drink sufficient milk or who have inadequate sunlight exposure. Iron requirements also vary with age, ranging from 6 mg/day for infants to 12 mg/day for adolescents. For children identified biochemically as being iron deficient, therapeutic iron at a daily dose of up to 5-6 mg/kg/day for 3 months is appropriate. Iron absorption from vegetables is enhanced when iron is ingested with vitamin C (ascorbic acid), which is found in citrus juices. Giving additional calcium or iron above the recommended daily intake to mineral-sufficient children has not been shown to be of therapeutic benefit in the treatment of lead poisoning.

For children with BLLs of ≥20 μg/dL, an abdominal x-ray should be considered to check for lead-based paint chips or leaded foreign bodies, if not already obtained. If radiopaque fragments are visualized on imaging, bowel decontamination (typically with whole bowel irrigation) should be initiated (see Chapter 94).

Drug treatment to remove lead is lifesaving for children with lead encephalopathy. In nonencephalopathic children, it prevents symptom progression and further toxicity. Guidelines for **chelation** are based on the BLL. *A child with a venous BLL of 45 μg/dL or higher should be treated.* Four drugs have been used in the United States: 2,3-dimercaptosuccinic acid (DMSA [**succimer**]), $CaNa_2EDTA$ (versenate), British anti-lewisite (BAL [dimercaprol]), and penicillamine. DMSA and penicillamine can be given orally, whereas $CaNa_2EDTA$ and BAL can be administered only parenterally. The choice of agent is guided by the severity of the lead poisoning, the effectiveness of the drug, and the ease of administration (Table 761.6). Children with BLLs of 44-70 μg/dL may be treated with a single drug, preferably DMSA. Those with BLLs of 70 μg/dL or greater require two-drug treatment: $CaNa_2EDTA$ in combination with either DMSA or BAL for those without evidence of encephalopathy, or $CaNa_2EDTA$ and BAL for those with encephalopathy. Published data on the combined treatment with $CaNa_2EDTA$ and DMSA for children with BLLs higher than 100 μg/dL are very limited. However, anecdotal information derived from the treatment of hundreds of severely lead-poisoned children in northern Nigeria indicates that single-drug treatment with DMSA is lifesaving, although the degree of long-term residual damage in survivors has not been reported.

Drug-related toxicities are minor and reversible. These include gastrointestinal distress, transient elevations in transaminases, active urinary sediment, and neutropenia. These types of events are least common for $CaNa_2EDTA$ and DMSA, and more common for BAL and penicillamine. All of the drugs are effective in reducing BLLs when given in sufficient doses and for the prescribed time. These drugs also may increase lead absorption from the gut and should be administered to children in lead-free environments. Some authorities also recommend the administration of a cathartic immediately before or concomitant with the initiation of chelation to eliminate any lead already in the gut.

None of these agents removes all lead from the body. Within days to weeks after completion of a course of therapy, the BLL rises, even in the absence of new lead ingestion. The source of this rebound in the BLL is believed to be release from bone. Serial examinations of bone lead content have shown that chelation with $CaNa_2EDTA$ is associated with a decline in bone lead levels, but that residual bone lead remains detectable even after multiple courses of treatment.

Repeat chelation is indicated if the BLL rebounds to 45 μg/dL or higher. Children with initial BLLs higher than 70 μg/dL are likely to require more than one course. A minimum of 3 days between courses is recommended to prevent treatment-related toxicities, especially in the kidney.

The indication for chelation therapy for children with BLLs <45 μg/dL is less clear. Although use of these drugs in children with BLLs from 20-45 μg/dL will result in transiently lowered BLLs, and in some cases reversal of lead-induced enzyme inhibition, few such children increase their excretion of lead significantly during chelation, raising the question of whether any long-term benefit is achieved. A study of 2-year-old children with BLLs of 20-44 μg/dL who were randomized to receive either DMSA or placebo found that the drop in BLLs was greater in the first 6 months after enrollment in the DMSA-treated group, but the levels converged by 1 year of follow-up. Mean cognitive test scores obtained at 4 and 7 years of age were not statistically different between the groups. Chelation with DMSA (and $CaNa_2EDTA$) is not recommended for all children with BLLs <45 μg/dL. Further work needs to be done to determine whether there are subgroups of children with BLLs <45 μg/dL who might benefit from chelation. It also remains to be demonstrated whether other chelating agents available in the United States or elsewhere are effective at either substantially reducing body stores (bone) of lead or reversing the cognitive deficits attributable to lead at these BLLs.

Table 761.6 Chelators Used for Lead Poisoning

CHELATOR	DOSAGE	INDICATIONS	CONTRAINDICATIONS	ADVERSE EFFECTS
Succimer (DMSA)	1050 mg/m^2/day divided into 3 doses for 5 days, then 700 mg/m^2/day divided into 2 doses for 14 days (maximum 500 mg per dose for children)	BLL >45 µg/dL	None	Nausea, vomiting Diarrhea Metallic taste Transient increase in AST/ALT
$CaNa_2EDTA$	1,500 mg/mm^2/day continuous intravenous (IV) infusion for encephalopathy *Otherwise:* 1,000 mg/m^2/day divided in 2 to 4 doses for up to 5 days, IV or IM	BLL >70 µg/dL (starting after first dose of BAL or succimer) May substitute for succimer if that drug is not tolerated	Severe renal disease Hepatitis	Nephrotoxicity Transient increase in AST/ALT Arrythmia (bradycardia)
Dimercaprol (BAL)	4 mg/kg deep IM injection every 4 hours for 5 days in children and adults	BLL >70 µg/dL and encephalopathy Consider succimer as alternative	Peanut allergy Organic mercury poisoning Hepatic insufficiency	Pain at injection site Hypertension and tachycardia Nausea, vomiting Headache Fever (especially in children) Nephrotoxicity in the setting of an acidic urine
D-Penicillamine	1-1.5 g/day (children: 20-30 mg/kg/day), in 3 or 4 divided doses for 1-6 months To minimize adverse reactions, start at 250 mg/day (children: 10 mg/kg/day) and increase to 50% during week 2 and to a full dose by week 3 Maximum adult daily dose is 2 g	BLL of 45 to 69 µg/dL AND succimer not tolerated	Penicillin allergy	Leukopenia Thrombocytopenia Enuresis Abdominal pain Rashes

Note: Indications for chelation and dosing regimens may change. Consult with a medical toxicologist or regional poison center for the most up-to-date recommendations.
BAL, British antilewisite; BLL, blood lead level; $CaNa_2EDTA$, calcium disodium ethylenediaminetetraacetic acid; DMSA, 2,3-dimercaptosuccinic acid; IM, intramuscular; AST, alanine transaminase; ALT, aspartate transaminase.
Modified from Theobald JL, Mycyk MB. Iron and heavy metals. In: Walls RM, ed. *Rosen's Emergency Medicine*, 10th ed. Philadelphia: Elsevier; 2023: Table 146.5.

With successful intervention, BLLs decline, with the greatest fall in BLL occurring in the first 2 months after therapy is initiated. Subsequently, the rate of change in BLL declines slowly, so that by 6-12 months after identification, the BLL of the average child with moderate lead poisoning (BLL >20 µg/dL) will be 50% lower. Children with more markedly elevated BLLs may take years to reach the current CDC reference level, 3.5 µg/dL, even if all sources of lead exposure have been eliminated, behavior has been modified, and nutrition has been maximized. Early screening remains the best way of avoiding and therefore obviating the need for the treatment of lead poisoning.

Visit Elsevier eBooks+ at eBooks.Health.Elsevier.com for Bibliography.

Chapter 762
Nonbacterial Food Poisoning

762.1 Mushroom Poisoning

Diane P. Calello and Katherine Baranowski

Mushrooms are an ideal food. They are low in calories, fat free, and high in protein, making them a great source of nutrition. Unfortunately, some are highly toxic if ingested. Picking (foraging) and consumption of wild mushrooms are increasingly popular in the United States. This rise in popularity has led to increased reports of severe and fatal mushroom poisonings.

The clinical syndromes produced by mushroom poisoning are divided according to the rapidity of onset of symptoms and the predominant system involved (Table 762.1). The symptoms are caused by the principal toxin present in the ingested mushrooms. The eight major toxins produced by mushrooms are categorized as cyclopeptide *(amatoxin and phallotoxin),* gyromitrin, muscarine, coprine, ibotenic acid and muscimol, psilocybin, orellanine, and gastrointestinal tract–specific irritants. The edible wild mushroom *Tricholoma equestre* is associated with delayed rhabdomyolysis, and *Clitocybe amoenolens* and *Clitocybe acromelalga* have been reported to cause erythromelalgia, although toxins responsible for these effects are unknown.

Symptoms after eating mushrooms may not be the direct effect of a toxin but may be an allergic reaction or a toxic effect of pesticides or other contaminants. In addition, all who ate the same mushroom may not become sick, or if they do, they may become sick at different intervals. Table 762.2 lists general principles of management. Wherever possible, identification of the implicated mushroom is encouraged via mycologist or regional Poison Control Center.

GASTROINTESTINAL

Rapid Onset

Many mushrooms from various genera (such as *Chlorophyllum* species) produce local gastrointestinal manifestations. The causative toxins are diverse and largely unknown. Within 1 hour of ingestion, patients experience acute abdominal pain, nausea, vomiting, and diarrhea. Symptoms may last hours to days, depending on the species of mushroom.

Treatment is mainly supportive. Children with large fluid losses may require parenteral fluid therapy. It is imperative to differentiate ingestion of mushrooms of this class from ingestion of *Amanita* and

Table 762.1 Summary of Common Mushroom-Associated Syndromes

TOXIN	SYNDROME	CLINICAL COURSE	TYPICAL CAUSATIVE MUSHROOM(S)
Cyclopeptides, principally amatoxins	Delayed gastroenteritis followed by hepatic failure	*Stage 1:* 6-24 hr after ingestion: onset of nausea, vomiting, profuse cholera-like diarrhea, abdominal pain, hematuria *Stage 2:* 12-48 hr after ingestion: apparent recovery; levels of hepatic enzymes are rising during this stage *Stage 3:* 24-72 hr after ingestion: progressive hepatic and renal failure, coagulopathy, cardiomyopathy, encephalopathy, convulsions, coma, death	"Deadly *Amanitas*," (*A. phalloides, A. bisporigera*) *Galerina* species
General gastrointestinal irritants	Early gastroenteritis, may be severe	30 min to 2 hr after ingestion: nausea, vomiting, abdominal cramping, diarrhea; may recover without treatment	*Chlorophyllum molybdites*, backyard mushrooms ("little brown mushrooms"), many others
Gyromitrin	Delayed gastroenteritis with central nervous system toxicity, seizures	6-24 hr after ingestion: nausea, vomiting, diarrhea, abdominal pain, muscle cramps, delirium, convulsions, coma; hemolysis, and methemoglobinemia may occur	*Gyromitra esculenta* ("false morel")
Orellanine	Delayed onset gastroenteritis and renal failure	Abdominal pain, anorexia, vomiting starting over 30 hr after ingestion, followed by progressive renal failure 3-14 days later	*Cortinarius* species
Muscarine	Cholinergic syndrome	30 min to 2 hr after ingestion: bradycardia, bronchorrhea, bronchospasm, salivation, perspiration, lacrimation, convulsions, coma	*Clitocybe* species, *Inocybe* species, *Boletus* species, some *Amanita* species
Coprine	Disulfiram-like reaction with ethanol	30 min after drinking ethanol (may occur up to 1 week after eating coprine-containing mushrooms): flushing of skin of face and trunk, hypotension, tachycardia, chest pain, dyspnea, nausea, vomiting, extreme apprehension	*Coprinus atramentarius*
Ibotenic acid and muscimol	Hyperactivity, delirium, coma	30 min to 2 hours after ingestion: delirium, hallucinations, and coma	*Amanita muscaria, Amanita pantherina*
Psilocybin	Hallucinations	30 min to 3 hr after ingestion: hallucinations, euphoria, drowsiness, compulsive behavior, agitation	*Psilocybe* species

Modified from Brent J, Palmer RB: Mushrooms. In: Shannon MW, Borron SW, Burns MJ, eds. *Haddad and Winchester's Clinical Management of Poisoning and Drug Overdose*, 4th ed. Philadelphia: WB Saunders; 2007: Table 23-1.

Table 762.2 General Management of Mushroom Ingestion

1. Determine history of ingestion: how many types of mushrooms ingested, what time, if anyone else ate them, and what symptoms are present.
2. Attempt to determine which of the possible syndromes (see Table 762.1) the patient may have. For example, gastrointestinal symptoms occurring more than 6 hr after ingestion strongly suggest cyclopeptide, gyromitrin, or *Cortinarius* poisoning.
3. Administer activated charcoal. If the patient has diarrhea, do not give a cathartic. If a cathartic is used, give it only with the first dose of activated charcoal. Use repeated doses of activated charcoal for suspected amatoxin poisonings.
4. If feasible and when indicated, send gastric aspirate or emesis, along with any remaining mushrooms, to a mycologist for identification.
5. Try to perform a preliminary identification of mushroom and spores. Start to develop a spore print as soon as possible.
6. Maintain supportive measures, including airway support, intravenous fluids, and vasopressors (if needed). Monitor volume status.
7. Avoid antispasmodics for gastrointestinal symptoms.
8. Anticipate the clinical course.

From Brent J, Palmer RB: Mushrooms. In: Shannon MW, Borron SW, Burns MJ, eds. *Haddad and Winchester's Clinical Management of Poisoning and Drug Overdose*, 4th ed. Philadelphia: WB Saunders; 2007: Box 23.1.

Galerina species containing cyclopeptide toxins, which present with symptoms after 6 hours of ingestion.

Delayed Onset

Cyclopeptide (Amatoxin) Poisoning

Poisonings by species of *Amanita* (death cap mushroom) and *Galerina* account for 95% of the fatalities from mushroom intoxication; the mortality rate for this group is 5–10%. Most species produce two classes of **cyclopeptide toxins:** (1) **phallotoxins,** which are heptapeptides believed to be responsible for the early symptoms of *Amanita* poisoning, and (2) **amatoxins,** octapeptides that inhibit nuclear RNA polymerase II and subsequent production of messenger RNA leading to impaired protein synthesis and cell death. Cells with high turnover rates, such as those in the gastrointestinal mucosa, kidneys, and liver, are the most severely affected. Other suggested toxin effects are induction of apoptosis, glutathione depletion in the liver, and oxygen free radical formation. Acute yellow atrophy of the liver and necrosis of the proximal renal tubules are found in lethal cases.

The clinical course of poisoning with *Amanita* or *Galerina* species is biphasic. Nausea, vomiting, and severe abdominal pain ensue 6-24 hours after ingestion. Profuse watery diarrhea follows shortly thereafter and may last for 12-24 hours or longer. During this time, patients become severely dehydrated. From 24 to 48 hours

after poisoning, jaundice, hypertransaminasemia (peaking at 72-96 hours), renal failure, and coma occur. Death occurs 4-7 days after the ingestion. A prothrombin time less than 10% of control is a poor prognostic factor. Of note, there are species of Amanita mushrooms that may present with earlier onset of symptoms and confound diagnosis, such as *Amanita smithiana,* which grows in the Pacific Northwest.

Treatment

Treatment for *Amanita* poisoning is both supportive and specific. Fluid loss from severe diarrhea during the early course of the illness is profound, requiring aggressive correction of fluid loss, electrolytes, and acid-base disturbances. In the late phase of the disease, management of renal and hepatic failure is also necessary.

Specific therapy for *Amanita* poisoning is designed to remove the toxin rapidly and to block binding at its target site. Oral activated charcoal is recommended as part of the initial treatment for children with *Amanita* poisoning. For significant ingestions, intravenous silibinin or intravenous penicillin G may be considered after discussion with a toxicologist or Poison Control Center. Silibinin and penicillin G inhibit binding of both toxins, interrupt enterohepatic recirculation of amatoxin, and protect the liver from further injury, although their effectiveness is controversial. *N-a*cetylcysteine should be given for hepatoprotective effect. Hemodialysis or hemoperfusion may be beneficial in removing toxin. Orthotopic liver transplantation may be required for children with severe hepatic failure.

Gyromitrin Poisoning

Species of *Gyromitra* contain **gyromitrin,** which decomposes in the stomach to form **monomethylhydrazine** (CH_3NHNH_2) and inhibits central nervous system (CNS) enzymatic production of γ-aminobutyric acid (GABA). Monomethylhydrazine also oxidizes iron in hemoglobin, resulting in methemoglobinemia. Children with *Gyromitra* poisoning often experience vomiting, diarrhea, and abdominal pain within 6-24 hours of ingestion of the toxin. CNS symptoms such as vertigo, diplopia, headache, ataxia, and seizures develop later in the clinical course. Hemolysis and methemoglobinemia (see Chapter 511.6) are rare but potential life-threatening complications of gyromitrin poisoning.

Treatment

Hypovolemia from gastrointestinal fluid losses and seizures require supportive intervention. **Pyridoxal phosphate,** the coenzyme that catalyzes the production of GABA, can reverse the effects of monomethylhydrazine when administered in high doses. Pyridoxine hydrochloride (25 mg/kg infused over 30 minutes) is given at a frequency that is dependent on clinical improvement. Diazepam is given for persistent seizures. Parenteral administration of methylene blue is indicated if the methemoglobin concentration exceeds 30%. Blood transfusions may be required for significant hemolysis.

RENAL

Orellanine Poisoning

Species of *Cortinarius* mushrooms contain the heat-stable toxin bipyridyl **orellanine,** which causes severe nonglomerular renal injury characterized by interstitial fibrosis and acute tubular necrosis. Although the exact mechanism of injury is not fully understood, a metabolite of orellanine is thought to inhibit renal protein synthesis. *Cortinarius* poisoning is characterized by delayed onset of nausea, vomiting, and diarrhea that manifest 36-48 hours after ingestion. Although the initial symptoms may be trivial, more serious renal toxicity occurs in several days. Acute renal failure occurs in 30–50% of those affected, beginning with polyuria and progressing to renal failure (see Chapter 572).

Treatment

Treatment for orellanine poisoning is supportive. Early presentation, within 4-6 hours after ingestion, can be treated with activated charcoal and gastric lavage. Hemodialysis may be needed in patients suffering from renal failure. Most patients recover within 1 month, but chronic renal insufficiency develops in one third to one half of patients who subsequently require renal transplantation.

AUTONOMIC NERVOUS SYSTEM

Muscarine Poisoning

Mushrooms of the genera *Inocybe* and, to a lesser degree, *Clitocybe* contain **muscarine** or muscarine-related compounds. These quaternary ammonium derivatives bind to postsynaptic receptors, producing an exaggerated cholinergic response.

The onset of symptoms is rapid (30 minutes to 2 hours after consumption), and intoxication is characterized by symptoms of cholinergic excess: diaphoresis, excessive lacrimation, salivation, miosis, bradycardia, hypotension, urinary and fecal incontinence, and vomiting. Respiratory distress caused by bronchospasm and increased bronchopulmonary secretions is the most serious complication. The symptoms subside spontaneously within 6-24 hours.

Treatment

Atropine sulfate, the specific antidote, is administered intravenously (0.01 mg/kg; maximum: 2 mg). This is repeated until the pulmonary symptoms resolve or the patient becomes overtly tachycardic.

Coprine Poisoning

Coprinus atramentarius and *Clitocybe clavipes* contain **coprine.** Like disulfiram (Antabuse; Odyssey Pharmaceuticals, Inc.), coprine inhibits the metabolism of acetaldehyde after ethanol ingestion. The clinical manifestations result from accumulation of acetaldehyde.

Coprine intoxication becomes apparent after ethanol ingestion and may be delayed up to 5 days after consumption of the mushroom. Hyperemia of the face and trunk, tingling of the hands, metallic taste, tachycardia, and vomiting occur acutely. Hypotension may result from intense peripheral vasodilation.

The syndrome typically is self-limited and lasts only several hours. No specific antidote is available. If hypotension is severe, vascular reexpansion with isotonic parenteral solutions may be required.

CENTRAL NERVOUS SYSTEM

Ibotenic acid and Muscimol Poisoning

Although *Amanita muscaria* and *Amanita pantherina* may contain muscarine, the toxins responsible for the CNS symptoms after ingestion of these mushrooms are primarily **muscimol** and **ibotenic acid,** the heat-stable derivatives of the isoxazoles. Muscimol, a hallucinogen, and ibotenic acid, an insecticide, act as GABA agonists. From 30 minutes to 3 hours after ingestion, CNS symptoms appear: obtundation, alternating lethargy and agitation, and occasionally seizures. Nausea and vomiting are uncommon. If large amounts of muscarine are contained in the mushroom, symptoms of cholinergic crisis also may occur.

Specific therapy must be carefully selected, and in most cases supportive care will suffice. If an exaggerated cholinergic response is observed, atropine should be administered. Conversely, because ingestions of *A. muscaria* or *A. pantherina* may cause anticholinergic findings, the acetylcholinesterase inhibitor physostigmine can be used to reverse the delirium and coma. Benzodiazepines also are used for the agitation and delirium. Seizures can be controlled with diazepam. In the majority of patients, however, early supportive care and close observation are all that is required.

Psilocybin Intoxication

Mushrooms belonging to the genus *Psilocybe* ("magic mushrooms") contain **psilocybin and psilocin,** two psychotropic compounds. Within 30 minutes after ingestion, patients experience euphoria and hallucinations, often accompanied by tachycardia and mydriasis. Fever and seizures have also been observed in children with psilocybin poisoning. These symptoms are short-lived, usually lasting for 6 hours after consumption of the mushroom. Treatment consists of rest and observation in a quiet environment. Severely agitated patients may respond to diazepam.

Visit Elsevier eBooks+ at eBooks.Health.Elsevier.com for Bibliography.

762.2 Solanine Poisoning

Katherine Baranowski and Diane P. Calello

Solanine is an alkaloid found in plants of the nightshade family (Solanaceae), specifically tomatoes, eggplant, paprika and pepper-based spices, and most significantly, white potatoes. The majority of solanine poisoning reported has arisen from the ingestion of greened potatoes. When exposed to light and allowed to turn green and/or sprout, potatoes produce several alkaloid glycosides containing the cholesterol derivative *solanidine*. Two of these glycosides, α-solanine and α-chaconine, are found in highest concentration in the peels and sprouts. Some solanine can be removed by boiling but not by baking. The major effect of α-solanine and α-chaconine is the reversible inhibition of cholinesterase. Cardiotoxic and teratogenic effects have also been reported.

Clinical manifestations of solanine and chaconine poisoning occur within 7-19 hours after ingestion. The most common symptoms are vomiting, abdominal pain, and diarrhea; in more severe instances of poisoning, neurologic symptoms, including drowsiness, apathy, confusion, weakness, and vision disturbances, are rarely followed by coma or death.

Treatment of solanine poisoning is largely supportive. In the most severe cases, symptoms resolve within 1-2 weeks.

Visit Elsevier eBooks+ at eBooks.Health.Elsevier.com for a Bibliography.

762.3 Seafood Poisoning

Diane P. Calello and Katherine Baranowski

CIGUATERA FISH POISONING

The most frequently reported seafood toxin illness in the world is ciguatera fish poisoning. Grouper is the most commonly identified source of the toxin, followed by snapper, kingfish, amberjack, dolphin, eel, and barracuda. Poisoning has also been associated with farm-raised salmon.

The dinoflagellate ***Gambierdiscus toxicus,*** a microscopic unicellular organism found along coral reefs, produces high concentrations of **ciguatoxin** and **maitotoxin.** The toxins are passed along the food chain from small herbivorous fish that consume the dinoflagellate to larger predatory fish and then to humans. These toxins are harmless in fish but produce distinct clinical symptoms in humans.

Ciguatoxins are odorless, colorless, and tasteless and are not destroyed by cooking or freezing. Ciguatoxins increase the sodium ion permeability of excitable membranes and depolarize nerve cells, actions that are inhibited by calcium and tetrodotoxin.

Between 2 and 30 hours after ingestion, ciguatera fish poisoning typically produces a biphasic illness. The initial symptoms are nonspecific and are of gastrointestinal origin (diarrhea, vomiting, nausea, and abdominal pain). The second phase occurs within a few days of ingestion and consists of intense itching, anxiety, myalgias, painful intercourse, feeling of loose teeth, and rash on palms and soles; the neurologic symptoms of **circumoral dysesthesias** and **cold allodynia** (reversal of hot and cold sensation) are characteristic of this disease and may last for months. Tachycardia, bradycardia, hypotension, and death occur very infrequently. Eating fish organs, roe, or viscera is associated with greater symptom severity. The diagnosis of ciguatera fish poisoning is based on clinical presentation and a compatible epidemiologic history; the diagnosis is confirmed by testing the ingested fish for toxin. There is no human biomarker to confirm ciguatera fish poisoning.

Treatment

Treatment of ciguatera fish poisoning is supportive. Intravenous fluids may be required for severe diarrhea, and careful observation for hypovolemic shock is advised. Once adequate hydration is established, mannitol (0.5-1.0 g/kg intravenously over 30-45 minutes), given within 48-72 hours of the toxic fish ingestion, is recommended for reduction of acute symptoms (especially neurologic symptoms) and possible prevention of chronic neurologic symptoms. Various other medications and herbal remedies have been tried, with variable results. Most cases are self-limited with a favorable prognosis.

SCOMBROID (PSEUDOALLERGIC) FISH POISONING

Ingestion of members of the **Scombridae** families, including albacore, mackerel, tuna, bonito, and kingfish, have been linked to major outbreaks of pseudoallergic fish poisoning. Non-scombroid fish such as mahi-mahi (dolphin fish), swordfish, and bluefish also are associated with poisoning.

The bacterial transformation of histidine to histamine is responsible for the clinical syndrome. Histidine is found in high concentrations in the flesh of scombroid fish; if refrigeration is inadequate, the action of bacterial decarboxylases during putrefaction converts histidine to histamine. Fish containing more than 20 mg of histamine per 100 g of flesh are toxic. In patients receiving isoniazid, a potent histaminase blocker, ingestion of fish flesh containing a lower concentration of histamine may be toxic.

The onset of clinical manifestations is acute and occurs within 10 minutes to 2 hours of ingestion. The most common symptoms and signs are diarrhea, erythema, sweating, flushing, diaphoresis, urticaria, nausea, and headache (Fig. 762.1). Abdominal pain, tachycardia, oral burning or numbness, dizziness, respiratory distress, hives, and facial swelling also occur. The illness is usually self-limited, terminating within 8-24 hours.

Treatment

Treatment is mainly supportive. With severe diarrhea, fluid replacement may be necessary. Antihistamines and antiemetics have been variably successful.

PARALYTIC SHELLFISH POISONING

Mussels, clams, oysters, scallops, and other filter-feeding mollusks may become contaminated during dinoflagellate blooms or **"red tides."** During periods of contamination, water in coastal areas can be colored red by the algae; this sign is the origin of the term *red tide*. (Such discoloration does not necessarily indicate the presence of toxin, and toxin may be present in high quantities without discoloration. Nonetheless, discolored water should be regarded with suspicion.) The dinoflagellates *Alexandrium* spp. and *Gymnodinium catenatum* often are responsible for these red tides and contain several potent neurotoxins. Paralytic shellfish poisoning is a distinctive neurologic illness caused by 20 closely related heat-stable paralytic shellfish toxins, generally referred to as **saxitoxins.** These compounds prevent nerve conduction by inhibiting the sodium-potassium pump. Consumption of bivalves, such as mussels, scallops, and clams, is the usual pathway of intoxication, although crustaceans and fish have been implicated as well.

The onset of clinical manifestations of paralytic shellfish poisoning occurs rapidly, 30 minutes to 2 hours after ingestion. Abdominal pain and nausea are common. Paresthesias are common and occur circumorally or in a stocking-glove distribution, or both. Perioral numbness or tingling, diplopia, ataxia, dysarthria, and the sensation of floating are seen less commonly. In severe cases, respiratory failure from diaphragmatic paralysis may result. Swimming in the water during a red tide episode does not appear to have neurologic sequelae, although skin or mucosal irritation may result.

Treatment

No antidote for paralytic shellfish poisoning is known. Supportive care, including mechanical ventilation, may be needed. Although the symptoms are usually self-limited and short-lived, weakness and malaise may persist for weeks after ingestion.

NEUROTOXIC SHELLFISH POISONING

Neurotoxic shellfish poisoning is a rare disease that occurs after consumption of molluscan shellfish contaminated with brevetoxins. Shellfish harvested along the Gulf of Mexico during or right after a red tide are at risk of contamination with brevetoxins produced by the

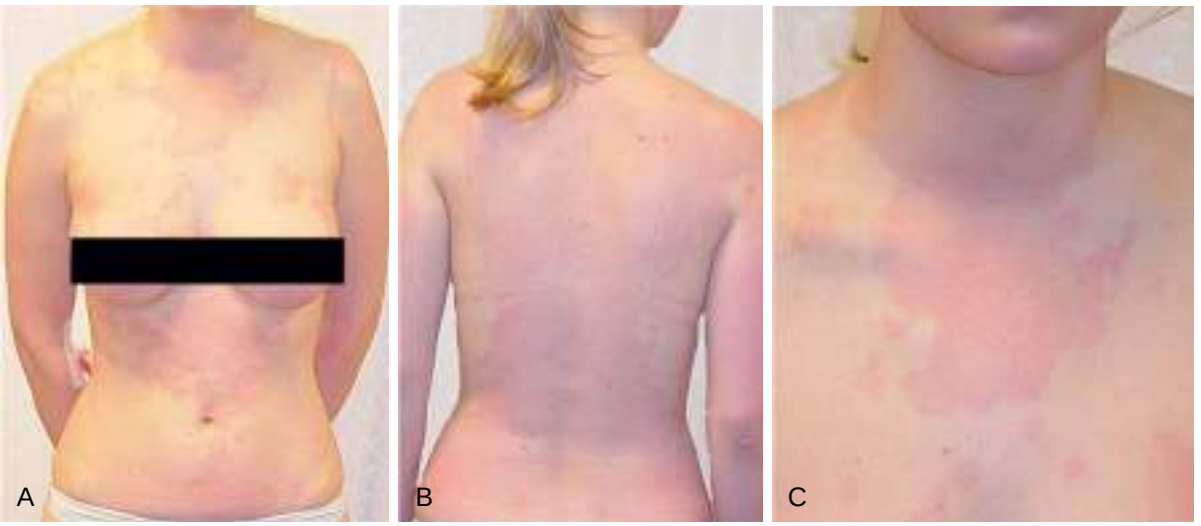

Fig. 762.1 Scombroid fish poisoning. **A** and **B**, Widespread erythematous rash predominantly on the face (not shown) and trunk of patient 1. **C**, Close-up view of the upper chest area. Note the absence of wheals. *(Modified from Jantschitsch C, Kinaciyan T, Manafi M, et al. Severe scombroid fish poisoning: an underrecognized dermatologic emergency. J Am Acad Dermatol. 2011;65[1]:246–247. Fig. 1.)*

dinoflagellate *Karenia brevis;* some raphidophytes (*Chattonella* spp.) also produce brevetoxins. **Brevetoxins** are a group of more than 10 lipid-soluble neurotoxins that activate sodium ion channels, causing nerve membrane depolarization. Shellfish are not affected by brevetoxins. Rinsing, cleaning, cooking, and freezing do not destroy the toxins, which also cannot be detected by taste or smell.

The onset of clinical manifestations of neurotoxic shellfish poisoning occurs from within a few minutes up to 18 hours after consumption. Most symptoms are gastrointestinal (nausea, vomiting, and diarrhea) or neurologic (numbness and tingling of the lips, mouth, face, and extremities, ataxia, partial limb paralysis, reversal of hot and cold sensation, slurred speech, headache, and fatigue). Neurotoxic shellfish poisoning is similar to a mild case of paralytic shellfish poisoning.

Treatment

There are no specific antidotes for brevetoxins. Treatment involves mostly supportive care. Brevenal, a natural antagonist of brevetoxin produced by *K. brevis,* may be used as a form of treatment in the future.

DIARRHETIC SHELLFISH POISONING

Several outbreaks of diarrhetic shellfish poisoning have been reported in Europe after consumption of mussels, cockles, and other shellfish. The dinoflagellates *Dinophysis* and *Prorocentrum* produce **okadaic acid** and its derivatives, the **dinophysistoxins.** These compounds inhibit protein phosphatases. The intracellular accumulation of phosphorylated proteins causes increased fluid secretion by gut cells via calcium influx, which is mediated by cyclic adenosine monophosphate and prostaglandins.

Patients have severe diarrhea. Care is supportive and directed at rehydration. The illness is self-limited, and recovery occurs in 3-4 days; few patients require hospitalization.

AMNESIC SHELLFISH POISONING

Amnesic shellfish poisoning has been identified after consumption of shellfish from the United States, Spain, and the United Kingdom. The responsible toxin, **domoic acid,** comes from a diatom, *Pseudonitzschia multiseries,* and is a potent glutamate agonist, disrupting neurochemical transmission in the brain. It also binds to glutamate receptors, which increase calcium influx, producing neuronal swelling in the hippocampal area of the brain and death.

The initial clinical manifestations are gastrointestinal with nausea, vomiting, diarrhea, and abdominal cramps within 24 hours of ingestion. Neurologic symptoms may follow including headache, confusion, and short-term memory loss. Memory loss is closely related to advanced age with those >50 years more likely to suffer from memory loss lasting months to years.

PUFFERFISH POISONING

The consumption of pufferfish (blowfish) in certain geographic areas such as Japan and the Indo-Pacific Ocean is associated with a lethal neurotoxic illness due to **tetrodotoxin**. Fugu, a Japanese delicacy, is sought after in part because of the subtle neurotoxic effects experienced upon eating, including perioral paresthesias and a dissociative feeling. While a trained fugu chef will remove the most toxic parts of the fish, the toxin is still found in varying degrees.

Tetrodotoxin, which is also found in the blue-ringed octopus, causes a paralytic illness due to the blockade of voltage-dependent sodium channels. Early symptoms include paresthesias, nausea, and dizziness, which progresses to weakness, numbness, and incoordination. Autonomic compromise may also occur with bradycardia and hypotension. In the most severe of cases, respiratory compromise requires assisted ventilation.

There is no specific antidote for tetrodotoxin pufferfish poisoning.

AZASPIRACID POISONING

The azaspiracids are a class of algal toxins associated with **harmful algal blooms (HABs).** Azaspiracid poisoning results from ingestion of contaminated bivalve shellfish, especially mussels. Azaspiracid toxins are distributed throughout the muscle tissue in the shellfish. Azaspiracid is cytotoxic to cells and an inhibitor of Ca^{2+} channels in plasma membranes. Symptoms start 6-18 hours after ingestion and include nausea, vomiting, severe stomach cramps, and diarrhea, which often persist up to 5 days.

Cyanobacteria (blue-green algae) also produce HABs; exposure is usually during recreational water sports and may be cutaneous or gastrointestinal. Symptoms include rash, cough, abdominal pain, diarrhea, nausea, emesis, muscle aches, watery eyes, weakness, or sore throat.

Visit Elsevier eBooks+ at eBooks.Health.Elsevier.com for Bibliography.

762.4 Melamine Poisoning

Katherine Baranowski and Diane P. Calello

Melamine (1,3,5-triazine-2,4,6-triamine, or $C_3H_6N_6$) is found in many plastics, adhesives, laminated products, cement, cleansers, fire retardant paint, and more. Melamine poisoning from food products was unheard of until 2007, when melamine-tainted pet food caused the death of many dogs and cats in the United States. In 2008, feeding of melamine-tainted infant formula to more than 300,000 children resulted in urolithiasis and resultant kidney injuries, 50,000 hospitalizations, and 6 deaths in China. This was the first reported epidemic of melamine-tainted milk products.

Melamine contains 66% nitrogen by mass. The illegal addition of melamine to infant formula can give the formula a milky appearance and falsely raise the protein content as measured by nitrogen testing. Melamine, combined with cyanuric acid, forms cyanurate crystals in the kidneys. Along with protein, uric acid, and phosphate, melamine forms renal calculi. The melamine stones and gravel can be treated with hydration, alkalinization, or lithotripsy. Acute renal failure requires supportive care and dialysis if needed.

Clinical manifestations are initially subtle and nonspecific. The severity is dose related. The first symptoms in affected infants are unexplained crying (especially when urinating), vomiting, and discolored urine caused by the formation of stones and gravel in the urinary tract. Urinary obstruction and acute renal failure follow. In the absence of a specific diagnosis, death from renal failure may occur. Whether children with melamine-induced renal failure will have chronic renal sequelae is currently unknown.

In addition to the more well-known renal toxicity, cognitive defects can be seen after acute, chronic, or prenatal exposure. Dissolved and insoluble melamine and its insoluble metabolites all have the potential to cause neurotoxicity.

Visit Elsevier eBooks+ at eBooks.Health.Elsevier.com for Bibliography.

Chapter 763

Biological and Chemical Terrorism

*Theodore J. Cieslak, Jonathan Newmark, and Mark G. Kortepeter**

In April of 2017, an attack on the town of Khan Shaykhun in Syria employed a poisonous "nerve agent" (likely sarin) that resulted in the deaths of at least 92 civilians, many of them young children. The attack intentionally targeted civilian neighborhoods at the time children were getting ready for school, which is strong evidence that its purpose was terror, not warfare. Terrorist actions targeting children are not novel. Brought to the forefront of American consciousness by Timothy McVeigh's references to child fatalities as "collateral damage" during the Oklahoma City bombing in April 1995, the intentional targeting of children became a global reality with the attack upon a school in Beslan, Russia, in September 2004. The attack, which left 334 dead (including 186 children), presaged additional attacks specifically directed against children. School shootings have become an all too frequent occurrence in the United States with over 175 children dying from mass shootings on school grounds since 1999.

Paralleling the targeting of children is an apparent trend toward the use of "unconventional" weapons of terror. In 1984, members of the Rajneeshee cult employed *Salmonella typhi* in a wave of intentional poisonings that affected 751 persons, including 142 teenage patrons of a popular pizza parlor. In 1995, the Aum Shinrikyo cult killed 12 and sickened thousands by intentionally releasing sarin nerve agent in the Tokyo subway system. A disgruntled scientist allegedly deployed anthrax spores via the U.S. mail in October 2001, killing 5 and injuring 17 in an attack upon a nation already reeling in the wake of the 9/11 attacks. Conflicts in Afghanistan, Syria, and Iraq from 2012 to 2016 led to another spike in chemical attacks.

These developments remind us that terrorists can strike at any time, utilizing any number of unconventional weapons, including biologic and chemical agents. Children will not be spared in these attacks on civilians, and indeed schools and daycare sites may be the targets of these actions.

ETIOLOGY

Although terrorists may choose to use **weapons of opportunity,** agents that are readily available to some member of the terrorist group, the motives of terrorists often are obscure and difficult to predict. Prevention and response strategies should thus concentrate not on those agents most likely to be used but, rather, on those agents that, if used, would constitute the gravest potential threats to public health and security.

Biologic threat agents, including pathogens and toxins, have been divided by the Centers for Disease Control and Prevention (CDC) into three categories, with **category A** including diseases caused by those six agents posing the greatest threat: anthrax, plague (see Chapter 249.3), tularemia (see Chapter 252), smallpox, botulism (see Chapter 256), and the viral hemorrhagic fevers, including Ebola (see Chapter 317).

Terrorists could also procure and release a vast array of potentially harmful chemicals. The Chemical Threat Risk Assessment prepared by the U.S. Department of Homeland Security lists over 170 chemical compounds as potential threats in accidental or deliberate scenarios. Tank cars full of flammable industrial gases and liquids, corrosive industrial acids and bases, poisonous compounds such as cyanides and nitrites, pesticides, dioxins, and explosives traverse our railways and roads daily. Four classes of "military-grade" chemicals with a history of use in warfare or manufactured specifically for use as weapons include the organophosphate-based nerve agents, vesicants, cyanides (misleadingly referred to as "blood agents"), and certain pulmonary irritants or "choking agents."

EPIDEMIOLOGY AND PEDIATRIC-SPECIFIC CONCERNS

Large-scale attacks on civilian targets will likely involve pediatric victims. Children may be more susceptible than adults to the effects of certain biologic and chemical agents (see Chapter 759). A thinner and less-keratinized epidermis makes dermally active agents, such as mustard or trichothecene mycotoxins, a greater risk to children than to adults. A larger surface area per unit volume further increases the problem. A small relative blood volume makes children more susceptible to the volume losses associated with enteric infections such as cholera and to gastrointestinal intoxications such as might be seen with exposure to the staphylococcal enterotoxins. The high minute ventilation of children, compared with that of adults, increases the threat of agents delivered via the inhalational route. The fact that children live "closer to the ground" compounds this effect when heavier-than-air chemicals are involved.

*The views expressed herein are those of the authors and do not necessarily reflect the position of the University of Nebraska, the U.S. Department of Defense, Health and Human Services, and Veterans' Affairs, or their component entities.

An immature blood-brain barrier may heighten the risk of central nervous system toxicity from nerve agents. Developmental considerations make it less likely that a child would readily flee an area of danger, thereby increasing exposure to these various adverse effects. Moreover, children are more likely to be terrified at the sight of responders in personal protective ensembles.

Children appear to have a unique susceptibility to certain agents that might be used by terrorists. Although adults generally suffer only a brief, self-limited incapacitating illness after infection with Venezuelan equine encephalitis virus, young children are more likely to experience seizures, permanent neurologic sequelae, and death. In the case of smallpox, waning herd immunity may disproportionately affect children. Vaccine-induced immunity to smallpox diminishes significantly after 3-10 years. Although most adults are considered susceptible to smallpox given that routine civilian immunization ceased in the early 1970s, older adults may have some residual protection from death, if not from the development of disease. Today's children are among the first to grow up in a world without any individual or herd immunity to smallpox.

Children also may experience unique disease manifestations not seen in adults. Suppurative parotitis is a common characteristic finding among children with melioidosis but is not generally seen in adults with *Burkholderia pseudomallei* infection (see Chapter 251.2). Seizures, often the presenting symptom of cyanide or nerve agent poisoning, may be much more difficult to recognize clinically in children than in adults, more likely presenting as unresponsiveness or change in mental status than tonic-clonic episodes.

Pediatricians are likely to experience unique problems in managing childhood victims of a biologic or chemical attack. Many of the drugs useful in treating such casualties are unfamiliar to pediatricians or have relative contraindications in childhood. The fluoroquinolones and tetracyclines are commonly cited as agents of choice in the treatment and prophylaxis of anthrax, plague, tularemia, brucellosis, and Q fever. Both drug classes are often avoided in children, although the risk of morbidity and mortality from diseases induced by agents of bioterrorism far outweighs the minor risk associated with short-term use of these agents. Ciprofloxacin received, as its first licensed pediatric indication, approval from the FDA for use in the prophylaxis of anthrax after inhalational exposure during a terrorist attack; doxycycline and levofloxacin are licensed specifically in children for the same indication. Levofloxacin is also licensed for postexposure prophylaxis of children against plague, and moxifloxacin is considered an acceptable alternative to first-line therapies for the treatment of plague in those less than 18 years of age. Immunizations potentially useful in preventing biologic agent–induced diseases are often not approved for use in pediatric patients. The available anthrax vaccine is licensed only for those between 18 and 65 years. The plague vaccine, currently out of production and probably ineffective against inhalational exposures, was approved only for individuals ages 18-61 years. The live replicating smallpox vaccine (ACAM2000), a live vaccine employing vaccinia virus, can cause fetal demise when given to pregnant women. A nonreplicating smallpox (and mpox) vaccine (Jynneos) was introduced in 2019.

Many otherwise useful pharmaceutical agents are not available in pediatric dosing regimens. The military distributes nerve agent antidote kits consisting of prefilled autoinjectors designed for the rapid administration of atropine and pralidoxime. Many emergency departments and some ambulances stock these kits. The doses of agents contained in the nerve agent antidote kit are calculated for soldiers and thus are inappropriate for young children, and pediatric pralidoxime autoinjectors are not yet available. Atropine autoinjectors specifically formulated for children are approved by the FDA, although their availability is limited. Unfortunately, there is no pediatric combination autoinjector containing atropine and pralidoxime, the backbone of acute nerve agent treatment in adults. Moreover, children smaller than 7 kg (15 pounds) are too small for safe use of atropine autoinjectors, while obtaining venous access may be time-consuming and extremely difficult in a contaminated environment.

Although physical protective measures and devices (e.g., "gas masks") are likely to be of little utility in a civilian terrorism setting, such commercially available devices are not often available in pediatric sizes. The Israeli experience during the first Gulf War suggests that frightened parents may improperly use such masks on their children, resulting in inadvertent suffocation.

In the event of a large-scale terrorist attack, there may be an insufficient number of pediatric hospital beds. In any large disaster, excess bed capacity might potentially be provided at civilian and veterans hospitals under the auspices of the National Disaster Medical System. Although that system now specifically tracks pediatric beds, none of these would be found in the Veterans Administration system and few are likely to exist elsewhere. The situation is even more dire regarding burn unit beds, which may be needed in an attack with vesicants such as sulfur mustard.

CLINICAL MANIFESTATIONS

Should a terrorist attack occur, clinicians may be called on to make prompt diagnoses and render rapid lifesaving treatments before the results of confirmatory diagnostic tests are available. Although each potential agent of terrorism produces its own unique clinical manifestations, it is useful for the frontline clinician to consider their effects in terms of a limited number of distinct clinical syndromes. This approach helps clinicians make prompt, rational decisions regarding empirical therapy. Casualties resulting from a terrorist attack would either experience symptoms immediately upon exposure to an agent (or within the first several hours after exposure) or would see their symptoms develop slowly over a period of days to weeks. In the former case, the sinister nature of the event is often obvious and the etiology more likely to be conventional or chemical in nature.

Biologic agents differ from conventional, chemical (see Chapter 759), and nuclear (see Chapter 758) weapons in that they have inherent incubation periods. Consequently, patients are likely to present distant in time and place from the point of an unannounced and unnoticed exposure to a biologic agent. Whereas traditional first responders, such as firefighters and paramedics, may be at the forefront of a conventional or chemical terrorism response, the primary care physician or emergency room is likely to constitute the first line of defense against the effects of a biologic agent.

Casualties can thus be categorized as either immediate or delayed in presentation. Within each of these categories, patients can be further classified as having primarily respiratory, neuromuscular, or dermatologic manifestations (Table 763.1). A limited number of agents may cause each particular syndrome, permitting institution of empiric therapy targeted at a short list of potential etiologies. The viral hemorrhagic fevers might manifest as fever and a bleeding diathesis; these agents are considered separately in Chapter 317. In most cases, supportive care is the mainstay of hemorrhagic fever treatment, although two drugs (Inmazeb, Ebanga) have recently been licensed for the treatment of adults and children with Ebola.

Sudden-Onset Neuromuscular Syndrome: Nerve Agents

The very rapid onset of neuromuscular symptoms after an exposure should lead the clinician to consider nerve agent intoxication. The nerve agents (*tabun, sarin, soman, and VX)* are **organophosphate** analogs of common pesticides that act as potent inhibitors of the enzyme acetylcholinesterase. The so-called "Novichok" agents, used in deliberate attacks upon Russian targets in Salisbury, UK (2018) and Tomsk, Russia (2020), also belong to this agent class. The nerve agents are hazardous via ingestion, inhalation, or cutaneous absorption (see Chapter 94).

The inhibition of cholinesterase by these compounds results in the accumulation of acetylcholine at neural and neuromuscular junctions, causing excess stimulation. The resultant **cholinergic**

Table 763.1 Diseases Caused by Agents of Chemical and Biologic Terrorism, Classified by Syndrome

	NEUROMUSCULAR SYMPTOMS PROMINENT	RESPIRATORY SYMPTOMS PROMINENT	DERMATOLOGIC FINDINGS PROMINENT
Sudden-onset or intermediate-onset	Nerve agents	Chlorine Phosgene Cyanide	Mustard Lewisite
Delayed-onset	Botulism	Anthrax Plague Tularemia Ricin	Smallpox

syndrome involves central, nicotinic, and muscarinic effects. Central effects are both muscarinically and nicotinically mediated and include altered mental status progressing rapidly to lethargy and coma, as well as ataxia, convulsions, and central respiratory depression. Studies on pesticide exposure suggest that children may be more prone to central neurologic dysfunction with organophosphate toxicity than adults. The most lethal effects are respiratory, which result not only from central effects but also from direct paralysis of the diaphragm and other respiratory muscles (nicotinic effects), as well as bronchospasm and bronchorrhea (muscarinic effects). Nicotinic effects include muscle fasciculations and twitching, followed by weakness, which can progress to flaccid paralysis as muscles fatigue. Importantly, flaccid paralysis is not present initially, as in a patient with botulinum toxin poisoning. In botulinum toxin poisoning, neurotransmitter cannot be released from the presynaptic terminal, whereas in nerve agent poisoning, excess neurotransmitter accumulates because acetylcholinesterase, the enzyme that turns off the transmitter, is inhibited. Muscarinic effects include miosis (the clinical hallmark of a patient who has suffered a non–life-threatening nerve agent challenge), visual blurring, profuse lacrimation, and watery rhinorrhea. Bronchospasm and increased bronchial secretions lead to cough, wheezing, dyspnea, and cyanosis. Cardiovascular manifestations include bradycardia, hypotension, and atrioventricular block. Flushing, sweating, salivation, nausea, vomiting, diarrhea, abdominal cramps, and urinary incontinence are also seen. In the absence of prompt intervention, death can quickly result from a combination of central effects and respiratory muscle paralysis.

The classic neuromuscular syndrome of extremely acute symptoms most commonly results from an aerosol or vapor exposure, the most likely route in a terrorist attack. But nerve agents are liquids at standard temperature and pressure and do not cause immediate irritation to skin. Liquid nerve agent may thus pass through the skin and enter the systemic circulation, causing cholinergic crisis. This can be delayed by minutes to hours, depending upon dose and body site. In children, because the stratum corneum of the skin forms only gradually, skin transit time will be reduced. Miosis may be a late development. *If the clinician suspects that the child may have been exposed to nerve agent via the cutaneous route, they should immediately treat, even if miosis has not yet developed.*

Cyanide poisoning is a major differential diagnosis of nerve agent poisoning in an attack scenario. Cyanide poisons cytochrome a3 in the mitochondrial electron transport chain and can cause an almost immediate and rather similar syndrome of loss of consciousness, immediate rapid breathing, status epilepticus, and rapid progression to cardiac arrest. Important clinical differential points include miosis, which is usually absent in cyanide poisoning, and the usual lack of cyanosis (ironically) due to the tissues' inability to use oxygen from the blood, causing venous blood to retain oxygen and remain red. In an emergency, it may be necessary to treat for both nerve agent and cyanide poisoning until the cause is definitively identified.

Delayed-Onset Neuromuscular Syndrome: Botulism

The delayed onset (hours to days after exposure) of neuromuscular symptoms is characteristic of botulism. Botulism, an intoxication rather than an infection, occurs after exposure to one of eight related neurotoxins produced by certain strains of *Clostridium botulinum,* a strictly anaerobic, spore-forming, gram-positive bacillus commonly found in soil. Naturally occurring botulism (see Chapter 256) usually follows ingestion of preformed toxin (food poisoning) or results from intestinal toxin production (infantile botulism). An aerosol exposure to the toxin would likely result in a case of clinical botulism indistinguishable from that caused by natural exposures.

Following exposure to botulinum toxin, clinical manifestations typically begin with bulbar palsies, causing patients to complain of ptosis, photophobia, and blurred vision resulting from difficulty in accommodation. Symptoms can progress to include dysarthria, dysphonia, dysphagia, and finally, a descending symmetric paralysis. Sensation and sensorium are typically not affected. In the absence of intervention, death often results from respiratory muscle failure. The mechanism of action of botulinum toxin is, in many ways, the opposite of that of nerve agent intoxication. Seizures, loss of consciousness, and peripheral twitching and fasciculations, typical of nerve agent poisoning, are not seen in botulism.

Sudden-Onset Respiratory Syndrome: Chlorine, Phosgene, and Cyanide

The acute onset of respiratory symptoms shortly after exposure should prompt the clinician to consider a range of potential chemical agents. Of note, nerve agents, discussed previously, may affect respiration via massive bronchial hypersecretion, bronchospasm, and respiratory muscle paresis. However, the nerve agent casualty will likely have generalized muscle involvement and central nervous system manifestations. In contrast, the toxic inhalants chlorine and phosgene produce respiratory distress without neuromuscular involvement or other features of cholinergic crisis. Several other pulmonary toxicants may produce similar clinical toxidromes.

Chlorine is a dense, acrid, yellow-green gas that is heavier than air. After mild to moderate exposure, ocular and nasal irritation occurs, followed by cough, a choking sensation, bronchospasm, and substernal chest tightness. Pulmonary edema, mediated by hydrochloric acid and free oxygen radical generation, follows moderate to severe exposures within 30 minutes to several hours. Hypoxemia and hypovolemia secondary to noncardiogenic pulmonary edema are the factors responsible for death.

Phosgene, like chlorine, is a common industrial compound that was used as a weapon on the battlefields of World War I. Its odor has been described as similar to "new-mown hay." Like chlorine, phosgene exposure also is thought to result in the generation of hydrochloric acid, contributing particularly to upper airway, nasal, and conjunctival irritation. Acylation reactions caused by the effects of phosgene on the pulmonary alveolar-capillary membrane lead to pulmonary edema. Phosgene lung injury also may be mediated, in part, by an inflammatory reaction associated with leukotriene production. Patients with mild to moderate exposures to phosgene

may be asymptomatic, a fact that may cause victims to remain in a contaminated area. Noncardiogenic pulmonary edema or "dry land drowning" occurs 4-24 hours after exposure and is dose dependent, with heavier exposures causing earlier symptoms. Dyspnea may precede radiologic findings. In severe exposures, pulmonary edema may be so marked as to result in hypovolemia and hypotension. As in the case of chlorine, death results from hypoxemia and asphyxia.

Cyanide, by contrast, is a cellular poison capable of causing protean clinical manifestations, not a pulmonary toxicant. Initially, cyanide toxicity is most likely to manifest as tachypnea and hyperpnea, progressing rapidly to apnea in cases with significant exposure (see Chapter 94). The efficacy of cyanide as a chemical terrorism agent is limited by its volatility in open air and relatively low lethality compared with nerve agents. Released in a closed room, however, cyanide could have devastating effects, as evidenced by its use in the Nazi gas chambers during World War II. Cyanide inhibits cytochrome a3, interfering with normal mitochondrial oxidative metabolism and leading to cellular anoxia and lactic acidosis. In addition to respiratory distress, early findings among cyanide victims include tachycardia, flushing, dizziness, headache, diaphoresis, nausea, and vomiting. With greater exposure, seizures, coma, apnea, and cardiac arrest may follow within minutes. An elevated anion gap metabolic acidosis is typically present and decreased peripheral oxygen utilization leads to an elevated mixed venous oxygen saturation value.

Delayed-Onset Respiratory Syndrome: Anthrax, Plague, Tularemia, and Ricin

A delayed onset of respiratory symptoms (days after exposure) is characteristic of several infectious diseases and at least one toxin that might be adapted for sinister purposes by terrorists. Among the most threatening and problematic of these are anthrax, plague, tularemia, and ricin.

Anthrax is caused by infection with the gram-positive spore-forming rod *Bacillus anthracis.* Its ability to form a spore enables the anthrax bacillus to survive for long periods in the environment and enhances its potential as a weapon.

The vast majority of naturally occurring anthrax cases are cutaneous, acquired by close contact with the hides, wool, bone, and other by-products of infected ruminants (principally cattle, sheep, and goats). Cutaneous anthrax is amenable to therapy with a variety of antibiotics and is readily recognizable to experienced clinicians in endemic areas; consequently, it is rarely fatal. Although it is common in parts of Asia and sub-Saharan Africa, only two cases of cutaneous anthrax had occurred in the United States in the 9 years that preceded the attacks of 2001 (when 11 cutaneous cases were seen). Gastrointestinal anthrax has been described only once in the United States, in a drum circle participant whose drum heads were made from imported animal hides. In general, however, it occurs after the ingestion of contaminated meat. In the past, inhalational anthrax, or **woolsorters' disease,** was an occupational hazard of abattoir and textile workers. Now eliminated as a naturally occurring disease in the United States, it is this inhalational form of anthrax that poses the greatest terror threat. Following an inadvertent release in 1979 from a bioweapons facility at Sverdlovsk in the former Soviet Union, 66 of 77 (86%) known adult victims of inhalational anthrax died. In the 2001 attacks involving contaminated mail in the United States, 5 of 11 (46%) patients with inhalational anthrax died. Whether better intensive care modalities, changes in antibiotic therapy, or earlier recognition accounted for this improved mortality rate remains unknown.

Symptomatic *inhalational* anthrax typically begins 1-6 days after exposure, although incubation periods of up to several weeks have been reported. The disease begins as a flulike illness, characterized by fever, myalgia, headache, and cough. A brief intervening period of improvement sometimes follows, but rapid deterioration then ensues; high fever, dyspnea, cyanosis, and shock mark this second phase. Hemorrhagic meningitis occurs in up to 50% of cases. Chest radiographs obtained late in the course of illness may reveal a widened mediastinum or prominent mediastinal lymphadenopathy; pleural effusions also may be seen. Bacteremia is often so profound that Gram stains of peripheral blood may demonstrate the organism at this stage. Prompt treatment is imperative. Death occurs in as many as 95% of inhalational anthrax cases if such treatment is begun more than 48 hours after the onset of symptoms.

Whereas inhalational anthrax is a disease primarily of mediastinal lymphatic tissue, exposure to aerosolized plague bacilli typically leads to a primary pneumonia. Endemic **plague** is usually transmitted via the bites of fleas and is discussed in Chapter 249.3. The causative organism of all forms of human plague, *Yersinia pestis,* is a bipolar-staining, gram-negative facultative intracellular bacillus. An ability to survive within the macrophage aids its dissemination to distant sites following inoculation or inhalation. "Buboes," markedly swollen, exquisitely tender regional lymph nodes in the distribution of a bite, are the hallmark feature of bubonic plague. Fever and malaise are typically present, and septicemia often develops as bacteria gain access to the circulation. Petechiae, purpura, and overwhelming disseminated intravascular coagulopathy commonly occur, and 80% of bubonic plague victims ultimately have positive blood cultures. Plague is extremely lethal, as illustrated by the fact that the "Black Death" eliminated one-third of the population of Europe during the Middle Ages.

Intentional aerosol dissemination of *Y. pestis* would likely result in a preponderance of pneumonic plague cases. Pneumonic plague may also arise secondarily after seeding of the lungs of septicemic patients. Symptoms include fever, chills, malaise, headache, and cough. Chest radiographs may reveal a patchy consolidation, and the classic clinical finding is blood-streaked sputum. Disseminated intravascular coagulation and overwhelming sepsis typically develop as the disease progresses. Untreated pneumonic plague has a fatality rate approaching 100%.

Tularemia is a highly infectious disease caused by the gram-negative coccobacillus *Francisella tularensis.* Naturally occurring tularemia is discussed in Chapter 252. The high degree of infectivity of *F. tularensis* (<10 organisms are thought to be necessary to produce infection via inhalation), as well as its survivability in the environment, contributes to its inclusion on the CDC's list of Category A agents. Several clinical forms of endemic tularemia are known, but inhalational exposure resulting from a terrorist attack would likely lead to a plaguelike primary pneumonia or to typhoidal tularemia, manifesting as a variety of nonspecific symptoms, including fever, malaise, and abdominal pain.

Ricin is a protein toxin derived from the castor bean plant *(Ricinus communis)* that inhibits ribosomal protein synthesis. It is highly toxic in animal studies when inhaled and may result in the delayed onset of respiratory distress, pulmonary edema, and acute respiratory failure. If injected, it may cause a sepsis-like syndrome that may progress to multiorgan system failure; ingestion can lead to severe gastroenteritis. Ricin-containing letters were mailed to a U.S. Senate office building in 2004, to President Obama and New York City Mayor Bloomberg in 2013, and to President Trump in 2020, although no persons were sickened in any of the attacks.

Intermediate-Onset Dermatologic Syndrome: Mustard and Lewisite

The development of skin lesions within hours to days of exposure is characteristic of the chemical vesicants. These compounds, often referred to as **blistering agents**, are cellular poisons and include the alkylating agent mustard and the organic arsenical agent lewisite. Injury to rapidly reproducing cells begins within minutes of contact with these agents. Clinical effects typically become evident several hours after exposure to mustard, whereas patients exposed to lewisite feel immediate pain. Both mustard and lewisite affect the eyes and respiratory tract, and their inadvertent ingestion may produce significant gastrointestinal symptoms. Mustard exposure may lead, several days later, to bone marrow suppression. With

a large inhalational challenge, mustard may also cause an acute respiratory syndrome, particularly affecting the upper airway and presenting with laryngospasm and stridor.

Delayed-Onset Dermatologic Syndrome: Smallpox

The appearance of an exanthem days to weeks after exposure is likely to be a presenting feature of smallpox. Caused by infection with variola virus, a member of the *Orthopoxvirus* family, smallpox has an incubation period of 7-17 days. This would likely permit the wide dispersal of asymptomatic exposed persons, thus contributing to the spread of an outbreak. During the incubation period, the virus replicates in the upper respiratory tract. A primary viremia ensues, during which time seeding of the liver and spleen occurs. A secondary viremia then develops, the skin is seeded, and the classic exanthem of smallpox appears.

Symptoms of smallpox begin abruptly during the phase of secondary viremia and include fever, rigors, vomiting, headache, backache, and extreme malaise. Within 2-4 days, macules appear on the face and extremities and then progress in synchronous fashion to papules, pustules, and finally scabs. As the scabs separate, survivors often are left with disfiguring, depigmented scars. The synchronous nature of the rash and its centrifugal distribution distinguish smallpox from chickenpox, which has a centripetal distribution. Historically, smallpox had a 30% mortality rate, with death typically resulting from visceral organ involvement.

DIAGNOSIS

In some cases, the terrorist nature of a chemical or biologic attack may be obvious; for example, a chemical attack in which victims succumb in close temporal and geographic proximity to a dispersal device or when terrorists announce their attack. In other instances, the clinician may need to rely on epidemiologic clues to suspect an intentional release of chemical or biologic agents. The presence of large numbers of victims clustered in time and space should raise the index of suspicion, as should cases of unexpected death or unexpectedly severe disease. Diseases unusual in a given locale, in a given age group, or during a certain season likewise may warrant further investigation. Simultaneous outbreaks of a disease in noncontiguous areas should cause one to consider an intentional release (as in the 2001 mail-borne anthrax attacks), as should outbreaks of multiple diseases in the same area. Even a single case of a rare disorder such as anthrax or certain viral hemorrhagic fevers would be suspicious, and a single case of smallpox would almost certainly be the result of an intentional dissemination. Large numbers of dying animals might provide evidence of an unnatural aerosol release, as would evidence of disparate attack rates between those known to be indoors and outdoors at a given time.

In a mass casualty setting, diagnoses may be made largely on clinical grounds. The diagnosis of nerve agent intoxication is based primarily on clinical recognition and patient response to antidotal therapy. Several simple rapid detection devices developed for military use can detect the presence of nerve agents in the environment. Some of these are now commercially available and are stocked in certain emergency departments and public safety vehicles. Measurements of acetylcholinesterase in plasma or erythrocytes of nerve agent victims may be helpful in long-term prognostication, but the correlation between cholinesterase levels and clinical effects is often poor, and the test is rarely available on an emergency basis.

Botulism should be suspected clinically among patients presenting with a symmetric, descending, flaccid paralysis. Although the differential diagnosis of botulism includes other uncommon neurologic disorders, such as myasthenia gravis and the Guillain-Barré syndrome, the presence of multiple casualties with similar symptoms should aid in the determination of a botulism outbreak. Electromyography is useful in supporting the diagnosis.

Initially the diagnosis of cyanide poisoning also will likely be made on clinical grounds in the presence of the appropriate toxidrome. An unusually high anion gap metabolic acidosis with elevated serum lactate and an oxygen concentration greater than expected in mixed venous blood lend support to the clinical diagnosis. Elevated blood cyanide concentrations can confirm the clinical suspicion.

Of all the chemical and biological agents, the only ones for which immediate therapy without waiting for definitive diagnosis is potentially lifesaving and mandatory are nerve agents and cyanide poisoning. If these are suspected, they should be treated before waiting for further diagnostic certainty.

Anthrax should be suspected upon finding gram-positive bacilli in skin biopsy material (in the case of cutaneous disease), blood smears, pleural fluid, or spinal fluid. Chest radiographs demonstrating a widened mediastinum in the context of fever and constitutional signs and, in the absence of another obvious explanation (e.g., blunt trauma or postsurgical infection), should also lead one to consider the diagnosis. Confirmation can be obtained by blood culture.

A diagnosis of plague can be suspected on finding bipolar "safety-pin"–staining bacilli in Gram or Wayson stains of sputum or aspirated lymph node material; confirmation is obtained by culturing *Y. pestis* from blood, sputum, or lymph node aspirate. The organism grows on standard blood or MacConkey TRA agars, but it is often misidentified by automated systems. *F. tularensis,* the causative agent of tularemia, grows poorly on standard media; its growth is enhanced on media containing cysteine. Because of its extreme infectivity, however, many laboratories prefer to make a diagnosis via polymerase chain reaction or serologically using an enzyme-linked immunosorbent assay or serum agglutination assay.

Smallpox should be suspected on clinical grounds and can be confirmed by culture or electron microscopy of scabs or vesicular fluid, although the manipulation of clinical material from suspected smallpox victims should be attempted only at public health laboratories able to employ maximum biocontainment (Biosafety Level 4) precautions. Similar caution should be exercised with specimens from patients with various viral hemorrhagic fevers.

PREVENTION

Preventive measures can be considered in both a preexposure and a postexposure context. **Preexposure protection** against a chemical or biologic attack may consist of physical, chemical, or immunologic measures. **Physical protection** against primary attack often involves gas masks and protective suits; such equipment is used by the military and by certain hazardous materials response teams, but it is unlikely to be available to civilians at the precise moment that a release occurs. Medical personnel need to understand the principles of physical protection as they apply to infection control and the spread of contamination.

Pneumonic plague is spread through respiratory droplets. Droplet precautions, including the use of simple surgical masks, are thus warranted for providers caring for patients with plague. Smallpox is transmitted by droplet nuclei. Airborne precautions, including (ideally) a high-efficiency particulate air filter mask, are thus warranted with smallpox victims. Patients with certain viral hemorrhagic fevers, such as those caused by filoviruses (Ebola, Marburg) and arenaviruses, should be managed using a combination of droplet and contact precautions, ideally in a specialized biocontainment unit. Most other biologic agent victims can be safely cared for with the use of standard precautions. In the case of chemical agents, residual mustard or nerve agent on the skin or clothing of victims might potentially pose a hazard to medical personnel. For such victims, whenever possible, clothing should be removed, and the patients decontaminated using copious amounts of water before extensive medical care is rendered. Most other chemical agents are volatile enough that spread of an agent among patients or from patient to caregiver is unlikely.

Preexposure chemical prophylaxis might be used on the basis of credible intelligence reports. Should officials deem that the threatened release of a specific biologic agent appears imminent, antibiotics might be distributed to a population before exposure. Opportunities to employ such a strategy are likely to be limited, although federal and state officials are examining various mechanisms for such employment. In military settings, pyridostigmine is FDA-approved as pretreatment against expected nerve agent attack. It is not approved for use in children, and it is not likely to be recommended in civilian settings.

Although licensed vaccines **(preexposure immunologic measures)** against anthrax and smallpox have been developed, widespread use of either vaccine is likely to be problematic, especially in children. The anthrax vaccine is licensed only for those persons age 18 years and older, is given as a five-dose series over 18 months, and requires annual booster doses. These considerations make civilian employment of the current anthrax vaccine on a large scale unlikely, although recombinant anthrax vaccines requiring fewer doses are in development.

Significant obstacles to the widespread employment of smallpox vaccine also exist, although public health officials have contemplated the resumption of a smallpox vaccination campaign. Whereas in the past, the live replicating smallpox vaccine (prepared from vaccinia virus, an *Orthopoxvirus* related to variola) was used safely and successfully in young infants, it has a relatively high rate of serious complications in certain patients. *Fetal vaccinia* and demise can occur when pregnant women are vaccinated. *Vaccinia gangrenosa*, an often fatal complication, can occur when immunocompromised persons are vaccinated. *Eczema vaccinatum* occurs in those with preexisting dermatoses (atopic dermatitis). Severe vaccine-related encephalitis was well known during the era of widespread vaccination; because it occurs only in primary vaccines, it would disproportionately affect pediatric patients. Autoinoculation can occur when the virus present at the site of vaccination is manually transferred to other areas of skin or to the eye. Young children would presumably be at greater risk for such inadvertent transmission. Myocarditis has been reported following vaccinations of military recruits. A new nonreplicating vaccine may alleviate some of these concerns.

To manage complications associated with use of the replicating vaccine, vaccinia immune globulin should be available when one is undertaking a vaccination campaign. Vaccinia immune globulin (6000 U/kg intravenously) may be given to vaccine recipients who experience severe complications or to significantly immunocompromised individuals exposed to smallpox and in whom vaccination would be unsafe. In 2018, tecovirimat was approved by the FDA for the treatment of persons (including children) experiencing severe complications from vaccine. Vaccine, as well as vaccinia immune globulin and tecovirimat, can be obtained as needed upon consultation with officials at the CDC. In addition to a potential role in preexposure prophylaxis, vaccination may be effective in postexposure prophylaxis if given within the first 4 days after exposure.

Anthrax vaccine might similarly be employed in a postexposure setting. Some authorities recommend three doses of this vaccine as an adjunct to postexposure chemoprophylaxis after documented exposure to aerosolized anthrax spores. Nonetheless, postexposure administration of oral antibiotics constitutes the mainstay of management for asymptomatic victims believed to have been exposed to anthrax as well as to other bacterial agents such as plague and tularemia. Table 763.2 lists appropriate prophylactic regimens for various biologic exposures.

TREATMENT

Although Tables 763.2, 763.3, and 763.4 provide recommended therapies for overt diseases caused by various chemical and biologic agents, it is likely that the clinician attending to victims will need to make therapeutic decisions before the results of confirmatory diagnostic tests are available and in situations in which the diagnosis is not known with certainty. In particular, decontamination by hospital personnel in appropriate personal protective equipment is required for patients exposed to chemical agents who have not been adequately decontaminated in the prehospital setting (see Table 763.4). In such cases, it is useful to note that many diseases and symptoms caused by chemical and biologic agents will resolve with supportive care. Most cases of chlorine or phosgene exposure can be successfully managed by providing meticulous attention to oxygenation and fluid balance. Mustard victims may require intensive multisystem support, but no specific antidote or therapy is available. Many viral diseases, including most viral hemorrhagic fevers, as well as equine encephalitides, are also managed supportively.

In addition to ensuring adequate oxygenation, ventilation, and hydration, the clinician may need to provide specific empiric therapies on an urgent basis. Patients suffering from the sudden onset of severe neuromuscular symptoms may have nerve agent intoxication and should be given atropine (0.05-0.1 mg/kg) promptly for its antimuscarinic effects. Although atropine relieves bronchospasm and bradycardia, reduces bronchial secretions, and ameliorates the gastrointestinal effects of nausea, vomiting, and diarrhea, it does not improve skeletal muscle paralysis. 2-Pralidoxime chloride (*2-PAM*) cleaves the organophosphate moiety from cholinesterase and regenerates intact enzyme if "aging" has not occurred. The effect is most prominent at the neuromuscular junction and leads to improved muscle strength. Its prompt use (at a dose of 25-50 mg/kg) as an adjunct to atropine is recommended in all serious cases.

Ideally, both atropine and pralidoxime should be administered intravenously (IV) in severe cases, although the intraosseous route is acceptable. In the field, as time is of the essence in treating nerve agent poisoning, first responders are trained to administer atropine IM via autoinjector. Some experts also recommend that atropine be given IM in the presence of hypoxia to avoid arrhythmias associated with IV administration. Many emergency management services stock military-style autoinjector kits consisting of atropine and 2-PAM for IM injection. Pediatric atropine autoinjectors containing 0.5 or 1 mg of atropine are licensed and held in the Strategic National Stockpile, although kits intended for adults (with 2 mg of atropine and 600 mg of pralidoxime) may be used in children >2-3 years of age (Table 763.5). Autoinjectors cannot easily be used in the smallest infants.

Animal studies support the routine prophylactic administration of anticonvulsant doses of benzodiazepines, even in the absence of observable convulsive activity. Although diazepam has long been employed for this purpose, midazolam was recently granted FDA approval, and animal studies have shown it to have superior efficacy in treating acute nerve agent poisoning. Military and civilian stocks of diazepam autoinjectors are being replaced by midazolam autoinjectors.

Delayed neuromuscular symptoms in the setting of terrorism might be due to botulism. Supportive care, with meticulous attention to ventilatory support, is the mainstay of botulism treatment. Such support may be necessary for several months, making the management of a large-scale botulism outbreak especially problematic in terms of medical resources. A licensed heptavalent antitoxin (types A-G) is available through the CDC (1-800-232-4636). Administration of this antitoxin is unlikely to reverse disease in symptomatic patients but may prevent further progression. In addition, a pentavalent product (containing antibody against toxin types A-E but licensed only for treatment of type A or B intoxication), Botulism Immune Globulin Intravenous (Human; BabyBIG), is available through the California Department of Health Services (1-510-231-7600) specifically for the treatment of infant botulism.

The *rapid onset of respiratory symptoms* may signal an exposure to chlorine, phosgene, cyanide, or a number of other toxic industrial chemicals. Although the mainstay of therapy in virtually all of these exposures consists of removal to fresh air and intensive supportive care, cyanide intoxication often requires the administration of specific antidotes.

Table 763.2 CDC Category A Agents of Bioterrorism

DISEASE	CLINICAL FINDINGS	INCUBATION PERIOD (DAYS)	ISOLATION PRECAUTIONS	INITIAL TREATMENT	PROPHYLAXIS
Anthrax (inhalational) Patients who are clinically stable after 14 days can be switched to a single oral agent (as described in the prophylaxis section of this table) to complete a 60-day course	Febrile prodrome with rapid progression to mediastinal lymphadenitis and mediastinitis, sepsis, shock, and meningitis	1-5	Standard	See Table 763.3.	**Ciprofloxacin 30 mg/kg/day PO divided q12h*** (max 500 mg/dose) *or* **doxycycline 4.4 mg/kg/day PO divided q12h** (max 100 mg/dose) *or* clindamycin 30 mg/kg/day PO divided q8h (max 900 mg/dose) *or* levofloxacin 16 mg/kg/day PO divided q12h (max 250 mg/dose) *or* **amoxicillin 75 mg/kg/day PO divided q8h**† (max 1 g/dose) or penicillin VK 50-75 mg/kg/day divided q6-8h
Plague (pneumonic)	Febrile prodrome with rapid progression to fulminant pneumonia, hemoptysis, sepsis, disseminated intravascular coagulation	2-3	Droplet (for first 3 days of therapy)	Gentamicin** 1.25- 2.5 mg/kg IV q8h *or* doxycycline 2.2 mg/kg IV q12h *or* ciprofloxacin 15 mg/kg IV q12h *or* levofloxacin 8 mg/kg IV/PO q12h	Doxycycline 2.2 mg/kg PO q12h *or* ciprofloxacin 20 mg/kg PO q12h *or* levofloxacin 8 mg/kg PO q12h
Tularemia	Pneumonic: abrupt onset of fever with fulminant pneumonia Typhoidal: fever, malaise, abdominal pain	2-10	Standard	Options same as for plague‡, gentamicin preferred	Same as for plague‡
Smallpox	Febrile prodrome with synchronous, centrifugal, vesiculopustular exanthema	7-17	Airborne (+ contact)	Tecovirimat *Oral dosage by body weight:* 13 kg to <25 kg: 200 mg q12h 25 kg to <40 kg: 400 mg q12h 40 kg to <120 kg: 600 mg q12h ≥120 kg: 600 mg q8h *Intravenous infusion dosage by body weight:* 3 kg to <35 kg: 6 mg/kg q12h by IV infusion over 6 hr 35 kg to <120 kg: 200 mg q12h by IV infusion over 6 hr ≥120 kg: 300 mg q12h by IV infusion over 6 hr	Vaccination may be effective if given within the first several days after exposure
Botulism	Afebrile descending symmetric flaccid paralysis with cranial nerve palsies	1-5	Standard	Supportive care; antitoxin (see text) may halt the progression of symptoms but is unlikely to reverse them	No licensed preexposure prophylaxis is available; postexposure administration of antitoxin may prevent the development of symptoms
Viral hemorrhagic fevers	Febrile prodrome with rapid progression to shock, purpura, and bleeding diatheses	4-21	Contact (consider airborne in cases of massive hemorrhage)	Supportive care; ribavirin may be beneficial in treating Lassa fever, and perhaps other arenaviral hemorrhagic fevers	Ribavirin has been shown to be efficacious in the postexposure prophylaxis of Lassa fever

*Preferred drugs are shown in **bold**.
**Some experts say 4.5-7.5 mg/kg/day.
†Penicillin and amoxicillin should only be used when the strain of *Bacillus anthracis* is known to be susceptible.
‡Levofloxacin (as well as moxifloxacin) is licensed by the U.S. Food and Drug Administration for the prophylaxis and treatment of plague in the setting of a bioterror attack, but not tularemia.
PO, By mouth; IV, intravenously.

Table 763.3 Treatment of Inhalational Anthrax in Children

WHEN MENINGITIS PRESENT OR HAS NOT RULED OUT*	WHEN MENINGITIS CAN BE RULED OUT*
1. A bactericidal fluoroquinolone: **Ciprofloxacin 30 mg/kg/day IV divided q8h**† (max 400 mg/dose) *or* Levofloxacin 24 mg/kg/day IV divided q12h (max 250 mg/dose) *or* Moxifloxacin 12 mg/kg/day IV divided q12h (max 200 mg/dose; for children 3 mo to 2 yr); 10 mg/kg/day IV divided q12h (for children 2-5 yr); 8 mg/kg/day IV divided q12h (for children 6-11 yr); 400 mg IV qd (for children >12 yr and >45 kg)	1. A bactericidal antimicrobial: **Ciprofloxacin 30 mg/kg/day IV divided q8h** (max 400 mg/dose) *or* Levofloxacin 20 mg/kg/day IV divided q12h (max 250 mg/dose) *or* Imipenem 100 mg/kg/day IV divided q6h (max 1 g/dose) *or* Vancomycin 60 mg/kg/day IV divided q8h *or* **Penicillin G 400,000 U/kg/day IV divided q4h** (max 4 MU/dose) [if PCN sensitive] *or* Ampicillin 200 mg/kg/day IV divided q6h (max 3 g/dose)
2. A second bactericidal antimicrobial: **Meropenem 120 mg/kg/day IV divided q8h** (max 2 g/dose) *or* Imipenem 100 mg/kg/day IV divided q6h (max 1 g/dose) *or* Doripenem 120 mg/kg/day IV divided q8h (max 1 g/dose) *or* Vancomycin 60 mg/kg/day IV divided q8h *or* **Penicillin G** 400,000 U/kg/day IV divided q4h**‡ (max 4 MU/dose) [if PCN sensitive] *or* Ampicillin 400 mg/kg/day IV divided q6h (max 3 g/dose)	
3. A protein synthesis inhibitor: **Linezolid 30 mg/kg/day IV divided q8h** (for children <12 yr); 30 mg/kg/day IV divided q12h (for children >12 yr; max 600 mg/dose) *or* Clindamycin 40 mg/kg/day IV divided q8h (max 900 mg/dose) *or* Rifampin 20/mg/kg/day IV divided q12h (max 300 mg/dose) *or* Chloramphenicol 100 mg/kg/day IV divided q6h	2. A protein synthesis inhibitor: **Clindamycin 40 mg/kg/day IV divided q8h (max 900 mg/dose)** *or* Linezolid 30 mg/kg/day IV divided q8h (for children <12 yr); 30 mg/kg/day IV divided q12h (for children >12 yr; max 600 mg/dose) *or* Rifampin 20/mg/kg/day IV divided q12h (max 300 mg/dose) *or* Doxycycline 4.4 mg/kg/day IV loading dose (for children <45 kg; max 200 mg), followed by 4.4 mg/kg/day IV divided q12h; 200 mg IV loading dose, followed by 100 mg IV q12h (for children >45 kg)

*Meningitis occurs in approximately 50% of patients with inhalational anthrax.
**Some experts provide a range of 400,000–600,000 U/kg/d.
†Preferred drugs are shown in **bold**.
‡Penicillin and amoxicillin should only be used when the strain of *Bacillus anthracis* is known to be susceptible.
IV, Intravenous; qd, every day; PCN, penicillin.
Data from Bradley JS, Peacock G, Krug SE, et al. Pediatric anthrax clinical management. *Pediatrics*. 2014;133:e1411–e1436. Appendices 3 & 4.

The classic **cyanide antidote** utilizes a nitrite along with sodium thiosulfate and is given in two stages. The methemoglobin-forming agent (e.g., sodium nitrite) is administered first, because methemoglobin has a high affinity for cyanide and causes it to dissociate from cytochrome oxidase. Nitrite dosing in children should be based on body weight to avoid excessive methemoglobin formation and nitrite-induced hypotension. For the same reasons, nitrites should be infused slowly over 5-10 minutes. A sulfur donor, such as sodium thiosulfate, is given next. This compound is used as a substrate by the hepatic enzyme rhodanese, which converts cyanide to thiocyanate, a less toxic compound excreted in the urine. Thiosulfate treatment itself is efficacious and relatively benign and may be used alone for mild to moderate cases. Sodium nitrite and sodium thiosulfate are packaged together in standard antidote kits, along with amyl nitrite, a sodium nitrite substitute that can be inhaled in prehospital settings in which IV access is not available.

Many first responder agencies in the United States have replaced the traditional two-part cyanide antidote kit with hydroxocobalamin, which exchanges its hydroxy group for cyanide, forming harmless cyanocobalamin (vitamin B_{12}) that is subsequently excreted by the kidneys. Hydroxocobalamin use is not complicated by the potential for nitrite-induced hypotension or methemoglobinemia, and it has low toxicity. The recommended dose is 5 g in adults or 70 mg/kg in children, administered IV over 15 minutes. A second dose (5 g in adults; 70 mg/kg in children) may be repeated in severely affected patients. Side effects include modest hypertension and reddening of skin, mucous membranes, and urine that may last several days. Although no human controlled trials are currently available to compare hydroxocobalamin with nitrite/thiosulfate-based therapies, many authorities believe that hydroxocobalamin's efficacy and safety profile favor it as the cyanide antidote of choice, especially for children in the mass casualty context. To use hydroxocobalamin, however, the solution must be mixed immediately before use, in the field if need be, so first responders need to be properly trained to employ it.

Animal research suggests a modest benefit of steroid therapy in mitigating lung injury after chlorine inhalation; thus steroids may be considered for patients with chlorine exposure, especially as an adjunct to bronchodilators in those with bronchospasm and/or a history of asthma. Symptomatic relief has also been reported following chlorine exposure with nebulized 3.75% sodium bicarbonate therapy, though the impact of this regimen on pulmonary damage is unknown. Animal models have also suggested a benefit from antiinflammatory agents, including ibuprofen and *N*-acetylcysteine, which appear to ameliorate phosgene-induced pulmonary edema, as well as the utilization of low tidal volume ventilation (protective ventilation), although the results of such interventions have not yet been reported in clinical trials.

In cases in which the delayed onset of respiratory symptoms may be the result of a terrorist attack, consideration should be given to the empirical administration of an antibiotic effective against anthrax, plague, and tularemia. Ciprofloxacin (10-15 mg/kg IV q12 hours), levofloxacin (8 mg/kg IV q12 hours), or doxycycline (2.2 mg/kg IV q12 hours) is a reasonable choice. Although naturally occurring strains of *B. anthracis* usually are quite sensitive to penicillin G, these agents are chosen because penicillin-resistant strains of *B. anthracis* exist. Moreover, ciprofloxacin and doxycycline are effective against almost all known strains of *Y. pestis* and *F. tularensis*. Concerns about inducible β-lactamases in *B. anthracis* have led experts to recommend one to two additional antibiotics in patients with inhalational anthrax. Rifampin, vancomycin, penicillin or ampicillin, clindamycin, and imipenem are reasonable choices based on in vitro sensitivity data. Because *B. anthracis* relies on the production of two protein toxins, edema toxin and lethal toxin, for its virulence, drugs that act at the ribosome to disrupt protein synthesis (e.g., clindamycin, the macrolides) provide a theoretical advantage. Frequent meningeal involvement among inhalational anthrax victims makes agents with superior central nervous system penetration desirable. The treatment of anthrax is detailed in Table 763.3.

Table 763.4 Critical Chemical Agents of Terrorism

AGENT	TOXICITY	CLINICAL FINDINGS	ONSET	DECONTAMINATION*	MANAGEMENT
NERVE AGENTS					
Tabun, sarin, soman, VX	Anticholinesterase: muscarinic, nicotinic, central nervous system effects	Vapor: miosis, rhinorrhea, dyspnea Liquid: diaphoresis, vomiting Both: coma, paralysis, seizures, apnea	Seconds: vapor Minutes to hours: liquid	Vapor: fresh air, remove clothes, wash hair Liquid: remove clothes, wash skin, hair with copious soap and water, ocular irrigation	ABCs. Atropine: 0.05-0.1 mg/kg IV[†], IM[‡] (min: 0.1 mg, max: 5 mg), repeat q2-5 min prn for marked secretions, bronchospasm AND Pralidoxime: 25-50 mg/kg IV, IM[§] (max: 1 g IV; 2 g IM), may repeat within 30-60 min prn, then again q1h for one or two doses prn for persistent weakness, high atropine requirement AND Diazepam: 0.3 mg/kg (max: 10 mg) IV *or* Lorazepam: 0.1 mg/kg IV, IM (max: 4 mg) *or* Midazolam: 0.2 mg/kg (max: 10 mg) IM prn for seizures or severe exposure
VESICANTS					
Mustard	Alkylation	Skin: erythema, vesicles Eye: inflammation Respiratory tract: inflammation	Hours	Skin: soap and water Eyes: water (effective only if done within minutes of exposure)	Symptomatic care
Lewisite	Arsenical		Immediate pain	Skin: soap and water Eyes: water (effective only if done within minutes of exposure)	Possibly British antilewisite (BAL) 3 mg/kg IM q4-6h for systemic effects of lewisite in severe cases
PULMONARY AGENTS					
Chlorine, phosgene	Liberate hydrochloric acid, alkylation	Eye, nose, and throat irritation (especially chlorine) Respiratory: bronchospasm, pulmonary edema (especially phosgene)	Minutes: eye, nose, and throat irritation, bronchospasm Hours: pulmonary edema	Fresh air Skin: water	Symptomatic care (see text)
CYANIDE					
	Cytochrome oxidase	Tachypnea, coma, seizures, apnea	Seconds	Fresh air	ABCs, 100% oxygen
	Inhibition: cellular anoxia, lactic acidosis			Skin: soap and water	Na bicarbonate prn metabolic acidosis; hydroxocobalamin 70 mg/kg IV (max: 5 g) *or* nitrite/thiosulfate, given as follows (see text): *Na nitrite (3%): dose (mL/kg)* (max: 10 mL) — *Estimated hemoglobin concentration (g/dL)* 0.27 — 10 0.33 — 12 (estimated for average child) 0.39 — 14 Followed by Na thiosulfate (25%): 1.65 mL/kg (max: 50 mL)

*Decontamination, especially for patients with significant nerve agent or vesicant exposure, should be performed by healthcare providers garbed in adequate personal protective equipment. For emergency department staff, this equipment consists of a nonencapsulated, chemically resistant body suit, boots, and gloves with a full-face air-purifier mask/hood.
[†]Intraosseous route is likely equivalent to intravenous.
[‡]Atropine might have some benefit via endotracheal tube or inhalation, as might aerosolized ipratropium. See also Table 741.5.
[§]Pralidoxime is reconstituted to 50 mg/mL (1 g in 20 mL water) for IV administration, and the total dose infused over 30 min, or may be given by continuous infusion (loading dose 25 mg/kg over 30 min, and then 10 mg/kg/hr). For IM use, it might be diluted to a concentration of 300 mg/mL (1 g added to 3 mL water—by analogy to the U.S. Army's Mark 1 autoinjector concentration) to effect a reasonable volume for injection. See also Table 741.5.
ABCs, Airway, breathing, and circulatory support; IM, intramuscularly; IV, intravenously; max, maximum; min, minimum; prn, as needed.
Adapted from Henretig FH, Cieslak TJ, Eitzen EM. Biological and chemical terrorism. *J Pediatr.* 2002;141:311–326.

Table 763.5 Pediatric Autoinjector Recommendations for Mass Casualties or Prehospital Care*

ATROPINE AUTOINJECTOR THERAPY			
APPROXIMATE AGE	**APPROXIMATE WEIGHT (KG)**	**AUTOINJECTOR SIZE (MG)**	
<6 mo	<7.5	0.25	
6 mo to 4 years	7.5-18	0.5	
5-10 years	18-30	1.0	
>10 years	>30	2.0	
PRALIDOXIME AUTOINJECTOR THERAPY			
APPROXIMATE AGE (YEARS)	**APPROXIMATE WEIGHT (KG)**	**NUMBER OF AUTOINJECTORS**	**PRALIDOXIME DOSE (MG/KG)**
3-7	13-25	1	24-46
8-14	26-50	2	24-46
>14	>50	3	<35

*Consider adult pralidoxime autoinjector use for severely affected mass casualties when intravenous (IV) access or more precise mg/kg intramuscular (IM) dosing is logistically impractical. The initial dose using atropine autoinjectors is one autoinjector of each recommended size. The initial dose using pralidoxime autoinjectors is the recommended number of (adult-intended, 600 mg) autoinjectors. These latter may also be injected into an empty sterile vile; the contents redrawn through a filter needle into a small syringe may then provide a ready source of concentrated (300 mg/mL) pralidoxime solution for IM injection to infants. Autoinjectors may become available that provide adult doses of both atropine and pralidoxime in one injector; these could be used in children ≥3 years in lieu of two individual injectors and dosed as noted above for pralidoxime alone.

Raxibacumab, a monoclonal antibody that inhibits anthrax antigen binding to cell receptors, thus preventing toxins from entering cells, is approved for the treatment of inhalation anthrax in combination with antibiotics, as is obiltoxaximab, which neutralizes anthrax toxins. The adult dose of raxibacumab is 40 mg/kg given IV over 2 hours and 15 minutes. The dose for children is weight based: ≤15 kg, 80 mg/kg; >15-50 kg, 60 mg/kg; >50 kg, 40 mg/kg. Premedication with diphenhydramine IV or by mouth (PO) is recommended 1 hour before the infusion.

In patients with an established diagnosis of tularemia, gentamicin (5 mg/kg IV/IM divided 2 or 3 times/day) is the preferred choice for therapy due to the limited availability of streptomycin (15 mg/kg IM q12 hours). Bioterrorism-related plague should be treated with two distinct antibiotic classes until sensitivity patterns are known; gentamicin, streptomycin, ciprofloxacin, and levofloxacin are all approved agents for treatment of pneumonic plague in children (see Table 763.2). To be effective, therapy for pneumonic plague must be initiated within 24 hours of the onset of symptoms. There is little clinical experience with ricin-induced pulmonary injury. The mainstay of therapy is expected to be supportive care.

The management of **vesicant-induced injury** is similar to that for burn victims and is largely symptomatic (see Chapter 89). The major difference between thermal burns and vesicant burns is that vesicant casualties do not need the large volumes of fluid required by thermal burn victims, as their epidermis remains intact. These patients are at risk of overhydration if treated using thermal burn protocols. Mustard victims will benefit from the application of soothing skin lotions such as calamine and the administration of analgesics. Early intubation of severely exposed patients is warranted to guard against edematous airway compromise. Oxygen and mechanical ventilation may be needed, and meticulous attention to hydration is of paramount importance. Ongoing research suggests a role for oral *N*-acetylcysteine in mitigating chronic pulmonary effects due to mustard injury. Lewisite victims can be managed in much the same manner as mustard victims. Dimercaprol (British antilewisite) in peanut oil, given IM, may help ameliorate the systemic effects of lewisite, although few hospitals or pharmacies are likely to have this drug on hand.

The management of symptomatic smallpox victims also is largely supportive, with attention to pain control, hydration status, and respiratory sufficiency of primary importance. The parenteral antiviral compound cidofovir, licensed for the treatment of cytomegalovirus retinitis in HIV-infected patients, has in vitro efficacy against variola and other orthopoxviruses. Its utility in treating smallpox victims is untested. Moreover, in the face of a large outbreak of disease, wide parenteral use of this drug would be problematic. Tecovirimat demonstrates excellent in vitro activity against orthopoxviruses, but its utility in treating patients with smallpox is likewise untested.

In all chemical casualties, but especially if a liquid agent such as VX or mustard is suspected, decontamination is crucial and should be considered a primary medical intervention. Although this has been part of casualty doctrine in the civilian and military environments for decades, a 2016 study showed that disrobing eliminated 90% of contamination in normal volunteers; following this with showering using water or soap and water eliminated 99% of contamination. This has huge implications for the hospital management of possibly contaminated casualties, including children, and hospitals must plan to execute the decontamination mission at all levels.

For those faced with an acute chemical emergency, especially a mass casualty situation, a useful resource is the Chemical Hazard Emergency Medical Management website (https://chemm.hhs.gov), maintained by the Assistant Secretary for Preparedness and Response within the U.S. Department of Health and Human Services. Among its features is a decision support tool, CHEMM-IST, which aids in identification of the chemical a patient was exposed to.

Visit Elsevier eBooks+ at eBooks.Health.Elsevier.com for Bibliography.

Chapter 764

Mass Psychogenic Illness

Jonathan W. Mink

Mass psychogenic illness refers to the rapid spread of illness signs and symptoms affecting members of a cohesive group, originating from a nervous system disturbance involving excitation, loss, or alteration of function, whereby physical complaints that are exhibited unconsciously have no corresponding organic etiology. Mass psychogenic illness shares features in common with **conversion disorder (functional neurologic system disorder)** (see Chapter 35) in that the symptoms are not consciously produced and are typically sensorimotor in nature. The physical symptoms are associated with significant distress and impairment; they commonly interfere with function at school or home and affect peer relationships. Some experts have argued that "functional" is a better used term than "psychogenic" because it does not imply etiology and does not reinforce dualist thinking about the mind being separate from the brain.

Much less is known about the biologic underpinnings and clinical features of mass psychogenic illness than is known about conversion disorder and other somatic symptom disorders. However, there are some important features in common with conversion disorder. These include sudden abrupt onset, inconsistency with known anatomy and physiology, atypical features, and inconsistency of symptoms over time. Specific features of mass psychogenic illness are the occurrence of these symptoms in a cohesive group; the presence of increased anxiety; spread of symptoms via sight, sound, or oral communication (including social media); and a high female:male ratio.

CLINICAL FEATURES AND DIAGNOSIS

There are many examples of mass psychogenic illness throughout history. The best known is perhaps that of the Salem "witches." Most widely reported examples of mass psychogenic illness are in adults, but there are several reports in children as well. In 2004, 10 teenage females from a school in rural North Carolina developed paroxysmal episodes resembling epilepsy or syncope. These females were from a cohesive social group (school-age students in a small school) and had similar symptoms. The symptoms were shown not to be consistent with either syncope or epilepsy, and they eventually resolved after a two-week holiday break from school. Another episode in Le Roy, New York, was an outbreak of a "tic-like" illness among high school students. The symptoms were atypical for tics because they were not preceded by a premonitory urge and could not be suppressed with effort. In addition, the symptoms were remarkably similar across the affected patients. Symptoms resolved over time. In the Le Roy example, there was likely an exacerbating role of both social media and mass media, which amplified the cohesiveness of the group. There has been a surge of cases of "tic-like" symptoms in adolescents during the COVID-19 pandemic. It has been suggested that social media, especially videos presented on the TikTok platform, has played an important role in the spread of these symptoms.

In a study of 280 environmental chemical incidents in the United Kingdom between 2007 and 2008, 7% were classified as mass psychogenic illness according to five diagnostic criteria: (1) presence of somatic (bodily) symptoms, (2) preexisting social connection between two or more of the affected people, (3) epidemic spread of symptoms, (4) attribution of symptoms by affected individuals (or by their parents or caregivers) to a threatening external agent of a physical (usually chemical, biologic, or radiologic) or spiritual nature, and (5) symptoms and signs that are not compatible with the environmental exposure specified by the affected individuals nor with any other environmental exposure that could reasonably be expected to have been present at the time of (or shortly before) the onset of symptoms.

One study has examined experimentally induced mass psychogenic illness. In a randomized controlled experiment, participants were assigned to one of three groups to study the effects of a simulated biologic threat and elements of social contagion. The three groups were (1) no-intervention control group, (2) psychogenic illness induction group, and (3) psychogenic illness induction plus media group. Groups 2 and 3 were told that the purpose of the study was to test the side effects of a carrier compound for an antiinfluenza medication. They were told that the compound did not produce serious side effects but was being evaluated with regard to mild side effects. In groups 2 and 3, professional actors were placed among the participants to feign illness during the study with symptoms of nausea, dizziness, and headache. Group 3 was also shown a documentary about the 1918 flu pandemic. The video contained interviews with survivors and vivid images of death and illness. The two psychogenic induction groups had 11 times more symptoms than did the control group. If a subject had a lifetime history of a traumatic event or depression, he or she was more likely to have symptoms. The documentary viewing was not associated with a higher rate of symptoms. This study confirmed the role of **"social contagion"** in mass psychogenic illness and provided a model for future studies of factors leading to such contagion.

TREATMENT STRATEGIES

Mass psychogenic illness is usually self-limited, but treatment requires careful reassurance and communication between physician and patient. Explanation models should be communicated in a sensitive manner so as not to appear dismissive of symptoms. When doctors and patients do not agree on the "reality" of the illness, the prognosis is worse. Thus media attention, medical and scientific disagreement, and legal proceedings must be managed in a way that does not exacerbate the symptoms or the illness.

In the Le Roy illness, treatment varied across individuals. The treatment strategies included cognitive-behavioral therapy, supportive psychotherapy, education, pharmacotherapy for coexisting anxiety, and alteration of social setting. Many of the patients sought multiple medical opinions. There were frequent discussions among public health and other medical officials and the local media outlets. Reduced media attention seemed to lead to more rapid improvement of symptoms in some patients.

It is helpful for healthcare providers to avoid the dichotomy of approaching illness using a medical model in which diseases are considered as being either physically *or* psychologically based. In contrast, a biobehavioral continuum of disease better characterizes illness as occurring across a spectrum ranging from a predominantly biologic etiology on one end to a predominantly psychosocial etiology on the other. It is beneficial to the patient for the treating physician to try to shift the emphasis from understanding the etiology to a path toward recovery.

Visit Elsevier eBooks+ at eBooks.Health.Elsevier.com for Bibliography.

Chapter 765

Animal and Human Bites

David A. Hunstad

Many animals, besides domestic and stray dogs and cats, inflict bites on humans. The profile of such bites varies by country and region, based on community and living conditions, indigenous species, and opportunity for encounter.

EPIDEMIOLOGY

Worldwide there are tens of millions of dog bites each year, resulting in nearly 60,000 deaths annually from rabies (see Chapter 320). **Dog bites** represent approximately 80–90% of all bites in the United States, while 5–15% are from cats, 2–5% from rodents, and the remainder from rabbits, ferrets, farm animals, monkeys, and reptiles. An estimated 4.5 million persons in the United States are bitten by dogs annually; over 800,000 of those seek medical care. Bites from dogs are also most common in Bangladesh, India, Pakistan, and Myanmar, whereas in Nepal cattle and buffalo account for more than half of bites, followed by dogs, pigs, and horses. Approximately 1% of dog bite wounds and 6% of cat bite wounds in the United States require hospitalization. During the past three decades, there have been several dozen deaths per year in the United States from dog-inflicted injuries; the majority of these occurred in children under 11 years of age. Various studies have examined the incidence of dog bite injuries by dog breed. Compared with other breeds, bites by pit bull terriers and mixed-breed dogs account for higher rates of hospital admission, lower Glasgow Coma Scores at admission, and an increased risk of death. Unaltered male dogs account for approximately 75% of attacks, while nursing female dogs may inflict injury when humans attempt to handle their puppies.

The majority of dog attacks on children in the United States occur between the ages of 6 and 11 years, with a slight predominance in males. Approximately 65% of attacks occur around the home, 75% of biting animals are known by the children, and 50% of attacks are said to be unprovoked. Similar statistics apply in Canada, where 70% of all bites reported in one study were sustained by children age 2-14 years; 65% of dogs involved in biting were part of the family or extended family.

Of the approximately 450,000 reported **cat bites** per year occurring in the United States, nearly all are inflicted by known household animals. Because rodent bites (rat, mouse, gerbil) do not represent reportable conditions, little is known about the epidemiology of these injuries or the incidence of infection after rodent-inflicted bites or scratches.

Few data exist on the incidence and demographics of **human bite** injuries in pediatric patients; however, preschool and early school-age children appear to be at greatest risk of sustaining an injury from a human bite, often in daycare or preschool settings. In some series, the proportion of human bites is highest among adolescents, an age group in which fist-to-teeth injuries (so-called "fight bites") become more common.

CLINICAL MANIFESTATIONS

Dog bite–related injuries can be divided into three categories of almost equal incidence: abrasions, puncture wounds, and lacerations with or without an associated avulsion of tissue. Bites from larger dogs may also involve crush injury to tissues. In contrast, the most common type of injury from cat bites is a puncture wound, often penetrating deep into tissue or joint spaces. Human bite injuries are of two types: an occlusion injury that is incurred when the upper and lower teeth come together on a body part, or a clenched-fist injury that occurs when the injured fist, usually on the dominant hand, strikes the teeth of another individual.

DIAGNOSIS

Management of the bite victim should begin with a thorough history and physical examination. Careful attention should be paid to the circumstances surrounding the bite event (e.g., species and number of animals, type of animal [domestic or wild], whether the attack was provoked or unprovoked, location of the attack), a history of drug allergies, and the immunization status of the child (tetanus) and animal (rabies). During physical examination, meticulous attention should be paid to the type, size, and depth of the injury; the presence of any foreign material in the wound; the status of underlying structures; and, when the bite is on an extremity, the exact location of the injury, an assessment of possibly involved structures, and the range of motion of the affected area. Photographs of the injury should be recorded in the patient's medical record. Radiographs of the affected part should be considered if it is likely that a bone or joint was penetrated or fractured or if foreign material is present in the wound. The possibility of a fracture or penetrating injury of the skull should particularly be considered in infants who have sustained dog bite injuries to the face or head.

COMPLICATIONS

Infection is the most common complication of bite injuries regardless of the species of biting animal. In most cases, culture specimens from a fresh dog bite wound are not likely to be clinically useful. Although potentially pathogenic bacteria have been isolated from up to 80% of dog bite wounds that are brought to medical attention within 8 hours of the bite, the infection rate for wounds receiving medical attention in <8 hours is relatively low (2.5–20%). Cultures should be obtained from the wound if there is clinical evidence of infection or if the patient is immunocompromised. *Capnocytophaga canimorsus* is isolated from approximately 5% of infected wounds in immunocompromised patients (especially asplenia) and can cause serious systemic infection in these individuals. In contrast to dogs, the infection rate in cat bite wounds, even those that receive prompt medical attention, is >50%; therefore cat bites should be closely monitored for signs of infection.

The rate of infection after rodent bite injuries is not known. Most of the oral flora of rats is similar to that of other mammals; however, up to 50% of rats, depending on worldwide geography, may harbor strains of *Streptobacillus moniliformis* and *Spirillum minus,* both of which cause rat bite fever (see Chapter 766).

All human bite wounds, regardless of the mechanism of injury, should be considered high risk for infection. Current recommendations do not support obtaining cultures at the time of the bite as it does not change empiric antibiotic therapy; however, any infected wounds should be cultured.

Table 765.1 lists common causes of soft tissue bacterial infections after dog, cat, or other animal bites. Bites of humans or cats, those in which treatment is delayed, those in immunocompromised patients, and those associated with deep puncture wounds or significant crush injury carry a higher risk for infection. An elevated risk for infection is also present if the bite is to certain anatomic regions (e.g., hand, foot, or genitals) or there is penetration of bone or tendons.

TREATMENT

Table 765.2 outlines the management of human or animal bite wounds to reduce risk for infection. The wound should be anesthetized, cleaned, and irrigated with sterile saline using moderate pressure. Irrigation with antibiotic-containing solutions provides no advantage over saline alone and may cause local irritation of the tissues. Puncture wounds should be thoroughly cleansed and

Table 765.1 Microorganisms Associated with Animal Bites

DOG BITES
Staphylococcus species
Streptococcus species
Eikenella species
Pasteurella species
Proteus species
Klebsiella species
Haemophilus species
Enterobacter species
Capnocytophaga canimorsus
Bacteroides species
Moraxella species
Corynebacterium species
Neisseria species
Fusobacterium species
Prevotella species
Porphyromonas species
CAT BITES
Pasteurella species
Actinomyces species
Propionibacterium species
Bacteroides species
Fusobacterium species
Clostridium species
Wolinella species
Peptostreptococcus species
Staphylococcus species
Streptococcus species
HERBIVORE BITES
Actinobacillus lignieresii
Actinobacillus suis
Pasteurella multocida
Pasteurella caballi
SWINE BITES
Pasteurella aerogenes
Pasteurella multocida
Bacteroides species
Proteus species
Actinobacillus suis
Streptococcus species
Flavobacterium species
Mycoplasma species
RODENT BITES
Streptobacillus moniliformis
Spirillum minus (in Asia)
PRIMATE BITES
Bacteroides species
Fusobacterium species
Eikenella corrodens
Streptococcus species
Enterococcus species
Staphylococcus species
Enterobacterales
Herpes B virus
LARGE REPTILE (CROCODILE, ALLIGATOR) BITES
Aeromonas hydrophila
Pseudomonas pseudomallei (in Asia)
Pseudomonas aeruginosa
Proteus species
Enterococcus species
Clostridium species

Adapted from Perkins Garth A, Harris NS, Spanierman CS. Animal bites in emergency medicine. Available at: http://emedicine.medscape.com/article/768875-overview, updated October 7, 2021; accessed November 27, 2021. Reprinted with permission from eMedicine.com.

Table 765.2 Initial Management of Bite Wounds

HISTORY
Animal bite: Ascertain the type of animal, whether the bite was provoked or unprovoked, and the situation/environment in which the bite occurred. Follow rabies guidelines (see Chapter 320) for details on management of bites that carry a risk of rabies.
Patient: Obtain information on antimicrobial allergies, current medications, splenectomy, liver disease, or immunosuppressive conditions.
PHYSICAL EXAMINATION
If possible, photograph the wound and record its location, type, and approximate depth; range of motion; possibility of joint penetration; presence of edema or crush injury; nerve and tendon function; and signs of infection.
CULTURE
Aerobic and anaerobic cultures should be taken from infected wounds (not from fresh wounds).
IRRIGATION AND DEBRIDEMENT
Irrigate with water or sterile saline and debride devitalized or necrotic tissue.
RADIOGRAPHS
Plain radiographs should be obtained if bony penetration is possible or suspected; radiographs can also provide a baseline for future evaluation of osteomyelitis.
WOUND CLOSURE
Primary wound closure is usually not advocated unless wounds are extensive and closure is necessary for cosmetic or functional reasons, especially large facial or neck wounds or those overlying the joints. When possible, delayed primary closure or allowing the wound to close by secondary intention is recommended.
ANTIMICROBIAL THERAPY
Early presenting (uninfected) wounds: provide prophylactic antimicrobials for (1) moderate-to-severe injuries, especially if preexisting edema or significant crush injury is present; (2) bone or joint space penetration; (3) deep hand wounds; (4) immunocompromised patients; (5) wounds adjacent to prosthetic material; and (6) wounds in close proximity to the genital area. In most cases, coverage should include *Pasteurella* (*Eikenella* in human bites), *Staphylococcus, Streptococcus,* and anaerobes including *Fusobacterium, Porphyromonas, Prevotella,* and *Bacteroides* spp. See Table 765.3 for recommended antibiotics.
Infected wounds: See Table 765.3 for oral antibiotic recommendations. In cases where intravenous antibiotics are deemed necessary, antimicrobial choices include ampicillin/sulbactam, piperacillin-tazobactam, cefoxitin, or ertapenem.
HOSPITALIZATION
Indications include signs and symptoms of systemic toxicity and worsening infection.
IMMUNIZATIONS
Provide tetanus and rabies immunization, if indicated.
ELEVATION
Elevation may be required if edema is present. Lack of elevation is a common cause of therapeutic failure.
IMMOBILIZATION
For significant injuries, immobilize the extremity, especially the hands, with a splint.
FOLLOW-UP
Patients should be reminded to follow up within 48 hours or sooner for worsening or unresolved infections and continued pain.
REPORTING
Reporting the incident to a local health department may be required.

Adapted from Goldstein EJC, Abrahamian FM. Bites. In: Bennett JE, Dolin R, Blaser MJ, eds. *Mandell, Douglas, and Bennett's Principles and Practice of Infectious Diseases*, 9th ed. Philadelphia: Elsevier; 2020: Table 315-3.

Table 765.3 Recommended Empirical Oral Antibiotics for Bite Wound Prophylaxis and Treatment

ANTIBIOTIC	RECOMMENDED ADULT DOSE	RECOMMENDED CHILD DOSE*
AGENT OF CHOICE		
(A) Amoxicillin-clavulanate	875/125 mg twice daily	45 mg/kg per dose (amoxicillin component) twice daily
ALTERNATE COMBINATION THERAPY: B OR C (WITH ANAEROBIC ACTIVITY) PLUS E, F, G, H, OR I		
(B) Metronidazole	500 mg three times daily	10 mg/kg per dose three times daily
Or:		
(C) Clindamycin	450 mg three times daily	10 mg/kg per dose three times daily
PLUS, ONE OF THE FOLLOWING:		
(D) Doxycycline	100 mg twice daily	Not for use in children <8 yr old
(E) Trimethoprim-sulfamethoxazole	160/800 mg (1 DS tab) twice daily	4 to 5 mg/kg (trimethoprim component) per dose* twice daily
(F) Penicillin V potassium	500 mg four times daily	12.5 mg/kg per dose four times daily
(G) Cefuroxime	500 mg twice daily	10 mg/kg per dose twice daily
(H) Moxifloxacin	400 mg once daily	Use with caution in children

*Child dose should not exceed recommended adult dose.
From Phillips LL, Semple J: Bites and injuries inflicted by wild and domestic animals. In Auerbach PS, Cushing TA, Harris NS (editors): *Auerbach's Wilderness Medicine*, 7th ed, vol 1. Philadelphia: Elsevier, 2017; Table 30.3, p. 623.

gently irrigated with a catheter or blunt-tipped needle; blind, high-pressure irrigation should not be employed. Avulsed or devitalized tissue should be debrided and any fluctuant areas incised and drained.

Surgical approaches to management of bite wounds may include primary closure, delayed primary closure (i.e., in 3-5 days), or healing by secondary intention. Factors to be considered are the type, size, and depth of the wound; the anatomic location; the presence of infection; the time since the injury; and the potential for cosmetic disfigurement. Appropriate surgical consultation (e.g., general pediatric surgery; plastic, hand, or orthopedic surgery) should be obtained promptly for all patients with deep or extensive wounds; wounds involving the hands, face, or bones and joints; and infected wounds that require open drainage. Although there is general agreement that visibly infected wounds and those that are more than 24 hours old should not be sutured, there is a spectrum of practice regarding the closing of wounds <8 hours old with no evidence of infection. Because all bite wounds to the hand are at high risk for infection, particularly if there has been disruption of the tendons or penetration of the bones, surgical consultation is almost always indicated, and delayed primary closure is recommended for many bite wounds of the hands. Facial lacerations are at lower risk for secondary infection because of the excellent blood supply to this region. Given this fact and cosmetic considerations, many plastic surgeons advocate primary closure of facial bite wounds that have been brought to medical attention within 8 hours.

Similarly, there are few comparative trials addressing the efficacy and selection of antimicrobial agents for **prophylaxis** of bite injuries. The bacteriology of bite wound infections is more often a reflection of the oral flora of the biting animal than the skin flora of the victim (see Table 765.1). Because many aerobic and anaerobic bacterial species colonizing the oral cavity of the biting animal have the potential to invade local tissue, multiply, and cause tissue destruction, most bite wound infections are polymicrobial.

Despite substantial homology in the oral bacterial flora of humans, dogs, and cats, important differences exist among the biting species, reflected in the types of wound infections that occur. The predominant bacterial species isolated from infected dog bite wounds are *Staphylococcus aureus* (20–30%), *Pasteurella multocida* (20–30%), *Staphylococcus intermedius* (25%), and *C. canimorsus;* approximately one-half of dog bite wound infections also contain mixed anaerobes. Similar species are isolated from infected cat bite wounds; however, *P. multocida* is the predominant species in at least 50% of cat bite wound infections. At least 50% of rats harbor *S. moniliformis* in the oropharynx, and approximately 25% in Asia harbor *S. minus,* a small, uncultivatable gram-negative organism. In infected human bite wounds, nontypable strains of *Haemophilus influenzae, Eikenella corrodens, S. aureus,* α-hemolytic streptococci, and β-lactamase–producing aerobes (~50%) are the predominant species. Clenched-fist injuries are particularly prone to infection by *Eikenella* spp. (25%) and other anaerobes (50%).

The choice between oral and parenteral antimicrobial therapy should be based on the severity of the wound, the presence and degree of overt infection, signs of systemic toxicity, and the patient's immune status. **Amoxicillin-clavulanate is an excellent choice for empiric oral therapy** for human and animal bite wounds because of its activity against most bacteria that are isolated from infected bites (Table 765.3). Similarly, **ampicillin-sulbactam or piperacillin-tazobactam is preferred for patients who will receive empiric parenteral therapy**. Penicillin G is the drug of choice for prophylaxis and treatment of rat bite injuries, as this agent has excellent activity against *S. moniliformis* and *S. minus*. Because first-generation cephalosporins have limited activity against *P. multocida* and *E. corrodens,* they should not be used for prophylaxis or empiric therapy of bite wound infections. Therapeutic alternatives for bite wound infections in penicillin-allergic patients are limited; clindamycin plus trimethoprim-sulfamethoxazole is the most commonly suggested regimen for these patients. Tetracycline is the drug of choice for penicillin-allergic patients who have sustained rat bite injuries.

Although **tetanus** occurs only rarely after human or animal bite injuries, it is important to obtain a detailed immunization history and to provide tetanus toxoid to all patients who are incompletely immunized or who received their most recent tetanus immunization more than five years prior. The need for postexposure **rabies** vaccination in victims of dog and cat bites depends on whether the biting animal is known to have been vaccinated and, most importantly, on local experience with rabid animals in the community. Bites from bats, foxes, skunks, and raccoons should be considered

high risk for rabies, and postexposure prophylaxis is uniformly indicated. For dogs, cats, and other animals that are known or captured, observation for 7-10 days by the local animal control department is indicated, and rabies prophylaxis can be delayed as long as the animal remains asymptomatic. If a biting dog or cat has escaped, a decision about rabies prophylaxis can be based on the circumstances surrounding the bite and advice from local infectious disease specialists and/or health department officials. Worldwide, animal bites and contacts result annually in more than 10 million courses of rabies postexposure prophylaxis.

In human bites where the biter's blood may have contaminated the wound, risk for hepatitis B, hepatitis C, and HIV infections should be considered (see Chapters 322 and 406).

PREVENTION

It is possible to reduce the risk of animal bite injury with anticipatory guidance. Parents should be routinely counseled during prenatal visits and routine health maintenance examinations about the risks of having potentially biting pets in the household. All patients should be cautioned against harboring exotic animals as pets. All young children should be closely supervised, particularly when in the presence of animals, and from a very early age should be taught to respect animals and to be aware of their potential to inflict injury. Reduction of the rate of human bite injuries, particularly in daycare centers and schools, can be achieved by good surveillance of the children and adequate teacher-to-child ratios.

Visit Elsevier eBooks+ at eBooks.Health.Elsevier.com for Bibliography.

Chapter 766

Rat Bite Fever

David A. Hunstad

ETIOLOGY

Rat bite fever is a generic term that has been applied to at least two distinct clinical syndromes, each caused by a different microbial agent. Rat bite fever caused by *Streptobacillus moniliformis* is most commonly reported in the United States as well as in Brazil, Canada, Mexico, Paraguay, Great Britain, and France; it has been identified elsewhere in Europe and in Australia. *S. moniliformis* is a gram-negative bacillus that is present in the nasopharyngeal flora of many laboratory and wild rats. Infection with *S. moniliformis* most commonly occurs following the bite of a rat; however, infection has also been reported in individuals who have been scratched by rats, in those who have handled dead rats, and in those who have ingested milk contaminated with the bacterium (termed **Haverhill fever**). Rat bite fever may also be transmitted by bites from wild mice. Rat bite fever caused by *Spirillum minus,* called **sodoku** (after the Japanese for "rat" and "poison"), is most commonly reported in Asia. *S. minus* is a small, spiral, aerobic gram-negative organism. Reports of rat bite fever from Africa are rare, suggesting under recognition rather than absence of the disease.

CLINICAL COURSE

The incubation period for the streptobacillary form of rat bite fever is variable, ranging from 3-10 days. The illness is characterized by an *abrupt* onset of fever up to 41°C (105.8°F) in over 90% of reported cases, as well as severe throbbing headache, intense myalgias, chills, and vomiting. In virtually all instances, the lesion at the cutaneous inoculation site has healed by the time that systemic systems first appear. Shortly after the onset of the fever, a polymorphous rash occurs in up to 75% of patients. In most patients, the rash consists of blotchy red maculopapular lesions that often have a petechial component; the distribution of the rash is variable, but it is typically most dense on the extremities (Fig. 766.1). Hemorrhagic vesicles may develop on the hands and feet and are very tender to palpation (Fig. 766.2).

Fig. 766.1 Morbilliform rash on the hands/palms (**A**) and feet (**B**) of a patient with rat bite fever. *(From Vetter NM, Feder HM Jr, Ratzan RM. Rat bite fever caused by a kiss. Am J Emer Med. 2015;34:1190.e3–1190.e4. Figs. 1 and 3.)*

Fig. 766.2 Hemorrhagic vesicles on the first and third toes of a patient with advanced rat bite fever. *(From Elliott SP. Rat bite fever and Streptobacillus moniliformis. Clin Microbiol Rev. 22007;20:13–22. Fig. 3.)*

Approximately 50% of patients have arthritis, which first manifests toward the end of the first week of disease; early on, the arthritis may be migratory. If untreated, fever, rash, and arthritis last from 14-21 days, often with a biphasic pattern to the fever and arthritis. A wide range of complications are reported in patients with rat bite fever, the most common being pneumonia, persistent arthritis, brain and soft tissue abscesses, and, less commonly, myocarditis or endocarditis. The mortality rate in untreated rat bite fever is estimated to be 10–15%.

The incubation period of sodoku is longer (14-21 days) than that of the streptobacillary form of disease. The hallmark of *Spirillum*-induced disease is fever associated with an indurated, often suppurative, nonhealing lesion at the bite site. Lymphadenitis and lymphadenopathy are invariably present in the regional nodes that drain the inoculation site, and many patients have a generalized macular rash most prominent

when fever is present. In untreated patients, sodoku has a relapsing and remitting course; symptoms abate after 5-7 days of chills and fever but recur 7-10 days later. There may be multiple cycles if the disease is not recognized and treated.

DIAGNOSIS

Diagnosis of the streptobacillary form of rat bite fever is difficult because the disease is uncommon and can be confused with Rocky Mountain spotted fever or (less commonly) meningococcemia. Furthermore, *S. moniliformis* is difficult both to isolate and to identify with classic bacteriologic techniques. The organism is fastidious and is inhibited by sodium polyanethol sulfonate, an additive present in many commercial blood culture bottles. Therefore the clinical microbiology laboratory should be notified when this infection is suspected so that additional media can be inoculated. A definitive diagnosis is made when *S. moniliformis* is recovered from blood or joint fluid or is identified in human samples by polymerase chain reaction (PCR), which has been used successfully in humans.

Diagnosis of sodoku is made on clinical grounds because there are no diagnostic serologic tests and culture of *S. minus* has not been achieved in laboratory media. Rarely, the organism may be visualized in Gram-stained smears of pus from the inoculation site. Approximately 50% of patients exhibit a false-positive Venereal Disease Research Laboratory (VDRL) test.

TREATMENT

Penicillin is the drug of choice for both forms of rat bite fever. Intravenous penicillin G or intramuscular penicillin G procaine is recommended for 7-10 days; a regimen of IV penicillin G for 5-7 days followed by oral penicillin V for an additional 7 days has also been used. Doxycycline, gentamicin, or streptomycin represent effective alternatives for penicillin-allergic patients. Patients with endocarditis caused by *S. moniliformis* require high-dose penicillin G for 4 weeks; the addition of streptomycin or gentamicin might be helpful.

Visit Elsevier eBooks+ at eBooks.Health.Elsevier.com for Bibliography.

Chapter 767
Mpox (Monkeypox)

David A. Hunstad

Since the eradication of **smallpox** (variola), mpox (formerly known as monkeypox) virus has, for humans, become the most important member of the genus ***Orthopoxvirus***. Monkeys are the predominant host for the virus; however, it may be endemic in African rainforest squirrels and is present in African rats, mice, domestic pigs, hedgehogs, and opossums. It has also been identified in and transmitted by imported prairie dogs in the United States and has affected elephants in zoos. Severity of infection varies by viral strain and by host; for example, disease is relatively mild in cynomolgus monkeys but severe in orangutans.

Mpox was first observed in humans from West and Central Africa in the 1970s at the time that smallpox had been eradicated from the area. In the 1970s, the secondary attack rate was around 3% (a stark comparison to the 80% seen in unvaccinated smallpox contacts). Few cases were observed over the next 2 decades; however, during a subsequent outbreak in the 1990s, when immunity to smallpox was no longer prevalent in the population, the secondary attack rate exceeded 75%. Mpox was introduced into the United States in 2003, presumably through rodents from Ghana that infected prairie dogs that were subsequently distributed as pets. Before 2022, primary transmission of the disease was from infected animal to human by bite or by human contact with an infected animal's blood, wound discharge, or other body fluids. Human-to-human transmission was previously thought to be uncommon, but a global outbreak in 2022 was linked to a shift to human-to-human transmission.

As of early 2023, nearly 87,000 cases were documented globally. Although children have comprised up to 40% of cases in previous outbreaks, the epidemiology of the current outbreak is different; less than 700 cases (<2%) have been reported in children and adolescents ≤20 years old. Mpox is currently spread predominantly through close human-to-human contact. The most recent outbreak has affected mostly gay, bisexual, and other men who have sex with men. Patients living with advanced HIV (with low CD4 counts) are at increased risk for severe disease. Although children typically acquire mpox from household contact, sexual contact is the primary route of transmission for adolescents. Mpox virus can persist on surfaces in households with an affected person.

CLINICAL COURSE

The classic clinical signs, symptoms, and course of mpox are similar to those of smallpox, although typically milder. After an incubation period of 10-14 days, during which the mpox virus replicates in lymphoid tissues, humans experience an abrupt onset of malaise, fever, myalgia, headache, and severe backache. Nonproductive cough, nausea, vomiting, and abdominal pain may be present. Generalized lymphadenopathy, a finding unusual in smallpox, is invariably present during the acute stages of mpox illness. After a prodrome of 2-4 days, an exanthem appears on the face and progresses inferiorly, including the palms and soles. As the rash spreads, fevers begin to abate. The rash is initially macular but transforms within hours to firm papules that rapidly vesiculate and become pustular over 2-3 days (Table 767.1). Unlike smallpox lesions but similar to chickenpox lesions, the lesions of mpox tend to occur in crops (Fig. 767.1). Late into the second week of illness, the lesions begin to desiccate, crust, scab, and fall off. During the 2022 global outbreak, lesions often occurred in the genital and anorectal areas and in the mouth (Fig. 767.2); cutaneous lesions are

Table 767.1 Mpox: Lesion Progression Through the Scab Stage

STAGE	STAGE DURATION (DAYS)*	CHARACTERISTICS
Enanthem		Sometimes, lesions first form on the tongue and in the mouth.
Macules	1-2	Macular lesions appear.
Papules	1-2	Lesions typically progress from macular (flat) to papular (raised).
Vesicles	1-2	Lesions then typically become vesicular (raised and filled with clear fluid).
Pustules	5-7	Lesions then typically become pustular (filled with opaque fluid) – sharply raised, usually round, and firm to the touch (deep seated). Finally, lesions typically develop a depression in the center (umbilication). The pustules will remain for approximately 5-7 days before beginning to crust.
Scabs	7-14	By the end of the second week, pustules have crusted and scabbed over. Scabs will remain for about a week before beginning to fall off.

*This is a typical timeline, but timelines can vary.
From Centers for Disease Control and Prevention. Key Characteristics for identifying Mpox. https://www.cdc.gov/poxvirus/mpox/clinicians/clinical-recognition.html

Fig. 767.1 A, Legs and feet of an mpox (endemic) patient. B, Legs and feet of a smallpox patient at an analogous stage of rash (pustular). *(A, Courtesy Joseph M. Harvey, MD. B, Courtesy J. Nobel, Jr., MD, Centers for Disease Control and Prevention.)*

Fig. 767.2 Clinical presentation of mpox. A, Pustules in the genital and pubic region, in which the initial umbilication has progressed to necrotic crust with central depression. B, Three semiconfluent pustular lesions with a depressed center located on the left side of the tongue dorsum. C, Pearly acral vesicles embedded in the thick stratum corneum of the palmar skin, shotty on palpation. D, Scattered papules, pustules, and umbilicated pustules surrounded by an erythematous halo on the lateral aspect of the chest and left arm. E, Pustules circumferentially distributed on the anal margin and perianal skin. F, A pustular lesion with a crusted center on the semimucosa of the lower lip, close to the right oral commissure. G, Primary inoculation site with a large, crusted lesion on the right cheek. H, The right palatine tonsil is reddened and enlarged and has a fibrin-covered ulcer. I, The penile glans and foreskin have lesions of varying sizes and stages of evolution, with edema surrounding the larger ulcer. *(From Tarín-Vicente EJ, Alemany A, Agud-Dios M, et al. Clinical presentation and virological assessment of confirmed human monkeypox virus cases in Spain: a prospective observational cohort study. Lancet. 2022;400[10353]:661–669. Fig. 1; Photos A–C, E–G, I taken by Eloy José Tarín-Vicente, MD; Photos D, H by Maria Ubals, MD.)*

Fig. 767.3 Left eye in a patient with HIV-associated immunocompromise and ocular mpox, with conjunctivitis and conjunctival lesion earlier in the course of mpox illness (**A**), and with conjunctival ulcer and peripheral keratitis later in the course of mpox illness (**B**) — United States, August–September 2022. *(**A** courtesy Nathanael Adjei-Kyeremeh. **B** courtesy Dharmendra R. Patel; From Cash-Goldwasser S, Labuda SM, McCormick DW, et al. Ocular monkeypox – United States, July–September 2020. MMWR. 2022;71:1343–1347. Fig. 2.)*

less often disseminated with occasionally only a single lesion noted. Additionally, fever and other systemic symptoms may occur before the rash, *after* the rash, or *not at all*. Disseminated systemic or focal disease may include encephalitis, pharyngitis, myocarditis, arthritis, proctitis, lymphadenopathy, pneumonia, and ocular involvement (Fig. 767.3).

Mpox should be suspected in any child or adolescent who has the characteristic prodrome associated with a poxlike eruption and a history of close contact with someone who has been diagnosed with mpox, residence in Africa, or contact with prairie dogs or exotic mammals such as Gambian rats and rope squirrels. Diagnosis is by isolation of mpox viral DNA by polymerase chain reaction (PCR) from a skin lesion, including exudate or lesion crust. Oropharyngeal swabs may be considered in high-risk contacts of known or probable cases who have not yet developed a rash that can be swabbed (Table 767.2).

Cowpox, another *Orthopoxvirus*, often acquired from a pet rat, may produce similar cutaneous lesions. Regional lymphadenopathy and mild system features may also be present. Diagnosis is confirmed by a specific cowpox virus PCR.

PREVENTION AND TREATMENT

In 2019, the U.S. Food and Drug Administration (FDA) approved a new live-attenuated, replication-deficient vaccinia virus vaccine (branded Jynneos in the United States and Imvamune in the European Union [EU]; Bavarian Nordic) for use in patients ≥18 years old who are at risk for mpox acquisition. Despite evidence that preexposure administration of classical smallpox vaccine is 85% effective in preventing or attenuating mpox disease, the rarity of mpox infection does not warrant universal vaccination. However, following the recent 2022 outbreak, the U.S. Centers for Disease Control and Prevention recommends vaccinating high-risk patients (Table 767.3). This vaccine has a very low side effect profile and can be safely used in immunocompromised individuals, a significant advantage over classical (replication-competent) live smallpox vaccines.

For most immunocompetent patients with mild to moderate disease, supportive care is recommended. However, treatment should be considered for those with severe disease (hemorrhagic disease, large number of confluent lesions, necrotic lesions, severe lymphadenopathy that is necrotic or obstructing, involvement of multiple organ systems and comorbidities, or those who require hospitalization) or those with involvement of anatomic areas where scarring or stricture might cause serious sequelae (Fig. 767.4). In addition, treatment may be considered in patients at high risk for severe disease, including children less than 1 year old, immunocompromised or pregnant patients, or those with reduced skin integrity (e.g., eczema). Treatment options include tecovirimat, brincidofovir, cidofovir, or trifluridine ophthalmic solution; these medications were originally developed for treatment of other viral infections and

Table 767.2 Mpox Case Definitions

CLINICAL AND LABORATORY CLASSIFICATION	CRITERIA
Suspected	New characteristic rash* **OR** Meets one of the epidemiologic criteria and has high clinical suspicion† for mpox
Probable	No suspicion of other recent *Orthopoxvirus* exposure (e.g., vaccinia virus in ACAM2000 vaccination) AND demonstration of the presence of • *Orthopoxvirus* DNA by polymerase chain reaction testing of a clinical specimen **OR** • *Orthopoxvirus* using immunohistochemical or electron microscopy testing methods **OR** • Demonstration of detectable levels of anti-*Orthopoxvirus* IgM antibody during the period of 4-56 days after rash onset
Confirmed	Demonstration of the presence of mpox virus DNA by polymerase chain reaction testing or next-generation sequencing of a clinical specimen **OR** Isolation of mpox virus in culture from a clinical specimen
EPIDEMIOLOGIC CLASSIFICATION	
Within 21 days of illness onset:	Reports having contact with a person or persons with a similar appearing rash or with a person who has received a diagnosis of confirmed or probable mpox **OR** Had close or intimate in-person contact with persons in a social network experiencing mpox infections. This includes MSM who meet partners through an online website, digital application ("app"), or social event (e.g., a bar or party) **OR** Traveled, within 21 days of illness onset outside the United States to a country with confirmed cases of mpox or where mpox virus is endemic **OR** Had contact with a dead or live wild animal or exotic pet that is an African endemic species, or used a product derived from such animals (e.g., game meat, creams, lotions, powders, etc.)
EXCLUSIONS	
A case might be excluded as a suspected, probable or confirmed case if:	An alternative diagnosis* can fully explain the illness **OR** A person with symptoms consistent with mpox does not develop a rash within 5 days of illness onset **OR** A case where high-quality specimens do not demonstrate the presence of *Orthopoxvirus* or mpox virus or antibodies to *Orthopoxvirus*

*The characteristic rash associated with mpox lesions involves the following: deep-seated and well-circumscribed lesions, often with central umbilication; and lesion progression through specific sequential stages: macules, papules, vesicles, pustules, and scabs. The rash can sometimes be confused with other diseases that are more commonly encountered in clinical practice (e.g., syphilis, herpes, and varicella-zoster). Historically, sporadic accounts of patients co-infected with mpox virus and other infectious agents (e.g., varicella-zoster, syphilis) have been reported; so patients with a characteristic rash should be considered for *Mpox virus* testing, even if tests for other infectious agents are positive.

†Clinical suspicion may exist if lesions consistent with those from more common infections (e.g., syphilis, herpes, and varicella-zoster) coexist with lesions that may be characteristic of mpox.

From Centers for Disease Control and Prevention. Updated case-finding guidance: Mpox outbreak – United States, 2022. https://emergency.cdc.gov/han/2022/han00468.asp#:~text

Table 767.3 Mpox Vaccination Basics

Centers for Disease Control and Prevention recommends vaccination against mpox if:

- You had known or suspected exposure to someone with mpox
- You had a sex partner in the past 2 weeks who was diagnosed with mpox
- You are a gay, bisexual, or other man who has sex with men or a transgender, nonbinary, or gender-diverse person who in the past 6 months has had any of the following:
  - A new diagnosis of one or more sexually transmitted diseases (e.g., chlamydia, gonorrhea, or syphilis)
  - More than one sex partner
- You have had any of the following in the past 6 months:
  - Sex at a commercial sex venue (like a sex club or bathhouse)
  - Sex related to a large commercial event or in a geographic area (city or county for example) where mpox virus transmission is occurring
  - Sex in exchange for money or other items
- You have a sex partner with any of the above risks
- You anticipate experiencing any of the above scenarios
- You have HIV or other causes of immune suppression and have had recent or anticipate future risk of mpox exposure from any of the above scenarios
- You work in settings where you may be exposed to mpox:
  - You work with orthopoxviruses in a laboratory
  - You are part of an *Orthopoxvirus* and healthcare worker response team

From Centers for Disease Control and Prevention. Mpox Vaccination Basics. https://www.cdc.gov/poxvirus/mpox/vaccines/index.html

are thought to complement the immune response by reducing replication, maturation, and spread of mpox. Vaccinia immune globulin intravenous (VIGIV) may be considered in immunocompromised patients who cannot mount an appropriate immune response to clear the virus. In addition to antiviral medications, careful attention should be paid to skin hygiene, maintenance of adequate nutrition and hydration, and prompt implementation of local or systemic therapy for secondary bacterial infection that may occur. Pain management is a common reason for hospitalization because both cutaneous and mucosal lesions can be very painful. For prevention of human-to-human spread of disease, a combination of contact, droplet, and airborne infection control procedures should be implemented.

Visit Elsevier eBooks+ at eBooks.Health.Elsevier.com for Bibliography.

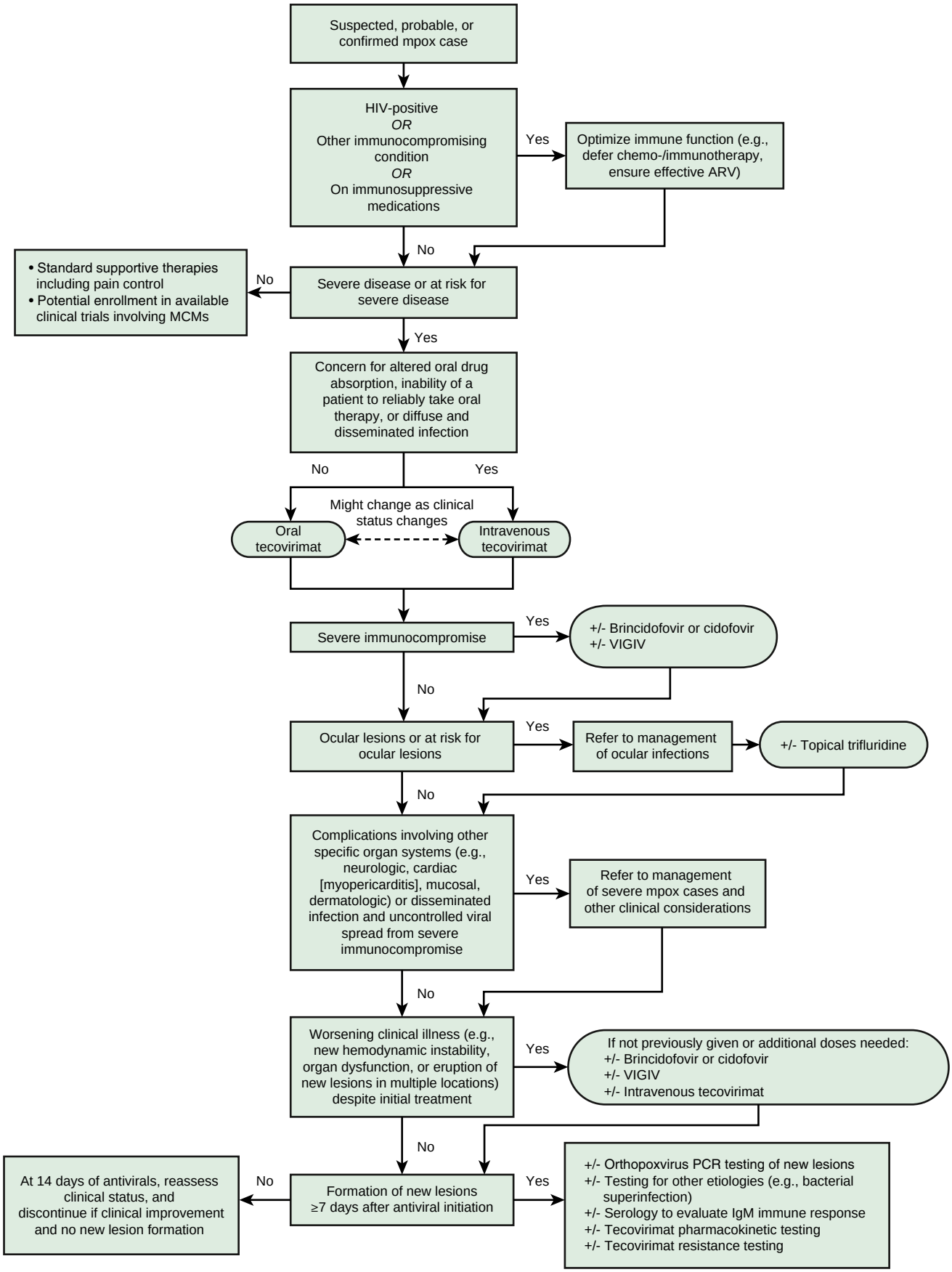
Suspected, probable, or confirmed mpox case
HIV-positive
OR
Other immunocompromising condition
OR
On immunosuppressive medications
Yes
Optimize immune function (e.g., defer chemo-/immunotherapy, ensure effective ARV)
No
Severe disease or at risk for severe disease
No
• Standard supportive therapies including pain control
• Potential enrollment in available clinical trials involving MCMs
Yes
Concern for altered oral drug absorption, inability of a patient to reliably take oral therapy, or diffuse and disseminated infection
No
Yes
Might change as clinical status changes
Oral tecovirimat
Intravenous tecovirimat
Severe immunocompromise
Yes
+/- Brincidofovir or cidofovir
+/- VIGIV
No
Ocular lesions or at risk for ocular lesions
Yes
Refer to management of ocular infections
+/- Topical trifluridine
No
Complications involving other specific organ systems (e.g., neurologic, cardiac [myopericarditis], mucosal, dermatologic) or disseminated infection and uncontrolled viral spread from severe immunocompromise
Yes
Refer to management of severe mpox cases and other clinical considerations
No
Worsening clinical illness (e.g., new hemodynamic instability, organ dysfunction, or eruption of new lesions in multiple locations) despite initial treatment
Yes
If not previously given or additional doses needed:
+/- Brincidofovir or cidofovir
+/- VIGIV
+/- Intravenous tecovirimat
No
Formation of new lesions ≥7 days after antiviral initiation
No
At 14 days of antivirals, reassess clinical status, and discontinue if clinical improvement and no new lesion formation
Yes
+/- Orthopoxvirus PCR testing of new lesions
+/- Testing for other etiologies (e.g., bacterial superinfection)
+/- Serology to evaluate IgM immune response
+/- Tecovirimat pharmacokinetic testing
+/- Tecovirimat resistance testing

Fig. 767.4 Algorithmic approach to treatment*,†,‡ of patients with severe§ or at risk¶ for severe manifestations of mpox** : United States, February 2023.††

* Treatment includes MCMs (i.e., tecovirimat, brincidofovir, cidofovir, VIGIV, and trifluridine) and supportive therapies, including pain management. https://www.cdc.gov/poxvirus/monkeypox/clinicians/pain-management.html

† Most immunocompetent patients should display signs of clinical improvement within 4 days of antiviral initiation (i.e., tecovirimat, brincidofovir, cidofovir, and trifluridine). Tecovirimat is expected to reach steady-state concentrations by day 6 of dosing in healthy volunteers; therefore worsening clinical illness after 7 days of treatment in patients with severe illness could prompt additional evaluations.

‡ Concern for altered drug absorption includes the inability to tolerate or take oral therapy (e.g., nothing by mouth), or possibility that the oral drug absorption might be altered because of inability to consume a high-fat meal, severity of symptoms (e.g., systemic illness), comorbidities (e.g., history of gastric bypass or underlying GI disease), or other factors that might alter oral drug absorption.

§ Hemorrhagic disease, a large number of confluent or necrotic lesions, severe lymphadenopathy that is necrotizing or obstructing (e.g., of the upper airway causing airway compromise or of the GI tract necessitating parenteral feeding), edema that is obstructing (e.g., of the lower GI tract), extradermatologic manifestations (e.g., pulmonary nodules, encephalitis, myopericarditis, or ocular infections), and sepsis. Detailed characteristics of severe disease are available at https://www.cdc.gov/poxvirus/monkeypox/clinicians/treatment.html#anchor_1655488137245.

¶ Persons with underlying medical conditions (e.g., severe or moderate immunocompromise [https://www.cdc.gov/poxvirus/monkeypox/clinicians/people-with-HIV.html]); bacterial superinfections; or complications, including strictures, edema, and infections of the penile foreskin, vulva, urethral meatus, or anorectum, which could require procedural intervention (e.g., urethral catheterization, colostomy, or surgical debridement). This also includes those with or at risk for ocular lesions (i.e., presence of eyelid lesions, facial lesions near the eyes, or finger or hand lesions in patients unable to avoid touching their eyes [for whom autoinoculation is a concern]). Detailed characteristics of persons at risk for severe disease are available at https://www.cdc.gov/poxvirus/monkeypox/clinicians/treatment.html#anchor_1655488137245.

** https://www.cdc.gov/poxvirus/monkeypox/clinicians/case-definition.html

†† This figure is a comprehensive synthesis of heterogeneous evidence and is intended to foster strategic decision-making rather than serve as a prescriptive treatment guideline.

ARV, Antiretroviral medications; GI, gastrointestinal; IgM, immunoglobulin M; MCM, medical countermeasure; PCR, polymerase chain reaction; VIGIV, vaccinia immune globulin intravenous. *(From Rao AK, Schrodt CA, Minhaj FS, et al. Interim clinical treatment considerations of severe manifestations of Mpox – United States, February 2023. MMWR. 2023;72:232–243.)*

Chapter 768

Envenomations

Sing-Yi Feng

Envenomations due to snakes, spiders, scorpions, and other venomous animals can cause significant morbidity and mortality, although the majority cause only localized pain and swelling. In the 2020 report of the American Association of Poison Control Centers, approximately 42,800 out of 2.1 million phone consultations were related to bites and stings of various creatures, with approximately 14,000 involving children <20 years of age.

Not every bite from a venomous creature is harmful. In many cases, no venom is injected; these are called **dry bites**. A dry bite may occur for many reasons, including failure of the venom delivery mechanism and depletion of venom. Up to 20% of pit viper, 80% of coral snake, and approximately 50% of all venomous snake bites are dry.

GENERAL APPROACH TO THE ENVENOMATED CHILD

Children may be bitten or stung as they play and explore their environment. The evaluation may be hampered by an unclear history of the circumstances and the possible offending organism, particularly with preverbal children. The overall effects of some venomous bites and stings may be relatively more severe in children than in adults because children generally receive a similar venom load from the offending animal yet have less circulating blood volume to dilute its effects.

General Management

The majority of envenomations require local wound care, pain control, and reassurance. However, the severely envenomated child may require advanced life support interventions including endotracheal intubation and mechanical ventilation. Intravenous access should be obtained in an unaffected extremity if possible (see Chapters 91 and 92) to provide fluids and vasopressors as needed. Early hypotension is usually due to vasodilation and should be treated with volume expansion using appropriate infusion of intravenous crystalloid solution (normal saline boluses of 20 mL/kg; repeated as needed up to three times). Shock unresponsive to volume repletion may require addition of a vasopressive agent such as epinephrine or norepinephrine (in addition to antivenom administration if appropriate). If the presentation is suspicious for an anaphylactic reaction to venom, treatment (including epinephrine) should be initiated as soon as possible (see Chapter 190) along with the appropriate **antivenom**.

The affected body part should be immobilized in a position of function and any areas of edema should be marked, measured, and monitored. If antivenom is available for the envenomation, efforts should be initiated to locate and secure an adequate amount to treat the patient. In the United States, regional poison control centers are available via the national phone number 1-800-222-1222 to facilitate this effort, especially if the species is exotic. Guidance in dosing the antivenom should be obtained from experienced toxicologists via the regional poison center.

General Wound Care

Bites and stings require basic wound care, including copious tap water or normal saline irrigation under pressure when possible. For small puncture wounds, this is impractical, but the skin should still be thoroughly cleansed with soap and water. Tetanus immunization should be updated as needed. Intact bullae should be left to act as a natural sterile dressing to prevent infection, whereas ruptured bullae should be debrided. Exposed tissue should be covered with wet to dry dressings. Necrotic wounds, as seen in some snake and spider bites, should be judiciously debrided, with removal of only clearly necrotic tissue. Reconstructive surgery with skin grafts or muscle/tendon grafts may be necessary later. Prophylactic antibiotics are usually not necessary because venom is bacteriostatic. Antibiotics should generally be reserved for signs of established secondary infection.

SNAKE BITES

Most snake bites are inflicted by nonvenomous species and are of no more consequence than a potentially contaminated puncture wound. Anatomic features including head shape, pupil shape, and anal plate arrangement can be used to differentiate venomous and nonvenomous snakes (Fig. 768.1). Medically important venomous snakes in the United States belong to two families: **Crotalinae** and **Elapidae** (Table 768.1). Most snakebites occur

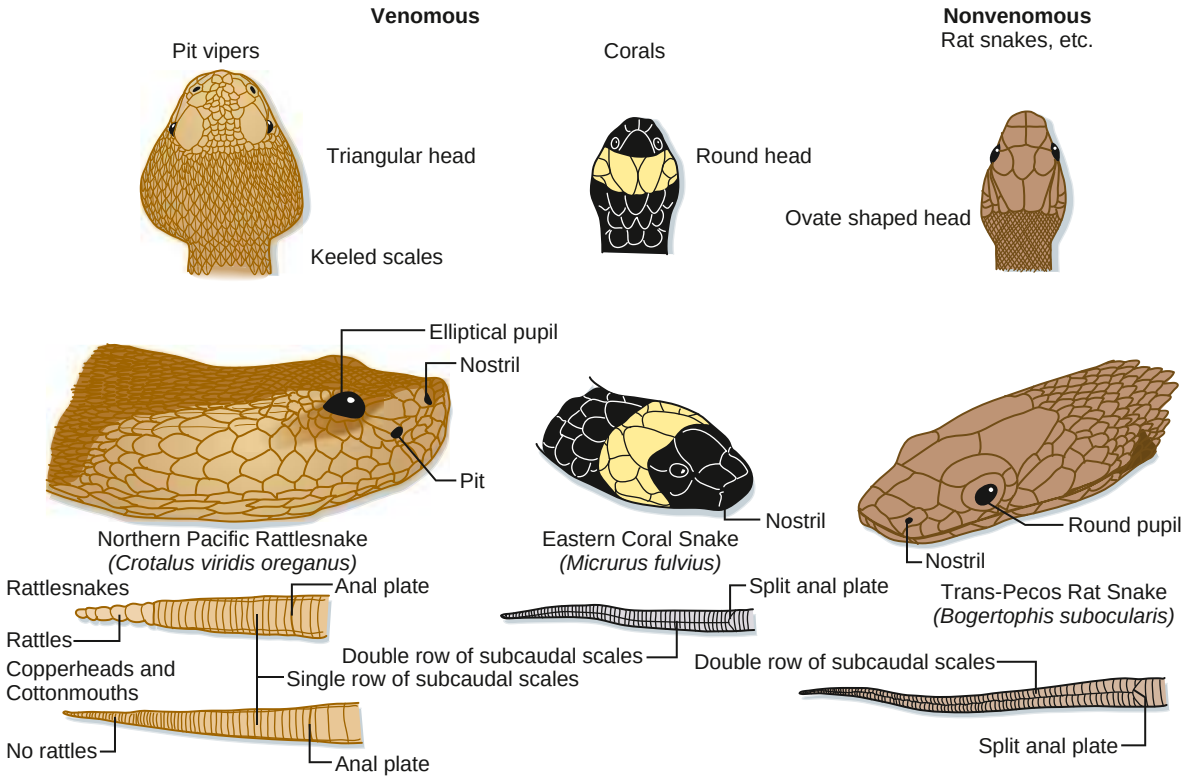

Fig. 768.1 Anatomic comparison of pit vipers, coral snakes, and nonvenomous snakes of the United States. *(Modified from Adams JG, ed. Emergency Medicine. Philadelphia: WB Saunders; 2008. Drawing by Marlin Sawyer.)*

Table 768.1 Important Venomous Snake Families in the United States

FAMILY	EXAMPLES	TOXIN EFFECTS/OTHER COMMENTS	ANTIVENOM
Crotalinae (pit vipers)	Rattlesnakes (*Crotalus* and *Sistrurus* spp.), cottonmouths and copperheads (*Agkistrodon* spp.)	Heat-sensing "pit" between each eye and nostril Toxins cause tissue damage, coagulopathy, cardiovascular collapse Exception: Mojave rattlesnake (*Crotalus scutulatus*) – neurotoxic venom	*Crotalinae* polyvalent immune Fab
Elapidae	Coral snakes (*Micrurus* spp.)	Venom is neurotoxic	Antivenin (*Micrurus fulvius*)

from April through September, when snakes are at their most active. Males sustain 75% of bites and children <5 years of age account for 10–15%. Bites are usually located on extremities, although other parts of the body have been reported. In the United States, approximately 98% of venomous snake bites are inflicted by pit vipers (Crotalinae). A small fraction of bites are caused by coral snakes (Elapidae) in the southern and southwestern states and by exotic pet snakes that have been imported.

Venoms and Effects

Snake venoms are complex mixtures of proteins including enzymes that cause local tissue destruction and other enzymes that have potentially lethal systemic effects including coagulopathy and neurotoxicity. The symptoms and severity of an envenomation vary according to the type of snake, the amount of venom injected, and the location of the bite. About 25% of snakebites are **"dry bites,"** where the patient has fang marks and puncture wounds but no pain, swelling, or systemic effects as no venom was injected. Most pit viper bites cause significant local pain, swelling, and ecchymosis and may result in necrosis of the affected extremity (Fig. 768.2). Pain and swelling typically begin quickly after the bite and may progress over hours to days. Serious envenomation may result in a consumptive coagulopathy, hypotension, and respiratory distress. In contrast, venom from the Elapidae is neurotoxic with little or no local tissue damage. These bites cause variable local pain, and the onset of systemic effects can be delayed for hours. Manifestations of neurotoxicity generally are caused by curare-like blockade at the neuromuscular junction. Symptoms usually begin with cranial nerve palsies such as ptosis, dysarthria, and dysphagia and may progress to respiratory failure and complete paralysis. Some pit vipers, including the Southern Pacific rattlesnake *(Crotalus oreganus helleri),* western diamondback rattlesnake *(Crotalus atrox),* timber rattlesnake *(Crotalus horridus),* and Mojave rattlesnake *(Crotalus scutulatus),* can also cause significant neurotoxicity, like the Elapidae. Regional poison control centers and toxicologists should be consulted early in the course of treatment.

Management

Prehospital care should focus on rapid transport to the emergency department while providing supportive care. Constrictive clothing, jewelry, and watches should be removed, and the injured body part should be immobilized in a position of function at the level of the heart. Many popularized field treatments for snake bites, such as

Fig. 768.2 Southern Pacific rattlesnake bite *(Crotalus oreganus helleri)* in a 2-yr-old child. Note the fang marks, swelling, and bruising of the tissues (photograph taken 2 hours following the bite). *(Courtesy Sean Bush, MD.)*

tourniquets, ice, electric shock, incision, and suction, have proven ineffective or deleterious.

At the hospital, supportive care should be continued as an effort is made to identify the offending snake and secure the appropriate antivenom (if applicable). In severe envenomations, advanced respiratory support may be required, including endotracheal intubation and mechanical ventilation. Intravenous access should be established in an unaffected extremity, intravenous fluids administered as needed, and standard laboratory specimens obtained, including complete blood count, coagulation studies, fibrinogen concentration, and serum chemistry analysis including total creatine kinase. Laboratory studies should initially be repeated every 4-6 hours to monitor the patient's progress and response to therapy. If tourniquets are placed in the field, they should be cautiously removed after venous access is obtained due to possible adverse effects that may follow from a sudden release of venom into the systemic circulation. The bitten extremity should be marked with the leading edge of the erythema and edema as well as the time to monitor progression of the swelling.

Assessment of the severity of the envenomation in the field and at the hospital is essential in determining the appropriateness of antivenom therapy for the snakebite victim (Table 768.2). Antivenoms are relatively specific for the genus of snake whose venom they are designed to neutralize. If it is determined that the patient requires antivenom, appropriating the correct antivenom should begin as soon as possible by discussing the matter with the hospital pharmacy, regional poison control center, and perhaps local zoos and museums that keep captive snakes because they often stock exotic snake antivenom.

Table 768.3 lists the indications for administering antivenom. CroFab, a Crotalinae polyvalent immune Fab antivenom (FabAV), is approved by the U.S. Food and Drug Administration (FDA) for use in crotalid envenomations. FabAV is derived from sheep (ovine) antibodies to crotalid snake venom, and side effects include both immediate and delayed hypersensitivity reactions. FabAV is derived from four snakes, three from the genus *Crotalus* (the eastern diamondback rattlesnake, the western diamondback rattlesnake, and the Mojave rattlesnake) and one from the genus *Agkistrodon* (the cottonmouth or water moccasin). It is effective against the venoms of all Crotalinae snakes in the United States. There is cross reactivity with FabAV against venom from copperhead snakes *(Agkistrodon contortrix)*. However, copperhead bites often do not require treatment with antivenom because they cause fewer systemic effects and less severe local tissue damage. Most copperhead envenomations cause only local tissue swelling, ecchymosis, and pain and generally do well with good supportive care and pain control. Any child with evidence of systemic toxicity should receive FabAV.

Initial dosing of FabAV is aimed at control of symptoms (progressive tissue swelling, thrombocytopenia, coagulopathy, neurotoxicity, or systemic toxicity). The dose is repeated until initial control of toxicity is achieved (see Table 768.3). Subsequent maintenance dosing may be needed to prevent or treat recurrence of venom effects because, due to its small molecular size, the half-life of FabAV is considerably shorter than that of crotalid venom constituents. Patients with significant envenomation should be followed for late hematologic abnormalities (coagulopathy) that can occur up to 2 weeks after the bite. Although these tend to be mild laboratory coagulopathies without clinical bleeding, rare cases of severe delayed bleeding have been reported. Further antivenom therapy should be considered for such delayed or recurrent coagulopathy as outlined in Table 768.4.

In April 2021, the U.S. FDA approved a crotaline immune Fab2 antivenin (Fab2AV) to treat adult and pediatric patients with North American Crotaline envenomations marketed as AnaVIP. This antidote is an equine-derived antivenin and, due to it being a Fab2 fragment, has a longer half-life than the FabAV. It has a similar side effect profile as the FabAV including anaphylactoid and hypersensitivity reactions. Initial dosing is 10 vials given intravenously over 60 minutes. If the symptoms continue to progress, then 10 vials can be given every hour until there is no further progression of symptoms. Patients should be observed for a minimum of 18 hours after the Fab2AV infusion. If a patient has reemerging symptoms including coagulopathies, then an additional four vials of the Fab2AV can be infused (Table 768.5).

Envenomation of the extremities can mimic compartment syndrome, with severe pain and swelling. It is important to treat these patients aggressively with FabAV or Fab2AV and pain control to control the severe pain and swelling. Although fasciotomy was once advocated for the treatment of crotalid snakebites of the extremities, it is now a treatment of last resort only if aggressive FabAV or Fab2AV treatment is unable to stop the progression of pain and swelling and true compartment syndrome is documented with measurement of intracompartmental pressure.

The antivenom for coral snakes *(Micrurus fulvius)* has been the recommended treatment for envenomation by the eastern coral snake *(M. fulvius)* and the Texas coral snake *(Micrurus tener)*. Indications for this antivenom are the development of any neurologic signs and symptoms of coral snake envenomation including paresthesias, slurred speech, respiratory difficulties, muscle weakness, and fasciculations. Due to it being equine in origin, its side effect profile includes anaphylaxis and allergic reactions. Most hospitals do not carry this antivenom and local poison centers should be notified to help locate supplies. Respiratory supportive care including endotracheal intubation and mechanical ventilation for respiratory failure remains the mainstay of treatment.

Disposition

If, after observation for 6-8 hours, a patient exhibits only fang-induced puncture marks with no local or systemic symptoms, the wounds can be considered dry bites and the patient can be safely discharged home. Patients with significant toxicity and those requiring treatment with antivenom should be admitted to the hospital. Patients with a history of eastern or Texas coral snakebite should be admitted to a monitored setting for 24 hours to observe for neurologic toxicity so that respiratory support can be provided as needed. Children should be admitted to an intensive care setting if they develop severe and progressive local tissue toxicity or evidence of systemic toxicity including coagulopathy, neurotoxicity, hemodynamic instability, or respiratory difficulties.

SPIDER BITES

In the United States, 18 genera of spiders have been identified that cause clinically significant envenomation. The spiders of importance in the United States include the *Latrodectus* species (the widow spiders) and the *Loxosceles* species (the recluse spiders).

Table 768.2 Pit Viper Envenomation Classification

GRADE	CLINICAL FEATURES	ANTIVENOM	DISPOSITION
0 (None)	No evidence of envenomation. A fang wound may be present. Pain is minimal, with less than 1 inch of surrounding edema and erythema. No systemic manifestations are present during the first 12 hr after the bite. No laboratory changes occur.	No	Observe for 8-12 hr. May be discharged if repeat labs are normal and no signs of envenomation develop.
I (Minimal)	Pain is moderate or throbbing and localized to the fang wound, surrounded by 1-5 inches of edema and erythema. No evidence of systemic involvement is present after 12 hr of observation. No laboratory changes occur.	No	Admission for 12-24 hr. Repeat labs every 6 hr. May be discharged if repeat labs are normal and no signs of envenomation develop.
II (Moderate)	There is more severe and widely distributed pain, edema spreading toward the trunk, and petechiae and ecchymoses limited to the area of edema. Nausea, vomiting, and a mild elevation in temperature are usually present.	Yes	Admission to intensive care unit.
III (Severe)	This may initially resemble a grade I or II; however, within 12 hr, edema spreads up the extremity and may involve part of the trunk. Petechiae and ecchymoses may be generalized. Systemic manifestations may include tachycardia and hypotension. Laboratory abnormalities may include an elevated white blood cell count, creatine phosphokinase, prothrombin time, and partial thromboplastin time, as well as elevated fibrin degradation products and D-dimer. Decreased platelets and fibrinogen are common. Hematuria, myoglobinuria, increased bleeding time, and renal or hepatic abnormalities may also occur.	Yes	Admission to intensive care unit.
IV (Very severe)	Sudden pain, rapidly progressive swelling that may reach and involve the trunk within a few hours, ecchymoses, bleb formation, and necrosis. Systemic manifestations, often commencing within 15 min of the bite, usually include weakness, nausea, vomiting, vertigo, and numbness or tingling of the lips or face. Muscle fasciculations, painful muscular cramping, pallor, sweating, cold and clammy skin, rapid and weak pulse, incontinence, convulsions, and coma may also be observed. An intravenous bite may result in cardiopulmonary arrest soon after the bite.	Yes	Admission to intensive care unit.

From Curtis AM, Erickson TB. Venomous animal injuries. Walls RM, ed. *Rosen's Emergency Medicine*, 10th ed. Philadelphia: Elsevier; 2023: Table 53.2, p. 696.

Table 768.3 Crotaline Fab Antivenom Dosing Guidelines

DOSE	RECOMMENDATIONS
Initial dose: four to six vials IV	• Reconstitute each vial of FabAV in 18 mL normal saline for injection and mix with continuous manual inversion at the rate of one to two inversions per second until no solid material is visible in the vial. • Further dilute four to six vials of reconstituted FabAV in 250 mL normal saline. • Infuse FabAV over 1 hr IV. • Start with slow infusion rate of 25-50 mL/hr for 10 min. • If no acute allergic reaction occurs, increase rate to 250 mL/hr to complete infusion. • The volume of the infusion may be decreased for the very small child or volume-sensitive patient. • Observe 1 hr after initial dose to assess for control of envenomation. • Repeat four to six vials of FabAV as needed to gain initial control.
Maintenance dose: two vials IV every 6 hr × 3 doses	• Monitor for delayed or recurrent toxicity requiring additional FabAV. • Antivenom dose requirements vary depending on the individual patient's response and clinical course. • Patients with mild envenomation may not require maintenance dosing beyond the initial dose.

Adapted from Goto CS, Feng SY. Crotalidae polyvalent immune Fab for the treatment of pediatric crotaline envenomations. *Ped Emerg Care*. 2009;25(4):273–279; and from Crofab Package Insert (revised 2018).

Table 768.4 Indications for Administration of Additional Antivenom in Patients with Recurrent Coagulopathy or Thrombocytopenia After Initial Control

- Evidence of clinically significant bleeding
- Platelet count below 25,000/mm^3
- International normalized ratio (INR) >3
- Activated partial thromboplastin time (aPTT) >50 seconds
- Fibrinogen <50 mg/dL
- Presence of multicomponent coagulopathy
- Worsening trend in a patient with prior severe coagulopathy
- High-risk behavior for trauma
- Certain comorbid conditions (e.g., systemic vasculitis, seizure disorders, prior stroke)

From Norris RL, Bush SP, Cardwell MD. Bites by venomous reptiles in Canada, the U.S. and Mexico. In: Auerbach PS, ed. *Wilderness Medicine*, 7th ed. Philadelphia: Elsevier; 2017.

Latrodectus Spiders

The *Latrodectus* species are found throughout the United States and include *L. mactans* (Fig. 768.3; **black widow** spider), *L. hesperus* (western black widow), *L. bishop* (red widow spider), *L. variolus,* and *L. geometricus* (brown widow spider). They are indigenous to every state except Alaska. The classic hourglass-shape marking is found only in *L. mactans*. They like to live close to the ground in secluded and dimly lit areas such as barns, sheds, and garages.

Venoms and Effects

Latrodectus spiders possess venoms that act at neuromuscular and autonomic nervous system synapses, resulting in excessive release of

Table 768.5	Crotaline Fab2 Antivenom Dosing Guidelines
Initial Dose: 10 vials (*no known maximum dose of Crotaline Fab2 antivenom)	• Reconstitute 10 vials for less than 1 min each using 10 mL sterile normal saline per vial • Combine all vials and dilute to a total volume of 250 mL sterile normal saline • Infuse at 25-50 mL/hr for 10 min; if tolerated at 250 mL/hr to completion
Evaluate for control	60 minutes after infusion, check for: • Local injury not progressing • Coagulation parameters improving • Systemic effects resolved
Observe	• Observe for at least 18 hr after initial control • If symptoms reemerge, can administer four vials in 250 mL

Adapted from AnaVIP package insert.

Fig. 768.3 Female black widow spider *(Latrodectus mactans).* Note the red hourglass-shaped marking on the underside of her abdomen. *(From The Centers for Disease Control and Prevention Public Health Image Library, Image #5449.)*

neurotransmitters. All of the widow spiders possess similar venoms, with the most important neurotoxin being α-latrotoxin.

Bites by the neurotoxic spiders tend to be very painful, and the offending spider is often seen. Systemic effects may include hypertension, tachycardia, bradycardia, hypersalivation, diaphoresis, and diffuse muscle spasm. Nausea, vomiting, abdominal pain, and abdominal rigidity may mimic appendicitis or another acute abdominal emergency.

Management

The management of a neurotoxic spider envenomation centers on sound supportive care. Generous doses of opioid analgesics and benzodiazepines should be utilized to ease severe pain and muscle spasm. *Latrodectus* antivenom (Wyeth) is equine-derived and may be considered to reverse severe systemic effects of widow spider envenomation. Although effective, it is associated with anaphylaxis, serum sickness, and anaphylactoid reactions and should be reserved for high-risk patients such as pregnant women at risk of spontaneous abortion due to the severe pain. One vial is administered via intravenous infusion. Efficacy is usually noted within 1 hour of administration, with reversal of systemic toxicity and relief of pain. Occasionally a second vial is necessary. Due to the possibility of severe or life-threatening reactions, the risks and benefits should be carefully considered and the antivenom infused slowly with continuous monitoring and preparation to treat anaphylaxis should it occur.

Fig. 768.4 Male recluse spider (*Loxosceles* spp.). Note the distinct violin-shaped marking on the dorsum of the cephalothorax. *(Courtesy Michael Cardwell/Extreme Wildlife Photography)*

Loxosceles Spiders

Venoms and Effects

The spiders most notorious for their dermonecrotic potential are the recluse spiders of the genus *Loxosceles*. The best-known member of this genus is the **brown recluse** (*Loxosceles reclusa*; Fig. 768.4), found in the midwestern and southern regions of the United States. The venom of *Loxosceles* spiders contains a phospholipase enzyme, sphingomyelinase D, as well as hyaluronidase. Hyaluronidase is the spreading factor that enables the venom to penetrate tissues, but it does not induce tissue damage. Sphingomyelinase D causes necrosis, red blood cell hemolysis, and platelet serotonin release. The bite of this spider is generally painless and initially goes unnoticed. A few hours after the bite, the area begins to blister and bleed and become painful. Within a day or two, the site will ulcerate and develop violaceous necrosis with surrounding ecchymosis and a rim of pale ischemia ("red, white, and blue" reaction). The lesion may gradually expand over a period of days to weeks until necrotic tissue sloughs and healing begins (Fig. 768.5).

Rare cases of systemic loxoscelism appear to be more common in young children. Patients present with systemic toxicity, including fever, chills, nausea, malaise, diffuse macular rash, and petechiae; they may experience hemolysis, coagulopathy, and renal failure.

In cases of necrotic dermal lesions with no identified spider as the culprit, a broad differential diagnosis must be considered to ensure appropriate management. The differential diagnosis includes skin infections (particularly methicillin-resistant *Staphylococcus aureus;* see Chapter 227), pyoderma gangrenosum, or ecthyma gangrenosum.

Management

The management of necrotizing spider bites includes good wound care, updating of tetanus status, and administration of antibiotics if there is secondary bacterial infection. Daily wound cleansing and splinting of the affected area should be provided until the wound has healed.

No therapy has been definitively proven effective in limiting the extent of necrosis after a recluse spider bite, including steroids, dapsone, colchicine, cyproheptadine, nitroglycerin, hyperbaric oxygen, and early excision of tissue. Meticulous wound care is the mainstay of treatment, and large lesions may require delayed secondary closure with skin grafting after clear tissue demarcation has occurred.

Patients with signs and symptoms of systemic loxoscelism should be admitted to the hospital for supportive treatment of hypovolemia, coagulopathy, hemolysis, and acute kidney injury. There is no commercially available antivenom in the United States for the management of necrotizing spider bites such as those from *Loxosceles* species.

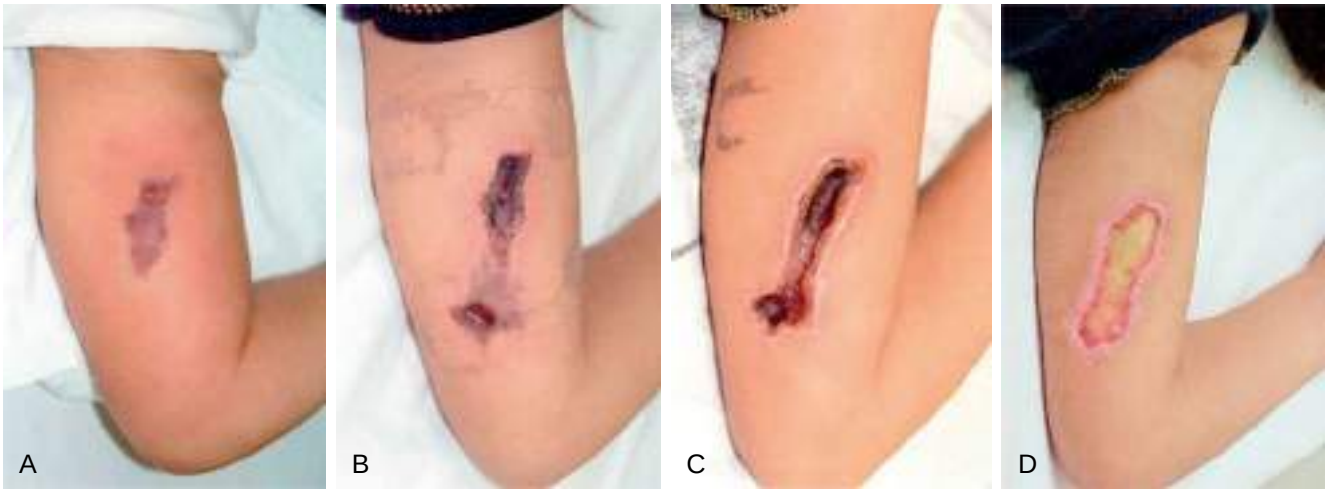

Fig. 768.5 Progression of cutaneous loxoscelism in a Brazilian patient who was bitten inside a house while putting on a shirt. Ulceration and necrosis at day 1 (**A**), day 9 (**B**), day 16 (**C**), and day 25 (**D**). *(From Isbister G, Fan HW. Spider bite. Lancet. 2011;378:2039–2046. Fig. 3. Photographs by Ceila MS Malaque.)*

Disposition

Victims with necrotic skin lesions should be monitored with frequent outpatient wound checks to determine progression of the lesion. Children with rapidly progressive dermonecrosis or systemic toxicity should be admitted to the hospital for supportive therapy, which may include intensive care admission for hemolysis, coagulopathy, renal failure, or hypotension.

SCORPION STINGS

There are more than 650 species of scorpions worldwide, some of which are capable of causing severe or lethal envenomation. In the United States, there are two clinically significant scorpions: ***Centruroides exilicauda*** (the bark scorpion) and ***Centruroides vittatus.*** Most scorpion envenomations occur in the southwestern United States, and fatalities are rare. In other regions of the world, especially Latin America, Africa, the Middle East, and Asia, a number of scorpions regularly cause fatalities.

Venoms and Effects

Centruroides scorpion venom contains phospholipase, acetylcholinesterase, hyaluronidase, serotonin, and neurotoxins, resulting in severe pain and paresthesia as well as systemic symptoms of excessive nerve depolarization and release of acetylcholine and catecholamines. The manifestations of scorpion stings in children vary from mild to severe and can include autonomic and somatic toxicity. Autonomic toxicity includes hypertension, tachycardia, hypersalivation, emesis, diaphoresis, and bronchoconstriction, although respiratory failure is rare. Somatic motor toxicity includes ataxia, fasciculations, myoclonus, and opsoclonus. Patients are often restless or agitated, and cranial nerve dysfunction may occur.

Management

Most scorpion stings do not produce severe effects and require only wound care and orally administered pain medications. However, patients with more severe symptoms may require intravenous opioids for analgesia and benzodiazepines for severe muscle spasm or agitation.

A bark scorpion–specific antivenom, Anascorp (Bioclon, Mexico), is approved by the FDA. This antivenom is recommended for critically ill patients with neurotoxicity or other severe symptoms, including intractable pain that is not responsive to adequate doses of opioid analgesics. Small children are more likely than adults to develop such severe symptoms. It is best to discuss antivenom therapy with the regional poison control center for guidance.

Disposition

Patients who have had mild scorpion stings with only local effects can be safely discharged home with wound care instructions, analgesics, and close outpatient follow-up. Patients with evolving symptoms, intractable pain, neurotoxicity, or other systemic toxicity should be admitted to the hospital, especially if scorpion antivenom is being considered. Those with severe toxicity should be admitted to an intensive care unit.

HYMENOPTERA STINGS

The insect order Hymenoptera includes the stinging ants, bees, and wasps, which are characterized by the presence of a modified ovipositor (the "sting" or "stinger") at the end of the abdomen through which venom is injected. Various members of the order can be found throughout the world.

Venoms and Effects

Hymenoptera venom is a complex mixture of proteins, enzymes, and vasoactive substances that result in local tissue injury and inflammation. Most stings cause only local pain, redness, and swelling followed by itching and resolution. Some patients experience a large local reaction in which swelling progresses beyond the sting site, possibly involving the entire extremity. Approximately 0.4–0.8% of children and 3% of adults are at risk for acute, life-threatening allergic reactions as a result of Hymenoptera venom sensitivity; anaphylaxis due to Hymenoptera envenomation causes an average of 62 deaths annually in the United States (see Chapter 187). Rare cases of delayed serum sickness can follow Hymenoptera stings (see Chapter 191). Africanized honeybees *(Apis mellifera scutellata)*, an aggressive hybrid of western honeybee species with African bee species, can cause massive stinging episodes resulting in systemic venom toxicity with hypotension, respiratory failure, shock, hemolysis, and renal failure.

Management

Patients with typical local reactions can be treated with supportive care including analgesics and antihistamines as needed. Patients with large local reactions should also receive a course of oral corticosteroids and a prescription for an epinephrine autoinjection kit including instructions in its use before discharge. Patients presenting with urticaria, angioedema, wheezing, or hypotension should be treated with aggressive supportive care including standard therapy for anaphylaxis such as intramuscular epinephrine, corticosteroids, antihistamines, intravenous fluids, oxygen, and airway management as needed (see Chapter 190). Patients suffering massive stinging episodes may also require critical care resuscitation.

Disposition

Patients with local reactions can be discharged with continued outpatient care that may include analgesia and antihistamines. More difficult disposition decisions are involved for children with systemic manifestations. Children with only diffuse urticaria who are stable after a period of observation can be discharged home to continue a short course of antihistamines and steroids and to carry an epinephrine self-administration kit. These children are at low risk for progressing to systemic anaphylaxis with future stings. Children suffering more than simple urticaria (e.g., wheezing, evidence of laryngeal edema or cardiovascular instability) should be treated aggressively and admitted for at least 24 hours of observation. They should receive a referral to allergy/immunology to test for Hymenoptera venom sensitivity and possible immunotherapy. Immunotherapy reduces the risk of systemic anaphylaxis from future stings in high-risk patients from 30–60% to <5%.

MARINE ENVENOMATION

The classes of venomous marine animals that cause the most morbidity and mortality in humans are the **Cnidaria** (including jellyfish, the Portuguese man-of-war, Pacific blue bottle, fire coral, sea nettles, anemones, and others), Mollusca (blue-ringed octopus and cone snails), Chondrichthyes (stingrays), and members of the family Scorpaenidae (lionfish, scorpionfish, and stonefish).

Venoms and Effects

All members of the Cnidaria have unique stinging cells called nematocysts. These cells contain a highly folded tubule that discharges on contact, penetrates the skin, and injects venom. The venom is antigenic and can be dermonecrotic, hemolytic, cardiotoxic, or neuropathic, depending on the species. The **Pacific box jellyfish** *(Chironex fleckeri)* of Australia, with its cardiotoxic venom, is known to cause stings that are rapidly fatal due to cardiac arrest and pulmonary edema. Although fatal anaphylaxis to jellyfish stings has been reported in coastal waters of the United States, these events are rare. For clinicians in the Americas, the primary concern with Cnidaria envenomation is localized pain that may be associated with paresthesias or pruritus. Occasionally, victims may have systemic symptoms such as nausea, vomiting, headache, and chills.

The phylum **Mollusca** includes octopi and cone snails (*Conus* sp.). The **octopus** of toxicologic significance is the *Hapalochlaena maculosa* (blue-ringed octopus), which is primarily found in Australian waters. The blue-ringed octopus secretes **tetrodotoxin** (the same toxin found in pufferfish) in its salivary gland. The beak of the octopus punctures the skin and delivers the tetrodotoxin. Tetrodotoxin blocks sodium channels in neurons, leading to paralysis. The venom also contains other toxins, including vasoactive agents and enzymes that cause local tissue injury. Cone snails have a hollow proboscis with a tooth that can be extended to inject venom into the victim. Venom of the *Conus* species contains conotoxins that target multiple receptors, including voltage, ligand, and G-mediated receptors. Conotoxins cause a variety of symptoms including severe pain, weakness, tissue ischemia, cyanosis, and numbness. Systemic symptoms are usually neurologic and include aphonia, aphasia, weakness, paralysis, respiratory failure, cardiovascular collapse, and ultimately death.

The **stingray** has a sharp, retroserrated spine and associated venom gland at the base of its tail. Envenomation often occurs when the victim steps on the animal hidden in the surf and the tail is whipped around to puncture the lower extremity. Injuries involve jagged lacerations from the spine, often with retained debris (spine fragments, glandular tissue, and sand). The venom has vasoconstrictive properties that can result in tissue necrosis and poor wound healing. Stingray envenomations are noteworthy for immediate and intense pain at the site of injury that lasts 24-48 hours. Some patients experience nausea, vomiting, and muscle cramps. Rarely, hypotension or seizures occur.

The Scorpaenidae have venomous dorsal, pelvic, and anal spines that become erect when the animal is threatened. The venom glands associated with these spines contain multiple toxins, enzymes, and vasoactive substances. Envenomation causes immediate severe pain that may persist for hours or days. Victims may experience local tissue destruction, and superinfections are common. Systemic symptoms include diaphoresis, nausea, vomiting, diarrhea, abdominal pain, muscle cramping, and headache. In severe cases, paralysis, respiratory failure, hypotension, dysrhythmias, and cardiovascular collapse have been reported.

Management

Treatment of Cnidaria stings should begin immediately after envenomation. Dousing the sting site with vinegar has been shown to inhibit nematocyst discharge. If vinegar is not immediately available, the area should be washed with seawater; freshwater should be avoided as it is thought to stimulate firing of remaining nematocysts. Visible tentacle fragments should be removed with a gloved hand or forceps, and microscopic fragments may be removed by gently shaving the affected area. Folk remedies such as rubbing the sting with sand and applying urine are not helpful and cause more irritation. Meat tenderizer is usually not effective. Antihistamines and corticosteroids are indicated for swelling and urticaria. An acute anaphylactic reaction should be treated with intramuscular epinephrine. Antibiotics are usually not necessary.

Patients who have been envenomated by Mollusca are treated supportively. There are no antivenoms available for either the blue-ringed octopus or the cone snails. Adequate pain control should be provided as needed. Cardiovascular support may be required, and severe neurologic toxicity such as respiratory failure should be managed via airway management and mechanical ventilation.

Treatment of stingray and Scorpaenidae stings is similar. These toxins are heat-labile, and immersion in hot water (approximately 42°C [107.6°F]) for 30-60 minutes denatures the protein constituents and decreases pain significantly. The wounds should be thoroughly cleansed and explored with use of local or regional anesthesia to rule out retention of spine or integument fragments. Stingray spines are radiopaque and may be seen on radiographs or identified by ultrasonography. Lacerations should be treated with delayed primary closure or allowed to heal by secondary intention. Systemic analgesia should be provided as needed. Because of the risk of secondary bacterial infection, there should be a low threshold for administering prophylactic antibiotics to cover *Staphylococcus, Streptococcus,* and *Vibrio* species, and wounds should be rechecked at 3 and 7 days postinjury. An equine Fab stonefish antivenom is available for severe stonefish envenomation with systemic toxicity or intractable pain.

Disposition

After wound care and effective analgesia, most victims can be discharged home. If there are significant systemic effects, the patient should be admitted for monitoring and further care as needed.

Visit Elsevier eBooks+ at eBooks.Health.Elsevier.com for Bibliography.

Laboratory Medicine

PART XXXIII

Chapter 769

Laboratory Testing in Infants and Children

Stanley F. Lo and Stephen M. Roper

Normal values **(reference intervals)** are difficult to establish within the pediatric population. Differences in genetic composition, physiologic development, environmental influences, and subclinical disease are variables that need to be considered when developing reference intervals. Other considerations for further defining reference intervals include partitioning based on sex and age. The most commonly used reference range is generally given as the **mean** of the reference population ±2 standard deviations (SD). This is acceptable when the distribution of results for the tested population is essentially gaussian (normal). The serum sodium concentration in children, which is tightly controlled physiologically, has a distribution that is essentially gaussian; the mean value ±2 SD gives a range very close to that actually observed in 95% of children (Table 769.1). However, not all analytes have a gaussian distribution. The serum creatine kinase level, which is subject to diverse influences and is not actively controlled, does not show a gaussian distribution, as evidenced by the lack of agreement between the range actually observed and that predicted by the mean value ±2 SD. In these cases, a reference interval defining the 2.5-97.5 percentiles is typically used.

Reference cutoffs are typically established from large studies with a healthy reference population. Examples of these cutoffs are illustrated by reference cutoffs established for cholesterol, lipoproteins, and neonatal bilirubin. Patient results exceeding these cutoffs have a future risk of acquiring disease. A final modification needed for reporting reference intervals is referencing the Tanner stage of sexual maturation (sexual maturity rating scale), which is most useful in assessing pituitary and gonadal function.

The establishment of common reference intervals remains an elusive target. Although some patient results are directly comparable between laboratories and methods, most are not. Careful interpretation of patient results must consider when testing was performed and what method was used. **Higher-order methods**, methods that are more accurate and precise, continue to be slowly developed. These will be critical to the standardization of tests and the establishment of common reference intervals.

COMMON CHALLENGES IN PEDIATRIC LABORATORY MEDICINE

There are several challenges in pediatric lab medicine that are encountered infrequently, are less consequential, or do not apply to adult populations. For example, the rate of in-vitro hemolysis is increased in children because of the use of inappropriate needle or tubes sizes, applying too much pressure to the site of a finger or heel-stick collection, or simply drawing a specimen rapidly to minimize the discomfort of the child. Hemolyzed specimens can lead to inaccurate results for several analytes because of spectrophotometric interference caused by hemoglobin, dilution effects, or because of the release of other red blood cell components (e.g., lactate dehydrogenase [LDH]). A related issue is the frequent occurrence of physiologic jaundice. Like hemoglobin, bilirubin can absorb light and influence with spectrophotometric analyses. Although many chemistry analyzers can detect these interferences and suppress affected results, specimens frequently must be recollected. Likewise, the increased hematocrit common in the first month of life can lead to decreased amount of plasma/serum from a given blood volume. This phenomenon can result in the need for repeat phlebotomy or larger starting volumes of whole blood. In addition to blood, urine is another difficult fluid to work with in children. Noninvasive urine collections from infants often require special collection techniques (bags, cotton balls) that may only capture small volumes. Coupled with the relatively dilute urine typically produced by newborns, urine specimens may require concentration, or analyzer measurement ranges may need to be adjusted to provide useful information. Other challenges in pediatric lab medicine include, but are not limited to, the use of small ("bullet") blood collection tubes that are incompatible with automated sample handlers, the need for specialized testing (e.g., sweat test, newborn screening), and working with specimens drawn from indwelling catheters that may be contaminated with IV or total parenteral nutrition (TPN) fluid.

ACCURACY AND PRECISION OF LABORATORY TESTS

Technical accuracy, or trueness, is an important consideration in interpreting the results of a laboratory test. Because of improvements in methods of analysis and elimination of analytic interference, the accuracy of most tests is limited primarily by their precision. **Accuracy** is a measure of the nearness of a test result to the actual value, whereas **precision** is a measure of the reproducibility of a result. No test can be more accurate than it is precise. Analysis of precision by repetitive measurements of a single sample gives rise to a gaussian distribution with a mean and an SD. The estimate of precision is the coefficient of variation (CV):

$$CV = \frac{SD}{Mean} \times 100$$

The CV is not likely to be constant over the full range of values obtained in clinical testing, but it is approximately 5% in the normal range. The CV is generally not reported but is always known by the laboratory. It is particularly important in assessing the significance of changes in laboratory results. For example, a common situation is the need to assess hepatotoxicity incurred because of the administration of a therapeutic drug and reflected in the serum alanine transaminase (aminotransferase) (ALT) value. If serum ALT increases from 25 units/L to 40 units/L, is the change significant? The CV for ALT is 7%. Using the value obtained ±2 × CV to express the extremes of imprecision, a value of 25 units/L is unlikely to reflect an actual concentration of >29 units/L, and a value of 40 units/L is unlikely to reflect an actual concentration of <34 units/L. Therefore the change in the value as obtained by testing is likely to reflect a real change in circulating ALT levels. Continued monitoring of serum ALT is indicated, even though both values for ALT are within normal limits. *Likely* in this case is only a probability. Inherent biologic variability is such that the results of two successive tests may suggest a trend that will disappear on further testing.

Table 769.1 Gaussian and Nongaussian Laboratory Values in 458 Normal Schoolchildren 7-14 Years Old

	SERUM SODIUM (MMOL/L)	SERUM CREATINE KINASE (UNITS/L)
Mean	141	68
Standard deviation (SD)	1.7	34
Mean ±2 SD	138-144	0-136
Actual 95% range	137-144	24-162

The precision of a test may also be indicated by providing *confidence limits* for a given result. Usually, 95% confidence limits are used, indicating that it is 95% certain that the value obtained lies between the two limits reported. Confidence limits are calculated using the mean and SD of replicate determinations:

$$95\,\%\ \text{ confidence limits} = \text{Mean} \pm t \times \text{SD}$$

where t is a constant derived from the number of replications. In most cases, $t = 2$.

Accuracy is expressed by determining the difference, or **bias**, between results from a comparative method and a definitive or reference method. A **definitive** or **reference** method provides results with increased precision and accuracy compared with the clinical laboratory. When these methods are used, along with highly purified materials (i.e., Standard Reference Materials from the National Institute of Standards and Technology) to establish values for assay calibrators used in the clinical laboratory, the accuracy of patient results is improved. Creatinine, hemoglobin A_{1c}, and neonatal bilirubin are examples in which the accuracy of these tests has been improved.

SENSITIVITY, ACCURACY, AND ANALYTIC TESTING

In some circumstances, the sensitivity and accuracy of an analysis are reduced or increased as functions of clinical purpose. For example, ion exchange chromatography of plasma amino acids for the diagnosis of inborn errors of metabolism is usually performed at an analytic sensitivity that allows measurement of all the amino acids with a single set of standards. The range of values is approximately 20-800 μmol/L, and accuracy is poor at values ≤20 μmol/L. The detection of homocysteine in this type of analysis suggests an inborn error of methionine metabolism. If the analysis is adjusted to achieve greater analytic sensitivity, it is possible to measure homocysteine accurately in normal plasma (3-12 μmol/L). This more sensitive test is used to assess cobalamin and folate status.

PREDICTIVE VALUE OF LABORATORY TESTS

Predictive value (PV) theory deals with the usefulness of tests as defined by their clinical **sensitivity** (ability to detect a disease) and **specificity** (ability to define the absence of a disease).

$$\text{Sensitivity} = \frac{\text{Number positive by test}}{\text{Total number positive}} \times 100$$

$$\text{Specificity} = \frac{\text{Number negative by test}}{\text{Total number without disease}} \times 100$$

$$\text{PV of positive test result} = \frac{\text{True-positive results}}{\text{Total positive results}} \times 100$$

$$\text{PV of negative test result} = \frac{\text{True-negative results}}{\text{Total negative results}} \times 100$$

The problems addressed by PV theory are *false-negative* and *false-positive* test results. Both are major considerations in interpreting the results of screening tests in general and neonatal screening tests in particular.

Testing for human immunodeficiency virus (HIV) seroreactivity illustrates some of these considerations. If it is assumed that approximately 1,100,000 of 284,000,000 residents of the United States are infected with HIV (prevalence = 0.39%) and that 90% of those infected demonstrate antibodies to HIV, then we can consider the usefulness of a simple test with 99% sensitivity and 99.5% specificity (see Chapter 322). If the entire population of the United States were screened, it would be possible to identify most of those infected with HIV:

$$1{,}100{,}000 \times 0.9 \times 0.99 = 980{,}100\ \ (89.1\%)$$

However, there will be 119,900 false-negative test results. And even with 99.5% specificity, the number of false-positive test results would be larger than the number of true-positive results:

$$284{,}000{,}000 \times 0.005 = 1{,}420{,}000$$

In addition, there will be 281,480,000 true-negative results:

$$\text{PV of positive test result} = \frac{980{,}100}{(980{,}100 + 1{,}420{,}000)} \times 100 = 41\%$$

$$\text{PV of negative test result} = \frac{281{,}480{,}000}{(281{,}480{,}000 + 119{,}900)} \times 100 = 99.96\%$$

Given the high cost associated with follow-up and the anguish produced by a false-positive result, it is easy to see why universal screening for HIV seropositivity received a low priority immediately after the introduction of testing for HIV infection.

By contrast, we can consider the screening of 100,000 individuals from groups at increased risk for HIV in whom the overall prevalence of disease is 10%, with all other considerations being unchanged.

$$\text{True-positive results} = 0.9 \times 0.99 \times 10{,}000 = 8{,}910$$

$$\text{False-positive results} = 0.005 \times 90{,}000 = 450$$

$$\text{False-negative results} = 10{,}000 - 8{,}910 = 1{,}090$$

$$\text{PV of positive test result} = \frac{8{,}910}{8{,}910 + 450} \times 100 = 95\%$$

$$\text{PV of negative test result} = \frac{89{,}500}{89{,}550 + 1{,}090} \times 100 = 99\%$$

These two hypothetical testing strategies show that the diagnostic efficiency of testing depends heavily on the prevalence of the disease being tested for, even with a superior test, such as the test for HIV antibodies. Because the treatment of pregnant women infected with HIV is effective in preventing vertical transmission, screening has now been expanded to all pregnant women. The proven effectiveness of current therapy in preventing neonatal infection has intensified screening for HIV early in pregnancy.

However, because of the long time needed to test for HIV antibodies, it was difficult to screen women during labor and provide the necessary therapy. Rapid HIV antibody testing procedures using a fingerstick or venipuncture to obtain whole blood, plasma, or serum, and tests using oral fluid were approved (Table 769.2). The HIV test results are usually obtained in <20 minutes. The collection of oral fluid samples provides an alternative for individuals who avoid HIV testing because of their dislike of needlesticks. HIV testing using whole blood or oral fluid is classified as a waived test under the **Clinical Laboratory Improvement Amendments of**

Table 769.2 Rapid HIV Antibody Tests and Status Under CLIA

RAPID HIV TEST	SPECIMEN TYPE	CLIA CATEGORY	TIME FOR PERFORMING ASSAY	WAIT TIME TO READ RESULTS	MANUFACTURER
OraQuick ADVANCE Rapid HIV-1/2 Antibody Test	Oral fluid Whole blood (fingerstick or venipuncture)	Waived Waived	<5 min	20-40 min	OraSure Technologies www.orasure.com
	Plasma	Moderate complexity			
Uni-Gold Recombigen HIV-1	Whole blood (fingerstick or venipuncture)	Waived	<5 min	10-12 min	Trinity Biotech www.trinitybiotech.com
	Serum and plasma	Moderate complexity			
Reveal G4 Rapid HIV-1 Antibody Test	Serum and plasma	Moderate complexity	<5 min	Read result immediately	MedMira www.medmira.com
MultiSpot HIV-1/HIV-2 Rapid Test	Serum and plasma	Moderate complexity	10-15 min	Result can be read immediately or up to 4 hr later	BioRad Laboratories www.bio-rad.com
Clearview HIV 1/2 STAT-PAK and Clearview COMPLETE HIV 1/2	Whole blood (fingerstick or venipuncture)	Waived	5 min	15-20 min	Alere www.alere.com
	Serum and plasma	Waived	5 min	15-20 min	Alere
Clearview Determine HIV1/2 Ag/Ab Combo	Whole blood (fingerstick or venipuncture)	Waived	5 min	20 min	Alere
	Serum and plasma	Waived	5 min	20 min	Chembio Diagnostic Systems; distributed by Alere

Ag/Ab, Antigen/antibody; CLIA, Clinical Laboratory Improvement Amendments of 1988; HIV, human immunodeficiency virus.

1988 (CLIA), and these tests are allowed in a point-of-care setting. *Waived tests* are laboratory procedures that use methodologies that are so simple and accurate as to render the likelihood of an erroneous result by the user negligible. A positive rapid HIV test result is then confirmed by nucleic acid amplification testing or immunofluorescence assay.

According to the U.S. Centers for Disease Control and Prevention (CDC), 174 infants were born with HIV in 2014 in the United States. Rapid HIV testing during labor allows for implementation of antiretroviral therapy for HIV-infected women who have not been tested or are unaware of their HIV status. The initiation of therapy at the time of labor or within the first 12 hours of an infant's birth significantly reduces the risk of mother-to-child transmission. In the mother–infant rapid intervention at delivery study, it was shown that the sensitivity and specificity of a rapid whole blood test for HIV during labor were 100% and 99.9%, respectively, with a positive PV of 90%. The median turnaround time for obtaining results from blood collection to patient notification was only 66 minutes. The performance of the rapid blood test was better than that of the standard HIV enzyme immunoassay, which had a sensitivity and specificity of 100% and 99.8%, respectively, with a positive PV of 76%. In addition, the median turnaround time from blood collection to patient notification was 28 hours. As a result, rapid whole blood HIV testing is now the standard of care for women in labor with undocumented HIV status.

Rapid HIV testing can also be used in developing countries. In resource-poor settings, because of the lack of properly equipped laboratories, skilled technologists, and basic resources, such as electricity and water, these self-contained, point-of-care HIV tests are very attractive. In areas of Asia and Africa where HIV is epidemic, screening pregnant women with rapid HIV tests and offering antiretroviral therapy can significantly reduce the transmission of HIV to hundreds of thousands of infants.

NEONATAL SCREENING TESTS

Almost all the diseases detected in neonatal screening programs have a very low prevalence, and for the most part, the tests are *quantitative* rather than qualitative. In general, the strategy is to use the initial screening test to separate a highly suspect group of patients from normal infants (i.e., to increase the prevalence) and then to follow this suspect group aggressively. Two common strategies are used to detect congenital hypothyroidism (see Chapter 603): one uses thyroid-stimulating hormone for the initial screen, and the other uses thyroxine. In the **thyroxine** strategy for congenital hypothyroidism, which has a prevalence of 25 in 100,000 liveborn infants, the initial test performed is for thyroxine in whole blood. Infants with the lowest 10% of test results are considered suspect. If all infants with hypothyroidism were included in the suspect group, the prevalence of disease in this group would be 250 in 100,000 infants. The original samples obtained from the suspect group are retested for thyroxine and are tested for thyroid-stimulating hormone. This second round of testing results in an even more highly suspect group composed of 0.1% of the infants screened and having a prevalence of hypothyroidism of 25,000 in 100,000 individuals. This final group is aggressively pursued for further testing and treatment. Even with a 1,000-fold increase in prevalence, 75% of the aggressively tested population is euthyroid. The justifications advanced for the program are that treatment is easy and effective and that the alternative if congenital hypothyroidism is undetected and untreated—long-term custodial care—is both unsatisfactory and expensive.

At its inception, newborn screening was driven by the selection of genetic diseases whose clinical manifestations developed postnatally, such as phenylketonuria, galactosemia, and hypothyroidism. Diseases selected for screening typically had to meet certain criteria. The prevalence of disease had to meet a minimum, typically 1 in 100,000. Disease selection required demonstrated reduction in morbidity and mortality in the neonatal period. Effective therapies needed to be available, and the cost of screening and the feasibility of laboratory testing were also considerations in this selection process.

More common diseases have also become targets for neonatal screening programs. **Sickle cell disease** (see Chapter 511.1), easily detected using liquid chromatography or isoelectric focusing, can be treated more effectively if it is diagnosed before clinical signs appear. In addition, the results of neonatal screening for **cystic fibrosis** (CF; see Chapter 454) show clear benefits associated with preclinical diagnosis but also some inherent difficulties associated with genetic screening for complex autosomal recessive diseases that are common and are caused by a rather large number of pathogenic variants (>1,500) of a single gene. The definitive diagnostic test for CF is the measurement of concentrations of chloride in sweat, a test that is not practical during the first week of life. Neonates with CF generally have elevations in whole blood trypsinogen. This test allows the identification of a group of neonates at risk for CF. Unfortunately, trypsinogen as an initial screening test has a high false-positive rate, an unfavorable characteristic that creates unnecessary anxiety among newborn parents and families and is costly because of the time and expense for medical follow-up. Performing DNA analysis for common variants that cause CF reduces the size of the suspect group and identifies neonates with a higher likelihood of disease. This two-tiered strategy identifies a manageable number of infants for whom to perform sweat tests. Problems include the following: (1) uncommon variants are not included in the screening panel, and cases of CF caused by these variants can be missed; (2) common variants that cause clinically innocent elevations of whole blood trypsinogen in heterozygous neonates cause potentially alarming false-positive findings; and (3) CF in patients with normal sweat test results is rare but is likely to be missed.

Tandem mass spectrometry (MS/MS) is a technically advanced method in which many compounds are initially ionized and separated by molecular weight. Each compound is then fragmented, and the identification of compounds is based on characteristic fragments. The process requires approximately 2 minutes per sample and can detect 20 or more inborn errors of metabolism. The effects of prematurity, neonatal illness, and intensive neonatal management on metabolites in blood complicate the interpretation of results. The PV of a positive screening result is likely to be <10%; that is, 90% of positive results are not indicative of a genetic disorder of metabolism. Nonetheless, MS/MS permits a diagnosis to be made before clinical illness develops and has revolutionized the purpose and ability of newborn screening. MS/MS is not directed toward diseases defined as treatable, but it is directed toward all the diseases, each of which is rare, that the technique can identify.

MS/MS permits the detection of rare inborn errors of metabolism and has been introduced as a newborn screening tool worldwide. Since 1998, when mass spectrometry was implemented in Australia, the rate of detection per 100,000 births has been 15.7, significantly higher than the rate of 8.6-9.5 in the six preceding 4-year periods. Disorders of fatty acid oxidation, particularly medium-chain acyl coenzyme A dehydrogenase deficiency (see Chapter 106.1), accounted for the majority of increased diagnoses. Expanded newborn screening programs using MS/MS increase the detection of inherited metabolic disorders. All states in the United States use MS/MS in their neonatal screening programs; the metabolic conditions screened range from 31 to >50.

In an attempt to standardize newborn screening programs, the American College of Medical Genetics (ACMG) recommended that every baby born in the United States be screened for a core panel of 29 disorders (Table 769.3). An additional 25 conditions were recommended as secondary targets because they may be identified while screening for the core panel disorders. The March of Dimes and the American Academy of Pediatrics also endorse the ACMG recommendations. However, expansion of the screening test menu raises several issues. The cost of implementation can be significant because many states will need multiple MS/MS systems. Staffing the laboratory with qualified technical personnel to run the MS/MS system and qualified clinical scientists to interpret the profiles can be a challenge. A number of false-positive results will also be obtained with these newborn screening programs. Many of these findings are the result of parenteral nutrition, biologic variation, or treatment and are *not* the result of an inborn error of metabolism. Consequently, qualified staff will be needed to ensure that patients with abnormal results are contacted and receive follow-up testing and counseling, if needed. Even with these concerns, the ACMG report is a step in the right direction toward standardizing guidelines for state newborn screening programs.

TESTING IN REFINING A DIFFERENTIAL DIAGNOSIS

The use of laboratory tests in refining a differential diagnosis satisfies PV theory because a correct differential diagnosis should result in a relatively high prevalence of the disease under consideration. An example of testing in refining a differential diagnosis is the measurement of urinary vanillylmandelic acid (VMA) for the diagnosis of **neuroblastoma** (see Chapter 547). A simple spot test for VMA is not useful in general screening programs because of the low prevalence of neuroblastoma (3 cases/100,000) and the low sensitivity of the test (69%). Even though the specificity of urinary VMA is 99.6%, testing of 100,000 children would produce 2 true-positive test results, 400 false-positive results, and 1 false-negative result. The PV of a positive result in this setting is 0.5%, and the PV of a negative result is 99.99%, not much different from the assumption

Table 769.3 American College of Medical Genetics Core Panel of Neonatal Screening Tests

Isovalericacidemia
Glutaric aciduria type 1
3-Hydroxy-3-methylglutaricaciduria
Multiple coenzyme A (CoA) carboxylase deficiency
Methylmalonic acidemia (mutase deficiency)
3-Methylcrotonyl CoA carboxylase deficiency
Methylmalonic acidemia (cobalamin [Cbl] A, B)
Propionic acidemia
β-Ketothiolase deficiency
Medium-chain acyl-CoA dehydrogenase deficiency
Very-long-chain acyl-CoA dehydrogenase deficiency
Long-chain L-3-hydroxy acyl-CoA dehydrogenase deficiency
Trifunctional protein deficiency
Carnitine uptake deficiency
Phenylketonuria
Maple syrup urine disease
Homocystinuria (because of cystathionine β-synthase deficiency)
Citrullinemia
Argininosuccinic acidemia
Tyrosinemia type 1
Sickle cell anemia (Hb SS disease)
Hemoglobin (Hb) S/β-thalassemia
Hb S/C disease
Congenital hypothyroidism
Biotinidase deficiency
Congenital adrenal hyperplasia (21-hydroxylase deficiency)
Classic galactosemia
Hearing loss
Cystic fibrosis

that neuroblastoma is not present. Testing for urinary VMA in a 3-year-old child with an abdominal mass, however, gives a useful result because the prevalence of neuroblastoma is at least 50% in 3-year-old children with abdominal masses. If 100 such children are tested and the prevalence of neuroblastoma in the group is assumed to be 50%, a satisfactory PV is obtained.

$$\text{PV of positive test result} = \frac{0.69 \times 50}{0.69 \times 50 + (0.004 \times 50)} \times 100 = 99\,\%$$

$$\text{PV of negative test result} = \frac{0.996 \times 50}{0.996 \times 50 + (0.31 \times 50)} \times 100 = 76\,\%$$

Thus, in this situation, a test with low sensitivity is powerful in refining the differential diagnosis because the PV of a positive result is almost 100% in the setting of high prevalence.

Serologic Testing

Using laboratory testing to refine a differential diagnosis poses problems, as exemplified by serologic testing for **Lyme disease**, which is a tick-borne infection by *Borrelia burgdorferi* that has various manifestations in both early and late stages of infection (see Chapter 268). Direct demonstration of the organism is difficult, and serologic test results for Lyme disease are not reliably positive in young patients presenting early with erythema chronicum migrans. These results become positive after a few weeks of infection and remain positive for a number of years. In an older population being evaluated for late-stage Lyme disease, some individuals will have recovered from either clinical or subclinical Lyme disease, and some will have active Lyme disease, with both groups having true-positive serologic test results. Of individuals without Lyme disease, some will have true-negative serologic test results, but a significant percentage will have antibodies to other organisms that cross-react with *B. burgdorferi* antigens.

This set of circumstances gives rise to a number of problems. First, the protean nature of Lyme disease makes it difficult to ensure a high prevalence of disease in persons to be tested. Second, the most appropriate antibodies to be detected are imperfectly defined, leading to a wide variety of tests with varying false-positive and false-negative rates. Third, the natural history of the antibody response to infection and the difficulty of showing the causative organism directly combine to make laboratory diagnosis of early Lyme disease difficult. Fourth, in the diagnosis of late-stage Lyme disease in older individuals, the laboratory diagnosis is plagued by misleading positive (either false-positive or true-positive, but not clinically relevant) results, typically an enzyme-linked immunosorbent assay (ELISA) that uses whole *B. burgdorferi* organisms. In a review of 788 patients referred to a specialty clinic with the diagnosis of Lyme disease, the diagnosis was correct in 180 patients, 156 patients had true seropositivity without active Lyme disease, and 452 had never had Lyme disease, even though 45% of them were found to be seropositive by at least one test before referral.

A two-step approach, similar to that used in HIV testing, is often used: a screening test that has high sensitivity (e.g., ELISA) and excellent negative PV, followed by a very specific confirmatory test for verification of positive screening test results (e.g., Western blot to detect antibodies to selected bacterial antigens). Negative screening test results and negative verification test results are reported as negative. Positive verification test results are reported as positive. However, standardization of the testing procedures is difficult in North America, where only one pathogenic strain of *B. burgdorferi* is found, and is more difficult elsewhere in the Northern hemisphere, where as many as three pathogenic strains are present.

Table 769.4 Laboratory Profile as a Review of Systems

LABORATORY TEST	ASSESSMENT FACILITATED BY TESTS
Complete blood cell count and platelets	Nutrition, status of formed elements
Complete urinalysis	Renal function/genitourinary tract inflammation
Albumin and cholesterol	Nutrition
ALT, bilirubin, GGT	Liver function
BUN, creatinine	Renal function, nutrition
Sodium, potassium, chloride, bicarbonate	Electrolyte homeostasis
Calcium and phosphorus	Calcium homeostasis

ALT, Alanine transaminase; BUN, blood urea nitrogen; GGT, γ-glutamyltransferase.

Identification of microbial DNA in body fluids by polymerase chain reaction is definitive but invasive.

Laboratory Screening

Screening profiles are used as part of a complete review of systems, to establish a baseline value, or to facilitate patient care in specific circumstances, such as (1) when a patient clearly has an illness, but a specific diagnosis remains elusive; (2) when a patient requires intensive care; (3) for postmarketing surveillance and evaluation of a new drug; and (4) when a drug is used that is known to have systemic adverse effects. Laboratory screening tests should be used in a targeted manner to supplement, not supplant, a complete history and physical examination (Table 769.4).

Bibliography

American Academy of Pediatrics. American Thyroid Association: newborn screening for congenital hypothyroidism. *Pediatrics*. 1987;80:745–749.

Bulterys M, Jamieson DJ, O'Sullivan MJ, et al. Rapid HIV-1 testing during labor: a multicenter study. *JAMA*. 2004;292:219–223.

Clayton EW. Issues in state newborn screening programs. *Pediatrics*. 1992;90:641–646.

Farrell PM, Kosrok MR, Rock MJ, et al. Early diagnosis of cystic fibrosis through neonatal screening prevents severe malnutrition and improves long-term growth. *Pediatrics*. 2001;107:1–13.

Galen RS, Gambino SR. *Beyond Normality*. New York: Academic Press; 1975.

Hu LT, Klempner MS. Update on the prevention, diagnosis, and treatment of Lyme disease. *Adv Intern Med*. 2001;46:247–275.

Minamitani K, Inomata H. Neonatal screening for congenital hypothyroidism in Japan. *Pediatr Endocrinol Rev*. 2012;10(suppl 1):79–88.

National Newborn Screening and Genetic Resource Center. Newborn screening information. http://genes-r-us.uthscsa.edu.

Rinaldo P, Tortorelli S, Matern D. Recent developments and new applications of tandem mass spectrometry in newborn screening. *Curr Opin Pediatr*. 2004;16:427–433.

Steere AC, Taylor E, McHugh GL, et al. The overdiagnosis of Lyme disease. *JAMA*. 1993;269:1812–1826.

Sun A, Lam C, Wong DA. Expanded newborn screening for inborn errors of metabolism: overview and outcomes. *Adv Pediatr*. 2012;59(1):209–245.

Watson MS, Mann MJ, Lloyd-Puryear MA, et al. Newborn screening: towards a uniform screening panel and system. *Genet Med*. 2006;8(Suppl):S12–S252.

Wilcken B, Wiley V, Hammond J, et al. Screening newborns for inborn errors of metabolism by tandem mass spectrometry. *N Engl J Med*. 2003;348:2304–2312.

Zytkovicz TH, Fitzgerald EF, Marsden D, et al. Tandem mass spectrometric analysis for amino, organic, and fatty acid disorders in newborn dried blood spots: a two-year summary from the New England Newborn Screening Program. *Clin Chem*. 2001;47:1945–1955.

Chapter 770

Reference Intervals for Laboratory Tests and Procedures

Stanley F. Lo and Stephen M. Roper

In Tables 770.1-770.5, the reference intervals apply to infants, children, and adolescents when possible. For many analyses, separate reference intervals for children and adolescents are not well delineated. When interpreting a test result, the reference interval supplied by the laboratory performing the test should always be used because these intervals are instrument and/or method dependent. Figures 770.1 and 770.2 provide estimations related to dosages. Figure 770.3 is a nomogram for risk assessment of hyperbilirubinemia.

Table 770.1 Prefixes Denoting Decimal Factors in Table 770.5

PREFIX	SYMBOL	FACTOR
mega-	M	10^6
kilo-	k	10^3
hecto-	h	10^2
deka-	da	10^1
deci-	d	10^{-1}
centi-	c	10^{-2}
milli-	m	10^{-3}
micro-	μ	10^{-6}
nano-	n	10^{-9}
pico-	p	10^{-12}
femto-	f	10^{-15}

Table 770.2 Abbreviations Used in Table 770.5

Ab	Absorbance	mm^3	Cubic millimeter, microliter (μL)
AU	Arbitrary unit	mm Hg	Millimeters of mercury
BB	Brain isoenzyme of creatine kinase	mmol	Millimole
cap	Capillary	mo	Month, months
CH_{50}	Dilution required to lyse 50% of indicator red blood cells; indicates complement activity	mol	Mole
Cr	Creatinine	mOsm	Milliosmole
CSF	Cerebrospinal fluid	MW	Relative molecular weight
F	Female	ND	Not detected
g	Gram, grams	nm	Nanometer (wavelength)
G6PD	Glucose-6-phosphate dehydrogenase	Pa	Pascal(s)
Hb	Hemoglobin	pc	Postprandial
HbCO	Carboxyhemoglobin	RBC	Red blood cell(s), erythrocyte(s)
hpf	High-power field	RT	Room temperature
hr	Hour, hours	SD	Standard deviation
IU	International unit(s) of hormone activity	sec	Second, seconds
L	Liter	Tr	Trace
M	Male	U	International unit(s) of enzyme activity
MB	Heart isoenzyme of creatine kinase	V	Volume
mEq/L	Milliequivalents per liter	WBC	White blood cell(s)
min	Minute, minutes	WHO	World Health Organization
		wk	Week, weeks
		yr	Year, years

Table 770.3 Abbreviations for Specimens in Table 770.5

S	Serum
P	Plasma
(H)	Heparin
(LiH)	Lithium heparin
(E)	Ethylenediaminetetraacetic acid (EDTA)
(C)	Citrate
(O)	Oxalate
W	Whole blood
(NH_4H)	Ammonium heparinate

Table 770.4 Key to Comments Section of Table 770.5

30°C, 37°C	Temperature of enzymatic analysis (Celsius)	l	Fluorometric method
a	Values obtained are significantly method dependent	m	Fluorescence-activated cell sorting (FACS)
b	Values in older males are higher than those in older females	n	Fluorescence polarization
c	Values in older females are higher than those in older males	o	Gas chromatography
d	Atomic absorption	p	High-performance liquid chromatography (HPLC)
e	Borate affinity chromatography	q	Indirect fluorescence antibody (IFA) assay
f	Cation-exchange chromatography	r	Ion-selective electrode
g	Vitros, a proprietary analytic system of Ortho Clinical Diagnostics	s	Nephelometry
i	Electrophoresis	t	Optical density
j	Enzymatic assay	u	Radial immunodiffusion (RID)
k	Enzyme-amplified immunoassay	v	Radioimmunoassay (RIA)
		w	Spectrophotometry

Table 770.5 Reference Intervals*

ANALYTE OR PROCEDURE	SPECIMEN	REFERENCE VALUES (U.S.)†		CONVERSION FACTOR	REFERENCE VALUES (SI)†	COMMENTS
COMPLETE BLOOD COUNT						
Hematocrit (HCT, Hct)	*W(E)*		*% of packed red cells (V red cells/V whole blood cells × 100)*		*Volume fraction (V red cells/V whole blood)*	
Calculated from mean corpuscular volume (MCV) and RBC count (electronic displacement or laser)		0-30 days	44-70%	×0.01	0.44-0.70	
		1-23 mo	32-42%		0.32-0.42	
		2-9 yr	33-43%		0.33-0.43	
		10-17 yr M	36-47%		0.36-0.47	
		F	35-45%		0.35-0.45	
		>18-99 yr M	42-52%		0.42-0.52	
		F	37-47%		0.37-0.47	
Hemoglobin (Hb)	*W(E)*		*g/dL*		*mmol/L*	
		0-30 days	15.0-24.0	×0.155	2.32-3.72	MW Hb = 64,500
		1-23 mo	10.5-14.0		1.63-2.17	
		2-9 yr	11.5-14.5		1.78-2.25	
		10-17 yr M	12.5-16.1		1.93-2.50	
		F	12.0-15.0		1.86-2.32	
		>18-99 yr M	13.5-18.0		2.09-2.79	
		F	12.5-16.0		1.93-2.48	
	P(H)	*See Chemical Elements*				
Erythrocyte indices (RBC indices)						

Continued

Table 770.5 Reference Intervals*—cont'd

ANALYTE OR PROCEDURE	SPECIMEN	REFERENCE VALUES (U.S.)†		CONVERSION FACTOR	REFERENCE VALUES (SI)†	COMMENTS
Mean corpuscular hemoglobin (MCH)	*W(E)*		*pg/cell*		*fmol/cell*	
		0-30 days	33-39	×0.0155	0.51-0.60	
		1-23 mo	24-30		0.37-0.46	
		2-9 yr	25-31		0.39-0.48	
		10-17 yr M	26-32		0.26-0.32	
		F	26-32		0.26-0.32	
		>18-99 yr M	27-31		0.27-0.31	
		F	27-31		0.27-0.31	
Mean corpuscular hemoglobin concentration (MCHC)	*W(E)*		*% Hb/cell or g Hb/dL RBC*		*mmol Hb/L RBC*	
			32-36	×0.155	4.96-5.58	
Mean corpuscular volume (MCV)	*W(E)*		*μm³*		*fL*	
		0-30 days	99-115	×1	99-115	
		1-23 mo	72-88		72-88	
		2-9 yr	76-90		76-90	
		10-17 yr	78-95		78-95	
		>18-99 yr	78-100		78-100	
Leukocyte count (WBC count)	*W(E)*	*×1,000 cells/mm³ (μL)*			*×10⁹ cells/L*	
		0-30 days	9.1-34.0	×1	9.1-34.0	
		1-23 mo	6.0-14.0		6.0-14.0	
		2-9 yr	4.0-12.0		45.0-12.0	
		10-17 yr	4.0-10.5		4.0-10.5	
		18-99 yr	4.0-10.5		4.0-10.5	
Leukocyte differential	*W(E)*	*%*			*Number fraction*	
Myelocytes		0%		×0.01	0	
Neutrophils ("bands")		3-5%			0.03-0.05	
Neutrophils ("segs")		54-62%			0.54-0.62	
Lymphocytes		25-33%			0.25-0.33	
Monocytes		3-7%			0.03-0.07	
Eosinophils		1-3%			0.01-0.03	
Basophils		0-0.75%			0-0.0075	
		Cells/mm³ (μL)			*×10⁶ cells/L*	
Myelocytes		0		×1	0	
Neutrophils ("bands")		150-400			150-400	
Neutrophils ("segs")		3,000-5,800			3,000-5,800	
Lymphocytes		1,500-3,000			1,500-3,000	
Monocytes		285-500			285-500	
Eosinophils		50-250			50-250	
Basophils		15-50			15-50	
Platelet count (thrombocyte count)	*W(E)*	*×10³/mm³ (μL)*			*×10⁹/L*	
		Newborn 84-478 (after 1 wk, same as adult)		×10⁶	84-478	(Buck, 1996)
		Adult 150-400			150-400	

Table 770.5 Reference Intervals*—cont'd

ANALYTE OR PROCEDURE	SPECIMEN	REFERENCE VALUES (U.S.)†		CONVERSION FACTOR	REFERENCE VALUES (SI)†	COMMENTS
Reticulocyte count	*W(E,H,O)*	*Adults 0.5-1.5% of erythrocytes or 25,000-75,000/mm³ (μL)*		*×0.01 ×10⁶*	*0.005-0.015 (number fraction) or 25,000-75,000 × 10⁶/L*	
			%		*Number fraction*	
	W(cap)	1 day	0.4-6.0	×0.01	0.004-0.060	
		7 days	<0.1-1.3		<0.001-0.013	
		1-4 wk	<1.0-1.2		<0.001-0.012	
		5-6 wk	<0.1-2.4		<0.001-0.024	
		7-8 wk	0.1-2.9		0.001-0.029	
		9-10 wk	<0.1-2.6		<0.001-0.026	
		11-12 wk	0.1-1.3		0.001-0.013	
Alanine transaminase (aminotransferase) (ALT, SGPT)	*S*	*0-7 days*	*6-40 U/L*	*×1*	*6-40 U/L*	37°C,[bgw] (Soldin, Savwoir, Guo, 1997; Lockitch Halstead, Albersheim, 1988)[g] (Meites, 1989; Soldin and Morse, 1998; Lockitch Halstead, Albersheim, 1988)
		8-30 days M	10-40		10-40	
		F	8-32		8-32	
		1-12 mo	12-45		12-45	
		1-19 yr	5-45		5-45	
Albumin (BCG)	P	Premature 1 day	1.8-3.0 g/dL	×10	18-30 g/dL	
		Full term <6 days	2.5-3.4		25-34	
		8 days-1 yr	1.9-4.9		19-49	
		1-3 yr	3.4-4.2		34-42	
		4-19 yr	3.5-5.6		35-56	
Ammonia	P		11-35 μmol/L	×1	11-35 μmol/L	[g]
Amylase	S,P	1-19 yr	30-100 U/L	×1	30-100 U/L	(Lockitch Halstead, Albersheim, 1988; Gillard et al, 1983)
			% pancreatic fraction		*% pancreatic fraction*	
Amylase isoenzymes	S,P(H)	Cord-8 mo	0-34%	×0.01	0-0.34%	
		9 mo-4 yr	5-56%		0.05-0.56%	
		5-19 yr	23-59%		0.23-0.59%	
Anion gap (sodium − [chloride + bicarbonate])	P(H)	7-16 mEq/L		×1	7-16 mEq/L	
Antideoxyribonuclease B titer (anti-DNase B titer)	*S*	*Age*	*Upper limit of normal*		*Upper limit of normal*	
		4-6 yr	240-480 U	×1	240-480 U	(Kaplan et al, 1998)
		7-12 yr	480-800 U		480-800 U	
Antidiuretic hormone (hADH, vasopressin)	*P(E)*	*Plasma osmolarity (mOsm/kg)*	*Plasma ADH (pg/mL)*		*Plasma ADH ng/L*	
		270-280	<1.5	×1	<1.5	
		280-285	<2.5		<2.5	
		285-290	1-5		1-5	
		290-295	2-7		2-7	
		295-300	4-12		4-12	

Continued

Table 770.5 Reference Intervals*—cont'd

ANALYTE OR PROCEDURE	SPECIMEN	REFERENCE VALUES (U.S.)†		CONVERSION FACTOR	REFERENCE VALUES (SI)†		COMMENTS
Antistreptolysin-O titer (ASO titer)	*S*	*Age*	*Upper limit of normal*		*Upper limit of normal*		
		2-5 yr	120-160 Todd units	×1	120-160 Todd units		(Kaplan et al, 1998)
		6-9 yr	240 Todd units		240 Todd units		
		10-12 yr	320 Todd units		320 Todd units		
Aspartate transaminase (aminotransferase) (AST, SGOT)	*S*		*U/L*		*U/L*		
		0-7 days M	30-100	×1	35-100		37°C,[9] (Soldin, Savwoir, Guo, 1997; Lockitch Halstead, Albersheim, 1988)
		F	24-95		24-95		
		8-30 days	22-71		22-71		
		1-12 mo	22-63		22-63		
		1-3 yr	20-60		20-60		
		3-9 yr	15-50		15-50		
		10-15 yr	10-40		10-40		
		16-19 yr M	15-45		15-45		
		F	5-30		5-30		
Base excess	*W(H)*		*mmol/L*		*mmol/L*		
		Newborn	(−10)-(−2)	×1	(−10)-(−2)		
		Infant	(−7)-(−1)		(−7)-(−1)		
		Child	(−4)-(+2)		(−4)-(+2)		
		Thereafter	(−3)-(+3)		(−3)-(−3)		
Bicarbonate	*S,P*		*mmol/L*		*mmol/L*		
		Arterial	21-28	×1	21-28		
		Venous	22-29		22-29		
Bilirubin, total	*S*		*mg/dL*		*μmol/L*		
		Newborn	See Bhutani nomogram (Fig. 770.3)	×17.1			(Bhutani et al, 1999)
		1 mo-adult	<1.0		<17		
C-reactive protein (high sensitivity)	*S*						*(Soldin et al, 2004)*
			M (mg/dL)	*F (mg/dL)*		*M (mg/L)*	*F (mg/L)*
		0-90 days	0.08-1.58	0.09-1.58	×10	0.8-15.8	0.9-15.8
		91 days-12 mo	0.08-1.12	0.05-0.79		0.8-11.2	0.5-7.9
		13 mo-3 yr	0.08-1.12	0.08-0.79		0.8-11.2	0.8-7.9
		4-10 yr	0.06-0.79	0.5-1.0		0.6-7.9	0.5-10.0
		11-14 yr	0.08-0.76	0.06-0.81		0.8-7.6	0.6-8.1
		15-18 yr	0.04-0.79	0.06-0.79		0.4-7.9	0.6-7.9
Calcium, ionized (Ca)	*S,P(H),W(H)*		*mg/dL*		*mmol/L*		
		Cord blood	5.0-6.0	×0.25	1.25-1.50		
		Newborn, 3-24 hr	4.3-5.1		1.07-1.27		
		24-48 hr	4.0-4.7		1.00-1.17		
		Thereafter	4.8-4.92		1.12-1.23		
		or	2.24-2.46 Eq/L	×0.5	1.12-1.23		

Table 770.5 Reference Intervals*—cont'd

ANALYTE OR PROCEDURE	SPECIMEN	REFERENCE VALUES (U.S.)†		CONVERSION FACTOR	REFERENCE VALUES (SI)†	COMMENTS
Calcium, total	*S*		*mg/dL*		*mmol/L*	
		Cord blood	9.0-11.5	×0.25	2.25-2.88	
		Newborn, 3-24 hr	9.0-10.6		2.3-2.65	
		24-48 hr	7.0-12.0		1.75-3.00	
		4-7 days	9.0-10.9		2.25-2.73	
		Child	8.8-10.8		2.20-2.70	
		Thereafter	8.4-10.2		2.10-2.55	
Carbon dioxide, partial pressure (P_{CO_2})	*W(H)*		*mm Hg*		*kPa*	
		Newborn	27-40	×0.1333	3.6-5.3	
		Infant	27-41		3.6-5.5	
		Thereafter M	35-48		4.7-6.4	
		F	32-45		4.3-6.0	
Carbon monoxide (carboxyhemoglobin)	W(E)	Nonsmoker	<2% HbCO	×0.01	HbCO fraction <0.02	
		Smoker	<10%		<0.10	
		Lethal	>50%		>0.5	
Chloride	S,P(H)	Cord blood	96-104 mmol/L	×1	96-104 mmol/L	
		Newborn	97-110		97-110	
		Thereafter	98-106		98-106	
Chloride, sweat	*Sweat*		*mmol/L*			(Farrell et al, 2008)
			≤29	CF unlikely		
			30-59	Intermediate		
			≥60	Indicative of CF		
Cortisol	*S,P(H)*		*μg/dL*		*nmol/L*	
		Newborn	1-24	×27.59	28-662	
		Adults, 8 AM	5-23		138-635	
		4 PM	3-15		82-413	
		8 PM	<50% of 8 AM	×0.01	Fraction of 8 AM	
					≤0.50	
Creatine kinase	S	Cord blood	70-380 U/L	×1	70-380 U/L	30°C,[b] (Jedeikin et al, 1982)
		5-8 hr	214-1,175		214-1,175	
		24-33 hr	130-1,200		130-1,200	
		72-100 hr	87-725		87-725	
		Adult	5-130		5-130	
Creatine kinase isoenzymes	*S*		*% MB*	*% BB*		
		Cord blood	0.3-3.1	0.3-10.5		
		5-8 hr	1.7-7.9	3.6-13.4		
		24-33 hr	1.8-5	2.3-8.6		
		72-100 hr	1.4-5.4	5.1-13.3		
		Adult	0-2	0		

Continued

Table 770.5 Reference Intervals*—cont'd

ANALYTE OR PROCEDURE	SPECIMEN	REFERENCE VALUES (U.S.)†			CONVERSION FACTOR	REFERENCE VALUES (SI)†			COMMENTS
Creatinine (IDMS)									
Enzymatic	*S,P*		*mg/dL*			*μmol/L*			g
		0-4 yr	0.03-0.50		×88.4	2.65-44.2			
		4-7 yr	0.03-0.59			2.65-52.2			
		7-10 yr	0.22-0.59			19.4-52.2			
		10-14 yr	0.31-0.88			27.4-77.8			
		>14 yr	0.50-1.06			44.2-93.7			
Creatinine clearance (endogenous)	S,P,U	Newborn 40-65 mL/min/1.73 m^2							
		<40 yr, M 97-137							
		F 88-128							
		Decreases <6.5 mL/min/decade							
Ferritin	*S*		*ng/mL*			*μg/L*			
		0-6 wk	0-400		×1	0-400			
		7 wk-365 days	10-95			10-95			
		1-9 yr	10-60			10-60			
		10-18 yr M	10-300			10-300			
		F	10-70			10-70			
Folate	S	Newborn 7.0-32 ng/mL			×2.265	15.9-72.4 nmol/L			
		Thereafter 1.8-9.0				4.1-20.4			
	W(E)	150-450 ng/mL RBCs				340-1,020 nmol/L cells			
Glucose	*S*		*mg/dL*			*mmol/L*			
		Cord blood	45-96		×0.0555	2.5-5.3			
		Premature	20-60			1.1-3.3			
		Neonate	30-60			1.7-3.3			
		Newborn							
		1 day	40-60			2.2-3.3			
		>1 day	50-90			2.8-5.0			
		Child	60-100			3.3-5.5			
		Adult	70-105			3.9-5.8			
	W(H)	Adult	65-95			3.6-5.3			
Glucose tolerance test (GTT) (see Chapter 629)	*S*		*mg/dL*				*mmol/L*		
Oral dose									
Adult: 75 g			*Normal*	*Diabetic*			*Normal*	*Diabetic*	
Child: 1.75 g/kg of ideal weight, up to a maximum of 75 g		Fasting	70-105	≥126	×0.0555		3.9-5.8	≥7.0	(Diabetes Care, 2019)
		120 min	70-120	≥200			3.9-6.7	≥11	
G6PD in erythrocytes		W(E,H,C)							
Bishop, modified		Adult				Adult			
		3.4-8.0 U/g Hb			×0.0645	0.22-0.52 mU/mol Hb			
		98.6-232 U/10^{12} RBCs			×10^{-3}	0.10-0.23 nU/10^6 RBCs			
		1.16-2.72 U/mL RBC			×1	1.16-2.72 kU/L RBC			
		Newborn: 50% higher				Newborn: 50% higher			

Table 770.5 Reference Intervals*—cont'd

ANALYTE OR PROCEDURE	SPECIMEN	REFERENCE VALUES (U.S.)†		CONVERSION FACTOR	REFERENCE VALUES (SI)†	COMMENTS
γ-Glutamyl transpeptidase (GGT, GGTP)	*S*		*U/L*		*U/L*	
		Cord blood	37-193	×1	37-193	37°C,[b] (Knight and Haymond, 1981)
		0-1 mo	13-147		13-147	
		1-2 mo	12-123		12-123	
		2-4 mo	8-90		8-90	
		4 mo-10 yr	5-32		5-32	
		10-15 yr	5-24		5-24	
Immunoglobulin A (IgA)	*S*		*mg/dL*		*mg/L*	
		Cord blood	1.4-3.6	×10	14-36	[s] (Meites, 1989)
		1-3 mo	1.3-53		13-530	
		4-6 mo	4.4-84		44-840	
		7 mo-1 yr	11-106		110-1,060	
		2-5 yr	14-159		140-1,590	
		6-10 yr	33-236		330-2,360	
		Adult	70-312		700-3,120	
Immunoglobulin D (IgD)	S	Newborn: none detected			None detected	
		Thereafter: 0-8 mg/dL		×10	0-80 mg/L	
Immunoglobulin E (IgE)	S	M 0-230 IU/mL		×1	0-230 kIU/L	
		F 0-170			0-170	
Immunoglobulin G (IgG)	S		mg/dL		g/L	
		Cord blood	636-1,606	×0.01	6.36-16.06	[s] (Meites, 1989)
		1 mo	251-906		2.51-9.06	
		2-4 mo	176-601		1.76-6.01	
		5-12 mo	172-1,069		1.72-10.69	
		1-5 yr	345-1,236		3.45-12.36	
		6-10 yr	608-1,572		6.08-15.72	
		Adult	639-1,349		6.39-13.49	
Immunoglobulin M (IgM)	*S*		*mg/dL*		*mg/L*	
		Cord blood	6.3-25	×10	63-250	[s](Meites, 1989)
		1-4 mo	17-105		170-1,050	
		5-9 mo	33-126		330-1,260	
		10 mo-1 yr	41-173		410-1,730	
		2-8 yr	43-207		430-2,070	
		9-10 yr	52-242		520-2,420	
		Adult	56-352		560-3,520	
Iron	P	All ages	22-184 μg/dL	×0.1791	4-33 μmol/L	(Lockitch Halstead, Wadsworth, 1988)
Iron-binding capacity, total (TIBC)	S	Infant 100-400 μg/dL		×0.179	17.90-71.60 μmol/L	
		Thereafter 250-400			44.75-71.60	
L-lactate (perchloric acid)	*W*		*mg/dL*		*mmol/L*	
		1-12 mo	10-21	×1	1.1-2.3	(Bonnefont et al, 1990)
		1-7 yr	7-14		0.8-1.5	
		7-15 yr	5-8		0.6-0.9	
D-lactate	P(H)					[j](Rosenthal and Pesce, 1985)
		6 mo-3 yr	0.0-0.3	×1	0.0-0.3	

Continued

Table 770.5 Reference Intervals*—cont'd

ANALYTE OR PROCEDURE	SPECIMEN	REFERENCE VALUES (U.S.)†			CONVERSION FACTOR	REFERENCE VALUES (SI)†			COMMENTS
Lactate dehydrogenase (LDH)	*S*		*U/L*			*U/L*			
		<1 yr	170-580		×1	170-580			37°C,[a] (Meites, 1989)
		1-9 yr	150-500			150-500			
		10-19 yr	120-330			120-330			
Isoenzymes	*S*		*% of total activity*						
			1-6 yr	7-19 yr					
		LD1	20-38	20-35					
		LD2	27-38	31-38					
		LD3	16-26	19-28					
		LD4	5-16	7-13					
		LD5	3-13	5-12					
Lead	*W(H)*		*μg/dL*			*mmol/L*			
		Child	<3.5*		×0.0483	<0.0024			
		Initiate chelation therapy	≥70			≥3.38			
Lipase	P,S	1-18 yr	145-216 U/L		×1	145-216 U/L			(Ghoshal and Soldin, 2003)
Magnesium	P(H)		mg/dL			mmol/L			
		0-6 days	1.2-2.6		×0.411	0.48-1.05			[gw](Meites, 1989)
		7 days-2 yr	1.6-2.6			0.65-1.05			
		2-14 yr	1.5-2.3			0.60-0.95			
		0.78 ± 0.37% of total Hb			×0.01	0.0078 ± 0.0037 (mass fraction)			
Osmolality	S	Child, adult							
		275-295 mOsm/kg H_2O							
Phosphatase, alkaline	*S*		*U/L*			*U/L*			
		1-9 yr	145-420		×1	145-420			37°C,[aw]
		10-11 yr	140-560			140-560			
			M	F			M	F	
		12-13 yr	200-495	105-420			200-495	105-420	
		14-15 yr	130-525	70-230			130-525	70-230	
		16-19 yr	65-260	50-130			65-260	50-130	
Phosphorus, inorganic	S,P(H)		mg/dL			mmol/L			
		0-5 days	4.8-8.2		×0.3229	1.55-2.65			[w](Meites, 1989)
		1-3 yr	3.8-6.5			1.25-2.10			
		4-11 yr	3.7-5.6			1.20-1.80			
		12-15 yr	2.9-5.4			0.95-1.75			
		16-19 yr	2.7-4.7			0.90-1.50			
Potassium	*S*		*mmol/L*			*mmol/L*			
		0-1 wk	3.2-5.5		×1	3.3-5.5			(Greeley et al, 1993) Increased by hemolysis; serum values systematically higher than plasma values
		1 wk-1 mo	3.4-6.0			3.4-6.0			
		1-6 mo	3.5-5.6			3.5-5.6			
		6 mo-1 yr	3.5-6.1			3.5-6.1			
		>1 yr	3.3-4.6			3.3-4.6			
	P(H)	3.5-4.5 mmol/L				3.5-4.5 mmol/L			

*https://www.cdc.gov/nceh/lead/prevention/blood-lead-levels.htm

Table 770.5 Reference Intervals*—cont'd

ANALYTE OR PROCEDURE	SPECIMEN	REFERENCE VALUES (U.S.)†		CONVERSION FACTOR	REFERENCE VALUES (SI)†	COMMENTS
Prealbumin (transthyretin)	*S*		*mg/dL*		*mg/L*	
		0-5 days	6.0-21.0	×10	60-210	s(Lockitch, Halstead, Quigley, 1988)
		1-5 yr	14.0-30.0		140-300	
		6-9 yr	15.0-30.0		150-300	
		10-13 yr	20.0-36.0		200-360	
		14-19	22.0-45.0		220-450	
Protein, total	*S*		*g/dL*		*g/L*	
		Premature	4.3-7.6	×10	43-76	(Meites, 1989)
		Newborn	4.6-7.4		46-74	
		1-7 yr	6.1-7.9		61-79	
		8-12 yr	6.4-8.1		64-81	
		13-19 yr	6.6-8.2		66-82	
Pyruvate (perchloric acid)	W	7-17 yr	0.076 ± 0.026 mmol/L	×1	0.076 ± 0.026 mmol/L	(Pianosi et al, 1995)
Sodium	*S,P (LiH, NH_4H)*		*mmol/L*		*mmol/L*	
		Newborn	133-146	×1	133-146	g(Greeley et al, 1993)
		Infant	134-144		134-144	
		Child	134-143		134-143	
		Thereafter	135-145		135-145	
Thyroid-stimulating hormone (TSH)	*S*		*mIU/L*		*mIU/L*	
		0-3 days	1.00-20.00	×1	1.0-20.00	g(Dugaw et al, 2001)
		4-30 days	0.5-6.5		0.50-6.50	
		1-5 mo	0.5-6.0		0.5-6.0	
		6 mo-18 yr	0.5-4.5		0.5-4.5	
Thyrotropin-releasing hormone (TRH)	P	5-60 pg/mL		×2.759	14-165 pmol/L	
Thyroxine-binding globulin (TBG)	*S*		*mg/dL*		*mg/L*	
		Cord blood	1.4-9.4	×10	14-94	
		1-4 wk	1.0-9.0		10-90	
		1-12 mo	2.0-7.6		20-76	
		1-5 yr	2.9-5.4		29-54	
		5-10 yr	2.5-5.0		25-50	
		10-15 yr	2.1-4.6		21-46	
		Adult	1.5-3.4		15-34	
Thyroxine (T_4), total	*S*		*μg/dL*		*nmol/L*	
		0-3 days	8.0-20.0	×12.9	103-258	g(Dugaw et al, 2001)
		3-30 days	5.0-15.0		64-193	
		31-365 days	6.0-14.0		77-180	
		1-5 yr	4.5-11.0		58-142	
		6-18 yr	4.5-10.0		58-129	

Continued

Table 770.5 Reference Intervals*—cont'd

ANALYTE OR PROCEDURE	SPECIMEN	REFERENCE VALUES (U.S.)†		CONVERSION FACTOR	REFERENCE VALUES (SI)†	COMMENTS
Thyroxine (T_4), free	*S*		*ng/dL*		*pmol/L*	
		0-3 days	2.00-5.00	×12.9	25.7-64.3	9(Dugaw et al, 2001)
		3-30 days	0.90-2.20		11.6-28.3	
		31 days-18 yr	0.7-2.00		9.0-25.7	
Thyroxine (T_4), total	W	Newborn screen (filter paper) 6.2-22.0 μg/dL		×12.9	80-283 nmol/L	
Triiodothyronine (T_3), free	*S*		*pg/dL*		*pmol/L*	
		Cord blood	20-240	×0.01536	0.3-3.7	
		1-3 days	200-610		3.1-9.4	
		6 wk	240-560		3.7-8.6	
		Adult (20-50 yr)	230-660		3.5-10.0	
Triiodothyronine (T_3), total	*S*		*ng/dL*		*nmol/L*	
		0-3 days	60-300	×0.0154	0.9-4.7	
		4-365 days		90-260		1.4-4.0
		1-6 yr	90-240		1.4-3.7	
		7-11 yr	90-230		1.4-3.6	
		12-18 yr	100-210		1.5-3.3	9(Dugaw et al, 2001)
Urea nitrogen	S,P		mg/dL		mmol/L	
		Cord blood	21-40	×0.357	7.5-14.3	
		Premature (1 wk)	3-25		1.1-9.0	
		Newborn	3-12		1.1-4.3	
		infant or child	5-18		1.8-6.4	
		Thereafter	7-18		2.5-6.4	
Uric acid	*S*		*mg/dL*		*μmol/L*	
		1-3 yr	1.8-5.0	×59.48	100-300	
		4-6 yr	2.2-4.7		130-280	
		7-9 yr	2.0-5.0		120-295	
		10-11 yr M	2.3-5.4		135-320	(Lockitch Halstead, Albersheim, 1988)
		10-11 yr F	3.0-4.7		180-280	
		12-13 yr M	2.7-6.7		160-400	
		14-15 yr M	2.4-7.8		140-465	
		12-15 yr F	3.0-5.8		180-345	
		16-19 yr M	4.0-8.6		235-510	
		16-19 yr F	3.0-5.9		180-350	

*In preparing the reference range listings, a number of abbreviations, symbols, and codes were used (see Table 770.2).
†Reference values are shown in SI units (International System of Units) and U.S. units (Traditional Units).

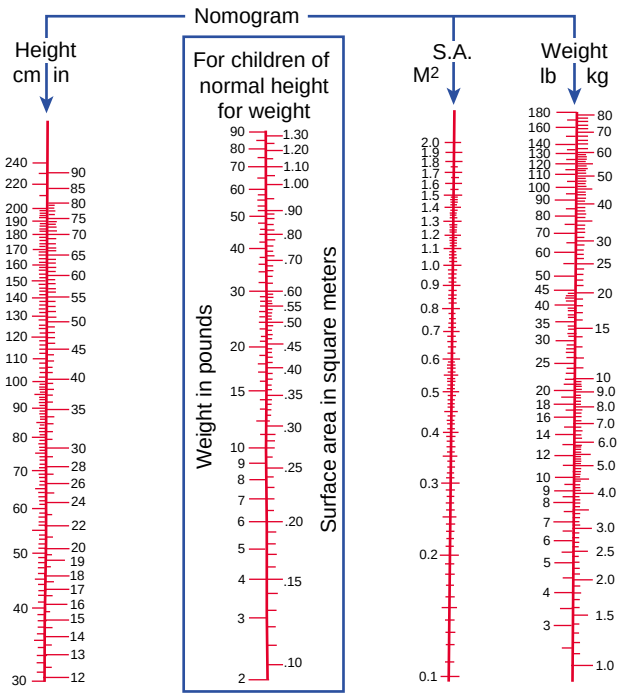

Alternative (Mosteller's formula):

$$\text{Surface area (m}^2) = \sqrt{\frac{\text{Height (cm)} \times \text{Weight (kg)}}{3600}}$$

Fig. 770.1 Nomogram for the estimation of surface area. The surface area is indicated where a straight line that connects the height and weight levels intersects the surface area column, or if the patient is roughly of average size, from the weight alone *(enclosed area). (Nomogram modified from the data of E. Boyd by CD West. See also Briars GL, Bailey BJ. Surface area estimation: pocket calculator v nomogram. Arch Dis Child. 1994;70:246–247.)*

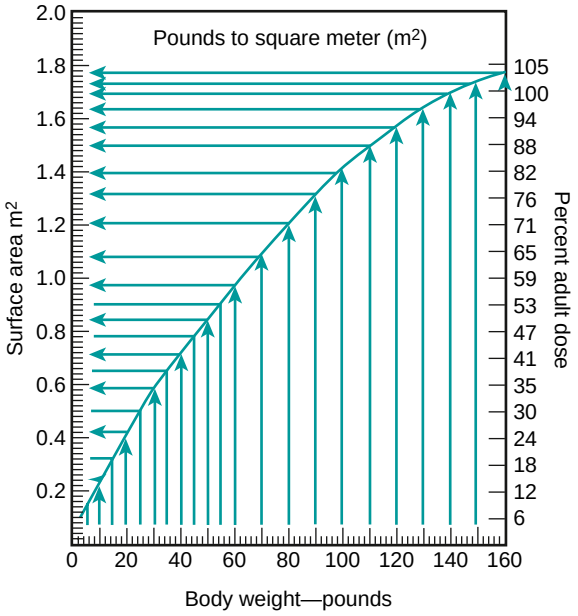

Fig. 770.2 Relationships between body weight (lb), body surface area, and adult dosage. The surface area values correspond with those set forth by Crawford JD, Terry ME, Rourke GM. Simplification of drug dosage calculation by application of the surface area principle. *Pediatrics.* 1950;5:783–790. Note that the 100% adult dose is for a patient weighing approximately 140 lb and having a surface area of approximately 1.7 m^2. *(From Talbot NB, Richie RH, Crawford JH. Metabolic homeostasis: a syllabus for those concerned with the care of patients. Cambridge, MA: Harvard University Press, 1959.)*

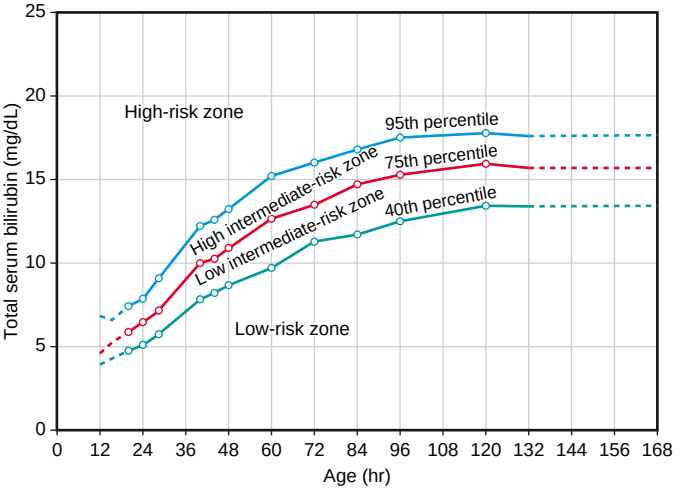

Fig. 770.3 Nomogram for risk assessment of hyperbilirubinemia. *(From Bhutani VK, Johnson L, Sivieri EM. Predictive ability of a predischarge hour-specific serum bilirubin for subsequent significant hyperbilirubinemia in healthy term and near-term newborns. Pediatrics. 1999;103:6–14. Fig 2.)*

Bibliography (for Table 770.5)

American Diabetes Association. Classification and diagnosis of Diabetes: Standards of Medical care in Diabetes - 2019. *Diabetes Care.* 2019;42:S13–S28.

Bhutani VK, Johnson L, Sivieri EM. Predictive ability of a predischarge hour-specific serum bilirubin for subsequent significant hyperbilirubinemia in healthy term and near-term newborns. *Pediatrics.* 1999;103:6–14.

Bonnefont JP, Specola NB, Vassault A, et al. The fasting test in children: application to the diagnosis of pathological hypo- and hyperketotic state. *Eur J Pediatr.* 1990;150:80–85.

Buck ML. Anticoagulation with warfarin in infants and children. *Ann Pharmacother.* 1996;30:1316–1322.

Diaz J, Tornel PL, Martinez P. Reference intervals for blood ammonia in healthy subjects, determined by microdiffusion. *Clin Chem.* 1995;41:1048.

Dugaw KA, Jack RM, Rutledge J. Pediatric reference ranges for TSH, free T_4, total T_4, total T_3 and T_3 uptake on the VitrosECi analyzer. *Clin Chem.* 2001;47:A108.

E. Endocrinology, C. Hills, CA 91301.

Farrell PM, Rosenstein BJ, White TB, et al. Guidelines for diagnosis of cystic fibrosis in newborns through older adults: Cystic Fibrosis Foundation Consensus Report. *J Pediatr.* 2008;153:S4–S14.

Ghoshal A, Soldin S. Evaluation of the Dade Behring dimension R × L: integrated chemistry system, pediatric reference ranges. *Clin Chim Acta.* 2003;331:135–146.

Gillard BK, Simbala JA, Goodglick L. Reference intervals for amylase isoenzymes in serum and plasma of infants and children. *Clin Chem.* 1983;29:1119–1123.

Greeley C, Snell J, Colaco A, et al. Pediatric reference ranges for electrolytes and creatinine. *Clin Chem.* 1993;39:1172.

Jedeikin R, Makela SK, Shennan AT, et al. Creatine kinase isoenzymes in serum from cord blood and the blood of healthy full-term infants during the first three postnatal days. *Clin Chem.* 1982;28:317–322.

Kaplan EL, Rothermel CD, Johnson DR. Antistreptolysin O and antideoxyribonuclease B titers: normal values for children ages 2 to 12 in the United States. *Pediatrics.* 1998;101:86–88.

Knight JA, Haymond RE. γ-Glutamyltransferase and alkaline phosphatase activities compared in serum of normal children and children with liver disease. *Clin Chem.* 1981;27:48–51.

Lockitch G, Halstead AC, Albersheim S, et al. Age- and sex-specific pediatric reference intervals for biochemistry analytes as measured with the Ektachem-700 analyzer. *Clin Chem.* 1988;34:1622–1625.

Lockitch G, Halstead AC, Quigley G, et al. Age- and sex-specific pediatric reference intervals: study design and methods illustrated by measurement of serum proteins with the Behring LN nephelometer. *Clin Chem.* 1988;34:1618–1621.

Lockitch G, Halstead AC, Wadsworth L, et al. Age- and sex-specific pediatric reference intervals and correlations for zinc, copper, selenium, iron, vitamins A and E, and related proteins. *Clin Chem.* 1988;34:1625–1628.

Meites S, ed. *Pediatric Clinical Chemistry, Reference (normal) Values.* 3rd ed. Washington, DC: American Association for Clinical Chemistry; 1989.

Muntau A, Streiter M, Kappler M, et al. Age-related reference values for serum selenium concentrations in infants and children. *Clin Chem.* 2002;48:555–560.

Nichols I. Diagnostics. San Juan Capistrano, CA 92675.

Nir A, Bar-Oz B, Perles Z, et al. N-terminal pro-B-type natriuretic peptide: reference plasma levels from birth to adolescence: elevated levels at birth and in infants and children with heart diseases. *Acta Paediatr*. 2004;93:603–607.

Pianosi P, Seargeant L, Haworth JC. Blood lactate and pyruvate concentrations, and their ratio during exercise in healthy children: developmental perspective. *Eur J Appl Physiol Occup Physiol*. 1995;71:518–522.

Rosenthal P, Pesce MA. Long-term monitoring of d-lactic acidosis in a child. *J Pediatr Gastroenterol Nutr*. 1985;4:674–676. 1985.

Sherry B, Jack RM, Weber A, et al. Reference interval for prealbumin for children 2 to 36 months old. *Clin Chem*. 1988;34:1878–1880.

Soldin SJ, Morse AS. Pediatric reference ranges for albumin and total protein in children <1 year old using the Vitros 500 analyzer. *Clin Chem*. 1998;44:A15.

Soldin SJ, Savwoir TV, Guo Y. Pediatric reference ranges for alkaline phosphatase, aspartate aminotransferase, and alanine aminotransferase in children less than 1 year old on the Vitros 500. *Clin Chem*. 1997;43:S199.

Soldin SJ, Brugnara C, Wong ED, eds. *Pediatric Reference Intervals*. 5th ed. Washington, DC: American Association for Clinical Chemistry; 2005.

Soldin O, Bierbower L, Choi J, et al. Serum iron, ferritin, transferrin, total iron binding capacity, hs-CRP, LDL cholesterol and magnesium in children: new reference intervals using the Dade Dimension Clinical Chemistry System. *Clin Chim Acta*. 2004;342:211–217.

Soldin SJ, Hicks JM, Bailey J, et al. Pediatric reference ranges for 25-hydroxy vitamin D during the summer and winter. *Clin Chem*. 1997;43:S200.